Fonseca

ORAL AND MAXILLOFACIAL SURGERY

third edition



FROST • POWERS • LE

Profession and Practice of Oral and Maxillofacial Surgery
Anesthesia and Pain Control
Dentoalveolar Surgery
Implant Surgery

ELSEVIER

About the pagination of this eBook

This eBook contains a multi-volume set.

To navigate this eBook by page number, you will need to use the volume number and the page number, separated by a hyphen.

For example, to go to page 5 of volume 1, type “1-5” in the Go box at the bottom of the screen and click "Go."

To go to page 5 of volume 2, type “2-5”… and so forth.

ORAL AND MAXILLOFACIAL SURGERY

third edition

VOLUME 1

Profession and Practice of Oral and Maxillofacial Surgery
Anesthesia and Pain Control
Dentoalveolar Surgery
Implant Surgery

This page intentionally left blank

ORAL AND MAXILLOFACIAL SURGERY

third edition

VOLUME 1

Profession and Practice of Oral and Maxillofacial Surgery
Anesthesia and Pain Control
Dentoalveolar Surgery
Implant Surgery

VOLUME EDITOR

Raymond J. Fonseca, DMD
Private Practice
Oral and Maxillofacial Surgery
Asheville, North Carolina;
Clinical Professor, Department of Oral and Maxillofacial Surgery
University of North Carolina
Chapel Hill, North Carolina

SECTION EDITORS

Michael P. Powers, DDS, MS
David E. Frost, DDS, MS
Bach Le, DDS, MD, FICD, FACD

ELSEVIER

ELSEVIER

3251 Riverport Lane
St. Louis, Missouri 63043

ORAL AND MAXILLOFACIAL SURGERY, VOLUME 1, THIRD EDITION Set ISBN: 978-0-323-41499-9
Volume 1 ISBN: 978-0-323-41497-5
Volume 2 ISBN: 978-0-323-41496-8
Volume 3 ISBN: 978-0-323-41495-1

Copyright © 2018 by Elsevier, Inc. All rights reserved.

Craig M. Misch retains copyright for the original images appearing in Chapter 30: Autogenous Bone Grafting for Dental Implants.

No part of this publication may be reproduced or transmitted in any form or by any means, electronic or mechanical, including photocopying, recording, or any information storage and retrieval system, without permission in writing from the publisher. Details on how to seek permission, further information about the Publisher's permissions policies and our arrangements with organizations such as the Copyright Clearance Center and the Copyright Licensing Agency, can be found at our website: www.elsevier.com/permissions.

This book and the individual contributions contained in it are protected under copyright by the Publisher (other than as may be noted herein).

Notices

Knowledge and best practice in this field are constantly changing. As new research and experience broaden our understanding, changes in research methods, professional practices, or medical treatment may become necessary.

Practitioners and researchers must always rely on their own experience and knowledge in evaluating and using any information, methods, compounds, or experiments described herein. In using such information or methods they should be mindful of their own safety and the safety of others, including parties for whom they have a professional responsibility.

With respect to any drug or pharmaceutical products identified, readers are advised to check the most current information provided (i) on procedures featured or (ii) by the manufacturer of each product to be administered, to verify the recommended dose or formula, the method and duration of administration, and contraindications. It is the responsibility of practitioners, relying on their own experience and knowledge of their patients, to make diagnoses, to determine dosages and the best treatment for each individual patient, and to take all appropriate safety precautions.

To the fullest extent of the law, neither the Publisher nor the authors, contributors, or editors, assume any liability for any injury and/or damage to persons or property as a matter of products liability, negligence or otherwise, or from any use or operation of any methods, products, instructions, or ideas contained in the material herein.

Previous editions copyrighted 2009 and 2000.

Library of Congress Cataloging-in-Publication Data

Names: Fonseca, Raymond J., editor.
Title: Oral and maxillofacial surgery.
Other titles: Oral and maxillofacial surgery (Fonseca)
Description: Third edition. | St. Louis, Missouri : Elsevier, [2018] |
Includes bibliographical references and indexes.
Identifiers: LCCN 2017002982| ISBN 9780323414999 (set : hardcover : alk. paper) | ISBN 9780323414975 (v. 1 : hardcover : alk. paper) | ISBN 9780323414968 (v. 2 : hardcover : alk. paper) | ISBN 9780323414951 (v. 3 : hardcover : alk. paper)
Subjects: | MESH: Oral Surgical Procedures | Face--surgery | Facial Bones--surgery | Maxilla--surgery
Classification: LCC RD523 | NLM WU 600 | DDC 617.5/2059--dc23 LC record available at https://lccn.loc.gov/2017002982

Senior Content Strategist: Jennifer Flynn-Briggs
Professional Content Development Manager: Jolynn Gower
Publishing Services Manager: Jeffrey Patterson
Senior Project Manager: Mary Pohlman
Design Direction: Ashley Miner

Printed in China.

Last digit is the print number: 9 8 7 6 5 4 3 2 1

ELSEVIER Book Aid International Working together to grow libraries in developing countries
www.elsevier.com • www.bookaid.org

To Chester, Lady, Cheerio, Moxie, Domino, Sasha, Tuxedo, Chairman Meow, Zoey, Apollo, Ayla, Annabelle, and Atticus for enriching our lives.

Raymond J. Fonseca

To Aubrey, Cam, and Katharine—it is wonderful to be your Dad.
To Dr. Raymond J. Fonseca, a tremendous mentor, educator, surgeon, and friend.
To Dr. Hans Bosker, an exceptional intellect, surgeon, gardener, and friend.
To Dr. David Frost, a superb humanitarian, surgeon, and friend.
And to Jennifer, with love.

Michael P. Powers

I dedicate my portion of this work to Travis A. "Bz" Witherington who saw something in me, encouraged me, and made everything else possible. He is one of the best teachers anywhere. To my mentors: Ray Fonseca, Bob Bays, John Gregg, Tim Turvey, and Khursheed Moos—they are teachers, researchers, mentors, confidants, and friends. Thank you all.

David E. Frost

To my wife Nancie for her unconditional support and my children Andrew, Dharma, Dana, and Bodhi, who inspire me and make me so proud.

Bach Le

In Memoriam

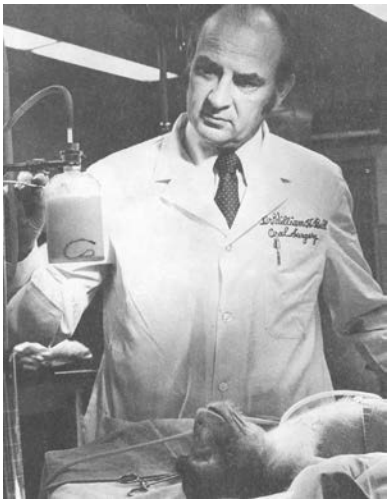

William H. Bell, DDS

We respectfully dedicate this edition of *Oral and Maxillofacial Surgery* to the memory of Dr. William "Bill" Harrison Bell. Matchless among his peers, Dr. Bell was an inimitable leader in surgery and medicine throughout his career.

In the early 1970s, Dr. Bell revolutionized oral and maxillofacial surgery through his landmark research on the biologic basis and clinical rationale for the Le Fort I osteotomy. In subsequent decades, he guided the hands of generations of surgeons, whether in academic medical centers across the world or through his meticulously detailed textbooks. It is a testament to Dr. Bell's always-passionate and always-persistent pursuit of excellence that his textbooks still remain contemporary decades after their publication.

While Dr. Bell was a revolutionary in our field, it is not simply in this spirit that we dedicate this book. Dr. Bell also served as an inspiration and mentor to us throughout our careers and lives, showing us always a readiness to inspire and a passion to change lives however he could. We are, quite simply, not alone in this feeling. It was this passion that compelled him to devote his life to improving patient care. It was this passion that affected so many others in our field. And it was this passion that also characterized so many areas of his vibrant and rich life—a life very well-lived.

It was an honor to learn from and know Bill. He was unwavering and uncompromising, and his love was unconditional. We know that the passion that burned in him to help others will continue to ignite the spirits of generations of surgeons to come. It will guide our hands and our actions as well.

Section Editors

David E. Frost, DDS, MS
Private Practice
OMSA
Chapel Hill, North Carolina

Bach Le, DDS, MD, FICD, FACD
Private Practice
Oral and Maxillofacial Surgery
Whittier, California;
Clinical Associate Professor
Department of Oral and Maxillofacial Surgery
The Herman Ostrow School of Dentistry of USC
Los Angeles County/USC Medical Center
Los Angeles, California

Michael P. Powers, DDS, MS
Private Practice
Oral and Maxillofacial Surgery
Kent, Ohio;
Clinical Assistant Professor of Oral and Maxillofacial Surgery
Department of Specialty Medicine
Heritage College of Osteopathic Medicine
Ohio University
Athens, Ohio;
Chair
Division of Oral and Maxillofacial Surgery
Department of Surgery
University Hospitals Portage Medical Center
Ravenna, Ohio

Contributors

Shelly Abramowicz, DMD, MPH
Assistant Professor
Oral and Maxillofacial Surgery
Emory University School of Medicine
Atlanta, Georgia
Chapter 13: Preoperative Evaluation

Payam Afzali, DDS, MD
Fellow, Oral/Head and Neck Oncology and Microvascular Reconstructive Surgery
Department of Oral and Maxillofacial Surgery
University of Michigan
Ann Arbor, Michigan
Chapter 28: Bone Grafting Techniques and Materials

Tara L. Aghaloo, DDS, MD, PhD
Associate Professor
Oral and Maxillofacial Surgery
UCLA School of Dentistry
Los Angeles, California
Chapter 28: Bone Grafting Techniques and Materials
Chapter 43: Peri-implant Disease

Diane Anthony-Costandi, DDS, MS
Private Practice
Periodontics
Los Angeles, California
Chapter 34: Peri-implant Soft Tissue Augmentation

Edmond Bedrossian, DDS, FACD, FACOMS, FAO
Diplomate, American Board of Oral and Maxillofacial Surgeons
Professor, Department of Oral and Maxillofacial Surgery
University of the Pacific
Director, Surgical Implant Training
University of the Pacific and Alameda Medical Center
San Francisco, California
Chapter 35: Zygomatic Implant: A Graftless Approach for Treatment of the Edentulous Maxilla

Edmond Armand Bedrossian Jr., DDS
PGY-2
University of Washington
Department of Prosthodontics
Seattle, Washington
Chapter 35: Zygomatic Implant: A Graftless Approach for Treatment of the Edentulous Maxilla

Gregory S. Bell, DDS
Private Practice
Conestoga Oral and Maxillofacial Surgery Ltd.
Lancaster, Pennsylvania
Chapter 19: Pediatric Pharmacosedation and General Anesthesia

Jeffrey D. Bennett, DMD
Chief, Oral and Maxillofacial Surgery
Roudebush VA Medical Center
Indianapolis, Indiana
Chapter 17: Anesthetic Concepts and Techniques

David A. Bitonti, BA Chemistry, DMD
Senior Military Advisor to the Commander
Walter Reed National Military Medical Center
Bethesda, Maryland
Chapter 3: Oral and Maxillofacial Surgery Career Alternatives to Private Practice

Terri Bradley, BA
Owner
Terri Bradley Consulting
Amesbury, Massachusetts
Chapter 8: Coding, Insurance, and Third-Party Payers

†Per-Ingvar Brånemark
President Brånemark Clinic
P-I Brånemark Institute Bauru
Bauru S.P. Brazil
Chapter 35: Zygomatic Implant: A Graftless Approach for Treatment of the Edentulous Maxilla

Andrea B. Burke, DMD, MD
Clinical Research Fellow
Diplomate, American Board of Oral and Maxillofacial Surgery
National Institutes of Dental and Craniofacial Research (NIDCR)
National Institutes of Health (NIH)
Bethesda, Maryland
Chapter 3: Oral and Maxillofacial Surgery Career Alternatives to Private Practice

† Deceased.

Kevin Butterfield, MD, DDS, FRCD(C), Dip.ABOMS
Division Chief, Dentistry
The Ottawa Hospital
Assistant Professor
Otolaryngology
University of Ottawa
Ottawa, Ontario, Canada
Chapter 17: Anesthetic Concepts and Techniques

John H. Campbell, DDS, MS
Associate Professor and Residency Director
Oral and Maxillofacial Surgery
University at Buffalo
Buffalo, New York
Chapter 20: Pediatric Dentoalveolar Surgery

Joshua Campbell, DDS
Assistant Professor
Department of Oral and Maxillofacial Surgery
University of Tennessee Graduate School of Medicine
Knoxville, Tennessee
Chapter 22: Complications of Dentoalveolar Surgery

Andrew Cheung, DDS
Clinical Assistant Professor (Gratis)
Oral and Maxillofacial Surgery
Vanderbilt University Medical Center
Nashville, Tennessee
Chapter 22: Complications of Dentoalveolar Surgery

Daniel R. Cullum, BSc, DDS
Private Practice OMS
President
Implants Northwest Live Learning Center
Coeur d'Alene, Idaho;
Guest Lecturer OMS
UCLA
Los Angeles, California;
Guest Lecturer OMS
Loma Linda University
Loma Linda, California
Chapter 27: Immediate Implants

Tony Daher, DDS, MSEd, FACP, FICD
Former, Clinical Associate Professor
Restorative Dentistry
Loma Linda University
Loma Linda, California;
Former, Lecturer
UCLA
Los Angeles, California;
Private Practice
LaVerne, California
Chapter 37: Mandibular Immediate Implant Loading with the Complete Arch Provisional Prostheses
Chapter 39: Implant Overdentures

Jeffrey Dembo, DDS, MD
Professor, Division of Oral and Maxillofacial Surgery
University of Kentucky College of Dentistry
Lexington, Kentucky
Chapter 16: Pharmacology of Drugs in Ambulatory Anesthesia

Martin E. Eichner, DDS
Private Practice
Oral and Maxillofacial Surgery
Adjunct Clinical Instructor
Department of Oral and Maxillofacial Surgery
University of Pittsburgh Medical Center
Pittsburgh, Pennsylvania
Chapter 3: Oral and Maxillofacial Surgery Career Alternatives to Private Practice

Joseph J. Fantuzzo, DDS, MD
Chairman and Residency Program Director
Oral & Maxillofacial Surgery
University of Rochester Medical Center
Rochester, New York
Chapter 18: Concepts in the Management of Acute Postoperative Pain

Scott D. Ganz, DMD
Private Practice
Ganz Sabrina-Fort Lee Dental Association
Fort Lee, New Jersey
Chapter 41: Three-Dimensional Imaging and Digital Workflow Protocols for Dental Implants and Bone Grafting

Jeremy R. Gies, DMD
Staff Surgeon
Department of Oral and Maxillofacial Surgery
Naval Hospital Beaufort
Beaufort, South Carolina
Chapter 15: Local Anesthetics

James A. Giglio, DDS, M.Ed.
Affiliate Professor, Department of Oral and Maxillofacial Surgery
School of Dentistry
Virginia Commonwealth University
Professor, Department of Surgery
School of Medicine
Virginia Commonwealth University
Richmond, Virginia
Chapter 25: Trigeminal Nerve Injuries

Charles J. Goodacre, DDS, MSD
Dean and Professor
Department of Restorative Dentistry
Loma Linda University School of Dentistry
Loma Linda, California
Chapter 39: Implant Overdentures

Scott E. Graham, MA, FACMPE, FAADOM
Executive Director
Oral Facial Surgery Institute
St. Louis, Missouri
Chapter 6: Business Management of the Oral and Maxillofacial Surgery Practice

John M. Gregg, DDS, MS, PhD
Adjunct Professor, Department of Oral and Maxillofacial Surgery
Virginia Commonwealth University, School of Dentistry
Adjunct Professor, Department of Biomedical Science
Virginia Tech Carilion School of Medicine
Blacksburg, Virginia
Chapter 25: Trigeminal Nerve Injuries

Alan S. Herford, DDS, MD
Chair, Oral and Maxillofacial Surgery
School of Dentistry
Loma Linda University
Loma Linda, California
Chapter 40: Implants in Acquired and Congenital Defects

Katsuhiro Horiuchi, DDS
Oral and Maxillofacial Surgery
Nara Medical University
Kashihara, Japan
Chapter 33: Osteoperiosteal Flaps and Distraction Osteogenesis

John W. Hultquist, DMD, MD
United States Air Force
Consultant to the Air Force Surgeon General for OMS
Department Chairman
Oral and Maxillofacial Surgery
Joint Base San Antonio
Lackland, Texas
Chapter 3: Oral and Maxillofacial Surgery Career Alternatives to Private Practice

N. Whitney James, DDS
Area/Regional Clinical Specialist
The Northern Navajo Medical Center/Shiprock Hospital
Shiprock, New Mexico
Chapter 3: Oral and Maxillofacial Surgery Career Alternatives to Private Practice

Ole T. Jensen, DDS, MS
Private Practice
Oral and Maxillofacial Surgeon
Clear Choice Dental Implant Center
Denver, Colorado
Chapter 33: Osteoperiosteal Flaps and Distraction Osteogenesis

Saj Jivraj, BDS, MS Ed
Clinical Associate Professor
Advanced Prosthodontics
Herman Ostrow USC School of Dentistry
Los Angeles, California
Chapter 26: Esthetic Implant Dentistry: Diagnosis and Treatment Planning
Chapter 36: Fixed Restoration of the Edentulous Maxilla

Samantha Jones, DDS, MD
Private Practice
Santa Barbara Center for Oral and Maxillofacial Surgery
Santa Barbara, California
Chapter 28: Bone Grafting Techniques and Materials

Nora Kahenasa, DMD
Private Practice
Oral and Maxillofacial Surgery
Lecturer
Department of Oral and Maxillofacial Surgery
UCLA School of Dentistry
Los Angeles, California
Chapter 28: Bone Grafting Techniques and Materials

Nicholas J. Kain, DDS
Private Practice
Oral and Maxillofacial Surgery
Greensboro, North Carolina
Chapter 24: Lasers in Oral Surgery

Karen M. Keith, DDS, MD
COL, DC, USA
OMS Consultant to The US Army Surgeon General
Chief, Oral and Maxillofacial Surgery
Vicenza Dental Clinic Command
Vicenza, Italy
Chapter 3: Oral and Maxillofacial Surgery Career Alternatives to Private Practice

Danny Ketola, BS Accounting
Administrator
Carolinas Center for Oral & Facial Surgery
Charlotte, North Carolina
Chapter 6: Business Management of the Oral and Maxillofacial Surgery Practice

Brian Kinard, DMD, MD
Resident
Department of Surgery, Division of Oral and Maxillofacial Surgery
Emory University School of Medicine
Atlanta, Georgia
Chapter 13: Preoperative Evaluation

Michael Kurtz, MS, MBA
Practice Administrator
University Oral and Maxillofacial Surgeons
St. Louis, Missouri
Chapter 6: Business Management of the Oral and Maxillofacial Surgery Practice

George M. Kushner, DMD, MD
Professor of OMFS
University of Louisville School of Dentistry
Louisville, Kentucky
Chapter 3: Oral and Maxillofacial Surgery Career Alternatives to Private Practice

Paul M. Lambert, DDS
Clinical Associate Professor
Advanced Education in General Dentistry Residency Program
Oral and Maxillofacial Surgery
Idaho State University-Meridian
Boise, Idaho;
Clinical Associate Professor
Department of Oral and Maxillofacial Surgery
Case Western Reserve University School of Medicine
Cleveland, Ohio;
Clinical Assistant Professor
Department of Surgery, Division of Oral and Maxillofacial Surgery
University of Cincinnati College of Medicine
Cincinnati, Ohio
Chapter 3: Oral and Maxillofacial Surgery Career Alternatives to Private Practice

Robert M. Laughlin, DMD
Oral & Maxillofacial Surgery
Naval Medical Center San Diego
San Diego, California
Chapter 15: Local Anesthetics

Bach Le, DDS, MD, FICD, FACD
Private Practice
Oral and Maxillofacial Surgery
Whittier, California;
Clinical Associate Professor
Department of Oral and Maxillofacial Surgery
The Herman Ostrow School of Dentistry of USC
Los Angeles County/USC Medical Center
Los Angeles, California
Chapter 31: Guided Tissue Regeneration in Implant Dentistry
Chapter 32: Contemporary Sinus-Lift Subantral Surgery and Graft
Chapter 37: Mandibular Immediate Implant Loading with the Complete Arch Provisional Prostheses
Chapter 42: Peri-implant Disease and Restorative Aspects of Dental Implants

Janice S. Lee, DDS, MD, FACS
Clinical Director
NIDCR/NIH
Chief, Craniofacial Anomalies and Regeneration Section
Bethesda, Maryland
Chapter 3: Oral and Maxillofacial Surgery Career Alternatives to Private Practice

Jesse W. Lee, DDS
Private Practice
Oral and Maxillofacial Surgery
Virginia Beach, Virginia
Chapter 3: Oral and Maxillofacial Surgery Career Alternatives to Private Practice

Luke L'Heureux, DMD, MD
Chief Resident
Department of Craniofacial Sciences
Division of Oral and Maxillofacial Surgery
University of Connecticut School of Dental Medicine
Farmington, Connecticut
Chapter 14: Monitoring for the Oral and Maxillofacial Surgery Patient

Stuart Lieblich, DMD
Clinical Professor
Oral and Maxillofacial Surgery
University of Connecticut
Farmington, Connecticut;
Private Practice
Avon Oral and Maxillofacial Surgery
Avon, Connecticut
Chapter 14: Monitoring for the Oral and Maxillofacial Surgery Patient

Trent W. Listello, DDS
Department of Oral and Maxillofacial Surgery
10th Medical Group
USAF Academy, Colorado
Chapter 19: Pediatric Pharmacosedation and General Anesthesia

Baldwin W. Marchack, DDS, MBA
Adjunct Professor
Continuing Education
Ostrow School of Dentistry of USC
Los Angeles, California
Chapter 38: Contemporary Restorative Options for the Single Implant

Vahik Paul Meserkhani, DDS, MSD
Private Practice
Prosthodontist/Implantology
Glendale, California
Chapter 37: Mandibular Immediate Implant Loading with the Complete Arch Provisional Prostheses

Craig M. Misch, DDS, MDS
Private Practice
Oral & Maxillofacial Surgery and Prosthodontics
Sarasota, Florida;
Associate Professor
Prosthodontics and Periodontics
University of Florida School of Dentistry
Gainesville, Florida
Chapter 30: Autogenous Bone Grafting for Dental Implants

Ololade I. Mitchell, MSN, MPH, RN
Risk Manager
OMS National Insurance Company, RRG
Tinley Park, Illinois
Chapter 7: Risk Management in Oral and Maxillofacial Surgery

Michael T. Mooney, DDS
Residency Program Director
Department of Oral and Maxillofacial Surgery
Naval Medical Center San Diego
San Diego, California
Chapter 15: Local Anesthetics

Michael Y. Nagai, DDS, MD
Academic Practice
Clinical Associate Professor
Department of Oral and Maxillofacial Surgery
University at Buffalo
Buffalo, New York
Chapter 20: Pediatric Dentoalveolar Surgery

Lindsey Nagy, DDS
Oral and Maxillofacial Surgeon
Oral and Maxillofacial Surgery
Methodist Medical Center
Oak Ridge, Tennessee
Chapter 22: Complications of Dentoalveolar Surgery

Gregory M. Ness, DDS
Professor—Clinical
Oral and Maxillofacial Surgery and Anesthesiology
The Ohio State University College of Dentistry
Columbus, Ohio
Chapter 21: Basic and Complex Exodontia and Surgical Management of Impacted Teeth

Joseph Niamtu III, DMD
Cosmetic Facial Surgery
Richmond, Virginia
Chapter 10: Marketing the Oral and Maxillofacial Surgery Practice

Brady Nielsen, DDS
Private Practice
Oral and Maxillofacial Surgery
Lakeshore Oral and Maxillofacial Surgery
Murrieta, California
Chapter 31: Guided Tissue Regeneration In Implant Dentistry

Katina Nguyen, DDS
Resident
Oral and Maxillofacial Surgery
Loma Linda University
Loma Linda, California
Chapter 40: Implants in Acquired and Congenital Defects

Howard H. Park, DMD, MD
Guest Lecturer
Oral and Maxillofacial Surgery
UCLA School of Dentistry
Los Angeles, California
Chapter 27: Immediate Implants

Larry P. Parworth, DDS, MS
Clinical Adjunct Faculty
Oral and Maxillofacial Surgery
University of North Carolina
Chapel Hill, North Carolina
Chapter 19: Pediatric Pharmacosedation and General Anesthesia

Joan Pi-Anfruns, DMD
Assistant Clinical Professor
Oral and Maxillofacial Surgery/Restorative Dentistry
UCLA School of Dentistry
Los Angeles, California
Chapter 28: Bone Grafting Techniques and Materials
Chapter 43: Peri-implant Disease

Crystal Piras, BA
Candidate for Doctor of Osteopathy 2018
Ohio University Heritage College of Osteopathic Medicine
Athens, Ohio
Chapter 16: Pharmacology of Drugs in Ambulatory Anesthesia

Pier Paolo Poli, DDS, MSc
Oral and Maxillofacial Surgery, Dentistry, Dental Surgery
Department of Biomedical, Surgical and Dental Science
University of Milan, Milano
Milano, Italy
Chapter 40: Implants in Acquired and Congenital Defects

Lee D. Pollan, DMD, MS
Professor Clinical Dentistry
Oral and Maxillofacial Surgery
Eastman Institute for Oral Health
Rochester, New York
Chapter 1: Professionalism and Ethics

Katharine C. Powers, DMD
Department of Orthodontics
Case Western Reserve University School of Dental Medicine
Cleveland, Ohio
Chapter 21: Basic and Complex Exodontia and Surgical Management of Impacted Teeth

Michael P. Powers, DDS, MS
Private Practice
Oral and Maxillofacial Surgery
Kent, Ohio;
Clinical Assistant Professor of Oral and Maxillofacial Surgery
Department of Specialty Medicine
Heritage College of Osteopathic Medicine
Ohio University
Athens, Ohio;
Chair
Division of Oral and Maxillofacial Surgery
Department of Surgery
University Hospitals Portage Medical Center
Ravenna, Ohio
Chapter 16: Pharmacology of Drugs in Ambulatory Anesthesia

Hari S. Prasad, BS, MDT, FICOI, MICOI
Assistant Director, Hard Tissue Research Laboratory
School of Dentistry
University of Minnesota
Minneapolis, Minnesota;
Adjunct Assistant Professor
College of Dentistry
University of Oklahoma
Oklahoma City, Oklahoma;
Adjunct Assistant Professor
Dental College of Georgia
Augusta University
Augusta, Georgia
Chapter 29: Bone Graft Biology and Histology

Mamaly Reshad, BDS, MSc
Honorary Clinical Teacher
Prosthodontics
Eastman Dental Institute
London, Great Britain
Chapter 26: Esthetic Implant Dentistry: Diagnosis and Treatment Planning
Chapter 36: Fixed Restoration of the Edentulous Maxilla

Sarah Ringdahl, Captain, USAF, DC
Periodontics Resident
US Air Force Postgraduate Dental School
Joint Base San Antonio
Lackland AFB, Texas
Chapter 16: Pharmacology of Drugs in Ambulatory Anesthesia

Michael D. Rohrer, DDS, MS
Director, Hard Tissue Research Laboratory
School of Dentistry
University of Minnesota
Professor, Division of Oral and Maxillofacial Pathology
University of Minnesota
Minneapolis, Minnesota
Chapter 29: Bone Graft Biology and Histology

James M. Rogér, DDS, MS
Resident
Oral and Maxillofacial Surgery
University of Rochester
Rochester, New York
Chapter 18: Concepts in the Management of Acute Postoperative Pain

Steven J. Sadowsky, DDS
Professor and Director of Implant Education
University of the Pacific Arthur A. Dugoni School of Dentistry
San Francisco, California
Chapter 39: Implant Overdentures

Navid Sharifzadeh, DDS, MS
Private Practice limited to Periodontics
Tehran, Iran;
Department of Periodontology and Oral and Craniofacial Biology
University of Southern California
Herman Ostrow School of Dentistry
Los Angeles, California
Chapter 34: Peri-implant Soft Tissue Augmentation

Keith H. Sherwood, DDS
Associate Professor
Orthodontics
Boston University Goldman School of Dental Medicine
Boston, Massachusetts
Chapter 23: Skeletally Based Implant Assisted Orthodontics

Stanley W. Smith, DDS, FACD
Chief of Oral and Maxillofacial Surgery
James J. Peters VA Medical Center
Bronx, New York;
Adjunct Assistant Clinical Professor of Dentistry
Icahn School of Medicine at Mount Sinai
Assistant Clinical Professor of Oral and Maxillofacial Surgery
Columbia University College of Dental Medicine
New York, New York
Chapter 3: Oral and Maxillofacial Surgery Career Alternatives to Private Practice

Martha J. Somerman, DDS, PhD
Director, National Institute of Dental and Craniofacial Research
National Institute of Health
Chief, Laboratory for Oral Connective Tissue Biology
National Institute of Arthritis and Musculoskeletal and Skin Diseases
National Institute of Health
Bethesda, Maryland
Chapter 3: Oral and Maxillofacial Surgery Career Alternatives to Private Practice

Robert A. Strauss, DDS, MD
Professor and Director
Residency Training Program
VA Commonwealth University Medical Center
Richmond, Virginia
Chapter 24: Lasers in Oral Surgery

James Q. Swift, DDS
Professor
Division of Oral and Maxillofacial Surgery
University of Minnesota
Minneapolis, Minnesota
Chapter 7: Risk Management in Oral and Maxillofacial Surgery

Raquel M. Ulma, DDS, MD
Fellow, Plastic and Reconstructive Surgery
UCLA Medical Center
Los Angeles, California
Chapter 28: Bone Grafting Techniques and Materials

Chandur Prem Karl Wadhwani, BDS, MSD
Private Practice Limited to Prosthodontics
Bellevue, Washington;
Adjunct Assistant Professor
Restorative Dentistry
Loma Linda University
Loma Linda, California;
Affiliate Faculty
Restorative Dentistry
University of Washington
Seattle, Washington
Chapter 42: Peri-implant Disease and Restorative Aspects of Dental Implants

Timothy O. Ward, MA, DDS
Staff Oral and Maxillofacial Surgeon
VA Medical Center
Richmond, Virginia
Chapter 3: Oral and Maxillofacial Surgery Career Alternatives to Private Practice

R. Dean White, DDS, MS
Private Practice—Retired
Oral and Maxillofacial Surgery
Past President, American Board of Oral and Maxillofacial Surgery
Granbury, Texas
Chapter 11: Challenges of Retirement
Chapter 12: Boundary Violations and Physical and Mental Impairments

R. Lynn White, DDS, FACD, FICD
Past President, American Association of Oral and Maxillofacial Surgeons
OMS Consultant, Phase II Associates
Austin, Texas
Chapter 4: OMS Practice Transition: Decisions for the New Surgeon and the Established Surgeon

Travis A. Witherington, DDS
Oral & Maxillofacial Surgeon
Oral Surgery Specialists of Tennessee
Oak Ridge, Tennessee
Chapter 2: The Philosophical Basis of a Successful Surgical Practice
Chapter 5: Performing Oral Surgery from the Sitting Position

Felix Kyle Yip, MS, DDS, MD
Chief Resident
Oral & Maxillofacial Surgery
University of Southern California
Los Angeles, California
Chapter 32: Contemporary Sinus-Lift Subantral Surgery and Graft

Homayoun H. Zadeh, DDS, PhD
Associate Professor
Director, Post-Doctoral Periodontology Program
Laboratory for Immunoregulation and Tissue Engineering
Division of Periodontology, Diagnostic Sciences and Dental Hygiene
University of Southern California
Ostrow School of Dentistry
Los Angeles, California
Chapter 34: Peri-implant Soft Tissue Augmentation

Mark David Zajkowski, DDS, MD
Private Practice Oral & Maxillofacial Surgeon
Oral & Maxillofacial Surgery Associates
South Portland, Maine
Chapter 9: Accreditation of Outpatient Surgery Facilities

Preface

We are excited to present the third edition of *Oral and Maxillofacial Surgery*. This three-volume text is the result of the collaboration of multiple contributors. The first edition, published in 2000, and the second edition, published in 2009, were very well-received. However, with all the advances in our profession, we felt it was time for a new edition. The section editors have done an excellent job recruiting the most knowledgeable individuals in their specific areas of expertise. The authors have submitted chapters that reflect the state of the art in their areas of responsibility.

This text is a comprehensive resource on oral and maxillofacial surgery. Every area in our specialty has been addressed. It defines the scope of the specialty. Every surgical procedure performed by an oral surgeon is covered in this text. This multi-volume text provides coverage of a wide range of issues related to surgical care, such as anesthesia, diagnostic imaging treatment planning, rehabilitation, physical therapy, and psychological considerations.

After an analysis of the changing field of oral and maxillofacial surgery, we strove to present a comprehensive, current book that covers the complete scope of our specialty. We hope that the reader appreciates and agrees with our efforts. We stated in the preface of the first edition that we hoped that our future attempts will present an even broader scope of oral and maxillofacial surgery. The fact that this edition has succeeded in that regard is a testament to the individuals who are constantly expanding the envelope.

Acknowledgments

The third edition of *Oral and Maxillofacial Surgery* is a team approach. The section editors—Michael P. Powers, David E. Frost, and Bach Le—were invaluable contributors to the success of this effort. They diligently pestered authors so that deadlines were almost met. This edition, like the last two, attempts to define the scope of oral and maxillofacial surgery and could not have come to fruition without these contributors.

Residents are the lifeblood of our specialty. Many have helped to contribute portions of chapters in this book. They have also provided us with friendship, dedication, intellectual stimulation, and humility, without which this book would not have been written.

Last, I would like to thank all the staff who helped to prepare these manuscripts and the editorial staff at Elsevier, who were so patient with our procrastination and meticulous in their development and editing of this book. Additionally, I would like to thank my staff—Laynee Adams, Sally Brown, Heather Early, Patty Martin, Sarah Merrill, Josie Ray, and Ashley Wood—who collectively and individually make my life so enjoyable.

Raymond J. Fonseca, DMD

Contents

VOLUME 1 CONTENTS

Profession and Practice of Oral and Maxillofacial Surgery, Anesthesia and Pain Control, Dentoalveolar Surgery, Implant Surgery

Volume Editor: Raymond J. Fonseca

Section 1: Profession and Practice of Oral and Maxillofacial Surgery

1 **Professionalism and Ethics 1**
Lee D. Pollan

2 **The Philosophical Basis of a Successful Surgical Practice 14**
Travis A. Witherington

3 **Oral and Maxillofacial Surgery Career Alternatives to Private Practice 23**
David A. Bitonti, Karen M. Keith, Jesse W. Lee, John W. Hultquist, N. Whitney James, Paul M. Lambert, Stanley W. Smith, Timothy O. Ward, George M. Kushner, Janice S. Lee, Martha J. Somerman, Andrea B. Burke, Martin E. Eichner

4 **OMS Practice Transition: Decisions for the New Surgeon and the Established Surgeon 39**
R. Lynn White

5 **Performing Oral Surgery from the Sitting Position 46**
Travis A. Witherington

6 **Business Management of the Oral and Maxillofacial Surgery Practice 58**
Danny Ketola, Scott E. Graham, Michael Kurtz

7 **Risk Management in Oral and Maxillofacial Surgery 73**
James Q. Swift, Ololade I. Mitchell

8 **Coding, Insurance, and Third-Party Payers 87**
Terri Bradley

9 **Accreditation of Outpatient Surgery Facilities 96**
Mark David Zajkowski

10 **Marketing the Oral and Maxillofacial Surgery Practice 102**
Joseph Niamtu, III

11 **Challenges of Retirement 138**
R. Dean White

12 **Boundary Violations and Physical and Mental Impairments 143**
R. Dean White

Section 2: Anesthesia and Pain Control

13 **Preoperative Evaluation 148**
Brian Kinard, Shelly Abramowicz

14 **Monitoring for the Oral and Maxillofacial Surgery Patient 164**
Stuart Lieblich, Luke L'Heureux

15 **Local Anesthetics 176**
Jeremy R. Gies, Michael T. Mooney, Robert M. Laughlin

16 **Pharmacology of Drugs in Ambulatory Anesthesia 191**
Crystal Piras, Sarah Ringdahl, Jeffrey Dembo, Michael Powers

17 **Anesthetic Concepts and Techniques 211**
Jeffrey D. Bennett, Kevin Butterfield

18 **Concepts in the Management of Acute Postoperative Pain 225**
James M. Rogér, Joseph J. Fantuzzo

19 **Pediatric Pharmacosedation and General Anesthesia 238**
Larry P. Parworth, Trent W. Listello, Gregory S. Bell

Section 3: Dentoalveolar Surgery

20 **Pediatric Dentoalveolar Surgery 257**
John H. Campbell, Michael Y. Nagai

21 **Basic and Complex Exodontia and Surgical Management of Impacted Teeth 275**
Gregory M. Ness, Katharine C. Powers

22 **Complications of Dentoalveolar Surgery 298**
Joshua Campbell, Andrew Cheung, Lindsey Nagy

23 **Skeletally Based Implant Assisted Orthodontics 311**
Keith H. Sherwood

24 **Lasers in Oral Surgery 327**
Robert A. Strauss, Nicholas J. Kain

25 **Trigeminal Nerve Injuries 354**
John M. Gregg, James A. Giglio

Section 4: Implant Surgery

26 **Esthetic Implant Dentistry: Diagnosis and Treatment Planning 391**
Saj Jivraj, Mamaly Reshad

27 **Immediate Implants 410**
Howard H. Park, Daniel R. Cullum

28 **Bone Grafting Techniques and Materials 426**
Tara L. Aghaloo, Joan Pi-Anfruns, Samantha Jones, Raquel M. Ulma, Payam Afzali, Nora Kahenasa

29 **Bone Graft Biology and Histology 437**
Michael D. Rohrer, Hari S. Prasad

30 **Autogenous Bone Grafting for Dental Implants 446**
Craig M. Misch

31 **Guided Tissue Regeneration in Implant Dentistry 475**
Bach Le, Brady Nielsen

32 **Contemporary Sinus-Lift Subantral Surgery and Graft 509**
Bach Le, Felix Kyle Yip

33 **Osteoperiosteal Flaps and Distraction Osteogenesis 526**
Ole T. Jensen, Katsuhiro Horiuchi

34 **Peri-implant Soft Tissue Augmentation 555**
Homayoun H. Zadeh, Diane Anthony-Costandi, Navid Sharifzadeh

35 **Zygomatic Implant: A Graftless Approach for Treatment of the Edentulous Maxilla 569**
Edmond Bedrossian, Edmond Armand Bedrossian Jr, Per-Ingvar Brånemark

36 **Fixed Restoration of the Edentulous Maxilla 584**
Mamaly Reshad, Saj Jivraj

37 **Mandibular Immediate Implant Loading with the Complete Arch Provisional Prostheses 605**
Tony Daher, Vahik Paul Meserkhani, Bach Le

38 **Contemporary Restorative Options for the Single Implant 624**
Baldwin W. Marchack

39 **Implant Overdentures 641**
Tony Daher, Charles J. Goodacre, Steven J. Sadowsky

40 **Implants in Acquired and Congenital Defects 665**
Alan S. Herford, Katina Nguyen, Pier Paolo Poli

41 **Three-Dimensional Imaging and Digital Workflow Protocols for Dental Implants and Bone Grafting 688**
Scott D. Ganz

42 **Peri-implant Disease and Restorative Aspects of Dental Implants 711**
Chandur Prem Karl Wadhwani, Bach Le

43 **Peri-implant Disease 723**
Tara L. Aghaloo, Joan Pi-Anfruns

1 Professionalism and Ethics

LEE D. POLLAN

Oral and maxillofacial surgery (OMS) training is an intense educational process that requires 4 to 6 years of residency beyond the traditional 4-year predoctoral dental educational curriculum. The OMS residency includes exposure and training to competency in the following disciplines: dento-alveolar surgery and implants, medicine, general surgery, anesthesiology, critical and intensive care, pathology, trauma management and reconstruction, cleft and craniofacial surgery, temporomandibular dysfunction, orthognathics, and cosmetic surgery. The Commission on Dental Accreditation also requires each resident to participate in scholarly activity and to be educated in coding and practice management.

The oral and maxillofacial surgeon enjoys a unique position among the dental specialties in that the educational process is longer and more intense, and it straddles the fence between medicine and dentistry. The OMS is often seen as the "go-to" person in dentistry and is often called on to assist in the diagnosis and treatment of patients who present with unique and perplexing problems in dental practice. Physicians will also refer patients who present with unusual problems of the head and neck. It is implied that as a health care provider, the OMS is given the privilege to provide care for patients, but also must demonstrate the responsibility to patients who place their trust in the OMS to care for them and their families. It is for these reasons that the OMS must function in a highly professional and ethical manner. It is this author's belief that the OMS curriculum is deficient in teaching and mentoring in the areas of professionalism and ethics.

What is the Definition of "Professionalism"?

The American Board of Medical Specialties (ABMS) states that *professionalism* is a belief system in which group members (professionals) declare to each other and to the public the shared competency standards and ethical values they promise to uphold in their work and what the public and individual patients can and should expect from medical (dental) professionals. At the heart of this concept is a three-part promise to acquire, maintain, and advance:

- An ethical value system grounded in the conviction that the professions exist to serve the patients' and the public's best interests.
- The knowledge and technical skills required for good practice.
- The interpersonal skills necessary to work together with patients.

There is a shared view that the members of a profession should work together, are committed to maintaining the standards and values that govern their practice, and monitor each others' adherence to their standards on behalf of the public. These standards are vetted through a process of internal debate and then are declared to the public to encourage open dialogue and ensure that the standards meet social needs and at the same time uphold core professional values. These standards are distributed to all stakeholders to ensure they are understood as part of the professional's contract with society, and then they must be enforced by the profession.[1]

Alan Norton, in a blog post published in 2010 at www.techrepublic.com, discusses 10 things that define a true professional. These are:

1. ***Put the customer (patient) first.*** Understanding and satisfying your patient's needs is the cornerstone of being a successful professional. Do what is necessary to meet those needs. Consider putting first the satisfaction of your co-workers.
2. ***Make expertise your specialty.*** The very word professional implies that you are an expert. Technical competence is essential.
   - Become an expert in the skills and tools necessary to do your job
   - Always perform to the best of your abilities
   - Keep your knowledge up to date
3. ***Do more than expected.*** Professionals aren't bound by a clock and have the ability to self manage their time. Professionals are expected to efficiently manage

their workload and frequently must work well beyond the standard 40 hour workweek. The professional is expected to produce results and meet or exceed expectations.

4. ***Do what you say and say what you can do.*** Professionals must walk the walk to back up talking the talk. To do less erodes the trust that patients have in their doctor.
5. ***Communicate effectively.*** A patient will go out of their way to seek out a doctor who has excellent communication skills. The professional takes time to explain treatment options, make recommendations, clearly state financial arrangements, and predict expected completion of treatment. This in turn empowers the patient to accept treatment plans and make appropriate treatment decisions.
6. ***Follow exceptional guiding principles.*** Professionals demonstrate appreciation of their employees, practice proper etiquette, and have high ethical and moral standards. Professionals are honest and fair in their dealings with others.
7. ***Praise your peers not yourself.*** Demonstrate respect for your peers. While you may not always agree with another provider's treatment, a professional should not denigrate the care provided by others.
8. ***Share your knowledge.*** If you believe in hoarding information and have the opinion that your knowledge is greater than that of others and will ensure your success, think again—no one is irreplaceable. Professionals should help their peers and are respected for doing so.
9. ***Say thank you (and don't be afraid to say I'm sorry).*** A simple "thank you" to a co-worker, employee, assistant, patient or referral source goes a long way to state your gratitude. Saying "I'm sorry" doesn't make you appear weak or imply a sense of guilt. It merely expresses your admission that you (and perhaps an outcome) are less than perfect. It expresses your humanity and a willingness to admit that a professional isn't always perfect.
10. ***Keep a smile on your face and the right attitude in your heart.*** Being pleasant and cheerful can be difficult when you are feeling unpleasant at times. Sharing the misery is not the mark of a professional.[2]

A Little History

Dental (and medical) education historically upheld the notion of professionalism. Numerous institutions hold "white coat ceremonies" inducting the student into the professional arena. Students in the early stages of clinical exposure to patients were called "doctor." Students were mandated to wear professional attire, act in a certain manner, and act respectfully toward peers and patients. But it wasn't until the mid-1990s that the concept of teaching professionalism began to emerge into health care and medical and dental education. The health care professions and the commitment to the patient were being challenged by external forces of change in society (e.g., managed care, health care financing challenges, governmental pressures). Numerous print and broadcast news segments have raised concerns about unprofessional and unethical behavior. It is the public's perception of dishonesty and a lack of professional integrity by physicians and dentists, and the resulting erosion of public trust, that forced health care into a renewed sense of professionalism.

The Physicians' Charter, published in *Lancet* in 2002, was a product of the American College of Physicians, the American Society of Internal Medicine, the American Board of Internal Medicine Foundation, and the European Federation of Internal Medicine. The Charter outlines three fundamental principles underlying professionalism:

- Primacy of patients' welfare
- Patients' autonomy
- Social justice

The Charter goes on to establish a set of 10 professional commitments to:

1. Professional competence
2. Honesty with patients
3. Patient confidentiality
4. Maintaining appropriate relationships with patients
5. Improving quality of care
6. Improving access to care
7. Just distribution of finite resources
8. Scientific knowledge
9. Maintaining trust by managing conflicts of interest
10. Professional responsibilities

The expanded definition of the Physician Charter commitments are a set of professional responsibilities that inform the public and the profession of the fundamental principles that help to ensure patient welfare and autonomy.

1. **Commitment to professional excellence.** Physicians must be committed to lifelong learning and be responsible for maintaining the medical knowledge and clinical and team skills necessary for the provision of quality health care. More broadly, the profession as a whole must strive to see that all of its members are competent and must ensure that appropriate mechanisms are available for physicians to accomplish this goal.
2. **Commitment to honesty with patients.** Physicians must ensure that patients are completely and honestly informed before the patient has consented to treatment and after treatment has occurred. This expectation does not mean that patients should be involved in every minute decision about medical care; rather, they must be empowered to decide on the course of therapy. Physicians should also acknowledge that in health care, medical errors that injure patients do sometimes occur. Whenever patients are injured as a consequence of medical care, patients should be informed promptly because failure to do so seriously compromises patient and societal trust. Reporting and analyzing medical mistakes provide the basis for appropriate prevention and improvement strategies and for appropriate compensation to injured parties.

3. **Commitment to patient confidentiality.** Earning the trust and confidence of patients requires that appropriate confidentiality safeguards be applied to disclosure of patient information. This commitment extends to discussions with persons acting on a patient's behalf when obtaining the patient's own consent is not feasible. Fulfilling the commitment to confidentiality is more pressing now than ever before, given the widespread use of electronic information systems for compiling patient data such as electronic medical records (EMRs) and an increasing availability of genetic information. Physicians recognize, however, that their commitment to doctor-patient confidentiality must occasionally yield to overriding considerations in the public interest (for example, when patients endanger others).
4. **Commitment to maintaining appropriate relations with patients.** Given the inherent vulnerability and dependency of patients, certain relationships between physicians and patients must be avoided. In particular, physicians should never exploit patients for any sexual advantage, personal financial gain, or other private purpose.
5. **Commitment to improving quality of care.** Physicians must be dedicated to continuous improvement in quality health care. This commitment entails not only maintaining clinical competence but also working collaboratively with other professionals to reduce medical error, increase patient safety, minimize overuse of health care resources, and optimize the outcomes of care. Physicians must actively participate in the development of better measures of quality of care and the application of quality measures to assess routinely the performance of all health care professionals, institutions, and systems. Physicians, both individually and through their professional associations, must take responsibility for assisting in the creation and implementation of mechanisms designed to encourage continuous improvement in the quality of care.
6. **Commitment to improving access to care.** Medical professionalism demands that the objective of all health care systems be the availability of a uniform and adequate standard of care. Physicians must individually and collectively strive to reduce barriers to equitable health care. Within each system, the physician should work to eliminate barriers to access based on education, laws, finances, geography, and social discrimination. A commitment to equity entails the promotion of public health and preventive medicine, as well as public advocacy on the part of each physician, without concern for the self-interest of the physician or the profession.
7. **Commitment to a just distribution of finite resources.** While meeting the needs of individual patients, physicians are required to provide health care that is based on the wise and cost-effective management of limited clinical resources. They should be committed to working with other physicians, hospitals, and payers to develop guidelines for cost effective care. The physician's professional responsibility for appropriate allocation of resources requires scrupulous avoidance of superfluous tests and procedures. The provision of unnecessary services not only exposes one's patients to avoidable harm and expense but also diminishes the resources available for others.
8. **Commitment to scientific knowledge.** Much of medicine's contract with society is based on the integrity and appropriate use of scientific knowledge and technology. Physicians have a duty to uphold scientific standards, to promote research, and to create new knowledge and ensure its appropriate use. The profession is responsible for the integrity of this knowledge, which is based on scientific evidence and physician experience.
9. **Commitment to maintaining trust by managing conflicts of interest.** Medical professionals and their organizations have many opportunities to compromise their professional responsibilities by pursuing private gain or personal advantage. Such compromises are especially threatening in the pursuit of personal or organizational interactions with for-profit industries, including medical equipment manufacturers, insurance companies, and pharmaceutical firms. Physicians have an obligation to recognize, disclose to the general public, and deal with conflicts of interest that arise in the course of their professional duties and activities. Relationships between industry and opinion leaders should be disclosed, especially when the latter determine the criteria for conducting and reporting clinical trials, writing editorials or therapeutic guidelines, or serving as an editor of a scientific journal.
10. **Commitment to professional responsibilities.** As members of a profession, physicians are expected to work collaboratively to maximize patient care, be respectful of one another, and participate in the processes of self-regulation, including the remediation and discipline of members who have failed to meet professional standards. The profession should also define and organize the educational and standard-setting process for current and future members. Physicians have both individual and collective obligations to participate in these processes. These obligations include engaging in internal assessment and accepting external scrutiny of all aspects of their professional performance.[3]

It is difficult to define professionalism in the style of a dictionary. Many individuals have made the tongue-in-cheek comment that pornography and professionalism have two similarities—they may be hard to define, but people know it when they see it. Defining professionalism becomes a little easier when one recognizes that there are common characteristics that define all professions. Autonomy is granted to the profession only if the profession meets the responsibilities placed on it by patients, third-party payers, state regulatory bodies, peers, and the institutions that grant privileges to the health care provider. In particular, the health care professions serve as guardians of social values and the professionals are

expected to articulate and hold these values publically. Professionalism is grounded within a series of behavioral patterns, moral values, honesty, integrity, and judgment. The profession then becomes a way of life with a moral value.[4]

In his article on defining medical professionalism, Swick states that medical professionalism comprises a series of behaviors. He says that health care providers:

- Subordinate their own interests to the interests of others.
- Adhere to high ethical and moral standards.
- Respond to societal needs, and their behaviors reflect a social contract with the community served.
- Project core humanistic values, including honesty and integrity, caring and compassion, altruism and empathy, respect for others, and trustworthiness.
- Exercise accountability for themselves and for their colleagues.
- Demonstrate a continuing commitment to excellence.
- Exhibit a commitment to scholarship and to advancing their field.
- Deal with high levels of complexity and uncertainty.
- Reflect upon their actions and decisions.[4]

This chapter has discussed many attributes of professional behavior, teaching of professionalism, the responsibilities of being a professional, and the expectations placed on the health care professional by society and regulatory bodies. Patrick Duff, MD, has enumerated several examples of unprofessional behavior in students. These include:

- Intellectual or personal dishonesty: a fabrication of research results or lab data, failure to follow through on assignments and cheating on examinations
- Arrogance and disrespectfulness: a student's inappropriate sense of entitlement
- Prejudice on the basis of gender, ethnicity, age, or sexual orientation
- Abrasive interactions with patients and co-workers: a student's exaggerated sense of self importance
- Lack of accountability for medical errors and administrative over sights; lack of student investment in a patient's outcome
- Fiscal irresponsibility: ordering expensive and unnecessary lab tests; receiving kick-backs for referrals or use of materials
- Lack of commitment to lifelong learning: failing to explore new technologies or seeking continuing education
- Lack of due diligence: carelessness, laziness, inattention to detail, and failure to follow through
- Personal excesses: substance abuse, high-stakes gambling, and high-risk behaviors
- Sexual misconduct: inappropriate advances or relationships with patients, co-workers, and students[5]

The trigger for professionalism in medical education initiatives was the Physicians' Charter. Professionalism has been identified as a core competency that needs to be evaluated in students and residents. The Group on Educational Affairs (GEA), the Association of American Medical Colleges (AAMC), and the Accreditation Council for Graduate Medical Education (ACGME) as well as many specialty boards have identified professionalism education as a priority.

Can Professionalism be Taught?

The oral and maxillofacial surgeon who is involved in predoctoral or residency education must decide: can professionalism be taught using the traditional Socratic method, or should it be taught by role modeling?

If professionalism is taught by role modeling, the mentor should answer the following:

- Am I modeling teamwork?
- Am I a role model for lifelong learning?
- Can the student see that I am honest and compassionate?
- Do I make the student aware of my advocacy efforts?

If professionalism is taught by conventional didactic means, the mentor might ask:

- Can I teach the student to be compassionate or respectful?
- Can I teach the student to self-monitor honesty and goals for excellence?
- Can I teach teamwork?[6]

Even though the concept of professionalism can be nebulous and very difficult to define, several organizations have elucidated constructs to assist with this definition. The ACGME has stated that professionalism is a core competency for all residents. The competencies expected are that "residents must demonstrate a commitment to carrying out professional responsibilities and an adherence to ethical principles. Residents are expected to demonstrate:

- Compassion, integrity, and respect for others
- Responsiveness to patient needs that supersedes self-interest
- Respect for patient privacy and autonomy
- Accountability to patients, society, and the profession
- Sensitivity and responsiveness to a diverse patient population, including but not limited to diversity in gender, age, culture, race, religion, disabilities, and sexual orientation

The Gold Humanism Foundation promotes the concept of a humanistic doctor as one who demonstrates integrity, excellence, compassion, altruism, respect, and service.

The University of Texas Medical Branch Professionalism Charter outlines a set of commitments that is expected of *every* employee: commitment to responsibility, service, diversity, competence, confidentiality, honesty, responsible use of resources, improving access to education and health care, quality, maintaining appropriate relations, managing conflicts of interest, and knowledge. It is incomprehensible that UTMB is the only institution that states these expectations.[7]

Evaluation of the Student (Resident) and Adherence to Professional Behavior

Since the ACCME and other accrediting bodies state that teaching of professionalism is a core competency as part

of residency education, what is the appropriate method of evaluating the resident and providing feedback to the resident?

All faculty at the predoctoral and postgraduate levels in dentistry must adhere to the standards of the Commission on Dental Accreditation (CODA). These standards include regular evaluation of the performance of the resident. The standards also allow for evaluation of the faculty by the resident.

If one subscribes to the foregoing discussion, it is clear that one of the major tenets of professionalism is *honesty*. It is not unusual for the mentor to question whether or not a specific resident evaluation is warranted. (Maybe I was ineffective as a teacher—maybe my evaluation was too harsh. Perhaps the student who receives a poor evaluation will recognize that I was the one who gave that bad evaluation and I will in turn receive a poor evaluation myself.) The simple answer is that honesty is one of the most important characteristics in solving this problem. If we are dishonest in our evaluations, are we, in turn, being truly unprofessional?

To demonstrate true professionalism, we must be able to be critical when reflecting on our own behaviors, regardless if we are the resident or the mentor. As the resident, it is appropriate to ask:

- How did I behave in that critical situation?
- If I had it to do over, would I do anything differently?
- What aspect of professionalism was challenging for me today?

As the mentor, it is appropriate to pose the following questions to the resident:

- How did you think you did in that difficult situation?
- If you had it to do over, would you do anything differently?
- What aspect of professionalism was challenging for you today?

As a professional, it is expected that one demonstrate CHARACTER:

C ompassion
H onesty
A ltruism
R esponsibility
A iming for excellence
C onfidentiality
T eamwork
E thical approach
R espect[8]

Paul S. Mueller, in his paper presented to the Keio Medical Society in Tokyo in 2008, lists eight reasons for teaching and assessing professionalism.[9]

1. Teaching and assessing professionalism does not occur by chance alone. The elements of the framework of professionalism should intentionally be taught (Figure 1-1).
2. Patients expect doctors to be professional. Patients expect the doctor to be confident, empathetic, personal, forthright, respectful, and thorough.

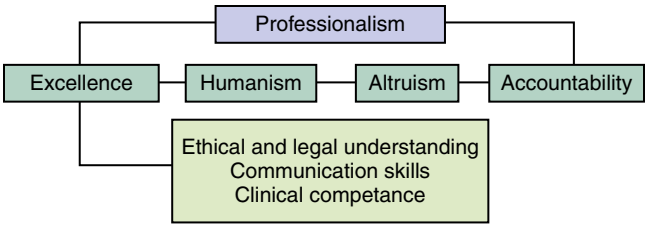

• **Figure 1-1** A framework for defining medical professionalism.

3. Medical and dental professional societies expect professionalism to be taught and assessed. Accrediting organizations such as the ACGME and the Joint Commission recommend that professionalism be included as a core competency in graduate medical education and accreditation of institutions. CODA has standards that require education in practice management and professionalism.
4. Professionalism is associated with improved medical outcomes. These are related to increased patient trust, better compliance, fewer patient complaints, and less patient litigation.
5. Unprofessional behavior is associated with adverse medical outcomes. These are related to reduced employee morale and productivity, reduced communication, burnout and depression.
6. Accrediting bodies require that professionalism be taught and assessed.
7. Professionalism can be taught and learned. Formal and informal curricula can influence values and beliefs about moral and ethical reasoning and behavior.
8. Informal educational processes (the hidden curriculum) that include conversations during rounds, hallways, call rooms, etc. can be powerful influences on trainees provided by role models and mentors.

There are several concepts for teaching professionalism that must be considered. According to Epstein and Hundert, these concepts include identifying the challenges of teaching professionalism, transitioning from measuring values to predicting behaviors, methodologies for teaching professionalism, and the importance of imparting the concept of professional behavior to the student.[10]

Today's students face pressures that seem daunting to them. Merely trying to understand the expectations of what professionalism encompasses is difficult for the student. Numerous students have negative role models based on their exposure to the print and broadcast media. Newspaper articles about health care professionals who have committed egregious acts are prominent. Many television shows portray health care professionals in a very unprofessional light.

A student's values can be very difficult to observe and measure. Providing feedback to a student about values can be threatening and imply character defects. Discussing deviations from expected behavior is less threatening and usually, more readily accepted. While educators generally have an easier time assessing cognitive skills, there often is greater

difficulty in discussing non-cognitive skills such as communication, integrity, and honesty.

Several steps are involved in teaching professionalism: setting expectations, performing assessments, remediating inappropriate behaviors, preventing inappropriate behaviors, and implementing cultural change.

Initially, expected behaviors must be defined. These expectations can be variable based on the culture of a particular institution. In addition, institutional processes such as reporting channels, due process, remediation processes, and lack of retaliation against those who report behavior issues may vary.

Educators, especially those who are involved in predoctoral education, must have the tools to provide uniform, consistent, and unbiased evaluation of students. The institution must provide this information to the faculty in order to make the evaluation process effective.

Last, the institution must provide the educators with the tools to remediate the student who does not comply with accepted defined patterns of professional behavior. The student must have information about the consequences of noncompliance with regard to faculty and institutional expectations for professional behavior.[11]

Causes of Unprofessional Behavior

Types of unprofessional behavior were previously discussed. It is important to note that unprofessional behavior does not necessarily indicate a character flaw or lack of a moral compass. It is generally believed that all medical and/or dental students enter professional school intending to become respected, successful, and contributory members of their respective professional communities. What happens that leads to an alteration in behavior within the individual who is deemed to be unprofessional?

According to Liselotte N. Dyrbye and her colleagues, there is a direct relationship between self-reported unprofessional conduct and burnout among medical students.[12] Of students who responded to a survey, 52.8% were experiencing burnout. Students with burnout were significantly more likely to have engaged in cheating and dishonest clinical behaviors. These students were less likely to hold altruistic values regarding a physician's responsibility to society, including serving underserved patient populations.

A study by Shalini T. Reddy published in the *Journal of Hospital Medicine* identified causes of unprofessional behavior among hospitalists.[13] Four key factors or patterns of unprofessional behavior included making fun of others, conduct in the learning environment (texting during conferences), workload management (celebrating transfer of a patient), and time pressures (signing out early). The most common unprofessional behaviors were having nonmedical, personal conversations in patient corridors, ordering a routine test as urgent to expedite patient care, signing out a patient by phone when it could have been done in person, and ridiculing physicians to colleagues.

According to a blog post published by Kaiser Health News on June 14, 2012, two thirds of doctors surveyed at three Chicago hospitals admit to having personal conversations within earshot of patients. Sixty-two percent have characterized a lab test as urgent in order to obtain the result faster. Forty percent mocked another physician. The same number made disparaging remarks about emergency room doctors for missing part of a patient's medical problems. Thirty percent made disparaging remarks about patients on rounds. Twenty-nine percent of respondents stated they had attended a dinner or social event sponsored by a drug or medical device manufacturer that stood to gain from a doctor's decision. The good news is that egregious behaviors such as falsifying patient records (6.4%) and performing procedures beyond the provider's skill level (2.6%) were much less common.[14]

The Link between Disciplinary Actions and Prior Behavior in Professional School

Maxine Papadakis and co-workers published a paper in the *New England Journal of Medicine* in 2005 that looked at the correlation between disciplinary action by state medical boards and prior behavior in medical school.[15] This case-controlled study investigated disciplinary actions against medical school graduates and the types of behavior that might be predictive of disciplinary action by state boards. The methodology evaluated physicians who were graduates of three respected, high-profile medical schools since 1990. The actions ranged from public reprimand to revocation of the medical license. The control group consisted of graduates who graduated within 1 year of the disciplined graduates and had no disciplinary actions on their record. The measurements used were admission applications, course grades, evaluation narratives, and scores from licensing examinations, administrative correspondence, and a dean's letter of recommendation to residency programs. Other predictor variables included undergraduate GPA, MCAT scores, and scores on the National Board of Medical Examiners or the USMLE Step 1. (See Table 1-1 for the results.)

TABLE 1-1 Comparison between Disciplined and Non-disciplined Physicians Based on Prior Academic Performance

Variable	Non-disciplined Physicians	Disciplined Physicians
Undergraduate GPA	Somewhat higher	Somewhat lower
MCAT scores	Slightly higher	Slightly lower
NBME/USMLE Step 1	Slightly higher	Slightly lower
Repeated course in medical school	Most likely did not fail a course	Twice as likely to have failed a course

What were the Types of Unprofessional Behavior?

- Irresponsibility
- Diminished capacity for self-improvement
- Poor initiative
- Impaired relationships with fellow students, residents, and faculty
- Impaired relationships with nurses and other non-physician health care workers
- Behaviors associated with being anxious, insecure, or nervous
- Unreliable attendance in clinic and poor follow-up related to patient care
- Failure to accept constructive criticism
- Argumentativeness
- Poor attitude with lack of motivation and enthusiasm, or passive affect

The two types of unprofessional behavior most likely to predict disciplinary actions were irresponsibility and diminished capacity for self-improvement.

What can be Done about this Problem?

- Standards for professional school admission and outcome objectives for graduation should be reviewed so that they contain specific language about professional behavior.
- Professionalism can be taught and modeled.
- Students should be provided with feedback that can motivate them and assist in remediating unprofessional patterns of behavior.

Without question, identifying students who exhibit a tendency toward unprofessional behavior early in their career can help them to minimize the likelihood of unprofessional behavior and possibly future disciplinary actions by administrators and state boards.

Based on the material discussed in this chapter, it is relatively easy to identify and enumerate the behavioral patterns that are unprofessional: putting one's self-interest above the interests of the patient, lack of honesty and integrity, and ignoring the consequences of actions that are not socially acceptable. In this author's opinion, a significant contributory influence in unprofessional activities is *greed*—maximizing income for the least amount of work. Being the consummate professional does not mean having the best clothes, driving the nicest car, giving the most lavish parties, or belonging to the most exclusive country club. A true professional is a caring, compassionate, and honest person. It is the true professional who gives back to the patients who seek care, contributes to the good of the local community, and earns the admiration of peers.

The financial gains from greed often result in penalties imposed by state boards, loss of reputation, erosion of the referral base, and generally being perceived as unprofessional and unethical.

The news media is laden with reports of fines, suspension or revocation of license, expulsion from professional societies or associations, or even incarceration. For example:

- An orthodontist was forced to repay $800,000 in a Medicaid fraud case for improper billing of claims. He was forced to resign as a Medicaid provider and not see any new patients.
- A New York dentist was found guilty of larceny charges for fraudulent billing and up-coding services for Medicaid-covered patients. A criminal and civil settlement was reached in excess of $480,000. He was sentenced to full restitution and community service for his felony conviction.
- A New York dentist was sentenced to 1 to 3 years in jail and will have to repay $700,000 in restitution for fraudulent Medicaid practices.
- The Board for Professional Medical Misconduct of the New York State Health Department recently barred a physician from practicing in New York after he was found guilty of harassing, abusing, or intimidating a patient, moral unfitness, and fraudulent practice.
- FORBA Holdings LLC, the management of FORBA, and several dentists who operated and owned numerous dental facilities in many states have been the target of legal and regulatory actions. The clinical facilities were operated as "Small Smiles Dental Centers." The dentists who owned, were employed by, and treated patients in these centers were charged with performing unnecessary procedures, failing to obtain proper informed consent, performing substandard care, and fraudulent billing practices. Some of the dentists were incarcerated. Some paid hundreds of thousands or, in some cases, millions of dollars to settle civil claims and repay financial gains from fraudulent billing practices. Some were required to inactivate and/or surrender their state dental licenses.
- A New Jersey oral and maxillofacial surgeon was found guilty of illegally selling human body parts obtained from funeral homes without the consent of the deceased person's family. The tissues harvested were used for tendon replacement, bone grafts, and other reconstructive surgical procedures. He was sentenced to 18 to 54 years' imprisonment and died in prison in July 2013.

How does this Information Relate to Oral and Maxillofacial Surgery?

In 2006, The American Association of Oral and Maxillofacial Surgeons published a DVD about professionalism and ethics. The intent was to distribute the DVD to first-year residents so that the door to teaching of professionalism could be opened. As previously stated, the teaching of professionalism has been identified as part of the core curriculum in predoctoral professional education in medicine, and should be a portion of the core curriculum in dental education. This concept is endorsed

and mandated by ACGME and CODA. The producers of the DVD identified four major aspects of professionalism that are germane to the OMS resident as well as the practitioner, regardless of experience or length of time in practice. These are:

- Ethics
- Giving back to the specialty
- Contributing to the community
- Contributing to education and research efforts

The late Dr. Robert V. Walker made several statements that speak volumes concerning the type of behavior, dedication, and personality of the consummate professional. Those who knew Dr. Walker understand that he was speaking to every person who has the title "Doctor." He stated,

> *Professionalism requires that you provide excellence in every conceivable way in the care of your patients. We should have a sense of excellence in giving back to our specialty that can be in many ways: monetarily, to contributing to research of the highest quality, commitment to your community, your church, the schools that you attended (both undergraduate and professional). You have to support them. . . . They provided the ticket for what I am. We are not an island unto ourselves. We all have had help to get where we are and if we don't give back to the institutions that have helped us, well then, we are being selfish to the institutions. Professionalism is a feeling that one has a debt to those who have gone before us.*

Dr. Rocco R. Addante, former chair of the AAOMS Commission on Professional Conduct, has stated that "ethics and professional behavior speaks volumes to your colleagues and patients. This includes the way one manages his practice to how one conducts himself in everyday life." Dr. Addante says, "We must take the high road and be honest while maintaining integrity. Patients are very perceptive of how the doctor treats the staff and what type of rapport the staff has with the doctor and how they support the doctor." Is the atmosphere in the office professionally respectful of the staff and patients? Does the staff look and speak to each other and to the patient in a respectful, caring manner? Referring doctors are also able to perceive that the office has a professional atmosphere that spawns a close, confident working relationship while caring for patients. This type of atmosphere goes a long way to positively promote the practice and generate referrals from other doctors as well as other patients. This type of perception and behavior is far more influential than print or Internet advertising.

How does a young professional new to practice get started? According to Dr. Robert M. Brandjord, Past President of the American Dental Association, involvement occurs early in one's career, and it begins on the local level. Early involvement in county and district dental associations is an important step in promoting your practice. More importantly, you develop a sense of community involvement, not only within dentistry, but also in the local community. It is not uncommon for a health care provider to be looked on as a "go-to" person or leader in the community. Demonstrating professional behavior enhances one's perceived standing in the community.

Dr. Brandjord says, "Involvement in local dental community activities gives one insight into the political process in achieving goals related to the needs of your specialty. Local involvement helps to build coalitions." He further believes that "the dental specialties should be involved in American Dental Association activities to share ideas, discuss common concerns, and gain better understanding of common concerns and issues."

Dr. Michael A. Menis, former chair of the Oral and Maxillofacial Surgery Political Action Committee, discusses the importance of professional association involvement and the establishment of relationships with local, state, and federal representatives. Fostering such relationships can allow the OMS to be proactive in discussing issues that may have an effect on the care of patients and the ability to practice the scope of our profession. Association involvement provides the knowledge base to enable the OMS to advocate for patients who may be affected by legislative measures adopted by local, state, and federal representative bodies.

Dr. David E. Frost, former chair of the Oral and Maxillofacial Surgery Foundation, believes that involvement in activities of the OMS Foundation makes the oral and maxillofacial surgeon aware of the mechanisms of fund raising and funding of the many research activities that lead to improved instrumentation and procedures that enhance the care of patients. Doctors Frost, J. Thomas Soliday, and Steven R. Nelson all have stated that volunteerism, locally and internationally, reinforces the sense of social responsibility and giving back to the communities that support the practice of the local OMS. We all have the ability to make a difference in the lives of those in the community who are economically, developmentally, and physically challenged. Caring for the disadvantaged has the capability to enhance the visibility of the OMS in the community and foster the professional outlook of the allied staff in the practitioner's office.

While CODA mandates specific criteria and minimal standards for accreditation of residency programs in oral and maxillofacial surgery, it is understood that many OMS program graduates do not practice the full scope of their education and training. Dr. Mark W. Ochs, Chair of Oral and Maxillofacial Surgery at the University of Pittsburgh Medical Center, believes that OMSs who have completed an accredited residency program have the skills to provide care in significant aspects of the core of oral and maxillofacial surgery. He has stated that "trauma management is a core of OMS training and when orthognathic surgery and trauma management is abandoned, you really narrow your scope and that at that point, you are not a strong player."

Dr. Steven Feinberg, a highly visible and respected research and academic oral and maxillofacial surgeon, states, "The true professional has the obligation to thank those who have served as our mentors by mentoring the young OMS."[16]

How are Ethics and Professionalism Linked?

Ethics is defined as a branch of philosophy and theology that is the systematic study of what is right and good with respect to character and conduct. Ethics seeks to answer two fundamental questions:

- What should we do?
- Why should we do it?

Ethics are the moral principles or virtues that govern the character and conduct of an individual group. The object of ethics is to emphasize the spirit (or intent) rather than law. Dental ethics applies the moral principles and virtues to the practice of dentistry. Ethics deal with moral conduct, duty, and judgment. Ethics are concerned with standards for determining whether actions are right or wrong. These are voluntary controls, not laws, and serve as a method of self-policing within the profession. Ethics deal with moral conduct, right and wrong, good and evil. The difference between ethics and the law is that legal issues are settled with the use of laws and court decisions. Ethical issues are subject to individual interpretation with regard to the right and wrong of a particular situation. Laws are very specific and written by people with the authority to write them. Laws are "black or white," whereas ethics are less specific and have more gray areas. Laws set the minimum standard of behavior; ethics set the highest standards of behavior.[17]

As a general rule, most professional associations, academies, colleges, and boards have written and adopted principles of ethics or codes of professional conduct. Members and fellows of such organizations are expected and mandated to adhere to the stipulations set forth is these types of documents. Fellows and members of the American Association of Oral and Maxillofacial Surgeons are responsible to adhere to the Code of Professional Conduct as written and overseen by the Commission on Professional Conduct (CPC). In addition, individuals who are also members of the American Dental Association (ADA) or the American Medical Association (AMA) must follow the mandates as put forth in the documents pertaining to principles of ethics and the code of professional conduct for those respective organizations. These documents have many similarities, but for the purposes of this chapter, the focus will be on the AAOMS CPC document and the Principles of Ethics as published by the ADA. In the case where the practitioner is not a fellow or member of any professional organization, complaints about unprofessional or unethical behavior are referred to state dental or medical boards.

The ADA Principles of Ethics and Code of Professional Conduct state that there are five basic principles that form the aspirational goals of the profession:

- The principle of patient autonomy (self-governance)
- The principle of non-malfeasance (do no harm)
- The principle of beneficence (do good)
- The principle of justice (fairness)
- The principle of veracity (truthfulness)

The Principle of Autonomy

The dentist has the obligation to respect the patient's rights to self-determination and confidentiality. The dentist is obligated to inform the patient of the proposed treatment plan as well as reasonable alternatives, which allows the patient to become involved in the treatment. The dentist is also obligated to safeguard the confidentiality of the patient records. The dentist has the ethical obligation upon request of the patient or the patient's new dentist to provide a copy of the record health history information, treatment performed, and copies of all pertinent imaging regardless of the patient's financial standing within the practice.

The Principle of Non-malfeasance

The dentist has the duty and responsibility to protect the patient from harm. This principle includes the responsibility to keep one's skills and education current. Especially important is the responsibility to know one's limitations and to seek consultation as well as referral of the patient to a specialist when appropriate. The specialist has the responsibility to send the patient back to the referring dentist for care that is not within the realm of the specialist. The dentist must protect the patient by delegating care by auxiliary personnel only to the extent of those duties that can be legally delegated. It is unethical for the dentist to practice while impaired by substance abuse. The dentist has the responsibility to inform any patient who may have been exposed to a blood-borne pathogen or other infectious materials. The dentist also must not discontinue treatment of a patient without adequate notice so as to give the patient the opportunity to seek care from another provider (abandonment of the patient).

The Principle of Beneficence

The dentist has the responsibility and duty to promote the welfare of the patient by using his or her skills, knowledge, and experience for the improvement of the dental health of the public. This responsibility also serves as encouragement for dentists to be leaders in their communities. Furthermore, the dental profession owes society the responsibility to regulate itself. Dentists are obligated to become familiar with the signs of abuse and

neglect and to report suspected cases to proper authorities as consistent with state law.

The Principle of Justice

The dentist has a duty to treat people fairly. Dentists may exercise reasonable discretion in selecting patients for their practice, but the dentist cannot refuse to provide services for a patient based on race, creed, color, sex, or national origin. Dentists are obligated to provide reasonable arrangements for emergency care for a patient of record when the dentist is not available to provide that care himself. The dentist is obligated to report to appropriate reviewing agencies instances of grossly negligent or continually faulty treatment by other dentists.

The Principle of Veracity

The dentist has the duty to communicate truthfully and to be honest as well as trustworthy in their dealings with people. The dentist shall not represent care being rendered to patients in a false or misleading manner. A dentist is deemed to be providing care unethically in instances where treatment is not based on accepted scientific knowledge or research. It is also unethical for a dentist to perform unnecessary services or procedures. Dentists must not misrepresent their training and competence in a manner that is false or misleading in any material respect.

The American Dental Association recognizes the following specialties. These specialties all have certifying boards that require successful completion of both an accredited educational program and a certifying examination:

- Dental Public Health
- Endodontics
- Oral and Maxillofacial Pathology
- Oral and Maxillofacial Radiology
- Oral and Maxillofacial Surgery
- Orthodontics and Dentofacial Orthopedics
- Periodontics
- Prosthodontics

Dentists are allowed to announce limitation of their practice to areas of special interest (non-ADA-recognized specialties) as long as they avoid any communication that implies or expresses specialization.[18]

The American Association of Oral and Maxillofacial Surgeons also has written a Code of Professional Conduct. The AAOMS Commission on Professional Conduct developed the code. The Commission (CPC) has the responsibility to review complaints brought by a member, fellow, or provisional member or fellow against another OMS, to refer complaints or violations of the code to state boards when appropriate, rule on violations of the code and provide appropriate sanctions, recommend changes to the code to reflect changing circumstances, and assist the AAOMS membership in interpretation of the code. The CPC's jurisdiction is limited to AAOMS fellows and members and their relationships with and privileges within the AAOMS.

The AAOMS Code of Professional Conduct and the ADA Code of Ethics mirror each other on many levels. Areas of parallelism include:

- Patient autonomy, self-determination, and confidentiality
- Ensuring proper professional education, training, and competence
- Avoiding personal impairment
- Promoting welfare of patients and the community
- Fairness and non-discrimination
- Patient abandonment
- Fairness in dealing with colleagues
- Honesty and truthfulness
- Advertising

Areas of the AAOMS Code of Professional Conduct that differ slightly from the ADA Code of Ethics include:

- Itinerant surgery
- Expert witness testimony
- Insurance consultants

Itinerant surgery is defined as elective oral and maxillofacial surgery performed in non-accredited surgical facilities other than the facility or facilities owned and/or leased by the oral and maxillofacial surgery practice employing the OMS. Fellows and members are strongly discouraged from making itinerant surgery a major part of their practice.

- It is unethical if the patient is unfamiliar with the surgeon who performs their surgery.
- It is unethical for the surgeon to delegate their primary patient responsibility.
- It is unethical for the surgeon to perform surgery in an unsafe or unsuitably equipped facility.
- It is unethical for the surgeon to perform surgery in an unsafe or unsuitably staffed facility.
- It is unethical for the surgeon to delegate postoperative care to a person who is not similarly qualified to recognize, treat, and manage all surgical complications.

These provisions of the code do not apply to the occasional performance by a fellow or member from performing surgery in a facility for the purposes of teaching or charity patient benefit.

Oral and maxillofacial surgeons are encouraged to serve as expert witnesses in legal proceedings to assist in finding the truth in matters under consideration. The qualifications for the Oral and Maxillofacial Surgeon expert witness include:

- The OMS expert witness must have direct clinical experience in the specific area of oral and maxillofacial surgery in question.
- The OMS expert witness should be a diplomate of the American Board of Oral and Maxillofacial Surgery.
- The OMS expert witness who is still engaged in private practice demonstrates enough familiarity with present practices to warrant designation as an expert witness.
- The OMS expert witness must have a current valid and unrestricted license to practice in the state in which he or she practices.
- The OMS expert witness must not serve as such in cases where they also served as one of the patient's treating doctors.

Oral and maxillofacial surgeons who serve as insurance consultants are expected to promote the best interests of the patient and fair claims practices by third-party payers.

- An insurance consultant must be currently engaged in the practice of oral and maxillofacial surgery or have enough familiarity with present practices to evaluate treatment on which he or she gives an insurance consultation.
- An insurance consultant must have a current and unrestricted license to practice; however, he or she need not have a valid license in every state in which he or she renders an insurance consultation.
- An insurance consultant should be a diplomate of the American Board of Oral and Maxillofacial Surgery.
- An insurance consultant has the duty to be fair in dealings with patients and providers.
- The consultant must avoid any conflict of interest that would compromise or influence decisions rendered by the consultant.
- The consultant must not prejudge any claim and must render decisions based solely on facts, merits, and clinical circumstances.
- The consultant must be able to explain the decision based on experience, clinical references, and generally accepted opinion in the specialty field.

The CPC also has the authority to rule on areas of advertising, as well as use of the AAOMS seal and the AAOMS slogan, "Saving Faces/Changing Lives." The CPC will respond to written complaints and written request for information submitted by AAOMS fellows and members.[19]

Ethical Dilemmas

This section of the chapter deals with ethical dilemmas that a practitioner may be faced with in the daily activities of a private or academic institution faculty practice. These dilemmas are modified to fit the oral and maxillofacial surgery model and are based on ethical dilemmas as published in various past ADA journals.

What are the ethics concerning a patient's request for you to refer him to a new general dentist? As the treating dentist, you are obligated to put the welfare of the patient first. Yet, you also must respect the patient's right to self-determination and confidentiality. It is fair to ask the patient why he is making this request. Has there been some problem with the other dentist's office, care, or other reason? Is this request due to a financial situation? Is this request merely a desire on the part of the patient to try another dentist? You have the obligation to encourage the patient to return to the referring dentist and discuss the concerns. Even if you, as the treating dentist, agree that there are issues with the treatment provided by the referring dentist, you must avoid making any disparaging remarks that could lead to a liability action or bring allegations of defamation against you. It is also appropriate to notify the dentist of the patient's request and relay the concerns brought up by the patient.

Who is ethically responsible for patient care in a corporate practice where you are an employee dentist? The doctor-patient relationship begins when you agree to treat the patient. You alone are responsible ethically and legally for the care and treatment of the patient, not the corporate entity. While corporate employment may alleviate day-to-day operational stress, the doctor-patient relationship exists between you and the patient. As part of a corporate practice, you must not allow potential performance pressure and production incentives to influence or coerce you into performing unnecessary procedures or up-coding the procedures you do perform.

While you are attending a local seminar, a member dentist shares with you information about behavior you believe may be unethical. The obligation of self-governance requires that the dentist be made aware of your ethical concerns. If the dentist informs you that he is able to maximize production by up-coding, billing for procedures not performed, or performing incomplete or ineffective treatment, you should inform him that these practices are fraudulent. It is also appropriate to inform him that these types of practices can lead to expulsion from participation with insurance carriers, charges of insurance fraud, and loss of his license to practice. You also have the ability to request that the dentist discontinue such practices. You have the responsibility to contact the ethics committee of the dental society to file a formal complaint.

What are the ethical implications of using social coupons to expand patient or referral base? This relatively new concept raises many ethical and legal issues. Many companies that provide discount coupons to patients collect the fee charged, keep a portion of the fee as part of their costs, and remit a portion to the dentist (the concept behind Groupon). This may be viewed as fee splitting. A better arrangement of this would be for the coupon company to pay the dentist the full fee and then have the dentist remit the promotional fee to the coupon company. This does not constitute fee splitting. Another ethical issue concerning discounting of fees has to do with billing the insurance company the discounted fee and not the usual and customary fee for a service. This practice constitutes insurance fraud and potentially violates the Stark law. This provision of CMS mandates that Medicare and Medicaid patients must be offered the same discounts as patients not covered by Medicare or Medicaid. If after a clinical examination, appropriate and necessary procedures are required that are not included as part of the coupon offer, the dentist is obligated to inform that patient before performing the procedures. The patient may view this practice as "bait and switch" and outside of informed consent for treatment.

A patient undergoes a procedure requiring antibiotic prophylaxis. The patient refuses to comply, and you dismiss him from your practice. The patient seeks care from another dentist but does not intend to inform the new dentist of this medical necessity, and states he would lie about it on a health history. Should I inform the new dentist of this? This is a conflict between ethical and legal issues. The patient has the responsibility to provide accurate, honest, and complete health history information.

The patient also has the right to accept, defer, or decline treatment recommendations. Health history information is confidential and privileged between the dentist and the patient. The privilege belongs solely to the patient and not the dentist, and violation of this privilege may subject to dentist to legal prosecution. Therefore, the patient has the right to refuse the premedication and the treatment.

The dentist has the duty and obligation to promote the welfare of the patient and to do no harm. The dentist can comply with the wishes of the patient by requiring a written signed request by the patient to send part or all of the record. This constitutes authorization to release confidential information. A signed release to transfer the record supersedes the oral request for confidentiality. As an alternative, the dentist can consider sending the entire record to the patient with a note suggesting that he provide all information to the new dentist.

What are the ethical obligations of a dentist who suspects his partner is impaired by addiction and substance abuse? A dentist has the duty to refrain from harming a patient. A dentist with an addiction has an ethical responsibility to refrain from practice that may adversely affect patients. All dentists have an ethical obligation to urge chemically impaired colleagues to seek treatment. All dentists are ethically responsible to report the colleague to the professional assistance committee of the appropriate dental society. The impaired dentist is not required to disclose his impairment to patients. The intent of these requirements is to protect the patient, the public, the practitioner, the partner, and the profession.

What are the ethical obligations of an OMS who places implants for patients in the office of a general dentist? It is considered itinerant practice of oral and maxillofacial surgery when the OMS provides care for patients outside of his or her own office location. In this instance, the OMS must adhere to the provisions of the Code of Professional Conduct as related to itinerant practice. The operating OMS has an obligation to the patient to discuss fully the treatment plan for that patient. The OMS must make records of treatment accessible to the patient, the restorative dentist, and other involved providers, and also make provisions for follow-up so as not to abandon the patient. If the OMS becomes unavailable to provide the continuity of care discussed in this section, this can be interpreted as meaning that the OMS did not have the best interests of the patient at heart, did not communicate truthfully with the patient in reference to the treatment plan (including procedures and costs), and may be abandoning the patient. These behaviors not only are unprofessional, but also can be construed as unethical.

The Politics of Town and Gown

The concept of town and gown is rooted in the Middle Ages and had to do with the competition between the students and faculty of the local universities and the citizens of the community directly adjacent to those universities. The gowns worn by the students and faculty of the university were originally designed to provide warmth and comfort for those who worked and studied in the cold and drafty rooms of the universities. These gowns often were adorned with the colors of the university and signified the scholar's affiliation with it. Ultimately, the gowns served as a social symbol that set apart and distinguished the student or faculty from the townspeople. This social interaction often became adversarial because of economic issues between the towns and the universities, as the universities often were financially independent of the town and were not under its civil authority. The confrontations between town and gown became violent on many occasions. Examples include the Battle of St. Scholastica Day at the University of Oxford in the 1300s, a confrontation between the students of Yale and the citizens of New Haven in the 1800s, and the infamous events at Kent State University in the 1970s. Fortunately, these types of confrontations have become less prevalent as universities in crisis have been "rescued" by the urban dynamics surrounding them. Universities and the communities surrounding them have an incentive to cooperate with each other, as the universities depend on the cities for services and approval for long-range plans, and the towns benefit from public services provided by the universities.[20,21]

The town-gown "confrontation" in medicine (and dentistry) is largely driven by competitive forces within the community that have a number of contributing factors:

1. Competition for the same patient population.
2. Concern that patients referred from the community will be absorbed by the university.
3. The shift from salaried "hard money" positions to fee-for-service models where the academic faculty is expected to generate patient care revenue as their primary income source.
4. The perception by the university providers that the community providers are "cherry picking" by referring underinsured or uninsured patients to university providers for care that could be rendered by community-based providers. This practice is often couched in terms stating that a particular case provides an excellent resident educational opportunity.[22]

These factors and the historical interaction between town and gown have the potential to create a level of mistrust and an adversarial relationship between community-based providers and providers affiliated with an academic institution. Almost all oral and maxillofacial surgeons who have completed a CODA-accredited residency program have met the same criteria of education, training, and experience to perform the procedures that were included in the clinical curriculum as part of their residency training programs. The community-based OMSs all have the ability to gain hospital privileges, provide care based on their residency experiences, and perform the same procedures for the same patient population as the university-based OMSs. The argument against this premise is that significant numbers of OMSs choose to perform only the procedures that are more lucrative and primarily office based. They see it as inconvenient to admit

patients to the hospital and burdensome to take hospital call, which disrupts the functioning of their offices. This practice has the potential to perpetuate the adversarial relationship between town and gown and further drive a wedge between the academic institution and the community-based providers. The reality is that both parties can and should work together for mutual benefit for private practitioners, academic practitioners, and patients from the community. Anything less may be interpreted as being unprofessional and unethical.

This chapter is unusual in that it does not contain strong evidence-based information that relies on years of laboratory research or numerous clinical trials. It does not contain the newest techniques for performance of a recently developed surgical procedure or reporting of a newly discovered disease or pathologic entity. It does contain several abstract ideas, philosophies, and moral and ethical issues that will test the OMS daily as he or she practices. It is designed to make one think about how one conducts themselves regularly within their communities, specialty, and the health care professions. It is this author's hope that the reader will reflect on this information and apply it to make him or her a better provider, a better teacher, a better mentor, and more importantly, a better person.

References

1. Hafferty FW, Papadakis M, Sullivan W, Wynia MK: ABMS professionalism definition developed by the Ethics and Professionalism Committee—ABMS Professionalism Work Group, *Adopted*, January 2012.
2. Norton A: *10 things that define a true professional*, www.techrepublic.com/blog/10-things/10-things-that-define-a-true-professional, July 2010.
3. Sox HC, editor: Annals of internal medicine. American Board of Internal Medicine Foundation. *Commitments of the Physician Charter*, 2012. www.abms.org. Accessed January 14, 2016.
4. Swick HM: Toward a normative definition of medical professionalism, *Acad Med* 75(6), 612–616, 2000.
5. Duff M: Teaching and assessing professionalism in medicine, *Obstet Gynecol* 104(6):1362–1366, 2004.
6. Niebuhr V: Defining professionalism. Professionalism in Medical Education. University of Texas Medical Branch, 2009.
7. Medical Professionalism Project: Medical professionalism in the new millennium: a physician charter, *Ann Intern Med* 136: 243–246, 2002.
8. Niebuhr V: Defining professionalism. Professionalism in Medical Education. University of Texas Medical Branch, 2009.
9. Mueller PS: Division of General Internal Medicine and Program in Professionalism and Bioethics: Incorporating professionalism into medical education: the Mayo Clinic Experience, *Keio J Med* 58(3):133–143, 2009.
10. Epstein RM, Hundert EM: Defining and assessing professional competence, *JAMA* 287:226–235, 2002.
11. Kirk LM: Professionalism in medicine: definitions and considerations for teaching, *Proc (Bayl Univ Med Cen)* 20(1):13–16, 2007.
12. Dyrbye LN, Massie Jr FS, Eacker A, et al.: Relationship between burnout and professional conduct and attitudes among U.S. medical students, *JAMA* 304(11):1173–1180, 2010.
13. Reddy ST, Iwaz JA, Didwania AK, et al.: Participation in unprofessional behaviors among hospitalists: a multicenter study, *J Hosp Med* 7(7):543–550, 2012.
14. Rau J: Doctors admit to unprofessional behavior in study at 3 Chicago hospitals, *Capsules: The Kaiser Health News Blog*, June 13, 2012.
15. Papadakis MA, Teherani A, Banach MA, et al.: Disciplinary action by medical boards and prior behavior in medical school, *New Engl J Med* 353:2673–2682, 2005.
16. American Association of Oral and Maxillofacial Surgeons: *OMS professionalism: opportunities for supporting your patients, the community, and the future of the specialty*, 2007. www.aaoms.org. Accessed January 14, 2016.
17. American College of Dentists: *Ethics handbook for dentists: an introduction to ethics, professionalism and ethical decision making*, 2012. Prepared by the American College of Dentists. www.acd.org. Accessed January 14, 2016.
18. American Dental Association: *Principles of Ethics and the Code of Professional Conduct, revised*, April 2012. Prepared by the American Dental Association Council of Ethics, Bylaws, and Judicial Affairs. www.ada.org. Accessed January 14, 2016.
19. American Association of Oral and Maxillofacial Surgeons: *The Code of Professional Conduct. Revised*, September 2012. Prepared by the AAOMS Commission on Professional Conduct. www.aaoms.org. Accessed January 14, 2016.
20. Town and gown in the Middle Ages. Available at http://en.wikipedia.org/wiki/Town and Gown.
21. Brezina D: Town and gown: A medical paradigm that endures today, albeit with promising new collaborations, *Hospitalist*, May 2007.
22. Wescoe WC: The town-gown syndrome: pathology, *JAMA* 186(8):785–786, 1963.

2

The Philosophical Basis of a Successful Surgical Practice

TRAVIS A. WITHERINGTON

It had long since come to my attention that people of accomplishment rarely sat back and let things happen to them. They went out and happened to things.

—Leonardo da Vinci

A successful surgical practice is not encountered as a random fortunate occurrence. It is created by intentional design, and it is sustained by active engagement of the owners. The design of the successful practice starts not at the architectural level with bricks and paint, but at the philosophical level with personal introspection and worldly study.

The Definition of Success

Beauty lies in the eyes of the beholder.

—PLATO

The variation among surgical practices is in the emphasis placed on the functional aspects of the practice (goals) and in the ownership arrangement of the company (business models). These goals and business models define the philosophy of the practice. They determine success, relative success, or failure.

A logical and systematic approach to creating a successful practice is to first investigate the goals of the owners. The second step should be to study the business models to determine which is most likely to allow fulfillment of the goals. After these two underlying fundamentals are in place, the efforts of the owners should be channeled toward achieving the identified success.

Goals

If you wish to converse with me, define your terms.

—VOLTAIRE

Goals are the deep, personal driving traits of the owners of the practice. They are the motivations that brought us first to advanced education, second to dentistry as a profession, and finally to surgery as a specialty.

These driving elements began at a very young age when we were asked, "What do you want to do with your life?" They matured and grew in college as we encountered social settings and academic courses that taught us what we found resonant in our hearts and souls. They became clearer during dental school, and they neared maturation in our surgical residencies as we finally envisioned a more singular professional lifestyle for our productive years.

These goals are particular to the individual, and variation is the norm. Understanding this fact is critical to the success of a practice, because a mismatch of goals among surgeons can lead to disharmony if it is not addressed.

Our profession of oral and maxillofacial surgery (OMS) is wonderfully positioned to allow us to realize many different professional and personal goals. We must carefully study these goals to determine their relative position in our hierarchy of assessment. Introspection and reevaluation should continue throughout one's career to correct its course and give it more resonance.

The following categories of goals influence the surgeon:

- Service to humankind
- Profits
- Working in a challenging professional atmosphere
- Freedom of choice
- Working alongside peers
- Education
- Diversity

Service to Humankind

Whenever the art of medicine is loved, there is also love of humanity.

—HIPPOCRATES

Service to humankind is the strongest driving force of OMS doctors. The desire to help others emerges early in life and becomes much stronger once an individual realizes that he or she has the capacity to enact that help. Relieving pain and suffering is a particularly strong motivator for those attracted to surgery, because the profession allows us to be effective quickly. This particular goal is satisfied every day in a surgical practice, but many surgeons are inclined to devote even more time, energy, and resources through donated service. This donated time taken away from a financially productive practice must be reconciled.

Profits

> *Lay not up for yourselves treasures upon earth, where moth and rust doth corrupt, and where thieves break through and steal: But lay up for yourselves treasures in heaven, where neither moth nor rust doth corrupt, and where thieves do not break through nor steal: For where your treasure is, there will your heart be also. No man can serve two masters: for either he will hate the one, and love the other; or else he will hold to the one, and despise the other. Ye cannot serve God and mammon.*
>
> **—MATTHEW 6:19-21, 24 (KJV)**

There is nothing wrong with making money unless the money is an object of worship. Most professionals incur significant loans to underwrite their education, and the surgical practice must make profits to retire those loans. Profits are also needed to support a surgeon's family, employees, and all of their dependents. Profits are needed to prepare for disabilities and life after surgery. Profits are needed in order to devote time and resources to donated surgical service. Clearly, profits are an appropriate key element in most surgeons' goals.

Working in a Challenging Professional Atmosphere

> *Life is either a daring adventure or nothing at all.*
>
> **—HELEN KELLER**

The opportunity to come to the aid of the sick, injured, or disfigured patient and perform healing surgery in a difficult environment is a significant driver for many surgeons. Trauma, academics, orthognathic surgery, pathology, and cosmetics are exciting and challenging sectors of our profession, and they can be strong attractors. Major surgeries or difficult cases inspire us to succeed because surgeons, in particular, rise to a challenge. Deep satisfaction can also be gained by understanding the complicated anatomy, physiology, pathology, and pharmacology that tip us toward difficult surgeries. It is common for a recently minted surgeon to embrace these complicated surgeries but then experience waning enthusiasm in later years in the face of diminished capacity to endure stress and long hours.

Freedom of Choice

> *Choose a job you love, and you will never have to work a day in your life.*
>
> **—CONFUCIUS**

Having been constrained by our parents, administrators, teachers, and attending staff for many years, the thought of being in charge of our lives becomes very attractive. The flexibility of being an owner allows a surgeon to adjust both personal and professional schedules to fit a desired lifestyle. That lifestyle might include a family, travel, donated service, sports, education, or avocation. Private practice ownership gives one much more control over life than the other business models, but it comes at a heavy price. That price is substantially increased responsibility.

Working Alongside Peers

> *Coming together is a beginning, keeping together is progress, working together is success.*
>
> **—HENRY FORD**

The opportunity to share the ups and downs of a professional life with another surgeon is attractive. Surgeons who work together can supply a network of support to endure difficulties and to celebrate successes. Building a surgical team of support staff can go a long way toward this goal, but sharing with a respected peer, and then gaining his or her trust and admiration, is a satisfying experience.

Education

> *Tell me and I forget. Teach me and I remember. Involve me and I learn.*
>
> **—BENJAMIN FRANKLIN**

Participation in academics runs deep in surgeons, and we embrace this endeavor as participants throughout our career. We must realize that a primary requirement to give rather than receive in education is a capacity to teach. A teacher's heart is a giving and sharing one. A teacher's mind is one that distills complicated issues and then presents them so they can be understood by students. As we think back on the professors that we have known in our lengthy education, we recall those who were gifted, and others who meant well but did not inspire. Before pursuing formal participation in academics, we must honestly gauge our capacity to teach as well as our motivation. Are we motivated by the potential growth of the student or by the glory of being called teacher?

Whether it is working as a full-time academic professor or as a visiting lecturer, sharing in the educational experience can be rewarding. Opportunities to participate in education exist at levels other than surgical residency. Cardiopulmonary resuscitation (CPR) instruction, lecturing at a community college, and presenting at a professional society are other ways to satisfy this goal.

Diversity

There is no such thing as a single goal in a surgical practice. Rather, there are composites of goals, some given more emphasis than others. A practice might emphasize delivering a diversity of procedures, or it might wish to limit certain

ones. A practice might emphasize profitability, or it might embrace OMS education at a local residency program. It might limit exposure to major hospital surgeries such as trauma, cancer, and orthognathics, or it might emphasize recruiting those types of patients. The owners might desire a flexible or reduced patient schedule to incorporate personal, professional, and family life outside the practice.

The desires and relative emphasis of the individual owners will define the practice. Consequently, each owner must consider these factors carefully before a practice is designed. Significant variation in emphasis should be expected among doctors, and that diversity should be celebrated and accommodated. The owners must be meticulously honest with themselves and with each other during this design process.

The ranking of these goals should be expected to change as the individual ages, so they should be revisited as time progresses. The cultivation of a successful practice is an ongoing task that does not end with the initial design.

Business Models

The majority of oral surgery practices are for-profit, closely held private companies of limited geographic scope, but there are major differences. Most depend on favorable relationships with patient-referring sources and employ a small number of managerial, clerical, and clinical employees. They typically have a single main office and might have a secondary one that serves a different geographic sector on a more limited basis.

The business models are legal and financial entities whose functions are governed by state law and binding agreements. During the design phase, significant time must be spent in conversation with experts in accounting, human resources, and the law.

The ownership arrangements or business models include variations on these themes:

- Solo
- True partnership
- Entrepreneurial
- Expense sharing

The development of the business model will have a direct impact on the ability of the practice to attain the goals of the owners. Sometimes the model will facilitate the goal. In other cases it will be an impediment.

Solo

The solo surgeon wears all hats. Although the greatest benefit of a solo practice is that issues never need to be brought to a vote, the greatest detriment is the isolation in which those same decisions are made. Taking emergency calls, deciding which insurance plans to enroll in, hiring and firing employees, and buying equipment and office space are all decisions that weigh on the shoulders of the solo owner. In order to succeed, the solo doctor must be adequately versed in all phases of clinical, administrative, financial, and legal business activities.

A solo practice gives the individual owner infinite freedom to select and modify his or her goals initially and in the future. The solo doctor has the most ability to design a practice that maximizes profits.

This business model, at first glance, gives the owner the ability to attain almost all goals because there is no opposition to the owner's choices. The downside is that the surgeon will be professionally isolated except for traveling to other locales and visiting with non-competing surgeons. It can be a lonely existence, but there will be no boardroom arguments over decisions, and the pace of the practice is firmly in the owner's control.

The single goal that is missing is the opportunity to work alongside a peer. However, even that goal might be satisfied when two surgeons share a complicated set of cases. There are work-with-others benefits that might be reaped from building a surgical and administrative employee team in a family atmosphere. The solo surgeon must be a fiercely independent person but will be most likely to succeed when surrounded with competent office staff and advisors.

True Partnership

In this model, the owners have a binding legal agreement that gives voting rights on the functional decisions of the company to each owner and that outlines expectations of performance. In most issues needing a decision, the majority of votes rule, but in major decisions, such as the acceptance or dismissal of a partner, the partnership agreement might require that a vote be unanimous or by a supermajority. The partnership agreement outlines these rights and obligations, and it deserves close analysis by an independent trusted advisor.

In the true partnership model, the ability of the individual owner to pick and choose among the goals is significantly limited by the vote of the other partners. Owners need to obtain permission from their partners to make changes that might conflict with another owner's goals. Consequently, freedom of choice is more limited than with the solo model.

Profitability is typically less in a practice with a true partnership than in a solo practice. The owners in a partnership tend to focus on enjoyable procedures and pursuits rather than on financially productive ones. A partnership also spends more on staff, equipment, and expenses, probably because of a false feeling of having diluted the expense.

The potential for conflict among the owners is so high that it should be expected, and resources should be gathered for conflict resolution.

Entrepreneurial

The entrepreneurial model is a blend of the other models. In this model, there is an owner of the company, and salaried associate doctors are hired to produce professional care. The owner has the right to make the decisions relevant to the practice; an associate doctor has only the rights of an employee.

In this model, the owner is well able to attain goals, but that ability is low for the salaried associate employee-doctors. The burden of responsibility is greater for the owner because of the number and class of employees and the greater amount of time involved in management issues.

Expense Sharing

The expense sharing model is a blend of other ownership models. It is a business relationship between multiple solo or true partnership practices, and the focus is on money. Because the relationship between the practices might be competitive, the only goal that is truly applicable is the one dealing with profits.

As the name implies, this business model focuses on expenses, not income. The intent is to increase profits by reducing expenses through economies of scale. Many financial advisors argue that profits are more readily increased by increasing production rather than by decreasing expense. As with all business models, expert advice is most appropriate before entry into this legal relationship.

Interpersonal Relationships for Success

Our society is based on interpersonal relationships, and our personal lives and our business practices are subsets of the world's society. A successful practice is an extension of a successful person who is fluent in interpersonal relationships.

The Relationship between the Surgeon and the World

> *We are what we repeatedly do. Excellence, then, is not an act, but a habit.*
>
> —ARISTOTLE

In descending order of importance, a simple list of the daily chores of a successful surgeon would be to:

- do excellent work,
- enjoy each day, and
- then do everything else.

> *To improve is to change; to be perfect is to change often.*
>
> —WINSTON CHURCHILL

First and foremost, a successful surgeon strives for surgical excellence. Obviously there is no such thing as a perfect procedure, but a surgeon can have a mindset of constantly striving for perfection. From the first day of practice to the day of retirement, the successful surgeon seeks to practice his craft with less pain, less swelling, less fear, quicker healing, more predictable outcomes, faster times, and less expense. His handwriting will be on each wound, his signature will be on each op note, and his name will be on each patient's mind. All movements and interactions move toward or away from the path to perfection.

Healthy and rewarding relationships allow a surgeon to enjoy each day. These relationships begin at home and follow the surgeon to the office, and to peers, staff, advisors, patients, and their families. All of these relationships are founded on trust, honesty, and communication. Associations of relationships are based on inference, love, solidarity, social commitment, or business interactions. Law, custom, or mutual agreement regulates these associations.

All else follows the first two chores. For the surgeon, there is nothing more important than performing excellent surgery while striving to enjoy professional life.

Relationships between Owners

The owners determine the philosophy of a practice. Only the owner is capable of formulating policy that affects the operational heart of the practice that all others follow. Even when the owner abdicates a role in decision making, that action is in itself a policy decision.

Solo

> *Most people do not really want freedom, because freedom involves responsibility, and most people are frightened of responsibility.*
>
> —SIGMUND FREUD

The solo surgeon must be a fiercely independent and resourceful person. He or she is more likely to succeed if surrounded by competent staff and advisors. This extended family will support the surgeon in daily activities and represent him in his absence.

Although not necessarily a loner, the solo surgeon must be comfortable with working in a relative vacuum of professional interaction. Often, a solo surgeon will miss critical information affecting decisions of the practice, and will need to scramble to catch up or stay abreast of trends.

True Partnership

> *More important than the deal is the person in the deal.*
>
> —RICHARD COLLIER

A successful partnership is based on trust, sharing, and communication. It is not necessarily based on money, but money has an important place in a business, and if there is not enough of it, this will become a divisive issue for the owners.

Sharing is the foundation on which all partnership decisions are made, and communication is a means to develop and maintain rewarding relationships and to reconcile conflicts. A good partner will have a sharing heart and seek the participation of others in professional affairs of education, management, marketing, and human resources. He will have a developed sense of communication and be sensitive to others as he speaks.

> *Relationships of trust depend on our willingness to look not only to our own interests, but also the interests of others.*
>
> —PETER FARQUAHARSON

Before signing the partnership agreement, each potential partner's goals must be carefully explored and stated. Conflicting goals should be discovered, and methods of compensation should then be determined to reconcile those conflicting forces. There are ways to make a partnership successful even in the face of conflicting goals. The

compensation might be in the form of differentially assigned duties, modification of pay and vacation days, a change in work hours, or differing loads of on-call.

Management

Dr. W., there is more to pulling teeth than pulling teeth.

—ANDREW C. CHEUNG

Although a group of partners might assume that the success of their business will be the sum of individual production of the owners, final success will be brought about by decision making and implementation of policy promulgated by the collective ownership. The management side of a partnership is a complex and difficult area for doctors to master, because they have had little or no formal business education. Yet, the business side dictates financial success, harmony with the employees, and the long-term momentum of the practice.

Management by a doctor requires a significant expenditure of time and energy, yet it has no quantification that can be referenced when it comes to allocating compensation among the partners. Whereas the value of surgeries can be quantified by dollars produced, the time spent in business affairs cannot be so readily identified and compensated. For this reason, some sort of division of management responsibilities among the doctors is appropriate. If a partner does not participate in this uncompensated managerial work, the others will resent it.

Management styles that are available to the partnership include:

- Rotation of management assignments among the owners
- Management by committees of owners
- A compensated managing partner (who is a surgeon)
- Salaried professional practice manager
- Chaos

Decision Making

Every man builds his world in his own image. He has the power to choose, but no power to escape the necessity of choice.

—AYN RAND

Even when no decision is made, that is still a decision, and it has its consequential impact. Owners will encounter difficult problems that are not readily solved, but that cannot be ignored or postponed indefinitely. In these cases, some decision must be made in order for the practice to move forward.

Although unanimous decisions are desirable, this is rarely the case. Unanimity should not be expected, and polite negotiations must be undertaken to arrive at a decision. A cautious eye should be kept for any individual who bullies or forces his opinion on the group. A referee or an advisor is appropriate to help in arriving at a decision in the presence of a bully.

Small partnerships allow more fluid decision making. However, the greater the number of individuals with voting authority, the more appropriate it becomes to formally conduct the business with *Robert's Rules of Order*.

Communication

Much unhappiness has come into the world because of bewilderment and things left unsaid.

—DOSTOYEVSKY

This critical trait of a partnership must be cultivated and planned and not left to chance. It is not enough to ask that partners speak to each other. The forum and time must be allocated and respected to allow that communication to occur. Without definite planning, communication will occur sporadically and at the whim of chance. It is too important for that.

The best way to provide a forum for communication is a regularly scheduled doctors' meeting. These meetings should be considered sacrosanct, and no conflicts should be allowed. These meetings are chances to explain and opportunities to apologize. Texting, phone calls, faxing, and emails are appropriate for transferring information, but face-to-face meetings are for communication.

The eyes are windows to the soul.

—CICERO

Doctors' meetings should follow a businesslike format with a chairman who collects the agenda, encourages a timely flow of business, brings issues to a vote, and records the decisions for the archive of minutes. This formality will provide fairness to each owner, help position the partnership in decision making, and leave a store of information for future reference.

Good doctor's meetings will serve many functions, including:

- Analysis of and decision making regarding business issues
- Consultation with partners about challenging cases and conundrums
- Sharing of information gleaned from journals, seminars, or educational meetings

Internal Competition

Competition within the partnership tends to occur because a posted schedule of daily procedures is readily available. Partners will compare their productivity, and this should provoke some healthy competition among friends and peers. However, if viewed in the wrong light, this can lead to resentment of the productive partner or suspicion of favoritism by clerical personnel. The true competition is outside the walls of the practice, and a reminder is occasionally needed to turn the focus outward.

Conflict Resolution

I've always believed that a lot of troubles in the world would disappear if we were talking to each other instead of about each other.

—RONALD REAGAN

An eye for an eye will only make the whole world blind.

—MAHATMA GANDHI

Pick your battles. In a partnership, there will be enough material to start a war. Life is a continuous confrontation with conflict, and a surgical partnership is a microcosm of life with all of the characteristics of a marriage except the intimacy. Either relationship can be destroyed by the same mechanisms.

The first step in conflict resolution among the partners is to create an opportunity to explain circumstances and offer apologies. If that opportunity is not made available, the chance of resolving the conflict is slim. All of us are subject to misunderstanding or mistaken beliefs about behavior, and a time and place must be made available for a clear dialogue to dispel the misunderstandings.

The End of a Partnership and Succession Planning

In this world, nothing can be certain, except death and taxes.

—BEN FRANKLIN

All partnerships come to an end. The ending mechanism is death, disability, or dissolution, and the ending should be carefully designed at the beginning of the company. This ending should be scripted for logic, fairness, and ease, because it will be used.

This true partnership model is the most common model among OMS practices, and it is the one with the most frequent failures. Common sources of acrimonious dissolution are a failure to reconcile the different goals among the owners and a failure to communicate.

A natural progression in a surgeon's career is retirement after a long and successful professional life. Planning for the next generation starts early in order to search for an individual with like-minded goals to assume the practice.

Entrepreneurial

The owner relationships in the entrepreneurial model are variations of the solo or true partnership designs. All decisions, including those affecting employees, will fall to the owners either as a solo owner or a partnership of owners.

While a doctor serving as an employee of a business entity will have a significant effect on the relationships within the practice, the owners will define the true practice philosophy. Many surgeons opt for serving as a salaried associate for a period of time, but because the associate is an employee and not an owner, he will be severely limited in his ability to attain any of his goals.

Expense Sharing Association

The expense sharing business model is strictly a financial arrangement and has little to do with sharing professional relationships. In fact, the owners involved are in competition with each other for business. This practice model should not be confused with a partnership. Although the word "sharing" is used in this title, the only sharing that comes about is in the sharing of money spent for production of income.

A key element in an expense sharing model is communication. The rules for this relationship must be clearly delineated. The rules can be negotiated by a third party, because they have nothing to do with friendship or personal relations.

The Relationship between Owners and Employees

Take care of your people, and they will take care of your customers.

—JOHN WILLIARD MARRIOTT

The surgeon will spend more time with staff than any other group of humans other than family. It follows then that surgeons should surround themselves with wonderful people and devote the time and energy to cultivate those relationships. The staff is a surgeons' extended family, but chosen by the surgeon—unlike his own family.

The success of a company is predicated on hiring the right people, but that process starts with owners who are actively engaged in recruiting, hiring, training, and managing. If owners take a passive role, the outcome may be unpredictable. The task of managing human resources in a surgical practice represents the most challenging, potentially vexing, and time-consuming job of ownership.

Start with good people, lay out the rules, communicate with your employees, motivate them and reward them. If you do all those things effectively, you can't miss.

—LEE IACOCCA

The practice owners must identify the company's mission and become actively involved in the human resources to match that mission. They must:

- Hire the best people and pay them well
- Empower their employees through education and support
- Give them the authority to do their jobs
- Expect good results
- Constantly evaluate their performance and provide feedback

Hiring

A surgeon's practice is a home away from home, and patients are to be greeted as if they were invited to that home. To provide this aura of welcome, the practice needs outwardly focused employees who have genuine smiles and truly care for people. The clinical staff must be gentle and nurturing to bring calm to those in pain and fear.

Those employees who answer the phone and greet the arriving patient have a unique opportunity to make a good first impression for the practice. There is only one chance to make a good first impression, and if that chance is lost, the remaining portion of the relationship with the patient may be difficult.

Team function is an important aspect of OMS practice, and the combination of the right people is a powerful tool for the delivery of expert, caring surgical services. All individuals have strengths and weaknesses. Some employees are masterful at interaction with children and the elderly, while others excel at organization. Some have extraordinary manual dexterity. For a team to function well, an effort must be made to match the assets of the members to cover all needed roles of the team.

Training

Owners are responsible for training an employee about expectations for job performance. The employee must be provided with feedback, because surgery is a continually changing profession. The owners should use outside resources such as seminars and conventions for education, but they should not hesitate to provide education solely for the individual employee. Education is an investment, and it will provide a return.

Assigning Value

All humans are inspired by expressions of appreciation and value. Words of affirmation, acts of service, and rewards are good ways to show employees that hard work and talent are noticed and valued.

For greater impact, give gifts in a public forum and positive feedback in front of patients and professionals. The employee review is an opportunity to foster meaningful dialogue for methods for improvement on both sides of the paycheck.

Autonomy

Trust, but verify.

—RONALD REAGAN

After acceptable performance standards have been outlined, employees should be given the autonomy to complete their tasks. The practice should verify compliance with the performance parameters by audits, and feedback should be provided to the employee.

Discipline

All humans make mistakes, and even reliable employees can make errors of judgment. Documentation and timely discussion allows the properly engaged employee an opportunity to learn, to grow, and to modify his behavior. If this does not happen, then the owners have a clear path to follow.

The Relationships between Owners and Referral Sources

Depending on the business model, referral sources might be located within the company, generated by external marketing, or made up of local professionals, especially family dentists. The fruitfulness of attempts to develop productive relationships with referring doctors varies, but communication and excellent service are always key elements of enduring relationships. Gifts and promotions can generate some good will, but once begun, the gift giving will be expected to continue, and it is subject to a competitor supplying a fancier prize.

A hard fact of life is the realization that these relationships are based on "What have you done for me lately?" Performing great work, communicating effectively, and promptly seeing emergencies are expected to continue throughout the lifetime of the relationship.

To refer a patient to a specific surgeon is an act of trust. If the patient has a good experience and the surgery is successful, then the referring doctor is rewarded with having made a good decision in his choice of specialist. Conversely, a poor experience or surgical result can taint the referring doctor as well as the surgeon.

Personal Communications

The most important thing in communication is hearing what isn't said.

—PETER DRUCKER

Personal time with a referring doctor is directly proportional to the volume of referred business. Texting, letters, and email are informational, a phone call is conversational, and a personal meeting is true communication. Do not underestimate the need for face-to-face meetings in order to communicate sincerity.

A surgeon may encounter a patient who is unhappy with his or her family dentist and asks the surgeon for a referral to another dentist. The surgeon should decline this opportunity. After the patient is dismissed, the surgeon should call the affected referring doctor to explain the circumstance and ask for advice on how to handle this delicate issue. This approach will help build a strong professional relationship with that referring doctor.

Educational Opportunities

A rising tide lifts all boats.

—JOHN F. KENNEDY

Because most referring doctors embrace education, presentations at professional societies and study clubs appeal to those interested in bettering themselves. Study clubs are particularly fertile for developing enduring relationships with referring doctors. All professionals enjoy interaction to compare cases and learn from others, so an educationally based club also offers all its members an opportunity to improve their professional care. This rising tide of knowledge brings with it the camaraderie of learning together. The employees of this subset of doctors will also enjoy this educational emphasis, and they will readily participate in a club for staff.

The Relationship between the Surgeon and the Patient

The practice of OMS is an uphill battle. We must entice patients to our business when they would rather be anywhere else. We frighten them. We hurt them. Then, we

make them pay us. After all of that, some of us believe we can make the patients like us.

Obligation to Educate

Only the educated are free.

—EPICTETUS

Although trained to cut and sew, surgeons have a most important secondary task, and that is to educate their patients and their families. The surgeon must clearly explain findings from examinations, treatment alternatives, consequences of the avoidance of treatment, outcome predictions, potential complications of treatment, and costs of each treatment option in terms of time, money, and morbidity. Finally, he should state how he would treat the condition if it were found in his own family member. All of this discussion takes time and produces no income, but it is critical to the development of a strong professional relationship with the patient.

Fear and Its Manifestations

Apprehension, uncertainty, waiting, expectation, fear of surprise, do a patient more harm than any exertion.

—FLORENCE NIGHTINGALE

Patients manifest fear and apprehension in different ways, and most manifestations are obvious and easily attended. For instance, fear can manifest as anger. Some individuals may assume an aggressive, verbally abusive attitude with clerical and clinical staff, but once face-to-face with the doctor, they become much more reasonable and compliant. The staff should be educated to recognize this aggression, understand its cause, handle it professionally, and not take it personally.

Just Say No

A surgeon will encounter patients who harbor unrealistic expectations of professional care. Ideally the surgeon will realize this during the initial patient encounter and before any treatment. If the surgeon explains that those expectations cannot be met and the patient continues to hold unrealistic beliefs, the patient should be gently but firmly released from the practice. The surgeon should say, "Ms. Jones, you need to find another surgeon." If the patient repeats her needs, the same dismissal phrase should be used. If the patient asks for a referral to another surgeon, the surgeon should decline that request. An unrealistic patient should not be referred to a peer. The surgeon should allow an unrealistic patient to find her own way from his practice so that the surgeon does not waste time, endure heartache, and engage malpractice attorneys. Declination of the opportunity to serve an unrealistic patient should be carefully documented.

I Don't Know

These are three of the most powerful, yet underused, words in a surgeon's vocabulary, but they can sometimes provide a simple solution to an unsolvable conundrum. Early in their careers, surgeons abhor these words, because they might represent a failure on the part of the doctor to study and learn. When a surgeon is presented with a difficult case such as vesiculobullous disease, early implant failure, atypical facial pain, or denied insurance coverage, the most truthful response is, "I don't know." Do not mislead the patient into believing that you know an answer to the problem when in fact you are guessing. It truly is OK not to know, and the patient will respect you for your honesty. There are many disorders of the human body that are understood poorly or not at all, and to admit that truth is not a defeat.

Errors

Don't be afraid to fail. Don't waste energy trying to cover up failure. Learn from your failures and go on to the next challenge. It's OK to fail. If you are not failing, you are not growing.

—STANLEY JUDD

All humans make errors. In the OMS profession those errors range from calling the patient by the incorrect name to removing the wrong tooth. Rather than being true surgical complications, these are basic errors that require admission and sincere apology by the surgeon. This act of being human and admitting it goes a long way toward maintaining healthy relationships with patients in the face of difficult circumstances.

Relationships between the Surgeon and Peers

Professional Organizations

All organizations need leadership. Good leadership comes from those who are inclined to help advance the members of their profession at the local, state, and national level. Join not for the limelight, but for the opportunity to serve and share.

Professional Jealousy

The worst part of success is trying to find someone that is happy for you.

—BETTE MIDLER

It is a rude awakening for a surgeon to learn that some of his colleagues are not interested in his successes. There will even be instances where professionals have propagated unflattering remarks to discredit a peer. One must learn to celebrate success within the self and turn a deaf ear to unflattering remarks. Only true friends will celebrate one another's accomplishments.

The Experienced Mentor

A mentor is an extension of education in the postgraduate world. Having such an experienced helping person is a blessing. If you don't ask, you will not know.

Visiting Peers

One of the most fruitful sources of help, information, and advice is a peer who is located just far enough away to avoid being a competitor. The entire staff can visit a peer and learn in all aspects of practice.

The Relationship between the Owners and the Community

We were born to unite with our fellow men, and to join in community with the human race.

—CICERO

Participation in community politics and organizations is more than being a good neighbor. It is an opportunity to market the practice. The encounters will build friendships in the community that will directly affect patient demand.

Membership, serving on committees and boards, and mentoring are valuable exposures in the local hospital, service organizations, churches, and educational institutions. OMS doctors who participate in community organizations are stating to the people of the community that they care about them, their businesses, and their families.

The Relationships between the Owners and their Advisors and Vendors

No man is an island.

—JOHN DONNE

Key relationships must be developed with legal, accounting, real estate, and financial advisors, and word of mouth is the best search engine. A surgeon spends many years learning to make an incision, but may be ignorant of the ways of the business world. In some instances, multiple advisors might be needed to find a consensus in a critical field.

Experienced vendor representatives have a broad knowledge of what works and what fails in practices because they have the opportunity to observe marketing and profitability from a distance. Treat them with respect and take advantage of their knowledge.

The Relationships between Owners and Third-Party Payers

No man can serve two masters: either he will hate the one and love the other, or else he will hold to the one and despise the other.

—MATTHEW 6:24 (KJV)

Surgeons owe their fidelity to their patients and not to their payments. If that premise is accepted, then in a dispute between a surgeon and the entity that pays for the treatment, a surgeon will defend the appropriateness of treatment rather than argue over the amount paid.

The Relationship between Surgeons and their Families

This above all: to thine own self be true.

—WILLIAM SHAKESPEARE THROUGH POLONIUS

There must be a logical division of time and energy among a surgeon's practice, his family, and himself. There are only 24 hours in a day, and it cannot be expanded. If too many of those precious hours are devoted to a surgical practice, there is insufficient time for family and personal health. If too few hours are allocated to personal fitness, then the surgeon's health will not support the quality time needed for family and loved ones. Time for fitness, for friends, and for family deserves scheduling just like consultations and surgeries. Do not leave this important part of life to chance.

Summation

The difference between a successful person and others is not a lack of strength, not a lack of knowledge, but rather a lack of will.

—VINCE LOMBARDI

Oral and maxillofacial surgery is a wonderful profession that affords OMS doctors the opportunity to bring relief to the suffering, to reap satisfaction from practicing a complex art, and to build dignity forged by hard work. It can be a deeply satisfying vocation enjoyed over a long career while allowing the surgeon to have meaningful interactions with other people.

It is not enough to be a good surgeon with adept fingers and a sharp eye. To be a success in our own eyes, we must study our souls for resonant goals and seek a compatible business model. We must search for like-minded partners, gifted employees, and faithful referring doctors. We must treat patients gently and honestly while we make peace with our peers. We must support our community and frequently seek the counsel of mentors and advisors. We must work as hard for ourselves and our families as we do for our practice. Work diligently toward excellence every day and recall that

When everything seems to be going against you, remember that airplanes take off against the wind, not with it.

—HENRY FORD

3

Oral and Maxillofacial Surgery Career Alternatives to Private Practice

DAVID A. BITONTI, KAREN M. KEITH, JESSE W. LEE, JOHN W. HULTQUIST, N. WHITNEY JAMES, PAUL M. LAMBERT, STANLEY W. SMITH, TIMOTHY O. WARD, GEORGE M. KUSHNER, JANICE S. LEE, MARTHA J. SOMERMAN, ANDREA B. BURKE, MARTIN E. EICHNER



Blue Angels and the *USS George H. W. Bush* (CVN 77).

Introduction

David A. Bitonti

The traditional career track for the largest percentage of oral and maxillofacial surgeons has been to transition from residency to a private practice opportunity. The purpose of this chapter is to provide information on potential career tracks that offer alternatives to this traditional practice model and that are academically, financially, and personally rewarding. These alternative career opportunities include public service, federal government employment, state government employment, academic and research employment, and a multispecialty dental services organization employment. It is important that practicing oral and maxillofacial surgeons be aware of these opportunities and understand some of what is involved in that particular type of practice, as well as the often unknown or misunderstood portions of these alternative practice opportunities. Whether a decision needs to be made early, following residency completion, or the decision is part of a career transition, these career alternatives to the

The views expressed are those of the authors and do not necessarily represent the views of the Department of Defense, Department of Health and Human Services, Department of Veterans Affairs, and Department of Justice; the United States Army, Navy, Air Force, Public Health Service, Indian Health Service, and Veterans Administration; or the Army, Navy, Air Force, Public Health Service, and Veterans Administration Medical Departments.

traditional private practice model warrant consideration by every oral and maxillofacial surgeon.

United States Army Oral and Maxillofacial Surgery Careers

Karen M. Keith

On March 3, 1911, President William Howard Taft signed legislation establishing the United States Army Dental Corps as a permanent corps of the Army Medical Department (AMEDD). Prior to this date, dental care within the Army was provided by hospital stewards or enlisted members with an interest or training as civilians. Assigned as a hospital steward at West Point in 1858, William Saunders was placed on orders as the first U.S. Army dentist in 1872. Graduate dental education was established in 1921, and the first dentist was sent for oral and maxillofacial surgery training in 1931.[1] The history of oral and maxillofacial surgeons (OMSs) within the Army is replete with significant clinical and command roles throughout the 104-year history of the U.S. Army Dental Corps. They continue to contribute immensely to leadership, research, academics, and surgical techniques, even when their time in service is complete.

During World War I, American Expeditionary Force maxillofacial teams that included a surgeon, a dental surgeon, and dental technicians were established with the vision of the plastic surgeon Major Vilray P. Blair. He recognized that dental expertise was required to properly care for the severity of gunshot wounds, complex jaw fractures, and avulsive soft tissue wounds. Protocols for wound management were developed that recognized the unique aspects of facial injuries. This included principles such as mechanical cleansing, minimal debridement, retention of bony fragments with soft tissue attachments, immediate fixation of jaw fractures, adequate drainage, and expeditious evacuation to base hospitals. With less than adequate logistical support, creative splinting techniques were employed.

During this era, wire fixation was used to temporize as well as to permanently stabilize bony fragments, rather than waiting for permanent dental splinting techniques. Oral and plastic surgeon Robert H. Ivy, who trained under Blair, is erroneously credited with the "Ivy loop" technique, but has stated that it originated with Colonel Robert T. Oliver. Oliver was a well-known oral surgeon who became the third chief of the Army Dental Corps from 1919 through 1924. Ivy should be better known for his soft tissue flap to reconstruct through-and-through facial wounds.[2] The early and consistent care touted by these pioneers continues with Army OMS as members of head and neck teams and as members of Combat Support Hospitals.

Another pioneer and exceptional leader, Major General Robert B. Shira, taught himself oral surgery in the Panama Canal Zone during World War II. Involved in World War II, Korea, and Vietnam, he made significant contributions during his 33-year career. His changes to dental delivery resulted in a 50% reduction in the number of Soldiers lost to battle in Vietnam because of dental disease. As Chief of the Army Dental Corps from 1967 to 1971, he helped establish the Army Dental Intern Program and an oral surgery residency program. At Walter Reed Army Medical Center, he pioneered closed-circuit color television demonstrations of surgical procedures for postgraduate courses. In 1966, he invited Professor Hugo Obwegeser from Zurich, Switzerland, to discuss new techniques in orthognathic surgery.[3]

This trajectory of illustrious careers and significant contributions of Army oral and maxillofacial surgeons continues throughout our history. Dr. Joe Hall Morris, best known for his Bi-Phase External Fixation Splint and the Orthognathic Surgery Simulating Instrument (OSSI), served 2 years at Fort Benning, GA, from 1951 to 1953. He played a significant role in the biomechanical aspects of the specialty. Ervin E. Hunsuck attained the rank of colonel and had a prolific research and academic career. Most noted for his bilateral sagittal split osteotomy modification, he also invested much research in trauma and fixation techniques. Colonel (Retired) Jan Faulk-Eggleston made her mark as the first female OMS to complete an Army OMS residency program and developed a niche in temporomandibular joint (TMJ) reconstruction. Numerous other OMS have contributed their expertise to the field of cosmetics, cleft lip/palate, and reconstructive techniques within the Army Dental Care System.

Currently, the Army OMS inventory is in the range of 113 officers, including residents. Eleven residents train at one of seven programs, with the number trained based on needs of the Army. In the summer of 2016, two Army residents will attend a civilian institution with the opportunity to earn the medical degree as well as the certificate of OMS completion. Efforts are underway to reinstitute the integration of medical school as part of the Army programs. It was offered from 1994 to 2001, and 86% of these surgeons stayed on active duty until retirement or still currently serve in excess of 20 years. One serves as the OMS Consultant to the Surgeon General (TSG), and four have served as OMS Residency Program Directors.

Two training programs are joint programs with our sister services. The National Capital Consortium (NCC) in Bethesda trains two Army residents annually at sites that include the Bethesda Naval Hospital, Fort Meade, and Fort Belvoir. San Antonio Military Medical Center (SAMMC) at Joint Base San Antonio, Texas, trains two Army OMSs annually with Air Force residents at Brooke Army Medical Center and at Wilford Hall Ambulatory Surgical Center.

Collocated with SAMMC is the prestigious Center for the Intrepid and the Dental Trauma and Research Detachment, part of the Triservice Battlefield Health and Trauma Research Institute. The other Army training sites are Eisenhower Army Medical Center at Fort Gordon, GA; Womack Army Medical Center, Fort Bragg, NC; William Beaumont Army Medical Center, Fort Bliss, TX; Madigan Army Medical Center, Joint Base Lewis McChord, WA; and Tripler Army Medical Center, Honolulu, HI.

Applicants to Army OMS residencies can be Health Professions Scholarship Program (HPSP) dental students as well as active duty dentists. Applications include a photograph, dental school transcripts, National Board Dental Examinations (NBDE) results, and results of the National Board of Medical Examiners (NBME). Applicants also complete a telephone interview with a panel of Army OMSs and submit letters of recommendation to attest to their integrity and potential. Potential applicants are strongly advised to spend at least 1 week at an Army training program to shadow residents and discern their commitment to the rigorous lifestyle. The Army Dental Corps conducts a specialty selection board once a year. Packets are independently assessed and rated, and an order of merit list determined. The best-qualified residents are selected for each program based on available positions. Board recommendations are forwarded to the Chief of the Army Dental Corps for approval. Human Resources Command (HRC), in consultation with the OMS Consultant to TSG, will assign residents to training locations based on the order of merit list, the residents' desires, and the OMS Program Directors' assessment.

The OMS residency is a 48-month certificate program accredited by the American Dental Association's Committee on Graduate Dental Education with an experience that rivals any civilian training program. Education is provided via experiences on the OMS service and rotations within the medical center. Trauma rotations are completed at the facility or with affiliated institutions known for high-volume encounters. The 5-month anesthesia rotation includes 1 month dedicated to pediatric anesthesia. Intubated general anesthesia is part of every Army OMS outpatient clinic training experience. A foundational skill, orthognathic surgery is an additional continual strength of all Army residencies.

Successful completion allows the graduate to apply for privileges in the full scope of the specialty. Attainment of board certification is advised as soon as practical. The new graduate should expect to serve a utilization tour for 3 to 4 years at a post where he or she might be the sole surgeon. Surgeons might serve at dental treatment facilities or within hospitals with inpatient and same-day surgery capabilities. Army OMSs also have the opportunity to compete for fellowship training. Craniofacial, cosmetic, temporomandibular joint, and trauma and reconstruction are among the potential fellowships current Army OMSs have completed.

Annual pay for Army oral and maxillofacial surgeons is based on rank, years of service, board certification, and several specialty specific pay incentives or bonuses. Other benefits of being a surgeon in the Army, available to all Army dentists, include the option of the Active Duty Health Professions Loan Repayment; 30 days of paid vacation earned annually; noncontributory retirement benefits with 20 years of qualifying service; and no-cost or low-cost medical and dental care for the Soldiers and their family. Dental Corps officers also have commissary (grocery store) and post exchange shopping privileges.

The Army Medical Department (AMEDD) has been undergoing a transformation over the past several years. As the health care system transforms, ensuring that the right people are at the right places will become critical. Preservation of surgical skills is vital while contributing to the readiness and wellness of Soldiers. OMS combat support roles have always been impressive. Oral and maxillofacial surgeons supported efforts in the Balkans. In February 2001, at the peak of the Persian Gulf War, 25 OMSs were deployed to support an Army force of 300,000.

Most recently, we have been a nation at war for the greater part of a decade. From 2003 to 2014, more than 30 OMSs deployed in support of Operation Iraqi Freedom or Operation Enduring Freedom, the vast majority of these volunteering. A completely updated oral and maxillofacial surgery instrument and equipment kit was fielded, and an assistant exclusively dedicated to the surgeon assigned. Panfacial trauma protocols were redeveloped in conjunction with our sister services to account for new injury patterns and concerns encountered with the implementation of improvised explosive devices (IEDs) over the past decade. Reconstructive challenges with tissue loss and burns exceeded even those seen during the trench warfare of WWI.[4] Technologies such as three-dimensional imaging, stereolithography, cone-beam scanners, and even virtual surgical planning have enhanced capabilities to render exceptional care to service members. Incredible advances in regenerative medicine offer promising therapies in the very near future. Collaboration with civilian research institutions has intensified our research strategies. Telemedicine has also proven a valuable asset, offering consultation services to front-line medics, dentists, and even NATO forces treating U.S. service members or handling complex humanitarian cases.

Career paths for Army OMS include education, research and command opportunities: Department of the Army Pamphlet 600-4, Army Medical Department Officer Development and Career Management, discusses the expectations, training, and utilization of Dental Corps Officers. The lifecycle model for surgeons includes: Oral and Maxillofacial Surgeon; Training Officer, Program Director, Assistant Program Director, Advanced Specialty Education Program in Oral and Maxillofacial Surgery; Chief, Surgery Branch, Dental Research Unit; Oral and Maxillofacial Surgery Consultant; OTSG; Chief, Department of Dentistry; Clinic Chief; and Researcher, U.S. Army Dental and Trauma Research Detachment (USADTRD). Oral and maxillofacial surgeons can even be part of Recruiting Command.

Surgeons are expected to continue their military education requirements as well as maintain their dental licensure educational requirements. Professional development includes clinical and military milestones depicted through various assignments requiring military education and professional training. Leaders are groomed through continuous professional study, self-development, and operational assignments. All officers are encouraged to attend the Combat Casualty Care Course (C4). Some might receive additional training at Airborne or Air Assault School if opportunities are available. Officers are encouraged to compete for and obtain the Expert Field Medical Badge (EFMB).

The AMEDD Captain's Career Course (CCC) should be completed between the third and sixth year of service. Intermediate Level Education (ILE) establishes a common Army operational war fighting culture to prepare field-grade officers for service at higher levels of responsibility and in conjunction with other services (joint assignments). Completion of ILE enhances competiveness for promotion to the rank of colonel and is required for Senior Service College (SSC) consideration and attendance. These courses prepare officers for higher-level command and staff duties. Surgeons are encouraged to accomplish the career milestones that make them eligible for the Surgeon General's "A" Proficiency Designator.

In addition to excelling in surgical skills and in surgical mentoring, Army OMSs continue to serve in leadership capacities outside of clinical practice. All Dental Corps officers have the opportunity to broaden their experiences as an Executive Dentist with diverse positions that include DENTAC Commander; Director of Dental Services; TOE Dental Unit Commander; Branch Chief, Dental Research Unit; Dental Staff Officer; OTSG; U.S. Army Medical Department Center and School Health Readiness Center of Excellence (Chief, Department of Dental Sciences); Combat Developments, AMEDD Personnel Proponent Directorate (APPD); Chief, Graduate Dental Education; Dental Surgeon, ACOM; USARC Dental Surgeon; FORSCOM Dental Surgeon; STARC; Regional Dental Command Commander; DENCOM Staff Officer; HRC Branch Chief; Career Development Officer, HRC; Corps Specific Branch Proponent Officer (CSBPO); and Forensic Dentist; U.S. Army Dental Command Commander. With the recent transformation of the Army Dental Corps within the AMEDD regiment, additional opportunities exist regarding the roles surgeons might have. OMSs and Army dentists in general will have the opportunity to command medical treatment facilities, and even strive for the role of Surgeon General.[5]

In the past decade, three Army OMSs have been Regional Dental Commanders. After his role as an OMS Residency Program Director and Regional Dental Commander, Colonel (Retired) Larry Hanson served as the eighth Dental Corps Commander from 2003 to 2006 and is the only oral and maxillofacial surgeon to have held that position. Oral and maxillofacial surgeons have commanded the USADTRD and have been involved with numerous research endeavors. Colonel (Retired) Robert Hale was instrumental in significantly accelerating research in regenerative medicine. Currently, several surgeons hold command positions, from a field dental unit to a Regional Dental Command. One OMS is serving at the Office of the Surgeon General. The 212th Combat Support Hospital in Germany has an OMS integral to that unit, heavily involved in training and preparation of assets to support European missions.[6]

Several Army OMSs have provided lectures at national or regional conferences, including the American Association of Oral and Maxillofacial Surgeons, the American Dental Society of Anesthesiology, and the annual Denver Board Review Course. Several former and current Army OMS serve as examiners for the American Board of Oral and Maxillofacial Surgery. Numerous former Army OMS have left military careers and become presidents of local professional societies, deans of universities, and presidents of national professional associations. They are highly desired candidates for competitive private-sector jobs upon leaving the service.

The contributions of all Army oral and maxillofacial surgeons continue to be appreciated. They provide subject matter expertise when updating field equipment, determining ancillary staff training, eliminating coding variance, and setting standards across the profession. As the Army continues to transform and reengineer its relevancy within our world, Army OMS will continue to ensure the highest level of training and professional development to provide the absolute best surgical services to Soldiers and to lead the Dental Corps into the next century.

United States Navy Oral and Maxillofacial Surgery Careers

Jesse W. Lee

The United States Navy (USN) Dental Corps has a long and storied tradition in which oral and maxillofacial surgeons have played an important role. The Dental Corps, established on August 22, 1912, recently celebrated its 103rd year of supporting America's Navy and Marines. The original authorization authorized 30 acting assistant dental surgeons to part of the Medical Department. The Dental Corps has since grown to more than 1000 officers.

When the United States entered World War I on April 6, 1917, 35 dental officers were on active duty. That number grew to more than 500 by the war's end. Most of these officers were assigned to ships or overseas activities. Two dental

officers were awarded the Medal of Honor during this conflict. World War 1 established the general recognition of the value of dentistry to the Naval Service. Early in 1922, the Bureau of Medicine and Surgery adopted a dental division and the U.S. Navy Dental School was established. By 1941, 759 dental officers were on active duty at 347 dental facilities. Two Dental Corps officers were among those killed in the attack on Pearl Harbor. Less than a month later, the Surgeon General directed that all dental officers become proficient in the treatment of casualties so they might assist in sick bays and operating rooms and assist in the delivery of anesthesia. This became the basis for the role oral and maxillofacial surgeons would play in the Navy in the future. Dental officers, assisted by dental technicians, performed such duties under duress and in some instances at the cost of their lives.

Dental personnel continued their support of our medical colleagues through the Korean conflict and Vietnam. The start of formal oral surgery residency training in the Navy had its roots in the Vietnam conflict. Oral surgeons provided front-line treatment for many injured service members and were an integral part of the forward-deployed medical units. The utility of forward-deployed dentists with medical training was demonstrated in the tragic bombing of the Marine Corps barracks in Beirut, Lebanon, in 1983. This attack left 241 American servicemen dead with 65 seriously wounded. All of the medical staff was killed in the attack. Two Navy dentists with their dental technicians coordinated and delivered emergency care and evacuations of the wounded. They both were awarded the Bronze Star for gallantry under fire.

In July 1984, the Navy began conversion of two supertankers to hospital ships. *USNS Mercy* (T-AH19) and *USNS Comfort* (T-AH20) were placed in service in December 1986 and August 1987, respectively. These platforms, with 1000 beds and 12 operating rooms, allow comprehensive oral surgery services worldwide, regardless of the situation, whether war or natural disaster. These, in addition to the forward-deployed fleet hospitals and surgical units allow oral and maxillofacial surgeons to treat patients in need anyplace, anytime.

Throughout the history of the United States Navy Dental Corps, oral and maxillofacial surgeons have played a vital role in the delivery of care. Oral and maxillofacial surgeons fill a wide array of positions across the globe. As with all dental and medical specialties, residency training is the foundation on which the specialty is built. As the specialty of Oral Surgery developed and grew, so did the Navy's programs. At first interested officers were sent to civilian institutions for training. The Navy also aggressively trained officers for 1 year in exodontia to alleviate the great numbers of servicemen requiring treatment. The Navy then instituted in-service training programs for oral and maxillofacial surgeons in the 1970s. Starting with 2 years of training, the programs grew as the specialty grew. Today, the three in-service programs offered by the Navy favorably compare with any in the civilian sector. The Navy trains six in-service residents a year in a 4-year certificate program and will usually send one or two officers to civilian programs as well. The Navy also sends on average one officer for subspecialty fellowship training a year for reconstruction, cosmetics, or craniofacial surgery. The selection process begins early, 16 months before the initiation of training. From scholarship students in their third year of dental school to senior dental officers, applications come from a wide variety of candidates. Unlike civilian residencies, the selections for the Navy programs are made by a selection board with close consultation from the OMS training community and specialty leader. Applications are evaluated on several criteria including undergraduate and graduate grades, class ranks, board scores, and scores on the Combined Basic Science Exanimation. Letters of recommendation, military potential, and professionalism are also evaluated. This rigorous approach ensures highly qualified, diverse candidates, many of whom have extensive clinical and leadership experience. Our 4-year certificate programs at the Naval Medical Center, Portsmouth, VA, and the Naval Medical Center, San Diego, have long been recognized for their excellence. The joint program with the Army at Walter Reed National Military Medical Center boasts state-of-the-art facilities with the heritages of both previously separated programs.

Each of the Navy's residency programs brings an educational opportunity comparable to any civilian program. A full, broad scope of practice gives residents outstanding hands-on experience in orthognathic surgery, cosmetic surgery, implant reconstruction, pathology including head and neck cancer with reconstruction, trauma, temporomandibular joint treatments, and dentoalveolar surgery. Each program is staffed with at least four full-time, board-certified oral and maxillofacial surgeons, a maxillofacial prosthodontist, pediatric dentist, orthodontist, endodontist, and orofacial pain specialist. Also, there are general dentists who assist in the General Practice Residencies that each of the training programs support. The Navy sponsors residents to participate in fellowship training in cosmetic surgery, palliative and reconstruction surgery, and craniofacial surgery. We support our residents in their pursuit of board certification with review courses and scheduled "mock board" sessions. The Navy Dental Corps candidates have a stellar 97% pass rate over the past 20 years on the ABOMS certification exam.

Oral and maxillofacial surgeons can join the Navy via direct accession and are eligible for the same benefits as surgeons who are trained while in the Navy. The financial assistance program is another avenue for non–active duty oral and maxillofacial surgeons who are interested in a career in the Naval Service while in residency. This program provides a stipend while in school as well as money toward fees, equipment, and housing and a bonus on graduation.

After completion of training, a world of opportunity is available to the OMS. From large training hospital to clinics, from sea to shore, the OMS selects his or her career path. Working closely with the Oral Surgery Specialty Advisor to the Surgeon General, each billet (job position) is carefully filled. With more than 80 spots from aircraft carriers,

hospital overseas, and clinics and hospitals stateside, the opportunities to find a spot that meets your personal and professional goals are many. Navy oral and maxillofacial surgeons practice in state-of-the-art facilities with the opportunity to use the latest technology in support of their practice. Digital radiology using cone beam CT imaging is now the standard of care at the majority of our facilities. Virtual treatment planning and remote splint fabrication are now standard at our training programs for orthognathic surgery, TMJ surgery, and implants. We use lasers and piezoelectric equipment in most of our hospitals and clinics. Our facilities at Walter Reed are on the cutting edge of facial reconstruction using transplant technology for our war trauma patients and patients with severe craniofacial anomalies.

The OMS who is looking for challenges beyond clinical care will find the Navy full of opportunity. Currently oral and maxillofacial surgeons have leadership roles throughout Navy Medicine. Positions include Residency Directors, Clinic Directors, Director of Surgical and Dental services, Executive Officers (civilian equivalent to Vice President of a hospital), and Commanding Officer of a clinic, dental battalion, or hospital (the civilian equivalent to CEO of a hospital). Oral and maxillofacial surgeons have served as the chief and deputy chief of the Navy Dental Corps, as Assistant to the Surgeon General of the Navy, and as commanding officers of large support commands. As rank and experience increase, the opportunities in executive medicine become more available. The interested OMS can tailor his or her career to any area of interest. This includes clinical, executive, research, education, or a combination of each. The group practice setting is unique and allows for multiple interests to be satisfied while providing the best in care for our patients. The ability to work closely with other oral and maxillofacial surgeons is one of the most appreciated benefits of military practice. Be it on a nuclear-powered aircraft carrier or overseas in one of our hospitals in Europe, Japan, or the Pacific, you always have the support of your colleagues and comfort in the knowledge that if you have a question or concern, there is another surgeon you can contact who will be able to help (Figures 3-1 and 3-2).

The experiences gained by the military OMS are valuable and readily transferred to the civilian practice of OMS. Former Navy oral and maxillofacial surgeons can be found in all aspects of the OMS community, from Program Directors of large university-based training programs to officers of the American Board of Oral and Maxillofacial Surgery. Most military oral and maxillofacial surgeons leave the military service to practice in the civilian community after their time in the Navy. Many take advantage of the liberal moonlighting policy the Navy has in place at most of its facilities. The Navy OMS truly can chart their own career course, wherever their interests might take them (Figures 3-3 and 3-4).

Oral and maxillofacial surgeons interested in a Navy career may receive additional information by contacting a local Navy Medical recruiter; by writing to the Navy Dental Corps, Career Planner, Bureau of Medicine and Surgery, 5113 Leesburg PK, Falls Church, VA 20598; or by calling



• **Figure 3-1** Aircraft carrier operating room.



• **Figure 3-2** Shipboard surgery suite.



• **Figure 3-3** *USNS Comfort* (T-AH 20) operating room.



• **Figure 3-4** *USNS* Mercy (T-AH 19) hospital ship.

703-681-8919. Additional information about practicing as a Navy dentist can be found at www.navy.com.

United States Air Force Oral and Maxillofacial Surgery Careers

John W. Hultquist

The United States Air Force (USAF) Dental Corps was established in 1949 along with the creation of the Air Force Medical Service. The OMS residency program at Wilford Hall USAF Medical Center on Lackland Air Force Base (AFB) in San Antonio, TX, was the first dental residency in the USAF Dental Corps. It was started in 1957 and graduated its first residents in 1959. Ten years later, an additional OMS training program was started at David Grant USAF Medical Center on Travis AFB in Fairfield, CA, and graduated its first residents in 1971. In 2013, the Air Force and Army programs in the San Antonio area combined to form the San Antonio Military Oral & Maxillofacial Surgery (SAMOMS) residency. SAMOMS functions out of two military facilities in San Antonio—Wilford Hall Ambulatory Surgical Center and San Antonio Military Medical Center. SAMOMS graduated its first residents in 2014.

Opportunities exist to become an OMS in the USAF Dental Corps other than through in-service training. Individuals can be selected for Air Force sponsored training through the Air Force Institute of Technology (AFIT) or by direct accession into the Air Force as an OMS. The Financial Assistance Program (FAP) is also available through the USAF Recruiting Service for OMS residents currently in training who are interested in joining the USAF Dental Corps upon graduation.

A wide range of career opportunities exist for the OMS in the Air Force Dental Corps and Medical Service. Career vectors include clinical, educational, and leadership roles. Each year, a Dental Corps Developmental Team meets and vectors AF officers into one of these tracks. A large majority of oral and maxillofacial surgeons in the Air Force will, at some point in their career, be vectored into all three areas depending on level of experience and interests. The size and mission of a particular base or assignment will determine what role an OMS will play.

Early in the career of an Air Force OMS (captains and majors), there is an increased emphasis on their role as a clinician. Most young Air Force OMSs become involved in the academic arena as a junior faculty member in one of the Air Force's multiple Advanced Education in General Dentistry (AEGD) programs. As their career progresses, opportunities arise for a larger role in postgraduate dental education and administration of clinical operations.

As an Air Force oral and maxillofacial surgeon's career progresses and they become a senior-grade officer (lieutenant colonels and colonels), more opportunities arise to become involved in graduate dental education, whether in the AEGD programs or in the Oral and Maxillofacial Surgery residency programs, and in the leadership realm in various administrative and command roles. Senior oral and maxillofacial surgeons function as Department Chiefs, Flight Commanders, or Element Leaders. Their responsibilities include overseeing daily operations and administration of the OMS department and the assigned personnel, officer and enlisted.

Other leadership opportunities exist in the Air Force including Squadron Commander and Group Commander. Squadron commanders oversee the operations and administration of an entire department of dentistry, which includes all specialties of dentistry. These positions require more administrative time, and thus clinical time is somewhat reduced. Group commanders manage much larger organizations beyond that of just dental personnel and operations. These organizations are usually larger outpatient medical facilities or can be complete inpatient facilities with full surgical capabilities.

As previously stated, Air Force OMSs can be involved in education throughout all aspects of their careers. Thirteen of 14 stateside locations maintain AEGD programs (1-year or 2-year). In addition, 12 full-time faculty positions are available at the Air Force OMS residency programs in San Antonio and at David Grant Medical Center in northern California. Included at these two sites are program chairmen positions and program director positions. These individuals function similarly to their civilian counterparts and are responsible for daily operations, educational curriculum, and accreditation.

Currently, there are a total of 19 locations worldwide that have at least one OMS assigned. Excluding Lackland AFB and Travis AFB, 13 locations have two assigned oral and maxillofacial surgeons and the remaining 4 have one OMS assigned. Of the 12 stateside locations being manned

by Air Force oral and maxillofacial surgeons, all but 1 of those maintains an AEGD program. Most of these programs are located in or near large metropolitan areas such as Washington, DC, San Francisco, Las Vegas, San Antonio, and St. Louis. Locations outside the lower 48 states include Anchorage, Japan, the United Kingdom, and Germany.

Another great opportunity in the Air Force is to be able to practice full-scope oral and maxillofacial surgery. OMS clinics are either located in large medical centers or large outpatient surgical facilities, or collocated within dental clinics. All locations have access to operating rooms and inpatient facilities, whether within the Air Force medical facility itself or at a civilian hospital that has an agreement with the military treatment facility.

Most bases provide a wide range of services to meet dental and medical needs from not only the active duty military population but also their dependents and military retirees and their dependents. Certainly dentoalveolar and implant surgical services are a large portion of the workload, but pathology and reconstructive services are also offered if available. Orthognathic surgery is available at all Air Force locations with OMSs; most locations have an in-house orthodontist for a treatment team to manage functional dentofacial abnormalities and malocclusions. Facial cosmetic surgery can also be provided on a fee-for-service basis.

The management of maxillofacial trauma is paramount to the mission of all military oral and maxillofacial surgeons. Craniofacial and neck injuries are managed via a team approach working side-by-side with otolaryngology, plastic surgery, and oculoplastic and neurosurgery colleagues, ensuring a well-orchestrated collaborative effort. Air Force OMSs also manage maxillofacial trauma locally as needed and as the facility capability allows. Typical injuries involve sports-related or recreational activities but can also encompass motor vehicle collisions or assaults.

All Air Force facilities with OMSs are outfitted with state-of-the-art equipment and technology. Digital radiography and cone-beam CT imaging is available at all locations with an OMS clinic. Full stereolithographic modeling capabilities are readily available and are used to enhance treatment of trauma, craniofacial anomalies, and pathologic conditions. Laser, piezoelectric surgery, and hyperbaric oxygen chambers are available at a select number of medical centers with OMS capabilities.

An Air Force OMS also enjoys the opportunity for professional collaboration with other Air Force OMSs or other dental and medical specialists. All oral and maxillofacial surgery practices in the Air Force exist within a large group practice setting with orthodontists, prosthodontists, periodontists, endodontists, and general dentists. Collaborative treatment planning conferences are standard practice in the Air Force. These include dentofacial deformities boards and implant boards, as well as collaboration with their medical colleagues on craniofacial anomalies, sleep medicine, and head and neck tumor boards. Opportunities also exist to collaborate with civilian colleagues. Local continuing education symposia, journal clubs, and professional societies are available in which to participate.

Board certification is emphasized in the Air Force Dental Corps, especially oral and maxillofacial surgery. The Air Force has an outstanding record in oral and maxillofacial surgery, with more than 97% or all eligible surgeons achieving diplomate status with the American Board of Oral and Maxillofacial Surgery while on active duty. Also, every opportunity is extended to Air Force OMSs for funding the costs of board certification and attendance at board review courses. Competency and currency are also a major emphasis of the Air Force Medical Service, so, whenever possible, attendance at national meetings and continuing education courses is granted and funded.

Each year, the Air Force Dental Education Committee convenes to consider applications for various postgraduate dental programs. Air Force OMSs can be selected for fellowship training, which includes facial cosmetics, temporomandibular joint, tumor and reconstructive surgery, and craniofacial and cleft surgery. The fellowships are sponsored through the Air Force Institute of Technology and are completed at accredited civilian locations.

There are multiple benefits of being active duty military. These include professional liability coverage, medical and dental health care, and access to commissary and base exchange shopping. Additionally, each base offers various recreational activities in the local area and reduced rates on tickets for sporting events, amusement parks, and other venues. There are also multiple bonuses offered to the Air Force OMS including a monthly dental bonus, yearly dental bonus, yearly incentive pay specifically for the OMS, and board certification pay. Housing is also available on base, or the OMS can receive a basic allowance for quarters to rent or purchase a home off-base. Active duty members and their families are moved to their locations at the government's expense.

United States Public Health Service Oral and Maxillofacial Surgery Careers

N. Whitney James

The United States Public Health Service (USPHS) is directly under the Health and Human Services and is one of the seven uniformed services. It is composed of branch services

that include the Indian Health Service, National Institute of Health, Center for Disease Control and Prevention, National Health Service Corp, Federal Bureau of Prisons, and the National Oceanic and Atmospheric Administration. It also provides substantial health care services to the United States Coast Guard and backup services for the Department of Defense. The scope of practice and career opportunities for the oral and maxillofacial surgeon (OMS) are varied with a broad scope of services in the USPHS in-patient and out-patient hospital based programs. These programs extend from urban community hospitals to isolated rural clinics as well as provide consultation to outlying satellite clinics as an OMS Area Regional Consultant to National policies as an OMS National Consultant. OMS providers also participated in providing continuing education to the medical and dental communities on local and national levels to elevate the knowledge and clinical skills of other health care providers in the Public Health Service environment. Supervisory, administrative, and research positions are also available.

The Indian Health Service is the largest of the branch services within the USPHS with the greatest number of hospitals and OMS providers. These providers come into the USPHS under three scenarios:

- An OMS provider may receive a Congressional Commission and function as a Commissioned Officer of the USPHS. As a Commissioned Officer of the USPHS, the OMS Dental Officer is assigned to a hospital-based program to provide in-patient and out-patient services for that program. The Commissioned Officer also, in coordination with other USPHS Service Branches, has opportunities to participate in deployments in the event of national emergencies or natural disasters, or to assist and support the Department of Defense in its various programs as needed. Some overseas opportunities are also available as needs arise. A commissioned officer may also be assigned to other positions of supervision, administration, or research in any of the various branches of service within the USPHS. Temporary duty station assignments and mobility are also an option to the commissioned officer
- An OMS provider may be hired as a federal employee functioning as a Civil Servant. The Civil Servant is directly hired by a Federal hospital program that is under the direction of the Indian Health Service. A Civil Servant does not participate in deployment activities. Mobility is an option for the Civil Servant.
- As a direct contracted hire to a Tribal Program. A Direct Tribal Hire is directly hired by a tribally governed program and is an employee of that tribe or group of tribes. These programs are directed and administered by a Native American Tribe or a group of Tribes known as a "638 or Self Determination Program." As a direct contract hire, temporary duty assignments or mobility is not an option.

Pay, retirement programs, and benefits vary with each working option within the U.S. Public Health Service.

Veterans Affairs Oral and Maxillofacial Surgery Careers

Paul M. Lambert, Stanley W. Smith, Timothy O. Ward

The Department of Veterans Affairs (VA) comprises three components: veteran health care (VHA), veteran benefits (VBA), and national military cemeteries (NCA). VHA provides health care through the VA Medical Centers (VAMC), Outpatient Clinics (OPC), Community-Based Outpatient Clinics (CBOC), and VA Community Living Centers (VA Nursing Home) programs. VHA evolved from the first federal soldiers' facility established for Civil War veterans of the Union Army in 1865.

In 1918, Congress tasked two Treasury agencies with operating hospitals specifically for returning World War I veterans. They leased hundreds of private hospitals and hotels for the rush of returning injured war veterans and began a program of building new hospitals. Today's VHA continues to meet veterans' changing and challenging medical, surgical, and quality-of-life needs. New programs provide treatment for traumatic brain injuries, post-traumatic stress, suicide prevention, women veterans, and more. VA has opened outpatient clinics and established telemedicine and other services to accommodate a diverse veteran population, and it continues to cultivate ongoing medical research and innovation to improve the lives of America's patriots.

VHA operates one of the largest integrated health care systems in the world and the largest in the United States with 150 medical centers, nearly 1400 community-based outpatient clinics, community living centers, Vet Centers, and Domiciliaries. Together these health care facilities and the more than 53,000 independent licensed health care practitioners who work within them provide comprehensive care to more than 8.3 million veterans each year.

VA oral and maxillofacial surgeons (OMSs) enjoy extremely fulfilling careers caring for those who have served in defense of our nation—the most appreciative patient population that you will ever be privileged to serve. Currently, personnel returning from Iraq and Afghanistan have challenged VA OMSs with the responsibility for reconstructing and rehabilitating patients suffering from major facial, head, and neck injuries. The magnitude of their oral and maxillofacial injuries provides a challenging scope of surgical practice.

A career as an OMS with VA offers a future that is dynamic, innovative, and collaborative. As valued members

of an interdisciplinary health care team, VA OMSs enjoy the flexibility to move within the VA structure and the freedom to practice wherever an opening exists. In return for their commitment to quality health care for our nation's veterans, the VA offers its dentists competitive salaries, first-rate employment benefits, educational support, and tuition reimbursement programs while still retaining the ability to practice privately.

The hospital-based practice of oral and maxillofacial surgery offers opportunities and challenges that typically are not found in other environments. VA dentists and other dental professionals use the full scope of their skills and knowledge in their daily practice and are regularly challenged by patients who can be medically, physically, or emotionally compromised. Many VA medical centers offer the opportunity to work in a rewarding and collaborative fashion with other specialists providing comprehensive cutting-edge care, including head and neck surgery. Appropriately trained OMSs also independently manage head and neck pathology. All patient care is performed in an environment that adheres to the strictest protocols for infection control and assurances for quality patient treatment.

The VA is committed to a philosophy of technology-driven care that enhances staff performance and improves patient results. VA dentists work with today's state-of-the-art technology that directly pertains to patient treatment. Digital imaging, clinical operating microscopes, dental implantology, cone beam radiographic imaging, stereolithographic modeling, and computer-assisted design/computer-assisted manufacturing (CAD/CAM) are but a few of the advances that are in use by VA dentists, on a daily basis in some centers.

After years of development, the VA now has the most comprehensive electronic health record system in the nation. The health record puts each veteran's medical records, laboratory results, consults, radiographs, ECGs, and much more at the fingertips of dentists and the entire patient care team as they work together to design treatment interventions. The dental record component of the electronic health record is a sophisticated program that allows the clinician to view treatment plans, write notes, and monitor progress while seamlessly recording production data and other administrative tasks. Because the system is linked to every VA facility across the country, the care team can instantaneously pull up a traveling veteran's records to examine critical components (e.g., medications, medical problem list, or imaging reports) while making informed patient care decisions.

The VA also uses technology to enhance professional development. Computer-based networking (mail groups), regular teleconferences, and monthly ADA CERP approved webinar programs and other online training enable VA dentists across the country to obtain new information, share research, and exchange best practices.

OMSs with a special interest in clinical research or training find a rich environment at the VA. Many VA OMSs help guide students' fieldwork experiences. Others conduct ongoing research in such wide-ranging areas as laser-guided imaging, chairside point-of-care diagnosis or disease management using proteomics, and dental implantology. Historically, VA OMSs have been well published in nationally recognized professional journals. These education and research missions are further strengthened by the VA's affiliations with all schools of dentistry and 107 of the 125 schools of medicine. The VA provides training for a majority of America's medical, nursing, and allied health professionals. Roughly 60% of all medical residents obtain a portion of their training at VA hospitals, and VA medical research programs benefit society at large. The VA supports 380 dental residency training programs, providing a rich educational opportunity that welcomes OMSs as part of the faculty. Faculty appointments are encouraged, and time is available for active participation.

The VA Office of Dentistry has established a dental practice-based research network known as VA Dentists Engaged in Research (VADER). This network is composed of VA dentists who conduct research in their practices to address the issues and challenges that clinicians face daily in treating their patients. All VA dentists are invited to participate. Study areas of particular interest to OMSs are currently being developed, including medication-related osteonecrosis of the jaw (MRONJ), hyperbaric oxygen therapy, and earlier diagnosis of oral cancer. The MRONJ problem is the type of issue suited for investigation by VA dentists and the VADER dental practice-based research network. Although case series manuscripts and treatment guidelines have been published, additional well-designed clinical studies are required. VA dentists also participate in the ADA Professional Products Review.

Those surgeons interested in leadership positions within VA may apply for several excellent leadership development programs offered locally, regionally, and nationally. These include the Leadership Development Institute, Executive Career Field Candidate Development Program, and Leadership VA. OMSs may follow in the footsteps of those who have gone before them and assume positions at the medical-center level, including but not limited to chief of dental service; chief of staff; associate chief of staff for education; and chief of primary care.

At the system-wide level, OMSs have served on work groups dealing with developing clinical pathways for acute and chronic pain management, and diabetes. They have occupied positions at the highest policy-making level, including Assistant Under Secretary of Health for Dentistry. In that capacity, they have directed the entire scope of dental service delivery, including recommendations for manpower, resource allocation, standards of care, performance measurement, technology, quality improvement, education, postdoctoral training, and a host of other related issues.

VA OMSs may participate in organized dentistry at the local, state, regional, and national level. OMSs may serve on and chair committees and may serve as delegates and officers. Many OMSs have been elected to leadership positions in regional and national health care organizations, including president of the American Association of Oral and Maxillofacial Surgeons.

OMSs interested in a VA career may receive additional information by contacting a medical center in their area directly; by writing to the Department of Veterans Affairs, Placement Service, 1555 Poydras Street, Suite 1971, New

Orleans, LA 70112; or by calling 1-800-949-0002. Employment information can also be found on the Internet at www.vacareers.va.gov. Additional information about practicing as a VA dentist can be found at www.va.gov/dental or https://www.usajobs.gov, keyword VA DENTIST.

Academic Oral and Maxillofacial Surgery Careers

George M. Kushner



University of Louisville Oral and Maxillofacial Surgery Team 2014-2015.

Academic surgeons play a critical role in the ongoing advancement of the specialty of oral and maxillofacial surgery. Residents are the lifeblood of any specialty, infusing new energy and ideas that advance our field. Training these residents is one of our most important roles as academic oral and maxillofacial surgeons. Ensuring that residents are properly trained is a time-intensive and lengthy process that occurs over 4 to 6 years. The academic oral and maxillofacial surgery faculty is an important component of the overall workforce of the specialty, as this is a major focus of our day-to-day activities. The academic faculty is charged with training the next generation of oral and maxillofacial surgeons.

One of the main reasons for choosing an academic career is being in a stimulating environment. Interacting with residents and students on a daily basis provides a constant source of motivation. Faculty are constantly pushed to explain "why" to our mentees. It is commonly said that you cannot adequately perform a procedure until you can teach it to someone else. Oral and maxillofacial training programs are often located within academic health sciences centers. These centers are tertiary care referral centers that receive the most challenging clinical patients. Trauma, pathology, infections, and reconstruction dilemmas are dealt with on a weekly basis. This affords faculty to have a wide scope of practice within our specialty. One of the factors that attracts potential faculty is the ability to have major surgery as a significant portion of their practice.[7] Academic oral and maxillofacial surgery faculty are part of a team and thus gain fulfillment from the collegial interaction with our colleagues. Cases can include a multidisciplinary dental rehabilitation patient with our orthodontic and prosthodontic colleagues; a trauma patient treated with our general surgeons, neurosurgeons, and orthopedic surgeons; or a complex medical patient undergoing organ transplant that requires extraction of teeth before the transplant procedure. Providing clinical care for these extremely complex patients demands teamwork from the treating doctors but is very rewarding.

Many of the oral and maxillofacial training programs are based in dental schools. The presence of strong oral and maxillofacial surgery faculty provides the unique opportunity to future practicing dentists as to the scope of our specialty. The current dental students are our future referral base.

How oral and maxillofacial surgery faculty interacts with dental students and other graduate dental residents can have a profound impact on future relationships. Another important charge to academic oral and maxillofacial surgery faculty is to foster and nurture good relationships within the dental schools.

Many oral and maxillofacial surgery training programs are hospital based. OMS faculty has the unique opportunity to interact with our medical colleagues in providing quality patient care. OMS training programs at academic health care centers frequently treat patients at a level 1 trauma center. Providing care of the injured patient is one of the basic provisions of surgical care. Oral and maxillofacial surgeons have a long history of providing excellent care of maxillofacial injuries at our trauma centers. OMS faculty lead the team of residents in providing care for some of the most critically injured patients the region. Providing care to the traumatized patient is a huge benefit the people of your community or region. The American College of Surgeons, the main organization involved in trauma center verification, has recognized oral and maxillofacial surgeons for their contribution in care of the injured patient.

All OMS training programs, whether dental school based, hospital based, or free-standing facilities, have the opportunity to interact with our medical colleagues on a very close basis. This interaction allows OMS faculty to educate our medical colleagues about our dental specialty. Many aspects of oral and maxillofacial surgery can be considered medical, such as trauma, pathology, reconstruction, cleft lip and palate, obstructive sleep apnea, and TMJ surgery.

Educating our medical colleagues as to the scope of our specialty can provide a source for additional patient referrals and strengthen the position of OMS within the health care system.

For example, the University of Louisville offers a 6-year double degree OMS training program. OMS residents spend 2 years in medical school and interact with medical students. The medical students and faculty know and understand what the specialty of oral and maxillofacial surgery entails. During the general surgery year, OMS residents rotate on other medical/surgical subspecialties and further advance the knowledge about our specialty. Just as important during OMS training is the resident interaction with our other dental specialties. This relationship solidifies future referral patterns and educates our dental colleagues

as to the scope of oral and maxillofacial surgery. The OMS faculty is the driving force behind this complex interaction of activities that forges the relationship of oral and maxillofacial surgery with both dental and medical colleagues.

Research is another important task that is largely delegated to the academic OMS faculty. Research is vital to advance any profession and is essential in the field of health care.[8] Much of the clinical care delivered today is based on research and named evidence-based care. The surgeon's practice in the future will surely change in ways based on the best available research.

Research simply asks "Why?" or "Is there a better way?" All accredited OMS training programs must engage in scholarly activities. Scholarly activity can range from having a fully funded research laboratory with PhD investigators to poster presentations at the local dental meeting showcasing OMS departmental activities. Either way, OMS training programs are advancing the science of the specialty of oral and maxillofacial surgery. The OMS faculty is again the driving force behind the research activities. In reviewing journals covering the specialty of oral and maxillofacial surgery, the majority of published articles come from academic institutions. OMS faculty also attempt to nurture the inquisitive quality within each resident in the hope that this will continue in the future. OMS faculty constantly motivates the residents to be the best surgeons that they can be. This is one way we can grow the next generation of academic OMS faculty.

According to the American Association of Oral and Maxillofacial Surgeons (AAOMS) website, the following statistics were obtained for 2014-2015:

Oral and Maxillofacial Surgery Training Program Statistics

Accredited OMS training programs 101
Single-degree programs 55
Double-degree programs 46
Programs offering both single- and double-degree training 19

Oral and Maxillofacial Surgery Training Program Locations

Hospital-based training programs 43
Dental school based training programs 38
Medical school based training programs 10
Federal services training programs 10

There are approximately 250 oral and maxillofacial surgery residents starting an accredited program each year.

One can easily ascertain that the diversity of academic OMS faculty must be significant to fulfill all of the needs of the OMS residents. There are common aspects of all OMS training that must be covered in every accredited OMS training program. However, many sites offer training expertise in expanded-scope oral and maxillofacial surgery. Head and neck oncology, pediatric craniofacial and cleft lip/palate, and cosmetic surgery are being advanced by OMS academic faculty at their respective institutions. Dental implantology is a rapidly growing field that is predicted to grow steadily in future years. Dental implants have given our patients options that were not available in the past. The acceptance of dental implants by patients is constantly increasing as the benefits of implant treatment are realized. Fellowships in these advanced areas are available to OMS residents who want to further pursue these areas of interest.

Despite the advantages of an academic OMS career, there is a constant shortage of OMS academic faculty. Inadequate faculty numbers is a common infraction at OMS site visits, which occur every 5 years. Many academic programs have vacant faculty positions and are currently looking for qualified OMS faculty members. Only a small number of graduating residents pursue an academic career. Academic OMS faculty, once on board at an institution, often leave for an alternative career pathway, which often is the private practice sector. Recruitment and retention are the major problems for qualified academic OMS faculty.[9]

There are many potential reasons for this disparity. Financial disparity is at the top of the list. Academic positions generally pay less than private practice opportunities. Graduating OMS residents often have a debt load in the hundreds of thousands of dollars.[5] This debt load may be increased if a double-degree program was completed where medical school tuition was required.

Graduating OMS residents may not be able to meet their loan payments and living expenses based on an academic salary. The salary disparity in conjunction with increasing student/resident debt has profound implications for all aspects of dentistry, both academic and the private sector.

Another disadvantage of the academic OMS is the loss of control of the practice. Many OMSs are fiercely independent and choose a career where they have greater control of the practice. The surgeons have devoted a significant portion of their lives and considerable expense to gain the goal of being an oral and maxillofacial surgeon. In return, the surgeon wants to "call the shots."

Private practice surgeons have the option of controlling practice hours, days of the week, participation in insurance plans, hiring and firing of staff, and employee compensation, along with other practice variables. In the academic realm, many of the decisions are made by the institution with little or no input from the surgeon.

Additionally, there appear to be declining resources for academic institutions. State-supported institutions have felt a continuous decrease in financial support to the sponsoring institutions, which trickles down to the dental school or medical school program. Federally funded research is declining and more difficult to obtain. The patient care workload increases along with the pressure to generate more clinical income to offset the losses from decreasing institutional support. The net effect is less time for research and scholarly activities. Many academic OMS faculty are feeling the squeeze and are disappointed and frustrated.

The future still remains very bright for academic oral and maxillofacial surgery. There is a dedicated core of OMS faculty. The faculty meets yearly at the AAOMS annual meeting to discuss problems and continually search for solutions. The OMS Faculty Section has a governing body and bylaws to function adequately in the complex milieu of academic health care. The OMS faculty section is a forum

• BOX 3-1 Advantages and Disadvantages of a Career in Academic Oral and Maxillofacial Surgery

Advantages

Stimulating environment (constant learning and education)
Wide scope of practice (major and minor surgery)
Opportunity to train the next generation of oral and maxillofacial surgeons
Part of a team with dental and medical colleagues
Opportunity for research and scholarly activities

Disadvantages

Generally lower pay than private sector
Giving up control of the clinical practice
Increasing financial pressures to generate clinical income to offset declining institutional support

for all academic educators, both graduate and undergraduate. The OMS Faculty Section communicates well with AAOMS and other stakeholders to help all involved understand OMS faculty challenges. There has been tangible change for the better. Academic OMS faculty salaries have been increasing and the gap with private practice salaries is closing.

Faculty Educators Development Awards (FEDAs) have been established to entice younger faculty to academic careers by decreasing the financial constraints. Financial incentives are paid to promising young OMS faculty who stay in academics. The Faculty Section has pooled resources to create a National Curriculum Database (NCD). Faculty were asked to contribute lectures in an area of their interest or expertise to a national databank. Accredited OMS training programs have access to this lecture bank to facilitate adequate training of their residents in areas where the faculty may not have expertise. Academic OMS faculty are sharing the resources for the betterment of all, rather than acting as lone entities. The specialty of oral and maxillofacial surgery has placed a tremendous responsibility on the academic OMS faculty, the charge of educating the next generation of oral and maxillofacial surgeons. As in the past, the academic OMS faculty have always risen to the challenge and performed. This dedication to the profession will continue into the future (Box 3-1).

Surgeon-Scientist Oral and Maxillofacial Surgery Careers

Janice S. Lee, Martha J. Somerman, Andrea B. Burke

Progress in medicine and dentistry relies completely on research to advance knowledge on health and disease and to improve methods of prevention, diagnosis, and treatment of diseases. Oral and maxillofacial surgery (OMS) is no exception. A research career in OMS can be extremely rewarding; it is a career path in which one can truly delve into questions and problems with widespread impact that can change the course of treatment and improve patient outcomes.

Most surgeon-scientists are in academia and affiliated with a university. However, there are career opportunities for surgeon-scientists in government institutes, such as the National Institutes of Health (NIH), U.S. Food and Drug Administration (FDA), and Centers for Disease Control and Prevention (CDC). The Department of Veterans Affairs (VA), along with the United States Army, Navy, and Air Force, also provide opportunities for research careers for oral and maxillofacial surgeons.[10] National organizations that also have research careers include the ADA Foundation Dr. Anthony Volpe Research Center (located on the campus of the National Institute of Standards and Technology). Other opportunities may be found in industry, where private-sector pharmaceutical, biotechnology, and medical device companies provide approximately 58% of U.S. biomedical research and development (R&D) funding.[11-13]

Research in OMS can include clinical, translational/applied, and basic science. Clinical research typically includes studies on patient outcomes and clinical trials, new methods and technologies, retrospective reviews, phenotype to genotype, and population-based or epidemiologic studies. Evidence-based medicine, particularly randomized clinical trials, remains the most valued method of research.[14] Translational research includes clinical, preclinical, or animal studies that provide an iterative loop from bench (laboratory/basic research) to bedside (clinical application) and back. The intent is to accelerate the transition from basic research to human application. On the other hand, knowledge gained from clinical research may highlight the need to address fundamental unknowns through basic research in order to improve clinical outcomes or address unexpected outcomes. Basic research focuses primarily on understanding the mechanisms at the cellular and molecular level that control cells, tissues, and organs in states of health and disease. Other categories may include educational research, health policy research, and biomedical informatics (big data) research. Each of these forms of research can provide substantial knowledge and progress in OMS.

The foundation for a successful career in research involves strong training in research and good mentoring. Ideally, the earlier the exposure to research and the earlier determination that research is a true interest for an individual, the more time and guidance a person may have to delineate specific areas of research interest. Students in high school and college now have biomedical programs that introduce them to careers in biomedical research and medicine/dentistry. Additional training programs that are offered by OMS departments and dental/medical schools should be explored to solidify an interest in research. The NIH and National Institute of Dental and Craniofacial Research (NIDCR) have several levels of training programs on campus (Bethesda, MD) through the Division of Intramural Research. This includes the Medical Research Scholars Program (a 1-year program for medical or dental students),

the Dental Summer Research Internship, the NIDCR Clinical Research Fellowship (for those who have obtained a DDS/DMD and have demonstrated a research background), and the standard research postdoctoral fellowships (www.nidcr.nih.gov/careersandtraining/Fellowships/). A surgeon-scientist fellowship at the NIDCR (for those who have been accepted into an OMS program or completed an OMS program with evidence of a research background) is being explored.

Previous studies have shown that resident research experience is correlated with a greater likelihood of pursuing an academic medical career.[15] Currently, there are few OMS programs that provide the full span of research; thus it requires a proactive effort, resourcefulness, multiple contacts, and networking to identify an OMS program that may foster future surgeon-scientists. Research is not done in isolation, and going beyond OMS departments may be necessary. Team science and collaborations with multiple researchers have made great strides in bridging the gap from basic science to application. Examples include (1) craniofacial tissue engineering that involves material scientists, cell biologists, bioengineers, and surgeons; (2) head and neck cancer therapies that involve immunologists, hematologist-oncologists, cell biologists, and surgeons; (3) craniofacial anomaly therapies that involve developmental biologists, biochemists, geneticists, bioinformaticians, and surgeons; and (4) TMJ therapies that involve pain specialists, neuroscientists, bioengineers, pharmacologists, cell biologists, immunologists, and surgeons.

A common question is the necessity of an additional degree, such as a master's or PhD. The NIH R01 funding data suggests that PhDs and MD-PhDs receive greater funding than MD or DDS/DMD awardees.[16] However, the type of research and the level of necessary funding should dictate a person's pursuit of additional degrees. Because of the time that these degrees add to an OMS residency, it behooves candidates to discuss these career options with mentors, associate deans for research, and OMS program directors. The length of time required to pursue these degrees, however, is not significantly different from other surgical specialties that train surgeon-scientists.

A distinguishing feature of surgeon-scientists, compared to their clinical colleagues, is the pursuit of research funding. In a climate where biomedical funding has not increased, as in the doubling period of the NIH, obtaining a grant of any kind has become extremely competitive. Grant-writing workshops, grant management teams, and solid research mentoring remain critical to the success of the surgeon-scientist.

The NIH and NIDCR have various grant mechanisms that may assist a surgeon-scientist at different levels of his or her career: pre- or postdoctoral fellow, career-development, new-investigator, and established scientist awards. Predoctoral fellow awards (F) provide support for those interested in a dual degree (DDS/DMD-PhD). Postdoctoral fellow awards (F) provide support for trainees at academic institutions to broaden their scientific background. Mentored or career development awards (K) provide clinician-scientists with the opportunity to continue training while pursuing independent research. Research project grants (R) are for investigator-initiated research studies, available for new investigators and established surgeon-scientists. The NIH also provides a Loan Repayment Program (www.lrp.nih.gov) to clinical investigators engaged in research.

The OMS Foundation provides research support grants and student research training awards (http://omsfoundation.org). And in an effort to support young academic surgeons, the American Association of Oral and Maxillofacial Surgeons (AAOMS) created the Faculty Educator Development Award (FEDA) to promote academic recruitment and retention. We have included a list of additional funding agencies to be considered.

The maintenance of integrity and professional conduct in research is of utmost importance. The surgeon-scientist must be prepared to understand conflict of interest in research, particularly in funding and funding sources. Conflict of interest has been defined as "a set of conditions in which professional judgment concerning a primary interest (such as a patient's welfare or the validity of research) tends to be unduly influenced by a secondary interest (such as financial gain)."[17] Additionally, the surgeon-scientist must have a thorough understanding of their institutional review board (IRB) in order to conduct research on human subjects, whether it is a survey, chart review, or interventional study. The function of the IRB is to protect human subjects throughout the course of a research project. These boards were formed in response to the research abuse of humans such as the Tuskegee Syphilis Study. The aftermath of such egregious violation of human protection includes informed consent, the 1979 Belmont Report, and the Office of Human Research Protections.[15]

Research in OMS can change the way we practice by determining the etiology of diseases, developing novel treatments, enhancing standards of care, and creating new health policies. The opportunities for a research career in oral and maxillofacial surgery are vast and can provide a career filled with variety, flexibility, and satisfaction.

Key points:

1. Research is critical to OMS clinical practice.
2. Start early in exploring your research interest and cast a broad net, even beyond OMS.
3. Mentors are important.
4. Research integrity includes understanding conflict of interest and human subject protections.

Funding Opportunities

- NIH/NIDCR (F-awards, K-awards, R-awards—www.nidcr.nih.gov/grantsandfunding/Types_of_Grants_Awarded_by_NIDCR/FundingMechanisms/Funding%20Mechanisms.htm)
- OMS Foundation (omsfoundation.org)
- AAOMS (www.aaoms.org)
- AO CMF (https://aocmf.aofoundation.org)
- American College of Oral and Maxillofacial Surgeons Foundation (www.acoms.org)

- American Dental Education Association (www.adea.org)
- American Cleft Palate-Craniofacial Association (www.acpa-cpf.org)
- Osteo Science Foundation (www.osteoscience.org)
- Defense Advanced Research Projects Agency (DARPA, www.darpa.mil)
- University funds/awards
- Patient-advocacy foundations (e.g., March of Dimes, www.marchofdimes.org)

Dental Support Organizations

Martin E. Eichner

Many recent oral and maxillofacial surgery residents graduate from their training programs with a tremendous debt load. Student loan balances from undergraduate, dental school, and in some cases medical school tuitions are commonly in the hundreds of thousands of dollars. This makes it very difficult to open a new practice, buy an existing practice, or buy in as a partner/shareholder to an existing practice. Paying off debt may add stress to the challenge of practicing oral and maxillofacial surgery after residency. Many new OMS practitioners would like to start a family and purchase a house, but are worried about cash flow immediately out of residency or fellowship. Dental Support Organizations (DSOs) give the new OMS an alternative to private practice oral and maxillofacial surgery.[18]

The traditional model of OMS has the doctor responsible not only for the clinical aspect of taking care of patients in the office and hospital, but the business aspect of running the practice. The doctor must set fees, collect fees, hire staff, fire staff, manage payroll, keep an eye on the overhead, be up to date with state and federal laws and regulations, buy supplies, maintain equipment, pay rent, sign insurance contracts, file insurance claims, market the practice, and run study groups.

Many new practitioners are overwhelmed by the business aspect of private practice, and want to concentrate on patient care and becoming proficient in all aspects of OMS.

DSOs exist in many forms. The ADSO, or Association of Dental Support Organizations, is a national organization that enables DSOs to collaborate and improve the model. When an OMS joins a DSO, he or she is able to concentrate on patient care. The DSO conducts the business aspect of the practice. The doctor receives a salary and the DSO employs all members of the office team. The DSO also manages all the aspects of private practice noted earlier. A DSO may claim that the OMS will be more productive because he or she is freed from running the business aspect of the practice. There are claims that more oral and maxillofacial surgery will be performed, which will address issues of access to care. The DSO may negotiate with retailers for discounted rates on supplies because they are able to buy larger quantities and in bulk for multiple locations. The DSO is able to market to member dentists on a larger scale as opposed to what individual doctors may be able to do on their own. DSOs also run continuing education programs for the doctors, and are able to monitor outcomes and care delivered to patients.

The ADSO member DSOs agree that they should not interfere with clinical judgment and treatment planning. All oral and maxillofacial surgery treatment planning is based on the doctor's clinical judgment, and all surgery is performed based on his or her own decision making.

This model of practice of OMS is rapidly changing, evolving, and growing. Where it will be in 10 to 20 years is unknown. The DSO is an alternative to private practice for OMS practitioners who want to free themselves from running the business side of an OMS practice. There may be more time for clinical growth and less time spent on other tasks.

Conclusion

David A. Bitonti

The traditional private practice of oral and maxillofacial surgery is the more often chosen career path following residency training. The goal of this chapter was to provide background information for the OMS completing residency training, as well as OMSs seeking a career change or transition. All of the mentioned career opportunities and paths provide an avenue for a rewarding practice in oral and maxillofacial surgery, regardless of the career stage. In certain career paths, there may be specific age restrictions and physical requirements; however, points of contact and clarifying information are easily readily available to the interested OMS. There are varying ways to give back and to contribute to the specialty that is our calling. Take advantage of researching and becoming informed about all career opportunities before making a final decision on a career path, and know that other, equally rewarding opportunities exist should a career path change be a part of the future.

References

1. Passo SA, King JE: Highlights in the history of Army dentistry, *US Army Med Dept J* 8–25, 2011. Jan-Mar.
2. Hyson JH, Whitehorne JWA, Greenwood JT: *A history of dentistry in the United States Army to World War II*, Washington, DC, 2008, Borden Institute.
3. Will MJ, Goksel T, Stone CS, et al.: Oral and maxillofacial injuries experienced in support of Operation Iraqi Freedom I and II, *Oral Maxillofac Surg Clin N Am* 17(3):331–338, 2005.
4. Chapter 8: Dental Corps. In *Department of the Army pamphlet 600-4*, Washington, DC, 2007, Army Medical Department Officer Development and Career Management Headquarters, pp 37–41.
5. Bitonti DA, Steinle MA, Powers DB, et al.: Oral and maxillofacial surgery careers in the military and Department of Veterans Affairs, *Oral Maxillofac Surg Clin N Am* 20(1):17–26, 2008.
6. Laskin DM: Factors influencing oral and maxillofacial surgeons to select or leave an academic career, *J Oral Maxillofac Surg* 52:174–176, 1994.

7. Aziz SR, Ziccardi VB, Janal M, Ramnauth S: Career perceptions of young academic oral and maxillofacial surgeons, *J Oral Maxillofac Surg* 65(4):762–765, 2007.
8. Walker TW, Cascarini L, Brennan PA: Educational paper: research in oral and maxillofacial surgery, *Br J Oral Maxillofac Surg* 48(8):629–632, 2010.
9. Lanzon J, Edwards SP, Inglehart MR: Choosing academia versus private practice: factors affecting oral and maxillofacial surgery residents' career choices, *J Oral Maxillofac Surg* 70(7):1751–1761, 2012.
10. Moses H 3rd, Dorsey ER, Matheson DH, Thier SO: Financial anatomy of biomedical research, *JAMA* 294:1333, 2005.
11. Dorsey ER, de Roulet J, Thompson JP, et al.: Funding of US biomedical research, 2003-2008, *JAMA* 303:137, 2010.
12. Olson S, Merrill SA, et al.: *Measuring the impacts of federal investments in research: a workshop summary*, Washington, DC, 2011, National Academies Press.
13. Lee JS: In search of the highest quality: levels of evidence in oral and maxillofacial surgery, *J Oral Maxillofac Surg* 72:2102, 2014.
14. Stewart RD, Doyle J, Lollis SS, Stone MD: Surgical resident research in New England, *Arch Surg* 135:439, 2000.
15. Feldman AM: The National Institutes of Health Physician-Scientist Workforce Working Group report: a roadmap for preserving the physician-scientist, *Clin Transl Sci* 7:289, 2014.
16. Thompson DF: Understanding financial conflicts of interest, *N Engl J Med* 329:573, 1993.
17. United States: *National Commission for the Protection of Human Subjects of Biomedical and Behavioral Research: The Belmont report: ethical principles and guidelines for the protection of human subjects of research*, Bethesda, MD, 1978, The Commission.
18. Management perspective on practice (special issue), *J Am Coll Dent* 82(1), 2015.

4

OMS Practice Transition: Decisions for the New Surgeon and the Established Surgeon

R. LYNN WHITE

Introduction

Probably the two most important decisions in the private practice life of an oral and maxillofacial surgeon (OMS) concerns how, when, and where a new surgeon enters into practice, then conversely, how and when a senior surgeon exits an established practice. These are also two of the decisions with the most important effect on personal finance and lifestyle issues. Both decisions should be the result of proactive preparation and careful planning.

As a backdrop for this discussion, we should look at some of the basic demographics of our specialty. The "baby boomer" generation is an expanding cohort within the OMS ranks. This generation represents the largest portion of established practitioners and the generation that might now be contemplating retirement and/or a significant reduction in practice hours. This subset group will be looking toward bringing a new surgeon into these respective practices. Roughly one half of the members of American Association of Oral and Maxillofacial Surgeons (AAOMS) are in solo practice, with another ~20% in a two-surgeon practice. The balance is spread over increasingly larger groups, although groups with more than six surgeons represent only ~5% of the total.[1]

The scenario of an expanding number of older-generation surgeons compared to the relatively small and static number of graduating OMS residents sets up an increasingly disproportionate supply-and-demand situation. Simply stated, the supply of graduating residents may not be able to meet the demand of established surgeons to bring in a new surgeon and bolster the needs of their existing practices. Ultimately, this will result in increased competition among existing practices to attract new surgeons and induce them to come on board.

The bottom line to consider is how best to plan for a practice transition that is fair, equitable, and transparent in its negotiations, structure, and ultimate agreed-upon settlement. The expectations and perspectives of all parties, regardless of the arrangement (associateship, partnership/buy in, buy out), need to be identified and understood.

What follows are guidelines for both the graduating resident and the established practitioner. They are written in the first and second person, so as to directly and personally address the issues of entrance planning considerations for the new surgeon(s) and exit planning strategies for the senior surgeon(s).

Entrance Planning: Considerations for the New Graduate Surgeon

Now What?

As some of you approach the last 2 years of your OMS residency, you should begin to assess how and where you want to begin your career in what I truly consider to be the best specialty in all of health care. Some of you will contemplate and hopefully pursue an academic faculty appointment. As I did when I was on the AAOMS Board of Trustees, I would heartily encourage you to do so. A small portion of you might consider a career in a branch of the federal services. Most of you, however, will pursue a career as a private practitioner. In doing so, you will have the following basic options:

1. Starting your own (solo) practice
2. Joining an existing solo practitioner
3. Joining an existing two surgeon practice

4. Joining an existing (larger) group practice
5. Signing on with a Dental Maintenance Service Organization (DMSO)
6. No commitment, only associate status with an existing practice

In your consideration of these choices, there are many questions (factors) that should go into your decision, many of which are obvious, and some of which may not be. I feel the most pertinent of these to be:

1. In what part of the country would you prefer to locate?
2. If you are married (or are about to be), where would your spouse want to live?
3. If you have children, where are the areas that are more "kid friendly" and have the best educational support systems?
4. What is your debt load, and what is the best situation to retire that debt?
5. Do you want to have solo responsibility for your practice?
6. Would you prefer to have a mentor and senior surgeon who can help you and support the practice while you transition into a more responsible role?
7. Do you only want to be an associate with no equity in a practice?
8. Do you want to practice the full scope of oral and maxillofacial surgery?

My commentary about the listed questions (and admittedly, there are more that could be posed) is that most are distinctly personal. I do, however, have a definitive comment about the last one. Given the horizon for health care delivery and health care economics, it is incumbent on the young oral and maxillofacial surgeon to establish a practice that embraces all aspects of our contemporary specialty. Granted, there are varied degrees of compensation for different procedures, especially given the expenditure of time and effort by the surgeon. Going forward, however, there will be significant competition for the "teeth and titanium" dollar as well as a drop off in the level of compensation for these procedures by third-party insurers. It is vital, therefore, that you remain a comprehensive and flexible practitioner as you begin your professional career.

Planting the Seeds

To have optimal success in private practice, you should plant positive seeds at the beginning—seeds that will germinate and grow into something of which you can be proud and which will go on to support you and your family well. Let's go back to the basic options that were mentioned earlier and examine each one with appropriate overview. They are as follows:

1. **Starting your own practice:** To borrow from Dickens, this can be "the best of times, and the worst of times." On the positive side, you will be your own boss and will have complete control of your staff. This gives you the opportunity to create a practice that reflects your personal and professional ideals. There can be significant upside if you have low debt, and if you can get your practice facility built out (before you arrive to practice), your staff selected, and your financing arranged to be reasonably loaded to allow for sequential payback. If, however, you enter practice with a significant debt load, you could very well find the stress of servicing past, present, and future debt to be quite burdensome. It is especially problematic to generate practice revenue flow while at the same time marketing your practice through face-to-face visitation with your referring doctors and their staffs. Add to this the responsibility of taking hospital call at various hours, and the need to "juggle all the balls in the air" becomes quite a task.
2. **Joining an existing solo practitioner:** This will probably be the most common scenario for someone entering into the private practice market of 2015–2018. The demographics of all regions of the country suggest that most of the baby boomer generation OMSs are in solo practice. Logic dictates that this demographic group will be the one that will present the greatest opportunity for flexibility and simplicity when you evaluate and negotiate becoming part of an existing practice. To me, the benefits of associating with an established practitioner far outweigh any downside possibilities, provided you are diligent in your selection process. The senior surgeon has already developed a referral base, has established a relationship and track record with a financing institution, and has a staff in place. This established practice will allow you the time to focus on developing your own referral base (which will probably include some of the existing referring doctors) and developing a relationship with your staff members (at least some of whom you might share with the senior surgeon). With the practice having an established banking relationship, you will get more favorable rates for your existing debt repayment, and for your anticipated buy-in to or buy-out of the practice. I will go into options and associated details for buying into, or buying out, a practice in a subsequent section.
3. **Joining an existing two-surgeon practice:** The characteristics of this choice will be similar to joining a solo practice, with the difference that you will be dealing with two individuals, with potentially different perspectives and personalities. Most probably, especially if the practice has been together for several years, there will be coherence and a shared practice philosophy between the partners. Typically, but not always, there is an age differential, with the senior surgeon considering retirement. Again, I will go into buy-in and buy-out options in a following section.
4. **Joining an existing (larger) group practice:** The dynamics and logistics of this scenario are more complex; however, many of these large groups have an established protocol for bringing a new surgeon into the group. Typically, these groups are in larger cities and have more than one practice location, often multiple locations.

5. **Joining a DMSO:** This primarily benefits you if you are unsure of where and how you want to practice and if you are willing to follow the dictates and practice philosophy of a large corporation.
6. **Practicing as an associate only:** Somewhat similar to the DMSO situation, this allows for some freedom and flexibility if you are not sure of where and how you want to practice. The upside is, if you feel this practice is probably in the geographic area where you want to locate, you can have the experience of living there without any financial commitments. There could also be an evolution of status, whereby you might be given an opportunity to buy into the practice at a later time. The downside is that the owner(s) of the practice may not want to offer you equity participation and would have no obligation to do so.

Closely Examining the Options

The previous sections gave you an overview of the various options you would have in the private practice arena. Most of you will not start up your own practice, but will instead be looking to become part of an existing practice, or buying one out. As mentioned before, there are quite a few benefits of joining an established practitioner or practitioners. I feel that it is important during this process to enlist the services of a practice transition specialist, especially one who is versed in the Objectives Based Practice Transition process. At some point, you probably want to get input from an attorney and accountant for review of documents. So, let's look more closely at the practice options and their ramifications.

1. **Associateship only (no equity):** There are a variety of compensation models:
   - straight salary
   - hybrid model with a (lower) base salary and a percentage of collections
   - only a percentage of collections or production

   Caveat: You should not enter into an associateship without a written employment agreement, which should at least stipulate the method of compensation along with the length of employment.
2. **Associateship leading to partnership via buy-in:** Even though this might be the most common approach to entering and eventually taking part in a practice, there are a variety of models through which this can be accomplished. To begin with, there is the "sweat equity" approach with a minimal salary for the associate, and a deferred partial buy-in (the percentage of which may be defined by how long the senior surgeon plans to continue practicing). It is important for both parties to discuss the method of compensation for the new associate—or, stated another way, the division of practice income for both the associating surgeon and the established surgeon(s). There are two remaining options, both of which have to do with the buy-out sale of the practice of a senior surgeon who has determined a timeline for exiting the practice, through either partial or complete retirement. These two options are discussed next.
3. **Pre-sale buy-out (with the senior surgeon staying in the practice):** This is an option where the established surgeon, moving toward retirement, sells the practice at the time the buyer/young surgeon begins his career. The financing of the practice buy-out is usually arranged through a banking institution, although the seller/established surgeon may elect, or be asked, to provide some degree of the financing. The ideal time to have the retiring surgeon stay in the practice is 1 to 4 years, most often on a part-time basis. This arrangement allows for an established cash flow from day 1, established staff support, and an established referral base. This also establishes a structured transition for eventual control of the practice by the younger surgeon. The essential components of a practice sale of this type are:
   - a completely transparent purchase agreement
   - independent advice from an attorney and accountant
   - guidance by a practice transition specialist
   - a detailed practice valuation/appraisal
   - a definitive non-compete/restrictive covenant agreement
   - a policy for division of income
4. **Deferred or incremental sale (established surgeon in practice with defined timeline):** This model for buying out the practice from the established surgeon structures the sale in deferred, or incremental, fashion over a defined period of time. There are several options for doing this. However, because the majority of established practices are incorporated, let's use the following example:
   - Dr. Buyer (young surgeon) creates a corporate entity (PC or Subchapter S), as does Dr. Seller (established surgeon) if he/she does not have one
   - In turn, an LLC is created; each corporation is a "member" of the LLC
   - All income goes into the LLC and all expenses are paid by the LLC
   - Compensation goes to each corporation based on the policy established by the purchase agreement (production/collections, equal distribution, etc.)
   - Dr. Buyer purchases 33.33% of the practice assets (tangible and intangible) at the sales closing (beginning of contract)
   - Dr. Buyer purchases another 33.33% after 2 years
   - Dr. Buyer then purchases the remaining 33.34% after 4 years of his practice life, which completes his contractual obligation. Dr. Seller can at this time completely retire from practice, or stay on if agreed to by Dr. Buyer, who at that time is the sole "Dr. Owner."

   The foregoing is only one example of several ways in which both the practice, and control of the practice, can transition from the established surgeon to the young surgeon/buyer. Although I think it is important that you consider having a practice transition specialist advise you with any practice arrangement you are considering, it is especially essential to do so with a

deferred or incremental sale. Again, as in the previous model, it is extremely important that you have:
- a completely transparent purchase agreement
- a definitive non-compete/restrictive covenant
- independent legal and accounting advice
- a detailed practice appraisal
- a clearly defined policy for division of income

5. **Walk-away sale (established surgeon retires upon sale of practice):** This is a total buy-out with the seller giving you total control of the practice from day 1. Having said this, I feel it is important to have him or her stay around long enough to acquaint you with whichever staff members elect to stay on, and whomever you wish to keep. It is also important for the seller to introduce you to his/her referring doctors, either individually or with a welcoming reception for those doctors, wives, and perhaps staffs. In the case of a walk-away sale, it is imperative to have a totally transparent purchase agreement. It is similarly imperative to engage an attorney and accountant, and advisable to have a practice transition specialist. Two other things are essential:
   - a detailed and comprehensive practice appraisal
   - a restrictive/non-compete agreement

With any of the listed buy-out or sales models, you should have a pro forma whereby you can see how, over a prescribed period of time (usually 6-8 years), you can retire the debt of the practice purchase while also producing a profit for income during this period. While the purchase of a practice may seem daunting, it is my belief that it is ultimately a very good economic decision for you to make.

Considering the Details of a Good Outcome

Regardless of the model chosen—associateship, partial buy-in of a partnership, or a buy-out of a practice—it is important to know the details and have a good understanding of the practice valuation and the employment, buy-in, or purchase, agreements to achieve a good outcome that is fair and equitable to all parties. I feel that these arrangements are all well facilitated by a practice transition specialist who is versed in Objectives Based Practice Transitions (OBT). So, what is that? OBT is a process that aligns the objectives and goals of both the young and established surgeons to achieve the best possible professional, personal, and financial outcomes. Success is accomplished when *both* surgeons win to a degree that could not have been accomplished without this practice transition process. Furthermore, I feel that although there is a clear fiduciary responsibility toward the established surgeon who is paying for the practice transition, it is also very important to be cognizant of, and responsive to, the needs of the young surgeon.

First, and this applies most to a practice buy-out and also to a buy-in, close attention must be given to the practice valuation and the methods by which it is achieved. There are standard procedures for appraisal of a practice, although there can be some variance of emphasis on certain aspects of any given practice and thus slight differences in the bottom-line valuation. The standard appraisal methods are as follows:

1. **The asset approach:** This needs to be detailed, consider depreciation, and be performed by an objective, experienced appraiser. Both tangible assets (real estate, building, equipment, supplies, furniture) and intangible assets (goodwill, restrictive covenant, practice culture) need to be considered.
2. **The income approach:** This should be a clear, reproducible, and reasonably precise valuation. It is derived by reviewing the practice accountant's provision of profit and loss statements along with tax returns of the present year and preceding 2 or 3 years. The present value of practice earnings can be computed by using currently available loan terms and interest rates.
3. **The market approach:** This will consider several factors such as demographics, traffic volume, and population trends. The practice history and patient volume should also be considered, as well as what management systems are in place, and finally, staff qualifications and their tenure in the practice.

After an objective review of the practice valuation, there needs to be subjective evaluation of the relationship issues between you and the individual(s) with whom you are associating or buying into, or buying out, their practice. There should be a philosophy of abundance over that of a zero-sum game; it is in everyone's best interest that each surgeon be successful. There should be excellent communication between both parties to prevent a lack of clarity, lack of unified focus, and any misinterpretation of intentions. There should also be clearly defined expectations so as to avoid any frustrations or any seeds of distrust during the negotiations of the practice transition. I feel these relationship issues are best facilitated by comprehensive needs analyses for both surgeons, performed and evaluated by the practice transition consultant. Further subjective evaluation should involve the practice culture. Was it created by, and is it characterized by, design or default? What is the practice culture's core ideology, its values, and its purpose? Are these consistent with your values, and will you have the ability to modify or change the culture, should you choose to do so?

In summary, let me present some brief comments to facilitate your focus as you contemplate your career choices:

1. Begin the process with the end goals in mind.
2. Use whatever legitimate resources are available to you.
3. Be respectful and understanding regarding the established surgeon's perspective.
4. Be reasonable and realistic with your own expectations.
5. Establish a core ideology early to support your decisions.
6. Identify and make use of your individual strengths as you integrate into your evolving practice.

I wish you well as you transition your life from residency to the practice of oral and maxillofacial surgery and join the ranks of the fine membership of the AAOMS.

Exit Planning: Strategic Considerations for the Established Senior Surgeon

Now What (and When)?

In speaking with a number of my peers who have been in the private practice of oral and maxillofacial surgery for many years, I hear common themes. Anecdotally expressed, they are:

- "I am getting more fatigued, physically and psychologically, with my practice."
- "I am working as hard as I feel I want to work."
- "I used to practice the full scope of oral and maxillofacial surgery procedures, but now have mainly an office procedure based practice."
- "I have made good money from my practice and I feel I am comfortable financially."
- "I would probably like to practice part time for another 1 to 3 years, but if someone buys my practice and wants complete autonomy, I would sure consider walking away."

I have received other input, but the above anecdotes represent more than 80% of the mindset of our baby boomer colleagues, and all of them are understandable. For those of you who have been in practice multiple years: what you do (and I have done) is hard work! Standing around an operating table or a dental chair for 6 to 10 hours/day is taxing, as is the demand that you do your best to attain an excellent surgical outcome. Add to that the stress of administering parenteral sedation and/or general anesthesia in the office, and you have the elements of a practice that can take its toll over a number of years, potentially leading to professional burnout.

The aforementioned scenarios can be mitigated by a proactive mindset to consider the possibilities for exiting clinical practice and doing so before burnout even becomes an issue. A well-developed exit strategy, with adequate time for implementation, is the best measure to ensure that you have the appropriate perspective for dealing with all the potentialities of practice transition. It will also help to ensure that you receive the optimal valuation for the practice that you have worked so hard to establish. It is essential to begin the exit planning process early enough that a strategic plan can be implemented with adequate time to be effective. I recommend a 2- or 3-year window as the optimum time frame for this process.

Planting the Seeds

Taking a proactive approach, the established surgeon(s) will have choices and options to consider. Moving forward toward practice transition, these considerations have to do with the logistics of the practice:

- solo practitioner versus small group versus large group
- single office site versus multiple office sites
- demographics of the patient population
- physical condition of the office
- quality and stability of the staff
- status of the equipment; is it state of the art (surgical, anesthetic/monitoring, radiographic, IT hardware/software)
- production, revenue stream, third-party penetration (including Medicaid), practice expense overhead, and miscellaneous other financial issues

As I stated in one of the introductory paragraphs, most OMSs are in a solo or a two-surgeon practice. Although there is a different dynamic involving these subsets, the inherent decisions for taking in a new surgeon are similar. These decisions are considerably different for a larger group, which most likely will have already established a protocol for bringing in a new surgeon.

Through this proactive approach you, as the established surgeon, have the discretion to best choose the timeline for reducing your hours of clinical practice and, more or less, when the actual retirement will take place. Obviously, your health can factor into this significantly and affect even the best-laid plans.

Once you have decided to transition the practice, there are several things to consider in preparation for this major event in your professional life. Foremost is to enlist a practice transition advisor to perform an objective and comprehensive appraisal of your practice. Regardless of the route chosen to transition the practice, you as an established OMS should be aware of the value of the practice as you seek to have someone share and participate in it with you. The best way for you to have confidence in that value is through a multiple-approach practice valuation by a certified appraiser. In the previous topic, I recommended a 2- to 3-year time frame for an exit strategy, because the practice appraisal is significantly factored on a 3-year performance as indicated in the financial statements of the practice.

Although I have gone into a more detailed description of the standard appraisal methods in the Entrance Planning section of this chapter, let me outline them again:

1. **The asset approach:** tangible (e.g., equipment) and intangible (e.g., goodwill) assets
2. **The income approach:** practice revenue and practice expenses
3. **The market approach:** demographics, practice history, patient volume, staff considerations

The practice valuation is generally based on a combination of these three methods, and perhaps another one or two considerations. It is very important for you and your accountant to provide the practice appraiser with accurate and complete financial information so that your practice can be appropriately judged and you can obtain the maximal fair market value. In my experience, the biggest delay in getting a practice placed on the market is due to some degree of inertia and communication issues between the doctor's office and the accountant doing the necessary balance sheets, profit and loss (P&L) statements, and practice tax returns.

Closely Examining the Options

In considering the options of taking in an associate, offering a partnership position, and entertaining a buy-in or buy-out, the central issue is determining the realistic timeline

for you to exit your practice. The longer I am in the business of practice transition, the more I have come to realize that most senior established surgeons have revised that timeline horizon downward, that is, toward exiting the practice sooner than they first anticipated.

As with the different methods of practice appraisal, I have gone into a little more detail on options for entering into an OMS practice in the section for the new surgeon. I will list these options again here, in somewhat less detail; however, I will address the considerations from an established practitioner's perspective. So let's look at your options:

1. **Offering an associate position only:** This is a way for you to take in someone who you are not certain will be the "right one" for a partnership offer. This may or may not be attractive for the new surgeon. If you are looking to retire from your practice in a year or two, having an associateship (only) without a prescribed partnership/buy-in or buy-out would probably not be advisable. It is imperative to have an employment contract that can be reviewed before the associate begins practice with you, and to have the terms of compensation and duration of employment spelled out.
2. **Offering a partnership and buy-in:** This is the advisable option if you feel good about the new surgeon and if you (and/or your existing partners) are planning to stay in the practice a few years (or more) going forward. Most graduating residents are looking for some assurance and continuity as they enter and plan for their practice life. It is essential to have the specifics of the partnership agreement laid out before the buy-in term begins. It is likewise essential to have your attorney, accountant, and practice transition specialist involved for the appropriate support and guidance throughout the process.
3. **Pre-sale buy-out:** This would probably be the simplest method by which you could sell your practice. It requires that the young surgeon/buyer be able to get familiar and comfortable with you, the office, and (most probably) your staff. The lending institution involved will require documentation regarding practice revenue, including balance sheets, P&L statements, and practice/corporate tax returns; probably all of these should go back 3 years. Although going with a bank/lending institution is the cleanest way of financing the purchase, you might elect to finance a portion of the sale yourself. I would advise you to be flexible as to how long you would stay in the practice part time (as an employee) and determine in your mind what would be required to truly facilitate and support the transition to the new doctor. Once again, your team of practice transition specialist, attorney, and accountant can guide both you and the surgeon buying the practice to achieve a fair and transparently negotiated asset purchase agreement (APA).
4. **Deferred or incremental sale:** Although this is somewhat more complex, if the valuation of your practice is in a higher range (>$1 million/established surgeon), the incremental sale approach may be the only feasible way for a new surgeon to purchase the practice. The agreed-upon purchase price is specified in the APA contract, as is the timeline for scheduled payments, beginning with the down payment (usually 25% to 33%), done at the closing of the sale and the beginning of the new surgeon's practice. The scheduled payout is typically done over a period of 2, 3, or 4 years, rendered in equal payments. An example of this type of sale is given in the Entrance Planning portion of this chapter, which in that case involved corporate entities. There are several ways in which this type of purchase can be structured. It is again advisable for you to be flexible regarding the length of time for you to continue in the practice on a part-time basis. It might be better for you to stay on for the same length of time as the payout, but that is not entirely necessary. Also, again, it is imperative that you engage your transition specialist, accountant, and attorney as you structure and negotiate all agreements inherent in this type of sale.
5. **Walk-away sale:** In this option, you would sell out completely to the new surgeon, who would then have total control of the practice upon the closing of the sale. Again it is important for you to be flexible and willing to be an employee of the practice for a few months to facilitate the transition with the office staff and to help the new surgeon become acquainted with, and accepted by, the referring doctors and their staffs. It is very important for you once again to have the guidance and support of your practice transition team as they work to make this transfer of assets and practice control most effective and efficient.

To finish this section, I should mention that with any buy-in or practice sale, you have to be willing to sign a Restrictive Covenant (Non-Compete Agreement) which will define a geographic radius and length of time within which you must not establish another practice. This is an integral part of the practice valuation and APA and is an important basis for a fair and transparent agreement in securing the transition of your practice.

Considering the Details of a Good Outcome

In this section, although I want to avoid repeating what was stated in the Entrance Planning portion of this chapter, I do want to re-emphasize the characteristics of a successful outcome in practice transition. Regardless of the model chosen (associateship, partnership/buy-in, buy-out/practice sale), it is very important to have a good understanding of your own perspective and that of the new surgeon. It is furthermore very important for you to have a good understanding of the details of the issues presented so that negotiations can begin and proceed effectively and eventuate in a fair, equitable, and transparent agreement.

This negotiated agreement should establish a structure that will provide for the success and satisfaction of both (or all) parties. As said before, when structuring a new venture in practice transition, there should be a philosophy of abundance over that of a zero-sum game in achieving this

successful agreement. Going further, a satisfactory and successful outcome is best obtained by open and honest communication between both/all parties involved. Also, your sincere consideration for, and appreciation of, the needs and expectations of the new surgeon is truly important as you prepare to either share, or turn over, the control of your practice.

Always remember that you have done more than just develop a practice that has become professionally and economically successful. You have truly established a legacy, and that legacy's survival is best accomplished by transitioning your practice to someone who will continue to make it viable and relevant. You owe this to your patients, your staff, your dental and medical community, and most of all, you owe it to yourself.

Let me conclude this Exit Planning portion of the chapter by saying that we have all, like you, been fortunate to have chosen oral and maxillofacial surgery as our professional life's field of endeavor. I hope this chapter has given you some degree of insight as to the best path to choose as you seek to move on with your life after practicing the best specialty in all of health care.

Reference

1. AAOMS: *Membership Database*, 2014.

5

Performing Oral Surgery from the Sitting Position

TRAVIS A. WITHERINGTON

Introduction

Engaging in oral surgery from the sitting position makes professional life easier and more enjoyable for both the surgeon and the staff. The successful adaptation of this style is not a simple matter of buying a couple of operator stools. The surgeon must study the technique, comprehend the ergonomics, educate his staff on their roles and duties, and use dedicated equipment.

Background

Early surgical residency experiences encountered in the hospital operating room produce bias toward working in the standing position. There is little equipment available in the operating room for sitting, and what is supplied forces the surgeon to assume a humped-over, arm-high posture. Consequently, for the remainder of our careers, we discard the notion of sitting for our profession (Figure 5-1).

Because of the Law of Primacy,[1] we extrapolate the habit of standing for surgery into the office environment even when a comfortable sitting arrangement is readily available. Once acclimated to standing, surgeons become reluctant to change. They may sporadically try sitting, but if the proper equipment or education is missing, they usually find the experience to be unacceptable. By contrast, surgeons who embrace, study, and learn sitting surgery will never abandon it.

Rationale

The occupation of surgery is stressful on the mind and the body, and if we can find ways to reduce the harmful effects of that stress, we can make the job much more pleasurable and productive. Our goal in private practice should be to finish our day of well-executed surgeries with minimal fatigue and to finish our career with no occupationally related injury.

To be able to sit down in a comfortable posture during completion of a procedure reduces strain on the body that is induced by having to hold oneself in an unusual position. Sitting during a busy day filled with multiple surgeries allows banking of energy to be allocated for completing the task rather than for enduring strain and discomfort (Figure 5-2).

Numerous studies have been undertaken to examine the incidence of work-related injury in dentists, physicians, veterinarians, and other health professionals. Of these groups, the dental group had the highest incidence of work injuries and disabilities.[2-7] Modern dentistry understands the benefits of the sitting posture, and the technique is well researched and developed.[8-13]

Administering General Anesthesia

The adaptation of sitting to the dental specialty of oral and maxillofacial surgery presents difficulties because of these issues:

- Delivery of general anesthetic agents requires IV lines, electrical leads, gas tubing, and patient restraints.
- Bulky anesthetic equipment, monitors, and other devices are required.
- The surgical team enlarges to three members with the addition of the anesthesia nurse.

Space must be allocated and positions determined for the equipment and the three team members. The interaction between the members must be designed and rehearsed to treat the anesthetized patient in an array of positions and circumstances.

Equipment Selection and Location

Surgical Chair

The operating chair should be a dental-type chair rather than a surgical table. A dental chair has a narrow and thin headrest that allows the operator to assume a position close to and under

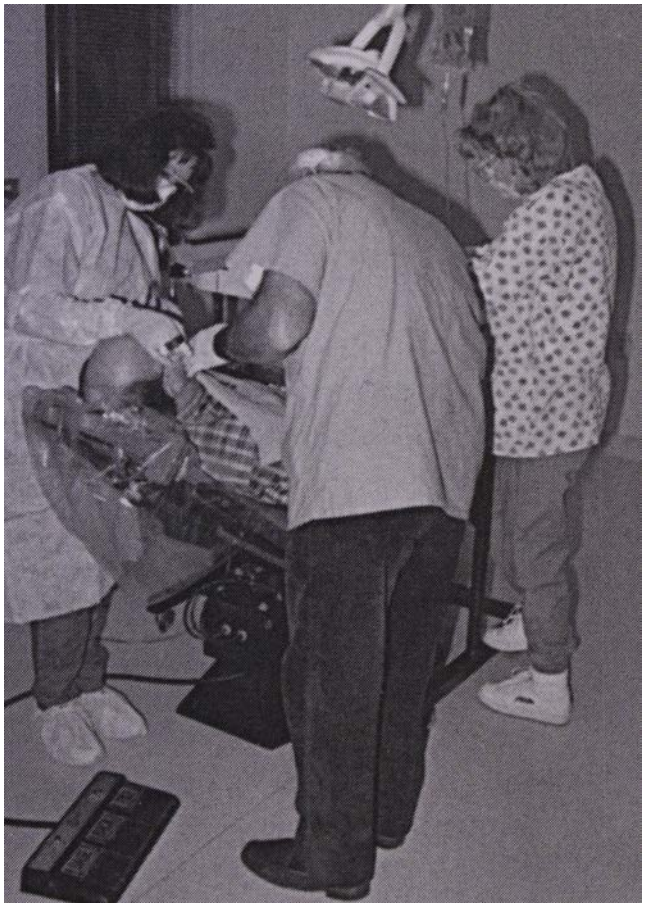

• **Figure 5-1** Oral surgery performed by a standing surgeon and team.



• **Figure 5-2** Oral surgery performed by a seated surgeon and team.



• **Figure 5-3** Narrow headrest on a dental chair.



• **Figure 5-4** Thin headrest on a dental chair.

the patient's reclined head (Figures 5-3 and 5-4). This narrow headrest allows the patient to be brought within the view of the correctly positioned surgeon rather than forcing the surgeon to assume an awkward position to observe the reclined head.

The arms of the patient are supported and restrained by slings that adjust to the reclining chair. The chair should be remotely adjustable by foot controls, because operating different areas of the mouth will require a frequent change of the patient's position. The physical size of the foot controls deserves mention. Some controls are large and bulky and can take up valuable foot space below the operator and the assistant (Figure 5-5).

Durability to corrosion is an important feature, because metal parts of the surgical chair will be subject to IV saline and corrosive surface cleaning agents.

Doctor's Stool

The doctor's stool allows the operator to assume a forward tilt proclination in modern dentistry.[14-16] A dental operator does not assume a position that is equivalent to the typical clerical office worker. Dentists are universally subjected to a



• **Figure 5-5** Foot controls for the dental chair and equipment.

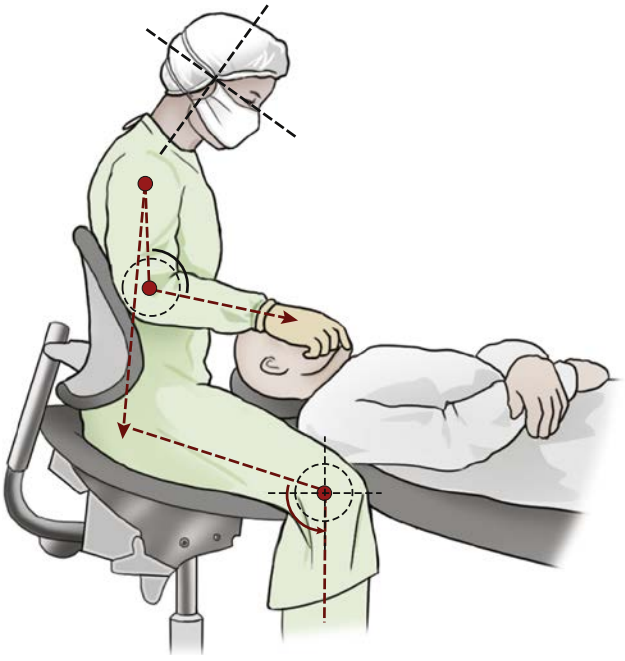

• **Figure 5-6** The operator assumes a forward tilt proclination.

forward tilt from the hip, and the seat support must reflect this special circumstance to allow the operator's lower back to maintain its natural curve. Most dental stools are variants of the basic office seating and do not allow this positive forward support (Figure 5-6).

Assistant's Stool

The surgical assistant uses an elevated dental assistant's stool with a foot ring and arm brace that allows leaning over the surgical field (Figure 5-7).

Overhead Light

Some surgeons prefer a headlight for their operations, but if an overhead track light is selected, there are some



• **Figure 5-7** The surgical assistant uses an elevated stool with a foot ring and arm brace.

features that are important for good function in sitting surgery. The lingual aspect of the anterior mandible is the most difficult area to illuminate in the fully reclined patient. If the horizontal position of the track mounting on the ceiling is incorrect, the light source will not be able to extend to a position to light this area. Consultation with an equipment representative is needed before mounting the track to the ceiling and locating the surgical chair (Figure 5-8).

The length of the vertical support column running from the track car to the light source is determined by the height of the ceiling and the surgical chair height in the operating position. A column length appropriate for sitting surgery will not work well for standing. During standing surgery the light source will then bump the surgeon's head. Consider using a headlight in this circumstance.



• **Figure 5-8** Overhead lighting should be carefully located and mounted.



• **Figure 5-9** Access to computers and digital radiography in the surgery suite.



• **Figure 5-10** Anesthesia, suction, irrigation, and handpiece equipment.

Computer

Because it displays digital radiographic images and electronic medical records, the computer monitor must be viewable by the team. The data entry keyboard is to be positioned so that the both the surgeon and anesthesia nurse can manipulate it. The best location for the monitor is adjacent to the keyboard, but the surgeon must turn to view the screen. A second monitor could be mounted on the wall at the patient's head so that the surgeon and surgical assistant have an easy view (Figure 5-9).

Anesthesia Monitor, Suction, Irrigation, and Handpiece Delivery

With the reclined patient's head at the 12 o'clock location, the anesthesia monitoring equipment is located at the 4 o'clock position so that both the surgeon (right handed) and the anesthesia nurse will have an unobstructed view. The monitor could be placed on a mobile platform so that its position can be adjusted as needed. Distant locations have the disadvantage of making it difficult to read the waveform.

Most dental manufacturers offer a chair-mounted delivery arm or mobile cart for high-speed handpieces, suction tubing, and three-way syringe. The routine dental equipment works well here. The sterile water supply is mounted on an adjacent wall (Figure 5-10).

The surgical drill should be within reach of the surgical assistant or anesthesia nurse so that it can be passed to the surgeon. A good position is at 4 o'clock and atop a mobile stand within the nurse's reach (Figure 5-11).

Anesthetic Gas Source

Wall delivery of anesthetic gases is common at either 12 o'clock or 9 o'clock. No matter which wall is used as the source, tubing snaked across the floor will present a tripping danger for personnel. Suspending the tubing with an extension overhead eliminates this issue (Figure 5-12).

Mayo Stand

This stand should be on rollers so that it can be readily moved to accommodate changing positions of the surgical assistant (Figure 5-13).



• **Figure 5-11** A good position for the surgical drill is 4 o'clock, on the mobile platform.



• **Figure 5-12** Anesthetic gases are wall delivered with suspended overhead tubing.

IV Delivery

Rather than a freestanding IV pole, a chain is hung from the ceiling to hold the bag near the nurse (Figure 5-14).

Counters and Cabinets

Cabinetry, countertops, and shelves are available on walls at 3 o'clock and 9 o'clock. The walls at 12 o'clock and 6 o'clock are best left blank to facilitate team movement. The countertop on the assistant's side is at standing height (36 inches) and has a sink. The countertop on the surgeon's side is at sitting height (30 inches) and runs the length of the room. There is no such thing as too much counter space (Figures 5-15 and 5-16).

Team Member Locations

The location of the team members starts with the surgeon, who is assumed to be right-handed. The surgeon assumes a comfortable sitting position that allows an unobstructed view of the surgical field. The other team members and equipment are then arranged into an efficient *pas de trois* with the reclined patient's face at 12 o'clock (Figure 5-17).



• **Figure 5-13** The Mayo stand is on rollers to accommodate shifts in position by the surgical assistant.

Surgeon

The surgeon moves to different positions that afford the best view of the operative field. This varies from 12 o'clock for the anterior mandible to 8 o'clock to work in the depth of the palate (Figures 5-18 through 5-20).

Surgical Assistant

The assistant positions herself opposite the surgeon and modifies her location to accommodate his changes. She is vertically positioned about 3 inches higher than the surgeon to prevent occluding his view or obstructing the light source (Figure 5-21).

Anesthesia Nurse

The anesthesia nurse will stand often and change positions frequently. Her location at 7 o'clock gives freedom of movement and access to the IV, anesthetic monitor and gases, computer, camera, cabinets, and countertops (Figure 5-22).



• **Figure 5-14** IV fluids are delivered from a bag hanging from a chain from the ceiling to eliminate clutter and make movement easier.

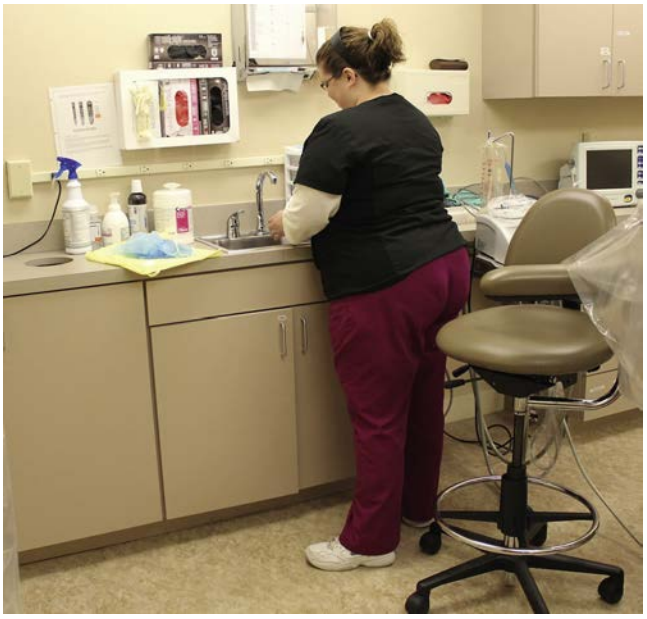

• **Figure 5-15** The countertop on the surgical assistant's side should be standing height and should have a sink.



• **Figure 5-16** The countertop on the surgeon's side should be sitting height.

Team Member Roles and Duties

The Surgeon

It is understood that the surgeon is the captain of the ship and assumes the responsibility of safely and accurately completing the surgery. The surgeon plans and directs the operation, so his distractions are minimized to allow him to visualize "the next two steps" of the surgical progression.

He calls for team members to hand instruments, obtain supplies, and initiate procedures as he observes the surgical site and immediate surroundings. Within his visual field, he can perceive oxygenation, bleeding, airway protection, and anesthesia effectiveness.



• **Figure 5-17** Overhead view of the surgical team and patient.



• **Figure 5-18** The surgeon's default position.



• **Figure 5-19** The surgeon moves his stool to gain a better view of the palate.

The surgeon responds to issues noted by the team members and decides on a course of action. With experience, the well-rehearsed team will develop silent signals to convey information during the surgery. That development will help build a strong sense of satisfaction within the team.

The Surgical Assistant

Although the surgical assistant's duties obviously include suctioning and retracting, she also functions as the guardian of the airway. She observes that the pharyngeal drape is appropriately positioned and is dry enough to absorb the fluids of surgery. The patient's head is tilted up by pressure on the underside of the mandible or to the anterior hard palate and premaxilla (Figure 5-23).

Manipulations by the surgeon deflect the head of the anesthetized patient, so the assistant counteracts these pressures by keeping the head stabilized within the surgeon's view. The head must be rigidly held during the use of sharps (Figure 5-24).

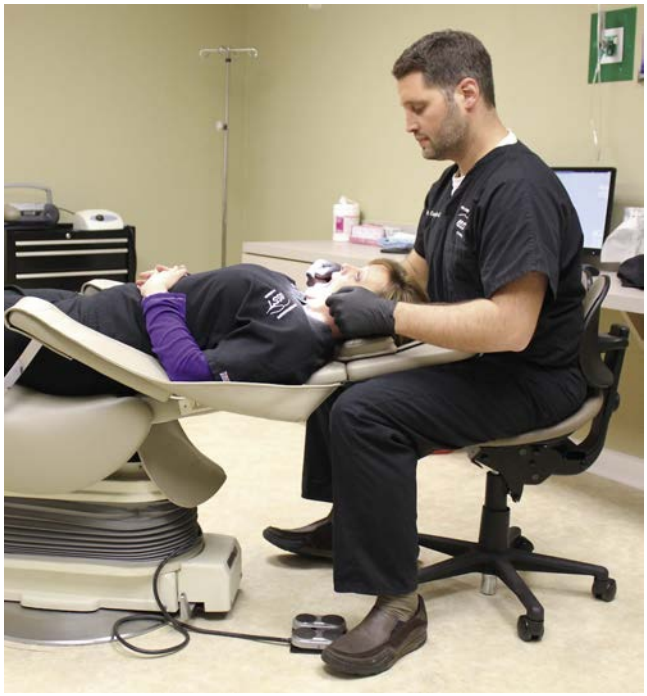

• **Figure 5-20** The surgeon moves to view the anterior mandible.



• **Figure 5-21** The surgical assistant should be seated about 3 inches higher than the surgeon to avoid interfering with the surgeon's view of the patient's mouth.

To avoid distracting the surgeon's attention from the field, the assistant is responsible for handing instruments to the surgeon as he calls for them (Figure 5-25).

During appropriate moments, the assistant rearranges the Mayo so that instruments are returned to their normal positions and easily found. This prevents searching for an instrument on a crowded, messy tray (Figure 5-26).



• **Figure 5-22** The anesthesia nurse's location at 7:00 o'clock gives her freedom of movement and access to the patient's IV, the anesthetic monitor, gases, the computer, camera, cabinets, and countertops.



• **Figure 5-23** The surgical assistant uses finger pressure under the chin for head tilt and airway control.

The surgical assistant intertwines the suction tip into the fingers of her left hand that is holding the patient's chin and tissues. This will free her right hand for picking and handing instruments from the Mayo (Figure 5-27).

The Anesthesia Nurse

The nurse's primary duty is ensuring patient safety by monitoring signs and patient movements. She administers medications at the direction of the surgeon and restrains the patient's limbs during the use of sharps by the surgeon (Figure 5-28).

Because the anesthesia nurse is not scrubbed, she functions as a circulator who deploys supplies, communicates



• **Figure 5-24** The patient's head must be rigidly held during the use of sharps.



• **Figure 5-25** The surgical assistant is responsible for handing instruments from the Mayo to the surgeon as he calls.

with outside personnel, and positions equipment for use (Figure 5-29).

The anesthesia nurse takes photographs while the surgeon and assistant retract (Figure 5-30).

Additional Suggestions

Patient Positioning

The anesthetized patient has a tendency to slide down to the foot of the chair as it is reclined. After sedation is administered and the patient is reclined, reposition the patient so that the head is in the top and center of the headrest (Figure 5-31).

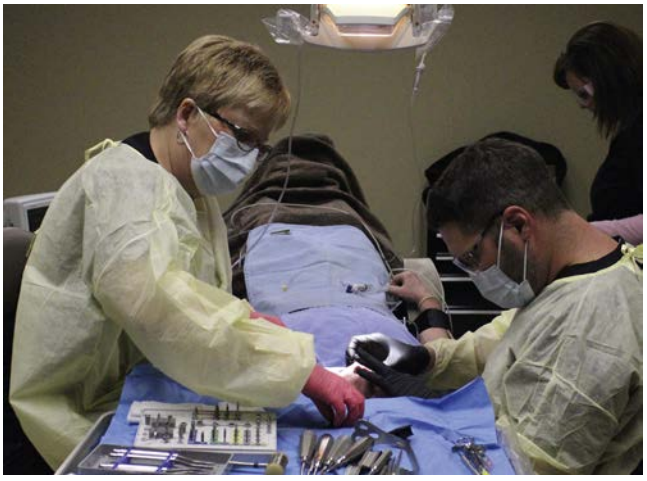

• **Figure 5-26** During appropriate moments, the surgical assistant reorganizes the Mayo stand.



• **Figure 5-27** The surgical assistant holds the suction tip in the fingers of her left hand while picking instruments from the Mayo with her right.

Lumbar Support

Lengthy procedures may produce back discomfort in the patient. Anesthetized patients may show this by attempting to roll onto their sides and flex their knees. Place a memory foam pad in the lumbar area as well as one under the knees before the start of a long procedure (Figure 5-32).

Pharyngeal Drape and Nasal Trumpet

A 4 × 4 sponge is opened and folded into a 2 × 8 shape to protect the pharynx. With dry fingers, the surgeon pulls the tongue forward, then gently tucks the sponge behind the tongue. This holds the tongue forward and helps maintain the airway. The tail of the sponge is brought outside the lips (Figure 5-33).



• **Figure 5-28** The anesthesia nurse restrains the patient's limbs during the use of sharps.

In more recalcitrant airway obstruction from a large tongue, a nasal trumpet can be lubricated and inserted (Figure 5-34).

Agitated Patient

The anesthesia nurse is in a good position to restrain the arms and legs while protecting the IV site. Restraining the head, controlling bleeding, and maintaining the airway falls to the surgeon and the surgical assistant.

Each of the team members is in a unique position to observe agitation in the anesthetized patient and should be polled as to their opinion of the cause. The causes include:

1. Inadequate local anesthesia
2. Hypoxia
3. Anxiety
4. Full bladder
5. Back pain

When the patient moves with an avoidance gesture, apprehension is always suspected, but inadequate local anesthesia is the most common cause if movement is observed during the use of sharps. Accurately administer additional local anesthesia and consider using a different agent.

Movement during luxation or elevation could be from apprehension and should be treated with more general anesthetic agent. Do not attempt to reposition the patient's head and continue surgery until the general anesthetic is effective.

When a patient is combative, it may be more beneficial to raise the level of consciousness by withholding the anesthetic and surfacing the patient. Verbal reasoning after the patient surfaces usually brings cooperation and less movement.



• **Figure 5-29** The anesthesia nurse deploys supplies, communicates with outside personnel, and positions equipment for use.

Unforeseen Circumstances and Running the Code

The simplest procedure can turn into chaos for the surgical team. Accessory equipment and supplies must be arrayed so that when things turn more complex, the anesthesia nurse can deploy the needed devices and call for help. A panic button is made available to the anesthesia nurse for calling a code in the office (Figure 5-35).

The surgical team must practice emergency protocols in the surgical suite in order to determine timing, sequence, and roles. Tasks must be assigned to each team member. Who calls for help, when and how? Who maintains the airway while the ambu is being deployed? Who does chest compressions, and who switches for relief? Who administers the emergency drugs? Who keeps the written record of the code? Where is the crash cart kept, and who fetches it?



• **Figure 5-30** The anesthesia nurse photographs procedures.



• **Figure 5-31** After reclining, reposition the patient to the top and center of the headrest.

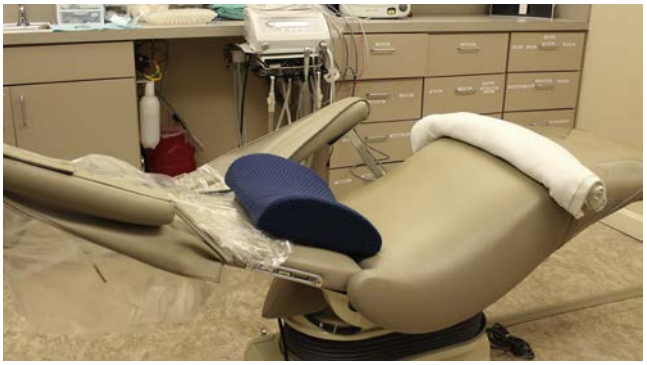

• **Figure 5-32** To prevent back pain in the patient during a long procedure, place pads in the patient's lumbar area and under the knees.



• **Figure 5-33** A carefully placed sponge protects the airway.



• **Figure 5-34** A lubricated nasal trumpet may be used to enhance the airway.



• **Figure 5-35** The operating room should have a panic button.

Summary

The rational use of the sitting position to accomplish oral and maxillofacial surgery provides greater comfort to the operating team while helping to protect them from occupational injury.

References

1. Aviation Instructor's Handbook: *Federal Aviation Administration*, 1999.
2. *Elements of Ergonomics Programs: A Primer Based on Workplace Evaluations of Musculoskeletal Disorders*, NIOSH Publication No. 97–117, 1997.
3. Murphy DS: *Ergonomics and the Dental Care Worker. American Public Health Association*, Washington, DC, 1998, United Book Press.
4. Valachi B, Valachi K: Mechanisms leading to musculoskeletal disorders in dentistry, *J Am Dent Assoc* 134:1344–1350, 2003.
5. Musculoskeletal Disorders and Ergonomics in Dentistry. USAF Dental Evaluation & Consultation Service.
6. Torén A: Muscle activity and range of motion during active trunk rotation in a sitting posture, *Appl Ergon* 32:583–591, 2001.
7. Marklin RW, Cherney K: Working postures of dentists and dental hygienists, *J Calif Dent Assoc* 33:133–136, 2005.
8. Ergonomics and Disability Support Advisory Committee (EDSAC) to the Council on Dental Practice (CDP): An introduction to ergonomics: risk factors, MSD's, approaches and interventions, *ADA*, 2004.
9. Posturing for relief, *ADA News*, July 15, 2013.
10. Ergonomics for Dental Students: *American Dental Association*, 2011.
11. Parsell DE, Weber MD, Anderson BC, et al.: Evaluation of ergonomic dental stools through clinical simulation, *Gen Dent* 48:440–444, 2000.
12. An Introduction to Ergonomics: Risk Factors, MSDs, Approaches and Interventions. A Report of the Ergonomics and Disability Support Advisory Committee (EDSAC) to Council on Dental Practice, *American Dental Association*, 2004.
13. Ergonomics and Dental Practice: Preventing work-related musculoskeletal problems, *ADA Professional Product Review*, November 01, 2014.
14. Ahearn D: The Eight Keys to Selecting Great Seating for Long-Term Health, *Dent Today* 24:128–131, 2005.
15. Valachi B, Valachi K: Operator Seating: The Tall and Short of It, *Dent Today* 24:108–110, Jan 2005.
16. Finkbeiner BL: *Four-Handed Dentistry: A Handbook of Clinical Application and Ergonomic Concepts*, Upper Saddle River, NJ, 2001, Prentice Hall.

6

Business Management of the Oral and Maxillofacial Surgery Practice

DANNY KETOLA, SCOTT E. GRAHAM, MICHAEL KURTZ

Introduction

Most people don't separate the business of oral and maxillofacial surgery from the clinical practice. In fact, they are very distinct from one another. Clinical oral and maxillofacial surgery focuses on delivering quality patient care to the patients, whereas the business focuses on the financial and related nonclinical aspects of the practice.

Oral and maxillofacial surgeons in training focus their time and energy on learning surgical skills and have very little exposure, didactic or otherwise, to the business side of dentistry and medicine. It is critical in today's medical and dental environment that practitioners gain knowledge of how to run a business. Otherwise, they are setting themselves up for a career that is less rewarding and will result in goals, financial or otherwise, not being met. This chapter focuses on the business side of oral and maxillofacial surgery from an operational, human resource, and financial perspective.

Operational Issues

The legal and compliance environment in dental and medical practices has changed drastically over the past several decades and will continue to evolve and change. With the recent passing of the Affordable Care Act,[1] changes occur at an exponential rate and predicting what health care will be like in the coming years is impossible. Consider the trend of corporate dentistry. A recent statistic shows the percentage of general dentists practicing in a group increased from 27% in 2003 to 38% in 2011.[2] Corporate dentistry continues to grow in scope of services and will continue to have an impact on specialists.

Keeping up-to-date and constantly assessing the business climate and adjusting will be the only way that private practices can survive. The "scope" of knowledge a clinician needed from a business perspective has broadened considerably over the last decade. This includes legal and compliance issues, Stark laws, banking and loans, insurance contracting, information technology, electronic billing, fraud, and embezzlement.

A surgeon fully engaged on the business side will need to have more than a basic knowledge of these subjects to be successful. These include but are not limited to governance, engaging advisors, assessing and evaluating operations, organizational issues, human resources, financial management, legal matters including managing risk, and information technology.

Legal Entities

Practices may take the form of several legal entities. Each of these present various advantages and disadvantages. Tax implications and personal liability are two of the most important differences. Possible practice structures include sole proprietorship (SP), general partnership (GP), limited partnership (LP), limited liability company (LLC), C corporations, or S corporations.

Unincorporated entities include SP, GP, limited liability partnership (LLP), and LLCs. For the oral and maxillofacial surgeon who does not plan to work in a group practice, the SP is a very convenient way to organize a practice. The surgeon-owner signs all contracts and collects revenues in his or her name. The surgeon-owner is also liable for all obligations of the practice, and personal assets could be attached if there is a settlement against the practice.

Each of the unincorporated partnerships generally have the following characteristics: There are two or more persons or entities in a business for profit, and any income or loss flows through to the partners for income tax purposes. The partnerships are therefore not taxable entities.

The GP is also a convenient entity to establish when there are a limited number of surgeons in the group. Typically, partners share equally in the profit and loss of the partnership, or, by proxy, alternative methods for revenue and expense sharing can be established. The personal assets of all partners are at potential legal risk, and all can be responsible for obligations incurred by other partners.

An LLP typically consists of at least one general partner and one limited partner. The general partner(s) can be liable for all obligations of the partnership, whereas the limited partner receives some shielding from debts and obligations of the partnership.

An LLC has characteristics of both a partnership and a corporation, and ownership may consist of multiple persons. Members of an LLC are not responsible for the debts and obligations of the LLC. Earnings pass through to the owners for tax purposes.

C and S corporations provide shielding from debt and other obligations for the shareholders. A C corporation is managed through a board of directors selected by the shareholders. The board of directors elects officers who are responsible for executing the policies. The C corporation is subject to double taxation because taxable income is subject to corporate income tax earnings, and funds distributed to the shareholders are individually taxed. S-corporation earnings, on the other hand, flow through to the shareholders for federal and state income purposes. A comparison of legal entities is shown in Table 6-1. Because of the complexity and potential tax implications of the legal structure, it is highly advisable to seek a knowledgeable accountant to guide your legal structure. Once the entity is formed and operational, it can be expensive to change entity structure down the road. Initial setup is important and should be designed for the long term.

Legal Documents

Basic legal document requirements of an OMS practice include articles of incorporation and/or operating agreement, employment agreements, buy-sell agreements, lease agreements, and third-party payer contracts. The number and complexity will vary greatly depending on the legal structure of the practice, local and state requirements, and advice from attorneys and other professionals.

Articles of Incorporation/Operating Agreement

The operating agreement specifies and formalizes how the entity shall run, whether a C or S corporation, LLC, or GP, and includes formation, election of officers, ownership, how reporting should take place, meetings, and dissolution.

TABLE 6-1 Comparison of Legal Entities

Entity	Corporation (C Corp and S Corp)	Partnership	Limited Liability Company (LLC)
Definition	Corporation for profit organized under the state corporations act S corporation designation under federal Internal Revenue Code	An association of two or more persons to carry on, as co-owners, a business for profit	Hybrid. An LLC formed under state LLC statute.
Designation of owners	Shareholders	Partners	Members
Liability of owners in organization	Shareholders generally not personally liable for debts of corporation, but liable for own acts	Partners are jointly liable for the obligations of the partnership	Members and managers are not liable for any debt, obligation, or liability of the LLC.
Management	Directors and officers	Partners	Members or managers
Persons in position to bind organization	Officers	Partners	Members or managers
Governing documents	Articles of incorporation, bylaws, and shareholders agreement	Partnership agreement	Articles of organization, operating agreement
Type and number of owners	No limits on type or number in C corp. S corp. limited to 75 persons.	No limit on type. Must have at least two partners.	No limits, although individual managers and members must be 18. Can have as few as one member in many states.
Ownership classes	Different stock classes allowed in C corp. S corp. is limited to one class of stock.	Any financial arrangement between partners allowed	Any financial arrangement allowed. In absence of agreement, interests are proportional based upon level of contribution/ capital account balance.
Tax treatment	As a C corp. unless S corp. is elected for tax purposes	Almost always as a partnership for federal tax purposes	Generally, as a partnership for federal tax purposes

Employment Agreement

Employment agreements describe the terms of employment for shareholders in the practice, associate physicians, and other key employees. These agreements should define the capacity in which the employee serves, compensation, benefits, termination, covenant not to compete, and future ownership. Box 6-1 is an example of a surgeon employment agreement, but it should not be construed as all-inclusive.[3] Variations will depend on the will and intent of the shareholders (given legal constraints) to provide an equitable work environment for those employed under these agreements.

Buy-Sell Agreements

Buy-sell agreements are the legal documents that cover a change in practice ownership and include provisions for surgeons entering and leaving the practice. Ownership should be considered a mutually agreeable arrangement between the surgeons and not a right or obligation.

Whether being bought out of or buying into a practice, the method of valuing the practice must be clearly spelled out. Practice valuation is typically based on several factors: gross production, collection percentage, hard assets, accounts receivable, and goodwill. Hard assets include equipment, such as computers, radiology equipment, surgical chairs, and other office furnishings. Accounts receivable includes monies owed the practice from patients and payers and should be discounted to the net collection rate of the practice. If the accounts receivable is $600,000 and the net collection rate is 95%, then the valuation of accounts receivable would be $570,000. Goodwill is often the most difficult asset to determine and will vary considerably in different geographic and socioeconomic situations.

• BOX 6-1 Surgeon Employment Agreement Outline

I. Duration of the Contract
  A. Length of the contract
    1. Option: annual with automatic renewal
  B. Effective date of the contract
II. Conditions Under Which Contract Can Be Terminated
  A. Voluntary termination by employee or employer with thirty (30) days' written notice
  B. Death of employee
  C. Suspension, revocation, or cancellation of employee's right to practice medicine or dentistry in the state of (state)
  D. Employee loses privileges to any hospital at which the practice regularly maintains admission privileges
  E. Employee fails or refuses to follow reasonable policies or directives established by the practice
  F. Employee commits acts amounting to gross negligence or willful misconduct to the detriment of the practice or its patients
  G. Employee is convicted of a crime involving moral turpitude, including fraud, theft, or embezzlement
  H. Employee breaches terms of the employment contract
  I. Employee becomes and remains disabled in excess of three (3) consecutive months
III. Compensation
  A. Amount of annual salary
  B. Incentive bonus, calculated as follows: (formula)
  C. Determine amount and duration surgeon will be paid during a period of disability
IV. Benefits
  A. Health insurance
  B. Retirement plan contribution
  C. Malpractice insurance and tail-end premium
  D. Dues, books, and periodicals
  E. Licenses
  F. CME expenses
    1. Annual allowance of $ (dollar amount)
  G. Entertainment
  H. Automobile
  I. Relocation
  J. Vacation leave
  K. Sick leave
  L. Life and disability insurance
  M. Cellular phone
  N. Pager
  O. Other
V. Outside Income
  A. Decide on the type of outside income the surgeon can retain and the type of outside income earned by the surgeon that the practice will be entitled to retain.
  B. At the same time as (A), discuss the surgeon's restrictions on outside employment.
VI. Surgeon's Duties
  A. Required work hours
  B. Required on-call schedule
  C. Discuss any restrictions on the acceptance of new patients by the surgeon.
  D. Discuss any provision if the surgeon is called to jury duty or other duty, such as military reserves.
VII. Termination Compensation
  A. Determine how much the surgeon will be paid if employment is terminated.
VIII. Opportunity to Buy into Practice Ownership
  A. How long after joining the practice?
  B. What exactly will the physician be allowed to buy into?
    1. Accounts receivable
    2. Hard assets of the practice
    3. Goodwill
  C. How will the assets be valued?
    1. By independent appraiser
    2. By fixed formula
  D. If applicable, how will accounts receivable be valued?
  E. How will fixed assets be valued?
  F. How will the buy-in price be paid for?
IX. Reasonableness of Covenant Not to Compete
  A. What is the duration of noncompete?
  B. What is the geographic area of noncompetition?
  C. What are the prospective penalties and/or compensatory damages?
  D. Is there a buyout clause?
  E. Is the covenant too restrictive?

From: Tinsley R: *Medical practice management handbook,* ed 8, 2002. Reprinted with permission from Reed Tinsley, CPA.

A professional firm experienced in practice valuation can be a valuable resource.

Practice valuation of a five-shareholder OMS practice:
Hard assets $450,000
Accounts receivable $570,000
Goodwill $620,000
Total practice value $1,640,000/5 shareholders
Per share value $328,000

In a multiple-physician practice, the ideal scenario would be equal valuation of a buy in and a buyout. Variables in this formula revolve around the length of payment in or out and interest or other fees. In the previous example, a surgeon buying into the practice would pay a total of $328,000 over 5 years ($65,600 annually or $5666 monthly). In the case of a surgeon being bought out, the practice could reimburse the partner over an extended time period so that the cash flow is not adversely affected. Box 6-2 is an outline of a sample buy-sell agreement. Because tax laws are constantly changing, the ramifications of the practice's buy-sell agreements should be regularly reviewed by the accountant, attorney, and shareholders.[3]

If a solo practitioner is selling his or her practice, the process of purchasing shares may be different from that in a group situation. The selling surgeon must agree on a price with the prospective buying surgeon. The buyer can work in the seller's practice for a specified period of time, which generates revenues, an agreed-upon portion of which can be used toward the purchase. During this time, the purchasing surgeon also has an opportunity to gain vast knowledge regarding the overall operation and administration of the business.

Another commonly used method is the capitalization of excess earnings. In this method the income statement is normalized to subtract items that personally accrue to the doctor. Then the normalized expenses are subtracted from the revenue to give the excess earnings. The past 3 years are then weighted, with the current year being weighted more heavily than the second, which is weighted more heavily than the third. This average excess earnings is then divided by the capitalization rate, which is based on more subjective factors. A typical capitalization rate is 0.25.

Other overly simplified valuation methods commonly used to determine the value of a practice are the W-2 method and Percentage of Gross Production. The W-2 method is a simplified version of the Capitalization of Excess Earning method discussed earlier. It essentially takes an average W-2 amount over a 5-year period and can be adjusted for factors such as increasing or decreasing volume trend, increase or decrease in local competition, changing market, or debt. The percentage of gross production method values a practice by taking the gross revenue and applying a percentage, usually between 60% and 70%, and adjusting for factors listed earlier.

Lease Agreements

The practice and/or shareholders may own or lease the office space they occupy. There are a multitude of possible ownership entities, including a sole ownership, LLC ownership, leasing from outside sources, or shared arrangements with other professional organizations. The decision is based on tax implications, geographic limitations, and other legal obligations. A contract is required, which has parameters including liability, duration of the agreement, shared responsibilities, and the financial obligations between the parties. Lease documents include rental rate per square foot, liability, duration of lease, leasehold improvements, and responsible party for utilities, repairs, property taxes, and maintenance. When the building is owned by the doctor, the practice leases the facility from the doctor. A retiring doctor who is selling the practice may choose to keep the building, using his lease payments to help maintain his lifestyle after retirement.

Risk Management

Risk management encompasses both the clinical and administrative aspects of the practice. Federal laws and guidelines will dictate many of the practices' protocols, whereas shareholder prerogatives guide others. Risk management in an OMS practice includes the following areas: informed consent, quality assurance, treatment protocols, collection protocols, OSHA and HIPAA compliance, and insurance laws, including private contracts, Medicaid, Medicare, and workers' compensation. Knowing these laws and what you can and can't do is necessary to avoid inadvertently committing insurance fraud.

• BOX 6-2 Buy-Sell Agreement Checklist

- Buyout events:
  Death
  Disability
  Retirement
  Voluntary and involuntary termination
- Agreement specifies details of buyout in the event of a disability.
- Agreement specifies any age restrictions for retirement (withdrawal before age 62 is voluntary and carries tax implications).
- Specify notification requirements for voluntary withdrawal.
- In the case of a voluntary withdrawal, agreement specifies whether there will be penalties to the buyout price if the owner forms a competing practice, joins a competing practice, or violates the employment contract.
- Vote requirements to admit a new surgeon into the practice.
- Periodic review of buyout calculations and methodology of payments.
- Qualifications of firm used for any appraisals.
- Routine review of tax consequences for the practice and surgeons for buy in and buyout.
- The buyout amount has been calculated for each owner using the current formula in the agreement.
- Periodic shareholders review of all contracts.

From: Tinsley R: *Medical practice management handbook,* ed 8, 2002. Reprinted with permission from Reed Tinsley, CPA.

The AAOMS provides information and continuing education opportunities on the topic of risk management. OMS National Insurance Company (OMSNIC) is OMS surgeon owned and provides professional liability insurance for OMS providers, and they have regular seminars and online formats for their clients.

Informed Consent

The informed consent process begins with the first contact that the surgeon makes with the patient. All discussions and decisions must be documented in writing in the clinic note and then ultimately on a consent form specifically designed for the process. Some procedures will require a lengthier and more detailed educational process before obtaining a signed consent form. This process can take the form of printed materials or brochures, audiovisual presentations, or one-on-one discussion with the surgeon and/or designated staff members. It is important that the patient or legal guardian be given adequate opportunity to ask questions regarding their treatment plan, and that all alternatives be presented. The age at which a patient can legally give consent is generally 18 years. Exceptions may exist when a patient is emancipated from parental control or if they are married before 18 years of age. It is advisable that every practice verify with their attorney what their state laws are. In the event that the patient is incapacitated, it is necessary to carry out the entire presurgical discussion with the power of attorney and get their signature. Obtaining a signed consent form does not eliminate the possibility of legal action, but having good patient rapport, adequate discussion, and a well-documented patient record prevents many possible future problems.

Quality Assurance

Much as a hospital or surgical center requires certification and documentation of quality assurance, it is incumbent on every OMS practice to be vigilant regarding every aspect of patient care provided in their facility. Unsigned consents or missing documentation forms should be monitored and addressed. Periodic chart reviews can identify deficiencies that would otherwise go unnoticed. Patient complaints should be assessed, and an action plan established to prevent repeating a problem. If there have been any staff injuries or complaints, they need to be documented, along with any remedial action taken. Treatment protocols are helpful when complex procedures are expected. This protocol, which may be as simple as the route and type of drug used for subacute bacterial endocarditis prophylaxis or as complex as the work-up for an orthognathic or implant surgery, provides a road map for the treating team to follow.

Managed Care Contracting

In many areas of the country, some companies have employees enrolled in capitation insurance plans. Because of the large potential patient pool, it becomes a financial necessity for the OMS practice to consider participating in these plans. The ability for the practice to competently negotiate with third-party payers is a key factor in their financial success. The terms of reimbursement and the contractual language must be scrutinized carefully. If the surgeon is not familiar with these negotiations, then a consultant should be involved. Third-party payer contracts may also spell out terms for patient scheduling, emergency call, professional liability, and assignment of court costs in case of a lawsuit, all factors that may weigh heavily on the overall operations of the practice.

Practice Advisors

No individual can possess all of the comprehensive knowledge base that is necessary to establish and maintain a successful practice. A surgeon should surround himself or herself with a team of professional advisors, which include accountants, attorneys, bankers, insurance brokers, retirement plan administrators, other practitioners, an office manager, and, in larger practices, a practice administrator.

Selecting an Advisor

Selecting an advisor can be a daunting task and can have huge financial and quality-of-life implications. Consider selecting a financial advisor who brings a 3% higher return over the course of one's career, or an attorney who gives bad legal advice when it comes to an HR issue and a lawsuit is filed against you. How much could a good accountant save you in taxes during your career? As you can see, the right selection is extremely important, and the choice should be made systematically and after much research, thought, and consideration. If the selection is done correctly, it will only need to be done once, unless the advisor retires.

A good system to follow is to gather all the references you can via your network and relationships and then research them. After you have completed your research, set a meeting up and interview them. Be careful not to commit to the first one you interview. Many of them are trained at getting people to say "yes" and will tell you what you want to hear. Tell them up front you will be interviewing several candidates and a selection will not be made until all the interviews have been completed. You will find that you will gain a much better understanding after each interview, and at the end of the process you'll understand the purpose and need for such an advisor much better than when you started.

Many advisors overlap each other, and you will need to decide which advisors you will use in each area. An example is your accountant; many accountants also do financial advising. Do you want to use your accountant, banker, insurance agent, or stand-alone financial advisor? You may also seek advice from all of them and then make your decision. After the interview process, you will have a better understanding of the skills they possess and when and

how to use them. This is similar to how a dental patient can choose to use their dentist or an oral surgeon for an extraction. They both offer the services, but one choice may be better than the other.

Accountant

An accountant who has achieved the licensure of a certified public accountant (CPA) generally has a college degree or has completed significant course work in accounting, has successfully completed a comprehensive examination, and has practiced with an accounting firm for 2 years. Individual states may have specific licensure requirements. Typically a CPA can provide services including bookkeeping, creating a financial statement with analysis, tax return preparation and a good understanding of business entities. A person or firm that has health care experience and specializes in health care can give invaluable advice regarding every financial decision. The CPA should be proactive communicating to the management team with advice regarding decreasing overhead, improving cash flow, and increasing revenue. It is also important that they be aware of changes in the tax codes germane to the practice.

Attorney

The attorney or firm selected by the practice should have a comprehensive working knowledge of health care law, including malpractice, contract and corporate law, and tax and estate planning.

The attorney drafts legal documents pertaining to practice entity formation and other ownership entities, such as real estate or life insurance policies. Employment and buy-sell agreements are of particular importance to a group OMS practice to facilitate a smooth transition from the associate position to ownership and eventually to retirement. The quality of these agreements becomes particularly important should a dispute arise between partners, associates, or heirs. A surgeon contemplating joining an existing practice should hire his or her own attorney to review and make recommendations regarding any contracts. It is important to consult with an attorney before joining or starting a practice and working out the agreements. Once a disagreement arises, it is difficult if not impossible to work out the details.

Banker

A lender is selected before the inception of the OMS practice to establish guidelines for the financing of capital equipment, computers, or the purchase of office space. Discussion should include the possibility of a cash flow shortfall. Many banks offer special service lines that are tailored to health care organizations and surgical practices. A solid banking relationship is important over the life of a practice, and an effort should be made to find the right banking relationship and maintaining that relationship.

Insurance Broker or Representative

The insurance professional is an integral part of the professional organization's advisor team. This person can assist with decisions on how to protect business and property. They can also assist with buy-sell agreements and help get coverage in place. Other important areas include key person insurance, retirement planning, group insurance, and personal insurance for the surgeon-owner. You will need to decide how to use your agent and which services you will want him to provide.

Selection of an insurance representative is based on education, health care experience, and their access to a variety of insurance options. Various professional designations include chartered life underwriter, chartered financial consultant, certified financial planner, Master of Business Administration, and others.

Retirement Plan Advisor and Administrator

The professional life of an OMS surgeon can easily extend to 30 years or more, which enables the individual to potentially accumulate substantial retirement assets. A retirement plan administrator is usually partnered with a financial adviser to make up the team to provide plan administration and investment advice. Plan administration includes drafting documents, accounting for participants' account balances, and filing annual tax returns. As firms are interviewed, factors such as fees for administering the plan, timely reporting, and investment selection should be taken into consideration. Options for calculating service fees include a percentage of the total assets, a per-participant fee, and/or charges to carry out the testing of the plan. The team should provide cost projections and be prepared to discuss each facet. Once an investment team is selected, a 3- to 5-year timeline is established to achieve the investment objectives of the practice. There are multiple plan options, including but not limited to 401(k)s, self-employed pension plans (SEPs), Individual Retirement Accounts (IRAs), pension plans, and defined benefit plans. The type of investments selected for the retirement plan(s) will be driven by the risk tolerance and investment goals of the practice and its shareholders.

Practice Administrator

The practice administrator is an integral part of the management team and is responsible for ensuring that the practice functions in a seamless manner. If the employee charged with the direct oversight of the practice business and nonclinical areas does not have the core competencies, education, or experience required to manage a practice, ultimately a myriad of difficulties can develop. There are several organizations where candidates can be found: American College of Health Care Executives (ACHE), American College of Medical Practice Executives (ACMPE), and the Medical Group Management Association (MGMA).

Competent administrators will be well versed in finance, accounting, human resources, compliance/risk management, governance, information systems, and strategic planning. Many offices promote from within, so that someone who started at the front desk eventually becomes the office administrator. Practice owners should be careful in doing this and should make sure the staff member they have in this position has the skills necessary to perform all the functions you will require of them. Some practices elect for the surgeon to also fill the role of a practice manager. This can be time consuming and should be considered carefully. A surgeon filling this role must be aware that the time he spends on this may affect his bottom line and quality of life. This should only be done if the surgeon has a desire to run all business aspects and is dedicated to gaining the knowledge needed to do so.

Marketing and Public Relations

An OMS surgical practice is mostly referral driven; therefore, the importance of marketing and public relations cannot be overstated. Communication on multiple levels with the referral base is the cornerstone of a marketing strategy, but this is changing with the proliferation of corporate dentistry, and oral surgeons need to consider and learn how to market to the general public as well. Websites, social media, educational events, and so on all market to the public, and the person you put in charge of this should market the message you want given. Because each practice is unique, it is impossible to list or diagram a marketing scheme that fits all situations. More information on this subject can be found in Volume 1, Chapter 10 on marketing.

Benchmarking

Custom-designed surveys that are completed by patients and referrals are of great value to evaluate the health of a practice, although the need to survey patients is diminishing with the proliferation of electronic media. To find out how patients feel about your services, just go onto the Internet, and you can usually find some type of patient review. You will need to focus on getting positive reviews, as most people only give reviews if they have a negative experience. A digital marketing manager is a good person to have as an advisor, as he or she knows the landscape and can help build practice feedback via electronic means.

To effectively evaluate your practice from the referral standpoint, you should engage in effective relationship building. If you have a good relationship with your referrals, they are more likely to call if any issues arise. The sooner you are aware of an issue, the sooner it can be addressed and any negative impact can be limited.

If a practice chooses to solicit feedback from traditional surveys, it is best to limit them to around 5 questions. Surveys that are much longer are often ignored, as most people are not willing to spend their time on a survey that cannot be completed very quickly.

Organizational Structures

Solo Practice

The primary advantage that a solo practitioner possesses is the ability to set his or her own schedule and make all decisions. A solo practitioner normally has an independent personality, has a high energy level, and is not hesitant to simultaneously tackle the administrative and clinical challenges.

Overhead and staffing issues are far less complex in an SP situation. Unless the surgeon hires outside expertise, it will be necessary to manage multiple tasks that in group practice may be shared, such as computer repair, insurance coding, human resources, or accounts payable management.

Group Practice

Three possible advantages inherent in a group practice include sharing after-hours call coverage, potential leverage during managed care contracting and purchasing, and having colleagues to discuss various clinical issues, such as diagnosis and treatment planning.

As a group practice grows, it is possible to have a division of labor among the surgeons. Surgeons tend to gravitate toward a specific area of interest in the management arenas, such as marketing, staff education, or the financial aspects of practice management. Regardless of personal preferences, each member of a group practice must have an overall knowledge of the clinical and administrative aspects of the practice.

A managing partner is the initial liaison with the practice administrator or office manager. A managing partner should be a shareholder, should be elected by the other shareholders, and can be compensated for his or her additional responsibilities. A senior partner with practice experience is ideal for this position. As a group grows, it becomes increasingly difficult for a managing partner to provide the comprehensive supervision necessary. Larger groups can form committees with one or more of the surgeons as chairperson.

- *Finance*—retirement plan administration, review of financial statements, and decisions regarding capital investments and buy-sell arrangements.
- *Human resources*—continuing education, compensation, and benefits.
- *Quality assurance and risk management*—review of morbidity and mortality, infection rates, chart review, and site accreditation.
- *Compliance*—radiology regulatory issues, Occupational Safety and Health Administration (OSHA), and Health Insurance Portability and Accountability Act (HIPAA).
- *Information systems*—hardware and software, imaging, and electronic health records (EHR).

Associate or Salaried Position

At the end of the long process through undergraduate education, dental school, and residency, the individual is often

faced with a significant debt. For this reason, becoming a salaried associate without any additional financial responsibilities may be attractive. An existing practice can offer a potential associate a trial period of 1 to 2 years. The time period selected allows both the associate and the owners an opportunity to evaluate each other's working style, personality, and personal goals. Near the end of a surgeon's career, an associate position may enable them to step away from some of the responsibilities typically tied to practice and partnership.

Advantages of an associate position include a guaranteed salary and benefits with few administrative responsibilities and limited debt exposure. Disadvantages include limited involvement in practice decisions, no incentive for increased income with increased production, and no control of the benefits received.

Human Resources

Most dental practices are small businesses with sizeable gross revenue, multiple employees, sizeable real assets, and a large expense budget, yet dental schools or residency programs do little in the way of preparing a health care provider to manage such an enterprise. Irrespective of the finance and accounting operational functions, the human resource function can be the most daunting. Consider that labor costs can be 60% of a providers expense budget, probably the single most important task that contributes to practice success is getting the employment process right.

French philosopher and political commentator Jean Baudrillard used the term postmodernism, defined as a reaction to or rejection of the dogma, principles, or practices of established modernism, to reflect the dramatic changes and turmoil we see in life today.[4] Employees in this environment are much more likely to question authority. They will move to another job for a higher salary or at the first sign of conflict or dissatisfaction with working conditions. Arguably, turnover can be quite expensive and can create chaos that results in a negative impact on the bottom line.

Consider this; a recent Gallup survey found that 50% of American workers are not engaged in their work, and 20% of those workers are actively disengaged.[5] Martha Irvine, writing for the Associated Press, refers to Generation Xers in today's workforce as gloomy slackers who have the reputation of expecting a high salary and flexibility, yet have little willingness to take on grunt work or remain loyal. Simply put, yesterday's rules—where ability plus motivation plus environment equaled performance—do not apply.[6]

In fact, many management gurus now believe it's a myth that people are the greatest asset of an organization. According to Jim Collins, the *right* people are the greatest asset of an organization.[7] So the challenge is to get the wrong people off the bus and the right people on it. This section is a primer for hiring and retaining good employees, complying with labor laws and regulations, and engaging alternatives for managing the human resource function.

Assessment

Begin by taking a T-inventory of your current staff. Divide them into the three T's: termites, transmitters of the status quo, and transformers.

Termites are easy to identify. They are the negative types who consistently perform poorly and drag down the rest of the staff. They convey a simple message to patients: go somewhere else! And as with termites, by the time you realize it, they have already done considerable damage.

Transmitters of the status quo are the ultimate average employees. More often than not, transmitters do what they are told and nothing more. These employees show up for work every day and make few mistakes. However, alongside a termite they can be easily swayed to the dark side. Most employees fall into this category.

Transformers are those rare employees who are always positive and go out of their way to exceed patient expectations. They see themselves as stakeholders in your practice. Transformers exhibit what Daniel Goleman calls emotional intelligence (EQ).[8] Emotionally intelligent employees recognize feelings, are better at mood management, and are self-motivated and able to direct themselves toward a goal. They recognize feelings in others and are good at tuning in to verbal and nonverbal cues. Cooperation is their hallmark. People with high EQs understand the importance of managing relationships, handling interpersonal interaction, resolving conflict, and negotiating. Most hiring managers today agree that a high EQ supersedes a high IQ.

Hiring

The T-inventory process forces the practice to begin working toward improvement of all aspects of the practice. It is absolutely essential to develop *accurate* job descriptions. This includes a brief list of principal job responsibilities, a list of the knowledge skills and abilities required, education or licensure required, pay range for the position, and a summary of the working conditions. Most practices use job descriptions as a prequel to hiring.

The next step is to develop a job application form. Many practices simply ask for curriculum vitae or resume. However, it's important to remember this is the candidate's marketing material. The goal of the job application is to find out things the candidate is unwilling to tell up front but that you need to know to decide whether or not to bring him or her in for an interview. It also avoids wasting time interviewing candidates who have no chance of getting hired.

Appropriate items for a job application include a work history, salary history, reason for leaving previous employment, and at least three professional references. Include a check box to allow the candidate to consent to a criminal record check and drug screening along with permission to check references. A search on the Internet will provide several templates for you to choose from when looking for an application to use. In today's social media environment a search of Facebook may reveal applicant traits both desirable and undesirable that could affect the hiring decision. Be sure to become familiar with your state laws to make

sure you don't discriminate when making your hiring decision.

With the job descriptions and applications developed, it's time to get down and dirty with recruitment. Advertising on Internet venues or dental society publications is often very effective. Depending on the position offered and the job market in your community, it may be necessary to engage the services of a recruitment firm. Having a larger pool of applicants improves your chances of finding the one who will transform your practice. An important but often-violated rule is that no one should be hired out of desperation to put a warm body chairside. The cost of using a temporary agency pales in comparison to the damage that can result from hiring the wrong person.

Candidates who make the cut should have a personal interview. Always have more than one person interview candidates, because they can often pinpoint strengths and weaknesses you may miss. Preselect questions for the interview, and ask the same questions of all applicants to avoid bias. Questions might include: Why are you applying for this position? What made you choose this field of employment? How might you calm a nervous or angry patient? Why are you leaving your current position? Why do you feel you are the best candidate for this position?

After you have narrowed your candidates to one or two finalists, conduct a second interview. This often gives you a clearer definition of the candidate. It does not matter if you think you've found the diamond in the rough or may lose the candidate to competing job offers. Always take the extra time to check references and perform a criminal record check and a substance abuse screening. There are a number of companies that provide these services to small businesses for a nominal fee with a short turnaround time.

Retention

Even though we said that the most important thing practice managers do is hire, in no way is this the end of the staffing process. A well-designed orientation program can make a new employee productive from the first day. This first day should be a celebration, with either a breakfast or lunch period where the new employee can be introduced to everyone in the practice.

Assign a preceptor to the new employee. This is a staff member who is responsible for making sure the newbie is welcomed and who will serve as both trainer and mentor throughout the orientation period.

To ensure that the orientation is complete, create a new employee orientation checklist and start a personnel file that includes the job application, interview records, reference check information, and verifications of any credentials or certifications. Complete any necessary paperwork such as INS Form I-9, employment eligibility verification, employment agreement, receipt of your employee handbook, W-4 form for payroll withholding, personal data sheet for emergency contacts, home address and telephone number, social security number, benefit coverage election, and beneficiary designation forms.

In the first few days, the preceptor should explain the following practices and procedures of your organization, which should also be carefully addressed in your employee handbook: work hours and attendance/tardiness policy, payroll periods, when paychecks are delivered and when first check will arrive, rates of pay, overtime rules, parking arrangements, dress code, and training or introductory employment periods. The handbook should also contain all employee benefits for which the new employee is or may become eligible, including medical insurance, sick leave, vacation, personal leave, jury duty, holidays, pension programs, savings programs and/or stock plans, and life, disability, and accident insurance.

Also provide the new employee with copies of the following documents: employee handbook, safety plan, letter explaining COBRA (Consolidated Omnibus Budget Reconciliation Act of 1988) governing continuation of benefits following payroll separation, and an employee benefit booklet explaining each offered benefit. Show the employee any marketing or informational materials used with your patients. Play any videos or audio recordings you have prepared for employees or patients that explain your practice's offerings. Explain your practice's mission and philosophy.

Orientation should continue with in-depth training of technical and clinical aspects related to the employee's specific job. The preceptor and new staff member are accountable for the training's success. The orientation period ends with a formal evaluation of performance during this time. The OMSNIC and AAOMS websites are great sources for training material.

Before you can accurately evaluate an employee's performance, you must establish a system to measure that performance. This entails developing performance standards and goals appropriate to each position. Performance standards describe what workers in a particular job should accomplish and how you want the job done. These standards apply to every employee who holds the same position.

For example, a standard for a practice manager might be to maintain accounts receivable at no more than 45 days' unadjusted production. Make sure your standards are achievable and directly related to the employee's job.

Unlike performance standards, goals should be tailored to each employee, keeping in mind the individual's strengths and weaknesses. For example, a goal for a dental assistant might be to become certified with expanded function. Your staff can help you figure out what reasonable goals should be.

The first performance review should take place immediately after 90 days. This period is designed to make sure that the employee is a good fit for the practice. If for any reason you believe the person is not a good fit, then both parties can engage in a "no-fault divorce," and the employee can be released. This is not an orientation or probationary period. This is a result of employment at will. It serves as a fail-safe for mistakes or misperceptions during the hiring process. Schedule other performance reviews at 6 months and 1 year. Subsequent reviews are done annually unless performance lags.

Check with your attorney or advisor regarding employment-at-will in your state.

Deal with poor performance issues immediately, and follow up with a performance improvement plan that documents the areas of performance that need improvement, what the employee needs to do to correct the poor performance, and the consequences of not making the improvements, up to and including termination. Termination of a poor performer should never come as a surprise to an employee. A record of poor performance should be well documented. If this is done correctly, litigation will never be an issue. On the other hand, a practice should never keep a poorly performing employee because of fear or threat of litigation.

To retain emotionally intelligent employees who expect more from their employers, another step is necessary. Job enrichment motivates employees by giving them a career track that includes higher pay, increased responsibility, and variety. As the job becomes more interesting, employees become more energized. This has a positive impact on attitude and productivity and allows employees to have more control over planning their work and deciding how it should be accomplished.

This taps into the natural desire most employees have to do a good job, to be appreciated for their contributions, and to become stakeholders. Consequently, it may be beneficial to review your job descriptions to ensure that your practice is maximizing all of the available energy. An example of this would be to have different job descriptions for a specific category—such as surgical tech I, surgical tech II, or surgical tech III—with tiered responsibilities and tasks.

By using these steps, you will be able to concentrate on practicing dental medicine and not be bogged down in patient satisfaction issues related to staff problems. This creates a competitive edge that will result in higher profit and better performance.

Compliance

Navigating the federal and state employment regulatory minefields can be difficult, but the results of noncompliance can be expensive. Labor laws governing hiring practices, discrimination in the work place, health and safety, wage and hour laws, benefit and leave issues, termination, and privacy make it necessary to become and stay informed, as regulations change frequently. Make sure your employee handbook contains all necessary tools informing employees of their rights. The practice safety annual or OSHA handbook should be distinct from the employee handbook. Annually, have a training session on health and safety, sexual harassment, and privacy issues. Do not make any exceptions for policies or procedures that are dictated by federal regulations. Make sure the all labor law posters and notifications are posted in a place that all employees have access to. Remember, there are whistleblower laws and disgruntled and released employees are great sources of a practice's dirty laundry. Do not hesitate to seek the advice of your attorney.

HR Alternatives

An alternative to internally managing the HR function can be to contract with a professional employment organization (PEO). This can enable a practice to cost-effectively outsource the management of human resources, employee benefits, payroll, and workers' compensation. This allows a practice to focus on their core competencies to maintain and grow their bottom line without worrying about managing these increasingly complex human resource issues. Practices can contract with a PEO to assume these responsibilities and provide the necessary expertise. These services are integrated seamlessly into everyday practice operations and can be accomplished completely online. Advantages include improved employee practices; reduction of practice liability by improved risk management; access to comprehensive benefits that would only be available to a large employee pool, thus helping the practice to be competitive in the labor market; and improved productivity and profitability.

Managing an oral surgery practice's human resource function is a complex task. However, done properly, it can result in a workplace where staff and doctors can reach their full potential and where patient-centered care is delivered competently and efficiently. Successful HR management leads to high employee engagement and patient satisfaction, which translates into a bigger bottom line.

Financial Management

Unfortunately, dental school and OMS residency training curriculum has little to no financial management content. This places the new practitioner in a position where they must rely on other professionals to provide advice and guidance in the early stages. Your CPA and/or administrator will help a great deal in this area, but the practice owner must be involved to make the final decisions. Following are the areas that you will need to be familiar with to properly manage a practice from a business perspective.

Budgeting

Depending on the size of the organization, a budget may or may not be used for financial management. It is a good idea to use a budget or alternative method regardless of size as a benchmark to see where there are areas of improvement.

A budget is an essential part of the planning process for the practice and can include 1-, 3-, and 5-year projections. In today's practice environment, however, it is getting more difficult to plan out 5 years, and a 5-year budget is used mostly for large expenditures or for expansion. By comparing projected production, net revenue, and expenses against actual numbers, a variance can be derived. At any point in time over the fiscal year, it is possible to make decisions and adjustments based on performance compared with projections. Figure 6-1 is an example of a monthly budget variance report. Budget variances should be reviewed monthly

	Jan - Dec 14		Budget	$ Over Budget	% of Budget
Ordinary Income/Expense					
Income					
Gross Production	5,935,148		5,663,581	271,567	104.8%
Total Net Collected Fees	4,096,818		4,051,169	0	1.01
Gross Profit	4,096,818		4,051,169	45,648	101.13%
Expense					
Salaries/Wages	788,329	19.24%	805,000	(16,671)	97.93%
Payroll Taxes	90,658	2.21%	92,575	(1,917)	97.93%
Contract salary/expense	58,047	1.42%	79,350	(21,303)	73.15%
Employee related exp	350,380	8.55%	390,443	(40,063)	89.74%
Auto Related Exp	30,924	0.75%	32,054	(1,130)	96.48%
Equipment Loans-Master	114,926	2.81%	114,891	35	100.03%
Clinical Supplies	158,186	3.86%	138,384	19,802	114.31%
Major Surg-Ortho/Implan	176,802	4.32%	191,609	(14,807)	92.27%
Office Supplies	69,058	1.69%	91,860	(22,802)	75.18%
Building Rent	252,586	6.17%	249,600	2,986	101.2%
Rep & Maint/Equip Purch	198,121	4.84%	148,702	49,419	133.23%
Advertise/Brochure/sign	75,932	1.85%	29,142	46,790	260.56%
Travel & Entertainment	44,393	1.08%	31,345	13,048	141.63%
Prof & Admin costs	191,208	4.67%	180,604	10,604	105.87%
Total Expense	2,599,550	63.45%	2,575,558	23,992	100.93%
Net Ordinary Income	1,497,268	36.55%	1,475,612	21,656	101.47%

• **Figure 6-1** A sample of a monthly budget variance report.

to determine reasons for revenue and cost differences from the projected amounts.

Alternatives to using a budget can be equally effective in managing the practice, and the method selected should be what you feel fits your practice best. Other alternatives include comparing current data to the previous year. This method is especially helpful for monitoring trends in production or expenses and can help determine if certain decisions or changes had the expected impact in any one area. Another method is to use national or regional percentage data and track expenses as a percentage of production.

Accounting

There are many software programs that can be used for accounting, and your accountant or administrator will help you select the correct program.

An important concept in accounting for an oral surgeon to know is accrual accounting versus cash accounting. For tax purposes, your accountant will need to keep financial statements using the accrual method. As an owner, you will most likely want to see only financial statements on a cash basis and have the accountant discuss the accrual statements with you for planning purposes.

Revenue Cycle

There are nine steps in the revenue cycle as the patient enters the practice and continues through to the completion of treatment: scheduling, registration, financial counseling, charge capture, coding, claims processing, denial management, account resolution, and payment posting.

Revenue cycle performance is one of the most critical elements in the practice's financial status and must be monitored regularly. In many instances, it may be 60 to 90 days until all of the fees are collected. Each step in the revenue cycle is dependent on the next for timely reimbursement. Practices typically fall into two categories: fee for service and those that participate with managed care plans. Practices that are fee for service are able to set their own financial policy. This should include the collection of a portion or all of the surgical fees at the time of service, leaving any unpaid portion to be billed to the patient. A fee-for-service practice is able to generate considerable cash flow on the front end of the revenue cycle. A practice that participates in a managed care plan will typically collect the appropriate co-payment at the time of service, file the insurance claim, and wait for reimbursements. If the claim is not filed accurately and needs to be refiled,

there are added days until the funds are collected. Whether to operate as a fee-for-service practice or to participate in managed care is a big decision, and many factors will need to be considered, as they can operate much differently from one another.

Financial Policy

The practice's financial policy describes expectations for patient and third-party payment and includes fees, a timeline for expected payment, interest charges for delay of payment, collection costs, allowable discounts, and any relationship with third-party payers. When a patient is initially scheduled, fees are quoted for the consultation, data gathering, diagnostic records, and treatment planning aspects. After the consultation is completed, fees and the financial obligations for the treatment are discussed with the patient. The patient signs an agreement acknowledging their understanding, which then forms the basis of a contractual relationship. The structure of the policy, along with the manner in which it is presented, forms one of the most important impressions that patients and families form of any practice.

The financial arrangements may vary if the treatment is provided on the same day as the surgery. The overall goal in all policy objectives is to minimize the time that accounts are unpaid and to maximize the practice's cash flow.

The following examples illustrate the financial effect with two different practice philosophies. In both scenarios, the fee for service is $1200. In practice A, the patient is required to pay one third of the fee at the time of treatment. This is followed by a second one third payment within 30 days and the balance within 60 days. Practice B requires half of the payment at the time of surgery and the balance within 60 days.

By collecting $400 at the time of treatment, practice A has $800 of its fee at risk, whereas Practice B has only $600 at risk. Practice A therefore has 16.6% more money at risk for non-collection. The risks for non-collection decrease with a higher percentage of insurance coverage. Local trends within the medical and dental community regarding payment for services and any contracts you have in place may need to be taken into account when forming your financial policy.

Financial Statements

Financial statements represent a formal record of the financial activities of an entity. These are written reports that quantify the financial strength, performance, and liquidity of a company. Financial statements reflect the financial effects of business transactions and events on the entity. These statements can be difficult for most people to interpret and are not necessarily needed for the surgeon or administrator to effectively manage the business, although they are necessary for your accountant to keep. The four main financial statements typically used are:

1. Balance sheet—this statement provides the financial statements on a given date and lists assets, liabilities, and owners' equity.
2. Income statement—this statement is also known as the profit & loss statement or P&L. It gives the financial performance in terms of profit or loss over a given period.
3. Cash flow statement—this statement outlines how cash flowed in the organization over a certain period.
4. Statement of changes in equity—this shows the movement in owners' equity over a period.

As stated earlier, your accountant will keep formal financial statements, and you will want to look at them when they are issued, but for most purposes it is best to use a modified financial summary that is easy to understand and gives the information that is relevant to your business. A good financial summary should contain information that is timely, relevant, and helpful in guiding the financial decisions of your practice (Figure 6-2).

Financial Trend Analysis

A useful financial tool is a trend analysis, which can be easily accomplished by comparing current-year data to previous-year data.

Through trend analysis, a practice is able to identify changes in costs over time and can make adjustments accordingly from month to month and year to year. A positive variance indicates a lowering of costs or higher revenues. Although costs typically rise over time, it is the rate of change that is most relevant. If revenues do not keep pace with costs, then profitability decreases.

Ratio analysis of the financial statements provides an ongoing assessment of the financial health of a practice. Commonly used ratios include gross collection ratio, net collection ratio, overhead ratio, and accounts receivable turnover.

Gross Collection Ratio

Gross collection ratio = cash collections/gross charges

The gross collection ratio is a measure of payment for services rendered over a specific time. It is affected by the practice's fee schedule, the patient financial policy, the prevalence of managed care plans and payer mix, and the manner in which the revenues are collected. If gross charges for a month are $600,000 and the cash collections are $480,000, then the gross collection ratio is 80%. The 20% not collected typically would result in contractual adjustments required by the managed care contracts in force with the practice. For example, if a practice has a contract with a payer that states that the payer will reimburse 80% of the usual and customary charges, then there will be a 20% contractual adjustment.

Net Collection Ratio

Net collection ratio = cash collections/net charges

Statistical Summary June 30, 2014

	MTD			YTD		
	2013	2014	Change	2013	2014	Change
Gross Production	$145,852	$161,251	110.56%	$752,000	$845,675	112.46%
			Percent of Production			Percent of Production
Courtesy W/O's	$4,506	$5,200	3.22%	$25,360	$27,850	3.29%
Bad Debt W/O's (Net)	$2,048	$3,048	1.89%	$11,550	$16,525	1.95%
Insurance W/O's	$8,702	$9,384	5.82%	$22,300	$23,560	2.79%
Medicaid/Medicare/Workers Comp W/O's	$8,501	$4,506	2.79%	$22,575	$14,560	1.72%
Xray Write-off	$1,225	$1,450	0.90%	$6,900	$8,740	1.03%
Other Adjustments	$856	$960	0.60%	$5,860	$8,980	1.06%
Total	$25,838	$24,548	15.22%	$94,545	$100,215	11.85%
Gross Collections	$112,542	$125,685	111.68%	$620,140	$751,250	121.14%
Refunds	$9,506	$11,152	117.32%	$45,660	$52,660	115.33%
Net Collections	$103,036	$114,533	111.16%	$574,480	$698,590	121.60%
			Collectable =	$675,905	$770,725	114.03%
			Net Collected =	$574,480	$698,590	121.60%
			Collection %	84.99%	90.64%	5.65%
			Gross Collection % =	76.39%	82.61%	6.21%

	Current	30-60	61-90	91-120	121+	Unapplied
Aged Receivables - 2014	$68,850	$21,580	$12,058	$8,560	$5,600	$22,580
Aged Receivables - 2013	$52,450	$18,542	$16,542	$8,240	$5,420	$18,450

Total Outstanding Receivables	2014	$139,228
	2013	$119,644
Cash Flow		
Cash on Hand as of June 30, 2014		**$142,586**
Cash on Hand as of June 30, 2013		**$120,548**

Notes: Dr. Jones was on vacation for 1 week in June of 2014.
We started accepting XYZ Insurance in May of 2014

• **Figure 6-2** A sample of a financial summary.

The net collection ratio measures collections after allowing for managed care contractual write-offs. It reflects the effectiveness of the collection process in place. For example, if a practice has gross charges of $100,000 for the month and their contractual write-offs are 20%, then their net charges are $80,000. If they collected $75,000, then their net collection ratio would be 93.75% (75,000/80,000). The percentage not collected would typically be due to bad debt or a delay in insurance processing. If the practice is heavily involved with managed care, changes can be seasonal, and it's a good idea to use a rolling average or compare to the same period as the previous year.

Overhead Ratio

Overhead ratio = overhead expense/cash collections

The overhead ratio demonstrates the percentage of income that currently is used to operate the practice. Physician's compensation and benefits are normally not included in the overhead costs. For example, if practice collects $100,000 for the month and their expenses are $50,000, then their overhead expense would be 50%. Overhead can vary greatly among practices due to geographical demographics and/or expense and management philosophy. Some practices choose to run more expenses through a practice, and it will be up to the owner and accountant to decide which expenses are allowable under IRS guidelines.

Accounts Receivable Turnover

Accounts receivable turnover =
annual net production / average monthly A / R

The accounts receivable turnover ratio indicates how long monthly production typically spends in accounts receivable and will vary depending on payer mix, structure of managed care contracts, patient financial policy, and effectiveness of the collection process. Accounts receivable turnover also varies throughout the year, and a rolling average is recommended as well as comparison to the same period for the previous year. Financial reporting is normally done monthly.

Compensation Plans

Compensation plans assume a variety of forms and complexity. In a solo practice, a surgeon is compensated the net of revenues minus all expenses. In a multiple-surgeon

TABLE 6-2 Equal Share and Production–Based Compensation Model

	Dr. X	Dr. Y	Dr. Z	Total
Gross charges	$745,000	$600,000	$540,000	$1,885,000
Collection percentage	×0.80	×0.80	×0.80	×0.80
Cash collections	$596,000	$480,000	$432,000	$1,508,000
Percent of total	40	32	28	100
Equal Share Distribution Compensation Formula				
Collections allocated	$502,667	$502,667	$502,667	$1,508,001
(–) Overhead costs (50%)	$251,333	$251,333	$251,333	$754,000
Compensation	$251,333	$251,333	$251,333	$754,000
Compensation as % of collections	42%	52%	58%	
Production-Based Compensation Formula				
Collections by surgeon	$596,000	$480,000	$432,000	$1,508,000
(–) Overhead costs (50%)	$298,000	$240,000	$216,000	$754,000
Compensation	$297,000	$240,000	$216,000	$754,000
Compensation as % of collections	50%	50%	50%	50%

practice, the calculation of compensation may take the form of equal shares, a production-based formula, or a hybrid of both. Designing a fair compensation plan takes into account differences in practice style, production, and possibly other duties beyond treating patients. As the size of a group increases, the possibility of disproportionate production and income also increases.

The basic formula for physician compensation, whether in solo or group practice, is:

Net revenue – overhead costs (fixed, variable, and direct) = surgeon compensation

Equal Share Model

In an equal share model, the surgeon compensation is split equally among the shareholders. Table 6-2 illustrates how each surgeon receives identical compensation, despite different production levels. An equal share compensation model works well when providers have a similar range of production and do similar surgical procedures.

Production-Based Model

In a production-based model, compensation is based on the individual surgeon's collections and is useful if there are varied production levels. A potential disadvantage exists if there is competition for patient referrals within the same group.

Hybrid or Base-Plus Bonus Model

A base plus bonus model achieves a middle ground between the equal shares and production model(s). A base salary is established, which is not affected by production. It may be necessary to adjust the base from time to time to ensure that it is below the break-even point (B/E). In Table 6-3, the calculated B/E point is $50,000 in total monthly gross charges, and the amount by which each surgeon exceeds the base is bonus collections. A 50% overhead is illustrated in this example, which is allocated equally, and the predetermined base salary is $20,000 per month. The collection percentage for the practice month is 90% of gross charges. The overhead costs and the base salary are subtracted from the collected amount, which leaves $20,000 for bonuses. Distribution of the bonus is based on his or her production percentage of gross charges.

Compensation plans are not a governance tool, but a mechanism to equitably distribute the net revenue of the practice to the surgeons. Annual or semiannual reviews allow for adjustments. Modifiers to compensation can be added if there are additional duties that the individual surgeon carries out or lifestyle choices by some of the partners—for example, if they want to take more time off for family.

Collection Protocol

Patient financial policy and the associated counseling is the initial component of the collection protocol. As discussed in the revenue cycle section of this chapter, the practice's decision regarding what to collect at the initial visit (in a fee-for-service practice) is important in determining what will be "at risk." In practices that primarily participate with third-party payers, the decision is far less critical. The contract will determine the co-payment and subsequent reimbursement. The office policy needs to include a plan to manage delinquent payments. There are vendors that can externally act as collection agencies for the practice. There are state and federal guidelines pursuant to the collection of delinquent accounts.

TABLE 6-3 Hybrid or Base Plus Bonus Model

	Dr. X	Dr. Y	Dr. Z	Total
Gross charges	$62,500	$58,400	$56,100	$177,000
Amount exceeding B/E	$12,500	$8400	$6100	$27,000
Collection ratio	0.90	0.90	0.90	0.90
Cash collections	$56,250	$52,560	$50,490	$159,300
Percent of total gross charges	35%	33%	32%	100%
Overhead (50%)	$26,550	$26,550	$26,550	$79,300
Base salary	$20,000	$20,000	$20,000	$60,000
Amount available for bonus				$20,000
Bonus	$7000	$6600	$6400	$20,000

Summary

Management of an OMS practice can be challenging regardless of the number of surgeons, employees, or offices. It is improbable that one person can carry out all the aspects of business that are required each day. Surrounding oneself with an experienced team is the first step to success, but maintaining a daily active role will solidify the future. Taking CE opportunities to learn more about running a business and keeping up with the changes in the specialty will help the surgeon achieve a career that is rewarding both financially and in quality of life.

References

1. *Patient Protection and Affordable Care Act*, 2010. 42 U.S.C. § 18001.
2. Hassan, Blake W. CPA, JD. Edited by John K. McGill. *The McGill Advisory* (John K. McGill & Company Inc.) 30, no. 1 (January 2015): 8.
3. Tinsley R: *Medical practice management handbook*, ed 8, New York, 2002, Aspen.
4. Kellner Douglas: *Jean Baudrillard: from Marxism to postmodernism and beyond*, Stanford, CA, 1989, Stanford University Press.
5. Harper Ed, O'Boyle Jim: *Report: state of the American workplace*, www.gallup.com/services/176708/state-american-workplace.aspx, September 22, 2014 (accessed Feb. 28, 2015).
6. Irvine Martha: *"Study: Millennials Less Trusting than Gen X,"* Associated Press, September 2014.
7. Collins Jim: *Good to great: why some companies make the leap... and others don't*, New York, 2001, HarperCollins.
8. Goleman Daniel: *Working with emotional intelligence*, New York, 1998, Bantam Books.

7

Risk Management in Oral and Maxillofacial Surgery

JAMES Q. SWIFT, OLOLADE I. MITCHELL

The purpose of this chapter is to provide the reader a general understanding of the concept of risk management as it relates to oral and maxillofacial surgery. Each reader should be able to identify some of the basic, more prominent, nonclinical risks associated with oral and maxillofacial surgery, and understand how proactive and reactive risk management can promote patient safety, minimize a surgeon's risk for legal prosecution and aid with his or her defense.

Clinical practice affects clinical outcomes. From the decision tree used to develop differential diagnoses to the development and execution of a treatment plan, the clinical decisions, surgical techniques, and treatment an oral and maxillofacial surgeon employs can greatly affect patient safety and determine if the surgeon can be defended in a court of law. The same is true for nonclinical practice decisions. Communication and documentation, two core risk management principles, have a significant impact on patient safety and can be the factor(s) that decide the disposition of a legal case, in some situations, regardless of the treatment outcome. Because of their importance, these two core principles are a focus of this chapter.

What Is Risk Management?

Performing oral and maxillofacial surgery, or any type of medical procedure, has inherent risk. According to Rattan and Tiernan, a risk is "the probability that a given hazardous event" such as a jaw fracture, nerve injury, or anesthesia complication "will occur, and that this event will have consequences" such as the need for further treatment, loss of normal daily function and sensation, or even, in rare cases, death.[1] Rattan and Tiernan describe consequences as those occurrences that "are deemed to be negative by some or all of those who are exposed to it" (i.e., the patient).[1] After first considering the pros and cons, namely the risks, benefits, and alternatives of treatment, each patient presents with personal fears, considerations, or concerns when they agree to proceed with oral and maxillofacial surgical care and/or sedation or general anesthesia. Consider the simple extraction of an erupted third molar with periodontal impact on an adjacent second molar as an example. Even in the best of hands, a patient can be exposed to a number of dreadful postoperative side effects that are not life-threatening and usually temporary (e.g., pain and swelling). The manner by which each patient reacts to these expected risks will be largely dependent on his or her own perception, past experiences, and understanding of the risk.

The spectrum of oral and maxillofacial surgery extends from simpler procedures, such as less invasive dentoalveolar surgical procedures, to very complex procedures such as invasive orthognathic and facial cosmetic surgery. This wide range of surgical procedures introduces varying degrees of risk. The fact of the matter is, adverse events are inevitable with oral and maxillofacial surgery. In the Institute of Medicine (IOM) publication *To Err Is Human: Building a Safer Health System*, the Quality of Healthcare Committee of the Institute of Medicine reported that although a vast majority of medical errors that occur are preventable, most medical errors are not the fault of brash (negligent) individuals or groups. Instead, the IOM found that most errors are the result of a broken system(s) and conditions that cultivate mistakes or fail to keep them from occurring. The report did not imply that health care providers and systems would not be held liable for irresponsible actions, nor did it suggest that providers should be negligent. The IOM finding was projected to create a foundation for the development of better health care systems—"systematically design safety into processes of care."[2]

Although risks are an inherent part of a surgical practice, some, because of their nature and extent, can and should be averted. Risk management is a process of risk mitigation that

has been defined over the years in many ways. According to Douglas Hubbard, "Risk management is the identification, assessment, and prioritization of risks followed by coordinated and economical application of resources to minimize, monitor, and control the probability and/or impact of unfortunate events."[3] In the world of finance, "Risk management refers to the practice of identifying potential risks in advance, analyzing them and taking precautionary steps to reduce/curb the risk."[4] In health care, risk management is a process of making and carrying out decisions that will assist in prevention of adverse consequences and minimize the adverse effects of accidental losses on an organization. Simply put, it is "the evaluation and monitoring of clinical practice to recognize and prevent patient injury."[5] The premise of risk management is patient safety, and the process of risk avoidance or mitigation is a key component in proactive risk management (claim prevention and claim mitigation) and reactive risk management (claim management).

Why Risk Management: Preventing and Mitigating Risk

The next two cases illustrate proactive risk management practices.

Case Example #1

In preparation for dentures, a 52-year-old man was referred to an oral and maxillofacial surgeon for removal of all of his remaining teeth. When he presented for evaluation and consultation, he reported no health problems, no previous surgeries, and no medication history. Informed consent was obtained for extraction of teeth #6, 11, 17-25, 27 and 30-32 under general anesthesia. That same day, in the surgeon's office, the extractions were performed without apparent complication. Recovery from general anesthesia was uneventful. Hemostasis and discharge criteria were achieved. The patient was discharged home with his wife. He was instructed to use gauze with pressure to control expected bleeding, call with any questions, and return to the office or go to a local emergency room if any problems arose. When the patient got home, he reportedly experienced "significant bleeding" and vomited "coffee ground" emesis. Subsequently, the patient's wife called the surgeon's office. She was informed by the office assistant that the patient's symptoms were normal and advised to elevate the patient's head. The next day, the emergency medical services (EMS) were activated and the patient was transported to a local emergency department (ED). The EMS providers recorded that the patient had "profuse bleeding from his gums" and "black emesis was noted on the wall next to his bed." In the ED, attempts were made to attain hemodynamic stability and hemorrhage control, but they were unsuccessful. The patient died the following morning, 2 days after the surgical extractions. The cause of death was identified as "hemorrhagic shock from tooth extractions." Chronic alcohol abuse was identified as a contributing factor.

A lawsuit was filed by the deceased's estate. The claims included an allegation of wrongful death against the oral and maxillofacial surgeon. Expert opinion was obtained by both the defense and the plaintiff. According to the expert for the oral and maxillofacial surgeon, the patient had preexisting liver disease that was not reported on the health history form. He opined that the decedent likely developed aggressive bleeding and eventual disseminating intravascular coagulopathy (DIC).

Although the defense had a plausible argument, significant challenges existed in the case, unrelated to the anesthetic and surgical care rendered. Review of the decedent's chart exposed illegible, scant, and incomplete chart notes that lacked thorough detail of the care and treatment rendered to the decedent. Preoperative radiographs identified that the majority of the teeth requiring extraction were periodontally compromised, but not bony impacted or likely to have required surgical removal. However, billing records for the procedure indicated coding for surgical extractions.

In the absence of the allegation of fraudulent billing and poor documentation, this claim would have been medically defensible. The billing issue, coupled with advice from the surgeon's private counsel, resulted in the case being settled at mediation.

Case Example #2

A 50-year-old man was referred for evaluation of a "nonrestorable" tooth #19 with extensive prior treatment. After a comprehensive oral exam, extraction and placement of an immediate implant at #19 was recommended. The risks, benefits, and alternatives were discussed with the patient, and a written informed consent delineating the procedure was obtained. A few days later, the patient returned and the procedure was completed. A postoperative radiograph of the surgical site revealed that the apical tip of the implant was positioned near the superior margin of the inferior alveolar nerve canal. On the basis of the radiographic finding, the surgeon elected to immediately withdraw the implant and reposition it coronally. The complication and treatment alternatives, addressing the complication, were well documented. A post-repositioning radiograph indicated successful coronal implant repositioning.

The patient called the office a few days later and reported that he was experiencing numbness in his lower lip and cheek. He was asked to return to the office. When the patient returned, neurosensory testing was conducted and documented. The test showed he had diminished sensation to the left lower lip (paresthesia). The patient was followed over the next several weeks and continued to have residual paresthesia with reported slight improvement. One month following the procedure, a referral to a micro-neurosurgeon for nerve repair evaluation was discussed, but the patient declined the referral. He continued to report improvement. All interactions with the patient were documented

thoroughly. Several months later, the patient went to another oral and maxillofacial surgeon with new complaints of dysesthesia in the left lower lip.

Shortly thereafter, the patient retained an attorney and brought suit against the initial oral and maxillofacial surgeon. He was seeking to recover economic damages for the costs of treatment, both past and future, as well as compensation for alleged pain and suffering. The patient suggested the initial implant was the wrong size, was not backed out far enough, and that additional diagnostic imaging should have been obtained before the procedure.

In this case, the oral and maxillofacial surgeon's documentation was excellent. Chart notes were timely, readable, and complete. A strong, supportive defense was obtained and a motion for early dismissal of the plaintiff's claim was requested. The motion was granted, despite rigorous opposition from the plaintiff.

Although the outcome for these two cases is different, each illustrates that preventative measures executed prior to an event (prevention) or before a patient's pursuit of legal action (mitigation) can greatly alter the disposition of the case. In Case Example #1, by no fault of his own, the oral and maxillofacial surgeon was not privy to the patient's significant comorbidity at the time of the surgical procedure. Hence, his decision to proceed with the operation was justifiable. According to the defense expert, the oral and maxillofacial surgeon performed a fairly routine procedure, and there was no reason why it should not have been done. The oral and maxillofacial surgeon evaluated the patient before proceeding with the case and he obtained informed consent, all of which are very important in practice. However, the oral and maxillofacial surgeon failed to maintain detailed records, and because of that, he essentially made the case difficult to defend.

In Case Example #2, along with maintaining excellent records, the oral and maxillofacial surgeon immediately responded to findings on the postoperative radiograph, performed a nerve function assessment, and monitored the patient's nerve function. He even offered and executed timely referral to a specialist for follow-up care. This surgeon's ability to request a motion for dismissal was directly correlated to his nonclinical practice and less to the adverse event.

Documentation

It cannot be overemphasized that a clear-cut pathway to proactively mitigate a potential claim is to maintain superlative records. Everyone is familiar with the adage "If it is not documented, it was not done." In a court of law, poor and incomplete documentation is considered the plaintiff attorney's best piece of artillery. Comprehensive clinical records are frequently the single largest deterrent to a claim.

An accurate and complete record serves many purposes. It contributes to the continuity of care, establishes whether or not the standard of care was met, improves the quality of care, and is the key to the defense of regulatory claim or a lawsuit. In Case Example #1, the lack of good records contributed to a settlement for an otherwise defensible case. There was limited documentation of the patient's medical and dental history, and inclusion of billing records in the clinical charting opened the defendant to a subsequent review of billing charges that were found to be questionable. In Case Example #2, record keeping was contemporaneous and complete. The patient's complaints, all reported symptoms, and testing were well memorialized within the chart. In this case, the record was the leverage used for the motion for dismissal.

Information about the patient's condition, the treatment rendered, and the rationale behind the treatment are the basic elements of a good record. A record should be organized as follows:

- **History & Physical:** The history of present illness, past medical/dental history, and the findings from the physical examination
- **Treatment Plan:** The determination of a need to treat with inclusion of treatment options and the associated risk and alternatives (including no treatment)
  - Clinical Examination & Differential Diagnosis
  - Informed Consent
- **The Procedure:** The details associated with the surgical procedure as well as the surgical outcome, including the determination that the discharge criteria have been satisfied
  - Time-Out
  - Anesthesia Record
  - Operative & Discharge Note
- **The Follow-up:** Subjective and objective postoperative findings with an explanation of any future surgical plans as applicable
  - Progress Note

Using this outline, the next section will explore the various components of the health record and identify some nonclinical practice considerations.

The History and Physical

All oral and maxillofacial surgeons should obtain and review a health history for every patient. In an office, oral and maxillofacial surgeons should use a health history form/questionnaire that is completed by the patient, before evaluation and treatment. When delivering acute care in a hospital setting, a patient's medical history is usually obtained during the initial history and physical (H&P) examination. Oral and maxillofacial surgeons treating patients in an operating room or surgical suite in a health care facility should use the health history form/questionnaire contained in or referenced to in the admission H&P.

Irrespective of the approach used to obtain a patient's health history, the elements, including the history of present illness and past medical/dental history, should be comprehensive. An oral and maxillofacial surgeon should use the health history form/questionnaire, for example, in addition to having an in-depth conversation with the patient. A patient's current health condition and health

history has the potential to affect the decisions made in an operating room during a surgical procedure. Envision the patient who has massive cardiopulmonary issues but omits checking the questionnaire box related to lung disease. A discussion or review of a patient's respiratory effort and cardiovascular reserve, triggered by the health history form/questionnaire and confirmed by the review, for example, can assist with assessing the patient's fitness to undergo surgery. If a patient or family member fills out the office health history form/questionnaire, it should be reviewed for completeness. Before treatment, the surgeon and/or his or her clinical staff should sign the form/questionnaire to confirm it was reviewed. Alternatively, if an H&P is used and it is obtained from a medical colleague or other qualified health care provider, the H&P should be based on both subjective and objective findings and reviewed by the treating oral and maxillofacial surgeon. Having a complete health history will ultimately increase patient safety.

The health history form/questionnaire should include all major medical conditions and medications pertinent to treatment, including herbals, vitamins, birth control medications, medical marijuana, daily aspirin and other anticoagulants, as well as bisphosphonates and other antiresorptive/antiangiogenic medications. When classifying temporomandibular joint (TMJ) disorders, be sure to include descriptors of TMJ symptoms (painful clicking/popping of the jaw joint) on the form. TMJ-related diseases and symptoms, although rare, can be quite costly if the patient suffers from them. It is not unheard of for an oral and maxillofacial surgeon to be accused of causing TMJ symptoms only to later find out this was a preexisting condition. Documenting this preexisting problem can save an oral and maxillofacial surgeon from a potential malpractice claim. In addition to the medical conditions and medications, consider including a comment section for items that may not be on the form, but may be relevant. This will provide the patient an area to describe any additional items directly on the form. In general, the health history form/questionnaire should be reviewed for relevancy annually, and any patient being seen for repeated visits should have his or her health history form/questionnaire updated at each visit.

Treatment Plan: Clinical Examination and Differential Diagnosis

During claim-related reviews of a health record, it is often noted that the oral and maxillofacial surgeon's thought process to a final diagnosis or "differential diagnosis" is omitted. A differential diagnosis, characterization of a particular condition from other conditions that present with similar symptomology, can often be the only manner in which an oral and maxillofacial surgeon can diagnose a specific disease or at least eliminate more life-threatening ones. Documentation of this speculation (i.e., infectious lesion vs. cancerous lesion) to support the course of action taken (i.e., prescribe antibiotics vs. biopsy) may be the difference in successfully defending a failure-to-diagnose claim.

All oral and maxillofacial surgical procedures should be performed in accordance with or in response to a provisional diagnosis made by the surgeon. This diagnosis should be a designation of the pathologic entity that is to be managed. For example, a description of the potential pathologic site (i.e., impacted third molar) is not a diagnosis but rather a clinical observation. Non-restorable carious lesion or periodontal disease on the distal aspect of a second molar adjacent to a partially erupted third molar is a diagnosis of pathology for which surgery may be recommended or necessary.

Let's look at another example. A patient presents to an office with a nonpainful swelling on the roof of his mouth, adjacent to a fractured tooth. The oral and maxillofacial surgeon quickly identifies that the swelling could be an infection or a neoplasm. The oral and maxillofacial surgeon realizes the seriousness of the possible diagnoses and the anatomic location, and documents exactly how he plans to treat the swelling (i.e., antibiotics and continued observation) and how he will manage follow-up (i.e., regularly scheduled visits). He also adds the alternative courses of treatment he plans to offer the patient (i.e., biopsy), if the treatment fails to resolve the swelling. When the patient returns for follow-up, if the lesion is larger, more painful, or both, the oral and maxillofacial surgeon may decide to biopsy versus continued structured and regular observation. Alternatively, he may refer the patient to a colleague or health care provider who has expertise in the management of oral and maxillofacial pathology. Documenting the differential diagnosis makes the process clean and concise, allowing the surgeon to update the status of the patient at future visits and determine any need or indication for an alternate course of therapy.

A differential diagnosis is a well-thought-out guide. It may be information that, when provided to a subsequent doctor, can hasten the process of determining the accurate diagnosis—but only if it is well documented. Think of it as documentation that any other oral and maxillofacial surgeon can pick up and read and fully understand what was done and why it was done. Adding diagrams and photographs may be helpful to demonstrate the differential diagnoses and validate the thought process that led to the ultimate diagnosis and treatment.

Treatment Plan: Informed Consent

Many oral and maxillofacial surgeons are aware of the need for an informed consent form, but they do not always recognize that the consent process does not begin and end with a signature on a paper or electronic device. True informed consent is initiated with a discussion between the oral and maxillofacial surgeon performing the surgical procedure and the patient. This discussion gives the oral and maxillofacial surgeon an opportunity to explain the pros and cons of surgical treatment to the patient so he or she can consider the options and make an informed decision. Think about the last time you saw a prescription drug commercial on TV. At the very end, the pharmaceutical company rattles off all the risks and potential complications

associated with the specific drug. So in addition to the words that appear on the TV screen, the pharmaceutical company supplies its consumers with verbal information they believe to be necessary to make a choice. Could a patient make an informed decision with only information flying across the TV screen? Prescription drug commercials are only part of the patient education process. In addition to this, patients are instructed to use their local pharmacists and receive careful instructions from the providers who prescribed the medication, but imagine the potential consequence if they were not.

Following the conversation, consider noting the discussion in the patient's record. Documentation of the informed consent discussion in the record serves to verify that the conversation took place. This chart entry bolsters the strength of the informed consent form and serves as a "second" documentation that connects the form to the patient and the office visit. If an adverse event results in litigation, patients will sometimes claim they did not read or understand the consent form, and therefore did not know about the possible complications of the procedure. Documenting the discussion in the record gives great credence to the oral and maxillofacial surgeon, who may not recall the specific conversation but can testify that the conversation took place. Consider using a phrase like this:

> *Confirmed procedure with [patient]. [Patient] identified [Tooth # or Teeth #] need to be extracted. Discussed with the above named patient the risks, intended benefits, and alternatives of this procedure (including no treatment), obtained verbal consent and signature. [Patient] had a chance to ask questions in my presence. [Patient] voices an understanding of and accepts treatment.*

This note may also prevent plaintiff's attorneys from separating the informed consent form from the remainder of the patient's record. In a number of states (i.e., Florida, Oregon, and Virginia), the courts have barred the presentation of the written informed consent form to the jury if the plaintiff has not alleged a lack of informed consent in the complaint. In these and other types of cases, the court will rule the informed consent document is not relevant, therefore allowing a plaintiff's attorney to prevent the jury from learning that the patient was advised about the risks or known complications. This is an even stronger reason for memorializing the informed consent discussion in addition to having the patient sign the informed consent form. It will ensure there is additional evidence that the patient was aware of the possibility of known complications.

In addition, some courts may not allow the written informed consent form to be introduced into a case if it was signed before the consent discussion. To ensure that the consent process is executed correctly, the discussion must take place before the patient or legal guardian signs the written consent form. The entire informed consent process must be executed before the surgical procedure is initiated, which includes induction of anesthesia and/or administration of a relaxant or sedative medication. The written informed consent form is not valid if it was signed when the patient was not of sound mind and judgment as a result of receiving a sedative. Consider those patients who are asked to come to the office the day of surgery after self-administering a prescribed opioid. The consent process should precede the diminution of mental function associated with opioid analgesics.

The performance of oral and maxillofacial surgery has some basic, less severe risks, such as those associated with any surgical procedure (i.e., pain, swelling, infection), but it also has some unique and more severe risks (i.e., paresthesia, anesthesia, osteomyelitis, or death). Let's look at a third molar extraction as an example. According to Brauer and colleagues, the frequency of complications from third molar extractions range from 2.6% to 30.9%.[6] The removal of teeth #1, 16, 17, and 32 can result in temporary or permanent inferior alveolar (0.3%) or lingual (<0.4%) nerve injury, immediate or late fracture of the mandible, unusual inflammatory processes and abscess formation, and displacement of the third molar or an instrument.[6] The informed consent discussion and associated form for a third molar extraction should identify these known material risks and should attempt to spell out the risks in layperson's terms (i.e., loss of feeling to the tongue). Informing a patient of all possible risks is impossible. An oral and maxillofacial surgeon is required to inform his or her patients of all those complications that another reasonably sound oral and maxillofacial surgeon would consider essential to making an educated decision to proceed with a procedure.

Not identifying a well-known potential complication on a written informed consent form or during the discussion could compromise the defensibility of a claim. Here's an example of this: An oral and maxillofacial surgeon obtains written consent from a patient and explains the possible risk of nerve injury. The patient, who signed the consent, later claims he was aware that the surgery could result in nerve injury, but alleges that he was not aware that the nerve injury may result in a permanent loss of taste (a very rare complication that can accompany a lingual nerve injury). In this example, loss of taste was not discussed or delineated on the consent form as a risk. A plaintiff's attorney would be able to prove that a reasonable person would have refused to undergo surgery if they knew that there was a potential for loss of taste. In addition to specifying well-known potential risks, both the consent discussion and form should describe the benefits of and alternatives to treatment. Remember, a valid treatment alternative is no treatment at all.

Two additional relevant aspects of informed consent are consent in an emergency situation and consent for patient refusal. When an oral and maxillofacial surgeon is faced with an urgent situation, where a patient presents (most likely in a hospital setting) and he or she is unable to consent and there is no power of attorney available, the oral and maxillofacial surgeon is required to use

his or her best professional judgment to proceed or not proceed with potential life-sustaining treatment without "consent." On the other hand, a patient who presents in an urgent situation, but is of sound mind, has the right to consent to or refuse recommended treatment. If a patient chooses to refuse treatment, it is extremely important that he or she be fully aware of the risks associated with this refusal.

Patients who are not lucid cannot refuse to receive *emergency care* and treatment, but the effort to support the clinical decision of "bad judgment" on the patient's part requires evaluation by a licensed psychiatrist, a process that is onerous at best. Treating contrary to a patient's wish should not be managed in an office setting, but may be necessary in a hospital setting where a patient might present with facial trauma and refuse emergency care. To support the informed refusal discussion, an oral and maxillofacial surgeon may choose to request the patient sign an informed refusal form. Patients may or may not agree to sign the informed refusal form, so there should be corresponding documentation to support the discussion in the patient's health record.

The Procedure: Time-Out

Many oral and maxillofacial surgeons perform a surgical time-out before proceeding with surgical procedures. This practice, if performed accurately, has the potential to prevent errors such as wrong-site tooth extractions or anesthetizing a patient who failed to remain NPO (refrain from eating and drinking) overnight. The time-out procedure requires the surgeon and his/her staff to address the basic preoperative necessities, preventing the surgical team from cutting corners. Just as important as it is to perform a time-out, it is equally as important to document that the surgical time-out was done. Document the process by using a Time-Out Checklist. This communication tool will employ a system of checks and balances and will ensure patient safety before any procedure, holding the entire surgical team accountable for every patient's individualized care.

The Procedure: Anesthesia Record

If a claim arises and there is an anesthesia component, the oral and maxillofacial surgeon's office records will be compared to a hospital anesthesia record. Brief and insufficient notes about the anesthesia or sedation used during a procedure are difficult to defend. An anesthesia record with a timed log that incorporates the patient's vital signs (including capnography and pulse oximetry), the type, amount, and time of medication administered, and the patient safety measures employed clearly demonstrates how the procedure progressed. In addition, an anesthesia record should include verification that a signed consent form is on file, the patient's pre-sedation ASA classification (I-V), body mass index (BMI), Mallampati Assessment score, cervical mobility, any limitation of mobility of the mandible that may complicate direct laryngoscopy, denial of pregnancy, and the patient's NPO status. In the midst of a busy day, having another documented trigger (in addition to the time-out) that evaluates the appropriateness for anesthesia or sedation promotes patient safety. This information will be important to have if the care comes into question in the case of an adverse outcome.

The Procedure: Operative and Discharge Notes

For a surgeon, the need to document the surgical details (i.e., type of instruments used, incision, surgical access, ostectomy employed, number of teeth removed, the condition of the teeth, etc.) of an operation is eminent. Less eminent, though, may be the need to accurately reflect what was done in the operatory as well as the patient's disposition. If a procedure was complicated or an unusual finding was identified and a change in the original treatment plan occurred, the operative note should explain that. Likewise, the condition in which the patient left the operatory and the office should also be detailed in a discharge note. It is important to document that the discharge criterion were met. Postoperative instructions are regularly given, but are not always followed by patients (i.e., the need for an escort and 24-hour postop care). The oral and maxillofacial surgeon cannot control what occurs when the patient leaves the office, but he or she can document what postoperative instructions were given and the name of the patient's escort. Whether and when the patient is scheduled for a return appointment should also be documented.

When documenting postoperative findings and discharge instructions, be wary of doing so in advance. Employees with good intentions, in an effort to save time, may complete the discharge note before the patient's actual discharge. If an emergency or a complication arose and the patient's record was out of sequence, it would appear careless when presented in the courtroom and would be hard to defend.

The Follow-Up: Progress Note

The SOAP (*S*ubjective *O*bjective *A*ssessment *P*lan) format is one documentation style well-known to oral and maxillofacial surgeons. When this format is used as an outline for the progress note, it is easy for any reviewer or other treating provider to assess the patient's condition, diagnosis, and plan for future care. The SOAP format allows a quick overview of the patient's clinical course to determine what has been and what still needs to be done. Outlining the progress note in the SOAP format will also help to ensure that the note contains only clinical information. All administrative information, including insurance and billing, should be maintained in the nonclinical part of the chart. The only exception is if the information will directly affect care. For instance, if a patient refuses or wishes to delay recommended care and treatment because of a lack of funds or insurance, noting this in the progress notes is pertinent to the care of the patient. If a claim for failure to treat were to occur, this documentation could explain why the treatment was not performed or was performed later.

Document a patient's status update at each and every visit. Most patients come to the oral and maxillofacial surgeon's office with a problem or concern, and documentation in the

chart usually reflects that primary complaint. However, when the condition or pain resolves, the subsequent resolution is often times omitted. For example, if a patient presented with pain to the lower right mandible and that pain resolved, but a new onset of pain to the left upper maxillary is reported, both should be documented. The patient may have selective memory and forget that the original issue was resolved. If that same patient claims that the oral and maxillofacial surgeon never did anything about his/her condition, a note such as, "I don't have pain anymore" will clearly refute the patient's claim. Similarly, if a referring specialist is treating the patient, he or she would be able to discern if the patient's issue is resolving or getting worse.

When composing a progress note, remember that patients and subsequent treating providers can access these records. If records are requested for legal purposes, an additional host of other people (i.e., attorneys) will also be able to access them. Imagine your record magnified on a courtroom screen. What is the jury going to see? What about the judge? All documentation in the health record should be composed in an objective manner. In most cases, this is not a difficult task, but documentation of disgruntled or difficult patients can make documenting objectively more challenging. For example, composing effective objective notes that demonstrate the patient's anger by using the patient's quote (i.e., patient screamed "expletive" and hung up) is a useful tool. This can reflect the situation without having to describe it with opinion and without personalization.

With the development of templates, in both paper and electronic form, new documentation issues have arisen. It is easier to enter or select incorrect information or omit pertinent information. Distinct from the paper templates, electronic templates are often pre-populated with the most common answers, clinical findings, etc. Using templates saves time and adds efficiency to charting, but if the oral and maxillofacial surgeon is not diligent in ensuring that the preselected information is accurate for the patient of record, documentation errors can occur. Errors in documentation can lead to serious patient safety issues, especially if follow-up care is needed. When creating a template, be sure it can be tailored to an individual patient. When completing it, pay careful attention to the selected responses.

The copy and paste function and the use of charting by exception are additional charting nuances that have added to the complexity of record keeping.[7] Here is an example that resulted in a pre-trial settlement: An oral and maxillofacial surgeon with a busy practice found himself reliant on the copy and paste functionality of a patient's operative record. After receiving a Summons and Complaint with a request for health records of two unhappy patients, he quickly copied and pasted the surgical procedure from one patient's chart to another. He failed to customize the notes and was later found to have unreliable documentation in both patients' records as a result of identical notes. Charting by exception, an additional charting nuance, or identifying conditions as "within normal limits" has the potential to omit necessary patient-specific conditions as well.[7] Be extra cautious when using these features in clinical charting.

The health record has evolved over time. In the past, all notes were maintained in a manila folder or colored binder and formulated on paper. With a desire to achieve contemporaneous documentation, templates and eventually the electronic medical record were developed as tools to make charting more efficient. Time constraints remain a huge factor in achieving contemporaneous documentation. For most surgeons, keyboarding takes more time than dictating, writing, or transcribing notes. Because we tend to forget a large portion of information we receive almost instantly, it is good practice to document concurrently. Document the progress note immediately after the treatment is rendered to ensure that nothing is inadvertently left out. If necessary, revisit the note to add any additional thoughts in an addendum. Adhering to this practice standard can be beneficial, especially in cases where a patient might be operated on by one oral and maxillofacial surgeon, but followed up by another. This is also an important practice to adhere to when documenting electronically, because of the significance of "metadata." Metadata "allows no ambiguity with a chart."[7] It is "the data on data entry and no computer is exempt from it," nor is it exempt from discovery.[7] In general, all entries are time stamped, but if there is concern of "fictitious, self-serving" entries in the record, metadata can be subpoenaed. However, unlike the paper record, there is no uncertainty as to the findings. Here's an example: A nurse states that she took a patient's blood pressure at 8 PM, but by way of metadata she was found to be in another part of the hospital at that time.

Noncompliance

Noncompliance is another important element of documentation that should be included in the health record. Even though it may not apply to all patients, the issue is important enough to warrant some discussion. The scenario presented earlier in Case Example #2 demonstrated how a lack of patient compliance can cause problems. The patient developed paresthesia and was referred for follow-up with a micro-neurosurgeon, but refused to be evaluated. A general thought may be that when a patient chooses to be noncompliant with recommendations, he or she should be responsible for any problems that might arise from his or her noncompliance. However, this is not always the case. Often, patients and their attorneys try to shift the responsibility to the doctor. As explained in the informed consent/refusal section, it is imperative that an informed discussion with the patient of the consequences of noncompliance be demonstrated in the record. If the issue related to noncompliance is more of a refusal to stop an activity such as smoking, it is also important to address it and document all steps taken at each visit ("patient states still smoking, warned to stop and suggested a nicotine patch"). An oral and maxillofacial surgeon should use his or her judgment to determine when the discussions and recommendations become futile and consider sending a notice of noncompliance letter.

A notice of noncompliance letter is a letter addressed to the patient that spells out the recommended care or treatment along with the frank consequences of noncompliant behavior. An oral and maxillofacial surgeon's genuine concern about the patient's care should also be mentioned in the letter. If the patient fails to follow the advice, the oral and maxillofacial surgeon may choose to dismiss the patient from the practice. It is important to apply focused professional judgment when considering when to stop treating a noncompliant patient. To prevent claims alleging patient abandonment, patient dismissal should be initiated at a good stopping point in a treatment plan, and a letter of dismissal should be sent. This letter should include the reason for dismissal, a notice of intent to provide emergency treatment for a minimum of 30 days, a referral source to find another oral and maxillofacial surgeon, an offer to transfer records to another provider and/or the patient, and an Authorization for Release of Medical Records form. Both the notice of noncompliance letter and the dismissal letter should be sent via certified and regular mail with a return receipt request. Consider state regulations to determine state-specific requirements and consult with local dental societies for guidelines.

Record Altering

A health record entry should *never be altered*. Altered records make a claim indefensible and can shatter an oral and maxillofacial surgeon's credibility, leading to a claim of spoliation, a criminal offense. In addition, juries can award amounts above the various limits set by state laws for personal injury cases, if a record is found to be altered. If there is a need to edit a paper record entry that is written in error, make use of the single-line strikethrough and date and initial the change. Perform the authorized technique used by the specific electronic health record program for editing errors in the electronic record. Some electronic health records save all versions of a note after an edit is done, ensuring that the original entry can still be retrieved even if it is "deleted." Contact the IT specialist or program developer used at your office for specific instructions.

Communication

Poor communication is one of the main reasons patients file lawsuits. Studies show that roughly 80% of all malpractice claims contain some component of failure to communicate, including a lack of interpersonal skills from the doctor.[8] Communication, both verbal and nonverbal, has the power to affect the disposition of a claim. When communicating with a patient, a surgeon must consider the tone, the posture, the facial expression, and the body language that is shown. Is the patient upset? What are his or her nonverbal cues? Statistically speaking, only 8% of our day-to-day communication is accomplished verbally. The other 92% is expressed through facial and other nonverbal cues.[9] Remember the saying, "You attract more bees with honey than you do with vinegar"? The same can be said for patients. Treating patients with empathy should be a foregone conclusion, but frequently this is not the case. "Treat[ing] others [your patients] as you would want to be treated" can make for a rewarding practice and a rewarding life. Patients who like their surgeon(s) are less likely to take them to court. Consider the use of empathetic gestures and remarks during conversations even in the midst of a good outcome. Dr. Jerome Groopman, author of the *New York Times* bestseller *How Doctors Think* (2007), said that patients are interrupted by their doctors within the first 18 seconds of a conversation.[10] Although there are probably time constraints within an office setting that makes being fully engaged and participating in a two-way conversation difficult, the use of active listening skills can save time on the back end. That time pales in comparison to the time it takes to get through a lawsuit that drags on for 3 or 4 years.

Employing good communication skills is most helpful when the communicator knows his audience. After an initial meeting with a patient, gauge his or her level of interest, educational capacity, and what they already know about the treatment. Explain and educate patients about their procedures in a way they understand, breaking it down as appropriate. Consider that "one in five American adults read at a fifth grade level or below and that the average American reads at an eighth and ninth grade level."[11] Poor understanding of the planned procedure can easily result in lack of compliance and dissatisfaction with the results. Be clear about expectations. Remember that technology has greatly affected the delivery of care. The patient may have accessed a wealth of information on the Internet before arriving at your office, but may not have a thorough understanding of the procedure, anticipated outcome and associated risks.

Technological advances to obtain medical information are growing at or faster than the pace that medicine is evolving. A new generation of patients is arising. "Today's patients are less likely to take what a physician tells them at face value, and often come to appointments armed with a self-diagnosis backed up by information they obtain from WebMD and Google."[12] According to Bendix and colleagues, "nearly 60% of patients are considered online diagnosers."[12] Although the idea of having knowledgeable patients is intriguing, the notion does pose its own potential problems. Treating these new-age patients requires a new mindset as it relates to the hierarchical nature of medicine, with the physician at the top and the patient at the bottom. Bendix suggested that although "Dr. Google" is widely consulted, an astounding percentage of patients are now informing their treating doctors about what they have read before they consider their options.[12]

Communication guidelines within a practice setting can also be beneficial. Consider an example where a developing infection went undetected because of a lack of communication between an office assistant and the oral and maxillofacial surgeon. In this example, the defense was complicated because the evidence showed that the patient

made several phone calls to the office after third molar extractions, but was never asked to come in to be evaluated. During the discovery phase of the claim, the depositions turned into a "he said–she said" blame game, which resulted in questions regarding the oral and maxillofacial surgeon's credibility. Questionable credibility in the midst of a claim can make the case difficult to defend. The person who answers the phone in the office has a great deal of responsibility. Does he or she have the qualifications to manage the office calls? Is there a protocol for calls received postoperatively? Is there a chain of command established? Staff training and office-based policies and protocols that establish communication guidelines are critical to delivering consistent and timely care, supporting patient safety. The time to train is before an untoward event occurs.

Another important issue that involves communication is patient referral. In the nerve injury case discussed earlier, the patient was appropriately referred to a micro-neurosurgeon a month after the oral and maxillofacial surgeon noted that the paresthesia was not fully resolved. Determining the best time to refer a patient to a specialist can be dependent on the reason for referral, the mechanism of the injury, patient-specific factors, and the comfort level of the oral and maxillofacial surgeon. Recommendations for the proper referral process have been published in the literature. According to Alhassani and AlGhamdi, referral to a micro-neurosurgeon is indicated within 2 months of failed improvement.[13] Alhassani and AlGhamdi added, "early referral will allow for early management before distant degeneration of the nerve takes place."[13] On average, degeneration of the nerve was found to occur about 4 to 6 months after the nerve injury. Renton suggests immediate referral for endodontic, implant, and third molar–related nerve injuries to ensure that lingual nerve exploration occurs before 12 weeks.[14] It is important that an oral and maxillofacial surgeon be aware of the research related to referrals to ensure compliance with the standard of care. Knowledge of the practices employed by other reputable oral and maxillofacial surgeons and decisions based on theory can be supported in a lawsuit.

Anesthesia/Emergency Preparedness

Proactive risk management is not a task that can be executed alone. Oral and maxillofacial surgeons practice in many different arenas (office, hospital, group practice, solo practice) with an array of clinical and nonclinical staff. Practicing in an environment with additional personnel only adds to the complexity of the profession. The precautions necessary to ensure that everyone is prepared to act or react in a given situation are the responsibility of the oral and maxillofacial surgeon.

Consider this example: A 21-year-old patient presents for third molar extractions following a previous consult visit. The patient develops respiratory distress after receiving anesthetic medications (midazolam, fentanyl, ketamine, lidocaine, and propofol). The respiratory distress develops into an airway obstruction, and attempts to maintain the airway are futile. The patient becomes bradycardic. He eventually goes into cardiopulmonary arrest and dies shortly after being transferred to a local emergency room. Review of the in-office emergency care revealed that the resuscitative efforts performed were substandard. The bag valve mask was nonfunctional, so positive pressure oxygen could not be provided. It was opined that the administered emergency medication, two sub-intubating doses of succinylcholine, contributed to the bradycardia. According to the EMS providers, the office staff was not prepared to manage the emergency. It was alleged that the emergency response failed to prevent the cardiopulmonary arrest and the eventual demise of the patient. The patient's family pursued legal action. Discovery (disclosure of facts and documents) in this case resulted in findings that demonstrated negligence (failure to exercise proper care resulting in injury) on behalf of the oral and maxillofacial surgeon and his staff. In addition to the staff being ill prepared, the equipment was damaged and nonfunctional. The case was deemed indefensible and was settled before trial.

Anesthesia complications in-office can be difficult to manage, but the fact is, the surgeon is ultimately responsible for the patient's well-being. In 2014, the American Association of Oral and Maxillofacial Surgeons (AAOMS) mandated that all surgeons begin using capnography as one more failsafe to promote a "culture of safety" in anesthesia delivery whenever possible. For complicated cases, CRNAs and dental anesthesiologists may be a useful asset for in-office anesthesia as well. Patients in need of oral and maxillofacial surgery may also be referred to treatment in a hospital setting, where an anesthesiologist will be responsible for the anesthetic management of the patient.

Regardless, it is essential to establish emergency preparedness before attempting to sedate or anesthetize any patient. The oral and maxillofacial surgeon and anesthesia team must understand the risks every patient presents with and deliver the appropriate anesthesia. Some surgeons believe moderate to deep sedation should not be performed in the office if the surgeon does not think he/she can get the patient intubated in the office. All in all, as an oral and maxillofacial surgeon, you must be honest with yourself and your patients, especially when their lives are at stake.

As for emergency equipment, check the equipment for functionality and ensure that backup equipment is available. If you are treating and anesthetizing pediatric patients in your practice, be sure to have the proper and necessary equipment to resuscitate a pediatric patient. Create a schedule of emergency training for the office staff, and challenge them to be accomplished at all tasks. Practice makes perfect. Because emergencies do not happen often, regular training is essential. If and when an emergency does occur, have a designated staff member document all treatments given and the time of delivery.

This will help the EMS and emergency department staff, who may be subsequent treating clinicians, understand the treatment already provided, and show the surgeon's expertise in treating emergencies.

Failure to Diagnose

Just as important, OMS National Insurance Company, RRG (OMSNIC) claims that experience indicates that failure-to-diagnose cases commonly involve a delay in the diagnosis of cancer, infection and/or osteomyelitis, and jaw fractures. Although only a small percentage of all claims, failure to diagnose accounts for over $30 million in indemnity and expense payments combined, since the inception of the company. Failure to diagnose is another area where interoffice collaboration is essential to reducing the number of claims.

Some failure-to-diagnose claims are the direct result of a lost or undelivered pathology specimen. This can happen for a number of reasons, one of which is that the pathology specimen was lost in the mail. A lost biopsy specimen can be disastrous. Therefore, it is a good idea to send every pathology specimen by a mail service where the package can be tracked (e.g., UPS, Fed Ex, USPS Express Mail). Be sure that all packages are securely wrapped and protected so that the specimen itself cannot fall out and be lost.

Lost or ignored pathology reports have also been the source of claims related to failure to diagnose. There are incidents where the pathology report was lost in the mail, sent to another doctor with the same name, or just not sent out at all. Consider using a laboratory log to track biopsy specimens and perhaps combining it with tracking of other items such as surgical guides. Having one place to look for items sent out will make it easier to keep track of them. Once a biopsy report comes in, the oral and maxillofacial surgeon should review it before it is filed. This will help ensure that a patient is not left waiting for a report that never comes. If the patient was referred for treatment, send a copy of the report with your assessment to the referring dentist or other practitioner.

Why Risk Management: Managing Risk

Now let's switch gears. Imagine you just finished seeing your last patient of the day. The office is quiet, and you can faintly hear some of your staff saying "goodbye" and "goodnight" as you slowly close your office door. You take a seat behind your office desk and pick up a handful of mail. You have seasoned and responsible staff. Your primary administrative staff places all your mail in your office inbox and tags them green, yellow, and red for "routine," "important," and "urgent." For the first time in weeks, you have an "urgent" document. You assume it's an urgent lab result, but you notice the letterhead reads "The Law Office of Johnson & Johnson." You realize you're reading your first legal claim letter. The attorney who authored the letter is informing you that all communications regarding your patient, who you thought was simply lost to follow-up, must now go through him. What do you do?

Professional Liability Insurance

Medical professional liability insurance or malpractice insurance provides coverage that protects health care providers from bearing the full cost of a defense related to a demand for compensation or claim of negligence or intentional harmful treatment decisions. This type of insurance coverage helps transfer some or all of the associated risks, which can be significant. Malpractice insurance does not cover criminal charges or punitive damages, but any reputable professional liability carrier typically provides (1) a robust defense for claims, grievances, and/or requests for compensation that are not yet lawsuits; (2) the associated costs of defense and monetary damages; (3) a competent defense against complaints filed with the department of professional regulation or board of dentistry/medicine; and (4) risk management education. Nearly all states require that physicians have liability insurance.[15] Most, if not all hospitals require proof of coverage in order to maintain hospital privileges. Although some physicians decide to take the risk and practice without coverage ("go bare"), they are the exceptions.[15] In a litigious society, where nearly 1 in 10 oral and maxillofacial surgeons may face a claim each year, why risk it?

When purchasing insurance, often the primary focus is cost. Although important, price should not be the only consideration. Imagine selecting a dental school or residency program simply because it is the cheapest. Other factors, such as the program's reputation, the quality of faculty, your "fit" with other students and residents, should also be considered. The same process should be considered when choosing a malpractice insurance carrier. How much does the carrier know about the oral and maxillofacial specialty?

Claims Data

According to data collected by OMSNIC, over the past decade, the frequency of claims filed against oral and maxillofacial surgeons has remained stable, but the amount of indemnity payments has risen substantially. The number of significant indemnity payments has increased, and a jury no longer considers $1 million to be a large award. With attorney fees consistently rising, defense expenses have also increased at a steady rate. By the end of 2013, OMSNIC researched and closed over 11,000 claims. Of these closed claims, approximately 71% were related to dentoalveolar surgery, 10% were related to dental implants, and 6% or less were related to orthognathic surgical procedures, TMJ surgery, maxillofacial trauma, and facial cosmetic surgery. It's no surprise that dentoalveolar surgery, the procedures that are performed most often by an oral and maxillofacial surgeon, accounted for the majority of the claims and

indemnity payments. TMJ-related procedures accounted for the second largest number of claims and indemnity payments. Dental implants and orthognathic surgery claims closely followed TMJ surgery, leaving maxillofacial trauma and facial cosmetic procedures with the fewest number of claims.

Of all the indemnity and defense costs paid out since the inception of the company, many were related to nerve injury. Malpractice claims ranked by percentage of indemnity and defense expense are nerve injury, improper performance of surgery, wrong tooth extraction, failure to diagnose, infection, and office or hospital death. It should be noted that wrong tooth extraction continues to be a common claim. However, our research tells us that most cases could have been avoided since they may be caused by both diagnostic and communication failures, specifically those between the referring dentist and the oral and maxillofacial surgeon. Even if a referral is incorrect, the oral and maxillofacial surgeon may be held responsible for extracting the wrong tooth. The cost to resolve lawsuits is significant, and it is certainly more expensive than any sum associated with taking the steps to avoid them in the first place.

The Tripartite

To better understand how reactive risk management can help improve care and benefit the bottom line, let's first outline the relationship between risk managers, claims professionals, and defense attorneys, a modern-day tripartite affiliation. This (tripartite) collaboration promotes risk mitigation, reduces litigation costs, and, essentially, improves the delivery of oral and maxillofacial surgery. When a lawsuit is filed against an oral and maxillofacial surgeon, the defense attorney is the lawyer who defends the allegations made against the surgeon. The claims professional is the professional liability insurance company representative who works alongside the defense attorney overseeing the claims file, producing reports, and performing additional litigation-related duties. The risk manager is the company professional behind the scene who dissects the case to identify its risks and uses the case-specific strengths and weaknesses to deliver oral and maxillofacial surgeon focused education.[16] In the hospital setting, the roles of a risk manager and a claims professional might overlap. The claims professional handles pre-litigation suits, but the risk manager is the first responder for all reported incidents. Often, in a hospital setting, the risk manager initiates the contact with the provider and interviews all of the parties involved in the case, prepares the report, manages the file, and hands it over to the claims professional if or when an actual claim is filed.

Regardless of the setting, failure to report the incident or claim to the appropriate party within a reasonable time frame could jeopardize the possible resolution of the claim and lead to the plaintiff (the patient) filing a lawsuit. As a general rule of thumb, one should contact their professional liability insurance carrier or hospital legal department immediately when there is:

- Death of a patient during or after treatment under any circumstances,
- Request(s) for release of medical records,
- Legal action against a colleague involving a patient you have treated,
- Receipt of a subpoena or suit papers,
- Contact by an attorney, peer reviewer, licensing agency or state dental board,
- Request for compensation or refund from a patient, or
- Any incident, adverse event or patient complaint that may later turn into a claim or suit.

Doing so can only benefit the results of a case.

The Incident versus the Claim

An incident is considered an adverse event or bodily injury that is believed to have the potential to result in a demand for money or services as compensation. A claim is a demand for money or services as compensation or reimbursement for a loss or bodily injury alleged to be the result of alleged negligence. Claims are typically initiated with a demand (i.e., request for compensation) made directly to the provider (the surgeon). The demand often alleges that an injury (i.e., nerve damage or death of a patient) was caused by an act or omission that fell below the standard of care (medical malpractice). Standard of care is generally defined as the level and type of care that a reasonably competent and skilled health care professional with a similar background would provide. As a medical specialist, the oral and maxillofacial surgeon's standard of care is defined by the care and treatment delivered by other oral and maxillofacial surgeons across the country who serve as expert witnesses. After the demand is made by the claimant, the oral and maxillofacial surgeon immediately reports it to his or her medical professional liability insurance carrier or hospital legal department, and a claim file is opened. The claims professional will then contact the claimant's attorney and commence an investigation.

During the claim phase, a monetary demand for damages and other appropriate compensation is typically made by the claimant. A claim may be resolved by means of a negotiated settlement or a denial. In some instances, an unresolved claim will lead to litigation. Litigation is not always preceded by notice of a claim. Sometimes it commences without prior notice in the form of a Summons and Complaint to the oral and maxillofacial surgeon.

The Lawsuit

The litigation process is initiated by the patient (the plaintiff) or the patient's attorney filing a legal complaint (Summons and Complaint) that is served upon the oral and maxillofacial surgeon (the defendant) by a sheriff or other law enforcement official. The Summons and Complaint must be followed by an official response from the defendant, typically within 30 days of receipt.

As mentioned before, it is essential that at this juncture, the oral and maxillofacial surgeon's professional liability insurance company or hospital legal department be contacted immediately so as to initiate the tripartite process. All communications by the oral and maxillofacial surgeon concerning the case and the patient should be limited to the claims professional and the defense attorney assigned to the case. The claims professional will obtain the relevant information, hire a defense attorney, and provide the oral and maxillofacial surgeon guidance on how to proceed. The defense attorney will follow up with a detailed conversation with the oral and maxillofacial surgeon and will prepare a Response to the Complaint. The defense attorney and the surgeon share an attorney-client privilege that prohibits third parties from gaining access to the communications shared between them. Disclosure of the confidential conversations to a third party generally waives this privilege. In other words, be sure to not discuss the case with anyone except your attorney or claims professional.

Depending on the complexity, the length of a case from start to finish can be as little as a few months or as long as several years. Imagine being on a roller coaster ride with a never-ending lift hill (upward-sloping section of the roller coaster track). There is a steep climb upward, but the point at which the train hits the peak in the track is unknown. With over 25 years of experience, OMSNIC has managed small claims as short as 3 months as well as more tenuous interminable claims that went on for 10 to 14 years. "On average, it takes 4 to 5 years to resolve a claim from the date of the incident."[15] Within this time, information is exchanged between parties to assist with the investigation (discovery). During the discovery period, the involved parties and appointed expert witnesses undergo a formal question-and-answer session called a deposition, which is conducted by counsel and recorded by a court reporter. The defense attorney preps the oral and maxillofacial surgeon and seeks his or her advice regarding the retention of an appropriate consulting expert. Throughout this process, the claims professional evaluates the case and reports to an internal committee or hospital board that oversees and reviews all of the cases, including those that are in the claim phase. For example, at OMSNIC, a committee of oral and maxillofacial surgeons reviews and evaluates the care, treatment, and expert findings. An informed and reasonable decision to resolve the lawsuit is then made.

The Resolution: Dismissal and Settlement

A lawsuit will be resolved in one of three ways. The case can be dismissed by a motion (a formal request to the court to take a particular action) either by the defense or by the plaintiff if he or she believes the chances of winning the case are nonexistent. The case can also be settled. Sometimes, a determination to settle is made when a case is perhaps medically defensible, but compromised because of poor documentation, weak support from the expert witness, or lack of informed consent. In other instances, a case is not deemed medically defensible and may need to be settled. If necessary, a form of alternative dispute resolution (i.e., mediation, arbitration, professional review panel) can be used to achieve settlement.

The Resolution: Trial

The final and most well-known type of lawsuit resolution is a trial. A trial is an arduous, foreign journey for most surgeons, and the outcome is never guaranteed. Jurisdiction, as it relates to geographic location, may have the same steering potential in the court of law as it does with politics. Some states are considered more litigious than others and are known to have more verdicts in favor of the plaintiff. Others are more known to favor the defendant. The time it takes to get to trial, the pool of jurors, the judge, the laws, the need for a unanimous or majority verdict, and the monetary damages allocated for a case are all matters that are affected by jurisdiction. The trial process begins with jury selection and concludes with jury deliberation. Although jurors are cautiously selected, their lack of knowledge and experience can greatly affect their ability to be impartial. Consider the pool of jurors that is convened to render a verdict for a pediatric oral and maxillofacial surgeon who resides in the same state where the top local story is about two children who died after receiving anesthesia in a dental office. Disclosure of the case to the public along with a great deal of media attention has the potential to limit the impartiality of the jurors.

After jury selection, the plaintiff and defense attorney deliver their opening statements, present the evidence to the jury by way of testimony, and conclude the trial with closing remarks. Once the final verdict is presented, the judge either agrees or disagrees and the final judgment is entered. If there is a defense verdict, it means no negligence was found and the plaintiff is not awarded any money. If there is a plaintiff verdict, it means negligence was determined and monetary damages (indemnity) are awarded to the plaintiff. If by chance, neither a defense nor plaintiff verdict is reached, the jury is considered "hung," and a new trial may take place at a later date.

Some basic but not fail-proof tips to help minimize the chances of participating in a claim or lawsuit include:

- Be aware of your patients' level of satisfaction. Intervene early. Be cognizant of a patient's complaint and take the time to resolve the complaint at the patient–provider level.
- Be an integral part of the review process before sending a patient to collections. Know if a patient who has failed to complete payment for treatment suffered from an adverse event or was dissatisfied with the care received.
- Once served with legal documents, never attempt to respond on your own or contact the patient or the attorney who is representing the patient; notify your insurance company and let your claims professional do that.

- When there is a known adverse event or unwarranted surgical outcome, notify your professional liability insurance company or hospital legal department before a claim is filed.
- If you don't have professional liability insurance and you are not covered by the hospital, you will be responsible.

Emotional Rollercoaster

According to Williams (as cited in Tang[17]), roughly 50 years ago, doctors were sued far less than they were 20 years ago. As a specialty, nearly 1 in 10 oral and maxillofacial surgeons has a claim per year, suggesting that there is a strong likelihood that an oral and maxillofacial surgeon will have to defend a lawsuit at least once over the course of his or her career. "For many physicians, the prospect of being sued for medical malpractice is a singularly disturbing aspect of modern clinical practice."[18] Even with state-enacted tort reforms, the medical-legal climate remains tenacious. Jury verdicts are becoming more and more difficult to predict and claim resolution payments are steadily increasing.

Being involved in litigation can be stressful, especially when the involvement is coupled with uncertainty and unpredictability of the litigation process and injured self-esteem. The stress encountered in litigation is not the same type of stress a surgeon learns to cope with in school or in practice. This stress can manifest itself physically (fatigue, anxiety, loss of sleep), economically, and in relationships (peers, family, etc.). The truth is, much of what goes on in the litigation process is beyond the surgeon's control. The timing of the trial, the length of discovery, and the retention of experts subpoenaed by plaintiffs are all matters that are dealt with as they occur. The best way to deal with the stress and anxieties that come with the words "You've just been served" is to learn as much as possible about the case and malpractice litigation in general, and engage in activities outside the practice to keep from dwelling on the litigation issues. The more knowledge one has about the process, the more confidence and comfort he/she can have about the case. As exasperating of a time as this could be, understand that participating actively in the defense will help restore your sense of balance.

Regulatory Awareness

While practice trends are advancing, health laws are adapting. Staying current with the most recent industry trends, laws, and regulations, both state and federal, can feel like an impossible task. However, the cost of not doing so could result in an untoward action against an oral and maxillofacial surgeon's dental, medical, or DEA license. For example, some oral and maxillofacial surgeons dispense pharmaceuticals in their offices. In some states, dispensing medication is not permitted by law, and not knowing is not an acceptable excuse.

We are constantly bombarded with information from various resources each and every day, making it a real challenge to stay organized. Consider setting aside a block of time, maybe 10 to 20 minutes each day, to peruse various industry sites and publications. Maintaining a folder of new information is a great way to keep track of and monitor current issues affecting your practice. There are several sites specific to oral and maxillofacial surgeons that can be helpful as well. The AAOMS website contains an Advocacy E-Newsletter and Government Affairs section, where information on legislation and regulatory activity on both state and federal levels is stored. The ADA Advocacy page is another great resource that provides links to current government and regulatory issues. When time permits, review the various oral and maxillofacial trade journals and the local dental society publications. Taking the extra step to stay informed will only serve to promote a successful practice and avoid unnecessary pitfalls.

A long-standing and well-known health law is the Health Insurance Portability and Accountability Act (HIPAA), which has been in place since 1996. HIPAA privacy and security requirements apply to all health care providers. All individuals involved in the health care delivery system should have HIPAA Privacy plans in place and be compliant with them. Here is an abbreviated overview of compliance practices to consider.

- Ensure that patient sign-in sheets include only limited information;
- Do not leave paper charts around the office or in clear plastic chart holders on exam room doors;
- Ensure that computer screens with electronic health records are not visible to patients or visitors;
- Do not post patient schedules in plain view;
- Do not hold confidential conversations where they can be overheard;
- Regularly change passwords and safeguard access to work areas;
- Give only authorized staff accessibility to medical records, lab reports, and faxes;
- Document safeguards for transfer of paper/electronic patient records and lab specimens;
- Document policies for termination of employment, including return of all keys, cards, and code and lock changes;
- Document procedures to protect confidential information if office equipment or files are taken from the premises;
- Inventory computer systems and software, and do a regular virus check;
- Develop a disaster recovery plan in the event of systems failure; and
- Protect email communications containing confidential information.

Concluding Thoughts

Applying good risk management practices before a complaint, claim, or lawsuit is filed is pivotal to the effectiveness of proactive risk management, but sometimes, despite excellent clinical care and good reactive risk management practices, lawsuits

are filed. The legal process is much different from rendering clinical care and guaranteed to not be as enjoyable. Why wait until a patient is in the chair with a serious concern to realize the value of proactive and reactive risk management? Being armed with tools to help prevent an incident, mitigate a claim, or manage a lawsuit is like knowing how to defend a claim before one arises. Risk management's proven techniques for communication and documentation have reduced the incidence of lawsuits, and if one does face litigation, the techniques have bolstered their defense.

By now, you might be asking yourself, "How am I supposed to do *all* of that or remember any of the information I just read?" Understanding risk management and more importantly, managing risk and promoting patient safety is not a job or task to be memorized or accomplished in a day. It takes time to change behavior, incorporate new practices, and obtain buy-in from your staff. Implementing good risk management practices requires time and commitment. Consider risk management practices like lifting weights for the first time. You may not be able to lift the 50-pound weight 10 times, but you may be able to lift the 10-pound weight 50 times. Eventually, the reps or sets will increase and before you know it, you're at your goal—but not without practice. Mastering good risk management skills takes consistent (daily) practice.

References

1. Rattan R, Tiernan J: *Risk management in general dental practice*, London, 2004, Quintessence.
2. Kohn LT, Corrigan JM, Donaldson MS, editors: *To err is human: building a safer health system*, Washington, DC, 2000, National Academies Press.
3. Hubbard DW: *The failure of risk management: why it's broken and how to fix it*, Hoboken, NJ, 2009, Wiley.
4. The Economic Times: Risk management definition (website). Available from http://economictimes.indiatimes.com/definition/risk-management.
5. *Certified Professional in Healthcare Risk Management (CPHRM): preparation guide*, Chicago, 2014, American Society for Healthcare Risk Management of the American Hospital Association.
6. Brauer HU, Green RA, Pynn BR: Complications during and after surgical removal of third molars, *Updated version of unusual complications associated with third molar surgery: a systematic review, Quintessence* 40:565–572, 2009 *Oral Health*, 2013.
7. Keris MP: *Electronic medical records and litigation*, New York, 2014, Thomson Reuters.
8. Wojcieszak D, Saxton JW, Finkelstein MM: *Sorry works!: Disclosure, apology, and relationships prevent medical malpractice claims*, Bloomington, IN, 2007, AuthorHouse.
9. Egan G: *The skilled helper: a systemic approach to effective helping*, ed 3, Belmont, CA, 1986, Thomson Brooks/Cole.
10. Groopman J: *How doctors think*, New York, 2007, Houghton Mifflin.
11. National Patient Safety Foundation: *Health literacy: statistics at-a-glance (pdf)*. Available from www.npsf.org/askme3/.
12. Bendix J, Verdon DR, Ritchie A, et al.: Top 10 challenges facing physicians in 2014, *Med Econ*, 2013. Available from http://medicaleconomics.modernmedicine.com/.
13. Alhassani AA, AlGhamdi AST: Inferior alveolar nerve injury in implant dentistry: Diagnosis, causes, prevention and management, *J Oral Implantol* 36(5):401–407, 2010.
14. Renton T: Prevention of iatrogenic inferior alveolar nerve injuries in relation to dental procedures, *Dent Update* 37: 350–363, 2010.
15. Mello MM: Understanding medical malpractice insurance: a primer, *The Robert Wood Johnson Foundation: Research Synthesis Report* 8:1–14, 2006.
16. Chidichimo P: Claims & litigation: a working relationship among risk managers, defense attorneys and claims professionals, *ASHRM FORUM* Q4:10–14, 2014.
17. Tang EY: *First, do no harm: the cure for medical malpractice* by Ira E. Williams, *Journal of Health & Biomedical Law* 2(1):143–155, 2006.
18. Mello MM, Studdert DM, Kachalia A: The medical liability climate and prospects for reform, *JAMA* 312(20):2146–2155, 2014.

8

Coding, Insurance, and Third-Party Payers

TERRI BRADLEY

General Overview

As an oral surgeon, you will be billing to both medical and dental carriers. Your participation status notwithstanding, every service you do in your office is going to be billable to an insurance carrier whether you're contracted or not. (The only caveat to this rule would be if you were performing a cosmetic procedure; however, the patient may still request a claim to be submitted on their behalf.) Thus, you will need to become familiar with several different code sets. Dental insurance requires the use of Current Dental Terminology (CDT) codes on the ADA claim form. Except in limited cases, diagnosis codes are not required for the dental claim form. Medical carriers use Current Procedural Terminology (CPT) as their primary code set for the reporting of procedure codes. Medical carriers will also allow the use of Healthcare Common Procedure Coding System (HCPCS) codes (oral and maxillofacial surgeons would use it most often to report for medications, supplies, and dental procedures). In 2011, because of copyright agreements, the ADA codes or CDT codes were no longer available in the downloadable HCPCS files on the Center for Medicare and Medicaid Services (CMS) website. However, the ADA dental procedure codes are still a part of the HCPCS code set and can be reported on the CMS 1500 form to report for services provided not adequately described by a CPT code.[1] Unlike dental carriers, medical carriers do require providers to report diagnosis codes with every procedure.

Although some procedures are billed to both a medical carrier and a dental carrier, there are many instances when you will only be dealing with one carrier for a procedure. Medical carriers are billed for orthognathic cases, temporomandibular joint (TMJ) surgery, and oral pathology, whereas dentoalveolar procedures are submitted to dental carriers. The majority of dental implants and grafting are considered dental unless the procedure is being done to replace teeth lost by trauma and/or to reconstruct an arch that was damaged due to neoplastic diseases. Unfortunately, not everything is covered by insurance, and just because there is a code and the procedure needs to be done does not mean it will always be covered by the insurance carrier. I recommend determining whether or not a procedure is a covered benefit before performing the service. The majority of medical carriers have a list of their medical coverage determination guidelines on their website. From these guidelines, it is possible to research a particular carrier's policy on the majority of OMS procedures, such as sleep apnea, orthognathic surgery, or TMJ. Having access to this information ensures that you are not wasting time and resources submitting a claim for services that may not be covered.

An important caveat is that everything submitted on a claim form (medical or dental) must be substantiated by the documentation in the patient's medical record. The adage "If it is not recorded in the chart, it did not happen" holds true for billing. You as the doctor are ultimately responsible for the information and codes submitted on a claim form. The basic principles of documentation were established several years ago by the American Health Association, American Managed Care and Review Association, American Medical Association, American Peer Review Association, Blue Cross Blue Shield, and the Health Insurance Association of America. These include the following: The medical record should be complete and legible; the documentation of each patient encounter should include or provide reference to the reason for the encounter and any relevant history and examination findings, any prior diagnostic test results as appropriate, assessment clinical impression or diagnosis, the plan for care, and the legible identity of the observer. If not specifically documented, the rationale for ordering diagnostic and other ancillary services should be easily inferred. The past and present diagnoses should be accessible to the treating and/or consulting physician. The appropriate health risk

factors should be identified. The patient's progress, response to, and changes in treatment and revision of the diagnosis should be documented. And, last, the CPT and ICD CM (International Classification of Diseases, Clinical Modification) codes reported on a health insurance form or billing statement should be supported by the documentation in the medical record.[2]

Billing to medical insurance carriers is done on the CMS 1500 form. When reporting on a CMS 1500 form, CPT is the primary medical procedure code, if a specific code exists. If there is not a specific CPT code but an appropriate CDT exists, use of the CDT code is allowable. For example, there is no specific CPT code for removal of an impacted third molar. The only option is CPT code 41899, which is "unlisted procedure dentoalveolar structure." This code could represent many things; it could be a crown, a filling, an extraction, or a full bony impaction. Because the code is so vague, CDT code D7240, "removal of impacted tooth—completely bony" is reported. The most specific code available must be reported, whether it be a CPT, HCPCS, or CDT code. Any CPT codes ending in 89 or 99, such as 41899, require a narrative to describe the services being reported. This narrative can be reported in the shaded area of box 24 on the CMS 1500 form or in free-form text in box 19. Detailed instructions on how to complete the form can be found at www.nucc.org, the website for the National Uniform Claims Committee. The first thing the carriers check is whether or not the claim was submitted correctly with the most current codes. CPT, CDT, and ICD codes are updated annually. Carriers also want to be sure that the ICD code listed is at the highest level of specificity and that signs and symptoms are not listed as a primary, definitive diagnosis.

Medicare, as well as many commercial carriers, utilizes the National Correct Coding Initiative or CCI edits when processing claims. The Correct Coding Initiative was implemented to promote correct coding methodologies and to control improper coding leading to inappropriate payments (i.e., unbundling).[3] The CCI edits have basically matched procedure codes that are not billable separately except under specific circumstances. The edits are broken down into columns, Column 1 (comprehensive codes) and Column 2 (component codes), which, when billed together on the same day of service, are not both reimbursable.[3] This is often referred to as unbundling. In some circumstances it may be appropriate to report an additional modifier to override the CCI edit; however, this would be case specific. For example, the codes for debridement and repair of wounds are now bundled into a CCI edit. Now, in order to bill debridement of a wound prior to repair, it is necessary to report using a modifier that would explain the extenuating circumstances (has to be gross debridement) as to why you are billing separately for a service that the CCI edits consider part of the repair (i.e., cleaning the wound before you repair the wound). In addition to the Column 1 and Column 2 edits, there are also the Medically Unlikely Edits. MEUs are edits based on maximum number of units of services being reported and link between procedure and anatomy, as well as codes that are not usually performed at the same session.[3] These CCI edits are updated quarterly, and the updates are listed on the CMS website. Because the edits change so often, it is not uncommon for a provider to have claims for services they have been billing for quite some time suddenly begin to be denied as bundled by carriers. Keeping updated on the changes that affect the specialty of OMS and the procedure codes you bill frequently will help keep you informed.

Currently, all CPT codes are assigned a relative value unit, and these values are used to determine fee schedules based on RBRVS (Resource-Based Relative Value Scale). Carriers multiply the relative value unit by a conversion factor and thus develop their fee schedule for providers. Medicare's conversion factor is public information and is updated annually; however, the majority of the private carriers do not publish this information, and it is difficult to determine exactly what their conversion factor is.

The RBRVS is broken down into four categories for each code: the work relative value unit, which is the physician's skill and effort; the practice expense relative value unit (RVU), which is the office overhead—rent, supplies or staff; the malpractice expense, which is the cost of the liability insurance; and finally, the geographic practice cost index. The GPCI is the only category in that it will differ from practice to practice, factoring in the increased costs in operating in large urban settings versus suburban or rural settings. The RBRVS is considered budget neutral. Thus, if an RVU is increased for one code, it has to decrease for another code. I recommend reviewing the RVUs for the procedures you are performing within your practice when developing your own balanced fee schedule. There should be a relationship between your office fees and RVUs. You may want to develop your own internal conversion factor to help you determine your fees for CPT procedures.

Relative value units play a significant role when billing for multiple procedures at the same operative session. Medical insurance carriers apply the multiple procedure discount if you are performing more than one operative procedure on the same day. They will reimburse 100% of their allowable fee schedule for the first procedure (the first reported line) and 50% for each additional operative item. Many software programs will list procedures based on the highest fee, not necessarily by the highest RVU. Given that, it is easy for practices to lose money if their fee schedule has no correlation between their fee and the RBRVS used by insurance carriers. A great example of that is for sequencing for bone grafts of the mandible and the maxilla. Code 21210, bone graft of the maxilla, has a relative value unit of approximately 65.81. CPT code 21215, bone graft of the mandible, has a relative value unit of 117.75. Therefore, if you were doing both of these procedures at the same time and happened to charge the same for both, it would behoove you to list the code with the highest RVU (CPT 21215) first. The difference in reimbursement from a carrier could be thousands of dollars.

It should be noted that while RBRVS is the current standard for fee schedules, carriers are beginning to move toward a value-based payment modifier. Section 1848 (p) of the Social Security Act requires that Medicare establish a value-based payment modifier (Value Modifier) that providers for differential payment under the Medicare Fee Schedule (PFS) based on the quality of care furnished compared to the cost during a performance period. Section 1848 (p) required that the Value Modifier be applied to specific physicians and groups of physicians the Secretary determines to be appropriate starting January 1, 2015, and to all physician and groups of physicians by 2017. The statute requires the Value Modifier to be budget neutral. Budget neutrality means that, in aggregate, the increased payments to high-performing physician and groups of physicians equal the reduced payments to low-performing physicians and groups of physicians. Beginning in calendar year (CY) 2015, the Value Modifier will be applied to all groups of physicians with 100 or more eligible professionals. Proposals are anticipated in future rule-making on how to apply the Value Modifier to groups with fewer than 100 eligible professionals and to solo practitioners.[4] Although Medicare is at the forefront of this shift, what Medicare does, other carriers will follow in their guidelines. This is yet another topic that will have to be watched carefully as it unfolds, and the impact on payments to your practice as well as the additional administrative burden of reporting these values will have to be considered.

Insurance Contracts

Becoming a participating provider requires a great deal of consideration. You need to evaluate it not only from a patient care standpoint, but also from a business standpoint. When considering a contract, be sure to review the entire document, not just the fee schedule. Make sure you review the language in the contract such as the claims submission guidelines, non-covered services, termination clause, hold harmless clauses, and pre-authorization requirements. I always recommend to my clients that when evaluating a fee schedule, it's helpful to start by examining your top 25 procedures and comparing the allowable reimbursement rates for those procedures among all contracted or potential carriers. This will allow you to compare "apples to apples" before making any decisions. Many fee schedules can be negotiated, usually either annually or biannually.

When signing a contract, especially through dental carriers, it is important to consider which other carriers will now be able to use the fee schedule, such as with umbrella PPO plans or third-party administrators. Some companies such as Connection Dental and Dentemax are not insurance companies, but rather third-party administrators that create a network of providers and insurance carriers that essentially rent their network and their network fees. In essence, when you sign on with one of these companies such as Connection Dental, you are becoming an in-network provider for several carriers; sometimes the list can be up to 30 carriers with networks of patients that can now access your practice as an in-network provider. The same relationships exist on the medical side as well; companies such as Multi Plan are third-party administrators that rent out their networks to providers and carriers all across the country. In addition to these third-party administrators, more and more medical carriers are sharing networks. As a way to provide more coverage to their patients, smaller local insurance carriers are joining forces with the larger commercial plans so they can create a network across the country that will service their patients. New relationships between carriers are constantly being formed, and it is up to providers to keep up with these changes and the overall impact on their practice. The constant changes in the industry and keeping up to date can be burdensome for the administrative staff; however, it is necessary from a business standpoint to have a clear understanding of which carriers you are an in-network provider with, and what other networks can access you based on the initial contract that was signed. In some cases these third-party administrative contracts can be a good thing for a practice; in other cases it may be more beneficial to contract directly with a carrier. Be sure to do your due diligence in reviewing the fee schedule options and contract between the third-party administrator and the individual carrier to see which fits best with your business model. The American Dental Association and the American Association of Oral and Maxillofacial Surgeons can do a review of insurance contracts for you before sign up with a carrier.[5]

Code Sets

As mentioned at the beginning of this chapter, oral surgery is unique in that it is one of the few specialties that can and does bill both medical and dental insurances. Thus, it is important that oral surgeons be conversant with multiple different code sets in order to run a successful business.

The two main procedural code sets are CPT and CDT. CPT is the primary code set for billing to medical insurance carriers. It is copyrighted by the American Medical Association and updated annually.[2] The updated books are published in December, and the new codes take effect in January. CDT is the primary code set for dental billing; it is copyrighted and owned by the ADA and, like the CPT codes, it is updated annually. HCPCS is another HIPAA-approved procedural code set. There are several sections of codes within this HCPCS set that you would use—for example, pharmaceuticals (medications used in the office, such as Zofran) and durable medical equipment codes (oral appliance codes) are found in this code set. You can also find CDT codes or "D" codes. CDT codes, although copyrighted by the ADA, are also considered a HCPCS Level II code set, which allows providers to use dental codes on medical claim forms when appropriate. Although CPT and CDT are, by in large, stable code sets with annual updates and modifications, the diagnosis code set is currently undergoing an immense change.

The United States recently transitioned from the ICD-9 CM (diagnosis) code system to the ICD-10 CM code

system. The ICD-10 CM code set became effective on October 1, 2015. This was a big leap for the health care system. Robert Tennant, senior policy adviser in MGMA's government affairs department called switching to ICD-10 codes "probably the biggest change in healthcare since Lyndon Johnson signed Medicare into law in the 1960s."[6]

The ICD-9 CM code set contains approximately 14,000 codes. The ICD-10 code set has approximately 69,000 codes. Much of the world has already transitioned to ICD-10; health care worldwide has outgrown ICD-9, which simply did not have enough codes to accurately describe diseases and conditions. Thus, it was overhauled to ICD-10, which was adapted by the World Health Organization (WHO) in 1993 and here in the United States in 2015.

Medical insurance carriers require the submission of a diagnosis code with every procedure code reported on a CMS 1500 form. The diagnosis code that is reported should be that which best supports the medical necessity of the procedure performed based on the documentation in the patient's medical record. Diagnosis and procedure codes must be properly linked for the claim to be paid, and one should always code to the highest degree of specificity and certainty. The primary code should support the medical necessity of the service rendered. When determining the priority of the diagnosis codes, the primary consideration should be the cause of the immediate problem or, why the patient is in the chair. Any further symptoms or conditions can be reported as secondary codes.

Currently, diagnosis codes are not always required on dental claim forms; however, there is a section on the newest claim form that does allow for providers to report diagnosis codes. Within the industry, the expectation is that diagnosis codes will be required in the future (Table 8-1).

Medicare

There are a myriad of options regarding Medicare enrollment. You can enroll as a participating provider, as a non-participating provider, as an ordering and referring provider only, or as a DMEPOS (Durable Medical Equipment Prosthetics, Orthotics and Supplies) provider; or you can choose to formally opt out of Medicare. Should you choose to opt out, a formal affidavit prohibiting providers and participants from billing Medicare for 2 years must be signed. If you sign the opt-out affidavit, you must enter into a private contract with each Medicare patient before performing a Medicare-covered service. (For more information on this, contact CMS.) A formal choice regarding Medicare enrollment must be made and declared by each provider; the lack of a choice is not an option if services are being provided to Medicare patients. According to Medicare, "Dentists, including oral surgeons, must enroll in the Medicare program to receive reimbursement for services furnished to Medicare beneficiaries or to order covered items or services for Medicare beneficiaries. Oral surgeons would complete the same paper forms, or on-line application, as any other practitioner enrolling in PECOS" (the Provider Enrollment Chain and Ownership System).[7]

As an ordering or referring provider, you are enrolling as a provider that can order or refer services (laboratory, radiology, etc.) for Medicare beneficiaries, and will not submit claims for services furnished to Medicare patients. Medicare requires providers that order or refer services for Medicare patients to be enrolled in the Medicare system. Therefore, if you are not enrolled in the Medicare system (with any option listed earlier) and you refer a patient to a laboratory for testing, the lab fees would not be covered. DMEPOS is a separate enrollment process from traditional Medicare. If you are planning on providing oral sleep apnea appliances to Medicare patients, enrollment in this process is required.[7] Providers that have opted out of Medicare are not allowed to enroll as DMEPOS providers only. Enrolling in any of these options can be done through the online program PECOS.[7] Once the enrollment is completed, this same system can be used for re-validation and also for changing of status.

Whether you are enrolled as a participating provider or a non-participating provider, by federal law there is a mandatory claims submission for all services covered by Medicare.[7] For services that may not be covered by Medicare, if the patient requests that you submit a claim to Medicare, you are required to do so. Participating providers are required to accept assignment on all Medicare claims and to accept the approved amount as payment in full. Medicare will pay 80% of the Medicare-allowable fees, and the patient (or the supplemental Medigap plan) will pay the other 20%.

As a non-participating provider, you can accept assignment on a case-by-case basis. The approved fee for non-participating providers is 5% less than it is for providers that are participating providers. Non-participating providers can

TABLE 8-1 Diagnosis Codes

ICD-9	ICD-10
3-5 characters in length	3-7 characters in length
Approximately 14,000 codes	Approximately 69,000 codes
First character may be alpha or numeric Characters 2-5 are numeric	First character is alpha Characters 2-7 are alpha or numeric
Limited space for new codes	Flexibility for adding new codes
Lacks laterality	Has laterality
Difficult to analyze because of nonspecific codes	Specificity improves coding accuracy and depth of data for analysis
Codes do not adequately define diagnoses needed for medical research	Details improve the accuracy of data used in medical research
Does not support interoperability because it is not used in other countries	Supports interoperability and the exchange of health care data between other countries and the United States

charge Medicare patients more than the non-participating approved amount; however, charges are limited to 115% of the Medicare approved amount for non-participating providers.

Here's an example: If the Medicare allowable is $100, a participating provider would receive $80 from Medicare and $20 from either the patient or the Medigap plan. Using the same example for a non-participating provider: If the Medicare allowable is $100, the allowable becomes $95. Medicare would pay $76, the patient or supplemental insurance would pay $19, and the provider would thus receive 95% of the Medicare fee schedule for covered services. If the claim is unassigned, then the limiting charge is set at 115% of the allowable. For example, a fee schedule is $100 allowable; a 5% adjustment as a non-par status brings it down to $95. Limited charge is $95 × 115% or $109.25, the maximum amount you could bill a patient as a non-participating unassigned claim.

Participating and non-participating providers are required to inform patients if a service potentially may not be covered by Medicare (usually due to lack of medical necessity). This is done by the completion of an Advanced Beneficiary Notice, or ABN, form. The form must be completed for the individual patient with the specific reason why you expect Medicare to deny the services, along with the service being provided, the expected reason for the denial, and the estimated cost recorded on the form and reviewed with the patient before the services are rendered. If this process is not completed before the patient receives the service, and the claim is denied by Medicare, the patient cannot be billed.[7] ABNs are reported to Medicare on the claim form using modifiers. The GA modifier is used to let the carrier know that you have a completed ABN on file. The GY modifier attached to the procedure code would let the carrier know that this particular procedure is statutorily excluded; however, the patient wants the provider to submit the claim form. The GX modifier indicates that there is a notice of liability issues and it is voluntary under the payer policy. The GZ modifier indicates that the service is expected to be denied, and the GJ modifier is letting the carrier know that you have opted out, but the services you just provided for this Medicare patient were emergency based.[7] You cannot, of course, have every single patient that comes in your office over the age of 65 sign an ABN. There needs to be an open conversation between the doctor and the patient about services being provided and the potential that Medicare may not pay for them. Although Medicare generally does not cover many dental services, medical services such as excision of lesions are generally covered.

Section 1862-A-12 of the Social Security Act delineates the statutory dental exclusion

> *Where such expenses are for services in connection with the care, treatment, filling, removal or replacement of teeth or structures directly supporting the teeth except that payment may be made under Part A (hospital charges) in case of inpatient services in the connection with the provision of such dental services if the individual, because of his underlying medical condition and because of the severity of the dental procedure, requires hospitalization.*[7]

The dental services Medicare does cover are limited. Medicare will pay for those dental services that are an integral part of either a covered procedure such as reconstruction of the jaw following an accidental injury or for extractions done in preparation for radiation treatment of neoplastic diseases involving the jaw.[7] It will also pay for oral examinations, but not treatment preceding kidney transplantation or heart valve replacement under certain circumstances.[7]

Trauma

It is important to understand that the descriptions for repair of fractures in CPT are per *fracture*. Therefore, if a patient has multiple fractures being repaired, there needs to be separate CPT and diagnosis codes for each one. For example, a right angle fracture and left symphysis fracture would have separate diagnosis codes, each one linking to the proper CPT code describing the fracture repair. One common error I often find in client offices is the use of the multiple approaches code (CPT 21470). The description of this code is "open treatment of complicated mandibular fracture by multiple surgical approaches including internal fixation, interdental fixation, and/or wiring of the denture or splints."[8] Note that the description is mandibular *fracture,* not *fractures;* this code is often misused when reporting multiple mandibular fractures, which is incorrect. Also of note, multiple approaches does not mean separate incisions. Each fracture repair should have its own CPT code. Another common misconception involves billing for arch-bar placement and removal as their own procedures. The placement of arch bars is common in fracture repair and is included in some of the descriptions for the repair of fractures. If it is included in the description for the repair, arch-bar placement cannot be billed separately. However, the removal of arch bars during the postoperative period can be billed. The removal was not included as part of the RVU determination for the fracture codes and can therefore be billed separately. Although this is billable, it does fall within the 90-day global surgical package (GSP). In order to bill properly, the 58 modifier for stage procedure should be used.[8] While the procedural coding for fractures will remain the same with the transition to ICD-10, the diagnosis codes for trauma will now require much more detailed and in-depth reporting.

There are very significant changes in ICD-10 when reporting diagnosis codes for trauma cases. These codes are found in Chapter 19 of the ICD-10 code book. Within this section in the code set, you will be required to also report codes for the external causes of the trauma.[9] These codes capture how the injury happened (cause), the intent (unintentional or accidental; or intentional, such as suicide or assault), the place where the event occurred, the activity of the patient at the time of the event, and the person's status (e.g., civilian, military).[9] Another change in ICD-10 is the use of the seventh character in the code. In the S02 section

(fractures of the skull and facial bones), a seventh character (an alpha character) is needed to properly report the code: A, initial encounter for closed fracture; B, initial encounter for open fracture; D, subsequent encounter for fracture with routine healing; G, subsequent encounter for fracture with delayed healing; K, subsequent encounter for fracture with nonunion; and S, sequela.[9] This seventh character must be in the seventh space of the code; for any codes that are less than six characters, the letter "X" is used as a placeholder. For example, in ICD-10 to report a closed fracture of the angle of the mandible, the following code would be used: S02.65XA (fracture of the angle of the mandible, closed fracture, initial encounter). As the patient's treatment progresses, the seventh character will change. If you were to see the patient for postoperative x-rays and the healing was routine, the diagnosis code would be S02.65XD (fracture of the angle of the mandible, subsequent encounter for routine healing).[9]

Pathology

When coding for oral pathology, it is the recommendation of the American Medical Association as well as the CPT Board that you always wait for the final pathology report before you assign a diagnosis code.[10] This is done for several reasons, the most important being that coding is done based on specificity and certainty, and until the pathology report comes back, the final diagnosis is technically uncertain. It is incorrect to submit a diagnosis based on "rule out" or "suspected"; those are signs and symptoms only, and the words following rule out (such as "rule out malignancy") should not be used unless the diagnosis has been confirmed by a pathology report. There are diagnosis codes for uncertain behavior; those codes are to be used when the pathologist is uncertain about the behavior of the lesion, not when the surgeon submits the specimen to pathology.

It is also important to wait for the final pathology, as there may be specific procedure codes for removal of benign lesions versus removal of malignant lesions. In the areas where there are specific procedure codes to report for removal of malignant lesions, the RVUs are higher due to the additional coordination of care that will have to occur postoperatively. Specificity is not limited to benign versus malignant. It may also involve specific areas within the oral cavity. One of the more common areas of confusion is related to the lips. Procedures performed on the lipstick area should be coded as the skin of the lip; for areas inside the mouth, code using the vestibule; for the lip (non-lipstick area), code as the lip. Within each of these codes you will find codes for biopsy, excision without repair, with simple repair, complex repair, and so on. A suture is considered a repair and should be coded as such; to do otherwise is to undercode for the services performed. When determining whether to report for a biopsy or excision of lesion, you must consider the intent. If the intent is to remove a small portion for further pathologic review, then you would choose a biopsy code. If the intent is to remove the entire lesion, then choose the excision lesion code.[11]

With the advent of ICD-10, there is another shift in the reporting of diagnosis codes for oral pathology. In many sections you will have to report additional codes for contributing factors, such as tobacco and alcohol use. There are notations to report whether or not the patient has any alcohol abuse or dependence, whether there has been exposure to environmental tobacco smoke, and whether there is a history of tobacco use or tobacco dependence or current tobacco use. All of that information is currently not required under ICD-9 but will have to be reported in ICD-10.

E&M Codes

Although there are very few dental codes to choose from when coding for evaluation and management (E&M) services, there are more than 15 codes in CPT for billing to medical insurance for these services. Additionally, there is no clear cross code between the dental and medical codes. Therefore, it is important to become familiar with the descriptors and understand the various differences among the code levels.

Choosing the correct code for office visits and consultations (evaluation and management codes) depends on where you saw the patient: inpatient, outpatient, or emergency room. Coding for outpatient visits is determined by the status of the patient: a new patient visit (by CPT definition, a new patient is someone who has not been seen or treated by you or someone within your group for 3 years), an established patient (someone seen or treated within the past 3 years), or a consultation.[8] The outpatient visit codes start with a 992; the fourth character is based on type of the encounter (new patient, established patient, or consultation). New patient visits are in the 99201-99205 series of codes, established patients are 99211-99215 series, and consultations are the 99241-99245 series of codes.[8] The last character of the code is based on the level of the visit. Choose the correct level from a level 1 to a level 5 visit based on the documentation in the medical record. Specific criteria exist for the different levels based on the extent of the medical history, the physical examination, and medical decision making. The higher the level of the code, the higher reimbursement you will receive from the carriers. However, not all visits can be a level 4 or 5 visit. Documentation requirements for those levels are quite extensive. The details of documenting for the different levels are beyond the scope of this chapter, but they can be found in 1995 and the 1997 E&M guidelines through CPT.[8]

Several years ago, Medicare stopped accepting the consultation codes from providers for services rendered to patient. Their reason for no longer allowing the codes was based on the definition of "consultation" and the blurred lines between asking for another provider's opinion versus transferring care.[12] Since that time, other carriers have also adopted the same policy when it comes to billing for E&M services, and you will find several carriers that do not accept consultation codes.

When reporting for E&M visits for patients seen in the hospital, it is important to remember that once you operate on a patient, the global surgical package countdown begins, and this will include all routine postoperative visits. Thus, daily hospital visits and discharge services for patients who have been operated on cannot be billed so long as the global surgical package is still in effect.[8] Global surgical packages typically last for 90 days for major surgeries and 10 days for minor surgeries.[8] However, if you have not operated on a patient, then you can bill for daily hospital visits, admission, and discharge so long as you have provided the services. For example, if you admit a patient to the hospital for IV antibiotics for an infection, you can bill for admission and daily hospital visits (one visit per day) and discharge if no surgery occurs. If the patient is operated on, the billing of daily hospital visits would be appropriate until the surgery. The criteria change a bit for choosing the correct level of the code for inpatient versus outpatient E&M services. Where the outpatient E&M codes are based on three key components, the inpatient codes are often chosen by the amount of time the provider spends on the floor. It does not have to be face to face with a patient (as it does on the outpatient codes).

Modifiers

Modifiers are a way to communicate additional information to the carrier. They may help to improve the efficiency of claims processing if used appropriately and may also result in increased reimbursement when used appropriately. A complete list of modifiers can be found in Appendix A of the CPT book; the following is a review of the modifiers that are less straightforward and may require an explanation of their proper use.[11]

Some of the more common modifiers that you may report for the E&M visits are:

- 24: "Unrelated evaluation and management service by the same physician or other qualified health care professional during a post-operative period." Use of this modifier will require a different, separate diagnosis code than the one reported for the original procedure.[11]
- 25: "Significant, Separately Identifiable evaluation and management service by the same physician or other qualified health care professional on the same day of the procedure or other service."[11] This has to be above and beyond the usual E&M done on the same day as a procedure. It is most often reported with minor procedures (those with a GSP of 10 days). The reporting of this modifier on E&M codes has been heavily audited by carriers and has resulted in some carriers no longer allowing for this if the E&M is reported on the same day as a minor procedure. According to a recent Medicare bulletin, "both the medically necessary E&M service and the procedure must be appropriately and sufficiently documented to support the claim for the services."[13] Medically necessary E&M are the key words here—just because it is the first time you are seeing a patient, that does not mean that you can necessarily bill for an E&M service on the same day as a minor procedure.
- 57: "Decision for Surgery." Use this to report an E&M visit that results in the decision to perform surgery.[11] For example, if you see a patient in the emergency room for a fracture and then elect to treat the fracture that day, you would report the E&M with the 57 modifier.

Some of the more common surgery modifiers:

- 22: "Increased Procedure Services." To report this modifier, the work required to perform the service must be substantially greater than typically required.[11] Additional documentation to the carrier will be required.
- 51: "Multiple Procedures." This modifier is used to report multiple procedures on the same day of service.[11] This modifier is not usually required or even considered by the majority of insurance carriers. By reporting multiple lines on a claim form, the carrier is aware you performed multiple procedures.
- 52: "Reduced Services." In some circumstances a procedure or service may be reduced or eliminated.[11] For example, when reporting a maxillary bone graft CPT 21210, the description in the code specifically states it includes harvesting the bone; there is not a CPT code that describes the graft without the harvesting of the bone. So if the surgeon did not harvest the patient's bone and instead used bank bone to perform the graft, the procedure would be reported with the 52 modifier to reflect the reduced services. Another example would be if a surgeon not otherwise involved in the surgery harvested the bone.
- 53: "Discontinued Procedure." If the provider determines that it is unsafe for a patient to continue a procedure that has already been started, modifier 53 can be reported.[11] This modifier should not be used to report elective cancellation of a procedure. Also note that the procedure has to have been started by the surgeon.
- 58: "Staged or related procedure or service by the same physician or other qualified health care professional during the post-operative period." This modifier can be used when the procedure was planned or anticipated, when it was more extensive than the original procedure, or for therapy following a surgical procedure.[11] For example, modifier 58 could be reported when removing arch bars during the postoperative period for treatment of a fracture patient. In oral pathology cases, if you perform a biopsy and within the postoperative period remove the lesion, modifier 58 would be added to the excision of the lesion; otherwise the claim would be denied.
- 59: "Distinct Procedural Service." Use this modifier to report a procedure that was distinct or independent from other services on the same day. Documentation must support a different session, different procedure of surgery, different site or organ system, separate incision/excision, separate lesion, or separate injury not ordinarily encountered or performed on the same day by the same individual.[11] This modifier should only be used if there is not a better more descriptive modifier to report.

- 62: "Two Surgeons." Use this to report when two surgeons are working as primary surgeons performing distinct parts of the procedure.[11] This should *not* be used if you are acting as an assistant surgeon.
- 76: "Repeat Procedure or Service by the same physician or other qualified health care professional." If you are reporting the same CPT code within the postoperative period, report using this modifier.[11] For example, if you removed a lesion on the tongue and, when the pathology report was returned, it required you to re-excise the lesion to get a wider margin, and you are reporting the same CPT code, add the 76 modifier to the re-excision code.
- 77: "Repeat procedure or service by another physician or other health care professional." Use this modifier when reporting repeat procedures by a different provider.[11]
- 78: "Unplanned return to the operating room/procedure room by the same physician or other qualified health care professional following initial procedure for a related procedure during the post-operative period."[11] Do not use this modifier if the procedure was planned, such as removal of arch bars. The procedure has to be related to the original procedure.
- 79: "Unrelated procedure or service by the same physician or qualified health care professional during the postoperative period." The use of this modifier would require a different diagnosis than that reported with the original procedure.[11]

Radiology Codes

All radiology codes inherently have two components: one to take the film (technical component) and one to read the film (professional component). If you report a radiology code without any modifiers attached, you are letting the carrier know that you took the film and also read the film. For example, a panoramic x-ray 70355 submitted without modifiers tells the carrier that you took the film in your office and you also interpreted the film. If you did not do both components, then you should report using the appropriate modifier.

TC Technical component
26 Professional component

Coding and Billing for Patients with Systemic Diseases, Cancer, Diabetes, and Other Comorbidities

For patients with systemic diseases such as diabetes or Sjögren's, or patients with cancer and other comorbidities, coverage under their medical carrier for dental services varies from carrier to carrier and, in some cases, from plan to plan. You can do a great service for your patients if you can maximize the benefits available to them under their medical plans. This may take a little bit of work from the outset, but the level of customer service provided to the patient outweighs the additional work.

When trying to determine if a procedure is covered for a particular patient, the best way to start the research is online. The majority of the major insurance carriers have medical and clinical policy guidelines available online that detail their clinical criteria and coverage guidelines. I always recommend to clients to do the research before treating the patient and submitting claims so that everyone is aware up front what the coverage may be. You do not have to be a contracted provider to access this information; it is easily attainable through an Internet search. Some carriers even go so far as to list the covered CPT and ICD codes under the plan. The policies will give you detailed information on what specific conditions the patient must have in order to have coverage. For example, Medicare does not cover extractions for patients who are having extractions done prior to cardiac surgery.[14] Other plans will cover for patients in this circumstance, and some will cover for extractions for patients who are immunocompromised. Some plans will cover for dental implants when related to a trauma; other plans will not only cover the implants but the restorative treatment fees as well. I had one client who was able to have fees covered for both surgical and restorative fees for a patient with a cancer diagnosis. When a patient does have coverage for the services, it is always recommended that a letter of medical necessity describing the patient's condition, the services to be rendered, and the supporting medical documentation on their condition be submitted before the services are performed. This, along with reporting the most accurate and specific diagnosis codes, will maximize a patient's available benefits.

Over the past few years there has been a major shift in coverage by carriers, some of these related to the Affordable Care Act, and others related to the connection between dental care and overall health of a patient. More carriers now allow for additional dental benefits for patients with specific conditions such as diabetes or pregnancy. Although coverage has increased under dental carriers, the total dollar amount of benefits available has not; so although a diabetic patient may now be allowed to have more hygiene visits per year, the dollar amount available to that patient has remained the same. The same holds true for dental implants: More and more carriers are now "allowing" coverage for dental implants, yet very few have increased their benefits. This leaves the provider trying to explain to the patient how dental benefits work, regardless of whether or not there is coverage available. There are very few policies with a maximum benefit high enough to pay in full for an extraction, grafting, dental implant, and restoration, yet patients with implant coverage will and do expect the insurance to pay for the procedure. Understanding dental benefits and being able to explain this to your patients in a customer-friendly way is extremely important for any dental provider. I like to use the analogy of dental benefits being the equivalent of a gift card. Your "gift card" gets loaded at the beginning of the year with the maximum dollar amount of your benefits, and once the benefits are depleted, there is no more money available on that gift card.

Medical plans work very differently; it is less common to see a maximum dollar amount on medical plans for services provided in oral surgery. Thus, whenever services can be covered under a patient's medical plan, it may benefit the patient and the practice (depending on your contract status with the carrier) to bill the medical carrier. Over the past few years, there has been an increase in the number of plans with high deductibles that must be met before the carrier reimburses for any services. It is important that your staff be aware of these plans and how they work so your patients can be educated prior to receiving services.

Affordable Care Act

The Affordable Care Act is just unrolling as I am writing this chapter. Many parts of the ACA were supposed to be effective as of January this year and have been pushed out further and further. It is a topic that is under constant discussion and scrutiny from both Democrats and Republicans. There have been many changes made since the initial ACA, and I am sure there will be more changes as it unfolds. My best advice to you is to do your best to keep up with the changes, get information from multiple credible sources (AAOMS, AMA, ADA, CMS, and your local and state societies). Be proactive when it comes to the insurance contracts you have signed and are considering signing; read the fine print, and educate yourself and your staff on the changes as related to coding and billing for the practice. Use and rely on outside sources if necessary so you can continue to do what you do best, surgery. We are in the middle of a significant paradigm shift, with more and more involvement of third parties, to fee for service, to value-based fee reimbursement. It is going to be quite a ride over the next few years. Stay focused, stay aware, and prepare yourself to be able to make the necessary changes when the time comes.

References

1. American Dental Association: Centers for Medicare and Medicaid Services begin sending ADA dental billing codes directly to Medicaid and Medicare programs. Available at www.ada.org. Accessed April 2014.
2. American Medical Association: CPT—Current Procedural Terminology. Available at www.ama-assn.org. Accessed April 2014.
3. Centers for Medicaid and Medicare Services: How to use the National Correct Coding Initiative. Available at www.cms.gov. Accessed April 2014.
4. Centers for Medicaid and Medicare Services: Fee for service payment. Available at http://www.cms.gov/Medicare/Medicare-Fee-for-Service-Payment/PhysicianFeedbackProgram/Downloads/CY2015ValueModifierPolicies.pdf. Accessed March 2014.
5. American Dental Association: Insurance contracts. Available at www.ada.org. Accessed March 2014.
6. *MGMA*, San Diego, CA, 2013, Annual Conference.
7. Centers for Medicaid and Medicare Services: PECOS. Available at www.cms.gov. Accessed March 2014.
8. Optum Encoder Pro. www.encoderpro.com. Accessed April 2014.
9. Optum: *ICD-10-CM, 2014 edition*, Salt Lake City, UT, 2013, Optum.
10. American Medical Association: Pathology coding. Available at www.ama-assn.org. Accessed March 2014.
11. American Medical Association: *Current Procedural Coding Expert, 2014 Edition*, Salt Lake City, UT, 2013, Optum.
12. Centers for Medicaid and Medicare Services: Evaluation and management codes. Available at www.cms.gov. Accessed April 2014.
13. Centers for Medicaid and Medicare Services: Global surgery fact sheet. Available at http://www.cms.gov/Outreach-and-Education/Medicare-Learning-Network-MLN/MLNProducts/downloads/GloballSurgery-ICN907166.pdf. Accessed February 2014.
14. Centers for Medicaid and Medicare Services: Medicare dental coverage. Available at www.cms.gov. Accessed March 2014.

9

Accreditation of Outpatient Surgery Facilities

MARK DAVID ZAJKOWSKI

The history of oral and maxillofacial surgery is richly intertwined with advances in outpatient surgery and anesthesia. On October 16, 1846, William Morton successfully demonstrated the use of ether as an anesthetic for removal of a neck mass. Like Crawford Long and Horace Wells before him, Morton helped usher in a new era of medicine. Never before could patients imagine surgery without pain or recollection of the events surrounding it. Naturally, anesthetic techniques and agents continued to evolve, as did their applications and the settings in which they could be offered. Today, mounting pressure from third-party payers for cost containment and patient demands for convenience and affordability have created a surge in demand for outpatient surgery and anesthesia.

In 2010, an estimated 57 million outpatient surgeries took place among dozens of provider types in a vast array of patient settings.[1] This increase in outpatient surgery and anesthesia has subsequently raised public awareness of complications in these settings, often with sensational headlines.[2] As a consequence to well-publicized mishaps, hurdles for providers who offer outpatient anesthesia have arisen in several states via legislation, regulation, or third-party payer policies. These regulations include limitation on the types of providers and types of facilities, or they mandate certification by a private agency. In 1988, New Jersey became the first state to regulate OBS offices, followed by California, Pennsylvania, and Rhode Island.

These states approached regulation in a varied format, with differing levels of scrutiny including some endorsing adoption of the American Society of Anesthesiologists guidelines and reporting of adverse events.[3] The closest challenges to date to mandate certification of OMS offices came in New York State in 2007 and Nevada in 2009. Both potential mandates aimed to require OMSs with a medical degree to have their facilities certified by a national accrediting agency. This was rebuffed with intense lobbying in New York, but OMS practices in Nevada were not so fortunate, as practitioners with an active medical license must submit to unannounced inspections and annual reporting of all anesthetics, with harsh penalties for noncompliance. In the Nevada case, the legislation was spurred not by an anesthetic mishap, but by an alleged breach in infection control protocol in an outpatient endoscopy center. Clearly, any type of outpatient setting that falls under public scrutiny reopens the debate on safety on a nationwide level for all specialties practicing in an ambulatory setting. For information regarding current state-by-state regulations for ambulatory facilities, online references are available.[4]

The push for transparency and safety in health care settings is not new. This movement can be traced to Boston in 1910, when Dr. Ernest Codman championed the concept of recording patient outcomes in a process that he referred to as an "end result system of standardization."[5] Codman also pioneered the first morbidity and mortality conferences and eventually founded his own hospital, aptly named the "End Result Hospital." Based on Codman's system, the American College of Surgeons (ACS) formed the first "Hospital Standardization Committee" to ensure quality of care, which then led to the *Manual of Hospital Standardization,* a guide to improve process and outcomes for patient care. By 1946, the federal government joined the movement, allowing funding only for hospitals that applied these standards of care.[6]

As the certification movement gained acceptance, the ACS worked with the American Medical Association, the American Hospital Association, and the American College of Physicians to form the Joint Commission on Accreditation of Hospitals (JCAH) in 1951.[7] By 1965, the JCAH gained recognition in the Social Security Amendments to further broaden the influence and scope of the accreditation process. The JCAH (now known as

The Joint Commission) now accredits nearly every major hospital in the United States as well as more than 2000 non-hospital facilities. These settings include ambulatory and office-based surgery centers, medical group practices, urgent care centers, imaging centers, sleep centers, laboratories, and more. Unlike hospital accreditation, however, many of these nontraditional sites are accredited voluntarily.

As certification of hospitals took root and gained widespread acceptance, oral surgeons understood the need to demonstrate safe practice in their outpatient setting, particularly with their anesthetic techniques. With the development of the office-based anesthesia evaluation by the Southern California Society of Oral Surgeons in 1968, the specialty had a template for oral surgeons to demonstrate their preparation for emergencies and ensure proper equipping of offices that provided anesthesia, naming it the office anesthesia evaluation (OAE). In some ways, these paralleled the standards development in hospitals and have served to quantify outcomes in this surgical setting, albeit to a less thorough degree. Many states still accept some form of this evaluation in allowing OMS facilities to provide outpatient anesthesia, particularly with the operator-anesthetist model. Indeed, Perrott et al. demonstrated a complication rate of only 1.3 per 100 patients in these settings, with the vast majority of complications deemed minor and a patient satisfaction rate of 94%.[8]

Discussion of voluntary certification (accreditation) in oral and maxillofacial surgery offices requires consideration of the role of the specialty in the greater health care picture, particularly with regard to patient safety. The 1999 Institute of Medicine (IOM) report *To Err is Human*[9] proved to be a seminal moment in the quality movement in patient care. Based on its reporting that tens of thousands of patients die annually from medical errors and hundreds of thousands more suffer nonfatal injuries, the inevitable conclusion that a high-quality care system would prevent these was formed. In the follow-up report, *Crossing the Quality Chasm: A New Health System for the 21st Century,* the IOM found "a health care system that frequently falls short in its ability to translate knowledge into practice, and to apply new technology safely and appropriately." In other words, medicine is using outdated systems to deliver care, and a *redesign of our care delivery systems is necessary,* including the use of information technology to support clinical and administrative processes.[10] With regard to errors, medicine traditionally has focused on the personal failings of the individual, leading to a culture of repetitive errors and the "culture of blame." Some argue that this has led to medical excess, with the practice of defensive medicine (which deviates from sound medical practice) and a subsequent increase in costs with unnecessary diagnostic tests and procedures, prescriptions, and patient referrals.[11] James Reason, a British psychology professor, described this recognition of human errors as either via the *person* approach (focusing on the individual's role in errors) or the *system* approach (assigns errors to failure of work systems).[12] Most, if not all, high-functioning organizations understand the need to focus on the *system* approach to minimize errors, create a culture of success and reliability, and engage and retain employees. This belief and practice in the system approach is the central principle in accredited offices and facilities.

In describing how major errors occur from a broad perspective, Reason developed the *Swiss cheese model*.[12] Reason's model vividly describes how a series of weaknesses in a system's defense must "align" to result in an untoward event. Simply put, one large error is often caused by a sequence of smaller errors that propagate, causing a catastrophe. Think of a particular clinical process as a block of Swiss cheese. Each step in the process represents one slice of cheese, including the holes. Each hole represents a weakness or hazard in the system. As we go through each successive step, the hole either continues (error propagated) or is blocked by the next slice (the hazard or error is corrected or no longer propagated). Each successive slice could be seen as safeguards in a process. In a catastrophic event, one error (hole) is continuous throughout the entire process and is propagated, culminating in the loss or adverse event.

Taking Reason's Swiss cheese model further, we can identify medical as well as nonmedical fields to understand the concept of the system approach to process improvement by studying *high-reliability organizations (HROs)*. These organizations are institutions where individuals work together in high-acuity situations facing great potential for error and disastrous consequences yet consistently deliver positive results.[13] HROs all share the goals of constant improvement through the use of measurement tools to eliminate unnecessary variation and to document the continuous improvement via outcomes.[14] The two major themes of HROs are *anticipation* (constant vigilance for potential error sources as a cultural baseline) and *containment* (immediate actions taken to reduce further damage when an error is identified). Five key principles are shared by HROs[15]:

1. **Preoccupation with failure:** Every error or near miss is reviewed to address system failures.
2. **Reluctance to simplify:** Does not allow a process to rely on a single person without redundancy.
3. **Sensitivity to operations:** Encourages situational awareness and information sharing.
4. **Committed to resilience:** Ability to recover from a system failure and limits its effects.
5. **Deference to expertise:** Those with the most relevant skill set are empowered to fix problems.

Office-based OMS practices that provide anesthesia are immersed in a high-risk environment that would be well served if it operated much like an HRO. These offices share several common errors with hospitals. These include (but are certainly not limited to) medication errors, wrong site/wrong patient/wrong implant errors, needlestick injures, and flow disruptions (issues surrounding team

communication, equipment failures, etc.).[16] Organizations that follow the HRO model treat "near misses" (close call, but no poor or unexpected outcome) as a gift, because they occur 3 to 300 times more frequently than adverse events and can act as powerful reminders of system hazards. Much like six-sigma manufacturing processes that stress constant improvement, outpatient surgery centers that follow accreditation standards enjoy a culture of systems reviews and safety that is unmatched in non-certified offices. Rather than focus blame on an individual who participated in one of a series of errors, the HRO-focused office understands that the system has vulnerabilities and works constantly to reduce and redesign processes to minimize hazards for patients.

Hupp contrasts the HRO-like performance of the aviation industry (with its corresponding decrease in deaths, injuries, and costs) with the current state in most dental (and OMS) offices.[17] He opines that adoption of such a culture will reap similar rewards in a health care setting, and outlines the mechanism for a dental or OMS practice to develop a culture of safety as six relatively straightforward steps:

1. Embrace the value of having a safety culture in the practice
2. Adopt a culture of safety as a practice core value
3. Work with the dental team to identify dangers to patients and team members
4. Determine if and how such dangers can be minimized
5. Implement protocols and practices to limit risks
6. Review and refine culture of safety practices regularly

What Does It Mean to "Be Accredited"?

Accreditation is an external, independent review of a health care delivery organization against nationally recognized standards and its own policies, procedures, processes, and outcomes.[18] In other words, accreditation is a tool to transform a practice into a high-reliability organization. In the United States, the three main agencies that accredit OMS offices are *The Joint Commission (TJC),* the *Accreditation Association for Ambulatory Health Care (AAAHC),* and the *American Association for Accreditation of Ambulatory Surgery Facilities (AAAASF)*. Each agency creates manuals specific to different types of office settings that govern the accredited office. For example, The Joint Commission typically accredits OMS practices under the ambulatory surgery center (ASC) or office-based surgery (OBS) programs, dependent largely on the number of OMS providers in the office. AAAHC offers similar programs, also based on the number of providers and/or number of operating or procedure rooms, but offers specific standards more tailored for OMS practices. AAAASF is unique in creating a specific certification program designed for OMS offices. It classifies offices based on the types of anesthesia delivered and defines the type of provider who is allowed to administer the anesthesia. Each agency also offers the ability of a facility to gain "deemed" status as a Medicare facility.

Each agency bases the review of accredited practices on global areas that are given chapters in their respective accreditation standards manuals. Table 9-1 compares the

TABLE 9-1 Comparison of Focus Areas among Accrediting Agencies

Joint Commission	AAAHC	AAAASF
Environment of Care	Facilities and Environment	General Environment
Emergency Management		General Safety
Human Resources	Administration	Personnel
Infection Prevention and Control	Infection Prevention and Control	
Information Management	Quality Management and Improvement	
Leadership	Governance	
Life Safety		Post Anesthetic Procedure Recovery Area
Medication Management		IV Fluids and Medication
National Patient Safety Goals	Quality of Care Provided	
Performance Improvement	Professional Improvement	Quality Assessment, Quality Improvement
Provision of Care, Treatment and Services	Surgical and Related Services	Procedure Room Policy, Environment and Procedures
Record of Care, Treatment and Services	Clinical Records and Health Information	Medical Records
Rights and Responsibilities of the Individual	Patient Rights	
Transplant Safety		
Waived Testing	Anesthesia Services	Anesthesia

areas of review for each agency; a brief description of these focus areas is found in Table 9-2.

Benefits of Accreditation

Becoming an accredited OMS facility can offer a number of advantages. These may include:

- Demonstration of the practice's commitment to the highest level of safety and patient care
- Certification by independent third party recognized by key stakeholders (boards, licensing agencies, regulators, payers)
- Increased reimbursement with preferred contracting by third-party payers
- Competitive advantage in the practice community
- Creation of a culture of "doing things right" that persists even with turnover of leadership
- Enhanced ability to recruit and retain staff and alignment with practice culture
- Ability to benchmark performance with similar practices nationwide

The decision to become accredited is a major one and requires an expenditure of time, staff resources, and money. Todd and colleagues[19] compared accreditation experiences with each of the three major agencies in a recent review. The authors all felt that some aspects of the accreditation process improved their practices and offered suggestions to tailor the process as more of a specialty-specific process.

Although each agency follows a different process and standards to initially certify and subsequently recertify offices, there are some commonalities among them. Any office seeking accredited status should review each of the agencies and choose one that fits their individual organization best. Once this is completed, the applicable standards must be reviewed and integrated into the practice. Some practices choose to hire consultants to shepherd them through the process and help build group engagement during the pre-survey readiness phase. Consultants can offer customizable templates and forms for key documents such as policy and procedure manuals, audits, studies, monitoring logs, in-services, and inspections that document compliance with accreditation standards. In many instances, existing forms that the office uses to document critical areas such as spore testing are adequate or need just minor modifications.

At the initial survey, the focus of the site visit is not only to assess compliance with the standards, but also on educating the practice on methods to improve patient care and safety. This session also allows the practice to demonstrate to the surveyor methods or techniques that it successfully

TABLE 9-2 Description of Accreditation Manual Chapters for Joint Commission Accredited Facilities

Chapter Title	Contents
Environment of Care	Reviews the space where care is provided, the equipment involved and all people in the facility involved in minimizing risk
Emergency Management	Assesses ability of facility to manage disruptions in care due to emergencies such as natural disasters, power loss, or community events
Human Resources	Reviews skills, knowledge and motivation of staff involved in patient care
Infection Prevention and Control	Assesses practice infection control plan, monitoring of sterilization equipment and practice efforts in minimizing infection risk
Information Management	Ensures security, privacy and integrity of health information
Leadership	Reviews role of leaders in maintaining culture of safety, provision of adequate resources, and ongoing performance improvement
Life Safety	Assesses ability of practice to manage patients incapacitated from anesthesia in event of fire or evacuation
Medication Management	Assesses storage, dispensing, delivery and monitoring of medications used in facility
National Patient Safety Goals	Updated annually. Core safety initiatives integrated into practice
Performance Improvement	Ensures measurement of processes used to deliver care, and data used for improvement
Provision of Care, Treatment and Services	Reviews entire episode of patient care from appointment to post-discharge
Record of Care, Treatment and Services	Assesses adequacy of medical records and documentation
Rights and Responsibilities of the Individual	Ensures patients notified of their rights and responsibilities to participate in their care
Transplant Safety	Ensures adherence to proper protocol, documentation and safety with transplanted tissues
Waived Testing	Applies to laboratory testing performed in facility to meet accuracy standards

TABLE 9-3 Comparison of Accrediting Agencies*,†

	Joint Commission	AAAHC	AAASF
OMS-only facilities accredited as OBS	27	50	17
OMS-only facilities accredited as ASC	11	17	0
Length of certification cycle	3 years	3 years	3 years
Application fee	$1700‡	$775	None
Survey fee	$3130	$5000 est	$2000
Annual fee	$2100	None	$1105
Inspection type	Unannounced	Announced	Announced
Offer Medicare deemed status	Yes	Yes	Yes

*All information from accreditation websites. Available at: www.jointcommission.org, www.aaahc.org, and www.aaaasf.org.
†Estimated fees for two doctor one location facility.
‡Application fee credited towards survey fee.

uses to meet certification standards. After the site survey and findings are reviewed, the practice has a finite amount of time to address standards that were not fully met, if any. This can usually be completed with documentation of compliance over a defined period and submitted electronically, and the practice then gains full accredited status. Depending on the agency, provisional accredited status may be granted while the practice brings the identified areas into compliance.

Once accredited, compliance with the standards must remain continuous. The entire exercise of becoming an accredited office means that a commitment exists to constantly measure processes, review data, and develop action plans to improve on the results to optimize patient care. Agencies generally resurvey a facility every 3 years but may do so sooner in circumstances that may call the quality of care or services into question. As mentioned previously, consultants may be used to assist with compliance by updating the practice on new standards, as well as assisting with in-house peer review and quality improvement studies and the development of monthly or weekly checklists that staff can use to monitor critical processes. Table 9-3 is a brief summary of the differences among the three agencies in the accreditation process.

In an era of ever-increasing transparency in health care, accreditation of OMS practices offers many benefits for both the OMS and the patient. From the patient perspective, accreditation makes sense. Much as the public expects airline travel to be safe and reliable because of systems implemented in the aviation field, so too should they expect the system approach to patient safety in an office setting. The ability of oral and maxillofacial surgery to offer safe and cost-effective care is rooted in the safe provision of anesthesia in outpatient settings. The 20th-century surgeon created the standard for outpatient care, but the 21st-century OMS would be wise to elevate that standard, particularly with the current national focus on quality, safety, and value. Accreditation offers a unique opportunity to demonstrate a specialty's dedication to safety and quality of care for OMS patients, and it can transform the specialty for generations that follow.

References

1. McCook A: Reuters Web site. More outpatient surgery centers, more surgeries. Available at: http://www.reuters.com/article/2011/02/23/us-outpatient-surgery-idUSTRE71M4XQ20110223. Accessed July 22, 2014.
2. Palmer O, McIver P: Joint Commission of Accreditation of Healthcare Organizations accreditation for the office-based oral and maxillofacial surgeon, *Dent Clin North Am.* 52:641–651, 2008.
3. Sutton JH: Office-based surgery regulations: improving patient safety and quality care, *Bull Am Coll Surg* 86:8, 2001.
4. American Association for Accreditation of Ambulatory Surgery Facilities website. Available at: www.aaaasf.org. Accessed Dec 2, 2014.
5. Mallon JW: The genesis of the end result. In Amory Codman Ernest, editor: *The end result of a life in medicine*, Philadelphia, 2000, WB Saunders, pp 47–70.
6. Shell CM, Dunlap KD: Florence Nightingale, Dr. Ernest Codman, American College of Surgeons Hospital Standardization Committee, and the Joint Commission: four pillars in the foundation of patient safety, *Perioperative Nurs Clin* 3:19, 2008.
7. Brauer CM: *Champions of quality in health care*, Lyme, CT, 2001, Greenwich, pp 17–109.
8. Perrott DH, Yuen JP, Andresen RV, et al.: Office-based ambulatory anesthesia: outcomes of clinical practice of oral and maxillofacial surgeons, *J Oral Maxillofac Surg* 61:983, 2003.
9. *To err is human: building a safer health system*. Available at: http://www.iom.edu/reports/1999/to-err-is-human-building-a-safer-health-system.aspx, November, 1999. Accessed Aug 2, 2014.
10. Crossing the Quality Chasm: The IOM Health Care Quality Initiative. Available at: http://www.iom.edu/Reports/2001/crossing-the-quality-chasm-a-new-health-system-for-the-21st-century.aspx. Accessed Aug 4, 2014.

11. Hoffman JR, Kanzaria HK: Intolerance of error and culture of blame drive medical excess, *BMJ* 349:5702, 2014.
12. Reason J: Human error: models and management, *BMJ* 320:768, 2000.
13. Sundar E, Sundar S, Pawlowski J, et al.: Crew resource management and team training, *Anesthesiol Clin* 25:283, 2007.
14. James BC: Implementing practice guidelines through clinical quality improvement, *Front Health Serv Manage* 10:3, 1993.
15. Sanchez JA, Barach PR: High reliability organizations and surgical microsystems: re-engineering surgical care, *Surg Clin North Am* 92:1, 2012.
16. Benike L, Cognetta-Rieke C, Dahlby M, et al.: Quality and safety in home and ambulatory settings, *Nurs Clin North Am* 47: 323–331, 2012.
17. Hupp J: Creating a culture of safety, *JADA* 145(4):321–326, 2014.
18. Accreditation Association for Ambulatory Health Care website. Available at: www.aaahc.org. Accessed on Oct 22, 2014.
19. Todd D, Nannini V, Kellig T, et al.: Office accreditation experiences with 3 accrediting agencies and suggestions for changes in private oral and maxillofacial surgery facility evaluations, *J Oral Maxillofac Surg* 69:258–270, 2011.

10

Marketing the Oral and Maxillofacial Surgery Practice

JOSEPH NIAMTU, III

Well over a decade ago, I had the honor to author a chapter on marketing the oral and maxillofacial surgery (OMS) practice in Dr. Fonseca's text series. I consider it a further honor to once again be asked to update this marketing chapter. No one can dispute that a lot has changed since the original writing of this chapter. Huge paradigm shifts have occurred in our profession. In the original chapter, I described OMS marketing as it existed 15 years ago. At the time of the original writing:

- Most oral and maxillofacial surgeons were slaves to referring dentists; now many referrals are a virtue of participation (or lack thereof) in insurance plans, HMOs, PPOs, and so on.
- Most oral and maxillofacial surgeons were involved in the considerable practice of orthognathic and temporomandibular joint (TMJ) surgery, and now (for various reasons) many shun these procedures.
- Most oral and maxillofacial surgeons took on-call duties at local hospitals, and now (unfortunately) many oral and maxillofacial surgeons have abandoned this responsibility and privilege.
- Dental implants were popular, but now they represent a virtual "new age" in our profession.
- I practiced full-scope OMS, and now my practice is limited to cosmetic facial surgery.
- Having a website was a cute means of having some identity. Today it is not only the main way that society communicates and seeks information, it is essential for marketing, patient education, and registration and is expected by the public.
- The Yellow Pages were the mainstay of marketing; today the Internet has displaced telephone book advertising. We have gone from "Let your *fingers* do the walking" to "Let your *finger* do the walking."
- Mailing panoramic radiographs to and from referring sources was the standard; today digital imaging and electronic transfer of images is replacing hard copy transfer.
- Cellular telephones were a luxury; today one must post "turn off your cell phone" signs in the office so as not to be continually interrupted.
- This chapter discussed mailing newsletters to referring sources, and today an email blast is a more popular option.

Considering all of these changes, there is a new spin on some parts of marketing our wonderful profession. This chapter will repeat a lot from the past chapter because some of this material is timeless. Other information has been updated, changed, or refuted to reflect the contemporary changes of oral and maxillofacial surgeons.

To devote a chapter to marketing in such a comprehensive oral and maxillofacial textbook is indicative of progress. This progression has been made on many fronts. First and foremost is the progress made within our profession.

Whether in the military or in sports, the first rule of competitive strategy is to know your adversary. In the consideration of marketing the OMS practice, we too must realize the adversarial barriers.

OMS occupies a realm in the public perception interposed somewhere between that of dentistry and medicine. This fact has shrouded our identity and services with an air of ambiguity from the onset of the recognition of OMS as a specialty. This ambiguity of services rendered and the public's lack of awareness of our training and education presents a further marketing barrier. Finally, the voracious and aggressive increase in our scope of practice and procedures has sped up exponentially, leaving the consumer confused about what exactly we do or used to do.

The aforementioned situations cumulatively have held us back in the marketing and public awareness arena. Ask the man on the street what a plastic surgeon does, and he will likely give you an accurate description. That same question

posed to the same person about OMS will more than likely not be representative of the scope of services we perform. In my opinion, this public appreciation of scope has not increased proportionately, even though our national organization has made great strides in publicly conveying our training.

Entering this discussion with these principles in mind facilitates and obviates the barriers we face and the direction we, as a specialty, must pursue.

Social Media: The Game Changer

I have had the honor of writing and rewriting this chapter for three editions of this textbook. The first time was more than 10 years ago when I was performing full-scope oral and maxillofacial surgery, and practice management and marketing were topics of personal interest. At the second edition, my practice was (as it is now) limited to cosmetic facial surgery, and I added enhancements relative to this topic. It is amazing how things have changed over the past 5 or 6 years. Although social media existed then, it was in its infancy and really had little impact on the goings-on of the average oral and maxillofacial surgery practice. Today, this is simply not true, as social media can enhance or detract from any health care practice.

In the "old days" when a new doc finished residency, he or she had to go into a community as the low person on the totem pole, and often struggled with the long road of developing a practice. In short, surgeons who had been established for years had the upper hand in controlling referrals. That was always the way it was. Traditional marketing consisting of print, TV, and radio is extremely expensive and generally out of reach for new graduates. Because of all this, the road from opening a new office to getting busy often took decades.

Today, you can see situations where a new graduate enters a community and hits the street with a great website and mobile website, an intuitive Facebook page, an active Twitter account, numerous YouTube videos, a progressive Constant Contact marketing campaign, a great Instagram and Pinterest app, and this list could continue. He or she can develop an overnight patient following, and in some cases out produce the entrenched competition. I have seen it happen, and have done it myself with cosmetic facial surgery.

Many older patients follow traditional marketing lines and still use the Yellow Pages, but the majority of patients today are very tech savvy. They don't limit themselves to traditional information sources such as a phone book, local word of mouth, or even general practitioner referrals. They make their own way to a given surgeon through social media.

Your name is your reputation. In this digital age, no marketing option is as powerful as the surgeon's own name. The first thing anyone reading this article needs to do is to try to grab a "dotcom" with their name. If it is Niamtu, it is easy; if it is Johnson, then you may be out of luck. Always keep in mind the power of your own name and start early to capitalize and own any domain you can get with your name in it. "Your name" is what people will search for when looking for information and reviews.

Website

The mother of all contemporary marketing is an exceptional website. Patients don't want to see a "storefront" website with a picture of the doc and office hours. Today's sophisticated patients expect the "whole nine yards" in a website. They want print information, animations, videos, before and after pictures, and interaction. They expect a link to ask the doctor a question and to schedule an appointment. They expect online registration and online access to all patient forms.

The topic of website is so complex that it should have its own chapter. Some doctors hire firms to do all of the website work, while others (like me) have total control of content. I have a company to host my site and update templates, but I have personally written every word and posted all of the 8000 pictures on my site.

Those doctors that are personally involved with their sites most frequently have much more advanced and up-to-date content.

I can't stress the importance of dynamic site content that changes regularly. Patients who see the same unchanging website will migrate to your competition that stays contemporary.

Contemporary websites should also have a blog, and the blog needs regular updates. There should also be an "Ask the Doctor" section where patients can ask questions that are answered in a timely manner by the doctor.

Look at any top leader in any field, and you will see what it takes to have a successful website. It must blend with all the social media that will be discussed here.

Doctor Rating Sites and Reviews

Physician reviews are second only to restaurants in terms of the importance of online reputation for choosing a business. Your online reputation has never been more important, and you must take steps to protect it.

Surgeons must learn how to acquire positive patient feedback on a daily basis so that service and satisfaction can be monitored, and put to work to market the practice. When negative reviews occur (and they will), it is much easier to bury them underneath scores of positive reviews. If the surgeon does not have positive reviews, then he or she will scramble to try to obtain them, which is unethical and obvious to the reader. Remember, today's patients look for reviews and take them to heart when choosing doctors. Contemporary marketing shows money is being spent on fostering patient *loyalty* more than ever before. Keeping current customers happy and engaged is the best route to practice success in the coming years, especially when you take into account patients' social connections and raised expectation levels.

One of my friends always says, "When practices spend good money after bad on marketing, it's like diagnosing and treating the wrong ailment and expecting a healthy outcome." Some surgeons spend hundreds of thousands of dollars on marketing but provide mediocre patient care. They will be outshined by surgeons who hardly spend any money on traditional marketing, but offer superior patient experiences and receive positive rating feedback. Something as simple as the way the phone is answered or the speed of an email response can have a significant impact on revenue. It does not take many mishandled patients to detract from your practice, and many practices drive business to their competitors without realizing it. Patient service does not occur by happenstance. It takes concentrated effort with regular practice, studying, and discussion to truly develop an experienced team for exceptional customer service. It is never coincidence!

Whether you like them or not, or believe in them or not, doctor rating sites are important and here to stay. In some respects this is a positive aspect, as in the past a doctor could be rude, arrogant, and dismissive of customer service, and still fly under the radar. Today it is a different game, and no surgeon who cares about his or her business wants a negative review.

Is it fair? No. My sister can go online and give me a glowing review, while my jealous competitor's staff can pose as an unhappy patient. Given this unreliability, a few bad reviews are not usually overly damaging. If you have 100 positive reviews and 3 negative ones, they are offset, but if you have 5 reviews with 3 bad ones, it is damaging. Again, the key is to find a way to let patients know that their opinion is important. I have a review section on my website, and we have cards we give to patients letting them know how to rate us if they desire. It is awkward for a surgeon to ask a patient for a positive review, but when a patient tells a staff member how happy they are with the treatment and service, it is simple for the staff to tell the patient that an online rating will enhance our practice and ability to continue this service. Don't wait for negative reviews to get positive reviews; that is like waiting for an emergency to get emergency drugs. Be proactive.

What can you do about negative reviews? First, take a breath and look in the mirror. Is it true? If it is, vow to change things and respond to the review (most sites allow a response) with a humble and contrite tone. "We are truly sorry that Mrs. Smith had to wait so long at her appointment. Her time is as valuable as ours, and we take that seriously. Most often we run on time, but occasionally we have to see an emergency patient, and that has to take precedent. If it were Mrs. Smith or her family with the emergency, we would do the same thing. We apologize and hope Mrs. Smith will give us another chance."

Never, never be defensive or argumentative. The online community does not like arrogance, and it will work against you. If you are truly getting abused, you may say something like, "Due to patient confidentiality, we cannot discuss this case, but if all the facts were known, the reader might have a better understanding."

Finally, if the review is untrue, abusive, or slanderous, you can petition the review site to censor or remove it, and frequently they will.

What is the best way to get positive reviews? This is a multifaceted question, and there are numerous answers. Personally, I think the easiest way is for your staff to guide the patient. So, commonly, a patient will compliment the surgeon, staff, or office. This is a perfect time for the staff to say, "If you want to make the doctor's day and help us, a positive online review will be greatly appreciated." I will say this myself when a patient is complimentary. The problem is that you can't just leave the conversation at that point. You have to provide the patient some information on how to leave an online review and what site(s) to leave it on. I have printed glossy postcards that we leave out in the reception room and hand to patients who offer a review (Figure 10-1). It provides the exact site and instructions to leave the review.

It's All about That Blog

Blog is short for "web log" and is a means of writing about anything you wish. Obviously most of your blogging would involve your profession, but it is not uncommon to blog about anything else in the world that may be of interest



• **Figure 10-1** An example of the online review card that the office provides for patients interested in leaving an online review.

for someone to read. Having said this, when I first started blogging, I thought, "Who the heck cares about what I write?" Well, I was sorely wrong, and my blog has surpassed 1 million views (Figure 10-2). The point is that the World Wide Web truly is worldwide. It is simply amazing that somebody, somewhere cares to read what you write. I write almost exclusively about cosmetic facial surgery, but also do personal topics or other health topics of interest. One must be careful to keep the practice blog neutral and not get into topics such as politics or religion, as you can also offend or drive patients away. Blog entries should be short, concise, and informative. Also, readers love pictures and videos, and a plain print blog is boring. Sites such as WordPress (www.wordpress.com) make blogging easy and free.

One very important point about blogging is that it must be regular. You frequently see a doc bust out with five blog entries in a month, then drop the ball. If you want a following, you must post regularly. Even if you only do it once a month, do it regularly. The topic can be unlimited, so if you get writer's block, just write about some trendy topic or health topic or a charity you support. The material is endless. Lazy docs can get ghost writing services to do your blog, but to me, this takes the true personality out of writing. Your blog should obviously be linked to your webpage and simultaneously publish to your practice Facebook and Twitter pages.

YouTube Videos

One thing that has really changed in my 15-year tenure in cosmetic surgery is the information that patients want to see before choosing a surgeon. A decade ago I would never have considered showing a patient an intraoperative video of their proposed surgical procedure. It just was not something that was done. Today, with social media exposure, many patients are not only eager to see their actual procedures, they frequently choose a surgeon in this manner. I have treated patients from all over the country and world because they had viewed my YouTube videos on cosmetic surgery procedures. Such videos should not only show surgery, but should be informative like a lay lecture. They should discuss the diagnosis, procedure, and postoperative care. By "speaking" to the viewer, the surgeon also has a chance to introduce his or her personality to prospective viewers.

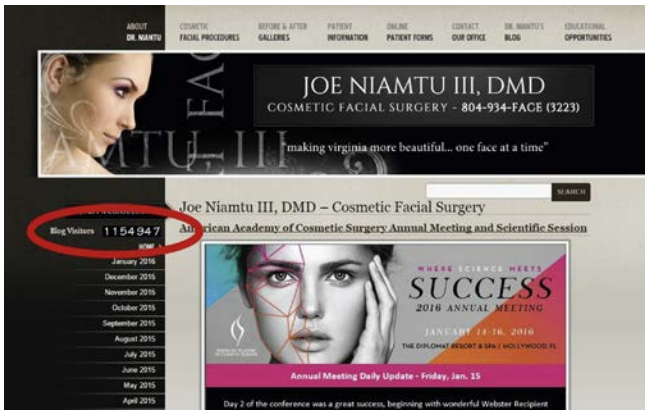

• **Figure 10-2** I thought my blog would go unnoticed and at the time of this writing have over 1 million visits.

At the time of this writing I have 4670 subscribers and more than 3.5 million views. I am amazed by this, as my thoughts about doing my first video were, "Who will watch it"?

It is not time consuming or difficult to produce relatively professional videos. YouTube has free editing software, but I prefer the video editor from AVS4you.com. This company has extremely powerful, simple, and intuitive video, photo, and audio programs, and it is unbelievably affordable.

Flickr Photo Sharing

I have always said "the best doctors take the most pictures," and I still feel that way. Pictures are mainstream, especially for cosmetic surgery procedures, and I have almost 100,000 jpg photos on my laptop and 8000 pictures on my website. These pictures not only serve as patient record but also work for me in many ways to promote my services and practice.

With thousands of images, keeping them organized can be difficult. Flickr has revolutionized my life, as all of my images (with patient consent) are stored online and I can easily create before-and-after galleries on my webpage where the images can be displayed from thumbnail size to full size. This service is free, but if you exceed a certain data amount, a very nominal fee is charged.

Facebook

Facebook has become the king of them all. More than 1 billion people communicate 24/7 on this site, which can serve as both a personal and business page. As much as I like and use social media, I am not a fan of receiving and answering messages all day and night—especially information like "on my way to the gym, just had a yummy muffin." I do spend about 30 minutes a day answering patient questions from my website and various social media outlets, but it is business focused. I don't do much with my personal Facebook page, but when I post on my blog, it goes to both my personal and business Facebook pages. This is a little redundant, but at the same time reaches different audiences. I do have colleagues who spend a lot of time on Facebook speaking with patients, doing contests and giveaways, and when I am with them, they are always typing on their phone. Not my cup of marketing tea, but nonetheless effective for some docs.

Regardless of your use or intent, to remain competitive, you must have a Facebook presence, even if it is basic info about your life and office. Remember that many young people use social media as their main source for searching and researching. This includes OMS and cosmetic surgery.

Pinterest, Instagram, and Twitter

As much as I enjoy and participate in social media, I have to admit that I don't have much presence on these sites.

I am not a "tweeter" and barely have enough time to do the things I have to do in life. All of my blog posts do go to Twitter, and that is the extent of my use. I have cosmetic facial pictures on Pinterest but don't feel it has spawned any direct patient encounters. At the time of this writing I do not participate in Instagram, but I have friends who are all over these three sites, and if they are not the prime movers, they have staff who do all the legwork.

RealSelf

RealSelf (realself.com) is a phenomenal site that links cosmetic surgery patients with prospective surgeons. It is an interactive site where doctors can advance through higher levels of visibility (higher levels cost money) and the users of this site treat it like gospel. I know of many plastic and facial plastic surgeons who obtain the vast majority of their cosmetic patients from this site. The big problem is that they will not allow single- or dual-degree OMSs to interact with most common cosmetic facial procedures. The list of "allowable" participation for OMSs (regardless of degree, training, and fellowship) include "teeth whitening, Invisalign, chin implant surgery, facial liposuction, and orthognathic surgery." Even though I do almost 100 facelifts a year, far more than their average plastic surgeon, I am prevented from soliciting or discussing this surgery with patients. This is an obvious slight controlled by competing specialties for patients and dollars. For this reason, I have discontinued participation with this site. It is powerful, but discriminatory.

Seeing Out-of-Town Patients

One caveat about using social media is the fact that it can propel your talents on a national and international level. I went from seeing patients from all over the city, to all over the state, to all over the country, to all over the world. This did not happen overnight and involves 30 years of practicing and marketing, but it was social media that made the biggest impact. In the past several months (as hard as it is to believe) I have seen patients from Europe and other continents for mole removal, cheek implants, facelift, otoplasty, and other common procedures I perform. Although this is a distinct honor for me, it is not without extra work for me and my staff. Out-of-town patients want to come in and out, and you must have stringent requirements for when they arrive and when they can leave post op. They also want to do online consults and Skype, and they expect exact diagnoses without a hands-on examination, which is difficult and illegal. These patients are, by definition, needy, as they are not local and need extensive information about travel, meals, housing, and caregivers. When you are set up for it, it becomes routine, but it is more time intensive than treating local patients. Also, the Web can be a magnet for younger patients with body dysmorphic disorder. There are many recognizable red flags, but most commonly young patients present with extreme image dissatisfaction, requesting surgeries uncommonly performed in that age group, or they want to look like a given movie star or celebrity. Avoid these patients at all costs.

The Bottom Line

One thing to keep in mind is that a surgeon must be competent to succeed. You can market extensively, but to keep the cycle going, you must have happy patients. Social media is a game changer, and this will not only progress in the current tangent, but will be exponential. The best docs will need to be on top of it in order to remain viable and contemporary with younger competing docs of the same and different specialties. This stuff is happening fast, and each time I update this chapter, there is new material. It will be exciting to see what the next version will reveal.

What's in a Name?

The majority of dentists graduating today receive a DDS degree, which implies surgical expertise to the public. The more descriptive DMD degree is of progressive thinking and public understanding. The specialty of OMS was in line for a name change for a long time. As a result of the politics of teaching institutions, many reputable OMS residency-training programs were forced to pursue nondentoalveolar procedures in a surreptitious manner. As a result of our excellent training in general anesthesia, many programs were able to perform some of the advanced procedures within their own clinic because of fear that other competing surgical specialties might protest. This proved, and in some programs still proves, to be a double-edged sword. On one hand, we were being trained in trauma, cosmetics, and so on, but on the other hand, this secretive approach breeds the mindset that propagates anonymity. For years we would not mention the word *cosmetic* because of fear of noncoverage by third-party carriers or criticism from other surgical specialties.

Some very progressive leaders in our national organization foresaw the need to change these preconceived limitations and levied for a name change within our specialty. Unbelievably, they met with resistance; however, history led us into the new profession of OMS.

The good news of the name change was that it was certainly more descriptive of our scope and gave us pride in pursuing procedures and techniques that were sometimes done in the after-hours clinic. The bad news is that the term *maxillofacial* is not understood by the general public and, in my opinion, has further masked what exactly it is that we do. I predict that the name of our specialty will be changed to "oral and facial surgery" within the next decade.

On top of this, our public perception is further hampered by the fact that much of what we do is painful, inconvenient, expensive, and without a tangible physical appreciation for the patient. Third molar surgery would be a perfect example of this concept.

Academic Marketing

Marketing is a popular major for many college students, and in the first-year courses, they learn the basics of the profession. Because many health care providers seem confused about the differences among marketing, selling, and advertising, it is appropriate to review the textbook definitions in Marketing 101.

Selling is concerned with the plans and tactics of trying to get the customer to exchange what they have (money) for what you have (goods and services).

Marketing is primarily concerned with the much more sophisticated strategy of trying to have what the customer or patients want.

By these definitions, one can clearly see that selling focuses on the needs of the seller, whereas marketing focuses on the needs of the buyer. Selling is concerned with the seller's need to convert their product or service to cash, whereas marketing is satisfying the needs of the customer.

A marketing-oriented office provides value-satisfying service that patients want. It provides the generic product (in our case, surgery), but also important is how the service is made available. Extended hours, payment plans, patient insurance assistance, a modern facility, state-of-the-art procedures, and painless treatment are just a few of the ways this service is made better.

Learning from Big Business

In the nineteenth century, the United States became a production-oriented economy and, over the past century, has shifted to a consumption economy. The energy and thoughts of the business community were once devoted to developing and improving ways of manufacturing. We now take our ability to manufacture for granted; the emphasis has shifted to a marketing orientation, and the energy and thought start with the customer (or in our case, the patient).

After the end of World War II, the General Electric Company pioneered the marketing concept in industry. The marketing concept is described as "a way of life in which all resources of an organization are mobilized to create, stimulate, and satisfy the customer and profit for the owner." If one truly understands this definition, they can begin to understand what marketing is really all about.

Corporations speak of the four Ps of marketing: product, price, promotion, and place. *Product* refers to making sure that the product is the right one and of superior quality. *Price* refers to establishing a price that makes the product as attractive as possible and still maintains a profit. *Promotion* is simply communicating with one's clients or potential clients. *Place* refers to putting the product where it can be most effectively used.

The correct analysis and mix of the four Ps are important, and marketing experts further maintain that a marketing leader must:

1. Determine the nature of changes in the market.
2. Identify and cultivate customers for the company's existing or potential services.
3. Meet the needs and wants of customers or potential customers.
4. Maintain a profitable position.

All of these factors are applicable to our profession. One merely needs to substitute the word *patient* for customer or client.

The second item in the list just given is very often overlooked. Historically, there have been many changes in the fee-for-service practice in medicine and dentistry. Before insurance coverage, patients understood their obligation to be responsible for health care costs. With the advent of health insurance plans, the burden of responsibility, at least in the mind of the patient, passed to the doctor. With the advent of exponentially increasing medical technology, the price of health care soared and became beyond the reach of most self-pay patients. Physicians' and hospitals' fees became obtrusive, and cost-cutting measures were instituted with shifts toward less hospital time and generalized cost containment. Managed care then entered the scene and has caused profound changes in our profession. There is now a shift to having primary care physicians triage patients, and surgeons are looking for ways to provide their services without the time and monetary expense of hospitals.

Physicians who had the ability to see these trend shifts were able to adjust their marketing and business strategies to meet the current need. Those who do not adapt may fail to thrive in this managed market.

Anyone who has read about corporate marketing is familiar with the concept of paradigm shifts. A paradigm is a model, and the paradigm for marketing OMS practices has been the same for years. Be a good physician, PR your referring sources, and you will prosper. We are now in the midst of a paradigm shift. With managed care, larger practices with multiple locations have positioned themselves to be attractive to the managed care plans of large companies. Now many patients are referred to a given surgeon, not because the general dentist wanted to send the patient, but rather because they had to use a participating specialist. Surgeons who refuse to explore managed care options may be driven out of business because they have not anticipated this paradigm shift.

A commonly used example of the loss of business domination from paradigm shifts is the Swiss watch-making industry. For hundreds of years, the Swiss dominated the making of watches and timepieces throughout the world. The paradigm for success was a mechanical product that was made from complex mechanical manufacturing and assembly of labor-intense intricacy. The Rolex chronometer wristwatch is an example of the fine product produced under this paradigm. The Swiss prospered and literally controlled the world production of wristwatches. In 1968 the Swiss controlled 65% of the world market in timepieces. They reaped 80% of the profit in the timepiece industry and employed 65,000 workers.

Around 1968 a Swiss company invented the liquid crystal watch and set up a booth at the 1968 World Watch Congress in Switzerland and introduced their new technology.

This concept was staggering. The watch had no moving parts, did not require movement or winding to function, and delivered accuracy 1000 times that of the finest Swiss timepieces. Although this timepiece technology was astounding, the major Swiss watchmakers were indifferent and did not even patent their own invention. Why? Because it did not fit their paradigm for what a wristwatch should be. Two companies, Seiko and Texas Instruments, did take notice, however, and saw the old paradigm for timepieces go out the door. They realized the potential of this new product and were able to move with this new paradigm. The rest is, of course, history. The Swiss workforce lost 50,000 employees and dropped from 80% of the market share to 10%. Today the Japanese dominate the world timepiece market; they had virtually no market share in 1968.

The point is that what works in marketing today may not be effective in the future, and the ability to predict and adapt is critical. Marketing is dynamic, not static.

Staying abreast of current technology is also important in the paradigm model. The bread and butter of our profession was once the extraction of carious teeth. It was only several decades ago that multiple full-mouth extractions were common on the office schedule of most oral and maxillofacial surgeons. Today because of fluoridation and education, full-mouth extractions have diminished rapidly to the point that some dental schools have trouble finding denture patients. Having four difficult impacted third molars removed simultaneously was not common 40 or 50 years ago. With the advent of high-speed drills, effective ambulatory anesthesia, and antibiotics, this procedure has become the mainstay of most OMS practices. Anytime a single procedure dominates the well-being of any business, its obsolescence could doom the business. The insurance coverage of third molars may fall into disfavor or be otherwise manipulated by insurance companies. We must, as a profession, be aware of this possible paradigm shift for what constitutes OMS.

Fortunately, our leaders have seen these caveats, and many of our ranks are entering the arenas of implant surgery, cosmetic surgery, and other nontraditional OMS procedures.

It is not uncommon to find physicians who are very averse to marketing in the form of advertising. These physicians say that they do not market. This is such a fallacy; we all present an image, and this is marketing. Some physicians are actually doing negative marketing by having poor staff and lack of policy while condemning an office committed to excellence.

Marketing Your Practice

I am fortunate enough to enjoy a mix of private practice and academic environments. The phrase "Always be a teacher and always be a student" drives many of our ranks to excel in both venues. I have written and lectured extensively on the subject of marketing the OMS practice and have found that, regardless of the community, state, or country, many physicians are in search of the "secrets of marketing." The delusion of these individuals confounds me time and time again. Practitioners want to know "what to do to get referrals." Sometimes, after a well-prepared and well-presented course on marketing, participants will confront me at the end of the lecture and say, "All of that is fine and well, but what is it that you really do to get patients? Do you give holiday presents? Do you do lunches? Do you need fancy imaging?" These physicians have missed the entire point. The correct answer is all of these and none of these.

Marketing is not the act of giving something to receive a patient on a one-to-one basis. Marketing is more of a mindset and a practice lifestyle. There are many successful practices that spend tens of thousands of dollars on marketing events and gifts, and there are just as many practices that thrive without spending a dime on those things. The latter type of practice focuses on two things: superlative patient care and simply knowing how to say thank you.

In addition to these examples, there are physicians who do all the correct marketing, even employing professional firms, yet have stagnant practices. These practices go through the motions, but have poor leadership principles and staffs that negate their marketing investment.

Successful marketing, as stated earlier, is a grass-roots level of excellence that starts before the patient ever gets a foot in the door. The bane of existence of any specialist in any discipline is the reliance on others for referrals. It is rare for a patient to see a sign for an OMS and drop in, whereas a "Family and Cosmetic Dentistry" sign may cause people to walk in and begin a relationship. In a thriving practice, one will see a constant trend of patients referred from sources other than general dentists. If an OMS office provides a warm, loving, and caring environment, patients of record and reputation will bring in as many or more patients than do primary referral sources. It is usually at this point that a physician really begins to feel and enjoy independence.

Getting to this point usually takes a number of years, but can be greatly accelerated by attention to basic communication skills and common sense.

The grass-roots level, of which we spoke, must literally permeate every aspect of one's practice, and it must be stressed that the staff is far more important in the spectrum of marketing than the physician. Most offices that are stressful and unprofitable suffer from poor leadership. Most physicians have no experience at human resource management and have accumulated what knowledge they have from hard knocks. It is shocking but correct to say that most employee problems are the fault of the employer and not the employee. Leadership is essential to make any team of individuals with a common goal cohesive and effective. In my opinion, 98% of the problems that make practitioners dislike their jobs stem from poor hiring and firing practices and the lack of leadership. There can be only one leader in an office, and that must be the physician. Leadership cannot be confused with management. One can delegate management and hire managers, but again there can only be one leader, and leadership cannot be delegated.

For the sake of comparison, let us envision two separate practices. One practice is a thriving, progressive, profitable practice that continues to grow. This office always seems to be on the forefront of the profession, and when you walk in, you are overcome with the energy of the staff. The environment is modern, clean, bright, and friendly and employs the latest technology. The physician and staff are aesthetically presentable, and smiles and warmth abound. When you have been in the office for awhile, it becomes evident that the office represents the leader. It is if she is "working at home." It is also evident that the physician has a passion for her profession, and practice is a joy and a privilege. The staff is cohesive; their careers seem enjoyable, and they work as if it is fun. This office presents an image, and that image is impressed on the patients who are exposed to this environment. It seems to rub off on them, and they leave with an enthusiasm for this staff. They sense the energy and the warm, friendly treatment and are impressed enough to comment to their friends and neighbors. Although they do not look forward to surgery, they do not mind and may even enjoy visiting the office. They enjoy being part of the energy and enjoy the special attention that seems so rare in this fast-moving technological era. The referring physicians and their staffs have the same feelings about this office and are confident that when they refer a patient, he will thank them for sending him to such a compassionate office. If a patient goes back to a referring dentist and says that the OMS was expensive, the surgery made them sore, and the recovery was extended, but thanks for sending them to such a warm, caring, and compassionate specialist, megamarketing has been accomplished. This is never a coincidence; it is the result of great effort and attention to detail. It is a result of the pursuit of excellence, based on the principles of leadership and policy.

Let us now contrast this office with one of mediocrity. This office may be right next door to our previous example, but always seems to be "chasing its tail." The office does not glow and is unkempt. The staff is stressed and bickering. The physician and the staff do not convey an aesthetic image and seem to have a goal of reaching 5:00 PM. Confusion and happenstance seem to rule, and there is an obvious lack of organization. The general atmosphere seems tense and rushed, and fun seems to be the last thing that anyone is having. The entire experience is reminiscent of old-fashioned dentistry. The staff turnover is high, and the future of health care seems bleak to these folks.

Although these contrasting examples are fictitious, we all can probably relate to a real-life example of each scenario. We must ask ourselves what exactly it is that makes such a difference. Knowing the answer to this question illuminates the principles of successful marketing. These are again leadership and human resource skills.

What Is Your Vision?

The first principle to discuss is vision. There are very few successful people in any walk of life who achieved their success by chance. Virtually everyone who has succeeded and reached professional contentment is a visionary. Such a person must have a clear idea of their goals and a plan for approaching them. Without this, chaos will rule. If asked, any oral and maxillofacial surgeon should be able to state their vision or guiding principles and their end point. This should also be second nature to the staff; after all, if you as a leader do not have a vision, then how can you expect your staff to know where you are going as an office? Your vision must be communicated with the staff and constantly reinforced. If you do not do this, you cannot build a cohesive team. It sounds trivial, but it is the single most important factor in beginning a journey to excellence. It is said that excellence is a journey, not a destination. In other words, there is no finish line; improvement and superlative patient care and the love of what you do are the dividends. If while reading this text you cannot immediately stop and write down your particular vision, then you should stop reading and start writing it—because it is the first rung of the ladder to excellence. By the same token, if you and your staff are not pursuing excellence, then you should send your patients elsewhere so that they will receive the best care available. Obviously, this sounds drastic, but it underscores the point.

A vision must be practical, ethical, and attainable; have a time frame; and be modifiable to bend with the curves of life. My own vision has been to: (1) build a large group practice that is enjoyable to both owners and staff and to serve patients with a warm, loving, and compassionate environment; (2) pursue technical excellence and to stay abreast of the forefront of our specialty; (3) become financially independent and serve those less fortunate with the ability to obtain our services through community work; (4) become a well-known entity for going out of the way to better provide for patients and referring offices; and (5) to have fun in the pursuit of excellence in OMS.

After you have developed a clear vision, the next critical step is to assemble a team of individuals capable of carrying out this vision. In any major team sport, tryouts are given, and the leaders search for certain critical attributes to best serve the effort. The vision is clear; it is to win. Can you imagine a team that merely selected its players without tryouts? They would never win because finding the right person for the right position would be all too random. With this in mind, it becomes obvious why some practices fail to win: The selection process is random.

Selecting the proper employees is a skill and can evade even the largest of businesses. There are scientific statistical methods for selecting the proper person for a job; however, the real answers are simple when applied to real life. For the sake of comparison, we will call a perfect employee a 10 on a 1 to 10 scale. In most progressive practices, a 7 or less is unacceptable. If a physician can surround themselves with 9s and 10s, marketing can be as easy as showing up for work. Because the caliber of employee is paramount and usually directly proportional to the success and stress level of any practice, the importance is obvious.

Hiring and Firing

Anyone who thinks that this topic is inappropriate in a marketing chapter already has serious misconceptions. Inevitably, when one closely examines the details of a successful OMS practice, exemplary hiring and firing practices exist. The converse is true for poorly run or unsuccessful stress-ridden practices. For the sake of comparison, I will continually compare the details of two practices. One practice is profitable, user friendly, energetic, and sets new standards for the community, and it has a physician and staff who enjoy their careers.

The other practice withers on profit, has a frustrated staff and physician, does not experience sufficient growth, has high staff turnover, and just is not fun to work for.

By contrasting the factors that differentiate these two practices, we can gain tremendous insight to some of the most common marketing problems. It is not going out on a limb to make two important statements. First, most problems a practice may have concerning marketing and communication can in some way be directly attributable to the hiring and termination policies of the practice. Second, the extent of the leadership of the physician will directly affect the policies or lack thereof in the office and will contribute to the employee relations problems. Most such problems are the fault of the employer, not the employee.

One of the inherent problems that have, for a long time, affected professionals in all branches of health care is the dearth of business courses offered to the physician in his or her preprofessional training. A thrust of today's medical and dental school curricula is the inclusion of business and practice management courses. Even in the most progressive didactic environments, this topic is usually too little, too late.

A compounding modifier to all this is the fact that medical and dental practices have traditionally evolved as small, independent, closed-circuit, business models that have been resistant to outside consultation or changes in the structural and managerial paradigm. This has created a very inbred system of strong independence, but little thrust toward interdependence. Although there certainly are positive points associated with this structure, it fails to adapt to changing paradigms, and because of this, physicians' offices tend to be trapped in a whirlpool of poor management, communications, and lack of adaptability. Inflexibility in this arena, to my mind, has led to our inability to predict the current managed care crisis. Cost containment and efficiency issues should have been predicted and dealt with a decade ago, instead of now. The ability to foresee and adapt to change is essential to succeed in any facet of business, including medicine.

The other component that has crippled the business of private practice surgery, in my opinion, is the failure to pay attention to changes in corporate America. We have been so steeped in autonomy that we have ignored the current trends in big business. Corporate America approaches management strategies with the same statistical scientific scrutiny that we afford our surgical literature. There exists a wealth of knowledge on human resources and marketing that has basically been ignored by health care providers. It is usually only through consultants that we gain exposure to this information. Because of this, we are constantly reinventing the wheel, which increases stress levels and decreases efficiency. It is a safe bet that the successful practices that we contrast already have an understanding of all of this.

Professional Consultation

The term consultant has been mentioned several times already, and now is an appropriate time to expound on this. We all seek advice from outside sources, especially in situations where the source knows more than we do about what we want to accomplish. Most oral and maxillofacial surgeons would not take apart their own engines if their car stops running, nor would they consider taking the transistors out of their TV if it falls into disrepair. Our everyday lives revolve around professional advice. Therefore, it is difficult to believe that so many physicians resist obtaining outside consultation. Our autonomy sometimes gets in the way. Anyone who runs a practice has very strong emotions and opinions about the way that practice runs. When you add partners to the scheme, these emotions and opinions increase logarithmically. It is very difficult to make prudent decisions in the face of emotional issues. Anyone who has made decisions to institutionalize a parent, euthanize a pet, terminate a marital relationship, or deal with similar issues will testify that it is very hard to make such decisions because emotions cloud the clarity of the issue. In these instances, we usually turn to those we trust to separate the issue from the emotions.

This emotional attachment to our practices often causes warped perceptions of the way the practice runs. To make rational decisions, one must have the big picture. A good metaphor for this situation would be a person enjoying a scenic boat ride along a beautiful river. The person in the boat is overcome with the beauty of the trees, water, and wildlife. The boat ride is absolutely wonderful—except that something ominous is happening. A person in an airplane that is flying over this boat can see more of the picture: 10 miles downriver is a huge waterfall that will kill everyone currently enjoying the boat ride. The person in the boat is disadvantaged by not seeing the entire picture, and the person in the airplane can avert disaster by alerting the captain of the boat to the impending danger. This metaphor illustrates the role that a consultant can play in your practice. Given the level of quality that we all seek in everyday life, it is unfathomable that so many physicians resist these ideas. In numerous practices, I have seen the entire office awakened by qualified consultants. Adapting an old adage, a physician who refuses to seek business advice has a fool for an advisor.

Another pitfall that I experience is "pseudoconsultation." This involves taking advice from the wrong people. Frequently, surgeons turn to their accountants or attorneys

for this type of advice because these individuals are familiar with the practice. However, most of these professionals have little practice management experience and often prove to be poor advisors. A frequent excuse for not seeking outside assistance is cost. Some physicians say that they quite simply cannot afford it. I am on record as saying that you quite simply can afford it.

Successful general dental practices have multiple hygienists doing recall visits. The dentist may pay these hygienists $200 per day. This can be a significant expense. These physicians may make a clear profit of $1000 per day after paying the hygienist. Many dentists never hire a hygienist because they "can't afford one." Again, how can they afford not to? A qualified practice management consultant and team may cost up to $10,000 for several days of work. If these people can institute changes that increase your accounts receivable, billing, coding, and staff relations by several percentage points, the payoff in profit and stress reduction may be tenfold. Why are so many physicians resistant to this concept? If a physician is truly interested in excellence, he or she must take the first step. Yet many cannot ever commit to take that step. As stated earlier, if someone is not about excellence, then they should send their patients to another oral and maxillofacial surgeon so they can have the best care.

Employee Relations

Because many new practitioners will be reading this chapter, I will begin at an elementary level and progress. The basis of the chapter is important for all employers, regardless of their time in practice.

There are universal situations that enhance or detract from any business, regardless of type, and choosing the correct employees is paramount. This applies especially to all service-oriented businesses, of which health care happens to be one. Unfortunately, many physicians never grasp the concept that their business is based around service and therefore struggle and endure unnecessary stress, whereas their colleagues who do understand the concept have fulfilling and profitable practices.

In any service-related industry, it is usually the level of service that sets businesses apart. For instance, if you had to ship one of your most prized possessions somewhere overnight and were ultimately concerned about its safe and timely arrival, would you choose Federal Express or the U.S. Postal Service? Most people would choose Federal Express because of their perceived high level of customer service and the lackadaisical attitude often attributed to government employees. Serving your customer or patient base is the key to success. A physician may be a genius and the best surgeon in a given area, but if the staff is abusing patients, the practice will not prosper. On the other hand, a mediocre physician can be elevated to hero status by a staff that nurtures their patients. Most physicians are clueless on correct hiring and firing concepts, and the ones with experience have often earned their knowledge through hard knocks. When I lecture to large groups of physicians in any locality, I always name employee relations as one of the top three factors in practice stress.

In the past, poor hiring and termination practices may have only meant increased employee turnover and physician stress. In today's litigious environment, improper human resource skills frequently lead to lawsuits. Wrongful discharge, sexual harassment, discrimination, and other employment-related litigation is on the rise. For a suit-prone employee, the ability to win a hugely unreasonable settlement holds much better odds than a lottery ticket. Sexual harassment suits have been settled for millions of dollars for innocently intended gestures or actions. This is a frank reality of modern employment law and circumstances. And it's the wrong arena in which to learn by mistake. Suits for sexual harassment are not covered by malpractice or umbrella insurance and are the responsibility of the defendant. Guilty or not, subsequent publicity can be very damaging to the morale, reputation, and pocketbook of the physician. Because most OMS offices involve a male physician with a female staff, I strongly advise all new practitioners to make a thorough study of local employment laws.

Initially, a new oral and maxillofacial surgeon will probably require a staff of at least three employees. The American Association of Oral and Maxillofacial Surgeons (AAOMS) recommends that two employees assist at surgery, and someone needs to tend to the front desk and clerical duties. Some new physicians may economize by using two employees and placing the telephones on a recorder during surgery; however, this compromises your availability to your referring physicians. There is no doubt that as soon as you can afford adequate staff, you will enjoy a safer and more efficient practice.

The easiest positions to fill are surgical assistants. There is a strong pool of dental assistants, nurses, surgical techs, and so on. As with any business, previous experience is preferable. A seasoned assistant can actually teach many things to a new physician. It is also preferable to hire an assistant who can also obtain hospital assisting privileges. As with all positions, a friendly, compassionate, presentable, mature assistant is optimal. One potential problem of hiring new employees is the age and experience levels of the applicant pool. This pay and experience level is filled with young, inexperienced women. Many have little experience, and their reliability and maturity levels may not suit the demands of the job. In addition, this segment of potential employees is often transient as a result of schooling, relationships, and childbearing. I have taken pride in hiring this type of employee and watching her grow into an excellent staff member. This, however, has been in the presence of superlative staff members who had the opportunity to mold her into a polished employee. Hiring this type of person without nurturing can lead to many employee-employer difficulties.

The job of practice receptionist is much more challenging. This employee is literally the ambassador of the practice and, more than any other employee, can add or detract from it. She is usually the first person to give an impression of the

spirit of your practice. In many cases, prospective patients call the office and are confronted by many barriers. Pain, expense, inconvenience, apprehension, third parties, and lack of appreciation of services are just some of the common barriers between physicians and their patients. Many of these patients are "shopping around" to find a caring and reassuring environment or the ability to tailor finances. An exceptional receptionist will attract these patients, whereas a rude or noncompassionate person may drive them away. This position calls for multitasking, especially for a new physician with a small staff. In addition to her duties as a receptionist, this employee must assist in coding, billing, insurance, accounts receivable, and collections. All of these functions are as vital to the success of the practice as the skill of the physician. This position begs for a mature, experienced individual and will command a higher salary. It is money well spent, because this person can literally help shape the future of the practice.

Where to Find Good Employees

This is a question posed by all businesspeople. Experience is very important, and the optimal situation is to hire someone who has worked in an OMS practice. I strongly advise against hiring an employee from a colleague's office, unless you discuss it up front with the other physician. A new physician can count on intimidating existing practitioners, and there is no need to start off in a deeper hole.

Local dental societies usually have newsletters with employment sections that can prove useful. The want ads in the local area are a traditional means of finding help. I would warn you not to place anyone's home telephone number in the ad for applicants. It is not unusual to have many, many calls at all hours of the day and night. Instead, I suggest a neutral address or P.O. box to which applicants can send résumés. If the new physician does not have hiring experience, it is best if a qualified party assists in the interview process. It is important to hire someone with the correct "fit," who will augment the personality of the physician. Many employment situations are a roll of the dice, but I caution against hiring someone who makes you feel suspicious. This is also no place for a demure introvert. Hire someone with good eye contact, a good smile, and an enthusiastic attitude. An employee who "glows" is a keeper and will infect the other employees and patients with that glow.

As the practice prospers, additional employees will be needed. It is not unusual for an OMS practice to have three to six employees per physician. As discussed later in this section, many offices believe that they are understaffed, when in reality, they are actually overstaffed.

New physicians are frequently in a quandary about starting salaries. By surveying colleagues in the general dental community, you can establish a scale for given positions in a given community. Additionally, many of the "throwaway" dental periodicals offer yearly regional staff salaries and regional fees.

For many people, one of the major incentives to work is to obtain insurance benefits. In health care professions, it is pretty much a given to offer health insurance as a benefit. Although there are many means of doing this, some of the most common are as follows.

Many companies offer group health plans at a substantial savings, whereas other employers give their staff a monetary sum for the employee to use for the plan of their choice. Because many employees may have coverage from spouses, they may not need all the benefits that another employee would. So-called cafeteria plans are a popular option, presenting a menu of options that employees can choose from. Other benefits include sick leave, holidays, uniform allowance, and retirement benefits. Most physicians have pension and profit-sharing plans and therefore are required to match funds for employees. This is a tremendous benefit and is often overlooked. An employee with longevity can save thousands of dollars in 401(k) plans or similar vehicles. This benefit must be fully explained to be appreciated and extends the gift of ownership to one's staff.

Let us now direct our attention to the actual art and science of hiring and firing. If there is one element of running a business for which most physicians are unprepared, it is finding, keeping, and terminating employees. Almost every seasoned practitioner bears some emotional scar from improper handling of employee issues. Many in our ranks have been parties to lawsuits for violating the most basic tenets of employment procedures. In discussing several commandments of hiring, it is important to include some absolute basics. Many of these principles probably existed in the marketplaces of ancient Rome, yet millions of bosses make these mistakes 2000 years later.

I strongly believe that it is an absolute mistake to hire spouses or family members as employees. Nepotism will at some time cause employee problems. I have lectured all over the country on this subject and am often met with resentment for stating this opinion. It never fails that at the end of a lecture a physician or spouse will confront me in stern disagreement. My response is that there are always exceptions to the rule, but I know of countless problems involving family. This is especially difficult for partners or other employees because they may perceive preferential treatment. In addition, the spouse may have the "coach's son syndrome" and apply stresses that are unnecessary. There is no doubt that it is difficult for a partner or manager to reprimand his or her spouse, and if there is a dispute, it is rarely the other person who must leave the practice. I have observed many state-of-the-art practices over the past 20 years, and it is rare to find an exceptional practice with family members as employees. Two exceptions are having family help at the very beginning of the practice as a cost-saving step, or casual summer employment for odd jobs.

On the subject of nepotism, it is also an unwise practice to hire relatives of current staff. The same pitfalls apply, and many embezzlement schemes have involved this type of situation.

Although it appears painfully obvious, professional physician-employee relationships should stay just that. In this era of sexual harassment, even the most benign of gestures can be grounds for a successful suit. I know of multiple cases throughout the country, involving very expensive and embarrassing outcomes for a surgeon—suits brought for telling off-color jokes, inappropriate body contact that was a "back rub," and commenting on an employee's attire or physical traits.

Another common violation is the temptation to manipulate money. Some physicians may pocket cash that comes across the front desk and believe that it is untraceable. Always remember that if a staff member witnesses a physician evading taxes or doing anything illegal, he now has a partner. If the physician can steal cash and no one knows, then why shouldn't the employee also steal?

Physicians spend as much or more time with staff than they do with their own family, and there exists a temptation to bare one's soul. I cannot stress enough the need to always keep some distance between your private life and what the employee knows or hears. I know several exceptional surgeons who were dragged through the mud by a terminated and disgruntled employee. Never underestimate the diabolic nature of a scorned employee. As in a nasty divorce, they will use any weapon of destruction, so don't give them ammunition.

Let us get back to hiring and discuss the interview process. There is a true art to being a good interviewer—the art of listening. Not only listening to what the employee says, but being able to read between the lines to know what he or she means. I will elaborate on this later.

First of all, the dress and demeanor of an interviewee is important. Given the fact that most people are at their best in dress and behavior at an interview, it is usually safe to assume that what you see is the best you will ever see. If dress or demeanor is inappropriate at an interview, it will only go downhill.

I believe strongly in hiring bubbly, enthusiastic employees, and an applicant who does not smile and show strong eye contact is usually a poor choice.

An additional caveat is an applicant who speaks negatively of previous employers. This should be a severe warning, especially if the applicant claims to be a "victim." There is little doubt that you will be the next bad guy in line.

As stated earlier, experience should be high on the list of employment attributes. Training someone to do a job is okay, but for a new physician, it merely adds further stress. For the new physician, it is better to hire a "teacher" than a "student." Interviews need not be exhaustive and should be standardized. In short, you have two people sizing each other up. Do not forget that the applicant is also interviewing you as a boss, and when an employee resigns, they are effectively firing you as a boss. It is a two-way street. One good question to ask is what the applicant liked or disliked about their previous job. This can extract key information about how they may fit in in your office. It is important to know if they can meet your standards in terms of overtime, Saturdays, and so on.

The next most important thing is to be able to relate your vision and the goals of your practice. You must actually present written documentation of who you are, where you are going, and how you plan to have this applicant assist your journey. Many physicians do not have these guiding principles in writing. How can an employee relate to goals that don't exist? Again, you should provide the applicant with his or her job description and discuss it in detail. If you want an exceptional practice, you need to employ exceptional people. If you do not have written job descriptions, you must settle for mediocrity. I suggest making an audiotape or videotape containing the guiding principles and visions of the practice. This will standardize the interview process and simplify this task.

If you have properly defined your goals and visions, you can effectively ask the applicant if he or she wants to play on your team and follow your rules. If you haven't defined the rules of the game, then how can you possibly expect the employee to play? I have sometimes done this with applicants who then stated that they could not comply with our expectations. They did both of us a tremendous service, because months of frustration might have passed before the employee quit or was terminated. The point is that if we did not have the job description and rules of the game defined, then we could not have gained this information.

Employee references can be perfunctory or very significant. Unfortunately, legal precedents have been set, and references can be grounds for a suit. Many employers are delighted to get rid of a problematic employee and want no backlash from a bad reference, so their word may not be accurate. On the other hand, an employer may be afraid to give an accurate reference because of concern about legal recourse. You will probably need to speak to several individuals to actually obtain an accurate impression. To simplify this process, it is important to ask the previous employer if he or she would hire that employee again. It is also prudent to ask them if the applicant possessed the attributes or lack thereof that we are about to discuss. This gives some standardization to the referral process and allows the new employer to find out more about the applicant's ability to fit into their office.

Any employer must be extremely careful about providing a negative reference. If an applicant can prove that you have prevented them from getting a job, you may be liable. Million-dollar damage awards have been won by employees who were able to prove defamation. I strongly caution any employer against giving a verbal or written negative reference, especially to a stranger. Many large companies will only verify employment history, the date an employee was hired, and the period of time that the employee worked. These companies refuse to comment on subjective questions. If an employer wants to provide a negative reference without jeopardizing himself, the statement "I cannot comment on this employee under advice from my attorney" should make the point without creating liability.

There is no doubt that hiring the incorrect employee can cost thousands of dollars. The cost of training, the loss of efficiency, and the negative impact are immeasurable.

I believe that there are eight attributes that make a perfect employee. For the sake of measurement, we will refer to a perfect employee as a "10." What we desire is to be able to screen for employees who are a "7" or above. The attributes listed in Box 10-1 will greatly assist this evaluation process. (I am grateful to Howard Rochesti of the Mercer Corp. in Santa Barbara, CA, for his ability to distill this valuable information into simple categories.)

Competency and Presentation

Competency is the foremost attribute required in the consideration. Again, in any service-oriented business, customers or patients expect and seek a certain level of care and service. When a person goes to a fine restaurant, they know in advance that it will be expensive. For that expense, they expect a high level of service (e.g., prompt seating, polite treatment, accurate ordering, fast service, and attention to detail). A waiter who cannot meet those expectations is incompetent. If you order a rare steak and salad with dressing on the side and get a well-done steak and a salad drenched in dressing, that is incompetence. This incompetence will, across the board, cause unhappy customers and invariably harm the reputation of the owner. What is frustrating here is that the restaurant owner may really have paid attention to detail. He may have a beautiful facility with ample parking. He may purchase only the finest ingredients, and he may have hired the best chef in the area. Despite all the attention to detail, a single incompetent employee can shatter his dream of having a fine restaurant by negating his attention to detail. There is a difference between inexperience and incompetence. If our waiter had a badge that said "waiter in training," we might expect a lesser level of service. This employee may become an excellent waiter, but should not be turned loose on the public without someone supervising. Presentation is also a very important factor to consider in our business. The discipline of OMS involves cosmetics, aesthetics, and health. One of your most powerful marketing principles is the appearance of the physician and staff. Slovenly, out-of-shape staff with yellow teeth or fingers from smoking or excessive body piercings or tattoos is not the image that we are trying to convey. An obese employee who is bubbly and neat may be an asset, but someone with cellulite bulging from dingy polyester white scrubs does not help with your marketing efforts.

• BOX 10-1 Key Interview Points to Consider When Interviewing Potential Employees

1. Competency and presentation
2. Unconditionally committed
3. Givers or takers
4. Offensive or defensive
5. Superstar or team player
6. Joyous
7. Self-managing
8. Learner

Unconditional Commitment

Unconditional commitment is defined as commitment without conditions. The closest example that I can find is a resident in a training program. As residents, we could not allow anything to take precedence over our work. None of us would have dreamed of telling our respective program chairman that we could not meet a deadline because we ate lunch and did not have time. We were in an environment where lunch was not a priority, and our work took precedence. Now, when we are called to the ER in the middle of the night, we cannot say, "It's late—call me in the morning." These are examples of unconditional commitment.

Owners of businesses have much more impetus to be unconditionally committed because they reap more of the benefits or failures than the employees. For this reason, it is rare to find this level of commitment in an employee. One thing about any society is that people identify and bond with cohesive organizational units that work toward a common goal. Fraternities, sororities, social clubs, sports fans, bowling leagues, scouting, and church groups are examples of situations where people unite and develop sometimes extreme loyalties. There is usually little monetary incentive in these groups; the point is that we are social animals and will expend great effort for "the cause." This same social nature extends into office settings, and when employees bond and identify, they will put forth great effort for the good of the practice. When you have a good leader, clear-cut goals, and the right employees, the business is a beautiful machine. Physicians who have exceptional and profitable practices probably are good leaders and have exceptional employees with a well-defined common goal.

An unconditionally committed employee will perform within reason to accomplish the task at hand. An applicant who will not work overtime or on Saturdays or follow your rules of the game is only conditionally committed and does not meet our criteria.

Finally, an employee may be unconditionally committed to you and not your vision. If an employee is only committed to you and you come into work with a poor attitude, then they will take on your attitude. However, if an employee is committed to your vision, then she will pull you aside and remind you of your commitment to excellence and point out that your attitude that particular day is not what our goals define.

Givers versus Takers

Everyone is either a giver or a taker. A giver is a loving, compassionate person who truly enjoys giving of themselves. These people understand the win-win concept and fully realize that the more they give, the more they will receive in return. They exude a generosity that is not measured in physical gifts, but more importantly, in the subjective sense. These people give gifts of advice, time, compassion,

empathy, and service. You should, by now, be getting a picture of what it is that we want in an employee.

A taker, on the other hand, operates in the win-lose environment: For them to win, someone else must look bad or lose. This was the student who reminded the teacher that she did not collect the homework assignments in school. The student's purpose was not to serve as a reminder, but rather to look good at the expense of others. This is a malignant personality trait and is manifested in all sections of culture. An oral and maxillofacial surgeon who refers to other ORL and maxillofacial surgeons as competitors instead of colleagues is another example of a taker. Any person who speaks negatively about anything to enhance their own identity is a taker. A giver would compliment the other person on their efforts and then focus on their own. Although it is impossible to screen for this attribute in an interview, this behavior must be identified and these people removed from your staff. One bad apple can spoil the whole bunch. If, as an employer, you ever come across the "What's in it for me?" attitude, you must take action. If an employee must have someone lose for them to win, guess who will be losing? The losers are the boss, the other staff, and the patients.

Offensive and Defensive Employees

In this categorization, we are referring to one's ability to accept change. Change is the basis for all molecular structure and all of life. Everything from the subcellular level on up involves motion, change, and energy. If you examine successful people and successful practices, you will see that they thrive on change. Change should breed excitement, but for many people, it causes fear and insecurity. If physicians are truly interested in approaching excellence, they must continually change all aspects of their practice to increase efficiency and service. I challenge and reward my staff for changing. We look at our forms, our policies, our furnishings, and so on and brainstorm, as a group, on how to improve. Accepted employee suggestions are validated by monetary rewards.

Some employees are intimated by change and take the "If it ain't broke, don't fix it" attitude. This is poison in a motivated practice. Employees who encourage and accept change are termed *offensive,* whereas those who fear and resist change are termed *defensive*.

I recently made significant changes to the charting system in my office. These changes meant altering the status quo of everyone's interaction with the structure and handling of the office charts. It was truly enlightening as an employer to witness the offensive staff immediately recognize the potential for increased efficiency and service, whereas the defensive staff members could only see problems. For these defensive staff, this meant doing things differently, and even though it was actually less work on their part, they resisted as a result of their personality trait.

It is appropriate for staff to challenge change. When I first proposed the charting system changes, I did not consider some shortcomings and was enlightened by challenge from the offensive staff. It was interesting that the pitfalls put forth by the defensive staff were less amenable to improving anything.

We all like change because it counters boredom. If we all wore the same clothes every day and ate the same food at every meal, life would not be as interesting. The same holds true in the workplace. A valid leader understands that not all change may be effective and must concede to their staff if a plan is not working. It is all right to make mistakes, but don't dwell on them. Better to move forward and, by trial and error, enhance the service to your patients. Successful practices have offensive players.

Superstars versus Team Players

The term *superstar* is not a positive adjective in the sense we are using it. A superstar is the type of employee who can do it all. Although this might be appropriate or even desirable for your first employee, you will have problems when you begin adding staff. The superstar manipulates situations so that all the attention swirls around them. It is not about winning the game; it is about how many points they scored. The superstar believes that because of their previous experience or superior intellect, they can "do better." They feel superior and are often overprotective of the physician and the practice. Their attitude is that they must "save" the practice from the incompetent hands of the other employees. These employees may take some time to recognize because they seem so dedicated on the surface. If you examine the attitudes of their co-workers, it will become evident if they are respected leaders and role models or self-servingly critical.

There are tricks to ferret out this personality type. They frequently place themselves in situations that "no one else can do." For instance, they are the only ones who can back up the computer or the only ones who do the payroll. They thrive on being needed for important functions. They frequently do this to become indispensable. They may cause many employee problems and know that the other employee will be fired, because the practice cannot run without the efforts of the superstar.

You cannot fire these employees because no one else can perform the vital functions, such as backup or payroll. The key to neutralizing superstar status is cross-training. Give several staff responsibility for critical functions. This is good business sense and lessens the chance of fraud and embezzlement. Cross-training prevents superstardom.

The examples I just gave do not mean that one person should not have responsibility. The difference is in the person. The superstar wanted other staff kept in the dark, but a team player would have communicated the important responsibilities to the other staff so that the office would function in his or her absence. Look for, hire, and reward team players; they will make your life and practice less stressful.

Although OMS is not physically challenging, many physicians go home at night exhausted and stressed. They are not exhausted from doing surgery; they are exhausted from having to constantly manipulate staff members to keep peace. Superstars embezzle from the practice—not

money, but energy. They are like sponges, and they steal the energy and excitement from the other staff or even patients. To counter this type of behavior in these "indispensable" staff, the physician must constantly be manipulating situations and environment. This is what becomes stressful and exhausting. Surround yourself with team players and you will be energized. Synergy occurs when the total is greater than the sum of the parts. Team players, offensive staff, and givers blend harmoniously to create synergy.

Enthusiasm, Joy, and Energy

Knowing that we spend a significant part of our time with our staff, it makes sense to seek enthusiastic, joyous, and energetic people. Happiness and enthusiasm are contagious and are self-perpetuating. Friendly people with high energy levels are a welcome addition to any group. If you truly believe that there are no dress rehearsals in life, then you should make the most out of every waking second. For movers and shakers, there is no room for pessimism. The form of OMS is not particularly exciting for the patient, but an enthusiastic, joyous, energetic staff member can greatly enhance the service and happiness level of patients through attitude. Surround yourself with enthusiastic, joyous, energetic employees, with the other previously mentioned attributes, and your practice will prosper.

Self-managing

Once you have found staff with these positive attributes, you need to make sure that they are self-managing. Some employees know just what to do, but will not perform unless directly supervised. This is a drain because you need two people to do the job of one. There is nothing wrong with the concept of a manager, but if you must literally stand over someone to ensure progress, you have an employee who is not self-managing. Self-managing employees are a pleasure to work with and take all the effort out of management.

Termination

If I could point to a single entity that holds back progress and perpetuates turmoil, it would be the ignorance and hesitancy of physicians to terminate an employee. You must make a decision whether to run a practice or an employee repair service. There is no doubt that terminating an employee is a decision that is fraught with emotional and legal ramifications. Firing someone or being fired can provoke so many emotions in both parties that many physicians procrastinate or endure years of unnecessary stress because they cannot bring themselves to "pull the trigger."

In this situation, we again ignore the tenets of big business. In the corporate world, termination and the factors leading to it are clearly defined, and it is not uncommon for an employee to be terminated in the presence of co-workers while a company security guard hands them a box in which to place their belongings, then escorts them to the door. It is very traumatic for an employee to be terminated, because it signifies failure and humiliation. It is even worse when the employee believes that they were unfairly terminated. If an employee is terminated for being tardy and has the retort that "Mary Ann is always late," your credibility is lost, and you may open yourself up for a wrongful termination suit. The best way to prevent termination is to use correct hiring principles. This sounds trite, but in most offices hiring is such a haphazard event that it becomes a roll of the dice. I am constantly amazed in my travels at the lack of attention to basic human resources policy. Time after time, well-established offices do not have written job descriptions, policy manuals, employee documentation files, or other basic information. Every office should have a written policy on exactly what it takes to be an excellent employee and what it takes to be terminated. In addition to this, employers must be consistent with these policies with every employee. If an employee does not know the goals of the practice, the day-to-day policies, and what is expected of them, how can they be expected to perform? Without structure, one has chaos. Unfortunately, many practices function in a chaotic state.

For all of these reasons, every practice needs a map and a compass. The map is the policy manual, and the compass is the leader of the practice, the physician. No one can get from point A to point B in unfamiliar territory or inclement weather without navigational aids. Can you imagine an NFL team with no one designated as the quarterback? If there was no leader and anyone could call any play at any time, chaos would rule, and the team would never advance. Similarly, if the team had a quarterback who knew all the plays but there was no playbook for the rest of the team, the same chaos would rule. Any successful team must have a leader and a playbook, and any pilot must have a map and a compass. Similarly, every office must have a leader and rules of the game, which we will enumerate later.

When the performance of an employee begins to falter, the leader must conscientiously ask himself or herself if it is an employee or employer problem. Often, as we have pointed out, the perceived employee problem is actually a leadership problem. If it is truly an employee problem and the employee can be salvaged, then a written warning and a second chance may be extended for a probationary period. If the employer believes that the employee is not catching on or is unsalvageable, then it is better to face the inevitable as quickly as possible. It is also important to document employee shortcomings and proof of counseling of the employee. This is critical in terms of defending a wrongful discharge suit or an unemployment claim.

If the proper pre-termination steps have been carried out, the actual task of termination need not be complicated. The single most important point is to have the entire script well prepared and clear in your mind. This is no time to ad lib or fumble around; absolute clarity is essential. It is also important to realize that if you are unhappy with the performance of a staff member, they are probably aware of this; they are also probably unhappy, and sometimes the termination of employment is actually a relief to both parties. I always terminate an employment relationship on a Friday afternoon, unless a significant infraction, such as theft

or substance abuse, has occurred. It is important to have a private environment away from other employees, and it is mandatory to have an employee, preferably of the opposite sex, present to document and witness. I very simply tell the employee that the employment relationship is not working. I further tell the employee that I believe that they are a fine person, but they are just not a good fit for the practice. I tell them that I have a certain vision and direction for the practice; the employee is not moving toward the goals of the practice, and again, it is not a good fit. I always prefer not to delve into specifics, because it opens the door for argument or comparison with other employees. If the employee pushes in that direction, I take control of the situation, reiterate that the topic is not open for discussion, and move on. It is imperative not to insult the employee and leave them with low self-esteem. If the situation is applicable, I offer the employee the ability to resign with severance benefits or be terminated with no benefits. I enter the interview with two predrafted letters, one for resignation and one for termination, and give the employee a choice. If I believe that there may be legal implications or retribution, I have the practice attorney present.

It is acceptable to have a manager or attorney do the actual firing, as long as the proper channels are followed. In fact, it may be wise for the physician to distance himself or herself from these proceedings. I have 8 partners and more than 50 employees. As a result of this size, we have an administrator with medical group management experience and a trained and experienced human resources manager. Hiring and firing is an ongoing occurrence and is beyond the scope and training of the physicians.

Although it may seem cold, it is an absolute necessity to obtain any keys, credit cards, or other practice possessions immediately. There are many cases of documented sabotage where this was not done. An even greater temptation for sabotage is to terminate an employee with 2 weeks' notice. This is a perfect invitation for this person to be unproductive or harmful within your office. A prudent employer will already have a replacement lined up to step right into the position. I said earlier that some physicians commit serious errors in judgment by taking money from the front desk, having affairs with staff, or allowing staff to know personal or family information. It is after firing an employee that they become disgruntled and expose any deceit or retribution. This is a real and all too common situation; do not fall victim.

Initiating a Marketing Plan

Although until now I have downplayed the specifics of a marketing plan, they are very important. But they are only relevant after the physician and staff are committed to understanding the theory and mindset of excellence and patient-centered care.

We, as physicians, have a dual commitment that is nonexistent in most other businesses. We have taken an oath and are expected to sacrifice for the well-being of our fellow man. Going to the ER in the middle of the night to treat a patient without funds is a good example of some of the problems that set us aside from other profitable businesses. In addition, what we do is expensive, and traditionally, people have a low priority for paying physician's bills. No one would go to a restaurant, order and enjoy a meal, and then be shocked to receive a bill and have to pay on the spot. This mentality has, in the past, not carried over to physicians because the general public considers health care a right and not a privilege. Things are quite simply different today, and we must again adapt to be profitable. Most physicians are compassionate and realize that their profession assists many people who may not have the ability to pay. On the other hand, without sufficient profit, the business will not thrive to a point to provide that service. We walk a tightrope, with patient care and medical ethics on one side and the need for aggressively structured business on the other side. An improper mix can detract from our humanity or force us out of business.

This is an opportune time to discuss profit. When I lecture on the subject, some physicians find the mere mention of profit objectionable or unprofessional. Yet this is a capitalistic society, and our economic thrust is profit. Profit is not a four-letter word, but loss is. There are few businesspeople who do not desire the amenities that society offers. Having a profitable business allows them to pursue their careers more contentedly, in addition to offsetting the mix of indigent treatment. Many of the frustrated practitioners in OMS are frustrated because of their lack of profit. Their poor hiring and firing practices and lack of formal policy and leadership are impeding their profitability and enjoyment, and this is all tied together in the marketing equation.

I have stressed the leadership concept and the importance of the staff to the success of the office. Let us now examine the role of the physician in the image of the office, because, after all, image and marketing are inseparable.

Most successful practitioners have a passion for their profession. In this day and age it is difficult to find time, but a marketing plan starts with clinical excellence. A physician needs to be well read and attend continuing education, concerning what is current and contemporary. By doing this, he or she is satisfying the public thirst for what is new. People are constantly intrigued by newer and better ways to accomplish mundane tasks. The mere incorporation of lasers, advanced implant technology, advanced imaging, minor cosmetic procedures, and advanced practice management systems will enhance the image of the practice. But this advancement will only occur if your patients and referral base know about the advances. Failure of communication is a pitfall for many physicians. You may be the most advanced surgeon in the area, but if your referral base and patients are not aware of it, you have sacrificed valuable marketing opportunities.

Communication is the essential measure of a successful practice and, in this age of computers, has never been easier. I believe that a physician should view his or her practice as a team, a family, and a center. This center is the nucleus



• **Figure 10-3** Personalized stationery and related communications convey a professional and team image. Some OMS have stationery for their OMS practice and separate stationery for Implants or Cosmetic Surgery which they use selectively depending upon the communication.

for what is current and best serves the patient. Generalists will rank the lack of communication with specialists high on their list of complaints. In the generalist relationship, they see a given patient and their family several times each year for many years and develop a special communication with these patients. The specialist may see most patients for two or three visits and be faced with the barriers of pain, expense, and fear. It is definitely more difficult to develop the level of communication experienced by the general dentist in just a few visits. We therefore must work harder and make a stronger impression. When a general dentist refers a patient to a specialist, he or she may not see that patient for months. If the oral and maxillofacial surgeon fails to send a referral letter detailing the surgery, it is very embarrassing for the dentist, who is ultimately responsible for the global care of his or her patients. Smart specialists realize that anytime they can communicate with their referring physician, it is free marketing. Each time your letterhead crosses the desk of a referring source, it makes a subliminal marketing impression. Communicate in writing with personalized stationery and, when possible, handwritten personalized notes (Figure 10-3). An astute surgeon will continually search for ways to communicate.

The previous areas of discussion are primarily philosophical, but, nonetheless, vital to understanding the global nature of marketing. We will now focus on some basics that can actually be applied to your individual practice. It is important to mention that the ideas expressed here are by no means exhaustive. They only scratch the surface as to important guidelines. I once participated in an AAOMS seminar in which five practitioners presented a slide show of a patient's journey through their office. This lecture focused on each physician's image, physical plant, referral and marketing strategies, patient care, and so on. Many simple but thought-provoking ideas were presented. The point is that satisfying a patient is an inexhaustible process, and there are endless means, some big, some little, of improving service and thanking referral sources.

When you consider the basics of your marketing plan, try to imagine your favorite restaurant. What is it that you like about it? They probably have a clean environment, with friendly and accommodating staff. Their service is probably excellent, and their food is unparalleled in presentation and taste. The restaurant probably has reasonable prices and has amenities such as staff who remember the patrons, easy parking, and a way of always making you feel that you are their only customer, even on their busiest nights. Try to apply this thought process to all the details of your practice. No matter how busy, we should try to make each patient feel that they are the only patient in our practice. Concierge care is all the rage in medical practices, but astute physicians have been providing concierge care free of charge all along.

Image and Logo

The most basic of basics in marketing is identity. The first thing that you need to do is to be remembered. Can you imagine if one of the major soft drink companies did not stress their logo? All people would remember is "that" company with the good taste. The cola wars are a Madison Avenue example of how essential image is. These companies spend billions of dollars making sure that society remembers their name. Some image marketing is so effective that a product name becomes the moniker for all products of that type. When you hear someone ask for Scotch tape or a Xerox, they probably are speaking in a generic sense. This psychology applies to health care marketing, and without a logo, it is much more difficult to gain an identity.

There are many ways to create a logo. You can consult with a graphic artist or marketing firm, or make it a project with your staff to do it internally. The logo should represent you and your practice. If sailing is your passion, a tasteful logo centered around a sailboat makes a point and is fun. Once decided, you should obtain a service mark for the logo to protect its unlawful usage. The logo should be distinctive and colorful and should be used whenever possible. I use my logo on prescription forms, all stationery, newsletters, invitations, and virtually anything that represents the practice, including scrubs (Figure 10-4).

When people see this logo, they think of our practice. If the logo is not distinctive, it is not as effective. I believe that the commonly used logo of a retrognathic and prognathic profile and a normal profile has been overused in our profession. It is also effective to have a slogan to complement your logo. It should say it all in a nutshell.



• **Figure 10-4** The author and his team. All teams have uniforms, and ours is no exception.

Uniformity

In my opinion, one of the beneficial aspects of the stringent Occupational Safety and Health Administration (OSHA) requirements was the widespread acceptance of surgical scrubs in the office. Having freshly laundered scrubs with the practice logo and the name of the employee embroidered on the scrub top is a functional and professional look and also designates the players on the team to the patients. The office is one place that you should be able to tell the players without a program. Going back to the sports metaphor, all teams have uniforms. The issue of name tags for employees is also important. When a patient is placed in the unfamiliar environment of an OMS office, he or she can feel intimidated. The unusual sights, sounds, and smells coupled with the fear of surgery and pain does not exactly present a relaxing environment. The patient, in this situation, looks for any vestige of warmth, friendliness, or compassion and will bond with these people, thus mitigating these fears. When you call a patient by name, this automatically puts him or her one step closer to a bond. If you examine the habits of very successful people, they inevitably are quick to remember a new name and use it frequently in a conversation. People like to hear their names. Many physicians write the first name of a patient on the chart in very large letters that can be seen across the room so that the entire staff can refer to the patient by name. Some offices use a chalkboard with "Welcome, Bill Smith" inside the treatment rooms. In any event, it is helpful and should be mandatory for all employees to have some sort of name tag. If for no other reason, it will allow a patient to be specific when they compliment or criticize an employee's performance.

The Art of the Evaluation: Breaking the Ice

The anxiety associated with visiting a physician is sometimes palpable. Some people become diaphoretic and obviously stressed. There are many subtle tricks that most seasoned practitioners employ to place patients at ease and make it a positive experience. First and foremost is to avoid isolation. In busy practices, the patient is often whisked into the



• **Figure 10-5** Many patients are nervous while waiting for the surgeon. A bubbly and caring staff member is a great icebreaker and can gather important information and educate the patient before the doctor enters the room.

treatment room and left alone while the team is seeing other patients. Leaving a patient alone in a room is negative marketing. A staff member should always accompany a waiting patient and engage them in relaxing conversation and discussion about their current visit. This is a great time for the employee to gather important information, bond with the patient, and engage in patient education (Figure 10-5). I have made an investment in large-screen television sets in all patient rooms (Figures 10-6 and 10-7). It is okay to leave a patient unattended if he or she has something to do, and handing them a remote for the big-screen TV will help them pass the time and reduce the feeling of waiting.

Nothing is more important than a smile. As a result of the stress associated with our career, we must sometimes force a smile, but no physician or employee should ever enter a treatment room without a smile. No other body language is as reassuring. In addition to smiling, patients like to be touched. Classic medicine from thousands of years ago talks of "the laying of the hands." There is something about appropriate compassionate touching that helps the physician-patient relationship. A hand shake or a pat on the shoulder is sometimes all that is necessary. Unhappy patients who feel rushed through one's office will frequently say, "The doctor didn't even touch me." There is an art to making people wait for your services without feeling that they waited too long. If you can keep them engaged and occupied, they will not realize the length of the wait.

Posture is also important when speaking to apprehensive patients, or any patient. Again, no matter how rushed a physician is, they should always sit down at some point during the patient conversation. It is better to be eye level with the patient; this shows that you are "into the patient."



• **Figure 10-6** Wide-screen TVs can serve to occupy or educate the patient. **A,** They can watch television while waiting for the doctor. I personally use my website on the wide-screen to assist in consultation, as all my pictures, animations, and videos are available **(B).**



• **Figure 10-7** In addition to recreation and education, the wide-screens can also be used as anesthesia monitors during surgery.

Masters of communication will always begin a professional visit by making small talk with the patient. People are impressed by the fact that a busy physician would ask about their hobbies, families, vocation, etc. Again, taking 30 seconds to informally chat with a patient can lessen the appearance of being too busy. A patient is really impressed when you remember a personal fact months later, and astute communicators will make a notation on the chart "Patient likes riding horses," etc. When the patient returns months later and you ask about their horses, it truly makes the patient feel appreciated and impressed with the surgeon.

Some patients are difficult to warm up, and complimenting them is a nice way to begin a conversation. The color of a dress, the smell of perfume, a piece of jewelry, or the patient's children are all easy compliments. Complimenting the great work of the patient's dentist serves to reinforce the patient's faith in their dentist, and they frequently repeat this fact the next time they visit the dentist, which has a positive marketing appeal for you.

There are many times that we are truly rushed in trying to accommodate overbooking, emergencies, and all the other problems with a busy schedule, but paying attention to the details just discussed can change the patient's perception. If a staff member precedes the physician and communicates in the same manner, a cumulative effect results. Every physician and staff member should always ask if there are any questions before discharging the patient. With positive communications, one can accomplish in 5 minutes what may take others 25 minutes. Providing a variety of high-quality and informative material on the physician, the staff, and the office will also help pass the time in a constructive manner and assist your marketing.

The Art of Waiting

Waiting is one thing that patients hate. This is one reason we refer to the lobby as a reception room and not a waiting room. Industries such as fast-food companies, banks, and retail stores have done many studies on waiting. Fast-food chains have found that people do not mind waiting as much if their order is taken immediately, even if there is a significant wait afterward. In addition, people who cannot wait are served first. Drive-through windows take precedence over counter customers. Retail businesses have found that customers pay less attention to time if they have something free. This may be a bowl of candy or a self-serve coffee station. We, as physicians, can take advantage of this type of psychology. In addition, if a patient is going to experience a long wait, they will do much better if they are informed of this. A progressive office will update the patients on the status of the wait and offer anyone the opportunity to use the telephone to adjust their other business, or reschedule the appointment. People become quite agitated when held in limbo. Again, if you are truly interested in marketing, make these patients comfortable, provide them with useful information about your office and services, and give them something to do.

I always apologize to patients for an unreasonable wait and tell them that their time is just as valuable as my own. In addition, I will often adjust the fee in the interest of patient relations. We further explain to the angry patient that we had to care for a patient with an emergency—if it

were the angry patient who needed our services, we would be there for them, and others would have to wait. Our office also sends an apology letter to patients who have experienced substantial waits.

Running behind on a schedule is a fact of life in many offices, but some common sense and special attention can mitigate this factor in patient dissatisfaction. This is marketing in its purest form.

Physical Plant

In the institution of a marketing plan, few things are as important as the home base. Although the first impression of your office usually begins before the patient arrives, the first 5 minutes in the reception room probably defines much of the patient's attitude. It is important to remember that our profession is about well-being and aesthetics, and our offices must represent this. From time to time, I will sit in my reception room during business hours and just observe. It is interesting to see how people interact with your office and to make observations yourself. Many intimidating and offensive things occur in our offices. When we walk through our own office, we are sometimes oblivious to these factors because of our accommodation. When we walk through the fragrance department of a large department store, we are usually impressed by the mix of fragrances; however, the employees behind the perfume counter do not notice the smell. In this case the smell is a positive factor—but the smell of burning flesh from a cautery, strong disinfectants or medications, burning dentin, and so on, is certainly not pleasant to your patients, even if you and your staff do not notice it. The same thing can be said about noise. There are few things more worrisome to anyone than the sound of a drill or the shriek of a patient in pain. Couple this with the sound of a patient with airway problems or anesthetic gagging, and you are subjecting your patients in the reception area to a cacophony of scary and unwelcome sounds. How are they supposed to feel if they are next to be treated, or if it is their family member in surgery?

Not all noxious sounds come from patients. In a professional environment, we must be very careful about staff and physician conversations being audible to patients. In the Capitol building in Washington, DC, there is a popular attraction that illustrates the peculiarities of acoustics. If you stand in a certain spot in one of the large rooms adjacent to the rotunda and whisper, the words can be heard with clarity in another area some 60 feet away. It is astounding that the acoustics carry a whisper that far.

This same acoustical situation can and does exist in offices. Patients often overhear remarks from the staff or physician, personal telephone calls, or employee bickering. Also, they may misinterpret what they hear. In many offices, receptionists make collection calls or speak with patients about sensitive financial or health information. The wrong conversations can provoke ill will or even legal problems.

I always recommend sound attenuation techniques for the reception room, the surgical suite, and the physician's private office. In addition, it is important to keep professional decorum at all times in the company of patients.

An office need not be elegant to make a good impression. Practice management experts will attest that cleanliness is one of the biggest factors that patients notice. In this day and age of potentially fatal communicable diseases, sterility and cleanliness are paramount. Many practitioners have signs posted throughout their office extolling their extra attention to sterilization and the like. This is pure marketing.

This is a good point to bring attention to another important point of marketing. If you go out of your way to improve service for someone, it is imperative to let them know. When we send cleaning to a dry cleaner and we get a shirt or blouse back with a tag attached to a button informing us that the cleaners saw that the button was missing and replaced it, we recognize extra service. Just think how frustrated you would be if you packed that shirt or blouse for an important out-of-town meeting and found, getting dressed before the meeting, that the button was missing. In this case the dry cleaner was providing exemplary service, and you only realized it because they pointed out their extra effort. Had you unpacked the clothing for the meeting and there was no tag on the button, you would have never realized the extra effort. When you go above and beyond the call of duty to extend service, let your patients know of your efforts or they may go unappreciated. As consumers, sometimes we pay extra for a superior product. We have all purchased something that was more expensive than usual, because it was explained to us that only the best parts were used and the guarantee is exceptional. People will pay more money for goods or services that they deem to be exceptional. If your office is exceptional, you need to point it out in every respect to your staff and patients.

It is great promotion to have the staff compliment the physician and vice versa. Patients often make telephone rounds with multiple offices to find the one that "feels" best. If a receptionist says to a patient, "Oh, you will love our doctor—she's so gentle and friendly; you'll just love her," the patient will believe that she really goes out of her way to make sure you have as pleasant an experience as possible. As a practitioner, I am absolutely positive that many patients who were on the fence or telephone shopping came to the office because of the complimentary nature of the staff. In return it also says a lot about a physician if he or she compliments the staff in front of a patient. Most of us are probably very appreciative of our staff, but fall far short in expressing thanks. Complimenting a staff person in the presence of a patient raises the morale of the employee and reinforces the cohesive nature of the team to your patient. If there is one fault that we all are guilty of as employers, it is having an employee that does 99% of things correctly and we jump on them for the 1% they do wrong. The world needs more compliments.

It pays to take a weekly stroll through your entire office when there are no patients present to visually inspect the state of your facility. Some subtle details will jump out that may not be noticeable in "the heat of battle." Outdated or

wrinkled periodicals, dirty carpeting, unhealthy plants or flowers, messy aquariums, outdated or worn furniture, dirty windows, and crooked pictures are just a few things that should be inspected by the staff and physician on a regular basis. The clinical areas must be clear of difficult-to-notice objects, such as wire, impression material, bits of suture, etc.

I strongly recommend redecorating the entire office every 5 years, whether you think it needs it or not. First of all, it probably does need renovation, and second, it is amazing how little things, such as paint, wallpaper, and furniture, can increase morale. Many of us spend as much or more time in the office than at home. For this reason alone, it should be nice and represent you and your interests. Although unfinished or pine furniture was once popular, it now portrays a yard sale image.

Identifying a Target Market

Again, image and marketing are inseparable. Every businessperson struggles for a way to identify their target market and spread the word of their goods or services. There is no disputing that word of mouth is a very effective means of marketing, but it is also the slowest. There are many means by which to mass market, and we will discuss them later.

Identifying the target market for any business is very challenging. It may cost several hundred thousand dollars to find out that Pepsi drinkers are 23-year-old Republican college graduates. Fortunately, for our profession, our target market is obvious. For the vast majority of us, general dentists or dental specialists are the funnel for our business. When I speak to new practitioners, I make the point that 10 general dentists could support an oral and maxillofacial surgeon if they were prudent practitioners and properly screened their patients. The problem for most of us is that we are not the only show in town. There are usually many choices for a dentist, so why choose our particular practice?

An entire text could be devoted to this question alone. Initially, many established referral relationships begin when a practitioner enters practice, and, if the service is appropriate, continue as habit. Why did this dentist originally begin referring to a new surgeon in the first place? Age distribution has an influence, in that many dentists refer to specialists of comparable age. They may know each other or at least relate. Established physicians may refer to a new physician because they have empathy for the new practice, or simply because the physician is just new and different. Perhaps they believe that the new physician has skill in the latest techniques. There are many reasons why an established general dentist might stop sending patients to an established practice and begin sending them to a newer or different practice. The biggest problem, however, is that it often has to do with a change in service.

When a practitioner first enters the practice, he or she is usually enthusiastic and hungry for business. As a result of this, new practitioners do all the right things. They see any patient at any time, they work until the job is done, they are quick to express gratitude for referrals, they are very friendly to patients and referring dentists, and they will bend over backward to get new business. They are humble but confident and are usually excited if not supercharged about OMS.

With this willingness and attitude in mind, it is easy to deduce not only why new physicians get patients, but also why experienced physicians might lose them. Obviously, most of us lose some vigor as we age, but too many physicians fall into a false sense of security as a specialist and assume that a decade-old referral relationship will continue out of habit. This could not be further from the truth. If physicians continually decrease their level of service, they are literally inviting competition into their referral area. When considering a marketing plan, remember to try and do as many of the things that made you successful as you can, and never, never let your guard down out of overconfidence. It requires much less energy to maintain a favorable referral relationship than to try to reenter one.

Pre-entry Materials

The best time to market is always. Many physicians are under the impression that they need not concentrate on marketing patients until the patient contacts the office. This is not true. First, many physicians mount tasteful and effective media marketing campaigns, and we will discuss these specifics later. More important is the ability to obtain a favorable position with the gatekeepers of your target market (e.g., the general dentist, dental specialists, local physicians, ERs, and pharmacies). A busy general dentist is very similar to a busy ER physician in that both need to get problem patients out of their facilities to stay on schedule. They will take the path of least resistance to get the patient to another caregiver, usually a specialist. If your office is easy to get a patient into, you are in the most favorable position; if your line is busy or your receptionist makes the general dentist's staff jump through hoops, then you are in an unfavorable position. A prudent specialist will constantly adapt their office to make it easy to make an appointment. If you are unsure of how hard or easy it is to make an appointment at your own office, have a friend call monthly to make sham appointments with different scenarios. Example scenarios would include an emergency appointment, a pushy patient, a handicapped patient, and so on. It is quite a learning experience to do this. It is also helpful to use the "secret shopper" scenario. This involves having an anonymous patient (one not even the physician knows) make an appointment with the practice for an evaluation. The secret shopper should document all aspects of care, conversations, office observations, waiting times, staff and physician demeanor, and so forth. This is then filed as a report and shared with the staff. I have done this many times, and it always serves to point out deficiencies.

There are many techniques to facilitate a favorable referral position. Many physicians supply the referral base with referral pamphlets with pictures of the physician and staff and pertinent information about the surgical experience.

These brochures often have a map to the specialist's office and important telephone numbers. Some practitioners include promotional gifts with the brochure, such as refrigerator magnets, fast-food coupons, discounts for surgical evaluation, adolescent-oriented coupons, etc.

A presurgical packet makes a nice presentation for a patient to receive and helps the patient identify with the specialty office before they ever walk through the door. I have found this to be an efficient and timesaving method that allows the office to schedule more patients, who will experience less waiting. In addition, we have found the patients to be more accurate when they can fill out forms at their leisure.

Any marketing, business, and promotion should involve the Internet. Many offices now employ online patient registration and appointment ability. Contemporary practices have a professional website that details all aspects of the practice and offers advance registration. Not having a website in this day and age is an obvious deficiency that makes a practice stand out in a negative way. Just having it is not enough—it must be attractive and informative. Contemporary patients seek information.

Making It Easy

Because most general dental offices have panoramic radiographs on their patients, they usually send them to the oral and maxillofacial surgeon for the patient's appointment. Sending the referring office a self-addressed stamped Panorex envelope greatly facilitates this process and puts that office in a more favorable position. Electronic transfer of digital radiographs is even better, assuming one's referral sources are as advanced. There are hundreds of ideas being used by successful offices. The challenge for us all is to constantly think of service-oriented ideas to better serve our referral bases and patients. It is fun and rewarding to challenge your staff to dissect everything that constitutes your office and try to reassemble it for better patient service.

Synergy in Marketing

Synergy occurs when the whole is greater than the sum of its parts. This can be applied to marketing only when the physician involves his or her staff. A physician can have the best marketing mind in the world, but be tremendously reduced in effectiveness if the staff is not involved. McDonald's fast-food chain has a policy of training their managers and franchise owners. They require these executives to literally begin at the bottom. Managerial trainees must flip burgers on the grill, run the French fryer, and make milkshakes for several weeks before putting on their white-collar clothes. Many businesses take this grass-roots approach because it brings home an enormous point. A manager is more effective if he or she understands everyone else's job. In addition, this experience will stimulate the innovative mind to find a more efficient and profitable way to get the job done. It is shameful that, as physicians, we do not spend one day of the year as a receptionist or surgical assistant. We would gain much insight into our practices. Our staff hears, sees, and feels things that elude the physician.

If a physician has the right staff (if you do not, you are negative marketing), they will exponentially complement the marketing experience. It is essential to communicate and formally launch a marketing campaign. It is very effective to refer to this as a patient-service enhancement campaign. I recommend canceling patients and having a half-day meeting. The purpose of this meeting is to point out to the staff the importance of patient-centered care and to explain the benefit of superlative service. Each staff position should have a specific job description, and it is imperative to challenge the staff to be innovative and try to improve each detail of the patient's experience. The physician must be prepared to reward the staff with some type of incentive for their contribution. This is a win-win situation because when the staff wins, the physician wins more. Once you have challenged the staff and they respond to the challenge, the increase in energy level is almost palpable. The ensuing enthusiasm serves to further fuel the synergy engine and draws the entire team to a common goal: superior patient service. I am continually amazed at the endless ideas submitted by the staff and frequently ask, "Why didn't I think of that?"

I require each employee to submit at least two ideas and reward them with a monetary bonus. An employee who does not submit two ideas cannot be reviewed until this is completed, and no review means no raise. An employee without an idea on how to improve patient service has no place in an office in pursuit of excellence.

Failing to enlist your staff in the marketing of your practice will deprive you of your most effective and most economical asset.

In 1995, the American Society for Quality conducted a survey on the reasons for customers switching service providers. Following are the interesting results:

- Death: 1%
- Moved away: 3%
- Influenced by friends: 5%
- Lured away by competition: 9%
- Dissatisfied with work: 14%
- Attitude of indifference on the part of an employee: 68%

This survey probably applies to every type of business on the planet. Most of us can relate to a restaurant that has great food but mediocre service; one rude waiter or waitress can ruin the best of products.

Patient Surveys

The quintessential marketing question is "What is it that I can do to better serve my patients, staff, and referral base?" This also translates into "How can I be more profitable?" Individuals spend thousands of dollars to find this answer when it is actually right under their noses. Ask your patients, staff, and referring physicians what they want and how you can better serve them, and they will tell you for free. Place a

two-dollar bill in the return envelope with the survey as an extra incentive for return of information.

The survey need not be exhaustive, and the more to the point it is, the more participation you will probably have. There are several schools of thought on how to execute this type of polling process. Many physicians believe that anonymity is important to obtain true and unbiased input. Some physicians will use a professional marketing firm to do this, although I believe that this is unnecessary. If you believe that bias is a possibility, a neutral return address and P.O. box can be used. I know of practitioners who rent a P.O. box and have envelopes and stationery printed with a fictitious company, such as "Martin Market Research." The survey contains a cover letter that states that they are a market research company conducting a survey for Dr. X's practice. Proponents of this type of approach believe that referring offices may be more candid with a third-party firm than they would be with the office itself.

I have experience with multiple methods of referral surveys, and I still prefer performing surveys from my own office on my own letterhead. Referrals have been very candid and specific and frequently sign the survey. I give the responder the option to sign or remain anonymous.

In this day and age and with the state of junk mail, it is difficult to get people to fill out a long form. The survey should be 10 to 15 yes-or-no questions followed by an open-ended area asking for any specific input on how we can improve our office.

Some of the basic questions asked are as follows:

- Is it easy to refer patients to our office?
- Are our hours of operation convenient?
- Is it easy to reach us for emergency patients?
- Is our after-hours answering service polite and effective?
- Do your patients generally relate a positive experience when returning from our office?
- Do our insurance and billing personnel serve your patients well?
- Is our office efficient in communicating about your referrals and prompt in returning your referral records?
- Does your office enjoy our educational and social functions?
- Do you have any suggestions for future social or educational functions?
- Please list any positive comments you have about our office.
- Please list any negative comments you have about our office.
- Please list any additional comments that may assist our office in serving your staff and patients.

These are merely examples of meat-and-potatoes survey questions. It is less important what you ask than the fact you care about asking. An office that does not take advantage of this powerful tool on a regular basis has surely missed the marketing boat.

If a given referral source makes a negative or interrogatory comment and signs the survey, it is important to respond in writing as soon as possible. Failure to do this may be ignoring a truthful critique of the physician and may be taken as offensive.

It is possible to oversurvey a referral base. This task should be done only every 2 years. I also use what I refer to as precision surveys. This is a very specific survey, concentrating on a single subject or procedure. An additional precision survey I use is one that is mailed only to referral staff and not intended as a physician survey. These can be even more accurate because it is often the staff that actually makes a referral. The general dentist may simply tell the assistant or hygienist to "send this patient to the oral surgeon for their wisdom teeth." From that point on, it is the staff of the dentist who deals with the patient and the specialist. In the consideration of a marketing plan, never, never overlook referring staff, because they may be your greatest allies.

Although a referral survey is an integral instrument for an office interested in excellence and patient-centered care, it only tells half of the story. To really discover how to better serve your patients, ask them, too.

I have gained tremendous insight into the perception of patients from random patient surveys. The operative word here is random. There are obviously multiple phases of the surgical experience, and, depending in what phase you catch a given patient, the survey may or may not be accurate. For instance, a patient who has been to the office for an evaluation may be very pleased, whereas a patient with a dry socket and a postoperative nerve dysesthesia may be disgruntled just then. By the same token, a patient may have had an excellent experience all the way through the office; however, 3 months later they become unhappy about their lack of insurance coverage and resultant balance owed to the office.

As a result of the temporal differences, you will not gain a representative sampling of the true global office experience unless all sectors are queried. I recommend a suggestion box in the reception area and a monthly random sampling of patients in various phases of their surgical experience. It is also significant to reinforce the need for statistically significant responses. Sending out 10 surveys may be futile, although any input is better than wondering, and this is especially important for negative criticisms.

The next link in the survey triad is your own staff. As I have said time and time again, the staff is your most powerful marketing tool. They work closely with patients in ways that we as physicians never see. Your staff has input that is vital to achieving excellence and a patient-centered office. Ask them, listen to them, and reward them for making things better. Once you have input from the survey and begin to institute changes, you will begin to notice a difference. It is also at this point that your patients will notice a difference. When this whole process gains momentum, a beautiful thing happens—it is called marketing. You can actually see and feel it. It is no coincidence, and it can and will work for anyone willing to take some time and follow some basic steps.

Lunches and Marketing

If there were a time-honored PR entity, it surely would be the business lunch. Many big deals have been negotiated

over a restaurant table, and many referring physicians have been courted over the same table.

This is one area that I believe is minimally effective as a PR tool, with notable exceptions. Our lives have continued to become more and more hectic, and people have accommodated in a variety of ways. Many people who sat around the breakfast table with the family as a child are now gulping down breakfast in the car on the way to work. Lunch for many businesspeople is a time to return telephone calls or catch up on the morning's work. It is safe to assume that most medical and dental offices run behind schedule. Trying to force a harried luncheon date of a social nature into a tight schedule can make a usually pleasant experience undesirable. By the time two people drive to a destination and order food, it is already time to leave. Instead of enlightening a referring physician, a rushed lunch may actually be an imposition. Exceptions to this are extended lunch hours that would allow both parties time to relax or if the referring physician is a good friend. In the case of a strong existing friendship, there is much less social strain to court the other physician. Another problem with lunches is that many specialists pursue referring physicians, and they sometimes are "lunched to death." A referring physician may actually be put off by the thought of a long lunch, but be embarrassed to turn you down. It is perhaps best to schedule a dinner or a weekend event that is not so bound by time constraints. Obviously, these matters are personal and do not apply to every situation; nonetheless, the subject warrants consideration.

It is sometimes wise to leave a referral relationship strictly the way it is. It is human nature to try to become close to someone who is sending you business. The referring office is probably sending you patients because you and your staff treat their patients well. Sometimes the best thing to do is to concentrate on the treatment and not the social value. A referring physician need not become your best friend, but you do need to find a means of saying "thank you." Really successful offices are those that know how to say it. Once you figure out how to do this by different means on a consistent basis, you have figured out marketing.

Obtaining Outside Consultation

I touched on the importance of this strategy in the beginning of this chapter, and additional discussion is warranted because it relates to the topics at hand.

Oral and maxillofacial surgeons are leaders by virtue of what they have achieved. Their ranks hold a most impressive array of talented men and women. I am always impressed when attending our annual meeting by the caliber of our membership. Many have entered this specialty to be independent, and it is sometimes difficult to look to others for assistance. One of the most beneficial things that I have done to benefit my practice is the use of outside consultants. Again, for many OMS practices, it would be unthinkable to consider a consultant because they believe that they know their practices or cannot justify the expense. With the proper consultant, this is so very far from the truth. We all believe that we know our practices, but we are blinded by a subjective factor—emotion. All practitioners truly want their practice to prosper, but unnecessary stress and inefficiency burden many physicians. These physicians assume that the practice must entail this drudgery and are destined to tolerate it for the sake of their careers. They have cheated themselves and given in to the cop-out that OMS "is not what it used to be" and cannot be enjoyed. They believe that they have an intimate knowledge of their practice and community, but they cannot see the burden that their emotion has created.

This same situation exists in our practice because a trained professional can see and appreciate things that we cannot. "A fish cannot see water because he is in it all the time" sums up the need for outside consultation. I have found this to be a constant breath of fresh air and change. It has been especially effective for partner relations, managerial selection, associate buy-in, employee relations, and plotting the course for the future. To spend $10,000 or $12,000 to make 5 to 10 times that in profitability seems a no-brainer. And the monetary gains are probably overridden by increased efficiency and decreased stress.

It is not only problematic or inefficient practices that require professional consultation. Thriving, prosperous practices also need preventive maintenance. It is always wise to change the oil before the engine blows up.

Often the product of a consultation visit leads to gross changes. Closing or opening satellites, terminating senior staff or associates, changing fee structures, and altering buy-in and buy-out policies are a few of the changes that I have experienced, but these have all been retrospectively beneficial for the entire practice.

Where does one find a qualified consultant? Professional associations often maintain lists of consultants recommended by the membership. One caveat is that just because a consultant calls himself or herself qualified does not mean that he or she can carry the load. The field of health care is replete with "consultants," and a former dental hygienist may not have the professional background to make hard business and accounting decisions. Another beneficial source is the Medical Group Management Association (MGMA). This professional organization is a nationwide entity with valuable health care resources. Any practice with a manager should require membership with this group. They have publications, multispecialty practice figures and forecasts, employment opportunities, and a vast network of printed material available. This organization can recommend a list of qualified consultants.

When considering a given consultant, always ask for references and check them thoroughly. Good people come highly recommended. Maintain a reasonable expectation of any consultant. Most mature practices have problems that took years to occur and cannot be fixed overnight. A good consultant will be able to focus on the main areas of weakness and initiate short- and long-term goals for the practice.

I would no more consider practicing without a consultant than without malpractice insurance.

Community Service

It has been said that what you give to your community, you will get back tenfold. I truly believe that this applies to OMS. There are many positives about being an active participant in community service programs. First of all, it gives a local physician a means of paying back and thanking the community. In any community, there are people who cannot afford our services, but are in great need. This type of charity work really brings a good feeling to the caregiver, and inevitably the community will notice. A caring physician donating his or her services to those in need is an impression that sticks in the mind of the citizenry and frequently generates publicity that further reinforces the giving role. My partners and I have had much experience with a multitude of community service projects, and everyone involved becomes a winner. It is a powerful means of assisting the less fortunate and building a reputation for compassion.

Procedure-Specific Marketing

There are procedures we perform as physicians that provide more clinical and economic satisfaction than the removal of carious teeth. It is these rewarding operations that most physicians wish to proliferate in their practices. It probably can be safely stated that the best means of marketing dentoalveolar procedures is to market to the general dental offices. Although this certainly holds true with such expanded procedures as implants, temporomandibular disorders (TMD), surgical orthodontics, and cosmetics, the general dental office in itself may not be the optimal marketing target. For one thing, certain referring dentists may not do or believe in such areas of surgery as TMD or implants. There are practitioners who have a captive audience of possible implant or TMD patients, but because of previous bad experiences or because the dentist has failed to stay current, their patients may be told on a daily basis that "implants don't work" or "TMJ surgery is ineffective" or "cosmetic surgery can only be provided by plastic surgeons." Obviously, this caliber of referring dentist is beyond the casual "go see the oral surgeon" mentality that more frequently exists. It is for reasons like this and the broader markets available that procedure-specific marketing can greatly enhance one's patient base.

The first and foremost factor in subspecialty marketing is clinical excellence. To profess this excellence, a physician must be on the cutting edge of education in a given area. Being on top of continuing education gives you information that you can disseminate to referring colleagues. It sets you apart as an expert and opens the door for preferred referral and confidence. Equally important is the need for OMS to achieve good treatment results. Nothing succeeds like success, and this certainly applies to specialty marketing. Once this type of relationship is established, it is not uncommon for a given referral source to continue to send patients to another oral and maxillofacial surgeon but send the procedure-specific cases to you because of your efforts and results. In many cases, this allows you to "get a foot in the door" to obtain all the patients referred from a given office. Without technical excellence, it is much more difficult to market to referring physicians or the public because they may be more informed than the treating physician. A specialist preaching antiquated techniques will soon lose the confidence of referrals.

Another reason that general dentists may not be an adequate target for procedure-specific marketing is that cosmetic surgery is beyond their training or interest, or they are simply uninformed. This brings us to the second important point in procedure-specific marketing: educating your target market. It is absolutely imperative that your primary marketing target, the referring dentists, is knowledgeable and aware of your services. The key is to educate this group to be aware of indications for the techniques that you offer. Given the emphasis on aesthetic dentistry, there is a fertile market and opportunity to present literature and discuss your given level of interest.

The specialist with these goals in mind needs to prepare information packets for referring dentists to give to patients and an educational experience to inform the dentist and staff.

The second half of the equation for successful procedure-specific marketing is the dissemination of information to the secondary target market, which is the public. We will discuss this specifically at a later point.

As the oral and maxillofacial surgeon matures in practice, he or she will find areas of the specialty that are more personally and financially rewarding, and most will desire to "subspecialize" or, in some cases, limit their practice to these specific techniques. I began the pursuit of cosmetic facial surgery over a decade ago and progressively began doing more and more such surgery each year. This became a passion and eventually led to limiting my practice solely to cosmetic facial surgery. At first this was met with some skepticism from the local dental community, but after I published more than 150 articles and lectured internationally on the subject, the naysayers warmed up and are quite supportive.

Internal Marketing

This is the most overlooked marketing tool in our profession. We are in somewhat of a unique situation in that our reception rooms hold a captive audience. We, on a daily basis, have patients escorted to our offices by individuals of varying ages. These people sometimes must wait for a long time and are frequently bored. Many people bring books or trust that physician's offices have magazines. The latest issue of *People* magazine will do little to promote your procedure-specific marketing efforts.

If a surgeon is truly interested in cultivating given areas of practice, then every person who walks in and out of that office becomes a prospective patient or referral source. It is

shameful that many of our colleagues are doing truly dramatic expanded OMS procedures on the other side of the door, yet the majority of potential patients a few yards away remain unaware.

With multiple advances in personal computers, it is now easy to make excellent display and educational materials that only 5 years ago would have required expensive professional assistance. Now anyone with a PC, desktop publishing software, and a color inkjet printer can make high-grade, quality pictures, pamphlets, newsletters, and a multitude of other promotional material. It is quite simple to make a Microsoft PowerPoint presentation of one's given clinical passion and display this in the reception room and other treatment rooms. Creative Memories or SnapFish are online companies that allow the user to send in pictures and text, and in several days an extremely professional glossy-cover photo book is ready to proclaim your talent to your patients at a very affordable price.

The choice is yours—a patient can wallow in boredom or pass time by looking at before-and-after photos, case presentations, educational videos, and interactive CD-ROMs (see Figure 10-6, *B*). People thrive on information and, especially in that environment, will read or look at anything put before them. I have not only found this to be an effective marketing tool, but have also created a broad area of interest for staff members to develop and become involved. This enhances the team concept because it makes the staff believe that they are truly contributing more directly.

Your reception room can have Norman Rockwell pictures or posters of functional and cosmetic patients in the preoperative and postoperative stages. If you are a contributor to the professional or media literature, it is very effective to display these articles in the reception room. Anything that shows the public your expertise or interest in specific expanded procedures is of great marketing advantage (Figure 10-8).

Although the patient can gain much information from a well-displayed reception room, it is imperative to give them information to take home. Brochure racks with informational and educational procedure-specific pamphlets are very popular with patients. Physicians who pursue the powerful potential of internal marketing will attest that many patients comment, "I didn't realize that oral surgeons did that." If a surgeon believes that it is too aggressive to place pictures and posters on the wall, then tasteful coffee table photo albums can serve the same purpose. If you have a clinical passion, brag about it, and the patients will become interested.

In all considerations of marketing, you must constantly ask the question, "How can I spread the word about these procedures that I enjoy doing?" The answer is to take everything to the next step. If you are making promotional media for your own office, how about distributing it to the offices of your known referral sources? A tastefully prepared album demonstrating the given procedure or procedures may well be a welcome addition to the reception rooms of your referring dentists.



• **Figure 10-8** Patients love to go to recognized doctors, and any awards and publications that are posted in the office breed pride and confidence in your patients.

Finally, and it may sound trite, I strongly recommend actually telling patients that you have expertise in or enjoy particular procedures. It is amazing how much people talk, and word of mouth is and always will be the ultimate marketing tool.

Offering wireless Internet service in your reception room or having a PC that is always online is also a welcome convenience for patients.

Newsletters and Media Packs

The following is dated, as virtually all newsletters are now electronic, but the styling is still relevant.

As is true of all marketing, informing a target referral or a target patient market of your services is key. We assume that most general dentists and patients are well acquainted with our professional capabilities. It has always amazed me that even newly graduating dental students are frequently misinformed about our capabilities.

Newsletters have become very trendy, but many of them are probably discarded without being read. The key to effective use of this powerful marketing tool is presentation and content. A Xerox copy of a newsletter on a folded white 8.5 × 11 piece of paper just does not get attention. In addition, a recipe for summer punch is not relevant. One can literally spend thousands of dollars in the development of a professional newsletter, but it can be done for almost nothing with a PC and a copy center.

First, people like reading news. It does not even have to be news that relates directly to your specific procedure. Almost everyone will listen to health-related news. Articles from the *New England Journal of Medicine* or the vast array of health news and studies available on the World Wide Web serve as good filler. If one is truly pursuing excellence in a specific

procedure, chances are that they are well acquainted with the current literature. Great articles can be built around scientific journal literature. Anything new, controversial, or of interest is likely to draw attention.

In most referral circles, referring offices are well acquainted with the specialty office, and some personal information may be of interest. Interoffice news, such as courses attended by the physicians, articles published, awards of physicians and staff, and other "gossip," may hold interest. There are many things that can be disseminated through newsletters. Office hours, new staff, seminars, insurance and coding information, and the like are very relevant. Pictures, graphs, tables, and color all enhance such a publication.

I should, however, warn of several pitfalls in using newsletters. To be effective, the newsletter must be consistent. Many offices begin with a very energetic newsletter and a commitment to continue, only to fizzle out after one or two issues. A well-constructed newsletter is work intensive, and setting realistic goals is paramount. It is far more effective to have a quality quarterly newsletter than a mediocre monthly publication. I suggest finishing the future issue before the present issue is released. This forces the office to have issues "in the can" for future uses. The other important point is to involve everyone in the practice. If each employee and physician is responsible for a given duty, the workload is dispersed and organized.

If you are serious about producing a newsletter that a referring office will appreciate, the quality and quantity cannot be overlooked. If you are truly providing useful information, chances are that your referring offices will wish to keep the publications. A personalized three-ring notebook with your office name and logo will give the physicians somewhere to store your newsletter and enhance the perceived value of your medium. Obviously, also offering the newsletter via email is advantageous.

A media pack is the equivalent of a fragmented newsletter intended for one's referring offices. An example may include brochures about your office, scientific article reprints, promotional freebies for the referring physician, actual case presentations of aesthetic or functional results, medical emergency tips, personalized pens, magnets, Post-it notes, and so on. This marketing tool is intended as a promotional "care package," and its contents can be innovatively constructed with the efforts of your staff (Figure 10-9).

Also on the subject of marketing for referrals, many offices miss a vital link—the referring staff. As I pointed out earlier, it is frequently the general dentist's assistant, hygienist, or receptionist who actually makes the referrals. Yet these individuals rarely receive a direct thank-you from referring offices. When this is done, it leaves a serious impression. Never underestimate the power of ancillary referring staff. Our practice has numerous CME activities, specifically for referring physicians and staff. This is typically done on a Friday (a bad time for an oral and maxillofacial surgeon to miss work, but a common day for the general dentist and specialist). These seminars discuss common OMS procedures and those that may be especially relevant to the dental practice. ACLS, office emergencies, cosmetic facial surgery, advances in dental implants, and antibiotic and medication updates are popular subjects. Our practice makes this a fun day and raffles some gifts, such as an iPod, Botox injection coupons, and other goodies. In addition, the staff and physicians receive continuing education credit for these meetings. Ladies' night out events are done once or twice a year, and a cosmetic surgery presentation to 250 women in elegant surroundings is a great referral source (Figure 10-10).



• **Figure 10-9** A ready stock of "goodie bags" is a great icebreaker for referral visits or new patients.



• **Figure 10-10** Public information seminars can be a truly effective technique to educate patients and introduce them to an exceptional doctor and staff.

Media Networking

Our nation and the world now seem smaller because of the ability to report news events as they unfold. In 1864, it took weeks for some rural people to find out about the assassination of President Lincoln. Most of the country, on the other hand, observed the events of Operation Desert Storm live. There are many sources of news and informational services, including satellite, cable TV, network TV, local TV stations, magazines, newspapers, and other printed material on national and local levels. With all these sources of news, these companies have a constant need to report anything of interest. Editors scramble to find anything that might provide interest to sell their respective media.

This need for news coupled with the rapid advances in our specialty provide a fertile situation for newsworthy material. The baby boomers are now into their 50s, and we have as health conscious a society as ever. People want to know and understand their health and disease. It is not unusual to turn on the television and see an actual surgical operation. Virtually every form of media has a health news section, and as oral and maxillofacial surgeons, we need to take advantage of this.

Many of the procedures we perform produce dramatic results and are therefore newsworthy. In addition, we are doing many new procedures that are even more interesting to the general public. Even such simple operations as dentoalveolar surgery hold interest for the public because they and their families will undergo many of these experiences.

There are many ways to gain this type of exposure. In some cases, editors will call local physicians to inquire about specific procedures. This is a hit-and-miss situation. Some physicians employ professional marketing firms to initiate a media campaign and usually obtain adequate results at a significant expense. The methods used by professional agencies are basically to saturate all media sources. This requires compiling press releases and distributing them to the usual sources. It is basically a simple procedure and requires little more than the ability to write and some mailings.

Instead of spending serious money on professional services, the average practitioner can do this in-house. A press release is no more than a short story with an interesting headline. "Teeth in One Day" or "Weekend Face-Lift" would be typical headlines followed by a several-paragraph description. It is important to keep these releases informational and not promotional and to focus on the operation and not the physician. Generally, the practitioner will be quoted, and the marketing is in associating his or her name with the technique. Sometimes, depending on the topic, the editor may do an in-depth article, and a subliminal promotion is usually appreciated by the public. It is important to remain accurate and quote average success rates and so forth. Sensationalism or fictitious information can severely reflect on the credibility of the editor and the company.

It is important for anyone who begins this type of media promotion to understand that the return may be one hit in 50 releases and not become discouraged with the ratio. It is persistence that frequently wins out. In addition, many health editors file away this type of information, only to use it months later when a related topic or article surfaces. It definitely helps to have a working relationship with local newspapers, television, and radio news or health editors (Figure 10-11).



• **Figure 10-11** Establishing a media relationship can take years, but if a surgeon can become the community expert, it is worth thousands in free marketing.

Finances

Many practitioners fail to see payment options as a significant marketing tool. This can be a true practice builder. Our country has been built by making it possible for people to purchase goods and services without paying for them at the time of purchase. Department stores established this concept years ago and issued charge cards. This has existed in our society for many years from the corner store to the biggest of businesses.

The thrust of insurance coverage will shift to significant patient responsibility, whereas many patients may be left without any coverage. All of this accentuates the need for a financial program. For most patients, what we do is a middle-class luxury, and we are a low priority for payment. It is not uncommon for a patient not to realize that they have impacted third molars until their dentist points them out. They are then referred for removal and undergo inconvenience, discomfort, and expense without any easily perceived benefit. People do not mind paying for something they see as important, but are quicker to default on items or services without obvious value.

If you extend payment plan options, you must inform the target market to turn this into a marketing tool. Obviously, a sensible ratio exists for each practice, and you do not want to set up too many payment plans. Keep in mind that when you extend someone credit, you are actually giving them an interest-free loan. Most physicians do not want to be in the banking business, but those with true business sense realize that a vast potential exists.

Although there are many honest individuals who will be compliant, payment options must be set up with the

noncompliant patient in mind. Payment options must be stringent and have signed contracts stating what happens in the event of default. Most of us are used to paying home or auto loans, and if we were to default, we would face consequences. The same must be instituted when formulating a payment plan. First, you must determine the patient's credit risk. My practice, like many others, maintains a modem connection with the credit bureau and can check on the record of a patient. It is interesting to see a credit history, because it is not uncommon for people to have good credit with banks, but multiple infractions with health care providers. Needless to say, a patient in this category is a poor risk. If a patient defaults on a payment plan, the balance is due immediately and will go to collections with the signed patient agreement. The agreement also states that it is the patient who is responsible for the attorney's fees. If default consequences are not explained up front, the plan is ineffective. In my office, there are certain requirements to qualify for credit, and a credit report is filed. Some patients remain ineligible, but the majority of applicants do qualify. A down payment is required at the time of surgery, and experience has shown that patients who are unable to pay this or resist doing so will have a high default rate. If a surgical procedure has a $1000 fee, we require one-third of the amount on the day of service and extend the remaining balance for three to six equal payments. The patient is issued a computer-generated coupon book similar to car loan coupons and an expected payment schedule. As stated earlier, if payments are tardy or missed, the account may be turned over to collections.

Many offices charge a reasonable interest rate on their loans, and this can be a profitable situation. It also takes some of the sting out of lending money.

There are corporations, such as Care Credit (www.carecredit.com), that greatly automate and simplify credit operations, and many offices have shifted most credit situations to this type of service.

Yellow Pages Advertising

In the previous edition of this text and chapter, I dedicated much space to this subject. Since the first printing, the Internet has overtaken the telephone book as a primary information source. Many practices have significantly backed down their emphasis on Yellow Pages advertising. It may still be important to have a presence here, but a generic ad that lists services and locations will probably suffice, and the money saved is better spent on Web services.

Cosmetic Surgery Marketing

In the past 30 years, we have witnessed an explosion in the scope of our profession. We have advanced from dentoalveolar and trauma specialists into orthognathic surgery, which increased our aesthetic awareness and opened the door for progress into the facial cosmetic arena. This says a lot about the aggressiveness and ability of our ranks.

Although at present, full-blown cosmetic practices constitute a mere fraction of our membership, this area promises great excitement and growth potential. Aesthetic surgery is especially attractive to the oral and maxillofacial surgeon for a variety of reasons. First of all, we have been doing cosmetic and nasal surgery with our osteotomies for some time. We have an excellent understanding of the face and are enthusiastic about providing surgical techniques that someone actually wants or looks forward to. Our ability to perform outpatient ambulatory surgery allows us a cost-effective forum, and, finally, with the current state of managed care, all specialties are looking for noninsurance reimbursement. This underscores the point I have made several times: that people will spend money on something that they perceive to be adding value to their lives. With the aging baby boomers, there is a more fertile market than ever before. The door is wide open for our specialty, providing we make cosmetic surgery part of our grass-roots training. Most residency programs teach cosmetic facial surgery procedures; it is part of the OMS board exam and is covered by OMS malpractice insurance. It represents part of the evolving contemporary scope of our profession.

For those of us already in practice, the challenge to keep up exists along with the ability to expand our practices. Someday in the future, people may well wander into an OMS office and ask for a face-lift. For now, however, we must raise the public's awareness of what it is that we do.

We are very lucky because we have a captive audience in our reception rooms on a daily basis. All of us who have done osteotomies and genioplasties should have enough before-and-after pictures to construct an interesting display in the reception and evaluation areas. As stated so many times earlier, to successfully market a technique, you must possess expert status and have significant experience with the technique and its complications. For this reason, you should tread lightly and not overmarket commensurate to experience. I believe that skin care, genioplasty, facial liposuction, facial mole and lesion removal, repair of split earlobes from pierced ears, chemical facial peels, lip and wrinkle enhancement with injectable fillers, and Botox injections are procedures that can be performed in the office and are easily within the capabilities of most oral and maxillofacial surgeons. With a basis of these procedures, it is possible to build a cosmetic surgery base with little expense. Some physicians may be satisfied with only these procedures, whereas others will progress to laser resurfacing, eyelid, nasal, and face-lift procedures. These obviously will take a significant commitment on the part of the physician and on our specialty as a whole. Fortunately, there are many worthwhile courses to enhance our education. A potential drawback may be the dental practice acts in some states. Most of us practice under the auspices of the dental laws, and they need to be constantly updated to remain current with our progression and advancement. It is imperative that our political ranks pursue this in all states.

A much simpler means of expanding one's practice into the cosmetic arena is to hire an associate with the expanded

training. This associate can kick off the introduction of the procedures and teach the other partners how to perform them.

Most cosmetic surgery practices cater to an affluent patient base. For most patients, aesthetic surgery is a luxury, and these patients are used to luxurious environments. An office dedicated to cosmetic surgical procedures cannot project the proper image with unfinished pine furniture and NASCAR magazines. These offices must look as nice as the living room of the clients seeking your consultation. Formal furniture with a professional decoration scheme is of utmost importance, in my view. Most patients seeking facial cosmetic procedures are female, and this is an important point to keep in mind and tailor the office to.

Confidentiality in cosmetic surgery is an entirely different ballgame, and neighbors or acquaintances do not necessarily want to be seen in this environment. In addition, the reception room is not the place for a prospective laser patient to see a 48-hour postoperative laser patient. Private entrances and cubicles can assist this situation immensely.

Cosmetic surgeons are keyed into informational sources and have a vast array of informational and skin care products available for their patients (Figure 10-12).

A cosmetic-oriented practice should be well stocked with literature explaining various procedures and techniques because these frequently open the door for various procedures. When performing chemical peels or laser resurfacing, there are many products that may be sold through the office that will assist the patient and income stream of the practice. In addition, there is an added convenience for the patient to be able to purchase their required products without going somewhere else. Many plastic surgery practices have ancillary staff who generate significant income from consultation and sales of pretreatment, posttreatment, and maintenance products. This should not be overlooked, but the staff must be well trained.

There are many avenues available to market the cosmetic practice. This is easy lecturing because of the level of public interest associated with this topic. As stated earlier, many social clubs and organizations exist that actively seek patients. This is grass roots marketing and will interest male and female members. To truly tap the prospective market, you must gain exposure to female clientele. There are many women's clubs, and speaking to a group like this can be a tremendous marketing experience. If one thinks about the habits of cosmetically inclined individuals, then beauty shops, makeup counters, and clothing stores are good marketing sources when tastefully done. Ear piercing kiosks at malls, tanning salons, and health clubs are also excellent sources of prospective patients. Providing referring dentists and OB-GYN offices with personalized informational brochures on cosmetic procedures can also be effective, although many physicians may not choose to display such material. Some practitioners publicize the fact that they offer significant discounts to staff of medical or dental offices. The strong testimonial from a satisfied medical staff person can provide powerful marketing.



• **Figure 10-12** For a cosmetic facial surgery practice, skin care products are a great way to instill interest and introduce patients into the mix.

Internal marketing is a good way to inform prospective patients and stay under the radar screen of competing specialists, who may go to unbelievable lengths to limit one's scope of practice. External marketing is effective, but will more likely bring on the wrath of the competition. Professional marketing firms are established in all cities and can initiate personalized marketing plans commensurate with given budgets. I spend a significant amount of time and money on cosmetic surgery marketing. It is more of a lifestyle than a task. Being extremely involved in publishing and lecturing says a lot about any surgeon and is a great asset when the public is informed. The dissemination of advertising in our practice includes television, radio, newspapers, local "throwaway" papers, websites, seminars, sponsoring of local events and charities, donating goods or services to local events, and performing pro bono cosmetic surgery on needy patients. I believe that it is important to segregate the cosmetic side of the practice from the dentoalveolar side because the competition has done its best to confuse the public about having cosmetic surgery from a "dentist." I am proud of my profession, but the difference between cosmetic surgery and dentoalveolar surgery is less confusing than segregating the two. Some practitioners physically segregate the facility, and others see cosmetic patients only at certain times or on particular days.

The cosmetic patient must be marketed from the first visit and continually thereafter. A welcome gift is provided for each patient and contains various marketing and informational materials, cosmetic sample product brochures, bottled water, magnets, pens, and sometimes discount or promotional coupons. In addition, each patient is sent a personal letter after their evaluation appointment thanking them for choosing our office. I do not charge for cosmetic evaluations and believe that charging is a barrier that can deter even wealthy patients. Often patients have been seen for a free cosmetic evaluation who have also been seen by competing specialists and end up choosing our office because they saw how special we are. In addition, offering same-day

procedures (same day as the evaluation), such as Botox or mole or spider vein removal, can build patient loyalty. I have performed many face-lifts on patients who wandered into the office for a Botox injection. Discount coupons are sometimes used that provide a free Botox injection; after nine injections, the tenth treatment is free. Alternatively, if a patient brings a friend for Botox or filler injection, they each receive a discount. Some physicians do not feel comfortable with this type of marketing, but all patients love it.

If the physician or a staff member is an interesting public speaker, many venues lie waiting for cosmetic presentations. Salons, spas, health clubs, and women's groups are excellent marketing opportunities.

Considering all possible marketing strategies, nothing can replace compassion and availability. I give my cell phone number and email to all cosmetic patients, and this level of availability is priceless for marketing. Calling postoperative patients (not only cosmetic surgery patients, but all postoperative patients) is also an unexpected and appreciated service.

Most of the marketing techniques applicable to procedure-specific marketing, as discussed in an earlier part of this chapter, are effective in the cosmetic arena. The use of a professional and educational website is invaluable. I have treated many patients from out of town and even out of the country solely as a result of Internet exposure. Most of our patients truly study the Web pages before making an appointment and by the time of the evaluation are already well educated.

Any physician who is serious about marketing needs to have a good camera and use it constantly. If one physician performs 100 procedures with no documentation, whereas another physician performs 10 procedures with great follow-up images and statistics, the second physician can market more effectively because of these valuable tools. Often the one who better tells the story better wins the prize. Digital imaging has changed the paradigm for taking and archiving images and has made this a much simpler task. Preoperative and postoperative images of cosmetic surgery (or any procedure) are invaluable for marketing, medicolegal considerations, and the patient record.

Call-on-Hold

You can promote your practice with call-on-hold devices. In a well-run office, patients on hold will be rare. Few things put patients off more than a long hold, especially when calling for an initial appointment. The receptionist should take a number and return the call within 5 minutes, rather than put the patient off. A long hold on the telephone is basically telling the patient that they are not a priority.

All offices, however, will experience holding telephone patients, and recorded promotional messages can be helpful. One caution I would offer is to have a script that stands out from others, because these devices are very popular, and many seem to use similar words. These devices may be purchased inexpensively from communication companies or telephone stores, or for a larger price, a professional company will take care of the hardware and scripting. We live in the information age, and patients want information.

Calling Postoperative Patients

In my opinion, this is the single most important PR technique that a physician can do. No other type of marketing can do so much for so little investment.

Many oral and maxillofacial surgeons call their patients in the evening to check on their status. These "phone rounds" are quite rare in the medical world, and many patients are taken aback by the fact that their surgeon took the time to personally call. Many times, patients have told me that the reason that they returned to the office or sent another patient was the exemplary fact that I called them after surgery.

If the physician cannot call the patient, then the surgical assistant should call, or the receptionist can dial up the patient the following day to have the physician say hello. The impact, however, is much more significant when the physician personally calls the patient the night of the surgery. If a surgeon did no other PR, he or she would get a lot of mileage out of this technique.

Activity Sponsorship

Marketing is recognition, and community sponsorship directly relates to recognition and helping individuals. My partners and I are active in many community groups, including Big Brothers Big Sisters, area mentally disabled citizens groups, scouting, Rotary Club, YMCA, minority groups, athletic teams, and charity groups. Some of this activity includes direct participation or speaking, whereas other involvement includes team sponsorship, buying uniforms with our name and logo, or placing ads in athletic programs or posters. Most aggressive marketing offices follow the tenet "every little bit helps."

Managed Care and Marketing

The fee-for-service environment along with the laws of supply and demand have set the stage for referral favoritism for a century. We are now in the midst of a managed care revolution, and many rules are rapidly changing. Although no one likes the fact that we are doing more and being paid less, we must learn to adapt to a thin environment. With all the negative talk, one positive is that managed care has made many of us better businessmen and businesswomen. Physicians have been notorious for being remiss in many business functions, but as a result of the previous profitability, they could afford to be sloppy with their business practices. The ensuing changes have forced many physicians to take a hard look at their coding, billing, collection, purchasing, and other business line items to control costs and raise profitability. Some physicians have actually found that attention to business detail will make them more profitable than before.

Because managed care companies recruit closed groups of participating physicians and specialists, there may be no choice as to specialists. In other words, we may have a captive audience of general dentists who have no choice but to refer patients to our office because of contractual participation. This negates many of the previous referral tactics that have been traditionally used to gain preference. There is still no substitute for superlative patient care, but depending how long managed care stays popular, traditional specialist marketing may become much less of an issue.

Do You Know What Is Happening at Your Front Desk?

As we have stated so many times previously, your staff is your greatest or worst marketing asset. Because the physician is usually far away from the front desk, many of us are unaware of what is truly going on. As stated earlier, I have sent "sham" patients to make appointments and progress, unknown to all staff and physicians, through the office. The office administrator or consultant are the only individuals who know the identity. At the next staff meeting, the "mystery patient" comes and presents his or her input and observations. This has been quite informative, in addition to keeping everyone on his or her toes. I also have individuals call to make appointments to check on the courtesy and consistency of the staff. And, it can be interesting to drop a $20 bill in your petty cash to see what happens with the monthly reconciliation.

An exceptional receptionist is the keystone of a successful office. This person can bond with prospective patients or drive them away in hordes. The key to being busy is to make it easy to make an appointment at your office. As stated earlier, there are many barriers to OMS. It hurts; it is expensive; insurance is complicated; it adds inconvenience; it causes apprehension; and patients perceive little value in many of the procedures performed. A great receptionist will work on these barriers with the prospective patient and turn an inquiry telephone call into an appointment. When a patient calls and is obviously afraid, a good receptionist will tell them how good the physician is and how gentle and painless the surgery is. If a patient calls and is concerned about finances, an astute receptionist will bring the patient in for a complimentary consult and explain to them that the practice has payment options. If the patient's concern is insurance hassles, the proficient receptionist will tell them the name of their personal insurance person in the practice who will process their insurance. If the concern is about inconvenience, a good receptionist will work the patient into the schedule to suit them. Many patients call various offices to shop for price or just a general feel of office demeanor. A smiling, energetic, enthusiastic receptionist will "attack" these patients with kindness and service and win them over. We use the word *smile;* although you cannot see a smile on the telephone, you can certainly sense it. All of our offices have signs at the front desk that say, "Always answer the phone with a smile." This is truly the first rule of service. We all have bad days from time to time, but they must stop when the telephone rings. It is absolutely imperative to treat every telephone call as if it was your best friend. Remember that the patient is our boss. I have some very trusted and competent employees who are not allowed to answer the telephone because of their rough edges when dealing with the public.

There are many simple tricks that an excellent receptionist can use. When a new patient comes to the front desk, and the receptionist asks, "Have you ever been a patient here before?" this can be very negative. This patient may have a purged chart, been a patient several years, and had a $15,000 osteotomy, and we are asking her if she has ever been here. This is an insult; the appropriate greeting is "When is the last time you have been to our office?" At worst, they will say "Never." When a patient of record calls, the staff should act obviously excited and engage in a minor conversation. People adore being remembered or being recognized. In this harsh world of automated answering, a smiling, friendly voice is a rare find. This is paramount when any referring physician calls. If your front desk people do not know something personal about your referring physicians, then you have the wrong staff. "Dr. Niamtu, it is so good to hear your voice, how have you been, are you still making people beautiful?" is much better than "How do you spell that name?" Making contributions to someone's office and not being recognized is a real turnoff. Even new employees must act like referring physicians, and patients are old friends.

One thing that occurs in all offices is cancellations. Most offices have patients who make appointments, but fall through the cracks for various reasons, usually finances, time, or fear. An excellent receptionist will reschedule a broken appointment before the patient hangs up. If the appointment is cancelled, this patient should be placed on a list and be called multiple times to reappoint. Staying busy involves working broken, missed, or cancelled appointments.

These same characteristics need to carry over to the clinical staff as well. These clinical and clerical positions are usually distinctly different, and if communication is lacking between "the front" and "the back," the office cannot be efficient. If you examine successful, happy, profitable offices, they invariably find a harmony between clerical and clinical employees. The key to this communication is cross-training. It is impossible for someone to truly appreciate someone's job unless they have done it themselves. We earlier alluded to the policy of fast-food chains, requiring their managers to spend time on the grill and French fryer as part of their training. During a citywide blizzard, I once assisted in answering the telephones, and from that day on I had ultimate respect for the ability to manage multiple telephone lines and maintain a smile. If an office stresses cross-training, then every employee will know the rigors of each other's job. If your receptionist cannot take a Panorex or assist in surgery, or if your assistant cannot make appointments, then you are shortchanging your patients, your staff, and yourself.

The clinical staff also has very special requirements involving patient service. A good assistant is a buffer between a

busy physician and apprehensive patients. On the evaluation, these employees can assist in filling in the blanks that the physician has not expressed. They can assist in patient treatment decisions and can quite often sway a patient toward a given treatment plan. Compassion is essential for these staff members. The ability to calm apprehensive patients and hold the hand of a preanesthetic patient can truly mold the entire surgical experience. This is no place for a gruff employee.

Putting It All Together through Communication

I have outlined many theories and techniques related to marketing and patient service. I have used the term "content, happy, and profitable practice" many times throughout this chapter. Anyone who has built this type of office will testify that it is a significant task, and the pursuit of excellence is never-ending. It is said that excellence is a journey, not a destination, because there is no finish line. If you are truly dedicated to their profession and practicing with enjoyment and profitability, then study the following tenets:

- Hire and maintain the correct staff.
- Provide leadership and enthusiasm.
- Make clear what is expected through a policy manual.
- Train the staff to be patient-centered service providers.
- Reward them for their efforts.
- Pursue excellence in all facets of your practice.
- Know when to terminate an employee.
- Constantly improve the level of training and communication.
- Always be a teacher and a student.

These tenets are key to set the stage for organized marketing. Without these, there is no marketing, unless it is negative marketing. A common misconception is that marketing merely involves the physical techniques mentioned earlier. A surgeon cannot market alone, and an uninformed or undertrained staff cannot market at all. Constant communication and consultation are vital to keeping the team sharp. No football team would ever reach the Super Bowl without practice. For the oral and maxillofacial surgeon, this practice involves staff communication. Any progressive practice has regular meetings with the physicians and managers and the staff. Even though your staff may know what to do and what to say, it has to be continually stressed to stay aware and sharp. Enthusiasm is contagious, and the same may be said of its lack. This team spirit must be perpetuated. I have monthly staff meetings with the partners and manager, quarterly staff meetings with everyone included, and an annual retreat for staff focused on communication, patient service, and continuing education. In addition to this, the manager has regular meetings with various locations. You do not need to have a group to do this; it is actually much easier with a smaller office. Regardless of size, everything in this chapter applies to all offices.

To enhance optimal communication, one must have policy and consistency in all positions. My partners and I have used a set of communication principles that is referred to as "the rules of the game." This is an excellent list from which to build and a valuable tool to show a prospective employee you are contemplating hiring.

As stated so many times earlier, every game has rules, and to win, you must be acutely aware of all of them to prevent a disqualification. The winners in OMS are happy, profitable practices, and the losers are those who go home exhausted and frustrated and dislike what they do for a living.

The following principles are referred to as the "rules of the game," and in my office they take precedence over all other forms of communication. All partners, managers, and employees are aware of the rules, and they are posted throughout the office in bright Day-Glo laminated frames. I believe that it is essential for every person in the practice to have intimate knowledge of the rules, and like referees in sports, the owners and managers must have even greater understanding. We will examine each rule and its implication as it relates to OMS.

- **Rule 1: Be willing to support our missions, values, and guiding principles.** This rule, although obvious, is the most often overlooked. I am amazed and confounded by how many OMS practices do not have a written policy manual with distinct job descriptions and a clear outline of the vision or goals of the practice. If you do not communicate these with an employee, how can you possibly expect them to support them?
- **Rule 2: Speak with good purpose.** Gossip among physicians and employees is one of the most destructive forces in an office. This involves speaking about someone outside his or her presence. This is done by idle, unchallenged employees and can undermine your entire staff and effort. It should be grounds for termination and strictly prohibited. This also applies to those who say one thing and do another. A leader must truly practice what they preach. As your mom said, "If you can't say anything nice, don't say anything!" This especially holds true for pessimists.
- **Rule 3: Be open and honest in your communication with each other.** Actually expressing true feelings is sometimes very difficult. We are often afraid to hurt someone's feelings, rock the boat, or cause friction, so it may seem easier to agree with someone or support their improper behavior than to express the truth. This is one of the most difficult things for some people to do, but if this rule is not followed, the others are meaningless. You must be able to look partners, managers, and employees in the eye and tell them exactly how you feel. If you do this consistently, you will be respected. For this to work, all individuals must take a pledge to be open and honest. This breaks the ice and paves the way for open communication. Failure to do this will perpetuate the problems of communication that plague many practices.
- **Rule 4: Complete agreements and be responsible to others and yourself.** When people sit down to iron out problems, it is human nature for everyone to want to jump on the bandwagon and to volunteer to take

responsibility to make a change. This frequently involves a task, a behavior change, or a sacrifice. All too often, those who are enthusiastic at the start lose their vigor or neglect to follow through on the task or the behavior that they promised. This is common and is one huge reason why some practices never get out of the hole. When someone says that they will do something, they must take the responsibility to follow through, and the leader of the practice must take the responsibility to coach them through their stated work and insist on its timely completion. Everyone must realize that when they fail to follow through on a task, they let down themselves and the practice.

a. Make only agreements that you are willing and intend to keep.
b. Clear up any broken or potentially broken agreements at the first appropriate time with the appropriate person. This is especially important. If you see that they are missing their promise or timeline, then it is important to discuss this with the correct person at the correct time. The immediate leader for this staff position must be made aware of the possible lack of follow-through, and it should be expressed immediately. Complaining to the incorrect person may be gossip, and failing to notify the leader immediately will compound the problem by procrastination.
c. Do not commit to others unless there is agreement. If a given individual believes that he or she has the correct idea or action, that does not make it correct. This must be clearly communicated to the group, and a positive response must ensue, which requires rule 3.

- **Rule 5: If a problem arises, look first at the system, not the people, then make the correction.** If there is one thing that many employers are guilty of it, is this. As I said earlier, most employee problems are the result of the employer, not the employee. This is usually true. Employees often take the brunt of criticism when the employer is guilty of being a poor leader. If there is no policy manual, no job descriptions, no vision or goals, then whatever occurs is happenstance or coincidence. Your chances of having an enjoyable, profitable practice become the chances of winning the lottery. Virtually any employee problem can be traced to improper leadership. Next time you are disappointed with an employee, stop and look in the mirror and ask yourself as a leader, "Did I do everything possible to make the rules and goals known and set clear standards to be followed in this case?" It takes a big person, but so often a leader cannot answer this in the affirmative. A true leader will admit the shortcoming and do better; a poor leader will continue to be a blamer.
- **Rule 6: Do not be a blamer.** No one likes taking criticism or being wrong, but blaming others for your own failure or shortcomings will only perpetuate mediocrity. The three hardest words to say are "I was wrong." Once you can speak with honesty and admit this, you will be respected and open the door to other individuals to exhibit this honesty. For this environment to exist, the other staff must be supportive and accept an apology and honesty and not persecute the individual or dwell on the admission.
- **Rule 7: Commit to add value by making more out of less.** For any business to thrive, each person must add value. It is when staff or physicians decrease value that stress and waste occur. The key to operating a successful business in this day of managed care and business is to be lean, economical, innovative, and value conscious, not only in physical spending, but also in decisions and the entire aura of the practice. Waste in policy or expenditures will severely affect the ability for some physicians to enjoy their work and make a profit. Staff members should constantly challenge each other and the practice to do more with less, and when an employee's suggestion is valid, he or she should be rewarded.
- **Rule 8: Have the willingness to win and allow others to win.** In a win-win situation, the attitude is, if I allow others to win, then I win also. With an employer, the win is even bigger. This is a competitive world, and many people are used to winning—to being promoted or advancing. Unfortunately, many of these people believe that they can only win if someone else loses. This creates a backstabbing environment, and for the person to win, someone must lose. If this person is your employee, then the practice will ultimately lose. These people are very goal oriented and are difficult to control. A win-win person, on the other hand, progresses and advances just as fast, but with less trouble, because they realize that by allowing others to win, they will win and may win bigger. It is this type of employee who portrays altruism and is a valuable asset to any practice. The world needs more winners.
- **Rule 9: Focus on what works, retreat on what does not.** Many times the best intentions are put forth with ideas or policies, only to have them fail or fall short of the intended benefit. A progressive leader will realize that some ideas, no matter how good they seem, are not possible. These leaders will admit the shortcoming, regroup, and attack the problem from another angle. A poor or resistant leader will not admit to the shortcoming and beat a dead horse, even though it is not in the best interest of the practice. Some leaders remain hardheaded and will propagate poor policy just because they cannot admit to being incorrect. No matter how good it sounded, if it does not work, move on. What is also important here is not to focus too much on the past. If you are surrounded by individuals who will not forget a mistake and continually reflect on what did not work, you are not fostering the proper environment to admit a mistake. Don't dwell on the past; learn from mistakes and move on.
- **Rule 10: Encourage the risk of innovation.** You must focus on the very best communication for the staff and the best service and care for the patients. To do this often requires going outside of the usual parameters for practice and service. If you follow the usual

procedures for running a practice, then you will have a usual practice. To have an exceptional practice, you must constantly challenge the leaders and the staff to think of innovative means to better the communication and patient service and care. Sometimes staffs are shy or hesitant to provide input. Sometimes those who provide input are ridiculed or ignored, or worse yet, go unrewarded. Big business learned decades ago that it pays to have good ideas, and one should pay for good ideas. If someone makes a suggestion that makes a difference, they deserve reward. They win, you win bigger, and your patients win biggest.

An example is how our practice decreased after-hour calls by 90%. No one loves being on call, and we all get nuisance calls. Many or most of the after-hours calls involve medications. Some are warranted, and many are drug seeking. Our practice simply put a message on our after-hours recorder that "No prescriptions are filled after hours or on weekends." We also posted these signs throughout the office. We initially feared that we might offend legitimate patients in pain, but we were wrong. Legitimate patients called during office hours, and drug seekers called someone else. We literally decreased our emergency calls by 90%.

- **Rule 11: Do not shoot the messenger.** Upon hearing bad news, the king would kill the messenger, or so the story goes. None of us want to hear bad things about our practice, but to ignore them only makes things worse. "Ignorance is bliss" is only for someone that wants to work in a stressful and nonprofitable environment. A good leader must demand to know what is good and what is bad and must liberate the staff, patients, and referring physicians to have unencumbered input. If you make it hard for someone to tell you negative things, you will never hear them. This is not reality. Sometimes it requires a negative to make a positive. True leaders have an open-door policy for constructive criticism and will act accordingly. Before criticizing someone, first try to understand the principles of the policy and always offer criticism in a positive and constructive manner, as stated in rule 3. Encourage critique.
- **Rule 12: Raise the "red flag" when overloaded.** Leadership requires energy, and sometimes, with the best of intentions, we put too much responsibility and burden on ourselves. Even though we think we can handle it, we become overloaded and begin to break rule 4. This, although with good intentions, actually encumbers the practice and skews all the other rules. We all have limits on the responsibility that we can handle and must maintain a good mix of relaxation and outside activities. If you become overloaded trying to make something better, you may actually make it worse. We all tend to multitask, and sometimes, instead of advancing a few prime goals, we wallow in stagnation. This leads to inefficiency and burnout. In addition, if our managers "raise the flag," we can appreciate their honesty, instead of admonishing them months later when we see that the projects are not done. It is far more advantageous to admit overload and ask for help to keep the practice on track. Never be afraid to ask for assistance, and never create an environment where this is frowned on.
- **Rule 13: Always maintain a sense of humor.** Life is a short ride, and we all have only so many heartbeats to enjoy it. Sometimes we take things far too seriously. There is a time for seriousness and a time for levity. Most influential and successful people I have had the pleasure of being associated with always find humor in life and make the best out of all situations. As oral and maxillofacial surgeons, we live in a high-stress environment and face sometimes grave decisions on a daily basis. No matter how bad things seem in a given crisis, history tells us that the crisis will pass. Optimism is a virtue and is contagious. Try to smile every second, and try to find humor in things. There are no dress rehearsals in life. How would you treat people tomorrow if you knew it was your last day on earth? The button that fell off your shirt or the flat tire would carry much less aggravation.

Summary

I have attempted to illustrate that marketing is not a specific task, but rather a lifestyle. If you examine very successful practices, you will invariably find an excited, energetic leader with an enthusiastic and caring staff that enjoys what they do for a living. Marketing, as I have illustrated, goes far beyond the bounds of a gift or party and is a total commitment to excellence and the desire to share this with patients, referring physicians, and the public. Marketing, like underwear, is very personal, and the same techniques will not work for every physician or locale. Each one of us needs to find his or her own comfort level and do as much as they can with what they have. Marketing need not be advertising or yelling and screaming. Target patients can be subtly informed of your services. Oral and maxillofacial surgeons are innovative individuals, and I could not possibly cover all the various strategies of marketing. I have tried to dissect the theoretical aspects of marketing and to present various options as I see them. "The customer is always right," "Do unto others as you would have done unto you," "Offer an excellent product at an affordable price," and "Always be a teacher and always be a student" are admonitions that may be centuries old. Certain common-sense factors in how you present your product or service will have an enormous impact on the success of your business and your happiness in their profession. Whether an office consists of multiple physicians and locations or a one-physician, five-employee single office, the theories and techniques presented here apply across the board.

Suggested Readings

Baker M: Risk management programs: a means to lower premiums, *Bull Am Coll Surg* 93(3):24–26, 2008.

Finley M: Is solo simpler? *Minn Med* 91(2):10–11, 2008.

Frank EK: Why my cash-only practice failed, *Med Econ* 85(5):54–57, 2008.

Gendusa J: Marketing that pulls, *Mark Health Serv* 28(1):18–21, 2008.

Guglielmo WJ: Job sharing: flexibility has a price, *Med Econ* 85(2): 40–43, 2008.

Kasinec DT: How does your output grow? Measuring billing department productivity, *MGMA Connex* 6(2):26–27, 2006.

Lowes R: Smarter scheduling puts you in control, *Med Econ 18* 18;85(2):50–52, 54, 56–57, 2008.

Mandell DB, O'Dell JM: Tips on selling your medical practice, *Nephrol News Issues*(3)51–52, 2008.

Master MA, Eveloff SH: How to prevent employee fraud, *Med Econ* 85(4):63–65, 2008.

Rudolph J: Bond with patients when time is scarce, *Med Econ* 85(5):50–53, 2008.

Seymour J: How to keep the lawyers away. Protecting business and personal assets from lawsuits, *MGMA Connex* 6(2):29–30, 2006.

Swerdlick M: Everything matters to marketers, *Mark Health Serv* 28(1):12, 2008.

Weiss GG: Employed? What your boss wants from you, *Med Econ* 85(2):25–26, 30, 33, 2008.

Weiss GG: Use marketing to draw in more patients, *Med Econ* 85(5):29–30, 33–34, 37, 2008.

Weiss GG: When patients cancel, you're on the line, *Med Econ* 85(5):22–24, 28, 2008.

11

Challenges of Retirement

R. DEAN WHITE

Introduction

For some, retirement will come earlier than for others; some will be forced to retire, while others will do so voluntarily, but we all will have to hang up the spurs sometime. This chapter is written to help prepare you for this major life change mentally, psychologically, physically, and emotionally. Preparing for retirement is not about getting your finances and investments in order; it is more about learning to invest in your life after a busy career as an oral and maxillofacial surgeon.

Richard Rovit, MD, probably said it best: "Each segment of the journey of life should be embraced fully and actively, ever mindful, however, that is a continuous passage with new challenges (opportunities). It is fair to reminisce about what has gone before, but it is neither helpful nor realistic to fight the ongoing stream, attempting to remain fixed in one area beyond one's allotted time."[1]

Change and Its Challenges

Some think that planning for retirement beyond financials is silly; why not move to south Florida and play golf and gin rummy and enjoy the golden years? The truth is that many of us will have a difficult time going from a healing profession where the focus is on the patient to just thinking about ourselves. Golf and gin rummy are fun for a while, but what will you do when you wake up one day feeling bored and unfulfilled?

Throughout our lives, we change cognitively, spiritually, and physically, regardless of our efforts otherwise. As we transition from our professional roles to retirement, many fear becoming irrelevant or meaningless. Many medical professionals have spent a lifetime in training and practicing a profession at the expense of other interests or endeavors. Retirement is the time to consider what you would have done had you not become an oral and maxillofacial surgeon. Think of it as a retrograde "bucket list." Have you fantasized about teaching high school biology? Coaching tennis? Being a fishing guide? Writing a novel? Going to seminary? Earning an MBA? The list of possibilities is endless.

The Importance of Balance

To avoid boredom during retirement, it is wise to start practicing a balanced life now. Euripides (480-406 BC) emphasized balance when he said, "The best and the safest thing is to keep balance in your life, acknowledge the great powers around us and in us. If you can do that, and live that way, you are really a wise man."

Many of us have not maintained balance in our working lives, but as we age, balance becomes critical for a healthy and meaningful retirement.

The four elements we all need to keep in balance are the following:

- Work
- Family and friends
- Recreation
- Spirituality

Many Type A, highly functioning personalities seem to neglect all but work, and the consequences are evident in their personal lives and relationships (e.g., anxiety, stress, strained relationships). Even if you previously lacked insight and commitment to balance, it becomes a necessity to your physical and mental health as your retire.

Work

The work part of balance will mean different things to different people. All of us will need to continue some form of "work." It may be volunteering at a local school, helping build homes for Habitat for Humanity, or other professional pursuits. You may elect to go on medical missionary trips, either faith-based or secular. Health Volunteers Overseas, Heal the Children, or countless other organizations are always looking for qualified professionals. It is critical to continue to serve as you have done your entire career. Don't stop helping others because you don't get paid. In fact, when there is no paycheck involved, the reward is greater.

Family and Friends

Family and friends are the second part of the balance equation. When you retire you will find yourself at home more often. Your spouse, who has gotten used to your long hours at the office and hospital, may look at you and say, "You can't stay home all the time." You can't go home and give your spouse a list of duties or rearrange the kitchen or the garage. You and your spouse need to learn how to live together again. Sure, you may have slept in the same bed for the past 30 years, but your sudden constant presence changes the balance of the home.

The next aspect of the balance equation is to have an in-depth conversation with your spouse or significant other, ideally before your final day at work. Talk together (key word) about finances, the possibility of moving to a new location, and goals and objectives as you go forward together. Retirement can be a tough time and needs to be dealt with prospectively. Single folks need to consider how they can best connect or reconnect with their friends, family, and the community.

Enjoy your children if you have any, but really enjoy your grandchildren. You can always give them back to their parents! They grow up fast.

Take time for your friends, new and old. Take time for visits, trips, meals, and just visiting together. Don't isolate yourself. Connecting with family and friends is one of the keys to health and happiness when you give up your day job. All of this takes time and effort, so take the initiative to include family and friends in your daily life.

Recreation

The third piece of the balance equation is recreation. Recreation should include physical and mental exercise because both are important for long-term health. Read, write, play word games, learn a new language, join a bridge club, or do whatever else makes you think. Learn square dancing or to play the piano. Mix social games with solitary games. Both are healthy.

Physical exercise is probably the most important factor that leads to physical and cognitive health as we age. My dad once said he was going to take up jogging when he saw just one jogger smiling. He died at 95 and never did jog, but he did stay healthy doing activities that engaged him. The type of physical activity is up to you, but pick a few different activities to keep your mind and body engaged. Variety will also keep you motivated.

Spirituality

The fourth element of the balance equation is spirituality. Spirituality is different for everyone, but it is crucial for maintaining a happy and healthy existence when you retire. Spirituality does not necessarily require a religious affiliation. It is simply the practice of recognizing you are part of something larger than yourself. Spirituality can be walking in the woods, attending religious services, yoga, prayer, meditation, fasting, or reading and contemplating religious or spiritual texts.

Mitchell Krucoff, MD, a professor of medicine and cardiology at Duke Medical Center, states that "prayer is the most ancient widely practiced therapy on the face of the earth." Father James Martin, a Jesuit priest, summed up his view of religion when he wrote, "False religion is the idea that if you believe, all will go well, and there is nothing to worry about. Real religion is the idea that if you believe, all may not go well, but, in the end there is nothing to worry about."[2]

Retirement will not always go well. One of my favorite books is written by a Harvard-trained neurosurgeon, Alan Hamilton, MD. He wrote *The Scalpel and the Soul: Encounters with Surgery and the Supernatural and the Healing Power of Hope*. He concludes this book by stating, "We cannot be ordered to love God, as powerful as God may be, no authentic love could exist between a human being and God without the freedom to choose. God's love may be everlasting, but each one of us alone must decide whether to declare it mutual."[3]

As you enter the fourth quarter of life, consider balance as a great strategy. None of us get out of this alive, so make the "back nine" meaningful and relevant.

Leaving a Legacy

Pericles (495-429 BC) said over 2000 years ago, "What you leave behind is not what is engraved in stone on a monument, but what is woven into the lives of others." What would you like your legacy to be?

Most of us don't like to think about leaving a legacy, as it sounds self-serving. But we all leave a legacy; it might be a good one, it might not. I suspect most of you will leave a pre-retirement legacy, one that involves an illustrious career with lots of happy patients and a staff that appreciated you and your work. Most of you reading this chapter will have accomplished a great deal in life outside of oral and maxillofacial surgery. I challenge you to use your personal and professional experiences and leadership skills to help others. For example, you could mentor a struggling clinician or someone with addiction or behavioral problems. Volunteer opportunities are endless. Big Brother/Big Sister, Habitat for Humanity, the local food bank, homeless shelters, and countless others all can use empathetic, service-oriented volunteers. Try it—you might like it. I assure you that you will receive a greater benefit than those you help.

Leaving a legacy doesn't have to be structured. Simply spend time with friends, some older and some younger. Your values may be contagious. It you were proficient with your personal and professional finances, help someone who is struggling to get back on track. Being a mentor or volunteering your time means you have to get out of your comfort zone, but you will be surprised at the results.

Behavioral Health

Leaving a busy practice where your patients and staff think you are the greatest can be a real challenge to your psyche. Most of us, during our education, training, and practice, probably did not have a lot of spare time or time for ourselves, which can be considered good and bad. There will be times after you retire that you just simply don't have enough to do. Solitude can be a blessing and a curse. Blaise Pascal, a French philosopher in the 15th century, wrote, "All unhappiness of men arises from one single fact, that they cannot stay quietly in their room . . . we require things to distract us from ourselves. Hence it comes people so much love noise and stir. It comes that the pleasure of solitude is a thing incomprehensible."

Use your newfound solitude to your advantage. It can be part of the balance equation. For example, some forms of recreation and spirituality require solitude. Use your time to write, read, paint, create, walk, run, cycle. Use it to contemplate. Go fishing. Henry David Thoreau said, "Many men go fishing all their lives without knowing that it is not fish they are after."

Unwanted solitude can lead to boredom, which can lead to situational depression, which is only one reason why it is crucial to plan your retirement. *Bored* may just be another word for *lazy*, or it can be a form of worry. Remember that staying engaged and productive is your responsibility and yours alone. The distinction between boredom and depression is that boredom is a lack of interesting things to do, as opposed to depression, which is not having any interest in doing things. Boredom is temporary, but depression may not be.

Gratitude

Another element of behavioral health as we retire and enter the "winter" of our lives is thankfulness and gratefulness. There is a fair amount of science demonstrating that thankful, appreciative people are healthier and happier than those who go through life glum and complaining. Cicero (106-43 BC) wrote, "Gratitude is not only the greatest of virtues, but the parent of all others."

P. Murali Doraiswamy, MD, head of behavioral psychology at Duke University, makes a strong case for working on your thankfulness skills. He states, "If thankfulness were a drug, it would be the world's best-selling product with a healthy benefit to every major organ system." His research has shown that a thankful attitude has measurable effects on chemical mood transmitters (serotonin and norepinephrine), reproductive hormones (testosterone), social bonding hormones (oxytocin), cognitive and pleasure related hormones (dopamine), inflammatory and immune system hormones (cytokines), and stress hormones (cortisol), as well as cardiac and ECG rhythms, blood pressure, and blood glucose. How is that for a list of benefits without side effects?

One way to exercise gratitude is to make a point of thanking those who have helped you in the past (they will not be here forever). Call or write that coach, teacher, professor, pastor, mentor, residency director, or attending and just say thanks for helping you along the way. You will be surprised at how good it makes you feel, even if you never receive a response.

Along the same line as thankfulness is apology. Consider apologizing to anyone you may have hurt or offended. This is a tough exercise. Many of us go through the majority of our lives without being able to admit when we were wrong, rash, or just plain stupid. Some of us are not very good at admitting when we fall outside of the rigid boundaries that we set for ourselves. Apologizing will save relationships, mend past hurts, and help you start this next chapter of your life with a clean slate.

The Agony and Ecstasy of Aging

Aging is inevitable, unless, of course, you die young. The average life expectancy in the United States in 2011 was 78.4 years, and it increases every year. The quality of life is infinitely more important than the quantity of life, but if we can have both, so much the better. The two goals of achieving a long, full life are the dreaded words "diet" and "exercise." I used to hate both—now I just dislike them.

We all know what we should eat and drink for the most part, but for the sake of argument, a paragraph on proper diet is in order. A proper diet should include daily intake of fresh fruits and vegetables. If possible, a vegetarian diet is healthiest. Lower your sugar and carbohydrate intake and minimize the amount of fried food you consume. In other words, cut back on the Twinkies and pimento loaf. Lower your cholesterol by diet, exercise, or medications, or a combination of all of them. It will save your heart and your head. Lower your intake of saturated fats, which for the most part are animal-based, and increase your unsaturated fats, which are derived from plants. Eat more fish. Throw away the salt shaker.

Most people decrease their alcohol consumption as they age, but one study showed that physicians, as they get older, not only drink more, but also drink more often than the rest of the aging population. The U.S. Department of Agriculture Center for Nutrition Policy and Promotion recommends that women should have no more than one glass of wine a day, and men should not have more than two. Moderate alcohol intake is probably beneficial, but excessive alcohol has many deleterious effects. Use alcohol as a drink, not a coping mechanism.

Exercise is just as important as proper diet. For a long time, I subscribed to the theory that we are only given a finite number of heartbeats, and you could use them up quickly or slowly, but my mind has changed over the years.

The key is to make exercise a habit. It can be vigorous cycling or brisk walking—choose an activity that feels good and keeps you motivated. Exercise makes you feel better; usually you will benefit from a mood boost within minutes of moderate exercise.[4] Physical activity can help alleviate short-term depression, and it can prevent long-term

depression.[5] Exercise may also help to slow mild to moderate dementia. A *Journal of the American Geriatric Society* study found that an exercise regimen of 1 hour twice a week resulted in significantly lower cognitive decline for patients in retirement centers.[6]

Dr. William Buchan, an eighteenth-century Scottish physician, wrote, "Of all the causes which conspire to render the life of man short and miserable, none has a greater influence than the want of proper exercise." The best recipe is cardiovascular training, strength training, and flexibility and balance exercises. The bottom line is that if you don't use it, you will lose it.

Cognitive health and the prevention of dementia are at the forefront of medical research today. Most of this research is driven by compassion for the patients and families who have or will have to deal with this devastating process, but much of the effort is to diminish the sheer overwhelming cost to society to take care of these patients. The one constant is that exercise slows down mental decline. Medications have not been developed that actively prevent or slow down the progression of the disease. The latest research has identified spinal fluid markers that may predict who will have Alzheimer's, and scientists are hopeful that this discovery will lead to strategies and pharmaceuticals that will cure the disease. Most patients develop Alzheimer's disease over a 30- to 40-year period. The key is for all of us to implement a lifestyle and diet and exercise program and a medication regimen that can "treat" the disease early. (See Chapter 12, on boundaries and impairments, for a more complete discussion of Alzheimer's disease.)

Piddling, Potholes, and Pearls

Most of us who have practiced or are practicing oral and maxillofacial surgery are constantly busy, with little time for other thoughts or activities. I practiced with the ever-present thought that Monday is coming. In other words, it was difficult for me to relax, think about nothing, or to not be planning cases 2 weeks in advance. I suffered from the tyranny of the urgent. As you enter this stage of your life, I encourage each of you to find the time to be unproductive and to truly enjoy your freedom. Napoleon once said that nothing is more difficult and therefore more precious than to be able to decide. Decision making can be difficult, and sometimes we don't get it right—but at least we have the freedom to do our own thinking. Retirement is your chance to decide how to spend your time.

Piddling

One benefit of retirement is the ability to piddle. I always had a difficult time piddling. Piddling is spending time in a wasteful, trifling, or ineffectual way. Piddling is relaxing. You don't get paid for it, or at least you shouldn't. You don't piddle with a time constraint, and you don't enjoy the fruits of your piddling. Piddling is mentally healthy. You could wax your car, even if it does not need it. Whittling something out of wood without a template or plan could be piddling. You don't need an education to piddle; in fact the more education you have, the more difficult it is to piddle. Piddling is personal. It clears the mind and helps purge our Type A personalities. It helps us live longer.

Potholes

I consider potholes to be unseen and unanticipated events or occurrences, such as the death of a spouse, the sudden loss of income, or a diagnosis of cancer. You are bound to hit a few potholes as you enter retirement. Some you don't see coming until it's too late, but lack of planning can also lead to potholes. For example, poor financial planning, not enough insurance, or a lack of balance are pretty deep potholes, and it is expensive and time consuming to repair the damage.

Self-pity can turn into a pothole. Don't focus on what you used to do, but on what you are going to do. I asked my mother on her 93rd birthday what she was doing with her time. She had had a stroke a year earlier and was living in an assisted living facility. She replied, "Nothing, and I don't start that until noon." Then she laughed. We should all have that perspective as we age. She stayed optimistic, understanding that we are all dealt a short hand every once in a while, instead of sinking into self-pity.

Another pothole is worrying about the state of affairs and the affairs of state. You can ruin a perfectly good day by reading too many newspapers. Agonizing about things over which you have very little control is not worth the energy. If the cause or issue is important to you, vote, volunteer, contribute, blog, but don't just sit there and tell everyone the world is going to hell. No one likes to sit next to that person at the Thanksgiving table.

As stated earlier, avoid the pothole of regret and unhappiness. Settle past conflicts and disagreements. Apologize and move on. A hateful heart is not a healthy heart. The deepest pothole is inactivity. Physical, mental, and spiritual inactivity will age you faster than time.

Pearls

Pearls are simple thoughts that personify what makes retirement meaningful and relevant. They can make each day a gift and help us work on thankfulness. They can help us grow and continue to learn, which in turn will make our lives longer and more meaningful. Pearls are different for everyone. What I consider a pearl, you may think is a lump of coal. The following is a list of pearls I have collected over the years; some are mine and some are borrowed.[7]

- Be kind to everyone.
- Journal daily, not what you did but what you thought.
- Remember we are all struggling, so treat everyone with empathy and respect.
- Try not to judge; be tolerant, but do not forsake your values.
- Make your spouse your partner.

- Share.
- Don't let someone else determine your happiness.
- Write something.
- Read something.
- Teach.
- Build something or create something for someone else.
- Challenge yourself, not others.
- Get outside your comfort zone by learning a language, how to fly a plane, or to dance.
- If you are fortunate enough to have a long-time spouse, thank him or her for putting up with you.
- Cultivate friendships.
- Pay it forward.
- Perform a random act of kindness.
- Give things away.
- Try not to worry about things you have no control over.
- Enjoy the birds and the flowers.
- Listen to others.
- Remember that your legacy may be unintended.
- Practice being alone; solitude is good for the soul.
- Get a dog or a cat.
- You will not be happy if you lose your options, so stay healthy.
- Thank people who helped you along the way.
- Be truly thankful for every day.
- Laugh, especially at yourself.
- Exercise your body, mind, and soul.
- Love.

The key to all this advice is to stay in the present. You can't go back, and you don't have any control over the future. Enjoy each and every day that you are given.

References

1. Rovit R: To everything there is a season and a time to every purpose: Retirement of the neurosurgeon, *J Neurosurg* 100:1123–1129, 2004.
2. Martin J: *Between Heaven and mirth: why joy, humor and laughter are the heart of the spiritual life*, New York, Harper One, 2011.
3. Hamilton A: *The scalpel and the soul: encounters with surgery and the supernatural and the healing power of hope*, New York, Puritan, 2008, p 214.
4. American Psychological Association: *Monitor on psychology*, www.apa.org/monitor/2011/12/excercise.aspx, Dec 2011.
5. Barbour KA, Edenfield TM, Blementhal JA: Exercise as a treatment for depression and other psychiatric disorders: a review, *J Cardiopulm Rehabil Prev* 6:359–367, 2007.
6. Rolland Y, Pillard F, Klapouszczak A, et al.: Exercise program for nursing home residents with Alzheimer's disease, *J Am Geriatr Soc* 55:148–165, 2007.
7. White RD: *What the hell do I do now: a professionals' guide to a meaningful retirement*, Bradenton, FL, Book Locker, 2012.

12

Boundary Violations and Physical and Mental Impairments

R. DEAN WHITE

Introduction

Anyone in a high-pressure career will, at some point, be faced with non-technical decisions that may have grave consequences that could affect his or her ability to practice. Some of the consequences of boundary violations, addiction, or aging are avoidable; some are based on an individual's genetics and background; and some are inevitable. This chapter is dedicated to helping the reader understand how personal boundaries can affect one's medical practice and when boundary violations constitute impairment.

Maintaining Proper Boundaries

We, as humans, are social beings, and that is a good thing. Based on my own experience, oral and maxillofacial surgeons, in general, have some of the best physician-patient relationships in all of medicine and dentistry. Oral and maxillofacial surgeons tend to have better communication skills than other types of practitioners and an empathetic approach to patients that is commendable.

However, at the risk of ignoring common sense for the sake of political correctness, medical professionals are all susceptible to boundary crossings and violations, as well as episodes of disruptive behavior that can compromise our patient care and, ultimately, our ability to practice.

Most of us are not aware of the boundary crossings and violations that we engage in on a daily basis. Most are not harmful; in fact, some are helpful at times. Patting a colleague on the shoulder, hugging a distressed patient in the office, and complimenting someone's attire can all be helpful acts of caring, but they can be misinterpreted by others as offensive or awkward. These examples are boundary crossings for the most part, depending on the intent. They can lead to a breakdown in the patient, employee, or hospital staff relationship as well.

Unfortunately, medical professionals don't get to decide what is or is not a boundary violation. By the nature of their education and degrees, medical professionals are the responsible ones in the room. They enjoy the power of the profession; therefore, they must be aware of this responsibility and use it wisely.

Most boundary violations are not a problem until an outside party perceives it as a problem. For example, dating an employee where you practice might not seem like a problem. Everyone may live happily ever after, or it can lead to ethical and legal problems that could affect the practitioner's licensure.

The inappropriate use of electronic media also puts medical professionals at risk of crossing boundaries. Emails, Facebook postings, tweets, and other online communications can all be positive, but if they are inappropriate, they can serve as a permanent record of inappropriate and unprofessional comments or behavior that can haunt you for your entire career. Pictures and comments spread on the Internet like a virus, so think twice before telling the off-color joke, forwarding the inappropriate email, or commingling personal postings with those of the practice.

Avoiding Disruptive Behavior

All of us want the best outcomes for our patients. Unfortunately, if a medical professional lacks empathy or appropriate social skills or had a mentor who thought condescending and argumentative behavior was effective, then he or she may be prone to disruptive behavior.

Most of us don't wake up in the morning with the intent of "losing it" when things don't go as planned. Physicians and surgeons who exhibit disruptive behavior are not bad practitioners; in their opinion, they are using the most effective tactics to get the outcomes they want. However, extensive literature suggests that disruptive behavior, such as

raising your voice or using sarcasm to call out a nurse's error, does not beget better patient outcomes.

Alan Rosenstein, MD, MBA, documented in the *American Journal of Nursing* in 2002 that 93% of his respondents had witnessed disruptive behavior in the hospital setting. Disruptive behavior isn't just throwing surgical instruments across the room or yelling at a nurse. It can take a more subtle form that eats away at professional and patient relationships.[1] One respondent to an American College of Physicians Executives survey in 2009 stated, "The worst behavior is not the most egregious; it is the everyday lack of respect and communication that affects patient care and staff morale."[2]

Continued disruptive behaviors can lead to a total breakdown of communication among the health care team, which can lead to untoward patient complications and medical errors that would not ordinarily be a problem and are totally preventable. Good communication is critical to good outcomes when you are working as part of a team. Any erosion of good communication puts patient safety at risk.

Lack of empathy (for example, an arrogant attitude or not fully listening to others) can be considered disruptive behavior. Thus, the goal is for all medical professionals to treat everyone (e.g., patients, patients' families, hospital staff, and employees) with empathy and respect. Empathy is not just understanding the other person's point of view, but also feeling it. Empathy in the clinical setting is not just about being nice to the patient or other members of the health care team. It is about recognizing the significance of illness in the patient's life and understanding why the surgical nurse may have handed you the wrong tool (did you communicate well?). A surgeon who cannot empathize with patients or understand his or her own role in any problems that might arise within the health care team cannot be an effective surgeon. It is sometimes difficult for physicians and surgeons to connect the disease to the patient. As surgeons, we were trained to find the problem and fix it, but the awesome privilege of taking care of another human being requires much more than technical skills.

Emotional Intelligence

If you are prone to disruptive or inappropriate behavior, consider the principles of emotional intelligence first published by Daniel Goleman in 1995.[3] Emotional intelligence is the ability to identify, use, understand, and manage your own emotions in positive and helpful ways, and understanding the four aspects of emotional intelligence may help alter disruptive or inappropriate behavior. There are four aspects of emotional intelligence:

1. Self-awareness
   - The ability to recognize your own emotions and the affect they have on others
2. Self-regulation
   - The ability to control impulses and manage your own emotional states by using positive self-talk
   - Taking the initiative and maintaining motivation
   - Following through with commitments
   - Having the ability to deal with change
3. Social awareness
   - Having empathy for others
   - Picking up on social cues
   - Interacting socially
   - Recognizing the power of a group or organization
4. Social and relationship skills
   - Recognizing the effect your emotions have on others
   - Communicating clearly
   - Inspiring and influencing others
   - Working well within a team
   - Managing conflict

We cannot alter our personalities or our intelligence quotients, but we can improve our emotional intelligence and thus reduce the incidence of disruptive behavior.

Addictions

When someone has an addiction, it is the elephant in the room, which no one wants to acknowledge, discuss, or confront. Demographically speaking, as with any disease, individuals suffering from addiction are distributed throughout the population regardless of education, training, or background. In other words, medical professionals are not exempt. In fact, they may be more prone to addiction given the pressure of their profession, the belief that they can effectively self-medicate, and the ready access to narcotics and other addicting drugs.

The American Society of Addiction Medicine defines addiction as a primary, chronic, neurobiological disease with associated psychosocial, environmental, and genetic factors. It is characterized by one or more of the following behaviors:

- Using drugs inappropriately or in the wrong dosages to obtain a certain result (e.g., an emergency department physician who uses stimulants to stay awake and alert during overnight shifts)
- Compulsive drug use
- Continued abuse of drugs despite consequences
- Craving

The neurobiological foundations of any addiction are dopamine and glutamate, which are released by the brain in response to a drug or other behavior. They, in turn, act as excitatory neurotransmitters that create a feeling of pleasure and satisfaction. That feeling becomes the center of the addict's life.

Substance Abuse

Ten percent to 14% of physicians and surgeons will become drug or alcohol addicts at some point in their careers. If alcohol is excluded, then the percentage becomes 2% to 3%. Because they have easy access to them, physicians misuse opioids and benzodiazepines more than the general population, and fentanyl is the intravenous narcotic of choice. Males tend to abuse more than females.[4]

The etiologies of substance abuse for medical professionals do not differ from those for the general population, except that medical professionals have easier access to narcotics. Of physicians with a substance abuse problem, 75% report a family history of addiction. The family of origin is often dysfunctional and disruptive, and the individual's history typically includes physical and/or sexual abuse. Physicians and surgeons are less likely as a group to seek help and are more likely to self-medicate.[5] Fifty-two percent to 98% of physicians and surgeons begin to self-medicate early in their careers. Unfortunately, they do not medicate themselves appropriately. Toxicology reports on physicians who committed suicide revealed that the physicians medicated themselves but did not prescribe antidepressants. They were using the wrong drugs to treat the depression because they were either in denial about having depression or did not know how to treat it effectively.[6]

Not all medical professionals who self-prescribe abuse medications, but 40% to 75% of those who do abuse medications, started by self-medicating.[7]

Sexual Addiction

The concept of sexual addiction is controversial. Many people consider it a moral failing and a weakness, not a disease. However, if you think of addiction as compulsive behavior, it can involve everything from substance abuse to gambling to sexual activity. Inappropriate sexual behavior that continues despite adverse consequences is an addiction.

Some addictions come in pairs. For example, individuals who exhibit sexual addiction also have a 38% chance of having a chemical dependence.[8] Cybersex is as addictive as crack cocaine, as documented by Deborah Corley, PhD. The prevalence of this addiction is 6% to 8% of the general population, and 20% of those affected are women. It is as difficult to treat as any other addiction and carries the same origins as other addictions.[9]

Individuals who have sexual addictions are likely to act out their addictions in the workplace, which can lead to allegations of sexual misconduct and harassment. Any allegation, no matter how minor, may severely jeopardize one's ability to practice medicine.

Treating Addictions

The good news is that addictions are treatable. Addiction is a chronic disease; there is no cure, but with proper treatment, support, counseling, advocacy, and follow-up, good outcomes are achievable.

Physician health programs have an excellent track record in the management of all types of addiction. These programs are present in most hospital staff organizations or are part of the state medical or dental association structures. They are manned by volunteers, are confidential, and practice both accountability and advocacy for the individual medical professional. Such programs are based on the three principles of support, advocacy, and consequences. The programs include frequent random urinary drug screens, 12-step programs, acute management of relapses, continued care for at least 5 years, a focus on lifelong recovery, and the management of coexisting psychiatric disease.[10] The success rate of these programs range from 70% to 90%; almost 80% of the physicians who have gone through a physician health program remain in recovery and still practice medicine.[11]

Impairment

An individual can become impaired through alcohol or substance abuse, sexual addictions, depression, physical or mental illness, or aging. Many of these issues are preventable or treatable (such as some forms of depression), but some are not (such as aging). It is therefore critical for hospitals and health care organizations to have strategies in place that can identify, confront, and treat medical professionals when they become impaired.

The signs of impairment are just as varied as the reasons for impairment and have to be taken in context. What that means is that some behaviors may not necessarily indicate addiction, but taken in the context of an individual's performance, they raise a red flag. A combination of the following behaviors might indicate an impairment:

- Mood swings
- Sudden personality or behavior changes
- Deficient personal hygiene or appearance
- Multiple physical complaints
- Unexplained tremulousness or sweating
- Watery eyes or runny nose
- Thick or slurred speech
- Missed appointments and unexplained absences

Practice patterns that might indicate impairment could include the following:

- Writing inappropriate orders
- Sloppy handwriting or charting
- Clinical misadventures that are unexplained
- Unavailability at night or during the day
- Behavioral problems with the staff and practice partners

If these signs or symptoms arise, then some investigation is in order. A spouse, good friend, another colleague, a golfing buddy, or another person close to the individual in question can help confirm a suspected problem. If there is a strong possibility that the individual has an addiction, then an intervention is in order. An intervention can be arranged by the physician health committee or a state medical or dental association.

Short-Term Illness

Most of us, at some point in our careers, will have to take a medical leave of absence. Most are short term. The number one goal of every medical professional should be patient safety ("First do no harm"). We all think we are bullet-proof and can work no matter what comes our way, but of course, that is foolhardy. Take a short-term illness or disability in stride, follow your physician's advice, and don't return to providing patient care too quickly.

Most hospital medical staffs will require a "return to work" authorization by your physician if you are away from your practice for longer than 45 days. If your leave is longer than that, the medical staff may require a test for current competence. Don't be insulted; remember that the hospital's primary purpose is to ensure patient safety. Your cases may be monitored, proctored, or reviewed. Depending on your illness or disability, you may want to start slowly. In other words, do not schedule a 4-hour double jaw surgery your first day back. Use your partners and empower them to help you by giving them permission to question your judgment or skill if they think you are not acting or performing in the best interests of patient safety.

Progressive Disease or Illness

Progressive disease or illness may include multiple sclerosis, heart disease, cancer, or any other significant diagnosis. Work as long as you are able, but recognize your limitations. Again, employ your partners to help you and empower your physicians and your partners to tell you when it is time to hang up the spurs. Your surgical privileges may need to be limited or altered as the disease progresses, but finish as a professional with patient welfare as your primary goal. All of us want to finish our careers on a high note, not with a train wreck.

Aging Impairments

If we are fortunate enough to practice over many decades, old age will eventually affect all of us. The effects may be cognitive and/or physical, but in either case, it is critical to recognize this eventuality. Make plans for the transition. (This transition is discussed in more detail in Chapter 11.)

In the *Annals of Internal Medicine,* Choudry and co-workers reviewed all existing literature concerning clinical experience and age and concluded that the majority of studies showed an inverse relationship between performance and years in practice.[12] The deficits were attributed to memory loss, deterioration of cognitive skills, decrease in reaction time, hearing or visual impairments, and a decrease in concentration during highly stressful situations.

Further, Waljee and colleagues reported in the *Annals of Surgery* that surgeons over 60 years of age had higher mortality rates, particularly in complex surgeries, than their younger counterparts.[13] Interestingly, the lower the surgical case volume, the higher the mortality rate. Wilson and co-workers reported in 1999 that "cognitive impairment in physicians is responsible for 63% of all cases of medical adverse events and that most were preventable."[14]

Dementia and Alzheimer's disease are two major risk factors for aging physicians. Betsy Williams, a neuropsychologist who has written extensively on dyscompetence in physicians, states that "age related dementias have been shown to affect not only memory, but executive function, the same capacity required for complex medical reasoning."[15] She adds, "There is currently no mechanism other than peer review and wellness committees to cause a physician with possible dementia to undergo assessment for mental and clinical decline" (Box 12-1).

• BOX 12-1 Executive Function

Executive function is the ability to plan and make decisions, troubleshoot and correct errors, succeed in situations that are not well learned or contain novel sequences or actions, successfully handle dangerous or technically difficult decisions, and overcome strong habitual responses in certain circumstances.

The prevalence of Alzheimer's disease is 0.6% for ages 65 to 69, 1.0% for ages 70 to 74, 2.0% for ages 75 to 79, 3.3% for ages 80 to 84, and 8.4% for ages over 85. Alzheimer's disease is usually diagnosed by MRI, PET scans, spinal markers, and neuropsychological testing.

Neuropsychological tests are a battery of tests performed by a neuropsychologist that assess cognitive abilities, as well as visual and spatial relations, and, to some degree, hand-eye coordination. The tests generally take 4 to 6 hours to administer and have been standardized and validated over many years. One of the batteries frequently used is the Halstead-Reitland Battery, but the neuropsychologist may use other individual tests, as well as groups of tests, depending on the suspected impairment. Neuropsychological tests typically measure progression of a stroke, special disability, and other areas of cognitive function, but they are probably most valuable in determining cognitive decline and whether it is progressive. Most neuropsychologists adjust for IQ and education, and many adjust for the age of the patient.

Many physicians and surgeons practice safely into their later years because of what is referred to as "crystallized intelligence," which is a component of long-term memory. A surgeon's crystallized intelligence compensates for his or her loss of "fluid intelligence," a component of short-term memory, but it does not compensate indefinitely.

Neuropsychological tests can determine if the surgeon has memory loss due to aging, mild cognitive impairment, or the loss of executive function. Memory loss due to aging or mild cognitive impairment is not reason to retire, but if a medical professional loses executive function, there is reason for concern. Given the definition of executive function, losing it equals losing the ability to practice safely.

The bottom line is that every practitioner and every practice must have a policy in effect that addresses possible impairment and provides a means to deal with it in a fair, compassionate, and safe manner. Regardless of age, if a medical professional exhibits signs of dementia or clinical or behavioral aberrations that are difficult to explain, has a significant head injury, has evidence of substance or alcohol abuse, or has a diagnosis of Parkinson's disease or other neurologic disease, then the individual should be evaluated using appropriate physical and mental status examinations. Many times, a practice can be altered to remain safe with the help of partners and employees, but this is a difficult situation at best. Remember—the patient is more important than the surgeon.

Conclusion

In an ideal world, no one would need to deal with these issues and impairments, but the odds are that you or a practice partner will encounter some of these "potholes." The key is to be objective and fair and have a policy in place that addresses all types of addiction and impairment before problems arise. Most of these issues are solvable and will not end a career, but if not confronted early and completely, they could end in disaster for everyone involved. We have been given an enormous privilege and responsibility by society. It is incumbent on us to not violate that trust.

References

1. Rosenstein A: Nurse-physician relationships: impact on nurse satisfaction and retention, *Am J Nurs* 1021(6):26–31, 2002.
2. Johnson C: 2009 Doctor-Nurse Behavior Survey, *Physician Executive* 6–11, 2009.
3. Goleman D: *Emotional intelligence*, New York, 1995, Random House.
4. Carinci AJ, Christo PJ: Physician impairment: is recovery feasible? *Pain Physician* 12(3):487–491, 2009.
5. Domino KS, Hornbein TF, Polissar NL, et al.: Risk factors for relapse in health care professionals with substance abuse disorders, *JAMA* 293:1453, 2005.
6. Gold KJ, Sen A, Schwenk TL: Details on suicide among U.S. physicians: data from the National Violent Death Reporting System, *Gen Hosp Psychiatry* 35(1):45–49, 2013.
7. Hughes PH, Brandenburg N, Baldwin Jr DC, et al.: Prevalence of substance abuse among U.S. physicians, *JAMA* 267:2333–2339, 1992.
8. Irons RR, Schneider JP: Sexual addiction: significant factor in sexual exploitation by health care professionals, *Sex Addict Compulsivity* 1(3), 1994.
9. Carnes P, Nonemaker D, Skilling N: Gender differences in normal and sexually addicted populations, *Am J Prev Psychiatry Neurol* 3:16–23, 1991.
10. Dupont RL, McLellan AT, White WL, et al.: Setting the standard for recovery: physicians' health programs, *J Subst Abuse Treat* 36:159–171, 2009.
11. Carinci AJ, Christo PJ: Physician impairment: is recovery feasible? *Pain Physician* 12(3):487–491, 2009.
12. Choudry NK, Fletcher RH, Soumerai SB: Systematic review of the relationship between clinical experience and quality of health care, *Ann Intern Med* 142:411–415, 2005.
13. Waljee JF, Greenfield LJ, Dimick JB, Birkmeyer JD: Surgeon age and operative mortality in the United States, *Ann Surg* 244:353–422, 2006.
14. Wilson RM, Harrison BT, Gibber RW, Hamilton JD: An analysis of the cause of adverse events from the Quality in Australian Health Care Study, *Med J Aust* 170:411–415, 1999.
15. Williams BW: The prevalence and special education requirements of dyscompetent physicians, *J Contin Educ Health Prof* 26:173–190, 2006.

13 Preoperative Evaluation

BRIAN KINARD, SHELLY ABRAMOWICZ

Introduction

Preoperative evaluation and risk stratification guides perioperative management, venue of surgical intervention, and anesthetic for each patient. This evaluation consists of a complete history and physical, possible laboratory tests, imaging, specialist consultations, and/or diagnostic/therapeutic interventions. Only preoperative testing indicated by information gained during the history and physical should be obtained.[1] A thorough review of this information allows the surgeon to stratify a patient's risk during the operation and to provide a personalized surgical plan.

The goals of this chapter are to provide a framework in a systems based approach for the preoperative evaluation of the oral and maxillofacial surgery (OMS) patient.

History and Physical Examination

A complete history and physical examination is the practitioner's opportunity to identify abnormalities that require further evaluation or planning before an elective operation. The history consists of medical, surgical, and anesthetic history. A patient's medications should be reviewed. Screening for exposure to antiresorptive and antiangiogenic medications that predispose to medication-related osteonecrosis of the jaws (MRONJ) should be part of the medication review process.[2] Certain medications are indicated for perioperative adjustment or discontinuation; however, most medications should be continued[3] (Table 13-1). Allergies and adverse reactions to medications or medical supplies (latex, tape, etc.) and specific allergic reactions should be recorded.

Surgical and anesthetic history should be reviewed. Previous complications, airway difficulties, and effective pain control should be recorded. Patients should be screened for previous anesthetic exposure, as well as a family history of anesthetic exposure to screen for malignant hyperthermia or pseudocholinesterase abnormalities.[3] A social history should be reviewed, including previous or current tobacco, alcohol, or illegal drug abuse with screening for pertinent sequelae. Women should be considered for pregnancy testing if of child-bearing age.[4]

The review of systems is a series of questions organized by body system that provides details regarding the severity of known medical conditions and potential undiagnosed new medical conditions. Positive responses should be further explored and, if not consistent with known medical comorbidities, may require further workup. Information gained from the history and review of systems can be further detailed by asking pertinent follow-up questions. For example, if a patient reports a history of shortness of breath, the practitioner should then ask additional questions to gain insight to their level of pulmonary dysfunction (for example, functional capacity, exacerbating or alleviating factors, or need for supplemental oxygen).

The physical exam should be organized, thorough and tailored for each patient. The physical exam includes vital signs, examination of head and neck, airway, cardiac, pulmonary, and gastrointestinal, with expansion to other systems if relevant from history. Information gained from the history and physical should be used to generate a perioperative, surgical, and anesthetic plan for the patient. Accordingly, the surgeon determines if further preoperative testing or consultations are indicated. The most-used risk stratification system is the American Society of Anesthesiologists (ASA) physical status classification system (Box 13-1).

Conducting the Preoperative Evaluation

Cardiovascular

Cardiovascular complications contribute significantly to perioperative morbidity and mortality. The risk of a major cardiac complication (cardiac death, nonfatal myocardial infarction, nonfatal cardiac arrest, and cardiogenic pulmonary edema) in a non-selected population is reported as 0.8% to 1.5%.[5] Many prediction models exist to assess and stratify perioperative risk of a cardiac complication for noncardiac surgery. The revised Goldman cardiac risk index

TABLE 13-1 Medications, Anesthetic Implications, and Recommendations for Preoperative Management

Medications	Anesthetic Implications	Recommended Management
Aminoglycosides	Can potentiate nondepolarizing relaxants	Monitor neuromuscular relaxants carefully
Aspirin	Platelet dysfunction, bleeding potential	Consider preoperative discontinuation for at least 10-14 days; discuss with prescribing physician regarding risk of stroke, myocardial infarction (MI), or thrombosis with discontinuation
Clonidine	Acute withdrawal can cause hypertensive crisis; decrease anesthetic requirements	Continue therapy the day of surgery; can use dermal delivery perioperatively; decrease anesthetic requirements intraoperatively
Lithium	Potentiate neuromuscular blockers, induce hypothyroidism in some patients; lithium concentrations increase with decreased serum sodium	Monitor neuromuscular blockade carefully, obtain thyroid function tests preoperatively if indicated; monitor serum sodium and avoid sodium-wasting diuretics
Monoamine oxidase inhibitors (isocarboxazid, pargyline, phenelzine, tranylcypromine)	Increased catecholamine stores; hepatotoxicity; rare but potentially fatal reactions with opioids, especially meperidine	Avoid indirect-acting sympathomimetics and use reduced doses of direct-acting agents; serum liver function tests if not done; avoid opioids, especially meperidine; for elective surgery, request psychiatrist to discontinue for 14-21 days unless suicide risk; less time needed for pargyline and tranylcypromine because reversibly bound
Warfarin	Excessive intraoperative bleeding	Manage with prescribing physician; withdrawal in advance; substitute with heparin; heparin may be stopped immediately preoperatively and restarted postoperatively

From Longnecker DE, Murphy FL: *Dripps/Eckenhoff/Vandam: Introduction to anesthesia*, vol 1, ed 9, Philadelphia, 1997, WB Saunders, p 13.

• BOX 13-1 ASA Physical Status Classification

I. Healthy patient
II. Mild systemic disease—no functional limitation
III. Severe systemic disease—definite functional limitation
IV. Severe systemic disease that is a constant threat to life
V. Moribund patient not expected to survive without the operation

(RCRI) was published in 1999 and has been externally validated by multiple studies.[5] The RCRI model allows for identification of patients at increased risk for a major cardiac complication. Six independent risk factors for cardiac complications were identified (Table 13-2). Patients undergoing head and neck surgery with no risk factors are estimated to have a 0.5% risk of a major cardiac complication, whereas those with three or more risk factors are estimated to have an 11% risk.[5]

The American College of Cardiology and the American Heart Association (ACC/AHA) guidelines, last updated in 2014, are another resource for risk assessment and cardiac evaluation for patients undergoing non-cardiac surgery. The ACC/AHA guidelines use the patients' functional capacity and planned surgery to estimate risk and provide perioperative recommendations (Figure 13-1).[6] The ACC/AHA guidelines measure functional capacity in total metabolic equivalents (METs). One MET is defined as 3.5 mL O_2 uptake/kg per min, which is the resting oxygen uptake in a sitting position. Perioperative cardiac and long-term risks are increased in patients unable to meet a 4-MET demand during most normal daily activities (Table 13-3).[6]

Coronary revascularization and other preoperative interventions are not indicated for the sole purpose of reducing perioperative risk. If they are indicated on their own merit, they should be performed prior to elective surgery. Following percutaneous intervention, it is recommended that an elective operation be delayed 7 days after balloon angioplasty, 30 days after bare metal stent, and 365 days after drug-eluting stent. Any decision to modify antiplatelet therapy should include all treating physicians as well as the patient.[6]

The optimal timing for an elective operation after a myocardial infarction (MI) is greater than 60 days. Morbidity and mortality decrease linearly after an MI, with the largest decrease in risk occurring in the first 60 days.[6] Age greater than 65 years and previous cerebrovascular incident are both independent risk factors for major adverse cardiac event in the perioperative setting.[6] Patients with heart failure undergoing a major non-cardiac operation have an increased risk of perioperative major cardiac event. The risk of perioperative mortality was shown to increase if left ventricular ejection fraction (LVEF) is less than 40% and the risk of death was further elevated for patients with LVEF <29%.[6]

TABLE 13-2 Revised Cardiac Risk Index

Risk Factor	Points
Cerebrovascular disease	1
Congestive heart failure	1
Creatinine level > 2.0 mg per dL (176.80 μmol per L)	1
Diabetes mellitus requiring insulin	1
Ischemic cardiac disease	1
Suprainguinal vascular surgery, intrathoracic surgery, or intro-abdominal surgery	1

Risk of Major Cardiac Event	
Points	**Risk % (95% confidence interval)**
0	0.4 (0.05 to 1.5)
1	0.9 (0.3 to 2.1)
2	6.6 (3.9 to 10.3)
≥3	≥11 (5.8 to 18.4)

Feely M, Collins CS, Daniels PR, et al: Preoperative testing before noncardiac surgery: guidelines and recommendations, *Am Fam Physician* 87(6):414-418, 2013.

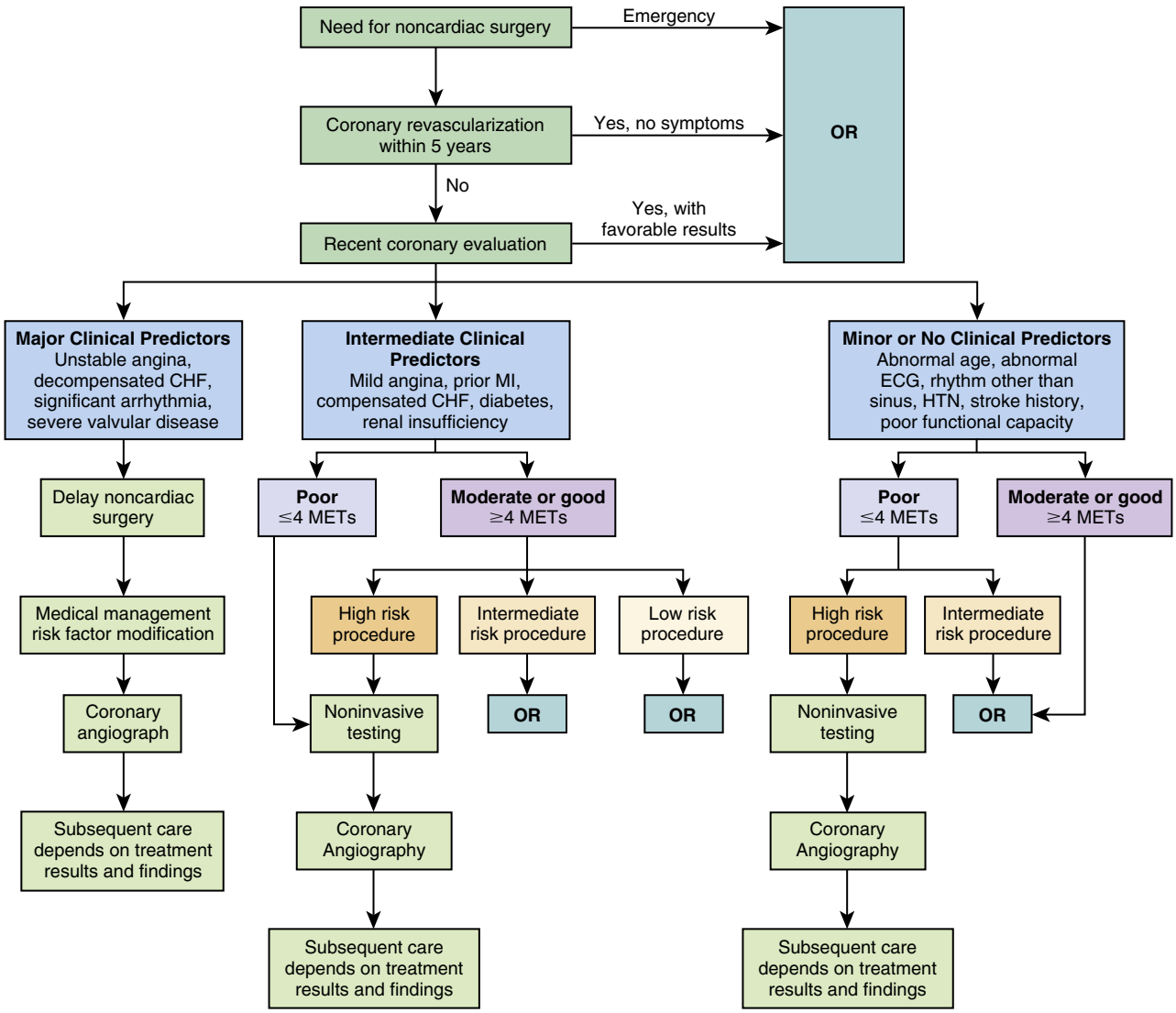

• **Figure 13-1** Stepwise approach to preoperative cardiac assessment. (Eagle KA, et al: ACC/AHA guideline update for perioperative cardiovascular evaluation for noncardiac surgery: a report of the American College of Cardiology/American Heart Association Task force on Practice Guidelines (Committee to Update the1996 Guidelines on Perioperative Cardiovascular Evaluation for Noncardiac Surgery), *Circulation* 105:1257-67, 2002.)

TABLE 13-3 Total Metabolic Equivalents

Less Than 4 METs	Greater Than 4 METs
• Walk a block or two on level ground • Light to moderate work around the house like dusting, washing dishes, carrying groceries • Golfing with a cart • Walking at approximately 2 mph to 3 mph	• Climbing a flight of stairs • Walking up a hill • Walking on level ground at 4 mph • Performing heavy work around the house like scrubbing floors or lifting or moving heavy furniture

From Fleisher LA, Fleischmann KE, Auerbach AD, et al: 2014 ACC/AHA guideline on perioperative cardiovascular evaluation and management of patients undergoing noncardiac surgery: a report of the American College of Cardiology/American Heart Association Task Force on Practice Guidelines, *J Am Coll Cardiol* 64(22):e77-137, 2014.

Previously, the addition of a beta-blocker was recommended in the perioperative period to reduce cardiac morbidity and mortality. However, a recent ACC/AHA systematic review found that the risks may outweigh the benefits.[7] The systematic review reports beta-blockade started 1 day or less before non-cardiac surgery decreases the risk of nonfatal myocardial infarctions; however, it increases risks of stroke, death, hypotension, and bradycardia. Patients who chronically take beta-blockers should maintain use of beta-blockers through the perioperative period.[7] The AHA recommendations for antibiotic prophylaxis to reduce the risk of infective endocarditis were last published in 2007 (Tables 13-4, 13-5, and 13-6).[8]

Pulmonary

Postoperative pulmonary complications are as prevalent as cardiac complications and contribute to similar morbidity and mortality. The incidence of postoperative pulmonary complications is reported as 5% for general surgical patients, but as high as 20% for high-risk patients and procedures.[9] The most morbid of these complications are atelectasis, pneumonia, respiratory failure, and exacerbation of underlying chronic disease.[10] A thorough history and physical may be able to detect the most prevalent pulmonary diseases.

The severity of pulmonary disease should be documented, including onset of symptoms, diagnosis, current therapy, and functional limitations. Common tests available to characterize pulmonary disease include oxygen saturation, chest radiography, arterial blood gas analysis, and pulmonary function tests.

Patient related risk factors for perioperative pulmonary complications include chronic obstructive pulmonary disease, age greater than 60 years, ASA score of 2 or greater, functional dependence, hypoalbuminemia, and/or congestive heart failure.[1] Procedure-related risk factors for perioperative pulmonary complications are prolonged surgery, head and neck surgery, emergency surgery, and the use of general anesthetics.[11]

TABLE 13-4 Cardiac Conditions Associated with the Highest Risk of Adverse Outcome from Endocarditis for Which Prophylaxis with Dental Procedures Is Recommended

Prosthetic cardiac value
Previous infective endocarditis (IE)
Congenital heart disease (CHD)*
- Unrepaired cyanotic CHD, including palliative shunts and conduits
- Completely repaired congenital heart defect with prosthetic material or device, whether placed by surgery or by catheter intervention, during the first 6 mo after the procedure†
- Repaired CHD with residual defects at the site or adjacent to the site of a prosthetic patch or prosthetic device (which inhibit endothelialization). Cardiac transplantation recipients who develop cardiac valvulopathy

*Except for the conditions listed above, antibiotic prophylaxis is no longer recommended for any other form of CHD.
†Prophylaxis is recommended because endothelialization of prosthetic material occurs within 6 mo after procedure.

From Wilson W, Taubert KA, Gewitz M, et al: Prevention of infective endocarditis: guidelines from the American Heart Association: a guideline from the American Heart Association Rheumatic Fever, Endocarditis, and Kawasaki Disease Committee, Council on Cardiovascular Disease in the Young, and the Council on Clinical Cardiology, Council on Cardiovascular Surgery and Anesthesia, and the Quality of Care and Outcomes Research Interdisciplinary Working Group, *Circulation* 116(15):1736-1754, 2007.

TABLE 13-5 Dental Procedures for Which Endocarditis Prophylaxis Is Recommended for Patients in Table 13-4

All dental procedures that involve manipulation of gingival tissue or the periapical region of teeth or perforation of the oral mucosa*

*The following procedures and events do not need prophylaxis: routine anesthetic injections through noninfected tissue, taking dental radiographs, placement of removable prosthodontic or orthodontic appliances, adjustment of orthodontic appliances, placement of orthodontic brackets, shedding of deciduous teeth, and bleeding from trauma to the lips or oral mucosa.

From Wilson W, Taubert KA, Gewitz M, et al: Prevention of infective endocarditis: guidelines from the American Heart Association: a guideline from the American Heart Association Rheumatic Fever, Endocarditis, and Kawasaki Disease Committee, Council on Cardiovascular Disease in the Young, and the Council on Clinical Cardiology, Council on Cardiovascular Surgery and Anesthesia, and the Quality of Care and Outcomes Research Interdisciplinary Working Group, *Circulation* 116(15):1736-1754, 2007.

There is no high-quality evidence for the routine use of chest radiography as a screening tool, and chest radiography rarely alters perioperative management.[1] Chest radiography should be considered in patients who have history of smoking, recent upper respiratory infection, chronic obstructive pulmonary disease, or cardiac disease.[4]

Chronic Obstructive Pulmonary Disease

Chronic obstructive pulmonary disease (COPD) is characterized by airflow limitation that is usually progressive

TABLE 13-6 Regimens for a Dental Procedure

Situation	Agent	Adults	Children
Oral	Amoxicillin	2 g	50 mg/kg
Unable to take oral medication	Ampicillin *or* Cefazolin or ceftriaxone	2 g IM or IV 1 g IM or IV	50 mg/kg IM or IV 50 mg/kg IM or IV
Allergic to penicillins or ampicillin—oral	Cephalexin *or* Clindamycin *or* Azithromycin or clarithromycin	2 g 600 mg 500 mg	50 mg/kg 20 mg/kg 15 mg/kg
Allergic to penicillins or ampicillins and unable to take oral medication	Cefazolin or ceftriaxone *or* Clindamycin	1 g IM or IV 600 mg IM or IV	50 mg/kg IM or IV 20 mg/kg IM or IV

Regimen: single dose 30 to 60 min before procedure.

From Wilson W, Taubert KA, Gewitz M, et al: Prevention of infective endocarditis: guidelines from the American Heart Association: a guideline from the American Heart Association Rheumatic Fever, Endocarditis, and Kawasaki Disease Committee, Council on Cardiovascular Disease in the Young, and the Council on Clinical Cardiology, Council on Cardiovascular Surgery and Anesthesia, and the Quality of Care and Outcomes Research Interdisciplinary Working Group, *Circulation* 116(15):1736-1754, 2007.

and associated with an enhanced chronic inflammatory response in the airways and lung to noxious particles or gases.[12] The relative risk of pulmonary complication in this disease group ranges from 1.8% to as high as 18%.[9,10] The relative risk of complications correlates with disease severity. Elective procedures should be delayed for patients with acute exacerbations. Bronchodilator therapy should be used throughout the perioperative period, and medications that may induce bronchospasm should be avoided.[9]

Smoking

Tobacco smoking is an independent risk factor for perioperative pulmonary complications.[13] For non-cardiac surgery, smoking increases the risk of postoperative pulmonary complications up to fourfold.[9] Smoking impairs ciliary clearance and thickens mucus, increasing the risk for re-intubation, pneumonia, aspiration, bronchospasm, and hypoxemia.[9] Smoking cessation results in a transient increase in sputum production, and the relative risk of perioperative pulmonary complications increases for 8 weeks after smoking cessation and then decreases to below that of a smoker.[11] Early smoking cessation for elective procedures should be emphasized, and smoking cessation resources should be used.

Asthma

Asthma can be classified by symptoms, treatment, and pulmonary function tests (PFTs) (Table 13-7). Patients with well-controlled symptoms and normal PFTs are not at an increased risk for postoperative pulmonary complications. Patients with pulmonary symptoms and abnormal PFTs have been shown to be at an increased risk.[9,14] Preoperative review should include current medications, stimuli, and severity and frequency of exacerbations. A patient with well-controlled asthma should continue to use routine inhalers. Patients with poorly controlled asthma require aggressive treatment before an elective operation.

Renal

Acute Kidney Injury

Acute kidney injury (AKI) is diagnosed and classified through a change in serum creatinine concentration, a change in urine output, or both (Table 13-8).[15] The perioperative incidence of AKI is reported to between 0.8% and 10%.[16] The majority of AKI in the perioperative period is associated with relative hypoperfusion of the kidneys and/or exposure of the kidneys to nephrotoxins such as intravenous contrast, angiotensin-converting enzyme inhibitors, and antibiotics (i.e., aminoglycosides and fluoroquinolones).[15] A recent multivariate analysis identified four independent risk factors for perioperative AKI: age, diabetes, increased revised cardiac risk index, and increased ASA physical status.[16] Patients with AKI had more cardiovascular complications and up to 3 times higher in-hospital mortality rate.[16,17]

Chronic Kidney Disease

Approximately 1 of every 10 adults in the United States has chronic kidney disease (CKD) with the greatest prevalence in patients greater than 65 years of age.[18] In the United States, diabetes mellitus, hypertension, and glomerulonephritis are responsible for approximately 75% of all CKD.[18] CKD is defined as glomerular filtration rate (GFR) <60 mL/min/1.73 m^2 or evidence of kidney damage (proteinuria, glomerular hematuria, abnormal imaging, or abnormal renal biopsy) for 3 months and is staged by GFR (Table 13-9).[19]

CKD is an independent risk factor for postoperative death and cardiovascular events.[19] Surgical optimization and management of CKD sequelae (Table 13-10) through

TABLE 13-7 Classifying Asthma Severity and Initiating Treatment for Patients 12 Years and Older

Classification of Asthma Severity ≥ 12 Years of Age*				
Components of Severity	**Intermittent**	**Persistent-Mild**	**Persistent-Moderate**	**Persistent-Severe**
Impairment				
Symptoms	≤2 days per week	>2 days per week, but not daily	Daily	Throughout the day
Nighttime awakenings	≤2 times per month	3 to 4 times per month	>Once per week, but not nightly	Often 7 times per week
Short-acting beta agonist use for symptom control (not for prevention of exercise-induced bronchospasm)	≤2 days per week	>2 days per week, but not more than once per day	Daily	Several times per day
Interference with normal activity	None	Minor limitation	Some limitation	Extremely limited
Lung function	Normal FEV, between exacerbations; FEV, >80% of predicted; FEV/FVC normal	FEV, ≥80% of predicted; FEV/FVC normal	FEV, >60% but <80% of predicted; FEV/FVC reduced 5%	FEV, <60% of predicted; FEV,/FVC reduced >%
Risk				
Exacerbations requiring oral systemic corticosteroids	0 to 1 per year†	≥2 per year†	≥2 per year†	≥2 per year†
	Consider severity and interval since last exacerbation; frequency and severity may fluctuate over time for patients in any severity category; relative annual risk of exacerbations may be related to FEV			

FEV, forced expiratory volume in one second; FVC, forced vital capacity.
Note: Normal FEV,/FVC by age is 85% for 8 to 19 years; 80% for 20 to 39 years; 75% for 40-59 years; and 70% for 60 to 80 years.
*Level of severity is determined by assessment of impairment and risk; assess impairment domain by patient's or caregivers recall of previous two or four weeks and spirometry; assign severity to the most severe category in which any feature occurs.
†At present, there are inadequate data to correspond frequencies of exacerbations with different levels of asthma severity. In general, more frequent and intense exacerbations (e.g., requiring urgent, unscheduled care; hospitalization; admission to intensive care) indicate greater underlying disease severity. For treatment purposes, patients who had two or more exacerbations requiring oral systemic corticosteroids in the past year be considered the same as patients who have persistent asthma, even in the absence of impairment levels consistent with persistent asthma.

Adapted from National Heart, Lung, and Blood Institute, National Asthma Education and Prevention Program: Expert Panel Report 3: guidelines for the diagnosis and management of asthma. *Summary Report* 2007:344. http://www.nhlbi.nih.gov/guidelines/asthma/asthgdln.htm. Accessed January 8, 2009.

TABLE 13-8 Rifle Criteria for Acute Kidney Injury

Stage	Glomerular Filtration Rate (GFR) Criteria	Urine Output Criteria
Risk	Increased serum creatinine ×1.5 or GFR decrease >25%	Urine output <0.5 mL/kg/h ×6 hours
Injury	Increased serum creatinine ×2 or GFR decrease >50%	Urine output <0.5 mL/kg/h ×12 hours
Failure	Increased serum creatinine ×3 of GFR decrease >75% or serum creatinine ≥4 mg/dL* (acute rise ≥0.5 mg/dL†)	Urine output <0.3 mL/kg/h ×24 hours or anuria ×12 hours
Loss	Persistent acute kidney injury = complete loss of kidney function >weeks (i.e., dialysis dependence for 4 weeks)	
End stage kidney disease	End stage kidney disease (i.e., dialysis dependence for >3 months)	

*≥353.6 μmol/L.
†≥44.2 μmol/L.
Source: Borthwick E, Ferguson A: Perioperative acute kidney injury: risk factors, recognition, management, and outcomes, *BMJ* 341:c3365, 2010.

TABLE 13-9 Chronic Kidney Disease Stages

Stage	Description	Glomerular Filtration Rate (eGFR) (mL/min/1.73m^2)*
1	Chronic kidney disease with normal glomerular rate but other kidney damage (e.g., hematuria and proteinuria)	≥90
2	Mild chronic kidney disease and other kidney damage	60 to 89
3a	Mild to moderate chronic kidney disease	45 to 59
3b	Moderate to severe chronic kidney disease	30 to 44
4	Severe chronic kidney disease	15 to 29
5	Established end stage renal disease	<15 or on dialysis

*eGFR is an estimate of kidney function, based on serum creatinine but taking into account age, race, and sex. In the UK, whenever a creatinine test is requested, laboratories will report a corresponding eGFR and the eGFR can be thought of as an approximate percentage of normal kidney function that the individual has. For some individuals, a preoperative assessment might be the first time they have had a creatinine check and therefore may be the first opportunity for chronic kidney disease to be diagnosed.

Source Borthwick E, Ferguson A: Perioperative acute kidney injury: risk factors, recognition, management, and outcomes, *BMJ* 341:c3365, 2010.

TABLE 13-10 Physiologic Disorders of Renal Failure That Affect Preoperative Management

Disorder	Consequence
Cardiovascular	
Increased renin secretion	Hypertension
Increased cardiac output, as a result of anemia	High-output failure
Left ventricular hypertrophy	Myocardial Infarction
AV shunt for dialysis	High-output renal failure
Volume overload or deficiencies following dialysis	CHF or hypovolemic hypotension
Associated diabetes > accelerated atherosclerosis	Myocardial infarction, stroke
Renal	
Failure to excrete potassium	Progressive hyperkalemia 7 mEq/L: Tall peaked T waves 8 mEq/L: Prolonged RR interval, QRS widening 9 mEq/L: P wave disappears, QRS widens further
Failure to excrete fixed acid	Progressive acidemia
Water excretion: Failure to excrete water (oliguria or anuria) Failure to concentrate urine	Volume overload, pulmonary edema Fasting dehydration, hypotension, salt wasting
Pulmonary	
Pulmonary calcification	Decreased diffusing capacity
Diaphragmatic elevation with peritoneal dialysis	Decreased functional residual capacity, restriction
Nervous System	
Uremic toxemia	Mental slowing, fatigue, seizures, myoclonus, coma
Sensory peripheral neuropathy	Lower extremity numbness
Dysautonomia	Orthostatic hypotension, gastroparesis
Gastrointestinal	
Increased volume and acidity of gastric contents	Increased risk of aspiration pneumonia
Ulcers	Gastrointestinal bleeding
Anorexia, nausea, vomiting	
Hematologic	
Erythropoietin secretion decreased	Anemia
Decreased red cell life span	Anemia
Dialyzable toxins impair platelet aggregation	Platelet dysfunction

TABLE 13-10 Physiologic Disorders of Renal Failure That Affect Preoperative Management—cont'd

Disorder	Consequence
Immune System	
Uremia impairs leukocyte chemotaxis Steroid treatment Loss of immunoglobulin	Infection, sepsis
Pharmacokinetics	
Diminished excretion of water-soluble drugs and metabolites	Accumulation of active metabolites of morphine, Demerol, benzodiazepines
Hypoalbuminemia	Increased free fraction of drugs bound to albumin
Acidosis	Drugs with acid pK_a are less ionized, have greater volumes of distribution and longer half-lives
Impaired function of blood-brain barrier	Accentuated effects of drugs with central nervous system effects

From Longnecker DE, Murphy FL: *Dripps/Eckenhoff/Vandam: Introduction to anesthesia*, vol 1, ed 9, Philadelphia, 1997, Saunders, p 316.

medications, treatments (Table 13-11), and consults should be considered. Nephrotoxic drugs such as nonsteroidal anti-inflammatory drugs (NSAIDs), morphine, and aminoglycoside antibiotics should be used with caution or avoided in patients with CKD.

Gastrointestinal

Gastrointestinal and hepatic disease can predispose to many generalized complications such as: poor wound healing, excessive bleeding (thrombocytopenia, decreased production of procoagulant proteins), cardiovascular demise secondary to decreased peripheral vascular resistance, fluid and electrolyte imbalance, severe anemia, and medication toxicity.[15] Identification of certain signs and symptoms during a thorough history and physical examination may raise concern for diagnosed or suspected gastrointestinal (GI) disease. Some of many possible signs and symptoms concerning for GI disease are dyspepsia, abdominal pain, nausea, vomiting, diarrhea, hematochezia, steatorrhea, pruritus, fatigue, and melena. Potential signs or risk factors of hepatic disease, such as history of hepatotoxic treatment, jaundice, history of blood transfusion, hepatomegaly, splenomegaly, ascites, asterixis, encephalopathy, icterus, spider angioma, and delirium, should raise suspicion and be further explored.

Gastroesophageal Reflux Disease

Gastroesophageal reflux disease (GERD) is a common disease process affecting up to one third of the U.S. population at least once a month.[20] GERD is characterized by decreased lower esophageal sphincter tone resulting in reflux of gastric contents into the esophagus. Symptoms of GERD include retrosternal chest pain that occurs after meals and while lying flat. It is possible for gastric contents to reach the larynx, resulting in cough, hoarseness, sensation of food on the back of the tongue, or burning mouth syndrome. Mild

TABLE 13-11 Preoperative Management of Renal Failure

Considerations	Management
Anemia	
Hgb ≥8 g/dL chronic	No treatment
Hgb <8 g/dL (physiologic changes)	Further evaluation and possible transfusion
Coagulopathy	
Uremic platelet dysfunction	Dialysis 24 hr before and possibly 24 hr postoperatively Desmopressin or cryoprecipitate can be considered
Hyperkalemia	
>5.5-6.0 mEq/L	Dialysis Gastrointestinal reduction (Kayexalate) Intracellular shift (insulin/glucose) Cardiac membrane stability (bicarbonate)
Infection	
Malnutrition Functional abnormality of neutrophils, monocytes, and macrophages	Antibiotic prophylaxis Aseptic technique
Symptomatic hypocalcemia	Replace calcium
Hyperphosphatemia	Phosphate binding antacids
Anesthetic and medication clearance	Adjust doses based on renal creatinine clearance
Hypervolemia or hypovolemia	Dialysis, consider invasive monitoring if congestive heart failure
Avoid nephrotic agents	Nonsteroidal anti-inflammatory, aminoglycosides, contrast dye, chemotherapeutic agents

GERD can be managed by diet and behavior modification as well as over-the-counter antacids. Chronic GERD is managed with proton pump inhibitors and H_2 blockers. These medications should be continued preoperatively as rebound can occur. Patients with well-controlled GERD who continue their medications are managed similarly to healthy patients, although anesthetic induction may be modified. An elective operation should be delayed in patients with poorly controlled GERD until their disease is better managed. If an emergent procedure is indicated, H_2 blockers, rapid sequence induction, and nasogastric suctioning may reduce risk of aspiration.

Peptic Ulcer Disease

Peptic ulcer disease (PUD) is an ulceration in the lining of the stomach or first part of the duodenum. PUD often presents with periodic exacerbation and remission, a result of an imbalance between the digestive (acids, pepsin) and protective factors.[21] Long-term use of NSAIDs or infection with *Helicobacter pylori* predisposes patients to developing PUD. Patients with PUD have variable symptoms ranging from painlessness to severe epigastric pain that can be alleviated or aggravated by eating.

Patients with symptoms of PUD are often treated empirically with medications such as proton pump inhibitors or H_2 blockers to allow healing. These patients should cease use of NSAIDs and be tested for and treated if *H. pylori* is present. A definitive diagnosis is obtained through upper gastrointestinal endoscopy, which allows for visualization and biopsy of the ulcer.

TABLE 13-12 Child-Pugh Scoring System

	Points		
	1	2	3
Encephalopathy	None	Stage I or II	Stage III or IV
Ascites	Absent	Slight (controlled with diuretics)	Moderate despite diuretic treatment
Bilirubin (mg/dL)	<2	2-3	>3
Albumin (g/L)	>3.5	2.8-3.5	<2.8
PT (prolonged seconds)	<4	4-6	>6
INR	<1.7	1.7-2.3	>2.3

Class A = 5-6 points; Class B = 7-9 points; Class C = 10-15 points.
INR, International normalized ratio; PT, prothrombin time.
Child CG, Turcotte JG: Surgery and portal hypertension. In Child CG, editor: *The liver and portal hypertension,* Philadelphia, 1964, Saunders, pp 50-64.

Hepatic Disease

Patients with hepatic disease are at increased perioperative risk for morbidity and mortality.[22] This risk is a factor of the type and extent of hepatic disease, type of anesthesia, and the surgical procedure.

Screening for hepatic disease includes a review of risk factors for hepatic disease such as tattoos, history of intravenous drug use, chronic alcohol intake, blood transfusions, and family history of jaundice or hepatic disease. Signs and symptoms concerning for hepatic disease include spider angiomas, telangiectasia, gynecomastia, ascites, pruritus, fatigue, and testicular atrophy in males. Patients with liver disease should be assessed for the presence of jaundice, coagulopathy, electrolyte disturbances, renal dysfunction, thrombocytopenia, ascites, and encephalopathy. Some of these sequelae may require treatment prior to surgery, and all should be considered in perioperative management.

Surgical risk can be estimated through the Child-Turcotte-Pugh classification or the Model for End Stage Liver Disease (MELD) score. Historically, the Child-Pugh score (Table 13-12) was the standard for estimating perioperative risk. However, recently the MELD score (Figure 13-2) has been shown to be a more accurate predictor of perioperative risk.[23] For major surgery, patients with a

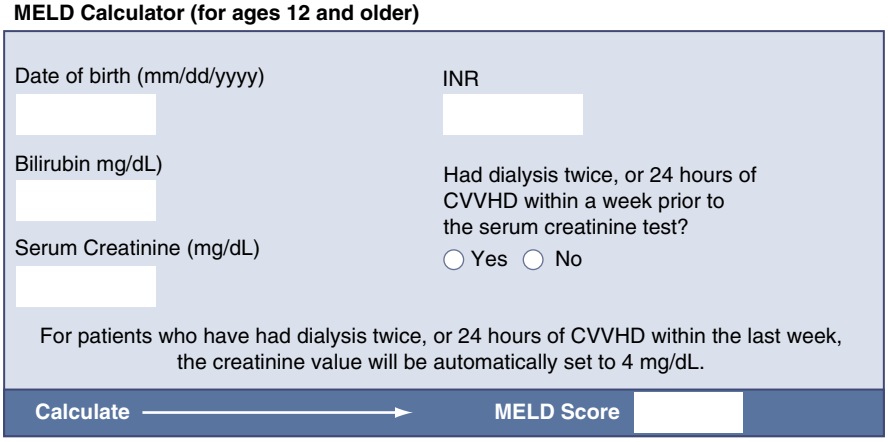

• **Figure 13-2** MELD Score. (From http://optn.transplant.hrsa.gov.)

Child-Pugh score less than 8 were found to have risk equal to patients without cirrhosis.[24] It is recommended that patients with a MELD score less than 10 be able to undergo elective surgery, patients with a MELD score of 10 to 15 undergo elective surgery with caution and surgical optimization, and those with a MELD score greater than 15 not be considered for elective surgery.[23]

Endocrine

Diabetes Mellitus

Approximately 8.3% of the U.S. population is reported to have diabetes. An additional 35% of the U.S. population has an above normal HgA1c level.[25] The American Association of Endocrinologists define diabetes at a fasting blood glucose (BG) >126 mg/dL or HgA1c >5.7%.[26] Diabetes is classified as type 1 (insulin dependent) or type 2 (non-insulin dependent). Type 1 diabetes is an autoimmune process that leads to destruction of pancreatic insulin-producing beta cells. Type 2 diabetes begins as an insulin resistant state with compensatory increase in insulin production by the beta cells. Severe type 2 diabetics can progress to a state where beta cells decompensate, requiring exogenous insulin. Infections, illnesses, and surgical procedures can alter carbohydrate metabolism and present a risk for the diabetic patient.

As many as 40% of non-cardiac surgical patients have a BG above 140 mg/dL and 25% above 180 mg/dL. Hyperglycemia in the perioperative period is associated with increased morbidity, mortality, and an increased use of health care resources.[27] Hyperglycemia causes dehydration and electrolyte disturbances, impairs immune function and vascular permeability, and increases pathogen growth. In the intensive care setting, relaxed perioperative BG goals of 140 to 180 mg/dL were found to have equally beneficial outcomes as intense management with BG of 80 to 110 mg/dL with 4 times less adverse events such as hypoglycemia.[27] Diabetes is the leading cause of kidney failure in the United States.[25] Diabetic patients are at an increased risk for cardiovascular disease, which is the major cause of perioperative mortality in the diabetic patient.[28] Presence of gastroparesis increases the risk of aspiration.

Chronic hyperglycemia has long-term sequelae such as microvascular complications (nephropathy, autonomic and peripheral neuropathy) and macrovascular complications (cardiovascular and peripheral vascular diseases).[29] These sequelae should be factored into the perioperative plan as they can alter management.

Most inpatients are transitioned from their home oral regimen and switched to an insulin-based regimen, which allows for more predictable and controllable BG. In 2011, the Society for Ambulatory Anesthesia released a consensus statement for perioperative management of antidiabetic oral medications and insulin (Table 13-13).[30] Operations for diabetic patients should be scheduled as early in the morning as possible. The surgeon, anesthesiologist, and internist or endocrinologist should collaborate to control the blood glucose levels throughout the perioperative period.

Thyroid

Thyroid hormone regulates multiple body systems. Thyroid hormone abnormalities are a result of an excess of thyroid hormone (hyperthyroidism) or a deficit of thyroid hormone (hypothyroidism) (Table 13-14).

TABLE 13-13 Instructions to Patient Regarding Preoperative Insulin and Noninsulin Injectable Administration

Insulin Regimen	Day Before Surgery	Day of Surgery	Comments
Insulin pump	No change	No change	Use "sick day" or "sleep" basal rates.
Long-acting, peakless insulins	No change	75-100% of morning dose	Reduce nighttime dose if history of nocturnal or morning hypoglycemia On the day of surgery, the morning dose of basal insulin may be administrated on arrival to the ambulatory surgery facility.
Intermediate-acting insulins	No change in the daytime dose 75% of dose if taken in the evening	50-75% of morning dose	See the comments for long-acting insulins
	No change		
Fixed combination insulins	No change	50-75% of morning dose of intermediate-acting component	Lispro-protamine only available in combination; therefore use NPH instead, on day of surgery. See the comments for long-acting insulin
Short and rapid-acting insulin	No change	Hold the dose	
Noninsulin injectables	No change	Hold the dose	

From Joshi GP, Chung F, Vann MA, et al: Society for Ambulatory Anesthesia consensus statement on perioperative blood glucose management in diabetic patients undergoing ambulatory surgery, *Anesth Analg* 111(6):1378-1387, 2010.

TABLE 13-14 Distinguishing Factors of Hyperthyroidism and Hypothyroidism

System	Hypothyroidism	Hyperthyroidism
General	Fatigue, cold intolerance, coarse/dry skin	Weight loss, heat intolerance, warm/moist skin, increased appetite, proptosis
Neurologic	Myxedema coma, cognitive impairment	Tremor, nervousness, hyperactive reflexes
Cardiovascular	Bradycardia, decreased cardiac output, decreased stroke volume, atrioventricular conduction defects, pericardial effusion, orthostatic hypotension, prolonged QRS, arrhythmia	Tachycardia, atrial fibrillation, congestive heart failure, increased stroke volume, widened pulse pressure, mitral valve prolapse insufficiency
Pulmonary	Decreased alveolar ventilation (blunt response to anoxia and hypercarbia), pleural effusion	Dyspnea, increased carbon dioxide production, decreased vital capacity, increased oxygen consumption
Renal	Decreased glomerular filtration rate, decreased plasma volume, decreased creatine clearance, peripheral edema, hyponatremia	Polyuria, hypomagnesemia, hypercalcemia and hypercalciuria
Gastrointestinal	Delayed gastric emptying, gastrointestinal bleeding, constipation	Hypermotility, diarrhea
Hematology	Anemia, platelet hyperaggregability, factor VIII and IX deficiency	
Musculoskeletal	Myopathies, increase of creatinine	Myopathies, protein wasting, bone resorption
Etiology	Idiopathic atrophy, Hashimoto thyroiditis, subtotal thyroidectomy	Graves disease, toxic multinodular goiter
Confirmatory laboratory tests	Decreased T_3 (triiodothyronine) Decreased T_3 resin uptake Increased thyroid-stimulating hormone (TSH) (unless cause from hypothalamic or pituitary dysfunction) Increased thyroxine-binding globulin (TBG)	Increased T_4 (levothyroxine) Increased T_3 resin uptake (RU) Increased T_3 RU/T_4 Decreased TSH Decreased TBG

Longnecker DE, Murphy FL: *Introduction to anesthesia,* vol 1, ed 9, Philadelphia, 1997, WB Saunders.

Hyperthyroidism

Hyperthyroidism is reported to involve 0.05% to 1.3% of the U.S. population, with the majority of individuals subclinical in presentation. Hyperthyroidism is commonly a result of Graves disease, multinodular goiter, or exogenous thyroid hormone.[29]

Hyperthyroidism is associated with fever, tremor, hyperdynamic cardiac functioning with hypertension, tachycardia, and increased cardiac output. Patients are at risk for arrhythmias such as sinus tachycardias and atrial fibrillation. A perioperative complication of hyperthyroidism is thyroid storm, which can be fatal in 10% to 75% of patients.[21,31] Thyroid storm has been associated with both the anesthetic and post-anesthetic period and can be incited by infection or surgical stress. Thyroid storm is a clinical diagnosis with nonspecific symptoms such as hyperpyrexia, tachycardia, and delirium. It is necessary to begin treatment empirically with beta-blockers, antipyretics, and thionamides.[31]

For an elective operation, a patient should be made euthyroid. This can be achieved with propylthiouracil, methimazole, or iodide treatment. Clinical response may take up to 8 weeks. In case of an emergent procedure, beta-blockers, such as propranolol, are the mainstay of treatment.[32]

Hypothyroidism

Hypothyroidism affects approximately 1% of the U.S. population, is more common in women, and most commonly a result of primary hypothyroidism or autoimmune hypothyroidism (Hashimoto thyroiditis). Hypothyroidism manifests as lethargy, fatigue, anorexia, depression, weight gain, and cold intolerance.[31] Studies do not provide clear evidence that patients with mild to moderate hypothyroidism are at a higher risk of anesthetic complication during an operation. However, physiologic changes that occur in hypothyroidism should be considered.[32] Hypothyroidism is associated with decreased cardiac output secondary to decreased stroke volume and heart rate, decreased ventilation response to hypercarbia and hypoxia, and impaired baroreceptor function. In severe cases, these patients can progress to myxedema coma.[29] These physiologic changes can alter sensitivity to medications and anesthetics. Consistent thyroid hormone replacement therapy, such as levothyroxine, can reverse these physiologic changes over time.

Adrenal Insufficiency

Patients undergoing surgery rely on adrenal glucocorticoid reserve to tolerate the physiologic stress response associated with the procedure. Cortisol, as the primary glucocorticoid in humans, plays the role of potentiating the effects of other hormones especially catecholamines. The hypothalamic-pituitary-adrenal (HPA) axis, which is regulated through a negative feedback loop, regulates the amount of cortisol secreted. Adrenal insufficiency (AI) is classified based on the site of dysfunction in the hypothalamic-pituitary-adrenal axis.

TABLE 13-15 Causes of Glucocorticoid Deficiency

- Withdrawal of glucocorticoid medications
- Idiopathic (presumably autoimmune)
- Tuberculosis
- AIDS
- Lymphoma
- Enzyme inhibitors
- Inborn errors of metabolism
- Fungal infections
- Metastatic cancer
- Pituitary disease
- Cytotoxic agents

Autoimmune adrenalitis (primary AI) and the withdrawal of chronic steroid use (secondary AI) are the most common reasons for glucocorticoid deficiency (Table 13-15).[21]

Patients who report recent corticosteroid use or have a review of systems positive for symptoms of AI should be considered for possible adrenal axis suppression or failure. Patients on chronic steroid therapy, such as transplant patients, are at low risk for AI. However, they may require stress-dose steroids should volume refractory hypotension occur.[33] Patients receiving physiologic corticosteroid replacement therapy are at increased risk, and patients who have taken >20 mg of prednisone (or equivalent) per day for more than 5 days are at risk, for axis suppression. Longer duration of 20 mg prednisone (or equivalent) therapy may suppress the HPA axis for 6 to 12 months.[31,33] Clinically, AI manifests as hypotension and decreased cardiac output despite fluid therapy and is treated with IV corticosteroids. [32] There are specific perioperative corticosteroid replacement recommendations for patients believed to have axis suppression or other forms of AI (Table 13-16).[34]

TABLE 13-16 Recommendations for Perioperative Glucocorticoid Supplements in Patients Believed to Have Adrenocorticoid Deficiency[34]

Level of Stress	Recommendation (Hydrocortisone Equivalent/Day)
Minor surgical stress (third molar extraction, genioplasty, etc.)	25 mg × 1 day
Moderate surgical stress (double jaw surgery, panfacial fractures, etc.)	50-75 mg × 2 days
Major surgical stress (large head and neck resection and reconstruction, etc.)	100-150 mg × 2-3 days

Hematology

Initial hematologic assessment relies on the history and physical examination. Bleeding diatheses may be detected through a history of easy bruising or excessive bleeding. Anemia may be detected through a history of dyspnea on exertion and pallor on physical exam. The severity of known or suspected hematologic abnormalities is obtained through laboratory tests including complete blood count (CBC), prothrombin time (PT), partial thromboplastin time (PTT), bleeding time, and fibrin split products.

Anemia

Anemia is defined as a hemoglobin concentration of less than 14 g/dL in males and 12.3 g/dL in females.[21] The history and physical exam may reveal symptoms such as malaise, dyspnea, palpitation, pallor, and cyanosis. If anemia is detected, an iron study and reticulocyte count may give insight into the etiology (Figure 13-3). Correctable causes of anemia, such as iron deficiency, may be addressed if time allows. Transfusion may be considered for time-sensitive procedures or the postoperative phase.

The American Association of Blood Banks recommends, with high quality of evidence, that transfusion should be considered at Hgb concentrations of 7 mg/dL or lower in hemodynamically stable patients and at concentrations of 8 mg/dL or lower in symptomatic patients (chest pain, orthostatic hypotension, or tachycardia unresponsive to fluid resuscitation) or congestive heart failure.[35]

Emergent operations with expected blood loss may require transfusions if the patient is likely to fall below the thresholds just given.

Sickle Cell Disease

Sickle cell anemia is the most common hemoglobinopathy. Approximately 1 of every 500 African Americans have sickle cell disease, and more than 2 million African Americans have the sickle cell trait. Hemoglobin S (HbS) occurs as a result of a genetic mutation substituting a valine for glutamic acid in the sixth position of the beta chain of the hemoglobin molecule.[21] Individuals who are heterozygous for HbS are described as having sickle cell trait and mostly have benign disease. Individuals who are homozygous for HbS manifest sickle cell disease.[36] The resulting alteration in the shape of the erythrocyte when the hemoglobin is deoxygenated can lead to anemia, chronic hemolysis, and vascular occlusion.[21] Multiple end-organ damage can result from these vaso-occlusive events.

History should include the time of last crisis, interval between crises, inciting events for crises, and need for previous blood transfusion. Perioperative management is focused on managing possible inciting events through oxygenation, adequate hydration, maintaining warm temperature, prophylactic antibiotics, maintaining patient comfort, and managing anxiety. A hematology consult is recommended to assess hemoglobin S and hemoglobin A levels to determine if transfusions or other treatments are indicated.

Bleeding Diatheses

A bleeding diathesis is a state in which an individual is predisposed to abnormal bleeding. The bleeding diathesis can be a result of numerous disease states. Commonly, it is a result of

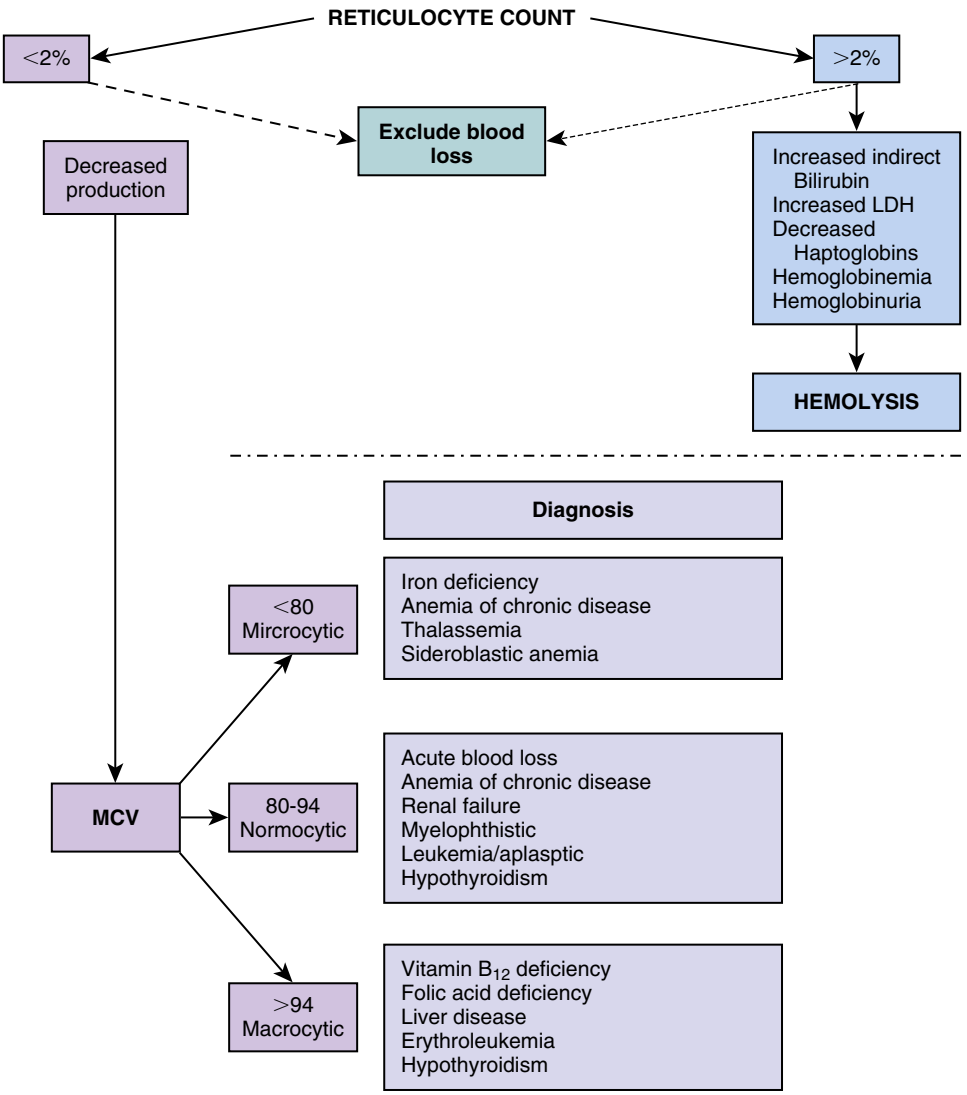

• **Figure 13-3** Evaluation of anemia.

low or abnormal platelet function or abnormalities in the coagulation cascade. A history of easy bruising; excessive bleeding with previous surgery or trauma; history of hematuria, hematochezia, melena, or hemarthroses; and physical exam findings of petechiae, purpura, ecchymoses, and mucosal bleeding are suggestive of a bleeding diathesis and require further evaluation.

Thrombocytopenia

Thrombocytopenia is a quantitative platelet disorder, where there is increased platelet destruction, decreased platelet production, or abnormal distribution and/or increased sequestration. A common cause of thrombocytopenia is immunologic, where autoantibodies destroy existing platelets. This disorder could present with other autoimmune disorders (lupus or autoimmune hemolytic anemia), human immune deficiency virus, or chronic lymphocytic leukemia. This patient subset may be treated preoperatively with corticosteroids, immunoglobulin, or platelet transfusions.[21]

Other causes of decreased platelet levels include a decrease in production as a result of insufficient megakaryocytes[21] (Table 13-17) or an increase in splenic sequestration. In a normal state, up to one third of all the circulatory platelets are sequestered by the spleen. In patients with splenomegaly, up to 80% to 90% of the circulatory platelets may be sequestered by the spleen.[37]

TABLE 13-17 Etiology of Megakaryocyte Suppression[21]

Medications	Chloramphenicol, phenylbutazone, parenteral gold, alcohol, thiazide diuretics, sulfa drugs
Cytotoxic chemotherapy and radiation	
Infection	Hepatitis
Bone marrow infiltration	Leukemic or lymphomatous infiltrates, fibrosis, granulomas, metastatic cancer
Nutritional	Vitamin B_{12} or folate deficiency

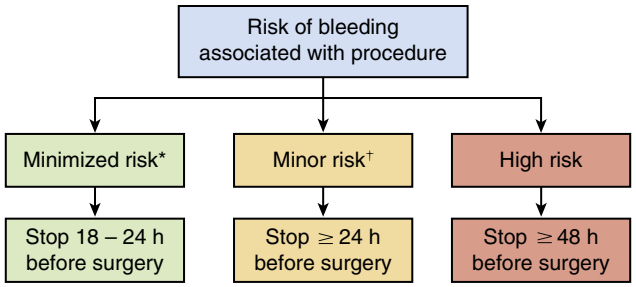

• **Figure 13-4** Management of New Age Anticoagulants. (From Lai A, Davidson N, Galloway SW, Thachil J: Perioperative management of patients on new oral anticoagulants, *Br J Surg* 101(7):742-749, 2014.)

Platelet transfusion should be considered when platelet count is less than 50,000 /μL or higher if significant blood loss is expected. A single platelet concentrate usually yields an incremental rise in platelet levels of 10,000/μL/m^2.[21] A platelet count should be obtained approximately 1 hour after the appropriate transfusion amount is administered to confirm the platelet count.[21] In general, a patient with a platelet count of 60,000 to 100,000/μL or greater can tolerate most routine operations.

Coagulation Disorders

Hemophilia

The most commonly inherited clotting factor defect is hemophilia A (factor VIII deficiency). Hemophilia B (factor IX deficiency) is less frequent; however, it shares in the X-linked pattern of inheritance with hemophilia A.[37] Hemophilia A and B patients typically have an increased activated partial thromboplastin time (aPTT) and a normal PT. The severity of hemophilia A corresponds to the levels of factor VIII. Those with mild hemophilia A can at times be successfully treated with deamino-D-arginine vasopressin (DDAVP), which increases the level of circulating factor VIII. Those with more severe disease require supplementation with factor VIII.[35]

Von Willebrand Disease

Von Willebrand disease is the most commonly inherited abnormality affecting platelet function and is caused by a deficiency or dysfunction of von Willebrand factor (vWF).[35] Von Willebrand factor is the carrier protein for factor VIII and, when activated, binds platelets to exposed collagen. The most common type and mildest form of von Willebrand disease, type 1, is a partial quantitative deficit of vWF. Type 2 and 3 are less common, generally more severe where vWf is either deficient qualitatively or quantity, respectively.[21,35] Symptoms are typically recurrent mucosal bleeding (e.g., epistaxis, bruising, and GI bleeding). Prothrombin time may be elevated, as vWF carries factor VIII. Preoperative management of von Willebrand includes DDAVP or vWF/factor VIII concentrate.[35]

Anticoagulant and Antiplatelet Therapy

Preoperative management often includes the management of anticoagulant therapy (warfarin, heparin, factor Xa inhibitors, direct thrombin inhibitor) or antiplatelet therapy (clopidogrel, aspirin). A medication history should include the indication for anticoagulant or antiplatelet therapy, duration of therapy, and previous adverse events associated with medication changes. Anticoagulation therapy with warfarin can be measured with the international normalized ratio (INR), through an aPTT for heparin or factor Xa inhibitors or direct thrombin time for direct thrombin inhibitors. Antiplatelet therapy levels can be measured through a bleeding time study. Elective procedures should include discussion with the patient and prescribing physician to formulate a perioperative medication plan. Emergent procedures may require anticoagulant reversal or supportive care for factor Xa inhibitors and direct thrombin inhibitors, as no reversal agent currently exists (Figure 13-4).[38]

Neurology

Seizures

Approximately 1% of the U.S. population has been diagnosed with epilepsy, and a much larger number of individuals with a seizure history.[39] A history should include the inciting event, if provoked; type, duration, and frequency of seizure; and current antiepileptic medication.

Perioperative management includes minimal changes in antiepileptic drug therapy, minimizing physical and psychological stress, and avoidance of pro-convulsive medications. The risk of perioperative seizures is proportionately related to the baseline frequency of seizures. A history of seizures has not been shown to increase the risk of postoperative complications.[39]

Cerebrovascular Accident

Cerebrovascular accident (CVA), or stroke, is the fourth most common cause of death in the United States. Each year, approximately 800,000 U.S. citizens experience a stroke. Approximately 90% of CVAs are ischemic, and the remaining 10% are hemorrhagic.[40] Patients who have endured a CVA and present for preoperative evaluation should be evaluated for their current anticoagulant regimen and current deficits, as well as receiving a focused vascular exam that includes assessment of distal pulses and auscultation for bruits.

The risk of a major cardiovascular event, including a new ischemic stroke, acute myocardial infarction, or cardiovascular mortality is most increased in the first 9 months following an ischemic stroke. After 9 months, the risk plateaus at a stable yet still elevated level.[41]

Conclusions

Preoperative evaluation and risk stratification guides perioperative management, venue of surgical intervention, and anesthetic for each patient. This information allows the surgeon to stratify a patient's risk during the operation and to provide a personalized surgical plan.

Acknowledgment

The authors thank Dr. Amin Kazemi for his previous contribution to this chapter.

References

1. Feely M, Collins CS, Daniels PR, et al.: Preoperative testing before noncardiac surgery: guidelines and recommendations, *Am Fam Physician* 87(6):414–418, 2013.
2. Ruggiero S, Dodson TB, Fantasia J, et al.: American Association of Oral and Maxillofacial Surgery position paper on medication-related osteonecrosis of the jaws—2014 update, *J Oral Maxillofac Surg* 72(10):1938–1956, 2014 Oct.
3. Longnecker DE, Murphy FL: ed 9, *Introduction to anesthesia*, vol. 1. Philadelphia, 1997, WB Saunders.
4. Committee on Standards and Practice Parameters, Apfelbaum J, Connis RT, et al.: American Society of Anesthesiologists Task Force on Preanesthesia Evaluation: Practice advisory for preanesthesia evaluation: A report by the American Society of Anesthesiologists Task Force on Preanesthesia Evaluation, *Anesthesiology* 96:485–496, 2002.
5. Lee TH, Marcantonio ER, Mangione CM, et al.: Derivation and prospective validation of a simple index for prediction of cardiac risk of major noncardiac surgery, *Circulation* 100:1043–1049, 1999.
6. Fleisher LA, Fleischmann KE, Auerbach AD, et al.: 2014 ACC/AHA guideline on perioperative cardiovascular evaluation and management of patients undergoing noncardiac surgery: a report of the American College of Cardiology/American Heart Association Task Force on Practice Guidelines, *J Am Coll Cardiol* 64(22):e77–137, 2014.
7. Wijeysundera DN, Duncan D, Nkonde-Price C, et al.: Perioperative beta blockade in noncardiac surgery: a systematic review for the 2014 ACC/AHA guideline on perioperative cardiovascular evaluation and management of patients undergoing noncardiac surgery: a report of the American College of Cardiology/American Heart Association Task Force on Practice Guidelines, *Circulation* 130(24):2246–2264, 2014.
8. Wilson W, Taubert KA, Gewitz M, et al.: Prevention of infective endocarditis: guidelines from the American Heart Association: a guideline from the American Heart Association Rheumatic Fever, Endocarditis, and Kawasaki Disease Committee, Council on Cardiovascular Disease in the Young, and the Council on Clinical Cardiology, Council on Cardiovascular Surgery and Anesthesia, and the Quality of Care and Outcomes Research Interdisciplinary Working Group, *Circulation* 116(15):1736–1754, 2007.
9. Taylor A, DeBoard Z, Gauvin JM: Prevention of postoperative pulmonary complications, *Surg Clin North Am* 95(2):237–254, 2015.
10. Qaseem A, Snow V, Fitterman N, et al.: Risk assessment for and strategies to reduce perioperative pulmonary complications for patients undergoing noncardiothoracic surgery: a guideline from the American College of Physicians, *Ann Intern Med* 144:575–580, 2006.
11. Smetana GW, Lawrence VA, Cornell JE: Preoperative pulmonary risk stratification for noncardiothoracic surgery: systematic review for the American College of Physicians, *Ann Intern Med* 144:581–595, 2006.
12. Global Initiative for Chronic Obstructive Lung Disease (GOLD): Global strategy for the diagnosis, management, and prevention of chronic obstructive pulmonary disease: 2015. (Accessed March 1, 2014) www.goldcopd.org.
13. Townsend CM: *Sabiston textbook of surgery*, ed 17, Philadelphia, 2004, Saunders.
14. Guidelines for the diagnosis and management of asthma. National Heart, Lung, and Blood Institute, National Asthma Education Program, expert panel report. X. Special considerations, *J Allergy Clin Immunol* 88(suppl):523–534, 1991.
15. Borthwick E, Ferguson A: Perioperative acute kidney injury: risk factors, recognition, management, and outcomes, *BMJ* 341:c3365, 2010.
16. Biteker M, Dayan A, Tekkesin AI, et al.: Incidence, risk factors, and outcomes of perioperative acute kidney injury in noncardiac and nonvascular surgery, *Am J Surg* 207(1):53–59, 2014.
17. Abelha FJ, Botelho M, Fernandes V, Barros H: Determinants of postoperative acute kidney injury, *Crit Care* 13(3):R79, 2009.
18. Kalamas AG, Niemann CU: Patients with chronic kidney disease, *Med Clin North Am* 97(6):1109–1122, 2013.
19. National Kidney Foundation: K/DOQI clinical practice guidelines for chronic kidney disease: evaluation, classification, and stratification, *Am J Kidney Dis* 39(2 Suppl 1):S1–S266, 2002.
20. Tantawy H, Mysaljek T: Diseases of the gastrointestinal system. In Hines RL, Marschall KE, editors: *Stoelting's anesthesia and coexisting disease*, ed 6, Philadelphia, 2012, Elsevier Saunders, pp 287–304.
21. Lubin MF, Walker HK, Smith III RB: ed 3, *Medical management of the surgical patient*, vol. 1. Philadelphia, 1992, JB Lippincott.
22. Hanje AJ, Patel T: Preoperative evaluation of patients with liver disease, *Nat Clin Pract Gastroenterol Hepatol* 4(5):266–276, 2007.
23. O'Leary JG, Yachimski PS, Friedman LS: Surgery in the patient with liver disease, *Clin Liver Dis* 13(2):211–231, 2009.
24. Macaron C, Hanouneh IA, Suman A, et al.: Safety of cardiac surgery for patients with cirrhosis and Child-Pugh scores less than 8, *Clin Gastroenterol Hepatol* 10:535, 2012.
25. Centers for Disease Control and Prevention: *National diabetes fact sheet: national estimates and general information on diabetes and prediabetes in the United States, 2011*, Atlanta, 2011, U.S. Department of Health and Human Services, Centers for Disease Control and Prevention.
26. Garber A, et al.: American Association of Clinical Endocrinologists' Comprehensive Diabetes Management Algorithm 2013 Consensus Statement—executive summary, *Endocr Pract* 19(Suppl 2):1–48, 2013.
27. Evans CH, Lee J, Ruhlman MK: Optimal glucose management in the perioperative period, *Surg Clin North Am* 95(2):337–354, 2015.
28. Haffner SM: Mortality from coronary heart disease in subjects with type 2 diabetes and in nondiabetic subjects with and without prior myocardial infarction, *N Engl J Med* 339:229–334, 1998.
29. Agarwal R, Porter MH, Obeid G: Common medical illnesses that affect anesthesia and their anesthetic management, *Oral Maxillofac Surg Clin North Am* 25(3):407–438, vi. 2013.
30. Joshi GP, Chung F, Vann MA, et al.: Society for Ambulatory Anesthesia consensus statement on perioperative blood glucose management in diabetic patients undergoing ambulatory surgery, *Anesth Analg* 111(6):1378–1387, 2010.
31. Kohl BA, S. Schwartz S: Surgery in the patient with endocrine dysfunction, *Med Clin North Am* 93(5):1031–1047, 2009.
32. Connery LE: Assessment and therapy of selected endocrine disorders, *Anesthesiol Clin North Am* 22(1):93–123, 2004.
33. Njoku MJ: Patients with chronic endocrine disease, *Med Clin North Am* 97(6):1123–1137, 2013.
34. Salem M, et al.: Perioperative glucocorticoid coverage. A reassessment 42 years after emergence of a problem, *Ann Surg* 219:416, 1994. In Longnecker DE, Murphy FL: Introduction to anesthesia, vol 1, ed 9, Philadelphia, WB Saunders 1997.
35. Douglas WG, Uffort E, Denning D: Transfusion and management of surgical patients with hematologic disorders, *Surg Clin North Am* 95(2):367–377, 2015.

36. Stanley AC, Christian JM: Sickle cell disease and perioperative considerations: review and retrospective report, *J Oral Maxillofac Surg* 71(6):1027–1033, 2013.
37. Hoffman R, Benz EJ, Shattil SJ, et al.: *Hematology: basic principles of practice*, ed 4, Philadelphia, 2005, Churchill Livingstone.
38. Lai A, Davidson N, Galloway SW, Thachil J: Perioperative management of patients on new oral anticoagulants, *Br J Surg* 101(7):742–749, 2014.
39. Probasco J, Sahin B, Tran T, et al.: The preoperative neurological evaluation, *Neurohospitalist* 3(4):209–220, 2013.
40. Koton S, Schnider AL, Rosamond WD, et al.: Stroke incidence and mortality trends in US communities, 1987 to 2011, *JAMA* 312(3):259–268, 2014.
41. Jørgensen ME, Torp-Pedersen C, Gislaslon GH, et al.: Time elapsed after ischemic stroke and risk of adverse cardiovascular events and mortality following elective noncardiac surgery, *JAMA* 312(3):269–277, 2014.

14

Monitoring for the Oral and Maxillofacial Surgery Patient

STUART LIEBLICH, LUKE L'HEUREUX

Introduction

The available literature continues to demonstrate that appropriate use of monitoring during the provision of anesthesia strongly correlates with a decrease in morbidity and mortality. The term *monitor* is a derivative of the Greek word *monere*, "to warn, advise." In the following discussion, monitoring refers to the investigative methods and instruments used to generate meaningful information in the evaluation of a patient.

Because of the time-sensitive nature of most abnormalities discovered on routine monitoring, significant efforts have been put forth in developing diagnostic instruments that quickly and accurately detect changes in vital signs. The ideal monitor is one that is accurate, noninvasive, reliable, inexpensive, easy to read, and can be used continuously. In addition to recognizing the indications for each of the monitors to follow, it is crucial to understand how they work so that the operator is aware of their limitations and can appropriately interpret the results.

According to the standards put forth by the ADA, monitoring and documentation will vary based on the levels of sedation and anesthesia administered to the patient. However, certain patients with potentially unstable medical conditions may still benefit from more extensive monitoring than indicated by the planned level of anesthesia. These may include assessments of level of consciousness, oxygenation (color and oxygen saturation), ventilation (chest rise, auscultation, end-tidal CO_2, or verbal communication), and circulation (blood pressure [BP], heart rate, continuous electrocardiogram [ECG]). The following definitions are those approved by the House of Delegates at the 2012 Annual Meeting of the American Dental Association and reflect the practice guidelines for sedation and analgesia by non-anesthesiologists.[1] These definitions provide the basis for understanding the goals of anesthesia delivery in the oral and maxillofacial surgery practice (Table 14-1).

Definitions

- **Minimal sedation:** a minimally depressed level of consciousness, produced by a pharmacologic method, that retains the patient's ability to independently and continuously maintain an airway and respond normally to tactile stimulation and verbal command. Although cognitive function and coordination may be modestly impaired, ventilator and cardiovascular functions are unaffected.[2] Under this definition it is understood that the medications and techniques used to provide this level of consciousness should carry a margin of safety that does not allow rendering of an unintended loss of consciousness.
- **Moderate sedation:** more recently referred to as moderate sedation, conscious sedation is a drug-induced depression of consciousness during which patients respond purposefully to verbal commands, either alone or accompanied by light tactile stimulation. No interventions are required to maintain a patent airway, and spontaneous ventilation is adequate. Cardiovascular function is usually maintained.[2]
- **Deep sedation:** a drug-induced depression of consciousness during which patients cannot be easily aroused but respond purposefully following repeated or painful stimulation. The ability to independently maintain ventilatory function may be impaired. Patients may require assistance in maintaining a patent airway, and spontaneous ventilation may be inadequate. Cardiovascular function is usually maintained.[2]
- **General anesthesia:** a drug-induced loss of consciousness during which patients are not arousable, even by painful stimulation. The ability to independently maintain ventilator function is often impaired. Patients often

TABLE 14-1 Levels of Sedation and Anesthesia

	Minimal Sedation Anxiolysis	Moderate Sedation (Conscious Sedation)	Deep Sedation	General Anesthesia
Responsiveness	Normal response to voice	Purposeful response to tactile stimulation	Purposeful after repeated or painful stimulation	Unarouseable
Airway	Unaffected	No intervention needed	Intervention may be required	Intervention is required
Spontaneous ventilation	Unaffected	Adequate	May be inadequate	Frequently inadequate
Cardiovascular function	Unaffected	Usually maintained	Usually maintained	May be impaired
Examples in dental anesthesia	Oral benzodiazepine (low dose) and/or nitrous oxide	Low-dose intravenous benzodiazepine	Intravenous benzodiazepine + opioid + low-dose intravenous agent (e.g., propofol)	Higher dose intravenous agents, multiple drug technique. Potent inhalational agents (e.g., sevoflurane)

Adapted from American Society of Anesthesiologists. *ASA Standards, Guidelines and Statements*, amended October 2009. www.asahq.org/For-Members/Standards-Guidelines-and-statements.aspx.

require assistance in maintaining a patent airway, and positive pressure ventilation may be required because of depressed spontaneous ventilation or drug-induced depression of neuromuscular function. Cardiovascular function may be impaired.[2]

- **Continual:** repeated regularly and frequently in steady succession.[2]
- **Continuous:** prolonged without any interruption at any time.[2]
- **Time-oriented anesthesia record:** documentation at appropriate time intervals of drugs, doses, and physiologic data obtained during patient monitoring.[2]

History and Evolution of Monitoring Guidelines

"Practice guidelines" are a collection of recommendations provided by authorities in a specialty that are founded on sound evidence. They are often periodically updated and meant to help providers practice at a common level; however, they are not considered requirements. "Standards of care" relate to recognized recommendations to which providers in a given region will be held. These are often brought up in legal settings as a means of comparing what happened to what should have happened. Even as such, they still are not requirements. "Requirements" are acknowledged proceedings that are considered mandatory by a governing body and often supported by irrefutable evidence.

Circulatory System Monitoring

Intraoperative monitoring of the circulatory system is done using electrocardiography, pulse oximetry, blood pressure assessment, and physical diagnosis. Capnography, as noted later, also provides information regarding cardiac output and general metabolism. These modalities allow for evaluation of cardiac conduction, heart rate, blood pressure, and oxygen saturation.

Blood Pressure Monitor

Blood pressure is one of the fundamental parameters for the assessment of cardiovascular health and a critical tool for monitoring the anesthetized patient. The use of an occlusive cuff for measurement of blood pressure (BP) during surgery was first described in 1903 by Harvey Cushing. Large and abrupt changes in BP are often seen in the intraoperative and perioperative periods. These large swings, if not managed appropriately, can lead to significant morbidity. Of particular importance is rapid-onset hypotension, which during the intraoperative period may herald cardiovascular collapse. Less severe, although far more common, is the mild hypotension that results from bolus infusion of vasoactive medications. This hypotension is often offset by surgical stimulation; however, if the hypotension is prolonged, there may be significant end organ damage. Hypertension can similarly be very detrimental to the overall well-being of the patient. Severe hypertension can lead to decreased coronary artery perfusion and increased stress on the myocardium. Therefore, regardless of the direction of the abnormality, substantial alterations in BP can lead to myocardial ischemia and eventual infarction. It is for these reasons that frequent BP assessment is important for safe and effective anesthesia.

Previously, the most common method used to assess blood pressure was the auscultatory technique. During this technique a provider listens for the appearance and disappearance of Korotkoff's sounds as the pressure is relieved from a blood pressure cuff that is occluding an artery (conventionally the brachial artery). The pressure at which the first sound appears as the cuff is deflated is recorded as the systolic blood pressure, and the pressure at

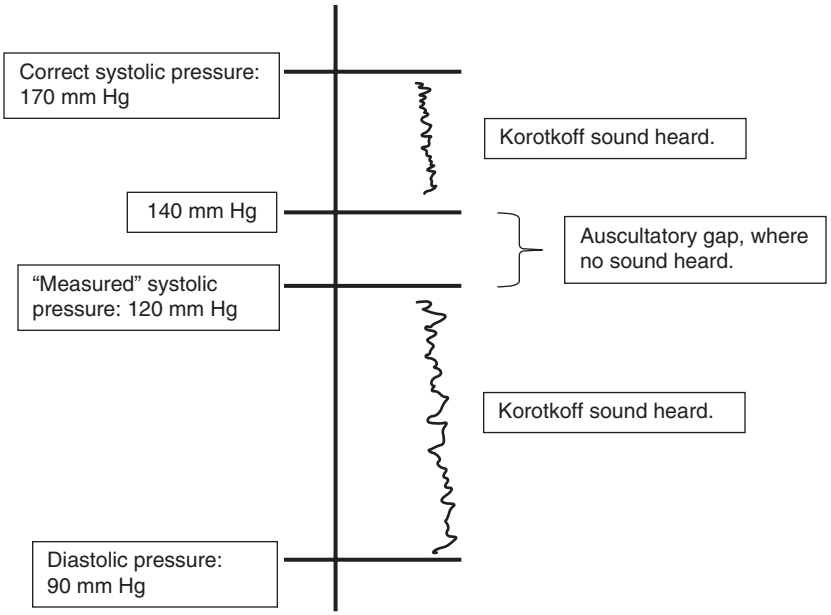

• **Figure 14-1** Representation of an auscultatory gap. If the cuff pressure was not pumped up greater than 140 mm Hg in this example, then the true systolic pressure would be under the true value.

which the sounds cease is recorded as the diastolic blood pressure. As with many of the instruments in the discussions to follow, there are several factors that affect the accuracy of any given measurement. One of the most common errors in BP determination is choosing an improperly sized blood pressure cuff. In fact, in the outpatient setting, the most common error in BP assessment is miscuffing (84% of errors).[3] The proper cuff should have a bladder length that is 80% of the arm circumference, and bladder width that is at least 40% of the arm circumference.[4] When a small cuff is used inappropriately, one can expect a falsely elevated BP, and conversely when a larger than recommended cuff is used, one can expect a falsely reduced BP. The presence of an auscultatory gap (Figure 14-1) can lead to underestimating the true systolic pressure in a patient. This presents as a loss and reappearance of the Korotkoff sounds during deflation of the cuff. If a radial pulse is still palpable even though there are no sounds heard as the cuff is inflated, then there is an underestimation of the true systolic pressure. By inflating the cuff above the point that the radial artery pulsations are not palpable, a more accurate recording of the systolic pressure will be identified. Auscultatory gaps are more prevalent in patients with systemic sclerosis. Using electronic oscillometric devices avoids this issue (see later discussion).

Other factors of great importance in the measurement of blood pressure are the location of the cuff during a measurement and the position of the extremity. As one moves distally along an extremity, the systolic blood pressure increases and the diastolic blood pressure decreases. In patients with significant atherosclerotic disease, calcifications within the distal arteries may prevent complete occlusion even at suprasystolic blood pressures. In this instance, an overestimation of the systolic blood pressure results. When measuring BP, the location of the cuff should be level with the patient's heart. If the cuff is above the patient's heart, a falsely low BP will result. On the other hand, if the cuff is below the level of the patient's heart a falsely elevated BP will result.

Although the auscultatory method can be used, its use is not practical when frequent recordings are necessary. Most automated systems today use the oscillometric method for BP determination. This method depends on oscillations of a manometer needle due to arterial pulsations as the cuff is deflated from a suprasystolic pressure. Systolic, mean, and diastolic pressures are believed to correspond with the time of rapid increase in oscillation, maximum oscillation, and disappearance of oscillation, respectively.[5]

Automated systems are easy to use and allow for objective and consistent readings. As they do not depend on an operator's ability to detect auditory pulsations, they also work well in the noisy environment of an operatory or operating room. Although automated BP assessment techniques are noninvasive and convenient, they are not without risk. Compartment syndrome and nerve palsies have been documented.[6,7] Thus it is important to avoid excessively repeated cycles of pressure measurement, and to also avoid placement of the cuff across a joint where nerves may be traumatically compressed. Caution should also be observed when using automated blood pressure cuffs in patients with preexisting neuropathies and arterial or venous insufficiency, as they are at increased risk of complication.

Electrocardiogram

The coordinated electrical activity across the heart as individual cells depolarize can be read by electrodes placed on the skin surface. Willem Eintoven first recorded the ECG in a clinically relevant scenario at the beginning of the twentieth century using a string galvanometer.[8] Since

that time, several of his successors have made improvements in lead configuration and have demonstrated its use in diagnosing cardiac dysrhythmias and acute disease. The standard ECG tracing contains repeated complexes made up of upward and downward deflections from an isoelectric baseline. These deflections have an amplitude and duration that become helpful in diagnosing pathologic conditions.

Today the ECG is still an essential tool in the monitoring of the sedated patient. In fact, the standards for basic anesthetic monitoring put forth by the American Society of Anesthesiologists (ASA) require that every patient receiving moderate sedation or deeper levels of anesthesia have an ECG continuously displayed.[9] With the standard three-lead ECG, as used by Einthoven in the early 20th century, one may detect changes in heart rate, rhythm or conduction abnormalities, electrolyte disturbances, and even ischemia. It is common practice to use bipolar lead II during intraprocedure sedation because of its ability to detect inferior wall ischemia, the clarity of the P wave, and its tremendous potential in picking up dysrhythmias.[10] Lead II however, should be supplemented with a precordial lead in patients with significant risk factors for cardiac events. For instance, lead II and V_5 together have been found to detect a significant proportion of ischemic episodes. Blackburn and Katigbak, in an exercise lab, found that the combination of leads II and V_5 detected 96% of ischemic events.[11] In a more common clinical setting, London and colleagues found that V_5 and II were able to detect 80% of ischemic episodes.[12] In their study, patients were either known or suspected of having significant coronary artery disease (CAD) and were undergoing noncardiac surgery.

As mentioned earlier, the ECG is an extremely valuable tool for detecting myocardial ischemia. One established ECG change that may signify ischemia is ST segment elevation or depression of greater than 1 mm from the baseline. Another such change is T wave inversion, although this is also seen in ventricular hypertrophy, some bundle branch blocks, and digoxin therapy. When present in multiple leads, ST elevation and depression can represent an area of ischemia localized to a certain vessel or region of the heart. Though criteria for detecting ischemia are known, putting them into useful practice has its limitations. Mangano and co-workers demonstrated that on visual inspection, ST segment changes are only detected 50% of the time or less.[13,14] Leung and colleagues, however, demonstrated that the ST segment trend analysis used in many current monitors has a potential for 78% sensitivity and 90% specificity in detecting ischemia.[15]

Respiratory System Monitoring

Much of the focus of monitoring during an anesthetic procedure is directed toward securing and maintaining an appropriate airway (Figure 14-2). Monitoring the respiratory system is a truly multimodal undertaking. On visual inspection, one can appreciate the chest rise or color changes of the mucous membranes. Breath sounds can be heard with the use of a precordial stethoscope. Even the tactile sense is used in practice to monitor for the presence or absence of respirations. Despite the many physical methods available to monitor respirations, they are not enough to ensure a patent and secure airway. Additional tools at our disposal and required by many national and international specialty groups are pulse oximetry and capnography. These additional instruments are able to detect early respiratory compromise, which is often found to precede significant untoward events during sedation and anesthesia.



• **Figure 14-2** The oral surgery anesthesia team is depicted. One assistant is the surgical assistant while a second assistant maintains the airway and is observing the monitors. During a deep sedation, a patient's airway reflexes are obtunded, so a throat pack (gauze behind surgical site) and protection of the upper airway are provided.

Precordial/Pretracheal Stethoscope

The precordial/pretracheal stethoscope is a simple tool for the continuous assessment of the circulatory and respiratory systems. It consists of a weighted stethoscope head, conduction tubing, and custom monaural earpiece. For best assessment of the respiratory system it is placed over the trachea on the anterior neck. In this *pretracheal* position, it allows for clear, unobstructed auscultation of breath sounds. In the oral and maxillofacial surgery office setting, this may be the ideal position for the stethoscope head, as respiratory depression and apnea are more common than cardiovascular compromise from the sedative agents used there. In the *precordial* position, one is able to listen to both breath sounds and heart sounds. The ideal location for the stethoscope head is placed on the skin of the chest wall on a line between the sternal notch and the left nipple. Despite the low cost and minimal maintenance needed for this device, its routine use has fallen out of favor. The lack of quantitative information, automation, and alarm system have made other systems used in evaluation of the respiratory and cardiovascular systems more desirable. Some clinicians avoid its use due to a feeling of being tethered to the patient. The use of a Bluetooth device can avoid this connection

and even be sent to an external speaker to allow the entire anesthesia team to hear the breath sounds during a procedure.

Pulse Oximeter

The pulse oximeter is a widely used and indispensable tool in anesthesia monitoring. As the name implies, it provides the user with information on both the heart rate and percent oxygen saturation of the hemoglobin molecules in a patient's blood. In the oral and maxillofacial surgery setting, these measures are critical, and it has been estimated that a desaturation of 10% occurs in as many as 53% of anesthetized patients.[16]

Before oximetry, detection of hypoxemia was reliant on either arterial blood gas measurement or the observer's ability to recognize the clinical manifestations of cyanosis. As hypoxemia can have severe and long-lasting adverse effects on all tissues, early detection and reversal is paramount. Detection of cyanosis by even the most seasoned health professionals is notoriously unreliable. Regardless of the total hemoglobin, approximately 5 g of reduced hemoglobin per 100 mL of capillary blood is necessary to yield visually detectable cyanosis.[17] The earliest time at which some clinicians are able to detect cyanosis is when oxygen saturations drop to approximately 80%, with 25% of clinicians unable to detect cyanosis at oxygen saturations of 71% to 75%.[18] Even with the ability to detect cyanosis, it is a relatively late finding and requires a significant reduction in concentration of oxygenated hemoglobin.

Reduced hemoglobin and oxygenated hemoglobin differ in many regards, one of which is the ability to absorb light. Pulse oximeters emit and detect two wavelengths of light, 660 nm, which is in the red spectrum, and 940 nm, which is in the infrared spectrum. This light passes through a capillary bed, most often that of a finger, and is picked up by an opposing photodetector. At 660 nm, oxygenated hemoglobin allows passage of more light than deoxygenated hemoglobin, and at 940 nm, the converse is true. This differentiation allows for the determination of the arterial oxygen saturation in a capillary bed using a predefined algorithm. Another important feature of the pulse oximeter is the ability to differentiate between arterial and venous blood. It is able to detect the arterial flow by noting the changing volume of the vascular bed with each pulsation. Multiple reviews have been conducted to assess the accuracy of monitoring. Manufacturing standards are able to produce less than 3% error at oxygen saturations of greater than 70%, which has been verified by multiple studies.[19] At these levels, pulse oximetry has even been shown to be as accurate as arterial blood gas sampling.[19,20] Below 70% oxygen saturation, pulse oximetry remains relatively accurate, although there appears to be a trend toward overestimation of the determined oxygen saturation by as much as 4%.[21] However, those inaccuracies are not clinically significant, as rapid intervention is still necessary.

Despite its ubiquitous use and incredible value, there are several limitations to the use of pulse oximetry. Most errors are due either to inappropriate quantity of signal (improper placement, low-flow state) or to a secondary influence on the signal (ambient light, electrocautery, movement). Both prospective and retrospective studies have confirmed comparable pulse oximeter failure rates. In one large prospective study of 11,046 patients, a failure rate of 1.12% was discovered.[22] In this particular study, a documented failure had occurred only after all conventional sites had been tried and all mechanical errors had been ruled out.

One source of error in pulse oximetry that deserves special attention is the mechanism in which the oxygen saturation is interpreted. When presented with carboxyhemoglobin and oxyhemoglobin, the pulse oximeter is unable to tell the difference.[23] In one laboratory study assessing a patient with carbon monoxide poisoning, the saturation level detected by the pulse oximeter was found to be the sum of the carboxyhemoglobin saturation level and the oxyhemoglobin saturation level.[24] Thus, in the setting of carbon monoxide poisoning or tobacco smoke inhalation, a normal oxygen saturation as determined by pulse oximetry may not reflect the actual percent of oxygenated hemoglobin. Another form of hemoglobin that may contribute to an inaccurate measurement on pulse oximetry is methemoglobin. Methemoglobin, like oxyhemoglobin, absorbs light at 660 nm and 940 nm. The effect of methemoglobin on pulse oximetry readings is that readings decrease by about half of the methemoglobin percent concentration (up to methemoglobin concentrations of 20%).[25] At higher methemoglobin concentrations, there is a trend toward a fixed pulse oximetry reading of 85%. When interpreting pulse oximetry readings, it is essential to note that in normal, nonsmoking individuals, carboxyhemoglobin concentrations are less than 2%,[26] and methemoglobin concentrations are less than 1%.[27] This becomes important when clinical findings do not correlate with an apparently normal pulse oximetry reading. Some substances that may contribute to this scenario are cigarette smoke and carbon monoxide, which significantly increase carboxyhemoglobin concentrations. Local anesthetics, including prilocaine and benzocaine sprays, sulfonamide antibiotics, and nitrites, can increase methemoglobin concentrations in susceptible patients.[28]

Pulse oximetry overall has significantly reduced the morbidity of sedation, and it appears to be best used as a monitor for desaturation. Although there are several known sources of error related to pulse oximetry, it is important to be mindful of abnormal readings and treat them as representing a low arterial oxygen content until disproven by other methods.

Capnography

Probably the most recent change to anesthesia monitoring, especially in the outpatient setting, is the attention to end-tidal CO_2 monitoring. Although, as noted earlier, pulse oximetry does provide an accurate measurement of oxygen saturation, decreases are often delayed in presentation because the patient is receiving supplemental oxygenation. Capnography provides a more rapid appreciation of the ventilation status of the patient.

According to the most recent AAOMS Parameters of Care, end-tidal CO_2 monitoring should be a consideration in any moderate sedation, and is indicated for any

deep sedation or general anesthesia unless precluded by the nature of the procedure or patient specific issues.[29] Although capnometry, or the measuring of the partial pressure of CO_2 during the respiratory cycle, was initially introduced to the clinical setting in the 1940s, it was only mandated by the ASA for their use in endotracheal general anesthesia in 1996.[30]

The device used in measuring the inhaled or exhaled CO_2 concentration is referred to as the capnometer, and it outputs the capnograph, or the graphic record of the measured CO_2 concentrations. Most capnometers use infrared absorbance or mass spectrometry passed across a sample of gas to determine a partial pressure of carbon dioxide in the sample. Ideally the sample of gas is obtained from a sampling line that directly attaches to a closed circuit. More commonly, however, the sample is obtained from a modified nasal cannula or a sampling line passed through or under a nasal hood (Figure 14-3). Although not ideal, several studies have corroborated that end-tidal CO_2 measurements obtained in this manner correlate well with measured arterial partial pressures of carbon dioxide.[31,32]

Circulation

End-tidal CO_2 measurements can also be used to indirectly assess a patient's circulatory status. In a normal, healthy individual, the end-tidal CO_2 ($EtCO_2$) measurement is lower than the arterial partial pressure of CO_2 ($PaCO_2$) by 2 to 5 mm Hg [(aEt)CO_2 gradient].[33] As a patient's cardiac output increases, there is a corresponding increase in alveolar perfusion and delivery of CO_2 for elimination. In this circumstance the (aEt)CO_2 gradient is minimized and remains in the normal range. Conversely, as a patient's cardiac output decreases, there is a decrease in alveolar perfusion and delivery of CO_2 for elimination. When this occurs, the (aEt)CO_2 gradient increases; therefore, a sharp decrease in end-tidal CO_2 or increase in the (aEt)CO_2 gradient in an unwell patient can herald circulatory collapse.

Metabolism

Carbon dioxide and H_2O are normal byproducts of cellular metabolism, and hence increases in their production can signify a hypermetabolic state, altered circulation, or change in ventilation. In a continuously and mechanically ventilated patient, increases in $EtCO_2$ most likely represent hypermetabolism. Other conditions that increase metabolic activity of tissues and thus increase $EtCO_2$ include hyperpyrexia, metabolic acidosis, pain, and muscle activity. One notable condition in which $EtCO_2$ increases before any measurable temperature increase is malignant hyperthermia. In this condition, elevated $EtCO_2$ can be the first abnormality to present.

Respiration

One of the primary uses for $EtCO_2$ monitoring is for the evaluation of a patient's respiratory status. The normal

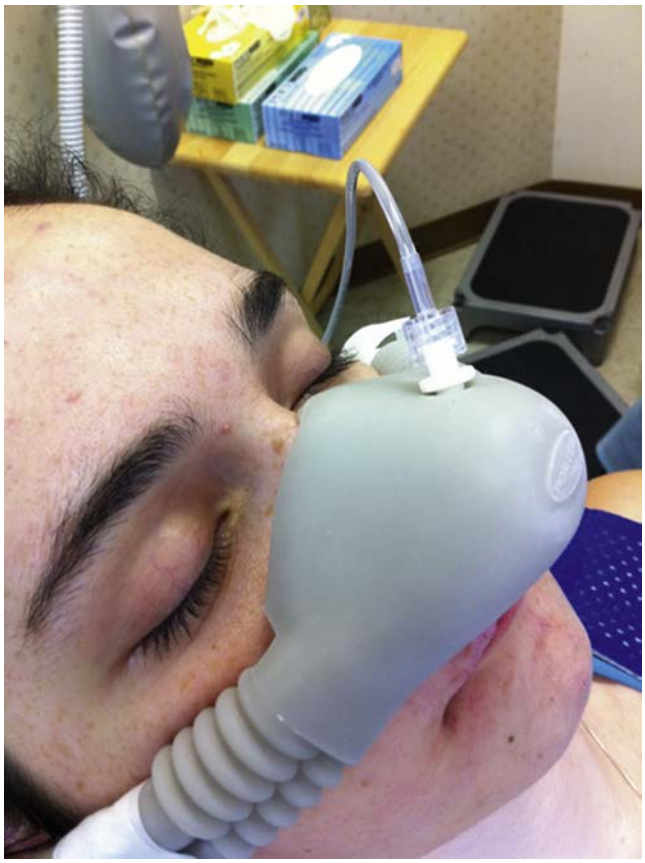

• **Figure 14-3** Example of side stream sampling of end-tidal CO_2. The barb perforates both layers of the nitrous oxide scavenging hood. As long as the patient is breathing through their nose, good measurements of $EtCO_2$ are obtained.

expected range for $EtCO_2$ is approximately 40 to 48 mm Hg, with the capnogram exhibiting four distinct phases (ascending phase, alveolar plateau, inspiratory limb, and deadspace ventilation).[34] In phase I the airway deadspace is exhaled and the partial pressure of CO_2 is essentially zero. As exhalation progresses and alveolar gas is expelled (phase II) there is a sharp increase in CO_2. For the rest of the exhalation, the partial pressure of CO_2 remains relatively stable (often has a gentle upward slope) and there is a plateau phase (phase III) that reflects the partial pressure of CO_2 that exists in the alveoli. The maximum level of CO_2 during phase III represents the $EtCO_2$ value. Finally, with inhalation, the partial pressure of CO_2 rapidly returns to zero and the cycle repeats itself.

The normal capnogram is not age exclusive and has the following traits: the four main phases are discernable, the CO_2 concentration starts at zero and returns to this baseline with each cycle, there is a maximum CO_2 concentration that is reached with each breath, the amplitude depends on the $EtCO_2$, the width depends on the expiratory time, and there is a characteristic rectangular or trapezoidal shape to the capnogram (Figure 14-4).[34] Any variation from the normal capnogram signifies a clinically relevant condition, and actions should promptly be taken to correct the abnormality.

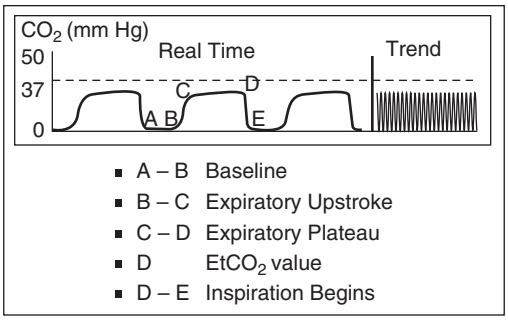

• **Figure 14-4** Normal morphology of the capnogram exhibiting the five distinct phases.

In the clinical setting, capnography has gained significant popularity for procedural sedation because it promptly identifies respiratory abnormalities. Multiple studies in pediatric[35,36] and adult[37] populations have demonstrated that capnography is able to identify respiratory depression in cases where pulse oximetry and clinical examination could not. Additionally, in cases of acute respiratory compromise identifiable by both pulse oximetry and capnography, capnography was able to identify an abnormality as much as 4 minutes earlier than pulse oximetry.[38]

Temperature Monitor

The AAOMS Parameters of Care mandate that a means for assessing a patient's temperature be immediately available.[29] Indeed, not all sedated patients require continuous temperature monitoring; however, in instances where fluctuations in temperature are expected, core temperature should be documented as frequently as every 5 minutes. Normally, neurohumeral mechanisms allow for tight regulation of body temperature within a well-tolerated range. This steady state is achieved via a combination of thermoregulatory effectors that upregulate metabolic heat production, reduce heat loss, and/or increase dissipation of heat to the environment.

In the setting of general anesthesia, the normal range of acceptable temperatures for homeostasis is broadened, and the mechanisms used to prevent heat loss are recruited at a lower temperature.[39,40] Thus, the vast majority of patients undergoing general anesthesia become hypothermic by 1° to 3° C.[41] Studies demonstrate that the changes in core temperature during general anesthesia follow a distinctive pattern. Characteristically, there is a rapid 1° to 1.5° C drop in temperature in the first hour, followed by a slow linear decrease over the next 2 to 3 hours.[42] Typically a plateau in temperature is finally achieved as compensatory mechanisms allow for a match between heat production and heat loss to the environment.[43] The most important factor in combating the cutaneous heat loss during general anesthesia is sympathetically mediated vasoconstriction.[44] In fact, in a quantitative study of corporeal heat distribution during anesthesia, it was discovered 65% of the decrease in core temperature over the initial 3 hours was due to redistribution of blood flow.[45]

Several adverse effects of perioperative hypothermia have been well documented. Those complications that have a causal relationship include increased blood loss,[46] morbid myocardial outcomes,[47] prolonged post-anesthetic recovery[48] and hospitalization,[49] negative nitrogen balance,[50] and surgical site infection.[49]

Temperature monitors vary greatly in their makeup and their site of use. The most ubiquitous transducers are thermistors and thermocouples, which use differences in electric potential to determine temperature. Most temperature probes used in anesthesia are thermistors.[51] A thermistor is composed of a semiconductor, the resistance of which varies indirectly with temperature. This predictable correlation allows conversion of the voltage output into a temperature value. Since thermistors are solid-state devices, they can be made into small sizes and accommodate many different environments. A thermocouple, also commonly used, differs in that it is composed of two different metals that generate an electromotive force when a temperature difference exists between them.[52] The advantages of the thermistor and thermocouple probes are that they are disposable, sensitive to small temperature changes, accurate, and relatively low cost. Alternatives to thermocouples and thermistors are liquid crystal thermometers and infrared thermometers. Liquid crystal thermometers depend on the thermal properties of a series of organic compounds. These thermometers are also inexpensive, disposable, and noninvasive; however, they are less accurate and may be adversely influenced by external heat sources and humidity. Infrared thermometers have become popular for spot temperature monitoring and are commonly used in the ear canal. These thermometers are generally accurate and determine temperature by recording the amount of infrared radiation emitted by an object.

As important as the device used in thermometry is the site of temperature measurement. Because the core temperature dictates the body's thermoregulatory response and is directly related to complications in the setting of hypothermia, it is crucial to choose a site that directly reflects core temperature. The gold standard for core temperature measurement remains the transducer on the end of the pulmonary artery catheter. Today, the most common sites for temperature measurement include the nasopharynx, esophagus, tympanic membrane, oral cavity, bladder, rectum, trachea, and skin of the axilla and forehead. Because of the nature of oral surgical procedures, probes placed in the nasopharynx and oral cavity may be obstructive and provide inaccurate readings. Similarly, the sedated patient will generally not tolerate tracheal, bladder, rectal, or esophageal temperature assessments. As a result, common and acceptable sites for temperature measurement during oral surgical procedures include the tympanic membrane and skin.

Neuromuscular Monitor

Neuromuscular blockade (NMB) is generally used to facilitate endotracheal intubation, abolish patient movement, and to allow for total control of respiratory variation.

Depending on the indication, differing degrees of relaxation may be desired. Given that there are numerous available neuromuscular blocking agents and that individuals may respond differently to the same agent, it is of vital importance to be able to monitor the depth of NMB in a sedated patient. The most common method employed to monitor NMB is through artificial stimulation of a peripheral nerve, commonly the ulnar nerve. During the assessment, 20 to 60 mA of current is applied between two electrodes placed on the skin surface over the nerve. The measured effect is the presence and degree of thumb adduction by the adductor pollicis.[27] When conducting this assessment, it is important to remember that different muscles return to function at different times. It is due to this fact that the facial nerve rather than the ulnar nerve is often chosen as the site of monitoring because it closely reflects the response of airway musculature.

Neuromuscular transmission monitoring has different purposes depending on the stage of the anesthetic procedure. During induction, NMB is directed at relaxing the laryngeal muscles enough to accommodate the endotracheal tube. Throughout the maintenance phase of anesthesia, the goal of NMB is to prevent patient movement, but to allow return of spontaneous respiration. Finally, assessment of NMB at the conclusion of the procedure is directed at determining both if the blockade is reversible and if the patient is suitable for extubation. Neuromuscular monitors themselves have several different methods of stimulation, each with differing interpretation. Single-twitch stimulus can be used to determine readiness for intubation, and the response to this stimulus is the same regardless of the class of neuromuscular blocking agent (depolarizing or nondepolarizing).

The train-of-four (TOF) pattern of stimulation, in which four repeated impulses are given, can be used to determine the type of neuromuscular blocking agent used and is also commonly used in determining readiness for extubation. However, it is not the most sensitive test for the latter purpose. Another commonly used test to determine extubation readiness is the ability to maintain a head lift for 5 seconds. Again, this usually indicates that a patient has sufficient tone to protect their airway. The most sensitive and objective test, however, is the ability to clamp the jaws closed and prevent removal of a wooden spatula. This test correlates with a TOF of greater than 0.86, compared to the 5-second head lift, which is associated with a TOF of 0.6.[53]

The last pattern of stimulus afforded by neuromuscular monitors is tetanic stimulation. Tetanic stimulation refers to repeated single-twitch stimuli that are on the order of 30 to 100 stimuli per second. When NMB is absent, there is a sustained contraction of the target muscle. In the setting of residual NMB from depolarizing muscle relaxants, the tetanic contractions are sustained but weakened uniformly. In contrast, with nondepolarizing muscle relaxants, the resulting tetanus is depressed but also not sustained. The advantage of tetanus over the other methods of stimulus is that it can be used in deeper levels of NMB when the single twitch or TOF are unsuccessful in generating a useful response.

Depth of Sedation

A reliable method for assessing depth of sedation is exceedingly desirable and would aid in providing patients with their expected experience while maintaining their safety. Under ideal circumstances, one would be able to preserve amnesia, analgesia, and anxiolysis all while preventing respiratory depression, hypotension, laryngospasm, and dysrhythmias.

In the past, measures such as heart rate, blood pressure, respiratory rate, and patient movement were used to assess anesthetic depth. Today, scales that use subjective criteria to score clinical findings are often used to assess a patient's level of sedation. These sedation scales are easy to use, and documentation of their use is a mandated part of the anesthesia record. Additionally, depending on the depth of sedation, a separate individual is required to focus solely on continuous assessment of the patient's level of consciousness.

Of all the scales commonly used for this assessment, one of the most widely used is the Ramsay Sedation Scale,[54] which scores level of consciousness into six categories based on the patient's ability to respond to a stimulus. As this scale requires a response by the patient, it cannot be used in the setting of NMB. Other available scales not widely used in the Oral and Maxillofacial Surgery setting include the Observer's Assessment of Alertness/Sedation Scale, the Riker Sedation-Agitation Scale, and the Motor Activity Assessment Scale. As with all subjective measures, accuracy may be compromised by differences in interobserver, and even intraobserver, interpretation of clinical findings.

Bispectral Index (BIS) Monitor

Because of the unreliable nature of the sedation scales in assessing level of consciousness, other methods of monitoring have been developed. The electroencephalogram (EEG) was an obvious target for further development as it is able to continuously monitor brain activity in a noninvasive manner. The cortical EEG of an awake patient is typically characterized by high-frequency and low-amplitude waveforms. In the initial stages of anesthesia, the frequency of activity decreases and the amplitude of the waves increases. As the sedation progresses and larger doses of medications are used, the waves further decrease in frequency and increase in regularity. Finally, at deep levels of sedation and general anesthesia, periods of isoelectric activity appear separated by bursts of undulation.[55]

One of the first products available for monitoring anesthetic depth that used intraoperative EEG recording was bispectral analysis (BIS). The BIS monitor was first approved for use in 1996 and has become the most widely used method for monitoring depth of anesthesia. The BIS

monitoring systems use a sensor applied to the forehead, which generates an EEG recording. The proprietary BIS algorithm is then applied to the EEG, and a BIS Index is generated. The BIS index is a number from 0 to 100 generated from statistical analysis of a series of EEGs in normal patients, where 0 represents an isoelectric EEG. Bispectral analysis incorporates several variables including EEG power and frequency, burst suppression, bicoherence, and β activation. The main hypothesis that underlies BIS monitoring is that specific EEG features can be correlated with depressed consciousness and that these are seen regardless of the method by which the depressed consciousness is achieved.

Since its introduction, several studies have been performed to validate the BIS index as an indicator of depth of anesthesia. From the results of these studies, several guidelines for sedation have been established. Awake patients will generally have a BIS index of 90 to 100. An index of 70 to 90 represents light to moderate sedation. Below a BIS index of 70, the likelihood of explicit recollection drops off rapidly, with an index of 60 to 70 representing deep sedation, and one between 40 and 60 representing general anesthesia.[55]

Use of BIS monitoring during sedation has several well-documented beneficial effects. In a meta-analysis looking at BIS monitoring in ambulatory anesthesia, it was shown to allow for decreased anesthetic drug requirement (19% reduction in consumption), decreased incidence of postoperative nausea and vomiting (PONV) (6% decreased incidence), and decreased length of recovery room stay (decreased by 4 minutes).[56] Although these findings are indeed significant, the overall reduction in each of the measured outcomes was marginal in most cases. For instance, the authors of the aforementioned study documented a number needed to treat (NNT) of 17 to prevent one instance of PONV. This was directly compared to the NNT for several common antiemetic agents (ondansetron, dexamethasone, and droperidol) when used for the same purpose (NNT 4 to 7).[56,57]

One potential factor that may preclude BIS monitoring use is that not all anesthetic agents produce the same predictable changes to an EEG of a sedated patient. One anesthetic agent in particular, ketamine, actually has an activating influence on the EEG. Ketamine, by increasing the high-frequency activity in the EEG, may lead to elevated BIS index values that will not correspond correctly to the apparent level of consciousness.[58] Other medications that contribute to error in BIS index monitoring include narcotics and nitrous oxide. These medications, in low doses, often contribute to a seemingly deeper level of anesthesia without a significant change in EEG.

Overall, the BIS monitor may provide a reliable objective measure of sedation in most instances; however, there are significant limitations for use in the typical oral surgery practice. These limitations stem directly from the unreliability of the BIS index when certain ubiquitous medications are used. Use of BIS monitoring has also demonstrated only a marginal cost savings, and therefore it has not been adopted by most oral and maxillofacial surgery practices.

The Anesthesia Record

The anesthesia record is a critical component of the patient chart. It should be a contemporaneous record of the care provided during a sedation visit. Included in this record must be the names and doses of all medications administered during the visit, as well as measurements of temperature and $EtCO_2$ when indicated, pulse oximetry, heart rate, blood pressure, and respiratory rate.[29] Also included in the record should be a documented interpretation of the ECG recording and level of sedation.

Although much of the anesthesia record is focused on the intraoperative period, the ASA's standards require that it be a comprehensive log of the perioperative period including the preoperative, intraoperative, and postoperative phases of care.[59] For moderate and deep sedation, the physiologic parameters monitored during the intraoperative period should continue to be recorded during the other stages of the visit.

As a permanent part of a patient's chart, the anesthesia record has multiple purposes. It may serve as a data log for medication use and baseline physiologic measurements, a patient management tool, and also as a medicolegal document. As a medicolegal document, it is extremely important for the content of the anesthesia record to be precisely and legibly recorded. Anesthesia information systems (AIS) are now available and in widespread use to simplify the gathering and recording of data. Anesthesia information systems, by nature of their digital format, are more legible, complete, and accurate sources of information relating to the office encounter. Though they are becoming more popular in the hospital setting, there has yet to be direct evidence for improved outcomes with daily use in the typical oral and maxillofacial surgery practice.

Monitoring During Recovery

Most hospitals and outpatient surgery centers have predefined discharge criteria and guidelines for monitoring patients as they return to their preoperative physiologic state. Recovery is often divided into stages which include: early recovery (Phase 1), which commences after the last anesthetic agent is discontinued and continues until recovery of protective reflexes; intermediate recovery (Phase 2), which is marked by readiness for transfer home; and late recovery (Phase 3), when the patient has finally returned to his or her preoperative physiologic state.[60] Although the same phases are observed following oral and maxillofacial procedural sedation, physical separation of the phases via transfer to a different unit is not practical.

Safe and timely progression through the stages of recovery is critical in the success of office-based anesthesia. One commonly employed scoring method to determine readiness for discharge is the Aldrete scoring system.[61] Using this system a patient receives a score from 0 to 10, with 0, 1, and 2 points given for each of five categories (motor activity,

TABLE 14-2 Modified Aldrete Scoring System

Parameter	Description of Patient	Score
Activity level	Moves all extremities voluntarily/ on command	2
	Moves two extremities	1
	Cannot move extremities	0
Respirations	Breathes deeply and coughs freely	2
	Is dyspneic, with shallow, limited breathing	1
	Is apneic	0
Circulation	Is 20 mm Hg ≤ preanesthetic level	2
	Is 20 to 50 mm Hg > preanesthetic level	1
	Is 50 mm Hg > preanesthetic level	0
Consciousness	Is fully awake	2
	Is arouseable on calling	1
	Is not responding	0
Oxygen saturation (by pulse oximetry)	Has level >90% when breathing room air	2
	Requires supplemental oxygen to maintain level >90%	1
	Has level <90% with oxygen supplementation	0
Maximum total score = 10		

Data from Aldrete JA: The postanesthesia recovery score revisited, *J Clin Anesth* 1:88-91, 1995.

respiration, circulation, consciousness, and color). With the addition of pulse oximetry, a modified Aldrete scoring system was devised (Table 14-2).[62] Under the modified system, a score of 9 corresponds to readiness for transition from phase 1 to phase 2 of recovery. In the oral and maxillofacial surgery practice, this often equates to readiness for discharge home[62] under the supervision of a responsible adult. Another similar scoring system devised by Chung[63] is the Postanesthesia Discharge Scoring System (PADSS). Similar to the modified Aldrete scoring system, patients are again given a 0, 1, or 2 for criteria in each of five categories (vital signs, ambulation, pain, PONV, and surgical bleeding). Once again, a score of 9 or higher signifies suitability for discharge home. Using the PADSS system, Chung was able to demonstrate that the majority of patients were suitable for discharge within 1 to 2 hours of surgery.[64] Today, there is still no universally accepted discharge scoring system. Regardless of the system used, it is important to be consistent with your evaluation and to document that an assessment of readiness for discharge was indeed performed.

Monitoring systems will continue to evolve and practice guidelines will continue to change as evidence for improved safety becomes available (Figure 14-5). Although some monitors are often able to perform many of the tasks once left to the anesthesia provider, they are unable to adjust

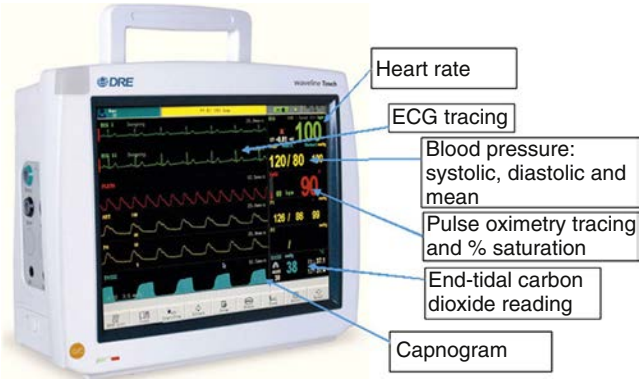

• **Figure 14-5** Example of multimodal monitor useful for outpatient anesthetic procedures. (Courtesy of DRE Medical, used with permission.)

appropriately to each individual patient and correlate their data with the overall clinical picture. Until that time, we as clinicians must remain contemporary in our understanding of the current equipment and be able to recognize situations in which there is conflicting data or adjust appropriately in the setting of equipment failure.

References

1. Practice guidelines for sedation and analgesia by non-anesthesiologists, *Anesthesiology* 96:1004–1017, 2002.
2. Guidelines for the use of sedation and general anesthesia by dentists: As adopted by the October 2012 ADA house of delegates, American Dental Association.
3. Manning DM, Kuchirka C, Kaminski J: Miscuffing: inappropriate blood pressure cuff application, *Circulation* 68(4):763–766, 1983.
4. Pickering TG, et al.: Recommendations for blood pressure measurement in humans and experimental animals: Part 1: Blood pressure measurement in humans: a statement for professionals from the Subcommittee of Professional and Public Education of the American Heart Association Council on High Blood Pressure Research, *Circulation* 111(5):697–716, 2005.
5. Hutton P, Prys-Robers C: The oscillotonometer in theory and practice, *Br J Anaesth* 54:581–591, 1982.
6. Celoria G, Dawson JA, Teres D, et al.: Compartment syndrome in a patient monitored with an automated blood pressure cuff, *J Clin Monit* 3:139, 1987.
7. Sy WP: Ulnar nerve palsy possibly related to the use of an automatically cycled blood pressure cuff, *Anesth Analog* 60:687–688, 1991.
8. Barold S: Willem Einthoven and the birth of clinical electrocardiography a hundred years ago, *Card Electrophysiol Rev* 7:99–104, 2003.
9. Standards for basic anesthesia monitoring: *American Society of Anesthesiologists*, 2010. Available at: http://asahq.org/~/media/Sites/ASAHQ/Files/Public/Resources/standards-guidelines/standards-for-basic-anesthetic-monitoring.pdf.
10. Skidmore SL, London MJ: Myocardial ischemia, *Anesthesiol Clin North Am* 19:651–672, 2001.
11. Blackburn H, Katigbak R: What ECG leads to take after exercise, *Am Heart J* 67:184–185, 1964.
12. London MJ, Hollenberg M, Wong MG, et al.: Intraoperative myocardial ischemia: localization by continuous 12-lead electrocardiography, *Anesthesiology* 69:232–241, 1988.

13. Mangano DT, Hollenberg M, Fegert G, et al.: Perioperative myocardial ischemia in patients undergoing noncardiac surgery—I: incidence and severity during the 4-day perioperative period, *J Am Coll Cardiol* 17:843–850, 1991.
14. Mangano DT, Wong MG, London MS, et al.: Perioperative myocardial ischemia in patients undergoing noncardiac surgery-II: incidence and severity during the 1st week after surgery, *J Am Coll Cardiol* 17:851–857, 1991.
15. Leung JM, Voskanian A, Bellows WH, et al.: Automated electrocardiogram ST segment trending monitors: accuracy in detecting myocardial ischemia, *Anesth Analg* 87:4–10, 1998.
16. Dorsch J: *Understanding anesthesia equipment*, ed 4, Baltimore, 1991, Williams & Wilkins.
17. Lundsgaard C, Van Slyke DD: Cyanosis, *Medicine* 2(1):1–76, 1923.
18. Comroe JH, Botelho S: The unreliability of cyanosis in the recognition of arterial anoxemia, *Am J Med Sci* 214(1):1–6, 1947.
19. Severinghaus JW, Kelleher JF: Recent developments in pulse oximetry, *Anesthesiology* 76:1018–1038, 1992.
20. Tremper KK, Barker SJ: Pulse oximetry, *Anesthesiology* 70(1): 98–108, 1989.
21. Hannhart B, Michalski H, Delorme N, et al.: Reliability of six pulse oximeters in chronic obstructive pulmonary disease, *Chest* 99:842–846, 1991.
22. Freund PR, Overand PT, Cooper J, et al.: A prospective study of intraoperative pulse oximetry failure, *J Clin Monit* 7:253–258, 1991.
23. Barker SJ, Tremper KK: The effect of carbon monoxide inhalation on pulse oximetry and transcutaneous PO_2, *Anesthesiology* 66:677–679, 1987.
24. Vegfors M, Lennmarken C: Carboxyhemoglobinemia and pulse oximetry, *Br J Anaesth* 66:625–626, 1991.
25. Barker SJ, Tremper KKI, Hyatt J, et al.: Effects of methemoglobinemia on pulse oximetry and mixed venous oximetry, *Anesthesiology* 70:112–117, 1989.
26. Sinex JE: Pulse oximetry: principles and limitations, *Am J Emerg Med* 17(1):59–67, 1999.
27. Dorsch J: *Understanding anesthesia equipment*, ed 4, Baltimore, 1991, Williams & Wilkins.
28. Buckley RG: The pulse oximetry gap in carbon monoxide intoxication, *Ann Emerg Med* 24(2):252–255, 1994.
29. Anesthesia in outpatient facilities: *Parameters of Care: Clinical and Practice Guidelines for Oral and Maxillofacial Surgery*, AAOMS, 2012.
30. American Society of Anesthesiologists: *Standards for basic anesthetic monitoring, ASA 1996 directory of members*, 1996. Park Ridge, IL.
31. McNulty SE, Roy J, Torjman M, et al.: Relationship between arterial carbon dioxide and end-tidal carbon dioxide when a nasal sampling port is used, *J Clin Monit* 6:93–98, 1990.
32. Friesen RH, Alswang M: End-tidal PCO_2 monitoring via nasal cannulae in pediatric patients: accuracy and sources of error, *J Clin Monit* 12:155–159, 1996.
33. Jacobsohn E, Aronson S, O'Connor M: Monitoring respiratory function, *Int Anesthesiol Clin* 34(3):1–36, 1996.
34. Krauss B, Hess D: Capnography for procedural sedation and analgesia in the emergency department, *Ann Emerg Med* 50: 172–181, 2007.
35. Hart LS, Berns SD, Houck CS, et al.: The value of end-tidal CO_2 monitoring when comparing three methods of conscious sedation for children undergoing painful procedures in the emergency department, *Pediatr Emerg Care* 13(3):189–193, 1997.
36. Lightdale JR, Goldman DA, Feldman HA, et al.: Microstream capnography improves patient monitoring during moderate sedation: a randomized, controlled trial, *Pediatrics* 117(6):e1170–1178, 2006.
37. Miner JR, Heegaard W, Plummer D: End-tidal carbon dioxide monitoring during procedural sedation, *Acad Emerg Med* 9(4):275–280, 2002.
38. Burton JH, Harrah JD, Germann CA, et al.: Does end-tidal carbon dioxide monitoring detect respiratory events prior to current sedation monitoring practices? *Acad Emerg Med* 13(5):500–504, 2006.
39. Kurz A, Go JC, Sessler DI, et al.: Alfentinil slightly increases the sweating threshold and markedly reduces the vasoconstriction and shivering thresholds, *Anesthesiology* 83:293–299, 1995.
40. Xiong J, Kurz A, Sessler DI, et al.: Isoflurane produces marked and non-linear decreases in the vasoconstriction and shivering thresholds, *Anesthesiology* 85:240–245, 1996.
41. Vaughan MS, Vaughaan RW, Cork RC: Postoperative hypothermia in adults: Relationship of age, anesthesia, and shivering to rewarming, *Anesth Analg* 60:746–751, 1981.
42. Cooper TE, Trezek GJ: Correlation of thermal properties of some human tissue with water content, *Aerospace Med* 42:24–27, 1971.
43. Sessler DI, Rubinstein EH, Eger II E: Core temperature changes during nitrous oxide/fentanyl and halothane/oxygen anesthesia, *Anesthesiology* 67:137–139, 1987.
44. Sessler DI, Moayeri A, Stoen R, et al.: Thermoregulatory vasoconstriction decreases cutaneous heat loss, *Anesthesiology* 73: 656–660, 1990.
45. Maatsukawa T, Sessler DI, Sessler AM, et al.: Heat flow and distribution during induction of general anesthesia, *Anesthesiology* 82:662–673, 1995.
46. Winkler M, Akìa O, Birkenberg B, et al.: Aggressive warming reduces blood loss during hip arthroplasty, *Anesth Analg* 91(4):978–984, 2000.
47. Frank SM, Fleisher LA, Breslow MJ, et al.: Perioperative maintenance of normothermia reduces the incidence of morbid cardiac events: a randomized clinical trial, *JAMA* 277:1127–1134, 1997.
48. Lenhardt R, Marker E, Goll V, et al.: Mild intraoperative hypothermia prolongs postoperative recovery, *Anesthesiology* 87:1318–1323, 1997.
49. Kurz A, Sessler DI, Lenhardt RA: Study of wound infections and temperature group. Perioperative normothermia to reduce the incidence of surgical-wound infection and shorten hospitalization, *N Engl J Med* 334:1209–1215, 1996.
50. Carli F, Emery PW, Freemantle CAJ: Effect of perioperative normothermia on postoperative protein metabolism in elderly patients undergoing hip arthroplasty, *Br J Anaesth* 63:276–282, 1989.
51. Miller RD: *Miller's anesthesia*, ed 7, London, 2010, Churchill Livingstone Elsevier.
52. Lake CL: *Stethoscopy and thermometry: clinical monitoring for anesthesia and critical care*, Philadelphia, 1990, WB Saunders.
53. Kopman AF, Yee PS, Neuman GG: Relationship of the TOF fade ratio to clinical signs and symptoms of residual paralysis in awake volunteers, *Anesthesiology* 86:765–771, 1997.
54. Chisholm CJ, et al.: Comparison of electrophysiologic monitors with clinical assessment of level of sedation, *Mayo Clin Proc* 81(1):46–52, 2006.
55. Bowdle TA: Depth of anesthesia monitoring, *Anesthesiol Clin* 24:793–822, 2006.
56. Liu SS: Effects of bispectral index monitoring on ambulatory anesthesia: a meta-analysis of randomized controlled trials and a cost analysis, *Anesthesiology* 101:311–315, 2004.

57. Gan TJ, Meyer T, Apfel CC: Department of anesthesiology DUMC: consensus guidelines for managing postoperative nausea and vomiting, *Anesth Analg* 97:62–71, 2003.
58. Overly FL, et al.: Bispectral analysis during pediatric procedural sedation, *Pediatr Emerg Care* 21(1):6–11, 2005.
59. Smith DF: *Conscious sedation, anesthesia, and the JCAHO*, Marblehead, MA, 1999, Opus Communications.
60. Awad IT, Chung F: Factors affecting recovery and discharge following ambulatory surgery, *Can J Anaesth* 53:858–872, 2006.
61. Aldrete JA, Kroulik D: A postanesthetic recovery score, *Anesth Analg* 49:924–934, 1970.
62. Aldrete JA: The post anesthesia recovery score revisited [letter], *J Clin Anesth* 7:89–91, 1995.
63. Chung F: Recovery pattern and home-readiness after ambulatory surgery, *Anesth Analg* 80(5):896–902, 1995.
64. Marshall S, Chung F: Assessment of "home readiness" discharge criteria and postdischarge complications, *Curr Opin Anesthesiol* 10:445–480, 1997.

15
Local Anesthetics

JEREMY R. GIES, MICHAEL T. MOONEY, ROBERT M. LAUGHLIN

History of Local Anesthetics

Local anesthesia forms the backbone of pain control techniques in oral surgery. Local anesthetic use can be traced as far back as the highlands of ancient Peru, where the Incas used the leaves of the coca plant as a local anesthetic to relieve fatigue and hunger and to produce a feeling of exhilaration.[1-3] Cocaine was isolated in 1860 and first used as a local anesthetic in 1884. In that year, at Roosevelt Hospital in New York, Richard John Hall and William Stewart Halsted were the first to describe regional block or "perineuronal" anesthesia.[1-3] Using cocaine, they performed what today is referred to as infraorbital and inferior alveolar nerve blocks for dental operations and later perfected many other regional anesthetic techniques.[2] The search for a less toxic and less addictive substitute led to the development of the amino ester local anesthetic stovaine in 1903 and procaine (Novocaine) in 1904. Since then, several synthetic local anesthetic drugs have been developed and put into clinical use, notably lidocaine synthesized by Nils Lofgren in 1943, bupivacaine in 1957, and prilocaine in 1959. Lidocaine has become the drug of choice in most clinical settings because of its potency, rapid onset, and lesser allergenicity.

Chemistry of Local Anesthetics

Nerve conduction involves the propagation of an electrical signal generated by the rapid movement of sodium (Na^+) and potassium (K^+) across a nerve cell membrane. Action potentials are generated by a sudden increase in the permeability of the nerve membrane to Na^+ ions and a resultant rapid influx of positively charged Na^+ ions, changing the electrochemical gradient of the membrane potential. This causes a depolarization, thus activating the nerve and sending a wave of sequential polarization down the nerve membrane. Repolarization takes place when sodium permeability decreases and K^+ permeability increases, resulting in an efflux of K^+ from within the cell and restoration of the electrical gradient. The Na^+-K^+-adenosine triphosphate pump restores both ions to their initial intracellular and extracellular concentrations. Na^+ channels in the nerve are characterized as voltage gated.

Local anesthetics prevent the generation and conduction of nerve impulses by binding to the α subunit of the Na^+ channel and preventing the influx of Na^+ into the cell, halting the transmission of the advancing wave of depolarization down the length of the nerve. The electrical gradient generated across the nerve membrane is initiated at the outermost surface of the nerve (mantle) and continues toward the center of the nerve (core). The outer surface is responsible for innervating the proximal structures, whereas the core is responsible for innervating distal structures. Consequently, the more proximal anatomic structures are blocked first, and blockage evolves from proximal to distal structures.

Structure and General Properties of Local Anesthetics

The local anesthetic molecule consists of three structural domains: a lipophilic aromatic ring, intermediate ester or amide chain, and terminal amine (Figure 15-1). The nature of the domains determines the pharmacologic properties of local anesthetic agents. The physicochemical properties of these agents largely influence their potency and duration of action.

The aromatic ring improves the lipid solubility of the compound, thus enhancing diffusion through nerve sheaths and nerve membranes. This property correlates with *potency* because a greater portion of an administered dose can enter neurons. Potency is a comparative term that estimates the effective amount of one drug relative to another (Table 15-1). Because bupivacaine is more lipid soluble than lidocaine, it is more potent and only a 0.5% solution (5mg/mL) is required to obtain a comparable local anesthesia to a 2% solution (20mg/mL). Unfortunately, greater lipid solubility increases toxicity, decreasing the therapeutic index.

The intermediate portion of the molecule affords the necessary spatial separation between the lipophilic and

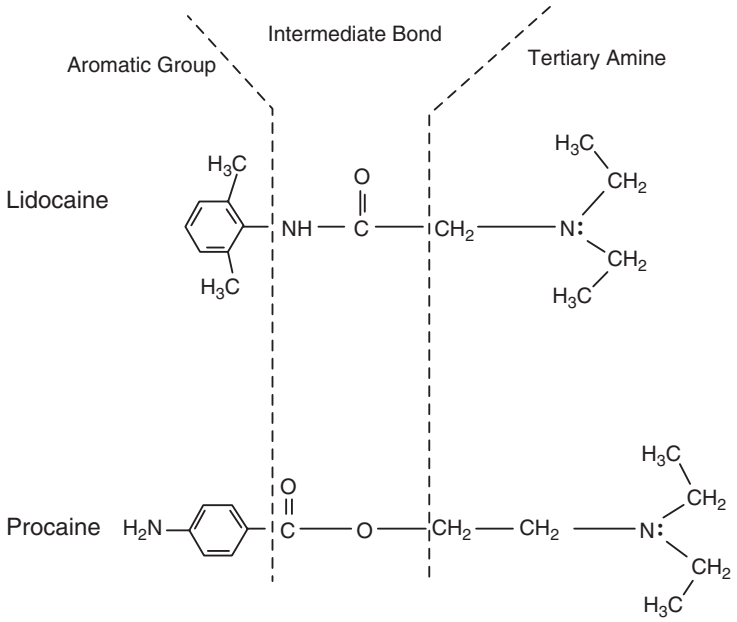

• **Figure 15-1** Lidocaine is the prototypical aminoamide. Procaine is the prototypical aminoester. (From Giovannitti JA, Rosenberg MB: Pharmacology of local anesthetics used in oral surgery, *Oral Maxillofacial Surg Clin N Am* 25:453-465, 2013.)

TABLE 15-1 Relationship between Lipid Solubility and Local Anesthetic Concentration

Drug	Lipid Solubility	Concentration
Articaine	40	4%
Mepivacaine	42	2%-4%
Prilocaine	55	4%
Lidocaine	110	2%
Bupivacaine	560	0.5%

Source: Jastak JT, et al: *Local anesthesia of the oral cavity*, Philadelphia, 1995, Saunders.

hydrophilic portions and divides local anesthetics into two distinct chemical classes: the esters (-COO^-) and the amides (-$NHCO^-$). Esters are primarily metabolized in the plasma by pseudocholinesterases. *para*-Aminobenzoic acid (PABA) is a by-product of this metabolic process and has been implicated in allergic responses by a small portion of the population. Amides are metabolized primarily in the liver and possess a lower risk of allergic reactions. Methylparaben, a chemical preservative structurally related to PABA, has been removed from dental cartridges after it was discovered to produce allergic reactions in some patients. Methylparaben can still be found in multidose vials.

The terminal amine exists in a tertiary form that is lipid soluble or as a quaternary form that is positively charged and renders the molecule water soluble. The terminal amine acts to allow the anesthetic to exist in either lipid-soluble or water-soluble conformations, which plays a pivotal role in the initiation of a conduction block. Once injected into tissue, the local anesthetics exist in both an ionized and a nonionized form. The coexistence of the two forms of the drug is important because drug penetration of the nerve membrane by the local anesthetic requires the base (unionized) form to pass through the nerve lipid membrane; once in the axoplasm of the nerve, the base form can accept a hydrogen ion and equilibrate into the ionized form. While in the nerve axon, the ionized form is predominant and produces a blockade of the Na^+ channel.

The pK_a generally correlates with the *speed of onset* of action of most amide local anesthetic drugs; the closer the pK_a of a local anesthetic to the pH of tissue (7.4), the faster the onset. The pK_a (the pH at which 50% of the drug is ionized and 50% is unionized) of the local anesthetic is related to pH and the concentrations of the cationic and base forms by the Henderson-Hasselbalch equation: $pH = pK_a + \log([\text{base}]/[\text{cation}])$. Local anesthetics are weak bases with a pK_a range of 7.7 to 8.9 (Table 15-2). When the local anesthetic is injected into an inflamed or acidic environment, the more hydrophilic portion of the drug will be preponderant, resulting in decreased neuronal penetration and potency. At physiologic pH of 7.4 or higher, local anesthetics with a lower pK_a, such as mepivacaine, lidocaine, and prilocaine, will have a higher percentage of their free base available for neuronal diffusion. Local anesthetics are typically manufactured as an acidic hydrochloride salt, with a pH ranging from 3.5 to 6.0. This improves the water solubility of the local anesthetic and stabilizes the vasoconstrictor. Because of the low pH, approximately 99% of local anesthetic will carry a positive charge. As a result of the buffering capacity of the soft tissue, it is only after injection that local anesthetic is converted into the free base form, capable of penetrating the nerve sheaths.

TABLE 15-2 Relationship between pK_a, Ionization, and Local Anesthetic Onset at a pH of 7

Drug	pK_a	% Cationic	% Free Base	Onset Time (min)
Mepivacaine	7.7	67	33	2-4
Lidocaine	7.8	71	29	2-4
Prilocaine	7.8	71	29	2-4
Articaine	7.8	71	29	2-4
Etidocaine	7.9	76	24	2-4
Bupivacaine	8.1	83	17	5-8
Propoxycaine	8.9	97	3	9-14
Procaine	8.9	97	3	14-18

Sources: Jastak JT, et al: *Local anesthesia of the oral cavity*, Philadelphia, 1995, Saunders; Malamed SF: *Handbook of local anesthesia*, ed 6, St Louis, 2014, Mosby.

Efficacy and Duration of Action of Local Anesthetics

Various factors influence the efficacy and duration of local anesthetic action. Of paramount importance is accurate anatomic placement of the local anesthetic in the vicinity of the desired nerve. This is especially true of the mandibular nerve, which has been shown to possess many accessory branches.[4,5] The second factor has to do with the actual chemical makeup of the local anesthetic. Properties such as the solubility of the local anesthetic into the nerve sheath or the presence or absence of a vasoconstrictor, along with the intrinsic activity of the local anesthetic, can make a difference in the efficacy and duration of action.

Local anesthetics can be used in three modes: topical application, local infiltration, and nerve blockade. A mixed peripheral nerve or nerve trunk consists of individual nerves surrounded by an investing epineurium. When a local anesthetic is deposited in proximity to a peripheral nerve, it diffuses from the outer surface toward the core along a concentration gradient. Nerves located in the outer mantle of the mixed nerve are blocked first, and the local anesthetic eventually diffuses inward to block the more centrally located fibers. In this way, the block evolves from proximal structures to distal structures.

The differential rate of blockade exhibited by fibers of varying sizes and firing rates is of considerable practical importance. The sensation of pain is usually the first modality to disappear; it is followed by the loss of sensations of cold, warmth, touch, deep pressure, and, finally, loss of motor function, although variation exists among patients and different nerves (Table 15-3).

Duration of Blockade/Protein Binding

The duration of nerve block anesthesia depends on the physical characteristics of the local anesthetics and the presence or absence of vasoconstrictors. Local anesthetics are in large part bound to plasma and tissue proteins. The most important binding proteins for local anesthetics in plasma are albumin and alpha1-acid glycoprotein (AAG), with local anesthetics binding to AAG preferentially compared with albumin. This property of protein binding correlated with their affinity for protein within sodium channels predicts how long they will sustain neural blockade.

Note that the fraction of drugs bound to protein in plasma correlates with the duration of local anesthetic activity: bupivacaine > etidocaine > mepivacaine > lidocaine > procaine. However, no direct relationship exists between local anesthetics plasma protein binding and binding to specific membrane-bound Na^+ channels. Rather, there is a direct correlation between protein binding and lipid solubility, as there is for all drugs. The more lipid soluble the drug, the more likely it will remain in the lipid-rich environment of the axonal membrane where the Na^+ channel resides.

In general, local anesthetics can be divided into three categories: short acting, intermediate duration, and long acting. The degree of block prolongation with the addition of a vasoconstrictor appears to be related to the intrinsic vasodilatory properties of the local anesthetic. As a general rule, the duration of anesthesia in soft tissues lasts longer than pulpal anesthesia by a factor of 2 to 3.7.[6-8] Table 15-4 displays the more commonly used dental anesthetic cartridges. For the listed local anesthetics, there is a range of maximum dosage recommendations, with the number in parenthesis based on Malamed's more conservative guidelines. The higher numbers are based on the package inserts and Jastak and colleagues.

Long-acting local anesthetics, such as bupivacaine, are highly lipid soluble and bind more tightly to protein and lipid structures within the nerve membrane than other local anesthetics.[6,9,10] When administered via mandibular block, these long-acting anesthetics with 1:200,000 epinephrine possess a longer duration of pulpal anesthesia than other marketed anesthetic solutions.[11,12] However, several studies of infiltrative or PDL injections of bupivacaine with 1:200,000 epinephrine show that in the maxilla, the pulpal anesthesia duration is not longer, and in some cases is even shorter, than the duration of 2% lidocaine with 1:100,000 epinephrine.[13,14] With a variety of local anesthetics to choose from, the local anesthetic should be tailored to the duration of the surgical procedure, need for hemostasis, and anticipated degree of pain.

Use of Vasoconstrictors

Vasopressors are combined with local anesthetics to provide local hemostasis in the operative field and to delay their absorption. Delayed absorption of local anesthetics not only reduces the risk for systemic toxicity, but also prolongs the duration of anesthesia.

Today the two most common vasoconstrictors used in dental anesthetic solutions in the United States are epinephrine and levonordefrin. Local anesthetics containing

TABLE 15-3 Nerve Fiber Types and Nerve Blocking

Neuron Type	Function	Myelination	Diameter (μm)	Order of Blockage—Signs
A alpha	Motor, proprioception	Myelinated	12-20	5th—Loss of motor function
A beta	Sensory—touch, pressure	Myelinated	5-12	4th—Loss of sensation to touch and pressure
A gamma	Motor—muscle spindles	Myelinated	3-6	3rd—Loss of proprioception
A delta	Fast pain, temperature	Myelinated	2-5	2nd—Pain relief, loss of temperature sensation
B	Autonomic, preganglionic sympathetic	Myelinated	<3	1st—Increased skin temperature
C	Slow pain, polymodal nociceptors	Unmyelinated	0.4-12	2nd—Pain relief

References 17, 21, 29, 30, 39, 42.

TABLE 15-4 Injectable Local Anesthetics

Anesthetic		Duration in Minutes: Maxillary Infiltration Pulp	Maxillary Infiltration Soft Tissue	Mandibular Block Pulp	Mandibular Block Soft Tissue	Maximum Dosage mg/kg	Maximum Dosage mg/lb	Maximum Total Dosage (mg)
Lidocaine	2% plain	5	60	10	120	4.5	2.0	300
	2% + 1:50,000 epinephrine	60	180	90	240	7.0 (4.5)	3.18 (2.0)	500 (200)*
	2% +1:100,000 epinephrine	60	180	85	240	7.0 (4.5)	3.18 (2.0)	500 (300)
Mepivacaine	3% plain	20	120	120	180	6.6 (4.5)	42.2 (2.0)	400 (300)
	2% + 1:100,000 epinephrine	60	170	170	190	6.6 (4.5)	2.2 (2.0)	400 (300)
	2% + 1:20,000 levonordefrin	45	120	120	240	6.6 (4.5)	2.2 (2.0)	400 (300)
Articaine	4% + 1:100,000 epinephrine	60	180	75	360	7.0 [5.0]†	3.2 [2.72]†	500 [144]†
	4% + 1:200,000 epinephrine	45	120	60	300	7.0 [5.0]†	3.2 [2.72]†	500 [144]†
Prilocaine	4% plain	20	105	60	240	8.0 (6.0)	3.64 (2.7)	600 (400)
	4% + 1:200,000 epinephrine	45	120	90	240	8.0 (6.0)	3.64 (2.7)	600 (400)
Bupivacaine	0.5% +1:200,000 epinephrine	45	240	240	540	1.3	0.6	90

*Based on the 200 mg of epinephrine limit.
†Represents maximum recommended dose in children ≤30 kg or ≤13.6 lb.

norepinephrine (NE) are no longer manufactured in the United States, but continue to be used elsewhere in the world.[15] In general vasoconstrictors are classified as adrenergic or sympathomimetic because they are, or closely resemble, the natural mediators of the sympathetic nervous system and are classified as catecholamines.[2,8,16]

The adrenergic system is composed of both α and β receptors. Each receptor type is further subdivided into α_1 or α_2 and β_1 or β_2. For the most part, the β-adrenergic system is mostly systemic, whereas the ? -adrenergic system is mainly peripheral with less systemic action.[17] The main action of the β_1 receptor is at the heart, where its activation increases heart rate and automaticity of the heart via the sinoatrial node, along with increasing contractility and conduction of the heart. β_2 receptors are located in the vascular beds of skeletal muscles and pulmonary vasculature. Their activation leads to vasodilation or relaxation of the trachea and bronchioles. On the other hand, α_1 receptors are found in the peripheral vasculature and cause severe vasoconstriction of the peripheral arterioles and veins on stimulation. Last, the stimulation of α_2 receptors, which are mostly found in the central nervous system (CNS), leads to decreased sympathetic outflow from the brain and a decrease in the release of NE from the presynaptic neurons.

The physiologic result of β_1 stimulation is an increase in blood pressure, whereas the stimulation of β_2 receptors tends to decrease blood pressure.[2,8,18] The α receptors mainly cause vasoconstriction at the peripheral circulation, skin, and mucous membranes, with a nominal increase in the blood pressure.[17,18]

When examining the actions of catecholamines, subtle differences are noted. Table 15-5 shows that epinephrine is the most potent with respect to α receptor stimulation, as compared with NE, levonordefrin, and phenylephrine. NE

stimulates the β_1 receptor preferentially over β_2, therefore causing an increase in blood pressure when used as a vasoconstrictor in local anesthetic. On the other hand, epinephrine has an equal affinity for both α and β receptors, causing no dramatic increases in blood pressure as a result of β2 vasodilation.[17] The vasodilatory β_2 receptors are believed to be more sensitive to low blood levels of epinephrine than are the vasoconstrictive α_1 receptors. This explains why small doses of epinephrine often increase heart rate and systolic blood pressure yet actually reduce diastolic blood pressure, with the mean arterial pressure (MAP) remaining unchanged.[2,8,19]

As a result of systemic side effects, NE was removed from most local anesthetic formulations in the United States.[20,21] Levonordefrin, which is the least potent of the catecholamines, is most similar to NE, possessing less α_1 but slightly more β_2 action. It is still available in a 1:20,000 solution (0.05 mg/mL). At low blood levels, its pressor effects closely resemble those of NE.[2,8,16,22] Even though NE and levonordefrin have less α_1 activity, one might think that they would be preferred over epinephrine in patients with heart disease. On the contrary—with the preservation of the patient's ability to increase their peripheral vascular resistance, more stress can be placed on the heart when NE or levonordefrin is given.[18] Hence patients with documented hypertension should not receive NE or levonordefrin because both will exert unrestricted activation of α_1 receptors, which could lead to uncontrolled increases in blood pressure. This is especially true in patients with severe, uncontrolled hypertension; refractory arrhythmia, myocardial infarction, or stroke within 6 months; uncontrolled congestive heart failure; and uncontrolled hyperthyroidism.[23]

Potential Benefits of Vasoconstrictors

The use of vasoconstrictors decreases the clearance of the local anesthetic, reduces the total required amount, increases the duration and depth of anesthesia, and aids in hemostasis of the surgical wound. Studies show that with the presence of a vasoconstrictor there is a delay and a reduction in the peak blood levels of the local anesthetic.[6,16,18,22,24,25] This is of importance because excessive blood levels of local anesthetics are known to cause systemic toxicity, especially in the pediatric dental population.[6,8,26,27]

In addition, local anesthetics, especially lidocaine, inherently cause vasodilation, further strengthening the need for vasoconstrictors. Experiments show that with the addition of vasoconstrictors, the duration of action of all local anesthetics is prolonged. This is especially true with lidocaine compared to mepivacaine or prilocaine. As shown in Table 15-4, 2% plain lidocaine possesses a pulpal anesthesia of about 5 to 10 minutes. With the addition of 1:100,000 epinephrine, the duration is increased tenfold to approximately 60 minutes. This increase in the duration of action is less dramatic with bupivacaine, possibly as a result of its higher lipophilic properties.[8,18,28]

TABLE 15-5 Vasoconstrictor Selectivity and Potency

Vasoconstrictor	β_1 Selectivity	β_2 Selectivity	Relative α Potency
Epinephrine	50%	50%	100%
Norepinephrine	85%	15%	25%
Levonordefrin	75%	25%	15%
Phenylephrine	95%	5%	5%

Source: Henslee TM et al: Vasoconstrictive agents commonly used in combination with local anesthetics: a literature review, *J Foot Surg* 26(6):504-510, 1987.

The presence of vasoconstrictor also seems to be beneficial in patients with cardiovascular disease because it reduces the release of reactionary endogenous NE.[29,30] Dental anxiety, fear, anesthesia, and surgery are all accompanied by physiologic, psychological, and biochemical changes. Physiologically, this translates into changes in the heart rate and blood pressure, cardiac arrhythmias, and release of endogenous catecholamines. Multiple studies show that in dental treatment, even with adequate anesthesia, there are increased levels of endogenous catecholamines. In turn, significant increases in blood pressure can be seen, leading to adverse reactions.[31,32,33]

It is generally agreed that the concentration of vasoconstrictors needs to be somewhere between 1:100,000 and 1:200,000 to improve duration of action.[16,22] Higher concentrations do not provide better onset or duration for inferior alveolar nerve block[34,35] or reduce local anesthetic serum concentrations.[36] However, greater concentrations may provide better hemostasis at the surgical site when this influence is desired. In one third molar study, there was a 50% reduction in blood loss with the use of 2% lidocaine plus 1:100,000 epinephrine versus 3% plain mepivacaine.[37] Hemostasis also lends itself to a more visible surgical field and decrease in the risk of aspiration of blood, especially during intraoral procedures. It is important to note that the optimum concentration of local anesthetic needed for adequate hemostasis is specific to each local anesthetic. Studies clearly indicated lidocaine with a concentration of 1:50,000 epinephrine is more effective than the less concentrated solutions of 1:200,000.[18,38] Along the same lines, 1:200,000 mixture of epinephrine seems to impart adequate hemostasis when used with prilocaine and bupivacaine.[8,18]

Potential Systemic Side Effects of Vasoconstrictors

Even though vasoconstrictors reduce systemic absorption of the local anesthetic, there is still systemic absorption of the vasoconstrictor itself, especially if there is an inadvertent intravascular injection.[19,39-44] There is continued debate regarding deleterious influences of vasopressors on patients with cardiovascular disease. Clinical trials have confirmed

unequivocally that even small doses of epinephrine in local anesthetic solutions have an influence on cardiovascular function. Dionne and colleagues[45] studied the influence of three cartridges of 2% lidocaine with 1:100,000 epinephrine. Submucosal injection of this dose increased cardiac output, heart rate, and stroke volume. Peripheral resistance was reduced, and mean arterial pressure remained essentially unchanged. The issue we must address is whether these influences pose a significant risk to patients with cardiovascular diseases. Putative standards and guidelines continue to be presented but in fact are all anecdotal. Ultimately, the decision requires the surgeon to exercise sound clinical judgment based on a thorough analysis of each patient under consideration.

In the event that vasoconstrictors cannot be used, 2% to 3% mepivacaine or 4% prilocaine are the two dental local anesthetics that can provide acceptable pulpal anesthesia without the use of vasoconstrictors.

Potential Drug-Drug Interaction with Vasoconstrictors

Drug-drug interaction with vasoconstrictors is one area that continues to evolve. Misconceptions regarding adverse interactions between vasoconstrictors and antidepressants persist despite literature that dispels this concern.[46] The concerns are related to pharmacokinetic interactions predicated on clearance of catecholamines. Although neuronal uptake is the principal method for termination of endogenous adrenergic neurotransmitters, hepatic biotransformation is the principal pathway for termination of exogenously administered adrenergic drugs.[47] Most noncatecholamines are metabolized in liver by monoamine oxidase, but those having a catecholamine structure are primarily inactivated by catechol-*O*-methyltransferase. Epinephrine and levonordefrin are catecholamines and are metabolized primarily by catechol-*O*-methyltransferase, not monoamine oxidase or neuronaluptake.[47,48] Patients treated with monoamine oxidase inhibitors are not hindered in clearing either of these vasopressors.[49] Newer antidepressants (e.g., fluoxetine [Prozac]) selectively inhibit serotonin reuptake and likewise are not a concern.

With regard to tricyclic antidepressants, this particular class of antidepressants has an ability to produce cardiac arrhythmias, which could be potentiated by a similar tendency shared by all sympathomimetic agents. For these patients, vital signs should be monitored continually if more than one or two cartridges containing any vasopressor are used.

The contaminant use of antihypertensive medications with vasoconstrictors has always been a critical question on the minds of many dentists. For this reason, in 1955 the American Heart Association addressed this topic by issuing a statement that recommended a maximum of 200 µg of epinephrine be used during one dental appointment in patients with heart disease. That equals 11 cartridges of 1:100,000 epinephrine, which is slightly below the 13.9 cartridge limitation for local anesthetic toxicity.[50] Then, in a joint statement in 1964, the American Heart Association and the American Dental Association concluded, "Concentrations of vasoconstrictors normally used in dental local anesthetic solutions are not contraindicated in patients with cardiovascular disease when administered carefully and with preliminary aspiration."[51] Subsequently, recommendations were made to use 23- to 30-gauge needles for intraoral injections because of their ease in aspiration. Any needle smaller than a 30-gauge makes aspiration very difficult and unreliable.[30]

β-Blocking agents have been used for years to treat hypertension and other medical conditions, such as angina and cardiac arrhythmias. β-Blockers are typically classified as either "nonselective," with both β_1 and β_2 activity, or "selective," meaning that they preferentially block β_1 receptors in the heart. If a nonselective β-blocker is used, the β_2 vasodilatory effects of epinephrine will be blocked, allowing only α_1 vasoconstrictive effect. This may lead to a serious increase in blood pressure, with a concomitant reflex bradycardia.[2,6,8,52,53] For this reason, some advocate complete avoidance of vasoconstrictor-containing local anesthetic solutions in patients receiving nonselective β-blockers, especially if hemostasis is not required.[52,53] Others recommend checking for any significant change in blood pressure before the initiation of the procedure. This can be accomplished by initially injecting a 1-mL test dose of vasoconstrictor-containing solutions and monitoring blood pressure for 5 to 10 minutes to identify any adverse reaction.[6,8,52]

Finally, it appears that the administration of lidocaine in combination with a vasoconstrictor has a cardioprotective effect, thus justifying its limited use in patients with cardiovascular disease. Previous concerns about the safety and efficacy of vasoconstrictors have been reduced based on more recent prospective, blinded, randomized, human clinical trials. They speak to the safety of epinephrine as a local anesthetic vasoconstrictor.[17,21,29,30,39,42]

Patient Considerations and Maximum Dosages for Vasoconstrictors

Certain patient populations may have difficulty tolerating additional increases in systemic epinephrine levels. Most patients with cardiovascular disease would be expected to be prone to adverse effects from catecholamine administration. Yet conflicting data fail to consistently show the deleterious effects of local anesthetics with vasoconstrictors in patients with hypertension or cardiovascular disease. Recommendations from various authorities range from absolute avoidance of vasoconstrictors to a maximum dose of 200 µg set by the American Heart Association in 1955.[54] The dosages shown in Table 15-6 are recommended for healthy American Society of Anesthesiologists (ASA) class I patients, keeping in mind that the 1:50,000 concentration should be used only for local hemostasis and not routinely.[6,8] Yet even with these recommendations, one must realize the great variability that exists in this patient population, for there are no absolutes when it comes to patient stratification. Last but not least are the ASA class III and IV patients with unstable angina and poorly controlled ventricular arrhythmias who

require emergency treatment under local anesthesia.[18] In this patient population, elective surgery should be delayed until the underlying medical condition is brought under control. Box 15-1 lists a number of conditions in which it would be prudent to completely avoid the use of vasoconstrictors.[6,55,56] In 1986, a joint statement by the American Heart Association and the American Dental Association concluded that "vasoconstrictor agents should be used in local anesthesia solutions during dental practice only when it is clear the procedure will be shortened or the analgesia rendered more profound. Extreme care should be taken to avoid intravascular injection and the minimum possible amount of vasoconstrictor used."[57]

Complications of Local Anesthetics

Allergy to Local Anesthesia

It is common for patients to claim they are allergic to local anesthetics. However, with further questioning their experience was a syncopal episode associated with the injection or cardiac palpitations attributed to epinephrine either contained in the solution or released endogenously. Although rare, reports of allergic reactions to local anesthetics have appeared in scientific literature, but none of these have confirmed an IgE-mediated hypersensitivity reaction.[46] Reported cases in the literature are attributed to preservatives (methylparaben) or antioxidants (bisulfites) contained in the solution.[58] Methylparaben is included in multidose vials to prevent microbial growth and is no longer found in single-dose vials or dental cartridges. Metabisulfites prevent the oxidation of vasopressors and are included only in dental cartridges containing epinephrine or levonordefrin.

As described by Adkinson,[59] for drugs to be immunogenic, they must be of high molecular weight and possess multiple valences to be recognized by the immune cells. Molecules that are too small must combine with other molecules that act as carriers, in which case the drug is described as a hapten, and this can elicit an allergic reaction. Frequently a metabolite of the drug is the actual molecule that functions as the hapten. This moiety is common to other derivatives of PABA such as methylparaben and some, but not all, ester local anesthetics. In these cases there may be the potential for cross allergenicity among similar compounds because of a common moiety. Articaine is classified as an amide local anesthetic because of the linkage between its lipid-soluble ring and terminal amine. Its thiophene ring contains a sulfur atom, which has no immunogenic property, and an ester side chain that renders the compound inactive after hydrolysis. However, articaine does not liberate a metabolite resembling PABA and does not introduce concern regarding immunogenicity. In contrast, procaine is representative of esters derived from PABA, and hydrolysis liberates a moiety that is potentially immunogenic.

If a patient describes a reaction that is clinically consistent with allergy, avoid using the offending agent until the patient

• BOX 15-1 Conditions in Which the Use of Vasoconstriction Should Be Avoided or Minimized

Heart Diseases

Resting blood pressure >200/115 mm Hg
Unstable angina
Myocardial infarction (MI) within 6 mo
Cerebrovascular accident (CVA) within 6 mo
Coronary artery bypass graft (CABG) within 6 mo
Uncontrolled cardiac arrhythmias
Decompensated congestive heart failure (CHF)

Thyroid Disease

Untreated hyperthyroidism

Asthma

Sulfite-sensitive asthma
True allergy to sulfite antioxidant

Sources: Malamed SF: *Handbook of local anesthesia*, ed 6, St Louis, 2014, Mosby; Perusse R, Goulet JP, Turcotte JY: Contraindications to vasoconstrictors in dentistry: part I. Cardiovascular diseases, *Oral Surg Oral Med Oral Pathol* 74(5):679-686, 1992; Perusse R, Goulet JP, Turcotte JY: Contraindications to vasoconstrictors in dentistry: part II. Hyperthyroidism, diabetes, sulfite sensitivity, cortico-dependent asthma, and pheochromocytoma, *Oral Surg Oral Med Oral Pathol* 74(5):687-691, 1992.

TABLE 15-6 Maximum Recommended Dosages of Vasoconstrictors Derived from the 1955 American Heart Association Guidelines

Drug	Concentration		Maximum Recommended Dose		No. of Cartridges
	mg/mL	Parts/1000	mg	mL	
Epinephrine	0.02	1:50,000*	0.2	10	5
	0.01	1:100,000	0.2	20	11
	0.005	1:200,000	0.2	40	11†
Levonordefrin	0.05	1:20,000	1.0	20	11

From Use of epinephrine in connection with procaine in dental procedures: report of the special committee of the New York Heart Association, Inc. on the use of epinephrine in connection with procaine in dental procedures, *J Am Dent Assoc* 50:108, 1955.
*Should only be used for local hemostasis.
†Maximum number of cartridges is limited by the local anesthetic.

is evaluated by an allergist. In the event an anesthetic is required before medical clearance can be obtained, the wisest choice would be either mepivacaine or prilocaine without vasopressors.[46] Conventional wisdom holds that, if local anesthetics do indeed produce allergies, esters of PABA would be capable of cross-reacting, but this would not be likely among amide local anesthetics. Furthermore, by avoiding those solutions containing vasopressors, one avoids bisulfites that are included as antioxidants. Sensitivity to bisulfites is possible, especially among asthmatic or atopic patients.

Prolonged Sensory Alteration

In 1989 the Ontario (Canada) high court ruled that prolonged sensory alteration did not need to be an essential part of informed consent because the risk was so "infinitesimal, minimal, extremely small, or in order of magnitude 1:800,000."[60] Based on Dower's data analysis, the frequency of paresthesia is most common with articaine at 1:219,949 and least frequent with lidocaine at 1:4,405,130.[61] Even though the chance of prolonged sensory alteration is quite small, every clinician should try to prevent this outcome because each case can become a nuisance, not just for the patient but also for the clinician. Persistent sensory alteration is reportedly the most common reasons for lawsuits against oral and maxillofacial surgeons.[62]

Prolonged sensory alteration is defined as persistent anesthesia or altered sensation, such as itching or tingling, that persists well beyond the expected duration of anesthesia. It can also mean dysesthesia, painful sensation, or hyperesthesia. The most common complaints as a result of paresthesias are speech changes, loss of taste, and drooling, with the lingual nerve being the most common cause. Most of these are transient sensory alterations that resolve within 8 weeks, but they may also become irreversible.[60] If the damage to the nerve is more severe, the risk of permanent paresthesia is increased, most commonly involving the tongue, then the lower lip.[60] If the patient's neurodeficit persists beyond 2 months, he or she should be referred to an oral surgeon or a neurologist for consultation. In a study by Hillerup, third molar extractions accounted for the majority of injuries to the lingual, inferior alveolar, and buccal nerves. The injection of local anesthetics was the second most frequent cause. In the same study, the female gender was overrepresented in incidence of injured nerves, although no gender difference was found in the severity of paresthesias.[63,64]

Although it is known that the most frequent cause of prolonged sensory alteration is direct surgical trauma,[65-67] studies show that the local anesthetic itself can be a source of nerve trauma. In a 21-year retrospective study in Ontario, Canada, Haas and Lennon demonstrated in nonsurgical extractions cases that 4% articaine and 4% prilocaine were significantly more likely to cause prolonged neurologic deficits than were other local anesthetic solutions.[60] It should be noted that both articaine and prilocaine are marketed as 4% solutions, the highest concentrations available in dentistry. All reported cases involved anesthesia of the mandibular arch, with symptomatic tongue or the lip. Articaine was the offending anesthetic in 49% of cases, prilocaine in 42.2%, lidocaine in 4.9%, and mepivacaine in 3.9%. Table 15-7 indicates that 4% articaine is 20 times more likely to cause prolonged sensory alteration than is 2% lidocaine.[60] This claim has been further strengthened by another study in Denmark where 54% of nerve injuries were associated with 4% articaine, a substantial increase in the number of injuries after its introduction in the Danish market.[64]

Based on all the reported data, nerve damage seems to be concentration dependent, which would explain the increase in paresthesia cases. Yet contradictory results were obtained by Hoffmeister, who studied direct nerve injury caused by toxicity. He noted no histologic changes with intrafascicular administration of articaine, claiming that "when used in normal concentrations, local anesthesia does not have a toxic effect."[68] The jury is still out on this issue, requiring further investigation into this matter before making any definitive conclusions. For this reason, some recommend 4% articaine and 4% prilocaine only be used for infiltrative anesthesia and not for inferior alveolar nerve blocks.[69] The package insert from the articaine manufacturers puts the overall rate below 1%, based on clinical trials in the United States and United Kingdom.[70]

In terms of direct injury to the lingual or inferior alveolar nerve, the neurovascular bundle can be traumatized by the sharp needle tip.[60,65-67] Using the "traditional" inferior alveolar block, otherwise known as the Halstead approach, local anesthetic is deposited near the mandibular foramen. Coincidentally, the lingual nerve is directly in the path of needle insertion. Furthermore, with the mouth wide open during the injection, the lingual nerve becomes more taut, reducing its chance of being deflected by the searing needle. This will lead to a greater likelihood that the needle will penetrate the nerve potentially (1) severing nerve fiber; (2) damaging small blood vessels located within the epineurium

TABLE 15-7 Distribution of Analgesic Solution and Nerve Affected Including 54 Nerve Injuries in 52 Patients

Local Anesthetic	Inferior Alveolar Nerve	Lingual Nerve	Sum N (%)
Articaine 4%	5	24	29 (54%)
Prilocaine 3%	4	6	10 (19%)
Lidocaine 2%	3	7	10 (19%)
Mepivacaine 3%	0	4	4 (7%)
Mepivacaine 3% + Articaine 4%	0	1	1 (2%)
Number of nerve injuries	12	42	54 (100%)

From Hillerup S, Jensen R: Nerve injury caused by mandibular block analgesia, *Int J Oral Maxillofac Surg* 35(5):437-443, 2006.

and leading to intraneural hemorrhage; or (3) damaging connective tissues within the nerve via edema. All three events can lead to prolonged sensory alteration, which may be transient or permanent.

Trismus

Trismus is a relatively uncommon complication after local anesthetic injection. It may be due to injury, spasm, or infection within the medial pterygoid muscle, which is typically violated during an inferior alveolar nerve block. This can be prevented by following the basics of atraumatic injection technique.[6] With application of hot, moist towels to the affected side, in conjunction with range-of-motion exercises, improvement should be noted in about 2 to 3 days.

Hematoma

This is typically seen right after the injection as a localized mass of extravasated blood that follows inadvertent injury to the underlying blood vessels. Vessels most commonly involved are the pterygoid plexus of veins, the posterior superior vessels, and the mental vessels.[71] Prevention is the best measure, by reducing the number of times the mucosa is penetrated. If a visible hematoma develops, apply direct pressure. Ice can be applied immediately to the area to minimize pain and potentially reduce the size of the hematoma by vasoconstriction. Heat can be applied the following day to vasodilate the area and carry blood products away. Analgesics may be indicated. Inform the patient that the hematoma should slowly resolve over 1 to 2 weeks. The patient should expect discoloration in the area during this time, and should return for evaluation with any concerns for increasing size. Document hematoma occurrence and follow-up findings in the patient's record.

Pain on Injection

This is most often due to the speed of local anesthetic delivery. If the solution is injected too quickly, it distends the tissue rapidly, causing a painful stimulus. Furthermore, if the temperature of the anesthetic is too high or too low, more pain will be sensed. According to Malamed, each cartridge should be injected over a 1-minute period, and the anesthetics should be stored at room temperature.[30]

Needle Breakage

Although uncommon, a sudden unexpected movement from the patient or a bent needle can lead to needle breakage, which most commonly occurs at the hub. As expected, smaller-diameter needles, such as 30-gauge needles, tend to break more often than larger-bore needles of 25 gauge or higher. To prevent this complication, the following are recommended: The needle should not be bent more than once, never insert the needle up to its hub, and do not apply excessive force or redirect the needle once within the soft tissue. If breakage occurs, inform the patient and document the event. Refer the patient to an oral and maxillofacial surgeon with all the pertinent radiographic images and documentation for prompt retrieval of the foreign object.[71]

Facial Nerve Paralysis

Because the facial nerve (CN VII) traverses the parotid capsule, it is not surprising that transient paralysis can occur if the local anesthetic is deposited within the parotid capsule. Again prevention is the best medicine, paying attention to the direction and depth of the needle. If facial paralysis occurs, reassure the patient, create an eye patch to protect the cornea, and have the patient remove contact lenses if indicated. Eye drops may also be indicated. Return of function will occur within a few hours, depending on the type of local anesthetic used.

Systemic Complications from Local Anesthesia

As the injected local anesthetic diffuses away from the site of injection, it is systemically distributed and absorbed by the internal organs for metabolism and excretion. The typical doses of local anesthetic used in dentistry are minimal, and therefore systemic effects tend to be uncommon. However, in susceptible patients with repeated injections over the recommended limits, systemic overdoses and even death have occurred. The initial sign of a systemic overdose may be muscle twitching, tremors, shivering, or even tonic-clonic seizures.[72] This excitatory reaction is thought to be due to the disinhibition of select inhibitory neurons within the limbic system of the CNS. As the toxic blood concentrations continue to rise, drowsiness, lethargy, sedation, and respiratory depression will follow. Eventually, with extremely toxic levels, cardiovascular conductivity will be disrupted, leading to cardiac arrhythmia and bradycardia.

Long-acting local anesthetics, bupivacaine and etidocaine, are known to possess a greater risk of cardiotoxic events than do other local anesthetics.[8,27,73] Bupivacaine's cardiotoxic property is related to its ability to produce a dose-dependent or high-frequency blockade at normal heart rates. The treatment of these types of toxic events is largely supportive, making prevention the first and foremost strategy in avoiding systemic toxicities. The local anesthetic dosing guidelines are typically based on body weight, and because of this, children tend to be at greater risk for toxic reactions. True dose-dependent toxicities to local anesthetics are reported in the pediatric population.[74] Because local anesthetics have a relatively narrow therapeutic index, most overdoses in children are seen with formulations greater than the 2% concentrations without epinephrine.[30,75] This is commonly seen in children receiving plain 3% mepivacaine or 2% lidocaine with 1:100,000 epinephrine, without any regard for maximum dosing guidelines.[75-79a]

Methemoglobinemia is another unique reaction that can be seen with the use of local anesthetics. It typically occurs 1 to 3 hours after the administration of the local anesthetic. Other medications, such as nitrates and sulfonamide antibiotics, can also act as the initiating factor. In terms of local anesthetics, prilocaine is thought to cause oxidation of the iron atom in hemoglobin from the reduced Fe^{2+} state to the oxidized Fe^{3+} state, leading to a deficient oxygen transport phenomenon characterized by a cyanotic-appearing patient.[8] The clinical signs of cyanosis are initially noted as the level of methemoglobin reaches 10% to 20%. With an increase in the level nearing 35% to 40%, dyspnea and tachycardia will ensue. Fortunately, in patients without significant cardiovascular or pulmonary disease, this reaction is well tolerated. However, in pediatric patients and patients with hereditary methemoglobinemia who already have a portion of their hemoglobin in the Fe^{3+} state, small quantities of prilocaine can cause a serious reaction. Other risk factors for this reaction include patients with glucose-6-phosphate dehydrogenase and methemoglobin reductase deficiency. In these patient populations, an alternative local anesthetic solution should be used. If a patient becomes cyanotic, treat appropriately with intravenous methylene blue (1 to 2 mg/kg).

Table 15-4 lists the maximum recommended dosages of various local anesthetic solutions. Because these dosages are based on a patient's body weight, a 14-kg pediatric patient can theoretically tolerate only one fifth of the local anesthetic given to a 70-kg or greater adult patient. It is important to realize the local anesthetic agent being used, percentage, and presence or absence of a vasoconstrictor to avoid toxic dosing. Studies have failed to show that 3% mepivacaine produces a shorter duration of lip and tongue anesthesia than an equal volume of 2% lidocaine plus 1:100,000 epinephrine. For this reason, the use of 3% mepivacaine and 4% prilocaine should be avoided in young children. Note that in very obese children, the maximum dose should be calculated using the ideal body weight and not the true body weight.

Local Anesthetic Comparisons

As previously mentioned, local anesthetic drugs are classified as esters or amides (see Figure 15-1). Esters are no longer packaged in dental cartridges and are used infrequently in comparison to amide local anesthetics.

Ester-Linked Local Anesthetics

Ester-linked local anesthetics are hydrolyzed at the ester linkage in plasma by pseudocholinesterase. The rate of hydrolysis of ester-linked local anesthetics depends on the type and location of the substitution in the aromatic ring. However, the rate of hydrolysis of all ester-linked local anesthetics is markedly decreased in patients with atypical plasma pseudocholinesterase. Another hallmark of metabolism of ester-linked local anesthetics is that their hydrolysis leads to the formation of PABA. PABA and its derivatives carry a small risk potential for allergic reactions as discussed earlier.

Cocaine

Cocaine occurs naturally in the leaves of the coca shrub and is an ester of benzoic acid. The clinically desired actions of cocaine are blockade of nerve impulses and local vasoconstriction secondary to inhibition of local norepinephrine reuptake. However, its toxicity and the potential for abuse have precluded wider clinical use of cocaine in modern practice. Its euphoric properties are due primarily to inhibition of catecholamine uptake, particularly dopamine, at CNS synapses. Cocaine is unique in that it is the only local anesthetic to cause vasoconstriction. Currently, cocaine is used primarily to provide topical anesthesia of the upper respiratory tract, where its combined vasoconstrictor and local anesthetic properties provide anesthesia and shrinking of the mucosa with a single agent.

Procaine

Procaine, an amino ester, was the first synthetic local anesthetic. Procaine is characterized by low potency, slow onset, and short duration of action. Consequently, although it was once widely used, its popularity declined after the introduction of lidocaine, and it is no longer used in dentistry.

Benzocaine

Benzocaine is commonly used for topical pain relief. Benzocaine is poorly water soluble, making it the drug of choice for anesthetizing mucosal surfaces because it is not absorbed systemically. In spite of this, benzocaine is not totally innocuous, as evidenced by case reports of methemoglobinemia in children who received large doses.[80] Methemoglobinemia is more likely to occur with benzocaine in patients with predisposing conditions, such as glucose-6-phosphate dehydrogenase deficiency or concurrent use of medications that cause methemoglobin. As mentioned earlier, if a patient becomes cyanotic, treat appropriately with intravenous methylene blue (1 to 2 mg/kg), if medically indicated. A 20% ointment is typically sufficient at the mucosal surface and will reduce needlestick pain. Its onset and duration characteristics are similar to those of 5% lidocaine ointment, with the onset typically between 2 to 3 minutes and a duration of 15 minutes.

Tetracaine

Tetracaine is an ester local anesthetic that is highly lipid soluble and rapidly absorbed when placed on mucous membranes. It is the most potent topical anesthetic and thus the most toxic. It is typically sold in a spray form, composed of 14% benzocaine, 2% butyl aminobenzoate, and 2% tetracaine and sold under the name Cetacaine. It is indicated for the production of anesthesia and control of pain at all accessible mucous membranes except the eyes.

It has been used to control gagging during endoscopy and other surgical procedures of the ear, nose, mouth, pharynx, larynx, trachea, bronchi, and esophagus.[30] Because of its rapid absorption and toxic potential, the maximum recommended dose for an adult is only 20 mg. Care should be taken not to exceed the "2-second spray" rule. Average expulsion rate of residue from spray, at normal temperatures, has been calculated at 200 mg/sec. On rare occasions, methemoglobinemia has been reported in connection with Cetacaine as a result of the presence of benzocaine. Injudicious administration, especially in the form of unmetered sprays for widespread surface anesthesia or to reduce the gagging reflex, can lead to serious toxicity; fatalities have been reported.[8] Remember that the onset of action is rapid, approximately 30 seconds, and the duration of anesthesia is typically 30 to 60 minutes.

Amide-Linked Local Anesthetics

As opposed to ester-linked drugs, amide-linked local anesthetics are metabolized in the liver by a dealkalization reaction in which an ethyl group is cleaved from the tertiary amine. The hepatic blood flow and liver function determine the hepatic clearance of these anesthetics. Consequently, factors that decrease hepatic blood flow or hepatic drug extraction both result in an increased elimination half-life. Renal clearance of unchanged local anesthetics is a minor route of elimination, accounting for only 3% to 5% of the total drug administered.

Lidocaine

Lidocaine was introduced in 1948 by the Swedish drug manufacturer Astra, and it remains the most versatile and widely used local anesthetic. Lidocaine can be used in almost any peripheral nerve block in which a local anesthetic of intermediate duration is needed. A concentration of 1% or 2% with or without the addition of epinephrine is most commonly used for surgical anesthesia. Two percent lidocaine with 1:100,000 epinephrine is the most commonly used dental anesthetic.

Mepivacaine

Mepivacaine, introduced in 1957, is an intermediate-duration amino amide local anesthetic. Pharmacologic properties are similar to those of lidocaine. Mepivacaine, as well as prilocaine, has less vasodilatory activity than lidocaine.[6] Solutions of 3% mepivacaine in the absence of a vasoconstrictor can produce pulpal anesthetic durations in the 20- to 55-minute range, which makes mepivacaine ideal in a patient who cannot tolerate epinephrine.

Prilocaine

Prilocaine is an intermediate-duration amino amide local anesthetic with a pharmacologic profile similar to that of lidocaine. The primary differences are a lack of vasodilatation and an increased volume of distribution, which reduces its CNS toxicity. However, it is unique among amide local anesthetics for its propensity to cause methemoglobinemia, an effect of metabolism of the aromatic ring to *o*-toluidine. The development of methemoglobinemia depends on the total dose administered (usually requiring 8 mg/kg) and does not have significant consequences in healthy patients. If necessary, it is treated by intravenous administration of methylene blue (1 to 2 mg/kg).

Articaine

Articaine (Septocaine) is an intermediate-acting amide local anesthetic approved by the U.S. Food and Drug Administration (FDA) in 2000. Although articaine is classified as an amide because of linkage of its intermediate chain, the thiophene ring also contains an ester side chain. This chain is hydrolyzed by plasma esterases, rendering the molecule inactive. The result is that articaine has a half-life of only 20 minutes, compared with about 90 minutes for lidocaine and other amides that require hepatic clearance. It should be clarified that articaine is classified molecularly as an amide, not an ester. It does not produce a metabolite resembling PABA, reducing chance for allergic reactions. Despite anecdotal claims regarding the superiority of articaine, double-blind studies have confirmed that its efficacy is comparable with that of lidocaine.[81,82]

Bupivacaine

Bupivacaine was introduced in 1963 and has been one of the most commonly used local anesthetics in regional and infiltration anesthesia. Its structure is similar to that of lidocaine, except that the amine-containing group is a butylpiperidine. Bupivacaine is a long-acting agent capable of producing prolonged anesthesia and analgesia that can be prolonged even further by the addition of epinephrine. It is substantially more cardiotoxic than lidocaine. Bupivacaine is implicated as one of the more painful agents during injection.[83-85]

Special Considerations

Pregnancy

Most local anesthetics have not been shown to be teratogenic in humans and are considered relatively safe for use during pregnancy. The recommendation for caution (category C) label placed on mepivacaine and bupivacaine is related to limited data collected in animal teratogenicity studies. Therefore, adverse drug effects to humans cannot be ruled out for these agents. Because all local anesthetics can cross the placenta and cause fetal depression, limiting the dose to the minimum required for effective pain control is obviously advisable. Epinephrine, a naturally occurring hormone, is generally considered to have no teratogenic effects when administered with dental anesthetics.[86] Because epinephrine is known to stimulate cardiovascular function, administration demands careful technique to prevent intravascular injection and proper dosing.

New Developments and the Future of Local Anesthetics

There is a continual search to improve anesthetic products, create techniques, and provide alternative methods in an effort to alleviate patient anxiety and pain associated with receiving local anesthesia. This effort must also include the goal of providing a safe, reliable anesthetic in a predictable manner. Although some of these alternative methods have been on the market for some time, some still require further perfecting before it will be widely accepted by the provider. Following is a brief synopsis of these products and techniques and what to expect in the near future; it is not meant to be comprehensive.

Extended Release Formulations

Postsurgical pain relief with extended duration of action local anesthetics is a desirable goal. Exparel (bupivacaine liposome injectable suspension; Pacira Pharmaceuticals, Parsippany, NJ) was approved by the FDA in October 2011 as a single-use injectable agent providing long-acting pain relief in the postsurgical period. Multivesicular liposomes—microscopic spherical structures with an aqueous, bupivacaine-containing core encapsulated by a phospholipid bilayer—allow extended release of the drug over time through progressive breakdown of the lipid bilayer.[87,88] The efficacy of Exparel compared to placebo was evaluated in two multicenter, randomized, double-blinded clinical trials. Soft tissue (hemorrhoidectomy) and orthopedic (bunionectomy) studies were used as trials.[87,89,90] Both trials demonstrated a significant reduction in pain intensity compared to placebo up to 24 hours postoperatively.[89,90]

Intraosseous Anesthesia

Intraosseous anesthesia is useful for anesthetizing a single tooth by providing local anesthesia directly into the cancellous bone surrounding the root of the indicated tooth. Two such systems create a hole in the cortical bone, allowing for a smaller-circumference needle to penetrate the cancellous bone and provide local anesthetic to the indicated teeth. Each system offers both advantages and disadvantages. Stabident (Fairfax Dental, Miami, FL) was the first such system developed, with the X t.i.p. (X t.i.p Technologies, Lakewood, NJ) introduced in 1999.

Computer-Controlled Injections

There are currently a number of computer-controlled injection devices. They also offer a number of advantages and disadvantages. As compared with traditional syringes, these devices are larger, require more space, and are more expensive. Because of a more aesthetically pleasing needle and handle, they are generally better received by patients with needle phobias. The computer is able to control the rate and the pressure of the injection, allowing for titration of the anesthetic for patient comfort. In 1997 Milestone Scientific launched a Computer Controlled Local Anesthetic Delivery System (CCLADS), known as the "wand," which has subsequently been renamed "CompuMed—Featuring the Wand Hand-Piece." The CCLAD was designed to deliver a potentially painless injection of local anesthetic. Since the availability of the CCLAD, numerous studies have been conducted to compare pain associated with the CCLAD and a hypodermic needle and syringe. In a study of 40 patients undergoing either Mohs microscopic surgery for treatment of skin cancer removal or a skin biopsy procedure to determine a positive skin cancer for Mohs surgery, the CCLAD was reported in patients with a normal to low tolerance to cause less pain than what was experienced with prior injections or the control group using hypodermic syringes.[91a] In a study of 101 patients undergoing hair transplant, True and colleagues reported that anesthesia with the CCLAD was less painful than the conventional syringe technique.[91] In contrast, Whalen and co-workers reported in their study that 11 of 15 patients experienced less pain with the traditional injection than with CCLAD-administered local anesthetic.[92] The contradictory results reported by these two groups could perhaps be due to the experience of the person administering the local anesthetic.

Needleless Injections

The administration of medication without the use of a needle has always been highly desirable. Initial reports of this novel approach were first reported in 1947 by Hingson and Hughes.[92a] Refinement of this technique took place over the next few decades; in the 1970s, multiple reports showed promising reduction of pain in patients with cancer. These systems can be divided into three types. The first group is the disposable, single-use tips, such as J-Tip and Biojector 2000. The second type has multiple-use nozzles, such as Ped-O-Jet, Med-E-Jet, and Syrijet. Syrijet Mark II (Keystone Industries, Cherry Hill, NJ) has the benefit of accepting standard dental cartridges.[93] The third type of device is designed for single-patient use: Medi-Jector, which is used for self-administration of variable doses of insulin. Generally speaking they all employ a technology based on a piston-pressure expulsion system that forces local anesthetic into the desired area. In 2000, Cooper and colleagues compared the efficacy of needle-free injections versus injections using 25-gauge needles before venous cannulation and found that patients reported less pain on injection with the needle-free system.[93a]

Electronic Dental Anesthesia (EDA)

Electronic dental anesthesia (EDA) is one of the latest developments in pain control. Based on the same principles as transcutaneous electronic nerve stimulation (TENS), it uses electrical wave forms and voltage/amperage parameters to facilitate the disruption of the neuronal pathways transporting the pain stimuli to the brain. Although this technology

has been used successfully in the field of medicine for back pain and sports injuries, its impact in the dental field still remains to be seen.

A local anesthetic reversal agent has been introduced that claims to effectively reverse the influence of vasopressors on submucosal vessels. Phentolamine (OraVerse) is an alpha receptor blocker formulated in dental cartridges. When it is injected into the identical site where anesthetic was administered, vessels dilate, leading to enhanced absorption of local anesthetic, which shortens the duration of anesthesia.[94] It will likely receive limited use because of its expense and the fact that sustained anesthesia is generally a benefit during the postoperative period for pain management. However, it may be useful in the management of small children or patients with special needs who may be prone to self-inflected injury while tissues remain numb. A consideration may also be given to the fragile diabetic or elderly patient for whom adequate nutritional intake maybe hindered by prolonged numbness. Reversal may also be offered to the busy patient who must return to work and communicate effectively.

References

1. Hersh EV, Condouris GA: Local anesthetics: a review of their pharmacology and clinical use, *Compendium* 8(5):378–381, 1987. 374, 376.
2. Jastak JT, et al.: *Local anesthesia of the oral cavity*, Philadelphia, 1995, Saunders.
3. Covino BG, Vassallo HG: *Local anesthetics: mechanisms of action and clinical use. The scientific basis of clinical anesthesia*, New York, 1976, Grune & Stratton.
4. Wilson S, Johns P, Fuller PM: The inferior alveolar and mylohyoid nerves: an anatomic study and relationship to local anesthesia of the anterior mandibular teeth, *J Am Dent Assoc* 108(3):350–352, 1984.
5. Pyle MA, et al.: Prevalence and implications of accessory retromolar foramina in clinical dentistry, *Gen Dent* 47(5):500–503, 1999.
6. Malamed SF: *Handbook of local anesthesia*, ed 6, St Louis, 2014, Mosby.
7. Yagiela JA: Local anesthetics, *Anesth Prog* 38(4-5):128–141, 1991.
8. Jastak JT, Yagiela JA: Vasoconstrictors and local anesthesia: a review and rationale for use, *J Am Dent Assoc* 107(4):623–630, 1983.
9. Moore PA: Long-acting local anesthetics: a review of clinical efficacy in dentistry, *Compendium* 11(1):22, 1990. 24–26, 28-30.
10. Sisk AL: Long-acting local anesthetics in dentistry, *Anesth Prog* 39(3):53–60, 1992.
11. Chapman PJ, Macleod AW: A clinical study of bupivacaine for mandibular anesthesia in oral surgery, *Anesth Prog* 32(2):69–72, 1985.
12. Giovannitti JA, Bennett CR: The effectiveness of 1.5% etidocaine HCl with epinephrine 1:200,000 and 2% lidocaine HCl with epinephrine 1:100,000 in oral surgery: a clinical comparison, *J Am Dent Assoc* 107(4):616–618, 1983.
13. Danielsson K, Evers H, Nordenram A: Long-acting local anesthetics in oral surgery: an experimental evaluation of bupivacaine and etidocaine for oral infiltration anesthesia, *Anesth Prog* 32(2):65–68, 1985.
14. Johnson GK, Hlava GL, Kalkwarf KL: A comparison of periodontal intraligamental anesthesia using etidocaine HCl and lidocaine HCl, *Anesth Prog* 32(5):202–205, 1985.
15. Yagiela JA, Neidle EA, Dowd FJ: Pharmacology and therapeutics for dentistry. In Yagiela JA, editor: *Local anesthetics*, ed 4, St Louis, 1997, Mosby.
16. Sisk AL: Vasoconstrictors in local anesthesia for dentistry, *Anesth Prog* 39(6):187–193, 1993.
17. Nakamura Y, et al.: Cardiovascular and sympathetic responses to dental surgery with local anesthesia, *Hypertens Res* 24(3):209–214, 2001.
18. Yagiela JA: Vasoconstrictor agents for local anesthesia, *Anesth Prog* 42(3-4):116–120, 1995.
19. Chernow B, et al.: Local dental anesthesia with epinephrine. Minimal effects on the sympathetic nervous system or on hemodynamic variables, *Arch Intern Med* 143(11):2141–2143, 1983.
20. van der Bijl P, Victor AM: Adverse reactions associated with norepinephrine in dental local anesthesia, *Anesth Prog* 39(3):87–89, 1992.
21. Niwa H, et al.: Cardiovascular response to epinephrine-containing local anesthesia in patients with cardiovascular disease, *Oral Surg Oral Med Oral Pathol Oral Radiol Endod* 92(6):610–616, 2001.
22. Cassidy JP, Phero JC, Grau WH: Epinephrine: systemic effects and varying concentrations in local anesthesia, *Anesth Prog* 33(6):289–297, 1986.
23. Holm SW, et al.: Hypertension: classification, pathophysiology, and management during outpatient sedation and local anesthesia, *J Oral Maxillofac Surg* 64(1):111–121, 2006.
24. Goebel WM, Allen G, Randall F: The effect of commercial vasoconstrictor preparations on the circulating venous serum level of mepivacaine and lidocaine, *J Oral Med* 35(4):91–96, 1980.
25. Cannell H, et al.: Circulating levels of lignocaine after peri-oral injections, *Br Dent J* 38(3):87–93, 1975.
26. Hersh EV, Helpin ML, Evans OB: Local anesthetic mortality: report of case, *ASDC J Dent Child* 58(6):489–491, 1991.
27. Bacsik CJ, Swift JQ, Hargreaves KM: Toxic systemic reactions of bupivacaine and etidocaine, *Oral Surg Oral Med Oral Pathol Oral Radiol Endod* 79(1):18–23, 1995.
28. Chilton NW: Clinical evaluation of prilocaine hydrochloride 4 percent solution with and without epinephrine, *J Am Dent Assoc* 83(1):149–154, 1971.
29. Knoll-Kohler E, Fortsch G: Pulpal anesthesia dependent on epinephrine dose in 2% lidocaine: a randomized controlled double-blind crossover study, *Oral Surg Oral Med Oral Pathol* 73(5):537–540, 1992.
30. Knoll-Kohler E, et al.: Cardiohemodynamic and serum catecholamine response to surgical removal of impacted mandibular third molars under local anesthesia: a randomized double-blind parallel group and crossover study, *J Oral Maxillofac Surg* 49(9):957–962, 1991.
31. Katzung BG: *Clinical pharmacology, '88/'89. A Lange clinical manual*, Norwalk, CT, 1988, Appleton & Lange.
32. Brand HS, et al.: Cardiovascular and neuroendocrine responses during acute stress induced by different types of dental treatment, *Int Dent J* 45(1):45–48, 1995.
33. Brown RS: Local anesthetics, *Dent Clin North Am* 38(4):619–632, 1994.
34. Dagher FB, Yared GM, Machtou P: An evaluation of 2% lidocaine with different concentrations of epinephrine for inferior alveolar nerve block, *J Endod* 23:178–180, 1997.
35. Tofoli GR, Ramacciato JC, de Oliveira PC, et al.: Comparison of effectiveness of 4% articaine associated with 1:100,000 or 1:200,000 epinephrine in inferior alveolar nerve block, *Anesth Prog* 50:164–168, 2003.

36. Scott DB, Jebson PJR, Braid DP, et al.: Factors affecting plasma levels of lignocaine and prilocaine, *Br J Anaesth* 44:1040–1049, 1972.
37. Sveen K: Effect of the addition of a vasoconstrictor to local anesthetic solution on operative and postoperative bleeding, analgesia and wound healing, *Int J Oral Surg* 8(4):301–306, 1979.
38. Buckley JA, Ciancio SG, McMullen JA: Efficacy of epinephrine concentration in local anesthesia during periodontal surgery, *J Periodontol* 55(11):653–657, 1984.
39. Cioffi GA, et al.: The hemodynamic and plasma catecholamine responses to routine restorative dental care, *J Am Dent Assoc* 111(1):67–70, 1985.
40. Tolas AG, Pflug AE, Halter JB: Arterial plasma epinephrine concentrations and hemodynamic responses after dental injection of local anesthetic with epinephrine, *J Am Dent Assoc* 104(1):41–43, 1982.
41. Knoll-Kohler E, et al.: Changes in plasma epinephrine concentration after dental infiltration anesthesia with different doses of epinephrine, *J Dent Res* 68(6):1098–1101, 1989.
42. Lipp M, et al.: Examination of central venous epinephrine level during local dental infiltration and block anesthesia using tritium-marked epinephrine as vasoconstrictor, *Anesthesiology* 69:A371, 1988.
43. Dionne RA, Goldstein DS, Wirdzek PR: Effects of diazepam premedication and epinephrine-containing local anesthetic on cardiovascular and plasma catecholamine responses to oral surgery, *Anesth Analg* 63(7):640–646, 1984.
44. Troullos ES, et al.: Plasma epinephrine levels and cardiovascular response to high administered doses of epinephrine contained in local anesthesia, *Anesth Prog* 34(1):10–13, 1987.
45. Dionne RA, Goldstein DS, Wirdzek PR: Effects of diazepam premedication and epinephrine-containing local anesthetic on cardiovascular and catecholamine responses to oral surgery, *Anesth Analg* 63:640–646, 1984.
46. Becker DE, Reed KL: Essentials of local anesthetic pharmacology, *Anesth Prog* 53(3):98–108, 2006.
47. Hoffman BB: Catecholamines, sympathomimetic drugs, and adrenergic receptor antagonists. In Hardman JG, Limbird LE, Gilman AG, editors: *Goodman and Gilman's The pharmacological basis of therapeutics*, ed 10, New York, 2001, McGraw-Hill.
48. Lawson NW, Meyer DJ: Autonomic nervous system physiology and pharmacology. In Barash PG, Cullen BF, Stoelting RK, editors: *Clinical anesthesia*, ed 3, Philadelphia, 1997, JB Lippincott.
49. Yagiela JA: Local anesthetics. In Dionne RA, Phero JP, Becker DE, editors: *Management of pain & anxiety in the dental office*, St Louis, 2002, WB Saunders/Elsevier Science.
50. Little JW: *Dental management of the medically compromised patient*, ed 6, St Louis, 2002, Mosby.
51. Akutsu A, et al.: Management of dental problems in patients with cardiovascular disease, *J Am Dent Assoc* 68:333–342, 1964.
52. Becker DE: Drug interactions in dental practice: a summary of facts and controversies, *Compendium* 15(10), 1994. 1228, 1230, 1232 passim.
53. Perusse R, Goulet JP, Turcotte JY: Contraindications to vasoconstrictors in dentistry: part III, Pharmacologic interactions, *Oral Surg Oral Med Oral Pathol* 74(5):692–697, 1992.
54. Use of epinephrine in connection with procaine in dental procedures: report of the special committee of the New York Heart Association, Inc. on the use of epinephrine in connection with procaine in dental procedures, *J Am Dent Assoc* 50:108, 1955.
55. Perusse R, Goulet JP, Turcotte JY: Contraindications to vasoconstrictors in dentistry: part I. Cardiovascular diseases, *Oral Surg Oral Med Oral Pathol* 74(5):679–686, 1992.
56. Perusse R, Goulet JP, Turcotte JY: Contraindications to vasoconstrictors in dentistry: part II. Hyperthyroidism, diabetes, sulfite sensitivity, cortico-dependent asthma, and pheochromocytoma, *Oral Surg Oral Med Oral Pathol* 74(5):687–691, 1992.
57. Kaplan EL: *Cardiovascular disease in dental practice, American Dental Association, American Heart Association*, Dallas, 1986, American Heart Association.
58. Schatz M: Adverse reactions to local anesthetics, *Immunol Allergy Clin North Am* 12:585–609, 1992.
59. Adkinson Jr NF: Drug allergy. In Adkinson Jr NF, Yunginger JW, Busse WW, et al.: *Middleton's allergy: principles and practice*, ed 6, Philadelphia, 2003, Mosby.
60. Haas DA, Lennon D: A 21 year retrospective study of reports of paresthesia following local anesthetic administration, *J Can Dent Assoc* 61(4):329–330, 1995. 319-320, 323-326.
61. Dower Jr JS: A review of paresthesia in association with administration of local anesthesia, *Dent Today* 22(2):64–69, 2003.
62. Colin W, Donoff RB: Restoring sensation after trigeminal nerve injury: a review of current management, *J Am Dent Assoc* 123(12):80–85, 1992.
63. Hillerup S: Iatrogenic injury to oral branches of the trigeminal nerve: records of 449 cases, *Clin Oral Investig*, 2006.
64. Hillerup S, Jensen R: Nerve injury caused by mandibular block analgesia, *Int J Oral Maxillofac Surg* 35(5):437–443, 2006.
65. Pogrel MA, Bryan J, Regezi J: Nerve damage associated with inferior alveolar nerve blocks, *J Am Dent Assoc* 126(8):1150–1155, 1995.
66. Pogrel MA, Kaban LB: Injuries to the inferior alveolar and lingual nerves, *J Calif Dent Assoc* 21(1):50–54, 1993.
67. Pogrel MA, Thamby S: Permanent nerve involvement resulting from inferior alveolar nerve blocks, *J Am Dent Assoc* 131(7):901–907, 2000.
68. Hoffmeister B: Morphological changes of peripheral nerves following intraneural injection of local anesthetic, *Dtsch Zahnarztl Z* 46(12):828–830, 1991.
69. Yagiela JA: Recent developments in local anesthesia and oral sedation, *Compend Contin Educ Dent* 25(9):697–706, 2004.
70. Wynn RL, Bergman SA, Meiller TF: Paresthesia associated with local anesthetics: a perspective on articaine, *Gen Dent* 51(6):498–501, 2003.
71. Haas DA: Localized complications from local anesthesia, *J Calif Dent Assoc* 26(9):677–682, 1998.
72. Moore PA: Adverse drug interactions in dental practice: interactions associated with local anesthetics, sedatives and anxiolytics. Part IV of a series, *J Am Dent Assoc* 130(4):541–554, 1999.
73. Clarkson CW, Hondeghem LM: Mechanism for bupivacaine depression of cardiac conduction: fast block of sodium channels during the action potential with slow recovery from block during diastole, *Anesthesiology* 62(4):396–405, 1985.
74. Moore PA, Goodson JM: Risk appraisal of narcotic sedation for children, *Anesth Prog* 32(4):129–139, 1985.
75. Moore PA: Preventing local anesthesia toxicity, *J Am Dent Assoc* 123(9):60–64, 1992.
76. California Board of Dental Examiners: Dentist loses license in child death case, *Anesth Prog* 26:24–25, 1979.
77. Goodson JM, Moore PA: Life-threatening reactions after pedodontic sedation: an assessment of narcotic, local anesthetic, and antiemetic drug interaction, *J Am Dent Assoc* 107(2):239–245, 1983.

78. Moore MA: Current management of hypertension, *Am Fam Physician* 32(6):129–136, 1985.
79. Tarsitano JJ: Children, drugs and local anesthesia, *J Am Dent Assoc* 70:1153–1158, 1965.
79a. Guideline on appropriate use of local anesthesia for pediatric dental patients. In *Reference manual 2005-2006*, American Academy of Pediatric Dentistry, 2005.
80. Yagiela JA, Neidle EA, Dowd FJ: Pharmacology and therapeutics for dentistry. In Yagiela JA, editor: *Local anesthetics*, ed 4, St Louis, 1997, Mosby.
81. Malamed SF, Gagnon S, Leblanc D: Efficacy of articaine: a new amide local anesthetic, *J Am Dent Assoc* 131:635–642, 2000.
82. Mikesell P, Nusstein J, Reader A, et al.: A comparison of articaine and lidocaine for inferior alveolar nerve blocks, *J Endod* 31:265–270, 2005.
83. Morris R, McKay W, Mushlin P: Comparison of pain associated with intradermal and subcutaneous infiltration with various local anesthetic solutions, *Anesth Analg* 66:1180–1182, 1987.
84. Wahl MJ, Overton D, Howell J, et al.: Pain on injection of prilocaine plain vs. lidocaine with epinephrine. A prospective double-blind study, *J Am Dent Assoc* 132:1396–1401, 2001.
85. Wahl MJ, Schmitt MM, Overton DA, Gordon MK: Injection pain of bupivacaine with epinephrine vs. prilocaine plain, *J Am Dent Assoc* 133:1652–1656, 2002.
86. Miller MC: The pregnant dental patient, *J Calif Dent Assoc* 23(8):63–70, 1995.
87. Candiotti K, Haas E: Addressing current challenges in managing postsurgical pain with Exparel, a new DepoFoam formulation of bupivacaine, *Anesthesiol News* 38(3), 2012.
88. Chahar P, Cummings 3rd KC: Liposomal bupivacaine: a review of a new bupivacaine formulation, *J Pain Res* 5:257–264, 2012.
89. Gorfine SR, Onel E, Patou G, Krivokapic ZV: Bupivacaine extended-release liposome injection for prolonged postsurgical analgesia in patients undergoing hemorrhoidectomy: a multicenter, randomized, double-blind, placebo-controlled trial, *Dis Colon Rectum* 54(12):1552–1559, 2011.
90. Golf M, Daniels SE, Onel E: A phase 3, randomized, placebo controlled trial of DepoFoam bupivacaine (extended-release bupivacaine local analgesic) in bunionectomy, *Adv Ther* 28(9):776–788, 2011.
91. Anderson ZN, Podros SM, Shirley-King R: Patient satisfaction during the administration of local anesthesia using a computer controlled local anesthesia delivery system, *Dermatol Nurs* 15(4):329–330, 2003.
91a. True RH, et al.: Microprocessor-controlled local anesthesia versus the conventional syringe technique in hair transplantation, *Dermatol Surg* 28(6):463–468, 2002.
92. Whalen K, Rabinovitz HS, Oliviero MC: Microprocessor-controlled local anesthesia versus the conventional syringe technique in hair transplantation, *Dermatol Surg* 29(1):113, 2003.
92a. Hingson R, Hughes J: Clinical studies with jet injection: a new method of drug administration, *Curr Res Anesth Analg* 26:221–230, 1947.
93. Saxena P, et al.: Advances in dental local anesthesia techniques and devices: an update, *Natl J Maxillofac Surg India* 4(1):19–24, 2013.
93a. Cooper JA, Bromley LM, Baranowski AP, Barker SG: Evaluation of a needle-free injection system for local anaesthesia prior to venous cannulation, *Anesthesia* 55:247–250, 2000.
94. Moore PA, Hersh EV, Papas AS, et al.: Pharmacokinetics of lidocaine with epinephrine following local anesthesia reversal with phentolamine mesylate, *Anesth Prog* 55:40–48, 2008.

16

Pharmacology of Drugs in Ambulatory Anesthesia

CRYSTAL PIRAS, SARAH RINGDAHL, JEFFREY DEMBO, MICHAEL POWERS

Introduction

The use of ambulatory anesthesia has increased throughout the practice of dentistry. Less invasive procedures and safer anesthesia have allowed patients to undergo procedures in the office with anesthesia provided by the practicing dentist. Different drugs are useful with each subset of patients and offer unique, beneficial side effects that allow procedures to occur with fewer complications. In this chapter, we outline the history, mechanism of action, and clinical side effects of benzodiazepines, opiates and opioids, intravenous sedating hypnotics, ketamine, and inhalation anesthetics.

Benzodiazepines

Discovery and Development

During the summer of 1949, neurochemistry researcher Eugene Roberts was working in a laboratory in Bar Harbor, Maine, studying the amino acid content of neuroblastomas in mice. Using paper chromatography, Roberts analyzed brain extracts of mice with neuroblastoma to compare them with mice that were tumor free. He discovered a chemical that was present in the tumor-free mice and was absent when neuroblastoma was present. This chemical was soon afterwards identified as γ-amino butyric acid (GABA), but its role was unclear at the time. It was not until 1957 that GABA was identified as an important inhibitory neurotransmitter of the central nervous system (CNS).[1]

The 1950s also represented an earnest search for sedative-hypnotics that could work as effectively as the barbiturates and phenothiazines but with fewer side effects and lower abuse potential. Dr. Leo Sternbach, a scientist at Hoffman-LaRoche, was working with a class of compounds that held promise as barbiturate replacements, but found only one compound in this group that had any chemical activity. The compound was shelved and forgotten for several years, and, while cleaning his laboratory, Sternbach came across the compound and decided to test it further. This compound was chlordiazepoxide, a benzodiazepine (BZD)—it was found to have sedative and muscle relaxant properties and later to also possess anticonvulsant and amnestic effects (Figure 16-1).[2] It was approved by the FDA in 1960 and marketed by Hoffman-LaRoche as Librium, the prototype of a drug group that would dramatically change the landscape of anesthesia practice.

The connection between the BZDs and GABA was not fully elucidated until the 1970s, when GABA receptors were identified in mammalian CNS.[3] This led to the development of additional BZD agonists and the search for antagonists. The first true antagonist, flumazenil, was synthesized in 1979.

Structure and Activity of Benzodiazepines

All BZDs are characterized by having one benzene ring fused to a seven-membered diazepine ring. They act in two locations: at central receptors on neuronal membrane and peripherally on receptors on mitochondria. The

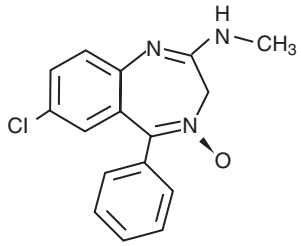

Chlordiazepoxide

• **Figure 16-1** Chlordiazepoxide. (Modified from López-Muñoz, Francisco: The discovery of chlordiazepoxide and the clinical introduction of benzodiazepines: half a century of anxiolytic drugs, *Journal of Anxiety Disorders*, 25:4, 554-562, 2011.)

pharmacologic actions of the BZD are closely related to the inhibitory neurotransmitter GABA. GABA exerts its inhibitory effect by opening the chloride ion channel on neuronal membranes, thus hyperpolarizing the cell membrane and making it less likely to depolarize (Figure 16-2). BZDs bind to benzodiazepine receptors presynaptically and postsynaptically, which facilitates the binding of GABA and potentiates its activity, causing CNS inhibition. In the absence of GABA, the BZDs have no innate pharmacologic effects.

The GABA-BZD receptor complex has been studied extensively and, although the precise three-dimensional configuration has not been mapped, there is general agreement that it is a macromolecular complex containing at least 16 different types of subunits.[4] These subunits include $GABA_A$ receptors, a BZD receptor, a barbiturate receptor, and a chloride channel. A BZD receptor must be linked to $GABA_A$ receptors, but not all $GABA_A$ receptors are paired with BZD receptors.[5] It is still unknown why a BZD receptor exists, because to date no endogenous BZD-like chemicals have been identified. All BZDs, both agonists and antagonists, bind to the receptors reversibly and competitively.

Other drugs have been found to bind to the GABA-BZD receptor complex, although their relationships to GABA activity do not appear to be as specific as the BZD. These include barbiturates, propofol, steroids, etomidate, and inhalation anesthetic agents (Figure 16-3). Other anesthetics, such as ketamine and nitrous oxide, appear to have no activity at the GABA-BZD receptor complex.

Clinical Effects

The pharmacodynamic effects of BZDs have been well characterized and include anxiolysis, sedation-hypnosis, muscle relaxation, amnesia, and anticonvulsant activity (Figure 16-4, *A*). Each BZD has a differing affinity for the receptor, causing differences in potency and pharmacokinetics between drugs. Nevertheless, regardless of the BZD administered, the clinical effects are similar between drugs and are closely related to receptor saturation.[6] At present the clinical effects are linked, and one cannot administer a BZD to achieve one therapeutic effect (e.g., anxiolysis) without risking amnesia or sedation. However, there are ongoing research efforts to identify and isolate compounds that can selectively create anxiolysis alone without creating amnesia, sedation, or muscle relaxation. As more is learned about the BZD receptor subunits, it may provide future clinicians with classes of drugs that can selectively provide anxiolysis with no other effects.[7]

Anxiolysis is the first therapeutic effect achieved when titrating a BZD. There are few studies that support any particular BZD as being most effective in creating anxiolysis.

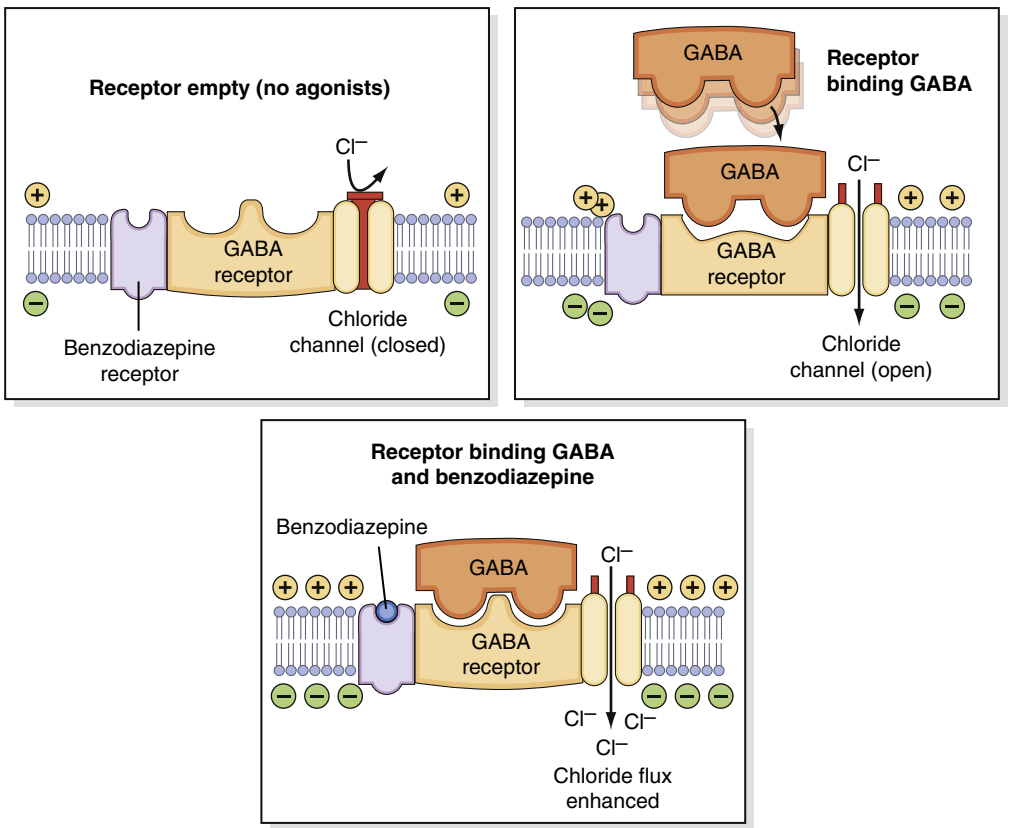

• **Figure 16-2** Benzodiazepine–γ-aminobutyric acid (GABA)–chloride ionophore complex. Benzodiazepines increase the frequency of channel opening. Barbiturates increase the length of time that the channels remain open. Both of these increase the function of the GABA receptor. (Modified from Pazdernik TL, Kerecsen L: CNS *Rapid review pharmacology,* ed 3, St Louis, 2010, Elsevier.)

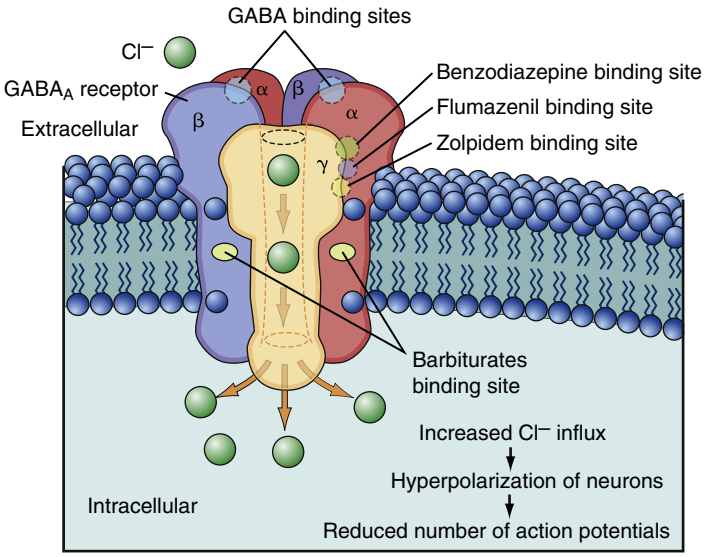

• **Figure 16-3** Structure and function of GABA receptor and drug interactions. GABA binds to its receptor in a different location than benzodiazepines, flumazenil, zolpidem, and barbiturates. Binding of all of these molecules results in an increase in chloride transport which hyperpolarizes neurons and reduces the number of action potentials. (Modified from Raffa RB: Drugs used in disorders of the central nervous system and treatment of pain. In *Netter's illustrated pharmacology updated edition*, vol 3, St Louis, 2014, Saunders, pp 57-91.)

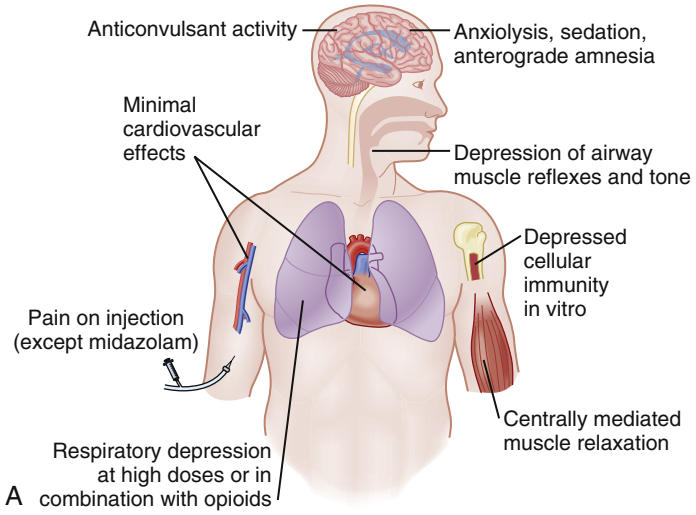



• **Figure 16-4** Side effect profile of benzodiazepines. **A,** Side effects of benzodiazepines and their associated organ system. **B,** Verrill sign, a common sign of the induction of sedation, is relaxation causing ptosis of the eyelids to the point that the lower border of the eyelid bisects the pupil. (**A,** Modified from Garcia P: Intravenous anesthetics. In Hemmings HC, Egan TD, editors: *Pharmacology and physiology for anesthesia*, St Louis, 2013, Saunders, pp 137-158. **B,** From Malamed SF: *Sedation: a guide to patient management*, St Louis, 2009, Mosby, pp 316-354.)

The level of anxiolysis is dose related. Older textbooks instructed clinicians to titrate a BZD until Verrill sign was noted (i.e., relaxation causing ptosis of the eyelids to the point that the lower border of eyelid bisected the pupil; see Figure 16-4, *B*). However, Verrill sign is a sedative—not an anxiolytic—end point, and it is possible that some patients will have benefited sufficiently from anxiolytic doses of the BZD that there would be no need to administer additional drug toward a sedative end point. The inherent benefit of titrating to an anxiolytic end point would be to minimize the total drug dose and therefore decrease the time for recovery. The liability of this practice, however, is that amnesia to the surgery would occur less predictably.

The sedative-hypnotic effects of the BZDs are linearly related to dose and receptor saturation. Anxiolysis is produced when less than 20% of receptors are occupied; sedation occurs when there is 30% to 50% occupancy; and unconsciousness when more than 60% of receptors are occupied.[8]

Anterograde amnesia is a well-documented effect of the BZD and is dependent on dose and route of administration. For example, diazepam 10 mg given orally can provide anxiolysis and sedation, but only 40% of patients will have some degree of amnesia.

For more than 70% of patients to be amnestic, oral doses of 20 mg or more would have to be administered. Intravenously, doses of 5 mg and 10 mg of diazepam can produce amnesia in 50% and 90% of patients, respectively.[9] The incidence is similar with midazolam, with complete amnesia in 67% of patients who received 5 mg midazolam intravenously.

Patients often appreciate being amnestic to an oral surgical procedure, and the degree of amnesia roughly follows in a linear fashion the depth of sedation. However, despite an adequate depth of sedation, it is possible there still may be recall, and there are no reliable predictors to tell us which patients may remember portions of the surgery. Therefore, unless absolute general anesthesia is planned throughout the entire surgery, it would be wise to inform patients that awareness during the anesthetic may occur and the patient may retain some memory of the surgery.

The muscle relaxant effect of the BZD occurs both centrally and at the spinal cord. Glycine is the major inhibitory neurotransmitter in the brainstem and spinal cord, and BZDs mimic glycine, thus causing decreased muscle tone (Figure 16-5).[10] The actions of the BZDs are not related to the motor end plate or neuromuscular transmission.

The BZD depress the central respiratory drive and CO_2 response curve. When BZDs are used alone and in typical doses to achieve conscious sedation, the respiratory depressant effects rarely cause clinically significant hypoventilation or apnea. However, when used with other agents (e.g., opioids) or when used in elderly or medically compromised patients, the respiratory depressant effects can be significant and long lasting. It was in elderly patients undergoing endoscopic procedures that the respiratory depressant effects of midazolam were first noted to be potentially dangerous, primarily because of respiratory arrest. For diazepam there may be a 50% to 65% decrease in minute ventilation, and for midazolam it can be anywhere from a 25% to 65% decrease that can last for hours.

When used alone in healthy patients, BZDs cause very slight changes in heart rate, blood pressure, left ventricular end diastolic pressure, and systemic vascular resistance (see Figure 16-4, *A*). This cardiovascular stability is thought to result from the maintenance of normal baroreceptor function. Diazepam has a beneficial effect on coronary blood flow, increasing it 22% in healthy patients and 73% in patients with coronary disease.[11] Midazolam neither increases nor decreases coronary blood flow.

Whereas the effects of BZDs in younger patients may not become clinically significant, the elderly are much more sensitive to these effects and may, in fact, show significant cardiovascular changes. Even with modest doses and with minor surgical procedures, a significant number of patients can experience hypotension after administration of midazolam.[12]

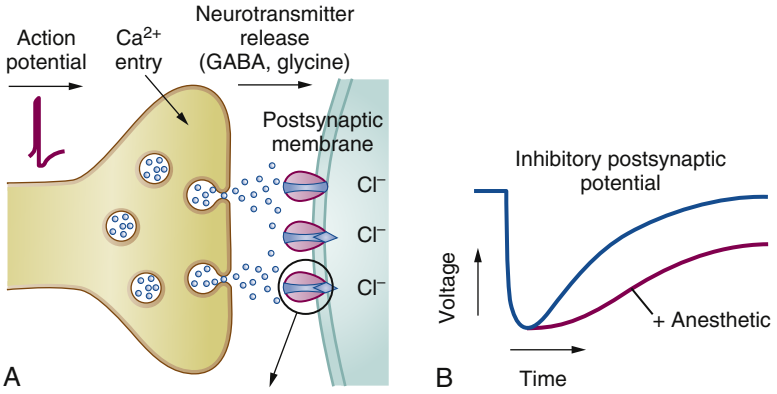

• **Figure 16-5** The effect of anesthetics on inhibitory synaptic transmission of the GABA receptor. **A,** When bound to its receptor, GABA increases the release of chloride into the postsynaptic neurons. **B,** Anesthetics cause a greater increase in the release of chloride, which causes a larger inhibitory effect than GABA, as shown with the decrease in voltage over time. (Modified from Hudson AE: Pharmacology of inhaled anesthetics. In Hemmings HC, Egan TD, editors: *Pharmacology and physiology for anesthesia*, St Louis, 2013, Saunders, pp 159-179.)

When the BZDs are combined with other drugs (e.g., opioids), there may be significant changes in mean arterial pressure, systemic vascular resistance, cardiac index, and stroke volume.

Pharmacokinetics and Metabolism

Plasma concentrations of BZDs follow a linear to slightly sigmoid dose-response curve (Figure 16-6). All are highly bound to plasma proteins, with slight differences between drugs (Table 16-1). Metabolism occurs in the liver through glucuronide conjugation and hepatic microsomal enzymes (Table 16-2). Because liver function can diminish with age and with disease, metabolism can be expected to occur more slowly in the elderly and in patients with cirrhosis or hepatitis. Concomitant administration of certain drugs can also increase elimination time; this includes erythromycin, oral contraceptives, and calcium channel blockers. All BZDs are eliminated through the kidneys.

The BZDs have among the widest toxic-therapeutic ratios of any agent used for sedation and anesthesia, making them a safe drug class. There have been reported cases of ingestion of 2000 mg diazepam orally by an adult and 300 mg by a 2-year-old, with complete recovery in both cases.[13]

The only true contraindications to the use of any BZD are allergy to the drug and acute narrow-angle glaucoma.

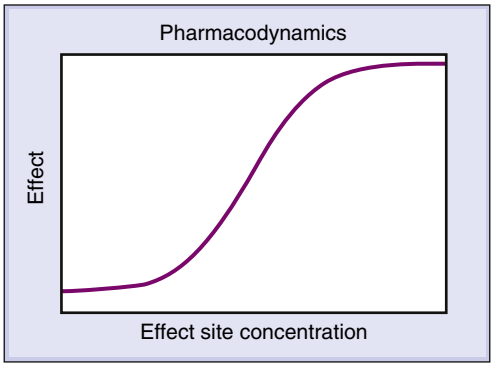

• **Figure 16-6** Basic sigmoidal drug plasma concentration graph. Benzodiazepines exhibit a similar graph. (Modified from Obara S: Pharmacokinetic and pharmacodynamic principles for intravenous anesthetics. In Hemmings HC, Egan TD, editors: *Pharmacology and physiology for anesthesia*, St Louis, 2013, Saunders, pp 20-42.)

TABLE 16-1 Benzodiazepine Half-Lives and Protein Binding

	Elimination Half-Life (hr)	% Protein Bound
Midazolam	1-5	95
Diazepam	20-40	97
Lorazepam	10-20	88-92
Triazolam	1-5	85-90
Alprazolam	9-15	70
Flumazenil	0.7-1.3	54-64

Modified from Smith RB, Corey SE, Kroboth PD: Pharmacokinetics of benzodiazepines. In Bowdle TA, Horita A, Kharasch ED, editors: *The pharmacologic basis of anesthesiology*, New York, 1994, Churchill Livingstone, p 263.)

Diazepam

In 1965 the introduction of diazepam to dental practice greatly improved the dentist's ability to provide conscious sedation (Figure 16-7). In contrast to the multidrug regimens that were commonly used, diazepam could be very effective as the sole sedative and anxiolytic agent.

The pH of diazepam ranges from 6.2 to 6.9, and it has an elimination half-life of more than 40 hours.

Because it is not water soluble, a number of different solvents have been used over the years to create a preparation for parenteral use. The preparation approved by the FDA included the solvent propylene glycol, whose irritating properties cause the risk of phlebitis and venous thrombosis. To minimize this risk, the manufacturer's package insert cautions that the drug must be administered slowly—no more than 1 mL (5 mg) per minute—and it should not be injected into small veins, such as the dorsum of the hand or the wrist.[14] The injectable solution also contains 10% ethanol, 5% sodium benzoate (a buffer), and 1.5% benzyl alcohol (a preservative). For several years, a preparation of diazepam was available that used a solvent containing the same lipid emulsion as propofol (Dizac), but this product was discontinued in 2000.

Diazepam is metabolized into several other BZDs, some of which have sedative properties (see Figure 16-7). The long half-life of the drug and the presence of active metabolites make this drug less than ideal for use in elderly patients or those who are medically compromised.

Midazolam

Midazolam was synthesized in 1975 and introduced for clinical use in 1986, offering several notable advantages over diazepam: It had a much shorter half-life, did not have active metabolites, and was water soluble (see Figure 16-7). This provided shorter recovery time for patients and avoided the injection of solvents that were irritating to veins. Midazolam's water solubility derives from an imidazole ring that can selectively open and close, depending on ambient pH. At an acidic pH of less than 4.0, the ring is open, making the molecule hydrophilic and thus water soluble. Hence midazolam is packaged in vials that have an adjusted pH of 2.9 to 3.7. Once the solution is injected and is exposed to plasma pH of 7.4, the ring closes, and the molecule becomes lipophilic and is able to bond to receptors on the neural membrane. The ring closure is not instantaneous, and complete closure may not occur for 5 to 10 minutes after injection.[15] Because the clinical effects cannot occur until the ring has closed, peak drug effects may not be seen immediately after injection.

Its water solubility has permitted midazolam liquid to be administered intramuscularly, nasally, rectally, and orally, routes that were not available for use with diazepam. Oral

TABLE 16-2 Metabolic Reactions of Drugs in the Liver

Conjugation Reaction	Endogenous Conjugant	Intracellular Sites	Common Substrates	Drug Examples
Acetylation	Acetyl-CoA	Cytosol	—OH, —COOH, —NH_2, —NR_2, —SH	Clonazepam, dapsone, isoniazid, sulfonamides, valproate
Glutathione conjugation	Reduced form of γ-Glu-Cys-Gly (the most common intracellular thiol)	Cytosol and microsomes	Electrophilic benzyl halides, aliphatic nitrate esters, epoxides, and quinines	Acetaminophen, ethacrynic acid
Gly (amino acid) conjugation	Gly, Glu, others	Mitochondria	—COOH	Benzoic and salicylic acid
Glucuronidation	UDPGA (uridine-5′-diphospho-α-D-glucuronic acid)	Microsomes	Hydroxyl, amino, or sulfhydryl groups	Acetaminophen, codeine, diazepam, disulfiram, ethinyl estradiol, fentanyl, galantamine, lorazepam, modafinil, morphine, propranolol, paroxetine, sulfonamides
Methylation (*N*-, *O*-, and *S*-)	CH, from *S*-adenosylmethionine (SAM)	Cytosol (e.g., COMT)	—OH, —NH_2, —SH	Oxprenolol (*N*-), clomethiazole and isoproterenol (*O*-), captopril (*S*-)
Sulfate conjugation	3′-Phosphoadenosine-5′-phosphosulfate (PAPS)	Cytosol	—OH, —NH_2	Acetaminophen, ethinyl estradiol, methyldopa, paroxetine, steroids, triamterene

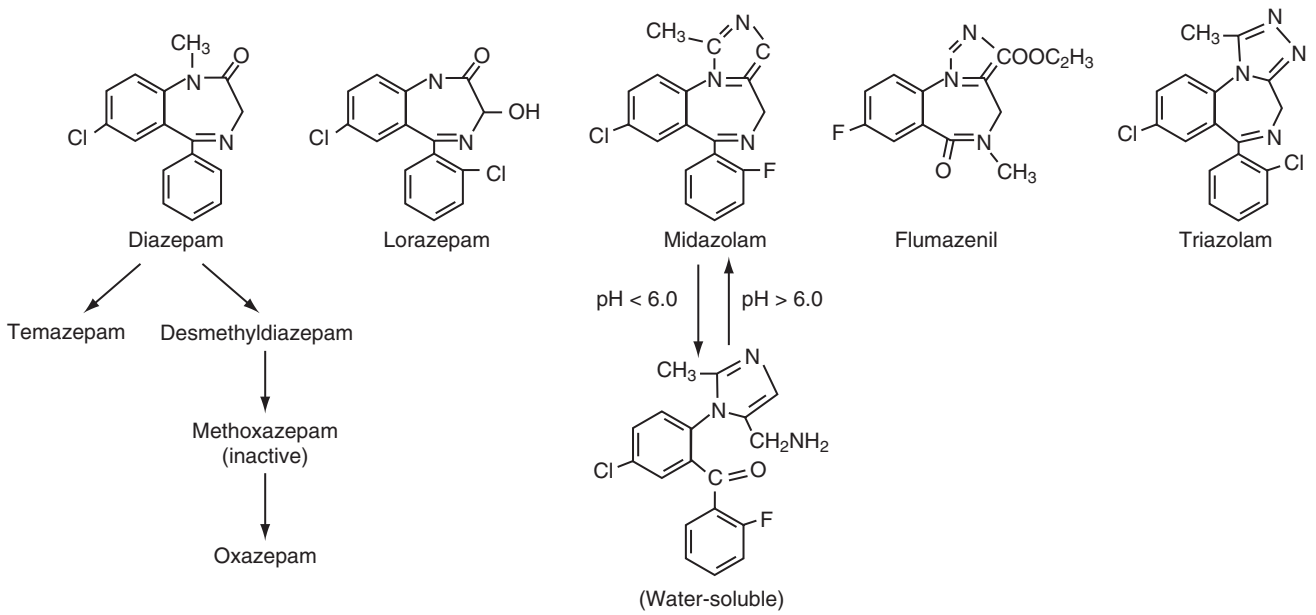

• **Figure 16-7** Structures of commonly used anesthetics in dental anesthesia, some of which are also active anesthetics. (Modified from Reves JG: Intravenous anesthetics. In Miller RD et al., editors: *Miller's anesthesia.* Philadelphia, 2010, Churchill Livingstone, pp. 719-768.)

administration of midazolam was first investigated in 1988, and a number of clinical studies confirmed its effectiveness in children. In 1997 the FDA approved the use of midazolam in children, and it became available in an oral syrup form in 1998.

Triazolam (Halcion)

This BZD was originally marketed in the Netherlands in 1977 as a hypnotic and suspended from use after allegedly causing "raving madness" in some patients, but a thorough investigation failed to provide sufficient evidence to keep

the drug off the market. A similar concern was raised in the United States, but it was never removed from the market, although the manufacturer discontinued manufacturing the highest dose (0.5 mg) tablet.

It has a rapid onset of action (1 hour) and a short elimination half-life, and it is eight times more effective than diazepam as a hypnotic. Because of its favorable pharmacokinetics, it has remained popular as an oral premedicant before outpatient surgical procedures. Most recently there has been increased attention focused on sublingual administration of triazolam (see Figure 16-7). Because the first-pass effect through the liver is eliminated compared with traditional oral administration, there is a 28% increase in bioavailability of the drug when given sublingually compared with orally, causing greater anxiolysis and amnesia.[16]

Lorazepam

Lorazepam (Ativan; see Figure 16-7), frequently used in intensive care units for prolonged sedation, does not have a favorable profile for ambulatory anesthesia. It has a short distribution half-life and a long elimination half-life. As a result of its lower lipid solubility, its effects do not reach a peak until 30 to 60 minutes after the initial IV dose. It is more effective at producing amnesia than diazepam, and the amnestic effects may last many hours after administration.

Flumazenil

At the time the most popular BZDs, diazepam and midazolam, were introduced for clinical use, there were no specific antagonists available. Nonspecific antagonists, physostigmine or aminophylline, were used to reverse the effects of BZDs. The "reversal" effects were actually generalized CNS excitation that frequently would overshadow some of the sedative effects of the BZD. However, this was not true reversal, because no specific action occurred at the BZD receptor. Flumazenil, the first true antagonist, was synthesized in 1981 and introduced into clinical practice in 1992 (see Figure 16-7). Flumazenil is an imidazobenzodiazepine that interacts with the GABA-BZD complex and competitively displaces the BZD (see Figure 16-3). It is not protein bound, and its half-life is roughly 1 hour, making resedation a risk when a longer-acting BZD or high doses have been administered. Flumazenil reverses all BZD effects, but does not antagonize the effects of other drugs that affect the GABA receptors, such as ethanol, barbiturates, opioids, or ketamine.

Flumazenil is a very safe drug, with extremely high doses reported to be given with generally no adverse effects. The few adverse effects that have been reported, including anxiety, crying, tachycardia, and nausea and vomiting, are likely related to the sudden reversal of the therapeutic effects of the BZD.

Opiates and Opioids

Discovery and Development

Archaeologic evidence and written records confirm that the pharmacologic effects of the juice from the opium poppy, *Papaver somniferum,* were known to prehistoric man and early ancient civilizations (Figure 16-8). Over centuries of time, opium was used as an analgesic, antidepressant, antidiarrheal, and cough suppressant. The drug was ingested orally as a tea or mixed with alcoholic beverages, and it was smoked.



• **Figure 16-8** *Papaver somniferum*. Opioids including morphine and codeine are alkaloids of opium obtained from the seed capsules of this plant. (Modified from Larson, MD: History of anesthetic practice. In Miller RD, et al, editors: *Miller's anesthesia.* Philadelphia, 2010, Churchill Livingstone, pp. 1-41.)

In 1805 morphine was isolated from opium in Germany. It and its methylated derivative codeine are still produced today directly from commercially grown opium. In the mid-1800s, when the syringe and needle became available, morphine was the first drug injected using the newly designed syringe. Hence by the time of the Civil War, it was possible to treat soldiers injured in combat by injecting morphine.

The first semisynthetic opioids were heroin and hydromorphone (Dilaudid), produced by making simple chemical changes to morphine's piperidine ring, the portion that confers its pharmacologic activity (Figure 16-9). The next breakthrough was the synthesis of meperidine, discovered during the search for an atropine-like drug. It was serendipitously learned that meperidine, in addition to antimuscarinic effects, also possessed opiate-like effects even though its chemical structure was different. Later, the phenylpiperidine structure of meperidine was used as the basis for creating a whole series of synthetic opioids beginning with fentanyl, and later alfentanil, sufentanil, and remifentanil (Figure 16-10). The only ones in the fentanyl series that have not been used for humans are carfentanil and

Nonproprietary name	Chemical radicals and position			Other changes
	3	6	17	
Morphine	–OH	–OH	$–CH_3$	—
Heroin	$–OCOCH_3$	$–OCOCH_3$	$–CH_3$	—
Hydromorphone	–OH	=O	$–CH_3$	(1)
Oxymorphone	–OH	=O	$–CH_3$	(1), (2)
Levorphanol	–OH	–H	$–CH_3$	(1), (3)
Levallorphan	–OH	–H	$–CH_2CH=CH_2$	(1), (3)
Codeine	$–OCH_3$	–OH	$–CH_3$	—
Hydrocodone	$–OCH_3$	=O	$–CH_3$	(1)
Oxycodone	$–OCH_3$	=O	$–CH_3$	(1), (3)
Nalmefene	–OH	$=CH_2$	$–CH_2$–	(1), (2)
Nalorphine	–OH	–OH	$–CH_2CH=CH_2$	—
Naloxone	–OH	=O	$–CH_2CH=CH_2$	(1), (2)
Naltrexone	–OH	=O	$–CH_2$–	(1), (2)
Buprenorphine	–OH	$–OCH_3$	$–CH_2$–	(1), (4)
Butorphanol	–OH	–H	$–CH_2$–	(1), (2), (3)
Nalbuphine	–OH	–OH	$–CH_2$–	(1), (2)
Methylnaltrexone	–OH	=O	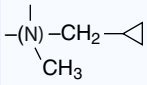	(1), (2)

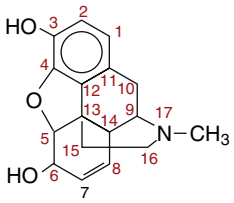

Morphine

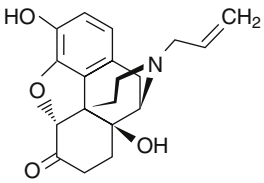

Naloxone

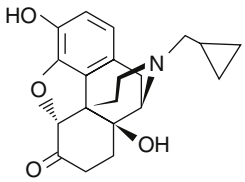

Naltrexone

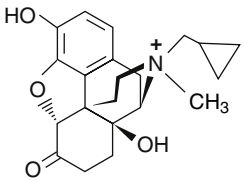

Methylnaltrexone

• **Figure 16-9** Morphine and its analogs that have been synthesized and used throughout the history of anesthesia. (From Section II. Neuropharmacology. In Brunton LL, Chabner BA, Knollman BC, editors: *Goodman & Gilman's The pharmacological basis of therapeutics*, 12e, New York, 2011, McGraw-Hill.)

lofentanil. Their potency is so great that they are generally considered to be useful only for veterinary management of large animals.

A class of agonist-antagonists was also developed, beginning with pentazocine (Talwin), which was introduced in 1967. The major goal of developing this class of drugs was to provide dose-dependent analgesia while limiting the adverse effects (e.g., respiratory depression). Later, other agonist-antagonists were developed, including butorphanol (Stadol), nalbuphine (Nubain), buprenorphine (Buprenex), and dezocine (Dalgan).

Structure and Activity

From the 1950s until the early 1970s, the idea of an opioid receptor had been postulated but remained unproven. In 1973 the first articles appeared demonstrating the presence of opiate receptors, followed by studies that demonstrated the presence of endogenous opiates.[17,18] Later a number of different opiate receptor subtypes were characterized. There are three major receptors (mu, delta, kappa) with as many as eight subtypes.

The agonist-antagonists possess partial agonist activity at μ and other receptors in addition to competitive antagonist activity. This has been shown to create a ceiling effect that limits respiratory depression regardless of dose administered. It also limits the possibility of physical dependence.

The antagonists competitively bind at opioid receptors, displacing any agonists present and thus reversing the effects of the agonist.

Clinical Effects

The primary desirable effect of opioids is analgesia. Analgesia can be created at the spinal level through activation of presynaptic opioid receptors. This leads to decreased levels of neurotransmitters and thus decreased transmission of pain-induced action potentials. Supraspinal analgesia occurs by activation of postsynaptic opioid receptors in the brainstem and midbrain, leading to hyperpolarization and thus

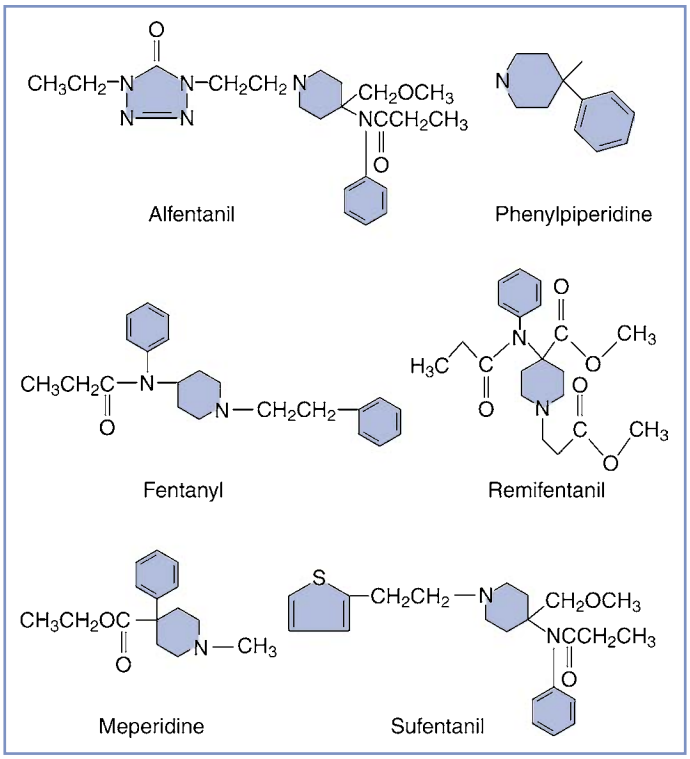

• **Figure 16-10** Fentanyl and its analogs that have been synthesized and used throughout the history of anesthesia. (From Bucklin BA: Local anesthetics and opioids. In Chestnut DH et al, editors: *Chestnut's obstetric anesthesia: principles and practice*, ed 9, St Louis, 2014, Saunders, pp 261-299.)

neuronal inhibition. Analgesia may also be created through peripheral mechanisms, as evidenced by reduction of pain when morphine is injected directly into joints postoperatively (Figure 16-11).[19]

When used as an adjuvant drug for ambulatory anesthesia, the desired effects of opioids and opiates are not necessarily analgesia but rather sedation and euphoria, both of which supplement and augment the actions of other sedative agents.

The respiratory depressant effects of the opioids are caused by a dose-dependent depression of the brainstem response to increased CO_2 and decreased O_2. The respiratory pattern changes as well, characterized by a low respiratory rate with a large tidal volume. Respiratory depression is accentuated by a variety of factors, including increasing age, concomitant administration of other CNS depressants, circadian rhythms, and sleep deprivation (Figure 16-12).

Opioids are known to cause histamine release. There is also a central decrease in sympathetic tone, leading to a tendency toward vagal-dominated bradycardia. As a result of these two effects, direct and indirect vasodilation occurs (Box 16-1).

Opioids can rapidly cross the placental barrier and are found at significant concentrations in the breast milk of nursing mothers. After opioid administration has ceased, it can take up to 96 hours for these concentrations to clear, making it necessary for nursing mothers to feed their infants using stored milk and to express and discard breast milk produced during this period of time.[20]

Opioids have been associated with chest wall rigidity that usually occurs only after loss of consciousness and is associated with high doses and rapid administration. That said, cases have been reported where it occurred in an awake patient who received a small dose. The mechanism is still not completely understood. Some have concluded that it results solely from glottic closure.[21] Others have opined that it relates to the effects of opioids on specific sites in the CNS, such as the nucleus raphe pontis in the reticular formation of the brainstem.[22] It is not caused by direct stimulation of skeletal muscle, because it can be prevented by pretreatment with muscle relaxants. Of all the opioids, fentanyl is the one most prominently implicated in causing chest wall rigidity.

Meperidine

Meperidine, the first totally synthetic opioid, is also known by its non-U.S. name "pethidine" (see Figure 16-10). Its duration of action is anywhere from 3 to 5 hours.

The atropine-like effects of meperidine differ from those of other opioids: tachycardia, decreased myocardial contractility, and mydriasis. One of the metabolites, normeperidine, is long acting and pharmacologically active and can cause toxic effects in the CNS that can result in increased EEG activity, myoclonus, and seizures. These effects are not reversible by naloxone.

Of all the opioids, meperidine is the one most likely to cause histamine release. In one study, patients showed as high as a 200-fold increase in serum histamine levels several minutes after its administration, a far greater amount than either morphine, fentanyl, or sufentanil.[23] In addition to the potential to create symptoms similar to anaphylaxis, this

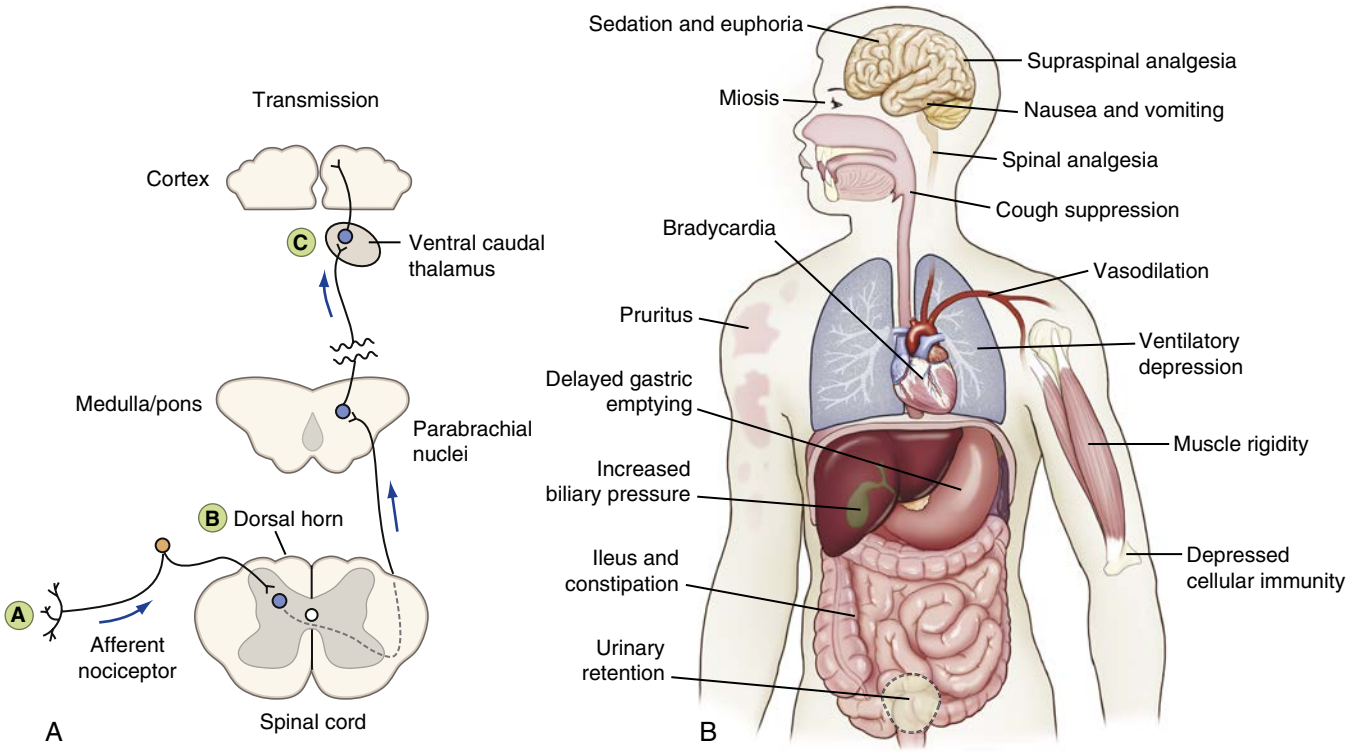

• **Figure 16-11** Actions of opioid analgesics within the nervous system and their clinical side effects. **A,** Sites of action of opioid analgesics presynaptically and postsynaptically. Inhibition occurs in the spinal cord and supraspinally in the thalamus. **B,** Clinical side effects of opiates based on their organ system. (**A,** modified from Schumacher MA, Basbaum AI, Way WL: Opioid analgesics and antagonists. In Katzung BG, Masters SB, Trevor AJ. *Basic and clinical pharmacology,* ed 12, New York, 2012, McGraw-Hill. **B,** modified from Ogura T: Opioid agonists and antagonists. In Hemmings HC, Egan TD, editors: *Pharmacology and physiology for anesthesia*, St Louis, 2013, Saunders, pp 253-271.)

histamine release may also be responsible for vasodilation that can lead to clinically significant hypotension.

Fentanyl

Fentanyl is 60 to 80 times more potent than morphine, and there is a 2 to 3 times greater affinity for fentanyl at the opiate receptor compared with morphine (see Figure 16-10).[24] After injection, fentanyl is characterized by a rapid onset of action owing to its ease of crossing the blood-brain barrier. It is rapidly eliminated, with 99% of a single dose cleared from the plasma within 60 minutes.[25]

Remifentanil

Remifentanil, the most recently introduced opioid, possesses unique properties by being μ-selective (see Figure 16-10). It also has an ester linkage and is thus metabolized by tissue and plasma esterases. This imparts an extremely short half-life and limits the accumulation of the drug in the tissues. This pharmacokinetic profile makes it ideal for continuous infusion because a steady-state level can be reached very rapidly, and after discontinuing the infusion, the level of detectable drug in the serum drops very quickly (see Figure 16-12).

Naloxone

This short-acting antagonist can be used to quickly reverse the effects of opioids (see Figure 16-9). Its short duration of action, however, implies there could be recurrence of the agonist effects when a long-acting opioid was used. Naloxone is associated with nausea and vomiting, the incidence of which increases with dose and rapidity of administration. Sudden reversal of an opioid with naloxone has also been associated with rebound sympathetic stimulation that can cause dysrhythmias, hypertension, myocardial infarction, stroke, and pulmonary edema.

Intravenous Sedative-Hypnotics

Discovery and Development

The barbiturates were the mainstay of intravenous anesthetic agents for more than 80 years. Their use began in 1864 with von Baeyer's discovery of barbituric acid, produced by mixing malonic acid with urea (Figure 16-13). Although it had no discernable pharmacologic properties, chemists substituted and added side chains to the molecule until, in 1903, the first pharmacologically active barbiturate, diethylbarbituric acid (Veronal), was identified. Shortly afterwards, in 1912, phenobarbital (Luminal) was synthesized, a drug that became popular as an anticonvulsant, sedative, and anxiolytic. Thiopental (Penthothal), a thiobarbiturate, was synthesized during this same time period and introduced into clinical

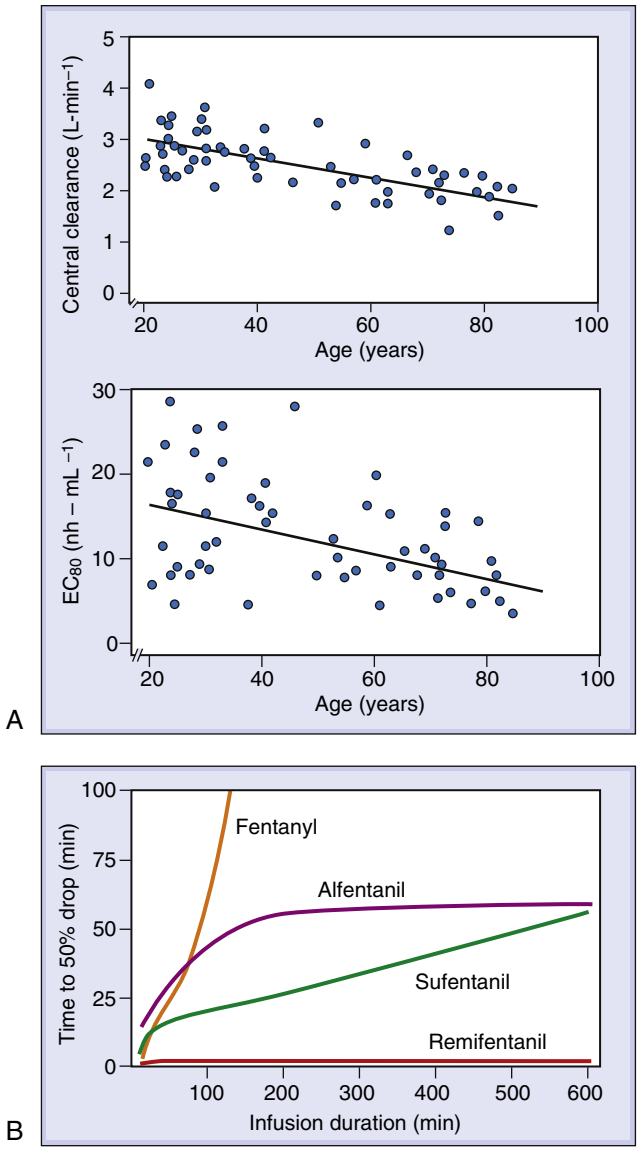

• **Figure 16-12** Infusion duration and clearance of remifentanil. **A,** Among many other factors, age decreases the central clearance of remifentanil, giving it a higher potency measured by EC50 or the effective concentration for 50% of maximal effect. **B,** The half-life concentration of remifentanil is very short compared to other opioids and is not influenced by the duration of the infusion. (**A,** modified from Ogura T: Opioid agonists and antagonists. In Hemmings HC, Egan TD, editors: *Pharmacology and physiology for anesthesia*, St Louis, 2013, Saunders, pp 253-271. **B,** modified from Butterworth JF, IV, Mackey DC, Wasnick JD: In *Morgan & Mikhail's clinical anesthesiology,* ed 5, New York, 2013, McGraw-Hill.)

practice in 1929. It became the prototype of an anesthesia induction agent owing to its rapid onset of action and short duration of action.

Methohexital, an oxybarbiturate, was adopted into clinical practice in the 1960s and was found to offer some advantages over thiopental, in particular a shorter duration of action. For this reason, it became among the most widely used parenteral anesthetics in dentistry. It is uncertain whether methohexital will remain a part of our anesthetic armamentarium because there have been intermittent shortages in the United States over the past decade, and its use in the United Kingdom has been discontinued since 1999.

In an effort to identify new intravenous nonbarbiturate anesthetics, propofol (2,6-diisopropyl phenol) was developed during the early 1970s (see Figure 16-13). Clinical trials began in 1977, resulting in availability for clinical use in the United Kingdom in 1986. Stuart Pharmaceuticals received FDA approval in 1989 for sale of propofol in the United States under the brand name Diprivan. Because propofol is not water soluble, it is formulated in a lipid emulsion containing soybean oil, egg phosphatide (lecithin), and glycerol. After its introduction, case reports of septicemia began to surface, with the subsequent discovery that the lipid emulsion was an excellent culture medium for bacteria. The manufacturer responded by adding a preservative, EDTA, to the preparation and by including a warning in the package insert stating that "strict aseptic technique must always be maintained during handling."[26] Over the past several years, two generic products have since been formulated with the only difference being the use of either sodium bisulfite or benzyl alcohol as preservatives instead of the EDTA that was used in the original patented product.

There is ongoing research using fospropofol, a prodrug that is converted by alkaline phosphatase to propofol once injected (Figure 16-14).[27] The putative advantage is that fospropofol is water soluble, avoiding the need for a lipid solvent. This eliminates the risk of bacterial growth in the solvent and diminishes pain on injection. However, owing to the fact that it takes time for the prodrug to be converted to active drug, there would be a potential delay in onset of action once injected.

• BOX 16-1 Undesirable Clinical Side Effects of Opioids

The significant side effects and precautions of opioids include:

- **Histamine release:** May lead to hypotension, bronchospasm, flushing, and urticarial (especially with morphine; use with caution in patients with compromised hemodynamics or reactive airway disease)
- **Respiratory acidosis and respiratory failure** due to blunting of hypoxic respiratory drive
- **Worsening hypotension** in hemodynamically compromised patients
- **Reduced gut transit or ileus**
- **Urinary retention**
- **Opioid withdrawal:** For patients exposed to high-dose narcotics for more than 1 week, opioid infusions should be decreased no more than 25% per day to avoid withdrawal symptoms

Structure and Activity

Methohexital and propofol are thought to exert their action by interacting with GABA receptors (see Figure 16-3). Although it is unclear whether they both have common sites of action, it is certain those sites are different from the sites associated with the BZD.

Clinical Effects

Methohexital

Excitatory effects, such as hiccups and myoclonic movement, have classically been associated with methohexital, occurring as frequently as 90% of the time in patients who receive it (Figure 16-15).[28] Methohexital causes tachycardia and hypertension because there is cardiac compensation for peripheral vasodilation. It also tends to cause increased EEG activity and has potential as an epileptogenic.[29] Methohexital and other barbiturates appear to lower the pain threshold and have been credited with antianalgesic properties, but there is still debate whether this is a real phenomenon.[30]

Propofol

Propofol tends to provide cardiovascular stability by exerting a central sympatholytic effect that maintains a stable heart rate (Figure 16-16). There is also an accompanying decrease in systemic vascular resistance, but in the healthy patient and in the doses typically used in oral and maxillofacial surgery, there might be a slight—but clinically insignificant—decrease in blood pressure.[31] However, in the patient with significant cardiac disease, in the hypovolemic patient, or when very large boluses are given, there may be hypotension on induction. Propofol appears to cause few changes in electrical activity of the heart and is not typically associated with dysrhythmias. Both propofol and methohexital can cause apnea following large induction doses.

Because sensitivity to propofol increases with age and clearance of the drug decreases, a 30% to 50% reduction in drug dose may be required to prevent oversedation.[32]

Propofol has relatively few side effects. It does not cause nausea and vomiting; to the contrary, it possesses antiemetic properties and has been administered in subhypnotic doses for the treatment of nausea and vomiting.[33] The mechanism for its antiemetic effect has not yet been elucidated.

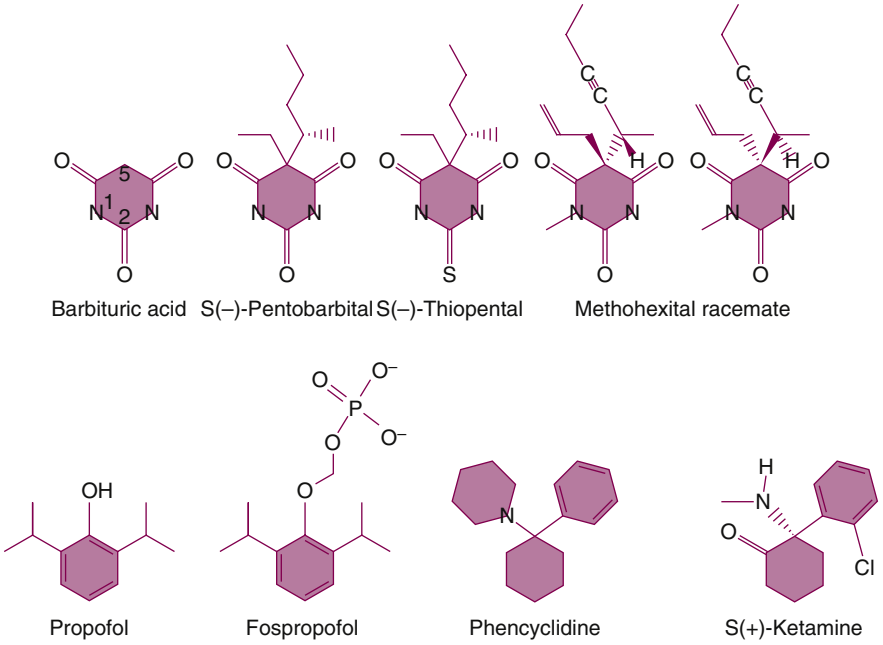

• **Figure 16-13** Chemical structures of intravenous anesthetics, including propofol and new agents such as fospropofol. (Modified from Garcia P: Intravenous anesthetics. In Hemmings HC, Egan TD, editors: *Pharmacology and physiology for anesthesia*, St Louis, 2013, Saunders, pp 137-158.)

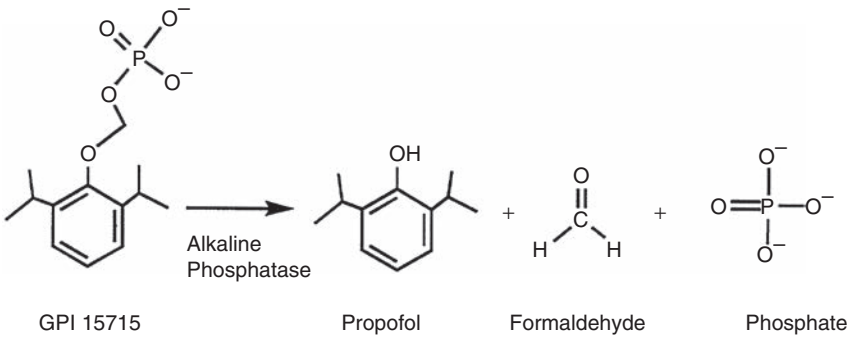

• **Figure 16-14** Activation of fospropofol. Fospropofol, here GPI 15715, is metabolized by the enzyme alkaline phosphatase into its active form, propofol. (From Melton MS: New medications and techniques in ambulatory anesthesia, *Anesthesiol Clin* 32(2):463-485, 2014.)

Propofol causes little or no histamine release and has not been associated with allergic reactions.[34] It has bronchodilating properties that may be due to direct effects on smooth muscle.[35] The literature also suggests that propofol may have analgesic effects, as evidenced by decreased need for postoperative analgesics by patients who received propofol compared with another anesthetic agent.[36]

Propofol does not cause tissue damage when given intraarterially or when accidentally infiltrated into tissues.[37] However, it is associated with pain on injection, particularly when small veins are used. Some clinicians have recommended injecting 1% lidocaine into the intravenous catheter before beginning injection of propofol, and others have admixed lidocaine into the vial or syringe containing propofol.[38]

A recently identified adverse effect associated with the drug has been labeled "propofol infusion syndrome." It tends to occur with propofol infusions longer than 48 hours, but has also been reported after short-term infusions using large doses. The syndrome is characterized by the combination of metabolic acidosis, acute bradycardia and/or asystole, and rhabdomyolysis, and it can be fatal (see Figure 16-16). Although the mechanism is not entirely understood, it is thought to result from direct effects on mitochondria.[39]

Pharmacokinetics and Metabolism

Methohexital

The short clinical effects of methohexital are due largely to redistribution of drug, first to vessel-rich tissues, then to muscle, and finally to fat. The elimination phase, however, is long, with slow metabolism of the active drug given up by extravascular tissues (Table 16-3). Although it would be possible to keep a surgical patient asleep for many hours using incremental boluses or a continuous infusion of methohexital, the patient would remain obtunded for a lengthy period of time postoperatively owing to significant pooling of nonmetabolized drug in muscle and fat (Figure 16-17).

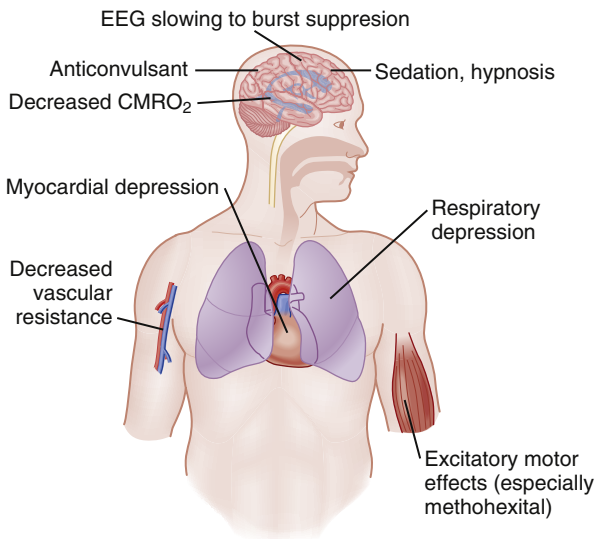

• **Figure 16-15** Clinical side effects of barbiturates. (Modified from: Garcia P: Intravenous anesthetics. In Hemmings HC, Egan TD, editors: *Pharmacology and physiology for anesthesia*, St Louis, 2013, Saunders, pp 137-158.)

Barbiturates, including methohexital, remain contraindicated in patients with inducible porphyria. Because methohexital induces the enzyme δ-aminolevulinic acid, porphyrin synthesis is increased, leading to increased production of heme and its precursors. In those with porphyria, this could lead to excessive accumulation of porphyrins and thus would exacerbate the disease.

Propofol

Propofol has a favorable pharmacokinetic profile because recovery from the drug is based on drug clearance and redistribution, not redistribution alone (see Table 16-2). There is a large volume of distribution and very rapid clearance as a result of rapid and efficient hepatic metabolism. At 30 minutes following a bolus dose of propofol, less than 20% of unchanged drug can be recovered from the serum.[40] Because propofol is metabolized so rapidly, there continues to be speculation that there are sites outside the liver where metabolism also occurs.[41] This rapid metabolism makes propofol an ideal drug for continuous-infusion anesthesia. When a propofol infusion is discontinued at the end of a 2-hour procedure, eye opening will occur within 5 minutes.[42]

The quality of recovery also appears to benefit from this rapid metabolism. Patients who received propofol typically appear to be alert and clearheaded, often within 20 minutes of discontinuing the agent.[43] This subjectively favorable recovery may also be due to the euphorigenic properties of propofol, promoting positive mood changes and thus a better quality of recovery.[44]

There is still concern regarding whether or not propofol can be used for patients with allergies to eggs or soy. Allergic reactions to food stems from an immune response to proteins or glycoproteins contained within that food. Until recently the propofol package insert only stated that a contraindication to the use of propofol was a "known hypersensitivity to propofol or its components." However, the FDA issued a labeling revision in February 2007 by adding a new caution regarding propofol infusion syndrome. The caution also became more explicit by stating that propofol is "contraindicated in patients with allergies to eggs, egg products, soybeans or soy products."[45] However, because the organic components (egg lecithin and soybean oil) are highly purified and protein free, it appears unlikely that propofol would trigger an allergic response even in a patient with an undiagnosed allergy to soy or eggs. The very low incidence of allergic reactions to all propofol preparations seems to bear this out, and the few reported cases of acute immune responses were usually characterized by co-administration of or sensitivity to other agents (e.g., muscle relaxants) that are more strongly associated with allergic reactions.[46]

Ketamine

Discovery and Development

Phencyclidine (PCP) was originally developed in the late 1950s for an analgesic screening program and was found to

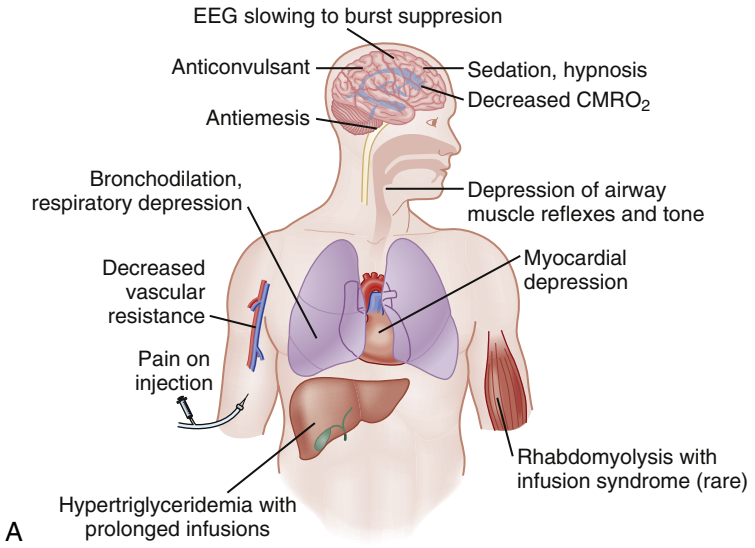

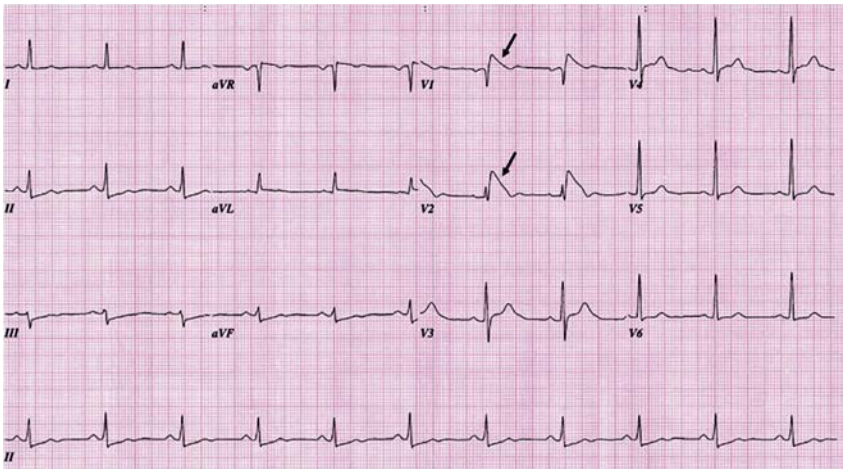

• **Figure 16-16** **A,** Propofol produces many clinical side effects including myocardial depression. **B,** The electrocardiogram (ECG) shows sudden nodal bradyarrhythmia seen in propofol infusion syndrome. Also shown is the coved-type ST-segment elevation in the right precordial leads (*arrows*). (**A,** Modified from Garcia P: Intravenous anesthetics. In Hemmings HC, Egan TD, editors: *Pharmacology and physiology for anesthesia*, St Louis, 2013, Saunders, pp 137-158; **B,** from Jorens PG: Propofol infusion syndrome with arrhythmia, myocardial fat accumulation and cardiac failure, *Am J Cardiol* 104:1160-1162, 2009. **B,** Ritchie JV, Juliano ML, Thurman R: ECG Abnormalities. In Knoop KJ, Stack LB, Storrow AB, Thurman R, editors: *The Atlas of Emergency Medicine*, ed 3, New York, 2010, McGraw-Hill, Chapter 23.)

produce anesthetic effects in monkeys (see Figure 16-13). It was introduced as the intravenous anesthetic Sernyl for human clinical trials in 1957. Its effectiveness was hampered by a high incidence of postanesthetic emergence reactions. Agitation, excitement, delirium, and hallucinations were seen in a significant number of patients, and these unpleasant side effects led the investigators to abandon further clinical investigation. PCP (also known as "angel dust") is now solely a drug of abuse and is used specifically for its hallucinogenic effects.

Following the negative experiences with PCP, a search began for a PCP analog that would retain the anesthetic effects but with a reduced incidence of emergence phenomena. This led to the discovery of ketamine in 1963. Clinical trials of ketamine began in 1966, and the drug was

TABLE 16-3 Pharmacokinetics of Intravenous Agents

	Distribution Half-Life (min)	Elimination Half-Life (hr)	Clearance (mL/min)
Midazolam	7-15	2-4	300-550
Diazepam	3-10	20-40	15-35
Methohexital	5-6	2-5	700-900
Propofol	2-4	1-3	1400-2800
Ketamine	11-17	2-3	1250-1400

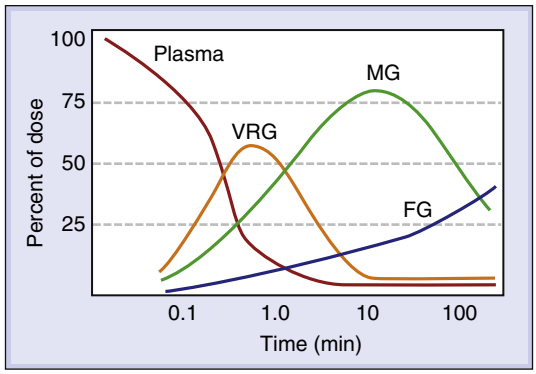

• **Figure 16-17** Distribution of methohexital occurs similarly to thiopental throughout the body over time. Body distribution includes plasma to the vessel-rich group (VRG; brain, heart, liver, kidney, endocrine glands), to the muscle group (MG), and finally to the fat group (FG). (Butterworth JF, IV, Mackey DC, Wasnick JD: Intravenous Anesthetics. In *Morgan & Mikhail's Clinical Anesthesiology,* ed 5, New York, 2013, McGraw-Hill, Chapter 9.)

introduced for clinical use as Ketalar in 1970. Although it has remained a cornerstone of veterinary anesthesia, there have been cycles of enthusiasm for its use in human anesthesia. Over the past decade, it has enjoyed a resurgence of popularity, particularly when used in lower doses and in combination with other intravenous anesthetics.

Structure and Activity

Glutamate is an excitatory neurotransmitter in the brain and is important for many higher CNS functions, including learning and memory. Glutamate receptors have multiple subtypes, of which the *N*-methyl-D-aspartate (NMDA) receptor is a cationic subtype (Figure 16-18, *A*). These receptors are found ubiquitously throughout the brain and spinal cord, but are concentrated more heavily at higher levels of the cerebral cortex. Glutamate, particularly in the presence of glycine, binds to the NMDA receptor and causes increased flow of sodium, potassium, and calcium, resulting in neural excitation.

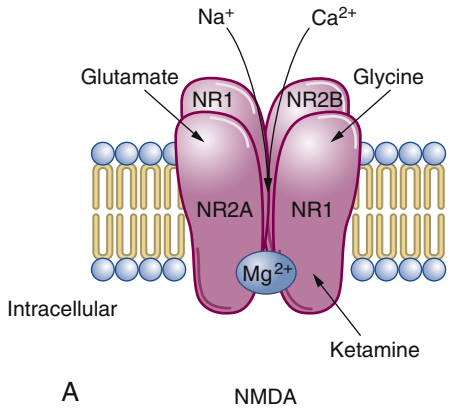

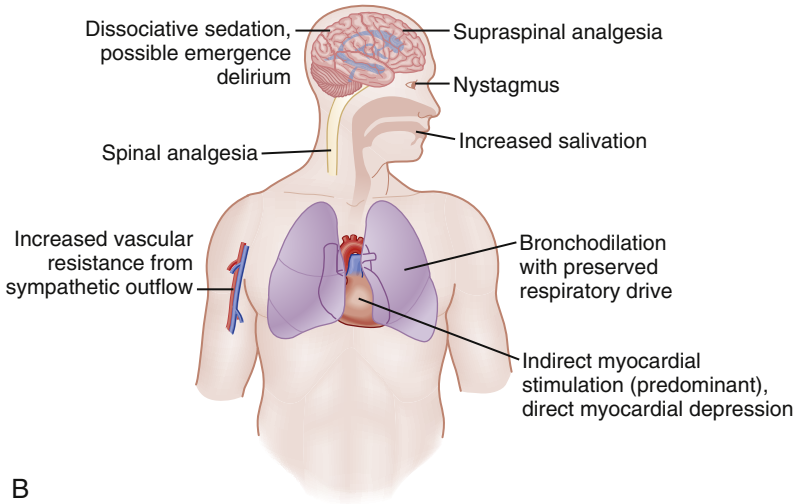

C

Absolute Contraindications	Relative Contraindications	Relative Contraindications continued
Hypersensitivity to ketamine	Moderate to severe hypertension	Intracerebral mass or hemorrhage, Increased ICP
Open eye procedures	Ischemic heart disease	Eye injury, increased intraocular pressure, glaucoma
Acute porphyria	Congestive heart disease	Psychiatric disorders: schizophrenia, acute psychoses
Liver failure	Pre-eclampsia	Non-controlled hyperthyroidism
	History of CVA	Patients taking thyroxin
	Acute or Chronic Alcohol Intoxication	Cerebral trauma

• **Figure 16-18** Phencyclidine and ketamine. **A,** NMDA receptor is the binding site of ketamine. Once ketamine is bound, glutamate activity is inhibited and sodium, magnesium, and calcium cannot cross the cell membrane into the cell. **B,** Clinical side effects of ketamine. **C,** Absolute and relative contraindications to the use of ketamine. (Modified from Garcia P: Intravenous anesthetics. In Hemmings HC, Egan TD, editors: *Pharmacology and physiology for anesthesia*, St Louis, 2013, Saunders, PP 137-158.)

Ketamine is a noncompetitive antagonist of NMDA, thus inhibiting glutamate activity and causing CNS depression. There are other drugs that cause NMDA antagonism as well, including certain opioids (e.g., methadone) and the over-the-counter antitussive dextromethorphan. Ketamine is also thought to selectively bind to opioid receptors, possibly providing an explanation for the analgesic effects of the drug.[47]

Ketamine is a water-soluble racemic mixture of S(+) and R(–) isomers. Its antagonism of the NMDA receptor is stereospecific, with the S(+) enantiomer possessing a three- to fourfold greater affinity for the NMDA receptor and has greater dissociative potency than the R(–) form, thus making it more potent than the racemic mixture.[48] The R(–) form, in addition to being less effective, is also associated with a greater incidence of emergence phenomena. Hence there is increasing interest in the clinical use of S(+) ketamine for anesthesia, postoperative analgesia, and sedation. In 2004 a U.S. patent was granted for a process to isolate S(+) ketamine and, although it is not yet commercially available, S(+) ketamine offers promise for use in ambulatory anesthesia in oral and maxillofacial surgery.

Ketamine has partial affinity for opioid receptors and thus can cause analgesia by inhibition of excitatory transmission at spinal and supraspinal sites. Despite the implication of involvement of opioid receptors, it does not appear that ketamine analgesia can be predictably reversed by naloxone.

Clinical Effects

Ketamine is described as causing a functional dissociation of EEG activity between the hippocampus and the thalamoneocortical system. Other sedative-hypnotics act more specifically on discrete locations within the midbrain and brainstem.

Ketamine causes a profound dose-dependent analgesia. Because the analgesia occurs at subanesthetic doses and outlasts the anesthetic effects, ketamine becomes a useful adjunct for patients where it is not possible to achieve absolute local anesthesia (e.g., when maxillofacial infections require incision and drainage). The analgesic effect of ketamine is equal to that of opioids along with the benefit of less respiratory depression.

Ketamine is sympathomimetic through direct CNS stimulation, thus causing an increase in heart rate, cardiac contractility, and rate pressure product (see Figure 16-18, *B*). This can result in increased coronary and cerebral blood flow and increased intracranial pressure (see Box 16-1). Regarding electrical activity in the heart, ketamine has been variably described as causing arrhythmias and preventing them.

Ketamine causes a mild respiratory depression that is not usually of clinical significance except when very large doses are given rapidly. The brainstem response to hypercarbia is maintained, as is the functional residual capacity. Ketamine is a bronchodilator by relaxing smooth muscle as a result of its sympathomimetic effects. There is increased secretion from respiratory mucous glands and salivary glands.

Pharmacokinetics and Metabolism

Ketamine is metabolized in the liver by the cytochrome P450 system, and the metabolites are excreted in the kidney. The principle metabolite is norketamine, an active drug that has been described as being anywhere from one-third to one-tenth the potency of ketamine. There are three other minor metabolites, all of which are inactive.

Contraindications and Adverse Effects

Over the decades that ketamine has been available, the adverse effects receiving the greatest amount of attention are the psychoactive effects. These can range from mild confusion and distorted perceptions to paranoia, delusions, and hallucinations. These psychoactive effects occur more frequently in adults than children and more often in females than in males. They are also more common with large doses (>2 mg/kg IV) and rapid administration (>40 mg/min). Patients with preexisting personality disorders or psychiatric disease are at greater risk for these psychoactive effects.

A number of studies have addressed the incidence and prevention of these psychoactive effects. Some benefit has been found from informing the patient about possible vivid imagery and playing music during the anesthetic, and nitrous oxide may also diminish the severity. However, coadministration of BZDs is the single most effective method of suppressing or eliminating psychoactive effects.

Contraindications to ketamine include patient situations where the sympathomimetic effects could be dangerous: uncontrolled hypertension, unstable angina, recent myocardial infarction, open globe injury, poorly controlled congestive heart failure, and uncontrolled hyperthyroidism (see Table 16-3). Ketamine would also be contraindicated in the presence of intracranial trauma or an open globe injury. Ketamine should be avoided for patients with psychiatric disorders with a history of recreational drug use.

Inhalation Anesthetics

Discovery and Development

The story of the discovery of nitrous oxide has been published extensively in many texts and articles. In the late 1700s, Joseph Priestley had discovered a number of gases, among them oxygen and nitrous oxide. At the end of the 18th century, Sir Humphry Davy reported on the pharmacologic effects of nitrous oxide, describing its analgesic and mood-altering properties, yet over the 40 years that followed, nitrous oxide was not used therapeutically, but was mainly a source of amusement at demonstrations. It was not until Horace Wells, a dentist in Hartford, Connecticut, attended a nitrous oxide demonstration that the therapeutic effects of nitrous oxide were explored. Wells had witnessed a young man who, under the influence of nitrous oxide at a town demonstration, injured his leg and appeared unaware of the injury. This caused Wells to

wonder if exodontia could be performed painlessly using nitrous oxide. The following day Wells self-medicated with nitrous oxide and had a fellow dentist remove one of his wisdom teeth. Afterwards Wells reported there was no pain with the extraction. Wells was permitted to demonstrate a tooth extraction on a patient under the effects at Harvard in front of a group of students and faculty; however, because the patient cried out during the extraction, Wells was booed off the stage.

Around the same period of time there was development of and experimentation with other gaseous agents, including diethyl ether and chloroform. Over the next 80 years, these agents, along with nitrous oxide, were the only inhaled anesthetics available to support the growing practice of surgery under anesthesia.

In the 1920s, there began a new effort to design drugs based on structure–activity relationships. It was during this time that divinyl ether (Vinethene), a flammable agent, was synthesized. A decade later cyclopropane, another flammable agent, was introduced for use in anesthesia. However, the dangerous risks of fire and explosion made these agents less than ideal, and research continued. In 1951 a new, nonflammable compound called halothane was synthesized and introduced as Fluothane for clinical use in 1956. Shortly after, methoxyflurane (Penthrane) was introduced, followed by enflurane (Ethrane) in 1966 and its isomer isoflurane (Forane) in 1971. These agents became the mainstay of inhalation general anesthesia for the next two decades. Two newer agents have all but replaced these because of their superior pharmacologic properties: desflurane (Suprane) and sevoflurane (Ultane), introduced in 1993 and 1995, respectively.

Structure and Activity

The activity of all inhalation agents is based on diffusion of the gas from the alveoli into the bloodstream. The amount and speed of diffusion is determined by the partial pressure of the gas in the alveoli compared with that in the bloodstream. Once in the bloodstream, the amount of gas available to exert its pharmacologic effect is determined by the blood-gas solubility coefficient (i.e., the amount of gas that can be dissolved in blood). The more soluble the gas, the less active gas is present to exert its effect. This property also influences the rapidity of onset of an agent and the recovery from its effects. Of all the gases, nitrous oxide is the least soluble, providing a very rapid onset of action and recovery (Table 16-4).

At least two locations have been identified at which inhalation agents exert their analgesic effect: supraspinal opiate receptors in the brainstem and adrenergic receptors in the spinal cord.[49] The precise location at which inhalation agents produce unconsciousness and amnesia has not been identified, although proposed sites of action include the hippocampus and the thalamus.[50] There is sufficient evidence, however, to indicate that the potent inhalation agents (not including nitrous oxide) increase inhibitory transmissions via the GABA pathway by interaction with the GABA receptor. Nitrous oxide, it appears, interacts with and blocks NMDA receptors and does not have any activity at the GABA receptor.[51]

The potency of anesthetic agents is described by the minimum alveolar concentration (MAC), the alveolar concentration of anesthetic at which 50% of patients are unresponsive to a standard surgical stimulus (see Table 16-4). However, there is a lower concentration at which most patients will be asleep—this has been termed the MAC_{awake}, or the alveolar concentration at which 50% of patients are asleep. MAC can be affected by many factors, most notably co-administration of other anesthetics or sedative drugs.

Clinical Effects

Nitrous Oxide

Nitrous oxide is a weak general anesthetic but a powerful analgesic. It has been estimated that a 20% concentration of nitrous oxide affords the same degree of analgesia as a dose of 15 mg of morphine.[52] Nitrous oxide is also a euphorigenic agent and a sedative.

Nitrous oxide is poorly soluble in blood and tissues, thus making induction and recovery rapid. Within 5 minutes

TABLE 16-4 Physical and Chemical Characteristics of Inhaled Anesthetics

	Nitrous Oxide	Halothane	Isoflurane	Desflurane	Sevoflurane
Boiling pt (°C)	50.2	48.5	22.8	58.5	
Vapor pressure (mm Hg)	Gas	244	240	669	170
Odor	Sweet	Organic	Ethereal	Ethereal	Ethereal
Stability in soda lime	Yes	No	Yes	Yes	No
Blood: gas partition coefficient	0.46	2.54	1.46	0.42	0.69
MAC (37° C)	104	0.75	1.17	6.6	1.80
% Metabolized	0.004	15-20	0.2	0.02	5

Modified from Stoelting RK: *Pharmacology and physiology in anesthetic practice*, ed 3, Philadelphia, Lippincott-Raven, 1999, pp 36, 67.

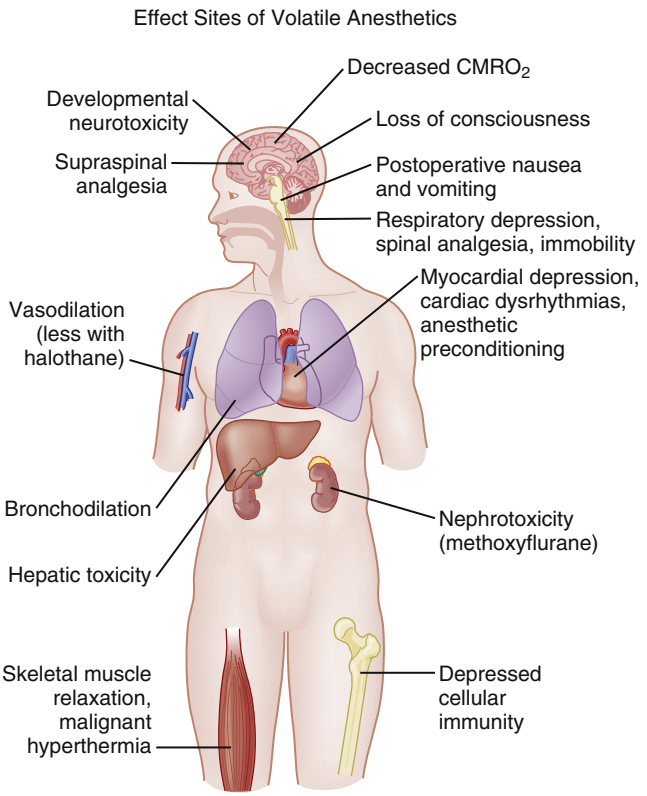

• **Figure 16-19** Clinical side effects of inhaled anesthetics including nitrous oxide. (Modified from Hudson AE: Pharmacology of inhaled anesthetics. In Hemmings HC, Egan TD, editors: *Pharmacology and physiology for anesthesia*, St Louis, 2013, Saunders, pp 159-179.)

after induction, tissue saturation is 90% of inspired concentration. Upon discontinuation of the agent, 95% will be eliminated after 10 minutes.

This rapid diffusion of N_2O from blood to lungs can result in a decreased CO_2 arterial tension, thus causing decreased stimulus for respiration (Figure 16-19). This rapid diffusion dilutes alveolar O_2 as well with a resultant hypoxic gas mixture in the alveoli. This leads to a potential effect called diffusion hypoxia, a phenomenon that is more theoretical than clinically significant. However, it is recommended in many texts that patients should receive 100% oxygen (and not room air) for 5 minutes after nitrous oxide is discontinued.

Nitrous oxide causes a decrease in myocardial contractility, peripheral vascular resistance, cardiac output, and blood pressure. It causes a decrease in respiratory rate but an increase in minute ventilation because of increased tidal volume. There is no change in the CO_2 response curve.

At higher doses, nitrous oxide can cause nausea and vomiting through a central effect.

The toxic effects of nitrous oxide continue to receive attention, particularly because of the prevalent use of nitrous oxide in dental operatories. Chronic exposure can lead to peripheral neuropathies and bone marrow suppression through inactivation of the methionine synthetase pathway. Surveys have suggested an increased incidence of spontaneous abortion and decreased fertility in health care providers exposed to nitrous oxide on a regular basis.

Nitrous oxide diffuses into empty body cavities because it displaces nitrogen. This can create morbidity in the presence of emphysema, pneumothorax, an open globe, or following middle ear surgery.

Isoflurane

Isoflurane is an ether that is nonexplosive. Its blood-gas partition coefficient is 1.4, making it the most soluble of the current gases in widespread use. Its MAC with oxygen is 1.15%, and when used with 70% nitrous oxide, it is 0.5%. Compared with the older gases, such as halothane, it has greater respiratory depression but less myocardial depression and does not sensitize the myocardium to catecholamines. There is no kidney or liver toxicity, and only 0.4% is metabolized. Its pungency does not make it a good choice for an inhalation induction.

Desflurane

Because of its low boiling point, desflurane requires a special heated vaporizer. Its blood-gas coefficient is 0.42, providing a rapid onset and recovery from the anesthetic. It is also less soluble in tissues compared with the other inhalation agents. The MAC of desflurane is 6% when used with oxygen and 3% when used with 70% nitrous oxide. The usual maintenance concentration is 6% to 8%. The pungent odor of desflurane precludes its use for inhalation induction. Desflurane causes little change in heart rate and a mild decrease in systemic arterial pressure. It is metabolized significantly less than other inhalation agents and does not cause any organ-specific toxicity.

Sevoflurane

This agent is nonflammable and has an MAC of about 2% alone and 0.66% when used with nitrous oxide. The usual maintenance concentration is 2% to 3%. Sevoflurane is a good agent to use for inhalation induction and does not cause the coughing and breath holding associated with isoflurane or desflurane.

Sevoflurane depresses respiration at high concentrations and relaxes bronchial smooth muscle. It decreases systemic arterial pressure and cardiac output while causing little change in heart rate. Sevoflurane has been associated with increased EEG activity and seizure-like activity. Some metabolism (2%) occurs in the liver, and two of its metabolites include formaldehyde and fluoride, the latter of which has the potential to cause renal toxicity.

Sevoflurane is known to react with certain carbon dioxide absorbents used in breathing circuits (soda lime and Baralyme) causing formation of several breakdown products. The one most studied has been termed Compound A. During a lengthy anesthetic with sevoflurane, there may be enough accumulation of Compound A to cause nephrotoxicity. Ongoing research is aimed at identifying absorbents that do not interact with sevoflurane.

Conclusion

Several different types of anesthetics are used in the ambulatory setting for dental procedures. Each class, including benzodiazepines, opiates, ketamine, intravenous, and inhalation anesthetics, has a specific known binding site and mechanism of action. Most of these drugs have similar clinical side effects, but the unique side effects offer benefits during procedures with different subsets of patients with comorbid conditions. It is important to understand the known contraindications and be able to recognize the clinical side effects when administering these medications.

References

1. Roberts E: The establishment of GABA as a neurotransmitter. In Squires RF, editor: *GABA and benzodiazepine receptors*, Vol I. Boca Raton, FL, 1988, CRC Press.
2. Randall LO, et al.: The psychosedative properties of methaminodiazepoxide, *J Pharmacol Exp Ther* 129:163, 1960.
3. Squires RF, Braestrup C: Benzodiazepine receptors in rat brain, *Nature* 266:732, 1977.
4. Martin IL, Dunn SMJ: GABA receptors, *Tocris Rev*(No 20), Mar 2002. http://www.biotrend.com/download/gabarev.pdf.
5. Briley MS, Langer SZ: Influence of GABA receptor agonists and antagonists on the binding of 3H-diazepam to the benzodiazepine receptor, *Eur J Pharmacol* 52:129, 1978.
6. Amrein R, et al.: Clinical pharmacology of flumazenil, *Eur J Anaesthiol Suppl* 2:65–80, 1988.
7. Basile AS, Lippa AS, Skolnick P: Anxioselective anxiolytics: can less be more? *Eur J Pharmacol* 500:441–451, 2004.
8. Stoelting RK: *Pharmacology and physiology in anesthetic practice*, ed 3, Philadelphia, 1999, Lippincott-Raven.
9. Dundee JW, Pandit SK: Anterograde amnestic effects of pethidine, hyoscine, and diazepam in adults, *Br J Pharmacol* 44:140, 1972.
10. Young AB, Zukin SR, Snyder SH: Interaction of benzodiazepines with central nervous system glycine receptors: possible mechanism of action, *Proc Natl Acad Sci* 71:2246, 1974.
11. Ikram H, Rubin AP, Jewkes RF: Effect of diazepam on myocardial blood flow of patients with and without coronary artery disease, *Br Heart J* 35:626, 1973.
12. Lind LJ, Mushlin PS, Schitman PA: Monitored anesthesia care for dental implant surgery: analysis of effectiveness and complications, *J Oral Implantol* 16:106, 1990.
13. Greenblatt DJ, et al.: Rapid recovery from massive diazepam overdose, *JAMA* 240(17):1872–1874, 1978.
14. *Valium injectable package insert*, Nutley, NJ, 1999, Roche Pharmaceuticals.
15. Stanski DR, Watkins WD: *Drug disposition in anesthesia*, New York, 1982, Grune and Stratton.
16. Berthold CW, Dionne RA, Corey SE: Comparison of sublingually and orally administered triazolam for premedication before oral surgery, *Oral Surg Oral Med Oral Pathol Oral Radiol Endod* 84:119, 1997.
17. Pert CB, Snyder SH: Opiate receptor: demonstration in nervous tissue, *Science* 179:1011, 1973.
18. Lord JAH, et al.: Endogenous opioids peptides: multiple agonists and receptors, *Nature* 267:495, 1977.
19. Stein C, et al.: Analgesic effect of intraarticular morphine after arthroscopic knee surgery, *N Engl J Med* 325:1123, 1991.
20. Wittels B, Scott DT, Sinatra RS: Exogenous opioids in human breast milk and acute neonatal neurobehavior: a preliminary study, *Anesthesiology* 73:864, 1990.
21. Bennett JA, et al.: Difficult or impossible ventilation after sufentanil-induced anesthesia is caused primarily by vocal cord closure, *Anesthesiology* 87:1070, 1997.
22. Blasco TA, et al.: The role of the nucleus raphe pontis and the caudate nucleus in alfentanil rigidity in the rat, *Brain Res* 386:280, 1986.
23. Flacke JW, et al.: Histamine release by four narcotics: a double-blind study in humans, *Anesth Analg* 66:723, 1987.
24. Bovill JG: Pharmacokinetics of opioids. In Bowdle TA, Horita A, Kharasch, editors: *The pharmacologic basis of anesthesiology*, New York, 1994, Churchill Livingstone.
25. McClain DA, Hug Jr CC: Intravenous fentanyl kinetics, *Clin Pharmacol Ther* 28:106, 1980.
26. *Diprivan package insert*, Wilmington, 2001, Del, AstraZeneca Pharmaceuticals LP.
27. Fechner J, et al.: Sedation with GPI 15715, a water-soluble prodrug of propofol, using target-controlled infusion in volunteers, *Anesth Analg* 100:701, 2005.
28. Mackenzie N, Grant IS: Propofol (Diprivan) for continuous intravenous anaesthesia. A comparison with methohexitone, *Postgrad Med J* 61(Suppl 3):70, 1985.
29. Reddy RV, et al.: Excitatory effects and electroencephalographic correlation of etomidate, thiopental, methohexital, and propofol, *Anesth Analg* 77:1008, 1993.
30. Kitahata L, Saberski L: Are barbiturates hyperalgesic? *Anesthesiology* 77:1059, 1992.
31. Werner ME, Bach DE, Newhouse RF: A comparison of propofol with methohexital and isoflurane in two general anesthetic techniques, *J Oral Maxillofac Surg* 51:1076, 1993.
32. Schnider TW, et al.: The influence of age on propofol pharmacodynamics, *Anesthesiology* 90:1502, 1999.
33. Borgeat A, et al.: Subhypnotic doses of propofol possess direct antiemetic properties, *Anesth Analg* 74:539, 1992.
34. Doenicke A, et al.: Effects of propofol (Diprivan) on histamine release, immunoglobulin levels and activation of complement in healthy volunteers, *Postgrad Med J* 61(suppl):15, 1985.
35. Smith I, et al.: Propofol-an update on its clinical use, *Anesthesiology* 81:1005, 1994.
36. Miranda AF, Kyi W, Sivalingam N: Propofol and methohexitone for elective caesarean-a comparative study, *Med J Malaysia* 47:280, 1992.
37. Chong M, Davis TP: Accidental intra-arterial injection of propofol, *Anaesthesia* 42:781, 1987.
38. Picard P, Tramer MR: Prevention of pain on injection with propofol: a quantitative systematic review, *Anesth Analg* 90:963, 2000.
39. Kam PC, Cardone D: Propofol infusion syndrome, *Anaesthesia* 62:690, 2007.
40. White PF: Propofol: pharmacokinetics and pharmacodynamics, *Semin Anesth* 7(suppl 1):4, 1988.
41. Shafer SL: Advances in propofol pharmacokinetics and pharmacodynamics, *J Clin Anesth* 5(Suppl 1):14S, 1993.
42. Edelist G: Propofol for laser endoscopic procedures, *Semin Anesth* 11(suppl 1):16, 1992.
43. Steegers PA, Foster PA: Propofol in total intravenous anaesthesia without nitrous oxide, *Anaesthesia* 43(suppl):94, 1988.
44. Zacny JP, et al.: Subjective and psychomotor effects of subanesthetic doses of propofol in healthy volunteers, *Anesthesiology* 76:696, 1992.
45. FDA Approved Drug Products. www.accessdata.fda.gov/scripts/cder/drugsatfda/index.cfm?fuseaction=Search.Label_ApprovalHistory. (Accessed 10/22/2007).

46. Laxenaire MC, et al.: Life-threatening anaphylactoid reactions to propofol ("Diprivan"), *Anesthesiology* 77:275, 1992.
47. Fink AD, Ngai SH: Opiate receptor mediation of ketamine analgesia, *Anesthesiology* 56:291–297, 1982.
48. Oye I, Paulsen O, Maurset A: Effects of ketamine on sensory perception: evidence for a role of *N*-methyl-D-aspartate receptors, *J Pharmacol Exp Ther* 260:1209, 1992.
49. Guo TZ, et al.: Antinociceptive response to nitrous oxide is mediated by supraspinal opiate and spinal alpha$_2$ adrenergic receptors in the rat, *Anesthesiology* 85:846, 1996.
50. Evers AS, Koblin DD: Inhalational anesthetics. In Evers AS, Maze M, editors: *Anesthetic pharmacology—physiologic principles and clinical practice*, Philadelphia, 2004, Elsevier.
51. Jevtovic-Todorovic V, et al.: Nitrous oxide (laughing gas) is an NMDA antagonist, neuroprotectant, and neurotoxin, *Nat Med* 4:460, 1998.
52. Chapman WP, Arrowood JG, Beecher HK: The analgesia effects of low concentrations of nitrous oxide compared in man with morphine sulfate, *J Clin Invest* 22:871, 1943.

17

Anesthetic Concepts and Techniques

JEFFREY D. BENNETT, KEVIN BUTTERFIELD

Introduction

Providing office-based sedation, anxiolysis, and analgesia to the oral and maxillofacial surgery patient has been standard practice for decades. The goal has always been to establish an environment in which the patient is comfortable, cooperative, and hemodynamically stable. The focus has also been on rapid patient recovery with efficient use of time. Numerous advancements in pharmacology, equipment, and techniques over the years provide the surgeon with various alternatives. There may be several different adequate choices in regard to anesthetic agent or technique for a particular situation. Many surgeons have a standard technique, which works well for them for most situations. However, the standard anesthetic regimen may be inappropriate for a particular patient or situation, and the surgeon must avoid a reflexive thought process of using the same drug or technique for all patients or all surgical procedures.

Levels of Sedation

Anesthesia is a continuum from consciousness to general anesthesia. The recognized levels of sedation are minimal sedation (formerly referred to as anxiolysis), moderate sedation/analgesia (formerly referred to as conscious sedation), deep sedation/analgesia, and general anesthesia. The patient's responsiveness, airway maintenance, spontaneous ventilations, and cardiovascular function categorize these different levels or depths of sedation.

Minimal sedation is defined as a "drug induced state during which patients respond normally to verbal commands. Although cognitive function and coordination may be impaired, ventilatory and cardiovascular functions are unaffected."[1,2]

Moderate sedation/analgesia (which we refer to as moderate sedation) is defined as a "drug induced depression of consciousness during which patients respond purposefully to verbal commands, either alone or accompanied by light tactile stimulation. No interventions are required to maintain a patent airway, and spontaneous ventilation is adequate. Cardiovascular function is usually maintained."[1,2]

Deep sedation/analgesia (which we refer to as deep sedation) is defined as a "drug induced depression of consciousness during which patients cannot be easily aroused but respond purposefully following repeated or painful stimulation. The ability to independently maintain ventilatory function may be impaired. Patients may require assistance in maintaining a patent airway, and spontaneous ventilation may be inadequate. Cardiovascular function is usually maintained."[1,2]

General anesthesia is defined as a "drug induced loss of consciousness during which patients are not arousable, even by painful stimulation. The ability to independently maintain ventilatory function is often impaired. Patients often require assistance in maintaining a patent airway, and positive pressure ventilation may be required because of depressed spontaneous ventilation or drug induced depression of neuromuscular function. Cardiovascular function may be impaired."[1,2]

These levels of sedation are not dependent on the route of drug administration nor the specific anesthetic agent or combination of agents administered. For example, given a large enough dose or a more typical dose in a medically compromised patient, an oral benzodiazepine could induce a level of moderate to deep sedation/analgesia. Various oral agents (e.g., benzodiazepines or chloral hydrate) when coadministered with nitrous oxide have produced more profound levels of sedation, inducing deep sedation/analgesia or general anesthesia.[3,4] Alternatively, propofol and methohexital, which are commonly associated with deep sedation/analgesia and general anesthesia, can be administered so as to produce levels of sedation that range from minimal sedation to moderate sedation/analgesia.

Goals of Sedation

The goals of sedation are to: (1) provide an optimal environment for completion of the surgical procedure, (2) minimize patient anxiety and optimize patient comfort, (3) control

the patient's behavior and movement and optimize patient cooperation, (4) optimize analgesia and minimize patient discomfort and pain, (5) maximize the potential for amnesia, and (6) optimize patient safety and maintain hemodynamic stability. Each situation (involving the patient and the specific surgical procedure) is independently evaluated to determine the depth or level of sedation required to achieve these goals.

The sedation of a child is different from that of an adult. For the young child, who lacks coping capability and social adaptability, the primary goal is to control the child's behavior and movement and to optimize patient cooperation. This differs from that of an adult patient, where the primary goal is to minimize patient anxiety and optimize patient comfort. Because of the different goals, the child frequently will require a greater depth of anesthesia. Alternatively, if moderate or deep sedation is used instead of a general anesthetic for the management of the pediatric patient, the practitioner will need to have a different level of tolerability. For example, the practitioner must be willing to accept some crying and possible movement that may require minimal restraint if moderate sedation (or possibly deep sedation) is planned for a pediatric patient.

The practitioner must also select which medications will be used to achieve the anesthetic plan. Although specific medications, such as propofol, may more commonly be used to achieve an anesthetic depth of deep sedation or general anesthesia, all of the anesthetic drugs that are used for "lighter" levels of anesthesia, such as minimal sedation, can result in effects associated with deep sedation or general anesthesia. Alternatively, in appropriate doses, propofol can be titrated to achieve a level of moderate sedation. The dissociative state resulting from ketamine provides a favorable surgical environment in which the patient becomes relatively immobile while maintaining an intact and stable airway. The desire to incorporate the drug into every technique needs to be weighed against an understanding of the drug's sympathetic effect. For example, injudicious use of the drug in a cardiovascularly compromised patient or a patient on a tricyclic antidepressant can have unfavorable consequences. In the former, the increased sympathetic stimulation can negatively affect the myocardial imbalance of oxygen supply and demand, and in the latter the patient may have prolonged sympathetic effects because of the interaction of the two drugs.

Concept of Rescue

There is a prevailing thought in medicine that human errors are inevitable and that these errors are not necessarily due to incompetence. An American Society of Anesthesiologists (ASA) closed claims analysis reported that up to 80% of anesthetic mishaps could have been prevented and were attributable to human error.[5] The concept of rescue therefore is essential to safe sedation. The office-based environment cannot be dependent on emergency medical services (EMS) as the primary intervention for adverse events. The office must be equipped and the staff able to manage the most serious of adverse events. The first line in preventing an adverse event is prevention. This has two components: (1) preoperative assessment and (2) ensuring that the practitioner who is administering the anesthetic is trained and capable of rescuing the patient from a deeper level of sedation than was initially planned.

Preanesthetic assessment is the focus of a separate chapter. However, there are a few points that I would like to emphasize here. The preanesthetic or preoperative assessment is the process in which the practitioner ensures that the patient is fit for anesthesia and surgery. The aim of the assessment is to obtain a good medical history and complete a focused physical examination. The medical history alone reveals up to 90% of the needed information. Two distinct types of office-based surgery practices exist among our oral and maxillofacial surgery colleagues: those who perform this preanesthetic assessment solely on the day of surgery; and those who perform this on a separate appointment before the scheduled surgery date. There are a few advantages to the latter methodology: (1) the ability to assess the patient's level of anxiety and provide psychological intervention either behaviorally or pharmacologically and (2) the ability to modify and direct treatment based on the patient's medical history (e.g., management of long-term medication, such as what medications should be taken and what should not be taken on the day of surgery).

Rescue therapies require continuous and repeated training to ensure a level of skill and knowledge. This is particularly important in an environment, such as the oral and maxillofacial surgery office, in which significant adverse events rarely occur. Several measures can be taken by the practitioner to prevent the occurrence of an adverse event or minimize its undesirable consequences. The practice of ambulatory office-based anesthesia in the oral and maxillofacial surgeon's office emphasizes team management. The concept of team management has been shown to optimize performance and minimize errors in medicine.[6,7] In addition, the practitioner and the anesthetic team should prepare for anesthetic care like a flight crew. Using this comparison, the anesthetic team must be comfortable and familiar with the anesthetic equipment. If the equipment is new to their office, this may entail a more detailed review to ensure familiarization. If the equipment is older, although the office may be familiar and fairly comfortable with it, its inspection must focus on potential effects resulting from age and ensure that it remains optimally functional. This requires a protocol in which the equipment (whether used for routine care or emergency intervention) is regularly inspected and the anesthetic team has the opportunity to practice with it. The latter point emphasizes the other concept in training and performance testing among pilots. Pilots use simulators to artificially create a scenario that is analogous to real life. Simulators can provide scenarios that represent normal anesthetic management and emergency situations. The ability to represent emergency situations is of particular interest because many individuals may never encounter a particular

emergency until they must deal with it during actual clinical patient care.

There are four different types of simulators: screen-based text simulators, screen-based graphical simulators, mannequin-based simulators, and virtual reality simulators. The mannequin-based simulator includes an anatomically correct physical model of a patient. The mannequins vary in complexity. The level of mannequin sophistication may allow the trainee to ventilate and/or intubate the mannequin, auscultate heart and lung sounds using anatomically placed speakers, assess respiratory efficacy by measuring end-tidal CO_2 and pulse oximetry, palpate carotid and radial pulses, and establish intravenous (IV) access. These simulators have been shown to enhance skills without endangering the health of patients.[8] They facilitate acquisition of knowledge and skills that are transferable back to clinical care. However, the mannequin simulators are expensive and lack easy portability. The screen-based graphical simulators attempt to visually recreate the clinical environment. The simulation programs provide physiologic data (such as heart rate, blood pressure [BP], electrocardiogram [ECG], oxygen saturation, and end-tidal CO_2), provide patient interaction (such as patient responses to preset questions), allow responses to physical examination (such as breath or heart sounds or level of responsiveness), and provide realistic responses to drug administration based on the pharmacokinetic and pharmacodynamic properties of the medications. Two studies completed at the University of Washington demonstrated that those trained using the screen-based graphical simulator demonstrated better retention and better application of skills and knowledge than those who used a text solely.[9,10]

Airway Assessment

Assessment of the airway is one of the most critical components of the preoperative assessment. This is exemplified by two separate ASA closed claims analysis publications that reported respiratory adverse events as the most common mechanism of injury to the patient. Forty-one percent of these claims were for death or permanent brain damage. The incidence of respiratory adverse events, most of which were inadequate oxygenation/ventilation, was comparable between monitored anesthesia care and general anesthesia.[11,12] The first step in preventing these adverse respiratory events is to identify a potential difficult airway.

Airway assessment consists of both history and examination. The history obtained from the patient should inquire about prior surgeries on the airway or difficulties with airway management during prior surgeries. The examination component of the assessment focuses on several anatomic components to the airway that can predict difficult airway management: (1) modified Mallampati test, (2) thyromental distance, (3) mandibular retrognathia, (4) interincisal opening less than 3 cm, (5) short neck, (6) thick neck (increased neck circumference of 17 inches for males and 16 inches for females), and (7) diminished range of motion of head and neck with the inability to extend or flex the neck (such that the tip of the chin can touch the chest). The modified Mallampati test assesses the airway based on the ability to visualize the uvula and faucial pillars when the mouth is wide open, the tongue is maximally protruded, the neck is extended forward into the sniffing position, and the patient phonates. The modified Mallampati classification has five categories that are defined in Table 17-1, with the higher class supposed to predict greater difficulty in intubation.

TABLE 17-1 Mallampati Classification

Class 0	Ability to see any part of the epiglottis on mouth opening and tongue protrusion
Class 1	Soft palate, fauces, uvula, anterior and posterior pillars seen
Class 2	Soft palate, fauces, and uvula seen
Class 3	Soft palate and base of uvula seen
Class 4	Soft palate only seen

The thyromental distance is a measurement from the mandibular menton to the prominence of the thyroid cartilage with the neck in full extension. The distance should be at least 6 cm or approximately three ordinary fingerbreadths. These tests were initially proposed, and most studies to date have investigated their ability to predict difficult intubations. Used independently, none of these tests was sufficient to consistently predict the difficulty of airway intubation.[13] Combining several different tests (such as the Mallampati test and the thyromental distance) to assess a patient's ease of intubation did result in a higher sensitivity, higher positive predictive value, and fewer false-negative results.[14] Because most office-based anesthesia for oral and maxillofacial surgery is done on the nonintubated patient, we are actually more interested in the ability to ventilate and to maintain airway patency than we are in the ability to intubate a patient. There are fewer studies assessing the ability to ventilate a patient or maintenance of airway patency. The incidence of being unable to ventilate a patient is approximately 5% of the general adult population. The Mallampati test was found to be no better in predicting difficult mask ventilation than difficult airway intubation. One publication did show a correlation in difficulty in mask ventilation among patients who were difficult to intubate[15] (Box 17-1).

Maintaining airway patency in the nonintubated patient is always potentially a risk because operating in the oral cavity can result in airway obstruction secondary to such factors as the positioning of the mandible, head-neck flexion-extension, or posterior displacement of the tongue. The above criteria provide some guidance as to the level of sedation, which would be appropriate or inappropriate for a particular patient in regard to the potential for airway difficulty. The surgeon may decide to manage the patient with significant findings with a minimal sedation in the office

• BOX 17-1 Difficult Mask Ventilation Predictors

Edentulousness
Lingual tonsil hypertrophy
Macroglossia
Skeletal abnormalities (e.g., retrognathia)
Poor atlanto-occipital extension
Facial hair
History of snoring
History of obstructive sleep apnea
BMI >26 kg/m^2

or may plan on using advanced airway techniques (either a laryngeal mask airway [LMA] or intubation) either in the office or in a hospital or surgery center. If the potential for a difficult airway is recognized, then appropriate preparations can be made to increase the likelihood of a good outcome. The complexity with the ability to predict a difficult airway lies not with the extremes of the assessment criteria but with those patients who fall in the middle. Other factors, such as obesity, history of snoring, abnormal oropharyngeal or neck masses, prior airway surgeries, or congenital, developmental, or acquired facial deformities (e.g., craniofacial syndromes, burns to the head and neck) may provide further guidance.

Obesity warrants further comment because its incidence is rapidly increasing in the United States, with a 2012 incidence in children and adolescents that is approximately 15% and in adults that approaches 40%. Physical findings previously discussed that are found in the obese patient include a decrease in cervical and mandibular range of motion, a decrease in thyromental distance, and a less favorable Mallampati class. The patient's airway is more likely to collapse during anesthesia, and the distribution of tissue in the patient's neck and chest will complicate airway management. This is compounded by the fact that the patient is more susceptible to developing hypoxemia or hypercapnia because of restrictive lung disease (an increased chest wall mass decreases chest wall compliance and diaphragmatic excursion), increased closing volume, and ventilation-perfusion mismatch. There is also a higher incidence of obstructive sleep apnea (OSA) in the obese patient. It is estimated that OSA is undiagnosed in 80% of patients who have the condition (Table 17-2). This extends the concern with airway and respiratory management beyond the intraoperative period into the postoperative period. The literature is insufficient to evaluate the effects of various analgesic medications on OSA. These patients will benefit from multimodal analgesic techniques (e.g., preemptive nonsteroidal anti-inflammatory) and minimization of opioids, and their respiratory depressant effects will most likely reduce the potential for adverse events.[16] The ASA guidelines suggest that the "OSA patient be monitored for a median of 3 hours longer than their non-OSA counterparts before discharge from the facility."[17]

TABLE 17-2 STOP BANG Questionnaire

Read the following questions and check Yes or No.	Yes	No
1. *S*noring: Do you *s*nore loudly (louder than talking or loud enough to be heard through closed doors)?		
2. *T*ired: Do you often feel *t*ired, fatigued, or sleepy during daytime?		
3. *O*bserved: Has anyone *o*bserved you stop breathing during your sleep?		
4. Blood *P*ressure: Do you have or are you being treated for high blood *p*ressure?		
5. *B*MI: *B*MI more than 35 kg/m^2?		
6. *A*ge: *A*ge over 50 yr old?		
7. *N*eck circumference: *N*eck circumference greater than 40 cm?*		
8. *G*ender: *G*ender male?		

High risk of obstructive sleep apnea (OSA): answering yes to three or more items
Low risk of OSA: answering yes to less than three items
*Neck circumference is measured by staff.
Adapted from Chung F, Yegneswaran B, Chung SA, et al: STOP Questionnaire: a tool to screen patients for obstructive sleep apnea, *Anesthesiology* 108:812-821, 2008.

Laryngeal Mask Airway

Traditional anesthetic management for intraoral surgery is unique in that the surgical site is contiguous with the unprotected nonintubated airway. The patient is susceptible to airway obstruction, airway irritation, and hypoventilation or apnea. This can necessitate surgical interruption to manipulate the airway to eliminate the obstruction and establish airway patency. This may be as easy as readjusting the pharyngeal curtain or performing a head-tilt maneuver. Various interventions may also be required to remove airway irritation. These could likewise include repositioning the pharyngeal curtain, which could be an irritant to the pharynx, or suctioning the pharynx of some irrigating solution that may have passed beyond the pharyngeal curtain. Rarely, the patient may require positive pressure ventilation.

The LMA forms an intermediate form of airway management between the face mask and the endotracheal tube. For intraoral surgery, it provides the ability to obtain, maintain, and secure a patent airway. The advantage of the LMA is that it is passed beyond the tongue, forming a seal with the laryngeal inlet and eliminating the most common cause of upper airway obstruction in the nonintubated patient. Because there is not a direct conduit into the trachea as achieved with endotracheal intubation, there is a potential for airway obstruction, which has been reported as high as 30%. This obstruction generally responds to head repositioning with no need to reposition the LMA or interrupt surgery. Breathing may be spontaneous, assisted, or

controlled with the LMA, avoiding the need to interrupt surgery to provide positive pressure ventilations. The LMA is also an excellent barrier against aspiration of irrigating solution, surgical debris, and blood. A pharyngeal curtain, however, is recommended to keep any surgical debris contained within the oral cavity and minimize the potential for aspiration of surgical debris when the LMA is removed.

General anesthesia is indicated when using the LMA. Using the standard technique, the LMA is inserted blindly after induction of general anesthesia. The blind insertion technique, which requires less airway manipulation compared with intubation, is associated with less sympathetic stimulation and potential hemodynamic fluctuations. Campbell and colleagues recommend laryngoscopy and direct visualization of LMA insertion as an alternative to optimize anatomic placement and minimize the epiglottis from impinging on the glottic opening.[18] Theoretically, this should improve airflow dynamics. These authors reported that the brief laryngoscopy for LMA placement did not adversely result in sympathetic stimulation and hemodynamic changes. Neither the blind nor the laryngoscopic insertion technique require neuromuscular blockade. The LMA is also advantageous compared with endotracheal intubation in that its anesthetic requirements during both maintenance and emergence are less.

Smoking

Approximately one quarter of the U.S. adult population smoke cigarettes.[19] Cigarette smoking is a cause of increased perioperative morbidity. This may be secondary to the chronic diseases associated with smoking, such as ischemic heart disease and chronic obstructive pulmonary disease. The constituents of cigarette smoke, such as nicotine and carbon monoxide, also have acute effects on both the cardiovascular and respiratory systems.

From a cardiovascular perspective, nicotine activates the sympathoadrenergic system. This increases heart rate, blood pressure, peripheral resistance, and oxygen demand. Expired carbon monoxide levels have also been shown to correlate with ST depression under general anesthesia.[20] Cigarette smoking also promotes a hypercoagulable state, contributing to arterial thromboembolism and coronary vasospasm.

Effects on the respiratory system include impaired mucociliary clearance and mucous hypersecretion, which results in increased airway irritability. This may be manifested clinically by a higher incidence of laryngospasm and airway obstruction. Small airway narrowing contributes to increased closing capacity, which results in ventilation-perfusion mismatch. Cigarette smoking also increases the blood carbon monoxide level and a leftward shift in the oxygen-hemoglobin dissociation curve. The increase in the carboxyhemoglobin level (8% to 10%) results in less oxygen being carried by hemoglobin. The leftward shift in the oxygen-hemoglobin dissociation curve results in less oxygen being released to the peripheral tissues. The net effect is a decrease in tissue oxygenation. Passive smoke exposure has also been shown to be a risk factor in children contributing to airway complications (laryngospasm ~5 times greater and airway obstruction ~3 times greater) during the intraoperative and postoperative period.[21]

Smoking can also have a detrimental effect on wound healing, including wound dehiscence, infection, and impaired bone healing.[22] This may be secondary to effects on the immune system or changes in tissue oxygenation.

Patients are usually counseled to stop smoking during the perioperative period. To achieve the greatest benefit from this counseling, the period of smoking cessation should be at least 6 to 8 weeks. The benefit from abrupt cessation before surgery is related to the half-life of nicotine and carboxyhemoglobin, which are 2 hours and 4 hours, respectively. The elimination of nicotine and carboxyhemoglobin decreases adrenergic stimulation, minimizing adverse cardiovascular effects, and increases both the oxygen-carrying ability of the blood and the amount of oxygen released to the peripheral tissues, resulting in increased tissue oxygenation. Overnight abstinence from smoking is beneficial, however, as the half-life of both nicotine and carboxyhemoglobin can be prolonged during sleep; a 24-hour "cigarette smoke-free" period is preferable.[23]

There has been controversy over smoking cessation beyond the initial 24 hours and a 6- to 8-week period. This controversy focuses on a paradoxic effect in which there is a transient increase in airway secretions and airway irritability associated with smoking cessation. This concept is best understood by recognizing that many smokers complain of increased airway secretions and airway irritability during the first several weeks after smoking cessation. Anesthetically, it is best to appreciate that it takes several weeks for the reduction in pulmonary complications to be apparent. During this time there may be a slight but not significant increase in pulmonary complications seen in anesthetized patients.[24,25]

The polycyclic hydrocarbons present in cigarette smoke are potent inducers of liver enzymes. Smoking cessation decreases these metabolic enzymes, potentially increasing blood levels of drugs that interact with the cytochrome P450 pathway. Coumadin is one drug that is metabolized by the affected enzymes, which may result in increased postoperative bleeding. Interestingly, postoperative nausea and vomiting are less in smokers. This may be attributed to the induction of liver enzymes. These enzymes may be responsible for the metabolization and excretion of various chemicals that may affect postoperative nausea and vomiting.[26]

Preoperative Fasting

The concept behind preoperative fasting is to minimize the risk of pulmonary aspiration, which may result in laryngospasm, chemical pneumonitis, or partial or complete airway obstruction as a result of particulate matter. The concept dates back to the mid-1940s, when Mendelson (who was an obstetrician) described a series of patients undergoing general anesthesia for vaginal delivery in which he documented respiratory complications secondary to

aspiration. He noted two distinct situations: (1) aspiration of particulate matter resulting in obstruction and (2) aspiration of liquid gastric contents resulting in dyspnea and cyanosis consistent with what is now referred to as aspiration pneumonitis.[27] Since this report, subsequent studies have sought to determine the minimum pH and volume of the aspirate. A pH less than 2.5 is associated with pathologic changes. The actual residual gastric volume associated with aspiration is more difficult to determine because not all regurgitated fluid is aspirated. A classic study suggested that a volume of 0.8 mL/kg with a pH of less than 2.5 when directly instilled into the trachea produces aspiration pneumonitis.[28] Other authors have suggested that this equates to a residual gastric volume of greater than 200 mL for passive regurgitation and pulmonary aspiration to occur during anesthesia. Gastric volumes of this magnitude may be found, but they are not normal. The typical residual gastric fluid volume in a patient fasted more than 8 hours for solids and 2 hours for clear liquids should be less than 30 mL.[29]

The basic premise of preoperative fasting is to minimize the volume and the acidity of the residual gastric fluid. The ASA adopted new fasting guidelines in 1999. A basic knowledge of gastric emptying times facilitates an understanding of these modifications. Gastric emptying for solid food is variable. A surgeon should be aware that approximately 50% of the contents of an ingested solid meal will remain in the stomach after 2 hours. Alternatively, gastric emptying for liquids is rapid, with a mean half-time of 10 minutes. Approximately 80% of ingested clear liquid will have passed into the duodenum after the first hour.

The current ASA recommendation allows the consumption of clear liquids up to 2 hours before the anesthetic. It is recommended that an individual fast for a minimum of 6 hours after the consumption of a "light meal" (e.g., toast, and avoidance of fat-containing solids and liquids) and up to 8 hours after the consumption of "fatty" solids.[30] The advantage of allowing clear liquid consumption up to 2 hours before the anesthetic is that it minimizes the risk of dehydration and hypoglycemia. It also decreases the potential for noncompliance and patient irritability (especially among children).

A preoperative evaluation assessing for comorbidities may result in a modification of the general guidelines of 2 hours with nothing by mouth (NPO) for clear liquids and 6 hours NPO for a "light meal." There are numerous situations that may delay gastric emptying: high sympathetic tone as a result of pain and anxiety, opioid use, cigarette smoking, cannabinoids, and functional dyspepsia. Several clinical conditions are associated with gastroparesis: diabetes mellitus, systemic lupus erythematosus, lack of coordination of swallowing or respiration, functional or mechanical obstruction to digestion, gastroesophageal dysfunction, Parkinson disease, and anorexia or bulimia. Of these, diabetes is the most commonly associated with gastroparesis. In the diabetic patient, the delay in gastric emptying is more significant for solids than for liquids. Obese patients do not present an increased risk for aspiration as a result of acidity and gastric volume, but have a higher incidence of difficulty in airway management with the potential for resultant gastric distention that may translate into an aspiration risk.

The use of gastrointestinal stimulants (e.g., metoclopramide), histamine-2 receptor antagonists (e.g., cimetidine), nonparticulate antacids (e.g., sodium citrate), and antiemetics to reduce the risk of aspiration is not routinely recommended in patients who have no increased risk of aspiration.

Fluid Administration

Total body water is approximately 60% of total body weight. It exists in two major compartments: intracellular and extracellular. Two thirds of the total body water is compartmentalized into the intracellular space, and the remaining one third is compartmentalized into the extracellular space. The extracellular compartment is further subdivided into intravascular and extravascular compartments. The intravascular compartment consists of one fourth of the extracellular body water or one twelfth of the total body water.

Sodium and chloride are primary extracellular electrolytes. These electrolytes are not diffusible between compartments. The distribution of free water is dependent on ionic and osmotic pressures.

Understanding fluid compartmentalization is critical to understanding intraoperative fluid administration. The administration of a hypotonic solution, such as D_5W, will result in a rapid redistribution of free water with only one twelfth of the water remaining in the intravascular space. Alternatively, the administration of an isotonic solution, such as 0.9% normal saline, will result in a preferential distribution of the fluid within the extracellular space. The fluid will remain within the intravascular compartment for 15 to 30 minutes before equilibration within the extracellular compartment. This provides the advantage of countering the vasodilatation secondary to the anesthetic agents.

The use of D_5W or the inclusion of dextrose in the intraoperative IV fluid is controversial for other reasons as well. The perioperative period is usually associated with a transitory hyperglycemia secondary to the release of the hormones: epinephrine, cortisol, and glucagon. The infusion of a dextrose solution may intensify the hyperglycemia. In the event of hypoxemia and anaerobic metabolism, the hyperglycemia will result in increased carbon dioxide production and intracellular lactic acidosis, potentially worsening neurologic injury associated with the hypoxemia.[31,32] The foregoing is relevant in regard to resuscitation of the trauma patient and fluid management for major surgery. It also has relevance in the event of resuscitation of a patient in the office. However, for dentoalveolar surgery, a minor risk surgical procedure as defined by the AHA/ACC, the stress induced hyperglycemia is transitory and can be followed by a period of hypoglycemia.[33] The postoperative hypoglycemia may be compounded by limited caloric intake during

this period because of local wound discomfort and soft tissue swelling that compromise the patient's ability and desire to take postoperative fluids.

Perioperative fluid administration for office-based surgery consists of the administration of crystalloid solutions (e.g., 0.45% saline, 0.9% saline, D_5/0.45% normal saline, D_5/0.9% saline). In minor surgery, there is no concern about fluid loss or fluid shift; however, fluid administration provides the ability to correct the preexisting fluid deficit secondary to preoperative fasting guidelines. Rehydration of the patient's fluid deficit during the perioperative period has been shown to improve the "quality" of recovery.[34] The fluid deficit can be calculated using the formula for maintenance requirements, which is 4 mL/kg/hr for the first 10 kg, 2 mL/kg/hr for the second 10 kg, and 1 mL/kg/hr for each additional kilogram. For a 70-kg lean individual who has fasted 8 hours (between midnight and 8 AM), the fluid deficit approximates 1 L. Whereas the current fasting guidelines allow unrestricted clear fluid consumption up to 2 to 3 hours before surgery, there are many patients who for various reasons have a 1- to 2-L fluid deficit. For office-based anesthesia in the healthy patient, it would be reasonable to administer 500 to 1000 mL of a crystalloid solution instead of using the IV access solely as a route of drug administration. Considering the patient's potential limited ability to take sustenance postoperatively, the administration of a 1-L dextrose-supplemented 0.45% or 0.9% saline solution could provide approximately 250 kcal of carbohydrate energy.

Whereas the preceding paragraph focuses on the recommendation to adequately rehydrate a patient, the practitioner must also be cognizant of excessive fluid administration. Most practitioners will be attentive to a patient who has a history of a systemic disease that requires fluid restriction, such as congestive heart disease. Special consideration must be given to the young pediatric patient. Overhydration can occur with any solution; however, with a hypotonic solution (such as D_5W), overhydration can rapidly result in cerebral edema and significant morbidity or patient mortality. This is merely another reason to consider administering either maintenance or replacement fluids (e.g., 0.45% or 0.9% normal saline). Prevention of overhydration can also be minimized by using a microdrip infusion set in the pediatric patient.

Anesthetic Techniques in Office-Based Anesthesia

The guiding principle of ambulatory anesthesia for office-based oral and maxillofacial surgery is to achieve adequate anxiolysis, sedation, amnesia, analgesia, and hemodynamic stability, so as to provide for a safe surgical environment resulting in rapid recovery and discharge of the patient home. There are several controversial aspects to anesthetic technique management. In this section, we focus on depth of anesthesia monitoring, anesthetic delivery techniques (bolus vs. continuous infusion), and choice of anesthetic agents or combinations.

Depth of Anesthetic Monitoring

When anesthetizing a patient in the office, the desired depth of anesthesia is most commonly assessed by subjectively assessing the patient's movements and facial expressions or lack thereof and objectively assessing the patient's respiratory (respiratory rate and oxygen saturation) and cardiovascular (blood pressure, pulse, and rhythm) function and stability. The anesthetic plan may be driven simply to achieve patient comfort and cooperation. Alternatively, the anesthetic plan may be dictated by the intent to maintain a specific anesthetic depth. Several factors influence the selection of the anesthetic plan: the patient's desired depth of anesthesia or lack of awareness; the surgeon's desired depth of sedation or amnesia; the surgical procedure; and/or the patient's systemic health.

Awareness with intraoperative recall is a major concern for all surgeons and anesthesiologists. Without minimizing the problem of intraoperative awareness, the situation is different in the intubated patient compared with the nonintubated patient. Awareness is frightening in the intubated patient because of a lack of ability to communicate both their awareness and inadequate anesthetic depth. For the nonintubated patient who always maintains the ability to communicate, there are different potential problems. For a planned general anesthetic, how does the surgeon optimally assess the anesthetic depth of a patient who appears relaxed, comfortable, eyes closed, and hemodynamically stable without unnecessarily administering an excess of anesthetic agent, which can be associated with adverse effects and delay recovery, or administer inadequate anesthetic agent such that the patient comments that they were awake despite appearing very comfortable and asleep?

The bispectral index (BIS) is a monitor that focuses on changes in the electroencephalogram (EEG) and uses an algorithm to assign a linear dimensionless number that correlates with anesthetic depth (Table 17-3). For the agents frequently used in oral and maxillofacial surgery (propofol, midazolam), BIS is relatively agent independent. However,

TABLE 17-3 Correlation of Bispectral Index (BIS) Value with Sedation Level

BIS Value	Sedation Level
100	Awake
70	Light hypnotic effect Low probability of recall
60	Moderate hypnotic effect Unconscious
40	Deep hypnotic effect

BIS is not entirely agent independent and does not reflect the clinical effects of ketamine or nitrous oxide in addition to the low dose of opioids generally used for office-based oral and maxillofacial surgery.[35] As many surgeons use nitrous oxide in combination with IV agents, and ketamine is making a resurgence as a component of the anesthetic cocktail in oral and maxillofacial surgery practices, BIS monitoring has clear limitations. In addition, there is individual variation in BIS's correlation with clinical indices of sedation, which may make it less accurate for any particular patient.[36] Sandler and colleagues have demonstrated the use of BIS in oral and maxillofacial surgery.[37] Although these studies demonstrated a strong positive relationship between BIS and the Observer's Assessment of Alertness and Sedation Scale (OAA/S) and a trend toward earlier return of motor function, they also showed a lack of correlation between BIS and the OAA/S at deeper levels of sedation consistent with deep sedation and only a trend toward earlier recovery. Periods of more intense stimulation balanced by less stimulating periods and relatively brief surgical procedures, which are not atypical for dentoalveolar surgery, may further limit BIS effectiveness in this environment.

Even if BIS is demonstrated to reliably define depth of sedation, what impact would this have on anesthetic management in the oral and maxillofacial surgery office? To use less drug and to expedite recovery, would the goal be to maintain a level of general anesthesia that is close to the transition between general anesthesia and deep sedation? Would titration of anesthesia to this specific zone increase the risk of the patient transitioning to a level of anesthetic excitability with its inherent risks? Alternatively, for the nonintubated patient who appears to be at an appropriate anesthetic depth and is dependent on spontaneous ventilation, would it be more appropriate to monitor ventilations and oxygen saturation in conjunction with clinical assessment of anesthetic depth or titrate the anesthetic agents based on BIS monitoring? Could administering anesthetic medications based on BIS readings potentially result in a patient who no longer maintains adequate ventilations or a patent airway? The literature is inadequate in regard to BIS analysis demonstrating that it optimizes anesthetic management and that it decreases anesthetic morbidity and mortality when incorporated into anesthetic care for the typical office dentoalveolar surgical procedure.

The preceding discussion focuses on the use of BIS in monitoring a deep sedation/general anesthetic. BIS may have more benefit in monitoring a patient with moderate to deep sedation for a prolonged procedure. The goal would be to maintain a BIS value between 70 and 80, which would correlate with eyelid ptosis and patient response only to loud or repeated calling of their name or mild prodding or shaking. A deviation outside these values would suggest a level of anesthesia either too light or too deep, warranting additional administration of the bolus agent, an increase or decrease in the continuous infusion, and/or more attentive monitoring to ensure airway patency and spontaneous ventilations.

Additional controversy focuses on BIS cost effectiveness. There is a cost for each unit and the disposable electrodes that may not be countered by the reduced anesthetic agent and ability to discharge the patient more rapidly. Obviously the questions raised cannot be taken individually, and a multitude of factors need be used in optimizing anesthetic management.

Anesthetic Delivery Technique and Choice of Anesthetic Agents or Combinations

Rapid recovery and early return to preoperative function are fundamental principles in ambulatory anesthesia. Pharmacokinetic and pharmacodynamic properties of many of the current IV and inhalational anesthetic agents facilitate these objectives. This section focuses on techniques of administration and choice of agent(s). A separate chapter discusses the pharmacology of the drugs.

IV anesthesia is the principal anesthetic technique used by oral and maxillofacial surgeons. It can be achieved with single or multiple IV drug combinations, with or without nitrous oxide. The anesthetic drug(s) can be administered solely at the beginning of the surgery or titrated throughout the surgery. The anesthetic drugs can be administered by intermittent bolus, by continuous infusion, or a combination of both. The goal for all forms of administration is to achieve and maintain an appropriate concentration of anesthetic drug at the effector site within the central nervous system to achieve a desired anesthetic depth.

The choice to administer anesthetic drugs solely at the beginning of the surgery is commonly for the following reasons: (1) this achieves a sedative depth to facilitate the local anesthetic administration; (2) the pharmacologic profile of the selected agents is such that they will provide a satisfactory depth of sedation of appropriate duration for the planned surgery; and/or (3) the surgical time is of such short duration that additional drug administration is not required.

The benzodiazepine-opioid combination of midazolam and fentanyl is commonly titrated to a selected anesthetic depth before the administration of the local anesthetic agent. The pharmacologic profile of these agents is such that they provide a satisfactory depth of sedation of appropriate duration for many surgeons to perform dentoalveolar surgery without additional drug administration. There is a benefit to this drug combination in that it provides anxiolysis, amnesia, sedation, and analgesia. Of additional benefit is the availability of a reversal agent for each class of drug. There is a limitation to the anesthetic combination in that the onset and recovery of each agent is relatively slow. An induction agent, such as propofol, may be administered as a bolus before the local anesthetic agent to provide a more profound anesthetic depth of brief duration.

The pharmacokinetics and pharmacodynamics of propofol are ideal for office-based anesthesia because they provide rapid onset and rapid recovery and return to "street readiness." An intermittent bolus technique remains the

most commonly used technique for administration of these agents in oral and maxillofacial surgery. The disadvantage to this technique is the potential for high peak plasma concentrations of anesthetic drug with resultant unwanted effects (primarily hypoventilation or apnea or airway obstruction). An alternative to the intermittent bolus technique is a continuous infusion technique with or without intermittent boluses.[38] The infusion pump is used in an attempt to parallel the simplicity of administering an inhalational agent with a vaporizer. The infusion can be titrated up or down in response to clinical signs and/or BIS monitoring. The intermittent bolus can be administered to adjust the sedative depth before an anticipated increased surgical insult. The sustained baseline plasma level achieved from the continuous infusion should result in a more rapid response to the intermittent bolus administration. Ideal application of this technique requires the use of an infusion pump in which the practitioner can set a dose per weight per time infusion. Newer target-controlled infusion delivery systems use pharmacokinetic models to achieve effect-site concentrations. Mathematical calculations alter the infusion based on interindividual variability and surgery. Advocates of a continuous infusion anesthetic technique claim that the technique will result in a more stable plasma level of anesthetic drug, which will provide a safer and more optimal anesthetic.[39]

Combined Infusions

The components of an anesthetic consist of anxiolysis, amnesia, sedation, analgesia, and hypnosis. Propofol produces anxiolysis, sedation, and amnesia and is frequently administered to produce hypnosis. Peripheral vasodilation and a central sympatholytic effect associated with the administration of propofol can result in a decrease in both blood pressure and heart rate. Ketamine establishes a dissociative state that creates a degree of "immobilization" in addition to analgesia. Its administration is frequently associated with an increase in both blood pressure and heart rate. Opioids produce analgesia. The goal of combining medications is to maximize the optimal effects of a medication and to minimize the agent's adverse effects. (For example, propofol and ketamine counter the detrimental effects of each agent: propofol—bradycardia with ketamine—tachycardia; propofol—hypotension with ketamine—hypertension; propofol—antiemetic with ketamine—emetic.)

Traditionally, each drug is administered as an individual bolus. The advantage of a continuous infusion is that it provides a stable plasma level with the goal of establishing a stable minimally fluctuating anesthetic depth. With an understanding of the pharmacokinetics of each agent, different combinations of agents have been combined into the same syringe and administered as a co-infusion. Propofol-remifentanil and propofol-ketamine combinations have been described in the literature (Table 17-4). Although these drug combinations are physically and chemically compatible such that they may be combined in the same syringe, they should be prepared just prior to the procedure and discarded immediately after the anesthetic.[40]

An alternative and nontraditional method of sedation is patient-controlled sedation. The concept of patient-controlled sedation is that it enables the patient to vary the degree of sedation. A patient has the ability to administer a predefined bolus of IV anesthetic agent. Various parameters can be set into the devices that limit the total amount of

TABLE 17-4 Propofol-Remifentanil and Propofol-Ketamine Combinations

Propofol-Remifentanil Mixture	
Mix 100 μg of remifentanil in 20 mL of propofol to create a 5 μg/mL remifentanil/,10 mg/mL propofol mixture	
For deep sedation, infuse mixture at a rate of propofol 75-100 μg/kg/min	For a 70-kg patient, this results in an infusion of 2.5 μg/min remifentanil. The sedation infusion rate for remifentanil is 0.4-0.1 μg/kg/min. If propofol were infused at a rate of 75 μg/kg/min, a remifentanil infusion rate of 0.4 μg/kg/min for a 70-kg patient would be 2.8 μg/min.
For general anesthesia, infuse mixture at rate of propofol 100-140 μg/kg/min	For a 70-kg patient this results in an infusion of 5 μg/min remifentanil. The general anesthesia infusion rate for remifentanil is 0.1-1 μg/kg/min. If propofol were infused at a rate of 140 μg/kg/min, a remifentanil infusion rate of 0.1 μg/kg/min for a 70-kg patient would be 7 μg/min.
Propofol-Ketamine Mixture	
Mix 1 mg of ketamine in 20 mL of propofol to create a 1 mg/mL ketamine to 10 mg/mL propofol mixture	
Initial bolus: 500 μg/kg propofol	For a 70-kg patient this results in: Propofol dose of 35 mg Ketamine dose of 3.5 mg
Maintenance infusion: 100 μg/kg/min propofol	For a 70-kg patient this results in: Propofol infusion of 7 mg/min Ketamine infusion of 0.7 mg/min

drug, the intervals at which a patient can self-administer the anesthetic agent, and the rate at which a drug is administered. Although various agents have been used, the pharmacokinetic properties of propofol make it the most appropriate agent for patient-controlled sedation.[41-43]

Inhalation Induction

Inhalation induction by mask is the technique most commonly used for pediatric patients by our anesthesiology colleagues because it can be achieved relatively easily and rapidly in most children and is less objectionable than the insertion of an intravenous catheter.

The average child is usually cooperative but may be frightened by the unusual environment. The most reassuring approach initially involves gentle banter, in a smooth nonthreatening tone, allowing for a constant conversation and communication between the child and the treating clinician. It is usually best if the treating clinician alone does the talking, and if it is continual. This should continue throughout the application of monitoring instrumentation (pulse oximetry, precordial stethoscope, ECG, and BP). If there is any concern that the application of monitoring will increase anxiety and compromise a smooth induction, minimal monitoring should include a pulse oximeter and precordial stethoscope (positioned over the left sternal border at the second to fourth intercostal space with a double-stick adhesive so that both the breath and heart sounds will be heard clearly). A full face mask is then gently introduced. The child needs repeated reassurance that he or she is doing well. Typically, 100% oxygen is introduced with the anesthesia mask being gently held close to the face without touching the skin at first. Apprehensive children can hold the mask to their face themselves. This instills a sense of self-control, thus reducing anxiety. Pleasing scents placed in the facemask will often improve child acceptance of the mask. Following a few minutes to allow for appropriate pre-oxygenation, 70% nitrous oxide is introduced, and the mask is held gently touching the skin of the face. Two to 3 minutes of nitrous oxide sedation will usually allow the introduction of sevoflurane. A gradual increase of sevoflurane, increasing 1% every 2 to 3 breaths, up to 2 MAC (minimum anesthetic concentration) will allow for appropriate induction. The concentration of sevoflurane can be increased rapidly to 6% to 8% in otherwise healthy patients without causing significant hypotension or bradycardia. A well-done study compared three techniques of sevoflurane induction: traditional incremental increases in sevoflurane, versus 8% sevoflurane, versus 8% sevoflurane and 1:1 mixture of N_2O and O_2.[44] Minimal differences were seen among the three techniques, with the addition of nitrous oxide reducing the time to eyelash reflex and incidence of excitement during induction.

Once eye closure is achieved, the child may not move, but may lose consciousness slowly and continue to hear very accurately. Apprehension may increase as the child becomes disoriented, requiring the clinician to continue to maintain reassuring contact with the child. Care is taken to not stimulate the child as induction is achieved, but adequate monitoring (ECG, pulse oximetry, capnography, noninvasive BP) must be established as soon as the patient is sufficiently asleep to tolerate this without causing excitement phase reflexes. The first sign of anesthetic induction is the presence of nystagmus; the eyes then close; respirations become slower, regular, and deeper, then shallower and more rapid, until the child settles into a more regular breathing pattern. Throughout this transition, the child should not receive any significant stimulation. Once the child does not respond to a voice and the eyelash reflex is absent, the IV can be placed. An assistant should be ready to help position the child and perform venipuncture as the treating clinician maintains the airway. Joshi found that the time for effective IV cannulation in 95% of patients is approximately 3.5 minutes (range 2.68 to 6.77 min) following the introduction of sevoflurane.[45] Once an IV is established, the sevoflurane can be continued at a reduced concentration, or intravenous agents can be introduced for a standard outpatient anesthetic technique. Knowledge of the signs of early induction is mandatory (see Table 17-1), in order to avoid stimulating the child during stage 2 of anesthesia.

Choice of Anesthetic Agent

Nitrous oxide is the most commonly used inhalational agent among oral and maxillofacial surgeons. Use of nitrous oxide in conjunction with either IV agents (e.g., propofol) or potent inhalational agents (e.g., sevoflurane) potentiates the effect of the other anesthetic agent. This can reduce the amount of required anesthetic agent and result in a shorter wake-up time. However, many surgeons feel that the excellent pharmacokinetic properties of the current IV agents minimize these benefits potentially achieved with nitrous oxide. It has also been suggested that nitrous oxide contributes to a higher incidence of nausea and vomiting, although this has been challenged.[43]

IV sedation is most commonly achieved with a combination of benzodiazepine (e.g., midazolam), opioid (e.g., fentanyl, remifentanil), and propofol. Ketamine is also popular and can be incorporated into a standard anesthetic regimen or used as a drug to scavenge an anesthetic. Ketamine provides two effects that are advantageous in optimizing the anesthetic. First, the cataleptic state establishes a degree of immobility, and as the patient recovers from the effect of ketamine, there is a slow "robotic" type of return to purposeful patient movement compared with the rapid and "violent" type of movement that may be seen with propofol. Second, when ketamine is administered as a slow bolus in doses of 0.25 to 1 mg/kg (which are customary for office-based ambulatory oral and maxillofacial surgery), airway patency, spontaneous ventilations, and functional residual capacity (FRC) are maintained.

Remifentanil is an ultrashort-acting opioid. It has advantages over other opioids because of its rapid onset (~90 seconds, compared with fentanyl ~5 minutes) and rapid offset (context-sensitive half-life of 3 to 6 minutes). Because of its

pharmacokinetic profile, it is frequently administered as an infusion. Remifentanil can be combined with midazolam (for amnesia and anxiolysis) instead of propofol.[47,48] The use of remifentanil provides a degree of intense analgesia in which the patient has excellent pain control. When combined with midazolam, the patient is frequently awake and less amnestic of the procedure than if propofol were administered. However, the use of remifentanil establishes a surgical environment in which the patient, although less sedated and clinically more awake, does not move and does not transition from lighter to deeper anesthetic depths with the associated patient movement and potential airway irritability. Attentive respiratory monitoring is required with remifentanil, with different authors reporting varying degrees of hypoxia and ventilator depression.

Dexmedetomidine

Dexmedetomidine is an α_2-adrenoreceptor selective agonist that produces hypnosis and analgesia without respiratory depression. Respirations are comparable to those of a patient during "natural" sleep. The drug can be used as a premedicant (administered intranasally to the pediatric patient) or as an induction or maintenance drug as a component of the anesthetic cocktail. Intravenously, the drug is typically administered as a slow bolus supplemented with a continuous infusion.

Dexmedetomidine may be advantageous in selected situations. The ability to provide sedation, anxiolysis, and analgesia without respiratory depression establishes an environment for awake intubation in the patient with a compromised airway. The same properties are ideal for a patient who is to remain intubated after surgery or to supplement postoperative analgesia and attenuate hemodynamic parameters. However, as an adjunct to ambulatory outpatient anesthesia, the data are controversial as to its benefit. as it may produce bradycardia and orthostatic hypotension and prolong recovery. Given the agent's cost, the authors do not feel that dexmedetomidine is an ideal anesthetic agent for ambulatory office-based oral and maxillofacial surgery.

Patient Positioning

Patient positioning for office-based oral and maxillofacial surgery is usually dependent on the surgeon's preference and the specific surgical procedure. The typical positioning varies from supine to a head-up position of approximately 60 degrees, with most surgeons using some variation of head-up positioning. Head-up positioning has some physiologic advantages.

In the erect individual, the rib cage, the diaphragm, and the abdomen expand with inspiration. In the supine individual, thoracic expansion is more dependent on rib cage expansion, abdominal expansion is lessened, and the contents of the abdomen displace the diaphragm cephalad. The cephalad displacement of the diaphragm in the supine patient can cause a decrease in the FRC of approximately 0.5 L.[49]

FRC is the lung volume at the end of normal expiration. In the normal adult patient, the FRC is approximately 2 L with the total lung capacity being approximately 5 L. In the anesthetized patient, the FRC can further decrease by another 0.5 L in the supine patient. The importance of the FRC is that it provides an oxygen reserve in the event of impaired ventilations. Several studies have demonstrated the benefit of head-up positioning of varying degrees on minimizing oxygen desaturation after preoxygenation and induction of anesthesia.[50,51]

In addition to nonerect patient positioning, several other factors decrease FRC, including obesity, pregnancy, restrictive pulmonary disease, and short stature.

Patient positioning is also important in regard to prevention of neurologic injuries. In an ASA closed claims analysis, nerve injuries were the second most common type of complaint. Ulnar neuropathies were preponderant in these case reports.[52] These injuries may occur secondary to stretching or compression. Diabetes, alcohol, or smoking may contribute to an increased incidence of postoperative neuropathies.[53] The patient seated in a dental surgical chair is most susceptible to ulnar or radial nerve injuries, as opposed to lower extremity nerve injuries. Whereas patient positioning may contribute to neural deficit, the present observation of ulnar or radial nerve injuries suggests that these neuropathies are not secondary to patient positioning.[54,55]

Postoperative Recovery and Discharge

Office-based surgery typically is of short duration with a focus on rapid recovery. Anesthetic recovery is a continuum from the end of surgery when the last sedative/anesthetic agent has been administered and the patient emerges from sedation/anesthesia (early recovery), to a time in which the patient has satisfactorily achieved "selected" criteria that indicate that the patient is stable to be discharged (intermediate recovery), to a time in which the patient returns to the preoperative physiologic state (late recovery). Clinically, early recovery is categorized by the patient awakening, having intact airway reflexes, maintaining a patent airway, ventilating, oxygenating, and being hemodynamically stable. Most patients who have been sedated without advanced airway devices for office-based oral surgery progress almost immediately through early recovery to the intermediary recovery phase. Until patients progress into the intermediary recovery phase, they need to be intensively observed, generally by the oral and maxillofacial surgeon or recovery nurse. Pediatric patients have less reserve and warrant diligent care.

During intermediary recovery, continued observation by an individual trained to recognize complications should persist until the patient is discharged. During intermediary recovery, the observation need not be as intensive, requiring one-on-one observation. Monitoring as described later, with set audible alarms and diligent periodic observation,

is acceptable. To avoid having the patient unattended, the patient's escort can be allowed to remain with the patient at this time.

Respiratory and cardiovascular monitoring should be continued throughout the early and intermediary phases of recovery. Respiratory monitoring should assess oxygenation (pulse oximetry) and ventilation (respiratory rate and airway patency). Oxygen administration is generally discontinued during the intermediary recovery period. This assesses the patient's ability to maintain oxygenation on room air. Cardiovascular monitoring should minimally assess blood pressure and pulse. Electrocardiographic monitoring is not absolutely mandated but should be immediately available. For selected patients with significant cardiovascular disease, continual ECG monitoring should be considered. Vital signs consisting of blood pressure, pulse, respiratory rate, and oxygen saturation should be recorded at regular intervals. IV fluid hydration is not routinely indicated at this time, and continued administration may mask hemodynamic stability or lack thereof. Maintaining IV access, however, provides the ability to manage adverse events if necessary and is recommended to be removed just before discharge.

Intermediary discharge criteria determining home readiness are a continuum from the several parameters mentioned above. Vital signs (blood pressure, pulse, respiratory rate, and oxygen saturation) must be stable and consistent with preoperative values within acceptable parameters. In general, blood pressure and pulse should be within 20% of preoperative values, and a deviation of 40% warrants investigation. Oxygen saturation should be maintained above 90% on room air or consistent with preoperative value in the undisturbed patient. The patient should be alert and oriented unless the mental status was initially abnormal, in which case the patient's mental status should have returned to baseline. The patient must be able to ambulate at preoperative levels. Nausea and vomiting should be minimal and responsive to treatment. Routine antiemetic prophylaxis is only indicated in selected patients with a high incidence of postoperative nausea and vomiting. There should be minimal to no pain. Good local anesthesia is beneficial in reducing the anesthetic requirements and providing prolonged patient comfort, minimizing sympathetic stimulation, which can adversely affect hemodynamic stability and nausea and vomiting (because sympathetic stimulation increases incidence of nausea and vomiting). Last, surgical bleeding should be minimal and consistent with that expected for the surgical procedure.[56] Gauze pressure dressing applied to the intraoral wound for hemostasis should consist minimally of 4 × 4 gauze sheets that partially protrude from the mouth until the patient has fulfilled discharge criteria. Smaller gauze sheets or gauze packed solely intraorally increases the potential risk for aspiration and airway obstruction.

For select patients, fluid intake (diabetic patient) and urinary voiding may be indicated. Routinely mandating fluid intake, however, is unnecessary and can contribute to nausea and vomiting, prolonging discharge.[57] There is a higher incidence of nausea and vomiting in ambulatory patients who have received opioids. This is secondary to the interaction between the labyrinthine vestibular system, opioids, and the chemoreceptor trigger zone. Because the potential for hypoglycemia and the associated morbidity as a result of a lack of glucose intake is high in the diabetic patient, both mandating fluid intake in the office before discharge and providing home instructions to ensure fluid intake and glucose monitoring upon discharge are critical. Urinary voiding is also not routinely recommended. Perioperative medications that could contribute to urine retention include the opioids and anticholinergic agents. For patients at low risk for urine retention, most have voided within 3 hours of surgery.[58] There are also several reasons as to why there may be a lack of urinary urgency in the ambulatory oral surgical patient. Many patients are asked to void before surgery. This has the benefit of minimizing perioperative bladder distention, which could contribute to patient discomfort, sympathetic stimulation (associated with hypertension and tachycardia), subsequent urine retention, and/or inadvertent urinary incontinence. In addition, unless the patient's fluid deficit is replaced during surgery, the patient may not have a volume of urine to void. Patients should be instructed to seek medical assistance if they are unable to void within 6 to 8 hours of discharge.

The final determination and responsibility to discharge the patient is the responsibility of the anesthetist-surgeon. This task should not be delegated to office staff. Patients should be discharged to a responsible adult who will accompany them home and provide postoperative care.

Know When to Stop

Sedation is a wonderful modality that optimizes the quality of care within our offices. Office-based anesthesia in oral and maxillofacial surgery is mostly accomplished in the nonintubated patient. The technique of providing such anesthesia is both art and science. The "art" in anesthesia as administered by the oral and maxillofacial surgeon involves the ability to establish a good surgical environment in a patient who maintains spontaneous ventilations. However, there are times in which the balance of having a good surgical environment in which the patient is "asleep, immobile, cooperative, and comfortable" and maintains a patent airway with spontaneous ventilations is not accomplished.

When such a situation arises, the anesthetic team is confronted with a decision. The question that most frequently is on individuals' minds is how to achieve the anesthesia and complete the planned surgery. It may be appropriate to consider alternative pharmacologic agents or techniques. Ketamine is one such alternative agent that many practitioners may consider. It can establish a dissociative state and "scavenge" many such anesthetics. Some practitioners may convert a failed anesthetic in the nonintubated patient to a technique in which the airway is secured with either an endotracheal tube or an LMA. However, ketamine may not "smooth" out the anesthetic, and the patient may have a difficult airway that cannot be secured with various airway devices.

When deviating from the planned anesthetic treatment, there must be limits as to what is acceptable. Not all patients can be anesthetized "as planned" in the office. For example, a patient who was planned for general anesthetic may only be able to be minimally or moderately sedated. If a patient requires a general anesthetic, it may be more appropriate to seek the assistance of an anesthesiologist. Although there is a natural desire not to want to admit defeat, optimal patient care is the goal, and the practitioner needs to "know when to stop."

References

1. Joint Commission on Accreditation of Healthcare Organizations: *Sedation and anesthesia care standards*, Oakbrook Terrace, IL, 2001, JCAHO. www.jcaho.org/standard/aneshap.
2. American Society of Anesthesiologists: Standards: continuum of depth of sedation/definition of general anesthesia and levels of sedation/analgesia. http://www.asahq.org/publicationsAndServices/standards/20.pdf, Jan 2007.
3. Litman RS, et al.: Upper airway obstruction during midazolam/nitrous oxide sedation in children with enlarged tonsils, *Pediatr Dent* 20:318, 1998.
4. Litman RS, Berkowitz RJ, Ward DS: Levels of consciousness and ventilator parameters in young children during sedation with oral midazolam and nitrous oxide, *Arch Pediatr Adolesc Med* 150:671, 1996.
5. Cooper JB, Newbower RS, Kitz RJ: An analysis of major errors and equipment failure in anesthesia: considerations for prevention and detection, *Anesthesiology* 60:34, 1984.
6. Sexton J, Thomas E, Helmreich R: Error, stress and teamwork in medicine and aviation: cross sectional surveys, *BMJ* 320:745, 2000.
7. Bellomo R, et al.: Prospective controlled trial of effect of medical emergency team on postoperative morbidity and mortality rates, *Crit Care Med* 32:916, 2004.
8. Abrahamson S, Denson JS, Wolf RM: Effectiveness of a simulator in training anesthesiology residents, *J Quality Safety Health Care* 13:395, 2004.
9. Schwid HA, et al.: Use of a computerized advanced cardiac life support simulator improves retention of advanced cardiac life support guidelines better than a textbook review, *Crit Care Med* 27:821, 1999.
10. Schwid HA, et al.: Screen based anesthesia simulation with debriefing improves performance in a mannequin-based anesthesia simulator, *Teach Learn Med* 13:92, 2001.
11. Bhananker SM, et al.: Injury and liability associated with monitored anesthesia care: a closed claims analysis, *Anesthesiology* 104:208, 2006.
12. Caplan RA, et al.: Adverse respiratory events in anesthesia: a closed claims analysis, *Anesthesiology* 72:828, 1990.
13. Lee A, et al.: A systematic review (meta-analysis) of the accuracy of the Mallampati tests to predict the difficult airway, *Anesth Analg* 102:1867, 2006.
14. Krobbuaban B, et al.: The predictive value of the height ratio and thyromental distance: four predictive tests for difficult laryngoscopy, *Anesth Analg* 101:1542, 2005.
15. Langeron O, et al.: Prediction of difficult mask ventilation, *Anesthesiology* 92:1229, 2000.
16. ASA Task Force on Obstructive Sleep Apnea: Practice guidelines for the perioperative management of patients with obstructive sleep apnea, *Anesthesiology* 120:268, 2014.
17. Joshi GP: Are patients with obstructive sleep apnea syndrome suitable for ambulatory surgery? *ASA Newsletter* 70(1), 2006.
18. Campbell RL, et al.: Fiberoptic assessment of laryngeal mask airway placement: blind insertion versus direct visual epiglottoscopy, *J Oral Maxillofac Surg* 62:1108, 2004.
19. Cigarette smoking among adults—United States, 2000, *Morb Mortal Wkly Rep* 51(642), 2002.
20. Woehlck HJ, et al.: Acute smoking increases ST depression in humans during general anesthesia, *Anesth Analg* 89:856, 1999.
21. Jones DT, Bhattacharyya N: Passive smoke exposure as a risk factor for airway complications during outpatient pediatric procedures, *Otolaryngol Head Neck Surg* 135:12, 2006.
22. Kwiathkowski TC, Hanley Jr EN, Ramp WK: Cigarette smoking and its orthopedic consequences, *Am J Orthop* 25:590, 1996.
23. Munday IT, et al.: The effectiveness of pre-operative advice to stop smoking: a prospective controlled trial, *Anaesthesia* 48:816, 1993.
24. Bluman LG, et al.: Preoperative smoking habits and postoperative pulmonary complications, *Chest* 113:883, 1998.
25. Moores LK: Smoking and postoperative pulmonary complications: an evidence-based review of the recent literature, *Clin Chest Med* 21:139, 2000.
26. Whalen F, et al.: Recent smoking behavior and postoperative nausea and vomiting, *Anesth Analg* 103:70, 2006.
27. Mendelson CL: The aspiration of stomach contents into the lungs during obstetric anesthesia, *Am J Obstet Gynecol* 52:191, 1946.
28. Raidoo DM, et al.: Critical volume for pulmonary acid aspiration: reappraisal in a primate model, *Br J Anaesth* 65:248, 1990.
29. Maltby JR, et al.: Drinking 300 mL of clear fluid two hours before surgery has no effect on gastric fluid volume and pH in fasting and non-fasting obese patients, *Can J Anesth* 51:111, 2004.
30. Practice guidelines for preoperative fasting and the use of pharmacologic agents to reduce the risk of pulmonary aspiration: application to healthy patients undergoing elective procedures. A report by the American Society of Anesthesiologists task force on preoperative fasting, *Anesthesiology* 90:896, 1999.
31. Hagerdal M, Caldwell CB, Gross JB: Intraoperative fluid management influences carbon dioxide production and respiratory quotient, *Anesthesiology* 49:48, 1983.
32. Nicolson SC: Glucose: enough versus too much, *J Cardiothorac Vasc Anesth* 11:409, 1997.
33. Gowan C: Fluid management for major surgical cases in the operating room, *Certified Registered Nurse Anesthetist* 7:81, 1996.
34. Bennett J, et al.: Perioperative rehydration in ambulatory anesthesia for dentoalveolar surgery, *Oral Surg Oral Med Oral Path Oral Radiol Endod* 88:279, 1999.
35. Barr G, et al.: Nitrous oxide does not alter bispectral index: study with nitrous oxide as sole agent and as adjunct to I.V. anaesthesia, *Br J Anaesth* 82:827, 1999.
36. Liu J, Singh H, White PF: Electroencephalographic bispectral index correlates with intraoperative recall and depth of propofol-induced sedation, *Anesth Analg* 84:185, 1997.
37. Sandler NA, Hodges J, Sabino M: Assessment of recovery of patients undergoing intravenous conscious sedation using bispectral analysis, *J Oral Maxillofac Surg* 59:603, 2001.
38. Bennett J, et al.: Incremental bolus versus continuous infusion for deep sedation/general anesthesia during dentoalveolar surgery, *J Oral Maxillofac Surg* 56:1049, 1998.
39. Cillo JE, Finn R: Moderate intravenous sedation for office based full face laser resurfacing using a continuous propofol pump, *J Oral Maxillofac Surg* 63:903, 2005.

40. Kramer K, Ganzberg S, Prior S, Rashid RG: Comparison of propofol-remifentanil versus propofol-ketamine deep sedation for third molar surgery, *Anesth Prog* 59(3):107–117, 2012.
41. Rodrigo C, et al.: Patient-controlled sedation with propofol in minor oral surgery, *J Oral Maxillofac Surg* 62:52, 2004.
42. Kucukyavuc Z, Cambazoglu M: Effects of low-dose midazolam with propofol in patient-controlled sedation (PCS) for apicectomy, *Br J Oral Maxillofac Surg* 42:215, 2004.
43. Oei-Lim VLB, et al.: Patient-controlled versus anesthesiologist-controlled conscious sedation with propofol for dental treatment in anxious patients, *Anesth Analg* 86:967, 1998.
44. Dubois MC, et al.: Comparison of three techniques for induction of anaesthesia with sevoflurane in children, *Paediatr Anaesth* 9:19–23, 1999.
45. Joshi A, et al.: An optimum time for intravenous cannulation after induction with sevoflurane in children, *Pediatr Anesth* 22:445–448, 2012.
46. Reference deleted in page proofs.
47. Akcaboy ZN, et al.: Can remifentanil be a better choice than propofol for colonoscopy during monitored anesthesia care? *Acta Anaesthesiol Scand* 50:736, 2006.
48. Mingus ML, et al.: The remifentanil 3010 study group: remifentanil versus propofol as adjuncts to regional anesthesia, *J Clin Anesth* 10:46, 1998.
49. Faust RJ, Cucchiara RF, Bechtle PS: Patient positioning. In Miller RD, editor: *Miller's anesthesia*, ed 6, Philadelphia, 2005, Elsevier Churchill Livingstone.
50. Altermatt FR, et al.: Pre-oxygenation in the obese patient: effects of position on tolerance of apnea, *Br J Anaesth* 95:706, 2005.
51. Lane S, et al.: A prospective, randomized controlled trial comparing the efficacy of pre-oxygenation in the 20 head up vs supine position, *Anaesthesia* 60:1064, 2005.
52. Cheney FW, et al.: Nerve injury associated with anesthesia, *Anesthesiology* 90:1062, 1999.
53. Warner MA, et al.: Lower extremity motor neuropathy associated with surgery performed on patients in a lithotomy position, *Anesthesiology* 81:6, 1994.
54. Warner MA, et al.: Ulnar neuropathy in medical patients, *Anesthesiology* 92:613, 2000.
55. Warner MA, et al.: Ulnar neuropathy in surgical patients, *Anesthesiology* 90:54, 1999.
56. Marshall S, Chung F: Assessment of "home readiness": discharge criteria and postdischarge complications, *Curr Opin Anaesthesiol* 10:445, 1997.
57. Kearney R, Mack C, Entwistle L: Withholding oral fluids from children undergoing day surgery reduces vomiting, *Paediatr Anaesth* 8:331, 1998.
58. Pavlin DJ, et al.: Voiding in patients managed with or without ultrasound monitoring of bladder volume after outpatient surgery, *Anesth Analg* 89:90, 1999.

18

Concepts in the Management of Acute Postoperative Pain

JAMES M. ROGÉR, JOSEPH J. FANTUZZO

"It would be a great thing to understand pain in all its meanings."

Peter Mere Latham

Introduction

The practice of oral and maxillofacial surgery requires that the practitioner be able to manage patients who have pain. Latham's quote is a lofty goal indeed, and although there is vast knowledge regarding neurogenic pathways and processing nociceptive stimuli, the surgeon must be able to clinically understand a patient's acute postoperative pain and provide appropriate therapy aimed at reducing and managing this pain following surgery. Pain management following oral and maxillofacial procedures can affect the immediate postsurgical patient experience as well as many quality-of-life outcomes.[1-6]

The association of pain with third molar extraction is so intertwined that it is a major clinical research model in which to evaluate postoperative pain therapy.[7] Pain is the result not only of tissue damage and peripheral neuron messaging but also of processing in the central nervous system. An individual's response to pain is difficult to quantify; this is summarized by Sessle's definition of pain as "a complex, multidimensional experience encompassing sensory-discriminatory, cognitive, affective, and motivational aspects."[8]

Pain serves as a diagnostic tool and a clinical alarm. The clinician must not assume that the patient's perception of postoperative pain is merely due to the controlled trauma that is part of surgery. Pain perception may in fact relate to further underlying neuropathic, pathogenic, and psychosocial processes. Management of a patient's expectations regarding pain associated with a given procedure begins long before the day of surgery. A discussion about the expected timeline of discomfort during the healing process, held during preoperative consultation appointment, will ultimately set the stage for the success of postoperative pain management. Additionally, the patient's anxiety about a procedure can be affected preoperatively by interactions with the surgeon's front office and clinical staff; pain management is everyone's job.

This chapter describes the use of pharmacotherapies in acute postoperative pain management. There have been substantial discussions regarding nonpharmacologic methods of pain management; they are not discussed here.[9] A brief review of relevant neuroanatomy and pathophysiology of pain is followed by a detailed discussion of the use of common pharmacologic agents, and concludes with a summary treatment strategy algorithm.

Review of Neuroanatomy and Pathophysiology of Pain

Tissue damage that occurs during oral and maxillofacial surgery is ultimately perceived by the higher brain centers via nociceptive pathways from the site of injury.[10] Extracranial tissue damage and pain nociception follows a slightly different pathway than pain sensation from the oral and craniomaxillofacial region. In the periphery, free nerve endings stimulated by mechanical, chemical, and thermal sensation act as afferent pain receptors synapsing in the dorsal horn. The impulse then crosses to the contralateral ascending spinothalamic tract and travels to the thalamus. In the dorsal horn, ascending impulses can be modulated by descending pain-modifying pathways from the cerebral cortex, midbrain, and brainstem.[11]

There are two main afferent nerve fibers associated with pain transmission: A-delta and C fibers. A-delta fibers are lightly myelinated, large diameter, and fast conducting. They are primarily activated by mechanical stimulation and are perceived as a sharp or shooting sensation. C fibers are activated by thermal, chemical, and mechanical stimuli. They are unmyelinated, small diameter, and slow conducting and are most associated with a dull or aching sensation.

Pain sensation from the oral and maxillofacial region occurs as just outlined, but with different specific nerves transmitted to higher brain centers. The main sensory nerve of the orofacial region is cranial nerve V (the trigeminal nerve). Cranial nerves VII, IX, X, and XII and branches of cervical spinal nerves C1, C2, and C3 also contribute sensory innervation from the orofacial region. Painful stimuli in tissue innervated by the trigeminal nerve is transmitted to the central nervous system (CNS) via the Gasserian (trigeminal) ganglion and then through a portion of the brainstem known as the trigeminal brainstem sensory nuclear complex (VBSNC). This bilateral, multinucleated structure resides in the dorsolateral brainstem extending from the pons to the upper cervical spinal cord.[8,12] After synapsing in the VSBNC, the impulses travel to the thalamus and are relayed to higher brain centers, including the somatosensory cortex and the limbic system. As in the peripheral pathway, descending pathways are present and can affect transmission and perception of pain (Figure 18-1).

Opioid Analgesics

The naturally occurring products of the opium poppy are opium, morphine, and codeine; they are referred to as opiates. Compounds that are manufactured to mimic the chemical structure of these products and are targets for the same receptors are termed opioids.

Regardless of their origin, opioids all target the opioid receptors: mu, kappa, and delta. The specific interaction of the molecule with the receptor further classifies opioids as agonists, partial agonists, or antagonists. Agonists bind their receptors and elicit their analgesic effect—for example, morphine and codeine are agonists at mu and kappa receptors. Antagonists bind opioid receptors but do not elicit a response—for example, naloxone will bind and displace other opioids but produces no analgesic effect. Naloxone is used to reverse the binding of other opioids. Finally, partial agonists, also known as agonists-antagonists, will elicit their effect at one type of receptor and bind as an antagonist at another—for example, pentazocine binds as an agonist at kappa and an antagonist at mu.

The effects of opioid compounds are dependent on the type and location of their receptor target. The analgesic effects are mostly due to inhibition of nociceptive impulses in the CNS. These receptors are found in the ascending pain pathways: the dorsal horn of the spinal cord, the brainstem, the thalamus, and the somatosensory cortex.[13] Receptors are also found in the midbrain and medulla and activate descending inhibitory pathways. Peripheral receptors can also modulate opioid analgesia but are most implicated in the negative effects of opioid use (Box 18-1).[14,15] Subsequent or concomitant administration of the peripheral-specific opioid antagonist methylnaltrexone has been shown to help reduce the extracerebral side effects of opioids.[16]

Binding of the opioid receptor leads to:

1. Decrease in calcium influx at afferent nerve terminals, leading to decreased presynaptic release of neurotransmitter
2. Increased potassium efflux, resulting in hyperpolarization of postsynaptic neurons
3. Inhibition of GABAergic transmission, leading to the excitation of descending inhibitory pathways.

The desired clinical effect of opioids is their analgesic property, but opioids and the activation of mu receptors are associated with many adverse side effects (see Box 18-1). Critically, the central activation of mu receptors will reduce the respiratory drive and rate, which is the leading risk in opioid-associated overdose and the most frequent cause of opioid-associated death. Other CNS effects include sedation and euphoria; all patients prescribed opioids should be counseled to avoid operating motor vehicles or heavy machinery and refrain from making important decisions while taking the opioid medication. Nausea, vomiting, and constipation are very common complaints. Recent evidence is promising that blocking peripheral opioid receptors concomitant with opioid therapy can reduce these effects.[17-19]

Opioid cardiovascular effects include vasodilation, which can result in hypotension. Along with pain control, vasodilation may benefit the patient having a myocardial infarction. Morphine is included in the common mnemonic "MONA greets all MIs," which suggests that all patients presenting with acute cardiogenic pain receive morphine, oxygen, nitroglycerine, and aspirin.

Opioids also cause an increase in smooth muscle tone, which may result in urinary retention and chest wall rigidity. Pruritus (itching) is common because of the release of histamine from mast cells and the disinhibition of itch-specific neurons.[20]

The subjects of addiction, dependence, abuse, and tolerance are central to the discussion of prescribing opioid medication. Tolerance in drug administration lowers the effect and raises the required effective dose/concentration required to obtain the same effect. Drug dependence, which can result in significant physical withdrawal symptoms when the drug is discontinued, is another concern. Physical and psychological symptoms that patients may experience from taking opioids can lead to abuse or even addiction. Abuse is defined as the use of a drug outside of clinical recommendations or for goals beyond the prescribed clinical endpoints. Abuse can lead to addiction, in which the behavior patterns of obtaining and consuming the drug dominate patient efforts.[21]

Oral and maxillofacial surgeons must consider these factors for each patient regardless of the duration (often short) of postoperative analgesia therapy. Many patients will present with unrelated chronic pain in addition to their potential acute oral pain/problem. Prescribers may consider "pain contracts," agreeing to manage the pain associated with the procedure only for a specified period of time with referral back to a patient's primary care provider for other complicating or lingering pain without obvious etiology.

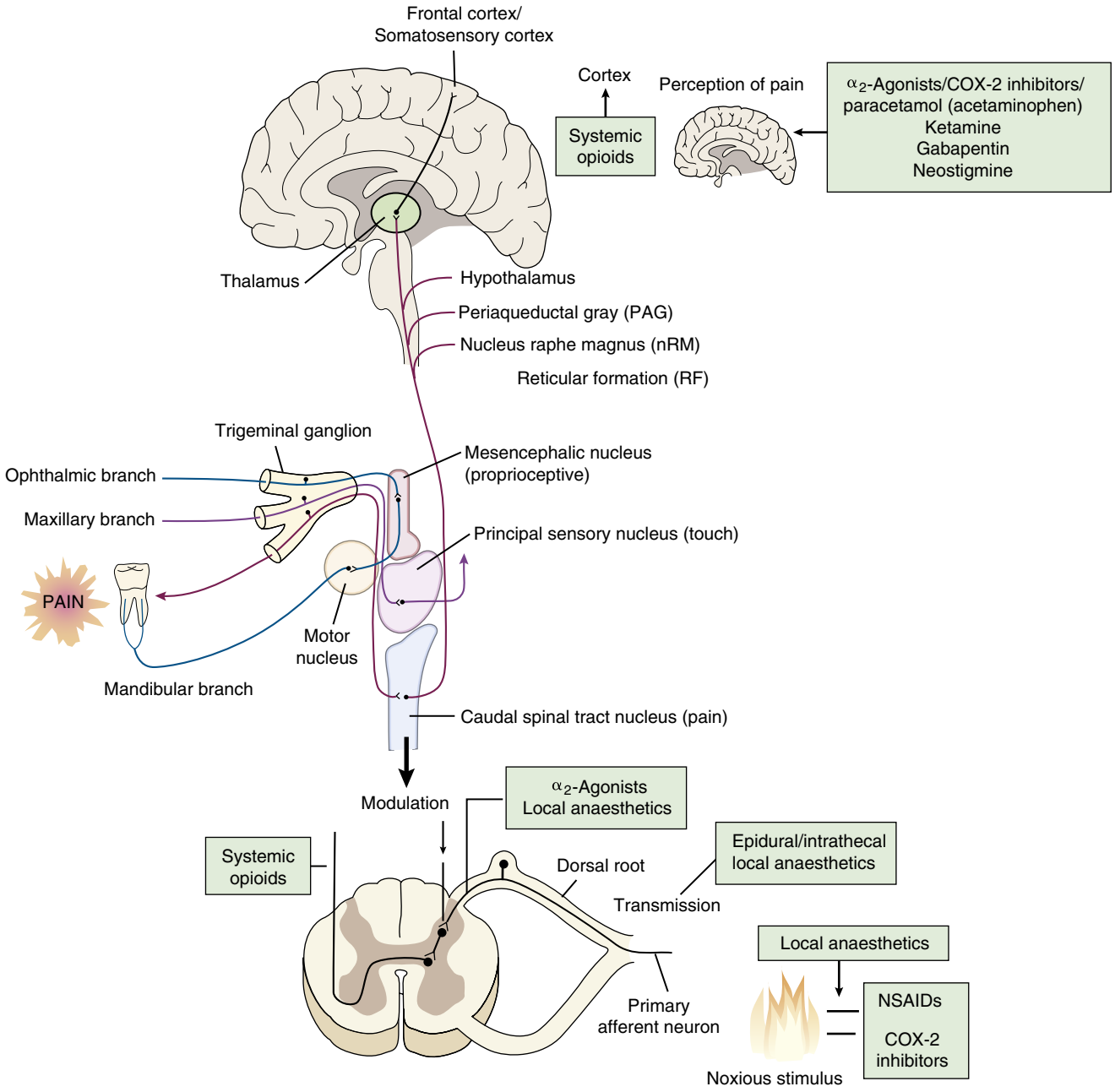

• **Figure 18-1** Sensory innervation of the orofacial region is predominately carried out by the trigeminal nerve. The first-order neurons have their cell bodies in the trigeminal ganglion. The peripheral processes of these cells innervate the orofacial structures, whereas the central processes enter the brainstem and synapse with the second-order neurons at various levels of the trigeminal brainstem sensory nuclear complex. This complex may be subdivided into the caudal spinal tract nucleus, which transmits pain, and the rostral principal sensory nucleus, which transmits afferent inputs such as touch. Proprioceptive impulses end in the mesencephalic nucleus, which is connected to the motor nucleus. The subnucleus caudalis extends into the cervical spinal cord and merges with the dorsal horn and peripheral sensory innervation. It possesses gating mechanisms capable of modulating painful stimuli. Specific locations of pharmacodynamic effects are indicated. *COX-2,* cyclooxygenase-2; *NSAID,* nonsteroidal anti-inflammatory drug. (From Ong CK, Seymour RA: Pathogenesis of postoperative oral surgical pain, *Anesth Prog* 50(1):5-17, 2003.)

This "acute on chronic pain" presents unique challenges in management. Therapy for these patients will include non-opioid analgesia and, when appropriate, likely higher doses of opioid analgesia.[22-24] The primary consideration should be to maximize the patient's analgesia while minimizing the adverse side effects.

Commonly Prescribed Opioids

Oral and maxillofacial surgeons most often prescribe oral formulations of the opioids listed in Table 18-1. It is important to remember that oral medications are subject to first-pass hepatic metabolism. In the office and hospital, opioids

• BOX 18-1 Adverse Effects of Opioid Administration

Abuse potential
Constipation
Respiratory depression
Nausea and vomiting
Sedation
Euphoria
Urinary retention
Impaired decision making

are also administered via intramuscular, intravascular, transdermal, transmucosal, subcutaneous, and rectal routes.

Regardless of the route of administration, the pharmacodynamics and pharmacokinetics of the agent must be considered. Table 18-2 provides summary data of the drug effective onset time and duration of action.

Although there are many different options available to the clinician, opioid potency can vary by route of administration as summarized in (Table 18-3).

Administration of IV opioid analgesics for severe acute pain should be done only in a monitored setting with initially low doses titrated to effect. Although opioids have a ceiling effect for analgesia, the clinical dose is a balance between the undesired effects and the analgesic properties. Of note: Meperidine is no longer commonly prescribed because of the neurotoxicity of one of its active metabolites, normeperidine. Meperidine also interacts with monoamine oxidase inhibitors, causing potential hypertensive crisis, hyperpyrexia, and cardiovascular collapse. Meperidine is included here because it is often used to reduce shivering in an inpatient anesthesia setting.[20]

When prescribing codeine, a weak mu agonist, doses greater than 60 mg are to be avoided because the adverse side effects will dominate the analgesic effects. Hydrocodone and oxycodone are available in the oral form and are commonly prescribed between 5 and 10 mg every 6 hours. These drugs are typically formulated with acetaminophen.

Tramadol is a synthetic opioid compound, which is chemically unrelated to the other synthetic agents. It has two mechanisms of action: (1) it is a weak mu agonist, and (2) it inhibits serotonin and norepinephrine reuptake. Because of the distinct chemical structure of tramadol, respiratory inhibition and abuse potential are lower. The equipotency of tramadol compares with that of codeine, and tramadol is commonly prescribed in 50- to 100-mg doses.[25,26]

In the acute postoperative setting, opioids, and opioid/acetaminophen combinations are often prescribed with nonsteroidal anti-inflammatory drugs (NSAIDs).

History, Legislation, and Clinicians' Attitudes about Narcotics Prescribing

Over the past two decades, a national epidemic of opioid use and abuse with associated consequences has escalated. Initial efforts were focused on increasing opioid use, citing the undertreatment of pain, which led to the liberalization of laws governing the prescribing of opioids for the treatment of chronic pain by individual state medical boards. Many arguments about the prescribing of opioids are based solely on history, tradition, and anecdotal observations.

Results of the 2010 National Survey on Drug Use and Health showed that of an estimated 22.6 million people aged 12 or older who were current or past month illicit drug users, 5.1 million had abused pain medication (second behind marijuana). It has also been shown that only one in six users of nontherapeutic opioids indicated that they received the drugs through a prescription from a single provider. In 2011, hydrocodone was the top prescribed drug with 136.7 million prescriptions, and total narcotic analgesics exceeded 238 million prescriptions.[27]

Individual laws, policies, and prescriber tools regarding the standard medical practice for opioid prescribing are being constantly revised. In some instances, state-run prescription drug monitoring programs are available to physicians. The level of participation in these programs varies by state. Effectiveness of and funding for continuation of these programs is an ongoing concern. With federal and state laws in flux, clinicians must remain abreast of these changes and the issues driving them, which will affect safe and appropriate care of patients in pain.[28]

A recent survey of oral and maxillofacial surgeons indicated that whereas most clinicians prescribe an average postoperative opioid course of 20 tablets and/or 5 days, many still (as many as 20%) routinely prescribe more tablets than are believed necessary to control pain after the removal of impacted third molars—up to and exceeding 40 tablets. These pills could become a source of drug diversion, and the provider must be mindful of patient comfort in balance with appropriate use of controlled substances.[29]

Joint Commission Standards and Pain Assessment and Pain Control

The Joint Commission on the Accreditation of Healthcare Organizations (JCAHO) introduced new pain management standards in 2000.[30] Since then, an increased awareness of the right to pain relief, growth of organizations supporting the use of opioids, and aggressive marketing by the pharmaceutical industry have contributed to the increase in opioid prescriptions (Box 18-2).

Non-opioid Analgesia

Nonsteroidal anti-inflammatory drugs (NSAIDs) are nearly the ideal postoperative analgesic, possessing both anti-inflammatory and antipyretic properties. They are a non-narcotic way to reduce pain, fever, and inflammation. The primary mechanism of action is the inhibition of cyclooxygenase (COX), thereby inhibiting the conversion of arachidonic acid to prostaglandin. There are two different isoforms of COX: COX-1 and COX-2. COX-1

TABLE 18-1 Common Opioid Analgesics

Name	Equianalgesic IM dose*	IM/PO Potency	Starting Oral Dose Range (mg)	Comments	Precautions
Morphinelike agonists					
Morphine	10	6	30-60†	Standard of comparison for opioid analgesics; sustained-release preparations (MS Contin, Oramorph SR, and Kadian)	Lower doses for aged patients; impaired ventilation; bronchial asthma; increased intracranial pressure; liver failure
Hydromorphone (Dilaudid)	1.5	5	4-8	Slightly shorter acting; HP IM dosage form for tolerant patients Good oral potency; long plasma half-life	Like morphine Like morphine; may accumulate with repetitive dosing, causing excessive sedation
Methadone (Dolophine)	10	2	10-20	Like methadone	Like methadone
Levorphanol (Levo-Dromoran)	2	2	2-4	Not available orally; available as a rectal suppository	Like IM morphine
Oxymorphone (Numorphan)	1	See comments	See comments	Immediate-release (Roxicodone and Oxy IR) and sustained-release (Oxycontin) forms; also lower doses in combination with nonopioids for less severe pain	Like morphine
Oxycodone	20	_	15-30	Slightly shorter acting; used orally for less severe pain	Normependine (toxic metabolite) accumulates with repetitive dosing causing CNS excitation; not for patients with impaired renal function or receiving monoamine oxidase inhibitors‡
Meperidine (Demerol)	75	4	Not recommended	Used orally for less severe pain	Like morphine
Codeine	130	1.5	See comments	Transdermal fentanyl (Duragesic); also oral transmucosal fentanyl citrate for breakthrough pain	Transdermal creates skin reservoir of drug; 12-hour delay in onset and offset; fever increases absorption
Fentanyl	0.1	_	_	Used orally for less severe pain; mixed agonist-antagonist	May cause psychotomimetic effects; may precipitate withdrawal in opioid dependent patients; not for myocardial infarction
Mixed agonist-antagonists					
Pentazocine (Talwin)	60	3	See comments	Not available orally; like IM pentazocine but not "scheduled" Not available orally like IM nalbuphine	Incidence of psychotomimetic effects lower than with pentazocine Like nalbuphine
Nalbuphine (Nubain)	10	See comments	See comments	Not available orally; sublingual preparation not yet in U.S.; does not produce psychotomimetic effects	May precipitate withdrawal in opioid-dependent patients; not readily reversed by naloxone; avoid in labor
Butorphanol (Stadol)	2	See comments	See comments		

Continued

TABLE 18-1 Common Opioid Analgesics—cont'd

Name	Equianalgesic IM dose*	IM/PO Potency	Starting Oral Dose Range (mg)	Comments	Precautions
Partial agonists					
Buprenorphine (Buprenex)	0.4	See comments	See comments		

For these equianalgesic IM doses (also see comments), the time of peak analgesia in nontolerant patients ranges from 30 minutes to 1 hour and the duration from 4 to 6 hours. The peak analgesic effect is delayed and the duration prolonged after oral administration. Oramorph SR and Roxicodone are manufactured by Roxane Laboratories (Columbus, OH); Kadian, by Faulding USA (Elizabeth, NJ); Oxycontin, by Purdue Pharma PL (Norwalk, CT): Dilaudid, by Knoll Pharmaceuticals (Mt. Olive, (New York, NY); Duragesic, by Janssen Pharmaceuticals (Titusville, NJ); Nubain, by Du Pont Merck Pharmaceuticals (Wilmington, DE); Stadol, by Bristol-Meyers Squibb (Princeton, NJ); and Buprenix, by Reckitt & Colman (Richmond, VA).
*These doses are recommended starting IM doses, from which the optimal dose for each patient is determined by duration and the maximal dose limited by adverse effects. For single intravenous bolus doses, use half the IM dose.
†A value of 3 is used when calculating an oral dosage regimen of every 4 hours around-the-clock.
‡Irritating to tissues on repeated administration.
CNS, Central nervous system; *IM,* intramuscular; *PO,* oral.
From Inturrisi CE: Clinical pharmacology of opioids for pain, *Clin J Pain* 18(4 suppl):S3-S13, 2002.

TABLE 18-2 Clinical Pharmacokinetics of Commonly Used Opioids[24,37]

Drug	Approximate Time to Onset of Action (min)	Approximate Time to Peak Effect (hr)	Approximate Duration of Effect (hr)	Approximate Bioavailability (%)
Hydromorphone	30-45	1.5-2	3-4	60
Meperidine	30-45	1.5	3	30
Methadone	30	2-3	6-12	80
Morphine (immediate release, sublingual)	30-45	1.5-2	3-4	30
Morphine (long acting)				
MS Contin (Purdue Pharma LP)				
Oramorph SR (aaiPharma), other generics	120	6-8	10-12	30
Kadian (Alpharma)	120	8-12	18-24	30
Avinza (Ligand)	45	4-6	18-24	30
Oxycodone (immediate release)	20-45	1.5-2	3-4	80
Oxycodone (controlled release)	30-60	4-6	10-12	80

is constitutively produced by many different cells in the body contributing to homeostasis in the gastrointestinal (GI) tract, kidney, heart, brain, and vasculature. COX action and prostaglandin production protects GI mucosal integrity via mucus and bicarbonate production. In the kidney, prostaglandins regulate blood flow, renin release, and salt and water absorption. Prostaglandins in the vasculature regulate platelet function. Production and action of COX-2 is specific to the inflammatory state caused by tissue insult. Prostaglandins produced via the action of COX-2 activate secondary inflammatory mediators such as histamine, leukotrienes, bradykinin, and substance P. The inflammatory modulators result in increased vasodilation and increased vascular permeability, edema, erythema, hyperalgesia, and pain—the classic signs of local inflammation.

NSAIDs decrease surgically induced inflammation by inhibiting COX-2 and prostaglandin production; this decreases sensation at the nociceptive nerve terminal and reduces afferent activity of nociceptive neurons. NSAIDs are the first-line choice for management of postoperative pain resulting from tissue injury and inflammation.

Many of the adverse effects of opioids are not seen with NSAID administration. NSAIDs do not have a sedative or respiratory depressant effect and do not directly interfere with bowel or bladder function. They have a high therapeutic index and a low dependence rate. When prescribed for acute postoperative pain, the course is usually short

(5 days), resulting in fewer side effects. Contraindications to administration of NSAIDs include patients with known GI disease (peptic ulcer, known alcohol abuse). Patients with chronic hepatic and/or renal disease may have effective plasma concentrations higher than those without because of altered NSAID-plasma protein binding. Consideration of patient-specific and NSAID-specific pharmacokinetic principles is critical.[31]

Numerous clinical trials have investigated the effectiveness of initiating NSAID therapy prior to surgery. Most often 400 mg oral (PO) ibuprofen was administered 30 minutes before surgery; it has been shown consistently that postoperative discomfort is improved.[32-34] Ibuprofen is the most tolerated cost-effective NSAID with the fewest side effects.[35] A maximum recommended "preemptive analgesic" dose of 400 mg of ibuprofen given preoperatively has been shown to delay onset and decrease severity of postoperative pain, as well as to reduce the immediate postoperative need for narcotic pain use.[36,37]

Additionally, patients treated with preoperative 30 mg of intravenous (IV) ketorolac reported significantly lower pain intensity scores when compared with those receiving ketorolac postoperatively. The pretreated patients also reported a significantly longer time to rescue analgesic and less postoperative analgesic consumption.[38] When comparing pretreatment with ketorolac with that with tramadol, the ketorolac patients reported less postoperative discomfort.[39]

TABLE 18-3 Opioid Equianalgesic Dosage Conversions

Drug	PO (mg)	IM/IV (mg)
Morphine	30-60	10
Meperidine	300	75
Fentanyl	N/A	0.1-0.2
Codeine	200	120
Hydrocodone	30	N/A
Oxycodone	20-30	N/A
Hydromorphone	6-7.5	1.5
Tramadol	100-150	100-150

From Schwartz SR: Perioperative pain management, *Oral Maxillofac Surg Clin North Am* 18(2):139-150, v, 2006.

• BOX 18-2 1999-2000 Comprehensive Accreditation Manual for Hospitals (CAMH) Assessment of Patients Chapter

Standard PE.1.4 Pain is assessed in all patients.

Examples of implementation for PE.1.4:

All patients at admission are asked the following screening or general questions about the presence of pain: Do you have pain now? Have you had pain in the last several weeks or months? If the patient responds "yes" to either question, additional assessment data are obtained about the following elements:

- Pain intensity (use a pain intensity rating scale appropriate for the patient population; pain intensity is obtained for pain now, at worst, and at best or least; if at all possible, the pain rating scale is consistently used in the organization and between disciplines);
- Location (ask the patient to mark on a diagram or point to the site of pain);
- Quality, patterns of radiation, if any, character (elicit and record the patient's own words whenever possible);
- Onset, duration, variation, and patterns;
- Alleviating and aggravating factors;
- Present pain management regimen and effectiveness;
- Pain management history (including a medication history, presence of common barriers to reporting pain and using analgesics, past interventions and response, manner of expressing pain);
- Effects of pain (impact on daily life, function, sleep appetite, relationships with others, emotions, concentration, and so forth);
- The patient's pain goal (including pain intensity and goals related to function, activities, quality of life); and
- Physical examination observation of the painful site.

Patients often have more than one site of pain. An assessment system or tools with space to record data on each site is provided on the assessment sheet.

A hospital may need to use more than one pain intensity measure. For example, a hospital serving both children and adults selects a scale to be used with each of those patient populations. Assessment of cognitively impaired patients may also require assessment of behavioral factors signaling pain or discomfort.

Staff are educated about pain assessment and treatment including the barriers to reporting pain and using analgesics. Staff encourage the reporting of pain when a patient and/or family member shows reluctance to discuss pain, denies pain when pain is likely to be present (e.g., postoperative, trauma, burns, cardiac emergencies), or does not follow through with recommended treatments.

Pain intensity scales are enlarged and displayed in all areas where assessments are conducted. For organizations using clinical pathways, pain assessment is incorporated in some way into every appropriate clinical pathway.

An organization selects pain intensity measures to ensure consistency across departments, for example, the 0-10 scale, the Wong-Baker FACES pain rating scale (smile-frown), and the verbal descriptor scale. Adult patients are encouraged to use the 0-10 scale. If they cannot understand or are unwilling to use it, the smile-frown or the verbal scale is used.

A unit caring for persons with Alzheimer's disease developed a pain scale for each resident based on the long-standing knowledge of their residents and their knowledge of common pain syndromes in elderly people.

A pediatric hospital includes in its orientation materials for parents information about pain and pain assessment, including the parent's role in interpreting behavioral changes of the child that may indicate pain or discomfort.

© Joint Commission Resources: *Comprehensive Accreditation Manual for Hospitals.* Oakbrook Terrace, IL: Joint Commission on Accreditation of Healthcare Organizations, 1999-2000, p. v. Reprinted with permission.

TABLE 18-4 Common Non-opioid Analgesics

Generic	Pain Level	Dose (mg eq)	Standard Interval	Maximum Dose (mg/hr)
Salicylic Acid Derivatives				
Aspirin	Mild	650-1000	q6h	4000
Diflunisal	Moderate	500*	q8h-q12h	1500
p-Aminophenol Derivatives				
Acetaminophen	Mild to moderate	650-1000	q6h-q8h	3000
Propionic Acid Derivatives				
Ibuprofen	Mild to moderate	225*	q8h-q12h	1375
Naproxen	Mild to moderate	25-50	q6h *or* q8h	
Ketoprofen	Mild to moderate			
Acetic Acid Derivatives				
Diclofenac—sodium salt	Mild to moderate	25-75*	q8h	150
Diclofenac—potassium salt	Moderate to severe	25-75	q8h	225
Ketorolac—IM	Mild to moderate	30,60	q6h	120
Ketorolac—IV		30	q6h	120
Ketorolac—PO†		20, 10	q6h	40
Indomethacin		25-50	q8h-q12h	200
Etodolac				1200
Coxibs				
Celecoxib		200-400	q12h-q24h	400

*Consider a loading dose 2× interval dose.
†Only for patients having already received IM/IV.
IM, Intramuscular; *IV,* intravenous; *PO,* oral.

Commonly Prescribed Non-opioid Analgesics

Although aspirin has proven consistently to provide effective analgesia, anti-inflammatory, and antipyretic activity, it has a low therapeutic index, and it can cause gastric ulcerations, bleeding (due to irreversible platelet inhibition), and possible development of Reye syndrome in children with viral infections. For this reason, the derivative diflunisal may offer safer application in the salicylic acid derivative class of drug (Table 18-4).

Acetaminophen, although not technically an NSAID, has tremendous therapeutic application in the postoperative period. It is often taken alone for mild pain or formulated with opioid medications (codeine, hydrocodone, and oxycodone) commonly prescribed by the oral and maxillofacial surgeon. Concerns for hepatic damage (contraindicated in alcohol abusers or patients with hepatic disease) and its low therapeutic ceiling require the clinician to assess the use of acetaminophen therapy alone or in combination based on the individual patient condition.

Diclofenac is an NSAID that is available in a potassium salt (immediate release) and a sodium salt (delayed-release and extended-release). In animal studies, diclofenac has shown superior action in acute inflammation models.[40] Modifications in the delivery formulations of diclofenac have made this NSAID a powerful tool for postextraction acute management.[41] Phase 3 trials to determine the effectiveness have elucidated that oral diclofenac/potassium salt is effective in providing patients a greater reduction in pain and a quicker time to pain reduction, and it required less rescue medication (re-dosing) versus placebo. Further studies confirmed that even a single postoperative dose was effective for pain relief following third molar extractions.[42]

As discussed earlier, the inhibition of COX-2 is the primary mechanism of action for NSAIDs. Inhibition of COX-1 is responsible for some of the adverse effects in the GI tract and vasculature. COX-2 specific inhibitors were first brought to market in 2004, and soon thereafter all but one agent was withdrawn.[10] Celecoxib is currently the only commercial COX-2 inhibitor available. In theory, by inhibiting only COX-2 prostaglandin production, celecoxib should be a superior postoperative agent, but little evidence has shown the analgesia of celecoxib to be superior to ibuprofen despite being substantially more expensive[43] (Box 18-3).

Local Anesthetics

Local anesthesia allows for painless manipulation of hard and soft tissue during surgery. By blocking sodium channels and inhibiting nerve ending excitation and nerve impulse propagation, surgeons are able to perform many different procedures in the office setting. Although local anesthesia plays its dominant role in the perioperative period, it should also be considered a powerful tool for postoperative acute pain management.

The pharmacology and modes of action of local anesthetics are addressed in another chapter. Lidocaine,

• BOX 18-3 Relative/Absolute Contraindications to NSAID Administration

Relative

History of gastric ulcers
Renal disease
Hepatic disease
Asthma

Absolute

History of allergy or intolerance to NSAID or aspirin
Pregnant or lactating

NSAID, Nonsteroidal anti-inflammatory drug.

mepivacaine, and articaine are commonly used during surgery and are of relatively short effective duration; when formulated with epinephrine, soft tissue may be anesthetized for 3 to 5 hours. Long-acting amide local anesthetics such as bupivacaine and etidocaine can block nociceptive input and nerve conduction for 8 to 12 hours (commonly formulated 0.5% bupivacaine with 1:200,000 epinephrine, and 1.5% etidocaine with 1:200,000 epinephrine).[44] The use of bupivacaine either as the primary agent or as an adjunct in third molar surgery has been shown to improve postoperative pain experience compared to lidocaine alone.[45] It has been suggested that the long-term blockade of nociceptive input combined with an overall decrease in hyperexcitability in the CNS can reduce the dose of required analgesia.[46]

When using local anesthesia, adherence to the principle of *aspiration before injection* and staying below the maximum doses of all the agents is critical. Initial signs of local anesthetic overdose begin with a period of excitation possibly followed by generalized tonic-clonic seizures. As levels of systemic local anesthetic increase, heart rate, blood pressure, and cardiac contractility decrease; respiratory rate declines, and ultimately circulatory collapse is possible.[44]

Adjunctive Medications

Steroids

Corticosteroids have long been used in oral and maxillofacial surgery to suppress acute edema following major procedures. Steroids act earlier in the inflammatory cascade, inhibiting arachidonic acid production with subsequent decrease in leukotriene and prostaglandin production.[10] Steroids also have central nociceptive suppression at the spinal cord level and antinausea effects.[47]

For procedures expected to cause a high degree of inflammation, such as orthognathic surgery or third-molar extraction, methylprednisolone or other oral steroids have been routinely prescribed. It has been shown that perioperative steroid therapy leads to greater opioid sparing and antiemetic effects compared with ketorolac.[48]

Considerations for the patient's postoperative condition, other pharmacologic agents, and comorbidities must be considered with steroid administration. Concomitant steroid and NSAID therapy can increase the risk of GI bleeding. Prolonged steroid therapy can suppress the immune response and is contraindicated in patients with acute infection.

Neuropathic Targeted Medications

Patients may experience different types of pain at the same time—for example, both visceral and somatic pain following third molar extraction. In the case where the inferior alveolar nerve has been stretched, bruised, or damaged, the patient may also have neuropathic pain. Neuropathic pain does not often respond well to standard NSAID and opioid postoperative therapy. Agents such as antidepressants (tricyclic) and anticonvulsants (gabapentin, pregabalin) have been shown to reduce continuous and episodic pain.[49]

Recent investigation into the usefulness of gabapentinoids has shown some reduction in total opioid use in the perioperative period and up to 24 hours following surgery for knee arthroplasty; this positive effect did not extend beyond postoperative day 4 or at longer-term follow up appointments.[50] In patients undergoing hemorrhoid surgery, pain was significantly reduced in the perioperative gabapentin group versus opioid only on postoperative days 1, 7, and 14; the gabapentin group also required less opioid, but this difference was not significant.[51]

Additional receptors and pathways have been elucidated as contributory to peripheral neuropathic pain. Interestingly, within the angiotensin-renin system, the binding of angiotensin II type 2 receptors has been shown to be effective in management of chronic neuralgia; these pipeline therapeutics may eventually assist in the management of acute and chronic neuralgia following oral surgery and/or nerve insult.[52]

Cannabinoids

Cannabinoid analgesia is based on the suppression of both spinal and thalamic nociceptive neurons and at peripheral sites of action. Pain that occasionally follows peripheral tissue or nerve injury often does not respond to traditional inflammatory pain management therapy. Recently, progress has been made in understanding the role of the endocannabinoid system in the modulation of postoperative and chronic pain.

Endocannabinoids have been shown to behave as analgesics in models of both acute nociception and clinical pain such as inflammation and painful neuropathy. The framework for such analgesic effects exists in the cannabinoid receptors, which are found in areas of the nervous system important for pain processing as well as those cells in the immune system that regulate the interactions that mediate inflammatory hyperalgesia. In vitro and in vivo studies have shown that cannabinoids can act on neuronal cells to inhibit the release of pro-inflammatory cytokines.

Cannabinoid administration has been found to suppress behavioral and neurophysiologic responses to all types of

nociceptive stimuli tested. In human clinical trials, administration of cannabinoid receptor agonists has been shown to be effective in treating neuropathic pain conditions and, in some instances, to rival the analgesic efficacy of morphine. It has been shown that low doses of smoked cannabis (D9-THC) can reduce the pain induced by intradermal capsaicin, whereas at higher doses the pain is increased.[53] In addition to smoked cannabis, other cannabinoids that have been approved in the United States or Europe include dronabinol, nabilone, and GW-100. All of these drugs contain D9-THC or an analogue and are nonselective with respect to cannabinoid 1 and cannabinoid 2 receptors.[54]

Muscle Relaxants

Generally, somatic and visceral pain following oral surgical procedures is well managed with NSAID and opioid therapy. These agents address the specific surgical trauma and subsequent inflammatory reactions, which are the primary mediators of postoperative pain. It is worth discussing the consequences of the logistics of the operation, including patient positioning, duration of surgery, and surgical access (usually defined by minimum incisal opening). In the case where a patient's postoperative discomfort is spasmodic or musculoskeletal in the neck or back or at the temporomandibular joint and/or musculature, consideration can be given to administration of a short course of muscle relaxants. There is evidence that cyclobenzaprine, carisoprodol, orphenadrine, and tizanidine are effective compared to placebo in patients with acute postoperative muscle spasm or suspected musculoskeletal pain (primarily back or neck pain).[55]

Anxiety Management

Preoperative and postoperative consideration of the patient's anxiety is paramount to any pain management plan. Oral diazepam has been shown to be a very good adjunct to the overall pain modulation strategy. Preoperatively and postoperatively, diazepam has the benefit of lowering the patient's anxiety level and potentiating the effects of opioid therapy, respectively. At low doses diazepam is shown to be a good muscle relaxant without causing profound muscle impairment. The clinician should not overlook the patient's attitude and anxiety level at the preoperative appointment and prescribe appropriate anxiolytic agents preoperatively.[56,57]

Acute Pain Management Strategies

Management of acute pain begins long before the day of surgery. The overall goal is to understand the individual patient's requirements regarding not just analgesia, but also perioperative anxiety, stress, nausea, and additional patient-specific concerns. Patient education before a painful and often emotionally demanding surgery can determine postoperative analgesic success.

The patient must also understand the appropriate timing and use of medications (opioid and non-opioid medications alike) for pain management following surgery. Often patients believe that the medications work best after the pain has started or by augmenting their medications at the peak of the pain, when in fact preemptive analgesia has been shown to be far more effective.

For the clinician: When a minimum interval and dosage are specified and the patient is allowed to receive the remainder of the expected analgesic requirement as a rescue dose, time and again, patients report much improved pain control[24] (Figure 18-2).

"Pain as the 5th Vital Sign"

To improve pain management, the Veterans Health Administration (VHA) launched the "Pain as the 5th Vital Sign" initiative in 1999, requiring a pain intensity rating (0 to 10) at all clinical encounters. This initiative was subsequently included in the JCAHO standards for pain assessment (presented earlier). Initially, it had four primary goals for performance improvement: a reduction in the percent of patients reporting moderate to severe pain, increased documentation of pain assessments, implementation of pain plans of care, and patient pain education.

Recognizing the rising use of opioid prescriptions, in 2008, the VHA launched a comprehensive patient safety initiative, including an Opioid—High Alert Medication Initiative, which served to provide policy guidance and specific recommendations to promote safe and effective use of opioid therapy for the management of acute and chronic pain in inpatient and outpatient settings.[58]

Patient Assessment and Reassessment

The most reliable source for determining both the existence and intensity of any pain is the patient. The most common type of pain relevant to oral and maxillofacial surgery is somatic pain (described as pinprick or sharp). Visceral pain (generalized aches or pressure) and neuropathic pain (described as burning or tingling) are also often experienced and present further challenges to management.[59]

One of the greatest challenges for the oral maxillofacial surgeon is the patient who presents more than 1 week postoperatively reporting lingering or consistent pain since the day of surgery. It is at this appointment that reassessment is critical, and any new pathology must be elucidated and treated. In the case where there is no new or different source of pain, the clinician must remember that according to published studies, half of our patients do not experience adequate analgesia with conventional pain management strategies.[60] The type of pain, reevaluation of the analgesic therapy/agents, and consideration of referrals to specialists, such as neurology for suspected neurogenic pain, should be considered.[59]

Inpatient Analgesia

Patient-controlled analgesia (PCA) is an option for the hospital patient. This self-directed analgesia allows the

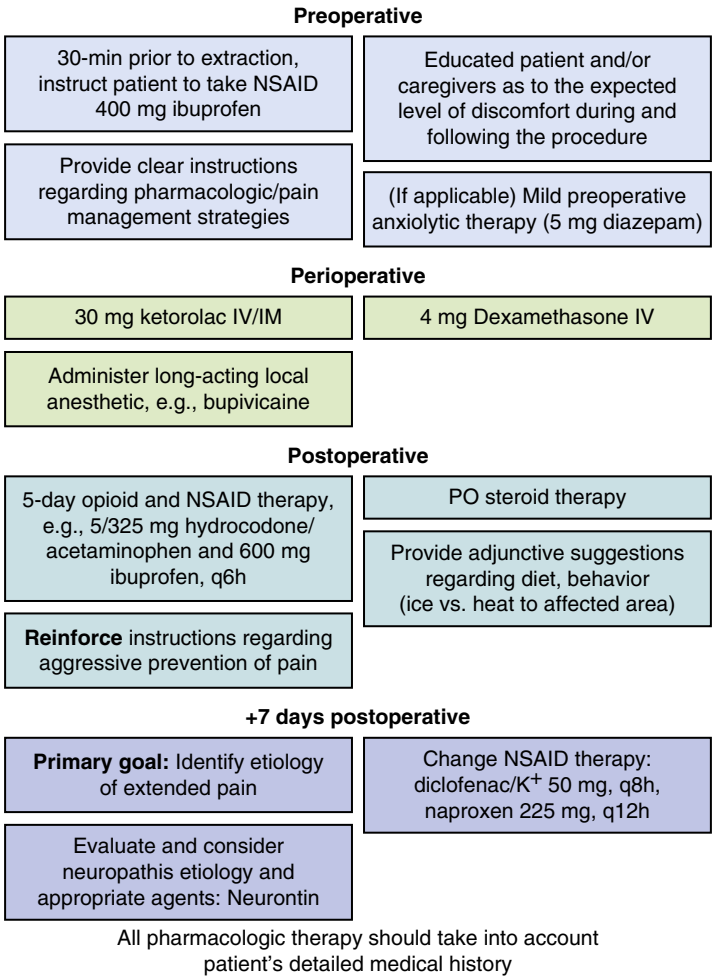

• **Figure 18-2** An example strategy for complete perioperative pain management. *IM,* Intramuscular; *IV,* intravenous; *NSAID,* nonsteroidal anti-inflammatory drug; *PO,* oral.

patient a minimum of control inside of the provider's broad pain management plan. A programmable infusion pump delivers narcotic medication at a specified rate in addition to a patient-controlled bolus function. Bolus frequency versus safety is managed via a lock-out interval specified by the prescriber. The primary advantages are preemptive pain management with a component of patient-centered control. In a review of more than 30 clinical trials comparing the efficacy of PCA with conventional opioid treatment, improved analgesia and decreased risk of pulmonary complications were observed using the PCA.

The idea of PCA is appealing. Theoretically, there is improved analgesia and satisfaction, because patients may independently titrate the analgesic to their individual level of pain. Trials have consistently come down in favor of PCA, and the authors have consistently noted that in almost all cases, patients prefer this option.[61]

Conclusion

Oral and maxillofacial surgeons must understand that pain is both a primary motivation for our patients to seek treatment and a natural but manageable sequela of the procedures that we perform. The provider must work to educate and directly help manage the patient's acute postoperative pain using combinations of non-opioid and opioid medications.

Consideration must be given to the patient's current level (if present) of chronic pain medications, and the surgeon should be prepared to augment these therapies in the acute setting in consultation with other providers. Recognizing that postoperative pain management can begin by administering preoperative NSAIDs is crucial to a broad effective strategy. The administration of appropriate combinations of *scheduled* medications rather than as-needed (PRN) directions is also important to preempt the pain.

Beyond the pharmacologic management of a patient's acute pain, the clinician must consider the overall experience for the patient. This begins at the front desk of the office even before the patient arrives. Preparing the patient for expected postoperative discomfort should begin at the consultation appointment so that the patient's expectations are well established long before the day of surgery and the acute postoperative period.

References

1. Conrad SM, et al.: Patients' perception of recovery after third molar surgery, *J Oral Maxillofac Surg* 57(11):1288–1294, 1999, discussion 1295–1296.
2. White Jr RP, et al.: Recovery after third molar surgery: clinical and health-related quality of life outcomes, *J Oral Maxillofac Surg* 61(5):535–544, 2003.
3. Slade GD, et al.: The impact of third molar symptoms, pain, and swelling on oral health-related quality of life, *J Oral Maxillofac Surg* 62(9):1118–1124, 2004.
4. Snyder M, et al.: Pain medication as an indicator of interference with lifestyle and oral function during recovery after third molar surgery, *J Oral Maxillofac Surg* 63(8):1130–1137, 2005.
5. Shugars DA, et al.: Assessment of oral health-related quality of life before and after third molar surgery, *J Oral Maxillofac Surg* 64(12):1721–1730, 2006.
6. Grossi GB, et al.: Assessing postoperative discomfort after third molar surgery: a prospective study, *J Oral Maxillofac Surg* 65(5):901–917, 2007.
7. Cooper SA, Beaver WT: A model to evaluate mild analgesics in oral surgery outpatients, *Clin Pharmacol Ther* 20(2):241–250, 1976.
8. Sessle BJ: Acute and chronic craniofacial pain: brainstem mechanisms of nociceptive transmission and neuroplasticity, and their clinical correlates, *Crit Rev Oral Biol Med* 11(1):57–91, 2000.
9. Pyati S, Gan TJ: Perioperative pain management, *CNS Drugs* 21(3):185–211, 2007.
10. Schwartz SR: Perioperative pain management, *Oral Maxillofac Surg Clin North Am* 18(2):139–150, 2006. v.
11. Matheson JH, et al.: Management of acute postoperative pain. In: *Oral and Maxillofacial Surgery*, Fonseca R, et al.: vol. 1. Philadelphia, 2009, Saunders, pp 78–92.
12. Ong CK, Seymour RA: Pathogenesis of postoperative oral surgical pain, *Anesth Prog* 50(1):5–17, 2003.
13. Inturrisi CE: Clinical pharmacology of opioids for pain, *Clin J Pain* 18(4 suppl):S3–S13, 2002.
14. Fields HL, et al.: Multiple opiate receptor sites on primary afferent fibres, *Nature* 284(5754):351–353, 1980.
15. Stein C, Schafer M, Hassan AH: Peripheral opioid receptors, *Ann Med* 27(2):219–221, 1995.
16. Reichle FM, Conzen PF: Methylnaltrexone, a new peripheral mu-receptor antagonist for the prevention and treatment of opioid-induced extracerebral side effects, *Curr Opin Investig Drugs* 9(1):90–100, 2008.
17. Porreca F, Ossipov MH: Nausea and vomiting side effects with opioid analgesics during treatment of chronic pain: mechanisms, implications, and management options, *Pain Med* 10(4):654–662, 2009.
18. Webster L, et al.: Alvimopan, a peripherally acting mu-opioid receptor (PAM-OR) antagonist for the treatment of opioid-induced bowel dysfunction: results from a randomized, double-blind, placebo-controlled, dose-finding study in subjects taking opioids for chronic non-cancer pain, *Pain* 137(2):428–440, 2008.
19. DeHaven-Hudkins DL, et al.: The involvement of the mu-opioid receptor in gastrointestinal pathophysiology: therapeutic opportunities for antagonism at this receptor, *Pharmacol Ther* 117(1):162–187, 2008.
20. Strassels SA, McNicol E, Suleman R: Postoperative pain management: a practical review, part 2, *Am J Health Syst Pharm* 62(19):2019–2025, 2005.
21. Ballantyne JC, LaForge KS: Opioid dependence and addiction during opioid treatment of chronic pain, *Pain* 129(3):235–255, 2007.
22. De Pinto M, Cahana A: Medical management of acute pain in patients with chronic pain, *Expert Rev Neurother* 12(11):1325–1338, 2012.
23. Fisher RB, Johnson QL, Reeves-Viets JL: Pain management mini-series. Part II. Chronic opioid drug therapy: implications for perioperative anesthesia and pain management, *MO Med* 110(3):231–235, 2013.
24. Strassels SA, McNicol E, Suleman R: Postoperative pain management: a practical review, part 1, *Am J Health Syst Pharm* 62(18):1904–1916, 2005.
25. Moore RA, McQuay HJ: Single-patient data meta-analysis of 3453 postoperative patients: oral tramadol versus placebo, codeine and combination analgesics, *Pain* 69(3):287–294, 1997.
26. Jung YS, et al.: Onset of analgesia and analgesic efficacy of tramadol/acetaminophen and codeine/acetaminophen/ibuprofen in acute postoperative pain: a single-center, single-dose, randomized, active-controlled, parallel-group study in a dental surgery pain model, *Clin Ther* 26(7):1037–1045, 2004.
27. Manchikanti L, et al.: Opioid epidemic in the United States, *Pain Physician* 15(3 Suppl):ES9–ES38, 2012.
28. Stayner RS, Copenhaver DJ: Opioids, pain management and the law, *Curr Opin Anaesthesiol* 25(5):566–571, 2012.
29. Mutlu I, Abubaker AO, Laskin DM: Narcotic prescribing habits and other methods of pain control by oral and maxillofacial surgeons after impacted third molar removal, *J Oral Maxillofac Surg* 71(9):1500–1503, 2013.
30. Joint Commission on Accreditation of Healthcare Organizations: *Comprehensive accreditation manual for hospitals*, Oakbrook Terrace, IL, 1999, The Joint Commission, p v.
31. Davies NM, Skjodt NM: Choosing the right nonsteroidal anti-inflammatory drug for the right patient: a pharmacokinetic approach, *Clin Pharmacokinet* 38(5):377–392, 2000.
32. Roszkowski MT, Swift JQ, Hargreaves KM: Effect of NSAID administration on tissue levels of immunoreactive prostaglandin E2, leukotriene B4, and (S)-flurbiprofen following extraction of impacted third molars, *Pain* 73(3):339–345, 1997.
33. Jackson DL, Moore PA, Hargreaves KM: Preoperative nonsteroidal anti-inflammatory medication for the prevention of postoperative dental pain, *J Am Dent Assoc* 119(5):641–647, 1989.
34. Dionne RA, et al.: Suppression of postoperative pain by preoperative administration of ibuprofen in comparison to placebo, acetaminophen, and acetaminophen plus codeine, *J Clin Pharmacol* 23(1):37–43, 1983.
35. Petersen JK: The analgesic and anti-inflammatory efficacy of diflunisal and codeine after removal of impacted third molars, *Curr Med Res Opin* 5(7):525–535, 1978.
36. Dionne RA, Cooper SA: Evaluation of preoperative ibuprofen for postoperative pain after removal of third molars, *Oral Surg Oral Med Oral Pathol* 45(6):851–856, 1978.
37. Hill CM, et al.: Ibuprofen given pre- and post-operatively for the relief of pain, *Int J Oral Maxillofac Surg* 16(4):420–424, 1987.
38. Ong KS, et al.: Preoperative ketorolac has a preemptive effect for postoperative third molar surgical pain, *Int J Oral Maxillofac Surg* 33(8):771–776, 2004.
39. Ong KS, Tan JM: Preoperative intravenous tramadol versus ketorolac for preventing postoperative pain after third molar surgery, *Int J Oral Maxillofac Surg* 33(3):274–278, 2004.
40. Menasse R, et al.: Pharmacological properties of diclofenac sodium and its metabolites, *Scand J Rheumatol Suppl* (22)5–16, 1978.

41. Zuniga JR, et al.: Analgesic safety and efficacy of diclofenac sodium softgels on postoperative third molar extraction pain, *J Oral Maxillofac Surg* 62(7):806–815, 2004.
42. Zuniga JR, et al.: Onset of action of diclofenac potassium liquid -filled capsules in dental surgery patients, *Curr Med Res Opin* 27(9):1733–1739, 2011.
43. Spink M, Bann S, Glickman R: Clinical implications of cyclo-oxygenase-2 inhibitors for acute dental pain management: benefits and risks, *J Am Dent Assoc* 136(10):1439–1448, 2005.
44. Malamed SF: *Handbook of local anesthesia*, ed 6, St Louis, 2013, Elsevier/Mosby.
45. Bouloux GF, Punnia-Moorthy A: Bupivacaine versus lidocaine for third molar surgery: a double-blind, randomized, crossover study, *J Oral Maxillofac Surg* 57(5):510–514, 1999, discussion 515.
46. Gordon SM, et al.: Blockade of peripheral neuronal barrage reduces postoperative pain, *Pain* 70(2-3):209–215, 1997.
47. Apfel CC, et al.: A factorial trial of six interventions for the prevention of postoperative nausea and vomiting, *N Engl J Med* 350(24):2441–2451, 2004.
48. Romundstad L, et al.: Methylprednisolone intravenously 1 day after surgery has sustained analgesic and opioid-sparing effects, *Acta Anaesthesiol Scand* 48(10):1223–1231, 2004.
49. Clarke H, et al.: The prevention of chronic postsurgical pain using gabapentin and pregabalin: a combined systematic review and meta-analysis, *Anesth Analg* 115(2):428–442, 2012.
50. Clarke HA, et al.: Perioperative gabapentin reduces 24 h opioid consumption and improves in-hospital rehabilitation but not post-discharge outcomes after total knee arthroplasty with peripheral nerve block, *Br J Anaesth* 113(5):855–864, 2014.
51. Poylin V, et al.: Gabapentin significantly decreases posthemorrhoidectomy pain: a prospective study, *Int J Colorectal Dis* 29(12):1565–1569, 2014.
52. Rice ASC, et al.: EMA401, an orally administered highly selective angiotensin II type 2 receptor antagonist, as a novel treatment for postherpetic neuralgia: a randomised, double-blind, placebo-controlled phase 2 clinical trial, *Lancet* 383(9929):1637–1647, 2014.
53. Wallace M, et al.: Dose-dependent effects of smoked cannabis on capsaicin-induced pain and hyperalgesia in healthy volunteers, *Anesthesiology* 107(5):785–796, 2007.
54. Zogopoulos P, et al.: The role of endocannabinoids in pain modulation, *Fundam Clin Pharmacol* 27(1):64–80, 2013.
55. Chou R, Peterson K, Helfand M: Comparative efficacy and safety of skeletal muscle relaxants for spasticity and musculoskeletal conditions: a systematic review, *J Pain Symptom Manage* 28(2):140–175, 2004.
56. Huang D, Wun E, Stern A: Current treatments and advances in pain and anxiety management, *Dent Clin North Am* 55(3): 609–618, 2011. x.
57. Goodman LS, et al.: *Goodman & Gilman's pharmacological basis of therapeutics*, ed 12, New York, 2011, McGraw-Hill.
58. Kerns RD, et al.: Implementation of the veterans health administration national pain management strategy, *Transl Behav Med* 1(4):635–643, 2011.
59. Institute for Clinical Systems Improvement (ICIS): Assessment and Management of Acute Pain, *ICIS*, 2006.
60. Carr DB, et al.: Acute pain management: operative or medical procedures and trauma, *MEDTEP Updates Archive*, 1994.
61. Walder B, et al.: Efficacy and safety of patient-controlled opioid analgesia for acute postoperative pain. A quantitative systematic review, *Acta Anaesthesiol Scand* 45(7):795–804, 2001.

19

Pediatric Pharmacosedation and General Anesthesia

LARRY P. PARWORTH, TRENT W. LISTELLO, GREGORY S. BELL

Introduction

Since the inception of the specialty of oral and maxillofacial surgery, the delivery of anesthesia has been the cornerstone of our practice. The control of pain and anxiety is a valuable service to the public, especially for the pediatric population. The majority of pediatric patients exhibit fear and anxiety when coming in for surgical treatment, and providing care for the pediatric patient can be a challenging but rewarding experience. When behavioral management techniques fail or when they are not practical, pharmacologic intervention will be necessary. The goals of pediatric anesthesia are to provide efficient, safe, reversible, and profound anesthesia, sedation, or analgesia to allow safe and effective completion of the surgical procedure.[1]

Children are not simply small adults. Children have unique anatomic and physiologic differences that provide special challenges during anesthetic management. Maintaining a patent airway can be problematic as a result of large tonsils, a pliable funnel-shaped trachea, and other things. Airway loss with subsequent hypoxia and resultant cardiovascular compromise account for the majority of poor outcomes during pediatric anesthesia.[1]

Preanesthetic assessment for children should have areas of focus different from that of adults. A complete review of systems must include screening for endocrine disorders, congenital cardiac defects, hematologic disorders, and any familial history of malignant hyperthermia. Children tend to have more frequent upper respiratory tract infections and a higher incidence of asthma, and thorough investigation is critical.

Safety in the practice of state-of-the-art anesthesia is of the utmost importance to all oral and maxillofacial surgeons. Conditions contributing to major morbidity from office anesthetic procedures include unfamiliarity with pediatric anesthesia.[2] One study concluded that the judgment and skill of the provider was one of the prime determinants related to anesthetic mortality.[3] Constant review of the literature, having a thorough knowledge of current advances in technology and techniques, and ensuring maintenance of pediatric anesthesia skills are essential to providing the highest quality of care for our young patients.

This chapter discusses pediatric anatomy and physiology, preanesthetic workup, and equipment and monitoring for the safe and effective delivery of anesthesia. Current anesthetic drugs and techniques are reviewed along with the more common complications and their prevention and management.

Pediatric Anatomic, Physiologic, and Pharmacologic Differences

The successful management of pediatric patients undergoing anesthesia requires a thorough understanding of the anatomic and physiologic differences between pediatric patients and adults. These differences lead to many modifications in the delivery of anesthesia from the preanesthetic evaluation to the actual delivery of pharmacologic agents.

Cardiovascular System

The cardiovascular system undergoes significant changes at birth and continues to change throughout childhood. Transitional circulation describes the changes that take place as the fetus adjusts to the circulatory changes after birth. The end product of these changes includes the closure of the foramen ovale, closure of the ductus arteriosus, and closure of the ductus venosus, the combination of which causes the fetal circulation to become an adult-type circulation. These shunts do not close definitively immediately after birth; as a result, certain clinical conditions may contribute to the persistence of fetal circulation or to the reappearance of fetal shunts under stress. Factors such as hypoxia, hypercarbia,

acidosis, infection, hypothermia, and anesthesia-induced changes in peripheral vascular tone, act as a stimulus for maintaining high pulmonary vascular resistance and a return to fetal circulation. Blood may be shunted past the lungs through the patent foramen ovale, and a rapid downhill spiral may occur and result in severe hypoxemia.[4,5] Furthermore, after the neonatal period, it is estimated that 50% of children younger than 5 years of age and 28% of adults will demonstrate probe patency of the foramen ovale,[6] indicating the need for careful elimination of all air bubbles from an intravenous (IV) line in a pediatric patient.

Cardiac Output and Blood Pressure

Cardiac output in pediatric patients is higher than in adults and is necessary to meet the higher demands for metabolic oxygen consumption.[7] Cardiac output is defined as stroke volume multiplied by heart rate. The myocardial structure of the pediatric heart is significantly less developed than in adults. In particular the volume of cellular mass devoted to contractility is less in the pediatric heart, resulting in a noncompliant and poorly developed left ventricle that has minimal ability to alter stroke volume.[4,8] Therefore without the ability to alter stroke volume, cardiac output in a pediatric heart is dependent on heart rate.

Mean arterial blood pressure is proportionate to cardiac output multiplied by systemic vascular resistance. The pediatric cardiovascular system has little ability to alter systemic vascular resistance; it is less able to respond to hypovolemia with vasoconstriction[4] and also is very sensitive to volume overloading, with little ability to compensate. Therefore blood pressure in the pediatric patient is largely dependent on cardiac output. Bradycardia is the most lethal arrhythmia in pediatric patients[7] leading to large decreases in cardiac output and a resultant decrease in blood pressure. Perhaps the most frequent cause of bradycardia in pediatric patients is hypoxemia. Other frequent causes include anesthetic overdose or activation of the parasympathetic nervous system (Table 19-1).

Neural Innervation

In pediatric patients, the sympathetic nervous system is not fully developed, giving the parasympathetic nervous system greater control and increased tone. A severe and sudden bradycardia can often be the result of this parasympathetic hypertonia or "increased vagal tone."[10] The clinician should always be prepared to treat a vagal induced bradycardia because it can happen in people of all ages; however, it is important to note that the incidence is inversely proportional to age with a sharp decline in incidence for children over the age of 3 years[11] (Table 19-2).

TABLE 19-1 Typical Vital Signs by Age

Age in Years	1	3	6	12	Adult
Respiration rate/min	25-35	20-30	18-25	15-22	8-15
Heart rate/min	100-140	80-125	80-120	75-110	60-80
Blood pressure mm Hg	90/60	100/60	110/60	110/65	125/80

Modified from Dembo JB: Pediatric outpatient anesthesia, *Selected Readings Oral Maxillofac Surg* 5(4):1-19, 1997.

Respiratory System

During the first years of life, the respiratory system undergoes significant changes. Immaturity of the respiratory system in young children (under age 2) makes anesthesia particularly dangerous and should only be attempted by providers adept in pediatric anesthesia. This section will discuss the changes that occur in the development of the respiratory system, which will be divided into the upper airways, the chest wall, and the lungs.

Upper Airways

Differences in airway anatomy between pediatric and adult airways make airway management and intubation difficult in pediatric patients. The upper airway of infants differs in a number of ways, making pediatric patients more prone to obstruction than adults.[4,12,13] First, the infant's tongue is large in relation to the oral cavity. Second, the laryngeal cartilage is located higher in the neck. Third, the epiglottis is large and can cover the soft palate, which makes the airway more prone to obstruction and encourages nasal breathing, often referred to as "obligatory" nasal breathing. Most infants can convert to oral breathing if the obstruction lasts more than 15 seconds,[14] and almost all infants can easily convert to oral breathing by 5 months of age.[15] Young children also have proportionately larger tonsils than adults, with tonsils and adenoids reaching their largest size between ages 4 to 10 years.[9]

Endotracheal intubation is also influenced by the upper airway anatomy of the pediatric patient. The pediatric larynx is funnel shaped and is narrowest at the cricoid cartilage, whereas the narrowest part of the adult airway is the glottic opening (Figure 19-1).

For this reason, endotracheal tubes that pass through the vocal cords of an adult will sit passively in the trachea. However, in pediatric patients, an endotracheal tube that passes through the vocal cords may be tight just below the cords

TABLE 19-2 Frequency of Bradycardia During Anesthesia in Children, by Age

	0-1 Yr	1-2 Yr	2-3 Yr	3-4 Yr
Total anesthetics	4645	1932	774	628
With bradycardia	59	19	5	1
% Bradycardia	1.27	0.98	0.65	0.16

Modified from Keenan RL, et al: Bradycardia during anesthesia in infants: an epidemiologic study, *Anesthesiol* 80:976, 1994.

in the area of the cricoid cartilage. Any endotracheal tube, cuffed or uncuffed, that is placed in a pediatric patient must be checked to ensure air will "leak" around the tube at no more than 25 cm H_2O. At pressures greater than 25 cm of H_2O the mucosal capillaries may become damaged leading to subglottic inflammation, a dangerous phenomenon leading to further narrowing of an already narrow airway. The small diameter of the airways and further narrowing profoundly increases resistance to airflow because resistance is inversely proportional to the radius raised to the fourth power.

Over the first 2 years of life, the epiglottis, larynx, and hyoid bone move downward. The facial skeleton grows vertically, and the mandible lengthens from front to back. This growth continues until the age of 10 to 12 years when the pediatric airway fully develops into an adult airway.

Another difference between the pediatric and adult upper airway is that the pediatric trachea is more compliant. The negative pressures generated during inspiration tend to collapse the trachea. The most compliant region of the upper airway is the pharynx, which makes this region most susceptible to collapse. The pharynx is usually protected from collapsing by the tone of the upper airway muscles, which also contract during inspiration. However, small upper airways have a higher resistance to flow and may necessitate greater negative pressures to produce sufficient inspiratory flow. This results in a greater tendency for the pediatric upper airway to collapse.[16,17]

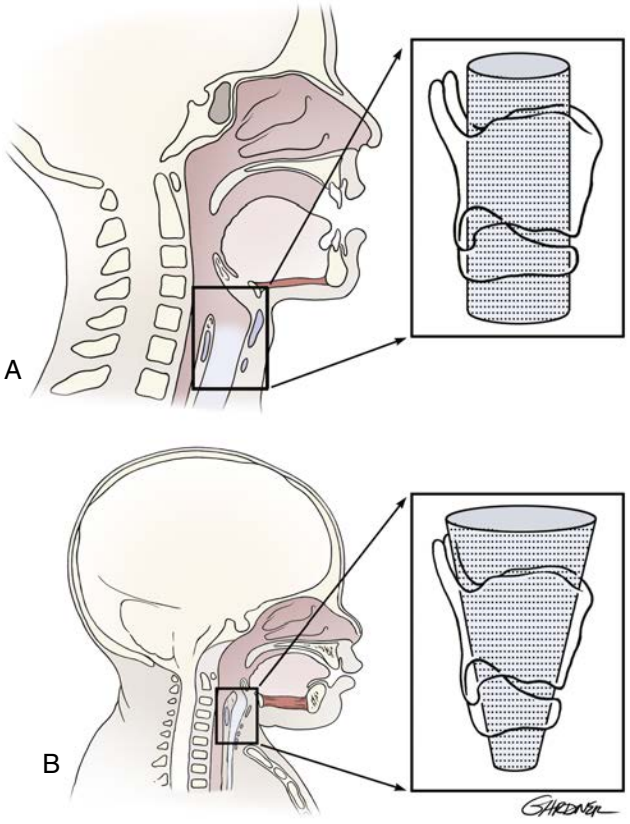

• **Figure 19-1** Sagittal section of the adult **(A)** and infant **(B)** airway. Notice that the adult larynx is cylindrical shaped with the narrowest part occurring at the glottic opening. The infant larynx is funnel shaped with the narrowest part occurring at the level of the cricoid cartilage.

Chest Wall

There are several properties of the chest wall and associated muscles of respiration that diminish the efficacy of ventilation in the pediatric population.

Pediatric ribs are very pliable because they are composed mainly of cartilage. As a result, the chest wall of an infant is very compliant and cannot easily maintain negative intrathoracic pressure, resulting in a decreased mechanical efficiency and less ventilatory reserve. In the infant, the compliance of the chest wall is almost three times that of the lung. By the age of 3 years, the ribs mineralize and become stiffer, making the chest wall and lung compliance similar.[16] The efficacy of ventilation in the pediatric patient is further diminished by the anatomy and composition of the respiratory muscles, which bear the load of respiration. In an infant, the diaphragm inserts in an almost horizontal fashion, compared with the oblique insertion in an adult[18] (Figure 19-2).

As a result, there is decreased contraction efficiency in infants; the flat diaphragm has a shorter downward course with less rib cage expansion. In addition to having a decreased inspiratory capacity, the composition of the intercostal muscles and the diaphragm allow little room to increase ventilation in the face of increased work of breathing. The diaphragm is made up of a mixture of fatigue-resistant and fatigue-susceptible muscle fibers. The number of fatigue-resistant fibers in the diaphragm at birth is approximately one half of the adult level. By 2 years of age, the diaphragm has matured to have approximately the same number of fatigue-resistant fibers as an adult.[16,19] This decreased inspiratory capacity coupled with less fatigue-resistant fibers places the pediatric patient at a higher risk to develop ventilatory fatigue quickly after small changes in respiratory load.

Lungs

There are several properties of the lungs that influence anesthesia delivery to the pediatric patient. Many anatomic differences exist between the pediatric and adult lung.

Respiration is not possible until both the pulmonary airways and vascular system have matured enough to allow gas

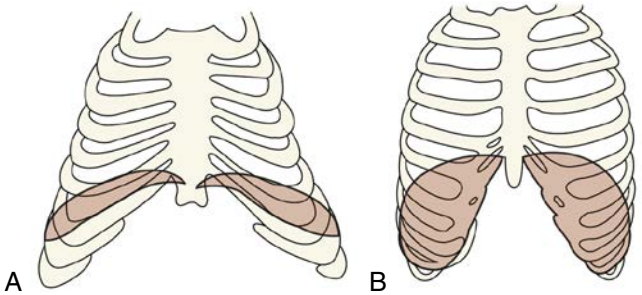

• **Figure 19-2** **A,** Newborn and **B,** adult rib cage. The shaded areas represent the anterior projection of the diaphragm.[16,18]

exchange. Marginal gas exchange capability is possible by approximately the 24th week of gestation, which is a critical step in allowing postnatal survival.[16] Alveoli form both before and after birth, and initial studies suggested that postnatal alveolar multiplication was slow after the age of 4 and ended by the age of 8.[20,21] However, more recent studies with larger groups of cases have shown that the great bulk of alveoli are present by the age of 2, and limited or no alveolar multiplication occurs thereafter.[22-25] Following the end of alveolar multiplication, lung development is considered complete, and the lung enters a period of normal growth until adulthood.[23,24]

In the newborn, the partial pressure of oxygen in arterial blood (PaO_2) is approximately 70 mm Hg, versus 97 mm Hg in the adult.[26-28] In theory, the low PaO_2 values may be due to ventilation-perfusion mismatch and a short capillary transit time that does not allow proper diffusion between the alveolar-capillary interface. The PaO_2 rises rapidly during the first 3 years of life with children aged 1 to 3 having an average PaO_2 of 83 mm Hg. The PaO_2 then slowly increases up to the age of 8 years.[27,28] Thereafter, PaO_2 values remain stable and similar to those seen in adults.[29] The fairly low PaO_2 values in infants and young children are close to the steep part of the oxygen-hemoglobin dissociation curve. Any further decrease in PaO_2 can induce severe oxygen desaturation.

The physiology of the pediatric lung is affected by the limited number of alveoli and compliant rib cage. Functional residual capacity (FRC) is the volume of gas remaining in the lung at the end of a normal tidal expiration. It represents the balance point between the inward elastic recoil of the lungs and the outward elastic recoil of the chest wall. In infants the chest wall is very compliant, making the outward elastic recoil very small.[30] Conversely the lung is stiff, making inward elastic recoil high, possibly as a result of the small and limited number of alveoli. As a result of this balance, the FRC of a pediatric patient is lower than that of an adult, promoting low residual lung volumes at expiration. During anesthesia FRC represents oxygen stores during periods of apnea. The closing capacity is the volume of air that is needed to keep the airways open. If FRC falls below the closing capacity, airway closure occurs leading to a shunt. The closing capacity is greater in the pediatric patient. A decreased FRC coupled with an increased closing capacity predisposes the pediatric patient to shunting, or perfusing areas of the lung that are receiving no ventilation. This requires more energy on top of an already higher metabolic demand and oxygen consumption rate. Clinically, this correlates to rapid oxygen desaturation during periods of apnea (e.g., during intubation or airway obstruction). In one model describing the rate of oxyhemoglobin desaturation during apnea, a child took 41 seconds to desaturate to 85%, whereas an adult took 84 seconds to desaturate to 85%[31] (Table 19-3).

Kidneys

Pediatric patients have decreased renal function under the age of 2. Multiple renal differences are seen early in life including decreased glomerular filtration rate, impaired sodium retention, and impaired glucose excretion. At birth glomerular filtration rate is approximately 15% to 30% of normal adult values. As a result, renal clearance of drugs is diminished. In addition, neonates are "obligate sodium losers" because their kidneys resorb less sodium in response to aldosterone than adult kidneys.[7] Finally, glucose excretion is impaired in neonates. This is intended to offset the impaired glycogen stores present in neonates and tendency toward hypoglycemia. Meticulous drug, fluid, and glucose regulation is important in early life before renal function maturation. Functional maturation may be delayed in premature infants; however, by the age of 2, functional maturation should be complete.[4,32]

Liver

At birth the liver is functionally immature, with minimal glycogen stores that may lead to hypoglycemia.[7] This is counterbalanced by decreased renal excretion of glucose as previously discussed. An immature liver is also reflected in immature liver enzyme systems. The cytochrome P-450 system, responsible for phase 1 drug metabolism of many lipophilic compounds, reaches approximately 50% of adult values at birth, suggesting decreased capacity for drugs metabolized by this system. Phase II reactions involving drug conjugation, which facilitates renal excretion, is also impaired. These immature reactions alter drug metabolism and lead to long drug half-lives. By age 1, these reactions achieve adult activity.[7,33]

Thermoregulation

Pediatric patients have a greater surface area to body weight ratio, or a larger surface area per kilogram than adults. They also have less muscle mass and less fat content than adults; as a result, pediatric patients quickly lose body heat to the environment. This makes pediatric patients more prone to hypothermia, which is associated with cardiac instability, respiratory depression, increased pulmonary vascular resistance, altered drug responses, and slower awakening from anesthesia. With a limited ability to shiver, infants respond to the stresses of a cold environment by increasing release of norepinephrine that enhances brown fat metabolism, a process called nonshivering

TABLE 19-3 Respiratory Variables

	Newborn	3 Yr	5 Yr	12 Yr	Adult
Tidal volume	21	112	270	480	575
Minimum ventilation	1.05	2.46	5.5	6.2	6.4
Vital capacity	120	870	1160	3100	4000
FRC	80	490	680	1970	3000

Modified from Dembo JB: Pediatric outpatient anesthesia, *Selected Readings Oral Maxillofac Surg* 5(4):1-19, 1997.

thermogenesis.[8,34] Environmental temperature is closely linked to the metabolic rates of infants, providing important sensory input.[35] Under resting conditions, ambient temperature is the most important determinant of metabolic rate.[16] An infant's metabolic rate is the lowest when environmental temperatures are within a neutral range. Cold stress will lead to increased metabolic rate of brown fat via nonshivering thermogenesis, increased oxygen consumption, hypoxemia, and metabolic acidosis.[4]

Developmental Pharmacology

Pediatric patients have a dramatically different response than adults to medications. Their response is altered by body composition, distribution of cardiac output, protein binding, and functional maturity of the liver and kidneys. As a result, drugs that have a very predictable response in adults may have a very unpredictable response in children.

The body composition of a person changes with age. The total body water in a term infant accounts for approximately 73% of body weight versus 60% for an adult. As the child grows, total body water decreases as fat and muscle content increase.[36] The implications of a drastically different body composition are twofold. First, drugs that are water soluble have a larger volume of water in which to distribute, which leads to initially larger doses to achieve the desired effect. Second, with less fat and muscle content, drugs that depend on redistribution into fat or muscle will remain intravascularly longer, leading to a longer clinical effect.

Distribution of cardiac output is different in pediatric patients, which results in unpredictable drug behavior. Pediatric patients have a higher cardiac output to vessel-rich groups (brain), which leads to a rapid onset of drugs. Pediatric patients also have decreased plasma levels of albumin leading to less protein binding and subsequently greater levels of free/active drug in the serum. Lastly, immature hepatic and renal function lead to long drug half-lives and decreased excretion.

As children grow, their body composition, distribution of cardiac output, protein binding, and functional maturity of the liver and kidneys all change to further affect drug behavior. The body composition of a child over the age of 2 is similar to that of an adult; they have normal adult values for protein, and the liver and kidney have functional maturity. Of particular importance is that a greater proportion of cardiac output is directed toward the already matured liver and kidneys, giving many medications a shorter half-life. As the child approaches adulthood, the half-life of many drugs lengthens to adult values. Overall most medications will have a prolonged elimination half-life in infants, a shortened half-life in children aged 2 to the early teen years, and a lengthening of half-life in those approaching adulthood.[4,37]

Preanesthetic Assessment

The ultimate goal of any preanesthetic assessment is to establish a treatment plan for the patient. Many medical problems discovered on the preanesthetic visit will prompt a change in patient management. One study found that the preanesthetic evaluation leads to changes in the treatment plan for more than 15% of American Society of Anesthesiologists (ASA) class I and II patients.[38] Although a similar study has not been conducted in pediatric patients alone, the significance of the study is understood. A focused history and physical examination with special attention to those medical conditions that will prompt a change in treatment is necessary. Whereas some medical conditions that require a change in patient management will be obvious and would not escape the attention of most parents (i.e., insulin-dependent diabetes mellitus, congenital cardiac defects), others are quite obscure and may only be brought to light with focused questions. Specific questions to ask should focus around gestational age, recent upper respiratory infection (URI), asthma, gastroesophageal reflux, and history of bleeding problems or hematologic disorders. Premature infants can have multiple medical problems usually caused by immaturity of major organ systems or intrauterine asphyxia.[8] Pulmonary complications of prematurity, including bronchopulmonary dysplasia, are particularly important to ask about because normal respiratory function may be delayed for many years, even up until age 6.[9,39] It is also important to ask about history of previous anesthesia and family history of musculoskeletal diseases or malignant hyperthermia.

The physical examination should include the child's general appearance, alertness, color, and activity level. Motor and verbal skills are also noted. Vital signs including height and weight are recorded. The physical exam should also focus on the cardiovascular, pulmonary, airway, and any other systems as indicated from the patient history. The presence of a heart murmur in a healthy, asymptomatic child is unlikely to indicate any significant cardiac pathologic condition.[8] Innocent murmurs are usually soft systolic ejection murmurs that are best heard along the upper left or lower left sternal border without significant radiation and may occur in more than 30% of normal children. Endocarditis prophylaxis is required for children with congenital heart defects. If any question exists in regard to the significance of a heart murmur, consultation with a pediatrician or pediatric cardiologist is recommended.

According to the American Association of Oral and Maxillofacial Surgeons clinical practice guidelines for anesthesia in outpatient facilities, most poor outcomes in pediatric anesthesia are related to loss of the airway.[1] The airway exam is extremely important in the physical examination of any patient undergoing anesthesia and especially in the pediatric patient with little respiratory reserve.

The airway exam should focus around three main characteristics that will help to detect a difficult airway. The first characteristic assesses the size of the tongue in relation to the oral cavity. The patient opens the mouth as widely as possible and protrudes the tongue as far as possible. The

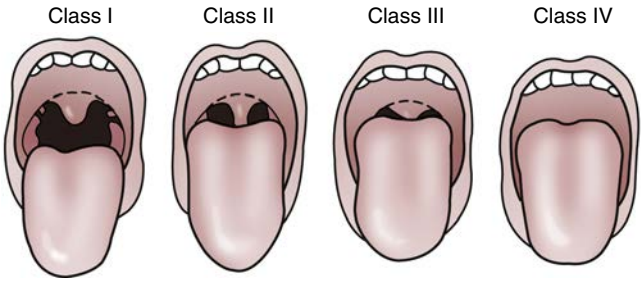

• **Figure 19-3** Classification of the upper airway in terms of the size of the tongue and pharyngeal structures visible upon mouth opening. In class I patients, the soft palate, fauces, uvula, and anterior and posterior tonsillar pillars can be seen; in class II patients, all of the above can be seen except the tonsillar pillars, which are hidden by the tongue; in class III patients, just the base of the uvula can be seen; and in class IV patients, not even the uvula can be visualized.[40,41]

airway can then be classified according to what pharyngeal structures can be seen, also known as the "Mallampati" classification (Figure 19-3).

This classification is important because the ability to see vocal cords on direct laryngoscopy is almost always good in class I patients and almost always poor in class IV patients.[40] Additional factors that can complicate airway management include large tonsils and loose teeth. The second characteristic assesses the atlanto-occipital joint extension. If the neck can be flexed to approximately 25 degrees to 35 degrees, the atlanto-occipital joint is extended, and the oral, pharyngeal, and laryngeal structures are nearly aligned, allowing for easier laryngoscopy. It should be noted that children with Down syndrome may have atlanto-occipital joint instability, and extension of the neck during intubation may lead to cervical dislocation and spinal cord trauma. Appropriate clinical assessment including extension and flexion lateral neck films may be necessary to detect instability before anesthesia for these patients.[41] The third characteristic in evaluation of the airway is measuring the mandibular space, also known as the thyromental distance. This is the space anterior to the larynx and is an indication for how easily the laryngeal axis will align with the pharyngeal axis during direct laryngoscopy. This value is expressed by the number of "fingerbreadths," with more "fingerbreadths" being indicative of easier laryngoscopy. Neonates should have at least one "fingerbreadth" and adolescents at least three to ease in direct laryngoscopy.[40,42-44]

Preoperative Fasting

Pediatric patients are more prone to dehydration than adults, and as a result their preoperative fasting guidelines have been less strict. Additionally, asking a pediatric patient to fast for an extended period of time will lead to increased irritability of the patient. Conversely, the incidence of aspiration is three times higher in pediatric patients than in adults (9 per 10,000 vs. 3 per 10,000), indicating the need for careful attention to the matter.[45] Fortunately, if aspiration does occur, serious respiratory morbidity is rare in the immediate postoperative period in pediatric patients.[45,46] In 1999 the ASA appointed a task force to establish practice guidelines for preoperative fasting and the use of pharmacologic agents to reduce the risk of pulmonary aspiration in healthy patients undergoing elective procedures (Table 19-4).

TABLE 19-4 Summary of Fasting Recommendations to Reduce the Risk of Pulmonary Aspiration

Ingested Material	Minimum Fasting Period (Hr)
Clear liquids	2
Breast milk	4
Infant formula	6
Nonhuman milk	6
Light meal	6

Modified from American Society of Anesthesiologists: American Society of Anesthesiologists task force on preoperative fasting and the use of pharmacologic agents to reduce the risk of pulmonary aspiration practice guidelines for preoperative fasting and the use of pharmacologic agents to reduce the risk of pulmonary aspiration: application to healthy patients undergoing elective procedures, *Anesthesiol* 90:896, 1999.

The ASA points out that with clear liquids there is no difference in the gastric volume of children who fasted 2 to 4 hours versus more than 4 hours. Examples of clear liquids include water, fruit juices without pulp, and carbonated beverages. The ASA also points out that nonhuman milk is similar to solids in gastric emptying time, and therefore the amount ingested must be considered when determining an appropriate fasting time. Finally, ASA notes that a "light meal" typically consists of toast and clear liquids. Meals that include fried, fatty foods, or meat may prolong gastric emptying leading to a fasting recommendation of 8 or more hours before elective procedures.[47] Whereas some published evidence supports the routine use of pharmacologic agents to reduce the risk of pulmonary aspiration, the ASA states that routine use of pharmacologic agents to reduce the risk of pulmonary aspiration in patients who have no apparent increased risk for aspiration is not recommended.[47]

Upper Respiratory Infection

During the preanesthetic evaluation, it is important to ask if the child has had any recent colds that may indicate a recent upper respiratory infection (URI). If the child has in fact had a recent cold, it is important to differentiate between a URI and simple rhinitis. Clear rhinorrhea is usually not a concern, and anesthesia is not contraindicated. A URI is usually associated with fever, mucopurulent green or yellow discharge, and a productive cough. Children with URIs have irritable airways and are at an increased risk for laryngospasm, breath holding, postintubation croup, atelectasis, pneumonia, and episodes of desaturation.[48-51] Furthermore, airway hyperreactivity may last for up to 6 weeks after a URI, and the incidence of

complications in children recovering from a URI is almost the same as in children who have active URIs.[51] The presence of URI in a child is particularly important because increased airway edema and inflammation in an already narrow airway will cause profound increases in resistance to airflow. Traditional guidelines for treatment of patients with URIs suggest that the procedure be delayed for 4 to 6 weeks after cessation of the URI to decrease the risk to the patient.

Asthma

Asthma is one of the most common chronic conditions in the United States, with the prevalence being highest for people under the age of 18.[52] Moreover, the prevalence among children aged 5 to 14 has increased 74% from 1980 to 1994 and 160% among children under the age of 4 from 1980 to 1994.[52] Given the degree of prevalence among the pediatric population it is likely that oral and maxillofacial surgeons will treat pediatric patients with asthma. Treating pediatric patients with moderate to severe asthma can be particularly dangerous because the overall mortality rates of asthma are highest between the ages of 5 to 14.[53] Moreover, acute and fatal bronchospasm can occur during anesthesia and endotracheal intubation in children with asthma. Whenever possible, endotracheal intubation should be avoided in these patients.[54]

In patients with asthma, elective cases should not be undertaken unless their asthma is well controlled. During preoperative assessment of the asthmatic patient, it is important that the disease is assessed by the cause, frequency and severity of attacks, hospital and intensive care admissions, and by drug history. A thorough examination is required, which may reveal expiratory wheezes, use of accessory muscles, or an overdistended chest. If a child is actively wheezing, elective surgery should be canceled. A child should be free of wheezing for at least 1 week before surgery. Attempts to control wheezing with an increase in β-agonists or the addition of steroids are indicated preoperatively. Preoperative steroids may be needed for children with asthma who continue to wheeze despite an increase in β-agonists or as a stress dose for children who have received steroids over the last year to control their asthma.[42,54] The addition of prednisone, 1 mg/kg given 24 and 12 hours before surgery, will considerably decrease airway reactivity.[42] If preoperative wheezing cannot be controlled with conservative therapy as an outpatient, admission for more aggressive therapy and consultation with a pediatrician is indicated.

Monitors

The ASA has set the standards for basic anesthetic monitoring for all anesthesia care.[55] The goal of these standards is to encourage quality patient care while noting that it is but one component of care and that the monitors alone do not offer patient safety guarantees. Two basic standards rely on both provider vigilance and basic monitoring. Although the various monitors and alarms are a very important component of anesthesia care, they do not replace the anesthesia provider.

The first standard states that a qualified anesthesia provider must be present in the room through all stages of anesthesia care. The objective of this standard is based on the need for a qualified anesthesia provider to monitor and address any of the possible rapid changes in patient status and to be present continuously. Although it is not currently necessary, it is highly recommended that providers administering anesthesia to children have current certification in Pediatric Advanced Life Support (PALS). The observation of levels of consciousness during anesthesia will reduce risks and most likely prevent many complications if adverse drug responses are detected in a timely manner.[56]

The second standard states how oxygenation, ventilation, circulation, and temperature are to be continually monitored. *Continually* is further defined as "repeated regularly and frequently in steady rapid succession."

Oxygen concentration is assessed in inspired gas and blood with pulse oximetry during any form of anesthesia delivery. Pulse oximetry will be accompanied by pitch pulse tone with audible, low threshold tone alarms. Adequate lighting will help with visual assessment of physical appearance to ascertain appropriate oxygenation of tissues. This is especially important in small children because of the rapid rate of desaturation and avoidance of hypoxic episodes.

Adequate ventilation should be evaluated by continual observance of qualitative clinical signs, such as chest expansion, reservoir breathing bag movements, and chest auscultation. Carbon dioxide detection is necessary during use of general anesthesia including verification of placement of an endotracheal tube or laryngeal mask airways (LMAs) and will be monitored continually unless undetectable as a result of nature of patient, procedure, or equipment. This will be done from initial placement of the airway device until removal. This measurement will be done with capnography, capnometry, or mass spectroscopy. Mechanical ventilation units must include an audible disconnect alarm. All other forms of anesthesia care should also be evaluated by continual observation of clinical signs and/or detection of exhaled carbon dioxide, although it would be expected to be lower if using a nonclosed breathing circuit, such as a nasal cannula, where the presence of exhaled carbon dioxide is the means of detection.

Circulation will be monitored by continuous electrocardiogram and heart rate display and arterial blood pressure display at a minimum of 5-minute intervals. Additional measures, such as pulse palpation or heart sound auscultation and intra-arterial pressure tracings, could also be used for general anesthesia patients. Blood pressure cuffs should be appropriately fitted for each child to ensure correct measurements because a cuff that is too large will underestimate readings. Each patient should be sized with a blood pressure

cuff that has a width 20% to 50% greater than the diameter of the patient's extremity.[57]

Every child receiving anesthesia shall have temperature monitoring when a clinically significant change in body temperature is intended, anticipated, or suspected.

Alternative Monitors

Adjuncts to standard monitors evaluate other clinical and physiologic processes. The use of a precordial stethoscope adds the ability to hear heart sounds and airway status easily. Bispectral analysis (BIS) is a noninvasive method to evaluate levels of anesthesia, and it is based on the principle that electroencephalogram (EEG) waveforms change with the level of alertness. The manufacturer has developed numeric value, known as the BIS index, based on an algorithm of EEG digital signals. The numeric value corresponds to level of sedation: 90 to 100 awake, 70 to 90 light to moderate sedation, 60 to 70 deep sedation, 40 to 60 general anesthesia, and less than 40 a deep hypnotic state. The BIS index has been shown to be closely associated to sedation scales, which would prevent possible oversedation.[58]

Transcutaneous capnometry is being studied as an alternative method of detecting ventilatory malfunction and prevention of hypoxemia in patients in addition to pulse oximetry. Pulse oximetry is always accompanied with a delay, and a combination of the two provides the advantage of monitoring both alveolar ventilation (capnometry) and oxygen transport to the periphery (pulse oximetry) noninvasively. Stein et al. investigated two transcutaneous capnometers for clinical use, but do not currently recommend their use in clinical conditions in the current form because they provide only an approximate estimation of $PaCO_2$.[59]

Alarms

Monitors and associated alarms may only alert the provider if they are activated. Block et al. reported that a majority of anesthesiologists routinely disable or mute audible alarms because of a number of false alarms.[60] False alarms are a common source of disruption and distraction in the operating suite because they alert the anesthesia provider of known information that is already being controlled or monitored by the anesthesia provider. The Joint Commission on Accreditation of Healthcare Organizations and the Anesthesia Patient Safety Foundation (APSF) both recommend the use of audible alarms.[61,62] Alarms have proven their importance by preventing and reducing the severity of anesthetic incidents, but sole reliance on monitors without clinical support may also lead to inappropriate interventions.[63] Providers should become familiar with their equipment and determine the proper alarm settings based on ASA guidance and clinical judgment.

Equipment and Room Preparations

The treatment of pediatric patients requires some adjustments to the setup in preparation for the procedure and presence of additional and often helpful elements in the operating arena. Some of these address emergency medications, equipment, fluid delivery access, and delivery. Initial preparations should be to change monitoring and anesthesia equipment to pediatric settings.

All pediatric operatories should have emergency equipment that is located in a well-known, easily accessible area. This equipment should be well maintained and inspected on a periodic basis. Appropriate algorithms and medicines to treat perioperative emergencies should be included in that location as well. A defibrillator with pediatric paddles along with emergency suction, auxiliary oxygen supplies, and alternative source of light should be available in case of loss of power. The oxygen source should be able to deliver under pressure for a minimum of 1 hour. At our institution, each pediatric patient has his or her information included in a worksheet that takes patient vital statistics and converts that information into appropriate equipment sizes, fluid replacement amounts, and doses of common perioperative medications. This form is then placed in the operative setting to be reviewed as needed (Figure 19-4).

Broselow Emergency Pediatric Tape provides a reference at each color bar on the tape to select equipment sizes to perform emergency resuscitation based on weight zone. The tape also shows precalculated medication dosages and infusion rates based upon each colored weight zone. Other commercial and institutional items are available to provide similar information.

An average setup of pediatric patient treatment begins with setup of room and equipment. Because infants and children have a greater surface area to body weight ratio causing greater body heat losses, temperature of the operating suite should be adjusted to between 80° F to 90° F.[64] Most oral surgery procedures completed as outpatient procedures are relatively short, so clinical judgment should determine suitability of additional measures, such as warm fluid and heating blankets.

Airway

Items needed to access and control the airway should be readily available; these include appropriately sized nasal cannulas, nasopharyngeal airways, oropharyngeal airway, endotracheal tubes, and LMAs (Table 19-5).

Pocket masks and bag-mask-valve devices with positive pressure ventilation ability should be included. Inclusion of a system of emergent airway access, such as a cricothyrotomy kit, should be available in case situations arise where other methods have failed to establish a patent airway. Transtracheal catheter jet ventilation may be considered for support of oxygenation when a surgical airway is required for pediatric patients, but only in situations where oxygenation and ventilation cannot be provided any other way.[65] Ravussin et al. used transtracheal jet ventilation during pediatric endoscopic laser treatment of laryngeal and subglottic stenosis.[66] Adequate control of the airway and satisfactory gas exchange were obtained in all cases; however, they reported

Patient Name:

Data Entry Box	
Age - Months (0-24)	
Age - Years (> 2)	
Weight - Pounds	
Height - Inches	
Hours NPO	
Respiratory Rate	
Hematocrit	
Minimum Allowable Hct	

Calculations

Weight Kilograms	
Height Centimeters	
BSA Square Meter	

Ventilation

Dead Space ml	
Minute Ventilation ml/min	
Alveolar Ventilation ml/min	
Tidal Volume ml (resting)	
Tidal Volume ml @ 10 ml/kg	
Endotracheal tube size mm	
ET-Tube Length @ nose cm	
ET-Tube Length @ teeth cm	
Minimum	
Maximum	
Newborn/Infant length @ lips	

Fluids/Blood

Maintenance ml/hr	
NPO Deficit Total ml	
Deficit Replacement ml	
1st Hour -	
2nd Hour -	
3rd Hour -	
Surgical Requirement ml/h	
Minor (3 ml/kg/hr) -	
Moderate (5 ml/kg/hr) -	
Major (7 ml/kg/hr) -	
Blood Replacement	
Estimated Blood Vol ml	
Allowable Blood Loss ml	
Packed RBC (ml) to- Hb 1 Gm	

Medications

Pre-operative			mg
Atropine	IM	0.02 mg/kg	
Glycopyrrolate	IV,IM	0.01 mg/kg	
Ketamine Stun	IM	5 mg/kg	
Metoclopramide	IV	0.15 mg/kg	
Midazolam	IV	0.05 mg/kg	
Midazolam	PO	0.5 mg/kg	
Midazolam	IM	0.1-0.15 mg/kg	
Midazolam	Nasal	0.2 mg/kg	
	Nasal	0.3 mg/kg	
Morphine	IM	0.1 mg/kg	

Induction			mg IV
Ketamine			
range =	1-2 mg/kg	0	
Propofol			
range =	2-3 mg/kg	0	
Thiopental			
range =	3-6 mg/kg	0	

		mg IV
Succinylcholine	2 mg/kg	
Succinylcholine	4 mg/kg(IM)	
Rocuronium	1.8 mg/kg(IM)	
Atropine	0.01 mg/kg	
Lidocaine	1 mg/kg	

Narcotics			mcg IV
Sufentanil	balanced induction		
range =	0.125-0.5 µg/kg		
Sufentanil	cardiac induction		
range =	2-10 µg/kg		
Fentanyl	balanced		
range =	1-5 µg/kg		

☆ Initial and Subsequent Dosing of Rectal Acetaminophen in Childre: A 24-Hour Pharmacokinetic Study of New Dose Recommendations: Patrick K.; Tobin, Michael J.; Fisher, Dennis M Anesthesiology. 94(3):385-389, March 2001.

Muscle Relaxants		mg IV
Atracurium		
Intubation	0.5 mg/kg	
Maintenance	0.1 mg/kg	
Cisatracurium		
Intubation range	0.1 mg/kg	
	0.2 mg/kg	
Maintenance	0.02 mg/kg	
Mivacurium		
Intubation	0.2 mg/kg	
Maintenance	0.08 mg/kg	
Pancuronium		
Intubation	0.1 mg/kg	
Maintenance	0.05 mg/kg	
Rocuronium		
Intubation	0.6 mg/kg	
Rapid sequence	1.2 mg/kg	
Maintenance	0.15 mg/kg	
Vecuronium		
Intubation	0.1 mg/kg	
Maintenance	0.025 mg/kg	

Reversal		mg IV
Atropine	0.015 mg/kg	
	0.02 mg/kg	
Edrophonium	0.75 mg/kg	
	1 mg/kg	
Glycopyrrolate	0.01 mg/kg	
Naloxone PRN	0.005 mg/kg	
Neostigmine	0.06 mg/kg	
may start with half this dose & repeat X1		

Peri-operative		mg IV
Diphenhydramine	1.0 mg/kg	
Droperidol	0.05 mg/kg	
Ephedrine PRN	0.2 mg/kg	
Hydrocortisone	1 mg/kg	
Labetalol	0.25 mg/kg	
Meperidine	0.5 mg/kg	
Morphine Sulfate	0.05 mg/kg	
	0.1 mg/kg	
Ondansetron	0.15 mg/kg	
Promethazine	0.5 mg/kg	

Emergency Medications		mg IV
Aminophylline	5 mg/kg	
Atropine mg (PRN X2)	0.02 mg/kg	
Atropine minimum dose 0.1 mg, maximum single dose 0.5 mg		
Calcium Chloride	10 mg/kg	
(max dose 500 mg)	20 mg/kg	
Dantrolene (to 10 mg/kg)	2 mg/kg	
Dexamethasone	0.15 mk/kg	
Dextrose	0.5 gms/kg	
Epinephrine mg (1:10,000)	0.01 mg/kg	
Subsequent dose (1:1000)	0.1 mg/kg	

Succinylcholine IM	4 mg/kg	
Fluid Bolus PRN	10 ml/kg	
	20 ml/kg	
Defibrillation Joules	2 J/kg	

Antibiotics		mg IV
Ampicillin	25-50 mg/kg IV q4-6h Max 2-3 g/d	
range =		
Cephapirin (Cefadyl)	10 - 20 mg/kg IV q6h Max 4 g/d	
range =		
Cefazolin (Kefzol)	8.3-25 mg/kg IV q6-8h max 6g/d	
range =		
Cefotetan (Cefotan) ✦	20-40 mg/kg IV q12h Max 6 g/d	
range =		
Cefoxitin (Mefoxin)	30-40 mg/kg IV q6h x 24 hrs	
range =		
Ceftriaxone (Rocephin)	25-50 mg/kg q12-24 hrs	
range =		
Clindamycin (Cleocin)	6.25-10 mg/kg IV q6h Max 4.8 g/d	
range =		
Gentamicin	1.5-2.5 mg/kg IV q8h	
range =		
Vancomycin	10 mg/kg IV q6h Max 1 g/dose	

Analgesics			mg IV
Acetaminophen	PO	15 mg/kg	
☆ loading dose	PR	40 mg/kg	
Ibuprofen	PO	10 mg/kg	
Ketorolac (IV)		0.5-0.75 mg/kg	

SBE prophylaxis		mg IV
Gemtamicin	1.5 mg/kg	
Ampicillian	50 mg/kg	

✦ Not FDA approved for prophylaxis is children

The authors have exerted every effort to ensure that the drug dosages set forth are in accordance with current recommendations at the time of publication.
The user is urged to check the drug's package insert for any changes in indications and dosages as well as for warnings and precautions.
The responsibility is ultimately that of the prescribing clinician.

• **Figure 19-4** Pediatric Anesthesia Worksheet.

TABLE 19-5 Laryngeal Mask Airway Sizes and Inflation Volume

Mask Size	Patient Selection Guidelines	*Maximum Cuff Inflation Volume (Air)
1	Up to 5 kg neonatal	up to 4 mL
1½	5-10 kg pediatric	up to 7 mL
2	10-20 kg pediatric	up to 10 mL
2½	20-30 kg pediatric	up to 14 mL
3	30-50 kg pediatric	up to 20 mL
4	50-70 kg adult	up to 30 mL
5	70-100 kg adult	up to 40 mL
6	Over 100 kg adult	up to 50 mL

*These are maximum volumes that should never be exceeded. It is recommended the cuff be inflated to 60 cm H_2O intracuff pressure.
Source: Quick Reference Guide, Teleflex Medical.

a severe life-threatening complication rate of 10.7% including pneumomediastinum and bilateral pneumothoraces (see Figure 19-4).

A simple method to size an oropharyngeal airway is by placing the anterior portion at the commissure and the posterior portion to the angle of the mandible. Endotracheal tubes should also be available and sized appropriately. A common method for sizing an endotracheal tube for children over 2 years old is found in the formula:

$$4 + (\text{age}/4) = \text{tube diameter (in mm)}$$

For example, an 8-year-old patient would likely require a 6-mm tube. An alternative method involves selecting an endotracheal tube size equivalent to the diameter of the child's fifth finger. Verification of the correct size is based on ease of passage into the larynx and the development of air leak at 15 to 20 cm H_20 pressure. Absence of air passage at that pressure is an indication that the selected tube is too large. If the leak is present at less than 10 cm H_20, the tube should be changed to the next larger size. If the patient is planned for intubation, two endotracheal tubes of selected size and one each of a size above and below should be available to allow rapid access if the size is incorrect. Length of the tube placed at the lips can also be figured with the following formula:

$$12 + (\text{age}/2) = \text{length of tube (in cm)}$$

These formulas are approximate and sizing should always be confirmed clinically by auscultating bilateral breath sounds, epigastric auscultation, chest expansion, and presence of exhaled carbon dioxide. A standard cutoff for use of a cuffed endotracheal tube has been 8 years or older, but with advent of low-pressure cuffs the use of cuffed tubes is becoming more common.[67,68] If desired nasal intubation can be performed with an RAE design nasal tube, appropriate-size laryngoscopes should also be available, and lights and attachments verified before each case. A narrow handle and straight blade aid intubation in children younger than 5 years old. A pediatric circuit should be used with appropriate face mask for mask induction or general anesthesia. Tidal volume (8 to 10 mL/kg) and respiratory rates (increased to 18 to 30) should be adjusted for each patient. A small dental suction should be nearby and functioning appropriately for evacuation of secretions. Reservoir bags should be 1 L for small children and 2 L for larger children. If the child is 8 years or older, an adult circuit may be used.

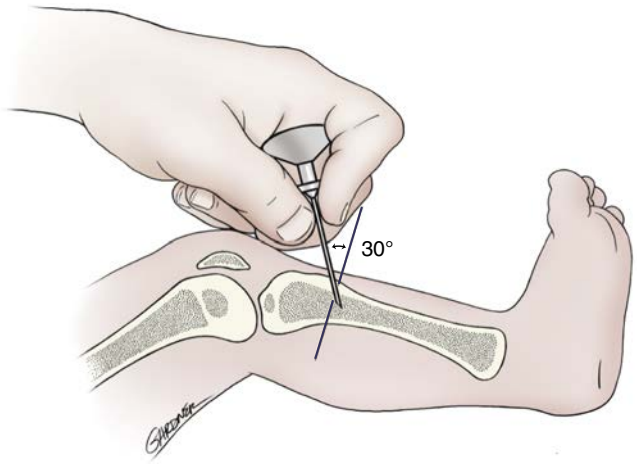

• **Figure 19-5** Emergent situations may call for placement of IO cannulation 1 to 3 cm below the tuberosity in the middle of the anteromedial surface of the tibia. Care is taken to avoid the epiphyseal plate while gently twisting the needle. Loss of resistance, aspiration of marrow, and upright needle when unsupported indicate proper placement. Resuscitation drugs, fluids, and blood products may be delivered through this route.

Intravenous Access

IV access may be accomplished in several ways. At the preoperative appointment, one can employ the "tell-show-do" method by showing how the procedure will proceed and also to see how the child reacts. Parents may also inform the providers how they think their child will handle the attempts. A popular choice for cutaneous anesthesia is the use of EMLA cream (lidocaine 2.5% and prilocaine 2.5%) under an occlusive dressing and intact skin. By applying a thick layer to the skin at two to three sites 90 minutes before the procedure, adequate skin anesthesia should be achieved for IV access.[69] Older children may benefit from subcutaneous injection of 2% lidocaine at the site of venipuncture. Younger children may be unable to cope with the process, and alternative methods may be used, such as mask induction before IV placement. Emergent situations may require the use of intraosseous (IO) placement of a catheter for delivery of resuscitation drugs, fluids, and blood products. An IO infusion needle kit with stylet is available from Cook Critical Care Co (Bloomington, IN). If an IO needle is not available, a butterfly or standard hypodermic needle can also be used. The location for IO cannulation is often the tibia, the site being approximately 1 to 3 cm below the tuberosity in the middle of the anteromedial surface of the tibia (Figure 19-5).

In this location, the tibia is close to the skin, and it is easy to palpate the flat, smooth surface to be cannulated. Other locations include distal femur, medial malleolus, and anterior iliac spine. The IO needle is inserted through the skin into the flat anteromedial surface of the tibia with a gentle twisting motion; it is directed perpendicular to the surface of the tibia or slightly toward the toes to avoid entering into the epiphyseal plate. If using another location, it is preferred to place away from the nearest joint space. When a loss of resistance is felt, stop the needle advancement and attempt marrow aspiration. If marrow is aspirated, irrigate to prevent obstruction of the needle. Other indications of proper placement include an upright needle when unsupported and a fluid delivery without subcutaneous edema.[70] IO placement has been shown to be performed easily after diverse training with minimal complications. Complications of IO access include osteomyelitis, subcutaneous access, compartment syndrome, extravasation, fracture, growth plate injuries, and fat emboli.[71] Fractured bones should not be accessed.

Intraoperative Fluids

Once IV access has been gained, fluid may be delivered. It has become common to use an IV delivery device, such as a buretrol or volutrol, with a microdrip chamber (60 drops/mL) attached between the IV fluid bag and the IV catheter; it is used to deliver IV fluids in a controlled manner with 100 mL placed at a time in the chamber. Lactated Ringer's (LR) or another balanced salt solution is usually adequate because of the fact that most outpatient oral surgery procedures are short, and hypoglycemia or electrolyte imbalances are not of concern. For longer outpatient cases in the operating room where hypoglycemia becomes a concern, 5% dextrose in LR may be added or used as the maintenance fluid itself.[72]

Fluid management is based on fluid maintenance, replacement, and deficit. Fluid maintenance is based on the 4:2:1 rule: 4 mL/kg for the first 10 kg, and then 2 mL/kg for the second 10 kg and 1 mL/kg/hr for each remaining kg. In a child weighing 30 kg, the calculations for maintenance regimen would be:

$$10 \text{ kg} \times 4 \text{ mL} = 40 \text{ mL}$$

$$10 \text{ kg} \times 2 \text{ mL} = 20 \text{ mL}$$

$$10 \text{ kg} \times 1 \text{ mL} = 10 \text{ mL}$$

$$30 \text{ kg} = 70 \text{ mL/hr}$$

Fluid replacement takes into consideration the amount of time in hours the patient was *nil per os* (NPO) multiplied by the fluid maintenance amount plus hourly maintenance, surgical blood loss, urine output, and insensible losses (1 to 3 mL/kg/hr for most oral surgery procedures). The fluid deficit is given back incrementally; half is given over the first hour and then the remaining half given over the next 2 hours. If a patient was NPO for 8 hours with a maintenance rate of 100 mL/hr, 400 mL would be given the first hour, then 200 mL given each of the next 2 hours. Surgical blood loss would be replaced with either crystalloid solution (LR) in a 3:1 ratio or 1:1 ratio for colloid (5% albumin) or actual blood replacement.

Pharmacosedation and General Anesthesia

Oral surgery on pediatric patients can be a very pleasant operative experience if the patients are reasonably calm and cooperative. Cooperation is important to provide for patient, provider, and staff safety; it also allows for proper monitoring and physical cooperation during the procedure. The primary goals of pediatric sedation are to reduce typical fear and anxiety, increase cooperation, and ensure patient comfort by providing adequate forms of amnesia and analgesia. Pharmacosedation or general anesthesia may be needed to meet these goals by providing the adequate level of anesthesia.

Premedication for Fear and Anxiety

Premedication is used to reduce presurgical anxiety. Children may be unable to communicate their fears and may express them in undesirable ways: scared looks, agitation, trembling, crying, and, most important, noncompliance. Most fear comes from anticipated pain and separation from parents. Fear of separation from parents is to be expected from children between the ages of 6 months and 6 years.[73] These fears may be addressed at the initial preoperative appointment when the routines of the day of surgery may be reviewed with the child and their parents, to include a visit to the surgery suite and a trial run of the placement of the IV access. Parents should be counseled to take part in allaying the fear and anxiety of patients by remaining calm themselves and providing gentle encouragement. At our institution, the health and physical exam is completed 2 days before the day of surgery, allowing for the child to become familiar with the surgical environment. The parents are given details of the patient's preoperative fasting, postoperative expectations, postsurgical care instructions, and use of analgesics at this appointment. This is also the time to determine the need for premedication and the extent the parents will play in the perioperative period and if their presence is needed at the time of induction of anesthesia. Although parental presence decreases their anxiety and increases satisfaction, parental presence has no effect on the child's anxiety.[73] Premedication not only allows for greater patient cooperation, it may also reduce the amount of anesthesia provided at induction and intraoperatively.[75]

Midazolam

Midazolam is a benzodiazepine with a rapid onset of action, short duration of action, has no active metabolites,

and provides retrograde amnestic properties. These qualities make midazolam ideal for both premedication and sedation. Midazolam is available for delivery in many forms, and its dose is determined by delivery choice. Oral midazolam is available in a cherry-flavored syrup; this method of delivery is the most popular and is delivered at 0.5 to 1.0 mg/kg with a maximum of 15 to 20 mg.[8,76,77] Orally delivered midazolam is effective in approximately 30 minutes and does not result in significant changes in heart rate, respirations, or blood pressure with doses of 0.5 to 0.75 mg/kg.[77] However, the disadvantages of orally administered drugs include inability to titrate, unreliable absorption as a result of hepatic first-pass metabolism, and moderate failure rates. At doses greater than 0.75 mg/kg, midazolam may not provide additional sedation at 30 minutes after premedication and in some instances may be associated with a greater incidence of side effects including dysphoria and blurred vision.[77] Midazolam may also be delivered nasally or rectally, both offering adequate sedation if the child is unwilling to swallow the syrup. Intranasal administration had been used often in the past, but is not well accepted by children because of irritation to nasal mucosa and taste of medication when swallowed, which also subjects the medication to absorption in the digestive tract. Roelofse et al. administered rectal midazolam (1 mg/kg) to 100 children 30 minutes before dental treatment.[78] The rectal delivery was well accepted by 70% of the patients with reliably good anxiolysis and sedation without loss of respiratory drive or protective airway reflexes. If patients have IV access, sedation can be accomplished with 0.1 to 0.15 mg/kg and titrated to effect. Because midazolam has no analgesic properties, it is necessary to achieve adequate local anesthesia with possible addition of other analgesic medications based on the amount time and expected stimulation of the procedure. Golparvar et al. reported an incidence of 3.4% of pediatric patients with paradoxical reactions with the use of IV midazolam.[79] Signs and symptoms included restlessness, violent behavior, physical assault, self-injury, restraint, panic, anger, dysphoria, and disorientation. The time of onset varied between 3 to 6 minutes and was unlikely to spontaneously resolve. Patients were treated successfully by the administration of the rescue tranquilizer ketamine.

Fentanyl

Fentanyl is an opioid agent that is most commonly used after IV access during surgery; it has a rapid onset of action and duration of action usually under an hour. It may be used for sedation often in concert with midazolam. Although it is available in lollipop form, it must be absorbed through the oral mucosa; if swallowed, effectiveness decreases as a result of liver first-pass metabolism.[80] Similar to other opioid agents, the most common side effects with fentanyl use are respiratory depression, pruritus, and postoperative nausea and vomiting.[81] Because of the potential respiratory depression and effects of synergism with additional medications such as midazolam, fentanyl should only be delivered with ASA monitors in place.

Ketamine

Ketamine is a dissociative anesthetic agent that produces an anesthetic state consisting of catalepsy, analgesia, amnesia, and different degrees of consciousness.[82] Ketamine produces a dissociative state that is created by the generation of dissociation between the cortical and limbic systems, which disrupts interpretation of visual, auditory, and painful stimuli from the brain.[83] At subanesthetic doses, ketamine has the advantage of providing analgesia without respiratory depression associated with opioids, and it also reduces the amount of additional opioids necessary in the postoperative period.[84] Ketamine directly stimulates smooth muscle dilatation, which decreases risk of bronchospasm. Ketamine is also beneficial because it usually maintains upper airway musculature tone and spontaneous respirations.[17] Ketamine increases saliva production, heart rate, blood pressure, and intracranial pressure (ICP). If a closed head injury is suspected, ketamine should not be used because of increases in ICP. Additional fluids produced by excess salivation may cause laryngospasm if secretions contact the vocal cords, so anticholinergics (atropine or glycopyrrolate) are often given before use of ketamine.[85] Emergence delirium is often cited as one of the possible side effects from use and can include hallucinations that are pleasant, bizarre, or terrifying. Risk factors for emergence delirium are age over 10 years, female gender, underlying psychiatric disorder, IV route, high doses, and excessive noise or stimulation on emergence.[86] The addition of Versed before ketamine use reduces the incidence of emergence delirium.

Ketamine is usually given parenterally, but it can also be given through oral, rectal, and intramuscular (IM) routes.[78] Oral ketamine has been investigated for use in sedating anxious pediatric dental patients.[87] Ketamine 6 mg/kg was given orally, with an onset of approximately 20 minutes and a mean duration of sedation of 36 minutes. Nitrous oxide 30% to 50% was also administered during treatment. The quality of sedation was rated as good for 65% of the patients, with a mean recovery time of 56 minutes. IM is also popular because patient cooperation is not required, and it has been shown to be an ideal medication for short procedures in the ER. This can be accomplished by using ketamine (4 mg/kg) combined with atropine or glycopyrrolate in a single injection to provide desired dissociation.[88] Alternative combinations described used ketamine 3 mg/kg, midazolam 0.05 mg/kg, and glycopyrrolate 0.005 mg/kg injected into the lateral thigh to provide sedation for children with minor facial injuries seen in the emergency department.[89] Satisfactory sedation was achieved in 32 of 37 patients, with 5 others requiring a second ketamine injection of 1 mg/kg. Onset of sedation was within 6 minutes, and adequate working time of 30 minutes was evident in those children receiving one injection. Emergence delirium and hallucinations were

not observed, and protective airway tone and respiratory drive were preserved.

Propofol

Propofol is an alkylphenol in an oil at room temperature and only slightly soluble in water with soybean oil, glycerol, and purified egg phosphatide. It is the only IV anesthetic that can be used for total IV anesthesia because the recovery period for others, such as ketamine and midazolam alone, would be too long. Propofol is chemically unrelated to benzodiazepines, steroids, opioids, and barbiturates.[90] Propofol can be used in infants and young children because it offers a safe and smooth induction with a low incidence of side effects.[91] Respiratory depression and apnea are common when used and may require some form of intervention in settings of sedation, including the simple but effective chin-lift procedures to open the airway or more aggressive intervention during deep sedation or general anesthesia. The length of apnea is slightly longer when compared with barbiturates.[92,93] The major advantage of using propofol is the lower incidence of laryngospasm, postoperative nausea and vomiting, and a rapid emergence.[91,94-96]

The major disadvantage for propofol use is pain at the injection site, which can be reduced by placing IV access in larger veins or the use of lidocaine 0.2 mg/kg either directly before or mixed in with propofol.[97] Other disadvantages of propofol are increased periods of hypotension and bradycardia at higher doses, both of which occur more often in children.[17]

Induction dosages vary with size of the child and whether it will be used for induction, sedation, or general anesthesia at higher levels. Propofol maintenance is ideal because of the rapid and short-acting mechanism of propofol. Infusion pumps may be used to titrate the drug to the desired level of sedation. Controlled boluses of propofol may also be used for short procedures (Table 19-6).

Inhalation Anesthesia

Nitrous oxide was the first anesthetic introduced by Horace Wells in 1844 and is currently known for having a wide margin of safety and few side effects, which supports its use in pediatric patients.[98] Advantages of nitrous oxide include rapid induction and emergence, insignificant cardiovascular and respiratory changes, and ability to produce analgesia. Nitrous oxide can be combined with other anesthetic agents producing sedation and analgesia during pediatric procedures. Litman et al. premedicated 34 children with 0.7 mg/kg of oral midazolam 15 to 20 minutes before administering 40% nitrous oxide during pediatric oral procedures.[99] This technique did not result in any clinically significant respiratory depression, but in three children resulted in a level of deep sedation and a level approaching general anesthesia in one child. Nitrous oxide can also be combined with volatile anesthetics, creating the "second gas effect," where uptake of the blood by the "first" gas (nitrous oxide) increases both the alveolar concentration of the "second" gas (e.g., sevoflurane) and the input of additional second gas into the alveoli via augmentation of the inspired volume.[100]

Inhalational anesthetics have two main uses in pediatric anesthesia, and both are amenable to same day procedures. Sevoflurane is an inhalation agent with a favorable profile, making it useful for mask induction and maintenance.

Sevoflurane is halogenated ether, which has rapid onset and recovery attributes. It has gained favor in oral surgery procedures in children as a result of decreased potential for side effects possible with other inhalation anesthetics, including sensitization of myocardium when local anesthetics with epinephrine are used, possible development of ventricular arrhythmias, cardiac depression, and hepatic necrosis. Sevoflurane produces a dose-dependent increase

TABLE 19-6 Pediatric Drug Doses

Drug	Comment	Dosage
Midazolam	Premedication (PO)	0.5 mg/kg
	Maximum dose (PO)	20 mg
	Premedication (intranasal)*	0.2-0.6 mg/kg
	Sedation (IM)	0.1-0.15 mg/kg
	Maximum dose (IM)	7.5 mg
	Sedation (IV)	0.05 mg/kg
Fentanyl	Pain relief (IV)	1-2 µg/kg
	Pain relief (intranasal)	2 µg/kg
	Premedication (Oralet)	10-15 µg/kg
	Anesthetic adjunct (IV)	1-5 µg/kg
	Maintenance infusion	2-4 µg kg/hr
	Main anesthetic (IV)	50-100 µg/kg
Ketamine	Initial dose (IM)	4 mg/kg
	Supplemental dose (IM)	1-2 mg/kg
	With adjunctive agent (N2O) (IM)	2 mg
	Low dose (PR)	5 mg/kg
	Dissociative dose (PR)	10 mg/kg
	Induction (IV)	1-2 mg/kg
	Sedation (IV)	0.5-1.0 mg/kg
	Maintenance infusion	25-75 µg/kg/min
	Premedication (PO)	6-10 mg/kg
Propofol	Induction (IV)	2-3 mg/kg
	Maintenance infusion	60-250 µg/kg/min

From Morgan GE, Mikhail MS, Murray MJ: Pediatric anesthesia. In *Clinical anesthesiology*, ed 4, New York, 2006, McGraw-Hill, pp 922-950; Gonty AA: Ketamine-a new look at an old drug, *Oral Maxillofac Surg Clin North Am* 4:815-823, 1992

*From Shankar V: Procedural sedation in the pediatric patient, *Anesthesiol Clin North Am* 23:635-654, 2005.

in respiratory rate and a decrease in tidal volume, as do most volatile anesthetics. The advantages of sevoflurane over halothane are decreases in incidence of breath holding and laryngospasm, faster onset of action and recovery, and improved patient acceptance.[101]

Mask induction with sevoflurane is successful because of patient acceptance and tolerance of large minimum alveolar concentrations (MAC). Sevoflurane demonstrates the least airway irritation of all the currently available inhalation agents. Morgan et al. describe two methods of mask induction.[8] Mask induction can be accomplished using a single-breath technique with 8% sevoflurane and 50% nitrous oxide and oxygen or with 100% oxygen. If the child is cooperative, then 0.5% incremental doses every 3 to 5 breaths of sevoflurane can be added as the child is breathing 70% nitrous oxide and oxygen 30%. Once the lid reflex is lost, IV access can be accomplished and appropriate methods of anesthesia can be delivered and maintained. The improved acceptance of mask induction is possible with the use of scented lip balm or sprays placed inside the mask. The MAC of sevoflurane is 2.5% for patients 6 months to 12 years and 3.2% to 3.3% for infants less than 6 months old if general inhalation anesthesia is used.[102]

Techniques of Deep Sedation/General Anesthesia

At our main office in Asheville, the majority of scheduled outpatient pediatric procedures are dentoalveolar surgeries lasting from 10 to 30 minutes under deep sedation or nonintubated general anesthesia for apprehensive children. Because of the previously mentioned anatomic and physiologic characteristics evident during early childhood, we limit our pediatric outpatient deep sedations and general anesthetics to include ASA 1 or 2 patients age 8 and older. Children under the age of 8 are scheduled in the main operating room and managed by an anesthesiologist.

Obtaining IV access preoperatively cannot always be accomplished in pediatric patients, but we have experienced good success with the application of EMLA cream 60 to 90 minutes before the appointment in the 8- to 12-year-old age group. Children in this age group may prefer an IV start to the pungent odor of volatile anesthetics during mask induction. Our preferred method of pediatric outpatient anesthesia for children able to cooperate for IV access consists of initial doses of 0.05 mg/kg of midazolam, and 0.50 mcg/kg of fentanyl. For procedures lasting less than 10 minutes, intermittent boluses of 0.25 to 0.50 mg of propofol are then administered until the desired plane of anesthesia is achieved. For cases anticipated to last longer than 10 to 15 minutes, we have found a modification of the technique described by Blankenstein[103] to be effective for pediatric patients. Boluses of midazolam and fentanyl are administered as described previously, followed by ketamine 0.2 to 0.3 mg/kg, injected slowly to reduce the incidence of apnea. Glycopyrrolate 0.01 mg/kg has been given as an antisialagogue to control secretions. After this an infusion of propofol at 75 to 125 mcg/kg/min is started and adjusted as necessary to maintain a plane of deep sedation/general anesthesia. If required, additional boluses of 0.25 mg/kg of propofol are added to deepen anesthesia and prevent undesirable patient movement. The use of ketamine and propofol together complement each other, and we find less airway obstruction than when using propofol alone. Also the cardiostimulant effects of ketamine and glycopyrrolate are reduced by the cardiodepressant effects of propofol. Another advantage of this technique is that the low dose of ketamine and the antiemetic properties of propofol together result in a low incidence of postoperative nausea and vomiting. Prolonged recovery and nausea have been shown to be insignificant when the total dose of ketamine is less than 0.4 mg/kg.[104]

Although other techniques of anesthesia are available for treating pediatric patients, we find that the preceding techniques provide excellent working time, maintenance of cardiovascular and respiratory function, smooth emergence, and quick recovery. However, we are always prepared to assist with ventilation as necessary, have emergency drugs drawn into syringes placed on the bracket tray, and have all equipment required for intubation immediately available if required.

Perioperative Complications

Regardless of the type of anesthesia delivered, there are several important complications that could occur. These may deal with surgical environment, medications given, and physical responses of each patient. Complications of the procedure and type of anesthesia to be delivered should be discussed during the preoperative appointments and at the time of consent. The parent's and child's questions should be answered and their understanding reviewed. Each practitioner providing anesthesia services should be well versed in the signs and symptoms of each complication to include rapid and appropriate identification and treatment.

Laryngospasm

A common and frightening anesthetic complication is the occurrence of laryngospasm, which is a forceful involuntary spasm of the laryngeal musculature, causing a partial or complete airway obstruction. It is caused by the stimulation of the superior laryngeal nerve by secretions or foreign bodies, such as an endotracheal tube passing through the larynx during extubation.[8] Signs of laryngospasm are the absence of sound in a complete obstruction or squeaks, grunts, or whistles in incomplete obstructions.[17] Methods of preventing laryngospasm would include controlling excess secretions, protecting against foreign body aspiration, avoiding stimulating the patient during "light" anesthesia, and deepening the level of anesthesia or extubating the spontaneously breathing patient while they are still deeply anesthetized.

Treatment of suspected laryngospasm would include an initial airway assessment with simple head-lift, jaw-thrust maneuver, elevation of the tongue, suction of oropharynx, and if confirmed, application of gentle positive pressure ventilation with anesthesia bag and mask using 100% oxygen. If this does not break the laryngospasm and hypoxia occurs, succinylcholine or rocuronium should be given to paralyze the laryngeal muscles, and atropine 0.02 mg/kg should be administered first when succinylcholine is used in children to prevent bradycardia. If laryngospasm occurs in patients where IV access is not available and in whom more conservative measures have failed, IM succinylcholine can be administered at a dose of 4 to 6 mg/kg.[8] The application of muscle relaxants should be followed by controlled ventilation until the patient regains adequate respiratory mechanics. Succinylcholine is for emergency use only in children because children with undiagnosed myopathies are more susceptible than adults to hyperkalemic cardiac arrest, malignant hyperthermia, and masseter muscle spasm.[8] If it is used in an emergency situation, the provider must be vigilant to the signs and symptoms of evolving malignant hyperthermia (MH) or hyperkalemia.

A severe complication that could occur from prolonged airway obstruction accompanied with respiratory efforts is negative pulmonary pressure edema, which is caused most commonly by larygnospasm.[106] Other causes include obstruction of the endotracheal tube or a misplaced LMA resulting in the folding of the epiglottis over the opening of the trachea. Although exact incidence is unknown, it is most likely caused by the generation of markedly negative intrathoracic pressure as a result of forced inspirations caused by the laryngospasm, resulting in transudation of fluid from pulmonary capillaries to the interstitium following relief of the upper airway obstruction. Upon relief of the obstruction, developing dyspnea with pink frothy sputum caused by pulmonary hemorrhage and frank hemoptysis could be seen. A chest radiograph would demonstrate bilateral pulmonary infiltrates. Supportive treatment would include observation for several hours in the hospital setting with maintenance of adequate oxygenation and airway patency. Most cases resolve without lasting consequences, but some patients may require diuretics (furosemide), intubation, and mechanical ventilation.[107]

Anaphylaxis

Anaphylaxis is generally an unanticipated severe allergic reaction that can occur suddenly. Anaphylaxis is a Gell and Coombs classification Type I immunoglobulin IgE-mediated hypersensitivity reaction causing direct activation of mast cells and basophils.[108] In the clinical setting, this can be caused by agents that are used commonly in the operative setting (Table 19-7).

During many same-day oral surgery procedures, the initial signs and symptoms could be easily recognized as a result of exposure of some or most of the skin, such as pruritus, flushing, urticaria, angioedema, and conjunctivitis. Severe hypotension, greater than 40% of baseline, after a slow infusion or small increments of drugs may indicate an allergic reaction.[109] Wheezing and dyspnea may be followed by abdominal pain, nausea, vomiting, diarrhea, and cardiovascular collapse and death.[108] Initial treatment would be immediate removal or discontinuation of the offending object or medication followed by immediate administration of epinephrine to treat hypotension, cardiovascular collapse, and provide smooth muscle relaxation. Diphenhydramine should be administered if urticaria and angioedema are present, and the addition of steroids and bronchodilators may also be considered.[110]

Bronchospasm

Bronchospasm is a constriction of bronchial smooth muscles and is common in the postoperative period. It can be caused by aspiration, histamine release secondary to medications, allergic response, or existing pulmonary conditions—especially asthma in the pediatric population. Bronchospasm may be caused by secretions, deep pharyngeal suctioning, aspiration, or intubation. Treatment consists of removing any possible irritants or drugs and administering inhaled β_2-sympathomimetic agents, such as albuterol. For uncooperative or obtunded patients, a subcutaneous injection of epinephrine is appropriate for most intraoperative occurrences. If the patient is intubated, approximately 5 to 10 puffs of albuterol can be administered through the endotracheal tube followed by positive pressure ventilation with 100% oxygen. Nebulized atropine or glycopyrrolate can be used to control excess secretions. IV epinephrine should not

TABLE 19-7 Drugs Involved in Perioperative Anaphylaxis

Substance	Incidence of Perioperative Anaphylaxis (%)	Most Commonly Associated With Perioperative Anaphylaxis
Muscle relaxants	69.2	Succinylcholine, rocuronium, atracurium
Natural rubber latex	12.1	Latex gloves, tourniquets, Foley catheters
Antibiotics	8	Penicillin and other β-lactams
Hypnotics	3.7	Propofol, thiopental
Colloids	2.7	Dextran, gelatin
Opioids	1.4	Morphine, meperidine
Other substances	2.9	Propacetamol, aprotinin, chymopapain, protamine, bupivacaine

From Hepner DL, Castells, MC: Anaphylaxis during the perioperative period, *Anesth Analg* 97:1381-1395, 2003.

be used unless hypotension is present and concurrent anaphylaxis is suspected. Intubation may be necessary if the patient continues to be hypoxic.[111]

Aspiration

Aspiration has been shown to be a cause of laryngospasm and bronchospasm and pneumonitis. Aspiration of gastric contents aspirated in greater than 0.3 to 0.5 mL/kg may cause the most serious consequences of aspiration, but the aspiration of food, pus, or dental materials is also serious and may need to be treated with antibiotic coverage, bronchoscopy, and removal of foreign objects. Of all aspirated contents, blood is the least worrisome. Pneumonitis had previously been treated with antibiotics and steroids, but the current standard of care is application of continuous positive airway pressure (CPAP) ventilation. Antibiotics are useful only in cases of purulent discharge aspiration.[112] Control of airway and secretions are necessary to prevent this type of injury, and the pediatric patient should have received appropriate perioperative medications and verification of NPO status before anesthesia is initiated. Proper surgical techniques, such as consistent use of throat packs, control of secretions, and securing small instruments continue to be the best preventative measures for preventing aspiration and its potential consequences.

Malignant Hyperthermia

Malignant hyperthermia (MH) is a hypermetabolic syndrome occurring in genetically susceptible patients after exposure to either a volatile anesthetic or succinylcholine. Muscle contraction is sustained as a result of a reduction in the reuptake of calcium from the sarcoplasmic reticulum, resulting in a hypermetabolic state, tachycardia, hypercarbia, hypoxemia, and increased heat production. The first signs of MH usually occur in the operating room, but may be delayed for more than 1 hour after termination of anesthesia. MH is rare, with a higher incidence in pediatric patients (1:15,000) than in adult patients (1:40,000).[8]

MH follows an autosomal pattern of dominance in about 50% of susceptible families, and an autosomal recessive form has also been associated with King-Denborough syndrome. Diagnosis can be established by exposing a fresh skeletal muscle biopsy to a contracture test with caffeine, halothane, or a combination of both. The earliest signs of MH are masseter muscle rigidity (MMR), tachycardia, and hypercarbia, with two or more of these signs greatly increasing the likelihood of MH. MMR occurs in only 15% to 30% of true MH episodes, but can also be present following administration of succinylcholine. The safest course is to assume that masseter spasm is due to MH and postpone elective surgery; however, some anesthesiologists may proceed if no other signs of MH are evident and then change over to nontriggering anesthetic agents.[8]

Treatment involves first discontinuing all triggering agents, changing breathing tubes, breathing bags, and soda lime. Hyperventilation is initiated with 100% oxygen, and dantrolene sodium is mixed with sterile water and administered 2.5 mg/kg as soon as possible. If a significant rise in body temperature is evident, cooling measures including ice packs applied to the body, cold IV fluids, and cold solution lavage of the stomach and body cavities should be initiated. Acidosis is treated with sodium bicarbonate, 1 to 2 mg/kg IV, and hyperkalemia is treated with IV insulin and glucose. Calcium channel blockers should not be used with dantrolene because hyperkalemia can result. Additional doses of dantrolene can be administered if needed, and the patient should be transferred to intensive care for at least 24 hours until vital signs have returned to normal.

Recovery and Discharge

All pediatric patients should be closely monitored while recovering from anesthesia until ready for discharge. Pediatric patients are vulnerable to postanesthetic laryngospasm that can occur in the recovery room as the patient wakes up and chokes on pharyngeal secretions.[8] For this reason, all pediatric patients should be recovered in the lateral position to allow oral secretions to drain away from the vocal chords.

Discharge criteria for children are different than those for adults. Each pediatric patient must appear fully awake and back to his or her baseline behavior with no clinical signs of complications from anesthesia or surgery. Pediatric discharge criteria should address each of the following: state of consciousness, vital signs, respiratory efforts, age-appropriate ambulation, return of normal airway reflexes, clear liquid tolerance, adequate pain control, and absence of postoperative nausea and vomiting.[113] Patel et al. reported that the most common cause of unplanned admissions after attempted same-day procedures in children was protracted vomiting.[112] Ondansetron, a serotonin receptor agonist, has been shown to reduce postoperative nausea and vomiting in pediatric patients when given at a dose of 0.05 to 0.15 mg/kg IV.[114] Dexamethasone has also been shown to decrease the incidence of postoperative nausea and vomiting in children following tonsillectomy at a dose of 1 mg/kg not to exceed a total dose of 25 mg.[115] Although postoperative vomiting was also the most common postoperative complication reported by parents after ambulatory surgery, the cost-effectiveness of routine prophylaxis is controversial.[112] Other common reported complications postoperatively are sore throat, headache, sore muscles, and surgical pain.[116] These issues are usually easily resolved by use of appropriate analgesia medications.

FDA Warning Against Codeine Use in Children[117]

The U.S. Food and Drug Administration (FDA) is reviewing reports of children who developed serious side effects or died after using codeine for postoperative pain management after tonsillectomy and/or adenoidectomy for obstructive sleep apnea syndrome. Recently three children aged two to

five died and one child suffered a nonfatal but life-threatening case of respiratory depression. These children all had evidence of an inherited ability to convert codeine into life-threatening or fatal amounts of morphine in the body. All children received codeine doses that were within the normal dose range.

The FDA issued a safety announcement dated February 2, 2013 by adding a new boxed warning to the drug label of codeine-containing products about the risk of codeine in postoperative pain management in children following tonsillectomy and/or adenoidectomy. The FDA is recommending health care professionals prescribe an alternative analgesic for postoperative pain control in children who are undergoing tonsillectomy and/or adenoidectomy. Codeine should not be used for pain in children following these procedures. For management of other types of pain in children, codeine should only be used if the benefits are anticipated to outweigh the risks.

Parents or caregivers who observe unusual sleepiness, confusion or difficult or noisy breathing in their child should discontinue the codeine and seek medical attention immediately because these are signs of an overdose.

Summary

The performance of oral surgery in children frequently requires pharmacosedation or general anesthesia to reduce fear and anxiety, increase cooperation, and ensure adequate forms of amnesia and analgesia to safely and effectively complete the surgical procedure. Selection of anesthetic technique is based on the patient's needs, the nature of the procedure, the facility, and the surgeon's training, experience, and level of comfort.

References

1. American Association of Oral and Maxillofacial Surgeons: Special considerations for pediatric anesthesia in outpatient facilities. In *Parameters of care draft 2007*, Rosemont, IL, 2006, American Association of Oral and Maxillofacial Surgeons.
2. Jastak JT, Peskin RM: Major morbidity or mortality from office anesthetic procedures: a closed-claim analysis of 13 cases, *Anesth Proc* 38:39, 1991.
3. Marx GF, Mates DV, Orkin LR: Computer analysis of post-anesthetic deaths, *Anesthesiol* 39:54, 1973.
4. Cote CT: Pediatric anesthesia. In Miller RD, editor: *Miller's anesthesia*, ed 6, Philadelphia, 2005, Elsevier, Churchill Livingstone.
5. Strafford MA: Cardiovascular physiology and care. In O'Neill JA, et al.: *Pediatric surgery*, ed 5, St Louis, 1998, Mosby-Year Book.
6. Scammon RE, Norris EH: On the time of obliteration of the fetal blood passages (foramen ovale, ductus arteriosus, ductus venosus), *Anat Rec* 15:165, 1918.
7. Vassallo SA: Anesthesia for pediatric surgery. In Hurford WE, editor: *Clinical anesthesia procedures of the Massachusetts General Hospital*, ed 6, Philadelphia, 2002, Lippincott Williams & Wilkins.
8. Morgan GE, Mikhail MS, Murray MJ: Pediatric anesthesia. In *Clinical anesthesiology*, ed 4, New York, 2002, McGraw-Hill.
9. Dembo JB: Pediatric outpatient anesthesia, selected readings, *Oral Maxillofac Surg* 5(4):1–19, 1997.
10. Wetzel RC: Evaluation of children. In Longnecker DE, Tinker JH, Morgan GE, editors: *Principles and practice of anesthesiology*, St Louis, 1998, Mosby-Year Book.
11. Keenan RL, et al.: Bradycardia during anesthesia in infants: an epidemiologic study, *Anesthesiology* 80:976, 1994.
12. Negus VE: The anatomy of the human larynx. In *The Comparative anatomy and physiology of the larynx*, New York, 1949, Grune & Stratton.
13. Eckenhoff JE: Some anatomic considerations of the infant larynx influencing endotracheal anesthesia, *Anesthesiol* 12:401–410, 1951.
14. De Almeida VL, et al.: The effect of nasal occlusion on the initiation of oral breathing in preterm infants, *Pediatr Pulmonol* 18:374–378, 1994.
15. Miller MJ, et al.: Effect of maturation on oral breathing in sleeping premature infants, *J Pediatr* 109:515–519, 1986.
16. Gaultier C: Developmental anatomy and physiology of the respiratory system. In Taussi LM, Landau LI, editors: *Pediatric respiratory medicine*, ed 1, St Louis, 1999, Mosby.
17. Bennett JD, Dembo JB, Butterfield KJ: Pediatric sedation. In *Peterson's principles of oral and maxillofacial surgery*, ed 2, Hamilton, Ontario, 2004, BC Decker.
18. Devlieger H, et al.: The diaphragm of the newborn infant: anatomic and ultrasonographics studies, *J Dev Physiol* 16:321–329, 1991.
19. Keens TG, et al.: Developmental pattern of muscle fiber types in human ventilatory muscle, *J Appl Physiol* 44:909–913, 1978.
20. Davies G, Reid L: Growth of alveoli and pulmonary arteries in childhood, *Thorax* 25:669–691, 1970.
21. Dunnil MS: Postnatal growth of the lung, *Thorax* 17:329–333, 1962.
22. Haddad GG, Fontan JJP: Development of the respiratory system. In *Nelson textbook of pediatrics*, ed 17, St Louis, 2004, Saunders.
23. Zeltner TB, et al.: The postnatal development and growth of the human lung. I. Morphometry, *Respir Physiol* 67:247–267, 1987.
24. Zeltner TB, Burri P: The postnatal development and growth of the human lung. II. Morphology, *Respir Physiol* 67:269–282, 1987.
25. Thurlbeck WM: Postnatal human lung growth, *Thorax* 37:564–571, 1982.
26. Koch G: Alveolar ventilation, diffusion capacity and the (A-a) PO_2 difference in the newborn infant, *Respir Physiol* 4:168–192, 1968.
27. Gaultier CL, et al.: Determination of capillary oxygen tension in infants and children, *Bull Eur Physiopathol Respir* 14:287–297, 1978.
28. Dong SH, et al.: Arterialized capillary blood gases and acid-base studies in normal individuals 29 days to 24 years of age, *Am J Dis Child* 139:1019–1022, 1985.
29. Levison HEA, Featherby EA, Weng TR: Arterial blood gases, alveolar-arterial oxygen difference, and physiologic dead space in children and young adults, *Am Rev Respir Dis* 101:972–974, 1970.
30. Papastamelos C, et al.: Developmental changes in chest wall compliance in infancy and early childhood, *J Appl Physiol* 78:179–184, 1995.

31. Farmery AD, Roe PG: A model to describe the rate of oxyhaemoglobin desaturation during apnea, *Br J Anaesth* 76:284–291, 1996.
32. McCrory WW: Quantitative measurement of renal function during growth in infancy and childhood. In *Developmental nephrology*, Cambridge, Mass, 1972, Harvard University Press.
33. Leeder JS, Kearns GL: Pharmacogenetics in pediatrics. In Implications for practice, *Pediatr Clin North Am* 44:55–77, 1997.
34. Himms-Hagen J: Cellular thermogenesis, *Annu Rev Physiol* 38:315–351, 1976.
35. Johnson P, Andrews DC: The role of thermometabolism on cardiorespiratory function in postnatal life. In Gaultier C, Escourrou P, Curzi-Dascalova L, editors: *Sleep and cardiorespiratory control*, vol. 227. Paris, 1991, Colloque INSERM/John Libbey.
36. Friis-Hansen B: Body composition during growth. In vivo measurements and biochemical data correlated to differential anatomical growth, *Pediatrics* 47:264–274, 1971.
37. Ginsberg G, et al.: Evaluation of child/adult pharmacokinetic differences from a database derived from the therapeutic drug literature, *Toxicol Sci* 66:185–200, 2002.
38. Gibby GL, et al.: How often does the preoperative interview change anesthetic management? [abstract], *Anesthesiol* 77:A1134, 1992.
39. Curran MA: Preoperative assessment of the pediatric patient. In Kaban LB, Troulis MJ, editors: *Pediatric oral and maxillofacial surgery*, Philadelphia, 2004, Saunders.
40. Mallampati SR, et al.: A clinical sign to predict difficult tracheal intubation: a prospective study, *Can Anaesth Soc J* 32:429, 1985.
41. Wetzel RC: Anesthesia and perioperative care. In Behrman RE, et al.: *Nelson textbook of pediatrics*, ed 17, Philadelphia, 2004, Saunders.
42. Benumof JL: Management of the difficult adult airway, with special emphasis on awake tracheal intubation, *Anesthesiol* 75:1087, 1991.
43. Cauldwell CB, Fisher DM: Ambulatory anesthetic and sedative techniques for children, *Oral Maxillofac Surg Clin North Am* 6(1):1–11, 1994.
44. Cote CJ, Todres ID: The pediatric airway. In Cote CJ, et al.: *A practice of anesthesia for infants and children*, ed 2, Philadelphia, 1993, WB Saunders.
45. Vischoff D, Limoges P: Outpatient anesthesia. In Bissonnette B, Dalens B, editors: *Pediatric anesthesia: principles and practice*, New York, 2002, McGraw-Hill.
46. Warner MA, et al.: Perioperative pulmonary aspiration in infants and children, *Anesthesiol* 90:66, 1999.
47. American Society of Anesthesiologists: American Society of Anesthesiologists task force on preoperative fasting and the use of pharmacologic agents to reduce the risk of pulmonary aspiration practice guidelines for preoperative fasting and the use of pharmacologic agents to reduce the risk of pulmonary aspiration: Application to healthy patients undergoing elective procedures, *Anesthesiol* 90:896, 1999.
48. McGill WA, Coveler LA, Epstein BS: Subacute upper respiratory infection in small children, *Anesth Analg* 58:331–333, 1979.
49. Schreiner MS, et al.: Do children who experience laryngospasm have an increased risk of upper respiratory tract infection? *Anesthesiol* 85:475–480, 1996.
50. Cohen MM, Cameron CB: Should you cancel the operation when a child has an upper respiratory tract infection? *Anesth Analg* 72:282–288, 1991.
51. Tait AR, et al.: Risk factors for perioperative adverse respiratory events in children with upper respiratory tract infections, *Anesthesiol* 95:299–306, 2001.
52. National Institutes of Health: National Heart, Lung, and Blood Institute: Data fact sheet, asthma statistics, 1999. Available at www.nhlbi.nih.gov/health/prof/lung/asthma/asthstat.pdf. Accessed Dec 2006.
53. Ruggiero SL: Evaluation, treatment, and management of the asthmatic patient, *Oral and Maxillofac Surg Clin North Am* 10(3):337–348, 1998.
54. Maxwell LG, et al.: Systemic disorders in pediatric anesthesia. In Motoyama EK, Davis PJ, editors: *Anesthesia for infants and children*, ed 6, St Louis, 1996, Mosby.
55. Standards for basic anesthetic monitoring (Approved by the House of Delegates on Oct 21, 1986, and last amended on Oct 24, 2005), American Society of Anesthesiologists Standards, Guidelines and Statements. . Available at www.asahq.org/publicationsAndServices/standards/02.pdf#2. Accessed Oct 2006.
56. Gross JB, et al.: Practice guidelines for sedation and analgesia by non-anesthesiologists. A report by the American Society of Anesthesiologists task force on sedation and analgesia by non-anesthesiologists, *Anesthesiol* 84:459–471, 1996.
57. Morgan GE, Mikhail MS, Murray MJ: *Clinical anesthesiology*, ed 4, New York, 2006, McGraw-Hill.
58. Overly FL, et al.: Bispectral analysis during deep sedation of pediatric oral surgery patients, *J Oral Maxillofac Surg* 63:215–219, 2005.
59. Stein N, et al.: An evaluation of a transcutaneous and an end-tidal capnometer for noninvasive monitoring of spontaneously breathing patients, *Respir Care* 51(10):1162–1166, 2006.
60. Block Jr FE, L Nuutinen L, Ballast B: Optimization of alarms: a study on alarm limits, alarm sounds, and false alarms, intended to reduce annoyance, *J Clin Monit Comput* 15:75–83, 1999.
61. Bhanaker SM, et al.: Injury and liability associated with monitored anesthesia care, *Anesthesiol* 104(2):228–234, 2006.
62. Stoelting RK: Audible information signals ("alarms") and their role in the operating room, ASA Newsletter 2004. . Available at www.asahq.org/Newsletters/2004/06_04/subNews06_04.html. Accessed Nov 2006.
63. James RH: 1000 anaesthetic incidents: experience to date, *Anaesthesia* 58:856–863, 2003.
64. Hurford EH: *Clinical anesthesia procedures of the Massachusetts General Hospital*, ed 6, Philadelphia, 2002, Lippincott Williams & Wilkins.
65. De Caen AR, Berg MC, Chameides L, et al.: Part 12: Advanced pediatric life support, *Circ J Am Heart Assoc* 112:169, 2005. Available at www.circulationaha.org. Accessed Jan 2007.
66. Ravussin P, et al.: Percutaneous transtracheal jet ventilation for peadiatric endoscopic laser treatment of subglottic lesions, *Can J Anaesth* 41:1200–1207, 1994.
67. Cox RG: Should cuffed endotracheal tubes be used routinely in children? *Can J Anaesth* 52:669–674, 2005.
68. Newth CJ, et al.: The use of cuffed versus uncuffed endotracheal tubes in pediatric intensive care, *J Pediatr* 144:333–337, 2004.
69. Kundo S, Achar S: Principles of office anesthesia: part II. Topical anesthesia, *Am Fam Physician* 66(1):99–102, 2002.
70. Hazinski MF: Vascular access. In *PALS provider manual*, Dallas, 2002, American Heart Association.
71. Fiorito BA, et al.: Intraosseous access in the setting of pediatric critical care transport, *Pediatr Crit Care Med* 6(1):50–53, 2005.
72. Winikoff SI, Rosenblum M: Anesthetic management of the pediatric patient for ambulatory surgery, *Oral and Maxillofac Surg Clin of North Am* 11(4):505–517, 1999.
73. Pang LM, Liu LMP, Coté CJ: Premedication and induction of anesthesia. In *A practice of anesthesia for infants and children*, ed 3, Philadelphia, 2001, Saunders.

74. Reference removed in pages.
75. Maranets I, Kain ZN: Preoperative anxiety and intraoperative anesthetic requirements, *Anesth Analg* 89:1346–1351, 1999.
76. Kain ZN, et al.: Premedication in the United States: a status report, *Anesth Analg* 84:427, 1997.
77. McMillan CO, et al.: Premedication of children with oral midazolam, *Can J Anaesth* 39:545–550, 1992.
78. Roelofse JA, Joubert JJ, Roelofse GR: Double blind randomized comparison of midazolam alone with midazolam combined with ketamine for sedation of pediatric dental patients, *J Oral Maxillofac Surg* 54:838–844, 1996.
79. Golparvar M, et al.: Paradoxical reaction following intravenous midazolam premedication in pediatric patients—a randomized placebo controlled trial of ketamine for rapid tranquilization, *Pediatr Anesth* 14:924–930, 2004.
80. Vischoff D, Limoges P: Outpatient anesthesia. In Bissonnette B, Dalens BJ, editors: *Pediatric anesthesia*, New York, 2002, McGraw-Hill.
81. Friesen RH, Lockhart CH: Oral transmucosal fentanyl citrate for preanesthetic medication of pediatric day surgery patients with and without droperidol as a prophylactic anti-emetic, *Anesthesiol* 76:46, 1992.
82. Bennett J: Intravenous anesthesia for oral and maxillofacial office practice, *Oral Maxillofac Surg Clin North Am* 11:601–609, 1999.
83. Kitahata LM, Taub A, Kosaka Y: Lamina specific suppression of dorsal-horn unit activity by ketamine hydrochloride, *Anesthesiol* 38:4–11, 1973.
84. Sadove MS, et al.: Analgesic effects of ketamine administered in subdissociative doses, *Anesth Analg* 50(3):452–457, 1971.
85. Gonty AA: Ketamine—a new look at an old drug, *Oral Maxillofac Surg Clin North Am* 4:815–823, 1992.
86. White PF, Way WL, Trevor AJ: Ketamine—its pharmacology and therapeutic uses, *Anesthesiology* 56:119, 1982.
87. Alfonzo-Echeverri EC, et al.: Oral ketamine for pediatric dental surgery sedation, *Pediatr Dent* 15:182–185, 1993.
88. Green SM, Johnson NE: Ketamine sedation for pediatric procedures: part 2, review and implications, *Ann Emerg Med* 19:1033–1046, 1990.
89. Pruitt JW, et al.: Intramuscular ketamine, midazolam, and glycopyrrolate for pediatric sedation in the emergency department, *J Oral Maxillofac Surg* 53:13–17, 1995.
90. Sebel PS, Lowdon JD: Propofol: a new intravenous anesthetic, *Anesthesiol* 71:260–277, 1989.
91. Hannallah RS, et al.: Propofol anesthesia in paediatric ambulatory patients: a comparison with thiopentene and halothane, *Can J Anaesth* 41:12–18, 1994.
92. Kraut RA: Propofol—a rival to methohexital, *Oral Maxillofac Surg Clin North Am* 4:825–830, 1992.
93. Reber A, et al.: Effect of combined mouth closure and chin lift on upper airway dimensions during routine magnetic resonance imaging in pediatric patients sedated with propofol, *Anesthesiol* 90:1617–1623, 1999.
94. Schrum SF, et al.: Comparison of propofol and thiopental for rapid anesthesia induction in infants, *Anesth Analg* 78:482–485, 1994.
95. Crawford MW, et al.: Recovery characteristics of propofol anaesthesia, with and without nitrous oxide: a comparison with halothane/nitrous oxide anaesthesia in children, *Pediatr Anaesth* 8:49–54, 1998.
96. Bart SM, et al.: Ondansetron with propofol reduces emesis and airway obstruction in pediatric outpatients, *Can J Anaesth* 46:359–362, 1999.
97. Cameron E, et al.: The minimum effective dose of lidocaine to prevent injection pain due to propofol in children, *Anesthesiol* 47:604, 1992.
98. Duncan GH, Moore PA: Nitrous oxide and the dental patient: a review of adverse reactions, *J Am Dent Assoc* 108:213–219, 1983.
99. Litman RS, et al.: Breathing patterns and levels of consciousness in children during administration of nitrous oxide after oral midazolam premedication, *J Oral Maxillofac Surg* 55:1372–1377, 1997.
100. Hurford EH: *Clinical anesthesia procedures of the Massachusetts General Hospital*, ed 6, Philadelphia, 2002, Lippincott Williams & Wilkins.
101. Lee M, Bennett HE, Gordon N: Sevoflurane general anesthesia: an alternative technique in the pediatric oral and maxillofacial surgery patient, *J Oral Maxillofac Surg* 61:1249–1252, 2003.
102. Lerman J, et al.: The pharmacology of sevoflurane in infants and children, *Anesthesiology* 80:114, 1994.
103. Blankenstein KC: Low-dose intravenous ketamine, an effective alternative to conventional deep conscious sedation, *J Oral Maxillofacial Surg* 64:691–692, 2006.
104. Blankenstein KC, Anderson J: A double-blind comparison of low-dose intravenous ketamine and methohexital in adults, *J Oral Maxillofac Surg* 49:468, 1991.
105. Reference removed in pages.
106. Padley SPG, Downes MO: Case report. Pulmonary edema secondary to laryngospasm following general anesthesia, *Br J Radiol* 67:654, 1994.
107. Kelly JP, Ciavarro C: Postobstructive pulmonary edema in an obese child after an oral surgery procedure under general anesthesia: a case report, *J Oral Maxillofac Surg* 60:1503–1505, 2002.
108. Hepner DL, Castells MC: Anaphylaxis during the perioperative period, *Anesth Analg* 97:1381–1395, 2003.
109. Campbell RL, Campbell JR: Anesthesia complications associated with ambulatory oral and maxillofacial surgery, *Selected Readings Oral Maxillofac Surg* 9(2), 2001.
110. Castells MC, et al.: Anaphylaxis. In Holgate ST, Church MK, Lichtenstein LM, editors: *Allergy*, ed 2, London, 2001, Mosby.
111. Complications and emergencies. In *Office anesthesia evaluation manual*, ed 6, Rosemont, IL, 2000, American Association of Oral and Maxillofacial Surgeons.
112. Patel RI, Hannallah RS: Anesthetic complications following pediatric ambulatory surgery: a 3-year study, *Anesthesiol* 69:1009–1012, 1988.
113. Hannallah RS: Outpatient anesthesia. In Coté CJ, Todres ID, Ryan JF, editors: *A practice of anesthesia for infants and children*, ed 3, Philadelphia, 2001, Saunders.
114. ASHP therapeutic guidelines on the pharmacologic management of nausea and vomiting in adult and pediatric patients receiving chemotherapy or radiation therapy or undergoing surgery, *Am J Health Syst Pharm* 56:729, 1999.
115. Pappas ALS, et al.: The effect of preoperative dexamethasone on the immediate and delayed postoperative morbidity in children undergoing adenotonsillectomy, *Anesth Analog* 87:57–61, 1998.
116. Steward DJ: Outpatient pediatric anesthesia, *Anesthesiol* 43:268–276, 1975.
117. U.S. Food and Drug Administration website: FDA Drug Safety Communication: safety review and update of codeine use in children; new Boxed Warning and Contraindication use after tonsillectomy and/or adenoidectomy. Available at www.fda.gov/Drugs/DrugSafety/ucm339112.htm. Accessed April 23, 2016.

20 Pediatric Dentoalveolar Surgery

JOHN H. CAMPBELL, MICHAEL Y. NAGAI

Introduction

Children are not simply small adults. Every surgeon is familiar with this concept, and from a physiologic standpoint, for children up to the age of 12 it is largely true. The major impact of pediatric physiologic differences, however, relates to administration of anesthesia rather than surgical intervention itself. In essence, hard and soft tissue dentoalveolar surgery may be somewhat more difficult because of a smaller operative site, but the techniques of surgery are largely similar to those provided for adult patients. Smaller instrumentation can help to alleviate access problems resulting from a "miniature" operative field, but with adequate care the pediatric patient should not experience an increase in surgical complications as a result of reduced surgical access.

Even adult patients may not relish surgical procedures; the child is still less likely to approach a planned oral surgery intervention in a completely cooperative fashion. For this reason, it is important to consider a consultation visit for even minor procedures in a child. The child's response to the office visit, ability to cooperate in performance of an oral examination, and general demeanor will assist greatly in planning a successful intervention. These factors will largely determine whether the patient is a candidate for local anesthesia, nitrous oxide inhalation analgesia, or more involved inhalation and/or intravenous anesthetic management.

A consultation visit should include the parent or guardian most familiar with the child's medical history, allergies, and medications. Other relatives or caregivers are often unfamiliar with conditions that may affect the surgeon's ability to safely perform a procedure, and they are unable to legally consent to a procedure for the patient. A parent cannot simply "assign" the responsibility for consent to another individual without appropriate legal documentation. In addition, it is important for the surgeon and staff to ascertain the interactions between parent and child that could indicate overprotective or negligent parental behavior which might predict a difficult surgery or recovery period.

This chapter is written to aid the reader in the assessment of conditions that may indicate the need for dentoalveolar surgery in the pediatric patient, and to suggest techniques that will lead to safe and effective surgical management when necessary. Anesthetic management is addressed elsewhere, and genetic, developmental, and pathologic conditions are not discussed except as they relate to management of dentoalveolar surgery in the pediatric population.

The Pediatric Demographic

The U.S. Food and Drug Administration defines the pediatric population as persons age 21 years or younger at the time of their diagnosis and/or treatment. Within this range are a number of subpopulations.[1]

- Neonates: Birth through the first 28 days of life
- Infants: 29 days of age to less than 2 years of age
- Children: 2 years of age to less than 12 years of age
- Adolescents: 12 years of age through 21 years of age

This creates a large and complex patient demographic that presents treating clinicians with unique challenges in physiology, anatomy, pathology, and patient management. Each subpopulation presents its own distinct treatment challenges, but for the purposes of this chapter, the "pediatric population" will be referred to as a single entity. It is important for surgeons to understand the nature and course of disease that is unique to the pediatric population, and that these patients, as previously indicated, are not "small adults" in a physiologic sense. Treatment decisions and timing of surgical intervention can have a profound impact on clinical outcomes and lifelong development. Nowhere is collaboration between subspecialists as important as in treating this demographic. A team approach among general dentists, pediatric dentists, orthodontists, oral surgeons, and pediatricians certainly provides the most comprehensive and thorough care for these young patients.

It should be the goal of the treating surgeon to address both patient and parental concerns regarding the nature of the office or hospital visit. Many times, it is difficult to identify a clear chief complaint in the pediatric population, as patients are often withdrawn, in pain, afraid, and unable to communicate clearly and effectively. Adding to the challenge is the sometimes superfluous information parents offer for what they believe is causing distress to their child.

Filtering out critical and pertinent information is an essential skill that can make the difference in a successful course of therapy. Acting within acceptable moral and ethical clinical standards, the general therapeutic goals for dentoalveolar surgery should include:[2]

- Elimination of acute and or chronic infection
- Reduction or elimination of pain
- Restoration of anatomic form
- Restoration of masticatory function
- Preservation of vital structures
- Limited period of disability
- Elimination of existing pathology
- Appropriate understanding by the patient and family of treatment options and acceptance of the treatment plan
- Appropriate understanding by the patient and family of the risks, benefits, and alternative treatments
- Prevention of future problems.

Pediatric Dental Development

Odontogenesis is a complex process with numerous mechanical and chemical interactions between mesenchymal and epithelial tissues. Teeth begin to develop within generally well-defined areas of the stomodeum, and, by maturational extension, are guided to the oral cavity and alveolar processes of the jaws. Confounding elements include the embryologic nature of Rathke's pouch, which can cause a number of associated developmental anomalies, including cysts and tumors, within the developing dental arches.[3] It is important to remember that during development, the oral and maxillofacial region contains remnants of salivary glands, seromucous glands, sinonasal epithelium, nasopalatine duct epithelium, and dermatologic epithelium, all of which can create pathologic entities. This complex synergism gives rise not only to the normal anatomic structures of the head and neck, but also to their associated diseases.

The formation of primary teeth typically begins between 6 and 8 weeks in utero with the development of the dental lamina. By the end of the eighth week, all 20 tooth buds have typically been formed. From this point, all subsequent development of both deciduous and permanent teeth will take place in a somewhat predictable pattern when growth proceeds normally.[4] Throughout this prolonged span of development, the teeth are subject to both genetic and environmental influences, and a deviation from this normal growth pattern may help a practitioner to recognize an underlying disease process that may require further investigation. This is highlighted by recommendations from the American Academy of Pediatric Dentistry (AAPD), the American Dental Association (ADA), and the American Academy of Pediatrics (AAP); all suggest a childhood dental visit by the age of 1 year.[5] It is certainly beneficial to approach pediatric dentoalveolar surgery from a preventive standpoint. Emergency visits create an unpleasant treatment experience and increase overall health care costs. Exposing pediatric patients to regular preventive care will allow them to develop good dental habits from an early age and build positive rapport with their providers, setting the stage for a lifetime of improved oral and systemic health.

There are a number of odontogenic epithelial stages that ultimately give rise to the functional dentition and surrounding structures. It is therefore important for oral and maxillofacial surgeons to understand and respect the intricate nature of development in order to best recognize and treat dilemmas in dentoalveolar surgery. Familiarity with normal eruption patterns is critical so that early recognition of eruption failure can be investigated and appropriate intervention instituted. Teeth not present in the oral cavity by the normal time frame can indicate failure of tooth development, genetic developmental anomalies, pathologic conditions, or tooth malposition, among others. Early recognition may reduce the likelihood of untoward permanent sequelae. Table 20-1 indicates normal eruption sequences for the human dentition.

Pediatric Anatomy

The many physical differences between children and adults can have a significant impact on treatment of pediatric patients. A characteristic example is the administration of local anesthetic in a young person. Often, accessory innervations of the mandible lead to difficulty in achieving profound anesthesia during inferior alveolar nerve block (IANB). The mandibular foramen is also situated at a level further below the occlusal plane and more proximal than in an adult. Thus, the injection must be made slightly lower and more posterior than in an adult (Figure 20-1).

It has recently been suggested that developing tooth buds have the potential for damage during routine administration of local anesthesia in children,[6] as the location of the third molar follicle is close to needle penetration during IANB. A statistically greater incidence of missing third molars was found in quadrants that had a definitive history of receiving IANB compared with quadrants that had no history of injection, but further research is needed to quantify clinical significance. In either case, it is important that clinicians understand and appreciate anatomic considerations when providing even basic care.

Pediatric patients also have smaller, more delicate structures in their mouths. This creates difficulties in access and visualization during treatment. When performing extractions, the teeth themselves may actually be easier to remove then their adult counterparts due to the more forgiving bone and widened periodontal ligament space present in children, but when combined with previously mentioned limitations, extraction of even routine teeth may become problematic. Of course, procedures can be made exponentially more difficult when the patient is precooperative or uncooperative. Other relevant anatomy that must be considered in dentoalveolar surgery includes the proximity of teeth to the developing permanent dentition, neurovascular structures, and airway dimension.

The anatomy of the pediatric airway differs significantly from that of adults, and although the majority of differences may be more pertinent during intubation for general

TABLE 20-1 Eruption Sequences of Primary and Permanent Dentition

Deciduous Dentition			Permanent Dentition		
Tooth	Eruption (mo)	Root Completion (yr)	Tooth	Eruption (yr)	Root Completion (yr)
Maxillary			**Maxillary**		
A	7	1½-2	1	7-8	10
B	8	1½-2	2	8-9	11
C	16-20	2½-3	3	11-12	13-15
D	12-16	2-2½	4	10-11	12-13
E	21-30	3	5	10-12	12-14
			6	6-7	9-10
			7	12-13	14-16
			8	17-21	18-25
Mandibular			**Mandibular**		
A	6½	1½-2	1	6-7	9
B	7	1½-2	2	7-8	10
C	16-20	2½-3	3	9-10	12-14
D	12-16	2-2½	4	10-12	12-13
E	21-30	3	5	11-12	13-14
			6	6-7	9-10
			7	12-13	14-15
			8	17-21	18-25

This table uses the Zsigmondy system of classification.



• **Figure 20-1** **A,** Inferior alveolar nerve enters pediatric mandible slightly more posterior and inferior than in the adult. **B,** Adult mandible.

anesthesia, the major differences should be known in the event that emergency maneuvers must be undertaken. The classic works by Fink, Demarest, Eckenhoff, and Negus form the foundation of our knowledge about the structure and function of the pediatric and adult airway.[7-9] They suggest that there are five major anatomic differences between the pediatric and adult airways: tongue, larynx, epiglottis, vocal folds, and subglottis. In the past, it was believed that a disproportionately larger tongue compared to the rest of the oral cavity was a major contributing factor

in airway obstruction. It is now felt that the tongue grows in relation to the bony structures of the oral cavity, and it is more likely that nasopharyngeal and epiglottic collapse contribute more to the obstructive potential.[10] The angles and dimensions of the smaller airway (inversely proportional to the radius of the lumen to the fourth power) also create a much higher resistance to air flow and, when coupled with even slight edema, can contribute to airway compromise. Proper airway management is always of paramount importance when performing any procedure, and an understanding of pediatric anatomy is critical to delivering safe and effective treatment.

Physiology

Children are physiologically distinct from adults. Body temperature, blood pressure, heart rate, and the ability of body systems to compensate in situations of stress differ tremendously from those in the healthy adult. A pediatric patient who presents to the office with an odontogenic infection may be severely ill without showing obvious signs of distress. To complicate matters, pediatric patients can often deteriorate rapidly, turning an urgent situation into an emergency. It is important that practitioners know the clinical signs of impending cardiopulmonary collapse and be prepared to handle an emergency if one should arise.

Often, it is difficult for the pediatric patient to convey what is wrong or if they are in pain. A thorough investigation of the medical, dental, and family histories, which includes input from parents and other family members, along with a focused physical exam, should be undertaken in each patient. The decision to treat a patient who may currently have an upper respiratory infection—or who underwent tonsillectomy a week earlier—will face each clinician, and all factors should be taken into consideration when treatment plans are developed. A thorough understanding of the Pediatric Advanced Life Support (PALS) and Basic Life Support (BLS) algorithms will help both doctor and office staff to approach the pediatric patient with the skills necessary to manage problematic circumstances. Waiting until a patient recovers from a respiratory infection before an elective extraction, or referring a patient back to his or her pediatrician or the emergency department, can be potentially lifesaving.

Hard Tissue Surgery

Dental Extraction

Size and anatomic differences of primary teeth may preclude use of adult extraction forceps for tooth removal. Deciduous teeth, in addition to their small size, have bulbous crowns, and molars have widely separated roots that predispose to root fracture unless there is resorption associated with underlying erupting bicuspids. The likelihood of root fracture is exacerbated in the event of ankylosis, which may be indicated by submersion of the crown in relation to the surrounding dentition and by altered percussion sounds.

Many adult instruments can, however, be used in treatment of the primary dentition. With the exception of forceps, the extraction armamentarium remains essentially the same as for the permanent dentition. It is important to be judicious with the use of dental elevators and forceps to avoid mobilization of adjacent partially resorbed deciduous teeth or permanent teeth with incompletely formed roots. Thin or resorbed roots of primary teeth may fracture during removal, and removal of residual fragments should be attempted. Consideration should be given to leaving the retained root in place if damage to an erupting permanent tooth or adjacent primary tooth is likely. These fragments will rarely cause problems and can be removed at a later date if clinically necessary.

Impacted Teeth

Impacted teeth are commonly encountered in an oral and maxillofacial surgery office, and it can often be difficult to coordinate treatment among referring providers, surgeons, and orthodontists.

When a tooth's eruption is delayed beyond the normal age-appropriate time frame, it is said to be impacted, and any tooth may become impacted. The literature suggests a broad prevalence of impaction, ranging from 1% to 18% in some populations.[11] Tooth positions may range from vertical to mesioangular, horizontal, distoangular, and even inverted, and teeth can appear in almost any region of the maxillofacial skeleton. If third molars are excluded, the maxillary canine is the most likely tooth to be impacted. Mandibular second premolars, mandibular and maxillary second premolars, and maxillary central incisors follow, in that order.[12] Primary teeth rarely become impacted, but when a primary tooth does fail to erupt, it is most likely to be a mandibular molar.[13] Etiologies of impacted teeth include both systemic and local disturbances. Illness and its treatment (radiation, for example), congenital syndromes, deficiencies in eruption space, ankylosed primary teeth, cysts, and tumors may all be associated with impacted teeth, and even dietary changes in modern civilization have been implicated.[14] In some cases, no specific etiology can be determined.[15]

Once a disturbance in eruption pattern has been identified clinically, it is important to obtain appropriate imaging studies to help evaluate the position of impacted teeth and rule out other pathology within the facial skeleton. The radiographic examination may include a panoramic film plus additional imaging modalities, when clinically indicated, to provide a three-dimensional (3D) picture.

Periapical films can aid in determining buccal or palatal position of impacted teeth. A periapical radiograph is first exposed according to conventional techniques. A second film is positioned in the same location as the first, but the x-ray source is moved either mesially or distally (Figure 20-2). The impacted tooth will seem to move in either the same or opposite direction as the beam source. If it moves in the same direction, it is palatal or lingual to the adjacent teeth (Figure 20-3). Movement in the opposite direction

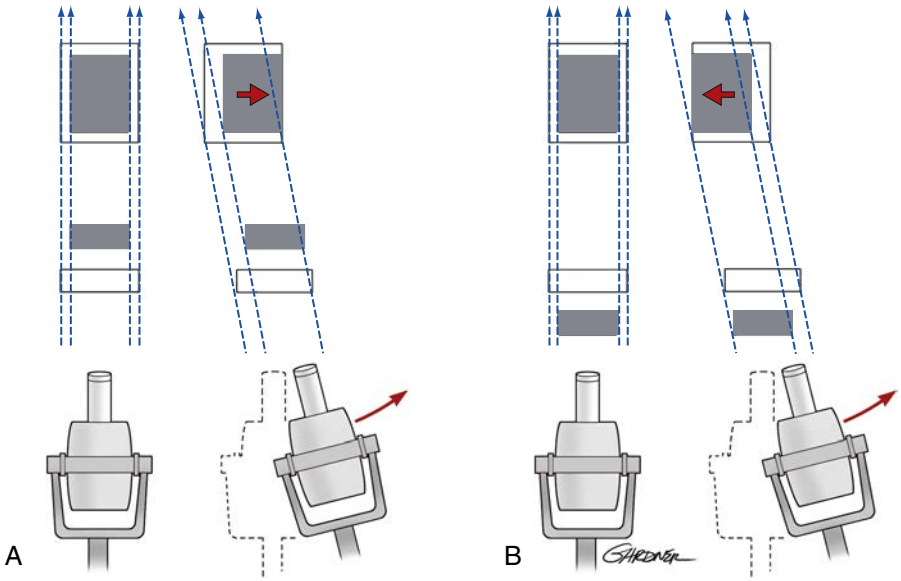

• **Figure 20-2** **A,** Tube-shift technique demonstrating a palatally impacted object. **B,** Depiction of a buccally impacted object.

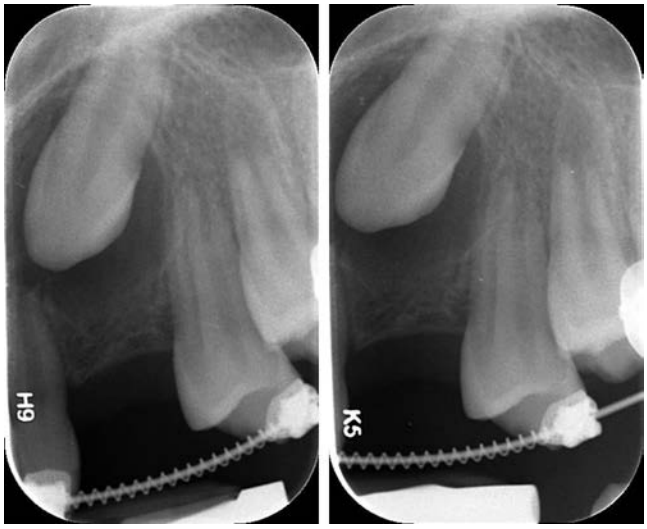

• **Figure 20-3** Periapical radiographs are helpful in localizing an impacted tooth. In the image on the right, the crown of the impacted cuspid is located in the edentulous space. As the x-ray source is moved forward (mesially), the cuspid crown also moves mesially and appears to approach the root of the lateral incisor *(left image)*. The cuspid is thus located on the palatal surface of the maxilla.

will indicate that the tooth is buccal or labial to the adjacent teeth. This is Clark's rule, commonly remembered by use of the acronym "S.L.O.B." (same = lingual; opposite = buccal). Minimal or no movement of the impacted tooth may indicate a mid-alveolar location.[16]

Occlusal films also provide an excellent diagnostic view if the patient can tolerate the larger film, and may be combined with panoramic radiography to determine the position of impacted teeth at or near the midline. In this case, the source beam is adjusted superiorly or inferiorly in a fashion similar to that used for Clark's rule. The x-ray source is typically positioned at 60 degrees superior or inferior to the horizontal plane to create enough separation to determine tooth position. This technique has the added advantage of visualizing the entire impacted tooth in many cases, and it necessitates only one, rather than two, additional films.[17,18]

With increasing frequency, intraoffice cone-beam computed tomography (CBCT) is used for surgical planning and assessment of adjacent structures. Determining the position of the impacted canine, for example, is crucial to determining the feasibility of surgery and planning a suitable approach to expose the tooth and predict the best vector for potential orthodontic force. Walker showed the benefits of 3D volumetric imaging of impacted canines, which can demonstrate the presence or absence of the canine, size of the follicle, inclination of the long axis of the tooth, relative buccal and palatal positions, amount of bone covering the tooth, 3D proximity and resorption of adjacent tooth roots, condition of adjacent teeth, local anatomic considerations, and overall stage of dental development.[19] The increased cost, time, radiation exposure, medicolegal issues, and lack of universal availability associated with CBCT have, however, limited its routine use.[20]

The Impacted Canine

Canine teeth are considered the "cornerstones" of the dental arches, essential to the normal and harmonious function of the dentition, optimization of the facial profile, and maintenance of esthetics. Failure of the maxillary canines to erupt into a proper position can result in compromised oral health including periodontal disease, loss of arch length, formation of cysts, and recurrent infection.[21] It has been suggested that maxillary canine impaction occurs in approximately 2% of the population and is twice as common in females as in males.[22] The prevalence of canine impaction in the maxilla is more than twice that in the mandible.[23] Historically, it was believed that approximately one third of impacted maxillary canines were located labially, and two thirds were

located palatally.[24,25] Some literature suggests a 6:1 ratio of palatal to labially impacted cuspids.[26] These data were based on plain film evaluation. Recent assessment of the canine position by use of CBCT scanning to definitively determine the position of the impacted maxillary canine showed a different distribution: 45.2% impacted buccally, 40.5% impacted palatally, and 14.5% impacted midalveolus.[27] This finding, however, may reflect only the population reported in the study and is not indicative of the experience of most surgeons.

The exact cause of canine impaction is unknown. It is likely multifactorial and due to a combination of local and systemic factors. The results of Jacoby's study showed that 85% of palatally impacted canines had sufficient space for eruption, whereas only 17% of labially impacted canines had sufficient space.[25] Therefore, arch length discrepancy is thought to be a primary etiologic factor for labially impacted canines. Two major theories associated with palatally displaced maxillary canines have been proposed: genetic and guidance. Proponents of the genetic theory believe that canine impaction is under genetic influences and cite increased occurrence of other dental anomalies, bilateral occurrence of impaction, familial occurrence, and population differences as support for this premise.[28] The guidance theory is based more on local factors influencing the proper eruption of the canine. It proposes that the canine erupts along the root of the lateral incisor, which serves as a guide, and if the root of the lateral incisor is absent or malformed, the canine will not erupt.[29] At present, no definitive answer explains why the maxillary canine is so variable in its pattern of eruption, and dental professionals need to be vigilant for signs of potential maxillary canine impaction. These include delayed eruption of the permanent canine, retention of the primary canine, absence of a labial bulge, presence of a palatal bulge, and crown tipping of the lateral incisor.[30] Once this problem is recognized, appropriate definitive care can be initiated.

Treatment

The simplest form of treatment is observation. Retention of the impacted canine in its impacted position, with serial imaging, is a viable option in certain circumstances. This, of course, would be determined by factors that include age, medical and dental comorbidities, patient preference, and local considerations.

In the pediatric population, most orthodontists and surgeons agree that some form of intervention is indicated, and that preventing maxillary canine impaction provides the best long-term results. Other treatment options are available and include:[31]

- Extraction of the impacted tooth and retention of the primary, which can be esthetically recontoured
- Extraction of the impacted tooth and primary canine followed by orthodontic space closure, substituting the first bicuspid for the extracted canine ("bicuspid substitution")
- Extraction of the impacted tooth and primary canine with replacement using an implant-supported crown
- Surgical exposure of the impacted canine with orthodontic alignment of the ectopic tooth after its surgical exposure
- Autotransplantation of the impacted tooth into its anatomic position in the arch after orthodontic pretreatment for space opening.

Extraction of deciduous canines can occur as early as 8 or 9 years of age. Interceptive treatment is influenced by the degree of impaction, the canine's position in relation to the lateral incisor, and the patient's age at diagnosis. Using panoramic techniques, Ericson and Kurol found that early extraction of primary maxillary canines could result in normal eruption of ectopically displaced permanent maxillary canines.[32] They proposed that extracting the primary canine before the patient is 11 years of age can allow eruption of the permanent canine in over 90% of cases if the crown of the canine is distal to the midline of the lateral incisor root. Eruption drops precipitously, however, (to about 64%) if the permanent canine crown is mesial to the midline of the lateral incisor root. Early intervention by practitioners may lead to a normal positioning of the canines and alleviate the need for future complex orthodontic and surgical treatment.

In the absence of preventive treatment, surgeons have several options to assist the movement of permanent canine teeth into their correct position within the dental arch. Orthodontic movement to create adequate space is the first line of treatment, followed by surgical exposure and/or assisted eruption. There is an obvious need for clear and unambiguous communication between specialists so as to approach the planning and surgical phases of treatment with a common goal. The conventional methods used to bring a palatally impacted canine into occlusion include surgically exposing the tooth and allowing it to erupt naturally during early or late mixed dentition,[33,34] or surgically exposing the tooth and placing a bonded attachment to the crown for application of orthodontic force.

Surgical options include "open eruption techniques," such as excisional uncovering and apically positioned flaps, or "closed eruption techniques." In the open technique, the surgical access created is left open to the oral environment. Exposure alone may allow eruption, but more commonly an orthodontic device is applied at the time of surgery or left for later placement at the discretion of the orthodontist. In the closed technique, the orthodontic device must be placed at the time of surgery, as the site is closed with mucosal tissue and only the orthodontic chain is visible for activation. Tooth position and the amount of attached gingiva in the area (in the case of labially positioned canines) help determine which method will be used.

Excisional uncovering may be employed to expose either labially or palatally impacted teeth. For labially located teeth, however, the position of the impaction is of significance. The majority of the crown must be located occlusal to the mucogingival line such that several millimeters of attached gingiva remain to withstand occlusal and chewing

forces. Lack of attached gingiva may lead to recession and root exposure.

Excisional uncovering is most often used to expose palatally impacted canines. It is relatively straightforward if the crown can be palpated, but more difficult if there is no observable palatal bulge. For palpable teeth, local anesthesia is administered routinely, with additional anesthetic infiltrated into the area adjacent to the tooth. This aids hemostasis and assists in separating soft tissue from the underlying tooth. A window is made in the soft tissue to expose the crown, and associated follicular tissue is removed with hand instruments. Exposure of the crown to approximate the cementoenamel junction is then accomplished with hand or rotary instrumentation. Some practitioners will use a dental elevator to assess for ankylosis, but even if the tooth can be mobilized, eruption is not assured. If attempting to allow spontaneous eruption, a dressing may be placed for comfort, although it can be difficult to stabilize at this site. Often an orthodontic appliance is placed for later application of traction. It can be difficult to maintain a dry field to adequately etch and apply an orthodontic bracket, but the newer cements can often adequately secure the device even in a moist field. If unsuccessful, it may be necessary to delay application of an appliance until some healing has taken place, usually in a week to 10 days. It is important to excise adequate soft tissue to prevent regrowth that can cover most, or in some cases all, of the crown.

If there is no palpable palatal bulge, excisional uncovering becomes more difficult. This may require a full-thickness palatal flap and a search for the tooth crown. Adequate preoperative imaging is particularly important in this scenario, as it is easy to become disoriented. Based on the radiographs, bone is judiciously removed at the site of the presumed tooth location. A color difference is usually noted when the crown is encountered, with the crown appearing whiter than the surrounding bone. Absence of bleeding is also an indicator that the crown has been encountered. Once adequate crown has been exposed, a needle penetrating the soft tissue flap can be used to mark the area of soft tissue that is to be removed. The flap is then returned to its anatomic position and sutured in place. A dressing or orthodontic appliance can then be placed.

Closed eruption is perhaps more routinely employed for palatally impacted cuspids because there is no annoying palatal opening present as the tooth erupts. A full-thickness flap is developed to expose the tooth (or teeth in the case of bilateral impactions), and bone is removed as for the excisional technique. An orthodontic appliance with attached chain is cemented to the crown, and the chain is brought out through the flap in the area of the crestal incision and secured to the arch wire or adjacent bracket (Figure 20-4).

The position of labially impacted cuspids determines the appropriate exposure technique. Unlike palatally impacted teeth where inadequate attached gingiva is unlikely, the lack of keratinized tissue can be problematic for labially positioned cuspids. Excisional uncovering can be accomplished if the crown is near the alveolar crest and 2 mm or more of keratinized tissue will remain for periodontal support after excision of the soft tissue.

More commonly, however, the crown will reside higher apically, and an alternative technique may be necessary. If the tooth is no higher than mid-alveolus, consideration may be given to an apically positioned flap. A crestal incision incorporating attached gingiva and both mesial and distal releasing incisions are made, before elevating a full-thickness flap to expose the crown. Beveling the vertical legs of the flap away from the anterior aspect of the mouth may aid esthetics after healing by altering light reflection from the resultant scars. Often there is minimal bone covering the crown of the impacted tooth, and follicular tissue is readily removed. The flap is positioned near the cementoenamel junction and sutured in place. A bracket may be placed if desired for later orthodontic traction. This technique should not be used for very high impactions because it has been associated with late reintrusion of the cuspid. In addition, moving the flap too far apically makes adequate closure difficult.

Labially positioned teeth above the mucogingival line are often better treated with the closed eruption

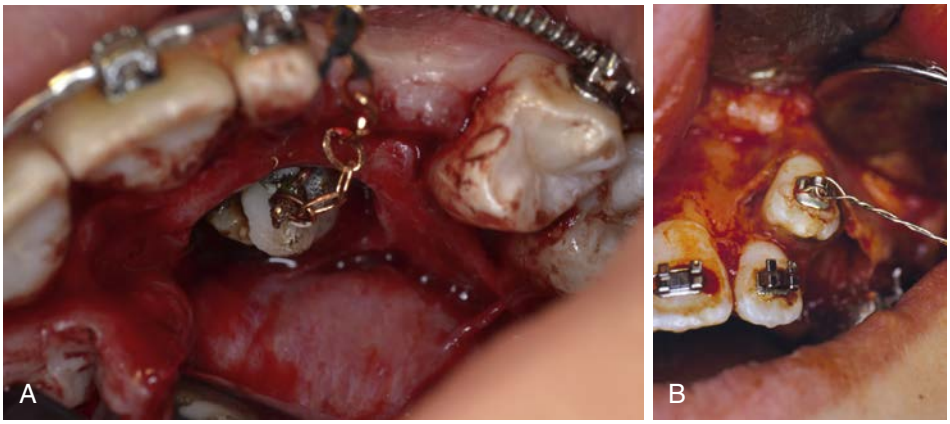

• **Figure 20-4** **A,** Closed eruption of a palatally impacted cuspid before flap closure. An orthodontic attachment has been bonded to the tooth and the chain secured to the arch wire. **B,** Closed eruption of a labially impacted cuspid before flap closure. An apically positioned flap here would compromise the periodontium of the lateral incisor.

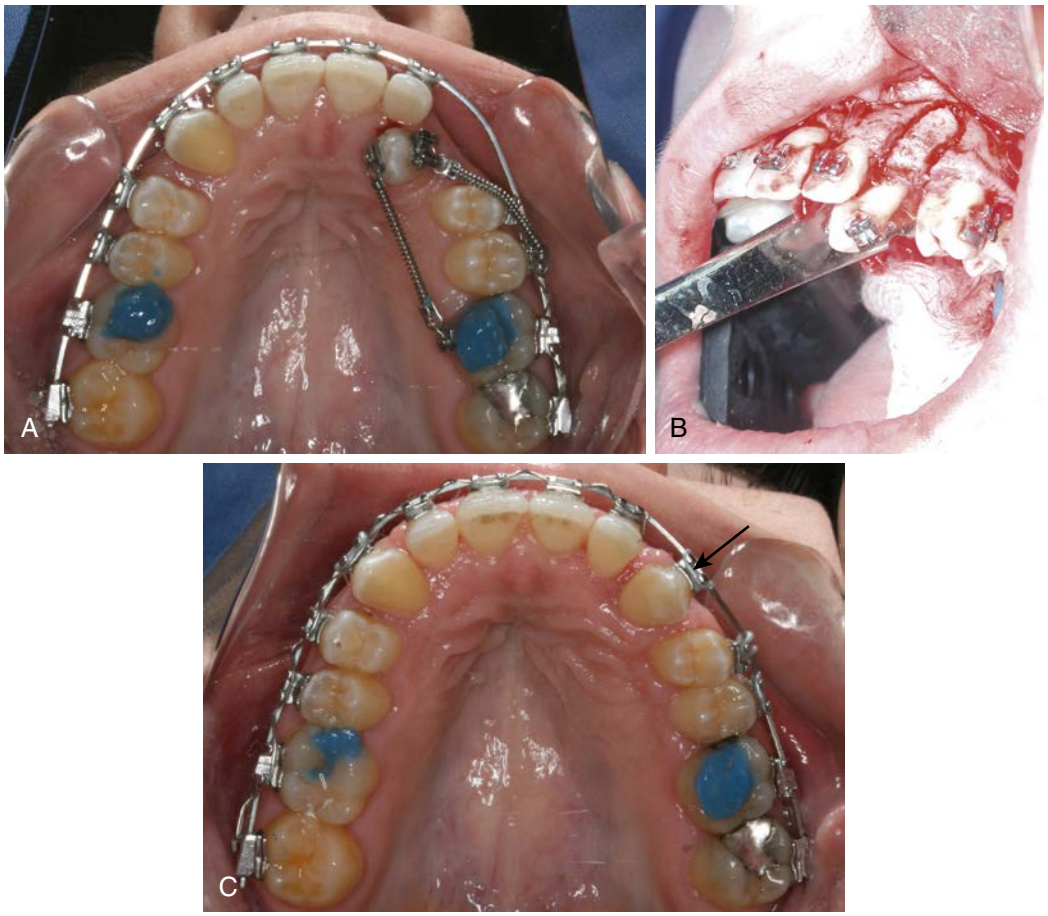

• **Figure 20-5** **A,** Palatally located cuspid that could not be moved orthodontically into the arch. **B,** Corticotomy performed to aid in orthodontic traction. **C,** Two months post-corticotomy, tooth is positioned within the dental arch *(arrow)*.

technique. This may require a generous flap, particularly if very superiorly located. A distal release is recommended if necessary because of esthetic concerns. Once the tooth is exposed, an appliance is cemented and a chain sutured to the arch wire for later activation. Bleeding is generally less of a problem compared with palatal impactions, and secondary re-bonding of a bracket is almost never necessary.

Occasionally, orthodontic traction alone will not be able to adequately position the tooth into the dental arch. In such cases, corticotomy may allow tooth movement. The cortical bone is removed with a small round bur to outline the tooth root, taking care to avoid exposing the root surface. This will often enable relatively rapid tooth positioning (Figure 20-5).

Unfortunately, orthodontic brackets occasionally become detached at some time during tooth movement. In this case, repeat exposure may become necessary. In the past, other traction methods were employed, including wire ligatures placed at the cementoenamel junction or pins incorporating an eye for wire placement that were screwed or cemented into the crown. With improved cements, however, these methods are not often necessary. Because they may damage teeth and directing forces can be more difficult, they should be avoided if possible.

The position of an eruptive device may have a significant impact on the ability to achieve appropriate orthodontic traction forces, and it is advisable to consult the orthodontist about bracket placement. An intraoperative photograph may be invaluable in providing the orthodontist with information about position of the impaction, location of the bracket, and preexisting damage to incisor roots from canine position.

A decision tree to aid clinicians in choosing the proper surgical technique based on imaging findings and tooth location is illustrated in Figure 20-6.

Intraoperative photographic documentation can be used as a means of communication with the orthodontist so that he or she will have a better understanding of the impacted tooth's position and a more precise idea of force vectors for activation of orthodontic traction. Rapid electronic transmission of such information can be achieved even during the surgical procedure in the event of questions regarding the placement of attachments or unanticipated findings such as root exposure or resorption. Feedback from the orthodontist may, in some circumstances, allow modification of the planned surgical procedure.

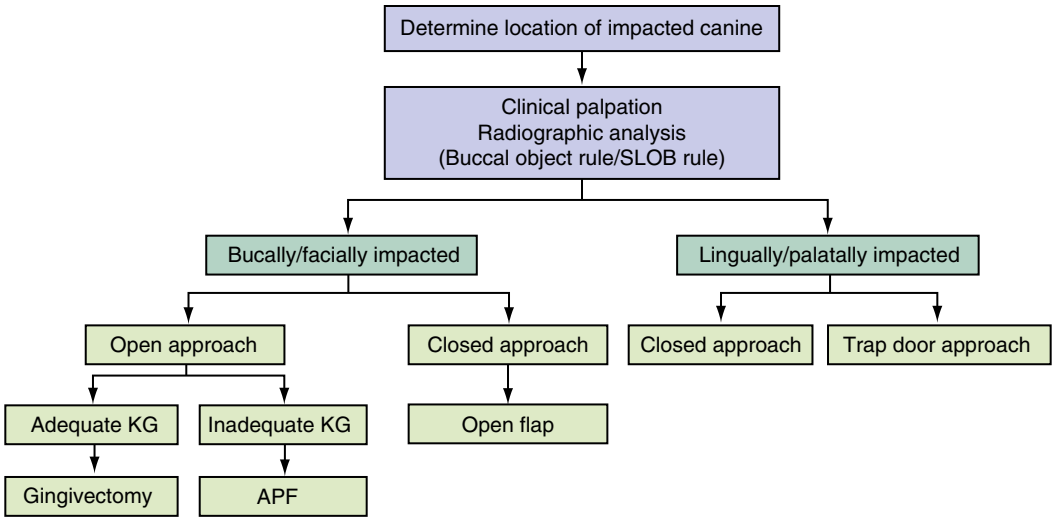

• **Figure 20-6** Decision tree proposed by Cooke and Wang for approach to impacted cuspid teeth. *APF,* Apically positioned flap; *KG,* keratinized gingiva. (From Cooke J, Wang HL: Canine impactions: incidence and management, *Int J Periodontics Restorative Dent* 26:483-491, 2006.)

Impacted Premolars

Mandibular second premolars rank third, after third permanent molars and maxillary permanent canines, in the frequency of impaction.[35] There is a relative paucity of literature relating to impacted premolars despite the fact that mandibular second premolars account for approximately 24% of all non–third molar dental impactions.[36] The overall prevalence of impacted premolars has been reported at 0.5%[37] and is under the influence of many physiologic, environmental, and local factors. Extractions are performed in a manner commensurate with the degree of impaction and overall treatment needs. It is often the case, however, that access is difficult because the tooth is in close approximation to the mental nerve, lingually positioned, or locked under the adjacent bicuspid and molar. Extreme care must be used in elevating flaps, and in some cases both buccal and lingual flaps must be raised for adequate tooth access. After judicious crown exposure, a small straight elevator may be helpful in assessing the malposed tooth for ankylosis. There is often an inadequate path for extraction of the tooth, and sequential sectioning of crown and root may be necessary for its removal.

Impacted Incisors

Impacted incisors are an infrequent occurrence in the oral and maxillofacial surgery office, but they can pose significant challenges. Incisors are a critical element in facial esthetics, especially in the maxillary arch. If a central incisor is lost, practitioners are left to deal with the unfortunate sequelae, including alveolar bone loss leading to a thin and deficient ridge, adjacent tooth movement, and gingival distortion that make an esthetic restoration extremely difficult. It is therefore advantageous if the natural tooth can be maintained and manipulated into position with the assistance of orthodontic or surgical means. Maxillary incisors may become impacted after early loss of the primary incisors, from local causes (such as odontoma, supernumerary teeth, or follicular cysts), or as a result of traumatic injury.[38] Open or closed eruption techniques, as described for the impacted cuspid, may also be performed for these teeth (Figure 20-7).

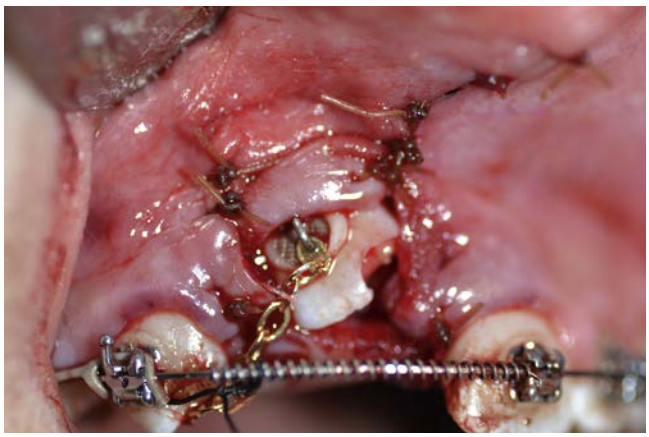

• **Figure 20-7** Apically positioned flap for exposure of an impacted central incisor. The mesial incisal edge has been disrupted by the associated compound odontoma.

Impacted Molars

The prevalence of impacted second molars is thought to be approximately 3 in every 1000 patients.[39] Most literature cites deficiencies in arch length as the primary reason for molar impaction. However, even with adequate space, mandibular second molars can be seen to become impacted in a mesial inclination under the distal of the first molar. Alling and colleagues[40] suggested that eruption of the second molar requires guidance by the distal root of the first molar, paralleling the "guidance" theory of maxillary canine eruption, described earlier. Of course, all of the previously



• **Figure 20-8** Impacted second and third molars. Late detection and associated pathology preclude orthodontic intervention.

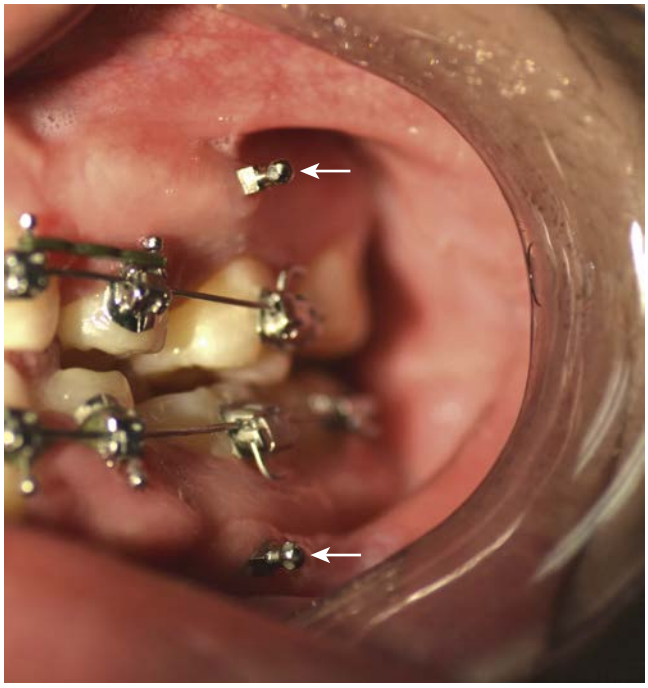

• **Figure 20-9** Temporary orthodontic anchorage devices (TADs) see *arrows*.).

discussed potential causes of tooth impaction apply to the molar teeth, and no definitive etiology has been accepted for its occurrence.

Failure of timely eruption of permanent molars warrants radiographic evaluation to determine the etiology, as there is little probability that a first molar will spontaneously erupt after age 7 years.[41] Agenesis or pathology must be considered (Figure 20-8); in many instances, however, the reason for eruption failure cannot be determined. Assisted eruption by orthodontic or combined surgical and orthodontic means has been reported by several authors,[42-45] but it is more difficult at this location because of limited options for orthodontic anchorage. Surgical access to molar teeth may be even more difficult than for impacted cuspids. Bone-anchored devices are available from several manufacturers, and these can provide significant assistance in appropriate anchorage and force vectors (Figure 20-9).

Surgical uprighting of a mesially inclined second molar provides a quick and predictable answer to these problems if performed at the proper time, and the technique has been described by multiple authors.[46-49] Some authors recommend consideration of criteria that include root length and form, available space within the dental arch, arc of rotation, occlusion, periodontal status, and jaw development.[50] The optimal root length should be one third to one half of the eventual length of the fully formed root to enhance the chance of revascularization after tipping and bodily movement. Before that, stabilization of the second molar in its new position can be compromised. If performed after root development is completed, a restricted blood supply from the constricted apical foramen can result in pulpal necrosis. To provide adequate space and access for the procedure, extraction of the third molar may also be necessary (Figure 20-10).

The management of impacted second molars is relatively straightforward. Often positioned mesioangularly and trapped below the height of contour of the adjacent first molar, these teeth may be surgically uprighted when about two thirds of the root has formed. To achieve this, a standard third molar incision is made from the external oblique ridge across the ridge crest to include the papilla of the first molar. No vertical release is made. The full-thickness flap will expose the area of the adjacent third molar, and the third molar should be removed after judicious bone excision. It is important to leave adequate bone at the mesial aspect of the third molar, for this will aid in stabilizing the second molar after uprighting. Bone covering the occlusal aspect of the second molar is then removed, and an elevator is wedged at the mesiobuccal line angle to upright the second molar to the level of the occlusal plane of the first molar. Hyperocclusion is not usually a problem, but the occlusal surface of the uprighted tooth can be slightly reduced if necessary. The mesial bone from the third molar socket will usually provide enough stability that the tooth will not require additional fixation to maintain its position. If there is excessive mobility, however, the tooth can be further stabilized with an orthodontic bracket and arch wire or other similar technique.

In most cases, the tooth will remain vital and can be positioned orthodontically into the dental arch. Mesial bone fill will occur in the majority of cases without further intervention.[45,47,48] On rare occasions, however, root fracture or devitalization may occur. Endodontic treatment may rarely be indicated. The angle of rotation for uprighting the second molar should not exceed 90 degrees according to Pogrel, who postulates that exceeding this limit would cause the tooth to behave like a transplant, thus diminishing the chance of future vitality.[47]

Supernumerary Teeth

Any tooth in addition to the normal 20 deciduous teeth and 32 permanent teeth is deemed "supernumerary" (Figure 20-11). The prevalence of supernumerary teeth

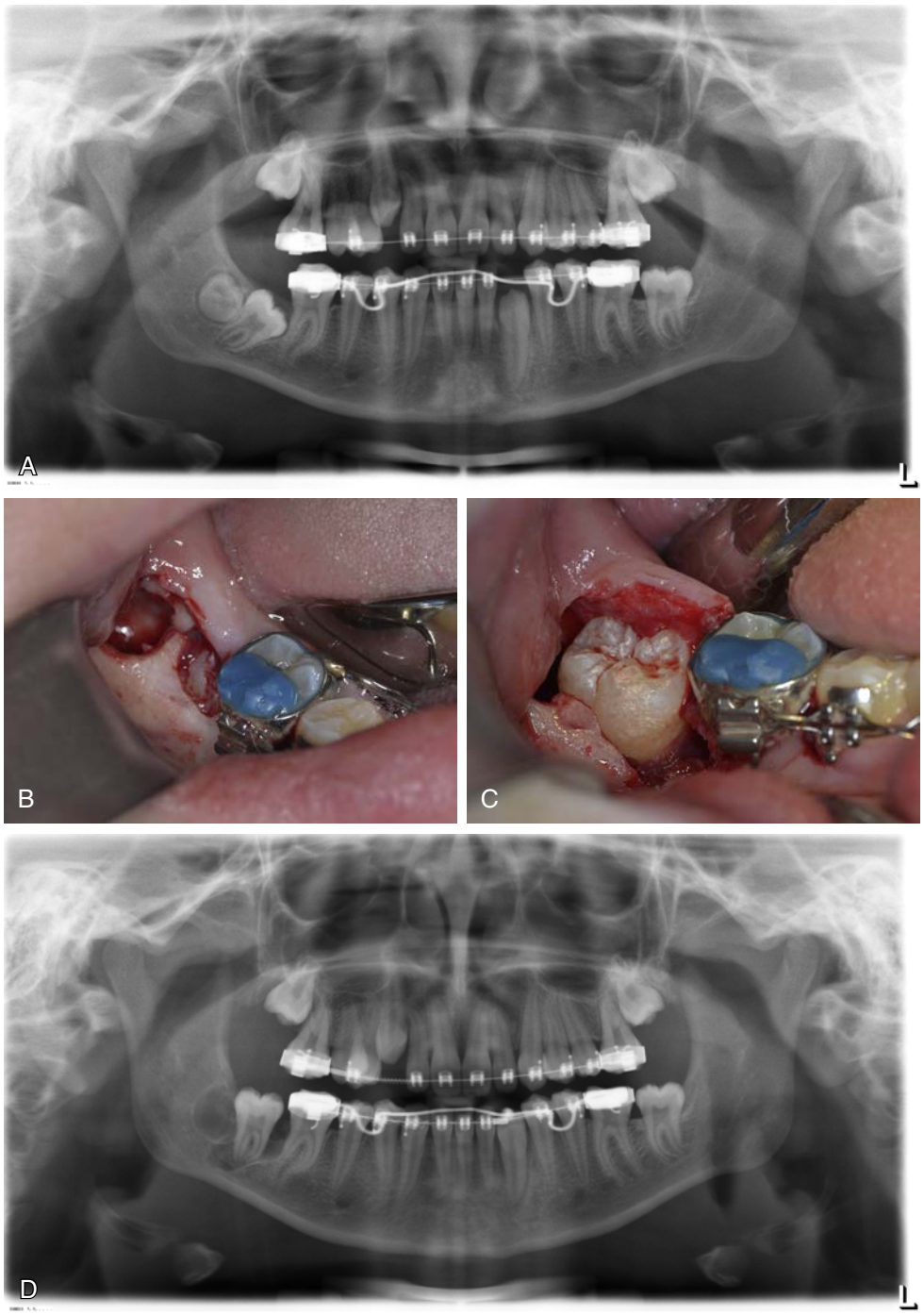

• **Figure 20-10** **A,** Radiograph illustrating impacted permanent second molar tooth prior to uprighting. **B,** Impacted third molar removed in preparation for uprighting second molar. **C,** Second molar uprighted; no stabilization was necessary. **D,** Postoperative radiograph illustrating adequate second molar position.

ranges from less than 1% to greater than 6% in various literature studies.[51] The etiology of supernumerary teeth has not been definitively determined, but genetic syndromes and familial influences have been associated with their occurrence.[52-55] Ethnicity also affects prevalence, with African Americans demonstrating a higher prevalence.[56] These anomalies are reported to occur with greater frequency in permanent teeth, and supernumerary teeth often have abnormal forms. (See reference 53 for review.)

Supernumerary teeth may, in some circumstances, impede eruption of deciduous or permanent teeth. As with any impacted tooth, they may be associated with pathologic conditions such as formation of dentigerous cysts. Because they can occur anywhere in the jaws, in some cases they may impede orthodontic tooth movement or surgical procedures such as dental implant placement. In the absence of a specific indication for their removal, and in the case of high surgical risk to other anatomic structures, supernumerary

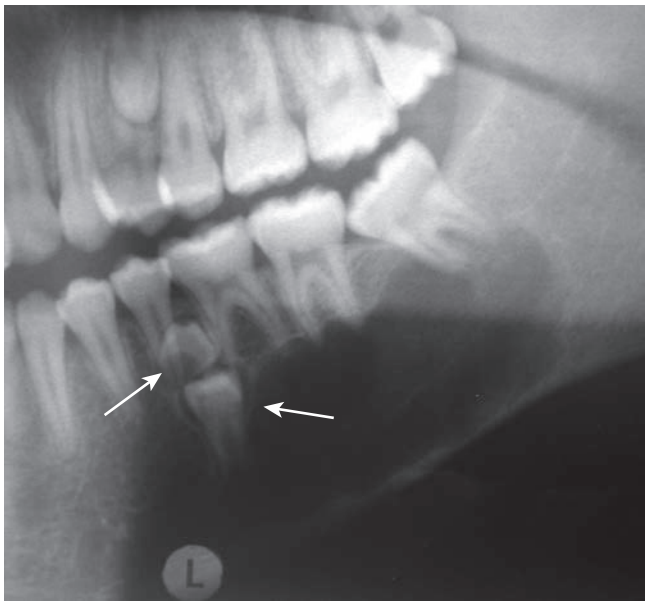

• **Figure 20-11** Supernumerary bicuspid teeth with associated lytic lesion in the left mandible. Note also the additional supernumerary tooth between the maxillary bicuspids.

teeth may be left in place. The patient and parent should, however, be informed that regular surveillance is necessary to identify pathology that may develop over time. It is not clear, however, if the risks of repeated radiographic surveys and probability of failure to follow up outweigh the risk of surgical removal for most patients.

The removal of supernumerary teeth is approached in a fashion similar to other dental impactions. The specifics of removal depend on tooth location, and adequate imaging is critical to determine the safest surgical approach. The imaging techniques described earlier in this chapter will aid in determining the relationship of the supernumerary tooth to adjacent roots and neurovascular structures. In some cases where an individual has lost a permanent tooth to disease or trauma, consideration may be given to transplant of an appropriately sized supernumerary tooth to an edentulous site.

Odontomas

Odontomas are hamartomas rather than true neoplasms.[57] They may resemble a collection of tooth-like calcifications called denticles in the compound type, or a more amorphous mass of calcified material in the complex type. They may impede eruption of teeth, and failure of eruption should elicit radiographic assessment of the cause. These lesions are generally surrounded by a radiolucent border that aids their excision. Removal should be performed as for supernumerary teeth. They do not recur (Figure 20-12).

Tooth Transplantation

Tooth transplantation may provide an attractive alternative to dental implants in the growing child. This procedure was first performed more than 50 years ago, but it has not gained general acceptance in many places despite high reported success rates. Unlike implants, transplanted teeth can behave just like other natural teeth, maintaining alveolar bone and occlusion as the child develops. Even if the transplant later fails and must undergo extraction, it has provided function and aided development of the alveolus so that dental implants can often be placed later without extensive site preparation.

Indications for transplant may include tooth loss due to trauma or pathology, failure of teeth to develop or erupt, and ankylosis resulting in nonfunctional teeth.[58] Donor candidates for autotransplantation include teeth planned for extraction due to dental crowding (especially bicuspids), grossly malpositioned impacted cuspids, third molars, and even supernumerary teeth. Although some authors suggest that the ideal time for tooth transplantation is when roots are between 50% and 75% formed, high survival rates are also reported with transplant after complete root formation.[59,60] When roots are only partially formed, endodontic therapy can often be avoided, and teeth may remain vital as root development continues. Survival rates for transplanted teeth are reported to be greater than 90% in some studies.[61,62]

Impacted cuspid teeth may sometimes be located in such an unfavorable position that exposure and orthodontic traction cannot adequately orient the tooth in the dental arch. If surgically accessible, these teeth can be extracted and placed in a socket freshly prepared in the alveolus. This may, however, require presurgical orthodontic space development.

Transplants can be very effective for replacement of missing central or lateral incisors. Maxillary second bicuspids are a good transplant choice when rotated 90 degrees about the vertical axis to expose the broadest surface of the tooth. This makes camouflage with tooth-colored materials relatively straightforward. Although lower bicuspid teeth may also serve as transplants in these sites, they are more difficult to contour to mimic a maxillary incisor. Endodontic treatment may sometimes be necessary because of the extent of tooth modification necessary to provide a good esthetic result.

Molar transplantation is more difficult because of greater root complexity and concomitant greater risk of root damage or fracture during extraction. Site preparation is also somewhat more difficult, but success rates are still within acceptable ranges.

Transplant technique varies based on location of donor and recipient sites, stage of root development, and size of tooth to be transplanted. Teeth with less than 50% or more than 75% root development have been shown to have higher root resorption rates rate than teeth with 50% to 75% formed root structures.[63] Teeth with open apices may not require root canal therapy, but those with fully formed roots are less likely to revascularize.[64] Site preparation requires a full-thickness mucoperiosteal flap and creation of a recipient "socket" with drills or trephines. Multirooted teeth make this process more complicated. Because maintenance of periodontal ligament cell vitality

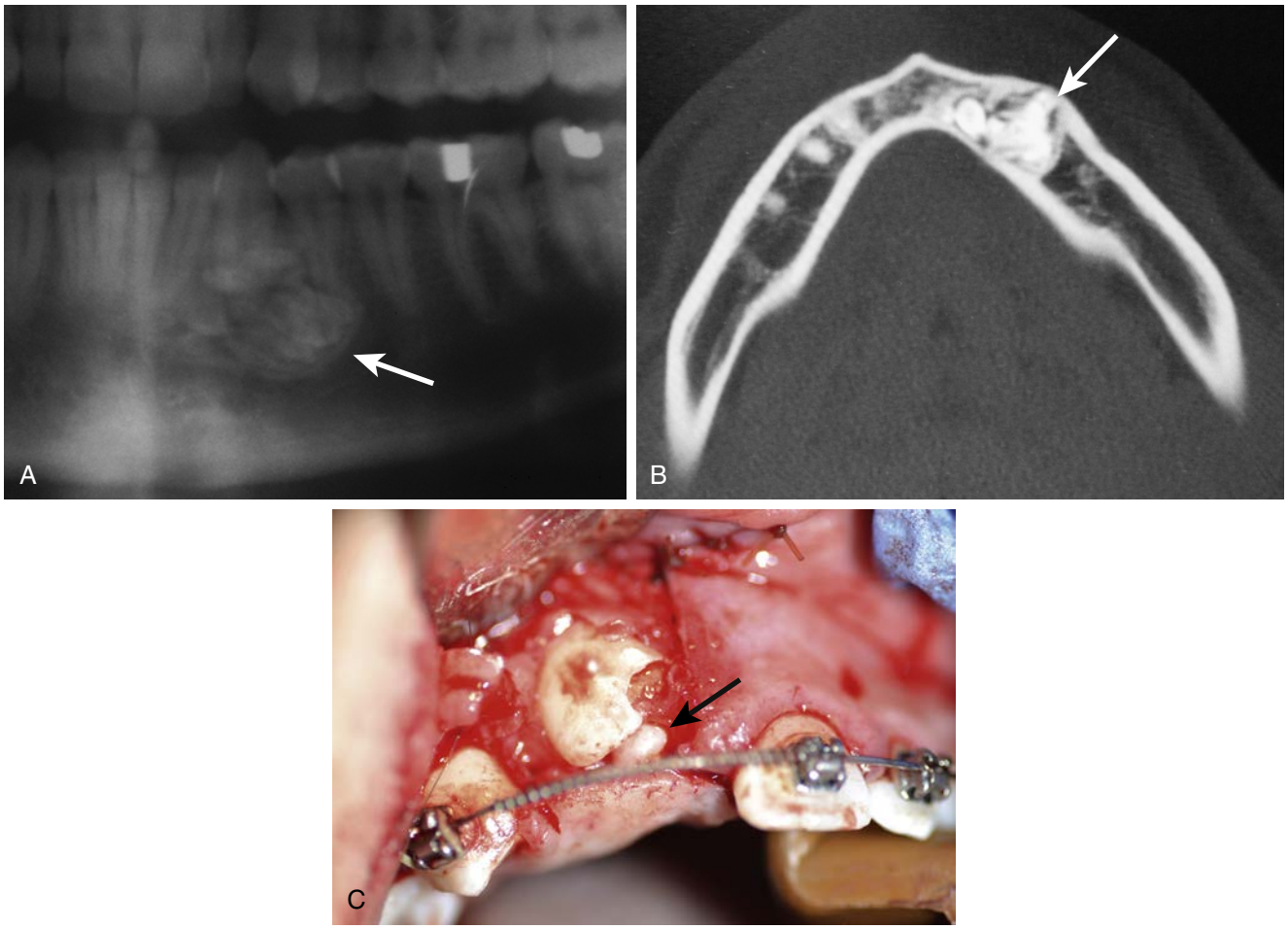

• **Figure 20-12** **A,** Compound odontoma of left mandible *(arrow)*. **B,** Computed tomographic image of odontoma in **A** *(arrow)*. **C,** One of several denticles associated with a compound odontoma preventing eruption of the permanent incisor *(arrow)*.

is thought to be critical to transplant success, the time between extraction of the transplant and its placement in the new location should be minimized. Some authors suggest completion of root canal therapy if possible before removal of the transplant from its socket to reduce explant time.[63] With increased availability of cone-beam imaging and rapid prototyping, it is now possible to fabricate a transplant analogue to aid in recipient site preparation before extraction of the donor tooth.[64] Both these techniques presume that the donor tooth will be extracted without significant damage or root fracture. Although some authors report no need for stabilization of the transplanted tooth or stabilization only with sutures, we recommend stabilization in slight infraocclusion with a resin and wire splint for 10 days to 2 weeks.

Despite the high success rate of tooth transplantation, complications may occur. These include infection, internal and/or external root resorption, poor periodontal healing, ankylosis, tooth fracture during extraction, and failure of the transplant to stabilize in its new location. Patients should be advised that additional procedures may be necessary to manage such complications, and that loss of the transplant could occur.

Dental Implants in Children

Although the permanent dentition, with the exception of third molars, is present in the oral cavity by the early teenage years, continued facial growth and tooth eruption continue well past puberty.[65,66] Because dental implants integrate with bone and lack a periodontal ligament, once placed they do not move occlusally as normal teeth do in the eruption process. They are, in effect, ankylosed. This may result in submersion of the implant as the other teeth assume their final place in the dental arches.[67,68] Correction of this problem may result in esthetic and mechanical compromise to the implant as longer abutments and crowns become necessary to reestablish the occlusion. For these reasons, dental implants are best avoided in most instances in growing children until the dentition is fully erupted.[69]

There are some circumstances, however, where implants should be considered before jaw growth and tooth eruption are complete. Syndromic (as in ectodermal dysplasia) and non-syndromic hypodontia, oligodontia, or anodontia can create significant esthetic and functional hurdles for afflicted individuals. Both conventional and mini dental implant reconstruction has been of benefit to many patients, and

fixed or removable prostheses can greatly aid both function and esthetics.[70-72] Implants do not seem to restrict jaw growth (with the exception of implant submersion in a height-restricted alveolus), and in the case of some congenital conditions the benefits may outweigh the risks associated with early implant placement.[73] Most of the literature regarding implants in growing children, however, is not of sufficient scientific rigor to provide strong evidence for the routine placement of dental implants in this population.

Soft Tissue Procedures

A frenum is a band of soft tissue that connects the lips, cheeks, or tongue to the maxilla or mandible. In the oral cavity, prominent frena are found in the midlines of the upper and lower lips connecting the mucosal surfaces of the lips to the corresponding alveolus, and in the floor of the mouth connecting the undersurface of the tongue to the lingual aspect of the mandible. Smaller attachments occur on the facial aspects of both the upper and lower arches and are sometimes termed frenulae, although these terms are generally used interchangeably. Frena are composed of mucosa and connective tissue and may contain skeletal muscle.[74]

Frena may be more prominent or absent in certain disease states and may thus serve as important indicators of underlying pathologic conditions. Prominent frenal attachments may also have a familial tendency, in some cases showing an autosomal dominant inheritance pattern.[75] In most cases, however, excessive frenal attachments are not associated with other disease states.

Both labial and lingual frena commonly attach near the alveolar crest at birth and in most cases recede as the alveolus grows and teeth erupt. A prominent maxillary labial frenum has been associated with difficulty in breastfeeding and persistence of a midline diastema.[76] In the lower jaw, buccal and lingual plaque and bleeding scores have been shown to increase when the frenum connects in the attached ginviga.[77] Excessive lingual frena may cause ankyloglossia and associated difficulty in breastfeeding and possible speech abnormalities, among other difficulties.[78,79] These potential problems have traditionally been treated by frenal release (frenotomy) or complete excision of the frenum (frenectomy). It should be noted, however, that the literature evidence for performance of these procedures is not compelling.[80-82] Neither is there significant evidence *against* surgical release of the prominent frenum. In light of the low risk of surgical complications, frenoplasty or frenectomy may be performed for treatment or prophylactic indications.

Surgery for the Labial Frenum

The maxillary midline frenal attachment may be so prominent as to cross the ridge crest and insert into the incisive papilla. Once the decision for frenal release is made, any of several techniques may be employed. Local anesthesia is generally adequate for these procedures. Use of a nitrous oxide nasal hood may impede adequate upper lip retraction and result in inadequate frenal release.

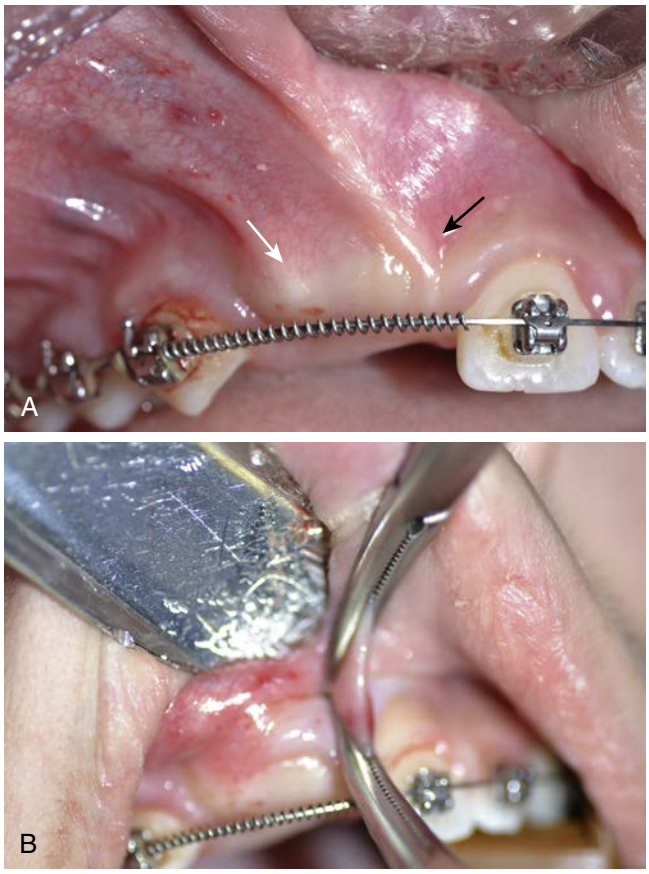

• **Figure 20-13** **A,** Maxillary labial frenum inserts into alveolar crest *(black arrow)*. Bulge representing permanent central incisor is visible submucosally *(white arrow)*. **B,** "Two-clamp" technique; frenum is isolated from labial and alveolar tissues by curved hemostats. After release of clamps, incision is made through crushed tissue to aid hemostasis. Labial mucosa is closed primarily, while keratinized gingival tissue is allowed to granulate.

Treatment of the prominent frenum is typically performed by one of three techniques: frenotomy (or vestibular extension), excision, or Z-plasty. Any of these techniques will adequately manage the frenum; maximum effect has been reported to be seen with Z-plasty, but frenectomy seems to have fewer postsurgical symptoms.[83]

Frenotomy releases the soft tissue attachment and repositions it at the depth of the vestibule. The lip is retracted superiorly (or inferiorly in the case of the lower labial frenum) and the alveolar portion of the frenum is incised with a scalpel, electrosurgery device, laser, or scissors. Minimal undermining toward the lip will allow repositioning of the frenum to the depth of the vestibule, where it is sutured to periosteum. The resultant V-shaped defect overlying the alveolus is left to heal by secondary intention. Pressure applied to the denuded area is generally adequate to obtain hemostasis.

Frenectomy is commonly performed with the "two-clamp" technique (Figure 20-13). Two small curved hemostats are placed, one on each arm of the frenum, after retraction of the lip. These are left in place for 30 to 60 seconds. After removal, the clamped tissue is excised, leaving a diamond-shaped defect. The labial mucosa is undermined and closed primarily, and the

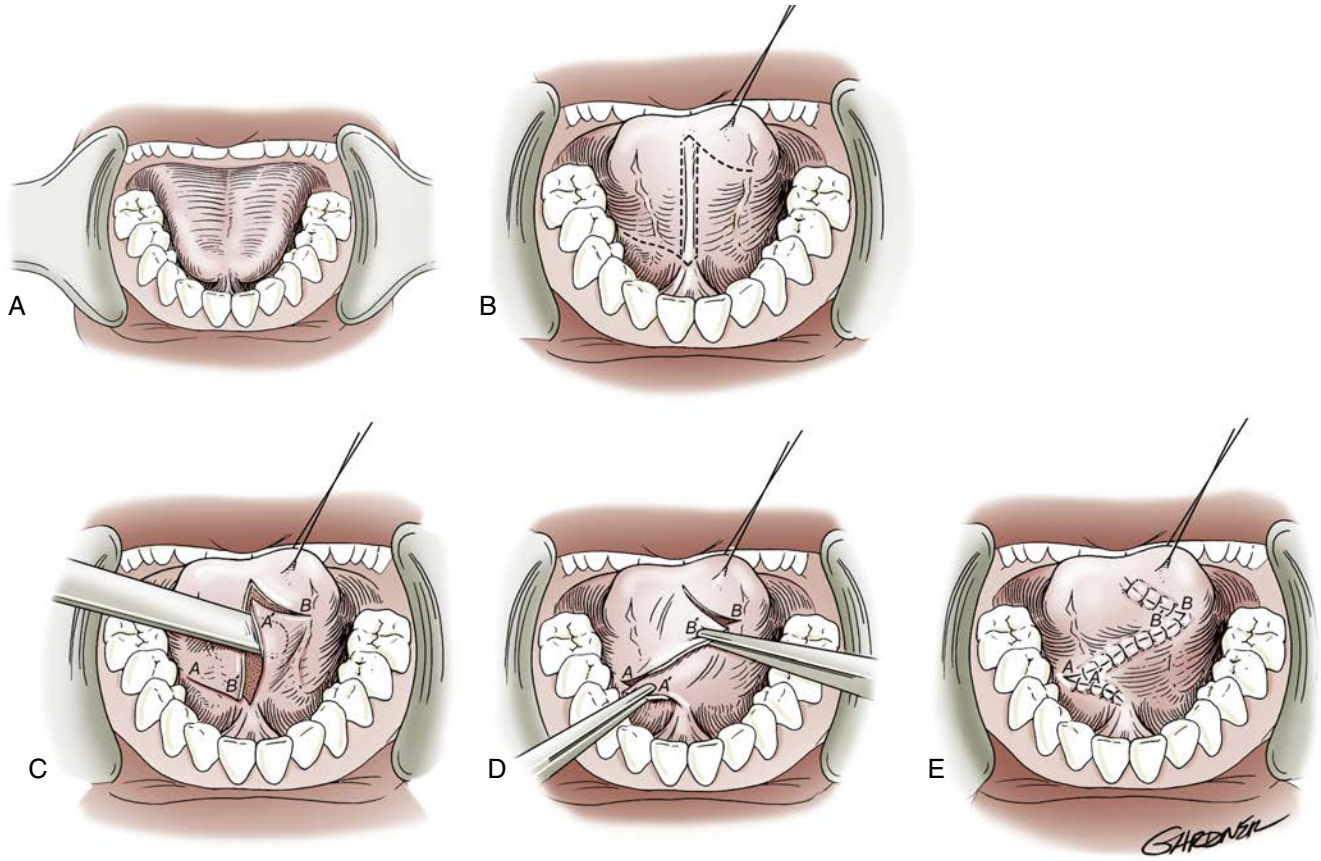

• **Figure 20-14** **A,** Preoperative depiction of a prominent lingual frenum. **B,** Proposed incisions for a lingual frenectomy with Z-plasty closure. **C,** Undermining wound margins. **D,** Transposition of Z-plasty flaps. **E,** Final closure.

alveolar portion is allowed to heal secondarily. Z-plasty or V-Y closure techniques are employed by some practitioners, but these are not necessary to achieve a successful result.

Complications are generally minimal for these procedures. Light bleeding, mild swelling, and infection are possible. For maxillary midline frena that reach the alveolar crest or insert into the incisive papilla, it is important to excise the full extent of the frenum if diastema closure is to be anticipated. Temporary altered sensation of the surgical area may occur, but this can be expected to resolve in most cases within weeks to a few months.

Surgery of the Lingual Frenum

A prominent lingual frenum may limit tongue movement, resulting in ankyloglossia (tongue tie). As breastfeeding has become more common, attention has again been focused on the lingual frenum and its role in effective infant nutrition. There is ample literature delineating adverse effects of limited tongue mobility in relation to breastfeeding and documenting improvement with release by lingual frenotomy.[84-86] There is limited evidence that ankyloglossia is associated with altered speech or that surgery will benefit periodontal status.

As with labial frenal surgery, there are several techniques proposed for ankyloglossia release. Frenotomy is straightforward and is reported in many instances without anesthesia,[86,87] although local anesthesia with vasoconstrictor may aid hemostasis. The infant is stabilized by an assistant (who may be the parent), and the surgeon is positioned cephalad to the child. The tongue is manually elevated, and a blunt-tipped scissor is used to cut the inferior aspect of the lingual frenum to free the tongue. Minimal undermining may be performed with an instrument or cotton-tipped applicators, and hemostasis is achieved with direct pressure without suturing. This technique has been reported to result in immediate or near-immediate improvement in feeding and maternal comfort during feeding, and it has the advantage of avoiding general anesthesia.[83,84]

Frenectomy techniques are more involved and are more likely to require advanced sedation or general anesthesia techniques, although local anesthesia may be adequate for a cooperative child. As for labial frenectomy, the two-clamp technique may be used, and the frenum can be incised with cutting instruments or laser.[87] After excision, the resulting diamond-shaped defect is undermined and closed primarily on the ventral surface of the tongue and floor of the mouth. Care must be exercised to avoid damage to the submandibular ducts during excision and closure.

Lingual frenectomy and closure with Z-plasty is illustrated in Figure 20-14. Either single or double Z-plasty may be used, and genioglossus myotomy may be performed; these

techniques have been suggested to provide additional tongue mobility when necessary.[88-90]

Potential complications of frenotomy and frenectomy include bleeding and hematoma formation, damage to the submandibular ducts or lingual nerves, infection, and recurrence. Complications are generally minor and self-limiting.

Pediatric Challenges

As discussed throughout this chapter, the pediatric population poses some great challenges in terms of physiology, anatomy, and treatment planning. One significant dynamic that must be considered whenever treating pediatric patients is their unpredictable and often uninhibited behavior. The simplest procedure can become impossible when a patient is unable or unwilling to be cooperative in the chair. Oral and maxillofacial surgeons have a variety of tools at their disposal to help alleviate some of the behavioral turbulence that often accompanies treatment. Both nonpharmacologic and pharmacologic techniques can be tailored to the individual patient and practitioner to allow for safe and effective care. "Behavior guidance" is a term developed by the American Academy of Pediatric Dentistry and is a continuum of interaction involving the dentist, the dental team, the patient, and the parent directed toward communication and education. Its goal is to ease fear and anxiety while promoting an understanding of the need for oral health and the process by which that is achieved.[91] Oral surgeons can use behavior guidance, various sedation techniques, or a combination thereof with many of the surgical procedures discussed in this chapter. Occasionally, however, a pediatric patient is unable to tolerate the proposed care, and alternative options must be explored. General anesthesia, either in-office or in a controlled operating room environment, can be offered in a situation where patient or provider safety is at risk or where quality of care could be compromised. Oral surgeons are in a unique position among dental providers, as they often have admitting privileges to hospitals and the medical background to handle complex pathologic processes. It is important that the specialty of oral and maxillofacial surgery accept and welcome these challenges to continue leadership in the delivery of safe and proficient care to the pediatric population.

References

1. U.S. Food and Drug Administration: FDA's final rule at 21 CFR 814.3(s) (79FR 1740, January 10, 2014) Definition of pediatric patients. http://www.fda.gov/downloads/medicaldevices/deviceregulationandguidance/guidancedocuments/ucm339465.pdf Accessed April 14, 2015.
2. Lieblich S, Kleiman M, Zak M: Dentoalveolar surgery, *J Oral Maxillofac Surg* 70:50–71, 2012.
3. Hellstein J: Odontogenesis, odontogenic cysts, and odontogenic tumors. In Flint P, et al, editors: *Cummings otolaryngology head & neck surgery*, ed 6, St. Louis, 2010, Elsevier, pp 1259–1278.
4. Digman S, Hayes S, Niel J: Pediatric dentoalveolar surgery. In Fonseca R, et al, editors: *Oral & maxillofacial surgery*, ed 2, St. Louis, 2009, Elsevier, pp 165–184.
5. American Academy of Pediatric Dentistry Web site: Guideline on periodicity of examination, preventive dental services, anticipatory guidance/counseling, and oral treatment for infants, children, and adolescents. Available at www.aapd/media/Policies_Guidelines/G_Periodicity.pdf Accessed April 14, 2015.
6. Swee J, Silvestri A, Finkelman M, et al.: Inferior alveolar nerve block and third molar agenesis: a retrospective clinical study, *J Am Dent Assoc* 144:389–395, 2013.
7. Fink BR, Demarest RJ: Anatomical background. In Fink BR, Demarest RJ, editors: *Laryngeal biomechanics*, Cambridge, MA, 1978, Harvard University Press, pp 1–14.
8. Eckenhoff JE: Some anatomic considerations of the infant larynx influencing endotracheal anesthesia, *Anesthesiology* 12:401–410, 1951.
9. Negus VE: *The comparative anatomy and physiology of the larynx*, New York, 1949, Grune & Stratton.
10. Litman RS, Wake N, Chan LM, et al.: Effect of lateral positioning on upper airway size and morphology in sedated children, *Anesthesiology* 103:484–488, 2005.
11. Hou R, Kong L, Ao J, et al.: Investigation of impacted permanent teeth except the third molar in Chinese patients through an x-ray study, *J Oral Maxillofac Surg* 68:762–767, 2010.
12. Moyers RE: *Handbook of orthodontics for the student and general practitioner*, ed 3, Chicago, 1973, Year Book Medical Publishers.
13. Zeitler DL: Management of impacted teeth other than third molars. In Miloro M, editor: *Peterson's principles of oral and maxillofacial surgery*, ed 2, Hamilton, ON, 2004, BC Decker, pp 131–137.
14. Lytle J: Etiology and indications for the management of impacted teeth, *Northwest Dent* 74:23–32, 1995.
15. Kaban LB, Needleman HL, Hertzberg J: Idiopathic failure of eruption of permanent molar teeth, *Oral Surg Oral Med Oral Pathol* 42:155–163, 1976.
16. Clark CA: A method of ascertaining the relative position of unerupted teeth by means of film radiographs, *Proc R Soc Med* 3:87–90, 1910.
17. Keur JJ: Radiographic localization techniques, *Aust Dent J* 31:86–90, 1986.
18. Jacobs SG: Radiographic localization of unerupted maxillary anterior teeth using the vertical tube shift technique: the history and application of the method with some case reports, *Am J Orthod Dentofacial Orthop* 116:415–423, 1999.
19. Walker L, Enciso R, Mah J: Three-dimensional localization of maxillary canines with cone-beam computed tomography, *Am J Orthod Dentofacial Orthop* 125:418–423, 2005.
20. Elefteriadis JN, Athanasiou AE: Evaluation of impacted canines by means of computerized tomography, *Int J Adult Orthodon Orthognath Surg* 11:257–264, 1996.
21. Bedoya M, Park J: A review of the diagnosis and management of impacted maxillary canines, *J Am Dent Assoc* 140:1485–1493, 2009.
22. Cooke J, Wang HL: Canine impactions: incidence and management, *Int J Periodontics Restorative Dent* 26:483–491, 2006.
23. Yavuz MS, Aras MH, Buyukkurt MC, et al.: Impacted mandibular canines, *J Contemp Dent Pract* 8:78–85, 2007.
24. Ericson S, Kurol J: Early treatment of palatally erupting maxillary canines by extraction of the primary canines, *Eur J Orthod* 10:283–295, 1988.

25. Mitchell L: *An introduction to orthodontics*, ed 3, New York, 2007, Oxford University Press, pp 147–156.
26. Jacoby H: The etiology of maxillary canine impactions, *Am J Orthod* 84:125–132, 1983.
27. Liu D, Zhang W, Zhang Z: Localization of impacted maxillary canines and observation of adjacent incisor resorption with cone-beam computed tomography, *Oral Surg Oral Med Oral Pathol Oral Radiol Endod* 105:91–98, 2008.
28. Peck S, Peck L, Kataja M: The palatally displaced canine as a dental anomaly of genetic origin, *Angle Orthod* 64:249–256, 1994.
29. Becker A: *The orthodontic treatment of impacted teeth*, ed 2, Abingdon, UK, 2007, Information Healthcare, pp 1–228.
30. Bishara SE: Impacted maxillary canines: a review, *Am J Orthod Dentofacial Orthop* 10:159–171, 1992.
31. Beadnell S: Management of the impacted canine. In Bagheri S, et al, editors: *Current therapy in oral & maxillofacial surgery*, St Louis, 2012, Elsevier, pp 135–145.
32. Ericson S, Kurol J: Early treatment of palatally erupting maxillary canines by extraction of the primary canines, *Eur J Orthod* 10:283–295, 1988.
33. Kokich VG, Mathews DA: Impacted teeth: Surgical and orthodontic considerations. In McNamara JA, Brudon WL, Kokich VG, editors: *Orthodontics and Dentofacial Orthopedics*, Ann Arbor, 2001, Needham Press, pp 395–422.
34. Schmidt AD, Kokich VG: Periodontal response to early uncovering, autonomous eruption, and orthodontic alignment of palatally impacted maxillary canines, *Am J Orthod Dentofacial Orthop* 131:449–455, 2007.
35. Alling C, Catone G: Management of impacted teeth, *J Oral Maxillofac Surg* 51:3–6, 1993.
36. Collett A: Conservative management of lower second premolar impaction, *Aust Dent J* 45:279–281, 2000.
37. Oikarinen V, Julku M: Impacted premolars, an analysis of 10,000 orthopantomograms, *Proc Finn Dent Soc* 70:95–98, 1974.
38. Koch H, Schwartz O, Klausen B: Indications for surgical removal of supernumerary teeth in the premaxilla, *Int J Oral Maxillofac Surg* 15:273, 1986.
39. Yehoshua S, Borell G, Nahlieli O, et al.: Second molar impactions, *Angle Orthod* 68:173–178, 1999.
40. Alling C, Helfrick JF, Rocklin D: *Impacted teeth*, Philadelphia, 1993, Saunders, pp 210–227.
41. Frank CA: Treatment options for impacted teeth, *J Am Dent Assoc* 131:623–632, 2000.
42. Giancotti A, Arcuri C, Barlattani A: Treatment of ectopic mandibular second molar with titanium miniscrews, *Am J Orthod Dentofacial Orthop* 126:113–117, 2004.
43. Johnson E: Managing second molars, *Am J Orthod Dentofacial Orthop* 140:269–273, 2011.
44. Dressner S: Surgical uprighting of second molars: rationale and technique, *Oral Maxillofacial Surg Clin N Am* 14:201–212, 2002.
45. Going Jr RE, Reyes-Lois DB: Surgical exposure and bracketing technique for uprighting impacted mandibular second molars, *J Oral Maxillofac Surg* 57:209–212, 1999.
46. Terry BC, Hegtvedt AK: Self-stabilizing approach to surgical uprighting of the mandibular second molar, *Oral Surg Oral Med Oral Pathol* 75:674–680, 1993.
47. Pogrel MA: The surgical uprighting of mandibular second molars, *Am J Orthod Dentofac Orthop* 108:180–183, 1995.
48. Boynton T, Lieblich SE: Surgical uprighting of second molars, *Atlas Oral Maxillofacial Surg Clin N Am* 21:235–237, 2013.
49. Anderson K, Murtagh K, Sacks HG: Soft tissue and occlusal management in the surgical uprighting of impacted molars: technical note, *J Oral Maxillofac Surg* 70:e438–e440, 2012.
50. Tinerfe TJ, Blakey GH: *Oral and maxillofacial surgery*, Philadelphia, 2000, Saunders, pp 308–316.
51. Anthonappa RP, King NM, Rabie ABM: Prevalence of supernumerary teeth based on panoramic radiographs revisited, *Pediatr Dent* 35:257–261, 2013.
52. Fleming PS, Xavier GM, Dibiase AT, et al.: Revisiting the supernumerary: the epidemiological and molecular basis of extra teeth, *Br Dent J* 208:25–30, 2010.
53. D'Souza RN, Klein OD: Unraveling the molecular mechanisms that lead to supernumerary teeth in mice and men: current concepts and novel approaches, *Cells Tissues Organs* 186:60–69, 2007.
54. Bufalino A, Paranaiba LM, Gouvea AF, et al.: Cleidocranial dysplasia: oral features and genetic analysis of 11 patients, *Oral Dis* 18:184–190, 2012.
55. Batra P, Duggal R, Parkash H: Non-syndromic multiple supernumerary teeth transmitted as an autosomal dominant trait, *J Oral Pathol Med* 34:621–625, 2005.
56. Harris EF, Clark LL: An epidemiological study of hyperdontia in American blacks and whites, *Angle Orthod* 78:460–465, 2008.
57. Boffano P, Zavattero E, Roccia F, et al.: Complex and compound odontomas, *J Craniofac Surg* 23:685–688, 2012.
58. Walden K, Barber SK, Spencer RJ, et al.: Indications for the use of auto-transplantation of teeth in the child and adolescent, *Eur Arch Paediatr Dent* 13:210–216, 2012.
59. Cohen AS, Shen TC, Pogrel MA: Transplanting teeth successfully: autografts and allografts that work, *J Am Dent Assoc* 126:481–485, 1995.
60. Sugai T, Yoshizawa M, Kobayashi K, et al.: Clinical study on prognostic factors for autotransplantation of teeth with complete root formation, *Int J Oral Maxillofac Surg* 39:1193–1203, 2010.
61. Kim E, Jung J-Y, Cha I-H, et al.: Evaluation of the prognosis and causes of failure in 182 cases of autogenous tooth transplantation, *Oral Surg Oral Med Oral Pathol Oral Radiol Endod* 100:112–119, 2005.
62. Andreasen JO, Paulsen HU, Yu Z, et al.: A long-term study of 370 autotransplanted premolars. Part II. Tooth survival and pulp healing subsequent to transplantation, *Eur J Orthod* 12:14–24, 1990.
63. Kallu R, Vinckier F, Politis C, et al.: Tooth transplantations: a descriptive retrospective study, *Int J Oral Maxillofac Surg* 34: 745–755, 2005.
64. Lee SJ, Jung IY, Lee CY, et al.: Clinical application of computer-aided rapid prototyping for tooth transplantation, *Dent Traumatol* 17:114–119, 2001.
65. Op Heij DG, Opdebeeck H, van Steenberghe D, et al.: Facial development, continuous tooth eruption, and mesial drift as compromising factors for implant placement, *Int J Oral Maxillofac Implants* 21:867–878, 2006.
66. Bernard JP, Schatz JP, Christou P, et al.: Long-term vertical changes of the anterior maxillary teeth adjacent to single implants in young and mature adults: a retrospective study, *J Clin Periodontol* 31:1024–1028, 2004.
67. Cronin Jr RJ, Oesterle LJ, Ranly DM: Mandibular implants and the growing patient, *Int J Oral Maxillofac Implants* 9:55–62, 1994.
68. Ledermann PD, Hassell TM, Hefti AF: Osseointegrated dental implants as alternative therapy to bridge construction or orthodontics in young patients: seven years of clinical experience, *Pediatr Dent* 15:327–333, 1993.

69. Carmichael RP, Sándor GKB: Dental implants, growth of the jaws, and determination of skeletal maturity, *Atlas Oral Maxillofacial Surg Clin N Am* 16:1–9, 2008.
70. Filius MA, Vissink A, Raghoebar GM, et al.: Implant-retained overdentures for young children with severe oligodontia: a series of four cases, *J Oral Maxillofac Surg* 72:1684–1690, 2014.
71. Sfeir E, Nassif N, Moukarzel C: Use of mini dental implants in ectodermal dysplasia children: follow-up of three cases, *Eur J Paediatr Dent* 15(2 Suppl):207–212, 2014.
72. Aydinbelge M, Gumus HO, Sekerci AE, et al.: Implants in children with hypohidrotic ectodermal dysplasia: an alternative approach to esthetic management: case report and review of the literature, *Pediatr Dent* 35:441–446, 2013.
73. Kearns G, Sharma A, Perrot D, et al.: Placement of endosseous implants in children and adolescents with hereditary ectodermal dysplasia, *Oral Surg Oral Med Oral Pathol Oral Radiol Endod* 88:5–10, 1999.
74. Ross RO, Brown FH, Houston GD: Histologic survey of the frena of the oral cavity, *Quintessence Int* 21:233–237, 1990.
75. Mintz SM, Siegel MA, Seider PJ: An overview of oral frena and their association with multiple syndromic and nonsyndromic conditions, *Oral Surg Oral Med Oral Pathol Oral Radiol Endod* 99:321–324, 2005.
76. Kotlow LA: Diagnosing and understanding the maxillary lip-tie (superior labial, the maxillary labial frenum) as it relates to breastfeeding, *J Hum Lact* 29:458–464, 2013.
77. Addy M, Dummer PMH, Hunter ML, et al.: A study of the association of fraenal attachment, lip coverage, and vestibular depth with plaque and gingivitis, *J Periodontol* 58:752–757, 1987.
78. Kupietzky A, Botzer E: Ankyloglossia in the infant and young child: clinical suggestions for diagnosis and management, *Pediatr Dent* 27:40–46, 2005.
79. Messner AH, Lalakea ML: The effect of ankyloglossia on speech in children, *Otolaryngol Head Neck Surg* 127:539–545, 2002.
80. Delli K, Livas C, Sculean A, et al.: Facts and myths regarding the maxillary midline frenum and its treatment: a systematic review of the literature, *Quintessence Int* 44:177–187, 2013.
81. Nguyen-Hieu T, Ha Thi BD, Do Thu H, et al.: Gingival recession associated with predisposing factors in young Vietnamese: a pilot study, *Oral Health Dent Manag* 11:134–144, 2012.
82. Webb AN, Hao W, Hing P: The effect of tongue-tie division on breastfeeding and speech articulation: a systematic review, *Int J Pediatr Otorhinolaryngol* 77:635–646, 2013.
83. Kahnberg KE: Frenum surgery. I. A comparison of three surgical methods, *Int J Oral Surg* 6:328–333, 1977.
84. O'Callahan C, Macary S, Clemente S: The effects of office-based frenotomy for anterior and posterior ankyloglossia on breastfeeding, *Int J Pediatr Otorhinolaryngol* 77:827–832, 2013.
85. Sethi N, Smith D, Kortequee S, et al.: Benefits of frenulotomy in infants with ankyloglossia, *Int J Pediatr Otorhinolaryngol* 77: 762–765, 2013.
86. Hogan M, Westcott C: Griffiths, M. Randomized, controlled trial of division of tongue-tie in infants with feeding problems, *J Paediatr Child Health* 41:246–250, 2005.
87. Junquiera MA, Cunha NNO, Costa e Silva LL, et al.: Surgical techniques for the treatment of ankyloglossia in children: a case series, *J Appl Oral Sci* 22:241–248, 2014.
88. Kaban LB, Troulis MJ: Dentoalveolar surgery. In *Pediatric oral and maxillofacial surgery*, Philadelphia, 2004, Saunders.
89. Heller J, Gabbay J, O'Hara C, et al.: Improved ankyloglossia correction with four-flap Z-frenuloplasty, *Ann Plast Surg* 54: 623–628, 2005.
90. Choi Y-S, Lim J-S, Han K-T, et al.: Ankyloglossia correction: Z-plasty combined with genioglossus myotomy, *J Craniofac Surg* 22:2238–2240, 2011.
91. American Academy of Pediatric Dentistry Web site: Guideline on behavior guidance for the pediatric dental patient. Available at www.aapd.org/media/Policies_Guidelines/G_BehavGuide.pdf Accessed Apr 14, 2015.

21

Basic and Complex Exodontia and Surgical Management of Impacted Teeth

GREGORY M. NESS, KATHARINE C. POWERS

Introduction

Despite advances in dental restorative techniques, simple extractions remain common, and the need to remove impacted teeth has remained a fixture in the repertoire of oral and maxillofacial surgeons. Extensive training, skill, and experience are necessary to perform extraction of an impacted tooth with minimal trauma. Inexperience of the surgeon leads to a significant rise in complications. Furthermore, tooth replacement is the gold standard of restorative dentistry, requiring the surgeon to manage and to maintain the site of extraction for use, rather than abandonment, in future treatment. Determining whether a tooth is non-restorable can be particularly problematic, as certain scenarios are determined by available scientific data and parameters, while others call on the surgeon's clinical experience and professional judgment. Even so, contemporary medical and dental practices demand evidence-based decision making, where the surgeon is called on more and more frequently to justify surgical procedures, including the removal of third molars.

Removal of Erupted Teeth

Indications for Exodontia

Caries

Dental decay is one of the most common diagnoses leading to dental extraction. Clinical and radiographic detection of caries is fundamental to dentistry, but decision making regarding restoration or extraction of a tooth is often challenging and may be influenced by a variety of factors extrinsic to the tooth itself. These include the location and position of the tooth, the health and number of adjacent teeth, the systemic health of the patient, other local or regional diseases or planned operations, and the relative financial and social costs of treatment alternatives. Clear communication among patient, surgeon, and restorative dentist is vitally important to forming a mutually satisfying treatment plan.

Periodontal Disease

Adult periodontitis remains a highly prevalent dental disease despite its almost completely preventable nature. Like dental caries, the presence of periodontitis is sometimes more easily and objectively determined than the prognosis of the tooth. However, extraction is indicated for teeth with a poor survival prognosis, those that have failed appropriate periodontal therapy, or where the other extrinsic factors noted earlier for caries become significant.

Orthodontic Purposes

Although orthodontists strive to attain ideal arch coordination without sacrificing adult teeth, in some cases of severe crowding or jaw size discrepancy it is useful to remove overcrowded teeth to allow alignment of the dentition within the available arch length. Typically first or second premolars are removed, but other teeth may also be considered according to individual circumstances and the orthodontic, and perhaps prosthodontic, treatment plan.

Other Indications

Teeth that are otherwise individually healthy or restorable may be removed for a variety of less common purposes. These include non-carious dental fracture, association with an adjacent pathologic or traumatic condition, interference with planned prosthodontic care, or risk of harm to the patient from future pathology. The last indication may be

particularly important in a patient who will undergo head and neck radiation, high-dose chemotherapy, or high-dose antiresorptive or antiangiogenic therapy.

Diagnosis and Treatment Planning

Global medical assessment and selection of appropriate anesthetic techniques are addressed in detail elsewhere in this text, and this knowledge and skill is essential to proper planning and execution of all dentoalveolar surgery. A thorough clinical examination of the head, neck, and oral cavity, as well as appropriate radiographs, is also essential to the surgical planning for dental extractions.

Clinical examination must include assessing access to the surgical area, which may be hampered by limited mouth opening, a small oral aperture, or soft tissue interferences from large or hyperactive cheeks or tongues. The overall dental and periodontal health should be evaluated, with special attention to any conditions adjacent to the surgical site that might add complexity or increase the risk of complications. These include large or overhanging adjacent restorations, interproximal decay in neighboring crowns, preexisting periodontal conditions, or other findings that would predispose adjacent teeth to damage during extraction. The periodontal status of nearby teeth should also be determined, as removing the most diseased tooth in the area may "unmask" a previously asymptomatic or unrecognized problem, even if it was preexisting. Patients must be informed of these risks before, not after, treatment. The presence of unusually dense bone, tori, or exostoses should be noted, as these all increase the difficulty of the planned extraction.

Radiographs must be of acceptable diagnostic quality and include the entire tooth to be removed as well as the immediate vicinity, especially any structures such as adjacent roots, the sinus floor or mandibular neurovascular canal, and so on. Periapical radiographs are often adequate, although a panoramic radiograph will allow better examination of a wider zone around the teeth. Although there is not yet a broadly accepted standard of care regarding the use of cone-beam imaging, the expanding availability of this very useful in-office imaging technique will only increase its role in diagnosing unusual or complex clinical situations, such as complex impactions, multiple superimposed teeth and roots, or a tooth's suspected proximity to vital structures. Teeth to be removed should be assessed for indicators of difficulty, such as absence of a defined periodontal ligament space or unusual bony density, missing or severely decayed crown to the level of supporting bone, large or dilacerated roots, ankylosis or external root resorption, or other complicating findings.

Principles of Simple Extraction

Simple extraction is accomplished by applying a controlled and focused force to the tooth. The steps of tooth removal are based on simple principles of mechanics and are easily understood, but the keen tactile sense that defines an excellent surgeon is developed only with time and experience. Successful extractions also depend on the surgeon's thorough and detailed understanding of the anatomy of the teeth involved, including the root form and angulation, their attachment to the periodontal apparatus, and the associated bone morphology and characteristics.

The extraction process begins with loosening the supracrestal soft tissue attachments as necessary, followed by minor alveolar bone expansion with elevator and/or forceps, separation of the periodontal ligament, and finally coronal delivery of the tooth.

Patient Positioning

In most cases, the patient position will be determined by the arch from which the tooth or teeth will be removed. When extractions are being performed in the lower arch, the patient is positioned so the mandible is parallel to the floor. When extracting a maxillary tooth, the patient should be reclined so the maxillary occlusal plane is 45 to 60 degrees to the plane of the floor. In both cases, the height of the chair should be adjusted so the surgeon's elbows remain comfortably relaxed, without tensing the shoulders to reach into the mouth with extraction instruments. The surgeon's position relative to the patient also varies, depending on which tooth is being extracted and on the surgeon's dominant hand (Figure 21-1).

During extraction, the surgeon's free hand may, if possible, hold the alveolar process in a "pinch grasp" with the thumb on one side and the forefinger on the other side. This allows direct palpation of any movement or bony expansion within the alveolus, helps to retract adjacent soft tissues, and provides a gauge of the degree and direction of force being applied to the tooth and the alveolar process.

Initial Elevation

In most cases, the extraction begins with separation of the soft tissue attachment around the neck of the tooth, usually with a No. 9 Moldt periosteal elevator or a No. 1 Woodson elevator. This maneuver also serves to verify soft tissue anesthesia at the site. Next, a narrow straight dental elevator is used to begin moving the tooth. This instrument may be inserted into the mesial interproximal space, perpendicular to the tooth being removed, and then rotated so the more coronal edge of its concave surface pushes the tooth distally, levering against the interproximal crestal bone, not the adjacent tooth. Alternatively, the instrument may be inserted vertically along the mesiobuccal line angle of the root and used as a wedge to disrupt the periodontal ligament and expand the tooth socket (Figure 21-2). In some periodontally diseased and mobile teeth, or in areas with thin or low-density alveolar bone, this technique is sufficient to elevate the tooth from its socket and deliver it into the mouth for retrieval. In other cases, the narrow elevator may be followed with a broad elevator to further mobilize the tooth and expand the alveolar bone.

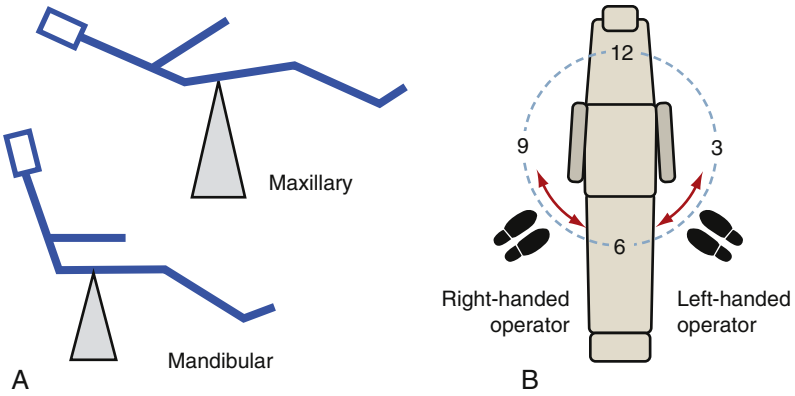

• **Figure 21-1** **A,** Controlled force is delivered most effectively when a low, upright chair position is used for the extraction of mandibular teeth. A higher, more reclined chair position is used for the extraction of maxillary teeth. **B,** Most extraction instruments are designed to be used from the right (or left) front chair location with the surgeon standing. (From Pedersen GW: Uncomplicated extraction. In Pedersen, GW: *Oral surgery*, Philadelphia, 1988, WB Saunders.)

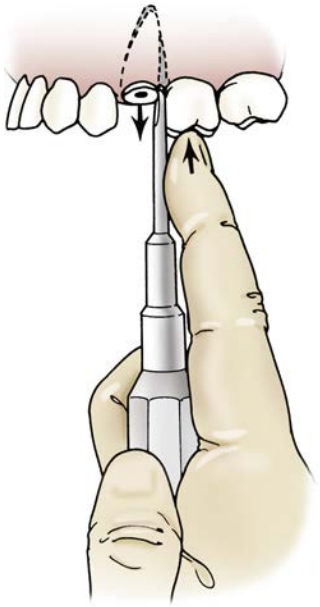

• **Figure 21-2** The elevator is forcing the root upward and outward as its blade is being forced apically into the periodontal ligament space. As the surgeon's experience increases, such forces can be used to direct the tooth's delivery. Note that the index finger is extended and can be used to control the forces required to remove the root. (Modified from Peterson LJ, editor: *Contemporary oral and maxillofacial surgery*, ed 3, St Louis, 1998, Mosby.)

Forceps Luxation

Dental extraction forceps are designed to engage the root surface of a tooth just below the cementoenamel junction and apply highly concentrated but controlled force to a very small area, with minimal movement. A wide variety of forceps are manufactured, with beaks shaped to fit well on specific teeth. However, most extractions may be accomplished with use of "universal" upper and lower forceps (No. 150 and No. 151, respectively), or with one of a limited selection of more specialized instruments. Choosing the right forceps is important to securely grasping the cervical portion of the tooth and eliminating movement of the forceps against the tooth. It is useful to think of seating the forceps as its own separate step in the process, as engaging the tooth effectively is necessary to transmit the luxating force directly to the tooth. The beaks should be pushed as far apically as possible, which shifts the tooth's axis of rotation apically as well. This allows the most effective alveolar bone expansion and reduces the risk of fracture at the root apex. Sharp elevators and forceps are desirable because they engage the tooth in a more firm and predictable manner and reduce slippage.

When extracting maxillary anterior lateral and central incisors and/or mandibular anterior teeth, the predominant extraction force is mainly rotational (Figure 21-3). For the maxilla, a universal No. 150 forceps or a straight-handled No. 1 forceps work well. In the mandible, a universal No. 151 or an Ash forceps, whose beaks are hinged 90 degrees compared to other American-style forceps, may be used.

The roots of maxillary canines and the lower anterior teeth, however, have oval cross-sections and are thinner in the mesiodistal dimension, and they require more buccal-palatal or labial-lingual luxation. The maxillary premolars often have root tips that are thin and easily fractured if early luxation is too vigorous. A maxillary universal forceps is typically used for these teeth to be extracted. Careful buccal-palatal movement, allowing time for the bone to expand under firm pressure, is repeated until the alveolar bone is expanded, the tooth is mobile, and the periodontal attachment loosened (Figure 21-4).

A similar technique is used for the maxillary molars, taking care to avoid excessive force which could fracture the buccal plate. A variety of specialized maxillary forceps have been designed with beaks that engage the buccal furcation and fit the larger palatal root securely (Figure 21-5).

Lower molar extraction is made difficult by the thick, dense alveolar bone anchoring the teeth, which often strongly resists efforts to expand it. A lower universal forceps (No. 151) is often used, but a No. 23 cowhorn forceps is frequently a useful choice as well. Unlike other forceps, the No. 23 has pointed beaks curving toward one another that are designed to seat in the buccal and lingual furcations of a lower molar. Once the beaks are seated, squeezing the forceps handles wedges the beaks into the

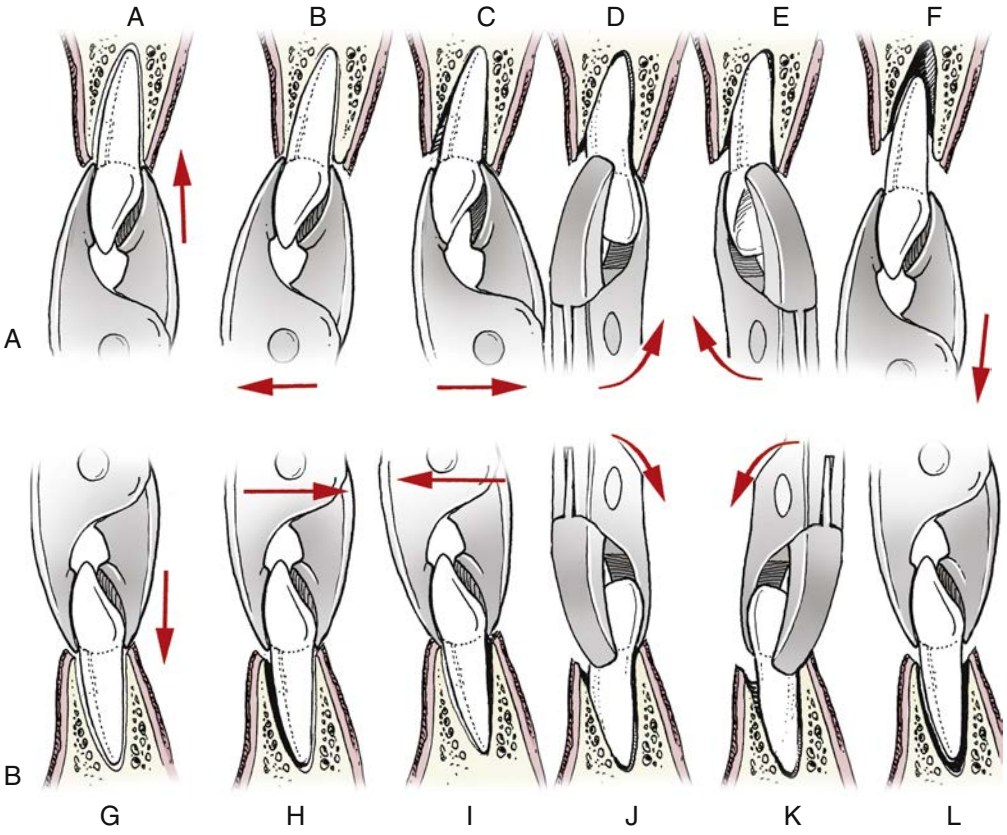

• **Figure 21-3** **A,** Rotation is performed with a No. 1 forceps or a No. 150 (maxillary universal) forceps. The forceps is seated against the tooth (*A*) and then forced apically. Continued apical pressure is applied, and buccal luxation begins (*B*), followed by palatal luxation. Once some mobility is noted, the conical root of the anterior maxillary teeth allows rotational forces to be used. The tooth is rotated distally (*C*) and then mesially (*D*). The process is repeated until the tooth can be delivered from its socket (*E* and *F*). This technique can be used for the maxillary lateral incisor and the canine. However, the canine often requires greater force and effort to remove it from its socket. **B,** The ideal forceps for the removal of the mandibular premolar is the English/Ash forceps or the No. 151 (mandibular universal) forceps. All anterior mandibular teeth can be extracted similarly with this technique. The forceps are placed and seated apically (*G*), and then light luxation is used to push the tooth lingually *(H)*, followed closely by buccal movements (*I*). Rotational movements *(J,K)* can be used because the roots are frequently single and conical in nature. Traction *(L)* should be minimal.

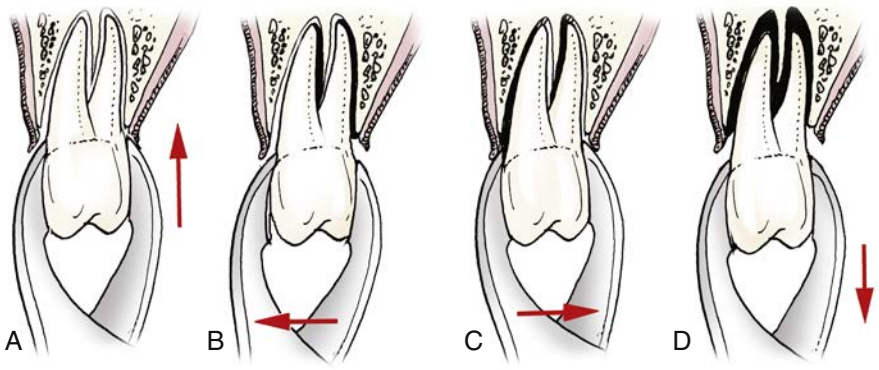

• **Figure 21-4** The maxillary premolar has two thin and slender roots of variable length. These can be easily fractured if careful technique is not used. Initially, the forceps is seated and pushed apically **(A).** Then the tooth is luxated buccally **(B),** and palatally **(C).** This is repeated in a careful and deliberate fashion. Occasionally, cautious figure-eight movements can be used until the tooth is removed from its socket **(D)** with minimal, gentle traction.

furcation and displaces the tooth coronally (Figure 21-6). Often the tooth elevates intact, but the cowhorn forceps may also divide the tooth into mesial and distal halves, which are usually mobile and less difficult to engage and remove separately.

Tooth Delivery and Socket Care

Once a tooth has been luxated to the point of separating the periodontal ligament attachment, it is generally delivered from the socket by gentle traction or luxation toward the

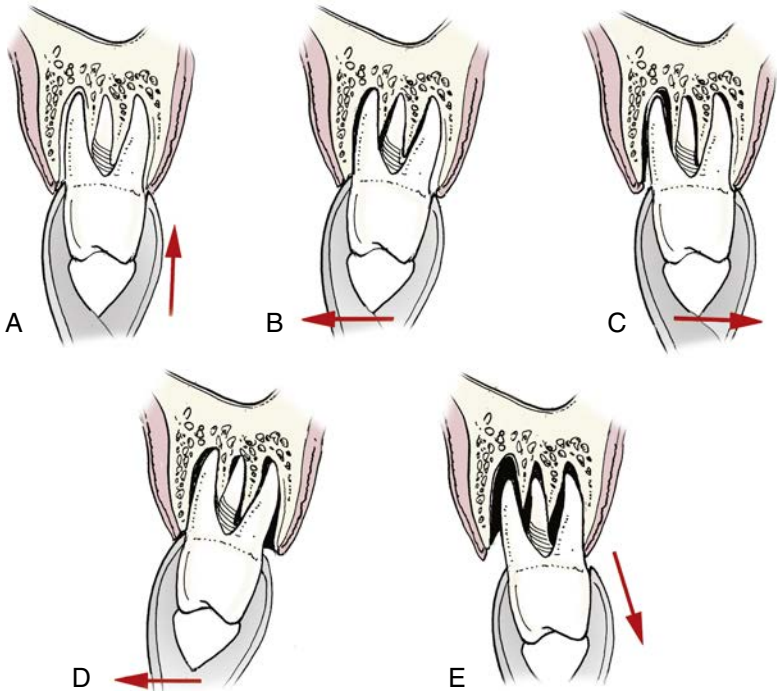

• **Figure 21-5** The maxillary molars are commonly removed with a No. 150 (maxillary universal), No. 210s, No. 53, or No. 88 L/R forceps. Their three-rooted nature can complicate a relatively simple-looking extraction with divergent or curved roots. The initial step is to seat the forceps and apply apical forces **(A)** and then to apply slow and deliberate forces in the buccal and palatal directions, allowing for initial expansion of the alveolus (**B** and **C**). Because the maxillary bone is less compact, large initial forces can result in buccal plate fractures and occasionally tuberosity fractures. Increasing forces and movements follow **(D),** until the tooth is then carefully delivered out of the mouth buccally **(E).** If the gingiva begins to tear, stop the extraction so that the likely buccal plate fracture causing it can be dissected free of the gingiva.

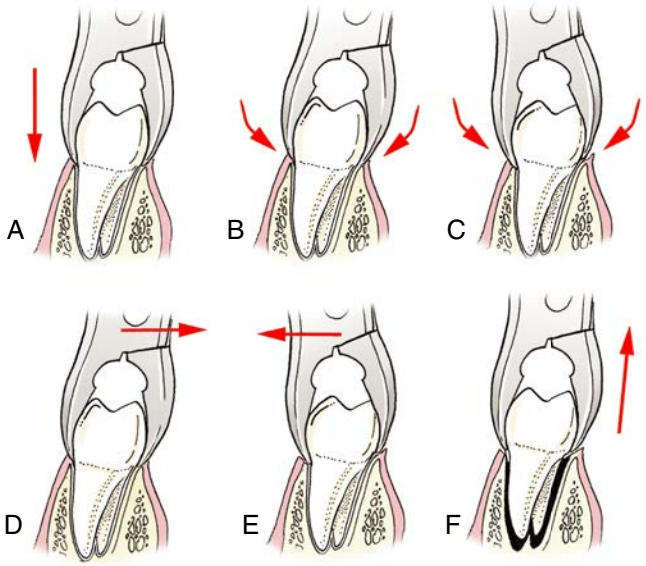

• **Figure 21-6** Mandibular molars are commonly removed with No. 151 (universal) or No. 23 (cowhorn) forceps. Once the forceps is seated **(A),** heavy apical pressure is applied. If a cowhorn forceps is being used, the tips of the beaks should be firmly seated into the furca of the tooth by squeezing the handles of the instrument and gently rocking the beaks into position (**B** and **C**). Once the beaks are tightly seated around the crown, heavy luxation of the tooth occurs in a buccal and lingual direction (**D** and **E**). When the tooth is adequately mobile, a rotating or figure-eight motion can be used to extract it from its socket **(F).**

path of least resistance at the thinner cortical plate of alveolar bone. In most cases this is toward the buccal, but lower second and third molars may be delivered lingually.

Older descriptions of dental extraction emphasize the need to compress the alveolar socket, but this step is actually counterproductive in the era of dental implants where preservation of maximal alveolar width is often essential. It is important, however, to carefully palpate the bony margins of the socket and ensure that no loose bone fragments or sharp, splayed bone margins are present. These must be removed or smoothed to prevent lingering pain and impaired healing. The socket should be curetted free of granulation tissue or periapical pathology, if present, and irrigated free of any debris or calculus. As soon as this is done, coagulation within the socket should be encouraged, as this is the first step toward uncomplicated healing.

Principles of Surgical Extraction

Not all erupted teeth will be removable by simple technique. Often, indicators of potential difficulty are present and detected on examination before the procedure, and surgical removal can be planned. Common indications for surgical extractions are listed in Box 21-1. However, even experienced exodontists are sometimes surprised by a seemingly easy extraction that turns complicated. In other cases, a tooth might be removable with forceps luxation and delivery, but at the cost of losing alveolar

• BOX 21-1 Indications for Surgical Extraction

- Retained roots with minimal radiographic periodontal ligament space
- Severely carious teeth that will fracture with forceps extraction
- Endodontically treated teeth
- Teeth with internal or external resorption
- Teeth with multiple, widely divergent roots
- Teeth with dilacerated or greatly curved roots
- Ectopic or severely crowded teeth in positions where forceps cannot be used
- Teeth that are positioned close to vital anatomic structures
- Unerupted teeth other than third molars
- Hypercementosis
- Ankylosed teeth
- Multi-rooted teeth located in areas of the jaw where bone preservation is critical for implant placement
- Tooth that will be used for autotransplant

cortical bone essential for future implant support or ideal esthetics. In such cases, the prudent surgeon will electively use surgical extraction technique to minimize the bone loss required. Finally, surgical extraction may be indicated when several adjacent teeth will be removed simultaneously, increasing the likelihood that alveoloplasty will be required. Thus, familiarity with surgical technique is essential for the provider who wishes to perform any but the simplest of extractions. A proper diagnostic workup and careful surgical planning before starting an extraction procedure will usually save time, reduce complications, and improve outcomes for patient and surgeon.

Basic Concepts

Surgical extraction, like all other oral and maxillofacial surgery procedures, demands careful planning, adequate surgical access and visibility, hemorrhage control, meticulous handling of hard and soft tissues, maintenance of good blood supply to flaps, proper instrument mechanics, cleanliness, and painstaking repair of the surgical wound. By definition, surgical exodontia requires one or more of the following steps:

1. Elevation of a mucoperiosteal flap
2. Bone removal
3. Sectioning of the tooth

These steps are followed by debriding the wound, smoothing any rough or sharp bony margins, thorough irrigation, and soft tissue closure with sutures as needed.

Flap Design

In surgical exodontia, a full-thickness mucoperiosteal flap is used to expose the underlying tooth or root fragment and its surrounding alveolar bone. Careful consideration must be given to the position of the incisions and to the type and shape of the flap. The following are principles for flap design for surgical extractions:

- Incisions should be placed over bone not planned for removal
- The incision should allow for a flap that will give sufficient exposure and permit retraction without tension or risk of tearing

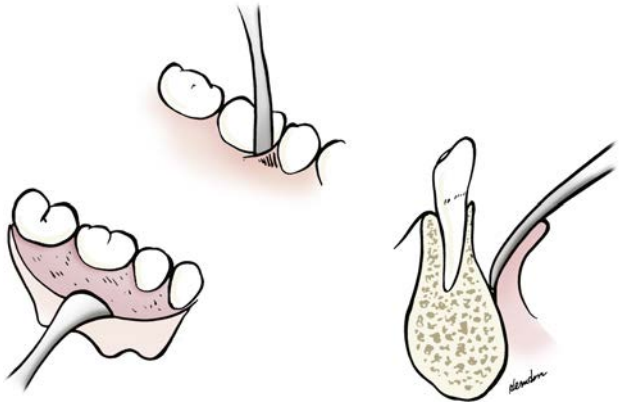

• **Figure 21-7** The envelope flap made with a periosteal elevator. (From Costich ER, White RP: *Fundamentals of oral surgery*, Philadelphia, 1971, WB Saunders.)

- The base of the flap should be wider than the reflected free margin
- Incisions must avoid vital structures such as the mental foramen or lingual nerve

Three basic designs are commonly used: the envelope flap, the triangle flap, and the trapezoidal flap.

Most surgical extraction can be accomplished well using an envelope flap. A sulcular incision is made with a No. 15 blade around the necks of the teeth, including the interdental papillae. Typically, the incision extends to include one tooth mesial to the extraction site to two teeth distal. The flap is elevated from the sulcular incision deep to the periosteum, which is reflected away to expose the alveolar bone buccal to the extraction site (Figure 21-7). If the exposure is not adequate or the flap is under excessive tension, a releasing incision may be added at the mesial end of the flap, converting it to a triangle flap (Figure 21-8, *A* and *B*). The release should be angled mesially away from the alveolar crest, making the flap's base wider than the free margin. Care must be taken to avoid the mental nerve when working in the mandible.

When additional working access is necessary, particularly in the molar area, a second vertical incision angled distally may be added, converting the triangular flap into a trapezoidal flap (Figure 21-9).

Bone Removal

In some cases, surgically exposing the crestal bone and the remaining tooth structure provides all the access needed to elevate the tooth without further bone removal. More often, some amount of alveolar bone must be removed to expose the underlying tooth and provide purchase for its removal. This is usually done with a dental burr in a surgical drill under constant irrigation (Figure 21-10, *A*). If the cortical bone is thin, a rongeur may be used.

As little bone as is necessary should be removed. In general, buccal bone removal should be done to expose roughly a third of the remaining root length. In most cases this amount of exposure will allow adequate purchase of an instrument on the exposed root structure (see Figure 21-10, *B*). In cases with unusually dense surrounding bone

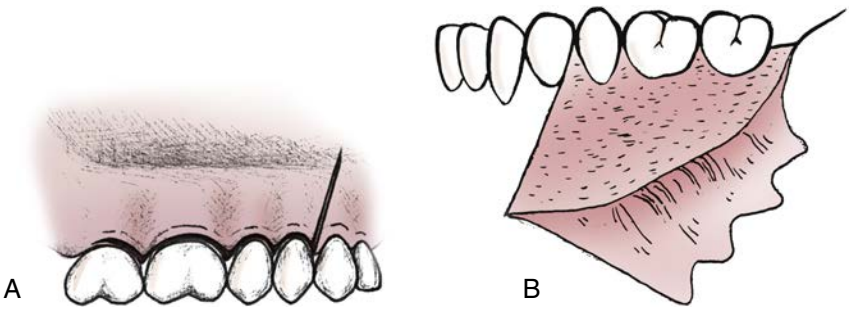

• **Figure 21-8** **A,** A sulcular incision with a vertical release. The release is angled to provide a wide base for the flap and meets the sulcular incision without including the interdental papilla. **B,** A mucoperiosteal flap with an anteriorly based releasing incision. (**A** adapted from Dym H, Ogle OE: *Atlas of minor oral surgery*, Philadelphia, 2001, WB Saunders. **B** adapted from Costich ER, White RP: *Fundamentals of oral surgery*, Philadelphia, 1971, WB Saunders.)

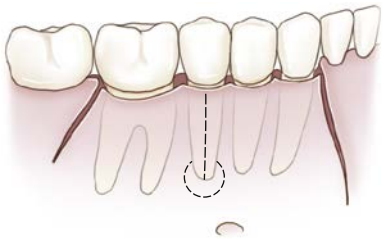

• **Figure 21-9** A sulcular incision in the posterior mandible with vertical releases anteriorly and posteriorly. The vertical release in the anterior should be at the canine or lateral incisor area to prevent injury to the mental nerve.

or heavily decayed, soft root structure, additional bone removal is often necessary. If adjacent teeth will not be threatened, bone can also be removed within the alveolus along the interproximal periodontal ligament space to allow the introduction of a narrow elevator.

Sectioning and Removal of Multi-Rooted Teeth

When removing multi-rooted teeth, the surgeon may gain considerable advantage by dividing the tooth so that each root may be removed separately. While unnecessary as a routine step, this is commonly necessary in cases with unusually dense alveolar bone, divergent or curved dental roots, when care must be taken to preserve the maximum alveolar bone, or where excessive force applied to remove the tooth intact would risk damage to adjacent teeth or structures.

Lower molars may be divided into mesial and distal halves (Figure 21-11) which are then removed with straight or Cryer elevators (Figure 21-12) or, if the crown is largely intact, with extraction forceps (Figure 21-13, *A* and *B*). Similarly, maxillary molars may be divided with a handpiece so the buccal and palatal roots are separated (Figure 21-14). The buccal roots are usually removed first (Figure 21-15), improving access to the larger buccal root, which is frequently angled palatally and delivered into the space vacated by the buccal roots.

Once the roots have been delivered, the socket is managed as described earlier for simple extraction. The socket and the space beneath the soft tissue flap must both be thoroughly irrigated to remove any debris, and the soft tissue is repositioned and sutured into place. Unless necessary for unusual circumstances such as impending radiation or chemotherapy, it is not necessary to achieve primary closure over the extraction socket, which would otherwise require additional alveoloplasty.

Complications of Erupted Tooth Removal

Bleeding

A minimal amount of postsurgical bleeding is normal and expected following dental extractions. Initial management with pressure using moist gauze should stop bleeding within several minutes. Patients should be instructed in how to properly replace the gauze and apply firm biting pressure as needed for any early recurrent bleeding. However, bleeding that persists, is not stopped by properly applied simple pressure, or recurs beyond the first 24 to 48 hours is not normal. Management of this complication requires clinical examination to determine if an identifiable and treatable local source exists, treatment with local hemostatic measures, and investigation for any contributing systemic coagulopathy.

Pain

Simple extractions generally result in mild pain for 1 or 2 days, which is well managed by over-the-counter pain medications and gentle but complete oral hygiene. Multiple extractions or surgical extractions involving soft tissue reflection, bone removal, or prolonged effort to retrieve roots may result in moderate pain lasting several days. Nonsteroidal anti-inflammatory drugs, elevation, ice, and rest are all useful means of controlling pain in the proper setting. Combination narcotic analgesics remain important and useful pain control adjuncts even in the current climate of concern over diversion and abuse of prescribed controlled substances. Pain control should never be a rote regimen but must be individualized for each patient, considering the patient's medical history, lifestyle and activity demands, and past responses to analgesics, in addition to the expected consequence of the surgery. Pain lasting more than a few days often indicates a healing complication, so a new assessment of the patient is necessary before re-prescribing medications.

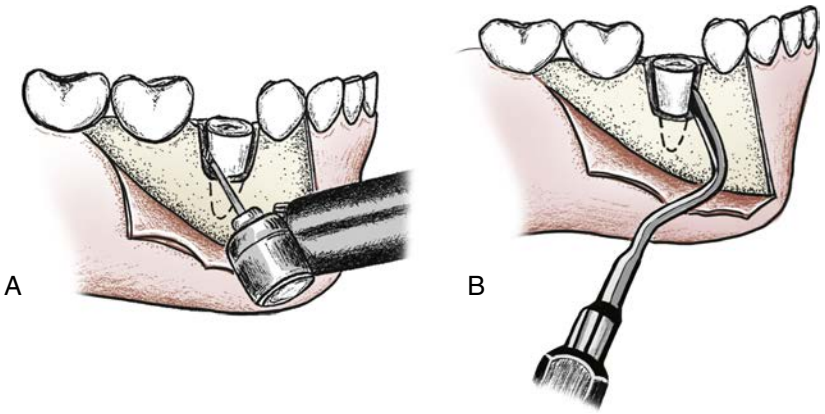

• **Figure 21-10** **A,** Teeth often fracture during extraction, leaving root fragments in alveolar bone. Adequate access must first be established by either an envelope or three-cornered triangle flap. Buccal plate is removed with a burr to expose root fragment. Space should be made to allow introduction of narrow elevator. **B,** Root is removed with elevator wedged between root and alveolar bone. Controlled luxation is performed to prevent root displacement and soft tissue injury. (From Dym H, Ogle OE: *Atlas of minor oral surgery*, Philadelphia, 2001, WB Saunders.)

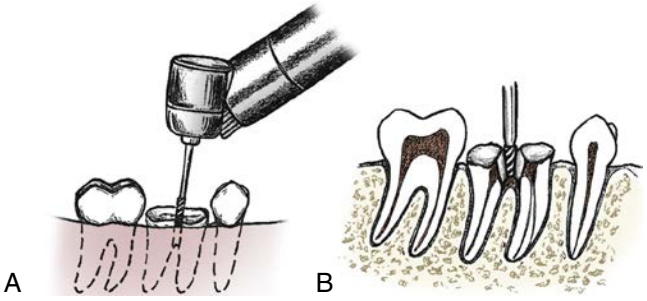

• **Figure 21-11** Division of a mandibular molar **(A),** resulting in two single-rooted segments **(B).** (From Dym H, Ogle OE: *Atlas of minor oral surgery*, Philadelphia, 2001, WB Saunders.)

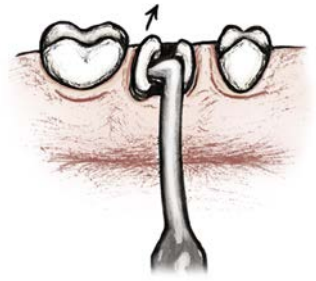

• **Figure 21-12** After one root of molar roots has been removed, the Cryer elevator is placed into the empty socket and turned with sharp point engaging interseptal bone and root to elevate remaining root. (From Dym H, Ogle OE: *Atlas of minor oral surgery*, Philadelphia, 2001, WB Saunders.)

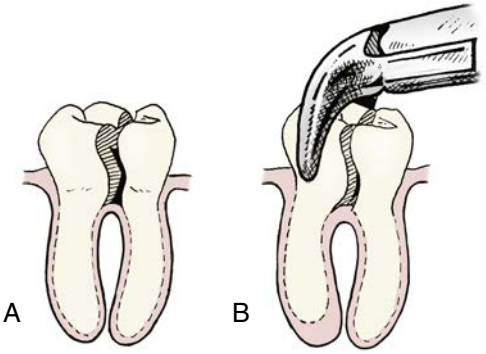

• **Figure 21-13** A mandibular molar with intact crown is sectioned into mesial and distal halves **(A),** allowing forceps removal of the segments **(B).** (From Archer WH, editor: *Oral and maxillofacial* surgery, vol 1, ed 5, Philadelphia, 1975, WB Saunders.)

Swelling

Removal of erupted teeth usually causes little or no extraoral swelling. When soft tissue flaps are elevated, swelling is generally localized to the adjacent gingiva and alveolus, mild, and self-limited. Removal of multiple or impacted teeth is more commonly associated with moderate extraoral swelling, which is minimized by head elevation, ice for the first 24 hours, administration of glucocorticoids perioperatively, and minimizing soft tissue dissection and trauma. When patients report this symptom in other settings, they should be reexamined for other complications such as infection.

Damage to Other Structures

It is an inescapable reality that removing a tooth leaves behind a defect, and that the defect may extend into adjacent alveolar bone and expose or damage adjacent tooth roots, the maxillary sinus, or the inferior alveolar nerve. The physical access required to deliver a tooth may jeopardize adjacent teeth, especially when they have large or overhanging restorations or fragile tooth structure undermined by caries.

These risks are almost always predictable, and the surgeon is wise to discuss them with the patient, as well as their potential short- and long-term consequences, before they might occur. Finally, tooth removal requires force, but if that force is not well controlled, instruments may collide with and damage teeth or soft tissues away from the extraction site. Care must be taken to minimize the risk of such an injury, which is usually the result of improper technique or instrument misuse.

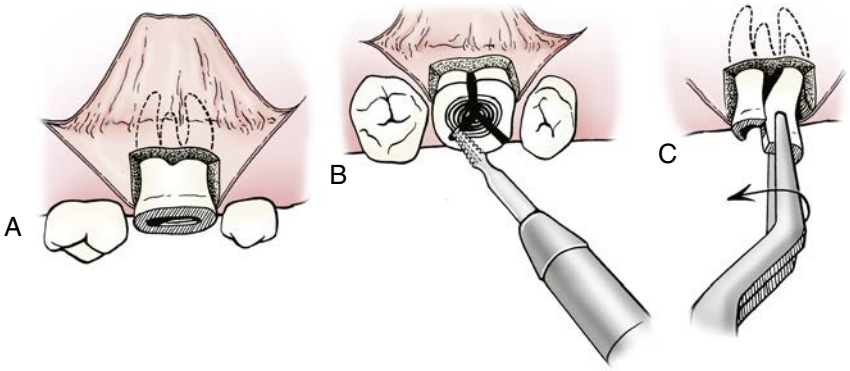

• **Figure 21-14** The maxillary molar is sectioned in a "Y" fashion to allow for removal of each root individually (**A-C**). (From Archer WH, editor: *Oral and maxillofacial surgery*, vol 1, ed 5, 1975, Philadelphia, WB Saunders.)

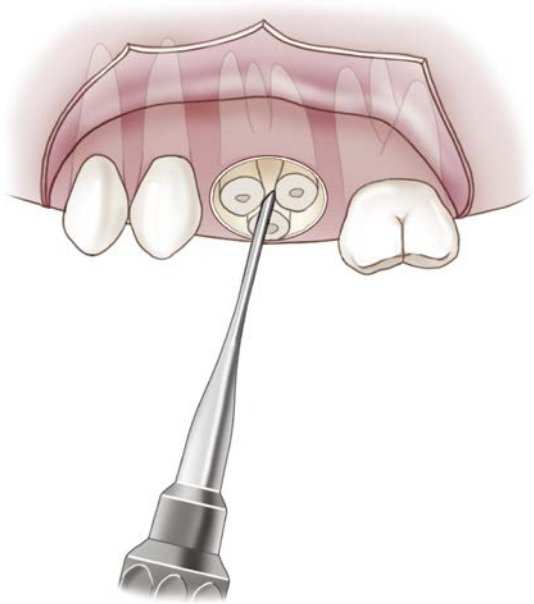

• **Figure 21-15** Buccal roots are separated and delivered with a straight elevator.

Dry Socket

Dry socket, or alveolar osteitis, results from premature loss of the blood clot within the socket, leaving a painful, malodorous, slow-healing defect with exposed alveolar bone within. The phenomenon is described more fully in the following section on impacted teeth, but it may occur with any extraction. Typically arising on the third or fourth day after surgery, it is best managed with one of many available dressing ointments to keep the area clean and less painful while awaiting initial healing, which may take 2 weeks or more. Smoking is a strong risk factor. Avoiding nicotine and providing good, gentle postoperative care to the extraction site are important steps the patient can take to minimize occurrence of this complication.

Infection

Postsurgical infection is exceedingly rare following routine dental extractions, even in the setting of periapical periodontitis or acute bacterial pulpitis. Patients should be advised to return if they are not experiencing resolution of pain or worsening of swelling in the area within a few days. Management of serious odontogenic infections is covered elsewhere in this text.

Impacted Teeth

Not all unerupted teeth are impacted. Impaction occurs when the expected development and timetable for eruption have passed and no reasonable expectation for eventual eruption can be achieved. Beyond radiographic interpretation and clinical experience, the surgeon must have intimate knowledge pertaining to development and eruption patterns of teeth in order to correctly diagnose impaction.

Any tooth in the mouth may be impacted, but third molars are the most commonly impacted teeth, followed by maxillary canines and mandibular premolars. This reflects the normal eruption sequence, with those teeth erupting last the most likely to have insufficient arch space available for eruption.

Indications for Impaction Removal

Just as not all unerupted teeth are impacted, not all impacted teeth require surgical intervention. The National Institutes of Health (NIH) last addressed guidelines for removal of third molars in 1979, noting that patients with impacted teeth who wait until symptoms occur before seeking removal have greater morbidity associated with their surgery. The least morbidity was also associated with third molar removal removed between the ages of 15 and 25 or when the roots are only two thirds formed, based on the roots being straight and not curved, bone being softer and more pliant, the inferior alveolar nerve being further away from the root apices, and more rapid potential healing. Clearly, early intervention in the surgical removal of impacted third molars will benefit most patients. More recently, the Third Molar Clinical Trials conducted a large scale, multicenter study supported by the American Association of Oral and Maxillofacial Surgery (AAOMS) and the Oral and Maxillofacial Surgery Foundation. A plethora of papers derived from this and related studies has been summarized in an AAOMS White Paper

updating recommendations regarding removal of third molars.[1] The following indications must be considered by the dentist and surgeon to determine the need for removal of impacted teeth.

Caries

Non-restorable decay is the leading cause of tooth extraction in general, and it remains an important indication for impacted third molars exposed to the oral cavity. In the mandibular third molar, the most common location of dental caries is at the cervical line, due to its inaccessibility to both the patient and the dentist in terms of adequately cleaning and restoring the decay. Approximately 15% of impacted mandibular third molars are extracted as a direct result of the presence of caries.[2]

Periodontal Disease

Periodontal disease in the third molar region is also directly related to the difficulty in keeping that area clean and free of plaque and bacteria, leading to attachment loss, pocket formation, pathogen formation, and inflammatory response at the distal of the second and third molars.[3-5] This accounts for 5% of impacted third molar removal.[6-10] In addition, the connection between third molars and periodontal disease has been well documented.[11]

Pericoronitis

Pericoronitis occurs when a third molar partially erupts through the oral mucosa, becoming a potential bacterial trap causing a mild to moderate, and in some rare cases severe, inflammatory response. This most commonly occurs in mandibular third molars, especially those with soft or hard tissue overlying the posterior aspect of the crown.[12] The inflammation can be caused by food debris that is often trapped under the soft tissue flap overlying the impacted wisdom tooth and cannot be effectively cleansed. As a result, bacteria, most commonly *Peptostreptococcus*, *Fusobacterium*, and *Bacteroides (Porphyromonas)*, can invade the site and initiate the infectious process.[13-15] Occlusal trauma from the opposing maxillary third molar can also damage the overlying soft tissue of the mandibular third molar, resulting in operculitis. Left untreated, pericoronitis can lead to mild infection or a severe fulminating infection that requires hospitalization and an aggressive surgical course of treatment.

Treatment of pericoronitis involves extraction of the offending tooth or opposing maxillary third molar, debridement of the periodontal pocket, and disinfection with an irrigation solution such as chlorhexidine or hydrogen peroxide. Only in severe cases is antibiotic therapy warranted. The primary prevention of pericoronitis is extraction of third molars that are at high risk of developing inflammation. Operculectomy has previously been recommended as a prevention tool; however, soft tissue regrowth is a frequent occurrence due to the available space between the anterior border of the ramus and the space and angulation of the erupting crown, making this an incomplete prevention technique.

Extraction of mandibular third molars due to pericoronitis accounts for 25% to 30% of overall extractions of impacted teeth.[6-10] One study found the incidence of pericoronitis in third molars to be as high as 43% in 1 year.[16] The incidence of pericoronitis increases with age, becoming a more prominent indication for removal of the offending tooth. Most significantly, pericoronitis is the main cause of impacted third molar extraction after the age of 20 years.

Cysts or Tumors

The most significant pathology that is related to impacted third molars is the dentigerous cyst. These occur when the follicular sac that is responsible for formation of the developing crown undergoes cystic degeneration within the mandibular bone. In rare cases, odontogenic tumors arise at the impacted tooth, very rarely with malignant transformation potential.[17] The general incidence of neoplastic change in impacted third molars has been reported to be around 3%.[18,19] However, other large retrospective studies have found that only 1% to 2% of all third molar extractions are due to the presence of odontogenic cysts or tumors.[6-10] It has also been postulated that the risk of neoplastic change around third molars decreases with age, as most associated pathologies are found in patients younger than 40 years of age.

Orthodontic Needs

For impacted teeth other than third molars, orthodontic considerations strongly influence whether the tooth might be extracted or exposed so that it can be moved into a functional position within the dental arch. Orthodontic consultation and collaborative treatment are essential in such cases. The decision to expose or remove a tooth is usually jointly made by the surgeon, orthodontist, and restoring dentist. Available or anticipated space, angulation, and age of the patient are all considerations.

Regarding impacted third molars, longitudinal reviews with large subject populations have provided solid evidence that they are not a significant cause of post-orthodontic anterior crowding.[20,21] However, an impacted third molar may obstruct orthodontic treatment, especially when the orthodontist attempts to move molars distally. If orthognathic surgery is planned, the mandibular third molar may interfere with the surgery. When the third molars are not removed before a mandibular osteotomy or advancement, the thickness and quality of the lingual bone at the proximal aspect of the distal segment, where internal fixation is applied, is reduced in quality. The surgeon must plan well in advance of these procedures, as it is best to remove the third molar and allow sufficient time for the extraction site to heal with mature bone before proceeding.

Other Indications

Resorption of Adjacent Roots

Just as permanent teeth resorb the roots of primary teeth during their normal eruption patterns, misaligned teeth and third molars have the ability to resorb the roots of adjacent teeth as well. Research has suggested that the occurrence of

significant root resorption affiliated with third molar causation is as high as 7%.[22] If root resorption is noted, the surgeon should remove the offending tooth as soon as possible; reparation of the resorbed root may occur with the deposition of a layer of cementum over the damaged area and the formation of secondary dentin. If the degree of root resorption is severe, however, removal of both the third molar and the affected tooth may be warranted.

Prosthetic Preparation

Retained impacted teeth may interfere with denture design, or they may become exposed as the overlying bone is resorbed, particularly if they have little or no overlying bone. The need to remove such impacted teeth must be carefully weighed against the expected morbidity of the procedure. Deeply impacted teeth without adjacent pathology and which are unlikely to become exposed may be safely retained and observed.

Pre-Radiation for Head and Neck Cancer

Radiotherapy has been linked to significant increases in xerostomia and soreness, which leads to increased incidence of decay and inflammation. The epithelium of the cells lining the mouth becomes prone to ulceration. It is important to adequately manage sites of decay or inflammation before beginning radiation treatment, most especially when the focus of the radiation will be on the head and neck. Impacted teeth are potential problems and, if there are no contraindications, are best removed before head and neck cancer treatments.[23]

Prevention of Jaw Fracture

An impacted third molar that is present along a fracture line presents an area of weakened resistance to fracture of the mandible.[24-26] It may be advisable that patients who play contact sports have their impacted third molars removed to prevent jaw fracture during competition. In addition, the presence of an impacted tooth invites a number of complications in the treatment of jaw fracture.

Pain of Unknown Origin

On rare occasions, patients may present complaining of pain whose origin cannot be confirmed on clinical or radiographic examination. Resolution of this pain can often be achieved by removal of the impacted tooth in question. Currently, no research provides an explanation as to the cause of this pain, but approximately 1% to 2% of mandibular third molars are extracted for this reason.[6-10] It is important that the surgeon ensure that all other potential sources of the unknown pain are ruled out before proceeding with extraction. It is also prudent to explain to the patient that removal of the tooth may not provide the sought-for relief.

Contraindications to Extraction of Impacted Teeth

Elective removal of impacted teeth, like all surgical procedures, should not be performed if the risks outweigh the expected benefits. Clearly, patients with significantly compromised and unstable medical conditions are not candidates for elective removal of impacted teeth showing no evidence of active pathology.

Age

It is the consensus of most surgeons that asymptomatic third molars in the adult population over the age of 50 years should not be removed routinely, especially if no inflammation or periodontal disease exists. As patients age, there is a decreased healing response,[27] which may result in greater bony defects postoperatively, as well as less toleration for the surgical procedure and longer recuperation periods. Bone also becomes more calcified with age, making the extraction more difficult and more likely to cause fracture. As a general rule, if a patient has a fully impacted third molar that is completely covered with bone, has no obvious potential source of communication with the oral cavity, and has no signs of pathology such as an enlarged follicular sac, and if the patient is over age 40, the tooth probably should not be removed. Long-term follow-up by the patient's dentist should be performed periodically, with radiographs performed every several years to ensure that no adverse sequelae are occurring. If signs of pathology develop, the tooth should be removed. If the overlying bone is very thin and a removable denture is to be placed over that tooth, the tooth should probably be removed before the final prosthesis is constructed.

It is also recommended that impacted teeth not be removed in the very young either. There have been reports of extraction of the tooth bud of third molars in patients as young as 8 or 9 years old,[28] but this may be imprudent, largely because of the inaccuracy of predictions as to whether a developing tooth will become impacted or erupt.

General Health

Another general contraindication to extraction of impacted teeth is a compromised medical status. As age increases, so does the incidence of cardiovascular disease, pulmonary disease, and a myriad of other complicating health problems. On the contrary, in younger patients with congenital coagulopathies, asthma, or epilepsy, it may be advisable to remove the tooth before the incipient diseases progress. The presence of compromising systemic disease requires close communication between the surgeon and the physician to determine the best course of action for the patient's overall health.

Risk to Adjacent Structures

The potential for surgical damage to adjacent structures, including nerves, teeth, and sinuses, sometimes makes it necessary to leave the impacted tooth in situ. This concern is commonly evident for the inferior alveolar nerve. If the impacted tooth is in close proximity to this nerve, leaving the tooth in place may be considered, if it is not symptomatic and is judged to present a low risk of future pathology. Similarly, surgical extractions that will result in significant bony defects, especially in older patients, may be

contraindicated if they pose a high risk of further deterioration of periodontal health or loss of adjacent teeth.

Impacted Third Molars

Third molars are the most frequently impacted teeth, followed by maxillary canines and mandibular premolars. Factors cited as causing this phenomenon include inadequate space in the dental arch for eruption, obstruction of the tooth eruption because of pathology (cyst, supernumerary tooth, or other tumors), or the angulation of the erupting tooth. In one study of 5000 army recruits, 10,979 impacted teeth were found, but only 212 were not third molars.[29]

Assessing Eruption Potential

The average age for third molar eruption is 20 years; however, the range of eruption age extends as late as 24 years. Although positioning of the third molar does not substantially change past the age of 25 years,[30] large studies suggest that movement is not completed until as late as the fourth decade of life.[31] It is important to remember that the position of the third molar in an 18-year-old will change; these impactions have as much as a 30% to 50% chance of fully erupting by the age of 25.[32-34]

The most important prognostic indicators for eruption are the angulation of the teeth and the space available within the dental arch.[35-38] Figure 21-16 illustrates the various angulations assumed by maxillary and mandibular third molars. Evaluated at age 18 to 20 years, mandibular third molars that are horizontal or significantly mesioangular are less likely to successfully erupt than those that are vertically oriented. Distoangular oriented teeth have a variable eruption success rate. Fortunately, the most common angulation, mesioangular, is also the least difficult to access and remove.

In terms of available space within the dental arch, a lower third molar is more likely to erupt if its crown is narrower than the horizontal radiographic space between the anterior mandibular ramus and the distal surface of the second molar. If this space is smaller than the third molar's crown, or if the molar is rotated away from the vertical, successful eruption of the third molar is unlikely.

Finally, delayed maturation of the third molar, with associated lagging of the dentition behind skeletal and mandible growth, has been shown to increase the incidence of impactions. Clinically, this manifests as third molars having a higher likelihood of impaction when the roots are partially developed, compared to a third molar with fully developed roots in a similar position at the same age.

Surgical Technique

Instrumentation

Box 21-2 lists the hand instruments necessary for third molar removal. In addition, a high-torque surgical handpiece with either a straight fissure burr or a round burr is used for bone removal and tooth sectioning. Irrigation with sterile saline and suction complete the armamentarium.

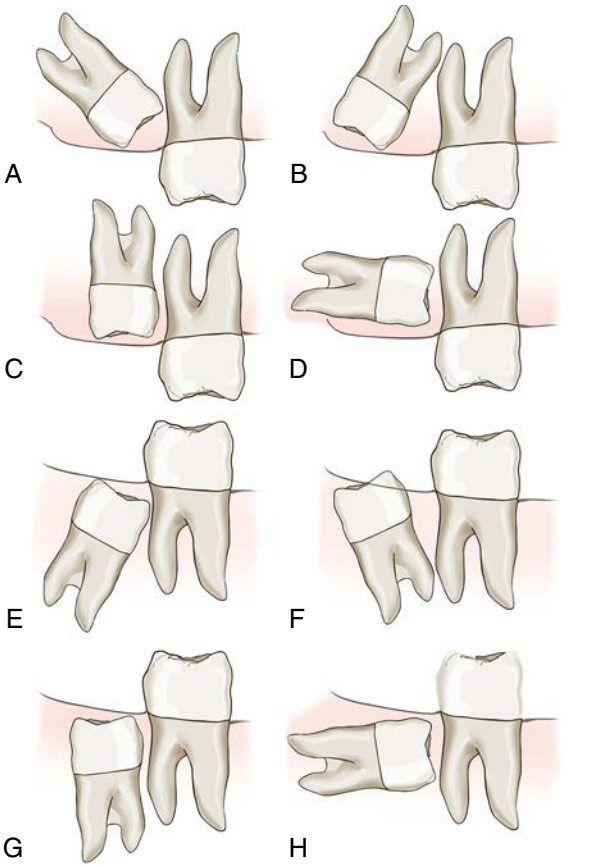

• **Figure 21-16** Angulation classification of impacted teeth. Maxillary third molar impactions: mesioangular (*A*), distoangular (*B*) vertical (*C*), and horizontal (*D*). Mandibular third molar impactions: mesioangular (*E*), distoangular (*F*), vertical (*G*), and horizontal (*H*).

• BOX 21-2 Hand Instruments for Impaction Surgery

- No. 15 blade
- Periosteal elevator
- Minnesota retractor
- Elevators (narrow, broad, Cogswell B, Crane)
- Bone file
- Needle holder
- Dean scissors

Flap Design

Mandibular impacted third molars are exposed by reflecting an envelope flap. The common description is a "hockey stick" incision with an arm extending distally from the distobuccal of the second molar posteriorly and laterally along the palpable ascending ramus. Care is taken to keep the incision on the retromolar pad angled buccally in order to avoid the lingual nerve, which may in some cases travel near the crest of the retromolar area. From the distobuccal of the second molar, the incision either drops inferiorly into the buccal vestibule as a mesial release (Figure 21-17, *A*) or runs anteriorly in the buccal sulcus of the second or first and second molars (see Figure 21-17, *B*).

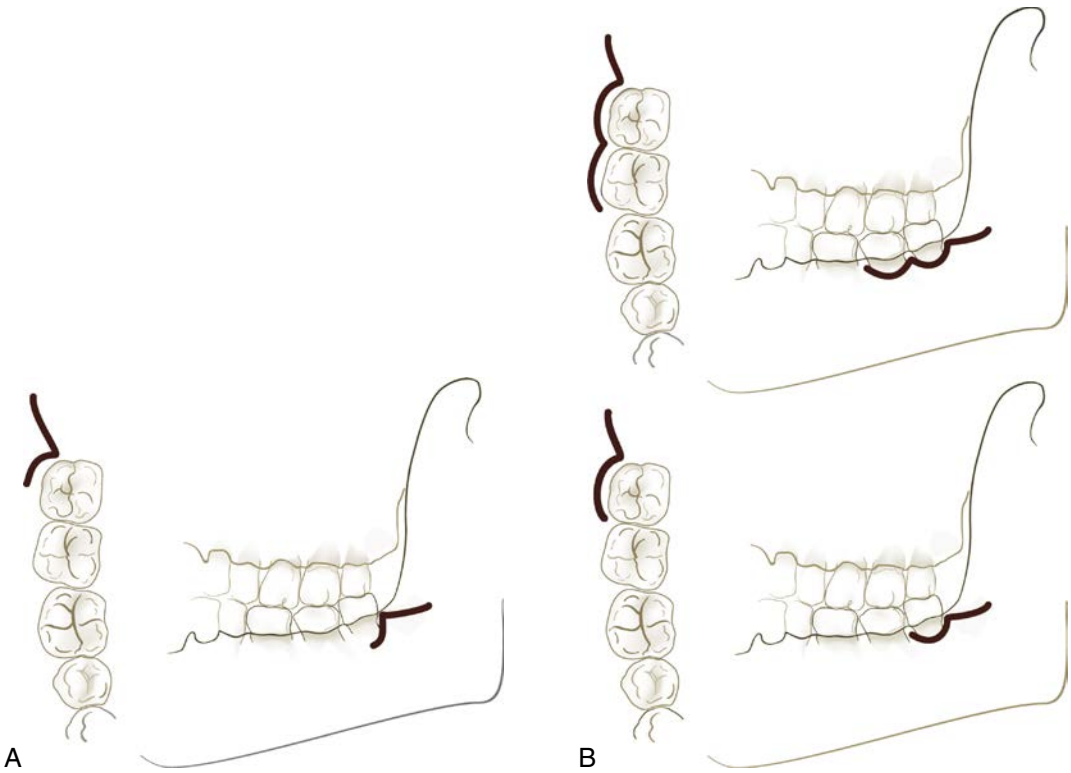

• **Figure 21-17** A well-designed, adequate mucoperiosteal flap allows appropriate access to the tooth. The distal release must follow the ascending ramus laterally **(A),** not aim lingually where it would jeopardize the lingual nerve. Some surgeons prefer an anterior release at the distal of the second molar as shown here. A common alternate flap design is an envelope flap carried anteriorly to the mesial of the second or first molar **(B).**



• **Figure 21-18** A high maxillary impaction is exposed more easily when a mesial vertical release is added to the incision. (From Dym H, Ogle OE: *Atlas of minor oral surgery*, Philadelphia, 2001, WB Saunders.)

Maxillary impacted third molars are exposed via similar incisions. When the occlusal surface of the third molar is at about one third or higher of the height of the second molar root, a mesial releasing incision is often useful (Figure 21-18).

Bone Removal

In the mandible, bone is removed with a burr under copious saline irrigation until most of the occlusal surface and the buccal surface are exposed to the level of the cervical height of contour or the cemento-enamel junction, depending on the expected difficulty of the procedure. Care is taken to avoid injury to the lingual aspect of the occlusal surface, where the lingual nerve may be injured. Bone is removed distally to fully expose the distobuccal line angle of the third molar crown, but excessive bone removal from the distal surface risks perforation lingually and often results in increased bony bleeding from the loose cancellous bone in the ramus just posterior to the third molar crown. Mesially, the mesiobuccal line angle must also be exposed to allow insertion of an elevator as a wedge from the mesial.

Buccal bone overlying the impacted maxillary third molar is often very thin and can be removed with a periosteal or dental elevator. It is rare that a handpiece is necessary to remove bone around maxillary third molars.

Tooth Sectioning

Using the surgical handpiece, the tooth is sectioned according to its angulation, unless it can be elevated intact easily, without undue force. Figure 21-19 illustrates the approaches used when sectioning a mesioangular third molar, and Figure 21-20 shows tooth sectioning for a distoangular lower third molar. Generally, mesioangular teeth are split into a mesial and distal half, directing the burr toward the root furcation. Distoangular and horizontally impacted teeth are often divided by cutting the crown free from the roots at the neck of the tooth, sometimes in two steps. If necessary, the roots are then divided. In all cases, care is taken not to cut too deeply either toward the lingual or inferiorly,

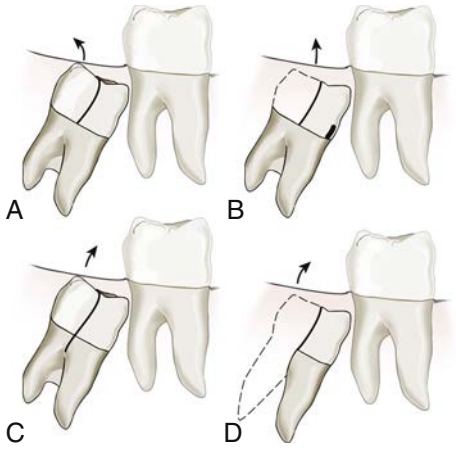

• **Figure 21-19** Mesioangular impaction: After bone removal is accomplished, the distal portion of the crown or the complete crown should be sectioned **(A),** fractured with an elevator, and removed **(B).** If possible, it is helpful to keep part of the mesial aspect of the crown attached to the mesial root to act as a handle and fulcrum for removal of the mesial root. Frequently the mesial and distal roots need to be sectioned from each other at the bifurcation **(C)** and removed independently **(D).**

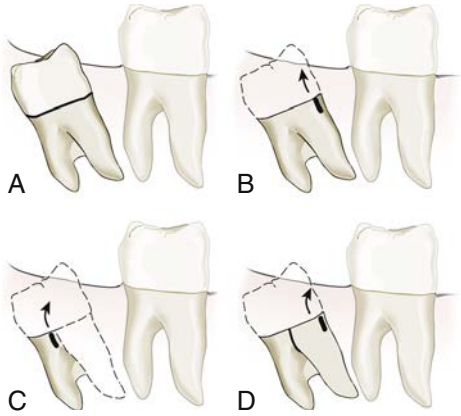

• **Figure 21-20** Distoangular impaction: The crown may be sectioned at the neck and removed completely **(A),** allowing elevation of the roots with a mesial purchase point if necessary **(B).** Alternatively, the roots may be divided once the crown is removed and then elevated separately **(C-D).**

where the lingual or inferior alveolar nerves may be at risk of injury. Generally, the tooth is not intentionally cut completely through to the lingual or inferior surface (when lying horizontally—see Figure 21-21) but is cut most of the way through and then split by insertion of an elevator and wedging the tooth segments apart.

Maxillary third molars rarely require division and are usually elevated intact (Figure 21-22). The overlying bone is thin and relatively elastic, and even when the bone is thicker, extraction can be achieved by removing relatively more bone rather than resorting to sectioning the tooth. Occasionally, a widely divergent buccal root or extreme root dilacerations will require sectioning the tooth into two or more pieces to remove the roots individually. Most surgeons find such cases among the most challenging of all impaction operations.

Tooth Delivery

The intact tooth or the sectioned portions of the tooth are elevated from the socket using a narrow dental, Cogswell B, or Crane elevator. More complicated impactions may require a series of sometimes delicate divisions, followed by careful separation and elevation of small segments.

Socket Care and Closure

Once the tooth is removed, any remaining follicle or granulation tissue is removed, particularly from the distal surface of the second molar. Care must be taken to avoid injuring the lingual soft tissue in the mandibular third molar socket out of caution for the lingual nerve. Any rough or very thin bony margins around the socket are smoothed with a file, and in the maxilla the posterior vestibule is palpated for any sharp margins under the flap that might create postoperative healing problems. The socket and flap are irrigated with large quantities of saline, and the flap closed. Most surgeons prefer a resorbable suture for this purpose. Paradoxically, a tight wound closure has been shown to increase the incidence of postoperative complications. In the maxilla, a vertical release must be closed if it was made, but often the reflected soft tissue will lie passively in place and a suture is not always necessary across the tuberosity area.

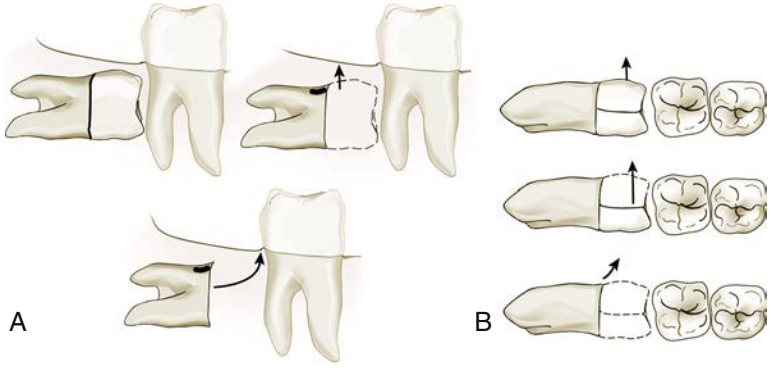

• **Figure 21-21** Horizontal impaction: The crown must be sectioned and removed completely before the roots can be displaced into the vacated space **(A).** Care must be taken to not cut too deeply the lingual or inferior directions when sectioning the crown. A useful alternative is removing the crown in several segments **(B),** allowing vision of the bony walls of the socket.

Impacted Maxillary Canines

Maxillary canines are the second most commonly impacted teeth, occurring in 1% to 2% of the general population and more commonly in females than males. Eighty-five percent of impacted maxillary permanent canines are palatal impactions, and 15% are labial.[39,40] The impaction of this tooth has considerable clinical implications, as the maxillary canine is the foundation of functional occlusion and an esthetic smile. Because of its importance, the impacted maxillary canine should be preserved when possible, and all necessary precautions should be taken to avoid a bone defect or root resorption when exposing and moving it.

Preoperative Planning

Because canine teeth are frequently retained and not removed, preoperative planning includes coordination with the treating orthodontist and general dentist to sequence the necessary care. In general, exposure and bonding of an impacted tooth is preceded by placing orthodontic appliances and beginning to create space into which the tooth can be guided orthodontically. The timing of extraction of any remaining deciduous teeth must also be determined.

The majority of impacted maxillary canines are located in the palate, although some are impacted buccally. Clinical examination may reveal their location through a visible or palpable bulge, but more often the location and angulation of the impacted tooth is determined radiographically. Multiple radiographs exposed at different angles are interpreted according to the "same lingual, opposite buccal" (SLOB) rule examining apparent movement of the impacted tooth versus those in the dental arch. When available, cone-beam imaging provides excellent localization of the impacted tooth as well as additional useful information on the proximity of adjacent roots and any resorption that may be already present.

Surgical Technique

Exposure

The principles of soft tissue exposure are very different between palatal and buccal impacted canines. On the palate, the thick, fully keratinized palatal soft tissue forms a robust flap that heals well with little or no consequence to the periodontal health of the canine or other adjacent teeth. In contrast, care must be taken on the buccal side to preserve the available keratinized gingival tissue in the canine site and ensure that the tooth erupts with that tissue on its facial surface.

The palatally impacted canine is approached through a posteriorly based palatal flap. A full-thickness mucoperiosteal flap is developed from a sulcular incision extending from the premolar or molar on the affected side to the midline or beyond, if necessary, for adequate tension-free exposure (Figure 21-23). If necessary, the incisive neurovascular bundle can be cut through without significant consequence. If both canines are to be exposed, the incision extends to the contralateral molar area, creating a single flap. A drill under irrigation is used to expose the most superficial surface of the impacted crown without damaging its enamel. The cementoenamel junction is not exposed unless the tooth will be removed.

On the labial side, the tooth may be exposed and bonded using a closed or open technique, depending on the vertical height of the impaction. In general, if the cusp tip of the canine is within several millimeters of the adjacent crowns, a trapezoidal flap with relatively parallel releases is reflected superiorly and repositioned apically above the facial surface of the exposed canine crown. Thin overlying bone is removed to expose enough enamel to bond a bracket or button, and the flap is sutured into its new position (Figure 21-24). If the tooth is more lateral or farther superior, a closed technique is used instead. An envelope incision with any needed release is developed, the

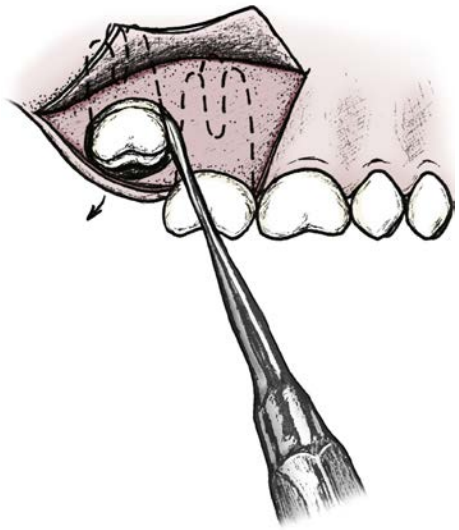

• **Figure 21-22** Using a straight elevator, the tooth is then elevated out of its bony crypt in a distobuccal direction. (From Dym H, Ogle OE: *Atlas of minor oral surgery*, Philadelphia, 2001, WB Saunders.)

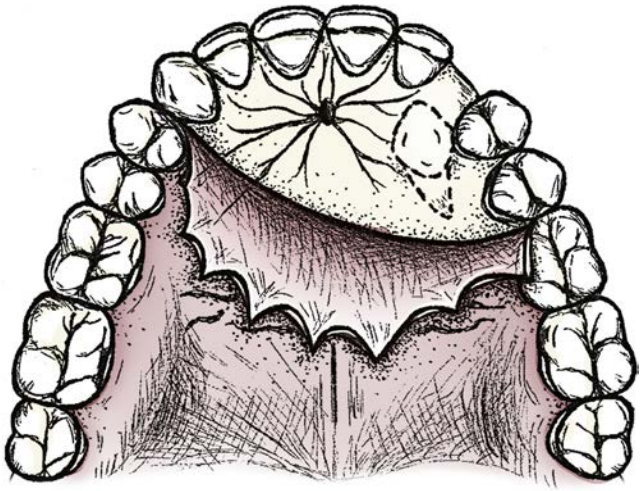

• **Figure 21-23** Palatal flap reflected and nasopalatine foramen contents incised. Impacted canine is now ready for exposure. (From Dym H, Ogle OE: *Atlas of minor oral surgery*, Philadelphia, 2001, WB Saunders.)

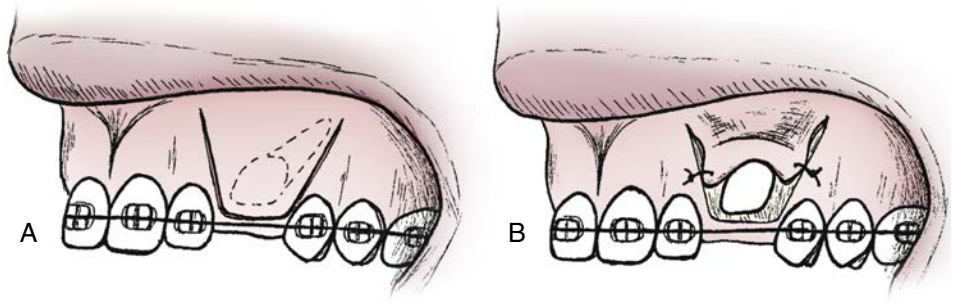

• **Figure 21-24** A trapezoidal incision to expose underlying buccal impacted canine **(A).** The flap is apically repositioned to expose canine crown **(B),** keeping the attached gingiva at the crown's neck, which is critical for periodontal long-term health of tooth. (From Dym H, Ogle OE: *Atlas of minor oral surgery*, Philadelphia, 2001, WB Saunders.)

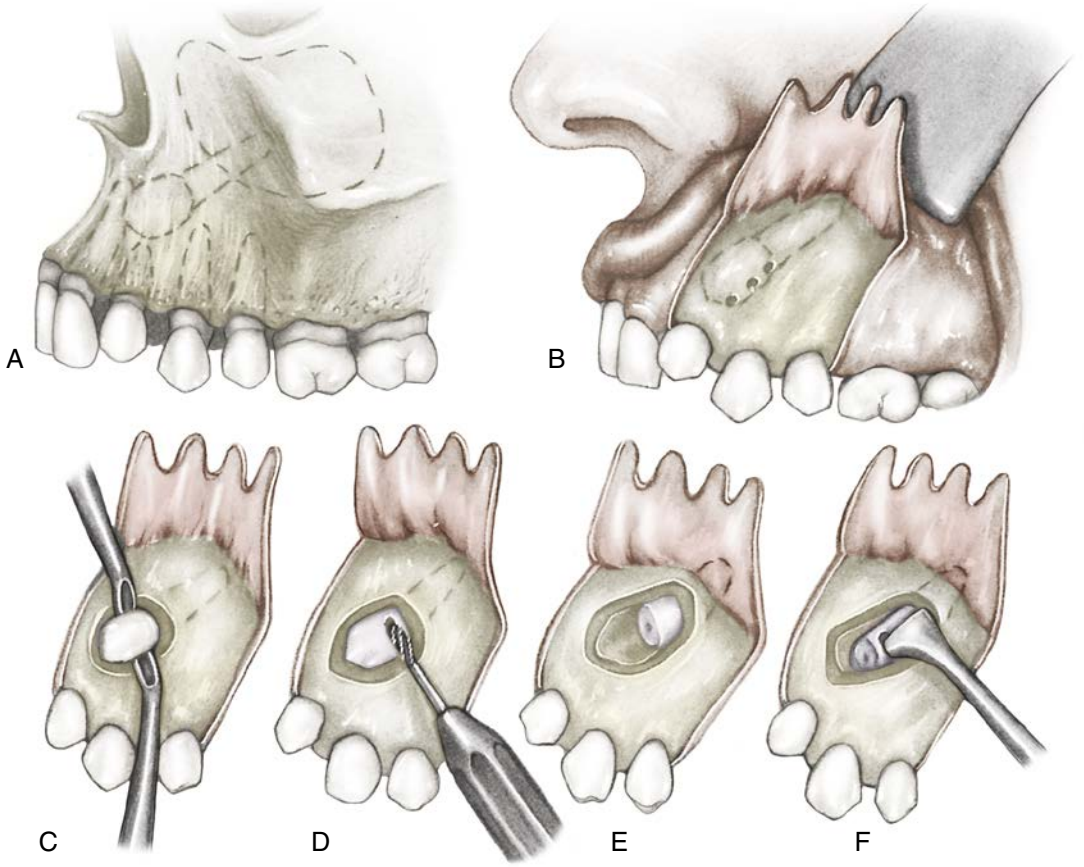

• **Figure 21-25** A labially impacted tooth **(A)** is exposed via a mucoperiosteal flap with limited bone removal around the crown **(B,C).** A similar approach may be used to bond a bracket to the tooth using the closed flap technique. In this case, the crown is sectioned **(D),** a purchase point is placed **(E),** and the root is elevated and removed **(F).** Great care is exercised to avoid adjacent tooth roots, the nasal floor, and the maxillary sinus during these procedures in the lateral and anterior maxilla. (From Archer WH, editor: *Oral and maxillofacial surgery*, vol 1, ed 5, 1975, Philadelphia, WB Saunders.)

crown exposed, and the flap replaced in its original position, not unlike the process used for palatal impactions (Figure 21-25).

Bonding or Extraction

If a palatally impacted canine will be extracted, the crown is sectioned and removed first, then the root displaced into the space vacated by the crown and removed as well. If fully developed, the root may be removed in sections to avoid making a larger intrabony defect and risking injury to adjacent roots.

If the tooth will be repositioned orthodontically, a bracket or a button and chain are bonded to the exposed enamel surface. This is accomplished using any of multiple

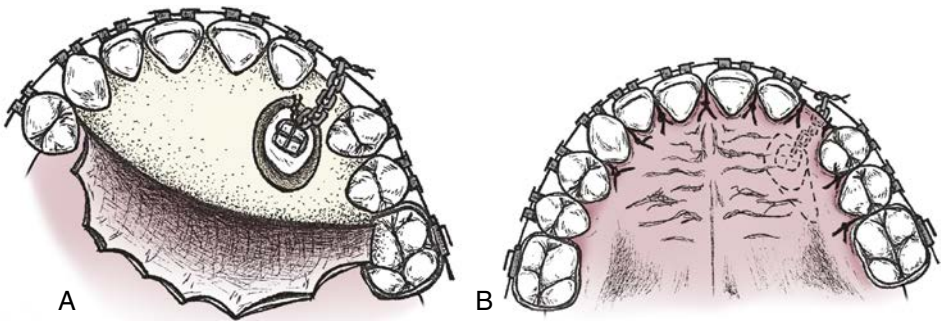

• **Figure 21-26** **A,** Palatal flap retracted with bracket applied to canine crown and chain attached to orthodontic arch wire. **B,** Palatal flap closed with the chain emerging at the crest of the alveolus in the edentulous space. (From Dym H, Ogle OE: *Atlas of minor oral surgery*, Philadelphia, 2001, WB Saunders.)

commercially available bonding agents, according to the manufacturer's instructions. Care must be taken to make the field as dry as possible, which means careful attention to hemostasis and removal of any follicular tissue with a curette. Local anesthetic with epinephrine can be injected into bleeding tissue to help achieve the necessary dry field. Once the bond is tested and found to be secure, the loose end of the chain is attached to the orthodontic appliances so that it will emerge from the soft tissue on the crest of the ridge in the tooth's proper site, and the flap is sutured back into place (Figure 21-26).

Other Impacted Teeth

The next most common impacted teeth after third molars and maxillary canines are mandibular premolars, mandibular canines, and maxillary premolars. These teeth are managed much like maxillary canines. When feasible, they are bonded and erupted into occlusion with orthodontic assistance; otherwise, they are generally removed. In the case of mandibular impactions, cone-beam imaging is particularly useful because these impacted teeth may be located buccally, lingually, or centered in the alveolus. Cone beam imaging also allows examination of the health of adjacent roots and aids in determining which of the several teeth present are the best candidates for long-term retention. Proximity of adjacent teeth and the mental nerve must be considered in deciding the best surgical approach: Sometimes it is necessary to approach impacted mandibular canines and premolars from both sides of the alveolus to minimize bone removal and gain access to bond, or section and remove, the impacted teeth. Figure 21-27 provides a schematic illustration of the principles of removing an impacted mandibular canine.

Maxillary premolars, other more rare impactions, and supernumerary teeth are managed in a similar fashion. Most impacted maxillary premolars are positioned with their crowns tipped toward the palate, and sometimes they can be removed by simple elevation with a small straight elevator. It is usually not possible to place extraction forceps, as the adjacent teeth are crowded against the impaction, and caution must be used to not mobilize these other teeth (Figure 21-28).

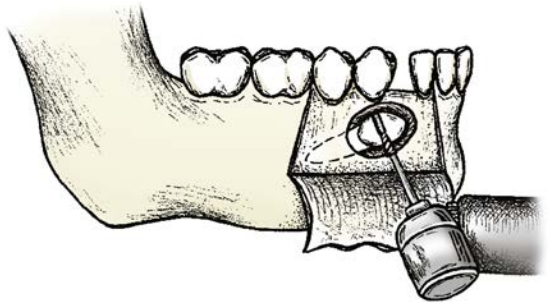

• **Figure 21-27** The mandibular impacted canine is most frequently located buccally, and the surgeon must be cognizant of the mental foramen in or near the surgical field. The underlying bone and canine are exposed through a vertical releasing incision and a posterior release if access is found to be restricted with only the one anterior release. The overlying bone is carefully removed and the crown sectioned. (From Dym H, Ogle OE: *Atlas of minor oral surgery*, Philadelphia, 2001, WB Saunders.)

Perioperative Management

Unlike removal of erupted teeth, surgery for impacted teeth has a significant impact on quality of life for several days after surgery. Third molar removal is by far the best studied impaction surgery, and even without complications patients should expect to curtail their usual activities significantly. However, impaction surgery for non-third molars should also be expected to result in many of the consequences described later.

Multiple studies have looked at the short-term impact of third molar removal on quality of life.[41-43] As expected, third molar removal has a profoundly negative impact for the first 4 to 7 days. Longer follow-up indicates that this rapidly improves, most likely due to elimination of chronic pain and inflammation, most often in the form of pericoronitis. This information is of particular importance to the surgeon and patient during the preoperative consult, not to mention when dealing with a patient experiencing complications following third molar extraction.

True complications occur with a 10% incidence following surgical removal of the third molars.[44] These complications range from the more common, mild, and transient, to severe and permanent. Predictable outcomes include swelling, pain, stiffness, and mild bleeding. Severe outcomes

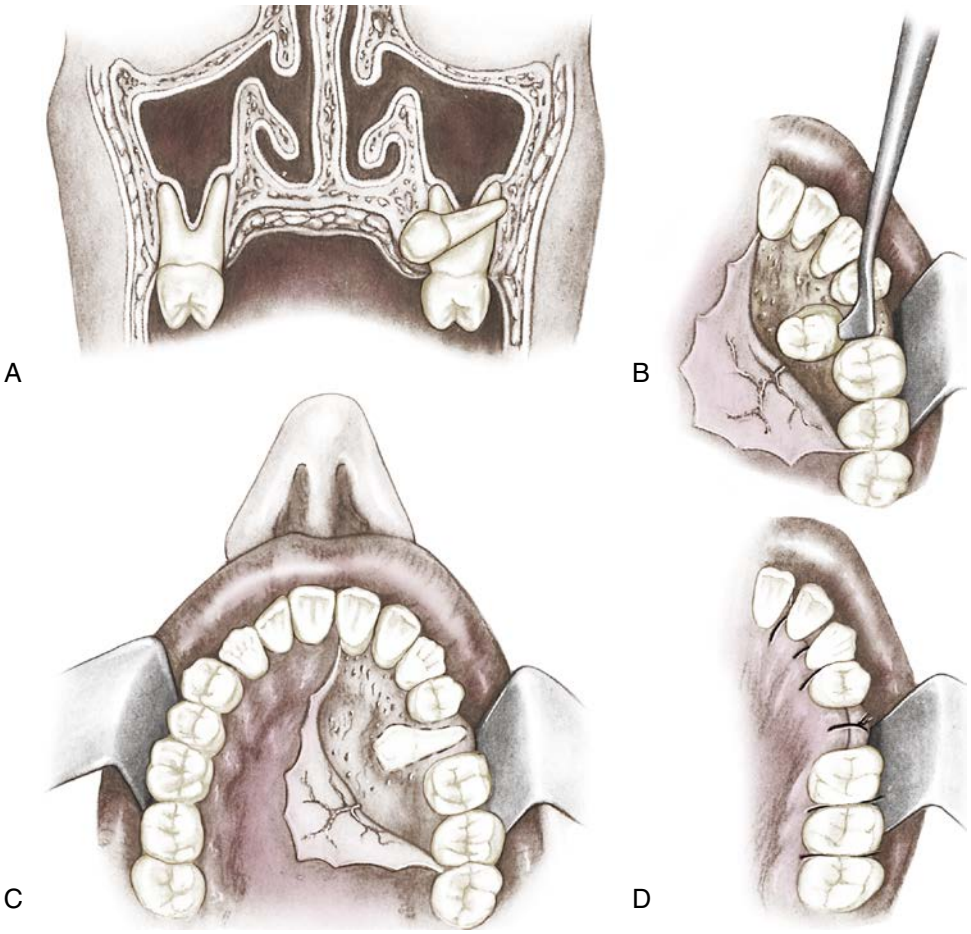

• **Figure 21-28** A maxillary impacted premolar **(A)** is exposed via a posteriorly based palatal flap extending from the second molar to the midline. The tooth may be elevated with a Cryer **(B)** when space permits, preserving the adjacent teeth and their alveolar bony support **(C).** The flap is reapproximated using interdental and interrupted sutures **(D).** (From Archer WH, editor: *Oral and maxillofacial surgery*, vol 1, ed 5, Philadelphia, 1975, WB Saunders.)

include inferior alveolar nerve anesthesia and fracture of the mandible. The depth of the impaction, presence of a complete bony impaction, and the age of the patient influence overall incidence and severity of the complications.[45] The experience and competence of the surgeon also play a role in the incidence. Less experienced surgeons will experience a higher incidence of complications compared to more experienced counterparts.[46,47]

Managing Bleeding

Postsurgical bleeding can be minimized by using a good surgical technique and by avoiding the tearing of flaps or excessive trauma to the overlying soft tissue. When a vessel is cut, the bleeding should be stopped to prevent secondary hemorrhage following surgery. The most effective way to achieve hemostasis following surgery is to apply pressure with moist gauze directly over the site of the surgery. In some patients, immediate postoperative hemostasis is difficult, either because of limited ability to cooperate or a surgical site (e.g., hard palate) where biting down is not useful. In such situations, a variety of techniques can be employed to help secure local hemostasis, including oversuturing and the application of topical thrombin on a small piece of absorbable gelatin sponge into the bony defect. The defect can also be packed with oxidized cellulose. Unlike the gelatin sponge, oxidized cellulose can be packed into the socket under pressure. In some situations, microfibrillar collagen can be used to promote platelet plug formation. Patients who have known acquired or congenital coagulopathies require extensive preparation and preoperative planning (e.g., determination of international normalized ratio, factor replacement, or hematology consultation) before third molars are removed surgically.

Postoperative Antibiotics

The exact incidence of infection following surgery of impacted third molars is unknown; it is generally a rare occurrence, meaning it is unusual to see pain, swelling, and purulence that require incision and drainage and antibiotic therapy. That being said, a competent and experienced surgeon would have an expected infection rate of 1% to 3% for all third molar procedures, which are considered clean-contaminated surgery.[48] It is difficult to reduce the incidence of infection below 3% by using prophylactic antibiotics; thus, many authorities believe

it is unnecessary to prescribe them routinely for a normal, healthy patient undergoing impaction surgery. Although the literature remains divided, there is good evidence that prophylactic antibiotics do not reduce postoperative infections in third molar cases.[49,50]

A more common occurrence following third molar extraction is the dry socket, or, more accurately, alveolar osteitis, described more completely later. Prophylactic antibiotic use has been shown to reduce the incidence of dry sockets postoperatively. Similar risk reduction has been found with copious irrigation, preoperative rinses with chlorhexidine, and placement of antibiotics directly into the extraction site.[47,51-56] Thus, although antibiotics are helpful, they may be no more effective than other local measures, some of which do not require active patient participation. On the other hand, broad increases in antibiotic-related complications such as antibiotic allergy, growth of resistant bacteria, gastrointestinal side effects, and secondary infections must be considered before routinely prescribing antibiotics. Consequently, many authorities do not recommend that postoperative systemic antibiotics be used routinely following the extraction of impacted molars.

Controlling Pain and Swelling

Corticosteroids are widely used to reduce postoperative swelling, trismus, and pain, as well as postoperative nausea and vomiting. The best-studied and most widely used steroids are methylprednisolone and dexamethasone, both pure glucocorticoids with little mineralocorticoid effect. Both these steroids also have limited depressing effect on leukocyte chemotaxis. Methylprednisone is most commonly given intravenously at 125 mg at the time of surgery, followed by lower doses at 40 mg orally, three or four times a day, for 2 days postoperatively. Dexamethasone is given in a 4- to 12-mg dose intravenously at the time of surgery, followed by 4 to 8 mg twice a day for 2 days postoperatively. Although high-dose, short-term steroid use is associated with minimal side effects, its method of use is highly variable, and it is hoped that further research will establish a most effective therapeutic regimen. Perioperative and postoperative steroid use is contraindicated in patients with gastric ulcer disease, active infections, and certain types of psychosis.[57-61]

Postoperative Instructions

Before patients are discharged, close inspection of the surgical site should be performed to check for hemostasis. The patient should be given both verbal and written postoperative instructions with a contact number to access the treating surgeon in case of emergency. Additional gauze pads should also be provided, along with any appropriate prescriptions.

Most postoperative instructions are based on clinical experience over decades, although there is little, if any, strong scientific evidence for many common recommendations. Even so, most authorities agree on the instructions described here. Patients should be advised to keep moist gauze directly on the surgical site with firm biting pressure for 20 to 60 minutes postsurgery, to avoid smoking and hard spitting or sucking on straws, to apply ice to the surgical area for the first 24 hours, and to eat soft foods, avoiding hot food or drink for the first 24 hours. Patients should be told to brush their teeth gently in the surgical site, avoiding scrubbing on the gums, and to rinse very gently during the immediate postoperative period. Patients are also advised to limit vigorous exercise activity for the first 24 hours following surgery for difficult impactions. The patient should be told to expect some swelling and discoloration and to take all prescriptions as directed. If persistent bleeding is a concern, aspirin should be avoided.

Complications

Infection

An uncommon postsurgical complication related to the removal of impacted third molars is infection. The incidence of infection following the removal of third molars is very low, ranging from 1.7% to 2.7%.[62] Infection after removal of mandibular third molars is almost always a minor complication. About 50% of infections are localized subperiosteal abscess-type infections, which occur 2 to 4 weeks after a previously uneventful postoperative course. These are usually attributed to debris that is left under the mucoperiosteal flap and are easily treated by surgical debridement and drainage. Of the remaining 50%, few postoperative infections are significant enough to warrant surgery, antibiotics, and hospitalization. Infections occur in the first postoperative week after third molar surgery approximately 0.5% to 1% of the time. This is an acceptable infection rate and would not be decreased with the administration of prophylactic antibiotics.

Tooth Fracture

One of the most frequent problems encountered in removing third molars is the fracture of a portion of the root, which may be difficult to retrieve. In these situations, the root fragment may be displaced into the submandibular space, the inferior alveolar canal, or the maxillary sinus. Uninfected roots left within the alveolar bone have been shown to remain in place without postoperative complications.[63] The pulpal tissues undergo fibrosis, and the root becomes totally incorporated within the alveolar bone. Aggressive and destructive attempts to remove portions of roots that are in precarious positions seem to be unwarranted and may cause more damage than benefit. Radiographic follow-up may be all that is required.

Alveolar Osteitis

The incidence of alveolar osteitis or dry socket following the removal of impacted mandibular third molars varies between 3% and 25%. Most of the variation is likely a result of the definition of the syndrome. When "dry socket" is defined in terms of pain that requires the patient to return to the surgeon's office, the incidence is probably in the range of 20% to 25%.[47,64-71]

The pathogenesis of alveolar osteitis has not been clearly defined, but the condition is most likely the result of lysis of a fully formed blood clot before the clot is replaced with granulation tissue. This fibrinolysis occurs during the third and fourth days and results in symptoms of pain and malodor after the third day or so following extraction. The source of the fibrinolytic agents may be tissue, saliva, or bacteria.[67] The role of bacteria in this process can be confirmed empirically based on the fact that systemic and topical antibiotic prophylaxis reduces the incidence of dry socket by approximately 50% to 75%. The periodontal ligament may also play a role in the development of alveolar osteitis.

The incidence of dry socket seems to be higher in patients who smoke and in female patients who take oral contraceptives.[68,69] Its occurrence can be reduced by several techniques, most of which are aimed at reducing the bacterial contamination of the surgical site. Presurgical irrigation with antimicrobial agents such as chlorhexidine reduces the incidence of dry socket by up to 50%.[47] Copious irrigation of the surgical site with large volumes of saline is also effective in reducing dry socket.[71] Topical placement of small amounts of antibiotics such as tetracycline or lincomycin may also decrease the incidence of alveolar osteitis.[64-66,70]

The goal of treatment of dry socket is to relieve the patient's pain during the delayed healing process. This is usually accomplished by irrigation of the involved socket, gentle mechanical debridement, and placement of an obtundent dressing, which usually contains eugenol. The dressing may need to be changed daily for several days and then less frequently after that. The pain syndrome usually resolves within 3 to 5 days, although it may take as long as 10 to 14 days in some patients. There is some evidence that topical antibiotics such as metronidazole may hasten resolution of the dry socket.[72]

In summary, alveolar osteitis is a disturbance in healing that occurs after the formation of a mature blood clot but before the blood clot is replaced with granulation tissue. The primary etiology appears to be one of excess fibrinolysis, with bacteria playing an important yet ill-defined role. Antimicrobial agents delivered by perioperative mouth rinses, topically placed in the socket, or administered systemically all help to reduce the incidence of dry socket. Mechanical debridement and copious saline irrigation of the surgical wound also are effective in reducing the incidence of dry socket. Combining multiple approaches would include preoperative chlorhexidine rinses for approximately 1 week before surgery, irrigating the wound thoroughly with normal saline at the conclusion of surgery, placing a small square of gelatin sponge saturated with tetracycline in the socket, and continuing chlorhexidine rinses for 1 additional week.

Nerve Disturbances

Surgical removal of mandibular third molars places both the lingual and inferior alveolar branches of the third division of the trigeminal nerve at risk for injury. The lingual nerve is most often injured during soft tissue flap reflection, whereas the inferior alveolar nerve is injured when the roots of the teeth are manipulated and elevated from the socket. The generally accepted incidence of injury to the inferior alveolar and lingual nerves following third molar surgery is about 3%.[73-75] Only a small proportion of these anesthesia and paresthesia problems become permanent. However, there is a significant incidence of some minor alterations of sensation after injury caused by third molar surgery. As many as 45% of nerve compression injuries, which are typical in third molar surgery, result in a permanent neurosensory abnormality.[75]

Inferior alveolar nerve injury is most likely to occur in specific situations. The first and most commonly reported predisposing factor is complete bony impaction of mandibular third molars. The angulation classifications most commonly involved are usually mesioangular and vertical impaction. In some cases, nerve proximity to the root is indicated by an apparent narrowing of the inferior alveolar canal as it crosses the root or severe root dilaceration adjacent to the canal. Other well-documented radiographic signs are diversion of the path of the canal by the tooth, darkening of the apical end of the root indicating that it is included within the canal, and interruption of the radiopaque white line of the canal.[76] In surgically verified inferior alveolar nerve injuries, the presence of more than one of these signs was highly sensitive but not highly specific for the risk of injury, whereas the absence of all of these signs had a strong negative predictive value.[77] When they are noted on a preoperative evaluation of the radiograph, the surgeon should take extraordinary precautions to avoid injury to the nerve, such as additional bone removal or sectioning of the tooth into extra pieces, and the patient should be counseled in advance regarding his or her increased risk of nerve injury.

When an injury to the lingual or inferior alveolar nerve is diagnosed in the postoperative period, the surgeon should begin long-term planning for its management, including consideration of referral to a neurologist and/or microneurosurgeon. These issues are dealt with elsewhere in this textbook.

Rare Complications

The complications already discussed are the more common occurrences, accounting for the great majority of complications in surgery to remove impacted third molars. Several additional complications occur only rarely and are mentioned briefly.

Maxillary third molars that are deeply impacted may have only thin layers of bone posteriorly separating them from the infratemporal fossa, or anteriorly separating them from the maxillary sinus. Small amounts of pressure in an errant direction can result in displacement of the maxillary third molar into these adjacent spaces. When a maxillary third molar is displaced posteriorly into the infratemporal fossa, the surgeon should try to manipulate the tooth back into the socket with finger pressure placed high in the buccal vestibule near the pterygoid plates. If this is unsuccessful, the surgeon can attempt to recover the tooth by placing the suction tip into the socket and aiming it posteriorly. If

both of these maneuvers are unsuccessful in recovering the tooth, the most effective technique is to allow the tooth to undergo fibrosis and to operate 2 to 4 weeks later to remove it. If the tooth is asymptomatic, is not causing any restriction in jaw movement, and is not causing pain, the surgeon should consider leaving the tooth in place. If the decision is made to remove the tooth, three-dimensional localization of the tooth should be made before surgery is initiated.

If the tooth is displaced into the maxillary sinus, retrieval is usually done by a Caldwell-Luc procedure at the same appointment. The surgeon should localize the tooth with at least a one-dimensional radiographic view and preferably a three-dimensional study before performing the retrieval surgery.[78]

Fracture of the mandible during the removal of impacted mandibular third molars is a rare occurrence. The typical situation is a deeply impacted third molar, most commonly in an older individual with dense bone. The surgeon places excessive pressure on the tooth with an elevator in an attempt to deliver the tooth or tooth section into the mouth; the fracture occurs, and the remaining portion of the tooth is easily retrieved. The surgeon should then perform an immediate reduction and fixation of the fracture. If the surgeon has the experience and the armamentarium available, rigid internal fixation with miniplates is an excellent choice in this unfortunate situation. Wire fixation and application of intermaxillary fixation is an acceptable alternative. Late mandible fractures usually occur 4 to 6 weeks following extraction in patients over age 40 years.

Periodontal Healing

Two of the important reasons for removing impacted third molars are to preserve periodontal health or to treat a periodontitis that already exists.[79,80] In contrast, removal of completely bony impacted teeth in older patients with good periodontal health is contraindicated, because it may actually create a persistent postsurgical defect.

Periodontal healing following third molar removal is best when the impacted tooth is removed before it becomes exposed in the mouth, before it resorbs bone on the distal aspect of the second molar, and when the patient is as young as possible.[81-83] If a third molar is partially exposed in the mouth, it should be removed as soon as possible. In such cases, there is by definition a deep and potentially destructive periodontal lesion under the operculum partially covering the third molar, which is difficult for the patient to maintain. Even if the patient is asymptomatic, removing the impacted tooth allows the best possible periodontal healing after surgery.

Acknowledgement

The authors would like to acknowledge the important influence of Drs. Manaf Saker, Orrett E. Ogle, and Harry Dym who wrote the previous edition of this chapter. We are grateful most especially for their illustrations, which are retained in this edition.

References

1. Pogrel MA, Dodson TB, Swift JQ, et al.: White paper on third molar surgery. Accessed http://www.aaoms.org/images/uploads/pdfs/white_paper_third_molar_data.pdf, October 13, 2015.
2. Santosh P: Impacted mandibular third molars: review of literature and a proposal of a combined clinical and radiological classification, *Ann Med Health Sci Res* 5(4):229–234, 2015.
3. Blakey GH, Marciani RD, Haug RH, et al.: Periodontal pathology associated with asymptomatic third molars, *J Oral Maxillofac Surg* 60:1227–1233, 2002.
4. White RP, Madianos PN, Offenbacher S, et al.: Microbial complexes detected in the second/third molar region in patients with asymptomatic third molars, *J Oral Maxillofac Surg* 60:1234–1240, 2002.
5. White RP, Offenbacher S, Phillips C, et al.: Inflammatory mediators and periodontitis in patients with asymptomatic third molars, *J Oral Maxillofac Surg* 60:1241–1245, 2002.
6. Khanuja A, Powers MP: Surgical management of impacted teeth. In Fonseca R, editor: *Textbook of Oral and Maxillofacial Surgery*, vol. 1. Philadelphia, 2000, Saunders.
7. Nordenram A, Hultin M, Kjellman O, Ramstrom G: Indications for surgical removal of the mandibular third molar, *Swed Dent J* 2:23–29, 1987.
8. Stanley HR, Alattar M, Collett WE, et al.: Pathological sequelae of "neglected" impacted third molars, *J Oral Pathol* 17:113–117, 1988.
9. von Wowern N, Nielsen HO: The fate of impacted lower third molars after the age of 20, *Int J Oral Maxillofac Surg* 18:277–280, 1989.
10. Schroeder DC, Cecil III JC, Cohen ME: Retention and extraction of third molars in naval personnel, *Mil Med* 148:50–53, 1983.
11. Assael L: Indications for elective therapeutic third molar removal: the evidence is in, *J Oral Maxillofac Surg* 63:1691–1692, 2005.
12. Leone SA, Edenfield MJ, Cohen ME: Correlation of acute pericoronitis and the position of the mandibular third molar, *Oral Surg* 62:245–250, 1986.
13. Heimdahl A, Nord CE: Treatment of orofacial infections of odontogenic origin, *Scand J Infect Dis* 46(Suppl):101–105, 1985.
14. Van Winkelhoff AJ, Carlee AW, deGraaff J: *Bacteroides endodontalis* and other black-pigmented *Bacteroides* species in odontogenic abscesses, *Infect Immun* 49:494–497, 1985.
15. Mombelli A, Buser D, Lang NP, Berthold H: Suspected periodontopathogens in erupting third molar sites of periodontally healthy individuals, *J Clin Periodontol* 17:48–54, 1990.
16. Berge TI, Boe OE: Symptoms and lesions associated with retained or partially erupted third molars, *Acta Odontol Scand* 51:115, 1993.
17. Curran AE, Damm DD, Drummond JF: Pathologically significant pericoronal lesions in adults: histopathologic evaluation, *J Oral Maxillofac Surg* 60:613–617, 2002.
18. Guven O, Keskin A, Akal UK: The incidence of cysts and tumors around impacted third molars, *Int J Oral Maxillofac Surg* 29:131–135, 2000.
19. Berge TI: Incidence of large third-molar-associated cystic lesions requiring hospitalization, *Acta Odontol Scand* 54:327–331, 1996.
20. Richardson ME: The etiology of late lower arch crowding alternative to mesially directed forces: a review, *Am J Orthod Dentofacial Orthop* 105:592–597, 1994.
21. Kahl B, Gerlach L, Hilgers RD: A long-term, follow-up, radiographic evaluation of asymptomatic impacted third molars in orthodontically treated patients, *Int J Oral Maxillofac Surg* 23:279–285, 1994.

22. Nitzan D, Keren T, Marmary Y: Does an impacted tooth cause root resorption of the adjacent one? *Oral Surg* 51:221–224, 1981.
23. Taylor SS: Dental evaluation in head and neck cancer patient. In Kountakis SE, editor: *Encyclopedia of otolaryngology, head and neck surgery*, New York, 2013, Springer, pp 670–675.
24. Yamada T, Sawaki Y, Tohnai I, et al.: A study of sports-related mandibular angle fracture: relation to the position of the third molars, *Scand J Med Sci Sports* 8:116–119, 1998.
25. Safdar N, Meechan JG: Relationship between fractures of the mandibular angle and the presence and state of eruption of the lower 3rd molar, *Oral Surg Oral Med Oral Pathol Oral Radiol Endod* 79:680–684, 1995.
26. Tevepaugh DB, Dodson TB: Are mandibular third molars a risk factor for angle fractures? A retrospective cohort study, *J Oral Maxillofac Surg* 53:646–649, 1995.
27. Amler MH: The age factor in human extraction wound healing, *J Oral Surg* 35:193–197, 1977.
28. Ricketts RM: Studies leading to the practice of abortion of lower third molars, *Dent Clin North Am* 23:393–411, 1979.
29. Grover PS, Lorton L: The incidence of unerupted permanent teeth and related clinical cases, *Oral Surg Oral Med Oral Pathol* 59:420–425, 1985.
30. Lysell L, Rohlin M: A study of indications used for removal of the mandibular third molar, *Int J Oral Maxillofac Surg* 17:161–164, 1988.
31. Kruger E, Thomson WM, Konthasinghe P: Third molar outcomes from age 18 to 26: findings from a population-based New Zealand longitudinal study, *Oral Surg Oral Med Oral Pathol Oral Radiol Endod* 92:150–155, 2001.
32. Venta I, Turtola L, Ylipaavalniemi P: Radiographic follow-up of impacted third molars from age 20 to 32 years, *Int J Oral Maxillofac Surg* 30:54–57, 2001.
33. Hattab FN: Positional changes and eruption of impacted mandibular third molars in young adults—a radiographic 4-year follow-up study, *Oral Surg Oral Med Oral Pathol Oral Radiol Endod* 84:604–608, 1997.
34. Lysell L, Rohlin M: A study of indications used for removal of the mandibular third molar, *Int J Oral Maxillofac Surg* 17:161–164, 1988.
35. Hattab FN, Abu Alhaija ESJ: Radiographic evaluation of third molar eruption space, *Oral Surg Oral Med Oral Pathol Oral Radiol Endod* 88:285–291, 1999.
36. Venta I, Murtomaa H, Ylipaavalniemi P: A device to predict lower third molar eruption, *Oral Surg Oral Med Oral Pathol Oral Radiol Endod* 84:598–603, 1997.
37. Venta I: Predictive model for impaction of lower third molars, *Oral Surg Oral Med Oral Pathol* 76:699–703, 1993.
38. Mollaoglu N, Cetiner S, Gungor K: Patterns of third molar impaction in a group of volunteers in Turkey, *Clin Oral Investig* 6:109–113, 2002.
39. Rayne J: The unerupted maxillary canine, *Dent Pract Dent Rec* 19:194–204, 1969.
40. Stellzig A, Basdra EK, Komposch G: The etiology of canine tooth impaction—a space analysis, *Fortshcr Kieferorthop* 55(3), 1994. 97-f.
41. McGrath C, Comfort MB, Lo ECM, Luo Y: Changes in life quality following third molar surgery—the immediate postoperative period, *Br Dent J* 194:265–268, 2003.
42. Shafer DM, Frank ME, Gent JF, Fischer ME: Gustatory function after third molar extraction, *Oral Surg Oral Med Oral Pathol Oral Radiol Endod* 87:419–428, 1999.
43. White RP, Shugars DA, Shafer DM, et al.: Recovery after third molar surgery: clinical and health-related quality of life outcomes, *J Oral Maxillofac Surg* 61:535–544, 2003.
44. Goldberg MH, Nemarich AN, Marco WP: Complications after mandibular third molar surgery: a statistical analysis of 500 consecutive procedures in private practice, *J Am Dent Assoc* 111:277–279, 1985.
45. Hinds EC, Frey KF: Hazards of retained third molars in older persons: report of 15 cases, *J Am Dent Assoc* 101:246–250, 1980.
46. Sisk AL, Hammer WB, Shelton DW, Joy Jr ED: Complications following removal of impacted third molars: the role of the experience of the surgeon, *J Oral Maxillofac Surg* 44:855–859, 1986.
47. Larsen PE: The effect of chlorhexidine rinse on the incidence of alveolar osteitis following the surgical removal of impacted mandibular third molars, *J Oral Maxillofac Surg* 49:932–937, 1991.
48. Loukota RA: The incidence of infection after third molar removal, *Br J Oral Maxillofac Surg* 29:336–337, 1991.
49. Happonen RP, Backstrom AC, Ylipaavalniemi P: Prophylactic use of phenoxymethylpenicillin and tinidazole in mandibular third molar surgery, a comparative placebo controlled clinical trial, *Br J Oral Maxillofac Surg* 28:12–15, 1990.
50. Bystedt H, Nord CE: Effect of antibiotic treatment on postoperative infections after surgical removal of mandibular third molars, *Swed Dent J* 4:27–38, 1980.
51. Bystedt H, yon Konow L, Nord CE: Effect of tinidazole on postoperative complications after surgical removal of impacted mandibular third molars, *Scand J Infect Dis* 26(Suppl):135–139, 1981.
52. Hellem S, Nordenra A: Prevention of postoperative symptoms by general antibiotic treatment and local bandage in removal of mandibular third molars, *Int J Oral Surg* 2:273–278, 1973.
53. Kariro GSN: Metronidazole (Flagyl) and *Arnica montana* in the prevention of post-surgical complications; a comparative placebo controlled clinical trial, *Br J Oral Maxillofac Surg* 22:42–49, 1984.
54. Krekmanov L, Nordenram A: Postoperative complications after surgical removal of mandibular third molars, *Int J Oral Maxillofac Surg* 15:25–29, 1986.
55. Krekmanov L, Hallander HO: Relationship between bacterial contamination and alveolitis after third molar surgery, *Int J Oral Surg* 9:274–280, 1950.
56. Krekmanov L: Alveolitis after operative removal of third molars in the mandible, *Int J Oral Surg* 10:173–179, 1981.
57. Hooley JR, Francis FH: Betamethasone in traumatic oral surgery, *J Oral Surg* 27:398–403, 1969.
58. Huffman GG: Use of methylprednisolone sodium succinate to reduce postoperative edema after removal of impacted third molars, *J Oral Surg* 35:198–199, 1977.
59. Pedersen A: Decadron phosphate in the relief of complaints after third molar surgery, *Int J Oral Surg* 14:235–240, 1985.
60. Beirne OH, Hollander B: The effect of methylprednisolone on pain, trismus, and swelling after removal of third molars, *Oral Surg* 61:134–138, 1986.
61. Bustedt H, Nordenram A: Effect of methylprednisolone on complications after removal of impacted mandibular third molars, *Swed Dent J* 9:65–69, 1985.
62. Nordenram A, Grave S: Alveolitis sicca dolorosa after removal of impacted mandibular third molars, *Int J Oral Surg* 12:226–231, 1983.
63. Knutsson K, Lysell L, Rohlin M: Postoperative status after partial removal of the mandibular third molar, *Swed Dent J* 13:15–22, 1989.
64. Swanson AE: A double-blind study on the effectiveness of tetracycline in reducing the incidence of fibrinolytic alveolitis, *J Oral Maxillofac Surg* 47:165–167, 1989.
65. Nordenram A, Sydens G, Odegaard J: Neomycin-bacitracin cones in impacted third molar sockets, *Int J Oral Surg* 2:279–283, 1973.

66. Goldman DR, Kilgore DS, Panzer JD, Atkinson WH: Prevention of dry socket by local application of lincomycin in Gelfoam, *Oral Surg* 35:472–474, 1973.
67. Nitzan DNW: On the genesis of "dry socket", *J Oral Maxillofac Surg* 41:706–710, 1983.
68. Sweet JB, Butler DP: The relationship of smoking to localized osteitis, *J Oral Surg* 37:732–735, 1979.
69. Meechan JG, MacGregor IDM, Rogers SN, et al.: The effect of smoking on immediate post-extraction socket filling with blood and the incidence of painful socket, *Br J Oral Maxillofac Surg* 26:402–409, 1988.
70. Hall HD, Bildman BS, Hand CD: Prevention of dry socket with local application of tetracycline, *J Oral Surg* 29:35–37, 1971.
71. Sweet JB, Butler DP, Drager JL: Effects of lavage techniques with third molar surgery, *Oral Surg* 42:152–168, 1976.
72. Mitchell L: Topical metronidazole in the treatment of "dry socket", *Br Dent J* 156:132–134, 1984.
73. Wofford DT, Miller RI: Prospective study of dysesthesia following odontectomy of impacted mandibular third molars, *J Oral Maxillofac Surg* 45:15–19, 1987.
74. Mason DA: Lingual nerve damage following lower third molar surgery, *Int J Oral Maxillofac Surg* 17:290–294, 1988.
75. Robinson PP: Observations on the recovery of sensation following inferior alveolar nerve injuries, *Br J Oral Maxillofac Surg* 26:177–189, 1988.
76. Rood JP: The radiological prediction of inferior alveolar nerve injury during third molar surgery, *Br J Oral Maxillofac Surg* 28:20–25, 1990.
77. Blaeser BF, August MA, Donoff RB, et al.: Panoramic radiographic risk factors for inferior alveolar nerve injury after third molar extraction, *J Oral Maxillofac Surg* 61:417–421, 2003.
78. Oberman M, Horowitz I, Ramon Y: Accidental displacement of impacted maxillary third molars, *Int J Oral Maxillofac Surg* 15:756–758, 1986.
79. Leone SA, Edenfield MJ, Cohen ME: Correlation of acute pericoronitis and the position of the mandibular third molar, *Oral Surg* 62:245–250, 1986.
80. White RP, Madianos PN, Offenbacher S, et al.: Microbial complexes detected in the second/third molar region in patients with asymptomatic third molars, *J Oral Maxillofac Surg* 60:1234, 2002.
81. Osborne WH, Snyder AJ, Tempel TR: Attachment levels and crevicular depths at the distal of mandibular second molars following removal of adjacent third molars, *J Periodontol* 53:93–95, 1982.
82. Kugelberg CF, Ahlström U, Ericson S, et al.: Periodontal healing after impacted lower third molar surgery in adolescents and adults. A prospective study, *Int J Oral Maxillofac Surg* 20(1):18–24, 1991.
83. Kugelberg CF, Ahlström U, Ericson S: Periodontal healing after impacted lower third molar surgery. A retrospective study, *Int J Oral Surg* 14(1):29–40, 1985.

22

Complications of Dentoalveolar Surgery

JOSHUA CAMPBELL, ANDREW CHEUNG, LINDSEY NAGY

See the positive side, the potential, and make an effort.

Dalai Lama

Introduction

The age-old saying is, "If you practice long enough, you are bound to have complications." This is just as true in oral surgery as in other medical fields. The key is understanding how to approach and manage complications when they arise.

Exodontia is the most common procedure performed by oral maxillofacial surgeons. The Public Health Service reports that "more than three-quarters of the total cost of payments for oral surgery procedures were allocated to removal of third molars."[1] It stands to reason that most of the complications we see are related to exodontia. These can be common or rare and can occur during or after treatment. Nevertheless, with careful treatment planning and adhering to good surgical techniques and principles, surgeons can minimize the frequency of complications. In addition, early recognition and proper management can help to improve the outcome of procedures. Considering the fact that complications are a risk and potential sequela of any surgery, it is imperative that surgeons notify patients of them while obtaining informed consent. Complications can occur even when the surgeon adheres to good surgical principles. Variations in anatomy and the patient's response to healing can result in complications even when the surgeon executes the surgical procedure within the standard of care.

Complications during exodontia include the following:

1. Removal of the wrong tooth
2. Injuries to teeth and adjacent structures
3. Residual root remnants
4. Displacement of teeth or root tips
5. Soft tissue injuries
6. Oroantral communications
7. Swallowing or aspiration of teeth, fragments of teeth, or restorations and crowns
8. Tissue emphysema
9. Sensory nerve injuries

Complications after exodontia:

1. Alveolar osteitis (dry socket)
2. Infection
3. Trismus, swelling, and pain
4. Temporomandibular joint problems
5. Bone spicules

Complications that can occur during or after exodontia:

1. Hemorrhage
2. Injuries to osseous structures

Complications during Exodontia

Removal of the Wrong Tooth

Extraction of the wrong tooth is one of the most dreaded complications in oral surgery. It can happen for a number of reasons: miscommunication between the referring doctor and the specialist, incorrectly labeled radiographs or referral slips, and disagreement between the dentist and the patient. The best way to prevent this complication is to take a careful history with a review of recent radiographs, and to make a thorough clinical examination.

If the inadvertent removal of the wrong tooth is discovered at the time of surgery, and the tooth is healthy and salvageable, it should be reimplanted immediately and stabilized. The patient should be informed that the tooth not scheduled to be removed was removed and should be placed on antibiotics, and a follow-up appointment should be scheduled. The patient must not be abandoned, and appropriated follow-up care is essential.

If the patient has a referring dentist, they should also be made aware of what occurred. Document the event carefully in the patient's chart.

Injury to Adjacent Structures

Damage to Adjacent Tooth or Crown of Tooth

Fractures and loosening of adjacent teeth and dislodging of large restorations or crowns can accidentally occur during



• **Figure 22-1** Radiograph of roots with a crown in close proximity.



• **Figure 22-2** Additional radiograph of roots with a crown in close proximity.

exodontia. Careful evaluation of the surrounding dentition and radiographs should be done before instituting treatment (Figures 22-1 and 22-2). Often this complication is unavoidable because of loose crowns or large restorations with recurrent decay under the restoration. The patient should be made aware of the potential for these events occurring. If teeth are partially avulsed during removal of adjacent teeth, they should be repositioned and stabilized. Any dislodged crowns from teeth that do not show signs of decay can be permanently re-cemented. Teeth under crowns with decay should be reinserted with temporary cement, and the general dentist should be informed of the event. Adjacent teeth that are fractured or that have large restorations dislodged should be temporized. The patient should be referred back to their general dentist for definitive treatment. The incident should be well documented in the patient's chart, and the patient should be made aware of the problem.

Fracture of the Root of an Adjacent Tooth

Unintentional excessive pressure and/or accidental introduction of the drill into adjacent tooth or root structures can pose a challenge for both the patient and the oral surgeon.

Depending on the severity (fracture of the root versus drilling into enamel, dentin, or pulp), it is recommended that an image be taken to determine the extent of damage. Oftentimes, observation with regular follow-up is recommended for a fractured root. If the root is fractured such that its removal is required, apply mineral trioxide aggregate (MTA) to the end of the root and close the area.

Similarly, if pulpal tissues are exposed, apply agents that are similar to MTA topically to assist with the recovery.

Residual Root Remnants

During exodontia, roots can often fracture in spite of good surgical technique. Usually this occurs because the root is dilacerated or divergent. If the remnant is a couple of millimeters in diameter and in close proximity to a vital structure, such as a nerve or the sinus, risks versus benefits should be considered. Usually a root remnant this size will be of no consequence if not grossly infected. If a decision is made to leave it, the patient should be informed, postoperative radiographs should be taken, documentation should be entered in the patient's chart, and the patient should be evaluated periodically both clinically and radiographically to ensure uneventful healing.

Displacement of Teeth and Root Tips

Displacement of teeth and root tips is a rare occurrence.[2-5] Some causative factors that have been implicated are inexperience of the surgeon, uncontrolled force, improper use of instrumentation, and difficult access with poor visualization and inadequate exposure.[2,6] Variations in anatomy, such as a thin lingual plate of bone in the mandibular molar area of the maxillary sinus wall extending between the roots of the maxillary molars, can increase the potential for the displacement of teeth or root tips into the floor of the mouth or maxillary sinus, respectively.

The sites most frequently involved are the maxillary sinus, the submandibular space, and the infratemporal fossa.[2-12] Some reports describe accidental displacement of a third molar into the lateral pharyngeal space.[2,10]

Displacement into the Maxillary Sinus

Displacement of root tips or impacted teeth into the maxillary sinus or infratemporal fossa usually occurs because of the close proximity and thinness of the sinus floor or wall. In removing a superiorly distally impacted third molar, adequate bone removal, good visibility with careful elevation, and a distal stop is a must. If inadvertently a tooth or root tip is dislodged into the sinus, an attempt should be made to retrieve it through the extraction site with a suction tip. If the attempt is unsuccessful, radiographs should be taken to localize the tooth and a Caldwell-Luc approach should be used to remove it (Figure 22-3).

Displacement into the Infratemporal Fossa

If a third molar is displaced into the infratemporal fossa, begin to solve the problem by taking radiographs to

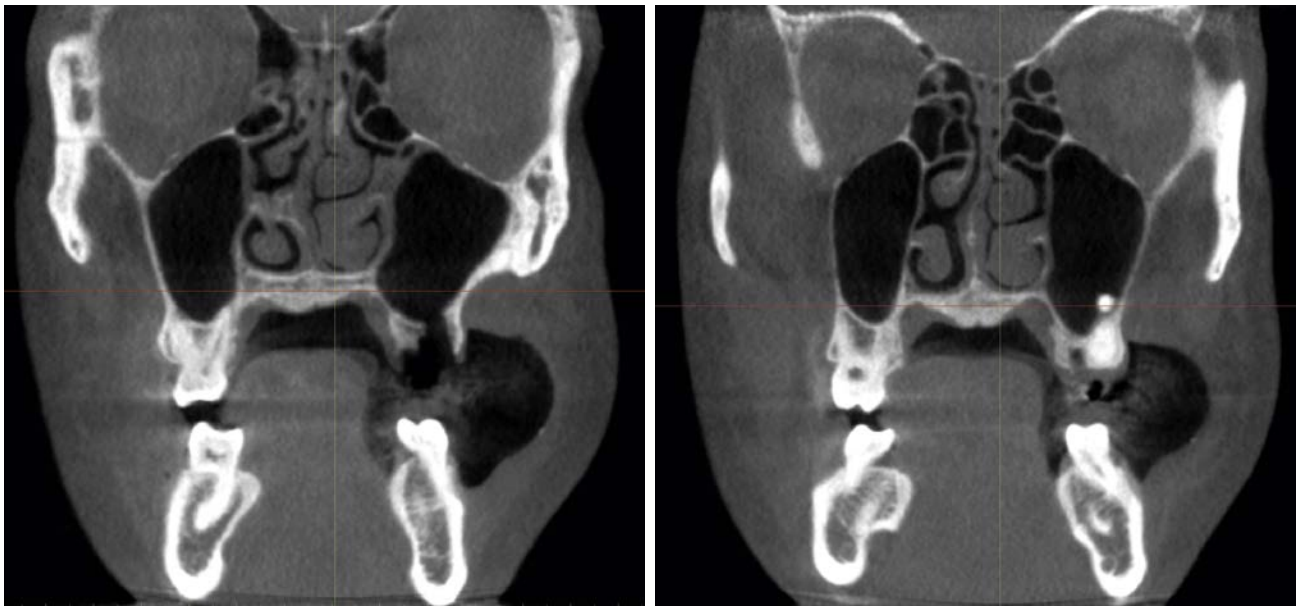

• **Figure 22-3** Cone-beam computed tomography of maxillary molar with root dislodged into maxillary sinus.

determine its position. There are two possible approaches when a tooth enters into the infratemporal fossa: immediate retrieval or a delayed approach.

The immediate approach almost always involves using a three-dimensional image to help locate the tooth. After determining fixed reference points/landmarks, extend an incision posteriorly to the tonsillar fauces, and with careful blunt dissection, attempt to identify and remove the molar with direct visualization.[6]

A C-arm can also be used intraoperatively to retrieve the tooth. Once the patient is asleep in the operating room, an initial image is presented to the surgeon. Another object such as a spinal needle can be advanced using serial imaging to pinpoint the location of the dislodged tooth. Once the spinal needle has located the tooth, make an incision with dissection to the tooth following the path of the spinal needle.

Another alternative for the immediate retrieval of the tooth at the hospital involves merging data from a three-dimensional image and a "real-time tracking" optical or electromagnetic surgical navigation unit. Not all medical centers provide this technology, and where it is available, it is only FDA approved for use in the maxilla.

An in-office unit (XNAV, Lansdale, PA) is available for oral and maxillofacial use to track and locate tooth and root fragments. Merging the three-dimensional image with a patient tracker with fiducial markers paired with the patient's anatomy can aid in guiding the surgeon to the remaining fragments.

Regardless of the approach, care must be taken to prevent injury to the pterygoid plexus of veins, which can result in brisk bleeding. If this happens, the procedure should be aborted and fibrosis should be allowed to develop around the tooth, from several days[13] to several weeks.[14] An attempt can be made to remove it by a hemicoronal or an intraoral approach after computed tomographic (CT) analysis to determine its location. Some authors recommend careful follow-up if the patient is asymptomatic.[14] One report indicated no adverse affects after 15 months.[14,15]

Displacement into the Submandibular Space

Care should be taken in attempting to remove the distal roots of third molars because the lingual cortex of the mandible curves laterally and is often thinner in the submandibular space. If a root tip is displaced into the sublingual space, first try to palpate it digitally and push it back into the socket (Figure 22-4). If this is unsuccessful, a full flap is raised on the lingual and the mylohyoid muscle is dissected free from its attachment, trying to keep the tip in position to prevent further displacement and thus facilitate its removal. Root tips rarely become displaced deep into the submandibular space, but if this should occur, let fibrosis take place. If removal is necessary, an extraoral approach can be used to retrieve it.

Infrequently, roots are punched through thin cortical plates in the maxillary bicuspid and molar regions. Usually, they can be palpated subperiosteally and pushed back through the socket, or an incision can be made below the socket to remove the root.

Some reports describe accidental displacement of third molars into the lateral pharyngeal space. Care must be taken with the use of surgical instruments to avoid such untoward effects during exodontia.

Infrequently, roots are pushed through thin cortical plates in the maxillary bicuspid and molar areas. Usually, they can be palpated subperiosteally and can be pushed back through the socket, or an incision can be made below it to remove it.



• **Figure 22-4** Cone-beam computed tomography of root tip of mandibular third molar dislodged into submandibular space.

Some reports describe accidental displacement of third molars into the lateral pharyngeal space.[2,10] Care must be taken with the use of surgical instruments to avoid such untoward effects during exodontia.

Soft Tissue Injuries

Soft tissue injuries can occur when performing exodontia. Soft tissue injuries include lacerations of the flap, burn injuries and abrasions from drills, puncture wounds, and tissue emphysema.

Lacerations of the Flap

Lacerations of the flap can be caused by inadequate reflection of the flap, by creating a flap that is too small (coupled with excessive pressure to reflect the flap), and by overretraction. These tears can increase the chance of wound dehiscence and can delay healing. If a tear does occur, reapproximate the margins and suture the wound carefully. Excise the edges before closing if the tear is jagged. Designing larger flaps with releasing incisions and using less retraction can prevent this complication.

Burns and Abrasions

Burns and abrasions are caused by rotary drills. Careful attention is necessary when using drills. Avoid catching the soft tissue with the shank of the burr and creating a laceration or shred injury. This injury usually occurs with the buccal mucosa and the corner of the mouth. Using a burr guard will help prevent this problem. These burns and/or abrasions are quite painful and are slow to heal. Antiinfective ointment or silver sulfadiazine can be used to treat these burns and/or abrasions. This complication can be prevented by careful attention of the assistant to the location of the shank of the burr when the surgeon is cutting. Maintenance of the burr guard is important to prevent overheating, which can cause severe burns to the lip.

Puncture Wounds

Puncture wounds to the soft tissue can be the result of uncontrolled forces with sharp instruments such as a No. 9 periosteal or a straight elevator. These injuries can often be prevented by using finger rest support from the opposite hand to protect the area from potential slippage with an instrument. But if a puncture wound occurs, small wounds should be left open and not sutured once hemostasis is achieved. If hemostasis cannot be achieved, sutures may be necessary. Because the instrument that punctured the soft tissue could contain debris and bacteria, place the patient on antibiotics.

Tissue Emphysema

Tissue emphysema is a complication that has been seen less frequently since the introduction of reverse turbine rotary instruments such as the Hall drill and electric hand pieces. It is caused by the introduction of air under pressure into the subcutaneous soft tissue. During the removal of bone or the sectioning of teeth with an air-driven dental handpiece, air can be forced under the skin and cause rapid swelling. Other causes are the use of an air syringe and a patient coughing or sneezing when a large flap is elevated.

When tissue with air in it is palpated, there is a feeling of crepitus; occasionally, the patient will acknowledge some tenderness associated with the site. Radiographs can show air in the soft tissue adjacent to the surgical site. Extensive subcutaneous emphysema can be life threatening or result in an infection leading to meningitis or mediastinitis.

Treatment consists of applying ice to the affected site, treating with systemic antibiotics, and monitoring. The condition usually resolves in several days; however, in severe cases, patients may require hospitalization and intravenous antibiotics.

Oroantral Communication

The roots of the maxillary premolars and molars are adjacent to the maxillary sinus. Occasionally a perforation can develop in the sinus when these teeth are extracted. It is important to discuss this possibility with the patient during the informed consent discussion.

If the maxillary sinus is exposed during the extraction, determine the course of treatment by the size of the communication. Do not probe the communication, as that could further tear the membrane.

For communications less than 2 mm, consider packing the site with a collagen plug. This will help maintain a good blood clot. Place the patient on special postoperative sinus instructions; advise him or her not to sneeze, smoke, rinse, spit, suck on a straw, or blow the nose for 1 month. If the

patient has obstructive sleep apnea and uses a continuous positive airway pressure (CPAP) machine, make sure to consult the patient's sleep specialist to help modify the pressure/cessation of the machine to assist with healing.

For moderate-sized communications (2 to 6 mm), place a collagen sponge with figure-of-eight sutures to prevent dislodgment. Place the patient on postoperative sinus instructions and prescribe a 1-week course of antibiotics, antihistamines, and nasal decongestants. Usually, amoxicillin/clavulanate (Augmentin), clindamycin, or cephalosporin can be prescribed to decrease the possibility of maxillary sinusitis.

For large communications (greater than 6 mm), the sinus communication must be primarily closed with a flap procedure. An advancement rotation flap can be used to assist with primary closure. Another option could involve use of the buccal fat pad as an interpositional pedicle flap under mucosa.

Swallowing or Aspiration of Teeth, Fragments of Teeth, or Restorations and Crowns

During exodontia, it is advisable to place an oral drape to prevent swallowing or aspiration of loose teeth, dislodged crowns or fragments of teeth, root tips, or dental restorations. In the event of a foreign body being swallowed, the patient should be sent to the hospital for radiographs to localize it. Usually posteroanterior (PA) and lateral chest radiographs and kidney, ureter, bladder (KUB) radiographs will identify the foreign body. If there is any doubt after these images have been taken, a spiral CT will further assist with identification of the dislodged foreign body.

If a tooth, root tip, or other foreign body is aspirated during surgery and it becomes lodged in the trachea, methods used in Advanced Cardiac Life Support, such as abdominal thrusts, back slaps, or the Heimlich maneuver, should be used in an attempt to remove it.[14] If the patient becomes unconscious, an attempt should be made to remove the object with a laryngoscope and a McGill forceps, or an emergency cricothyrotomy should be attempted. In the event the object passes the vocal cords, it will most likely enter the right mainstem bronchus or the right lung. The patient should be transported to the hospital where an emergency bronchoscopy can be performed to remove the object.

If the object has been swallowed, it will usually pass through the gastrointestinal tract uneventfully. A detailed description of the event should be recorded in the patient's chart.

Sensory Nerve Injuries

Sensory nerve injuries can occur with the removal of teeth whose roots are close to the inferior alveolar nerve, lingual nerve, or mental nerve. Temporary or permanent sensory nerve disturbances can occur anywhere from 0.4% to 2% of the time.[16] It is important for the surgeon to obtain a detailed informed consent from their patients concerning these complications. The incidence of sensory nerve injuries from third molar surgery is related to many factors. Tooth proximity to the inferior alveolar nerve canal and variation in the anatomic relation of the lingual nerve to the crown of the mandibular third molar are major factors that contribute to nerve injuries.[17]

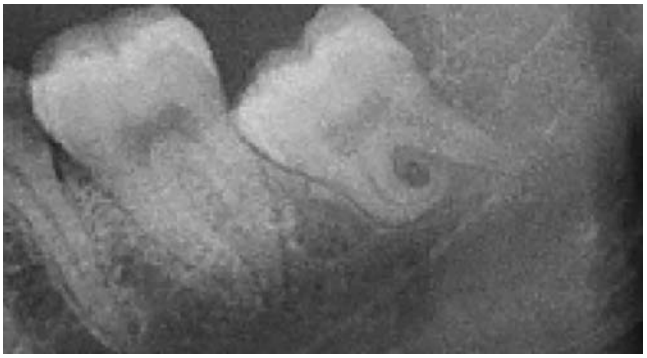

• **Figure 22-5** Radiograph of a mesioangular impacted third molar close to the canal.

A higher incidence of nerve injuries occurs with the removal of horizontally impacted teeth compared with mesioangular or distoangular impacted third molars[17] (Figure 22-5). The depth of the impaction, presence of completely developed roots, the use of rotary instruments, and sectioning of teeth can all contribute to nerve injuries. Division of the inferior alveolar nerve is infrequent, but pressure and compression of the nerve can take place during the removal of the third molar. Neurosensory alteration of the inferior alveolar nerve can occur when normal intraoperative and postoperative hemorrhage occurs and extends into the mandibular canal. Because this is a rigid osseous structure and the nerve is confined within this canal, the accumulation of blood within the canal can cause a compressing nerve injury. Usually the neurosensory alteration will be temporary, but it can be permanent. Injury to the lingual nerve occurs during the reflection of the flap, fracture of the lingual cortical plate, or perforation of the lingual cortical plate during sectioning of the tooth. The path of the lingual nerve as it passes on the lingual surface of the mandible near the mandibular third molar is variable. In approximately 17% of cases, the nerve lies above the crest of lingual bone and can be adherent to the follicle of the third molar. Therefore in these cases, a stretch injury or even a transection of the nerve can occur when the surgeon has performed the extraction technique within the standard of care.

The mental nerve can be injured during the removal of a premolar or during flap development or retraction. In the event of a high risk for nerve injury, the use of partial odontectomy may be indicated (see Figure 22-5). Seddon and Sunderland developed classifications for nerve injuries.[18,19] The Seddon classification is based on time from injury and degree of recovery. It includes neuropraxia, axonotmesis, and neurotmesis. Sunderland expands his classification to include first degree (neuropraxia), second degree (axonotmesis), third degree, fourth degree, and fifth degree (neurotmesis).

Neuropraxia results from minor nerve compression or traction injury. Since there is no loss of axonal continuity, usually there is complete recovery within 2 months. Microsurgery is not indicated. Axonotmesis is produced by blunt trauma, crushing, or a severe traction injury. Continuity of the axon is disrupted but not the epineurial sheath. Thus sensory recovery can take 2 to 6 months, though some cases have taken 1 year. Microsurgery is not indicated unless a foreign body is associated with it.

Sunderland's third- and fourth-degree nerve injury is the result of a compression, crush, or chemical injury. There can be some spontaneous recovery, but not completely, with a possible poor outcome. Microsurgery may be indicated if there is no improvement after 3 to 6 months. It should be emphasized that as long as the patient is exhibiting signs of improvement, microsurgery should be delayed.

Neurotmesis is the result of a complete transection of the nerve. The prognosis for spontaneous recovery is poor. Microsurgery is indicated for these injuries. Neurosensory testing should include two-point discrimination, light touch, brush strokes, vibrational sense, pain stimuli, and thermal discrimination. This will help determine the injury classification and recommended treatment. For the best results, nerve repairs should be performed by surgeons proficient in microsurgery.

Complications after Exodontia

Alveolar Osteitis (Dry Socket)

Dry socket, or alveolar osteitis, is one of the more commonly reported postoperative surgical complications. Some studies have shown the incidence to be as low as 3% with all extractions.[20-23] Other studies in the literature place the incidence of dry socket in the removal of mandibular third molars as high as 30%.[22-25] Dry sockets rarely occur in the maxilla. Although the cause is not known, data suggests that saliva with a high bacterial count may be the etiologic factor in causing destruction or malformation of the blood clot after extractions.[24] Other theories suggest fibrinolytic action as a possible cause because the use of antifibrinolytic agents demonstrated a decreased incidence of occurrence.[24,26,27] Additional factors that may be responsible for dry sockets occurring are smoking,[28] oral contraceptives,[25] experience of the surgeon,[29] complexity of the extraction,[30] and poor oral hygiene.[23]

The symptoms of a dull throbbing pain usually present themselves around the third to fifth day after surgery and are often confused with an earache, headache, or pain from another tooth with no evidence of pathologic condition. Neither narcotic analgesics nor nonsteroidal anti-inflammatory drugs give relief. Clinically, the classic signs of infection are not present, but there is a fetid odor, and the extraction site is devoid of a clot or shows evidence of poor healing and food debris. After irrigation and insertion of a medicated dressing, relief is experienced within minutes. Commercially prepared radiograph-detectable dressings containing 20% eugenol are available for use. Dry socket pastes containing eugenol, guaiacol, chlorobutanol, and balsam of Peru are also available and can be impregnated onto radiograph-detectable filament gauze for use as a dressing. The dressings are usually replaced every day or two after irrigation with normal saline. The symptoms dissipate after several days; however, on occasion they may persist longer. Beyond 3 weeks, radiographs should be taken and reviewed, and the patient should be examined clinically to rule out a different cause for the discomfort.

Infection

Postoperative infections can be minimized by following good surgical techniques, using copious irrigation, and adhering to principles of asepsis. Infections following extractions can occur even when the surgeon uses proper surgical techniques. The patient's local and systemic response to the surgery, the virulence of the bacteria on the area of the surgery, and the postoperative compliance or noncompliance of the patient can increase risk of infection.

Infections can occur postoperatively 3 to 4 days to several weeks after surgery. Most of these develop in third molar extraction sites, and the incidence has been reported to be anywhere from 3% to 5%.[30,31] Signs and symptoms include increased swelling, trismus, and tenderness along with redness, an elevated temperature, general malaise, and often a purulent exudate. Infection after dental extractions usually occurs in surgical cases requiring flap elevation and bone removal.[14] Patients who have poor oral hygiene or periodontal disease and are immunocompromised are more susceptible to postoperative dental infections.

Streptococcal species of bacteria appear to be the largest group causing postoperative oral infections, and studies have shown that these infections have an average of four different bacteria with anaerobic outnumbering aerobic species.[32] The most effective treatment continues to be penicillin. However, because of the increased recognition of anaerobic organisms in these infections, metronidazole or clindamycin can be substituted for penicillin.[22,32,33] When given prophylactically to patients with debilitating medical conditions or periodontal disease, antibiotics are thought to be of some value. Use of preoperative and postoperative antibiotics is still a controversial topic.[34-40] This practice may make treatment of subsequent infections more difficult because of resistant strains of bacteria.[36-40] There are some reports of a bacteremia being associated with the extraction of teeth.[41,42] This is a rare occurrence. In addition to antibiotic therapy, an incision and drainage should be performed and cultures obtained for sensitivity testing. In severe cases, consultation with an infectious disease specialist should be sought.

Infection can progress to osteomyelitis, even in a young, healthy patient. It is imperative to see and treat patients in a timely fashion to address this complication. The definition and treatment are outlined in a separate section of this textbook.

Medication-Related Osteonecrosis (MRON)

Oral bisphosphonates, such as Fosamax, Actonel, Boniva, Didronel, and Skelid, are being used to treat osteoporosis, osteopenia, Paget disease of bone, and osteogenesis imperfecta of childhood.[43-46] The intravenous bisphosphonates pamidronate disodium (Aredia) and zoledronic acid (Zometa) are being used in the treatment and management of cancer-related conditions.[46] In 2003 and 2004, oral surgeons published reports of nonhealing exposed bone in the maxillofacial region in patients on intravenous bisphosphonates (Figure 22-6). Subsequent to these reports, additional case series were published.[47-57] In 2004, health care professionals were notified by the manufacturer of the complications with intravenous (IV) bisphosphonates, and in 2005 a broader class warning was released that included the oral bisphosphonates.[57-59] The American Association of Oral and Maxillofacial Surgeons (AAOMS) considers a patient to have MRON if they have all three of the following characteristics:

1. Current or previous treatment with a bisphosphonate
2. Exposed bone in the maxillofacial region that has persisted for more than 8 weeks
3. No history of radiation therapy to the jaws

Currently the estimated cumulative incidence of MRON in patients on IV bisphosphonates, which is based on retrospective studies with limited sample sizes, is from 0.8% to 0.12%.[46,60-68] Patients on oral bisphosphonate therapy are at a much lower risk than those on IV therapy, with the estimated risk following extractions to be 0.09% to 0.34%; however, the risk appears to increase if the duration of therapy exceeds 4 years.[46]

In patients with a diagnosis of MRON, the goals of treatment should be to eliminate pain, control infection, and prevent the occurrence or progression of osteonecrosis.[46] Hyperbaric oxygen (HBO) therapy has not been proven to be effective in treatment of these patients,[46,69] and they do not respond as predictably to surgical treatments that are used for osteomyelitis and osteoradionecrosis.[48-50,55] The AAOMS has proposed the staging and treatment strategies listed in Table 22-1 for the treatment of patients with MRON.[46]

Any unsalvageable teeth should be extracted before IV bisphosphonate therapy begins. It has been proposed that if systemic conditions permit, oral bisphosphonates should be discontinued for 2 months before and should not be restarted until osseous healing has occurred. No alteration or delay of treatment is required for patients who are on oral bisphosphonates for less than 3 years and have no clinical risk factors. If these patients have also been taking steroids, because this may increase the risk of MRON, it is recommended that they take a drug holiday for 3 months until osseous healing has occurred. It is recommended that prescribing physicians be consulted about discontinuing oral bisphosphonates in patients for 3 months before treatment if they have been taking them with or without steroids. Therapy should not be restarted until osseous healing is complete.[46]



• **Figure 22-6** Medication-related osteonecrosis of the jaw after extractions.

Osteoradionecrosis

Osteoradionecrosis (ORN) is an avascular necrosis of bone caused by the three H (hypocellular, hypovascular, hypoxic) tissue effects of radiotherapy (Figure 22-7). It can develop when teeth are removed before radiotherapy but treatment is begun shortly thereafter (early trauma-induced ORN) or when a tooth is removed more than 3 years after therapy without HBO (late trauma-induced ORN).[71] Management of osteoradionecrosis is discussed in another chapter.

Trismus, Pain, and Swelling

Pain and swelling are a usual consequence of any surgical insult to the body. Swelling and pain are the result of the production of inflammatory mediators, such as leukotrienes, prostaglandins, and thromboxane A_2.[14] Most swelling reaches a peak in 24 to 48 hours, then gradually plateaus and begins to dissipate over the next 48 to 72 hours. Some factors that can contribute to increased swelling are the complexity of the extraction, excessive retraction, and the length of the operating time. The trismus that results is due to inflammation of the muscles of mastication and is probably a protective mechanism to limit function and further trauma. Either the surgical procedure or the administration of local anesthetic can cause trismus. Pain usually peaks several hours after surgery. Fisher and his colleagues placed peak pain at 3 to 5 hours after surgery.[72] Many studies have suggested the use of steroids and nonsteroidal anti-inflammatories to decrease swelling and pain. Preoperative intravenous steroids, such as dexamethasone and betamethasone, have also been shown to reduce postoperative swelling and pain that is associated with third molar surgery.[2,23,73] Narcotic combinations are used most frequently to control postoperative pain, but long-acting local anesthetics have also been shown to be effective in reducing postoperative discomfort. The reason for the effectiveness of local anesthetics is believed to be that anesthetic lasts longer than the peak pain period. Analgesics should be given before the local anesthetic wears off. Ice, which is advocated as a method to limit postoperative swelling by many practitioners, was not considered to be a considerable factor by Forsgren and his colleagues.[74] Paying close attention to good surgical techniques and using copious irrigation is also believed to be effective in reducing postoperative pain.[75-77]

TABLE 22-1 Staging and Treatment Strategies

MRONJ* Staging	Treatment Strategies†
At risk category: No apparent necrotic bone in patients who have been treated with either oral or IV bisphosphonates	• No treatment indicated • Patient education
Stage 0: No clinical evidence of narcotic bone, but non-specific clinical findings, radiographic changes and symptoms	• Systemic management, including the use of pain medication and antibiotics
Stage 1: Exposed and necrotic bone, or fistulae that probes to bone, in patients who are asymptomatic and have no evidence of infection	• Antibacterial mouth rinse • Clinical follow-up on a quarterly basis • Patient education and review of indications for continued bisphosphonate therapy
Stage 2: Exposed and necrotic bone, or fistulae that probes to bone, associated with infection as evidenced by pain and erythema in the region of the exposed bone with or without purulent drainage	• Symptomatic treatment with oral antibiotics • Oral antibacterial mouth rinse • Pain control • Débridements to relieve soft tissue irritation and infection control
Stage 3: Exposed and necrotic bone, or a fistula that probes to bone, in patients with pain, infection, and one or more of the following: exposed and necrotic bone extending beyond the region of aveolar bone (i.e., inferior border and ramus in the mandible, maxillary sinus and zygoma in the maxilla) resulting in pathologic fracture, extra-oral fistula, oral antral/oral nasal communication, or osteolysis extending to the inferior border of the mandible of sinus floor	• Antibacterial mouth rinse • Antibiotic therapy and pain control • Surgical débridement/resection for longer term palliation of infection and pain

Discontinuation of the IV bisphosphonates shows no short-term benefit. However, *if systemic conditions permit*, long-term discontinuation may be beneficial in stabilizing established sites of MRONJ, reducing the risk of new site development and reducing clinical symptoms. The risks and benefits of continuing bisphosphonate therapy should be made only by treating oncologist in consultation with the OMS and the patient.
Discontinuation of the oral bisphosphonate therapy in patients with MRONJ has been associated with gradual improvement in clinical disease. Based on the experience of two task force members managing 50 MRONJ patients who were treated with oral bisphosphonates, discontinuation of oral bisphosphonates for 6-12 mo may result in either spontaneous sequestration or resolution following débridement surgery. *If systemic conditions permit*, modification or cessation of oral bisphosphonate therapy should be done in consultation with the treating physician and the patient.
MRONJ, Medication-related osteonecrosis of the jaw.
*Exposed or probable bone in the maxillofacial region without resolution for greater than 8 weeks in patients treated with an antiresorptive and/or an antiangiogenic agent who have not received radiation therapy to the jaws.
†Regardless of the disease stage, mobile segments of bony sequestra should be removed without exposing uninvolved bone. The extraction of symptomatic teeth within exposed, necrotic bone should be considered since it is unlikely that the extraction will exacerbate the established necrotic process.
From American Association of Oral and Maxillofacial Surgeons: Position paper on medication-related osteonecrosis of the jaw—2014 update.



• **Figure 22-7** Osteoradionecrosis after extractions.

Bone Spicules

Occasionally, as the bone heals after an extraction, small fragments of bone will necrose and work their way through the soft tissue to be exfoliated (Figure 22-8). This process can be extremely painful for the patient. The soft tissue ulcerates and becomes inflamed. During this period, it can be helpful to reflect the overlying soft tissues and smooth the roughened bone. This can greatly reduce the length of the patient's discomfort.

Temporomandibular Joint Problems

Trauma to the temporomandibular joint during mandibular extractions is usually due to lack of support against lateral forces during exodontia. These lateral forces can be counteracted by providing support to the mandible with the other hand or by using a bite block. Patients will usually complain if too much force is being used during extractions.

It is very important to perform a thorough history and physical exam to document any previous temporomandibular



• **Figure 22-8** Bone spicule after extractions.

joint problem. Certain studies have shown that 60% of the population may suffer from some form of temporomandibular joint dysfunction, with the problem distributed equally between men and women.[75,78] Patients without a history of internal derangement of the temporomandibular joint may develop symptoms from extraction forces. Any history or signs of temporomandibular joint problems should be documented in the patient's chart before treatment. During the consultation, the patient should be made aware of this potential complication.

Surgical extractions may be indicated if the patient has a previous temporomandibular joint dysfunction or if too much force will need to be exerted during the procedure. Patients who develop symptoms after exodontia should be placed on a liquid or soft diet, instructed to limit their opening, apply moist heat to the affected side several times a day, and be prescribed nonsteroidal anti-inflammatories and muscle relaxants for 2 weeks. Rarely will splint therapy be necessary in these cases because the discomfort usually dissipates within a week or two. Most often if a patient requires splint therapy because of persistent discomfort, it is probably because they have a previous history of temporomandibular joint dysfunction. In extremely rare situations, magnetic resonance imaging (MRI) may be indicated to rule out a disc displacement.

Dislocation of the condyle is a more acute problem if it occurs during mandibular extractions. This complication can be prevented by applying appropriate support during extraction. If this complication occurs, it should be immediately corrected. Some surgeons stand behind the patient and place downward pressure on the external oblique ridge of the mandible with their thumbs to reduce the dislocation, whereas others stand in front with the patient lower and use similar maneuvers. The patient should then be placed on analgesics and a soft diet.

Complications that Can Occur during or after Exodontia

Hemorrhage

The majority of intraoperative or postoperative bleeding problems are not from coagulopathies but from local factors



• **Figure 22-9** Ecchymosis after extractions.

(Figure 22-9). Oral fibrinolysis has been suggested as a possible cause of hemorrhage from extraction sites in patients who have a normal bleeding profile and do not bleed after extraoral trauma.[75,80,81] For the most part, if there is history of previous extractions with no persistent hemorrhage, a local source should be identified and treated. It is wise to call patients to determine their status the evening after surgery. If there is a complaint of persistent bleeding, the patient should be instructed to remove any excessive exophytic clot from the area and rinse with a mixture of hydrogen peroxide and water, then salt water, followed by pressure with a moistened tea bag or a moistened gauze pad. If bleeding continues for 30 to 60 minutes, the patient should be seen. After the patient is anesthetized, any clots should be removed by curetting the socket, and an attempt should be made to identify the source. Remove any remaining granulation tissue. Bleeding from bone within the socket can be controlled by crushing or burnishing of the source with an instrument, placing bone wax, or cauterizing the site with a bovie/pocket cautery/laser/electrosurgery unit. If an arterial bleeder is identified, it should be ligated or cauterized. The surgical site should be resutured, and any persistent local oozing from the surgical site can be treated with the application of hemostatic agents, such as absorbable gelatin sponges (Gelfoam), oxidized regenerated cellulose (Surgicel), microfibrillar collagen (Avitene), absorbable collagen dressings (Collatape, CollaPlug), or topical thrombin applied to some of these agents.

Occasionally, when administering a posterior superior alveolar nerve block, swelling can develop rapidly in the

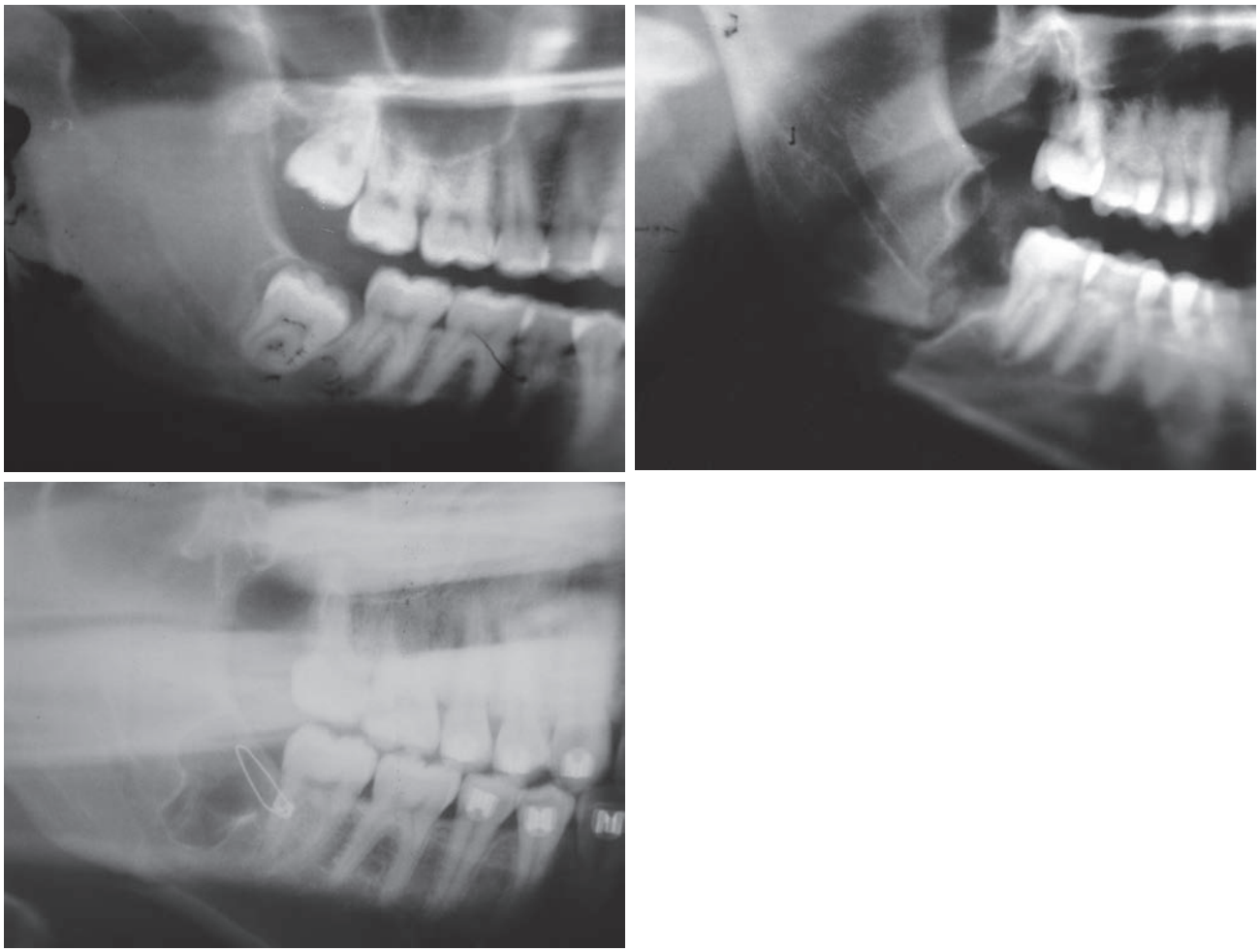

• **Figure 22-10** Fracture after extraction of mandibular third molar.

area of the cheek. This is a hematoma that is usually caused by perforating the posterior superior alveolar artery or vessels in the pterygoid plexus of veins. Treatment consists of immediate application of topical pressure and ice packs. In patients who are kept on anticoagulant therapy because of the potential for a thromboembolic event, local measures have been used to control postoperative bleeding. These include Surgicel and suturing. Other measures that have been used are a fibrin adhesive (Beriplast P, Centeon LTD, West Sussex, UK), tranexamic acid rinses, and an argon beam coagulator.[82-98]

Injuries to Osseous Structures

Bony fractures can occur in many areas. Some common sites are the labial and buccal plate in the areas of the maxillary and mandibular canine, bicuspid, and molar teeth.[99] Infrequently (0.00049% of cases), a bony fracture can occur in the mandible during the removal of third molars (Figure 22-10).[22,100] On occasion with removal of maxillary third molars, inadvertently the maxillary tuberosity fractures and the palatal mucosa will tear. It has been suggested that if the tooth is not carious, an attempt should be made to stabilize the tooth and segment with arch bars.[14] We have not had much success with this. Another alternative to stabilization with arch bars would be orthodontic brackets and heavy wire or wire ligatures. If a decision is made to remove the tooth with its bony tuberosity, it must be carefully dissected free from the soft tissue and the tissue tear closed. The site of the tear can be quite uncomfortable, and in spite of a careful repair, sloughing of the area can occur. The area usually heals and epithelializes by secondary intention. The bony segment can be used to graft the area.[14] A primary closure should be used to close the site, especially if the sinus was violated. When solitary teeth with a pronounced canine or buccal eminence are to be removed, it is advisable to reflect the mucosa and remove the tooth surgically to prevent a traumatic fracture and tissue tear. In the event of this happening, an alveoloplasty should be performed, and the tissue should be closed as judiciously as possible.

During the removal of third molars, if a nondisplaced fracture occurs, the fractured mandible should be treated immediately with a closed reduction using either arch bars or orthodontic brackets. If a fracture is severely displaced, arch bars or orthodontic brackets and a transoral open reduction can be attempted to reduce it. If this is

unsuccessful, the patient should be hospitalized, and an extraoral open reduction should be performed with internal rigid fixation using a Risdon or a percutaneous approach.

References

1. Friedman JW: Containing the cost of third-molar extractions, *Public Health Rep* 98:376–384, 1983.
2. Kerim O, et al.: Accidental displacement of impacted third molar into lateral pharyngeal space, *Turkish J Med Sci* 32:431–433, 2002.
3. Patel M, Down K: Accidental displacement of impacted maxillary third molars, *Br Dent J* 177:57–59, 1994.
4. Oberman M, Horowitz I, Ramon Y: Accidental displacement of impacted maxillary third molars, *Int J Oral Maxillofac Surg* 15:756–758, 1986.
5. Gay Escoda C, Berini-Aytes L: Pinera-Penalva M: Accidental displacement of a lower third molar, *Oral Surg Oral Med Oral Pathol* 76:159–160, 1993.
6. Archer WH: *Complications associated with oral surgery*, Philadelphia, 1975, WB Saunders.
7. Laskin DM: *Oral and maxillofacial surgery*, St Louis, 1985, Mosby.
8. Dormer BJ, Babett JA: Root section in the submaxillary space, *Oral Surg Oral Med Oral Pathol* 35:876, 1973.
9. Mellor TK, Finch DL: Displaced third molar, *Oral Surg Oral Med Oral Pathol* 64:131, 1987.
10. Pedlar J: Crown of a tooth in the lateral pharyngeal space, *Br Dent J* 161:335–336, 1986.
11. Peterson LJ: *Contemporary oral and maxillofacial surgery*, ed 2, St Louis, 1993, Mosby.
12. Skjelbred P, Lokken P: Post-operative pain and inflammatory reaction reduced by injection of a corticosteroid. A controlled trial in bilateral oral surgery, *Eur J Clin Pharmacol* 21:391, 1982.
13. Gulbrandsen SR, Jackson IT, Turlington EG: Recovery of a maxillary third molar from the infratemporal space via a hemicoronal approach, *J Oral Maxillofac Surg* 45:279, 1987.
14. Wells II DL, Capes JO, Powers MP: Complications of dentoalveolar surgery. In Fonseca RJ, editor: *Oral and maxillofacial surgery*, Philadelphia, 2000, Saunders.
15. Oberman M, Horowitz I, Ramon Y: Accidental displacement of impacted maxillary third molars, *Int J Oral Maxillofac Surg* 15:756, 1986.
16. Ziccardi VB, Assael LA: Mechanisms of trigeminal nerve injuries, *Atlas Oral Maxillofac Surg Clin N Am* 9:1–11, 2001.
17. Hill CM, et al.: Nerve morbidity following wisdom tooth removal under local and general anaesthesia, *Br J Oral Maxillofac Surg* 39:423–428, 2001.
18. Seddon HJ: Three types of nerve injury, *Brain* 66:237–288, 1943.
19. Sunderland S: A classification of peripheral nerve injury producing loss of function, *Brain* 74:491–516, 1951.
20. Field EA, et al.: Dry socket incidence compared after a 12 year interval, *Br J Oral Maxillofac Surg* 23:419, 1985.
21. Heasman PA, Jacobs DJ: A clinical investigation into the incidence of dry socket, *Br J Oral Maxillofac Surg* 22:115, 1984.
22. Srinivas M et al.: Third molar surgery and associated complications, *Oral Maxillofac Surg* 15(2):177–186, 2003.
23. Pogrel MA: Complications of third molar surgery, *Oral Maxillofac Surg Clin North Am* 2:3, 1993.
24. Larsen PE: Alveolar osteitis after surgical removal of impacted mandibular third molars, *Oral Surg Med Oral Pathol* 73:393–397, 1992.
25. Catellani JE, et al.: Effect of oral contraceptive cycle on dry socket (localized alveolar osteitis), *J Am Dent Assoc* 101:777–780, 1980.
26. Julis LL, et al.: Prevention of dry socket with local application of Terra-Cortril in gelfoam, *J Oral Maxillofac Surg* 40:285, 1982.
27. Gersel-Pederson N: Fibrinolytic activity of blood and saliva before and after oral surgery, *Int J Oral Surg* 10:114–121, 1981.
28. Sweet JB, Butler DP: The relationship of smoking to localized osteitis, *J Oral Surg* 13:160, 1979.
29. Sisk AL, et al.: Complications following removal of third molars: the role of the experience of the surgeon, *J Oral Maxillofac Surg* 44:855–859, 1986.
30. Alling CL, Kerr DA: Trauma as a factor causing delayed repair of dental extraction sites, *J Oral Surg* 15:3, 1957.
31. Osborn TP, et al.: A prospective study of complications related to mandibular third molar surgery, *J Oral Maxillofac Surg* 43:767–769, 1985.
32. Quayle AA, Rossell C, Hearn B: Organisms isolated from severe odontogenic soft tissue infections, *Br J Oral Maxillofac Surg* 25:34, 1987.
33. Labriola JD, Mascaro J, Alpert B: The microbiological flora of orofacial abscesses, *J Oral Maxillofac Surg* 41:711–714, 1983.
34. Bulut E, et al.: The value of routine antibiotic prophylaxis in mandibular third molar surgery; acute phase protein levels as indicators of infection, *J Oral Sci* 43:117–122, 2001.
35. Pieluch JF, Arzadon J, Lieblish SE: Prophylactic antibiotics for third molar surgery: a supportive opinion, *J Oral Maxillofac Surg* 53:53, 1955.
36. Curran JB, Kennett S, Young AR: An assessment of the use of prophylactic antibiotics in third molar surgery, *Int J Oral Surg* 3:1, 1974.
37. Laskin DM: Prophylactic antibiotics: a problem or a panacea, *J Oral Surg* 34:585, 1976.
38. Zeitler DL: Prophylactic antibiotics for third molar surgery: a dissenting opinion, *J Oral Maxillofac Surg* 53:61, 1995.
39. Paterson JA, Cardon VA, Strategos GT: An examination of antibiotic prophylaxis in oral and maxillofacial surgery, *J Oral Surg* 28:753, 1970.
40. MacGregor AJ: Antiprophylactic antibiotics, *J Oral Surg* 34:1063, 1976.
41. Rajasuo A, et al.: Bacteremia following surgical dental extraction with an emphasis on anaerobic strains, *J Dent Res* 83(2):170–174, 2004.
42. Okabe K, Nakagawa K, Yamamoto E: Factors affecting the occurrence of bacteremia associated with tooth extraction, *Int J Oral Maxillofac Surg* 24(3):239–242, 1995.
43. *Physician's desk reference*, ed 57, Montvale, NJ, 2003, Medical Economics.
44. Delmas PD, Mevnier PJ: The management of Paget's disease of bone, *N Engl J Med* 336:558–566, 1997.
45. Letocha AD, Cintas HL, Troendle JF, et al.: Controlled trial of pamidronate in children with types II and IV osteogenesis imperfecta, *J Bone Miner Res* 20:977–986, 2004.
46. American Association of Oral and Maxillofacial Surgery: Position paper on medication-related osteonecrosis of the jaw—2014 update. Available at: www.AAOMS.org.
47. Marx RE: Pamidronate (Aredia) and zoledronate (Zometa) induced avascular necrosis of the jaws: a growing epidemic [Letter], *J Oral Maxillofac Surg* 61:1115–1118, 2003.

48. Ruggiero SL: Osteonecrosis of the jaws associated with the use of bisphosphonates: a review of 63 cases, *J Oral Maxillofac Surg* 62:527–534, 2004.
49. Estilo CL, et al.: Osteonecrosis of the maxilla and mandible in patients treated with bisphosphonates: a retrospective study, *J Clin Oncol Proc Am Soc Clin Oncol* 22:8088, 2004.
50. Marx RE: Bisphosphonate-induced exposed bone (osteonecrosis/osteopetrosis) of the jaws: risk factors, recognition, prevention and treatment, *J Oral Maxillofac Surg* 63:1567–1575, 2005.
51. Migliorati CA, et al.: Bisphosphonate-associated osteonecrosis of mandibular and maxillary bone: an emerging oral complication of supportive cancer therapy, *Cancer* 104:83–93, 2005.
52. Purcell PM, Boyd IW: Bisphosphonates and osteonecrosis of the jaw, *Med J Aust* 1825:417–418, 2005.
53. Bagan JV, et al.: Jaw osteonecrosis associated with bisphosphonates; multiple exposed areas and its relationship to teeth extractions. Study of 20 cases [Letter], *Oral Oncol* 42:327–329, 2006.
54. Pires FR, et al.: Oral avascular bone necrosis associated with chemotherapy and bisphosphonate therapy, *Oral Dis* 11:365–369, 2005.
55. Woo SB, Hellstein JW, Kalmar JR: Systematic review: bisphosphonates and osteonecrosis of the jaws, *Ann Intern Med* 144:753–761, 2006.
56. Woo SB, Hande K, Richardson PG: Osteonecrosis of the jaws and bisphosphonates [Letter], *N Engl J Med* 353:100, 2005.
57. Hohnecker JA: *Novartis "Dear Doctor" precautions added to label of Aredia and Zometa*, September 24, 2004.
58. United States Food and Drug Administration Oncologic Drugs Advisory Committee: Combidex briefing information. www.fda.gov/ohrms/dockets/ac/05/ briefing/2005-4096B1.htm.
59. United States Food and Drug Administration Office of Drug Safety: Postmarketing safety review. www.fda.gov/ohrms/dockets/ac/05/briefing/2005-4095B2_03_04-FDA-TAB3.pdf.
60. Durie BGM, Katz M, Crowley J: Osteonecrosis of the jaws and bisphosphonates [Letter], *N Engl J Med* 353:99, 2005.
61. Bamias A, et al.: Osteonecrosis of the jaw in cancer after treatment with bisphosphonates: incidence and risk factors, *J Clin Oncol* 23:8580–8587, 2005.
62. Dimopoulos MA, et al.: Osteonecrosis of the jaw in patients with multiple myeloma treated with bisphosphonates: evidence of increase risk after treatment with zoledronic acid, *Haematologica* 91(7):968–971, 2006.
63. Dimopoulos M, et al.: The incidence of osteonecrosis of the jaw in patients with multiple myeloma who receive bisphosphonates depends on the type of bisphosphonate, *Blood* 106:637, 2005.
64. Tosi P, et al.: Bisphosphonates and osteonecrosis of the jaws: incidence in a homogeneous series of patients with newly diagnosed multiple myeloma treated with zoledronic acid, *Blood* 106:3461, 2005.
65. Pozzi S, et al.: Analysis of frequency and risk factors for developing bisphosphonate associated necrosis of the jaw, *Blood* 106:5057, 2005.
66. Cafro AM, et al.: Osteonecrosis of the jaw associated with chronic bisphosphonate therapy: an Italian experience, *Blood* 106:5152, 2005.
67. Zavras AI, Zhu S: Bisphosphonate are associated with increased risk for jaw surgery in medical claims data; is it osteonecrosis? *J Oral Maxillofac Surg* 64:917–923, 2006.
68. Hoff AO, et al.: Osteonecrosis of the jaw in patients receiving intravenous bisphosphonate therapy, *J Clin Oncol 2006 ASCO Annual Meeting Proceedings (post meeting edition)* 24:8528, 2006. http://meeting.jco.org/cgi/content/abstract/24/18_suppl/8528.
69. Chhoeu AH, et al.: A case series of hyperbaric oxygen treatment for non-radiation induced osteonecrosis of the jaw, *J Oral Maxillofac Surg* 64(Suppl):80–81, 2006.
70. Reference deleted in page proof.
71. Marx RE, Stern D: *Oral and maxillofacial pathology: a rationale for diagnosis and treatment*, Hanover Park, IL, 2003, Quintessence Publishing, pp 388–389.
72. Fisher SE, et al.: Factors affecting the onset and severity of pain following the surgical removal of unilateral impacted mandibular third molar teeth, *Br Dent J* 164:351, 1988.
73. El Hag M, et al.: The inflammatory effect of dexamethasone and therapeutic ultrasound in oral surgery, *Br J Oral Maxillofac Surg* 23:17, 1985.
74. Forsgren H, et al.: Effect of application of cold dressings on the postoperative course in oral surgery, *Int J Oral Surg* 14:223, 1985.
75. Pogrel MA: Surgical complications: complications of third molar surgery. In Kaban LB, Pogrel MA, Perrott DH, editors: *Complications in oral and maxillofacial surgery*, Philadelphia, 1997, WB Saunders.
76. Sweet JB, Butler DP, Drager JL: Effects of lavage techniques with third molar surgery, *Oral Surg* 41:152, 1976.
77. Butler DP, Sweet JB: Effect of lavage on the incidence of localized osteitis in mandibular third molar extraction sites, *Oral Surg* 44:14, 1977.
78. Rieder CE, Martinoff JT, Wilcox SA: The prevalence of mandibular dysfunction, *J Prosthet Dent* 50:81, 1983.
79. Reference deleted in page proof.
80. Bjorlin G: Local fibrinolysis in the oral cavity, *Scand J Hematol* 33:411, 1984.
81. Nilsson IM: Local fibrinolysis as a mechanism for hemorrhage, *Thromb Diath Haemorrh* 34:623, 1975.
82. Halfpenny W, et al.: Comparison of 2 hemostatic agents for the prevention of postextraction hemorrhage in patients on anticoagulants, *Oral Surg Oral Med Oral Pathol* 92(3):259.
83. Bailey BMW, Fordyce AM: Complications of dental extractions in patients receiving warfarin anticoagulant therapy: a controlled clinical trial, *Br Dent J* 155:308–310, 1983.
84. Martinowitz U, et al.: Dental extraction for patients on oral anticoagulant therapy, *Oral Surg Oral Med Oral Pathol* 70:274–277, 1990.
85. DeClerck D, Vinckier F, Vermylen J: Influence of anticoagulation on blood loss following dental extractions, *J Dent Res* 71:387–390, 1992.
86. Sindet-Pederson S, et al.: The effect of tranexamic acid mouthwash in anticoagulant treated patients undergoing oral surgery, *N Engl J Med* 320:840–843, 1989.
87. Throndson RR, Walstaad WR: Use of the argon beam coagulator for control of postoperative hemorrhage in an anticoagulated patient, *J Oral Maxillofac Surg* 57:1367–1369, 1999.
88. Rose SM, Rosenbloom B: Continued anticoagulant in oral surgery procedures, *Oral Surg Oral Med Oral Pathol* 40:448–457, 1975.
89. Donoff RB: *Massachusetts General Hospital manual of oral and maxillofacial surgery*, St Louis, 1987, Mosby.

90. Madura JA, Rookstool M, Wease G: The management of patients on chronic Coumadin therapy undergoing subsequent surgical procedures, *Am Surg* 60:542–546, 1994.
91. Johnson WT, Leary JM: Management of dental patients with bleeding disorders: review and update, *Oral Surg Oral Med Oral Pathol* 66:297–303, 1998.
92. Mulligan R, Weitzel KG: Pretreatment management of the patient receiving anticoagulant drugs, *J Am Dent Assoc* 117:479–483, 1988.
93. Hirsh J, Levine M: Confusion over the therapeutic range for monitoring anticoagulant therapy in North America, *Thromb Haemost* 59:129–132, 1988.
94. Poller L, Taberner DA: Dose and control of oral anticoagulant therapy and its control: an international collaborative survey, *Br J Haematol* 51:479–485, 1982.
95. Poller L: Laboratory control of anticoagulant therapy, *Semin Thromb Hemost* 12:9–13, 1986.
96. *British Medical Association and Royal Pharmaceutical Society of Great Britain: British national formulary, no 39*, London, 2000, The Pharmaceutical Press.
97. Devani P, Lavery KM, Howell CJT: Dental extractions in patients on warfarin: is alteration of anticoagulant regime necessary? *Br J Oral Maxillofac Surg* 36:107–111, 1998.
98. Hilfenhaus J, Weidman E: Fibrin glue safety: inactivation of potential viral contaminants by pasteurization of the plasma components, *Arzneimittelforschung* 11:1617–1619, 1985.
99. Peterson LJ: Postoperative patient management. In Peterson LJ, et al.: *Contemporary oral and maxillofacial surgery*, ed 3, New York, 1998, Mosby.
100. Libersa P, et al.: Immediate and late mandibular fractures after third molar removal, *J Oral Maxillofac Surg* 60:163–165, 2002.

23

Skeletally Based Implant Assisted Orthodontics

KEITH H. SHERWOOD

Introduction

In the past 15 years, implanted orthodontic anchor devices and techniques have evolved and become an important component of patient care. This chapter is designed to help the oral and maxillofacial surgeon understand this rapidly expanding and interesting field of surgical/orthodontic cooperation. It will include a comprehensive review of the literature, a description of the contemporary orthodontic implant options available, the evidence-based application, and enough of the orthodontic planning and treatment to allow cross specialty cooperation. Sharing this chapter with an orthodontic colleague will foster dialogue on the subject and improve communication and patient care.

History and Literature Review

Bone implants designed to provide anchors for orthodontic tooth movement have been proposed, studied, or used for nearly 40 years.[1,2] Most of the early fixture prototypes were abandoned because of problems with infection, difficulty with placement or removal, and premature mobility. However, in the 1980s, the success of endosseous dental implants led to a resurgence of academic interest in skeletal anchorage for orthodontics. Most of the early articles on implant-anchored orthodontic treatment were case reports describing dental implants recruited for dual use to assist with orthodontic treatment and dental restoration. Later studies were published on the temporary insertion of cylindrical implants in the retromolar area to be used for nonconventional orthodontic anchorage.[3] A short, cylindrical implant system designed specifically to be placed in the palate and connected to a transpalatal orthodontic appliance was briefly popular.[4]

Interest in miniplate-assisted orthodontics has been especially high as an alternative to certain types of orthognathic surgery. Jenner and Fitzpatrick published an early case report on the use of miniplates as anchors in the mandible to correct a skeletal Class III malocclusion.[5] In 1999, Umemori and colleagues reported on several extraordinary cases where miniplates were placed in the mandible to assist in orthodontically correcting major skeletal open bite.[6] Sherwood and co-workers later reported on the use of miniplates in the posterior maxilla as orthodontic anchors to intrude maxillary molars where skeletal open bite usually originates.[7]

Miniscrew implants (MSIs) or temporary anchorage devices (TADs) designed specifically for orthodontic anchorage were FDA approved in the United States in 2004 but have been researched and reported extensively in the literature for more than 15 years.[8,9] These implants have largely replaced the "onplant"[10] and the palatal endosseous implant for more straightforward anchorage use. The MSI is the easiest anchor to place, but success, especially long term, demands more rigorous control of the many technical variables involved than is necessary with other systems.

Most of the orthodontic implants mentioned are still widely used for skeletal anchorage, and each fixture has unique advantages and disadvantages. However, in contemporary practice, MSIs and miniplates are far more commonly studied and utilized by orthodontists, and will be discussed in depth. Although implant-anchored orthodontics is a relatively new field, research and experience is helping surgeons and orthodontists make informed decisions on choosing a suitable implant for a particular treatment objective.

Orthodontic Concepts for Surgeons

An in-depth discussion of orthodontic biomechanics is beyond the scope of this chapter. However, some general concepts will help the surgeon understand important factors in pretreatment communication with the referring orthodontist. Although the orthodontist may take the lead with treatment planning, much of the specifics of materials and methods associated with skeletal anchorage will be

left to the discretion of the surgeon. Clinical research and experience with orthodontic bone anchors suggests that implant type and specifications ideally should be matched to treatment goals. Attention to engineering details such as location, size, surface properties, and three-dimensional orientation can maximize predictability. Without understanding what the orthodontist is trying to do, the surgeon may place an implant that cannot be used optimally or will fail.

Moving teeth orthodontically in the direction needed to effectively correct a malocclusion, while preserving dental/periodontal health and improving cosmetics, is the complex challenge of orthodontics. An understanding of the fundamentals of orthodontics requires some knowledge of the biomechanics involved, which in turn are based on Newton's laws of physics. The important third law states in essence that each action has an equal and opposite reaction. Appreciating the clinical application of this law is critical to successful orthodontics. For example, if you attach an elastic chain to the bracketed teeth on either side of an edentulous area, each tooth will respond to the equal and opposite force moving it into the space, thus honoring Newton's law. However, orthodontics is never so simple. Retracting a canine into a first bicuspid extraction socket, for example, usually requires keeping the molars and second bicuspid teeth immobile while the canine moves posteriorly. To accomplish this, the posterior teeth may be ligated together to create an "anchorage block" or "anchor unit." In this tug of war, the molars and bicuspid act together as the anchor and will move mesially much less than the lone canine moves distally. Orthodontic anchorage is defined most simply as resistance to unwanted tooth movement. If anchorage is not controlled ("anchorage loss"), tooth movement is chaotic, may worsen malocclusion, and can cause irreparable root and bone damage.

There are two traditional types of orthodontic anchorage, dental and skeletal. The example just given, where several posterior teeth are used as an anchor unit to allow primarily the distal movement of a canine into an extraction socket, is an example of dental anchorage. In contrast, headgear is a type of skeletal or orthopedic anchorage. The skull and neck act as an anchor to retract the first molars or restrain maxillary anterior growth.

Implants are a type of skeletal anchorage. Some, such as endosseous implants and miniplates, may provide nearly "absolute" anchorage, whereas others such as miniscrews (TADs) often move slightly under orthodontic force. Implants can help the orthodontist avoid the anchorage loss often seen with dentally based anchorage. They may also allow orthodontic treatment of severe skeletally based malocclusions, such as open bite, that may be difficult or impossible to treat without orthognathic surgery.

Implant anchorage can be further subdivided into two categories, direct and indirect, based on how the implant is used. Direct anchorage is defined as placing orthodontic force directly from the implant to the tooth or teeth that need to be moved. Direct anchorage is demonstrated in Figure 23-1, where upper molars are being intruded with an elastic thread connected to an exposed inferior loop of a miniplate anchor that has been fixed superiorly to the cortical plate of the maxilla.



• **Figure 23-1** Miniplate tied to molars with an elastic thread for direct anchorage to intrude teeth.



• **Figure 23-2** Miniscrew implant ligated with wire to a first molar to provide indirect anchorage.

Indirect anchorage usually involves connecting the implant with a ligature wire to a tooth or teeth to create an anchorage unit. This is called "reinforced anchorage," because the implant is supporting the anchor teeth. Standard orthodontic forces can then be placed on the anchored teeth in the unit without the risk of significant anchorage loss. An example of indirect anchorage is shown in Figure 23-2, where a miniscrew implant inserted into the interproximal bone between the roots of a bicuspid and canine is attached with a wire ligature to the lateral incisor. The lateral incisor and miniscrew are now an anchor unit. Elastic chain has been stretched from the lateral incisor to the central incisors to close space and correct the midline to the left. With anchorage support from the miniscrew, the lateral incisor will remain in place while the midline is corrected.

Direct anchorage may require a more stable implant system to avoid fixture displacement, or a combination of shorter treatment time, more implants, or lighter orthodontic force. In contrast, indirect anchorage incorporates teeth into the anchor unit support, which reduces force on the implant. Understanding how the implant will be used affects the decision on the type of implant, its size, and where it should be placed.

Types of Orthodontic Implant Anchors

There are three major orthodontic implants types in contemporary use; miniplates, miniscrews, and endosseous cylinders. Most of these titanium implants are alloyed with other metals that affect properties like strength and ductility. Some even have surface treatment, such as standard dental implants meant to encourage healing. It is important to remember, however, that the orthodontic implant is usually temporary and will need to be removed within 6 to 24 months of placement. Whereas expedited healing and biocompatibility are essential, integration into bone is generally not desirable. Ease of placement and removal are important considerations for patient and clinician.

Most fixtures are designed to allow the orthodontist to attach springs, wires, or elastic chain and thread. Some implants have greater stability over time, so the duration and level of force the implant will be expected to support is important to determine preoperatively. When the patient is referred to the surgeon for treatment, the orthodontist may already have a strong opinion about what is preferable for an implant anchor type and anatomic positioning in the jaw. Others with less experience or understanding with implants may ask the surgeon to make recommendations.

This evidence-based, heavily referenced section is structured to help the surgeon and the orthodontist in choosing an implant type, placement location, and orientation that suits the goals of treatment, increases predictability, and satisfies the clinical needs of the orthodontist. Multiple references are provided where there is still significant disagreement on a topic. Familiarity with the commonly used implants will facilitate an understanding of the treatment planning process and clinical application reviewed in the next section.

Miniplate

Miniplate-assisted orthodontics has been reported for more than 30 years.[5] However, recently there has there been intense interest in the use of skeletal fixation devices as bone anchors in the management of complex malocclusions. A maxillary orthognathic surgery plate is often used with a loop or "working end" emerging transmucosally through the buccal vestibule or gingiva, and the other subperiosteal end secured to the buccal cortical bone with two or more short screws (Figure 23-3). They are particularly desirable where superior stability in the face of heavy orthodontic force over time is required. The multiple miniplate screws that secure the plate to cortical bone gives this orthodontic anchor the three-dimensional stability that is lacking with the popular miniscrew implant discussed later. Severe skeletal malocclusions such as open bite,[11] class III,[12] and class II[13,14] have been successfully treated orthodontically with the aid of miniplates, avoiding the need for orthognathics. Miniplates have also been attached to orthopedic appliances for distraction osteogenesis[15] and functional appliances that are used instead of headgear.[16]



• **Figure 23-3** Miniplate secured to the maxilla with two fixation screws. The working end is the terminal loop emerging through the wound.

One of the strongest indications for using miniplate anchors is to treat skeletal anterior open bite. Treatment of skeletal open bite with orthodontia only in teen and adult dentition is likely to relapse and risks resorption of delicate incisor roots due to elastic use.[17,18] Traditionally these patients have undergone orthognathic surgery in an effort to predictably treat this disabling malocclusion. Miniplate-assisted orthodontic closure of open bite has been reported extensively since the early studies confirming the efficacy and safety of the procedure.[19,20] The miniplate in this technique is used as skeletal anchorage to support intrusion of molars and bicuspids. This increases the interocclusal (freeway) space, thus allowing the mandible to autorotate superiorly and close the anterior open bite (Figures 23-4 and 23-5). There is no reported risk of sinus or inferior alveolar nerve damage from intruding roots.[21,22] Root resorption is minimal and in keeping with what is normally observed with orthodontic treatment.[23] Relapse, when seen, is comparable to that for patients having orthognathic surgery.[24] The technique is described in depth in the next section on Clinical Application.

Recently, several interesting studies by De Clerk have shown success with miniplates anchors placed in growing patients to correct class III malocclusion by growth modification in maxilla-deficient patients.[25-27] The plates have hooks to attach intraoral class III elastics or reverse pull headgear, to assist with stimulating orthopedic maxillary anterior growth and restraint of anterior mandibular growth (Figure 23-6).[28,29] Miniplate anchors keep the orthodontic forces in the basilar bone of the maxilla and mandible, thus avoiding tooth-borne orthodontic appliances that often cause unwanted tooth movement.[30] They can also reduce the need for patient compliance, which is a major issue with extraoral orthodontic appliances.

Studies have shown the miniplate to be one of the most stable and predictable implant anchors.[31-33] Where miniscrew implants have failed, miniplate anchors offer an excellent alternative. Miniplates also have the virtue of needing only small screws placed well away from roots. They are less likely to injure roots and generally do not create potential obstacles for tooth movement as other implants do.

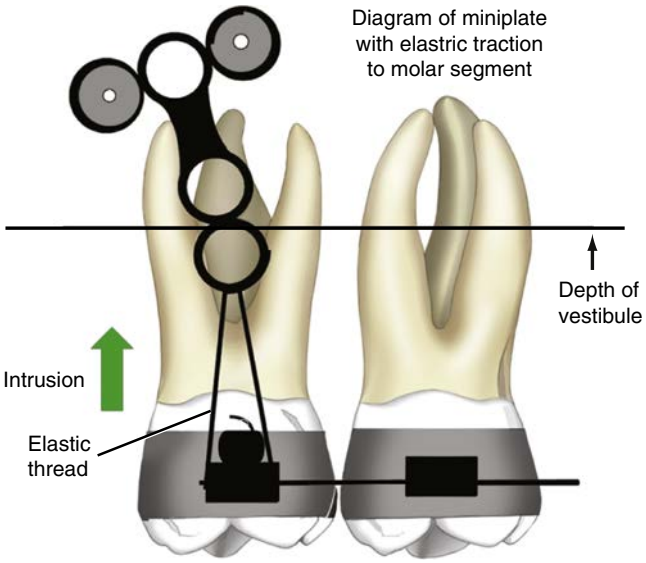

• **Figure 23-4** Miniplate anchorage setup for intruding molars with elastic thread to correct anterior open bite.

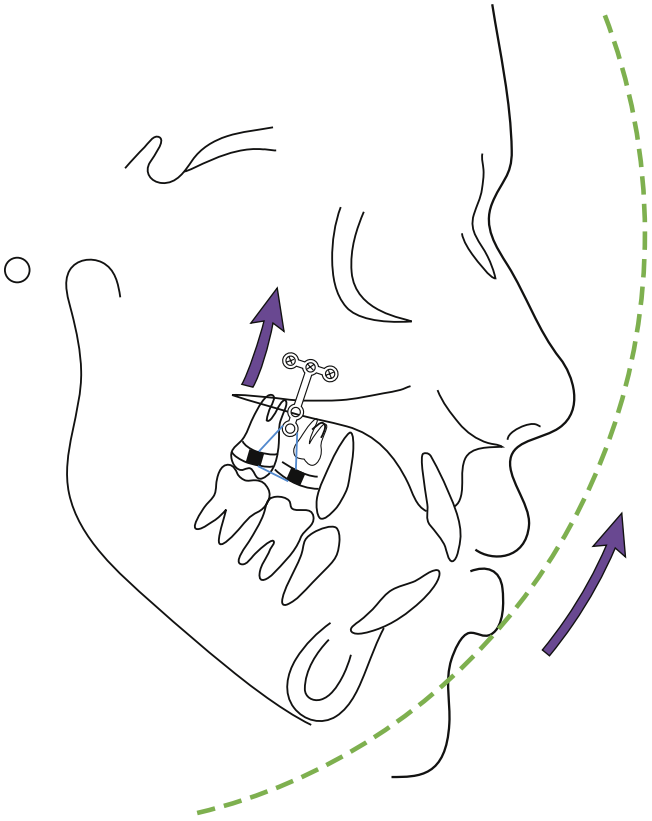

• **Figure 23-5** Arc of rotation of the mandible allowing closure of anterior open bite by intruding maxillary molars with miniplate anchors.

This allows for safe placement of the miniplate in the jaws almost anywhere the orthodontist needs an anchor to support orthodontic force. They are also the only implant that can be adjusted with bending to improve positioning. Many plating companies with ortho-implant systems have miniplates with orthodontic attachments welded to the exposed portion of the plate designed to accept ligatures and even

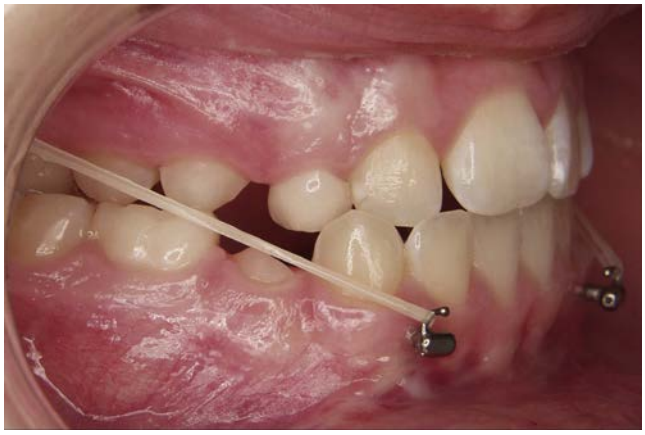

• **Figure 23-6** Bollard style miniplates used to attach elastics to correct preadolescent skeletal class III. (Courtesy Dr. Hugo De Clerk.)

arch wires. However, the exposed loop on a standard plate used for maxillary osteotomies is usually sufficient for open bite treatment.

Miniplates require significantly more surgery and expertise to place and remove than do miniscrew implants. Furthermore, they are usually less practical on the palate and the lingual of the mandible, where other implants are easier to insert. However, miniplates are well accepted by patients and providers and are an effective and predictable adjunct to orthodontic treatment of complex malocclusions.[32]

Miniscrew Implant

The popular miniscrew implant (MSI) or TAD (temporary anchor device), developed specifically for orthodontic anchorage, has been intensely studied and improved over the past decade. MSIs are designed to be threaded into the interproximal bone between teeth. All have some type of hole, hook, or grooved design in the external, exposed portion that allows the orthodontist to connect elastic chains or wire ligatures (Figures 23-7 and 23-8). They are relatively simple to place, although avoiding tooth roots can be a challenge.

Orthodontists, especially recent trainees, may place their own miniscrew implants because of the limited surgery involved. However, predictability varies tremendously between practitioners depending in part on experience. Studies looking at percent success (which often is creatively defined) give ranges from 50% to 95%.[33-35] The commonly used monocortical miniscrew anchors have less stability with orthodontic loading then bicortical screws and other types of implants.[36] Thus, most studies in the past 10 years have focused on MSI design and insertion protocols that increase predictability. Miniscrew characteristics, bone density, gingiva type and health, insertion technique, patient issues, and orthodontic forces are all factors that affect success rates. This evidence-based section summarizes the relevant literature on miniscrew implants and assists the surgeon with selecting an anchor system and surgical approaches that improve stability.



• **Figure 23-7** Miniscrews with button attachment or hole to attach elastic chain, ligature wires, or springs. (From Suzuki EY, Suzuki B: Placement and removal torque values of orthodontic miniscrew implants. *Am J Orthod Dentofacial Orthop* 139(5):669-678, 2011.)

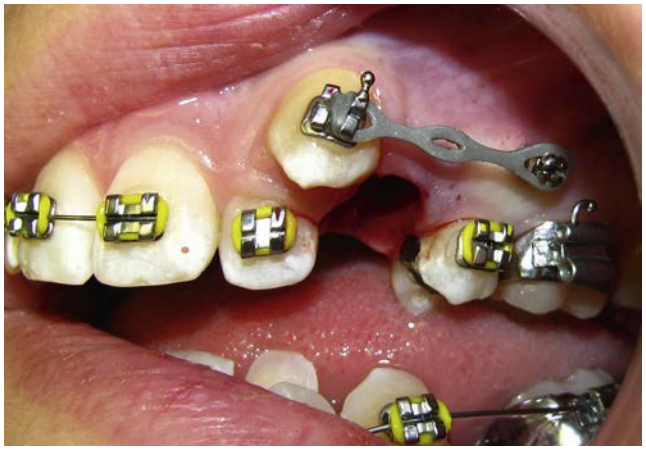

• **Figure 23-8** Miniscrew inserted between second bicuspid and molar used for direct anchorage to retract canine.

Miniscrew Design Factors

Ideal screw dimensions have been heavily investigated. The threaded portion of the screw should be at least 1.3 to 1.5 mm in diameter to prevent breakage during insertion or removal.[37] Wider-diameter and bicortical screws are more stable, although placement is more difficult and carries greater risk of tooth-root injury.[36,38] Realistically, 2-mm diameter threads are the maximum that should be used between tooth roots, because it is critical to avoid the periodontal ligament.[39] Insertion at least 5 mm into bone helps with stability, so the threaded portion should be at least 5 to 6 mm long.[40]

Several other design characteristics may affect MSI success at least initially. Increased pitch (frequency) of the threads[41-43] has benefit but also increases torque insertion forces (discussed later). A tapered threaded portion provides greater early stability as compared to the cylindrical shape, though there is not a significant long-term difference.[44] However, early stability may be important if the MSI is loaded immediately. Finally, a lower profile of the exposed portion of the MSI, which will be attached to a spring or elastic, may also lend greater stability by reducing biomechanical stress on the fixture and bone.[45]

Bone Considerations

After MSI design, bone factors that may affect clinical success have been studied most extensively. Despite this, there is still disagreement on ideal bone characteristics to support MSIs. The assumption that greater bone density and cortical bone thickness is beneficial has been confirmed in some studies,[42,46-49] but disputed in others.[50-52] The discrepancy may in part be caused by study design. Primary or immediate stability is clearly related to bone density and cortical bone thickness, whereas long-term stability over the course of months of orthodontic force application is affected by many other factors. Insertion torque, which is higher in denser, thicker bone, has been shown to be a good measure of primary stability with MSIs.[42,46,47,53] However, the presence of dense bone may lead to excessive torque pressure with MSI insertion. Some clinical studies have suggested that this leads to reduced stability over time, possibly secondary to necrosis.[54,55] Although optimum torque levels for clinical purposes have not been established, medium torque levels between 10 and 15 Ncm may be more predictable.[54,55] With higher torque, a small pilot hole should probably be drilled. Furthermore, wider-diameter, tapered-shape, self-drilling, and/or bicortical screws, which increase torque, may improve outcomes.[48,46,55] If torque is impractical to measure, anatomic knowledge of bone density and cortical thickness is important. In general, bone density is less in the alveolus than in the basilar bone, is greater in the mandible than the maxilla, and in the buccal alveolus increases progressively from anterior to posterior in both jaws.[56] There seems to be agreement in the literature that the alveolus from the second bicuspid to the first molar is, in general, optimum in terms of bone quality and other factors.[57-59] However, as discussed next, many other considerations are involved with selecting an ideal anatomic location for MSI insertion.

Technique Factors

Success with MSIs has been linked more closely with operator experience than other types of implants.[34] This likely speaks to the underlying instability of the monocortical miniscrew and the preponderance of factors that need to be controlled to allow predictability. However, attention to good technique can mitigate problems that contribute to screw failure even in the hands of the inexperienced clinician.

Root Proximity

Root proximity, especially when the periodontal ligament is invaded, is a major risk factor for early loss of the miniscrew fixture.[39,50] Minor root damage seems to be a manageable risk of MSI insertion. Studies have demonstrated repair without serious consequence when the injury is limited to abrasion of the cementum.[60] However, more serious injuries are possible, and ankyloses, root resorption, and pulpal necrosis have been reported.[61,62] If the periodontal ligament is contacted by the MSI, the patient will feel pain unless local anesthetic has been injected. Immediate radiographs are recommended. If there is tooth contact, the implant should be removed immediately. Surgical guides,[63] cone beam computed tomography, and stents[64-66] may help the inexperienced operator with safe MSI placement.

Drill versus Self-drill

Most MSIs are available with self-tapping (drilling required) and/or self-drilling (drill-free) options. In the maxilla, there does not appear to be a significant difference in clinical success between self-drilling and predrilled self-tapping screws long term.[67-70] However, for screw placement in the dense bone of the mandible or midline of the palate, drilling a small pilot hole is recommended to reduce high insertion torque.[67,71] It is also important to not heat the bone while drilling, which would lead to bone necrosis and fixture loss.[72]

Self-drilling screws are easier and quicker to place in the medium to soft bone of the maxilla. They usually require only topical anesthetic so patient comfort is improved. Furthermore, if injectable local anesthetic is avoided, the operator is alerted to root contact by patient discomfort. Self-drilling screws have higher insertion torque values, which could translate into better primary stability.[42,46,47,53]

Angle of Placement

The more closely an MSI long axis approximates the line of applied orthodontic force, the more stable and resistant to failure it will be.[73] For example, if the treatment plan requires vertical intrusion force on a tooth, the screw should be angled with the threaded portion aimed apically. Angulation along the long axis of the force vector may not be possible with mesio-distal forces and screw placement in the narrow bone between roots. Alternatively, placement of the screw at 90 degrees to the bone was found to be advantageous biomechanically for most applications.[74] Ideal angulation obviously requires communication with the orthodontist regarding treatment goals.

Orthodontic Loading

As explained in the section on biomechanics, direct or indirect orthodontic loading forces may be placed on the MSI by the orthodontist. With direct loading, the elastic chain or spring is tied from the exposed portion of the fixture to the tooth or teeth that are being moved. In contrast, with indirect loading, the fixture is tied passively with a wire ligature to stabilize a group of teeth, and orthodontic forces are then applied to the teeth instead of the implant. Indirect loading reduces forces on the implant and probably reduces the risk of MSI failure.[75]

Most studies and clinical experience with direct loading of MSIs suggest that immediate orthodontic forces of 100 to 200 g are safe, at least for the short term.[76-78] However, the amount of force the screw can tolerate is probably limited by screw length, bone density, and the other variables listed earlier. The monocortical MSI is not immobile, and excessive direct force may be detrimental. The phenomenon of drift, where an otherwise healthy functioning fixture tips slowly toward the origin of the force, may cause root or even nerve damage.[68,69,79]

It is the responsibility of the orthodontist to load the fixture judiciously. Whatever information the surgeon can communicate regarding bone density and screw properties will help the orthodontist decide how best to make use of the implant anchor.

Gingival Factors

It is debatable to what extent the nature of the gingiva through which a miniscrew is placed affects stability. Many studies suggest that failure rates are reduced when MSIs are placed through thin attached gingiva.[80-83] Other studies maintain that MSIs can be safely placed in sites that lack keratinized gingiva.[84] Gingiva type probably has little effect on short-term (primary) stability, because mechanical interlock in bone is paramount the first month postoperatively.[53] Long term, it seems logical that gingival issues could cause MSI instability from inflammation.[80,81,85] Along with good oral hygiene, locating the miniscrew in attached gingiva when possible will reduce inflammation and likely improves longevity.

Controlling the variables just discussed with miniscrew implant placement will reduce the risk of fixture failure and the resulting interruption of orthodontic treatment that is frustrating for patient and clinician.

Clinical Application and Case Presentation

This section on the clinical application of implant anchorage is organized to help the surgical-orthodontic team with treatment planning and to facilitate safe and effective implant placement. Although miniscrew implants or miniplates can often be used for similar malocclusions, the quality of bone, the duration and level of force with which the implant is to be loaded, and patient comfort should dictate the type of implant that is selected. Once an implant system is chosen, the orthodontist should determine the ideal location for the implant to meet the biomechanical goals of treatment. The cases reviewed reflect common application of implant-anchored orthodontics. In general, miniplates are used when the treatment time is expected to be long (up to a year or more), bone quality is questionable, or skeletal malocclusions are being treated. When miniscrews are used, treatment time is relatively short, bone quality good, and multiple fixtures or indirect anchorage employed to limit the force on individual implants.

Miniplates

Skeletal Anterior Open Bite Treatment

Growth-related (skeletal) anterior open bite is one of the most difficult malocclusions for the orthodontist to manage. Severe relapse is common, especially when orthodontic-only treatment is attempted on teen and adult patients and anterior teeth are intentionally or inadvertently extruded.[86] Studies have shown that skeletal anterior open bite often derives from excessive posterior vertical growth, especially in the molar alveolus.[87] Historically, this has been managed with orthognathic surgery. Advances in implant anchorage have enabled true orthodontic intrusion of molars, a treatment once thought to be biomechanically impossible. As shown by the diagram in Figure 23-5, intrusion of posterior

teeth increases freeway space, which permits autorotation of the mandible, leading to closure of anterior open bite. The ratio of molar intrusion to incisor open bite closure is 1:2 to 1:3. As will be seen, it is important for the orthodontist to determine preoperatively approximately how much intrusion will be needed.

Treatment begins with banding of the molars and bracketing of all the teeth including the second molars. Because of the accentuated curve of Spee usually seen with anterior open bite, sectional archwires often must be used to prevent undesirable extrusion of incisors that would occur with a continuous wire. The three wire sections usually include the canines and incisors together anteriorly and the bicuspids and molars in two separate posterior segments (Figure 23-9). To prevent buccal tipping of the molar segments during intrusion mechanics, a TPA (transpalatal arch) must be placed preoperatively by the orthodontist that is offset from the palate the distance the molars are expected to intrude (Figure 23-10).



• **Figure 23-9** Orthodontic setup for open bite closure with miniplate anchored intrusion of molars. Due to the curve of Spee, the maxillary archwire is in sections, canine to canine and bicuspids to molars.

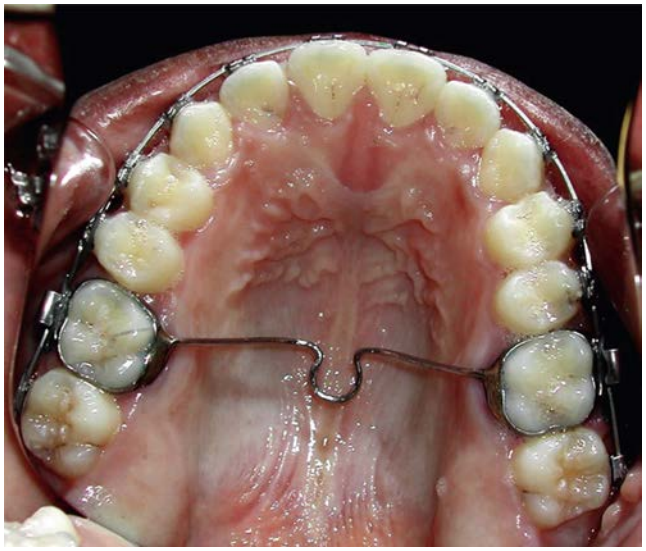

• **Figure 23-10** Transpalatal appliance (TPA) pre-surgery relieved from the palate the expected distance for orthodontic molar intrusion.

The miniplate insertion can be done using light sedation or even local anesthesia in tolerant patients. Plates from a maxillary orthognathic plating system (Figure 23-11) or orthodontic anchor kit (Figure 23-12) can be used. Standard plates should be positioned so that the last loop (working end) of the plate emerges from the mucosa far enough apically from the first molar band so that after intrusion is complete, the loop will not contact the most gingival tube on the band. This distance is determined by the number of millimeters of expected intrusion. For example, a 10-mm incisor open bite requires 5 mm of molar intrusion and a corresponding 5 mm or more of vertical space from the headgear tube to the miniplate loop (see Figure 23-9). Anteriorly-posteriorly, the loop should emerge between the first and second molars and should be bent buccally well clear of the tissue to allow easy access for the orthodontist and to prevent compression of the gingiva by the elastic thread or coil (Figures 23-1 and 23-13). The other end is fixed with two to three 3- to 5-mm-long screws (depending on bone thickness), placed far enough apical to the roots to guarantee that they will not contact the intruding root tips during treatment (Figure 23-14). The plate should be oriented so that its long axis is approximately in line with that of the teeth to be intruded (Figure 23-15).



• **Figure 23-11** Standard maxillary osteotomy plates and screws that can be used as skeletal anchors for molar intrusion. (Courtesy Stryker Corporation.)



• **Figure 23-12** Orthodontic only miniplates with hooks on working end. (Courtesy KLS Martin.)

The orthodontist will use an elastic thread or coil from the molar bands to the miniplate loop to intrude the posterior teeth (see Figures 23-1 and 23-13). The thread is changed every 4 weeks. Intrusion usually proceeds at approximately 1 mm per month but can advance faster in young patients and more gradually in older adults.



• **Figure 23-13** Working end of miniplate loop emerging through the mucosa between first and second molars and bent buccally to prevent compression of gingiva by attached coil spring.

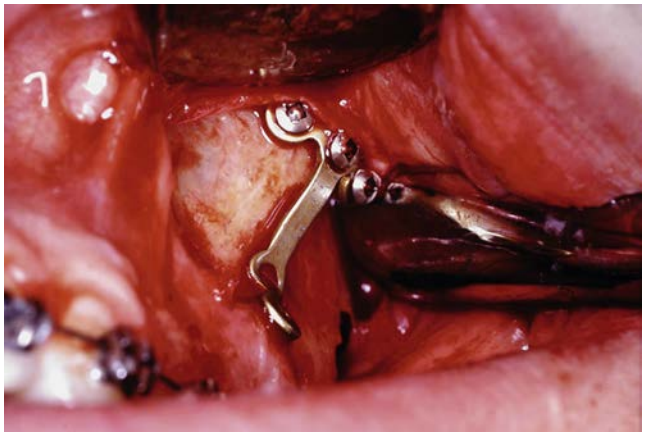

• **Figure 23-14** Surgical placement of miniplate anchor and fixation with three screws well above molar roots. Note contouring of plate to maxillary strut, emergence of plate through wound margin, and buccal bending of working loop off the gingiva.

It is recommended that third molars be removed in a jaw receiving miniplates.

The case presentation for this technique shows a 17-year-old patient with a severe, disabling skeletal anterior open bitethat in the past could only be treated with an osteotomy (Figure 23-16, *A*). The archwire was sectionalized distal to the canines, and miniplate anchored molar intrusion was initiated. Figure 23-16, *B* through *D*, shows the progression of bite closure exclusively by molar intrusion. After debracketing, the orthodontist elected to use standard retainers, and there has been good stability after 3 years. However, retainers with posterior bite blocks are recommended.

Molar Intrusion, Space Closure, Correction of Class III

This 28-year-old man had supererupted lower left molars due to missing maxillary posterior teeth, a class III dental relation on the left, an anterior crossbite, and a mandibular midline discrepancy (Figure 23-17, *A*). The patient refused maxillary appliances, so treatment goals were limited to creating vertical space for maxillary left implants and correcting the class III, anterior crossbite and lower incisor midline discrepancy.

After intrusion, the miniplate was ligated to the molars, creating an anchorage block. Extraction of the second premolar and elastic chain use from the intruded first molar to the anterior teeth allowed en masse (simultaneous multiple tooth) retraction and space closure, and correction of the anterior crossbite and midline discrepancy (see Figure 23-17, *B*). Maxillary posterior implants were placed during active orthodontic treatment. After completion of orthodontics (see Figure 23-17, *C*), they will be uncovered and restored before debracketing to prevent re-eruption of the orthodontically intruded lower molars.

Miniscrew Implants

The miniscrew implant anchorage case presentation section has been divided into direct and indirect anchorage applications. It demonstrates how monocortical MSIs are

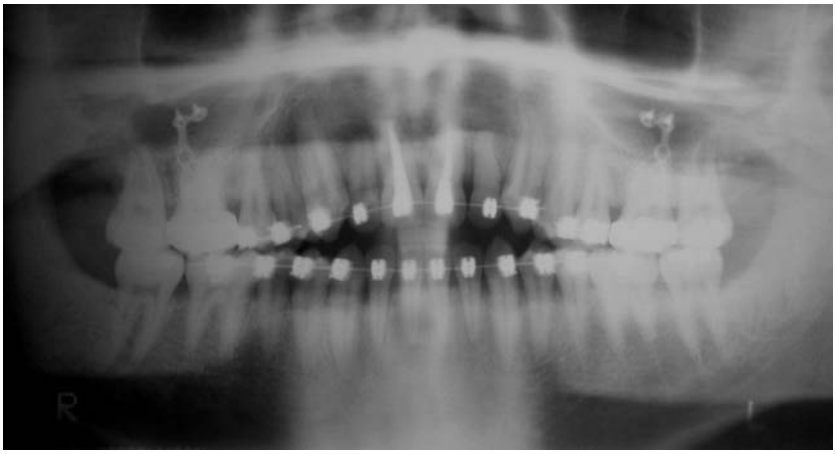

• **Figure 23-15** Panographic radiograph of orientation of miniplate to long axis of molars requiring intrusion.

commonly used as orthodontic anchors and can be safely loaded to avoid loosening or migration (drift).

Direct Anchorage

Direct Anchorage to Intrude Molars/Premolars and Retract Anterior Teeth

The adult patient shown in Figure 23-18, *A*, had hypererupted maxillary molars and bicuspids due to the lack of opposing dentition, posterior bite collapse, proclination of incisors, and a class II canine relationship. A bridge connected the lateral incisor and canine with a cantilevered first bicuspid pontic. The pontic was removed to create space, and miniscrew implants were placed mesial and distal to the first molar. An elastic thread was tied below the headgear tube on the band to create the vertical force to help intrude the molar. The miniscrews and molar/bicuspid teeth created an anchorage block that was then used to help retract and upright the anterior teeth en masse by using a coil spring stretched from the anterior miniscrew to a welded hook on the archwire (see Figure 23-18, *B*). After retraction of the incisors, they were stabilized with a ligature wire attached from the anterior miniscrew to the archwire hook, and the posterior space was closed with elastic chain (see Figure 23-18, *C*).

Direct Anchorage to Upright Impacted Second Molar

Impacted second molars are a common problem in orthodontic treatment. Orthodontic uprighting is the safest and most predictable method to treat this condition. If there is enough space and bone behind the second molar, a miniscrew implant can be placed in the retromolar area or ascending ramus and used to upright the molar. Ideally the third molar should be removed, the second molar exposed, and the miniscrew placed simultaneously.

Figure 23-19 demonstrates uprighting of a horizontally impacted mandibular left second molar in a 16-year-old patient who was missing the third molar. After exposure of the second molar, a button bracket was cemented to the disto-occlusal surface of the molar. A miniscrew was inserted into the bone well distal to the impacted tooth, at a 45-degree angle to the occlusal plane, and inferior enough to avoid the opposing maxillary second molar in centric occlusion. An elastic chain was connected from the bracket to the miniscrew to distally rotate and upright the molar.

Indirect Anchorage

Indirect Anchorage to Correct a Class II

This adult patient had a class II molar/canine malocclusion. A miniscrew was inserted buccally between the second bicuspid and first molar roots. A wire ligature was tied from the miniscrew to the bracket on the canine to create an anchor unit supporting the canine. A compressed expansion coil was threaded onto the archwire between the canine and first molar (Figure 23-20, *A*). The canine, which otherwise would be pushed mesially from the coil, was immobile because of its ligation to the miniscrew anchor. The force of the expansion spring opening distalized the molars into a class I relation (see Figure 23-20, *B*). The space created mesial to the premolar is caused by transseptal periodontal fiber pull from the distalized molar to the bicuspid. This space will allow the orthodontist to eventually retract the canine and premolar into a full class I relation.

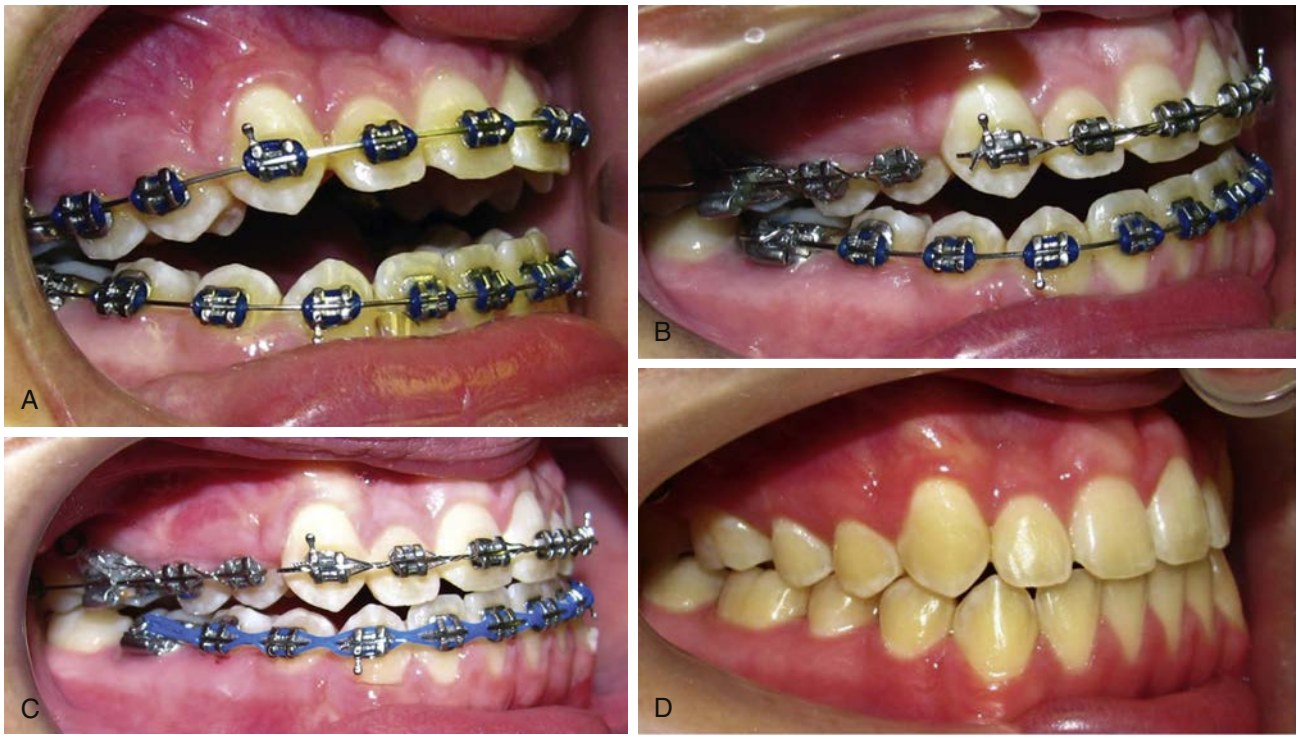

• **Figure 23-16** **A**, Preoperative view of patient with large anterior skeletal open bite. **B**, Improvement after 3 months of intrusion of molars with elastic thread tied to miniplate. **C**, Six months of intrusion of molars. Open bite almost eliminated. **D**, Finished case after debracketing.

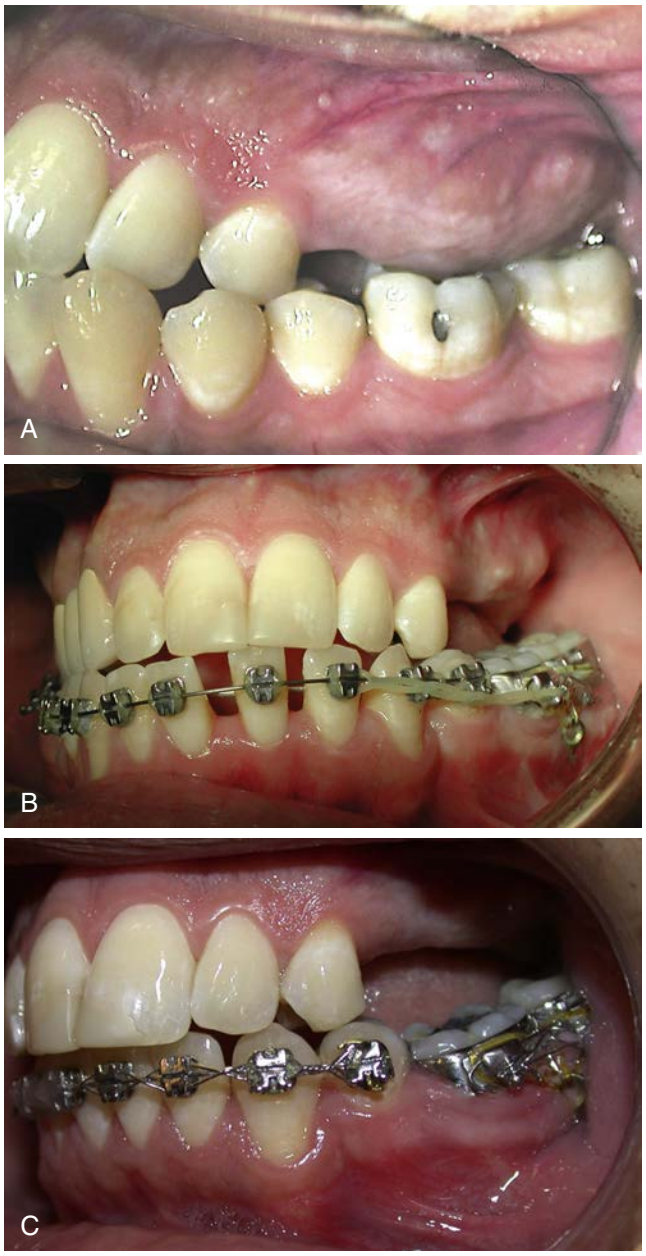

• **Figure 23-17** **A**, Pretreatment Class III malocclusion, supererupted mandibular left molars due to edentulous area in posterior maxilla, anterior and posterior crossbite, and proclination of mandibular incisors. **B**, Appearance after miniplate anchored intrusion of molars completed and extraction of the lower second premolar. The miniplate was ligated to the molars for indirect anchorage and an elastic chain from the molars to the other teeth used to close the premolar extraction space and upright the lower incisors. **C**, Treatment progress after 1 year of orthodontics and prior to uncovering of maxillary left posterior implants.

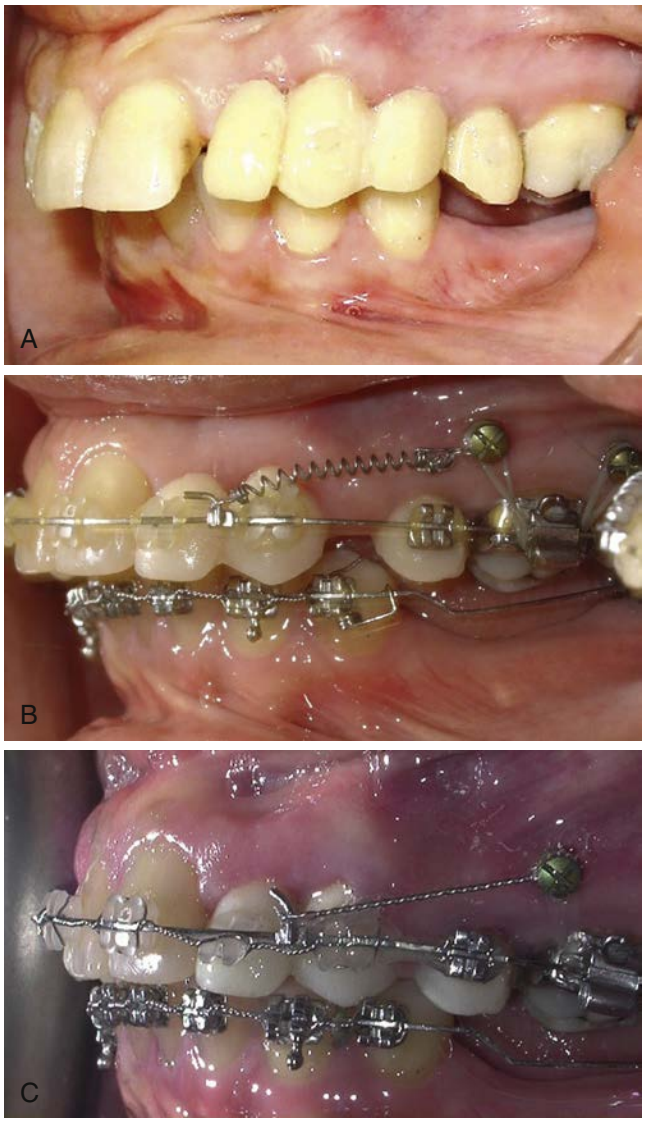

• **Figure 23-18** **A**, Patient with posterior bite collapse due to missing mandibular left molars. Maxillary molars are hypererrupted, and upper incisors proclined. A bridge connected teeth #10 and #11, and the #12 area was a cantilevered pontic. **B**, The pontic was removed, miniscrews placed mesial and distal to tooth #14, an elastic thread was connected to the miniscrews and used for direct anchorage to intrude the molar. A coil spring was attached from the mesial miniscrew to the hook on the archwire and used to retract and upright the anterior teeth en mass. **C**, Ligature wire connected from the miniscrew to the archwire hook to stabilize the correction while closing residual posterior space. (Images courtesy Dr. Gabriela Marquez.)

Surgical Techniques and Materials

Miniplate Implant Placement

Miniplates from a standard bone plating kit for maxillary orthognathic surgery are usually adequate and less costly for most orthodontic anchorage applications. The exposed end is the terminal plate loop to which elastic threads or coil springs can be attached. This plate can be trimmed to size if necessary. Alternatively, plates with orthodontic attachments on the working end may be needed if the orthodontist intends to have the patient wear elastics to the plate, for growth modification. The orthodontic attachment plates have an orthodontic tube or hook that can accommodate elastics, ligatures, and archwires (Figure 23-21). Short, 4- to 5-mm miniscrews are usually adequate to support the plate. Longer screws do not significantly add to stability and may interfere with tooth movement or cause injury if they contact a root or other structure. However, it is important

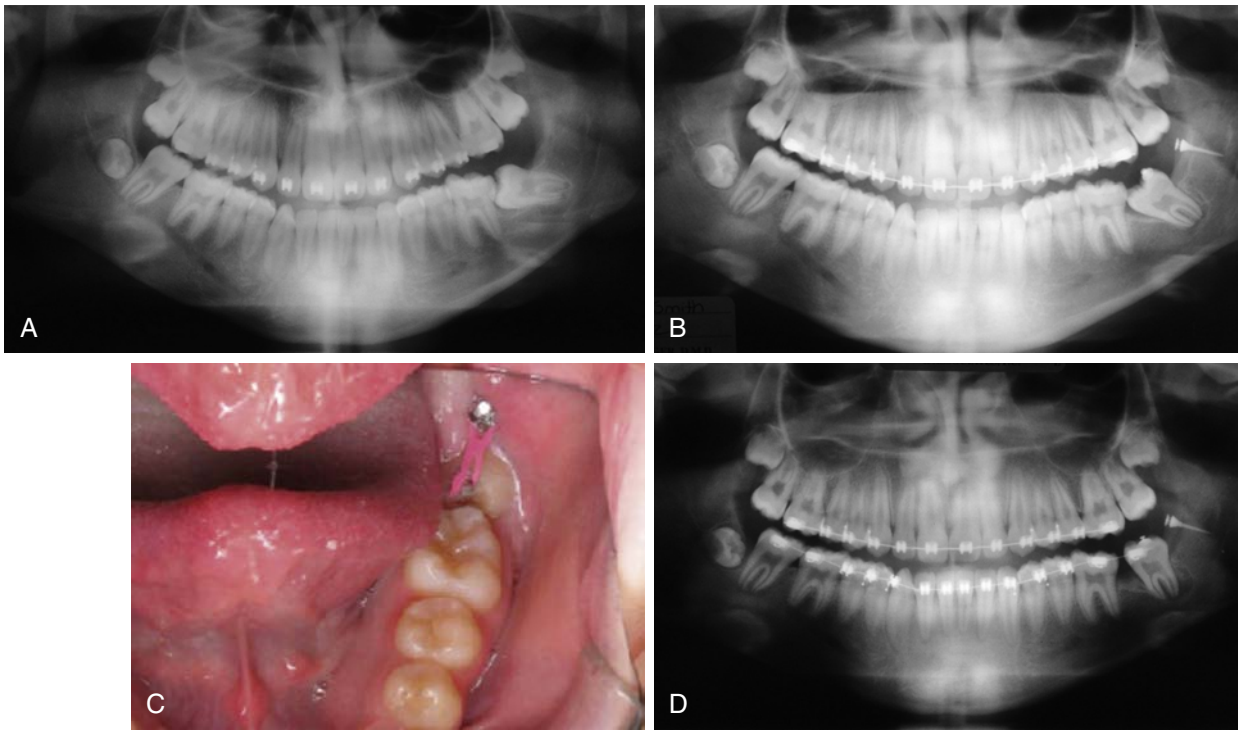

• **Figure 23-19** **A**, Pretreatment panographic radiograph showing impacted mandibular left second molar. **B**, Radiograph 2 weeks after exposure and disto-occlusal bracketing of second molar, insertion of miniscrew, and elastic chain uprighting. **C**, Clinical appearance at 2 weeks with elastic chain from occlusal button bracket to miniscrew implant. **D**, Radiograph 6 months after molar uprighting complete. (Images courtesy Dr. Gabriella Marquez.)

that the screw engage cortical bone and not be stripped or loose. Self-cutting/tapping screws work well in the maxilla. In the mandible, it may be necessary to predrill a screw hole because of bone density. At least two and ideally three miniscrews suffice for most applications, depending on cortical bone thickness.

Similar to trauma and orthognathic applications, miniplates placed in the maxilla are best supported in the thicker cortical bone of the zygomatic buttress and piriform rim. In the mandible, where bone density and cortical thickness is high, it is important to avoid overheating the bone when holes are drilled.

Miniplates can be placed with local anesthesia only, but because of the stretching and pressure associated with screw insertion, many patients prefer light sedation. A horizontal incision is made at the junction of the attached and unattached gingiva. Either a full-thickness envelope flap is raised or, for better visibility and access, a releasing incision is carried to the mucobuccal fold (Figure 23-22). The miniplate should be contoured to lie as passively as possible against the underlying bone to avoid dead space and reduce stress on the screws (see Figure 23-14). The plate will need to be positioned so that the screws avoid roots both at the time of placement and during the predicted orthodontic tooth movement. Ideally, the working (exposed) end should emerge through attached gingiva to avoid inflammation. However, because this is not always possible, the priority with positioning the plate is to make sure that it will function optimally for the anticipated tooth movement and orthodontic loading. Location and orientation was discussed in depth in the application section.

Miniscrew Implant Placement

Miniscrew implant insertion is less involved than surgery for miniplate implants. However, because of the risk of root contact and the latent instability of monocortical MSIs, careful pretreatment planning, skilled fixture placement, and control of the other variables discussed in the miniscrew section on anchor types are critical to success. Good preoperative films to evaluate root position are essential. At a minimum, a good quality panographic radiograph and one or more periapical films should be available.

Self-drilling MSIs can be used for most applications. In the maxilla the screw is directly threaded into the bone transmucosally. In the mandible, where bone density is high, drilling of a pilot hole without heating the bone is advisable. With drilling, a small incision or tissue punch may be appropriate to expose the underlying bone. The depth of the pilot hole depends on the expected thickness of the cortical plate of bone and is usually between 1.5 and 3 mm in the mandible.[88] The self-drilling screw is then introduced and threaded into the bone until its threads are covered. Heavy torque insertion forces that might lead to screw fracture or poor healing are discouraged.

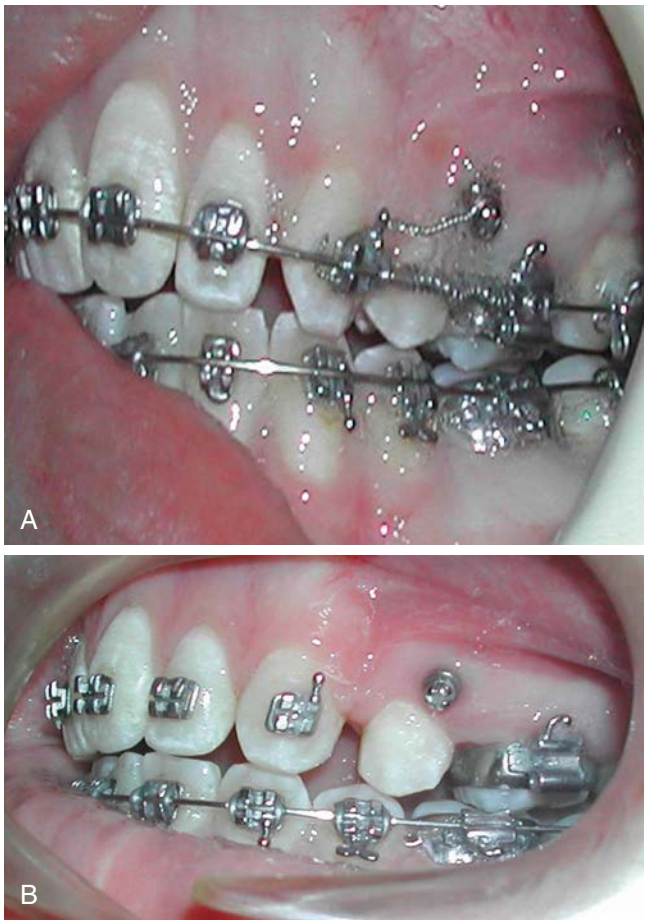

• **Figure 23-20** **A**, Adult patient with a class II molar/canine relation. A miniscrew was inserted between the maxillary first molar and bicuspid and ligature tied to the canine. An expansion coil spring was placed on the archwire between the molar and canine. **B**, Distalization of the molar into a strong class I in 6 weeks.



• **Figure 23-21** Orthodontic miniplates that can act as hooks or accept an archwire. (Courtesy Stryker Corporation.)

The miniscrew implant should be inserted perpendicular to the bone in attached gingiva (Figure 23-23) unless space allows orientation in the same direction as the orthodontic force. For example, with a planned bicuspid intrusion, the screw can be inserted slightly apically (i.e., the cutting tip is more apical than the exposed head) so that the long axis of the screw is more in line with the orthodontic force vector (Figure 23-24). Miniscrews always resist pullout forces better than tipping forces.

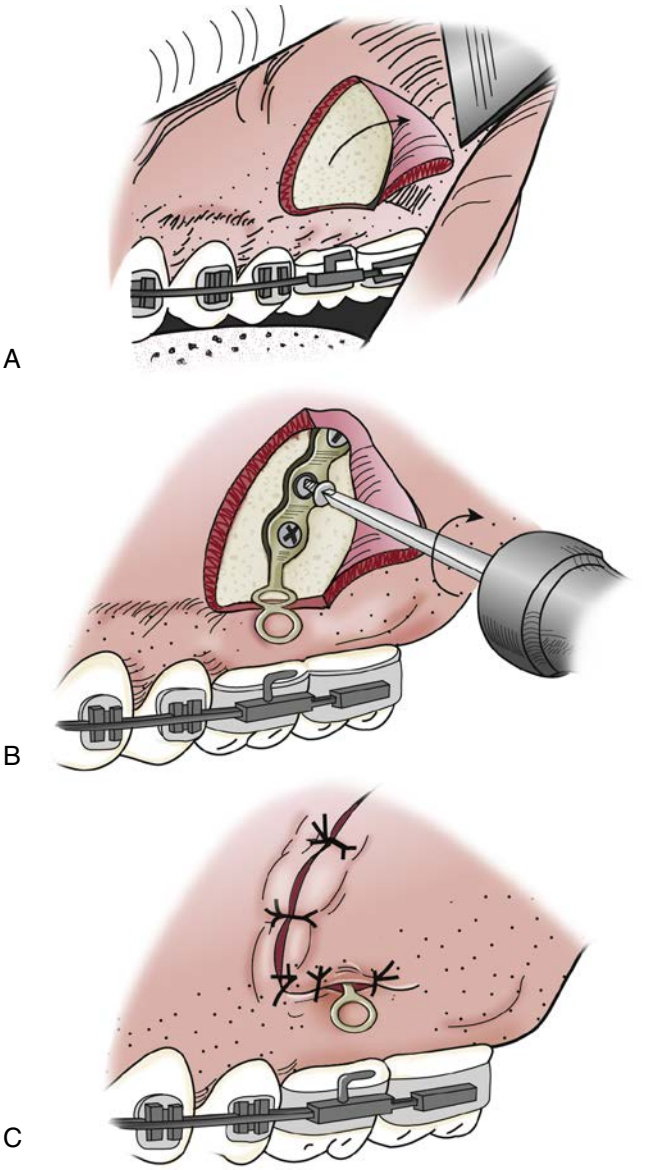

• **Figure 23-22** Placement of a maxillary anchor plate. **A**, Incision over maxillary buttress is horizontal along mucogingival junction then vertical release to depth of vestibule. **B**, Fixation of straight plate with three screws, and transmucosal inferior loop bent buccally. **C**, Primary closure leaving working end of plate exposed intraorally and well above band on first molar.

Adjunctive Care

Intraoperative or postoperative radiographs are recommended to evaluate screw positioning. As with most dental implants, a 7-day postoperative course of antibiotics may be beneficial.[89] Bacterial biofilms can attach to implant and gingival surfaces, leading to inflammation. Although good oral hygiene is the most important method to reduce oral bacterial levels, pre- and postoperative rinsing with chlorhexidine may be appropriate. Patients should be encouraged to look at the fixtures and keep them clean with a cotton tipped applicator soaked in peroxide or chlorhexidine. Smoking should be discouraged. MSI failure rate, in particular, has been shown to be higher in smokers.[90]



• **Figure 23-23** Perpendicular insertion angle of miniscrew implant mesial to first molar in attached gingiva.



• **Figure 23-24** Miniscrews inserted (angled) apically for intrusion of maxillary bicuspids. Elastic thread is tied as a sling over the occlusal wings of premolar brackets then to both miniscrews.

Prevention of Complications

Placement of orthodontic implant anchors is a relatively benign procedure with few serious risks. Complications of surgery both operatively and long term mirror those associated with dental implants. As discussed in previous sections, common problems relate primarily to premature loss of the fixture and poor orientation. More significant problems such as root or nerve damage and serious infections are possible but preventable and usually treatable. The purpose of this section is to summarize what the surgeon can do to avoid complications.

Planning orthodontic implant placement can be as detailed as planning dental implant therapy and even orthognathics. Interspecialty communication regarding treatment goals, fixture type, location, and orientation is essential. Referrals are usually initiated by the orthodontist, who should inform the surgeon about the biomechanical plan and preferences for implant type and location. At the preoperative visit, the surgeon must evaluate the patient and radiographs to determine bone availability and inter-root space, and to decide on an appropriate fixture.

Miniplates are more stable and are recommended where orthodontic treatment time is expected to be prolonged or heavy forces used. Treatment of open bite, growth modification, poor bone density, and a desire to keep screws away from roots for orthodontic reasons are good indications for using miniplates. Monocortical miniscrew implants are inherently unstable when loaded but require less surgery and are particularly useful when indirect anchorage is employed by the orthodontist or direct loading time is expected to be less than 6 months. Multiple mutually supported miniscrews or the use of bicortical screws lessens the concern with instability, but the surgical time, expense, and risks could potentially exceed those for a single miniplate.

Root contact is a major cause of miniscrew anchor failure. However, if root injury occurs, it is usually physiologically repairable as long as the damage is limited to the cementum and the screw is removed. Root contact will also interfere with orthodontic tooth movement and, if severe, could cause fracture or ankyloses.

Inadequate bone support may lead to fixture mobility, especially with MSIs. This may be caused by poor bone quality, technique problems, or fixture issues. Bone density is patient specific, but the surgeon should have a working knowledge of cortical bone thickness as previously described. Tapered self-drilling screws tend to have higher immediate stability but may be more difficult to place in dense bone. If the bone is too dense and excessive torque is needed to insert a screw, a hole should be drilled. Care must be taken to prevent excess torque and bone heating, both of which can cause bone necrosis and early fixture loss. The fixture should have at least 5 mm of thread embedded in bone. Miniscrew implants with 1.5- to 2-mm-diameter threads are less likely to fracture or contact tooth roots. If fracture occurs, retrieval of the segment may be difficult. Consultation with the orthodontist is recommended to determine if the embedded screw will interfere with tooth movement.

Inflammation and periodontal pathogens may lead to fixture failure or infection. Hygiene is easier to maintain in attached gingiva, and if possible the working end of the implant should emerge in keratinized tissue. However, locating the implant where it is most functional and accessible for the orthodontic treatment objectives always takes priority. Prophylactic use of antibiotics and chlorhexidine rinse is advocated by many, but good oral hygiene, as discussed in the last section, is more important in the long term. Patients with active, poorly controlled periodontal disease are poor candidates for implant anchors. If an implant anchor becomes infected but is stable, a trial course of antibiotics is appropriate. If the implant has loosened, however, it should be removed. A new fixture can be placed in a different site as soon as the infection is resolved.

Finally, orthodontic variables such as loading are largely beyond the purview and control of the surgeon. If the orthodontist overloads a miniscrew, it will drift or loosen. However, it is the responsibility of the surgeon to relay

concerns about bone or gingival quality and hygiene to the orthodontist. By making an effort to understand how the orthodontic forces will be loaded on an implant anchor, the surgeon can select, locate, and angle the fixture in a way that maximizes its stability and long-term functionality.

Conclusions

Implant-supported skeletal anchorage for orthodontics is a relatively new and exciting clinical field that has a burgeoning and evolving evidence base. Its application continues to expand, along with its acceptance by orthodontists as a vital component of contemporary clinical practice. In conjunction with other surgical techniques that facilitate correction of malocclusion, it will serve as yet another platform for collaboration between oral and maxillofacial surgeons and orthodontists.

References

1. Sherman AJ: Bone reaction to orthodontic forces on vitreous carbon dental implants, *Am J Orthod* 74(1):79–87, 1978.
2. Gray JB, Steen ME, King GJ, Clark AE: Studies on the efficacy of implants as orthodontic anchorage, *Am J Orthod* 83(4):311–317, 1983.
3. Roberts WE, Marshall KJ, Mozsary PG: Rigid endosseous implant utilized as anchorage to protract molars and close an atrophic extraction site, *Angle Orthod* 60(2):135–152, 1990.
4. Wherbein H, Feifel H, Diedrich P: Palatal implant anchorage reinforcement of posterior teeth: a prospective study, *Am J Orthod Dentofacial Orthop* 116(6):678–686, 1999.
5. Jenner JD, Fitzpatrick BN: Skeletal anchorage utilising bone plates, *Aust Orthod J* 9(2):231–233, 1985.
6. Umemori M, Sugawara J, Mitani H, et al.: Skeletal anchorage system for open-bite correction, *Am J Orthod Dentofacial Orthop* 115(2):166–174, 1999.
7. Sherwood KH, Burch JG, Thompson WJ: Closing anterior open bites by intruding molars with titanium miniplate anchorage, *Am J Orthod Dentofacial Orthop* 122(6):593–600, 2002.
8. Costa A, Raffainl M, Melsen B: Miniscrews as orthodontic anchorage: a preliminary report, *Int J Adult Orthodon Orthognath Surg* 13(3):201–209, 1998.
9. Fritz U, Ehmer A, Diedrich P: Clinical suitability of titanium miniscrews for orthodontic anchorage—preliminary experiences, *J Orofac Orthop* 65(5):410–418, 2004.
10. Block MS, Hoffman DR: A new device for absolute anchorage for orthodontics, *Am J Orthod Dentofacial Orthop* 107(3): 251–258, 1995.
11. Sherwood K: Correction of skeletal open bite with implant anchored molar/bicuspid intrusion, *Oral Maxillofac Surg Clin North Am* 19(3):339–350, 2007.
12. Sugawara J, Daimaruya T, Umemori M, et al.: Distal movement of mandibular molars in adult patients with the skeletal anchorage system, *Am J Orthod Dentofacial Orthop* 125(2):130–138, 2004.
13. Cornelis MA, De Clerck HJ: Maxillary molar distalization with miniplates assessed on digital models: a prospective clinical trial, *Am J Orthod Dentofacial Orthop* 132(3):373–377, 2007.
14. Nishimura M, Sannohe M, Nagasaka H, et al.: Nonextraction treatment with temporary skeletal anchorage devices to correct a Class II Division 2 malocclusion with excessive gingival display, *Am J Orthod Dentofacial Orthop* 145(1):85–94, 2014.
15. Akarsu B, Taner T, Tuncbilek G, Mavili ME: Maxillary protraction in adult cleft lip and palate by a rigid external distraction device with dentoskeletal anchorage, *Eur J Dent* 6(2):206–211, 2012.
16. Unal T, Celikoglu M, Candirli C: Evaluation of the effects of skeletal anchoraged Forsus FRD using miniplates inserted on mandibular symphysis: a new approach for the treatment of Class II malocclusion, *Angle Orthod* 85(3):413–419, 2015.
17. Lopez-Galvito G, Wallen TR, Little RM, et al.: Anterior open bite malocclusion, *Am J Orthod* 87(3), 1985. 175–i85.
18. Harris EF, Butler ML: Patterns of incisor root resorption before and after orthodontic correction in cases with anterior open bites, *Am J Orthod* 101(2):112–119, 1992.
19. Erverdi N, Keles A, Nanda R: The use of skeletal anchorage in open bite treatment: a cephalometric evaluation, *Angle Orthod* 74(3):381–390, 2004.
20. Erverdi N, Usumez S, Solak A, Koldas T: Noncompliance open-bite treatment with zygomatic anchorage, *Angle Orthod* 77(6):986–990, 2007.
21. Daimaruya T, Nagasaka H, Umemori M, et al.: The influences of molar intrusion on the inferior alveolar neurovascular bundle and root using the skeletal anchorage system in dogs, *Angle Orthod* 71(1):60–70, 2001.
22. Daimaruya T, Takahashi I, Nagasaka H, et al.: Effects of maxillary molar intrusion on the nasal floor and tooth root using the skeletal anchorage system in dogs, *Angle Orthod* 73(2): L158–L166, 2003.
23. Ari-Demirkaya A, Masry MA, Erverdi N: Apical root resorption of maxillary first molars after intrusion with zygomatic skeletal anchorage, *Angle Orthod* 75(5):761–767, 2005.
24. Kuroda S, Sakai Y, Tamamura N, et al.: Treatment of severe anterior open bite with skeletal anchorage in adults: comparison with orthognathic surgery outcomes, *Am J Orthod Dentofacial Orthop* 132(5):599–605, 2007.
25. De Clerck H, Cevidanes L, Baccetti T: Dentofacial effects of bone-anchored maxillary protraction: a controlled study of consecutively treated Class III patients, *Am J Orthod Dentofacial Orthop* 138(5):577–581, 2010.
26. De Clerck EE, Swennen GR: Success rate of miniplate anchorage for bone anchored maxillary protraction, *Angle Orthod* 81(6):1010–1013, 2011.
27. Nguyen T, Cevidanes L, Cornelis MA, et al.: Three-dimensional assessment of maxillary changes associated with bone anchored maxillary protraction, *Am J Orthod Dentofacial Orthop* 140(6):790–798, 2011.
28. De Clerck H, Nguyen T, de Paula LK, Cevidanes L: Three-dimensional assessment of mandibular and glenoid fossa changes after bone-anchored Class III intermaxillary traction, *Am J Orthod Dentofacial Orthop* 142(1):25–31, 2012.
29. Sar C, Sahinoglu Z, Ozcirpici AA, Uckan S: Dentofacial effects of skeletal anchored treatment modalities for the correction of maxillary retrognathia, *Am J Orthod Dentofacial Orthop* 145(1): 41–54, 2014.
30. Sar C, Arman-Ozcirpici A, Uckan S, Yazici AC: Comparative evaluation of maxillary protraction with or without skeletal anchorage, *Am J Orthod Dentofacial Orthop* 139(5):636–649, 2011.
31. Schatzle M, Mannchen R, Zwahlen M, Lang NP: Survival and failure rates of orthodontic temporary anchorage devices: a systemic review, *Clin Oral Implants Res* 20(12):1351–1359, 2009.

32. Cornelis MA, Scheffler NR, Nyssen-Behets C, et al.: Patients' and orthodontists' perceptions of miniplates used for temporary skeletal anchorage: a prospective study, *Am J Orthod Dentofacial Orthop* 133(1):18–24, 2008.
33. Tsui WK, Chua HD, Cheung LK: Bone anchor systems for orthodontic application: a systematic review, *Int J Oral Maxillofac Surg* 41(11):1427–1438, 2012 Nov.
34. Lim HJ, Choi YJ, Evans CA, Hwang HS: Predictors of initial stability of orthodontic miniscrew implants, *Eur J Orthod* 33(5):528–532, 2011.
35. Reynders R, Ronchi L, Bipat S: Mini-implants in orthodontics: a systematic review of the literature, *Am J Orthod Dentofacial Orthop* 135(5):564.e1–564.e19, 2009.
36. Brettin BT, Grosland NM, Qian F, et al.: Bicortical vs monocortical orthodontic skeletal anchorage, *Am J Orthod Denofacial Orthop* 134(5):625–635, 2008.
37. Carano A, Velo S, Incorvati C, Poggio P: Clinical applications of the Mini-Screw-Anchorage System (M.A.S.) in the maxillary alveolar bone, *Prog Orthod* 5(2):212–235, 2004.
38. Morarend C, Qian F, Marshall SD, et al.: Effect of screw diameter on orthodontic skeletal anchorage, *Am J Orthod Dentofacial Orthop* 136(2):224–229, 2009.
39. Kuroda S, Yamada K, Deguchi T, et al.: Root proximity is a major factor for screw failure in orthodontic anchorage, *Am J Orthod Dentofacial Orthop* 131(4Suppl):S68–S73, 2007.
40. Suzuki M, Deguchi T, Watanabe H, et al.: Evaluation of optimal length and insertion torque for miniscrews, *Am J Orthod Dentofacial Orthop* 144(2):251–259, 2013.
41. Topcuoglu T, Bicakci AA, Avunduk MC, Sahin Inan ZD: Evaluation of the effects of different surface configurations on stability of miniscrews, *Sci World J* 2013:396091, 2013.
42. Migliorati M, Benedicenti S, Signori A, et al.: Miniscrew design and bone characteristics: an experimental study of primary stability, *Am J Orthod Dentofacial Orthop* 142(2):228–234, 2012.
43. Brinley CL, Behrents R, Kim KB, et al.: Pitch and longitudinal fluting effects on the primary stability of miniscrew implants, *Angle Orthod* 79(6):1156–1161, 2009.
44. Yoo SH, Park YC, Hwang CJ, et al.: A comparison of tapered and cylindrical miniscrew stability, *Eur J Orthod* 36(5):557–562, 2014.
45. Liu TC, Chang CH, Wong TY, Liu JK: Finite element analysis of miniscrew implants used for orthodontic anchorage, *Am J Orthod Dentofacial Orthop* 141(4):468–476, 2012.
46. Shah AH, Behrents RG, Kim KB, et al.: Effects of screw and host factors on insertion torque and pullout strength, *Angle Orthod* 82(4):603–610, 2012.
47. Marquezan M, Mattos CT, Sant'Anna EF, et al.: Does cortical thickness influence the primary stability of miniscrews?: A systematic review and meta-analysis, *Angle Orthod* 84(6): 1093–1103, 2014.
48. Cha JY, Kil JK, Yoon TM, Hwang CJ: Miniscrew stability evaluated with computerized tomography scanning, *Am J Orthod Dentofacial Orthop* 137(1):73–79, 2010.
49. Iijima M, Takano M, Yasuda Y, et al.: Effect of the quantity and quality of cortical bone on the failure force of a miniscrew implant, *Eur J Orthod* 35(5):583–589, 2013.
50. Watanabe H, Deguchi T, Hasegawa M, et al.: Orthodontic miniscrew failure rate and root proximity, insertion angle, bone contact length, and bone density, *Orthod Craniofac Res* 16(1):44–55, 2013.
51. Papageorgiou SN, Zogakis IP, Papadopoulos MA: Failure rates and associated risk factors of orthodontic miniscrew implants: a meta-analysis, *Am J Orthod Dentofacial Orthop* 142(5):577–595, 2012.
52. Samrit V, Kharbanda OP, Duggal R, et al.: Bone density and miniscrew stability in orthodontic patients, *Aust Orthod J* 28(2):204–212, 2012.
53. McManus MM, Qian F, Grosland NM, et al.: Effect of miniscrew placement torque on resistance to miniscrew movement under load, *Am J Orthod Dentofacial Orthop* 140(3):e93–e98, 2011.
54. Giuliano Maino B, Pagin P, DiBlasio A: Success of miniscrews used as anchorage for orthodontic treatment: analysis of different factors, *Prog Orthod* 13(3):202–209, 2012.
55. Suzuki EY, Suzuki B: Placement and removal torque values of orthodontic miniscrew implants, *Am J Orthod Dentofacial Orthop* 139(5):669–678, 2011.
56. Park HS, Lee YJ, Jeong SH, Kwon TG: Density of the alveolar and basal bones of the maxilla and the mandible, *Am J Orthod Dentofacial Orthop* 133(1):30–37, 2008.
57. AlSamak S, Gkantidis N, Bisanis E, Christou P: Assessment of potential orthodontic mini-implant insertion sites based on anatomical hard tissue parameters: a systematic review, *Int J Oral Maxillofac Implants* 27(4):875–887, 2012.
58. Santiago RC, de Paula FO, Fraga MR, et al.: Correlation between miniscrew stability and bone mineral density in orthodontic patients, *Am J Orthod Dentofacial Orthop* 136(2):243–250, 2009.
59. Sabec Rda C, Fernandes TM, de Lima Navarro R, et al.: Can bone thickness and inter-radicular space affect miniscrew placement in posterior mandibular sites? *J Oral Maxillofac Surg* 73(2): 333–339, 2015.
60. Renjen R, Maganzini AL, Rohrer MD, et al.: Root and pulp response after intentional injury from miniscrew placement, *Am J Orthod Dentofacial Orthop* 136(5):708–714, 2009.
61. Dao V, Renjen R, Prasad HS, et al.: Cementum, pulp, periodontal ligament, and bone response after direct injury with orthodontic anchorage screws: a histomorphologic study in an animal model, *J Oral Maxillofac Surg* 67(11):2440–2445, 2009.
62. Lim G, Kim KD, Park W, et al.: Endodontic and surgical treatment of root damage caused by orthodontic miniscrew placement, *J Endod* 39(8):1073–1077, 2013.
63. Bae M, Kim JY, Park JT, et al.: Accuracy of miniscrew surgical guides assessed from cone-beam computed tomography and digital models, *Am J Orthod Dentofacial Orthop* 143(6):893–901, 2013.
64. Morea C, Hayek JE, Oleskovicz C, et al.: Precise insertion of orthodontic miniscrews with a sterolithographic surgical guide based on cone beam computed tomography data; a pilot study, *Int J Oral Maxillofac Implants* 26(4):860–865, 2011.
65. Qiu L, Haruyama N, Suzuki S, et al.: Accuracy of orthodontic miniscrew implantation guided by sterolithographic surgical stent based on cone-beam CT-derived 3D images, *Angle Orthod* 82(2):284–293, 2012.
66. Hatttarki R: A simplified stent for placement of miniscrews, *Int J Orthod Milwaukee* 23(4):37–38, 2012. Winter.
67. Gupta N, Kotrashetti SM, Naik V: A comparative clinical study between self tapping and drill free screws as a source of rigid orthodontic anchorage, *J Maxillofac Oral Surg* 11(1):29–33, 2012.
68. Wang YC, Liou EJ: Comparison of the loading behavior of self-drilling and predrilled miniscrews throughout orthodontic loading, *Am J Orthod Dentofacial Orthop* 133(1):38–43, 2008.
69. Son S, Motoyoshi M, Uchida Y, Shimizu N: Comparative study of the primary stability of self-drilling and self-tapping orthodontic miniscrews, *Am J Orthod Dentofacial Orthop* 145(4):480–485, 2014.

70. Jasoria G, Naik VR, Manchanda M, et al.: Comparison between drill and drill free screws as a source of rigid orthodontic anchorage: a prospective clinical study, *Int J Orthod Milwaukee* 24(3):51–57, 2013.
71. Hung E, Oliver D, Kim KB, et al.: Effects of pilot hole size and bone density on miniscrew implants' stability, *Clin Implant Dent Relat Res* 14(3):454–460, 2012.
72. Chen Y, Kyung HM, Zhao WT, Yu WJ: Critical factors for the success of orthodontic mini-implants: a systematic review, *Am J Orthod Dentofacial Orthop* 135(3):284–291, 2009.
73. Pickard MB, Dechow P, Rossouw PE, Buschang PH: Effects of miniscrew orientation on implant stability and resistance to failure, *Am J Orthod Dentofacial Orthop* 137(1):91–99, 2010.
74. Lee J, Kim JY, Choi YJ, et al.: Effects of placement angle and direction of orthopedic force application on the stability of orthodontic miniscrews, *Angle Orthod* 83(4):667–673, 2013.
75. Holberg C, Winterhalder P, Holberg N, et al.: Direct versus indirect loading of orthodontic miniscrew implants—an FEM analysis, *Clin Oral Invest* 17(8):1821–1827, 2013.
76. Crismani AG, Bertl MH, Celar AG, et al.: Miniscrews in orthodontic treatment: review and analysis of published clinical trials, *Am J Orthod Dentofacial Orthop* 137(1):108–113, 2010.
77. Manni A, Cozzani M, Tamborrino F, et al.: Factors influencing the stability of miniscrews. A retrospective study on 300 miniscrews, *Eur J Orthod* 33(4):388–395, 2011.
78. Zhu LY, Yan YQ, Gao YM: [A study on the stability of miniscrew on different loading time as orthodontic anchorage], *Shanghai Kou Qiang Yi Xue* 20(6):590–594, 2011.
79. Liu H, Lv T, Wang NN, et al.: Drift characteristics of miniscrews and molars for anchorage under orthodontic force: 3-dimensional computed tomography registration evaluation, *Am J Orthod Dentofacial Orthop* 139(1):e83–e89, 2011.
80. Sar C, Arman-Ozcirpici A, Uckan S, Yazici AC: Comparative evaluation of maxillary protraction with or without skeletal anchorage, *Am J Orthod Dentofacial Orthop* 139(5):636–649, 2011.
81. Viwattanatipa N, Thanakitcharu S, Uttaravichien A, Pitiphat W: Survival analyses of surgical miniscrews as orthodontic anchorage, *Am J Orthod Dentofacial Orthop* 136(1):29–36, 2009.
82. Tsaousidis G, Bauss O: Influence of insertion site on the failure rates of orthodontic miniscrews, *J Orofac Orthop* 69(5):349–356, 2008.
83. Park J, Cho HJ: Three-dimensional evaluation of interradicular spaces and cortical bone thickness for the placement and initial stability of microimplants in adults, *Am J Orthod Dentofacial Orthop* 136(3):314, 2009.
84. Chang C, Liu SS, Roberts WE: Primary failure rate for 1680 extra-alveolar mandibular buccal shelf miniscrews placed in movable mucosa or attached gingiva, *Angle Orthod* 85(6):905–910, 2015.
85. Chen YJ, Chang HH, Lin HY, et al.: Stability of miniplates and miniscrews used for orthodontic anchorage: experience with 492 temporary anchorage devices, *Clin Oral Implants Res* 19(11):1188–1196, 2008.
86. Janson G, Valarelli FP, Henriques JF, et al.: Stability of anterior open bite nonextraction treatment in the permanent dentition, *Am J Orthod Dentofacial Orthop* 124(3):265–276, 2003.
87. Frost Fonseca RJ, Turvey TA, Hall DJ: Cephalometric diagnosis and surgical-orthodontic correction of apertognathia, *Am J Orthod* 78(6):657–659, 1980.
88. Veli I, Uysal T, Baysal A, Karadede I: Buccal cortical bone thickness at miniscrew placement sites in patients with different vertical skeletal patterns, *J Orofac Orthop* 75(6):417–429, 2014.
89. Bafail AS, Alamri AM, Spivakovsky S: Effect of antibiotics on implant failure and postoperative infection, *Evid Based Dent* 15(2):58, 2014.
90. Bayat E, Bauss O: Effect of smoking on the failure rates of orthodontic miniscrews, *J Orofac Orthop* 71(2):117–124, 2010.

24

Lasers in Oral Surgery

ROBERT A. STRAUSS, NICHOLAS J. KAIN

Laser Physics

Because of their many advantages for certain procedures, lasers have become a ubiquitous tool in the armamentarium of the oral and maxillofacial surgeon. However, in order to choose the correct laser, and to use that laser correctly for any specific procedure, it is imperative to thoroughly understand the physics of light and its laser application. Unlike scalpel and electrocautery surgery, which rely primarily on one mechanism of depth control (pressure and power, respectively), lasers have a multitude of variables that can and should be employed to control their depth of penetration and effect. As lasers have a definite degree of risk when used improperly, it is incumbent on the surgeon to understand and apply the appropriate physics to any clinical situation in order to ensure the best and safest possible results.

Generation of Laser Light

Light amplification by stimulated emission of radiation (LASER) is based on the theoretical hypothesis of quantum theory developed by Albert Einstein and first reported in 1917.[1] Amazingly, it took another 40 years before Theodore Maiman, a physicist at the Bell Laboratories, introduced the first functional laser using a ruby diode. Since that time, many different types and wavelengths of laser have been produced; however, all are based on the same principles of physics. [2]

To understand stimulated emission one must first understand simple emission of energy from an atomic body. In the hypothetical and vastly simplified simulation of an atomic body, one thinks of a nucleus surrounded by electron shells. The electron shells closest to the nucleus represents the lower energy shells while the outer shells signify higher energy levels (Figure 24-1). Electrons, by nature, stay in the lower energy shell unless acted upon. When external energy is added to the system, typically by direct current electricity or a photo strobe light, the system becomes excited and electrons are pushed into the higher energy shells (see Figure 24-1, *A*). This is termed *absorption*. As this is not a stable state, the excited electrons will eventually fall back into the lower energy shells. The system will then emit a packet of energy as that electron goes from the higher to the lower energy shell. That packet of energy, or photon, is emitted in a specific wavelength that is related to the specific molecular body involved. This is termed *spontaneous emission* (see Figure 24-1, *B*). A good example of this is the process by which a neon sign works. The neon gas inside the tube is electrically excited, undergoes spontaneous emission, and gives off a photon of energy, which, based on the neon gas, is in the wavelength of the color red. Other colors of "neon" lights actually use alternative materials that emit different specific wavelengths (e.g., argon gas emits a green color).

When an atomic body already in the excited stage (i.e., with electrons in the unstable higher energy shell) is excited further, before it has the chance to undergo spontaneous emission, it can actually "force" the electron down into the lower energy shell. When this occurs, the atomic body will emit not one, but rather, two photons of energy. Thus we have *stimulated emission*. More importantly, these two emitted photons will be of the exact same wavelength and will be both parallel and in phase with one another, with all the peaks and troughs of the waves aligned with each other (see Figure 24-1, *C*). These two emitted photons can then be the exciting energy for two more atomic bodies, which undergo stimulated emission and can then provide the energy for four atomic bodies, and so on. In order for this system to sustain itself, more than 50% of the atomic bodies must be in the excited stage at any one time to allow the continued and increasing production of photons. This is termed *population inversion*, when there are more excited atomic bodies than normal ones, and explains why some materials can be used as laser mediums (e.g., carbon dioxide, argon) and others cannot. Only those materials capable of maintaining population inversion can be used as laser mediums.[3]

A laser tube is deceptively simple. It is merely a glass or metal tube that has the lasing medium inside (the lasing

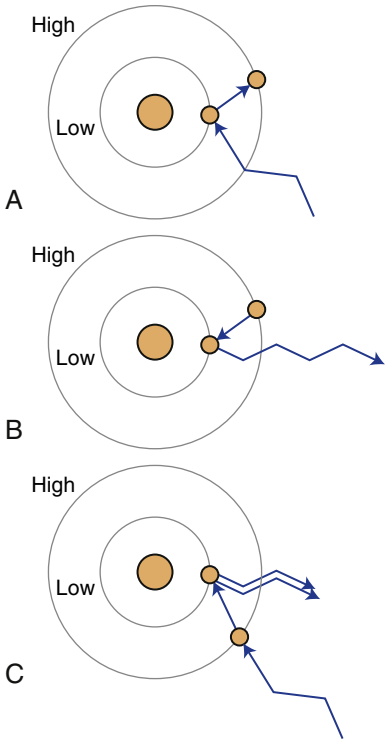

• **Figure 24-1** **A**, Absorption of energy. **B**, Spontaneous emission. One photon of energy is released. **C**, Stimulated emission. Note that two photons are released, and they are in phase and collimated.

medium being the material that will undergo stimulated emission), an energy source or *pumping mechanism* (again, typically an electric source or a photo strobe light) to impart energy for absorption, and two mirrors placed exactly parallel to each other at either end of the tube (Figure 24-2). One mirror is a standard one-way fully reflective mirror, and the other is a partially reflective–partially transmissive mirror (a so-called two-way mirror that at low light levels reflects light like any mirror but at high light levels allows some or all of the light to transmit or pass through the mirror). As the stimulated emission of light occurs inside the tube, the majority of the stimulated photons will pass harmlessly into the sides of the tube and are emitted as simple light or heat. When a photon happens to hit exactly perpendicular to one of the mirrors, it will bounce through the tube, hit the opposite mirror, and begin a period of oscillation between the mirrors. Of course, while this is happening many other photons are being given off, most of which are lost as light or heat into the container, but some will also oscillate between the mirrors. This process of recruitment continues until enough of the photons are oscillating between the mirrors that the energy they contain overwhelms the two-way mirror and a packet of light is emitted out of the end of the laser tube. Importantly, they will all be one wavelength based on the laser medium (monochromatic), parallel to each other (collimated), and synched in phase with one another (Figure 24-3). This defines laser, or *coherent light*, and because of the additive properties of these photon's energy, as a result of their coherency and uniformity of phase (unlike regular light,

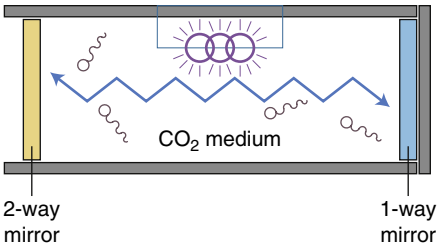

• **Figure 24-2** Components of a laser tube.

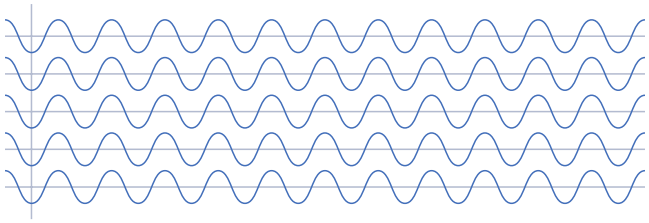

• **Figure 24-3** Coherent light showing a single wavelength, uniformity of phase, and collimation.

which spreads out in all directions from its source and loses its power quickly), the light is hugely concentrated and powerful.

Once produced, and depending on the wavelength, the light can be transmitted to the tissue by a series of articulated arms (hollow tubes with mirrored knuckles), hollow wave guides (flexible metal fibers whose entire internal surface is mirrored), or fiberoptic cables. Each of these has advantages and disadvantages related to ease of use, focusing abilities, and their ability to be used with microscopes and micromanipulators. [4]

Once laser light hits human tissue, one of several interactions may occur (Figure 24-4). The light can be transmitted through the tissue (imagine a laser being shined through glass, except that some lasers can travel right through solid tissues in a similar fashion), be reflected off the tissue, scatter inside the tissue, or be absorbed into the tissue (much as a black shirt absorbs sunlight and gets hot in the summer). There are many wavelengths of clinical lasers, ranging from the far infrared to the ultraviolet range (and likely the military has some in the x-ray and perhaps gamma ray range). Although the ability of a laser to transmit through tissue, and subsequently act on a deeper structure, has some allure and use in specific cases (e.g., for a port wine stain), choosing the correct laser in oral and maxillofacial surgery is usually (but not always) related to the ability of a particular laser to be absorbed into the intended target tissue. The material within the tissue that actually absorbs the energy (e.g., water, hemoglobin, or collagen) is termed a *chromophore* for that particular wavelength (Figure 24-5).[5] The major component of human soft tissue, water, is the primary chromophore for lasers in the mid and far infrared range, such as the carbon dioxide (CO_2) laser; the erbium:yttrium-aluminum-garnet (Er:YAG) laser, which uses a YAG crystal doped with the rare earth element erbium; and the similar erbium: chromium:YSGG laser. Thus, these lasers have excellent

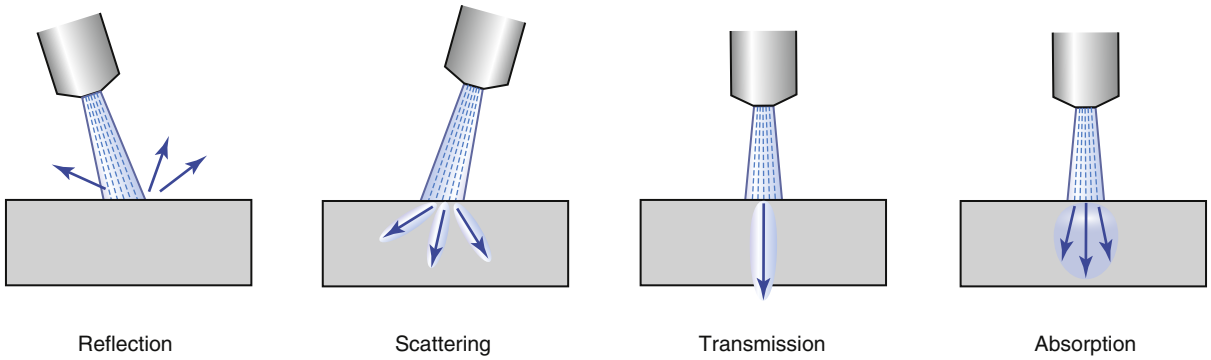

• **Figure 24-4** Tissue interactions.

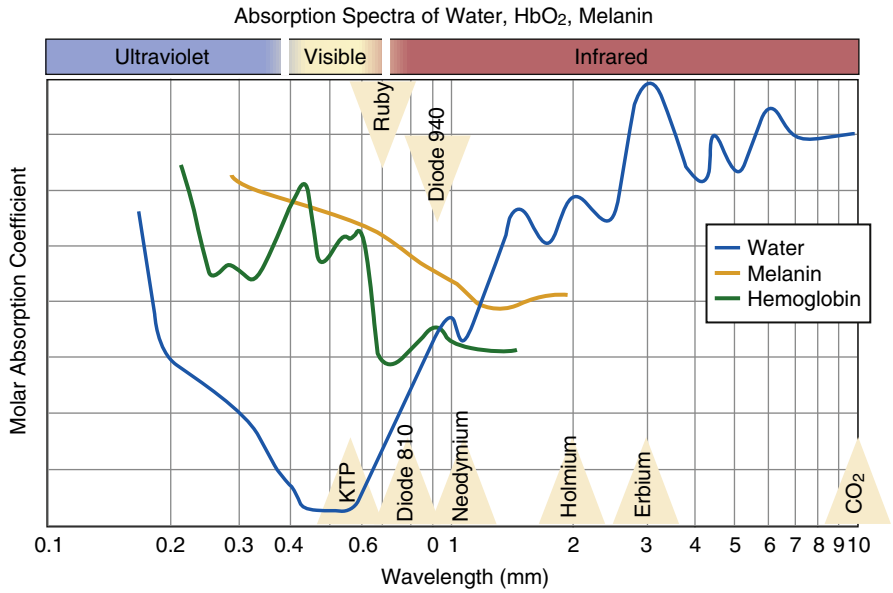

• **Figure 24-5** Laser absorption chart.

and useful effects on tissues that contain water. Another laser popular with non-surgeons is the diode laser. These small, inexpensive, and easily transported lasers use a small diode as the lasing medium and can be transmitted via fiberoptics. As they have little absorption for water, their primary tissue chromophore is pigment. In tissue that contains primarily water and no pigment, the laser will travel deep within the tissue before having an effect, leading to potentially uncontrolled tissue damage. In non-pigmented tissue, therefore, the only way for this laser to work safely and as expected on the surface tissue is to "initialize" the tip of the fiber with some pigmented material (e.g., carbon paper), which then picks up the laser and generates heat in the tip. Thus, much of this laser's effectiveness is based, not on direct tissue absorption by the laser, but rather on tip absorption and using the heat generated in the tip to affect the tissue. This hot tip cuts and cauterizes the surface using only the heat generated, not the laser wavelength itself, unless uninitiated and used for deeper pigmented tissue. Because of this, the diode laser is far less effective for surgical procedures, but is very popular with non-surgeons, who prefer this over the much more powerful and more efficient (but inherently more dangerous and difficult to control) lasers that directly use water as the chromophore.[6]

Lasers that have hemoglobin as their primary chromophore for absorption are often used when managing deep vascular lesions. Examples of these would include the copper or gold vapor lasers and the flashlamp-pumped tunable dye laser. Having a wavelength specificity for hemoglobin, and little for water in the surface cells, allows the laser to ablate vascular lesions with little to no effect on the overlying mucosa or skin.

Although the use of lasers in hard tissue has been more problematic, recent advances have made hard tissue laser surgery a possibility. Whereas intracellular water in soft tissue can be vaporized very quickly using a CO_2 or erbium laser, effectively vaporizing the rest of the cell, vaporizing hydroxyapatite in hard tissue with these lasers would require massive amounts of energy, and the resultant heat would damage adjacent structures. Newer erbium and CO_2 lasers, in the 9300-nm wavelength range rather than the typical 10,600-nm wavelength range, target the minute amount of water between the crystals of hydroxyapatite, causing them to explode and create a shock wave that removes hard tissue

somewhat effectively and with little heat generated. The new 9300 nm-CO_2 laser in particular has some allure for surgeons because it can be used for both hard and soft tissue.[7] However, few articles in the literature support these theoretical concepts as yet.

Regardless of the wavelength, all lasers in surgery use one of three operative techniques: incision, vaporization/ablation, and hemostasis/coagulation.[8] It is imperative that the surgeon understand when and how to apply these techniques, along with understanding their related physics, to obtain the best and safest surgical results. Incision is essentially using the laser as you would a scalpel to make a thin, deep cut in the tissue. This requires that the laser beam be focused down to a small point (with most lasers this is 0.1-0.4 mm), which concentrates the energy into a small volume, thus increasing the amount of energy per unit of area. This is termed power density (Figure 24-6). With a high power density and a small spot size of the laser, the result will be that the laser will cut deeply and thinly into tissue. This is the technique that would most commonly be used for incisions, excisions, biopsies, and so on. Vaporization/ablation is a technique that involves spreading out the laser energy into a larger spot size (generally 0.8-3 mm), resulting in a lower power density. This will produce very shallow removal of tissue, but over a larger area. Typically, this would be used to remove the surface tissues for leukoplakias, dysplasias, cosmetic skin resurfacing, and so forth. The final technique, hemostasis/coagulation, is used to control bleeding in tissue or to remove a vascular lesion. Lasers are inherently hemostatic when used for incision or vaporization, resulting from vascular contraction of adjacent vessels from the heat generated in lasered tissue. However, this will work only on vessels whose diameter is smaller than the zone of thermal spread from the laser wound. With regular (or continuous wave) CO_2 lasers, the zone of lateral thermal spread is approximately 300 to 500 μm. If a laser that is primarily absorbed by hemoglobin is used, deeper hemangiomas and vascular lesions can be ablated as well.

Accomplishing the techniques just described requires adjusting the spot size of the laser to change the power density. With fiberoptic lasers, which are mostly used in contact with the tissue, this is adjusted by choosing the width of the fiber (typically 300-800 μm). With non-contact lasers, such as the CO_2, this is most commonly done by moving the laser closer to or farther from the target, allowing expansion and contraction of the beam, much as one does with a magnifying lens. Putting the beam at the focal point, or smallest spot size, allows for high power density and incision. Moving the laser handpiece farther from the target allows for larger spot sizes, lower power density, and surface ablation.

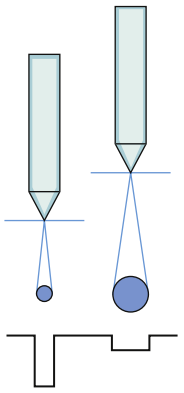

• **Figures 24-6** Focusing and defocusing the beam to decrease or increase the size of the beam, and thus power density. Focusing causes a thin but deep cut, whereas defocusing causes a wider but shallower ablation.

Power density is based on the amount of power per unit of spot size. It determines the depth of laser effect per unit of time. A specific power density, of any laser, will cut or vaporize tissue to a specific and repeatable depth for each unit of time applied. However, the total depth of effect is dependent on how long the laser is used in total. A simple hypothetical example would be that a laser at 5 W of power and a 1-mm spot size might cut 1 mm deep into tissue for every second of use (of course this will depend on the specific laser and how much of its chromophores are in that specific tissue). In 1 s it will, indeed, cut 1 mm deep, but if used for 2 s, it will cut 2 mm deep, and so on. Thus, the complete extent of the cut is based on both the power density and the total amount of time that the laser is applied to the tissue. This is termed *energy density* or *fluence*.

One of the most important factors to be aware of with the use of lasers is the lateral spread of heat away from the intended target. Lasers generally work by creating heat within the tissues. Enough heat with a CO_2 or erbium laser can vaporize intracellular water or the water trapped in enamel and cut or ablate soft tissue, bone, and tooth structure. However, given enough time, some of that heat will leak away in concentric circles from the target and can damage normal adjacent tissues. A 10,600-nm CO_2 laser applied to the enamel of a tooth would take so long to have an effect on the hard tissue that the heat generated would be devastating to adjacent tissues and dental pulp. The way to prevent this from happening, unless you purposely want some lateral heat to contract adjacent blood vessels, is to apply large amounts of energy density in a very short period of time (microseconds to nanoseconds). This limits the time for lateral thermal spread and allows for precise laser effect in the target tissue with little lateral thermal leakage. For example, a 9300-μm CO_2 laser applied in ultrashort and very powerful bursts of energy can remove hard tissue with little time for adjacent tissue damage.[7] Manufacturers have applied many names and used different mechanisms to obtain this concept, such as Superpulsing, Ultrapulsing, Q-Switching, and Flashlamp Pumping. All are various ways to increase energy density while decreasing the duration of laser pulses in order to limit the lateral spread of heat.

When considering or performing laser surgery, the surgeon must always consider the correct choice of laser wavelength, the mechanism of delivery, the appropriate base technique (incision, vaporization, or coagulation), the parameters of power–time–spot size that will be used, and

the distance from that target that will provide the correct spot size. As you read through the various procedures in this chapter, try to keep these concepts in mind.

Common Laser Wavelengths

Since the first laser was used in live surgery in 1970 (the CO_2 laser), many wavelengths of lasers have been used in oral and maxillofacial surgery.[8,9] Some have persisted and are still used today (e.g., CO_2), while others have seen their commercial availability diminish or disappear due to improved specificity of newer laser wavelengths (e.g., argon). Choosing the correct wavelength laser for any particular surgical indication is a function of many variables, such as the type of effect desired (incision, vaporization, or coagulation), the intended target tissue and the chromophores it contains, the need for a micromanipulator, the preferred delivery system, and laser cost and availability. Outlined next are several commonly used lasers in oral and maxillofacial surgery.

Carbon Dioxide Lasers (10,600 nm)

Carbon dioxide lasers were the first lasers used in clinical practice and today remain the most commonly used laser in oral and maxillofacial surgery. These are highly efficient lasers that can be used for cutting, ablation, and to some degree, coagulation (although there are better lasers for this). Its main chromophore is water, and because water is the primary component of all soft tissues, it is generally considered the gold standard laser for all soft tissue surgery.

As with all lasers, the CO_2 laser emits a single monochromatic wavelength; however, this laser now has three different monochromatic wavelengths that can be produced. These wavelengths are the mid-infrared 10,600 nm (the traditional wavelength used since the 1960s), 9,600 nm, and 9,300 nm. The latter are newer wavelength CO_2 lasers, which allow for some uses not traditionally associated with this laser. These include cutting hard tissues, including tooth structure and bone. One such 9,300-nm CO_2 laser, the unique wavelength created by replacing normal $C^{16}O_2$ with isotopic $C^{18}O_2$ as the lasing medium, has recently been FDA approved for both hard and soft tissue use because of its high absorption for both water and hydroxyapatite. Preliminary studies indicate that this wavelength has effects in soft tissue similar to those of the standard 10,600-nm CO_2 laser.[10] The FDA approval for hard tissue is for enamel and dentin, but cutting bone is equally possible. Because the incredibly short laser pulse can be too fast for the brain to recognize any pain in many, but not all, patients it is also possible to perform the cutting of tissues without the need for local anesthesia.

Certainly, this is an important factor for patient comfort, but an equally important variable is the speed with which the surgeon can cut hard tissue with a laser versus other methods. Although this new laser wavelength represents an improvement in this regard, its time efficiency and practicality in oral and maxillofacial surgery remain in question. Although as yet there are few data in the literature to support its widespread use in oral and maxillofacial surgery, the development of combined hard and soft tissue lasers is a promising sign of the future of lasers in our specialty.

The traditional 10,600-nm wavelength CO_2 laser is available from many manufacturers. The basic difference between them is primarily based on the temporal delivery of the beam. Although all can be emitted as continuous wave (i.e., continually delivered from the laser tube and controlled only by a foot pedal or optical or electronic shutter), some are capable of being electronically pseudo-pulsed within the tube itself. Because they are not able to be pumped by a flashlamp, traditional optical "pulsing" is not possible. Pseudo-pulsing involves electronically over pumping the laser tube to increase the peak power while simultaneously decreasing the pulse width. By limiting the time the laser is applied to the tissue, the time for lateral spread is reduced and there is minimal lateral thermal damage. This is particularly useful for skin surgery where even small zones of lateral thermal damage result in significant scarring. However, the reduced zone of lateral thermal effect also decreases the ability of the laser to seal adjacent blood vessels.

CO_2 lasers can be delivered to the tissues in several ways. Regardless of the delivery system, the CO_2 laser, unlike most fiberoptic lasers, is always used in a non-contact fashion. This has some advantages in terms of ablational ability, but as there is no tactile sensation, it requires some additional time to feel comfortable with its use and control. While current glass fiberoptic cables cannot transmit the infrared wavelength of carbon dioxide, other types of fiberoptic cables (e.g., silver halide) are being investigated to transmit this wavelength. It is only a matter of time until these fibers become common in the clinical environment.[11] In the meantime, CO_2 lasers must be transmitted via articulated arms, hollow metal tubes with prisms at the articulations, or via waveguides, hollow flexible fibers that are mirrored on the internal surface. Hollow waveguide technology has improved over the past decade, and they almost mimic fiberoptics in their ease of use (Figure 24-7). The hollow waveguides remain non-contact, however, and are not easily used via endoscopy. Articulated arm technology is more cumbersome, but it does allow for microscopic attachment and the use of a micromanipulator.

Diode Laser (805-1064 nm)

Many manufacturers produce diode lasers, delivering wavelengths in the range of 805 to 1064 nm. They are compact and portable in design, and are relatively inexpensive surgical units with fairly efficient and reliable benefits for use in some soft tissue *oral surg*ical procedures (Figure 24-8). Although not as efficient as the CO_2 laser for soft tissue procedures, their relative safety, incredibly low cost (many are commercially available for less than $2000, compared to $12,000-$60,000 for CO_2), ease of use, and versatility have made them a common choice for minor office-based surgery, primarily by non-surgeons. However, most oral and



• **Figures 24-7** A current office based CO_2 laser. Note the hollow wave guide that allows flexibility similar to a fiberoptic guide. (Courtesy LightScalpel, LightScalpel LLC, Woodinville, WA.)



• **Figures 24-8** Portable diode laser. Most such diode lasers are small, inexpensive, and use fiberoptics, but are less efficient than CO_2 lasers.

maxillofacial surgeons find them too slow for the majority of surgical procedures when compared to the CO_2 laser.

Diode lasers can be used in continuous-wave or gated-pulse modes, and in contact or out of contact with tissue. The primary chromophore for most diode lasers is tissue pigments, with relatively little absorption by water. Thus, they are relatively poorly absorbed by most non-pigmented tissues and rely on the use of an external pigment applied to the end of the optical fiber (e.g., articulating paper melted onto the end of the fiber). This leads to wavelength absorption not by the tissue itself, but by the pigment on the fiber. This results in the tip becoming essentially red hot, causing the fiber to have a cautery-like thermal effect on the tissue. It is this thermal effect, not an optical effect, that results in the tissue effects. The 980-nm diode laser, however, with an optical penetration of less than 300 μm, has significantly higher absorption in water making and cuts somewhat more optically than thermally. Romanos and Nentwig found that the 980-nm diode laser produced a more precise incision margin compared with other diode laser wavelengths.[12] In addition to various other soft tissue oral surgical procedures, the 980-nm diode lasers have become as popular as CO_2 lasers in the treatment of peri-implantitis because they offer a bactericidal effect without causing implant surface alterations.[13]

Neodymium:YAG Laser (1064 nm)

The neodymium:yttrium-aluminum-garnet (Nd:YAG) laser's active medium is a crystal of yttrium, aluminum, and garnet doped with neodymium ions.[14] By functioning in the near-infrared part of the spectrum at 1064 nm, the Nd:YAG laser exhibits minimal surface tissue absorption and maximal penetration. This allows for coagulation of tissue in depth, but relatively inefficient surface cutting.[15] The optical delivery is free-running but must be used in a "pulsed" mode because of the Nd:YAG laser's ability to penetrate deeply into soft tissues. Romanos reported that most procedures could be performed without local anesthesia because the pulse duration is shorter than the time required to initiate a nerve action potential.[16]

Comparing Nd:YAG laser surgery to conventional scalpel surgery, White and colleagues concluded that the laser could be used successfully for intraoral soft tissue applications without anesthesia and with minimal bleeding.[17] When the procedure involves significant ablation or resection of tissue, however, local anesthesia is necessary for patient comfort.[15]

As with the diode lasers, the Nd:YAG laser can be used in contact (excision) or in non-contact (coagulation) mode. These properties have led to its use in a variety of maxillofacial procedures, including coagulation of angiomatous lesions, hemostasis in bleeding disorders, arthroscopic surgery of the temporomandibular joint (TMJ), resections in vascular tissues (in combination with CO_2 wavelength), and palliation of advanced neoplasms.[18] The Nd:YAG laser has demonstrated some benefit with minimally invasive

periodontal therapies, including sulcular debridement and bacterial decontamination, resulting in potential new attachment of gingival tissues, regeneration of supporting bone, and regrowth of periodontal ligament.[19] This procedure, termed the Laser Assisted New Attachment Procedure (LANAP), despite having FDA approval, has limited data to support it and is considered quite controversial.

Erbium Lasers (2780-2940 nm)

The erbium family of lasers, including two similar wavelengths, the Er:YAG and the Er:Cr:YSGG, have gained recent popularity in general dentistry and in dental implant surgery because of properties that they share. The erbium lasers are free-running, pulsed lasers with thermal effects that interact solely with the surface layers of soft and hard tissue due to their exceptionally high degree of absorption by water.[20] The beams are reflected by polished metal surfaces such as titanium, so they have no direct adverse effects on dental implants.[21] Application of the erbium lasers in dental implant surgery has been advocated for the preparation of hard tissue, second-stage surgery, revision of soft tissue, and treatment of peri-implantitis.[21-23]

Although the erbium lasers are capable of osseous surgery, such as crown lengthening, harvesting autogenous bone grafts, and sectioning teeth, these procedures require significantly more time than traditional methods.[24] For this reason, oral and maxillofacial surgeons, who spend much of their time treating osseous tissue, have generally not embraced erbium laser technology.

Because they are so well absorbed by water, the erbium wavelengths are rapidly extinguished by superficial layers of tissue, and this prevents significant penetration into the tissue. Although this limits their usefulness for deeper cutting or ablational procedures, it also allows for very superficial vaporization of tissue, which is ideal in some ways for skin ablation as used in cosmetic skin resurfacing. Recovery from skin resurfacing is very rapid due to the superficial effect, but also results in less long-term effectiveness when compared to CO_2 skin resurfacing.[25]

Benefits of Laser Surgery

The benefits of using lasers in surgical procedures are significant, for both the oral and maxillofacial surgeon and the patient. Laser light is monochromatic, coherent, and collimated; therefore, it delivers a precise burst of energy to the targeted area. Laser energy incises tissue more efficiently than the scalpel, generates complete vaporization, and coagulates blood vessels. For contouring procedures, the laser is perhaps the surgical instrument of choice because of its ability to sculpt soft tissues by selective ablation.

The hemostatic effect created when the laser's energy thermally interacts with collagen in vascular walls minimizes or eliminates excessive bleeding, a factor that has traditionally hindered surgeons, and creates a clean surgical field. This allows for increased precision and greatly improves visualization of the surgical site, making laser surgery easier and more accurate. Certainly, those lasers with absorption by hemoglobin are best for this purpose, although any laser that creates enough heat in the tissue to contract collagen in blood vessel walls will seal the vessels, leading to near-bloodless surgery as well.

Examined histologically, laser wounds have been found to contain a significantly lower number of myofibroblasts.[26] This results in less wound contracture or scarring and, ultimately, improved healing.[27,28] Mobility to the dynamic tissues (lips, tongue, floor of mouth, soft palate) is attained more readily postsurgically. As a result of improved healing and hemostasis, intraoral laser wounds can often be left without sutures, healing by secondary intention, except when cosmesis is a concern.

With laser technology, the patient typically experiences less postoperative swelling and pain.[29-31] A compromised airway during oral surgery is less of a concern, mainly due to the decreased swelling. Although not always predictable, the decreased postoperative pain can be managed with over-the-counter, non-narcotic oral analgesics for most laser procedures. The physiology of this effect is still unknown but most likely correlates with decreased tissue trauma and an alteration of neural transmission.[15]

Because the patient typically has a painless surgical experience with minimal postoperative complications, many procedures are performed on an outpatient basis. Patients can often return to work within 1 day or even immediately after surgery.

Disadvantages of Laser Surgery

Despite the laser's many advantages, when determining the appropriate treatment for a patient, the clinician also must consider its drawbacks. Although the healing process following laser surgery is generally marked by considerably decreased scarring and increased function, some have found that the speed of healing is slightly prolonged compared with other types of wounds.[25] This delay in healing is undoubtedly caused by the sealing of blood vessels and lymphatic channels and the subsequent need for neovascularization during healing. Typical intraoral healing after laser surgery may take as long as 2 weeks for wounds that would otherwise take 7 to 10 days to completely heal. If sutures are indicated, delayed healing times must be taken into account when considering suture removal, to prevent premature dehiscence of the wound.[9]

Unsutured CO_2 laser wounds heal by forming a fibrinous coagulum that functions as a biological dressing. Because of the slow epithelialization of CO_2 laser wounds, the fibrinous coagulum may be present beyond 2 weeks.[29] A clinician new to lasers should not confuse this healing process for infection and unnecessarily perform a wound debridement or prescribe antibiotics when there is no indication. Unlike postsurgical healing after conventional techniques, an increase in pain 4 to 7 days postoperatively may occur as nerve tissue regenerates, which can normally be controlled

with minimal oral analgesics. The clinical appearance and anticipated discomfort after laser surgery should be discussed with patients to avoid confusion and prevent the perception of surgical complications.

Laser Safety

Lasers are incredibly useful tools in the armamentarium of the oral and maxillofacial surgeon. However, because of their optical properties—including non-contact surgery by many wavelengths and intrinsic collimated and coherent beams, which if not altered or focused, allow the beam to travel long distances with unrestrained effect—they also have inherent dangers. Therefore, laser safety is paramount to the use of lasers for oral and maxillofacial surgical procedures. All laser equipment should be thoroughly inspected and tested on an inert object, such as a moistened tongue blade, before patient use to confirm proper energy levels and safe operation of the laser. Adequate precautions must be taken to prevent inadvertent exposure of operating room personnel and the patient to unintentional laser energy not directed toward the therapeutic target tissue. Upon completion of the energy delivery to the operative site, the machine should be inactivated before moving the laser to prevent inadvertent laser burns to the patient or operatory personnel. The operatory room door must be closed during the procedure, and warning signs indicating the use of the laser and requiring additional eyewear must be placed on the operatory doors while the laser is in use (Figure 24-9). Generally, when performing laser surgery in an operating room, there will be a nurse designated as the "safety officer" to oversee laser use and ensure that proper safety measures are followed.

Problems of inadvertent laser exposure can include corneal or scleral scarring by direct exposure and retinal damage with some wavelengths not absorbed by water, making the use of wavelength-specific safety glasses with side shields mandatory (Figure 24-10). If the patient is receiving periorbital laser therapy, metal corneal shields with topical anesthetic and lubrication must be used (Figures 24-11 and 24-12). Otherwise, the patient's eyes should be completely covered with laser glasses or moistened towels.[32] The resultant laser plume should be properly evacuated via high-power vacuum with high-efficiency particulate arrestance (HEPA) filters held near the operative field, along with the use of viral filtering face masks to prevent possible contamination of operating room personnel with bacteria or viruses during laser procedures (Figure 24-13).[33]

The use of nonflammable surgical skin preparations containing no alcohol, such as povidone-iodine (Betadine) or hexachlorophene, should be followed by wiping with sterile water to prevent skin color changes. The use of isopropyl alcohol or chlorhexidine preparations containing alcohol should be avoided because of potential flammability with pooling in facial crevices or potential flammability with vaporization of the alcohol after the facial application.[33,34] Nonflammable patient drapes for use with lasers or moistened towels should also be used. The teeth must also be protected with moistened gauze or commercial silicone teeth protectors when using the laser around the mouth or intraorally because enamel can be damaged by absorbed laser energy along with possible thermal damage to pulpal tissue from heat conduction.[17] Protection of adjacent oral tissue from damage is also required, such as the use of wet sponges, moistened tongue blades, and nonreflective ebonized instruments, to prevent unintentional tissue damage.

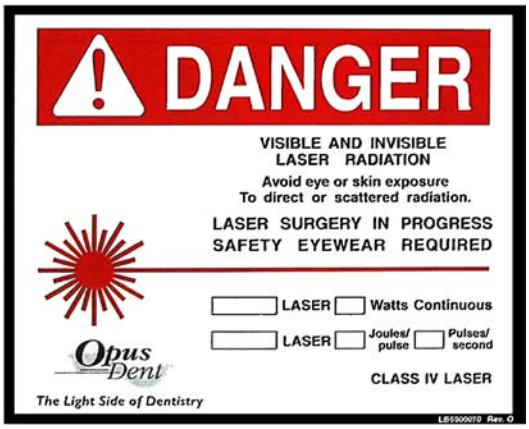

• **Figures 24-9** Warning signs indicating the use of the laser and requiring additional eyewear must be posted on the operatory doors while the laser is being used. (From Convissar RA: Principles and practice of laser dentistry, ed 2, St. Louis, 2016, Elsevier.)



• **Figures 24-10** Operator eyeglasses with side shields.



• **Figure 24-11** Corneal shields and laser glasses must be worn by patients receiving laser therapy.



• **Figure 24-12** Corneal shield. These are easily placed with topical anesthesia. When using a laser, the shield should be metal and not plastic to prevent perforation.



• **Figure 24-13** Typical laser HEPA evacuator.

The use of lasers in the presence of supplemental oxygen requires the use of precautions to prevent inadvertent fires. Patients under general anesthesia should be intubated with a commercially available reflective or absorptive material-covered endotracheal tube specific for laser use or have the tube wrapped with non-reflective foil to prevent a possible fire in the endotracheal tube, which with pressurized oxygen can create a torch-like effect. The cuff should be inflated with normal saline versus air, and the tube should additionally be protected with wet sponges if exposed intraorally. If the patient is being sedated and supplemental oxygen is used via a nasal cannula or face mask, care must be used to prevent ignition of items within the airway, and the oxygen delivery cannula or the mask should be wrapped in foil to prevent an airway fire. There are also commercially available reinforced endotracheal tubes wrapped with foil or silicone material.[34] Oxygen can be delivered through a nasopharyngeal airway under low flow while packing off the posterior pharynx with moistened gauze. Supplemental oxygen should be used at a low flow or can be turned off while the laser is being used. Many anesthesia machines are now fitted with compressed air tanks to limit the concentration of oxygen. The use of facial drapes that can cause a high oxygen concentration to accumulate under the drapes, possibly leading to a fire, should be avoided. Saline or sterile water should also be readily available to extinguish an airway fire if needed.

Intraoral Laser Soft Tissue Surgery

The use of lasers in oral and maxillofacial surgery has continued to evolve since its introduction in 1960 by Theodore Maiman.[2] Lasers have commonly been used to treat a variety of pathologic conditions, and the use of lasers for other modalities has continued to grow. The laser has proven to be a useful tool within the practice of oral and maxillofacial surgery for procedures, such as implant uncovering, gingival recontouring, surgical exposure of teeth, frenectomy, treatment of maxillofacial vascular and pathologic conditions, cosmetic skin resurfacing, laser-assisted arthroscopic TMJ surgery, and many other applications. The use of the laser within oral and maxillofacial surgery continues to progress with new radiant-energy wavelengths and lasing mediums, decreased cost of laser units, and new clinical indications and applications.

Polanyi initiated the use of lasers for oral and maxillofacial surgery with the use of a CO_2 laser to incise living tissue with the development of a handheld laser delivery system.[9] The CO_2 laser remains the most commonly used laser for oral and maxillofacial surgery as a result of the excellent absorption of the 10,600-nm infrared laser wavelengths by tissues with high water content. A multitude of other lasers (i.e., argon, holmium:YAG, erbium:YAG, neodymium:YAG, diode, copper vapor, low-level, KTP, dye, ruby, and alexandrite) are used for selected applications in oral and maxillofacial surgery.[8]

Oral mucosa has a 90% water composition, making it ideal for absorption of infrared CO_2 laser energy. CO_2 laser energy is absorbed by intracellular water, resulting in a photothermal effect. The laser energy–associated photothermal effect results in cellular disruption and vaporization of the mucosal tissue. A zone of lateral thermal damage (500 μm or less) is created in adjacent tissue via heat generation and conduction. This allows for coagulation of vessels of the same or less diameter.[8,32] CO_2 lasers provide excellent coagulation and hemostasis with an associated decrease in wound contracture and scarring, as a result of decreased fibrosis with wound healing.[26] Other benefits of laser surgery include decreased postoperative pain and edema. The laser can also be used in areas of limited exposure within the oral cavity where surgical access with conventional techniques can be difficult. Lasers do have the disadvantage of delayed wound healing (2 to 3 weeks) when compared to conventional surgical techniques (7 to 10 days) because laser wounds are slower to epithelialize. Mucosal laser wounds heal by secondary intention as a fibrous coagulum initially covers the wound and is slowly replaced by epithelial migration from the wound margins.[30]

Laser soft tissue surgery allows for minimal adjacent tissue damage, provides excellent wound hemostasis, decreases surgical and postoperative pain, and decreases surgical site infection via bactericidal effects.[30,33] Postsurgical bacteremia is also reduced via sealing of adjacent vascular and lymphatic vessels.[33] The CO_2 laser is set on a continuous wave in a range of 2 to 10 W with a spot size of 0.1 to 0.5 mm for most incisional and excisional procedures. In a focused mode the power per unit area is maximized, and at the focal point, the smallest spot size, the laser is used to produce an incision of a controlled depth and thinnest width. The laser can also be defocused to permit coagulation of blood vessels (up to 500 μm in diameter) to aid in hemostasis.[8]

During laser excision of a labial or lingual frenum, the mucosa and underlying muscles are easily excised (Figure 24-14). Following the administration of local anesthesia, the frenum attachments are separated and the surrounding tissue is preserved. The wound demonstrates complete hemostasis, and suturing is rarely required. Following laser frenectomy, the wound heals more slowly than those done with sharp dissection, although the patient will usually experience less postoperative pain.

The laser can be used to excise mucosal lesions, which is frequently performed in an elliptical manner (Figure 24-15). Including an additional soft tissue margin, usually extending 0.5 mm beyond the normal surgical margin, allows for a laser-induced zone of lateral necrosis within the specimen. This allows for more accurate histopathologic interpretation, as the zone of lateral necrosis can be difficult to interpret histologically.[8] The subsequent wound can be closed with sutures or left to granulate. Ranulas and mucoceles can be is treated with the laser by excising the covering layer of mucosa at the periphery for marsupialization or by undermining the lesion followed by complete excision (Figures 24-16 and 24-17). The laser will provide excellent hemostasis of the surgical site. The need for counter-traction is negated with the use of the laser in the floor of the mouth and other areas of freely movable mucosa. The surface of the ranula can be vaporized instead of marsupialized with no difference in recurrence.[35] Laser-assisted sialolith excision in the floor of the mouth is performed by incision through the mucosa and salivary duct in the area of the stone. A flash of light is noted once the stone is encountered with the laser, and then the sialolith can then be removed. The wound is left to granulate, without suturing, to prevent stricture or obstruction of the underlying salivary duct.[8]

Laser treatment has been advocated for benign and premalignant oral lesions, such as leukoplakia, erythroplakia, epithelial dysplasia, hyperkeratosis, lichen planus, nicotine stomatitis, actinic keratosis, and others. Laser treatment of mucosal lesions also permits the ablation or vaporization of tissue at controlled depths of less than 1 mm while simultaneously preserving the submucosal tissue (Figure 24-18). This is performed with the use of high power density at short application times or, more commonly, in a defocused mode to maximize the spot size and minimize the depth to the surface epithelium only. Mucosal lesions and premalignant lesions can be adequately managed with laser vaporization or ablation, as there is no significant increase in the number of recurrences when compared to traditional

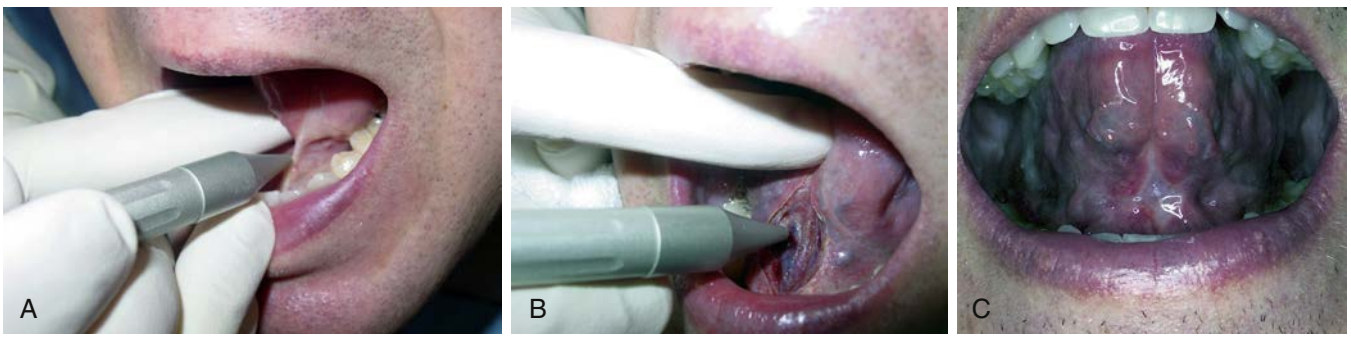

• **Figure 24-14** Frenectomy. **A**, Incising the frenum in focus. **B**, The frenum has been excised. Note the lack of bleeding. **C**, Healing after 2 weeks.



• **Figure 24-15** Laser excision of a benign lesion. **A**, Outline and incising around the lesion in focus. **B**, Undermining and removing the lesion in focus. **C**, Lesion removed and left open to heal.

methods of treatment.[8] All lesions should have a definitive diagnosis before laser therapy because laser vaporization or ablation does not provide a tissue sample for histopathologic review. Defocusing the laser beam produces a rapid bubbling of the epithelium and crackling noise as the epithelium turns opalescent, leaving a light-colored base after char removal.[33] The mucosal lesion is first outlined, and then treated by complete coverage of the entire lesion surface with the use of a vertical or horizontal paralleling "U" pattern to evenly treat the entire lesion. A second pass in a direction perpendicular to the first pass using a similar "U" pattern can be performed if an inadequate depth was obtained initially (Figure 24-19). This ensures complete and even treatment of the lesion.[8] In continuous mode, vaporization removes approximately 200 to 400 μm of epithelium per pass. Ablation to the level of the basement membrane preserves submucosal structures and prevents wound hemorrhage. Mucosal ablation allows re-epithelialization from the wound margins as well as from the epithelial adnexal structures. Ablated areas of 1 cm^2 or less generally re-epithelialize in 2 to 3 weeks.[36] Benefits of laser treatment versus standard excision include decreased scarring, less potential to damage associated vital structures, preservation of tissue elasticity, and decreased need for reconstructive surgery, which can alter the detection of recurrent lesions.[33] Laser treatment is advocated for the treatment of multifocal or diffuse mucosal lesions where

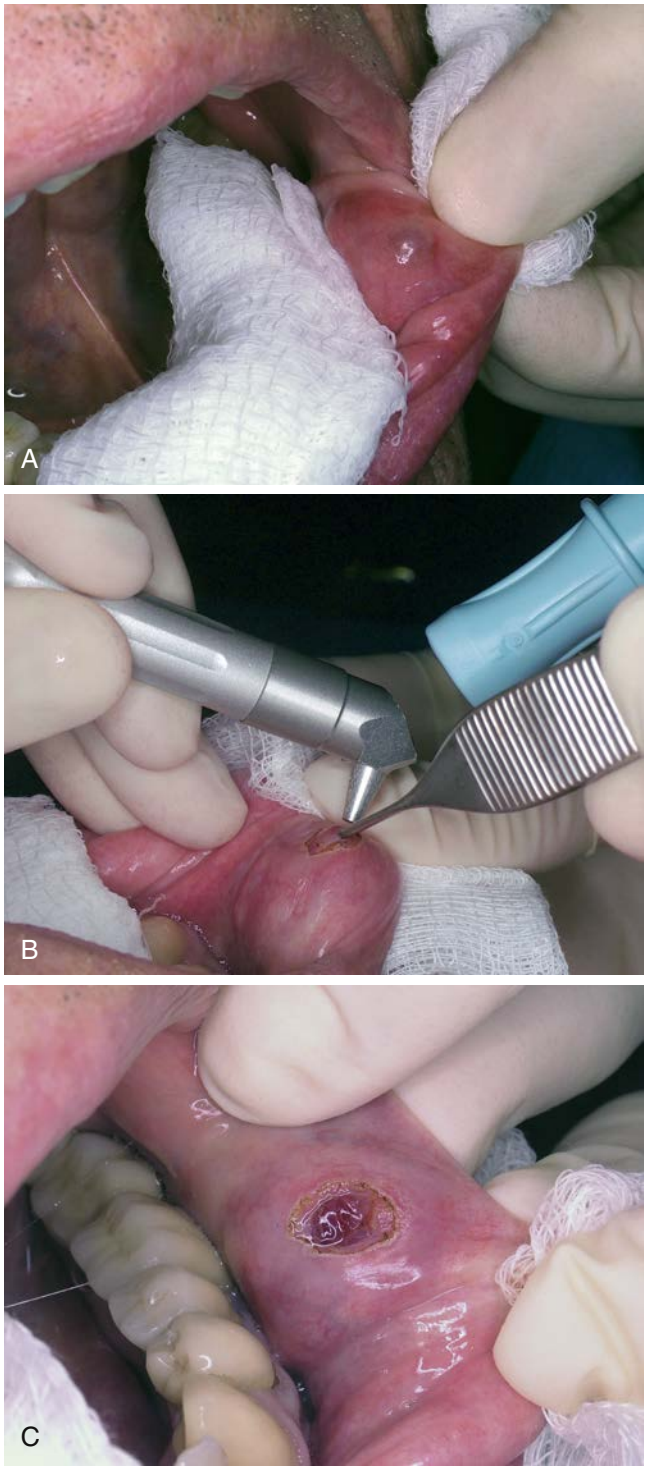

• **Figure 24-16** Mucocele removal. **A**, Outline and incising around the mucocele in focus. If the mucosa is intact, the overlying mucosa can be linearly incised rather than excised. **B**, Undermining and removing the lesion in focus. **C**, Lesion removed and left open to heal.

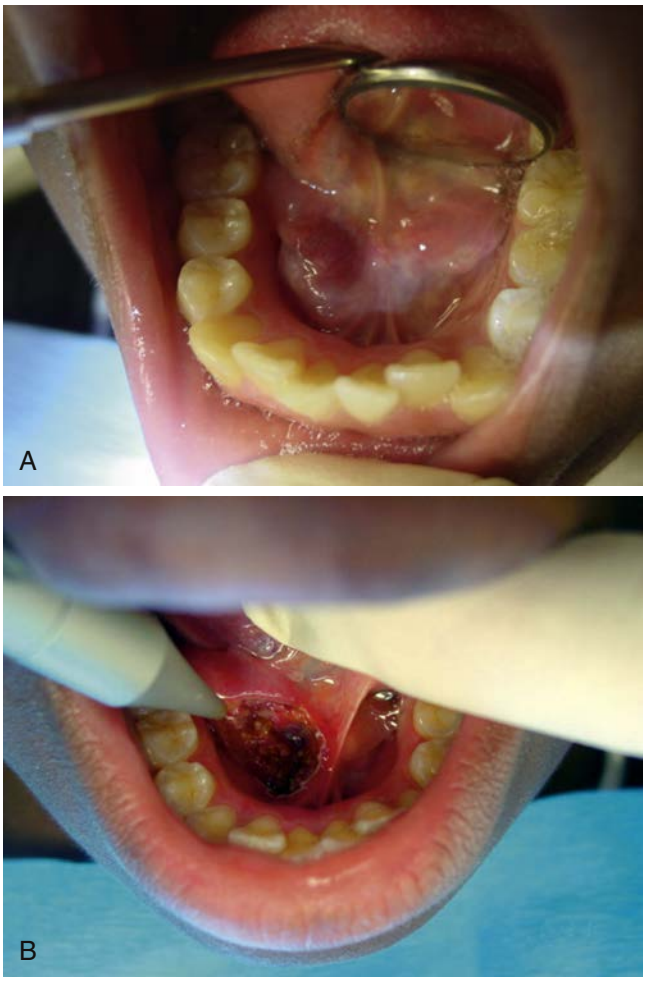

• **Figure 24-17** Ranula marsupialization. **A**, Ranula in anterior floor of mouth. **B**, Using the laser in focus to excise the top of the ranula, exposing the bottom of the ranula, which then becomes the floor of the mouth.

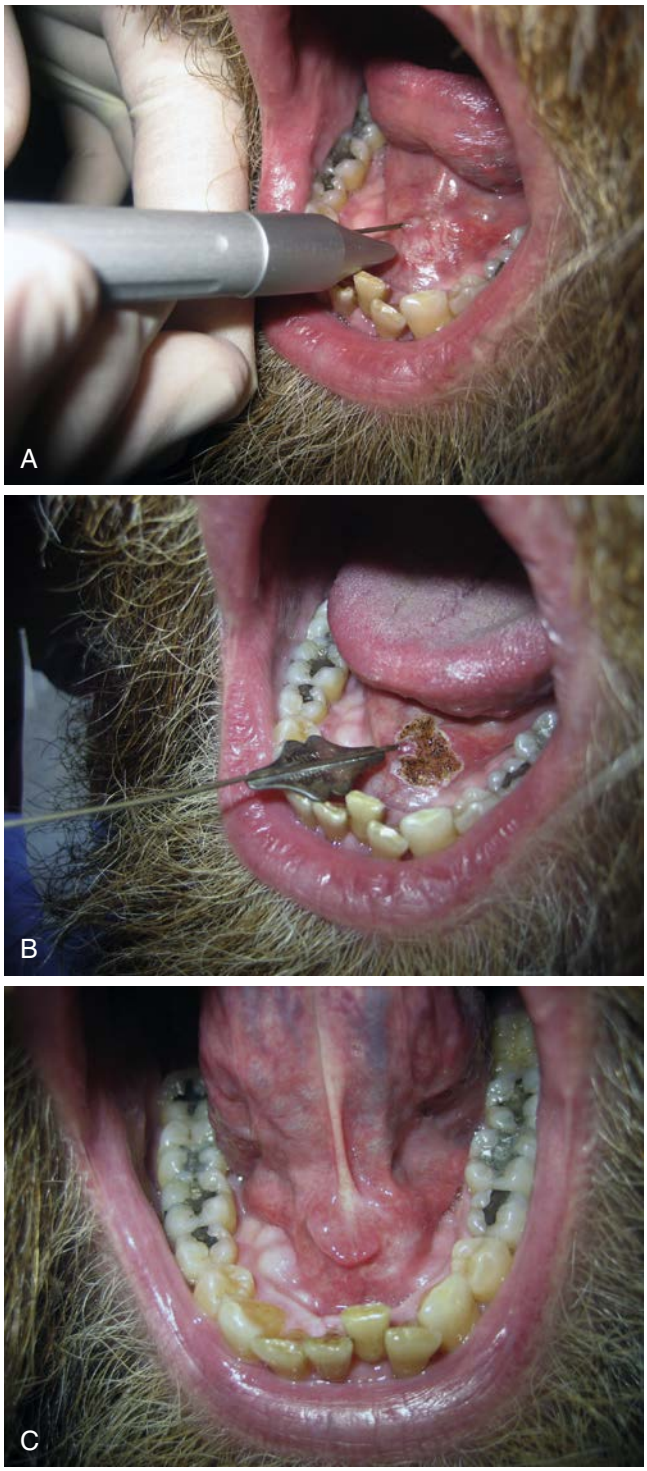

• **Figure 24-18** A, Dysplasia ablation. **B**, An area of moderate dysplasia in the anterior floor of mouth ablated in defocused mode. Note the lacrimal probe in Wharton's duct to protect it during the laser ablation. **C**, Healing at 3 weeks.

sharp excision is impossible due to the large surface area involved by the lesion. Laser treatment of diffuse or multifocal mucosal lesions avoids excision and produces minimal underlying or adjacent tissue damage while simultaneously minimizing pain, edema, and scarring.[37] The neomucosa formed by the lased wound behaves like normal mucosa



• **Figure 24-19** Ablation technique. The laser is defocused and used in a series of U-patterns to ensure even coverage of the lesion.

and permits additional laser treatment of recurrent lesions. As with any other surgical treatment of mucosal lesions, long-term reevaluation must be performed.

Histologic studies of wound healing following laser treatment have shown some carbonization, coagulation necrosis, intercellular voids, and areas of cellular vaporization.[38] The lasered wound exhibits fewer myofibroblasts in the wound with resultant minimal wound contracture and scarring.[37] The spread of malignant or premalignant cells is also limited by the laser-induced coagulation of adjacent blood and lymphatic vessels.[39]

Lasers can be used to treat intraoral vascular lesions (i.e., hemangiomas, telangiectasias, vascular lakes, and varicosities) because certain laser wavelengths are highly absorbed by hemoglobin and the lesion itself can be ablated (Figure 24-20). With lasers that are not absorbed well by hemoglobin, they can be used on adjacent normal margin tissue and the associated lateral thermal heat produced causes vascular constriction by contraction of collagen in the vessel walls (Figure 24-21). Thus, the vascular lesion can be excised in toto in the normal adjacent tissue without actually cutting into the vascular lesion and with little bleeding. The CO_2 laser, for example, can be used to contract vessels up to 500 μm in diameter. A variety of lasers can be used for the treatment of intraoral vascular lesions, including the CO_2, argon, copper vapor, tunable dye, and neodymium:YAG lasers using one of these techniques.[40]

Laser therapy has also been used as an adjunctive tool in oral medicine to treat ulcerations associated with aphthous and herpetic stomatitis. Aphthous stomatitis has responded well to diode laser therapy with an overall reduction in pain and duration of the lesions.[41]

Low-Level Laser Therapy

Traditional lasers that have physical effects, primarily the formation of heat, in tissue are termed *therapeutic* lasers. Some lasers are used at such lower powers that they have no heat-producing abilities within tissue and are termed *athermal* or *low-level lasers*. Low-level laser therapy (LLLT) uses

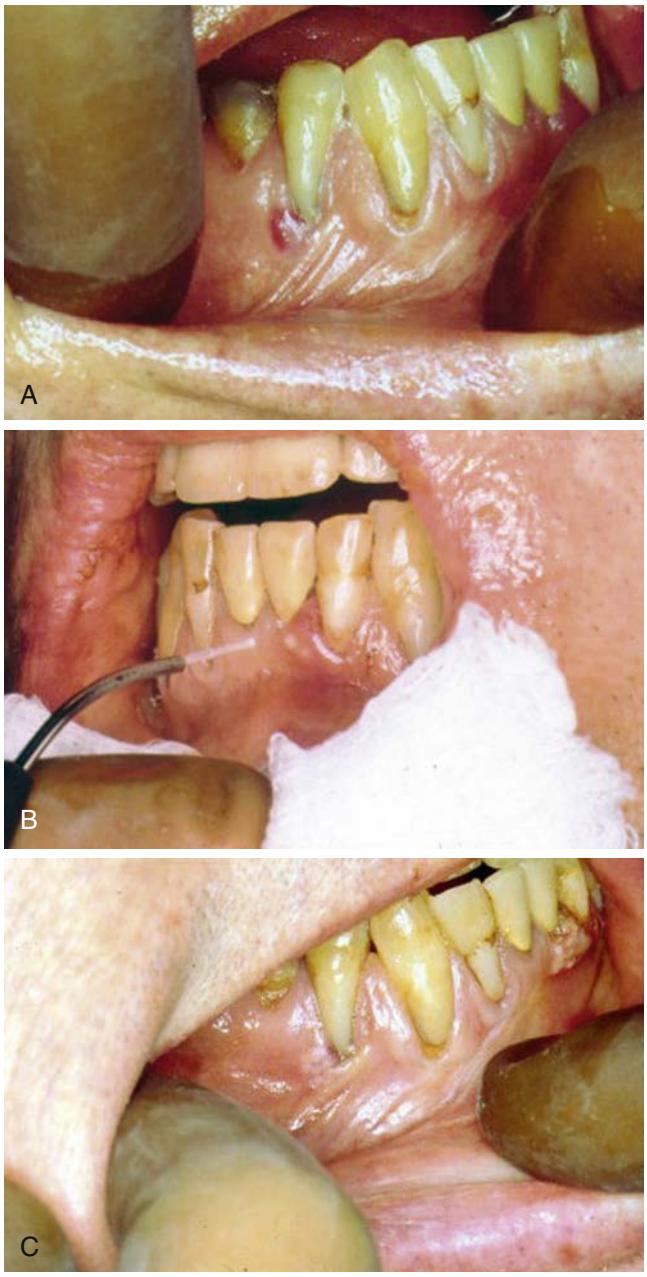

• **Figure 24-20** Vascular lesion removal using a KTP:YAG vascular specific laser. **A**, Hereditary hemorrhagic telangiectasia lesion of the right mandibular gingiva. **B**, The KTP:YAG laser used in non-contact fashion to ablate the lesion. **C**, The lesion is ablated after approximately 10 pulses.

a phototherapeutic process with wavelengths in the visible and near-infrared, invisible range of 400 to 980 nm and a low power of 1 to 75 mW.[42] Most of these devices are diode lasers and, when in the visible spectrum, essentially resemble large lecture-type laser pointers. Low-level lasers can be used for phototherapy to deliver a small amount of energy to exposed living cells with minimal to no appreciable heat production and beneficial cellular effects labeled as *biomodulation* or *biostimulation*. The effects of LLLT were not recognized in the United States as FDA-accepted therapy until recently, and there are still limited numbers of indications that have been proven to be objectively improved

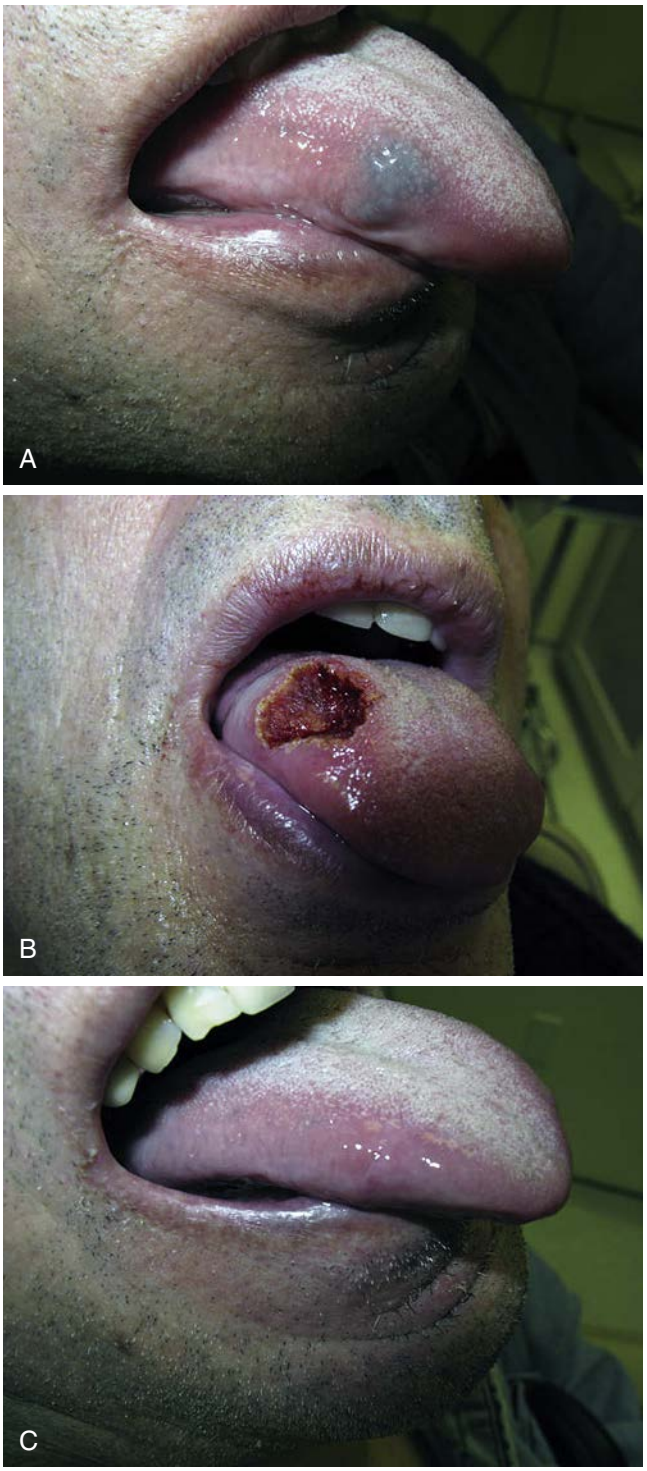

• **Figure 24-21** Vascular lesion of tongue. **A**, Hemangioma of right tongue. **B**, After laser excision using a CO_2 laser in focused mode. Note the lack of bleeding. **C**, Tongue healed after 6 weeks.

with LLLT. This has resulted in "off-label" use by health care practitioners and others for a wide variety of questionable indications. However, more recent data indicate that LLLT can indeed be of value in some cases, including TMJ disease, postoperative surgical management, and chronic mucositis.[43,44] Because they are of such low power, low-level lasers are classified by the FDA as having no significant associated

medical risks and require no specific precautions other than eye protection and avoidance of use on cancerous tissues, the thyroid, reproductive organs, infected wounds, with pregnant patients, and patients with cardiac pacemakers.

The effects of LLLT are not completely understood, but benefits on living tissues have been proposed as a result of multiple mechanisms that include changes in microcirculation, cell membrane potential, increased cellular metabolism, activation of cellular enzymes, increased wound healing, decreased inflammation, increased oxygen consumption, and other changes. There is recent evidence that many of the effects are related to the increase in adenosine triphosphate (ATP) production within the mitochondria of the cells involved.[45] The changes produced by LLLT result in a photochemical effect on biologic molecules within tissues to affect the cell by altering the cellular reactions, membranes, energy use, and metabolism to produce a therapeutic effect on the tissues in the area of the therapy. LLLT may also stimulate production of substances such as prostaglandins, endorphins, enkephalins, and other vasoactive or pain-modulating chemicals, resulting in decreased pain, decreased inflammation, and increased healing.[46]

Lasers and Wound Healing

There have been many studies undertaken to associate the use of LLLT with wound healing. The possible association of LLLT with increased wound healing has been postulated because of alteration of the fibroblast response and collagen production to result in more efficient and faster wound healing.[46] The effects have been documented in animal studies, and current beneficial applications include the possible use with diabetic wounds, infections, and tissue grafting.

Effects of Lasers on Postoperative Pain and Swelling

The use of LLLT to modulate the pain response has also been investigated and proven to be beneficial. LLLT has been shown to modulate the pain response by producing an analgesic-like effect, possibly by increasing the pain threshold and modulating the pain response of nerves. The inflammatory response to prostaglandins may also be altered to decrease the amount of overall inflammation, edema, and pain associated with surgical procedures postoperatively. Overall, results have been somewhat inconsistent regarding the pain response with LLLT following extraction or surgical removal of teeth, but meta-analysis does indicate some positive effects of LLLT.[47] The use of LLLT with nerve paresthesias has also been evaluated, with patients reporting improved sensation and comfort following the use of LLLT. Multiple studies have shown LLLT to be beneficial in the treatment of paresthesias, resulting in a reduction in the severity and a decrease in the overall distribution of the sensory changes. To date, however, most of the evidence regarding LLLT and nerve injury is not well proven.[48] The ability of LLLT to modulate healing and postsurgical pain needs additional investigation with controlled studies to determine the overall benefits of LLLT with surgical pain and edema because optimal laser energy levels, exposure times, and number of optimal treatments should be evaluated.

Laser Use in Dental Implant Surgery

Lasers can be used in dental implant surgery with the advantage of potentially soft tissue and bone cutting combined with hemostasis. Both types of laser use decrease pain and edema related to the surgical procedure as a result of decreased mechanical and thermal trauma to the adjacent tissue. The CO_2 laser is an excellent laser for peri-implant soft tissue surgery because the laser energy is not absorbed but reflected by titanium.[8]

The soft tissue flap for implant surgery can be incised with the laser through cellular water vaporization with thermal rupture producing tissue ablation. The thermal-mechanical tissue ablation results in minimal adjacent tissue damage of the extracellular collage matrix to 5 μm or approximately two cell widths. Minimal tissue shrinkage of 0.5 mm is encountered when compared with the 3 mm of shrinkage associated with incision of soft tissue with a blade.[49]

Laser therapy has proven beneficial in some adjunctive implant-associated procedures. Lasers can be used to osteotomize the lateral sinus wall with a decreased incidence of perforation of the sinus membrane during maxillary sinus augmentation. The use of the yttrium-scandium-gallium-garnet (YSGG) laser with a 2780-nm wavelength has been used to prevent iatrogenic perforation of the sinus membrane with the osteotomy and initial flap elevation.[49] The intact sinus membrane eliminates the need for placement of a covering membrane to prevent loss of grafted bone associated with sinus membrane dehiscence. The use of the YSGG laser for osteotomy of ramal bone or symphyseal bone has been described. Laser use for autogenous bone graft harvest decreases the amount of donor site bone necrosis, decreases the osteotomy diameter when compared to rotary instruments, and results in a quicker and less painful postoperative healing period.[50]

The laser can also be used for second stage implant uncovering (Figure 24-22). The laser results in less overall tissue trauma, allowing for preservation of the attached gingival tissue adjacent to the implants. The technique of laser exposure of implants can be beneficial for optimal soft tissue preservation and maintenance in the aesthetic zone.

Laser treatment of peri-implantitis is another area that has been investigated. Peri-implantitis can be a difficult-to-manage implant-related complication, resulting in progressive loss of peri-implant bone secondary to bacterial contamination and penetration of the tissues. Common treatment regimens have centered on antimicrobial therapy (chlorhexidine, citric acid, tetracyclines) in combination with surgical treatment to facilitate chemical or mechanical debridement of the contaminated implant surface. The therapeutic goal is to decontaminate the implant surface and surrounding tissues to promote

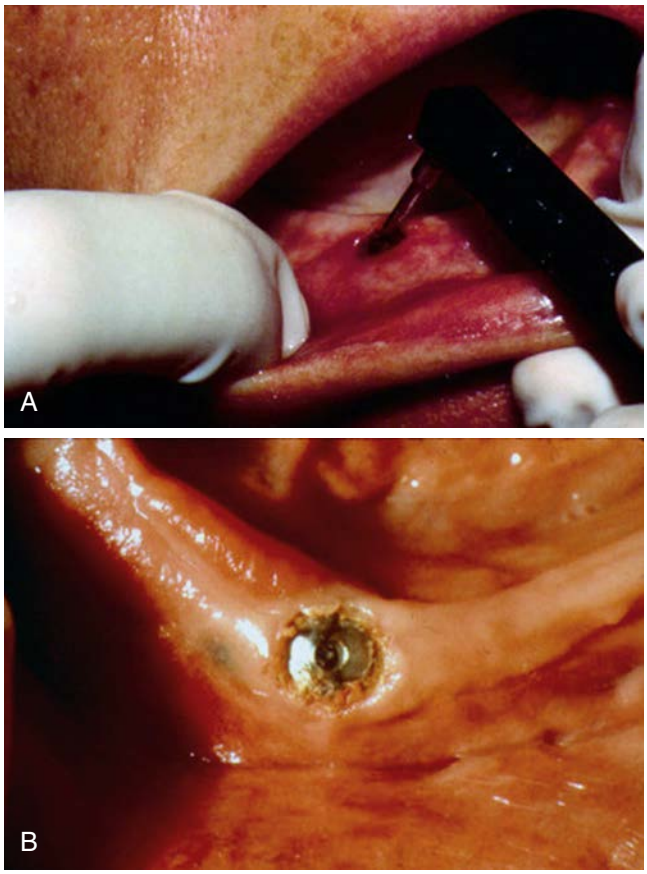

• **Figure 24-22** Implant uncovering. **A**, Using a CO_2 laser to remove the tissue overlying the implant. This can be done using a combination of focused and defocused mode. **B**, The implant exposed.

regeneration of the peri-implant bone and periodontium. Problems with traditional therapy include limited effectiveness of antimicrobials and potential damage to the implant surface with mechanical debridement.

Diode lasers have been proven to be beneficial for antimicrobial decontamination of the implant and peri-implant tissues. Treatment of peri-implantitis with the diode laser at 905 nm for 1 minute following application of toluidine blue to sensitize the bacterial cell membrane to the laser light has been reported.[13] The CO_2 laser has also been used for the treatment of peri-implantitis with no alteration of the implant surface, which has been encountered with the use of the Nd:YAG laser.[13] Laser treatment of peri-implantitis has been beneficial before bone grafting of peri-implant defects following removal of the surrounding tissue and implant surface contamination. Care should be taken when the laser energy is directed to the implant surface to prevent elevation in temperature of the implant-bone interface above the 47° C threshold of potential thermally related bone necrosis.[8]

Laser-Assisted Temporomandibular Joint Surgery

The use of lasers for treatment of pathologic conditions of the TMJ has developed over the past few decades as both laser and arthroscopic technology have progressed. The use of both lasers and arthroscopic access to the TMJ represent a major development for TMJ surgery by providing a less invasive form of treatment than traditional open joint surgery.

Ohnishi initiated arthroscopic surgery of the TMJ in 1975 with the first reported diagnostic arthroscopy.[51] McCain and Sanders advanced the use of diagnostic and therapeutic arthroscopic TMJ surgery within the United States in the 1980s.[52] Indresano and Koslin then initiated the use of laser-assisted arthroscopic TMJ surgery to provide visualization of the joint and simultaneously allow surgical manipulation of intra-articular tissues.[53,54]

Early difficulties in laser-assisted arthroscopic TMJ surgery included the inability to use a CO_2 laser as a result of the inflexible optical system and inability to transmit laser waves through a liquid medium.[54] The Nd:YAG laser presented difficulty in controlling the beam depth and adjacent tissue damage. The use in 1990 by Koslin of the holmium:YAG laser for arthroscopic use in small joints was a major achievement in arthroscopic TMJ surgery.[54] The holmium:YAG laser is able to transmit energy through a fluid medium with good absorption by tissue within the TMJ and minimal lateral thermal damage. The holmium:YAG laser has good adaptability for use with arthroscopic cannulae. Holmium:YAG laser assisted TMJ surgery can be used for synovectomy, disc repositioning procedures, intrajoint hemostasis, treatment of hypermobility, and recontouring of perforated discs.

Techniques of arthroscopic-assisted laser therapy of the TMJ are fairly standard. The joint is accessed by traditional arthroscopic techniques with the introduction of a second cannula for laser insertion. Correct portal placement through McCain's techniques using anatomic measurements and palpation allows adequate joint access while minimizing the potential complications of arthroscopic surgery.[55] Triangulation is used to position the laser for treatment of intraarticular pathologic conditions. Ohnishi developed a double cannula, which permits simultaneous and parallel positioning of the arthroscope and laser within the joint.[14]

The holmium:YAG laser can be used arthroscopically for the treatment of a variety of derangements of the TMJ as expertly described and documented through the excellent works of Koslin. Patients with painful anterior disc displacement and no improvement following conservative splint or nonsurgical arthroscopic manipulation are candidates for arthroscopic laser surgery. Nonsurgical treatment can rarely decrease the popping, clicking, or other loud noises with joint function.[55] Painful anterior disc displacement with or without close locking is commonly treated with laser-assisted arthroscopic surgery.

The laser-assisted surgery is performed by dividing the adhesions causing anterior release and freeing of the disc. The anterior synovial tissue and disc attachment are divided to the level of the lateral pterygoid muscle from a medial to lateral position. The laser is used by lightly contacting the synovial tissue at a power of 1 J and a setting of 8 pulses/s,

providing simultaneous resection of the synovium and hemostasis.[54] The thickened anterior disc tissue acts as a ridge limiting condylar movement and produces loud popping or clicking as the condyle passes onto the disc. The thickened disc tissue is thinned using the laser at 0.5 J and 14 pulses/s.[56] The disc is mobilized from the anterior attachments with the laser and then repositioned posteriorly with a blunt probe. A suture is placed through the posterior disc and synovial attachment and retrieved through the accessory portal. The disc is repositioned posteriorly with the aid of the suture, and the retrodisc synovial tissue is thinned using the laser. Care is taken to prevent lasing the tissue at the oblique protuberance to prevent tethering and limited mobility of the disc.[56] The disc is repositioned in a more posterior position and stabilized by the shrinkage of the posterior synovial tissue and the stay suture. Postoperatively the patient is placed into physical therapy with a goal maximum vertical opening of 35 mm.[56] The patient is maintained on a soft diet, and a splint can be maintained over a 3-month postsurgical recovery period to diminish postoperative pain and residual joint noise.[56]

Joint adhesions at one time were thought to be a significant contributor to TMJ dysfunction. Present literature and experience by Koslin has indicated that joint adhesions are not as common as once thought and only result from severe inflammatory joint disease or trauma-induced intraarticular joint bleeding.[56] Adhesions are most commonly seen in the anterior joint recess and can limit joint mobility and function. Arthroscopically aided lysis and lavage can be performed to break the adhesions with a combination of irrigation to distend the joint and arthroscope or blunt probe manipulation to sweep the joint. The holmium:YAG laser can also be used to break the synovial adhesions by ablation. The laser ablates the adhesions at the point of attachment to the fossae by using a 0.5-J setting at 14 pulses/s.[56]

Hypermobility of the TMJ is exhibited by patients who displace the condylar head anterior to the articular eminence, which results in the inability to reduce the joint or severe pain with reduction. TMJ hypermobility has been previously treated with eminectomy, translation-blocking osteotomies, bone grafts, plating, and lateral pterygoid myotomy. Laser therapy can treat TMJ hypermobility through coagulation and fibrosis of the retrodiscal tissue to produce a contractile force and stabilize the disc in its new position. Other treatment options include arthroscopic laser scarification of the oblique protuberance combined with suturing of the posterior disc attachment for disc stabilization. The holmium:YAG laser is used to coagulate the tissue at 20 W power for 0.5 seconds in conjunction with triangulation and positioning through the helium-neon aiming beam.[56] Joint hypermobility can also be treated with the use of a holmium:YAG laser on redundant tissue of the medial capsule to cause fibrosis and stabilization. The holmium:YAG laser provides less tissue penetration than the Nd:YAG laser. The KTP laser provides benefits similar to those of the holmium:YAG laser. All of the laser-assisted joint procedures reduce the anterior joint space and overall mobility of the condyle within the glenoid fossa. Postoperative physical therapy limits joint movement to prevent immediate subluxation of the joint. Ideally the joint opening should be restricted to 30 mm for a period of approximately 3 months to allow the joint tissue to normalize. The use of postoperative occlusal splint therapy is not necessary.[56]

Arthroscopic laser treatment of hyperplastic and hyperemic synovium can be performed as an alternative to motorized shavers or electrocautery devices.[56] Inflammatory joint disease is commonly a result of mobility or dysfunctional problems associated with the TMJ. Patients can also exhibit pain with no identifiable internal derangement on imaging, possibly related to parafunctional habits, excessive loading of the joint, or arthritides. These inflammatory conditions of the joint can be diagnosed by arthroscopy and treated with the use of lasers. Laser-assisted synovial surgery can target areas of synovial abnormality better than rotary shavers or electrocautery and spare healthy adjacent tissue from thermal or direct mechanical damage.[56] The use of the laser is much more precise and controlled than mechanical treatment of the synovial pathologic condition. The technique uses a holmium:YAG laser at a distance of approximately 3 mm from the synovium directed by a helium-neon guide beam at 0.5 J and approximately 10 pulses/s.[56] The synovium will slightly blanch from an erythematous state and constrict, with no burning or scar production, as the areas of pathologic synovium are treated with the laser. Selected steroid injections of the inflamed synovium can be performed before exiting the joint. Physical therapy, with a graduated goal of obtaining 40 mm of opening, is initiated along with the use of a soft diet and occlusal splint therapy.[56]

TMJ disc perforations can also be treated with the use of the arthroscope and laser. Traditional articular disc perforation surgery involved open-joint techniques of disc repair or meniscectomy, with or without replacement. Ideally, the condition of the bony condylar head should be evaluated radiographically before any laser treatment of a disc tear or perforation is performed. Bony changes of the condylar head on the articulating surface are a contraindication to any attempt at an articular disc repair. Arthroscopic laser-assisted treatment of disc perforations or tears is performed to attempt disc preservation and prevent the need for disc replacement procedures with grafting. Torn fragments of disc can be smoothed, and the disc can be recontoured with the laser. The Nd:YAG laser on 0.5 to 1 J of energy and 14 pulses/s can be used to remove and recontour fragmented discal tissue through triangulation techniques.[56] The reduction of any disc tears or fragments should permit the free function of the condyle. Disc recontouring can be combined with disc repositioning procedures through an anterior release to relocate the area of the perforation away from the area of condylar function.[56] Physical therapy, soft diet, and use of a splint are recommended postoperatively to prevent the development of disc adhesions immediately after surgery. Meniscectomies can also be performed by laser-assisted arthroscopy with the use of a holmium:YAG

laser to remove the disc followed by rotary contouring of the condylar head and glenoid fossa.[57]

Laser-assisted arthroscopic TMJ surgery can be associated with certain risks. The risks are similar to those for diagnostic and surgical arthroscopy of the TMJ and include facial nerve injury, otic injuries, including perforation of the tympanic membrane and external auditory canal, intracranial perforation, significant hemorrhage, extravasation of fluid, and instrument breakage.[58] The laser can actually be beneficial in relation to some complications of standard TMJ arthroscopy, such as intraoperative bleeding. The holmium:YAG laser can be used for hemostasis of small vessels during the arthroscopic procedures, although its effectiveness with profuse bleeding from larger vessels is limited.[56]

Low-level laser therapy (LLLT) has been advocated for the treatment of temporomandibular joint dysfunction and disorder (TMD). Commonly, TMD can have a variety of clinical conditions involving pathologic conditions of the masticatory musculature, TMJ, or both. LLLT has been used as another modality in the treatment of the muscular component of TMD in conjunction with nonsurgical therapies such as the use of anti-inflammatory medications, soft diet occlusal splints, and physical therapy.[59]

Phototherapy LLLT devices for the treatment of TMD have been used since the mid-1960s.[60] Recent studies have shown the effective use of LLLT for the treatment of musculoskeletal and neurogenic pain pathologic conditions associated with TMD. LLLT has been proven to be beneficial for pain fibers with applications, such as TMD and postherpetic neuralgia. Recent studies by Cetiner and colleagues have demonstrated that LLLT is an appropriate treatment for TMD and should be considered an alternative noninvasive therapy. The study revealed that patients treated with LLLT for TMD, including myogenic pain, limited mandibular mobility, chewing difficulty, and joint tenderness, had statistically significant improvement versus patients treated with a placebo laser therapy. The study used a gallium-aluminum-arsenide diode laser with a wavelength of 830 nm and duration of 162 seconds and a dosage of 7 J/cm^2 with application to the overlying skin of the most tender areas for 10 sessions daily for 10 weeks. The LLLT improved TMJ mobility by approximately 20% by comparison of maximal mouth opening measurements for the patient test group.[59]

The effects of LLLT in TMD may be beneficial as a result of both analgesic and anti-inflammatory effects by increasing the pain threshold, muscle stimulating effects, and alteration of neural sensation. The immediate effects of LLLT with pain reduction are possibly due to a direct effect on nerve cell membranes producing a local anesthetic-like effect limiting nerve conduction. The effects can last from days to weeks. Prior studies have also shown the benefit of the use of LLLT in patients with arthritides of the TMJ.[60] The optional application of LLLT in TMD needs further refinement regarding duration, dosages, and wavelengths for significant effects. Studies by Nunez and associates have also shown that LLLT is more effective for treatment of TMD than transcutaneous electrical nerve stimulation (TENS) on mouth opening.[61] Earlier studies by Gray have also shown that LLLT, ultrasound, and short-term diathermy are all beneficial for TMD treatment.[62] Therefore, LLLT can be an appropriate and alternative treatment of TMD as a result of its noninvasive nature and ease of use for myogenic pain and other TMD-related complaints.

Laser-Assisted Facial Skin and Cosmetic Surgery

Many oral and maxillofacial surgeons are involved in cosmetic procedures for facial rejuvenation and revision. Laser treatment of the face is a common modality for treatment of aging, sun-related skin damage, and traumatic and pathologic conditions of the face. Skin aging can be from intrinsic chronologic skin changes or from extrinsic sun-related photoaging.

Extrinsic photoaging from environmental ultraviolet light (UV) exposure results in cosmetic defects, including drying, coarseness, and roughened skin along with pigmentation, wrinkling, telangiectasias, and actinic keratosis.[63] Intrinsic skin aging results in thin, fragile, finely wrinkled, inelastic skin.[63]

Skin cancer is associated with both aging and photoaging with exposure to UVB radiation. Basal cell carcinomas, squamous cell carcinomas, premalignant actinic keratosis, and melanomas are all related to sun exposure. Treatment of premalignant and malignant skin lesions is necessary for overall health measures, unlike elective cosmetic-related skin procedures. Skin damage can be quantitated by the use of scales proposed by Griffiths and Glogau.[64,65] The Glogau skin classification provides specific criteria with five skin types based on the degree of skin wrinkling, photoaging, and acne scarring.[65] Another recently developed skin classification was developed by Obagi, which includes skin color, oiliness, thickness, laxity, and fragility along with suitable skin rejuvenation procedures, including preoperative and postoperative skin care recommendations.[66]

A multitude of treatments are available for photoaging including both topical treatments, such as retinoid vitamin A derivatives, alpha-hydroxy acids derived from fruit and dairy products, and antioxidants, such as vitamin C and E related compounds.[63] Rejuvenation procedures can include the use of botulinum toxin injection, augmentation of soft tissues with collagen or hyaluronic acid fillers, and resurfacing with peeling, dermabrasion, or laser resurfacing.

Skin resurfacing is used for the treatment of photodamaged skin by generalized controlled wounding, which stimulates new skin growth. The new skin replaces the photodamaged epidermal layers and tightens the dermal layers by shortening existing collagen along with the production of new collagen, improving the overall facial appearance.[67] Resurfacing can be accomplished through the use of chemical peels, mechanical dermabrasion, and laser skin resurfacing. All methods can be divided into superficial depth into

the stratum corneum and papillary dermis, mid-depth of the upper reticular dermis, and deep wounding of the mid-reticular dermis.[63]

Thorough evaluation of the patient, especially in regard to skin condition, is needed to determine the most effective skin resurfacing modality. Commonly, the depth of skin surface irregularities correlates to the depth of injury required by the resurfacing procedure. Consideration of scar formation must be discussed along with other important aspects of overall facial health, including any history of facial trauma, facial surgery, prior rejuvenation or resurfacing procedures, radiation therapy, and recurrent herpes viral infections.

An active herpes infection of the face is a contraindication for resurfacing, and the procedure should be postponed until complete resolution of the infection. Obagi suggest the patient should be started on prophylactic acyclovir at 400 mg twice a day starting 2 days before the procedure and maintained until 5 days after the procedure or, alternatively, valacyclovir (Valtrex) 500 mg twice a day with the same regimen.[68] Many other antiviral regimens exist and grossly depend on practitioner preference and bias. Additional attention should be paid to the use of medications that affect facial healing and possible hyperpigmentation, including isotretinoin, corticosteroids, and hormone replacement therapy. The Fitzpatrick skin classification system, which is based on skin color and ability to tan or burn, should also be used to screen potential candidates for laser skin resurfacing.[69] Patients with darker skin types (Fitzpatrick IV through VI) are at a greater risk of hypopigmentation with resurfacing procedures extending into the reticular dermis.

Anti-infective use with laser skin resurfacing for bacterial and fungal prophylaxis is controversial, with no conclusive literature supporting the use of anti-infectives. Again, anti-infective regimes depend on practitioner preferences. Generally, anti-infectives should be considered if occlusive skin dressings are used for more than 48 hours after laser skin resurfacing. Extended use of occlusive dressings can place the patient at risk for bacterial and fungal infections.[68]

The development of laser skin resurfacing has grossly replaced the use of dermabrasion procedures to correct superficial skin imperfections. Laser resurfacing most commonly uses pulsed CO_2 lasers to produce controlled photothermal skin damage of layers of the epidermis and outer dermis. Outer epidermal layers are vaporized, and additional heat transfer produces collagen shrinkage resulting in contraction of the dermis, which eliminates superficial skin imperfections along with an overall tightening of the facial skin.

The use of the CO_2 laser under various laser modalities, such as limited dwell time, pulsation, and delivery time, can limit overall thermal damage and provide superior results. Pulse duration can range from 600 µs to 1 ms.[70] Laser-delivered energy provides better depth control of wounding to the skin than the use of chemical peels. CO_2 lasers provide optimal treatment of cutaneous photoaging, especially for lighter skin types (Figure 24-23).

Laser skin resurfacing is well known to be useful for treatment of irregular pigmentation, acne scars, lentigines, fine wrinkles, shallow rhytids, actinic keratosis, and other effects of photodamage to skin. The treatment of deep rhytids with the CO_2 laser can lead to suboptimal results, scarring, and cutaneous depigmentation. Care must be demonstrated with full-face resurfacing because of possible hypopigmentation and erythema, although the use of hydration under the topical anesthetic EMLA (eutectic mixture of local anesthetic) can limit the incidence of thermal damage and injury, producing suboptimal results.[71]

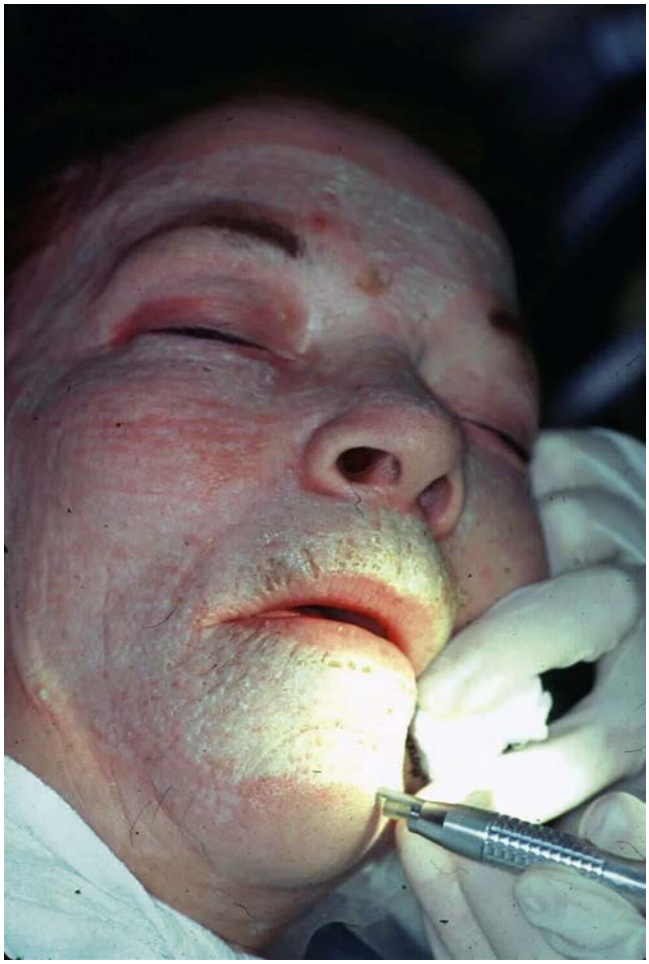

• **Figure 24-23** Full face laser cosmetic skin resurfacing (CSR). This is most easily accomplished using a mechanical scanner to uniformly distribute the laser over a large area.

The erbium:yttrium-aluminum-garnet laser (Er:YAG) can be used for patients with dark skin color or pigmentation to limit thermal injury because the Er:YAG laser energy is better absorbed by water than CO_2 laser energy, resulting in a shallower depth of penetration and less thermal damage.[63] The use of newer techniques, such as nonablative laser resurfacing, has limited epidermal damage via selective cooling while applying selective energy to the dermis. The overall benefit is improved healing as a result of limited epidermal damage, with less need for anesthesia of the skin and simplified wound care.[71] These nonablative laser skin resurfacing procedures fall under numerous names depending on the technique and individual laser unit used. These techniques can be used for all skin types and are useful to treat fine skin lines and shallow

rhytids not associated with muscular movement. It should be noted that the nonablative laser treatments are less effective than ablative laser skin resurfacing.

The use of skin conditioners can improve overall laser skin resurfacing results. The skin conditioners should be used both pre- and postoperatively. The preoperative benefits of skin conditioning include enhanced wound healing and limiting pigmentation changes associated with the resurfacing procedure. Regimens include the use of tretinoin to normalize keratinization, regulate skin depigmentation, and increase collagen production for faster wound healing. Hydroquinone, a skin lightener, is used to decrease melanocyte activity, which in turn minimizes hyperpigmentation during healing. In general, the epidermal cell cycle time is 6 weeks to allow maturation of keratinocytes from the basal layer to the stratum corneum. The skin-conditioning program should be started approximately 6 weeks before laser skin resurfacing.[68] The program should then be reinitiated after reepithelialization and healing, along with use of sunblocks when exposed to outdoor sun.

Generally, most surgeons prefer to avoid occlusive dressings and use topical creams such as Eucerin or Aquaphor. This allows easier cleaning and visibility. Wound healing after laser resurfacing can be improved, according to some authors, with the use of occlusive dressings and tretinoin. The overall healing period lasts from 5 to 14 days depending on the depth of resurfacing. Occlusive dressing, such as non-adhesive pads, silicone sheeting, and hydrogels, can promote faster reepithelialization and decrease pain.[68] The occlusive facial dressings are generally used for the first 48-hour period following laser treatment.[68] It should be noted that the use of occlusive dressings is practitioner dependent and there is wide variation in the preferred dressing technique. In any case, the patient is instructed to gently cleanse the face twice daily and to apply emollients.[63] Compresses with water and mild acetic acid are used every 4 to 6 hours to decrease bacterial skin counts. The compresses are followed by reapplication of the emollients. Sun exposure should be avoided for 3 to 6 months after the facial laser resurfacing treatment, and then a routine sun exposure regimen should be initiated.[63]

Contraindications to laser skin resurfacing include a multitude of conditions. Seasoned practitioners frequently combine cosmetic facial surgery procedures with facial laser skin resurfacing, but procedures, such as face-lifts, brow-lifts, and rhinoplasty, can interrupt lymphatic drainage and result in extensive edema after surgery.[68] Use of some medications, including steroids, retinoids, penicillamine, and phenytoin, is contraindicated with laser resurfacing.[68] Psychiatric disorders such as body dysmorphic syndrome, prior head and neck radiation therapy resulting in loss of adnexal structures, and any history of keloid or hypertrophic scar formation are all contraindications to laser skin resurfacing. Active skin disorders, such as rosacea, acne, psoriasis, or verruca infections, are also contraindications to laser skin resurfacing. Smoking can cause delayed healing following laser resurfacing.[68]

Common complications of laser skin resurfacing often result from overaggressive treatment (Figure 24-24). The complications can include persistent erythema, beyond 2 to 3 months, and hyperpigmentation, especially in patients with darker skin types, such as Asians, Hispanics, and African Americans.[72] Postoperative hyperpigmentation will usually resolve with time, sun exposure protection, and treatment with topical steroids, tretinoin, and hydroquinone as necessary. Hypopigmentation, as a result of overaggressive laser resurfacing, can be more serious because it can be permanent as a result of



• **Figure 24-24** Complications of laser skin resurfacing. **A**, Postoperative hyperpigmentation. **B**, Postoperative infection.

violation of melanocytes and will manifest as a late complication, months after treatment. Extreme care should also be taken in patients with vitiligo because the Koebner phenomenon can result in unmasking more areas of vitiligo.[72] There are no specific treatments for hypopigmentation, making it very problematic. Sun exposure will not fade or blend areas of hypopigmentation. Hypertrophic scarring is another complication of laser skin resurfacing and results from overaggressive treatment into the underlying deep dermal layers of the skin, especially in the perioral region of the face.[73] Hypertrophic scarring can be difficult to predict, although patients of dark skin types, such as African Americans or Asians, are more prone to this complication. Prevention by limiting the laser energy and only treating the skin to chamois or champagne color to prevent overtreatment into the dermis is advised.[72] Treatment of hypertrophic scars can include traditional methods, such as steroid scar injections, topical steroids, silicon sheeting, or customized elastomeric compression dressings, such as those used for burns.

Scar revision for both traumatic and surgical scars is another excellent indication for laser surgery (Figure 24-25). The ability to revise scars through the use of a pulsed dye laser, with a wavelength of 585 nm, has provided beneficial results with decreased erythema and hypertrophy. Pulsed dye lasers act on the chromophore oxyhemoglobin and specifically target blood vessels within the scar tissue, leaving the overlying epidermis intact. The laser stimulates collagen remodeling and production of new collagen along with minimizing the fibroblast scar response. Pulsed dye lasers reduce scar erythema and produce a less erythematous and softer, flatter scar. Multiple laser scar treatments may be needed to achieve optimal clinical results, and the laser scar revision therapy can be combined with other treatments, such as steroid injections.[74,75] Atrophic scars are best treated by ablation with the CO_2 or Er:YAG lasers. The laser-induced de-epithelialization helps soften scar depressions and stimulate neocollagenesis to fill the depressed scar defect. Slightly elevated scars are also treated easily and quickly with the CO_2 laser by standard skin resurfacing techniques. Spot laser ablative scar revision is indicated for small or localized scars, but for larger or multiple scars entire facial cosmetic units should be treated to prevent noticeable postoperative skin pigmentation and texture changes. Most scars require two to three passes with the ablative laser for optimal treatment. The procedure has the same risks and complications as laser skin resurfacing. Postoperative care is the same for the two ablative laser procedures.[74]

Blepharoplasty procedures have also be performed with a variety of lasers, including the CO_2, Nd:YAG, and KTP lasers (Figure 24-26). The goal of blepharoplasty surgery is to create aesthetic and functional eyelids with the removal of prolapsed fat and redundant eyelid skin and muscle.[76] The laser aids in providing excellent hemostasis and allows a clean dissection to minimize postoperative ecchymosis and edema. Preparation includes the use of metal corneal



• **Figure 24-25** Laser scar revision. **A**, Preoperative view showing elevated scar. **B**, After laser resurfacing of scar to the level of adjacent tissue

shielding. Incision through skin can be made with a scalpel or laser, and the dissection is then continued with the laser in a cutting, focused mode to continue the dissection to remove the excess skin and redundant orbicularis muscle. The removal of the herniated fat pads is also performed with the laser. The overall procedure results in better hemostasis with the use of the laser than surgery with the use of blades and electrocautery.[76] The option of laser skin laser resurfacing is also provided if any skin redundancy exists when a transconjunctival access is used for lower lid blepharoplasty. Laser skin resurfacing modalities can be used to treat skin wrinkles of the lower lid alone, in combination with a transconjunctival blepharoplasty procedure, or combined with a delayed blepharoplasty procedure using cutaneous incisions. The laser skin resurfacing of the lower lid is performed with a CO_2 laser as a single pass to treat fine skin wrinkles.[76]

Complications of laser-assisted blepharoplasty procedures include potential damage to the globe, the associated periorbital skin and appendages, and the lacrimal apparatus. Complications associated with traditional and laser-assisted blepharoplasty procedures include ectropion, entropion, excessive scleral show, and wound infection or breakdown. Laser-assisted blepharoplasty or laser skin resurfacing of the eyelids should be performed with extreme caution in patients who have had previous blepharoplasty procedures

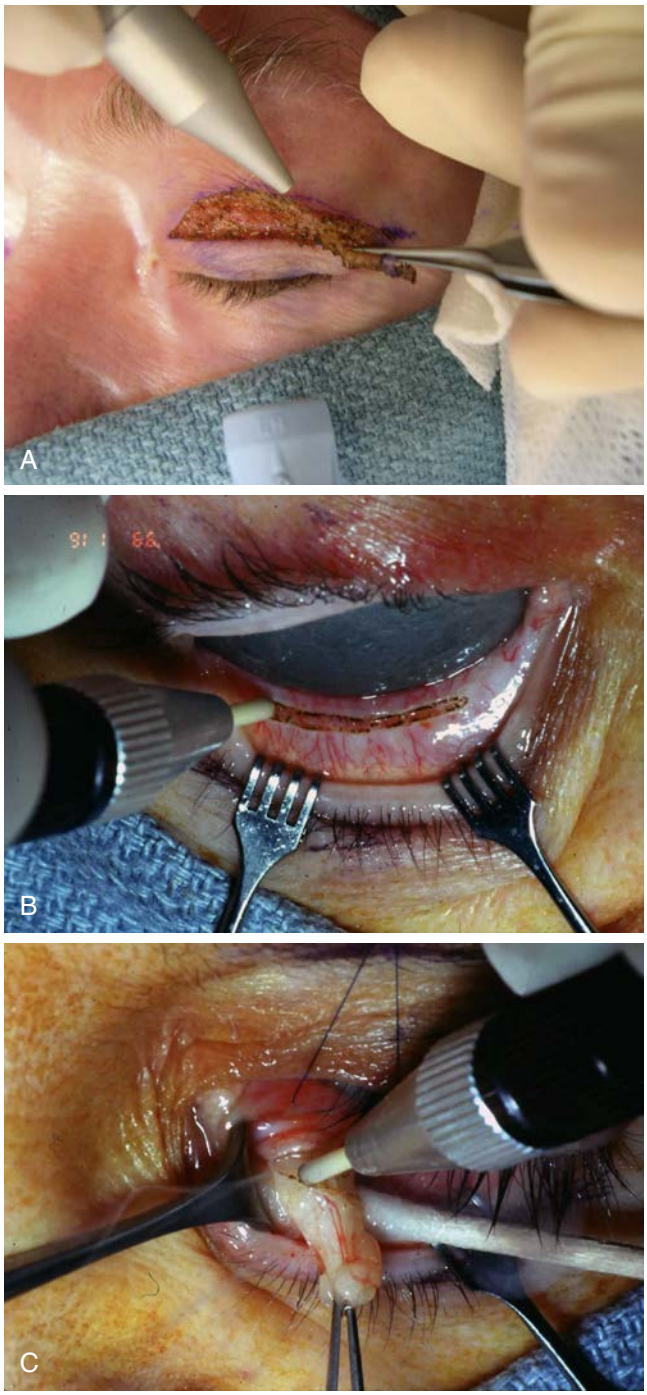

• **Figure 24-26** Laser blepharoplasty. **A**, Upper blepharoplasty. **B**, Lower lid transconjunctival laser incision. Note the metal eye shield for protection. **C**, Laser excision of the lower lid fat pad.

because these patients are very prone to ectropion with additional procedures.[72]

Laser Treatment of Vascular Lesions

Laser-assisted treatment of vascular lesions of the face prevents the excision of tissue, reducing scar and cosmetic defects. The use of the pulsed dye laser at 585 nm and short pulses of 450 μs is the preferred treatment for vascular lesions, including hemangiomas, vascular malformations, and ectasias.[77] The chromophore for the pulsed dye laser is oxyhemoglobin. The thermal relaxation time of small- to medium-sized blood vessels is approximately 1 to 5 ms. The short pulse permits selective energy transfer to the targeted blood vessels and hemoglobin while minimizing heat conduction and damage to the overlying epithelium and adjacent tissue. Melanin and hemoglobin are both chromophores that compete for yellow light, leading to potential nonselective absorption of laser light in the 500- to 600-nm wavelengths. Increased melanin absorption of the laser light is more pronounced in patients with pigmented skin or suntan. Melanin in the epidermis and dermis may overlie the vascular lesion, decreasing the effectiveness of the laser treatment. It is best to spot test the laser in an inconspicuous area prior to treatment of vascular lesions to prevent gross pigmentation alterations secondary to melanin destruction.[77] Selecting a laser type for use in treating vascular lesions depends on surgeon preference, lesion type, lesion depth, and availability of the laser apparatus.

Hemangiomas are a common benign vascular lesion present at birth or shortly thereafter, with approximately 80% appearing in the head and neck region. Hemangiomas can be superficial or deep and exhibit a growth phase of approximately 18 months followed by an involution phase of 3 to 10 years. Even though most hemangiomas involute, the lesion may be cosmetically and socially unacceptable while present.[77] Vascular malformations are always present at birth, vary in color, do not demonstrate a proliferation or involution phases, and grow slowly in conjunction with the patient's overall growth. Ectasias are permanently dilated vessels in the skin that are visible to the naked eye and do not exceed 1 mm in diameter. Telangiectasias are acquired and grow with age and can be associated with intrinsic factors such as cutaneous disorders, including rosacea, and systemic diseases, including carcinomas, collagen vascular diseases, or pregnancy. Telangiectasias can also be associated with extrinsic factors, such as alcohol ingestion, estrogen use, and facial trauma.[77]

The pulsed dye laser has been used to treat cutaneous vascular lesions of the face, such as ectasias and port-wine stains, with the laser energy focusing on the oxyhemoglobin chromophore within the vasculature of the lesion while sparing the adjacent normal tissue. Ectasias can often be treated with a single session, whereas larger port-wine stains require multiple sessions. A major drawback of using the pulsed dye laser is the resultant purpura of the treated skin secondary to vessel rupture due to the rapid energy absorption of the lasing energy. This purpura can last for 10 or more days postoperatively.[77]

Deeply seated vascular lesions are difficult to consistently treat with the pulsed dye laser due to its limited depth of penetration. Oxyhemoglobin has separate broad peak absorption of energy of 800- to 1,200-nm wavelengths. The 1064-nm Nd:YAG laser can be used for deep vascular

lesions as it is excellently absorbed by oxyhemoglobin and has coagulative effects at approaching 6 mm depth of penetration.

Laser Treatment of Pigmented Lesions and Tattoos

Treatment of cutaneous pigmented lesions is another common use for lasers with either ablation or resurfacing techniques (Figure 24-27). The pigmented melanocytes allow effective laser treatment, and the type of laser used and wavelength will depend on the depth of the lesion. The depth of the melanocyte can be determined with the use of a Wood's lamp. Epidermal melanin will light up under the Wood's lamp, indicating a superficial lesion, whereas dermal melanin is not visible.[77] The need for accurate diagnosis of cutaneous pigmented lesions is absolute, and a biopsy should be performed before any laser treatment with the patient being well informed about the possible need for additional treatment depending on the final histopathologic diagnosis.

Ablative lasers, such as the CO_2 (10,600 nm) and Er:YAG (2940 nm), can be used, but do not target any specific chromophore; therefore, careful removal of the lesion must be demonstrated to prevent scarring.[77] Conservative treatment with ablative lasers is encouraged, as it is easier to re-treat or touch up pigmented lesions than to treat scar. Lesions should be treated until the base is a chamois-leather color. Smaller, superficial pigmented lesions such as lentigines, keratosis, ephelides, dermatosis, and dermatosis papulosa nigra can be successfully treated with the 532-nm diode laser. The need to establish the depth of the melanocytes either into epidermis or deeper into dermis must be diagnosed because the deeper lesions cannot be superficially ablated. The use of non-contact Nd:YAG or the Q-switched ruby laser has been useful to treat deeper pigmented lesions, including melanotic nevi, nevi of Ota, blue nevi, and solar lentigines. These lasers generate longer wavelengths of high peak energy at rapid pulses, allowing deeper tissue penetration without excess scarring or overlying and adjacent tissue destruction.[78] Q-switched ruby lasers have the benefit of targeting melanin as a chromophore, but have absorption by oxyhemoglobin, leaving vessels undamaged.[77]

The use of the laser for removal of intentional or traumatic tattoos is another commonly performed cosmetic procedure. Removal of tattoos is often desired because the patient will often perceive the tattoo as unaesthetic for a variety of reasons, including fading of the ink, nonprofessionally produced tattoos, or wanting to remove a symbol or letter after a period of time. Tattoos were previously treated with CO_2 laser in the 1990s, although the use of the CO_2 laser for this purpose has been replaced by other types of lasing wavelengths specific for certain tattoo color chromophores.[79] The removal of tattoos has been successful through the use of the Q-switched ruby laser.[77] Tattoo pigment within the dermis selectively absorbs the laser waves and is fragmented into small particles, which are phagocytized by macrophages within the body to produce a gradual fading of the tattoo over time without affecting the overlying epithelium. Multiple laser removal sessions can be required for some tattoos. Results are better than previously attempted methods, such



• **Figure 24-27** Removal of benign pigmented nevus. **A**, Preoperative view; **B**, postoperative view.

as dermabrasion or excision, because of a lower incidence of pigmentation alteration and decreased scarring.

Laser Hair Reduction/Removal

Laser removal of unwanted hair or laser hair reduction is one of the most commonly performed cosmetic procedures. Excessive hair growth represented by either hirsutism, hair in unusual places, or hypertrichosis, representing excessive non-androgenic hair growth in men and women, can be localized or generalized throughout the body.[75] Laser hair reduction is regulated by U.S. Food and Drug Administration guidelines, which require a 30% reduction of hair growth at 3 months following a single laser hair reduction treatment. The need for an additional three to five treatments is not uncommon.[75] Laser hair reduction is based on the affinity of exogenous chromophores or melanin within the hair shaft to laser waves, with the heat production killing the hair follicle. Ruby (694 nm), alexandrite (755 nm), Nd:YAG (1064 nm), and diode (810 nm) lasers can be used for laser hair reduction with wavelengths of approximately 500 to 1000 nm at pulsations greater than 100 μs to destroy hair follicles while preserving the epidermis.[80] Intense pulsed light (IPL) with a wavelength of 515 to 695 nm can also be used for hair reduction. Laser hair reduction can only occur in the telogen phase, when the follicle is preparing to grow new hair and the chromophores are most sensitive to the laser energy. Laser hair reduction may therefore require multiple intermittently spaced laser treatments to increase the success of overall hair reduction. Thermal relaxation time of hair follicles depends on diameter and is estimated to be 10 to 100 ms. Laser pulses longer than 100 ms have been found to be more conducive to long-term hair reduction.[80]

Laser Use in General Dentistry

The application of lasers for general dental use continues to grow, with routine use for restorative dentistry, periodontal care, orthodontics, and dental hygiene. The use of soft tissue lasers is becoming increasingly popular for preprosthetic gingival procedures. The benefit of hemostatic control with the excision of gingival tissue can produce optimal restorative and prosthetic results.[81] Restorative and prosthetic treatment often requires the removal of gingival tissue to gain access and moisture control for the treatment of tooth structure below the gingiva.

Gingival tissue can be removed by the use of a scalpel, electrosurgery, or laser. The scalpel has the disadvantage of eliciting bleeding, which is a major problem for subsequent restorative dental treatment. Electrosurgery can also be used to remove gingival tissue with good hemostasis. However, excess heat can be generated, which can cause irreversible recession of the soft tissue at the gingival margins and possibly damage the underlying alveolar bone.[81] The recession can lead to exposure of restorative margins, resulting in suboptimal aesthetics in the anterior portion of the mouth. Lasers can offer a greater degree of control for the removal of gingival tissue with minimal damage to the adjacent soft tissue. Diode lasers offer the advantage of operating at wavelengths that are absorbed by gingival tissue and not by adjacent tooth structure.[81]

Aesthetic crown lengthening can be performed with the use of a diode laser with 810-nm wavelengths.[81] The use of the diode laser provides greater operator control for the creation of more precise gingival margins. Before the use of the diode laser for gingival recontouring or crown lengthening, a thorough periodontal evaluation should be performed with attention to the biologic width, indicating the amount of attached gingival tissue and the location of crestal bone. The possible need for osseous contouring via flap surgery versus soft tissue contouring alone can be determined. The use of the diode laser also facilitates the placement of final direct bonded or provisional prosthetic restorations as hemostasis is achieved.

Diode lasers at a wavelength of 810 nm exhibit little or no affinity for hard tooth structure, metal alloys, composites, or porcelain.[81] This benefit allows the laser to be used for soft tissue recontouring procedures around tooth structures or dental implants. The laser has little to no effect on cementum or enamel and does not conduct or produce heat through existing metal tooth-related structures. This prevents thermal pulpal injury.

The diode laser is used with the tip contacting, with aiming facilitated by a guide beam. The removal or contouring of gingival tissue is performed along the tip of the laser. Shallow tissue penetration produces slower and more controlled soft tissue cutting than an electrosurgical unit. The diode laser is usually used in a pulsed mode to minimize thermal conduction to adjacent tissue, carbonization, and char formation. The development of an external bevel to provide optimal gingival contour can be done with hemostasis, providing increased patient comfort.[81]

The use of the laser to aid in taking accurate impressions can produce optimal prosthetic results. Exposure of subgingival finish lines combined with good moisture control through hemostasis can be obtained with the use of the diode laser. This technique eliminates the need for retraction cord and produces minimal adjacent tissue necrosis. This allows preservation and complete regeneration of adjacent soft tissue with little to no gingival recession.[81]

Lasers are increasingly being used for minor soft tissue procedures related to orthodontic treatment.[82] Lasers can be used to treat gingival hyperplasia secondary to orthodontic treatment as a result of poor oral hygiene measures. Aesthetic tissue contouring with altered tooth eruption and soft tissue exposure of unerupted teeth can be performed to provide optimal orthodontic results.

The diode laser is an excellent tool for soft tissue recontouring procedures, with no effect on the teeth or related hard tissue components. The laser energy results in production of some heat, which vaporizes cells through a photothermal effect called ablation. The resultant soft tissue

wound heals faster and with minimal pain because the wound is sealed, sanitized, and protected by a biodressing.[82]

The creation of optimal aesthetics following orthodontic treatment can be planned because the orthodontist can achieve ideal embrasures and gingival contours. Delayed passive eruption limiting crown exposure can be treated with the diode laser to facilitate proper orthodontic bracket placement. Proper bracket placement allows proper orientation and alignment of the tooth with the use of preformed wires. The diode laser can also be used to expose unerupted teeth with excellent hemostasis for orthodontic bonding.

The diode laser can also be used to debride hyperplastic tissue associated with inflammation as a result of poor oral hygiene with orthodontic treatment.[82] The diode laser removes hyperplastic inflamed papillae and pseudopocketing to improve overall gingival health. The diode laser has also been used to performed crestal fiberotomies to aid in prevention of orthodontic relapse and to assist in the rotation of teeth as a quick and bloodless procedure.[82]

The diode laser has been recently used as an adjunct treatment of periodontal disease in combination with scaling and root planing (SRP). The adjunctive effects of the diode laser with conventional SRP have been proven to be beneficial.[83] The use of the diode laser for the treatment of periodontal disease is based on the model that periodontal disease is an inflammatory response of the periodontal tissue to bacterial infection and the presence of a biofilm in the periodontal pocket. The diode laser has offered the dental professional an advantage in the treatment for periodontal disease as a result of the bactericidal effect of the laser in combination with SRP.[84] The use of the diode laser with SRP was noted to decrease postoperative pain. The microbiology of the periodontal pocket revealed a decrease in the number of microbial colony-forming units in laser-treated sites following SRP, including decreased levels of *Actinobacillus actinomycetemcomitans*, which is associated with aggressive periodontal disease.[83] The use of the diode laser provided an alternative means of treatment of *A. actinomycetemcomitans* with periodontal disease versus traditional treatment with antibiotic therapy.

The reduction in bacterial colony forming units and the overall reduction in *A. actinomycetemcomitans* bacteria has been postulated to be a result of the bacteria responding to the diode laser energy at 810 nm at 0.8 W, although this has not been confirmed.[83] The diode laser has also been used to alter soft tissue in furcations to allow access to the furcation for periodontal maintenance. The diode laser also results in faster wound healing with SRP, resulting in increased comfort of the patient following the periodontal therapy.

Overall the diode laser at a wavelength of 810 nm and power of 0.8 W was equivalent to the treatment of chronic periodontitis with SCP in regard to reduction of subgingival bacterial counts and pocket depth. The use of the diode laser did not result in a statistically significant increase in periodontal attachment levels.[83]

The technique involves placement of the tip of the diode laser in the periodontal pocket, and the laser is moved in a sweeping motion from anterior to posterior to the base of the pocket. The optical fiber system to deliver the laser energy is only end-lasing, with the energy exiting at the end of the fibers and not from the side wall. The laser is directly on the root surface. The laser produces a stimulatory effect on the gingival soft tissue while reducing pocket depth and resulting in faster and less painful healing. The laser energy is not used to remove tissue. It is only focused on the tissue within the pocket to produce a nonablative thermal event, which decontaminates the periodontal pocket by reducing the number of bacteria within it, along with a decrease in the exotoxins, such as hyaluronidase and collagenase, that are responsible for periodontal tissue destruction.[84] The laser-assisted SRP procedure provides the benefit of hemostasis with a less invasive procedure than flap surgery.

The latest application of the diode laser for periodontal therapy involves its use with initial pathologic pocket formation as indicated by loss of clinical attachment, bleeding on probing, the presence of inflammation, and loss of alveolar bone height. The diode laser is used as a preventive measure in combination with SRP before pocket formation. The diode laser has been used to control periodontal disease through tissue debridement and bacterial reduction. Studies have assessed the effect of the laser to decrease bleeding on probing when used in combination with SRP versus SRP alone. The laser can also be used to palliate pericoronitis through the excision of the operculum in patients unable to have the third molar removed at the initial appointment. The patient is informed of the need for third molar removal at a later date.[84]

General dental treatments where the laser has been beneficial include the use of lasers for power bleaching of teeth. A diode laser raises the temperature of hydrogen peroxide to accelerate the chemical bleaching process.[85]

The use of lasers with operative dentistry includes their use for tooth preparation. The Er:YAG laser has been used for removal of enamel, dentin, and nonmetallic restorations.[85] The treatment is based on the expansion of hydroxyapatite by laser energy heating the water within the hydroxyapatite structure and ablating the crystal. The laser can be used to remove decay or sound tooth structure and decreases the need for local anesthetic use because the friction and heat production with drilling is eliminated.

In endodontic treatment, the use of the laser has been established for debridement of infected tissue and associated bacteria. The laser has been shown to be an excellent tool to clean and sterilize the root canal system. Studies have shown the laser energy to be superior for removal of microorganisms within the canal and smear layer of the surrounding dentin of the canal versus chelating agents or chemical irrigants, such as hypochlorite.[86] The lasers also have a bacterial effect to sterilize the canal before obturation. The use of lasers for endodontic treatment is becoming more common and has known benefits over traditional rotary instrumentation of canals, such as ease of use, decrease in the separation of instruments, and decrease in the number of endodontic failures.[85]

Laser Use in Craniofacial Surgery

Laser scan–based registration can be used for the treatment of patients with tumors, bone malformations, and foreign bodies of the craniofacial complex.[87] The laser scan uses the registration of complete areas and surfaces instead of single-point registration markers, producing a more accurate surgical navigation system. The laser scanner registers approximately 200,000 measuring points on a patient's face within a 2-second period, allowing for function as a surgical system navigator. The laser scan–based system was more accurate than marker-based registration systems. The radiation associated with some scanning systems, such as computed tomography, and the need for placement of artificial markers such as titanium pins or screws are both avoided.[87,88]

Laser scanners are also currently being used clinically to identify and quantify the severity of craniofacial asymmetries and defects. This aids in both patient understanding and education regarding his/her specific abnormalities. This quantitative understanding also facilitates ideal and achievable surgical treatment planning by the craniomaxillofacial surgeon.[89]

References

1. Einstein A: On the quantum theory of radiation, *Phys Zeitschr* 18:121, 1917.
2. Maiman TH: Stimulated optic radiation in ruby, *Nature* 187:493–494, 1960.
3. Guttenberg SA, Emery RW: Laser physics and tissue interaction, *Oral Maxillofac Surg Clin North Am* 16:143–145, 2004.
4. Colt HG, Mathur PN: Basic principles of laser-tissue interactions, *UpToDate*, 2004. version 14.3:1–5.
5. Thajudheen CP, Jyothy K, Priyadarshini A: Treatment of port-wine stains with flash lamp pumped pulsed dye laser on Indian skin: a six year study, *J Cutan Aesthet Surg* 7(1):32–36, 2014.
6. Romanos GE: Diode laser soft tissue surgery: advancements aimed at consistent cutting, improved clinical outcomes, *Compend Contin Educ Dent* 34(10):752–757, 2013.
7. Fantarella D, Kotlow L: The 9.3-um CO_2 dental laser: technical development and early clinical experiences, *J Laser Dent* 22(10):10–27, 2014.
8. Wlodawsky RN, Strauss RA: Intraoral laser surgery, *Oral Maxillofac Surg Clin North Am* 16:149–163, 2004.
9. Polanyi TG, Bredemeier H, Davis T: A CO_2 laser for surgical research, *Med Biol Eng* 8:541–548, 1970.
10. Wilder-Smith P, Arrastia A-MA, Liaw L-H, Berns M: Incision properties and thermal effects of three CO_2 lasers in soft tissue, *Oral Surg Oral Med Oral Pathol Oral Radiol Endod* 79(6):685–691, 1995.
11. DeRowe A, Ophir D, Katzir A: Experimental study of CO_2 laser myringotomy with a hand-held otoscope and fiberoptic delivery system, *Lasers Surg Med* 15(3):249–253, 1994.
12. Romanos GE, Nentwig GH: Immediate functional loading in the maxilla using implants with platform switching: five-year results, *Int J Oral Maxillofac Implants* 24(6):1106–1112, 2009.
13. Romanos G: Point of care: Is there a role for lasers in the treatment of peri-implantitis? *J Can Dent Assoc* 71(2):117–118, 2005.
14. Bradley P: A review of the use of the neodymium YAG laser in oral and maxillofacial surgery, *Br J Oral Maxillofac Surg* 35:26–35, 1997.
15. Strauss R, Fallon S: Lasers in contemporary oral and maxillofacial surgery, *Dent Clin North Am* 48:861–888, 2004.
16. Romanos G: Clinical applications of the Nd:YAG laser in oral soft tissue surgery and periodontology, *J Clin Laser Med Surg* 12:103–108, 1994.
17. White J, Goodis H, Rose C: Use of the pulsed Nd:YAG laser for intraoral soft tissue surgery, *Lasers Surg Med* 11:455–461, 1991.
18. White JM, Chaudhry SI, Kudler JJ, et al.: Nd:YAG and CO_2 laser therapy of oral mucosal lesions, *J Clin Laser Med Surg* 16:299–304, 1998.
19. Gregg RH, McCarthy DK: Laser periodontal therapy for bone regeneration, *Dent Today* 21(5):54–59, 2002.
20. Li Z, Reinisch L, van de Merwe W: Bone ablation with Er:YAG and CO_2 laser: study of thermal and acoustic effects, *Lasers Surg Med* 12:79–85, 1992.
21. Fornaini C, Merigo E, Vescovi P, et al.: Different laser wavelengths comparison in the second-stage implant surgery: an ex vivo study, *Lasers Med Sci* 34(4):461–466, 2014.
22. Nevins M, Nevins ML, Yamamoto A, et al.: Use of Er:YAG laser to decontaminate infected dental implant surface in preparation for reestablishment of bone-to-implant contact, *Int J Periodontics Restorative Dent* 34(4):461–466, 2014.
23. Tosun E, Tasar F, Strauss R, et al.: Comparative evaluation of antimicrobial effects of Er:YAG, diode, and CO_2 lasers on titanium discs: an experimental study, *J Oral Maxillofac Surg* 70(5):1064–1069, 2012.
24. Romeo U, Libotte F, Palaia G, et al.: Is erbium:yttrium-aluminum-garnet laser versus conventional rotary osteotomy better in the postoperative period for lower third molar surgery? Randomized split-mouth clinical study, *J Oral Maxillofac Surg* 73(2):211–218, 2015.
25. Farshidi D, Hovenic W, Zachary C: Erbium:yttrium aluminum garnet ablative laser resurfacing for skin tightening, *Dermatol Surg* 40(Suppl 12):S152–S156, 2014.
26. Zeinoun T, Nammour S, Dourov N, et al.: Myofibroblasts in healing laser excision wounds, *Lasers Surg Med* 28(1):74–79, 2001.
27. Fisher SE, Frame JW, Browne RM, Tranter RM: A comparative histological study of wound healing following CO_2 laser and conventional surgical excision of canine buccal mucosa, *Arch Oral Biol* 28:287–291, 1983.
28. Roodenburg JL, ten Bosch JJ, Borsboom PC: Measurement of the uniaxial elasticity of oral mucosa in vivo after CO_2 laser evaporation and surgical excision, *Int J Oral Maxillofac Surg* 19:181–183, 1990.
29. Fisher S, Frame J: The effects of the carbon dioxide surgical laser on oral tissues, *Br J Oral Maxillofac Surg* 22:414–425, 1984.
30. Strauss RA: Lasers in oral and maxillofacial surgery, *Dent Clin North Am* 44(4):851–873, 2000.
31. Sanz-Moliner JD, Nart J, Cohen RE, Ciancio SG: The effect of an 810-nm diode laser on postoperative pain and tissue response after modified Widman flap surgery: a pilot study in humans, *J Periodontol* 84(2):152–158, 2013.
32. Pogrel MA, McCracken KJ, Daniles TE: Histologic evaluation of width of soft tissue necrosis adjacent to carbon dioxide incisions, *Oral Surg* 70:564–568, 1990.
33. Kaminer R, Liebow C, Margarone JE, Zambon JJ: Bacteremia following laser and conventional surgery in hamsters, *J Oral Maxillofac Surg* 48:45–48, 1990.

34. Roy S, Smith LP: Prevention of airway fires: testing the safety of endotracheal tubes and surgical devices in a mechanical model, *Am J Otolaryngol* 36(1):63–66, 2015.
35. Mintz S, Barak S, Horowitz I: Carbon dioxide laser excision and vaporization of nonplunging ranulas: a comparison of two treatment protocols, *J Oral Maxillofac Surg* 52(4):370–372, 1994.
36. Carruth JA, Simpson JT: CO_2 laser surgery of the oral cavity, *Year Book Otolaryngol* 132, 1988.
37. Clayman L: Management of mucosal pre-malignant lesions, *Oral Maxillofac Surg Clin North Am* 6(4):431–441, 1994.
38. Horch H, Gerlach KL, Schaefer H: CO_2 laser surgery of oral premalignant lesions, *Int J Oral Maxillofac Surg* 15:19, 1986.
39. Milhaski S, et al.: Laser surgery in otolaryngology-interactions of the CO_2 laser and soft tissue, *Ann NY Acad Sci* 267:263, 1976.
40. Sexton J: Laser management of vascular and pigmented lesions. In Catone G, Alling C, editors: *Laser applications in oral and maxillofacial surgery*, ed 1, Philadelphia, 1997, WB Saunders.
41. Parkins F: Lasers in pediatric and adolescent dentistry, *Dent Clin North Am* 44(4):821–830, 2000.
42. Kahraman S: Low level laser therapy in oral and maxillofacial surgery, *Oral Maxillofac Surg Clin North Am* 16:277–288, 2004.
43. Fekrazad R, Chiniforush N: Oral mucositis prevention and management by therapeutic laser in head and neck cancers, *J Lasers Med Sci* 5:1–7, 2014.
44. Chang WD, Lee CL, Lin HY, et al.: A meta-analysis of clinical effects of low-level laser therapy on temporomandibular joint pain, *J Phys Ther Sci* 26(8):1297–1300, 2014.
45. Amat A, Rigau J, Nicolau R, et al.: Effect of red and near-infrared light on adenosine triphosphate in the luciferine-luciferine reaction, *J Photochem Photobiol A Chem* 168(1):59–65, 2004.
46. Farivar S, Malekshahabi T, Shiari R: Biological effects of low level laser therapy, *J Lasers Med Sci* 5(2):58–62, 2014.
47. He WL, Yu FY, Li CJ, et al.: A systematic review and meta-analysis on the efficacy of low-level laser therapy in the management of complication after mandibular third molar surgery, *Lasers Med Sci* 30(6):1779–1788, 2015.
48. Coulthard P, Kushnerev E, Yates JM, et al.: Interventions for iatrogenic inferior alveolar and lingual nerve injury, *Cochrane Database Syst Rev* 4:CD005293, 2014.
49. Kusek ER: Use of the YSGG laser in dental implant surgery: scientific rationale and case reports, *Dent Today* 98–102, 2007.
50. Lee CY: Procurement of autogenous bone from the mandibular ramus with simultaneous third-molar removal for bone grafting using the Er,Cr:YSGG laser: a preliminary report, *J Oral Implantol* 31:32–38, 2005.
51. Ohnishi M: Clinical applications of arthroscopy in temporomandibular joint diseases, *Bull Tokyo Med Dent Univ* 27:141, 1980.
52. McCain JP, et al.: Temporomandibular joint arthroscopy: a 6 year multicenter retrospective study of 4831 joints, *J Oral Maxillofac Surg* 50:926–930, 1992.
53. Indresano AT: Surgical arthroscopy as the preferred treatment for internal derangements of the temporomandibular joint, *J Oral Maxillofac Surg* 59:308–312, 2001.
54. Koslin M: Laser applications in temporomandibular joint arthroscopic surgery, *Oral Maxillofac Surg Clin North Am* 16:269–275, 2004.
55. McCain JP, de la Rua H: Principles and practice of operative arthroscopy of the human temporomandibular joint, *J Oral Maxillofac Surg* 1:135–152, 1989.
56. Koslin M: Advanced arthroscopic surgery, *Oral Maxillofac Surg Clin North Am* 18:329–343, 2006.
57. Mazzonetto R, Spagnoli D: Long term evaluation of arthroscopic discectomy of the temporomandibular joint using Holmium YAG laser, *J Oral Maxillofac Surg* 59(9):1018–1023, 2001.
58. Dolwick MF, Armstrong JW: Complications of temporomandibular joint surgery. In Kaban L, Pogrel A, Perrott D, editors: *Complications in oral and maxillofacial surgery*, Philadelphia, 1997, WB Saunders.
59. Cetiner S, Kahraman S, Yucetas S: Evaluation of low-level laser therapy in the treatment of temporomandibular joint disorders, *Photomed Laser Surg* 24(5):637–641, 2006.
60. Kulekcioglu S, et al.: Effectiveness of low-level laser therapy in temporomandibular joint disorder, *Scand J Rheumatol* 32:114–118, 2003.
61. Nunez SC, et al.: Management of mouth opening in patients with temporomandibular disorders through low-level laser therapy and transcutaneous electrical neural stimulation, *Photomed Laser Surg* 24:45–49, 2006.
62. Gray RJ, et al.: Physiotherapy in the treatment of temporomandibular disorders: a comparative study of four treatment methods, *Br Dent J* 176:257–261, 1994.
63. Hegedus F, et al.: Non-surgical treatment modalities of facial photodamage: practical knowledge for the oral and maxillofacial professional, *Int J Oral Maxillofac Surg* 35(5):389–398, 2006.
64. Griffiths C: The clinical identification and quantification of photodamage, *Br J Dermatol* 127:37–42, 1992.
65. Glogau RG: Aesthetic and anatomic analysis of the aging skin, *Semin Cutan Med Surg* 15(3):134–138, 1996.
66. Obagi ZE: Skin classification. In Obagi ZE, editor: *Obagi skin health restoration and rejuvenation*, New York, 2000, Springer.
67. Weistein C: Ultrapulse carbon dioxide laser rejuvenation of facial wrinkles and scars, *Am J Cosm Surg* 14:3–10, 1997.
68. Obagi S: Pre- and postlaser skin care, *Oral Maxillofac Surg Clin North Am* 16:181–187, 2004.
69. Fitzpatrick TB: The validity and practicality of sun reactive skin types I through VI, *Arch Dermatol* 124:869–871, 1988.
70. Holck DE, Ng JD: Facial skin rejuvenation, *Curr Opin Ophthalmol* 14:246–252, 2003.
71. Airan LE, Hruza G: Current lasers in resurfacing, *Facial Plast Surg Clinic North Am* 10:87–101, 2002.
72. Niamtu J: Common complications of laser resurfacing and their treatment, *Oral Maxillofac Surg Clin North Am* 12(4):579–592, 2000.
73. Grover S, Apfelberg DB, Smoller B: Effects of varying density patterns and passes on depth of penetration in facial skin utilizing the carbon dioxide laser with automated scanner, *Plast Reconstr Surg* 104:2247, 1999.
74. Kilmer SL: Cutaneous lasers, *Facial Plast Surg Clin North Am* 11:229–243, 2003.
75. Boyden DK: A brief overview of noninvasive lasers in cosmetic maxillofacial surgery, *Oral Maxillofac Surg Clin North Am* 16:231–237, 2004.
76. Cook Jr BE, Lemke BN: Cosmetic blepharoplasty, *Oral Maxillofac Surg Clin North Am* 12(4):673–687, 2000.
77. Niamtu J: The treatment of vascular and pigmented lesions in oral and maxillofacial surgery, *Oral Maxillofac Surg Clin North Am* 16:239–254, 2004.
78. Chan HH, et al.: Recurrence of nevus of Ota after successful treatment with O-switched lasers, *Arch Dermatol* 136:1175–1176, 2000.
79. Goldman MP, Fitzpatrick RE: Treatment of tattoos, *Facial Plast Surg Clin North Am* 4(2):295–306, 1996.

80. Dierickx CC: Hair removal by lasers and intense pulsed light sources, *Dermatol Clin* 20:135–146, 2002.
81. Lee EA: Laser-assisted gingival tissue procedures in esthetic dentistry. In Tarnow DP, editor: *Applications of 810 nm diode laser technology. A clinical forum*, Mahwah, NJ, 2006, Montage Media.
82. Sarver DM: Use of the 810 nm diode laser: soft tissue management and orthodontic applications of innovative technology. In Tarnow DP, editor: *Applications of 810 nm diode laser technology. A clinical forum*, Mahwah, NJ, 2006, Montage Media.
83. Ciancio S: Wound healing of periodontal pockets using the diode laser: an interview. In Tarnow DP, editor: *Applications of 810 nm diode laser technology. A clinical forum*, Mahwah, NJ, 2006, Montage Media.
84. Press J: Effective use of the 810 nm diode laser with the wellness model. In Tarnow DP, editor: *Applications of 810 nm diode laser technology. A clinical forum*, Mahwah, NJ, 2006, Montage Media.
85. Convissar RA: Lasers in general dentistry, *Oral Maxillofac Surg Clin North Am* 16:165–179, 2004.
86. Takeda FH, et al.: A comparative study of the removal of the smear layer by three endodontic irrigants and two types of lasers, *Int Endodon J* 32(1):32–39, 1999.
87. Marmulla R, et al.: Laser-scan-based navigation in craniomaxillofacial surgery, *J Craniomaxillofac Surg* 31(5):267–277, 2003.
88. Da Silveira AC, Daw Jr JL, Kusnoto B, et al.: Craniofacial applications of three-dimensional laser surface scanning, *J Craniofac Surg* 14(4):449–456, 2003.
89. Yu Z, Mu X, Feng S, et al.: Flip-registration procedure of three-dimensional laser surface scanning images on quantitative evaluation of facial asymmetries, *J Craniofac Surg* 20(1):157–160, 2009.

25

Trigeminal Nerve Injuries

JOHN M. GREGG, JAMES A. GIGLIO

During their careers, most oral and maxillofacial surgeons practicing full-spectrum treatments will have patients who have sustained trigeminal nerve injury.[1,2] These patients will present with a wide range of disturbing symptoms and impaired functions (Table 25-1). Although acute neurosensory symptoms in lingual and inferior alveolar nerve (IAN) regions are frequently present 1 week after routine surgeries such as third molar removal, most symptoms will resolve spontaneously by 3 weeks.[3] An unfortunate patient subset of 15% to 25%, however, will retain abnormal sensations and impaired orofacial functions for 3 months or more, and accumulating studies indicate that more than half of nerve-injured patients will experience some level of long-term disturbing paresthesias and neuropathic pain.[4,5] Neuropathies persisting more than 1 year are considered permanent and may not be surgically reversible.

Some trigeminal nerve injuries may be unavoidable because of disease conditions that require treatment. At especially high risk for injury to trigeminal nerves are patients treated for orofacial trauma, developmental deformities, reconstructive surgeries with endosseous implants, and, most commonly, pathology associated with third molar surgery. And, unfortunately, nerve injury complications are still presumed by uninformed patients to be evidence of surgical negligence.

There have been significant advances, however, in understanding the mechanisms of traumatic neuropathies and improvements in surgical and nonsurgical treatments. Most notably, more than 3 decades' experience with nerve injury surgeries have demonstrated marked functional improvements for more than half of treated patients.[6-8] Microsurgical repairs of lingual nerves have proven to be more effective than inferior alveolar repairs. And, because early medical treatments and timely surgeries of acute nerve injuries may prevent the transition to chronic refractory neuropathies and intractable dysesthesias, it is recommended that patients be treated within 3 to 6 months of injury, if possible.[9,10] Results also have shown that microsurgical repairs are likely to improve on lost sensory functions but less likely to eliminate preexisting chronic neuropathic pain.[11] Internal neurolysis procedures and traditional autologous nerve grafting procedures have yielded disappointing outcomes and secondary morbidities, whereas microsurgical decompressions with neuroma resection and direct reanastomoses have yielded the most favorable results.[12-14] Most significantly, this past decade has seen the development and clinical application of a promising cadaver-processed allograft for patients with extensive nerve tissue loss injuries.[15,16]

Causes, Classification, and Injury Responses

Maxillofacial trauma is likely the most common source of orofacial dysfunction, trigeminal sensory loss, and neuropathic pain.[17] They are most often associated with maxillomandibular lacerations and fractures, where the inferior alveolar and infraorbital nerves are almost always affected and chronic impairment persists in up to 35% to 50% of patients.[18] Injuries to inferior alveolar and lingual nerves occur in 0.1% to 10% of cases during third molar surgery, are the overwhelming iatrogenic cause of neuropathy, and result in the full spectrum of mechanical damages from transient mild compressions to complete nerve lacerations and gap avulsions.[2,5,19,20] Endosseous implant surgery accounts for an increasing number of cases of injury to mandibular nerves, especially in patients with more severe bony atrophy and in those who have undergone nerve repositioning surgeries.[21,22] Chronic post-traumatic neuropathies from local anesthetic injuries, although rare as mechanical injuries in comparison to the number of injections carried out, appear to be increasing in incidence caused by chemical neurotoxities.[23,24] Nerves acutely injured by caustic root canal or surgical medicaments are associated with extreme pain and require immediate clinical treatments.[25,26] Orthognathic surgery, particularly sagittal mandibular osteotomy, has a high incidence of

TABLE 25-1 Nerve Injury Clinical Terms

Term	Description
Paresthesia	Abnormal sensation(s), whether spontaneous or-evoked
Dysesthesia	Unpleasant or painful abnormal sensations, spontaneous or evoked
Anesthesia	Absence of responsiveness to any level of tissue stimulation; may be due to traumatic nerve injury or pharmacologically induced by local or centrally acting agents
Hypoesthesia	Decreased responsiveness to stimulation in neural distribution(s)
Hyperesthesia	Increased responsiveness to stimulation in neural distributions(s)
Allodynia	Pain due to natural or applied tissue stimuli that do not normally provoke pain; may lead to painful response(s)
Hyperpathia	Burning or shocking pain due to blunt, non-noxious repetitive stimuli applied over abnormal nerve or its distribution
Hyperalgesia	Increased pain response(s) to noxious stimuli; includes excess responses to mechanical, thermal or environmental stimuli
Sensitization	A state of increased nociceptor irritability and drop in thresholds; may display spontaneous discharges and spread of affected fields; includes peripheral and central sensitization
Trigeminal Neuralgia	Pain caused by lesions of the peripheral trigeminal structures; includes classic trigeminal neuralgia (idiopathic vs. neuralgia); includes syndromes caused by mechanical injuries (traumatic trigeminal neuralgia), infections (herpes zoster), chemical neurotoxicities (local anesthetics, endodontic, surgical agents); differentiated from central malignant or degenerative disorders
Ageusia	Loss of taste as revealed by subjective patient reports and objective testing; may be "partial taste loss" isolated to specific chorda-lingual nerve distribution(s) or more generalized, reflecting possible systemic causation

Adapted from definitions of the International Association for the Study of Pain (www.iasp-pain.org).

intraoperative nerve injuries, good levels of early spontaneous recovery, but some degree of long-term altered sensation in up to 50% of patients.[27,28]

A Mechanistic Classification of Nerve Injuries

Sir Herbert Seddon and Sir Sydney Sunderland developed nerve injury classifications that still provide a useful framework for characterizing nerve injuries.[29,30] Seddon's hypothesis was that increasing nerve damage results in greater permanent loss of sensation. Sunderland's scheme emphasized a progressive destruction of nerve structures with wallerian axon degeneration, and disruption of endoneurial, perineurial, and finally epineurial tissues. The value of combining these two classification schemes has been shown by quantitative sensory testing (QST), which has verified that the depth of trigeminal sensory loss correlates generally with increasing physical nerve destruction.[31,32] The Seddon-Sunderland linear injury scales also correlate well with decreasing potential for spontaneous nerve recovery, with increasing likelihood of dysfunctional neuroma formation, and with increasing need for surgical repair interventions. More recently, Mackinnon modified the Seddon-Sunderland classification scheme by adding a sixth injury type to account for "mixed injuries"[33] (Table 25-2).

Sunderland type 1 (Seddon "neuropraxia") injuries result from ischemic effects of minor nerve trunk traction, mild compression from edema, hematoma, or temporary increases in local inflammation. Paraneural heat in the 48° to 54° C range, generated by rotating surgical instruments, may produce type 1 damage. The neurologic effects are primarily conduction block resulting in slowed stimulus responses. Although isolated sites of neural demyelination may occur, wallerian axon degeneration is not expected and there are no grossly visible effects on the epineurium. Rapid spontaneous recovery toward normal sensation and sensory functions is expected within days to a few weeks. Microsurgery is not indicated except for the removal of compressive paraneural foreign bodies.

Sunderland type 2 (Seddon "axonotmesis") injuries result from more forceful crush or abrupt nerve traction greater than 25 g.[34] Partial compression from implants or displaced bone may induce this level of injury. QST reveals deeper loss of sensory responses, particularly for fine touch discrimination. Some degree of axon degeneration may occur, but the endoneurium, perineurium, and epineurium remain intact. Therefore, axonal regeneration and sensory recovery is expected within 2 to 4 months. Extraneural hematoma and secondary scarification may be associated with this level of injury and perpetuate mild neuropathy. In such cases surgical decompression may enhance recovery.

TABLE 25-2 Nerve Injury Classifications, Injury Responses, Surgical Indications

Injury Classification	Causes	Responses	Recovery	Microsurgery
Neuropraxia (Seddon) First-degree injury (Sunderland)	Minor nerve compression, stretch, thermal, acute infection	Neuritis, paresthesias, conduction block, no structural damage	Spontaneous recovery, less than 2 months	Not indicated unless foreign body preventing nerve recovery
Axonotmesis (Seddon) Second-degree injury (Sunderland)	Partial crush, traction, thermal, chemical injury, hematoma, chronic infection	Intact epineurium, isolated axon loss, episodic dysesthesia	Spontaneous recovery in 2-4 months	Repair not indicated except decompression if foreign body or perineural fibrosis
Third-degree injury (Sunderland)	Traction, crush, puncture, thermal, chemical injury	Wallerian axon loss, some internal fibrosis, peripheral sensitization	Recovery crude senses, >1 year neuropathy	Decompression and repair if poor function, sustained pain at 3 months
Fourth-degree injury (Sunderland)	Full crush, extreme stretch, high thermal, direct chemical injury	Neuroma-in-continuity, hypoesthesia, triggered hyperpathia	Permanent injury, minimal spontaneous recovery	Repair, neuroma resection if intolerable dysfunction, pain after 3 months
Neurotmesis (Seddon) Fifth-degree injury (Sunderland)	Transection, tear, laceration, avulsion of nerve trunk	Amputation neuroma, anesthetic, evolving deafferentation pain	Permanent injury, no spontaneous recovery	Neuroma resection with neurorrhaphy or graft if intolerable dysfunction and intractable neuropathic pain
Sixth-degree injury (Mackinnon)	Mixed partial mechanical, chemical, anesthetic, compression, ischemia	Neuroma-in-continuity, endo-to-epineural damage	Partial spontaneous recovery	Surgical decompression, micro repair if intolerable dysfunction, dysesthesia

Type 3 Sunderland injuries are caused by more severe mechanical crush, puncture, high-concentration local anesthetics, and chemical and thermal traumas and result in wallerian degeneration at the injury site and some degree of cell loss in the trigeminal ganglion.[35,36] The endoneurium is also damaged, and some intraneural bleeding and scarification may potentially interfere with complete axon recovery. For this reason, this injury level may be associated with permanent neurosensory disturbances. Painful burning paresthesias and hyperphenomena may be seen within hours of type 2 and type 3 injuries and may prompt surgical exploration and repair if sensory test responses fail to show satisfactory recovery within 3 months.

Type 4 Sunderland injuries result from extreme nerve crush, thermal effects above 55° C, instrument punctures, intraneural local anesthetic injections, high-concentration local anesthetics, and caustic medicaments in contact with the nerve. The epineurium is grossly intact, although contused, and may be devascularized; internal nerve structures are damaged, however, and are replaced by disorganized scar. Trigeminal ganglion cell necrosis occurs, and central deafferentation effects can be measured as high as thalamic levels, resulting in centralized and spontaneous pain syndromes along with severe peripheral sensory loss.[37,38] QST reveals deep hypoesthesia to all stimuli, and percussion of the injury site may elicit a hyperpathic aching pain and paresthesia. Neuroma-in-continuity has formed in such cases, and microsurgical resection and repair will be required if functional sensory reflexes are to be restored.

Sunderland type 5 (Seddon "neurotmesis") is the most extreme injury type where there has been complete transection of the nerve trunk, loss of significant trigeminal cells with centralized effects, and amputation neuromas forming at the injury site. Patients who have sustained full transection injuries of intrabony inferior alveolar nerves, yet have retained good nerve-end apposition and support within the mandibular canal, may undergo satisfactory levels of spontaneous recovery. Many type 5 injured patients, however, will experience poor oral-facial functions and intractable pain and may benefit from repair. In almost all type 5 injuries to lingual and infraorbital nerves, satisfactory spontaneous recovery will not occur, and such an injury should be microsurgically repaired as soon as its nature is confirmed by sensory testing demonstrating anesthesia, with or without dysesthesia (see Table 25-2).

Type 6 (Mackinnon) mixed nerve injuries may be caused by direct mechanical instrument trauma, puncture or crush injuries, or chemical, anesthetic, or ischemic damage. Because of their mixed nature, type 6 injuries may involve pathologic changes in all portions of the nerve from endoneurium through epineurium and result in highly varied clinical combinations of sensory losses, paresthesias, and dysesthesias.

Determinants of Nerve Injury Responses

A number of factors, both local and host-related, will determine the neurologic responses to injury.[39] The *type of injury* is a primary determinant of the neurologic responses.

Clean-incision lacerations are less problematic than irregular or avulsive lacerations.[40] Injuries are clinically more disruptive when they involve mixed nerve receptor types, such as combinations of somatosensory mechanoreceptors and taste receptors, and somatosensory-autonomic fiber combinations, such as maxillary nerve branches that contain post-ganglionic parasympathetic fibers. Injuries that occur at proximal positions on the peripheral nerve are more significant than those that occur at more distal sites, as they are more likely to result in loss of trigeminal ganglion cells and initiate retrograde deafferentation effects into the central nervous system. Multiple nerve injuries are also more significant than isolated injuries because of accumulative central deafferentation effects.[41]

Complete nerve lacerations or avulsions produce markedly different responses than partial or incomplete nerve injuries. Paradoxically, lesser neurotrauma, as seen with Sunderland types 2 and 3 injuries and partial or puncture injuries, is more likely to be associated with early hyperesthesias such as triggered pain, hyperalgesia, allodynia, and immediate post-injury dysesthesias. Severe type 4 internal nerve damage and type 5 complete laceration or avulsion injuries, by contrast, are often not immediately painful but eventually lead to the formation of dysfunctional chronic neuroma-in-continuity and amputation neuromas. These initially anesthetic lesions are with time often associated with poor oral-facial functions, referred and radiating forms of unpleasant paresthesias, and spontaneous pain.[32,42]

Host factors are also significant determinants of the responses to nerve injury. Female gender and greater age are associated with higher incidences of nerve injuries and poorer recoveries from injury.[43-46] Genetic factors, although inadequately understood at this time, may be important determinants through effects such as increased intraneural collagenization, extraneural scar, and autonomic derangements.[47,48] The presence of chronic inflammation, secondary bacterial infections, or herpes simplex or zoster viral outbreaks in the nerve injury distributions can also interfere with the injury response and the recovery process.[49,50] Even low-grade repetitive irritations of the injured nerve trunk or neuroma may induce a retrograde process of central sensitization known as "wind-up."[37]

Systemic influences also may influence nerve injury responses; they include neurovascular diseases such as chronic arthritis, systemic lupus, and diabetic neuropathy. Exposure to environmental neurotoxins, therapeutic medicaments, nicotinic acid, and nitrosamine components of tobacco may all influence nerve injury responses by impairing Schwann cell regenerative functions.[51]

Clinical Measurement and Diagnoses

Arriving at distinct diagnosis and establishing a sound basis for nerve injury treatments requires an assessment of both subjective and objective injury effects. Evaluation begins with a review of injury sources, the recent clinical course, and a recording of patient reports of impaired functions, discomfort, and pain. This may be facilitated by the use of patient input questionnaires. Evaluation then proceeds to objective neurosensory testing and pictorial mapping of measured sensory losses and painful responses to test stimuli. When dysesthesia is present, patient responses to nerve block testing also may be useful. Finally, when these baseline clinical assessments are complete, a diagnostic impression statement can be recorded, and the patient's current level of neural functional recovery can be rated.

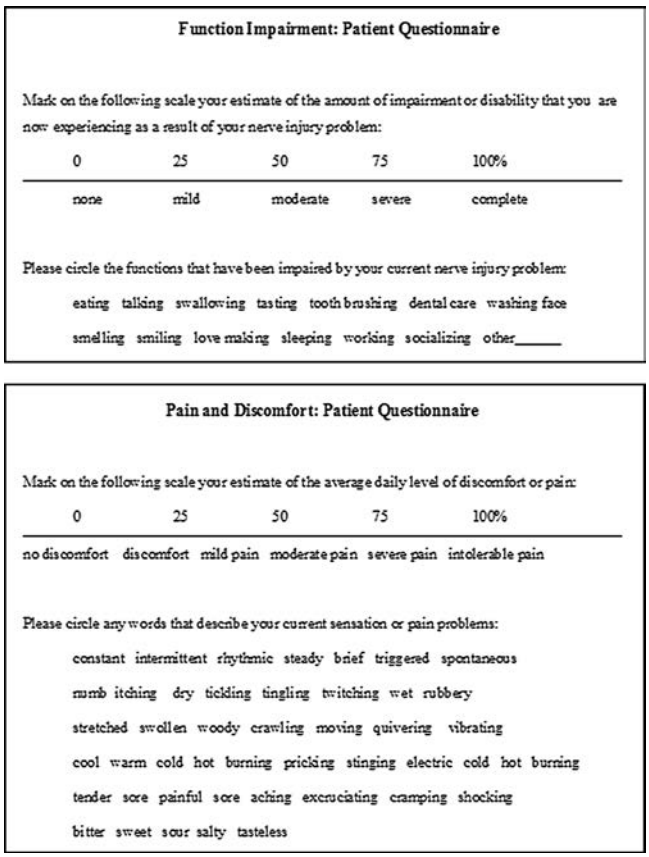

Function Impairment: Patient Questionnaire

Mark on the following scale your estimate of the amount of impairment or disability that you are now experiencing as a result of your nerve injury problem:

0	25	50	75	100%
none	mild	moderate	severe	complete

Please circle the functions that have been impaired by your current nerve injury problem:

eating talking swallowing tasting tooth brushing dental care washing face

smelling smiling love making sleeping working socializing other_____

Pain and Discomfort: Patient Questionnaire

Mark on the following scale your estimate of the average daily level of discomfort or pain:

0	25	50	75	100%
no discomfort	discomfort	mild pain	moderate pain	severe pain	intolerable pain

Please circle any words that describe your current sensation or pain problems:

constant intermittent rhythmic steady brief triggered spontaneous

numb itching dry tickling tingling twitching wet rubbery

stretched swollen woody crawling moving quivering vibrating

cool warm cold hot burning pricking stinging electric cold hot burning

tender sore painful sore aching excruciating cramping shocking

bitter sweet sour salty tasteless

• **Figure 25-1** Patient questionnaire for entering complaints of function impairments and/or unpleasant/painful sensations after trigeminal nerve injury. (Pain descriptors adapted from McGill pain questionnaire; Melzack R, Terrance C, Fromm G, et al: Trigeminal neuralgia and atypical facial pain: use of the McGill Pain Questionnaire for discrimination and diagnosis, *Pain* 27:297-302, 1986.)

Patient-Reported Impaired Functions

Trigeminal nerve injuries disrupt both orofacial and general life functions. Questionnaires that assist patients in communicating and quantifying the severity of their stated impaired functions are useful (Figure 25-1). Assessments are made of global life functions (sleeping, eating, working, socializing) as well as function levels specific to the oral-facial region (eating, speaking, kissing, oral hygiene). These same function impairment assessments are to be used at follow-up patient visits to monitor progress over time and after treatments.

Patient-Reported Discomfort and Pain (Dysesthesia)

Patient questionnaires modified from the extensively verified McGill Pain Inventory are useful for eliciting patient-perceived levels of neurosensory discomfort and pain.[52] These include visual analogue scaling on which patients are instructed to focus on their region of nerve injury and rate their disturbed sensations (paresthesias) and current pain (dysesthesia) levels on global scales ranging from zero through 100%.

A list of McGill verbal neurologic descriptors is presented to patients to elicit qualitative information about their neuropathy (see Figure 25-1). These can be helpful in revealing underlying mechanisms of sensory abnormality, pain, and dysfunction. Particular patterns of verbal descriptors may help the clinician discriminate between different categories of pain and paresthesias.[53] Certain forms of traumatic neuropathies have been linked by the McGill descriptors, including hypoesthesia ("numb, rubbery, swollen"), paresthesia ("tingling, tickling, itching"), and dysesthesia ("tender, pricking, burning").[54]

A note of caution for clinicians interpreting verbal symptom complaints after nerve injury: Most English-speaking patients, when asked about altered sensation in their affected nerve distributions, use the term "numbness." However, quantitative sensory testing reveals that there is a wide range of objective sensory loss among patients who use the term "numbness;" some patients test severely hypoesthetic and even anesthetic, whereas other "numb patients" display near-normal stimulus responses with objective testing.[55] It is also important to recognize this communication factor when final assessments of the success of spontaneous recovery or surgical treatments are made. Even in cases where there have been significant improvements in objective neurosensory functions, some patients may interpret their recovery as "unsuccessful" or "incomplete" because they still retain "numbness."

Clinical Neurosensory Testing

Clinical neurosensory testing is done to determine the degree of sensory loss, detect unpleasant or painful neuropathic states, monitor recovery, and help determine whether trigeminal nerve repair is indicated. Although a wide range of protocols for experimental and clinical quantitative sensory testing are currently in use, no single system is universally accepted.[56-58] Neurosensory testing of patients with altered sensation measure two signs of neuropathy: *loss* of sensory stimulus detection (deafferentation) and *excess* unpleasant responses (sensitization) to sensory stimuli (Figure 25-2). In QST protocols, a range of stimuli from light mechanical (Level A) through repetitive crude touches (Level B) to noxious stimuli (Level C)

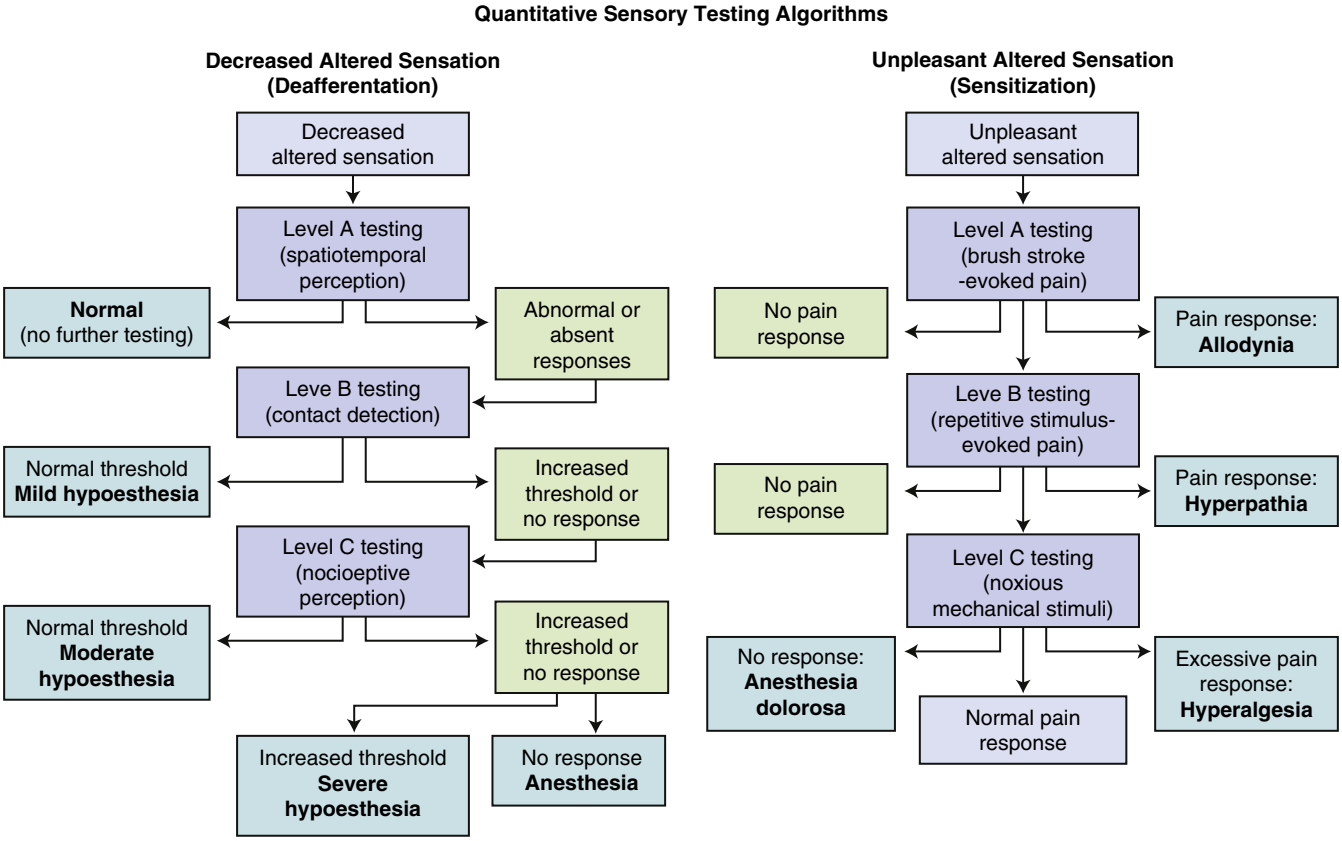

• **Figure 25-2** Algorithms for neurosensory testing of nerve-injured patients who complain of decreased altered sensation (deafferentation) and/or unpleasant/painful altered sensation (sensitization). Diagnoses are in bold print. (Adapted from Zuniga JR, Essick GK: A contemporary approach to the clinical evaluation of trigeminal nerve injuries, *Oral Maxillofac Surg Clin N Am* 4:353-367, 1992; Meyer RA, Bagheri SC: Clinical evaluation of nerve injuries. In Miloro M, editor: *Trigeminal nerve injuries*, Berlin, 2013, Springer, pp 167-198.)

are presented to the patient's region of nerve injury, and patients' responses are compared to "control" responses from their own (contralateral) uninjured tissues.

Quantitative sensory testing begins with *Level A testing,* the stimulation of large, myelinated A-beta nerve fibers associated with fine touch spatiotemporal discrimination (see Figure 25-2, *A*). A-beta fibers are the most susceptible to mechanical nerve injuries and the least likely to regenerate fully ("first to degenerate, last to recover").[59] This is in contrast to "Level C" testing of small nociceptor C fibers, which are the least susceptible to compressive injury but tend to regenerate excessively within traumatic neuromas.[60,61]

Level A stimulus techniques include choices such as two-point touch discrimination, static touch stimuli with light von Frey (Semmes-Weinstein) monofilaments, or directional detection of dynamic brushing or cotton wisp stroking.[58] The patient's level of correct detection in nerve-injured zones is compared to uninjured "control" tissues, and the quantified results are recorded numerically or on a response scale and then mapped on an oral-facial picture (Figure 25-3). Level A testing may result in normal control levels of patient stimulus detection, or complete loss of fine-touch discrimination.

Level A fine touch stimuli are also used to expose signs of abnormal "excess" sensory responses that indicate neurologic sensitization (see Figure 25-2, *B*).[57] In this test phase, patients may report that fine touch stimulations such as brush stroking increase their unpleasant altered sensations (paresthesias) or trigger varied levels of pain (dysesthesias). Fine touch-elicited pain is known as *allodynia,* defined as "pain due to a stimulus which does not normally provoke pain."[62] If allodynia has been elicited, patients are then asked to rank these excess responses as mild, moderate, or severe (+1 to +3). The neural mechanisms of allodynia found with Level A testing may be due to entrapment of sensitized A-beta fibers within neuroma-in-continuity as well as peripherally initiated central sensitization.[59,63-65]

If Level A tests indicate measured sensory loss, neurosensory testing next proceeds to *Level B testing* of the patient's crude touch contact detection, mediated by the smaller A-beta and the small myelinated A-delta nerve fibers. More intense, blunt, and repetitive punctate forms of mechanical stimuli are used, such as thick von Frey monofilaments, non-noxious light pin touching, or Q-tip wood pressures. The stimulus intensities required for patients to detect these Level B stimuli are recorded and mapped as with Level A. Patients who display deficits for (Level A) fine discriminative stimuli, yet have good detection levels for crude touch Level B stimuli without pain, are not usually candidates for microsurgery, as this is considered a functionally useful sensory recovery level that is not reliably surpassed by surgical repairs.

Level B crude touch stimuli, however, may also elicit excess patient responses, including uncomfortable paresthesias and pain responses. Applying Level B stimuli and

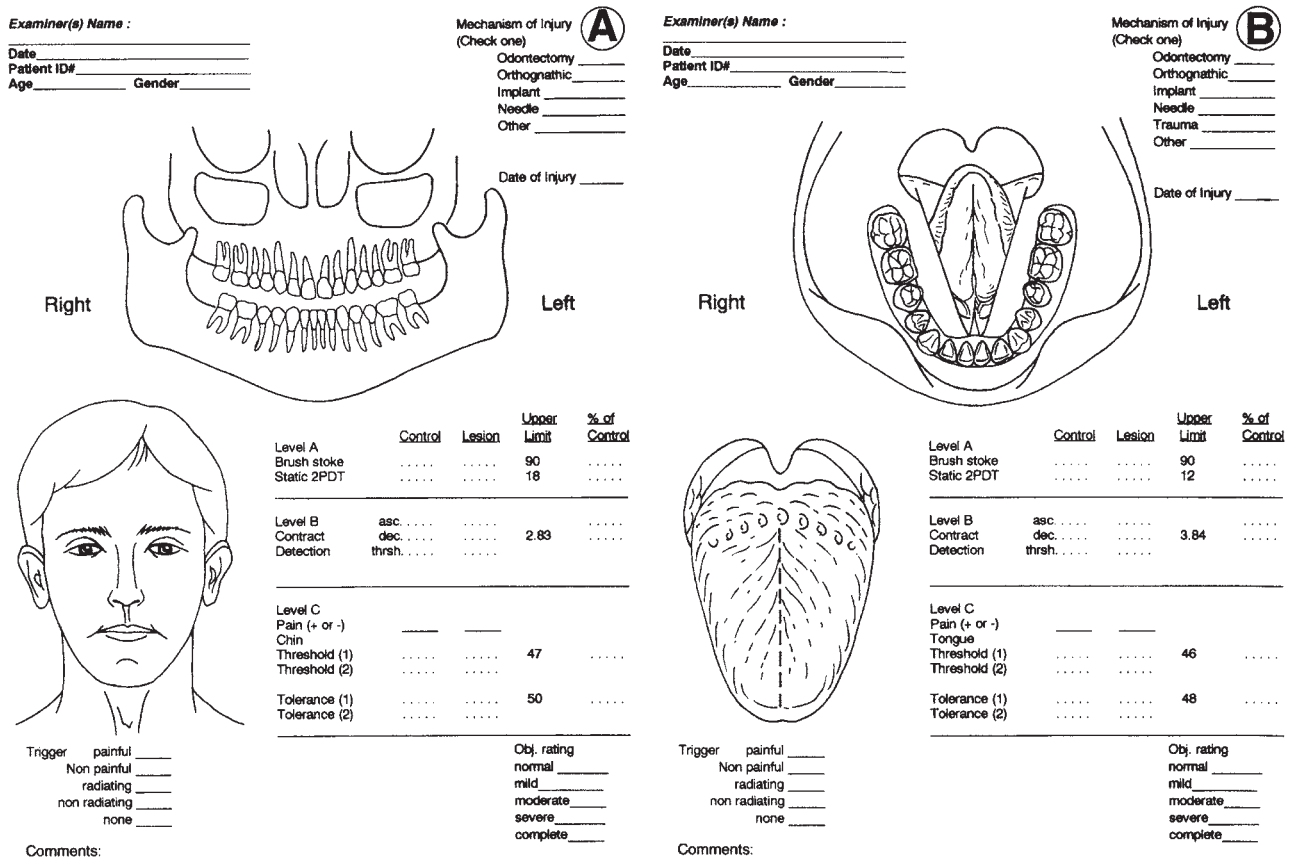

• **Figure 25-3** Quantitative Sensory Test Recording and Neuropathic Mapping Form.

supplemental digital pressures or tapping over the injured nerve trunk distribution may elicit the excess response known as Tinel *hyperpathia,* defined as "a painful syndrome characterized by an abnormal painful reaction to a stimulus, especially a repetitive (mechanical) stimulus, as well as increased threshold."[62] Radiating and shocking hyperpathic trigger responses are likely due to presence of sensitized A-beta or A-delta fibers entrapped in neuromas and may localize injury target sites for nerve repair.[59,65]

Level C testing presents noxious stimuli to the injured nerve distribution, testing for the level of C fiber protective abilities. Useful Level C clinical stimuli include deep pin pressures, calibrated hemostat pinches, or instruments heated to 48° to 50° C. Non-radiating hyperpathic shocking responses to digital percussion may signify a site of amputation neuroma, excess C fiber regeneration, and Class V injury type.[60] Patients who respond to noxious stimulation by reporting pain well above that experienced from stimulation of their control tissues are hyperalgesic. *Hyperalgesia* is defined as "an increased response to a stimulus which is normally painful."[62] It represents another form of neural sensitization due to both peripheral and central sensitization.[63,64,66]

Patients who fail testing at levels A and B but have retained or regained basic detection of noxious stimuli can usually protect themselves from secondary autotraumas such as lip or tongue biting. However, they often have difficulties with orofacial functions such as mastication and speech, and they are candidates for microsurgery to improve on these functions. Patients who are anesthetic to Level C noxious stimuli are obvious candidates for surgical repair.

Recording Neurosensory Responses and Neural Recovery Scales

When completed, neurosensory test results are recorded and pictorially mapped as baselines for monitoring future patient progress (see Figure 25-3).

A final task is to grade the patient's current nerve injury recovery level. A four-level Nerve Injury Recovery Scale (NIRS) is suggested (Table 25-3). This scale has been modified from the Medical Research Council Scale (MRCS), which places emphasis on measured sensory losses, and also the German Research Network on Neuropathic Pain (DFSN), which focuses on measures of excess stimulus responses.[57,58,67] In the NIRS recovery scale, zero grading represents no measurable neurosensory recovery (anesthetic), zero to 1 the recovery range of Level C noxious detection functions, 1 to 2 the recovery range of Level B crude touch functions, 2 to 3 the recovery range of Level A fine tactile functions, and 4 full normal (control level) functions with no excess stimulated pain or unpleasant paresthesias.

A word of caution to clinicians regarding the limitations of neurosensory recovery scaling based solely on objective neurosensory testing: It should be recognized that patients' primary concerns are their impaired daily functions and the levels of unpleasantness and pain associated with altered sensations. These patient concerns are not fully addressed by any existing recovery scale.

Evaluating Patients with Traumatic Neuropathic Pain

Sustained, unpleasant altered sensation and varied forms of neuropathic pain occur in more than 50% to 70% of trigeminal nerve-injured patients presenting for treatment.[68,69] Their pain syndromes reflect mechanisms of deafferentation, peripheral and central sensitization, and dysautonomia.

Patients commonly cluster in two differing dysesthesia profiles: hypoesthetic pain and hyperesthetic pain.[41,42,55] Those with predominantly hypoesthetic patterns complain immediately after injury of "numbness" and often report minimal neuropathic pain at this stage. When examined with quantitative sensory testing, these patients are markedly

TABLE 25-3 Nerve Injury Recovery Scale

Recovery Grade*	Stimulus Detection Levels	Excess Stimulus Responses
4 (normal)	Full control level detection, all stimuli	No excess stimulus responses present
3	Full control level detection, all stimuli	Allodynia, hyperpathia, hyperalgesia may be present
2.5	Intermediate detection, fine touch stimuli	Allodynia, hyperpathia, hyperalgesia may be present
2.0	Full detection, crude touch stimuli Some, minimal detection, fine touch stimuli	Allodynia, hyperpathia, hyperalgesia may be present
1.5	Intermediate detection, crude touch stimuli	Hyperpathia, hyperalgesia may be present
1	Full detection, light noxious stimuli Some, minimal detection, crude touch stimuli	Hyperpathia, hyperalgesia may be present
0.5	Some detection, deep noxious stimuli	Hyperalgesia may be present
0 (anesthetic)	No responses to any stimuli	

Modified from Medical Research Council Scale (MRCS) and German Research Network on Neuropathic Pain (DFSN).
*Grades 2, 3, 4 indicate useful functional sensory recovery (FSR) on MRCS scale.

deficient in neurosensory responses for all types and levels of neurosensory testing. Days to weeks after injury, however, hypoesthetic patients gradually report intensifying paresthesias and pain perceived diffusely in the injured nerve region and complain of "constant, dull, deep, crawling, and especially burning" discomfort.[68,69]

When presented with Level B crude touch stimuli, patients with hypoesthetic patterns often experience intensified "phantom" paresthesias, afterimaging, and radiating, burning hyperpathias. Studies have shown that many of these patients have formed traumatic neuroma-in-continuity from Sunderland type 4 injuries or amputation neuromas from type 5 or type 6 injuries.[41,61] If identified within a few weeks after nerve injury, these patients may respond favorably to early surgical exploration and repair.

Unfortunately, with longer post-injury time, many patients with hypoesthetic neuralgias will experience further increases in constant, spontaneous, and spreading pain that does not respond well to local anesthetic blocks applied to the injured nerve trunks, suggesting that central sensitization has developed.[50,63] This pattern is central deafferentation syndrome, or "anesthesia dolorosa," and is associated with severe nerve lesions, permanent loss of trigeminal ganglion cells, and distorted afferent input to the brainstem.[38,64] It has been postulated that major deafferentation leads to "irritable foci" that develop through glial activation in the spinal cord and extend to thalamic and even cortical levels.[37,70,71] Deafferentation pain syndromes, if sustained for weeks or months after nerve injury, may become refractory to both medical therapies and delayed surgical repairs.[55,72]

Patients with predominantly hyperesthetic pain patterns, in contrast to those with hypoesthetic neuralgias, often have more severe pain within hours to days of nerve injury. Their primary verbal descriptors are "shocking, tingling, burning, electric, and episodic."[50,54] Early, intense responses more likely follow partial nerve injuries, such as traction, compression, puncture, local anesthetic, chemical, and burns.[55,73]

A prime clinical feature of hyperesthetic post-traumatic neuralgias is the presence of triggered paresthesias, allodynia, and hyperalgesia, phenomena that may be expressions of both peripheral and central sensitization.[65,71,74] Local anesthetic nerve blocks produce a transient but complete pain remission from these excess stimulus responses. Patients with hyperesthetic patterns are candidates for surgical decompression and repair if their triggered pain and dysfunctions are intolerable or refractory to medical treatments.

It is also important that hyperesthetic neuralgia patients be closely monitored through serial neurosensory examinations after injury to detect signs of emerging central sensitization, seen as a spread of the neuropathic symptoms to adjacent nerve distributions (referred pain, surround hyperalgesia) as well as possible symptoms contralateral to the injured nerve distribution (mirror pain).[75-77]

Rare patients with both hypo- and hyperesthetic nerve injury patterns will also display signs of complex regional pain syndrome type II (CRPS II), formerly known as causalgia (Box 25-1).[62] Although CRPS most commonly follows appendage and spinal nerve injuries, head and neck CRPS cases have also been well documented.[78,79] Patients typically describe their CRPS pain as long-standing, with both sustained spontaneous burning and episodic shocking elicited by oral-facial movements, touching the face, and exposure to cold. Triggered pain is also experienced well beyond the anatomic limits of the original nerve trauma. In addition, many patients also display diffuse swelling throughout their hemifacial regions. Examination of patients with CRPS-II most commonly reveal signs of elicited hyperesthesias, specifically allodynia and hyperalgesia. Less frequently, episodes of facial edema and skin discolorations (reddening) are seen (Figure 25-4). CRPS II has been linked to both peripheral and central nervous sensitization. In addition, post-traumatic autonomic derangements, specifically sympathetic components, have long been implicated as a primary pathophysiologic mechanism; hence the term *sympathetic mediated pain* (SMP).[80,81] Stellate ganglion diagnostic blocks may confirm the presence of head and neck SMP.[82] Unfortunately, CRPS in all body regions is refractory to most medical and reparative surgical therapies. Serial sympathetic blocks may achieve transient remissions, and intravenous ketamine and topical blocking by the alpha-2 adrenergic agent clonidine have been used with limited success.[78,83,84] Recently, trigeminal neurectomy has been revisited as a potential therapy for refractory CRPS.[85]

For all patients with post-traumatic dysesthesias, anesthetic trigeminal nerve block testing may help define the specific neuropathic mechanisms and predict the likelihood of success or failure of nerve repairs. Small amounts of lidocaine 1% are first administered adjacent to the distal portions of injured nerves, and patients are asked after a few minutes to quantify the level of pain reduction experienced compared to their baseline. Subsequent small anesthetic blocks are then instilled at more proximal nerve sites, noting responses in the patient's dysesthetic nerve region. Pain reductions of less than 50% after any blockade are

• BOX 25-1 Complex Regional Pain Syndrome, Type II Following Trigeminal Nerve Injury

Diagnostic factors:

1. Injury to trigeminal nerve, documented by history and/or measured sensory loss
2. Neuropathic pain greater than 3 months' duration, spontaneous and/or elicited, and disproportionate to any inciting event
3. Spread of pain beyond the originally injured nerve territory
4. Clinical features of regional autonomic derangement

Modified from Harden RN, Bruel S, Stanton-Hicks M, Wilson PR: Proposed new diagnostic criteria for complex regional pain syndrome, *Pain Med* 8:327-331, 2007.



• **Figure 25-4** **A**, Complex regional pain syndrome type II, 2 years after local anesthetic injections; allodynia treated with stellate ganglion blocks and ketamine infusions. **B**, Complex regional pain syndrome type II, 12 months after apical escape of sodium hypocholorite during maxillary endodontic treatment, treated acutely with incision and drainage. **C**, Complex regional pain syndrome type II, 14 months after third molar removal, unresponsive to medical and neurolytic treatments.

considered placebo-level "negative" responses and inaccurate identifiers of neuroma site or reliable predictors of therapeutic value with surgical repairs. Nerve block testing may also help the clinician differentiate neuropathic from non-neuropathic peripheral sources of pain.

Nonsurgical Treatments

Acute Nerve Injuries: Prevention and Early Care

The primary goals of immediate and early nerve injury treatments are to remove sources of ongoing or secondary nerve injuries, create a tissue environment for optimal nerve recovery, and prevent the development of chronic neuropathic sensitizations.

Minimizing chronic neuropathic sensitization is important for all surgical patients, but especially those at high risk for intraoperative nerve injury and those with preexisting regional pain. Evidence has shown that use of multimodal analgesics in the perioperative period may block the transfer of acute surgical pain to chronic neuropathic pain.[86] Presurgically applied analgesics, including gabapentinoids, COX-2 inhibitors, and an alpha-2 adrenergic agonist (clonidine), have been shown to prevent centralization.[87,88] Intraoperatively, NMDA (ketamine) infusions are recommended as well as regional nerve blocks with long-acting agents such as bupivacaine.[89,90] These multimodal therapies should extend

into the immediate postsurgical period among patients at risk for nerve injury.

When acute nerve injury has occurred, immediate supportive interventions are indicated. Soft diet is advised, hypermobile fractures stabilized, and cryotherapy applied to the region. Injured nerves, if visualized, should be freed of compressing foreign bodies, bone or tooth fragments, toxic materials, or implants. Infection and inflammation control, both topically and systemically, should be maximized. Exposed nerves should be cleansed with isotonic solution, gently coapted, and stabilized with temporary 6-0 or 7-0 epineural sutures if possible. Toxic socket dressings such as eugenol should be avoided.

Anti-inflammatory, opiate analgesic and psychosedative agents for anxiety control and sleep promotion are used to minimize acute CNS excitation in the first week after nerve injury. This would also include local anesthetic nerve blocks with long-acting agents.[90] A course of systemic corticosteroids such as dexamethasone 8 to 12 mg per day may minimize perineural inflammation during the first post-injury week.[91,92] A time-based nonsteroidal anti-inflammatory such as ibuprofen 200 to 400 mg every 6 hours is also advised during the first weeks after injury and may prevent development of chronic neuropathic pain.[93] Rapid-acting anticonvulsant agents such as clonazepam, given preventively in divided doses at 2 to 10 mg daily, are useful at this stage; in cases where more severely painful neuropathic shocking and triggering are present and unresponsive to opioid analgesics, the anticonvulsant pregabalin is useful, titrated from 75 mg three times daily to pain relief.[94,95] Sub-anesthetic doses of ketamine as well as 12-hour-release analgesic 5% lidocaine dermal patches applied over the surgical nerve distributions may further prevent early development of dysesthesias.[89,96]

Baseline clinical examination with quantitative sensory testing should be done at this acute stage and the affected nerve distributions mapped. Patients should be openly counseled regarding the nature of the nerve injury, the optional need for secondary consultations, and the possibility of a protracted course of nerve recovery.

Chronic Nerve Injuries: Nonsurgical Patient Care

Because many trigeminal nerve injury cases are not conducive to immediate or early repairs, or surgery is delayed, supportive and palliative treatments are needed. It is especially important when clinical exam exposes spontaneous dysesthesias, triggered allodynias, and incapacitating spread of symptoms over time, a possible indication of emerging central sensitization in spinal trigeminal subnucleus, thalamus, and the large area of third-order trigeminal neurons projecting to the cerebral cortex. And clinical depression, whether previously present or of recent onset, is a common comorbidity of chronic neuropathy and neuralgia.[97] Those patients for whom surgical treatments are not indicated should also understand that complete resolution of their pain and paresthesias may not be possible with nonsurgical treatments. The goals for those patients are improved oral-facial functions and reduced pain. Their nonsurgical treatments will rely on the use of topical and systemic analgesic agents, chemical nerve blockade, sensory reeducation, and behavioral therapies.

Topical Analgesics

Topical analgesics are useful and safe adjuncts for dysesthesia management, avoiding the significant central side effects of directly administered systemic drugs, particularly somnolence and cognitive impairment. The primary topical agents are local anesthetics, capsaicin patches, and compounded drug combinations with proven analgesic effects on neuropathic pain.

Lidocaine

A lidocaine dermal patch or mucosal gel can help provide localized relief of pain symptoms. Twelve-hour lidocaine release patches are self-adhesive and can be cut to fit over the affected areas on the skin.[96] Patients should be monitored for signs of adhesive contact dermatitis.

Capsaicin

Capsaicin, available as 5% and recently marketed as 8% patches, has demonstrated sustained neuropathic pain relief for post-herpetic neuralgias following single patch treatments.[98] There are no reports yet available, however, that indicate efficacy for traumatic trigeminal neuralgias, and patients with hypersensitive neuropathic symptoms have difficulty applying the irritating capsaicin chemicals to their skin.

Compounded Analgesics

Analgesic agents compounded in a lipuronic acid cream carrier are widely used in rehabilitation medicine and have also proven useful in the treatment of neuropathic trigeminal injury pain.[99,100] Combinations of agents with known neuropathic analgesic actions include ketamine 10%, 0.2% clonidine, 8% gabapentin, and 10% and 5% lidocaine. These are prescribed and formulated in 60-g creams at a compounding pharmacy. Topical ketamine has shown particular efficacy for controlling refractory allodynias after nerve injury through both peripheral and central action.[101] Other useful topical compounds for neuropathic pain include co-medication with lidocaine and amitriptyline as well as anti-inflammatory formularies applied to regions of neuroma formation.[102,103]

The compounded creams are applied directly to areas of facial skin innervated by the injured branches of the trigeminal nerve, typically three to five times daily as needed. Care must be taken if the patient is taking clonidine or comparable antihypertensive agents, as there may be an additive effect leading to hypotension.

Intraoral neural lesions may be treated with oral troches compounded as gabapentin 80 mg, ketamine 50 mg, and lidocaine 2 mg. The troches dissolve slowly when placed directly over the posterior lingual mucosa at the base of

the tongue for treatment of lingual neuralgias and over the mental foramen for inferior alveolar neuralgias. Clonidine is not included in the troche preparations because the more rapid absorption through the vascular mucosa compared to skin may cause marked hypotension.

Systemic Analgesics

Current systemic analgesics used for management of traumatic neuropathic pain consist of "first-line" analgesics (anticonvulsant and antidepressant agents), and "second line" analgesics (opiates and novel developing agents).[104]

Anticonvulsants

Titrated anticonvulsant (antiepileptic) agents have a long history of effective treatment for trigeminal neuralgias, most prominently with carbamazepine and the chemically related oxcarbazepine. Their effects on trigeminal nerve-injured pain models appear to be on the suppression of ectopic activity in damaged axons.[105] Because of undesirable side-effect profiles, however, including bone marrow suppression and co-sensitivity with tricyclic antidepressants, these agents have been largely displaced by the less toxic gabapentinoid class of anticonvulsants.[95,104]

Gabapentin, a GABA analogue, is used to treat partial seizure disorders and has also demonstrated potential for reversal of nerve injury sensory deficits, paresthesias, and mechanical allodynia.[106] Patients also report improved spontaneous pain relief, sleep, and quality of life.[87] Depending on symptoms and patient side effect tolerance, initial dosage is 100 to 300 mg per day in divided doses and titrated to pain relief in therapeutic ranges of 1800 to 2400 mg daily.

Pregabalin, another anticonvulsant medication, is a more potent and rapidly acting alternative to gabapentin, useful either for treatment of early post-injury pain or in cases where gabapentin is not effective.[107] Initial dosing is at 75 mg twice a day and can be titrated to 600 mg per day as needed. Pregabalin may be better tolerated than gabapentin.

Side effects of the gabapentinoids are dizziness, memory loss, somnolence, weight gain, dry mouth, and, according to recent warnings, increased suicidality.[108] Before prescribing gabapentin, the indications and contraindications, side effects, and drug interactions should be reviewed and patients advised accordingly.

Antidepressants

Three classes of antidepressant drugs with known analgesic efficacy for neuropathic pain are the tricyclics, the SNRI (serotonin–norepinephrine reuptake inhibitor) and NMDA (*N*-methyl-D-aspartate) antagonists. Analgesic effects of the antidepressants precede and are independent of their antidepressant actions, and these agents are increasingly being used as co-medicants with anticonvulsant agents.[109]

Amitriptyline, the most fully evaluated tricyclic antidepressant, has long been proven as an effective analgesic in the management of neuropathic pain.[110] Suggested dosing begins with 25 mg at bedtime and can be increased to 100 mg daily. Side effects of the tricyclics are similar to those of gabapentin and pre-gabalin but also involve fluid retention, weight gain, and allergy development.

The more recently developed SNRI class of antidepressants has shown positive analgesic action for neuropathic pain without some of the side effects of the tricyclics.[111] The most extensively tested SNRI has been duloxetine (Cymbalta) in dose ranges of 60 to 120 mg per day. Side effects include nausea, hypersomnolence, and xerostomia, and the SNRIs are contraindicated for patients with severe hepatic dysfunction or unstable arterial hypertension.[112]

The NMDA antagonist ketamine, a clinically potent analgesic with antidepressant actions, has a well-established role in the treatment of acute and chronic pain.[113,114] Outpatient protocols using intravenous infusions of both subanesthetic and anesthetic doses of ketamine have resulted in sustained relief of refractory deafferentation pain and spreading centralized pain with phantom, allodynia, and hyperalgesia features.[84] Unfortunately, the full use of NMDA antagonist agents for neuropathic analgesia is limited by their psychotomimetic side effects.

Opiates

It has been documented over a 30-year time frame that traditional morphine-equivalent opiate analgesics are not as effective for sustained neuropathic pain as for acute nociceptive and surgical pain.[115] Classically cited reports have found reliable opiate pain relief in only one of three patients and their estimated pain reductions at 30%.[116,117] And, rapidly developing drug tolerance is known to stimulate increasing opiate dosing requirements, leading to potential abuse.[115] For these reasons, opiate analgesics are now considered second-line agents for management of nonmalignant neuropathic pain. They remain useful, however, for specific subpopulations of well-selected patients who have failed first-line medical or surgical therapies.[118]

Tramadol, a centrally acting synthetic opioid analgesic combined with the NSAID agent acetaminophen, has also been recommended as a short-term neuropathic pain management formulation. If used for chronic episodes of "breakthrough" pain, however, there are risks of drug interaction with serotonin reuptake agents and especially among elderly patients for renal or hepatotoxicity due to overuse of acetaminophen.[115]

Cannabinoids

Definitive laboratory investigations have shown that delta-9-tetrahydrocannabinol, the primary psychoactive component of marijuana, is a potent analgesic for nerve injury pain, including trigeminal dysesthesias, acting on both peripheral neural and central endocannabinoid receptors.[119,120] Centuries of anecdotal testimonies and early clinical reports indicate considerable promise for the development of useful novel cannabinoid analgesics.[121,122] With the current legal

and societal attitude changes regarding medical uses of marijuana, the near future may see full clinical trials reporting on the safety, efficacy, and guidelines for prescribing cannabinoid agonists for treatment of traumatic neuralgias.[123]

Chemical Nerve Blockade

Local Anesthetics

Peripheral nerve blocks, applied at nerve terminals, trunks, and ganglia, with long-acting local anesthetics such as bupivacaine 0.5%, often combined with corticosteroids, are a mainstay of pain management for a wide range of chronic pain conditions.[124] This is based on the long-standing demonstration that blocking chronic pain cycles by injecting muscle tender points or neuropathic trigger sites often induces pain remissions that far outlast the expected duration of drug action.[125] Although employed empirically by many therapists for pain palliation, anesthetic block therapy has scant literature support from controlled studies.

Botulinum Neurotoxin Type A (BoNT-A)

Injections of Botox into painful regions of previous trigeminal nerve injuries may induce transient remissions for weeks to months.[126,127] Peripherally deposited BoNT-A has no effect on acute pain thresholds. However, chronic pain relief from BoNT is attributed to reduced sensitization of nociceptors by antagonizing the effects of local-released afferent peptides SP and CGRP.[128,129] In those clinical cases where traumatized trigeminal nerves are adjacent to masticatory or facial muscles, Botox injections may also relieve pain because of their known mechanism of action on acetylcholinesterase-mediated neuromuscular endplates.

In Botox therapy, approximately one half carpule of long-acting local anesthetic is administered first. This has the benefit of opening the tissue planes and allowing nerve access for the Botox. Ten to 50 units for a total of less than 100 units is injected into neural trigger sites or administered similar to IAN, lingual, or infraorbital anesthetic blockade.[130] Care must be taken to confine the Botox solutions to areas in direct proximity to the injured nerve, and injections should not be made into infected tissues.

Sensory Reeducation

As a simple but effective stimulus to sensory normalization, sensory reeducation is a psychophysical intervention that promotes "perceptual relearning" of functional connections at somatosensory and associative hippocampal cortical levels.[131]

Recovery of sensory functions depends on the inherent "plasticity" of the CNS, and there is strong evidence that recovery may be hastened and final results enhanced by applying psychophysical exercise protocols that assist the brain in interpreting newly configured sensory input.[132] Research has shown that recovery of more "normal" sensations perceived in lips, chin, oral mucosa, tongue, and face can be enhanced by having patients regularly perform tactile, visual, and imagery "reeducation" exercises during active stages of neural regeneration.[54,133] Patients are instructed in the purposes and applications of sensory reeducation and are given a written protocol (Figure 25-5).

Behavioral Pain Management

For patients with long-term trigeminal painful neuropathies, referral to consultants in pain management, neurology, psychiatry, and clinical psychology may be essential resources for a multidisciplinary team approach to recovery. Pain management and neurology specialists, however, are often more familiar with managing body regions other than the oral-facial complex and may lack full appreciation of trigeminal injury patients' specific problems and needs. Therefore it is incumbent on the oral and maxillofacial surgeon to contact and speak directly with a pain specialist to carefully outline the nature of the injury and treatments thus far rendered. Periodic communications between the surgeon and pain management specialist are essential for effective patient management.

Because depression is a near-universal comorbidity with chronic neuropathies and chronic pain, active psychiatric care and use of psychopharmacology may be indispensable for comprehensive treatment.[97,134] Clinical psychologists consulted should be well versed in behavioral techniques such as acceptance and commitment therapy (ACT) and especially cognitive-behavioral therapy (CBT), which has been shown to have potential to reduce nerve injury—induced central sensitization hyperalgesias.[135,136]

Surgical Management of Nerve Injuries

Surgical Management: Purposes and Patient Selection

Neurosurgical interventions for patients who have sustained trigeminal injuries have two main purposes: to restore oral-facial sensory functions and to manage pain and discomfort. Repairs are done on sensory trigeminal branches only, the motor root being inaccessible except for major cranial-base procedures. The sensory trigeminal nerves most commonly amenable to repair are the inferior alveolar-mental, lingual, and infraorbital nerves, and less frequently the supraorbital and supratrochlear branches. The long buccal nerves are often damaged during routine oral surgeries; however, symptom complaints of posterior gingival and buccal mucosa triggered pain are infrequently reported.[137] The auriculotemporal nerves are also susceptible to injury during facial trauma and surgeries for parotidectomy and temporomandibular joint reconstruction. Although pain and dysfunction are also encountered following auriculotemporal injuries, there are no definitive reports of microneurosurgical treatments for these conditions.

Indications

Indications for surgical exploration and repair of trigeminal nerves are: (1) observed mechanical nerve injuries with immediate post-traumatic symptoms, (2) presence

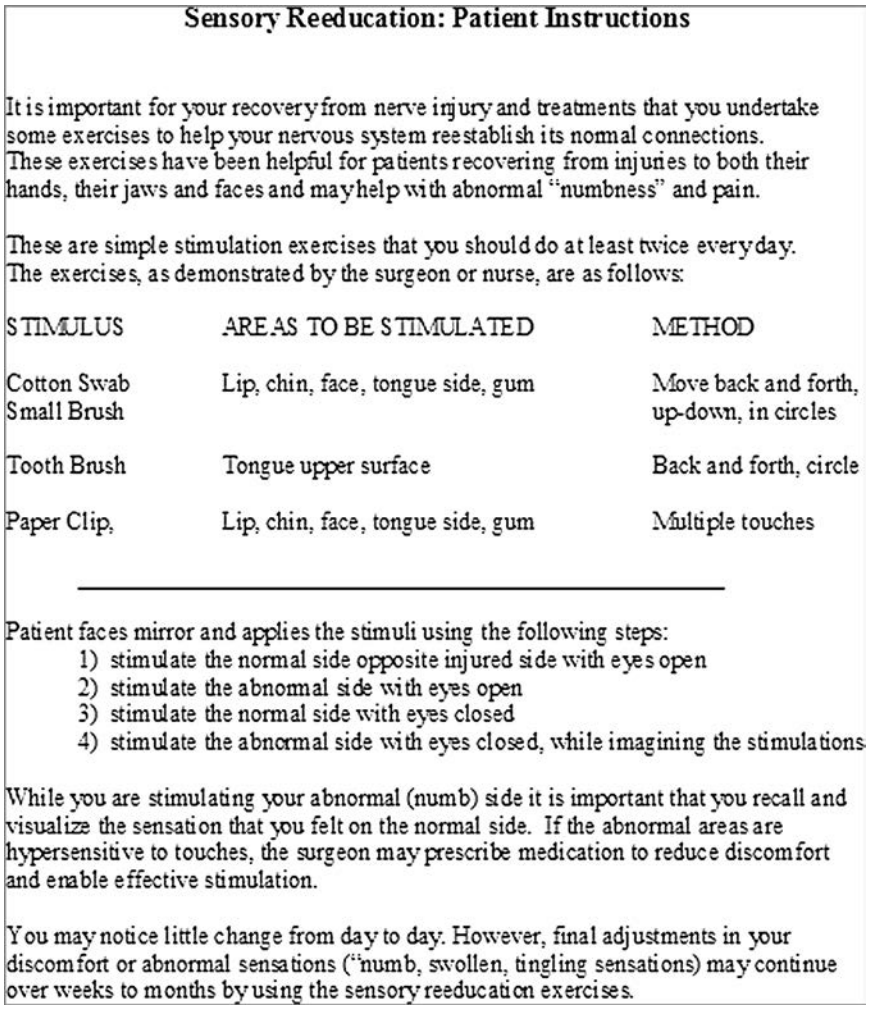

Sensory Reeducation: Patient Instructions

It is important for your recovery from nerve injury and treatments that you undertake some exercises to help your nervous system reestablish its normal connections. These exercises have been helpful for patients recovering from injuries to both their hands, their jaws and faces and may help with abnormal "numbness" and pain.

These are simple stimulation exercises that you should do at least twice every day. The exercises, as demonstrated by the surgeon or nurse, are as follows:

STIMULUS	AREAS TO BE STIMULATED	METHOD
Cotton Swab Small Brush	Lip, chin, face, tongue side, gum	Move back and forth, up-down, in circles
Tooth Brush	Tongue upper surface	Back and forth, circle
Paper Clip,	Lip, chin, face, tongue side, gum	Multiple touches

Patient faces mirror and applies the stimuli using the following steps:

1) stimulate the normal side opposite injured side with eyes open
2) stimulate the abnormal side with eyes open
3) stimulate the normal side with eyes closed
4) stimulate the abnormal side with eyes closed, while imagining the stimulations

While you are stimulating your abnormal (numb) side it is important that you recall and visualize the sensation that you felt on the normal side. If the abnormal areas are hypersensitive to touches, the surgeon may prescribe medication to reduce discomfort and enable effective stimulation.

You may notice little change from day to day. However, final adjustments in your discomfort or abnormal sensations ("numb, swollen, tingling sensations) may continue over weeks to months by using the sensory reeducation exercises.

• **Figure 25-5** Sensory reeducation patient instructions.

of paraneural neurotoxic chemicals or impinging foreign bodies such as tooth or bone fragments or endosseous implants, (3) unchanging anesthesia or dysfunctional hypoesthesia more than 3 months after injury, and (4) medically intractable neuropathic pain. Additional clinical indicators that are predictive of surgical success include presence of specific dysesthetic (hyperpathic) trigger points indicating possible underlying traumatic neuroma, and significant relief of pain after local anesthetic test nerve blockade.

Contraindications

Contraindications for trigeminal surgical exploration and repair, although not absolute, are: (1) objective signs of improving neurosensory functions based on serial quantitative sensory testing, (2) patient acceptance of existing levels of impaired functions, discomfort, or pain, (3) deafferentation pain not relieved by local anesthetic nerve blocks, (4) signs of central sensitization including spreading regional dysesthesia, secondary hyperalgesia, and referred pain, (5) clinical signs of autonomic derangement (burning sensations, erythema, or facial swelling), (6) extremes of age or systemic or neurologic disease, (7) excessive time since original nerve injury, and (8) unrealistic patient expectations (restoration of full normal, pain-free neurosensory functions).

Timing of Surgery

Surgeries are categorized according to their time of repair relative to their injury dates. They are primary (immediate), delayed primary, and secondary. Primary repairs are done in those instances when the nerve has been exposed and the injury was observed, as is common during surgeries for trauma, dentoalveolar pathology, and orthognathic, implant-reconstruction, and some third molar surgeries. Immediate (primary) nerve surgeries, if technically possible, are the preferred time of repair from a biologic perspective. Axonal regeneration is known to be optimal at earlier time frames, within the first 3 weeks after injury, and before neuroma formation and restrictive secondary scarring can occur. Limited acute primary nerve repairs may be possible even in office or operating room settings. Surgical loupes can enable nerve decompression, passive nerve apposition, limited epineurial suturing, and placement of alloplastic barriers around the exposed nerve. Observed nerve injuries

may also be treated by "delayed primary" repairs if needed, done within a few weeks of injury when regional tissues have recovered from acute trauma effects and plans can be made for definitive nerve microsurgical repair.

Unobserved trigeminal nerve injuries are the more common circumstance and require secondary surgical repairs under controlled conditions and after patients have adequately met the surgical indication criteria. The question of optimal timing for secondary surgeries remains controversial and the subject of ongoing research.[9,138,139] There is much evidence that earlier surgical repairs, within one to a few weeks following injury, are preferred over longer delays for three basic reasons: (1) optimal regenerative capacity occurs within the first few weeks after injury, (2) early intervention may prevent the development of traumatic neuromas and both peripheral and central sensitization, and (3) tissue quality is superior compared to chronic injury status. With longer delays, microsurgical repairs become more difficult because of retraction and progressive atrophy of nerve segments, increased extraneural and intraneural collagen deposition, and Schwann cell scarring. Outcome analyses have shown that lingual nerve and inferior alveolar repairs done within 90 days of injury can result in functional sensory recovery levels as high as 66% to 93% at the 1-year mark.[8,10] These same reports have shown, however, that useful sensory recovery levels as high as 63% can be gained for selected cases operated after 90 days. Other studies support the conclusion that there is no association between delayed repairs and sensory outcomes.[12,140]

The timeline for successfully repairing soft tissue nerve injuries such as lingual, infraorbital, and mental nerves is much shorter than for intrabony nerve injuries such as inferior alveolar. This is due to the very limited capacity for spontaneous regeneration of transected soft tissue nerves as compared to intrabony branches where the mandibular canal can act as a natural conduit for nerve recovery, given enough time.[141]

Surgical Principles and Techniques

The surgical principles for effective trigeminal microsurgery emphasize gentle tissue management, avoidance of secondary damage to epineurium, and minimizing ischemic injuries to surface microvasculature. Hemostasis should be optimized to enhance repairs and attention given to removal of paraneural foreign bodies and adhesive scar. Careful identification and excision of dysfunctional neuroma segments are required, and transected nerve segments should be aligned and rejoined under minimal tension. In those less optimal circumstances when direct neurorrhaphy is not possible, the surgical goal is to create a microenvironment that permits effective axonal downgrowth to nerve receptors, through either interpositional nerve grafting or entubulation.

Trigeminal nerve repairs require a quiet and controlled operating room environment. Surgical assistants familiar with the goals and procedures of the microrepair are essential. The microsurgical environment is more demanding of surgical assistants because of the limited surgical field access and the extra requirements of stable retraction, hemorrhage control, and delicate tissue management. Endotracheal intubation with selective muscle relaxation is needed to prevent inadvertent patient movements. Hemostasis can be enhanced with reverse Trendelenburg positioning and local anesthesia with vasoconstrictor field blocking. Hypotensive general anesthesia may be required to assist in hemorrhage control, along with bipolar electrocautery used to avoid collateral injuries to the nerve under repair. Although nerve access, nerve release, and decompression can be accomplished with minimal magnification such as 3× to 4× surgical loupes, many experienced surgeons prefer an operating microscope with greater than 250-mm focal length and multiple heads for assistant views of the operating field. Primary microsurgical instruments for intraoral repairs also require extra-length micro instruments and also include a selection of small retractors, vein and nerve hooks, varied-length microforceps, straight and curved needle holders, and microscissors. Self-retaining flat vascular spreaders and vascular clamps can be used in some circumstances. Preferred sutures are nonreactive nylon or Prolene, 7-0 through 9-0. Nonreflective background materials such as opaque foils or rubber matting are helpful for visibility and tissue control and to assist in atraumatic microsuctioning. A selection of nerve wrap cylinders should be available for protecting the microrepair sites. Their purposes are to eliminate dead space, minimize compression ischemia, prevent paraneural hematoma and scarification, and prevent secondary collagen ingrowth at the repair sites.

Nerve Access

Lingual Nerve

Lingual nerve injuries are approached through incisions placed either in the paralingual floor of mouth or via a modified lateral vestibular incision similar to third molar or bilateral sagittal split osteotomy (BSSO) incisions. The paralingual approach is effective if minimal dissection or distal floor of mouth locations are required. It may be inadequate if there is need for wider nerve release, for injuries higher in the medial ramus, and for full neuroma resection and repair. The paralingual incision may also be inadequate if the nerve has been fully transected and has retracted proximally into the pterygomandibular space.

The more common lateral vestibular incision leads to mucoperiosteal flap elevation over the external oblique ridge for approximately 2 cm. A second full-thickness lingual mucoperiosteal flap is also developed by incising the lingual gingival papillae and elevating a flap from the retromolar pad anteriorly to the first molar. The lingual flap elevation should be done carefully, as the damaged lingual nerve may have been positioned at a "high" alveolar crest level when injured or has retracted and become entrapped superficially within the lingual flap. Once the lingual nerve is identified, it may be released distally into the floor of the mouth if needed, avoiding exposure beyond its crossing by the submandibular duct.

Infraorbital Nerve

Infraorbital nerve injuries that have occurred distal to the orbital rim are easily approached through transoral vestibular

incisions. More proximal injuries that include trauma to the orbital floor are best approached through a subconjunctival blepharoplasty incision. Proximal infraorbital nerve injuries in the orbital floor may require decortication of the canal roof within the orbital floor as well as osseous relief at the infraorbital rim before repair can be done.

Inferior and Mental Alveolar Nerves

The surgical access for damaged mental and inferior alveolar nerves is dictated by the anatomic site and nature of the nerve injury as determined by history and clinical exam. For inferior alveolar injuries in the mandibular mid-body, superficial third molar region, and distal IAN injuries including those near mental foramen, a transoral buccal plate osteotomy exposure is recommended.[14] Lateral bone cuts are made vertically from alveolar crest to the inferior border 1.5 cm proximal and distal to the targeted nerve injury site using a tapered fissure diamond bur or piezotome blades. A parasagittal superior alveolar bone burr cut then joins the two vertical cuts. A final lateral scoring can be made at the inferior border using the angled semilunar or piezotome saw. The rectangular buccal osteotomy is then released using small curved osteotomes.

For more inferior and medially positioned mandibular nerve injuries where longer nerve lesions are suspected, as with angle fractures, endodontic paste injuries, and in chronic cases related to previous sagittal osteotomy orthognathic nerve injuries, an exposure through sagittal osteotomy may be required. Injuries to the IAN in the posterior third molar or lateral angle region may require submandibular Risdon incision approach and lateral cortical block osteotomy for nerve exposure.

Damaged mental nerves are approached through free gingival margin incisions, with careful subperiosteal flap exposure of the usual three branches and the bone overlying the IAN proximal to the mental foramen. The nerve trunk and mental branches are further exposed through "donut hole" osteotomy widening of the foramen and gentle lateralization of the distal portions of IAN.

The "Surgical Repair Cascade"

Once access to the injured nerve has been accomplished, a "surgical cascade" of nerve repair options is undertaken (Figure 25-6). The cascade includes (1) soft or hard tissue *decompression* of entrapped injured nerves with removal of foreign bodies and release of paraneural compressing tissues or scars, (2) inspection and resection of traumatic neuromas and internal *nerve fibrosis and traumatic neuroma,* (3) microsurgical repair with *neurorrhaphy* (direct reanastomosis), and (4) *nerve graft repair* if direct neurorrhaphy cannot be accomplished, (5) placement of *protective "nerve wrap" cylinders*. Second-line nerve repair techniques may be considered for special circumstances, and include (6) *entubulation,* (7) *internal neurolysis,* and, when nerve repair is not technically possible or effective, (8) *neurectomy* and *nerve redirection*.

Decompression

Also known as "external neurolysis," nerve exposure and microsurgical decompression is the first phase of all nerve repair procedures. Soft tissue injured nerves are approached through flap incisions placed adjacent to the nerve injury site. Once identified, the nerve is released from paraneural scar using 3× to 6× magnification. The freed nerve is fully mobilized and controlled by placing umbilical tapes proximal and distal to the gross nerve injury site. Access to intrabony nerve lesions is gained by careful osteoplasty of

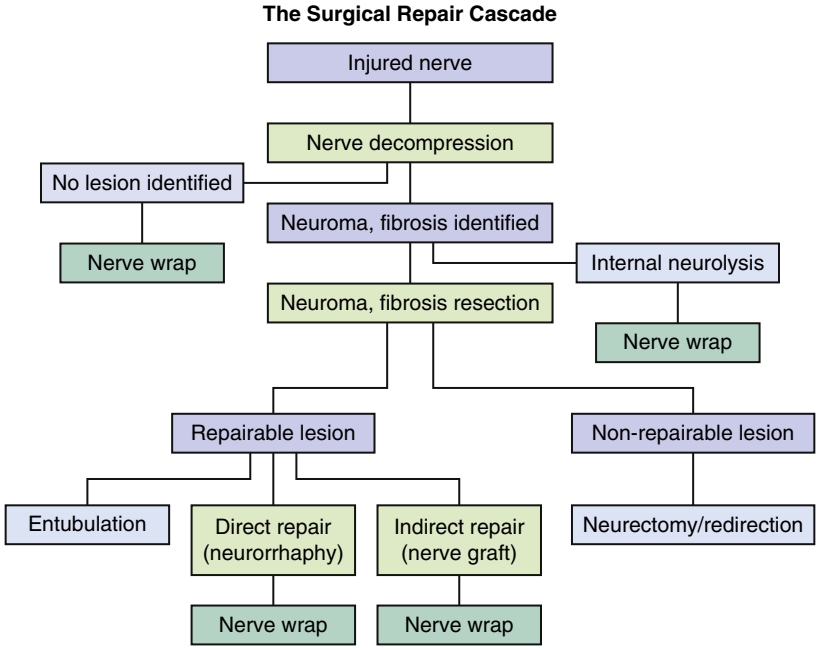

• **Figure 25-6** "Surgical repair cascade" algorithm for treating trigeminal nerve injuries.

lateral bone plates or opening of constrictive bony foramina, done ideally by using piezotome burrs. Impinging foreign bodies, bone or tooth fragments, and constricting scar tissues are then removed while preserving the epineurium and its microvasculature. The nerve injury site is then inspected, observing for nerve discontinuity and presence of amputation neuroma, one of the varied neuroma-in-continuity types, or signs of internal neural fibrosis.

In cases of Sunderland type 1 or 2 injuries, when high-magnification nerve inspection and palpation have failed to reveal signs of nerve fibrosis or neuroma, decompression may be the only surgery required. Nerve decompressions, especially when applied in cases of compressive intrabony nerve lesions from dentoalveolar or implant trauma, have a convincing history of favorable outcomes, improving sensation and reducing dysesthesia.[12,142-144] As a final step, the decompressed nerves are wrapped with barrier protection tubules.

Resection of Neuromas and Nerve Fibrosis

After decompression, nerves are inspected using magnification and transillumination, searching for signs of neuroma and internal fibrosis. Trigeminal neuromas present as varied physical types (Figure 25-7).[41,145] The most easily recognized type is the discontinuity *amputation neuroma*, the result of Class V and Class VI injures with complete internal fibrosis. These neuromas will require excision, nerve-end trimming and microrepair with neurorrhaphy, entubulation or interpositional nerve grafting. *Neuroma-in-continuity* presents as four subtypes: the fusiform *expanded, atrophic narrowed, lateral exophytic,* and *lateral adhesive* variants (Figures 25-7, 25-8, *A*, and 25-9, *A*).

The extent of nerve internal fibrosis of neuroma lesions is determined by transillumination at high magnification, noting signs of nerve opacity or loss of surface vasculature, and testing for internal fibrosis by gently compressing the nerve with microforceps. Fibrotic and neuroma lesions are resected sharply with a Beaver blade 2 to 3 mm proximal and distal to the damaged tissue and submitted for histologic analysis. Satisfactory excision produces a normal herniation of axoplasm from intact fascicles within the proximal nerve stump. Adequacy of neuroma resection can also be determined by submitting 1-mm cross-sectional biopsies for frozen-section histologic finding of normal nerve fascicles. The tissue stumps are finally trimmed in preparation for microsurgical nerve repair.

Neurorrhaphy

In those cases where neuroma or severe nerve fibrosis have been found and these lesions fully resected, the residual proximal and distal segments are trimmed and then gently coapted using microforceps to determine the feasibility of direct reanastomosis, known as neurorrhaphy. Direct epineural microsurgical neurorrhaphy is best done using 6× to 12× magnification, placing 7-0 to 9-0 nonreactive sutures at three to five circumferential locations (see Figure 25-8, *B*). Completed neurorrhaphies should display no bulging or wrinkling between sutures, and the nerve should lie passively when released. Minimal repair line tension is significant as it has been shown that tension greater than 25 g across nerve microrepair sites may inhibit axon downgrowth to the distal nerve.[146] When neurorrhaphy is complete, the repair site is further protected from hematoma, fibrous tissue in-growth, and secondary neuroma formation by entubulating the nerve with an alloplastic protective nerve wrap. In cases of proximal infraorbital neurorrhaphies, an alloplastic graft barrier is secured in the floor of the orbit.[147]

Nerve Graft Repairs

In cases of more severe nerve injuries, direct neurorrhaphy repair may not be feasible. Clinical experience has shown that nerves gap-injured within intrabony sites such as the mandibular or orbital canals cannot be easily mobilized to permit direct neurorrhaphy. Even soft tissue injuries such as lingual nerve gaps greater than 15 mm cannot be routinely bridged by direct neurorrhaphy without requiring excessive nerve dissection release that risks ischemia and excessive tension at the repair site. Therefore, a range of interpositional nerve graft procedures have been developed to repair more extreme avulsive injuries or neuroma resection gaps. They include autologous nerve grafts, the recently developed allogeneic processed cadaver grafts, and interpositional entubulation.

Autologous Grafting

The "gold standard" for trigeminal nerve gap repairs over the past few decades has been autologous donor nerves from the sural, greater auricular, and antebrachial cutaneous nerves.[148,149] Advantages of autografting are their immunocompatibility and the very adequate donor tissue lengths of 6 cm or more that can be obtained. Grafts are attached with minimal epineural microsuturing using the fewest possible sutures because of the friability of donor nerves. The entire graft complex is finally wrapped using protective nerve cuffs.

Comorbidities with autologous grafts are significant, however, and include complaints of disturbing paresthesias, dysesthesias, and occasional neuroma formation at the donor sites.[150] In the case of sural nerve donors, the lateral and posterior foot may display deficits and difficulties with hyperesthesia from shoe contact and ankle movements. Patients whose greater auricular nerves have been harvested may complain of paresthesias over the lateral neck and jaw angle, a problem for those patients with adjacent trigeminal injury neuropathies.

An added technical problem with autologous nerve grafts is the poor match in shape, size, and fascicle numbers between grafted nerves and trigeminal nerves. The lingual nerve averages 3.2 mm in diameter and the IAN 2.4 to 3.1 mm, with both nerves being generally cylindrical in shape. This contrasts with the sural nerve at approximately 2.1 mm in diameter and greater auricular 1.5 mm, both being

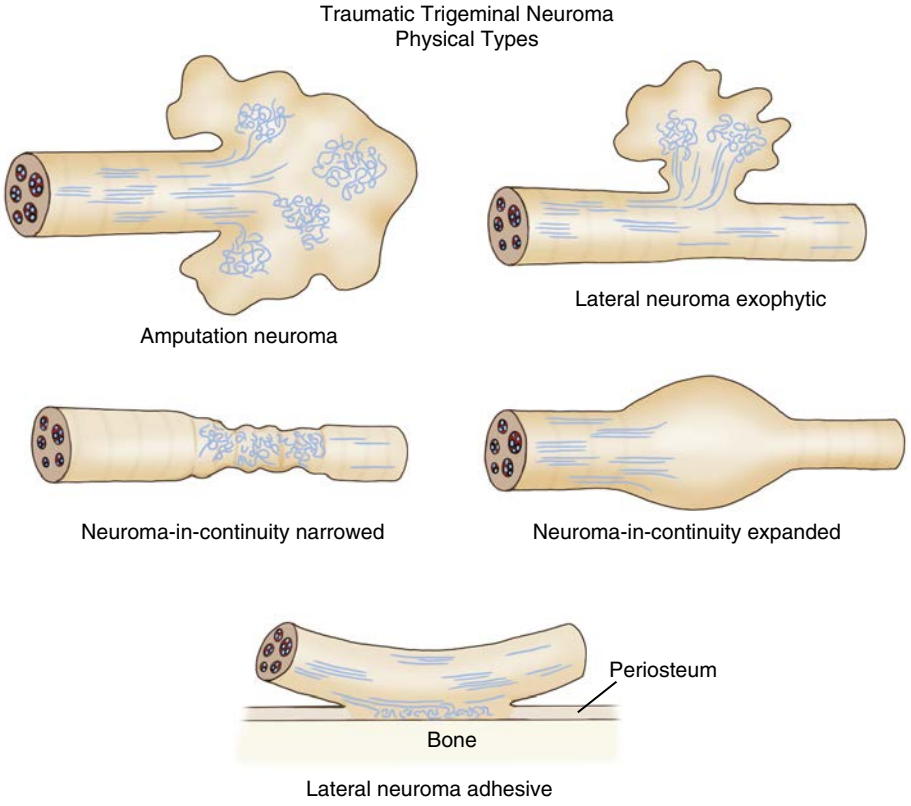

• **Figure 25-7** Traumatic trigeminal neuroma physical types. (Adapted from Gregg JM: Studies of traumatic neuralgias in the maxillofacial region: surgical pathology and neural mechanisms, *J Oral Maxillofac Surg* 48: 228-237, 1990.)

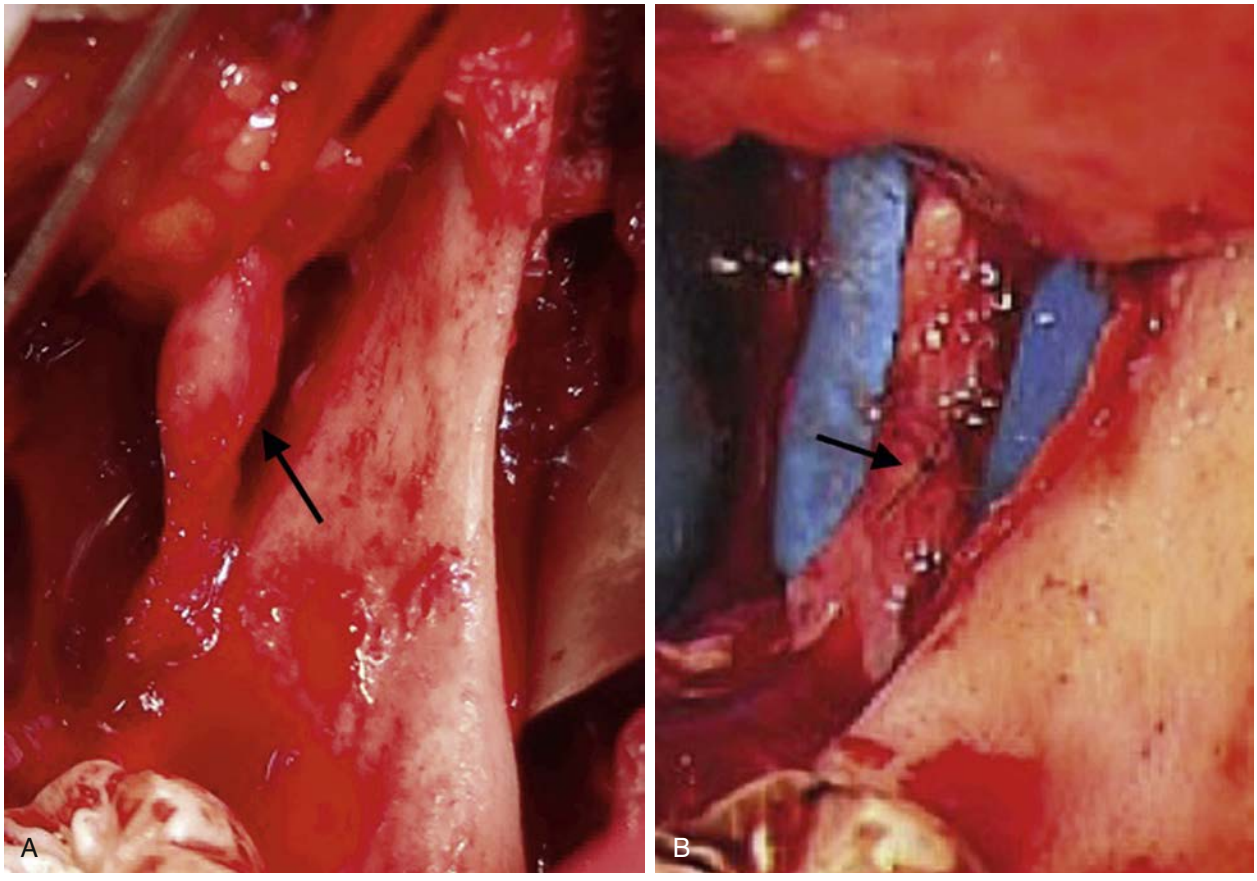

• **Figure 25-8** **A**, Expanded lingual traumatic neuroma-in-continuity following intraneural puncture during mandibular third molar removal (*arrow*). **B**, Direct microsurgical neurorrhaphy repair of excised lingual neuroma discontinuity (*arrow* at suture repair site).

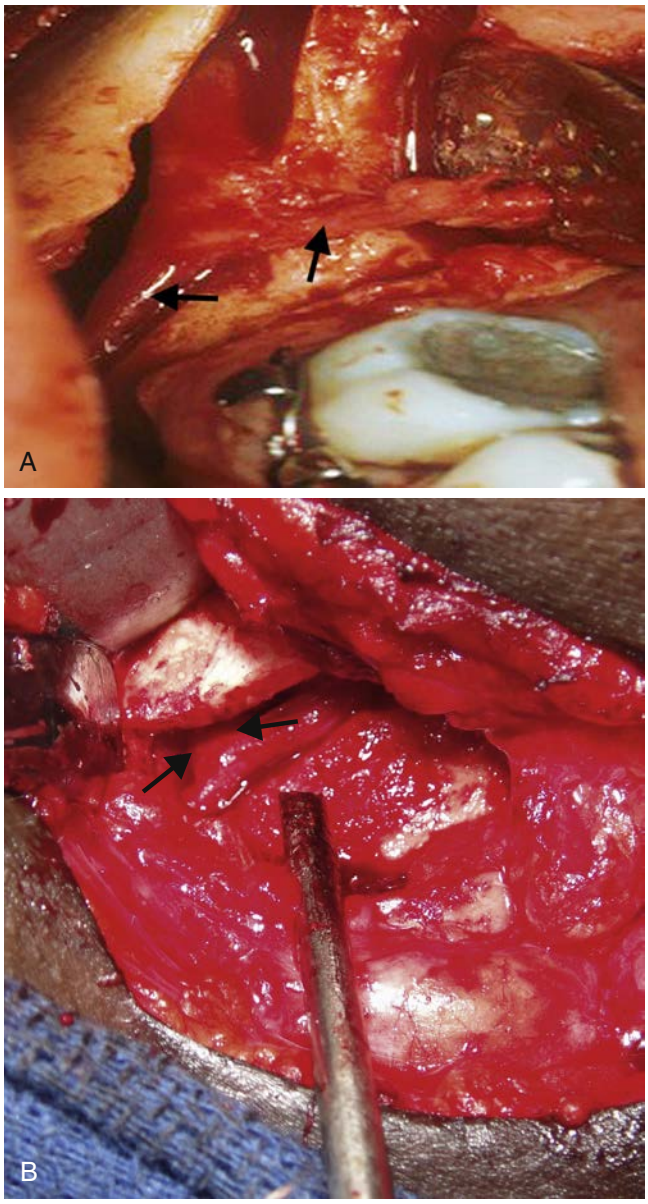

• **Figure 25-9** **A**, Inferior alveolar lateral neuroma exposed via sagittal osteotomy at mandibular third molar extraction site and requiring graft repair (*arrows* at nerve trunk and neuroma). **B**, Inferior alveolar lateral neuroma exposed via Risdon corticotomy at mandibular third molar burr puncture site (*arrows* at neuroma stalk).

generally flat in shape and with far fewer fascicles than the trigeminal branches.[151] Direct fascicular alignment between graft and trigeminal nerve in the grafting procedure is therefore inexact and encourages disorganized axonal regeneration across the repair sites. Given the potential problems with autologous donor site morbidities, the search for alternative grafting procedures continues.

Processed Allogeneic Cadaver Grafting

A potential major advance in the surgical management of trigeminal injuries is the recent introduction of allogeneic (human cadaver) processed nerve grafts. The "Avance" allografts (AxoGen, Alachua, FL) became available in 2007 and were tested in experimental and mixed nerve injury models.[15,152,153] Successful trigeminal clinical grafts were then reported in a case series of eight patients with a 50% success rate followed by confirmation at other treatment centers.[16,154] A recent series of 23 lingual and IAN discontinuities treated with the allogeneic graft has demonstrated an impressive 87% improvement in neurosensory scores without adverse clinical effect.[16] In addition, 2-year patient outcomes after 29 allogeneic lingual nerve graft repairs were found to be objectively and subjectively superior to outcomes after 18 direct neurorrhaphy repairs.[155]

The Avance grafts are processed by exposing cadaver nerves to chondroitinase enzymatic decellularization and DNA removal detergents, secondary gamma irradiation, and freeze-thaw cycles.[156] The final products are then sent to operating room storage units, maintained at –80° C, and are readied for clinical use through thaw and hydration.

The clear advantage of the processed grafts is the elimination of need for donor site surgery and systemic immunosuppression; these grafts retain the basal lamina and endoneurial scaffolding that serve as conduits for nerve fiber regeneration. Primary applications of the decellularized grafts have been for large gap injuries of lingual nerve and especially IAN gap injuries where the mobilization of nerves for direct neurorrhaphy is limited (Figure 25-10, *B*).

Nerve Wrapping

The placement of protective nerve wraps has been shown to improve recovery outcomes from nerve decompressions and all types of nerve repairs by minimizing perineural hematomas, reducing recurrent scarring, stabilizing suture repairs, and enhancing sensory improvement.[13,157,158] There is also evidence that nerve wraps may reduce recurrent traumatic neuralgias.[159,160] Both alloplastic and autologous wraps are in use.

Alloplastic Wraps

Two nerve wrap alloplastic products have been used the biodegradable collagen type I NeuraGen sleeve (Integra LifeSciences, Plainsboro, NJ) and the more recently developed porcine nerve cuff AxoGuard (AxoGen) (Figure 25-11). Wrap stability may be improved by placing tacking microsutures through the wrap before final site closure.

Autologous Wraps

Inside-out vein cuffs used to wrap lingual repair sites have recently resulted in superior functional recoveries compared to non-wrapped nerves.[161]

Entubulation

Successful alternatives to neurorrhaphy and graft repairs of nerve gap injuries have been sought for decades and include both biologic autologous and alloplastic conduits.[149]

Autograft Entubulation

Arterial and venous autograft tubules are attractive potential donors because their harvesting is minimally invasive and

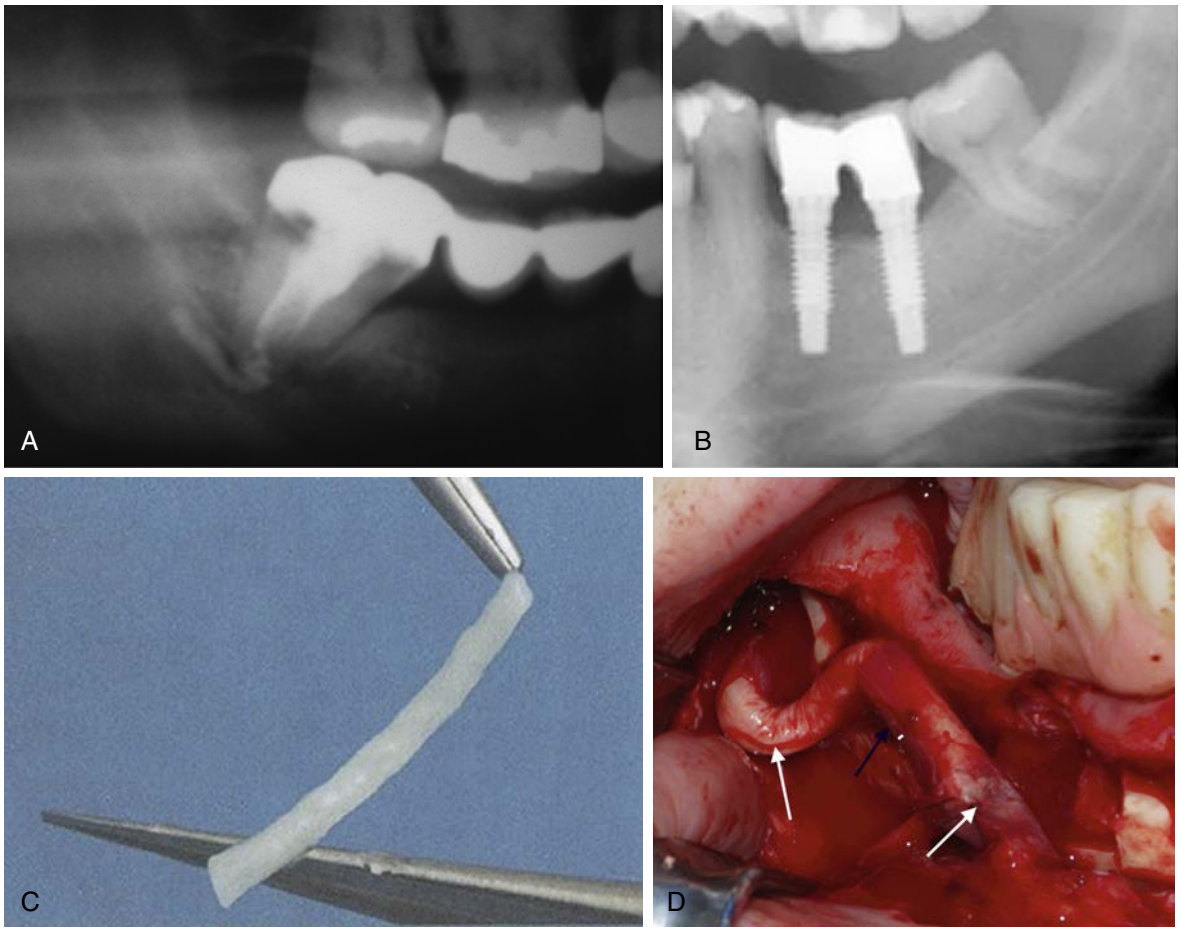

• **Figure 25-10** **A**, Overextended endodontic filling material within the mandibular canal requiring immediate decompression, material excavation, possible nerve graft. **B**, Implant fixture in mandibular canal of anesthetic patient, requiring implant reposition or removal, nerve decompression, possible nerve graft. **C**, Avance allogeneic cadaveric nerve graft prepared for suture repair. **D**, Avance nerve graft microrepair of inferior alveolar nerve discontinuity (*white arrows*, Avance graft and repair site; *black arrow*, AxoGen wrap). (Photo courtesy Dr. John R. Zuniga, Dallas, TX.)

these tissues are readily available. Vascular entubulation grafts to date, however, have not resulted in acceptable sensory recovery levels, perhaps because of collapse of the grafted vessels and consequent interference with axonal downgrowth.[162,163]

Alloplast Entubulation

The search for a successful *alloplast* that would promote bridging of nerve gaps has a lengthy history. Alloplastic grafts have the obvious advantages of availability and avoidance of the morbidities found at nerve graft donor sites. The nonbiodegradable conduits silicone and Gore-Tex (polytetrafluoroethylene) have been used successfully for digital and limited inferior alveolar repairs, but have yielded poor outcomes for lingual repair gaps greater than 6 mm, a level of discontinuity that is usually manageable with direct neurorrhaphy.[164,165]

Biodegradable synthetic conduits, however, have been used more successfully for both digital and trigeminal case repairs beginning with a polyglycolic acid product Neurotube (Synovis Life Technologies, St Paul, MN).[166,167] The most thoroughly tested tubules in current clinical use have been the bovine collagen type I nerve guide products NeuraGen (Integra LifeSciences) and Neuroflex (Collagen Matrix, Franklin Lakes, NJ). More recently, the porcine-based product AxoGuard (AxoGen) has become available as a potential tubulation. The porcine tubes are not fully resorbed as are the collagen tubules, but become incorporated and vascularized as an extraneural biologic layer.

Stem Cell Entubulation

A recent innovation for improving nerve injury sensory outcomes and reducing dysesthesia has been the seeding of repair tubules with progenitor neuronal stem cells.[168,169] Cultured Schwann cells, bone marrow, and adipose-derived stem cells with tubules have all shown promise for experimental nerve injury models.[170,171] Definitive reports of successful clinical trigeminal applications of stem cell entubulation, however, are not yet available.

Internal Neurolysis

A procedure used successfully in the treatment of in-continuity injuries of large spinal nerves is known as internal

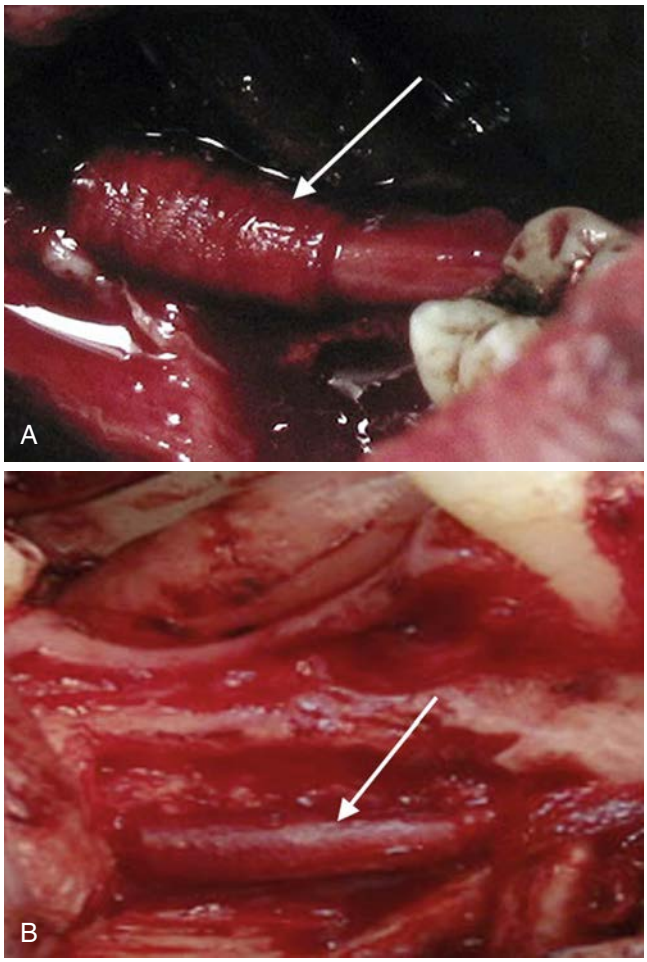

• **Figure 25-11** **A**, Lingual nerve repair wrap using "NeuraGen" collagen-based product; **B**, Inferior alveolar repair wrap using "AxoGen" porcine-based product.

neurolysis and has also been used for trigeminal nerve injuries.[13,172,173] In this procedure, saline is injected beneath the epineurium in the nerve-injured zone. The fluid-ballooned region is then incised longitudinally, exposing the internal nerve microstructure. When effective, this permits release of internal nerve scar constrictions and frees the nerve fascicles. The most urgent indication for internal neurolysis is the removal of intraneural neurotoxic foreign materials such as endodontic sealants, which must be done within the first 24 to 72 hours after intraneural contamination. Internal neurolysis has also been used for milder cases of chronic internal fibrosis from Sunderland types 2 and 3 mechanical injuries. If no fascicular release occurs, however, and internal nerve fibrosis remains after microdissection, the affected zone must be excised and followed by neurorrhaphy. Internal neurolysis has a long history of successful use for treatment of spinal or digital nerves where there are large fascicles and thick perineuria. Similar techniques are less feasible for trigeminal nerves, however, where fascicles are smaller and perineuria are thinner. Unfortunately, there are no convincing published reports of internal neurolyses being used effectively for trigeminal nerve repairs, and patients treated by this chapter's authors with internal neurolysis alone have had disappointing outcomes.

Neurectomy and Nerve Redirection

For those unfortunate circumstances in which inspection reveals that trigeminal nerve repair is not possible, and after all other options for conservative treatment have been exhausted, neurectomy and nerve redirection may be used. Their primary indications would be cases of nerve inaccessibility, absence or severe atrophy of the transected proximal or distal nerve trunks, failed surgical repairs, and medically intractable dysesthesias.

Neurectomy

Surgical ablations of peripheral nerves for relief of neuralgias were a mainstay of neuralgia management well into the twentieth century.[174] These procedures fell out of favor, however, and were largely considered obsolete because of complications of stump neuroma reformation, neuralgia recurrence, and centralized "anesthesia dolorosa" dysesthesias.[175] There has been renewed interest in the use of ablative trigeminal neurectomies; however, recognizing that they may reverse sympathetic mediated pain syndromes, may induce immediate pain relief for months and are relatively simple procedures that can be repeated if needed.[176,177]

Nerve Redirection

A logical extension of neurectomy is the use of nerve redirection. In this procedure, originally developed for orthopedic applications and now with applications for trigeminal injuries, the residual proximal nerve trunk is engaged and sutured into adjacent viable static skeletal muscle such as the mylohyoid or masseter muscles.[14,178-180] Nerve redirection is believed to decrease the likelihood of reformation of active traumatic neuroma at the proximal nerve stump interface, but will result in permanent deafferentation, with or without pain.

Post–Nerve Repair Management

Following surgical nerve repairs at any stage, patient counseling reinforces information about their anticipated course of recovery. An expected period of minimal pain and subjective "numbness" of 6 weeks or more is explained to patients, and a limited soft diet is recommended to avoid secondary accidental tissue trauma. A restricted range of mandibular motion is also anticipated, especially where lingual nerve repairs have been carried out; this may require temporomandibular physical therapies for restoration of full joint functions and mandibular range of motion.

Early postoperative medical support uses a 5-day tapering course of corticosteroid such as dexamethasone or methylprednisolone.[91,92] A short-acting anticonvulsant-psychosedative agent such as clonazepam (Klonopin) 0.5 mg twice daily, combined with titrated opiate analgesics, is used to prevent central sensitization.[94]

During intermediate and later stages of neurosensory recovery after surgery, transient episodes of hyperesthesia often occur. Supportive medical therapy at these stages stresses use of anticonvulsant, antidepressant, and topical analgesic lidocaine therapies (see "Nonsurgical Treatments").[95,96,106,107,109] Patients are instructed to begin active sensory reeducation exercises within the first month after surgical repairs (see Figure 25-5). Counseling after nerve repair stresses the expected gradual recovery of functions over a minimum 1-year time frame. Patients are recalled regularly to monitor their recovery of orofacial and neurosensory functions, and adjust their palliative therapies as needed.

Clinical Applications

Postsurgical Pain

Postsurgical pain is expected following most oral and maxillofacial surgery. It usually lasts 1 to 4 weeks depending on the procedure and is the primary focus of patients' quality-of-life concerns.[181] Although full recovery from the painful state occurs spontaneously for most patients after many types of surgery, others experience persistent postsurgical pain (PPSP) of 2 or more month's duration, and for some patients postsurgical pain becomes permanent.[182]

The prevalence of PPSP for oral and maxillofacial procedures varies greatly by procedure but may approach 25%.[5,65] The underlying etiology of transitions from postsurgical acute to chronic pain is unclear. Systematic reviews of PPSP from wide-ranging types and locations of surgeries has concluded that PPSP is primarily a neuropathic condition.[86,183] Nerve injury is considered a frequent source of acute inflammation that activates a pathway leading to a high incidence of chronic central sensitization.[184] In the case of maxillofacial PPSP, acute trigeminal neuritis often stems from combinations of nerve trauma and chronic inflammatory conditions such as osteomyelitis and unresolved temporomandibular dysfunction.[27,185] The overall goals of postsurgical pain management, therefore, are to maximize the management of the acute stage of postsurgical pain, to recognize key clinical signs of neuropathic transition, and to take steps to prevent the establishment of chronic central sensitization (Table 25-4).

Acute-Phase PPSP

Acute-phase PPSP maxillofacial postsurgical pain lasts a few days to weeks, depending on the operation, and is characterized by classic neurogenic inflammatory responses to musculoskeletal and trigeminal trauma. Clinical signs of peripheral sensitization include sustained swelling, discoloration, reduced range of motion, dull pain aggravated by percussion, and complaints of "tingling and numbness."

Perioperative treatments of acute-phase postsurgical pain are primarily pharmacologic, using intraoperative and postoperative ketamine, trigeminal nerve blocks, and oral and parenteral corticosteroids.[89,90,92] Postoperatively, oral or transdermal opioids are prescribed on a time-based schedule with supplements added for breakthrough pain. Sedative and antispasmodic agents are also used at the acute stage to manage anxiety and muscle spasms.

Transition-Phase PPSP

Transition-phase PPSP, typically spanning 2 to 6 weeks, is characterized by nonresolving peripheral sensitization and emerging clinical signs of central and autonomic sensitization. These present as (1) both constant and elicited ("triggered") pain, (2) allodynia, hyperpathia, and hyperalgesia, (3) pain phantoms and afterimaging, (4) anatomic spread of neuropathic symptoms beyond damaged territory, and, less frequently, (5) neurovascular episodes of edema and discolorations.[186,187] In cases of known direct damage to trigeminal nerves, painful traumatic neuromas that have formed in the few weeks after surgery may be an added peripheral source of transitional pain. Treatments for the transition phase shift from reliance on short-acting agents to antiepileptic and antidepressant combinations titrated to pain relief and side effect tolerance (see "Nonsurgical Treatments").[87,106] Topical compounds of multimodal analgesics are helpful at this stage, as are periodic trigeminal nerve blocks. Time-based and limited NSAID blood levels are maintained, and opioids become second-line agents except for closely monitored pain breakthroughs.[93,104]

Chronic PPSP

Chronic PPSP is characterized by established neuropathic peripheral, central, and autonomic sensitizations. Cognitive-behavioral problems develop, with sustained anxiety and depression, social dysfunctions, and sleep impairments. Pain becomes refractory to conventional physical, medical, and surgical therapies. Functional brain imaging has shown that cortical degenerative and demyelinative changes are present in response to nerve injuries and may be a common mechanism of chronic postsurgical pain.[188,189] If firmly established and refractory 2 or more months after surgery, PPSP often requires multidisciplinary pain management (see Table 25-4).[134-136]

Maxillofacial Trauma Nerve Injuries

Maxillofacial traumas, especially those involving fractures, are associated with high levels of trigeminal neuropathy that often go undiagnosed, untreated, and underreported. This may be attributed in part to patient factors; traumatized patients tend to not complain or even be aware of sensory problems in the acute stages of their injuries and often are not available for long-term follow-up neurosensory assessments and treatments.

In addition, surgeons treating patients with maxillofacial fractures in the past have understandably focused their attention on stabilizing the multisystem-injured patient, reestablishing normal facial contours, achieving anatomic reduction and fixation of fractures to promote union, and regaining functional dental occlusions. Often these goals

TABLE 25-4 Management of Persistent Postsurgical Pain

Clinical Signs		Treatments		
		Preoperative	Intraoperative	Postoperative
Acute Pain (1-4 weeks)	Inflammation Sensory loss Neuritis Myalgia Arthralgia	Counseling NSAIDs	Corticosteroids V nerve blocks Ketamine	Oral corticosteroids V nerve blocks (bupivacaine) Timed NSAID/opioids Sedative-antispasmodics (cyclobenzaprine/diazepam) Breakthrough opioids
Transitional Pain (2-6 weeks)	(Neuropathic Sensitization) Allodynia Hyperpathia Hyperalgesia Neuroanatomic symptom spread Episodes of edema/discoloration		NSAIDs (ibuprofen) Topical multimodal analgesics Titrated antiepileptics (gabapentinoids) Titrated antidepressants (duloxetine, tricyclics) V nerve blocks (bupivacaine) Breakthrough opioids	
Chronic Pain (>2 months)	(Neuropathic Sensitization) Cognitive/behavioral dysfunctions Incomplete responses to analgesics		NSAIDs Topical multimodal analgesics Antiepileptic/antidepressant co-medications Behavioral, physical therapies Multidisciplinary pain management	

NSAIDs, Nonsteroidal anti-inflammatory drugs.

have been achieved to the exclusion of assessment and treatment of associated sensory neuropathies.[190,191] In recent years, however, protocols from level-1 trauma centers and the American Association of Oral and Maxillofacial Surgeons have increasingly recognized the importance of restoring neurologic functions for patients with maxillofacial trauma.[192-194]

Neuropathy Prevalence

Cumulative studies estimate that post-traumatic neurosensory disorder of inferior alveolar-mental nerve injuries occurs in 46% to 58% of patients with mandibular angle and body fractures. Immediately following treatment of these fractures, neuropathy may rise transiently to as high as 91% of patients, and permanent (1 year) neurosensory disorders average 38.8%.[17,18,34]

Acute infraorbital nerve neuropathies assessed by quantitative sensory testing are found in 76% of patients with zygomatic-maxillary fractures and rise to 100% among patients with orbital floor involvement.[195] Permanent infraorbital neuropathy has an QST-determined patient average of 60% 1 year after treatment.[196] Unfortunately, there is little published information on chronic levels of dysesthesia after facial trauma.

Neuropathy Determinants

Increases in permanent neurosensory deficits are found among female and older patients.[17,34] Deficits are greater when fracture displacements are greater than 5 mm, occurring in 73.5% of patients as compared to 25% of those with nondisplaced fractures, and when time intervals are greater than 1 week between injury and repair; rigid fixation produces more neuropathies than non-rigid; and mandibular open reduction treatments result in more sensory neuropathies than closed reductions, with neuropathy levels actually increasing after open reductions compared to the pre-repair levels.[197,198] Interestingly, the reverse recurs with open reductions of zygomatic-maxillary fractures where neuropathies decrease after open reductions as compared to preoperative levels.[199]

Acute Injury Nerve Repair

Acute injury nerve repair is ideally done at the time of fracture repair. Nerve management is indicated when the fractures are displaced greater than 3 to 5 mm, when the nerves are seen to be transected, gapped, or significantly displaced. Nerves must be accessible for repair, and the surgeon must have the necessary skills, instrumentation, and operative environment. Immediate epineurial neurorrhaphy repair is done placing 2 to 4 nylon sutures of 6-0 to 8-0 gauge. The osseous mandibular canal or mental or infraorbital foramen is enlarged to prevent secondary compression during osseous recovery. Finally, the injury-repair site is enturbulated with a protective nerve wrap. Postoperatively, acutely nerve-injured trauma patients should begin sensory reeducation

psychophysical exercises within the first 2 weeks after treatment.

If primary nerve repair is not feasible, however, the damaged nerve should be tagged with 6-0 or 7-0 nylon suture in anticipation of secondary microsurgical repair that may be done after fracture union is assured.

Secondary (Delayed) Microsurgical Repair

Secondary (delayed) microsurgical repair treatments are indicated for maxillofacial trauma patients who (1) test anesthetic after 3 to 6 months, (2) have disabling orofacial sensory dysfunctions, or (3) have developed intolerable chronic neuropathic pain. The full protocol of the nerve injury "surgical repair cascade" may be needed, and treatment outcomes for nerve repaired maxillofacial trauma patients have compared favorably with outcomes from repairs done for other nerve injury causes, achieving overall useful sensory recovery levels as high as 86%.[17,34]

Local Anesthetic Injection Nerve Injuries

Acute Trigeminal Nerve Injuries

Acute trigeminal nerve injury symptoms after local anesthetic injections are common; the exact incidences are unknown and probably underreported, with estimates that 1 in every 200 mandibular blocks will be associated with a "traumatic episode" of pain or paresthesia.[200,201] Over 80% of acutely symptomatic patients fortunately will experience resolution within 1 week. However, approximately 10% to 17% will have some level of sustained or permanent neuropathy resulting in function impairment and burning dysesthesias (see Figure 25-4, *A*).[202,203]

Chronic Nerve Injuries

Permanent nerve injuries have been reported in both lingual and inferior alveolar nerves once in every 26,000 to 800,000 mandibular blocks.[23] Lingual neuropathies occur most frequently, are more incapacitating, and have higher incidence of burning dysesthesias as compared to injured IANs. If lingual neurosensory recovery has not been near completion by the fourth week after injection, 86% will not recover further and are considered permanent.[23] These data alone suggest that any full-time dental clinician will have at least one patient during his or her career who has permanent nerve involvement resulting from mandibular nerve blocks. Clinicians have also noted less frequent but increasing cases of cranial nerve injuries following anesthetic blocks involving long buccal, infraorbital, nasopalatine, and superior alveolar branches.[34,204,205]

Mechanisms of Local Anesthetic Injuries

Three potential mechanisms have been considered causes of anesthetic neuropathies: (1) vascular damage, (2) mechanical nerve injuries, and (3) indirect chemical neurotoxicities.

Vascular-based injuries include punctures or tears of extraneural vessels resulting in hematomas that may become organized and chronically compress the nerve.[206] Tears of extrinsic plexuses of epineural microvasculature may also cause segmental nerve ischemia. Trauma to intrinsic plexuses (vasa nervorum) may result in intraneural hematoma, causing axon irritability and intraneural fibrosis.

Another vascular basis for local anesthetic neuropathies is inadvertent intravascular injection, producing rapid-onset regional trigeminal pain, swelling, mucocutaneous ischemia due to vasoconstriction, and distant spread along the valveless facial vessels. Extreme cases of spreading intravascular local anesthetics may result in cranial motor nerve effects in facial musculature and extraocular muscles, as well as visual-field optic effects.[205,207]

Mechanical injuries may theoretically result from direct intrafascicular penetrations or indirect needle trauma from a barbed needle tip.[208] There is much evidence, however, that needle contact with nerve during injection, producing "electric shock" for the patient, is not likely a prime cause of nerve injury. Multiple clinical series show no correlation between the frequency of "shocking" during injection and subsequent sustained neuropathies.[202,203] The same conclusions come from experimental studies with human cadavers and experimental animals showing that needles penetrating the much larger peripheral nerves will pass harmlessly through without damaging the nerve fascicles.[209] Direct local anesthetic mechanical needle injuries, therefore, appear to be of minor importance as a cause of sustained sensory neuropathies following local anesthetic injections.[210]

Chemical neurotoxicity appears to be the most significant factor causing post-anesthetic neuropathies. Several experimental studies have proven that all local anesthetic agents are potentially neurotoxic, and there are direct correlations between the concentration of the anesthetic and degrees of axonal degeneration, necrosis of cultured ganglion cells, and nerve conduction deficits.[210-212]

Convincing clinical evidence also points to chemical neurotoxicity as the primary cause of trigeminal anesthetic injuries. Early clinical reports showed markedly higher rates of nerve injuries in relation to market shares of higher-concentration anesthetics, specifically 4% articaine and prilocaine, after their introduction in Europe in the 1970s.[213] Similar findings were reported after 4% articaine became available in 2000 in the United States.[203,214] A landmark epidemiologic report then appeared in the 2010 U.S. dental literature, showing a threefold to sevenfold greater incidence of neuropathy than expected by market penetration following use of articaine 4% compared to 2% lidocaine.[215] These findings have been confirmed and supplemented by studies that indicate no advantage in surgical anesthesia for articaine compared to lidocaine.[216,217]

Neuropathies attributed to articaine most commonly affect the lingual nerves, found in 70% to 80% of reported cases after mandibular blocks.[215] Less frequently, patients with neuropathies have been encountered following 4% anesthetic nerve blocks of infraorbital and superior alveolar nerves.[34,204] The weight of evidence regarding the increased risks of trigeminal neuropathy and neuralgias with use of 4%

articaine has convinced faculty of many oral and maxillofacial training centers and schools of dentistry in the United States and Canada to discontinue routine use of this agent.[201]

Anesthetic Injury Prevention

There are no current anesthetic techniques or protocols that absolutely prevent anesthetic nerve injuries, in part because of the "blind" nature of all injections. There are preventive guidelines, however, that may minimize their severity: (1) Avoid purposeful stimulation of paresthesias during injection to assist in localizing the nerve, (2) minimize multiple injections into similar anatomic zones, (3) avoid bone contact with needle tips, and replace the needle if a barb is detected at the tip, and (4) if there are intraoperative signs of shocking-burning pain, indicating that nerve contact may have been made, the needle should be retracted a few millimeters prior to release of anesthetic solution.

Anesthetic Injury Treatments

Sensory reeducation psychophysical treatments should be prescribed for patients with sustained post-anesthetic paresthesias. Those with chronic dysesthesias may receive modest benefits from palliative medical therapies consisting of titrated combinations of anticonvulsants such as pregabalin or gabapentin and antidepressant agents—tricyclics or SRNIs. (See the "Nonsurgical Treatments" section earlier in this chapter.)

Surgical interventions for patients with long-standing post-anesthetic lingual burning pain, taste loss, and lip-chin allodynia have thus far failed to significantly improve patient symptoms.[218] This may be due in part to physical differences between chemically injured and mechanically traumatized nerves. An isolated report based on a postal survey of U.S. microneurosurgeons who had exposed lingual nerves injured by local anesthetic injections revealed few objective signs of mechanical injury.[203] The typical appearance of the exposed nerves was of minimal perineural fibrosis, visible perineural microvasculature, slightly reduced nerve transparency upon transillumination, and intact nerve fascicles. The nerves displayed remarkably normal microanatomy, even in those cases where patients had reported dysesthesia. These experiences and lack of objective clinical trials have led to a general consensus among maxillofacial microneurosurgeons that surgical repair attempts of trigeminal nerves traumatized by local anesthetic blocks are not indicated.

Surgical Medicament and Endodontic Injuries

Oral and maxillofacial surgeons may encounter neuropathic complications when using topical medicaments for treatment of dentoalveolar infections, controlling intrabony hemorrhage, relieving post-extraction osteitis, or treating cysts or malignant pathologies. Surgeons may also be called upon to assist in the management of patients with acute endodontic nerve injuries whose injuries may be severe and require immediate attention to avoid permanent neuropathies.[34,219,220]

Surgical Medicament Injuries

Historically, tetracycline powders were placed in third molar extraction sockets for prevention of osteitis. However, studies have questioned the effectiveness of this treatment and also found signs of chronic paraneural inflammatory responses when tetracycline has been placed near IANs.[221] Rare cases have also been cited of persistent neuropathies among patients with post-extraction alveolar osteitis treated with topical applications of eugenol pastes on exposed IANs.[221]

Inferior alveolar nerves are at particular risk during socket and alveolar hemorrhage control using direct packing with low-pH agents such as oxidized regenerated cellulose (Surgicel) and gelatin sponges.[222] The overuse of these acidic agents in contact with human peripheral nerves is therefore discouraged. Control of intrabony hemorrhage with bovine collagen and bone wax, however, appears to be well tolerated by peripheral nerves, as is intra-alveolar liquid nitrogen used to prevent recurrences of enucleated keratocysts.[223,224]

Endodontic Injuries

Trigeminal injuries from endodontic treatments appear to have decreased in frequency and severity over the past 3 decades; this may be due to development of the specialty of endodontics with improved techniques, greater awareness of the toxicities of medicaments, and the implementation of operating microscopes. However, endodontic neural injuries are among the most severely debilitating events, potentially involving multiple cranial nerves and representing true surgical emergencies. The exact incidence of trigeminal nerve injuries resulting from endodontic treatments is not known, as the available literature consists mainly of case series of 10 or fewer patients. There are three proposed mechanisms of nerve injuries resulting from endodontic treatments: (1) direct nerve trauma, (2) compression trauma ischemia, and (3) chemical burn neurotoxicities.[34,219,220]

Direct Nerve Trauma

Especially if the posterior mandibular root apex is close to the underlying inferior alveolar canal, endodontic broaches and files may pass beyond the apex, penetrate the canal, and puncture the IAN. This may result in immediate pain, intraneural bleeding, and nerve disruption with partial or complete severance.[225]

Compression Injuries

Overfilling of root canals, even with usually inert filling materials such as gutta percha and zinc oxide eugenol, may lead to compression of the IAN, either outside the mandibular canal or directly on the nerve itself (see Figure 25-10, *A*). In such cases the compressing materials and associated hematoma are acting in a closed compartment and their presence perpetuates the resulting neuropathy; their prompt removal, therefore, is imperative.[226]

Chemical Burns

The endodontic medicaments most associated with chemical paresthesias are sodium hypochlorite irrigant, phenols, aldehydes and halides, and paraformaldehyde found in the formerly used Sargenti (N2) pastes. Milder chemical effects also are also seen with the use of calcium hydroxide, gutta percha, steroids, and antibiotics.[219] The primary determinants of chemical burn nerve injury appear to be the amount and concentration of foreign agents in contact with the nerve, the duration of contact, the agent's pH, and associated epineural mechanical injury.[225]

Calcium hydroxide and gutta percha, although widely used and safe in small intra-alveolar quantities, are high in alkalinity. If placed under pressure at high temperatures, these agents may migrate periapically and enter into the mandibular canal, where they migrate further proximally and distally. In such cases there may be widespread wallerian degeneration, neural necrosis, minimal regenerative capacity, and intractable burning neuropathic pain.[226]

Sodium hypochlorite (bleach solution) is the most common irrigating solution in current use because of its excellent proteolytic and antibacterial actions. Unfortunately, sodium hypochlorite is also extremely neurotoxic with pH levels of 10 to 12. This markedly increases vascular permeability, allowing the agent to spread rapidly into periapical, periodontal, and adjacent anatomic spaces. The risk of these events occurring is increased by the presence of accessory canals, root perforations, apex overinstrumentation, or irrigation done under excessive pressure.[220,227]

Most cases of endodontic neuropathies have been associated with inferior alveolar injuries. However, profound maxillary endodontic injuries have also been reported, with the primary offending toxic agent having been sodium hypochlorite.[228] Sodium hypochlorite may escape into loose maxillary spaces such as the canine fossa, maxillary sinus, orbit, or infratemporal fossa, often with dramatic clinical effects. There is sudden onset of severe burning pain, rapid mid-facial swelling, dentoalveolar bleeding and ecchymosis, facial muscle paresis, and hemifacial loss of sensation (see Figure 25-4, *B*).

Surgical Treatments

Acutely injured endodontic patients require early and aggressive treatment as soon as the complications are recognized. Imaging is done with plain films or cone-beam computed tomography (CBCT) to help define injury limits. Systemic corticosteroids, palliative analgesics, and preventive antibiotics are prescribed, and cold packs are applied. Patients should be scheduled for surgery, ideally in an operating room setting, using general anesthesia and within 48 to 72 hours if possible. The primary goals are to remove foreign body materials, decompress effected nerves, and irrigate and drain the regional tissues.

Acutely injured nerves are exposed by lateral decortication decompression of the mandibular canal, followed by removal of chemical foreign bodies, irrigation of the nerves with isotonic solution, and placement of nerve barrier protections.[229] In cases where sealant materials appear to have penetrated the epineurium, internal neurolysis through longitudinal nerve incision will be required to remove the toxic foreign materials and allow placement of protective nerve wraps.[13,173]

Surgical treatment of patients with chronic sensory loss and dysesthesia after endodontic injuries will usually require wider exposure through decortication or sagittal osteotomy.[229] This is dictated by imaging signs of extensive spread of neurotoxic materials in the mandibular canal. If surgical exposure reveals extensive nerve necrosis, fibrosis, or gapping of the IAN, liberal resection of damaged nerve segments is carried out and repairs done with nerve grafting and entubulation in order to promote secondary regeneration.

Orthognathic Nerve Injuries

Neurosensory disorder is a known potential complication of orthognathic surgery, involving inferior alveolar, lingual, and infraorbital nerves and occasionally the maxillary trunk.[230] Although neuropathy is present for many patients following orthognathic surgery, most appear to tolerate even long-term mild neurosensory disorder in order to correct their dentoskeletal discrepancies and improve orofacial functions and esthetics.[28]

Injuries may result from direct instrument lacerations, stretches during osteotomy mobilizations, or punctures or nerve compression during placement of transosseous pins or plate fixation. After injury, orthognathic patients may display the full range of hypoesthesias, hyperesthesias, nonpainful paresthesias, and dysesthesias. The greatest functional difficulties and dissatisfactions, however, are cases where there are frequent long-term triggered paresthesias and dysesthesias.[54,65]

Neuropathy Prevalence

Neuropathic symptoms in the first week after BSSO are nearly universal. Subjective analyses and objective quantitative sensory testing have found IAN disorder in as many as 97% of BSSO patients 1 week after surgery.[54,231,232] Acute lingual neuropathy has been reported at between 9% and 18%.[233,234] Six months after orthognathic surgery, 63% of a large patient series reported abnormal spontaneous sensations and 84% had abnormality in response to tissue stimulations.[235] One year or more after sagittal osteotomy surgery, inferior alveolar neurosensory disorders range from 9% to 35%.[28,230,235] The 1-year postoperative neuropathies, presumed to be permanent, were rated as "mild" by 32% and "disturbing" by 3%.[231] Other surveys have shown that even permanent sensory complications do not serve as the most significant determinant of patient satisfaction after orthognathic surgery. Patients report that functional gains and esthetic improvements outweigh residual neurosensory disorder when asked about "quality of life" satisfaction after surgery.[235,236]

Neurosensory complications to lingual and maxillary nerves after BSSO are much less common than IAN injuries

and are attributed to retractor compression and improper transosseous plate placements.[233,237]

Sustained neuropathic pain after orthognathic surgery is also rare. Studies of sagittal osteotomy patient cohorts showed prevalence of chronic pain and disturbing paresthesias to be 0.5% to 5%.[59,65,238]

Neuropathy Determinants

The highest rates of neurosensory deficits occur among patients older than 35, as high as 50% after age 40.[235,239] Long-term disorder is higher among women than men, and patients with history of depression and obstructive sleep apnea.[238] Neuropathies are more common when monocortical plate fixation is used rather than rigid bicortical pin fixation, and for longer advancements of retrognathic mandibles.[28] Other factors increasing the risk of IAN injuries include mandibular canals located less than 0.8 mm of the lateral mandibular cortex surface, if impacted third molars have been retained, and when the rate of advancement in distraction osteotomies is greater than 1 mm per day.[239-241] Manipulation of soft tissues of the pterygomandibular space immediately medial to the mandibular lingula has also been associated with higher levels of sensory disorder.[28] Combining BSSO with genioplasty slightly raises neuropathy incidence, whereas combining BSSO with maxillary osteotomy has not proven to increase risk of neuropathy.[236] Nor have biodegradable screws and plates for osseous fixation been associated with higher levels of sensory disturbances.[242]

Lingual nerves are at higher risk for injury if not protected from horizontal drilling during bicortical pin fixation in the retromolar mandible and if pins are overextended through the medial cortex into the sublingual space.[233] Lingual nerves injured at the level of the mandibular lingula prior to or during the medial osteotomy cut may not be repairable because of their inaccessibility.

The most important determinants of chronic sensory neuropathies among BSSO patients are nerve entrapment in the proximal ramus segment and compression of nerves during fixation of the osteotomy segments.[28,230]

Acute Surgical Nerve Repairs

There are limited published reports that address surgical treatments of intraoperative orthognathic trigeminal injuries. It is recommended, nevertheless, that direct neurorrhaphy be carried out immediately if possible when nerve separation is observed during orthognathic surgery.[243] The specific technique will be dictated by the site and nature of injury. When the IAN is injured proximally at the point of entrapment in the medial aspect of the distal osteotomy segment, it is necessary to complete the osteotomy split in order to access the nerve for repair. In the event of IAN injury during the vertical cutting of lateral cortex, the nerve may need to be freed by lateral corticotomy and released peripherally to the mental foramen. This is especially important for mandibular advancement cases in order that the nerve may be repaired without tension. If the nerve has been transected or significantly disrupted, immediate microsurgical repair is ideal treatment using epineurial neurorrhaphy or, if available, interpositional allogeneic cadaver graft repair. All nerves traumatized during BSSO, whether suture repaired or not, will benefit from internal widening of the exposed mandibular canal and from placement of protective nerve wrap entubulation.

Secondary (Delayed) Surgical Nerve Repairs

For those patients with long-term unacceptable sensory loss, secondary trigeminal nerve repairs are typically delayed for 12 weeks after orthognathic surgery to allow for bone healing. The surgical approach will be dictated by the likely site and dimensions of nerve injury; these are determined by operative history and objective clinical signs such as narrowed compressing bony nerve canals as revealed by CBCT, and the presence of percussion-triggered hyperpathias (Tinel sign) indicating traumatic neuroma formation. Because nerves traumatized during BSSO may have lengthy neuroma-in-continuity, microsurgical repair with grafting may require wide exposure through secondary sagittal osteotomy.

Outcomes of secondary repairs of a series of 54 patients with chronic orthognathic neuropathies have shown that 85% regained acceptable sensory functions.[243]

Implant Nerve Injuries

Since their introduction in the 1980s, there have been dramatic increases in the number of dental implants placed as more dental practitioners carry out these surgeries. The most significant frequent complications result from implants placed in the posterior mandible, damaging the IANs, and less frequently the lingual nerves.[244] Implant nerve injuries result in a spectrum of symptoms from mild transient paresthesias to permanent anesthesias and neuropathic pain as well as impaired orofacial functions for speech, eating, touching the face, shaving, and kissing.[21,245]

Incidence of acute nerve injuries after implants have been reported as high as 40% with permanent neuropathies reaching 19%.[21,245,246] Early studies of patient outcomes where nerve repositioning (transposition and lateralization) was done to facilitate implantation resulted in 100% acute paresthesias and permanent loss of crude touch abilities in 10% to 40% of patients.[247] More recent outcomes have fortunately improved as repositioning techniques have evolved.[22] The current prevalence of both acute and chronic neuropathies following implant placements are not fully known and are probably underreported because of inconsistent reporting and lack of an international registry.

Nerve Injury Causes

Implant nerve injuries are caused by: (1) inaccurate and incomplete presurgical planning, (2) direct nerve trauma during drilling, (3) indirect compression injuries during implant placement, and (4) secondary factors such as flap nerve injuries and peri-implant factors such as infection and hematoma.[248]

Incomplete pre-implant planning includes failure to calculate root lengths such that implants are placed closer than 2 mm from the inferior alveolar canal. This may be due to inaccurate measurements resulting from the known 10% to 40% distortions inherent in some panoramic radiographs. Surgeons may also inadequately prepare drill "guides" and "stops" calculated from computed tomography (CT)-based navigation systems.[249] Nerve injury risks may also be increased by incomplete preoperative assessments of bone quality and atrophy and failure to compensate for patient factors of increased age, being female, having chronic systemic disease, and using tobacco.[250]

Direct nerve injuries during the pilot twist drilling are probably the main cause of implant neuropathies.[14] Overly deep drilling may be due to "slippage" in less dense spongy bone found in the posterior mandible, leading to mandibular canal penetrations.[250] In such cases nerve injury has occurred even though the postoperative imaging may indicate proper implant positioning. Drill penetration nerve injuries may be partial or complete, but tend to be qualitatively "ragged" compared to incision injuries.[40] For this reason IAN injuries from twist drill injuries will often require nerve grafting for successful repair. Nerve injuries may also result from drill-generated bone heat exceeding 47° C, potentially causing both IAN damage and peri-implant bone necrosis.[251]

Implant placement nerve injuries may result from both compression collapse of the mandibular canal bone as well as direct nerve crushes within the canal from the implant.[245] Concurrent bleeding and hematoma formations in or around the mandibular canal further exacerbate the nerve injury in this "closed box" compartment.[248]

Treatment of Implant Nerve Injuries

When acute nerve injury symptoms have occurred, patients should return ideally within 24 to 36 hours of surgery so that the nature of their altered sensation and discomforts in the surgical region can be documented, baseline maxillofacial examination and sensory testing carried out, and postoperative imaging assessment obtained to determine the anatomic relation of the implant to the mandibular canal. Corticosteroid medical therapy and titrated sedative-analgesics are begun at this time.

If there are no imaging signs of implant encroachment on the mandibular canal, supportive treatments and serial QST should be done. However, when there are signs of possible canal encroachment, imaging should advance to CT or CBCT analyses. If implant encroachment on IAN and patient sensory loss are confirmed, immediate implant position changes are urgently needed: either partial "backing out" or complete removal of the implant and possible replacement with a shorter and wider implant.[248]

For those patients with measurable, unresolving sensory losses, disturbing paresthesias or intractable neuropathic pain continuing 4 to 6 weeks beyond implant placement, microsurgical referrals for possible surgery should be considered. This timing is selected before neuroma has formed, before centralized symptoms have developed, and before implant osseointegration has occurred. Definitive nerve repairs may require decompression through lateral mandibular corticotomy, direct or graft-assisted repair, and nerve wrap protection (see Figure 25-10, *C* and *D*). Nerve repositioning lateralization may also be considered at this operative stage to retain healthy and integrated implants.[22]

Mandibular Third Molar Nerve Injuries

Injury to trigeminal nerves is the most significant and potentially long-term complication associated with the removal of impacted mandibular third molars.[19] Classic works by Alling and Kipp pointed to potential problems with impairments in speech, mastication, swallowing, social functions, and sustained paresthesias and dysesthesias.[4,5,252] Inferior alveolar nerves are injured more often than lingual nerves. However, lingual nerve injuries are functionally more disabling and have lower spontaneous recovery rates.[13,14] The long buccal nerve frequently may also be injured during mucosal incision and flap reflection, but symptomatic long buccal neuropathies are rarely reported and have few functional consequences.[34]

Nerve Injury Prevalence

The overall reported acute incidence of IAN injuries ranges from 0.3% to 8.4% and lingual nerve injuries from 1% to 22%.[2,5,46] Approximately 15% to 25% of patients who sustain acute exodontic nerve injury will have residual and probably permanent effects 1 year after injury.[4,19,20,252]

A recent survey of 535 oral and maxillofacial surgeons reported that 94.5% had patients with acute symptomatic IAN injuries over a 12-month period, and 53% reported lingual nerve injuries; permanent career injuries to IAN occurred in 76% of OMS practices and permanent career lingual nerve injuries in 46%.[2]

Nerve Injury Risks: Patient Factors

Increasing age is a primary risk factor for third molar injuries to IAN, but interestingly, older age is not a factor for lingual nerve injury.[39,45,46,253] This may be attributed to progressive root formation with aging and its related pathology as well as the known negative effects of age on recovery from all types of nerve injuries and after repairs. Being female is also an increased risk factor, particularly for lingual injuries, possibly a consequence of smaller mandibles.[34,45]

The depth and type of impaction is significant for inferior alveolar injuries; mesioangular and deeper horizontal impactions are associated with the highest paresthesia rates and dysesthesias.[254] Depth of impaction does not influence lingual nerve injuries, but increased risks are found with distoangular impactions.[255]

Preexisting pathology also increases risk of lingual nerve injuries. These include lingually positioned ankylosed teeth, root penetrations of the lingual cortex, and erosion of the lingual plate by chronic infection, cyst, or malignancy.[253,255] These factors increase the likelihood of injury to the exposed

nerve during extraction or during socket curettage of residual follicles or cysts containing entrapped nerves.

The strongest patient-based predictor of IAN damage is the anatomic relationship between nerve canal and dental roots as seen on imaging.[256] The key imaging risk signs are: (1) diversion and narrowing of the mandibular canal, (2) darkening and deflection of the roots, and (3) interruption of the white line of the canal. Studies have demonstrated that when one of these radiographic predictors are present, there is a 16% occurrence of nerve damage, and when two or more predictors are present, the incidence is 30%.[256] Properly executed periapical radiography and panoramic methods are sufficient for identification of these key indicators of root-nerve superimpositions.[257] With the advent and increasing availability of low-dose CBCT technology, more accurate three-dimensional imaging may better clarify the anatomic relationship between the IAN and the lower third molar.

Nerve Injury Risks: Surgical Factors

The primary surgical determinants of third molar trigeminal nerve injuries are; (1) incision and flap techniques, (2) nerve exposures, and (3) alveolar ostectomies.

Incisions and Flap Techniques

The *lingual nerve* is at increased risk for injury when opening incisions are placed on the lingual aspect of the retromolar ridge instead of over the external oblique ridge in the lateral vestibule.[5] Retromolar incisions that follow the line of the posterior dental occlusion risk dropping the blade directly into the pterygomandibular space because of the lateral flare of the mandibular ascending ramus. There is strong evidence-based consensus, therefore, that mandibular third molar incisions and flap elevations should be confined to the lateral buccal vestibule.[5] Incisions in the lingual and mid-retromolar pads are within the known anatomic "danger zone" for direct lingual nerve trauma. Several cadaver and MR imaging studies have revealed the high variability of normal lingual nerve locations, showing that between 10% and 25% of lingual nerves lie superficially and unprotected by bone within 1.2 mm of the lingual alveolar crest and in contact with the cortical bone plate.[258-261] In rare cases the nerve is found within the retromolar mucosal pad itself. These anatomic risk factors may help explain the occasional reports of bilateral lingual nerve injuries and the common reports by operating surgeons of lingual nerve injury "surprises" following simple removal of superficially impacted third molars.

Intraoperative Nerve Exposures

In the majority of cases of third molar lingual nerve injuries, the cause of injury is reported by surgeons as unknown, that is, the nerve injury was not observed.[2] The IAN, however, is frequently exposed and visualized in extraction sockets. When exposed, there is a 20% risk of acute sensory alteration and 30% of those exposed will retain altered sensation at 1 year, for an overall 1-year sensory alteration incidence of 6%.[262] From a clinical standpoint, therefore, the finding of an exposed, intact IAN bundle during third molar surgery suggests there is a 1 in 5 chance of developing paresthesia and those patients with postoperative paresthesia have a 1 in 4 chance of neuropathy persisting 1 or more years.

Alveolar Ostectomies

The greatest iatrogenic causes of lingual nerve injury appear to be perforations, fractures, or ostectomies of the lingual cortical plate, causing direct lacerations or nerve punctures.[39] This is most likely to occur from overdrilling during crown sectioning or bone "trenching" done blindly under the flap posterior to the impacted third molar.[5,255] The highest levels of inferior alveolar paresthesia and dysesthesia have been shown to result from ostectomy inferior and mesial to horizontally impacted teeth.[34,39]

Two controversial surgical techniques have been advocated for prevention of third molar surgery-related trigeminal injuries: planned exposure and retraction protection of the lingual nerve, and coronectomy for avoidance of root damage to IAN.

Lingual Nerve Retraction

The purposeful reflection of a lingual flap, identification of lingual nerve, and placement of subperiosteal protective separators is a technique that has been traditionally taught in some parts of the world.[12,263] This approach does allow greater access for special cases of lingually positioned third molars and may prevent crown or root displacement into the paralingual space. Although markedly higher rates of paresthesias occur 1 week after lingual nerve retractions, permanent neuropathy rates after lingual retractions done by surgeons specifically trained in this technique have resulted in outcomes comparable to buccal-only flap elevations.[255,264] However, the weight of evidence from retrospective and prospective studies has led to the conclusion that lingual flap elevations significantly increase the risks of permanent lingual neuropathies and should be avoided as a routine practice.[5,46,265]

Coronectomy

Also called partial odontectomy or deliberate root retention, coronectomy may be considered for patients at extreme risk for IAN injury during conventional one-stage removal of impacted roots.[266,267] This technique is indicated if preoperative imaging reveals an intimate relationship between the root of the tooth and the IAN, including nerve encirclement by roots.[268] The technique is not indicated for teeth or roots that are mobile, where there is active root or apical infection, or with horizontally impacted teeth in direct contact with the nerve.[266]

The goals of coronectomy are to leave the parts of roots in direct contact with the nerves undisturbed, and to not mobilize the retained roots. The crowns are transected with a narrow fissure burr and enough root is removed to permit bone to form superiorly, usually at least 3 mm inferior to the bony crest. Coronectomy has an overall failure rate of

5%.[269] It also has known risks that include root migrations, pulp necrosis, apical infections and osteomyelitis, increased antibiotic and radiography needs, and possible risk to lingual nerves from bone perforations.[270]

Since its introduction 25 years ago, however, there has been accumulating international evidence that coronectomy reduces IAN damage without significant complications when compared to similar high risk patients treated with conventional complete odontectomies.[5,271]

Acute Third Molar Nerve Injury Surgical Treatments

Lingual Nerves

Lingual nerves are infrequently exposed in third molar surgical fields, but if they appear to be intact, they will likely recovery satisfactorily without microsurgical repair. Placing a perineurial protective wrap around the exposed lingual nerve may minimize secondary scarring and enhance regeneration. Completely separated (Class 5) lingual nerve injuries observed during third molar surgery, however, have almost no potential for spontaneous recovery and microsurgical repair is indicated as soon as possible.[13] Immediate placement of 6-0 or 7-0 epineurial sutures is ideal treatment. Because that may not be feasible at the time of third molar surgery, the cut nerve ends should be tagged with nylon suture in preparation for delayed microsurgical repair (see "The 'Surgical Repair Cascade'").

Inferior Alveolar Nerves

Inferior alveolar nerves are more frequently exposed during third molar surgery and also require immediate attention. Osseous hemorrhage should be controlled with bleeding point pressure and bone wax as needed, avoiding pressure directly on the nerve or collapsing bone into the adjacent mandibular canal. If the nerve appears intact and is supported by the mandibular canal bone floor and at least one wall, simple supportive care is carried out using mild irrigation with isotonic saline to clean the nerve of foreign bodies and excess blood. If a protective nerve wrap tubule is available, it may be possible to place it around the exposed nerve.

For IANs found to be completely transected, satisfactory spontaneous recovery may occur if the cut nerve ends can be placed passively in direct apposition and are supported by intact surrounding bone. Ideally, and if access permits, 7-0 or 8-0 epineural suture and nerve wrap may be placed at this time. However, IA nerves observed to be transected, gapped, lacking bone support, and with nerve ends that cannot be passively aligned may require secondary microsurgical repairs if unsatisfactory spontaneous recovery does not occur (see "The 'Surgical Repair Cascade'"). In preparation for possible secondary repair, the cut nerve ends should be tagged by nylon microsuture to assist in localizing the injury site.

If early post-extraction infectious or inflammatory complications such as alveolar osteitis occur, no topical medicaments should be placed over the nerve exposed in the third molar socket. In all cases of acutely injured trigeminal nerves, supportive physical therapy and medical care with analgesic, anticonvulsant, and anti-inflammatory agents should be initiated.

Chronic Nerve Injury Surgical Treatments

Delayed secondary repairs of inferior alveolar and lingual nerves are preferably carried out within 6 months of injury and as soon as patients meet the primary criteria for nerve repairs: sustained dysfunctional sensory loss and intractable dysesthesia. Secondary surgeries for third molar nerve injury patients may require the full spectrum of decompression, neuroma resection, direct neurorrhaphy or graft-assisted nerve repair (see "The 'Surgical Repair Cascade'").

Outcomes and Conclusions

The majority of acutely injured patients experience acceptable spontaneous recoveries within weeks of injury. For a minority, however, symptoms and function impairments become sustained; if they are not treated, spontaneous recovery after 6 months is rare and after 1 year, zero.[6,12] By comparison, accumulating outcome reports indicate generally positive improvements among nerve injury patients who have been actively treated.[7,8] However, these improvements must be weighed against the potential for treatment failures and complications after surgical repairs.[272]

The efficacy of nerve injury treatments are based on two general criteria: patient "subjective" ratings and clinician "objective" measures of neurosensory functions. Patients subjectively relate their levels of (1) *orofacial functions* (speech, eating, hygiene, facial washing, kissing), (2) impressions of *normalcy of sensation* (lack of "numbness" or paresthesias of any degree, and (3) levels of *discomfort and pain*, either spontaneous or elicited ("triggered"). Clinician outcome assessments are mainly based on "objective" neurosensory test responses.

Clinician (Objective) Outcome Ratings

Current microsurgical options result in improved objective stimulus-response measures (QST) in more than half of operated patients, with overall reports of useful sensory recovery functions ranging from 51% to 90%.[8,10] Best improvements are reported for young male patients with non-painful type 4 or 5 Sunderland injuries. Primary gains are reported for C-fiber and A-delta fiber functions that afford protection against secondary injuries such as lip or tongue biting and improve on patient perceptions of crude pressures.

Early post-injury lingual nerve repairs with direct neurorrhaphy have the most favorable outcomes for measurable neurosensory functions and regaining modest levels of touch discrimination.[7,13] This may reflect in part the improved awareness among oral and maxillofacial surgeons of the value of timely patient referrals and early surgical

treatments of lingual nerve injuries. IAN-injured patients, by comparison, experience better spontaneous recoveries given enough time.

IANs treated by surgical decompressions result in the best overall improvements.[142,144] However, full IAN microsurgical repairs result in poorer overall outcomes compared to lingual nerves; they are technically more difficult, resist repair without nerve grafting, and are associated with more complications.[14,272]

No single nerve repair procedure has been identified that compensates for all types of nerve injury. The most appropriate procedures must be selected and applied from the "surgical repair cascade" options, dictated by the physical and physiologic characteristics of the damaged nerve.

Patient Outcome Ratings

For an unfortunate subset of nerve-injured and surgically repaired patients, the good successes in restoring clinician-measured useful sensory functions are not mirrored by improvements in patient ratings of functional "normalcy" and pain relief. Patients report that annoying abnormal sensations (paresthesias) have rarely been eliminated by surgical or nonsurgical treatments, and complain of varying degrees of sustained "numbness," tingling-shocking, "crawling" phantom sensations, "after-imaging," and exacerbations during cold, hot, or inclement weather.

There are no nonsurgical therapies available that have significant influences on regeneration of damaged trigeminal nerves. Modern nonsurgical multimodal pain management therapies combine behavioral, peripheral topical and neurolytic blockade, and systemic combinations of anticonvulsant and antidepressant agents. These treatments often improve tolerance of impaired orofacial functions and dysesthesias, and cognitive-behavioral therapies with sensory reeducation may hasten recovery of more normal central nervous system perceptual functions.[236]

There is a notable knowledge gap regarding the effectiveness of neurosurgical repairs for patients with traumatic dysesthesias. Microsurgical repairs rarely induce new or additional forms of pain among patients who were pain-free before repair.[11,12] The best outcomes for relief of neuropathic pain after repair surgeries are those patients who had short-term hyperesthetic post-traumatic pain, responded favorably to local anesthetic test blocks in the distribution of nerve injury, had sustained recent Sunderland type 4 or 5 injury, and displayed amputation or severe in-continuity neuromas at the time of surgical repairs.[145]

Although more than half of repaired patients report satisfaction with regard to pain reduction, more than 35% report that long-term pain was not improved by surgery, suggesting that patient selection may be a prime determinant of responses to surgery.[8,11] The poorest pain relief outcomes following nerve repairs have been reported for older female patients operated at longer time intervals after their original injuries and those patients with pre-repair pain of three types: deafferentation pain ("anesthesia dolorosa"), centrally sensitized pain (spreading hyperalgesias), and those showing signs of dysautonomia (sympathetic mediated pain, swelling, erythema episodes).[41,42,69] Outcomes for these patients tend to match the poor levels of relief seen with nonsurgical treatments. The clinician's burden is to correctly identify the patients who are most at risk.

Complete Recovery after Nerve Repair

The consensus of many experienced surgical clinicians who treat trigeminal nerve-injured patients is that recovery of 100% normal sensation, absence of all unpleasant paresthesias, and complete pain relief is "uncommon," "unlikely," and "rarely if ever" complete.[8,11,12,272] "Successful treatment of unpleasant paresthesias and dysesthesias after trigeminal nerve injuries, therefore, remains one of the most difficult (and unsolved) clinical management problems."[12]

References

1. Fielding AF, Raschiele DP, Frazier G: Lingual nerve paresthesia following third molar surgery: a retrospective clinical study, *Oral Surg Oral Med Oral Pathol Oral Radiol Endod* 84:345, 1997.
2. Robert RC, Bacchetti P, Pogrel MA: Frequency of trigeminal nerve injuries following third molar removal, *J Oral Maxillofac Surg* 63:732–736, 2005.
3. Haug RH, Perrott DH, Gonzales ML, et al.: The American Association of Oral and Maxillofacial Surgeons age-related third molar study, *J Oral Maxillofac Surg* 63:1106–1114, 2005.
4. Alling CC: Dysesthesia of the lingual and inferior alveolar nerves following third molar surgery, *J Oral Maxillofac Surg* 44:454–457, 1986.
5. Valmaseda-Castellon E, Gay-Escoda C: Third molar injuries of the trigeminal nerve. In Miloro M, editor: *Trigeminal nerve injuries*, Berlin, 2013, Springer, pp 73–86.
6. Gregg JM, Zuniga JR: An outcome analysis of clinical trials of the surgical treatment of traumatic trigeminal sensory neuropathy, *Oral Maxillofac Surg Clin N Am* 13:377–392, 2001.
7. Rutner TW, Zaccardi VB, Janal MN: Long-term outcome assessment for lingual nerve microsurgery, *J Oral Maxillofac Surg* 63:1145–1149, 2005.
8. Bagheri SC, Meyer RA, Cho SH, et al.: Microsurgical repair of the inferior alveolar nerve: success rate and factors that adversely effect outcome, *J Oral Maxillofac Surg* 70:1978–1990, 2012.
9. Ziccardi VB, Steinberg MJ: Timing of trigeminal nerve microsurgery: a review of the literature, *J Oral Maxillofac Surg* 65:1341–1345, 2007.
10. Bagheri SC, Meyer RA, Kahn HA, et al.: Retrospective review of microsurgical repair of 222 lingual nerve injuries, *J Oral Maxillofac Surg* 68:715–723, 2010.
11. Zuniga JR, Yates DM, Phillips CL: The presence of neuropathic pain predicts postoperative neuropathic pain following nerve repair, *J Oral Maxillofac Surg* 72:2422–2427, 2014.
12. Robinson PP, Smith KG, Hillerup S: Outcomes of trigeminal nerve repair. In Miloro M, editor: *Trigeminal nerve injuries*, Berlin, 2013, Springer, pp 317–342.
13. Ziccardi VB, Shanti RM: Surgical management of lingual nerve injuries. In Miloro M, editor: *Trigeminal nerve injuries*, Berlin, 2013, Springer, pp 229–238.

14. Pogrel MA: Surgical management of inferior alveolar nerve injuries. In Miloro M, editor: *Trigeminal nerve injuries*, Berlin, 2013, Springer, pp 239–253.
15. Green J: Use of decellularized human nerve grafts for IAN and LN, *J Oral Maxillofac Surg* 67(Suppl 2):54–55, 2009.
16. Zuniga JR: Sensory outcomes after reconstruction of lingual and inferior alveolar nerve discontinuities using processed nerve allograft—a case series, *J Oral Maxillofac Surg* 73:734–744, 2015.
17. Bagheri SC, Meyer RA, Ali Khan H, et al.: Microsurgical repair of peripheral trigeminal nerve injuries from maxillofacial trauma, *J Oral Maxillofac Surg* 67:1791–1799, 2009.
18. Marchena JM, Padwa BL, Kaban LB: Sensory abnormalities associated with mandibular fractures: incidence and natural history, *J Oral Maxillofac Surg* 56:822–826, 1998.
19. Hillerup S: Iatrogenic injury to oral branches of the trigeminal nerve: records of 449 cases, *Clin Oral Invest* 11:133, 2007.
20. Jerjes W, Swinson B, Moles DR, et al.: Permanent sensory impairment following third molar surgery: a prospective study, *Oral Surg Oral Med Oral Pathol Oral Radiol Endod* 102(4):e1–e7, 2006.
21. Alhassani AA, Al-Ghamdi AS: Inferior alveolar nerve injury in implant dentistry: diagnosis, causes, prevention, and management, *J Oral Implantol* 36:401–407, 2010.
22. Hassani A, Saadat S: Nerve repositioning injuries of the trigeminal nerve. In Miloro M, editor: *Trigeminal nerve injuries*, Berlin, 2013, Springer, pp 109–135.
23. Pogrel MA: Permanent nerve damage from inferior alveolar nerve blocks: an update to include articaine, *J Calif Dent Assoc* 35:271–273, 2007.
24. Hillerup S, Jensen RH, Ersboll BK: Trigeminal nerve injury associated with injection of local anesthetics: needle lesion or neurotoxicity? *J Am Dent Assoc* 142:531–539, 2011.
25. Pogrel AM: Damage to the inferior alveolar nerve as a result of root canal therapy, *J Am Dent Assoc* 138:65–69, 2007.
26. Matthews J, Merrill RL: Sodium hypochlorite-related injury with chronic pain sequelae, *J Am Dent Assoc* 145:553–555, 2014.
27. Monnazzi MS, Real-Gabrielli MF, et al.: Cutaneous sensibility impairment after mandibular sagittal split osteotomy: a prospective clinical study of the spontaneous recovery, *J Oral Maxillofac Surg* 70:696–702, 2012.
28. Westermark A: Orthognathic injuries of the trigeminal nerve. In Miloro M, editor: *Trigeminal nerve injuries*, Berlin, 2013, Springer, pp 137–148.
29. Seddon HJ: Three types of nerve injury, *Brain* 66:237, 1943.
30. Sunderland S: A classification of peripheral nerve injuries producing loss of function, *Brain* 74:491, 1951.
31. Zuniga JR, Meyer RA, Gregg JM, et al.: The accuracy of clinical neurosensory testing for nerve injury diagnosis, *J Oral Maxillofac Surg* 56:2–8, 1998.
32. Jaaskelainen SK, Teerjoke-Oksa T, Forssell H: Neurophysiologic and quantitative sensory testing in the diagnosis of trigeminal neuropathy and neuropathic pain, *Pain* 117:349–357, 2005.
33. Mackinnon SE: New directions in peripheral nerve surgery, *Ann Plast Surg* 22(3):257, 1989.
34. Meyer RA, Bagheri SC: Etiology and prevention of nerve injuries. In Miloro M, editor: *Trigeminal nerve injuries*, Berlin, 2013, Springer, pp 27–62.
35. Gregg JM: Post-traumatic pain: experimental trigeminal neuropathy, *J Oral Surg* 29:260–267, 1972.
36. Eriksson L, Hillerup S, Reibel J, et al.: Traumatic changes of the inferior alveolar nerve and Gasserian ganglion after removal of a mandibular third molar: report of a case, *J Oral Maxillofac Surg* 64:1821–1823, 2006.
37. Dubner R, Ren K: Brainstem mechanisms of persistent pain following injury, *Orofac Pain* 18:299, 2004.
38. Sessle BJ, Yao D, Nishiura K, et al.: Properties and plasticity of the primate somatosensory and motor cortex related to orofacial sensorimotor function, *Clin Exp Pharmacol Physiol* 32:109, 2005.
39. Kim JW, Cha IH, Kim MR: Which risk factors are associated with neurosensory deficits of inferior alveolar nerve after mandibular third molar extraction? *J Oral Maxillofac Surg* 70:2508–2514, 2012.
40. Pogrel MA, Le H: Etiology of lingual nerve injuries in the third molar region: a cadaver and histologic study, *J Oral Maxillofac Surg* 64:1790–1794, 2006.
41. Gregg JM: Studies of traumatic neuralgias in the maxillofacial region: surgical pathology and neural mechanisms, *J Oral Maxillofac Surg* 48:228–237, 1990.
42. Rasmussen PV, Sindrup SH, Jensen TS, Bach FW: Symptoms and signs in patients with suspected neuropathic pain, *Pain* 110:461–469, 2004.
43. Benoliel R, Zadik Y, Eliav E, et al.: Peripheral painful traumatic trigeminal neuropathy: clinical features in 91 cases and proposal of novel diagnostic criteria, *J Orofac Pain* 26:49–58, 2012.
44. Fillingim RB, King CD, Ribeiro-Dasilva, et al.: Sex, gender, and pain: a review of recent clinical and experimental findings, *J Pain* 10:447–485, 2009.
45. Bruce RA, Frederickson GC, Small GS: Age of patients and morbidity associated with mandibular third molar surgery, *J Am Dent Assoc* 101:240, 1980.
46. Valmaseda-Castellon E, Berini-Aytes L, Gay-Escoda C: Lingual nerve damage after third molar surgical extraction, *Oral Surg Oral Med Oral Pathol Oral Radiol Endod* 90:567, 2000.
47. Mailis A, Wade J: Profile of Caucasian women with possible genetic predisposition to reflex sympathetic dystrophy: a pilot, *Clin J Pain* 10:210, 1994.
48. Devor M, del Canho S, Raber P: Heritability of symptoms in the neuroma model of neuropathic pain: replication and complementation analysis, *Pain* 116:294–301, 2005.
49. Nurmikko TJ, Rasanan A, Hakkinen V: Clinical and neurophysiological observations on acute herpes zoster, *Clin J Pain* 6:284, 1990.
50. Jensen TS, Baron R: Translation of symptoms and signs into mechanisms in neuropathic pain, *Pain* 102:1, 2003.
51. Diatchenko L, Nackley AG, Slade GD, et al.: Idiopathic pain disorders—pathways of vulnerability, *Pain* 123:226–230, 2006.
52. Melzack R, Terrance C, Fromm G, et al.: Trigeminal neuralgia and atypical facial pain: use of the McGill Pain Questionnaire for discrimination and diagnosis, *Pain* 27:297–302, 1986.
53. Bouhassira D, Attal N, Fermanian J, et al.: Development and validation of the Neuropathic Pain Symptom Inventory, *Pain* 108:248–257, 2004.
54. Phillips C, Essick G, Zuniga JR, et al.: Qualitative descriptors used by patients following orthognathic surgery to portray altered sensation, *J Oral Maxillofac Surg* 64:1751–1766, 2006.
55. Gregg JM: Abnormal responses to trigeminal nerve injury, *Oral Maxillofac Surg Clin N Am* 4:339–351, 1992.
56. Zuniga JR, Essick GK: A contemporary approach to the clinical evaluation of trigeminal nerve injuries, *Oral Maxillofac Surg Clin N Am* 4:353–367, 1992.

57. Rolke R, Baron R, Maier C, et al.: Quantitative sensory testing in the German Research Network on Neuropathic Pain (DFSN): standardized protocol and reference values, *Pain* 123:231–243, 2006.
58. Meyer RA, Bagheri SC: Clinical evaluation of nerve injuries. In Miloro M, editor: *Trigeminal nerve injuries*, Berlin, 2013, Springer, pp 167–198.
59. Jaaskelainen SK, Teerijoki-Oksa T, Virtanen A, et al.: Sensory regeneration following intraoperatively verified trigeminal nerve injury, *Neurology* 62:1951, 2004.
60. Cruccu C, Leandri M, Iannetti GD, et al.: Small-fiber dysfunction in trigeminal neuralgia, *Neurology* 56:1722, 2001.
61. Vora AR, Loescher AR, Craig GT, et al.: A light microscopical study on the structure of traumatic neuromas of the human lingual nerve, *Oral Surg Oral Med Oral Pathol Oral Radiol Endod* 99:395, 2005.
62. Harden RN, Bruel S, Stanton-Hicks M, Wilson PR: Proposed new diagnostic criteria for complex regional pain syndrome, *Pain Med* 8:327–331, 2007.
63. Woolf CJ: Central sensitization: Implications for the diagnosis and treatment of pain, *Pain* 152:S2, 2011.
64. Piao ZG: Activation of glia and microglial P38 in medullary dorsal horn contributes to tactile hypersensitivity following trigeminal sensory nerve injury, *Pain* 121:219–231, 2006.
65. Haroutounian S, Nikolajsen L, Bendtsen TF, et al.: Primary afferent input critical for maintaining spontaneous pain in peripheral neuropathy, *Pain* 155:1272–1279, 2014.
66. Sessle BJ: Glia: non-neural players in orofacial pain, *J Orofac Pain* 21:169–170, 2007.
67. Birch R, Bonney G, Wynn Perry CB: *Surgical disorders of the peripheral nerves*, Edinburgh, 1998, Churchill-Livingstone, pp 235–236.
68. Robinson PP: Characteristics of patients referred to a UK trigeminal nerve injury service, *J Oral Surg* 4:8–14, 2011.
69. Renton T, Yilmaz Z: Profiling of patients presenting with post-traumatic neuropathy of the trigeminal nerve, *J Orofac Pain* 25:333–344, 2011.
70. Davis KD, Taylor KS, Anastakis DJ: Nerve injury triggers changes in the brain, *Neuroscientist* 17:407–422, 2011.
71. Woolf CJ, Salter MW: Neuronal plasticity: increasing the gain in pain, *Science* 288:1765–1768, 2000.
72. Friedman AH: Treatment of deafferentation pains following peripheral nerve injury, *Adv Pain Res Therap* 19:321–330, 1991.
73. Djouhri L, Koutsikou S, Fang X, et al.: Spontaneous pain, both neuropathic and inflammatory, is related to frequency of spontaneous firing in intact C-fiber nociceptors, *J Neurosci* 26:1281–1292, 2006.
74. Benoliel R, Zadik Y, Eliav E, Sharav Y: Peripheral painful traumatic trigeminal neuropathy: clinical features in 91 cases and proposal of novel diagnostic criteria, *J Orofac Pain* 26:49–58, 2012.
75. Xu M, Kim CJ, et al.: NMDA receptor-mediated activation of medullary pro-nociceptive neurons is required for secondary thermal hyperalgesia, *Pain* 127:253–262, 2007.
76. Essick GK, Patel S, Trulsson M: Mechanosensory and thermosensory changes across the border of impaired sensitivity to pinprick after mandibular nerve injury, *J Oral Maxillofac Surg* 60:1250–1266, 2012.
77. Cheng CF, Cheng JK, Chen CY, et al.: Mirror-image pain is mediated by nerve growth factor produced from tumor necrosis factor a-activated satellite glia after peripheral nerve injury, *Pain* 155:906–920, 2014.
78. Melis M, Zawawi K, Lobo SL, et al.: Complex regional pain syndrome in the head and neck: a review of the literature, *J Orofac Pain* 16:93–104, 2002.
79. Heir GM, Nasr-Heir C, Thomas D, et al.: Complex regional pain syndrome following trigeminal nerve injury: report of 2 cases, *Oral Surg Oral Med Oral Pathol Oral Radiol* 114:733–739, 2012.
80. Jorum E, Orstavik K, Schmidt R, et al.: Catecholamine-induced excitation of nociceptors in sympathetically maintained pain, *Pain* 127:296–301, 2007.
81. Caty G, Hu L, Alegrain V, et al.: Psychophysical and electrophysical evidence for nociceptive dysfunction in complex regional pain syndrome, *Pain* 154:2521–2528, 2013.
82. Drummond PD, Finch PM: Sensory changes in the forehead of patients with complex regional pain syndrome, *Pain* 123:83–89, 2006.
83. Sakamoto E, Shiiba S, Noma N, et al.: A possible case of complex regional pain syndrome in the orofacial region, *Pain Med* 11:274–280, 2010.
84. Schwartzman R, Alexander GM, Grothusen JR, et al.: Outpatient intravenous ketamine for the treatment of complex regional pain syndrome: a double-blind placebo controlled study, *Pain* 147:107–115, 2009.
85. Watson CPN, Mackinnon SE, Dostrovsky JO, et al.: Nerve resection, crush and relocation relieve complex regional pain syndrome type II: a case report, *Pain* 155:1168–1173, 2014.
86. Katz J, Seltzer Z: Transition from acute to chronic post-surgical pain: risk factors and protective factors, *Expert Rev Neurother* 9:723–744, 2009.
87. Gilron I: Gabapentin and pregabalin for chronic neuropathic and early postsurgical pain: current evidence and future directions, *Curr Opin Anaesthesiol* 20:456–472, 2007.
88. Lavandihomme PM, Weiya M, DeKock M, Eisenach JC: Perineural alpha 2A-adrenoreceptor activation inhibits spinal cord neuroplasticity and tactile allodynia after nerve injury, *Anesthesiology* 97:972–980, 2002.
89. McCartney CJ, Sinha A, Katz J: A qualitative systemic review of the role of *N*-methyl-d-aspartate receptor antagonists in preventive analgesia, *Anesth Analg* 98:1385–1400, 2004.
90. Bouloux GF, Punnia-Moorthy A: Bupivacaine versus lidocaine for third molar surgery: a double-blind, randomized, crossover study, *J Oral Maxillofac Surg* 57:510–514, 1999.
91. Barron RP, Benoliel R, Zeltser R, et al.: Effect of dexamethasone and dypyrone on lingual and inferior alveolar hypersensitivity following third molar extractions: preliminary report, *J Orofac Pain* 18(1):62–68, 2004.
92. Romunstad L, et al.: Methylpredisonolone intravenously one day after surgery has sustained analgesic and opioid-sparing effects, *Acta Anaesthesiol Scand* 48:1223–1231, 2004.
93. Moore RA, Derry S, Straube S, et al.: Faster, higher, stronger? Evidence for formulation and efficacy for ibuprofen in acute pain, *Pain* 155:14–21, 2014.
94. Bartusch SL, Sanders BJ, D'Alessio JG, et al.: Clonazepam for the treatment of lancinating phantom pain, *Clin J Pain* 12:59, 1996.
95. Martin WJJM, Forouzanfar T: The efficacy of anticonvulsants on orofacial pain: a systematic review, *Oral Surg Oral Med Oral Pathol Oral Radiol Endod* 111:627–633, 2011.
96. Lin P, Fan S, et al.: Analgesic effect of lidocaine patch 5% in the treatment of acute herpes zoster: a double-blind and vehicle-controlled study, *Reg Anesth Pain Med* 33:320–325, 2008.

97. Gerrits MMJG van Oppen P, van Marwijk HWJ, et al.: Pain and the onset of depressive and anxiety disorders, *Pain* 155:53–59, 2014.
98. Mou J, Paillard F, Turnbull B, et al.: Efficacy of Qutenza (capsaicin) 8% patch for neuropathic pain: a meta-analysis of the Qutenza Clinical Trials Database, *Pain* 154:1632–1639, 2013.
99. Vadaurri V: Topical treatment of neuropathic pain, *Int J Pharm Compd* 12:183–190, 2008.
100. Heir G, Karolchek S, Kalladka M, et al.: Use of topical medication in orofacial neuropathic pain: a retrospective study, *Oral Surg Oral Med Oral Pathol Oral Radiol Endod* 105:466–469, 2008.
101. Finch PM, Knudsen L, Drummond PD: Reduction of allodynia with complex regional pain syndrome: a double-blind placebo-controlled trial with topical ketamine, *Pain* 146: 18–25, 2009.
102. Ho K-Y, Huh B, White W, et al.: Topical amitriptyline versus lidocaine in the treatment of neuropathic pain, *Clin J Pain* 24:51–55, 2008.
103. Dong X-D, Svensson P, Cairns BE: The analgesic action of topical diclofenac may be mediated through peripheral NMDA receptor antagonism, *Pain* 147:36–45, 2009.
104. Renton T: Nonsurgical management of trigeminal nerve injuries. In Miloro M, editor: *Trigeminal nerve injuries*, Berlin, 2013, Springer, pp 213–228.
105. Yates JM, Smith KG, Robinson PP: The effect of carbamazepine on injury-induced ectopic discharge in the lingual nerve, *Brain Res* 1051:1–7, 2005.
106. Gordh TE, Stubhaug A, Jensen TS, et al.: Gabapentin in traumatic nerve injury pain: a randomized, double blind, placebo-controlled, cross-over, multicenter study, *Pain* 138:255–266, 2008.
107. Taylor CP: Mechanisms of analgesia by gabapentin and pregabalin calcium channel Alpha 2-delta ligands, *Pain* 142:13–16, 2009.
108. Pereira A, Gitlin MJ, Gross RA, et al.: Suicidality associated with antiepileptic drugs: implications for the treatment of neuropathic pain and fibromyalgia, *Pain* 154:345–349, 2013.
109. Tesfaye S, Wilhelm S, Lledo A, et al.: Duloxetine and pregabalin: high-dose monotherapy or their combination? The "COMBO-DN study"—a multinational, randomized, double-blind, parallel-group study in patients with diabetic peripheral neuropathic pain, *Pain* 154:2616–2625, 2013.
110. Sharav Y, Singer E, Schmidt E, et al.: The analgesic effect of amitriptyline on chronic facial pain, *Pain* 31:199–209, 1987.
111. Alba-Delgado C, Mico JA, Sanchez-Blazquez P, Berrocoso E: Analgesic antidepressants promote the responsiveness of locus coeruleus neurons to noxious stimulation: implications for neuropathic pain, *Pain* 153:1438–1449, 2013.
112. Finnerup NB, Sindrup SH, Jensen TS: The evidence for pharmacological treatment of neuropathic pain, *Pain* 150:573–581, 2010.
113. Matsuura N, Shibuhhawa Y, et al.: Ketamine, not fentanyl, suppresses pain-related magnetic fields associated with trigeminally innervated area following CO_2 laser stimulation, *Neurosci Res* 62:105–111, 2008.
114. Machado-Viera R, Salvadore G, Diaz G, Zarate CA: Ketamine and the next generation of antidepressants with a rapid onset of action, *Pharmacol Ther* 123:143–150, 2009.
115. Sullivan MD, Howe CQ: Opioid therapy for chronic pain in the United States: Promises and perils, *Pain* 154:S94–S100, 2013.
116. Portenoy RK, Foley KM: Chronic use of opioid analgesics in non-malignant pain: report of 38 patients, *Pain* 25:171–186, 1986.
117. Sindrup S, Jensen T: Efficacy of pharmacological treatments of neuropathic pain: an update and effect related to mechanism of drug action, *Pain* 83:389–400, 1999.
118. Rowbotham MC, Twilling L, Davies PS, et al.: Oral opioid therapy for chronic peripheral and central neuropathic pain, *N Engl J Med* 348:1223–1232, 2003.
119. Papanastassio AM, Fields HL, Meng ID: Local application of the cannabinoid receptor agonist, WIN 55,212-2, to spinal trigeminal nucleus caudalis differentially affects nociceptor and non-nociceptive neurons, *Pain* 107:267–275, 2004.
120. Anand U, Otto WR, Sanchez-Herrara D, et al.: Cannabinoid receptor CB2 localisation and agonist-mediated inhibition of capsaicin responses in human sensory neurons, *Pain* 138:667–680, 2008.
121. Nurmikko TJ, Serpell MG, Hoggart B, et al.: Sativex successfully treats neuropathic pain characterized by allodynia: a randomized, double-blind, placebo-controlled clinical trial, *Pain* 133:210–220, 2007.
122. Azim S, Nicholson J, Rebecchi MJ, et al.: Endocannabinoids and acute pain after total knee arthroplasty, *Pain* 156:341–347, 2015.
123. Maione S, Costa B, Di Marzo V: Endocannabinoids: a unique opportunity to develop multitarget analgesics, *Pain* 154:S87–S93, 2013.
124. Johansson A, Sjolund B: Nerve blocks with local anesthetics and corticosteroids chronic pain: a clinical follow-up study, *J Pain Sympt Manag* 11:181–187, 1996.
125. Bonica JJ: *The management of pain. With special emphasis on the use of analgesic block in diagnosis, prognosis and therapy*, Philadelphia, 1953, Lea & Febiger.
126. Yoon SH, Merrill RL, et al.: Use of botulinum toxin type A after trigeminal nerve injury, *Pain Med* 4:107, 2010.
127. Ngeow WC, Nair R: Injection of botulinum toxin type A (BOTOX) into trigger zone of trigeminal neuralgia as a means to control pain, *Oral Surg Oral Med Oral Pathol Oral Radiol Endod* 109:47–50, 2010.
128. Mustafa G, Anderson EM, Bokrand-Donatelli Y, et al.: Antinociceptive effect of a conjugate of substance P and light chain of botulinum toxin type A, *Pain* 154:2547–2553, 2013.
129. Marino MJ, Tereshima T, Steinauer JJ, et al.: Botulinum toxin B in the sensory afferent: transmitter release, spinal activation and pain behavior, *Pain* 155:674–684, 2014.
130. Magid OW: Clinical use of botulinum toxins in oral and maxillofacial surgery, *Int J Oral Maxillofac Surg* 39:197–207, 2010.
131. Flor H: Cortical reorganization and chronic pain: implications for rehabilitation, *J Rehabil Med* 4:66–72, 2003.
132. Dellon AL: *Evaluation of sensibility and re-education of sensation in the hand*, Baltimore, 1988, John J Lucas.
133. Meyer RA, Rath EM: Sensory rehabilitation after trigeminal nerve injury or nerve repair, *Oral Maxillofac Surg Clin N Am* 13:365–376, 2001.
134. Simons LE, Elman I, Borsook D: Psychological processing in chronic pain: a neural systems approach, *Neurosci Biobehav Rev* 39:61–78, 2014.
135. Morley S, Williams A, Hussain S: Estimating the clinical effectiveness of cognitive behavioral therapy in the clinic: evaluation of a CBT informed pain management programme, *Pain* 137:670–680, 2008.

136. Salomons TV, Moayedi M, Erpelding N, Davis KD: A brief cognitive-behavioral intervention for pain reduces secondary hyperalgesia, *Pain* 155:1446–1452, 2014.
137. Bagheri SC, Meyer RA, Etezadi H, et al.: A retrospective review of microsurgical repair of long buccal nerve injuries, *J Oral Maxillofac Surg* 68:85–86, 2010.
138. Meyer RA: Applications of microneurosurgery to the repair of trigeminal nerve injuries, *Oral Maxillofac Surg Clin N Am* 4:405–416, 1992.
139. Robinson PP, Smith KG: A study on the efficacy of late lingual nerve repair, *Br J Oral Maxillofac Surg* 34:96–103, 1996.
140. Fagin AP, Susarla SM, Donoff RB, et al.: What factors are associated with functional recovery following lingual nerve repair? *J Oral Maxillofac Surg* 70:2907–2915, 2012.
141. Gregg JM: Surgical management of inferior alveolar nerve injuries (Part II): the case for delayed management, *J Oral Maxillofac Surg* 53:1330–1333, 1995.
142. Merrill RG: Further studies in decompression for inferior alveolar injury, *J Oral Surg* 24:233–238, 1966.
143. Greenwood M, Corbett IP: Observations on the exploration and external neurolysis of injured inferior alveolar nerves, *Int J Oral Maxillofac Surg* 34:252, 2005.
144. Robinson PP, Yates JM, Smith KG: A prospective, quantitative study on the clinical outcome of inferior alveolar nerve decompression and neurolysis, *Oral Surg* 1:35–44, 2008.
145. Gregg JM: Studies of traumatic neuralgia in the maxillofacial region: symptom complexes and response to microsurgery, *J Oral Maxillofac Surg* 48:135–140, 1990.
146. Terzis J, Faibisoff B, Williamson HB: The nerve gap: suture under tension vs. graft, *Plast Reconstr Surg* 56:166, 1975.
147. Epker BN, Gregg JM: Surgical management of maxillary nerve injuries, *Oral Maxillofac Surg Clin N Am* 4(2):439–449, 1992.
148. Eppley BL, Snyders RV: Microanatomic analysis of the trigeminal nerve and potential nerve graft donor sites, *J Oral Maxillofac Surg* 49:612–618, 1991.
149. Wolford LM, Rodrigues DB: Nerve grafts and conduits. In Miloro M, editor: *Trigeminal nerve injuries*, Berlin, 2013, Springer, pp 271–290.
150. Miloro M, Stoner JA: Subjective outcomes following sural nerve harvest, *J Oral Maxillofac Surg* 63:1150–1154, 2005.
151. Pogrel MA, Renaut A, Schmidt B, Ammar A: The relationship of the lingual nerve to the mandibular third molar region: an anatomic study, *J Oral Maxillofac Surg* 53:1178–1181, 1995.
152. Siemionow M, Sonmez E: Nerve allograft transplantation: a review, *J Reconstr Microsurg* 8:511–520, 2007.
153. Brooks DN, Weber RV, Chao JD, et al.: Processed nerve allografts for peripheral nerve reconstruction: a multicenter study of utilization and outcomes in sensory, mixed and motor reconstructions, *Microsurgery* 32:1, 2012.
154. Shanti RM, Ziccardi VB: Use of decellularized nerve allograft for inferior alveolar nerve reconstruction: a case report, *J Oral Maxillofac Surg* 69:550–553, 2011.
155. Miloro M, Ruckman P, Kolokythas A: Lingual nerve repair: To graft or not to graft? *J Oral Maxillofac Surg* 73:1844–1850, 2015.
156. Neubauer D, Graham JB, Muir D: Chondroitinase treatment increases the effective length of acellular nerve grafts, *Exp Neurol* 207:163–170, 2007.
157. Farole A, Jamal BT: A bioabsorbable collagen nerve cuff (Neuragen) for repair of lingual and inferior alveolar nerve injuries, *J Oral Maxillofac Surg* 66:2058–2062, 2008.
158. Erakat MS, Chuang SK, Shanti RM, Ziccardi VB: Interval between injury and lingual nerve repair as a prognostic factor for success using Type I collagen conduit, *J Oral Maxillofac Surg* 71:833–838, 2013.
159. Inada Y, Morimoto S, Moroi K, et al.: Surgical relief of causalgia with an artificial nerve guide tube: successful surgical treatment of causalgia (CRPS, II) by in situ tissue engineering with a polyglycolic acid-collagen tube, *Pain* 117:251–258, 2005.
160. Shanti RM, Khan J, Eliav E, Ziccardi VB: Is there a role for a collagen conduit and anti-inflammatory agent in the management of partial nerve injuries? *J Oral Maxillofac Surg* 71:1119–1125, 2013.
161. Fugita S, Tojyo I, Yamada M, et al.: Outcome following lingual nerve repair with vein graft cuff: a preliminary report, *J Oral Maxillofac Surg* 72:1433.e7, 2014.
162. Wang J, Goodger NM, Pogrel MA: A method of invaginating the facial vein for inferior alveolar nerve repair, *J Oral Maxillofac Surg* 61:848–849, 2003.
163. Pogrel MA, Maghen A: The use of autogenous vein grafts for inferior alveolar and lingual nerve reconstruction, *J Oral Maxillofac Surg* 59:985–993, 2001.
164. Pogrel MA, McDonald AR, Kaban LB: Gore-Tex tubing as a conduit for repair of lingual and inferior alveolar nerve continuity defects, *J Oral Maxillofac Surg* 56:319–321, 1998.
165. Pitta MC, Wolford LM, Mehra P, Hopkin J: Use of Gore-Tex tubing as a conduit for inferior alveolar and lingual nerve repair: experience with 6 cases, *J Oral Maxillofac Surg* 59:493–496, 2001.
166. Crawley WA, Dellon AL: Inferior alveolar nerve reconstruction with a bioabsorbable nerve conduit, *Plast Reconstr Surg* 90:300, 1992.
167. Nakamura T: Clinical application of nerve conduits consisting of a polyglycolic acid (PGA)-collagen composite tube filled with collagen sponge, *Connect Tissue* 35:53, 2003.
168. Walsh S, Biernaskie J, Kemp SWP, et al.: Supplementation of acellular nerve grafts with skin derived precursor cells promotes peripheral nerve regeneration, *Neuroscience* 164:1097–1107, 2009.
169. Wang X, Luo E, Li Y, Hu J: Schwann-like mesenchymal stem cells within vein graft facilitate facial nerve regeneration and remyelination, *Brain Res* 1383:71–80, 2011.
170. Liu G, Cheng Y, Feng Y, et al.: Adipose-derived stem cells promote peripheral nerve repair, *Arch Med Sci* 4:592–596, 2011.
171. Silvia Franchi, Valsecchi AE, Borsani E, et al.: Intravenous neural stem cells abolish nociceptive hypersensitivity and trigger nerve regeneration in experimental neuropathy, *Pain* 153:850–861, 2012.
172. Mackinnon SE, Dellon AL: Internal neurolysis. In Mackinnon SE, Dellon AL, editors: *Surgery of the peripheral nerve*, New York, 1988, Thieme, pp 131–148.
173. Ziccardi VB: Microsurgical techniques for repair of the inferior alveolar and lingual nerves, *Atlas Oral Maxillofac Surg Clin N Am* 19:79, 2011.
174. Gregg JM: Historical perspectives on trigeminal nerve injuries. In Miloro M, editor: *Trigeminal nerve injuries*, Berlin, 2013, Springer, pp 1–6.
175. Noordenbos W, Wall PD: Implications of the failure of nerve resection or graft to cure chronic pain produced by nerve lesions, *J Neurol Neurosurg Psychiatry* 44:1068–1073, 1981.
176. Juretic CR, Gobic MB: Neurectomy of the trigeminal nerve branches: clinical evaluation of an "obsolete" treatment, *J Cranioamaxillofac Surg* 37:388–391, 2009.

177. Devor M, Tal M: Nerve resection for the treatment of chronic neuropathic pain, *Pain* 155:1052–1054, 2014.
178. Dellon AL, Mackinnon SE, Pestronk A: Implantation of sensory nerve into muscle: preliminary clinical and experimental observations on neuroma formation, *Ann Plast Surg* 12:30–39, 1984.
179. Watson CPN, Stinson JN, Dostrovsky JO, et al.: Nerve resection and relocation may relieve causalgia: a case report, *Pain* 132:211–217, 2007.
180. Watson CPN, Mackinnon SE, Dostrovsky JO, et al.: Nerve resection, crush and relocation relieve complex regional pain syndrome type II: a case report, *Pain* 155:1168–1173, 2014.
181. Barden J, Edwards JE, McQuay HJ, Moore RA: Pain and analgesic response after third molar extraction and other postsurgical pain, *Pain* 107:86–90, 2004.
182. Kehlet H, Jensen T, Woolf C: Persistent postsurgical pain: risk factors and prevention, *Lancet* 367:1618–1643, 2006.
183. Macrae WA: Chronic post-surgical pain: 10 years on, *Br J Anaesth* 101:77–86, 2008.
184. Shipton EA: The transition from acute to chronic post surgical pain, *Anaesth Intensive Care* 39:824–836, 2011.
185. Juhl GI, Jensen TS, Norholt SE, et al.: Central sensitization after third molar surgery: a quantitative sensory testing study, *Eur J Pain* 12:116–127, 2008.
186. Slade GD, Smith SB, Zaykin DV, et al.: Facial pain with localized and widespread manifestations: separate pathways of vulnerability, *Pain* 154:2335–2343, 2013.
187. Von Hehn CA, Baron R, Woolf CJ: Deconstructing the neuropathic pain phenotype to reveal neural mechanisms, *Neuron* 73:638–652, 2012.
188. Davis KD, Taylor KS, Anastakis DJ: Nerve injury triggers changes in the brain, *Neuroscientist* 17:407–422, 2011.
189. Youssef AM, Gustin SM, Nash PG, et al.: Differential brain activity in subjects with trigeminal neuropathy and painful temporomandibular disorder, *Pain* 155:467–475, 2014.
190. Bagheri SC, Dierks EJ, Kademani D, et al.: Application of a facial injury severity scale in craniomaxillofacial trauma, *J Oral Maxillofac Surg* 64:408–414, 2006.
191. Schultze-Mosgau S, Erbe M, Rudolph D, et al.: Prospective study on post-traumatic sensory disturbances of the inferior alveolar and infraorbital nerve in mandibular and midfacial fractures, *J Craniomaxillofac Surg* 27:86, 1999.
192. Haug RH, Dodson TB, Morgan JP: Trauma surgery. In Haug RH, editor: *Parameters and pathways: clinical practice guidelines for oral and maxillofacial surgery*, Chicago, 2001, AAOMS (AAOMS ParPath 01), version 3.0.
193. Bell RB: The role of oral and maxillofacial surgery in the trauma care center, *J Oral Maxillofac Surg* 65:2544–2553, 2007.
194. Bagheri SC, Dimassi M, Shahriari A, et al.: Facial trauma coverage among level-1 trauma centers of the United States, *J Oral Maxillofac Surg* 66:963–967, 2008.
195. Fogaca WC, Fereirra MC, Dellon AL: Infraorbital nerve injury associated with zygoma fractures: documentation with neurosensory testing, *Plast Reconstr Surg* 113:834, 2004.
196. Taicher S, Ardkian L, Samet N, et al.: Recovery of the infraorbital nerve after zygomatic complex fractures: a preliminary study of different treatment methods, *Int J Oral Maxillofac Surg* 22:339, 1993.
197. Ibizuka T, Lindquist C: Rigid internal fixation of fractures of the angular region of the mandible: an analysis of features contributing to different complications, *Plast Reconstr Surg* 91:265–271, 1993.
198. Halpern LR, Kaban LB, Dodson TB: Perioperative neurosensory changes associated with treatment of mandibular fractures, *J Oral Maxillofac Surg* 62:576–581, 2004.
199. Thurmuller P, Dodson TB, Kaban LB: Nerve injuries associated with facial trauma. Natural history, management and outcomes of repair, *Oral Maxillofac Surg Clin N Am* 13:283–293, 2001.
200. Harn SD, Durham TM: Incidence of lingual nerve trauma and postinjection complications in conventional mandibular block anesthesia, *J Am Dent Assoc* 121:519–523, 1990.
201. Hillerup S: Injection injuries of the trigeminal nerve. In Miloro M, editor: *Trigeminal nerve injuries*, Berlin, 2013, Springer, pp 63–72.
202. Pogrel MA, Thamby S: Permanent nerve involvement resulting from inferior alveolar nerve blocks, *J Am Dent Assoc* 131:901–907, 2000.
203. Pogrel MA, Schmidt BL: Trigeminal nerve chemical neurotrauma from injectable materials, *Oral Maxillofac Surg Clin N Am* 13:247–253, 2001.
204. Gregg JM, Giglio JA. (Unpublished, 2015.)
205. Kini YK, Kharkar VR, Kini A: Transient diplopia with ipsilateral abducent nerve palsy and ptosis following a maxillary local anesthetic injection, *Oral Maxillofac Surg* 16:373–375, 2012.
206. Rayan GM, Pitha JV, Wisdom P, et al.: Histologic and electrophysiologic changes following subepineural hematoma induction in rat sciatic nerve, *Clin Orthop Relat Res* 229:257–264, 1988.
207. Webber B, Orlansky H, Lipton C, Stevens M: Complications of an intra-arterial injection from an inferior alveolar nerve block, *J Am Dent Assoc* 132:1702–1704, 2001.
208. Stacy GC, Hajjar G: Barbed needle and explicable paresthesias and trismus after dental regional anaesthesia, *Oral Surg Oral Med Oral Pathol* 77:585–588, 1994.
209. Pogrel MA, Bryan J, Regezi J: Nerve damage associated with inferior alveolar nerve blocks, *J Am Dent Assoc* 126:1150–1155, 1995.
210. Hillerup S, Jensen RH, Ersboll BK: Trigeminal nerve injury associated with injection of local anesthetics: needle lesion or neurotoxicity? *J Am Dent Assoc* 142:531–539, 2011.
211. Johnson ME, Saenz JA, DeSilva AD, et al.: Effect of local anesthetic on neuronal cytoplasmic calcium and plasma membrane lysis (necrosis) in a cell culture model, *Anesthesiology* 97:1466–1476, 2002.
212. Hillerup S, Baake M, Larson JO, et al.: Concentration-dependent neurotoxicity of articaine: an electrophysiological ad stereological study of rat sciatic nerve, *Anesth Analg* 112:1330–1338, 2011.
213. Haas DA, Lennon D: A 21-year retrospective study of reports of paresthesia following local anesthetic administration, *J Can Dent Assoc* 61:319–330, 1995.
214. Smith MH, Lung KE: Nerve injuries after dental injection: a review of the literature, *J Can Dent Assoc* 72:559, 2006.
215. Garisto GA, Gaffen AS, et al.: Occurrence of paresthesia after dental local anesthetic administration in the United States, *J Am Dent Assoc* 141:836–844, 2010.
216. Moore PA, Haas DA: Paresthesias in dentistry, *Dent Clin N Am* 54:715–730, 2010.
217. Silva LC, Santos TD, Santos JA, et al.: Articaine versus lidocaine for third molar surgery: a randomized clinical study, *Med Oral Patol Oral Cir Bucal* 17(1):140–145, 2012.
218. Renton T, Yilmaz J: Managing iatrogenic trigeminal nerve injury: a case series and review of the literature, *Int J Oral Maxillofac Surg* 41:629–637, 2012.

219. Conrad SM: Neurosensory disturbances as a result of chemical injury to the inferior alveolar nerve, *Oral Maxillofac Surg Clin N Am* 13:255–263, 2001.
220. Pogrel AM: Damage to the inferior alveolar nerve as a result of root canal therapy, *J Am Dent Assoc* 138:65–69, 2007.
221. Moore JW, Brekke JH: Foreign body giant cell reaction related to placement of tetracycline-treated polylactic acid: report of 18 cases, *J Oral Maxillofac Surg* 48:808–812, 1990.
222. Alkan A, Inal S, Yildirim M, et al.: The effects of hemostatic agents on peripheral nerve function: an experimental study, *J Oral Maxillofac Surg* 65:630–634, 2007.
223. Olson RAJ, Roberts DL, Osbon DB: A comparative study of polylactic acid, Gelfoam, and Surgical in healing extraction sits, *Oral Surg Oral Med Oral Pathol* 53:441, 1992.
224. Schmidt BL, Pogrel MA: Neurosensory changes after liquid nitrogen cryotherapy, *J Oral Maxillofac Surg* 62:1183–1187, 2004.
225. Morse DR: Endodontic-related inferior alveolar nerve and mental foramen paresthesia, *Compendium* 18:963–983, 1997.
226. Poveda R, Bagan JV, Fernandez JM, Sanchis JM: Mental nerve paresthesia associated with endodontic paste within the mandibular canal, *Oral Surg Oral Med Oral Pathol Oral Radiol Endod* 102(5):246–249, 2006.
227. Mehdipour O, Kleier DJ, Averbach RE: Anatomy of sodium hypochlorite accidents, *Compend Contin Educ Dent* 28(10):544–546, 2007.
228. Matthews J, Merrill RL: Sodium hypochlorite-related injury with chronic pain sequelae, *J Am Dent Assoc* 145(6):553–555, 2014.
229. Scolozzi P, Lombardi T, Jaques B: Successful inferior alveolar nerve decompression for dysesthesia following endodontic treatment: report of 4 cases treated by mandibular sagittal osteotomy, *Oral Surg Oral Med Pathol Oral Radiol Endod* 97:625–631, 2004.
230. Westermark A, Bystedt H, von Konow L: Inferior alveolar nerve function after sagittal split osteotomy of the mandible: correlation with degree of intraoperative nerve encounter and other variables in 496 operations, *Br J Oral Maxillofac Surg* 36:433–492, 1998.
231. Panula K, Finne K, Oikarinen K: Incidence of complications and problems related to orthognathic surgery: a review of 655 patients, *J Oral Maxillofac Surg* 59:1128–1137, 2001.
232. Marchiori EC, Barber JS, Williams WB, et al.: Neuropathic pain following sagittal split osteotomy of the mandible: prevalence, risk factors and clinical course, *J Oral Maxillofac Surg* 71:2115–2122, 2013.
233. Zuniga J: Lingual nerve injury as a complication of sagittal split osteotomy, *J Oral Maxillofac Surg* 48:647–648, 1990.
234. Cunningham LL, Tiner BD, Clark GM, et al.: A comparison of questionnaire versus monofilament assessment of neurosensory deficit, *J Oral Maxillofac Surg* 54:454–459, 1996.
235. Al-Bishri A, Rosenquist J, Sunzel B: On neurosensory disturbance after sagittal split osteotomy, *J Oral Maxillofac Surg* 62:1472–1476, 2004.
236. Phillips C, Essick G, Preisser JS, et al.: Sensory retraining after orthognathic surgery: effect on patients' perception of altered sensation, *J Oral Maxillofac Surg* 65:1162–1173, 2007.
237. Posnick JC, Al Qattan MM, Pron G: Facial sensitivity in adolescents with and without clefts 1 year after undergoing Le Fort I osteotomy, *Plast Reconstr Surg* 94:431–435, 1994.
238. Marchiori EC, Barber JS, Williams WB, et al.: Neuropathic pain following sagittal split osteotomy of the mandible: prevalence, risk factors and clinical course, *J Oral Maxillofac Surg* 71:2115–2122, 2013.
239. Baas EM, Horthius RBG, de Lange J: Subjective alveolar nerve function after bilateral sagittal split osteotomy or distraction osteogenesis of the mandible, *J Oral Maxillofac Surg* 70:910–918, 2012.
240. Yamamoto R, Nakamura A, Ohno K, Michi KI: Relationship of the mandibular canal to the lateral cortex of the mandibular ramus as a factor in the development of neurosensory disturbance after bilateral sagittal split osteotomy, *J Oral Maxillofac Surg* 60:490–495, 2002.
241. Levine MH, Goddard AL, Dodson TB: Inferior alveolar nerve canal position: a clinical and radiographic study, *J Oral Maxillofac Surg* 65:470–474, 2007.
242. Kallela I, Laine P, Suuronen R, et al.: Assessment of material and technique-related complications following sagittal split osteotomies stabilized by biodegradeable polylactic screws, *Oral Surg Oral Med Oral Pathol Oral Radiol Endod* 99:4–10, 2005.
243. Bagheri SC, Meyer RA, Kahn HA, et al.: Microsurgical repair of peripheral trigeminal after mandibular sagittal split ramus osteotomy, *J Oral Maxillofac Surg* 68:2770–2782, 2010.
244. Theisen FC, Shultz RE, Elledge DA: Displacement of a root form implant into the mandibular canal, *Oral Surg Oral Med Oral Pathol* 70:24–28, 1990.
245. Juodzbalys G, Wang HL, Sabalys G: Injury of the inferior alveolar nerve during implant placement: a literature review, *J Oral Maxillofac Res* 2:e1, 2011.
246. Bartling R, Freeman K, Kraut RA: The incidence of altered sensation of the mental nerve after mandibular implant placement, *J Oral Maxillofac Surg* 57:1408–1412, 1999.
247. Haers PE, Sailer HF: Neurosensory function after lateralization of the inferior alveolar nerve and simultaneous insertion of implants, *Oral Maxillofac Surg Clin N Am* 7:707, 1994.
248. Bagheri SC, Meyer RA: Dental implant-related injuries of the trigeminal nerve. In Miloro M, editor: *Trigeminal nerve injuries*, Berlin, 2013, Springer, pp 87–108.
249. Gaggl A, Schultes G, Karcher H: Navigational precision of drilling tools preventing damage to the mandibular canal, *J Craniomaxillofac Surg* 29:271–275, 2001.
250. Hegedus F, Diecidue RJ: Trigeminal nerve injuries after mandibular implant placement: practical knowledge for clinicians, *Int J Oral Maxillofac Implants* 21:111–116, 2006.
251. Tehemar SH: Factors affecting heat generation during implant site preparation: a review of biologic observations and future considerations, *Int J Oral Maxillofac Implants* 14:127–136, 1999.
252. Kipp DP, Goldstein BH, Weiss Jr WW: Dysesthesia after mandibular third molar surgery. A retrospective study and analysis of 1,377 surgical procedures, *J Am Dent Assoc* 100:185, 1980.
253. Nguyen E, Grubor D, Chandu A: Risk factors for permanent injury of inferior alveolar and lingual nerves during third molar surgery, *J Oral Maxillofac Surg* 72:2394–2401, 2014.
254. Valmaseda-Castellon E, Berini-Aytes L, Gay-Escoda C: Inferior alveolar nerve damage after lower third molar surgical extraction: a prospective study of 1117 surgical extractions, *Oral Surg Oral Med Oral Pathol Oral Radiol Endod* 92:377, 2001.
255. Renton T, McGurk M: Evaluation of factors predictive of lingual nerve injury in third molar surgery, *Br J Oral Maxillofac Surg* 39:423, 2001.
256. Sedaghatfar M, August MA, Dodson TB: Panoramic radiographic findings as predictors of inferior alveolar nerve exposure following third molar extraction, *J Oral Maxillofac Surg* 63:3–7, 2005.

257. Pawelzik J, Cohnen MD, Willers R, Becker J: A comparison of conventional computed tomography images in the preoperative assessment of impacted mandibular third molars, *J Oral Maxillofac Surg* 60:979–984, 2002.
258. Kiesselback JE, Chamberlain JG: Clinical and anatomic observations on the relationship of the lingual nerve to the mandibular third molar region, *J Oral Maxillofac Surg* 42:565–567, 1984.
259. Pogrel MA, Renault A, Schmidt B, et al.: The relationship of the lingual nerve in the third molar region. An anatomic study, *J Oral Maxillofac Surg* 53:1178–1181, 1995.
260. Miloro M, Halkias LE, Slone HW, et al.: Assessment of the lingual nerve in the third molar region using magnetic resonance imaging, *J Oral Maxillofac Surg* 55:134–137, 1997.
261. Behnia H, Kheradvar A, Shahrokhi M: An anatomic study of the lingual nerve in the third molar region, *J Oral Maxillofac Surg* 58:649–651, 2000.
262. Tay ABG, Go WS: Effect of exposed inferior alveolar neurovascular bundle during surgical removal of impacted lower third molars, *J Oral Maxillofac Surg* 62:592–600, 2004.
263. Robinson PP, Smith KG: Lingual nerve damage during removal of lower third molar: a comparison of two surgical methods, *Br Dent J* 180:456–461, 1996.
264. Pogrel MA, Goldman KE: Lingual flap retraction for third molar removal, *J Oral Maxillofac Surg* 62:1125–1130, 2004.
265. Pichler JW, Beirne OR: Lingual flap retraction and prevention of lingual nerve damage associated with third molar surgery: a systematic review of the literature, *Oral Surg Oral Med Oral Pathol Oral Radiol Endod* 91:395–401, 2001.
266. Pogrel MA, Lee JS, Muff DF: Coronectomy: a technique to protect the inferior alveolar nerve, *J Oral Maxillofac Surg* 62:1447–1452, 2004.
267. Renton T, Hankins M, Sproate C, McGurk M: A randomized controlled clinical trial to compare the incidence of injury to the inferior alveolar nerve as a result of coronectomy and removal of mandibular third molars, *Br J Oral Maxillofac Surg* 43:7–12, 2005.
268. Cilasun U, Yildirim T, Guzeldemir E, Pektas ZO: Coronectomy in patients with high risk of inferior alveolar nerve injury diagnosed by computed tomography, *J Oral Maxillofac Surg* 69:1557–1561, 2011.
269. Frenkel B, Givol N, Shoshani Y: Coronectomy of the mandibular third molar: a retrospective study of 185 procedures and the decision to repeat the coronectomy in cases of failure, *J Oral Maxillofac Surg* 73:587–594, 2015.
270. Assael LA: Coronectomy: a time to ponder or a time to act? *J Oral Maxillofac Surg* 62:1445–1446, 2004.
271. Leung YY, Cheung LK: Safety of coronectomy versus excision of wisdom teeth: a randomized controlled trial, *Oral Surg Oral Med Oral Pathol Oral Radiol Endod* 108:821–827, 2009.
272. Miloro M, Schlieve T, Kolokythas A: Complications of trigeminal nerve repair. In Miloro M, editor: *Trigeminal nerve injuries*, Berlin, 2013, Springer, pp 291–300.

26

Esthetic Implant Dentistry: Diagnosis and Treatment Planning

SAJ JIVRAJ, MAMALY RESHAD

Introduction

Achieving esthetics with implant restorations is significantly more challenging than with conventional restorations. Diagnosis and appropriate treatment planning are critical in obtaining a successful outcome. Implant concepts have undergone a significant evolution,[1,2] not only in terms of designs, materials, and surfaces but also in clinical and technical management. Clearer understanding of the soft tissue and bone responses to implants enables the clinician to better plan the esthetic outcomes of implant treatment.

Providing an esthetic outcome requires understanding of the objective and subjective criteria related to hard and soft tissue esthetics.[3,4] Ceramists can often produce restorations to match adjacent teeth in terms of color, but if the surrounding tissues are not reconstructed, an esthetic outcome is not likely (Figures 26-1 and 26-2). The ultimate aim is for the implant restoration to harmonize into the frame of the smile, face and, more importantly, the individual.

The predictability of the esthetic outcome of an implant restoration is dependent on many variables including, but not limited to:

1. Patient selection and smile line
2. Tooth position
3. Root position of the adjacent teeth
4. Biotype of the periodontium and tooth shape
5. The bony anatomy of the implant site
6. The position of the implant

Patient Selection and Smile Line

Patients' esthetic expectations must be evaluated together with their lip activity and lip length.[5] A high smile line poses considerable challenges when planning for implant supported restorations in the esthetic zone because the restoration and gingival tissues are completely displayed. In these types of clinical situations maximal effort toward maintaining peri-implant tissue support throughout the planning, provisional, surgical, and restorative phases will be required.

The low smile line is a less critical situation because the implant restoration interface will be hidden behind the upper lip. However, this cannot be assumed, and the patient's input must be sought to confirm this.

Tooth Position

The tooth needs to be evaluated in three planes of space: apicocoronal, faciolingual, and mesiodistal. The existing tooth position will significantly influence the presenting gingival architecture. In many instances, teeth with a poor prognosis are thoughtlessly extracted. These teeth can significantly influence both the hard and soft tissue configuration.

Apicocoronal

Assessment of the apicocoronal position of the tooth may show it to be more apical, more coronal, or ideal and mimicking the level of the adjacent gingival margin. Numerous authors have shown that following extraction and insertion of an ovate pontic there is likely to be up to 2 mm of gingival recession,[6] and on extraction and placement of an implant immediately the migration of the gingival margin is likely to approximate 0.2 mm.[7]

Thus, if there is a hopeless tooth positioned ideally or apically that is extracted, the gingival margin is likely to migrate apically. Restoratively, long clinical crowns, pink porcelain, or visible metal margins will compromise the esthetic outcome. These teeth can benefit from orthodontic extrusion (Figures 26-3, 26-4, and 26-5) prior to extraction, which will serve to position the gingival level at a more harmonious level.[8,9]



• **Figure 26-1** Implant restoration utilizing pink ceramics. Although the patient was satisfied, this could only be achieved in a patient with a low smile line.



• **Figure 26-2** Patient's smile; transition line is hidden. (Lab work by Jungo Endo, CDT).



• **Figure 26-3** Orthodontic extrusion is utilized to overcompensate and bring tissue level more coronally.

It is the author's opinion that a cone beam scan should be taken of the area of concern. There must be sufficient bone labial to the tooth for orthodontic extrusion to be effective.



• **Figure 26-4** Implant is placed in adequate bone volume.



• **Figure 26-5** Provisional restoration is used to sculpt tissue levels. Patient is left in a provisional restoration for 3 to 6 months.

Faciolingual

In this dimension the tooth position may present with different concerns. The tooth may be positioned too far facially, which often results in very thin or nonexistent labial bone. These teeth are not good candidates for orthodontic extrusion because of inadequate underlying bone. Extraction of these teeth results in significant vertical bone loss and collapse of the gingival architecture. This type of situation benefits from bone and soft tissue augmentation procedures prior to implant placement. A tooth positioned more lingually benefits from the presence of an increased amount of facial bone. This situation is more favorable prior to extraction because the resultant discrepancy in the facial free gingival margin may be minimal.[8,10]

Mesiodistal

The proximity of the adjacent teeth necessary to provide proximal support and volume of interdental papillae should be evaluated. Ideally, the mesiodistal tooth width should be equal to that of the contralateral tooth so that an esthetic outcome can be achieved (Figures 26-6 and 26-7). Excesses or deficiencies in this dimension should be addressed through



• **Figure 26-6** The space of the tooth being replaced should be equal to the contralateral tooth.



• **Figure 26-7** Esthetic integration can be achieved with symmetry. Implant restoration in upper right central incisor.

the use of orthodontics, enameloplasty, or restorations. For patients with diastemas, it is imperative that the decision to maintain or close the space be made prior to implant placement. If the patient refuses these presented options to close the space and insists on closing the space with the implant restoration, there is a likelihood that a black triangle may ensue. This results from inadequate support from the adjacent tooth to maintain the papilla. It is important that the clinician discusses this with the patient ahead of time to avoid disappointment with the final outcome (Figures 26-8, 26-9, and 26-10).

Root Position of the Adjacent Teeth

Part of the diagnostic work for patients who need implants is a periapical radiograph, because root position often will preclude placing of implants. Many of these patients can benefit from orthodontics to reposition malposed teeth.

Teeth with root proximity also possess very little interproximal bone. This thin bone creates a greater risk of lateral resorption, which will decrease the vertical bone height after extraction or implant placement. When teeth are present,



• **Figure 26-8** Patient was going to lose central incisors but also wanted diastema between anterior teeth closed.



• **Figure 26-9** Implants placed in central incisor region.



• **Figure 26-10** Bonded porcelain restorations used to close diastema.

the use of orthodontics serves as a valuable adjunct to create space. This can be advantageous for support of proximal gingival architecture.[11,12]

Biotype of Periodontium and Tooth Shape

The position of the gingival tissue around a tooth is determined by the connective tissue attachment and the bone level. Two periodontal biotypes have been described in



• **Figure 26-11** Patient showing thin biotype.



• **Figure 26-12** Patient showing thick biotype.

relation to the morphology of the interdental papilla and osseous architecture: the thin, scalloped periodontium and the thick, flat periodontium.[13]

The thin, scalloped periodontium, found in less than 15% of cases, is characterized by a delicate soft tissue curtain, a scalloped underlying osseous form, and often has dehiscence and fenestrations present and a reduced quantity and quality of keratinized mucosa. Generally, interproximal tissue does not completely fill the space between adjacent teeth. This form of gingiva reacts to insults by receding facially and interproximally. As recession occurs and the inter-root bone resorbs, the subsequent soft tissue loss compromises the overall esthetic result (Figure 26-11).

The tooth form in this type exhibits a contact point toward the incisal third, essentially triangular anatomic crowns, and contact areas of teeth that are small faciolingually and apicocoronally. Due to extreme taper of the roots, the interproximal bone tends to be thicker.

Characteristics of the soft tissue biotype will play a prominent role in final planning for the shoulder position of the implant. A thin biotype with highly scalloped tissue requires the implant body and shoulder to be placed more palatal to mask any titanium show-through. When implants are placed toward the palate, a slightly deeper placement is required to allow for proper emergence profile.

The combination of factors in a patient with a high lip line and a thin biotype is extremely difficult to treat. Patients who fit into these treatment categories should be made aware of the challenges involved in obtaining an esthetic result before treatment begins.

The thick, flat periodontal biotype is characterized by a denser, more fibrotic soft tissue curtain; a flat, thicker underlying osseous form; and an increased quantity and quality of attached keratinized gingiva. This tissue often reacts to insults by pocket formation. Flat gingiva is associated with a tooth form that is more bulbous, with contact areas located more toward the middle third of the tooth, primarily square anatomic crowns, and contact areas that are wide faciolingually and apicocoronally (Figure 26-12).

Tooth morphology appears to be correlated with the soft tissue quality. The triangular tooth shape is associated with the scalloped and thin periodontium. The contact area is located in the coronal third of the crown, underlining a long and thin papilla. The square anatomic crown shape combines with a thick and flat periodontium. The contact area is located at the middle third, supporting a short and wide papilla.

Loss of interproximal tissue in the presence of a triangular tooth form will display a wider black triangle than in a situation where a square tooth is present. In some cases when the adjacent teeth are to be restored, the crown form can be modified prosthetically to compensate for partial interproximal tooth loss. The contact area of the prosthetic tooth is positioned more cervically, reducing the volume of the interdental space.

The presenting tooth shape will also influence the implant restoration shape. The implant restoration should mimic its contralateral natural tooth coronal to the free gingival margin. However, apical to the free gingival margin the implant restoration will not be an anatomic replica. A delicate balance must be developed that provides adequate support of the gingival architecture yet does not provide excessive pressure. The subgingival contour of the restoration must take into account the existing height of the free gingival margin and its comparison with the contralateral tooth. If the existing free gingival margin is apical, a concave subgingival contour is encouraged to allow the soft tissue to drape more coronally (Figure 26-13). If the existing free gingival margin is more coronal, a fuller subgingival contour is required to push the soft tissue more apically.

Bony Anatomy of the Implant Site

For successful esthetic restoration of implants, the bony housing must have a three-dimensional configuration that permits placement of an implant in a restoratively ideal position.[14] If the bony anatomy is inadequate, a bone grafting procedure may be required to enhance the site. When these situations are encountered the patient must be made to understand that a successful outcome will involve more than just replacing a "missing tooth." The patient must understand that the missing hard and soft tissue architecture also will need to be rebuilt so that optimum esthetics can be achieved.

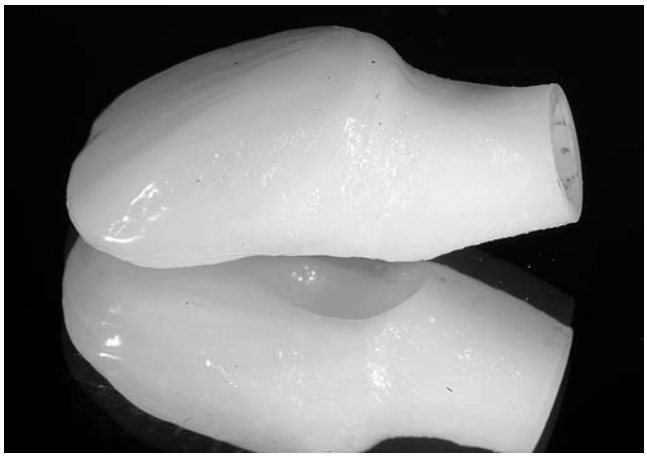

• **Figure 26-13** A concave subgingival contour allows tissue to drape more coronally.

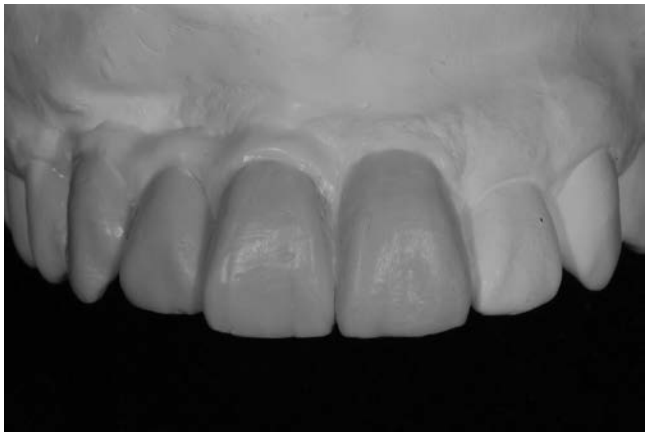

• **Figure 26-14** A diagnostic wax-up should replace missing tooth and tissue so the treating clinician can anticipate the esthetic challenge.

The definitive implant restoration needs to be surrounded by a hard and soft tissue environment that is in harmony with the surrounding dentition. It is not only the amount of bone and soft tissue present prior to implant surgery, but also the precision of surgical execution that leads to an overall favorable outcome. Several key analyses must be performed prior to commencing with implant placement. A diagnostic wax-up, which highlights tissue deficiencies and final tooth positioning, can assist in the planning process (Figure 26-14).

Faciolingual ridge anatomy should be evaluated to determine if there is sufficient crest width to house the implant. Deficient alveolar crest width will require a bone augmentation procedure to allow the implant to be placed in the ideal position. A cone beam scan can assist in diagnosing deficiencies in this dimension.

Mesiodistal space should be equal to that of the contralateral tooth; excess or deficiency in this dimension need to be addressed through orthodontics, enameloplasty, or restoration either prior to or after implant placement.

The most critical dimension remains the apicocoronal dimension. Deficiencies in this dimension can result from periodontal disease, trauma, atrophy, and infection. Vertical



• **Figure 26-15** Sounding to the bone gives the clinician an indication of how much tissue recession will occur after extraction.

grafting is complex and the site may require several surgeries to achieve an optimal configuration.

Two anatomic structures are important in determining predictability of soft tissues after implant placement. The first is the height and thickness of the facial bony wall and the second is the bone height of the alveolar crest in the interproximal areas.

Height and Thickness of Facial Bony Wall

The position of the osseous crest is an important predictor for gingival levels. A survey of 100 patients[15] classified patients as having high, normal, or low crests based on the vertical distance of the osseous crest to the free gingival margin. The greater the distance from the osseous crest to the free gingival margin, the greater the risk of tissue loss after an invasive procedure. Kois proposed that if the total vertical distance of the total dentogingival complex on the midfacial aspect is 3 mm, a slight apical loss of tissue up to 1 mm is anticipated after extraction and immediate implant placement. Greater or lesser than 3 mm indicates the change will be relatively negligible to more than 1 mm. Measuring the distance from the free gingival margin to the osseous crest prior to extraction is an important diagnostic predictor of the anticipated final position of the free gingival margin (Figures 26-15 and 26-16).

Height of Bony Crest in the Interproximal Area

The interproximal bony crest plays a critical role in the presence or absence of peri-implant papillae. A clinical study measured the distance from the interproximal contact to the vertical height of bone and observed how frequently the interproximal space was filled completely by soft tissue.[11] When the contact point to the bone was 3 to 5 mm, papilla always filled the space. When the distance was 6 mm, papilla was absent 45% of the time and with a distance of 7 mm, papilla did not fill the space 75% of the time.

A difference of 1 to 2 mm is significant in obtaining soft tissue esthetics. This has been confirmed with implant supported restorations,[16] and multiple authors have also shown that the height of peri-implant papillae in single tooth gaps is



• **Figure 26-16** Radiograph of patient in Figure 26-15, showing bone loss. The clinician cannot anticipate that papilla will be maintained in this situation and must consider utilizing a long contact area to disguise the loss of tissue.

independent of the proximal bone level next to the implant but is dependent on the interproximal bone height of the adjacent teeth. From a diagnostic perspective, sounding from the tip of the papilla to the interproximal bone crest of the adjacent tooth is an important predictor. If this distance is 5 mm or less there is an increased likelihood that the interproximal tissues will be predictably maintained following implant placement and restoration. If the distance is greater than 5 mm the papilla cannot be predictably maintained after surgical intervention.

Implant Position

Esthetic implant placement is driven by both a restorative and biological philosophy. Esthetically, the implant should be placed to satisfy the parameters of contour so that the restoration is pleasing. Biologically, it should be placed to allow maintenance of both hard and soft tissue architecture. If the tooth to be replaced has not yet been removed, several determinations should be made prior to the extraction.

Placing the implant immediately after extraction helps to shorten the treatment time and may reduce the amount of ridge width reduction that accompanies tooth extraction. In addition, if bone deficiencies are present, orthodontic eruption of the tooth prior to extraction can help to increase the amount of hard and soft tissue in the future implant site.[17]

In most situations involving a single anterior implant restoration, esthetic considerations are more important than functional considerations. As such, axial loading is not as critical as it is with posterior implant restorations. Implant position is critical to the final esthetic outcome and should be considered in all three dimensions and in relation to the adjacent teeth. Misalignment of the implant in the prosthetic space can have adverse esthetic consequences.

Apicocoronal Placement

Apicocoronal positioning appears to be the most critical aspect. Deficient tissue in this dimension can result from several factors, and this type of tissue must be addressed during treatment planning. Because of the complexity of vertical hard and soft tissue grafting, these patients are placed in a high-risk group.

Most often tooth loss is followed by bone loss of minor or major importance. It is necessary to evaluate the discrepancy between the bone level at the proposed implant site and the level at the adjacent teeth. Too large a difference represents a risk to both periodontal and peri-implant tissue health. In this case, the surgeon should consider reconstructing the ridge prior to implant placement.

The apicocoronal positioning of the implant is the vertical discrepancy between the occlusal surface of the implant and the peaks of the bony septa proximal to the adjacent teeth; the most pleasing esthetic result occurs when this discrepancy is minimal.

To obtain appropriate apicocoronal positioning of the implant a diagnostic wax-up should be completed and from this a surgical guide is made. The emergence profile and the shape of the restoration are reproduced on the guide to verify the implant positioning on placement.

A maxillary central incisor measures on average 7 to 8 mm mesiodistally and 6 mm faciolingually at the emergence from the soft tissue. A 4.0-mm implant needs to be placed 3 to 4 mm apical to the gingival margin of the contralateral tooth to allow the restoration to emerge with a natural profile. A vertical distance of 3 to 4 mm is needed for gradual transition from the 4-mm diameter of the implant platform to the 7 to 8 mm dimension at the gingival margin. If a lateral incisor were being replaced, the implant would not have to be placed so apically because the average diameter of the crown at the gingival margin is 5 mm and less room is required for transition (Figure 26-17).

Situations in which there is excess tissue height also require attention. In these types of patients a bone scalloping procedure is required to allow placement of the implant shoulder in a subgingival position; once again, the most efficient way to examine this is through a surgical guide highlighting the proposed gingival margin.

Errors in apicocoronal implant placement can have serious esthetic and biomechanical implications. An implant placed too coronally will not allow adequate transition from the head of the implant to the point where the restoration exits from the free gingival margin. The restoration will look short in comparison to the contralateral tooth. The only prosthetic "bailout," for this type of situation is to provide a ridge-lapped restoration with contours that are pleasing to the observer's eye but may have long-term repercussions on the health of the soft tissue (Figure 26-18).

Problems can also result when implants are placed too apically. Clinically, if an implant is placed too apically

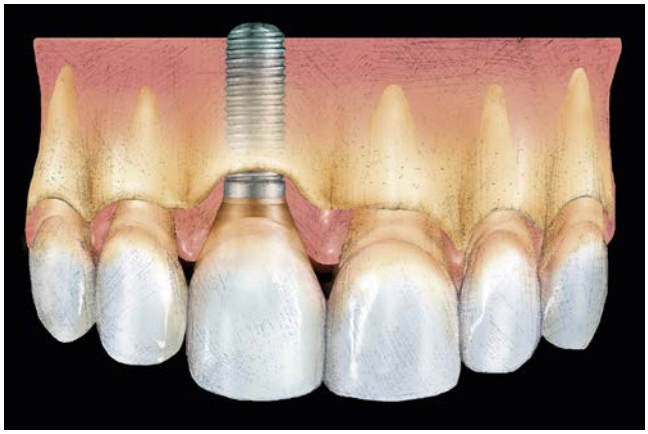

• **Figure 26-17** Ideal placement of the implant should be 3 to 4 mm apical to the free gingival margin.

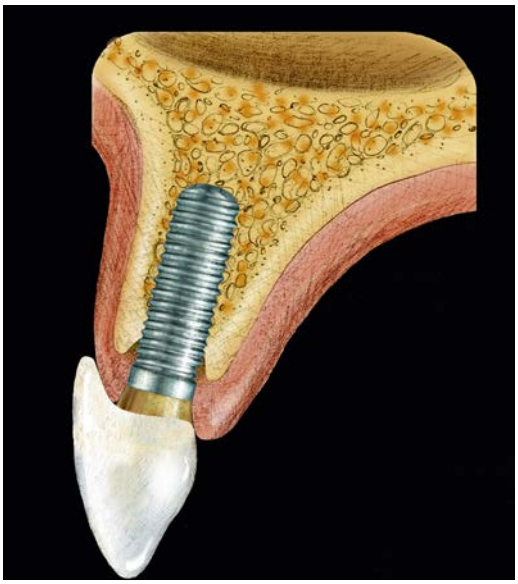

• **Figure 26-18** If the implant is placed too shallowly, a ridge lap may be required on the facial, which may compromise soft tissue health.

with excessive countersinking procedures, an unnecessary amount of bone loss will occur (Figure 26-19). Because this bone loss takes place circumferentially it will affect not only the proximal bone structure but also the height of the facial bone wall, and can lead to undesirable soft tissue contours.

A practical problem in placing an implant too deeply is access for instrumentation. Making an impression of a deeply placed implant can be a difficult experience (Figure 26-20); the soft tissue tends to collapse, there is tissue impingement when trying to locate the head of the implant, and seating is difficult to evaluate. This is specific to external hex systems.

If an implant is placed too deep, a screw-retained restoration is the treatment of choice. The literature shows that removing all the cement when an implant is placed so deeply can prove to be a difficult endeavor. Agar et al.[18] found that when six experienced investigators were asked to remove cement there was a surprising amount of cement left behind; this can lead to serious soft tissue complications.

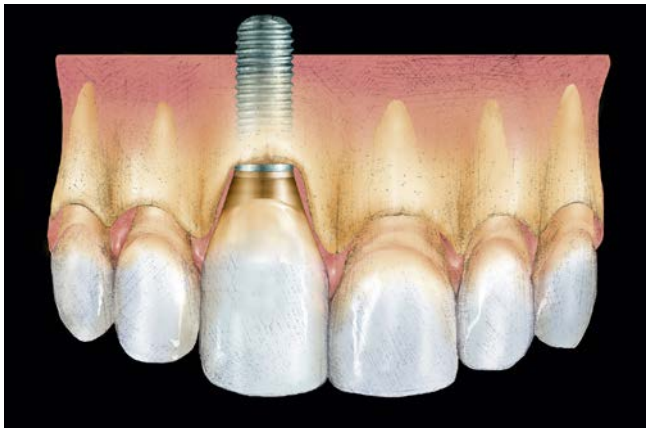

• **Figure 26-19** Too deep an implant placement can cause instrumentation problems for the treating clinician.



• **Figure 26-20** Too deep an implant placement can also jeopardize the health of the adjacent teeth.

Mesiodistal Placement

Improper mesiodistal positioning of implants can have a substantial effect on the generation of interproximal papillary support as well as on the osseous crest of the adjacent tooth. An implant should be placed 1.5 mm to 2 mm from an adjacent tooth. Placement too close to the adjacent tooth can cause resorption of the interproximal alveolar crest to the level of that on the implant.[19] With this resorption comes a reduction in papillary height. Restorative problems exist as well. Poor embrasure form and emergence profile will result in a restoration with a long contact zone and compromised clinical outcomes.

The loss of crest height on adjacent teeth is caused by circumferential bone loss routinely found around the implant shoulder in implants. This has two dimensions, horizontal and vertical. Radiographs only demonstrate the horizontal aspect of the bone loss; the proximal bone loss measures 1 to 1.5 mm from the implant surface. This distance must be respected on implant placement to prevent vertical bone loss on adjacent teeth.[20]

Faciolingual Placement

The crest width must be examined to determine the presence or absence of bone atrophy. Placement will vary

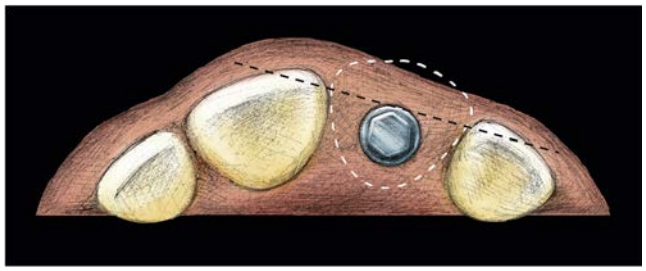

• **Figure 26-21** Ideal faciolingual placement of the implant.



• **Figure 26-22** Implants placed too palatally will result in biomechanical compromise.

depending on the mechanism of retention of the final restoration (screw retained versus cement retained). Deficient alveolar crest width may require augmentation so that the implant can be positioned in the correct faciolingual position.

Computerized tomographic scan techniques are useful in assisting to determine width. The amount of bone available should be at least 1 mm greater than the implant diameter on each side. Hence a 4-mm diameter implant would require 6 mm of bone. The single implant placed in the maxillary anterior region should be situated palatal to an imaginary line that outlines the curve of the arch formed by the facial surfaces of the adjacent teeth (Figure 26-21). Implants placed too palatally complicate development of hygienic contours (Figures 26-22 and 26-23). Implants are often mistakenly placed too facially. This error can result in excessive resorption of the supporting osseous structure, resulting in a restoration that will appear long in comparison to the contralateral tooth. From a prosthetic perspective, this clinical scenario requires use of custom abutments in the provisional and definitive phases of the restorations (Figures 26-24 through 26-28).

Strategies to Reduce Bone Loss Around Implants

Clinicians have often questioned the reasons for small changes in crestal bone height following implant restoration.



• **Figure 26-23** Contours of the restoration must be designed so they are cleansable. Note the facial cantilever.



• **Figure 26-24** Implant placed too deep and too facially.



• **Figure 26-25** A customized acrylic abutment is fabricated for provisional restoration.



• **Figure 26-26** Provisional restoration fabricated.



• **Figure 26-27** The cement margin should follow the contour of the tissue.



• **Figure 26-28** Provisional restoration in place.

Several theories exist as to the observed changes in crestal bone height. Among them are:

1. Surgical trauma
2. Stress concentration at the coronal region of the implant when implants are placed into function[21]
3. Bacterial leakage due to configuration and position of the implant-abutment microgap[22]
4. Localized inflammation at the implant-abutment interface[23]
5. Biological width theory whereby the soft tissue attempts to establish a mucosal barrier around the coronal aspect of the implant[24]
6. Micromovement of the prosthetic components
7. Repeated screwing and unscrewing of the abutment[25]
8. Implant neck geometry
9. Presence of infection

Implant companies have attempted to address the causes of bone loss and have incorporated design features to attempt to minimize it. Clinicians have also varied implant placement techniques to maximize bone preservation. Features to minimize bone loss include:

1. Altering the implant neck design
2. Microthreads at the coronal aspect of the implant
3. Altering implant surface characteristics
4. Altering the diameter of implant used
5. Use of one-piece implants
6. Placing implants in relation to the alveolar crest[7]
7. Platform switching

Altering Implant Neck Design

There is no evidence to show that marginal bone preservation is improved by altering the marginal neck geometry. Bateli et al.[26] performed a systematic review that included changes in implant neck length and design, implant surface characteristics, implant diameter, and/or insertion depth; the addition of microthreads; the use of one-piece implants; and the concept of platform switching. After subsequent filtering, 20 studies were finally selected and involved the following methods: the use of microthreads (1 study); modifications in implant surface characteristics (11 studies), implant diameter (4 studies), or insertion depth (2 studies); the use of one-piece implants (3 studies); and platform switching (1 study). Because of the heterogeneity of the studies, it was not possible to analyze the data statistically. No evidence was found regarding the effectiveness of any specific modification in the implant neck area in preserving marginal bone or preventing marginal bone loss. They concluded that current literature provides insufficient evidence about the effectiveness of different implant neck configurations in the preservation of marginal bone. Long-term randomized controlled clinical trials are needed to elucidate the effects of such modifications.

Microthreads at the Coronal Aspect of the Implant

Microthreads have been added in the implant neck area by manufacturers, their purpose being to distribute the forces around an implant when an implant is under functional load and also to increase the bone-to-implant contact. Commercially available implant systems employing this modification present a pitch distance of 0.185 mm between threads. A five-year prospective study by Palmer et al.[27] looked at Astra-tech implants with microthreads. The mean marginal bone loss in the study was 0.39 mm after 5 years, which is much lower than the original

machined surface external hex implants. However, the research did not specifically isolate this design feature, so the conclusion cannot be made that the microthreads were responsible for the bone preservation.

Implant Surface Characteristics

There have been many modifications of the implant surface in an attempt to increase bone-to-implant contact. Techniques such as oxidizing, sandblasting, and acid etching have been employed to accelerate the process of osseointegration. The rough surface implants do have a better osteoconductive capacity than the machined implants and have improved bone-to-implant contact.[28]

Surfaces have been compared to determine if a rougher surface resulted in better bone maintenance of bone around dental implants. Wennstrom et al.[29] compared implant groups with the same implant design that differed only in their surface characteristics. Their conclusion was that no significant difference was attributable to the enhanced surface. There is no evidence to support marginal bone preservation for any specific surface modification.

Implant Diameter

Wide diameter implants were designed to be placed in compromised situations where available bone height and quality were limited. Manufacturers suggested that wide diameter implants may exhibit less horizontal bone resorption than regular diameter implants. It was claimed that increasing the diameter of the implant would decrease the stress and strain on the alveolar crest and lead to less bone loss. Ivanoff[30] showed that 5-mm diameter implants demonstrated the highest failure rates in comparison to 3.75-mm and 4.00-mm implants. Long-term randomized controlled trails with split-mouth designs are needed to substantiate the claim that wide diameter implants are effective in preservation of marginal bone levels.

One-piece Implants

A one-piece implant is defined as an implant in which the bone anchoring portion, the soft tissue traversing portion, and the prosthetic abutment are all in one piece.[31] The theory behind one-piece implants is that they are placed in a one-stage surgery and therefore bypass the two-stage procedure, avoiding further manipulation of the soft and the hard tissues, and are supposed to eliminate the implant abutment microgap. It was claimed that the elimination of the microgap through the use of one-piece implants resulted in less bone loss.[32] Other studies have shown no difference in bone loss when a two-piece implant system was compared to a one-piece implant system.[33] Currently the evidence is not clear if one-piece implants serve an advantage over two-piece implants in terms of bone maintenance.

Insertion Depths

Clinicians have altered the placement of two-piece implants at varying locations with respect to the gingival margin and marginal bone levels to determine if this has an influence on bone loss. Callan et al.[34] suggested that more bone loss was associated with implants where the implant abutment interface is placed below the gingival margin. Hartman and Cochran[35] found a relationship between the amount of bone remodeling and the location of the rough-smooth border placed at or near the alveolar crest. Although these studies provide us with some information, the possible interference of surface modifications in the studies referring to insertion depth makes it difficult to draw any reliable conclusions about the outcome of the varying locations of the implant abutment interface in two-piece implants with respect to the gingival margin or alveolar crest.

Platform Switching

This concept refers to the inward horizontal repositioning of the implant abutment junction so that it is positioned away from the outer edge of the implant and adjacent bone. Lazzara and Porter[36] introduced the concept by using standard diameter components on wide platform implants. They found a reduction of the expected postrestoration crestal bone remodeling in comparison to the "standard" implants. There are multiple theories as to why the platform-switching concept works.

The Biomechanical Theory

Connecting the implant to a smaller diameter abutment may limit bone resorption by shifting the stress concentration zone away from the crestal bone–implant interface and directing the forces of occlusal loading along the axis of the implant.

The Biologic Width Theory

Shifting the implant-abutment connection may medialize the location of the biologic width and minimize the marginal bone resorption. Placing the IAJ at or below the crestal bone level may cause vertical bone resorption to reestablish the biologic width.

The Inflammation at IAJ Theory

This theory postulates that bone resorption is caused by an inflammatory infiltrate at the IAJ. The presence of periimplant microbiota was suggested to influence the crestal bone resorption by maintaining the inflammatory cell infiltrate at the IAJ. The physical repositioning of the IAJ away from the outer external edge of the implant and neighboring bone may limit bone resorption by containing the inflammatory cell infiltrate within the angle formed at the interface away from the adjacent crestal bone.

The question becomes, does platform switching influence bone remodeling? Canullo et al.[37] placed 22 implants of 5.5-mm diameter immediately in extraction sockets in the maxilla. They were randomly divided where 11 implants were connected with 3.8-mm diameter abutments and 11 implants had 5.5-mm diameter abutments. The follow-up was 25 months. What they found was lower crestal bone loss in the platform-switched group compared to the non-platform-switched. They also found a wider and more resistant zone of connective tissue in the platform-switched group compared to the platform-matched group.

Hurzeler et al., Atieh et al., and Rodriguez-Ciurana et al.[38,39,40] found similar results supporting the platform-switching concept. The conclusions from these studies were that the biologic width around platform-switched implants is located more coronally and there is a reduction in the vertical and horizontal components of bone loss.

Just as there are many studies supporting the concept there are many studies refuting the claim that platform switching actually works. Studies by Baffone et al., Batelli et al., Enkling et al., Van Steenbergh et al., and Jacobs et al. question the platform-switching concept.[41-44] Conclusions from their studies included:

1. Geometry of the implant abutment connection was of limited importance in preservation of hard and soft tissues.
2. No evidence in a meta-analysis showed that the implant neck configuration contributed to preservation of marginal bone level, and marginal bone loss occurred regardless of all the efforts to eliminate it.
3. Bacterial colonization can occur as a consequence of leakage at the IAJ or as a result of contamination during implant placement.
4. A split-mouth design comparing Astra Tech and Branemark implants showed that there was no significant difference in probing depths, presence of plaque, or change in marginal bone level.
5. Mean radiographic bone loss after the first year was small and was less than 0.5 mm for both implant systems up to 15 years after prosthetic loading.

There are many causes of bone loss around dental implants and many clinicians have studied various aspects of implant design in an attempt to reduce the bone loss that is seen. Manufacturers have attempted to incorporate all the features within their individual systems to aid clinicians in achieving the ultimate in esthetics and biomechanics. The clinician's goal is to produce a restoration that mimics nature. As our quest for perfect restorations continues, we must realize there still is much that is unknown and despite our best efforts to maintain bone, the bone loss is multifactorial and cannot be isolated to one aspect of implant design. Operator variables and systemic health of the patient will also influence the bone loss that is seen. As clinicians we can only utilize all the tools that are available to us in the hope that the bone will be maintained and this will ultimately result in a life-like restoration.

Considerations for Multiple Implants

Patients with extended edentulous spaces present greater anatomic and esthetic challenges, making it even more difficult to obtain an esthetic result with certainty. Following extraction and wound healing of two adjacent teeth, the ensuing apical and faciolingual resorption results in an edentulous segment that is flattened. The same diagnostic considerations need to be addressed as when looking at single-tooth edentulous sites.

The aim prior to implant placement is to have a three-dimensional configuration of hard and soft tissue, which will allow placement of implants in an ideal position. The placement of two missing central incisors poses an additional challenge. Following surgical placement, additional peri-implant bone remodeling takes place. In the frontal plane, two processes occur: one between the implant and the adjacent natural tooth and one between the two adjacent implants.

On the tooth implant side, the predictability of the interdental papilla is governed by the height of the interproximal bone crest of the tooth. If this height is favorable there is a good certainty that the interdental papilla will be maintained following implant placement. The bone crest between the two implants is likely to undergo further resorption in an apical direction. This is accompanied by a loss of inter-implant soft tissue that, in the case of multiple edentulous sites, will result in black triangles between the adjacent restorations.

Many clinicians have sought after the ideal implant distance required to maintain the interdental papilla. Tarnow et al.[45] performed a radiographic study to address this clinical problem. Radiographic measurements were taken at a minimum of 1 and 3 years after implant exposure. All radiographs were taken with a paralleling technique. Radiographs were computer scanned and magnified for measurement. The following measurements were taken:

1. Lateral distance from the crest of the inter-implant bone to the implants
2. Vertical crestal bone loss
3. Distance between the implants at the implant/abutment interface

When implants were placed too close together, the bone remodeling overlapped to a great degree and consequently resulted in loss of vertical bone height and this subsequently had soft tissue implications. When implants were separated by 3 mm and greater, lateral bone loss from the adjacent implants did not overlap, with minimal resultant crestal bone loss.

They concluded that it is more difficult to create or maintain papilla between two adjacent implants than it is between an implant and a natural tooth. Their recommendation was that when two implants are placed adjacent to each other in the esthetic zone a minimum of 3 mm of bone should be retained between them at the implant-abutment level. If implants are placed too close together this can compromise the contours of the restoration (Figures 26-29 through 26-32).

This particular study addressed bone loss between the implants. It should be remembered that the bone loss has two dimensions, horizontal and vertical. Radiographs only demonstrate the horizontal aspect of bone loss. Bone loss occurs circumferentially around the implant and, when two implants are placed adjacent to each other, facial bone loss also occurs (Figure 26-33). This has implications in terms of stability of the facial gingival margin. If the implants are placed too far facially there will be less facial bone and this will ultimately result in apical migration of the free gingival margin (Figure 26-34).

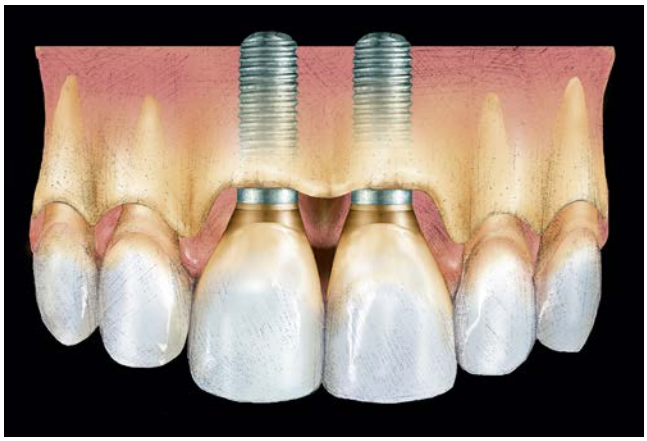

• **Figure 26-29** Implants placed too close together can compromise the contours of the restoration.

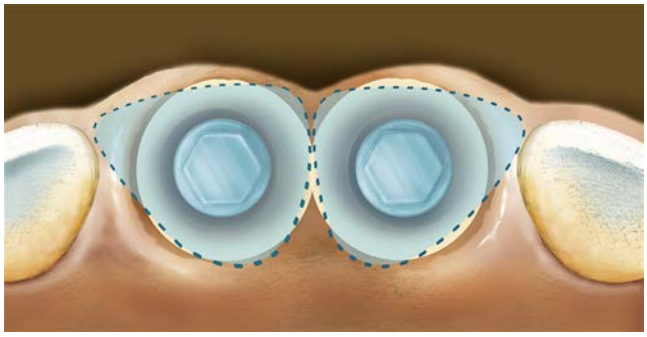

• **Figure 26-30** Contours compromised mesial to both planned restorations.



• **Figure 26-31** Implants placed too close together. Note loss of papilla and flattening of tissue.



• **Figure 26-32** Restorations fabricated with long contact area to disguise loss of tissue.

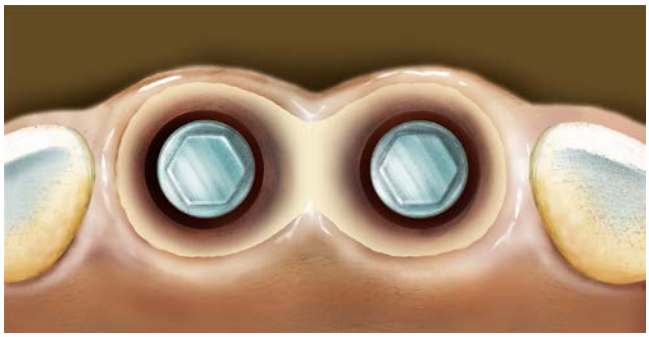

• **Figure 26-33** Implants ideally should be placed at least 3 mm apart; however, this must take into account the size of the anticipated teeth.

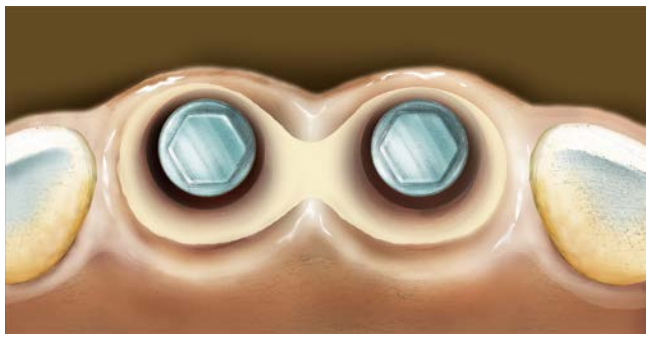

• **Figure 26-34** Implants placed too facially will result in thinning of bone. Consequences can be tissue recession and loss of interproximal papilla.

Tarnow et al.[45] also performed a study to determine the height of the soft tissue to the crest of the bone between two adjacent implants. This was done independent of the location of the contact point. They looked at 136 interimplant papillary heights in 33 patients by eight examiners. A standardized periodontal probe was used and placed from the height of the papilla to the crest of the bone. They found that the mean height of papilla between two adjacent implants was 3.4 mm, with a range of 1 to 7 mm.

Although this was a retrospective study and there were many variables such as operator, implant type, placement, and so forth, it did give us information that soft tissue between two adjacent implants in the esthetic zone is not entirely predictable. The patient must be aware of this when treatment planning or alterations must be made in the treatment plan to provide an esthetic result.

Recreating interdental papilla between two adjacent implants is a formidable task. Restoratively, clinicians alter the position of the contact point to give the illusion of



• **Figure 26-35** Patient presented with two central incisors failing.

papilla. The thin spicule of bone remaining between the implants may be sufficient to maintain the papilla during the first few years of the restorations service but may resorb over time, resulting in loss of soft tissue.

To achieve a result that is as close to ideal as possible, two adjacent implants should be placed in a correct three-dimensional position. If primary stability permits, provisional restorations should be fabricated and the implants loaded the same day. The provisional restorations act as a scaffold around which the soft tissue heals. Particular attention should be paid to the subgingival contours of the restoration so as to not compress the tissue. Interproximal and occlusal contacts should also be relieved in the provisional phase. The patient should be given instructions to maintain a soft diet. Following healing, the soft tissue contours can be transferred to the laboratory technician at which time the definitive restorations can be fabricated (Figures 26-35 through 26-43).

Another clinically challenging situation is replacement of a maxillary canine and adjacent lateral incisor. This becomes more challenging because the edentulous space is smaller and the inter-implant soft tissue tends to be less voluminous. Consideration in this instance should be given to placement of a single implant in the canine region and cantilevering a lateral incisor from it. Placement of the implant should follow all the principles discussed previously.

Replacement of several missing teeth with implants allows for the use of fixed partial dentures and the opportunity to utilize pontic form to help support the soft tissue and give an illusion of papillae.

The authors have encountered many situations where a "one implant per tooth" philosophy has been utilized. This can be particularly detrimental in the esthetic zone. The literature is quite clear that maintaining papillae between implants is not predictable. Even with the advent of more sophisticated implant designs there are no long-term studies showing papilla maintenance. For an esthetic outcome, it is more predictable to place implants away from each other so that the intervening soft tissue can be sculpted to give the illusion of papilla. If the patient is missing maxillary lateral incisor to lateral incisor, there are many combinations of

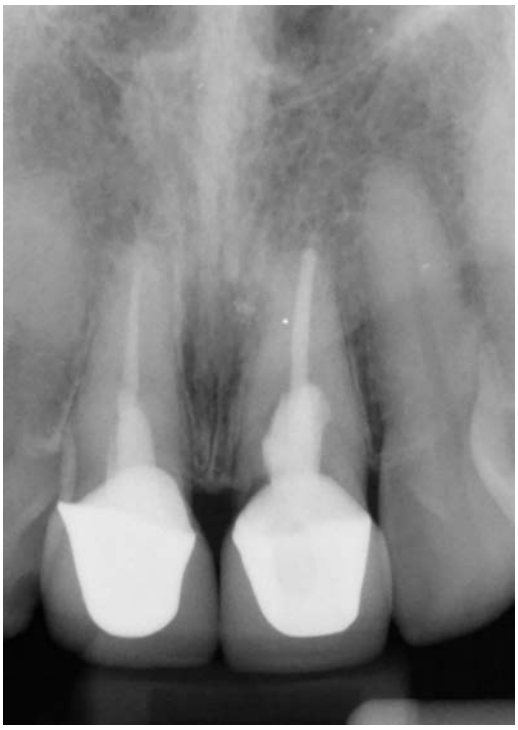

• **Figure 26-36** Radiograph of patient in Figure 26-35.



• **Figure 26-37** Teeth extracted and implants placed immediately into extraction sockets. (Surgery by Dr. Hooman Zarrinkelk.)



• **Figure 26-38** Accurate pilot hole preparation is critical to correct three-dimensional placement of the implants.



• **Figure 26-39** Screw-retained acrylic provisional restorations are fabricated and delivered on the day of surgery. All occlusal and interproximal contacts are relieved.



• **Figure 26-40** Healing at one month.



• **Figure 26-41** Sculpting of the interproximal tissue by the provisional restorations.

implant placement which can be considered. The clinician must look at the variables that will influence the esthetic outcome, which include but are not limited to the following:

- Ridge width
- Soft tissue volume
- Smile line

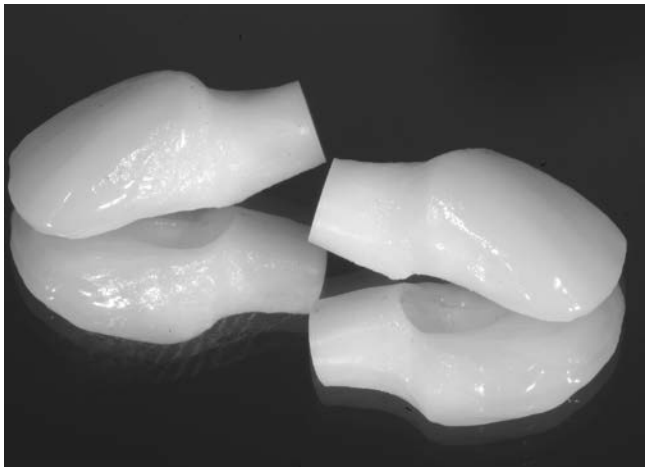

• **Figure 26-42** Subgingival contour of definitive restorations is concave to allow tissue to drape more coronally.



• **Figure 26-43** Screw-retained single unit definitive restorations.

If there is an adequate volume of bone, placement of two implants in both lateral incisor regions and fabrication of a fixed partial denture, sculpting the intervening tissue with ovate pontics is likely to produce an illusion of papilla, which will be more pleasing to the observer's eye.[46] The diameter of implant selected will be relative to the bone width, with the clinician's objective being to have a maximal amount of bone facial to the implant. This placement philosophy can also be reserved for extended edentulous spans where esthetics is of paramount importance (Figures 26-43 through 26-47).

Unfortunately, patients often present with existing edentulous spaces where thickness of soft tissue is not optimal for ovate pontic development. In these situations alternative pontic designs have to be considered. Cascione et al.[47] introduced a novel design in which pontic site development is facilitated by scoring of the master casts in the pontic area. This allows compression of tissue and the topography of these sites is changed gradually with pressure. Provisional restorations are fabricated to test the soft tissue response, with the ultimate goal being optimum soft tissue health and pleasing esthetics. Once this has been satisfied, the definitive restoration is fabricated (Figures 26-48 through 26-61).



• **Figure 26-44** If bone dimensions allow, implants should be placed in the lateral incisor position.



• **Figure 26-45** Note sculpting of pontic area. Abutments are designed so that margins follow contour of tissue to allow easier clean-up of cement.



• **Figure 26-46** Definitive four unit restoration; note excellent tissue response.



• **Figure 26-47** Restoration must have ideal emergence profile.

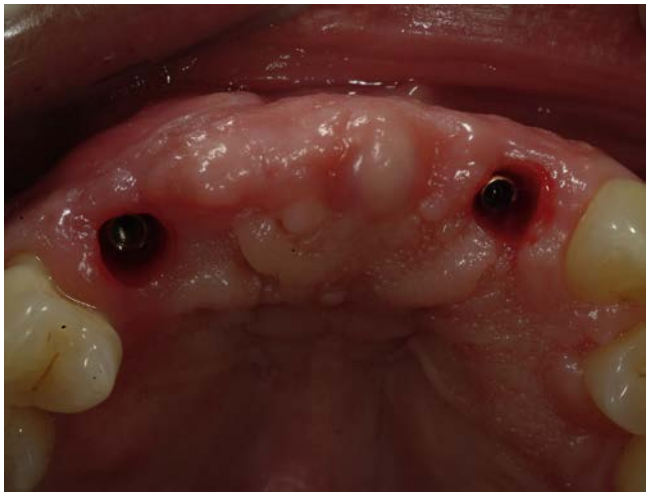

• **Figure 26-48** Patient presentation; two implants have been placed for an extended edentulous span.



• **Figure 26-49** The edentulous span will require correct three-dimensional positioning of the teeth.

Placement of implants in multiple edentulous spaces must follow the same principles as for single-tooth situations; placement must follow appropriate diagnosis and treatment planning, which includes a diagnostic wax-up and fabrication of a surgical guide to facilitate implant placement. If these techniques are not followed, it is all too easy to find implants in the wrong position, requiring utilization of prosthetic strategies to satisfy the patient's demand for esthetics. In situations like these, patient expectations are unlikely to be met.

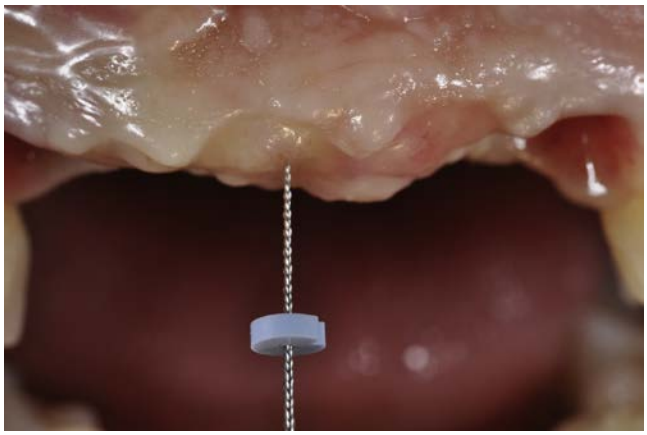

• **Figure 26-50** Tissue is sounded. Note that there is insufficient tissue to develop ovate pontics.



• **Figure 26-51** Diagnostic wax-up completed.



• **Figure 26-52** An outline is scribed on the cast.



• **Figure 26-53** An occlusal view of the outline of the wax-up. The cast will be scored in this region.



• **Figure 26-54** Cast is scored so that the provisional restoration will compress the tissue by 1 mm.



• **Figure 26-55** Layered provisional restoration fabricated.



• **Figure 26-56** Provisional restoration on the day of delivery; note the blanching of tissue.



• **Figure 26-59** Definitive layered zirconia restoration.



• **Figure 26-57** Provisional restoration one month post-delivery.



• **Figure 26-60** Lateral view to demonstrate pseudopapilla.



• **Figure 26-58** Note how provisional restoration has sculpted pseudopapilla. The tissue appears pink and healthy.



• **Figure 26-61** Smile of patient shown in Figures 26-59 and 26-60.

Summary

Esthetic restoration of anterior teeth with implant-supported restorations is one of the most difficult procedures to execute. Bone resorption following anterior tooth extraction often compromises gingival tissue levels for the implant restoration. In the last 10 years the focus has shifted from osseointegration to creation of an implant-borne restoration that is in harmony with the surrounding hard and soft tissue. Complete reconstruction of tooth and gingival esthetics remains the primary objective and in some instances can be very difficult to achieve. The predictability of esthetic success depends on the tissue loss present at the initiation of treatment. The greater the amount of bone and soft tissue loss, the more difficult it becomes to produce an ideal esthetic result. Improvements in implant design, surfaces, and materials have assisted us in obtaining esthetic results. However, the ultimate esthetic result can be obtained only through a correct diagnosis and appropriate treatment planning.

Acknowledgment

The authors would like to thank Domenico Cascione for assistance with the laboratory work.

References

1. Mankoo T: Maintenance of interdental papillae in the esthetic zone using multiple immediate adjacent plants to restore failing teeth—a report of ten cases at 2 to 7 years followup, *Eur J Esthet Dent* 3(4):304–322, 2008.
2. Sullivan RM: Perspective on esthetics in implant dentistry, *Compendium* 22(8):685–692, 2001.
3. Belser UC: Esthetic checklist for the fixed prosthesis. Part II: Biscuit bake try in. In Scharer P, Rinn LA, Kopp FR, editors: *Esthetic guidelines for restorative dentistry*, Chicago, 1982, Quintessence, pp 188–192.
4. Magne P, Belser U: *Natural oral esthetics. In Bonded porcelain restorations in the anterior dentition. A biomimetic approach*, Chicago, 2002, Quintessence, pp 57–99.
5. Tjan AH, Miller GD, The JG: Some esthetic factors in a smile, *J Prosthet Dent* 51(1):24–28, 1984.
6. Kois JC: Esthetic extraction site development: The biological variables, *Contemp Esthet Restor Pract* 2:10–18, 1998.
7. Khzam N, Mattheos N, Roberts D, Bruce WL, Ivanovski S: Immediate placement and restoration of dental implants in the esthetic region: clinical case series, *J Esthet Restor Dent* 26(5):332–344, 2014.
8. Kois JC: Predictable single tooth peri-implant esthetics: five diagnostic keys, *Compendium* 25(11):895–905, 2004.
9. Salama H, Salama M, Kelly J: The orthodontic-periodontal connection in implant site development, *Pract Periodontics Aesthet Dent* 8(9):923–932, 1996.
10. Urban IA, Nagursky H, Lozada JL, Nagy K: Horizontal ridge augmentation with a collagen membrane and a combination of particulated autogenous bone and anorganic bovine bone-derived mineral: a prospective case series in 25 patients, *Int J Periodontics Restorative Dent* 33(3):299–307, 2013.
11. Tarnow DP, Cho SC, Wallace SS: The effect of inter-implant distance on the height of inter-implant bone crest, *J Periodontol* 71(4):546–549, 2000.
12. Tarnow DP, Magner AW, Fletcher P: The effect of distance from the contact point to the crest of bone on the presence or absence of the interproximal dental papilla, *J Periodontol* 63:995–886, 1992.
13. Becker W, Ochsenbein C, Tibbetts L, et al.: Alveolar bone anatomic profiles as measured from dry skulls. Clinical ramifications, *J Clin Periodontol* 24(10):727–731, 1997.
14. Martin WC, Pollini A, Morton D: The influence of restorative procedures on esthetic outcomes in implant dentistry: a systematic review, *Int J Oral Maxillofac Implants* 29(Suppl):142–154, 2014.
15. Kois JC, Kan JY: Predictable per-implant gingival esthetics. Surgical and prosthodontic rationales, *Pract Periodont Aesthet Dent* 13:691–698, 2001.
16. Nisapakultorn K, Suphanantachat S, Silkosessak O, Rattanamongkolgul S: Factors affecting soft tissue level around anterior maxillary single-tooth implants, *Clin Oral Implants Res* 21(6):662–670, 2010.
17. Chen ST, Buser D: Esthetic outcomes following immediate and early implant placement in the anterior maxilla—a systematic review, *Int J Oral Maxillofac Implants* 29(Suppl):186–215, 2014.
18. Agar J, Cameron SM, Hughbanks JC, Parker MH: Cement removal from restorations luted to titanium abutment with simulated subgingival margins, *J Prosthet Dent* 78(1):43–47, 1997.
19. Thilander B, Odman J, Jemt T: Single implants in the upper incisor region and their relationship to the adjacent teeth. An 8 year follow up study, *Clin Oral Implants Res* 10:346–355, 1999.
20. Esposito M, Ekestubbe A, Grondahl K: Radiological evaluation of marginal bone loss at tooth surfaces facing single Branemark implants, *Clin Oral Implants Res* 4(3):151–157, 1993.
21. Albrektsson T, Zarb G, Worthington P, Eriksson AR: The long term efficacy of currently used dental implants. A review and proposed criteria for success, *Int J Oral Maxillofac Implants* 1:11–25, 1986.
22. Pillar RM, Deporter DA, Watson PA, Valiquette N: Dental implant design. Effect on bone remodeling, *J Biomed Mater Res* 25:467483, 1991.
23. Cappiello M, Luongo R, Di Iorio D, et al.: Evaluation of peri-implant bone loss around platform-switched implants, *Int J Periodontics Restorative Dent* 28:347–355, 2008.
24. Canullo L, Pellegrini G, Allievi C, et al.: Soft tissues around long-term platform switching implant restorations: A histological human evaluation. Preliminary results, *J Clin Periodontol* 38: 86–94, 2011.
25. Abrahammson I, Berglundh T, Lindhe J: The mucosal barrier following abutment dis/reconnection: An experimental study in dogs, *J Clin Periodontol* 24(8):568–572, 1997.
26. Bateli M, et al.: Implant neck configurations, for preservation of marginal bone level: A systematic review, *Int J Oral Maxillofac Implants* 26(2):290–303, 2011.
27. Palmer RM, Palmer PJ, Smith BJ: A 5 year prospective study of Astra single tooth implants, *Clin Oral Implants Res* 11:179–182, 2000.
28. Albrektsson T, Wennerberg A: Oral implant surfaces: Part 1. Review focusing on topographic and chemical properties of different surfaces and in vivo responses to them, *J Dent Res* 85:496–500, 2006.

29. Wennstrom JL, Ekkestubbe A, Grondahl K, Karlsson S, Lindhe J: Oral rehabilitation with implant supported fixed partial dentures in periodontitis susceptible subjects. A 5 year prospective study, *J Clin Periodontol* 31:713–724, 2004.
30. Ivanoff CJ, Grondahl K, Sennerby L, Bergstrom C, Lekholm U: Influence of variations in implant diameters: A 3 to 5 year retrospective clinical report, *Int J Oral Maxillofac Implants* 14:173–180, 1999.
31. Ding X, Zhu SH, Zhang XH, Zhang L: Effect of diameter and length on stress distribution of the alveolar crest around immediately loaded implants, *Clin Implant Dent Rel Res* 11:279–287, 2009.
32. Jones AA, Cochran DL: Consequences of implant design, *Dent Clin North Am* 50:339–360, 2006.
33. Heijdenrijk K, Raghoebar GM, Meijer HJ, Stegenga B, Van de Reiiden WA: Feasibility and influence of the microgap of two implants placed in a non-submerged procedure: A five year follow up clinical trial, *J Periodontol* 77:1051–1060, 2006.
34. Callan DP, O'Mahoney A, Cobb CM: Loss of crestal bone around dental implants: A retrospective study, *Implant Dent* 7:258–266, 1998.
35. Hartman GA, Cochran DL: Initial implant position determines the magnitude of crestal bone remodeling, *J Periodontol* 75:572–577, 2004.
36. Lazzara RJ, Porter SS: Platform switching: a new concept in implant dentistry for controlling post-restorative crestal bone levels, *Int J Periodontics Restorative Dent* 26(1):9–17, 2006.
37. Canullo L, Iurlaro G, Ianello G: Double blind randomized controlled trial study on post extraction immediately restored implants using the switching platform concept. Soft tissue response. Preliminary report, *Clin Oral Implants Res* 20(2):141–151, 2009.
38. Hurzeler M, Fickl S, Zuhr O, Wachtel H: Peri-implant bone level around implants with platform switched abutments: Preliminary data from a prospective study, *J Oral Maxillofac Surg* 65(7): 33–39, 2007.
39. Atieh MA, Ibrahim HM, Atieh AH: Platform switching for marginal bone preservation around dental implants. A systematic review and meta analysis, *J Periodontol* 81(10):1350–1366, 2010.
40. Rodriguez-Ciurana X, Tarnow DP: The effect of interimplant distance on height of the interimplant bone crest when using platform switched implants, *Int J Periodontics Restorative Dent* 29(2):141–151, 2009.
41. Baffone GM, Botticelli D, Pantani F, et al.: Influence of various platform configurations on peri-implant tissue dimensions: An experimental study in dog, *Clin Oral Implants Res* 22(4):438–444, 2011.

41a. Bateli M, et al.: Implant neck configurations, for preservation of marginal bone level: a systematic review. *Int J Oral Maxillofac Implants* 26(2):290–303, 2011.

42. Enkling N, Jöhren P, Klimberg V, et al.: Effect of platform switching on peri-implant bone levels: A randomized clinical trial, *Clin Oral Implants Res* 22(10):1185–1192, 2011.
43. Van Steenberghe D, De mars G, Quirynen M, et al.: A prospective split mouth comparative study of two screw shaped self tapping pure titanium implant systems, *Clin Oral Implants Res* 11(3):202–209, 2000.
44. Jacobs R, Pittayapat P, van Steenberghe D, et al.: A split mouth comparative study up to 16 years of two screw-shaped titanium implant systems, *J Clin Periodontol* 37(12):1119–1127, 2010.
45. Tarnow D, Elian N, Fletcher P, et al.: Vertical distance from the crest of bone to the height of the interproximal papilla between adjacent implants, *J Periodontol* 74(12):1785–1788, 2003.
46. Salama MA, Salama H, Garber DA: Guidelines for aesthetic restorative options and implant site enhancement, *Pract Proced Aesthet Dent* 14:125–130, 2002.
47. Cascione D, Reshad M, Kim T: A novel approach for non-invasive pontic site development, *QDT* 33:218–223, 2010.

27

Immediate Implants

HOWARD H. PARK, DANIEL R. CULLUM

Introduction

Schulte[1] is credited with being the first clinician to attempt immediate implant placement into fresh extraction sockets, his work having been published in German in 1978. Lazzara[2] in 1989 revisited the concept with respect to restorative advantages. The concept of placing implants into fresh extraction sockets has recently regained the interest of clinicians and scientists to reduce treatment time. Minimizing the number of surgical procedures required to restore a missing tooth has obvious advantages for patients who are in need of implant therapy. Immediate implant survival rate has been studied under various factors: presence of infection, vertical fracture, failing endodontic treatment, and antibiotic therapy. The only statistically significant factor seen to increase the survival rate was postoperative antibiotic therapy.[3] Immediate placement of dental implants into fresh extraction sockets with an immediate delivery of a provisional restoration in the esthetic zone is a concept first reported by Wöhrle[4] in 1998. In a randomized prospective study with 2-year follow-up, Crespi and colleagues[5] reported a 100% survival rate with no statistically significant radiographic differences when immediate implants with immediate provisionalization (IIIP) was compared with delayed implants with immediate provisionalization in single maxillary anterior tooth replacement. Cornelini and co-workers[6] reported 22 cases with 12 months of follow-up utilizing IIIP (within 24 hours) in 2005. The authors reported a 100% survival rate with Jemt's papilla index[7] of 2 (at least half of the height of papilla present) on 27 papillae and 3 (the papilla is present in the entire interproximal space) on 17 papillae. Valentini and colleagues[8] also reported a 95.3% survival rate, with 78% of the subjects scoring papilla index of 3 in 1 year follow-up in a similar study. De Rouck and associates[9] reviewed 11 studies on maxillary anterior single IIIP (within 24 hours) and reported survival rates between 93.5% and 100% (6 to 52 months of follow-up), but cautioned against this technique, as midfacial gingival recession was identified as a common esthetic complication. Kan and co-workers[10] reported a 100% survival rate in 35 IIIPs. The authors reported increased marginal bone level and spontaneous papilla regeneration with a mean follow-up time of 4 years, but also reported continuing recession of the facial gingival tissue. With the high survivals reported with immediate implant therapy, discussions in this chapter will primarily focus on factors that affect the esthetic outcome of this treatment modality.

Esthetic Complications

Relative contraindication for immediate implant placement in the maxillary esthetic zone include smoking, periodontally involved teeth, infection, and compromised buccal bone plates. All of these risk factors can lead to esthetic failure of restored implants. The most common complications reported when implants are placed in the esthetic zone include apical recession of the facial gingival margin and the loss of papilla height[5,8-12] (Figures 27-1 and 27-2). Investigators have identified key components related to these complications. Currently recognized major factors include, but are not limited to, buccal plate integrity,[18-22] gingival phenotype,[18] implant positioning,[23] flap elevation,[24] abutment design,[25] and smoking.[26,27] Controversies exist in the literature regarding the proper management of compromised extraction sockets with respect to the integrity of the buccal plate. Historically, much of the literature has recommended avoiding immediate implants in the esthetic zone when the buccal plate is compromised.[28,21,22] Most studies evaluating the effect of compromised buccal plates on facial gingival margin involved raising a full-thickness flap to visually confirm the buccal defect and to perform subsequent hard and soft tissue grafting.[28-33] However, elevation of a full-thickness flap compromises blood supply to the residual alveolar bone and increases subsequent resorption.[24] In 2007, Kan and colleagues[30] treated 23 consecutive patients with immediate implants and immediate provisionalization restoration and found that in 15 of the 23 patients it was necessary to raise full-thickness flaps for guided bone regenerations due to compromised buccal plates. These results showed marked facial gingival recession greater than 1.5 mm 1 year after restorations in patients with



• **Figure 27-1** Apical migration of mid-facial marginal gingiva on tooth #8.



• **Figure 27-2** Shortened distal papilla of restored implant #9 with exposed restorative margin of #10.



• **Figure 27-3** Five years post restoration #7.

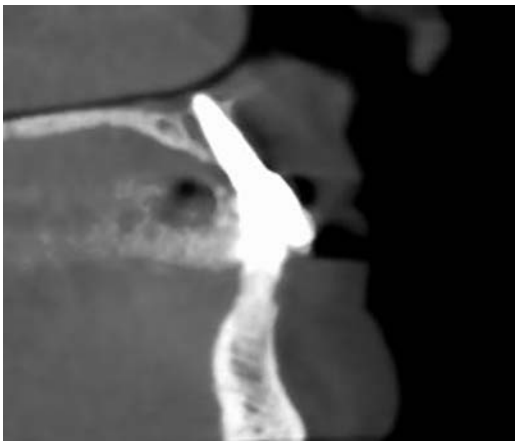

• **Figure 27-4** Cone-beam computed tomography showing little or no facial bone on #7 implant.

large buccal plate defects. This occurred despite guided bone regenerations and subepithelial connective tissue grafts. Based on these findings, they concluded that compromised buccal plates led to more gingival recession, confirming the notion that immediate implant placement should not be attempted in sockets with compromised buccal plates. However, recent studies suggest that a positive esthetic result can be achieved even in sites with a compromised buccal plate. Valentini and colleagues[8] reported in 2010 on treatment of 40 patients with compromised buccal plates (confirmed by visual inspection with flap elevation) by placing immediate implants with immediate or early (7 days postoperative) provisionalization restoration. Follow-up after 12 months showed minimal marginal bone loss with average papilla index of 2.81, but the level of midfacial gingival margin was not studied. More recently, using flapless technique, Rosa and co-workers[34] treated 18 patients with compromised buccal plates by placing autogenous bone into the buccal defect followed by IIIP. During the average of 58 months of follow-up, they reported no facial gingival recessions on any of these patients. Valentini's study required flap elevation to confirm the buccal plate defect, whereas Rosa's used periodontal probes to "map out" the defect through the extraction socket without raising flaps. Both studies emphasized the importance of placing the implants in a more palatal position to create enough labial space for augmentation.

When cone-beam computed tomography (CBCT) is used to evaluate the presence of facial bone on restored implants, it is sometimes surprising to see no visible bone despite adequate esthetic results (Figures 27-3 and 27-4). Quantifying the amount of facial bone in restored implants with CBCT has its limitations. Because of the beam-hardening effect of CBCT technologies, bone thickness of less than 1.0 mm next to the implant body is difficult to visualize, making buccal plate evaluation a challenge.[35] Benic and colleagues[36] followed 14 patients for 7 years and noted that 5 patients did not show any detectable buccal bone facial to the implant on CBCT and yet only showed 1 mm recession on facial-free gingival margin. It is probable that there was indeed bone present in the amount not detectable by the CBCT in their study.

Thin gingival phenotype has been associated with post-restoration midfacial recession.[18] Commonly accepted methods to identify the thin phenotype are using a probe in the sulcus and by visual inspection. Kan and associates[37] studied the gingival phenotype of 48 patients who were scheduled to have maxillary anterior teeth removed for immediate implant

placements. Two calibrated clinicians were asked to evaluate patients before extraction to determine their gingival phenotype by either using a probe in the sulcus or by visual inspection. Following extraction, the soft tissue thickness was measured with calipers at 2 mm apical to the free gingival margin. When these direct measurements were correlated with pre-extraction findings, 15 of 39 patients who were visually assessed as thick had less than 1.0 mm of soft tissue thickness, while 9 of 30 patients who were probed and probe-assessed as thick, had less than 1.0 mm soft tissue thickness. Based on these findings, Kan and colleagues recommended treating every esthetic case as if the patient had a thin gingival phenotype.

Smoking has been associated with a higher failure rate of implants and compromised esthetics.[26] Raes and co-workers[27] reported a prospective study involving 39 smokers and 46 nonsmokers who received a single dental implant in a healed ridge of the maxillary anterior area with immediate provisionalization. After 2 years in function, they noted more midfacial gingival recession and shortened papilla among smokers.

Preoperative Workup

Risk of esthetic complications and any limitations should be thoroughly discussed with the patients during the preoperative record collection. Periapical radiographs are required to identify proximal bone levels on adjacent teeth. Adjacent teeth with compromised proximal bone levels may have shortened papilla heights. An adequate amount of palatal bone must be available in order to engage the implant (Figure 27-5). Lau and colleagues,[38] in a retrospective review of 500 CBCTs, reported 98% of maxillary central incisors have enough palatal bone for implant placement. Kan and coworkers[39] also retrospectively studied CBCTs of 100 patients and concluded that 87.6% of the patients had adequate palatal bone to engage the implants. With the broad application of CBCT technologies, three-dimensional imaging is now cost effective with minimal radiation exposure. CBCT is a powerful tool to allow formulation of a comprehensive diagnosis and treatment plan and should be incorporated as a routine part of preoperative record collection. Chronically infected teeth with fistula tracts do not necessarily preclude the option of immediate implant placement.[40] The height of interdental papilla around the implant restoration is determined by the interproximal bone height of the adjacent teeth.[11,41,42] Patients with high smile lines, class II div II deep bites, or thin gingival phenotypes with "high scalloped" papillae should be avoided until the clinician becomes very comfortable with this technique. Patients with restorations on adjacent teeth such as full-coverage crowns, veneers, or cervical or interproximal composite restorations can have risk of restorative margin exposure due to soft tissue recession after immediate implant placement (Figures 27-6 and 27-8).

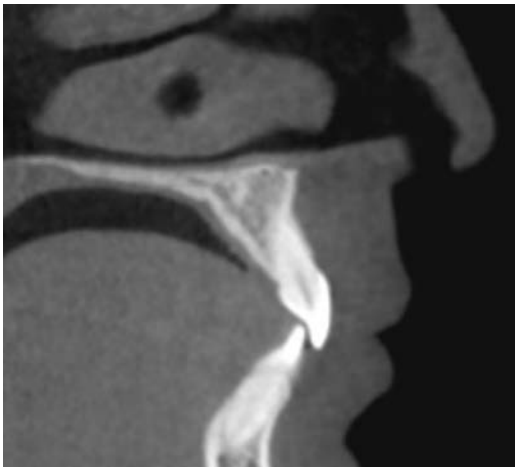

• **Figure 27-5** Typical findings on maxillary central incisor with available palatal bone.

Surgical and Restorative Principles for Immediate Implant Placement

Peri-implant Biological Width

Biological width refers to the vertical dimension of "seal" around the dentogingival junction.[43] It is made up of the



• **Figure 27-6** Preoperative view of fractured #8 crown to be removed.



• **Figure 27-7** Four weeks after immediate implant with immediate provisionalization via flapless procedure on the right maxillary central showing exposed restorative margins on adjacent teeth.

sulcus depth, junctional epithelium, and connective tissue attachment and averages about 3 mm in healthy periodontium.[44] Around dental implants, a similar soft tissue structure exists with similar dimensions.[45] This corresponds to about 2 mm of vertical bone loss[45] as originally defined by Albrektsson and colleagues,[46] with less than 0.2 mm of vertical bone loss per year thereafter. In a healthy peri-implant environment, consistent inflammatory cell infiltrates can be found around the micro-gap, and yet the amount of bone loss is limited to about 1.5 mm in the vertical dimension.[47] Such findings suggest that this type of self-limiting bone loss is an adaptive response to the local condition, supporting the theory that a new peri-implant biological width is being established.[45] This is in contrast to conditions leading to "peri-implantitis," which is defined by chronic inflammation of peri-implant mucosa accompanied by a progressive crestal bone loss beyond the dimension of biological width requiring therapeutic interventions.[48]

A significant change in macro-design of implant/abutment interface described as "platform switching"[49] has led to minimizing this marginal bone loss. Platform switching refers to an "act of changing an implant abutment to one with a smaller diameter, so as to place the implant-abutment interface medial to the edge of the implant platform,"[50] and its effect on marginal bone loss was discovered when a mismatched abutment was inadvertently used in a wide platform implant.[49] The net effect of platform switching is to reduce the inflammatory response at the implant-abutment junction, thereby minimizing bone loss.[51] A split-mouth animal study by Makigusa and colleagues[51] showed that the "bone was maintained vertically and new bone formed horizontally around the platform-switched implants," whereas non–platform switched implants showed both vertical and horizontal bone loss. A meta-analysis of 13 randomized controlled trials revealed significantly less vertical marginal bone loss at implants with the platform-switched configurations.[52] The biological seal around the implant, however, has two more dimensions to be elucidated. The horizontal dimension that extends mesiodistally is reported to be about 1.4 mm[53] and has a direct correlation with the papilla height, especially when two implants are placed next to each other in the esthetic zone.[53] A similar distance exists in the bucco-palatal dimension, and violating this dimension by placing the implants too close to the facial plate has led to facial gingival recession[23,54] CBCT has allowed clinicians to visualize and measure the bucco-palatal dimension[55,56] (Figure 27-9). This dimension is a critical factor in determining the proper bucco-palatal positioning of the implant in the maxillary esthetic zone. In fresh extraction sockets, there is typically a "gap" separating the implant from the buccal plate, and the ideal gap size is debatable, but most agree it should be at least 2 mm.[9,57]

Buccal Plate Remodeling Following Immediate Implant Placement

A recent systematic review by Lang and colleagues[3] showed that within 6 months of extraction, the alveolar ridge will result in 3.8 mm of horizontal reduction and 1.24 mm of vertical reduction. Although studies have shown that the horizontal dimension of the ridge is still reduced regardless of the techniques and types of material used for grafting, most clinicians now accept that socket preservation technique should be used to minimize bone volume loss, especially in the maxillary esthetic zone.[58] CBCT has allowed visualization of bone volume not previously possible with conventional radiographs. Several CBCT studies have shown that the thickness of buccal plate near the crest is less than 1.0 mm in the majority of patients.[59,60] This thickness has been independently verified by others who took direct measurements following extractions.[32] Most of the crestal buccal bone consists of bundle bone (lamina dura) providing the attachment surface for Sharpey fibers of the periodontal ligament. The thickness of this bone layer varies from anterior to posterior teeth ranging from 0.22 mm to 0.54 mm.[61] Bundle bone receives 100% of its blood supply from the periodontal ligament (PDL) and thus is resorbed completely when the tooth is removed. When one considers that the blood supply only comes from three sources (PDL, periosteum, and marrow space), raising a full-thickness flap to remove teeth can greatly compromise the blood supply to this area.[62] As most studies looking at the buccal plate remodeling process included flap elevation



• **Figure 27-8** Teeth #7, #8, and #9 were restored with new restorations.

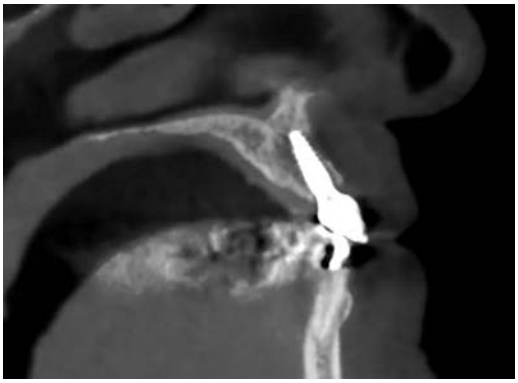

• **Figure 27-9** Palatofacial dimension can be measured on cone-beam computed tomography.

for direct measurements, the question remained whether flapless procedures would make a difference in the amount of buccal plate resorption. Studies comparing an open flap versus flapless procedures on the effect on labial tissue volume loss showed clear advantage of flapless procedures.[63,64] Using CBCT to evaluate the buccal plate, Lee and associates[65] were able to show minimal amount of remodeling when IIIP technique was combined with flapless procedure. Roe and colleagues[56] noted a mean horizontal facial bone reduction of 1.23 mm at the level of implant platform 12 months after the immediate implant placement using flapless technique combined with IIIP.

Implant Positioning

Maxillary anterior implants should be placed in a three-dimensionally correct position in order to achieve maximum esthetic results: bucco-palatal, apico-coronal, and mesiodistal. For the purpose of discussion, it is assumed that a root form, self-tapping bone-level implant is used for immediate maxillary anterior implant placements. A surgical guide based on CBCT is recommended for less experienced clinicians who are contemplating immediate maxillary anterior implants. The guide should be designed to allow the implant abutment screw to emerge through the cingulum of the future implant crown. This will help to ensure that the implant shoulder will not be too close to the buccal plate, leaving the desired larger gap between buccal bone and implant for grafting. Bressan and colleagues,[66] in an experimental study in dogs, found a higher degree of bone formation at buccal plate when the immediate implants were placed more lingually. Evans and coworkers[67] found three times more facial gingival recession when implants were positioned more buccally. Le and associates[68] studied the relationship between crestal labial soft tissue thickness and implant bucco-lingual angulation of maxillary anterior implants. They found a strong correlation between implant angulation and the labial soft tissue thickness, especially when there was less than 2 mm thickness of facial bone. Implants with labial angulation had thinner facial soft tissue thickness compared to implants with cingulum angulation. This correlation disappeared when more than 2 mm of facial bone thickness was found around the implant. Because soft tissue thickness less than 2 mm has been associated with increased marginal bone loss and thinner underlying bone, a connective tissue graft to thicken the soft tissue has been recommended for long-term gingival stability.[69,70]

The extraction should be completed preferably without flap elevation. If the surgical guide is not available, the clinician must control the direction of the osteotomy to minimize deflection of the drill off the palatal wall. A 2.0-mm round burr can be used to create a slot along the coronal third of the palatal socket wall to prevent "slippage" of the drill as described by Hwang and Park.[71] Root-form or tapered implant fixtures have a natural tendency to deflect towards the buccal plate as they are seated apically. Unless side-cutting drills are used, it is often necessary to prep the palatal wall using a Lindeman burr or piezosurgery to prevent the implant from moving facially as it is seated. When the implant is placed following these principles, it is common to visualize exposed facial threads of the coronal two thirds of the implant within the buccal bone gap (Figure 27-10). The horizontal bone resorption following immediate implants has been reported to be about 1.9 mm.[71,72] In healed sockets, implant placement requires 2 mm of facial bone thickness remaining to account for 1.4 mm of biological width.[58] When immediate implants are placed in the maxillary anterior sockets, a distance of at least 2 mm should be present between the buccal plate and the implant shoulder[9,72,73] (Figure 27-11). In an animal study, Pluemsakunthai and Le[73] reported that a 3-mm gap distance led to more bone formation than a 2 mm or 1 mm gap distance. This minimum gap distance of 2 to 3 mm appears to ensure predictable bone regeneration to cover the exposed threads of the implant. Proper apico-coronal positioning of the implant is dictated by the desired final position of the free gingival margin. If the existing free gingival margin is acceptable, the gingival zenith can be used as the reference point,[74] and the implant is seated approximately

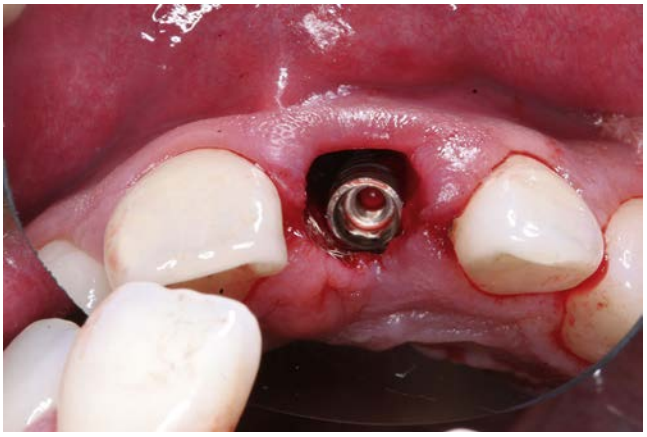

• **Figure 27-10** Exposed implant threads visible on facial aspect away from the buccal plate.



• **Figure 27-11** Minimum of 2 to 3 mm of gap should be available for grafting.

3 to 4 mm apical, to allow adequate "running room" for a proper emergence profile. If the implant is seated too apically, it will lead to excessive bone loss as the biological width reestablishes around the micro-gap. If the implant is seated too shallow, there will not be enough prosthetic space to develop a proper emergence profile for the crown. The mesiodistal position of the implant should be at least 1.5 mm away from the PDL of adjacent teeth.[75] Use of a platform-switched restorative design may allow the implant to be as close as 1.0 mm to the adjacent teeth in reported cases.[75]

Peri-implant Grafting: Hard and Soft Tissue Augmentation

Peri-implant grafting (hard and soft tissue) is done primarily to augment the horizontal facial tissue volume for esthetic results. Grafting of the facial bone gap is suggested for long-term maintenance of facial bone volume and soft tissue support. New bone will regenerate spontaneously without the need for grafting. Some studies have shown that grafting the gap will minimize horizontal bone loss,[58] while others found no beneficial effect of grafting the gap.[76] Most clinicians recommend a gap distance of at least 2 mm.[9,72,73] Average horizontal bone resorption measured 4 to 6 months after immediate implant placement has been reported to be as much as 1.9 mm.[72,73] It should be noted that in these studies, the extractions were done after raising full-thickness flaps. It is also believed that the overlying connective tissue becomes thinner following a tooth extraction.[62] Recent studies showed that when immediate implants are placed without raising a flap, a lesser degree of horizontal tissue volume loss is seen,[62,63] supporting the idea that preserving blood supply to the alveolar crest will lead to less tissue volume loss. Tarnow and colleagues[62] reported that flapless extractions with gap grafting with anatomic healing abutments or immediate provisionalization produced less than 0.4 mm of horizontal tissue volume reduction compared to the average of 1.0 mm when the gap was not grafted. To preserve the horizontal and vertical dimension of the extraction socket from this inevitable volume loss, augmentative procedures should be performed with minimal or no flap elevation. Grunder[69] proposed "extra-alveolar" concomitant connective tissue grafting to augment the labial tissue volume at the time of immediate implant placement in the maxillary anterior region. He reported average tissue collapse of 1.06 mm in the horizontal dimension with no connective tissue augmentation and 0.34-mm gain when connective tissue grafting was done (Figures 27-12 through 27-15). A study by Rungcharassaeng and colleagues[70] also supports concomitant labial connective tissue grafting as beneficial to conceal underlying restorative materials. In their study, the average gingival tissue thickness, measured 2 mm apical to the free gingival margin, was only 1.15 mm following a flapless extraction. Because a gingival tissue thickness greater than 2 mm is ideal for esthetics, the authors recommend soft tissue



• **Figure 27-12** Frontal view of #8 restored implant with good esthetic result.



• **Figure 27-13** Occlusal view of #8 showing the collapse of buccal plate.



• **Figure 27-14** Frontal view of #8 restored implant with good esthetic results.



• **Figure 27-15** Occlusal view of #8 showing the benefit of labial connective tissue graft.



• **Figure 27-16** A screw-retained molar provisional crown made from an alginate impression taken before the extraction.

augmentation with a connective tissue graft in all maxillary anterior cases. Le and co-workers,[68,78,79] however, have reported that the thickness of the labial crestal soft tissue after implant placement can be influenced by multiple variables such as implant position, angulation, and labial bone thickness.

Immediate Provisionalization

Comparable implant survival rates have been reported when implants were placed in healed sites with immediate provisionalization (100%),[11] or when a traditional delayed loading approach was used (97%).[12] Similarly, the immediate provisional restoration has no adverse affect on the survival rate of immediate implants, and the advantages of IIIP have been well documented.[3-6,8-10] They include reduced treatment time, increased case acceptance by the patient, and optimal esthetic results by preserving soft tissue architecture. It is recommended that 35 N-cm of insertion torque is achieved to gain primary stability before immediate provisionalization is considered. The Implant Stability Quotient (ISQ) is a value from 1 to 100 which indicates the level of the implant stability in bone. The number is derived from an instrument which sends magnetic pulses to a sensor that is attached to the implant being tested, and vibrates with certain frequency. Determining the specific frequency an object vibrates is a technique known as resonance frequency analysis (RFA). In general, the higher the frequency the implant vibrates, the higher the ISQ value, inferring higher implant stability. Some clinicians rely on high ISQ values of RFA as a predictor for success with immediate implants. However, a systemic review and meta-analysis of 15 RFA studies with 2,236 immediate-loaded implants by Atieh and colleagues[80] showed poor predictive value and discriminative ability. The osteotomy site is typically "underprepped" in order to increase the insertion torque. Underprepped osteotomy sites, however, make it more difficult to prevent "slippage" of the implant facially during insertion and may necessitate enlarging the osteotomy site to allow a proper angle of insertion.



• **Figure 27-17** Occlusal view of immediate molar provisional with screw access filled.

Provisional crowns can be made from a dental laboratory in advance to maximize the esthetic result. A stock of commercially available prefabricated polymethylmethacrylate (PMMA) shells or plastic denture teeth can also be used. In case of molars with intact crowns, an impression can be taken before the extraction to duplicate the shape of the tooth (Figures 27-16 through 27-18). In the hands of experienced clinicians, an existing restoration such as porcelain-fused metal (PFM) (Figures 27-19 through 27-23) or the patient's own tooth (Figures 27-24 through 27-28) can be used to convert to a screw-retained provisional restorations. The screw-retained method is preferred to avoid potential cement entrapment in the fresh extraction site and frequent loss of retention. Two temporary abutment



• **Figure 27-18** Buccal view of immediate molar provisional restoration.



• **Figure 27-19** Preoperative view of #7 to be removed. #8 is a restored implant.



• **Figure 27-20** Porcelain-fused metal (PFM) of #7 is hollowed with undercuts to create mechanical lock with self-curing acrylics during the direct pick up of the temporary abutment.

options are polyetheretherketone (PEEK) and titanium. For a single-tooth restoration, an engaging abutment is used to prevent rotation of the temporary crowns. For immediate provisional restoration, the authors prefer PEEK abutments and "direct" intraoral pickup technique using flowable



• **Figure 27-21** Porcelain-fused metal (PFM) is being modified extraorally by adding additional acrylics to contour the cervical portion of the provisional crown #7.



• **Figure 27-22** Immediate postoperative view of #7 provisional restoration.

composite or self-curing acrylic as luting agents.[81] Once the temporary abutment and the crown are luted together in the mouth, it is removed and the subgingival portion of the provisional crown is contoured using either composite or acrylic. A flat or concave labial emergence profile will help encourage coronal tissue migration and increase the gingival tissue thickness on the facial aspect of the provisional crown (Figure 27-29). The provisional restoration is relieved to be out of occlusion, and the screw access is filled with either cotton pellets or Teflon tape over the screw head before



• **Figure 27-23** Definitive restoration of #7. Note the presence and level of interimplant papilla between #7 and #8.



• **Figure 27-24** Preoperative view of tooth #24 to be removed due to external resorption of the root.

closing the access with temporary filling materials. When a provisional restoration is not needed, a custom healing abutment can be fabricated to maintain the soft tissue architecture of the extraction socket (Figure 27-30).

Immediate Molar Implants

The application of immediate implant treatment modality has expanded recently to the molars. High survival rates (93.9% to 100%)[13,14] have been reported for immediate molar implant placements, and the marginal bone loss around immediate molar implants has been studied and shown to be comparable to that in implants placed in healed sockets.[15,16] Several different socket configurations exist for maxillary and mandibular molars,[17] each with its own technical challenges for achieving primary stability and proper positioning. Placing a standard-diameter implant into one of the existing root sockets of a multirooted molar has been reported; however, it invariably led to a compromised emergence profile, off-axis loading, and a cantilever effect.[17,82] Larger diameter implants placed in the center of the socket have been recommended for ideal axial loading and



• **Figure 27-25** Natural crown of #24 is used as a veneer and luted to the temporary abutment.



• **Figure 27-26** Immediate postoperative view of #24 provisional restoration.

restorations.[83] A three-dimensionally correct placement is important to minimize ridge-lap or overcontoured restorations. Smaller diameter implants should be placed deeper in order to have adequate "running room" for a proper emergence profile. Ideally, the molar is extracted with a flapless approach by sectioning the crown and removing the roots



• **Figure 27-27** Two weeks postoperative view.



• **Figure 27-28** Definitive restoration of #24.



• **Figure 27-29** Typical concave midfacial contour of the provisional restoration.



• **Figure 27-30** Provisional restoration of #8 is contoured to the soft tissue level as a custom healing abutment.

individually to prevent inadvertent loss of the inter-radicular bone.[17] Skillfully engaging this native mature bone to achieve primary stability is the key to success of immediate molar implants. Some advocate placing the implant before removing the roots to ensure correct mesiodistal placement, as it can be difficult to center the drill in the interfurcal bone without dropping into one of the root sockets.[84] Larger diameter implants may allow greater engagement of the apical and lateral walls of the socket and the bone beyond the socket depth. Proximity to the sinus cavity and inferior alveolar nerve can limit the availability of the apical engaging bone. If 3 to 4 mm of mandibular apical bone is not available for primary stability, the lateral walls of the socket can be engaged otherwise, use of a staged approach must be considered.[85] Implants with diameter greater than 5 mm have been advocated, and implants as large as 10 mm in diameter have been reported.[86] Short implants less than 10 mm in length[87] have been used with high success in the atrophic posterior mandible and maxilla.[88] The use of wide diameter implants in fresh molar extraction sockets has been described.[13-17,89] However, a controlled clinical trial by Atieh and colleagues[89] reported an unusually low success rate of 66.7% for immediate molar implants. These immediate molar implants were immediately loaded within 48 hours with provisional restorations. The fact that majority of the failures occurred within 3 months of definitive restoration suggests the possibility of premature loading. Some

authors suggest the implant platform should be flushed with the furcal bone while others advocate placing the implant 2 to 3 mm below the intact buccal plate.[86] Grafting of the residual gap around the implant may not be necessary for successful osseointegration but is recommended to reduce the ridge remodeling.[14,15,17] A minimum insertion torque of 15 N-cm is recommended for primary stability, with higher insertion torque leading to higher success rates.[90] When excessive maxillary sinus pneumatization limits apical engagement, the sinus floor can be augmented in combination with immediate implant placement. Augmenting the sinus floor using osteotomes via the extraction socket was introduced by Summers[91] as a less invasive technique than a conventional "lateral window" approach. Some controversy exists regarding the minimum residual bone height required to engage the implant for a successful outcome. It is generally accepted that a minimum residual bone height of 4 mm is needed for adequate primary stability.[17,93]

Multiple Immediate Implants and Adjacent Implants in the Esthetic Zone

When multiple teeth are extracted simultaneously, the loss of interdental bone may result in a poor esthetic outcome.[58,94,95] The space between two adjacent implants should be at least 2.8 to 3.0 mm apart to avoid lost of the interimplant alveolar bone height, which can lead to shortened papilla height[58,94] (Figure 27-31). The average interimplant papilla height in the esthetic zone is reported to be 3.5 mm, which is significantly shorter than the normal 5 mm found between 2 healthy natural teeth[95] (Figure 27-32). For this reason, the replacement of adjacent maxillary central and lateral incisors with inadequate mesial-distal space for two implants should consider the use of a pontic to maximize the esthetic outcome.[95] The soft tissue height between an implant and a pontic is reported as high as 5.5 mm,[96] (Figures 27-33 and 27-34). When two central incisors are missing, the central papilla between the two implants may be shortened, but the relative sulcular symmetry can be maintained[97] (Figures 27-35 and 27-36). In 2007, Salama and colleagues[98] reintroduced the root submergence technique[99] for pontic site development adjacent to dental implants (Figures 27-37 through 27-40). Intentionally leaving root remnants to prevent resorption to maintain tissue support was soon applied to immediate implant placement. Case reports of implants placed in direct contact



• **Figure 27-31** Interimplant papilla is absent between #7 and #8.



• **Figure 27-32** #7, #8, #9, #10 are individual implant restorations.



• **Figure 27-33** Preoperative view of a three-unit provisional restoration from #9 to #11 with pontic at #10.



• **Figure 27-34** Definitive restoration. #11 is replaced with an implant with a pontic at #10. Note the height of papilla between #10 and #11.

with ankylosed root with more than 5 years of follow-up showed no detrimental effects from the retained roots[100] (Figures 27-41 and 27-42). These experimental studies coupled with case reports on human subjects have led to the concept of the "socket shielding" technique proposed by Hürzeler and co-workers in 2010.[101] In an animal study, a buccal segment of the root was intentionally left intact against the buccal plate, with an implant placed lingual to the root fragment. While preserving the buccal plate from remodeling, this technique showed successful osseointegration of the implant with new cementum formation where the implant came in direct contact with the root fragments. Various modifications of this technique has been advocated to preserve the interproximal and buccal bone after



• **Figure 27-35** Preoperative view of #8 and #9 to be removed.

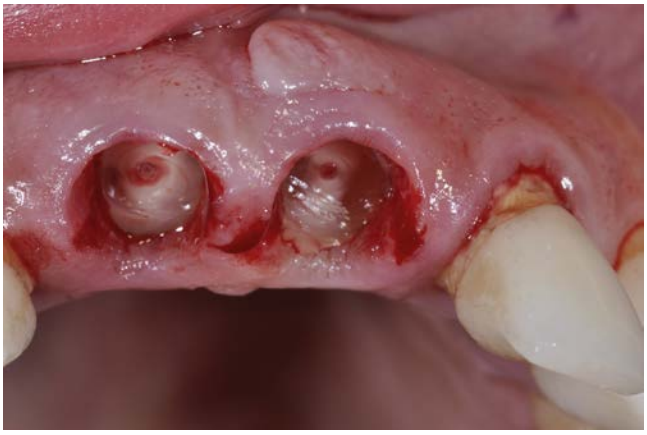

• **Figure 27-38** Root banking #8 and #9.



• **Figure 27-36** 2 years after restoration, showing shortened central papilla.



• **Figure 27-39** Four months with four unit screw-retained provisional restorations with implants at #7 and #10 and with pontics at #8 and #9.



• **Figure 27-37** Preoperative view of periodontally involved #7, #8, #9 and #10 to be removed.



• **Figure 27-40** Definitive restoration.

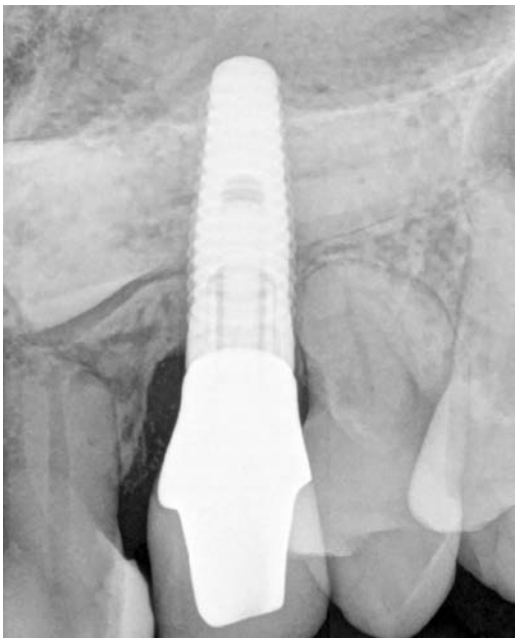

• **Figure 27-41** #11 implant placed through the impacted canine on a 75-year-old patient who declined extraction of the impacted canine, bone grafting and subsequent implant placement. The deciduous canine was removed and immediate implant was placed.



• **Figure 27-42** Three years post-restoration showing mild facial gingival recession showing crown-zirconia abutment margin.

immediate implant placement. A "proximal socket shield" of intentionally leaving a root remnant in the interproximal areas adjacent to an implant was introduced by Kan and Rungcharassaeng to preserve the interimplant papilla.[102] Similarly, a "root membrane" technique was introduced by Siormpas and colleagues[103] to preserve the facial bone from remodeling. Clinicians are advised to use discretion when considering these unconventional techniques until more long-term studies are available.

Summary

Achieving an esthetically pleasing result with immediate dental implants requires application of the prosthetic and surgical principles discussed in this chapter. Using flapless procedures for extraction of the tooth, hard/soft tissue grafting, proper implant positioning in three dimensions, and immediate provisional restoration provide the best prospect for achieving an optimal esthetic outcome. Immediate provisional restoration delivery provides a convenient service for the patient by eliminating a removable appliance, while maintaining near-normal gingival architecture and avoiding an additional tissue training period.

References

1. Schulte W, Kleineikenscheidt H, Lindner K, et al.: The Tübingen immediate implant in clinical studies, *Dtsch Zahnarztl Z* 33:348–359, 1978.
2. Lazzara RJ: Immediate implant placement into extraction sites: surgical and restorative advantages, *Int Periodontics Restorative Dent* 9:332–343, 1989.
3. Lang N, Pun L, Lau K, et al.: A systematic review on survival and success rates of implants placed immediately into fresh extraction sockets after at least 1 year, *Clin Oral Implants Res* 23(suppl. 5):39–66, 2012.
4. Wöhrle P: Single-tooth replacement in the aesthetic zone with immediate provisionalization: Fourteen consecutive cases report, *Pract Periodontics Aesthet Dent* 10:1107–1114, 1998.
5. Crespi R, Capparé P, Gherlone E, et al.: Immediate versus delayed loading of dental implants placed in fresh extraction sockets in the maxillary esthetic zone: a clinical comparative study, *Int J Maxillofac Implant* 23:753–758, 2008.
6. Cornelini R, Cangini F, Covani U, et al.: Immediate restoration of implants placed into fresh extraction sockets for single-tooth replacement: a prospective clinical study, *Int J Periodontics Restorative Dent* 25:439–447, 2005.
7. Jemt T: Regeneration of gingival papillae after single-implant treatment, *Int J Periodontics Restorative Dent* 17:327–333, 1997.
8. Valentini P, Abensur D, Albertini J, et al.: Immediate provisionalization of single extraction-site implants in the esthetic zone: a clinical evaluation, *Int J Periodontics Restorative Dent* 30:41–51, 2010.
9. De Rouck T, Collys K, Cosyn J: Single-tooth replacement in the anterior maxilla by means of immediate implantation and provisionalization: a review, *Int J Maxillofac Implants* 23:897–904, 2008.
10. Kan J, Rungcharasseang K, Lozada J, et al.: Facial gingival tissue stability following immediate placement and provisionalization of maxillary anterior single implants: a 2-to-8-year follow-up, *Int J Oral Maxillofac Implants* 26:179–187, 2011.
11. Grunder U: Stability of the mucosal topography around single-tooth implants and adjacent teeth: 1-year results, *Int J Periodontics Restorative Dent* 20:11–17, 2000.
12. Levin L, Sadet P, Grossman Y: A retrospective evaluation of 1387 single-tooth implants: a six-year follow-up, *J Periodontol* 77:2080–2083, 2006.
13. Fugazzoto PA: Implant placement at the time of mandibular molar extraction: description of technique and preliminary results of 341 cases, *J Periodontol* 79:737–747, 2008.

14. Cafiero C, Annibali S, Gherlone E, et al.: Immediate transmucosal implant placement in molar extraction sites: a 12-month prospective multicenter cohort study, *Clin Oral Implant Res* 19:476–482, 2008.
15. Peñarrocha-Oltra D, Demarchi CL, Maestre-Ferrín L, et al.: Comparison of immediate and delayed implants in the maxillary molar region: a retrospective study of 123 implants, *Int J Oral Maxillofac Implants* 27:604–610, 2012.
16. Prosper L, Crespi R, Valenti E, et al.: Five-year follow-up of wide-diameter implants placed in fresh molar extraction sockets in the mandible: immediate versus delayed loading, *Int J Oral Maxillofac Implants* 25:607–612, 2010.
17. Matsuda H, Borzabadi-Farahani A, Le BT: Three-dimensional alveolar bone anatomy of the maxillary first molars: a cone-beam computed tomography study with implications for immediate implant placement, *Implant Dent* 25(3):367–372, 2016.
18. De Rouck T, Collys K, Cosyn J: Immediate single-tooth implants in the anterior maxilla: a 1-year case cohort study on hard and soft tissue response, *J Clin Periodontol* 35:649–657, 2008.
19. Chang M, Wennstrom J, Odman P, et al.: Implant supported single-tooth replacement compared to contralateral natural teeth: crown and soft tissue dimensions, *Clin Oral Implants Res* 10:185–194, 1999.
20. Small P, Tarnow D: Gingival recession around implants: a 1-year longitudinal prospective study, *Int J Oral Maxillofac Implants* 15:527–532, 2000.
21. Hämmerle C, Chen S, Wilson T: Consensus statement and recommended clinical procedures regarding the placement of implants in extraction sockets, *Int J Oral Maxillofac Implants* 19(suppl):26–28, 2004.
22. Lang NP, Pun BL, Lau IKY, et al.: A systemic review on survival and success rates of implants placed immediately into fresh extraction sockets after at least one year, *Clin Oral Implant Res* 23(suppl. 5):39–66, 2012.
23. Grunder U, Gracis S, Capelli M: Influence of the 3-D bone-to-implant relationship on esthetics, *Int J Periodontics Restorative Dent* 25:113–119, 2005.
24. Blanco J, Nunez V, Aracil L, et al.: Ridge alteration following immediate implant placement in the dog: flap versus flapless surgery, *J Clin Periodontol* 35:640–648, 2008.
25. Chee WW, Donovan TE: Treatment planning and soft tissue management for optimal implant aesthetics, *Ann Acad Med Singapore* 24:113–117, 1995.
26. Strietzel FP, Reichart PA, Kale A, et al.: Smoking interferes with the prognosis of dental implant treatment: a systemic review and meta-analysis, *J Clin Periodontol* 34:523–544, 2007.
27. Raes S, Rocci A, Raes F, et al.: A prospective cohort study on the impact of smoking on soft tissue alterations around single implants, *Clin Oral Implant Res* 00:1–5, 2014.
28. Kan J, Rungcharassaeng K: Immediate placement and provisionalization of maxillary anterior single implants: a surgical and prosthodontic rationale, *Pract Periodontics Aesthet Dent* 12:817–824, 2000.
29. Groisman M, Frossard W, Ferreira H, et al.: Single-tooth implants in the maxillary incisor region with immediate provisionalization: 2-year prospective study, *Pract Proced Aesthet Dent* 15:115–122, 2003.
30. Kan J, Rungcharassaeng K, Sclar A, et al.: Effect of the facial osseous defect morphology on gingival dynamics after immediate tooth replacement and guided bone regeneration: 1-year results, *J Oral Maxillofac Surg* 65(suppl 1):13–19, 2007.
31. Chen ST, Darby IB, Reynolds EC: A prospective study of non-submerged immediate implants: Clinical outcomes and esthetic results, *Clin Oral Implants Res* 18:552–562, 2007.
32. Huynh-Ba G, Pjetursson B, Sanz M, et al.: Analysis of the socket wall dimensions in the upper maxilla in relation to immediate implant placement, *Clin Oral Implants Res* 21:37–42, 2010.
33. Schropp L, Kostopoulos L, Wenzel A: Bone healing following immediate versus delayed placement of titanium implants into extraction sockets—a prospective clinical study, *Int J Oral Maxillofac Implants* 18:189–199, 2003.
34. Rosa JC, Rosa AC, Fransichone CE, et al.: Esthetic outcomes and tissue stability of implant placement in compromised sockets following immediate dentoalveolar restoration: results of a prospective case series at 58 months follow-up, *Int J Periodontics Restorative Dent* 34:199–208, 2014.
35. Razavi T, Palmer R, Davies J, et al.: Accuracy of measuring the cortical bone thickness adjacent to dental implants using cone beam computed tomography, *Clin Oral Implants Res* 21:718–725, 2010.
36. Benic GI, Mokti M, Chen CJ, et al.: Dimensions of buccal bone and mucosa at immediately placed implants after 7 years: a clinical and cone beam computed tomography study, *Clin Oral Implants Res* 23:560–566, 2012.
37. Kan J, Morimoto T, Rungcharassaeng K: Gingival biotype assessment in the esthetic zone: visual versus direct measurement, *Int J Periodontics Restorative Dent* 30:237–243, 2010.
38. Lau S, Chow J, Li W, et al.: Classification of maxillary central incisors—implications for immediate implant in the esthetic zone, *J Oral Maxillofac Surg* 69:142–153, 2011.
39. Kan JYK, Roe P, Rungcharassaeng K, et al.: Classification of sagittal root position in relation to the anterior maxillary osseous housing for immediate implant placement: a cone beam computed tomography study, *Int J Oral Maxillofac Implants* 26:873–876, 2011.
40. Chrcanovic BR, Martins MD, Wennerberg A: Immediate placement of implants into infected sites: a systemic review, *Clin Implant Dent Rel Res* 17:e1–e16, 2015.
41. Salama H, Salama MA, Garber D, et al.: The interproximal height of bone: a guidepost to predictable aesthetic strategic and soft tissue contours in anterior tooth replacement, *Pract Periodontics Aesthet Dent* 10:1131–1141, 1998.
42. Tarnow DP, Magner AW, Fletcher P: The effect of the distance from the contact point to the crest of bone on the presence or absence of interproximal dental papilla, *J Periodontol* 63:995–996, 1992.
43. Ingber JS, Rose LF, Coslet JG: The "biological width"—a concept in periodontics and restorative dentistry, *Alpha Omegon* 10:62–65, 1977.
44. Gargiulo Aw, Wentz FM, Orban B: Dimensions and relations of the dentogingival junction in humans, *J Periodontol* 32:261–267, 1961.
45. Hermann JS, Buser D, Schenk RK, et al.: Biologic width around titanium implants. A physiologically formed and stable dimension over time, *Clin Oral Implants Res* 11:1–11, 2000.
46. Albrektsson T, Zarb G, Worthington P, et al.: The long-term efficacy of currently used dental implants: a review and proposed criteria of success, *Int J Oral Maxillofac Implants* 1:11–25, 1986.
47. Ericsson I, Persson LG, Berglundh T, et al.: Different types of inflammatory reactions in peri-implant soft tissues, *J Clin Periodontol* 22:255–261, 1995.

48. Lang NP, Berglundh T: Periimplant diseases: where are we now? Consensus of the Seventh European Workshop on Periodontology, *J Clin Periodontol* 38(suppl 11):178–181, 2011.
49. Lazzara RJ, Porter SS: Platform switching: a new concept in implant dentistry for controlling postrestoration crestal bone levels, *Int J Periodontics Restorative Dent* 26:9–17, 2006.
50. Laney WR: *Glossary of oral and maxillofacial implants*, Berlin, 2007, Quintessence.
51. Makigusa K, Toda I, Yasuda K, et al.: Effects of platform switching on crestal bone around implants: a histomorphometric study in monkeys, *Int J Periodontics Restorative Dent* 34(suppl):s35–s41, 2014.
52. Strietzel FP, Neumann K, Hertel M: Review article. Impact of platform switching on marginal peri-implant bone-level changes. A systemic review and meta-analysis, *Clin Oral Implant Res* 26:342–358, 2015.
53. Tarnow DP, Cho SC, Wallace SS: The effect of inter-implant distance on the height of inter-implant bone crest, *J Periodontol* 71:546–549, 2000.
54. Peng M, Fei W, Hosseini M, et al.: Influence of implant position on clinical crown length and peri-implant soft tissue dimensions at implant-supported single crowns replacing maxillary central incisors, *Int J Periodontics Restorative Dent* 33:785–793, 2013.
55. Benic G, Mokti M, Chen C, et al.: Dimension of buccal bone and mucosa at immediately placed implants after 7 years: a clinical and cone beam computed tomography study, *Clin Oral Implants Res* 23:560–566, 2012.
56. Roe P, Kan J, Rungcharassaeng K, et al.: Horizontal and vertical dimensional changes of peri-implant facial bone following immediate placement and provisionalization of maxillary anterior single implants: a 1-year cone beam computed tomography study, *Int J Oral Maxillofac Implants* 27:393–400, 2012.
57. Botticelli D, Berglundh T, Lindhe J: Hard-tissue alterations following immediate implant placement in extraction sites, *J Clin Periodontol* 31:820–828, 2004.
58. Vignoletti F, Matesanz P, Rodrigo D, et al.: Surgical protocols for ridge preservation after tooth extraction. A systemic review, *Clin Oral Implants Res* 23(suppl 5):22–38, 2012.
59. Vera C, De Kok I, Reinhold D, et al.: Evaluation of buccal alveolar bone dimension of maxillary anterior and premolar teeth: a cone beam computed tomography investigation, *Int J Maxillofac Implants* 27:1514–1519, 2012.
60. Januçrio A, Duarte W, Barriviera M, et al.: Dimension of the facial bone wall in the anterior maxilla: a cone-beam computed tomography study, *Clin Oral Implants Res* 22:1168–1171, 2011.
61. Hubar JS: Quantification of the lamina dura, *J Can Dent Assoc* 59:997–1000, 1993.
62. Tarnow DP, Chu SJ, Salama MA, et al.: Flapless postextraction socket implant placement in the esthetic zone: Part 1. The effect of bone grafting and/or provisional restoration on facial-palatal ridge dimensional change—a retrospective cohort study, *Int J Periodontics Restorative Dent* 34:323–331, 2014.
63. Tsoukaki M, Kalpidis CDR, Sakellari D, et al.: Clinical, radiographic, microbiological, and immunological outcomes of flapped vs. flapless dental implants: a prospective randomized controlled clinical trial, *Clin Oral Implant Res* 24:969–976, 2013.
64. Job S, Bhat V, Naidu EM: In vivo evaluation of crestal bone heights following implant placement with "flapless" and "with-flap" techniques in sites of immediately loaded implants, *Indian J Dent Res* 19:320–325, 2008.
65. Lee EA, Gonzalez-Martin O, Fiorellini J: Lingualized flapless implant placement into fresh extraction sockets preserves buccal alveolar bone: a cone beam computed tomography study, *Int J Periodontics Restorative Dent* 34:61–68, 2014.
66. Bressan E, Sivolella S, Stellini E, et al.: Healing of buccal dehiscence defects at implants installed immediately into extraction sockets—an experimental study in dogs, *Clin Oral Implants Res* 24:270–277, 2013.
67. Evans C, Chen S: Esthetic outcomes of immediate implant placements, *Clin Oral Implants Res* 19:73–80, 2007.
68. Le BT, Borzabadi-Farahani A, Pluemsakunthai W: Is buccolingual angulation of maxillary anterior implants associated with the crestal labial soft tissue thickness? *Int J Oral Maxillofac Surg* 43:874–878, 2014.
69. Grunder U: Crestal ridge width changes when placing implants at the time of tooth extraction with and without soft tissue augmentation after a healing period of 6 months: report of 24 consecutive cases, *Int J Periodontics Restorative Dent* 31:9–17, 2011.
70. Rungcharassaeng K, Kan J, Yoshino S, et al.: Immediate implant placement and provisionalization with and without a connective tissue graft: an analysis of facial gingival tissue thickness, *Int J Periodontics Restorative Dent* 32:657–663, 2012.
71. Hwang KG, Park CJ: Ideal implant positioning in an anterior maxillary extraction socket by creating an apico-palatal guiding slot: a technical note, *Int J Oral Maxillofac Implants* 23:121–122, 2008.
72. Covani U, Bortolaia C, Barone A, et al.: Bucco-lingual crestal bone changes after immediate and delayed implant placement, *J Periodontol* 75:1605–1612, 2004.
73. Pluemsakunthai W, Le BT, Kasugai S: Alveolar ridge alteration following immediate implant placement in different buccal gap distance: a microcomputed tomography analysis in dogs, *Implant Dent* 24:70–76, 2015.
74. Buser D, Martin W, Belser UC: Optimizing esthetics for implant restorations in the anterior maxilla: anatomic and surgical considerations, *Int J Oral Maxillofac Implants* 19(suppl):43–61, 2004.
75. Vela X, Méndez V, Rodriguez X, et al.: Crestal bone changes on platform-switched implants and adjacent teeth when the tooth-implant distance is less than 1.5 mm, *Int J Periodontics Restorative Dent* 32:149–155, 2012.
76. Favero G, Botticelli D, Favero G, et al.: Alveolar bony crest preservation at implants installed immediately after tooth extraction: an experimental study in the dog, *Clin Oral Implants Res* 24:7–12, 2013.
77. Jung RE, Sailer I, Hämmerle CHF, et al.: In vitro color changes of soft tissues caused by restorative materials, *Int J Periodontics Restorative Dent* 27:251–257, 2007.
78. Le B, Borzabadi-Farahani A, Nielsen B: Treatment of labial soft tissue recession around dental implants in the esthetic zone using guided bone regeneration with mineralized allograft: a retrospective clinical case series, *J Oral and Maxillofacial Surg* 74(8):1552–1561, 2016.
79. Le BT, Borzabadi-Farahani A: Labial bone thickness in area of anterior maxillary implants associated with crestal labial soft tissue thickness, *Implant Dent* 21:406–410, 2012.
80. Atieh MA, Alsabeeha NH, Payne AG: Can resonance frequency analysis predict failure risk of immediately loaded implants? *Int J Prosthodont* 25:326–339, 2012.

81. Park HH: A chair-side technique for immediate implant placement with immediate provisionalization to optimize esthetic outcome, *Selected Readings in Oral and Maxillofacial Surgery* (19)2, 2011.
82. Acocella A, Bertolai R, Sacco R: Modified insertion technique for immediate implant placement into fresh extraction socket in the first maxillary molar sites: a 3-year prospective study, *Implant Dent* 19:220–228, 2010.
83. Shin SW, Bryant SR, Zarb GA: A retrospective study on the treatment outcome of wide-bodied implants, *Int J Prosthodont* 17:52–58, 2004.
84. Hamouda NI, Mourad S, El-Kenawy MH, et al.: Immediate implant placement into fresh extraction socket in the mandibular molar sites: a preliminary study of a modified insertion technique, *Clin Implant Dent Rel Res* 17(s1):e107–e116, 2015.
85. Arlin M: Immediate placement of dental implants into extraction sockets: Surgically related difficulties, *Oral Health* 83:23–27, 1993.
86. Vandeweghe S, Hattingh A, Wennerberg A, et al.: Surgical protocol and short-term clinical outcome of immediate placement in molar extraction sockets using a wide body implant, *J Oral Maxillofac Res* 2:e1–e12, 2011.
87. Feldman S, Boitel N, Weng D, et al.: Five-year survival distributions of short-length (10 mm or less) machined-surfaced and Osseotite implants, *Clin Implant Dent Rel Res* 6:16–23, 2004.
88. Renouard F, Nisand D: Impact of implant length and diameter on survival rates, *Clin Oral Implants Res* 17(3):5–51, 2006.
89. Atieh MA, Alsabeeha NH, Duncan WJ, et al.: Immediate single implant restorations in mandibular molar extraction sockets: a controlled clinical trial, *Clin Oral Implants Res* 24:484–496, 2013.
90. Walker L, Morris G, Novotny PJ: Implant insertion torque values predict outcomes, *J Oral Maxillofac Surg* 69:1344–1349, 2011.
91. Summers RB: A new concept in maxillary implant surgery: the osteotome technique, *Compend Contin Educ Dent* 15:152–160, 1994.
92. Lai HC, Zhuang LF, Ly XF, et al.: Osteotome sinus floor elevation with or without grafting: a preliminary clinical trial, *Clin Oral Implants Res* 21:520–526, 2010.
93. Câlin C, Petre A, Drafta S: Osteotome-mediated sinus floor elevation: a systemic review and meta-analysis, *Int J Oral Maxillofac Implants* 29:558–576, 2014.
94. Tarnow D, Elian N, Fletcher P, et al.: Vertical distance from the crest of bone to the height of the interproximal papilla between adjacent implants, *J Periodontol* 74:1785–1788, 2003.
95. Spear FM: The use of implants and ovate pontics in the esthetic zone, *Compend Contin Educ Dent* 29:72–74, 2008.
96. Salama H, Salama MA, Garber D, et al.: The inter-proximal height of bone: a guidepost to predictable aesthetic strategies and soft tissue contours in anterior tooth replacement, *Pract Periodontics Aesthet Dent* 10:1131–1141, 1998.
97. Priest G: The esthetic challenge of adjacent implants, *J Oral Maxillofac Surg* 65(suppl 1):2–12, 2007.
98. Salama M, Ishikawa T, Salama H, et al.: Advantages of the root submergence technique for pontic site development in esthetic implant therapy, *Int J Periodontics Restorative Dent* 27:521–527, 2007.
99. Casey DM, Lauciello FR: A review of the submerged-root concept, *J Prosthet Dent* 43:128–132, 1980.
100. Szmukler-Moncler S, Davarpanah M, Davarpanah K, et al.: Unconventional implant placement part III: Implant placement encroaching upon residual roots—a report of six cases, *Clin Implant Dent Rel Res*1–10, 2014. July.
101. Hürzeler MB, Zuhr O, Schupbach P, et al.: The socket-shield technique: a proof-of-principle report, *J Clin Periodontol* 37:855–862, 2010.
102. Kan JYK, Rungcharassaeng K: Proximal socket shield for interimplant papilla preservation in the esthetic zone, *Int J Periodontics Restorative Dent* 33:e24–e31, 2013.
103. Siormpas KD, Mitsias ME, Kontsiotou-Siormpa E, et al: Immediate implant placement in the esthetic zone utilizing the "Root-Membrane" technique: clinical results up to 5 years postloading, *Int J Oral Maxillofac Implants* 29:1397–1405, 2014.

28

Bone Grafting Techniques and Materials

TARA L. AGHALOO, JOAN PI-ANFRUNS, SAMANTHA JONES, RAQUEL M. ULMA, PAYAM AFZALI, NORA KAHENASA

Introduction

Bone grafting is an essential component of the surgeon's armamentarium for successful treatment outcomes in implant dentistry. In the United States alone, more than 1 million bone grafting procedures are performed each year, with a 13% annual increase and a market reaching $1 billion a year.[1] Mandibular and maxillary bony defects occur as a result of dental extractions, as residual defects following surgical treatment of pathology, or as congenital alveolar bone defects. Regenerative procedures in the form of bone grafts are often performed to solve these problems. Each defect is unique and requires a tailored treatment plan for reconstruction. Increased understanding of implant success has shown that there is no significant difference in implant survival when bone grafting is performed as compared to implants in native bone.[2,3] The goal of such procedures is to create an optimal site for implant placement and support of soft tissues. Prosthetically driven implant dentistry should focus on form, function, and esthetics. The goal of these reconstructive procedures is to provide a three-dimensional housing that will support and maintain gingival contours in a predictable manner.[4] In recent years, the dental profession has come to understand that implant therapy and placement of endosseous implants must be prosthetically driven, thereby often necessitating alveolar reconstruction to achieve ideal implant placement. Since the first documented bone graft by Van Meekeren in 1668,[5] extensive research has been performed to evaluate a number of bone graft substitutes, but the sheer abundance of biomaterials and techniques currently available can be confusing when making a selection for a particular case. As with any surgical procedure, the clinician must weigh the potential benefits against the risk of complications in order to provide the best treatment possible for the patient.

Bone Biology and Healing

Bone grafting outcomes can be improved by simply understanding the physiology of bone healing and detailed analysis of the properties of materials used. The biology of nonvascularized bone grafting can essentially be described through understanding basic bone healing and regeneration[6-10]:

1. Osteogenesis: The survival of cellular elements within a donor graft allows synthesis of new bone at the recipient site.
2. Osteoinduction: Active recruitment of host mesenchymal stem cells, including growth factors and bone morphogenetic proteins, from the surrounding tissue allows formation of new bone.
3. Osteoconduction: Graft material facilitates invasion of blood vessels and connection of bone cells to the lattice framework.[11]

An ideal bone graft or bone graft substitute should possess these osteogenic, osteoinductive, and osteoconductive characteristics, while maintaining a favorable environment for bone formation without early resorption.

As with normal bone repair, bone grafts heal in three major phases: inflammation, proliferation, and remodeling.[6-10] The inflammation phase begins at the time of injury and continues for up to 5 days. As in all wound healing, inflammation results from blood vessel injury and triggers hemostasis. Platelets assist with hemostasis, and vasoconstriction allows a blood clot to form, beginning the healing process. Inflammatory and phagocytic cells such as neutrophils and macrophages debride the wound site and help decrease bacterial accumulation. The proliferation phase of graft healing results in the production of a disorganized osteoid, or new bone woven by the bone graft cells. In the remodeling phase that follows, the immature bone is resorbed and replaced by organized lamellar bone. The grafted cells initially survive (the first 3 to 5 days) by

diffusion of nutrients from the recipient bed. This process is known as plasmatic inhibition. Adequate graft nutrition is therefore dictated by the quality of the recipient bed. For example, a densely scarred recipient bed would not be an optimal site, as imbibition and vascularization will likely be compromised.

Vital graft cells are needed to form the new osteoid. Angiogenesis is also an important principle for graft healing and integration to occur and is dictated by growth factors secreted by macrophages and platelets in response to the hypoxic graft bed environment. Approximately 3 to 5 days after grafting, budding vessels infiltrate from the surrounding soft tissues and bone edges into the graft. Cancellous bone is revascularized faster than corticocancellous or cortical bone grafts, as the budding vasculature is free to inosculate throughout the large spaces between trabeculae in cancellous bone without having to follow the existing cortical bone haversian system. Early revascularization is key for osteoid apposition, as blood vessels will bring the osteoblasts much-needed oxygen and nutrients and aid in metabolic waste removal. The cortical components serve as an osteoconductive scaffold. The scaffold is resorbed by osteoclasts and remodeled, before osteoid is laid down by osteoblasts. The osteoid and endosteum fuse, and the new bone consolidates.[12]

The remodeling phase starts at about 2 weeks and lasts months to even years, depending on the type of bone graft material used. So long as the bone graft remains immobilized, maintains an adequate blood supply, and remains free of infection, the remodeling stage will complete the healing process. Osteoclasts gradually resorb the immature bone and more organized lamellar bone is laid down. The lamellar bone is mechanically stronger than woven bone. The gradual osteoclastic resorption of immature woven bone with osteoblastic bone formation and maturation to lamellar bone is known as creeping substitution.[13]

Each bone graft type has its own set of material characteristics, including composition, structure, particle size, bone growth method, and resorption time. The surgeon may select a single bone graft material, or a combination of materials, based on individual material properties, advantages, and disadvantages. Bone grafts can be combined or layered to maximize specific properties of each material. Quite often these materials are mixed to combine preferable properties in a particular site.[14,15]

Bone grafts can be categorized according to morphology. Particulate, marrow, or block grafts each have properties that may be better suited to restoring a particular recipient site, and thus choice of material should take form into consideration.[16] Cortical block grafts have structural stability and are valuable for horizontal and vertical defects, yet take comparatively longer to revascularize and have little osteogenic potential compared to marrow and cancellous grafts.[17] Particulate graft structure is lower in density than a block graft and allows for more rapid revascularization of the graft, but also necessitates a scaffold to provide structure. Guided bone regeneration is based on the concept of using a resorbable or nonresorbable barrier membrane to stabilize the blood clot and create a space into which bone cells can grow without interference of the more quickly proliferating soft tissue cells.[18]

Bone grafts can also be classified according to the source from which they were derived. Autografts are composed of tissue from the same individual, allografts are taken from another individual of the same species, xenografts are from a different species than the recipient, and alloplastic grafts are composed of synthetic material. Current research is focusing on creating the ideal versatile graft. Bone graft substitutes are based on the concept of bone tissue engineering, which focuses on improving their osteogenic, osteoconductive, and osteoinductive potential by incorporating bone progenitor cells and growth factors to stimulate cells into a scaffold made of various natural or synthetic materials or their combination, which mimic the bone microenvironment.[19]

Autogenous Grafts

Autogenous bone is considered the "gold standard" for grafting, as it possesses all the necessary features of an ideal graft material.[20-22] Autogenous bone has the ability to induce undifferentiated stem cell maturation through secretion of growth factors and has the biomechanical stability of a framework, allowing invasion of blood vessels and bone cells. Autogenous grafting can include harvesting of cancellous bone or cortical bone. Cancellous bone heals primarily by osteogenesis and possesses a greater concentration of osteocompetent cells than cortical bone, which has a slower turnover and remodeling rate. Autogenous bone remains the only type of bone graft containing osteocompetent cells that can undergo osteogenesis; they contain growth factors and bone morphogenetic proteins (BMPs) that induce bone regeneration and promote soft tissue healing and angiogenesis.

Once harvested, the autogenous graft should be promptly transplanted into the recipient bed to maximize the number of live cells transferred to the recipient site (Figure 28-1). The graft may be temporarily stored in sterile normal saline (or other sterile normotonic solution) until ready for use, and it is recommended that the time to transplantation be minimized so as to ensure graft vitality. Little is known about the influence of the intraoperative storage of autologous bone or the exact amount of time for graft vitality to diminish. However, it is recommended to avoid intraoperative storage of cancellous bone under dry conditions, and longer storage times (more than 2 hours) should be performed in saline solution.[23] This is of particular importance because the amount of new bone formed is directly dependent on the number of osteoblasts that survive transplantation.

Autografts can be of cancellous, corticocancellous, or cortical origin. Although cancellous, corticocancellous, and cortical bone differ in the concentration of osteoblasts that they house, all three contain growth factors and BMPs within an osteoconductive scaffold. Cancellous bone has

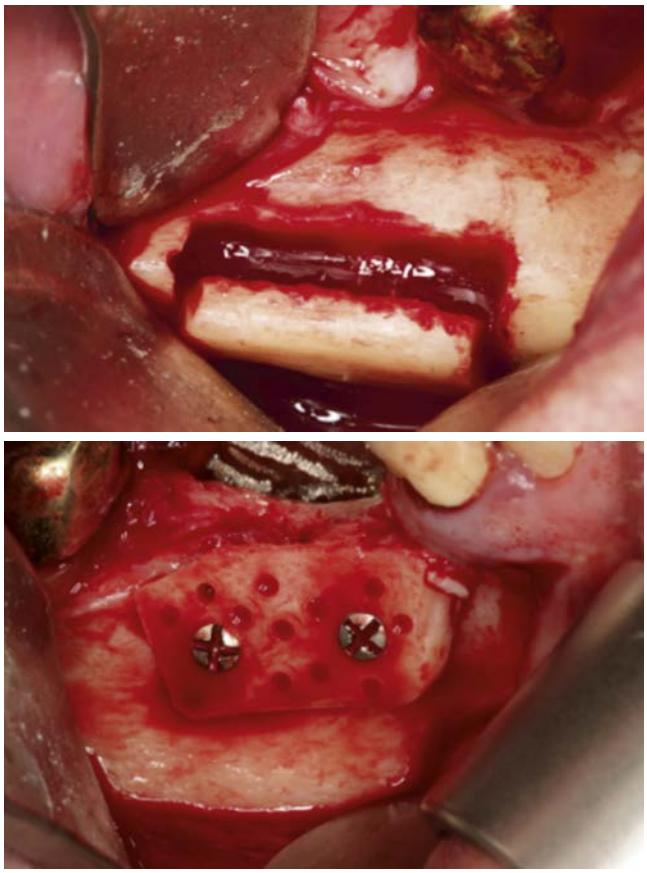

• **Figure 28-1** Block graft harvested from mandibular ramus and fixated into position as a veneer graft for horizontal augmentation.

higher concentrations of osteoblasts, which will eventually deposit new bone, as compared to corticocancellous and cortical bone grafts. Cancellous bone grafts (particulate) inherently contain more progenitor cells and osteoblasts and therefore have more osteogenic and osteoinductive properties than cortical bone. The surgeon must consider all the factors discussed here for each type of autogenous bone graft and choose the one most suited to the recipient site based on these properties, along with their ability to maintain the reconstructed space.

There is an inherent morbidity associated with a second surgical site needed for harvesting autogenous bone, which can be a downfall of our "gold standard." There are a number of potential sites for autogenous grafts. Intraoral sites include mandibular ramus, symphysis, and maxillary tuberosity. Extraoral sites include anterior and posterior iliac crest, proximal tibia, and calvarium. These autogenous donor sites, as well as surgical techniques, are discussed in depth in a subsequent chapter. There are numerous studies substantiating the effectiveness of autogenous grafts for applications in implant dentistry. Aghaloo and Moy in 2007 found that for maxillary sinus grafting in a total of 5128 implants the survival was 92% (confidence interval [CI]: 87.2-96.8) for implants placed into autogenous and autogenous/composite grafts, 93.3% (CI: 83/1-92.9) for implants placed into allogeneic/nonautogenous composite grafts, 81% (CI: 67.5-94.5) for implants placed into alloplast and alloplast/xenograft materials, and 95.6% (CI: 91.1-100) for implants placed into xenograft materials alone.[24] A systematic review by Al-Nawas and Schiegnitz in 2014, looking at implant survival in both sinus floor and alveolar ridge augmentation, found that implant survival seems to be independent of the biomaterial used, with no evidence that autogenous bone grafting is superior to bone substitute materials.[25]

Allografts

Allografts are bone grafts from a donor of the same species, derived from living or deceased donor bone. In 1878, William MacEwen performed the first human bone allograft by reconstructing the infected humerus of a 4-year-old with a graft obtained from the tibia of a child with rickets.[26] Interest in methods of preserving and storing bone showed that bone refrigerated for as long as 3 weeks could be successfully transplanted in dogs.[27] As an alternative to autogenous material, allogeneic bone has recently demonstrated similar efficacy to autogenous bone grafts with decreased patient morbidity.[1,28] Harvesting from an intraoral or extraoral site requires a second surgery, increasing the duration as well as invasiveness of the procedure, and in turn the morbidity of the patient. The various allograft options that are available include fresh-frozen bone allograft (FFBA), freeze-dried bone allograft (FDBA), and demineralized freeze-dried bone allograft (DFDBA).[1,28] Implant survival rates in allografts have been more than 95% in numerous published case series and approaching 99% in some, demonstrating the reliability of this alternative means of bone grafting.[5,28,29] The FFBA is considered osteoconductive, promoting bone regeneration from forming a scaffold allowing the ingrowth of cellular and vascular components.[30-32] FFBA microparticulate allografts lag considerably behind their freeze-dried counterparts in inducing bone healing.[33]

In the freeze-drying process, the water is removed from the ice as vapor. Thus the ice disappears without melting and the water vapor is resolidified through cool temperatures. This significant process has been attributed to alterations in protein configuration or the blocking of hydrophilic sites of proteins.[5,29,32,33] Freeze-dried bone allografts should be rehydrated before implantation to preserve their mechanical strength and resiliency. However, in oral surgical procedures, bone preparations become rehydrated by body fluids relatively quickly and bone preparation rehydration is not as important.[29,32,33] This demonstrates the durability of freeze-dried microparticulate allografts for use in oral and maxillofacial surgery. DFDBA forms are processed by acid demineralization in 0.5 to 0.6 M hydrochloric acid; as a result, 40% of the mineral content is removed, leaving the organic matrix intact.[32] Although this process preserves the BMPs present in bone, DFDBA has very weak osteoinductive properties. To determine the osteoinductive properties of a material, it has to be tested in a rat subcutaneous ectopic implant model. If the material tested is osteoinductive, it should be able to form a bony nodule after 2 weeks of

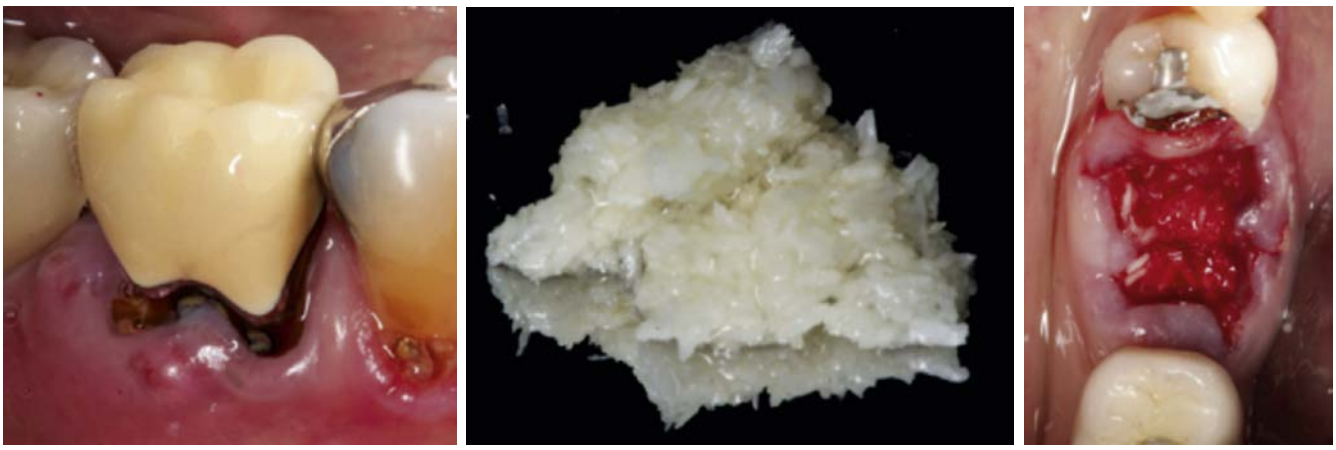

• **Figure 28-2** Tooth #19 planned for extraction. Cortico-cancellous mineralized freeze-dried allograft used for socket augmentation.

implantation in an ectopic site (subcutaneous). Because of the faster rate of bone formation in rats, a material's osteoinductive potential should also be tested in a higher order species, where a higher potency is needed to induce bone formation. If the material tested is able to induce new bone formation in these two models, it is then likely to induce bone formation in humans.[34]

Once the allograft is harvested, it is processed through several methods, including physical debridement to remove soft tissue and reduce cellular load, ultrasonic washing to remove remnant cells and blood, ethanol treatment to denaturalize proteins and deactivate viruses, antibiotic wash to kill bacteria, and sterilization through gamma radiation and ethylene oxide for spore elimination.[35,36] The antigenicity and infectivity of allogeneic materials depend on donor selection and this purification process, which has been reduced because of this more extensive removal of cells.[36] The rigorous protocol for bone processing, which eliminates living cells and consequently the risk of transmission of diseases, and the reduced immunologic reaction to the graft have increased clinical and scientific interest in FFBA.[37-39] The transmission of hepatitis C and human immunodeficiency virus (HIV) after transplantation of allograft material has been documented.[40] The risk of HIV infection through allograft implantation has been estimated to be 1 in 1.6 million, compared with the risk of 1 in 450,000 in blood transfusions.[35]

Bone allografts commonly used in reconstructive oral surgical procedures can be broadly divided into particulate and structural grafts, as the former are used most frequently. Both FDBA and DFDBA are preferably obtained from cortical bone of long bones because of its high levels of inductive proteins and lower antigenic activity compared with cancellous bone.[32] Bone allografts come in various configurations, including but not limited to powder, ground bone, and cancellous and cortical bone chips (Figure 28-2).[32] Particulate grafts are used for filling defects with largely intact walls. The structural grafts are bone plates, sections of mandibles, and cortical and cancellous bone blocks.[41]

Xenografts

The first reported use of demineralized bone dates back to 1889, when Senn used xenogeneic, decalcified bone to repair canine skull defects.[38] Bone xenografts are bone tissues harvested from one species and implanted into a different species. Xenograft bone used in oral and maxillofacial surgery is usually anorganic bovine bone (ABB), but can also be porcine or equine in origin. It has a crystalline structure and a calcium-to-phosphate ratio similar to human bone.[42,43] Xenografts are deproteinized to remove all organic material, alleviating the risk of inducing a host immune response.[44] The remaining inorganic components provide a natural matrix as well as an excellent source of calcium. The structure consists of a wide interconnective pore system with a particle size of 0.25 to 1 mm that can easily be invaded by blood vessels, resulting in osteoblastic migration. ABB is up to 75% porous and has a high specific surface area of almost 100 m^2/g that results in increased angiogenesis and strong osteoconduction properties promoting bone growth.[45,46] ABB lacks osteoinductive and osteogenetic properties, because it is rigorously treated to reduce antigenicity.

The disadvantage of xenografts beyond only having osteoconductive properties is that the resorption rate of bovine cortical bone is slow. In addition, despite being extremely rare, patients may have sensitivity to mad cow disease or bovine spongiform encephalitis as well as religious beliefs against its usage.[47] Cornelini and colleagues evaluated the use of a porous bone mineral matrix xenograft (Bio-Oss) as an adjunct to a biodegradable barrier membrane (Bio-Gide) to support healing following the immediate placement of transmucosal implants into extraction sockets.[48] The soft tissue margin was located 2.6 mm more coronal than the shoulder of the implant in the test group, compared to 1.3 mm in the control group. They concluded that the use of ABB as a membrane support at immediately placed implants may offer advantages in terms of soft tissue support[28] (Figure 28-3).

Lee and co-workers compared the osteoconductive effects of deproteinized bovine bone mineral (DBBM), irradiated



• **Figure 28-3** Anorganic bovine bone (xenograft) and resorbable collagen membrane placed for guided bone regeneration with simultaneous implant placement.

cancellous allograft (ICA), and solvent-dehydrated allograft (SDA) in preserving the extraction socket of 20 patients. DBBM induced more new bone deposition in the periphery of the native bone particles than ICA or SDA, whereas ICA and SDA were more frequently surrounded by fibrous tissue than DBBM. In addition, DBBM retained more residual graft bony particles than ICA or SDA, producing a more rigid bony structure. It is therefore suggested that DBBM may be more favorable for the preservation of extraction sockets than allogeneic graft materials.[42]

In regards to sinus grafting, Aghaloo and Moy demonstrated xenograft superiority with survival of 92% for implants placed into autogenous and autogenous/composite grafts, 93.3% for implants placed into allogeneic/nonautogenous composite grafts, 81% for implants placed into alloplast and alloplast/xenograft materials, and 95.6% for implants placed into xenograft materials alone.[24] In a randomized controlled trial by Merli and colleagues in 2013, no differences apart from chair time were observed when comparing autogenous bone and deproteinized bovine bone matrix grafts with simultaneous implant placement in sinus elevation.[49] Esposito and co-workers researched the efficacy of bone augmentation for implants through a Cochrane systematic review of randomized control trials and found Bio-Oss to be as effective as autogenous bone in regard to sinus lift procedures in extremely atrophic maxillas.[50] All these studies demonstrated excellent success of xenograft in sinus lift procedures.

Alloplasts

Alloplastic biomaterials offer advantages in autogenous bone harvest morbidity and no disease transmission to allograft and xenografts. An alloplast with osteogenic potential will be a welcome addition to a surgeon's treatment of localized alveolar ridge defects. Conflicting opinions about the superiority of autogenous bone grafts were found in several articles, which reported that bone substitutes, whether alone or combined with other materials, were as effective as autogenous bone.[51]

Alloplasts have the benefits of osteoconductivity and no donor site morbidity. However, alloplasts incur the risk of incomplete graft material resorption, a process that may take months to years. Alloplastic bone graft material is in essence a scaffold (Figure 28-4).

Alloplasts are synthetic biocompatible bone graft materials such as calcium phosphate (hydroxyapatite derived), calcium carbonate (coral-derived), or bioactive glass ceramics.[9] Hydroxyapatite is a synthetic bone graft, which is most used now because of its osteoconduction properties and acceptability of bone. Calcium carbonate is being used less because it is completely resorbable in a short time and makes the bone easier to break. Finally used is tricalcium phosphate in combination with hydroxyapatite, thus giving effect of both osteoconduction and resorbability. Biphasic calcium phosphate (BCP), composed of hydroxyapatite (HA) and β-tricalcium phosphate (β-TCP), is a bone graft substitute that resembles the inorganic phase of human bone tissue. The insoluble HA retains its form and structure to maintain space, while the β-TCP will stimulate new bone formation by dissolving into calcium and phosphate ions. Alteration of the HA/β-TCP ratio has been demonstrated to positively influence the substitution rate as well as the bioactivity of these materials.

Preclinical trial provides clinical and histologic evidence to support three formulations of HA/β-TCP as efficacious bone substitutes for regenerating large alveolar ridge defects to receive osseointegrated dental implants.[52] HA presents some disadvantages related to its resorption, because it is hardly absorbed, which hampers remodeling and new bone formation, resulting in poor local stability or permanent stress concentration. Currently, biphasic calcium phosphates, mixtures containing HA/β-TCP (ç-TCP or ë-TCP), are preferably used in clinical practice with varied proportions of HA and TCP because of their considerable difference in the resorption rate—HA reabsorbs very slowly

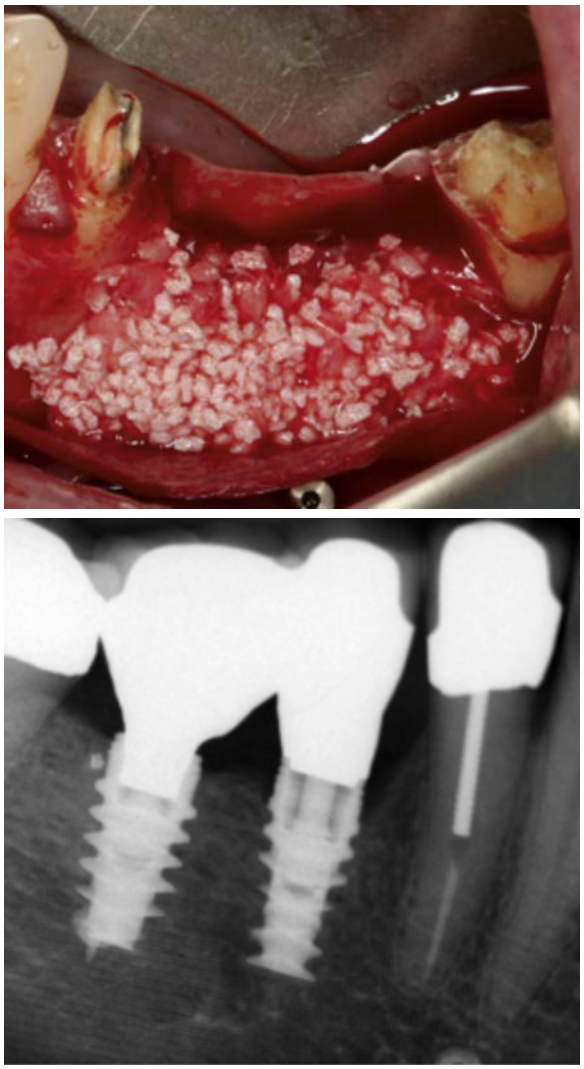

• **Figure 28-4** Alloplastic materials combined with autogenous bone grafts are used for guided bone regeneration procedures that can eventually support dental implants.

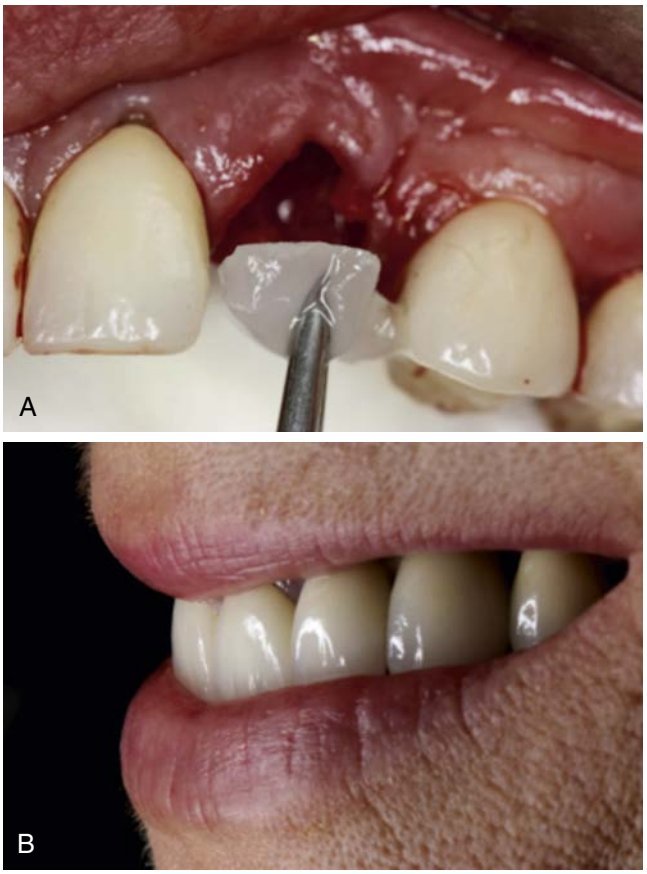

• **Figure 28-5 A,** Rh-BMP2 delivered on an absorbable collagen sponge for socket augmentation after extraction of tooth #11. **B,** Final restoration.

compared with TCP. The difference in the resorption rate influences in the osteoconductive property of these materials. TCPs are more osteoconductive than HA because of their greater biodegradability rate, and clinical and experimental studies have shown that a mixture of HA and TCP promotes intense activity of bone formation with high osteoconductivity.[53,54] However, even though the resorption rate of TCP is faster than that of HA, clinical studies that used only TCP reported the presence of TCP particles long-term postoperatively in maxillary sinus lift and mandible defects.[53-55]

One formulation of BCP (60% HA and 40% β-TCP) is being used more commercially because of its success in alveolar ridge augmentation, maxillary sinus grafting, and the treatment of implant dehiscence and fenestrations.[56] The percentage of new bone formation in human sinus augmentation procedures has ranged from 28% to nearly 38% in less than 8 months.[55,57] So BCP has been shown to be safe, biocompatible, and bioresorbable and can effectively serve as a scaffold for new bone formation. Previous studies have also shown that BCP bone substitute material can be successfully used to reconstruct large alveolar bone defects with excellent clinical and histologic evidence.

Growth Factors

Growth factors are signaling peptides involved in wound healing. Clinically, recombinant growth factors are used to accelerate the healing process.[9] More information on growth factors is detailed in a subsequent chapter. Currently two growth factors are U.S. Food and Drug Administration (FDA) approved for use in bone grafting of intraoral sites: Bone morphogenetic protein (BMP) and platelet-derived growth factor (PDGF).

BMPs are growth factors that bind to pluripotent cells and induce expression of osteoblast markers to stimulate bone formation. BMP-2 is part of a family of osteoinductive proteins that stimulate endochondral and intramembranous bone formation from mesenchymal cells in situ.[58] BMP-2 is an osteoinductive material for bone regeneration in preparation of implants that rivals autogenous bone grafts. For clinical use it is formulated as recombinant human bone morphogenetic protein-2 (rhBMP-2), which is reconstituted with sterile water and placed on an absorbable collagen sponge as the carrier (Figure 28-5, *A*). Postoperative edema is a major anticipated side effect as it is extremely

chemotactic, drawing in inflammatory cells. It is currently FDA-approved for maxillary sinus augmentation and grafting of localized alveolar ridge defects (extraction sites) in adults (see Figure 28-5, *B*). It has been used in large continuity defects, to extend or enlarge a bone graft for alveolar clefts or augment the maxillary sinus.[59,60]

PDGF aids in wound healing by promoting cellular proliferation and angiogenesis.[61] Recombinant PDGF has also been shown to reduce periodontal defects. The biologic profile of PDGF, including its ability to recruit osteoprogenitor cells, makes it particularly suited to address the skeletal defects that are seen with comorbid conditions such as osteoporosis, diabetes, and the effects of smoking.[62] The clinical success and safety that have been demonstrated with use of recombinant human PDGF (rhPDGF) in the repair of periodontal defects have led to FDA approval of rhPDGF for this indication.

Preoperative Evaluation

Bone grafting, soft tissue augmentation, and dental implant placement all require an in-depth evaluation of the patient's medical history to ensure that there are no absolute or relative contraindications to the procedures necessary to provide a successful outcome. Once the patient has been deemed medically stable to proceed with the implant therapy, the clinician must evaluate and use the appropriate biomaterials, including the proper selection of bone augmentation material, technique, and source, in addition to the specific implant type and dimension. Though the surgeon must know how to manage the complications associated with the surgical procedure and materials used, the most important factor for success is to select the most appropriate approach with the highest level of predictability and lowest risk of complication.

The proper placement and successful restoration of the dental implant is directly dependent on the alveolar bone morphology, symmetry, space, and alignment. Stark differences are apparent when an implant is placed and restored without proper attention to the alveolar bone height and soft tissue contours. To ensure graft success, the recipient site must be of good quality, with angiogenic potential, and must remain free of infection. Evaluation with adequate imaging is necessary for planning what type of graft is to be placed. Computed tomography (CT) is used for three-dimensional assessment of bony defect dimensions as well as potential intraoral donor sites. It is vital to quantify the defect as well as assess the quality of the bone from imaging, along with clinical examination.

Factors leading to suboptimal healing can be categorized as systemic or local. Systemic conditions such as advanced age, diabetes, malnutrition, immunosuppression, and tobacco use can adversely affect bone graft healing; thus it is also important to optimize the patient's medical comorbidities and nutritional status. As with wound healing, bone grafts can be compromised by any factor that extends the inflammatory phase of healing, resulting in nonunion of bone grafts, graft loss, fibroplasia, increased tissue scarring, and wound contracture. Local factors that impair graft healing include graft mobility, infection, and poor recipient bed quality. For a bone graft to succeed, it must remain immobile, maintain the reconstructed space, and be free of pressure from an overlying prosthesis. Tension-free and adequate soft tissue closure is crucial in preventing wound dehiscence and graft loss (Figure 28-6). The graft must also be permitted adequate time for healing and bone regeneration prior to implant placement.

Factors Contributing to Suboptimal Bone Graft Healing

Systemic Factors

Aging

Physiology changes with age, and wound healing may decrease with age. Older patients generally have more health problems and take multiple medications, which may interfere with or adversely affect healing. Vascularity is also often compromised, with poor perfusion, friable tissues, and potential for delayed wound healing. These factors are important to consider in the patient's overall treatment plan, especially because a large portion of patients seeking dental implant therapy are of advanced age and more likely to require bone grafting. In order to reduce the risk of poor wound healing associated with advanced age, patients should undergo preoperative optimization of comorbid conditions.[63,64] It is vital for the surgeon to review the patient's medication list, including vitamins, herbal supplements, and alternative medications. It is important to conduct preoperative medication reconciliation, as certain prescription medications, vitamins, and supplements may lead to undesired perioperative events such as increased bleeding and alter the metabolism of other medications. Nutritional status is an extremely important consideration in all wound healing, as it is with consolidation of bone grafts.[64,65]



• **Figure 28-6** Wound dehiscence after 6 months of healing. A guided bone regeneration procedure was performed with xenograft and titanium reinforced non-resorbable membrane.

Diabetes

Patients with diabetes, especially those with inadequate glucose control, are at risk for compromised healing and decreased wound vascularity from microvascular disease. Poor glucose control also affects neutrophil and lymphocyte function, chemotaxis, and phagocytosis, causing greater incidence of wound infection. Release of oxygen to tissues is also reduced, as glycosylated hemoglobin has a higher affinity for oxygen than nonglycosylated hemoglobin. Further, uncontrolled blood glucose decreases red blood cell permeability and microvascular blood flow to the wound. The combination of poor cell recruitment and wound ischemia is detrimental to overall wound healing (Figure 28-7, *A*), often requiring longer healing times (see Figure 28-7, *B*).[66] Good serum glucose control is recommended to improve the likelihood of graft healing. Perioperative antibiotic therapy should be considered for diabetic patients undergoing bone grafting procedures and implant placement.

Smoking

Smoking is known to inhibit wound healing and thus is a risk factor for failure in bone grafts. Smoking tobacco causes release of nicotine, which is known to influence normal bone turnover. Nicotine affects bone metabolism by preventing vascular ingrowth and slowing the formation of osteoblasts, as well as diminishing osteoblast function during the proliferative stage and decreasing the number of osteoclasts.[67] Tobacco releases chemicals, including carbon monoxide and nitrosamine, in turn reducing oxygen delivery to peripheral tissues secondary to vasoconstriction by epinephrine and norepinephrine, causing tissue hypoperfusion and hypoxia. It also causes platelet aggregation and neutrophil dysfunction and increases collagen deposition and blood viscosity, negatively affecting wound healing.[10,64,68] Smoking has been associated with bone graft failure, as demonstrated by Lindfors and colleagues.[69] One of the main findings in this study was that smoking influenced the healing of guided bone regeneration procedures. The study evaluated 27 ridge augmentations performed with particulate autogenous bone and titanium-reinforced ePTFE membrane. Success rates of 94.7% in nonsmokers and 62.5% in smokers ($p = .031$)[69] were found. In a study by Moy and co-workers, smoking was found to increase the risk of implant failure (RR= 1.39; $p = .03$) in a cohort of 1140 implants placed.[64] The authors suggested a smoking cessation protocol prior to elective surgery, where patients should be advised to discontinue tobacco use for at least 2 weeks and should refrain from smoking until wound healing is complete.[68]

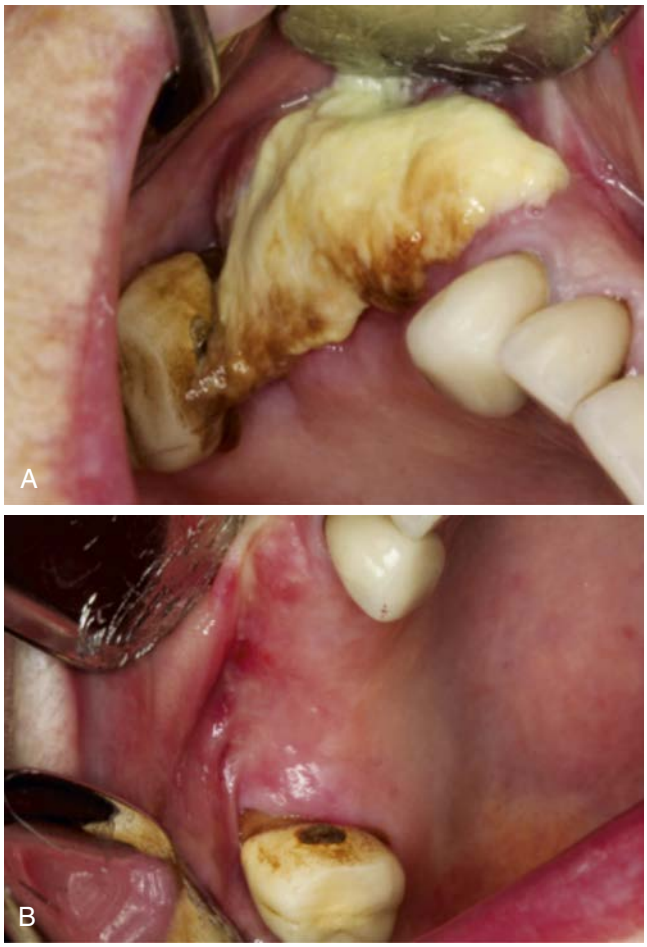

• **Figure 28-7** After sinus augmentation surgery in a poorly controlled diabetic patient, the soft tissue wound healing was significantly delayed. The combination of poor cell recruitment and wound ischemia is detrimental to overall wound healing **(A)** often requiring longer healing times **(B)**.

Local Factors

Infection

Infection is a major cause of impaired wound healing and bone graft loss.[70] Traditionally, wounds are described as sterile, contaminated, colonized, or infected. This classification depends on the mechanism of injury (surgical vs. traumatic wound) and the wound's location with respect to normal bacterial flora. In the oral cavity, surgical wounds are clean-contaminated, as they are in contact with endogenous oral and respiratory microbial flora. The bacterial burden increases in sites associated with odontogenic infection. In order to reduce the risk of graft loss, all sources of infection must be addressed before bone grafting is undertaken. A more detailed discussion of antibiotic prophylaxis in implant dentistry is found in a subsequent chapter.

Adherence to surgical principles and aseptic techniques is also crucial in the prevention of postsurgical infections and graft contamination.[70] Whenever possible, incisions should be made on intact keratinized tissue. Tissues should be handled gently to avoid crushing and compromising vascular perfusion. The recipient bed should be gently debrided free of granulation tissue and irrigated to dilute bacterial load. Bone graft particles should be kept away from saliva and other contaminants. Antibiotic solution (i.e., intravenous clindamycin, penicillin, or cefazolin) may be added to the bone graft material prior to placement. The incision should be closed primarily in a tension-free manner to avoid dehiscence, contamination of the graft, and graft loss. If needed, periosteum can be scored to allow flap advancement over the graft.

If not properly addressed, bone grafts can become infected. A high microbial burden within a surgical wound increases the host's inflammatory response to the area. Bacteria release endotoxins and metalloproteases that destroy the extracellular matrix of healing tissue and cause cell lysis. Bacterial infection and increased inflammation can result in further tissue damage and graft loss. Bacteria also compromise wound healing by competing with the healing tissue for nutrients and oxygen. Infected wounds should be addressed with adequate debridement, removal of graft particles and foreign bodies, and irrigation. Such measures decrease bacterial load and optimize host defenses. Systemic antibiotics can be administered in conjunction with incision and drainage or debridement. Whenever possible, cultures should be obtained prior to initiating empiric antibiotic therapy. Targeted antibiotic therapy should be instituted based on culture antibiotic sensitivity results. Avoidance of broad-spectrum antibiotics helps reduce the risk of developing antibiotic-resistant organisms.

Graft Mobility and Pressure

There is greater chance of graft failure if the bone graft is mobile. Nonunion results when the graft does not form bone-to-bone contact with the host bed, but instead remains bridged by fibrous tissue. Rigid fixation for onlay grafts can minimize mobility during consolidation similar to principles of repairing fractures and achieving anatomic reduction. Repeated microtrauma to a bone graft can also result in graft loss, therefore it is crucial to explain this to the patient so that any function on the grafted area is limited during consolidation. Continuous or extreme tension will produce mobility at the graft site and favor formation of cartilage or fibrous tissue rather than bone.[10,17] Excessive pressure over the bone graft can lead to bone resorption. This is usually encountered when an interim prosthesis has not been adequately relieved. Careful inspection and adjustment of the temporary prosthesis is essential to prevent resorption.

Vascular Compromise

Periosteal preservation during bone graft has been shown to improve graft survival in the craniofacial region. This attests to the importance of early revascularization in bone graft survival, as it is believed that the periosteum facilitates this process.[71] Graft orientation is also crucial to survival and is maximized when the graft's cancellous surface abuts the freshened edges of the host bone and the periosteal surface is in contact with the soft tissues.[72]

References

1. Gruskin E, Doll BA, Futrell FW, Schmitz JP, Hollinger JO: Demineralized bone matrix in bone repair: history and use, *Adv Drug Deliv Rev* 64:1063, 2012.
2. Bazrafshan N, Darby I: Retrospective success and survival rates of dental implants placed with simultaneous bone augmentation in partially edentulous patients, *Clin Oral Implants Res* 25:768, 2014.
3. Agamy EM, Niedermeier W: Indirect sinus floor elevation for osseointegrated prostheses. A 10-year prospective study, *J Oral Implantol* 36:113, 2010.
4. El-Ghareeb M, Moy PK, Aghaloo TL: The single-tooth dental implant: practical guidelines for hard tissue augmentation, *J Calif Dent Assoc* 36:869, 2008.
5. Nissan J, Marilena V, Gross O, et al.: Histomorphometric analysis following augmentation of the anterior atrophic maxilla with cancellous bone block allograft, *Int J Oral Maxillofac Implants* 27:84, 2012.
6. Siddiqui NA, Owen JM: Clinical advances in bone regeneration, *Curr Stem Cell Res Ther* 8:192, 2013.
7. Roberts TT, Rosenbaum AJ: Bone grafts, bone substitutes and orthobiologics: the bridge between basic science and clinical advancements in fracture healing, *Organogenesis* 8:114, 2012.
8. Einhorn TA: The cell and molecular biology of fracture healing, *Clin Orthop Relat Res* S7, 1998.
9. Aghaloo T, Felsenfeld AL: Principles of repair and grafting of bone and cartilage. In Bagheri S, Bell RB, Khan H, editors: *Current therapy in oral and maxillofacial surgery*, Philadelphia, 2012, Saunders.
10. Ulma R, Aghaloo T, Freymiller E: Wound healing. In Fonseca RJ, Barber HD, Powers MP, Frost DE, editors: *Oral and maxillofacial trauma,* ed. 4, St Louis, 2013, Elsevier, p 9.
11. Greenwald AS, Boden SD, Goldberg VM, et al.: American academy of orthopaedic surgeons. The committee on biological I: bone-graft substitutes: facts, fictions, and applications, *J Bone Joint Surg Am* 83-A Suppl 2 Pt 2:98, 2001.
12. Goldberg VM, Stevenson S: The biology of bone grafts, *Semin Arthroplasty* 4:58, 1993.
13. Canter HI, Vargel I, Mavili ME: Reconstruction of mandibular defects using autografts combined with demineralized bone matrix and cancellous allograft, *J Craniofac Surg* 18:95, 2007.
14. Urban IA, Nagursky H, Lozada JL, Nagy K: Horizontal ridge augmentation with a collagen membrane and a combination of particulated autogenous bone and anorganic bovine bone-derived mineral: a prospective case series in 25 patients, *Int J Periodontics Restorative Dent* 33:299, 2013.
15. Rickert D, Sauerbier S, Nagursky H, et al.: Maxillary sinus floor elevation with bovine bone mineral combined with either autogenous bone or autogenous stem cells: a prospective randomized clinical trial, *Clin Oral Implants Res* 22:251, 2011.
16. Draenert FG, Huetzen D, Neff A, Mueller WE: Vertical bone augmentation procedures: basics and techniques in dental implantology, *J Biomed Mater Res A* 102:1605, 2014.
17. Hupp J: Wound repair. In Peterson L, editor: *Contemporary oral and maxillofacial surgery*, St Louis, 2003, Mosby, p 49.
18. Buser D, Bragger U, Lang NP, Nyman S: Regeneration and enlargement of jaw bone using guided tissue regeneration, *Clin Oral Implants Res* 1:22, 1990.
19. Polo-Corrales L, Latorre-Esteves M, Ramirez-Vick JE: Scaffold design for bone regeneration, *J Nanosci Nanotechnol* 14:15, 2014.
20. Janicki P, Schmidmaier G: What should be the characteristics of the ideal bone graft substitute? Combining scaffolds with growth factors and/or stem cells, *Injury* 42(Suppl 2):S77, 2011.
21. Keating JF, McQueen MM: Substitutes for autologous bone graft in orthopaedic trauma, *J Bone Joint Surg Br* 83:3, 2001.
22. Finkemeier CG: Bone-grafting and bone-graft substitutes, *J Bone Joint Surg Am* 84-A:454, 2002.
23. Maus U, Andereya S, Gravius S, et al.: How to store autologous bone graft perioperatively: an in vitro study, *Arch Orthop Trauma Surg* 128:1007, 2008.

24. Aghaloo TL, Moy PK: Which hard tissue augmentation techniques are the most successful in furnishing bony support for implant placement? *Int J Oral Maxillofac Implants* 22(Suppl 49), 2007.
25. Al-Nawas B, Schiegnitz E: Augmentation procedures using bone substitute materials or autogenous bone—a systematic review and meta-analysis, *Eur J Oral Implantol* 7(Suppl 2):S219, 2014.
26. Chase SW, Herndon CH: The fate of autogenous and homogenous bone grafts, *J Bone Joint Surg Am* 37-A:809, 1955.
27. Roe SC, Pijanowski GJ, Johnson AL: Biomechanical properties of canine cortical bone allografts: effects of preparation and storage, *Am J Vet Res* 49:873, 1988.
28. Acocella A, Bertolai R, Ellis 3rd E, et al.: Maxillary alveolar ridge reconstruction with monocortical fresh-frozen bone blocks: a clinical, histological and histomorphometric study, *J Craniomaxillofac Surg* 40:525, 2012.
29. Schlee M, Rothamel D: Ridge augmentation using customized allogenic bone blocks: proof of concept and histological findings, *Implant Dent* 22:212, 2013.
30. Roden Jr RD: Principles of bone grafting, *Oral Maxillofac Surg Clin North Am* 22:295, 2010.
31. Wang RE, Lang NP: Ridge preservation after tooth extraction, *Clin Oral Implants Res* 23(Suppl 6):147, 2012.
32. Piattelli A, Scarano A, Corigliano M, Piattelli M: Comparison of bone regeneration with the use of mineralized and demineralized freeze-dried bone allografts: a histological and histochemical study in man, *Biomaterials* 17:1127, 1996.
33. Malinin T, Temple HT: Comparison of frozen and freeze-dried particulate bone allografts, *Cryobiology* 55:167, 2007.
34. Zhang M, Powers Jr RM, Wolfinbarger Jr L: A quantitative assessment of osteoinductivity of human demineralized bone matrix, *J Periodontol* 68:1076, 1997.
35. Khan SN, Tomin E, Lane JM: Clinical applications of bone graft substitutes, *Orthop Clin North Am* 31:389, 2000.
36. Spin Neto R, Felipe Leite C, Pereira LA, et al.: Is peripheral blood cell balanced altered by the use of fresh frozen bone block allografts in lateral maxillary ridge augmentation? *Clin Implant Dent Relat Res* 15:262, 2013.
37. Buffoli B, Boninsegna R, Rezzani R, et al.: Histomorphometrical evaluation of fresh frozen bone allografts for alveolar bone reconstruction: preliminary cases comparing femoral head with iliac crest grafts, *Clin Implant Dent Relat Res* 15:791, 2013.
38. Marx RE, Carlson ER: Tissue banking safety: caveats and precautions for the oral and maxillofacial surgeon, *J Oral Maxillofac Surg* 51:1372, 1993.
39. Fretwurst T, Spanou A, Nelson K, et al.: Comparison of four different allogeneic bone grafts for alveolar ridge reconstruction: a preliminary histologic and biochemical analysis, *Oral Surg Oral Med Oral Pathol Oral Radiol* 118:424, 2014.
40. Conrad EU, Gretch DR, Obermeyer KR, et al.: Transmission of the hepatitis-C virus by tissue transplantation, *J Bone Joint Surg Am* 77:214, 1995.
41. Beitlitum I, Artzi Z, Nemcovsky CE: Clinical evaluation of particulate allogeneic with and without autogenous bone grafts and resorbable collagen membranes for bone augmentation of atrophic alveolar ridges, *Clin Oral Implants Res* 21:1242, 2010.
42. Lee DW, Pi SH, Lee SK, Kim EC: Comparative histomorphometric analysis of extraction sockets healing implanted with bovine xenografts, irradiated cancellous allografts, and solvent-dehydrated allografts in humans, *Int J Oral Maxillofac Implants* 24:609, 2009.
43. Block MS: Treatment of the single tooth extraction site, *Oral Maxillofac Surg Clin North Am* 16:41, 2004.
44. Misch CE, Dietsh F: How to select, use bone substitute materials in conjunction with root-form implants, *Dent Implantol Update* 4:93, 1993.
45. Hammerle CH, Chiantella GC, Karring T, Lang NP: The effect of a deproteinized bovine bone mineral on bone regeneration around titanium dental implants, *Clin Oral Implants Res* 9:151, 1998.
46. Rodriguez A, Anastassov GE, Lee H, et al.: Maxillary sinus augmentation with deproteinated bovine bone and platelet rich plasma with simultaneous insertion of endosseous implants, *J Oral Maxillofac Surg* 61:157, 2003.
47. Berglundh T, Lindhe J: Healing around implants placed in bone defects treated with Bio-Oss. An experimental study in the dog, *Clin Oral Implants Res* 8:117, 1997.
48. Cornelini R, Cangini F, Martuscelli G, Wennstrom J: Deproteinized bovine bone and biodegradable barrier membranes to support healing following immediate placement of transmucosal implants: a short-term controlled clinical trial, *Int J Periodontics Restorative Dent* 24:555, 2004.
49. Merli M, Moscatelli M, Mariotti G, et al.: Autogenous bone versus deproteinised bovine bone matrix in 1-stage lateral sinus floor elevation in the severely atrophied maxilla: a randomised controlled trial, *Eur J Oral Implantol* 6:27, 2013.
50. Esposito M, Grusovin MG, Coulthard P, Worthington HV: The efficacy of various bone augmentation procedures for dental implants: a cochrane systematic review of randomized controlled clinical trials, *Int J Oral Maxillofac Implants* 21:696, 2006.
51. Garlini G, Redemagni M, Donini M, Maiorana C: Maxillary sinus elevation with an alloplastic material and implants: 11 years of clinical and radiologic follow-up, *J Oral Maxillofac Surg* 68:1152, 2010.
52. Kim DM, Nevins ML, Lin Z, et al.: The clinical and histologic outcome of dental implant in large ridge defect regenerated with alloplast: a randomized controlled preclinical trial, *J Oral Implantol* 39:148, 2013.
53. Ohayon L: Maxillary sinus floor augmentation using biphasic calcium phosphate: a histologic and histomorphometric study, *Int J Oral Maxillofac Implants* 29:1143, 2014.
54. Tosta M, Cortes AR, Correa L, et al.: Histologic and histomorphometric evaluation of a synthetic bone substitute for maxillary sinus grafting in humans, *Clin Oral Implants Res* 24:866, 2013.
55. Kolerman R, Goshen G, Joseph N, et al.: Histomorphometric analysis of maxillary sinus augmentation using an alloplast bone substitute, *J Oral Maxillofac Surg* 70:1835, 2012.
56. Lee JH, Jung UW, Kim CS, et al.: Histologic and clinical evaluation for maxillary sinus augmentation using macroporous biphasic calcium phosphate in human, *Clin Oral Implants Res* 19:767, 2008.
57. de Melo L, Piattelli A, Lezzi G, et al.: Human histologic evaluation of a six-year-old threaded implant retrieved from a subject with osteoporosis, *J Contemp Dent Pract* 9:99, 2008.
58. Urist MR: Bone: formation by autoinduction, *Science* 150:893, 1965.
59. Herford AS, Boyne PJ: Reconstruction of mandibular continuity defects with bone morphogenetic protein-2 (rhBMP-2), *J Oral Maxillofac Surg* 66:616, 2008.
60. Herford AS, Boyne PJ, Rawson R, Williams RP: Bone morphogenetic protein-induced repair of the premaxillary cleft, *J Oral Maxillofac Surg* 65:2136, 2007.

61. Wieman TJ, Smiell JM, Su Y: Efficacy and safety of a topical gel formulation of recombinant human platelet-derived growth factor-BB (becaplermin) in patients with chronic neuropathic diabetic ulcers. A phase III randomized placebo-controlled double-blind study, *Diabetes Care* 21:822, 1998.
62. Hollinger JO, Hart CE, Hirsch SN, et al.: Recombinant human platelet-derived growth factor: biology and clinical applications, *J Bone Joint Surg Am* 90(Suppl 1):48, 2008.
63. Shetty V, Schwartz HC: Wound healing and perioperative care, *Oral Maxillofac Surg Clin North Am* 18:107, 2006.
64. Moy PK, Medina D, Shetty V, Aghaloo TL: Dental implant failure rates and associated risk factors, *Int J Oral Maxillofac Implants* 20:569, 2005.
65. McCoy J, Hudson J: *Oral and maxillofacial clinics of North America*, Philadelphia, 1996, Saunders.
66. Tecilazich F, Dinh T, Veves A: Treating diabetic ulcers, *Expert Opin Pharmacother* 12:593, 2011.
67. Yuhara S, Kasagi S, Inoue A, et al.: Effects of nicotine on cultured cells suggest that it can influence the formation and resorption of bone, *Eur J Pharmacol* 383:387, 1999.
68. Chen Y, Guo Q, Pan X, et al.: Smoking and impaired bone healing: will activation of cholinergic anti-inflammatory pathway be the bridge? *Int Orthop* 35:1267, 2011.
69. Lindfors LT, Tervonen EA, Sandor GK, Ylikontiola LP: Guided bone regeneration using a titanium-reinforced ePTFE membrane and particulate autogenous bone: the effect of smoking and membrane exposure, *Oral Surg Oral Med Oral Pathol Oral Radiol Endod* 109:825, 2010.
70. Murray CK, Obremskey WT, Hsu JR, et al.: Prevention of combat-related infections guidelines: prevention of infections associated with combat-related extremity injuries, *J Trauma* 71:S235, 2011.
71. Oppenheimer AJ, Tong L, Buchman SR: Craniofacial bone grafting: Wolff's law revisited, *Craniomaxillofac Trauma Reconstr* 1:49, 2008.
72. Hardesty RA, Marsh JL: Craniofacial onlay bone grafting: a prospective evaluation of graft morphology, orientation, and embryonic origin, *Plast Reconstr Surg* 85:5, 1990.

29

Bone Graft Biology and Histology

MICHAEL D. ROHRER, HARI S. PRASAD

Introduction

The need for bone augmentation and bone growth–enhancing strategies is great in both medicine and dentistry. In the maxillofacial region, the need can be the result of trauma, postsurgical reconstruction, loss of alveolar bone due to periodontal disease, or the need to increase the amount and quality of bone to accept an endosseous implant. For many years the technique accepted as the gold standard was the harvesting of autologous (autogenous) bone and transplanting it to the needed recipient site.[1,2] Although highly desirable biologically, harvesting autologous bone from a patient at the time of maxillofacial bone augmentation presents several problems. The anatomic site that provides the most bone is the iliac crest. Occasionally other long bone areas are used. This results in a second operation and the accompanying morbidity. Autologous bone can be harvested from the jaws, but the yield is often too low to be satisfactory for augmentation in other parts of the jaws.

Concerns about the morbidity of additional surgical procedures to obtain autologous bone or stem cells and the fear of transferring infectious organisms from animal or human products[3] have led to the development of a wide variety of biologic and synthetic materials to accomplish bone augmentation.[4] In this chapter we will discuss the various materials available, emphasizing the histologic findings of placing these materials in the maxillofacial region.

Classification of Bone Substitute/ Augmentation Materials

A graft is any tissue or organ used for implantation or transplantation. An implant is an object or material partially or totally inserted or grafted into the body for prosthetic, therapeutic, diagnostic, or experimental purposes. Although many of the materials used to augment bone could be called implants, we do not use that term because *implant* in dentistry is strictly defined as an alloplastic material implanted into the oral tissues beneath the mucosal or periosteal layer or within the bone to provide support and retention to a partial or complete denture.

The following definitions are needed for an understanding of grafted or implanted materials:

- Autologous (autogenous)—originating within the individual itself.
- Allogeneic (allogenic)—tissues that are from the same species but a different individual (genotype). Types of donors are cadaveric, living related, and living unrelated.
- Alloplastic—an inert or synthetic foreign material.
- Xenogeneic (xenogenic)—tissues that are from a different species.
- Biomaterial—any material, synthetic or natural, that can be used as a system or part of a system that treats, augments, or replaces any tissue, organ, or function of the body.
- Biologic (biological)—medicinal preparations made from living organisms and their products.

Allogeneic and xenogeneic materials could be considered a graft (tissue), but more frequently they are considered as biomaterials. It is often easier, however, to refer to them as allografts or xenografts. Generally xenografts have been treated in some manner to change the character of the bone, for instance with heat so that they are considered a ceramic. A reasonable classification of bone substitute and augmentation materials is the following, which restricts the term "graft" to living tissue.

Bone Grafts, Biomaterials, and Biologics

Grafts

Autologous bone; fresh/frozen
Autologous stem cells
Allogeneic—not used in dentistry
Xenogeneic; fresh/frozen—not used in dentistry
Osteoblast cell constructs (experimental)

Biomaterials

Bone derivatives (processed cadaver bone)
    Allogeneic bone implants (demineralized and mineralized freeze-dried allogenic bone; deproteinized allogenic bone)

Xenogeneic bone implants (deproteinized and heat-treated bovine bone mineral)
Bone substitutes (alloplasts, synthetic bone)
Ceramics
β-Tricalcium phosphate (β-TCP)
Hydroxyapatite (HA)
Ca_2SO_4 (plaster of Paris)
Calcium phosphate cements
Bioactive glass
Coral and marine algae derivatives
Polymers

Biologics

Matrix factors (fibronectin, vitronectin, thrombospondin-1, amelogenins)
Growth factors (PDGF, TGF-β, IGF-1, VEGF)
Differentiation factors (BMP-2, OP-1/BMP-7, GDF-5)
Peptides (thrombin peptide, TP508, P-15)
Small molecules (PGE receptor agonists)
Platelet-rich plasma

Classification of Bone Growth Enhancing Materials Related to the Influence on Bone Growth

Materials used to enhance bone growth are classified as osteogenic, osteoinductive, or osteoconductive.[5,6]

Osteogenic: An osteogenic substance is one that is derived from or composed of any tissue that is concerned in the growth or repair of bone. Therefore, there must be living osteogenic tissue, either viable osteoblasts or stem cells capable of differentiating into osteoblasts, which can only come from autologous bone or autologous stem cells.

Osteoinductive: An osteoinductive substance stimulates osteogenesis. This is primarily restricted to biologics, not biomaterials. Some authors have proposed that residual substances in biomaterials, such as allogeneic or xenogeneic bone, or alloplastic substances are osteoinductive. However, this is very unlikely and difficult to differentiate from osteoconduction.

Osteoconductive: This generally refers to a biocompatible resorbable or nonresorbable material that aids in the spatial growth of bone. Most frequently this is thought of as a scaffold process whereby the bone can be aided in going in a desired direction from one place to another, generally filling a void, by a "stepping stone" effect.

The optimal outcome of any bone enhancement strategy is the formation of vital cancellous bone. Bone physiology will not tolerate dense cortical bone thicker than is normal for a particular area. Clinicians often want the result of bone enhancement to be type I bone, described as "solid oak." This type of bone can only be found in the anterior mandible where the lingual and facial cortical bones are so close that there is no apparent cancellous bone. The optimal outcome is cancellous bone characterized by trabeculae of sufficient girth and a typical interconnected architecture. The quality of the three-dimensional interconnected architecture is described in two-dimensional analysis as "connectivity" of the trabeculae. When histologically analyzing new bone formation, one has to be tolerant of some "free floating" trabeculae, and numerous trabeculae that in two dimensions do not appear to be continuous with other trabeculae. However, the experienced observer can judge how much two-dimensional connectivity translates to a good interconnected architecture of healthy cancellous bone.

Histologic Examples of Different Bone Augmentation Techniques

Autologous Bone

Influence on Bone Growth: Osteogenic

Although considered the "gold standard" of bone augmentation techniques, in histologic samples, autologous bone is difficult to demonstrate. We feel the main reason is that the autologous bone is devitalized at the time of harvest. The possible surviving osteocytes and progenitor cells may contribute almost immediately to new bone formation. The calcified portion of the autologous bone may be quickly incorporated into the new bone and revitalized with neovascularization and rapidly remodeled or rapidly resorbed. Core specimens in areas of autologous bone grafting lack areas of very mature lamellar trabeculae of bone in the resulting new bone formation. The possibility exists that the calcified portion of the devitalized autologous bone is very quickly resorbed by osteoclasts during active and rapid osteogenesis. Figure 29-1 shows an example of a core sample of autologous bone grafting.

Autologous Adult Stem Cells

Influence on Bone Growth: Osteogenic

Autologous stem cells are progenitor cells for bone retrieved by bone marrow aspiration. Complications have been associated with autogenous bone-harvesting procedures. It has been

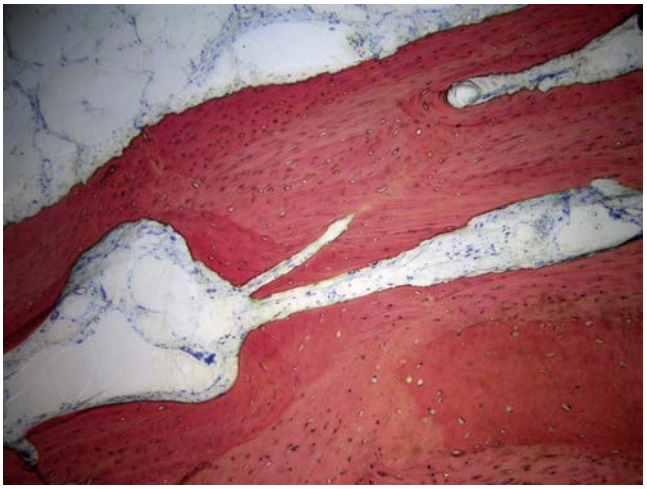

• **Figure 29-1** Autologous bone graft particles (lighter stain) surrounded by newly formed bone (darker red stain). (Stevenel's blue and Van Gieson's picro fuchsin × 200.)

suggested that an alternative approach, grafting with autogenous bone marrow aspirate, may work as well as autologous bone grafting with less comorbidity.[7-11] Bone marrow provides a rich source of adult stem cells as well as growth factors that facilitate osteogenesis. Mixed with a resorbable matrix or scaffold, bone marrow aspirate has the potential to reconstitute various bony defects in the mouth to reconstruct the severely atrophic maxilla and mandible. Figure 29-2 shows examples of core samples of autologous adult stem cell grafting.

Allogeneic Bone

Influence on Bone Growth: Osteoconductive

Demineralized allogeneic bone has been used for a very long time as an osteoconductive material to increase bone formation in areas requiring enhanced new bone formation and was referred to as bone formation by autoinduction.[12] In humans it is very important to have the demineralized allogeneic bone placed in an area of potential bone formation. In our experience the osteoconductive properties of demineralized allogeneic bone are enhanced in areas where vital bone is very close by. Early concepts of the fate of demineralized allogeneic bone included very rapid resorption and replacement by new bone formation. It has been very clear to us for decades that two things can happen to the demineralized allogeneic bone. First, the osteoconductive capabilities of the demineralized allogeneic bone encourage new bone formation around the periphery of the particles of demineralized allogeneic bone. When the particles are close enough together, the new bone bridges among the particles, forming a cancellous bone pattern. This is the desired outcome of any nonresorbable particulate introduced to enhance bone growth. Second, the best result is if the demineralized allogeneic bone can then become recalcified or "reossified." The apparent process is that the demineralized bone matrix in the right location and in the milieu of possible bone formation becomes revascularized. Following revascularization, the demineralized matrix is repopulated by stem cells that take up residence in the empty lacunae and transform into osteocytes. Once the cells are functioning as osteocytes, they control the calcification of the collagen matrix. This recalcification takes place in the collagen matrix of the previously demineralized bone. Polarized images prove that the previously demineralized bone must be totally "reossified" before remodeling can occur. Figure 29-3 shows examples of core samples of demineralized allogeneic bone and new bone formation.

Mineralized allogeneic bone is a relatively recent addition to the armamentarium in the attempt to enhance bone

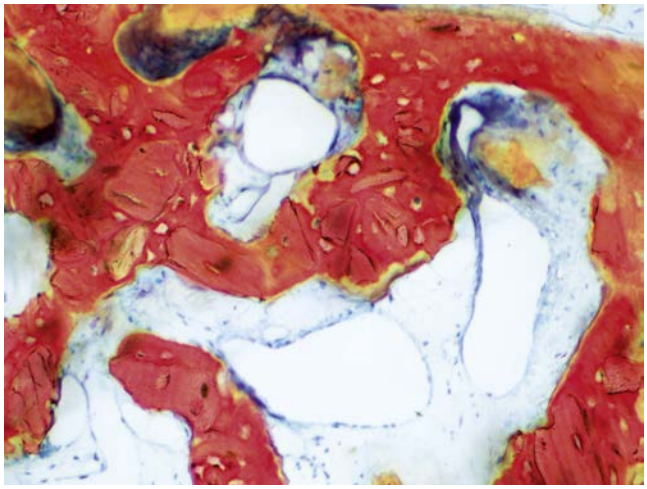

• **Figure 29-2** A combination of mineralized allograft and bone marrow–derived stem cells resulted in this cancellous bone pattern. Small, irregular particles of mineralized allograft are surrounded by new bone formation. Green-staining osteoid is produced by osteoblasts that surrounds the mineralized allograft and transforms into red-staining bone. (Stevenel's blue and Van Gieson's picro fuchsin, 200×.)

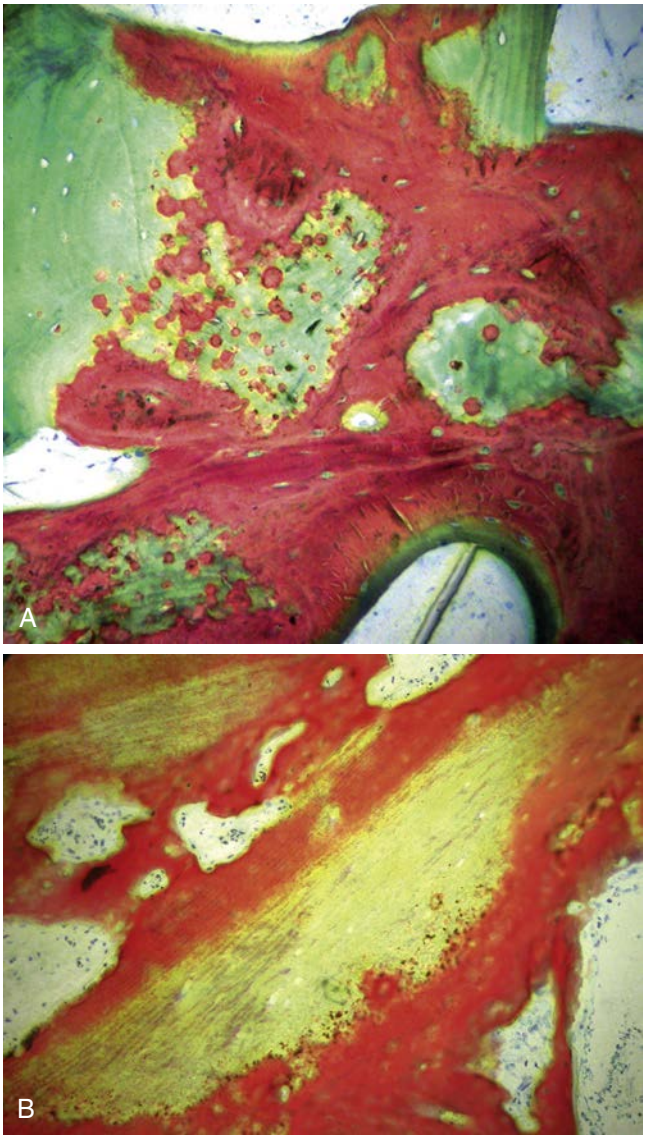

• **Figure 29-3** **A,** The demineralized allograft stains green, and the lamellar pattern of the bone and the empty lacunae are evident. Droplet calcification of this matrix occurs with eventual recalcification of the demineralized matrix. Osteocytes repopulate the empty lacunae as the matrix reossifies. (Stevenel's blue and Van Gieson's picro fuchsin, 200×.) **B,** Particles of green-staining demineralized allograft are becoming recalcified. Simultaneously, new bone is forming bridges among the particles, which will result in a pattern of cancellous bone. (Stevenel's blue and Van Gieson's picro fuchsin, 200×.)

growth.[13-16] This bone is deproteinized to remove fat, cells, and antigens and to inactivate pathogens, but no attempt is made to remove the calcium from the collagen matrix of the bone. The product is supplied as both cortical and cancellous particles of various sizes. The reaction in vivo is different than that for demineralized allogeneic bone. There is no recalcification step, and the particles appear to be very osteoconductive and very quickly become part of a new bone matrix. Being rapidly assimilated into the newly formed bone, the mineralized allogeneic bone seems to become revascularized and repopulated with osteocytes very quickly. This results in rapid remodeling. Histologic observation of this material reveals a relatively good amount of new bone formation and minimal recognizable allogeneic bone within a short time, much faster than is seen with demineralized allogeneic bone. Figure 29-4 shows examples of core samples of mineralized allogeneic bone and new bone formation.

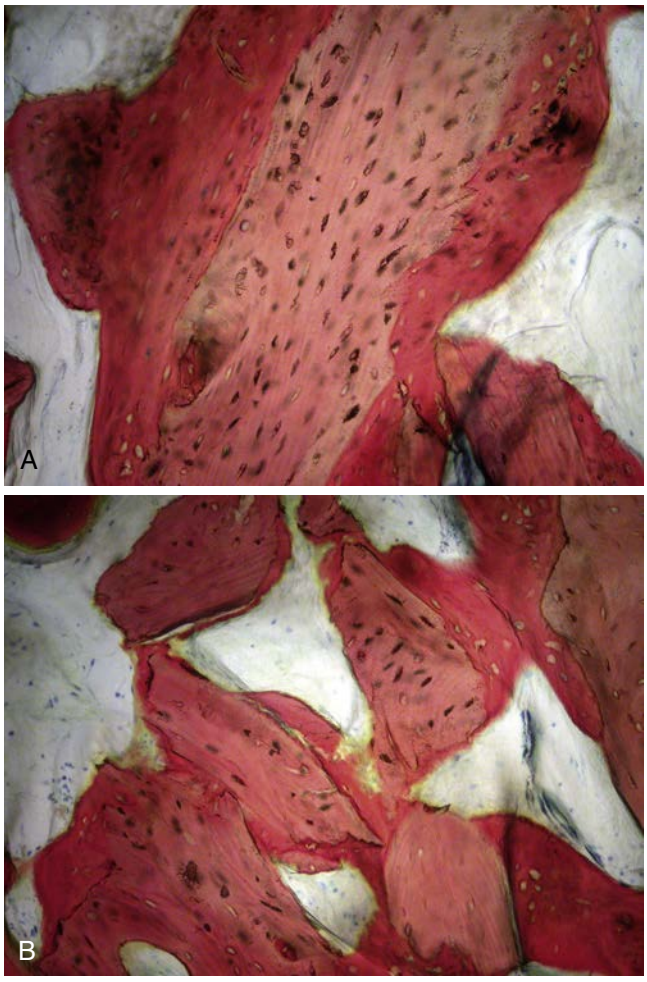

• **Figure 29-4** **A,** The light red–staining bone is mineralized allograft surrounded by darker red–staining new bone formation. Irregular outlines of the mineralized allograft being transformed into vital bone can be seen. This transformation to vital bone takes place relatively fast once the mineralized allograft is incorporated into a mass of newly formed vital bone. (Stevenel's blue and Van Gieson's picro fuchsin, 200×.) **B,** Particles of light red–staining mineralized allograft being surrounded by green-staining osteoid formed by osteoblasts. The osteoid becomes immature bone that bridges among the mineralized allograft particles, resulting in a cancellous bone pattern. (Stevenel's blue and Van Gieson's picro fuchsin, 100×.)

Xenogeneic Bone

Influence on Bone Growth: Osteoconductive

Xenogeneic bone is generally bovine derived. There is a great deal of interest recently in equine derived bone. This bone is treated to render it a ceramic. The level of the sintering temperature determines the physical properties of the resulting calcium phosphate material. Low temperature sintering maintains the structural morphology of the bone (Figure 29-5,*A*). High temperature sintering converts the bone entirely into a ceramic, totally losing the natural structure of the bone (see Figure 29-5,*B*). Xenogeneic bone remains in place and is resorbed extremely slowly, if at all. The goal when using xenogeneic bone is to have it act as a scaffold in osteoconduction and become part of the cancellous bone pattern.[17-20] Although the sintered xenogeneic bone does not remodel, the new bone formation associated with it does remodel to accommodate the insertion of a dental implant. Xenogeneic bone is extremely biocompatible, and histologic examination for several decades has not shown adverse effects when the titanium implants are in direct contact with the residual xenogeneic bone. Figure 29-5 shows examples of core samples of xenogeneic bone and new bone formation.

Alloplastic Implants

Influence on Bone Growth: Osteoconductive

A large group of substances considered bone substitutes, synthetic bone, or alloplastic implants are used in attempts to augment or enhance bone growth. They can generally be grouped into ceramics, polymers, and coral and marine algae derivatives. In the ceramics category, β-tricalcium phosphate (β-TCP),[21] hydroxyapatite,[22] and calcium phosphate cements are calcium phosphate products, perhaps owing their success to the relationship to bone as a calcium phosphate tissue.[23-26] Ca_2SO_4 (plaster of Paris)[27] has been used for years and is quite successful. Bioactive glass seemed to have good potential some years ago but does not seem to be used very frequently at this time.[28,29] Bioactive glass has the advantage of forming a porous, gel-like calcium phosphate, hydroxyapatite-like substance on the surface of the glass when subjected to a physiologic environment. The chemical formula and the size and shape of the bioactive glass particles seem to be very critical in the formation of bone along the surface of the glass. Coral has been used because it is a natural hydroxyapatite substance, often with a geometry and microarchitecture thought to be advantageous for bone growth enhancement. The use of calcified marine algae has also been advocated.[30] Histologic examination shows osteoconductivity but also calcification within the small cell-like structure of the algae. In our experience over the years, polymers have not been very successful as bone augmentation or bone enhancement materials. Histologic specimens have often shown decreased bone formation in the area of polymer

placement. Figure 29-6 shows examples of core samples of alloplastic implants and new bone formation.

Biologics

Influence on Bone Growth: Osteoinductive

Biologics are medicinal preparations made from living organisms and their products. In general, these can be referred to as growth factors. The growth factor that has been receiving the most attention is a group called bone morphogenetic proteins (BMP).[31] The rationale is to mimic the natural osteoinduction through proteins that send signals among cells and enter the cell nucleus where osteoblast differentiation genes are controlled. The goal is to cause bone to be induced to grow. Often clinicians wish to induce bone growth without introducing osteoconductive materials that may or may not resorb and may, in fact, impede the natural or stimulated growth of bone into an area. A host of matrix factors, growth factors, differentiation factors, bone growth peptides, and plasma rich in platelets (in order to get platelet-derived growth factor, PDGF) have been used. In our experience with histologic examination of attempts to use these various biologics, the method of delivery and the concentration of the biologic are critical. Our laboratory has had the most experience with rhBMP-2,[31] P-15 peptide,[32,33] and platelet-rich plasma.[34]

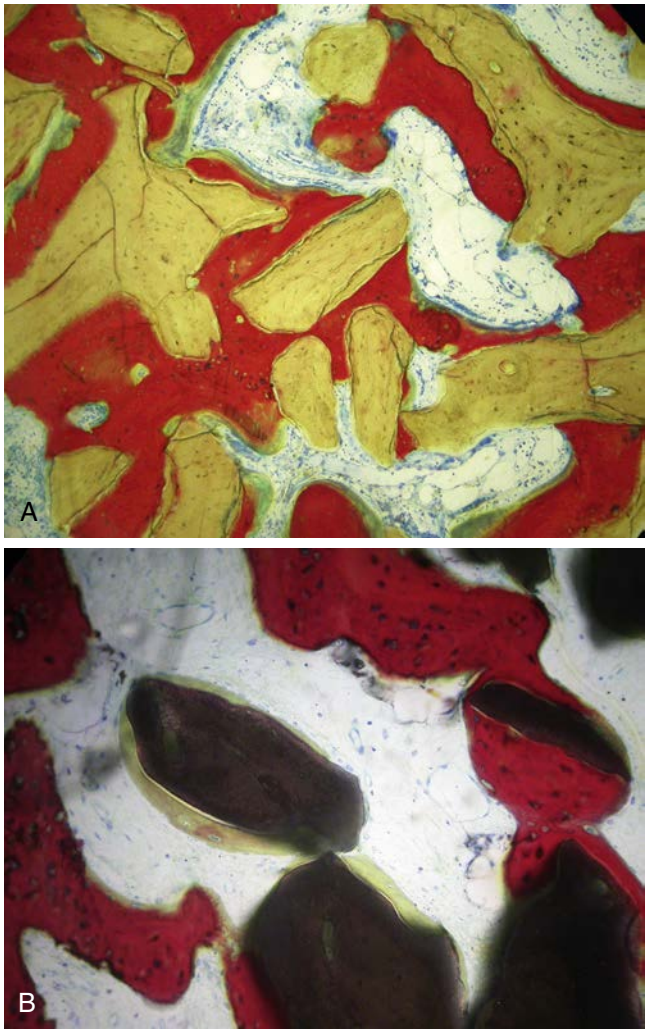

• **Figure 29-5** **A,** Particles of bovine-derived xenograft are surrounded by new bone formation that bridges among the particles, resulting in a dense cancellous bone pattern. A rim of green-staining osteoid lined by osteoblasts can be seen on the surface of the new bone. (Stevenel's blue and Van Gieson's picro fuchsin, 100×.) **B,** Bovine-derived xenograft ceramic being surrounded by green-staining osteoid that calcifies and becomes bone. The osteoblasts seen entrapped in the osteoid are now considered osteocytes and will control the biochemical activities that will result in calcification of the osteoid matrix. A slight red color around the osteocytes in the osteoid surrounding the xenograft particle in the center of the image is an example of this. (Stevenel's blue and Van Gieson's picro fuchsin, 200×.)

Factors Involved with Poor Results

Simply choosing a bone augmentation strategy or a particular material because of intensive literature research, promotions of manufacturers, a lecture from a clinician on the circuit, or suggestions from a colleague will not guarantee success. We are often asked, "There are so many different bone grafting materials—what is the best for me to use?" Many factors regarding the patient and the clinician influence the outcome. We have witnessed greatly disparate results from the same excellent clinicians using the same material. Several new materials showed dismal histomorphometric results when first used clinically and examined histologically. This was often followed by very rapid improvement, which may have been due to technique adaptations or improvements, not changes in the formulation of the materials. Most causes of poor results cannot be discerned histologically. However, a common factor noted histologically is overpacking. This appears to cause lack of bone formation due to an inability of granulation tissue to fill the spaces among the particles of graft or biomaterial. The granulation tissue contains the vascularity, stromal cells, and bone progenitor cells needed to form bone. In these cases the introduced material is truly "osteo-obstructive" rather than "osteoconductive" (Figure 29-7). Another problem noted histologically is the failure to place the graft or biomaterial within the area where bone will form. Osteoconductive materials cannot make bone form in an area such as gingiva and submucosa superficial to the area where bone would normally occur. An exception to this is a technique of forming a protective area by providing a "tent," whereby an increase in the actual height of maxillary or mandibular alveolar bone can be accomplished.[35-37]

Evaluation of Bone Augmentation Procedures

Bone augmentation and enhancement strategies can be evaluated clinically by visualization, measurement, radiography, and ultimate success or failure of dental implants placed in the area of augmentation. However, the best

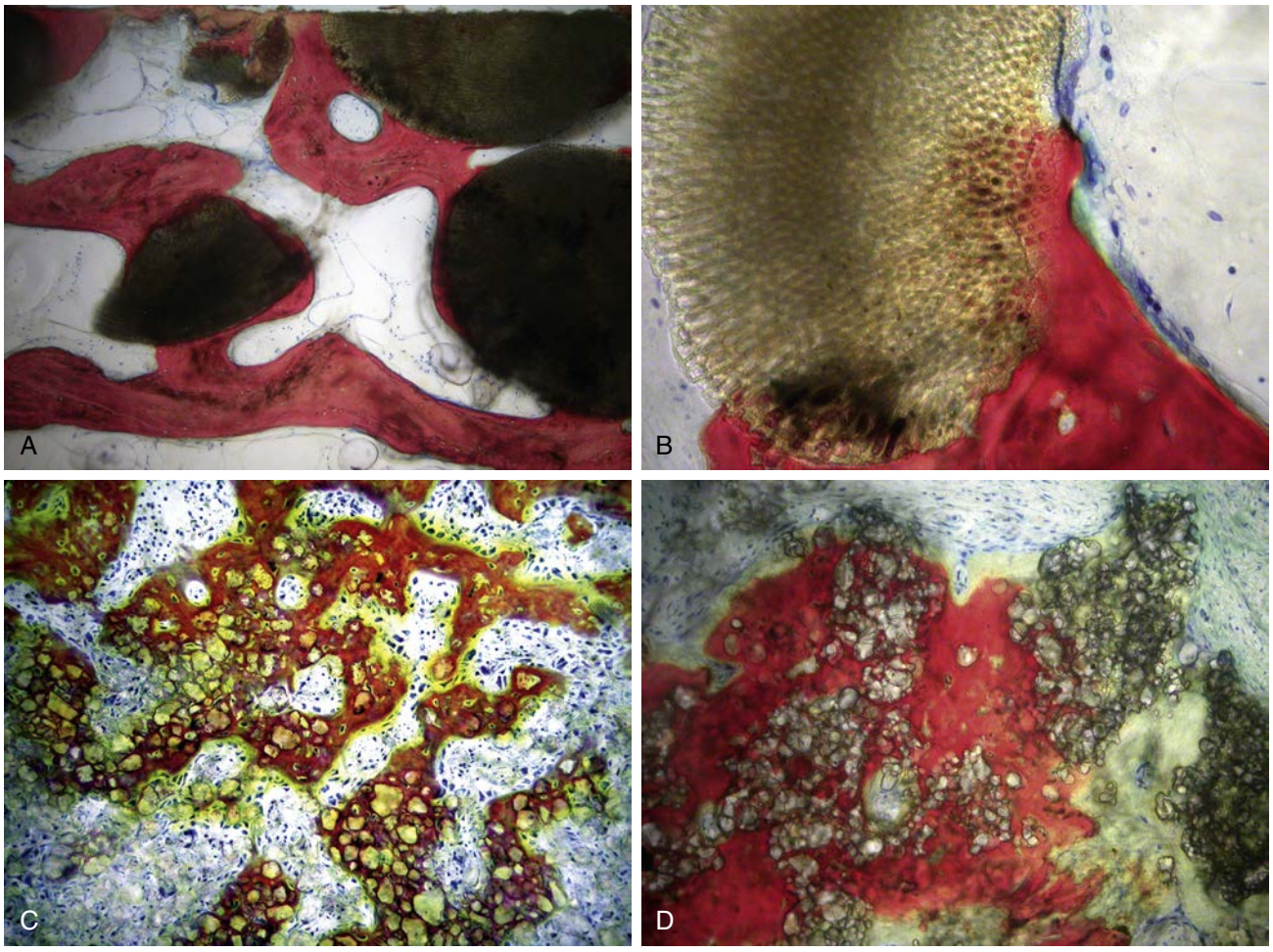

• **Figure 29-6** **A,** New bone formation around particles of mineralized natural marine algae has formed an excellent cancellous bone pattern with trabeculae of good size and connectivity. The bone marrow is delicate and non-inflamed. (Stevenel's blue and Van Gieson's picro fuchsin,100×.) **B,** The new bone formation associated with this particle of mineralized natural marine algae exhibits calcification of the fine, regular cellular pattern of the algae. The dark blue–staining osteoblasts have deposited bright green–staining osteoid. (Stevenel's blue and Van Gieson's picro fuchsin, 200×.) **C,** New bone forms a cancellous network as it forms around particles of calcium sulfate. Plump osteoblasts line the trabeculae. This slightly polarized image emphasizes the osteoid being produced by the osteoblasts that is becoming cancellous bone. (Stevenel's blue and Van Gieson's picro fuchsin, 100×.) **D,** New bone forms around particles of calcium sulfate. Osteoblasts form green-staining osteoid that engulfs the calcium sulfate and matures to calcified bone. The calcium sulfate will totally disappear from the resulting bone formation. (Stevenel's blue and Van Gieson's picro fuchsin, 200×.)



• **Figure 29-7** Core specimen of alloplastic graft showing overpacking resulting in no bone formation. (Stevenel's blue and van Gieson's picro fuchsin, 25x.)

way to evaluate the efficacy and success of osteogenic, osteoinductive, or osteoconductive strategies is to histologically evaluate bone from the area of interest. In order to evaluate all of the possible materials, and especially to differentiate between bone and demineralized allogeneic bones, the bone must be examined histologically without subjecting it to acidic decalcification. Although properly called mineralized specimens, because the standard method of microscopically examining bone for more than 100 years has been decalcification, the common designation is non-decalcified specimens. Additionally, numerous materials either cannot be sectioned even if the bone is decalcified, or, because they are calcium based, will disappear upon decalcification. Several methods have been

adapted from mineralogy research or have been specifically developed in order to produce tissue sections of calcified material capable of being examined with light microscopy. Professor Dr. (mult.) Karl Donath at the University of Hamburg, Germany, invented a system that was further refined with his help by the EXAKT company in Norderstedt, Germany (Donath/EXAKT Technique).[38,39] With this technique, samples may include titanium, ceramics, calcified material, polymers, glass, or almost any traditionally non-sectionable material, and thin sections capable of light microscopic examination can be routinely produced. Staining techniques have been used over the years by bone researchers in order to identify different areas of bone such as osteoid, different maturity levels, and growth patterns. For many years our laboratory has used and has modified Stevenel's blue and Van Gieson's picro fuchsin stains so that they are the most helpful in differentiating osteoid and demineralized bone from mineralized bone, and qualitatively differentiating immature bone from mature bone. The different staining colors and qualities are striking, so that computer image analysis is improved. All of the photomicrographs in this chapter are of bone sections stained in this manner (Figure 29-8). Polarization examination and vital staining is much more successful with non-decalcified sections. Stain introduced into a living organism (vital, or in vivo staining) in both humans and animals can determine the rate and precise location of bone growth. More stains are available for animal studies than are acceptable for humans, and frequently specimens are triple or quadruple labeled (Figure 29-9). Polarization is most useful for determining whether the bone is mature (lamellar) or immature (woven) (Figure 29-10).

Histomorphometric analysis is the method of quantification of various components in a bone sample. Numerous computer analysis-histomorphometric programs are available, including NIH Image, Bioquant, OsteoMeasure, Quantimet 720, and Morphomet. Outside of research, the major use for histomorphometric analysis is the management of osteoporosis. We prefer the accuracy and ease of use of NIH Image combined with Adobe Photoshop. In a non-decalcified bone sample we can differentiate and measure BIC (bone-implant contact), total bone, vital and nonvital, mineralized and demineralized, bone marrow, osteoid, non-bone grafts, and biomaterials. The histology slides are two-dimensional, so one can only measure area. The more sections examined, the closer one comes to measuring volume, which is the goal and the assumption when bone and biomaterial percentages are reported and compared in the literature. Micro–computed tomography (micro-CT) is beginning to become available, and with the numerous "slices" available, nearly three-dimensional analysis of small specimens is possible. Micro-CT together with histology and histomorphometric analysis will give a very accurate picture of the quantity, identity, and quality of material in augmented bone areas.

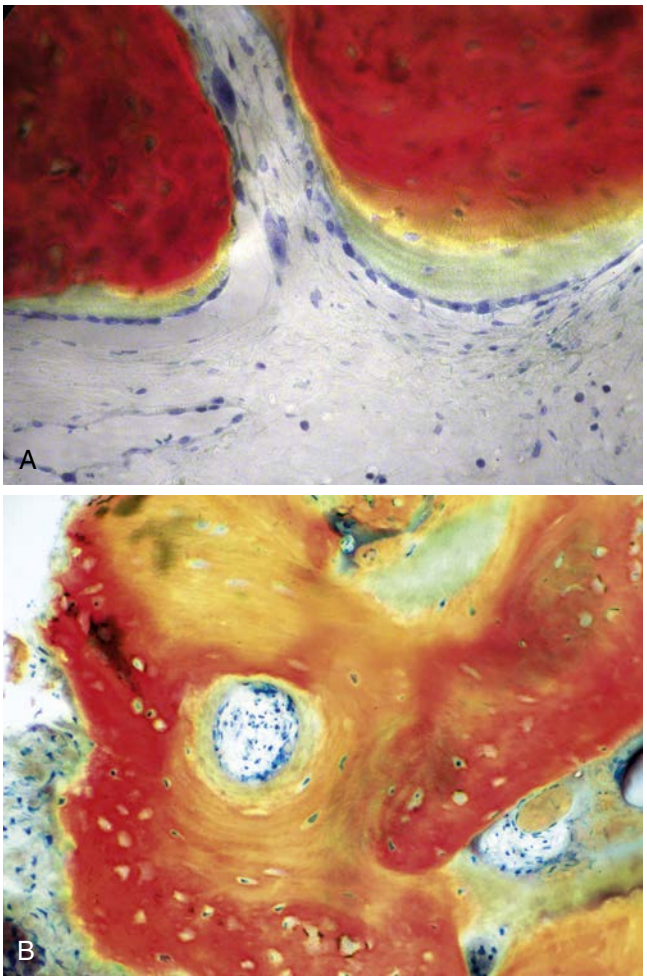

• **Figure 29-8** **A,** The advantage of non-decalcified sections and Stevenel's blue and Van Gieson's picro fuchsin stains is that the osteoid stains a dramatically different color from calcified bone. Calcified bone stains different colors depending on the maturity of the bone. In this image the transition from uncalcified osteoid to calcified bone is seen through color changes from green to red. The dark blue–staining osteoblasts as well as other cells of the delicate bone marrow can be easily identified. The strikingly different colors make computer image analysis easier. (Stevenel's blue and Van Gieson's picro fuchsin, 400×.) **B,** This image of very immature bone shows the advantage of non-decalcified sections and Stevenel's blue and Van Gieson's picro fuchsin stain. The osteoid stains green, the osteoblasts stain dark blue, and the bone stains progressively more red as it matures. Osteocytes are easily seen in the lacunae of the very immature bone. (Stevenel's blue and Van Gieson's picro fuchsin, 200×.)

Advantages and Limitations of Human Bone Core Specimens

The ability to secure and analyze human specimens of bone-augmented areas has clear advantages but numerous limitations in comparison with animal experimental specimens. The most obvious advantage is the ability to study the reaction of human bone to different bone augmentation strategies in the exact areas that bone augmentation and implant placement will take place, in patients who

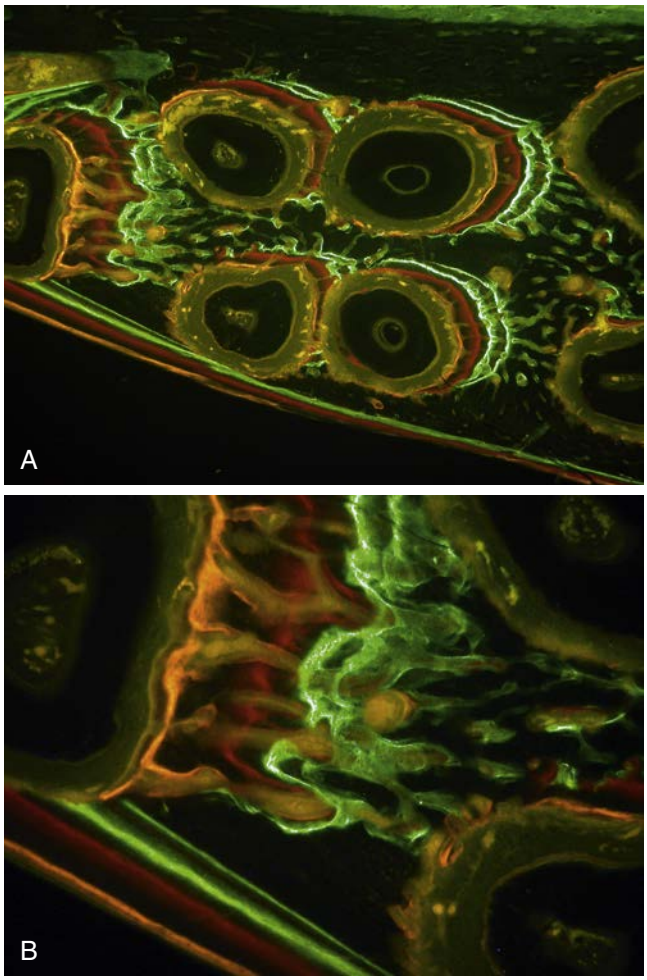

• **Figure 29-9 A,** This cross section of a rat molar being moved orthodontically shows quadruple labeling with vital stains. The amount of bone formation per unit time can be determined with vital staining. (Fluorescent stains excited by ultraviolet light, 200×.) **B,** The different pattern of cortical versus cancellous bone formation is readily seen in this very high power image of a rat maxilla. (Fluorescent stains excited by ultraviolet light, 400×.)



• **Figure 29-10 A,** This is a very immature network of newly formed cancellous bone. Polarization shows a "woven" or "basketweave" pattern. The different colors are only indicative of the pattern of the light wave direction resulting from the polarization filter. Polarizing filter and (Stevenel's blue and Van Gieson's picro fuchsin, 100×.) **B,** This is an example of polarization of very mature bone exhibiting lamellar bone. Cortical haversian bone consisting of multiple osteons is seen at the bottom and trabecular bone at the top. The different colors are only indicative of the pattern of the light wave direction resulting from the polarization filter. (Polarizing filter and Stevenel's blue and Van Gieson's picro fuchsin, 100×.)

are actually undergoing that treatment. The fortuitous situation of bone needing to be removed (which would ordinarily be discarded) in the creation of a pilot hole for implant placement creates an excellent opportunity for human-based clinical research. An immediate limitation is that the outside diameter of the trephine drill that will obtain the specimen must be equal to or less than the diameter of the implant pilot hole. This size is often less than ideal. The biggest disadvantage is that the area of bone augmentation, often an extraction socket or a sinus lift, is not a critical size defect. Defects of a size that will not heal during the lifetime of the animal may be termed critical size defects. Critical size defects have been established in the calvaria of rats, rabbits, and dogs.[27,40,41] Wikesjö has developed a critical size defect in canines related to testing bone growth related to implants.[42] However, critical size defects have not otherwise been established in mandibles of dogs and monkeys.

References

1. Triplett RG, Schow SR: Autologous bone grafts and endosseous implants: complementary techniques, *J Oral Maxillofac Surg* 54(4):486–494, 1996.
2. Greenwald AS, Boden SD, Goldberg VM, et al.: Bone-graft substitutes: facts, fictions, and applications, *J Bone Joint Surg* 83(90022):98–103, 2001.
3. Wenz B, Oesch B, Horst M: Analysis of the risk of transmitting bovine spongiform encephalopathy through bone grafts derived from bovine bone, *Biomaterials* 22(12):1599–1606, 2001.
4. Giannoudis PV, Dinopoulos H, Tsiridis E: Bone substitutes: an update, *Injury* 36(3S):20–27, 2005.
5. Misch CE, Dietsh F: Bone-grafting materials in implant dentistry, *Implant Dent* 2(3):158, 1993.

6. Al Ruhaimi KA: Bone graft substitutes: a comparative qualitative histologic review of current osteoconductive grafting materials, *Int J Oral Maxillofac Implants* 16(1):105–114, 2001.
7. Soltan M, Smiler D, Prasad HS, Rohrer MD: Bone block allograft impregnated with bone marrow aspirate, *Implant Dent* 16(4):329, 2007.
8. Smiler D, Soltan M, Lee JW: A histomorphogenic analysis of bone grafts augmented with adult stem cells, *Implant Dent* 16(1):42, 2007.
9. Smiler DG: S135: Autogenous stem cells for bone grafting: rationale and technique, *J Oral Maxillofac Surg* 65(9s):86, 2007.
10. Smiler D, Soltan M, Albitar M: Toward the identification of mesenchymal stem cells in bone marrow and peripheral blood for bone regeneration, *Implant Dent* 17(3):236, 2008.
11. Soltan M, Smiler D, Choi JH: Bone marrow: orchestrated cells, cytokines, and growth factors for bone regeneration, *Implant Dent* 18(2):132–141, 2009.
12. Urist MR: Bone: formation by autoinduction, *Science* 150(3698):893–899, 165.
13. Xu H, Shimizu Y, Asai S, Ooya K: Grafting of deproteinized bone particles inhibits bone resorption after maxillary sinus floor elevation, *Clin Oral Implants Res* 15(1):126–133, 2004.
14. Froum SJ, Tarnow DP, Wallace SSJ, et al.: The use of a mineralized allograft for sinus augmentation: an interim histological case report from a prospective clinical study, *Compendium* 26(4), 2005.
15. Noumbissi SS, Lozada JL, Boyne PJ, et al.: Clinical, histologic, and histomorphometric evaluation of mineralized solvent-dehydrated bone allograft (Puros) in human maxillary sinus grafts, *J Oral Implantol* 31(4):171–179, 2005.
16. Tsao YP, Neiva R, Al-Shammari K, et al.: Effects of a mineralized human cancellous bone allograft in regeneration of mandibular Class II furcation defects, *J Periodonto* 77(3):416–425, 2006.
17. Pinholt EM, Bang G, Haanaes HR: Alveolar ridge augmentation in rats by Bio-Oss, *Eur J Oral Sci* 99(2):154–161, 1991.
18. Froum SJ, Tarnow DP, Wallace SS, et al.: Sinus floor elevation using anorganic bovine bone matrix (OsteoGraf/N) with and without autogenous bone: a clinical, histologic, radiographic, and histomorphometric analysis—Part 2 of an ongoing prospective study, *Int J Periodontics Restorative Dent* 18(6):528–543, 1998.
19. Richardson C, Mellonig J, Brunsvold M, et al.: Clinical evaluation of Bio-Oss: a bovine-derived xenograft for the treatment of periodontal osseous defects in humans, *J Clin Periodonto* 26(7):421–428, 1999.
20. Artzi Z, Givo N, Rohrer MD, et al.: Qualitative and quantitative expression of bovine bone mineral in experimental bone defects. Part 1: description of a dog model and histological observations, *J Periodontol* 74(8):1143–1152, 2003.
21. Horowitz RA, Mazor Z, Foitzik C, et al.: β-Tricalcium phosphate as bone substitute material: properties and clinical applications, *Int J Dent Implants Biomater* 1(2):2–11, 2009.
22. Donath K, Rohrer M, Beck-Mannagetta J: A histologic evaluation of a mandibular cross section one year after augmentation with hydroxyapatite particles, *Oral Surg Oral Med Oral Pathol* 63(6):651–655, 1987.
23. LeGeros R: Calcium phosphate materials in restorative dentistry: a review, *Adv Dent Res* 2(1):164–180, 1988.
24. Daculsi G, LeGeros R, Nery E: Transformation of biphasic calcium phosphate ceramics in vivo: Ultrastructural and physicochemical characterization, *J Biomed Mater Res* 23(8), 1989.
25. LeGeros RZ: Calcium phosphates in oral biology and medicine, *Monogr Oral Sci* 15:1–201, 1991.
26. LeGeros R, Lin S, Rohanizadeh R, et al.: Biphasic calcium phosphate bioceramics: preparation, properties and applications, *J Mater Sci Mater Med* 14(3):201–209, 2003.
27. Reynolds MA, Aichelmann-Reidy ME, Kassolis JD, et al.: Calcium sulfate-carboxymethylcellulose bone graft binder: histologic and morphometric evaluation in a critical size defect, *J Biomed Meter Res B Appl Biomater* 83(2):451–458, 2007.
28. Schepers E, Ducheyne P, Barbier L, Schepers S: Bioactive glass particles of narrow size range: a new material for the repair of bone defects, *Implant Dent* 2(3):151, 1993.
29. Froum S, Cho SC, Rosenberg E, et al.: Histological comparison of healing extraction sockets implanted with bioactive glass or demineralized freeze-dried bone allograft: a pilot study, *J Periodontol* 73(1):94–102, 2002.
30. Ewers R: Maxilla sinus grafting with marine algae derived bone forming material: a clinical report of long-term results, *J Oral Maxillofac Surg* 63(12):1712–1723, 2005.
31. Wikesjö UME, Qahash M, Thomson RC, et al.: rhBMP-2 significantly enhances guided bone regeneration, *Clin Oral Implants Res* 15(2):194–204, 2004.
32. Krauser J, Rohrer M, Smiler D, Wallace S: Human histologic and histomorphometric analysis of pepgen p-15 (tm) in sinus and ridge augmentation cases, *Clin Oral Implants Res* 12(4):406, 2001.
33. Hahn J, Rohrer MD, Tofe AJ: Clinical, radiographic, histologic, and histomorphometric comparison of PepGen P-15 Particulate and PepGen P-15 Flow in extraction sockets: a same-mouth case study, *Implant Dent* 12(2):170, 2003.
34. Froum SJ, Wallace SS, Tarnow DP, Cho SC: Effect of platelet-rich plasma on bone growth and osseointegration in human maxillary sinus grafts: three bilateral case reports, *Int J Periodontics Restorative Dent* 22(1):45–54, 2002.
35. McGuire TP, Sandor G, Clokie C: Advanced mandibular resorption: reliable reconstruction with autogenous graft tent pole technique, *J Oral Maxillofac Surg* 61(8S):74–75, 2003.
36. Hearne JC: Poster 033: Screw "tent-pole" grafting technique for vertical augmentation of the severely atrophic alveolar ridge for implant site preparation, *J Oral Maxillofac Surg* 66(8S):86–87, 2008.
37. Le B, Rohrer M, Prasad HS: Screw "tent-pole" grafting technique for reconstruction of large vertical alveolar ridge defects using human mineralized allograft for implant site preparation, *J Oral Maxillofac Surg* 68(2):428–435, 2009.
38. Donath K, Breuner G: The Sage-Schliff (sawing and grinding) technique, *J Oral Pathol Med* 11(4):318–326, 1982.
39. Rohrer M, Schubert C: The cutting-grinding technique for histologic preparation of undecalcified bone and bone-anchored implants: improvements in instrumentation and procedures, *Oral Surg Oral Med Oral Pathol* 74(1):73–78, 1992.
40. Schmitz JP, Hollinger JO: The critical size defect as an experimental model for craniomandibulofacial nonunions, *Clinical Orthop Relat Res* 205(205):299–308, 1986.
41. Mokbe N, Bou Serhal C, Matni G, Naaman N: Healing patterns of critical size bony defects in rat following bone graft, *Oral Maxillofac Surg* 12(2):73–78, 2008.
42. Wikesjö UME, Susin C, Qahash M, et al.: The critical-size supraalveolar peri-implant defect model: characteristics and use, *J Clin Periodontol* 33(11):846, 2006.

30

Autogenous Bone Grafting for Dental Implants

CRAIG M. MISCH

Introduction

Autogenous bone has long been considered the gold standard of graft materials. It has earned this distinction from both a historical and biologic perspective.[1] Autogenous bone has been used for many years in oral and maxillofacial reconstruction including trauma repair, preprosthetic surgery, and repair of mandibular discontinuity or ablative defects. The use of autogenous bone grafting for dental implants was originally researched by Branemark and colleagues.[2] Early studies focused on the use of iliac bone grafts in the treatment of the edentulous atrophic maxilla and mandible.[3] As implant treatment became more widely used, clinicians realized the need for bone augmentation to place implants in prosthetic-driven positions. Over the years numerous techniques have been used for implant site development. The utility of autogenous bone has been well documented for use in guided bone regeneration, block bone grafting, interpositional grafting, particulate grafting with titanium mesh, and sinus bone augmentation. Alternative donor sites to the ilium have been evaluated, including the calvarium, proximal tibia, and intraoral harvest from the maxillofacial region. Autogenous bone can be used in several forms, including cancellous marrow, particulate graft, or cortical and corticocancellous blocks.

Autogenous bone grafts offer several advantages over bone substitutes. Autogenous bone has superior biologic qualities compared to osteoconductive bone substitutes. Viable bone-forming cells transplanted with the graft, such as osteoblasts and mesenchymal stem cells, can actively form new bone. Bone morphogenetic proteins found in the graft recruit and induce pluripotent cells to become osteoblasts. The healing time of autogenous bone grafts is shorter than that of bone substitutes.[4] This permits earlier implant placement and shorten treatment length. Implants can usually be placed after only 4 months of graft healing. In addition, the newly formed bone is often of superior quality. This is especially noted with cortical or corticocancellous block grafts compared to guided bone regeneration using bone substitutes. Denser bone quality can shorten implant healing times and provide improved implant stability. This can allow one-stage implant healing or the option of immediate implant loading. Patients will accept the use of their own tissue and may object to using cadaver bone or products derived from animal sources. From an economic perspective, autogenous bone lowers overhead costs for the surgeon. The inherent disadvantages of using autogenous bone must also be considered. It does require additional clinical time to procure bone, especially when remote donor sites are used. There can be added morbidity from the bone harvest procedure. There are also limitations on the amount of bone that can be harvested from a particular donor site. Donor sites such as the calvarium and iliac crest usually require the use of a hospital operating room unless the surgeon's office has been designed for these more advanced procedures. General anesthesia or intravenous sedation is often necessary for patient comfort and safety. However, most of these augmentation procedures can be done in an outpatient setting and do not require hospitalization of the patient.

Advancements in biologic engineering will produce alternatives to autogenous bone that may very well exceed existing clinical outcomes and replace traditional indications for its use.[5,6] However, the increased costs of technology can be an obstacle to routine use of new products. Autogenous bone grafting offers a well-proven and predictable method of defect repair and ridge augmentation for dental implant placement.

Bone Biology

Autogenous bone is the only graft material with osteogenic properties that can directly form bone. Bone cells, in higher concentration in the cancellous marrow, that survive transplantation can produce new bone. In addition, bone

morphogenetic proteins (BMPs) and growth factors present within the autograft induce bone formation in the surrounding tissues.[7] BMP is chemotactic for osteocompetent mesenchymal cells. These cells proliferate and are transformed into osteoblasts through osteoinduction. The cortical portion of the autogenous bone graft acts as an osteoconductive scaffold for bone formation.[8] The graft is remodeled and replaced with new bone over time. Free autogenous bone grafts must become revascularized in order to incorporate. The cancellous portion of the graft revascularizes faster than the cortex.[9] The denser cortical bone revascularizes through its existing haversian system.[9] In addition, cancellous bone grafts heal differently than do cortical grafts. Bone is directly deposited along the existing trabeculae of the cancellous graft.[9] Thereafter, the trabeculae are resorbed, leaving only the new formed one. Cortical bone grafts incorporate through creeping substitution.[9] Cutting cones remodel the graft through the existing haversian system of the cortical graft. The graft is slowly resorbed as new bone is formed. This results in an admixture of grafted and new bone that eventually completely turns over (Figure 30-1).

The subject of embryologic origin of autologous bone grafts has received much attention regarding graft incorporation and resorption. Membranous bone grafts, from the mandible or calvarium, reveal less resorption than grafts from endochondral sites, such as the iliac crest.[10-13] More recent studies examining graft loss have challenged the hypothesis of embryologic origin and emphasize the microarchitecture of the bone used for grafting.[8,14] Ozaki and Buchman found that regardless of their embryologic origin, cortical bone grafts reveal less volume loss than cancellous bone grafts. Cancellous grafts require protection, such as titanium mesh or a barrier membrane, to maintain their volume for onlay augmentation. Cortical bone grafts from the mandible exhibit minimal resorption and maintain their dense quality, making them ideal for onlay augmentation prior to implant placement[15] (Figures 30-2 and 30-3).

Following harvest, the bone graft should immediately be stored in sterile saline to maintain cell vitality, and minimal time should elapse between graft procurement and placement.[16] The fewer number of viable cells contained in cortical grafts may be less significant in new bone formation. If block grafts or trephine cores are milled, the size of the particles should be limited. Some burrs or mills pulverize the bone graft into a powder or paste. Whereas bone powder is quickly resorbed, slightly larger particles are more osteoconductive and act as a better scaffold for bone formation.[17-19] The other potential disadvantages of bone particles collected through a suction trap include the negative effects of heat generated in bone preparation, desiccation, and bacterial contamination.[20] Bone scrapers produce ribbon-like shavings that have a favorable three-dimensional morphology for revascularization and graft incorporation[21] (Figure 30-4).

The choice of a particular augmentation technique or graft material will depend on several factors, including the degree of atrophy and the morphology of the osseous defect. Regeneration and repair of an osseous defect primarily originates from the surrounding bony walls. The ingrowth of blood vessels from the surrounding bone provides a path for osteoprogenitor cells and new bone formation. Therefore the morphology of a bone defect should influence the choice of material or technique. Sites with fewer surrounding osseous

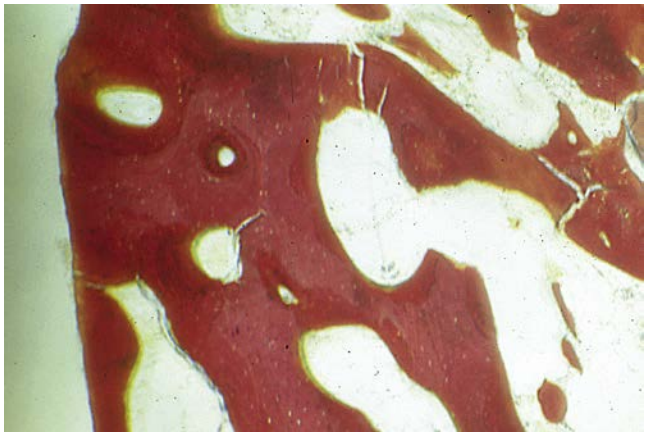

• **Figure 30-1** Histologic view of a healing cortical bone graft. Note the osteoid *(green)* and the new bone *(red)* lining the haversian canals of the graft *(pink)*.

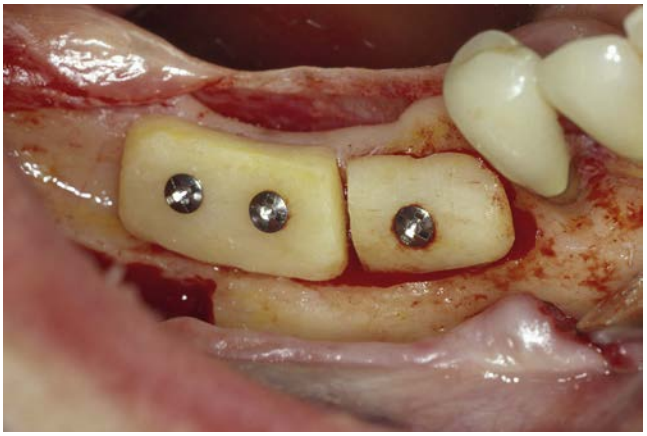

• **Figure 30-2** Reconstruction of the posterior mandible with cortical block bone grafts.

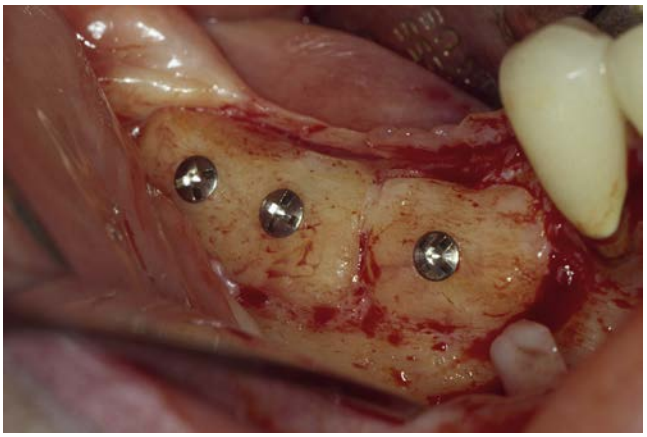

• **Figure 30-3** Incorporation of the cortical graft after 4 months healing. Minimal graft resorption is noted.

walls and greater jaw atrophy are more demanding and require materials and/or techniques that offer greater biologic activity and regenerative capacity. As a general rule, vertical onlay bone augmentation is more biologically and clinically challenging than horizontal bone augmentation. Explanations for this difference include fewer osseous walls, graft stability, soft tissue coverage, space maintenance during healing, and avoidance of graft loading. Most classification systems used to describe maxillary atrophy focus on the pattern of progressive ridge resorption.[22,23] Recently the Cologne Classification for Alveolar Ridge Defects[24] was proposed to address the morphology of the defect as well as augmentation needs. The orientation of the defect is described as horizontal, vertical, or combined. The relationship of the augmentation and defect region is classified as internal (inside the bony contour) or external (outside the bony contour). This distinction is important, as bone defects inside the bony contour are much easier to reconstruct than onlay augmentations required outside the osseous contour. Intrabony defects have a higher regenerative capacity with greater ease in achieving soft tissue coverage (Figures 30-5 through 30-7).



• **Figure 30-4** Electron microscopic view of a bone shaving harvested with a scraping device. (Courtesy Maxillon Laboratories.)

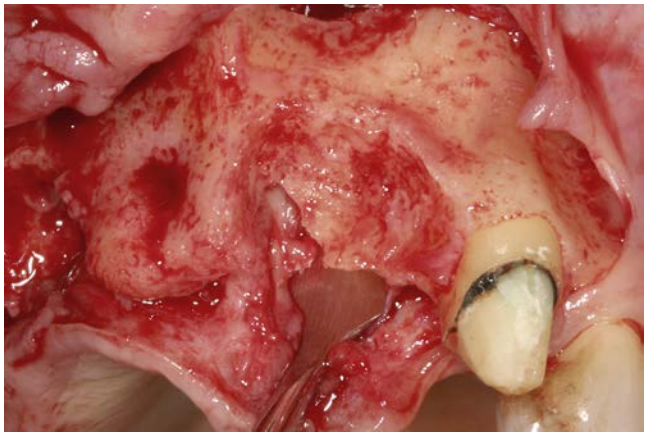

• **Figure 30-5** Intraosseous defect in the anterior maxilla.

Preoperative Evaluation

A comprehensive evaluation of the site is necessary for planning of bone graft surgery. It is also important to define the prosthetic goals before the reconstruction. The design of the final prosthesis determines the size and number of implants required and their ideal positions. If there is inadequate available bone for implant placement in the desired locations, then bone augmentation is considered. This concept has been termed "prosthetic guided bone augmentation."[25] Mounted study casts and diagnostic wax-ups allow the clinician to better appreciate the ridge morphology in relationship to planned prosthetic outcome (Figure 30-8).

Panoramic and periapical radiographs can be used to evaluate the bone defect, surrounding dentition and regional anatomy. Computed tomography is preferred for three-dimensional viewing of the bone deficiency and surrounding area. It can also be used to assess intraoral donor sites for bone harvest. Many surgeons have cone beam computed tomography (CBCT) machines in their office. CBCT exposes the patient to less radiation and allows an immediate assessment of the patient's condition. The diagnostic wax-up may also be used for the fabrication of a

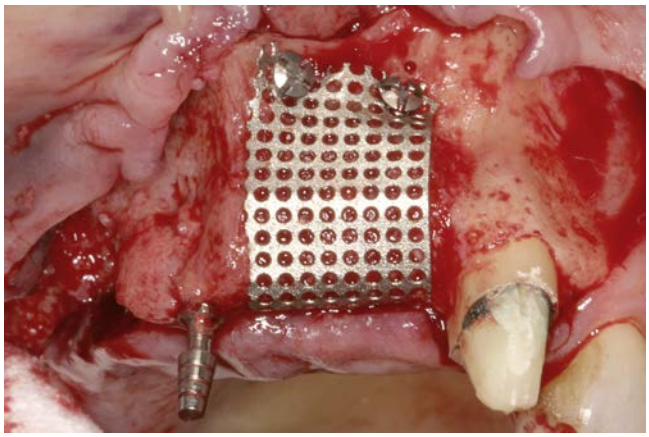

• **Figure 30-6** Intraosseous defect filled with particulate autograft and covered with a titanium mesh.

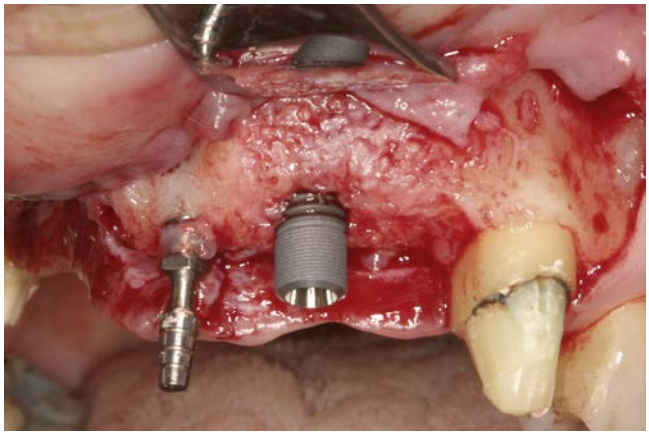

• **Figure 30-7** The defect is completely repaired after 6 months of healing.

radiographic computed tomography (CT) scan template[26] (Figure 30-9). The template is worn during the scan and reveals the radiopaque outline of the prosthetic tooth position in the tomographic view of the residual ridge (Figure 30-10). This allows a determination of graft size requirements and donor site options.

Implant planning software can be used with the scan to more precisely evaluate the reconstructive needs of the patient.[26,27] Virtual implants are positioned in the preferred sites to determine the amount of augmentation required. A stereolithographic model of the jaw can be generated from the CT scan to further plan the case[25] (Figure 30-11). This model can be used before surgery to cut and shape titanium mesh, plates, or membranes. It may also be sterilized and used intraoperatively to assist in the fitting of block bone grafts or placement of bone plates or titanium mesh. A template of the planned prosthetic tooth position is also helpful for use during graft surgery to confirm graft positioning and fulfillment of the grafting requirements.

Treatment of the anterior maxilla requires an esthetic zone evaluation.[28] This includes determination of the high lip line and need for lip support. A diagnostic wax-up will help determine tooth length and need for vertical augmentation to develop the correct tooth size. An emphasis must be placed on creating adequate osseous volume for implant placement as well as providing a proper soft tissue profile for the implant restoration. The surgeon and restorative dentist must determine if the missing hard and soft tissue will be surgically reconstructed or replaced with the prosthesis. Even when skilled surgeons obtain a successful repair of the defect, the restoring dentist and patient may find esthetic shortcomings in the final result. Longer prosthetic teeth, missing papilla, and lack of facial contour are not uncommon flaws when reconstructing larger defects. An alternative to surgical repair is to replace the missing hard and soft tissues prosthetically using gingival colored porcelain,



• **Figure 30-8** Diagnostic wax-up of a maxillary defect from trauma. Pink wax is used to assess the missing hard and soft tissue.



• **Figure 30-9** The diagnostic wax-up is converted into a radiographic template with barium teeth.

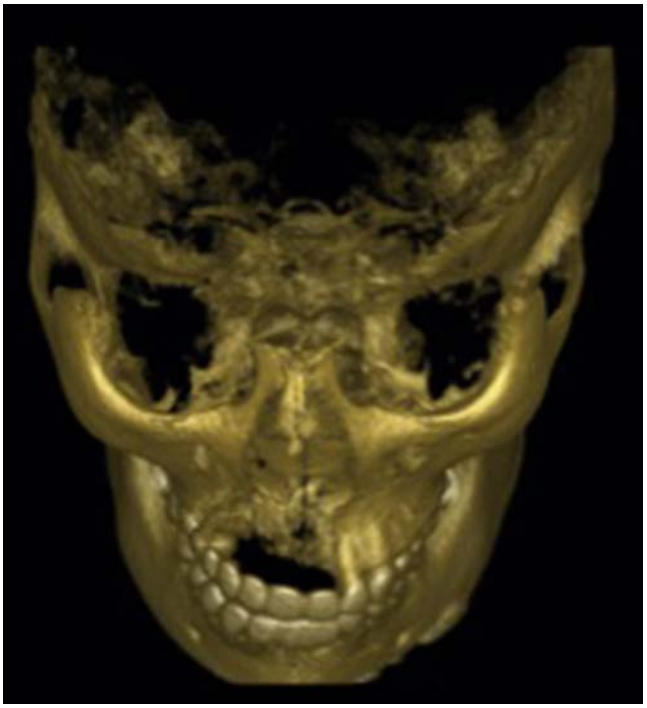

• **Figure 30-10** Computed tomography scan is taken with the radiographic template to show the planned prosthetic tooth position in relation to the bone defect.

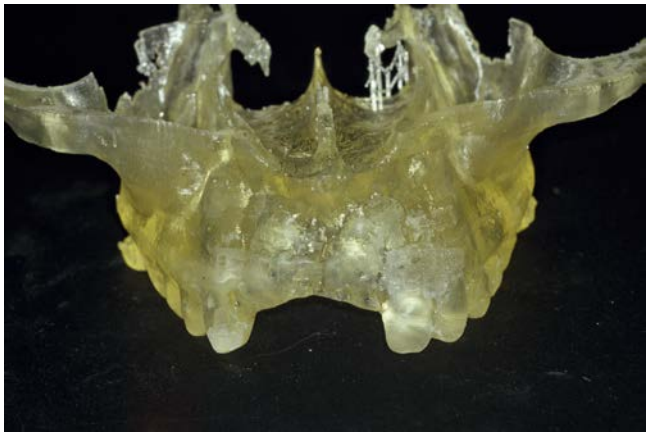

• **Figure 30-11** A stereolithographic model of a maxilla with an anterior bone deficiency.

acrylic, or composite. It is also important to determine if the transition area between the prosthesis and the ridge is above or below the high lip line. It is very difficult to make this transition area between artificial gingiva and the mucosa appear natural. In many cases, if it is not feasible to rebuild the ridge to obtain normal tooth length, it may be better to reduce the ridge height and camouflage the prosthetic transition area under the lip.[29] The need for lip support is evaluated when multiple teeth are missing. This is more significant when a fixed prosthesis, without a flange, is planned. A diagnostic wax-up without a flange can be used to assess the need for lip support.

The soft tissue character of the recipient site should be assessed, including quantity of keratinized tissue, gingival biotype, mucosal thickness, vestibular depth/muscle attachments, and the presence of scar tissue. It is often better to correct soft tissue problems before bone grafting. The lack of keratinized tissue in a region is best treated with autogenous free gingival grafts from the palate (Figures 30-12 through 30-16). Thin mucosa is a risk for flap perforation or erosion of titanium mesh through the tissue. Areas of thin alveolar mucosa can be enhanced with the interpositional placement of connective tissue grafts or allogeneic dermis. A frenum, a high vestibular muscle attachment, and/or a lack of vestibular depth can restrict the ability to advance a flap. Vestibuloplasty or frenectomy techniques can be employed to address these issues. The removal of scar tissue improves blood supply to the area and helps improve the mobility of the soft tissue flap over the bone graft. Soft tissue corrective surgery should be performed at least 8 weeks prior to bone graft



• **Figure 30-12** Maxillary defect from failed implants. Note the loss of keratinized gingiva and thin mucosa.

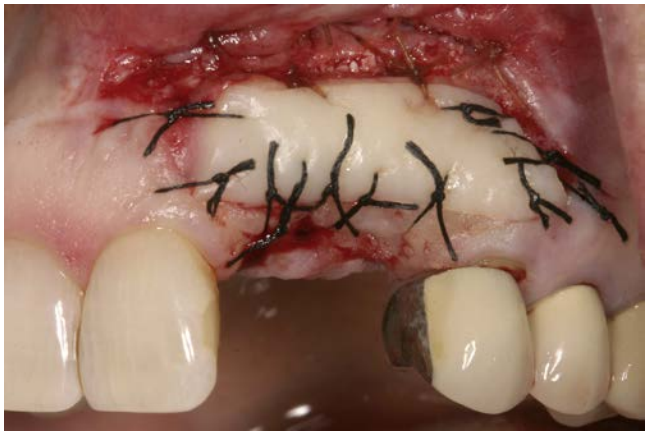

• **Figure 30-13** A free gingival graft from the hard palate is used to augment the soft tissue defect.



• **Figure 30-14** Healing of the gingival graft after 2 months. Note the improved tissue character.

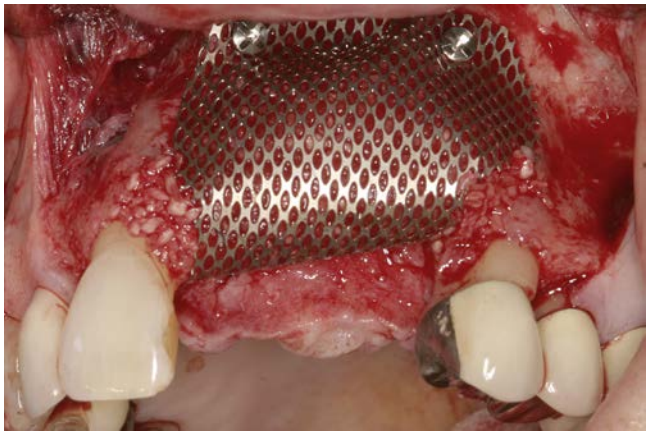

• **Figure 30-15** The bone graft is performed after incorporation of the gingival graft.

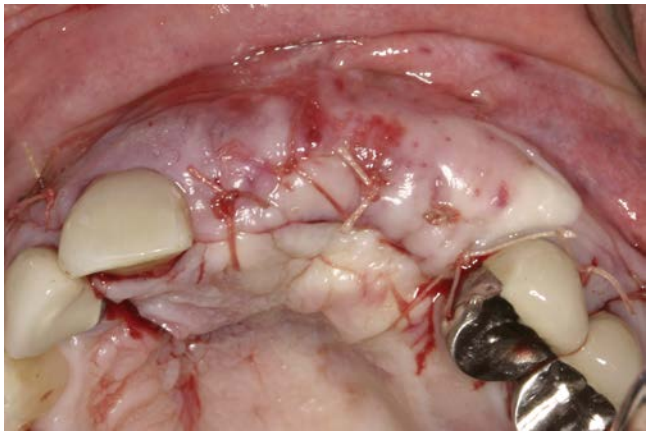

• **Figure 30-16** Flap closure over the bone graft. The improved character of the soft tissue facilitates flap coverage.

surgery to allow incorporation of any grafts and reestablishment of vascularity to the area. The surgeon should be aware that facial flap advancement over a bone graft moves the mucogingival junction more palatal or lingual. The keratinized gingiva can be repositioned during subsequent surgical procedures, or connective tissue grafting can be performed.

The periodontal health and endodontic status of teeth adjacent to the graft recipient site should be evaluated before grafting. It may be prudent to extract hopeless teeth before grafting, especially if infection is present. The marginal bone height on the teeth bordering the bone defect determines the level that can be achieved with vertical bone augmentation. It may be necessary to extract stable teeth if they have marginal bone loss that limits the augmentation needs. It is usually preferred to extract compromised teeth 8 weeks before the bone graft surgery and allow soft tissue healing over the site.

Patient Preparation

Patients undergoing autogenous bone grafting require antibiotic prophylaxis. The antibiotic of choice for most cases is amoxicillin. For patients allergic to amoxicillin, either a cephalosporin or clindamycin may be considered. A loading dose of antibiotic should be administered prior to surgery and continued for 1 week. The use of short-term glucocorticoids can diminish postoperative facial swelling, local flap edema, and discomfort. Dexamethasone can be administered intravenously before surgery, and then a tapered oral dose is prescribed. The use of a long-acting local anesthetic, such as bupivacaine, is helpful to delay the onset of postoperative pain. Some studies have found bacterial contamination of orally harvested bone grafts, especially when suction traps are used to collect drilled bone debris.[30] Chlorhexidine rinsing before surgery has been shown to significantly reduce this problem. Preoperative antisialogogue agents, such as glycopyrrolate, are also useful to decrease salivary flow that may carry bacteria into the graft site. Aseptic surgical technique should be maintained, as these reconstructive procedures are more involved and may often require more operative time. Most cases involving autogenous bone grafting in the office are performed under intravenous anesthesia. Shorter, less involved graft procedures may be carried out using oral sedation or simply local anesthesia.

Smoking has been associated with a high rate of wound dehiscence and graft failure.[31] Unless the patient will commit to no smoking during the early postoperative course, onlay bone grafting is discouraged. A smoking cessation protocol may be employed, including the use of prescription medications, such as bupropion and the nicotine transdermal patch. The use of electronic cigarettes may be an alternative to regular cigarettes, but the effect of nicotine on wound healing is still detrimental. Patients are instructed to quit 1 week prior to surgery and told not to smoke at least until the incision is healed (2 weeks). The use of a platelet concentrate under the flap closure may be beneficial in this patient population to improve wound healing.

Bone Graft Donor Sites

Local Bone Grafts

Harvesting a bone graft from the same surgical field as the area of augmentation adds minimal morbidity to the procedure. Particulate autogenous bone can be obtained using drills or scraping devices. The particle size influences the behavior of the graft. Bone slurry or smaller particles from drilling are more quickly resorbed.[32] Larger particles from bone scrapings or a bone mill not only provide better scaffolding, they show higher cell viability and stronger osteogenic potential.[33] The particulate bone can be used for guided bone regeneration of implant dehiscent defects.[34] Small block bone grafts or particulate bone may be harvested from the palate or zygomatic buttress.[35] Circular blocks of bone can be harvested with a large trephine burr from the superior aspect of the edentulous ridge or above the surrounding tooth roots (Figures 30-17 and 30-18).

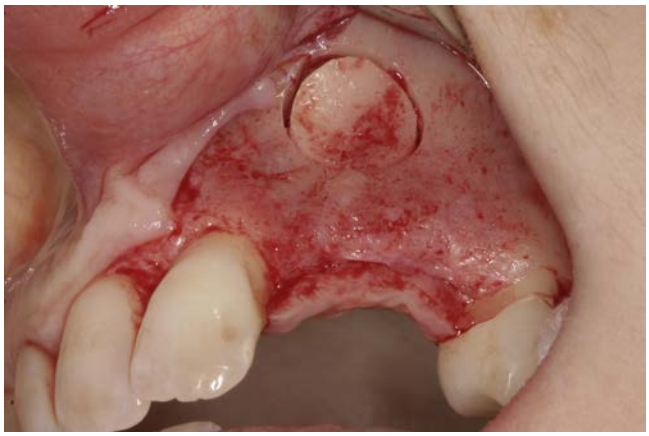

• **Figure 30-17** A large trephine burr is used to harvest a circular block from the edentulous site.

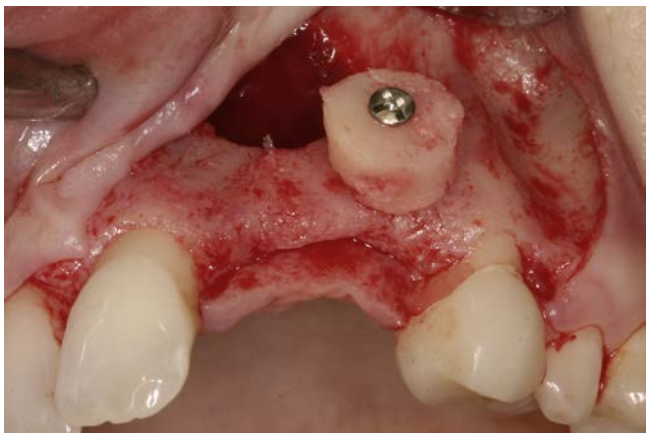

• **Figure 30-18** The circular block bone graft is fixed to the maxilla with a screw.

These larger trephine cores can be morselized or used as a circular block with a fixation screw (Figures 30-19 and 30-20).

Maxillary Tuberosity

Although the maxillary tuberosity offers a smaller amount of bone than other donor sites, the softer consistency of the graft is often favorable for filling bone defects.[36] The tuberosity graft can be used in block form or easily particulated with a rongeur. The bone in the tuberosity area is porous, and the outer cortical layer is thin. The amount of bone that may be obtained can be deceiving, as the mucosa over the tuberosity is usually much thicker. Computerized tomography of the maxillary sinus region can allow three-dimensional quantification of the area. The anatomical limitations of tuberosity bone harvest include the maxillary sinus, pterygoid plates, molar teeth, and greater palatine canal. To gain access to the area for bone harvest, an incision is made along the ridge crest over the tuberosity. A vertical releasing incision is made along the lateral aspect of the posterior maxilla. Mucoperiosteal reflection exposes the tuberosity, ridge crest, and lateral maxilla. The palatal tissue should also be elevated to reveal the entire width of the tuberosity. The graft may be harvested with a chisel, rongeurs, or a piezoelectric saw (Figures 30-21 through 30-24). The chisel edge should be kept slightly superficial to the maxilla to shave off pieces of tuberosity bone and avoid entering the sinus. Inadvertent sinus communication is usually not a problem, as the flap is easily closed and the tissue is thick.[37] The tuberosity is in the same surgical field when performing sinus grafting, so it should be routinely considered for bone harvest.[38] The sinus is grafted in layers with particulated tuberosity placed along the sinus floor.



• **Figure 30-19** Particulate autograft and bovine hydroxylapatite are used around the block graft to complete the reconstruction of the defect.

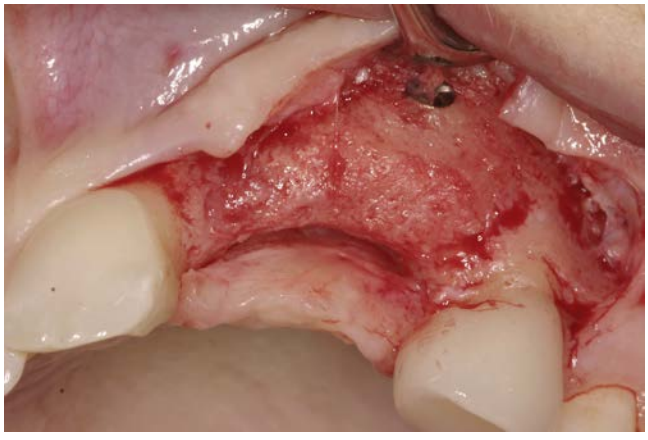

• **Figure 30-20** Incorporation of the bone graft after 4 months of healing.

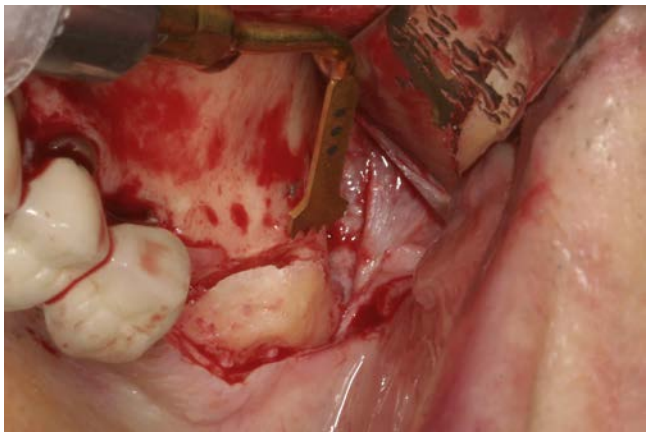

• **Figure 30-21** A piezoelectric saw is used to harvest a block bone graft from the maxillary tuberosity.

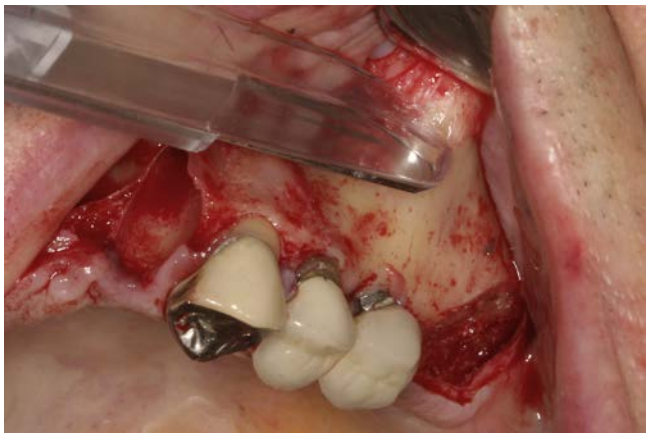

• **Figure 30-22** A bone scraping device is used to harvest particulate bone from the zygomatic buttress area.

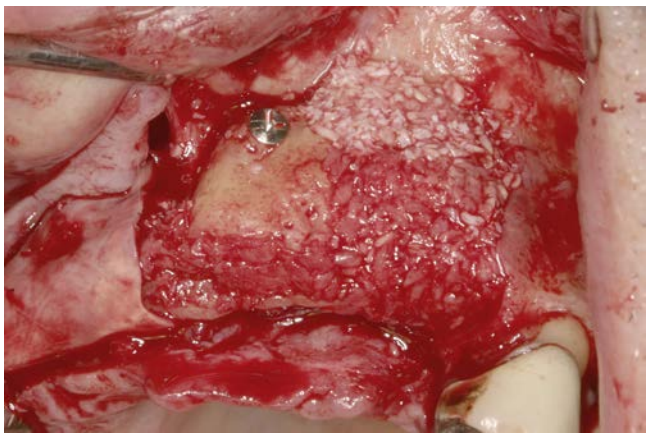

• **Figure 30-23** The tuberosity block bone graft is fixated to the maxilla with a screw, and particulate bone is packed around the graft.

A thin piece of cortical bone can be obtained from the posterior lateral maxilla with a chisel to cover the window following grafting of the sinus floor (Figures 30-25 through 30-27).

Mandibular Symphysis

The symphysis of the mandible has been used extensively for sinus and onlay bone grafting.[15,39-44] Techniques to harvest block or particulate bone grafts from the anterior mandible have been reported. The symphysis donor site offers the greatest volume of intraoral bone. The average interforaminal distance is approximately 5.0 cm, and the depth of the anterior mandible usually exceeds 1.0 cm.[45] A panoramic radiograph or CT scan is used to evaluate the available bone in this donor site. A lateral cephalometric radiograph can be useful to determine the anteroposterior dimension of the anterior mandible. Periapical radiographs give a more accurate measurement of the length of the tooth roots.

The ease of surgical access is one of the main advantages of the symphysis region. Exposure of the symphysis may be obtained through a sulcular or vestibular incision. The vestibular incision is made in the mucosa between the cuspid teeth approximately 1 cm from the mucogingival junction. Limiting the distal extent of the incision will reduce the risk of mental nerve injury. A vestibular approach allows easy access but produces more soft tissue bleeding and possible intraoral scar formation. The sulcular approach should not be used when mucogingival defects are present and may result in gingival recession if the biotype is thin. The sulcular incision should extend to the premolar regions bilaterally. A mucoperiosteal flap is reflected to expose the mental foramina and the anterior aspect of the inferior border of the mandible. Additional local anesthesia is often needed at the base of the mandible to block cervical innervation.

After the symphysis region is exposed, the osteotomies for graft harvest are planned. The bone volume needed to reconstruct the recipient site determines the dimensions of the graft. Osteotomies should be kept at least 5 mm from the root apices and the mental foramina.[15,46,47] In most cases the inferior and lingual cortices of the mandible are left intact. The facial cortex is thick, and the underlying cancellous bone is usually dense. The osteotomies may be made with a carbide fissure burr (No. 557, No. 701) in a surgical handpiece, sagittal saw, or piezoelectric saw (Figures 30-28 through 30-30). Following the osteotomies through the outer cortex and into the cancellous bone, the graft is removed with a chisel. A unibeveled chisel is tapped along the osteotomies, with the exception of the inferior border, to fracture the

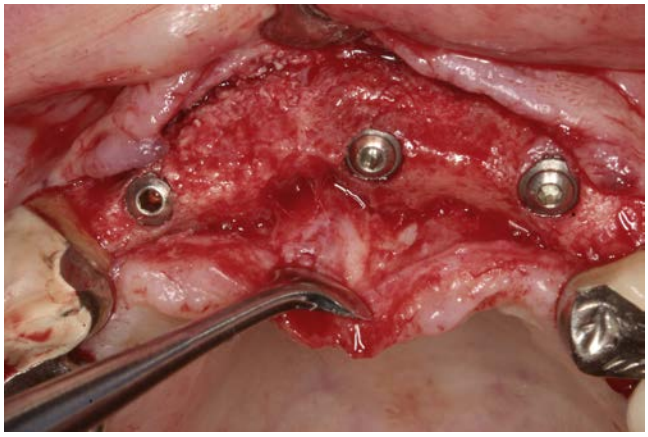

• **Figure 30-24** Dental implants are placed following 4 months of graft healing.

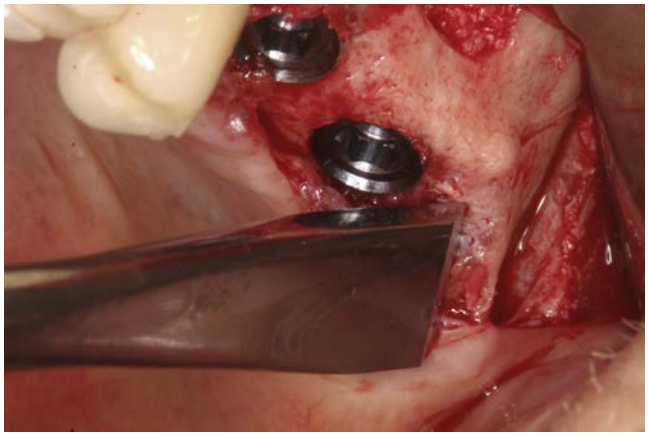

• **Figure 30-25** A chisel is used to harvest a thin piece of cortical bone graft from the posterior maxilla.

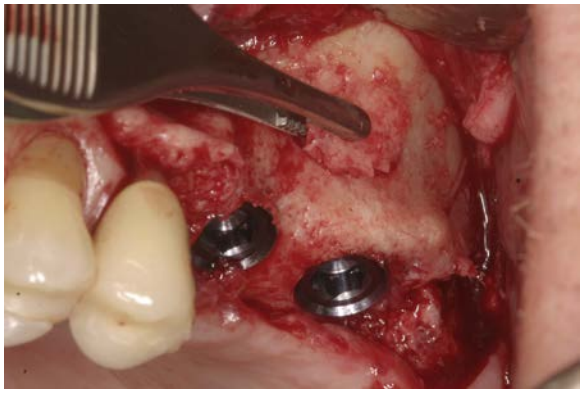

• **Figure 30-26** The thin cortical bone graft is used to cover the sinus window.

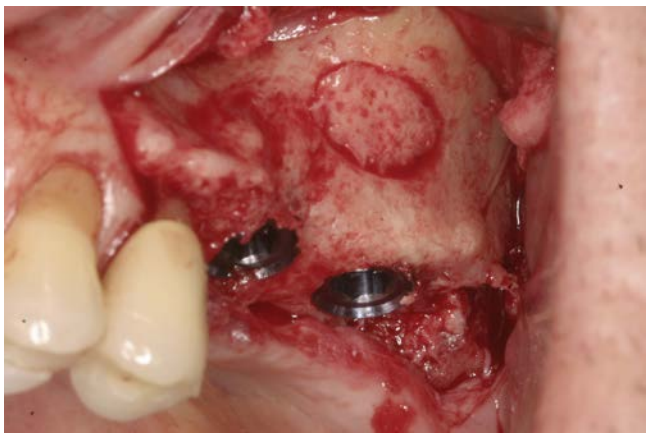

• **Figure 30-27** The thin piece of cortical bone acts as a biologic barrier over the sinus bone graft.

block from its base. The block bone graft may also be harvested in segments by sectioning the rectangular piece in the midline. Two bone blocks are often easier to harvest, as the second block can be fractured from its lingual base with the chisel. After the block is removed, some additional cancellous bone may be procured with a curette, chisel, rongeur, or trephine, but the volume is usually meager.[45] Following the removal of the block graft, hemostatic materials, such as collagen or gelatin, may be placed over the cancellous bone. When larger bone grafts are harvested, the donor site should be filled with a bone substitute, such as bovine hydroxylapatite, to maintain facial contour.[15] Smaller or particulate bone grafts may be procured using trephine burrs, bone collection traps, or bone scraping instruments[21,48,49] (Figures 30-31 and 30-32). Closure of the donor site is typically performed after the graft is inserted into the recipient site. This minimizes the time between graft harvest and placement. The mucosa superior to the vestibular incision is reflected to reduce tension on the flaps from edema and lip movement. The vestibular incision is closed in layers using resorbable sutures. The deeper layers may be sutured with 4-0 polyglactin, and the superficial mucosa can be closed primarily with 4-0 chromic gut. Postoperative pressure dressings are used over the chin to reduce edema, hematoma formation, and incision line opening.

The use of the mandibular symphysis has diminished, as it is associated with a higher incidence of postoperative complications than other maxillofacial donor sites.[42,50,51] Altered sensation of the lower anterior teeth is a relatively common postoperative symptom when bone blocks are



• **Figure 30-28** An oscillating saw blade is used to perform the osteotomies in the symphysis.

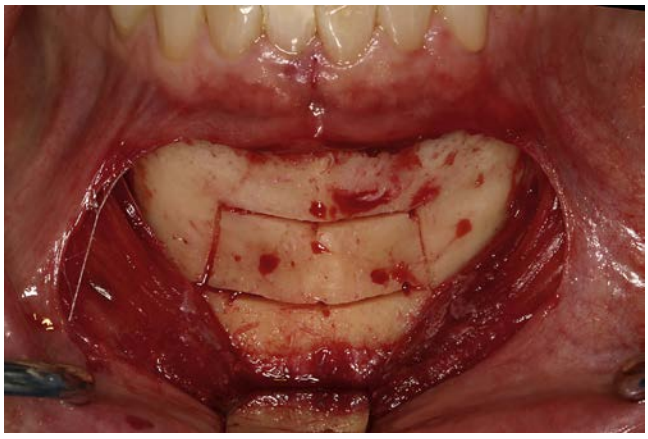

• **Figure 30-29** The outline of the symphysis bone graft osteotomies.

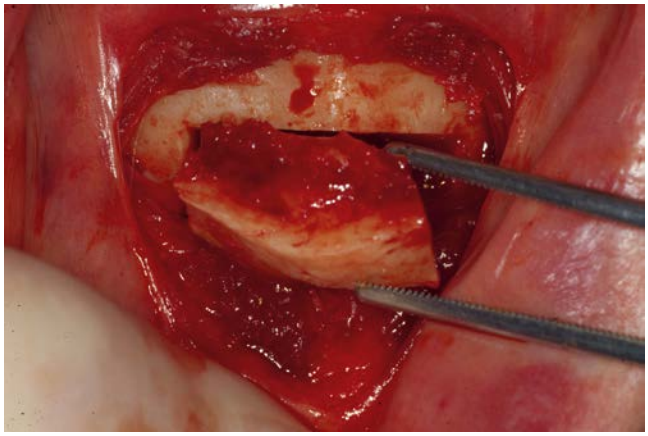

• **Figure 30-30** The block bone graft is removed from the site with a chisel.

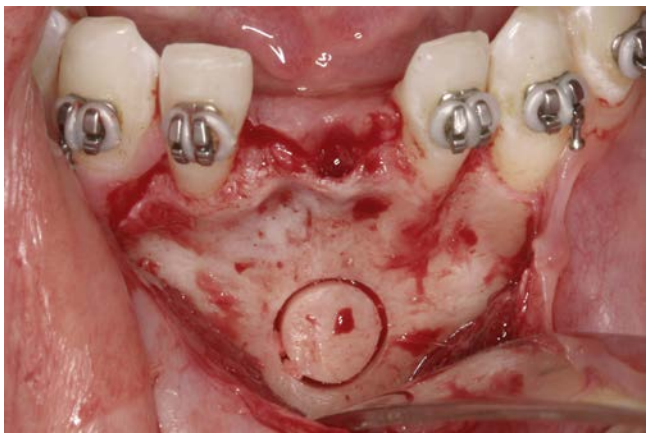

• **Figure 30-31** A large trephine burr is used to harvest a circular block bone graft from the symphysis.

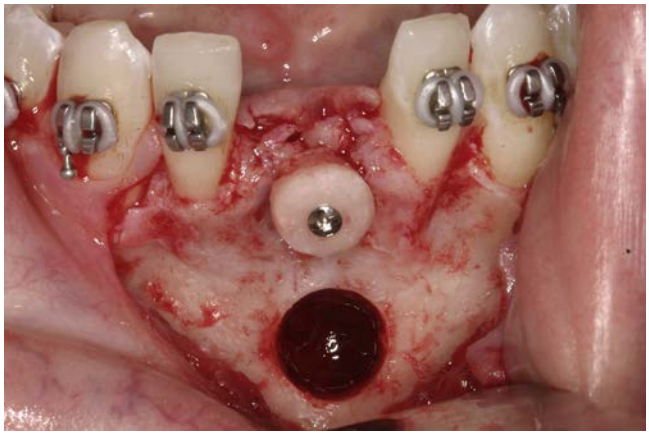

• **Figure 30-32** The circular block bone graft is fixated to the ridge defect with a screw.

removed.[15,42,50,51] The contents within the incisive canal of the symphysis that innervate the teeth are disrupted during bone harvest. Patients describe dullness in sensation of the incisors, which usually resolves within 6 months. The need for endodontic treatment of anterior teeth is rare. Neurosensory disturbances in the chin region also may be encountered, even when a sulcular incision is used.[50,51] The incidence of temporary mental nerve paresthesia for symphysis graft patients is usually low but has been found to be as high as 43%.[50] Permanent neurosensory deficits have been reported. Meteorotropism of the chin has also been found.[50] Although the vast majority of these nerve injuries recover, they are disconcerting to patients. It is prudent to discuss the possibility of temporary altered sensation of the teeth and chin prior to surgery. Although no postoperative alteration in soft tissue chin contour has been reported, patients are often concerned with the possible esthetic consequences of bone removal from this area.[50] Radiographic evidence of incomplete bony regeneration has been reported in elderly patients.[52] Filling the donor site with a bone substitute, such as bovine bone, can help alleviate patient concerns.[15] Ptosis of the chin has not occurred and can be prevented by avoiding complete degloving of the mandible.[53]

Mandibular Ramus

The posterior mandible is an excellent donor site for bone harvest, and this region offers several advantages over the symphysis.[42,54-56] A CT scan or panoramic radiograph is used to evaluate the bony anatomy, including the ramus, external oblique ridge, and mandibular canal. The incision design for access to this region differs for block and particulate bone harvest. When taking a block graft, the incision is made similar to one used in third molar removal. A sulcular incision is made along the posterior teeth. The incision is continued posteriorly and lateral at a 45-degree angle from the distobuccal aspect of the second molar, or the base of the retromolar pad if no molar is present. The incision extends superiorly along the ascending ramus. Following the incision, a mucoperiosteal flap is reflected to expose the lateral ramus and body of the mandible. The masseter muscle is reflected laterally with a large retractor to form a large open pocket. Additional local anesthesia is often required in this area to block cervical innervation. The limits of harvesting bone from the ramus area are dictated by clinical access in addition to the coronoid process, molar teeth, and mandibular canal. The average anteroposterior dimension of the mandibular ramus is 30.0 mm, and the lingula is typical in the posterior third.[57]

Four osteotomies are made to harvest a block bone graft—external oblique, superior ramus, anterior body, and inferior.[55] The bone volume needed to reconstruct the site determines the length of the osteotomies. The cortical cuts are made with a carbide fissure burr (No. 557, No. 701) in a straight handpiece under sterile saline irrigation. A piezoelectric saw may also be used, as the cuts are thinner (Figure 30-33). The external oblique cut is made along the anterior border of the ramus approximately 4.0 to 6.0 mm medial to the external oblique ridge. This osteotomy can extend as high as the base of the coronoid process and anteriorly up to the first molar area. This can produce a graft that may approach 40.0 mm in length. The superior ramus cut is made through the lateral cortex of the ramus and perpendicular to the external oblique cut. It may extend as far posteriorly on the ramus as the opposing lingula on the medial side of the ramus. However, the length of this cut is typically about 10.0 mm. The anterior body cut may often extend over the path of the mandibular canal. Although the bucco-lingual position of the mandibular canal is variable, the distance from the canal to the medial aspect of the buccal cortex (medullary bone thickness) was found to be greatest at the distal half of the first molar (mean 4.05 mm).[58] Therefore, the anterior body cut should be made in this area and not in the third molar region, where the canal is closer to the buccal surface. This anterior body cut is progressively deepened until bleeding from the underlying cancellous bone is visible. The inferior osteotomy is only a partial thickness cut made with a round carbide burr (No. 8). It connects the inferior aspects of the superior ramus and anterior body cuts. This osteotomy on the lateral aspect of the ramus parallels the external oblique cut and creates the base of the rectangular bone block. It extends only partially through the cortex and creates a line of fracture. The block graft is then removed with a chisel wedged within the external oblique osteotomy. Care should be taken to parallel the chisel with the lateral surface of the mandible and limit the depth of penetration. An alternative technique is to insert an extraction elevator and pry the graft free (Figures 30-34 and 30-35). This donor site is not augmented with bone substitutes, as the inferior alveolar nerve may be exposed and irritated by the graft particles. The incision is closed primarily with resorbable sutures such as 4-0 chromic gut. A rectangular piece of bone approximately 4.0 mm in thickness may be harvested from the ramus (Figure 30-36). This morphology is well suited for veneer grafting to gain additional ridge width, or the block may be particulated in a bone mill.

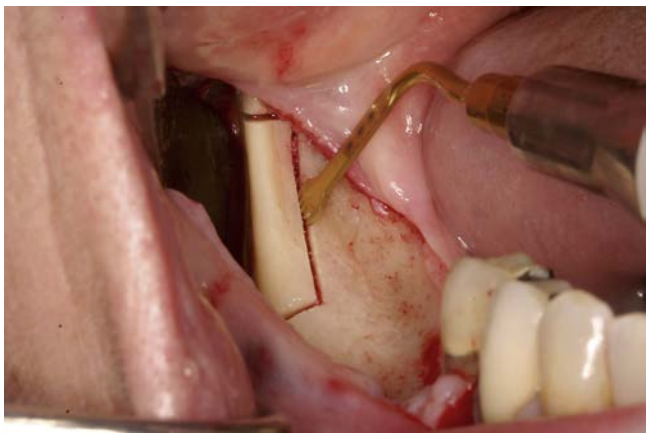

• **Figure 30-33** The osteotomies for ramus graft harvest are performed with a piezoelectric saw.

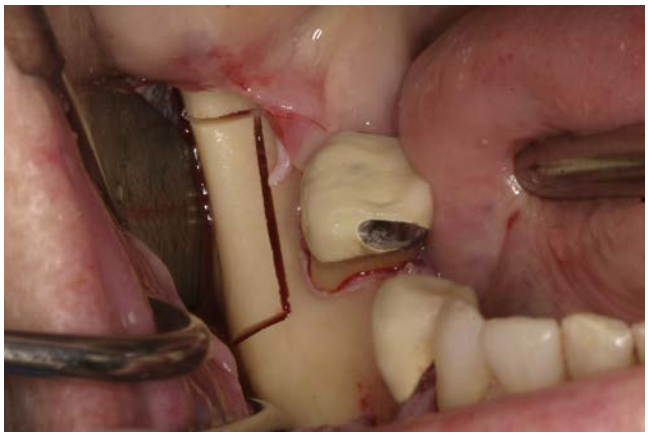

• **Figure 30-34** A piezoelectric saw creates thin bone cuts, allowing bone harvest lateral to the molar.

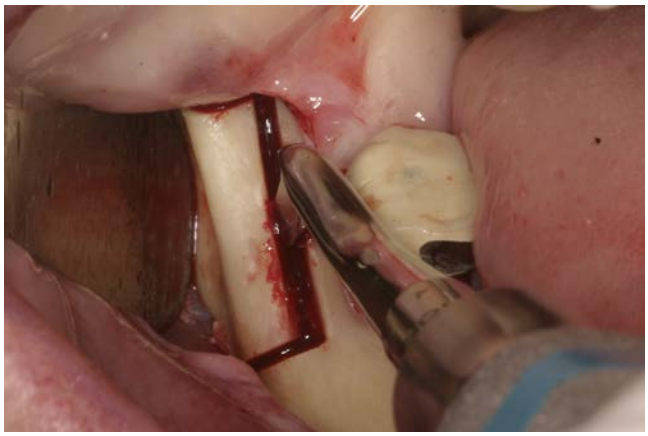

• **Figure 30-35** The cortical block bone graft is pried from the donor site with an extraction elevator.

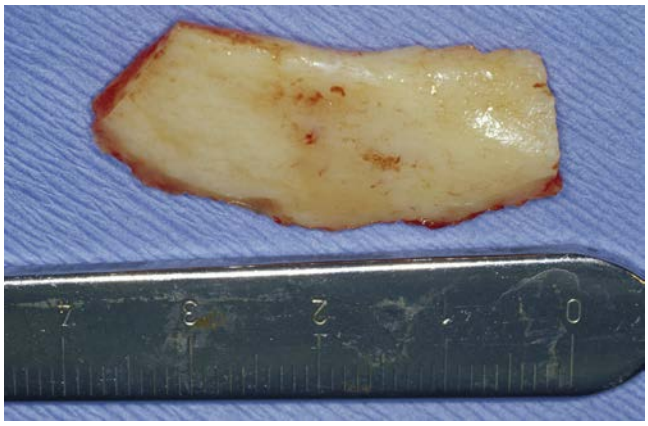

• **Figure 30-36** A cortical bone graft, 40.0 mm × 10.0 mm, harvested from the mandibular ramus.

The mandibular ramus is also convenient donor site for bone harvest in conjunction with third molar removal.[59] This is often planned for the repair of alveolar deficiencies from congenitally absent teeth in young adults. If the third molar is partially erupted, the tooth is removed prior to bone harvest. If the molar is bony impacted, then the block graft is harvested and the tooth can be removed laterally

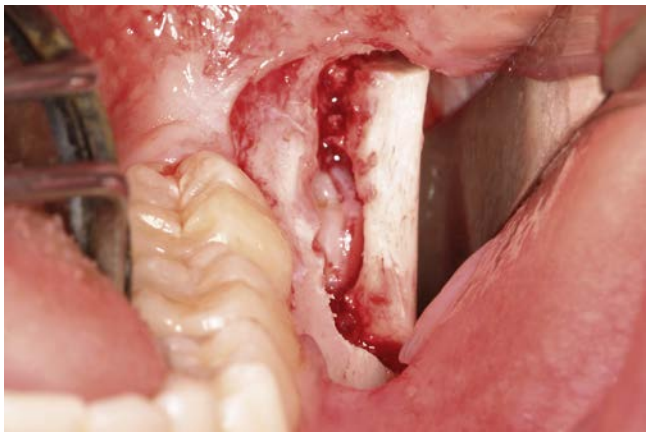

• **Figure 30-37** Harvesting a ramus bone graft in conjunction with third molar removal in a younger patient.

through the donor site (Figure 30-37). The cortical block graft can be used to reconstruct the ridge deficiency.

The posterior mandible is the preferred area for harvesting large amounts of particulate bone with a scraper device.[21] The initial incision for this approach is made in the buccal vestibule, similar to one used in a sagittal split osteotomy. It is made just lateral to the external oblique ridge and extends the length of the molar regions. This incision design requires minimal time to reflect and gain access to the mandible and is equally as easy to close. A larger area of mandibular exposure allows longer strokes with the scraper blade and expedites graft harvest (Figure 30-38). The dense cortical bone should be repeatedly lubricated with sterile saline during the scraping. Routinely, 4.0 mL of particulate autograft may be harvested from the ramus and body of the mandible (Figure 30-39). There is minimal morbidity in harvesting bone from the cortical surface with a scraper blade.

Compared with the symphysis region, the ramus donor site is associated with a much lower incidence of complications.[42,56] Patients have shown less concern with bone removal from the ramus area. The masseter muscle provides soft tissue bulk, and augmentation of this donor site has been unnecessary. Although damage to the inferior alveolar nerve is possible, the incidence of this complication is very low.[60] It is important to plan osteotomies in the posterior mandible around the position of the mandibular canal. The use of a piezoelectric saw has been postulated to decrease the risk of nerve injury, as the ultrasonic blade does not cut soft tissue.[61] In contrast to the common complaint of altered sensation of the incisors with chin bone harvest, no ramus graft patients have noted numbness of their molar teeth.[42,56] Although the posterior incision along the external oblique ridge could possibly damage the buccal nerve, reports of sensory loss in the buccal mucosa are rare and will most likely go unnoticed.[62] Ramus graft patients appear to have fewer difficulties with managing postoperative edema and pain compared with chin graft surgery.[42,56] Patients may experience trismus following surgery and should be placed on postoperative glucocorticoids and nonsteroidal

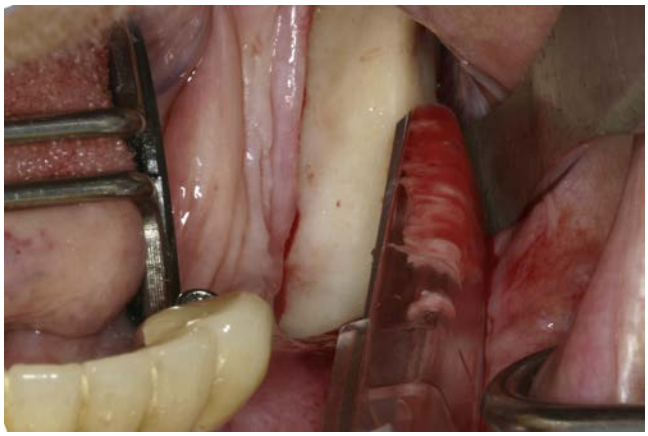

• **Figure 30-38** A bone scraping device is used to harvest particulate bone from the posterior mandible.



• **Figure 30-39** The bone scrapings from the mandible are collected and stored in sterile saline.

anti-inflammatory medications to help reduce dysfunction. The mandibular ramus has significantly less morbidity than the symphysis and has become the preferred donor site of many clinicians.[21,42,51,56]

Tibia

The proximal tibial metaphysis provides an excellent source of cancellous bone for grafting.[63-65] This donor site offers up to 40 mL of cancellous bone with low reported morbidity.[63,64] The surgery may be performed in an office environment under intravenous sedation. The most common approach to the donor site is laterally at Gerdy's tubercle, a bony protuberance located 1.5 cm below the articulating surface of the tibia[63] (Figure 30-40). However, a medial approach to the tibia has also been proposed.[66] The leg is elevated with a rolled towel or firm pillow and the knee is slightly bent. The leg is shaved, and the skin is prepped with an antimicrobial solution (povidone-iodine or chlorhexidine). Sterile drapes are positioned to isolate the surgical field, and the surgical team should follow strict aseptic technique including sterile gowns and gloves. A sterile surgical marking pen is used to plan the incision and local anesthetic



• **Figure 30-40** The incision planned on the lateral aspect of the proximal tibia over Gerdy's tubercle.

with a vasoconstrictor is infiltrated along the site. The local anesthetic needle is then directed to the bone for additional infiltration over the area. A 2.0- to 3.0-cm oblique incision is made through the skin on the anterolateral aspect of the leg directly over Gerdy's tubercle.[64] No major nerves or arteries are located in this site. Therefore, placement of a tourniquet is usually unnecessary and bleeding is controlled with electrocautery. After incising through the subcutaneous and fascial layers of the iliotibial tract, the periosteum is visualized. An oblique incision is made over the bone with short inferior releasing incisions. The periosteum is reflected to expose the cortex of the tibia. Rake retractors are helpful in reflecting the dense tissue flaps. The 1.5-cm opening through the cortical bone is made with a carbide fissure burr (No. 702). Alternatively a large trephine burr (10.0 mm) may be used (Figure 30-41). The surgeon should direct the burr medially and inferiorly to avoid the knee joint. The cortex is fairly thin, so the block piece of cortical bone may be pried from the donor site and placed aside for reconstruction of the ridge defect (Figure 30-42). The cancellous bone is harvested using orthopedic bone curettes or a No. 2-4 Molt curette. Studies have found that the amount of cancellous bone that may be obtained is the same as an anterior iliac harvest[67] (Figure 30-43). If needed, hemostatic agents, such as microfibrillar collagen or gelatin, may be placed into the bony void. The wound is closed in layers with resorbable sutures such as 3-0 polyglactin. The skin is closed with sutures (5-0 nylon) or staples. Antibiotic ointment is applied, and the knee is wrapped with an elastic pressure dressing. Patients are encouraged to keep the leg elevated and apply ice. They may begin ambulation on the donor leg following the surgery, but should avoid full weight bearing

for a few days. Although normal activities can be resumed thereafter, the patient should avoid strenuous exercise for 4 to 6 weeks.

Postoperative pain from tibia bone harvest is well managed with moderate narcotic analgesics. Ecchymosis of the leg distal to the donor site is quite common. There has been a low incidence of significant complications with this procedure.[63-65,68] Complications may include hematoma formation, wound dehiscence, infection, and fracture. Although quite rare, most cases of tibia fracture are due to a bony access too low on the leg.[69]



• **Figure 30-41** A trephine burr is used to perform the osteotomy into the proximal tibia.



• **Figure 30-42** The cortical bone plug is removed to gain access to the cancellous bone.



• **Figure 30-43** The cortical bone plug and cancellous bone harvested from the proximal tibia.

Ilium

The grafting of larger areas of bone deficiency often requires bone harvest from the ilium. As the tibia offers a convenient site for harvesting cancellous bone, the ilium is most often reserved for cases requiring corticocancellous block grafting. Currently the atrophic edentulous mandible is less often grafted using iliac bone. Even with more severe mandibular atrophy, short implants may be used for prosthetic support.[70] However, iliac bone grafts are still useful for treatment of the severely atrophic edentulous maxilla. A LeFort I osteotomy with interpositional iliac bone has been well documented for the reconstruction of the atrophic maxilla. The maxilla is downfractured and moved inferior and anteriorly. Corticocancellous blocks are placed between the midface and maxilla, and plates are used to secure the advancement. Earlier reports on this technique detailed simultaneous placement of machine surface implants.[71,72] Delayed implant placement after graft healing and the use of moderately rough implant surfaces may increase implant survival.[73-75] LeFort I interpositional grafting addresses both bone volume and interarch relationship problems that are common in the long-term edentulous patient, but pose significant challenges such as hospitalization, long operating time, and general anesthesia. Another method to reconstruct the atrophic edentulous maxilla is to combine block onlay bone grafting anteriorly and sinus bone grafting posteriorly. The grafted maxilla is allowed to heal for delayed implant insertion 4 to 6 months later. This allows prosthetic-driven implant placement for overdenture support or a fixed prosthesis. Large bone defects in the partially edentulous patient, resulting from trauma, pathology, or infection, can be well managed with corticocancellous blocks.[28] Although the use of recombinant human bone morphogenetic protein-2 (rhBMP-2) with allograft has been proposed as an alternative to autograft for maxillary reconstruction, this method is an off-label application of the product and lacks long-term data on implant survival.[76] In addition, the quality of the bone regenerated by rhBMP-2 is often less dense compared to autogenous cortical/corticocancellous block grafts.[77,78]

In most cases adequate bone may be harvested using an anterior approach to the hip. A posterior approach to the ilium is less often required and is usually reserved for major reconstructive surgeries requiring large amounts of cancellous bone. In addition, the need to rotate the patient after posterior bone harvest is an inherent disadvantage. Although posterior bone harvest is reported to result in less postoperative pain, the postoperative use of an anesthetic pain pump can minimize the problem with anterior harvest.[79-82]

There are varying shapes of blocks that may be harvested from the hip. A reciprocating saw and chisels are used to

perform the osteotomies for bone harvest. Square or rectangular corticocancellous blocks used for width augmentation are harvested from the medial cortex or lateral cortex.[83] The crestal osteotomy should begin at least 1.0 cm from the anterior iliac spine. Otherwise the remaining anterior segment of bone may be weakened and fracture.[83] The iliac crest is cut along its length for unicortical bone harvest, leaving the opposing cortex intact (Figures 30-44 and 30-45). When thicker pieces of bone are needed for vertical bone augmentation, a bicortical bone graft may be harvested from the entire width of the crest. The gluteal muscle attachments are reflected from the lateral cortex along the crest of the ilium. This graft geometry is typically used for reconstructing the severely atrophic premaxilla (Figure 30-46). Following the harvest of the corticocancellous block(s), significant amounts of additional cancellous bone may be harvested with bone curettes. The edges of the iliac cortex should be smoothed with a rasp or file before closure. Following the removal of the bone graft, hemostatic materials, such as a sheet of microfibrillar collagen or gelatin, can be placed over the cancellous bone. A pain pump with long-acting local anesthetic catheter is placed into the wound following closure of the periosteal layer (Figure 30-47). The muscle layers and subcutaneous tissues are closed with polyglactin mattress and interrupted sutures. The skin may be closed with nylon interrupted sutures or surgical staples. The pain pump is removed a few days after surgery when the local anesthetic has been pumped out. The patient is instructed to avoid full leg weight bearing on the side of graft harvest for 1 week. Crutches or a walker may be used for ambulatory assistance. Using the left hip for harvest allows patients to return to driving their car earlier. The patient should avoid exercise and heavy lifting for 6 weeks following surgery.[84]

The iliac crest provides the greatest source of bone for jaw reconstruction but also has the greatest morbidity of any donor site. Postoperative pain from the hip is usually the most common complaint.[83] Although acute postoperative pain can be significant, the use of a local anesthesia infusion device can provide exceptional pain control that exceeds the duration of pharmacologic activity.[82,85] The infusion device delivers controlled amounts of local anesthetic to the area for improved postoperative pain management. Preemptive use of analgesics is also beneficial for patient comfort. Chronic pain of the donor site has been reported.[86] Temporary gait disturbances may require ambulatory assistance for a week or longer. There is a low incidence of hematoma



• **Figure 30-44** A bone chisel is used with a surgical mallet to harvest a corticocancellous bone graft from the anterior iliac crest.

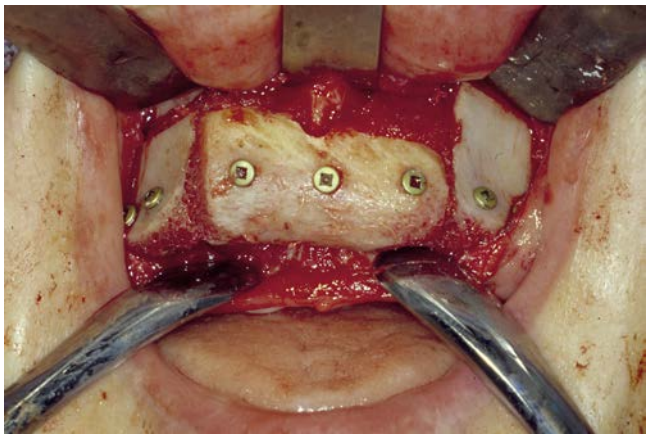

• **Figure 30-46** A bicortical bone graft is harvested from the anterior iliac crest to vertically reconstruct the anterior maxilla.

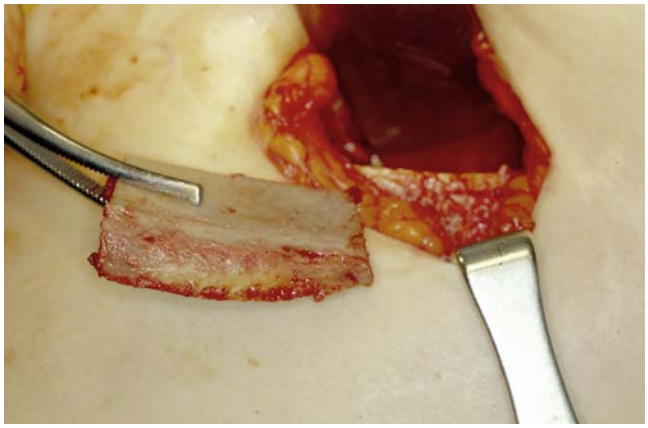

• **Figure 30-45** A corticocancellous bone graft harvested from the anterior iliac crest.

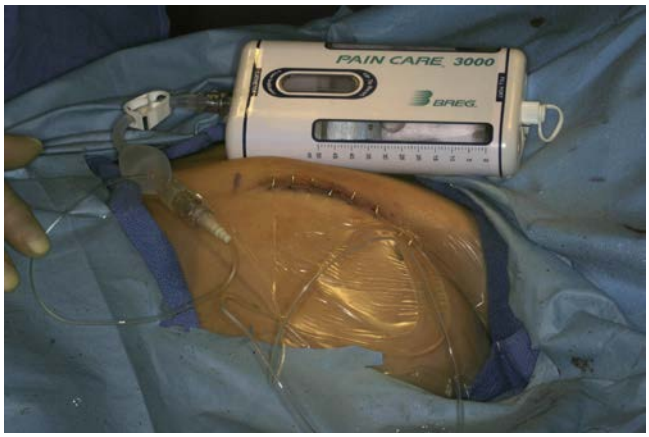

• **Figure 30-47** The catheter from the bupivacaine pump infuses local anesthetic into the donor site for patient comfort after bone harvest.

formation. Cutaneous paresthesia of the thigh area has been reported with an anterior approach to the iliac crest, but this is usually temporary.[86,87] Although it is usually covered by underwear, some patients may object to the appearance of a scar. Anterior iliac spine fractures are rare.[86] Assessment studies on patients who had iliac bone grafting of the maxilla found low morbidity and high patient acceptance, supporting its use.[83,84,88,89]

Graft Recipient Site

The bone defect is usually exposed and prepared prior to bone graft harvest. This allows a better determination of the need for bone repair and minimizes the length of time from bone harvest to graft placement. The flap design is an important consideration in bone augmentation and should be well planned prior to surgery. Incisions to expose the recipient site are typically made along the ridge crest through attached gingiva. As blood vessels do not cross over the ridge crest (facial-palatal/lingual), a crestal incision maintains vascular supply to the flap.[90] Divergent releasing incisions remote to the defect facilitate closure and also help maintain blood supply to the flap. Making vertical releasing incisions one tooth lateral to the graft site is prudent. For larger grafts in the anterior edentulous maxilla or mandible, a vestibular incision through the mucosa may be considered, especially if vertical augmentation is planned. The mucoperiosteal reflection is made over a broad area well beyond the defect margins. This provides a larger flap for advancement over the augmented site. Several perforations of the cortical surface of the bone may be performed with a small round burr to release local growth factors and expedite revascularization of the graft[91] (Figures 30-48 and 30-49).

The addition of supplemental autologous growth factors, such as platelet-rich plasma, has been reported to enhance and accelerate the incorporation of autologous cancellous bone grafts.[92] In addition, platelet-rich plasma may be useful as a matrix for soft tissue repair, for adhesion of bone graft particles, and for improving hemostasis. Adding a prepared concentrate of the patient's platelets to the grafted site may also enhance and accelerate soft tissue wound healing. The various cytokines and mediators found in the alpha granules of the platelets promote angiogenesis and collagen synthesis.[93] This may diminish the risk of wound dehiscence and bone graft exposure to the oral cavity (Figures 30-50 through 30-52). The platelet concentrate is placed over the graft and under the flap margins prior to closure.

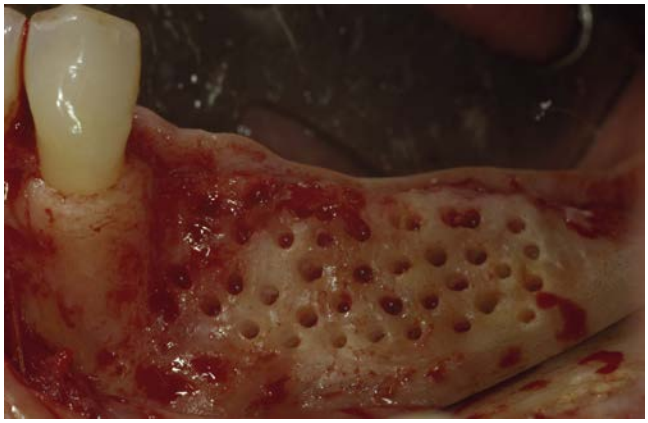

• **Figure 30-48** Perforation of the cortical bone in the recipient site to facilitate incorporation of the bone graft.

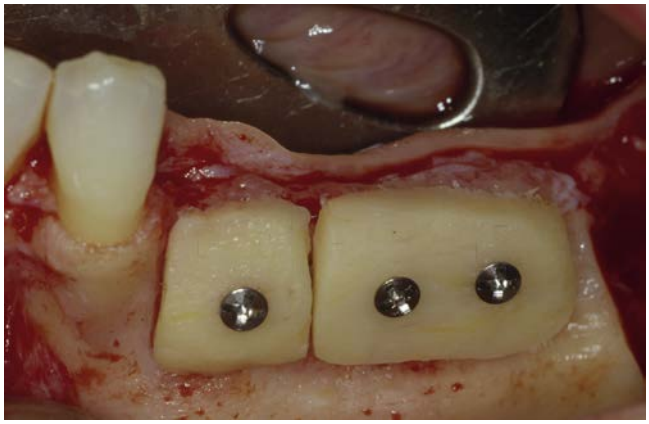

• **Figure 30-49** Cortical bone grafts are fixated onto the lateral aspect of the posterior mandible.

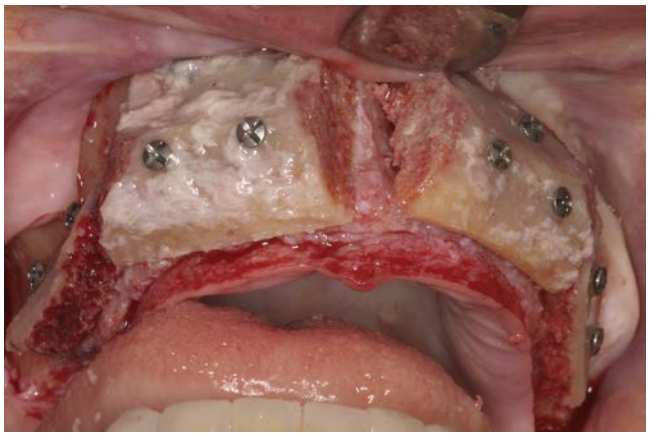

• **Figure 30-50** Corticocancellous block bone grafts from the iliac crest are used to reconstruct the atrophic maxilla.

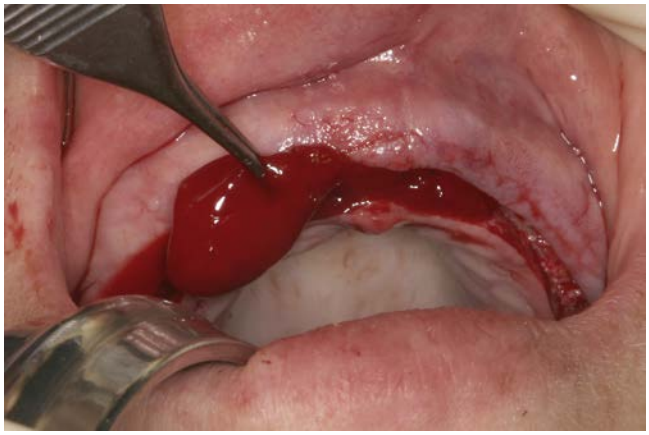

• **Figure 30-51** Platelet concentrate is placed over the bone graft and under the flaps during closure of the incision.

Complete flap coverage and tension free closure is essential to the successful incorporation of the bone graft. Incision of the periosteum along the base of the facial flap allows advancement of the flap over the grafted site. After the periosteal releasing incision is made the flap is gently stretched to assess closure without tension. If resistance to the adaptation of the wound margins is noted then further flap release can be obtained with blunt dissection through the periosteal release and beyond the vestibular depth. Blunt scissors or a hemostat can be advanced through a plane parallel to the facial bone. This will avoid compromising the blood supply to the flap. Procedures to enhance graft coverage will usually result in a loss of vestibular depth. This is rarely a problem with implant supported restorations as the prosthesis does not require a soft tissue seal for retention. Patient may complain of some reduced lip mobility. The advancement of the facial flap over the graft may often reposition the keratinized gingiva more palatal or lingual. In some cases soft tissue grafting may be necessary but the keratinized tissue can usually be moved facially during second stage uncovery of the implants. Although it is important that the flap margins are well approximated, the sutures should not be pulled too tightly or ischemia will occur. The flaps should be closed over the bone graft with suture materials that maintain their tensile strength until the wound has completely healed. Polyglactin and polytetrafluoroethylene (PTFE) suture is preferred over materials such as chromic gut or silk. Horizontal mattress sutures evert the flap margins and coapt the connective tissue surfaces. Multiple interrupted sutures are used to close the vertical releasing incisions.

Postoperative Care

It is imperative that the graft not be traumatized during healing. A fixed provisional prosthesis, such as a temporary bridge or bonded prosthesis, is preferred if possible. A removable vacuum formed or Essix retainer is another excellent option for cosmetic tooth replacement, as it is supported by the teeth and does not place any pressure on the graft site. The use of any soft tissue borne removable prosthesis is discouraged for the first few weeks until the incision has healed. If the removable prosthesis is only replacing posterior teeth, then patients should avoid using it during the entire healing period. Removable prostheses should be adjusted to minimize any contact with the grafted site. The facial flange is completely removed, and the ridge area over the graft is relieved. The prosthesis may be relined with tissue conditioner, and denture adhesive is often necessary for added retention. The patient is instructed to use the removable prosthesis for cosmetic appearance and minimize function. Unfavorable concentration of forces from the opposing dentition should be avoided, and a broad distribution of occlusal contacts is preferred.[94] Patients wearing removable prostheses over larger bone grafts should maintain a softer diet for at least 2 months after surgery. After this time period, the onlay graft has formed a union to the host bone and relies less on the fixation screws for immobility. Small-diameter temporary or transitional mini-implants have been used successfully to support fixed interim prostheses for patients less tolerant of complete or partial removable dentures.[95] The transitional implants should be placed in native bone and not within the graft.



• **Figure 30-52** A postoperative view of the incision line after 1 week of healing.

Postoperatively the patient should continue antibiotic therapy for at least 1 week. The continued short-term use of glucocorticoids can diminish swelling and edema of the soft tissues. Narcotic analgesics are prescribed for use after surgery. Thereafter the patient may transition into the use of nonsteroidal anti-inflammatory medications for pain control. Chlorhexidine rinsing is used for oral hygiene until the sutures are removed. Smoking has been associated with a high rate of wound dehiscence and graft failure.[96] Patients are instructed to quit 1 week prior to surgery and told not to smoke at least until the incision is completely closed.

Block Bone Grafts

Autogenous block bone grafting is a well-proven and predictable method to augment the maxilla and mandible for dental implant placement. Block bone grafts may be preferred to other techniques (ridge splitting, distraction osteogenesis, interpositional grafts), as they can better three-dimensionally reconstruct the lost anatomic ridge contour. Smaller cortical blocks can be harvested from intraoral donor sites (symphysis, ramus). Corticocancellous blocks from the iliac crest have proven to be very effective in managing larger bone defects and greater atrophy[28] (Figures 30-53 through 30-56).

The osseous recipient bed is prepared to improve the fit and contact of the bone block to the ridge. Perforation of the cortex with a small round burr releases growth factors, expedites revascularization of the graft, and improves graft-to-host union.[91] The bone graft should have intimate contact with the underlying host bone. The clinician should preferably decorticate the host bone to mortise the cortical bone block to the ridge rather than significantly adjusting the graft.[91] Block bone grafts should be oriented with the cancellous side against the host bone. Corticocancellous

block grafts from the iliac crest require less adjustment, as the softer cancellous bone will mold to the ridge. Block grafts do not tolerate micromovement and will fail to incorporate unless rigidly fixated. The graft is mortised into position and fixated to the ridge with screws. Fixation screws typically range from 1.0 to 2.0 mm in diameter. A screw length that maximizes retention within the host bone should be selected. A lag screw technique is used for fixation of cortical onlay bone grafts. The screw engages and threads the host bone but fits passively through the cortical bone graft to compress and rigidly fixate the block. Although one screw may be considered for small block grafts, two or more screws should be used for larger grafts. The fixation screws may also have a positive effect on graft retention, as they tent the periosteum during remodeling. The periphery of the block graft and small discrepancies between the graft and host bone may be filled with a variety of graft materials. If available, autogenous cancellous bone is preferred. An alternative is to locally harvest cortical shavings using a bone scraping device. Particulate mineralized bone allograft may also be considered for grafting the borders of the block.

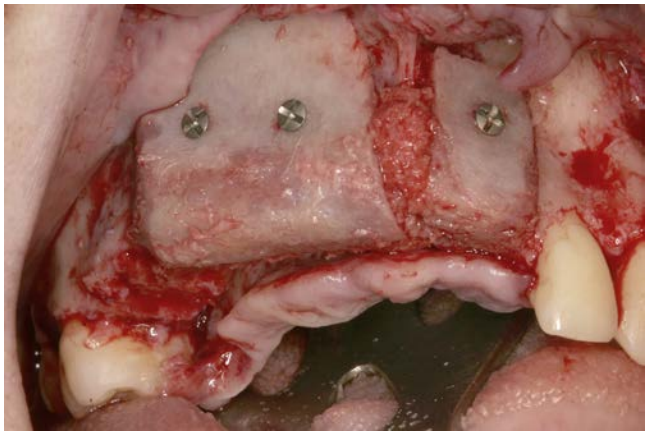

• **Figure 30-53** Corticocancellous block bone grafts from the iliac crest are used to reconstruct the maxillary bone defect (patient from Figures 30-8, 30-9, and 30-10).

The routine need for barrier membrane coverage over block bone grafts has been a debated topic. Although some studies have found that membranes have a positive influence on graft healing, others dispute their significance.[97,98] Cortical bone grafts exhibit minimal resorption and do not typically require membrane protection.[14,15,99,100] Cancellous bone and particulated bone grafts are more susceptible to volume loss and would benefit from membrane use. The use of a barrier membrane may improve the incorporation of the peripheral particulate graft around a block (Figures 30-57 through 30-59). Bovine hydroxylapatite has also been found to reduce graft loss when placed over and around autograft blocks.[101] Collagen membranes are preferred over PTFE as they are associated with fewer complications such as exposure and infection.[102]

Guided Bone Regeneration

Guided bone regeneration (GBR) uses the principle of selective cell repopulation to repair bone defects. A barrier membrane is used to occlude soft tissue cells and allow slower growing bone cells to repopulate the defect and regenerate bone.[103] The barrier membrane is shaped to extend beyond the bone defect margins and cover the area during healing. The original studies on GBR used an expanded PTFE membrane.[103] This nonresorbable membrane allows the barrier to remain intact during the entire healing period but also requires removal thereafter. To prevent migration and exposure, a PTFE membrane needs to be sutured or fixated into place with sutures, tacks, or screws. Development of resorbable membranes simplified the technique, as removal is unnecessary and there is less need for fixation. Collagen membranes have several unique and favorable properties, including improved hemostasis, chemotaxis for fibroblasts, and ease of manipulation.[104] Many resorbable membranes

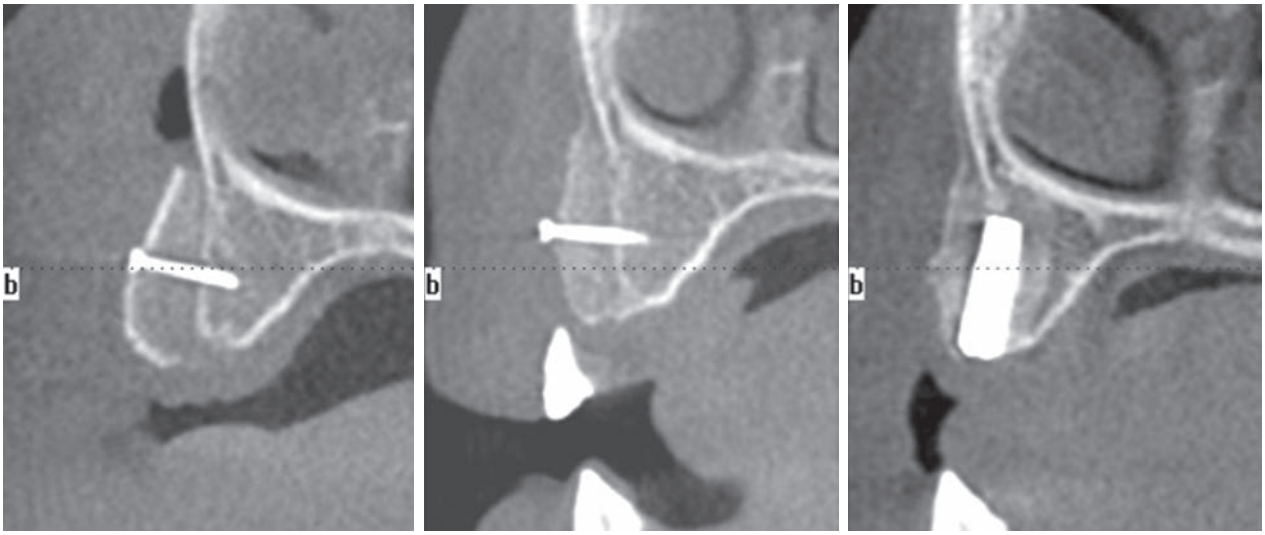

• **Figure 30-54** Computed tomography scan images of the corticocancellous block after placement, after 4 months of healing, and after implant insertion.

are made from bovine or porcine type I collagen. Bovine pericardium and allogeneic dermis also have suitable properties for use as barrier membranes for GBR.[105,106] Crosslinking of the collagen fibers is a laboratory modification that acts to prolong the resorption time of the membrane, increasing barrier function.[104] Crosslinked collagen membranes may last 2 to 6 months or longer. However, as GBR is a volume-dependent process, a resorbable membrane must remain intact long enough for bone cells to repopulate the area. Larger bone defects or vertical augmentation treated by GBR may necessitate use of a nonresorbable membrane. In most cases a particulate bone graft material is placed under the membrane to act as an osteoconductive scaffold for bone replacement. Several types of bone graft materials have been used for this purpose, including autogenous bone, allografts, xenografts, and alloplastic bone substitutes. Particulate autograft may be obtained from the local surgical area or posterior mandible using a scraping device or drills.[21] Block autogenous bone may also be harvested from the posterior mandible area and particulated with a bone mill. Tenting screws, titanium plates, or even a dental implant can also be used to assist in space maintenance under the membrane.[107,108] The inclusion of titanium reinforcement within a PTFE membrane prevents collapse and allows the clinician to shape the desired contour.[109,110] The healing period of membrane-protected defects typically ranges from 6 to 9 months. Larger vertical defect require longer healing periods, whereas smaller dehiscent-type defects may require less time.

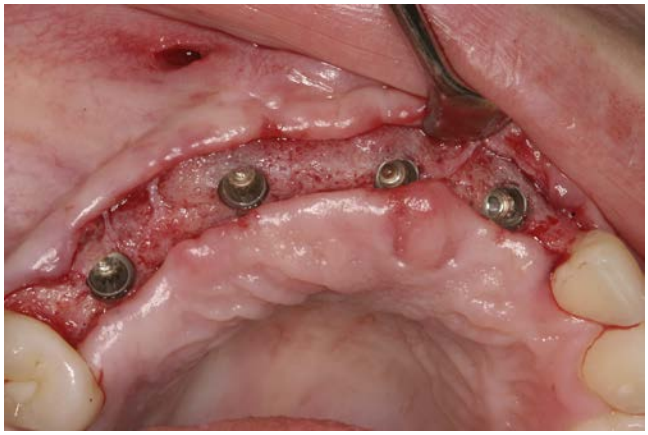

• **Figure 30-55** Placement of dental implants in the maxilla after 4 months of healing.



• **Figure 30-56** An immediate-load fixed provisional prosthesis is placed onto the maxillary implants.

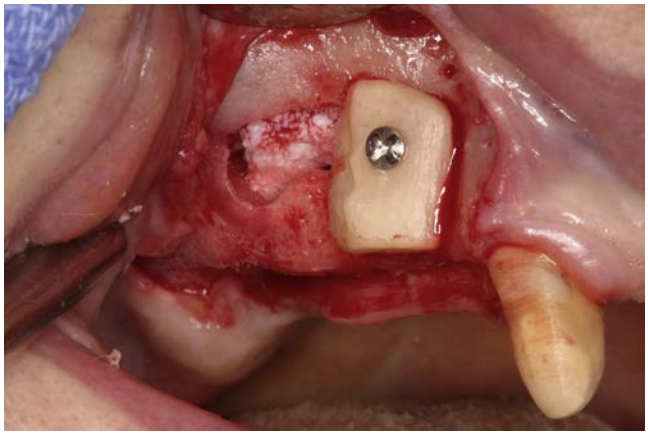

• **Figure 30-57** Sinus bone graft and cortical onlay bone graft to reconstruct the right posterior maxilla.

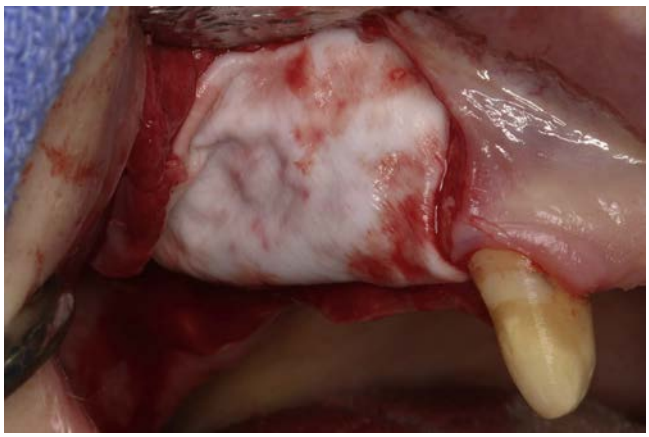

• **Figure 30-58** Particulate autograft is packed around the block graft, and the site is covered with a collagen barrier membrane.

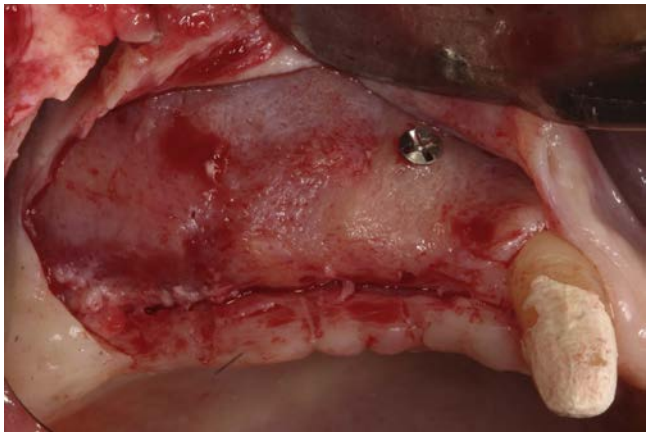

• **Figure 30-59** The block bone graft and surrounding particulate graft are well incorporated after 4 months of healing.

Horizontal Bone Augmentation Using GBR

Guided bone augmentation is often used to repair dehiscent defects around dental implants. In the anterior maxilla, resorption of the facial plate following extraction often results in a ridge width deficiency. The greatest area of bone volume loss is at the facial ridge crest. Therefore it is not uncommon to need bone augmentation around the neck of the implant. Guided bone regeneration has proven to be a very reliable method to repair localized bone defects with simultaneous implant placement.[111] In most cases a bone substitute and a resorbable collagen membrane will suffice. If local bone can be harvested, this may be used to cover exposed threads. When facial ridge contour is also deficient, it can be restored with a slower resorbing graft material under the membrane, such as bovine hydroxylapatite.[112] The grafted implant can be covered by the flap and submerged for protected healing.

In the case of more extensive bony width defects, precluding implant placement, a delayed implant protocol following lateral ridge augmentation is indicated. The amount of horizontal bone augmentation with using GBR has been reported to range from 2.0 to 4.5 mm.[113] The osseous bed may be prepared by perforation of the cortex with a small burr. The intramarrow penetration can facilitate angiogenesis and allow osteogenic cells to migrate into the grafted area.[114] Modest gains in ridge width may be obtained using bone substitutes, such as mineralized bone allograft, and a resorbable collagen membrane. Slightly greater horizontal gains have been found using a mixture of particulate autograft and bovine hydroxylapatite with a collagen membrane.[115]

Vertical Bone Augmentation Using GBR

Although simultaneous vertical bone augmentation and implant placement has been reported, a two-stage procedure is usually indicated.[116,117] As vertical bone augmentation is more biologically challenging, the GBR technique may require modification. The majority of studies evaluating GBR for vertical bone augmentation used particulate autograft with a titanium-reinforced PTFE membrane[117,118] (Figures 30-60 and 30-61). Often a secondary donor site is needed for harvesting larger amounts of particulate bone. The use of a bone scraping device within the mandibular ramus and body has been shown to be a useful technique with low morbidity.[21] The titanium-reinforced PTFE membrane should be stabilized with tacks or screws. It is helpful to fixate the membrane on the palatal or lingual bone before adding the bone graft and then rotating it over the augmented site. Flap advancement procedures are then performed to obtain tension-free primary closure.

The most frequent postoperative complication of GBR is membrane exposure.[117] Surgical methods to passively advance the flaps during closure over the membrane must be employed. Exposure of expanded PTFE membranes has been shown to significantly reduce bone regeneration.[116]

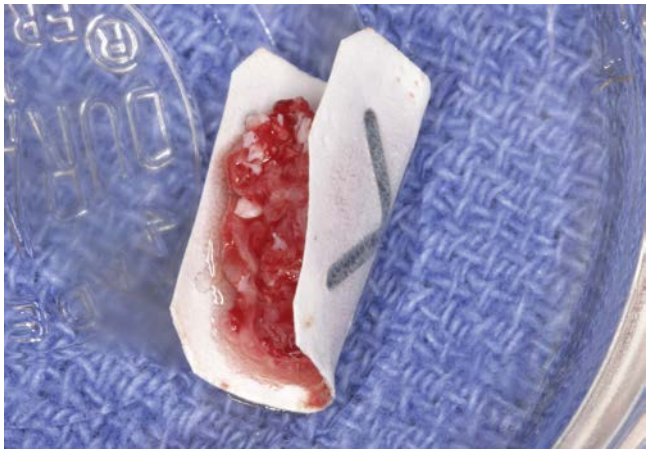

• **Figure 30-60** A titanium-reinforced polytetrafluoroethylene (PTFE) membrane is filled with particulate autogenous bone and bovine hydroxylapatite.

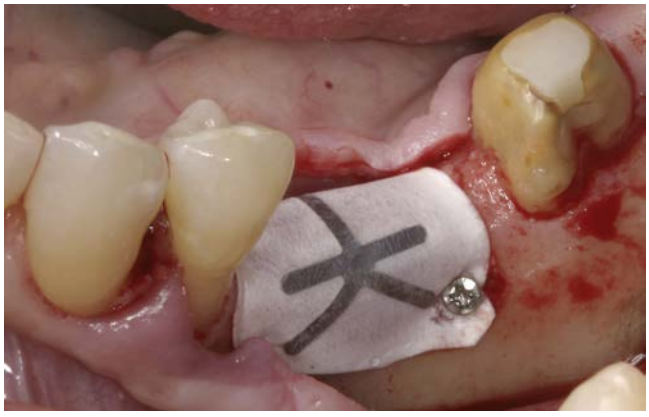

• **Figure 30-61** The vertical defect in the posterior mandible treated with a titanium-reinforced polytetrafluoroethylene (PTFE) membrane filled with particulate autogenous bone and bovine hydroxylapatite.

Exposure rates as high as 31% resulting in infection and GBR failure have been reported.[119] A membrane made of high-density polytetrafluoroethylene (d-PTFE) was developed for use in socket grafting.[120] Dense PTFE membranes have also been found to be as effective as the expanded version when used for ridge augmentation.[121] However, primary closure and avoidance of membrane exposure are advised with this application. Exposure of collagen membranes to the oral cavity increases the rate of degradation and loss of barrier function.[122]

Sinus Bone Grafting

It is often unnecessary to consider a secondary donor site for bone harvest when performing sinus augmentation. Over the years numerous bone substitutes have been successfully used for sinus grafting. The 1996 Sinus Graft Consensus evaluated retrospective data on various graft materials and concluded that they all seemed to perform well.[123] However, the data analysis did not factor the amount of residual bone below the sinus. Bone substitutes have been suggested for the posterior maxilla with less resorption or modest

sinus pneumatization. The highly pneumatized sinus with minimal bone along the floor can be biologically challenging to graft with bone substitutes alone. There has been concern for resorption and volume loss when using cancellous marrow for sinus floor grafting. Mixing the cancellous bone with a slow-resorbing graft material, such as bovine hydroxylapatite, can diminish volume changes with healing. In the management of the pneumatized sinus, rhBMP-2 has been compared with autogenous bone with favorable results.[5]

There are many possible advantages in using autologous bone in sinus grafts, especially when minimal bone remains below the sinus floor.[124-126] Several studies have found an increase in bone formation when autologous bone is used alone or added to other grafting materials in sinus grafts.[124,127-129] Froum and colleagues[127] found a significant increase in vital bone formation when as little as 20% autologous bone was added to bovine-derived grafts. As previously discussed, local bone can be easily harvested from the tuberosity or collected from a bone scraper passed over the lateral maxilla and zygomatic buttress. The use of a barrier membrane over the sinus window has also been advocated to increase vital bone formation when bone substitutes are used.[130] Instead of using a commercially available membrane, a thin piece of cortical bone obtained from the tuberosity area can be used as an autologous barrier to cover the window. A membrane may not even be necessary when a significant portion of the graft is autologous bone.

Compared to bone substitutes, the healing time requirements of autologous bone grafts are shorter, especially in larger pneumatized sinuses. The healing period for sinuses grafted with autologous bone can be as short as 4 months compared to the 8 to 10 months often recommended for bone substitutes.[127] The addition of autologous bone to composite bone grafts can also shorten healing times.[56,127] This offers a significant advantage, as patients often object to extended treatment lengths. Not only do autologous bone grafts heal faster than bone substitutes, the quality of the regenerated bone is often better. Histological studies have shown greater bone formation and higher bone-implant contact when autologous bone grafts are used compared with allografts in sinus grafting.[129] This improved bone formation at an earlier time can allow for shorter implant healing periods compared to the use of bone substitutes. The use of growth factors, such as rhPDGF, may offer an alternative to using autograft to accelerate graft healing.[131]

It may also be beneficial to use autologous bone for sinus grafting when additional simultaneous onlay augmentation is desired. The posterior maxilla resorbs medially following tooth loss, and this pattern of bone loss often results in an unfavorable ridge relationship with the opposing lower dentition. It is not unusual to require sinus bone grafting to increase the vertical bone dimension as well as onlay bone grafting to augment the ridge width and/or correct bone deficiencies in the posterior maxilla. Autologous bone may be harvested for sinus bone grafting and simultaneous residual ridge reconstruction using autologous block grafts. The healing period of the onlay block and sinus bone grafts will be similar, allowing for earlier implant placement. This approach may be preferred to a staged reconstruction where sinus grafting is performed first using bone substitutes and autologous block bone grafts are placed at a later date.

Titanium Mesh Grafts

The use of titanium mesh for bone augmentation should not be confused with guided bone regeneration techniques. Guided bone regeneration uses a cellular occlusive barrier membrane to impede soft tissue penetration and allow the slower growing bone cells to repopulate the osseous defect.[103] Titanium mesh acts as a protective matrix to maintain space and facilitate bone fill but is not cellular occlusive. The mesh lattice is porous and allows passage of nutrients, cells, and vascular ingrowth. One study on mesh pore size suggests that macroporous openings may be preferable to a micropore mesh.[132]

Traditionally, the titanium mesh technique used cancellous autogenous bone graft from the iliac crest[133,134] (Figures 30-62 through 30-64). This approach has been shown to produce significant vertical bone augmentation gains exceeding 1.0 cm.[135,136] However, a secondary donor site, such as the iliac crest or tibia, is required with the associated morbidity of graft harvest. As an alternative, particulate intraoral autograft may be combined with bone substitutes using titanium mesh, but the reported volume gains are modest.[137,138] Use of rhBMP-2 has been actively studied as an alternative to harvesting autogenous bone.[28,76,78] Marx and colleagues[76] compared cancellous autograft with a composite graft of rhBMP-2/ACS with mineralized bone allograft and platelet-rich plasma and found similar outcomes for vertical ridge augmentation using titanium mesh.

The titanium mesh may be cut and formed before surgery. The traditional preparation of the mesh involved making a maxillary impression and pouring a stone cast. A mock buildup of the reconstructed ridge was made on cast and the mesh was cut and shaped over it. The formed mesh would then be cleaned and sterilized. With the advent of CBCT technology, a stereolithographic model can replace the stone cast, allowing the surgeon to have an exact replica of the bony anatomy. If this is prepared before surgery, the clinician should use gloved hands when handling the mesh to avoid surface contamination. Titanium mesh is easy to cut, shape, and adapt to the residual ridge. It takes little time for an experienced surgeon to accomplish this task at the time of surgery. Clinical trials have been performed on custom titanium shells made before surgery.[139] Resorbable scaffolds are also under development.

The mesh should extend well onto the palatal bone and be cut to avoid any contact with adjacent teeth. The edges of the cut mesh should be smoothed and well adapted to the bone. The mesh thickness should be adequate to resist flexing and micromovement during healing but thin enough to easily mold. A 0.2-mm thickness mesh appears to fulfill these requirements. The bone graft is packed into the formed mesh and molded onto the site. Platelet-rich plasma

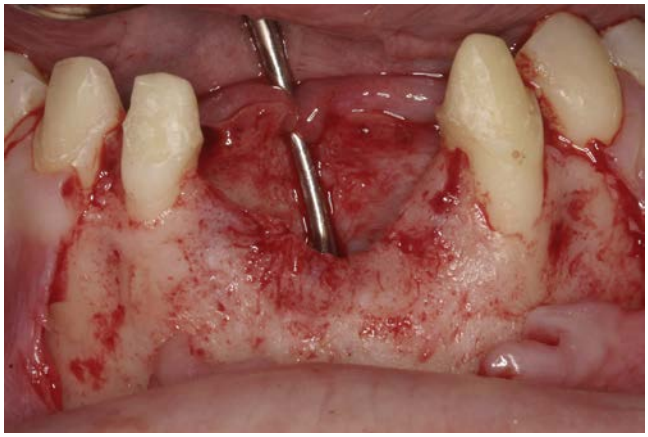

• **Figure 30-62** A vertical bone defect in the anterior mandible.

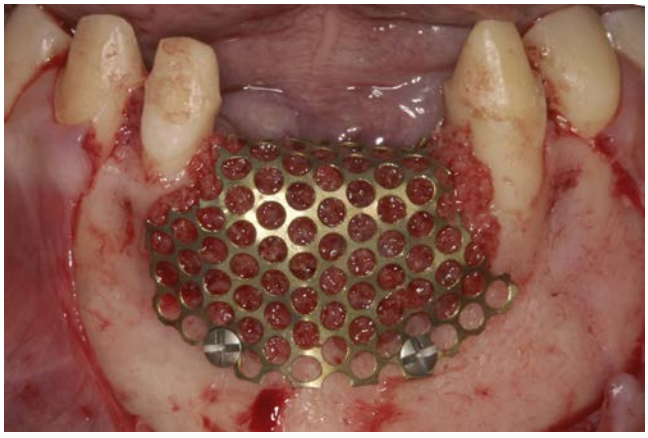

• **Figure 30-63** The defect is reconstructed with cancellous autograft and covered by a titanium mesh.

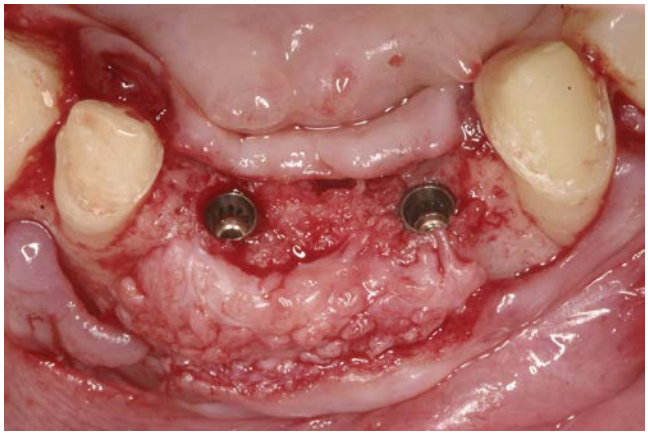

• **Figure 30-64** The bone graft is well incorporated after 6 months of healing.

helps with containment of the particulate graft. Monocortical fixation screws (4.0 mm) can be used to secure the mesh. Self-drilling screws can be used in the maxilla, eliminating the need for site preparation. The screws are placed along the outer edge of the mesh and should avoid the surrounding tooth roots. Often the placement of screws into the facial cortex is adequate for mesh stabilization. However, the use of a palatal screw is encouraged for added fixation.

Exposure of the titanium mesh is the most common complication with this technique.[135] As previously discussed, the need for tension-free primary closure is of paramount importance. The use of platelet-rich plasma or a collagen membrane over the mesh has been shown to reduce exposures.[140,141] Early mesh exposure, within the first 2 weeks, is of greater concern as the graft is more prone to infection and failure.[76] Late mesh exposure may well be tolerated and does not seem to have a significant negative influence on underlying bone formation.[135] During healing, the mesh can erode through the thinner facial mucosa. There should be no pressure on the area from a soft tissue–borne prosthesis. The patient can clean the exposed mesh with chlorhexidine on a cotton ball or sponge. Rarely does the exposed mesh need to be prematurely removed unless the exposure is significant.

The titanium mesh grafted site is re-entered after at least 6 months of healing for implant placement. A mucoperiosteal flap is reflected to completely expose the mesh. The fixation screws are removed, and the edge of the mesh can be grasped with a hemostat to facilitate its removal. The mesh may be cut and pried off the bone. A fibrous layer or "pseudo-periosteum" is typically found under the mesh covering the newly formed bone.[134]

This tissue can be incised along the ridge crest and reflected, leaving it intact. The quality of the bone regenerated by this technique is often less dense (type 3).

Graft Resorption

Bone graft remodeling is a necessary biologic aspect of autograft healing and incorporation to the osseous recipient site. There are several factors that may affect the amount of graft resorption during healing. Bone grafts inserted between osteotomized segments (interpositional grafts) resorb less than onlay grafts placed outside the bone contour.[142] Vertical bone grafts are more technically demanding and subject to greater volume changes than horizontal augmentations.[117] The osseous microarchitecture of the graft will also influence graft healing. Denser cortical grafts, from the calvarium or mandible, tend to resorb less than those containing a greater cancellous component, such as the iliac crest.[143-145] The volume loss of cortical bone grafts used for onlay augmentation has been measured as less than 25%.[100,145] Corticocancellous bone grafts from the ilium are associated with greater resorption (up to 50%) due to the thinner outer cortex and more porous cancellous component.[146,147] Although some studies have reported significant graft resorption, they still conclude that onlay bone grafting is a predictable technique for implant placement.[145,146,148,149] When using iliac bone, it may be prudent to overbuild the reconstructed ridge in anticipation of volume loss upon healing (Figures 30-65 through 30-71). Reconstruction of the atrophic ridge is usually staged with implant placement after graft healing to allow for remodeling (Figures 30-72 and 30-73). Enough time should elapse for graft incorporation, but

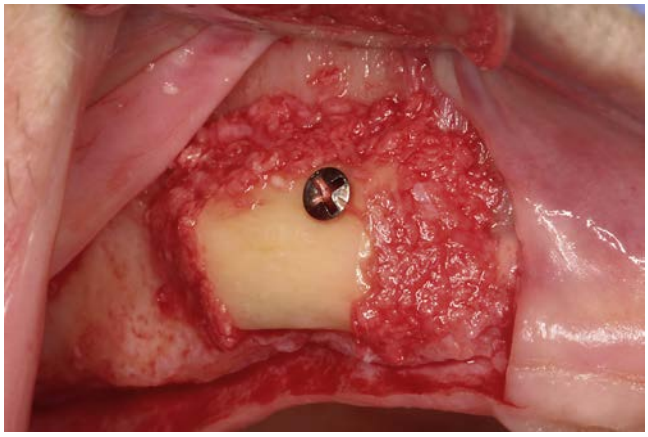

• **Figure 30-65** The thin anterior edentulous maxilla is augmented with a cortical block bone graft from the mandibular ramus.

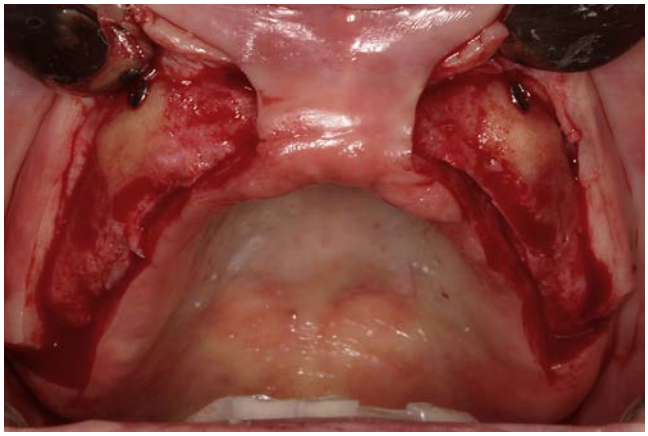

• **Figure 30-66** The cortical bone graft is well incorporated after 4 months of healing.

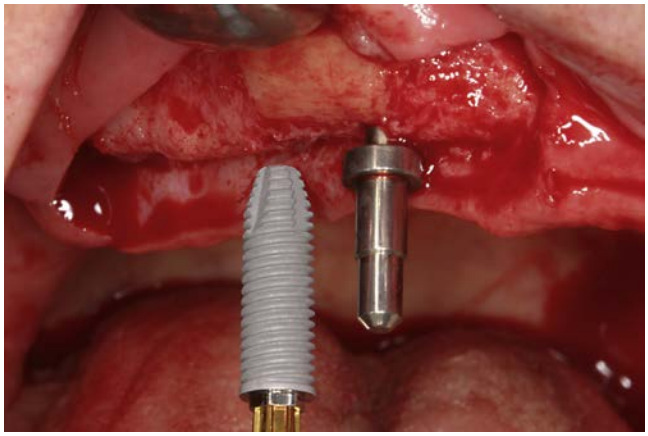

• **Figure 30-67** Placement of implants into the dense bone graft sites results in favorable primary stability.



• **Figure 30-68** The maxillary implants are restored with an immediate-load fixed provisional prosthesis.



• **Figure 30-69** Defect in the anterior maxilla following implant failure and failed attempts at repair.

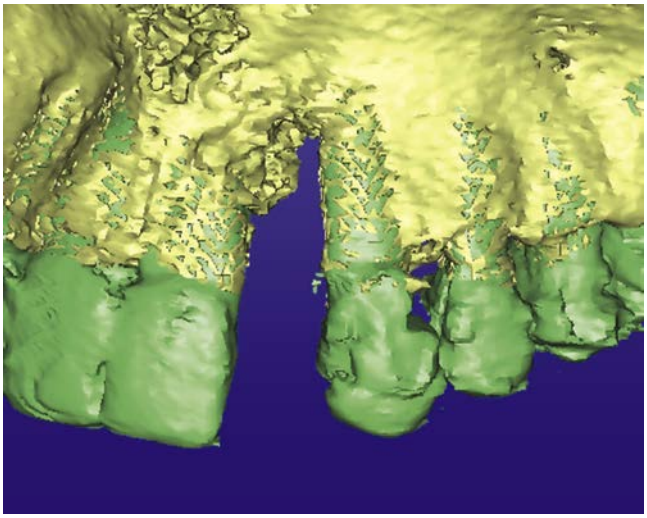

• **Figure 30-70** A computed tomography scan of the maxilla reveals the significant vertical defect and loss of alveolar bone around the teeth.

implants should be inserted early enough to stimulate and maintain the regenerated bone.[150] Most studies report that the majority of the resorption occurs within the first year and thereafter is low.[143,146,147,151] Although the degree of iliac bone resorption can be variable and in some cases significant, it does not appear to be detrimental to long-term dental implant survival.[146,147,149,152] Several studies document minimal marginal bone loss after implant placement and loading in grafted sites.[72] This may be a factor of implant surface and/or neck design.[72,153]

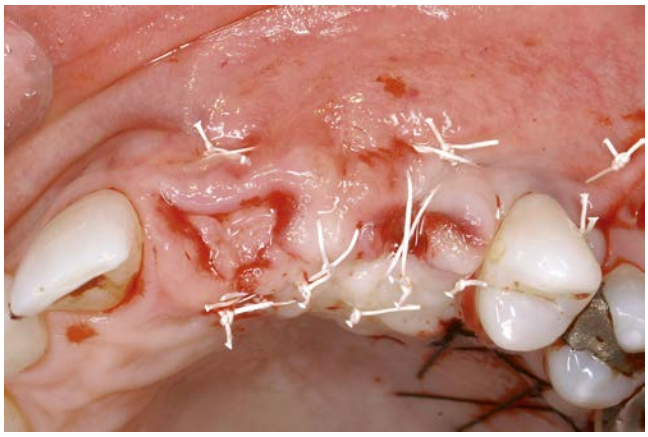

• **Figure 30-71** The teeth bordering the defect are extracted and socket bone grafts and connective tissue grafts were performed.



• **Figure 30-72** Incorporating of the soft tissue grafts after 2 months of healing.



• **Figure 30-73** A CT scan of the vertical bone defect in the anterior maxilla.

Implant Placement in Grafted Sites

It is well accepted that survival is typically higher when implants are placed into native bone.[154-156] Several studies on autogenous onlay bone grafts report lower implant survival rates. There are several variables that can account for this finding. The most significant factor is the use of machined-surface dental implants. During the developmental and early routine periods of reconstructing severely atrophic jaws, machined surface implants were used with iliac bone grafts.[3] The lower survival of machined surface implants in the maxilla and poorer quality bone is well documented.[157,158] The use of textured surface implants in onlay bone grafts can provide implant survival rates similar to native bone.[159]

Simultaneous placement of dental implants into block autografts also has a much lower survival rate than staged insertion after graft healing.[3,40,160,161] This approach was used initially in an attempt to fixate the bone graft, decrease the number of surgeries, and shorten treatment length. A staged technique is preferred, allowing the bone graft to remodel and incorporate before implant insertion. This approach has been shown to result in higher bone-to-implant contact and higher implant survival.[159] It also allows the surgeon to place implants in more ideal prosthetic positions. Enough time should elapse for graft incorporation, but implants should be inserted early enough to stimulate and maintain the regenerated bone.[146] Autogenous block grafts should heal for approximately 4 months before implant placement.[15,162] Particulate cancellous bone grafts with barrier membranes or titanium mesh used for ridge augmentation often require longer healing periods of at least 6 months. A CT scan is taken to evaluate the augmented site and plan the implant surgery.

The placement of implants into healed bone grafts is similar to their use in sites that have not been grafted. However, with horizontal augmentation, the implant site is often at the junction between the block and host bone. The surgeon should be careful not to displace the block from the ridge during the implant osteotomy and placement. Fixation screws are usually removed before implant insertion. Elevation of large flaps simply for screw removal is discouraged as this disrupts the vascular supply to the healed graft. A small mucosal incision over the screw head allows for easy retrieval. If a fixation screw is not in the path of implant insertion, it may be left intact, especially if it will provide added stability to the graft. Upon healing, the quality of block mandibular bone grafts is often dense regardless of the original quality of the recipient bone. An appropriate drilling sequence for dense bone and even tapping may be necessary for implant insertion in cortical bone grafts.

The healing period of implants placed into incorporated bone grafts is similar to that for native bone. Microtextured implant surfaces have decreased implant healing periods to as little as 6 weeks.[163] Immediate implant loading in grafted bone may even be considered if primary implant stability is adequate[163] (Figures 30-74 through 30-77). Additional graft resorption following implant placement and delayed loading has not been noted radiographically.[72,164-166]

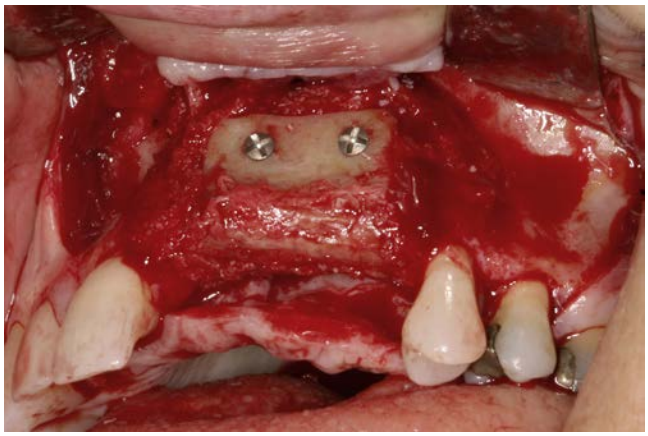

• **Figure 30-74** A corticocancellous block bone graft from the iliac crest is used to reconstruct the defect.

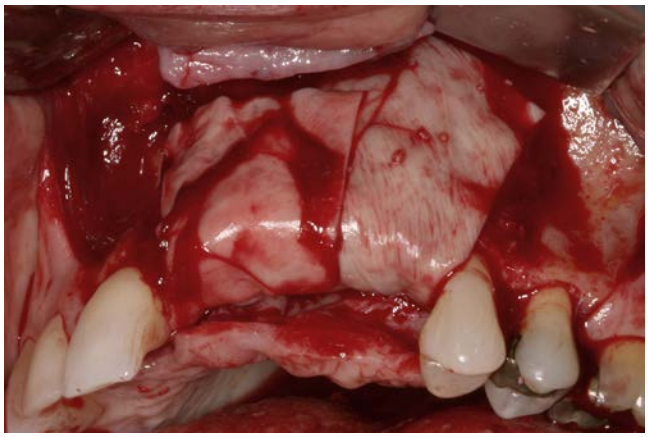

• **Figure 30-75** The bone graft is covered with collagen membranes soaked in a platelet concentrate.

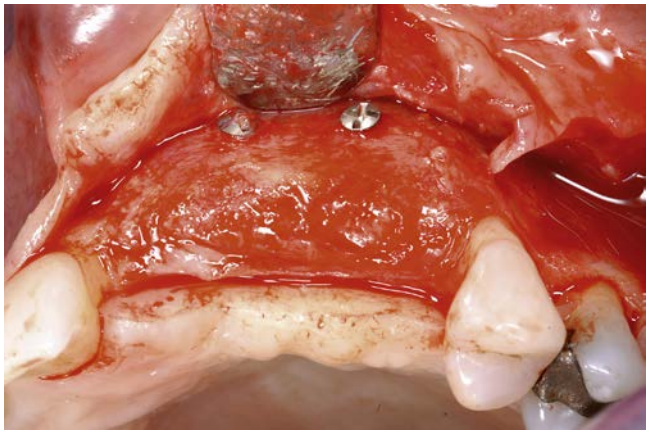

• **Figure 30-76** Incorporation of the bone graft after four months healing.

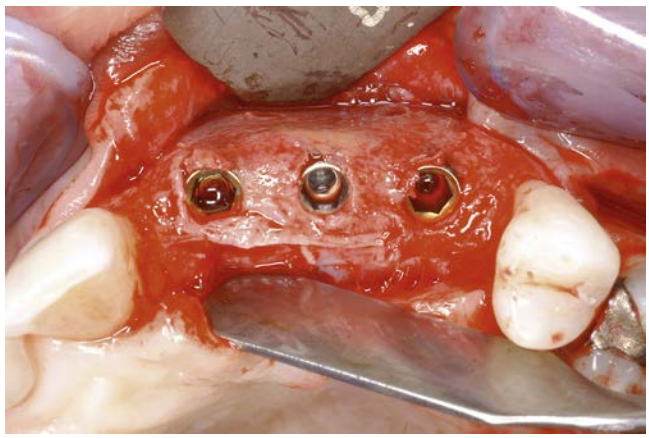

• **Figure 30-77** Placement of dental implants in the healed bone graft.

References

1. Misch CM: Autogenous bone: is it still the gold standard? *Implant Dent* 19:361, 2010.
2. Branemark P-I, Lindstrom J, Hallen O: Reconstruction of the defective mandible, *Scand J Plast Reconstr Surg* 9:116–128, 1975.
3. Breine U, Branemark PI: Reconstruction of alveolar jaw bone. An experimental and clinical study of immediate and preformed autologous bone grafts in combination with osseointegrated implants, *Scand J Plast Reconstr Surg* 14:23–48, 1980.
4. Jensen SS, Broggini N, Hjorting-Hansen E, et al.: Bone healing and graft resorption of autograft, anorganic bovine bone and β-tricalcium phosphate. A histologic and histomorphometric study in the mandibles of minipigs, *Clin Oral Implants Res* 17:237–243, 2006.
5. Boyne PJ, Lilly LC, Marx RE, et al.: De novo bone induction by recombinant human bone morphogenic protein-2 rhBMP-2 in maxillary sinus floor augmentation, *J Oral Maxillofac Surg* 63:1693–1707, 2005.
6. Spagnoli DB, Marx RE: Dental implants and the use of rhBMP-2, *Dent Clin North Am* 55:883–907, 2011.
7. Goldberg VM, Stevenson S: The biology of bone grafts, *Semin Arthroplasty* 4:58–63, 1993.
8. Manson PN: Facial bone healing and bone grafts. A review of clinical physiology, *Clin Plast Surg* 21:331–348, 1994.
9. Burchardt H: The biology of bone graft repair, *Clin Orthop Relat Res* 174:28–42, 1983.
10. Smith JD, Abramson M: Membranous vs. endochondral autografts, *Arch Otolaryngol* 99:203–209, 1974.
11. Zins JE, Whitaker LA: Membranous vs endochondral autografts: implications for craniofacial reconstruction, *Plast Reconstr Surg* 72:778–785, 1983.
12. Lin KY, Barlett SP, Yaremchuk MJ: The effect of rigid fixation on the survival of onlay bone grafts: an experimental study, *Plast Reconstr Surg* 86:449–456, 1990.
13. Hardesty RA, Marsh JL: Craniofacial onlay bone grafting: a prospective evaluation of graft morphology, orientation and embryonic origin, *Plast Reconstr Surg* 85:5–14, 1990.
14. Ozaki W, Buchman SR: Volume maintenance of onlay bone grafts in the craniofacial skeleton: micro-architecture versus embryologic origin, *Plast Reconstr Surg* 102:291–299, 1998.
15. Misch CM, Misch CE, Resnick RR, Ismail YH: Reconstruction of maxillary alveolar defects with mandibular symphysis grafts for dental implants: a preliminary procedural report, *Int J Oral Maxillofac Implants* 7:360–366, 1992.
16. Steiner M, Ramp WK: Short-term storage of freshly harvested bone, *J Oral Maxillofac Surg* 46:868–871, 1988.

17. Fonseca RJ, Clark PJ, Burkes EJ: Revascularization and healing of onlay particulate autologous bone grafts in primates, *J Oral Surg* 38:572–577, 1980.
18. Dado DV, Izquiedo R: Absorption of onlay bone grafts in immature rabbits: membranous versus endochondral bone and bone struts versus paste, *Ann Plast Surg* 23:39–48, 1989.
19. Pallesen l, Schou S, Aaboe M: Influence of particle size of autogenous bone grafts on the early stages of bone regeneration. A histologic and serologic study in rabbit calvarium, *Int J Oral Maxillofac Implants* 17:498–503, 2000.
20. Kurkcu M, Oz IA, Koksal F, et al.: Microbial analysis of the autogenous bone collected by bone filter during oral surgery: a clinical study, *J Oral Maxillofac Surg* 63:1593–1598, 2005.
21. Peleg M, Garg AK, Misch CM, Mazor Z: Maxillary sinus and ridge augmentations using a surface-derived autogenous bone graft, *J Oral Maxillofac Surg* 62:1535–1544, 2004.
22. Lekholm U, Zarb GA: Patient selection and preparation. In Branemark P-I, Zarb GA, Albrektsson T, editors: *Tissue-integrated prostheses: osseointegration in clinical dentistry*, Chicago, 1985, Quintessence, pp 199–209.
23. Cawood JI, Howell RA: A classification of the edentulous jaws, *Int J Oral Maxillofac Surg* 17:232–236, 1988.
24. Cologne Classification for Alveolar Ridge Defects. http://www.bdiz.eu/pdf/Konsensus-Leitfaden-2013_engl.pdf.
25. Misch CM: Use of a surgical template for autologous bone grafting of alveolar defects, *J Prosthodont* 8:47–52, 1999.
26. Mecall RA, Rosenfeld AL: Influence of residual ridge resorption patterns on fixture placement and tooth position, part III: presurgical assessment of ridge augmentation requirements, *Int J Periodontics Restorative Dent* 16:322–337, 1996.
27. Rosenfeld AL, Mecall RA: The use of interactive computed tomography to predict the esthetic and functional demands of implant-supported prostheses, *Compend Contin Educ Dent* 17:1125–1128, 1996.
28. Misch CM: Maxillary autogenous bone grafting, *Oral Maxillofac Surg Clin North Am* 23:229–238, 2011a.
29. Coachman C, Salama M, Garber D, et al.: Prosthetic gingival reconstruction in a fixed partial restoration. Part 1: introduction to artificial gingiva as an alternative therapy, *Int J Periodontics Restorative Dent* 29:471–477, 2009.
30. Young MP, Korachi M, Carter DH, et al.: The effects of an immediately pre-surgical chlorhexidine oral rinse on the bacterial contaminants of bone debris collected during dental implant surgery, *Clin Oral Implants Res* 13:20–29, 2002.
31. Levin L, Herzberg R, Dolev E, Schwartz-Arad D: Smoking and complications of onlay bone grafts and sinus lift operations, *Int J Oral Maxillofac Implants* 19:369–373, 2004.
32. Kon K, Shiota M, Ozeki M: Bone augmentation ability of autogenous bone graft particles with different sizes: a histological and micro-computed tomography study, *Clin Oral Implants Res* 20:1240–1246, 2009.
33. Miron RJ, Gruber R, Hedbom E: Impact of bone harvesting techniques on cell viability and the release of growth factors of autografts, *Clin Implant Dent Relat Res* 15:481–489, 2013.
34. Buser D, Wittneben J, Bornstein MM, et al.: Stability of contour augmentation and esthetic outcomes of implant-supported single crowns in the esthetic zone: 3-year results of a prospective study with early implant placement postextraction, *J Periodontol* 82:342–349, 2011.
35. Sittitavornwong S, Gutta R: Bone graft harvesting from regional sites, *Oral Maxillofac Surg Clin North Am* 22:317–330, 2010.
36. Ten Bruggenkate CM, Kraaijenhagen HA, van der Kwast WAM: Autogenous maxillary bone grafts in conjunction with placement of ITI endosseous implants: a preliminary report, *Int J Oral Maxillofac Surg* 21:81–84, 1992.
37. Silva FM, Cortez AL, Moreira RW, Mazzonetto R: Complications of intraoral donor site for bone grafting prior to implant placement, *Implant Dent* 15:420–426, 2006.
38. Misch CE: Maxillary sinus augmentation for endosteal implants: organized alternative treatment plans, *Int J Oral Implantol* 4:49–58, 1987.
39. Sindet-Pedersen S, Enemark H: Reconstruction of alveolar clefts with mandibular or iliac crest bone grafts: a comparative study, *J Oral Maxillofac Surg* 48:554–558, 1990.
40. Jensen J, Sindet-Petersen S, Oliver AJ: Varying treatment strategies for reconstruction of maxillary atrophy with implants: results in 98 patients, *J Oral Maxillofac Surg* 52:210–216, 1994.
41. Lundgren S, Moy P, Johansson C, Nilsson H: Augmentation of the maxillary sinus floor with particulated mandible: a histologic and histomorphometric study, *Int J Oral Maxillofac Implants* 11:760–766, 1996.
42. Misch CM: Comparison of intraoral donor sites for onlay grafting prior to implant placement, *Int J Oral Maxillofac Implants* 12:767–776, 1997.
43. Khoury F: Augmentation of the sinus floor with mandibular bone block and simultaneous implantation: a 6-year clinical investigation, *Int J Oral Maxillofac Implants* 14:557–601, 1999.
44. Pikos MA: Mandibular block autografts for alveolar ridge augmentation, *Atlas Oral Maxillofac Surg Clin North Am* 13:91–107, 2005.
45. Buhr W, Coulon JP: Limits of the mandibular symphysis as a donor site for bone grafts in early secondary cleft palate osteoplasty, *Int J Oral Maxillofac Surg* 25:389–393, 1996.
46. Borstlap WA, Heidbuchel KLWM, Freihofer HPM, Kuijpers-Jagman AM: Early secondary bone grafting of alveolar cleft defects: a comparison between chin and rib grafts, *J Craniomaxillofac Surg* 18:201–205, 1990.
47. Hoppenreijs TJM, Nijdam ES, Freihofer HPM: The chin as a donor site in early secondary osteoplasty: a retrospective clinical and radiographic evaluation, *J Craniomaxillofac Surg* 20:199–224, 1992.
48. Hunt DR, Jovanovic SA: Autogenous bone harvesting: a chin graft technique for particulate and monocortical bone blocks, *Int J Periodontics Restorative Dent* 19:165–173, 1999.
49. Zide MF: Autogenous bone harvest and bone compacting for dental implants, *Compend Contin Educ Dent* 21:585–590, 2000.
50. Raghoebar GM, Louwerse C, Kalk WWI: Morbidity of chin bone harvesting, *Clin Oral Implants Res* 12:503–507, 2001.
51. Nkenke E, Schulze-Mosgau S, Radespiel M: Morbidity of harvesting of chin grafts: a prospective study, *Clin Oral Implants Res* 12:495–502, 2001.
52. Jensen J, Sindet-Pedersen S: Autogenous mandibular bone grafts and osseointegrated implants for reconstruction of severely atrophied maxilla: a preliminary report, *J Oral Maxillofac Surg* 49:1277–1287, 1991.
53. Rubens BC, West RA: Ptosis of the chin and lip incompetence: consequences of lost mentalis support, *J Oral Maxillofac Surg* 4:359–366, 1989.
54. Misch CM: Ridge augmentation using mandibular ramus bone grafts for the placement of dental implants: presentation of a technique, *Pract Periodont Aesthet Dent* 8:127–135, 1996.

55. Misch CM: Use of the mandibular ramus as a donor site for onlay bone grafting, *J Oral Implantol* 26:42–49, 2000.
56. Hallman M, Hedin M, Sennerby L: A prospective 1 year clinical and radiographic study of implants placed after maxillary sinus floor augmentation with bovine hydroxylapatite and autogenous bone, *J Oral Maxillofac Surg* 60:277–284, 2002.
57. Smith BR, Rajchel JL, Waite DE, et al.: Mandibular anatomy as it relates to rigid fixation of the sagittal ramus split osteotomy, *J Oral Maxillofac Surg* 49:222–226, 1991.
58. Rachel J, Ellis E, Fonseca RJ: The anatomic location of the mandibular canal; its relationship to the sagittal ramus osteotomy, *Int J Adult Orthod Orthognathic Surg* 1:37–42, 1986.
59. Misch CM: The harvest of ramus bone in conjunction with third molar removal for onlay grafting prior to placement of dental implants, *J Oral Maxillofac Surg* 57:1376–1379, 1999.
60. Misch CM: Distance between external cortical bone and mandibular canal for harvesting ramus graft: a human cadaver study [Letter], *J Periodontol* 81:1103–1104, 2010.
61. Happe A: Use of a piezoelectric surgical device to harvest bone grafts from the mandibular ramus: report of 40 cases, *Int J Periodontics Restorative Dent* 27:241–249, 2007.
62. Hendy CW, Smith KG, Robinson PP: Surgical anatomy of the buccal nerve, *Br J Oral Maxillofac Surg* 34:457–460, 1996.
63. O'Keefe RM, Reimer BL, Butterfield LS. Harvesting of autogenous cancellous bone graft from the proximal tibial metaphysic: a review of 230 cases, *J Orthop Trauma* 5:469–474, 1991.
64. Catone GA, Reimer LB, McNeir D: Tibial autogenous cancellous bone as an alternative donor site in maxillofacial surgery: a preliminary report, *J Oral Maxillofac Surg* 50:1258–1263, 1992.
65. Mazock JB, Schow SR, Triplett RG: Proximal tibia bone harvest: review of technique, complications, and use in maxillofacial surgery, *Int J Oral Maxillofac Implants* 19:586–593, 2004.
66. Herford AS, King BJ, Audia F, Becktor J: Medial approach for tibial bone graft: anatomic study and clinical technique, *J Oral Maxillofac Surg* 61:358–363, 2003.
67. Gerressen M, Prescher A, Riediger D, et al.: Tibial versus iliac bone grafts: a comparative examination in 15 freshly preserved adult cadavers, *Clin Oral Implants Res* 19:1270–1275, 2008.
68. Chen YC, Chen CH, Chen PL, et al.: Donor site morbidity after harvesting of proximal tibia bone, *Head Neck* 28:496–500, 2006.
69. Thor A, Farzad P, Larsson S: Fracture of the tibia: complication of bone grafting to the anterior maxilla, *Br J Oral Maxillofac Surg* 44:46–48, 2006.
70. Stellingsma K, Raghoebar GM, Visser A, et al.: The extremely resorbed mandible, 10-year results of a randomized controlled trial on 3 treatment strategies, *Clin Oral Implants Res* 25:926–932, 2014.
71. Isaksson S, Ekfeldt A, Alberius P, Blomqvist JE: Early results from reconstruction of severely atrophic (Class VI) maxillas by immediate endosseous implants in conjunction with bone grafting and Le Fort I osteotomy, *Int J Oral Maxillofac Surg* 22:144–148, 1993.
72. Nystrom E, Nilson H, Gunne J, Lundgren S: Reconstruction of the atrophic maxilla with interpositional bone grafting/Le Fort I osteotomy and endosteal implants: an 11-16 year follow-up, *Int J Oral Maxillofac Surg* 38:1–6, 2009.
73. Hallman M, Mordenfeld A, Strandkvist T: A retrospective 5-year follow-up study of two different titanium implant surfaces used after interpositional bone grafting for reconstruction of the atrophic edentulous maxilla, *Clin Implant Dent Relat Res* 7:121–126, 2005.
74. Sjostrom M, Sennerby L, Nilson H, Lundgren S: Reconstruction of the atrophic edentulous maxilla with free iliac crest grafts and implants: a 3-year report of a prospective clinical study, *Clin Implant Dent Relat Res* 9:46–59, 2007.
75. Chiapasco M, Brusati R, Ronchi P: Le Fort I osteotomy with interpositional bone grafts and delayed oral implants for the rehabilitation of extremely atrophied maxillae: a 1-9-year clinical follow-up study on humans, *Clin Oral Implants Res* 18:74–85, 2007.
76. Marx RE, Armentano L, Olavarria A, Samaniego J: rhBMP-2/ACS grafts versus autogenous cancellous marrow grafts in large vertical defects of the maxilla: An unsponsored randomized open-label clinical trial, *Oral Craniofac Tissue Eng* 1:33–41, 2011.
77. Misch CM: Bone augmentation of the atrophic posterior mandible for dental implants using rhBMP-2 and titanium mesh: clinical technique and early results, *Int J Periodontics Restorative Dent* 31:581–589, 2011b.
78. Misch CM, Jensen OT, Pikos MA, Malmquist JP: Vertical bone augmentation using recombinant bone morphogenetic protein, mineralized bone allograft, and titanium mesh: a retrospective cone beam computed tomography study, *Int J Oral Maxillofac Implants* 30:202–207, 2015.
79. Marx RE, Morales MJ: Morbidity from bone harvest in major jaw reconstruction: a randomized trial comparing the lateral anterior and posterior approaches to the ilium, *J Oral Maxillofac Surg* 46:196–203, 1988.
80. Ahlmann E, Patzakis M, Roidis N, et al.: Comparison of anterior and posterior iliac crest bone grafts in terms of harvest-site morbidity and functional outcomes, *J Bone Joint Surg Am* 84-A:716–720, 2002.
81. Nkenke E, Weisbach V, Winckler E, Kessler P: Morbidity of harvesting of bone grafts for the iliac crest for preprosthetic augmentation procedures: a prospective study, *Int J Oral Maxillofac Surg* 33:157–163, 2004.
82. Hahn M, Dover MS, Whear NM, Moule I: Local bupivacaine infusion following bone graft harvest from the iliac crest, *Int J Oral Maxillofac Surg* 25:400–401, 1996.
83. Cricchio G, Lundgren S: Donor site morbidity in two different approaches to anterior iliac crest bone harvesting, *Clin Implant Dent Relat Res* 5:161–169, 2003.
84. Kalk WW, Raghoebar GM, Jansma J, Boering G: Morbidity from iliac crest bone harvesting, *J Oral Maxillofac Surg* 54:1424–1429, 1996.
85. Hoard MA, Bill TJ, Campbell RL: Reduction in morbidity after iliac crest bone harvesting: the concept of preemptive analgesia, *J Craniofac Surg* 9:448–451, 1998.
86. Almaiman M, Al-Bargi HH, Manson P: Complication of anterior iliac bone graft harvesting in 372 adult patients from May 2006 to May 2011 and a literature review, *Craniomaxillofac Trauma Reconstr* 6:257–266, 2013.
87. Zouhary KJ: Bone graft harvesting from distant sites: concepts and techniques, *Oral Maxillofac Surg Clin North Am* 22:301–316, 2010.
88. Falkensammer N, Kirmeier R, Arnetzl C, et al.: Modified iliac bone harvesting—morbidity and patients' experience, *J Oral Maxillofac Surg* 67:1700–1705, 2009.
89. Fasolis M, Boffano P, Ramieri G: Morbidity associated with anterior iliac crest bone graft, *Oral Surg Oral Med Oral Pathol Oral Radiol* 114:586–591, 2012.
90. Whetzel TP, Sanders CJ: Arterial anatomy of the oral cavity: an analysis of vascular territories, *Plast Reconstr Surg* 100:582–587, 1997.

91. Carvalho P, Vasconcellos L, Pi J: Influence of bed preparation on the incorporation of autogenous bone grafts: a study in dogs, *Int J Oral Maxillofac Implants* 15:565–570, 2000.
92. Marx RE, Carlson ER, Eichstaedt RM: Platelet-rich plasma: growth factor enhancement for bone grafts, *Oral Surg Oral Med Oral Pathol* 85:638–646, 1998.
93. Cromack DT, Porras-Reyes B, Mustoe TA: Current concepts in wound healing: growth factor and macrophage interaction, *J Trauma* 30:S129–S133, 1990.
94. Becktor JP, Eckert SE, Isaksson S, Keller EE: The influence of mandibular dentition on implant failures in bone grafted edentulous maxillae, *Int J Oral Maxillofac Implants* 17:69–77, 2002.
95. Castagna L, Polido WD, Soares LG, Tinoco EM: Tomographic evaluation of iliac crest bone grafting and the use of immediate temporary implants to the atrophic maxilla, *Int J Oral Maxillofac Surg* 42:1067–1072, 2013.
96. Levin L, Schwartz-Arad D: The effect of cigarette smoking on dental implants and related surgery, *Implant Dent* 14:357–361, 2005.
97. Gielkens PF, Bos RR, Raghoebar GM, Stegenga B: Is there evidence that barrier membranes prevent bone resorption in autologous bone grafts during the healing period? A systematic review, *Int J Oral Maxillofac Implants* 22:390–398, 2007.
98. Heberer S, Ruhe B, Krekeler L, et al.: A prospective randomized split-mouth study comparing iliac onlay grafts in atrophied edentulous patients: covered with periosteum or a bioresorbable membrane, *Clin Oral Implants Res* 20:319–326, 2009.
99. Dongieux JW, Block MS, Morris G, Gardiner D: The effect of different membranes on onlay bone graft success in the dog mandible, *Oral Surg Oral Med Oral Pathol Oral Radiol Endod* 86:145–151, 1998.
100. Proussaefs P, Lozada J, Kleinman A: The use of ramus autogenous block grafts for vertical alveolar ridge augmentation and implant placement: a pilot study, *Int J Oral Maxillofac Implants* 17:238–248, 2002.
101. Cordaro L, Torsello F, Morcavallo S: Effect of bovine bone and collagen membranes on healing of mandibular bone blocks: a prospective randomized controlled study, *Clin Oral Implants Res* 22:1145–1150, 2011.
102. von Arx T, Buser D: Horizontal ridge augmentation using autogenous block grafts and the guided bone regeneration technique with collagen membranes: a clinical study with 42 patients, *Clin Oral Implants Res* 17:359–366, 2006.
103. Dahlin C, Linde A, Gottlow J, Nyman S: Healing of bone defects by guided tissue regeneration, *Plast Reconstr Surg* 81:672–676, 1988.
104. Bunyaratavej P, Wang HL: Collagen membranes: a review, *J Periodontol* 72:215–229, 2001.
105. Steigmann M: Pericardium membrane and xenograft particulate grafting materials for horizontal alveolar ridge defects, *Implant Dent* 15:186–191, 2006.
106. Borges GJ, Novaes Jr AB, Grisi MF, et al.: Acellular dermal matrix as a barrier in guided bone regeneration: a clinical, radiographic and histomorphometric study in dogs, *Clin Oral Implants Res* 20:1105–1115, 2009.
107. Merli M, Lombardini F, Esposito M: Vertical ridge augmentation with autogenous bone grafts 3 years after loading: resorbable barriers versus titanium-reinforced barriers. A randomized controlled clinical trial, *Int J Oral Maxillofac Implants* 25:801–807, 2010.
108. Le B, Rohrer MD, Prasad HS: Screw "tent-pole" grafting technique for reconstruction of large vertical alveolar ridge defects using human mineralized allograft for implant site preparation, *J Oral Maxillofac Surg* 68:428–435, 2010.
109. Jovanovic SA, Nevins M: Bone formation utilizing titanium-reinforced barrier membranes, *Int J Periodontics Restorative Dent* 15:56–69, 1995.
110. Simion M, Jovanovic SA, Trisi P, et al.: Vertical ridge augmentation around dental implants using a membrane technique and autogenous bone or allografts in humans, *Int J Periodontics Restorative Dent* 18:8–23, 1998.
111. Aghaloo TL, Moy PK: Which hard tissue augmentation techniques are the most successful in furnishing bony support for implant placement? *Int J Oral Maxillofac Implants* 22(suppl): 49–70, 2007.
112. Buser D, Chappuis V, Kuchler U, et al.: Long-term stability of early implant placement with contour augmentation, *J Dent Res* 92(12 Suppl): 176S-182S, 2013.
113. Chiapasco M, Zaniboni M, Boisco M: Augmentation procedures for the rehabilitation of deficient edentulous ridges with oral implants, *Clin Oral Implants Res* 17:136–159, 2006.
114. Gordh M, Alberius P, Lindberg L, Johnell O: Bone graft incorporation after cortical perforations of the host bed, *Otolaryngol Head Neck Surg* 117:664–670, 1997.
115. Urban IA, Nagursky H, Lozada JL, Nagy K: Horizontal ridge augmentation with a collagen membrane and a combination of particulated autogenous bone and anorganic bovine bone-derived mineral: a prospective case series in 25 patients, *Int J Periodontics Restorative Dent* 33:299–307, 2013.
116. Simion M, Trisi P, Piattelli A: Vertical ridge augmentation using a membrane technique associated with osseointegrated implants, *Int J Periodontics Restorative Dent* 14:496–511, 1994.
117. Rocchietta I, Fontana F, Simion M: Clinical outcomes of vertical bone augmentation to enable dental implant placement: a systematic review, *J Clin Periodontol* 35(Suppl. 8):203–215, 2008.
118. Urban IA, Lozada JL, Jovanovic SA, et al.: Vertical ridge augmentation with titanium-reinforced, dense-PTFE membranes and a combination of particulated autogenous bone and anorganic bovine bone-derived mineral: a prospective case series in 19 patients, *Int J Oral Maxillofac Implants* 29:185–193, 2014.
119. Lang NP, Hammerle CH, Bragger U, et al.: Guided tissue regeneration in jawbone defects prior to implant placement, *Clin Oral Implants Res* 5:92–97, 1994.
120. Hoffmann O, Bartee BK, Beaumont C, et al.: Alveolar bone preservation in extraction sockets using non-resorbable dPTFE membranes: a retrospective non-randomized study, *J Periodontol* 79(121):1355–1369, 2008.
121. Carbonell JM, Martín IS, Santos A, et al.: High-density polytetrafluoroethylene membranes in guided bone and tissue regeneration procedures: a literature review, *Int J Oral Maxillofac Surg* 43:75–84, 2014.
122. Tal H, Kozlovsky A, Artzi Z, et al.: Cross-linked and non-cross-linked collagen barrier membranes disintegrate following surgical exposure to the oral environment: a histological study in the cat, *Clin Oral Implants Res* 19:760–766, 2008.
123. Jensen OT, Shulman LB, Block MS, Iacono VJ: Report of the Sinus Consensus Conference of 1996, *Int J Oral Maxillofac Implants* 13(Suppl):11–45, 1998.
124. Block MS, Kent JN: Sinus augmentation for dental implants: the use of autogenous bone, *J Oral Maxillofac Surg* 55:1281–1286, 1997.
125. Misch CM: Discussion. A prospective 1 year clinical and radiographic study of implants placed after maxillary sinus floor augmentation with bovine hydroxylapatite and autogenous bone, *J Oral Maxillofac Surg* 60:285, 2002.

126. Misch CM: Maxillofacial donor sites for sinus floor and alveolar reconstruction. In Jensen OT, editor: *The sinus bone graft*, Chicago, 2006, Quintessence, pp 130–147.
127. Froum SJ, Tarnow DP, Wallace SS, et al.: Sinus floor elevation using anorganic bovine bone matrix (OsteoGraf/N) with and without autogenous bone: a clinical, histologic, radiographic and histomorphometric analysis—part 2 of an ongoing study, *Int J Periodontics Restorative Dent* 18:529–543, 1998.
128. Lorenzetti M, Mozzati M, Campanino PP, Valente G: Bone augmentation of the inferior floor of the maxillary sinus with autogenous bone or composite bone grafts: a histologic-histomorphometric preliminary report, *Int J Oral Maxillofac Implants* 13:69–76, 1998.
129. Jensen OT, Sennerby L: Histological analysis of clinically retrieved titanium microimplants placed in conjunction with maxillary sinus floor augmentation, *Int J Oral Maxillofac Implants* 13:513–521, 1998.
130. Tarnow DP, Wallace SS, Froum SJ, et al.: Histologic and clinical comparison of bilateral sinus floor elevations with and without barrier membrane placement in 12 patients: part 3 of an ongoing prospective study, *Int J Periodontics Restorative Dent* 20:116–125, 2000.
131. Froum SJ, Wallace S, Cho SC, et al.: A histomorphometric comparison of Bio-Oss alone versus Bio-Oss and platelet-derived growth factor for sinus augmentation: a postsurgical assessment, *Int J Periodontics Restorative Dent* 33:269–279, 2013.
132. Gutta R, Baker RA, Bartolucci AA, Louis PJ: Barrier membranes used for ridge augmentation: is there an optimal pore size? *J Oral Maxillofac Surg* 67:1218–1225, 2009.
133. Richter HE, Boyne PJ: New concepts in facial bone healing and grafting procedures, *J Oral Surg* 27:557–559, 1969.
134. Boyne P: *Osseous reconstruction of the maxilla and the mandible: surgical techniques using titanium mesh and bone mineral*, Carol Stream, IL, 1997, Quintessence, pp 1–100.
135. Louis PJ, Gutta R, Said-Al-Naief N, Bartolucci AA: Reconstruction of the maxilla and mandible with particulate bone graft and titanium mesh for implant placement, *J Oral Maxillofac Surg* 66:235–245, 2008.
136. Miyamoto I, Funaki K, Yamauchi K, et al.: Alveolar ridge reconstruction with titanium mesh and autogenous particulate bone graft: computed tomography-based evaluations of augmented bone quality and quantity, *Clin Implant Dent Relat Res* 14:304–311, 2012.
137. Proussaefs P, Lozada J, Kleinman A, et al.: The use of titanium mesh in conjunction with autogenous bone graft and inorganic bovine bone mineral (Bio-Oss) for localized alveolar ridge augmentation: a human study, *Int J Periodontics Restorative Dent* 23:185–195, 2003.
138. Pieri F, Corinaldesi G, Fini M, et al.: Alveolar ridge augmentation with titanium mesh and a combination of autogenous bone and anorganic bovine bone: a 2-year prospective study, *J Periodontol* 79:2093–2103, 2008.
139. Jensen OT, Lehman H, Ringeman JL, Casap N: Fabrication of printed titanium shells for containment of BMP-2 composite graft materials for alveolar bone reconstruction, *Int J Oral Maxillofac Implants* 29:e103–e105, 2014.
140. Degidi M, Scarano A, Piattelli A: Regeneration of the alveolar crest using titanium micromesh with autologous bone and a resorbable membrane, *J Oral Implantol* 29:86–90, 2003.
141. Torres J, Tamimi F, Alkhraisat MH, et al.: Platelet-rich plasma may prevent titanium-mesh exposure in alveolar ridge augmentation with anorganic bovine bone, *J Clin Periodontol* 37:943–951, 2010.
142. Motoki DS, Mulliken JB: The healing of bone and cartilage, *Clin Plast Surg* 17:527–544, 1990.
143. Carinci F, Farina A, Zanetti U, et al.: Alveolar ridge augmentation: a comparative longitudinal study between calvaria and iliac crest bone grafts, *J Oral Implantol* 31:39–45, 2005.
144. Mertens C, Decker C, Seeberger R, et al.: Early bone resorption after vertical bone augmentation—a comparison of calvarial and iliac grafts, *Clin Oral Implants Res* 24:820–825, 2013.
145. Cordaro L, Amadé DS, Cordaro M: Clinical results of alveolar ridge augmentation with mandibular block bone grafts in partially edentulous patients prior to implant placement, *Clin Oral Implants Res* 13:103–111, 2002.
146. Nystrom E, Ahlqvist J, Kahnberg KE, Rosenquist JB: Autogenous onlay bone grafts fixed with screw implants for the treatment of severely resorbed maxillae. Radiographic evaluation of preoperative bone dimensions, postoperative bone loss, and changes in soft-tissue profile, *Int J Oral Maxillofac Surg* 25:351–359, 1996.
147. Reinert S, Konig S, Bremerich A, et al.: Stability of bone grafting and placement of implants in the severely atrophic maxilla, *Br J Oral Maxillofac Surg* 41:249–255, 2003.
148. Widmark G, Andersson B, Ivanoff CJ: Mandibular bone graft in the anterior maxilla for single-tooth implants, *Int J Oral Maxillofac Surg* 26:106–109, 1997.
149. Sbordone L, Toti P, Menchini-Fabris GB, et al.: Volume changes of autogenous bone grafts after alveolar ridge augmentation of atrophic maxillae and mandibles, *Int J Oral Maxillofac Surg* 38:1059–1065, 2009.
150. Nelson K, Ozyuvaci H, Bilgic B, et al.: Histomorphometric evaluation and clinical assessment of endosseous implants in iliac bone grafts with shortened healing periods, *Int J Oral Maxillofac Implants* 21:392–398, 2006.
151. Johansson B, Grepe A, Wannfors K, Hirsch JM: A clinical study of changes in the volume of bone grafts in the atrophic maxilla, *Dentomaxillofac Radiol* 30:157–161, 2001.
152. Dasmah A, Thor A, Ekestubbe A, et al.: Particulate vs. block bone grafts: three-dimensional changes in graft volume after reconstruction of the atrophic maxilla, a 2-year radiographic follow-up, *J Craniomaxillofac Surg* 40:654–659, 2012.
153. Chiapasco M, Casentini P, Zaniboni M: Implants in reconstructed bone: a comparative study on the outcome of Straumann tissue level and bone level implants placed in vertically deficient alveolar ridges treated by means of autogenous onlay bone grafts, *Clin Implant Dent Relat Res* 16:32–50, 2014.
154. Esposito M, Hirsch JM, Lekholm U, Thomsen P: Biological factors contributing to failures of osseointegrated oral implants. (II). Etiopathogenesis, *Eur J Oral Sci* 106:721–764, 1998.
155. Lekholm U, Wannfors K, Isaksson S, Adielsson B: Oral implants in combination with bone grafts. A 3-year retrospective multicenter study using the Branemark implant system, *Int J Oral Maxillofac Surg* 28:181–187, 1999.
156. Becktor JP, Isaksson S, Sennerby L: Survival analysis of endosseous implants in grafted and nongrafted edentulous maxillae, *Int J Oral Maxillofac Implants* 19:107–115, 2004.
157. Jaffin RA, Berman CL: The excessive loss of Branemark fixtures in type IV bone: a 5-year analysis, *J Periodontol* 62:2–4, 1991.
158. Jemt T, Lekholm U: Implant treatment in edentulous maxillae: a 5-year follow-up report on patients with different degrees of jaw resorption, *Int J Oral Maxillofac Implants* 10:303–311, 1995.
159. Chiapasco M, Casentini P, Zaniboni M: Bone augmentation procedures in implant dentistry, *Int J Oral Maxillofac Implants* 24(Suppl):237–259, 2009.

160. Adell R, Lekholm U, Grondahl K, et al.: Reconstruction of severely resorbed edentulous maxillae using osseointegrated fixtures in immediate autogenous bone grafts, *Int J Oral Maxillofac Implants* 5:233–246, 1990.
161. Friberg B: Bone augmentation at single-tooth implants using mandibular grafts: a one-stage surgical procedure, *Int J Periodontics Restorative Dent* 15:436–445, 1995.
162. Matsumoto MA, Filho HN, Francishone CE: Microscopic analysis of reconstructed maxillary alveolar ridges using autogenous bone grafts from the chin and iliac crest, *Int J Oral Maxillofac Implants* 17:507–516, 2002.
163. Attard NJ, Zarb GA: Immediate and early implant loading protocols: a literature review of clinical studies, *J Prosthet Dent* 94:242–258, 2005.
164. Buser D, Ingimarsson S, Dula K: Long term stability of osseointegrated implants in augmented bone: a 5-year prospective study in partially edentulous patients, *Int J Periodontics Restorative Dent* 22:108–117, 2002.
165. Nyström E, Nilson H, Gunne J, Lundgren SA: 9-14 year follow-up of onlay bone grafting in the atrophic maxilla, *Int J Oral Maxillofac Surg* 38:111–116, 2009.
166. Verdugo F, Simonian K, Frydman A, et al.: Long-term block graft stability in thin periodontal biotype patients: a clinical and tomographic study, *Int J Oral Maxillofac Implants* 26:325–332, 2011.

31

Guided Tissue Regeneration in Implant Dentistry

BACH LE, BRADY NIELSEN

Introduction

The concept of guided tissue regeneration (GTR) began many years ago in the field of neural regeneration. In the early 1940s it was observed that regeneration of a severed nerve was impaired by ingrowth of fibrous tissue and scarring.[1] However, when the principle of compartmentalization was applied, using allogeneic aorta as a protective conduit over the cut ends of the nerve, regeneration of the nerve was seen.

In 1957 the same principle was applied by Murray to bone regeneration in dog studies. He found that bone defects created in the ilium and protected with a plastic cage would later fill with new bone. The bone fill could even be enhanced beyond the original anatomy of the ilium if the protective cage created a compartment with an expanded volume.[2]

Hurley and colleagues were among the first to use guided bone regeneration (GBR) in humans in 1959. Their use of GBR for experimental spinal fusion involved the placement of a cellulose acetate filter over a grafted site to exclude the overlying, fully differentiated tissues from the bony defect.[3] Their work provided the foundation for GBR techniques still used in implant dentistry today. Over the next 20 years, the principle of compartmentalization to allow regeneration of a select tissue type was advanced until its widespread use in the field of dentistry occurred with the growth of dental implants during the 1980s.

During the developmental phase, many contributed valuable research and data on the topic of guided tissue regeneration by compartmentalization. Linghorne performed dog studies to demonstrate the regeneration of 15-mm long bony continuity defects created in the fibulae by application of a polyethylene tube across the defect.[4] Melcher placed cellulose acetate barriers over surgically created bone defects in rats to allow bony regeneration. He theorized that the importance of the membrane was to protect the hematoma from invasion by nonosteogenic soft tissues and to prevent distortion of the hematoma by pressure from the overlying tissue.[5] This reasoning still applies today.

In the field of dentistry, and specifically oral surgery, Philip Boyne was among the first to develop GTR in the 1960s. Boyne and Bassett tested microporous cellulose acetate laboratory filters in the healing of cortical defects in long bones and used cellulose acetate barriers for regeneration of mandibular defects.[6,7] Successful use of another barrier material, Teflon mantle leaf, was described by Kahnberg for the regeneration of mandibular defects in rabbits.[8]

Prior to the work by Hurley et al. on the concept of GBR, Linghorne and O'Connell in 1950 demonstrated the potential for regeneration of specific periodontal structures.[9] They observed that bone defects created adjacent to teeth and grafted with autogenous bone chips would only heal with regeneration of bone, cementum, and periodontal ligament when new connective tissue attachment formed coronal to the bony defect, thus serving as a barrier for unwanted gingival tissue ingrowth. Because membranes were not used in their studies, the more aggressive gingival epithelium would invade the bony defect in those cases where the connective tissue attachment did not form above the level of the bone defect. Their findings gave rise to the epithelial exclusion theory and served as a foundation for later studies in regenerative periodontics that would also contribute to our understanding of guided tissue regeneration.

In 1976 Melcher described the role of progenitor cells in periodontal regenerative treatment.[10] In the 1980s Karring and Nyman applied barrier membranes to periodontal regeneration research and discovered that the first cells to populate a wound area would determine the type of tissue to ultimately occupy that space.[11,12] Further studies supported the use of barrier membranes to isolate a defect area and allow regeneration of a specific tissue type.[13,14] The implications of guided tissue regeneration for alveolar bone regeneration began to be apparent, and the use of barrier membranes specifically for the regeneration of bone was further demonstrated.[15,16]

	Low Risk	Moderate Risk	High Risk
Type of Defect	Horizontal defect	Vertical defect (1-3 mm)	Vertical defect (>5 mm)
Edentulous Span	Single tooth	Two teeth defect	Multiple teeth
Number of walls	3 Wall defect	2 wall defect	1 wall defect (knife-edge)

• **Figure 31-1** Defect configuration.

The use of GTR in implant dentistry today, more specifically guided bone regeneration, is recognized as an effective method of alveolar ridge augmentation and a means for managing localized defects associated with dental implant placement.[17,18] Guided bone regeneration is now an important part of implant dentistry due to its ability to restore form, function, and esthetics through more ideal implant placement.[19]

Defect Configuration

An important prognostic factor for GBR success is defect configuration (Figure 31-1). Width of the edentulous span, the number of intact bony walls, and the horizontal and vertical component of the defect are critical factors affecting the success of GBR procedures. A single tooth site defect can be predictably augmented with GBR (Figure 31-2, *A*), whereas wider defects involving multiple missing teeth (see Figures 31-2, *B* and *C*) are much more difficult due to poor graft stability over a wide span.[20] Particulate grafts tend to migrate in larger defects due to greater flap reflection.

Another important variable in evaluating a defect is the number of bony walls. Defects with three or four intact walls (Figure 31-3, *A*), have better graft containment and osteogenic potential than two- or three-wall defects (see Figure 31-3, *B*). Socket preservation in intact socket defects is more predictable than that performed in sites where the buccal plate has been lost. For lateral augmentation, the shape and contour of the defect site are also important factors. A concave defect (Figure 31-4, *A*), is more predictably treated than a flat wall defect (see Figure 31-4, *B*), because its shape helps support and contain the graft.

Ridge defects with severe vertical components (see Figure 31-2, *C*), are more challenging to correct with GBR due to poor osteogenic potential, space maintenance, and graft stability. Titanium mesh, titanium re-enforced membrane, and tenting screws have been described to improve graft stability and space maintenance.[21,22] Defects with only horizontal components are more predictably treated due to better graft stability and more osteogenic surface area to support the graft.

Principles of GBR

Patient Selection

GBR is a viable treatment option for correction of the majority of localized alveolar ridge defects. Patients must understand that achieving the ideal esthetic result may require a lengthy course of treatment that could involve multiple procedures. In addition, patient factors such as uncontrolled diabetes, immunocompromised state, smoking, poor oral hygiene, history of radiation or bisphosphonate use, and heavy alcohol consumption may negatively affect treatment outcome.

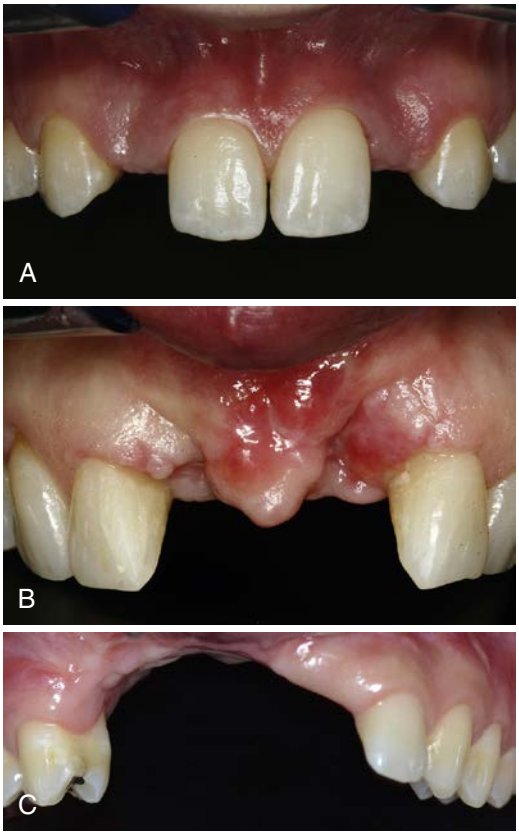

• **Figure 31-2** **A,** Single tooth defect sites are ideal for treatment with GBR. **B,** Multiple tooth defect is also treated predictably with GBR. **C,** Large, multiple tooth defect with significant alveolar deficiency. (**A** and **B** from Le B, Nielsen B: Esthetic implant site development, *Oral Maxillofac Surg Clin North Am* 27(2):283-311, 2015. **C** courtesy of Brady Nielsen, DDS, Los Angeles, CA.)

Incision Design

Various incision designs can be utilized for GBR, each with advantages and disadvantages. A wide flap access allows greater visibility, but may cause unwanted graft migration due to greater dissection. A narrow flap runs the risk of necrosis and dehiscence, and incisions made within the confines of the bony defect will limit the extent of augmentation. An important prerequisite of incision design is a broad-based flap to improve vascularity and prevent flap necrosis or dehiscence. A vertical incision facilitates release of the soft tissue to accommodate augmentation of larger defects.

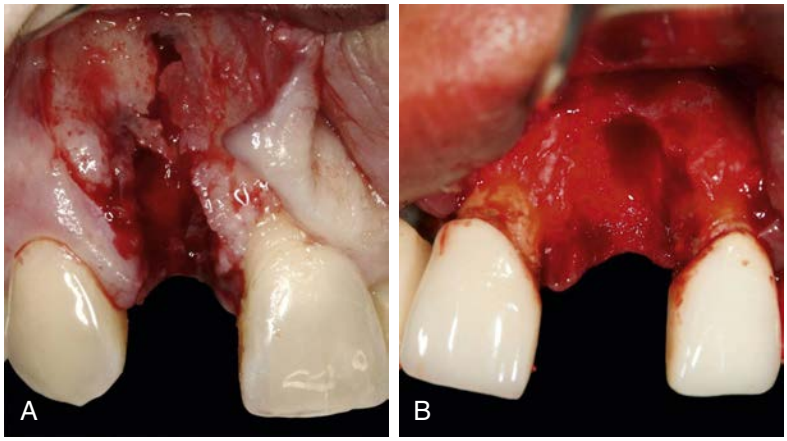

• **Figure 31-3** **A,** Narrow single wall defect with nearly 4 walls intact. **B,** Wide single wall defect with only three walls intact. (From Le B, Nielsen B: Esthetic implant site development. *Oral Maxillofac Surg Clin North Am* 27(2):283-311, 2015.)

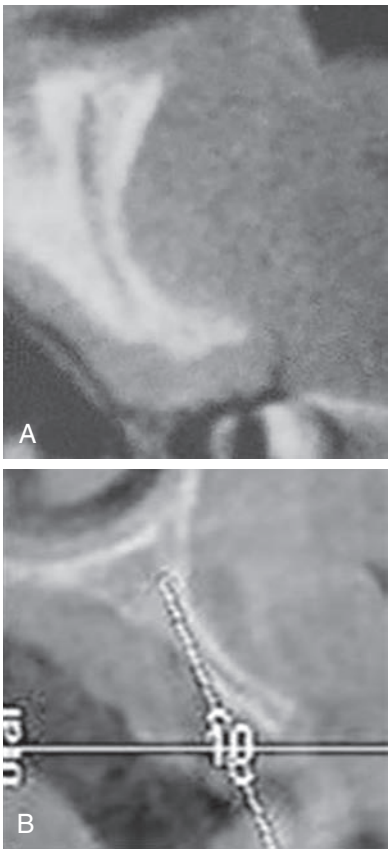

• **Figure 31-4** **A,** Concave defect shape supports and maintains the graft. **B,** Flat defect shape allows for graft migration. (From Le B, Nielsen B: Esthetic implant site development. *Oral Maxillofac Surg Clin North Am* 27(2):283-311, 2015.)

In situations where GBR is performed with extraction, it is also important to limit the amount of disruption to the existing soft tissue architecture. This requires careful planning to allow for adequate tissue release with as little disturbance to the existing normal anatomy as possible. Incisions must be placed outside defect margins on stable bone, and should never be made within the defect site.

In edentulous sites, the flap apex is generally created using a crestal incision. This incision can be extended into the sulcus of adjacent teeth as a sulcular incision for augmentation of small horizontal defects (1-2 mm). A vertical releasing incision typically is not necessary for small horizontal defects. If significant augmentation is required, a vertical releasing incision is used. The releasing incision is placed distal to the defect over the adjacent tooth. It allows for effective periosteal release and greater expansion of the soft tissue matrix. The vertical incision should begin as a curvilinear extension from the crestal incision, and may be done sparing the papilla (Figure 31-5, *A*). The incision extends distal to follow the mucogingival junction to the midline of the adjacent tooth. The vertical release is then made apically to the depth of the vestibule. This "open-book incision" is an effective technique to maximize release for augmentation while still preserving esthetics (see Figure 31-5, *B*).[23] This minimal access design also facilitates graft confinement and decreases graft migration common with wider dissection. In addition, the single site-specific vertical release design allows for sliding rotation of the distal arm of the flap coronally in cases where slight vertical augmentation is required to correct soft tissue defects (Figure 31-6). Bilateral vertical releasing incisions can be used for additional release, especially for significant vertical defects or when augmenting near the mental foramen.

Exposure should be carried to the depth of the vestibule and be sufficient to visualize healthy bony margins around the entirety of the defect. Keep in mind the desired area of augmentation to avoid placing incisions within the defect area. Unnecessary or excessive flap reflection should also be avoided because this will result in apical and lateral graft migration away from the crest of the ridge (Figure 31-7). Predictability of augmentation using particulate grafts is largely dependent on the ability to stabilize and maintain the soft tissue matrix. Maintenance of this space and graft containment becomes more difficult in wide edentulous spans or with excessive flap elevation. Another measure to mitigate apical graft migration is to ensure adequate basal

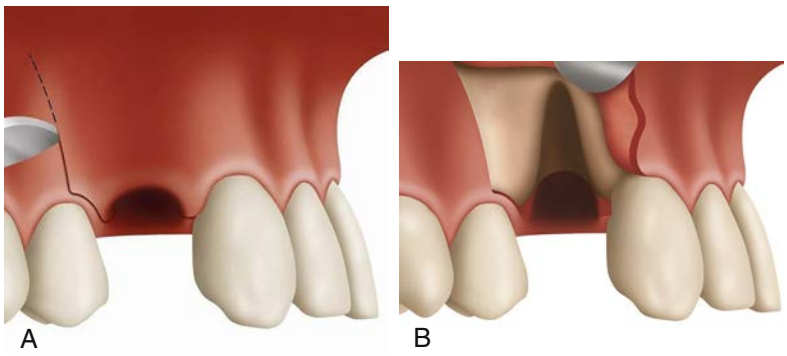

• **Figure 31-5** **A,** Incision design for the "open-book" incision. **B,** Flap reflection and exposure with the "open-book" incision. (From Le B, Nielsen B: Esthetic implant site development. *Oral Maxillofac Surg Clin North Am* 27(2):283-311, 2015.)

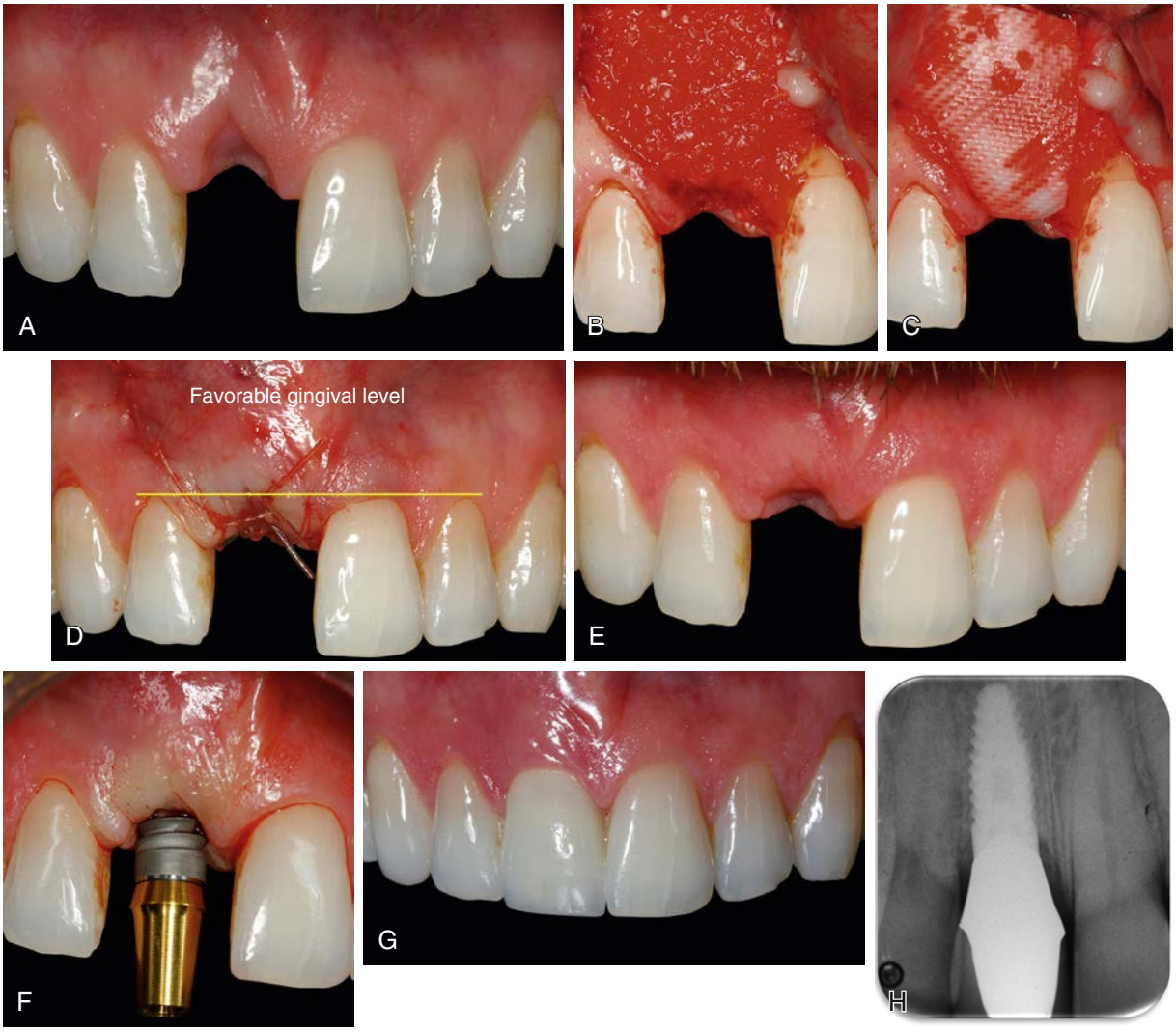

• **Figure 31-6** **A,** Single missing tooth #8 with both horizontal and vertical defects. **B,** Particulate grafting to occupy the defect. **C,** Membrane placement to allow guided bone regeneration. **D,** Soft tissue closure of the augmented site demonstrates an improved gingival level. **E,** The healed site following guided bone regeneration, now ready for implant placement. **F,** Flapless implant placement at #8 site. **G,** Final restoration of implant #8. **H,** Periapical radiograph demonstrates healthy interproximal bone levels. (Courtesy Bach Le, DDS, MD, Los Angeles, CA.)

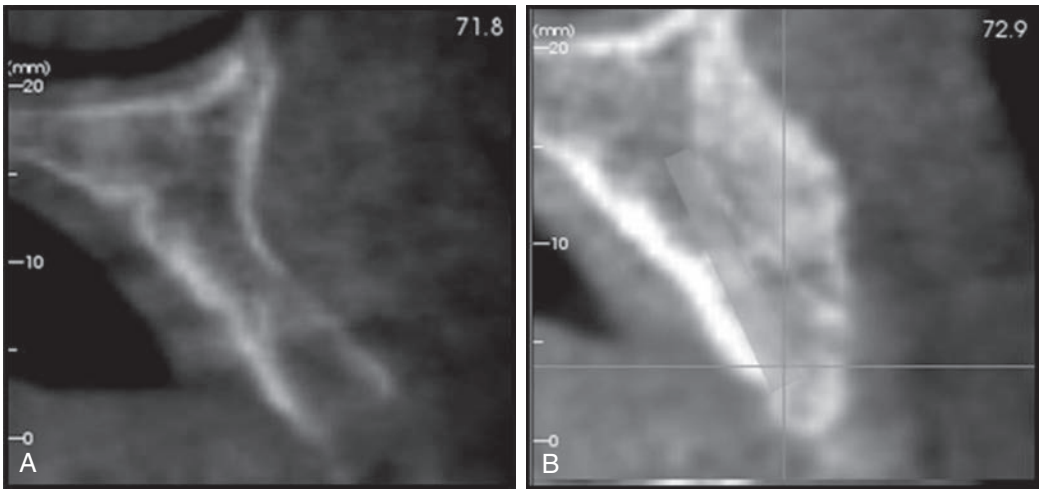

• **Figure 31-7 A,** Alveolar contours can affect graft migration, especially when there is excessive flap reflection. **B,** Post-operative CT scan demonstrating inadequate crestal bone volume due to undesirable apical migration of particulate bone graft. (Courtesy Bach Le, DDS, MD, Los Angeles, CA.)

graft volume to support the crestal portion of the grafted site. The analogy of building a sandcastle applies with the use of particulate grafts for ridge augmentation. When building a sandcastle, a wide base is needed first to support the sand at the highest portion.

Defect Site Preparation

Following elevation of the mucoperiosteal flap, any remaining soft tissue remnants must be removed to create an osteogenic bed for augmentation. The need for perforation of the recipient site in GBR is controversial. The blood supply to the graft and access to osteoprogenitor cells are thought to be made more available by perforation of the recipient site bone. This has been shown to improve graft success using autogenous bone block, but its benefits in GBR are debatable.[24,25] The senior author of this chapter does not routinely perforate the recipient bone bed and has not seen a difference in the outcome of the graft procedure.

Membrane Placement and Space Maintenance

Membranes should be prepared according to the manufacturer's guidelines. Some resorbable membranes are designed to have one side exposed to the compartment being augmented and the other side toward the overlying flap. Membranes should also be trimmed to properly fit the site. The membrane should extend slightly beyond the defect margins to allow the borders of the membrane to lie on stable bone.[26] This allows containment of the graft and isolation of the bony defect from the overlying soft tissue.

Stabilization of the augmented volume is the most important factor for GBR success. The compartmentalized space must be maintained to allow for bone regeneration and maturation. This is commonly done with the use of autogenous bone graft or bone substitute. The stability of the graft and membrane must be sufficient to prevent micromotion which prolongs the inflammatory phase and results in fibrous tissue formation or infection. Some resorbable membranes are soft and pliable, allowing intimate adaptation to the space-maintaining graft. These generally do not require additional methods for stabilization.[27] Rigid resorbable and non-resorbable membranes, such as PTFE or titanium reenforced membranes, often require the use of microscrews, tacks, or sutures for stabilization. An adequate amount of healthy tension on the overlying mucoperiosteal flap can also help prevent migration of the graft or movement of the membrane. The closure should not produce excessive tension capable of causing flap necrosis or dehiscence, but some amount of tension is desirable to stabilize and maintain the membrane and graft in the ideal position. This requires significant experience on the part of the clinician.

Soft Tissue Closure

In general, primary closure is advised for most GBR procedures. However, in some circumstances this may be difficult to achieve or undesirable. Certain membranes have been shown to provide predictable results even when exposed, and these membranes and clinical situations will be further discussed in the next section. Several techniques exist for releasing the flap to allow adequate advancement and primary closure. When a crestal incision with sulcular extension does not provide adequate release for closure, consider adding vertical releasing incisions from either end of the sulcular incision. Vertical releasing incisions should be carried high into the vestibule to allow for significant release. Additional flap release is achieved with deep horizontal cuts made at the base of the periosteal flap to both reduce the possibility of flap perforation and allow for maximum release (Figure 31-8).

Meticulous closure using interrupted sutures is recommended to achieve esthetic tissue approximation and provide a seal from the oral cavity. Interrupted sutures (3-0 gut) are placed first for approximation of the crestal incision,

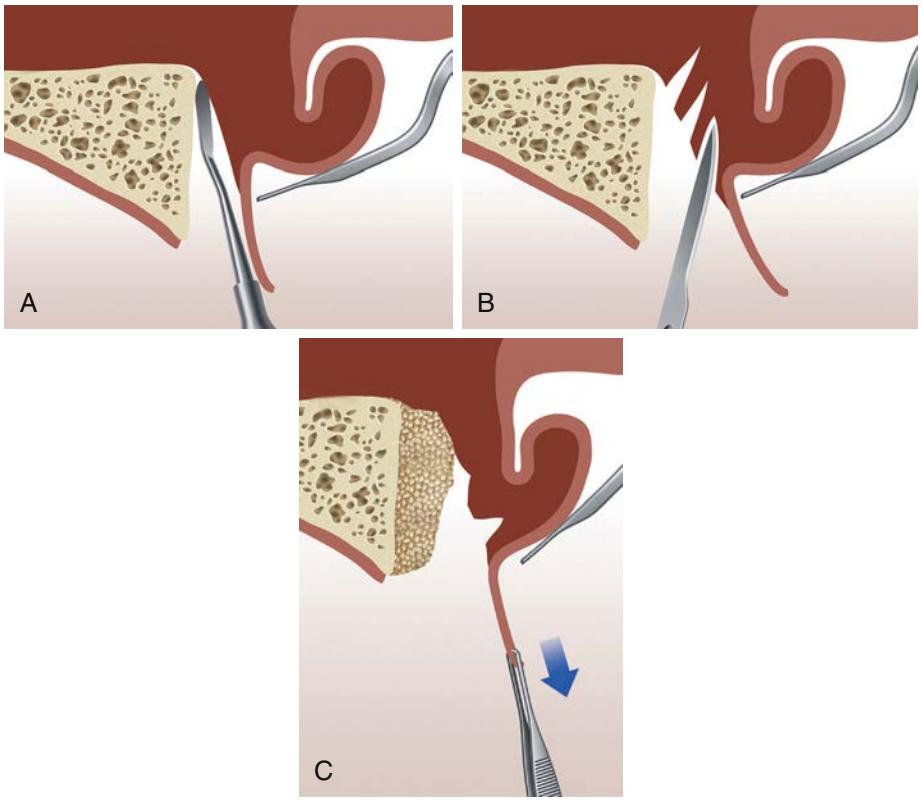

• **Figure 31-8** **A,** Flap reflection to the base of the defect. **B,** Deep, horizontal periosteal releasing incisions made at the base of the flap. **C,** Flap advancement for primary closure over the augmented site is facilitated by the periosteal releasing incisions. (Courtesy Bach Le, DDS, MD, Los Angeles, CA.)

followed by closure of the vertical arm using a smaller suture (5-0 gut). Some authors prefer a monofilament suture to protect against bacterial wicking.[28]

Primary closure may be undesired in some clinical situations. These include extraction defects where primary closure may cause excessive distortion of the natural gingival architecture. Certain membranes can also be used without primary closure, such as the dense polytetrafluoroethylene (PTFE) membranes and cross-linked resorbable collagen membranes. The various types of membranes available are discussed in more detail in the next section. Due to the varying properties of membranes, some can be used when primary closure is not attainable or undesired. This allows healing by secondary intention, which can maximize the amount of keratinized tissue.[29] This is most beneficial in socket preservation or augmentation. The membrane over the crest is intentionally exposed to heal by secondary intention and gain additional keratinized tissue migrating from the periphery of the defect (Figure 31-9).

Membrane Selection

The use of a barrier membrane to isolate the bony defect site from the surrounding epithelial cells is critical for regeneration of the defect with bone. Epithelial cells migrate 15 times faster than bone cells and would quickly fill the defect without the use of a barrier membrane.[30] The membrane not only functions to isolate the defect site for bony regeneration, but also helps to maintain the graft and blood clot in the desired location.

Functional requirements exist for membranes to be successful. The first of these requirements is stability. The smallest amount of motion at the regenerate site can prolong the inflammatory response, leading to fibrous tissue invasion and inhibited bone formation.[31] The membrane must provide sufficient stability to prevent micromotion of the grafted site.

The second requirement of membranes is the ability to facilitate space maintenance. This property depends largely on membrane rigidity and is an important factor for success. A common challenge encountered with GBR is soft tissue collapse into the space created for bony regeneration. This is especially true for larger defects. The use of bone graft substitute, tenting screws, and titanium reinforced membrane or mesh have been described to facilitate space maintenance.

A third requirement for GBR membranes is biocompatibility. The membrane should have minimal inflammatory response, no caustic breakdown products, and no harmful changes to local pH or the local environment. Biocompatibility varies among the several types of membranes commercially available, and their effects should be considered when deciding on a membrane.

The final requirement for barrier membranes is ease of use. The membrane should be easily manipulated to allow proper adaptation while still maintaining all of its other strengths, such as stability and biocompatibility. There are a number of membranes available on the market today that satisfy these requirements.

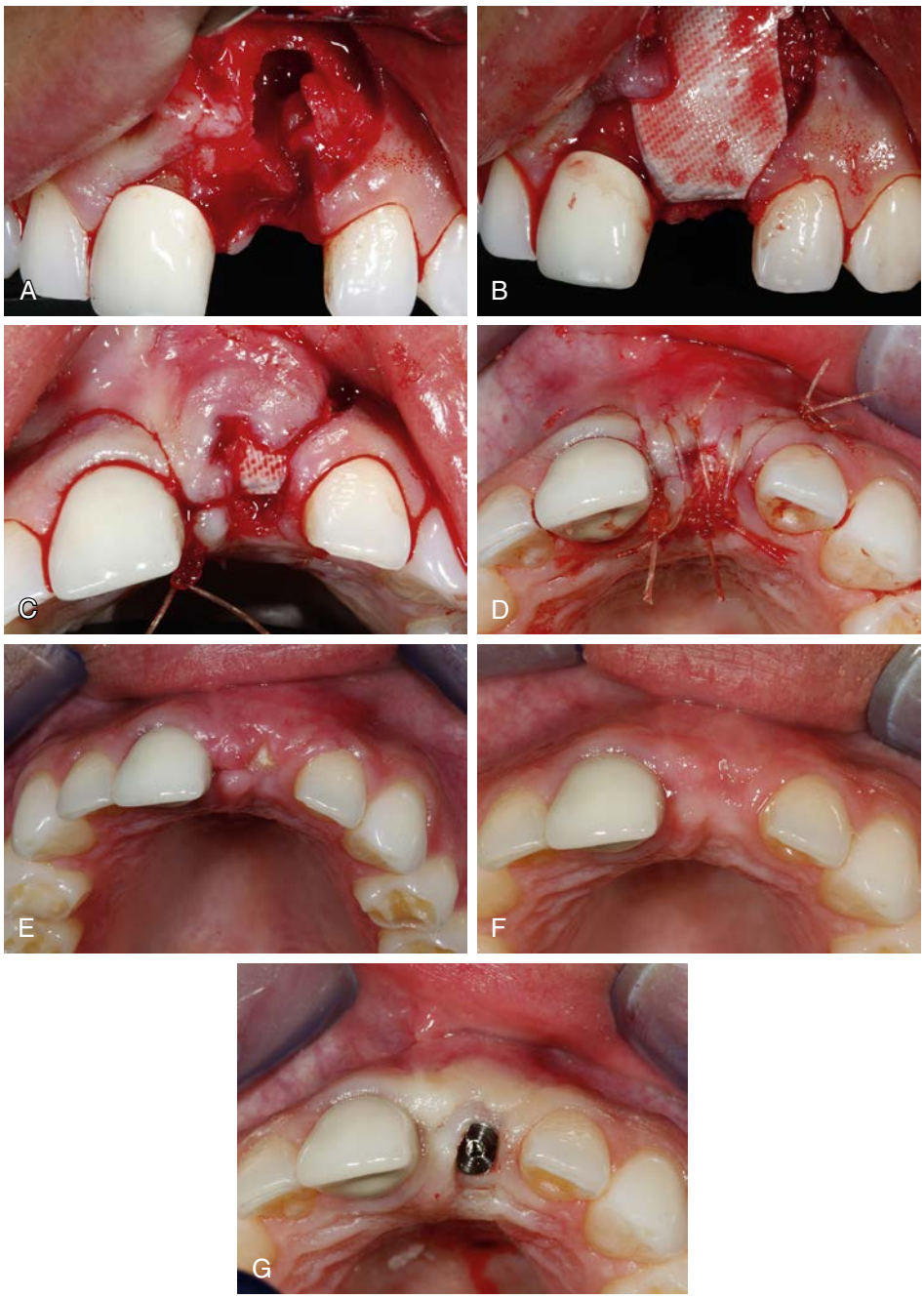

• **Figure 31-9** **A,** Facial wall defect following extraction of tooth #9. **B,** Treatment of the facial wall defect with GTR. **C,** Soft tissue closure at the extraction site intentionally leaves the membrane partially exposed. **D,** Partial membrane exposure allows healing by secondary intention to maximize keratinized tissue. **E,** Healing by secondary intention maximizes the amount of keratinized tissue. **F,** Healthy keratinized tissue after healing by secondary intention. **G,** Flapless implant placement is possible due to the thick zone of keratinized tissue. (Courtesy Bach Le, DDS, MD, Los Angeles, CA.)

Non-resorbable Membranes

Non-resorbable membranes were the first membranes used for guided bone regeneration. They were originally shown to be successful even without bone graft material.[32] A variety of non-resorbable membrane materials have been shown to be effective, including titanium foil, micro titanium mesh, Teflon mantle leaf, cellulose acetate, polytetrafluoroethylene, silicone sheet, and even rubber dam material.[26] A distinct advantage of non-resorbable membranes is their increased mechanical rigidity compared to their resorbable counterparts. This is important in large three-dimensional defects where space maintenance is critical for a successful outcome.

Among those available today, the most common are the expanded polytetrafluoroethylene (e-PTFE) and dense polytetrafluoroethylene (d-PTFE) membranes. Both are chemically identical, made of a synthetic

polymer that does not cause an immunologic reaction and is resistant to breakdown by the host tissue.[33] They differ in their preparation, which affects density and pore size. The e-PTFE is a sintered material with a large pore size, and the d-PTFE is a nonsintered material with a much smaller pore size. The d-PTFE membranes have a pore size less than 0.2 μm, compared to a pore size of 8 to 30 μm found in the e-PTFE membranes. Although the porosity of both the e-PTFE and d-PTFE membranes is capable of excluding epithelial cells, the improved microporosity of the d-PTFE membranes also prevents penetration by bacteria.[34]

Preventing membrane contamination by bacterial infiltration with premature exposure is critical to success. Machtei reported a six-fold decrease in bone formation at sites where a microporous membrane was exposed compared to sites where the membrane was not exposed.[35] One disadvantage of non-resorbable barrier membranes when compared to resorbable membranes is their tendency for premature exposure in the oral cavity (see Figure 31-9). A systematic review on the clinical outcomes of GBR to correct peri-implant defects by Chiapasco et al. reported a 20% exposure rate with nonresorbable membranes, compared to only 5% with resorbable collagen membranes.[36] However, the d-PTFE membranes have the distinct advantage of being able to withstand infection when exposed to the oral cavity due to their improved pore size.[37] Some denser collagen membranes also have this advantage and respond favorably even when exposed.[37,38] This characteristic offers a distinct advantage for the d-PTFE and resorbable collagen membranes when primary closure is not possible or when membrane exposure in the postoperative period is likely. The e-PTFE membranes, on the other hand, are at risk of bacterial colonization and infection with early exposure of the membrane. Premature removal of the membrane may then be required, resulting in impaired bone regeneration.[36,39-46]

Resorbable Membranes

Resorbable membranes are comprised of two main subgroups: natural membranes and synthetic membranes. Natural membranes are made of collagen which can be derived from human, bovine, and porcine sources. The raw collagen material is processed and purified to remove noncollagenous protein before forming the final product. Membranes can be cross-linked to provide biologic stability and slow the resorption rate of the membranes. Cross-linking can provide some protection in premature exposure by preventing early breakdown. Chemical cross-linking is done with a variety of methods including glycosylation and exposure to formaldehyde and glutaraldehyde, among other chemical agents. Nonchemical methods include ultraviolet radiation and dehydrothermal cross-linking.

Natural collagen membranes are widely used in GBR procedures and are well documented in human studies.[16,43,46] These membranes perform the function of a membrane barrier and may act to thicken the soft tissue at the surgical site.[47] Collagen membranes quickly integrate with host tissues to form new vascularization and are biodegradable without a foreign body reaction.[48-50] A distinct advantage of the high density collagen membranes is the ability to allow healing by secondary intention. When exposed, the dense collagen membranes allow epithelialization over the membrane, unlike non-resorbable e-PTFE membranes that tend to become infected.[38,46,51] Friedman et al. reported that in cases of collagen membrane exposure by gingival dehiscence, the exposure always resolved in the following weeks without affecting the healing process.[38]

Another factor to consider is the degradation time of the resorbable membrane. Collagen membrane degradation times vary significantly depending on chemical and enzymatic modifications made to the membrane.[49] Increased cross-linking is believed to prolong degradation time. However, it has also been reported to cause increased foreign body reactions, mucosal dehiscence, impaired soft tissue healing, infections, and decreased tissue integration.[50] Studies have shown that cross-linked membranes have at least the same or superior results compared to unmodified natural collagen membranes.[43,44] While the data may be inconsistent, the idea of a longer lasting resorbable membrane is favorable.

Synthetic membranes comprise the other group of resorbable membranes. These membranes are made of aliphatic polyesters including polylactic acid, polyglycolic acid, trimethylcarbonate, and other co-polymers.[33] Breakdown of these products occurs through hydrolysis, metabolically eliminating the polymers as CO_2 and water. The end products of degradation are nontoxic, but some concern exists over the possible adverse effects their breakdown could have on bone formation. Studies have shown significantly higher levels of the enzymes catalase and superoxide dismutase with synthetic membranes, which can negatively affect wound healing.[52] Another effect of these synthetic membranes is the change in local pH that occurs during degradation, causing a significant drop in local pH.[53] Other disadvantages include possible foreign body reaction and reduced defect fill compared to non-resorbable membranes.[54-58]

Newer forms of synthetic resorbable membranes include the form-stable polylactic acid/polyglycolic acid copolymer (PLGA) membranes modified with *N*-methyl-2-pyrrolidone as a plasticizer and the in situ polymerized polyethylene glycol membrane. Of the two co-polymers, polyglycolic acid is the weaker component, being more hydrophilic, more flexible, and demonstrating a faster degradation rate.[26] Polylactic acid, on the other hand, is the stronger co-polymer. It is more hydrophobic, brittle, and has a longer degradation rate. Varying the ratio of the two co-polymers does allow for some manipulation of the membrane properties. Due to the rigidity of these agents, they are generally prepared in a mesh-type design to improve flexibility. Another option is the addition of a plasticizing

agent or an additional polymer. Studies of the PLGA membranes have shown some limitations including membrane fracture in large defects when they are not supported by a graft material. Other disadvantages include reduced bone fill and more soft tissue complications when compared to non-resorbable membranes.[59,60] The in situ polymerized polyethylene glycol membrane does show promise due to the fact that it undergoes degradation by hydrolysis with no acidic byproducts capable of causing a foreign body reaction.[61,62] Early studies have shown it to be as effective in defect repair as non-resorbable barriers and other resorbable barriers such as natural collagen and polylactic acid membranes.[63-65]

In a prospective split-mouth study comparing the outcomes of horizontal augmentation using resorbable collagen membranes versus non-resorbable e-PTFE membranes with xenograft, a slight advantage was observed for resorbable membranes over the non-resorbable membranes, but was not statistically significant.[46] The advantage was likely due to the fact that the resorbable collagen membranes in the study experienced less dehiscence than the non-resorbable e-PTFE membranes. In the treatment of dehiscence and fenestration defects, a systematic review showed a slight advantage of resorbable collagen membranes over non-resorbable membranes. Use of the resorbable membranes resulted in a greater percentage of defect fill and lower rate of mucosal dehiscence when compared to the non-resorbable membranes. Although the trend did favor the resorbable membranes, the results again were not shown to be statistically significant.[66] The choice of membrane should be made after assessing the individual needs of the clinical situation and weighing the advantages and disadvantages of the various membranes.

Space Maintenance

Space maintenance can be facilitated by the use of bone grafts, bone substitutes, and auxiliary support mechanisms.

Bone Grafts and Substitutes

The most common method for achieving space maintenance in GBR is the placement of a bone graft or bone substitute under the membrane to support, maintain, and fill the defect area. Four categories of bone graft are available for use in GBR: autograft, allograft, xenograft, and alloplasts. Grafts are also available in multiple forms including block, particulate, putty, and injectable varieties.

All bone graft or bone substitutes used in GBR must have certain properties. They must be biocompatible, biodegradable, osteoconductive, provide mechanical support, and allow replacement bone formation by the host.[67-69] The rate of bone graft substitution by host bone is variable depending on the resorption characteristics of a given graft material.

The gold standard for bone graft has always been autogenous bone due to its innate osteogenic, osteoinductive, and osteoconductive properties. The disadvantages of autogenous bone graft are apparent, including donor site morbidity, limited graft availability, and less predictable graft resorption.[70-72] Autogenous bone graft is available in either a block or particulate form. Particulate autograft is resorbed more readily compared to bone blocks. Autogenous bone is obtained from a variety of intraoral and extraoral donor sites, including the mandibular ramus or symphysis, calvarium, proximal tibia, and iliac crest. Due to the limited volume of autograft available, it can be combined with bone substitute to increase the volume available for augmentation of larger defects.

Ridge augmentation has historically been performed using block grafts alone without a barrier membrane. The effectiveness of barrier membranes in decreasing block graft resorption and improving incorporation of the graft has been subject to debate.[73] Comparative studies evaluating outcomes of ridge augmentation using autogenous bone blocks with and without membrane coverage have shown mixed results.[74,75]

When long-term maintenance of the augmented volume is desired, a material with a slower substitution rate is advocated.[76,77] Among those with the slowest substitution rates are xenografts. Xenograft of bovine origin has been extensively studied and documented in dentistry.[66] In one study, deproteinized bovine-derived bone mineral particles were found unchanged in sites that underwent sinus floor augmentation after 11 years.[78] There is ongoing debate regarding the ability of deproteinized bovine-derived bone mineral to be resorbed. Other types of xenograft include bone substitutes of porcine, equine, coral, or algae origin, but their use is not as well documented as bovine-derived sources.[33] Xenografts can also be used as a composite graft by mixing with autograft or allograft.

Allografts comprise another category of bone substitute, including fresh-frozen bone, freeze-dried bone, and demineralized freeze-dried bone.[33] The turnover time for allograft is shorter than that of xenografts. Allografts have been shown to be effective for ridge augmentation in multiple clinical studies.[79-82] They are effectively used in both implant site development and treatment of periimplant defects as the only graft material or as a composite graft mixed with autogenous bone, xenograft, or alloplasts.

The last category of graft materials is alloplastic bone substitutes, including calcium phosphate, calcium sulfate, and bioactive glass and polymers.[33] Each of the alloplastic bone substitutes demonstrates different structures and resorption properties. A variety of calcium phosphate products exist and they are among the most studied of the alloplastic bone substitutes.[83,84] Hydroxyapatite is the least soluble of the naturally occurring calcium phosphates. On the other hand, tricalcium phosphate undergoes such rapid resorption that the amount of bone replacement is reduced compared to the original augmented volume.[77,85] This has led to the development of biphasic grafting compounds made

of hydroxyapatite and tricalcium phosphate to combine the space maintaining properties of hydroxyapatite with the substitution ability of tricalcium phosphates.[76] When compared to deproteinized bovine-derived xenograft, the biphasic alloplasts have been found to produce similar bone formation for sinus augmentation and the treatment of vertical defects, and even improved preservation of extraction sockets.[86-89] Alloplastic bone substitutes are best used as biphasic compounds or in combination with allografts and autografts.

Particulate xenograft, allograft, and autograft have been well documented for the treatment of peri-implant dehiscence and fenestration defects.[36,66] When used with either a resorbable collagen membrane or an e-PTFE membrane, studies have shown that autogenous bone grafts do not provide a superior result compared to bone substitute.[36,66]

Soft Tissue Matrix Expansion Technique

Three-dimensional ridge augmentation of the severely resorbed alveolar ridge was once fraught with difficulty and unpredictability, but is now done with the use of space maintaining mechanisms. In addition to the stability provided by rigid membranes and bone graft materials, the use of tenting screws, dental implants, and titanium mesh have been described to facilitate space maintenance in the treatment of large three-dimensional defects. Marx et al. described a tent-pole technique to predictably reconstruct the severely resorbed mandibular ridge from an extraoral incision.[90] Dental implants were used to tent the soft tissue matrix along with autogenous bone graft to gain adequate bone height for dental prosthesis rehabilitation. A problem encountered by many surgeons in using this technique is inaccurate placement of the dental implants through a transcutaneous approach. Use of a prefabricated, computer-generated surgical template when using this technique facilitates more accurate positioning of the dental implants (Figure 31-10).

Screw Tent-pole Technique

Tenting screws with mineralized allograft can also be used for bone augmentation to correct localized alveolar defects. Using particulate allograft and screws, horizontal and vertical height gain can be achieved to allow successful implant placement (Figures 31-11). This technique requires a membrane for optimal results and is technique sensitive. Vertical defects with large spans (two missing teeth or more) have a higher risk of wound dehiscence. Correction of these defects in a two-surgery grafting protocol of smaller increments per graft may reduce the risk of graft dehiscence. Vertical, single tooth defects may be corrected in a one-staged surgery protocol. Usually failure results from inadequate release of the flap leading to bone graft exposure and resorption. The resulting wound dehiscence can lead to more pronounced bone graft resorption. Proper flap design and manipulation is critical to prevent wound dehiscence when using these techniques.

Titanium Mesh

The use of titanium mesh with or without barrier membrane can provide effective space maintenance and graft stability for ridge augmentation. The ability to custom contour the size and shape of the mesh makes it an effective option for large three-dimensional defects. The use of titanium mesh in GBR is prone to dehiscence, premature exposure, and requires a secondary procedure for removal. Louis et al. reported on the use of titanium mesh for reconstruction of the severely atrophic maxilla or mandible using iliac crest bone graft with a 97% overall graft success rate.[91] The exposure rate of the titanium mesh was reported to be high (52%), and the obstacles to using iliac crest bone are obvious. In addition to the higher resorption rate of iliac crest grafts, other disadvantages include the high cost of hospitalization, risk of general anesthesia, and morbidity of the procedure.

Applications for Guided Bone Regeneration

Implant Site Development

Most post-extraction losses of alveolar ridge dimensions occur in the horizontal (width) rather than the vertical (height) plane.[92] Even when there is adequate bone to place implants, irregular ridge anatomy that is not corrected can result in an unnatural appearance of the final restoration (Figure 31-12). In a study by Sesma et al., 12.2% of dental implants placed for single tooth defects required some type of bone augmentation.[4] This number likely underestimates the true need for bone augmentation to allow for ideal implant placement and esthetics. The study also looked at only single tooth defects, and the need for bone augmentation is generally much greater for multiple tooth defects. Bone augmentation prior to or simultaneously with implant placement may allow for better implant position. Additionally, the augmented bone will correct ridge contour defects for a more natural looking restoration and increase facial bone support for long-term peri-implant soft tissue stability.

GBR with particulate bone graft alone has been shown to be effective for treatment of mild to moderate size horizontal defects.[51,93] Concave horizontal defects are easier to correct with GBR than flat one-walled defects. The use of tenting screws or other space maintenance mechanisms to prevent soft tissue collapse should be considered when augmenting large horizontal defects with unfavorable defect configuration (Figure 31-13).

Block and Degen described a minimally invasive tunneling technique using mineralized particulate allograft to horizontally augment partially edentulous defects for successful implant placement.[94] However, a disadvantage of the tunneling technique is that it can be difficult

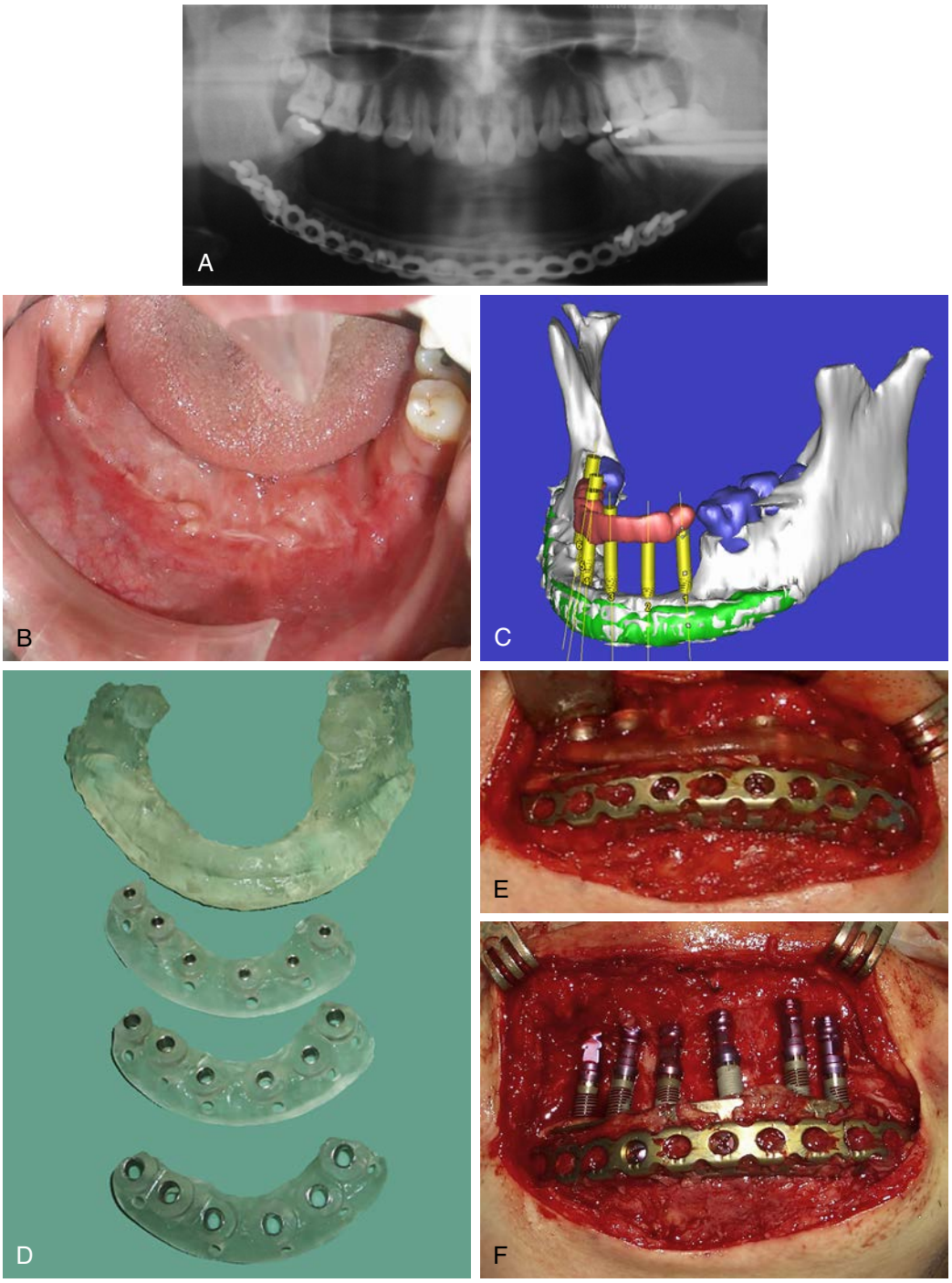

• **Figure 31-10** **A,** Severe vertical alveolar ridge defect status post resection of ameloblastoma and initial reconstruction of the continuity defect. **B,** Intraoral view of the alveolar defect and remaining soft tissue. **C,** Virtual planning for surgical implant placement. **D,** Use of a prefabricated, computer-generated surgical template to allow accurate positioning of the dental implants from a transcutaneous approach. **E,** Transcutaneous approach with surgical splint in place. **F,** Implant placement through the transcutaneous approach with the tent-pole grafting technique.

Continued











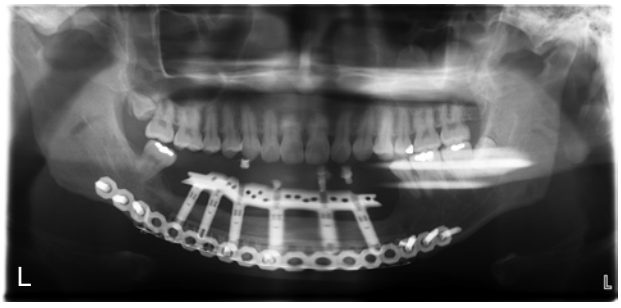

• **Figure 31-10, cont'd** **G,** Particulate bone graft from the iliac crest mixed with mineralized allograft in addition to dental implant "tent-poles" to expand the soft tissue matrix. **H,** Resorbable collagen membrane placement over graft material. **I,** Implant uncovering at 5 months post-operative. **J,** Restorative phase with metal framework try-in. **K,** The fixed prosthesis final restoration. **L,** Significant vertical bone height regenerated using the "tent-pole" technique.

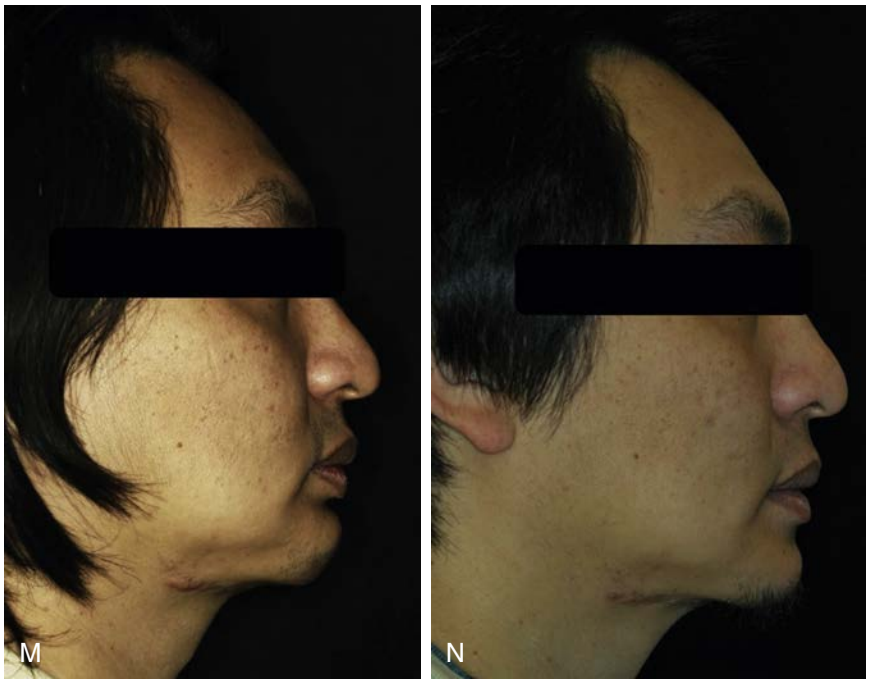

• **Figure 31-10, cont'd M-N,** Before and after photos showing improvement in facial profile. (Courtesy Bach Le, DDS, MD, Los Angeles, CA.)

to position and maintain the graft in a coronal position to augment the peri-implant soft tissue. Additional bone grafting is usually necessary at the time of implant placement to address this issue. Maintaining the graft in the crestal area is important for long-term peri-implant soft tissue stability.

Implant Placement With Simultaneous GBR: "Esthetic Contour Graft"

Two types of bony defects are commonly encountered when implants are placed at sites with reduced bony volume: dehiscence defects and fenestration defects. These defects can occur through either the buccal or lingual wall, but generally occur on the buccal. Buccal or facial defects are of greater concern due to their potential esthetic compromise.

When there is adequate basal bone and the lateral ridge deficiency is mild (<4 mm), implants can be placed simultaneously with the augmentation procedure. Traditional GBR procedures are performed as a staged approach with a second surgical intervention to place the implant. If simultaneous bone grafting is performed, it is usually followed by submerged implant site healing beneath the repositioned soft tissue flap. Submerge healing requires an additional surgical intervention for uncovering and can lead to shrinkage of an already thin keratinize mucosa. Le et al. described a bone grafting procedure, the "esthetic contour graft," done simultaneously with implant placement and nonsubmerged healing by adding a healing abutment to improve peri-implant tissue contour (see Figure 31-11).[95] This approach offers several advantages. The single-stage protocol minimizes compression and migration of particulate graft material, and allows the bony and soft tissue architecture to develop around the healing abutment during site healing. A healing abutment will provide some horizontal tenting of the peri-implant soft tissues and result in less apical migration of the graft material. This improves the prognosis for retaining the greatest width and height of the remaining crestal bone. Grafting at the time of implant placement also takes advantage of the regional acceleratory phenomenon that is induced by the trauma of implant placement, helping to accelerate healing.[96]

The esthetic contour graft can be done with two different conservative surgical incisions. In cases with small ridge defects (<2 mm), a sulcular flap without vertical releasing incisions can be used. In cases with more extensive defects, an open-book flap design is preferred to enhance visualization and access to the graft site. The latter consists of a crestal incision made slightly lingual to the ridge midline to ensure that there is an adequate amount of keratinized tissue present in the flap (Figure 31-14, *A* and *B*). This is followed by a distal, curvilinear, vertical incision that follows the gingival margin of the distal tooth. A wide subperiosteal reflection is made to expose two to three times the treatment area, and the papilla is then reflected on the mesial side of the edentulous site.

During implant placement, the implant's restorative platform is positioned at the desired level and a healing cap is attached to the implant (see Figure 31-14, *B*). The peri-implant soft tissue is released and advanced by scoring the periosteum so that tension-free closure is achieved around the neck of the implant. This is done because moderate graft resorption will occur if there is not an adequate tissue seal around the implant neck or if tension-free closure is not achieved.

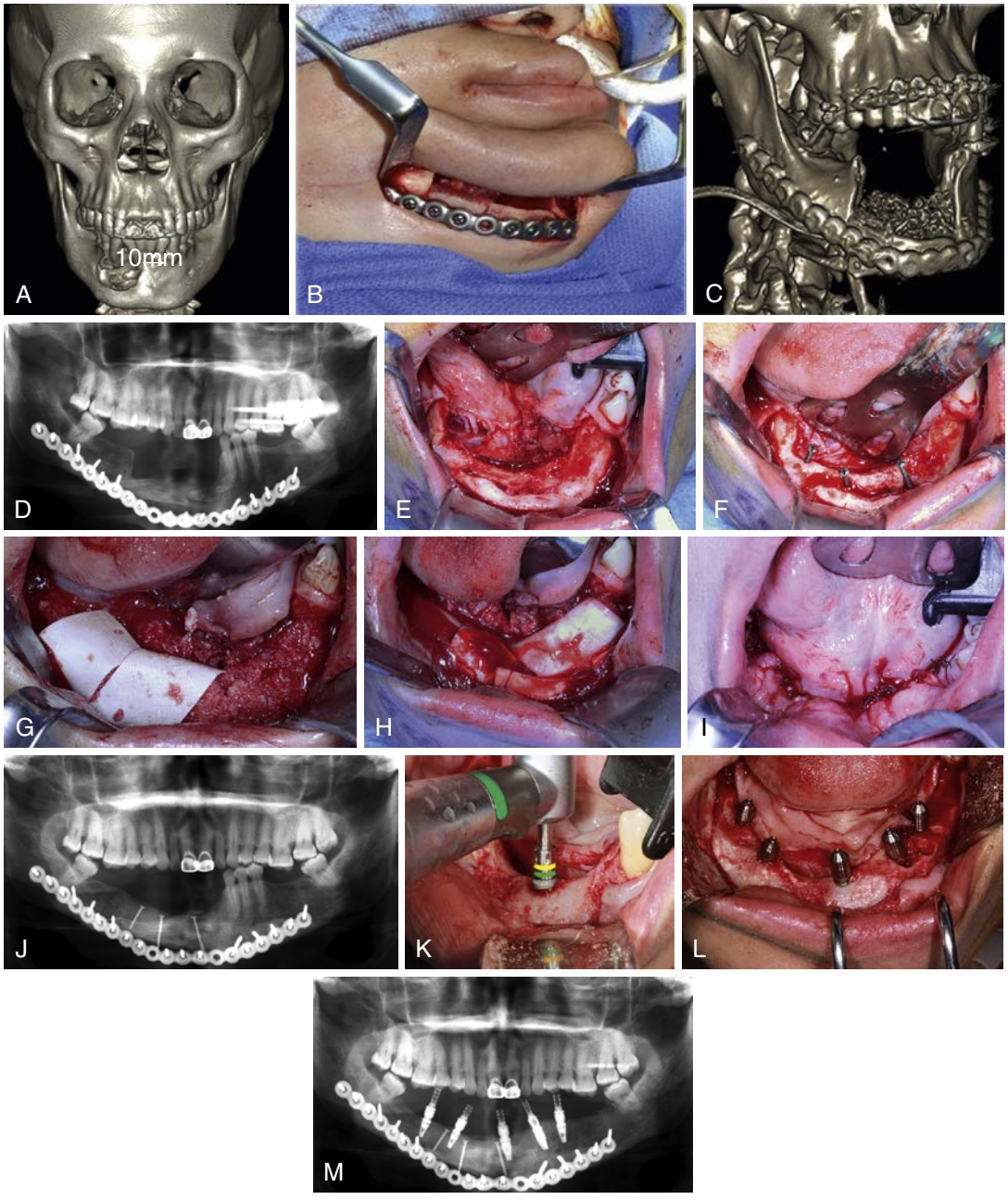

• **Figure 31-11** **A-C,** Resection of ameloblastoma and primary reconstruction of the continuity defect wth iliac crest bone graft. **D,** Panorex radiograph showing significant residual vertical defect. **E,** Transoral approach with exposure of bony defect. **F,** Tenting screws placed to support vertical augmentation. **G,** Particulate allograft mix with BMP/acelluar collagen sponge (ACS) placed to occupy the defect volume and support the expanded volume. **H,** Resorbable collagen membrane used to isolate the bony defect from the surrounding soft tissue. **I,** Soft tissue closure. **J,** Panorex radiograph at 4 months showing increased alveolar bone height. **K-L,** Dental implant placement into the reconstructed alveolus. **M,** Postoperative radiograph following implant placement.



• **Figure 31-12** Esthetic alveolar contour defect following restoration of implant #3. (From Le B, Nielsen B: Esthetic implant site development. *Oral Maxillofac Surg Clin North Am* 27(2):283-311, 2015.)

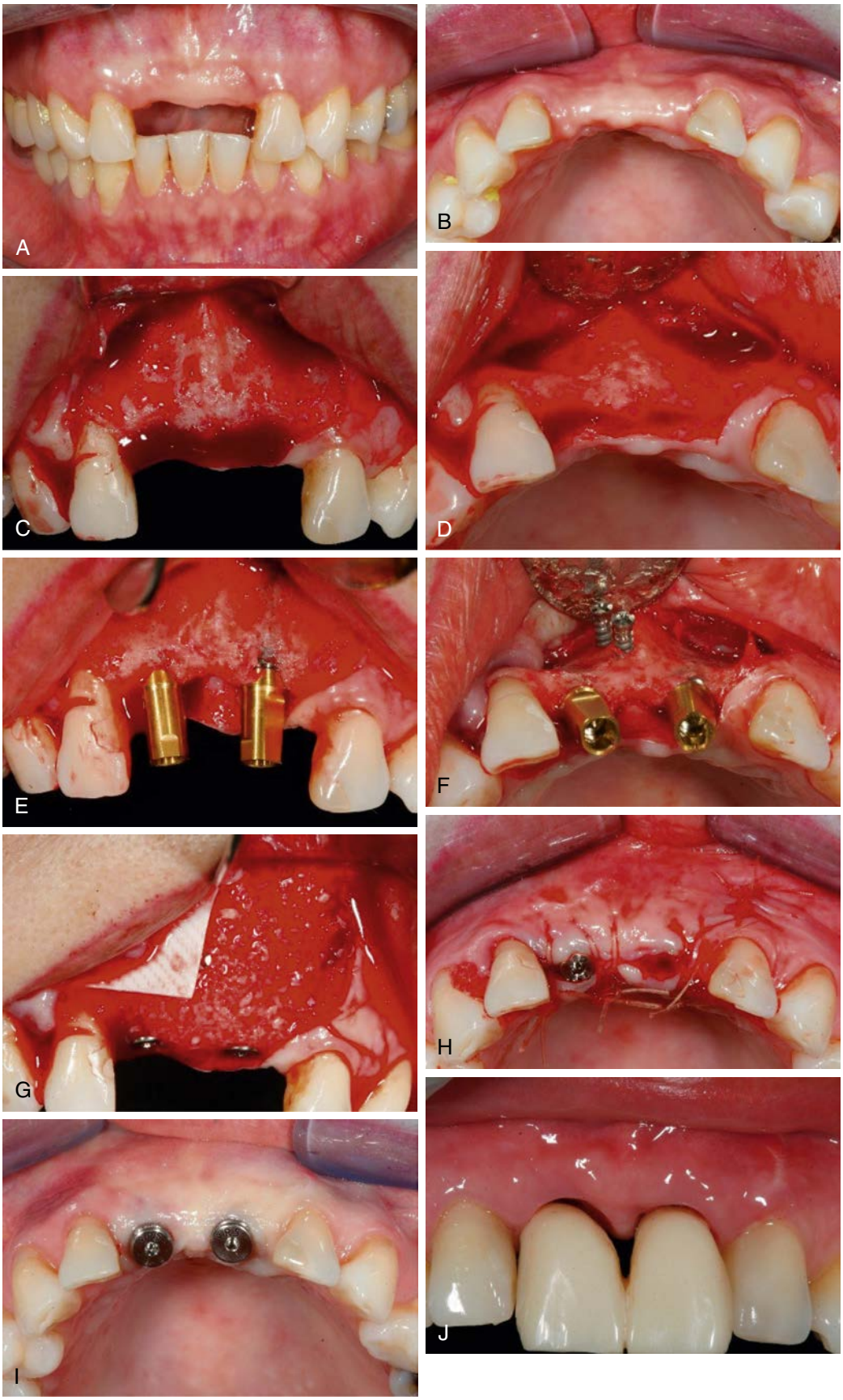

• **Figure 31-13** **A,** Alveolar ridge defect with flat gingival architecture. **B,** Collapsed horizontal dimension of the alveolus. **C,** Open-book flap design allows visualization of the defect. **D,** Severe horizontal alveolar defect. **E,** Dental implant placement. **F,** Tenting screws to allow horizontal augmentation simultaneous with implant placement. **G,** Particulate allograft and barrier membrane placed to occupy the defect volume. **H,** Soft tissue closure. **I,** Postoperative healing at 3 months. **J,** Screw-retained provisional restoration to groom the soft tissue.

Continued

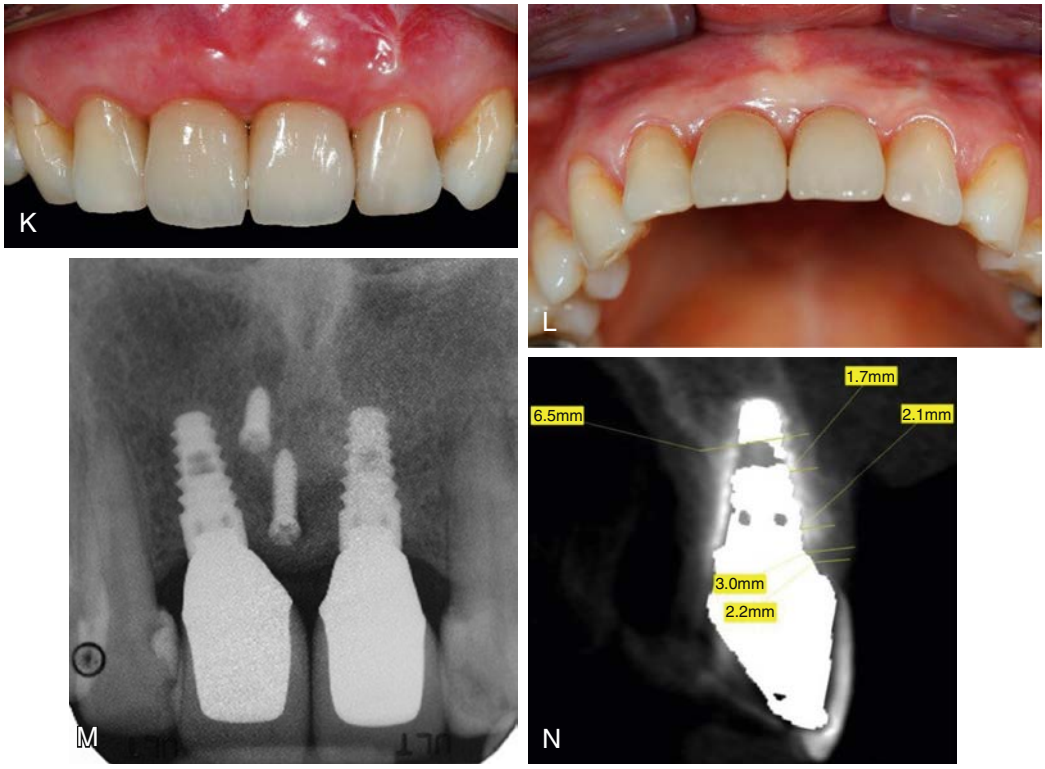

• **Figure 31-13, cont'd** **K-L,** Natural appearing final restorations at 1 year with restored alveolar contours. **M,** Radiograph shows healthy peri-implant bone levels. **N,** CBCT shows maintained labial bone at 1 year. (Courtesy Bach Le, DDS, MD, Los Angeles, CA.)

To induce bleeding in the graft site, periosteum release is performed as the last step just prior to graft placement. Human mineralized bone allograft is packed into the defect and overcontoured by approximately 20% to 30% to compensate for anticipated apical migration and resorption of the material (see Figure 31-14, *C*). Prior to surgery, the allograft is hydrated according to the manufacturer's directions and mixed with the patient's blood, which serves as a coagulant. After grafting, the allograft is covered with a resorbable membrane (e.g., Ossix Plus, OraPharma Inc., Warminster, PA), and a wide healing abutment is attached to the implant. A variation of Palacci's papilla regeneration technique helps to release the tissue tension around the healing abutment and augment the interdental height of the soft tissue papilla.[98] The soft tissues are approximated and sutured around the healing abutment (see Figure 31-14, *D*). This creates a tenting effect over the allograft and, together with the healing abutment, helps to hold the particulate material in place. The result is an esthetic, natural looking final restoration (see Figure 31-14, *E*).

Le et al. assessed the outcome of single-stage, nonsubmerged implant placement with simultaneous augmentation of vertical buccal bone dehiscence defects using a mineralized particulate allograft (Puros Cancellous; Zimmer Dental) covered with a collagen membrane (Ossix Plus; OraPharma Inc.).[97] The vertical buccal defects were classified as small (less than 3 mm in height), medium (3-5 mm in height), or large (greater than 5 mm in height). The initial defects were recorded by measuring the amount of implant rough surface exposure after implant placement. To assess site healing, sectional CBCT scans were obtained at 36 months post-grafting. Evaluation of the sites showed 100% bone regeneration of small vertical dehiscence defects and 79.3% for medium-sized defects. Large-sized defects showed only partial improvement. The likelihood of wound dehiscence, graft exposure and resorption, and subsequent implant thread exposure is increased when larger defects are treated simultaneously. A two-stage approach with the bone augmentation procedure followed by implant placement is recommended for large (>5 mm) defects.

In another published study, Jensen et al. analyzed the long-term stability of bone contour augmentation used in the esthetic zone with early implant placement (6 to 8 weeks of healing after tooth extraction).[99] Outcomes were assessed using biopsies harvested after various time intervals. Implant placement was performed with simultaneous contour augmentation using a combination of autogenous bone (placed in direct contact with the exposed implant surface) and deproteinized bovine bone mineral (DBBM) covered with a double layer of collagen barrier membrane. Biopsies collected after 14 to 80 months of healing were subjected to histologic and histomorphometric analysis. These biopsies consisted of 32.0 ± 9.6% retained DBBM particles and 40.6 ± 14.6% bone; 70.3 ± 14.5% of the



• **Figure 31-14** **A,** Alveolar width defect due to collapse following extraction. **B,** Implant placement results in a small dehiscence type defect. **C,** Simultaneous GBR with implant placement to correct a small width defect. **D,** Soft tissue closure using a variation of Palacci's papilla regeneration technique. **E,** Final result is an esthetic, natural appearing restoration. (From Le B, Nielsen B: Esthetic implant site development. *Oral Maxillofac Surg Clin North Am* 27(2):283-311, 2015.)

DBBM particle surfaces were covered with bone. The investigators concluded that their study confirmed previous findings that osseointegrated DBBM particles do not undergo significant resorption and substitution over time, and that this low substitution rate is likely the reason for the long-term clinical and radiographic stability of contour augmentations using this procedure.

Fenestration type defects occur when a perforation through a bony wall occurs, leaving a window-like defect where the marginal bone is still intact. This often occurs at sites where the crestal width is adequate for implant placement but a significant bony undercut exists facially. Fenestration defects can be missed without adequate flap reflection to visualize the facial alveolus. The risk of a fenestration defect can be minimized with the use of shorter implants with a tapered body design. Fenestration defects are easily corrected with GBR (Figure 31-15).

Vertical Defects

Severe vertical alveolar ridge defects are usually three-dimensional and present a difficult challenge to the implant surgeon. Patients with vertical defects usually have concomitant horizontal defects and these defects must be fully reconstructed in all dimensions to create an esthetic and functional result. This often requires a staged protocol where the horizontal defect is addressed first with GBR before the vertical defect is treated. Wide span vertical defects in the esthetic zone usually require multiple surgical interventions in conjunction with GBR (i.e., distraction osteogenesis and interpositional

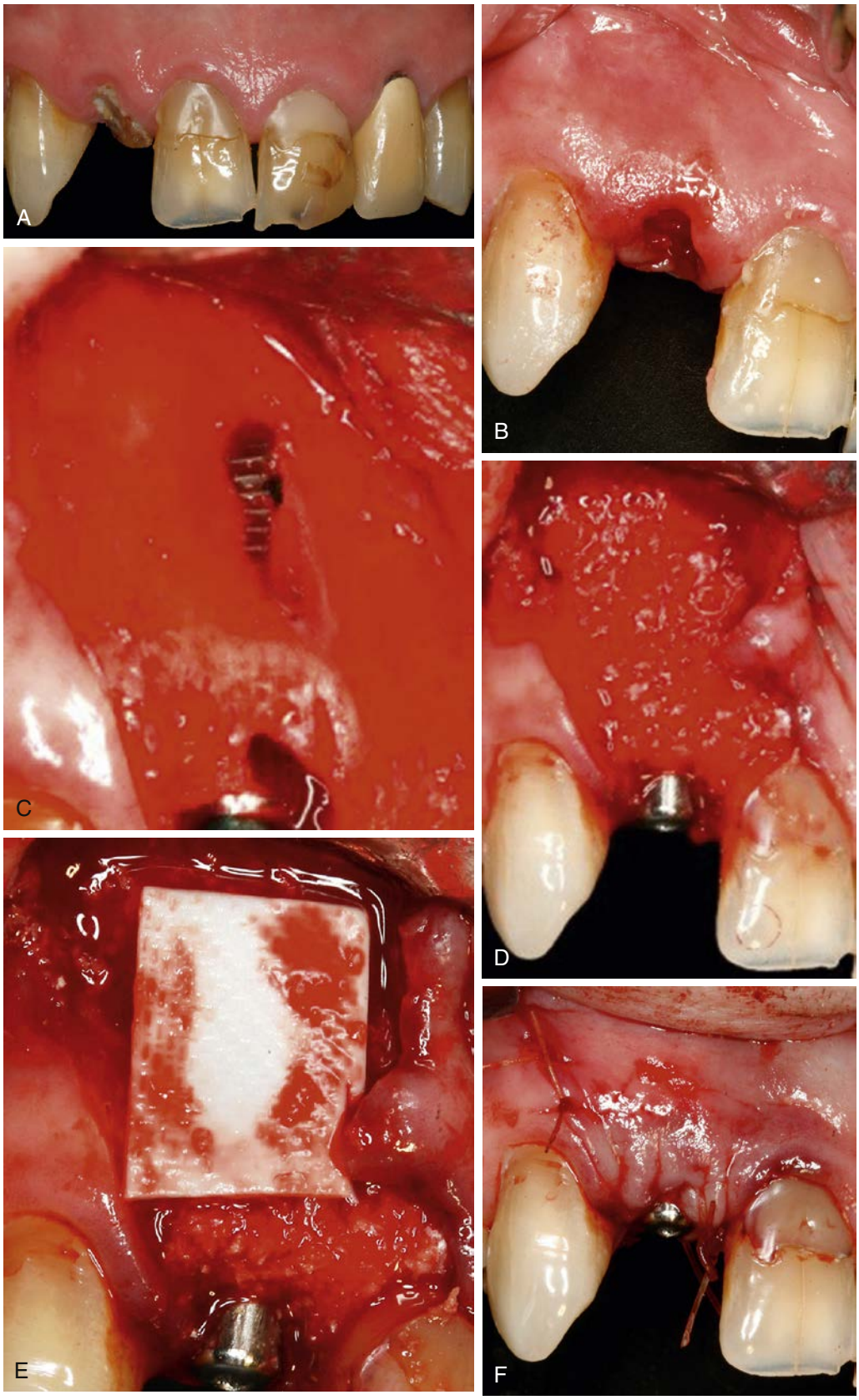

• **Figure 31-15** **A,** Decayed, retained root requiring extraction and immediate implant placement. **B,** Surgical site following atraumatic extraction of the root. **C,** Immediate implant placement resulting in a fenestration type defect. **D,** Open-book flap design to allow treatment of the fenestration defect with GBR using particulate allograft. **E,** Esthetic contour graft (GBR) with a barrier membrane to isolate the augmented site. **F,** Nonsubmerged healing of the dental implant. (Courtesy Bach Le, DDS, MD, Los Angeles, CA.)

osteotomies) to achieve an ideal result. Furthermore, many vertical defects also have loss of bone attachment on the teeth adjacent to the defect. In many instances, it is more beneficial to extract these teeth so that a healthy bone attachment level can be established adjacent to the defect prior to grafting. If multiple grafting procedures are planned for a severe defect, a consideration should be given to the timing of extraction to minimize the width of the edentulous span and maximize the outcome of any initial GBR procedure. Vestibuloplasty with free gingival graft after implant placement is often necessary to increase keratinized tissue attachment and improve esthetic outcomes (Case Study 31-9).

Socket Augmentation

Augmentation of extraction socket with labial wall defects is an additional application for GBR. Following tooth loss, a predictable resorptive pattern occurs with the more apical two-thirds of the extraction socket filling with bone and the more coronal one-third healing by soft tissue ingrowth.[100,101] Socket preservation results in complete bone fill of an extraction socket by 5 to 6 months.[102,103] Considerable postextraction remodeling occurs in the bucco-lingual dimension of up to 60% resorption of the alveolar ridge width.[58,104] This is seen even with immediate implant placement, although the magnitude is reduced.[105] Studies evaluating postextraction ridge remodeling occurring with and without GBR have shown a clear advantage for grafting. Use of either a resorbable or non-resorbable membrane for GBR at extraction site defects results in a statistically significant improvement in ridge dimensions compared to the untreated control sites.[106,107] Extraction sockets not treated with GBR can expect significant ridge width reduction following tooth loss of up to 4.5 mm.[108] When a barrier membrane is used without bone graft, ridge width decreases by only 1.3 to 1.8 mm. When bone graft is used in addition to the barrier membrane, similar improvements in ridge width preservation are observed and even vertical gains are possible. Another observed benefit of socket augmentation is improvement in soft tissue parameters (increase in soft tissue thickness and keratinize mucosa) through the use of healing by secondary intention. The senior author routinely utilize GBR in conjunction with the "open book" flap to address extraction defects where there is a lack of keratinize mucosa (Case Study 31-7).

Management of Labial Mucosal Recession

The efficacy of GBR surgical protocols in repairing localized hard tissue defects and dehiscence and fenestration defects around implants is well described in the dental literature .[109] However, the use of GBR for the management of labial soft tissue recession is a new application recently described by Le et al.[47-47b] The use of a pericardium membrane in combination with a particulate mineralized allograft and tenting screw resulted in approximately 1.0 mm of mean gain in soft tissue thickness, keratinized tissue width, and gingival height around implants with labial mucosal recession. Although the goal of the GBR procedure was to treat bone defects in this clinical case series, improvements were coincidentally observed not only in the soft tissue dehiscence, but also in the keratinized tissue width and soft tissue thickness. The authors hypothesize scoring of the periosteum and foreign-body reaction from placement of a biomaterial and resorbable membrane may result in scar tissue formation that augments the soft tissue profile. The authors also note the successful use of GBR in their group of patients could be attributable, in part, to the exclusion of patients with signs of infection and implants in poor position. The technique involves the removal of the crown on the implant, with strategic placement of a tenting screw on the labial bone adjacent to the implant. No surface treatment is used to decontaminate the exposed implant surface because implants with infection are excluded. A mineralized cancellous allograft is placed and covered with a resorbable membrane using the esthetic contour grafting protocol described here (non-sumerged healing; Figure 31-16).

Postoperative Considerations

Careful postoperative management of the surgical site is important for success. Patient controlled factors such as diet and hygiene should be managed through careful patient education. A soft diet and oral rinses with chlorhexidine gluconate or a saline solution are appropriate for at least the first week following surgery while the sutures remain. Ideally sutures are maintained for at least 10 days following surgery, at which time they should be promptly removed. Antibiotic therapy may also be prescribed prophylactically for up to 7 days postoperatively.

In the esthetic zone, a temporary restoration is generally required for patient satisfaction during the healing phase. Avoid the temptation to use any immediate temporary appliance that is tissue borne and would apply pressure to the grafted site in the early postoperative period. Even when the intention is to mold the soft tissue, it is better done later. The goal of the augmentation is to gain as much tissue height and width as possible, and this can be compromised by early loading of the tissue. Soft tissue contouring with temporary restorations can always be performed at a later date. Early loading of the tissues may risk tissue loss that could prove detrimental to the cosmetic result.

If a temporary restoration is to be used during the healing period, a tooth-borne temporary restoration is preferred to a removable tissue-supported appliance. Tooth-borne temporary restorations help prevent a reduction in graft volume or dehiscence that can be caused by early pressure on the tissues. If dehiscence of the incision and exposure of the membrane does occur during the healing period, it is best managed by topical application of chlorhexidine gluconate to clean the site. Oral rinses with normal saline or chlorhexidine gluconate are also appropriate. Exposed membranes can be removed after 3 weeks of healing with little risk of disrupting the GBR outcome.

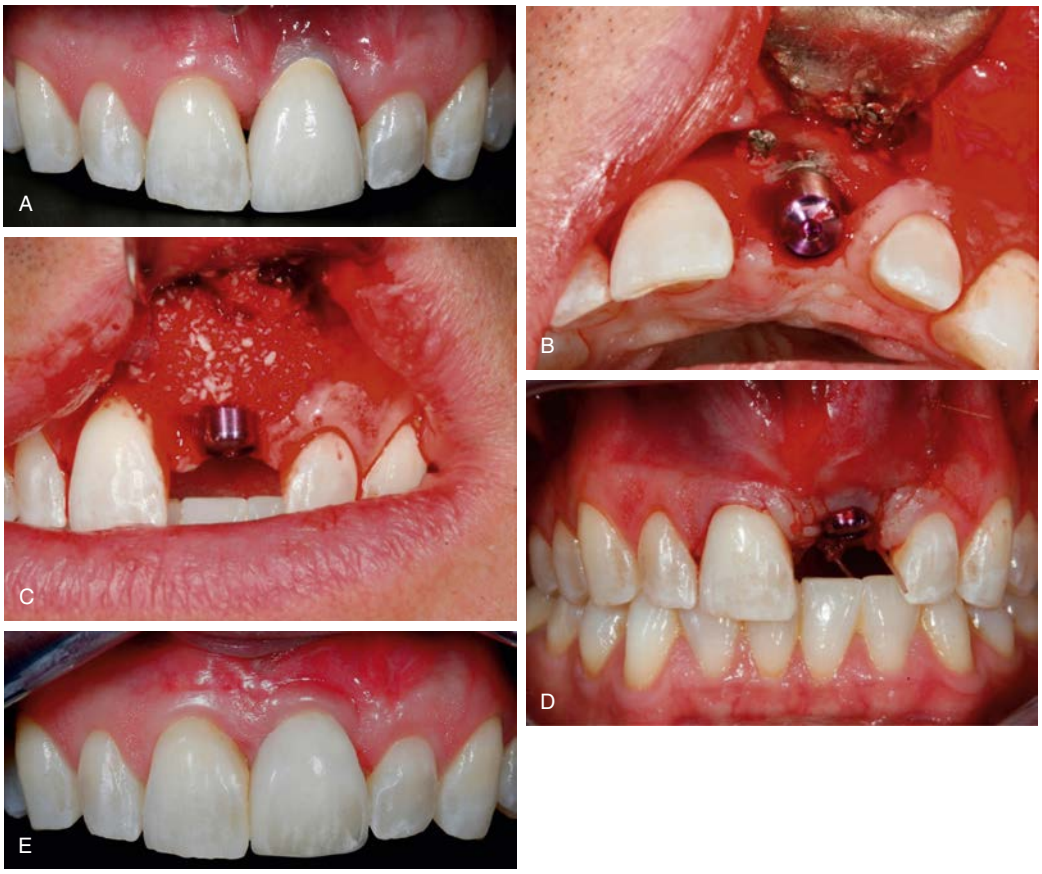

• **Figure 31-16** **A,** The ailing implant with esthetic compromise due to facial attachment loss. **B,** Open-book flap design and placement of a tenting screw for support. **C,** Particulate allograft is placed to occupy the augmented volume. **D,** Soft tissue closure for a tight seal around the healing abutment. **E,** Stable, natural appearing result 4 years after corrective surgery. (From Le B, Borzabadi-Farahani A, Nielsen B: Management of the ailing implant: An innovative technique for the treatment of labial gingival recession around dental implants. *Dental Implant Abstract/How I Do It Session,* AAOMS 96th Annual Meeting, 2014; Honolulu, HI.)

CASE STUDY 31-1

Implant Site Development With GBR

A 42-year-old female presented with missing teeth #4, #5, and #6. Clinical exam revealed an obvious collapse of the alveolus requiring augmentation prior to implant placement (Figure 31-17, *A*). The treatment plan involved a staged approach with second stage implant placement at #4 and #6 for an implant supported bridge after initial treatment with GBR alone. An open-book flap design was utilized to spare the distal papilla of tooth #7. Following flap reflection, the bony ridge defect was obvious (see Figure 31-17, *B*). The defect was occupied with particulate allograft bone substitute (see Figure 31-17, *C*), and then compartmentalized using a resorbable collagen membrane barrier (see Figure 31-17, *D*). After healing, the augmented site was ready for implant placement (see Figure 31-17, *E*).

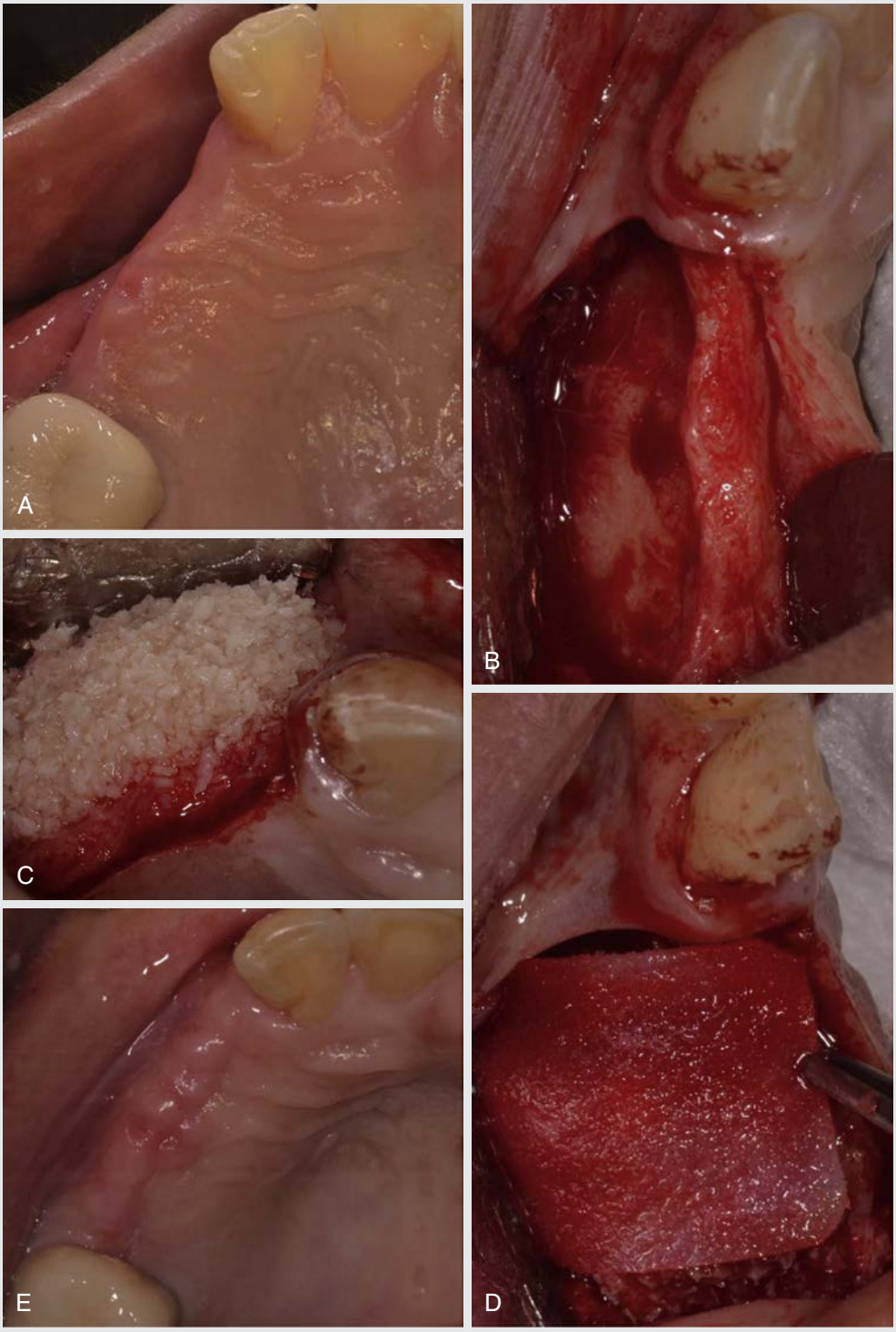

• **Figure 31-17** **A,** Clinically evident collapse of alveolar width. **B,** Obvious bony defect following flap reflection. **C,** Placement of particulate allograft to occupy the augmented volume. **D,** Resorbable collagen barrier membrane used for compartmentalization of the defect. **E,** Restored alveolar width following healing. (Courtesy Brady Nielsen, DDS, Los Angeles, CA.)

CASE STUDY 31-2

Implant Site Development With GBR

A 21-year-old female presented with missing teeth #9 and #10. The teeth had been lost 1 year prior and collapse of the alveolar width was evident on clinical exam (Figure 31-18, *A*). The patient was treatment planned for implant placement at #9 with a cantilevered pontic restoration at #10. The patient would first require augmentation of the deficient alveolus. Using the open-book flap design, the mesial papilla on #11 was spared with a distal vertical releasing incision. The incision was carried anteriorly in a sulcular fashion at #8. Upon flap reflection the labial ridge defect was visible (see Figure 31-18, *B*). The site was treated with GBR utilizing particulate allograft bone substitute with an overlying resorbable collagen membrane for compartmentalization of the defect (see Figure 31-18, *C*). Closure was achieved in a taut fashion using a combination of vicryl sutures at the alveolar crest and chromic gut sutures along the vertical release without excessive tension on the flap (see Figure 31-18, *D*). After 5 months of healing, the site was ready for implant placement. The alveolar width was noticeably improved (see Figure 31-18, *E* and *F*). Three months following implant placement the patient was transitioned to a screw-retained temporary appliance. After 6 months of soft tissue contouring with the temporary restoration, an acceptable esthetic result was obtained (see Figure 31-18, *G*).



• **Figure 31-18** **A,** Ridge width deficiency following tooth loss. **B,** Alveolar bone width deficiency. **C,** Particulate allograft bone and a resorbable collagen barrier membrane used to augment the site. **D,** Soft tissue closure of the augmented site. **E,** Significant clinical improvement in ridge width. **F,** Following healing, the bony dimensions are ideal for implant placement. **G,** After tissue sculpting with a temporary, screw-retained restoration, an esthetic result is obtained. (Courtesy Brady Nielsen, DDS, Los Angeles, CA.)

CASE STUDY 31-3

Implant Site Development With GBR

An 18-year-old male presented with congenitally missing lateral incisors (Figure 31-19, *A*). Clinical exam revealed a collapsed alveolar width at both sites #7 and #10 (see Figure 31-19, *B*). An Essix splint was fabricated for use as a temporary appliance. The splint was also used to determine ideal tooth shape and form, and to determine where additional tissue augmentation was needed (see Figure 31-19, *C*). 3D imaging was obtained with the radio-opaque Essix splint in place to evaluate the ideal tooth position in relation to the existing alveolus (see Figure 31-19, *D*). An open-book flap design was utilized at both sites to place particulate allograft bone substitute in the defect (see Figure 31-19, *E*). Following placement of the resorbable collagen barrier membrane, the flap was closed in a tension-free manner (see Figure 31-19, *F*). 3D imaging immediately following the procedure shows the augmented bone volume (see Figure 31-19, *G*). Clinical exam after 6 months of healing displays the improved alveolar width (see Figure 31-19, *H*). The improved alveolar dimensions allowed for ideal implant placement at both sites with cingulum access holes in the final restoration (see Figure 31-19, *I* and *J*). The natural alveolar contours allowed for an esthetic final restoration (see Figure 31-19, *K*).

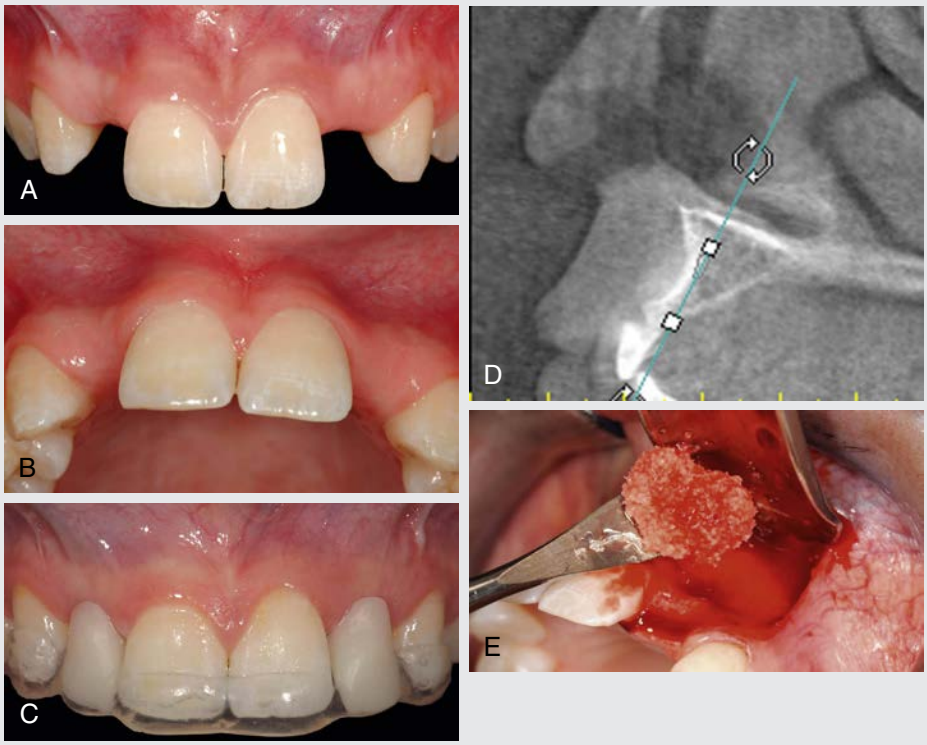

• **Figure 31-19** **A,** Missing lateral incisors with ridge width defect. **B,** Missing lateral incisors with ridge width defect. **C,** Essix splint used as a temporary restoration and to determine where additional augmentation is necessary. **D,** CBCT using the radio-opaque Essix splint to evaluate bone for implant placement. **E,** Placement of particulate bone allograft to occupy the defect volume.

Continued

CASE STUDY 31-3—cont'd

Implant Site Development With GBR

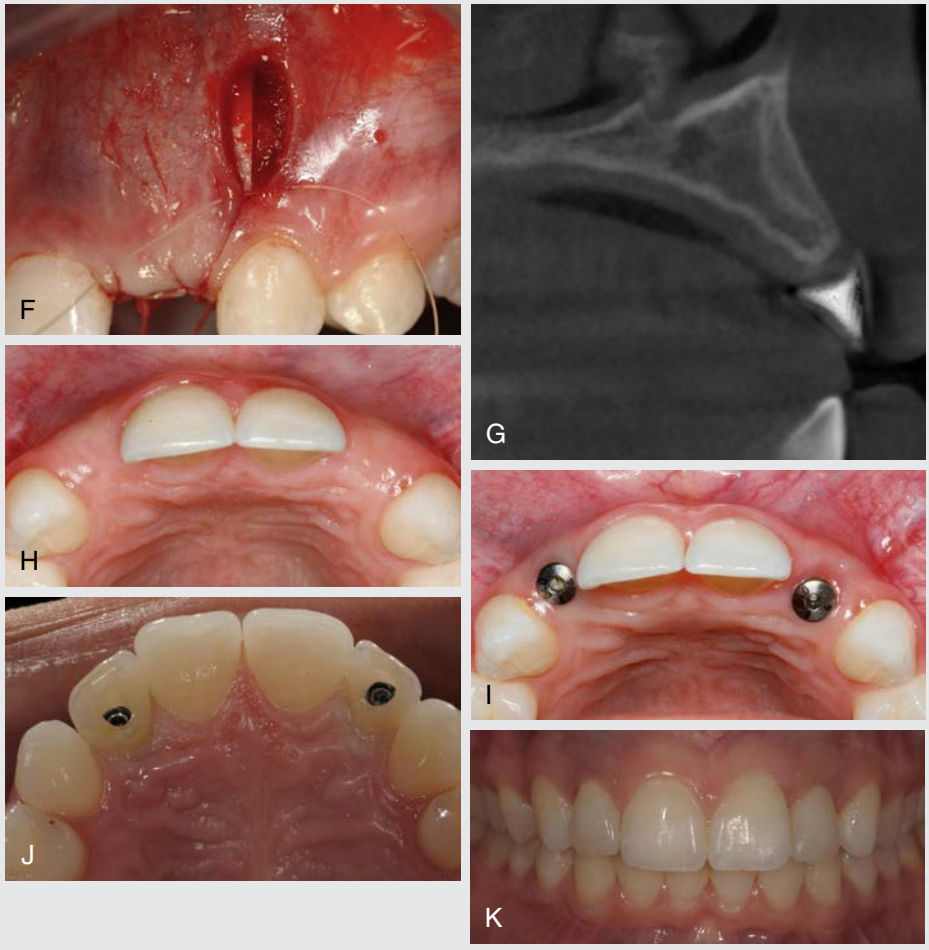

Figure 31-19, cont'd F, A resorbable collagen barrier was placed, followed by closure in a tension-free manner. **G,** Augmented bone volume evident on CBCT. **H,** Restored alveolar dimensions following healing. **I-J,** Ideal implant placement is possible due to the restored alveolar dimensions. **K,** Esthetic, natural appearing final restoration. (From Le B, Nielsen B: Esthetic implant site development. *Oral Maxillofac Surg Clin North Am* 27(2):283-311, 2015.)

CASE STUDY 31-4

Implant Placement With Simultaneous GBR

A 32-year-old male presented missing tooth #30 with obvious collapse of the alveolar width (see Figure 31-14, *A*). Open-book flap design was used to expose the edentulous site and allowed for implant placement. Due to ridge resorption, implant placement resulted in a small bony dehiscence defect on the buccal (see Figure 31-14, *B*). The implant achieved primary stability and a healing abutment was attached.

Treatment of the dehiscence defect was performed using particulate allograft bone substitute and placement of a resorbable collagen barrier membrane (see Figure 31-14, *C*). Closure was obtained around the healing abutment (see Figure 31-14, *D*). Following a healing stage, the implant was restored and provided a natural appearing, esthetic outcome (see Figure 31-14, *E*).

CASE STUDY 31-5

Immediate Implant Placement With Simultaneous GBR

A 26-year-old male presented with a fractured tooth #8 requiring extraction. An open-book flap design was used sparing the mesial papilla of tooth #7 and placing a distal vertical releasing incision. Anterior extension was performed with a sulcular incision at tooth #9. Following an atraumatic extraction and implant placement, a defect of the labial plate was observed (Figure 31-20, *A*). Due to the small nature of the defect and primary implant stability, a healing abutment was attached and the defect was treated with GBR (see Figure 31-20, *B*). Tension-free soft tissue closure was achieved around the healing abutment (see Figure 31-20, *C*). The implant was later definitively restored and provided a very natural appearing, esthetic outcome (see Figure 31-20, *D*).

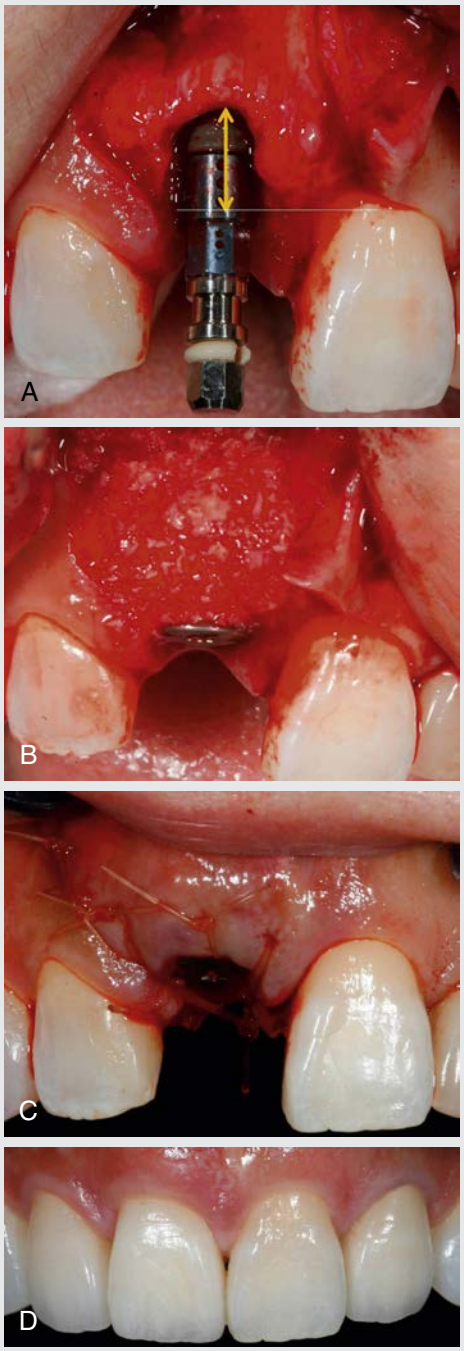

• **Figure 31-20** **A,** Dehiscence defect during immediate implant placement following tooth extraction. **B,** Simultaneous treatment of the defect using GBR. **C,** Soft tissue closure around the healing abutment. **D,** Final restoration with natural appearing alveolar contours. (From Le B, Nielsen B: Esthetic implant site development. *Oral Maxillofac Surg Clin North Am* 27(2):283-311, 2015.)

CASE STUDY 31-6

Socket Augmentation With GBR

A 19-year-old male presents with ankylosed tooth #8. Severe gingival margin discrepancy is noted between teeth # 8 and # 9. There is also a lack of labial keratinized mucosa on tooth # 8. The treatment plan involved orthodontic treatment to correct cross-bite and improve arch space. Forced orthodontic eruption was also attempted but failed to bring down tooth #8. Extraction of tooth # 8 with socket augmentation using GBR was performed with an "open book" flap design with intentional exposure to allow for healing by secondary intention.

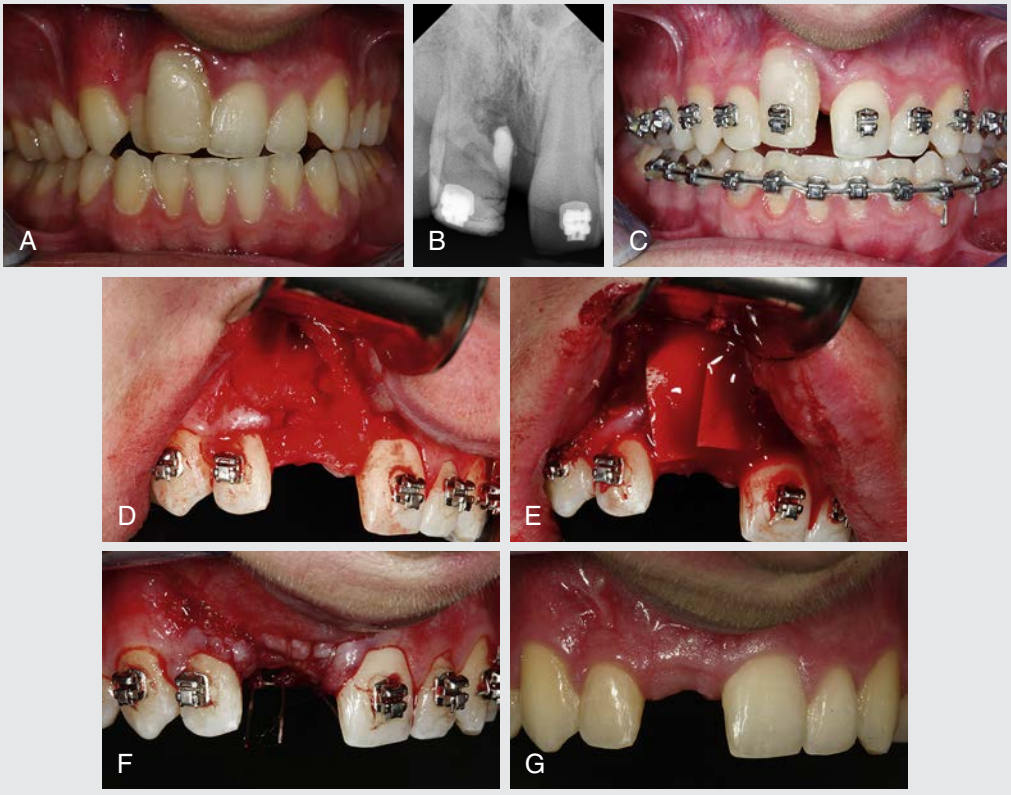

• **Figure 31-21** **A,** Ankylosed tooth # 8 with severe gingival margin discrepancy with contralateral central incisor and a lack of labial keratinized mucosa. **B,** Radiograph showing ankylosed tooth # 8. **C,** Clinical situation after orthodontic treatment with unsuccessful forced orthodontic eruption of tooth #8. **D,** Extraction of tooth #8 with "open book" flap design. **E,** Particulate allograft is placed into defect and covered with a resorbable collagen membrane. **F,** Coronal advancement flap with intentional slight exposure of collagen membrane at alveolar crest to allow for healing by secondary intention. **G,** Healing 1 year after treatment showing favorable gingival marginal level with increase in keratinized tissue. (Courtesy Bach Le, DDS, MD Los Angeles, CA.)

CASE STUDY 31-7

Vertical Augmentation With GBR

A 41-year-old male presented following traumatic loss of teeth #8 and #9 (Figure 31-22, *A*). A significant alveolar hard and soft tissue deformity was present. An open-book flap design was used to expose the alveolus (see Figure 31-22, *B*). Significant vertical defects were present. The site was treated with GBR using particulate allograft bone substitute for space maintenance (see Figure 31-22, *C*). A resorbable collagen membrane was applied to isolate the defect site for GBR. Following 6 months of healing, clinical exam revealed a significantly improved alveolar architecture (see Figure 31-22, *D*). Following implant placement, a natural appearing esthetic outcome was eventually achieved with the final restorations (see Figure 31-22, *E*).

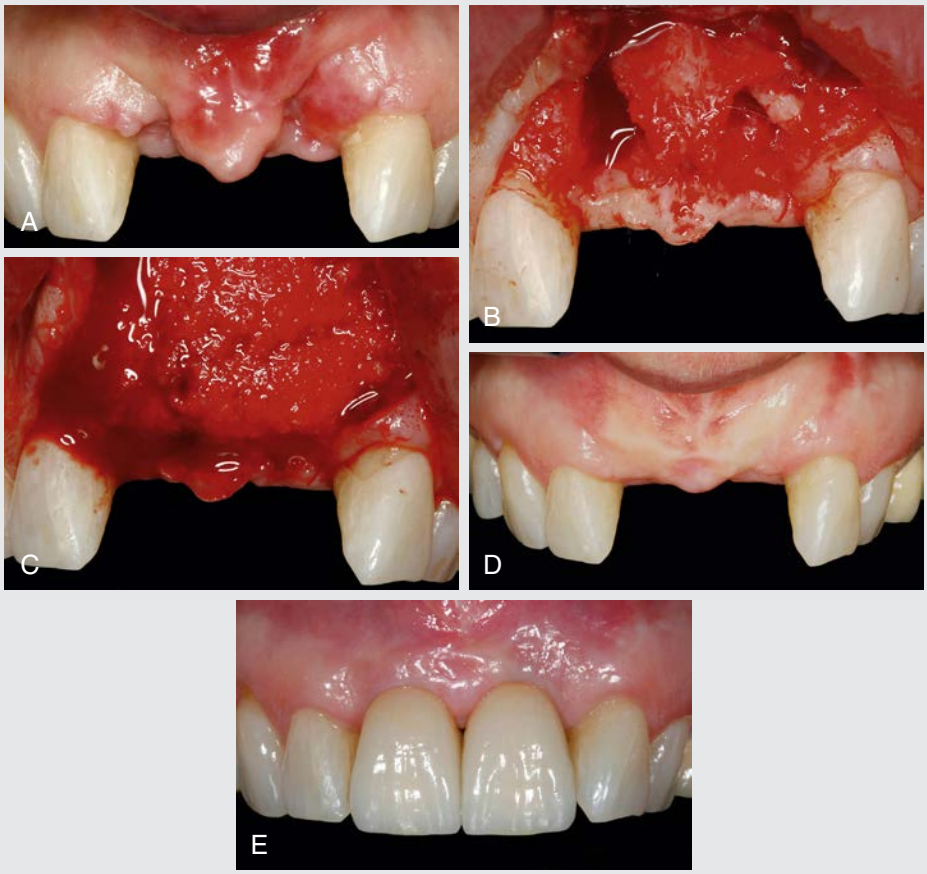

• **Figure 31-22** **A,** Significant alveolar defect following traumatic tooth loss. **B,** Open-book flap design used to expose the deficient alveolus. **C,** Placement of particulate allograft to occupy the augmented volume. **D,** After 6 months of healing the reconstructed alveolus is ready for implant placement. **E,** Esthetic final result due to the restored alveolar dimensions. (From Le B, Nielsen B: Esthetic implant site development. *Oral Maxillofac Surg Clin North Am* 27(2):283-311, 2015.)

CASE REPORT 31-8

Vertical and Horizontal Augmentation With GBR

A 36-year-old female presented following the loss of teeth #5, #6, and #7 due to pathology. A significant horizontal and vertical defect is clinically evident (Figure 31-23, *A* and *B*). The site was treated with GBR utilizing tenting screws as an additional support mechanism (see Figure 31-23, *C*). Particulate allograft bone substitute was packed into the defect site for space maintenance (see Figure 31-23, *D*). A resorbable membrane was then applied to compartmentalize the defect site (see Figure 31-23, *E*). Six months following treatment with GBR a significant improvement in alveolar dimensions was seen, making implant placement possible (see Figure 31-23, *F*).

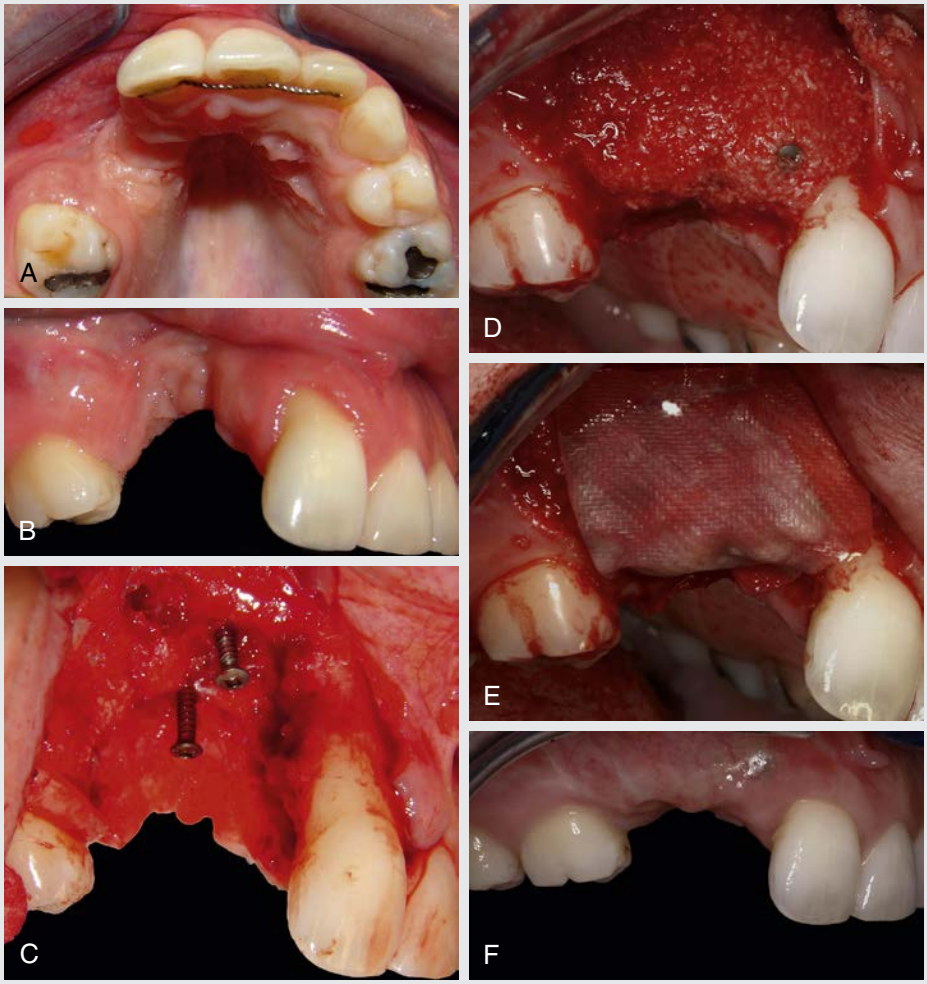

• **Figure 31-23** **A,** Significant vertical and horizontal defect. **B,** Significant vertical and horizontal defect. **C,** Tenting screws placed to support the augmented volume. **D,** Space maintenance achieved with tenting screws and particulate allograft. **E,** Resorbable barrier membrane used to compartmentalize the defect. **F,** After healing, the restored alveolar dimensions allow for implant placement. (From Le B, Nielsen B: Esthetic implant site development. *Oral Maxillofac Surg Clin North Am* 27(2):283-311, 2015.)

CASE STUDY 31-9

Severe Vertical Defect in the Anterior Maxilla Treated With Staged Surgical Approaches

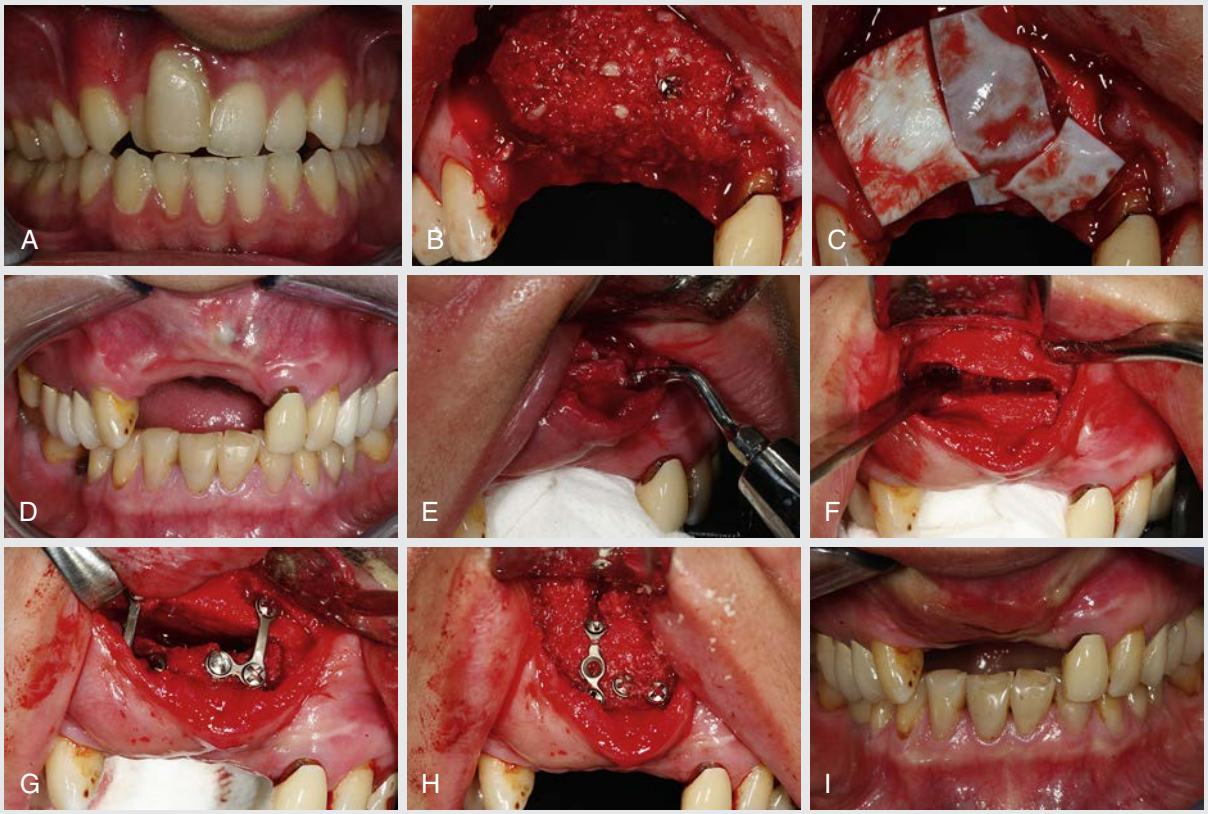

• **Figure 31-24** **A,** A severe, multiple-teeth span vertical defect will require a staged reconstruction. **B,** Initial staged GBR using the screw tent-pole technique to develop adequate horizontal width. **C,** The defect site filled with particulate allograft is isolated using a resorbable collagen barrier membrane. **D,** After 4 months of healing following the initial GBR, ridge width is improved but ridge height is still deficient. **E,** Second-stage surgery performed as an osteotomy and down-graft to restore ridge height. **F,** Down-grafting of the segment with an osteotomy. **G,** Segment stabilized with plates. **H,** Mineralized particulate allograft placed between osteotomy defect and covered with a collagen membrane. **I,** Healing after 4 months.

Continued

CASE STUDY 31-9—cont'd

Severe Vertical Defect in the Anterior Maxilla Treated With Staged Surgical Approaches

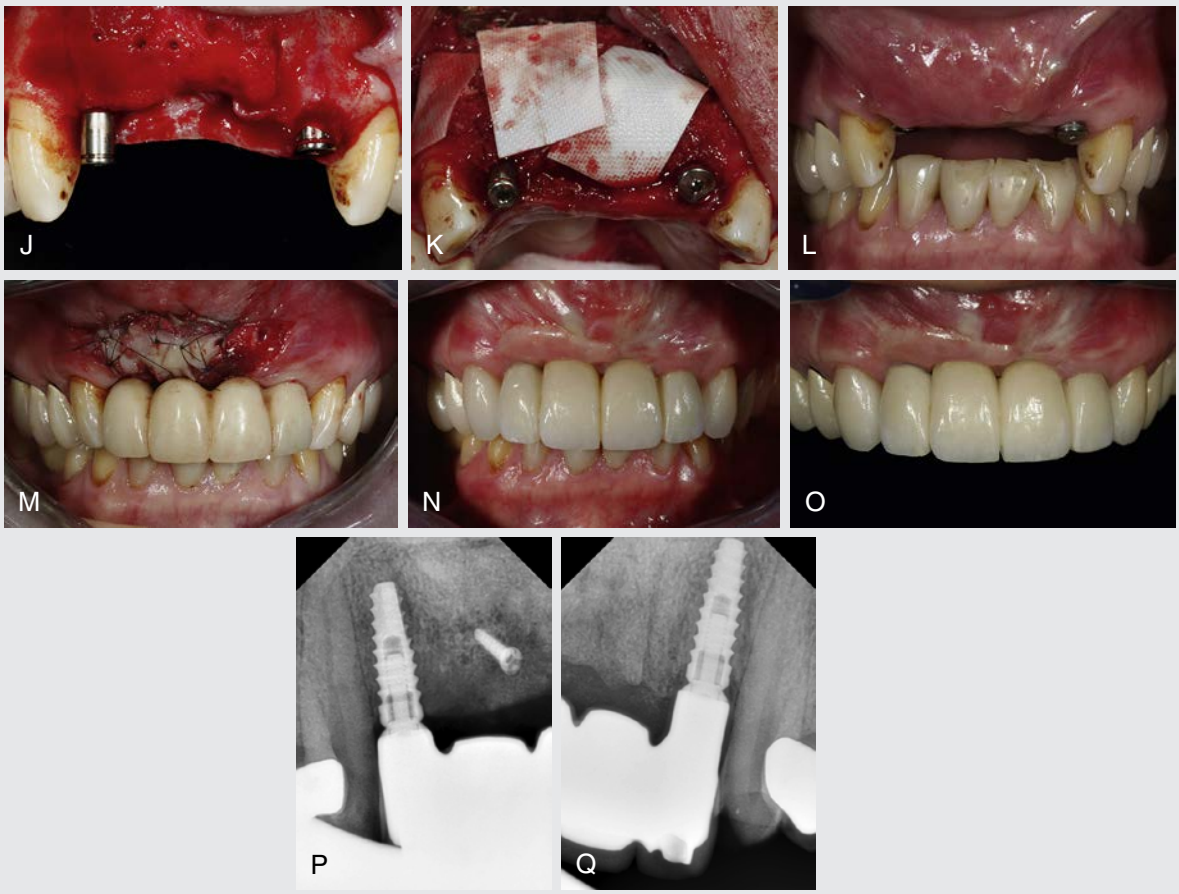

• **Figure 31-24, cont'd J-K,** Implants placed at site # 7 and # 10 with "esthetic contour grafting" protocol (non-submerged grafting). **L,** Healing after 2 months showing a lack of attached tissue and vestibular depth. **M,** Vestibuloplasty with free gingival graft from palate to increase the zone of attached tissue. **N,** Final restorations delivered at 1 year. **O,** 3 years follow-up. **P-Q,** Radiograph at 3 years follow-up. (From Le B, Nielsen B: Esthetic implant site development. *Oral Maxillofac Surg Clin North Am* 27(2):283-311, 2015.).

Summary

Since its origin in the early 1940s, guided tissue regeneration has evolved to become a predictable regenerative option and a critical technique in the field of implant dentistry. Compartmentalization to allow regeneration of a select tissue type is its guiding principle. A variety of techniques and materials exist, each with its advantages and disadvantages. The many applications for GBR in implant dentistry make possible the esthetic, natural appearing outcomes in implant dentistry.

References

1. Weiss PA, Taylor AC: The technology of nerve regeneration. A review. Sutureless tubulation and related methods of nerve repair, *J Neurosurg* 1:400–450, 1944.
2. Murray G, Holden R, Roachlau W: Experimental and clinical study of new growth of bone in a cavity, *Am J Surg* 93:385–387, 1957.
3. Hurley L, Stinchfield F, Bassett A, Lyon W: The role of soft tissues in osteogenesis. An experimental study of canine spinal fusions, *J Bone Joint Surg* 41(A):1243–1254, 1959.
4. Sesma N, Pannuti C, Cardaropoli G: Retrospective clinical study of 988 dual acid-etched implants placed in grafted and native bone for single-tooth replacement, *Int J Oral Maxillofac Implants* 27:1243–1248, 2012.

5. Saravanan P, Ramakrishnan T, Ambalavanan N, et al.: Efficacy of guided bone regeneration using composite bone graft and resorbable collagen membrane in Seibert's Class I ridge defects: radiological evaluation, *J Oral Implantol* 39(4):455–462, 2013.
6. Boyne P: Regeneration of alveolar bone beneath cellulose acetate filter implants, *J Dent Res* 43:827, 1964.
7. Boyne P: Osseous grafts and implants in the restoration of large oral defects, *J Periodontol* 45(5):378–384, 1974.
8. Kahnberg K: Restoration of mandibular jaw defects in the rabbit by subperiosteally implanted Teflon mantle leaf, *Int J Oral Surg* 8:449–456, 1979.
9. Linghorne W, O'Connell D: Studies in the regeneration and reattachment of supporting structures of the teeth. I. Soft tissue attachment, *J Dent Res* 29(4):419–428, 1950.
10. Melcher A: On the repair potential of periodontal tissues, *J Periodontol* 47:256–260, 1976.
11. Karring T, Nyman S, Lindhe J: Healing following implantation of periodontitis affected roots into bone tissue, *J Clin Periodontol* 7:96–105, 1980.
12. Nyman S, Karring T, Lindhe J, Planten S: Healing following implantation of periodontitis affected roots into gingival connective tissue, *J Clin Periodontol* 7:394–401, 1980.
13. Gottlow J, Nyman S, Karring T, Lindhe J: New attachment formation as the result of controlled tissue regeneration, *J Clin Periodontol* 11:494–503, 1984.
14. Gottlow J, Nyman S, Lindhe J, et al.: New attachment formation in the human periodontium by guided tissue regeneration. Case reports, *J Clin Periodontol* 13:604–616, 1986.
15. Nyman S: Bone regeneration using the principle of guided tissue regeneration, *J Clin Periodontol* 18:494–498, 1991.
16. Hammerle C, Jung R: Bone augmentation by means of barrier membranes, *Periodontol* 33:36–53, 2003.
17. Becker W, Becker B, Handlesman M, et al.: Bone formation at dehisced dental implant sites treated with implant augmentation material: a pilot study in dogs, *Int J Periodontics Restorative Dent* 10:93–101, 1990.
18. Seibert J, Nyman S: Localized ridge augmentation in dogs: a pilot study using membranes and hydroxyapatite, *J Periodontol* 61:157–165, 1990.
19. Hammerle C, Jung R, Feloutzis A: A systematic review of the survival of implants in bone sites augmented with barrier membranes (guided bone regeneration) in partially edentulous patients, *J Clin Periodontol* 29(Suppl. 3):226–231, 2002.
20. Belser U, Schmid B, Higginbottom F, Buser D: Outcome analysis of implant restorations located in the anterior maxilla: a review of the recent literature, *Int J Oral Maxillofac Implants* 19(Suppl):30–42, 2004.
21. Louis P: Vertical ridge augmentation using titanium mesh, *Oral Maxillofac Surg Clin North Am* 22(3):353–368, 2010.
22. Le B, Rohrer M, Prassad H: Screw "tent-pole" grafting technique for reconstruction of large vertical alveolar ridge defects using human mineralized allograft for implant site preparation, *J Oral Maxillofac Surg* 68(2):428–435, 2010.
23. Le B, Nielsen B: Esthetic implant site development, *Oral Maxillofac Surg Clin North Am* 27(2):283–311, 2015.
24. Oh K, Cha J, Kim C, et al.: The influence of perforating the autogenous block bone and the recipient bed in dogs. Part I: a radiographic analysis, *Clin Oral Implants Res* 22:1298–1302, 2011.
25. Greenstein G, Greenstein B, Cavallaro J, Tarnow D: The role of bone decortication in enhancing the results of guided bone regeneration: a literature review, *J Periodontol* 80:175–189, 2009.
26. Bartee B, Lignelli II J: Guided tissue regeneration in implant dentistry: techniques for management of localized bone defects. In ed 2, Fonseca R, editor: *Oral and maxillofacial surgery*, vol. 1. St Louis, 2008, Elsevier.
27. Triplett R: Guided tissue regeneration. In Assael L, Misiek D, editors: *Atlas of the oral and maxillofacial surgery clinics of North America. Anatomic problems in implant surgery*, Philadelphia, 1994, Saunders.
28. Banche G, Roana J, Mandras N, et al.: Microbial adherence on various intraoral suture materials in patients undergoing dental surgery, *J Oral Maxillofac Surg* 65(8):1503–1507, 2007.
29. Barone A, Ricci M, Romanos G, et al.: Buccal bone deficiency in fresh extraction sockets: a prospective single cohort study, *Clin Oral Implants Res* 26(7):823–830, 2015.
30. El Helow K, El Askary Ael S: Regenerative barriers in immediate implant placement: a literature review, *Implant Dent* 17:360–371, 2008.
31. Kalfas I: Principles of bone healing, *Neurosurg Focus* 10(4):1–4, 2001.
32. Buser D, Ingimarsson S, Dula K, et al.: Long-term stability of osseointegrated implants in augmented bone: a 5-year prospective study in partially edentulous patients, *Int J Periodontics Restorative Dent* 22:109–117, 2002.
33. Benic G, Hammerle C: Horizontal bone augmentation by means of guided bone regeneration, *Periodontol 2000* 66(1):13–40, 2014.
34. Waasdorp J, Feldman S: Bone regeneration around immediate implants utilizing a dense polytetrafluoroethylene membrane without primary closure: a report of 3 cases, *J Oral Implantol* 39:355–361, 2013.
35. Machtei E: The effect of membrane exposure on the outcome of regenerative procedures in humans: a meta-analysis, *J Periodontol* 72(4):512–516, 2001.
36. Chiapasco M, Zaniboni M: Clinical outcomes of GBR procedures to correct peri-implant dehiscences and fenestrations: a systematic review, *Clin Oral Implants Res* 20:113–123, 2009.
37. Barber H, Lignelli J, Smith B, Bartee B: Using a dense PTFE membrane without primary closure to achieve bone and tissue regeneration, *J Oral Maxillofac Surg* 65:748–752, 2007.
38. Friedmann A, Strietzel F, Maretzki B, et al.: Observations on a new collagen barrier membrane in 16 consecutively treated patients. Clinical and histological findings, *J Periodontol* 72:1616–1623, 2001.
39. Simion M, Trisi P, Maglione M, Piattelli A: A preliminary report on a method for studying the permeability of expanded polytetrafluoroethylene membrane to bacteria in vitro: a scanning electron microscopic and histological study, *J Periodontol* 65:755–761, 1994.
40. Tempro P, Nalbandian J: Colonization of retrieved polytetrafluoroethylene membranes: morphological and microbiological observations, *J Periodontol* 64:162–168, 1993.
41. Gotfredsen K, Nimb L, Buser D, Hjorting-Hansen E: Evaluation of guided bone generation around implants placed into fresh extraction sockets: an experimental study in dogs, *J Oral Maxillofac Surg* 51:879–884, 1993.
42. Hammerle C, Bragger U, Schmid B, Lang N: Successful bone formation at immediate transmucosal implants: a clinical report, *Int J Oral Maxillofac Implants* 13:522–530, 1998.
43. Moses O, Pitaru S, Artzi Z, Nemcovsky C: Healing of dehiscence-type defects in implants placed together with different barrier membranes: a comparative clinical study, *Clin Oral Implants Res* 16:210–219, 2005.

44. Schwarz F, Rothamel D, Herten M, et al.: Immunohistochemical characterization of guided bone regeneration at a dehiscence-type defect using different barrier membranes: an experimental study in dogs, *Clin Oral Implants Res* 19:402–415, 2008.
45. Simion M, Baldoni M, Rossi P, Zaffe D: A comparative study of the effectiveness of e-PTFE membranes with and without early exposure during the healing period, *Int J Periodontics Restorative Dent* 14:166–180, 1994.
46. Zitzmann N, Naef R, Scharer P: Resorbable versus nonresorbable membranes in combination with Bio-Oss for guided bone regeneration, *Int J Oral Maxillofac Implants* 12:844–852, 1997.
47. Le B, Borzabadi-Farahani A, Nielsen B, Management of the ailing implant: an innovative technique for the treatment of labial gingival recession around dental implants: *Dental Implant Abstract/How I Do It Session*, Honolulu, HI, 2014, AAOMS 96th Annual Meeting.

47a. Le B, Borzabadi-Farahani A: Treatment of labial mucosal recession around maxillary anterior implants with tenting screws, particulate allograft and xenogenic membrane: a case report, *J Oral Implantol* 42(5):427–431, 2016.

47b. Le B, Borzabadi-Farahani A, Nielsen B: Treatment of labial soft tissue recession around dental implants in the esthetic zone using guided bone regeneration with mineralized allograft: a retrospective clinical case series, *J Oral and Maxillofac Surg* 74(8):1552–1561, 2016.

48. Owens K, Yukna R: Collagen membrane resorption in dogs: a comparative study, *Implant Dent* 10:49–58, 2001.
49. Rothamel D, Schwarz F, Fienitz T, et al.: Biocompatibility and biodegradation of a native porcine pericardium membrane: results of in vitro and in vivo examinations, *Int J Oral Maxillofac Implants* 27:146–154, 2012.
50. Rothamel D, Schwarz F, Sager M, et al.: Biodegradation of differently cross-linked collagen membranes: an experimental study in the rat, *Clin Oral Implants Res* 16:369–378, 2005.
51. Friedmann A, Strietzel F, Maretzki B, et al.: Histological assessment of augmented jaw bone utilizing a new collagen barrier membrane compared to a standard barrier membrane to protect a granular bone substitute material, *Clin Oral Implants Res* 13:587–594, 2002.
52. Aliyev E, Sakallioglu U, Eren Z, Acikgoz G: The effect of polylactide membranes on the levels of reactive oxygen species in periodontal flaps during wound healing, *Biomaterials* 24:4633–4637, 2004.
53. Agrawal C, Athanasiou K: Technique to control pH in vicinity of biodegrading PLA-PGA implants, *J Biomed Materials Res* 38(2):105–114, 1997.
54. Mayfield L, Nobreus N, Attstrom R, Linde A: Guided bone regeneration in dental implant treatment using a bioabsorbable membrane, *Clin Oral Implants Res* 8:10–17, 1997.
55. Simion M, Misitano U, Gionso L, Salvato A: Treatment of dehiscences and fenestrations around dental implants using resorbable and nonresorbable membranes associated with bone autografts: a comparative clinical study, *Int J Oral Maxillofac Implants* 12:159–167, 1997.
56. von Arx T, Broggini N, Jensen S, et al.: Membrane durability and tissue response of different bioresorbable barrier membranes: a histologic study in the rabbit calvarium, *Int J Oral Maxillofac Implants* 20:843–853, 2005.
57. von Arx T, Cochran D, Schenk R, Buser D: Evaluation of a prototype trilayer membrane (PTLM) for lateral ridge augmentation: an experimental study in the canine mandible, *Int J Oral Maxillofac Surg* 31:190–199, 2002.
58. Lorenzoni M, Pertl C, Keil C, Wegscheider W: Treatment of peri-implant defects with guided bone regeneration: a comparative clinical study with various membranes and bone grafts, *Int J Oral Maxillofac Implants* 13:639–646, 1998.
59. Schneider D, Weber F, Grunder U, et al.: A randomized controlled clinical multicenter trial comparing the clinical and histological performance of a new, modified polylactide-co-glycolide acid membrane to an expanded polytetrafluorethylene membrane in guided bone regeneration procedures, *Clin Oral Implants Res* 25:150–158, 2014.
60. Jung R, Kokovic V, Jurisic M, et al.: Guided bone regeneration with a synthetic biodegradable membrane: a comparative study in dogs, *Clin Oral Implants Res* 22:802–807, 2011.
61. Herten M, Jung R, Ferrari D, et al.: Biodegradation of different synthetic hydrogels made of polyethylene glycol hydrogel/RGD-peptide modifications: an immunohistochemical study in rats, *Clin Oral Implants Res* 20:116–125, 2009.
62. Wechsler S, Fehr D, Molenberg A, et al.: A novel, tissue occlusive poly(ethylene glycol) hydrogel material, *J Biomed Mater Res A* 85:285–292, 2008.
63. Jung R, Halg G, Thoma D, Hammerle C: A randomized, controlled clinical trial to evaluate a new membrane for guided bone regeneration around dental implants, *Clin Oral Implants Res* 20:162–168, 2009.
64. Jung R, Zwahlen R, Weber F, et al.: Evaluation of an in situ formed synthetic hydrogel as a biodegradable membrane for guided bone regeneration, *Clin Oral Implants Res* 17:426–433, 2006.
65. Thoma D, Halg G, Dard M, et al.: Evaluation of a new biodegradable membrane to prevent gingival ingrowth into mandibular bone defects in minipigs, *Clin Oral Implants Res* 20:7–16, 2009.
66. Jensen S, Terheyden H: Bone augmentation procedures in localized defects in the alveolar ridge: clinical results with different bone grafts and bone-substitute materials, *Int J Oral Maxillofac Implants* 24:218–236, 2009.
67. Fugazzotto P: GBR using bovine bone matrix and resorbable and nonresorbable membranes. Part 1: histologic results, *Int J Periodontics Restorative Dent* 23:361–369, 2003.
68. Fugazzotto PA: GBR using bovine bone matrix and resorbable and nonresorbable membranes. Part 2: clinical results, *Int J Periodontics Restorative Dent* 23:599–605, 2003.
69. Jensen S, Aaboe M, Pinholt E, et al.: Tissue reaction and material characteristics of four bone substitutes, *Int J Oral Maxillofac Implants* 11:55–66, 1996.
70. Cordaro L, Torsello F, Miuccio M, et al.: Mandibular bone harvesting for alveolar reconstruction and implant placement: subjective and objective cross-sectional evaluation of donor and recipient site up to 4 years, *Clin Oral Implants Res* 22:1320–1326, 2011.
71. Nkenke E, Schultze-Mosgau S, Radespiel-Troger M, et al.: Morbidity of harvesting of chin grafts: a prospective study, *Clin Oral Implants Res* 12:495–502, 2001.
72. Schlegel K, Fichtner G, Schultze-Mosgau S, Wiltfang J: Histologic findings in sinus augmentation with autogenous bone chips versus a bovine bone substitute, *Int J Oral Maxillofac Implants* 18:53–58, 2003.
73. Gielkens P, Bos R, Raghoebar G, Stegenga B: Is there evidence that barrier membranes prevent bone resorption in autologous bone grafts during the healing period? A systematic review, *Int J Oral Maxillofac Implants* 22:390–398, 2007.

74. Proussaefs P, Lozada J: The use of resorbable collagen membrane in conjunction with autogenous bone graft and inorganic bovine bone mineral for buccal/labial alveolar ridge augmentation: a pilot study, *J Prosthet Dent* 90(6):530–538, 2003.
75. von Arx T, Buser D: Horizontal ridge augmentation using autogenous block grafts and the guided bone regeneration technique with collagen membranes: a clinical study with 42 patients, *Clin Oral Implants Res* 17(4):359–366, 2006.
76. Jensen S, Bornstein M, Dard M, et al.: Comparative study of biphasic calcium phosphates with different HA/TCP ratios in mandibular bone defects. A long-term histomorphometric study in minipigs, *J Biomed Mater Res B Appl Biomater* 90:171–181, 2009.
77. Jensen S, Broggini N, Hjorting-Hansen E, et al.: Bone healing and graft resorption of autograft, anorganic bovine bone and beta-tricalcium phosphate. A histologic and histomorphometric study in the mandibles of minipigs, *J Biomed Mater Res B Appl Biomater* 90:171–181, 2009.
78. Mordenfeld A, Hallman M, Johansson CB, Albrektsson T: Histological and histomorphometrical analyses of biopsies harvested 11 years after maxillary sinus floor augmentation with deproteinized bovine and autogenous bone, *Clin Oral Implants Res* 21:961–970, 2010.
79. Fugazzotto P: Success and failure rates of osseointegrated implants in function in regenerated bone for 6 to 51 months: a preliminary report, *Int J Oral Maxillofac Implants* 12:17–24, 1997.
80. Park S, Lee K, Oh T, et al.: Effect of absorbable membranes on sandwich bone augmentation, *Clin Oral Implants Res* 19:32–41, 2008.
81. Keith Jr J, Petrungaro P, Leonetti J, et al.: Clinical and histologic evaluation of a mineralized block allograft: results from the developmental period (2001-2004), *Int J Periodontics Restorative Dent* 26:321–327, 2006.
82. Nissan J, Ghelfan O, Mardinger O, et al.: Efficacy of cancellous block allograft augmentation prior to implant placement in the posterior atrophic mandible, *Clin Implant Dent Relat Res* 13:279–285, 2011.
83. Barrere F, van Blitterswijk C, de Groot K: Bone regeneration: molecular and cellular interactions with calcium phosphate ceramics, *Int J Nanomedicine* 1:317–332, 2006.
84. Daculsi G, Laboux O, Malard O, Weiss P: Current state of the art of biphasic calcium phosphate bioceramics, *J Mater Sci Mater Med* 14:195–200, 2003.
85. Artzi Z, Weinreb M, Givol N, et al.: Biomaterial resorption rate and healing site morphology of inorganic bovine bone and beta-tricalcium phosphate in the canine: a 24-month longitudinal histologic study and morphometric analysis, *Int J Oral Maxillofac Implants* 19:357–368, 2004.
86. Cordaro L, Bosshardt D, Palattella P, et al.: Maxillary sinus grafting with Bio-Oss or Straumann Bone Ceramic: histomorphometric results from a randomized controlled multicenter clinical trial, *Clin Oral Implants Res* 19:796–803, 2008.
87. Froum S, Wallace S, Cho S, et al.: Histomorphometric comparison of a biphasic bone ceramic to anorganic bovine bone for sinus augmentation: 6- to 8-month postsurgical assessment of vital bone formation. A pilot study, *Int J Periodontics Restorative Dent* 28:273–281, 2008.
88. Mardas N, Chadha V, Donos N: Alveolar ridge preservation with guided bone regeneration and a synthetic bone substitute or a bovine-derived xenograft: a randomized, controlled clinical trial, *Clin Oral Implants Res* 21:688–698, 2010.
89. Van Assche N, Michels S, Naert I, Quirynen M: Randomized controlled clinical trial to compare two bone substitutes in the treatment of bony dehiscences, *Clin Implant Dent Relat Res* 15:558–568, 2013.
90. Marx R, Shellenberger T, Wimsatt J, Correa P: Severely resorbed mandible: predictable reconstruction with soft tissue matrix expansion (tent pole) grafts, *J Oral Maxillofac Surg* 60(8):878–888, 2002.
91. Louis P, Gutta R, Saidalnaief N, Bartolucci A: Reconstruction of the maxilla and mandible with particulate bone graft and titanium mesh for implant placement, *J Oral Maxillofac Surg* 66:235–245, 2008.
92. Schropp L, et al.: Bone healing and soft tissue contour changes following single-tooth extraction: a clinical and radiographic 12-month prospective study, *Int J Perio Rest Dent* 23:313–323, 2003.
93. Fugazzotto P: Report of 302 consecutive ridge augmentation procedures: technical considerations and clinical results, *Int J Oral Maxillofac Implants* 13:358–368, 1998.
94. Block M, Degen M: Horizontal ridge augmentation using human mineralized particulate bone: preliminary results, *J Oral Maxillofac Surg* 62:67–72, 2004.
95. Le B, Burstein J: Esthetic grafting for small volume hard and soft tissue contour defects for implant site development, *Implant Dent* 17:136–141, 2008.
96. Frost H: The regional acceleratory phenomenon: a review, *Henry Ford Hosp Med J* 31:3–9, 1983.
97. Le B, Borzabadi-Farahani A: Simultaneous implant placement & bone grafting with particulate mineralized allograft in sites with buccal wall defects: a 3-year follow-up & review of literature, *J Cranio Maxillofac Surg* 42(5):552–559, 2014.
98. Palacci P, et al.: *Optimal implant positioning and soft tissue management for the Branemark system*, Chicago, 1995, Quintessence, pp 59–70.
99. Jensen S, Bosshardt D, Gruber R, Buser D: Long-term stability of contour augmentation in the esthetic zone. Histologic and histomorphometric evaluation of 12 human biopsies 14 to 80 months after augmentation, *J Periodontol* 10:1–15, 2014.
100. Amler M: The sequence of tissue regeneration in human extraction wounds, *Oral Surg Oral Med Oral Path* 27:309–318, 1969.
101. Amler M: Age factor in human alveolar bone repair, *J Oral Implantol* 19:138–142, 1993.
102. Wang H, Tsao Y: Histologic evaluation of socket augmentation with mineralized human allograft, *Int J Periodontics Restorative Dent* 28:231–237, 2008.
103. Minichetti J, D'Amore J, Hong A, Cleveland D: Human histologic analysis of mineralized bone allograft (Puros) placement before implant surgery, *J Oral Implantol* 30:74–82, 2004.
104. Simion M, Scarano A, Gionso L, Piattelli A: Guided bone regeneration using resorbable and nonresorbable membranes: a comparative histologic study in humans, *Int J Oral Maxillofac Implants* 11:735–742, 1996.
105. Covani U, et al.: Bucco-lingual crestal bone changes after immediate and delayed implant placement, *J Periodontol* 75(12):1605–1612, 2004.
106. Lekovic V, et al.: A bone regenerative approach to alveolar ridge maintenance following tooth extraction. Report of 10 cases, *J Periodontol* 68:563–570, 1997.
107. Lekovic V, et al.: Preservation of alveolar bone in extraction sockets using bioabsorbable membranes, *J Periodontol* 69:1044–1049, 1998.

108. Iasella J, Greenwell H, Miller R, et al.: Ridge preservation with freeze-dried bone allograft and a collagen membrane compared to extraction alone for implant site development: a clinical and histologic study in humans, *J Periodontol* 74:990–999, 2003.

109. Dahlin C, Lekholm U, Becker W, et al.: Treatment of fenestration and dehiscence bone defects around oral implants using the guided tissue regeneration technique: a prospective multicenter study, *Int J Oral Maxillofac Implants* 10:312–318, 1995.

32

Contemporary Sinus-Lift Subantral Surgery and Graft

BACH LE, FELIX KYLE YIP

Introduction

The atrophic, edentulous posterior maxilla is a frequent problem encountered in the modern dental implant era. Decreased vertical bone height as a result of tooth loss, aging, and pneumatization of the sinus result in alveolar bone height as low as 1 to 2 mm, precluding the successful placement of dental implants.[1,2] In order to address this limitation, several approaches have been described to increase the height of the alveolar ridge by augmentation of the maxillary sinus: lateral window, vertical or transcrestal, or Le Fort I approaches.[1-5] Most thin sinus floors can be augmented using the lateral or transcrestal approach.

Biologic and Anatomic Considerations

Morphology

The paired maxillary sinus, the antrum of Highmore, is the largest of the paranasal sinuses. It is located just lateral to the nasal cavity, inferior to the orbit, and extends into the zygomatic process[6] (Figure 32-1). The cavity is lined with pseudostratified columnar ciliated epithelium, as is the remainder of the respiratory tract, and is known as the Schneiderian membrane, named after a German anatomist of the 17th century.[7] It has an average thickness of 0.8 mm.[8] The sinus undergoes pneumatization throughout childhood and reaches a level parallel to the nasal floor by age 12 to 13.[9,10] Complete eruption of the maxillary molars marks the end of vertical growth of the sinus. Pneumatization is then complete by age 20 and is on average 5 mm inferior to the nasal floor.[10,11] The sinus typically extends from the canine fossa to the tuberosity. The average dimensions of the adult sinus are 2.5 to 3.5 cm wide, 3.6 to 4.5 cm tall, and 3.8 to 4.5 cm deep, with an estimated volume of approximately 12 to 15 cubic centimeters[6,12,13] and the shape of a quadrilateral pyramid.[8] A more acute angle formed by the lateral and medial sinus walls, often seen in the premolar region, can influence the risk of perforation during elevation of the Schneiderian membrane.[8,14,15] Cho and colleagues found a 28.6% to 37.5% perforation rate with angles of 60 degrees or less, and a 0% perforation rate with angles greater than 61 degrees.[14] The sinus drains into the middle meatus of the nasal cavity via the maxillary sinus ostium, which is located on the posterior-superior aspect of the medial wall and is approximately 2.4 mm in diameter.[16]

Pneumatization of the Sinus

Although the volume of the adult sinus remains stable after age 20,[9,10,17] multiple factors can cause further pneumatization. The primary cause is tooth loss, with the most vertical bone loss occurring after extraction of second molars.[11] This appears to occur within the first 4 to 6 months after extraction.[11] This inferior movement of antral bone is exacerbated by bone loss at the alveolar crest after tooth extraction, resulting in a combined reduction in vertical height that may be as low as 1 to 3 mm.

Septa

The presence of septa can increase the risk of membrane perforation.[8,15] Septa in the maxillary sinus were first described by Underwood in 1910 and are often referred to as Underwood septa.[18] They may occur as congenital, complete (primary) septa or acquired, incomplete (secondary) septa in the case of tooth and bone loss.[18,19] In a prospective series of 100 cases, Zijderveld found a prevalence of septa in 48%.[15] Other studies using prior computed tomographic (CT) and anatomic specimens have demonstrated a wide range of prevalence from 16% to 58%.[8,20-25] Septa are found more commonly in the premolar region and are more prevalent in atrophic edentulous maxilla.[15,21,22] Their orientation may vary in the sagittal (Figure 32-2, *A*) or medial-lateral direction (see Figure 32-2, *B*), as well as varying in height, and may affect the surgical approach.[23] Medial-lateral

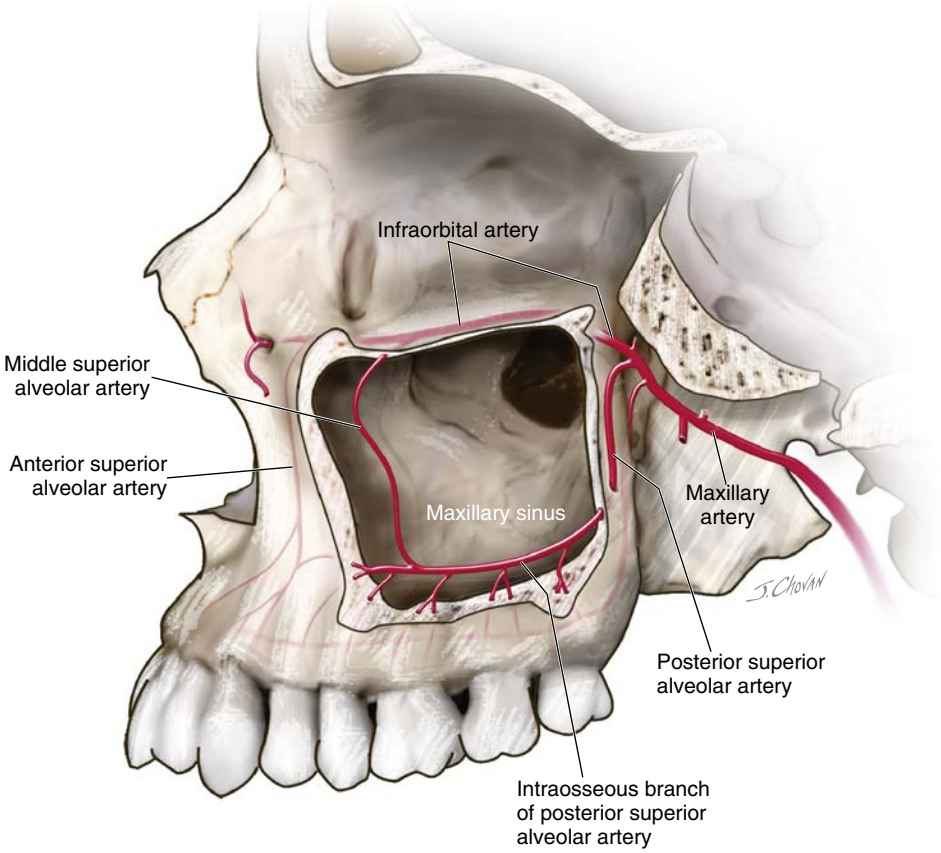

• **Figure 32-1** The maxillary sinus has an estimated volume of 12-15 cm^3. It is supplied by the maxillary artery via branches of the infraorbital artery and posterior superior alveolar artery. (From Kademani D, Tiwana PS: *Atlas of oral and maxillofacial surgery,* St Louis, 2016, Saunders.)

septa or multiple septa are often best approached from a lateral approach, using multiple windows (see Figure 32-2, *C*), whereas sagittally oriented septa may be managed from a crestal or lateral approach (see Figure 32-2, *D*).[23] A CT scan should be considered in the preoperative evaluation as Krennmair reported a 21% rate of false diagnosis of septa using panoramic imaging compared to CT scan.[21]

Thickness of the Schneiderian Membrane

Normal membrane thickness averages 0.8 mm. Wen reported membrane perforations were correlated with both overly thin (<0.5 mm) and overly thick (>3 mm) membranes.[26] Yilmaz, in a study of 50 patients, found a strong correlation between thick gingival phenotype and thicker Schneiderian membrane, and a moderate correlation between residual ridge height and membrane thickness.[27]

Pseudocysts

In a retrospective study of 109 patients undergoing maxillary sinus augmentation, 8 (7.3%) were found to have a pseudocyst (Figure 32-3).[28] The authors concluded that a pseudocyst of the maxillary sinus is not a contraindication for sinus augmentation. It is reported that most cysts spontaneously regressed or showed no significant change in size over the long term.[29] In the absence of associated complications, "wait and see" may be appropriate management of pseudocysts. The low frequency of sinus membrane perforation and postsurgery sinusitis associated with pseudocysts make the operation safe. In large lesions and in patients with an unclear diagnosis, further evaluation is needed before sinus augmentation.[28]

Vascular Supply

Blood Supply

The blood supply to the lateral aspects of the maxillary sinus comes from the maxillary artery via the posterior superior alveolar (PSA) artery and infraorbital (IO) artery (see Figure 32-1). The greater palatine artery supplies the remainder of the sinus. The PSA artery also supplies the mucoperiosteal layer on the lateral portions of the maxillary sinus wall.[30] Elian and colleagues reported that PSA and IO arteries may anastomose to form an intraosseous branch detectable by CT scan at least 50% of the time, with approximately 80% greater than 15 mm from the alveolar ridge.[31] Preoperative CT scan may aid in avoiding potential hemorrhage (Figure 32-4).

Pretreatment Considerations

Graft Materials

Debate remains as to which graft material is best for sinus augmentation. The 1996 Sinus Consensus concluded bone

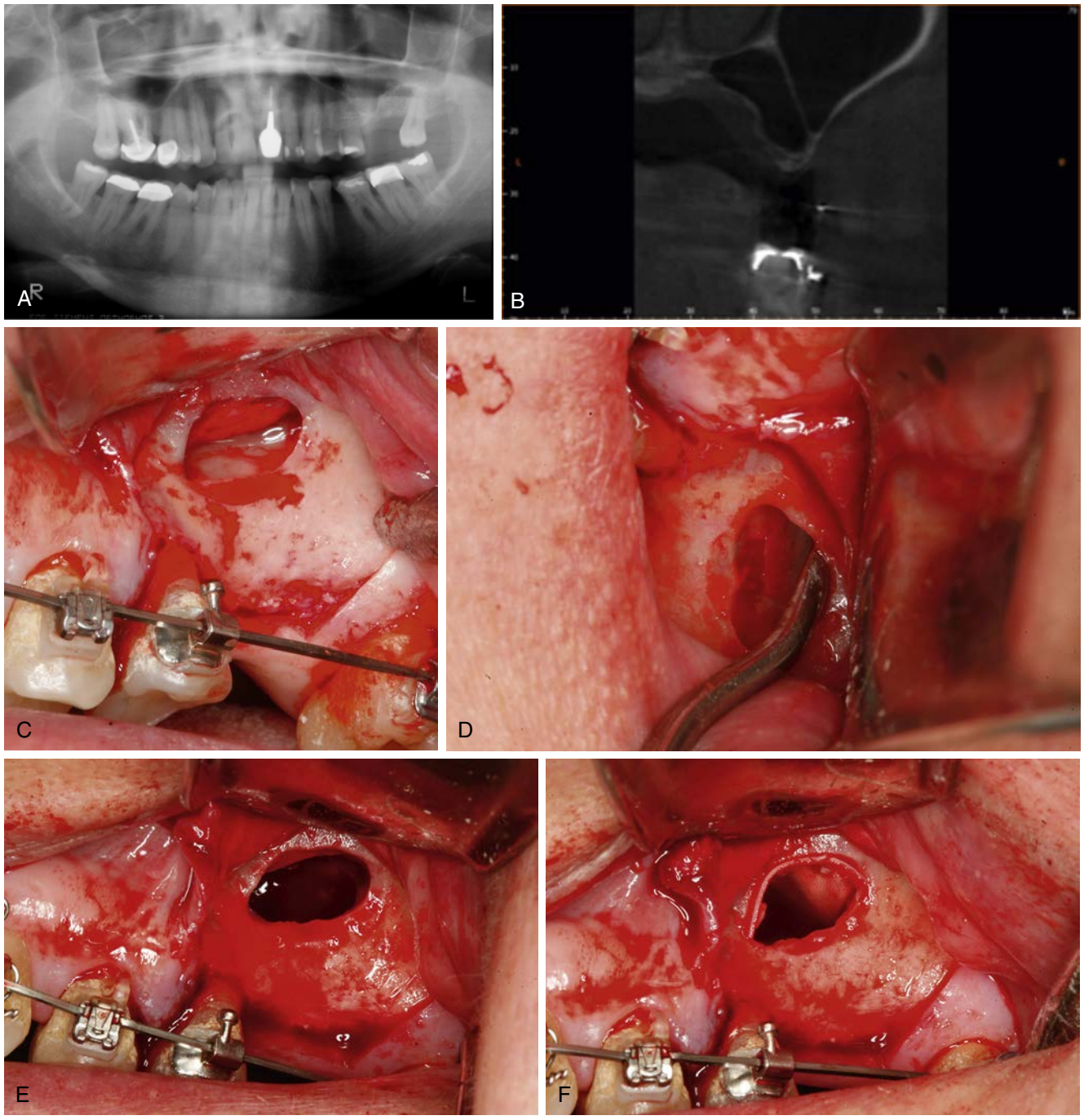

• **Figure 32-2** Septa can be found in a sagittal **(A-J)** or medial-lateral **(K-L)** orientation. Sagittally oriented septa can be managed through a crestal or lateral approach. **C**-**G**, Illustrate a lateral osteotomy approach to gain access to the sagittal septum and creating a second ostetotomy in the septum for augmentation of the medial compartment or the sinus. Medial-lateral septa are best approached via a lateral approach with multiple windows (**K** and **L**).

Continued

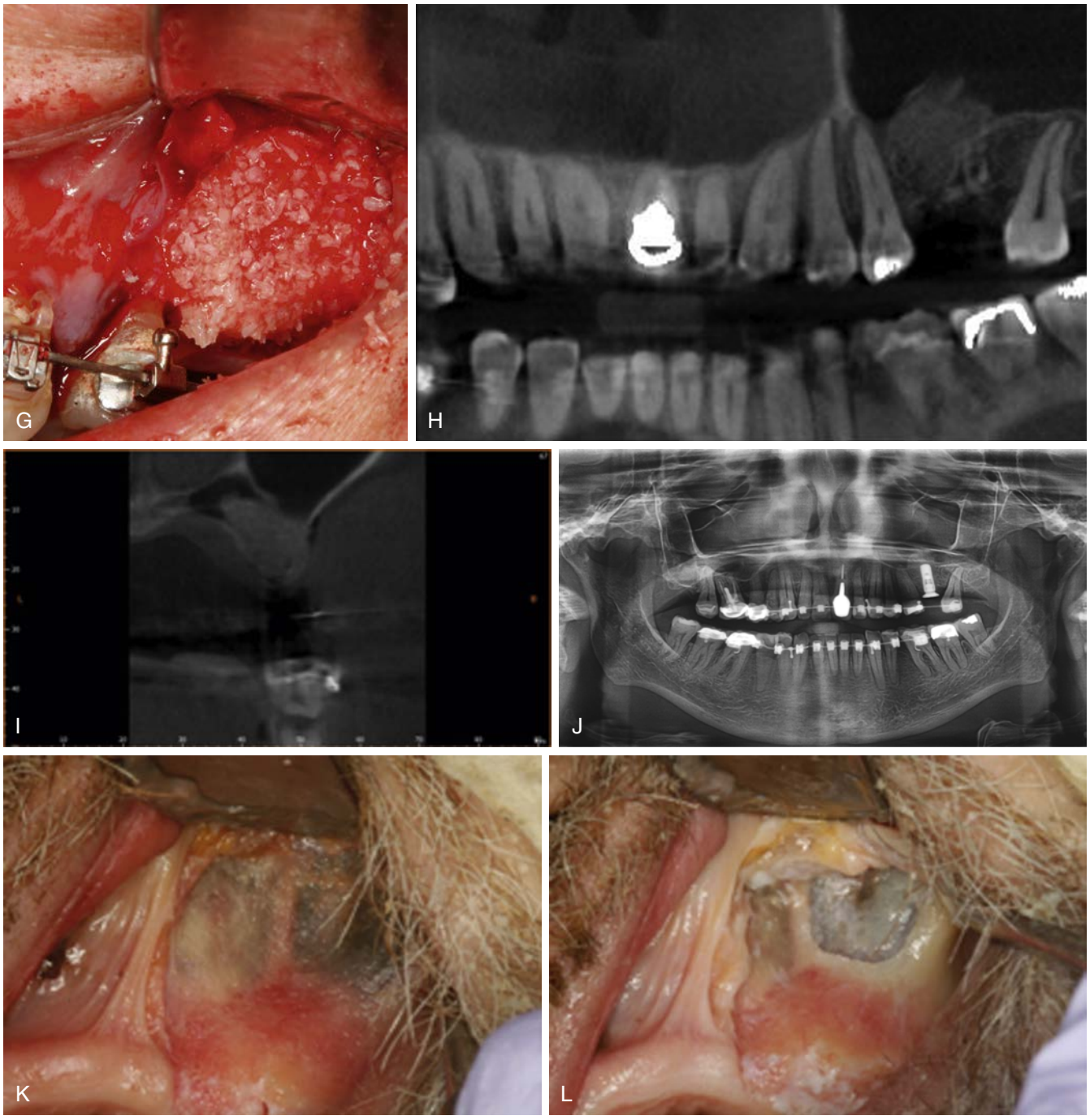

• **Figure 32-2, cont'd**

formation through the lateral window approach was predictable with various graft materials, but no consensus was reached on which material was best.[1] The original description for sinus augmentation recommended the use of autogenous bone for its inherent osteoinductive and osteogenic properties. Various bone substitutes such as bovine xenograft,[32,33] human allograft,[34] synthetic alloplasts,[35] and recombinant human bone morphogenic protein type 2 (rhBMP-2)[36] have since been shown to be equally effective for sinus augmentation. Platelet-derived products such as platelet-rich plasma and platelet-rich fibrin have shown inconclusive data.[34,37-39] Comparison studies and systematic reviews have not demonstrated any advantages for any of the listed materials.[40-44] Long-term studies have shown approximately 20% loss of bone height over the first 2 years regardless of autogenous or composite grafts,[32,45] although a recent systematic review by Shanbhag and co-workers suggests that greater reduction may be seen with autogenous bone (45%) than bone substitutes or composite grafts (20%).[46]

De novo bone formation using autogenous blood clot alone[47-50] or a hemostatic sponge,[47,51] without the presence of graft material, has also been demonstrated in prospective studies. This highlights the concept that inducing new bone in the sinus may not depend solely on bone type, but

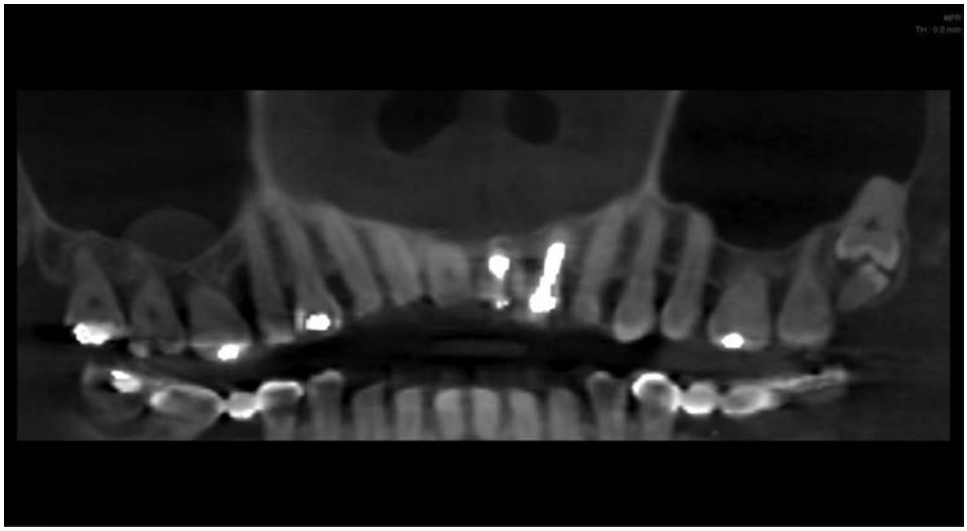

• **Figure 32-3** Pseudocysts can be detected on radiographic imaging.

rather space maintenance within an osteogenic environment surrounded by native bony walls and the Schneiderian membrane. Srouji and colleagues demonstrated new bone formation with sinus membrane cell transplants, indicating the innate osteogenic potential within the Schneiderian sinus membrane and its possible contribution to bone regeneration in sinus augmentation procedures.[52]

Barrier Membranes

The use of a barrier membrane to cover the lateral window is suggested to prevent soft tissue ingrowth and improve the quality of bone formation within the sinus cavity. Considerable controversy exists regarding the use of a membrane as it relates to implant survival. Some researchers found no differences in implant survival rates between membrane-covered and uncovered groups.[53,54] Garcia-Denche and colleagues, in a split-mouth study, reported that membrane coverage did not improve implant survival at 1 year, nor did it allow for histologically superior bone growth.[53] Others reported higher implant survival rates when antrostomy defects are covered with a membrane.[55-58] Duttenhoefer, in a systematic review and meta-analysis of 122 publications and 16,268 endosseous implants in grafted sinuses, reported that the application of membranes was the only significant variable to reduce the hazard ratio and improve long-term implant survival when compared to other variables (i.e., surgical approach, graft materials, implant types, implant surfaces, native bone height, and implant staging).[59]

Preoperative Evaluation

Medical Evaluation

Sinusitis

Acute sinusitis should be treated before the augmentation procedure.[16] Chronic sinusitis is considered a relative contraindication. The presence of sinus disease has been shown to range from 40% to 66% based on CT diagnosis

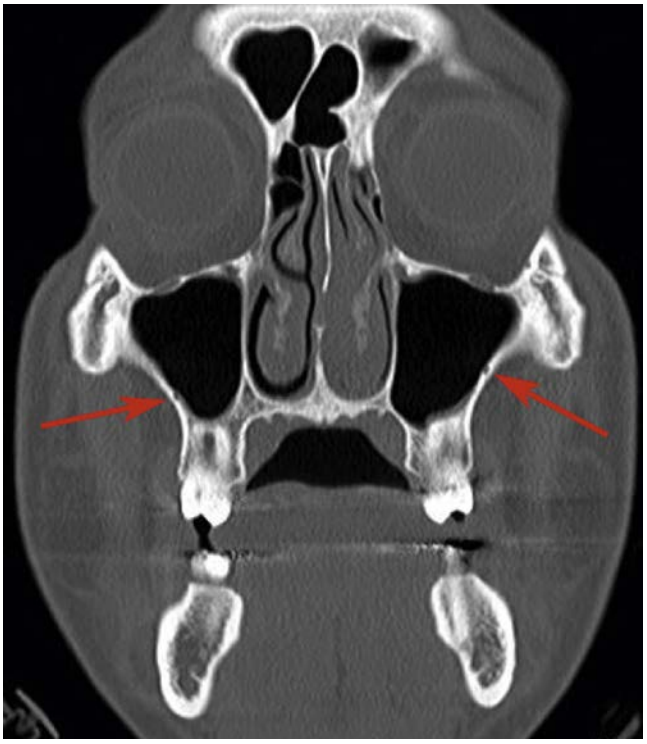

• **Figure 32-4** Preoperative computed tomography demonstrating the anastomosis *(red arrows)* between the infraorbital and posterior superior alveolar arteries in the lateral sinus wall.

of symptomatic patients, and even as high as 25% in asymptomatic patients.[60-62] Timmenga followed 45 patients for 1 to 5 years after sinus augmentation and implant placement and found postoperative sinusitis in 2 of 5 patients predisposed to sinusitis preoperatively, but none in the other 40 patients without disease.[63] In the healthy sinuses, Timmenga found, through endoscopy and biopsy, minimal histologic changes and no clinical consequences at 9 months.[64] Augmentation of a thickened sinus membrane in the setting of chronic sinusitis may cause obstruction of the osteomeatal complex and worsen sinusitis.[63,65] The presence of

septal deviation, allergies, and asthma may increase the risk of sinusitis.[66]

Smoking

The effect of smoking on dental implant treatment remains controversial. Smoking has been shown to decrease the success of dental implants, with an increased complication rate of up to 46% and decreased 5-year survival rate from 97.1% to 87.8% in one study.[67] Lambert and colleagues noticed a trend of greater failures in smokers between the time after uncovering and before insertion of the prosthesis.[68] Esposito et al. and De Bruyn and Collaert reported that smokers had a higher implant failure rate in the maxilla.[69,70] Higher implant failure rates have also been reported in smokers after rehabilitation of severely resorbed maxillae with and without bone grafts.[71,72] The maxillary bone is more sensitive to tobacco exposure, with heavy smokers exhibiting more marginal bone loss (MBL) than mild smokers.[71] A systematic review by Chambrone revealed a statistically significant increase in the risk of implant loss placed in augmented sinuses of smokers compared to nonsmokers.[73] Limited evidence has not demonstrated a clear detriment of smoking on the success of the sinus augmentation procedure itself.[67,74] Smoking has also been correlated with an increased risk of sinus membrane perforation.[75] Patients must therefore be counseled that smoking, although not an absolute contraindication, may adversely affect the reliability of sinus grafting and implant survival.

Radiographic Evaluation

Cone-beam CT (CBCT) has emerged as the definitive tool for accurate three-dimensional evaluation of the maxillary sinus for preoperative implant treatment planning.[76] Panoramic imaging has limitations and may result in distortions that preclude accurate measurement, underestimate the actual need for sinus augmentation,[76] and fail to reveal sinus anomalies or pathology.[62,77-79] Transcrestal approaches require accuracy to at least 1 mm for proper osteotomy preparation and sinus membrane elevation. CBCT will identify the bone thickness of the lateral antrostomy site, the presence of sinus pathology such as polyps, cysts, sinusitis, and the presence of abnormalities such as septa.[25,77-79] Preoperative identification of the position of the anastomosis between the PSA and IO arteries may reduce the risk of intraoperative bleeding.

Techniques

Lateral Approach

The lateral approach to the sinus via a lateral window osteotomy was first described separately by Caldwell and Luc in the late 19th century for treatment of sinus abscesses (Figure 32-5).[80,81] Using this approach, Tatum in 1975 developed a technique to increase alveolar bone height by placing a graft material under the sinus membrane before implant placement.[82] Boyne and James first published the technique in 1980.[83,84] Sinus augmentation has since been studied thoroughly and has produced excellent results with long-term graft stability and implant survival.[1,2,6,82,85-88]

Peleg and colleagues studied 2132 implants placed into the grafted sinus of 731 patients in a longitudinal study over 9 years and demonstrated cumulative survival of 97.9%, with survival rates of 95.0% in residual bone height of 1 to 2 mm and 98.4% in both 3 to 4 mm and more than 5 mm residual bone height groups.[89] Similarly, a systematic review by Del Fabbro reports an overall survival rate of implants over three years in grafted sinuses using lateral techniques to be 93.7%.[90] The conclusions of evidence-based reviews indicate that the use of bone substitutes,[46] rough-surface implants,[90] results in the best outcomes when considering implant survival. The use of piezoelectric surgery, rather than rotary diamond burrs, for lateral window preparation and membrane separation has decreased the occurrence of intraoperative complications of bleeding and membrane perforation.[54,74-76,91] Compared to indirect techniques, the lateral approach allows direct visualization of the sinus cavity for sinus membrane elevation and placement of biomaterial. This approach is recommended for ridges with residual height less than 4 mm.[59,90,92]

In appropriate cases with adequate bone height for primary implant stability, simultaneous sinus augmentation and implant placement can be accomplished.[93,94]

Protocol

A full-thickness flap is elevated to the depth of the vestibule using a crestal incision with a single anterior vertical release (Figure 32-6, *A*). An osteotomy of appropriate size is made using piezoelectric surgery instrumentation or rotary burrs (#6 or 8 round burr) (see Figure 32-6, *B*). A larger osteotomy may facilitate membrane exposure and elevation, but will decrease the osteogenic potential of the grafted site by removing supporting native bone. Avila-Ortiz and colleagues studied the effect of osteotomy dimensions on vital bone formation and reported that larger osteotomy dimensions were positively correlated with lesser vital bone formation.[95] The inferior border of the osteotomy should be 1 to 2 mm superior to the level of the sinus floor and can be estimated from preoperative radiographs (Figure 32-7). The superior osteotomy is made parallel to the inferior osteotomy and similar in length (see Figure 32-6, *C*).

If rotary burrs are used, care is taken to remove bone incrementally until only membrane or a thin layer of bone remains. A hand instrument such as a small curette can then be used to remove the remaining layer of bone and expose the Schneiderian membrane. Once the window is osteotomized circumferentially, elevation of the membrane begins at the superior aspect with a curved dissection elevator (see Figure 32-6, *D*). The sharp edge of the elevator is directed toward bone, with the back, curved surface of the instrument supporting the membrane. The bony window can be left attached to the membrane if it is firmly attached. The senior author prefers to make a small osteotomy without a bony window to increase the osteogenic potential of the grafted environment and to decrease the risk of

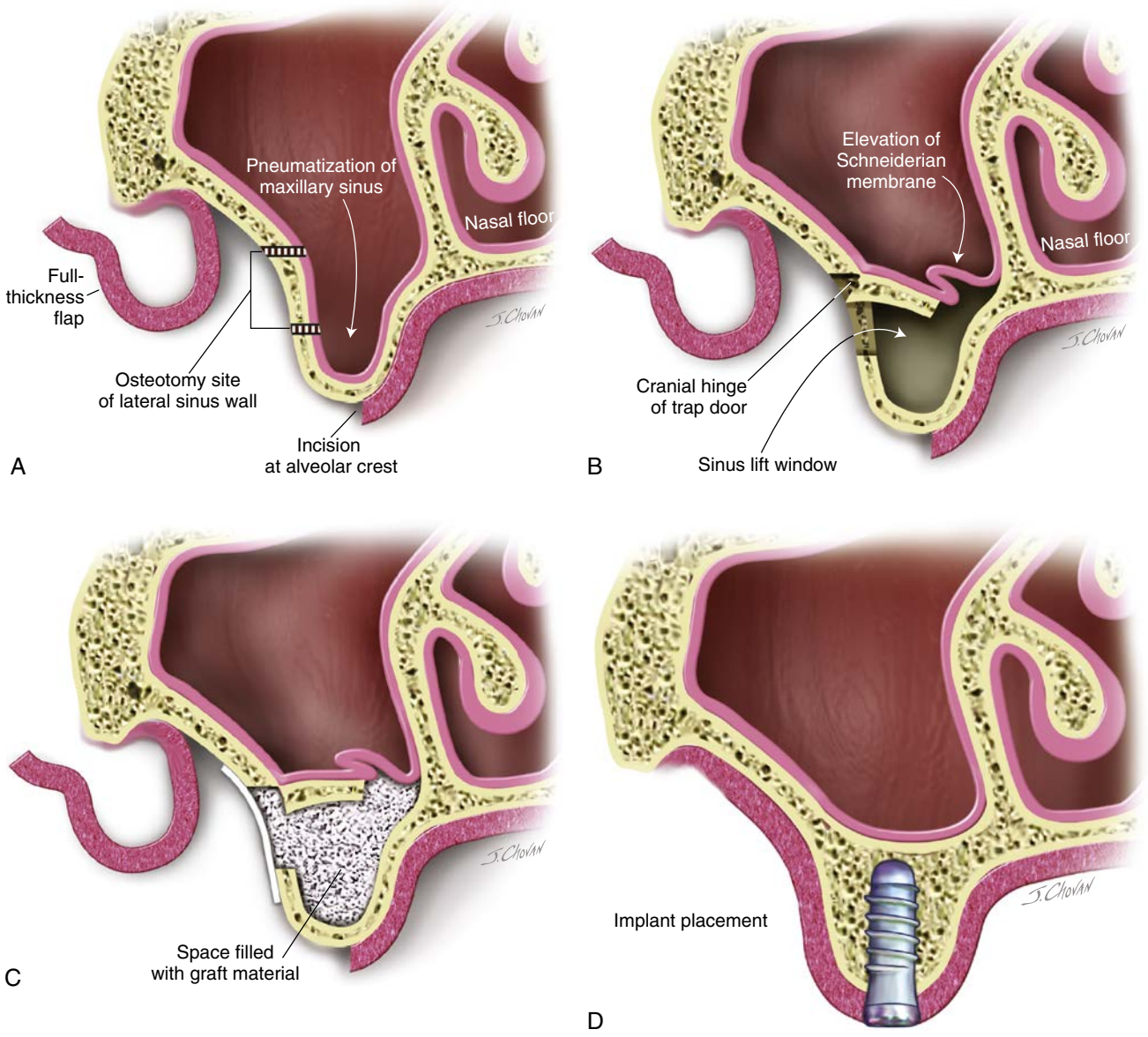

• **Figure 32-5** The lateral approach involves elevation of a full-thickness buccal flap and osteotomy through the lateral wall **(A),** infracture and elevation of the sinus membrane **(B),** placement of graft material **(C),** and simultaneous or delayed implant placement **(D).** (From Kademani D, Tiwana PS: *Atlas of oral and maxillofacial surgery*, St Louis, 2016, Saunders.)

bone sequestrum that can occur after loss of blood supply to the bony window. Membrane elevation is initially carried circumferentially around the osteotomy and slowly elevated from the sinus floor and carried out medially to the medial wall of the sinus (see Figure 32-6, *E*). As a result, the bony window is elevated superiorly in a "trap-door" fashion and lies horizontally above the graft site (see Figure 32-6, *F*).

If septa are present in a medial-lateral direction, two separate windows adjacent to the septation can be used, essentially creating two separate window osteotomies (see Figure 32-2, *A* and *B*).

Graft material is placed against the anterior and medial sinus walls first (see Figure 32-6, *G*) and subsequently filled laterally (see Figure 32-6, *H*) to avoid inadequate graft fill (Figure 32-8). If simultaneous implant placement is planned, graft material is placed before implant insertion to allow better access to the medial aspect of the sinus cavity (Figure 32-9). Care is taken not to overfill the sinus with graft material to reduce the risk of membrane necrosis and postoperative sinusitis. Doud Galli and colleagues reported that of 14 patients who developed sinusitis after sinus augmentation, more than half received more than the recommended volume (2-5 mL) of bone graft material.[65] A slow-resorbing collagen membrane is then placed over the lateral window to avoid fibrous ingrowth (see Figure 32-6, *I*). The mucoperiosteal flap is then closed with resorbing interrupted sutures.

Managing Perforations

Perforation of the Schneiderian membrane is the most common complication of sinus augmentation surgery.[96]

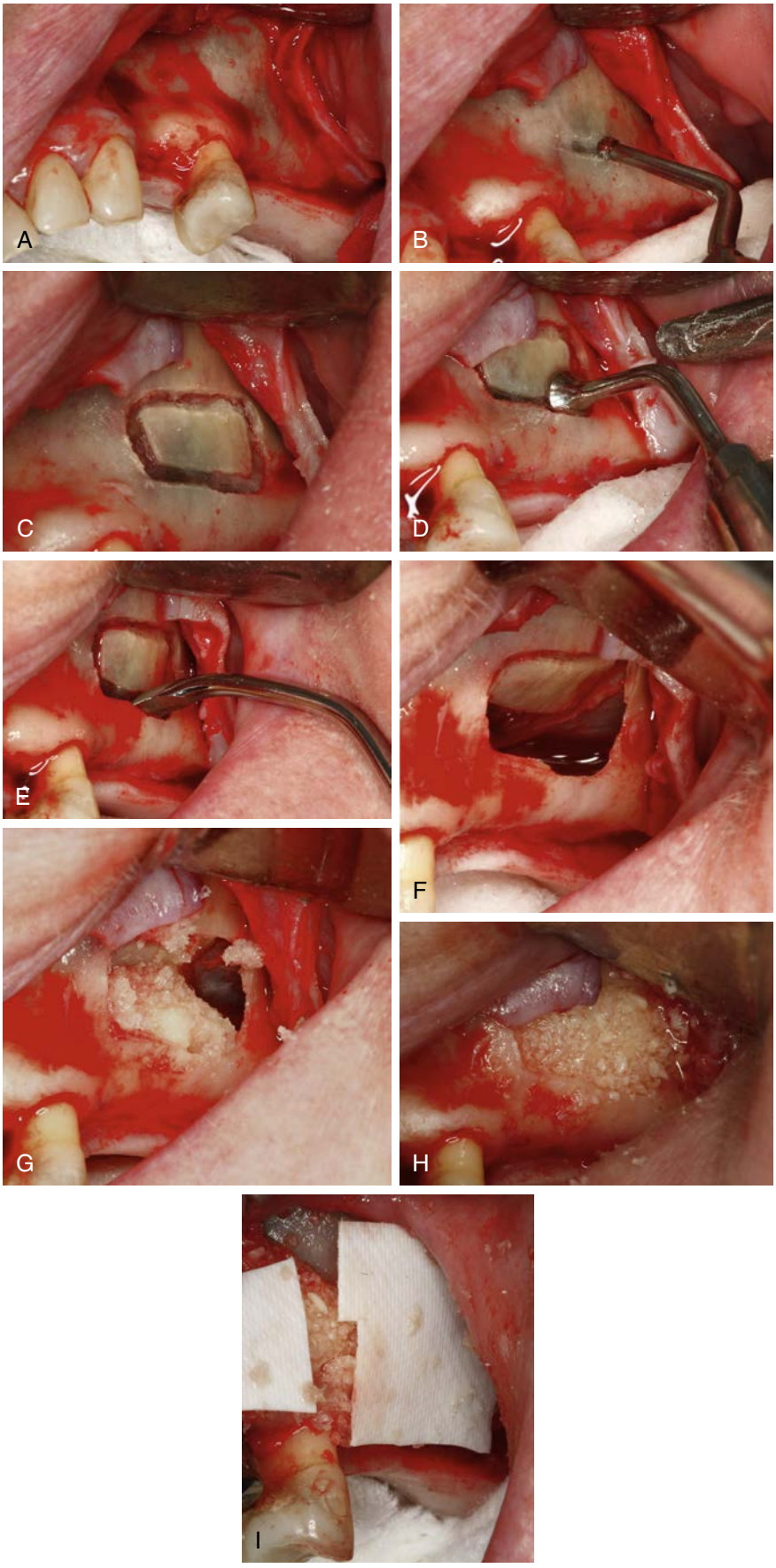

• **Figure 32-6** A full-thickness flap with an anterior release is elevated to the depth of the vestibule **(A).** An osteotomy is outlined with a piezoelectric instrument or rotary burr, staying 1-2 mm superior to the sinus floor **(B, C).** A curved osteotome or specialized blunt elevator infractures the window **(D)** and begins elevating the Schneiderian membrane from the sinus floor **(E).** Once the membrane and window are sufficiently elevated **(F),** graft material is placed against the anterior and medial walls **(G),** and filled laterally **(H).** A bioresorbable membrane covers the graft material **(I).**

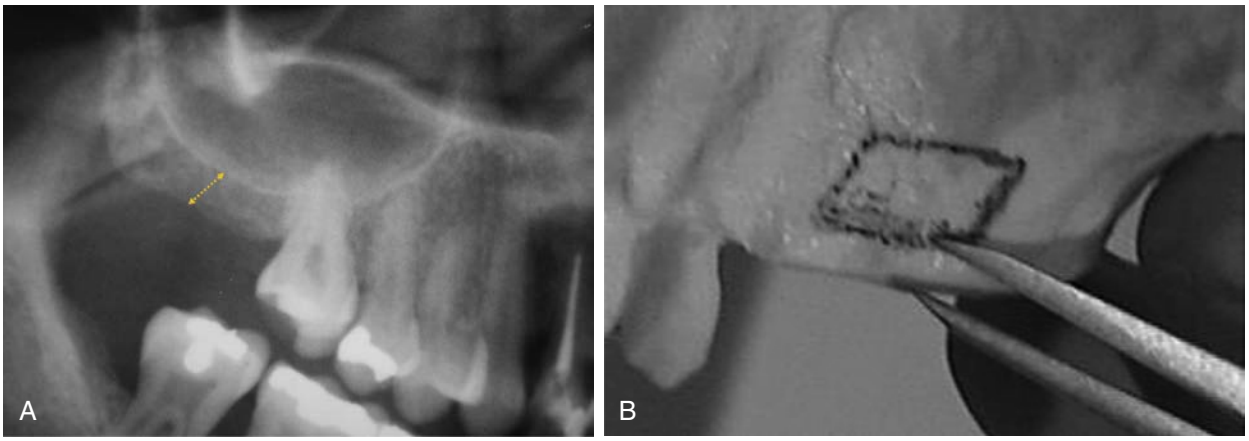

• **Figure 32-7** Preoperative imaging demonstrates the height of the sinus floor **(A)** and guides the osteotomy in situ **(B).**



• **Figure 32-8** Preoperative **(A)** and postoperative **(B)** cone-beam computed tomography demonstrating incomplete sinus fill of the anterior graft site.

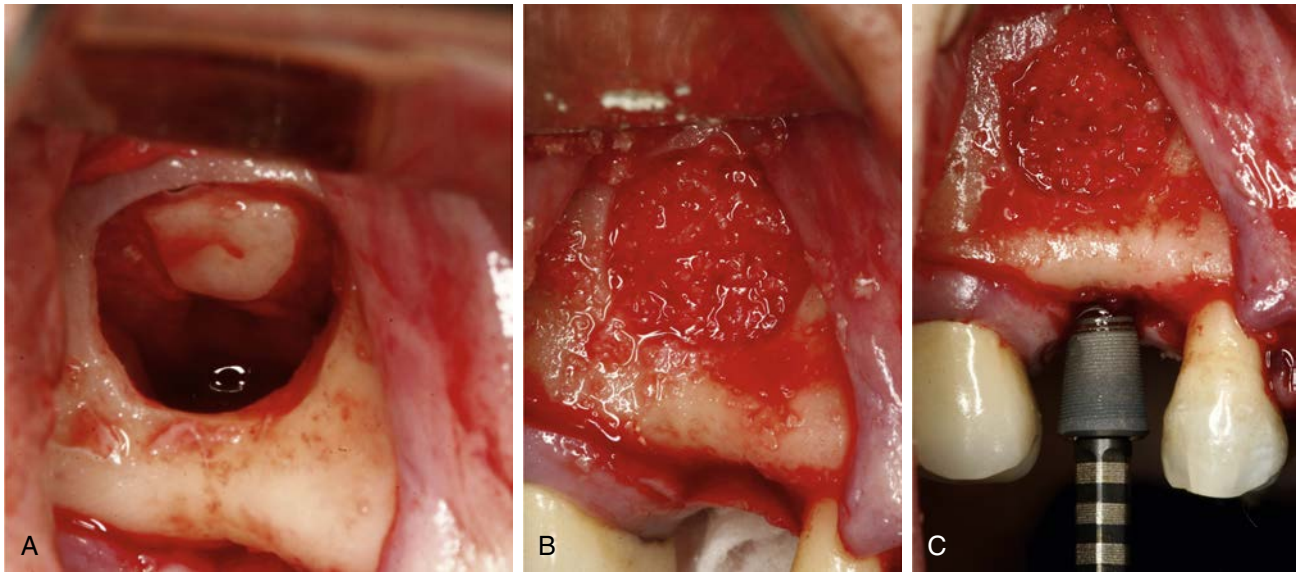

• **Figure 32-9** Simultaneous implant placement can be placed with sufficient native ridge height **(A).** Graft material is placed first **(B),** followed by implant osteotomy and placement **(C).**

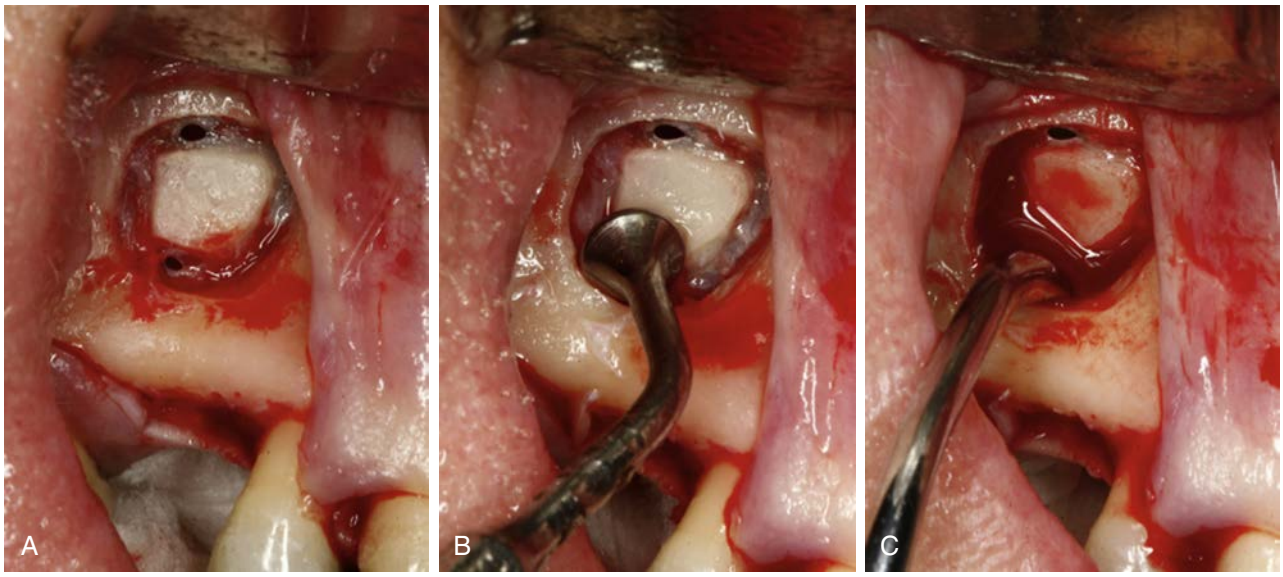

• **Figure 32-10** Small perforations (<5 mm) can be seen at the superior and inferior aspects of the lateral window **(A).** The window and membrane are carefully elevated **(B),** and the procedure can continue without propagating or repairing the perforations **(C).**

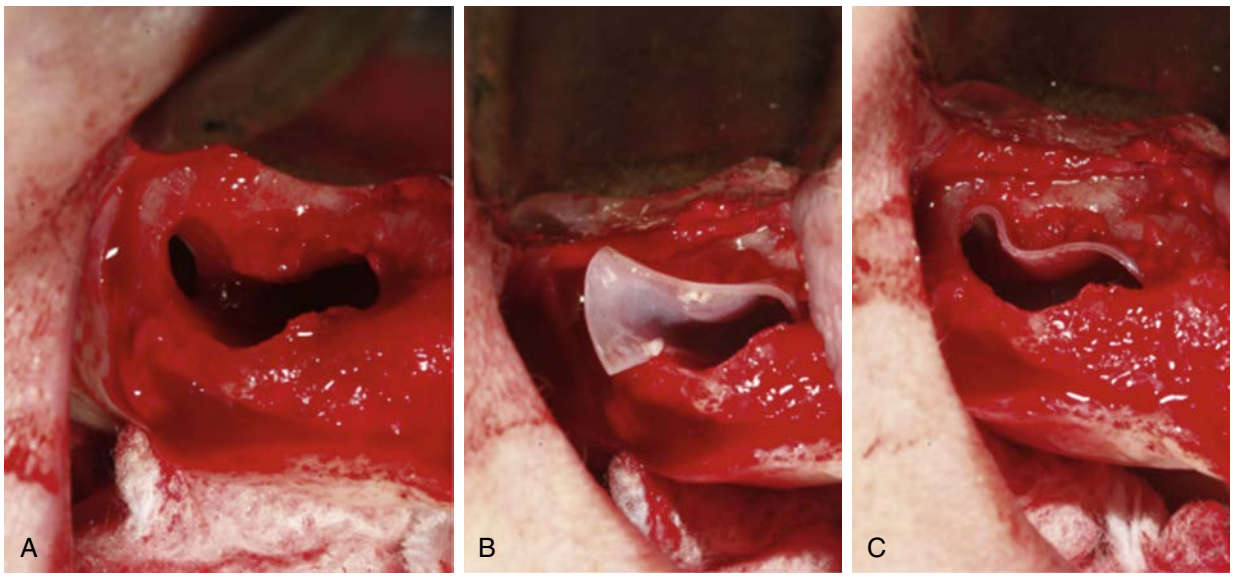

• **Figure 32-11** Larger perforations (>5 mm) in unfavorable locations **(A)** can be managed by occlusion with a bioresorbable membrane **(B),** allowing containment of the graft material **(C).**

Implant survival rate is reported as inversely proportional to the size of the perforation, with tears of less than 5 mm and 5 to 10 mm correlated with implant survival of 97% and 92%, respectively.[97] When tears were larger than 10 mm, implant survival dropped to 74%. Ardekian and colleagues demonstrated similar results with no significant difference between control groups and membrane perforations less than 10 mm.[75] Small tears less than 5 mm at the superior aspect of the window may not need repair, as the elevated membrane will fold together and will not impede graft containment (Figure 32-10). Small tears less than 5 mm toward the crestal aspect of the window can be directly repaired with resorbable sutures or occluded with a resorbable collagen membrane. Larger tears (5-10 mm) located in unfavorable areas can be occluded passively with a collagen membrane (Figure 32-11). Postoperative antibiotics are recommended, as Nolan and co-workers have reported a significantly higher rate of secondary infection requiring antibiotics in the presence of membrane perforation.[98]

Indirect (Transcrestal) Approach

The indirect, transcrestal approach through the alveolar ridge or extraction socket was first introduced by Summers in 1994,[4,5] consisting of an osteotomy through the alveolus and elevation of the sinus floor using specialized osteotomes (Figure 32-12).

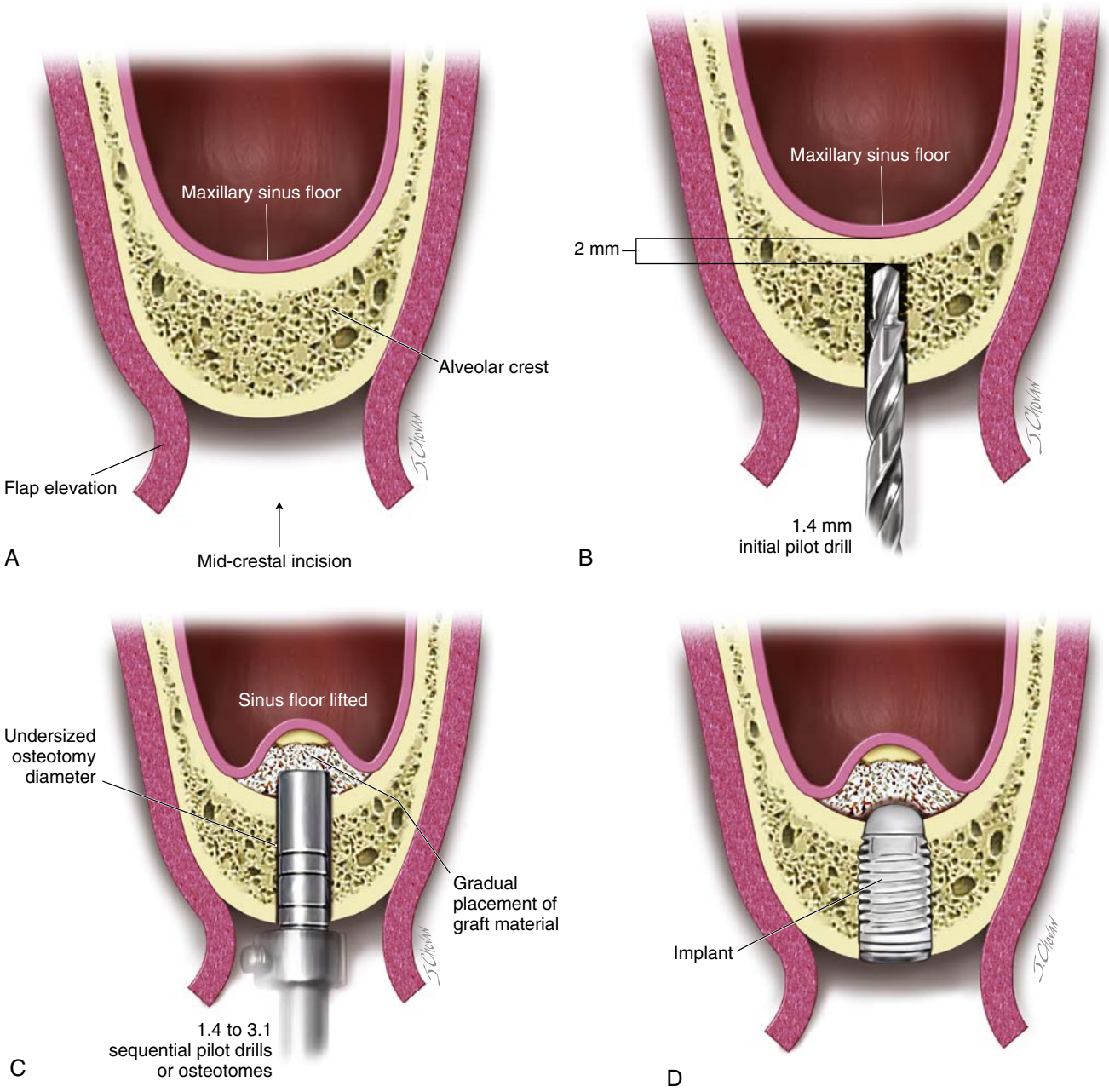

• **Figure 32-12** Indirect, crestal sinus-lift requires minimal flap elevation to approach the alveolar crest **(A).** A pilot drill is stopped 1-2 mm short of the sinus floor **(B).** The osteotomy is expanded with sequential drills or osteotomes and the sinus floor is subsequently infractured. A small amount of graft material may be used to buffer the impact **(C).** Simultaneous implant placement is achieved with sufficient native bone height **(D).** (From Kademani D, Tiwana PS: *Atlas of oral and maxillofacial surgery*, St Louis, 2016, Saunders.)

This technique has been modified over time to include drilling and use of ultrasonic cutting. Several systematic reviews have shown similar long-term implant survival rates between indirect sinus augmentation procedures and lateral window sinus augmentation, although these findings have been largely limited to cases with at least 5 mm of native bone.[59,90,99,100]

The transcrestal approach has gained popularity, as it provides a less invasive access to the maxillary sinus. The approach is carried out through the alveolus or a fresh extraction site by preparing the osteotomy just below the level of the sinus floor, then using piezoelectric instrumentation or osteotomes to elevate the sinus floor and membrane. A recent meta-analysis reviewing outcomes of osteotome sinus floor elevation showed bone height gain of 2.07 to 4.62 mm in ridges with residual bone height of 4.1 to 8.8 mm.[101] Simultaneous implant placement with indirect techniques is predictable when adequate residual bone height exists (>5 mm) for primary implant stability.[49,92,99,100,102] Several modifications to this technique, with the use of piezotomes, lasers, hydraulic balloons, and hydrodynamic pressure, have

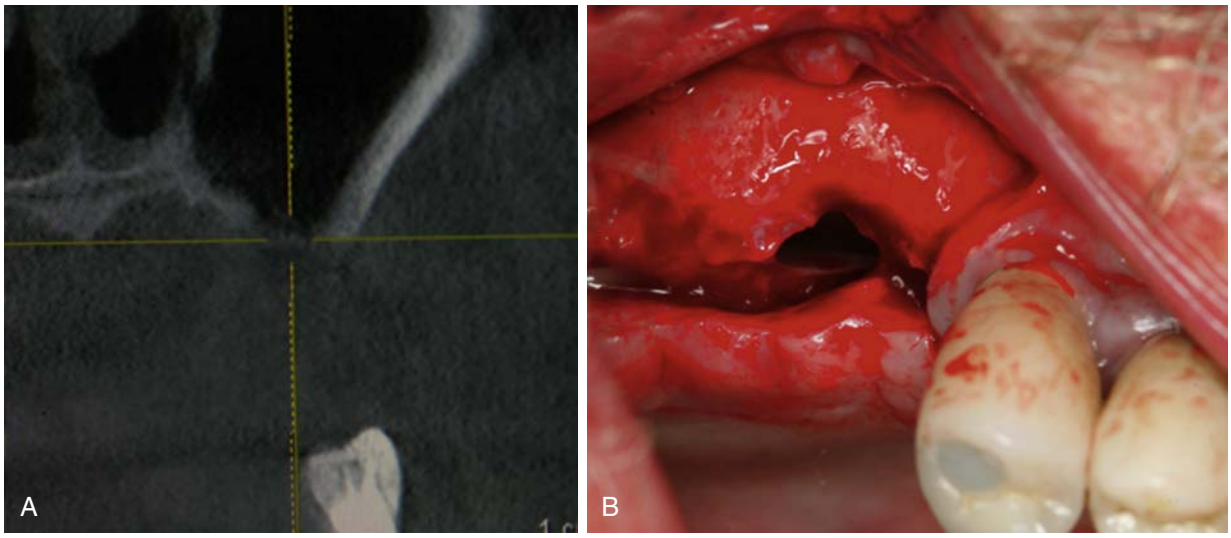

• **Figure 32-13** Fistula is seen on cone-beam computed tomography **(A)** and through alveolar crest **(B).**

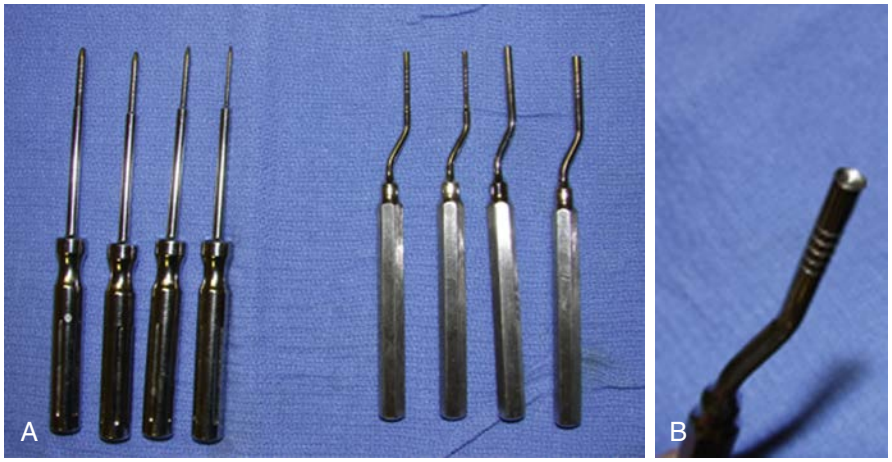

• **Figure 32-14** Specialized osteotomes for expansion of the osteotomy in soft bone **(A).** Concave osteotome for infracture of the sinus floor **(B).**

been reported to minimize membrane perforation.[103-108] Although indirect transcrestal sinus augmentation can be successfully performed in limited residual bone height, higher rates of complications such as sinus fistula formation, unpredictable bone fill, and implant failure may be associated with it (Figures 32-13).

Protocol

Minimal flap elevation or a flapless protocol can be used with the indirect technique (see Figure 32-15). The residual bone height is measured from the CBCT, and the implant site is then enlarged sequentially under copious irrigation to a length 1 mm short of the sinus floor. Drills manufactured specifically for sinus elevation, with mechanical height stops, can be used for this purpose. Tactile feedback with the 2-mm pilot drill may reveal the underlying quality of bone at the osteotomy site. In soft bone, osteotomy preparation is prepared using sequentially expanding osteotomes with gentle malleting after the pilot drill (Figure 32-14, *A* and Figure 32-15). Expansion of the osteotomy by either method stops at the diameter one step before the final diameter. A concave-tipped osteotome is gently tapped to infracture the sinus floor (see Figure 32-14, *B*). A small amount of graft material can be placed in the osteotomy to buffer the impact of the infracture. Alternatively, dental lasers or piezotomes can be used to access the remaining sinus floor before the placement of any graft material. A single-staged implant is then placed (see Figure 32-15, *E*).

Complications

Perforations

Membrane perforation during the transcrestal approach to sinus lift can be difficult to detect and avoid.[109] Studies report perforations occur with a frequency of 3.8 to 6.28% with indirect techniques.[92,100,110] The introduction of biomaterial through an unrecognized perforation can

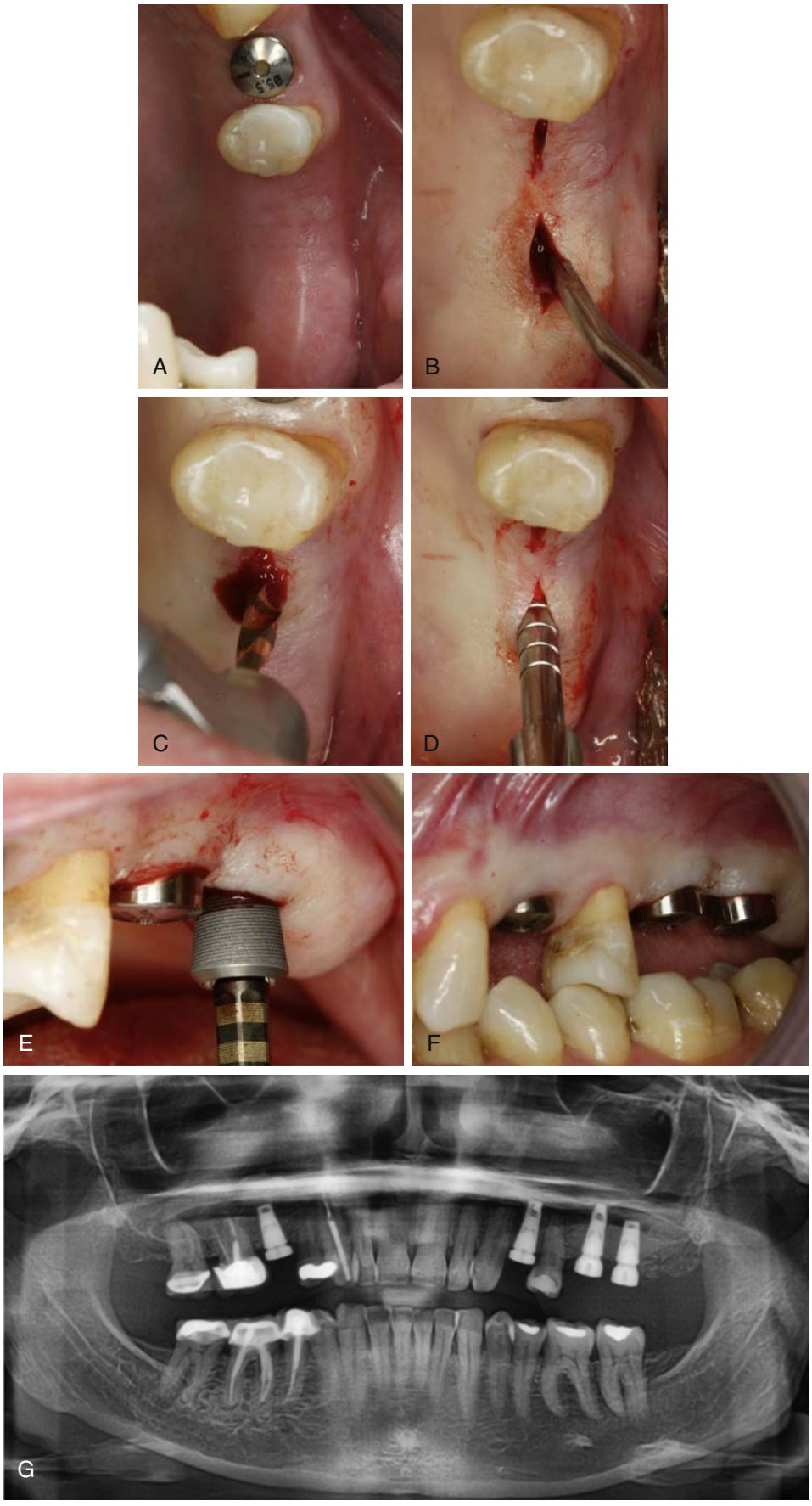

• **Figure 32-15** Indirect, crestal approach can be performed with minimal flap elevation **(A, B).** A pilot drill is carried 1-2 mm short of the sinus floor **(C),** and an osteotome infractures the sinus floor and elevates the membrane **(D).** Implants are placed with sufficient native bone **(E, F, G).**

result in potential sinusitis and should be avoided. De novo bone formation has also been demonstrated to be reliable in the absence of graft material, with only tenting of the membrane by simultaneous implant placement.[49,100,111,112] Nedir and colleagues, in a 10-year prospective study, followed 23 implants placed without graft material simultaneously with indirect sinus lifts, and found a mean gain of 3.0 mm.[112] Membrane elevation beyond 4 mm from the sinus floor increases the risk of membrane perforation. In cases with undetected membrane perforation, implants penetrating the maxillary sinus have shown minimal adverse effects.[113]

Paroxysmal Positional Vertigo

Surgical trauma induced by the percussive forces on the maxilla during osteotome sinus floor elevation procedure can lead to paroxysmal positional vertigo (PPV). The forces exerted by the mallet and osteotome can cause detachment of otoliths from the utricular macula while the patient's head position is hyper-extended. Di Girolamo and colleagues examined 146 patients undergoing maxillary surgery and found that four showed signs of PPV 1 or 2 days after the surgical procedure, which was treated with the Epley repositioning maneuver.[114] The use of piezosurgical instrumentation instead of osteotome may decrease the risk of PPV.

Postoperative

During the week following surgery, patients should be counseled to expect ecchymosis, swelling, minor nosebleeds, and mild to moderate discomfort. Perioperative antibiotics and decongestants are recommended based on clinical experience but are not supported by direct evidence.[115] In the case of larger membrane perforation, higher incidence of postoperative sinusitis, infection, and graft failure has been reported[98] and should be followed closely and lower the threshold for postoperative antibiotics.

Complications

Symptoms that present or persist beyond 2 weeks may be indicative of a postoperative complication such as sinusitis or infection. These findings warrant investigation clinically and with CBCT. A course of antibiotics with sinus coverage should be the first-line treatment, along with decongestants. More severe clinical findings such as purulence or drainage from the graft site or loss of containment of the graft may warrant surgical removal of the graft, irrigation and debridement, and antibiotics.

References

1. Jensen OT, Shulman LB, Block MS, Iacono VJ: Report of the Sinus Consensus Conference of 1996, *Int J Oral Maxillofac Implants* 13(Suppl):11–45, 1998.
2. Chanavaz M: Sinus graft procedures and implant dentistry: a review of 21 years of surgical experience (1979-2000), *Implant Dent* 9:197–206, 2000.
3. Chiapasco M, Casentini P, Zaniboni M: Bone augmentation procedures in implant dentistry, *Int J Oral Maxillofac Implants* 24(Suppl):237–259, 2009.
4. Summers RB: A new concept in maxillary implant surgery: the osteotome technique, *Compendium* 15(152):154–156, 1994. 158 passim; quiz 62.
5. Summers RB: The osteotome technique: Part 2—The ridge expansion osteotomy (REO) procedure, *Compendium* 15:422, 1994. 444, 446, passim; quiz 436.
6. Woo I, Le BT: Maxillary sinus floor elevation: review of anatomy and two techniques, *Implant Dent* 13:28–32, 2004.
7. Cattell HW: *Lippincott's new medical dictionary. n.p*, 1910.
8. van den Bergh JP, ten Bruggenkate CM, Disch FJ, Tuinzing DB: Anatomical aspects of sinus floor elevations, *Clin Oral Implants Res* 11:256–265, 2000.
9. Scuderi AJ, Harnsberger HR, Boyer RS: Pneumatization of the paranasal sinuses: normal features of importance to the accurate interpretation of CT scans and MR images, *AJR Am J Roentgenol* 160:1101–1104, 1993.
10. Ikeda A, Ikeda M, Komatsuzaki A: A CT study of the course of growth of the maxillary sinus: normal subjects and subjects with chronic sinusitis, *ORL J Otorhinolaryngol Relat Spec* 60:147–152, 1998.
11. Sharan A, Madjar D: Maxillary sinus pneumatization following extractions: a radiographic study, *Int J Oral Maxillofac Implants* 23:48–56, 2008.
12. Chanavaz M: Maxillary sinus: anatomy, physiology, surgery, and bone grafting related to implantology—eleven years of surgical experience (1979-1990), *J Oral Implantol*(16)199–209, 1990.
13. McGowan DA, Baxter PW, James J: *The maxillary sinus and its dental implications*, London, England, 1993, Wright, Butterworth-Heinemann.
14. Cho SC, Wallace SS, Froum SJ, Tarnow DP: Influence of anatomy on Schneiderian membrane perforations during sinus elevation surgery: three-dimensional analysis, *Pract Proced Aesthet Dent* 13:160–163, 2001.
15. Zijderveld SA, van den Bergh JP, Schulten EA, ten Bruggenkate CM: Anatomical and surgical findings and complications in 100 consecutive maxillary sinus floor elevation procedures, *J Oral Maxillofac Surg* 66:1426–1438, 2008.
16. Bell GW, Joshi BB, Macleod RI: Maxillary sinus disease: diagnosis and treatment, *Br Dent J* 210:113–118, 2011.
17. Ariji Y, Kuroki T, Moriguchi S, et al.: Age changes in the volume of the human maxillary sinus: a study using computed tomography, *Dentomaxillofac Radiol* 23:163–168, 1994.
18. Underwood AS: An inquiry into the anatomy and pathology of the maxillary sinus, *J Anat Physiol* 44(Pt 4):354–369, 1910.
19. Vinter I, Krmpotic-Nemanic J, Hat J, Jalsovec D: [Does the alveolar process of the maxilla always disappear after tooth loss?], *Laryngorhinootologie* 72:605–607, 1993.
20. Betts NJ, Miloro M: Modification of the sinus lift procedure for septa in the maxillary antrum, *J Oral Maxillofac Surg* 52:332–333, 1994,
21. Krennmair G, Ulm CW, Lugmayr H, Solar P: The incidence, location, and height of maxillary sinus septa in the edentulous and dentate maxilla, *J Oral Maxillofac Surg* 57:667–671, 1999, discussion 671–672.
22. Ulm CW, Solar P, Krennmair G, et al.: Incidence and suggested surgical management of septa in sinus-lift procedures, *Int J Oral Maxillofac Implants* 10:462–465, 1995.
23. Wen SC, Chan HL, Wang HL: Classification and management of antral septa for maxillary sinus augmentation, *Int J Periodontics Restorative Dent* 33:509–517, 2013.

24. Maestre-Ferrin L, Galan-Gil S, Rubio-Serrano M, et al.: Maxillary sinus septa: a systematic review, *Med Oral Patol Oral Cirug Bucal* 15:e383–e386, 2010.
25. Neugebauer J, Ritter L, Mischkowski RA, et al.: Evaluation of maxillary sinus anatomy by cone-beam CT prior to sinus floor elevation, *Int J Oral Maxillofac Implants* 25:258–265, 2010.
26. Wen SC, Lin YH, Yang YC, Wang HL: The influence of sinus membrane thickness upon membrane perforation during transcrestal sinus lift procedure, *Clin Oral Implants Res* 26(10):1158–1164, 2015.
27. Yilmaz HG, Tozum TF: Are gingival phenotype, residual ridge height, and membrane thickness critical for the perforation of maxillary sinus? *J Periodontol* 83:420–425, 2012.
28. Mardinger O, Manor I, Mijiritsky E, Hirshberg A: Maxillary sinus augmentation in the presence of antral pseudocyst: a clinical approach, *Oral Surg Oral Med Oral Pathol Oral Radiol Endod* 103:180–184, 2007.
29. Wang JH, Jang YJ, Lee BJ: Natural course of retention cysts of the maxillary sinus: long-term follow-up results, *Laryngoscope* 117:341–344, 2007.
30. Solar P, Geyerhofer U, Traxler H, et al.: Blood supply to the maxillary sinus relevant to sinus floor elevation procedures, *Clin Oral Implants Res* 10:34–44, 1999.
31. Elian N, Wallace S, Cho SC, et al.: Distribution of the maxillary artery as it relates to sinus floor augmentation, *Int J Oral Maxillofac Implants* 20:784–787, 2005.
32. Hatano N, Shimizu Y, Ooya K: A clinical long-term radiographic evaluation of graft height changes after maxillary sinus floor augmentation with a 2:1 autogenous bone/xenograft mixture and simultaneous placement of dental implants, *Clin Oral Implants Res* 15:339–345, 2004.
33. Somanathan RV, Simunek A: Evaluation of the success of beta-tricalciumphosphate and deproteinized bovine bone in maxillary sinus augmentation using histomorphometry: a review, *Acta Med* 49:87–89, 2006.
34. Ali S, Bakry SA, Abd-Elhakam H: Platelet rich fibrin in maxillary sinus augmentation: a systematic review, *J Oral Implantol* 41(6):746–753, 2015.
35. Jodia K, Sadhwani BS, Parmar BS, et al.: Sinus elevation with an alloplastic material and simultaneous implant placement: a 1-stage procedure in severely atrophic maxillae, *J Maxillofac Oral Surg* 13:271–280, 2014.
36. Freitas RM, Spin-Neto R, Marcantonio E Jr, et al.: Alveolar ridge and maxillary sinus augmentation using rhBMP-2: a systematic review. *Clin Implant Dent Relat Res*, 17 (Suppl 1): e192–e201, 2015.
37. Simonpieri A, Del Corso M, Vervelle A, et al.: Current knowledge and perspectives for the use of platelet-rich plasma (PRP) and platelet-rich fibrin (PRF) in oral and maxillofacial surgery part 2: bone graft, implant and reconstructive surgery, *Curr Pharm Biotechnol* 13:1231–1256, 2012.
38. Jeong SM, Lee CU, Son JS, et al.: Simultaneous sinus lift and implantation using platelet-rich fibrin as sole grafting material, *J Craniomaxillofac Surg* 42:990–994, 2014.
39. Zhang Y, Tangl S, Huber CD, et al.: Effects of Choukroun's platelet-rich fibrin on bone regeneration in combination with deproteinized bovine bone mineral in maxillary sinus augmentation: a histological and histomorphometric study, *J Craniomaxillofac Surg* 40:321–328, 2012.
40. Meloni SM, Jovanovic SA, Lolli FM, et al.: Grafting after sinus lift with anorganic bovine bone alone compared with 50:50 anorganic bovine bone and autologous bone: results of a pilot randomised trial at one year, *Br J Oral Maxillofac Surg* 53(5):436–441, 2015.
41. Rickert D, Slater JJ, Meijer HJ, et al.: Maxillary sinus lift with solely autogenous bone compared to a combination of autogenous bone and growth factors or (solely) bone substitutes. A systematic review, *Int J Oral Maxillofac Surg* 41:160–167, 2012.
42. Kuhl S, Payer M, Kirmeier R, et al.: The influence of particulated autogenous bone on the early volume stability of maxillary sinus grafts with biphasic calcium phosphate: a randomized clinical trial, *Clin Implant Dent Relat Res* 17:173–178, 2015.
43. Esposito M, Grusovin MG, Coulthard P, Worthington HV: The efficacy of various bone augmentation procedures for dental implants: a Cochrane systematic review of randomized controlled clinical trials, *Int J Oral Maxillofac Implants* 21:696–710, 2006.
44. Al-Nawas B, Schiegnitz E: Augmentation procedures using bone substitute materials or autogenous bone - a systematic review and meta-analysis, *Eur J Oral Implantol* 7(Suppl 2):S219–S234, 2014.
45. Zijderveld SA, Schulten EA, Aartman IH, ten Bruggenkate CM: Long-term changes in graft height after maxillary sinus floor elevation with different grafting materials: radiographic evaluation with a minimum follow-up of 4.5 years, *Clin Oral Implants Res* 20:691–700, 2009.
46. Shanbhag S, Shanbhag V, Stavropoulos A: Volume changes of maxillary sinus augmentations over time: a systematic review, *Int J Oral Maxillofac Implants* 29:881–892, 2014.
47. Lundgren S, Andersson S, Gualini F, Sennerby L: Bone reformation with sinus membrane elevation: a new surgical technique for maxillary sinus floor augmentation, *Clin Implant Dent Relat Res* 6:165–173, 2004.
48. Pinchasov G, Juodzbalys G: Graft-free sinus augmentation procedure: a literature review, *J Oral Maxillofac Res* 5:e1, 2014.
49. Nedir R, Nurdin N, Vazquez L, et al.: Osteotome sinus floor elevation without grafting: a 10-year prospective study, *Clin Implant Dent Relat Res*, 2015 Mar 18. [Epub ahead of print.]
50. Rammelsberg P, Mahabadi J, Eiffler C, et al.: Radiographic monitoring of changes in bone height after implant placement in combination with an internal sinus lift without graft material, *Clin Implant Dent Relat Res* 17(Suppl 1):e267–e274, 2015.
51. Khyshov VB, Klimova NA, Amkhadova MA: [Long-term results of hemostatic sponge use by sinus-lift with simultaneous dental implantation], *Stomatologiia* 92:69–72, 2013.
52. Srouji S, Ben-David D, Lotan R, et al.: The innate osteogenic potential of the maxillary sinus (Schneiderian) membrane: an ectopic tissue transplant model simulating sinus lifting, *Int J Oral Maxillofac Surg* 39:793–801, 2010.
53. Garcia-Denche JT, Wu X, Martinez PP, et al.: Membranes over the lateral window in sinus augmentation procedures: a two-arm and split-mouth randomized clinical trials, *J Clin Periodontol* 40:1043–1051, 2013.
54. Choi KS, Kan JY, Boyne PJ, et al.: The effects of resorbable membrane on human maxillary sinus graft: a pilot study, *Int J Oral Maxillofac Implants* 24:73–80, 2009.
55. Tawil G, El-Ghoule G, Mawla M: Clinical evaluation of a bilayered collagen membrane (Bio-Gide) supported by autografts in the treatment of bone defects around implants, *Int J Oral Maxillofac Implants* 16:857–863, 2001.
56. Tarnow DP, Wallace SS, Froum SJ, et al.: Histologic and clinical comparison of bilateral sinus floor elevations with and without barrier membrane placement in 12 patients: Part 3 of an ongoing prospective study, *Int J Periodontics Restorative Dent* 20: 117–125, 2000.

57. Wallace SS, Froum SJ, Cho SC, et al.: Sinus augmentation utilizing anorganic bovine bone (Bio-Oss) with absorbable and nonabsorbable membranes placed over the lateral window: histomorphometric and clinical analyses, *Int J Periodontics Restorative Dent* 25:551–559, 2005.
58. Wallace SS, Tarnow DP, Froum SJ, et al.: Maxillary sinus elevation by lateral window approach: evolution of technology and technique, *J Evid Based Dent Pract* 12(3 Suppl):161–171, 2012.
59. Duttenhoefer F, Souren C, Menne D, et al.: Long-term survival of dental implants placed in the grafted maxillary sinus: systematic review and meta-analysis of treatment modalities, *PloS One* 8:e75357, 2013.
60. Kennedy DW, Zinreich SJ: The functional endoscopic approach to inflammatory sinus disease: Current perspectives and technique modifications, *Am J Rhinol* 2, 1988.
61. Havas TE, Motbey JA, Gullane PJ: Prevalence of incidental abnormalities on computed tomographic scans of the paranasal sinuses, *Arch Otolaryngol Head Neck Surg* 114:856–859, 1988.
62. Beaumont C, Zafiropoulos GG, Rohmann K, Tatakis DN: Prevalence of maxillary sinus disease and abnormalities in patients scheduled for sinus lift procedures, *J Periodontol* 76:461–467, 2005.
63. Timmenga NM, Raghoebar GM, Boering G, van Weissenbruch R: Maxillary sinus function after sinus lifts for the insertion of dental implants, *J Oral Maxillofac Surg* 55:936–939, 1997, discussion 940.
64. Timmenga NM, Raghoebar GM, Liem RS, et al.: Effects of maxillary sinus floor elevation surgery on maxillary sinus physiology, *Eur J Oral Sci* 111:189–197, 2003.
65. Doud Galli SK, Lebowitz RA, Giacchi RJ, et al.: Chronic sinusitis complicating sinus lift surgery, *Am J Rhinol* 15:181–186, 2001.
66. Van Cauwenberge P, Watelet JB: Epidemiology of chronic rhinosinusitis, *Thorax* 55(Suppl. 2), 2000.
67. Levin L, Schwartz-Arad D: The effect of cigarette smoking on dental implants and related surgery, *Implant Dent* 14:357–361, 2005.
68. Lambert PM, Morris HF, Ochi S: The influence of smoking on 3-year clinical success of osseointegrated dental implants, *Ann Periodontol* 5:79–89, 2000.
69. Esposito M, Hirsch JM, Lekholm U, Thomsen P: Biological factors contributing to failures of osseointegrated oral implants. (II). Etiopathogenesis, *Eur J Oral Sci* 106:721–764, 1998.
70. De Bruyn H, Collaert B: The effect of smoking on early implant failure, *Clin Oral Implants Res* 5:260–264, 1994.
71. Bain CA, Moy PK: The association between the failure of dental implants and cigarette smoking, *Int J Oral Maxillofac Implants* 8:609–615, 1993.
72. Widmark G, Andersson B, Carlsson GE, et al.: Rehabilitation of patients with severely resorbed maxillae by means of implants with or without bone grafts: a 3- to 5-year follow-up clinical report, *Int J Oral Maxillofac Implants* 16:73–79, 2001.
73. Chambrone L, Preshaw PM, Ferreira JD, et al.: Effects of tobacco smoking on the survival rate of dental implants placed in areas of maxillary sinus floor augmentation: a systematic review, *Clin Oral Implants Res* 25:408–416, 2014.
74. Levin L, Herzberg R, Dolev E, Schwartz-Arad D: Smoking and complications of onlay bone grafts and sinus lift operations, *Int J Oral Maxillofac Implants* 19:369–373, 2004.
75. Ardekian L, Oved-Peleg E, Mactei EE, Peled M: The clinical significance of sinus membrane perforation during augmentation of the maxillary sinus, *J Oral Maxillofac Surg* 64:277–282, 2006.
76. Fortin T, Camby E, Alik M, et al.: Panoramic images versus three-dimensional planning software for oral implant planning in atrophied posterior maxillary: a clinical radiological study, *Clin Implant Dent Relat Res* 15:198–204, 2013.
77. Maestre-Ferrin L, Galan-Gil S, Carrillo-Garcia C, Penarrocha-Diago M: Radiographic findings in the maxillary sinus: comparison of panoramic radiography with computed tomography, *Int J Oral Maxillofac Implants* 26:341–346, 2011.
78. Vallo J, Suominen-Taipale L, Huumonen S, et al.: Prevalence of mucosal abnormalities of the maxillary sinus and their relationship to dental disease in panoramic radiography: results from the Health 2000 Health Examination Survey, *Oral Surg Oral Med Oral Pathol Oral Radiol Endod* 109:e80–e87, 2010.
79. Raghav M, Karjodkar FR, Sontakke S, Sansare K: Prevalence of incidental maxillary sinus pathologies in dental patients on cone-beam computed tomographic images, *Contemp Clin Dent* 5:361–365, 2014.
80. Caldwell GW: Diseases of the accessory sinuses of the nose, and an improved method of treatment of suppuration of the maxillary antrum, *NY Med J* 58:526–528, 1893.
81. Luc H: Une nouvelle methode operatoire pour la cure radicale et rapide de l'empyeme chronique du sinus maxillaire, *Arch Int Laryngol Otol Rhinol* 77–93, 1897.
82. Smiler DG, Johnson PW, Lozada JL, et al.: Sinus lift grafts and endosseous implants. Treatment of the atrophic posterior maxilla, *Dent Clin North Am* 36:151–186, 1992, discussion 187–188.
83. Boyne PJ, James RA: Grafting of the maxillary sinus floor with autogenous marrow and bone, *Journal of oral surgery* 38:613–616, 1980.
84. Tatum Jr H: Maxillary and sinus implant reconstructions, *Dent Clin North Am* 30:207–229, 1986.
85. Lazzara RJ: The sinus elevation procedure in endosseous implant therapy, *Curr Opin Periodontol* 3:178–183, 1996.
86. Garg AK: Augmentation grafting of the maxillary sinus for placement of dental implants: anatomy, physiology, and procedures, *Implant Dent* 8:36–46, 1999.
87. Sbordone L, Toti P, Menchini-Fabris G, et al.: Implant success in sinus-lifted maxillae and native bone: a 3-year clinical and computerized tomographic follow-up, *Int J Oral Maxillofac Implants* 24:316–324, 2009.
88. Beretta M, Poli PP, Grossi GB, et al.: Long-term survival rate of implants placed in conjunction with 246 sinus floor elevation procedures: results of a 15-year retrospective study, *J Dent* 43:78–86, 2015.
89. Peleg M, Garg AK, Mazor Z: Predictability of simultaneous implant placement in the severely atrophic posterior maxilla: a 9-year longitudinal experience study of 2132 implants placed into 731 human sinus grafts, *Int J Oral Maxillofac Implants* 21:94–102, 2006.
90. Del Fabbro M, Wallace SS, Testori T: Long-term implant survival in the grafted maxillary sinus: a systematic review, *Int J Periodontics Restorative Dent* 33:773–783, 2013.
91. Toscano NJ, Holtzclaw D, Rosen PS: The effect of piezoelectric use on open sinus lift perforation: a retrospective evaluation of 56 consecutively treated cases from private practices, *J Periodontol* 81:167–171, 2010.
92. Del Fabbro M, Corbella S, Weinstein T, et al.: Implant survival rates after osteotome-mediated maxillary sinus augmentation: a systematic review. *Clin Implant Dent Relat Res* 14(Suppl 1):e159–e168, 2012.

93. Bortoluzzi MC, Manfro R, Fabris V, et al.: Comparative study of immediately inserted dental implants in sinus lift: 24 months of follow-up, *Ann Maxillofac Surg* 4:30–33, 2014.
94. Degidi M, Daprile G, Piattelli A: Primary stability determination of implants inserted in sinus augmented sites: 1-step versus 2-step procedure, *Implant Dent* 22:530–533, 2013.
95. Avila-Ortiz G, Wang HL, Galindo-Moreno P, et al.: Influence of lateral window dimensions on vital bone formation following maxillary sinus augmentation, *Int J Oral Maxillofac Implants* 27:1230–1238, 2012.
96. Schwartz-Arad D, Herzberg R, Dolev E: The prevalence of surgical complications of the sinus graft procedure and their impact on implant survival, *J Periodontol* 75:511–516, 2004.
97. Hernandez-Alfaro F, Torradeflot MM, Marti C: Prevalence and management of Schneiderian membrane perforations during sinus-lift procedures, *Clin Oral Implants Res* 19:91–98, 2008.
98. Nolan PJ, Freeman K, Kraut RA: Correlation between Schneiderian membrane perforation and sinus lift graft outcome: a retrospective evaluation of 359 augmented sinus, *J Oral Maxillofac Surg* 72:47–52, 2014.
99. Corbella S, Taschieri S, Del Fabbro M: Long-term outcomes for the treatment of atrophic posterior maxilla: a systematic review of literature, *Clin Implant Dent Relat Res* 17:120–132, 2015.
100. Calin C, Petre A, Drafta S: Osteotome-mediated sinus floor elevation: a systematic review and meta-analysis, *Int J Oral Maxillofac Implants* 29:558–576, 2014.
101. Antonaya-Mira R, Barona-Dorado C, Martinez-Rodriguez N, et al.: Meta-analysis of the increase in height in maxillary sinus elevations with osteotome, *Med Oral Patol Oral Cirug Bucal* 17:e146–e152, 2012.
102. Vina-Almunia J, Maestre-Ferrin L, Alegre-Domingo T, Penarrocha-Diago M: Survival of implants placed with the osteotome technique: an update, *Med Oral Patol Oral Cirug Bucal* 17:e765–e768, 2012.
103. Trombelli L, Franceschetti G, Trisi P, Farina R: Incremental, transcrestal sinus floor elevation with a minimally invasive technique in the rehabilitation of severe maxillary atrophy. Clinical and histological findings from a proof-of-concept case series, *J Oral Maxillofac Surg* 73(5):861–888, 2015.
104. Catros S, Montaudon M, Bou C, et al.: Comparison of conventional transcrestal sinus lift and ultrasound-enhanced transcrestal hydrodynamic cavitational sinus lift for the filling of subantral space: human cadaver study, *J Oral Implantol* 41(6):657–661, 2015.
105. Al-Dajani M: Recent trends in sinus lift surgery and their clinical implications, *Clin Implant Dent Relat Res* 18(1):204–212, 2016.
106. Chan HL, Oh TJ, Fu JH, et al.: Sinus augmentation via transcrestal approach: a comparison between the balloon and osteotome technique in a cadaver study, *Clin Oral Implants Res* 24:985–990, 2013.
107. Stelzle F, Benner KU: Evaluation of different methods of indirect sinus floor elevation for elevation heights of 10mm: an experimental ex vivo study, *Clin Implant Dent Relat Res* 13:124–133, 2011.
108. Mazor Z, Kfir E, Lorean A, et al.: Flapless approach to maxillary sinus augmentation using minimally invasive antral membrane balloon elevation, *Implant Dent* 20:434–438, 2011.
109. Nkenke E, Schlegel A, Schultze-Mosgau S, et al.: The endoscopically controlled osteotome sinus floor elevation: a preliminary prospective study, *Int J Oral Maxillofac Implants* 17:557–566, 2002.
110. Tan WC, Lang NP, Zwahlen M, Pjetursson BE: A systematic review of the success of sinus floor elevation and survival of implants inserted in combination with sinus floor elevation. Part II: transalveolar technique, *J Clin Periodontol* 35(8 Suppl):241–254, 2008.
111. Brizuela A, Martin N, Fernandez-Gonzalez FJ, et al.: Osteotome sinus floor elevation without grafting material: results of a 2-year prospective study, *J Clin Exp Dent* 6:e479–e484, 2014.
112. Nedir R, Bischof M, Vazquez L, et al.: Osteotome sinus floor elevation technique without grafting material: 3-year results of a prospective pilot study, *Clin Oral Implants Res* 20:701–707, 2009.
113. Abi Najm S, Malis D, El Hage M, et al.: Potential adverse events of endosseous dental implants penetrating the maxillary sinus: long-term clinical evaluation, *Laryngoscope* 123:2958–2961, 2013.
114. Di Girolamo M, Napolitano B, Arullani CA, et al.: Paroxysmal positional vertigo as a complication of osteotome sinus floor elevation, *Eur Arch Otorhinolaryngol* 262:631–633, 2005.
115. Testori T, Drago L, Wallace SS, et al.: Prevention and treatment of postoperative infections after sinus elevation surgery: clinical consensus and recommendations, *Int J Dent* 365809, 2012. Epub 2012 Aug 9.

33

Osteoperiosteal Flaps and Distraction Osteogenesis

OLE T. JENSEN, KATSUHIRO HORIUCHI

Alveolar Osteotomy Space Maintenance Using Osteoperiosteal Flaps

Ole T. Jensen

Introduction

Alveolar bone mass deficiency can be corrected by multiple techniques, which frequently use onlay bone grafting or guided bone regeneration. These two techniques have been the mainstay of oral and maxillofacial surgery reconstruction for dental implants over the past 2 decades.[1,2]

A newer approach that has the advantage of less disturbance to osteogenic periosteum, improved continuity of crestal gingivoalveolar form, and greater resistance of the augmentation to resorption remodeling is the use of the osteoperiosteal flap.

The osteoperiosteal flap or "bone flap," commonly used in segmental orthognathic surgery, is a bone fragment moved in space without detachment of the investing periosteum. The best example of this concept in reconstructive alveolar surgery as it relates to implant osseointegration is the interpositional bone graft or "sandwich graft." Other uses of the bone flap in dentoalveolar augmentation are the alveolar split graft (book flap), edentulous alveolar repositioning osteotomy, and various alveolar distraction osteogenesis procedures that add width or height to an alveolar segment.[3-7]

Space Maintenance

A key principle in developmental biology is replacement of a space-maintaining preliminary structure in the process of generation *os novum* of the sustaining tissue. An example of this is Meckel's cartilage of the in utero mandible. Meckel's cartilage serves as a scaffold for bone replacement in several ways, including establishment of the primordial nerve and blood supply, acting as a strut for conversion to ossified tissue, and, not least of all, the establishment of three-dimensional space for the growing mandible. In sum, the cartilage serves as a template from which ossification from adjacent connective tissue elements form bone by bone morphogenetic protein (BMP) induction.

In surgical repair, conceptualization of a space-making procedure is derivative of developmental biology in that the surgical wound created must prepare space for regenerative capacity to operate. In this sense, de novo bone formation, as with the use of BMP-2/acellular collagen sponge, must have a closed environment, a space, in which to operate. Another example is the space-maintaining function of graft materials such as autograft or allograft, which provide a place for adjacent connective tissue elements, such as unreflected periosteum, to populate the wound with induced bone-forming elements. When surgical design and wound care are circumspect, the defined space can fill with bone regenerated in any number of combinations of formation methods, including de novo, inductive/conductive-appositional, or replacement by creeping substitution.

Space Maintenance Strategy

A defect can be treated in a number of technical ways and there is clinical controversy as what to do in many settings. A decision to treat a defect could be based on what method might best create adequate space for the reconstructive effort. Adequate space could be based on creating adequate bone for orthoalveolar form with optimal gingival esthetic profile or alternatively adequate bone stock to fix implants for prosthetic restoration. Three basic methods are used today including, guided bone regeneration (GBR) for small defects, osteotomies for larger defects, and titanium mesh with either BMP-2 or iliac graft for larger defects. Block

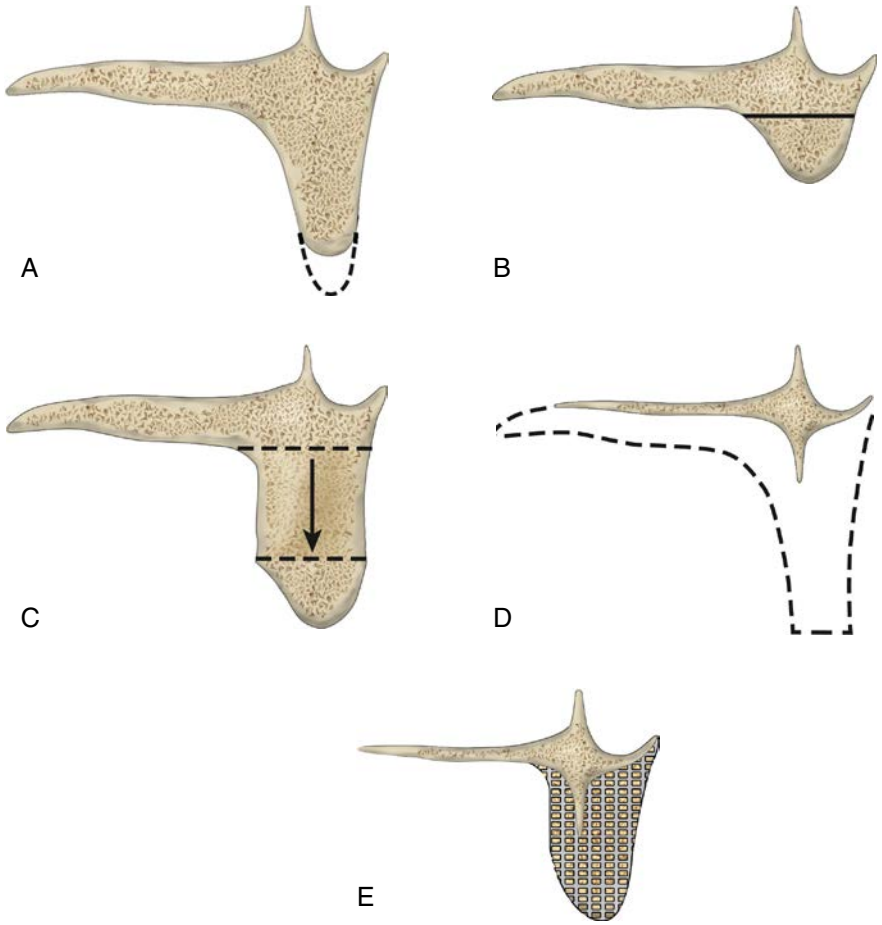

• **Figure 33-1** As bone is lost in the anterior maxilla shown in cross section above near the midline, modest alveolar defects are treated with guided bone regeneration **(A),** whereas more severe vertical defects can be treated with an osteotomy **(B)** that is then interpositionally grafted to gain vertical height **(C).** If bone loss is severe **(D)** then a mesh graft with BMP or iliac particulate is suggested **(E).**

bone grafting is also used but will not be discussed as an optimal alternative here.

When to use these three methods, GBR, osteotomy, or mesh, is based on the complexity of the osseous defect. Defects of a few millimeters vertical/horizontal, perhaps as much as 4 or 5 mm, can be treated with guided bone regeneration using a barrier membrane. Vertical defects greater than 4 or 5 mm, perhaps up to 10 mm can be treated by interpositional grafting using the sandwich osteotomy bone graft. (Alveolar distraction is used for vertical defects 10 mm or greater.) And titanium mesh with BMP-2/acellular collagen sponge (ACS)/allograft or iliac particulate are reserved for gross defects with both height and width deficiency—often over 10 mm vertical.

Figure 33-1 shows schematic treatment for three magnitudes of defect and possible management for the anterior maxilla. The surgical method of choice must take into account the simplicity of the proposed operative procedure as well as the medical necessity—that is, what will best heal in a given situation.

Osteoperiosteal flaps have great utility and advantage when bone is adequate for creating an osteotomy and the existing alveolar crest is not too thin or unstable from previous trauma. However, osteoperiosteal flaps have the disadvantage of being unidirectional in their augmentation strategy, meaning that either width or height can be increased but not both. Also, because of the indirect interpositional grafting technique, there is often a requirement for additional crestal bone grafting, which is commonly done at the time of implant placement to define final alveolar form.

Interpositional Bone Graft

The interpositional bone graft can be done anywhere in the mouth but is most indicated in the anterior esthetic zone and the posterior mandible. A depth-of-vestibule, horizontal incision is made to bone with complete reflection away from the alveolar crest and minimal reflection crestally. Vital structures, such as nerve, tooth roots, and the respiratory space, are identified to be avoided. The osteotomy design in the posterior mandible is shaped as a "smile line," tapering anterior and posterior with at least 5 mm of height in the middle of the segment suggested, noting that small bone volumes are less well vascularized and at greater risk for vascular embarrassment and late-term resorption. A through-and-through osteotomy is done from buccal plate to lingual plate, and an osteotome is used to gently free the segment. This is done taking care not to disturb the lingual pedicle.

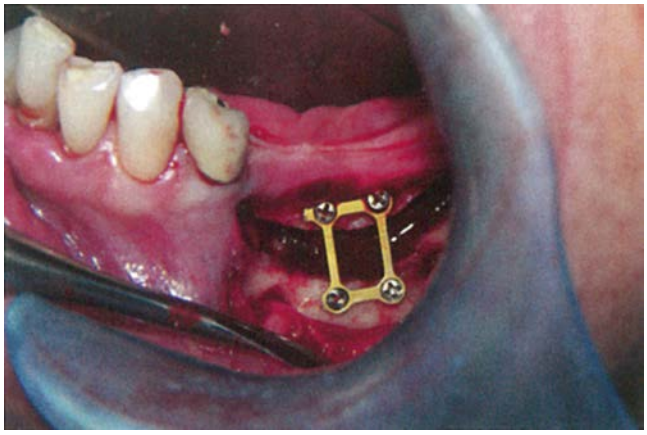

• **Figure 33-2** Alveolar elevation to the alveolar plane made with a "smile"-shaped osteotomy before graft insertion.

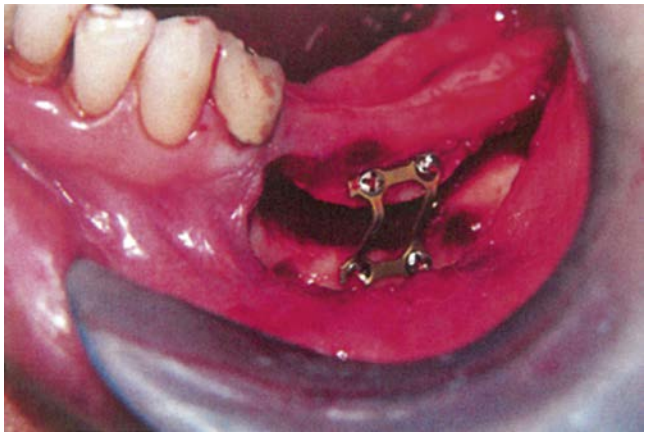

• **Figure 33-3** Particulate graft is inserted after bending the plate to orient the ridge into proper alignment.

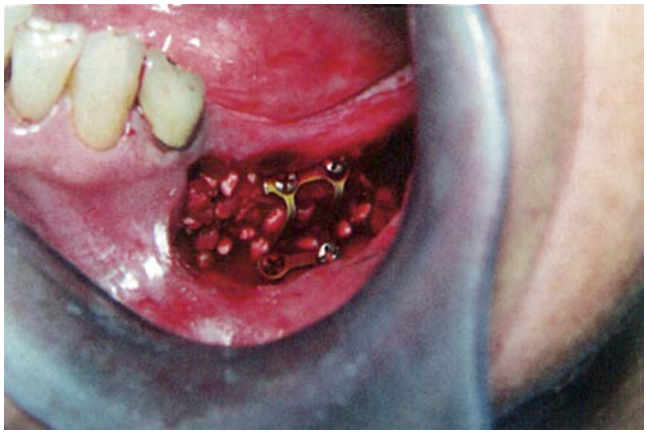

• **Figure 33-4** Particulate graft and PDGF-bb placed.

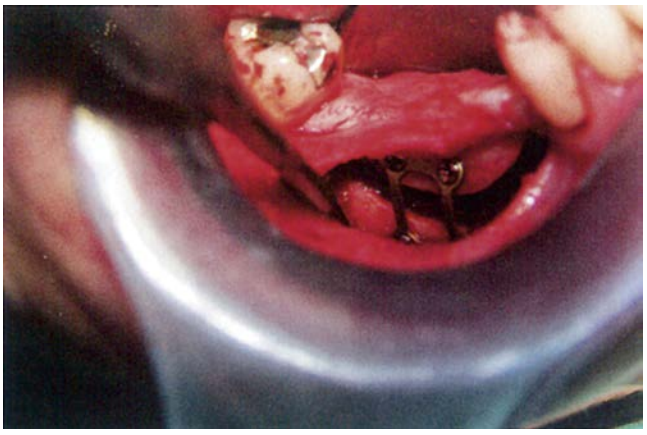

• **Figure 33-5** Right side "smile" osteotomy elevated 6 mm to the alveolar plane.



• **Figure 33-6** Wound closure (left side) of the vestibular incision is done in layers with resorbable suture.

The segment can be elevated up to 10 mm vertically (see Figure 33-1; Figures 33-2 through 33-6). A bone plate and interpositional graft material are placed, usually autograft, although bone morphogenetic protein (BMP-2), platelet-derived growth factor (PDGF-bb), and/or alloplast with PDGF-bb have been used successfully. Four months following bone healing, the plate is removed, and dental implants are placed. Often the alveolar ridge will need to be grafted laterally at the time of implant placement in these settings, but vertical augmentation should be adequate.[5]

The major advantage of an interpositional graft is an endosteal, marrow-accessed graft site—a highly vascular area conducive to graft incorporation. Very few seams, scar encleftations, bone graft exposure, bone graft resorption, or infections occur with this approach. Other advantages for using the interpositional graft technique are undisturbed alveolar crestal bone, improved gingival esthetic form in anterior locations, and a stable post-grafting architecture. One precaution in case selection is to avoid dense cortical bone, which may not be well vascularized and can lead to wound dehiscence and graft compromise.

Alveolar Split Graft (Book Flap)

The common alveolar finding from a late-healed extraction socket is a loss of alveolar width as a result of resorption of the buccal plate. The alveolus can be widened using a crestal incision that does not reflect beyond the crest buccally and lingually, but serves to identify the set point for osteotome or piezoknife osteotomy. Vertical cuts of the buccal plate are made blindly without flap reflection 1 or 2 mm from adjacent tooth roots and then connected sagittally to a depth of

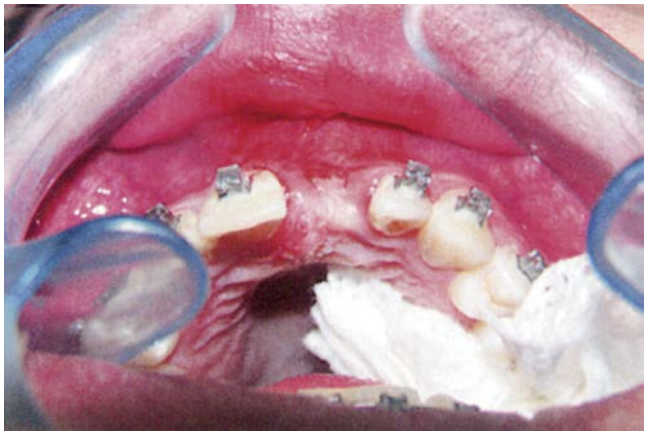

• **Figure 33-7** A moderately difficult single-tooth site, commonly the result of loss of the buccal plate.



• **Figure 33-8** Exposure of the site is done using a crestal incision made about 2 to 3 mm toward the palatal side.

about 10 mm. Then the buccal plate is split sagittally; the buccally directed out-fracture is done without detachment of the mucoperiosteum from the mobilized osseous segment (Figures 33-7 through 33-10).[6]

The intraosseous defect created is then grafted. Delayed implant placement is usually preferred in these settings. Primary closure is sometimes obtainable if the initial crestal incision is placed a few millimeters palatally. If the wound is left open, exposing the graft, collagen can be placed, such as that used for socket grafting to protect the graft. A good alveolar split gap is about 4 mm.

This technique requires about a 4-mm wide alveolar minimum, but if a piezoknife is used, a narrower width can be more easily managed. In practice, however, the use of titanium mesh is excellent for narrow ridges, so that a technical decision has to be made as to when a ridge is too narrow to split. A 4-mm width is a very conservative threshold to consider.

The alveolar split bone flap easily augments the majority of healed maxillary dental extraction sites. It can be used in the mandible, though hard bone is less flexible to greenstick fracture, and therefore flap detachment is a greater risk. For this reason, the split technique is used guardedly in the mandible.

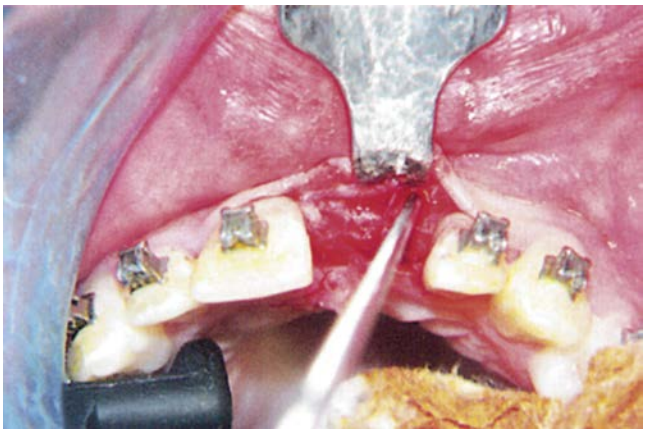

• **Figure 33-9** An alveolar split to widen the ridge is first limited by vertical cuts made about 2 mm from the adjacent tooth. This protects the subpapillary bone from fracturing off during the crest-splitting procedure.

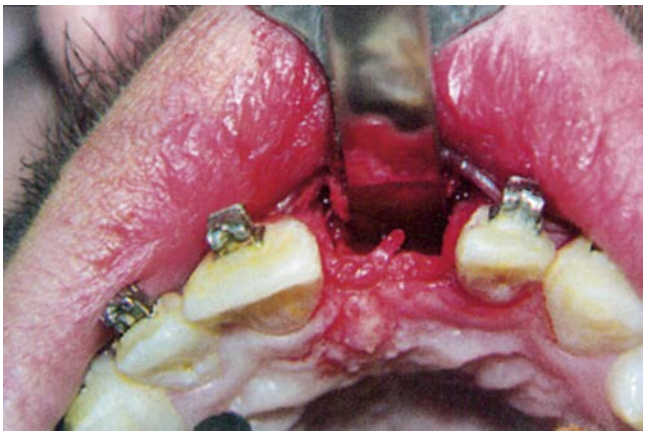

• **Figure 33-10** The alveolus is split crestally by inserting a straight osteotome about 10 mm, stopping at about vestibular depth. The wedged osteotome is then brought forward, spreading apart the alveolus until it greenstick out-fractures at the vestibular level. This is done without detachment of the mucoperiosteum. Bone graft is then placed in the gap and left to heal for 4 months before implant installation.

Alveolar Repositioning Osteotomies

Sometimes the alveolus has enough bone mass, but the alveolar crest is in an off-axis position, such as in an anterior or lateral (alveolar) cross bite. An alveolar segment can be freed and repositioned and fixed without grafting, as shown in Figures 33-11 through 33-14. And, of course, an entire jaw can be changed in position to optimize alveolar relation.

Implant Repositioning Osteotomy

Integrated dental implants that cannot be easily removed without leaving a substantial osseous defect can be moved with a segmental osteotomy. This is usually done to improve esthetic emergence of the implant (Figures 33-15 through 33-17).

Alveolar Width Distraction Osteogenesis

One area in which alveolar width can be achieved by distraction is the posterior mandible, a sometimes difficult area to

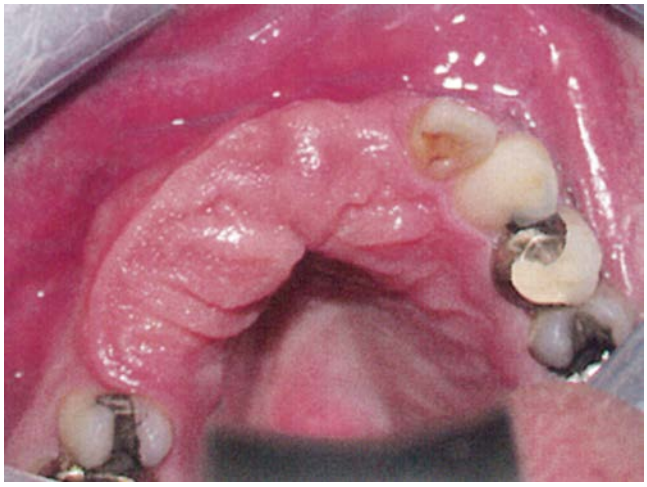

• **Figure 33-11** An anterior alveolar cross bite is present despite adequate alveolar width for implants.



• **Figure 33-12** Following segmental osteotomy to move the alveolus forward 4 mm, the guide stent shows the improved alveolar projection.

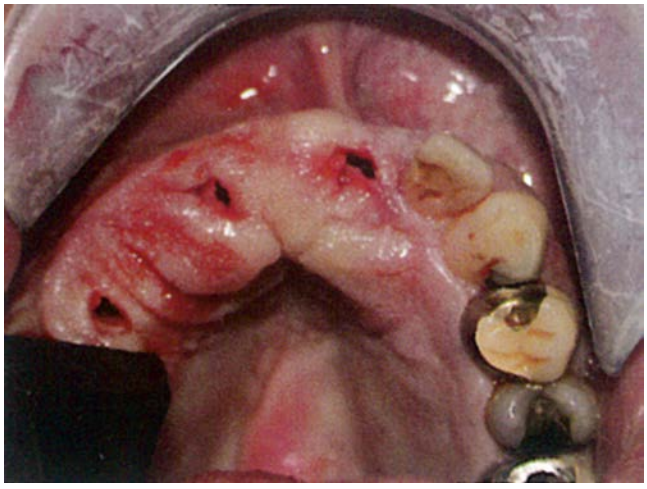

• **Figure 33-13** Transgingival implant placement is done using the guide stent.

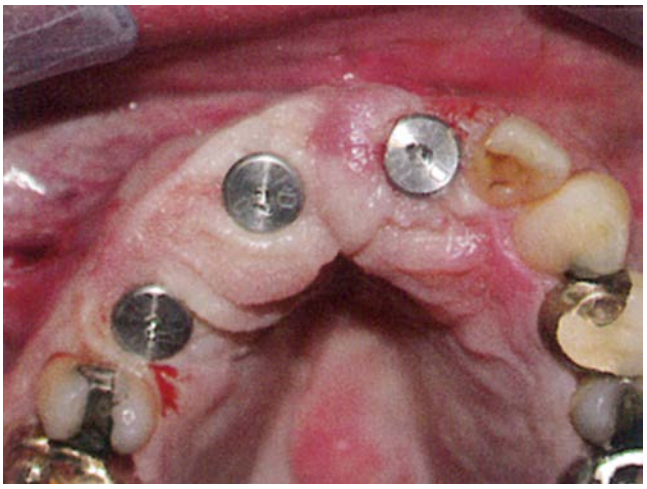

• **Figure 33-14** Implants are placed 3 mm below tissue level.

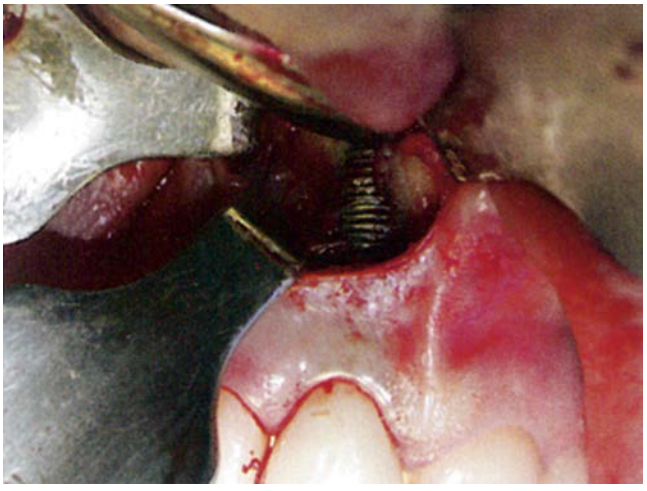

• **Figure 33-15** A poorly aligned dental implant can be moved bodily using a single-tooth osteotomy from a vestibular incision.

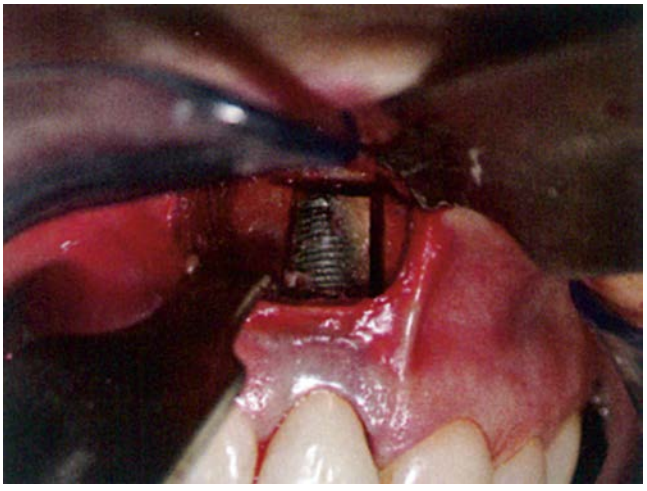

• **Figure 33-16** An implant transposition osteotomy is a risky one because tooth roots are likely nearby and it is difficult to keep enough bone on the implant to maintain osseointegration following mobilization of the implant segment.

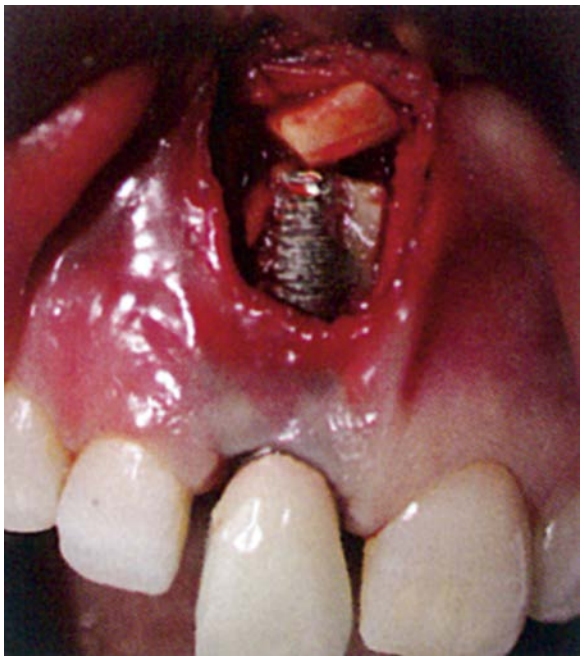

• **Figure 33-17** Once the implant cervical margin is placed at a more optimal position, typically a 4-mm coronal movement, grafting and stabilization of the implant can be done. The crown of the tooth is trimmed back to the occlusal plane to be remade at a later date. A healing time of 4 to 6 months is advisable before finalization in a setting like this for what is primarily done to improve the esthetic profile.

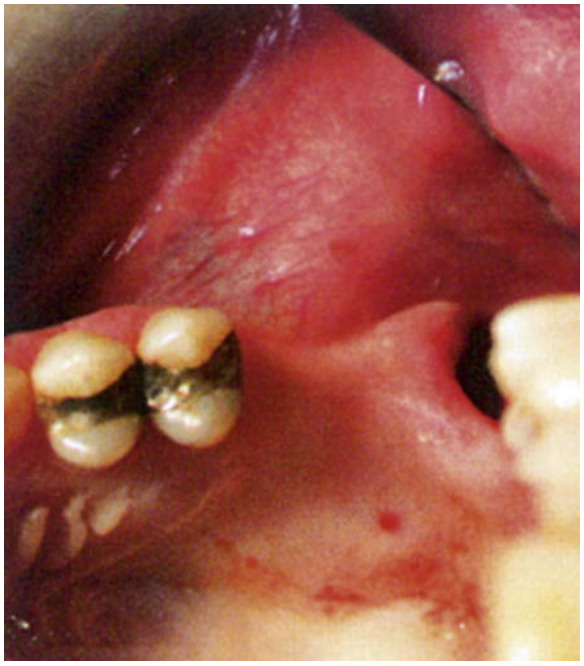

• **Figure 33-18** A narrow maxillary posterior alveolus can be widened by a split made through a crestal incision without periosteal reflection.

bone graft. It can be split through the crest in a relatively brief operation in which no bone graft is required. The wound can be left to heal for a week, and then at that point a bone spreader is tapped into place and activated. If the blood supply to the segment appears good, the device can be placed at the time of the initial surgery and activated 1 week later. Adequate width is

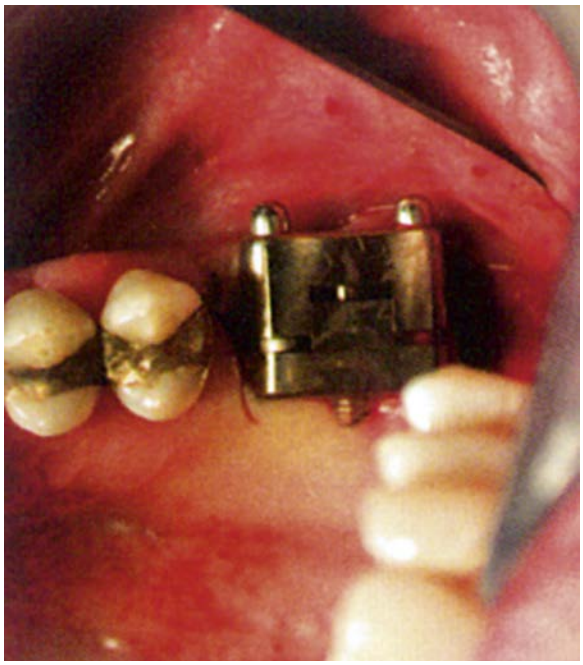

• **Figure 33-19** Following alveolar splitting, a bone spreader is placed.

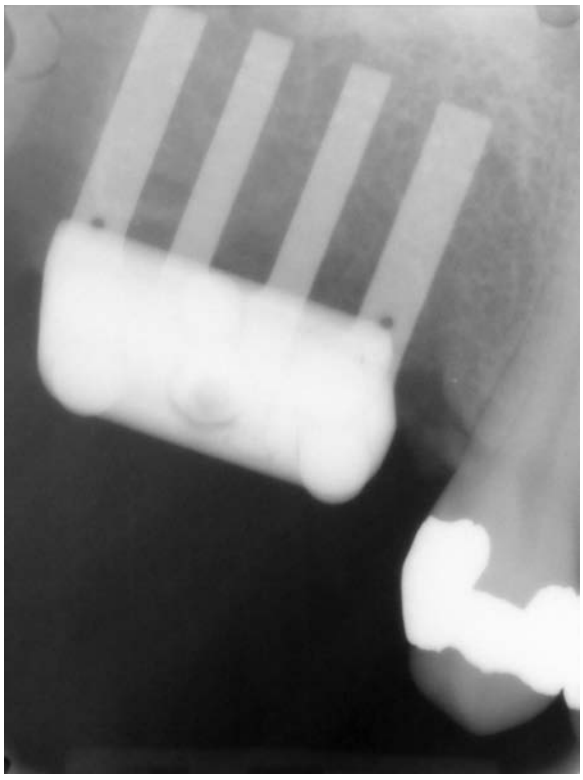

• **Figure 33-20** Immediate postoperative x-ray with a Laster crest distractor in place.

achieved in 7 to 10 days using an activation rate of 0.4 mm per day. Then the site is left to heal for a month, and implants are placed through the distraction zone, engaging into apical bone. Treatment time and morbidity are less for this approach when compared with onlay or veneer bone grafting. The procedure can be done in either the maxilla or the mandible, as shown in Figures 33-18 through 33-27.[7]

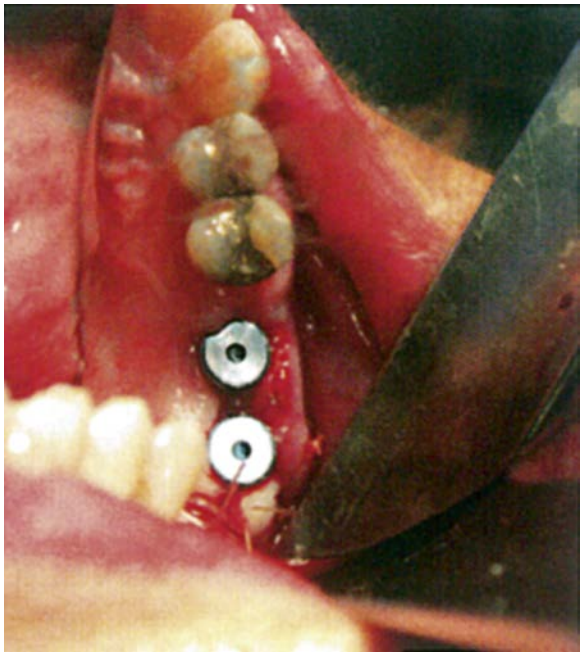

• **Figure 33-21** The distractor is removed 6 to 8 weeks later and implants are placed.

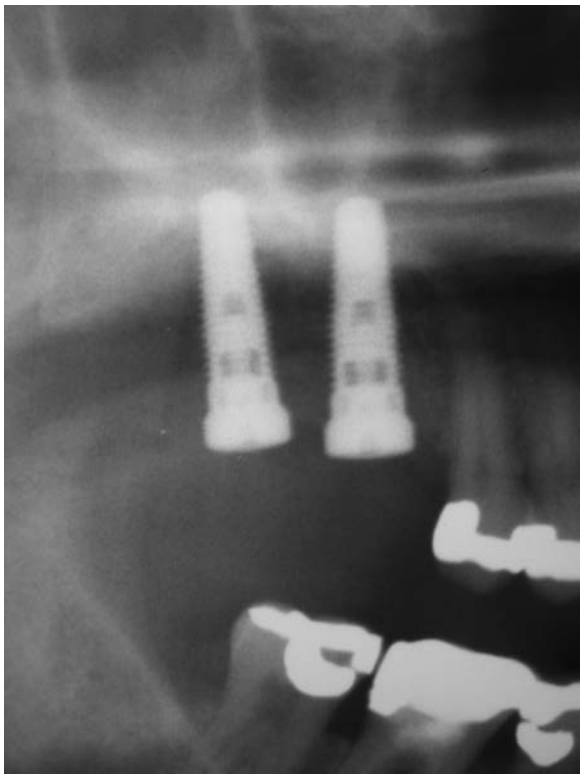

• **Figure 33-22** X-ray finding at the time of placement of two implants.

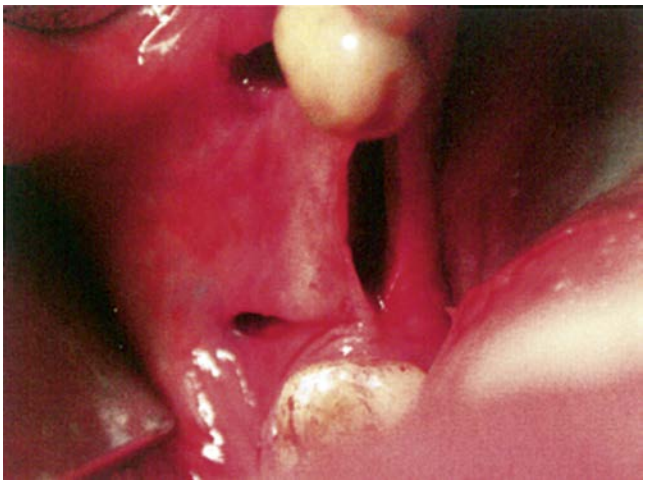

• **Figure 33-23** The alveolar width distraction flap should be carefully reflected. In the mandible, vertical cuts are made, but not reflected or connected to the crestal soft tissue wound. Bone cuts are made through these sites with very minimal reflection.

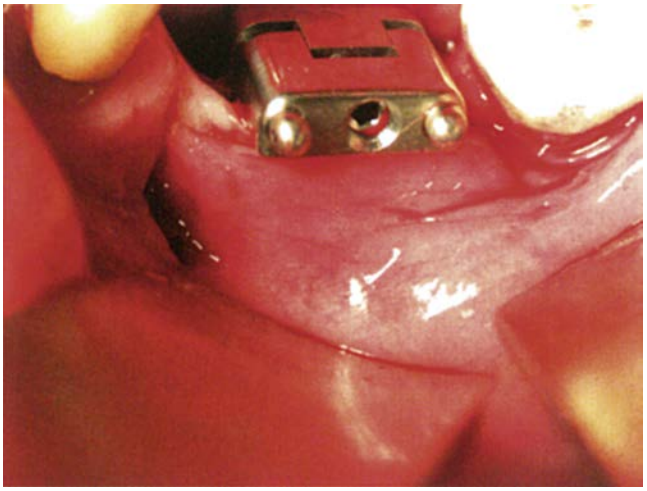

• **Figure 33-24** The distractor is placed.

Alveolar Vertical Distraction Osteogenesis

Alveolar vertical distraction osteogenesis is now well founded as a technique, but is still not broadly used because most vertical defects are less than 10 mm and can be more easily managed with the sandwich osteotomy or titanium mesh BMP-2/ACS. Also, vertical distraction almost always requires supplemental bone grafting before or after distraction. Vertical distraction osteogenesis is technically difficult, and therefore this factor must be a consideration for selecting this treatment alternative.

The most common indication for vertical distraction osteogenesis is in the anterior maxilla, where for esthetic reasons, the alveolus needs to be brought down and usually forward.

Figures 33-28 through 33-33 show an anterior maxillary defect treated with a bone flap translated by distraction. After the segment is cut and fixated with the distractor, the segment is moved down and forward at a rate of 0.8 mm per day until the segment engages the provisional or prosthetic guide. After a 4-month consolidation period, the implants follow with eventual prosthetic rehabilitation.[8,9]

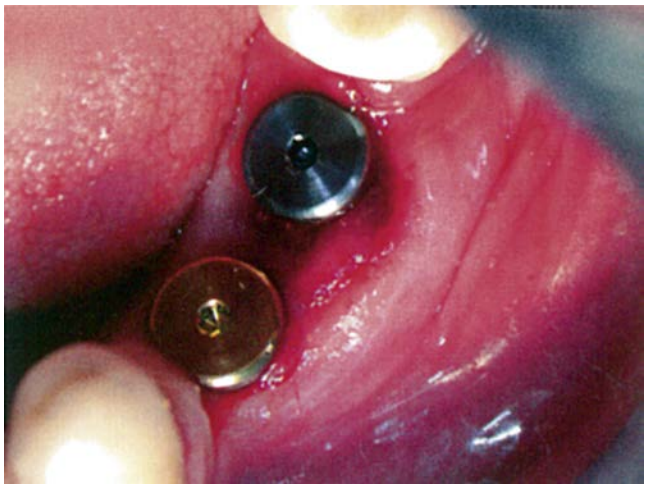

• **Figure 33-25** Implants are placed 2 months later.



• **Figure 33-28** A maxillary defect as a result of traumatic loss of #7, 8, 9, and 10 in a patient with apertognathia and a high smile line. X-ray findings show about 5 to 6 mm of vertical bone loss.

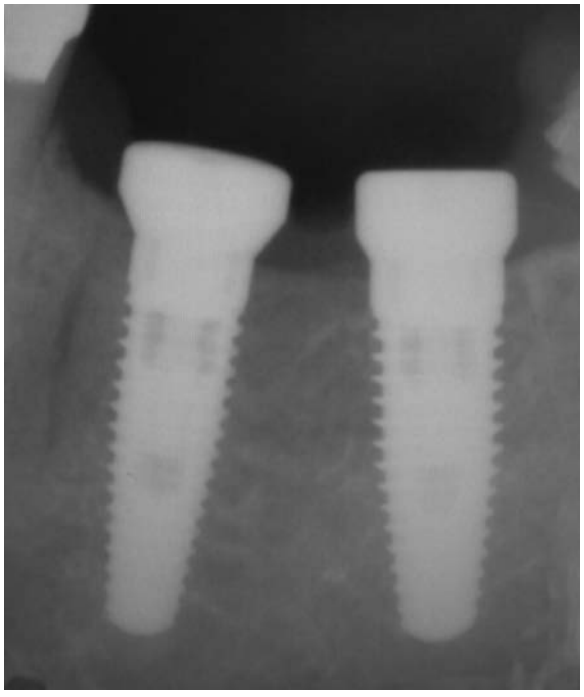

• **Figure 33-26** X-ray finding 4 months later.



• **Figure 33-29** Preoperative views.



• **Figure 33-27** Final restoration shows an increase in alveolar width.

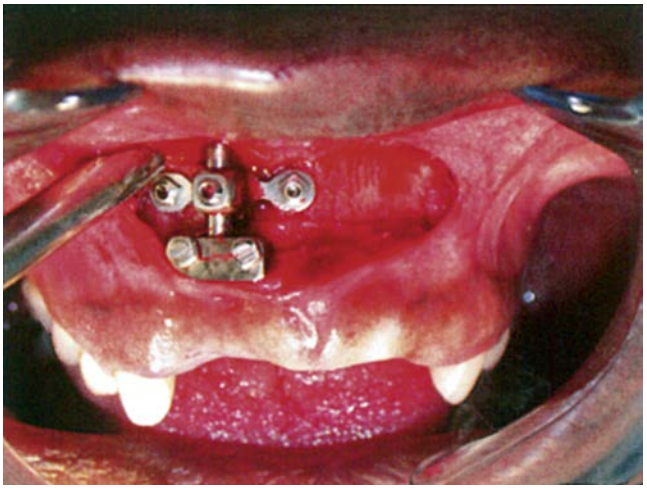

• **Figure 33-30** Placement of a vestibular bone distractor (Mommaerts-Laster) following osteotomy mobilization of the anterior segment.



• **Figure 33-31** The wound is closed primarily with a small access hole for distraction.



• **Figure 33-32** Following distraction and a 4-month healing time period, the distractor is removed, and implants are placed transgingivally.

Summary

In summary, the use of an osteoperiosteal flap is a space-maintaining strategy that allows the surgeon to handle most moderately atrophic dentoalveolar defects with a relatively simple surgical technique that requires no major bone grafting. It also allows for bone healing that is more stable, less likely to resorb, and more likely to consolidate or integrate into the graft site. The use of interpositional bone access engages the marrow vascular space—a place where graft material is less likely to sequester, become infected, or resorb away. The use of bone flap distraction also generates osteogenic bone of high quality, conducive to implant osseointegration.



• **Figure 33-33** Implants 4 months later before final single-tooth restorations.

Bone flap procedures in general present a more certain way of accomplishing greater alveolar width and height augmentation, with less complication than many other commonly used space-maintaining procedures.

Three-Dimensional Alveolar Distraction for Implant Placement

Katsuhiro Horiuchi

Introduction

The goal of prosthetically-driven implant therapy is to provide restorations with ideal functional and esthetic results. Tooth loss resulting from trauma, periodontal disease, tumor resection, or congenital absence leads to loss of height and width of alveolar bone and mucosa. Therefore, to achieve an esthetic and functional restoration using dental implants, the atrophic alveolus may need to be augmented. Recently, a variety of bone grafting procedures,[10-13] including guided bone regeneration (GBR)[14-17] and tissue engineering,[18,19] have gained popularity for alveolar ridge augmentation. GBR alone however, does not always induce predictable bone formation, especially for vertical ridge augmentation of more than 10 mm.[20] Though a variety of allogeneic bone and biomaterials has been developed, they are not always useful for extensive alveolar ridge augmentation.[21] Autogenous bone is still generally considered the best material for all types of osseous reconstruction, including alveolar ridge augmentation. However, it has some disadvantages, such as the need for a second surgical intervention, donor site morbidity, unpredictable bone resorption, and difficulty in managing soft tissue coverage and post-grafting soft tissue management.[21,22]

The first description of distraction osteogenesis was by Codivilla in 1905, when, after femoral osteotomy, he subjected the fragments to a strong tension using nails fixed in the bone.[23] With the design of new distraction devices and defined distraction rates by Russian orthopedist Gabriel

Abramowich Ilizarov in the early 1950s,[24,25] the concept has been widely applied to the lengthening and reconstruction of extremities. Distraction osteogenesis has some advantages compared to autogenous bone grafting: no additional surgery involving a harvesting procedure, no limit to lengthening, and simultaneous lengthening of the surrounding soft tissues, such as skin, muscle, blood vessels, and nerves. However, the disadvantages include a long treatment period, the need for a suitable distractor, patient inconvenience during distraction and consolidation, and risk of infection.[26,27]

In the field of oral and maxillofacial surgery, McCarthy and co-workers[28] first reported lengthening the human mandible by gradual distraction in hemifacial microsomia patients in 1992. Since this report, distraction osteogenesis has been used to lengthen or repair continuity defects in the mandible,[29,30] maxilla,[31-33] and cranial complex.[34,35]

In 1996, Block and colleagues demonstrated clinical, radiographic, and histologic vertical bone augmentation using alveolar distraction in dogs.[36] In the same year, Chin and Toth[37] described alveolar distraction and implant placement for a human in the reconstruction of an alveolar ridge defect following traumatic loss of teeth. Most reports on alveolar distraction have been related to vertical distraction in both mandible and maxilla. There have been few reports on horizontal or oblique alveolar distraction. In relatively small defects, veneer bone grafting or GBR can be used for alveolar ridge augmentation. In significant defects, however, bone augmentation is commonly done with iliac bone graft. In addition to complications and morbidity associated with the iliac bone graft, there is also the challenge of adequate soft tissue coverage, bone resorption, and inadequate vestibule depth.

All bone augmentation techniques are compromised when there is inadequate soft tissue present or when there is significant scar tissue. This is particularly problematic in the anterior maxilla and mandible when vertical hard and soft tissue defects exist after trauma or treatment of a pathologic condition. Tightly bound tissue in this area can make primary closure difficult.

Alveolar distraction osteogenesis techniques take advantage of the development of bone that results when an osteomized segment of bone is slowly moved, allowing new bone formation within the gap. The technique has the disadvantage of increased cost associated with the distraction device and esthetic compromise during the distraction phase. However, it is a predictable way to gain large vertical increases in hard and soft tissue, especially in difficult areas such as the anterior maxilla and mandible, including areas where there is significant scar tissue. Moreover, many patients with a severely resorbed alveolus require augmentation in not only vertical, but also horizontal and sometimes oblique direction. There have been few reports on alveolar distraction in such a direction. The authors have experienced three-dimensional alveolar distraction using ready-made or/and customized distraction devices for dental implant placement with good esthetic and functional results.

This section reports on alveolar distraction and a variety of three-dimensional aeolar distraction techniques, including anteroinferior (oblique) using a palatal distraction device,[38] fan-shape, and mesiodistal.

• BOX 33-1 Clinical Phases of Alveolar Distraction

Osteotomy:	Vestibular incision
Latency:	7-10 days
Distraction:	Distraction rate: 0.15-0.5 mm/day Distraction rhythm: once or twice/day
Consolidation:	2-3 months

Distraction Protocol

Alveolar distraction is one of the procedures using distraction osteogenesis and includes the concept of transport distraction osteogenesis.[39,40] There have been few long-term clinical reports with good esthetic and functional outcomes. Therefore, this is a subject for future analysis.

Since Chin and Toth[37] reported on alveolar distraction in 1996, a variety of the distraction devices have been developed and different distraction protocols have been established. However, the original clinical phases of distraction still remain the same: osteotomy, latency, distraction, and consolidation (Box 33-1).

Alveolar distraction involves cutting an osteotomy in the alveolar ridge to obtain the transport bone. After an initial latency period of 7 to 10 days that leads to soft tissue healing, the distractor is gradually activated to separate the transport bone at 0.15 to 0.5 mm per day. The gradual tension placed on the distracting bony interface produces continuous bone formation resulting from endochondral ossification.[41] In addition, the adjacent tissue including mucosa and attached gingiva expands and adapts to this gradual tension. Because the adaptation and tissue genesis involve a variety of tissue types in addition to bone, this concept should also include the term "distraction histogenesis."[42] The distracted segment and newly generated bone are allowed to heal for 2 to 3 months during the consolidation phase. The distractor is then removed.

Incision

For successful bone formation in distraction osteogenesis, Ilizarov emphasized that it required preservation of blood supply in the osteotomized area of the cortical bone.[24] However, Kojimoto and colleagues reported that preservation of the periosteum is more essential than preservation of blood supply in the osteotomized area of the cortical bone.[43] As alveolar distraction requires full-thickness osteotomy of the alveolus, not only the lateral cortex but also cancellous bone and inner cortex, it is critical not to damage the periosteum. Therefore, a vestibular rather than crestal incision is recommended to minimize reflection and damage of the periosteum. Moreover, careful and conservative dissection will maintain the vascularity of the transport segment,

decreasing excessive bone resorption and avoiding damage to adjacent structures, especially periosteum.

Osteotomy

The transport bone in alveolar distraction must be well-vascularized, similar to a pedicle vascularized bone graft.[39] When there is an inadequate volume of transport bone, moderate reflection of the periosteum has been shown to induce resorption of the transport segment in animal studies,[44,45] clinical reports,[46,47] and the author's experience. Therefore, the author recommends securing a transport segment more than 8 mm in height and more than 30 mm in length. A vestibular incision is recommended to minimize reflection of the periosteum, and the osteotomy must be performed carefully to minimize detachment of the palatal or lingual periosteum. A larger transport segment will avoid a higher rate of resorption. To prevent the transport bone from being caught up on the osteotomized edge during the distraction period, palatally (lingually) and apically convergent osteotomies must be performed. This is also very useful to decrease the lingual tipping of the distraction vector.

The osteotomy has been conventionally done with rotary burrs, bone saws, and osteotomes. González-García and colleagues reported that piezoelectric-assisted osteotomy for alveolar distraction significantly decreased surgical difficulty and the incidence of intraoperative complications, compared with conventional osteotomy.[48] A piezoelectric-assisted osteotomy may allow a deeper cut, decreasing the amount of chiseling required.

Latency Period

The latency period is defined as the time from the surgery seating the distraction device to the beginning of distraction. Saulacic and co-workers[49] reported that the most common latency period was 7 days to allow for healing of the mucoperiosteum and reduce the risk of wound dehiscence. In contrast, extended latency periods over 15 days were applied to ensure complete revascularization of the transport segment in cases where the mucoperiosteal pedicle is small or endangered.[49] The discrepancy in the effect of a latency period on bone healing might be related to the variation in the distraction parameters such as distraction rate, the amount of lengthening, and the post-distraction period that were used in the various studies.[49] A latency period may be essential for long bone lengthening (limb extension) but less crucial in the craniofacial region, where better vascularization may permit reduction or even elimination of a latency period.[50]

Distraction Period

The distraction period is the time between initial activation and the end of activation of the distractor device. The distraction period depends on the amount of distraction and distraction rate. The amount of distraction is generally based on the amount of tissue necessary to place the implant ideally. Some investigators recommend 20% to 30% of overcorrection (overdistraction), considering the amount of alveolar distraction relapse and bone resorption.[38,51,52]

Distraction Rate

The distraction rate is the daily amount of the transport bone to be distracted. Most investigators report a distraction rate of 1 mm per day in alveolar distraction osteogenesis of the maxilla and mandible as well as the extremity. Saulacic and colleagues reported in a systematic review that the mean distraction rate was 0.71 ± 0.27 mm per day.[53] They also noted a lower distraction rate of 0.4 to 0.5 mm in cases where distractor implants and horizontal distraction were used. According to Amir and colleagues, a distraction rate of 0.5 mm per day results in faster osteogenesis than a distraction rate of 1 mm in elderly patients.[54] Therefore, the rate of alveolar distraction was reported to be 0.3 to 1.0 mm, but there is still no established theory. Although manufacturers of alveolar distraction devices recommend a distraction rate of 1 mm, the author experienced a higher incidence of soft tissue dehiscence, poor bone formation, or non-union at this rate. With a distraction rate less than 0.5 mm, even in larger bone defects, such problems have not occurred. Gradual distraction results in less tension of the soft tissue than fast distraction at a rate of 1 mm, and seldom induces resorption of the transport bone. Therefore, the author recommends a gradual distraction rate of less than 0.5 mm per day, despite an increase in the distraction duration. In clinical situations with small transport bone, a distraction rate of 0.15 to 0.3 mm per day is likely to be more acceptable. Saulacic and co-workers also reported that the type of device used and an augmentation rate of more than 0.5 mm/24 h were significantly related to insufficient bone formation and evidence of complications.[55] Conversely, a slower distraction rate than usual may result in premature bone union during the distraction phase, which may require re-osteotomy. This author has experienced premature bony union requiring re-osteotomy in two cases where the defect included more than six teeth.

Distraction Rhythm

Distraction rhythm is the frequency of distraction activations per day. Saulacic and colleagues reviewed 209 distractions in 197 patients, where the rhythm of distraction was 1 (62%), 2 (35%) or 4 times daily (3%).[53] A more frequent distraction rhythm was correlated with a smoother alveolar distraction. The author recommends that the distraction rhythm should be twice per day when the patient or family can manipulate the distraction device. When this is impossible, the patient visits every day or every other day. However, there was no significant difference between the two when managed carefully.

Consolidation Period

A retention or consolidation period allows for maturation and corticalization of the regenerated bone. Amir and colleagues reported that bridging 10 mm of alveolar distraction gap with regenerated bone required at least 10 weeks.[54] It has been suggested that the poorly mineralized bone tissue found after 10 weeks of consolidation will start an adaptive

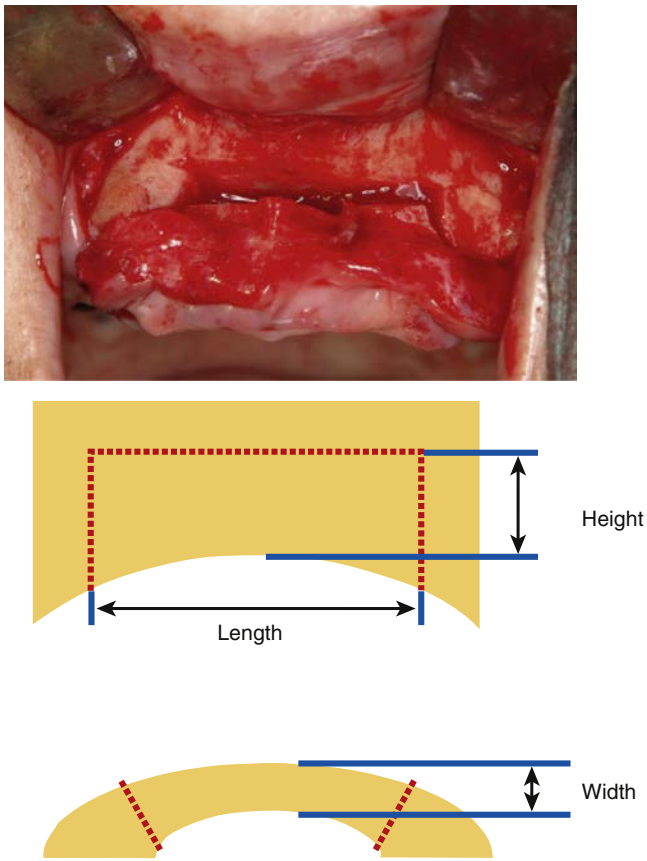

• **Figure 33-34** Prerequisites of alveolar distraction. Transport bone: well-vascularized with periosteal blood supply. Bone height >8 mm; bone length >30 mm (more than four teeth missing); bone width >6 mm.

response that would increase the bone matrix mineralization with placement of dental implants.[55] A systematic review of 209 cases in 20 articles found that the mean consolidation period was 12.22 ± 5.58 weeks.[53] Although some reports[56,57] recommend early implant placement, in the author's experience, early placement after only a 3 month consolidation period often results in increased crestal bone resorption of 1 to 2 mm. Therefore, the author recommends a consolidation period of at least 4 months to retain the transport bone until bone formation and resorption have stabilized. In addition, overdistraction of 2 to 3 mm should be done in anticipation of bone resorption or relapse.

In addition to the duration of the retention period, the prognosis of alveolar distraction depends on the stability of the transport bone. It is necessary to fix the transport bone rigidly with screws when the distraction device is removed earlier to seat the provisional restoration. Instability of the transport bone during the consolidation period will result in failure of alveolar distraction due to poor bone formation in the bone gap, resulting in non-union or pseudoarthrosis.

Indications for Alveolar Distraction Osteogenesis

Alveolar distraction has many advantages compared to other ridge augmentation procedures: no bone harvesting, no limitation of bone augmentation, simultaneous elongation of the surrounding soft tissue, and high predictability of tissue augmentation. In contrast, it has some disadvantages: the need for an adequate distraction device, the need for the patient's cooperation, the possibility of bone necrosis, and the inability to place implants simultaneously.

As for prerequisites of alveolar distraction, the transport bone must be well vascularized with periosteal blood supply[39] (Figure 33-34). Considering vascularization of the transport bone, small vertical defects of only one or two teeth tend to have a higher rate of complication when distracted and should usually be treated with conventional bone grafting techniques.[58] Bradley and Thomas reported that indications for alveolar distraction should include a minimum of 6 to 7 mm of bone height above vital anatomic structures and at least a 4-mm vertical defect of edentulous zone including three or more missing teeth.[59]

Jensen and Block proposed a site classification based on mild, moderate, and severe vertical bone loss (classes I to III) with a fourth class (class IV) designating significant loss of bone on adjacent teeth.[60] Class I is a mild, alveolar deficiency with up to 5 mm of vertical loss that ideally can be treated by a sandwich bone graft, although distraction can also be considered. In class II lesions with a defect of 6 to 10 mm, distraction is done more frequently to obtain ideal ridge form. If the residual alveolus is thin at the crest, a follow-up bone graft may be required. Class III lesions with a defect of greater than 10 mm need augmentation with a bone graft to increase the bone stock in order to do a distraction. Occasionally, when there is some bone present, the site is distracted first with follow-up grafting done to obtain an ideal ridge form.

Class IV lesions with significant loss of bone on adjacent teeth are best converted to class II or III sites by removal of the adjacent compromised teeth to make the problem more predictable and easier. A good rule of thumb is to remove any tooth with 50% bone loss or more unless orthodontic forced eruption is prescribed. In animal studies, attempts to improve the attachment level of natural teeth with distraction were unsuccessful.[61] With no evidence existing that the attachment level on teeth can be improved through distraction, it may be necessary to sacrifice a compromised tooth to optimize the amount of vertical bone improvement.[59]

Although the author mostly agrees with Jensen's classification, he has not suggested the prerequisites of the transport bone (or segment) for successful alveolar distraction. The author's opinion is that the transport bone should have a height of more than 8 mm, a length of more than 30 mm (more than four-tooth defect), and a width of more than 6 mm in order to maintain its viability. The author proposes four factors for selection of alveolar ridge augmentation procedures and indications for alveolar distraction. The four factors include the length of the bone defect, the remaining bone height, the remaining bone

width, and the amount of ridge augmentation (vertical and horizontal) (Box 33-2).

Factor 1: Length of the Bone Defect

In a single- to three-tooth defect, alveolar distraction should not be used, considering the viability of the transport bone.

• BOX 33-2 Guidelines for Selection of Alveolar Ridge Augmentation Procedures

Length of the Bone Defect

- Single- to 3-tooth: bone graft or guided bone regeneration (GBR)
- More than 4-tooth: case by case

Remaining Bone Height

- Less than 10 mm: vertical augmentation (onlay graft or vertical GBR) followed by alveolar distraction
- More than 10 mm: alveolar distraction, if needed

Remaining Bone Width

- Less than 6 mm: horizontal augmentation veneer graft or GBR
- More than 6 mm: no augmentation

Amount of Ridge Augmentation (Vertical, Horizontal)

- Vertical augmentation of less 5 mm: onlay graft or GBR
- Vertical augmentation of more than 5 mm: alveolar distraction, if needed
- Horizontal augmentation of less 5 mm: ramus veneer graft or GBR
- Horizontal augmentation of 5-10 mm: chin corticocancellous block bone graft
- Horizontal augmentation of more than 10 mm with the wide ridge of more than 6 mm: horizontal or oblique alveolar distraction

TABLE 33-1 Guidelines for Selection of Alveolar Ridge Augmentation Procedures in More Than Four-Tooth Defects

Remaining Alveolar Ridge Height ≥10 mm		
	Alveolar Ridge Width (ARW)	
VBD	ARW <6mm	ARW ≥6 mm
VBD ≤5 mm	BG	BG or AD
VBD >5 mm	AD→BG	AD

Remaining Alveolar Ridge Height <10 mm		
	Alveolar Ridge Width (ARW)	
VBD	ARW <6mm	ARW ≥6 mm
VBD ≤5 mm	BG	BG
VBD >5 mm	BG→AD	BG→AD

AD, Alveolar distraction; *BG,* bone grafting or guided bone regeneration; *VBD,* vertical bone defect.

This clinical scenario should be treated by bone graft or GBR. In defects with more than a four-tooth span, treatment planning should be determined on a case-by-case basis. Considering the factors mentioned next, the author would like to propose guidelines for selection of alveolar ridge augmentation procedures in more than a four-tooth defect.

Factor 2: Remaining Bone Height

Alveolar distraction requires a residual bone height of more than 10 mm to obtain a transport segment of at least 8 mm with remaining basal bone of at least 2 mm. Therefore, when the alveolar ridge height is less than 10 mm, onlay bone graft or vertical GBR should be first performed to gain the alveolar ridge height of minimum 10 mm prior to alveolar distraction.

Factor 3: Remaining Bone Width

When an implant with 4-mm diameter is placed, a bone width of more than 6 mm is necessary. If bone width is less than 6 mm, veneer bone graft or horizontal GBR is needed before or at the time of implant placement.

Factor 4: Amount of Ridge Augmentation (Vertical, Horizontal)

When the amount of vertical ridge augmentation is more than 5 mm, alveolar distraction is generally thought to be superior to bone graft or GBR.[18,60] Although there have been some reports on horizontal alveolar distraction for the narrow ridge,[62,63] it is generally not accepted because of resorption or loss of the transport bone and unpredictability. The author has sometimes employed horizontal or oblique alveolar distraction in a wide ridge of more than 6 mm to place implants in an ideal position.[38] For horizontal ridge augmentation of a narrow ridge of less than 6 mm, horizontal GBR or intraoral block bone graft is easier and more predictable. A corticocancellous symphyseal block bone graft can be used to augment up to approximately 10 mm of bone horizontally or vertically.

Alveolar distraction can be employed in the esthetic zone (the anterior maxilla and mandible). Vertical ridge augmentation in the posterior maxilla can be achieved by use of sinus augmentation or/and bone graft or GBR. Though alveolar distraction for vertical defects of the posterior mandible has been reported,[62-64] it has a variety of complications, such as fracture or resorption of the transport bone and mental paresthesia.[65-67] Moreover, if the defect also has a horizontal component, a more traditional approach with onlay bone graft or vertical GBR is recommended.[68,69]

Based on the aforementioned factors, guidelines for the selection of ridge augmentation procedures in sites with more than four-tooth defects are summarized in Table 33-1. More than four-tooth defects are classified into two groups according to whether the remaining bone height is greater or less than 10 mm. Defects with residual bone height greater than 10 mm are further

divided into two subgroups: those with a bone width greater than 6 mm and an amount of vertical ridge augmentation more than 5 mm, and those without. Defects with bone width less than 6 mm require veneer bone graft or horizontal GBR prior to or simultaneous with implant placement. In defects where the amount of vertical ridge augmentation is greater than 5 mm, alveolar distraction is the first choice because it is more predictable compared to conventional ridge augmentation. Even if the amount of vertical ridge augmentation is less than 5 mm, the large defect with the remaining bone width greater than 6 mm often requires horizontal or oblique alveolar distraction to place implants in an ideal position. In defects where the remaining bone height is less than 10 mm, conventional vertical ridge augmentation should be first performed, followed by alveolar distraction if needed.

Three-Dimensional Alveolar Distraction

Most severe alveolar ridge defects have both vertical, as well as, horizontal component, requiring three-dimensional ridge augmentation to achieve optimal implantation. In these severe defects, three-dimensional alveolar distraction (vertical, horizontal, oblique, fan-shaped, or mesiodistal) should be considered because conventional ridge augmentation with bone graft or GBR may not be able to resolve the entire defect. This is especially true in defects with massive loss of hard and soft tissue and where significant scar tissue is present.

Vertical Alveolar Distraction

All ready-made distraction devices are only vertical and are of three types; screw-type (LEAD System),[37] plate-type (TRACK PLUS System, KLS Martin, Germany),[44,46,53,56] and implant-type (ACE Distractor).[56,70]

In a bone defect with more than five teeth, it may be difficult for the LEAD System and ACE Distractor to distract the transport bone successfully using only one device. Therefore, in such a case, several devices are required, resulting in a problem of parallelism of devices. Moreover, both distractors need adjunctive fixation for stabilization. When the bone defect span is large, there are few remaining teeth for adjunctive fixation of a screw-type or implant-type device. In these bone defects involving more than five teeth, the rigid plate-type TRACK PLUS System (KLS



• **Figure 33-35** Severe vertical defect of the anterior mandible as a result of a failed implant placed at the left mandibular incisal region. **A,** Unsuccessful guided bone regeneration (GBR) was attempted twice by a referring clinician, resulting in severe attachment loss to both adjacent teeth. **B,** Radiograph showing vertical bone defect and failing implant. **C,** After extraction of both adjacent teeth, the alveolus had vertical bone defect of 8 mm and significant deficiency of the soft tissue. **D,** Soft tissue scarring due to failure of repeated GBR.

Continued

Martin) without adjunctive fixation is more suitable. The author recommends a plate-type distractor because of better rigid stabilization of the transport bone, compared with screw-type and implant-type devices. Vector control during alveolar distraction to achieve an optimal direction can be challenging because the pull from the oral musculature and the thick palatal tissue can alter the desired vector in a palatal or lingual direction.[71] Some techniques for vector control have included the use of adjuvant devices, elastomeric chain, wire splint, resin splint, and cross-arch elastics.[71,72] In addition, some reports have shown the clinical value of multidirectional alveolar distraction devices to better control the distraction vector.[73,74]

The author overcompensates by directing the unidirectional distractor more toward the facial to overcome the soft tissue pull, in addition to supporting the distractor rod with a provisional restoration. Unexpected distraction direction may be corrected by performing limited "molding" of the newly formed bone within 1 to 2 weeks after completion of the distraction.[71] In cases with a narrow alveolar ridge, adjunctive ridge augmentation with veneer bone graft or horizontal GBR may be needed (Figure 33-35).

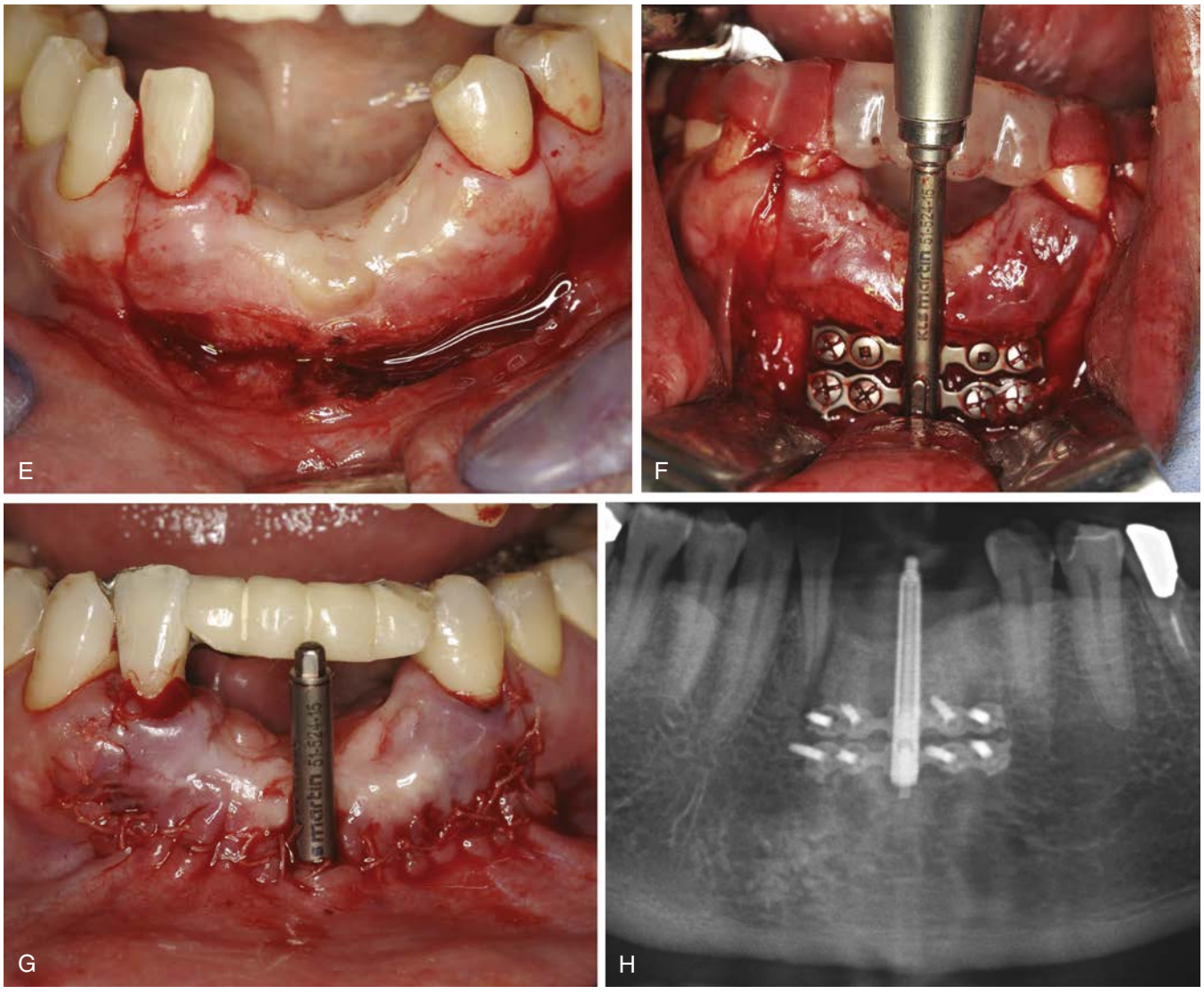

• **Figure 33-35, cont'd** **E,** To preserve the periosteal blood supply of the transport bone, a vestibular incision was made in combination with two vertical incisions to perform vertical osteotomy 1.5 mm mesial to the adjacent tooth. **F,** Horizontal and two vertical osteotomies were performed using a fissure burr and an oscillating bone saw, followed by a fine chisel. The transport segment must have a minimum height of 8 mm and length of 30 mm to reduce the amount of resorption. A plate-type alveolar distractor was placed with the micro-screws inclined in a more labial distraction vector to compensate for the pull from the lingual musculature. **G,** Wound closure. Alveolar distraction started after a latency period of 10 days for soft tissue healing. **H,** Radiograph showing alveolar distractor placement.

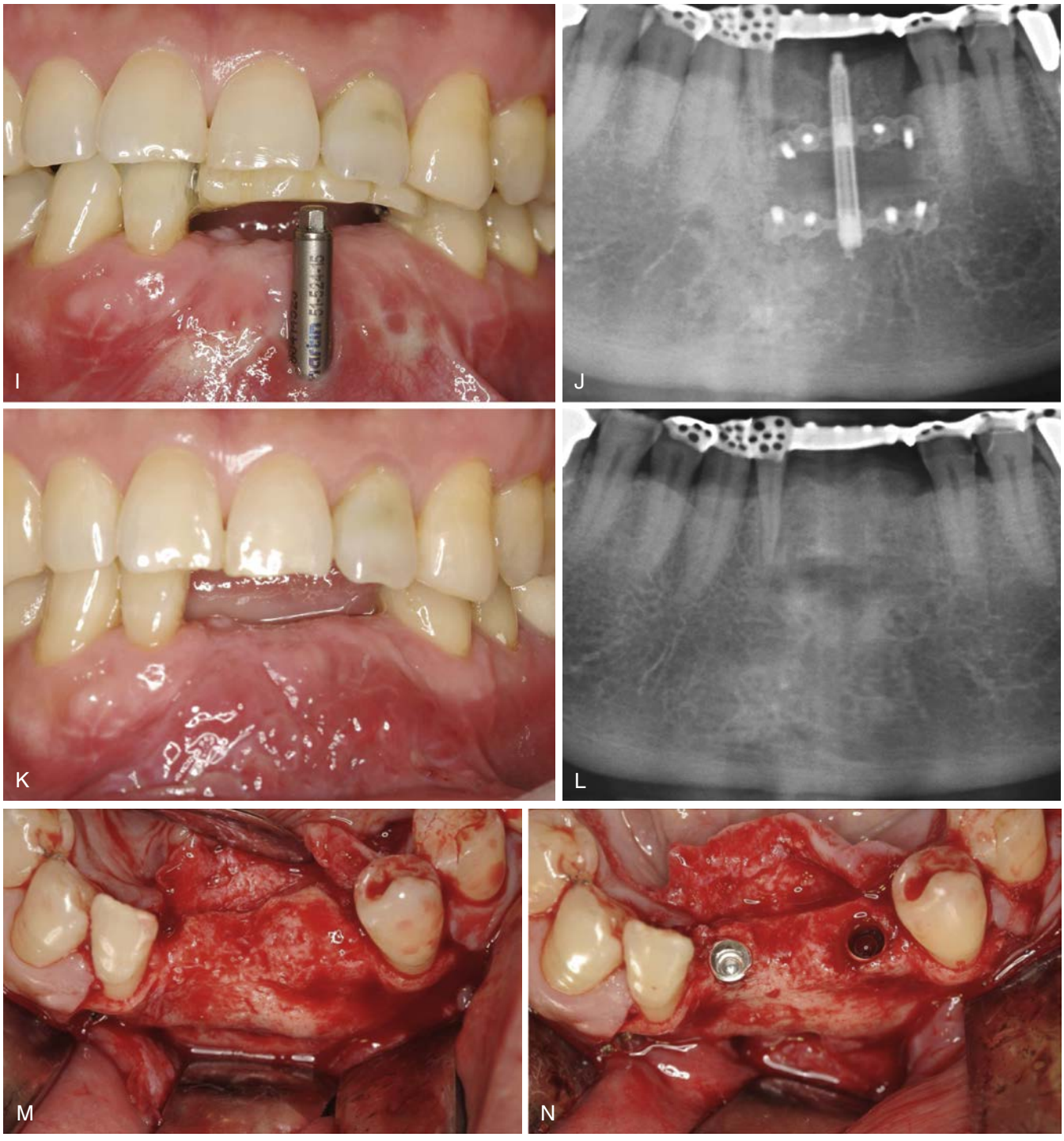

• **Figure 33-35**, **cont'd** **I,** Distraction rate was 0.15 mm per day because the defect was relatively small and had significant scarring. **J,** Vertical distraction of 11 mm completed for 11 weeks. Overcorrection of 3 mm of the transport segment was achieved in anticipation of future resorption. **K,** After a consolidation period of 3 months, the alveolar distractor was removed. Gradual distraction achieved lengthening of not only bone but also the surrounding soft tissue, despite the scar tissue. **L,** Most of the distraction gap was filled with radiopacity resulting from endochondral ossification. **M,** The transport bone was distracted 2 mm lingually, resulting from the pull of lingual musculature. **N,** Two implants were placed in an ideal position.

Continued

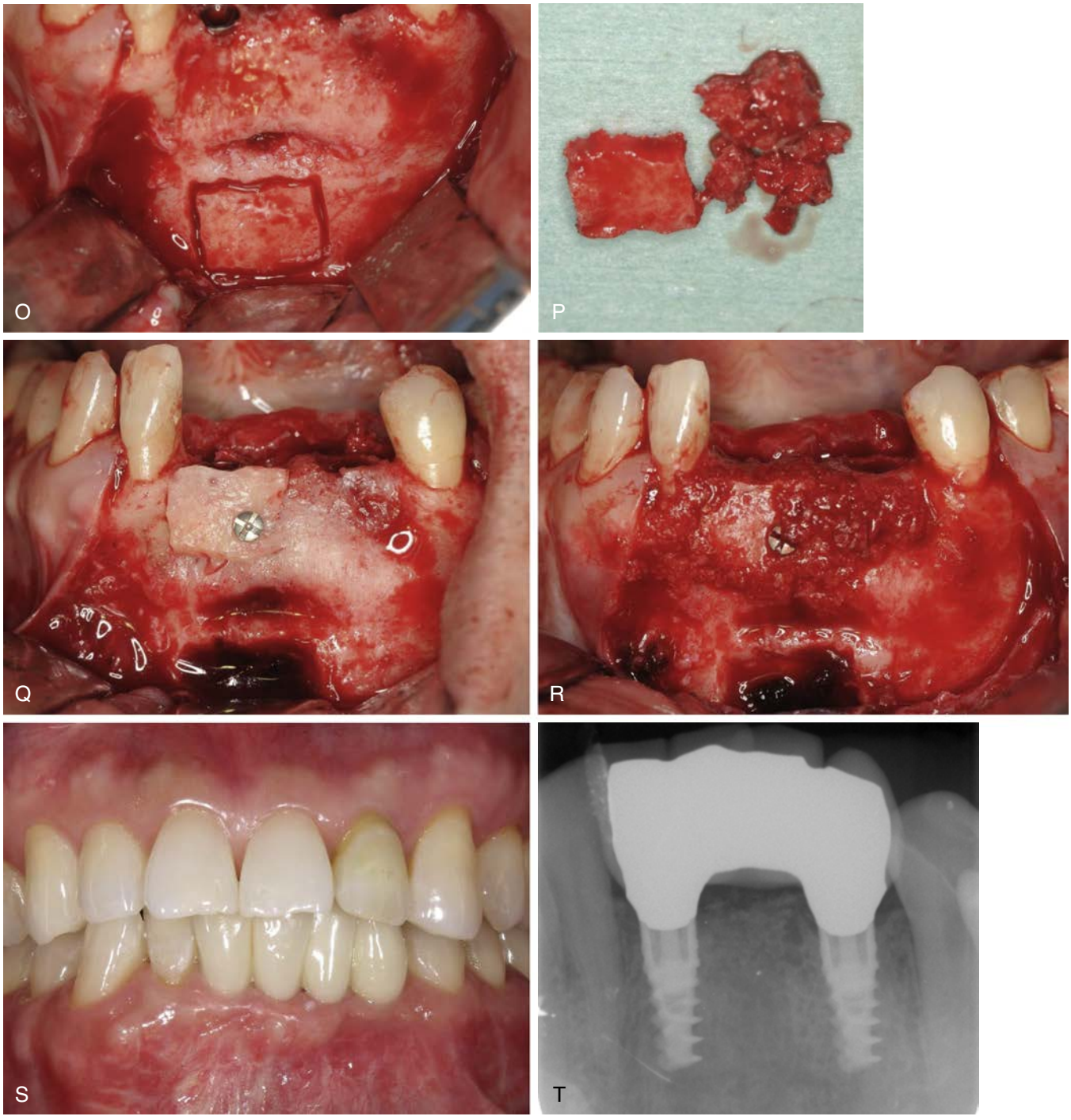

• **Figure 33-35**, **cont'd** **O,** To ensure adequate labial bone thickness for implant placement, additional horizontal bone augmentation is performed. Osteotomy was performed for harvesting the symphyseal bone. **P,** Cortical block bone and cancellous bone harvested. **Q-R,** Bone block fixated with micro-screw in combination with cancellous bone. **S,** Final restorations. Simultaneous lengthening of the soft tissue made vestibuloplasty unnecessary. **T,** The reconstructed alveolar crest is approximately 2 mm incisal to the junction between the implant and the abutment.

A ready-made plate-type distractor has the limitation of maximum distraction length of 15 mm. In cases with vertical defect of more than 20 mm, repeated vertical alveolar distraction is required (Figure 33-36).

Horizontal Alveolar Distraction

Some investigators have reported on horizontal alveolar distraction using a modified titanium screw with a 2-mm diameter or uniquely designed distractors.[62,63,70,75-78] All of these devices have in common a distraction rod that is fixed in the cortical lingual/palatal bone plate and allows for buccal/labial movement of the transfer segment.[77] Aparicio and Jensen reported that the most ideal area for horizontal distraction was a knife-edge posterior mandible with sufficient bone height and good access to the bone marrow.[75] However, the difficulty of performing an osteotomy in a narrow alveolar ridge, instability of the device, and resorption of the transport bone have greatly limited the use of horizontal alveolar distraction.[53,66,67,78] In most cases with horizontal alveolar deficiency, conventional ridge augmentation procedures with autogenous block bone graft or GBR are more advantageous than distraction osteogenesis.[75]

Oblique Alveolar Distraction

In the esthetic zone, it is important for the atrophic alveolus to be augmented to correct ridge form in three dimensions (vertical, horizontal, and oblique). Advancement of the total maxilla or anterior maxilla by distraction osteogenesis through a horizontal vector has been reported experimentally[79,80] and clinically,[31-33] but there have been few reports on oblique alveolar distraction. The author first reported anteroposterior (oblique) distraction of the atrophic subtotal maxillary alveolus for implant placement. The maxillary alveolus between the second premolars was distracted anteroinferiorly (horizontal 10 mm, vertical 5 mm) with an extraosseous custom-made distractor over the hard palate 0.25 mm twice a day for 25 consecutive days, which allowed placement of implants in a more ideal position. When the

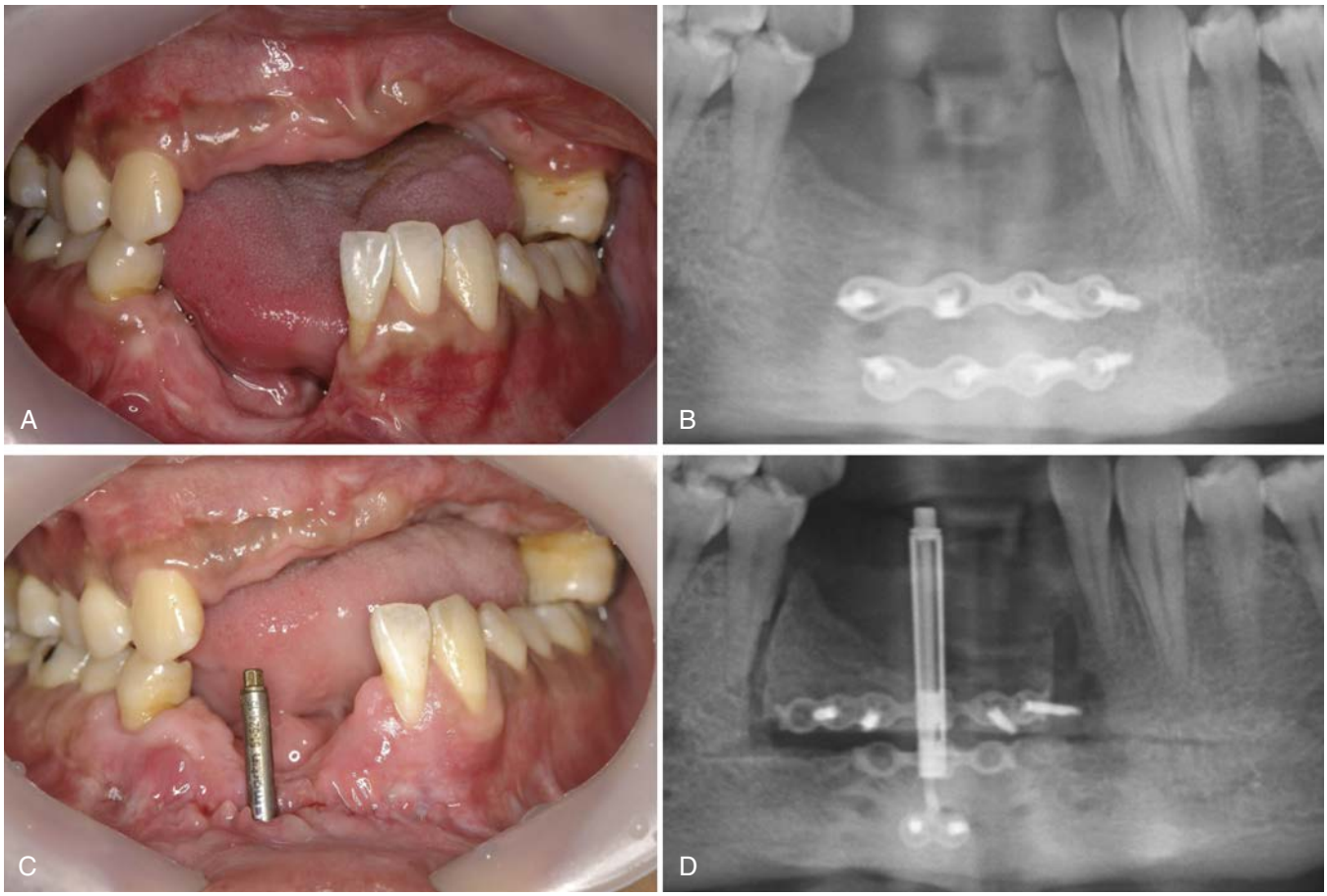

• **Figure 33-36** Severe vertical bone defect of 25 mm in the anterior mandible. **A,** The patient was involved in a motor vehicle accident 10 years ago resulting in mandibular fracture and avulsion of 3 teeth and bone in the anterior mandible. **B,** Mandibular fracture was treated with reduction and fixation using titanium plates and screws. A radiograph revealed severe attachment loss of the left mandibular central incisor. **C,** After extraction of left mandibular central incisor and removal of plates and screws, a plate-type alveolar distractor was placed for vertical ridge augmentation. **D**, Radiograph showing optimal positioning of the alveolar distractor to distract the transport bone up to 15 mm maximal capacity.

Continued

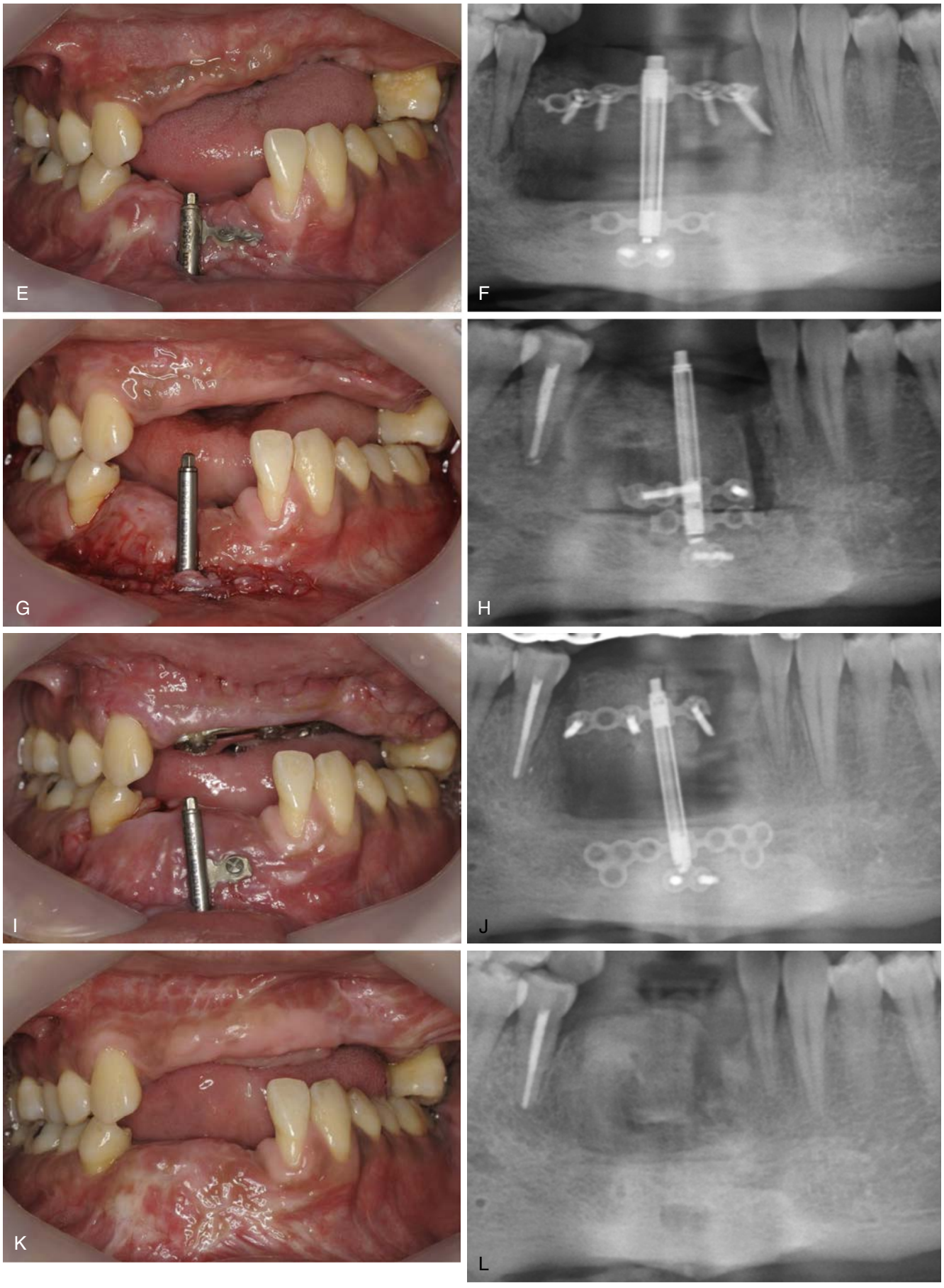

• **Figure 33-36, cont'd** **E-F,** After 15 mm of distraction, a vertical defect of approximately 10 mm still remained. **G-H,** For additional vertical ridge augmentation, the upper plate of the distractor changed the position to the lowest one. **I-J,** After additional 13-mm distraction (total 28-mm distraction), the alveolar crest was in a more ideal position. **K-L,** After a retention period of 4 months, the distractor was removed. Additional minor ridge augmentation was needed at the time of implant placement to achieve a more ideal bony architecture.

ratio of vertical direction in oblique distraction is greater than that of the horizontal one, a plate-type distractor can be employed facially. However, in cases with a greater ratio of horizontal vector, a palatal extramucosal distractor should be used to control the distraction direction more easily, usually parallel to the anterior palatal surface (Figure 33-37). The palatal distractor can be fixed rigidly with titanium micro-screws into the palatal mid-portion and bilateral sides. In addition, the transport bone can be secured to the distractor using 10-mm–long titanium microscrews in combination with adhesive resin cement. Alveolar distraction induces not only bone augmentation but also soft tissue elongation, which can improve the depth of the vestibule, despite the large bone augmentation of 13 mm.

Fan-Shaped Alveolar Distraction

Fan-shaped alveolar distraction describes a protocol where the transport bone is distracted at only one side with the pivot on the other side, similar to opening a fan. This technique can be employed when the alveolus has uneven height, where the defect site has more than a 10-mm discrepancy with the normal side. After osteotomies are performed, a

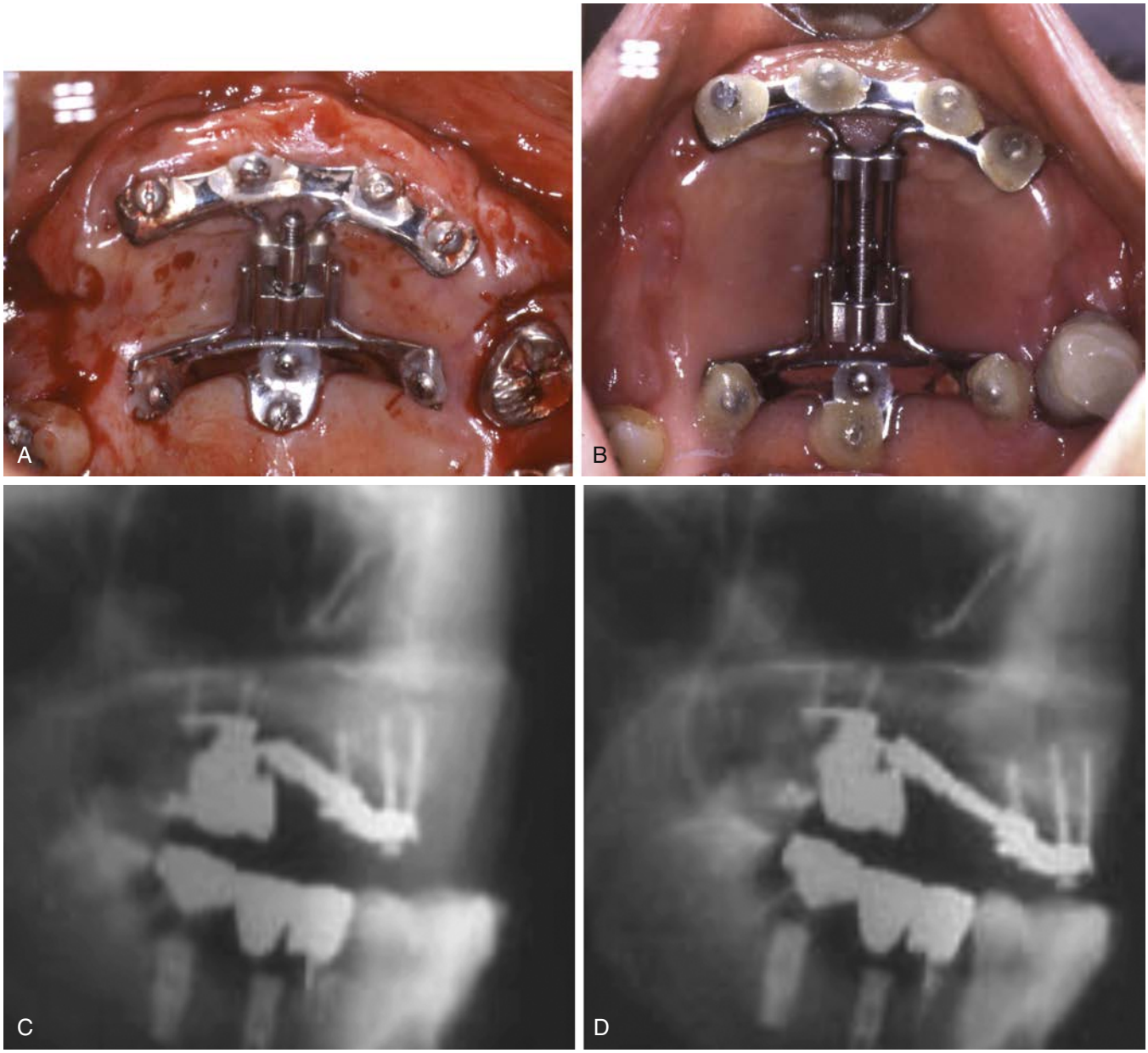

• **Figure 33-37** Severely atrophic subtotal maxilla resulting from severely advanced periodontitis. **A,** The anterior alveolar ridge was positioned 10 mm palatally and there was 5-mm vertical bone loss between the bilateral second premolar regions. For antero-inferior (oblique) alveolar distraction, a distraction device was seated with titanium mini-screws and adhesive resin cement over the hard palate. **B,** A lateral cephalogram revealed skeletal Class III. **C,** After a 7-day waiting period, the maxillary alveolus was distracted antero-inferiorly 0.25 mm twice a day for 25 consecutive days to an ideal ridge form. **D,** A comparison of pre- and post-distraction lateral cephalograms revealed 10 mm of anterior movement and 5 mm of inferior movement of the subtotal maxillary alveolus, converting from skeletal Class III to a Class I.

Continued

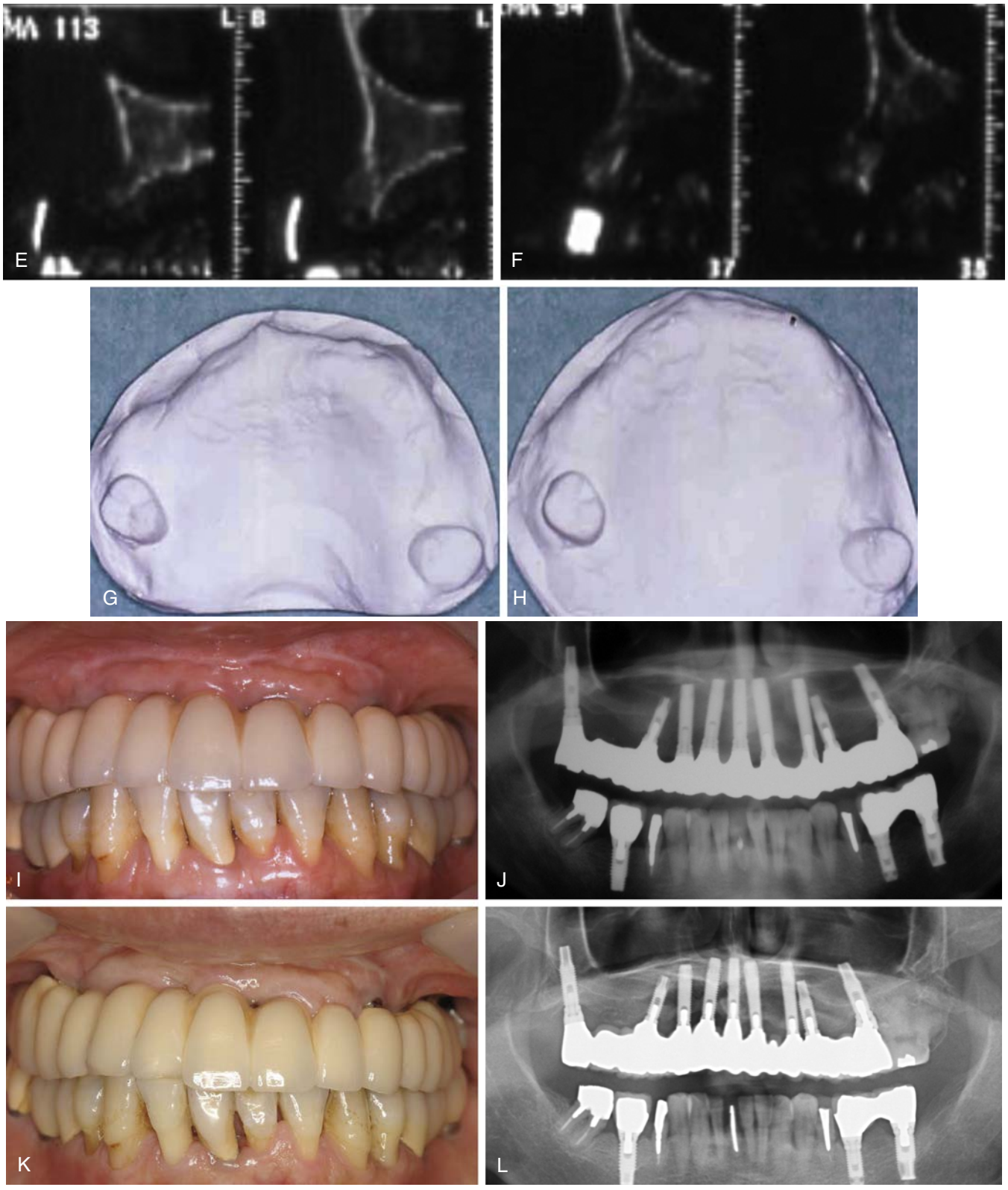

• **Figure 33-37, cont'd** **E,** DentaScans revealed that the anterior alveolar ridge was positioned 10 mm palatally and 5 mm apically. **F,** Post-distraction DentaScans demonstrated that the maxillary alveolus was adequately distracted to allow placement of implants in an ideal position. **G-H,** A comparison of pre- and postdistraction casts showed 13-mm of antero-inferior lengthening. **I-J,** The definitive restoration without artificial gingivae was possible. **K-L,** There was no significant marginal bone resorption around the implants 16 years after placement of the definitive restoration.

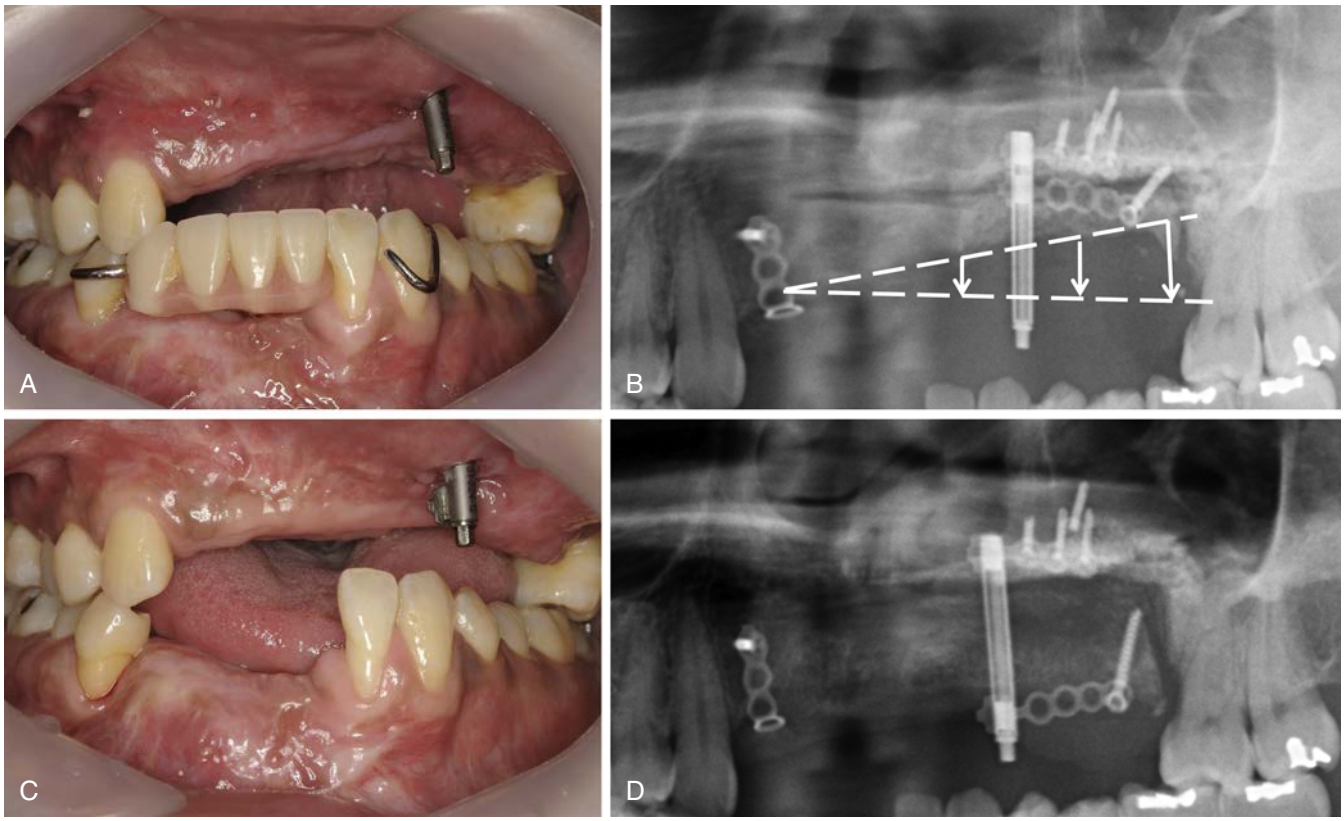

• **Figure 33-38** Uneven vertical bone defect in the maxilla secondary to maxillary alveolar fracture because of a traffic accident. **A-B,** The alveolus has uneven height with a 10-mm vertical defect on the left posterior and optimal height on the anterior maxilla. The transport bone is distracted on only one side with the pivot on the anterior maxilla, analogous to opening a fan. **C-D,** 12-mm fan-shaped distraction resulted in a more optimal and even ridge height.

plate-type distractor is fixed rigidly with the basal bone using titanium micro-screws. The transport bone is secured loosely with the distractor using one titanium bi-cortical micro-screw on the side with vertical bone defect and immobilized with a mini-plate or a wire on the other side with normal ridge height (Figure 33-38). In cases with an uneven ridge height greater than 15 mm, fan-shaped alveolar distraction may be applied repeatedly (Figure 33-39).

Mesiodistal Alveolar Distraction (Horizontal Alveolar Transport Osteogenesis)

Alveolar distraction is categorized as transport distraction osteogenesis and used mainly in vertical ridge augmentation. Mesiodistal alveolar distraction (horizontal alveolar transport osteogenesis) has been reported in cases with cleft palate,[81-85] segmental (or marginal) mandibulectomy, or maxillectomy.[86-88] The closure of wide alveolar clefts and fistulae in patients with clefts and the reconstruction of maxillary dentoalveolar defect in patients with trauma are challenging for both orthodontists and surgeons. This is because of the difficulty of achieving soft tissue closure with the limited local attached gingiva and the greater volume of bone required for the graft. Liou and co-workers first reported interdental distraction osteogenesis (IDO) for lengthening of the dental arch, minimizing the alveolar cleft/fistula, and reconstructing a maxillary dentoalveolar defect by approximating the native alveoli and gingivae.[82] IDO is a modification of bifocal distraction osteogenesis that has been used successfully in long bones[89] and in the correction of mandibular defects.[90] IDO in conjunction with rapid orthodontic tooth movement through the regenerate has many advantages, including minimizing the need for extensive alveolar bone grafting, eliminating tooth extraction in cases of dental crowding, and maintaining velopharyngeal function of those cleft patients who need distraction of the entire maxilla.[82] In addition, transport distraction osteogenesis is useful for the reconstruction of segmental maxillary and mandibular defects in selected patients with poor general health.[87]

Mesiodistal alveolar distraction can be beneficial in patients with large segmental maxillary defects (Figure 33-40). In the case shown in Figure 33-40, the transport bone of the anterior maxilla was distracted 20 mm distally using an intraoral, unidirectional device originally designed for the distraction of the ascending ramus and mandibular body (Zürich Pediatric Ramus Distractor, KLS Martin). The flexible activator improved patient's comfort, which resulted in better compliance. In large defects where the activating plate moves toward the basal one from a large distance, the distractor is activated as much as possible and should be

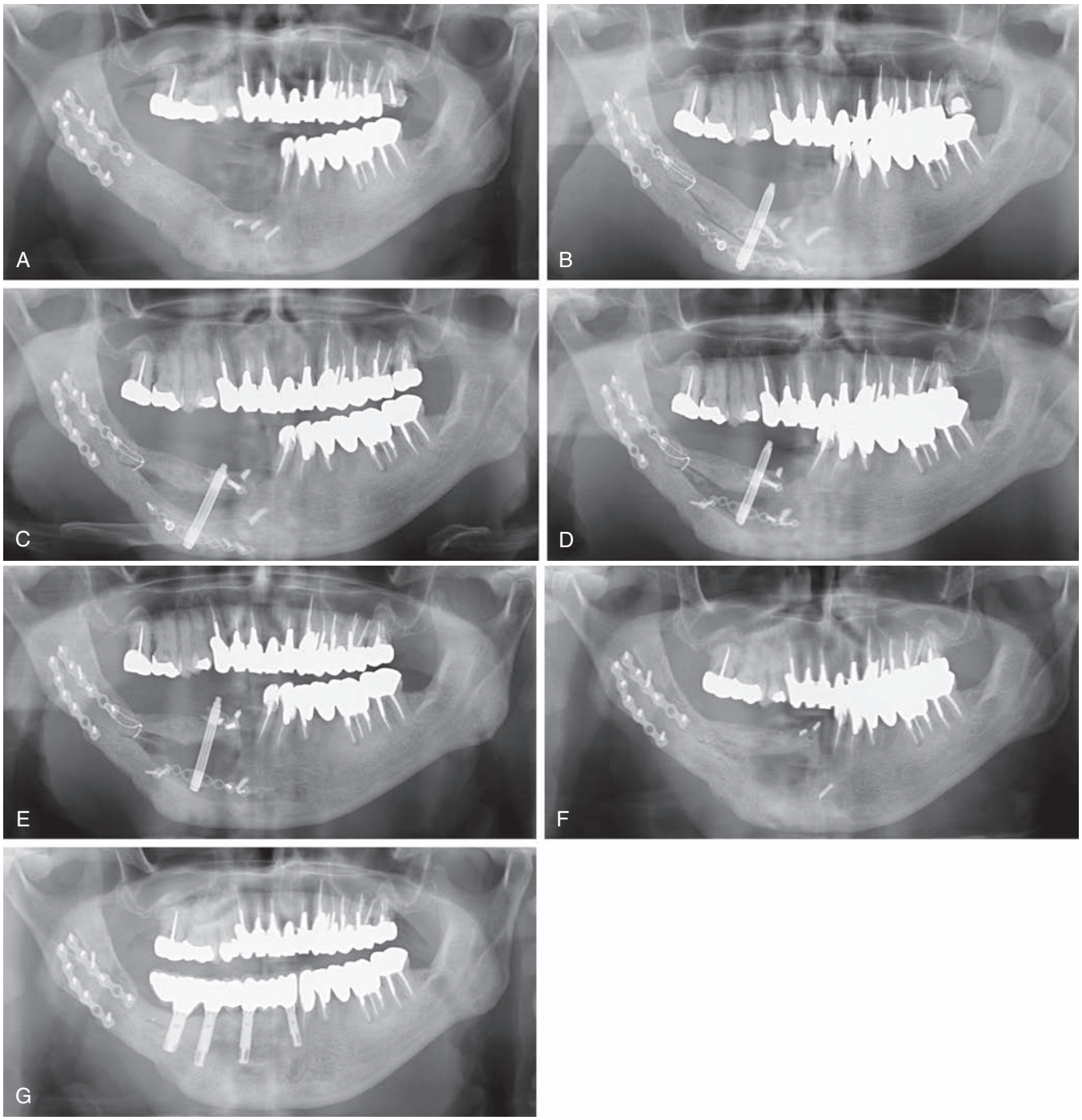

• **Figure 33-39** Severely atrophic hemi-mandible resulting from segmental resection due to ameloblastoma followed by iliac bone graft. **A,** In the mesial end of the defect, there was a 20-mm vertical bone defect. The distal end of the defect had no bone defect. **B,** For fan-shaped distraction, a plate-type distractor was placed in the mesial portion of the defect and the transport bone was immobilized with a wire in the distal end with normal ridge height. **C,** Even after 12-mm fan-shaped distraction, a vertical bone defect still remained. **D,** For additional 10-mm vertical augmentation, the distractor and the upper plate changed optimal position. **E,** Total of 22-mm fan-shaped distraction made the ridge height ideal. **F,** The distractor was removed after a consolidation period of 4 months. **G,** The bone gap between the mesial portion of the transport bone and the native mandible was filled with autogenous bone graft, and four implants were placed in an ideal position simultaneously.

inactivated (closed) to distract the transport bone for reconstructing the bony defect. Transport distraction osteogenesis is usually followed by a minor bone graft procedure to fill in the residual bone gap between the transport bone and basal bone.

Conclusions

Alveolar distraction, categorized as pedicle vascularized bone graft and transport distraction osteogenesis, is a reliable, predictable option to gain large vertical increases of hard and soft tissue in difficult areas such as the anterior maxilla and mandible. It is also beneficial in cases with compromised or inadequate soft tissue and scar tissue. As for prerequisites for alveolar distraction, the transport bone must be well vascularized with periosteal blood supply. Patient selection is critical for success of alveolar distraction. The author's opinion is that the transport bone should have a height of more than 8 mm, length of more than 30 mm (more than a four-tooth defect), and width of more than 6 mm in order to maintain its viability and minimize resorption. In single- to three-tooth defects, bone graft or GBR is simpler and more predictable than alveolar distraction, considering the viability of the transport bone. When the alveolar ridge height is less than 10 mm, onlay bone graft or vertical GBR should be first performed to gain an alveolar ridge height of at least 10 mm before alveolar distraction. If the ridge width is less than 6 mm, veneer bone graft or horizontal GBR is needed before or after alveolar distraction. If the alveolar crest is very thin but a few millimeters apical from the alveolar crest is adequately thick, the transport bone can be overdistracted and the thin ridge reduced at the time of implant placement, leading to a more ideal ridge. Overdistraction of 2 to 3 mm should be necessary because of resorption and relapse of the transport bone in all patients. A gradual distraction rate of less than 0.5 mm/day results in no dehiscence of the



• **Figure 33-40** Massive segmental bone defect in the maxilla resulting from failure of orthognathic surgery. **A-B,** The patient underwent anterior segmental osteotomy of the maxilla followed by partial bone necrosis, which resulted in bilateral bone defects. **C,** There were bilateral segmental bone defects in the maxilla. The right defect included the loss of four teeth.

Continued

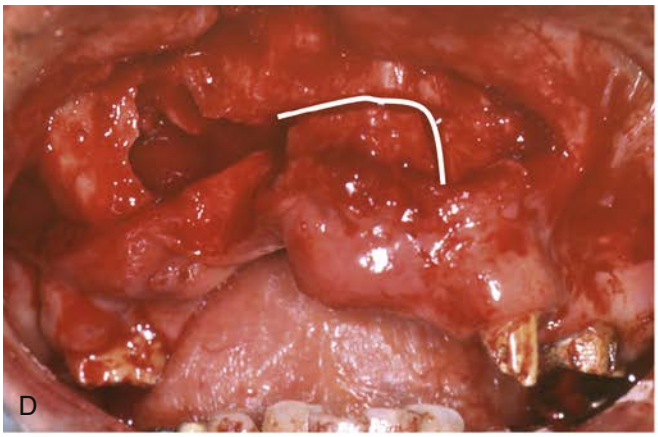

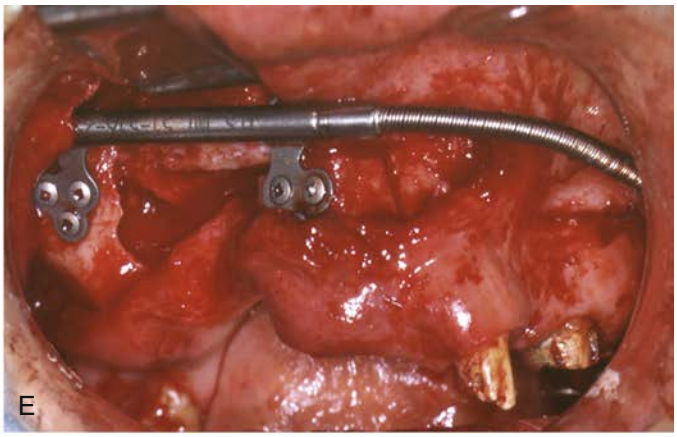

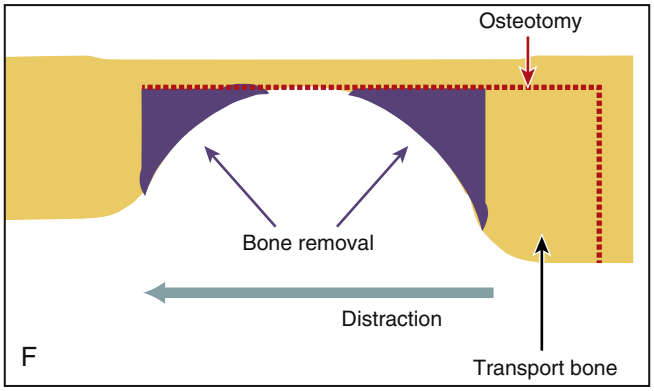



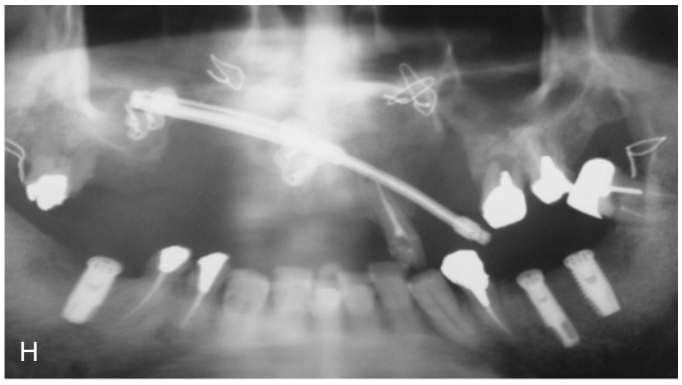



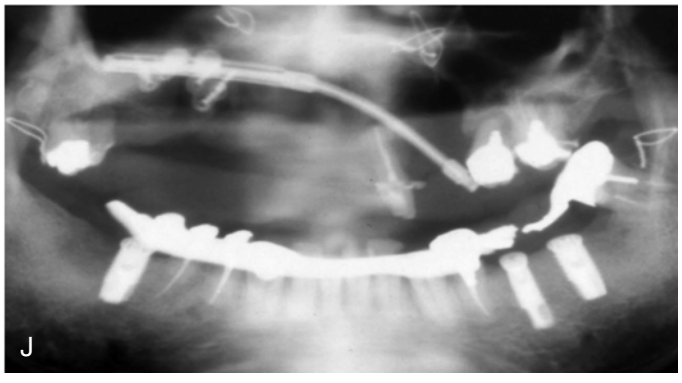

• **Figure 33-40, cont'd** **D,** For mesiodistal alveolar distraction, a reversed L-shaped osteotomy was performed in the anterior maxilla. **E,** An intraoral, unidirectional device for the distraction of the ascending ramus and mandibular body (Zürich Pediatric Ramus Distractor, KLS Martin, Germany) was placed. **F,** The distractor which has been activated as much as needed should be inactivated (closed) to distract the transport bone for reconstructing the bony defect. **G-H,** At the time of starting mesiodistal alveolar distraction. **I-J,** At the time of completing mesiodistal alveolar distraction, the right segmental defect was mostly reconstructed.

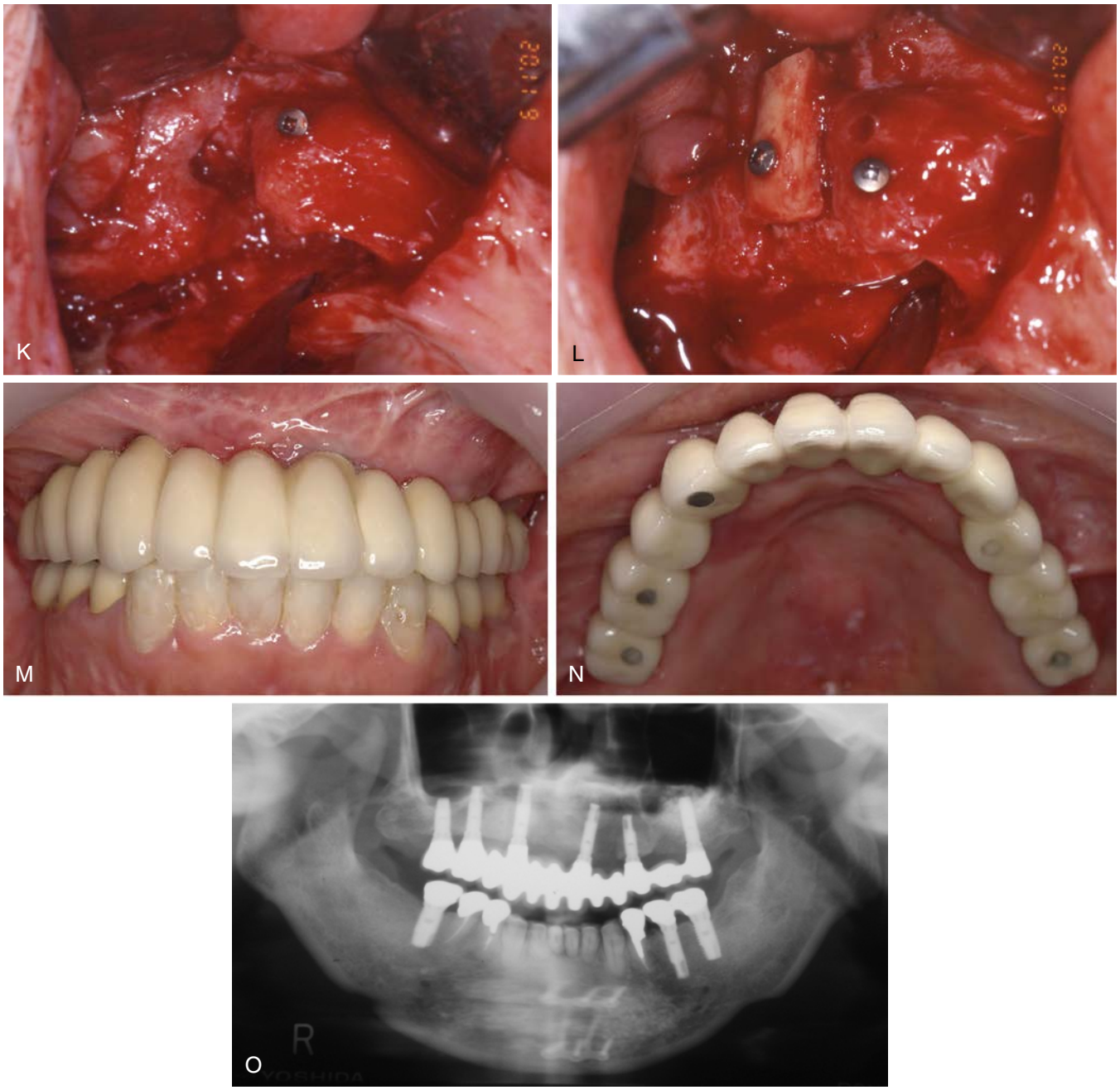

• **Figure 33-40, cont'd** **K-L,** Minor bone graft from the ramus was performed in the bone gap between the transport bone and basal one. In the left, segmental bone defect was reconstructed with ramus bone graft simultaneously. **M-O,** The fixed definitive restoration was supported by six implants. The patient obtained good functional and acceptable esthetic results, though she refused additional ridge augmentation.

soft tissue, better bone formation, and decreased risk of non-union compared with a distraction rate of 1 mm/day.

As complexity or severity of the bone defects increases, there is an increased need for bone grafting before or after distraction is done. In addition, patients must be informed of the difficulty of treating a defect with exposed root surface in an esthetic manner without dental extraction or orthodontic forced eruption. Three-dimensional alveolar distraction (vertical, horizontal, oblique, fan-shaped, or mesiodistal) can be useful in complex defects where conventional ridge augmentation with bone graft or GBR cannot resolve all of the defect, especially massive bone and soft tissue defects with scar. To succeed in three-dimensional alveolar distraction, the use of an optimal distractor and the control of distraction vector are important factors.

References

1. Collins T: Onlay bone grafting in combination with Branemark implants, *Oral Maxillofac Surg Clin North Am* 3:893–902, 1991.
2. Buser D, Bragger U, Lang S: Regeneration and evaluation of jaw bone using guided tissue regeneration, *Clin Oral Implants Res* 1:22–32, 1990.
3. Jensen OT: Alveolar segmental "sandwich" osteotomies for posterior edentulous mandibular sites for dental implants, *Int J Oral Maxillofac Surg* 64:471–475, 2006.
4. Jensen OT, et al.: Alveolar segmental sandwich osteotomy for anterior maxillary vertical augmentation prior to implant placement, *J Oral Maxillofac Surg* 64:290–296, 2006.
5. Jensen OT: Smile osteotomy. In Jensen OT, editor: *The osteoperiosteal flap*, Chicago, 2011, Quintessence, pp 165–174.
6. Jensen OT, Ellis E: The book flap: a technical note, *J Oral Maxillofac Surg* 66(5):1010–1014, 2008.
7. Jensen OT, Leopardi A, Gallegos L: The case for bone graft reconstruction including sinus grafting and distraction osteogenesis for the atrophic edentulous maxilla, *J Oral Maxillofac Surg* 62:1423–1428, 2004.
8. Laster Z, Rachmiel A, Jensen OT: Alveolar width distraction osteogenesis for early implant placement, *J Oral Maxillofac Surg* 12(63):1724–1730, 2005.
9. Jensen OT, et al.: Alveolar distraction osteogenesis, *Selected Readings Oral Maxillofac Surg* 10(4):1, 2002.
10. Misch CM, Misch CE, Resnik R, Ismail Y: Reconstruction of maxillary alveolar defects with mandibular symphysis grafts for dental implants: Preliminary procedural report, *Int J Oral Maxillofac Implants* 7:360–366, 1992.
11. Pieri F, Aldini NN, Marchetti C, Corinaldesi G: Esthetic outcome and tissue stability of maxillary anterior single-tooth implants following reconstruction with mandibular block grafts: a 5-year prospective study, *Int J Oral Maxillofac Implants* 28(1):270–280, 2013.
12. Laino L, Iezzi G, Piattelli A, et al.: Vertical ridge augmentation of the atrophic posterior mandible with sandwich technique: bone block from the chin area versus corticocancellous bone block allograft—clinical and histological prospective randomized controlled study, *Biomed Res Int* 2014:982104, 2014.
13. Waasdorp J, Reynolds MA: Allogeneic bone onlay grafts for alveolar ridge augmentation: a systematic review, *Int J Oral Maxillofac Implants* 25(3):525–531, 2010.
14. Jovanovic SA, Nevins M: Bone formation utilizing reinforced barrier membranes, *Int J Periodontics Restorative Dent* 15:57–69, 1995.
15. Simion M, Trisi P, Piattelli A: GBR with an e-PTFE membrane associated with DFDBA: histologic and histochemical analysis in a human implant retrieved after 4 years of loading, *Int J Periodontics Restorative Dent* 16(4):338–347, 1996.
16. Urban IA, Nagursky H, Lozada JL: Horizontal ridge augmentation with a resorbable membrane and particulated autogenous bone with or without anorganic bovine bone-derived mineral: a prospective case series in 22 patients, *Int J Oral Maxillofac Implants* 26(2):404–414, 2011.
17. Urban IA, Lozada JL, Jovanovic SA, et al.: Vertical ridge augmentation with titanium-reinforced, dense-PTFE membranes and a combination of particulated autogenous bone and anorganic bovine bone-derived mineral: a prospective case series in 19 patients, *Int J Oral Maxillofac Implants* 29(1):185–193, 2014.
18. Leknes KN, Yang J, Qahash M, et al.: Alveolar ridge augmentation using implants coated with recombinant human growth/differentiation factor -5 (rhGDF-5). Radiographic observations, *Clin Oral Implants Res* 24(11):1185–1191, 2013.
19. Chiang T, Roca AL, Rostkowski S, et al.: Reconstruction of the narrow ridge using combined ridge split and guided bone regeneration with rhPDGF-BB growth factor-enhanced allograft, *Int J Periodontics Restorative Dent* 34(1):123–130, 2014.
20. Chiapasco M1, Romeo E, Casentini P, Rimondini L: Alveolar distraction osteogenesis vs. vertical guided bone regeneration for the correction of vertically deficient edentulous ridges: a 1-3-year prospective study on humans, *Clin Oral Implants Res* 15(1): 82–95, 2004.
21. Aghaloo TL, Moy PK: Which hard tissue augmentation techniques are the most successful in furnishing bony support for implant placement? *Int J Oral Maxillofac Implants* 22(Suppl): 49–70, 2007.
22. Clavero J, Lundgren S: Ramus or chin grafts for maxillary sinus inlay and local onlay augmentation: comparison of donor site morbidity and complications, *Clin Implant Dent Relat Res* 5(3):154–160, 2003.
23. Codivilla A: On the means of lengthening in the lower limbs, the muscles, and tissues which are shortened through deformity, *Am J Orthop Surg* 2:353, 1905.
24. Ilizarov GA: The tension-stress effect on the genesis and growth of tissue: part 1. The influence of stability of fixation and soft tissue preservation, *Clin Orthop Relat Res* 238:249–281, 1989.
25. Ilizarov GA: The tension-stress effect on the genesis and growth of tissue: Part 2. The influence of the rate and frequency of distraction, *Clin Orthop Relat Res* 239:263–285, 1989.
26. Paley D, Catagni MA, Argnani F, et al.: Ilizarov treatment of tibial nonunions with bone loss, *Clin Orthop Relat Res* 241: 146–165, 1989.
27. Sproul JT, Price CT: Recent advances in limb lengthening. Part I: clinical advances, *Orthop Rev* 21(3):307–314, 1992.
28. McCarthy JG, Schreiber J, Karp N, et al.: Lengthening the human mandible by gradual distraction, *Plast Reconstr Surg* 89:1–8, 1992.
29. Annino Jr DJ, Goguen LA, Karmody CS: Distraction osteogenesis for reconstruction of mandibular symphyseal defects, *Arch Otolaryngol Head Neck Surg* 120:911–916, 1994.
30. Havlik RJ, Bartlett SP: Mandibular distraction lengthening in the severely hypoplastic mandible: a problematic case with tongue aplasia, *J Craniofac Surg* 5(5):305–310, 1994.
31. Betts NJ, Vanarsdall RL, Barber HD, et al.: Diagnosis and treatment of transverse maxillary deficiency, *Int J Adult Orthod Orthognath Surg* 10:75–96, 1995.
32. Polly JW, Figueroa AA: Management of severe maxillary deficiency in childhood and adolescence through distraction osteogenesis with an external, adjustable, rigid distraction device, *J Craniofac Surg* 8:181–186, 1997.
33. Cohen SR, Burstein FD, Stewart MB, Rathburn MA: Maxillary-midface distraction in children with cleft lip and palate: a preliminary report, *Plast Reconstr Surg* 99:1421–1428, 1997.
34. Maull DJ: Review of devices for distraction osteogenesis of the craniofacial complex, *Semin Orthod* 5:64–73, 1999.
35. Tavakoli K, Stewart KJ, Michael DP: Distraction osteogenesis in craniofacial surgery: a review, *Ann Plast Surg* 40:88–99, 1998.
36. Block MS, Chang A, Crawford C: Mandibular alveolar ridge augmentation in the dog using distraction osteogenesis, *J Oral Maxillofac Surg* 54:309–314, 1996.
37. Chin M, Toth B: Distraction osteogenesis in maxillofacial surgery using internal devices: review of five cases, *J Oral Maxillofac Surg* 54:45–53, 1996.
38. Horiuchi K, Uchida H, Yamamoto K, Hatano N: Anterioinferior distraction of the atrophic subtotal maxillary alveolus for implant placement, *Int J Oral Maxillofac Implants* 17:416–423, 2002.

39. Prokuski LJ, Marsh JL: Segmental bone deficiency after acute trauma. The role of bone transport, *Orthop Clin North Am* 25:753–763, 1994.
40. DeCoster TA, Simpson AH, Wood M, et al.: Biologic model of bone transport distraction osteogenesis and vascular response, *J Orthop Res* 17:238–245, 1999.
41. Sawaki Y, Ohkubo H, Yamamoto H, Ueda M: Mandibular lengthening by intraoral distraction using osseointegrated implants, *Int J Oral Maxillofac Implants* 11:186–193, 1996.
42. Aston Jr JW, Williams SA, Allard RN, et al.: A new canine cruciate ligament formed through distraction histogenesis. Report of a pilot study, *Clin Orthop Relat Res* 280:30–36, 1992.
43. Kojimoto H, Yasui N, Goto T, et al.: Bone lengthening in rabbits by callus distraction: the role of periosteum and endosteum, *J Bone Joint Surg [Br]* 70-B:543–549, 1988.
44. Oda T, Sawaki Y, Ueda M: Alveolar ridge augmentation by distraction osteogenesis using titanium implants: an experimental study, *Int J Oral Maxillofac Surg* 28:151–156, 1999.
45. Nosaka Y, Kobayashi M, Kitano S, Komori T: Horizontal alveolar ridge distraction osteogenesis in dogs: radiographic and histologic studies, *Int J Oral Maxillofac Implants* 20:837–842, 2005.
46. Enislidis G, Fock N, Millesi-Schobel G, et al.: Analysis of complications following alveolar distraction osteogenesis and implant placement in the partially edentulous mandible, *Oral Surg Oral Med Oral Pathol Oral Radiol Endod* 100:25–30, 2005.
47. Ettl T, Gerlach T, Schüsselbauer T, et al.: Bone resorption and complications in alveolar distraction osteogenesis, *Clin Oral Investig* 14(5):481–489, 2010.
48. González-García A, Diniz-Freitas M, Somoza-Martín M, García-García A: Piezoelectric and conventional osteotomy in alveolar distraction osteogenesis in a series of 17 patients, *Int J Oral Maxillofac Implants* 23:891–896, 2008.
49. Saulacic N, Martin MS, Camacho ML, Garcia GA: Complications in alveolar distraction osteogenesis: a clinical investigation, *J Oral Maxillofac Surg* 65:267–274, 2007.
50. Amir LR, Everts V: ALJJ Bronckers: Bone regeneration during distraction osteogenesis, *Odontology* 97:63–75, 2009.
51. Saulacic N, Somoza-Martin M, Gándara-Vila P, Garcia-Garcia A: Relapse in alveolar distraction osteogenesis: an indication for overcorrection, *J Oral Maxillofac Surg* 63:978–981, 2005.
52. Kanno T, Mitsugi M, Furuki Y, et al.: Overcorrection in vertical alveolar distraction osteogenesis for dental implants, *Int J Oral Maxillofac Surg* 36:398–402, 2007.
53. Saulacic N, Iizuka T, Martin MS, Garcia AG: Alveolar distraction osteogenesis: a systematic review, *Int J Oral Maxillofac Surg* 37:1–7, 2008.
54. Amir LR, Becking AG, Jovanovic A, et al.: Vertical distraction osteogenesis in the human mandible: a prospective morphometric study, *Clin Oral Implants Res* 17:417–425, 2006.
55. Marchetti C, Corinaldesi G, Pieri F, et al.: Alveolar distraction osteogenesis for bone augmentation of severely atrophic ridges in 10 consecutive cases: a histologic and histomorphometric study, *J Periodontol* 78:360–366, 2007.
56. McAllister BS, Gaffaney TE: Distraction osteogenesis for vertical bone augmentation prior to oral implant reconstruction, *Periodontology* 33:54–66, 2000.
57. Laster Z, Rachmiel A, Jensen OT: Alveolar width distraction osteogenesis for early implant placement, *J Oral Maxillofac Surg* 63:1724–1730, 2005.
58. Jensen OT, Cockrell R, Kuhike L, Reed C: Anterior maxillary alveolar distraction osteogenesis: a prospective 5-year clinical study, *Int J Oral Maxillofac Implants* 17:52–68, 2002.
59. Bradley SM, Thomas E: Distraction osteogenesis for vertical bone augmentation prior to oral implant reconstruction, *Periodontology* 33:54–66, 2000.
60. Jensen OT, Block M: Alveolar modification by distraction osteogenesis, *Atlas Oral Maxillofac Surg Clin N Am* 16(2):185–214, 2008.
61. Bavitz JB, Payne JB, Dunning D, et al.: The use of distraction osteogenesis to induce new suprabony periodontal attachment in the beagle dog, *Int J Periodontics Restorative Dent*597–603, 2000.
62. Oda T, Suzuki H, Yokota M, Ueda M: Horizontal alveolar distraction of the narrow maxillary ridge for implant placement, *J Oral Maxillofac Surg* 62:1530–1534, 2004.
63. Watzak G, Zechner W, Tepper G, et al.: Clinical study of horizontal alveolar distraction with modified micro bone screws and subsequent implant placement, *Clin Oral Implants Res* 17: 723–729, 2006.
64. Takahashi T, Funaki K, Shintani H, et al.: Use of horizontal alveolar distraction osteogenesis for implant placement in a narrow alveolar ridge: a case report, *Int J Oral Maxillofac Implants* 19:291–294, 2004.
65. Robiony M, Polini F, Costa F, Politi M: Osteogenesis distraction and platelet rich plasma for bone restoration of the severely atrophic mandible: preliminary results, *J Oral Maxillofac Surg* 60:630–635, 2002.
66. Enislidis G, Fock N, Millesi-Schobel G, et al.: Analysis of complications following alveolar distraction osteogenesis and implant placement in the partially edentulous mandibles, *Oral Surg Oral Med Oral Pathol Oral Radiol Endod* 100:25–30, 2005.
67. Ettl T1, Gerlach T, Schüsselbauer T, et al.: Bone resorption and complications in alveolar distraction osteogenesis, *Clin Oral Investig* 14:481–489, 2010.
68. Louis PJ: Vertical ridge augmentation using titanium mesh, *Oral Maxillofac Surg Clin North Am* 22(3):353–368, 2010.
69. Gutta R, Waite PD: Outcomes of calvarial bone grafting for alveolar ridge reconstruction, *Int J Oral Maxillofac Implants* 24: 131–136, 2009.
70. Gaggl A, Schultes G, Kärcher H: Distraction implants—a new possibility for augmentative treatment of the edentulous atrophic mandible: case report, *Br J Oral Maxillofac Surg* 37:481–485, 1999.
71. Herford AS, Audia F: Maintaining vector control during alveolar distraction osteogenesis: a technical note, *Int J Oral Maxillofac Implants* 19:758–762, 2004.
72. Mehra P, Figueroa R: Vector control in alveolar distraction osteogenesis, *J Oral Maxillofac Surg* 66:776–779, 2008.
73. Iizuka T, Hallermann W, Seto I, et al.: Bi-directional distraction osteogenesis of the alveolar bone using an extraosseous device, *Clin Oral Implants Res* 16:700–707, 2005.
74. Kanno T, Mitsugi M, Sukegawa S, et al.: Computer-simulated bi-directional alveolar distraction osteogenesis, *Clin Oral Implants Res* 19:1211–1218, 2008.
75. Jensen OT: Distraction osteogenesis and its use with dental implants, *Dent Implantol Update* 10 (5):33–36, 1999.
76. Garcia-Garcia A, Somoza-Martin M, Gandara-Vila P, et al.: Horizontal alveolar distraction: a surgical technique with the transport segment pedicled to the mucoperiosteum, *J Oral Maxillofac Surg* 62:1408–1412, 2004.
77. Aikawa T, Iida S, Senoo H, et al.: Widening a narrow posterior mandibular alveolus following extirpation of a large cyst: a case treated with a titanium mesh-plate type distractor, *Oral Surg Oral Med Oral Pathol Oral Radiol Endod* 106:111–117, 2008.

78. Bulut E, Muglali M, Celebi N, Bekcioglu B: Horizontal alveolar distraction of the mandibular canine regions for implant placement, *J Craniofac Surg* 21:830–832, 2010.
79. Block MS, Brister GD: Use of osteogenesis for maxillary advancement; preliminary result, *J Oral Maxillofac Surg* 52:282–286, 1994.
80. Yamamoto H, Sawaki Y, Ohkubo H, et al.: Maxillary advancement by distraction osteogenesis using osseointegrated implants, *J Craniomaxillofac Surg* 25:186–191, 1997.
81. Binger T, Katsaros C, Rücker M, Spitzer WJ: Segment distraction to reduce a wide alveolar cleft before alveolar bone grafting, *Plast Reconstr Surg* 105:1262–1272, 2000.
82. Liou EJ, Chen PK, Huang CS, Chen YR: Interdental distraction osteogenesis and rapid orthodontic tooth movement: a novel approach to approximate a wide alveolar cleft or bony defect, *Plast Reconstr Surg* 105:1262–1272, 2000.
83. Dolanmaz D, Karaman AI, Durmus E, Malkoc S: Management of alveolar clefts using dento-osseous transport distraction osteogenesis, *Angle Orthod* 73:723–729, 2003.
84. Rachmiel A, Emodi O, Aizenbud D: Three-dimensional reconstruction of large secondary alveolar cleft by two-stage distraction, *Cleft Palate Craniofac J* 51:36–42, 2014.
85. Mitsugi M, Ito O, Alcalde RE: Maxillary bone transportation in alveolar cleft-transport distraction osteogenesis for treatment of alveolar cleft repair, *Br J Plast Surg* 58:619–625, 2005.
86. González-García R, Naval-Gías L: Horizontal alveolar transport osteogenesis (HATO) in case of marginal mandibular resection or inferior maxillectomy, *Br J Oral Maxillofac Surg* 48:185–186, 2010.
87. Neelakandan RS, Bhargava D: Transport distraction osteogenesis for maxillomandibular reconstruction: current concepts and applications, *J Maxillofac Oral Surg* 11:291–299, 2012.
88. Ugurlu F, Basel B, Sener BC, Sertgöz A: Maxillary tuberosity reconstruction with transport distraction osteogenesis, *Case Rep Dent* 2012:1–4, 2012.
89. Tucker HL, Kendra JC, Kinnebrew TE: Tibial defects: reconstruction using the method of Ilizarov as an alternative, *Orthop Clin North Am* 21:629–637, 1990.
90. Block MS, Otten J, McLaurin D, Zoldos J: Bifocal distraction osteogenesis for mandibular defect healing: case reports, *J Oral Maxillofac Surg* 54:1365–1370, 1996.

34

Peri-implant Soft Tissue Augmentation

HOMAYOUN H. ZADEH, DIANE ANTHONY-COSTANDI, NAVID SHARIFZADEH

Peri-implant Soft Tissue Interface

During the initial years after the discovery of osseointegrated dental implants the focus was on the bone-to-implant interface. Bone of sufficient volume and density has been regarded as the most important factor in the success of dental implants. The reason for the emphasis on bone quantity and quality has been to provide initial stability, which is to be supplanted by secondary stability (i.e., osseointegration). Peri-implant soft tissues have predominantly been discussed in the context of esthetics. An important question is whether peri-implant mucosa has any significance beyond esthetic aspect.[1-4] Prior to considering the functional significance of the soft tissue interface around implants, it will be important to review the anatomy of the peri-implant mucosal tissues.

Anatomy of Peri-implant Mucosa

The soft tissue interface around implants has many features in common with that of teeth, including a sulcus, junctional epithelium, and connective tissue attachment.[5] However, subtle differences exist between teeth and implants.[6] The peri-implant connective tissue attachment is in direct contact with the implant surface and consists of two zones (Figure 34-1). The zone immediately adjacent to the implant surface is characterized by an abundance of fibroblasts and an absence of blood vessels. The deeper zone in the connective tissue has more collagen fibers and blood vessels and fewer fibroblasts. This anatomic structure of the peri-implant mucosal interface is distinctly different from the connective tissue attachment around teeth, where connective tissue fibers directly attach into the root cementum.[7-9]

Significance of Peri-implant Mucosa

Animal and clinical studies have addressed the quantitative and qualitative significance of peri-implant mucosa on the stability of peri-implant tissues. The influence of peri-implant mucosal thickness was investigated in a canine study by Berglundh and Lindhe.[10] Three months after bilateral placement of implants in canine mandible, mucosal thickness was maintained on the control side. On the experimental side, mucosa was thinned to 2 mm or less. Results at 6 months postoperatively demonstrated establishment of a transmucosal attachment that was similar on both sides of the mandible, with 2 mm of epithelial attachment and 1.3 mm of connective tissue attachment. On the other hand, peri-implant bone loss was observed on the experimental side, where mucosa was thinned. This study concluded that the dimensions of the biologic width are predetermined, and in cases of thin mucosa, peri-implant bone loss occurs in order to create the space for this biologic width. These results are confirmed in human studies, where increased marginal bone loss is observed in sites with thin mucosa.[11,12]

In addition to the demonstrated significance of quantitative properties of peri-implant mucosa, qualitative differences in peri-implant mucosa have also been shown. The significance of keratinized mucosa has been documented in a canine study.[13,14] In this study, at the time of implant installation the entire zone of peri-implant keratinized mucosa was excised from the flap in the experimental group, while in the control group a zone of keratinized mucosa was present. Increased bone resorption and mucosal recession was observed in experimental sites where the keratinized mucosa was removed. Interestingly, complete removal of peri-implant keratinized mucosa led to bone resorption in sites with thick (2 mm) as well as thin (1 mm) buccal alveolar bone plates. A free gingival graft in sites with deficient keratinized mucosa reduced the magnitude of the peri-implant bone resorption and soft tissue recession.[14]

A number of clinical studies have been conducted to investigate the role of peri-implant keratinized mucosa on the success of implants.[3,6,13,15,16] Most of these studies have demonstrated that in patients with good oral hygiene and regular implant maintenance, less than 2 mm of peri-implant keratinized mucosa is associated with increased plaque accumulation, inflammation, and progression of recession.[3,6] Therefore, it is clear that peri-implant mucosa is

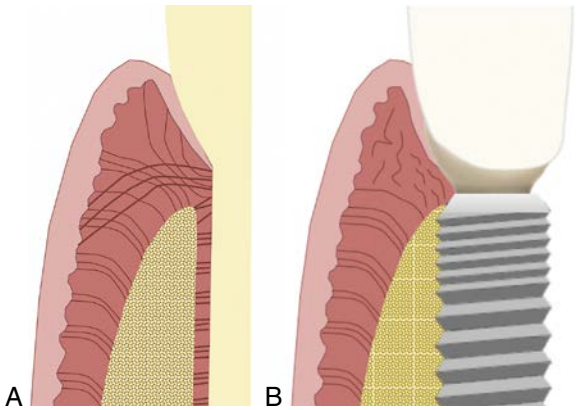

• **Figure 34-1** Soft tissue interface around teeth and implants. The periodontal attachment apparatus includes junctional epithelium that can be attached to enamel, dentin, or both **(A).** There is also supra-alveolar connective tissue attachment which connects gingiva to cementum on roots. The peri-implant mucosal attachment has the same two components of junctional epithelium and connective tissue attachment, though the nature of these attachments is different. In particular, connective tissue attachment includes a zone closest to the implant surface composed of many fibroblasts that are flattened against the surface. This peri-implant zone has no blood vessels and has low collagen content. The collagen fibers near the implant surface are also oriented parallel to implant surface, unlike periodontal fibers, which are perpendicular to tooth surface. **B,** The peri-implant zone deeper in the tissues is more vascular and contains less fibroblasts and more collagen fibers.

important, not only for esthetics, but also for the long-term stability of peri-implant bone and soft tissue attachment.

Peri-implant Soft Tissue Augmentation

An array of techniques have been utilized for soft tissue augmentation around teeth and implants.[17-23] Whereas the efficacy of soft tissue augmentation around teeth has been extensively investigated,[24] scant evidence exists for peri-implant soft tissue augmentation. Systematic reviews of available evidence have demonstrated that autogenous tissue grafting using epithelialized or connective tissue grafts are the best-documented methods to increase the width of keratinized mucosa.[16,25-29] Autogenous grafts improve soft tissue thickness and esthetics compared to nongrafted sites.

Free Autogenous Grafts

Free autogenous grafts are harvested from either the palate or tuberosity. The free graft may have an intact epithelial layer, in which case it is referred to as free gingival graft (FGG). Alternatively, the graft may be harvested without the epithelial layer, referred to as subepithelial connective tissue graft (SCTG), or simply CTG.

FGG is very efficient in increasing the zone of keratinized gingiva and increasing the vestibular depth. A clinical example of FGG application is illustrated in Figure 34-2. This patient had minimal zone of keratinized mucosa, shallow vestibular depth, and was planned to receive an implant-supported overdenture (see Figure 34-2, *A*). Crestal incision was made in such manner to reposition most of the keratinized mucosa toward the lingual aspect of the implant healing abutments. A supraperiosteal sharp dissection was carried out on the facial aspect, extending apically past the mucogingival junction to the vestibular fornix (see Figure 34-2, *B*). A recipient bed lined with periosteum was created that was devoid of any muscle or movable elastic fibers of the frenal attachments. FGG grafts were harvested bilaterally from the palate, near the edentulous alveolar crest in the premolar region (see Figure 34-2, *C* and *D*). The grafts had uniform thickness of approximately 2 mm. The FGGs were secured with 6-0 polypropylene sutures to the underlying periosteal recipient bed through a series of interrupted sutures (see Figure 34-2, *E*), Criss-cross sutures were anchored in the periosteum of the vestibular fornix and slung around the healing abutments to adapt the grafts securely against the recipient bed. Following a 6-week healing period, a dense keratinized band of attached mucosa was created on the facial aspect of the implants. The vestibule was also deepened by this procedure (see Figure 34-2, *F*).

Although epithelialized grafts are very efficient at creating peri-implant keratinized attached mucosa and increasing the vestibular depth, the main drawback is that the grafted area has a distinct color and texture which does not match that of the recipient site. Therefore, in the esthetic zone, application of this procedure may lead to unacceptable esthetics (Figure 34-3).

Another important disadvantage of free autogenous grafts is their significant shrinkage following the augmentation procedure.[30-32]

Pediculated Soft Tissue Grafts

To overcome the problem with shrinkage of free autogenous grafts, pediculated grafts have been applied for ridge defects augmentation.[33-36] It has been speculated that pedicle connective tissue grafts have less volumetric shrinkage because of intact blood supply.[35]

In the maxilla, pedicle graft can be achieved by modifying the incision design during mucoperiosteal flap elevation. The objective of this modified flap design is to reposition the keratinized mucosa and associated connective tissue from the palatal to buccal aspects. This entails initiating the incision palatal to the mucosal crest and repositioning the flap in a buccal direction. The diagrams in Figure 34-4 illustrate the surgical steps involved in repositioning keratinized mucosa from the palatal to buccal aspect of implants. To increase the zone of keratinized mucosa on the buccal aspect, the initial incision is made on the palatal aspect of the alveolar ridge crest (see Figure 34-4, *A*). The blade is directed parallel to the surface mucosa to undermine the palatal tissues. The objective of this sharp partial thickness dissection is to create a palatal flap that is uniformly 2 mm in thickness (see Figure 34-4, *B*). The buccal flap is then apically repositioned to deepen the vestibule and increase the zone of keratinized mucosa on the buccal aspect

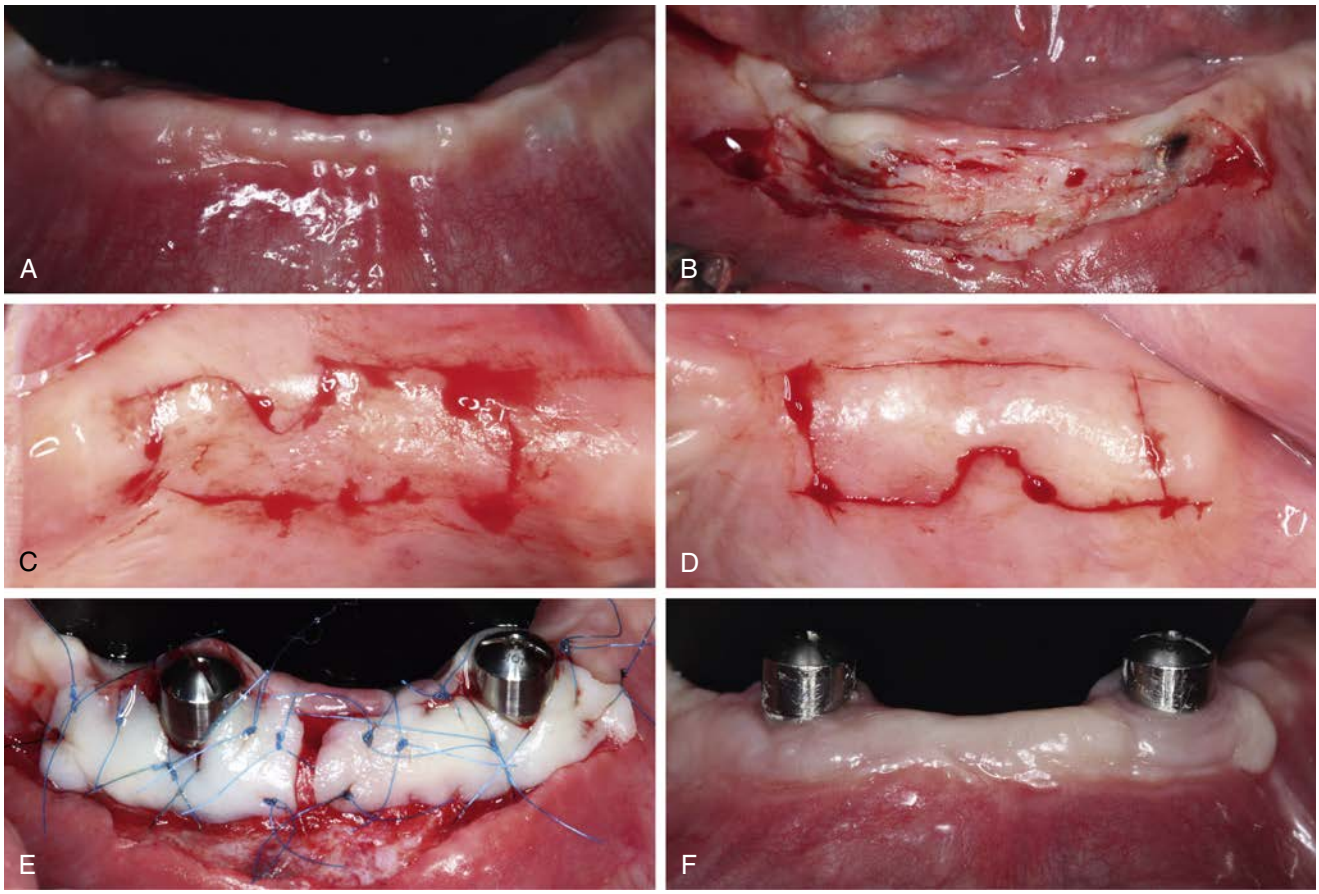

• **Figure 34-2** Free gingival graft for augmentation of keratinized mucosa and vestibular depth. The initial condition following healing of two-stage implant installation showed minimal zone of keratinized mucosa and shallow vestibular depth **(A).** Recipient bed was prepared by sharp dissection to reposition the movable alveolar mucosa in apical direction **(B).** All elastic fibers from frena and muscle attachments were removed to produce a uniform recipient bed lined by periosteum. FGG grafts were harvested bilaterally from the premolar regions of the palate near the edentulous alveolar ridges with uniform thickness of approximately 2 mm **(C, D).** The grafts were secured with 6-0 polypropylene sutures to the underlying periosteal recipient bed **(E).** At three months postoperatively, dense keratinized band of attached mucosa had been created on the facial aspect of the implants **(F).** The vestibule was also deepened by this procedure.



• **Figure 34-3** Unfavorable esthetic result of a free gingival graft in the esthetic zone. The FGG does not match surrounding host tissues in terms of color, texture, and contour.

(see Figure 34-4, *C*). In this arrangement, part of the connective tissue without surface epithelium may be exposed. In some cases, the objective is not to increase the vestibular depth but to increase the buccal mucosal thickness. In such cases, the palatal connective tissue that is contiguous with the buccal flap is folded under the buccal flap margin (see Figure 34-4, *D*). This approach is particularly useful when the palatal connective tissue is thin.

The clinical case shown in Figure 34-5 is a common manifestation, where the edentulous alveolar ridge exhibits lack of keratinized mucosa on the buccal aspect with coronal frenum attachment (see Figure 34-5, *A*). The flap design includes a horizontal incision palatal to the alveolar crest with the blade oriented to undermine the palatal flap (see Figure 34-5, *B*). At the base of the flap, the incision is directed to reach the palatal bone (see Figure 34-5, *C*). The reflected flap shows connective tissue harvested from the palatal region that is contiguous with the buccal flap (see Figure 34-5, *D*). The buccal flap is then apically repositioned (see Figure 34-5, *E*) and approximated in a position to allow an increased zone of buccal keratinized mucosa (see Figure 34-5, *F*). Comparison of initial presentation prior to tooth extraction (see Figure 34-5, *G*) and postoperative condition (see Figure 34-5, *H*) shows an increase in the zone of keratinized mucosa on the facial aspect of

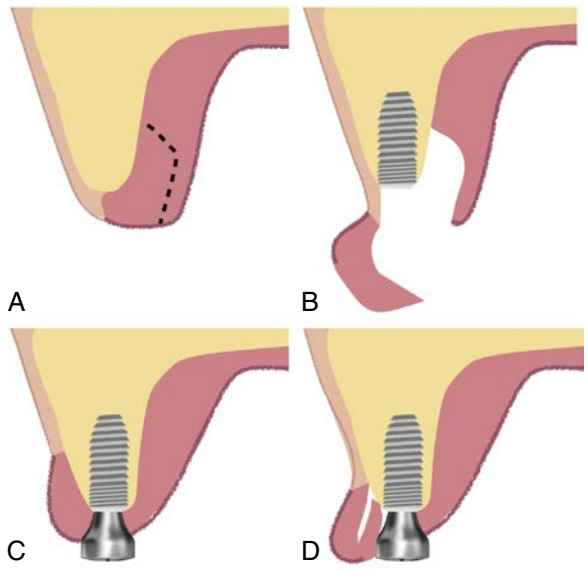

• **Figure 34-4** Strategies for augmentation of keratinized mucosa and ridge defects in the maxilla. In cases with minimal zone of keratinized mucosa, initial incision is made in parallel with the palatal surface contour in an effort to undermine the palatal connective tissue, while leaving a 2-mm overlying mucosal flap. **A,** At an appropriate point, determined by the desired width of postoperative keratinized mucosa, the incision is directed toward the palatal bone. Following reflection of the mucosal flap, the palatal connective tissue harvested will be contiguous with the buccal flap **(B).** The buccal flap is apically repositioned to deepen the vestibule and increase the zone of keratinized mucosa on the buccal aspect **(C).** In cases where the harvested palatal connective tissue is not too thick, or it is desired to maximize restoration of crestal mucosal contour, the buccal flap margin is folded under the flap **(D).**

implant restorations with apical positioning of the frenal attachments.

A variation of the pedunculated graft is the vascularized interpositional (VIP) graft. This entails repositioning palatal connective tissue graft with an intact base that can serve both as an anchorage point for rotating the graft from the palatal to buccal, and as the source of vascular support. In recent study, Akcalı et al.[37] utilized three-dimensional volumetric analysis to compare volumetric gain of tissue achieved by free and pediculated connective tissue grafts for ridge defects soft tissue augmentation. They clearly demonstrated that pediculated connective tissue grafts lead to increased volumetric tissue gain.

The clinical case in Figure 34-6 illustrates the clinical scenario of a patient with a high smile with significant alveolar contour deficiency. In this case, ridge preservation was performed in conjunction with tooth extraction, yielding sufficient volume of bone for implant therapy. Soft tissue augmentation was necessary to correct the significant contour deficiency (see Figure 34-6, *A*). In view of the large volume of contour augmentation required, VIP graft was performed. This entailed a crestal incision with mucoperiosteal reflection of the alveolar crest to allow access for implant installation. Just past the alveolar crest, a deep supraperiosteal soft tissue pouch was prepared by sharp dissection extending apically past the mucogingival junction and laterally to the neighboring teeth. On the palatal aspect, horizontal incisions were made approximately 3 mm apical to the gingival margins of maxillary posterior teeth. Partial thickness dissection was carried out, reflecting a mucosal flap with uniform thickness of 1.5 mm (see Figure 34-6, *B*). The connective tissue and underlying periosteum were incised at superior, posterior, and apical borders, leaving the anterior aspect of the graft attached to its vascular bed (see Figure 34-6, *C*). The pediculated graft was rotated facially to augment the crest and facial contour (see Figure 34-6, *D*). Flap margins were approximated to achieve primary closure (see Figure 34-6, *E*). Following healing, the contour deficiency has been corrected (see Figure 34-6, *F*). Final restoration shows acceptable soft tissue contour around implant restorations (see Figure 34-6, *G*). Radiograph taken at one year postoperatively shows the stability of the alveolar bone during the early healing period. The trumpet-shaped transmucosal contour of the CAD/CAM abutments was designed to maximize the peri-implant mucosal thickness.

Application of Graft Substitutes For Peri-implant Soft Tissue Augmentation

Autogenous soft tissue grafts harvested from palate or tuberosity with or without epithelium are very effective at increasing the peri-implant zone of attached keratinized mucosa. However, limitations of this procedure include the morbidity associated with autogenous tissue harvesting. In addition, where augmentation is required for large regions of the oral cavity, limited autogenous tissue is available. Moreover, some patients have anatomic limitations such as shallow palatal vault, proximity of greater palatine foramen or the presence of palatal exostoses, which limit the availability of autogenous tissues. Alternatives to autogenous tissue include acellular dermal matrix (ADM) allograft and xenogenic collagen matrix (XCM). Collagen matrix has been demonstrated to lead to less gain in keratinized mucosa, although it has been associated with less morbidity and decreased surgery time.[38] In a randomized controlled clinical trial, the efficacy of CTG and ADM for peri-implant mucosal augmentation have been compared. The result of this study demonstrated increased mucosal thickness, decreased concavity dimensions, and reduction of peri-implant recession.[39]

A representative clinical case illustrating application of ADM is shown in Figure 34-7. The patient presented with a significant mucosal concavity around the second premolar with coronal frenal attachment. (see Figure 34-7, *A*) The first premolar was slated for extraction and immediate implant placement. The incision design included undermining the palatal tissue to have increased connective tissue associated with the buccal flap. Once the implants were placed, an ADM (Perioderm, Dentsply Sirona Implants, Waltham, MA) was positioned on the buccal

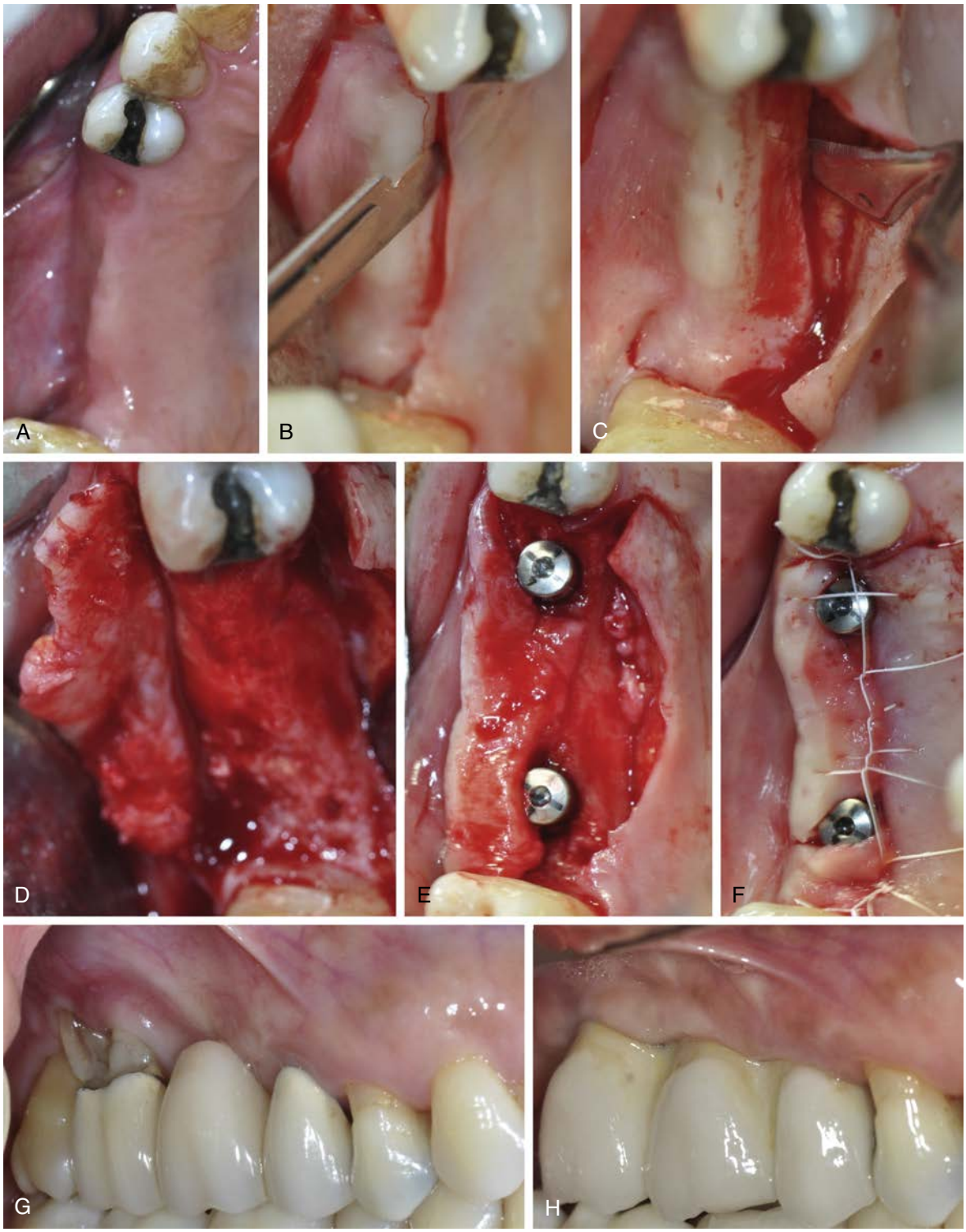

• **Figure 34-5** Augmentation of keratinized mucosa in posterior maxilla by buccal repositioning of palatal connective tissue. A clinical case with minimal zone of attached keratinized mucosa and coronal frenal attachment in posterior maxilla **(A).** The flap design includes horizontal incision palatal to the alveolar crest with the blade oriented to undermine the palatal flap **(B).** At the base of the flap, the incision is directed to reach the palatal bone **(C).** Connective tissue harvested from the palatal region was contiguous with the buccal flap **(D).** The buccal flap is then apically repositioned **(E)** and approximated to achieve primary closure **(F).** Comparison of initial presentation prior to tooth extraction **(G)** and postoperative condition shows increase in zone of keratinized mucosa on the facial aspect of implant restorations with apical positioning of the frenal attachments **(H).**

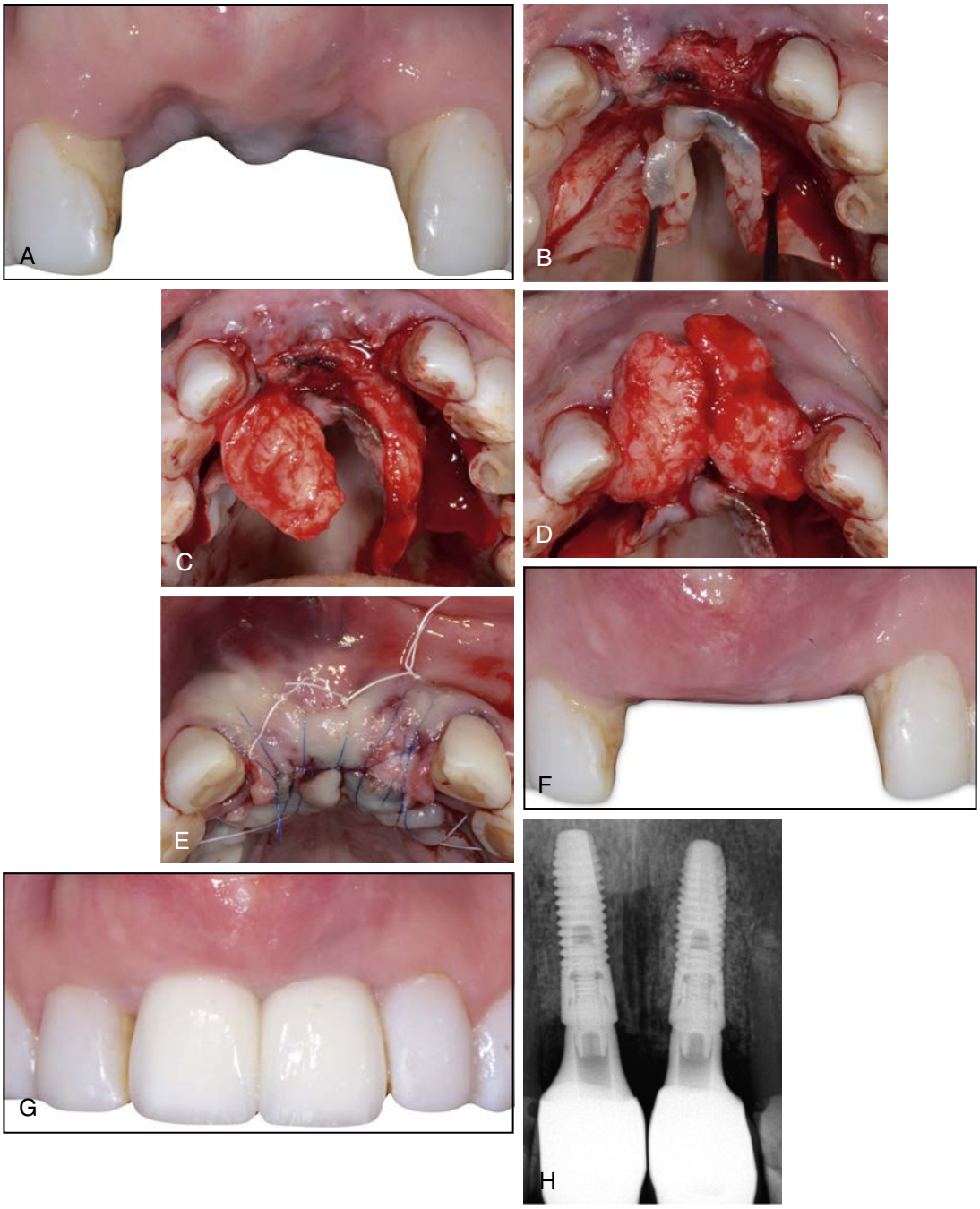

• **Figure 34-6** Soft tissue augmentation of major alveolar ridge contour defect with VIP graft. Clinical case with significant soft tissue contour deficiency **(A).** Partial thickness dissection was carried out, reflecting a mucosal flap with uniform thickness of 1.5 mm **(B).** The connective tissue and underlying periosteum were incised at superior, posterior, and apical borders, leaving the anterior aspect of the graft attached to its vascular bed **(C).** The pedunculated graft was rotated facially to augment the crest and facial contour **(D).** Flap margins were approximated to achieve primary closure **(E).** Following healing, the contour deficiency has been corrected **(F).** Final restoration shows acceptable soft tissue contour around implant restorations **(G).** Postoperative periapical radiograph illustrates subgingival contours of the implant-supported maxillary central incisor restorations **(H).**

aspect of the implants (see Figure 34-7, *B*) and adapted around the healing abutments (see Figure 34-7, *C*). This augmentation procedure lead to improved buccal soft tissue contour, peri-implant mucosal thickness, deepening of the vestibular depth, and associated frenal attachment (see Figure 34-7, *D*).

Another method to increase the band of keratinized mucosa and vestibular was proposed by Urban.[40] This method utilizes xenogenic collagen matrix and a narrow strip of epithelialized FGG. The concept is to create a recipient bed of periosteum and suture a narrow strip of FGG at the vestibular depth. The space between this FGG and

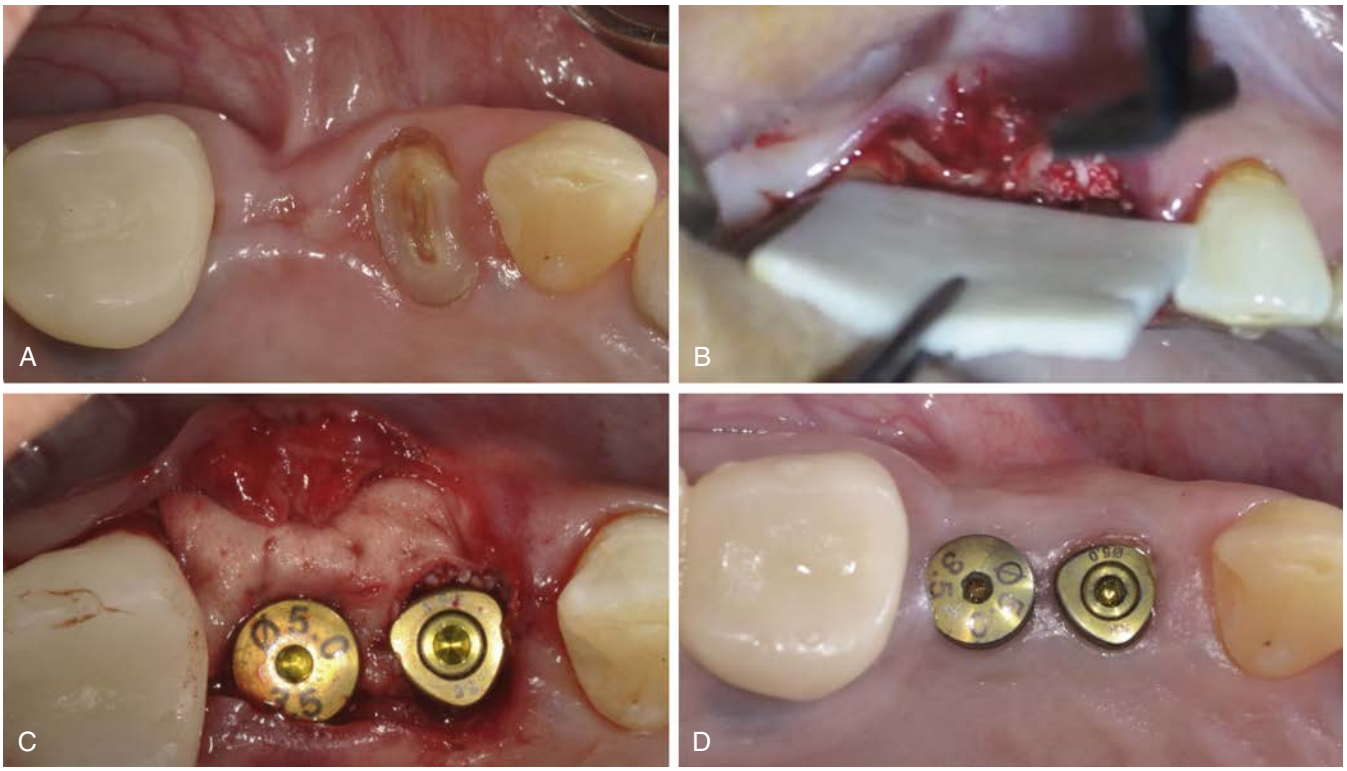

• **Figure 34-7** Correction of soft tissue ridge contour deficiency and frenal attachment with acellular dermal matrix allograft. Initial clinical presentation showed soft tissue concavity, minimal zone of keratinized mucosa, and coronal frenum attachment **(A).** Mucoperiosteal flaps were reflected on buccal and palatal aspects, dissecting the buccal flap to the vestibular fornix, followed by insertion of an acellular dermal matrix allograft **(B).** An implant was installed immediately into the extract socket of the maxillary right first premolar and another one in the healed site of the second premolar. The horizontal gap between the implant and socket walls was filled with anorganic bovine bone minerals and covered by the acellular dermal matrix allograft **(C).** Six months postoperative outcome shows the correction of the soft tissue depression, increase in mucosal thickness, and loss of the coronal frenum attachment **(D).**

the crestal keratinized mucosa is filled with an XCM, which is also sutured to underlying periosteum. During the healing, cellular infiltration from the crestal keratinized mucosa and apical FGG leads to a wide band of attached keratinized mucosa. This is particularly useful in cases of extensive alveolar ridge augmentation, which typically lead to loss of vestibular depth.

A clinical example is depicted in Figure 34-8, where a patient with severely atrophic anterior maxilla was reconstructed with guided bone regeneration and as a result had significant loss of vestibular depth. Sharp dissection was performed to expose a uniform bed of periosteum without any movable elastic fibers or muscle attachment (see Figure 34-8, *B*). A narrow strip of epithelialized FGG, which was 5 mm in width, was harvested from the posterior maxilla near the alveolar crest during second-phase surgery to expose posterior implants. The FGG strips were sutured to the recipient periosteal bed at the apical border of the vestibule. Keratinized mucosa was present at the alveolar crest. An XCM (Mucograft, Geistlich, Wolhusen, Switzerland) was stabilized on the recipient periosteal bed in between the crestal keratinized mucosa and apical FGG strips (see Figure 34-8, *C*). The site was covered with light-cured periodontal dressing (Barracaid, Dentsply), which was left in place for two weeks (see Figure 34-8, *D*). Healing of the site after 3 weeks showed clearly the increase in the vestibular depth as well as gain of attached keratinized mucosa (see Figure 34-8, *E*).

Vestibular Incision Subperiosteal Tunnel Access

One of the techniques used for soft tissue augmentation around teeth and implants is vestibular incision subperiosteal tunnel access (VISTA).[22,41] The initial access for VISTA begins with a vertical incision in the vestibule remotely from the therapeutic target. The position of the initial incision is dictated by convenience of access and prevention of injury to vital structures such as the mental neurovascular bundle. A typical initial incision in the maxillary anterior area is the midline frenum. For access to the maxillary or mandibular posterior region, the vestibular region anterior of the canines is a suitable location for the initial vestibular incision. Beginning from the initial access incision, a subperiosteal tunnel is created using a series of specially designed elevators (VISTA elevators, Dowell Dental Products, Rancho Cucamonga, CA). The subperiosteal tunnel is extended to the depth of the



• **Figure 34-8** Augmentation of keratinized mucosa and vestibular depth with xenogenic collagen matrix (XCM) in conjunction with FGG strips. Following extensive horizontal and vertical alveolar ridge augmentation, shallow vestibular depth and minimal zone of keratinized mucosa were present **(A).** Partial thickness dissection was performed, leaving a border of keratinized mucosa at the alveolar crest with a uniform bed of periosteum at the recipient site **(B).** Two narrow strips of FGG were harvested from the posterior alveolar crest and sutured to the periosteum at the most apical border of the recipient bed **(C).** The gap between the keratinized tissue at the crest and the FGGs was covered with XCM. The site was covered with light-cured periodontal dressing that was left in place for two weeks **(D).** Healing of the site after three weeks showed abundant zone of attached keratinized mucosa and increase in the vestibular depth **(E).**

vestibule, and any muscle attachments found within the tunnel are released to allow for a tension-free tunnel. If the objective of soft tissue augmentation is also coronal repositioning of the mucosal margins of teeth/implants, a suture is placed in the mucosal margin and is fixated to the coronal tooth/restoration. Wound stability is of paramount importance during the initial stages of the healing.[42] The fixation of the gingival margin during the healing process assists with wound stabilization. The tensile strength at the interface between the tooth/flap following periodontal flap surgery has been demonstrated to progressively increase during the first 2 weeks of healing.[43,44] Therefore, it is recommended to leave the coronally anchored suture in for more than 2 weeks to ensure that the integrity of the attachment between the flap margin and the tooth cannot be easily disrupted. An appropriate soft tissue graft, which will include autogenous connective tissue

graft (CTG), acellular dermal matrix (ADM), or xenogenic collagen matrix (XCM), is inserted inside the tunnel.

VISTA offers a number of advantages, which include maintaining the integrity of mucosa and the periosteum to preserve their vascular supply intact. In the presence of a thin biotype, the full thickness dissection aids in maintaining flap coverage. The tension-free tunnel facilitates coronal advancement of the mucosal margin. To maintain the coronal position of the mucosal margins, a suture is placed and fixated to each tooth or restoration with flowable composite.

The patient depicted in Figure 34-9 presented with implant-supported restoration in the posterior mandible with minimal peri-implant keratinized mucosa, as well as coronal frenal attachments (see Figure 34-9, *A* and *B*). Despite thorough oral hygiene practice, as well as regular periodontal maintenance therapy, persistent mucosal inflammation was present at two years post-implant therapy (see Figure 34-9, *C* and *D*), Therefore, peri-implant mucosal augmentation was achieved using VISTA. Initial vestibular incisions were made anterior to each of the mandibular canines. Subperiosteal tunnels were created to beyond the most posterior implants. Two subepithelial connective tissue grafts were harvested from each side of the palate and placed within each mandibular tunnel. Because the main objective of the surgery was not to cover exposed implant components, the mucosal margins were not coronally repositioned (see Figure 34-9, *E* and *F*). Healing was uneventful and resulted in increased mucosal thickness with widened vestibular depth. However, the attached mucosa did not exhibit surface keratinization. The clinical images demonstrate improved mucosal health that was maintained at 4 years following soft tissue augmentation (see Figure 34-9, *G* and *H*). The clinical phenotype achieved by VISTA typically is characterized by nonkeratinized surface mucosa. This may be attributed to the fact that in VISTA, the connective tissue graft is subperiosteally placed. This leads to the formation of thicker attached tissue, which is devoid of frenal attachments. Therefore, it is usually not necessary to perform an additional frenectomy.

The patient in Figure 34-10 was referred because of concern for improper implant positioning. The implant had been placed too far facially and apically (see Figures 34-10, *A* and *B*). The optimal implant position is 2 mm palatal of the cervical contour of the restoration.[45] When the implant is placed facial of the recommended position, the likelihood of mucosal recession is increased.[46] Restoration of the implant in its current state would have led to an elongated restoration. The adjacent canine also exhibited a 3-mm gingival recession. Because the patient had a high smile line, this led to an unesthetic outcome. VISTA was used for soft tissue augmentation of the implant to add extra mucosal bulk and reposition its facial soft tissue margin to a more coronal level. Additionally, periodontal root coverage was attempted on the adjacent canine. The treatment began with replacement of the healing abutment on the implant with a cover screw (see Figure 34-10, *C*). The cervical root prominence of the canine was reduced by odontoplasty followed by root conditioning with 24% EDTA gel with neutral pH (Prefgel, Straumann, Andover, MA) for 3 minutes. A vestibular incision was made at the midline frenum and a subperiosteal tunnel was created that extended both in an apical direction and past the first premolar tooth (see Figure 34-10, *C*). Connective tissue grafts were harvested from the palate, as well as from the tuberosity (see Figure 34-10, *D*). The tuberosity graft was de-epithelialized ex vivo.

The tuberosity generally consists of dense fibrous connective tissue with fewer glands, less fat, and fewer blood vessels. As a result, the donor site is generally more comfortable postoperatively and bleeds less than the palate. Moreover, the sites augmented with the tuberosity graft exhibit less volumetric shrinkage than palatal CTG. The tuberosity CTG was positioned within the subperiosteal tunnel on the facial aspect of the implant, and the palatal CTG was used for augmentation of the adjacent canine (see Figure 34-10, *E* and *F*). The gingival margin of the canine was coronally repositioned using a 6-0 polypropylene suture, which was bonded to the tooth with flowable composite (see Figure 34-10, *G*). The mucosal margin of the implant was coronally repositioned. An all-resin Maryland bridge was used as the interim restoration with the pontic site relieved to allow room for expansion of the tissue during healing. Healing after 3 months revealed improvement of the keratinized mucosa in the vertical and horizontal dimension, resulting in a more esthetic appearance and lack of space between the implant and restoration (see Figure 34-10, *H*). During the restorative phase, a CAD/CAM zirconia restoration (Atlantis abutment, Dentsply Sirona Implants, Waltham, MA) was created (see Figure 34-10, *I* and *J*). The abutment was angled palatally and designed with as little material on the facial cervical area as possible. Following restoration of the implant, the dimensions of the restoration were symmetric with the contralateral tooth (see Figure 34-10, K and *L*). Complete root coverage was achieved around the canine (see Figure 34-10, *M* and *N*).

Conclusions

Evidence has clearly demonstrated that the quantity and quality of peri-implant mucosal tissues can influence not only the esthetics, but also the long-term stability of peri-implant bone and soft tissues. It is important to perform risk assessment for implants, which includes evaluation of the zone of keratinized mucosa, position of the implant, oral hygiene level, and esthetic requirements. Soft tissue augmentation may be considered for the following conditions:

- In the absence of a minimum of 2 mm of keratinized and/or attached peri-implant mucosa
- For implants positioned too far facially (i.e., beyond the recommended position of 2 mm palatal of the cervical contour of the restoration)
- When the patient is unable to perform adequate oral hygiene because of thin peri-implant mucosa
- In cases of high esthetic demand

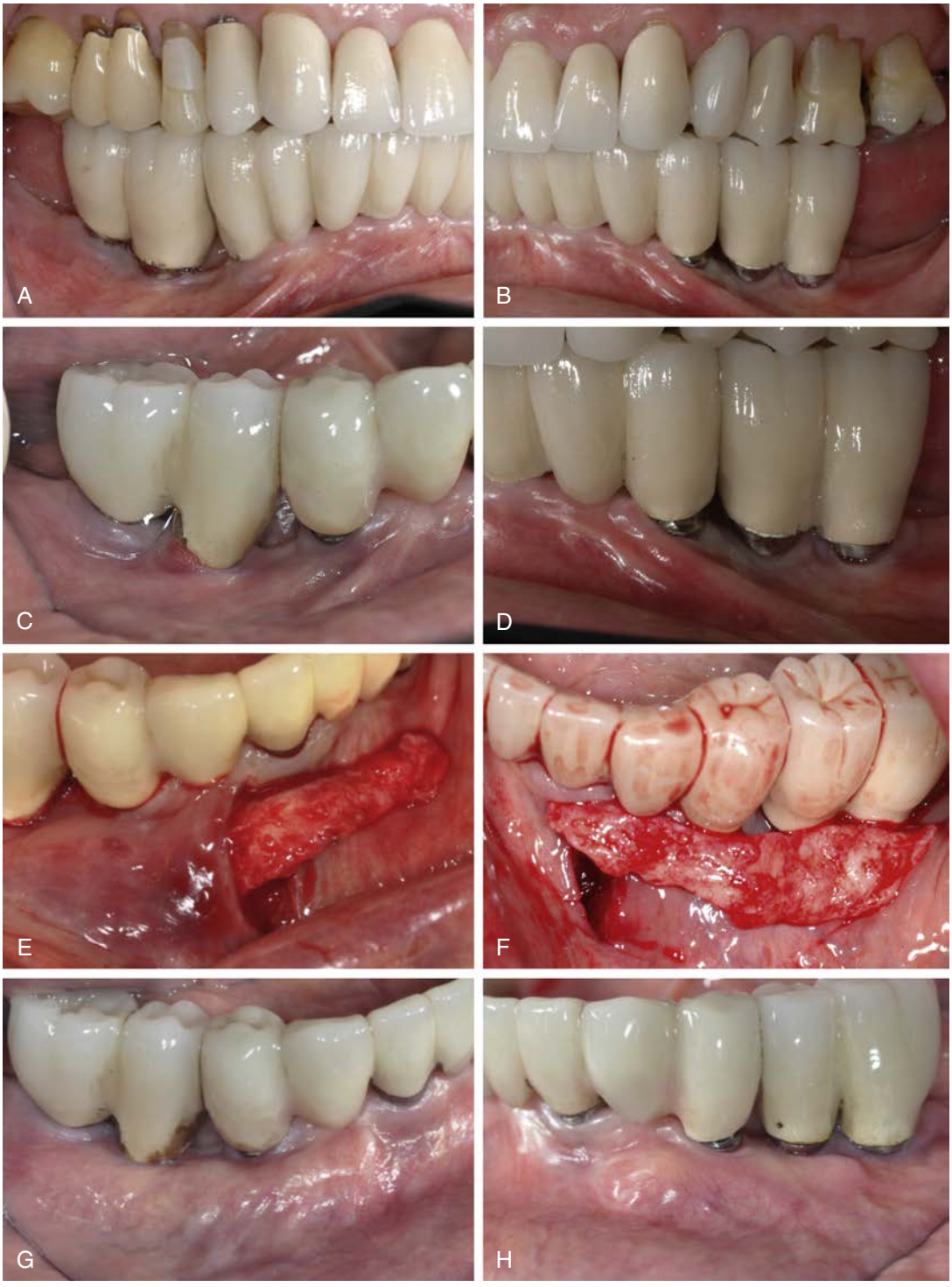

• **Figure 34-9** Peri-implant soft tissue augmentation with connective tissue graft. Clinical view of a patient at 6 months post-implant restoration **(A, B)** illustrating lack of keratinized attached mucosa and coronal frenum attachments. Clinical view at 2 years shows presence of inflammation despite patient's extensive efforts in oral hygiene **(C, D).** Subepithelial connective tissue graft harvested from the palate has been positioned within the subperiosteal tunnel through a vestibular access incision **(E, F).** Clinical images at 4 years post soft tissue augmentation **(G, H)** illustrate increase in mucosal thickness and the zone of attached tissue.

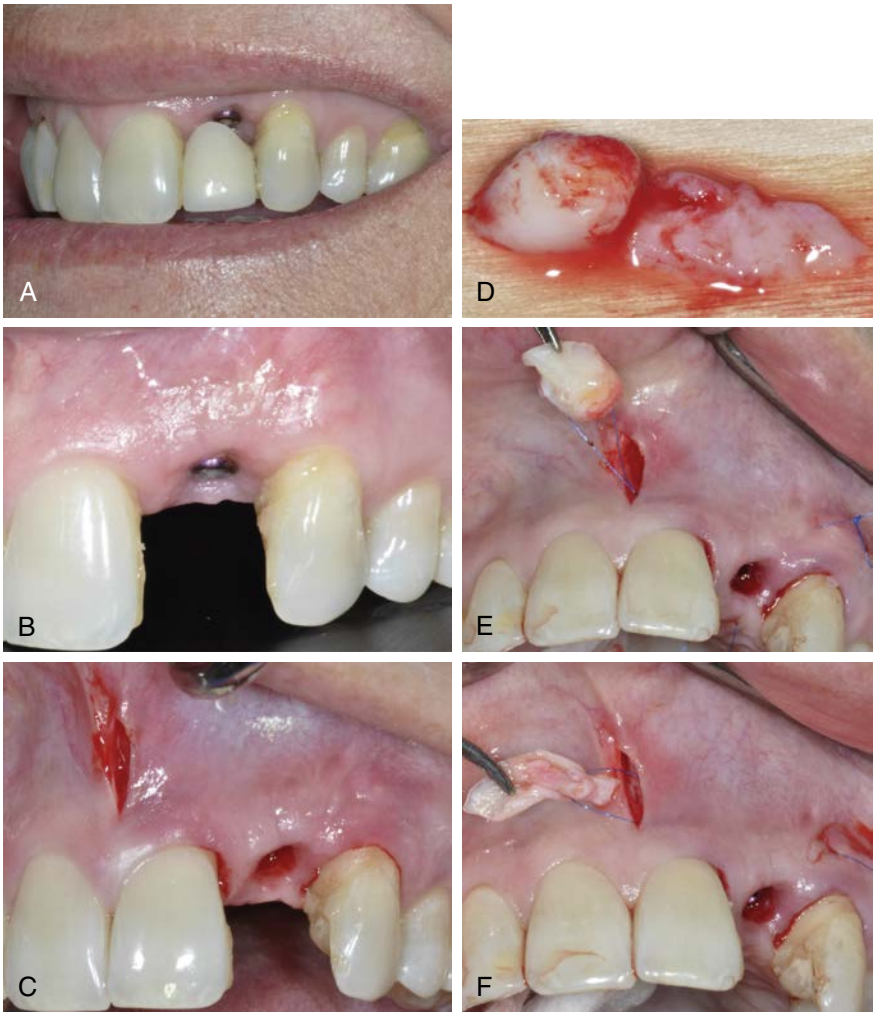

• **Figure 34-10** Peri-implant and periodontal soft tissue augmentation. Preoperative clinical appearance of the patient with a high lip line **(A).** The existing implant was placed too far facially and apically, and the adjacent canine exhibited a 3-mm gingival recession **(B).** Soft tissue augmentation was performed by VISTA, starting with a vestibular incision in the midline frenum and subperiosteal tunnel extending to the implant and beyond the canine planned for periodontal root coverage **(C).** The healing abutment was replaced with a cover screw to facilitate positioning of the soft tissue graft. Donor tissues harvested included palatal tissue, as well as tuberosity tissue that were de-epithelialized ex vivo **(D).** The tuberosity was used for augmentation of the implant **(E)** and the palatal tissue was used for periodontal root coverage on the canine **(F).**

Continued

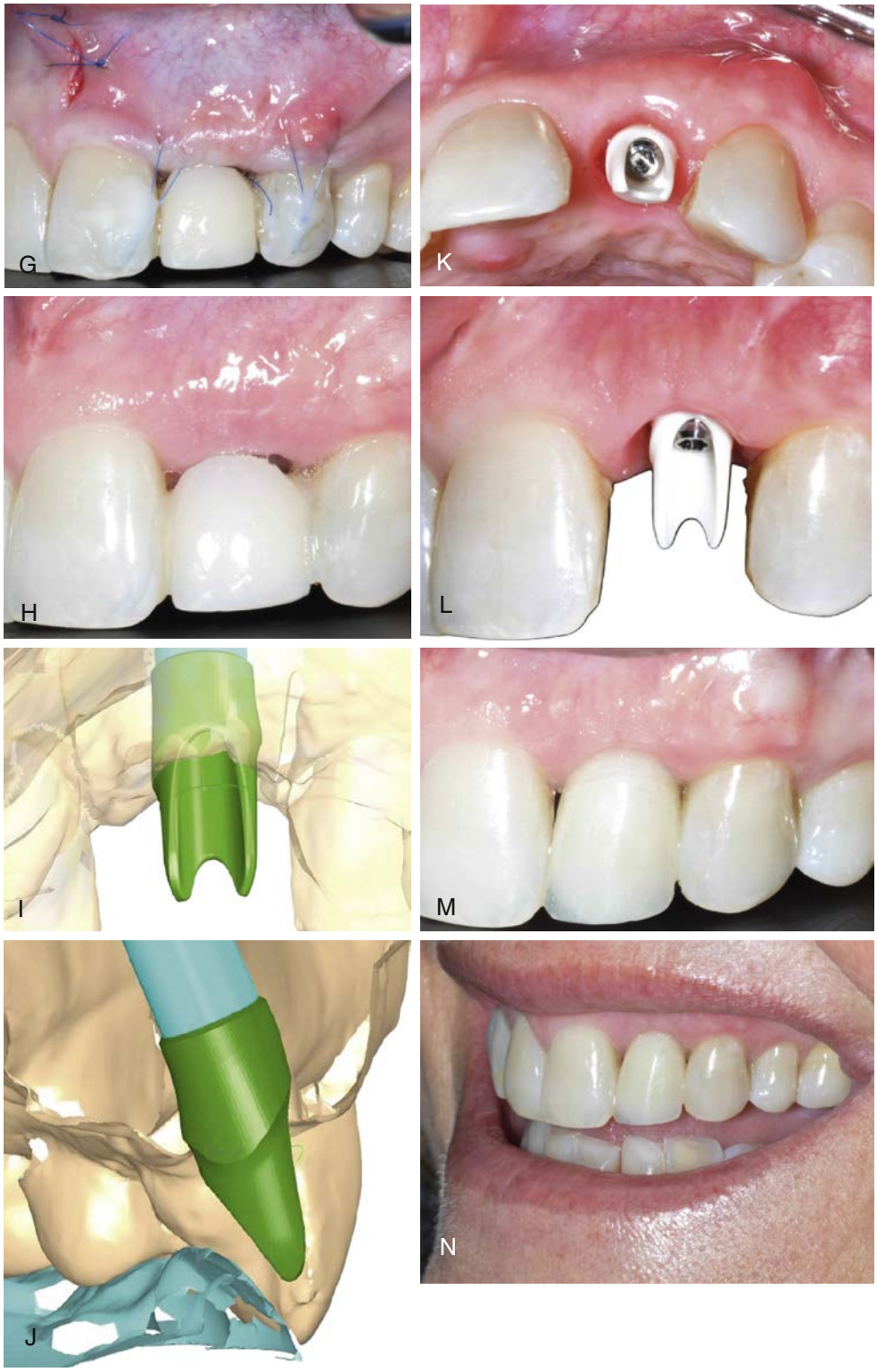

• **Figure 34-10, cont'd** The gingival margin of the canine was coronally positioned and the suture was bonded to the tooth with flowable composite and the tuberosity donor tissue was stabilized to the overlying mucosa within the tunnel **(G).** Clinical image of the healed tissues three months post-augmentation with a bonded interim restoration **(H).** Design of CAD/CAM abutments **(I, J)** was made to reposition the abutment in palatal direction and allow as little material on the facial as possible **(K, L).** Final restoration and the mucosal contour **(M)** demonstrate harmony of the tissue level with complete root coverage achieved on the canine. The smile line shows optimized restoration contour for the implant and gingival contour of the canine **(N).**

A variety of therapeutic techniques and materials are available for soft tissue augmentation. These include application of free autogenous epithelialized or subepithelial connective tissue graft, as well as pedunculated vascularized connective tissue graft. Alternatives to the application of autogenous soft tissue include acellular dermal matrix and xenogenic collagen matrix. The decision for application of different tissues depends on the following factors:

- In the maxilla, where small or moderate volumes of augmentation are required, it is often possible to reposition palatal connective tissue to the facial aspect. Where correction of large contour defects is desired, VIP graft is very effective.
- In areas with low esthetic priority, epithelialized free gingival graft can be very effective in increasing the zone of keratinized mucosa and deepening the vestibule.
- The tuberosity provides effective donor tissue, which can achieve a large volume of soft tissue augmentation that remains stable over time.
- Where autogenous harvesting is not an option due to limited donor site availability, large volume of tissue required, or where decreased morbidity is desired, acellular dermal matrix or xenogenic collagen matrix are viable options.

In terms of methods of soft tissue augmentation, the traditional partial or full thickness flaps have many drawbacks, including compromised blood supply, scar formation, and increased morbidity. For these reasons, VISTA offers some advantages for introduction of graft tissues to sites to be augmented, including a single incision in a remote area from the therapeutic target, providing an effective access for creation of a tension-free tunnel, maintenance of intact mucoperiosteal complex, coronal repositioning, and fixation of sutures to allow for stability of the tissue level during healing.

References

1. Bouri A, Bissada N, Al-Zahrani MS, et al.: Width of keratinized gingiva and the health status of the supporting tissues around dental implants, *Int J of Oral Max Impl* 323–326, 2008.
2. Kim BS, Kim YK, Yun PY, et al.: Evaluation of peri-implant tissue response according to the presence of keratinized mucosa, *Oral Surg Oral Med Oral Pathol Oral Radiol Endod* 107:e24–e28, 2009.
3. Schrott AR, Jimenez M, Hwang JW, et al.: Five-year evaluation of the influence of keratinized mucosa on peri-implant soft-tissue health and stability around implants supporting full-arch mandibular fixed prostheses, *Clin Oral Implants Res* 29(10):1170–1177, 2009.
4. Zigdon H, Machtei EE: The dimensions of keratinized mucosa around implants affect clinical and immunological parameters, *Clin Oral Implants Res* 19(4):387–392, 2008.
5. Berglundh T, Lindhe J, Ericsson I, et al.: The soft tissue barrier at implants and teeth, *Clin Oral Implantsntsl* 2(2):81–90, 1991.
6. Moon IS, Berglundh T, Abrahamsson I, et al.: The barrier between the keratinized mucosa and the dental implant. an experimental study in the dog, *J Clin Periodontol* 26(10):658–663, 1999.
7. Abrahamsson I, Berglundh T, Wennström J, Lindhe J: The peri-implant hard and soft tissues at different implant systems. a comparative study in the dog, *Clin Oral Implants Res* 7:212–219, 1996.
8. Abrahamsson I, Zitzmann NU, Berglundh T, et al.: The mucosal attachment to titanium implants with different surface characteristics: an experimental study in dogs, *J Clin Periodontol* 29:448–455, 2002.
9. Berglundh T, Abrahamsson I, Welander M, et al.: Morphogenesis of the peri-implant mucosa. an experimental study in dogs, *Clin Oral Implants Res* 18:1–8, 2007.
10. Berglundh T, Lindhe J: Dimensions of the peri-implant mucosa. Biological width revisited, *J Clin Periodontol* 23:971–973, 1996.
11. Linkevicius T, Apse P, Grybauskas S, Puisys A: Influence of thin mucosal tissues on crestal bone stability around implants with platform switching: a 1-year pilot study, *J Oral Maxillofac Surg* 68(9):2272–2277, 2010.
12. Vervaeke S, Dierens M, Besseler J, De Bruyn H: The influence of initial soft tissue thickness on peri-implant bone remodeling, *Clin Implant Dent Relat Res* 16(2):238–247, 2014.
13. Bengazi F, Botticelli D, Favero V, et al.: Influence of presence or absence of keratinized mucosa on the alveolar bony crest level as it relates to different buccal marginal bone thicknesses. an experimental study in dogs, *Clin Oral Implants Res* 25:1065–1071, 2014.
14. Bengazi F, Lang NP, Caroprese M, et al.: Dimensional changes in soft tissues around dental implants following free gingival grafting: an experimental study in dogs, *Clin Oral Implants Res* 26(2):1065–1071, 2013.
15. Lin GH, Chan HL, Wang HL: The significance of keratinized mucosa on implant health: a systematic review, *J Periodontol* 84(12):1755–1767, 2013.
16. Thoma DS, Mühlemann S, Jung RE: Critical soft-tissue dimensions with dental implants and treatment concepts, *Periodontol 2000* 66(1):106–118, 2015.
17. Oates TW, Robinson M, Gunsolley JC: Surgical therapies for the treatment of gingival recession. a systematic review, *J Periodontol* 8(1):303–320, 2003.
18. Allen AL: Use of the supraperiosteal envelope in soft tissue grafting for root coverage. II. Clinical results, *Int J Periodontics Restorative Dent* 14(4):302–315, 1994.
19. Langer B, Langer L: Subepithelial connective tissue graft technique for root coverage, *J Periodontol* 6(12):715–720, 1985.
20. Kennedy JE, Bird WC, Palcanis KG, et al.: A longitudinal evaluation of varying widths of attached gingiva, *J Clin Periodontol* 12(8):667–675, 1985.
21. Zucchelli G, Clauser C, De Sanctis M, et al.: Mucogingival versus guided tissue regeneration procedures in the treatment of deep recession type defect, *J Periodontol* 69(2):138–145, 1998.
22. Zadeh HH: Minimally invasive treatment of maxillary anterior gingival recession defects by vestibular incision subperiosteal tunnel access and platelet-derived growth factor BB, *Int J Periodontics Restorative Dent* 31(6):653–660, 2011.
23. Migliorati M, Amorfini L, Signori A, et al.: Clinical and aesthetic outcome with post-extractive implants with or without soft tissue augmentation: a 2-year randomized clinical trial, *Clin Implant Dent Related Res* 17(5):983–995, 2015.
24. Tatakis DN, Chambrone L, Allen EP, et al.: Periodontal soft tissue root coverage procedures: a consensus report from the AAP regeneration workshop, *J Periodontol* 86(Suppl 2):S52–S55, 2015.

25. Esposito M, Grusovin MG, Maghaireh H, et al.: Interventions for replacing missing teeth: management of soft tissues for dental implants, *Cochrane Database Syst Rev July* 18(3):1–43, 2007.
26. Esposito M1, Maghaireh H, Grusovin MG, Ziounas I, Worthington HV: Soft tissue management for dental implants: what are the most effective techniques? a cochrane systematic review, *Eur J Oral Implantol* 5(3):221–238, 2012.
27. Thoma DS1, Buranawat B, Hämmerle CH, et al.: Efficacy of soft tissue augmentation around dental implants and in partially edentulous areas: a systematic review, *J Clin Periodontol* 41(Suppl 15):S77–S91, 2014.
28. Rotundo R, Pagliaro U, Bendinelli E, et al.: Long-term outcomes of soft tissue augmentation around dental implants on soft and hard tissue stability: a systematic review, *Clin Oral Implants Res* 26(Suppl 11):123–q38, 2015.
29. Suárez-López Del Amo F, Lin GH, Monje A, et al.: Influence of soft tissue thickness upon peri-implant marginal bone loss: a systematic review and meta-analysis, *J Periodontol* 16:1–18, 2016.
30. Mörmann W, Schaer F, Firestone AR: The relationship between success of free gingival grafts and transplant thickness. revascularization and shrinkage-a one-year clinical study, *J Periodontol* 52(2):74–80, 1981.
31. Studer SP1, Lehner C, Bucher A, Schärer P: Soft tissue correction of a single-tooth pontic space: a comparative quantitative volume assessment, *J Prosthet Dent* 83(4):402–411, 2000.
32. Thoma DS, Jung RE, Schneider D, et al.: Soft tissue volume augmentation by the use of collagen-based matrices: a volumetric analysis, *J Clin Periodontol* 37(7):659–666, 2010.
33. Abrams L: Augmentation of the deformed residual edentulous ridge for fixed prosthesis, *Compend Contin Educ Gen Dent* 1(3):205–213, 1980.
34. Scharf DR, Tarnow DP: Modified roll technique for localized alveolar ridge augmentation, *Int J Periodontics Restorative Dent* 12(5):415–425, 1992.
35. Sclar A: *Soft tissue and esthetic considerations in implant therapy*, Hanover Park, IL, 2003, Quintessence.
36. Park SH1, Wang HL: Pouch roll technique for implant soft tissue augmentation: a variation of the modified roll technique, *Int J Periodontics Restorative Dent* 32(3):e116–e121, 2012.
37. Akcalı A, Schneider D, Ünlü F, et al.: Soft tissue augmentation of ridge defects in the maxillary anterior area using two different methods: a randomized controlled clinical trial, *Clin Oral Implants Res* 26(6):688–695, 2015.
38. Sanz M, Lorenzo R, Aranda J, et al.: Clinical evaluation of a new collagen matrix (mucograft prototype) to enhance the width of keratinized tissue in patients with fixed prosthetic restorations: a randomized prospective clinical trial, *J Clin Periodontol* 36(10):868–876, 2009.
39. Anderson LE, Inglehart MR, El-Kholy K, et al.: Implant associated soft tissue defects in the anterior maxilla: a randomized control trial comparing subepithelial connective tissue graft and acellular dermal matrix allograft, *Implant Dent* 23(4):416–425, 2014.
40. Urban IA, Monje A, Wang HL: Vertical ridge augmentation and soft tissue reconstruction of the anterior atrophic maxillae: a case series, *Int J Periodont Restor Dent* 35(5):613–623, 2015.
41. Zadeh HH, editor: *Ästhetische Zahnmedizin: Josef Schmidseder*, ed 2, Stuttgart, 2008, Thieme Medical, pp 281–314.
42. Susin C, Fiorini T, Lee J, et al.: Wound healing following surgical and regenerative periodontal therapy, *Periodontol 2000* 68(1):83–98, 2015.
43. Hiatt WH, Stallard RE, Butler ED, et al.: Repair following mucoperiosteal flap surgery with full gingival retention, *J Periodontol* 39(1):11–16, 1968.
44. Sandberg N, Zederfeldt B: The tensile strength of healing wounds and collagen formation in rats and rabbits, *Acta Chir Scand* 126:187–196, 1963.
45. Cooper LF: Objective criteria: Guiding and evaluating dental implant esthetics, *J Esthet Restor Dent* 20(3):195–205, 2008.
46. Cosyn J, Sabzevar MM, De Bruyn H: Predictors of inter-proximal and midfacial recession following single implant treatment in the anterior maxilla: a multivariate analysis, *J Clin Periodontol* 39(9):895–903, 2012.

35

Zygomatic Implant: A Graftless Approach for Treatment of the Edentulous Maxilla

EDMOND BEDROSSIAN, EDMOND ARMAND BEDROSSIAN JR, PER-INGVAR BRÅNEMARK

The edentulous maxillae has a unique anatomic presentation, which limits the number and the distribution of implants within the alveolar ridge. The maxillary sinuses bilaterally and the position of the nasal floor in the premaxillary region may limit the vertical volume of alveolar bone available for placement of implants in the maxilla for a fixed, implant-supported prosthesis. The palatal and posterior resorption pattern of the edentulous maxillae may also limit the horizontal bony volume necessary to house endosseous implants. Therefore, in review of the literature,[1] the recommended treatment for the edentulous maxilla has been the tissue-supported, overdenture appliance. To establish support for a fixed prosthesis, reconstruction of the maxilla with various bone grafting techniques has been designed to recreate the alveolar volume and topography needed for stabilization of dental implants.[2-5] If the sinuses are pneumatized, sinus grafting[6] or tilted implants[7-9] have also been recommended.

For patients with significant anterior extension of their maxillary sinuses into the bicuspid region, the zygomatic implant is recommended. The zygomatic implant allows for establishing posterior maxillary support by using the limited crestal alveolar bone in the bicuspid region and the os zygomaticum for establishing initial stability of the implant. The use of the zygomatic implant has been reported internationally with a success rate between 94% and 100%.[10-15]

The 94% survival, as reported by Branemark et al., represents three failures out of 52 zygoma fixtures placed in their initial study. The first failure was due to enveloping of muscle tissue around the zygoma fixture. The second involved the inadequate centering of the implant within the zygomatic bone. The third failure occurred in a patient with Paget's disease who had loosely textured and low density bone.[14] Overall, this highly predictable implant allows for establishing posterior maxillary support for reconstruction with a fixed prosthesis without the need for bone grafting.

Historical Perspective

The treatment of the moderately to severely resorbed maxillae presents a challenge for the implant surgical-restorative team. The typically large pneumatized sinuses in this group of patients require extensive bone grafting if conventional implant placement is envisioned. Various procedures have been available for treatment of the resorbed maxillae. Adell,[16] and Breine and Branemark[17] used composite grafts to provide a tooth anchorage system. Le Fort I osteotomy[18] and iliac block graft[19,20] have also been used to reestablish bony volume for placement of implants. To create bone mass in the posterior maxillae, sinus-lift grafting procedures[19-22] have been performed. Survival of implants in sinus-lift procedures was studied in the sinus consensus conference.[6] The conclusion reached was similar to Tolman's report in 1995: The material was so "multivariate and multifactorial that it was difficult to draw definitive conclusions; these must await controlled prospective studies."[23] Grafting of the maxillae with delayed implant placement has been described in the literature.[24] Rasmusson presented success with autogenous grafting to establish favorable topography of the resorbed maxillae for implant placement using inlay, onlay, and/or Le Fort I procedures.[25] A success rate of 80% was reported for grafting with delayed implant placement and 77% for grafting with simultaneous implant placement. The success rate of implants placed in nongrafted bone was only 89% in the group studied. Keller et al., who used inlay grafts in their report on the reconstruction of the compromised maxillae,[24] reported an 87% implant survival rate and a prosthetic survival of 95%. The somewhat limited success with these adjunctive procedures has deterred patients from seeking reconstruction of their resorbed maxillae. An alternative for the treatment of

this group of patients is the zygomatic implant, which was introduced by Professor Brånemark in 1988.

Patient Selection

A systematic preoperative evaluation of the patient is required before the surgical treatment.[45] Both surgical and prosthetic needs must be considered before initiation of the surgical treatment to allow for a predictable outcome. The preoperative evaluation protocol takes into consideration the available alveolar bone in the different zones of the maxilla (Figure 35-1). It also determines whether the final prosthesis is a ceramometal bridge or profile prosthesis.[26] The determination is based on the lack or the presence of composite defect.[12] Evaluation of the esthetics of the final prosthesis is made by recognizing the transition line between the prosthesis and the residual edentulous crestal soft tissues (Figure 35-2). The zygomatic implant is considered in the group of patients who demonstrate bone in zone 1 only. In patients who also have limited horizontal alveolar width in zone 1, veneer grafting[27] before placement of the conventional implants for the anterior support is considered. A separate group of patients with advanced maxillary alveolar atrophy present with complete lack of the alveolus. This group may be candidates for the quad zygoma treatment concept (Figure 35-3).[14] The surgical procedure may be performed in the hospital setting using general anesthesia or in the office under IV sedation and local anesthesia.[12] The surgical candidate should be free of any sinus disease before consideration for this treatment concept.

Radiographic Evaluation

Although computerized and conventional tomography can be used, the Panorex radiograph is critical in the initial evaluation of the patient.[12,13,15] The presence of alveolar bone in the premaxilla (zone 1) and the lack of bone in the bicuspid and the molar regions, zones 2 and 3 respectively, are the indications for considering the zygomatic concept. Axial CT scans can be obtained to further evaluate the maxillary sinus. The width of the residual alveolar bone and the width and height of the zygomatic body can be visualized in frontal reformatted sections of the axial CT scans.

Further evaluation of the zygomatic bone has also been described.[27] Although not absolutely necessary, the reformatted frontal images in 2- to 3-mm cuts afford the less experienced operator more information for planning the

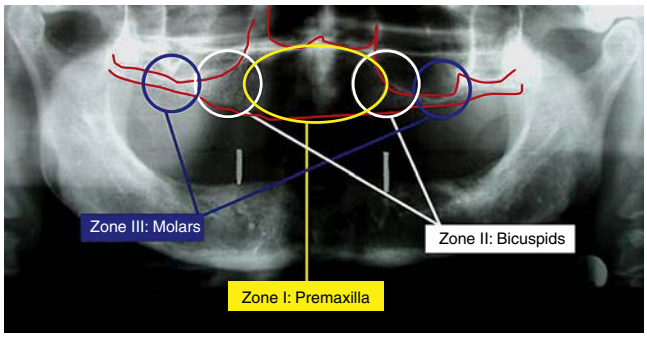

• **Figure 35-1** Zones of the maxilla. (From Bedrossian E: *Implant treatment planning for the edentulous patient,* St Louis, 2011, Mosby.)



• **Figure 35-3** Quad zygoma. (From Bedrossian E: *Implant treatment planning for the edentulous patient,* St Louis, 2011, Mosby.)

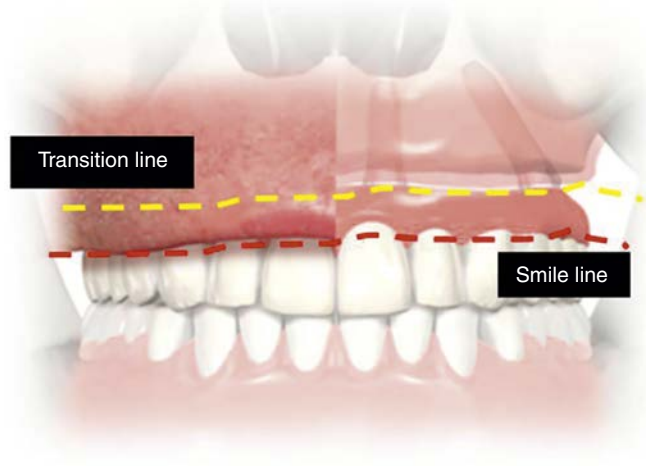

• **Figure 35-2** Smile line as it relates to the transition line. (From Bedrossian E: *Implant treatment planning for the edentulous patient,* St Louis, 2011, Mosby.)

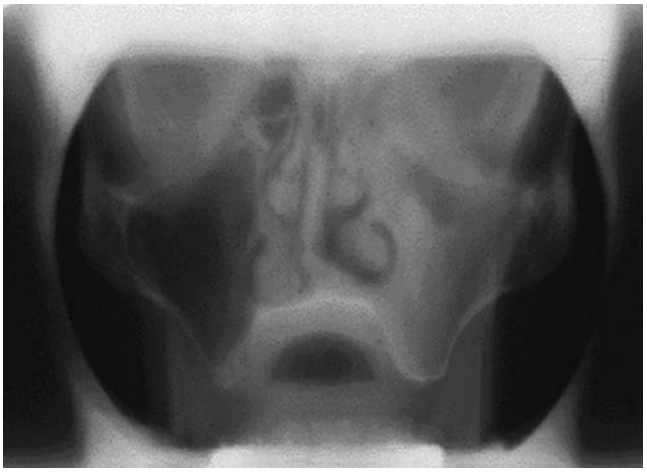

• **Figure 35-4** Frontal CT demonstrating the os zygomaticum. (From Bedrossian E: *Implant treatment planning for the edentulous patient,* St Louis, 2011, Mosby.)

surgery (Figure 35-4). The presence of sinus pathologic conditions including, but not limited to, thickening of the schneiderian membrane and air fluid levels, may be ruled out in both the Panorex and tomographic studies.

Os Zygomaticum: Regional Anatomy

The quantity and the quality of the zygomatic bone have been studied and reported by Nkenke et al.[27] The morphology and the microstructure of the os zygomaticum were assessed by quantitative computer tomography and histomorphometry. Bone mineral density of 30 human zygomatic bone specimens was studied. The trabecular bone mineral density, the trabecular bone volume, and the trabecular bone pattern factor were correlated with each other. The conclusion reached suggested that the trabecular bone of the os zygomaticum was not a favorable site for implant placement. However, Nkenke further suggests that the success seen with the zygomatic implant is due to the engagement of four cortices during the placement of the implant. The lingual cortex of the maxillary alveolus along with the cortical floor of the maxillary sinus provide for bicortical stabilization at the crestal portion of the implant. The superior-lateral portion of the roof of the maxillary sinus is formed by the inferior portion of the zygomatic bone. This portion of the zygoma along with its lateral superior cortical covering form the bicortical stabilization at the apical portion of the zygomatic implant.

To quantify the dimensions of cortical and trabecular bone of the os zygomaticum, morphometric analysis of the zygomatic bone was consistent with the following results: mediolateral dimension of 7.6 mm in males and 8.0 mm in females. The anterior-posterior dimension of the zygoma body was 25.4 mm in males and 24.9 mm in females. The lateral cortical thickness was 1.75 mm in males and 1.71 mm in females. The length of the zygomatic implant within the zygomatic bone was 16.5 mm in males and 14 mm in females. Zygomatic implants placed following ablative surgery have been reported by Weingart et al.[28] The implant survival rate was 65% to 75%. However, with the increased popularity of the zygomatic implant used in the atrophic maxilla, implant survival has increased to 97% to 100%.[10-15]

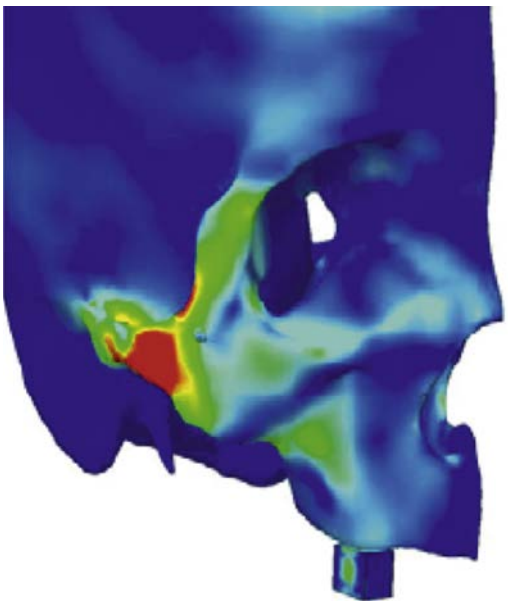

• **Figure 35-5** Ujigawa model demonstrating the load-bearing zygoma bone.

Primary Load-Bearing Bone Under Function

The indication for the placement of the zygoma implant is lack of bone in zones 2 and 3 (bicuspid and the molar region, respectively). For patients where the zygoma implant is considered there is less than 1 mm of residual maxillary alveolar bone remaining in the bicuspid and molar regions. Therefore, after placement of the zygoma implant, minimal bone to implant contact is achieved at the alveolar crest. Knowing that bone to implant contact (BIC) is limited at the maxillary crest, the question becomes: how important is BIC at the maxillary crest in distribution of the occlusal forces? Is there a benefit for having crestal maxillary bone at the implant platform?

Ujigawa and colleagues,[46] in an elegant finite element analysis, described the weight-bearing bones associated with the use of the zygoma implant. In their 2007 Finite Element Analysis paper, they reported that the zygoma bone, and not the maxilla, supports the simulated occlusal loads (Figure 35-5). However, in 2013 and 2015, Freedman et al.[47,48] corrected the observation in the Ujigawa study. The highlighted area over the lateral cortex of the zygoma reported as the load-bearing area in the Ujigawa study was instead the origin of the masseter muscle under activation. Freedman et al. demonstrated in their papers that the maxillary crest plays a role in the distribution of the occlusal loads and the preservation and the anchoring of the implant in the maxillary crest is recommended.

Deformation Under Function

In the Ujigawa study the prosthetic loads were considered using two different models. Each model had two zygoma implants, one in each posterior quadrant as well as two anterior maxillary implants. The difference was that in the first model, the implants were rigidly cross-arch splinted whereas in the second model all implants were lone standing without any cross-arch splinting under function.

When both models were subjected to simulated occlusal loading (centric occlusion), there were two areas that were identified as load bearing along the implant: the abutment-implant platform interface *(yellow arrow)* and the mid-portion of the implant *(red arrow)* (Figure 35-6). In the unsplinted model, the magnitude of the loads was significantly higher than in the splinted model. Significant increase in the magnitude of the load distribution pattern was seen in lateral excursions with the highest loads seen in the unsplinted zygoma implant model which can lead to stress fractures at the neck of the zygoma implant *(red arrow)* (Figure 35-7).

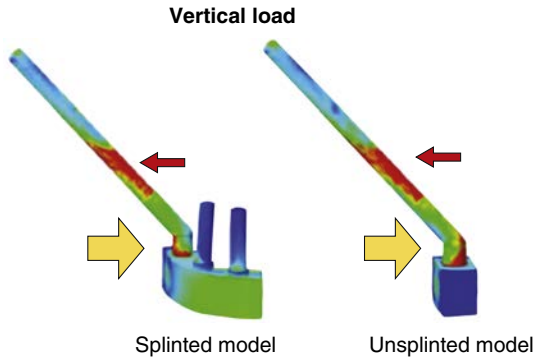

• **Figure 35-6** The *arrows* indicate two areas of stress under occlusal loading.

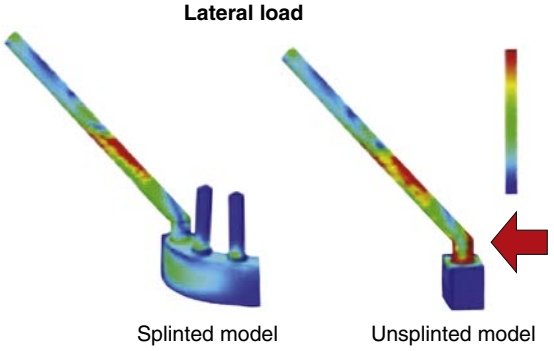

• **Figure 35-7** The unsplinted model demonstrates concentration of stress at the neck of the implant and the abutment as shown by the *red arrow*.

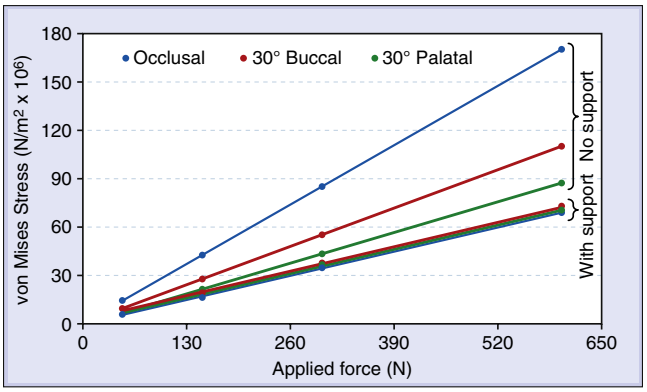

• **Figure 35-8** Zygoma implants with lack of crestal bony support demonstrate increased stress under load.

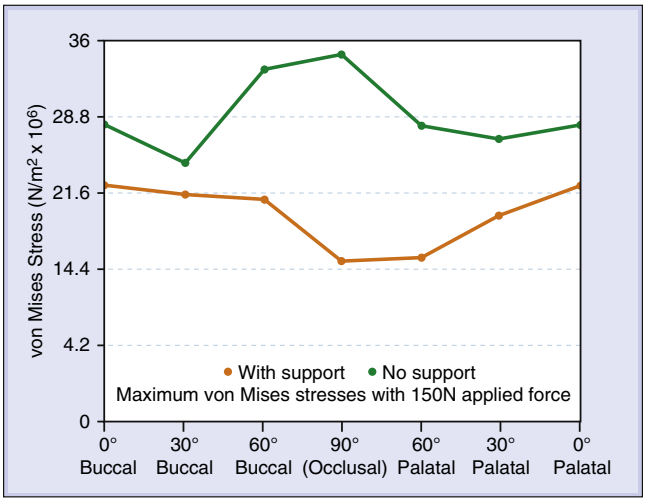

• **Figure 35-9** Maximum von Mises stress (N/m² × 10⁶) for models with and without alveolar support.

Past clinical reports[32] support the observation in this study highlighting the importance of cross-arch splinting zygoma implants with other stable implants within the arch to allow for a more favorable force distribution.

In 2013, the objective of the Freedman et al. study[47] was to investigate the influence of maxillary alveolar bone on the stress distribution of zygomatic implants. Two study models were created. The first model had the zygomatic implants placed in the skull supported by the zygoma and the maxillary alveolar bone with rigid cross-arch stabilization by a fixed bridge. The second model duplicated the first model, however, the area of the maxillary alveolar bone supporting the zygomatic implants was removed. Occlusal and lateral forces were applied to both models and the maximum von Mises stresses were recorded. In the model lacking alveolar support higher maximum stresses were noted. Occlusal stresses were higher than lateral stresses in the model with no alveolar support. The zygoma bone demonstrated low stresses in both models. Therefore, the authors concluded that the maxillary alveolar bone support is beneficial in the distribution of forces for zygomatic implants.

In 2015, Freedman et al.[48] addressed the extra-sinus placement of the zygoma implant. The first model had two zygomatic implants placed in the skull in an extra-sinus position connected by a rigid cross-arch splinted bridge. The second model was the duplication of the first with the area of the maxillary alveolar bone supporting the implants removed, which is an inherent consequence of this type of implant placement. Occlusal and lateral forces were applied with higher maximum stresses noted in the model with no alveolar support (Figure 35-8). Occlusal stresses were higher than lateral stresses in the model with no alveolar support (Figure 35-9). Occlusal stresses were lower than lateral stresses in the model with alveolar support. Low stresses were noted in the zygomatic bone in both models. They concluded that, "Maxillary alveolar bone support is beneficial in the distribution of forces for zygomatic implants placed in an extra-sinus position."

It is important for surgeons to recognize that there is a single trajectory of the zygoma implant as described by the ad modum Brånemark technique. It is also important to recognize that Aparicio[49] has described the relationship of the zygoma implant to the varying anatomy of the lateral maxillary wall; the trajectory of the zygoma implant does not change regardless of the maxillary anatomy being ZAGA 0 or ZAGA 4. The zygoma implant is recommended when there is less than 2 to 3 mm in zones 2 and 3. Under function and in time, the minimal crestal bone may resorb. However, it is prudent to follow the ad modum Brånemark

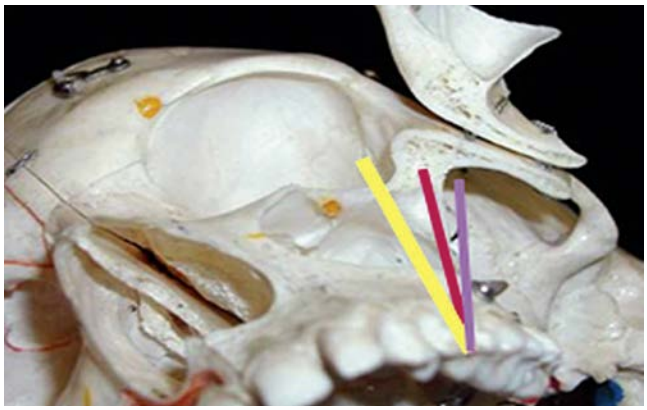

• **Figure 35-10** Axis of zygoma implant. (From Bedrossian E: *Implant treatment planning for the edentulous patient,* St Louis, 2011, Mosby.)

technique to allow initial stabilization of the implant as well as better force distribution as described by Freedman and co-workers.

Preoperative Considerations

The surgical procedure is usually performed in the office setting under IV sedation.[12] All patients are premedicated 1 hour before the surgical procedure. The proper administration of sufficient local anesthesia is critical in the management of these patients under IV sedation. The various infiltrations and nerve blocks include circumvestibular infiltration of the maxilla, greater palatine blocks, and bilateral transcutaneous infiltration of the temporal areas over the zygomatic body. Bilateral inferior alveolar nerve blocks are considered to allow retraction of the lower jaw during the surgery without undue stimulation of the sedated patient. It is recommended that the path of the implant from the premolar area to the base of the zygoma be directly visualized whenever possible.[12,30] Direct visualization of the base of the zygomatic body has also been advocated in clinicians who have used computer-assisted treatment planning and surgical templates for placement of the zygomatic implant.[30] Having a clear view of the path of the instruments needed in establishing the osteotomy and visualizing the path of the implant during its insertion prevent disorientation and potential complications associated with placement of the zygomatic implant. Generally, three potential axes of insertion are possible. The proper axis is a path extending from the bicuspid region through the maxillary sinus, entering the midportion of the zygomatic body. If the entry point in the zygomatic body is more anterior to this line axis, potential for penetration into the orbit exists. However, if the line axis is posterior to this line, the potential for entering the pterygomaxillary space, leading to soft tissue enveloping and the subsequent lack of osseointegration of the implant, along with the potential for unexpected hemorrhage exists (Figure 35-10). The zygomatic implant has a unique design. The diameter of the apical two thirds of the implant is 4.0 mm, yet the alveolar one third widens to a diameter of 5.0 mm. The zygomatic implants are available in lengths ranging from



• **Figure 35-11** Implant and available drill sizes. (From Bedrossian E: *Implant treatment planning for the edentulous patient,* St Louis, 2011, Mosby.)

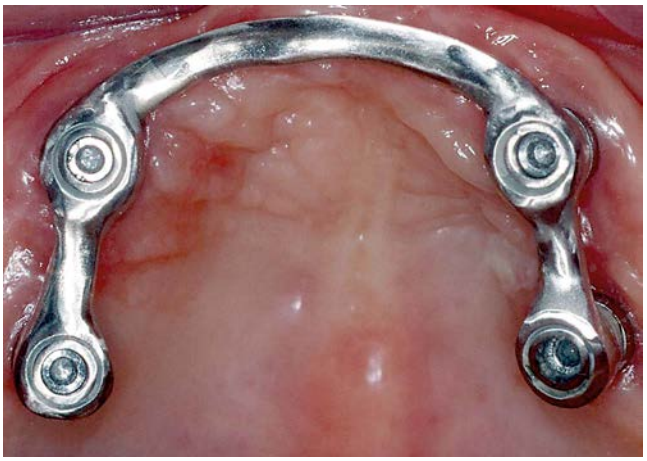

• **Figure 35-12** Cal bar stabilizing implants at stage II surgery. (From Bedrossian E: *Implant treatment planning for the edentulous patient,* St Louis, 2011, Mosby.)

30 to 52.5 mm. A specialized series of long zygoma drills are used to prepare the osteotomy (Figure 35-11).

Surgical Options

In reconstruction of the edentulous maxilla with the zygomatic implant, the traditional two-stage protocol[10,12,29] or the immediate-load protocol[12,30] may be considered. The two-stage protocol requires the immediate cross-arch splinting of the zygoma implants at the time of the uncovering procedure. This can be accomplished efficiently by using the Cal technique (Figure 35-12) for the fabrication of a passive bar before the uncovering procedure.[32] However, the alternative immediate-load technique cross-arch splints the zygomatic implants with each other by conversion of the patient's existing denture into a fixed provisional bridge. The immediate loading of the zygomatic implants has been reported in the literature with favorable results.[26,30]

Surgical Protocol

The surgical procedure begins by making a crestal incision across the edentulous maxillary arch. Bilateral releasing incisions are made over the maxillary tuberosity, similar to the hockey stick incisions for removal of maxillary wisdom teeth. A vertical window is made on the lateral wall of the maxilla paralleling the junction of the posterior aspect of the lateral maxillary wall and the lateral aspect of the posterior maxillary wall accessing the sinus (Figure 35-13). The schneiderian membrane may be removed or reflected away from the inside of the lateral wall of the maxillary sinus (Figure 35-14). It is critical to be aware of the position of the schneiderian membrane and to ensure that it does not attach to the zygomatic implant during its insertion into the body of the zygoma. Introduction of the soft tissue schneiderian membrane into the body of the zygoma will lead to nonosseointegration of the zygomatic implant.

The osteotomy is initiated by the use of a round bur (Figure 35-15) followed by a 2.9-mm twist drill (Figure 35-16). A 2.9- to 3.5-mm pilot drill stabilizes the 3.5-mm drill, which completes the osteotomy both at the maxillary crest and the body of the zygoma (Figure 35-17). If greater than 3 mm of crestal bone is identified, the alveolar portion of the osteotomy is completed by introduction of the 4.0-mm twist drill. In cases where there is a limited crestal bone width and or height, the 4.0-mm drill is not used. Before implant placement and at all times during preparation of the osteotomy (Figure 35-18), the entire surgical paths of the drills are visualized.[12,30]

The 45 degree angulations of the zygomaticus implant (Figure 35-19) allow for the platform of the implant to be in the same plane as the vertically placed implants in the premaxilla. To facilitate implant placement, the premounted implant carrier allows for easy handling of the implant with the straight zygomatic handpiece (Figure 35-20). To ensure proper orientation of the angulated implant head, the premounted fixture carrier screw head is used as a guide. Once the zygoma implant is placed to the proper depth a "stargrip" screwdriver is inserted into the head of the fixture screw, which secures the implant carrier to the 45 degree zygoma implant platform (Figure 35-21).The shaft of this

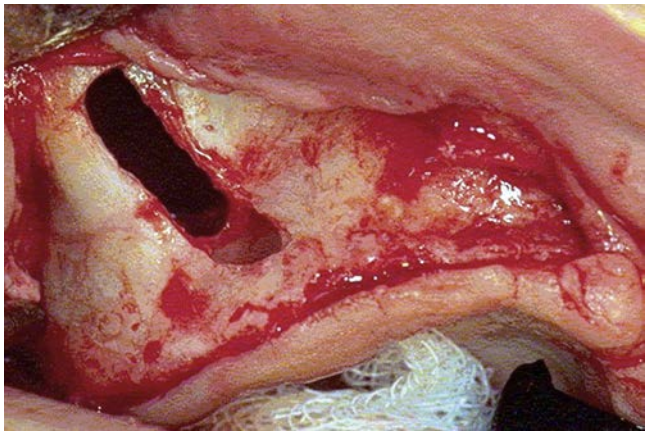

• **Figure 35-13** Access into the right maxillary sinus. (From Bedrossian E: *Implant treatment planning for the edentulous patient,* St Louis, 2011, Mosby.)

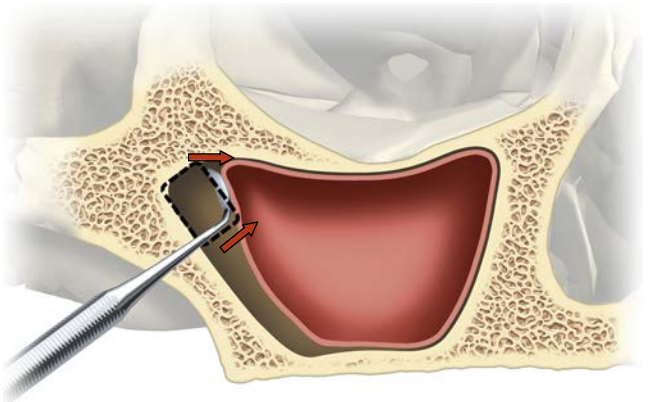

• **Figure 35-14** Reflecting the schneiderian membrane after accessing the sinus. (From Bedrossian E: *Implant treatment planning for the edentulous patient,* St Louis, 2011, Mosby.)

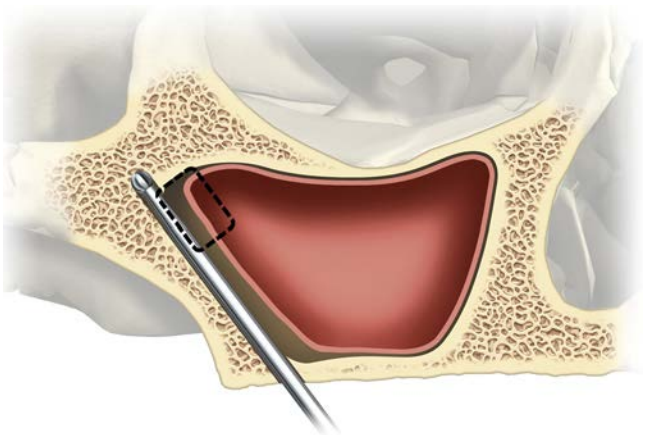

• **Figure 35-15** Round drill. (From Bedrossian E: *Implant treatment planning for the edentulous patient,* St Louis, 2011, Mosby.)

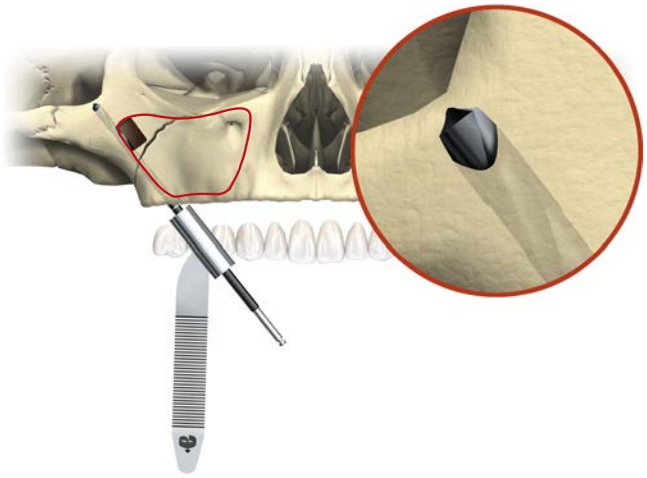

• **Figure 35-16** 2.9-mm drill. (From Bedrossian E: *Implant treatment planning for the edentulous patient,* St Louis, 2011, Mosby.)

screwdriver must be at right angles to the edentulous ridge to ensure proper orientation of the implant platform.

A minimum of two premaxillary implants are required (Figure 35-22).[33] If four implants can be distributed evenly within the premaxilla (zone 1), it may be considered. In the two-stage protocol where both the premaxillary and the zygomatic implants are submerged, single-thread NobelSpeedy Groovy (Nobel Biocare, Goteborg, Sweden) implants have been used. However, in cases where immediate loading is considered, the double-thread NobelSpeedy implants (Nobel Biocare, Goteborg, Sweden) have been used. The zygomatic implant is an external hex implant. The use of the external hex premaxillary implants is recommended to maintain uniformity and ease during the restorative treatment. All immediate premaxillary implants were placed with an initial insertion torque setting of 20 Ncm. Upon "stalling" of the handpiece, the insertion torque setting is increased to 40 Ncm, allowing complete insertion and seating of the implants. The "onion" hand insertion instrument (Figure 35-23) is used in cases where the handpiece stalls at the 40 Ncm setting. The zygomatic implant is hand driven to its final insertion depth, where the implant platform is intimately in contact with the lateral wall of the maxillary alveolus. The criteria for the immediate loading of the premaxillary implants and the zygoma implants include a minimum of 40 Ncm of insertion torque.[26]

The surgical wound is closed using 4-0 Vicryl sutures in cases where the implant surgery was performed in the

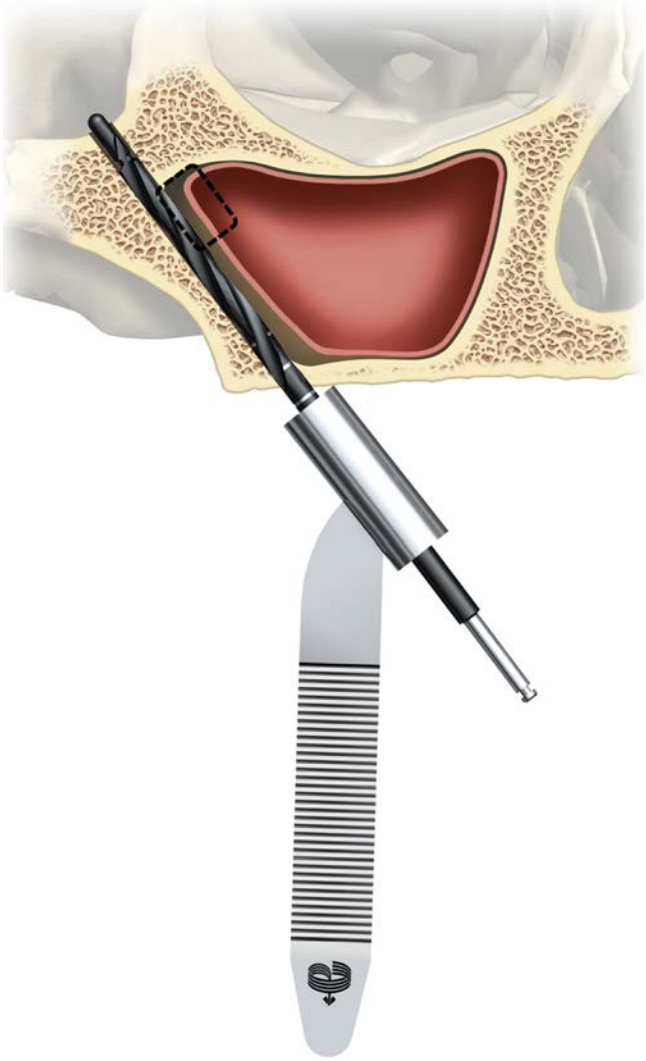

• **Figure 35-17** 3.5-mm drill. (From Bedrossian E: *Implant treatment planning for the edentulous patient,* St Louis, 2011, Mosby.)

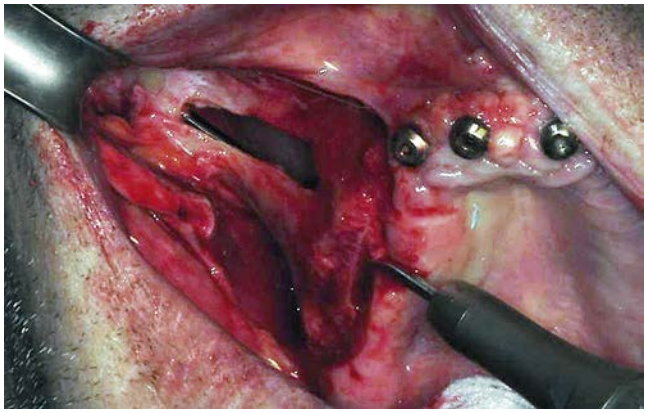

• **Figure 35-18** Direct visualization of the osteotomy. (From Bedrossian E: *Implant treatment planning for the edentulous patient,* St Louis, 2011, Mosby.)



• **Figure 35-19** 45-degree platform. (From Bedrossian E: *Implant treatment planning for the edentulous patient,* St Louis, 2011, Mosby.)



• **Figure 35-20** Premounted fixture carrier, straightening the implant. (From Bedrossian E: *Implant treatment planning for the edentulous patient,* St Louis, 2011, Mosby.)

two-stage manner. The denture base over the gingiva covering the platform of the zygomatic implants is relieved to prevent loading and wound breakdown. In patients who received immediate provisional fixed prostheses, 3-0 gut is used to close the soft tissue wound, and their existing full denture is converted to the immediate provisional fixed prostheses by the use of multiunit abutments and titanium temporary cylinders (Figure 35-24).

The Trajectory of the Zygoma Implant

Preparing the trajectory of the osteotomy for placement of the zygomatic implant is a critical step. Orientation of the proper trajectory may take several attempts by the surgeon. Once the trajectory of the osteotomy, hence the implant, is established, the steps needed to complete the osteotomy are readily achieved.

The platform of the zygomatic implant is generally in the second bicuspid or the mesial half of the first maxillary molar. The initial drill enters the maxillary sinus through the crestal osteotomy. Its path is directly visualized through the bony window established through the lateral wall of the maxillary sinus. The goal is for the round drill to create a small indentation in the roof of the maxillary sinus allowing for the purchase of the 2.9 mm twist drill. Once the round drill enters the floor of the sinus, it travels through the maxillary sinus and its apex exits at the front zygomatic notch.

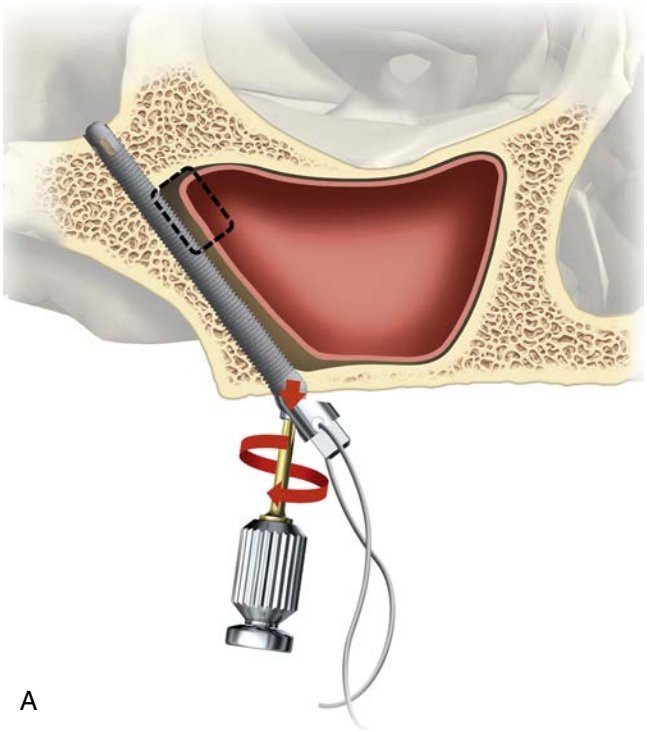



• **Figure 35-21** **A,** Confirming orientation of the zygoma implant platform. **B,** Platform of the zygoma implants in same plane as premaxillary implants. (From Bedrossian E: *Implant treatment planning for the edentulous patient,* St Louis, 2011, Mosby.)

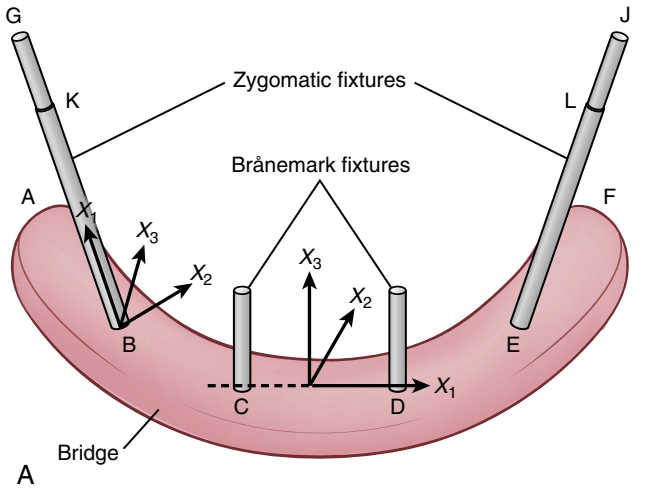

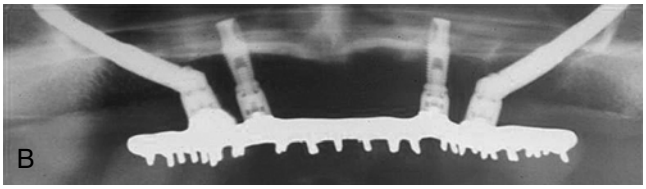

• **Figure 35-22** **A,** Zhao-Skalak-Brånemark's biomechanical analysis. **B,** Zygoma implant with minimum of two premaxillary implants. (From Bedrossian E: *Implant treatment planning for the edentulous patient,* St Louis, 2011, Mosby.)



• **Figure 35-23** The onion driver. (From Bedrossian E: *Implant treatment planning for the edentulous patient,* St Louis, 2011, Mosby.)

The shaft of the round drill is immediately parallel to the posterior wall of the maxilla (Figure 35-25).

In order to achieve this trajectory—the ad modum Brånemark technique[31,32]—the lateral maxillary wall needs to be studied. After exposing the posterior maxillary alveolar ridge and the lateral wall of the maxilla, the distal portion of the lateral maxillary wall as it turns medially to form the posterior maxillary wall needs to be identified. This is a vertical "corner" of the posterior portion of the maxillary sinus as represented with the black dotted lines in Figure 35-26. By following this trajectory, a "quad-corticalization" of the zygoma implant is achieved. Once the implant has been fully seated, its proper trajectory is confirmed by the distal portion of the zygomatic implant body being immediately adjacent to and in intimate contact with the posterior wall of the lateral maxillary wall (Figure 35-27).

Aparicio in 2011 described the various relationships the midportion of the zygoma implant may have with the lateral maxillary wall.[49] The lateral maxillary wall may be "straight" or "concave." If it is concave, then a portion of the midshaft of the zygoma implant may be "outside" the maxillary sinus. The classification described by Aparicio is ZAGA 0 (straight lateral maxillary wall with the midportion of the zygoma implant inside the sinus) to ZAGA 4, which is the most extreme resorption of the maxillary sinus where the midportion of the implant is "outside the maxillary sinus" due to lack of bone. The authors emphasize that the trajectory of the osteotomy for the placement of the zygoma implant is to be followed as described by Professor Brånemark, regardless of the intra- or extra-sinus relationship of the midportion of the implant (Figure 35-28, *A*). The surgeon must appreciate that the presence of the midportion of the implant directly beneath the vestibular depth may lead to erosion of the mucosa and exposure of the implant shaft (Figure 35-28, *B*). A limited number of case reports have been published for the management of these exposures.[50,51] In extreme cases such as ZAGA 3, ZAGA-4, or in cases of total or partial maxillectomy, the zygoma implant will be immediately below the soft tissues of the vestibule and the occurrence of soft tissue dehiscence cannot be prevented. In all other cases, attempts should be made to place the midportion within the sinus following the Brånemark protocol. The inclusion of the buccal fat pad graft either at time of the initial surgery or as a "preventative" measure against soft tissue dehiscence only adds unnecessary morbidity for the patients. Therefore, it is the recommendation by the authors to continue the ad modum Brånemark technique as described earlier in order to minimize the long-term response of the soft tissues.



• **Figure 35-24** Temporary titanium cylinders. (From Bedrossian E: *Implant treatment planning for the edentulous patient,* St Louis, 2011, Mosby.)

Prosthetic Conversion Technique

To provide the surgical patient with a fixed provisional prosthesis immediately following the surgical procedure, conversion of the patient's existing full denture or the

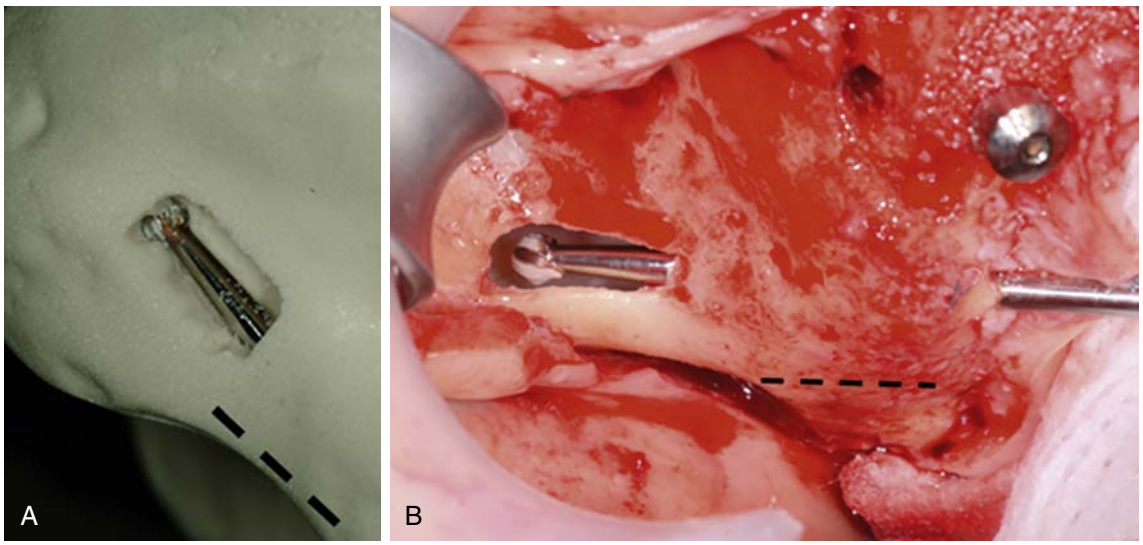

• **Figure 35-25** Lateral **(A)** and inferior **(B)** view of the model with holes around the coronal portion of the implants, removing extra support from the alveolar bone.

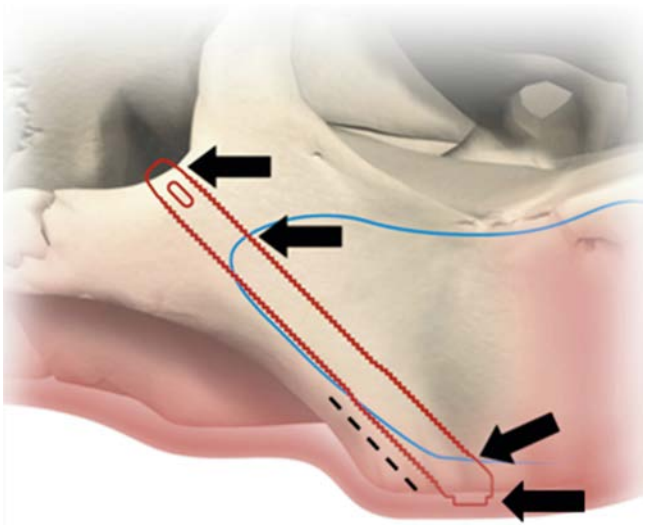

• **Figure 35-26** The shaft of the round drill parallels the *"black dotted line"* which represents the lateral-posterior corner of the maxillary sinus.

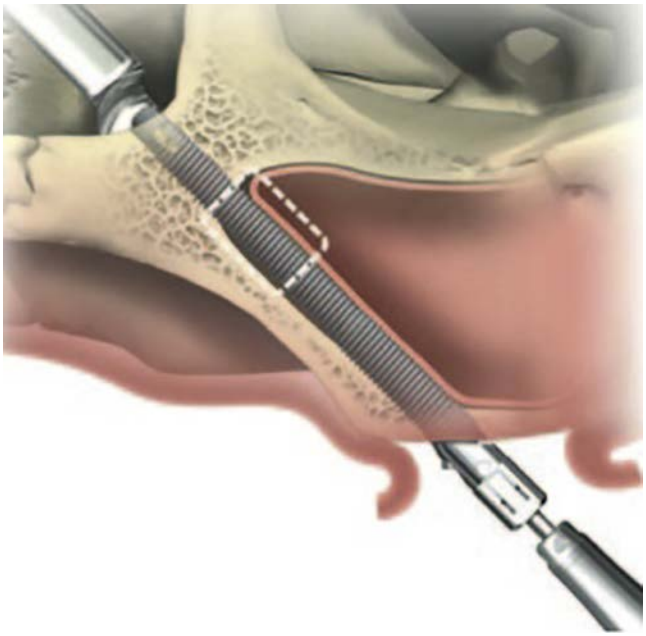

• **Figure 35-27** Ad Modum Brånemark Trajectory of the zygoma implant.

conversion of the newly fabricated immediate denture is undertaken.[26,37] The preoperative denture should be at the proper vertical dimension of occlusion (VDO) and proper tooth position.[34-36] Once the implants have been placed with 40 Ncm insertion torque, healing abutments are connected. The heights of the healing abutments are chosen so that after suturing of the crestal incision, 1 mm of the healing abutment is above the soft tissue line. The patient's denture is adjusted to allow passive seating without interference from the healing abutments and distortion of the soft tissues. Blue mouse bite registration is flowed into the denture as it is seated in the mouth, ensuring proper occlusion with the apposing dentition and proper midline orientation. The positions of the healing abutments are imprinted into the blue mouse as it sets (Figure 35-29). An acrylic bur is used to perforate the denture base, marking and relating the positions of the implants with the denture acrylic. Care must be taken not to make excessive holes or to fracture the denture base. The denture with the prepared holes is once again seated in the mouth in the proper position. Relating the position of the temporary healing abutments to the holes in the denture base allows one to determine whether straight, 17 degree, or 30 degree abutments will be used for the fabrication of the screw-retained provisional profile prosthesis. Once the abutments are chosen and seated onto the implants, reconfirmation of the screw access holes is made by proper seating of the denture in the patient's mouth. The abutments are torqued to 35 Ncm (Figure 35-30). To fabricate this fixed prosthesis, temporary multiunit titanium cylinders are used (Figure 35-31). The temporary titanium cylinders are cold cured to the denture base using quick-setting denture repair acrylic (Figure 35-32). Upon hardening of the acrylic, the denture is removed from the patient's mouth by unscrewing the retaining screws. The voids on the tissue surface of the denture base, around the temporary titanium cylinders, are further reinforced with the quick-setting acrylic, ensuring that no acrylic is introduced into the seating surfaces of the cylinders (Figure 35-33). The palate and the denture flanges are removed. Recontouring of the acrylic on the undersurface of the prosthesis is completed in an attempt to remove all concavities, which may trap food. The patient's occlusion is checked, ensuring group function and uniform loading across the entire prosthesis in centric occlusion.[38,39] To avoid bending moments, as close as possible to 0 degree teeth are used in the fabrication of this provisional prosthesis. A temporary material of choice is used to cover the retaining screw holes (Figure 35-34).

Postoperative Care

Patients are asked to maintain a soft diet. Incising of food is discouraged for the first 3 months. Postoperative medications include oral antibiotics for 1 week and an analgesic of choice, as needed. All patients are asked to use 2% chlorhexidine rinse 20 minutes before sleeping every night. A 1-week follow-up appointment is made to ensure proper occlusion, wound healing, and stability of the prosthesis. If screw loosening is encountered, occlusion is checked, eliminating hyperocclusion on selected areas and interference in lateral excursions. Patients are seen as needed over the next 6 months. Bruxism on occasion will result in the fracture of the provisional prosthesis. The prosthesis may be repaired intraorally or indexed and removed for a laboratory repair at the fracture site. The use of night guards made for the provisional prosthesis and the continual use of a new night guard made after the fabrication of the final definitive prosthesis may aid in management of the excessive forces generated by this group of patients.

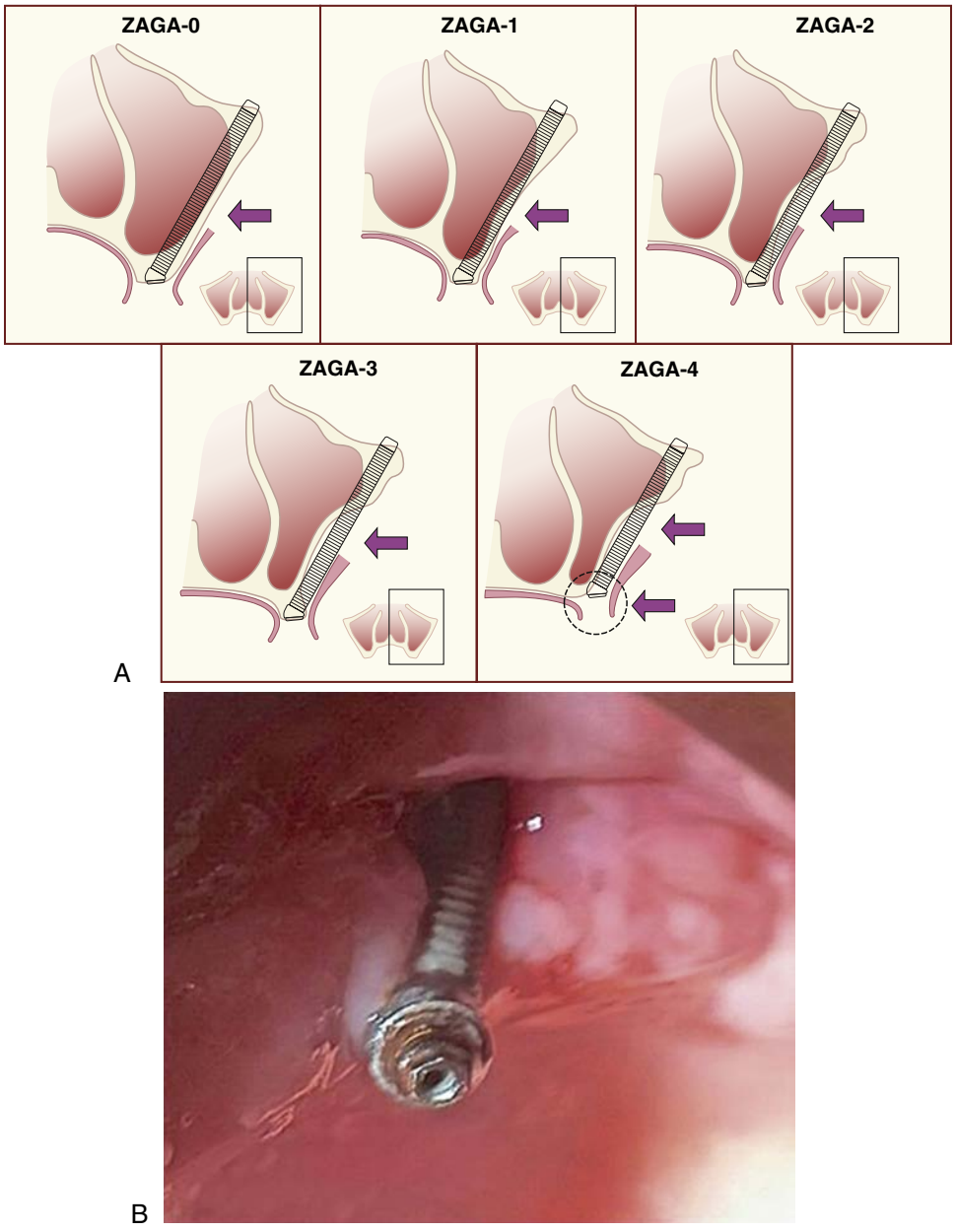

• **Figure 35-28** **A,** ZAGA classification, describing the relationship of the midportion of the implant to the lateral maxillary wall. **B,** The potential for soft tissue breakdown and exposure of the implant is possible in ZAGA 4 cases as well as when following the extra-maxillary technique.

Surgical Complications

Potential complications include penetration of the orbit and the pterygomaxillary space. Inability to place the zygomatic implant in patients with abnormal anatomy secondary to congenital deformities, trauma, and postcancer resection cases has been reported.[40] Several authors have reported on complications with the zygomatic implant and its management.[15,40,41] Potential complications include soft tissue irritations around the abutment connection with the zygomatic implant,[15,41] which were corrected by minor soft tissue procedures. Delayed acute sinusitis was reported by Aparicio[15] 14, 23, and 27 months after surgical procedures. These infections were resolved following oral antibiotic regimens without further complications. Bjorn Peterson reported on foreign bodies in the nose and the maxillary sinus[55] (Figure 35-35). One-year follow-ups of 14 patients, using an endoscope for rhinoscopy and sinoscopy, determined no signs of infection or inflammation in the mucosa around the fixtures.[29]

Management of Sinus Infections

Delayed sinus infections, 3 to 5 years postoperatively, have been reported by Aparicio et al.[15] The majority of sinus infections are reported as being unilateral (Figure 35-36). The maxillary sinus drains via the osteomeatal complex (Figure 35-37). The opening of the sinus into the nose is

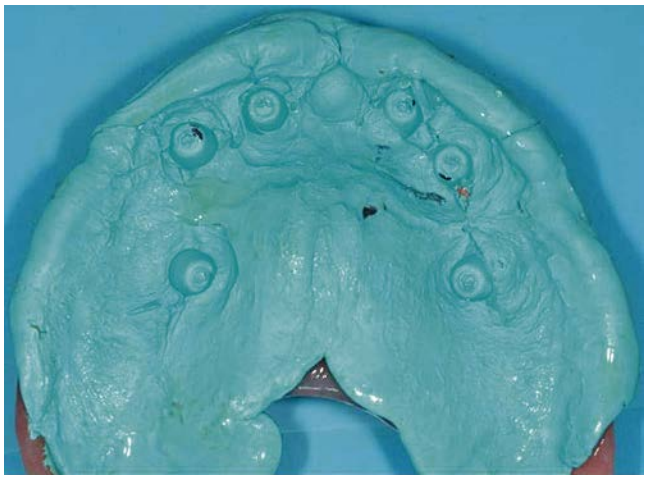

• **Figure 35-29** Imprint of implant positions. (From Bedrossian E: *Implant treatment planning for the edentulous patient,* St Louis, 2011, Mosby.)

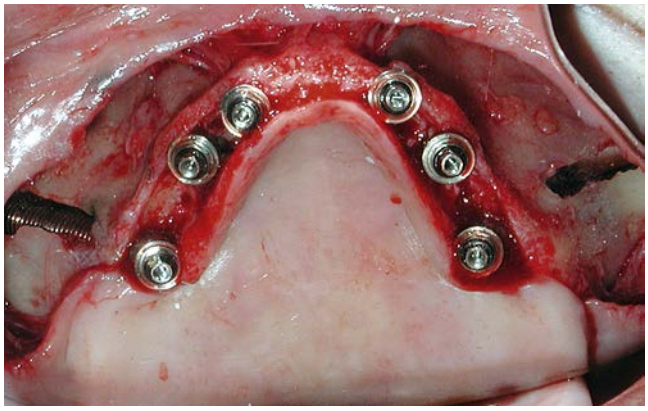

• **Figure 35-30** Multiunit abutments seated. (From Bedrossian E: *Implant treatment planning for the edentulous patient,* St Louis, 2011, Mosby.)

simply a bony orifice lined by mucosa. The size of the bony orifice is consistent and free of any congenital malformations measuring 2.4 to 4 mm in diameter.[52] However, the incidence of hyperactive mucosa overlying the bony opening may be congenital.

Triggered by various allergens, the mucosa overlying the ostium may become hyperactive and block the path of drainage from the maxillary sinus.[53] In cases of acute episodes of sinus allergy or infection, simple oral measures such as prescribing Mucinex for thinning the mucosa, Sudafed to decrease the edema within the mucosa and antibiotics, Augmentin, for the first episode and Levaquin for recurring episodes, may be prescribed. However, if the infection does not resolve, functional endoscopic sinus surgery (FESS) is indicated[53,54] (Figure 35-38). The authors have not experienced the incidence of bilateral sinus infections; infections seem to be unilateral, affecting the maxillary sinus and at times the ipsilateral ethmoid sinuses and on very rare occasion the ipsilateral frontal sinus. The "acceptance" of the zygoma implant within the maxillary sinus has been reported favorably in the past.[55] Therefore, the authors agree

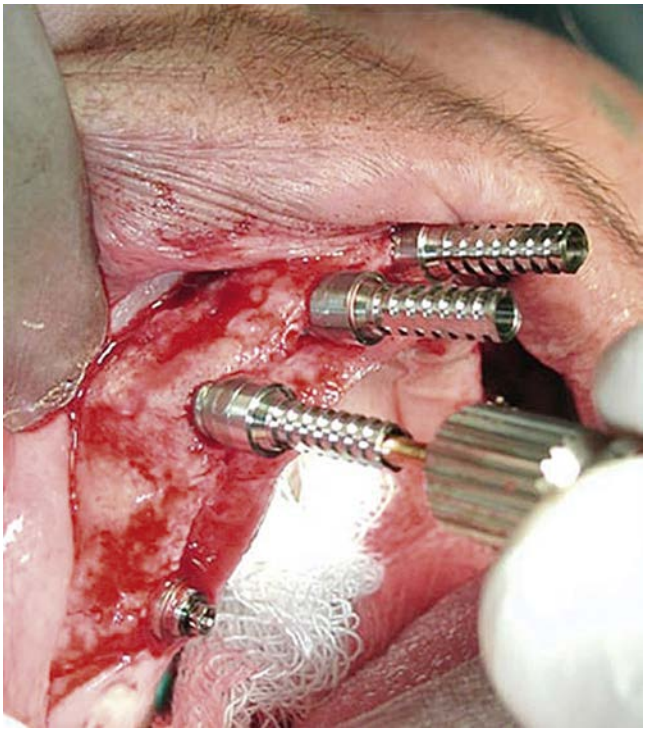

• **Figure 35-31** Temporary cylinders placed. (From Bedrossian E: *Implant treatment planning for the edentulous patient,* St Louis, 2011, Mosby.)

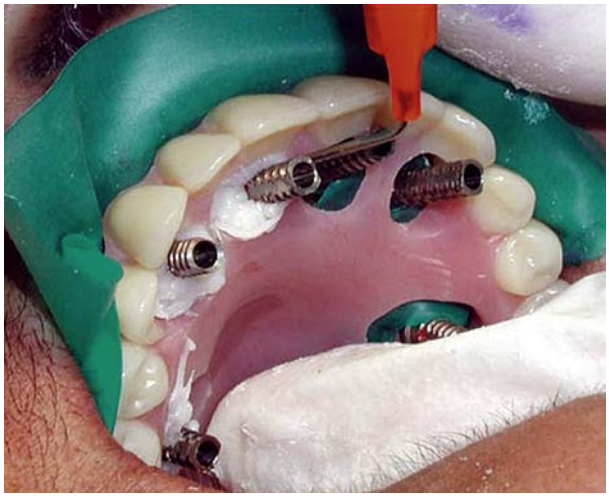

• **Figure 35-32** Luting of the temporary cylinders to the denture. (From Bedrossian E: *Implant treatment planning for the edentulous patient,* St Louis, 2011, Mosby.)

with Petruson's report in 2004 that the zygoma implant is not the cause of the sinus infections and does not act like a foreign body. It is strongly recommended that surgeons placing the zygoma implant understand and communicate this information with their otolaryngology colleagues.

Neurosensory disturbance of the zygomaticofacial nerve has been reported as a result of commonly encountering this nerve during the soft tissue reflection over the lateral aspect of the zygomatic body.[42] Failure of one immediate-load zygomatic implant has been experienced by this author. The failed zygomatic implant was noted at initiation of the



• **Figure 35-33** Keeping the inner surface of the temporary cylinder clean. (From Bedrossian E: *Implant treatment planning for the edentulous patient,* St Louis, 2011, Mosby.)



• **Figure 35-34** Completed immediate load prosthesis. (From Bedrossian E: *Implant treatment planning for the edentulous patient,* St Louis, 2011, Mosby.)



• **Figure 35-35** Sinoscopy of maxillary sinus. (From Bedrossian E: *Implant treatment planning for the edentulous patient,* St Louis, 2011, Mosby.)

fabrication process for the final prosthesis. The zygomatic implant rotated during a reverse torque test. This was corrected by the simultaneous removal of the one failed zygomatic implant and placement of a new zygomatic implant immediately below the existing failed osteotomy site. The new zygoma implant was immediately loaded by connecting

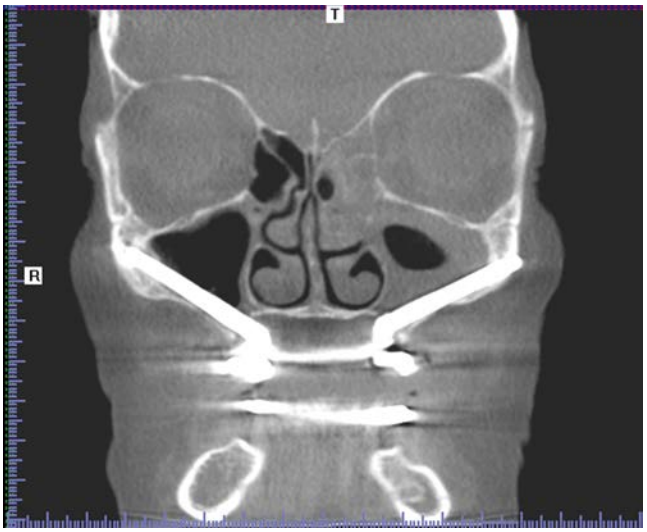

• **Figure 35-36** The majority of acute sinus infections are unilateral.

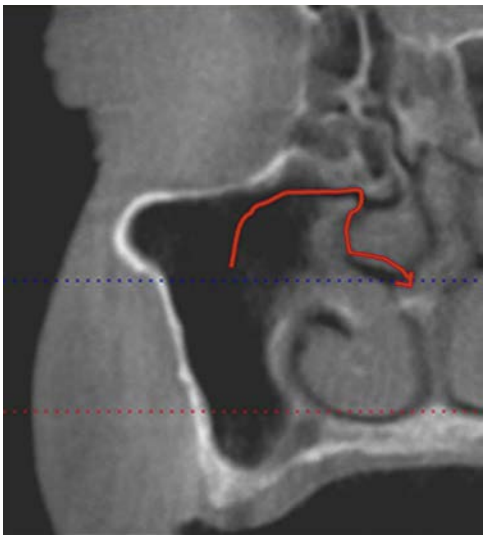

• **Figure 35-37** The drainage of the maxillary sinus through its ostium.

it to the existing provisional prosthesis. After an additional 6-month osseointegration period, all implants were stable, and the final profile prosthesis was completed.

Final Prosthesis Fabrication

After 6 months of osseointegration time, the prosthesis is removed and the stability of the implants is checked. Osseointegration is confirmed by observation of the lack of mobility of the implants and the lack of sensitivity during percussion. Fazad et al.[43] measured implant stability using Osstell (Integration Diagnostics, Savedalen, Sweden). Resonance frequency analysis showed mean ISQ values for the premaxillary implants and zygomatic implants to be 61.6 (range 48 to 71) and 65.9 (range 42 to 100), respectively. Aparicio et al.[15] used the Periotest (Siemens AG, Bensheim, Germany) measurement values, which compared favorably with previously reported measurements of osseointegrated implants. Zwahlen et al.[40] used the reverse torque

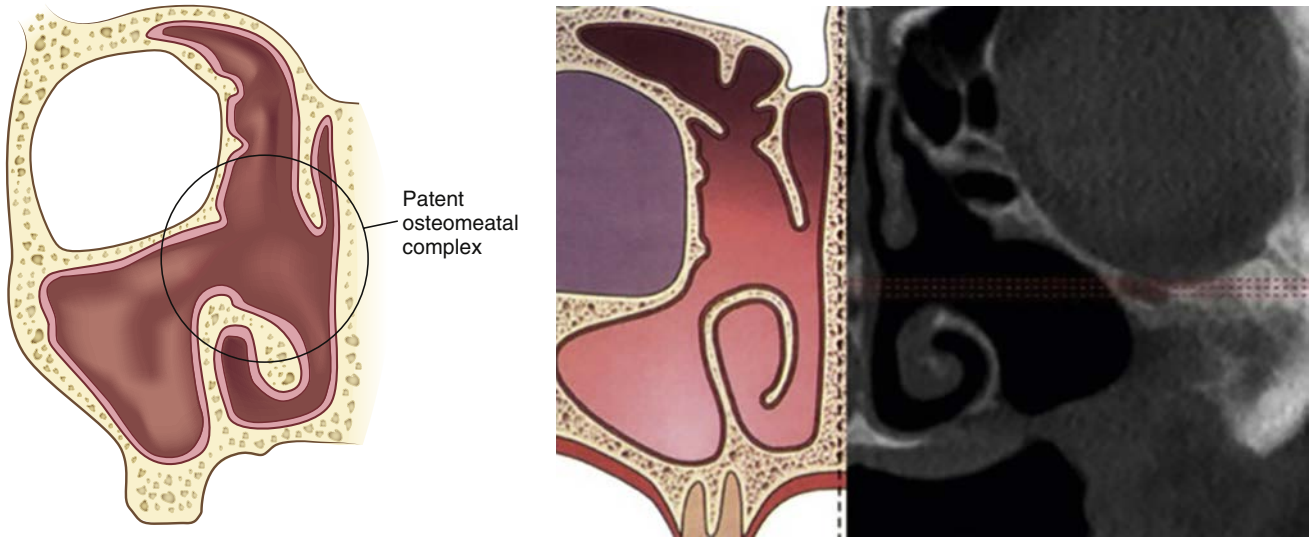

• **Figure 35-38** Completed functional endoscopic sinus surgery (FESS) procedure.

technique (10 Ncm) at the second-stage surgery, 6 months after placement of the implants, to determine osseointegration. Upon determination of osseointegration, the patient is ready for either the fabrication of an all-acrylic profile prosthesis[44] or a metal-based and acrylic profile prosthesis using resin teeth.

Summary

The zygomatic implant is a predictable fixture to establish posterior maxillary support for a fixed, implant-supported maxillary prosthesis without the need for bone grafting. In the hands of experienced surgical and prosthetic teams, the zygomatic implant is a viable addition to existing treatment modalities. The implant may be used in either the two-stage protocol or the immediate-load protocol with favorable long-term stability.

References

1. Wood M, Vermilyea SG: A review of selected dental literature on evidence-based treatment planning for dental implants: report of the committee on research in fixed prosthodontics of the Academy of Fixed Prosthodontics, *J Prosthet Dent* 92:447–462, 2004.
2. Breine U, Branemark PI: Reconstruction of alveolar jaw bone. An experimental and clinical study of immediate and performed autologous bone grafts in combination with osseointegrated implants, *Scand J Plast Reconstr Surg* 14:23–48, 1980.
3. Issaksson S, et al.: Early results from reconstruction of severely atrophic (class VI) maxillas by immediate endosseous implants in conjunction with bone grafting and Lefort I osteotomy, *J Oral Maxillofac Surg* 22:144–148, 1993.
4. Adell R, et al.: Reconstruction of severely resorbed edentulous maxillae using osseointegrated fixtures in immediate autogenous grafts, *Int J Oral Maxillofac Implants* 5:233–246, 1990.
5. Isaksson S, Alberius P: Maxillary alveolar ridge augmentation with onlay bone grafts and immediate endosseous implants, *J Craniomaxillofac Surg* 20:2–7, 1992.
6. Jensen OT, et al.: Report of the sinus consensus conference of 1996, *Int J Oral Maxillofac Implants* 13(suppl 1):11–32, 1998.
7. Fortin Y, Sullivan RM, Rangert BR: The Marius implant bridge: surgical and prosthetic rehabilitation for the completely edentulous upper jaw with moderate to severe resorption: a 5-year retrospective clinical study, *Clin Implant Dent Relat Res* 4:69–77, 2002.
8. Krekmanov L, et al.: Tilting of posterior mandibular and maxillary implants for improved prosthesis support, *Int J Oral Maxillofac Implants* 15:405–414, 2000.
9. Aparicio C, Perales P, Rangert B: Tilted implants as an alternative to maxillary sinus grafting: a clinical, radiologic, and Periotest study, *Clin Implant Dent Relat Res* 1:39–49, 2001.
10. Stevenson ARL, Austin BW: Zygomatic fixtures—the Sydney experience, *Ann R Australas Coll Dent Surg* 15:337, 2000.
11. Higuchi KW: The zygomatic fixture: an alternative approach for implant anchorage in the posterior maxilla, *Ann R Australas Coll Dent Surg* 15:28–33, 2000.
12. Bedrossian E, Stumpel LJ: The zygomatic implant: preliminary data on treatment of severely resorbed maxillae. A clinical report, *Int J Oral Maxillofac Implants* 17:861–865, 2002.
13. Malevez C, et al.: Clinical outcome of 103 consecutive zygomatic implants: a 6-48 month follow-up study, *Clin Oral Implant Res* 115:18–22, 2004.
14. Branemark PI, et al.: Zygoma fixture in the management of advanced atrophy of the maxilla: technique and long-term results, *Scand J Reconstr Surg Hand Surg* 38:70–85, 2004.
15. Aparicio C, et al.: A prospective clinical study on titanium implants in the zygomatic arch for prosthetic rehabilitation of the atrophic maxilla: a follow-up of 6 months to 5 years, *Clin Implant Dent Res* 8:114–122, 2006.
16. Adell R, et al.: A 15-year study of osseointegrated implants in the treatment of the edentulous jaw, *Int J Oral Surg* 10:387–416, 1981. 198.

17. Breine U, Branemark PI: Reconstruction of alveolar jaw bone. An experimental and clinical study of immediate and performed autologous bone grafts in combination with osseointegrated implants, *Scand J Plast Reconstr Surg* 14:23–48, 1980.
18. Issaksson S, et al.: Early results from reconstruction of severely atrophic (class VI) maxillas by immediate endosseous implants in conjunction with bone grafting and Lefort I osteotomy, *J Oral Maxillofac Surg* 22:144–148, 1993.
19. Adell R, et al.: Reconstruction of severely resorbed edentulous maxillae using osseointegrated fixtures in immediate autogenous grafts, *Int J Oral Maxillofac Implants* 5:233–246, 1990.
20. Isaksson S, Alberius P: Maxillary alveolar ridge augmentation with onlay bone grafts and immediate endosseous implants, *J Craniomaxillofac Surg* 20:2–7, 1992.
21. Boyne PJ, James RA: Grafting of the maxillary sinus floor with autogenous marrow and bone, *J Oral Surg* 38:613–616, 1980.
22. Wood RM, Moore DI: Grafting of the maxillary sinus with intraorally harvested autogenous bone prior to implant placement, *Int J Oral Maxillofac Implants* 3:209–214, 1988.
23. Tolman DE: Reconstructive procedures with endosseous implants in grafted bone: a review of the literature, *Int J Oral Maxillofac Implants* 10:275–294, 1995.
24. Keller E, Tolman DE, Eckert SE: Maxillary antral-nasal inlay autogenous bone graft reconstruction of compromised maxillae: a 12-year retrospective study, *Int J Oral Maxillofac Implants* 14:707–721, 1999.
25. Rasmusson L, et al.: The influence of simultaneous versus delayed placement on stability of titanium implants in onlay bone grafts. A histologic and biomechanic study in rabbit, *Int J Oral Maxillofac Surg* 28:224–231, 1999.
26. Bedrossian E, et al.: Immediate function with the zygomatic implant-a graftless solution for the patient with mild to advanced atrophy of the maxilla, *Int J Oral Maxillofac Surg* 21:1–6, 2006.
27. Nkenke E, et al.: Anatomic site evaluation of the zygomatic bone for dental implant placement, *Clin Oral Implants Res* 14:72–79, 2003.
28. Weingart D, Schilli W, Strub JR: Preprosthetic surgery and implantology, *Schweizer Monatsschrift Zahnmedizin* 102:1075–1082, 1992.
29. Bedrossian E, Tawfilis A, Alijanian A: Veneer grafting: a technique for augmentation of the resorbed alveolus prior to implant placement: a clinical report, *Int J Oral Maxillofac Implants* 15:853–858, 2000.
30. Chow J, et al.: Zygomatic implants-protocol for immediate loading: a preliminary report, *J Oral Maxillofac Surg* 64:804–811, 2006.
31. Branemark PI: *Surgery and fixture installation. Zygomaticus fixture clinical procedure*, Goteborg, Sweden, 1995, Nobel Biocare.
32. Bedrossian E, Stumpel L: Immediate stabilization at phase II of zygomaticus fixtures: a simplified technique, *J Prosthet Dent* 86(1):10–14, 2001.
33. Zhao Y, Skalak R, Branemark PI: *Analysis of a dental prosthesis supported by zygomatic fixtures*, The Institute for Applied Biotechnology, Gothenberg, Sweden.
34. Swerdlow H: Vertical dimension literature review, *J Prosthet Dent* 15:241–247, 1965.
35. Frush J, Fisher R: Introduction to dentogenic restorations, *J Prosthet Dent* 11:586–595, 1955.
36. Rothman R: Phonetic considerations in denture prosthesis, *J Prosthet Dent* 11:214–223, 1961.
37. Balshi TJ: The Biotes conversion prosthesis: a provisional fixed prosthesis supported by osseointegrated titanium fixtures for restoration of the edentulous jaws, *Quintessence Int* 16:667–677, 1985.
38. Gapski R, et al.: Critical review of immediate implant loading, *Clin Oral Implants Res* 14:515–527, 2003.
39. van Steenberghe D, et al.: A custom template and definitive prosthesis allowing immediate implant loading in the maxilla: a clinical report, *Int J Oral Maxillofac Implants* 17:663–670, 2002.
40. Zwahlen R, et al.: Survival rate of zygomatic implants in atrophic or partially resected maxillae prior to functional loading: a retrospective clinical report, *Int J Oral Maxillofac Implants* 21:413–420, 2006.
41. Farzad P, et al.: Rehabilitation of severely resorbed maxillae with zygomatic implants: an evaluation of implant stability, tissue conditions, and patient's opinion before and after treatment, *Int J Oral Maxillofac Implants* 21:399–404, 2006.
42. Reichert TE, et al.: The zygomatic implant indications and first clinical experiences,, *Zeitschrift fur Zahnarztliche Implantologie* 15:65–70, 1999.
43. Olive J, Aparicio C: The Periotest method as a measure of osseointegrated oral implant stability, *Int J Oral Maxillofac Implants* 5:390–400, 1990.
44. Malo P, Rangert B: All-on-4 immediate function concept with Branemark system implants for completely edentulous maxillae: 1 year retrospective clinical study, *Clin Implant Dent Rel Res* 1:S88–S94, 2005.
45. Bedrossian E, et al.: Fixed prosthetic implant restoration of the edentulous maxilla: a systematic pretreatment evaluation method, *J Oral Maxillofac Surg* 66:112–122, 2008.
46. Ujigawa K: Three-dimensional finite elemental analysis of zygomatic implants in craniofacial structures, *Int J Oral Maxillofac Surg* 36:620–625, 2007.
47. Freedman M, Ring M, Stassen LFA: Effect of alveolar bone support on zygomatic implants: a finite element analysis study, *Int J Oral Maxillofac Surg* 42:671–676, 2013.
48. Freedman M, Ring M, Stassen LFA: Effect of alveolar bone support on zygomatic implants in an extra-sinus position—a finite element analysis study, *Int J Oral Maxillofac Surg* 44:785–790, 2015.
49. Aparicio C: A proposed classification for zygomatic implant patients based on the zygoma anatomy guided approach (ZAGA): a cross-sectional survey, *Eur J Oral Implantol* 4(3):269–275, 2011.
50. Moraes E: Closure of oralantral communication with buccal fat pad flap in zygomatic implant surgery: a case report, *Int J Oral Maxillofac Implants* 23:143–146, 2008.
51. Moraes E: The buccal fat pad flap: an option to prevent and treat complications regarding complex zygomatic implant surgery. Preliminary report, *Int J Oral Maxillofac Implants* 27:905–910, 2012.
52. Bell GW, et al.: Maxillary sinus disease: Diagnosis and treatment, *Br Dent J* 210:113–118, 2011.
53. Tomomatsu N, et al.: Aperture width of the osteomeatal complex as a predictor of successful treatment of maxillary sinusitis, *Intl Journal of Oral & Maxillofac Surg* 43:1386–1390, 2014.
54. Bedrossian E: Rehabilitation of the edentulous maxilla with the zygoma concept: a 7-year prospective study, *Int J Oral Maxillofac Implants* 25:1213–12215, 2010.
55. Petruson B: Sinus copy in patients with titanium implants in the nose and sinuses, *Scand J Plast Reconstr Surg Hand Surg* 38: 86–93, 2004.

36

Fixed Restoration of the Edentulous Maxilla

MAMALY RESHAD, SAJ JIVRAJ

Introduction

Implant rehabilitation of the edentulous maxilla continues to challenge from a surgical and prosthodontic perspective. However, with proper planning, communication, and execution, these treatments can be highly rewarding and predictable. Difficulties tend to arise from a number of complex situations affecting both the esthetic and functional aspect of the prosthesis.[1] Among the prosthetic designs used to treat the edentulous maxilla are fixed or removable implant-supported restorations. Because the esthetic requirements and preoperative situation of each patient vary, considerable effort must be exercised in accurate diagnosis and planning to ensure that patient needs are met and predictable outcomes are achieved. The purpose of this chapter is to identify key diagnostic factors and compare treatment options and contemporary prosthetic designs for the edentulous maxilla.

With careful consideration given to diagnosis and treatment planning, criteria will be specified to guide the practitioner in deciding what type of prosthesis should be offered to each patient. This objective can be achieved by reviewing various patient cases with regard to changeable design considerations and factors influencing the decision-making process. An overview and introduction of an esthetic classification system and material selection for definitive fixed prosthesis will be presented.

As in all phases of dentistry, diagnosis is critical in obtaining an anticipated outcome. An incomplete or erroneous diagnosis can generate inferior results.

The initial phase in understanding how to restore the edentulous maxilla is to recognize the resorption patterns in this arch. The maxilla does not resorb evenly, nor do all edentulous patients go through the same morphogenic changes.[2] So, one must analyze each patient critically and tailor the restoration to the individual arch. The end result must be clearly visualized from the outset of treatment and communicated with all treatment providers involved.

When evaluating the resorption of the maxilla after tooth loss, the following issues in particular must be considered, as they will affect treatment planning:

1. Subsequent to the loss of all anterior maxillary teeth, horizontal bone resorption is almost twice as pronounced as vertical resorption (Figure 36-1).[2]
2. 65% of all maxilla arches examined were ovoid (Figure 36-2), 25% were triangular, and 10% were irregular.[3]
3. An unquantified number of edentulous patients display their entire maxillary ridge with a high smile (Figure 36-3).

Diagnosis

The decision-making constraints when rehabilitating patients require the clinician to decide whether a fixed or a removable prosthesis would be more fitting. Several designs can be used to restore patients.

With overdenture-type designs, one can obtain support from both the implants and the mucosa; in the presence of an adequate number of dental implants, the restoration can be entirely implant supported. Zitzmann and Marinello[4] described, in detail, parameters that need to be evaluated. A fixed restoration should not be guaranteed to a patient until all diagnostic criteria are evaluated. These criteria must include quality and quantity of bone available to support implants, lip line, lip support, and esthetic needs. Implants should not be placed until a definitive treatment plan has been established, as implant positions may vary depending on type of prostheses to be delivered (Figure 36-4).

This section discusses key diagnostic elements that will help in planning the restoration of an edentulous maxilla.

Facial and Lip Support

Facial and lip support analysis must be performed before any surgical act. Often it is very difficult to create adequate lip support, proper emergence, and healthy pontic ridge relationships, if the implants have already been placed (see Figure 36-3). Lip support must be evaluated and established

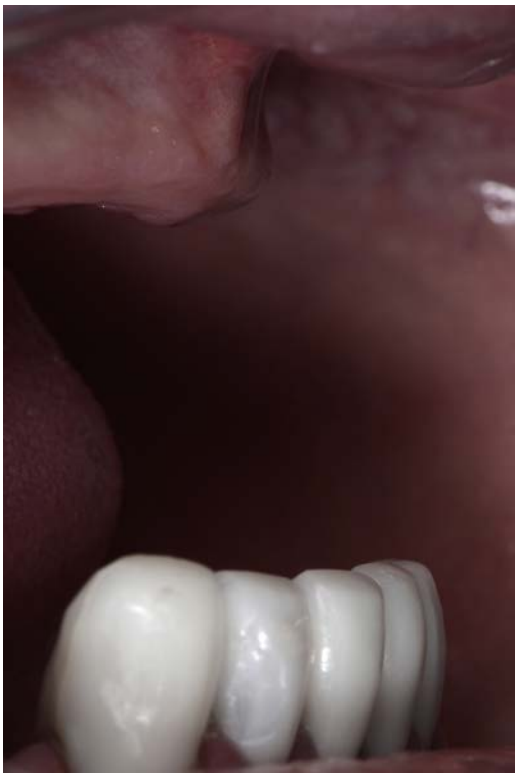

• **Figure 36-1** Intraoral sagittal view of a patient with no maxillary teeth. Bone loss is more pronounced in the horizontal than the vertical dimensions.

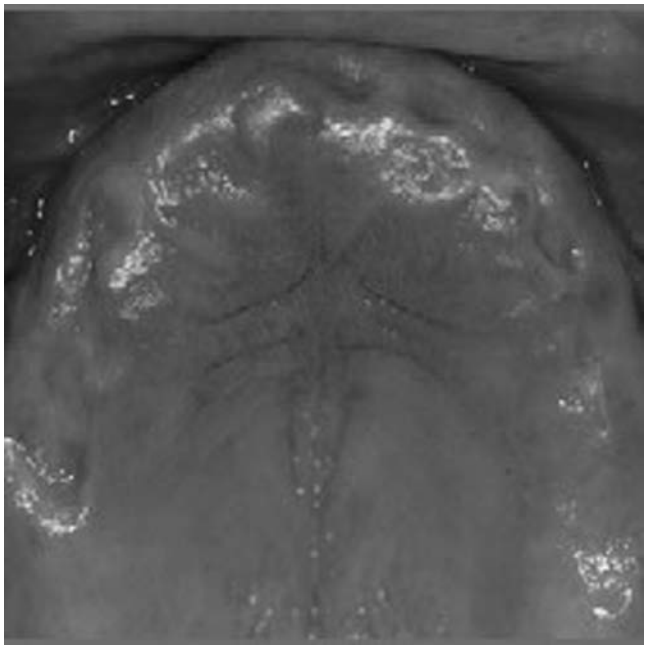

• **Figure 36-2** Occlusal intraoral view of a patient with an oval maxillary arch form.

with flangeless try-ins before implant placement (Figures 36-5 through 36-7). Surgical guides must be fabricated after this evaluation to place implants at the correct depth and angulation for ideal emergence. The surgical or bone reduction guide should be almost identical to the planned



• **Figure 36-3** Shows patient smiling and displaying the maxillary alveolar ridge and failed implant prosthesis.

definitive restoration. Figure 36-8 shows how the emergence of the prosthesis can be adversely affected by inadequate apical bone reduction. Functional and biologic complications may ensue with such a steep emergence angle. Figure 36-9 demonstrates how with suitable planning, a restoration with a flat angle of emergence can be fabricated. Appropriate emergence must objectively be evaluated from the sagittal view with a bone reduction guide and prior to implant placement. Empirically, it has been suggested that if the angle of emergence from the ridge crest exceeds 45 degrees from the vertical, functional complications will be more likely.

Lip support can be classified into four groups:

1. Natural teeth present
   a. Natural teeth and ridge provide adequate lip support (Figure 36-10)
   b. Natural teeth and ridge do not provide adequate lip support (concave profile)
2. Natural teeth missing
   a. Existing ridge provides adequate lip support
   b. Existing ridge does not provide adequate lip support (see Figure 36-5)

Patients who are about to receive an implant-supported maxillary prosthesis may present as dentate or edentulous. This classification system provides a road map for proper diagnosis and planning.

The dentate patients in group 1b are likely to present a challenge. After extractions, the lack of lip support will worsen. The clinician must identify this group at the diagnostic phase. A prudent clinician must also pay attention to the facial profile. A concave facial profile is the most challenging situation to manage clinically. A pronounced chin and a "turned-up" nose exacerbate the appearance of the lack of lip support. The patient in Figure 36-5 has a mildly concave facial profile as well as a pronounced chin that exacerbates his lack of lip support. If the patient's nose were turned upward, the lack of lip support would worsen still. Image manipulation (Figure 36-11) explains this concept.[5] By identifying patients with a concave profile before implant placement, the clinician is likely to be more

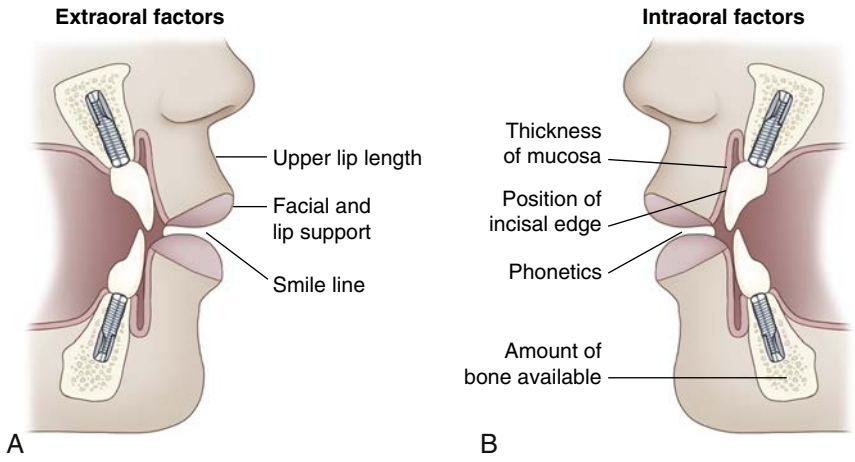

• **Figure 36-4** **A,** Extraoral parameters that should be evaluated for a fixed maxillary restoration. **B,** Intraoral parameters that should be evaluated for a fixed maxillary restoration.



• **Figure 36-5** Sagittal facial view of patient not wearing a maxillary denture and with a lack of lip support.



• **Figure 36-6** Sagittal facial view of patient wearing a flangeless maxillary wax tooth try-in with adequate lip support.



• **Figure 36-7** Intra-oral view of the patient in Figures 36-5 and 36-6 wearing a flangeless maxillary wax tooth try-in.

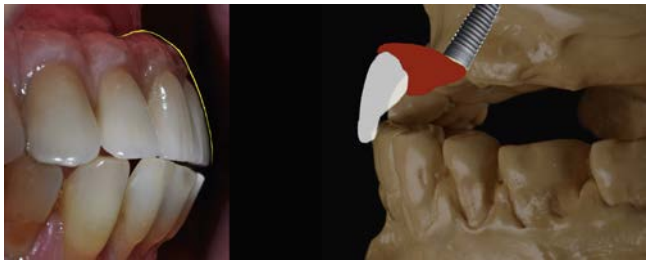

• **Figure 36-8** Sagittal view analysis and illustration show nonideal emergence of the prosthesis at the ridge crest. This area can accumulate food, impede lip mobility, and create patient discomfort. Dental implants were placed too shallowly.



• **Figure 36-9** Sagittal view analysis and illustration show ideal emergence of the prosthesis at the ridge crest. This device is cleansable and tolerated well by the patient. Dental implants were placed at the correct depth for this situation.

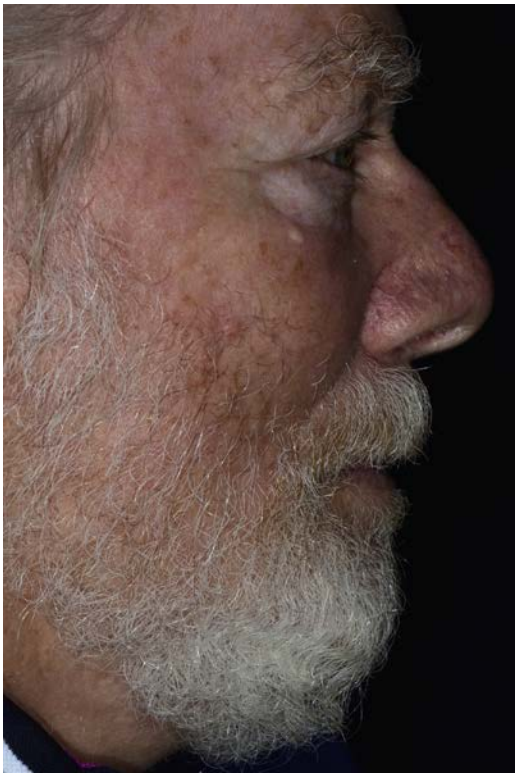

• **Figure 36-10** Natural teeth and ridge provide adequate lip support.



• **Figure 36-11** Manipulation of the patient photo in Figure 36-5. Turning the nose upward causes the lack of lip support to be more pronounced.

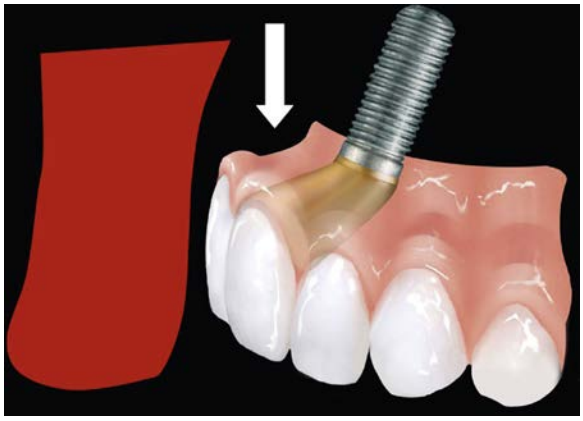

• **Figure 36-12** Diagram to illustrate discrepancy between ideal tooth position and implant placed into an existing ridge. Poor emergence can cause various functional and esthetic problems.

successful in identifying potential esthetic problems. Flat and convex profiles are simpler to manage.

When patients present with missing teeth, the clinician must identify and photograph patients in group 2b. These patients must go through an additional diagnostic phase to establish whether a fixed restoration without a flange can be delivered. The most reliable method to establish whether adequate lip support can be achieved is to perform a flangeless try-in (see Figure 36-7). It has been suggested that adequate lip support equates to a nasolabial angle of between 85 and 110 degrees. The patient in Figure 36-6 has a nasolabial angle of 90 degrees. This figure is within an acceptable range for adequate lip support.

Lip support is derived from the alveolar ridge shape and cervical crown contours of the anterior teeth.[6] Resorption of the edentulous maxilla advances cranially and medially, and this often results in a retruded position of the anterior maxilla.[3]

When evaluating a diagnostic setup with the anterior teeth in correct relation to the lip, the position of the anterior teeth is frequently anterior to the alveolar ridge. Depending on the severity of the resorption, there can be a discrepancy between the ideal location of the teeth and the ridge. This in turn leads to a discrepancy of the anticipated position of the implants in relation to the teeth (Figure 36-12). This divergence must be taken into consideration to achieve a prosthesis that satisfies the parameters of adequate speech,



• **Figure 36-13** Cross section of a tooth indicating bone levels.

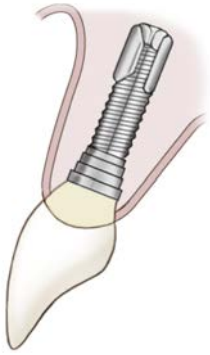

• **Figure 36-14** With minimal resorption, conventional implant-supported fixed partial dentures can be provided.

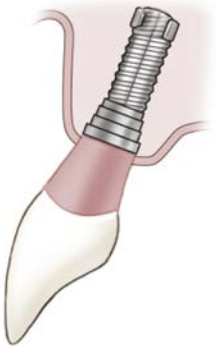

• **Figure 36-15** With moderate resorption, pink porcelain may be required to disguise tooth length if the patient desires a fixed restoration.

lip support, sufficient tongue space, and patient acceptance. When judged to be large, the discrepancy can be managed only with the flange of a removable prosthesis (Figures 36-13 through 36-16). The patient must be made aware of this from the outset; it must be conveyed that unless extensive grafting procedures are carried out, it is unlikely that a fixed restoration can be provided. When moderate resorption of the anterior maxilla occurs, it may be possible to reestablish lip support while maintaining adequate contours and emergence of the prosthesis. This is achieved by performing a resective procedure in the anterior maxilla. The limiting factor here is the nasal floor and whether enough bone volume will remain to house implants in this area. Consideration must be given to the angle of emergence of the prosthesis

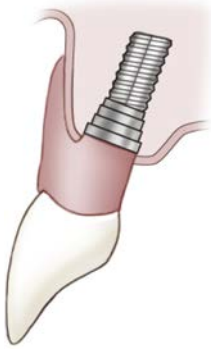

• **Figure 36-16** With excessive resorption, a flange of a removal restoration is required to satisfy parameters of lip and facial support.



• **Figure 36-17** Patient with a high and wide smile with thin lips. These groups of patients are at risk of developing a horizontal line across the upper lip after a maxillary reconstruction.

and a hygienic soft tissue contact at the ridge crest for the future prosthesis. An empirical rule exists that the prosthetic angle of emergence form the ridge must not exceed 45 degrees. Otherwise, lip movement may be impeded and food impaction apical to the prosthesis may occur.

There are some additional risk factors that must be accounted for at the diagnostic phase. Following a maxillary implant-supported reconstruction, it has been reported that patients with thin lips, high smile lines, and a wide smile are at risk of an upper lip with a horizontal line across it as the end result (Figure 36-17).[7] This line appears on the lip just superficial to the fixture head. These patients must be warned before the start of treatment and advised that dermal fillers will be required for routine maintenance.

Smile Line and Lip Length

The mobility of the upper lip during function must be evaluated. Tjan and colleagues[8] described the average smile as having the position of the upper lip such that 75% to 100% of the maxillary incisors and interproximal gingiva are exposed. In a high smile-line situation, additional gingiva was visible, and with a low smile line, less than 75% of the maxillary anterior teeth were displayed. Patients should be asked to smile



• **Figure 36-18** Patient with a low smile line, smiling without upper denture in situ.

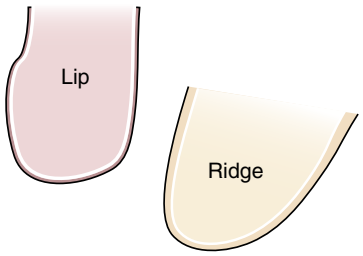

• **Figure 36-19** Sagittal diagrammatic illustration of patient with a very high smile line. If undiagnosed prior to implant placement, this may have disastrous esthetic consequences.



• **Figure 36-20** Improper esthetic diagnosis and evaluation has led to an unacceptable outcome. The horizontal transitional line or the junction between the pink ceramics and ridge crest is visible.

without the denture in situ (see Figure 36-3; Figure 36-18). If the alveolar ridge is visible when the patient smiles without a denture, the esthetics can be very challenging, as the junction between the restoration and the gingival complex will be visible (see Figure 36-3; Figures 36-19 and 36-20). Lip support should also be evaluated, as it influences the position of the maxillary anterior teeth. In a patient with a short upper lip, the maxillary anterior teeth will be exposed in repose, whereas in patients with a long upper lip, the anterior teeth will usually be covered. A long upper lip is more favorable than short for the treating restorative dentist (Figures 36-21 and 36-22).



• **Figure 36-21** Short upper lip. Lips in repose and displaying 3 mm of central incisors.

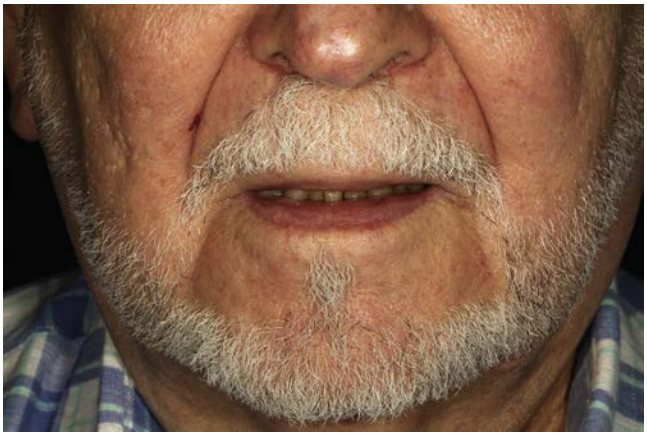

• **Figure 36-22** Long upper lip.

Evaluation of the smile line and level of tooth and gingival display is arguably the most important factor from a patient's viewpoint. In order to be consistent and be able to satisfy patients' esthetic needs, one must incorporate certain observations into the treatment planning process. The situation that will potentially cause esthetic challenges during treatment, typically related to the patient with excess gingival display. The cause of excess display must be identified.[9] With proper diagnosis, the correct treatment will be implemented.

The causes of excess gingival display are as follows:

1. Short and hyperactive upper lip
2. Altered passive eruption
3. Dentoalveolar extrusion
4. Vertical maxillary excess
5. Multiple etiologic factors

The next step in the esthetic diagnosis is to decide which of the following structures will be replaced:

1. Tooth only (Figure 36-23)
2. Tooth and gingival tissues (Figure 36-24)

This can objectively be evaluated with a flangeless tooth try-in.

After this step, the clinician needs to determine whether an augmentative or resective procedure is required. Esthetics

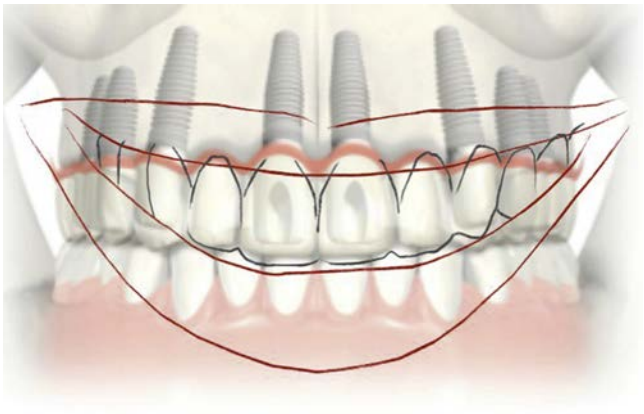

• **Figure 36-23** Teeth only to be replaced.

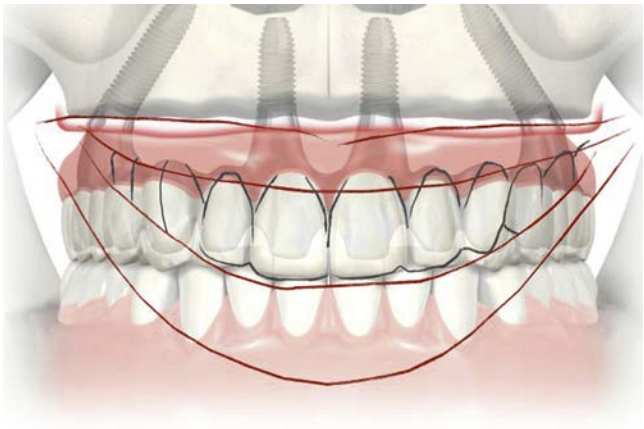

• **Figure 36-24** Teeth and gingival tissues to be replaced.

will be of paramount importance in this part of the planning. The objective is to avoid the following:

1. A visible horizontal transitional line between pink prosthesis and patient's own ridge crest (see Figure 36-20)
2. Long (more than 12 mm) maxillary incisors that are completely visible

A restorative classification will help in visualizing the future prosthesis. This classification is made during an extreme smile and frontal view.

Class 1a: Tooth replacement only. The whole tooth and ridge is visible (Figure 36-25).

Class 1b: Tooth replacement only. The tooth is only partially visible (Figure 36-26).

Class 2a: Tooth and gingival replacement. The horizontal transitional line is visible (see Figure 36-20).

Class 2b: Tooth and gingival replacement. The horizontal transitional line is not visible (Figure 36-27).

Class 3: Tooth and gingival replacement with severe lack of lip support. (See Figures 36-1, 36-5, 36-6, 36-7, and 36-16.)

The clinician must identify Class 1a and Class 2a at the diagnostic phase. Class 1a will create an esthetic challenge if central incisor teeth are either longer than 12 mm, or if, in attempting to avoid unnaturally long incisor teeth, the



• **Figure 36-25** Class 1a: Fixed maxillary implant reconstruction. Incisors and maxillary anterior alveolar ridge are visible.





• **Figure 36-26** **A,** Class 1b: Smile view. Tooth replacement only. The tooth is only partially visible. **B,** Class 1b: Intraoral anterior view.

clinician attempts to reduce tooth length by adding pink ceramics. This will simply make matters worse by converting a class 1 situation into a class 2a situation (see Figure 36-20). If at the tooth try-in stage, it appears that the patient will have very long incisors, vertical and horizontal hard and soft tissue grafting must be employed to increase ridge height and shorten the length of the definitive incisor teeth. For a patient with a class 1b situation, the length



• **Figure 36-27 A,** Class 2b: Tooth and gingival replacement. The horizontal transitional line is not visible. **B,** Class 2b: Intraoral anterior view.

of the central incisor teeth becomes irrelevant, as it will be hidden by the upper lip during all movements. However, a small group of patients may desire ideal gingival contours and tooth length even if the lip eliminates visibility of the cervical aspect of these teeth.

Similarly, for a patient who presents with a class 2a situation where the horizontal transitional line may be visible after completion of the maxillary reconstruction (see Figure 36-20), it is essential to move the horizontal transitional line in an apical direction by a minimum of 5 mm at the highest smile. Moving the horizontal transitional line apically is usually achieved by osseous reduction in an apical direction. Apical movement of the horizontal transitional line must only be performed after correct diagnosis of the cause of excess gingival display. Certain etiologic factors in excess gingival display will require treatment other than osseous reduction. Table 36-1 demonstrates the appropriate mode of treatment in order to minimize gingival display.

Some patients with edentulous maxillae may require augmentative and others require preservative or resective procedures. A prudent clinician should be familiar with the classification presented in order to achieve predictable esthetic outcomes.

Extraoral Examination

Incisal Edge Position

Evaluation of the incisal edge position should follow examination of the residual ridge. It is paramount that this position be determined before implant placement. The clinician

TABLE 36-1 Appropriate Mode of Treatment to Minimize Gingival Display

Etiologic Factors: Excess Gingival Display	Treatment for Class1b	Treatment for Class 2b
Short upper lip	Graft or resect anterior maxilla to establish central incisor length of 11 mm at appropriate incisal edge position.	**Mild cases:** After tooth extraction, apical reduction of maxillary ridge height to desired levels. **Severe cases:** a. Maxillary impaction. b. Overdenture with flange when lack of lip support is preexisting.
Hyperactive upper lip	Reduce upper lip mobility: Botulinum toxin, or surgical intervention.	Reduce upper lip mobility: Botulinum toxin, or surgical intervention.
Dentoalveolar extrusion	After tooth extraction, apical reduction of maxillary ridge height to desired levels.	After tooth extraction, apical reduction of maxillary ridge height to desired levels.
Vertical maxillary excess	Maintain or resect anterior maxilla to establish central incisor length of 11 mm at appropriate incisal edge position.	Maxillary impaction for severe cases. Apical ridge reduction for mild to moderate cases.
Multiple etiologic factors	Address most dominant causes only.	Address most dominant causes only.

must visualize the tooth in three dimensions. Esthetics and the level of desired tooth display determine the incisor vertical position.[8] Tooth display should be measured while the lips are in repose (at rest; see Figure 36-21). A minimum display of 0.5 mm is desirable.[10] Otherwise the patient may appear edentulous at rest, leading to dissatisfaction. The horizontal position is determined predominantly by speech. If the maxillary anterior teeth are placed more palatally and restrict tongue space, patients may sound as if they are whistling when attempting to pronounce the letter "S." When the maxillary incisor teeth are placed too facially, the tip of the tongue may not be able reach to the palatal aspect of the maxillary incisor teeth, and the "S" sound will be pronounced like a "Sh." The "S" sound is the dominant factor in determining the horizontal position of the maxillary incisor.[11,12]

The secondary factor for horizontal positioning of the maxillary anterior teeth is lip support. The relationship between lip support and horizontal positioning of the upper incisor teeth has already been discussed. The angulation of the upper incisor teeth is determined by the ability to pronounce the "F" sound. The "F" sound is pronounced when the upper incisors create a seal by grabbing the vermilion border of the lower lip. The cervical border of the incisor is placed on average 10.5 mm apical to the incisal edge position.[13,14] By paying attention to maxillary incisor positioning, the clinician can ensure patient satisfaction in terms of speech and esthetics. The remainder of the tooth setup in the maxilla must follow basic denture prosthodontic principles.[13,14] Attention must be afforded to esthetic principles for tooth arrangement, the occlusal planes, and buccal corridors.[15] To determine if a fixed or removable restoration would be appropriate, a wax try-in is prepared without a flange. For a fixed restoration, the clinical crown should ideally end up at the soft tissue level of the alveolar ridge. In this situation, minimal resorption has occurred, inter-arch space is favorable, and an optimal tooth-lip relationship is present (see Figures 36-13 and 36-26). When a large vertical distance exists between the cervical aspect of the tooth and the alveolar ridge but the tooth-lip relationship is favorable, pink ceramic may be used to disguise the tooth length, and a fixed restoration is still possible (see Figures 36-15 and 36-27). When there is both a vertical and horizontal discrepancy between the ideal position of the tooth and the alveolar ridge, and the tooth-lip relationship is not optimal, this may be an indication for use of a removable prosthesis. The flange will provide adequate lip support, and the teeth can be positioned appropriately to satisfy the parameters of esthetics (see Figure 36-16; Figure 36-28).

Treatment Planning

The long-term success of implant rehabilitation of the edentulous maxilla is dependent on consideration of all the factors previously discussed. Treatment planning must address these diagnostic findings. It must also tackle the patient's singular grievances and meet the patient's expectations. The patient needs to have a reasonable awareness of how the definitive restorations will appear. Esthetics is a major cause of failure; going through a lengthy, expensive treatment only to achieve a result that is esthetically inferior to a complete denture can be hugely disappointing. Patient communication at the outset is of utmost importance. To avoid any surprises, a great deal of time must be devoted to educating the patient on the relative advantages and disadvantages of projected treatment. Informed consent becomes important. The patient must fully understand and acknowledge the limitations of the planned treatment, including the possibility of implant failure. The patient must understand that treatment plan modifications may be obligatory and the fact that placement of additional implants may be indicated. Informed consent must include the surgical risks of treatment and also the treatment's possible shortcomings in adequately addressing the patient's chief complaint and expectations.

In treatment planning, the following factors must be considered:

1. Esthetics and patient desires
2. Type of support
3. Amount of resorption and inter-arch space
4. Number of implants
5. Implant distribution
6. Economics

1. Esthetics and Patient Desires

Meeting patient expectations is paramount when planning treatment. As discussed earlier, patients prefer to discard their removable appliance in favor of a fixed alternative. The clinician must know early in treatment if this is possible. Promising a patient a fixed reconstruction when diagnostic deliberations determine otherwise may result in a dissatisfied patient. Patients are also pleased with the esthetic appearance of a complete denture. In particular the appearance of the soft tissues is uniform and interdental papillae between denture teeth are reproduced well with pink acrylic resin (Figure 36-29). When a patient then transitions to a fixed reconstruction, interdental papillae between implants are often absent. An artistic dental technician can create an illusion of interdental papilla by altering the position of the contact point between adjacent teeth and using interproximal stain (Figure 36-30).

2. Type of Support

Fundamentally, with the edentulous maxilla there are two categories of prosthesis, fixed and removable. Fixed prostheses include ceramic-based restorations supported by implants and, depending on the severity of the bone resorption, some pink porcelain may be required to simulate gingival contours. The removable category includes implant-supported overdentures and implant-retained and tissue-supported overdentures. A removable prosthesis can be retained by various methods, including, bar and clip, magnet, ball attachments, or the use of precision-milled or spark-eroded components.



• **Figure 36-28** **A,** Sagittal intraoral view of patient with severe maxillary resorption and implant-supported bar. **B,** Lack of lip support without maxillary prosthesis. Profile view. **C,** Prosthesis with flange provides lip support. Profile view.



• **Figure 36-29** Complete dentures can appear very realistic.



• **Figure 36-30** Pink interproximal ceramic staining to simulate dental papilla.

The diagnostic factors previously discussed will allow the clinician to decide which type of prosthesis will be more suitable.

3. Amount of Resorption and Inter-arch Space

This parameter dictates the type of prosthesis to be fabricated. The clinician must evaluate whether the patient exhibits minimal, moderate, or advanced resorption. Each type of prosthesis has a unique dimensional tolerance, as previously discussed. Patients who exhibit minimal or moderate resorption are candidates for a fixed restoration, providing parameters of facial and lip support are satisfied. Patients with advanced resorption can be satisfied esthetically by fabrication of a removable prosthesis with a flange; this replaces necessary support that has been lost as a result of resorption. If patients in this category request a fixed restoration, they will need to understand that extensive grafting or resective procedures may be required and that even after that, the esthetic outcomes may not meet their expectations.

4. Number of Implants

Many authors have discussed treatment concepts for restoration of the edentulous maxilla with a fixed prosthesis. Recommendations have been made with respect to anticipated prosthesis designs and implants. Placement of four to eight implants has been proposed for a fixed implant prosthesis with cantilever pontics.[16,17] Recommendations have also been made with regard to removable restorations on implants—four to six implants have been recommended for both implant-supported and implant- and tissue-supported restorations.[17,18] Deciding on the number of implants to place is not directed by a formula and is dependent on multiple factors. The number of implants to place in each patient is determined by:

a. Quality of bone
b. Anticipated force to be placed on the restoration
c. Relationship between the shape of the residual ridge and the dental arch form

a. Quality of Bone

Frequently type 3 and 4 bone is encountered in the maxilla. On occasion the quality of the bone is such that conventional drills cannot be used to place the implant, and underpreparation of the osteotomy sites is required. The success of implants in the maxilla is less certain than in the edentulous mandible.

When the quality of bone is not optimal, often the surgeon and restorative dentist consider placing additional implants. These implants are placed to allow the restorative dentist to continue with the anticipated prosthesis should one or two implants fail. Overengineering in the maxilla can be advantageous, but consideration should also be given to the costs that may be encountered should all the implants integrate. Frequently the restorative dentist will have to purchase additional abutments, and the costs of these will need to be passed on to the patient. When the patient has had posterior teeth missing for a considerable length of time, the maxillary sinuses pneumatize, and often there is insufficient bone for implant placement in these areas. If the patient refuses to undergo additional augmentation procedures, the concept of the shortened dental arch can be used and fewer implants placed. The restoration of the maxilla with only four implants is an acceptable contemporary approach. The concept of a shortened dental arch may be used with this protocol.

b. Anticipated Force to be Placed on the Restoration

Part of the extraoral examination should also involve analysis of the patient's build and facial musculature. The masseter muscles should be observed for any hypertrophy that may be present. Bruxers often present with a pronounced antegonial notch, and this can be indicative of the likely force to be placed on the restorations. In these types of patients it is wise to overengineer and place additional implants for added support and distribution of force.

The opposing occlusion also has to be evaluated. Patients are likely to exert less force if a complete denture opposes the implant restorations, as compared to the force that can be exerted when the patient has natural dentition opposing them.



• **Figure 36-31** Square arch form.

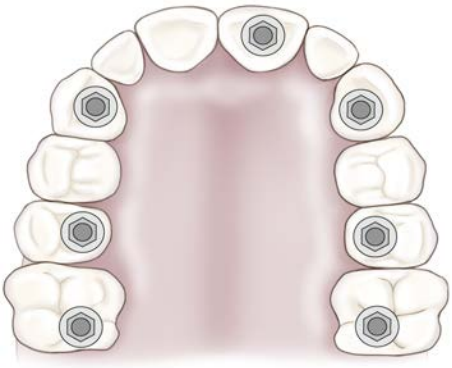

• **Figure 36-33** Ovoid arch form.

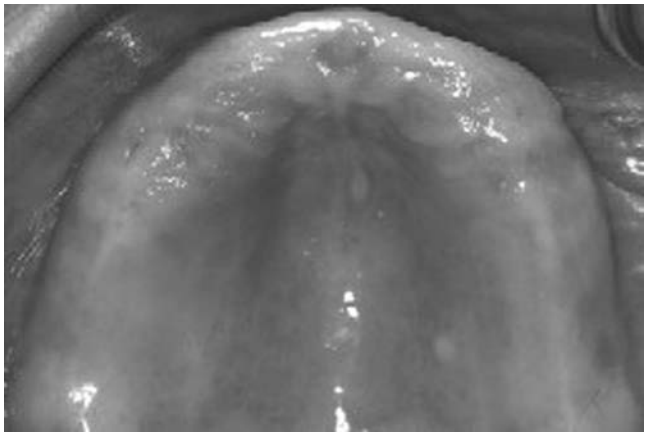

• **Figure 36-32** Square ridge form.

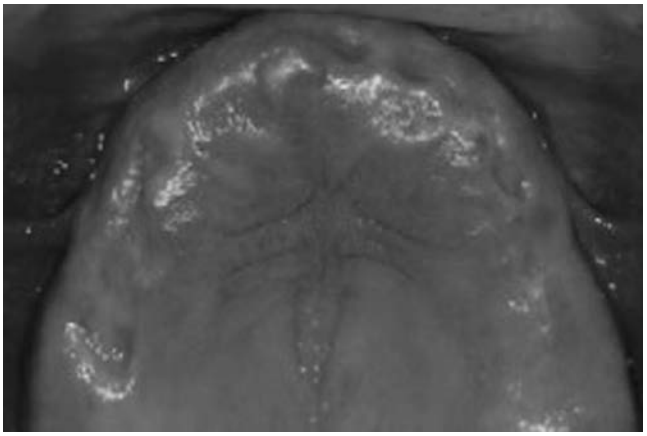

• **Figure 36-34** Ovoid ridge form.

The greater the probable force on the implant restorations, the more implants should be allowed for.

c. Relationship between Shape of Residual Ridge and the Dental Arch Form

Three typical arch forms are prevalent: square, ovoid, and tapering. The edentulous maxillary residual ridge may also have three arch forms.

Esthetic requirements may require a dental arch form different from the residual ridge form. The dental arch form is determined by the final teeth position in the premaxilla and not from the residual ridge form. The final tooth position may need to be cantilevered to the facial in the final prostheses. In a dental square arch, lateral and central incisors are not cantilevered facially, compared with the canine position (Figure 36-31). Mandibular excursions and occlusal forces may be reduced on the canine implants. As a result, implants in the canine position may suffice, especially if they are splinted to posterior implants. The four pontics between the canines create reduced forces because forces are lowest in the incisor region and the square arch form has less cantilevered occlusal forces to the incisors (see Figure 36-31; Figure 36-32).[19]

In a dental ovoid arch (65% of edentulous patients), there should be three implants in the pre-maxilla, not two as in the square arch form (Figures 36-33 and 36-34).

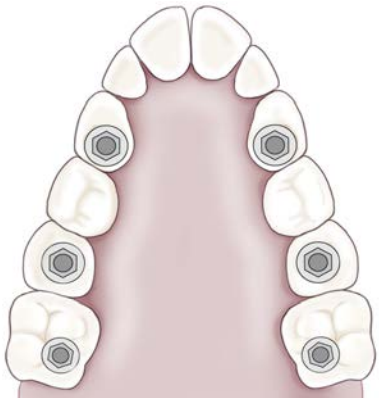

• **Figure 36-35** Tapering arch form.

Sometimes this may require bone augmentation. For an ovoid retraction of mandibular anterior teeth, dental arch form planning for implants in the canine positions and at least one additional implant, preferably in the central incisor region, is imperative. The additional implant in the incisor region resists the additional forces created by this arch form, and biomechanically the prosthesis design will be more stable, as there will be less stress on the abutment screws. The restoration of a tapering arch form places the greatest stresses on the anterior implants, especially when the pontics replace the incisors (Figures 36-35 and 36-36).



• **Figure 36-36** Tapering ridge form.



• **Figure 36-37** Lingual view showing proximal implant placement.

The anterior teeth are cantilevered facially from the incisor position with increased forces in maximum intercuspation and in excursions. In this case four implants need to be placed in the premaxilla to replace the six anterior teeth. The worst-case scenario is a patient with a tapered dental arch form to be restored on a square residual ridge form. Four implants are then required to compensate for the anterior tooth position. In this case bone grafting may be required.[19]

5. Implant Distribution

Implant distribution and placement are critical in order to obtain the optimum emergence profile for the definitive restorations, as well as enabling the patient to maintain adequate hygiene. For a patient who presents with minimal resorption and is treatment planned for ceramic-based restorations on implants, precise placement of implants is imperative and should be facilitated by the use of a surgical guide based on the diagnostic wax-up (see Figure 36-26, *B*). Implants placed in interproximal positions can cause problems from both an esthetic and hygiene perspective. For those patients who display moderate resorption but still qualify for a fixed restoration with the use of pink porcelain, implant placement is not critical, but implant distribution is. Implants placed in interproximal tooth positions will not affect the esthetics, as this will be disguised by the use of pink porcelain



• **Figure 36-38** Lateral intraoral view of patient in Figure 36-37. Proximal implant position has no bearing on esthetics.

(Figures 36-37 and 36-38). Implant distribution is critical because implants will need to be placed so the load can be shared equitably. Splinting the implants is also advantageous, as this improves the biomechanics of the prosthesis design.

6. Cost

Restoration of the edentulous maxilla is costly, whichever method is used to restore the patient. Fixed reconstructions require more laboratory support and implant parts and hence are much more expensive. However, cost needs to be well thought out not only during fabrication of the prosthesis but also during maintenance. Overdentures seem to have more postinsertion maintenance than their fixed counterparts.[20] If this is consistent, it could be questioned whether choosing an overdenture could be justified on an economic basis when there is sufficient bone to support implants for a fixed prosthesis. The patient must be made aware that maintenance costs for removable prostheses on implants will be higher than those for a fixed prosthesis.

Empirical rules cannot encompass all clinical situations. There will always be "gray areas" when planning treatment of the edentulous maxilla. By combining common sense, the evidence base, and clinical experience, one can find solutions for treating even the most complex situations. It is highly recommended that the patient test all parameters of the proposed final prosthesis in the provisional phase. The provisional restoration serves as a blueprint for the definitive restoration. With the advent of CAD-CAM technology, it is now possible to copy and mill the provisional or acrylic resin prototype restorations very accurately.[21] This will allow form, function, phonetics, and esthetics to be replicated with relative ease and accuracy. This chapter introduces some empirical rules to help make appropriate restorative clinical decisions.

The following factors must be considered when planning a definitive restoration:

1. Amount of tooth and gingival display (see classification)
2. Esthetic demands

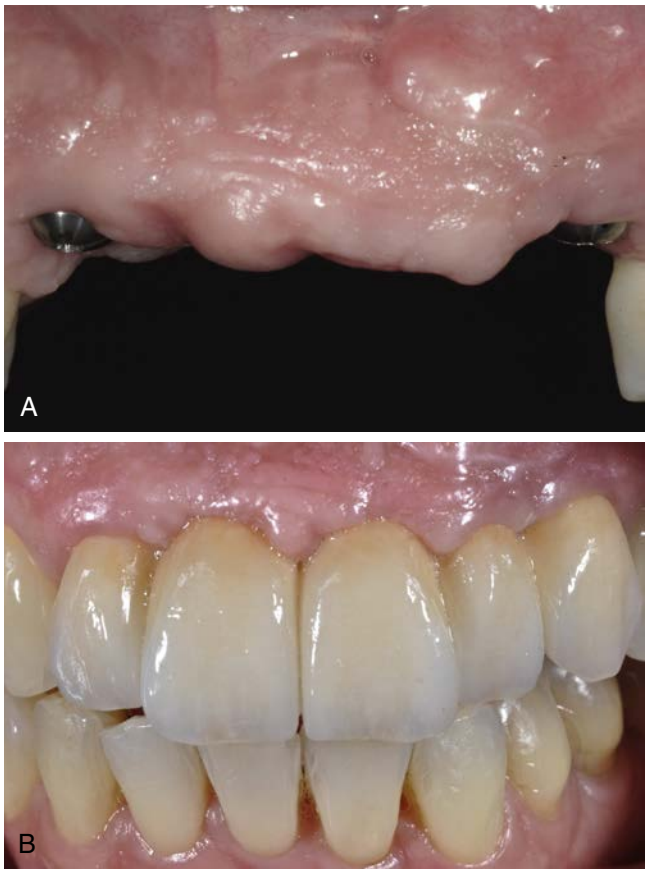

• **Figure 36-39** **A,** Maxillary anterior ridge requiring tooth replacement only. **B,** Same patient with definitive ceramic (teeth only) prosthesis.

3. Screw access trajectory
4. Restorative space (acrylic resin vs. ceramics)
5. Opposing occlusion (denture, teeth, implants)
6. Occlusal forces (high or low)

As discussed, patients in Classes 1a and 2a will present with the greatest risk as far as esthetics is concerned. One must decide before implant placement whether an augmentative or resective procedure will need to be employed for optimal results. Class 1a situations require meticulous soft tissue management both surgically and prosthetically in order to create and simulate papillae (Figure 36-39). In the anterior esthetic chapter, clinical situations to demonstrate maintaining and preserving the anterior ridge are discussed. Results are more predictable when Class 2a situations are treated with resective procedures. Resection will convert a Class 2a to a 2b situation, which is more manageable. A controlled and reliable protocol to achieve an appropriate angle of emergence, convex pontic ridge relationship, and acceptable esthetics is demonstrated (Figure 36-40). Stabilizing the surgical guide on posterior teeth that will eventually be removed controls osseous reduction. The bone reduction guide (see Figure 36-40, *D*) is very similar in terms of emergence and form to the definitive restoration (see Figure 36-40, *F*) and serves as a good objective tool for communication between surgeon and restorative dentist.

Material Selection

Acrylic Resin and Titanium

Framework designs for a full-arch, one-piece, implant-supported acrylic resin and titanium–based restoration have changed significantly since the transition from gold frameworks to titanium. Different manufacturers have different designs available, and despite technological advances, a framework with similar characteristics to gold frameworks is not available. This is due to limitations in scanning and milling, but technology is advancing at a rapid rate. Even with the titanium frameworks that are available today, a few key parameters become important; we cannot ignore what we have learnt from gold frameworks.

Two types of frameworks to support acrylic resin teeth exist. The minimalist framework where acrylic is wrapped around the tissue surface is made from acrylic resin, and it is more cost effective. It can be relined, but little is known about its longevity in terms of biomechanics. Anecdotally, numerous colleagues have experienced fractures of this type of framework. Failures may be due to excessive cantilever or inadequate bar shape (Figure 36-41).

The second type of framework may include I- or L-shaped bar designs to maximize rigidity. Adequate space and retention for acrylic resin maximizes thickness in the cantilever area. The evidence base is also lacking with this design. Although these frameworks have served many patients well, particularly in the edentulous mandible, success in the mandible does not automatically translate to success in the maxilla. The authors have anecdotal evidence of repeated fractured teeth, acrylic resin delamination, and denture teeth wearing in the anterior maxilla (Figure 36-42). The problem is exacerbated in patients who present with signs of bruxism. Wear of posterior teeth will eventually overload anterior teeth and result in fractures.[22] In order to avoid premature damage to maxillary anterior denture teeth, it is wise to extend the metal framework onto the occlusal surfaces. The fabrication of prototypes with selective and controlled cut-back procedures will allow accurate copy milling and incorporating metal posterior occlusal surfaces into the framework.

In summary, this type of framework is still considered a "workhorse" in prosthodontics. They are cost effective and can be used in a variety of situations.

Ideally at least 15 mm of restorative space is required for bulk of material (Figure 36-43). Compromise in restorative space will inevitably result in fracture of teeth or delimitation of acrylic resin.

These designs can be used in high- and low-force situations. In high-force situations, the teeth will wear much more quickly and will need to be replaced. Although it is possible to make attractive restorations with denture teeth, the pink acrylic does lose its sheen over time and can accumulate stain. It would be preferable for the opposing arch to have less rigid and hard occlusal surfaces to reduce impact on the maxillary restoration.

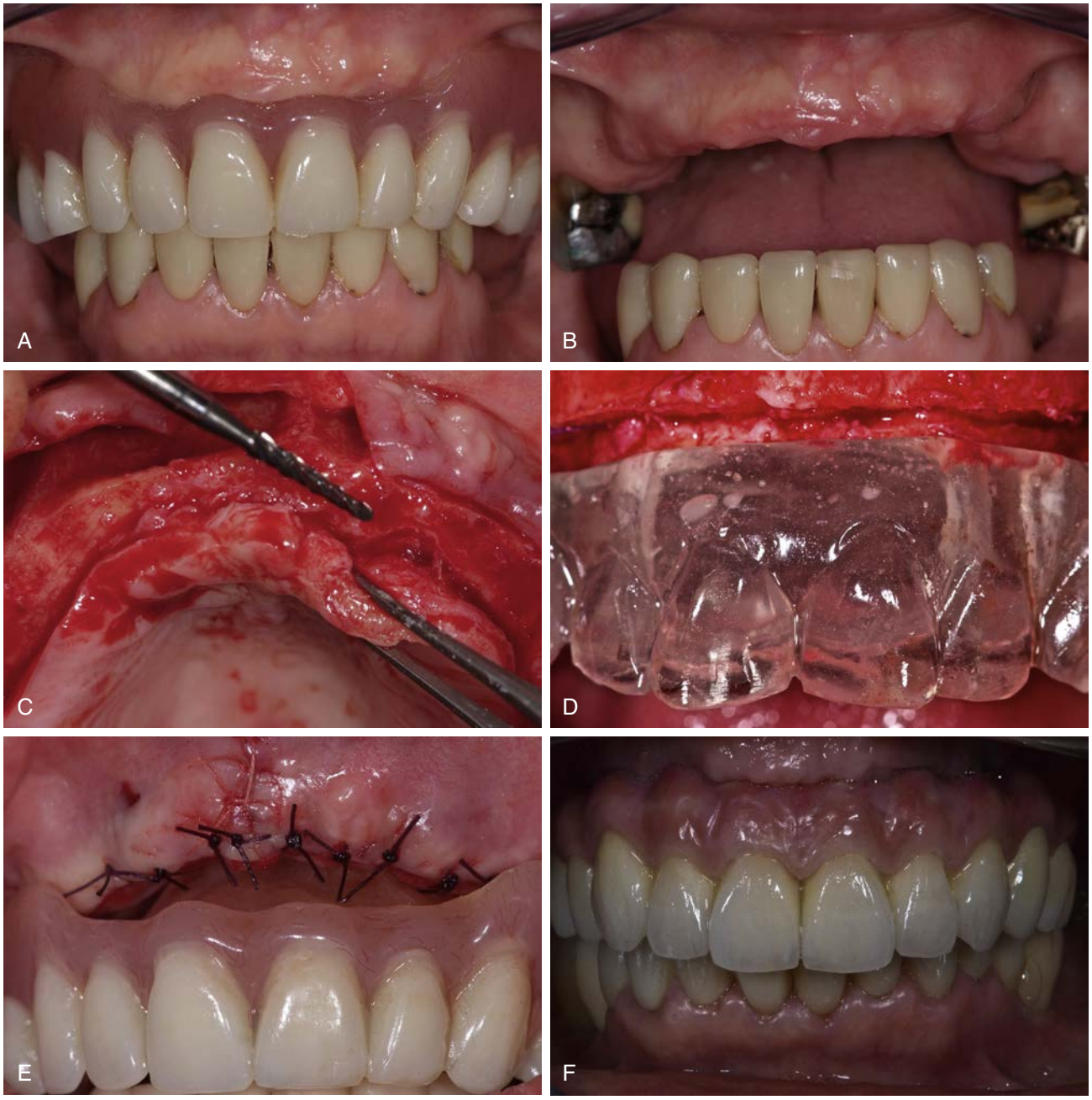

• **Figure 36-40** **A,** Preoperative situation of a patient requiring an implant-supported maxillary prosthesis. The existing upper denture has poor contours and concave undersurface. **B,** Upper molars will stabilize the bone reduction guide. **C,** Controlled osseous reduction. **D,** Bone reduction guide stabilized on molar teeth bilaterally and an objective tool for communication. **E,** The restoration in **A** in situ, showing adequate bone reduction. **F,** Definitive prosthesis in situ with adequate shape and emergence form.



• **Figure 36-41** An acrylic resin wraparound prosthesis.



• **Figure 36-42** Patient complaining of repeated fractures of maxillary anterior teeth with a wraparound prosthesis.

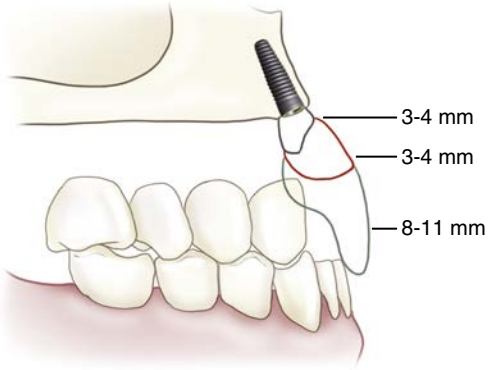

• **Figure 36-43** Ideally 17 mm of restorative space is required for a metal and acrylic resin restoration.

In the appropriate situations, this prosthesis remains an acceptable and cost-effective restoration for the edentulous maxilla with moderate to severe resorption.

Milled Cobalt Chromium Frameworks

Cobalt chromium frameworks have had a major resurgence in recent years.[23] All of the traditional problems with fit, bonding, and corrosion related to cast designs have been eliminated with the inception of milled framework designs.[24-26] CAD-CAM designs allow better control of ceramic thickness, passive frameworks, predictable ceramic bonding, and less bending than high Nobel frameworks, especially in cantilevers. Cobalt chrome frameworks are particularly advantageous when less than 15 mm of restorative space is available and a posterior cantilever is present. The restoration can withstand occlusal forces even at minimal thickness. The main attraction, however, seems to be the cost as compared to gold-based frameworks. The only disadvantages are laboratory based, as an industrial milling machine is required, with a skilled dental technician.

In summary, this framework design would be useful where there is limited restorative space of less than 15 mm, posterior cantilevers are present, ceramics are planned, and cost is a moderate factor.

Zirconia Frameworks

Zirconia frameworks currently have huge popularity as a restorative material for maxillary implant-supported prostheses. The primary advantage of zirconia is the whitish color of the framework, which allows the fabrication of a restoration that can predominantly be of monolithic design. Additionally, the white color of zirconia makes it beneficial in esthetic areas of the oral cavity and is suitable material for anterior restorations.

Zirconia technology has had a noteworthy impact in the restoration of the edentulous maxilla because of its biocompatibility, esthetics, and strength.[27-29] Zirconia has a high flexural strength, which makes it suitable as a framework in maxillary reconstructions. These properties have resulted in the increase use of zirconia in the fabrication of maxillary frameworks. The scientific literature lacks data regarding complete mouth zirconia frameworks supported by implants. Clinical reports have evaluated restorations with a zirconia structure supported by implants and have provided some insight; however, a significant amount of data is lacking in relation to this material and its application.

There are many clinical reports with one or two patients treated who have been followed up for 4 years or more. However, from an evidence-based perspective, the literature is lacking wide-ranging data to support monolithic full arch frameworks at this time. This statement should not be considered a deterrent, but caution must be exercised during case selection.

It is possible to achieve strength and maximum esthetics by minimal layering of zirconia frameworks. However, a few clinical studies are showing that unsupported veneered ceramic has a higher risk of chipping (Figure 36-44).[30,31] So, in order to get the best out of the material, it would be wise to design the frameworks such that occlusal contact areas are in monolithic zirconia, minimal layering on the buccal surface, with anatomically shaped design to support the ceramic (Figure 36-45).

Cantilevers (see Figure 36-50) in implant dentistry are valuable for sites where anatomic structures such as the maxillary sinuses exclude the ideal placement of dental implants. Cantilevers are being used more often



• **Figure 36-44** Chipping of layered zirconia crown.



• **Figure 36-45** Minimal and controlled cut-back of zirconia to avoid fractures.

for graftless procedures. They may, however, negatively affect the biomechanics of implant restorations[32] and may result in mechanical and/or biologic problems. Presently, evidence is limited concerning breakage of cantilevered zirconia implant frameworks. This evidence is mainly limited to anecdotal and expert clinical reports. Well-designed, clinically relevant laboratory studies are needed to establish the mechanical properties of zirconia cantilever frameworks.

As cantilevers are unavoidable, one must air on the side of caution in order to reduce the chance of failure, fractures, and overloading.[32] The following are recommended:

1. Maximize connector dimensions, buccal-lingually and occlusal-gingivally.
2. Minimize cantilever length.
3. If cantilevers are unavoidable, ensure very light occlusal contacts in these areas.
4. In situations where low to moderate alveolar resorption has occurred, posterior restorative space is often limited and, in the presence of a cantilever, may result in failure (Figure 36-46).
5. Thicken the chimney around the most distal implant, and thicken the buccal and lingual walls around the chimney of the implant.
6. Well-polished monolithic zirconia is kind to the opposing dentition.[33] One must ensure that any grinding and polishing is performed during the prototype phase. This will also help with preserving the strength of the material and avoiding accelerated ageing failures in the presence of saliva.[34]



• **Figure 36-46** Posterior cantilevers and limited crown height place restorations at risk of fracture.

A potential problem of zirconia is the inherent accelerated ageing or low-temperature degradation problem that is exacerbated in the presence of water or saliva.[34] This leads to a decrease in physical properties by spontaneous phase transformation of the zirconia crystals from the tetragonal phase to the weaker monoclinic phase and may place zirconia-based restorations at risk of impromptu catastrophic failure. Current literature reports a relatively small number of framework fractures, which do not appear to have occurred spontaneously. In both in vitro and in vivo studies, it has been demonstrated that the exclusive mode of failure in all ceramic fixed partial denture frameworks was the fractures of the connectors where tensile forces are the greatest.[35] To prevent such failures, the connectors of all-ceramic fixed partial dentures (FPDs) must have sufficient height and width to withstand these forces. The suggested minimum dimensions for all-ceramic FPDs are greater than those for metal-ceramic FPDs. A minimal connector area of 7 to 16 mm^2 has been recommended for zirconia frameworks.

In contemporary treatment planning, one of the aims is to provide the patient with a retrievable restoration. Retrievability is achieved through screw retention. This allows simple detachment of the appliance and the chance to service the restoration or treat any implant-related problems. With proper implant placement, this can be achieved in most situations when treating the edentulous maxilla. However, despite clinicians' best intentions, anatomic limitations may not allow screw-retained implant placement in the anterior maxilla, even after correction with angled abutments. In these situations a "hybrid" between a monolithic design and individual cemented restoration may solve a challenging problem created by anterior implant trajectory (Figure 36-47).

There have been numerous anecdotal reports of the patient hearing a clicking sound when both maxillary and mandibular prostheses are made with implant-supported monolithic zirconia restorations. Currently, the consequence of forces being transmitted to the supporting implants is unknown. Last, there are very few data to show the longevity of the full arch zirconia maxillary and



• **Figure 36-47** A "hybrid design" for a zirconia framework. The anterior restorations are cemented because of unfavorable implant angulations.



• **Figure 36-48** Pilot study tested load to failure of cantilevers. Titanium zirconia frameworks fractured under much higher loads than monolithic zirconia frameworks.

mandibular situations, with continuous function against one another. In situations where the clicking noise might bother the patient and excess forces in a very rigid system are a concern, the authors recommend using a softer occlusal material (acrylic resin teeth) in the mandibular arch instead. The use of softer acrylic resin teeth can overcome the potential problems discussed earlier. This is achieved by using the preferential wear of acrylic resin teeth in the mandibular arch as a clinical advantage. The patient must be warned of a higher level of maintenance and need for resurfacing the mandibular prosthesis in due course.

In summary, zirconia frameworks may ideally be used where esthetics is a concern, posterior cantilevers are not present, and implant trajectory is ideal. These frameworks may be considered when posterior cantilevers are present, in the presence of adequate posterior restorative space (>15 mm).

Zirconia Titanium Frameworks

Although monolithic zirconia frameworks can be useful in many situations, they do have their limitations:

1. Lack of evidence for restoration survival in a posterior cantilever situation
2. Limited posterior vertical restorative space, weakening connector strength (see Figure 36-46)
3. Excessively facial anterior implant trajectory
4. Maintaining true screw retained situations and retrievability
5. The ability to segment restorations

The zirconia titanium framework design attempts to address all of the issues listed. This design consists of two frameworks. The primary titanium framework is attached to the implants and is screw retained. It eliminates the trajectory problem with implants. The secondary framework is made of monolithic zirconia with minimal facial layering. Pilot studies performed by the authors clearly demonstrate a mechanical advantage where posterior cantilevers are present and in situations with short connector height (Figure 36-48).

In summary the titanium zirconia framework may be used where anterior implant trajectory is unfavorable and posterior cantilevers exist, with less than 15 mm posterior restorative space.

Case Presentation

An overview of a patient treatment will help consolidate some of the concepts presented in this chapter. This patient presented complaining of repeated fractures of her existing implant restorations in both maxilla and mandibular arches (see Figure 36-42). On examination it was determined that the anterior teeth were under heavy occlusal loads, in both centric relation and protrusive movements. This patient reported nocturnal bruxism. Although adequate restorative space was present, the existing restorations were cantilevered posteriorly bilaterally. Restorative space decreased mildly posteriorly, approaching 15 mm in the molar region. One anterior implant presented with an unfavorable trajectory even after correction with an angled abutment.

The patient presented with a severe lack of lip support without her existing prosthesis. These restorations provided adequate lip support and hence served as a flangeless try-in. Existing failing implant prostheses can serve as excellent diagnostic tools, similar to dentures that are in need of replacement. Based on the patient's esthetic and functional demands, a wax try-in was fabricated and examined in vivo. After patient approval, these wax-based trial prostheses were copy milled with implant-supported acrylic resin prototypes. Occlusion was refined at this stage, and all parameters relating to form, function, phonetics, and esthetics were evaluated (Figure 36-49). With the aid of CAD-CAM technology, the prototypes were scanned and primary and secondary bars fabricated. The primary bar was cantilevered (Figure 36-50) and supported and was screwed to the secondary zirconia framework (Figure 36-51). As the patient demonstrated a history of bruxism, a primarily monolithic zirconia framework with minimal facial layering was designed (see Figure 36-45). The primary titanium bar could correct any misaligned implant



• **Figure 36-49** Acrylic resin prototype try-in.



• **Figure 36-50** Primary screw-retained titanium bar.



• **Figure 36-51** Lingual view of partially inserted secondary zirconia restoration on titanium primary bar.

trajectories. The prosthesis was completely screw retained and fully retrievable.

This patient situation demonstrates how with the application of basic diagnostic principles, the clinician can resolve a clinical problem. A satisfactory outcome with adequate form, function, and esthetics was achieved (Figures 36-52 through 36-55). Particular attention was afforded to creating a mechanically sound restoration to reduce maintenance problems.



• **Figure 36-52** Polished definitive restorations prior to delivery.



• **Figure 36-53** Intraoral views of restorations in Figure 36-52 after delivery.



• **Figure 36-54** Profile view to show adequate lip support after delivery.



• **Figure 36-55** Facial smile view with definitive restorations.

Summary

This chapter has explored diagnostic concepts as they relate to full maxillary implant-supported reconstructions. The application of these concepts at the presurgical phase of treatment increases the likelihood of esthetic and biologic and biomechanical success. Patient situations to demonstrate appropriate execution have been presented.

Acknowledgments

The authors would like to thank Domenico Cascione for assistance in the laboratory work.

References

1. Bosse LP, Taylor TD: Problems associated with implant rehabilitation of the edentulous maxilla, *Dental Clin North Am* 42: 117–127, 1998.
2. Tallgren A: The reduction in face height of edentulous and partially edentulous subjects during long term denture wear: a longitudinal roentgenographic cephalometric study, *Acta Odontol Scand* 24:195–239, 1966.
3. Pietrokovski J, Starinsky R, Arensburg B, Kaffe I: Morphologic characteristics of bony edentulous jaws, *J Prosthodont* 16: 141–147, 2007.
4. Zitzmann NU, Marinello CP: Treatment plan for restoring the edentulous maxilla with implant supported restorations: removable overdenture versus fixed partial denture design, *J Prosthet Dent* 82:188–196, 1999.
5. Bidra AS, Agar J: A classification system of patients for esthetic fixed implant-supported prostheses in the edentulous maxilla, *Compend Contin Educ Dent* 31:366–374, 2010.
6. Dong JK1, Jin TH, Cho HW, Oh SC: The esthetics of the smile: a review of some recent studies, *Int J Prosthodont* 12:9–19, 1999.
7. Calvani L1, Michalakis K, Hirayama H: The influence of full-arch implant-retained fixed dental prostheses on upper lip support and lower facial esthetics: preliminary clinical observations, *Eur J Esthet Dent* 2:420–428, 2007.
8. Tjan AH, Miller GD, The JG: some aesthetic factors in a smile, *J Prosthet Dent* 51:24–28, 1984.
9. Robins JW: Differential diagnosis and treatment of excess gingival display, *Pract Periodont Aesthet Dent* 11:265–272, 1999.
10. Vig RG, Brundo GC: The kinetics of anterior tooth display, *J Prosthet Dent* 39:502–504, 1978.
11. Silverman MM: The whistle and swish sound in denture patients, *J Prosthet Dent* 17:144–148, 1967.
12. Pound E: Let /S/ be your guide, *J Prosthet Dent* 38:482–489, 1977.
13. Frush JP, Fisher RD: Introduction to dentinogenic restorations, *J Prosthet Dent* 5:586–595, 1955.
14. Lombardi RE: The principles of visual perception and their clinical application to denture esthetics, *J Prosthet Dent* 29:358–382, 1973.
15. Scandrett FR, Kerber PE, Umrigar ZR: A clinical evaluation of techniques to determine the combined width of the maxillary anterior teeth and the maxillary central incisor, *J Prosthet Dent* 48:15–22, 1982.
16. Jemt T: Fixed implant-supported prostheses in the edentulous maxilla. A five-year follow-up report, *Clin Oral Implants Res* 3:142–147, 1995.
17. Rangert B, et al.: Forces and moments on Branemark implants, *Int J Oral Maxillofac Implants* 4:241–247, 1989.
18. Hutton JE, et al.: Factors related to success and failure rates at 3-year follow-up in a multicenter study of overdentures supported by Brånemark implants, *Int J Oral Maxillofac Implants* 10:33–42, 1995.
19. Misch CE: *Dental implant prosthetics*, UK, 2005, Elsevier Mosby, pp 265–281.
20. Jemt T, et al.: Failures and complications in 92 consecutively inserted overdentures supported by Brånemark implants in severely resorbed edentulous maxillae: a study from prosthetic treatment to first annual check-up, *Int J Oral Maxillofac Implants* 7:162–166, 1992.
21. Reshad M, Cascione D, Aalam AA: Fabrication of the mandibular implant-supported fixed restoration using CAD/CAM technology: a clinical report, *J Prosthet Dent* 102:271–278, 2009.

22. Davis DM, Packer ME, Watson RM: Maintenance requirements of implant-supported fixed prostheses opposed by implant-supported fixed prostheses, natural teeth, or complete dentures: a 5-year retrospective study, *Int J Prosthodont* 16:521–523, 2003.
23. Svanborg P, Längström L, Lundh RM, et al.: A 5-year retrospective study of cobalt-chromium-based fixed dental prostheses, *Int J Prosthodont* 26:343–349, 2013.
24. Vasconcellos LG, Nishioka RS, Vasconcellos LM, Nishioka LN: Effect of axial loads on implant-supported partial fixed prostheses by strain gauge analysis, *J Appl Oral Sci* 19:610–615, 2011.
25. Abduo J: Fit of CAD/CAM implant frameworks: a comprehensive review, *J Oral Implantol* 40:758–766, 2014.
26. Taher NM, Al Jabab AS: Galvanic corrosion behavior of implant suprastructure dental alloys, *Dent Mater* 19:54–59, 2003.
27. Larsson C, Vult Von Steyern P: Implant-supported full-arch zirconia-based mandibular fixed dental prostheses. Eight-year results from a clinical pilot study, *Acta Odontol Scand* 71:1118–1122, 2013.
28. Rojas-Vizcaya F: Full zirconia fixed detachable implant-retained restorations manufactured from monolithic zirconia: clinical report after two years in service, *J Prosthodont* 20:570–576, 2011.
29. Puri S, Parciak EC, Kattadiyil MT: Complete mouth reconstruction with implant-supported fixed partial dental prostheses fabricated with zirconia frameworks: a 4-year clinical follow-up, *J Prosthet Dent* 112:397–401, 2014.
30. Pozzi A, Tallarico M, Barlattani A: Monolithic lithium disilicate full-contour crowns bonded on CAD/CAM zirconia complete-arch implant bridges with 3 to 5 years of follow-up, *J Oral Implantol* 41(4):450–458, 2015.
31. Cheng CW, Chien CH, Chen CJ, Papaspyridakos P: Complete-mouth implant rehabilitation with modified monolithic zirconia implant-supported fixed dental prostheses and an immediate-loading protocol: a clinical report, *J Prosthet Dent* 109:347–352, 2013.
32. Chong KK, Palamara J, Wong RH, Judge RB: Fracture force of cantilevered zirconia frameworks: an in vitro study, *J Prosthet Dent* 112:849–856, 2014.
33. Jung YS, Lee JW, Choi YJ, et al.: A study on the in-vitro wear of the natural tooth structure by opposing zirconia or dental porcelain, *J Adv Prosthodont* 2:111–115, 2010.
34. Nakamura K, Harada A, Kanno T, et al.: The influence of low-temperature degradation and cyclic loading on the fracture resistance of monolithic zirconia molar crowns, *J Mech Behav Biomed Mater* 47:49–56, 2015.
35. Denry I, Kelly JR: Emerging ceramic-based materials for dentistry, *J Dent Res* 93:1235–1242, 2014.

37

Mandibular Immediate Implant Loading with the Complete Arch Provisional Prostheses

TONY DAHER, VAHIK PAUL MESERKHANI, BACH LE

Introduction

Earlier types of implants, such as blade implants, subperiosteal implants, and vitreous carbon implants, were subjected to immediate loading and exhibited an implant-fibrous tissue interface. Their higher incidences of failure formed the basis for concerns about immediately subjecting titanium root form implants to loading. The original Brånemark protocol placed special emphasis on the critical period of unloaded bone healing where the implant must be covered with soft tissue.

The 3- to 6-month healing phase needed for successful osseointegration of submerged implants is described in recent literature as empirical. Many implant studies, including systematic reviews, have shown that dental implants with immediate or early loading approaches demonstrated similar success rates to the original two-stage protocol or one-stage surgical protocol.[1,2]

Many definitions of immediate loading are given by different investigation centers according to the prosthetic protocol. The interval between placing the implants and the prosthetic fabrication has varied between 0 and 20 days. Because this procedure involves the placement of a provisional restoration, the term "immediate provisionalization" was proposed.

Immediate loading was developed because of the desire to reduce treatment time and provide patients with a stable, esthetic replacement of one tooth, multiple teeth, or all the teeth in an arch either the same day or within a very short time.

Treatments with immediate or early implant loading may be advantageous for many edentulous patients in several aspects. Edentulous patients struggle with inadequate prosthesis retention, and/or poor denture stability, and/or inadequate chewing ability.[3] For patients who have never worn a removable prosthesis, there can be significant psychological and functional difficulties throughout the submerged healing time when they have to wear an interim removable prosthesis. The surgical wound covering the implants will need several days of healing without an overlying removable prosthesis. The removable interim prosthesis will require multiple adjustments and soft reline procedures during the subsequent months to minimize loading of the soft tissues and underlying implants. This periodic relining requires additional appointments and creates inconvenience and additional expense for the patient.

Therefore, modifications to the original two-stage protocol were developed. The implant and prosthesis are placed the same day, providing the patient with an esthetic and stable replacement for the missing teeth in one appointment. The number of surgical procedures and total treatment time is reduced.

Immediate implant loading (IIL) or early implant loading (EIL) protocols provide many benefits to edentulous patients compared with the conventional delayed protocol. These include both functional and psychological advantages from the retention rendered by immediately connecting the provisional prostheses (Figure 37-1).

Literature Review

There is strong evidence that IIL or EIL protocols are predictable in the anterior mandible, irrespective of implant type, surface topography, and prosthesis design (success rates 90% to 100%).[3] Limited evidence is available for the edentulous maxilla (success rates 80% to 100%), underscoring the need for further research.[4]

Indications for immediate load on the edentulous mandible include systemic, psychological, morphologic, and functional factors.[5] Loading forces, anatomy of the area, surgical protocol, and level of oral hygiene will dictate the patient's candidacy.[6-8]



• **Figure 37-1** Before and after rehabilitation with complete dentures. Self-esteem is improved with a pleasing smile.

Immediate-load protocols are contraindicated in patients with delayed wound healing, such as those with hyperparathyroidism, diabetes, heavy smoking habits, current chemotherapeutic therapy, or history of radiation to head or neck.[9,10] Heavy bruxers or clenchers are also best excluded from immediate-load protocols.[11] Primary implant stability (torque >30 Ncm), implant length >10 mm, and surgical skill have been described as important criteria for success.[9,12-14]

IIL protocols offer many advantages over delayed protocols. These include reduced treatment time, increased patient comfort, improved prosthesis stability, and increased masticatory function during the implant healing phase. No additional appointments are necessary for soft reline procedures.[15]

IIL has been advocated to preserve bone and stimulate bone remodeling, enhance gingival contours,[16-18] improve esthetics,[19-21] and decrease the psychological impact of wearing a fixed prosthesis.[22] Immediate full-arch fixed provisional restoration after implant placement allows for improved function, stability, and distribution of load. The provisional restoration offers numerous additional advantages:

- It protects the sutured mucosa.
- It can be modified and serves as a prototype for the final prosthesis.
- It can be used as a verification jig.
- It preserves the original vertical dimension of occlusion.
- It aids in obtaining and transferring the inter-occlusal record.
- It assists long-term patient maintenance.
- It reduces treatment visits.

The advantages of its use clearly outweigh the disadvantages.[23,24]

For completely edentulous patients, IIL must follow strict protocols. The immediate-load concept is based on three important clinical findings:[25]

1. <150 µm of micromotion may constitute a threshold value for implants to osseointegrate properly.
2. Passive connection of all the implants together with the prosthesis will reduce the micromotion and facilitate the healing process.
3. All inserted implants must be stable in the bone with insertional torque values of at least 30 Ncm.

In addition, an optimum occlusal scheme of a balanced or group function is a must in these conditions. Patients should be put on a soft diet for the first few weeks.

Excellent long-term follow-up results have been reported when rigid prostheses are connected to the implants immediately after implant placement. Despite several advantages of immediate loading, there is no agreement on the technique

by which immediate loading can be achieved. The success of immediate loading relies on a number of variables: implant texture and shape, surgical protocol, operators' skills, and prosthetic restoration.

Excessive occlusal load often leads to excessive movement during the healing process and may cause fibrous encapsulation of the implant. To control load on the dental implants and to reduce micromotion at the bone-to-implant interface, various prosthetic and surgical approaches have been described.[26]

Surgical and Prosthetic Principles and Protocol in Relation to Immediate Implant Loading

Biological Principles for IIL Success

Osteogenesis is success relies on primary stability and achieving abundant interfacial bone formation to offset bone resorption resulting from implant placement. Surgical and prosthetic strategies must be directed to enhance osteogenesis, decreasing occlusal load and micromotion.[27]

Bone Quality Basis for IIL Success

The bone quality and density in edentulous ridges has a primary influence on treatment planning, implant design, surgical approach, healing time, and initial bone loading during prosthetic reconstruction.[28-30] Bone quality and density are defined by four types: Q for quality, Q1 to Q4, according to Lekholm and Zarb in 1985; where Q1 indicates homogenous compact bone, Q2 indicates thick layer of cortical bone surrounding dense trabecular bone, Q3 indicates thin layer of cortical bone surrounded by dense trabecular bone of favorable strength, Q4 indicates thin layer of cortical bone surrounding a core of low-density trabecular bone.[28] D for density, D1 to D4 according to Misch in 1988; where D1 indicates dense cortical bone, D2 indicates dense to thick porous cortical bone on the crest and coarse trabecular bone underneath, D3 indicates a thinner porous cortical crest and fine trabecular bone within, and D4 indicates almost no crestal cortical bone.[29,30] Anterior mandible is in general Q2 or D2, however, resorbed mandible is Q1 or D1.

The bone quality and density can be determined and grossly estimated by radiographic evaluation, but is better evaluated during surgery. The presence and thickness of cortical bone and the density of trabecular bone are easily determined during the osteotomy preparation. It is usually not difficult to achieve the primary implant stability needed for the immediate loading protocol.[29]

The amount of trauma generated during the osteotomy preparation is influenced by the bone quality of the surgical site. This creates a cascade of reactions at the bone-implant interface that affect the quality of the load-bearing surface.[30]

Surgical Principles for IIL Success

Three requirements are necessary for initial rigid fixation: (1) minimal trauma preparation, (2) close approximation between titanium and bone, and (3) absence of movement at the interface during healing.[31] Bone is susceptible to heat, so it is important to limit thermal and mechanical trauma to the surrounding tissues caused by rotary drills.[32] Several factors have been described to influence heat generation during osteotomy preparation: sequencing of drill sizes to the final drill for the preselected osteotomy, drill speed and time, and the use of irrigation. Without irrigation, drill temperatures can reach 100° C within seconds.[29] Copious irrigation is needed, especially in dense bone. The use of new sharp drills in an organized manner, starting with a pilot drill of 2-mm diameter, is always recommended. Additional factors such as internally versus externally cooled drills are less important.[29] The choice of a coolant is also important. Distilled water should not be used, as rapid cell death may occur. Intravenous dextrose or saline solutions are preferable.[29]

The use of three-dimensional planning software before the surgical appointment has many advantages compared to two-dimensional studies:[33] (1) more refined and precise implant placement to avoid critical anatomical structures, (2) better understanding of the quality and quantity of bone, and (3) precision that helps with the implant position, especially when more implants are necessary for adequate support of the fixed prosthesis.

Limitations to digital diagnostics include the added presurgical treatment time and added treatment cost; radiation dosages that may be greater than for two-dimensional studies; the difficulty of implant placement in the posterior region due to longer instrumentation; and the difficulty of cooling during the osteotomy preparation. Despite the limitations of the digital procedures, their advantages outweigh them.[33]

Prosthetic Principles for IIL Success

Restoration using the immediate loading protocol demands the application of six factors for prosthetic success:

1. Optimum esthetic and functional design of the presurgical prosthesis. It is advisable for patients to use the presurgical denture and to allow time for any adjustment to be made. There should not be any compromises at the level of esthetics and occlusal scheme. All basic principles of removable prosthodontics must be applied during denture fabrication.
2. Reduction of occlusal load by connecting all the implants together to achieve a passive fit and by using a soft food diet.[29]
3. Promotion of peri-implant health and controlling peri-implant inflammation. Using an antibiotic therapy before and after implant placement may be beneficial as well as instituting an oral hygiene regimen.[29]
4. Development of an optimum gingival contour with a well contoured provisional prosthesis.[29]
5. Minimizing the length of the cantilever extension to the width of a molar.
6. Customizing an oral hygiene protocol for the specific clinical situation and emphasizing its importance to the patient.[34]

Guided Surgery Principles for IIL Success

Collaboration between the restorative dentist and the implant surgeon is an important aspect of patient care to achieve an accurate diagnosis, thorough treatment planning, and a predictable outcome.[35] The final result is

addressing the needs and concerns of the patient. Incorporating the prosthetic details of the presurgical denture in the cone-beam computed tomography (CBCT) radiographs clearly defines the best location of the implants and renders the final prosthetic treatment predictable. The anticipated treatment outcomes will strengthen the relations between the restorative dentist, the surgeon, and the lab technician and enhance the patient's confidence in oral implantology. Using a preplanned surgical guide has many advantages[35]:

1. It reduces the amount of time required for the surgery.
2. It reduces the time of bone exposure, and consequently postsurgical comfort is improved.
3. It reduces interoperator variability during surgery, thus enhancing security for greater planning accuracy and better implant location.
4. It standardizes the osteotomies according to the final prosthetic outcome, optimizing accuracy in the fabrication and placement of the final prosthesis.
5. It benefits the patient by improved efficiency in treatment planning and simplified treatment.
6. It reduces the need for expensive components to correct angulation problem and reestablish adequate emergence for adequate gingival contour.
7. In maxillary situations, it improves the esthetic outcome to meet the patient's wishes.
8. It helps to determine if adequate interarch space is available for the interim fixed implant prosthesis by measuring the distance between the top of the bone and the intaglio surface of the denture.[35]

Cassetta and colleagues[36] performed an in vivo study of 116 patients to evaluate the accuracy of a computer-designed (SLA) surgical guide by comparing the three-dimensional positions of planned and placed implants. Preoperative and postoperative computed tomographic (CT) images were compared. They found deviations between the postoperative position and the preoperative plan at the coronal and apical portions of the implant, as well as in the angulation of the implant. Although the reported deviation values were extremely high, they do not appear to have resulted in important clinical complications. It suggested the necessity of always keeping a safety zone of at least 2 mm to avoid critical anatomical structures.[36]

Implant Angulation Principles for IIL Success

A minimum of four implants must be placed in the mandibular arch, as parallel as possible to each other for prosthetic and practical reasons, and must be spread as far apart as possible.[37] In case of lack of bone height in the posterior quadrants, it has become very popular to angulate the distal implants to increase the prosthetic arch and consequently decrease the cantilever arm length. The benefits of the tilted implants are: (1) avoidance of the mental foramina, (2) permitting longer implants in less bone, (3) eliminating the need for bone grafting, (4) allowing engagement of dense and mature bone, and (5) improved force distribution.[37]

Kim and colleagues[38] examined the photoelastic effect of the inclination of the two distal implants according to the "all-on-four" concept on the stress distribution within the supporting structure. The authors concluded that within the limitations of the photoelastic stress analysis, the use of tilted implants reduced the maximum stress in the distal crestal bone of the distal implant by approximately 17% relative to the axial implants.[38]

Mandibular Complete Denture Conversion to a Provisional Implant-Supported, Screw-Retained Fixed Prosthesis for Immediate Loading

The technique of immediate loading of endosseous root-form implants has been described mostly for the mandible in completely edentulous patients, with placement of a provisional fixed implant-supported prosthesis on the same day of implant surgery.[22,23,39-46]

The concept of converting removable complete dentures to provisional fixed restorations was described by Balshi in 1985.[46] Since then, many similar techniques with some variations have been described.[23,39-46]

Case Study

A 72-year-old white woman expressed dissatisfaction with the function and the esthetics of previously fabricated mandibular removable complete dentures (Figure 37-2). After various treatment options were discussed, it was decided to make a set of presurgical complete dentures; to place six root-form implants, four in the anterior segment of the mandible and one in each posterior segment; and to transform the mandibular presurgical complete denture into an implant-supported, screw-retained provisional fixed prosthesis and then fabricate the final fixed complete denture.

The presurgical set of maxillary and mandibular complete dentures was fabricated according to standard procedures for removable prosthodontics[47,48] (Figure 37-3). These complete dentures were to be worn for a period of time to rule out any problem from esthetic and functional perspectives (see Figure 37-3).

A copy cast of the maxillary denture was articulated with an ear-face-bow onto a semi-adjustable articulator programmed with appropriate condylar inclination specific to the patient. The mandibular complete denture was duplicated twice with a Lang duplicator and made of clear autopolymerizing acrylic resin. One duplicate was used as a custom impression tray using a three-visit-in-one technique.[49] The second duplicate was sent with the master cast to fabricate the CAD-CAM frame for the final mandibular fixed complete denture. The mandibular complete denture was prepared for CBCT radiographs as follows: Six to nine plastic radiopaque balls were glued to the cameo surfaces of the denture. (Figure 37-4). A bite registration polyvinyl siloxane (PVS) material was used between the two dentures to secure centric occlusion during radiographic procedures (Figure 37-5). Two CBCT radiographs were made: one with the patient wearing the mandibular denture, and another one just a scan of the denture itself (Figure 37-6). The two scans were uploaded to the Simplant software.



• **Figure 37-2** Esthetic and functional problems with the existing complete dentures. Patient's chief complaints are: "My dentures are very loose, uncomfortable, and ugly. And I cannot eat with them."



• **Figure 37-3** The presurgical set of maxillary and mandibular complete dentures were fabricated according to standard procedures of removable complete prosthodontics. Adequate pleasing esthetics and comfortable removable dentures.

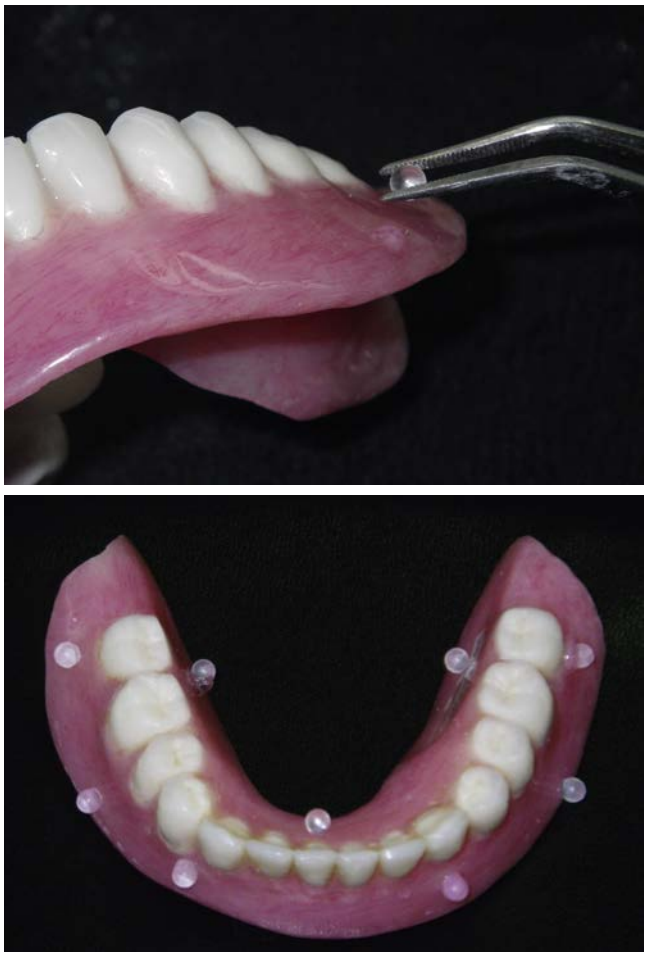

• **Figure 37-4** Six to nine plastic radiopaque balls are glued to the cameo surfaces of the mandibular denture. Care must be taken not to place them all on the same horizontal plane.



• **Figure 37-5** A bite index with radiolucent polyvinyl siloxane is necessary to ensure that the prosthesis remains well-positioned in centric occlusion and the jaws stabilized at the time of radiographic scanning.

A virtual treatment plan was done in which the six implants were virtually placed (Figure 37-7,). Then a surgical guide was designed (Figure 37-8, *A*) and emailed to Materialize for fabrication with a prescription (a) containing the type, diameter, and length of the implants and three fixation screws, and (b) asking the occlusal surfaces of the teeth to be kept as uninvolved as possible with the surgical sites.

With the guidance of a surgical guide that had been fabricated based on the mandibular presurgical complete denture,



• **Figure 37-6** Cone-beam computed tomography dual scan. **A,** The patient is scanned with the denture in. **B,** A second separate scan is done for the denture.

and secured with three fixations screws, six root-form implants were placed parallel to each other, following a detailed prescription compatible with the implant system used, with no flap required in this patient situation (see Figure 37-8, *B-D*). If all six implants were stable with at least 30 Ncm of torque, we would proceed to convert the mandibular complete denture to an interim implant-supported screw-retained fixed complete denture. Titanium or PEEK plastic polymer temporary abutments are needed for the procedure.

The conversion could be done with any of the following three techniques: intraorally, in the laboratory, or digitally planned and placed.

Intraoral Conversion Technique

Once the implants are placed, short healing abutments are placed over them (Figure 37-9).

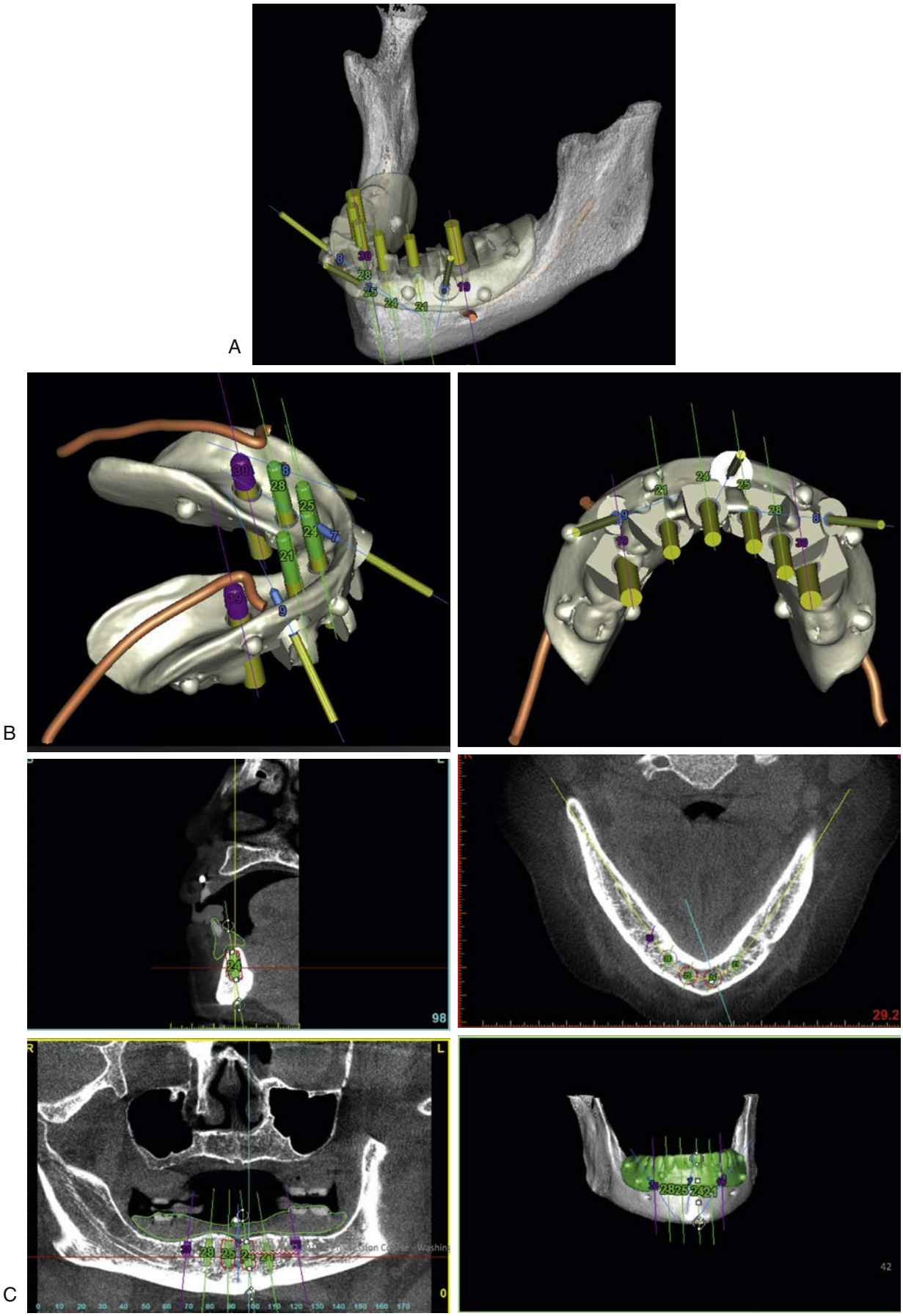

• **Figure 37-7** **A,** Virtual planning of the six implants. **B,** Intaglio and **(C)** cameo views of the surgical guide planning process.

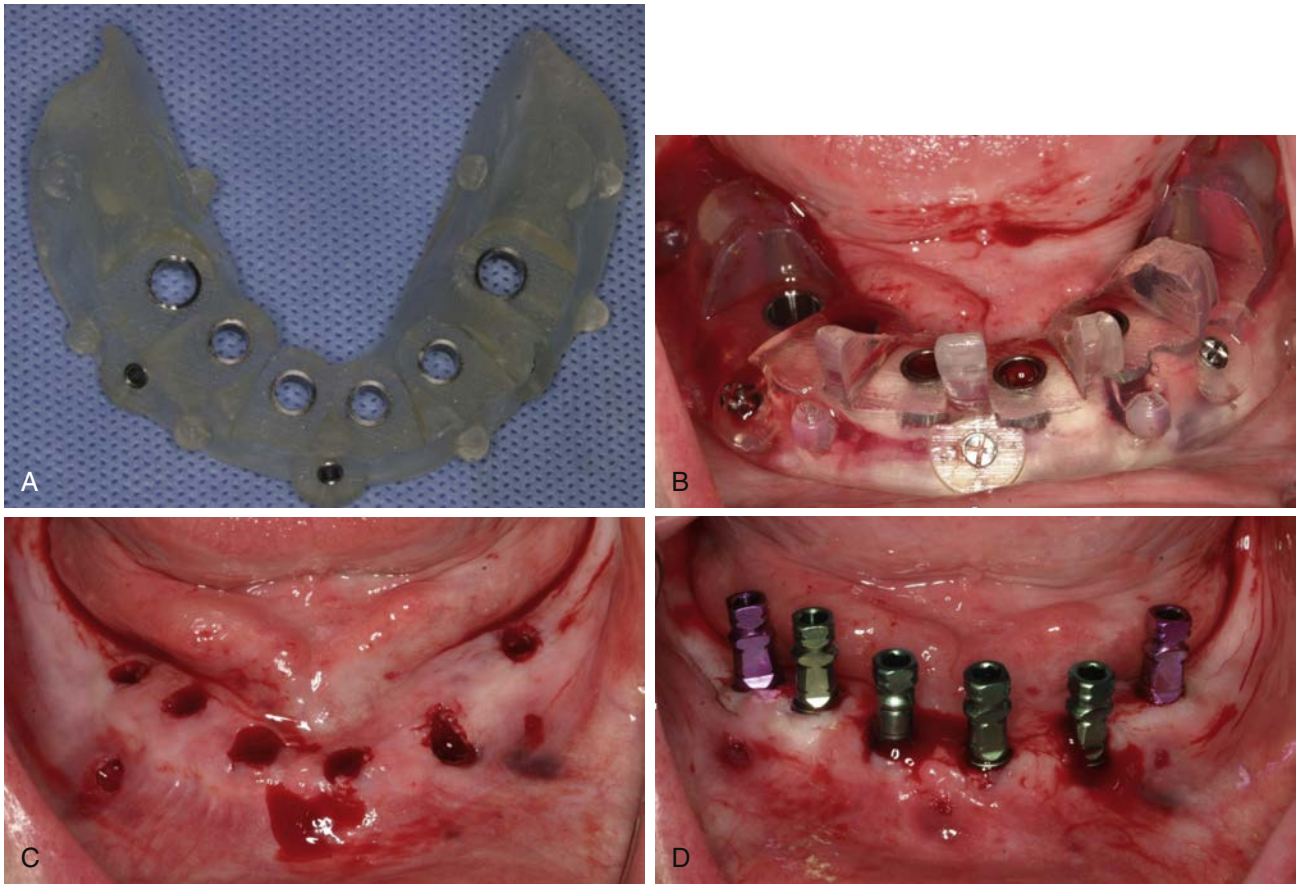

• **Figure 37-8** **A,** Surgical guide. **B**, Surgical guide secured in patient's mouth. **C,** Final flapless osteotomy sites. **D,** Six Zimmer Tapered Screw-Vent implants (Zimmer Dental, Carlsbad, CA) parallel to each other, with their mounts in the surgical sites.

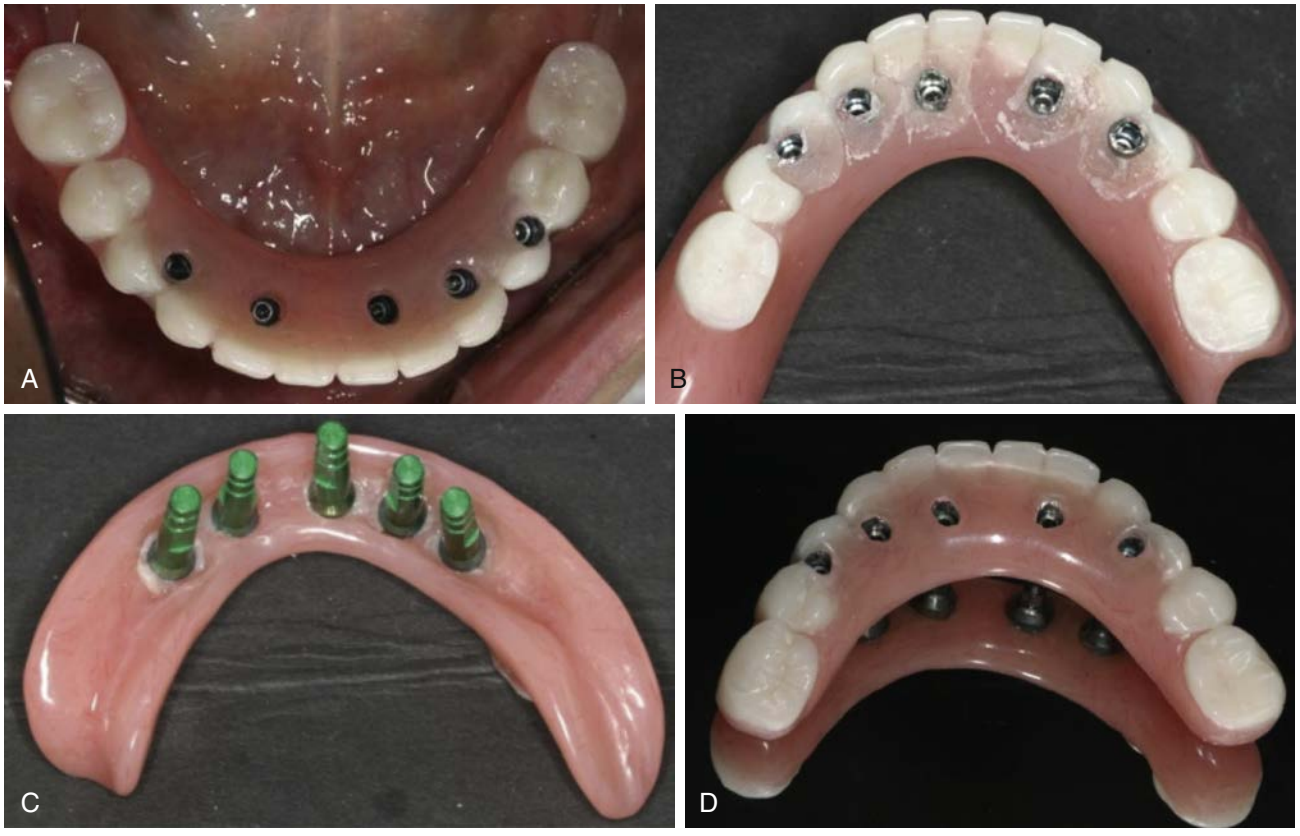

• **Figure 37-9** **A,** Mandibular denture with the implant respective openings in the patient mouth. **B,** The temporary abutments are luted to the denture, and **(C)** implant lab analogues are placed onto the temporary abutments, then sent to the lab to be boxed for making a master stone cast. **D,** Then the flanges are removed. The intaglio surface is rounded. The conversion denture is finessed and polished, then screwed in patient's mouth.

A light to medium viscosity of PVS impression material is placed on the intaglio surface of the mandibular denture, then seated over the healing abutments, making the mandibular denture contact the maxillary denture in centric occlusion. After the setting of the PVS, the mandibular denture it is removed and the contacts of the healing abutments with the intaglio surface are marked with a permanent marker. Using a pear-shaped acrylic carbide burr, openings are made through the marked areas. The denture is then placed and centric occlusion is verified. Temporary abutments are placed over the implants using either a short or long screw, after removing the healing abutments. If the long screw interferes with the opposing occlusion, a short one is used. A space of at least 2 mm should exist around the temporary abutments and the denture acrylic base.

A small increment of autopolymerizing acrylic resin is placed and bead-brushed around an anterior temporary abutment and the adjacent denture acrylic. Then the patient is asked to close in centric occlusion until polymerization of the acrylic resin is complete. Now the denture is secured in place, and all other abutments are luted to the denture using either pink or tooth-colored acrylic resin where the access hole is at an occlusal surface (see Figure 37-9).

When the acrylic resin is completely set, the screws of the temporary abutments are removed, and the mandibular complete denture is removed from the patient's mouth . Healing abutments are placed back over the implants, and implant analogues are placed at the intaglio area of the denture to make a cast (see Figure 37-9).

Autopolymerizing acrylic resin is bead-brushed and then poured around the provisional copings and along the intaglio area of the denture. The acrylic resin is allowed to polymerize in a pressure pot with hot water under 25 psi to increase the strength and reduce the porosity of the acrylic material.[50]

After polymerization, excess acrylic resin material and the denture flanges are removed. A reduced distal cantilever is developed by limiting its length to the width of a molar. A mandibular master cast is fabricated with type IV dental stone. Pink-colored condensation silicone is used to simulate soft tissue.[51]

The mandibular denture is mounted on a semi-adjustable articulator against the mounted maxillary cast. This step is important in the fabrication of the final fixed complete denture. The denture thus is converted into an implant-supported, screw-retained fixed prosthesis. The acrylic resin material of the intaglio surface is shaped into a convex surface 2 mm above the gum area to allow access for oral hygiene (see Figure 37-14, *E* and *F*).[39]

Extraoral Conversion Technique

After the placement of the implants, the clear acrylic mandibular denture duplicate can be prepared to be used as a custom tray (Figure 37-10). Or, the surgical guide can be prepared for use as a custom tray for the fabrication of the master cast as follows: All the metal cylinders of the surgical guide are removed by heating it, leaving wider openings for the final impression (Figure 37-11, *A*)

The impression copings are placed over the implants and connected together and to the guide as follow: A small increment of fast setting auto polymerizing acrylic resin or BIS-GMA type of resin, is to be placed and bead-brushed around an anterior impression coping on the adjacent denture acrylic. Then the patient is asked to close in centric occlusion till the complete polymerization of the acrylic resin. Now the guide-custom tray is secured in place, all other impression copings will be luted to the denture using the same acrylic resin. (see Figures 37-10 and 37-11). The patient is then asked to close in centric. This will verify that the guide tray is in the right position and is maintaining the centric and occlusal vertical dimension positions after connecting all impression copings together and to the guide custom tray.

In some situations, where there are not enough occlusal surfaces to maintain the mandibular centric position, bite-registration PVS material can be placed in the mouth over the intact occlusal surfaces of the surgical guide (see Figure 37-11, *D*). The patient is dismissed after placing appropriate healing abutments over the implants. The patient is briefed about the reason why he or she will leave without the interim screw retained fixed complete denture, and will return the next day to receive the interim prosthesis.

A mandibular master cast is fabricated with type IV dental stone after boxing the impression with irreversible hydrocolloid impression material (Figure 37-12). Pink-colored condensation silicone is used to simulate the soft tissue.[51]

The mandibular cast is mounted on a semi-adjustable articulator against the already mounted maxillary cast. The guide tray is removed from the cast. The patient's mandibular denture is fitted onto the master cast. Then temporary abutments are placed one by one and the patient's denture is fitted over them. The opposing cast is closed over to verify that the maxillary and mandibular opposing teeth are in centric occlusion (Figure 37-13). The mandibular denture is finished as in the intraoral technique. The advantage of this technique is that it is done in the lab, minimizing chairside time (Figure 37-14). It is convenient and less stressful to the patient and doctor, and the prosthesis contours and occlusion can be refined easily with clinically and laboratory predictable results (Figure 37-15).

Digitally Planned and Converted Technique

The presurgical dentures are fabricated previously using a CAD-CAM generated milled denture system (Figure 37-16). The surgical guide can be milled from a clear acrylic puck block using the same digital file as for the presurgical denture, or by duplicating the worn presurgical denture. Six to nine fiduciary radiopaque markers are luted at different vertical levels to the cameo surfaces of the duplicate denture. The conversion denture is done as follows. A new digitally fabricated and milled mandibular denture is made using the stored digital information collected from the CBCT images of the radiographic template and of the patient's mandible. The virtual implant positions are then used and superimposed over the digital denture information to fabricate a digital mandibular conversion denture with

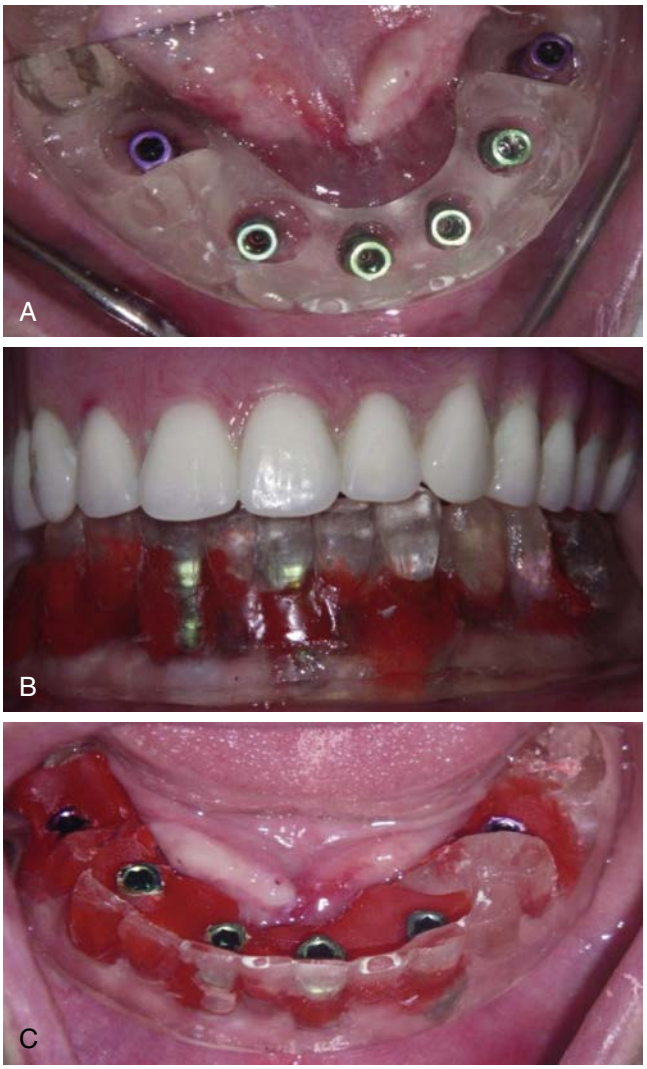

• **Figure 37-10** **A,** The duplicate of the presurgical denture with implant openings before the connection procedure in the patient's mouth. **B-C,** Implants are connected at the existing occlusal vertical dimension in a centric occlusion position.

channels milled corresponding to the implant positions.[52] These channels should have adequate openings to clear the temporary abutments corresponding to the implant system used. Temporary abutments are then placed over immediately placed implants, and autopolymerizing acrylic resin is flowed to connect them together and to the mandibular denture following the technique described previously. The finishing steps of the converted denture are done as previously described.

The mandibular provisional implant-supported, screw-retained prosthesis is placed in the patient's mouth immediately after implant surgery (see Figure 37-14). The fit of the mandibular prosthesis can be evaluated through the alternate pressure technique,[53,54] and the occlusion is refined if needed. Light viscosity PVS is placed and trimmed back to 3 mm, and provisional cement is placed into the occlusal access openings. Postoperative medications and instructions are given orally and in a written format with an emphasis on a custom oral hygiene instructions and on using a soft diet for the initial healing phase.

In the case described earlier, healing after implant surgery was uneventful. The patient was followed at 1 week, 2 weeks, and monthly until the third month with no surgical or prosthetic complications. Once the implants were osseointegrated, the final prosthesis was started (see Figure 37-16).

The provisional fixed prosthesis allowed the patient and the treating dentist to evaluate appearance, function, and oral hygiene before the fabrication of the definitive fixed-detachable restoration (Figure 37-17). The technique described can also be used with the conventional two-stage approach at second-stage surgery. It can certainly be applied to partially edentulous patients by transforming the provisional removable partial denture into an implant-supported, screw-retained provisional fixed partial denture.

Fabrication of the Definitive Screw-Retained Fixed Complete Denture

The previously fabricated articulated master mandibular cast and the duplicate of the presurgical denture are sent to a CAD-CAM center for the fabrication of CAD-CAM milled frame. Then denture teeth are set in wax and tried in for verification. After the dentist's and patient's approval, the trial fixed complete denture is flasked, lab remounted, finished, polished, and placed in the patient's mouth (Figure 37-18). Care instructions are delivered orally and in a written format.



• **Figure 37-11 A,** The surgical guide can be transformed to a custom tray by heating the metal cylinders and removing them from the acrylic resin. **B-C,** The guide used as an impression tray, in patient's mouth during the connection of all temporary abutments together and to the acrylic portion of the tray, preserving the centric position and occlusal vertical dimension. **D,** A bite registration polyvinyl siloxane material placed over the occlusal surfaces to capture the centric occlusion at the correct occlusal vertical dimension. **E,** Implant lab analogues are placed onto the temporary abutments and a master cast is made.



• **Figure 37-12** **A-B,** Cameo and intaglio views of the indexed denture duplicate. **C-D,** Duplicate is boxed with irreversible hydrocolloid impression material, and a stone material is poured over. **E,** The indexed guide over the final cast that is ready to be articulated to the opposing cast. **F,** Wax is flowed at the intaglio surface to fill in any voids before the boxing and stone cast fabrication.



• **Figure 37-13** The conversion of the presurgical denture starts. Temporary abutments are placed one at a time after making openings with pear-shaped carbide burrs. Mandibular presurgical denture is fitted over the final cast. Care must be taken not to lose the centric position by closing the articulator and making the mandibular occlusal surfaces contact the opposing respective surfaces.



• **Figure 37-14 A,** Pink and tooth-colored autopolymerizing acrylic resin is placed to fill the voids between the temporary abutments and the denture. **B,** Long screws or wooden sticks are used to prevent the resin from clogging the openings of the temporary abutments. While the added autopolymerizing acrylic resin is setting, the articulator is closed in centric occlusion. **C**-**D,** Denture flanges are removed and the intaglio surfaces are made convex for proper oral hygiene. **E**-**F,** The finished and polished mandibular interim screw-retained fixed complete denture. Note the space between the denture intaglio surface and the soft tissue to facilitate oral hygiene practices.



• **Figure 37-15** **A,** The prosthesis is in the mouth in centric occlusion. **B-C,** Views of the interim fixed screw-retained prosthesis in working and balancing articulation. **D,** Patient's pleasing smile.



• **Figure 37-16** Presurgical CAD-CAM fabricated dentures are done using the AvaDent technique. **A,** Maxillary and mandibular final impressions, a maxillo-mandibular relations record, and a prescription sheet are sent to AvaDent center for the fabrication of digital dentures. **B,** Digital setup of the denture teeth. **C,** Milled mandibular denture base with the corresponding tooth sockets ready for the gluing of artificial teeth.

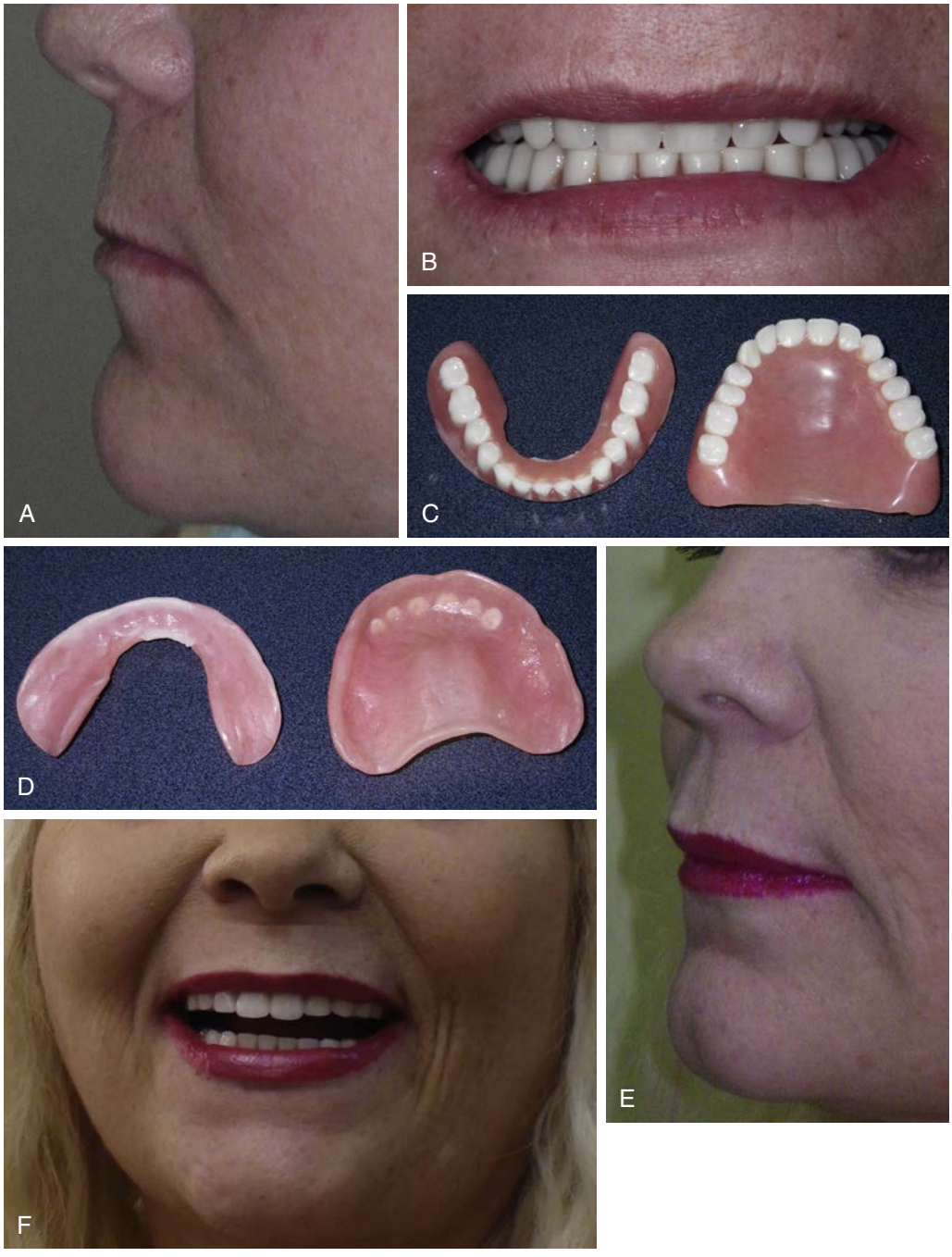

• **Figure 37-17** **A,** Before: Inadequate facial profile. **B,** Unpleasing smile with the old prosthesis. **C-D,** Old, inadequate complete dentures. **E,** Adequate lip support with the new dentures and pleasing profile. **F,** Pleasing smile with the new prostheses.

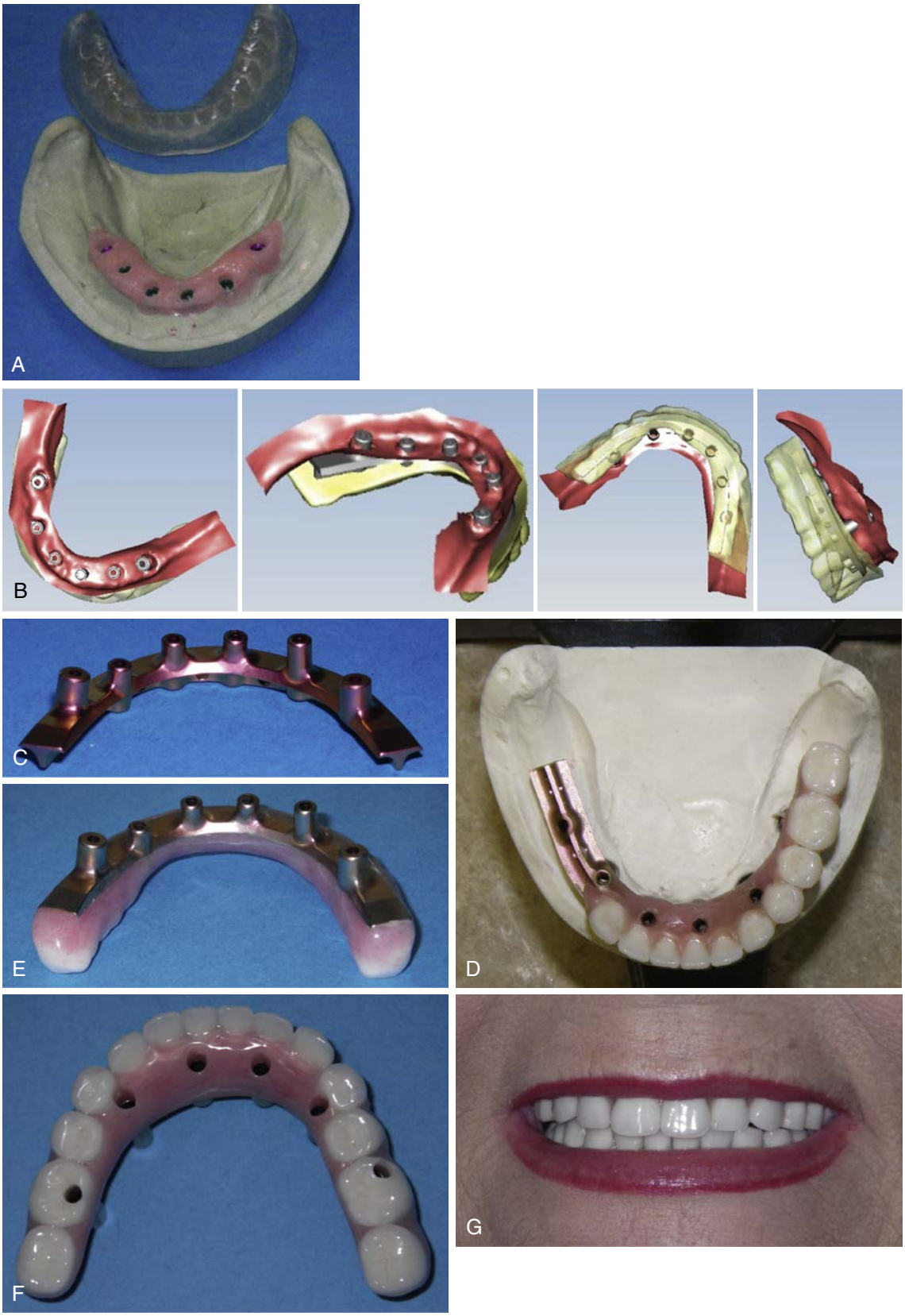

• **Figure 37-18** **A,** The master cast and a duplicate of the presurgical denture are sent to CAD-CAM center (Cagenix, Memphis, TN) for the fabrication of a milled titanium frame. **B,** Digital pictures of the designed final titanium fixed framework for the final mandibular fixed screw-retained complete denture done by Cagenix.com. The CAD-CAM frame is designed according to the "final destination": the silhouette of the presurgical denture. **C,** Intaglio view of the CAD-CAM milled metal framework with T-shaped cross-section and butt-joint finish lines and retention holes to strengthen the acrylic resin base. **D,** Prosthetic teeth are set up over the titanium frame. **E-F,** Intaglio and cameo views of the finished final mandibular fixed complete denture. **G**, Final smile.

References

1. Horwitz J, Zuabi O, Peled M, et al.: Immediate and delayed restoration of dental implants in periodontally susceptible patients: 1-year results, *Int J Oral Maxillofac Implants* 22:423–429, 2007.
2. Sanz-Sánchez I, Sanz-Martín I, Figuero E, Sanz M: Clinical efficacy of immediate implant loading protocols compared to conventional loading depending on the type of the restoration: a systematic review, *Clin Oral Implants Res* 26(8):964–982, 2015.
3. Redford M, Drury TF, Kingman A, et al.: Denture use and the technical quality of dental prostheses among persons 18-74 years of age: United States, 1988-1991, *J Dent Res* 75(Spec Iss):714–725, 1996.
4. Attard NJ, Zarb GA: Immediate and early implant loading protocols: a literature review of clinical studies, *J Prosthet Dent* 94 :242–258, 2005.
5. Misch CE, Wang H-L, Misch CM, et al.: Rationale for the application of immediate load in implant dentistry: part I, *Implant Dent* 13:207–217, 2004.
6. Gapski R, Wang HL, Mascarenhas P, et al.: Critical review of immediate loading, *Clin Oral Implants Res* 14:515–527, 2003.
7. Attard NJ, David LA, Zarb GA: Immediate loading of implants with mandibular overdentures; one year clinical results of a prospective study, *Int J Prosthodont* 18:463–470, 2005.
8. Sadowsky SJ: Immediate load on the edentulous mandible: treatment planning considerations, *J Prosthodont* 19:647–653, 2010.
9. Esposito M, Grusovin MG, Willings M, et al.: The effectiveness of immediate, early, and conventional loading of dental implants: a Cochrane systematic review of randomized controlled trials, *Int J Oral Maxillofac Implants* 22:893–904, 2007.
10. Chiapasco M, Abati S, Romeo E, et al.: Implant-retained mandibular overdentures with Brånemark system MKII implants: a prospective comparative study between delayed and immediate loading, *Int J Oral Maxillofac Implants* 16:537–546, 2001.
11. Jaffin RA, Kumar A, Berman CL: Immediate loading of implants in partially and fully edentulous jaws: a series of 27 case reports, *J Periodontol* 71:310–319, 2000.
12. Horiuchi K, Uchida H, Yamamoto K, et al.: Immediate loading of Brånemark system implants following placement in edentulous patients: a clinical report, *Int J Oral Maxillofac Implants* 15:824–830, 2000.
13. Esposito M, Grusovin MG, Willings M, et al.: Interventions for replacing missing teeth: different times for loading dental implants, *Cochrane Database Syst Rev* 4:CD003607, 2009.
14. Strub JR, Jurdzik BA, Tuna T: Prognosis of immediately loaded implants and their restorations: a systematic review, *J Oral Rehabil* 39:704–717, 2012.
15. Kronström M, Widbom T, Löfquist LE, et al.: Early functional loading of conical Brånemark implants in the edentulous mandible: a 12-month follow-up clinical report, *J Prosthet Dent* 89: 335–340, 2003.
16. Tortamano P, Orii TC, Yamanochi J, et al.: Outcomes of fixed prostheses supported by immediately loaded endosseous implants, *Int J Oral Maxillofac Implants* 21:63–70, 2006.
17. Jaffin R, Kolesar M, Kumar A, et al.: The radiographic bone loss pattern adjacent to immediately placed, immediately loaded implants, *Int J Oral Maxillofac Implants* 22:187–194, 2007.
18. Kinsel RP, Liss M: Retrospective analysis of 56 edentulous dental arches restored with 344 single-stage implants using an immediate loading fixed provisional protocol: statistical predictors of implant failure, *Int J Oral Maxillofac Implants* 22:823–830, 2007.
19. Cooper L, de Kok I, Reside G, et al.: Immediate fixed restoration of the edentulous maxilla after implant placement, *J Oral Maxillofac Surg* 63:97–110, 2005.
20. Gallucci GO, Mavropoulos A, Bernard JP, et al.: Influence of immediate implant loading on peri-implant soft tissue morphology in the edentulous maxilla, *Int J Oral Maxillofac Implants* 22:595–602, 2007.
21. Tortamano P, Camargo L, Bello-Silva M, et al.: Immediate implant placement and restoration in the esthetic zone: a prospective study with 18 months of follow-up, *Int J Oral Maxillofac Implants* 25:345–350, 2010.
22. Balshi TJ, Wolfinger GJ: Immediate loading of Brånemark implants in edentulous mandibles: a preliminary report, *Implant Dent* 6:83–88, 1997.
23. Balshi TJ, Wolfinger GJ: Conversion prosthesis: a transitional fixed implant-supported prosthesis for an edentulous arch-a technical note, *Int J Oral Maxillofac Implants* 11:106–111, 1996.
24. Tortamano P, Orii TC, Yamanochi J, et al.: Outcomes of fixed prostheses supported by immediately loaded endosseous implants, *Int J Oral Maxillofac Implants* 21:63–70, 2006.
25. ElGhoul W, Chidiac JJ: Prosthetic requirements for immediate implant loading: a review, *J Prosthodont* 21:141–154, 2012.
26. Quinlan P, Nummikoski P, Schenk R, et al.: Immediate and early loading of SLA ITI single-tooth implants: an in vivo study, *Int J Oral Maxillofac Implants* 20:360–370, 2005.
27. Cooper LF: Biologic determinants of bone formation for osseointegration: clues for future clinical improvements, *J Prosthet Dent* 80:439–449, 1998.
28. Lekholm U, Zarb GA: Patient selection and preparation. In Brånemark PI, Zarb GA, Albrektsson T, editors: *Tissue-integrated prostheses*, Chicago, 1985, Quintessence.
29. Misch CE: Density of bone: effect on surgical approach and healing. In Misch CE, editor: *Contemporary implant dentistry*, St Louis, 2008, Mosby Elsevier.
30. Misch CE: Density of bone: effect on treatment plans, surgical approach, healing, and progressive bone loading, *Int J Oral Implantol* 6:23–31, 1990.
31. Adell R, Lekholm U, Rockler B: A 15-year study of osseointegrated implants in the treatment of the edentulous jaw, *Int J Oral Surg* 10:387–416, 1981.
32. Sharawy M, Misch CE, Weller N, et al.: Heat generation during implant drilling: the significance of motor speed, *J Oral Maxillofac Surg* 60:1160–1169, 2002.
33. Marchack CB, Moy PK, Anderson M: Digitally guided surgery and immediate loading. In *Implant dentistry DVD*, Loma Linda University & ACP Edition, 2006.
34. Cagna DR, Massad JJ, Daher T: Use of a powered toothbrush for hygiene of edentulous implant-supported prostheses, *Compend Contin Educ Dent* 32:84–88, 2011.
35. Tardieu PB, Rosenfeld AL: The art of computer-guided implantology. In *Tardieu and Rosenfeld, The art of computer guided implantology*, Quintessence, 2009, pp 2–3.
36. Cassetta M, Stefanelli LV, Giansanti M, et al.: Accuracy of implant placement with a stereolithographic surgical template, *Int J Oral Maxillofac Implants* 27:655–663, 2012.
37. Goodacre CJ, Goldstein G, Tuminelli FG: Implant complete fixed dentures. In *Implant dentistry DVD*, Loma Linda University & ACP Edition, 2006.
38. Kim KS, Kim YL, Bae JM, et al.: Biomechanical comparison of axial and tilted implants for mandibular full-arch fixed prostheses, *Int J Oral Maxillofac Implants* 26:976–984, 2011.

39. Schnitman PA, Wöhrle PS, Rubenstein JE: Immediate fixed interim prostheses supported by two-stage threaded implants: methodology and results, *J Oral Implantol* 16:96–105, 1990.
40. Schnitman PA, Wöhrle PS, Rubenstein JE, et al.: Ten year results for Brånemark implants immediately loaded with fixed prostheses at implant placement, *Int J Oral Maxillofac Implants* 12: 495–503, 1997.
41. Tarnow DP, Emtiaz S, Classi A: Immediate loading of threaded implants at stage 1 surgery in edentulous arches: ten consecutive case reports with 1- to 5-year data, *Int J Oral Maxillofac Implants* 12:319–324, 1997.
42. Siirila HS, Nordberg L, Oikarinen VJ: Technique for converting an existing complete denture to a tissue-integrated prosthesis, *J Prosthet Dent* 59:463–467, 1988.
43. Randow K, Ericsson I, Nilner K, et al.: Immediate functional loading of Brånemark dental implants. An 18-month clinical follow-up study, *Clin Oral Implants Res* 10:8–15, 1999.
44. Simon H, Marchack CB: A simplified approach to implant-supported metal-ceramic reconstruction, *J Prosthet Dent* 91: 525–531, 2004.
45. Kammeyer G, Proussaefs P, Lozada J: Conversion of a complete denture to a provisional implant-supported screw retained fixed prosthesis for immediate loading of a completely edentulous arch, *J Prosthet Dent* 87:473–476, 2002.
46. Balshi TJ: The Biotes conversion prosthesis: a provisional fixed prosthesis supported by osseointegrated titanium fixtures foe restoration of the edentulous jaw, *Quintessence Int* 16:667–677, 1985.
47. Daher T, El Sherif M, Davis WJ, et al.: Successful and predictable custom complete dentures, *Dent Today (March)* 86–89, 2016.
48. Morrow RM, Rudd KD, Eissmann HF: *Dental laboratory procedures, vol. 1: Complete dentures*, St Louis, 1980, Mosby, pp 386–397.
49. Daher T, Meserkhani PV, Baba NZ, et al.: Time-saving method for the fabrication of a definitive cast for an implant supported prosthesis, *J Prosthet Dent* 98:70–71, 2007.
50. Donovan TE, Hurst RG, Campagni WV: Physical properties of acrylic resin polymerized by four different techniques, *J Prosthet Dent* 54:522–524, 1985.
51. Breeding LC, Dixon DL: Transfer of gingival contours to a master cast, *J Prosthet Dent* 75:341–343, 1996.
52. Lozada JL, Garbacea A, Goodacre CJ, Kattadiyil MT: Use of a digitally planned and fabricated mandibular complete denture for easy conversion to an immediately loaded provisional fixed complete denture. Part 1. Planning and surgical phase, *Int J Prosthodont* 27:417–421, 2014.
53. Henry PJ: An alternative method for the production of accurate casts and occlusal records in osseointegrated implant rehabilitation, *J Prosthet Dent* 58:694–697, 1987.
54. Jemt T: Failures and complications in 391 consecutively inserted fixed prostheses supported by Brånemark implants in edentulous jaws: a study of treatment from the time of prostheses placement to the first annual checkup, *Int J Oral Maxillofac Implants* 6: 270–276, 1991.

38

Contemporary Restorative Options for the Single Implant

BALDWIN W. MARCHACK

Introduction

In the more than three decades since osseointegrated dental implants were first introduced, the use of implant-supported restorations for oral rehabilitation has become a predictably successful treatment, one embraced by patients and dentists worldwide. During that time, recognition has grown that the best functional and esthetic results can be achieved when the surgeon, restorative dentist, and dental laboratory technician work together to plan and achieve the optimal outcome for each individual patient. This chapter provides an overview of the information oral surgeons need in order to collaborate with their restorative dentists on the design and fabrication of successful implant-supported solutions for single posterior sites and single anterior sites in both the maxilla and mandible.



• **Figure 38-1** Screw-retained implant restoration.

Restorative Options

The Single Posterior Implant

When restoring the single posterior implant, the restorative dentist may choose between a screw-retained restoration (Figures 38-1 and 38-2) or a cement-retained restoration (Figures 38-3 and 38-4).

Cement-Retained Single Posterior Implant Restorations

Cement-retained single posterior restorations may be cemented on either a custom (patient-specific) abutment (Figures 38-5 and 38-6) or a stock (prefabricated) abutment (see Figure 38-4; Figure 38-7). Two varieties of stock (prefabricated) abutments are typically available.

- One has a flat, circular margin (Figure 38-8) with accompanying impression copings (Figure 38-9), abutment replicas (see Figure 38-7), and healing caps (Figure 38-10). Implant companies offer these abutments



• **Figure 38-2** Screw-retained implant restoration attached to implant replica on working model.



• **Figure 38-3** Cement-retained implant crown.

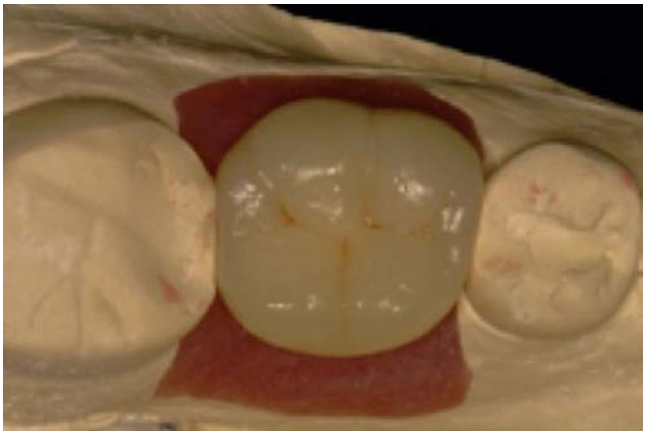

• **Figure 38-6** Cement-retained implant crown placed on custom abutment.



• **Figure 38-4** Cement-retained implant crown placed on abutment replica.

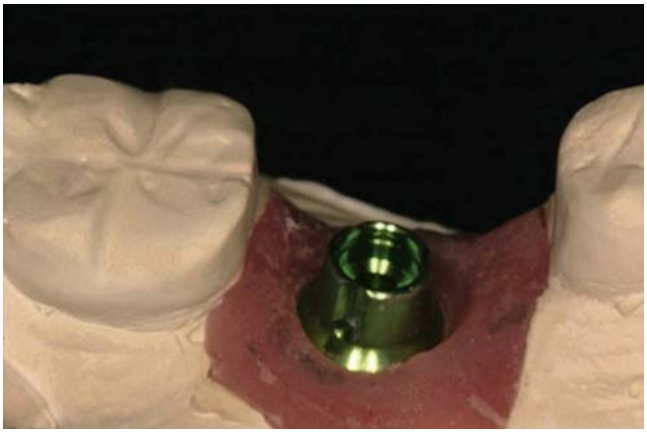

• **Figure 38-7** Abutment replica.

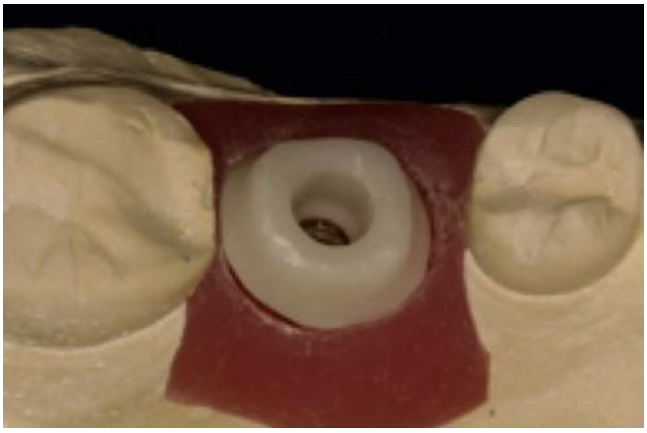

• **Figure 38-5** Custom zirconia abutment attached to implant replica on working model.



• **Figure 38-8** Stock abutment with flat circular margin (Snappy, Nobel Biocare, Yorba Linda, CA).

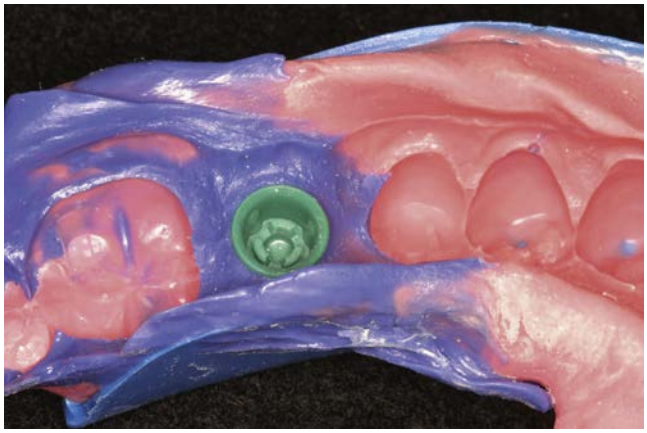

• **Figure 38-9** Impression coping for stock abutment (Snappy, Nobel Biocare, Yorba Linda, CA).

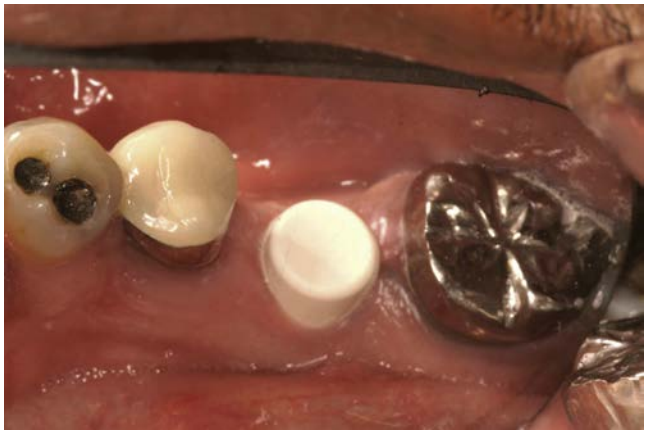

• **Figure 38-10** Healing cap placed on stock abutment (Snappy, Nobel Biocare, Yorba Linda, CA).



• **Figure 38-11** Snappy abutment (Nobel Biocare, Yorba Linda, CA).



• **Figure 38-12** Cementable abutment (Straumann, Andover, MA).



• **Figure 38-13** Direct abutment (Dentsply, York, PA).



• **Figure 38-14** Cement-retained implant crown, cemented to stock abutment (Snappy, Nobel Biocare, Yorba Linda, CA).



• **Figure 38-15** Esthetic abutment (Nobel Biocare, Yorba Linda, CA).

under various names, such as the Snappy Abutment (Figure 38-11) from Nobel Biocare (Yorba Linda, CA); the Cementable Abutment (Figure 38-12) from Straumann (Andover, MA); and the Direct Abutment (Figure 38-13) from Dentsply (York, PA). The margins of all such abutments cannot be altered, and, if any attempt is made to modify them, the accompanying components will be rendered useless. Figure 38-8 is an example of such a non-modifiable stock abutment. Figure 38-14 shows it after the cementation of a porcelain-fused-to-zirconia implant crown.

- The second type of stock or prefabricated abutment can be modified. The margins of such abutments are not flat but have a somewhat scalloped design and are intended to be altered to accommodate the existing gingival contours at the site. Again, implant companies have different names for these types of abutments, such as Nobel Biocare's Esthetic abutment (Figure 38-15), Straumann's



• **Figure 38-16** Anatomic abutment (Straumann, Andover, MA).



• **Figure 38-17** TiDesign abutment (Dentsply, York, PA).



• **Figure 38-18** Stock abutment with margins altered (TiDesign, Dentsply, York, PA).



• **Figure 38-19** Cement-retained implant crown, cemented to stock abutment (TiDesign, Dentsply, York, PA).



• **Figure 38-20** Custom zirconia abutment attached to implant.



• **Figure 38-21** Cement-retained implant crown, cemented to custom abutment.

Anatomic abutment (Figure 38-16), and Dentsply's TiDesign abutment (Figure 38-17). Figure 38-18 is an example of such a modifiable stock abutment. Figure 38-19 shows it after the cementation of a porcelain-fused-to-zirconia implant crown.

Custom abutments may be cast with gold alloy or milled from zirconia or titanium to fit the space constraints and soft-tissue conditions at the restorative site. They are patient-specific and site-specific. Examples of the proprietary systems for manufacturing such custom abutments include Procera (Nobel Biocare), Cares (Straumann), and Atlantis (Astra Dentsply). Figure 38-20 shows a custom zirconia abutment before the cementation of a porcelain-fused-to-zirconia crown. Figure 38-21 shows the crown after cementation.

Screw-Retained Single Posterior Restorations

Early implant-supported restorations that were screw-retained were typically non-segmented restorations made from cast gold and veneered with porcelain. As CAD/CAM technology developed for dental applications, the milling of screw-retained restorations from titanium and zirconia became possible. Essentially, variations on this approach made the abutment and crown a single entity milled from zirconia, with the restoration designed to have the full anatomic contours of the tooth or milled



• **Figure 38-22** Screw-retained, one-piece, milled zirconia implant restoration.



• **Figure 38-23** Screw-retained, milled zirconia implant restoration, with titanium base.



• **Figure 38-24** Titanium stock (prefabricated) abutment attached to implant replica on working model.



• **Figure 38-25** Milled monolithic zirconia implant crown with pre-milled screw channel, being cemented on stock abutment.

to almost the full contours and then veneered with feldspathic porcelain to complete the anatomic tooth contours (Figure 38-22).

However, one-piece zirconia abutments for internal connection implants exhibit significantly lower fracture resistance, specifically fracturing at the apical portion of the abutment.[1] Because of the relative tensional weakness of zirconia, the use of zirconia restorations with a titanium base is preferable, especially if the design permits the entire assembly to be connected by means of abutment screws (Figure 38-23).

The use of the original manufacturer's components is always recommended.[2] However, a screw-retained anatomically contoured monolithic zirconia restoration with a titanium implant interface may be desired, even though only cement-retained components are available from the manufacturer.[3,4] In such situations, transforming the cement-retained components into a retrievable restoration that more closely resembles the classical screw-retained restoration can be easily achieved by using a modified protocol. This involves obtaining a titanium abutment intended for cement retention (Figure 38-24), designing a cement-retained patient-specific zirconia crown that also incorporates a screw-access channel that will align with that of the abutment screw channel, and then cementing the milled and sintered zirconia crown to the abutment extraorally (Figure 38-25).

After removing any excess cement extraorally (Figure 38-26), the abutment/crown assembly can be seated and secured to the implant with the abutment screw delivered through the access channel milled into the crown (Figure 38-27); the access channel can then be sealed with composite resin (Figure 38-28). The accompanying diagram summarizes the options for the single posterior implant restoration.

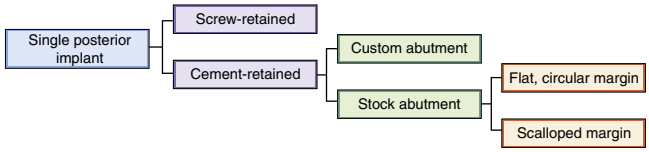



• **Figure 38-26** Milled monolithic zirconia implant crown, extraorally cemented to stock abutment. This screw-retained unit is actually a retrievable cement-retained implant restoration.



• **Figure 38-27** Retrievable cement-retained implant restoration fastened to implant.



• **Figure 38-28** Restoration torqued to place, screw head protected, and screw channel sealed with composite resin.



• **Figure 38-29** Facial view of a single anterior, milled zirconia, screw-retained implant restoration.



• **Figure 38-30** Lingual view of a single anterior, milled zirconia, screw-retained implant restoration.



• **Figure 38-31** Milled zirconia custom abutment for a single anterior implant.

The Single Anterior Implant

When restoring the single anterior implant, the restorative dentist may again choose between a screw-retained restoration (Figures 38-29 and 38-30) and a cement-retained restoration (Figures 38-31 and 38-32).



• **Figure 38-32** Cement-retained implant crown placed on custom abutment.



• **Figure 38-33** Stock abutment on a single anterior implant (Esthetic, Nobel Biocare, Yorba Linda, CA).

Cement-Retained Single Anterior Implant Restorations

Cement-retained single anterior restorations may be cemented on a stock (prefabricated) abutment (Figures 38-33 and 38-34) or a custom (patient-specific) abutment (Figures 38-35 and 38-36). Because anterior single implants are often esthetically demanding and the tissue is usually scalloped with well-defined papillae, stock abutments with flat circular margins are often inappropriate. In the esthetic zone, only stock abutments with scalloped adjustable margins (see Figures 38-15 through 38-17) should be used.



• **Figure 38-34** Porcelain fused to zirconia, cement-retained implant crown cemented to stock abutment (Esthetic, Nobel Biocare, Yorba Linda, CA).



• **Figure 38-35** Milled zirconia custom abutment fastened to single anterior implant.

As with the single posterior implant, custom abutments for the single anterior implant may be cast with gold alloy or milled from zirconia or titanium to fit the space constraints and soft-tissue conditions at the restorative site. However, because metal abutments may cause a blue or gray discoloration of the soft tissue, zirconia abutments are preferred in the anterior esthetic zone. Figure 38-35 shows an anterior



• **Figure 38-36** Porcelain fused to zirconia, cement-retained implant crown, cemented to custom abutment.



• **Figure 38-37** Facial view of a single anterior, milled zirconia, screw-retained implant restoration.

custom abutment milled from zirconia, and Figure 38-36 shows it after cementation of the definitive all-ceramic crown.

Screw-Retained Single Anterior Implant Restorations

As with the posterior restorations, screw-retained single anterior implant restorations may be made from cast gold veneered with porcelain or milled from zirconia. If milled from zirconia, the restoration may be milled as a single entity entirely out of zirconia or milled to almost the full contours and then veneered with feldspathic porcelain to complete the anatomic tooth contours. Figure 38-37 shows a milled zirconia restoration, with minimal porcelain veneering on the facial surface only, torqued into place and with the screw access sealed with composite (Figure 38-38).



• **Figure 38-38** Lingual view of a single anterior, milled zirconia, screw-retained implant restoration, with screw access sealed with composite resin.

The accompanying diagram summarizes the options for the single anterior implant restoration.

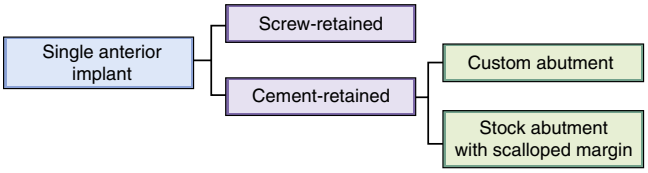

Screw Retention versus Cement Retention

Given the various restorative options, restorative dentists will often seek advice from oral surgeons regarding the best choice for any given patient. Throughout the course of modern dental implant history, opinions have shifted about whether cement or screw retention is best. In the earliest days, when prostheses frequently had to be removed to remove failing implants, screw retention was regarded as clearly superior.[5] However, implant survival rates climbed quickly as understanding of the biomechanics of dental implants grew, better products appeared on the market, and techniques evolved for placing and restoring them. With success rates predictably reaching 90% and above, concerns about occlusion and esthetics moved to the forefront, and cement retention gained proponents.[6] They cited not only the improved esthetic results achievable with cemented prostheses but also their relative simplicity, fewer problems with screw loosening, passivity of fit, better control of occlusion, and economy. More recently, however, new concerns about cement retention have arisen.[7]

As a means of securing prostheses to implants, both cementation and screw retention have limitations and advantages. Some of the most important considerations are discussed in the following sections.

Retrievability

Proponents of cementation argue that, when used properly, cement can be used to retain implant-supported prostheses and still allow for their removal if necessary.[6] Nonetheless,

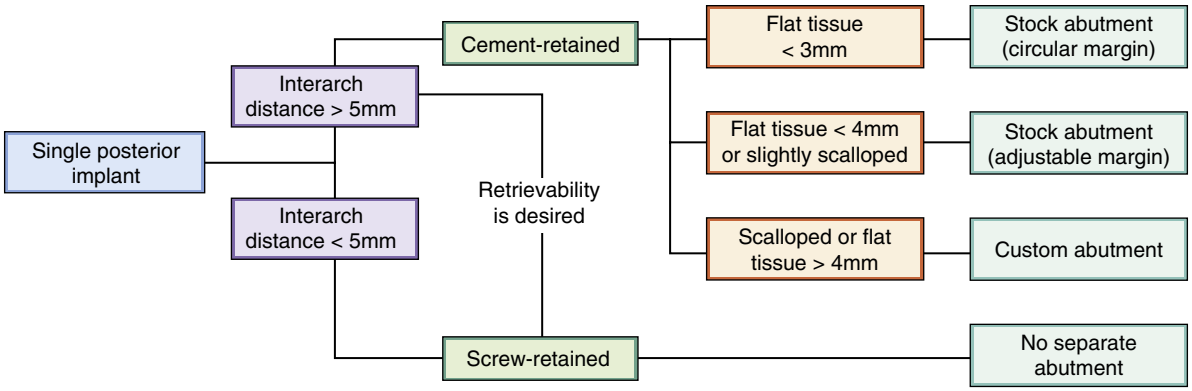

• **Figure 38-39** The Posterior Abutment Decision Tree.

screws are designed to be removed and present the simplest and most straightforward option for easy retrievability.

Implant Positioning Requirements

In order for screw-retained restorations to be esthetic, the screw-access hole must not be visible. Until quite recently, poorly placed anterior implants have eliminated any possibility of using screw retention. Careful placement of the implant, preferably with the aid of three-dimensional imaging technology and the use of a surgical guide, has been essential. Although a few manufacturers have recently introduced angled components that enable the screw-emergence position of even poorly positioned implants to be hidden from view,[8] such components are not yet available for all implants.

Effects on the Peri-implant Soft Tissue

The most significant concern that has arisen with regard to cement retention relates to its effect on the peri-implant soft tissue. More than 15 years ago, reports of complications resulting from cement extrusion into the subgingival peri-implant tissues began to appear.[9,10] Wilson in 2009 reported that excess dental cement was associated with signs of peri-implant disease in 81% of the implants included in a prospective clinical study, with the presence of the disease going undetected in many patients for years after cementation of the prosthesis.[7] Although in that study signs of the disease were absent in 74% of the test implants after removal of the excess cement, the detection and removal of residual cement can be problematic even when the height of the implant crown cement finish line is controlled. Weber and co-workers found that over the course of their multicenter, 3-year prospective study, the use of cement-retained crowns appeared to increase plaque and bleeding index scores, whereas the use of screw-retained crowns lowered those scores.[11] Any excess cement left on the implant or the surrounding soft tissues appears to significantly increase the risk of peri-implant disease.[12] Micro-organisms retained within the cement are believed to play a major role in the etiology of both mucositis and peri-implantitis.[13] The cement may also be a mechanical irritant.[7]

Decision Making

Given the gravity of the risk to implant survival posed by peri-implant disease, one may conclude that most implant-supported prostheses should be screw-retained. However, certain conditions may preclude that option. Situations that may require cement retention include the following:

- When the implant is positioned so that any screw-access channel is visible on the facial surface of the restoration (and no components are available to correct for that).
- When the incisal or occlusal surface is likely to be compromised either esthetically or in terms of structural stability because of the presence of the restorative material necessary to seal the screw access.

Single Posterior Implants

Limitations on the interocclusal space at any given implant site may also significantly affect the choice between screw or cement retention. This is because, among the many factors influencing the amount of retention that can be achieved by luting a restoration to an implant, the height of the abutment is one of the most significant. (Other factors include the width, taper, and surface treatment of the abutment and the type of luting agent used.[14]) When Abbo and colleagues compared the retention strength of four titanium abutments with different heights and tapers, they found that the least retentive abutment was 4 mm high with an 8-degree taper, while the most retentive was 8 mm high with an 8-degree taper.[15] They found that increasing the height of a 4.3-mm titanium abutment by 1 mm significantly increased the dislodgment resistance of zirconia copings.

Recognizing that one of the most frequent questions the novice restorative dentist will ask the surgeon is "What kind of abutment should I use?" and with all the preceding considerations in mind, the author has developed the following decision trees (Figure 38-39).

For single posterior implants, the first consideration must be the dimensions of the interarch distance. As discussed earlier, cemented crowns can be easily dislodged when the abutment height is less than 4 mm. In addition, cemented crown margins should not be more than 1 mm



• **Figure 38-40** Single posterior implant with limited interarch space.



• **Figure 38-41** Screw-retained implant restoration indicated for limited interarch space.



• **Figure 38-42** Single posterior implant with flat peri-implant tissue contour (Nobel Replace, Nobel Biocare, Yorba Linda, CA).

below the gingival margin; otherwise, excess cement may not be easily removed. With this in mind, if the **distance** between the peri-implant tissue and the opposing dentition is **less than 5 mm**, the space will not be sufficient to accommodate a 4-mm high abutment and a crown. Instead, the implant should be restored with a non-segmented screw-retained restoration such as the one illustrated in Figures 38-23, 38-40, and 38-41. However, the screw-access hole must emerge near the center of the occlusal table.



• **Figure 38-43** Stock abutment fastened to single posterior implant (Snappy, Nobel Biocare, Yorba Linda, CA).



• **Figure 38-44** Milled zirconia cement-retained implant crown.

If the screw-access hole emerges on the facial or lingual surface or on a working cusp, then cement retention is the only option. If, however, the position of the screw-access hole allows for screw retention, recent research findings suggest that this option is more likely to promote long-term tissue health.

If the **distance** between the implant platform and the opposing dentition is **greater than 5 mm**, attention should shift to whether the patient has a bruxing habit or whether retrievability is desired. If so, a screw-retained abutment is still recommended.

If the **distance** between the implant platform and the opposing dentition is **greater than 5 mm and retrievability is not an issue**, either cement or screw retention are acceptable options. At this point, if the referring restorative dentist prefers a cemented restoration, the tissue biotype and shape must be considered. If the tissue is flat and not too deep, and the cement margin can be accessed easily, a simple stock abutment with a flat circular margin such as the Snappy, Cementable, or Direct Abutment (see Figures 38-11 through 38-13) can be used. Figure 38-42 is an example of a patient with flat tissue that is not too deep. In this patient, a Snappy Abutment (Figure 38-43) was used, and a simple cementable crown (Figure 38-44) was



• **Figure 38-45** Healing cap attached to stock abutment (Snappy, Nobel Biocare, Yorba Linda, CA).



• **Figure 38-46** Milled zirconia cement-retained implant crown, cemented to stock abutment (Snappy, Nobel Biocare, Yorba Linda, CA).

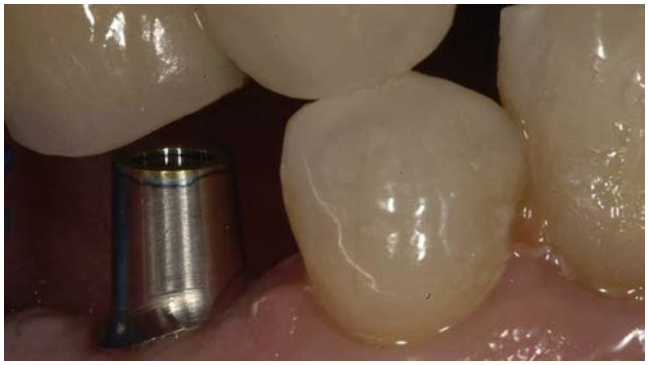

• **Figure 38-47** Stock abutment used with uneven and asymmetric peri-implant tissue contour (Esthetic, Nobel Biocare, Yorba Linda, CA).



• **Figure 38-48** Stock abutment after modification of margins (Esthetic, Nobel Biocare, Yorba Linda, CA).



• **Figure 38-49** Milled zirconia cement-retained implant crown, cemented to stock abutment (Esthetic, Nobel Biocare, Yorba Linda, CA).

fabricated. In a situation such as this, the surgeon would typically supply the dentist with the impression coping for an abutment-level impression and an abutment replica and send the patient back with a prefabricated healing cap (Figure 38-45). Upon cementation, margins are easily accessible for the removal of any excess cement (Figure 38-46).

To confirm, if the tissue contours are flat, the biotype is thick, and the implant is not too deep, a stock abutment can be used for the restoration. The restorative margins will be accessible, enabling cleaning and ensuring the long-term viability of the restoration. Depending on the implant used, a simple abutment such as the Snappy Abutment (Nobel Biocare), Cementable Abutment (Straumann), or Direct Abutment (Dentsply) (see Figures 38-11 through 38-13) would be indicated. Typically, all are easy to restore.

However, if the tissue is not flat, this type of simple stock abutment should not be used. Instead, selecting an abutment that has a margin that can be modified to follow the tissue contour is recommended (Figures 38-47 and 38-48), offering a simple cemented solution (Figure 38-49). If the tissue is a little deeper or only minimally scalloped, a different kind of stock abutment can be chosen. Commercially available abutments of this type include the Esthetic Abutment (Nobel Biocare), Anatomic Abutment (Straumann), and TiDesign Abutment (Dentsply) (see Figures 38-15 through 38-17). Whereas simple stock abutments cannot be altered at all without jeopardizing the fit of the components, the margins of these abutments can be modified.

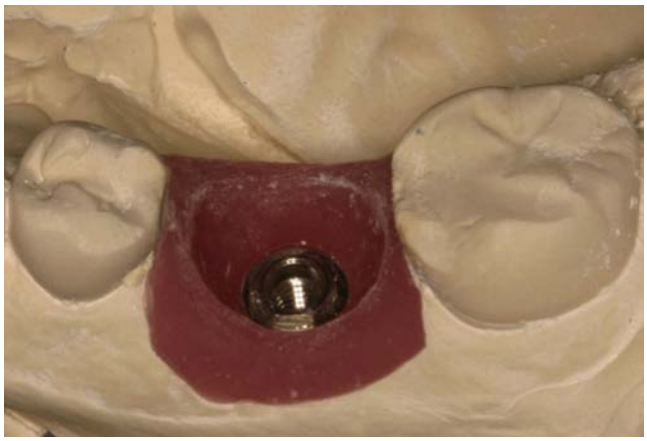

• **Figure 38-50** Laboratory model of single posterior implant with deep peri-implant tissues.



• **Figure 38-51** Custom abutment allows crown margins to be located just below tissue level.



• **Figure 38-52** Cement-retained implant crown, cemented to custom abutment.

Finally, if the tissue is very scalloped or very deep (Figure 38-50), a custom abutment will be necessary (see Figures 38-5 and 38-6) to obtain margins that are high enough to provide adequate access for cement removal when the crown is cemented (Figures 38-51 and 38-52). If the site conditions dictate the use of a custom abutment, a final consideration is whether that abutment should be custom milled or cast from precious metal alloys.

In summary, successful single posterior implant-supported cemented restorations must have adequate access to cement margins, adequate interarch clearance, and adequate abutment height to provide long-term retention.

Single Anterior Implants

In the anterior, other concerns come into play, namely esthetic considerations. The following questions should be asked:

- Is the tissue very scalloped or only minimally so?
- How well-defined are the papillae?
- Does the tissue require surgical augmentation? That is, is there sufficient hard and soft tissue to allow an esthetic result?
- Can the soft tissue be managed prosthetically?

Whereas responsibility for ensuring the presence of adequate hard tissue and augmentation of the soft tissue may be delegated to the surgical team member, the restorative dentist can also contribute to soft-tissue sculpting by using screw-retained provisional restorations.

Once the soft tissue esthetics have been established, the following anterior abutment decision tree can be used to guide the restorative decision-making process (Figure 38-53).

The first question to consider is where the screw-access hole would be positioned if the restoration were visualized at full contour. If the position were on the lingual surface (see Figures 38-29 and 38-30), the restoration could be screw-retained (see Figures 38-37 and 38-38), offering the benefits of retrievability. Screw retention also appears to be more beneficial to soft-tissue health and avoids the risk of residual cement leading to peri-implant disease.

If the screw-access hole emerges on the facial or the incisal aspect, the only choice is cement retention, with the exception of unique components that would allow the repositioning of the screw channel. These systems and components are discussed in more detail in the following section. Of course, if the screw-access hole exits on the lingual surface, the restoration can also be cement-retained if the restorative dentist prefers.

The relevant question then becomes, what are the soft-tissue contours? As with single posterior restorations, if the contours are flat or minimally scalloped, a stock abutment, other than the ones with flat circular margins can be used (see Figures 38-15 through 38-17). An example of this type of abutment was previously discussed (see Figures 38-33 and 38-34).

Most commonly, however, the anterior tissue will be deep and/or scalloped. The use of a custom abutment then becomes imperative. Besides providing the necessary marginal access for cleaning, the use of custom abutments to support single anterior prostheses can significantly shape the soft tissue (see Figures 38-35 and 38-36).

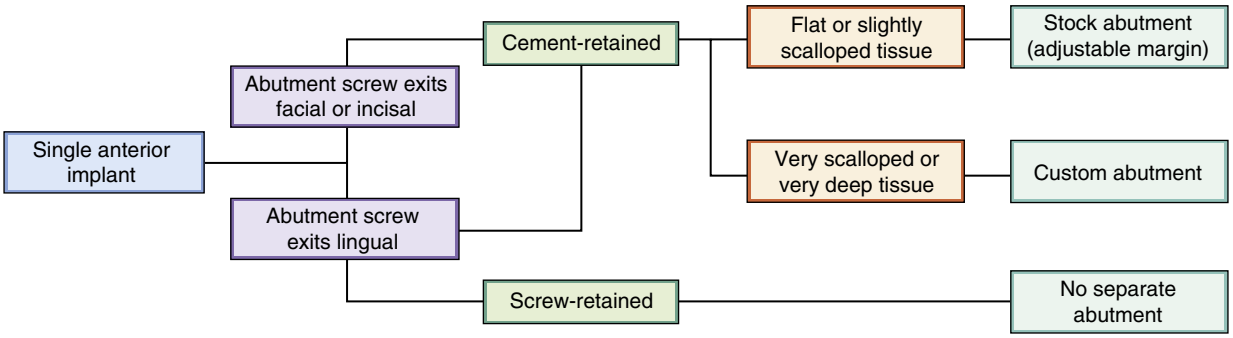

• **Figure 38-53** The Anterior Abutment Decision Tree.

Discussion

Abutment Material Choices

Implant abutments are fabricated from one of three main materials: gold, titanium, or zirconia. Whereas gold was once the standard for custom abutments, today it appears to have significant disadvantages compared with either titanium or zirconia.

For one thing, gold has been demonstrated to be less biocompatible. When Welander and colleagues placed implants in dog mandibles and restored them 1 month later with abutments made of titanium, zirconia, or gold/platinum alloy, they found that the soft-tissue dimensions around the titanium and zirconia abutments remained stable.[16] In contrast, around the gold alloy abutments, an apical shift of the barrier epithelium and the marginal bone occurred between 2 and 5 months of healing. Furthermore, the connective-tissue zone lateral to the gold alloy abutments contained lower amounts of collagen and fibroblasts and larger fractions of leukocytes than the corresponding connective tissue zone of the titanium and zirconia abutments.[16]

Gold abutments must be cast, an analog process that is susceptible to distortion.[17] In contrast, custom titanium and zirconia copings that are fabricated using computer-aided design and computer-aided manufacturing (CAD/CAM) technology in conjunction with computer-numerically controlled (CNC) milling machines depend less on manual laboratory procedures than do conventional casting protocols. This allows for better control of the precision of fit. When Ortorp and co-workers used a coordinate-measuring machine to compare the precision of fit of 20 milled titanium frameworks with five conventional cast ones, they found a statistically better fit and higher precision of fabrication in the CNC frameworks.[18]

Kimura and associates found evidence of hemidesmosomal attachment to both mirror-surfaced commercially pure titanium and yttria-stabilized tetragonal zirconia polycrystals (Y-TZP). Although after 1 hour they documented less attachment of the TZP than the titanium in terms of mRNA expression and protein expression of laminin γ2 and integrin β4 ($p < 0.05$), the epithelial attachment at 48 hours was similar.[19]

When Rimondini and co-workers assessed microbial colonization of Y-TZP and pure titanium, they found that in vivo Y-TZP accumulated fewer bacteria than titanium in terms of the total number of bacteria and the presence of potential pathogens such as rods.[20] A systematic review by Nakamura and colleagues of published data on zirconia abutments found them to be both biologically and mechanically reliable in the anterior region and potentially less conducive to early plaque retention compared with titanium.[21]

The final question to be considered when choosing between titanium and zirconia abutments is the effect on esthetics. When Jung and associates considered the effect of all-ceramic crowns and ceramic abutments versus porcelain-fused-to-metal crowns on titanium or gold abutments on marginal peri-implant soft-tissue color, they found that if the soft tissue were thicker than 2 mm, the abutment material choice made no difference in the definitive result. However, they concluded that the marginal tissue on all-ceramic restorations matched the tissue color of adjacent natural teeth significantly better than PFM crowns on titanium or gold abutments.[22]

Compatible Components

This chapter has attempted to describe all the available options for screw-retained and cement-retained restorations for single posterior implants and single anterior implants. Although some techniques or materials may have been omitted, the author has attempted to thoroughly describe the reasons for selecting one method over another or one material over another.

Sometimes, the restorative dentist may need to be creative in finding solutions that are available from one manufacturer but not from another. For example, a situation might arise in which an anatomic-contour, monolithic zirconia restoration is desirable for strength with a titanium implant interface that is screw-retained using the implant manufacturer's components. One reason for using the same manufacturer's components is demonstrated in the study by Kim and colleagues.[2] The authors attempted to measure the removal torque after the cyclic loading of the abutment screws from similar implants when the abutments and screws used were made by four different manufacturers. Whereas the removal torque was successfully measured when the abutments and screws from the implant manufacturer were used, broken screws, broken abutments, and

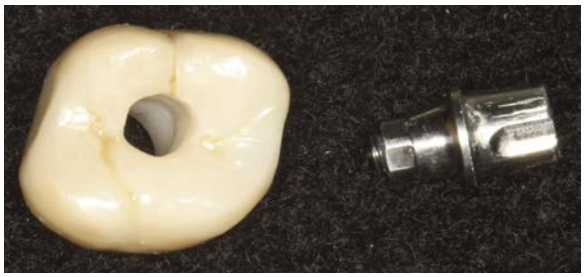

• **Figure 38-54** Stock abutment for conical connection implant with milled zirconia implant crown.



• **Figure 38-55** Milled zirconia implant crown being cemented extraorally to stock abutment.

even broken implants were reported for components from other sources. In fact, the study could not be completed as designed. Thus different material hardnesses and different fit tolerances may pose some risk when components other than those produced by the same implant manufacturer are used.

Retrievable Cement-Retained Restorations

Another issue is the use of zirconia for the apical portion of abutments manufactured for internal connection implants. Foong and co-workers[1] discovered that when abutments were made entirely of milled zirconia for internal connection implants, in one study, all of the apical portions of the zirconia abutments fractured under loading. This led the authors to conclude that the apical portion of abutments for internal connection implants should not be made of



• **Figure 38-56** Retrievable cement-retained implant restoration with all excess cement removed.



• **Figure 38-57** Retrievable cement-retained implant restoration fastened to conical connection implant.

zirconia, but rather of titanium, in order to be compatible with titanium implants. In such patients, the retrievable cement-retained restoration concept (Figures 38-54 through 38-57) as suggested by Chee and colleagues[3] and Rajan and associates[4] should be considered.

Implants with internal connections have become the preferred choice for single missing teeth instead of external connection implants, and Yamanishi and co-workers have shown that internal conical connection implants have a more stable joint.[23] Titanium and zirconia are now also recognized to be the best abutment materials in terms of the interface with the transitional epithelium.[19-21] Also, sometimes zirconia is better for esthetic reasons.[22] In such patients, creativity may be necessary to achieve an end result with an abutment that has a titanium internal connection component manufactured by the same manufacturer as the implant (Figures 38-58 and 38-59), with zirconia as it traverses through the transitional epithelium to avoid discoloration of the soft tissue (Figure 38-60), and with an all-ceramic crown for maximum esthetics (Figures 38-61 and 38-62).

Off-Axis Screw Channels

When the surgeon is forced to facially incline an anterior implant because of bone anatomy, the screw channel will

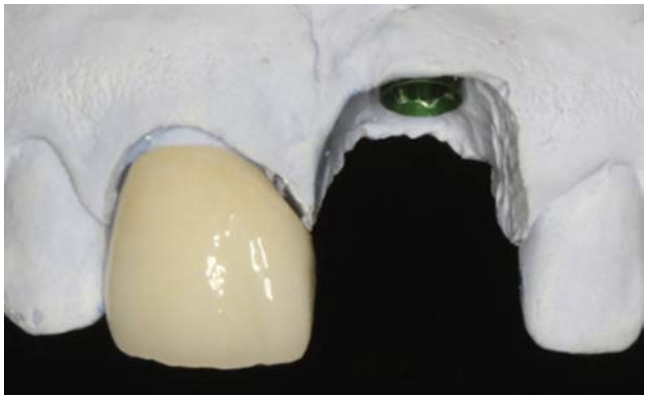

• **Figure 38-58** Single anterior internal connection implant.



• **Figure 38-59** Stock abutment allows internal apical portion to be titanium.



• **Figure 38-60** Milled zirconia sleeve cemented to the stock abutment converts it to a custom abutment allowing zirconia to contact the transitional tissue.



• **Figure 38-61** Crowns for both the natural tooth and the implant are milled from lithium disilicate for strength and esthetics.



• **Figure 38-62** Custom abutment is fastened, and lithium disilicate crowns are luted with resin cement for strength and esthetics.

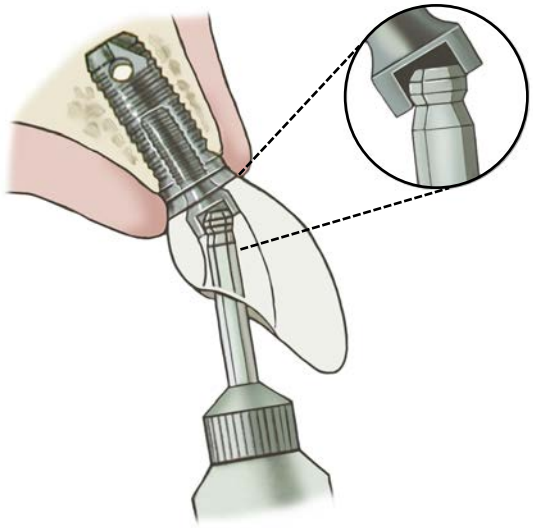

• **Figure 38-63** Enlarged screw access hole allows use of a ball-hex driver as described by Parel and Sullivan in 1987.

emerge on the facial or incisal surface of the definitive restoration, making it impossible to fabricate a screw-retained restoration. Since the 1980s, a solution has been sought to this problem. In 1987, Parel and Sullivan described a solution whereby the screw-access opening was enlarged (Figure 38-63) and a ball hexagon screwdriver was used to engage a hexagon-headed screw for an angulation correction of as much as 30 degrees.[24] However, the fit of such a screwdriver to the manufacturer's hexagon-headed screw was not perfect, and the concept was not popular.

It was not until 2004 that a company in Spain (Talladium International Implantology, Lleida, Spain) developed the so-called Dynamic Abutment (Figure 38-64), which



• **Figure 38-64** Dynamic Abutment (Talladium International Implantology, Lleida, Spain). The burn-out chimney can be rotated up to 28 degrees.



• **Figure 38-65** Angulated Screw Channel allows correction up to 25 degrees (Nobel Biocare, Yorba Linda, CA).

allowed an angulation correction of as much as 28 degrees. This abutment is available for several well-known implant systems such as Astra Tech, BioHorizons, Biomet 3i, Nobel Biocare, Straumann, and Zimmer.[8] Although not all components are available in the United States, the Angulated Screw Channel for conical connection implants by Nobel Biocare can correct the angulation of the screw channel by up to 25 degrees. This is accomplished by using specially provided screws and matching screwdrivers (Figure 38-65).

Avoiding Excess Cement Retention

If cementation is unavoidable or preferable, steps that can minimize the risk of complications include the following:

- Using custom abutments that enable careful control of the cement margin.
- Using a displacement cord to prevent extrusion of the cement apically on the abutment surface.
- Using the putty die technique described by Caudry and colleagues[25] or the Blue Mousse die as described by Wadwhani and Piñeyro[26] to prevent material extrusion into the peri-implant tissues.
- Using radiopaque cements.
- Making a post-cementation radiograph.

Conclusion

In conclusion, no right or wrong way exists to restore the single implant. Several variables must be considered in every patient. Although there are many advantages to selecting a screw-retained solution, such as retrievability, avoidance of cement, healthier tissues, and security in minimal interarch spaces, such a solution is technically more difficult to execute. Implant position and angulation must be ideal, and the presence of a screw-access hole covered with a restorative material may not be esthetically ideal. Cement-retained solutions are technically easier to execute, have better esthetics, and are more flexible when implant positions or angulations are less than ideal. However, careful cementation techniques must be used, and the tradeoff of lack of retrievability must be accepted.

References

1. Foong JKW, Judge RB, Palamara JE, et al.: Fracture resistance of titanium and zirconia abutments: an in vitro study, *J Prosthet Dent* 109:304–312, 2013.
2. Kim SK, Koak JY, Heo SJ, et al.: Screw loosening with interchangeable abutments in internally connected implants after cyclic loading, *Int J Oral Maxillofac Implants* 27:42–47, 2012.
3. Chee WWL, Torbati A, Albouy JP: Retrievable cemented implant restorations, *J Prosthodont* 7:120–125, 1998.
4. Rajan M, Gunaseelan R: Fabrication of a cement- and screw-retained implant prosthesis, *J Prosthet Dent* 92:578–580, 2004.
5. Adell R, Lekholm U, Rockler B, et al.: A 15-year study of osseointegrated implants in the treatment of the edentulous jaw, *Int J Oral Surg* 10:387–416, 1981.
6. Hebel KS, Gajjar RC: Cement-retained versus screw-retained implant restorations: achieving optimal occlusion and esthetics in implant dentistry, *J Prosthet Dent* 77:28–35, 1997.
7. Wilson Jr TG: The positive relationship between excess cement and peri-implant disease: a prospective clinical endoscopic study, *J Periodontol* 80:1388–1392, 2009.
8. Berroeta E, Zabalegui I, Donovan T, et al.: Dynamic Abutment: a method of redirecting screw access for implant-supported restorations: technical details and a clinical report, *J Prosthet Dent* 113:516–519, 2015.
9. Pauletto N, Lahiffe BJ, Wealton JN: Complications associated with excess cement around crowns on osseointegrated implants: a clinical report, *Int J Oral Maxillofac Implants* 14:865–868, 1999.
10. Gapski R, Neugeboren N, Pomeranz AZ, et al.: Endosseous implant failure influenced by crown cementation: A clinical case report, *Int J Oral Maxillofac Implants* 23:943–946, 2008.
11. Weber HP, Kim DM, Ng MW, et al.: Peri-implant soft-tissue health surrounding cement- and screw-retained restorations: a multi-center, 3-year prospective study, *Clin Oral Implants Res* 17:375–379, 2006.
12. Wadhwani C, Rapoport D, La Rosa S, et al.: Radiographic detection and characteristic patterns of residual excess cement associated with cement-retained implant restorations: a clinical report, *J Prosthet Dent* 107:151–157, 2012.

13. Raval NC, Wadhwani C, Jain S, et al.: The interaction of implant luting cements and oral bacteria linked to peri-implant disease: an in vitro analysis of planktonic and biofilm growth—a preliminary study, *Clin Implant Dent Relat Res* 17(6):1029–1035, 2015.
14. Kent DK, Koka S, Banks SB, et al.: Factors influencing retention of a CeraOne gold cylinder, *Implant Dent* 5:96–99, 1996.
15. Abbo B, Razzoog ME, Vivas J, et al.: Resistance to dislodgement of zirconia copings cemented onto titanium abutments of different heights, *J Prosthet Dent* 99:25–29, 2008.
16. Welander M, Abrahamsson I, Berglundh T: The mucosal barrier at implant abutments of different materials, *Clin Oral Implants Res* 19:635–641, 2008.
17. Carr AB, Stewart RB: Full-arch implant-framework casting accuracy: preliminary in vitro observation for in vivo testing, *J Prosthodont* 2:2–8, 1993.
18. Ortorp A, Jemt T, Bäck T, et al.: Comparisons of precision of fit between cast and CNC-milled titanium implant frameworks for the edentulous mandible, *Int J Prosthodont* 16:194–200, 2003.
19. Kimura Y, Matsuzaka K, Yoshinari M, et al.: Initial attachment of human oral keratinocytes cultured on zirconia or titanium, *Dent Mater J* 31:346–353, 2012.
20. Rimondini L, Cerroni L, Carrassi A, et al.: Bacterial colonization of zirconia ceramic surfaces: an in vitro and in vivo study, *Int J Oral Maxillofac Implants* 17:793–798, 2002.
21. Nakamura K, Kanno T, Milleding P, et al.: Zirconia as a dental implant abutment material: a systematic review, *Int J Prosthodont* 23:299–309, 2010.
22. Jung RE, Holderegger C, Sailer I, et al.: The effect of all-ceramic and porcelain-fused-to-metal restorations on marginal peri-implant soft tissue color: a randomized controlled clinical trial, *Int J Periodontics Restorative Dent* 28:357–365, 2008.
23. Yamanishi Y, Yamaguchi S, Imazato S, et al.: Influences of implant neck design and implant-abutment joint type on peri-implant bone stress and abutment micromovement: three-dimensional finite element analysis, *Dent Mater* 28:1126–1133, 2012.
24. Parel SM, Sullivan DY: *Esthetics and osseointegration*, ed 1, Dallas, 1989, Osseointegration Seminars, University of Texas Health Science, pp 64–65.
25. Caudry S, Chvartszaid D, Kemp N: A simple cementation method to prevent material extrusion into the periimplant tissues, *J Prosthet Dent* 102:130–131, 2009.
26. Wadhwani C, Piñeyro A: Technique for controlling the cement for an implant crown, *J Prosthet Dent* 102:57–58, 2009.

39

Implant Overdentures

TONY DAHER, CHARLES J. GOODACRE, STEVEN J. SADOWSKY

Introduction

The concept of implant-supported/retained overdentures has been used for many years. Osseointegrated implants have been used successfully to support/retain these overdentures in the maxilla and mandible and considerable information has emerged regarding comparisons with other prostheses, such as their impact on function, quality of life, success/failure/complications, design guidelines, and clinical procedures. Implant overdentures have typically been complete arch prostheses (Figure 39-1), but partial overdentures have also been used, whereby natural teeth function in conjunction with implants (Figure 39-2).

From a biomechanical standpoint, overdenture prostheses can be either tissue supported and implant retained (Figure 39-3) or implant supported and implant retained (see Figure 39-1).

General Guidelines in Treatment Planning

Natural Tooth Overdentures and Implant Overdentures Compared

For decades, roots of natural teeth have been used to preserve bone and to support/retain removable prostheses. Dentures supported by natural teeth have been studied, and many types of complications occur such as periodontal problems that lead to root extraction, recurrent caries, repairs, denture adjustment, relines, and even remakes.[1] When overdentures are supported by implants rather than by roots of natural teeth, there is a higher tendency for success.[2] Long-term survival and success of oral implants retaining overdentures on both arches have been documented in a prospective study.[3]

Conventional Complete Dentures and Implant Overdentures Compared

There have been publications comparing implant overdentures with conventional complete dentures. Patient satisfaction improved when prosthesis retention and stability increased[4] and therefore satisfaction increased when mandibular implant overdentures were used instead of conventional complete dentures.[5] In fact, patients were more satisfied after 10 years with mandibular implant overdentures as compared to complete dentures even if vestibuloplasty was performed prior to fabricating the new

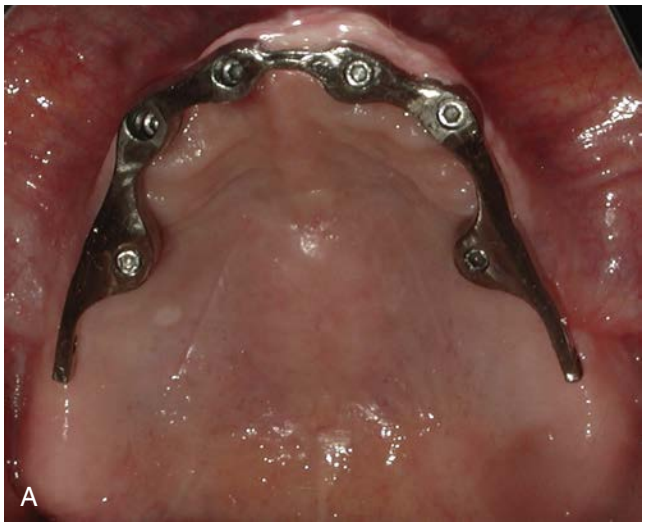



• **Figure 39-1** Six-implant prosthesis; Implant supported and retained by six implants. **A,** CAD-CAM bar with snap pin attachment. **B,** Intaglio view of a metal-reinforced overdenture prosthesis.

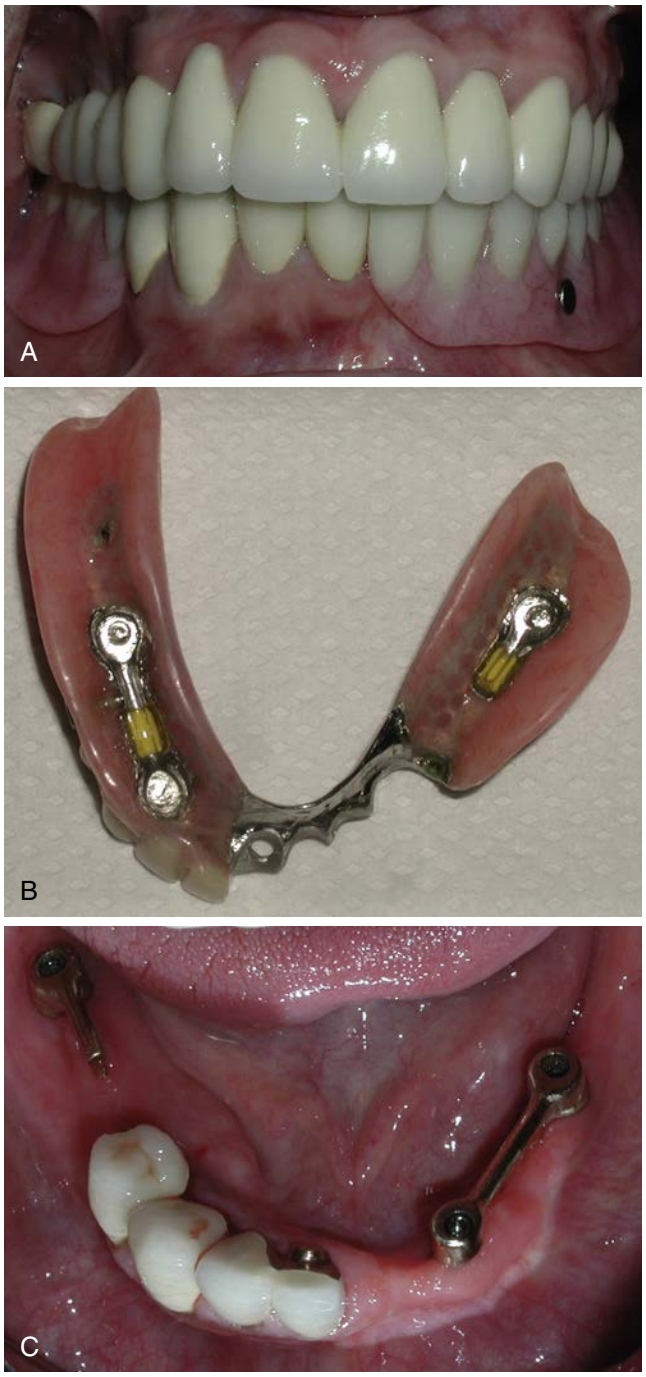

• **Figure 39-2** A mandibular implant-supported and retained overpartial denture. **A,** A frontal view of the mandibular overpartial denture in centric occlusion. **B,** Intaglio view of mandibular prosthesis with Hader clips, ball, and snap pin attachments. **C,** Intraoral view of the prosthesis abutments.

mandibular complete dentures.[6] Implant overdentures generally offer the advantages of improved comfort, support, retention, and stability.

When conventional complete dentures are worn for many years, substantial bone resorption occurs beneath the dentures (Figures 39-4 and 39-5), and this bone loss is about fourfold the amount of bone change that occurs adjacent to dental implants that are used with overdentures.[7]

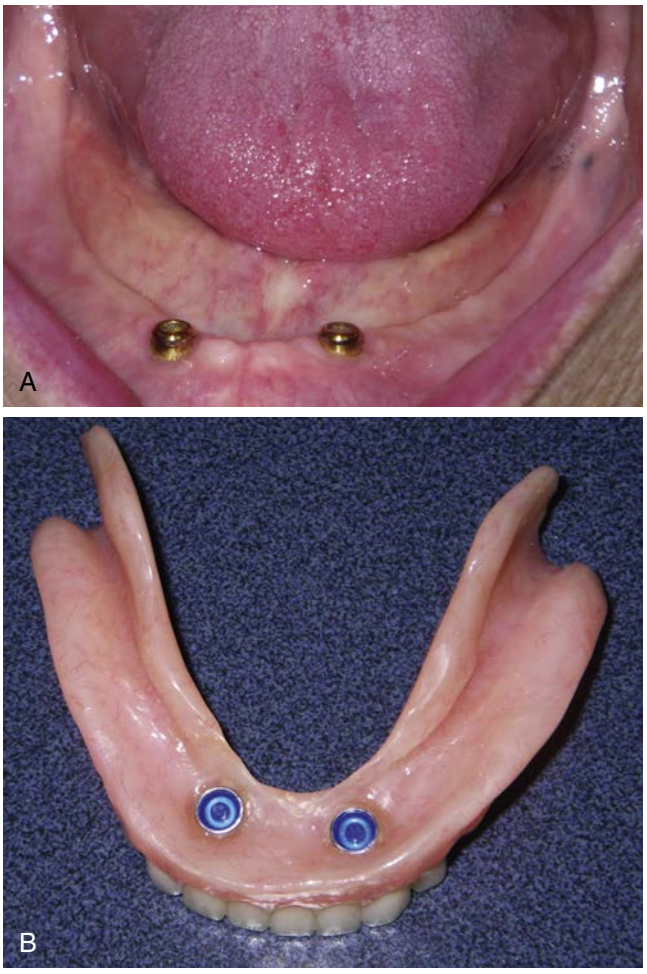

• **Figure 39-3** A two-implant prosthesis. **A,** Intraoral view of two locator abutments over implants. **B,** Implant-retained and tissue-supported overdenture; note the two blue least retentive Locator clips in their metal housings.

Implant-Fixed Complete Dentures and Implant Overdentures Compared

Although fixed complete dentures provide unparalleled prosthesis stability, clinicians have identified several potential advantages of implant overdentures compared to implant-fixed complete dentures[8]:

1. It may be possible to use a smaller number of implants and thereby decrease the cost.
2. It may be possible to provide better support of the facial soft tissues and improved phonetics for completely edentulous patients.
3. Patients have enhanced access for oral hygiene and better access for inspection of the surgical site.
4. There may be a better result when unfavorable jaw relationships are present (Figure 39-6).
5. When there is an opposing complete denture, it may be more stable; particularly when there is a resorbed residual ridge.
6. It is easier to make modifications to the prosthesis base.

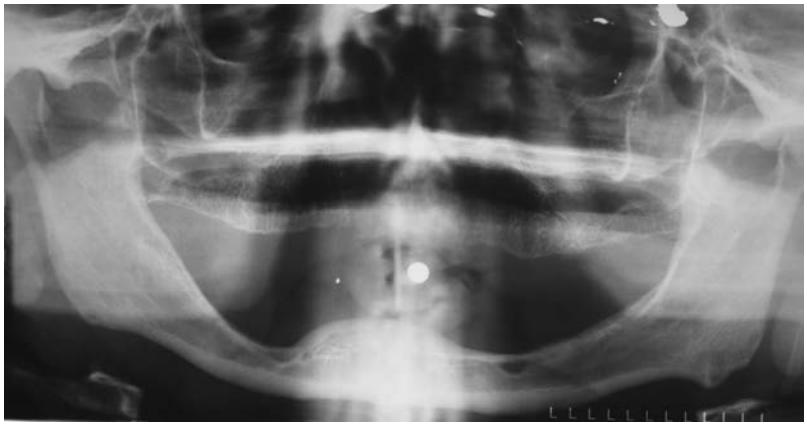

• **Figure 39-4** Excessive bone resorption under a mandibular denture. Note the two mental foramen above the ridge.

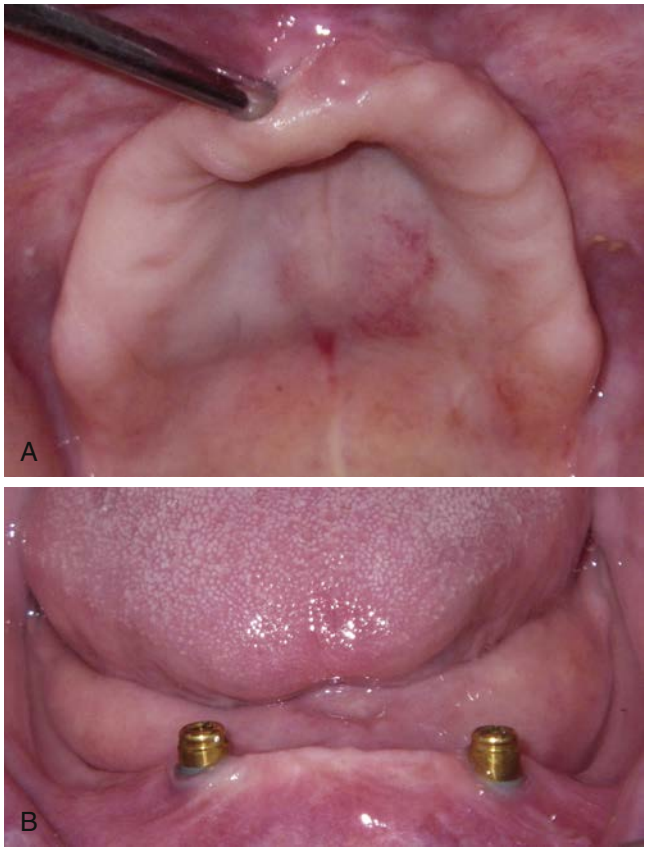

• **Figure 39-5** **A,** Continuous resorption observed in the edentulous maxilla with **(B)** a mandibular bar overdenture supported by two interforaminal implants.

When the same patients comparatively wore both implant overdentures and implant-fixed complete dentures, they indicated the fixed complete dentures permitted them to more effectively chew harder foods. However, the general satisfaction of the patients was comparable.[9]

Patient attitudes and expectations should be evaluated when guiding patients in their choice of a prosthesis. Some patients consider stability to be their primary prosthesis requirement, and they would therefore prefer a fixed complete denture. Other patients identify ease of cleaning as the most important factor guiding their choice of prosthesis design, and they preferred an overdenture.[10]

The most frequently cited disadvantage of implant overdentures has been their incidence of complications, which is higher than other implant prostheses. In comparing the maintenance and repair required with implant-fixed complete dentures and implant overdentures, it was determined that implant overdentures accounted for 78% of the total number of repairs and 80% of the prostheses that required repairs. The number of repeat repairs was also substantially greater with overdentures than with fixed complete dentures.[11-13]

Clinicians have calculated the average time spent maintaining mandibular implant overdentures. An average of 72 to 98 minutes of professional time was required per patient during the first year after placement for prosthodontic maintenance (adjusting retentive mechanisms, replacing dislodged or fractured retentive mechanisms, repairing fractured dentures, relining prostheses, and remaking prostheses).[14]

The prosthodontic time required of a clinician (almost 5 hours) and number of appointments to provide mandibular implant overdenture treatment has been compared with the time required to provide conventional mandibular complete denture treatment and it was determined to be comparable (implant overdenture was attached to two implants using individual ball abutments).[15] However, the two-implant overdenture requires more initial expense and aftercare over a 10-year period than conventional denture treatment.[16]

Consensus and Controversy Associated with Mandibular Implant Overdentures

Burns published a literature review of implant overdenture treatment in the edentulous mandible and identified areas of "general consensus" and areas of "controversy."[17] The following areas of general consensus were identified[17]:

1. Complete edentulousness is a substantial health issue and will continue to be a significant issue in the future.
2. Conventional complete dentures create more problems in the mandible than they do in the maxilla.

3. Retention and stability have a substantial negative effect on the treatment outcomes of conventional mandibular complete dentures.
4. Mandibular anterior dental implants are highly successful and may slow the bone resorption process.
5. Mandibular overdentures that use dental implants have many benefits and increased patient satisfaction compared to conventional complete dentures.
6. The response of peri-implant mucosa and bone has been favorable.
7. Complications are a concern, and particularly during the first year of usage.
8. There is a need for routine recall and follow-up care because of the potential for complications to occur.

The following areas of controversy were identified[17]:

1. When the remaining natural teeth require complex treatment, their extraction and replacement with an implant overdenture "may be the best option" but there is a need for decision guidelines.
2. The number of implants required for an appropriate mandibular implant overdenture "remains open to debate."
3. The need for rigid connection of implants placed in the anterior mandible "has not been definitively determined."
4. There is a need for "additional understanding" regarding the effect of a mandibular implant overdenture on the anterior maxilla (the combination syndrome).
5. The "necessity" of placing implants into attached peri-implant mucosa versus unattached alveolar mucosa "is unresolved."
6. A "paradigm shift" may be occurring in dentistry whereby the mandibular implant overdenture becomes the "future standard of care for the edentulous mandible."



• **Figure 39-6** Unfavorable jaw relation implies the placement of the bar under the prosthetic teeth. (Courtesy of Dr. J. Kan.)

Success, Failure, and Complications Data

Conventional implant overdentures are associated with more complications than any other type of implant prosthesis. However, the complications do not negate the benefits these prostheses provide for patients. Implant overdentures have been more successful in the mandible than in the maxilla.[7,18,19] Maxillary overdentures have a much higher number of mechanical problems than mandibular overdentures.

Goodacre et al[20] showed that the most common implant complications for implant overdentures (those with a greater than 15% incidence) were loosening of the overdenture retentive mechanism (33%) (Figure 39-7),



• **Figure 39-7** Loosening of the overdenture retentive Hader bar clip mechanism.

implant loss in irradiated maxillae (25%), resin veneer loss, implant loss with maxillary overdentures (21%), overdentures needing to be relined (19%), implant loss in type IV bone (16%), and overdenture clip/attachment fracture (16%) (Figure 39-8). It was not possible to calculate an overall complications incidence for implant prostheses because there were not multiple clinical studies that simultaneously evaluated all or most of the categories of complications. Although the implant data had to be obtained from different studies, they do indicate a trend toward a greater incidence of complications with implant prostheses than single crowns, fixed partial dentures, all-ceramic crowns, resin-bonded prostheses, and posts and cores.[20]

A systematic review[21] of the incidence of biologic and technical complications reported in prospective longitudinal studies with at least 5 years of follow-up included 15 studies of implant overdentures. A meta-analysis of the studies determined that implant loss prior to functional loading occurs in about 2.5% of the implants, a rate comparable to that found with implant-fixed partial dentures and implant-fixed complete dentures. After functional loading, 5.6% to 5.9% of the implants are lost, creating a total loss of over 8% during a 5-year period. The authors indicated that the higher implant loss after functional loading was mainly related to the higher loss occurring in the maxillary arch. A systematic review showed that there are no detrimental effects on marginal bone levels using early or immediate loading protocols. Significantly more biologic and mechanical problems were found with overdentures compared to fixed implant prostheses.[21] However, patients with chronic problems with their maxillary denture preferred the maxillary long-bar overdenture to the fixed-implant denture 2 to 1 in a crossover study,[22] because of ease of speaking and cleaning (Figure 39-9).



• **Figure 39-8** Multiple overdenture cracks noticed on the cameo **(A)** and on the intaglio **(B)** surfaces, due to lack of adequate intra-arch space that resulted in thinning of the acrylic resin bases.

Design Principles

Number of Implants for Mandibular Implant Overdentures

A consensus conference was held on May 24-25, 2002 at McGill University in Montreal, Quebec, Canada that included 21 recognized authorities in the field of implant dentistry.[23] They published the following concluding statements: "The evidence currently available suggests that the restoration of the edentulous mandible with a conventional denture is no longer the most appropriate first-choice prosthodontic treatment. There is now overwhelming evidence that a two-implant overdenture should become the first choice of treatment for the edentulous mandible." However, patient selection and patient mediated factors such as available time and money for the treatment may dictate a different optimal first choice such as a fixed implant complete denture.[24] The study by Brennan et al[25] on patient satisfaction and oral health–related quality of life (OHQOL) outcomes of implant overdentures and fixed complete dentures found that among all patients who had similar numbers of implants placed, those who received an implant overdenture were less satisfied and had lower OHQOL than the patients who had a fixed prosthesis. Because patient and dentist preferences influenced the type of prosthesis provided, it is likely that subjective, patient-related factors are major determinants of satisfaction and treatment outcomes.

The number of implants used with mandibular overdentures has included one midline implant,[26] two individual implants or implants connected with a bar, and three or more implants connected by a bar (Figure 39-10). In the mandible, clinicians have successfully used one implant and have also successfully used multiple implants. The use of four implants and a bar was compared with two implants and a bar. Batenberg et al[27] evaluated plaque, calculus, bleeding scores, probing depths, gingival recession, and implant percussion, and made standardized radiographs. No differences were noted in the clinical or radiographic parameters, and the authors suggest that two implants may be sufficient in the mandible.[27] However, they did theorize that four implants might be beneficial for patients with



• **Figure 39-9** This patient with chronic problems with a maxillary denture preferred the maxillary long-bar overdenture to the fixed implant denture because of ease of speaking and cleaning. **A,** Intaglio and **(B)** cameo views of the maxillary and mandibular implant supported overdentures. **C,** Computer aided design of the mandibular bar according to the prosthetic teeth. **D,** Intra-oral view of the maxillary and mandibular CAD-CAM Hader bars fabricated by Cagenix, Memphis, TN. **E,** Final smile with the overdentures in place.

the following conditions: minimal bone height that would result in the use of shorter implants; a narrow mandibular arch; a dentulous or partially dentulous maxillary arch and sore, painful mandibular ridges because more force would be supported by the implants and bar rather than the edentulous mucosa.[27] Other criteria have been proposed that identify clinical conditions where more than two implants in the mandible may be advantageous. These conditions include the presence of a large V-shaped anterior ridge (Figure 39-11), reduced flanges due to high muscle attachments, increased occlusal forces (dentate maxilla present or parafunctional habits present), atrophic ridges that require implants of less than 3.5 mm in width or less than 8 mm in length, and patients with an extreme gag reflex.[28]

Number of Implants for Maxillary Implant Overdentures

It has been proposed that maxillary overdentures without palatal coverage (Figure 39-12) be supported by at least four implants evenly distributed around the arch and connected by a bar.[29] When there are risk factors present such as compromised quality/quantity of bone, off-ridge relations, or high applied forces, palatal coverage may improve implant prognosis.[30] Because of the higher implant loss in the maxilla,[31] Eckert[32] recommended placing at least six well-distributed implants to ensure against dramatic changes in prosthetic design.[32] Higher success rates have been reported with implants greater than 10 mm in length.[33-35] In addition, using textured implants was shown in a meta-analysis[36] to achieve stronger bone anchorage and higher clinical success rates than smooth surfaces.

Types of Implants for Implant Overdentures

In a systematic review and meta-analysis of the literature of marginal bone loss around implants retaining or supporting overdentures that identified a total of 4,200 implants from 13 manufacturers, Çehreli et al[37] concluded that there was no difference in marginal bone loss around implants retaining/supporting mandibular overdentures relative to implant type or attachment design.[37]

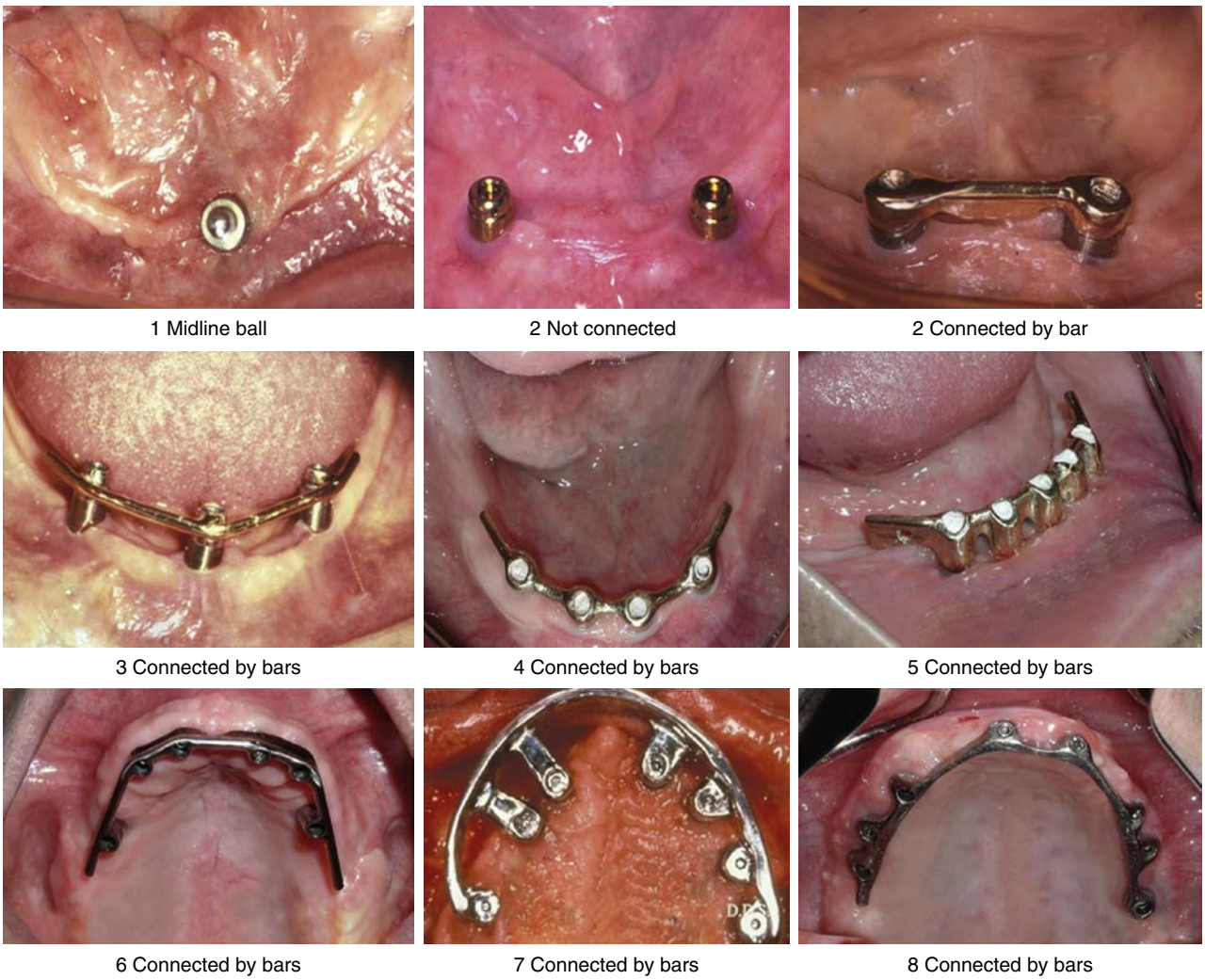

• **Figure 39-10** Possible number of implants according to each clinical situation.

Individual Versus Connected (Splinted) Implants

Several clinical studies have compared individual implants with implants connected by a bar. Study of photoelastic stress patterns indicated that individual implants with ball/o-ring attachments transferred less stress to the implants than the design that used two implants connected by a bar.[38,39] However, in an in vivo study by Kenny and Richards[39] on force transmission onto implants supporting overdentures, rigid bars were found to contribute to load sharing.[39] Greater prosthesis retention has been attained when the implants were connected by a bar than when they were separated.[40] Naert et al demonstrated that there were no biologic differences between the two designs (individual implants or connected implants) when used in the mandible.[41] Patients rated the two mandibular designs similarly in terms of their satisfaction.[41] A study by Naert et al[42] showed that after 2 to 4 years of function, 72% of the 86 implant overdentures were properly retained. However, the authors noted that the maintenance/adjustments of a bar-retained overdenture required more effort from the dentist and technician than prostheses retained by individual implants.[42] In a study by Cekic et al[43] on the effects of attachment design on strains around implants supporting overdentures, they found that the force distribution does not occur for implants supporting ball-retained overdentures, and such implants are subjected to more load than those supporting bar-retained and distal cantilevered bar-retained overdentures.[43]

Three studies on the maxilla[42,44,45] found greater bone loss when individual implants were used. Although the number of prostheses evaluated was limited (five in one study,[44] six in another study,[42] and eight in the third study[45]), the information suggests it may be prudent to connect multiple implants in the maxilla until more definitive data become available. Even when multiple maxillary implants have been connected with a bar, increased bone loss was found to occur around some implants.[46] In a study on 5 consecutive patients with 25 textured-surface implants placed to retain overdenture prostheses, with a minimum of 4 implants per patient, these patients were followed for 12 to 48 months post-loading. None of the implants had lost osseointegration, and radiographic marginal bone levels were stable.

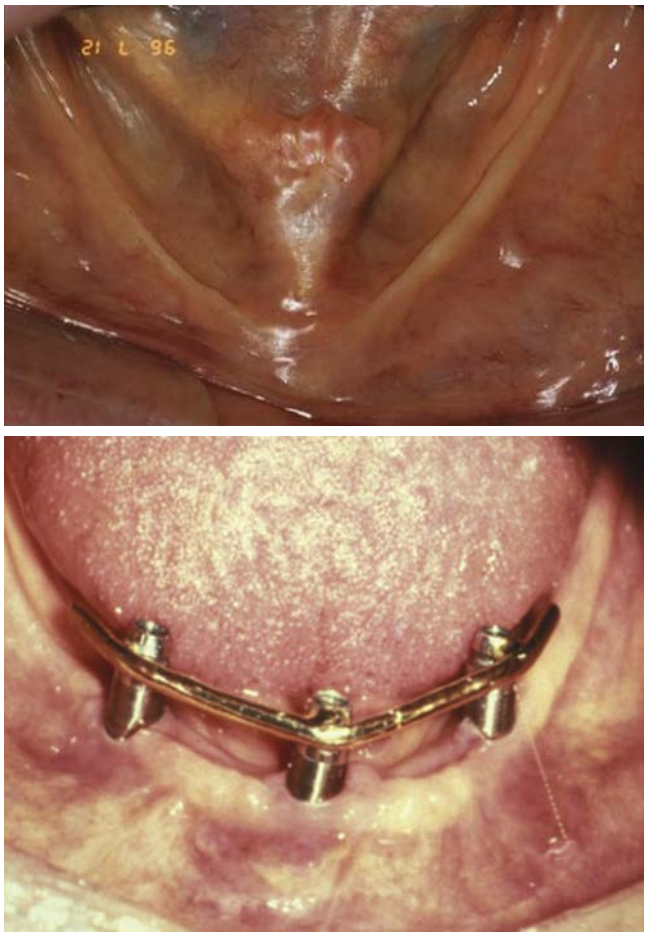

• **Figure 39-11** A three-implant prosthesis is indicated when the mandibular ridge is triangular in shape.

Patients were able to maintain soft tissue health around the unsplinted implants. The patients verbally indicated that they were comfortable and that their maxillary overdentures function well. It appears that unsplinted maxillary implants can be used to retain a maxillary overdenture.[47]

The controversy regarding splinted versus unsplinted anchorage systems persists due to the lack of standardization of research methodology, such as implant number, length, distribution, as well as prosthetic design, which has plagued an objective assessment of the preferred retention system for maxillary implant overdentures.[48] Using a splinted design, the type of framework may impact implant survival. A resilient design (Dolder bar) when loaded has demonstrated higher bending moments on implants than a rigid design.[49] In fact, when implant length was at least 12 mm, a lower implant failure rate and reduced incidence of prosthetic complications were demonstrated using a rigid (milled bar) design as opposed to a resilient (Dolder bar) design on the maxilla.[50,51] Posteriorly placed bilateral bars with sinus grafting procedures may allow for longer implants than an anterior array and may accommodate a sagittal discrepancy of maxillomandibular relations[51] (Figure 39-13).

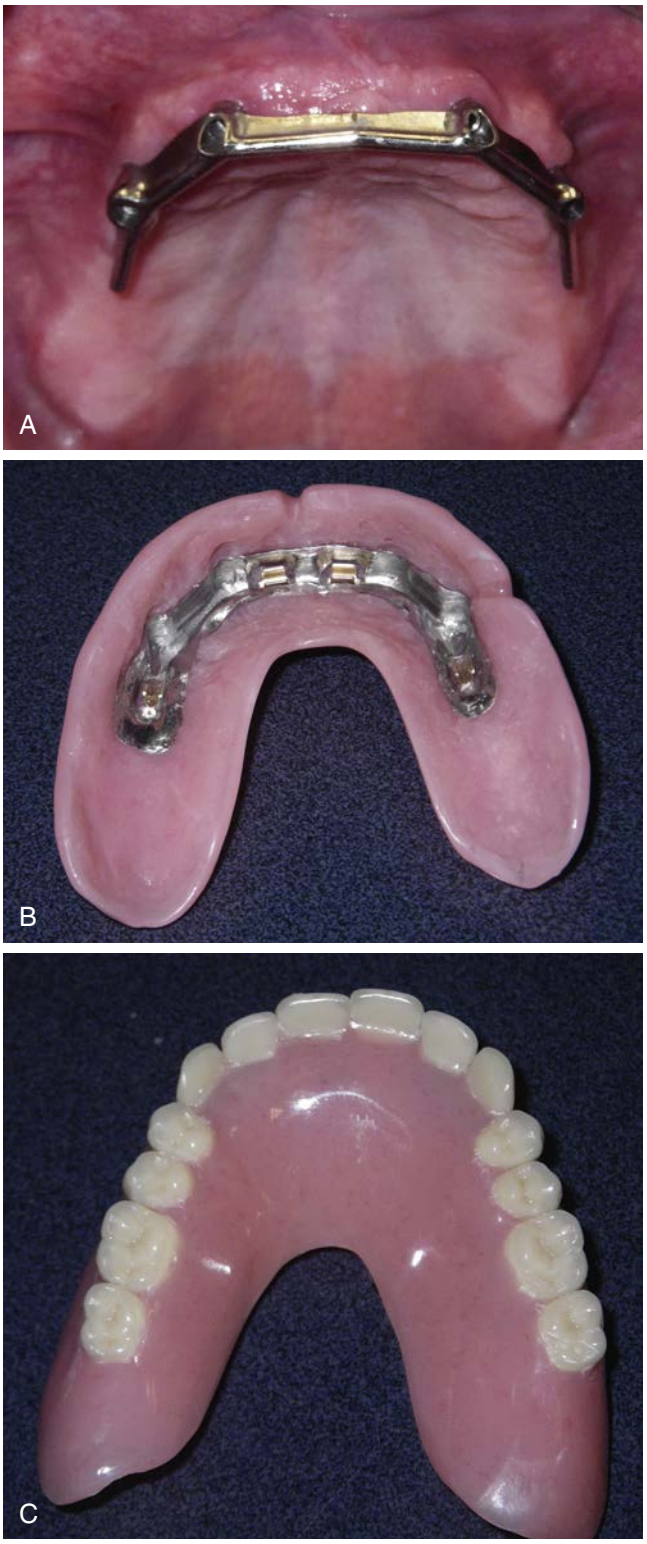

• **Figure 39-12** A good indication for a maxillary overdenture without palatal coverage is when it can be supported by at least four implants, evenly distributed around the arch and connected by a bar. **A,** A four-implant CAD-CAM Hader bar in the maxillary arch. **B,** Intaglio view of the four-implant overdenture reinforced with the chrome-cobalt alloy frame. **C,** Four gold Hader clips secured in place by the denture acrylic resin. (Laboratory work was done by Mr. Jack Danilov MDT, Carmichael, CA.)



• **Figure 39-13** A 7-year-old maxillary four-implant prosthesis opposing a complete complement of mandibular teeth. Posteriorly placed bilateral two implants and two bars with sinus grafting procedures were done to make the prosthesis implant supported. **A,** Intraoral view of the two-implant Hader bars. Note the mucositis due to poor oral hygiene and the negative pressure gradient. **B.** Patient's smile. **C,** Extra-oral view of the overdenture intaglio surface. Note the metal rest stops and the metal major connector of the prosthesis. **D,** Extra-oral view of the overdenture cameo surface. Note the use of Dr. Levin's lingual bladed denture teeth needed against porcelain mandibular occlusal surfaces.

Cost, technique sensitivity, and lack of patient dexterity may be contraindications for the milled design.[50]

In light of the reported implant and prosthetic complications of maxillary implant overdentures, a crossover study addressed the risk/benefit calculus. When comparing patient satisfaction with a maxillary implant overdenture (with or without palatal coverage) and a newly constructed complete denture, the researchers found no significantly higher ratings in stability, retention, esthetics, mastication, or speech.[52]

Because no clear biologic advantages have been associated with the number of implants used in the mandible (individual or connected), the numerical decision should be based on retention, support, and stability requirements. For many patients, two individual implants with associated retentive mechanisms provide good patient satisfaction and the treatment is less costly than a bar overdenture. For patients with retention as a primary requirement (as evidenced by active oral musculature and functionally demanding eating expectations or anatomic or occlusal force considerations), the use of three, four, or more implants and rigid overdenture design with locking attachments system is recommended (Figure 39-14).

Payne and Solomons[53] found no significant differences were noted in the required maintenance between the bars connected to two implants and those connected to three or four implants. The maintenance requirements were greatest during the first year, with 75% of the adjustments occurring during that time.[53] One patient required 12 adjustments during the first year. Most of these adjustments were to ridge contacting areas.[54]

Location of the Implants

The implants should be located so they are contained within the normal form of the denture base and spread out around the arch. Their form and location should ideally produce no substantial changes in the dimensions of the denture base.

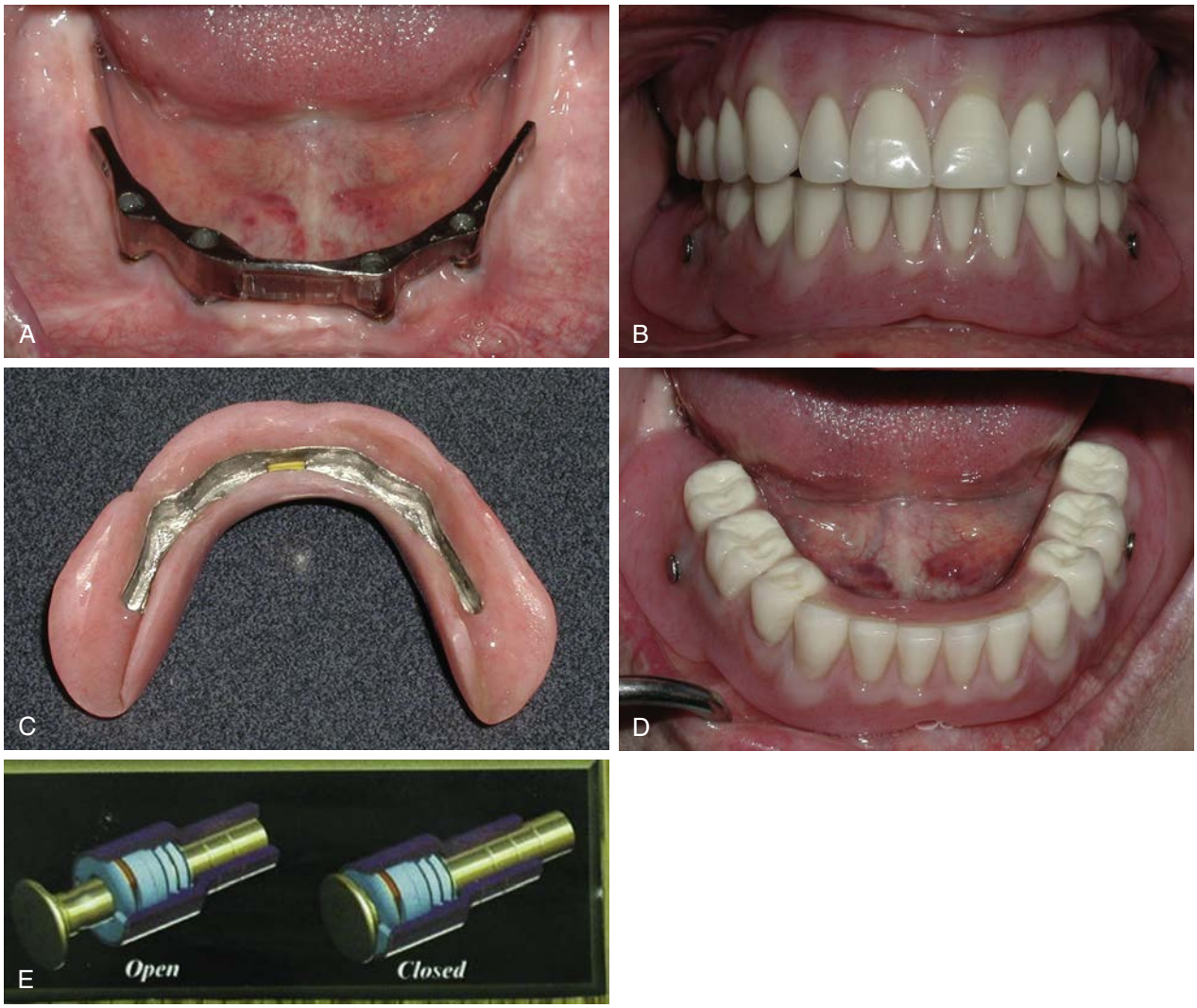

• **Figure 39-14** This patient has functionally demanding eating expectations, so the support and the retention of the prosthesis are a primary requirement. The use of four well spread around the arch, and rigid overdenture design with locking attachments system was made. **A,** Four-implant bar. **B,** Four-implant mandibular prosthesis in centric occlusion. **C,** Intaglio view of the reinforced mandibular overdenture. The rigid frame helps to strengthen and retain by friction the overdenture. **D,** The mandibular overdenture in place, retained by the two snap-pins and the intimate contact of the prosthesis frame and the Hader bar. **E,** Snap-pin attachments; shown in open and closed positions.

For a two-implant mandibular denture, the canine areas often serve as appropriate locations for implants. A study by Scherer et al[55] found that the lowest stress and best stability of implants in mandibular two-implant overdentures were obtained when implants were inserted in lateral incisor areas with shorter attachments and were placed parallel to the long axes of the teeth.[55] It is important to determine the location of the prosthetic teeth and the size and form of the denture base prior to implant placement. These characteristics are identified through development and the placement of a presurgical denture using conventional complete denture procedures. The clinical procedures are described later. Implants that support/retain overdentures are commonly located in the anterior area of the mouth and should be centered beneath the prosthetic teeth or slightly lingual to the center of the prosthetic teeth. When the implants are located anterior to (Figure 39-15) or substantially posterior to the teeth, the denture base has to be enlarged to encompass the implant and retentive mechanism. The enlarged base dimensions prolong the time it takes for a patient to adapt to the new prosthesis and can make the adaptation challenging. It is noted in a study that retention and stability of an implant overdenture prosthesis increase with the number of implants, when the implants are widely distributed, and the abutment.

Implant Alignment

When individual implants and retentive mechanisms will be used, placing the implants so they are parallel to each other or have their long axes nearly aligned with each other facilitates the prosthodontic phase of treatment by allowing the use of standardized components. With malaligned implants, efforts



• **Figure 39-15** This patient was complaining of poor chewing efficiency, poor esthetics, and two "bubbles" showing on speaking with these recently made prostheses. **A,** Two stud Locator abutments poorly selected on misplaced and misaligned implants. Note the poorly contoured surrounding adjacent tissues. **B,** Two-implant mandibular overdenture opposing maxillary complete denture. Note the lack of posterior occlusion and the thin anterior flange caused by poorly selected implant abutments. **C,** Poor esthetics due to poor maxillary and mandibular lip support from poor denture teeth set-up.

are commonly made to reduce the amount of resin base overcontouring and this process frequently leaves only thin areas of resin over the retentive mechanisms. The thin resin is more prone to fracture. When implants are placed posteriorly, they should be centered beneath the prosthetic teeth. Ball attachments coincided with the highest levels of retention and stability followed by Locator, o-ring, and ERA[55] (Figure 39-16). When individual implants are not aligned, custom abutments may be used to correct for implant angulation variations. Manufactured angle-correcting abutments also can be used.[56] Malalignment of individual implants with stud abutments can make prosthesis placement more difficult and the attachments are pinched more often during placement and removal, producing attachment wear and earlier loss of retention. Careful selection of attachment type is needed and depends on the ability to address the angulation problem of the implants. In one study[57] the master casts of 41 patients who had received 2 implants and ball abutment/o-ring overdentures were measured to determine the effect of implant alignment on the number of adjustments/repairs.[57] When a perpendicular relationship of the implant to the residual ridges was used as a reference angulation, implants that were inclined 6 degrees or more to the lingual or less than 6.5 degrees to the facial were associated with a significantly higher number of repairs.[57] When an implant is placed substantially out of alignment with other



• **Figure 39-16** Locator attachment has the lowest vertical height when compared with other stud attachments.



• **Figure 39-17** When implants are malaligned, a situation frequently encountered between resorbed premaxilla and posterior maxillae due to the angulation of the residual bone, the use of a CAD-CAM fabricated bar is indicated. **A,** Nonparallel implants on the final cast. **B,** CAD-CAM bar connecting all the misaligned implants. **C,** Lab analogues connected to the bar, showing the implant angulation problem. **D,** CAD-CAM bar is placed into the maxillary overdenture.

sources of retention in partially edentulous arches, the fabrication of custom components may be necessary.[56]

Castable bars or CAD-CAM milled bars have frequently been used to connect multiple implants. One of the many reasons clinicians have used bars is malalignment between multiple implants, a situation frequently encountered between resorbed premaxilla and posterior maxillae due to the angulation of the residual bone (Figure 39-17). A bar connecting multiple implants permits correction of modest implant malalignment because the screw access holes can vary in their location and orientation in the bar while still allowing the bar to possess retentive elements at the desired position(s) and angulation(s). CAD-CAM generated milled bars are being used frequently as the first choice in overdenture treatment due to their affordable cost compared with gold bars. In addition, Örtorp et al[58] investigated and compared the precision of fabrication in repeatedly produced computer numeric controlled (CNC) milled framework with conventional



• **Figure 39-18** When an implant bar is used it is advisable to reinforce the prostheses with a metal suprastructure.

castings, and demonstrated that it is possible to fabricate implant-supported frameworks by means of the computer milled technique with very high precision and repeatability.[58] When an implant bar is used, it is advisable to reinforce the prostheses with a metal suprastructure (Figure 39-18). The advantages are many: strength, optimal frictional retention, and easier reline procedures for the prostheses.

Implant Component/Retentive Mechanism: Height Above the Soft Tissue

After development of the wax trial denture, or preferably during the insertion of the presurgical complete denture, it is important to assess the vertical and horizontal base dimensions to determine the amount of space available for implant components and retentive devices before the surgical placement of dental implants (Figure 39-19). The height of implant components and retentive mechanisms should be reduced as much as possible because they weaken the prosthesis base. However, the height should be sufficient to allow bars to be fabricated in such a manner that some space is present beneath the bar. It is recommended that a 1- to 2-millimeter space be present between the underside of metal bars and the edentulous ridge mucosa. It is felt that the potential for adverse soft tissue responses is related to minimal space underneath a bar. It has also been suggested[59] in one publication that adverse responses under bars occur more often when unattached mucosa is present. In contrast, a study[60] of 62 patients found that attached mucosa was not a prerequisite for the maintenance of healthy function. Peri-implant soft tissue complications were more frequently encountered with maxillary implant overdentures and it has



• **Figure 39-19** One way to measure the inter-arch distance needed for the selection of a stud or a bar attachment is by measuring the occlusal surface of the denture teeth to the intaglio surface of the denture.



• **Figure 39-20** Peri-implant inflammation/hyperplasia is shown here that is severe enough to require surgery.

been suggested[61] that they may be related to the reduced vertical space available in the maxilla.

Mandibular resorption frequently creates more vertical space than occurs in the maxilla, causing retentive bars to be placed closer to the soft tissue in the maxilla. It has been stated[62] that good oral hygiene is the main factor in preventing adverse soft tissue responses. Some peri-implant soft tissue complications are severe enough to require surgery. One paper reported that 11 of 25 patients had peri-implant inflammation/hyperplasia and 2 of those patients required surgery[12] (Figure 39-20).

All bar and clip retentive mechanisms require an occlusocervical space of at least 12 mm (including retentive mechanism, overlying base material, and space under bars), while solitary anchors such as the Locator only require 8 to 9 mm of occlusocervical space.[63] It is advantageous to have two or more millimeters of resin thickness surrounding the retentive mechanism when possible. Available base thickness will help determine the type of mechanism that can be used. When there is not sufficient space available, a change in the type of retentive mechanism may be necessary or the base may have to be thickened or bone removal is necessary before implant placement. For diagnostic purposes, the presurgical denture can be duplicated in clear acrylic resin and used to assess available space (Figure 39-21).

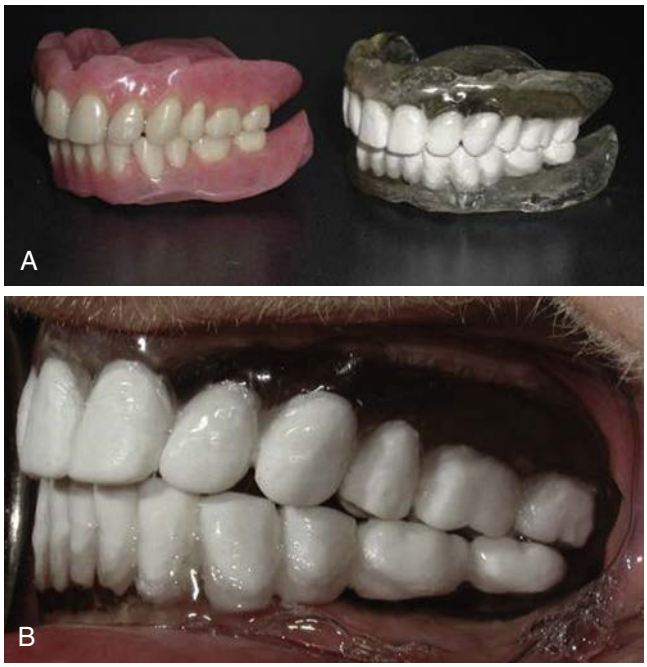

• **Figure 39-21** **A,** Presurgical dentures with their duplicates. These duplicates are used as radiographic templates and later as surgical templates. **B,** Radiographic templates are placed in the mouth. They can be used also to diagnose interarch space. At the maxillary incisors only the clinical crown is missing; but at the premolar-molar area the clinical crown and soft and hard tissues are missing, and at this location the interarch space is adequate for a stud or bar attachments.

Comparison of Retentive Mechanisms

There are several types of retentive mechanisms available, including stud attachments such as Locator or ball attachments, bar(s) and clip(s), and other types of mechanical attachments such as snap pin attachments (see Figure 39-14, *A*). The choice has largely been determined by practitioner preference with bars/clips being one of the mechanisms frequently selected to support and retain overdentures when more than two implants were used. Ideally, the retentive mechanism should be positioned so it cannot be seen through the visible portion of the denture base, does not interfere with proper positioning of prosthetic teeth, and does not excessively enlarge the denture base. An in vitro comparison of the retentive properties of ball and Locator attachments for implant overdentures by Türk et al[64] demonstrated that both attachment systems showed decreased retentive forces after 5,000 insertion-separation cycles. However, after 5,000 insertion-separation cycles, locator attachments showed better retentive properties than ball attachments. When bars are used, a casting is required which increases cost and complexity. Bars have been found to provide greater retention than balls/o-rings (Figure 39-22), which may be important with patients exhibiting high functional activity and the need for maximal retention. Bars and associated retentive devices require more space within the denture base than do stud attachments. All mechanisms are subject to retention deterioration over time and the need for regular adjustment/replacement.[64] An in vitro study by Nascimento et al[65] compared the photoelastic characteristics

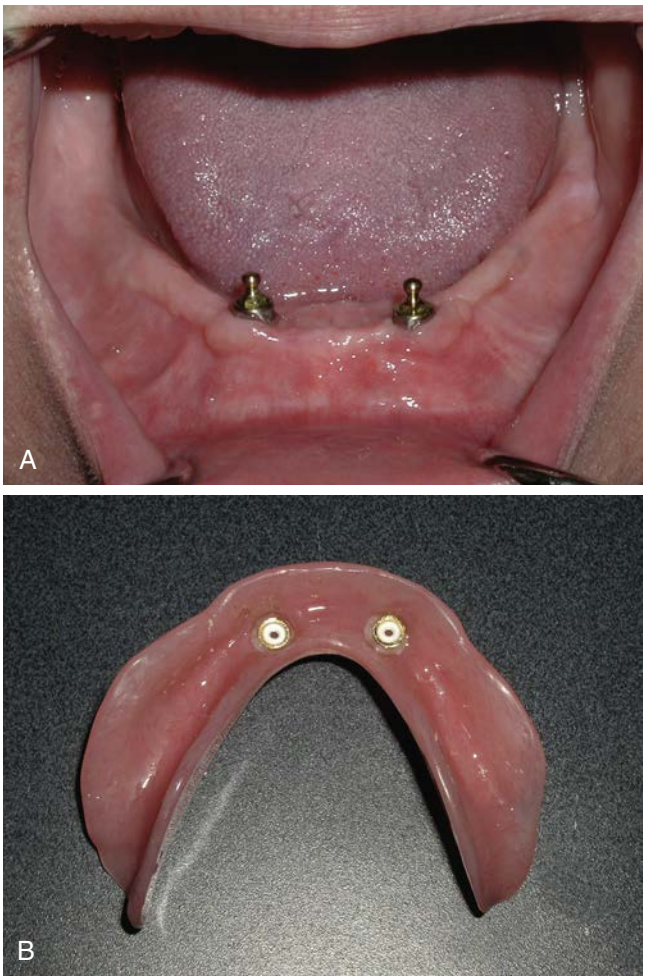

• **Figure 39-22** Two-implant prosthesis using a ball type attachment. This type of an o-ring ball attachment requires the implants to be placed as parallel as possible. **A,** Clinical view of the ball abutments with an adequate gingival cuff height. **B,** Intaglio view of the prosthesis showing two white clinical o-rings. (From Daher T: A simple, predictable intraoral technique for retentive mechanism attachment of implant overdenture attachments, *J of Prosthodont* 12: 202–205, 2003.)

of stress transfer around the implant in a single-implant mandibular overdenture using different types of attachments (ERA Sterngold, CNG Brazil, Conexão Brazil, Dalla Bona Brazil, Locator FL, Neodent). They found, within the limitations of the study, that the load transferred to the implant in a single-implant mandibular overdenture was evenly distributed around the implant with low stress concentration. No discernible differences were observed among the different attachment systems.[65]

Base Adaptation and Contact with Edentulous Ridge

Using a photoelastic model of a human edentulous mandible with four anterior implants, load transfer characteristics of four overdenture designs were studied.[66] Properly fitting extension bases were found to contribute significantly to even force distribution and appear to be as important as the type of retentive anchorage system in load transfer.

Base Reinforcement

When the denture base will be thin or there are heavy occlusal forces present, it may be prudent to reinforce the denture base with a metal or fiber mesh framework incorporated into the denture base or use a cast metal base (see Figure 39-13, *B*). Evaluating prosthetic tooth wear on an existing prosthesis provides an indication of the magnitude of forces present. When aggressive wear facets are noted on the prosthetic teeth of an existing denture, a hostile environment is likely to be present and the use of reinforcement may be advisable, as well as metal occlusal restorations.[67] It is also important to remember that patients who have implants can place greater occlusal force on the prosthesis than they could with their conventional complete denture. However, the maximal occlusal force applied by patients with mandibular implant overdentures was found to be less than the force developed by patients with teeth and patients who have fixed complete dentures.[68]

Occlusion, Tooth Positioning

Although there are no clinical data documenting the effect of occlusion on implant success, clinicians have felt that occlusion can affect implant success. Clinicians have frequently recommended that a balanced occlusion be used with implant overdentures, particularly when the opposing arch is edentulous. When the occlusion is properly balanced, there will be greater prosthesis stability than when the occlusion is not balanced (Figure 39-23).

Our preferences for an optimal occlusal scheme for implant overdentures is a balanced type of articulation, either a lingualized[69] or linear occlusion,[70] no matter what the opposing arch is. This will distribute the occlusal stress on multiple denture teeth instead of on one acrylic denture tooth, thus preventing fracture of the canine on a canine disclusion occlusal scheme.



• **Figure 39-23** Balanced occlusal scheme. **A,** Prostheses in centric occlusion. No centric contact from canine to canine. **B,** Right working movement. Note the working right occlusal contacts and left balancing occlusal contacts.

Synopsis of Design Guidelines[8]

- In the mandible, one symphyseal implant can be used which has been shown to be especially suitable for the geriatric population; however, when two implants are employed they can be left unattached (separate from one another) from the standpoint of implant success.
- Because of the higher implant loss in the maxilla (19%), for a palatal-less overdenture, a minimum of four implants has been proposed. It may be propitious to place at least five to six implants so that the prosthesis can still function satisfactorily should an implant be lost. Use of implants more than 10 mm long and 3.7 mm wide has been reported by clinicians to have higher implant survival for maxillary overdentures.
- In the maxilla, it is considered prudent to connect the implants together using a bar so the prosthesis can continue to function should an implant be lost. The use of a rigid (milled bar) design has been shown to reduce bending moments on loaded implants, resulting in higher implant survival and reduced prosthetic complications.
- Position the implants so they are contained within the normal form of the denture base and centered beneath the prosthetic teeth. For anterior implants, a location slightly lingual to the center of the prosthetic teeth is also appropriate.
- Align the implants so they are parallel or nearly parallel to one another whenever possible. This alignment is particularly important when individual (not connected) implants will be used.
- Minimize the height of the implant components and retentive mechanisms.
- The choice of retentive mechanism is based on personal preference and the need for maximal retention in certain patients. Bars and associated retentive devices provide the greatest retention.
- When individual implants will be used to retain an overdenture, clinicians have reported favorable results in terms of retention and longevity of the retention with Locator attachments.
- When the denture base will be thin or there are heavy occlusal forces present (parafunction), the use of metal reinforcement in the resin base will help prevent prosthesis fracture, and metal occlusal restorations will reduce denture tooth wear and loss of vertical dimension.

Clinical Procedures for Two-implant Overdenture and Three- or Four-implant Overdenture

Examination, Diagnosis, and Treatment Planning

A clinical examination, medical and dental history, panoramic radiograph, and mounted casts (with prosthetic teeth appropriately arranged and articulated) are required to plan treatment. In addition, cone beam computed tomography (CBCT) images may be needed to relate the prosthetic tooth positions to the underlying bone and vital structures.

The medical and dental history are used to identify patients more likely to experience implant failure so a thorough assessment of the risks/benefits of the treatment can be made. The history information also helps identify patients in whom implant treatment is contraindicated.

The clinical examination and radiographic information are used to evaluate bone health, bone quality, and incisocervical/occlusocervical bone dimensions in relation to the prosthetic teeth. The positions of the prosthetic teeth determine where the implants should be located. Several factors determine the most appropriate prosthetic tooth positions, including: esthetics, tooth-lips relationships, phonetics, anatomic landmarks, horizontal and vertical mandibular positions, and muscular neutrality (neutral zone) (Figures 39-24 through 39-27).



• **Figure 39-24** Accudent System 1 kit for complete denture irreversible hydrocolloid impressions.

Clinical Situation for a Two-implant Overdenture Using Locator Attachments

The presurgical complete dentures are fabricated using all the clinical and laboratory steps required to locate the most appropriate prosthetic tooth positions. Once the postoperatory check for any troubleshooting is done and no sore spots are present; a duplication of the denture is done to make a radiographic implant template using a Lang Duplicator.

CBCT radiographic series are made and evaluated. The "Rules of 10"[71] specify that for any implant-retained overdenture there must be a minimum of 10 mm of alveolar inferior/superior dimension, a minimum of 10 mm of interocclusal restorative dimension measured from the soft

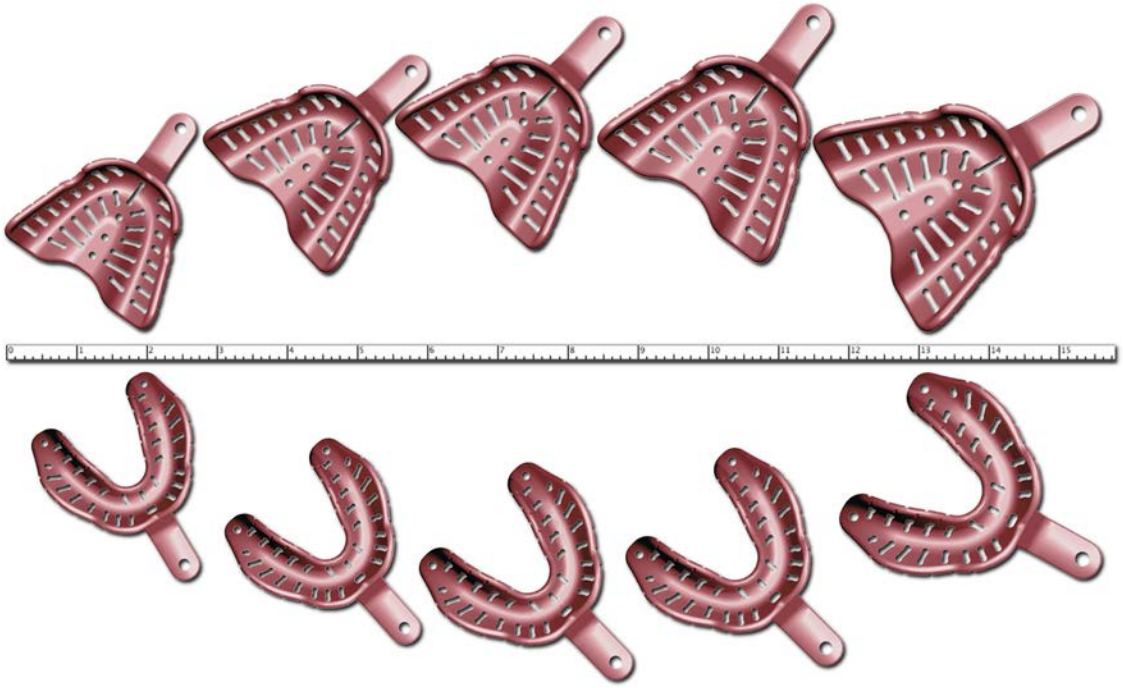

• **Figure 39-25** Massad impression trays LT for making polyvinyl siloxane impressions. These trays are placed in 170° F water, and then custom molded in the patient's mouth before making the impression.

tissue ridge crest to the occlusal plane, and at least 10 mm of anterior-posterior space between two implants.

The radiographic template is transformed into a surgical template by making occlusal holes or by making a cut-off of the lingual anterior flange where the dental implants will be placed (Figure 39-28, *A*). Then two or four implants are placed in the selected locations according to the agreed treatment plan. If the surgical technique is a two-stage technique, it is advisable to mark on the surgical template the location of the implants in case the implants are going to be submerged (see Figure 39-28, *A*). This will help in locating the implants to be exposed during the second-stage surgery (see Figure 39-28, *B* and *C*). The mandibular intaglio surface of the denture is adjusted according to the situation. An osteotomy sometimes is needed to increase the interarch space to accommodate the height of a stud attachment or a bar attachment. In this situation the use of a temporary soft liner is advisable to improve the fit during the healing phase.

Once the implants are osseointegrated and gingival tissue is healed around the healing abutments, the soft tissue height is measured with a periodontal probe after removing the implant healing abutment from each implant. The height is then used to determine the proper cuff height of

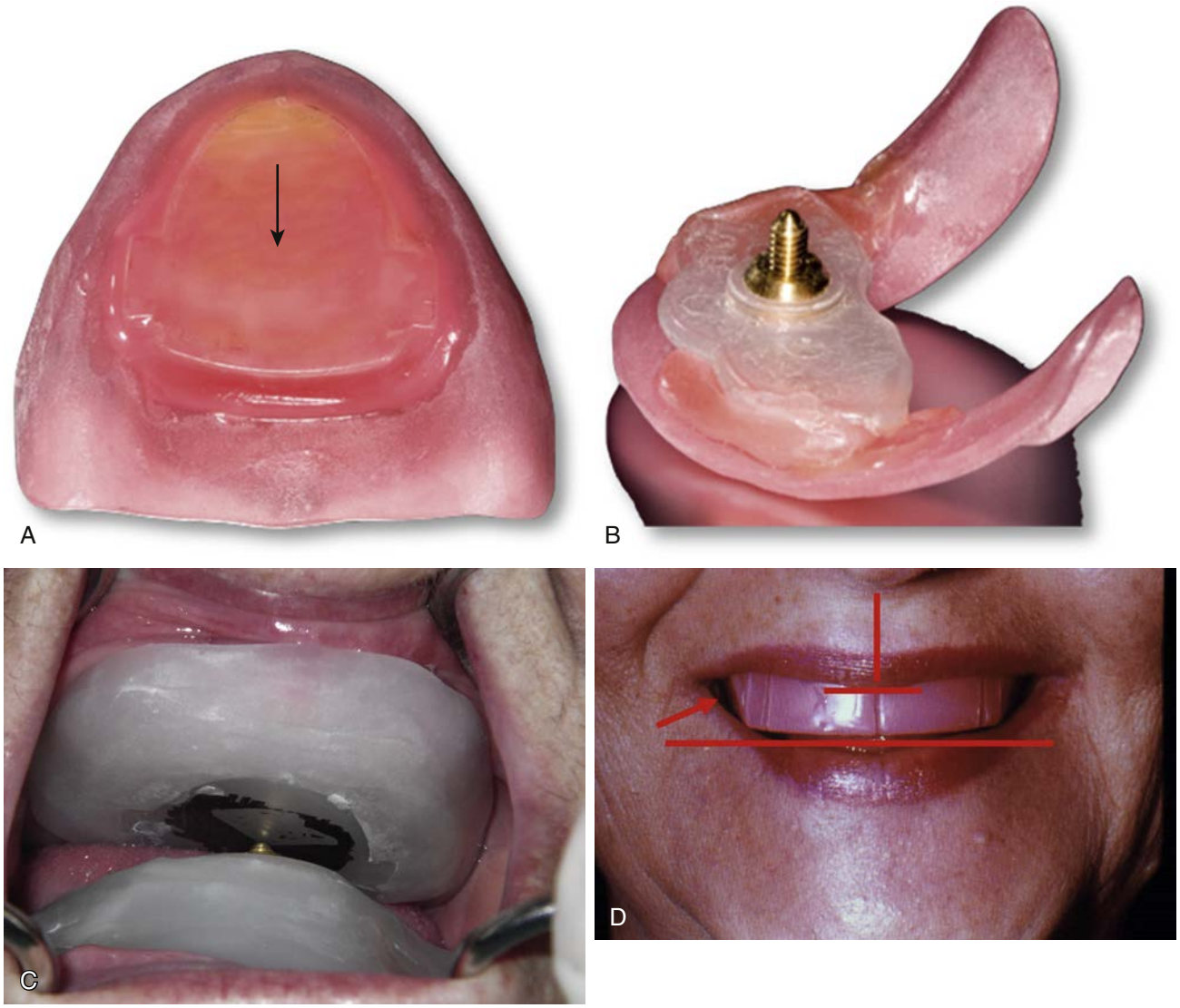

• **Figure 39-26** Massad jaw disposable recorders. **A,** Maxillary striker plate showing the gothic arch tracers. **B,** Mandibular pin reciever plate. Note the brass pin is in a ball and socket brass piece enabling the pin to be always perpendicular to the striking plate during jaw movements. The pin height is adjusted at the occlusal vertical dimension before making the tracing. **C,** The jaw recorders assembly intraorally showing the gothic arch tracings. The apex of the arch is the centric jaw position; it is a retruded, unstrained, repeatable, learnable position, and it is the start of all mandibular movements. **D,** During the same patient visit of jaw recording, the esthetic control base (ECB) or the maxillary wax rim is adjusted for an adequate upper lip support, for a horizontal occlusal plane, and for adequate buccal corridor. Also, the midline and the high lip line are marked on the labial surface of the ECB.



• **Figure 39-27** After a heat-cured lab reline and during the placement of the mandibular overdenture, the denture fit is improved by applying the pressure indicator paste (PIP) and adjusting the pressure areas. **A,** Few tissue contacts are showing before denture adjustment. **B,** Wider tissue contacts are achieved after a few adjustments with PIP. No contact should be present between the implant abutments and denture base during the adjustment visit. This step is important to create a denture that is tissue supported and implant retained. (From Daher T: A simple, predictable intraoral technique for retentive mechanism attachment of implant overdenture attachments, *J of Prosthodont* 12: 202–205, 2003.)

the Locator abutment that will be used. Laboratory heat-cured reline is sometimes needed and is done after placing a duplicate Locator housing over the Locator abutments. The denture is processed on a cast that includes the copy of the Locator retentive housing. The extra dimensions produce a recess in the denture (see Figure 39-27, *A*) that is large enough to permit the denture to seat over the Locator abutments and its housing with a little bit of adjustment without impingement.

In case of a bar-retained overdenture, an impression is made to generate an accurate master cast. A practical time-saving impression technique[72] with four objectives is used to achieve accuracy in a single clinical visit: (1) impression of the soft tissue, (2) impression and position of the implants, (3) registration of the maxillomandibular relationships, and (4) arrangement of the artificial teeth (Figure 39-29). Duplicate the mandibular denture twice. One is to be used as a custom tray, and is made by duplicating the presurgical complete denture by using a denture duplicator, irreversible hydrocolloid, and clear autopolymerizing acrylic resin. The second denture duplicate will be fitted over the cast and sent the CAD-CAM center to make a CAD-CAM titanium milled bar confined to the scanned duplicate denture outlines (Figure 39-30). A trial denture is made over the CAD-CAM bar and tried in the mouth and evaluated and adjusted as needed. The same procedure can be done for the maxillary overdenture.

Pressure indicating paste (PIP) is used to improve the fit of the intaglio surface before attaching the denture to the implant with Locator clips. Oral hygiene and instructions must be given before dismissing the patient. The denture is placed and worn by the patient with adjustments made as needed. When stability and comfort are achieved, the retentive caps are ready to be attached to the overdenture on a separate visit. Doing this ensures that the denture is tissue supported and implant retained.

In case of a bar, the denture is processed with a metal cast base that accommodates the bar assembly. The denture is fitted over the tissue using PIP, and then the bar is placed and again the fit is checked before attaching the denture to the bar with Hader clips or with Swiss Loc NG attachments.

The prosthesis is placed intraorally so the patient can be shown how to properly seat and remove the prosthesis. The patient is then given the opportunity to demonstrate the ability to remove and reseat the prosthesis. Oral hygiene instructions will be reinforced before dismissing the patient. Various means of plaque removal from implant components and prostheses have been suggested, including manual and powered toothbrushes (Figure 39-31), interproximal brushes, dental super floss, antimicrobial rinses and gels, and subgingival irrigation systems. It is advisable to give a patient a powered toothbrush with a wide variety of brush attachments[73] (Figure 39-32) that may prove beneficial for those seeking manageable methods for maintaining the cleanliness of implant overdenture prostheses, ensuring the health of the peri-implant supporting hard and soft tissues.

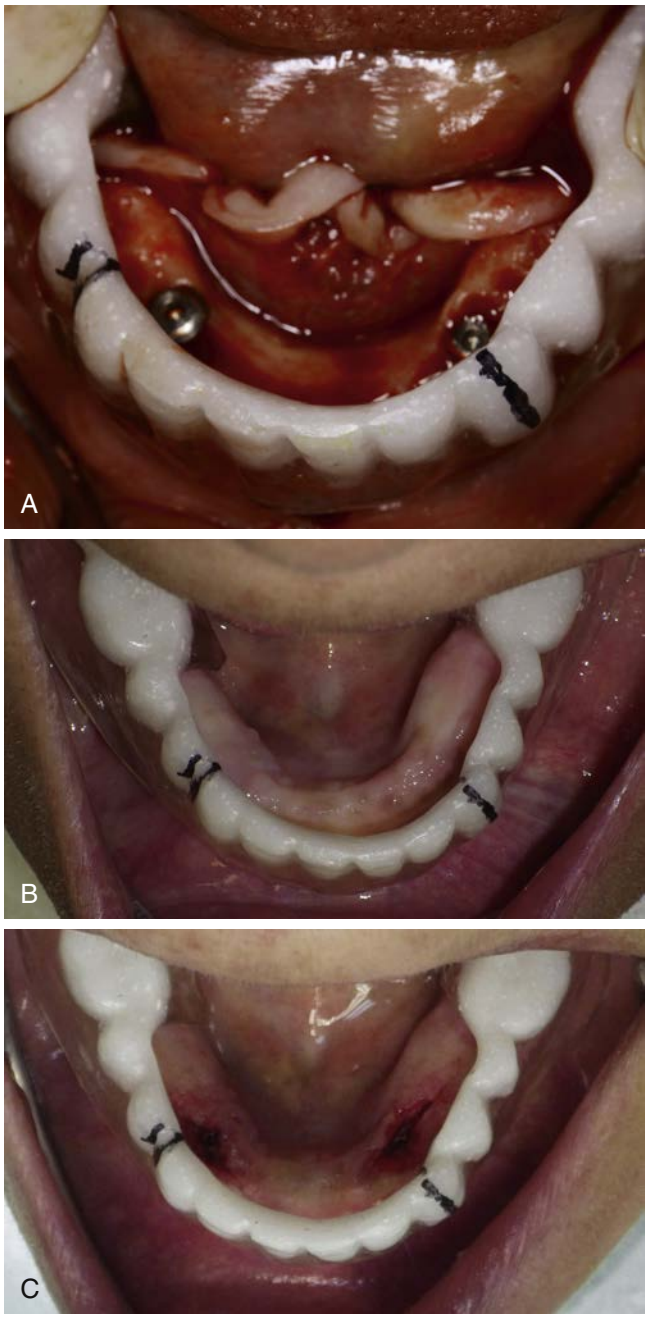

• **Figure 39-28** The mandibular surgical implant template during its uses. **A,** Two implants are placed according to final destination marked by the duplicate denture used as a surgical template. **B** and **C,** After a complete implant osseointegration, the same surgical template is used to locate and expose the two implants.

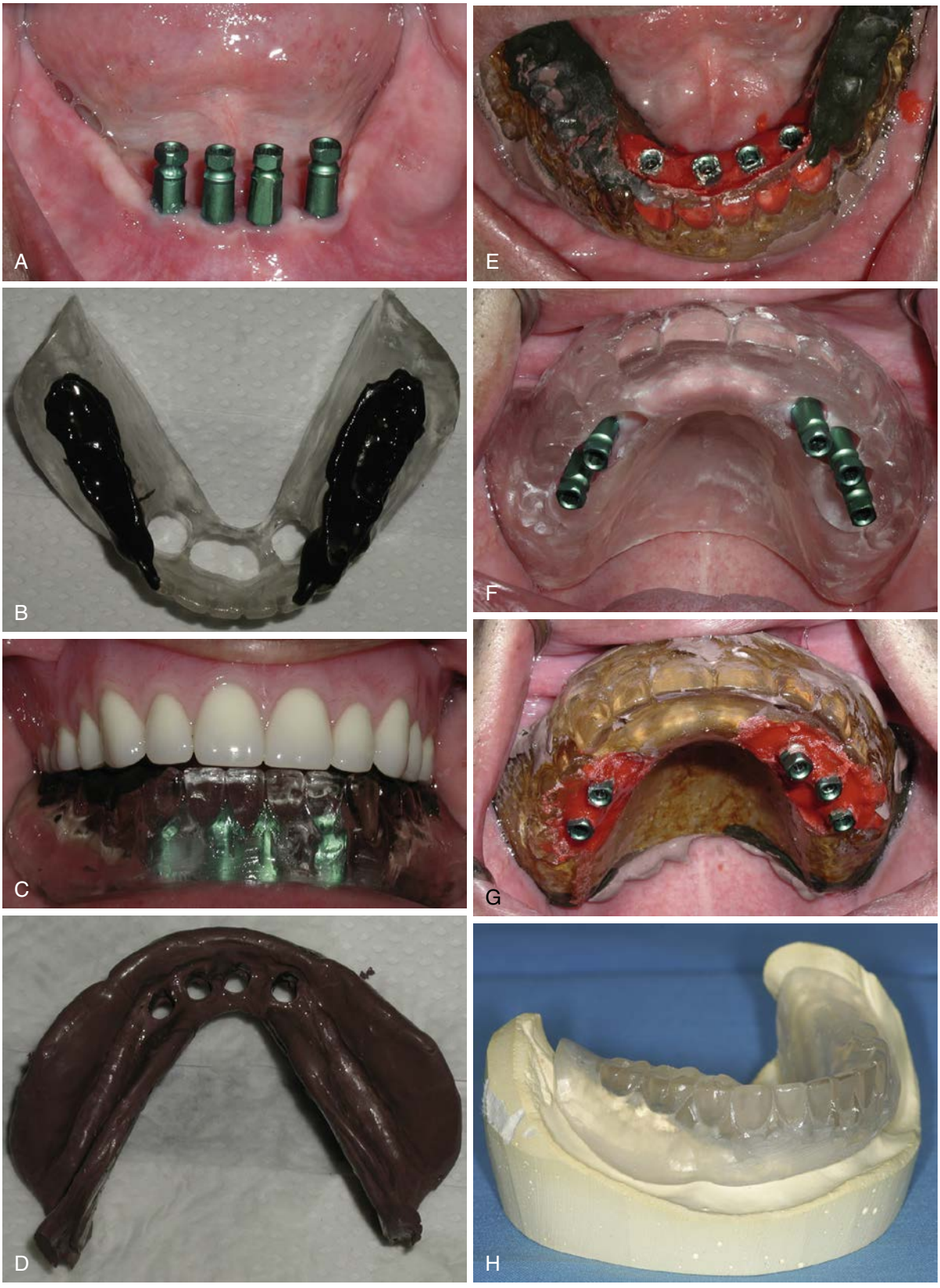

• **Figure 39-29** The 4-in-1 visit for the fabrication of the master cast, the CAD-CAM bar, and the trial denture. **A,** The impression copings are placed intraorally on the implants. **B** and **C,** The presurgical denture duplicate is fitted over the impression copings, making sure that most of the length of the copings extrudes from the denture. It is advisable to add green stick modeling composition on the occlusal surfaces to secure the centric occlusion during the setup of the acrylic resin. **D,** A final tissue impression with a light bodied impression material is made in a close position in centric. Then the excess impression material is removed, making it ready for the next step. **E,** The tray is then placed and auto-polymerizing acrylic resin or composite resin is placed over it to connect the copings together and to the hard portion of the tray. The patient is asked to close in centric during the setup of the resin. **F** and **G,** The same technique can be applied to the maxillary arch. **H,** After the boxing of the impression, the final cast is made, trimmed, and articulated before separating the tray from the cast. Then the final cast and the second duplicate of the presurgical denture is sent to a dental laboratory for the fabrication of the CAD-CAM bar and the trial denture. (From Daher T, Meserkhani PV, Baba NZ, et al.: Time-saving method for the fabrication of a definitive cast for an implant supported prosthesis, *J Prosthet Dent* 98:70–71, 2007.)

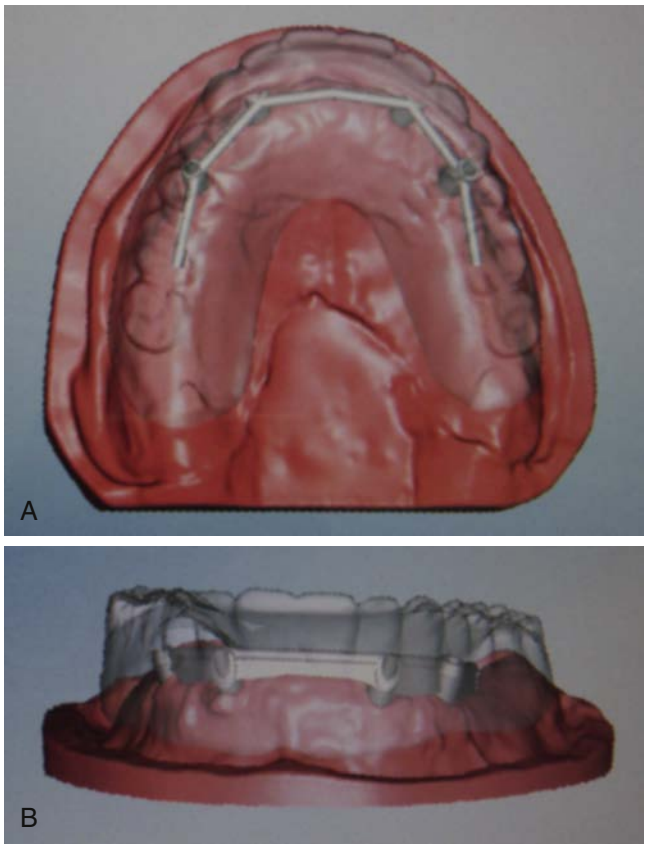

• **Figure 39-30** Computer designing process for the fabrication of the CAD-CAM bar by Cagenix software. **A,** Occlusal view and **(B)** frontal view of the bar with its relation to the denture teeth. These digital pictures are sent by email with its software to evaluate the bar design before its milling step.



• **Figure 39-31** Oral hygiene instructions are an important step in maintaining the implants and the prostheses using specific rotary brushes.



• **Figure 39-32** Powered toothbrush with a wide variety of brush attachments.

References

1. Ettinger RL, Taylor TD: Scandrett FR: Treatment needs of overdenture patients in a longitudinal study: Five-year results, *J Prosthet Dent* 52:532–537, 1984.
2. Visser A, Meijer HJ, Raghoebar GM, et al.: Implant-retained mandibular overdentures versus conventional dentures: 10 years of care and aftercare, *Int J Prosthodont* 19:271–278, 2006.
3. Romeo E, Lops D, Margutti E, et al.: Long-term survival and success of oral implants in treatment of full and partial arches: a 7-year prospective study with the ITI dental implant system, *Int J Oral Maxillofac Implants* 19:247–259, 2004.
4. Burns DR, Under JW, Elswick Jr RK, et al.: Prospective clinical evaluation of mandibular implant overdentures: Part I—retention, stability, and tissue response, *J Prosthet Dent* 73:354–363, 1995.
5. Burns DR, Unger JW, Elswick Jr RK, et al.: Prospective clinical evaluation of mandibular implant overdentures: Part II—patient satisfaction and preference, *J Prosthet Dent* 73:364–369, 1994.
6. Raghoebar GM, Meier HJA, van't Hof MA, et al.: A randomized prospective clinical trial on the effectiveness of three treatment modalities for patients with lower denture problems. A 10 year follow-up study on patient satisfaction, *Int J Oral Maxillofac Surg* 32:498–503, 2003.
7. Jemt T, Chai J, Harnett J, et al.: A 5-year prospective multicenter follow-up report on overdentures supported by osseointegrated implants, *Int J Oral Maxillofac Implants* 11:291–298, 1996.
8. Goodacre CJ, Sadowsky SJ, Daher T: Implant overdenture. In *Implant dentistry DVD*, Loma Linda University & ACP Edition, 2006.
9. de Grandmont P, Feine JS, Taché R, et al.: Within-subject comparisons of implant-supported mandibular prostheses: psychometric evaluation, *J Dent Res* 73:1096–1104, 1994.
10. Feine JS, de Grandmont P, Boudrias P, et al.: Within-subject comparisons of implant-supported mandibular prostheses: choice of prosthesis, *J Dent Res* 73:1105–1111, 1994.
11. Walton J, MacEntee M: A retrospective study on the maintenance and repair of implant-supported prostheses, *Int J Prosthodont* 6:451–455, 1993.
12. Hemmings KW, Schmitt A, Zarb GA: Complications and maintenance requirements for fixed prostheses and overdentures in the edentulous mandible: a 5-year report, *Int J Oral Maxillofac Implants* 9:191–196, 1994.
13. Watson RM, Davis DM: Follow up and maintenance of implant supported prostheses: a comparison of 20 complete mandibular overdentures and 20 complete mandibular fixed cantilever prostheses, *British Dent J* 181:321–327, 1996.
14. Watson GK, Payne AGT, Purton DG, et al.: Mandibular overdentures: professional time for prosthodontic maintenance during the first year of service using three different implant systems, *Int J Prosthodont* 15:379–384, 2002.
15. Takanashi Y, Penrod JR, Chehade A, et al.: Does a prosthodontist spend more time providing mandibular two-implant overdentures than conventional dentures? *Int J Prosthodont* 15:397–403, 2002.
16. Visser A, Meijer HJ, Raghoebar GM, et al.: Implant-retained mandibular overdentures versus conventional dentures:10 years of care and aftercare, *Int J Prosthodont* 19:271–278, 2006.
17. Burns DR: Mandibular implant overdenture treatment: consensus and controversy, *J Prosthod* 9:37–46, 2000.
18. Hutton JE, Heath MR, Chai JY, et al.: Factors related to success and failure rates at 3-year follow-up in a multicenter study of overdentures supported by Brånemark implants, *Int J Oral Maxillofac Implants* 10:33–41, 1995.
19. Watson RM, Jemt T, Chai J, et al.: Prosthodontic treatment, patient response, and the need for maintenance of complete implant-supported overdentures: an appraisal of 5 years of prospective study, *Int J Prosthodontics* 10:345–354, 1997.
20. Goodacre CJ, Bernal G, Rungcharassaeng K, et al.: Clinical complications with implants and implant prostheses, *J Prosthet Dent* 90(2):121–132, 2003.
21. Berglundh T, Perssson L, Klinge B: A systematic review of the incidence of biological and technical complications in implant dentistry reported in prospective longitudinal studies of at least 5 years, *J Clin Periodontol* 29:197–212, 2002.
22. Heydecke G, Boudrias P, Awad MA, et al.: Within-subject comparison of maxillary fixed and removable implant prostheses: Patient satisfaction and choice of prosthesis, *Clin Oral Implants Res* 14:125–130, 2003.
23. McGill consensus statement on overdentures: *Int J Oral Maxillofac Implants* 17:601–602, 2002.
24. Fitzpatrick B: Standard of care for edentulous mandible: a systematic review, *J Prosthet Dent* 95:71–78, 2006.
25. Brennan M, Houston F, O'Sullivan M, et al.: Patient satisfaction and oral health–related quality of life outcomes of implant overdentures and fixed complete dentures, *Int J Oral Maxillofac Implants* 25:791–800, 2010.
26. Cordioli G, Majzoub Z, Castagna S: Mandibular overdentures anchored to single implants: A five-year prospective study, *J Prosthet Dent* 78(2):159–165, 1997.
27. Batenburg RHK, Raghoebar GM, Van Oort RP, et al.: Mandibular overdentures supported by two or four endosteal implants, *Int J Oral Maxillofac Surg* 27:435–439, 1998.
28. Mericske-Stern RD, Taylor TD, Belser U: Management of the edentulous patient, *Clin Oral Implants Res* 11:108–125, 2000.
29. Mericske-Stern R: Treatment outcomes with implant-supported overdentures: Clinical considerations, *J Prosthet Dent* 79:66–73, 1998.
30. Palmqvist S, Sondell K, Swartz B: Implant-supported maxillary overdentures: outcome in planned and emergency cases, *Int J Oral Maxillofac Implants* 9:184–190, 1994.

31. Bergendal T, Engquist B: Implant supported overdentures: a longitudinal prospective study, *Int J Oral Maxillofac Implants* 13:253–262, 1998.
32. Eckert SE, Carr AB: Implant-retained maxillary overdentures, *Dent Clin North Am* 48:585–601, 2004.
33. Engquist B, Bergendal T, Kallus T, et al.: A retrospective multicenter evaluation of osseointegrated implants supporting overdentures, *Int J Oral Maxillofac Implants* 3:129–134, 1988.
34. Narhi TO, Hevinga M, Voorsmit RA, et al.: Maxillary overdentures retained by splinted and unsplinted implants: a retrospective study, *Int J Oral Maxillofac Implants* 16:259–266, 2001.
35. Krennmair G, Krainhofner M, Piehlslinger E: Implant-supported maxillary overdentures retained with milled bars: Maxillary anterior versus maxillary posterior concept—A retrospective study, *Int J Oral Maxillofac Implants* 23:343–352, 2008.
36. Cochran DL: A comparison of endosseous dental implant surfaces, *J Periodontol* 70:1523–1539, 1999.
37. Çehreli MC, Karasoy D, Kokat AM, et al.: A systematic review of marginal bone loss around implants retaining or supporting overdentures, *Int J Oral Maxillofac Implants* 25:266–277, 2010.
38. Payne AGT, Solomons YF: Mandibular implant-supported overdentures: a prospective evaluation of the burden of prosthetic maintenance with 3 different attachment systems, *Int J Prosthodont* 13:246–253, 2000.
39. Kenney R, Richards MW: Photoelastic stress patterns produced by implant-retained overdentures, *J Prosthet Dent* 80:559–564, 1998.
40. Mericske-Stern RD, Piotti M, Sirtes G: 3-D in vivo force measurements on mandibular implants supporting overdentures. A comparative study, *Clin Oral Implants Res* 7:387–396, 1996.
41. Naert I, Gizani S, Vuylsteke M, et al.: A 5-year prospective randomized clinical trial on the influence of splinted and unsplinted oral implants retaining a mandibular overdenture: prosthetic aspects and patient satisfaction, *J Oral Rehabil* 26:195–202, 1999.
42. Naert I, Quirynen M, Theuniers G, et al.: Prosthetic aspects of osseointegrated fixtures supporting overdentures. A 4-year report, *J Prosthet Dent* 65:671–680, 1991.
43. Cekic C, Akca K, Cehreli MC: Effects of attachment design on strains around implants supporting overdentures, *Quintessence Int* 38:525.e291-297, 2007.
44. Närhi TO, Hevinga M, Voorsmit RACA, et al.: Maxillary overdentures retained by splinted and unsplinted implants: a retrospective study, *Int J Oral Maxillofac Implants* 16:259–266, 2001.
45. Quirynen M, Naert I, van Steenberghe D: Fixture design and overload influence marginal bone loss and fixture success in the Brånemark® system, *Clin Oral Impl Res* 3:104–111, 1992.
46. Mericske-Stern R, Oetterli M, Kiener P, et al.: A follow-up study of maxillary implants supporting an overdenture: clinical and radiographic results, *Int J Oral Maxillofac Implants* 17:678–686, 2002.
47. Cavallaro Jr JS, Tarnow DP: Unsplinted implants retaining maxillary overdentures with partial palatal coverage: report of 5 consecutive cases, *Int J Oral Maxillofac Implants* 22:808–814, 2007.
48. Sadowsky SJ: Treatment considerations for maxillary implant overdentures: A systematic review, *J Prosthet Dent* 97:340–348, 2007.
49. Jemt T, Carlsson L, Boss A, et al.: In vivo load measurements on osseointegrated implants supporting fixed or removable prostheses: a comparative pilot study, *Int J Oral Maxilofac Implants* 6:413–417, 1991.
50. Ferrigno N, Laureti M, Farrali S, et al.: A long-term follow-up study of non-submerged ITI implants in treatment of totally edentulous jaws. Part 1: Ten-year life table analysis of prospective multicenter study with 1286 implants, *Clin Oral Implants Res* 13:260–273, 2002.
51. Krennmair G, Krainhofner M, Piehlslinger E: Implant-supported maxillary overdentures retained with milled bars: Maxillary anterior versus maxillary posterior concept—A retrospective study, *Int J Oral Maxillofac Implants* 23:343–352, 2008.
52. de Albuquerque Jr RF, Lund JP, Tang L, et al.: Within-subject comparison of maxillary long-bar implant retained prosthesis with and without palatal coverage: patient based outcomes, *Clin Oral Implants Res* 11:555–565, 2000.
53. Payne AGT, Solomons YF: Mandibular implant-supported overdentures: a prospective evaluation of the burden of prosthetic maintenance with 3 different attachment systems, *Int J Prosthodont* 13:246–253, 2000.
54. Hong HR, Pae A, Kim Y, et al.: Effect of implant position, angulation, and attachment height on peri-implant bone stress associated with mandibular two-implant overdentures: a finite element analysis, *J Oral Maxillofac Implants* 27:e69–e76, 2012.
55. Scherer MS, McGlumphy EA, Seghi RR, et al.: Comparison of retention and stability of implant-retained overdentures based upon implant number and distribution, *Int J Oral Maxillofac Implants* 28:1619–1628, 2013.
56. Dario LJ: A maxillary implant overdenture that utilizes angle-correcting abutments, *J Prosthodont* 11:41–45, 2002.
57. Walton JN, Huizinga SC, Peck CC: Implant angulation: A measurement technique, implant overdenture maintenance, and the influence of surgical experience, *Int J Prosthodont* 14:523–530, 2001.
58. Örtorp A, Jemt T, Bäck T, et al.: Comparisons of precision of fit between cast and CNC-milled titanium implant frameworks for the edentulous mandible, *Int J Prosthodont* 16:194–200, 2003.
59. Engquist B, Bergendal T, Kallus T, et al.: A retrospective multicenter evaluation of osseointegrated implants supporting overdentures, *Int J Oral Maxillofac Implants* 3:129–134, 1988.
60. Mericske-Stern R: Clinical evaluation of overdenture restorations supported by osseointegrated titanium implants: a retrospective study, *Int J Oral Maxillofac Implants* 5:375–382, 1990.
61. Johns RB, Jemt T, Heath MR, et al.: A multicenter study of overdentures supported by Brånemark implants, *Int J Oral Maxillofac Implants* 7:513–522, 1992.
62. Naert I, De Clercq M, Theuniers G, et al.: Overdentures supported by osseointegrated fixtures for the edentulous mandible: a 2.5-year report, *Int J Oral Maxillofac Implants* 3:191–196, 1988.
63. Phillips K, Wong KM: Space requirements for implant-retained bar-and-clip overdentures, *Compend Contin Educ Dent* 22(6):516–522, 2001.
64. Türk PE, Geckili O, Türk Y, et al.: In vitro comparison of the retentive properties of ball and locator attachments for implant overdentures, *Int J Oral Maxillofac Implants* 29(5):1106–1113, 2014.
65. Nascimento JFM, Aguiar-Ju´ nior FA, Nogueira TE, et al.: Photoelastic stress distribution produced by different retention systems for a single-implant mandibular overdenture, *J Prosthodont*, 2015 http://dx.doi.org/10.1111/jopr.12269. Article first published online: 6 FEB 2015.
66. Sadowsky SJ, Caputo AA: Effect of anchorage systems and extension base contact on load transfer with mandibular implant-retained overdentures, *J Prosthet Dent* 84:327–334, 2000.

67. Ferrigno N, Laureti M, Farrali S, et al.: A long-term follow-up study of non-submerged ITI implants in treatment of totally edentulous jaws. Part 1: Ten-year life table analysis of prospective multicenter study with 1286 implants, *Clin Oral Implants Res* 13:260–273, 2002.
68. Mericske-Stern R, Geering AH, Bürgin WB, et al.: Three-dimensional force measurements on mandibular implants supporting overdentures, *Int J Oral Maxillofac Implants* 7:185–194, 1992.
69. Lang BR, Razzoog ME: Lingualized integration: tooth molds for an occlusal scheme for edentulous implant patients, *Implant Dent* 1:204–211, 1992.
70. Jameson WS: The use of linear occlusion to treat a patient with combination syndrome: A clinical report, *J Prosthet Dent* 85:15–19, 2001.
71. Cooper LF, Limmer BM, Gates WD: "Rules of 10"—guidelines for successful planning and treatment of mandibular edentulism using dental implants, *Compend Contin Educ Dent* 33(5): 328–335, 2012.
72. Daher T, Meserkhani PV, Baba NZ, et al.: Time-saving method for the fabrication of a definitive cast for an implant supported prosthesis, *J Prosthet Dent* 98:70–71, 2007.
73. Cagna DR, Massad JJ, Daher T: Use of a powered toothbrush for hygiene of edentulous implant-supported prostheses, *Compend Contin Educ Dent* 32:84–88, 2011.

40

Implants in Acquired and Congenital Defects

ALAN S. HERFORD, KATINA NGUYEN, PIER PAOLO POLI

Introduction

Both acquired and congenital defects can present unique challenges for the reconstructive surgeon. Standard reconstructive techniques may be useful for repairing the majority of these defects. More complicated deficits may require advanced techniques, such as the use of growth factors or microvascular free tissue transfer of tissue from one part of the body to another.

There are many causes for acquired defects involving the upper or lower jaws. These include major trauma that can lead to both hard and soft tissue deficits. Both benign and malignant tumors can lead to loss of tissue, requiring reconstruction. Defects that result from the removal of malignant pathology can present with unique circumstances, including loss of significant hard and soft tissue as well as the possibility of postoperative radiotherapy. These characteristics can make reconstruction of defects more challenging and thus may require a more complex reconstructive approach.

Congenital defects can affect the maxillofacial skeleton and often require reconstruction of the missing tissue in order to optimize function for the patient. One of the most common congenital defects is an alveolar cleft lip, alveolus, or palate, with an incidence rate of 1:500 to 1:700 worldwide.[1] Bony defects to the maxilla affects approximately 75% of cleft lip or cleft lip and palate patients.[1] Other congenital defects include, but are not limited to, ectodermal dysplasia and congenitally missing teeth. All of these congenital disorders contribute to missing or hypoplastic tissue discrepancies in the maxilla and/or mandible that necessitate surgical intervention to restore function and esthetics. Reconstructing these deficits in a growing child with primary or mixed dentition can present unique challenges.

Dental implants have led to increased patient satisfaction. In restoring missing tissue, the goal is to provide enough bone to place dental implants and provide the patient with a functional reconstruction. This chapter focuses on specific acquired and congenital defects. We discuss the surgical options as well as advantages and disadvantages of various reconstructive options.

Acquired Defects

Major Trauma

Car accidents, assaults, and firearm injuries continue to be a major public health problem. In particular, firearm-related injuries are the second leading cause of injury-related death in the United States, with predominance in males and young adults.[2] The mechanism of injury is important and can help determine the preferred management for a specific wound. An example is high-velocity gunshot wounds, which typically result in avulsive-type injuries with a significant blast effect. These wounds are severely contaminated and are associated with a high incidence of infection. The current trend in facial gunshot injury comprises early conservative debridement, removal of traumatic tattoos and nonviable tissues, and use of primary reconstruction, when possible.[3,4]

Surgical management of traumatic facial wounds is divided into three stages: (1) debridement, fracture stabilization, and primary or secondary closure; (2) reconstruction of hard tissues, provided soft tissue coverage is adequate; and (3) rehabilitation of the oral vestibule, alveolar ridge, and secondary correction of residual deformities and reconstruction with dental implants.[3,5] Primary treatment of injuries to bone and soft tissues of select wounds may be carried out at the time of debridement, thereby minimizing the rates of hospitalization, procedures, and complications.[6] In the past, conservative methods for treatment of wound fractures have been recommended to avoid periosteal stripping of small, partially devitalized segments.[7,8]

Primary versus Delayed Reconstruction

Facial wounds represent a complex set of challenges for the surgeon due to significant soft tissue and bone defects. After

skeletal fixation, soft tissue coverage is crucial. In the acute and subacute setting, tissue coverage depends on wound dimension as well as the overall patient status. Although some surgeons advocate free flaps, others prefer "temporary" coverage and defer lengthy definite procedures to a time when the patient has stabilized. Secondary bone reconstruction typically ranges from 3 to 12 months following revitalization of injured tissues and maturation of scars[9,10] (Figure 40-1).

Classically, surgeons selecting delayed treatment have advocated for conservative debridement of soft tissue injuries and stabilizing bony injuries. After edema has resolved and soft tissues have healed to cover the wounds, final reconstruction can be performed. However, in a review of 33 facial reconstructions, Vásconez and colleagues observed similar infection rates between delayed and immediate postgunshot wound reconstruction.[11] The delayed group also demonstrated an increased incidence of wound contracture, which resulted in significantly more structural and functional deformity. In two other comparative reviews, Gruss and Vayvada and their associates also present improved results of immediate over traditional delayed approaches. These authors proposed that fewer and less complex revisionary procedures are necessary for patients who undergo immediate definitive reconstruction.[12,13] Motamedi advocates early management of facial gunshot defects, including early primary reconstruction of bone defects using fractured segments.[14]

Decisive factors for successful bone reconstruction are the severity of the injury, the degree of destruction of the soft tissue, and the degree of bone fragmentation. Correct positioning of the arch helps establish the proper facial width and frames the face. Improper reconstruction of the arch may result in incorrect framing for the remainder of the reconstruction. When a mandibular fracture is a component of gunshot wounds, reestablishing mandibular continuity and thus restoring occlusion first is advisable. Midface and mandibular bone defects larger than 5 mm should be bone grafted.[15] The donor area is determined by the degree of bone loss as well as the need for soft tissue reconstruction. Commonly used donor sites include the iliac crest and microvascular grafts from the fibula.

The final stage of reconstruction attempts to achieve optimal functional and esthetic results. Important components of secondary revision include flap debulking, dental implant placement, and scar revision.[3,16] Although recent reports link early definitive reconstruction with a decreased need for revisional surgery, a majority of patients might request some form of revision.

Pathology

Acquired defects of the jaws are often secondary to removal of various types of pathology. A wide range of tumors with different behaviors affects the jaws, ranging from benign to malignant. Characteristics including the type of pathology as well as location and size are important when considering treatment options. Considerations for the type of tumor may help plan for a significant soft tissue defect that may affect the treatment plan. Many malignant tumors will require resections and result in a large defect of both hard and soft tissue. These patients also may require postoperative radiotherapy, which can affect the decision on which type of reconstruction should be performed.

Segmental resection of the mandible due to inflammatory disease, congenital deformities, osteonecrosis (secondary to radiation or bisphosphonate use), or benign and malignant tumors may cause considerable functional, esthetic, and social problems. Segmental resection in the anterior mandible causes the muscles of the floor of the mouth and tongue to lose their insertion to the mandible. Support of the lower lip and the chin is also lost, which can lead to inadequate lip closure with drooling. Thus, oromandibular reconstruction is mandatory to restore mandibular continuity and surrounding soft tissues with sufficient bone height and adequate muscle attachment to allow for normal function improving the oral health–related quality of life.[17]

Mandibular reconstruction can be performed simultaneously with the resection or delayed, using either nonvascularized bone grafts or vascularized free flaps. The choice may be influenced by the patient's medical condition and age, quality of the vessels, vascularity of the recipient site, expected donor-site morbidity, the possible need for a two-team approach, surgeon's skills, and preference and available facilities.[18]

Grafting Options

Maxillomandibular defects can be treated by a variety of techniques. Characteristics of the defect, including geometry, size, and type of tissue missing are important considerations. Patient factors such as age, health status, and need for radiotherapy are also important. For defects that involve extremely large segments of missing bone with a soft tissue defect, strong consideration should be given to the use of a microvascular free graft. The fibula is associated with a high success rate for complex defects and may be the treatment of choice. A disadvantage of reconstruction utilizing the fibula is that the mandibular height is often not as high as the native mandible and may benefit from additional grafting.

Non-vascularized Bone Grafts

Several donor sites have been used to bridge defects of the mandible. At present, cortico-cancellous block graft taken from the anterior or posterior iliac crest is considered the method of choice in cases of defects less than 5 cm and characterized by good soft tissue using an extraoral approach. There are, however, risks associated with the donor site as well as the recipient site.[19] Non-vascularized bone grafts are often used in cases of benign lesions, where watertight closure of the intraoral wound is possible and in cases where the mucosa remains intact.[18,20] For large defects, the posterior ilium donor site may be considered because it provides a large quantity of bone and exhibits less morbidity when compared to the anterior iliac crest.[21,22] The survival of these non-vascularized grafts depends largely on revascularization

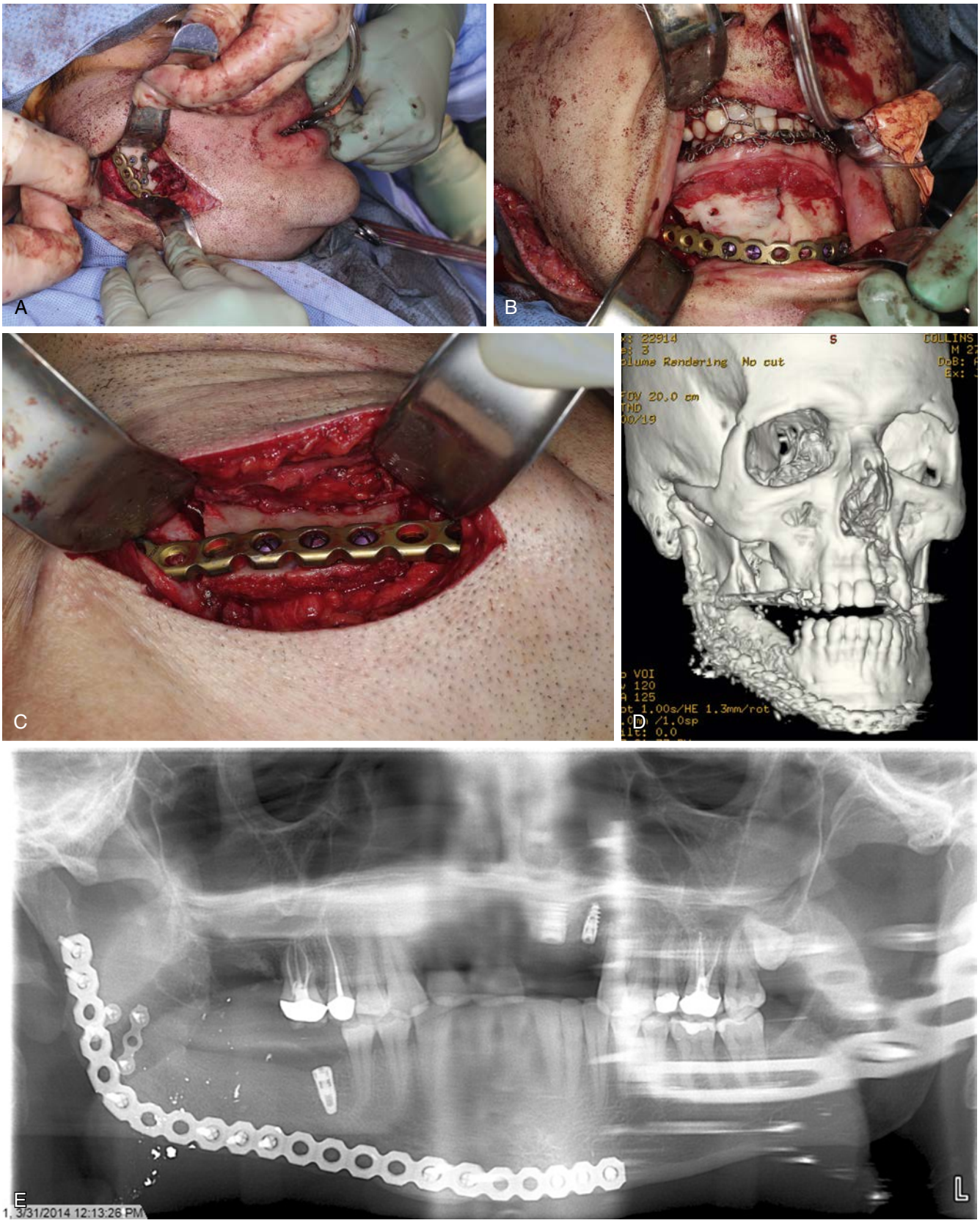

• **Figure 40-1** **A,** Gunshot wound with reduction and fixation of fractures. **B,** A reconstruction plate was used to provide continuity to the jaw. **C,** Placement of an iliac crest bone graft secured to the plate. **D,** Postoperative CT showing the restored continuity of the mandible. **E,** Radiograph showing implant reconstruction of grafted area.

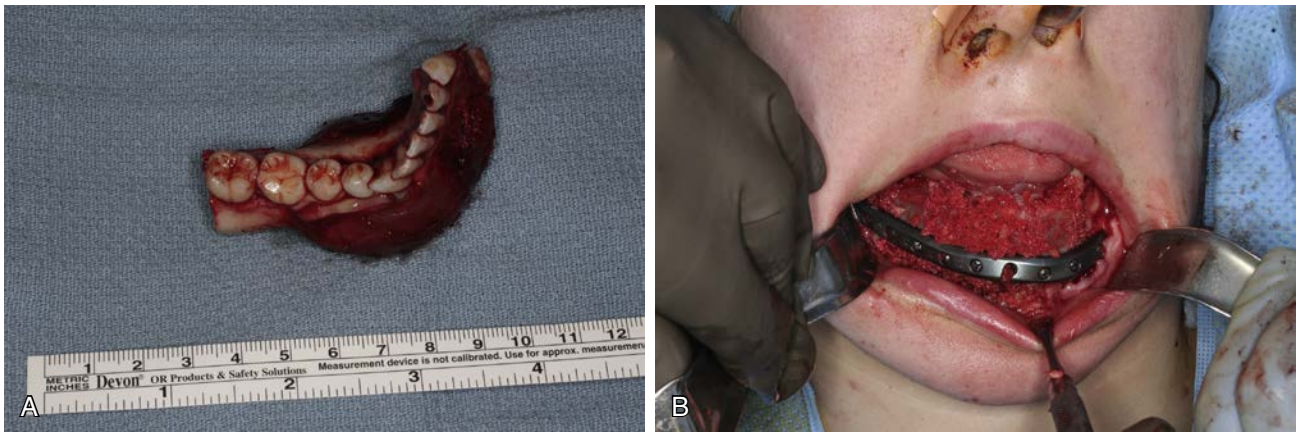

• **Figure 40-2** **A,** Resected bone segment. **B,** Blocks of bone are secured to the plate to aid in maintaining the mandibular height.

from the recipient site, by which the transplanted tissue undergoes resorption and deposition of new bone through the "creeping substitution" process. Grafts can be mainly cortical or cancellous in structure or a combination. Blocks of bone are often secured to a reconstruction plate to help maintain the desired height of reconstruction (Figure 40-2). Block grafts can restore continuity of the mandible as well as provide adequate height for implant reconstruction. The width of these grafts is usually sufficient to receive implants, which allows for occlusal rehabilitation; however, they are reserved for specific anatomic and clinical situations.[20]

Defects involving the anterior mandible as well as those that are grafted via an intraoral approach have been shown to be more difficult to reconstruct, with complication rates ranging from 20% to 36%.[18,23] Segmental resection in the anterior mandible causes the muscles of the floor of the mouth and tongue to lose their insertion to the mandible. Support of the lower lip and the chin may also be compromised. Intraoral wound dehiscence is a frequent complication, probably related to the intraoral approach and contamination of the wound with oral microorganisms.[24] Contamination can also occur postoperatively by leakage of saliva into the graft area, especially if rigorous suction of the wound drainage is applied.[25] The presence of dead space and a lengthy surgical procedure may also increase the risk of wound infection and dehiscence. Surgeons should therefore avoid contamination of the wound with oral microorganisms in general; if there is a communication of the wound with the oral cavity preoperatively, the mucosa should be closed with watertight sutures before placement of the bone graft. Cigarette smoking adversely affects wound healing and success of implant-related grafting procedures.[26,27] Therefore cessation of tobacco use is advised during the healing period.

Another reconstructive option is to use growth factors that are combined with a carrier. These grafts may be combined with an allograft, xenograft, or autogenous graft. When considering this type of reconstruction, note that providing a protected space for the bone formation is important for success. A titanium mesh has been described as beneficial for providing this "space maintenance."[28] RhBMP-2 (Infuse, Medtronic, Nashville, TN) has been used in an off-label manner for repair of these types of defects (Figure 40-3).

Transport distraction osteogenesis is another potential option to reconstruct segmental defects. An advantage of this technique is that both hard and soft tissues are reconstructed; however, a second surgery is required to remove the distractor. Distraction osteogenesis is also a consideration for increasing the height of the reconstructed bone secondarily (Figure 40-4).

Vascularized Free Flaps

Advancements in microvascular surgery allow a free tissue graft to be transferred with an intact blood supply to the recipient bed, due to microvascular anastomosis. Provided the graft is properly fixed, it will heal primarily at the site of the defect. Success rates of free vascularized bone flaps for the reconstruction of the mandible of 95% or higher have been reported.[29,30] No single type of free flap, however, is versatile enough to cope with the wide variety of composite mandibular defects. The choice of flap depends on several factors, including the type of bone and soft tissue (skin and/or oral) defect, vessel geometry of the donor and recipient sites, donor site morbidity, whether the patient is dentate or edentulous, need for dental implant rehabilitation, and often the type of training and individual preference of the surgical team.[20] Potentially, four donor sites are available for vascularized bone used in osseous reconstruction of the mandible: fibula, iliac crest, radius, and scapula; however, only the first two provide an adequate amount of bone for implant placement purposes. The scapula is associated with poor bone quality that may be unsuitable for dental implants, except in larger male patients.[31,32] The osseous fibular flap can provide up to 26 cm of strong cortico-cancellous bone with sufficient height to support osseointegrated dental

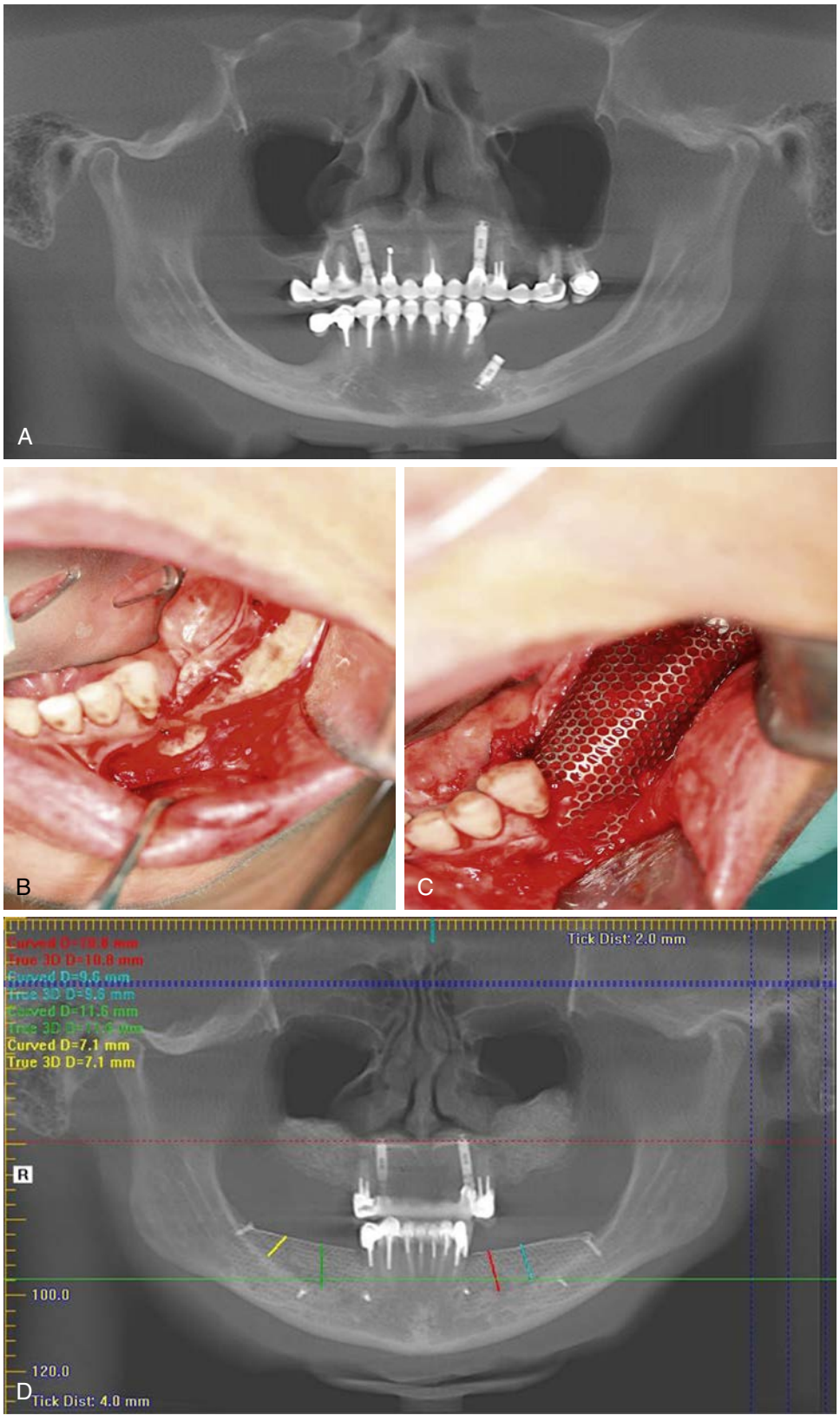

• **Figure 40-3** **A,** Preoperative radiograph showing deficient mandibular ridges. **B,** Exposure of deficient ridge. **C,** Use of a titanium mesh to maintain the graft in the desired location. **D,** Postoperative radiograph.

Continued

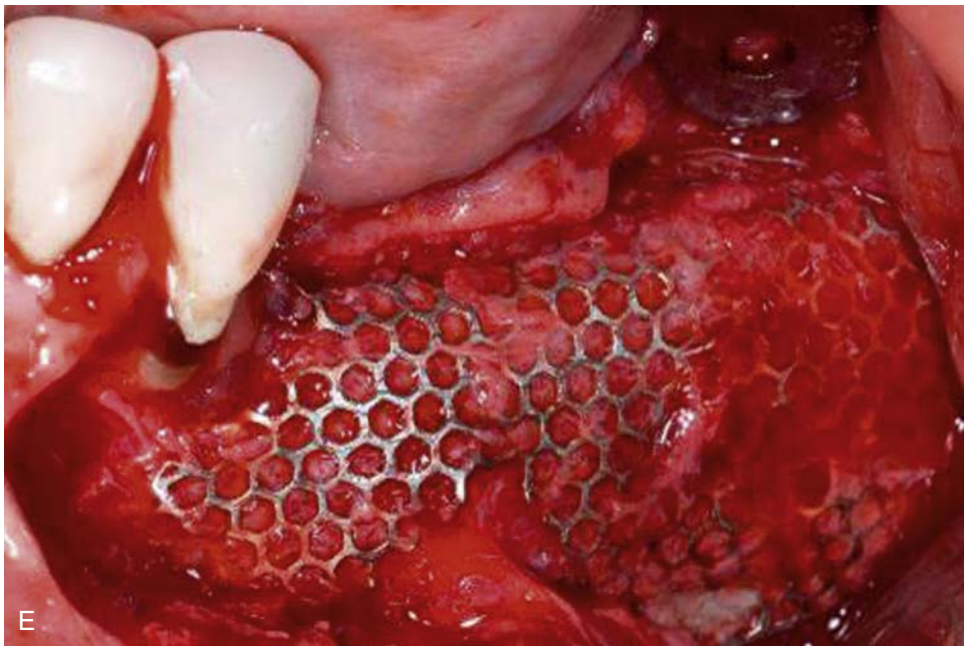

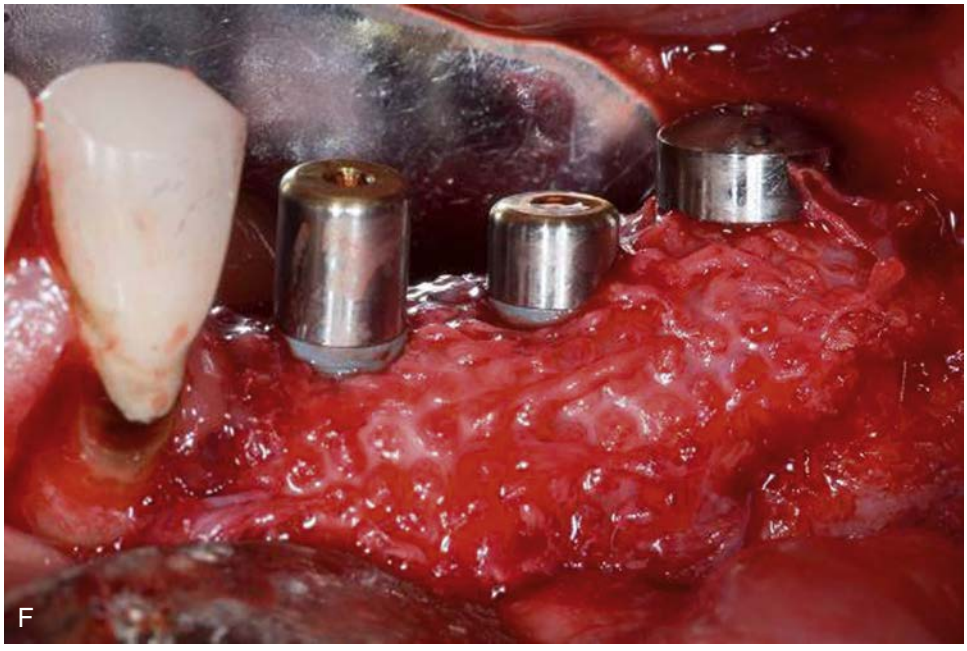

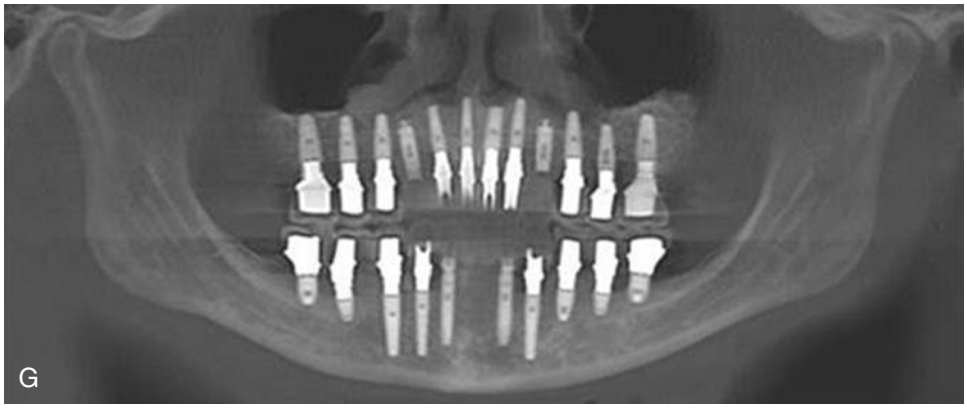

• **Figure 40-3, cont'd** **E,** The titanium mesh prior to removal. **F,** Placement of dental implants in the regenerated bone. **G,** Postoperative radiograph.

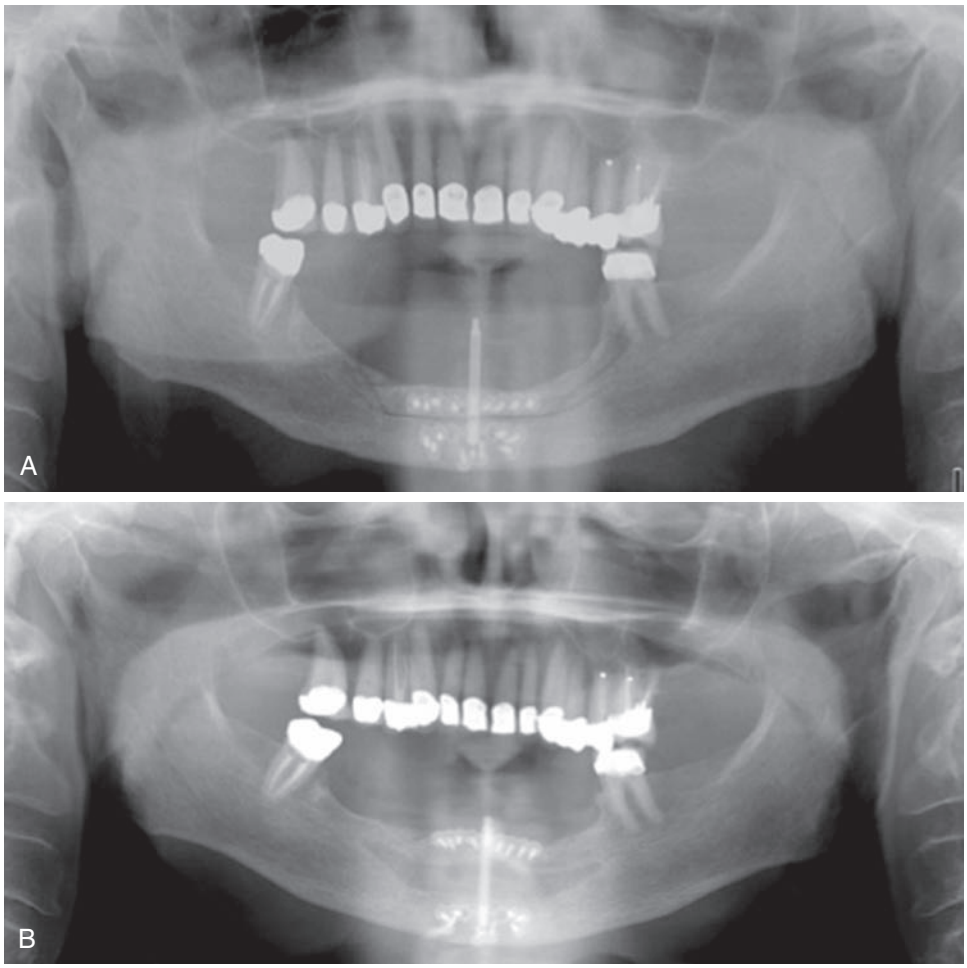

• **Figure 40-4** **A,** Distraction device in place. **B,** At completion of activation phase.

Continued

implants.[33] To achieve better implant:crown ratio after autogenous reconstruction of the mandible with fibula free flap, different techniques have been suggested, including the use of double-barreled reconstruction, distraction of the recipient site, and additional free bone grafting and cortico-cancellous iliac grafts (Figure 40-5). In double-barreled reconstruction, there is risk of blocking the blood supply to the graft, which causes flap failure. Distraction osteogenesis avoids issues with donor site morbidity, soft tissue limitations of the recipient site, and unpredictable graft resorption.[34]

Maxillary Reconstruction

The basic principle of reconstruction is to rebuild anatomic structures with tissue as similar as possible to that found in the resected area in order to restore not only the occlusion, but also the contours of the midface and the resulting esthetics (Figure 40-6). Various classification systems have been proposed for maxillectomy defects to predict both the functional and esthetic outcome likely to result from surgery and relate that to the method of obturation or reconstruction for each type of defect.[35] The surgical defect is classified according to the vertical dimension of the maxillectomy (Class I to IV), which relates to the involvement of the orbit and skull base and the resultant esthetic deformity.

Reconstruction depends on the amount of deficient tissue, goal of reconstruction (anatomic reconstruction vs. full dental rehabilitation), and the preexisting situation, including the presence of vessels after tumor ablation, previous surgery, and/or radiotherapy in combination with a neck dissection.[35] Obturation has been the traditional method of rehabilitation for a maxillectomy patient, but in recent years a wide variety of reconstructive options have become available.[36] Class I defects can be reconstructed without particular problems by relatively simple local flaps. With the help of microsurgical flaps, reconstruction may achieve an esthetic and functional result, which may meet the patient's expectations and demands. Composite flaps consisting of bone and soft tissue can simultaneously reconstruct the soft and hard tissue components of the defect, and later on, implants for dental rehabilitation can be inserted to accomplish a more functional and esthetic appearance, especially in the midface. The length of the vascular pedicle is an important factor, as are the thickness of the skin, muscle,



• **Figure 40-4, cont'd** **C,** Restored dentition. **D,** Postoperative radiograph.

and subcutaneous fat. Additionally, the volume of the available tissue, the durability and thickness of the bone, and the morbidity of the donor site are important factors that should be considered.[37] In comparison with other bone flaps, the fibula osteocutaneous flap is often the preferred method in large facial reconstruction, providing bone dimensions adequate for implant placement.[38,39]

Dental Implants

Osteointegrated dental implants have had a great impact on patients' quality of life following jaw reconstruction. Osseointegrated implants have afforded major advances in the reconstructive management of patients with oral neoplasms because they allow stabilization of implant-supported and implant-retained prostheses. This results in improved mastication and esthetics, as well as psychological benefits.[40,41] Implant survival rates are reported to be 81% to 99%, averaging 87% in studies ranging from 0 to 10 years in head and neck cancer patients.[42] Factors considered in selecting patients for this procedure include patient general condition, surgical timing, ablative procedure and type of graft, perioperative radiation therapy, implant placement technique, and dental prosthesis.[43]

The orofacial anatomic alterations resulting from tumor resection, regional surgery, and placement of a pedicle or microsurgical flap include an increase in thickness as a result of the skin of the flap used, insensitivity, changes in the masticatory muscles, loss of proprioceptive sensitivity and of labial vestibular space, altered tongue mobility, and irregularities in bone contour. Many patients are unable to wear removable dentures. If radiotherapy is applied, the patient will have xerostomia and mucosal atrophy, which further complicates the wearing of removable dentures because of local irritation, ulceration, and bone exposure.[40]

Patient General Conditions

The presence of inadequate mouth opening, severe periodontal disease, caries, stomatitis, or any adjacent mucosal infection may compromise osseointegration of the

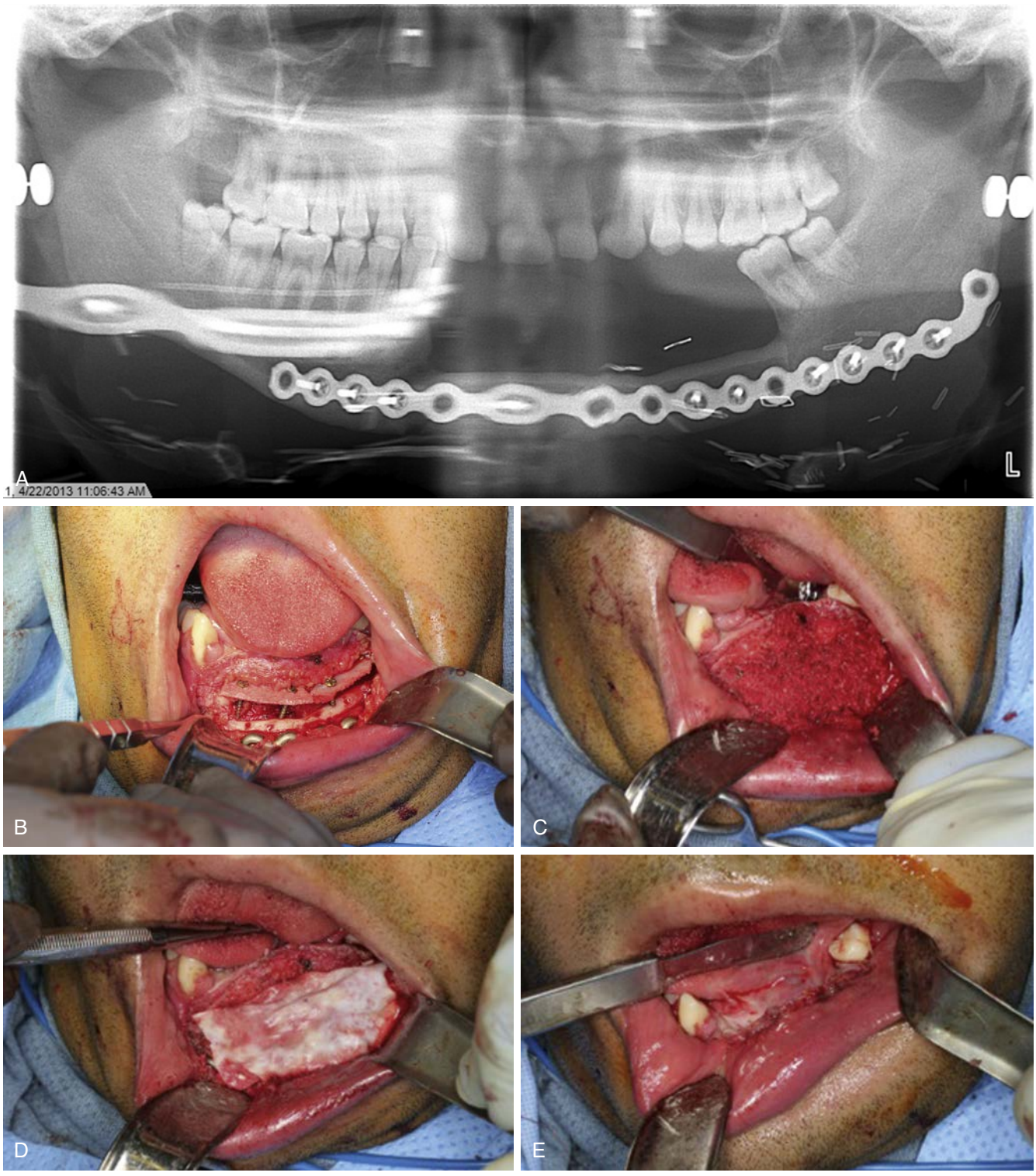

• **Figure 40-5** **A,** Radiograph showing inadequate height for dental implants. **B,** Placement of iliac crest bone grafts to restore height of mandible. **C,** Placement of cancellous graft into the defect. **D,** Coverage with a collagen membrane. **E,** Closure over graft.

Continued

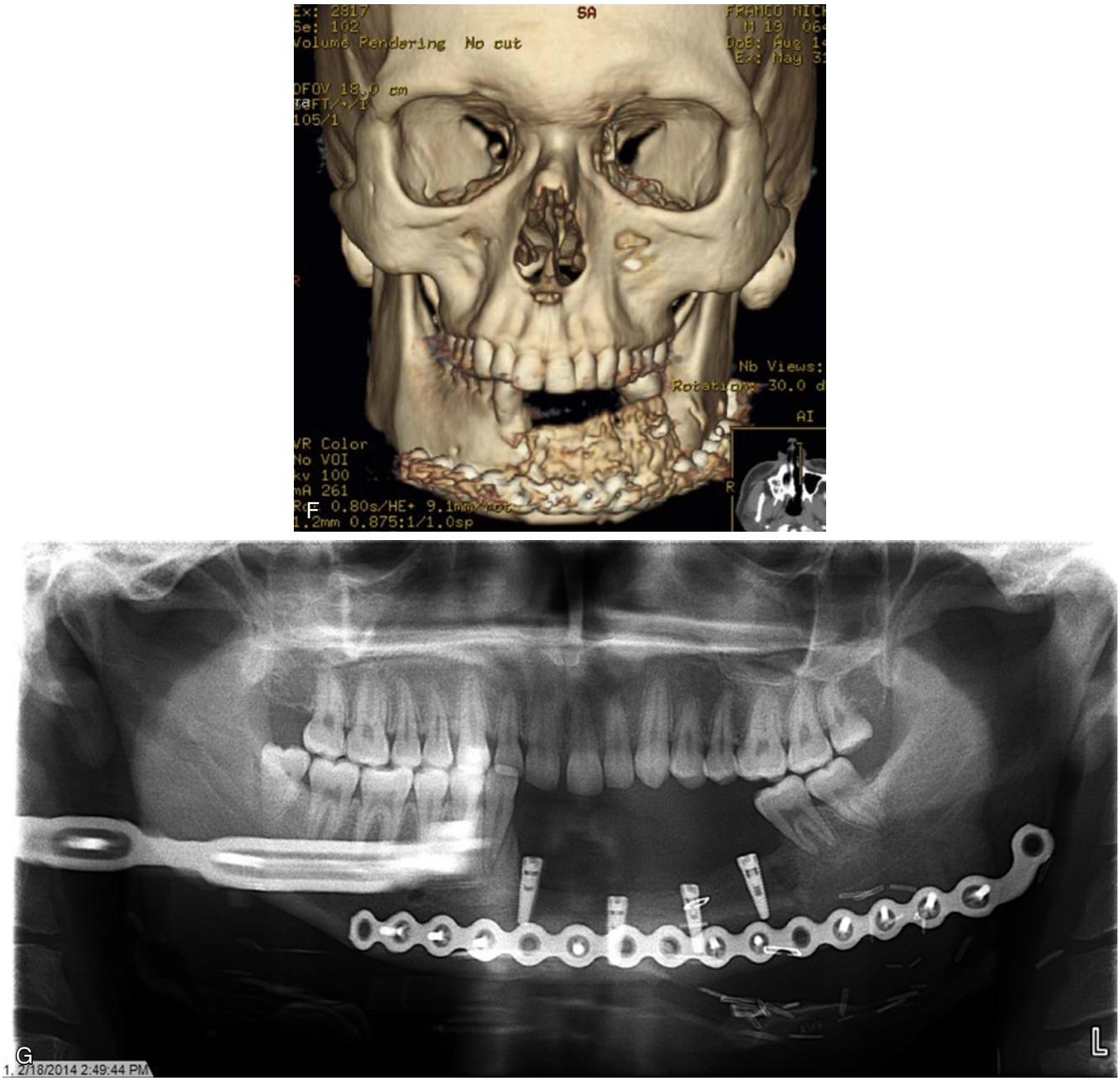

• **Figure 40-5, cont'd** **F,** Postoperative radiograph. **G,** Implants in place.

implants.[44] Meticulous oral hygiene after the surgery must be extensively explained to the patient, as this is critical for the long-term success and maintenance of dental implants. Also important are patient expectations and motivation. Understanding and cooperation are needed to continue with subsequent stages of prosthetic rehabilitation.

Surgical Timing

Implants can be placed primarily at the time of reconstruction or secondarily at a later date. Riediger described placing deferred implants in microsurgical flaps, whereas Urken and colleagues pioneered immediate implant placement at the time of free flap reconstruction.[45,46] The placement of implants simultaneously with the reconstruction increases operative time and may be less precise. This can result in minor implant misalignment, which may mean that patients must wear a removable rather than a fixed dental appliance. In addition, simultaneous implants may have to be removed in case of tumor recurrence, the incidence of which is highest during the first postoperative year.[30,47] On the other hand, proponents for primary placement of dental implants into vascularized bone grafts describe some advantages, such as eliminating one surgical

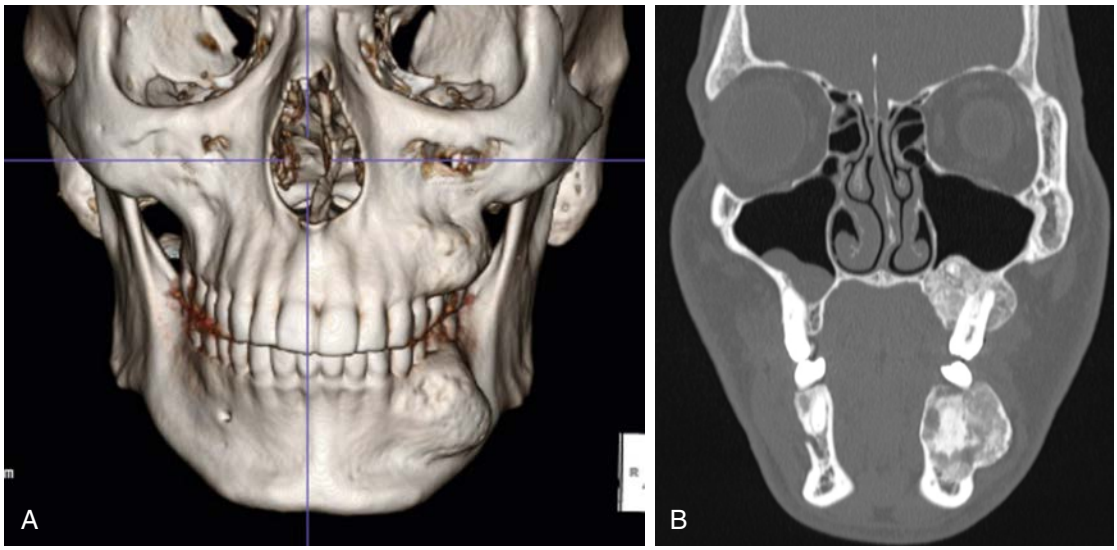

• **Figure 40-6** **A,** Radiograph showing a maxillary and mandibular tumor. **B,** Coronal radiograph showing the area of the lesions.

Continued

procedure for the patient and having better access to the bone at the time of reconstruction. The ability to obtain adequate dental ridge relationships and avoid inclination of the implants as well as the ability to achieve earlier dental rehabilitation and psychological stability are other possible advantages. Furthermore, the implantation site has not been compromised as a result of radiotherapy, thereby bypassing the need for preventive antibiotics and hyperbaric oxygen therapy prior to implantation to reduce the risk of osteoradionecrosis.[48] When dealing with malignant tumors, recurrence rate and general prognosis must be carefully considered before proceeding with simultaneous placement of osseointegrated implants together with primary reconstruction.

At the time of implant uncovering, the skin paddle can be thinned or removed and replaced by a skin graft. Finally, the dental prosthesis is secured to the implants approximately 1 month later.[49] In a recent retrospective study, with respect to implant loss in relation to postoperative radiation, no statistically significant differences were seen between implants placed during ablative surgery into free flaps as compared to those that were delayed. Both groups showed an implant failure rate of 9%.[50] This result corroborates a systematic review comparing failure rates for implants placed either before or after irradiation. Failure rates (5.4% and 3.2%, respectively) for both groups were similar and not statistically significant.[51]

Ablative Procedure and Type of Graft

Although vascularized free flaps and non-vascularized bone grafts are both widely used to reconstruct the mandible, significant differences exist when considering the reliability of each form of reconstruction. Foster and coworkers were the first to directly compare bone healing and osseointegrated implant success between vascularized and non-vascularized grafts.[30] Patients reconstructed with vascularized grafts were older and had larger defects, and most had undergone postoperative radiotherapy. The incidence of bony union in these patients was higher, they required fewer operations to achieve union, and implant success rate was significantly greater than for patients reconstructed with non-vascularized bone grafts. The significant difference in osseointegration rates between vascularized and non-vascularized grafts is believed to be related to the structure of the bone graft and to the level of osteoblastic activity throughout the graft. Because of the uneven distribution in the blood supply of a non-vascularized graft, the osteoblastic activity, which is important to bone integration, is variable. Furthermore, the graft may lack sufficient cortical bone for stabilization of the implant fixture at the time the implants are placed in the graft. When vascularized grafts are used for mandibular reconstruction, the time span from tumor resection to the completion of the dental restoration is significantly shorter than when non-vascularized grafts are used, particularly if dental implants are placed at the time of the mandibular reconstruction (10 vs. 21 months, respectively). A trend for reduced implant survival in fibula free flaps as compared with the native mandible and maxilla (91.8%, 97.4%, and 97.8%, respectively) was reported; however, this difference did not reach statistical significance.[43]

Irradiated Patients

Besides surgery and chemotherapy, radiotherapy is an essential part of treatment in patients suffering from head and neck cancer. After radiotherapy, the vascularization and regenerative ability of irradiated tissues decreases and the process of osseointegration may be impaired. Initial changes in the bone caused by radiotherapy arise from direct injury to the remodeling system.[52] Radiation results in damage to the osteoclasts and decreases proliferation of bone marrow, collagen, and blood vessels.[53] Furthermore, vascular injury

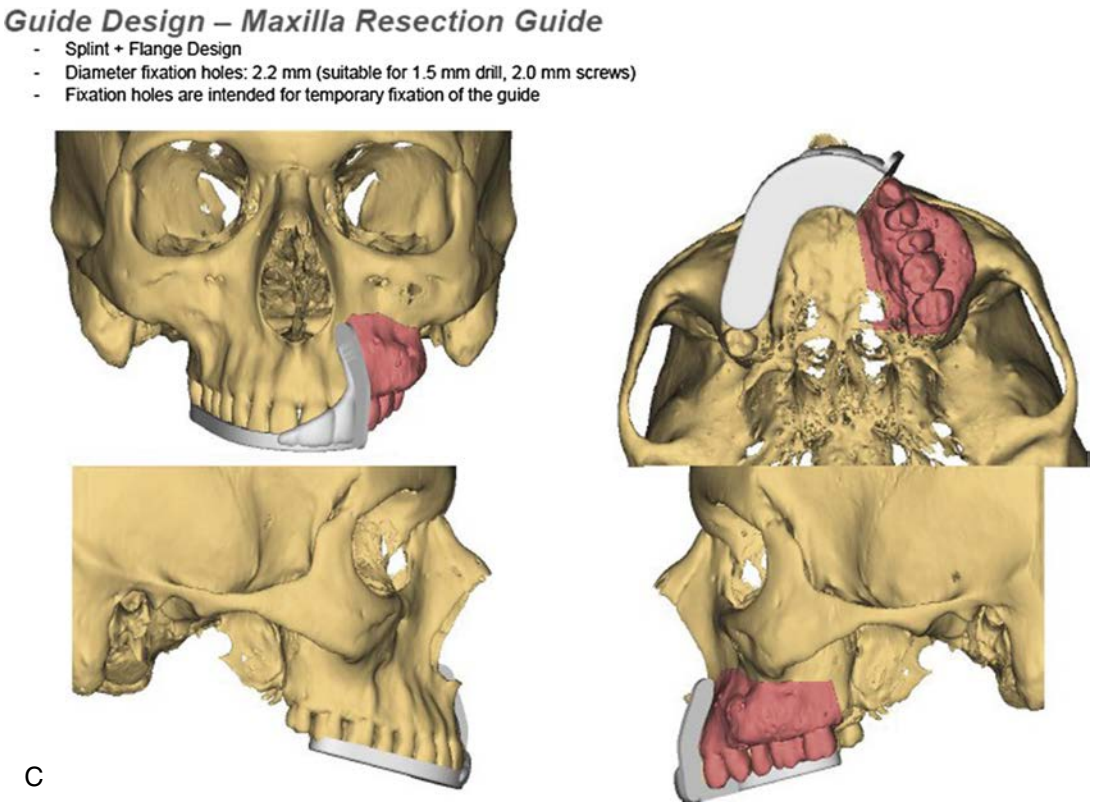

C

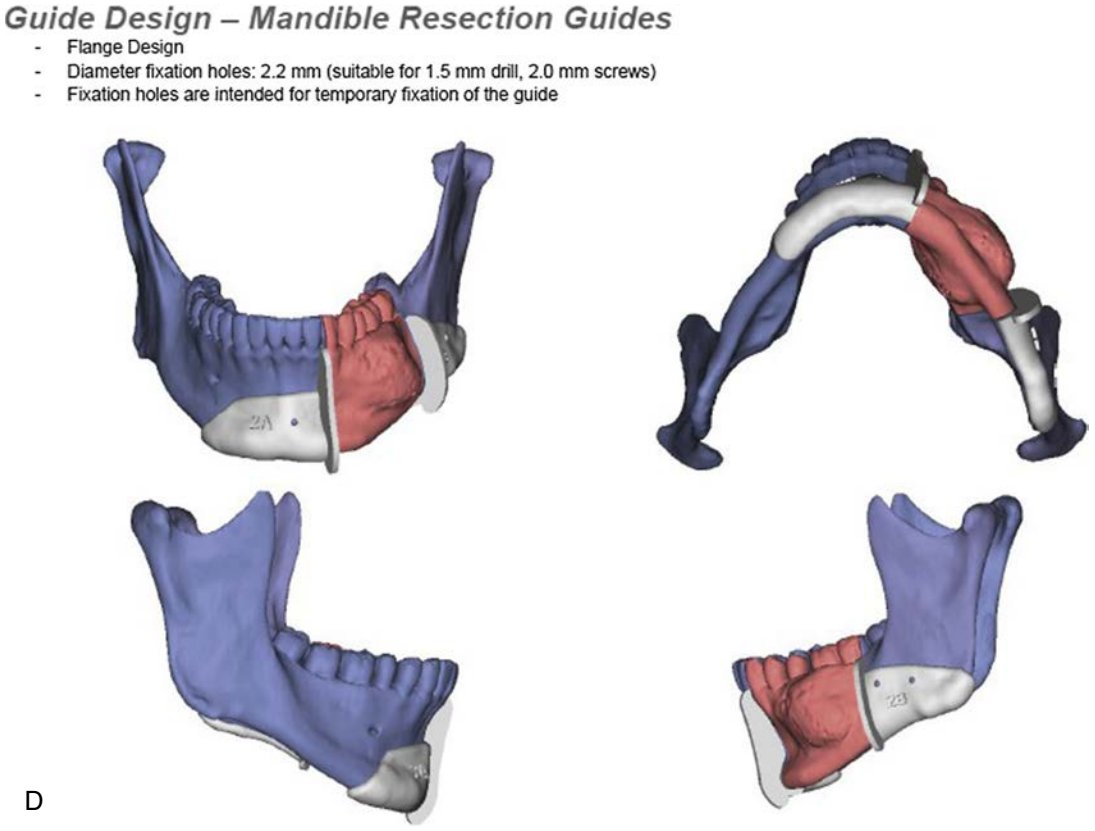

D

• **Figure 40-6, cont'd** **C,** Surgical guides for maxilla resection. **D,** Surgical guides for mandibular resection.

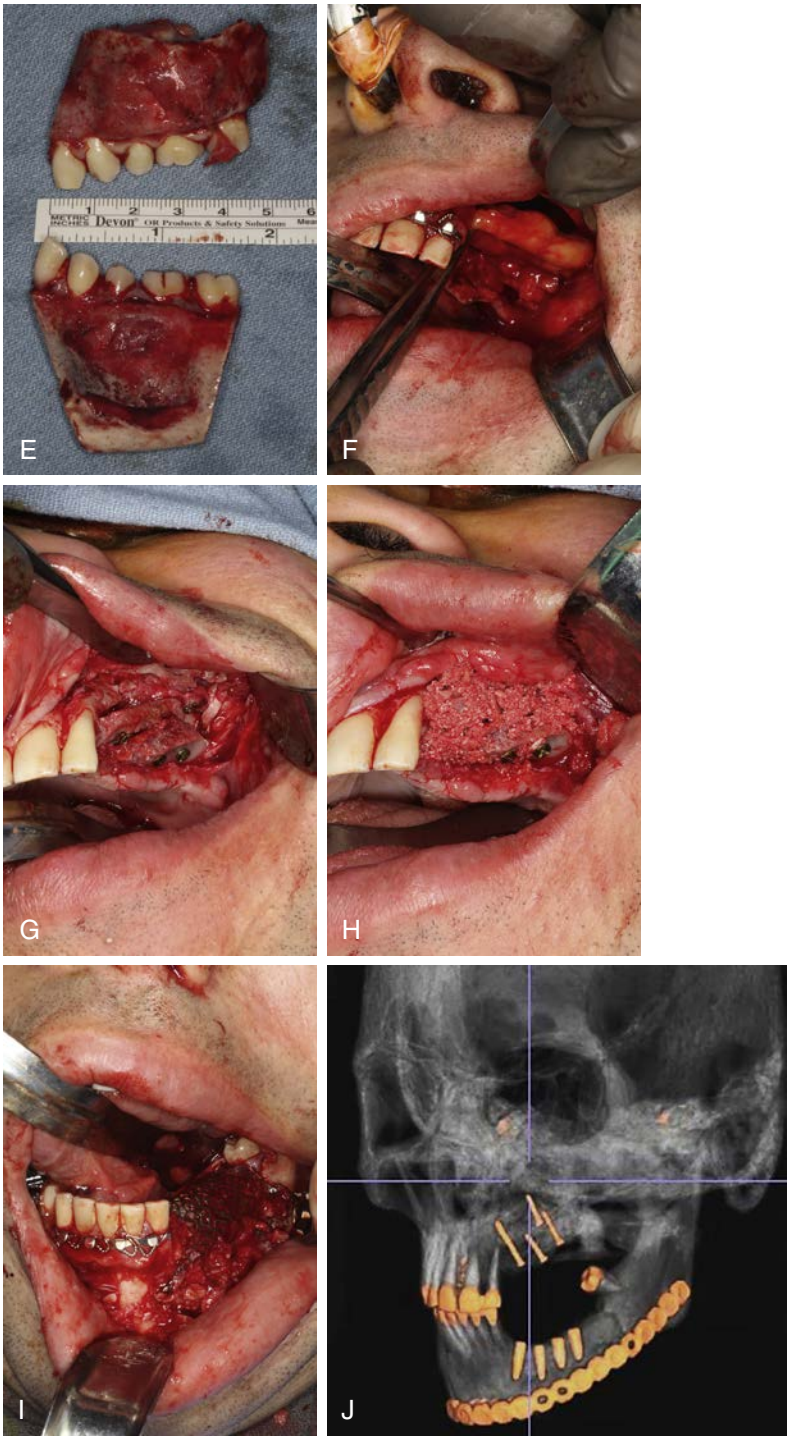

• **Figure 40-6, cont'd** **E,** Resected tumors. **F,** Advancement of a fat pad flap to provide separation of the graft and maxillary sinus. **G,** Placement of an iliac crest bone graft. **H,** Placement of cancellous graft prior to closure. **I,** Reconstruction of mandibular defect. **J,** Postoperative radiograph showing implants in the mandible.

induces endarteritis with decreased microcirculation, as well as thrombosis with a progressive occlusion and obliteration of small vessels. With time, the bone marrow shows hypocellularity and hypovascularity with marked fibrosis and fatty degeneration.[52,54] These changes often lead to compromised bone healing and reduced viability that affects integration of the dental implant in bone.

Radiotherapy was initially considered a contraindication for placement of osseointegrated implants in patients with cancer.[55] Subsequently, high survival rates of implants placed in irradiated bone were reported, reinforcing the safety of placing implants in patients who have received radiotherapy as part of their treatment.[56-58] Survival rates of 92.6% and 96.5% for implants placed in patients with and without

irradiation were reported, respectively. Implant losses in patients with irradiation occurred mainly because of peri-implant infection or asymptomatic peri-implant bone loss and consecutive integration loss. A meta-analysis, including studies published from 2007 and 2013, compared implant survival between non-irradiated and irradiated native bone with a follow-up of at least 5 years. It revealed no statistically significant difference in implant survival. On the other hand, a meta-analysis of the implant survival between the irradiated native bone and the irradiated grafted bone indicated a statistically significant higher implant survival in the irradiated native bone compared with the irradiated grafted bone (72% to 100% vs. 54% to 98%, respectively). Hence, a coincidence of grafted bone and radiotherapy is a negative prognostic factor regarding implant survival.[59] Implant survival is significantly influenced by the location, the incidence of bone resection surgery in the jaw, and the irradiation dose. Visch and colleagues observed that: (1) implants inserted into the maxilla and mandible showed a significant survival difference (59% and 85%, respectively) due to differences in bone quality, bone volume, and vascularization; (2) a significantly lower survival rate was found for implants inserted into jaws treated with bone resections compared with that of implants inserted into jaws that did not undergo bone surgery (61% and 83%, respectively) because bone resections can result in unfavorable prosthetic circumstances by producing bulky and soft areas; (3) implants inserted into locations irradiated with greater than or equal to 50 gray have a significantly lower survival rate than implants in locations that are irradiated with less than 50 gray (73% and 84%, respectively).[60]

For implant osseointegration, clinical experience suggests that implants should be placed at least 6 months after the end of the consolidation period for non-vascularized grafts, and implant loading should be delayed 6 months after implant placement.[59,61] A secondary technique might allow better assessment of oral function, disease status, and possible recurrences and assists in achieving successful osseointegration in the irradiated jaw.[41,56] Esser and Wagner recommended a minimum interval of 9 to 12 months from radiotherapy to implant placement.[62] In a recent systematic review, post-implantation radiation therapy had a slightly better overall dental implant survival rate (92.2%) than pre-implantation radiation therapy (88.9%). However, this could not be verified statistically because of the marked differences in the numbers of studies reported in each group.[63] Thus, recommendations for an optimal time interval between radiotherapy and implant surgery are inconsistent and range from <6 months to >24 months.[64]

Hyperbaric Oxygen (HBO) Therapy

The success of implantation in irradiated bone may be improved using hyperbaric oxygen (HBO) therapy because HBO therapy results in increased oxygen tension in irradiated ischemic bone and provokes capillary angiogenesis and bone formation, improving healing capacity and, hence, the process of osseointegration.[65-67] There are, however, recent series in the literature that have reported acceptable outcomes in osseointegration of implants placed in irradiated bone without previous HBO therapy.[68,69] Despite the limited amount of clinical research available, it appears that HBO therapy in irradiated patients requiring dental implants may not offer any appreciable clinical benefits.[70] To date, more reliable studies are needed to determine a benefit for HBO therapy in preventing failure of dental implants or other serious complications, such as the death of bone in the jaw caused by radiotherapy treatment.[70]

Zygomatic Implants

In some clinical situations, including patients who underwent traumatic bone loss or resective surgery for oral cancer, there is insufficient bone to allow implant placement, or the patient may not be a candidate for harvest of a graft. Zygomatic implants may be an option for these select patients. Zygomatic dental implants are long screw-shaped implants developed as a partial or complete alternative to bone augmentation procedures for the severely atrophic maxilla. Currently, zygomatic implants are commercially available with an oxidized rough surface, a smooth mid-implant body, a wider neck at the alveolar crest, and a 55-degree angulation of the implant head.[71] Zygomatic implants can be used to fix maxillary prostheses and/or obturators as an alternative to non-implant retained obturators, local and regional flaps, and microvascular free flaps.[72] One to three zygomatic implants can be inserted through the posterior alveolar crest and the maxillary sinus to engage the body of the zygomatic bone. In order to use an anatomically and more prosthetically driven approach, the original technique has been modified by allowing an extra-sinus path for zygomatic implants. A recent retrospective study reported patient- and implant-related cumulative success rates of 97% and 98.8%, respectively, evaluating immediately loaded zygomatic implants placed in an extramaxillary manner for the rehabilitation of completely edentulous atrophic maxillae over a 5-year follow-up period, corroborating the satisfactory outcomes of the procedure.[73] Zygomatic implants can be left to heal submerged for up to 6 months, or they could be successfully loaded immediately.[74] It is believed that two zygomatic implants are not sufficient to hold a fixed denture, and that at least two additional conventional implants should be placed in the anterior portion of the maxilla. This can only be accomplished if there is sufficient bone in the anterior portion of the maxilla; otherwise, bone grafting is still needed. An alternative is to place two or three zygomatic implants in each zygoma.[75]

Contraindications to the use of zygomatic implants include acute sinus infection, maxillary or zygoma pathology, and patients unable to undergo implant surgery because of underlying uncontrolled or malignant systemic disease. Any pathology of the maxillary sinus should preferably be treated before placement of the zygomatic implant.[71] The most common and serious reported complications with zygomatic implants are sinusitis (up to 21% of patients[74]), zygomatic implant failures (up to 11% of patients[76]), and perforation

of the orbit (up to 6% of patients[77]). Other reported drawbacks included intrasinus osteitis, obstructed infundibulum, presence of an accessory ostium, and atelectasis.[78]

Despite several retrospective and prospective case series studies, no randomized controlled trials are available comparing zygomatic implants with or without bone augmentation techniques for the rehabilitation of the severely atrophic maxilla. Thus it is currently not possible to give reliable evidence-based advice to potential users with respect to the efficacy of zygomatic implants as an alternative to various augmentation procedures for severely deficient maxillae.[79]

Congenital Defects

Careful interdisciplinary treatment planning is necessary for rehabilitation of oral function in patients suffering from a congenital anomaly. There is not enough evidence to state that endosseous dental implants are a better treatment option than orthodontic gap closure in cleft patients; however, dental implants may result in a more esthetic and functional outcome in restoring the bony alveolar defect, especially in cases of unilateral cleft lip and palate. In ectodermal dysplasia patients, the considerable number of missing teeth necessitates the need for grafting and implant placement prior to prosthetic rehabilitation.

Congenitally Missing Teeth

A frequent dental anomaly is congenitally missing teeth. The most commonly missing are the maxillary lateral incisors, followed by the third molars and the mandibular first premolars[80] (Figure 40-7). Approximately 120 different syndromes are associated with missing teeth, such as ectodermal dysplasia, cleft lip and palate, and Down syndrome.[80] Missing teeth, especially in the anterior region, may affect esthetics and function, thus requiring surgical interventions, such as bone grafting and dental implants.

Cleft Lip and Cleft Lip and Palate

The alveolar cleft may affect the developing dentition and contribute to the collapse of alveolar segments. Failure to repair this defect in a timely manner may give rise to future issues of esthetics and function. Issues that may arise include oral-antral fistula, speech pathology, lack of bone support for anterior teeth, dental crowding, fluid reflux, anterior-posterior and transverse discrepancy of the maxilla, and facial asymmetry.[81] The reported incidence of missing teeth in the permanent dentition of cleft patients is approximately 30% to 50%, which is a sixfold higher rate than in non-cleft patients.[81] Although alveolar bone grafting has been widely accepted, there is still controversy as regards to the technique, timing, and bone grafting material.

Surgical Timing

The optimal time for bone grafting is controversial. Boyne and Sands described the steps of surgical grafting with chronological nomenclature based on age of the patient.[82] Primary bone grafting occurs when the patient is younger than 2 years of age. Early secondary bone grafting is carried out in patients between the ages of 2 and 5 years old. Secondary bone grafting occurs in patients more than 5 years of age. Tertiary bone grafting occurs when the patient has reached the age of 17 years. Adverse effects may occur with primary bone grafting, which include developmental defects affecting maxillary growth, severe crossbite, and poor alveolar morphology with unerupted or unsupported teeth.[83] Early secondary bone grafting improves orofacial development. The most commonly used method today is secondary bone grafting. The optimal age for secondary grafting is often described as being between 8 and 11 years old during mixed dentition, which should coincide with when the maxillary canine is approximately two-thirds developed.[83] Even with this accepted standard of care, there is still controversy as to the age at which the secondary bone grafting should take place, the type of bone graft, and whether orthodontic intervention should take place before or after the surgery.[84] Bone grafting materials such as hydroxyapatite or lyophilized bone are not suitable for cleft grafting because the materials do not allow tooth eruption, teeth are unable to migrate into the graft site, and teeth cannot be orthodontically shifted into the space.[85]

Secondary Bone Grafting Procedure

During the secondary bone grafting procedures, the following are the general steps. Initially, mucoperiosteal flaps of the palate and vestibular surfaces of the maxillary segments are made to expose the alveolar bony defect. The mucosa is inverted in order to establish the floor of the nose. Next, the graft is packed into the defect. All flaps will be sutured together to close the oral layer over the bone graft in the cleft site. An alternative to harvesting autogenous bone is to consider the off-label use of recombinant human bone morphogenetic protein-2 (rhBMP-2) combined with a collagen sponge, thus minimizing morbidity by eliminating the need for a secondary harvest site[86] (Figure 40-8).

Benefits of Secondary Bone Grafting

Grafting of the alveolar defects gives bony support to the teeth adjacent to the cleft and greatly enhances the follow-up orthodontic treatment. It gives a bony base for eruption of teeth in the line of the cleft and prevents drifting of proximal teeth into the cleft with subsequent premature loss. It provides union to the maxillary arch and reestablishes alveolar bone contour. This provides support for arch width and minimizes collapse of the maxillary arch. The maxillary segments are stabilized for the maintenance of the dentition and mastication. The oronasal fistula is eliminated to improve oral hygiene as well as speech. And above all, it provides the bony support needed to either place dental implants to restore the function and esthetics of the patient or move the laterals medial to substitute for a missing lateral incisor.[87]

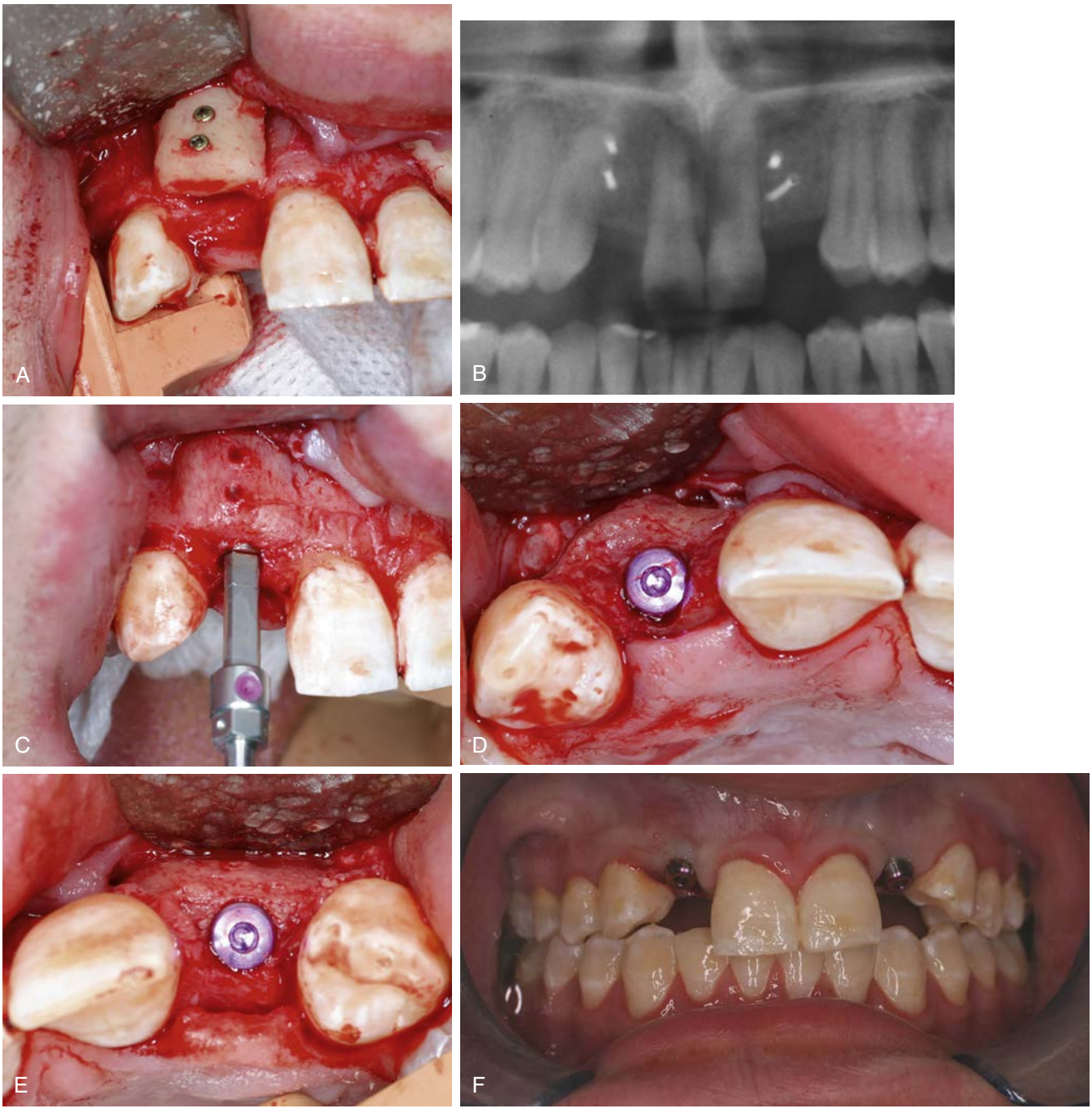

• **Figure 40-7** **A,** Placement of a ramus graft to restore missing lateral incisor. **B,** Postoperative radiograph. **C,** Placement of a dental implant. **D,** Implant in place on the right. **E,** Implant in place on the left. **F,** Osseointegrated implants.

Implants in Cleft Patients

Conventional treatment of the cleft lip and cleft lip and palate patient is usually with a fixed or removable prosthetic reconstruction. An alternative treatment option is bone grafting followed by subsequent dental implant placement. Implant placement is best done when orofacial growth is completed to ensure the best functional outcome. The issue with placing implants in a cleft patient is the lack of quality mucoperiosteum for reconstruction, and the fact that previous surgeries may have caused scar tissue in the desired implant site, which may affect the esthetics of the overall outcome in the anterior maxilla. Additional bone grafting is often necessary prior to implant placement to ensure adequate bone volume (Figure 40-9). The survival rate of implants is lower in cleft patients than in non-cleft patients. A systematic review has shown that 5-year implant survival rates for cleft patients are approximately 80% to 96%, with a mean of 88.6%.[85] Simultaneous tertiary bone grafting with immediate implant placement is not recommended;

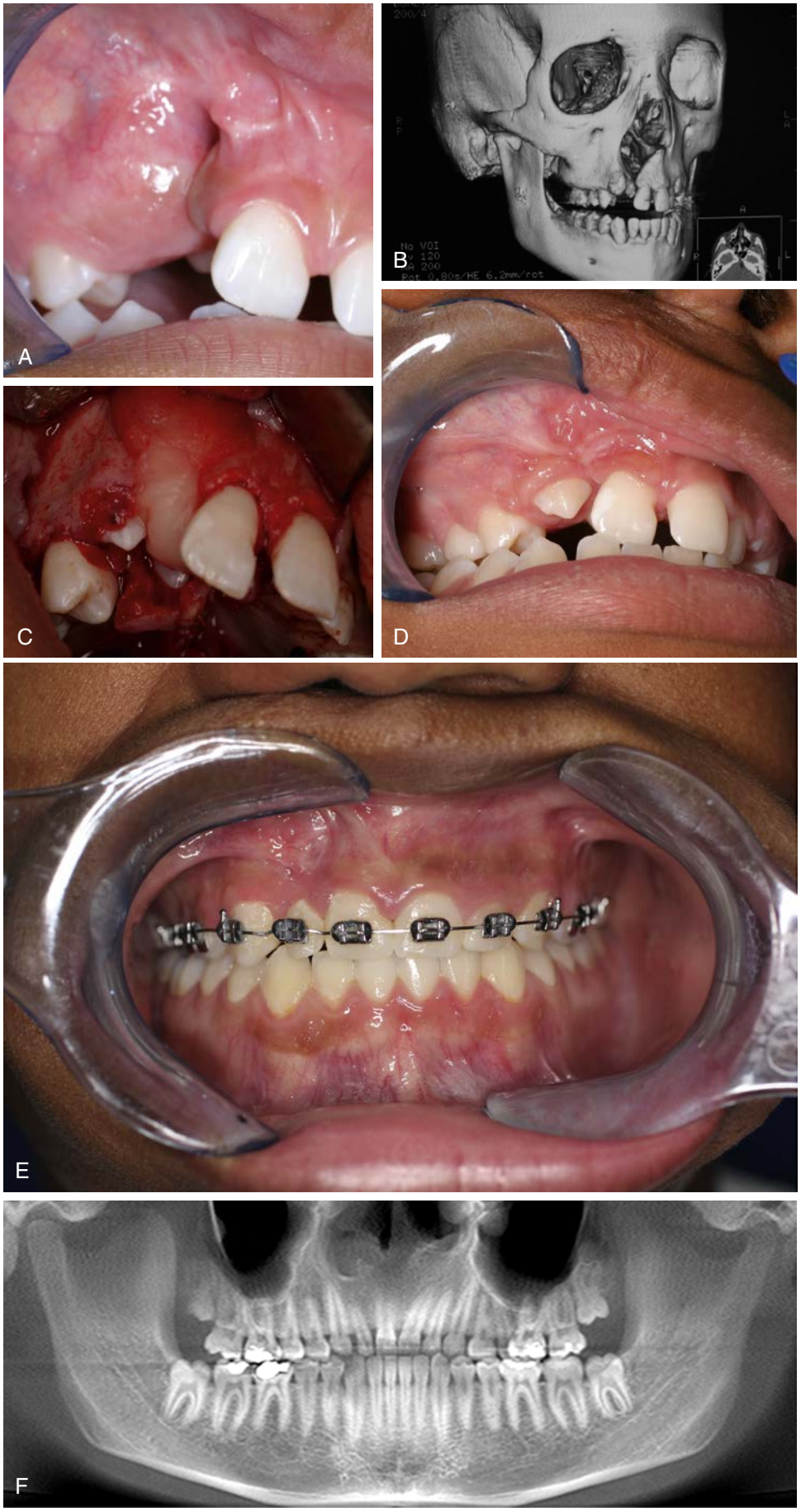

• **Figure 40-8** **A,** Alveolar cleft. **B,** Radiograph showing cleft area. **C,** Placement of rhBMP-2 with a collagen sponge into defect. **D,** One week after graft. **E,** Occlusion 5 years later. **F,** Radiograph showing excellent bone fill in area of cleft.

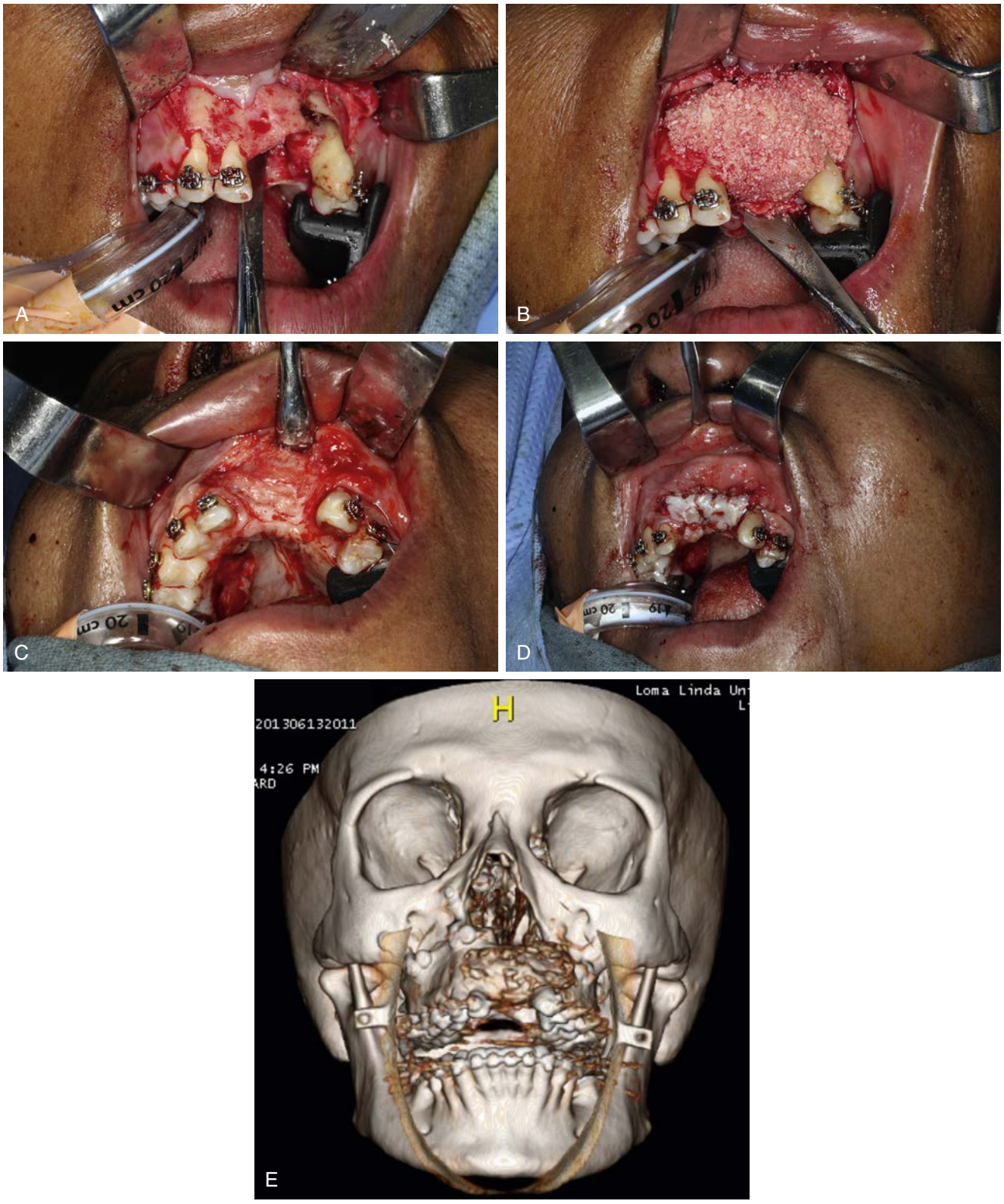

• **Figure 40-9 A,** Previously grafted cleft with inadequate bone for implants. **B,** Grafting of cleft. **C,** Exposure of reconstructed area. **D,** Placement of a free gingival graft for increased keratinization. **E,** Postoperative radiograph.

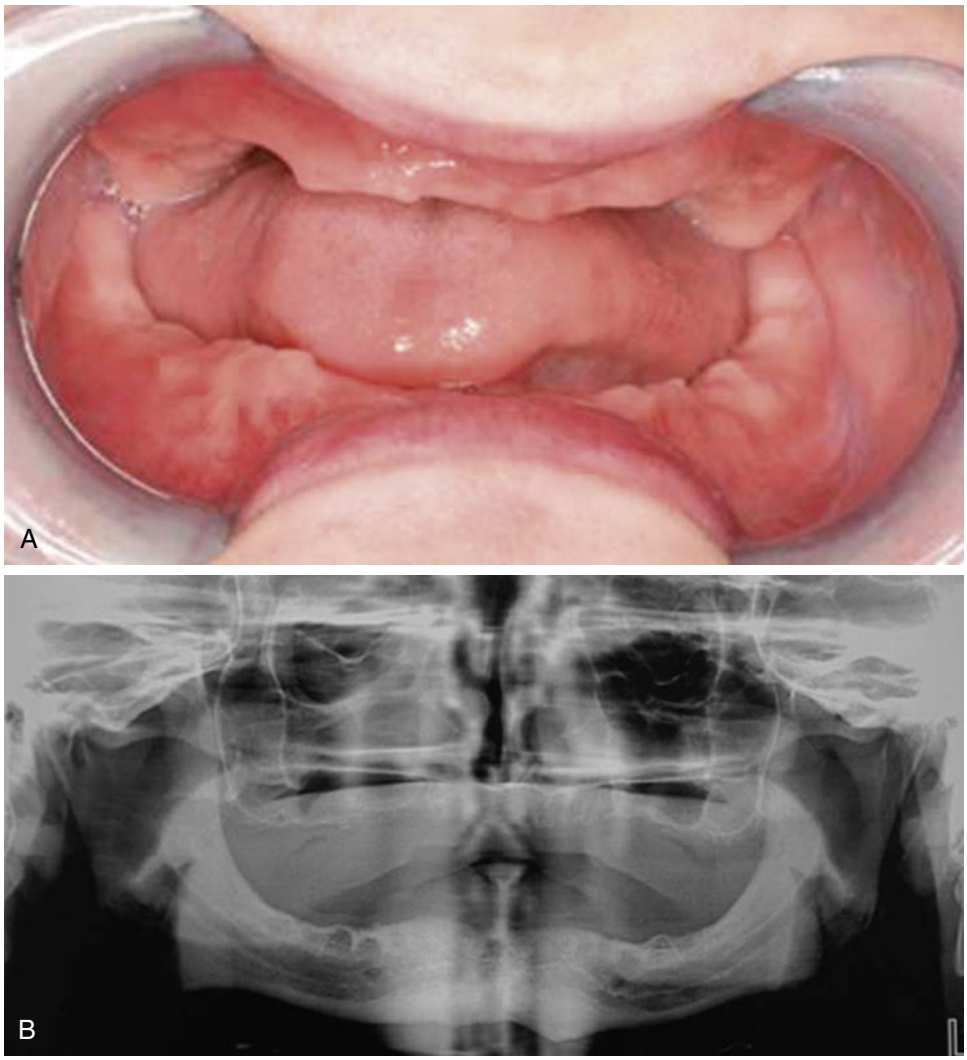

• **Figure 40-10** **A,** Inadequate ridge width in patient with ectodermal dysplasia. **B,** Preoperative radiograph.
Continued

a study showed that results were unfavorable in 43% of cases with approximately 86% partial bone loss.[88]

Ectodermal Dysplasia

Ectodermal dysplasia is an inherited disorder that is classified into two major types: hypohidrotic ectodermal dysplasia (HED) and hidrotic ectodermal dysplasia. HED is the more common type of ectodermal dysplasia, with an incidence rate of 0.63 per 10,000 people.[89] The typical clinical presentation of the HED patient includes the following characteristics: sparse hair, "saddle" nose, thick and protruding lips, "bat ears," a juga forehead and chin, missing or misshapen teeth, and wrinkling and pigment deposition around the ear and orbital areas.[90] Patients with anodontia often have maxillary hypoplasia, mandibular prognathia, bony atrophy of the jaws, and/or facial concavity.[91] If there is an unfavorable jaw relationship, orthognathic surgery may also be indicated. The congenital absence of teeth often results in bony atrophy with insufficiency in jawbone height and width, making it difficult to place dental implants to rehabilitate the dental occlusion.

Bone Grafting

The available methods for bone augmentation of severely atrophied jaws of HED patients include the options that are used for any patient with severe atrophy of the jaws (Figure 40-10). In a study by Lamazza and colleagues, it was noted that multiple bone augmentation procedures, onlay block graft for horizontal and distraction osteogenesis for vertical, were necessary to achieve sufficient bone volume.[92] Autogenous bone block grafts are often harvested from the iliac crest. Advantages of distraction osteogenesis are that it does not cause damage to healthy tissue and does not necessitate a second donor site. The recommended time to place endosseous implants is 3 to 6 months following bone augmentation.

Dental Implants

Most HED patients suffer from oligodontia or anodontia and require multiple implants to be placed. The recommended treatment for the patient is to have an

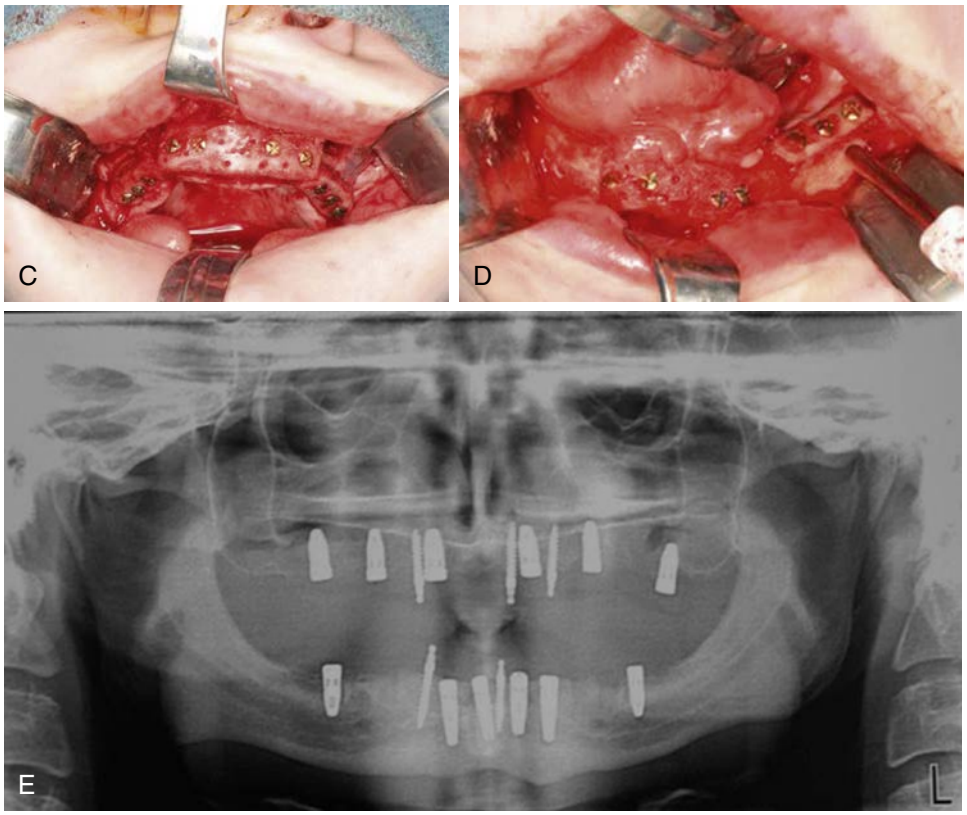

• **Figure 40-10, cont'd** **C,** Bone grafts secured into place in the maxilla. **D,** Bone grafts secured into place in the mandible. **E,** Postoperative radiograph.

implant-supported prosthetic appliance. This will help achieve the best esthetic outcome, as gingiva-colored porcelain can be used to recreate a more natural contoured result.

In a recent study of 179 implants placed in ectodermal dysplasia patients, the 3-year success and overall implant survival rate was 97.2%.[93]

Summary

Grafting and dental implants can provide a predictable way to restore both congenital and acquired defects. Each patient presenting with a defect should be evaluated systematically and an individualized technique chosen that will give the best and most successful result. Dental implants have resulted in improved outcomes for countless patients.

References

1. Duskova M, Kotova M, Sedlackova K, et al.: Bone reconstruction of the maxillary alveolus for subsequent insertion of a dental implant in patients with cleft lip and palate, *J Craniofac Surg* 18(3):630–638, 2007.
2. Gotsch KE, Annest JL, Mercy JA, Ryan GW: Surveillance for Fatal and Nonfatal Firearm-Related Injuries—United States, 1993-1998, *MMWR Morb Mortal Wkly Rep* 50:1, 2001.
3. Motamedi MH: Primary management of maxillofacial hard and soft tissue gunshot and shrapnel injuries, *J Oral Maxillofac Surg* 61:1390–1398, 2003.
4. Motamedi MH, Behnia H: Experience with regional flaps in the comprehensive treatment of maxillofacial soft-tissue injuries in war victims, *J Craniomaxillofac Surg* 27:256–265, 1999.
5. Ellis 3rd E, Muniz O, Anand K: Treatment considerations for comminuted mandibular fractures, *J Oral Maxillofac Surg* 61:861–870, 2003.
6. Danino AM, Hariss PG, Servant JM: Early management, with a minimal initial hospitalization length, of major self-inflicted rifle wounds to the face by a single latissimus dorsi free musculocutaneous flap: a 10-year experience, *Eplasty* 9:e23, 2009.
7. Baurmash HD: Closed reduction, an effective alternative for comminuted mandible fractures, *J Oral Maxillofac Surg* 62: 115–116, 2004.
8. Li Z, Li ZB: Clinical characteristics and treatment of multiple site comminuted mandible fractures, *J Craniomaxillofac Surg* 39(4):296–299, 2011.
9. Walker RV, Frame JW: Civilian maxillo-facial gunshot injuries, *Int J Oral Surg* 13:263–277, 1984.

10. Bartlett CS, Helfet DL, Hausman MR, Strauss E: Ballistics and gunshot wounds: effects on musculoskeletal tissues, *J Am Acad Orthop Surg* 8:21–36, 2000.
11. Vásconez HC, Shockley ME, Luce EA: High-energy gunshot wounds to the face, *Ann Plast Surg* 36(1):18–25, 1996.
12. Vayvada H, Menderes A, Yilmaz M, et al.: Management of close-range, high-energy shotgun and rifle wounds to the face, *J Craniofac Surg* 16:794–804, 2005.
13. Gruss JS, Antonyshyn O, Phillips JH: Early definitive bone and soft-tissue reconstruction of major gunshot wounds of the face, *Plast Reconstr Surg* 87:436–450, 1991.
14. Motamedi MH: Management of firearm injuries to the facial skeleton: outcomes from early primary intervention, *J Emerg Trauma Shock* 4(2):212–216, 2011.
15. Kaufman Y, Cole P, Hollier Jr LH: Facial gunshot wounds: trends in management, *Craniomaxillofac Trauma Reconstr* 2:85–90, 2009.
16. Doctor VS, Farwell DG: Gunshot wounds to the head and neck, *Curr Opin Otolaryngol Head Neck Surg* 15:213–218, 2007.
17. Cannon TY, Strub GM, Yawn RJ, Day TA: Oromandibular reconstruction, *Clin Anat* 25:108–119, 2012.
18. van Gemert JT, van Es RJ, Van Cann EM, Koole R: Nonvascularized bone grafts for segmental reconstruction of the mandible—a reappraisal, *J Oral Maxillofac Surg* 67:1446–1452, 2009.
19. Herford AS, Dean JS: Complications in bone grafting, *Oral Maxillofac Surg Clin North Am* 23(3):433–442, 2011.
20. Goh BT, Lee S, Tideman H, Stoelinga PJ: Mandibular reconstruction in adults: a review, *Int J Oral Maxillofac Surg* 37:597–605, 2008.
21. Ahlmann E, Patzakis M, Roidis N, et al.: Comparison of anterior and posterior iliac crest bone grafts in terms of harvest-site morbidity and functional outcomes, *J Bone Joint Surg Am* 84-a:716–720, 2002.
22. Kessler P, Thorwarth M, Bloch-Birkholz A, et al.: Harvesting of bone from the iliac crest—comparison of the anterior and posterior sites, *Br J Oral Maxillofac Surg* 43:51–56, 2005.
23. August M, Tompach P, Chang Y, Kaban L: Factors influencing the long-term outcome of mandibular reconstruction, *J Oral Maxillofac Surg* 58:731–737, 2000. discussion 738.
24. Egyedi P: Wound infection after mandibular reconstruction with autogenous graft, *Ann Acad Med Singapore* 15:340–345, 1986.
25. Koole R, Egyedi P: Postoperative contamination of mandibular osteotomy sites with saliva, *Int J Oral Maxillofac Surg* 16:554–558, 1987.
26. Schwartz-Arad D, Levin L, Sigal L: Surgical success of intraoral autogenous block onlay bone grafting for alveolar ridge augmentation, *Implant Dent* 14:131–138, 2005.
27. Levin L, Schwartz-Arad D: The effect of cigarette smoking on dental implants and related surgery, *Implant Dent* 14:357–361, 2005.
28. Cicciu M, Herford AS, Stofella E, et al.: Protein-signaled guided bone regeneration using titanium mesh and rh-BMP2 in oral surgery: a case report involving left mandibular reconstruction after tumor resection, *Open Dent J* 6:51–55, 2012.
29. Hidalgo DA, Pusic AL: Free-flap mandibular reconstruction: a 10-year follow-up study, *Plast Reconstr Surg* 110:438–449, 2002. discussion 450–451.
30. Foster RD, Anthony JP, Sharma A, Pogrel MA: Vascularized bone flaps versus nonvascularized bone grafts for mandibular reconstruction: an outcome analysis of primary bony union and endosseous implant success, *Head Neck* 21:66–71, 1999.
31. Hidalgo DA: Fibula free flap: a new method of mandible reconstruction, *Plast Reconstr Surg* 84:71–79, 1989.
32. Urken ML, Buchbinder D, Costantino PD, et al.: Oromandibular reconstruction using microvascular composite flaps: report of 210 cases, *Arch Otolaryngol Head Neck Surg* 124:46–55, 1998.
33. Neligan P, Wei F: *Microsurgical reconstruction of the head and neck*, ed 1, St Louis, MO, 2009, Quality Medical Publishing, pp 701–728.
34. Carbiner R, Jerjes W, Shakib K, et al.: Analysis of the compatibility of dental implant systems in fibula free flap reconstruction, *Head Neck Oncol* 4:37, 2012.
35. Brown JS, Rogers SN, McNally DN, Boyle M: A modified classification for the maxillectomy defect, *Head Neck* 22:17–26, 2000.
36. Lenox ND, Kim DD: Maxillary reconstruction, *Oral Maxillofac Surg Clin North Am* 25:215–222, 2013.
37. Mucke T, Holzle F, Loeffelbein DJ, et al.: Maxillary reconstruction using microvascular free flaps, *Oral Surg Oral Med Oral Pathol Oral Radiol Endod* 111:51–57, 2011.
38. Frodel Jr JL, Funk GF, Capper DT, et al.: Osseointegrated implants: a comparative study of bone thickness in four vascularized bone flaps, *Plast Reconstr Surg* 92:449–455, 1993. discussion 456–458.
39. Hidalgo DA: Aesthetic improvements in free-flap mandible reconstruction, *Plast Reconstr Surg* 88:574–585, 1991. discussion 586–587.
40. Cuesta-Gil M, Ochandiano Caicoya S, Riba-Garcia F, et al.: Oral rehabilitation with osseointegrated implants in oncologic patients, *J Oral Maxillofac Surg* 67:2485–2496, 2009.
41. Shaw RJ, Sutton AF, Cawood JI, et al.: Oral rehabilitation after treatment for head and neck malignancy, *Head Neck* 27: 459–470, 2005.
42. Merkx MA, Fennis JP, Verhagen CM, Stoelinga PJ: Reconstruction of the mandible using preshaped 2.3 mm titanium plates, autogenous particulate cortico-cancellous bone grafts and platelet rich plasma: a report on eight patients, *Int J Oral Maxillofac Surg* 33:733–739, 2004.
43. Ch'ng S, Skoracki RJ, Selber JC, et al.: Osseointegrated implant-based dental rehabilitation in head and neck reconstruction patients, *Head Neck*, 2014.
44. Smith DE, Zarb GA: Criteria for success of osseointegrated endosseous implants, *J Prosthet Dent* 62:567–572, 1989.
45. Riediger D: Restoration of masticatory function by microsurgically revascularized iliac crest bone grafts using endosseous implants, *Plast Reconstr Surg* 81:861–877, 1988.
46. Urken ML, Buchbinder D, Weinberg H, et al.: Primary placement of osseointegrated implants in microvascular mandibular reconstruction, *Otolaryngol Head Neck Surg* 101:56–73, 1989.
47. Hayter JP, Cawood JI: Oral rehabilitation with endosteal implants and free flaps, *Int J Oral Maxillofac Surg* 25:3–12, 1996.
48. Schepers RH, Slagter AP, Kaanders JH, et al.: Effect of postoperative radiotherapy on the functional result of implants placed during ablative surgery for oral cancer, *Int J Oral Maxillofac Surg* 35:803–808, 2006.
49. Schrag C, Chang YM, Tsai CY, Wei FC: Complete rehabilitation of the mandible following segmental resection, *J Surg Oncol* 94:538–545, 2006.
50. Mizbah K, Dings JP, Kaanders JH, et al.: Interforaminal implant placement in oral cancer patients: during ablative surgery or delayed? A 5-year retrospective study, *Int J Oral Maxillofac Surg* 42:651–655, 2013.
51. Colella G, Cannavale R, Pentenero M, Gandolfo S: Oral implants in radiated patients: a systematic review, *Int J Oral Maxillofac Implants* 22:616–622, 2007.
52. Tanaka TI, Chan HL, Tindle DI, et al.: Updated clinical considerations for dental implant therapy in irradiated head and neck cancer patients, *J Prosthodont* 22:432–438, 2013.

53. Ihde S, Kopp S, Gundlach K, Konstantinovic VS: Effects of radiation therapy on craniofacial and dental implants: a review of the literature, *Oral Surg Oral Med Oral Pathol Oral Radiol Endod* 107:56–65, 2009.
54. Marx RE, Johnson RP: Studies in the radiobiology of osteoradionecrosis and their clinical significance, *Oral Surg Oral Med Oral Pathol* 64:379–390, 1987.
55. Kluth EV, Jain PR, Stuchell RN, Frich Jr JC: A study of factors contributing to the development of osteoradionecrosis of the jaws, *J Prosthet Dent* 59:194–201, 1988.
56. Schliephake H, Neukam FW, Schmelzeisen R, Wichmann M: Long-term results of endosteal implants used for restoration of oral function after oncologic surgery, *Int J Oral Maxillofac Surg* 28:260–265, 1999.
57. Werkmeister R, Szulczewski D, Walteros-Benz P, Joos U: Rehabilitation with dental implants of oral cancer patients, *J Craniomaxillofac Surg* 27:38–41, 1999.
58. Weischer T, Mohr C: Ten-year experience in oral implant rehabilitation of cancer patients: treatment concept and proposed criteria for success, *Int J Oral Maxillofac Implants* 14:521–528, 1999.
59. Schiegnitz E, Al-Nawas B, Kammerer PW, Grotz KA: Oral rehabilitation with dental implants in irradiated patients: a meta-analysis on implant survival, *Clin Oral Investig* 18:687–698, 2014.
60. Visch LL, van Waas MA, Schmitz PI, Levendag PC: A clinical evaluation of implants in irradiated oral cancer patients, *J Dent Res* 81:856–859, 2002.
61. Mancha de la Plata M, Gias LN, Diez PM, et al.: Osseointegrated implant rehabilitation of irradiated oral cancer patients, *J Oral Maxillofac Surg* 70:1052–1063, 2012.
62. Esser E, Wagner W: Dental implants following radical oral cancer surgery and adjuvant radiotherapy, *Int J Oral Maxillofac Implants* 12:552–557, 1997.
63. Nooh N: Dental implant survival in irradiated oral cancer patients: a systematic review of the literature, *Int J Oral Maxillofac Implants* 28:1233–1242, 2013.
64. Chiapasco M: Implants for patients with maxillofacial defects and following irradiation. In Lang NP, Karring T, Lindhe J, editors: *Proceedings of the 3rd European Workshop on Periodontology*, Berlin, 1999, Quintessenz, pp 557–607.
65. Ueda M, Kaneda T, Takahashi H: Effect of hyperbaric oxygen therapy on osseointegration of titanium implants in irradiated bone: a preliminary report, *Int J Oral Maxillofac Implants* 8:41–44, 1993.
66. Granstrom G, Tjellstrom A, Branemark PI, Fornander J: Bone-anchored reconstruction of the irradiated head and neck cancer patient, *Otolaryngol Head Neck Surg* 108:334–343, 1993.
67. Taylor TD, Worthington P: Osseointegrated implant rehabilitation of the previously irradiated mandible: results of a limited trial at 3 to 7 years, *J Prosthet Dent* 69:60–69, 1993.
68. Brogniez V, Lejuste P, Pecheur A, Reychler H: Dental prosthetic reconstruction of osseointegrated implants placed in irradiated bone, *Int J Oral Maxillofac Implants* 13:506–512, 1998.
69. Niimi A, Ueda M, Keller EE, Worthington P: Experience with osseointegrated implants placed in irradiated tissues in Japan and the United States, *Int J Oral Maxillofac Implants* 13:407–411, 1998.
70. Esposito M, Worthington HV: Interventions for replacing missing teeth: hyperbaric oxygen therapy for irradiated patients who require dental implants, *Cochrane Database Syst Rev* 9, 2013. CD003603.
71. Aparicio C, Manresa C, Francisco K, et al.: Zygomatic implants: indications, techniques and outcomes, and the zygomatic success code, *Periodontology 2000* 66:41–58, 2014.
72. Schmidt BL, Pogrel MA, Young CW, Sharma A: Reconstruction of extensive maxillary defects using zygomaticus implants, *J Oral Maxillofac Surg* 62:82–89, 2004.
73. Malo P, Nobre Mde A, Lopes A, et al.: Five-year outcome of a retrospective cohort study on the rehabilitation of completely edentulous atrophic maxillae with immediately loaded zygomatic implants placed extra-maxillary, *Eur J Oral Implantol* 7:267–281, 2014.
74. Davo R: Zygomatic implants placed with a two-stage procedure: a 5-year retrospective study, *Eur J Oral Implantol* 2:115–124, 2009.
75. Bedrossian E, Stumpel 3rd LJ: Immediate stabilization at stage II of zygomatic implants: rationale and technique, *J Prosthet Dent* 86:10–14, 2001.
76. Branemark PI, Grondahl K, Ohrnell LO, et al.: Zygoma fixture in the management of advanced atrophy of the maxilla: technique and long-term results, *Scand J Plast Reconstr Surg Hand Surg* 38:70–85, 2004.
77. Davo R, Pons O: Prostheses supported by four immediately loaded zygomatic implants: a 3-year prospective study, *Eur J Oral Implantol* 6:263–269, 2013.
78. Bothur S, Kullendorff B, Olsson-Sandin G: Asymptomatic chronic rhinosinusitis and osteitis in patients treated with multiple zygomatic implants: a long-term radiographic follow-up, *Int J Oral Maxillofac Implants* 30:161–168, 2015.
79. Esposito M, Worthington HV: Interventions for replacing missing teeth: dental implants in zygomatic bone for the rehabilitation of the severely deficient edentulous maxilla, *Cochrane Database Syst Rev* 9, 2013. CD004151.
80. Rakhshan V: Congenitally missing teeth (hypodontia): a review of the literature concerning the etiology, prevalence, risk factors, patterns and treatment, *Dent Res J (Isfahan)* 12(1):1–13, 2015.
81. Wermker K, Jung S, Joos U, Kleinheinz J: Dental implants in cleft lip, alveolus, and palate patients: a systematic review, *Int J Oral Maxillofac Implants* 29(2):384–390, 2014.
82. Boyne PJ, Sands NR: Combined orthodontic-surgical management of residual palato-alveolar cleft defects, *Am J Orthod* 70(1):20–37, 1976.
83. Sawaki M, Ueno T, Kagawa T, et al.: Dental implant treatment for a patient with bilateral cleft lip and palate, *Acta Med Okayama* 62(1):59–62, 2008.
84. Aizenbud D, Hazan-Molina H, Emodi O, Rachmiel A: Advancement of the cleft maxilla using distraction osteogenesis—surgical and orthodontic considerations, *Alpha Omegan* 104(3-4):85–96, 2011.
85. Duskova M, Kotova M, Sedlackova K, et al.: Bone reconstruction of the maxillary alveolus for subsequent insertion of a dental implant in patients with cleft lip and palate, *J Craniofac Surg* 18(3):630–638, 2007.
86. Herford AS, Boyne PJ, Williams RP: Clinical applications of rhBMP-2 in maxillofacial surgery, *J Calif Dent Assoc* 35(5):335–341, 2007.
87. Guo J, Li C, Zhang Q, et al.: Secondary bone grafting for alveolar cleft in children with cleft lip or cleft lip and palate, *Cochrane Database Syst Rev*(6), 2011. CD008050.
88. Wermker K, Jung S, Joos U, Kleinheinz J: Dental implants in cleft lip, alveolus, and palate patients: a systematic review, *Int JOral Maxillofac Implants* 29(2):384–390, 2014.
89. Li D, Liu Y, Ma W, Song Y: Review of ectodermal dysplasia: case report on treatment planning and surgical management of oligodontia with implant restorations, *Implant Dent* 20(5):328–330, 2011.

90. Zou D, Wu Y, Wang XD, et al.: A retrospective 3- to 5-year study of the reconstruction of oral function using implant-supported prostheses in patients with hypohidrotic ectodermal dysplasia, *J Oral Implantol* 40(5):571–580, 2014.
91. Rad AS, Siadat H, Monzavi A, Mangoli AA: Full mouth rehabilitation of a hypohidrotic ectodermal dysplasia patient with dental implants: a clinical report, *J Prosthodont* 16(3):209–213, 2007.
92. Lamazza L, Cerulli GM, Favaretti F, De Biase A: Implant-prosthetic partial-arch restoration in a patient with ectodermal dysplasia characterized by oligodontia and localized bone deficiency: a case report, *Int J Oral Maxillofac Implants* 24(1):147–150, 2009.
93. Sclar AG, Kannikal J, Ferreira CF, et al.: Treatment planning and surgical considerations in implant therapy for patients with agenesis, oligodontia, and ectodermal dysplasia: review and case presentation, *J Oral Maxillofac Surg* 67(11 Suppl):2–12, 2009.

41

Three-Dimensional Imaging and Digital Workflow Protocols for Dental Implants and Bone Grafting

SCOTT D. GANZ

Introduction

The use of three-dimensional (3D) imaging modalities and interactive treatment planning software has evolved into highly effective, useful, and essential tools for surgical and restorative intraoral reconstructive dentistry. The ability to visualize patient anatomy based on 3D data from CT/CBCT (computed tomography/cone-beam computed tomography) provides clinicians with invaluable diagnostic capabilities for assessing potential implant receptor sites, identifying pathology, determining location and proximity of vital adjacent structures, and ascertaining the need and planning for bone grafting applications. The continuation of the diagnostic phase based on imaging modalities, can result in three different protocols of treatment as previously defined by the author. The first has been termed *diagnostic-freehand.* The clinician should first visualize the patient's anatomic data in all available views including panoramic, cross-sectional, coronal, sagittal, axial, and 3D reconstructive volume. Using the interactive features of the software to interpret the CT/CBCT, non-distorted measurements can be made; implant positions can be planned; communication can be established with the patient, implant team, and dental laboratory technician; and the surgical intervention is completed using a free-hand technique based on the clinician's personal level of experience. The second protocol, termed *template-assisted,* takes the information from the Digital Imaging and Communications in Medicine (DICOM) dataset and interactive treatment planning software to fabricate a surgical guide or template. There are three basic CT-derived template designs: bone borne, tooth borne, and soft tissue/mucosal borne. The templates provide guidance for the drilling sequence for implant placement. The third protocol, termed *full template guidance,* provides the most accurate and precise link between the original plan, the surgical guide, drill sequence, and the delivery of implants directly through the template based on manufacturer-specific surgical components. These protocols summarize the use of digital dentistry solutions for the assessment of implant receptor sites, and the placement of implants.

The use of surgical templates generated through interactive treatment planning software is not new. However, the overall use of surgical guides is still quite infrequent because of several factors: (1) the need to have a CT/CBCT scan; (2) the ability to properly understand and use the interactive treatment planning software for diagnosis; (3) the fact that clinicians may not be educated on how to use software tools for proper planning of dental implants; (4) the extra time required for the planning process and (5) the fabrication of the surgical guides at a distant site; (6) and the added expense related to the template fabrication and (7) obtaining the necessary instrumentation from the implant manufacturer to complete a guided surgery procedure. Despite these barriers, the importance of 3D diagnosis, use of surgical guides, and the acceptance of guided surgery procedures is increasing as the demand for more accurate and restoratively driven outcomes are increasing. In addition, the use of surgical templates is not limited to the placement of dental implants. New protocols and surgical templates have been designed to accurately reduce bone (bone reduction template) and facilitate bone grafting procedures as well. Use of this ever-expanding technology can only be beneficial for our patients, who require accuracy, precision, and consistency with dental implant placement and bone grafting procedures, to improve long-term quality of life while reducing complications.

Case Examples: Anterior Maxillary Deficiency

Three-dimensional CT/CBCT imaging analysis should begin with a review of the information contained within the scan data. Clinicians should institute a similar approach



• **Figure 41-1** The panoramic reconstructed image provides for a general assessment of the maxillomandibular relationship.

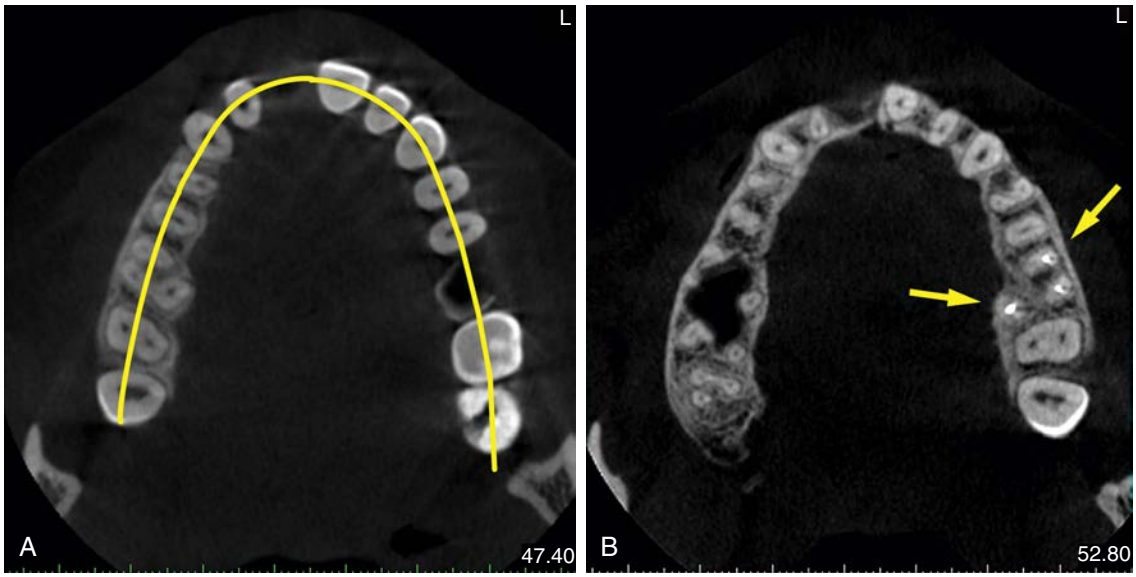

• **Figure 41-2** **A,** The panoramic view is contingent on the position of the "panoramic curve." **B,** This image reveals the buccal-palatal bone dimension and the gutta percha present in the maxillary left first molar tooth.

or protocol for the proper evaluation of each patient's individual anatomic presentation. It is important to understand that despite differences in the particular software application used, each should allow for inspection of slices in many views, including the panoramic, coronal, sagittal, cross-sectional, axial, and 3D reconstructed volumes. The panoramic reconstructed image provides for a general assessment of the maxillomandibular relationship, teeth and roots, which may be present or absent, the nasal cavity, bilateral maxillary sinuses, interarch space, location of the mental foramina, and sometimes the path of the inferior alveolar nerve (Figure 41-1). In this case, the patient's chief complaint, region of interest (ROI), and rationale for the CBCT scan was a single missing right maxillary central incisor tooth. The panoramic view is contingent on the position of the "panoramic curve," which can be automatically generated or manually positioned within the axial slice to aid in the visualization of region of interest (Figure 41-2, *A*). In addition, the horizontal slice related by the axial image can be changed in a superior or inferior direction to facilitate inspection of the entire anatomy captured by the scan (see Figure 41-2, *B*). Note that in Figure 41-2, *A,* the root morphology can begin to be appreciated without too much information about the width of the alveolar bone, whereas Figure 41-2, *B,* reveals more of the buccal-palatal bone dimension and even shows the gutta percha present in the maxillary left first molar tooth *(yellow arrow)*.

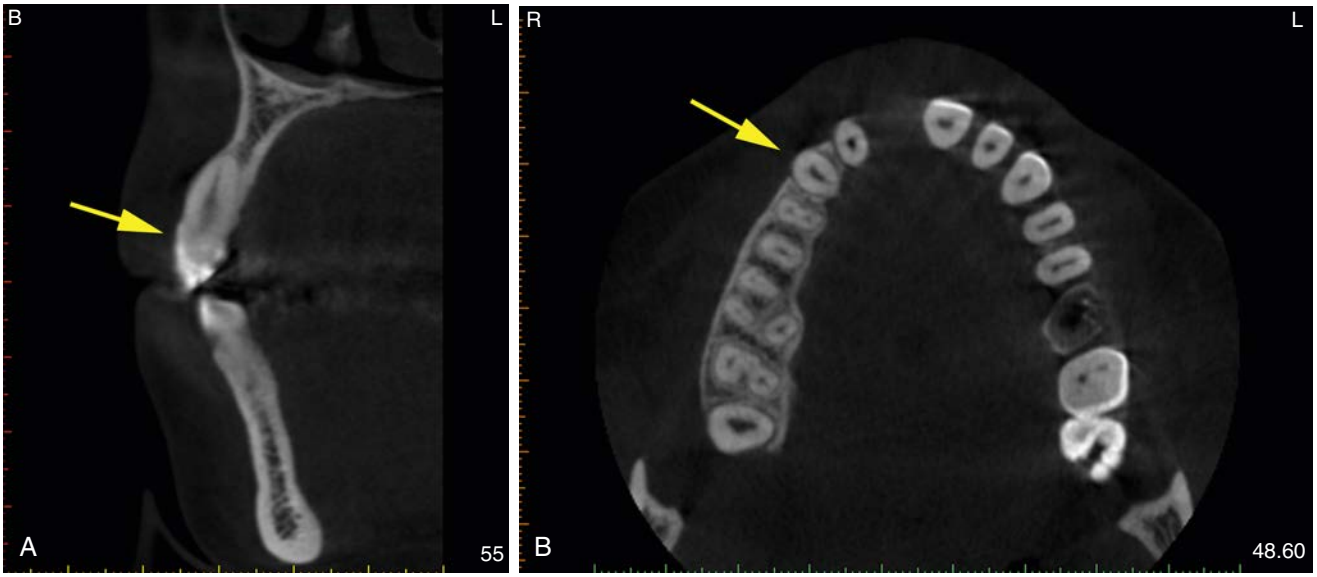

• **Figure 41-3** **A,** The cross-sectional slice of the right maxillary cuspid tooth *(arrow)*, and the axial slice **(B)** reveals almost no bone on both the facial and palatal aspect of the root.

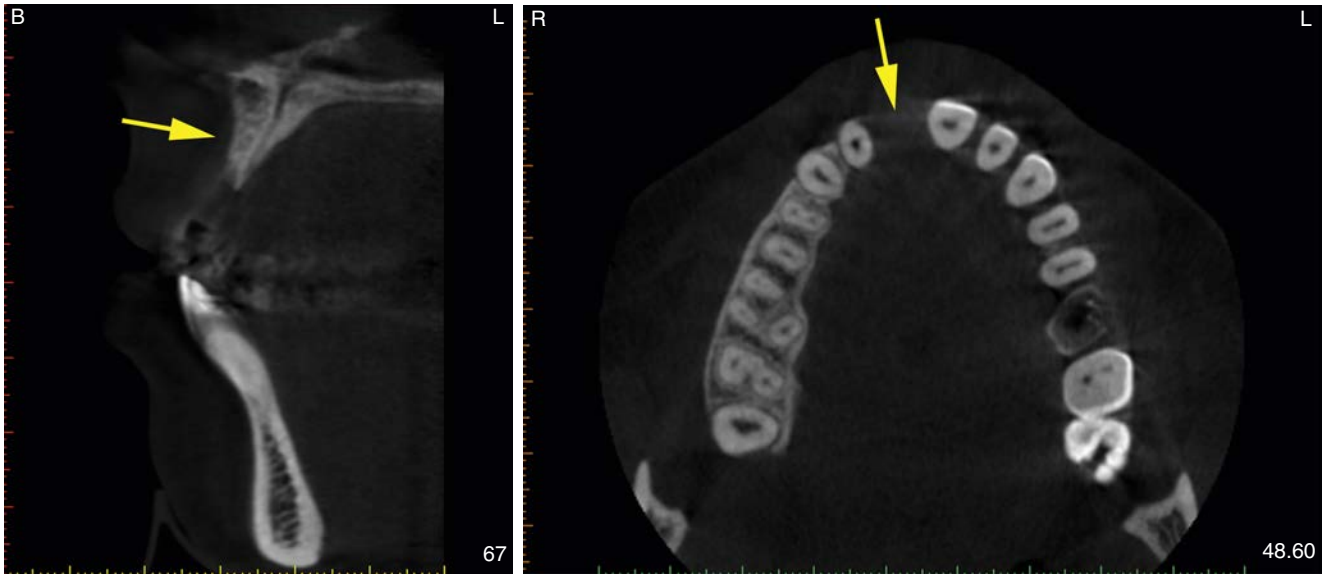

• **Figure 41-4** The missing right central incisor shows a total lack of alveolus, and insufficient support for an implant *(arrows)*.

The panoramic reconstructed image is an interactive representation of the maxilla and mandible based on the CBCT scan dataset and provides only a two-dimensional view. The teeth and roots may appear to be surrounded with bone; however, the actual volume of bone cannot be accurately assessed. Although viewing slices of the 3D scan separately and individually is important, the ability to assess multiple images simultaneously allows clinicians to assimilate the information in a more meaningful and synergistic manner. The cross-sectional slice of the right maxillary cuspid tooth *(yellow arrow)* and the axial slice seen in sequence reveal almost no bone on both the facial and palatal aspect of the root (Figure 41-3). The lack of bone contained in the alveolar housing is amplified by the finding that there is minimal bone width superior to the root apex *(red arrow)*. The original region of interest, the missing right central incisor, shows a total lack of alveolus and insufficient support for an implant *(yellow arrows)* (Figure 41-4). Following the surrounding teeth in the maxillary arch (from right to left) reveals a similar pattern of insufficient bone volume for the left central incisor *(yellow arrows)* (Figure 41-5). The loss of alveolus is most pronounced when evaluating the maxillary left lateral incisor (Figure 41-6, *A*). The tooth root seemed to be balanced on top of the alveolar crest without any bone support (Figure 41-6, *B*). The interactive 3D software

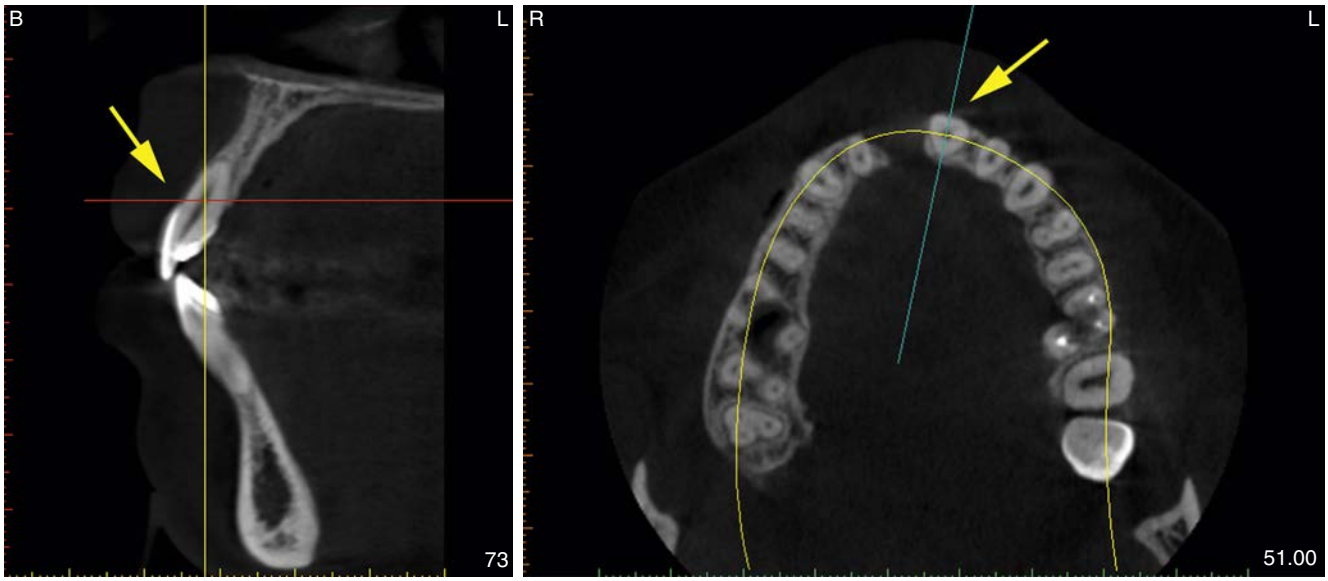

• **Figure 41-5** The surrounding teeth in the maxillary arch (from right to left) reveal a similar pattern of insufficient bone volume for the left central incisor *(arrows)*.

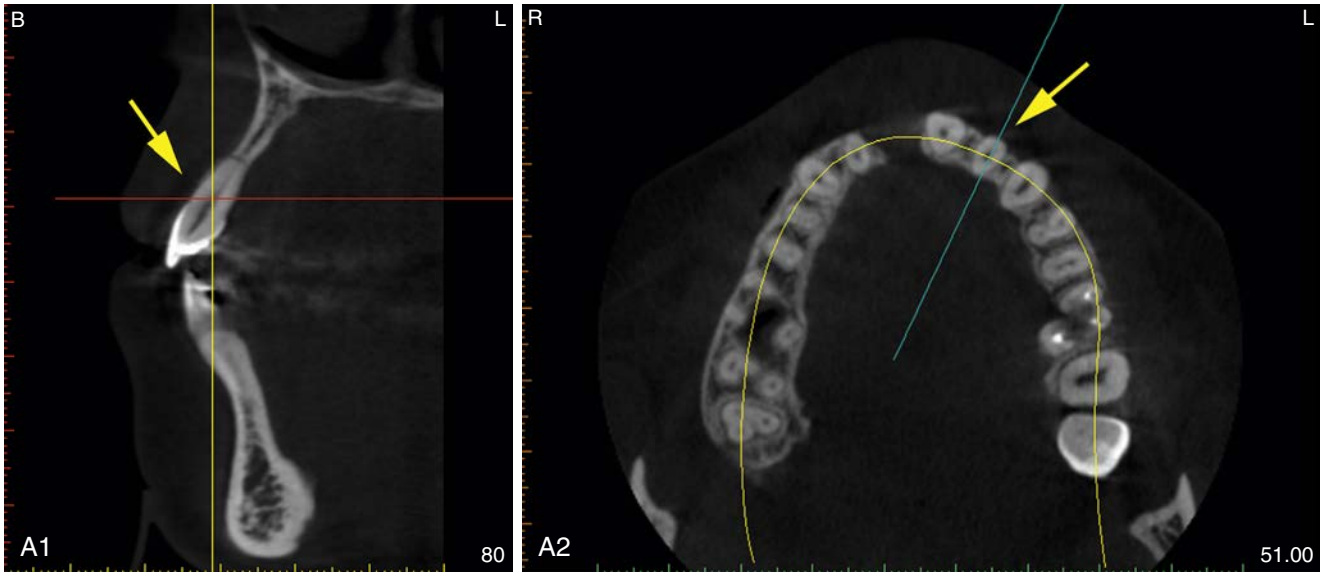



• **Figure 41-6** **A,** Two images show the loss of alveolus as more pronounced when evaluating the maxillary left lateral incisor *(yellow arrows)*. **B,** The tooth root seemed to be balanced on top of the alveolar crest without any apparent supporting alveolar bone.

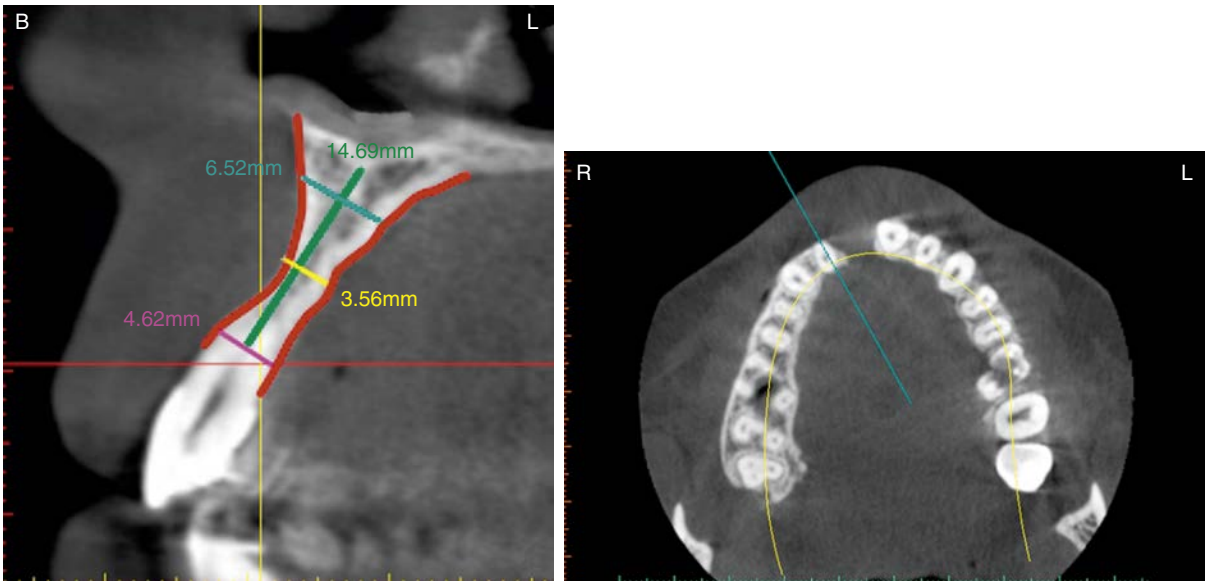

• **Figure 41-7** The width of the right maxillary lateral incisor root measured near the crest of the alveolus (4.62 mm), at the middle of the alveolus (3.56 mm), and at the widest area of the alveolus superiorly (6.52 mm). The height of the ridge was measured to be 14.69 mm.

provides specific tools for undistorted measurements of the existing anatomy, which is helpful when determining the appropriate treatment options. Figure 41-7 reveals measurements of the width of the right maxillary lateral incisor root near the crest of the alveolus (4.62 mm), at the middle of the alveolus (3.56 mm), and at the widest area of the alveolus superiorly (6.52 mm). The height of the ridge was measured to be 14.69 mm. The valuable measurements become part of the "blueprint" or architectural plan for the proposed treatment.

As computing power has increased, so has the ability to manage the large DICOM dataset from the CT or CBCT imaging device. The powerful graphics cards available for desktop workstations, portable notebooks, and even tablet computers allow the datasets to be quickly processed for rendering of 3D volumetric images even with large field-of-view (FOV) sensors. The large FOV devices provide adequate height and width to capture the entire maxillary and mandibular arches in occlusion (Figure 41-8). The bony defect and loss of volume in the area of the maxillary right central incisor can be completely visualized. If the mandibular arch is removed, the maxilla can be rotated completely in all views to better assess the regions of interest (Figure 41-9). Images can and should be enlarged to improve diagnostic capabilities. The quantity of bone volume loss and width of remaining bone can be further appreciated in Figure 41-10. Each volume should be assigned a level of opacity that can be varied to reveal underlying structures, a process defined by the author as "selective transparency." By managing the root opacity and changing the level of translucency of the bone, the roots can be clearly visualized (Figure 41-11, *A*), along with the path of the incisal nerve (see Figure 41-11, *B*).

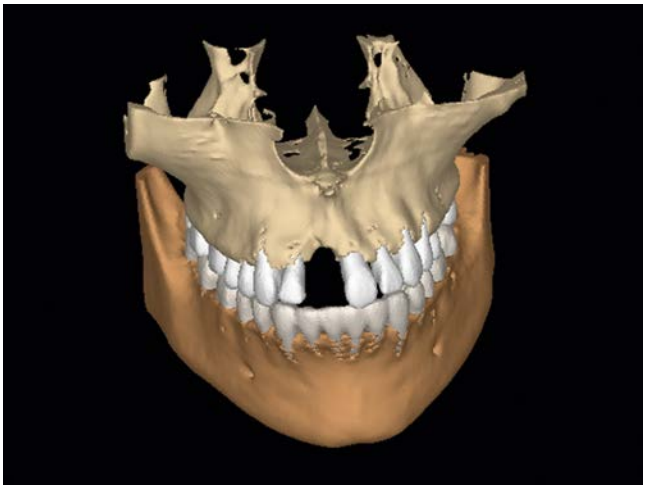

• **Figure 41-8** Largefield-of-view devices provide adequate height and width to capture the entire maxillary and mandibular arches in occlusion seen in the three-dimensional volumes.

It should be noted that when the initial DICOM data is processed, the software may in many cases be able to create beautiful and visually pleasing 3D reconstructed volumes. However, problems often occur when there are existing crowns or metal within the FOV, resulting in what has been termed "scatter" artifact. This scatter can mask underlying anatomy in critical regions that clinicians need to analyze, diminishing the diagnostic information that can be gleaned from the scan. Therefore the interactive treatment planning software must have the ability to help remove or diminish scatter artifact to improve the interpretation of the data within the diagnosis and planning phase. The process can be facilitated through ancillary superimposition of intraoral scan data or optical scans

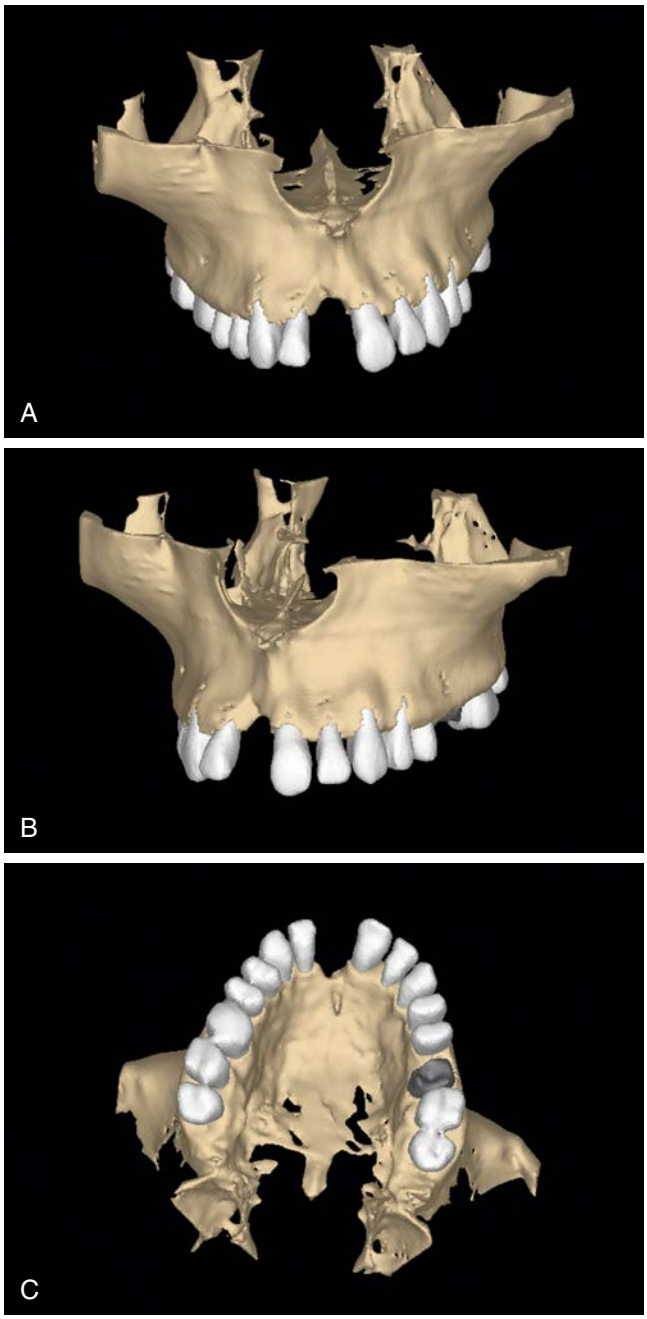

• **Figure 41-9** **A,** The bony defect and loss of volume in the area of the maxillary right central incisor can be completely visualized. **B-C,** The maxilla can be rotated completely in all views to better assess the regions of interest.

of stone casts that do not have scatter, which can exceed the surface accuracy inherent in the original scan data, as an additional aid for planning and the eventual fabrication of a variety of surgical templates.

The advanced capabilities of interactive treatment planning software provide for the simulation of dental implants as well as for bone grafting procedures. These useful tools are a valuable asset for clinicians when developing treatment alternatives for their patients. When evaluating bony concavities, and the limited alveolar bone volume, one

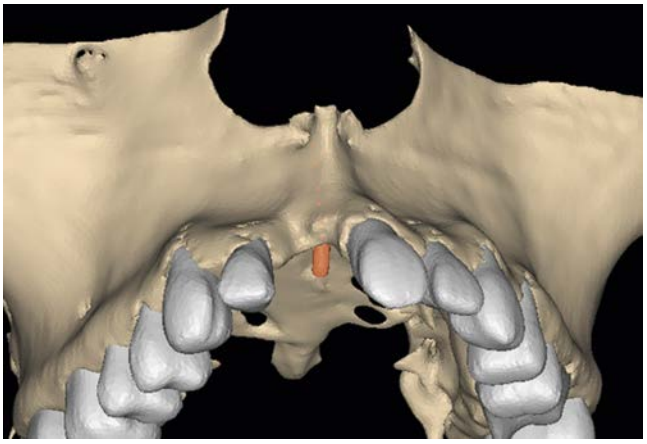

• **Figure 41-10** Image reveals the quantity of bone volume loss, width of remaining bone, and the simulated incisal nerve *(orange)*.

treatment alternative would be to improve the width of bone through grafting. Two separate grafting methods can then be used to gain adequate bone volume to allow for subsequent implant placement. The first is to use a block graft either from a sufficient autologous donor site, such as the hip, ramus, or symphysis or obtained from tissue-bank bone. The second option is to use particulate bone supported with tenting screws. The bilateral anterior facial concavities are apparent when evaluating the 3D volumetric reconstructed volume (Figure 41-12, *A*) and the amount of increased bone width required to establish a foundation for future dental implant placement (see Figure 41-12, *B*). The process of maintaining space or stabilizing block grafts can be simulated with realistic virtual components such as tenting or fixation screws (Figure 41-13). The use of selective transparency is also important when planning to place these fixation screws to avoid vital structures and potential complications (Figure 41-14). In this case, four horizontal screws were positioned to support bone within the concavities, and a vertical screw was positioned to support bone between the right lateral and left central incisor teeth (Figure 41-15). The simulation provides clinicians with an advanced knowledge of the underlying bony anatomy, and a hands-on clinical application, which may help to avoid surprises (Figure 41-16, *A*). The tenting screws should be ideally located to provide the needed support for the bone graft and placed to avoid adjacent vital structures (Figure 41-17). A bone graft with sufficient volume to fill the defect and form the foundation for implant placement was simulated using advanced bone grafting software modules (Figure 41-18).

Due to the significant loss of bone support and limited long-term prognosis of the anterior natural teeth, one plan was to remove the right lateral, left central, and left lateral incisors after the bone grafting procedure was completed. It was determined that four implants could be placed within the maxillary anterior region where the bone graft was to be placed and within the residual extraction sites. Each implant was simulated with an abutment projection

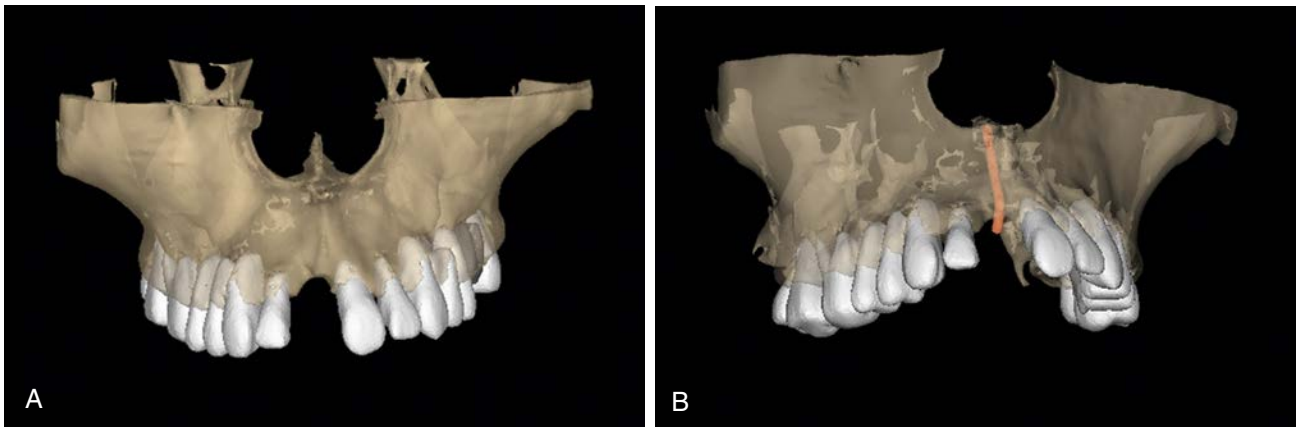

• **Figure 41-11** **A,** Changes in opacity reveal underlying structures. "Selective transparency," as defined by the author, allows for changing the level of translucency of the bone so that the roots can be clearly visualized. **B,** The path of the incisal nerve.

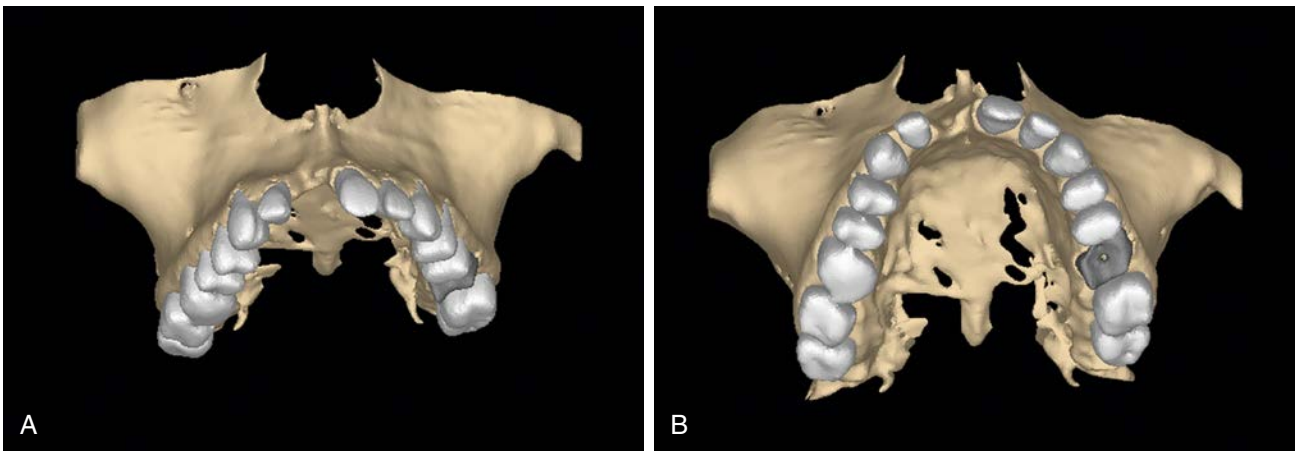

• **Figure 41-12** **A,** The bilateral anterior facial concavities become apparent when evaluating the 3D volumetric reconstructed volume. **B,** The amount of increased bone width required to establish a foundation for future dental implant placement.

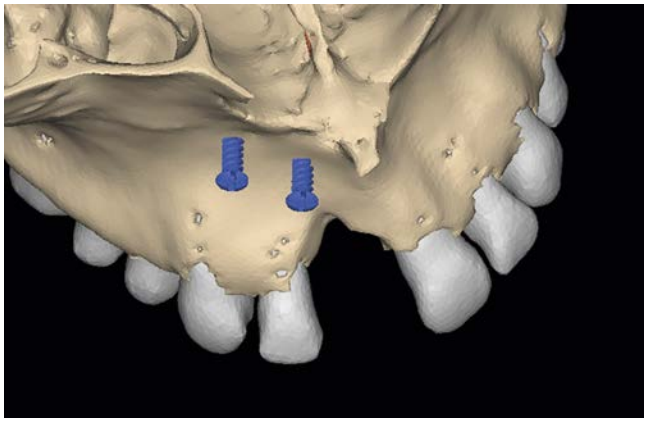

• **Figure 41-13** The process of maintaining space or stabilizing block grafts can be simulated with realistic virtual components such as "tenting" or fixation screws *(blue)*.

(yellow) to help define the trajectory within the restorative envelope of the existing natural dentition (Figure 41-19, *A*). Each abutment projection extended beyond the occlusal plane (see Figure 41-19, *B*), allowing the implant position to be evaluated in terms of the restorative goal, that is, screw- or cement-retained prosthetic design. The use of selective transparency combined with manufacturer-specific realistic implants and abutment projections *(yellow)* allows for a high level of planning precision. Without the bone grafting procedures, the implants could not be sufficiently fixated and would perforate the facial cortical plates (Figure 41-20). To facilitate the process of evaluating each potential implant receptor site, the DICOM data can be further manipulated through a process known as "segmentation" to virtually "extract" the anterior maxillary teeth in question (Figure 41-21). The virtual software capabilities are helpful in accurately planning the surgical and prosthetic

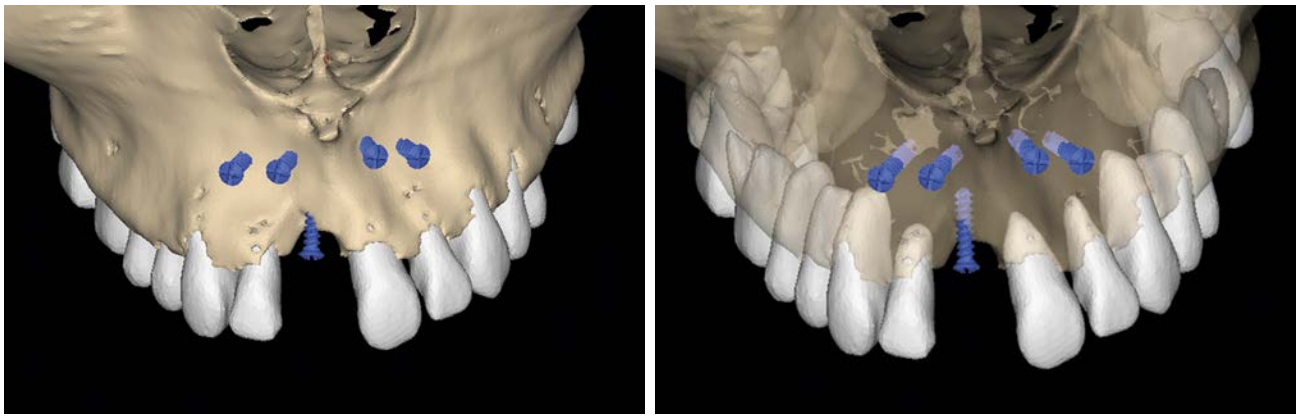

• **Figure 41-14** The use of selective transparency is important when planning to simulate the positioning of fixation screws to avoid adjacent vital structures and potential complications.

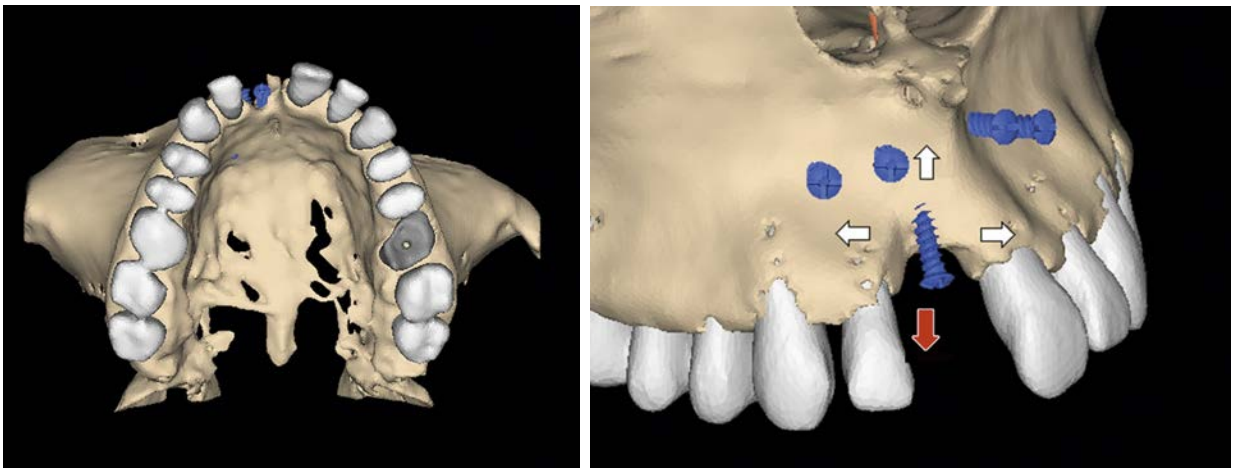

• **Figure 41-15** Four simulated horizontal screws were positioned to support bone within the bony concavities, including a vertical screw placed to support bone between the right lateral and left central incisor teeth.

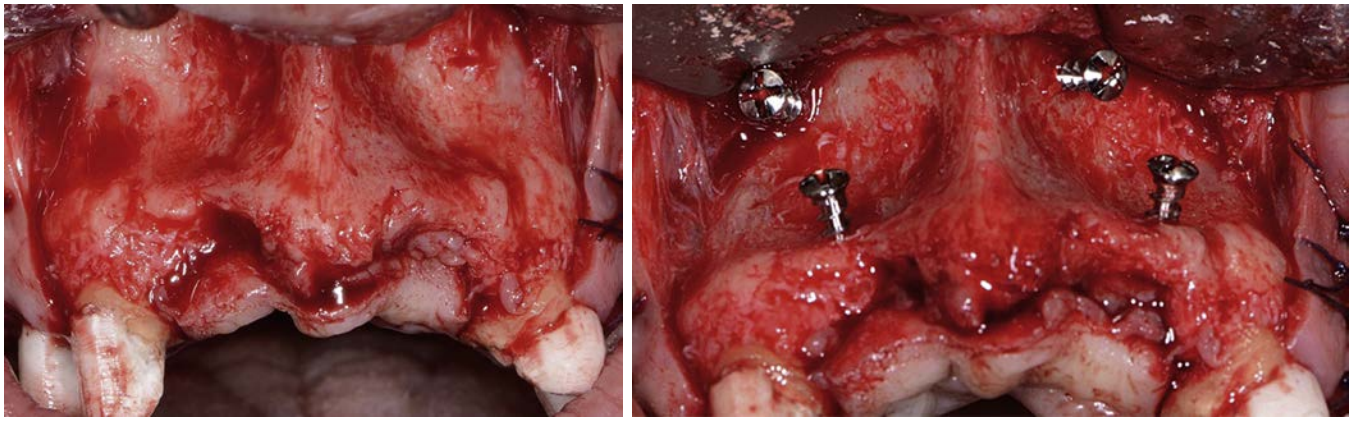

• **Figure 41-16** The simulation provides clinicians with an accurate preview of the underlying bony anatomy, which may help to avoid surprises at the time of surgical intervention. (Clinical photos courtesy Dr. Aida Rebai.)

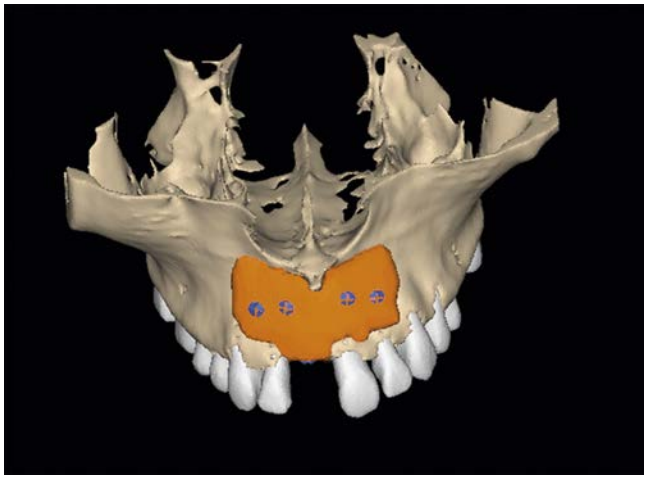

• **Figure 41-17** Tenting screws should be ideally located to provide support for the bone graft, while avoiding adjacent vital structures.

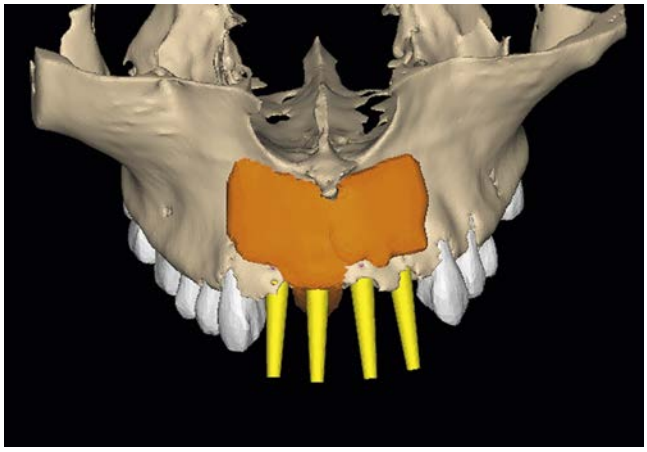

• **Figure 41-18** Using advanced software applications with a volumetric grafting module, a simulated bone graft *(orange)* is shown conformed to the facial defect, with sufficient volume to serve as the foundation for implant placement.

procedures by providing excellent visualization of the extraction sites (Figure 41-22, *A*), as well as the positions of the existing natural teeth and roots to refine the implant positioning (see Figure 41-22, *B*).

In order to achieve true restoratively-driven implant reconstruction as defined by the author, each implant requires placement within an adequate volume of bone, stability within the bone on placement, and an understanding of the definitive restorative design. Therefore the implants are simulated within the receptor site within the augmented bone of the cross-sectional slices for the right lateral incisor (Figure 41-23, *A*), the right central incisor (see Figure 41-23, *B*), the left central incisor (see Figure 41-23, *C*), and the left lateral incisor (see Figure 41-23, *D*). The plan is similar for the option of using particulate bone, block bone grafting, or tenting screws and reinforced membranes with various combination of biologic materials with the important goal of creating sufficient bone volume for implant placement. The simulated plan can be presented to the patient with the computer-generated images and shared with colleagues, members of the implant team, referring doctors, and dental laboratory technicians, providing an excellent communication tool leading to increased case acceptance. Once the plan has been accepted, the treatment can be successfully carried out with precision, and without surprises.

Biomedical Models/Stereolithography: Digital Workflow

Recent technology has also provided a path from the treatment plan with simulated virtual bone grafting volumes to rapid-prototyping such as 3D printing ("additive manufacturing"), stereolithography (SLA) for hand-milling, or CAD-CAM fabrication ("subtractive manufacturing") of actual biological material for implantation. In order for

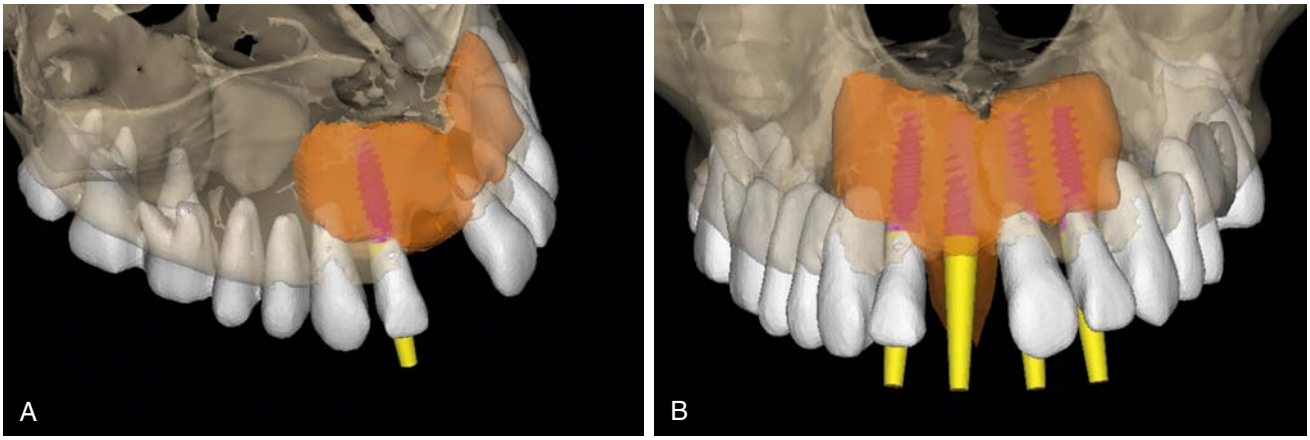

• **Figure 41-19** **A,** Each implant was simulated with an abutment projection *(yellow)* to help define the trajectory within the restorative envelope of the existing natural dentition. **B,** Each projection extended beyond the occlusal plane of the teeth.

this process to take place, the interactive treatment planning software must have the capability to export the reconstructed volumetric image dataset to standard triangulation files (STL) for the purposes of fabricating the biomedical model of the maxillary or mandibular bone and the graft shape. This process is also useful to plan the location of bone graft donor sites when autologous bone is required from the hip, symphysis, or ramus. The 3D representation of the graft volume, fixation screws, and maxillary arch can be seen in Figure 41-24, *A,* and secured to the maxilla in Figure 43-24, *B*. The reconstructed volume was first generated and then exported as an STL file to be imported into a 3D printer software application (Figure 41-25, *A*). The 3D printer can be a high-end, high-capacity, high-resolution industrial type, or the ever-evolving, lower-cost smaller devices for limited-quantity output at surprisingly high resolution, especially with SLA. In addition, the software can plan production for more than one part at a time based on the size of the build platform. The maxillary arch STL file and the separate bone graft STL file were positioned on the virtual production or build platform with the appropriate resin as seen in Figure 41-25, *B*. The stereolithography or SLA process manages a precise laser that is directed over a bath of liquid resin to solidify the resin layer by layer until the desired shape is completed. In order to complete the design process, structural elements must be incorporated to support the 3D printing process as the model is raised vertically out of the resin bath (Figure 41-26). The thinner each layer, the higher the resolution.

The simulation process can be further amplified by fabricating actual scale models of the anatomy in anticipation of the surgical procedure(s) (Figure 41-27). The deficient maxillary site can be completely visualized in the resin model (Figure 41-28). The maxillary arch and the 3D-printed bone graft shape are separate component parts used to simulate the graft placement (Figure 41-29). The simulated graft can be evaluated in terms of the desired intimate fit to the underlying facial alveolar bone (Figure 41-30). The use of rapid prototyping and 3D printing is an excellent aid to determine the size of the required donor graft material. Once the simulated graft has been fabricated in resin, the placement of fixation screws can be established on the model and with the CBCT images (Figure 41-31). The placement of the fixation screws can be therefore pre-determined within

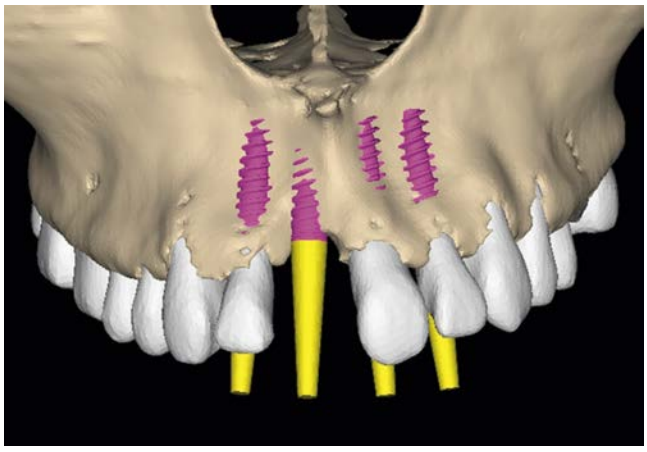

• **Figure 41-20** Without bone grafting, implants would perforate the facial cortical plates and could not be sufficiently fixated.



• **Figure 41-21** DICOM data manipulated through a process known as "segmentation" to virtually "extract" the anterior maxillary teeth in question.

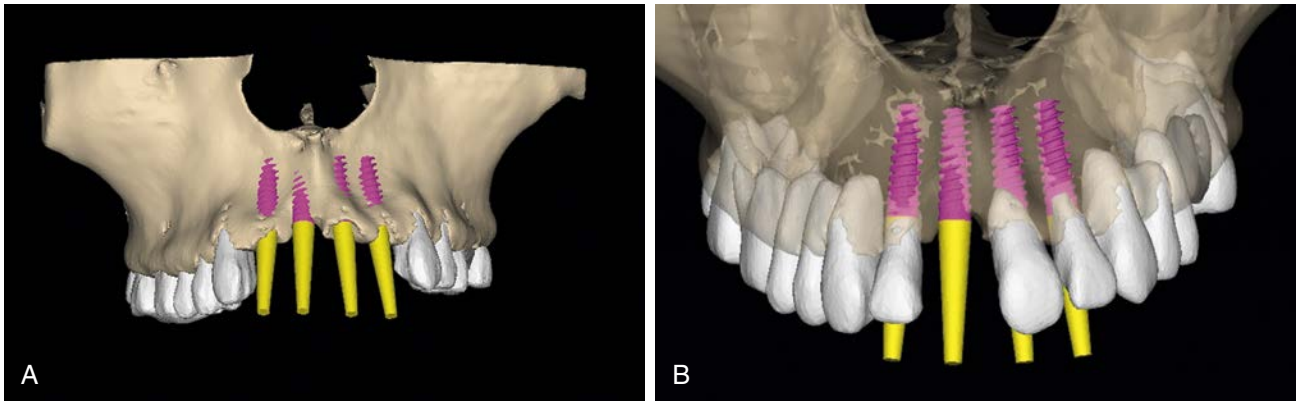

• **Figure 41-22** **A,** Advanced software applications are helpful in accurately planning the surgical and prosthetic procedures, providing excellent visualization of potential extraction sites. **B,** The positions of the existing natural teeth and roots to refine the implant positioning.

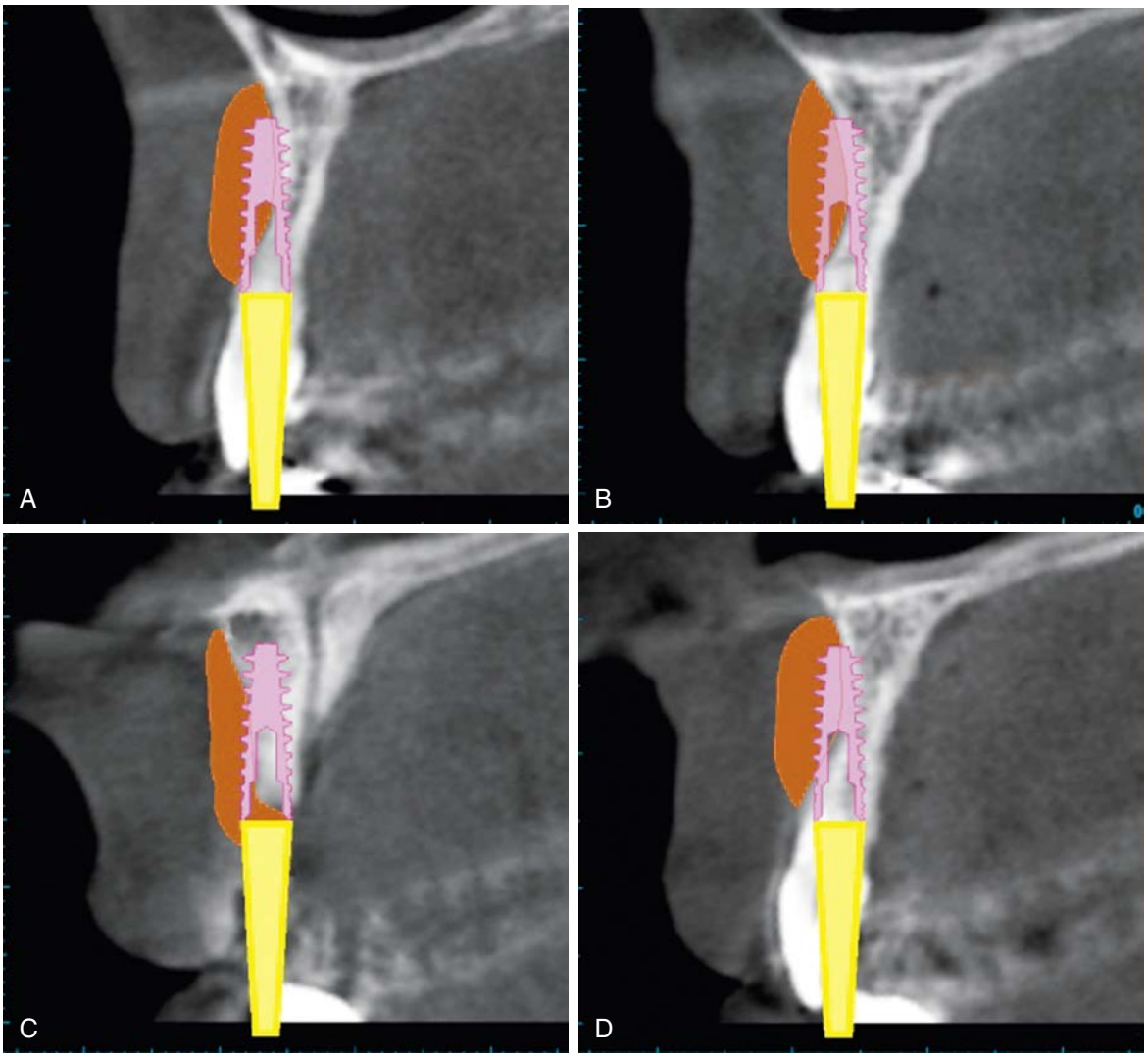

• **Figure 41-23** Implants simulated within the receptor site within the augmented bone of the cross-sectional slices for **(A)** the right lateral incisor, **(B)** the right central incisor, **(C)** the left central incisor, and **(D)** the left lateral incisor.

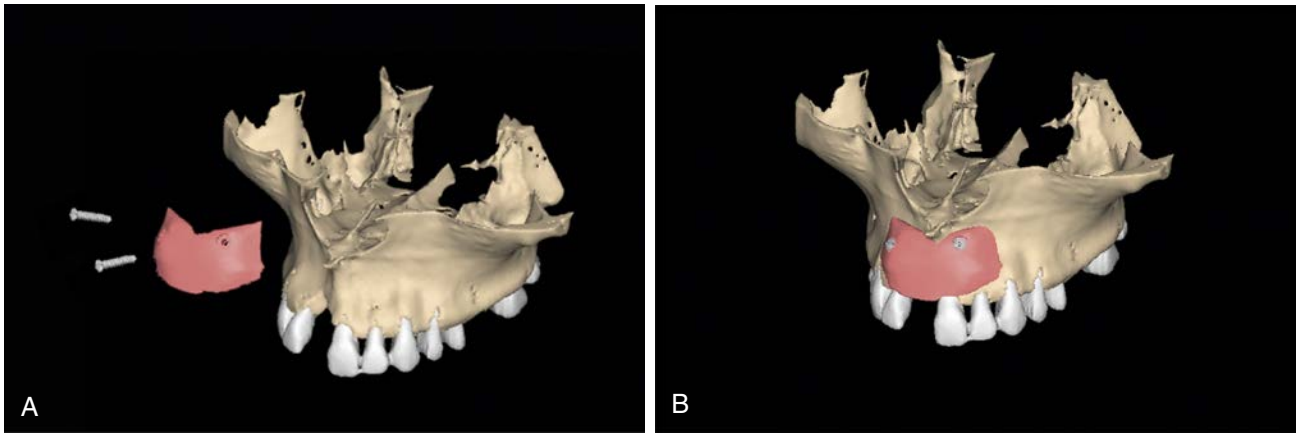

• **Figure 41-24** **A,** Three-dimensional representation of the graft volume, fixation screws, and maxillary arch. **B,** Secured to the maxilla.

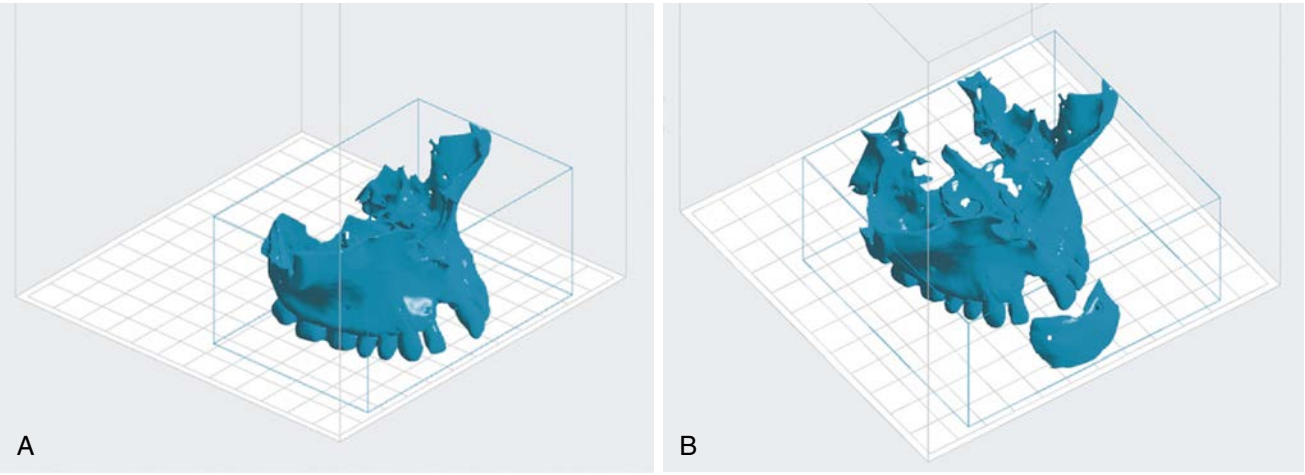

• **Figure 41-25** **A,** The reconstructed maxillary volume exported as an STL file imported into a 3D printer, and **(B)** positioned on the virtual production or build platform ready for fabrication with the separate grafting volume.

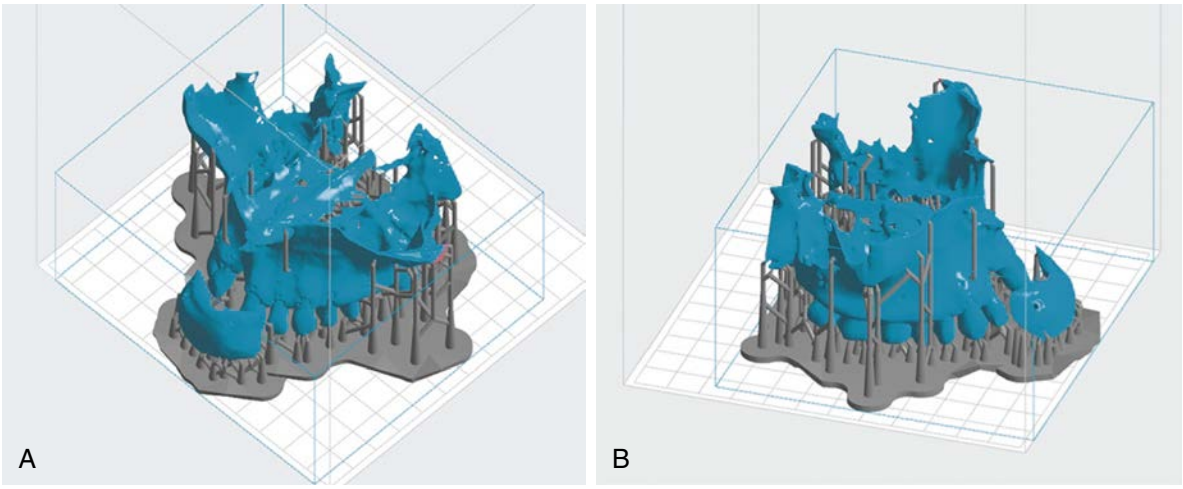

• **Figure 41-26** **A,** The stereolithography process involves a precise laser to be directed over a bath of liquid resin to solidify the resin, layer by layer, until the desired shape is completed. **B,** Structural elements may be incorporated to support the 3D printing process, as the model is raised vertically out of the resin bath.



• **Figure 41-27** The simulation process can be further amplified by fabricating actual scale models of the anatomy in anticipation of the surgical procedure(s).

the 3D-printed resin block. Using an appropriate fixation screw kit, the entire process can be simulated extraorally to enhance accuracy of graft positioning to insure precision of fit (Figure 41-32). The occlusal view of the resin models reveals the anticipated increased width of facial bone in the anterior maxilla (Figure 41-33).

Surgical Guide Fabrication: Bone-Borne Template Maxilla

The same digital workflow applies to the fabrication of the surgical guide for dental implant placement. The diagnosis phase is important to insure that implants are placed properly within enough volume of bone, and in a position to support the desired restoration. The cross-sectional image reveals the

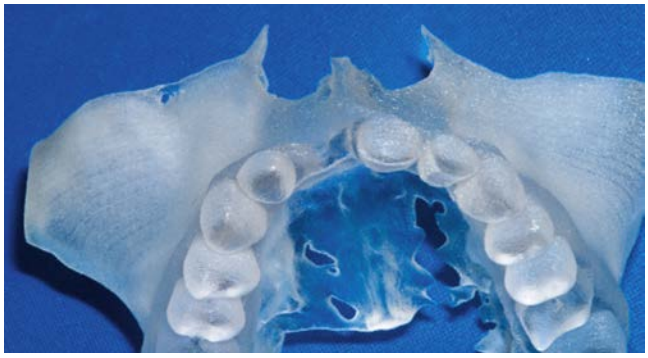


• **Figure 41-28** The deficient maxillary site can be completely visualized in the resin model.




• **Figure 41-29** The maxillary arch and the 3D printed bone graft shape are separate component parts used to simulate the graft placement.





• **Figure 41-30** The simulated graft can be evaluated in terms of the desired intimate fit to the underlying facial alveolar bone.

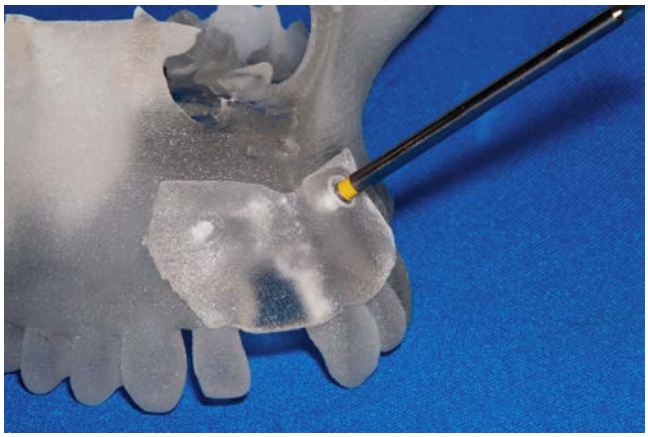


• **Figure 41-31** Once the simulated graft has been fabricated in resin, the placement of fixation screws can be established on the biomedical model.



• **Figure 41-32** Using an appropriate surgical fixation screw kit, the entire process can be simulated extraorally to enhance accuracy of graft positioning and ensure precision of fit.

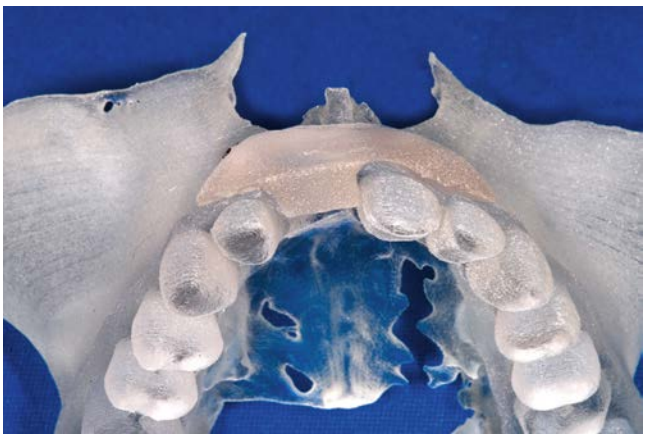

• **Figure 41-33** Occlusal view of the resin models reveals the anticipated increased width of facial bone in the anterior maxilla.

maxillary cuspid tooth with the surrounding alveolar housing (Figure 41-34, *A*). Using interactive treatment planning software, a simulated implant can be placed within the proposed implant receptor site (see Figure 41-34, *B*). However, the placement of the implant alone is not sufficient to achieve true restoratively driven implant restoration, as it does not show the link between the implant and the tooth. Therefore, in the author's opinion, it is important to create a projection from the implant body through the occlusal surface of the tooth to aid in establishing the proper trajectory *(yellow),* in anticipation of a cement or screw-retained restorative outcome (see Figure 41-34, *C*). To facilitate the diagnostic phase, the author has promoted the use of a simple cotton roll placed under the lip and into the vestibule, known as the "lip-lift" technique (Figure 41-35, *A*). Note the difference in diagnostic clarity when comparing these images to the cross-sectional images of the first case (see Figures 41-3 through 41-7). The pink line represents the soft tissue thickness over the alveolus and in the vestibule *(red arrow)* (see Figure 41-35, *B*). Using the lip-lift allows further definition of the soft tissue covering the facial aspect of the bone, and the relationship of the vestibule to the floor of the nose *(yellow arrow),* important if a flap needs to be raised for bone grafting. Advanced features contained in certain interactive treatment planning applications provide the ability to position realistic implants and implant abutments. The realistic manufacturer-specific abutment *(green shape)* can be placed on top of the implant and positioned to within the envelope of the restoration to be fabricated (Figure 41-36, *A*). The author's "Triangle of Bone" (TOB) concept maximizes the relationship between the volume of bone and an implant positioned within the receptor site to receive a cement-retained restoration. If the implant bisects the triangle as shown, it will be surrounded with the greatest volume of bone (see Figure 41-36, *B*).

Once the implants have been planned, and the surgical guide has been completed with the interactive treatment planning software, the surgical guide design data are then exported as an STL file and sent to the manufacturing device to produce the guide. The surgical guide can then be fabricated through a CAD-CAM, 3D printing, or SLA process. The STL file is then managed within the 3D printing software and positioned on the build platform

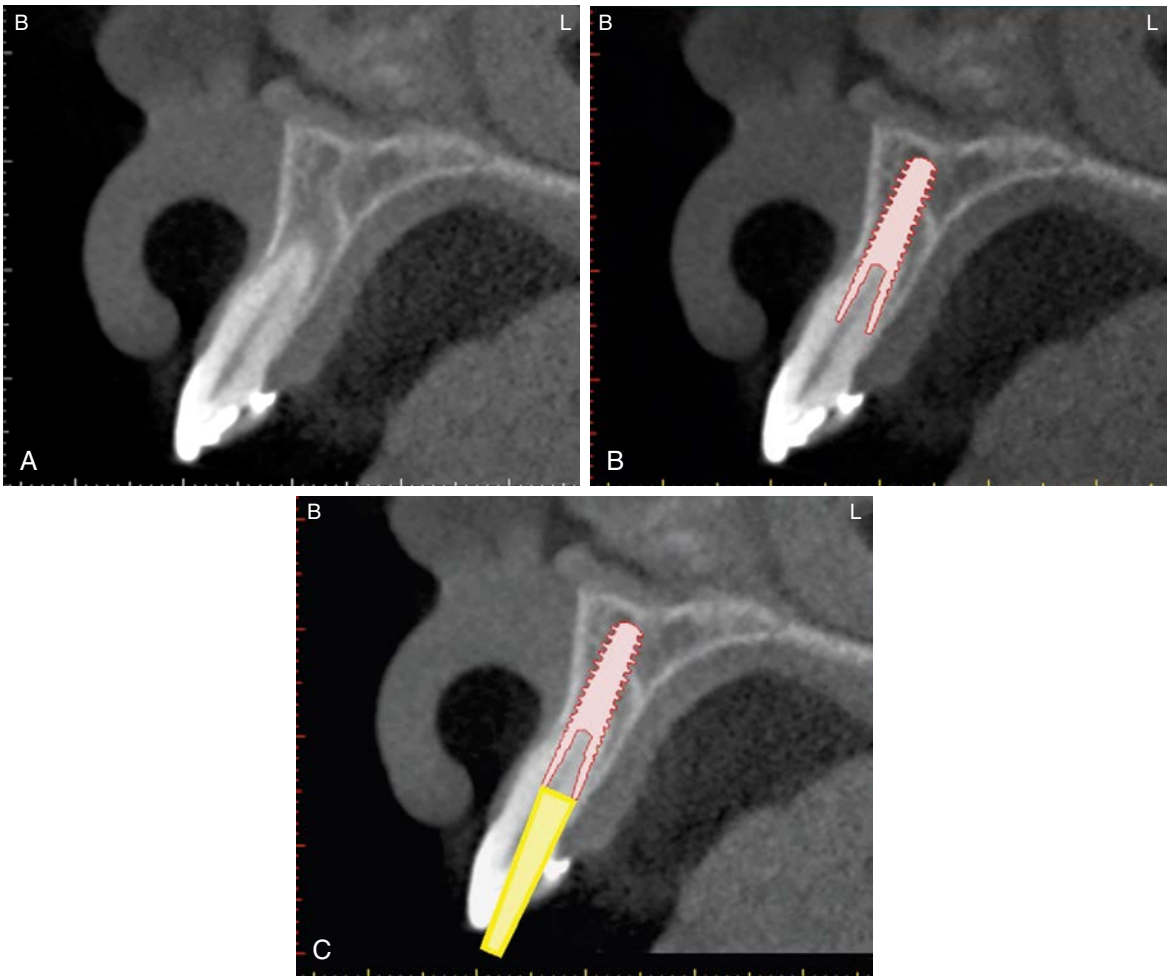

• **Figure 41-34** **A,** Cross-sectional image reveals the maxillary cuspid tooth with the surrounding alveolar housing. **B,** A simulated implant placed within the proposed implant receptor site. **C,** A projection from the implant body through the occlusal surface of the tooth aids in establishing the proper trajectory *(yellow),* in anticipation of a cement or screw-retained restorative outcome.

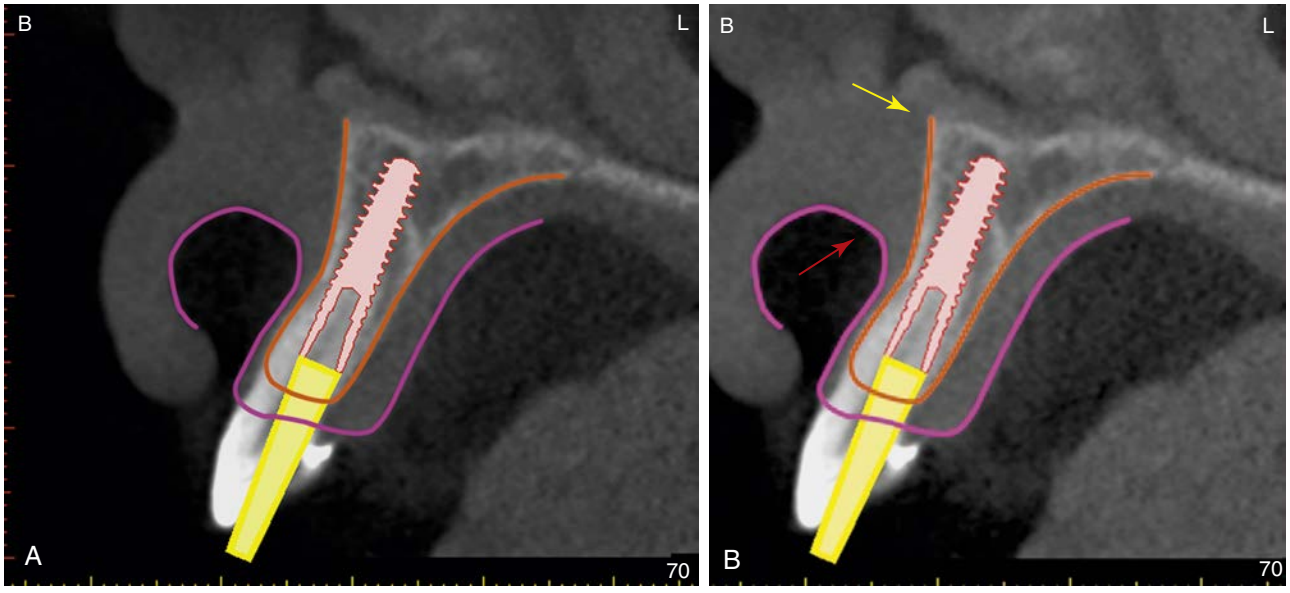

• **Figure 41-35** **A,** To facilitate the diagnostic phase, a simple cotton roll was placed under the lip and into the vestibule known as the "Lip-Lift" technique. **B**, The *pink line* represents the soft tissue thickness over the alveolus, and the extent of the vestibule *(red arrow)*.

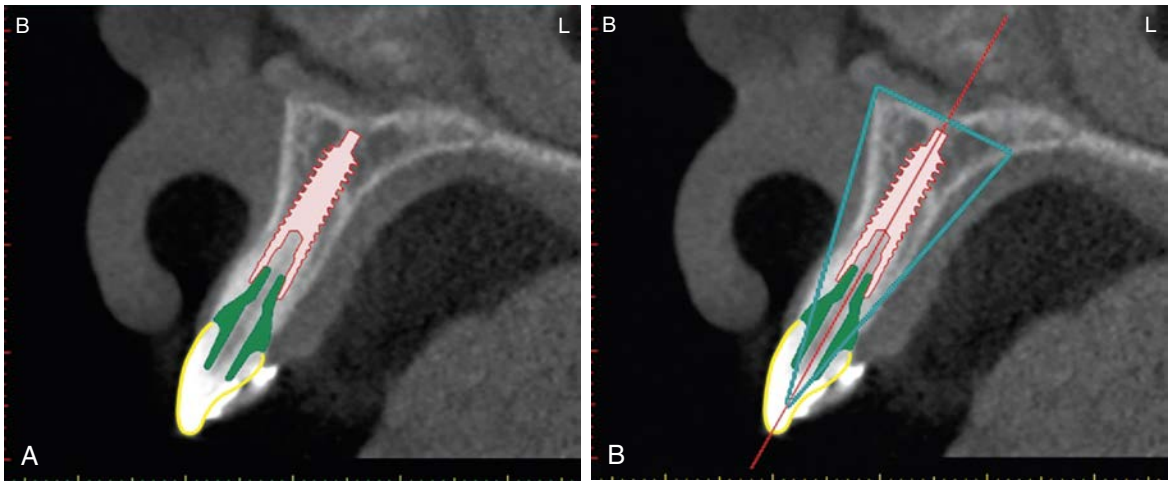

• **Figure 41-36** **A,** The realistic manufacturer-specific abutment *(green shape)* can be placed on top of the implant and positioned within the envelope of the desired restoration. **B,** "Bisecting" the Triangle of Bone to surround the implant with the most volume of bone.

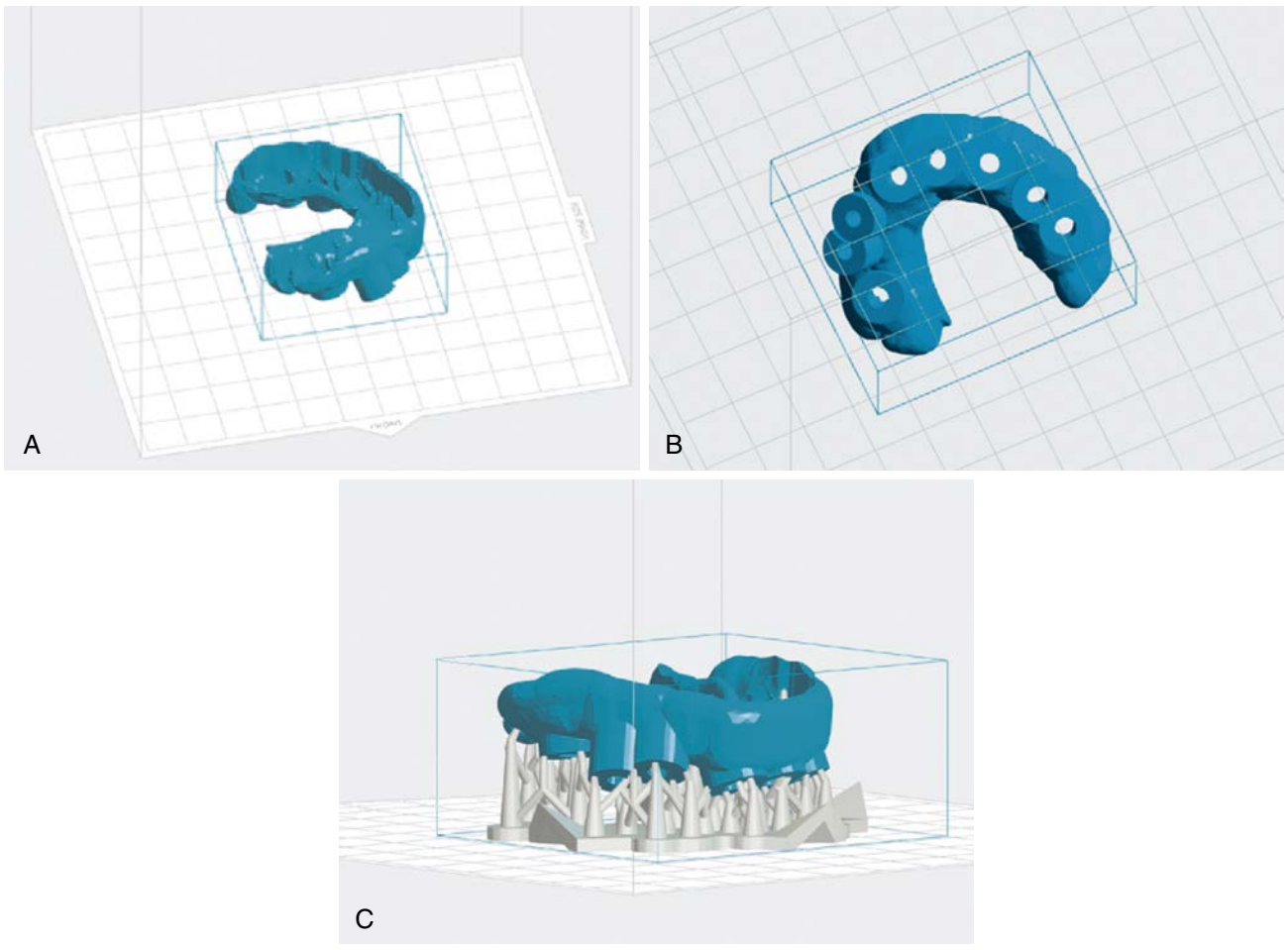

• **Figure 41-37** **A-B,** The STL file managed within the 3D printing software and positioned on the build platform. **C,** The supporting structures are then formulated, and the template is printed over a period of many hours.



• **Figure 41-38** The resulting resin pattern with supporting struts which will be cut away by hand, polished, rinsed, and then sterilized for use.

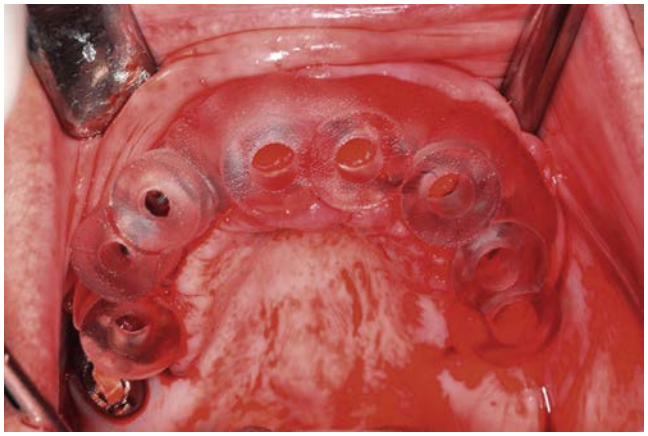

• **Figure 41-39** The maxillary bone-borne template, seen without any metal tubes, seated and ready for surgical intervention.

(Figure 41-37, *A* and *B*). The SLA supporting structures are then formulated, and the template is "printed" over a period of many hours (depending on desired resolution) as the laser gradually cures each layer (see Figure 41-37, *C*). The result is a resin pattern with supporting struts that will be cut away by hand, after which the pattern is polished, rinsed, and then sterilized for use (Figure 41-38). The template can be fabricated without metal guide sleeves, or metal guide sleeves can be added later. The maxillary bone-borne template, without any metal tubes, seated and ready for surgical intervention, is shown in Figure 41-39.

Innovative New Protocols: Donor Sites, Sinus Grafting, and Reconstruction Surgery

As the technology evolves, additional benefits have been derived from innovative and clinically useful concepts and protocols to enhance bone grafting procedures in preparation for placement of dental implants. The technology allows clinicians new tools to improve accuracy and efficiency and decrease surgical time and complications. To enhance grafting procedures, the mandible or maxillary bone can be fabricated through an SLA process, allowing for complete inspection of regions of interest as previously described and illustrated (see Figures 43-27 through 43-33). Once the defect has been identified and the grafting modality and region for the donor graft site has been established,

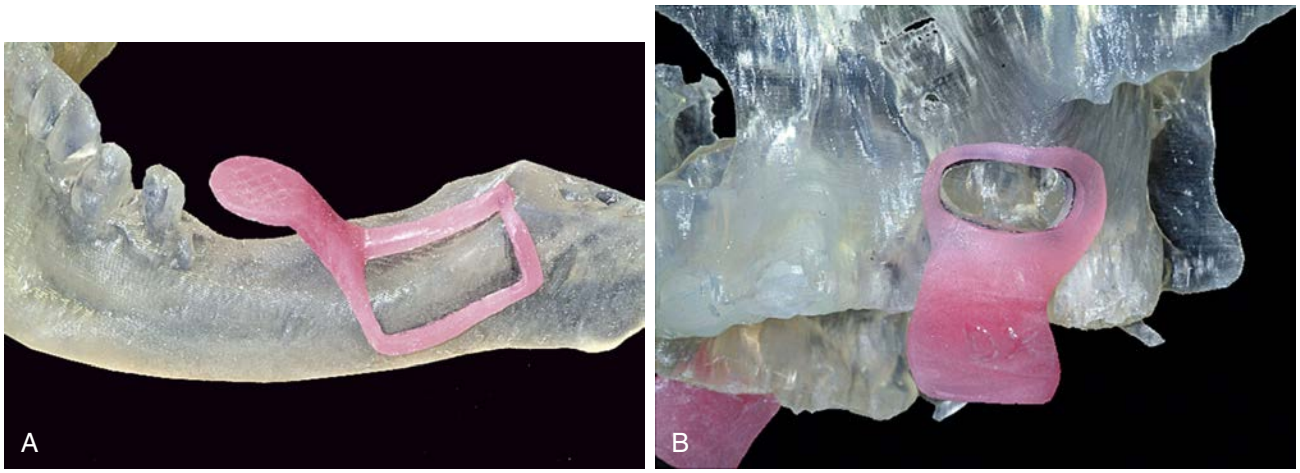

• **Figure 41-40** **A,** Once the biomedical resin model has been fabricated, the location of the donor graft site can be transferred to the model, as a "harvest guide," or **(B)** a "sinus graft guide" can be fabricated to be placed on the bone at the time of surgery to quickly and accurately transfer the position of the planned lateral window access to the maxillary sinus.

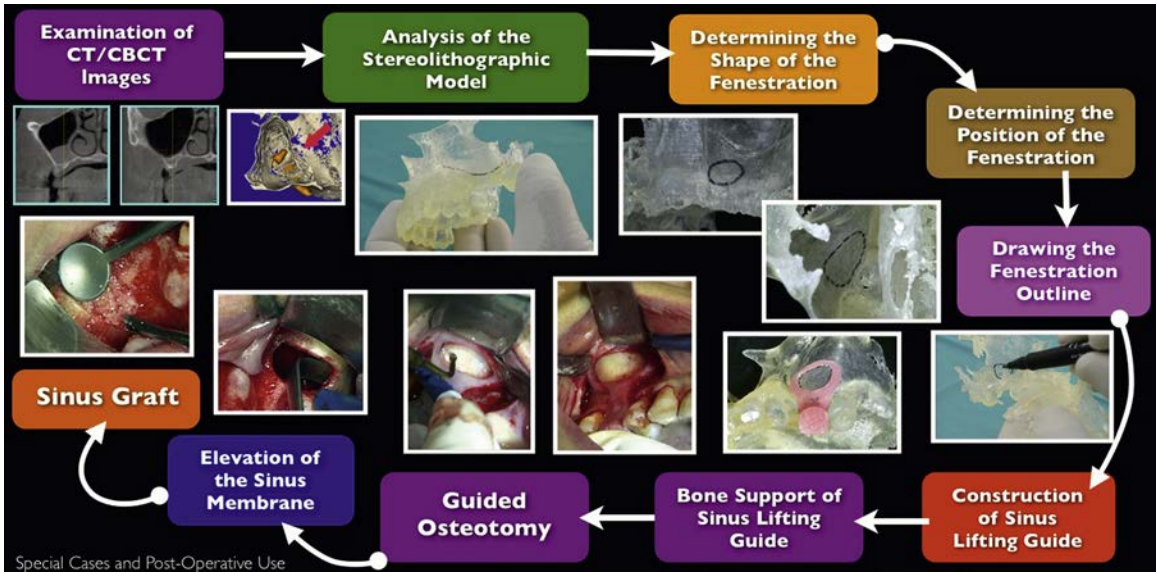

• **Figure 41-41** Protocol 1: Ganz-Rinaldi surgical protocol for sinus floor augmentation.

surgical templates can be useful to help define autologous donor graft sites, such as the mandibular ramus. Clinicians should first accurately assess potential donor sites with the 3D planning software to obtain the correct shape and volume of the donor graft while avoiding adjacent vital anatomy. Once the biomedical resin model has been fabricated, the location of the donor graft site can be transferred to the model, and a "harvest guide" can be fabricated (Figure 41-40, *A*). These concepts have been well described in the textbook *Computer-Guided Applications for Dental Implants, Bone Grafting, and Reconstructive Surgery*.

When planning for lateral window sinus augmentation procedures with 3D imaging and interactive treatment planning software, the shape and volume of the maxillary sinus can be evaluated. However, it is difficult for clinicians to transfer this information to the surgical site to determine exactly where the lateral window should be located, and the size and shape of the window fenestration to facilitate the grafting procedure. The fabrication of a biomedical model of the maxilla is useful in combination with the 3D planning software to accurately assess the position of the lateral window. Once the location has been determined, a "sinus graft guide" can be fabricated to be placed on the bone at the time of surgery to quickly and accurately transfer the position of the lateral window access to the maxillary sinus (see Figure 41-40, *B*). The Ganz-Rinaldi sinus augmentation lateral approach protocol is shown in Protocol 1 (Figure 41-41). The action flow

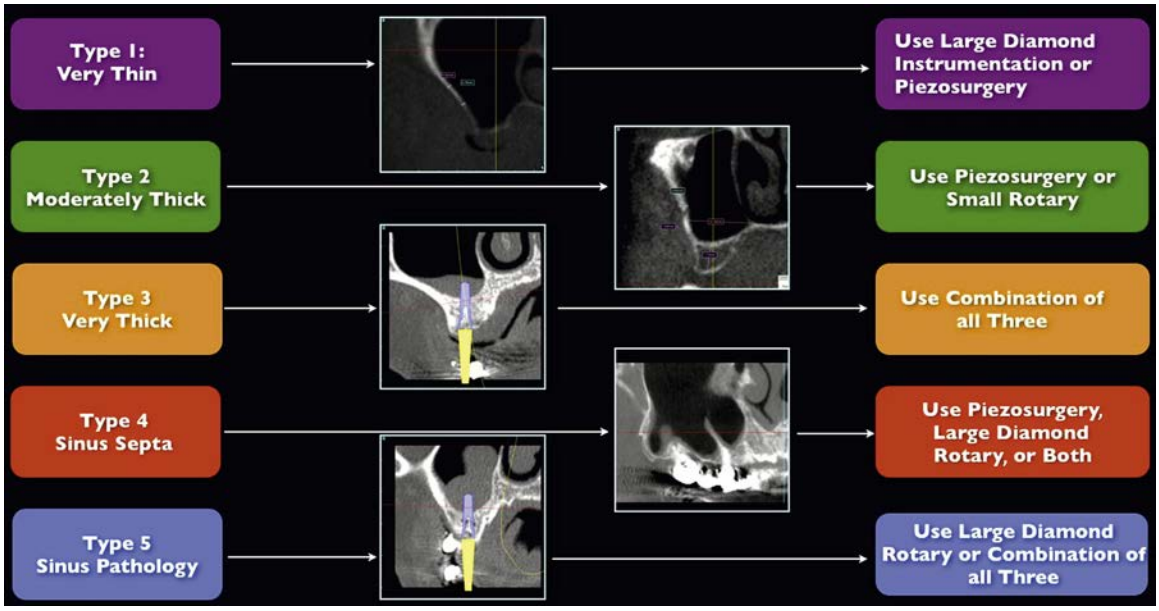

• **Figure 41-42** Protocol 2: Ganz-Rinaldi surgical protocol and classification for lateral sinus floor augmentation.

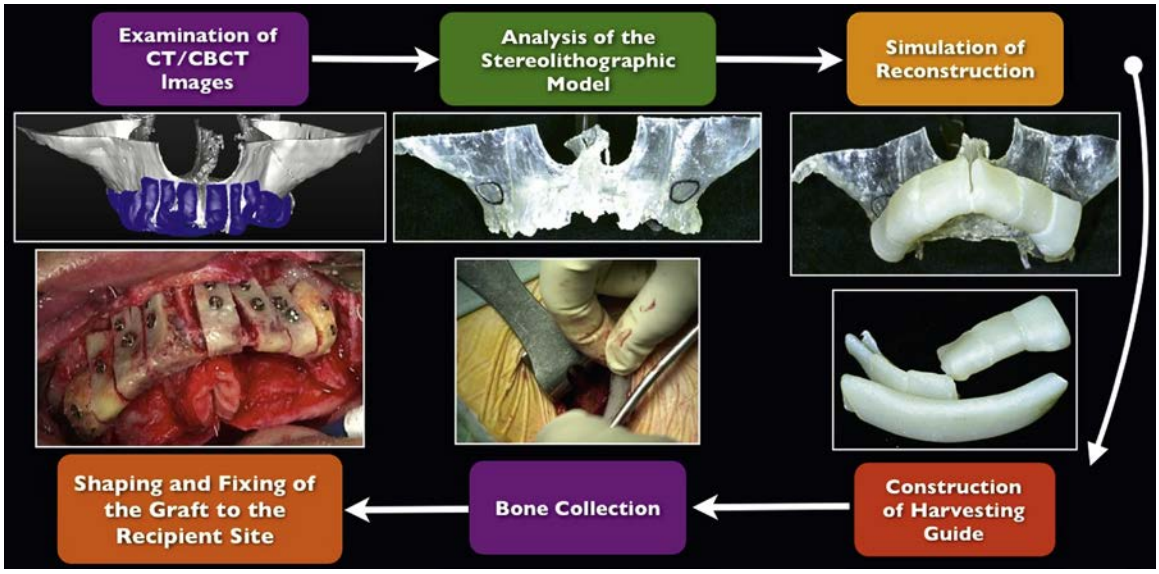

• **Figure 41-43** Protocol 3: Ganz-Rinaldi surgical protocol for reconstructive surgery.

describes the step-by-step process to achieve accurate location for the lateral window sinus augmentation procedure. The fabrication of sinus guides can be helpful with many different variations of the lateral window approach for single or bilateral procedures, and when septa may require two separate windows.

The use of 3D imaging can also provide clinicians with new protocols to help define and designate the proper instrumentation needed to access the sinus based on the diagnostic information gleaned from the CT/CBCT scan. The Ganz-Rinaldi sinus augmentation instrumentation protocol explains how the lateral wall thickness, bone density, presence of septa, and presence of pathology can determine which instrumentation would be appropriate to expedite the process (see Protocol 2 in Figure 41-42). The protocol describes five different categories or types of lateral sinus wall bone, and the use of three different instrumentation types: large diamond rotary instruments, piezosurgery instrumentation, or small rotary instrumentation. Finally, Protocol 3 (Figure 41-43) demonstrates the Ganz-Rinaldi reconstructive surgery protocol to simulate and then execute larger maxillofacial reconstruction with donor bone grafts and multiple recipient sites. In addition to the three presently described protocols, the Ganz-Rinaldi sinus augmentation crestal approach, harvesting protocol, and zygomatic implant protocol are presented in the textbook cited earlier.

Conclusion

The ability to visualize patient anatomy in three dimensions provides clinicians with invaluable diagnostic capabilities for assessment of potential implant receptor sites, and determination for bone grafting applications. The use of surgical templates generated through interactive treatment planning software is not new. However, the overall use of surgical guides is still quite infrequent owing to several factors: (1) the need to have a CT/CBCT scan; (2) the ability to use the interactive treatment planning software for diagnosis; (3) clinicians may not be educated on how to use software tools for proper planning of dental implants; (4) the extra time required for the planning process; (5) the extra time required for the fabrication of the surgical guides at a distant site; and (6) the added expense related to the template fabrication; and (7) the extra expense in obtaining the necessary instrumentation to complete a guided surgery procedure. Despite these barriers, the importance of 3D diagnosis, use of surgical guides, and the acceptance and adoption of guided surgery procedures is increasing to enhance one-stage, two-stage, and immediate-load/immediate restoration protocols. Use of this ever-expanding technology can only be beneficial for our patients who require accuracy, precision, and consistency with dental implant placement and bone grafting procedures to improve long-term quality of life. New and innovative protocols have been presented to illustrate the present and future potential applications of the evolving technology. Further research and case documentation is recommended to help identify further innovative concepts for diagnosis, treatment planning, surgical and restorative applications, and fabrication of surgical guides for a variety of different treatment modalities.

Suggested Readings

Aghaloo TL, Moy PK: Which hard tissue augmentation techniques are the most successful in furnishing bony support for implant placement? *Int J Oral Maxillofac Implants* 22(Suppl):49–70, 2007.

Alqerban A, Jacobs R, Souza PC, Willems G: In-vitro comparison of 2 cone-beam computed tomography systems and panoramic imaging for detecting simulated canine impaction-induced external root resorption in maxillary lateral incisors, *Am J Orthod Dentofacial Orthop* 136(6):764.e1–764.e11, 2009, discussion764–765.

Amet EM, Ganz SD: Functional and aesthetic acceptance prior to computerized tomography or implant placement, *Implant Dent* 6(3):193–197, 1997.

Angelopoulos C, Aghaloo T: Imaging technology in implant diagnosis, *Dent Clin North Am* 55(1):141–158, 2011.

Araryarachkul P, Caruso J, Gantes B, et al.: Bone density assessments of dental implant sites: 2. Quantitative cone-beam computerized tomography, *Int J Oral Maxillofac Implants* 20:416–424, 2005.

Arisan V, Karabuda ZC, Ozdemir T: Accuracy of two stereolithographic guide systems for computer-aided implant placement: a computed tomography-based clinical comparative study, *J Periodontol* 81(1):43–51, 2010.

Basten CH: The use of radiopaque templates for predictable implant placement, *Quintessence Int* 26:609–612, 1995.

Behneke A, Burwinkel M, Behneke N: Factors influencing transfer accuracy of cone beam CT-derived template-based implant placement, *Clin Oral Implants Res* 23(4):416–423, 2012.

Benavides E, Rios HF, Ganz SD, et al.: Use of cone beam computed tomography in implant dentistry: the International Congress of Oral Implantologists consensus report, *Implant Dent* 21(2):78–86, 2012.

Benington PC, Khambay BS, Ayoub AF: An overview of three-dimensional imaging in dentistry, *Dent Update* 37(8):494–496, 2010. 499-500, 503–504.

Berco M, Rigali PH Jr, Miner RM, et al.: Accuracy and reliability of linear cephalometric measurements from cone-beam computed tomography scans of a dry human skull, *Am J Orthod Dentofacial Orthop* 136(1):17.e1–17.e9, 2009. discussion 17–18.

Berdougo M, Fortin T, Basten CH, Kois JC: The use of barium sulfate for implant templates, *J Prosthet Dent* 76:451–454, 1996.

Borrow W, Smith Justin P: Stent marker materials for computerized tomograph-assisted implant planning, *Int J Periodontics Restorative Dent* 16:61–67, 1996.

Chan HL, Misch K, Wang HL: Dental imaging in implant treatment planning, *Implant Dent* 19(4):288–298, 2010.

Chia HN, Wu BM: Recent advances in 3D printing of biomaterials, *J Biol Eng* 9:4, 2015.

Chiapasco M, Zaniboni M, Boisco M: Augmentation procedures for the rehabilitation of deficient edentulous ridges with oral implants, *Clin Oral Implants Res* 17(Suppl 2):136–159, 2006.

Chiapasco M, Casentini P, Zaniboni M: Bone augmentation procedures in implant dentistry, *Int J Oral Maxillofac Implants* 24(Suppl):237–259, 2009.

Cohen A, Laviv A, Berman P, et al.: Mandibular reconstruction using stereolithographic 3-dimensional printing modeling technology, *Oral Surg Oral Med Oral Pathol Oral Radiol Endod* 108(5):661–666, 2009.

Cordaro L, Torsello F, Roccuzzo M: Implant loading protocols for the partially edentulous posterior mandible, *Int J Oral Maxillofac Implants* 24(Suppl):158–168, 2009.

Cortes AR, Cortes DN, Arita ES: Cone beam computed tomographic evaluation of a maxillary alveolar ridge reconstruction with iliac crest graft and implants, *J Craniofac Surg* 23(1):e12–e14, 2012.

Danza M, Zollino I, Carinci F: Comparison between implants inserted with and without computer planning and custom model coordination, *J Craniofac Surg* 20(4):1086–1092, 2009.

De Vos W, Casselman J, Swennen GR: Cone-beam computerized tomography (CBCT) imaging of the oral and maxillofacial region: a systematic review of the literature, *Int J Oral Maxillofac Surg* 38(6):609–625, 2009.

Di Giacomo GA, Cury PR, de Araujo NS, et al.: Clinical application of stereolithographic surgical guides for implant placement: preliminary results, *J Periodontol* 76(4):503–507, 2005.

Dreiseidler T, Mischkowski RA, Neugebauer J, et al.: Comparison of cone-beam imaging with orthopantomography and computerized tomography for assessment in presurgical implant dentistry, *Int J Oral Maxillofac Implants* 24(2):216–225, 2009.

Dula K, Mini R, van der Stelt PF, Buser D: The radiographic assessment of implant patients: decision-making criteria, *Int J Oral Maxillofac Implants* 16(1):80–89, 2001.

Eggers G, Patellis E, Mühling J: Accuracy of template-based dental implant placement, *Int J Oral Maxillofac Implants* 24(3):447–454, 2009.

Ersoy AE, Turkyilmaz I, Ozan O, McGlumphy EA: Reliability of implant placement with stereolithographic surgical guides generated from computed tomography: clinical data from 94 implants, *J Periodontol* 79(8):1339–1345, 2008.

Farley NE, Kennedy K, McGlumphy EA, Clelland NL: Split-mouth comparison of the accuracy of computer-generated and conventional surgical guides, *Int J Oral Maxillofac Implants* 28(2):563–572, 2013 Mar-Apr.

Fortin T, Isidori M, Blanchet E, et al.: An image-guided system-drilled surgical template and trephine guide pin to make treatment of completely edentulous patients easier: a clinical report on immediate loading, *Clin Implant Dent Relat Res* 6(2):111–119, 2004.

Ganz SD: CT scan technology—an evolving tool for predictable implant placement and restoration, *Int Magazine Oral Implantol* 1:6–13, 2001.

Ganz SD: Use of stereolithographic models as diagnostic and restorative aids for predictable immediate loading of implants, *Pract Proced Aesthet Dent* 15(10):763–771, 2003.

Ganz SD: Use of conventional CT and cone beam for improved dental diagnostics and implant planning, *AADMRT Newslett*, Spring, 2005.

Ganz SD: Presurgical planning with CT-derived fabrication of surgical guides, *J Oral Maxillofac Surg* 63(9), 2005. Suppl 2:59–71.

Ganz SD: Conventional CT and cone beam CT for improved dental diagnostics and implant planning, *Dent Implantol Update* 16(12), 2005.

Ganz SD: Techniques for the use of CT imaging for the fabrication of surgical guides, *Atlas Oral Maxillofac Surg Clin North Am* 14:75–97, 2006.

Ganz SD: The reality of anatomy and the triangle of bone, *Inside Dent* 2(5):72–77, 2006.

Ganz SD: The reality of anatomy and the triangle of bone. Proceedings of ICOI World Congress XXIV, *Implant Dent* 14(suppl):182–191, 2006.

Ganz SD: 3-D imaging and cone beam CT is "where the action is!", *Inside Dent* 102–103, 2007.

Ganz SD: CT-derived model-based surgery for immediate loading of maxillary anterior implants, *Pract Proced Aesthet Dent* 19(5):311–318, 2007.

Ganz SD: Using interactive technology: "in the zone with the triangle of bone.", *Dent Implantol Update* 19(5):33–38, 2008.

Ganz SD: Defining new paradigms for assessment of implant receptor sites—the use of CT/CBCT and interactive virtual treatment planning for congenitally missing lateral incisors, *Compend Contin Educ Dent* 29(5):256–267, 2008.

Ganz SD: Restoratively driven implant dentistry utilizing advanced software and CBCT: realistic abutments and virtual teeth, *Dent Today* 27(7):122, 2008. 124, 126–127.

Ganz SD: Computer-aided design/computer-aided manufacturing applications using CT and cone beam CT scanning technology, *Dent Clin North Am* 52(4):777–808, 2008.

Ganz SD: Advances in diagnosis and treatment planning utilizing CT scan technology for improving surgical and restorative implant reconstruction: tools of empowerment. In Jokstad A, editor: *Osseointegration and dental implants*, London, 2009, Wiley-Blackwell, pp 88–116.

Ganz SD: Advanced case planning with SimPlant. In Tardieu P, Rosenfeld A, editors: *The art of computer-guided implantology*, Hanover Park, IL, 2009, Quintessence.

Ganz SD: Bone grafting assessment: focus on the anterior and posterior maxilla utilizing advanced 3-D imaging technologies, *Dent Implantol Update* 20(6):41–48, 2009.

Ganz SD: Implant complications associated with two- and three dimensional diagnostic imaging technologies. In Froum SJ, editor: *Dental implant complications: etiology, prevention, and treatment*, West Sussex, UK, 2010, Wiley-Blackwell, pp 71–99.

Ganz SD: The use of CT/CBCT and interactive virtual treatment planning and the triangle of bone: defining new paradigms for assessment of implant receptor sites. In Babbush C, Hahn J, Krauser J, Rosenlicht J, editors: *Dental implants: the art and science*, Maryland Heights, MO, 2010, Saunders, pp 146–166.

Ganz SD: Utilization of three-dimensional imaging technology to enhance maxillofacial surgical applications. In Miloro M, Ghali GE, Larsen P, Waite P, editors: *Peterson's principles of oral and maxillofacial surgery*, Shelton, CT, 2012, People's Medical House—USA, pp 179–200.

Ganz SD: Dental implantology: an evolving treatment modality, *Compend Contin Educ Dent* 34(8):628–629, 2013.

Ganz SD: Three-dimensional imaging and guided surgery for dental implants, *Dent Clin North Am* 59(2):265–290, 2015.

Ganz SD: Diagnostic imaging for patient evaluation and minimally invasive treatment planning. In Cullum D, Deporter D, editors: *Minimally invasive dental implant surgery*, West Sussex, UK, 2015, Wiley-Blackwell.

Guerrero ME, Jacobs R, Loubele M, et al.: State-of-the-art on cone beam CT imaging for preoperative planning of implant placement, *Clin Oral Investig* 10:1–7, 2006.

Haney E, Gansky SA, Lee JS, et al.: Comparative analysis of traditional radiographs and cone-beam computed tomography volumetric images in the diagnosis and treatment planning of maxillary impacted canines, *Am J Orthod Dentofacial Orthop* 137(5):590–597, 2010.

Harris D, Buser D, Dula K, et al.: E.A.O. guidelines for the use of diagnostic imaging in implant dentistry. A consensus work-shop organized by the European Association for Osseointegration in Trinity College Dublin, *Clin Oral Implants Res* 13:566–570, 2002.

Horwitz J, Zuabi O, Machtei EE: Accuracy of a computerized tomography-guided template-assisted implant placement system: an in vitro study, *Clin Oral Implants Res* 20(10):1156–1162, 2009.

Israelson H, Plemons JM, Watkins P, Sory C: Barium-coated surgical stents and computer-assisted tomography in the preoperative assessment of dental implant patients, *Int J Periodontics Restorative Dent* 12:52–61, 1992.

Jabero M, Sarment DP: Advanced surgical guidance technology: a review, *Implant Dent* 15(2):135–142, 2006.

Jacobs R, Adriansens A, Verstreken K, et al.: Predictability of a three-dimensional planning system for oral implant surgery, *Dentomaxillofac Radiol* 28(2):105–111, 1999.

Jacobs R, Mraiwa N, Van Steenberghe D, et al.: Appearance of the mandibular incisive canal on panoramic radiographs, *Surg Radiol Anat* 26:329–333, 2004.

Jacotti M, Barausse C, Felice P: Posterior atrophic mandible rehabilitation with onlay allograft created with CAD-CAM procedure: a case report, *Implant Dent* 23(1):22–28, 2014.

Jamali AA, Deuel C, Perreira A, et al.: Linear and angular measurements of computer-generated models: are they accurate, valid, and reliable? *Comput Aided Surg* 12(5):278–285, 2007.

Jensen SS, Terheyden H: Bone augmentation procedures in localized defects in the alveolar ridge: clinical results with different bone grafts and bone-substitute materials, *Int J Oral Maxillofac Implants* 24(Suppl):218–236, 2009.

Kang SH, Kim MK, Kim HJ, et al.: Accuracy assessment of image-based surface meshing for volumetric computed tomography images in the craniofacial region, *J Craniofac Surg* 25(6):2051–2055, 2014.

Katsoulis J, Pazera P, Mericske-Stern R: Prosthetically driven, computer-guided implant planning for the edentulous maxilla: a model study, *Clin Implant Dent Relat Res* 11(3):238–245, 2009.

Kim KD, Park CS: Effect of variable scanning protocols on the preimplant site evaluation of the mandible in reformatted computed tomography, *Korean J Oral Maxillofac Radiol* 29:21–32, 1999.

Kim KD, Jeong HG, Choi SH, et al.: Effect of mandibular positioning on preimplant site measurement of the mandible in reformatted CT, *Int J Periodontics Restorative Dent* 23(2):177–183, 2003.

Klein M, Cranin AN, Sirakian A: A computerized tomographic (CT) scan appliance for optimal presurgical and pre-prosthetic planning of the implant patient, *Pract Periodontics Aesthet Dent* 5:33–39, 1993.

Klein M, Abrams M: Computer-guided surgery utilizing a computer-milled surgical template, *Pract Proced Aesthet Dent* 13(2):165–169, 2001.

Lal K, White GS, Morea DN, Wright RF: Use of stereolithographic templates for surgical and prosthodontic implant planning and placement. Part I. The concept, *J Prosthodont* 15(1):51–58, 2006.

Lam EW, Ruprecht A, Yang J: Comparison of two-dimensional orthoradially reformatted computed tomography and panoramic radiography for dental implant treatment planning, *J Prosthet Dent* 74:42–46, 1995.

Lanis A, Álvarez Del Canto O: The combination of digital surface scanners and cone beam computed tomography technology for guided implant surgery using 3Shape implant studio software: a case history report, *Int J Prosthodont* 28(2):169–178, 2015.

Laster WS, Ludlow JB, Bailey LJ, Hershey HG: Accuracy of measurements of mandibular anatomy and prediction of asymmetry in panoramic radiographic images, *Dentomaxillofac Radiol* 34(6):343–349, 2005.

Lin MH, Mau LP, Cochran DL, et al.: Risk assessment of inferior alveolar nerve injury for immediate implant placement in the posterior mandible: a virtual implant placement study, *J Dent* 42(3):263–270, 2014.

Marra R, Acocella A, Rispoli A, et al.: Full-mouth rehabilitation with immediate loading of implants inserted with computer-guided flap-less surgery: a 3-year multicenter clinical evaluation with oral health impact profile, *Implant Dent* 22(5):444–452, 2013.

Mischkowski RA, Ritter L, Neugebauer J, et al.: Diagnostic quality of panoramic views obtained by a newly developed digital volume tomography device for maxillofacial imaging, *Quintessence Int* 38(9):763–772, 2007.

Mol A, Balasundaram A: In vitro cone beam computed tomography imaging of periodontal bone, *Dentomaxillofac Radiol* 37(6):319–324, 2008.

Moreira CR, Sales MA, Lopes PM, Cavalcanti MG: Assessment of linear and angular measurements on three-dimensional cone-beam computed tomographic images, *Oral Surg Oral Med Oral Pathol Oral Radiol Endod* 108(3):430–436, 2009.

Mraiwa N, Jacobs R, van Steenberghe D, Quirynen M: Clinical assessment and surgical implications of anatomic challenges in the anterior mandible, *Clin Implant Dent Relat Res* 5(4):219–225, 2003.

Naini RB, Nokar S, Borghei H, Alikhasi M: Tilted or parallel implant placement in the completely edentulous mandible? A three-dimensional finite element analysis, *Int J Oral Maxillofac Implants* 26(4):776–781, 2011.

Nickenig HJ, Eitner S: Reliability of implant placement after virtual planning of implant positions using cone beam CT data and surgical (guide) templates, *J Craniomaxillofac Surg* 35(4-5): 207–211, 2007.

Norton MR, Ganeles J, Ganz SD, et al.: 2010 Guidelines of the Academy of Osseointegration for the Provision of Dental Implants and Associated Patient Care, *Int J Oral Maxillofac Implants* 25(3):620–627, 2010.

Obregon F, Vaquette C, Ivanovski S, et al.: Three-dimensional bioprinting for regenerative dentistry and craniofacial tissue engineering, *J Dent Res* 94(9 Suppl):143S–152S, 2015.

Orentlicher G, Goldsmith D, Horowitz A: Computer-generated implant planning and surgery: case select, *Compend Contin Educ Dent* 30(3):162–166, 2009 Apr. 168-173.

Orentlicher G, Goldsmith D, Horowitz A: Applications of 3-dimensional virtual computerized tomography technology in oral and maxillofacial surgery: current therapy, *J Oral Maxillofac Surg* 68(8):1933–1959, 2010.

Ozan O, Turkyilmaz I, Ersoy AE, et al.: Clinical accuracy of 3 different types of computed tomography-derived stereolithographic surgical guides in implant placement, *J Oral Maxillofac Surg* 67(2):394–401, 2009.

Peñarrocha M, Boronat A, Garcia B: Immediate loading of immediate mandibular implants with a full-arch fixed prosthesis: a preliminary study, *J Oral Maxillofac Surg* 67(6):1286–1293, 2009.

Pistilli R, Felice P, Piatelli M, et al.: Blocks of autogenous bone versus xenografts for the rehabilitation of atrophic jaws with dental implants: preliminary data from a pilot randomised controlled trial, *Eur J Oral Implantol* 7(2):153–171, 2014.

Rinaldi M, Ganz SD, Mottola A: *Computer-guided applications for dental implants, bone grafting, and reconstructive surgery*, St Louis, 2015, Elsevier.

Rodriguez-Recio O, Rodriguez-Recio C, Gallego L, Junquera L: Computed tomography and computer-aided design for locating available palatal bone for grafting: two case reports, *Int J Oral Maxillofac Implants* 25(1):197–200, 2010.

Rosenfeld AL, Mecall RA: Use of interactive computed tomography to predict the esthetic and functional demands of implant-supported prostheses, *Compend Contin Educ Dent* 17:1125–1146, 1996.

Rosenfeld AL, Mecall RA: Use of prosthesis-generated computed tomographic information for diagnostic and surgical treatment planning, *J Esthet Dent* 10:132–148, 1998.

Rosenfeld A, Mandelaris G, Tardieu P: Prosthetically directed placement using computer software to insure precise placement and predictable prosthetic outcomes. Part 1: diagnostics, imaging, and collaborative accountability, *Int J Periodontics Restorative Dent* 26:215–221, 2006.

Rothman SLG: Computerized tomography of the enhanced alveolar ridge. In *Dental applications of computerized tomography*, Chicago, 1998, Quintessence, pp 87–112.

Rugani P, Kirnbauer B, Arnetzl GV, Jakse N: Cone beam computerized tomography: basics for digital planning in oral surgery and implantology, *Int J Comput Dent* 12(2):131–145, 2009.

Sakakura CE, Morais JA, Loffredo LC, Scaf G: A survey of radiographic prescription in dental implant assessment, *Dentomaxillofac Radiol* 32:397–400, 2003.

Sarment DP, Shammari K, Kazor CE: Stereolithographic surgical templates for placement of dental implants in complex cases, *Int J Periodontics Restorative Dent* 23:287–295, 2003.

Sbordone L, Toti P, Menchini-Fabris G, et al.: Implant survival in maxillary and mandibular osseous onlay grafts and native bone: a 3-year clinical and computerized tomographic follow-up, *Int J Oral Maxillofac Implants* 24(4):695–703, 2009.

Scherer MD: Presurgical implant-site assessment and restoratively driven digital planning, *Dent Clin North Am* 58(3):561–595, 2014.

Schlee M, Rothamel D: Ridge augmentation using customized allogenic bone blocks: proof of concept and histological findings, *Implant Dent* 22(3):212–218, 2013.

Shan XF, Chen HM, Liang J, et al.: Surgical reconstruction of maxillary and mandibular defects using a printed titanium mesh, *J Oral Maxillofac Surg* 73(7):1437, 2015.

Sonick M: A comparison of the accuracy of periapical, panoramic, and computed tomographic radiographs in locating the mandibular canal, *J Oral Maxillofac Implants* 9:455–460, 1994.

Tahmaseb A, De Clerck R, Wismeijer D: Computer-guided implant placement: 3D planning software, fixed intraoral reference points, and CAD/CAM technology. A case report, *Int J Oral Maxillofac Implants* 24(3):541–546, 2009.

Tahmaseb A, Wismeijer D, Coucke W, Derksen W: Computer technology applications in surgical implant dentistry: a systematic review, *Int J Oral Maxillofac Implants* 29(Suppl):25–42, 2014.

Tamimi F, Torres J, Al-Abedalla K, et al.: Osseointegration of dental implants in 3D-printed synthetic onlay grafts customized according to bone metabolic activity in recipient site, *Biomaterials* 35(21):5436–5445, 2014.

Terzioğlu H, Akkaya M, Ozan O: The use of a computerized tomography-based software program with a flapless surgical technique in implant dentistry: a case report, *Int J Oral Maxillofac Implants* 24(1):137–142, 2009.

Testori T, Robiony M, Parenti A, et al.: Evaluation of accuracy and precision of a new guided surgery system: a multicenter clinical study, *Int J Periodontics Restorative Dent* 34(Suppl 3):s59–s69, 2014.

Tischler M, Ganz SD: The CT/CBCT-based team approach to care: Part 2: communication with the surgeon to support the final prosthesis, *Dent Today* 31(10):108, 2012. 110, 112–115.

Tyndall DA, Price JB, Tetradis S, et al.: American Academy of Oral and Maxillofacial Radiology. Position statement of the American Academy of Oral and Maxillofacial Radiology on selection criteria for the use of radiology in dental implantology with emphasis on cone beam computed tomography, *Oral Surg Oral Med Oral Pathol Oral Radiol* 113(6):817–826, 2012.

Valente F, Schiroli G, Sbrenna A: Accuracy of computer-aided oral implant surgery: a clinical and radiographic study, *Int J Oral Maxillofac Implants* 24(2):234–242, 2009.

Verstreken K, Van Cleynenbreugel J, Martens K, et al.: An image-guided planning system for endosseous oral implants, *IEEE Trans Med Imaging* 17(5):842–852, 1998.

42

Peri-implant Disease and Restorative Aspects of Dental Implants

CHANDUR PREM KARL WADHWANI, BACH LE

Introduction to the Association of Residual Excess Cement and Peri-implant Disease

The debate over the advantages of screw- versus cement-retained implant prostheses has become a topic of interest within the dental community. Recent systematic reviews and consensus statements[1-4] have reported on the success and survival of these two retention mechanisms with the aim of introducing evidence-based restorative guidelines. Currently, it appears that the choice of retention in implant prostheses still mainly depends on the individual clinician's preference and experience.[1] The goal of this chapter is to give the clinician an understanding why cementation can cause issues, as well as to provide useful techniques and alternatives that may reduce the risks of peri-implant disease induced by residual excess cement.

Restorative dentists have a preference for cement-retained implant-supported restoration. Developed to mimic procedures used in traditional tooth-supported prostheses, it helped overcome issues with esthetics and occlusion, and it also has benefits related to cost, potential for a better passive fit when dealing with a multiple-unit prosthesis, and reduced chair time.[5,6] Although dentists prefer this system over the screw-retained alternative, patients, when surveyed, did not appear to have any definite preference.[7]

Along with the reported benefits of using cemented implant restorations have come some new concerns, such as cement retention in the restoration and retrievablity.[8,9]

As implant therapy has gained popularity, so has the use of the cement-retained restorative; one study reporting on the outcome of implants and restorations in general dental practice noted that 93% of the restorations were cement retained.[10] However, in the late 1990s and onward, implant site health issues began to emerge, initially restricted to clinical reports on complications associated with excess cement around crowns on osseointegrated implants.[10-18] Prospective multicenter studies were developed to compare the peri-implant soft tissue health surrounding cement- and screw-retained implant restorations. The authors concluded that the peri-implant soft tissues responded more favorably to screw-retained crowns than to cement-retained crowns.[7] Systematic reviews have also concluded that cement-retained reconstructions exhibited more technical and biological complications compared with screw-retained reconstructions.[3,4]

Wilson's pivotal study evaluated 42 implants in 39 patients who showed signs of inflammation (peri-implant mucositis or peri-implantitis) and reported a positive link between excess cement and peri-implant disease.[19] This endoscopic study found excess residual cement associated with 81% of diseased sites. The study also reported on resolution, suggesting that once peri-implant disease is found, the earlier the cement is removed, the more likely it is that resolution would occur. However, he also reported that the time for the disease to be discovered varied from 4 months to almost 9½ years after the crown was cemented.

Furthermore, in January 2013 the American Academy of Periodontology, under the direction of the task force on peri-implantitis, developed a position paper that highlighted residual excess cement as an etiologic factor.[20]

Cemented Restorations and Issues Related Specifically to Dental Implants

The tooth-supported cemented restoration has existed for well over 100 years with few, if any, biological issues related to the supporting soft and hard tissues. However, the same cannot be said when it comes to the cemented implant restoration (Figures 42-1 and 42-2).

Cement excess can elicit adverse soft tissue responses ranging from increased plaque accumulation[7] to inflammation with bleeding[13] to peri-implantitis with associated bone loss, which ultimately can result in implant failure.[10,14]

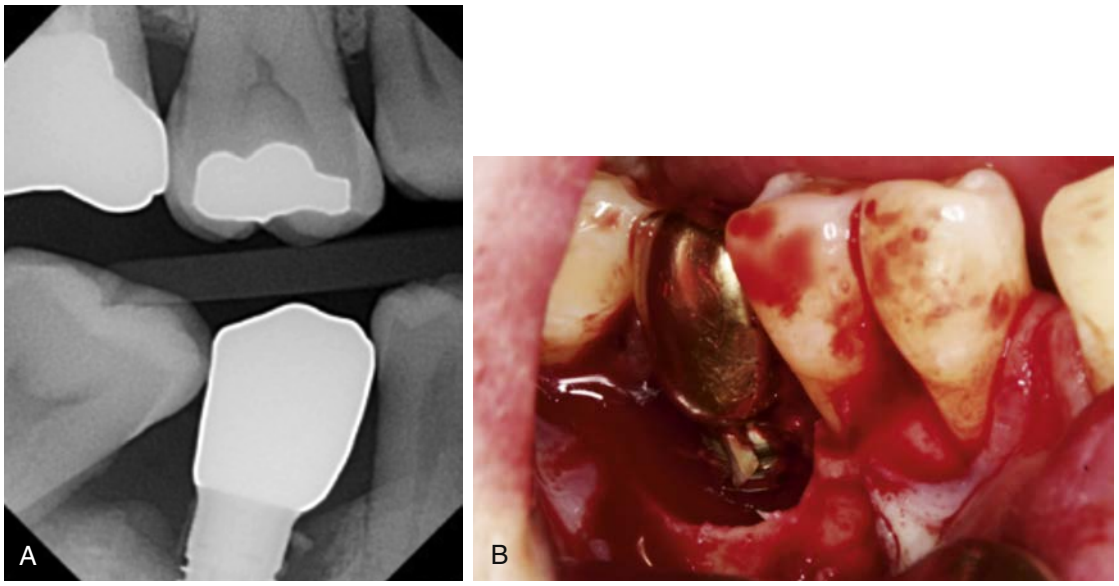

• **Figure 42-1** **A**, Radiograph indicating bone loss and peri-implantitis associated with residual excess cement. **B**, Surgical site confirming cement residue and extent of bone loss. (Courtesy Dr. Amy Fuller.)

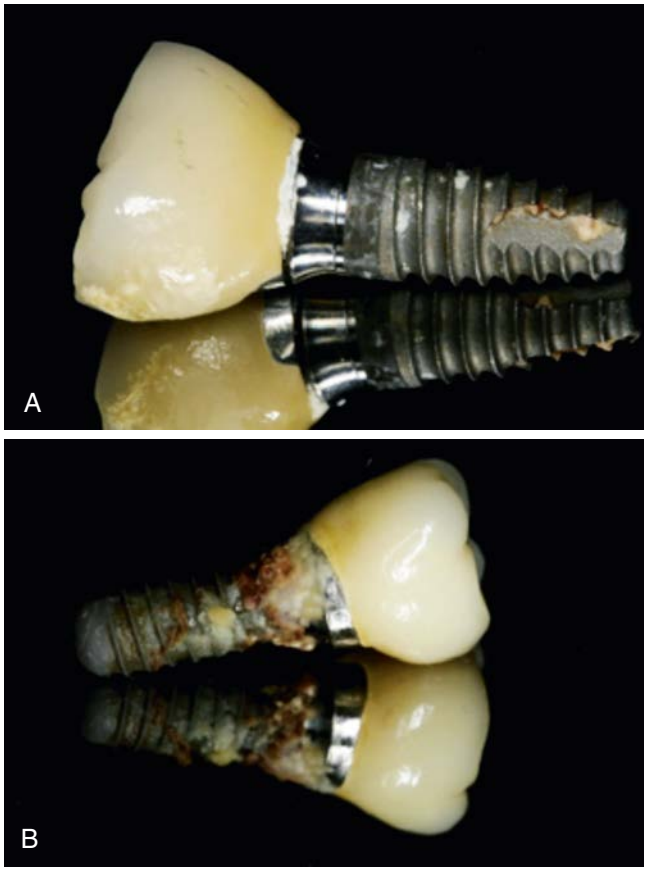

• **Figure 42-2** Examples of failed, removed implants—residual excess cement is clearly present.

Factors such as biology of the soft tissue (hemidesmosomal) attachment to the implant, subgingival cement margin placement, poor control of cement flow, and inappropriate cement use all contribute to an increased likelihood of peri-implant disease.[21]

Biology of the Soft Tissue Attachment to a Dental Implant

The periodontal soft tissue attachment of the natural tooth is very different from the peri-implant soft tissue of the dental implant.[22]

Keratinized epithelium exists at the base of the gingival sulcus with a natural tooth, unlike in the case of the implant sulcus. Also, the junctional epithelium is adherent, is less permeable, and has a greater ability to regenerate around a tooth.[23] The soft connective tissue periodontium of a healthy tooth has another major biological advantage over the peri-implant soft tissues in the presence of supracrestal collagen fiber bundles. Sharpey fibers insert directly into living cementum on the root surface of the tooth (see Figure 42-1),[24] which is highly protective and serves as a seal to protect this area. The periodontal fiber bundles also form a compartment-like structure around the tooth, which localizes and limits the spread of inflammation and disease. By comparison, the soft tissue attachment to the implant site that develops through healing within a few days is far more fragile than the tissue related to a natural tooth and consists of a basic cellular hemi-desmosomal adhesion. There is no cementum associated with the dental implant, so no direct collagen fiber insertion can exist. Circumferential fibers do occur that encircle the dental implant that maintains the tissues in close apposition to the implant (Figure 42-3, *A*). This arrangement provides for a single compartment and, when inflamed, affects the implant in a generalized manner (see Figure 42-3, *B*).[22]

Implant Depth and Cement Margin Site

Again, in comparing the natural tooth with the implant site, distinct differences are noted. With natural tooth,

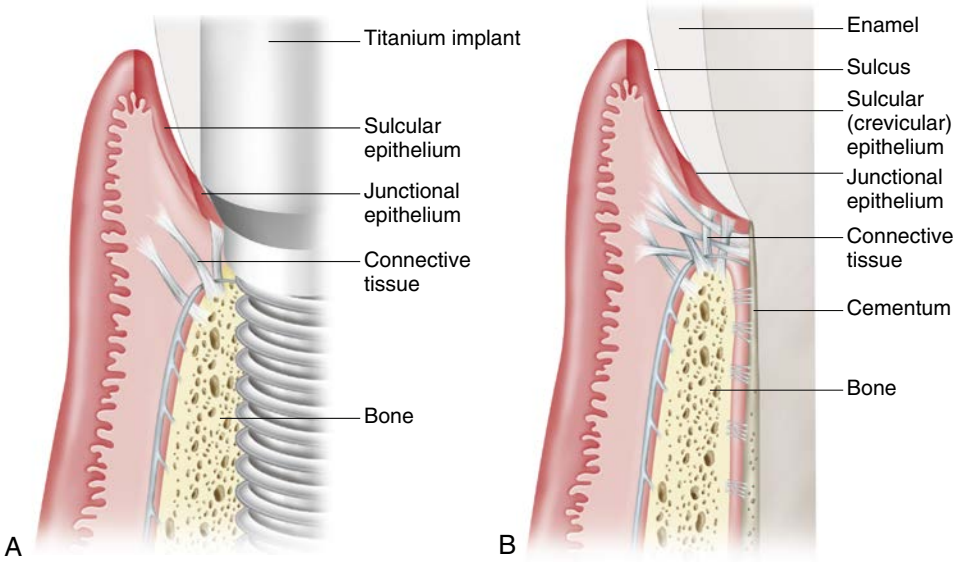

• **Figure 42-3** **A**, Biological attachment to a dental implant. There is no insertion of connective tissue fibers into the implant surface. **B**, Biological attachment of a natural tooth. Connective tissue fibers insert into the root apical to the junctional epithelium. (From Rose LF, Mealey BL: *Periodontics: medicine, surgery, and implants*, St. Louis, 2004, Mosby.)

preparations for a cement-retained restoration limit the cement finish line no deeper than 0.5 mm into a healthy gingival sulcus, which is still considered a compromise.[25] The prepared tooth margins also closely follow the outline of the gingival crest, moving more coronally to follow the outline of the papillae and remaining supragingival wherever possible, so the tooth site is easily accessible.

For the implant site, the soft tissue attachment tends to occur at a deeper level when compared with the soft tissue attachment in the natural dentition. When the platform (or top) of an implant is surgically placed according to the facial soft tissue crest, it is usually placed 3 mm deep. This allows for development of an emergence profile for the restoration. However, where papillae exist adjacent to this site, the scallop of the soft tissues may result in the flat top of the implant now being located 5-7 mm deep.[26] Maintaining and cleaning deeper than 4 mm is impossible with routine scaling instruments,[27] and the microbiota at deeper sites tends to favor the more pathogenic gram-negative bacteria known to cause peri-implant diseases.[28,29]

Cement extrusion from the implant crown margin site during seating can present problems with the ability to both detect and remove this foreign material. Anecdotal recommendations of acceptable implant crown margin depths of 1-3 mm[30,31] relative to the soft tissue level have been made based on esthetics. Recently, however, the ability to remove residual excess cement at different soft tissue depths has been evaluated. The influence of the cementation margin position with respect to the amount of undetected cement was reported by Linkevicius and colleagues.[32] In a prospective clinical study they compared cement margin sites that were equal with tissue level, 1 mm subgingival, 2 mm subgingival, and 3 mm subgingival. Statistical significant differences existed among the four groups: the deeper the position of the margin, the more undetected cement was discovered. The conclusions of the study indicated that, ideally, cement margins on abutments should always be visible for intraoral cementation.

Currently, new protocols are being developed with the surgical placement of an implant now more closely related to the bone rather than soft tissue height. With the implant frequently placed even deeper to the soft tissue attachment, the removal of excess cement and routine maintenance become even more of a challenge.

Controlling Cement Flow

One of the most common procedures in restorative dentistry is the use of luting cements for crowns and bridges, which for many dentists occurs on a daily basis. As ubiquitous as cementing a crown is, it appears that most dentists have never been taught or trained on proper technique; and have little if any idea where to place the cement or even how much is required[33] (Figure 42-4).

This has resulted in little thought as to how the cement system actually works. In fact it should be considered to be an engineering-type system, essentially similar to a piston driven into a fluid chamber. The abutment behaves as a piston, the intaglio of the crown as a chamber and the fluid is cement. The clinician must now understand how the cement flows based on parameters such as cement loading site, amounts required, implant abutment design, and fluid mechanics of the material used.[34]

The factors that will then determine how the cement flows can be readily evaluated using models such as clear drinking beakers[35] or using more complex fluid dynamics and supercomputers.[36]

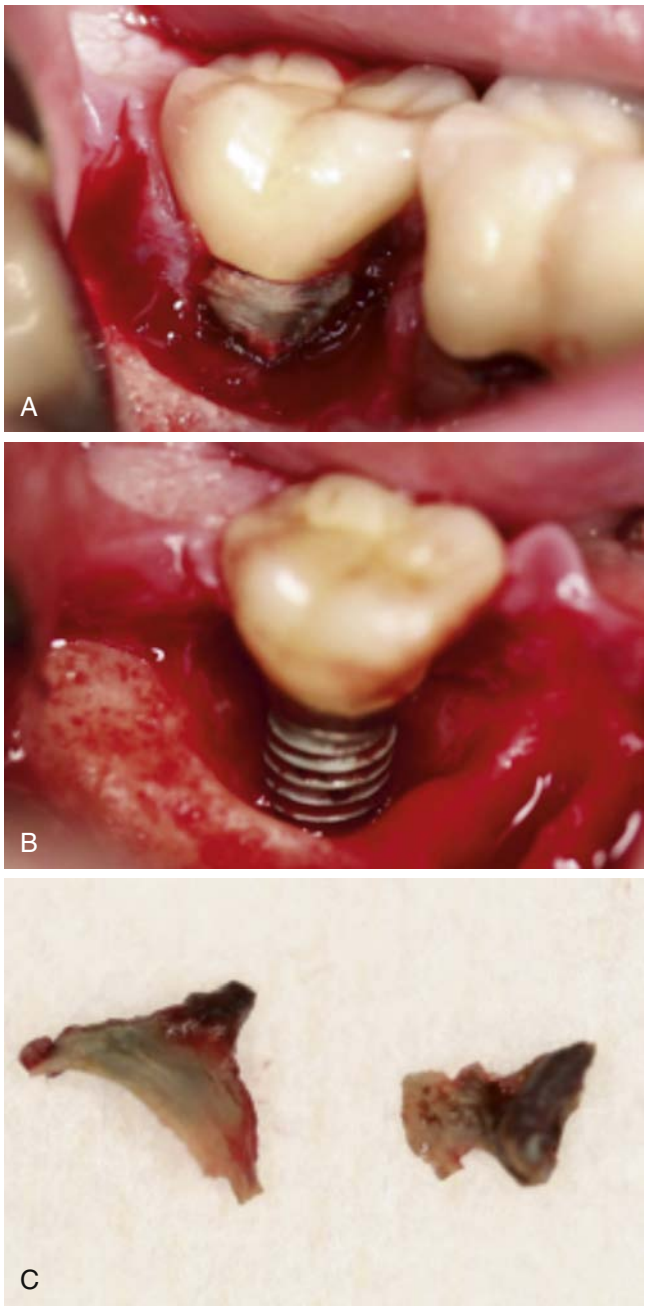

• **Figure 42-4** **A**, Typical example of peri-implantitis bone loss associated with residual excess cement indicating poor control over cementation technique. **B**, Cement removed. **C**, Cement remnants. (Courtesy Dr. Franco Audia.)

Studies evaluating cement flow and force of extrusion using cd-Adapco software simulations have been useful in determining the most appropriate site to place cement, which is close to the crown margin.[37] Also, the software program computed the most appropriate speed to use as the crown is seated, which should be in the order of 14 mm per second to optimize the flow of the cement. The cement used in the simulation was a resin (RelyX ARC, 3M ESPE) chosen primarily because some data existed on its flow properties. Interestingly, cement manufacturers do not commonly publish the flow properties of cement, as they, too, do not consider this process to be anything but rudimentary!

Unfortunately, because of the lack of these data, it is much more difficult for the scientist/clinician to understand how the cement will behave as force is applied.

Another feature of the study was to evaluate different abutment designs, another area completely overlooked by implant component manufacturers. When one considers that cemented abutments mimic the shape of full gold crown preparations with bevels and lute space requirements designed more than 50 years ago, it is clear there is little if any science behind the abutment form.

For the clinician this presents huge issues: most clinicians have not had any education describing the fluid properties of cement, such as Newtonian or non-Newtonian; cement manufacturers do not provide adequate information; and implant companies do not supply components where form follows function.

The better the clinician understands this system, the more likely he or she is to be able to control the cement flow and limit the extent of cement extrusion that may result in adverse effects (Figure 42-5).

Luting Material Selection

Nearly all the dental cements that exist today were primarily designed for the natural tooth, with properties often completely unrelated to the requirements for the dental implant.[38,39] One such example is caries prevention—there is no need for a fluoride component for an implant cement, and in fact it may be detrimental. Also, dentin and enamel bonding—again, there is no reason cements for implant should contain materials with these properties.

When considering problems with residual excess cement, some desirable properties for implant cements include ease of excess cement cleanup and removal, detectability on a radiograph (Figure 42-6), an antimicrobial effect against organisms that affect the health of the peri-implant tissues, assurance that it will not damage the implant or associated components, and biological inertness.[40] Table 42-1 outlines some of the more appropriate properties required of implant cements and compares these to cement properties more ideal for natural teeth.

Studies on ease of cleanup have indicated this to be especially challenging when resin cements are used with implant restorations.[41] The greater the adhesive properties a cement has for titanium, the more difficult it will be to remove if it reaches the implant itself. Also, the greater the mechanical retention of a given cement to the implant materials used, the more difficult it will be to clean up excess cement.

Many cements used for implant restoration are poorly radiopaque, which makes excess cement detection more difficult.[42] The importance of early detection and removal of this foreign material cannot be overemphasized, as it may prevent the disease process from becoming established and allow for full resolution of the site to occur.[19] Post-cementation radiographs should be standard protocol



• **Figure 42-5** Computer fluid dynamic model shows crown abutment system to be a "piston in a chamber." Modeling shows how fluid flows as the crown seats.



• **Figure 42-6** Cement samples showing varying radiopacity at 1 mm thickness. Some may not be detected when in the tissues.

as well as the ability to recognize the radiographic characteristic effects of implant cement extrusion.[43]

Cement Interactions: Microbial Growth

Many studies have been undertaken to evaluate the antimicrobial effects of cements; however, they have been directed exclusively at how the materials behave in the presence of *Streptococcus mutans* and *Lactobacillus acidophilus*, which are the cariogenic microbes. [44,45] There is little if any relevance to implant restoration in which the effects of microbes that may result in peri-implant disease are completely different, and these should be the prime focus.

In 2014, Raval, Wadhwani, and colleagues published a study evaluating interactions between implant luting cements and oral bacteria linked to peri-implant disease.[46] Discs were made with a series of test cements (zinc oxide/eugenol, zinc oxide/non-eugenol, orthozinc phosphate, acrylic urethane, and resin-based cement) under aseptic, controlled conditions. Gram-negative anaerobes implicated

TABLE 42-1 Some Considerations for Material Selection Specific to Teeth and Implants Cemented Restorations

	Implant Restoration	Natural Tooth
Substructure	Metal, ceramic, acrylic	Dentin, enamel
Biologic tissue association	Peri-implant tissues	Periodontal tissues, pulp
Primary disease issue	Peri-implant disease	Caries, pulpal, periodontal
Restoration finish line	One to 2 mm below the gingival crest—often deeper	One mm below in anterior aesthetic sites, often above free gingival margin elsewhere
Cement margin	May or may not follow scallop of gingival tissues	Preparation follows gingival tissue
Need for cement seal	Questionable	Desired (prevent caries)
Anti-caries agents	May be detrimental	Desirable
Corrosion	Corrosive in contact with titanium	Not applicable
Radiopacity	Should be highly radiopaque	Similar to dentin
Microbial challenge	Bacteria found in peri-implant sites	*Streptococcus mutans, Lactobacillus* (caries producers)

From Wadhwani CP, Schwedhelm ER: The role of cements in dental implant success, part I. *Dent Today* 32(4):74-78, 2013.

in peri-implantitis were chosen: *Aggregatibacter actinomycetemcomitans* (*A. actinomycetemcomitans*), *Porphyromonas gingivalis* (*P. gingivalis*), and *Fusobacterium nucleatum* (*F. nucleatum*). The bacteria were grown in individual test wells, into which the cement discs were introduced. The concentration of bacteria was standardized for each test with measurements made using an optical spectrometer that correlated the opacity of the broth directly with the microbial content. The results indicated that zinc oxide/eugenol outperformed all other cements with regard to microbial inhibition when evaluating the test bacteria. Zinc is known to be highly effective as an antimicrobial, and when coupled with eugenol, also well known for its anti-inflammatory, antioxidative, and antimicrobial pharmaceutical properties; this is likely the reason for its effectiveness. The resin-based cements were found to poorly inhibit bacterial growth and in some instances appeared to behave as a substrate for the microbes.[46] These results have been replicated clinically, with zinc oxide/eugenol exhibiting less pathogenic microbial environments compared with resin cement.[47]

These studies indicated that cement selection should be considered with respect to how it might affect the environment into which it is placed. This may relate more to patients who are periodontically susceptible, as these patients present a greater risk of peri-implant disease[20] (Figure 42-7).

Cement Interactions: Foreign Body Reaction

Most dentists have encountered "amalgam tattoos," which are fragments of amalgam that lodge within the tissues, often migrating into adjacent sites. Cement particles have also been reported within excised soft tissue specimens.[48-50] One study looking at human soft tissue biopsies of failed removed implants found that 19 of 36 had cement particles present. Residual cement may act as a nidus for inflammatory cells both acutely and chronically, which in turn may elicit a cascading autoimmune destructive process. How the cement particles became embedded within the tissues is speculative. It may have occurred when the crown was initially seated with the hydrostatic force disrupting the fragile hemidesmosomal attachment of the epithelium to the implant. Subsequent cement cleanup, with the dislodgement of the set particles being forced into the tissues, may also be responsible. It is also possible that the cement was forced into bleeding sites that occur when the healing abutments are removed. It is known that intercellular tears within the epithelium occur during abutment removal, and the resulting wound may be contaminated by inoculation with cements that have thin film thickness.

Cement Interaction: Allergic Response

In 2010 it was reported that 73% of dental schools in the United States used a resin modified glass lonomer (RMGI) as the definitive medium for cementing restorations to implants,[42] which, interestingly, followed a similar pattern for cement selection for teeth (Figure 42-8). One of the constituents of the RMGIs is hydroxyethyl methacrylate (HEMA).[51] This material is extremely irritating to the tissues to the extent that the Material Safety Data Sheet (MSDS) advises that hands and mucosal tissue, such as eyes, be barrier protected when it is used. With implants, barrier protection is more difficult to achieve compared with the natural tooth. As the epithelial attachment adheres poorly at the dental implant site and is more permeable, it may be more susceptible to the effects of chemicals leaching out from materials.

Corrosion

The success of dental implants relates in part to the low corrosive susceptibility of the materials involved. Titanium



• **Figure 42-7** A 24-well plate with bacteria grown in media. Cement discs introduced to see how bacteria respond. Clear solutions show low bacterial content. Opaque solution indicates extensive microbial growth.

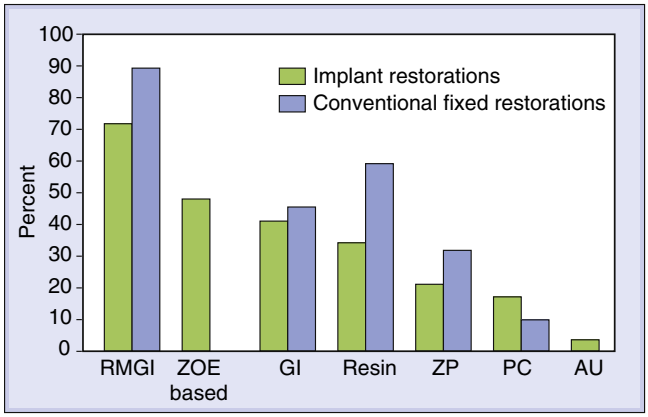

• **Figure 42-8** Definitive cements used for implant and conventional fixed restorations by prosthodontic residency directors in 2008. *AU,* Acrylic urethane; *GI,* glass ionomer; *PC,* polycarboxylate; *RMGI,* resin-modified glass ionomer; *ZOE,* zinc oxide eugenol; *ZP,* zinc phosphate. (Reprinted from Tarica D, Alvarado VM, Truong ST: Survey of United States dental schools on cementation protocols for implant crown restorations, *J Prosthet Dent* 103(2):68-79, 2010.)

appears well suited to the oral environment under most conditions.

However, recent reports have found a reactive issue with some materials commonly found in dental cements.[33,52,53] Fluoride, the ubiquitous anti-caries agent, in some forms is known to corrode titanium.[54] Corrosive elements are generally undesirable, as the surface alterations produce increased adhesion to anaerobic bacteria that produce peri-implant disease[55] and also result in reactive oxidative species being produced by the host.[56] The inflammatory response produced may be one mechanism that results in peri-implant disease. The cements identified as producing the conditions for corrosion include some polycarboxylates and some glass ionomer cements.[57] Durelon (3M-ESPE) alludes to this problem in the Instructions for Use (IFU), which is of interest as 17% of U.S. dental schools[36] admit to using it on implant restorations. This indicates the IFUs are not being followed or may not even be read.

To date no ideal implant luting cement exists—all have the potential to cause issues. However, the prudent clinician will carefully evaluate the material used, will elevate the cement margin to be readily accessible to cleaning, and will have a good biological understanding of the limitations of the dental implant.

Developing Clinical Protocols

Problems associated with cement selection and use have been described. Many of these result from the dentist considering the cementation selection and processes the same as for the natural tooth, when clearly they are not. By understanding the ideal properties required of an implant cement and how it flows, the clinician can also control cement by manipulation of the prosthesis.

If the residual excess cement can be detected and adequately removed, resolution is considered possible in many cases,[19] though this is not guaranteed (Figure 42-9). However, it is better to develop protocols that make the cementation process safer and more predictable, such as maintaining a supragingival margin on the abutment and allowing the cement extrusion site to be carefully controlled and readily accessed. Techniques such as producing a ceramic supragingival margin as part of the abutment



• **Figure 42-9** **A**, Residual excess cement located and removed. **B**, Series of radiographs showing subsequent resolution of the issues. (Courtesy Dr. Darrin Rapoport.)



• **Figure 42-10** Implant restoration with a supragingival porcelain margin replaces maxillary right central incisor. The cement margin is easily controlled, maintaining a distance from the soft tissues.

have been described (Figure 42-10).[58] This has an added advantage in that etched porcelain can be bonded—therefore a margin on the abutment can be directly bonded to the crown material, which if done carefully can produce a seamless esthetic result. The supragingival margin also allows for the use of a barrier of PTFE (Teflon plumber's tape) to protect the soft tissues from contact with cement and other chemicals.[59,60]

Other techniques available with the use of cement are cement pre-extrusion devices, such as the copy abutment technique.[61] Here, a copy of the intaglio of the crown or cemented prosthesis is made by placing a layer of PTFE against the inside (intaglio) of the crown (Figure 42-11). This has two important functions: first, it produces a 50-µm spacer that will give close to the required volume of cement—it should be remembered that most implant restorations are fabricated with a 40- to 50-µm luting space; second, it prevents the intaglio of the crown from getting contaminated with the polyvinyl siloxane (PVS) material.

To aid the placement of the PTFE, first coat the intaglio of the crown with pure petroleum jelly, then, using a brush, carefully adapt the PTFE so it adheres to the internal surface. Using a fast-setting PVS material (e.g., Blu-Mousse, Parkell, Edgewood, NY) with a fine-tip extruder, completely fill the internal aspect of the lined crown. Aim to capture the crown margins as much as possible. Continue expressing the PVS until a handle is formed. Allow to set, then remove the copy die, remove and discard the PTFE layer, and thoroughly clean out the intaglio of the crown, ensuring that all the petroleum jelly is removed. Inspect the copy die; it should resemble the inside of the crown, yet be smaller in dimension.

When the restoration is ready to be cemented, attach the original abutment to the implant in the usual manner and

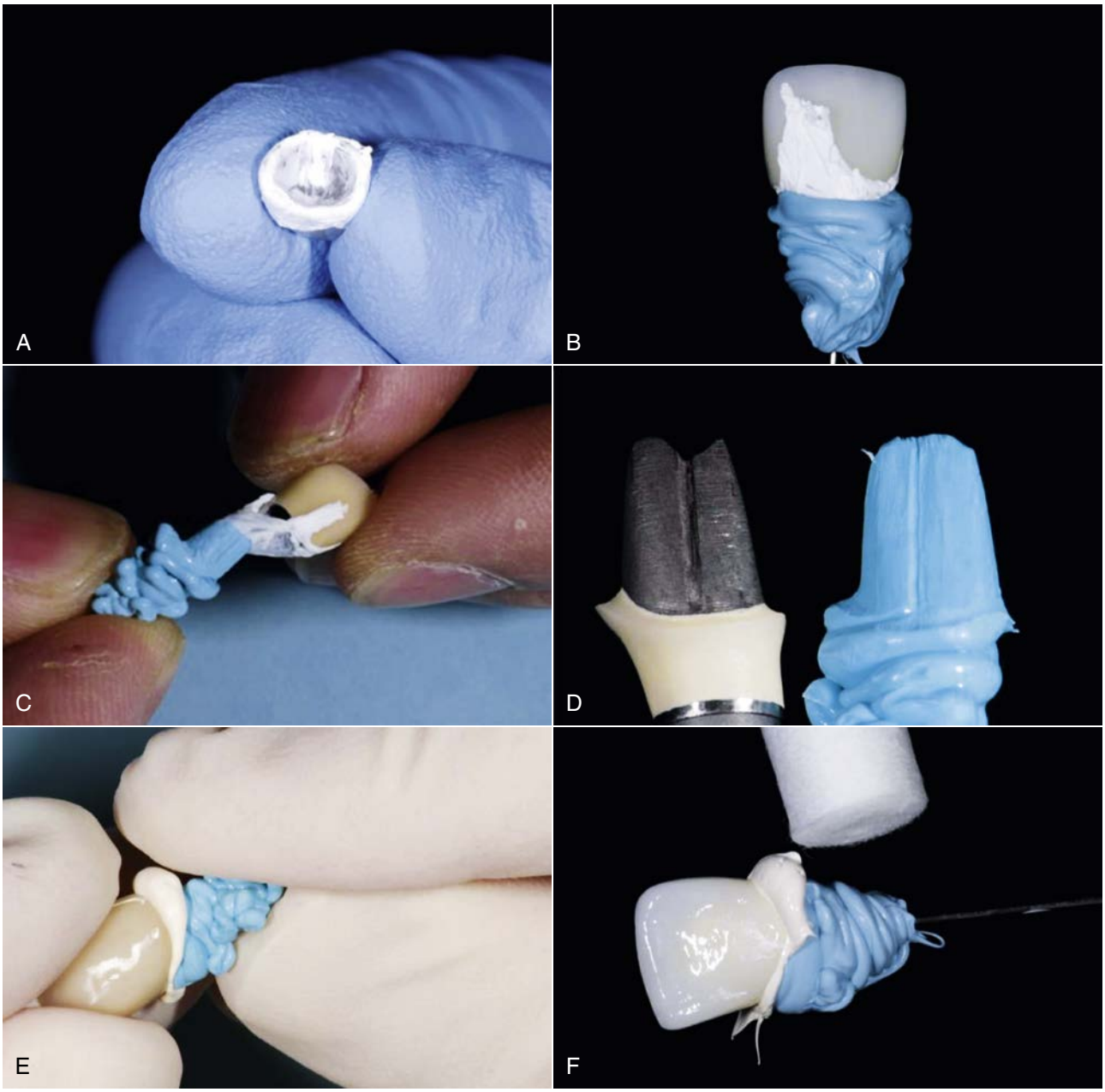

• **Figure 42-11** The custom copy abutment used to pre-extrude cement out from within the crown. The PTFE provides space for the cement lute. **A,** The internal aspect of the crown is lined with a disposable spacer material (PTFE tape works well, due to an approximate thickness of 50 microns). **B,** Fast setting polyvinylsiloxane material injected within crown until a handle is made that will become the copy abutment. **C,** Remove the copy abutment, discard the PTFE and thoroughly clean the inside of the crown. **D,** The copy abutment is similar to the actual implant abutment in form. E, Place cement within the inside of the crown, then introduce the copy abutment until it seats. This will express extra-cement outside of the mouth. **F,** Clean up excess cement, the crown is now loaded uniformly with approximately 50 micron layer of cement.

with the appropriate torque. The crown can be gross filled with cement. The PVS copy abutment is seated firmly into the crown, resulting in the extrusion of excess material. The cleanup extraorally is followed by inspection of the internal surface in which a uniform 50-µm layer of cement should exist. The crown is then cemented as usual, with minimal cleanup. Provided that all other parameters, such as cement margin height, control of seating forces, and speed of seating are controlled, the likelihood of cement extrusion into the tissues should be minimized. The technique is also suitable for multiple joined restorations, such as an implant-supported fixed dental prosthesis.

Other ways to control cement flow involve abutment modifications. The concept here is to alter the shape of the abutment so that an increase in cement held within the system results in a reciprocating reduction of cement extrusion. It was apparent that the U.S. dental schools[39] and implant component manufacturers directed clinicians to completely occlude the

screw access channel of the abutment. This site, if left partially unfilled (the screw head protected with a spacer), could act as a receptacle for cement during seating of the restoration.[61-63]

Whenever the screw channel is not sealed, there is the potential to allow cement to fill this space. Simply leaving the screw access channel open as an "open abutment" or leaving open and adding internal vent holes within the abutment walls provided a significant reduction in cement extrusion out through the margin site compared with closure of the abutment. An added benefit of manipulating cement flow within an abutment is that it significantly improves crown retention.[62,63]

The foregoing studies indicate the ability to alter cement flow by abutment modifications that are beneficial with respect to cement extrusion and crown retention effects. Although further scientific investigation is required, these seemingly easy steps can help the clinician.

Many other techniques exist that can potentially reduce cement extrusion, and the clinician can decide which is the most appropriate. Alternatively, screw-retained restorations may be chosen, especially if the surgical planning and placement has provided the ideal implant location. Although clinicians claim that esthetics and occlusal management are problematic, the skilled laboratory technician can readily overcome these issues, especially with the materials available today.[64]

One technique is to use a hybrid cemented-screw-retained crown (Figure 42-12). This provides a relatively inexpensive solution by combining a cemented crown with a stock abutment. The crown is cemented onto the abutment; then, either drilling into the crown or having a pre-prepared screw access hole in the crown allows this hybrid restoration to be attached with a screw.[65]

Implant manufacturers are becoming more aware of the issues with residual excess cement and the risks of peri-implant disease. Some are developing novel abutments that allow angle changes, which can be used when straight-line screw access would compromise the restorative outcome.[66]

Conclusion

The interactions between excess cement and peri-implant disease are not fully understood. Biological differences in attachment between an implant and a tooth appear to be the major reason why we do not have the same issues in traditional tooth-form dentistry. This compounds the effects of cements with regard to peri-implant microbes and the potential for foreign body reactions, corrosion effects, and allergic responses. Unlike natural teeth, where little regard is given to cement selection or techniques involved, protocols need to be established that also include careful monitoring of the implant site, as peri-implantitis may take years for signs or symptoms to develop. When residual excess cement is found related to the implant site, it must be considered undesirable and an immediate response to clean the site carried out.

Alternatives to the cemented restoration exist, which can be easily implemented and planned for at the surgical stages with a team approach—the surgeon and restorative dentists working together to provide the best treatment possible for the patient.

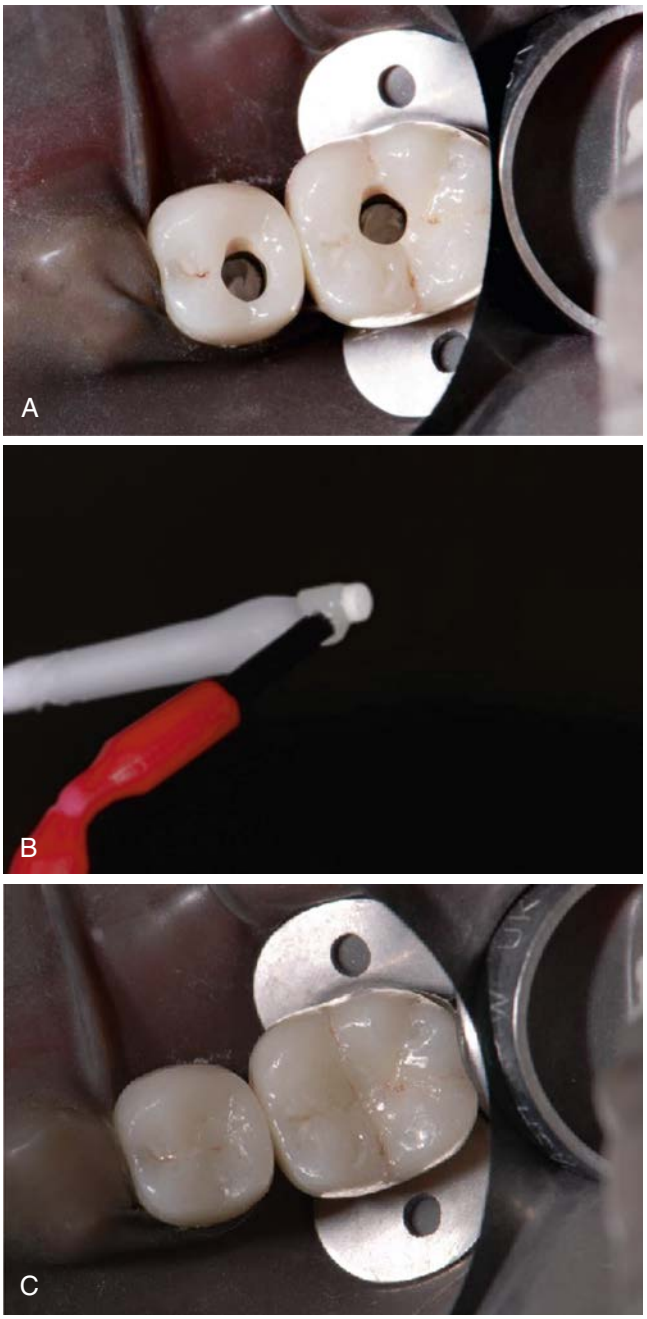

• **Figure 42-12** **A**, Esthetic screw-retained crowns prior to aesthetic porcelain plug being cemented. **B**, Porcelain plug, which has block-out stain to prevent gray show-through of metal, being loaded with cement prior to seating. **C**, Final restoration. Esthetics are excellent, and the occlusion can also be easily managed.

References

1. Ma S, Fenton A: Screw- versus cement-retained implant prostheses: a systematic review of prosthodontic maintenance and complications, *Int J Prosthodont* 28:127–145, 2015.
2. Chaar MS, Att W, Strub JR: Prosthetic outcome of cement-retained implant-supported fixed dental restorations: a systematic review, *J Oral Rehabil* 38(9):697–711, 2011.

3. Wittneben JG, Millen C, Brägger U: Clinical performance of screw- versus cement-retained fixed implant-supported reconstructions—a systematic review, *Int J Oral Maxillofac Implants* 29(Suppl):84–98, 2014.
4. Wismeijer D, et al.: Consensus statements and recommended clinical procedures regarding restorative materials and techniques for implant dentistry, *Int J Oral Maxillofac Implants* 29(Suppl):137–140, 2014.
5. Hebel KS, Gajjar R: Cement-retained versus screw-retained implant restorations: achieving optimal occlusion and esthetics in implant dentistry, *J Prosthet Dent* 77(1):28–35, 1997.
6. Taylor TD, Agar JR: Twenty years of progress in implant prosthodontics, *J Prosthet Dent* 88(1):89–95, 2002.
7. Weber HP, Kim DM, Ng MW, et al.: Peri-implant soft-tissue health surrounding cement- and screw-retained implant restorations: a multi-center, 3-year prospective study, *Clin Oral Implants Res* 17(4):375–379, 2006.
8. Alfaro MA, Papazoglou E, McGlumphy EA, Holloway JA: Short-term retention properties of cements for retrievable implant-supported prostheses, *Eur J Prosthodont Restor Dent* 12(1):33–37, 2004.
9. Mansour A, Ercoli C, Graser G, et al.: Comparative evaluation of casting retention using the ITI solid abutment with six cements, *Clin Oral Implants Res* 13(4):343–348, 2002.
10. Da Silva JD, et al.: Outcomes of implants and restorations placed in general dental practices: a retrospective study by the Practitioners Engaged in Applied Research and Learning (PEARL) Network, *J Am Dent Assoc* 145(7):704–713, 2014.
11. Pauletto N, Lahiffe BJ, Walton JN: Complications associated with REC around crowns on osseointegrated implants: a clinical report, *Int J Oral Maxillofac Implants* 14(6):865–868, 1999.
12. Tomson PL, Butterworth CJ, Walmsley AD: Management of peri-implant bone loss using guided bone regeneration: a clinical report, *J Prosthet Dent* 92(1):12–16, 2004.
13. Gapski R, Neugeboren N, Pomeranz AZ, Reissner MW: Endosseous implant failure influenced by crown cementation: a clinical patient report, *Int J Oral Maxillofac Implants* 23(5):943–946, 2008.
14. Korsch M, Obst U, Walther W: Cement-associated peri-implantitis: a retrospective clinical observational study of fixed implant-supported restorations using a methacrylate cement, *Clin Oral Implants Res* 25(7):797–802, 2014.
15. Wadhwani C, Rapoport D, La Rosa S, et al.: Radiographic detection and characteristic patterns of residual excess cement associated with cement-retained implant restorations: a clinical report, *J Prosthet Dent* 107(3):151–157, 2012.
16. Shapoff CA, Lahey BJ: Crestal bone loss and the consequences of retained excess cement around dental implants, *Compend Contin Educ Dent* 33(2):94–96, 98-101, 2012.
17. Linkevicius T, Puisys A, Vindasiute E, et al.: Does residual cement around implant-supported restorations cause peri-implant disease? A retrospective case analysis, *Clin Oral Implants Res* 24(11):1179–1184, 2013.
18. Callan DP, Cobb CM: Excess cement and peri-implant disease, *J Implant Adv Clin Dent* 1:61–68, 2009.
19. Wilson Jr TG: The positive relationship between excess cement and peri-implant disease: a prospective clinical endoscopic study, *J Periodontol* 80(9):1388–1392, 2009.
20. Peri-implant mucositis and peri-implantitis: a current understanding of their diagnoses and clinical implications, *J Periodontol* 84(4):436–443, 2013.
21. Wadhwani CP: Peri-implant disease and cemented implant restorations: a multifactorial etiology, *Compend Contin Educ Dent* 34, Spec No 7:32–37, 2013.
22. Wadhwani CP, Piñeyro AF: Implant cementation: clinical problems and solutions, *Dent Today* 31(1):56, 58, 60–62, 2012.
23. Ikeda H, et al.: Ultrastructural and immunoelectron microscopic studies of the peri-implant epithelium-implant (Ti-6Al-4V) interface of rat maxilla, *J Periodontol* 71(6):961–973, 2000.
24. Rose LF: *Periodontics: medicine, surgery and implants*, St Louis, 2005, Mosby, pp 612–613.
25. Goldberg PV, Higginbottom FL, Wilson TG: Periodontal considerations in restorative and implant therapy, *Periodontology* 2001(25):100–109, 2000.
26. Sadan A, Blatz MB, Bellerino M, et al.: Prosthetic design considerations for anterior single-implant restorations, *J Esthet Restor Dent* 16:165–175, 2004.
27. Stambaugh RV, Dragoo Smith DM, Carasali L: The limits of sub-gingival scaling, *Int J Periodont Restor Dent* 1:30–41, 1981.
28. Bumgardner JD, Adatrow P, Haggard WO, Norowski PA: Emerging antibacterial biomaterial strategies for the prevention of peri-implant inflammatory diseases, *Int J Oral Maxillofac Implants* 26:553–560, 2011.
29. Mombelli A, Décaillet F: The characteristics of biofilms in peri-implant disease, *J Clin Periodontol* 38(Suppl11):203–213, 2011.
30. Andersson B, Odman P, Lindvall AM, Branemark PI: Cemented single crowns on osseointegrated implants after 5 years: results from a prospective study on CeraOne, *Int J Prosthodont* 11: 212–218, 1998.
31. Belser UC, Buser D, Hess D, et al.: Aesthetic implant restorations in partially edentulous patients—a critical appraisal, *Periodontology* 1998(17):132–150, 2000.
32. Linkevicius T, Vindasiute E, Puisys A, et al.: The influence of the cementation margin position on the amount of undetected cement. A prospective clinical study, *Clin Oral Implants Res* 24:71–76, 2013a.
33. Wadhwani C, Hess T, Piñeyro A, et al.: Cement application techniques in luting implant-supported crowns: a quantitative and qualitative survey, *Int J Oral Maxillofac Implants* 27(4):859–864, 2012.
34. Goodwin S, Chung KH, Wadhwani C: Something to smile about: using simulations to improve dental implants, *Dynamics* 37:9–12, 2014.
35. Wadhwani CP, Chung KH: The role of cements in dental implant success, Part 2, *Dent Today* 32(6):48–51, 2013.
36. Wadhwani C, editor: *Cementation in dental implantology: an evidence based guide*, New York, Springer Medical 2015.
37. Wadhwani C, Goodwin S, Chung KH: Cementing an implant crown: a novel measurement system using computational fluid dynamics approach, *Clin Implant Dent Relat Res* 18(1):97–106, 2016.
38. Hill EE, Lott J: A clinically focused discussion of luting materials, *Aust Dent J* 56(Suppl 1):67–76, 2011.
39. Tarica D, Alvarado VM, Truong ST: Survey of United States dental schools on cementation protocols for implant crown restorations, *J Prosthet Dent* 103(2):68–79, 2010.
40. Wadhwani CP, Schwedhelm ER: The role of cements in dental implant success, part I, *Dent Today* 32(4):74–78, 2013.
41. Agar JR, Cameron SM, Hughbanks JC, et al.: Cement removal from restorations luted to titanium abutments with simulated subgingival margins, *J Prosthet Dent* 78:43–47, 1997.
42. Wadhwani C, Hess T, Faber T, Piñeyro A, Chen CS: A descriptive study of the radiographic density of implant restorative cements, *J Prosthet Dent* 103(5):295–302, 2010 May.

43. Wadhwani CP, Schuler R, Taylor S, Chen CS: Intraoral radiography and dental implant restoration, *Dent Today* 31(8), 2012 Aug. 66, 68, 70–71.
44. Klai S, Altenburger M, Spitzmüller B, et al.: Antimicrobial effects of dental luting glass ionomer cements on *Streptococcus mutans*, *Sci World J* 2014:807086, March 23, 2014.
45. Rohilla M, Pandit IK, Srivastava N: Why the carioprotective potential of luting cements crucial? *J Indian Soc Pedod Prev Dent* 27(4):219–223, 2009.
46. Raval NC, Wadhwani CP, Jain S, Darveau RP: The interaction of implant luting cements and oral bacteria linked to peri-implant disease: an in vitro analysis of planktonic and biofilm growth—a preliminary study, *Clin Implant Dent Relat Res* 17(6):1029–1035, 2015.
47. Korsch M, Marten SM, Dötsch A, et al.: Effect of dental cements on peri-implant microbial community: comparison of the microbial communities inhabiting the peri-implant tissue when using different luting cements, *Clin Oral Implants Res*, 2015.
48. Ramer N, Wadhwani C, Kim A, Hershman D: Histologic findings within peri-implant soft tissue in failed implants secondary to excess cement: report of two cases and review of literature, *N Y State Dent J* 80(2):43–46, 2014.
49. Wilson Jr TG, Valderrama P, Burbano M, et al.: Foreign bodies associated with peri-implantitis—human biopsies, *J Periodontol* 1–12, 2014.
50. Burbano M, Wilson Jr TG, Valderrama P, et al.: Characterization of cement particles found in peri-implantitis-affected human biopsy specimens, *Int J Oral Maxillofac Implants* 30(5): 1168–1173, 2015.
51. Nicholson JW, Czarnecka B: The biocompatibility of resin-modified glass-ionomer cements for dentistry, *Dent Mater* 24(12):1702–1708, 2008.
52. Wadhwani CP, Piñeyro AF: Implant cementation: clinical problems and solutions, *Dent Today* 31(1), 56, 58, 60–62, 2012.
53. Rodrigues DC, Valderrama P, Wilson Jr TG, et al.: Titanium corrosion mechanisms in the oral environment: a retrieval study, *Materials* 6:5258–5274, 2013.
54. Noguti J, de Oliveira F, Peres RC, et al.: The role of fluoride on the process of titanium corrosion in oral cavity, *Biometals* 25(5):859–862, 2012.
55. Barão VA, Yoon CJ, Mathew MT, et al.: Attachment of *Porphyromonas gingivalis* to corroded commercially pure titanium and titanium-aluminum-vanadium alloy, *J Periodontol* 85(9):1275–1282, 2014.
56. Tsaryk R, et al.: Response of human endothelial cells to oxidative stress on Ti6Al4V alloy, *Biomaterials* 28(5):806–813, 2007.
57. Horasawa N, Marek M: Effect of fluoride from glass ionomer on discoloration and corrosion of titanium, *Acta Biomater* 6(2): 662–666, 2010.
58. Wadhwani CP, Piñeyro A, Akimoto K: An introduction to the implant crown with an esthetic adhesive margin (ICEAM), *J Esthet Restor Dent* 24(4):246–254, 2012.
59. Hess TA: A technique to eliminate subgingival cement adhesion to implant abutments by using polytetrafluoroethylene tape, *J Prosthet Dent* 112(2):365–368, 2014.
60. Wadhwani C, editor: *Cementation in dental implantology: an evidence based guide*, New York, 2015, Springer Medical, pp 148–150.
61. Wadhwani C, Piñeyro A: Technique for controlling the cement for an implant crown, *J Prosthet Dent* 102(1):57–58, 2009.
61. Wadhwani C, Piñeyro A, Hess T, et al.: Effect of implant abutment modification on the extrusion of excess cement at the crown-abutment margin for cement-retained implant restorations, *Int J Oral Maxillofac Implants* 26(6):1241–1246, 2011.
62. Wadhwani C, Hess T, Pineyro A, Chung KH: Effects of abutment and screw access channel modification on dislodgement of cement-retained implant-supported restorations, *Int J Prosthodont* 26(1):54–56, 2013.
63. Wadhwani C, Chung KH: Effect of modifying the screw access channels of zirconia implant abutment on the cement flow pattern and retention of zirconia restorations, *J Prosthet Dent* 112(1):45–50, 2014.
64. Wadhwani C, Piñeyro A, Avots J: An esthetic solution to the screw-retained implant restoration: introduction to the implant crown adhesive plug: clinical report, *J Esthet Restor Dent* 23(3): 138–143, 2011.
65. Linkevicius T, Vladimirovas E, Grybauskas S, et al.: Veneer fracture in implant-supported metal-ceramic restorations. Part I: Overall success rate and impact of occlusal guidance, *Stomatologija* 10(4):133–139, 2008.
66. Wadhwani C, editor: *Cementation in dental implantology: an evidence based guide*, New York, 2015, Springer Medical, pp 136–137.

43

Peri-implant Disease

TARA L. AGHALOO, JOAN PI-ANFRUNS

Introduction

Definition of Peri-implant Mucositis and Peri-implantitis

The use of dental implants to replace missing teeth has become a successful treatment option for millions of patients since Professor P. I. Branemark's discovery of osseointegration more than 50 years ago. Even though dental implants are associated with high success rates, they are not exempt from complications. Adell and co-workers published the first report on dental implant complications and included gingival complications such as early perforation of the mucosa, gingivitis, and fistulae.[1] Implant survival rate is very high as reported in multiple large, long-term studies;[2-7] however, when implant success is objectively evaluated, where medical risk factors are included in the analysis, or when implant survival rate is calculated per patient instead of per implant, rates are often significantly lower.[8-15]

The development of biologic complications surrounding peri-implant tissues has spawned great interest in the past decade and has been classified as two distinct processes. *Peri-implant mucositis* is a reversible inflammation of the soft tissues surrounding an implant in function with no loss of supporting bone.[16] The clinical presentation includes swelling and redness of the soft tissue and bleeding on gentle probing (<0.25 N). *Peri-implantitis* is a distinct destructive inflammatory process associated with dental implants first described by Levignac in 1965[17] and later by Mombelli and colleagues in 1987.[18] It was not until 1994 that a consensus group at the First European Workshop on Periodontology accepted the definition of peri-implantitis as a destructive inflammatory process around osseointegrated implants in function, leading to peri-implant pocket formation and loss of supporting bone. The clinical presentation of peri-implantitis includes suppuration, bleeding on probing, and deepened pockets (>5 mm).[19]

Scope of the Problem—Prevalence and Classification

There is great variation in the literature regarding the prevalence of peri-implant mucositis and peri-implantitis, which may be due, in part, to the variety of dental implant systems available on the market. Differences in design and surface characteristics and changes at the micro and nano scale may play an important role in the development and progression of peri-implant diseases, but these factors are still under much investigation.[20,21] Moderately rough and rough implant surfaces have been shown to be more susceptible to the development of peri-implantitis, and disease progression.[22] (Figure 43-1).

Many attempts have been made to understand the prevalence or incidence of these inflammatory processes. In a recent cross-sectional report, Renvert and co-workers[23] found a prevalence of peri-implant mucositis of 80% of the subjects or 50% of the implant sites. Multiple studies examined show a widely varied prevalence of 1% to 2% to 44% with peri-implantitis.[6,23-26] Some investigators have suggested a prevalence of peri-implantitis of up to 56%.[27]

Classification of peri-implant disease has not been well standardized, other than the definitions of peri-implant mucositis and peri-implantitis. Studies that attempt to classify peri-implantitis have done so based on specific bacteria or biofilm characteristics, severity of disease, or time to disease development.[28,29] Although peri-implant diseases are diverse and complex, a universally accepted classification system is extremely important for consistent diagnosis, disease progression, and evaluation of treatment protocol effectiveness. In addition, communication with other dental and allied staff colleagues is compromised without a common classification or language. This will continue to increase in importance as implants have longer follow-up and demonstrate greater numbers and severity of peri-implant complications.

Risk Factors and Confounding Variables

A number of risk factors have been identified as important in the development of peri-implantitis. Strong evidence has been found linking peri-implant diseases with a history of prior periodontal disease, poor oral hygiene or lack of implant maintenance, diabetes, and smoking.[25,30-32] Periodontitis triggers the release of cytokines, with an

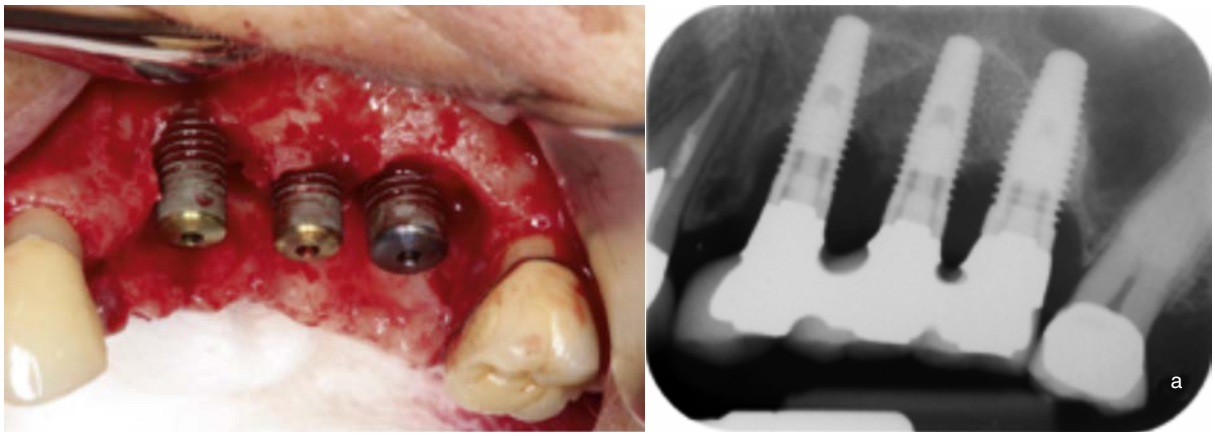

• **Figure 43-1** Peri-implantitis surrounding a three-unit fixed partial denture after 3 years of loading; clinical and radiographic appearance.

end result of attachment and bone loss. Poor oral hygiene inevitably causes plaque and bacterial accumulation, and smoking alters neutrophil activity and blood flow to the tissues and diminishes oxygen supply.[33,34] Other factors such as diabetes, alcohol consumption, rheumatoid arthritis, occlusal overload, residual cement, and genetic factors have been also identified, although with a lesser degree of evidence.[35-38]

Bacteria and Similarities/Differences between Periodontitis and Peri-implantitis

The formation of a biofilm and subsequent bacterial accumulation may play a role in the development of peri-implantitis.[39,40] These pathogens have largely been identified as gram-negative anaerobes, similar to those found in chronic periodontal patients.[41-43] In a recent cross-sectional study,[44] the authors collected samples for microbiologic analysis from three locations associated with dental implants: the peri-implant sulcus, inside the implant connection, and the gingival sulcus of adjacent teeth. A quantitative real-time polymerase chain reaction (PCR) assay was carried out for total bacterial count and for 10 pathogens. Orange complex species *Prevotella intermedia, Peptostreptococcus micros, Fusobacteria nucleatum* were most prevalent in all sites for both groups, and prevalence values were higher for the peri-implantitis group. In general, absolute loads and total bacterial counts were higher in the peri-implantitis group. Differences in prevalence between groups were more marked inside the implant connection, suggesting the implant connection as a potential microbial reservoir for peri-implant disease. The presence of peptostreptocci or staphylococci was also identified, confirming the findings of other studies that suggested the presence of certain microflora of a different nature.[39]

Prevention and Maintenance

Currently, peri-implantitis remains an unpredictable condition that is not always possible to treat and may lead to the ultimate failure of the dental implant. Therefore, it is imperative that efforts be directed toward preventing peri-implant related complications and adequate maintenance of healthy peri-implant tissues. Complications can occur at any stage during treatment. Poor patient selection, inadequate case planning, poor surgical or prosthetic execution, and lack of follow-up may lead to a higher rate of complications.[45] Identifying patients at risk, such as smokers, diabetics, or patients with previous periodontal disease is of the utmost importance.[26,30,31,46-48] Making sure that no iatrogenic risk factors for peri-implant disease exist can be verified by cleaning out all subgingival cement, preventing occlusal trauma, placing the implant in the appropriate anatomic position, and by ensuring appropriate prosthesis design and adequate space for oral hygiene.[44] In addition, providing a regular hygiene maintenance program with effective home care is paramount for continued success and prevention of peri-implantitis and mucositis.[5,49-51]

Studies and Protocols for Prevention

The prevention of peri-implantitis inherently begins with the prevention of peri-implant mucositis. A recent retrospective study showed that 43.9% patients affected by peri-implant mucositis who did not receive supportive therapy converted to peri-implantitis.[47] The measures available for prevention are delivered either by the patients themselves (toothbrush) or by a professional (hygienist), and these have been compared in a systematic review.[52] According to the review, patients were not always capable of completely eliminating the inflammatory process, although a reduction in the clinical signs of inflammation was always achieved. Similarly, the authors found that the intervention of a professional did not always achieve complete resolution. Multiple studies demonstrate the effectiveness of regular hygiene and professional maintenance to significantly decrease the prevalence of peri-implant mucositis and peri-implantitis. Simple programs such as one professional visit per year for 5 years,[49] or every 6 months for 2 years followed by yearly for 4 years,[53] are effective strategies. Even in patients with a history of periodontitis, aggressive hygiene and maintenance

programs can improve outcomes versus lack of maintenance that can increase failure and peri-implantitis.[5,25] Moreover, lack of effective home care may stem from inappropriate prosthesis design and lack of hygiene space.[44]

Education for Dentists and Patients

Even though resolution of peri-implant disease may not always be achievable, the recommendation continues to be focused toward adequate oral hygiene maintenance by the patient and regular follow-ups with the treating doctor, combined with professional hygiene services. More importantly, the focus should be on the prevention of these diseases, rather than the treatment. Oral health care providers have the obligation to educate patients on signs and symptoms of early peri-implant disease.[54] Patients should be periodically reminded and instructed on oral hygiene procedures. Dentists and allied staff also have the responsibility to continuously refresh their knowledge in all areas of implant dentistry, including implant maintenance and home care, even though there is lack of consensus for a defined preventive maintenance program and therapeutic strategy for treating peri-implant mucositis and peri-implantitis.[55]

Treatment and Outcomes

Several treatment modalities exist to address peri-implant pathologies. Despite the different approaches available, the end goal should always include:[56]

- Improvement of patient oral hygiene
- Decrease of bacterial plaque
- Decontamination of implant surface
- Bone regeneration

A number of approaches, sometimes in combination, are used to treat peri-implantitis, including mechanical debridement, local or systemic antibacterial therapy (such as subgingival chlorhexidine or local or systemic antibiotics), and open surgical debridement to remove bacteria, smooth the implant surface, and decontaminate the implant surface.[57,58] Bone regenerative procedures may also be included after debridement and decontamination. However, outcomes for these approaches are often unpredictable and difficult to assess.[58]

Nonsurgical—Debridement, Systemic and Local Antibiotics

Peri-implant mucositis, similar to gingivitis, is generally responsive to nonsurgical scaling or mechanical debridement that disrupts the biofilm on the implant.[59] Because it is reversible, further inflammation or progression can be followed up with improved oral hygiene practices and maintenance visits.[56,60] For peri-implantitis, nonsurgical debridement may be performed with plastic or metal scalers, ultrasonic devices, air-abrasive devices, or lasers. Simultaneously, the addition of antibiotic therapy (systemically or locally) has also been reported and recommended in consensus statements[56,57] (Figure 43-2).



• **Figure 43-2** Minocycline HCl available for local treatment of peri-implantitis.

In a randomized controlled trial, Buchter and co-workers[61] evaluated a local antimicrobial agent as an adjunct to manual debridement as well as manual debridement alone. Twenty-eight patients who had a total of 48 peri-implant defects were examined at baseline (week 0) and after 18 weeks. The measurements included bleeding on probing (BOP), pocket probing depths, and probing attachment levels at six sites for each tooth. For 2 to 18 weeks before week 0, all patients were treated for peri-implantitis, including motivation, oral hygiene instructions, and implant scaling with a plastic instrument. They were randomly assigned to continue with this treatment or to have additional mechanical debridement and local application of slow-release doxycycline. Patients in the test group showed a significantly greater gain in mean probing attachment levels than those in the control. Only subjects in the test group had a significant reduction in mean BOP ($P = 0.001$). Application of the biodegradable sustained release device after initial periodontal treatment resulted in a significant gain in mean probing attachment levels and a significant reduction in pocket probing depths. In another comparative study, Renvert and colleagues[62] evaluated local minocycline delivery as an adjunct to manual debridement in comparison with manual debridement with submucosal chlorhexidine application. The results showed that after a follow-up period of 12 months, a limited reduction in BOP was achieved and the mean peri-implant probing depth (PD) remained unchanged with the chlorhexidine group. In comparison, in the minocycline group, the reduction of BOP was greater and an overall improvement in the mean peri-implant PD was seen. The results suggested that the topical application of chlorhexidine may provide limited or no adjunctive clinical improvement when treating shallow peri-implant lesions as compared with mechanical debridement alone. In addition, in a recent systematic review[47] the authors concluded that the addition of systemic antibiotics and air-abrasive devices did not seem to improve the efficacy of professional hygiene treatments in the reduction of inflammation. Tang and co-workers[63] evaluated the effects of local delivery of 25% metronidazole gel and mechanical cleaning using an ultrasonic carbon fiber tip on dental implants with peri-implantitis. A total of 27 implants with peri-implantitis were randomly assigned to receiving either

25% metronidazole gel treatment or carbon fiber tip ultrasonic scaling. A statistically significant decrease ($P < 0.05$) in BOP, enzyme analysis, and plaque index occurred in both treatment groups at all time intervals compared to baseline. Probing depths decreased in both groups, but only the metronidazole group reached statistically significant levels ($P < 0.05$) at 2- and 6-week intervals compared to baseline.

In a single blind randomized clinical trial comparing an air-abrasive device versus manual debridement, Karring and colleagues[64] treated 11 patients with at least two screw-type implants with BOP, probing pocket depth (PPD) greater than 5 mm, and at least 1.5 mm radiographic bone loss and exposed implant threads. The test sites were treated with the straight or curved flexible carbon fiber tip combined with aerosol spray of fluid polish with hydroxyapatite particles (grain size approximately 10 μm), whereas the control sites with carbon fiber curettes. Oral hygiene around both test and control implants was improved at 3 and 6 months compared with baseline. At 6 months, four of the air-abrasive–treated sites and only one site treated with curettes had no BOP. In neither the test nor control group were there any differences between baseline and 6 months regarding PPD and bone levels. In a pilot study, Schwarz and co-workers[65] compared the effectiveness of an erbium-doped yttrium-aluminum-garnet (Er:YAG) laser to mechanical debridement using plastic curettes and antiseptic therapy for nonsurgical treatment of peri-implantitis. Twenty patients with moderate to advanced peri-implantitis lesions were randomly treated with either an Er:YAG laser using a cone-shaped glass fiber tip at an energy setting of 100 mJ/pulse and 10 pps, or mechanical debridement using plastic curettes and antiseptic therapy with chlorhexidine digluconate (0.2%). Mean value of BOP decreased in the laser group from 83% at baseline to 31% after 6 months ($P < 0.001$) and in the mechanical debridement group from 80% at baseline to 58% after 6 months ($P < 0.001$). The difference between the two groups was statistically significant ($P < 0.001$). The sites treated with laser demonstrated a mean clinical attachment level (CAL) change from 5.8 ± 1 mm at baseline to 5.1 ± 1.1 mm ($P < 0.01$) after 6 months. The manually debrided sites demonstrated a mean CAL change from 6.2 ± 1.5 mm at baseline to 5.6 ± 1.6 mm ($P < 0.001$) after 6 months. After 6 months, the difference between the two groups was not statistically significant ($P > 0.05$). The study concluded that at 6 months following treatment, both therapies led to significant improvements of the investigated clinical parameters, and that laser treatment resulted in a statistically significant higher reduction of BOP than manual debridement with curettes. A systematic review comparing nonsurgical debridement with air abrasion demonstrated a significant difference in BOP but not probing pocket depth in peri-implantitis. However, control measures also improved BOP scores.[66]

Surgical—Open Debridement

In the surgical approach, or open flap debridement, for the treatment of peri-implantitis, the primary goal is to obtain access for debridement and decontamination of the infected implant surface. Animal studies have suggested that this approach may be beneficial for the elimination of the inflammatory cell infiltrate[67] (Figure 43-3).

A secondary goal in these cases is the complete resolution of peri-implantitis, including tissue regeneration and the hypothetical reestablishment of osseointegration along previously contaminated implant surfaces. The nature of the defect plays an important role in the achievement of successful bone regeneration. Circumferential-type intrabony defects may yield better results than defects lacking one or more bony walls.[68] The use of barrier membranes has also been investigated. In a longitudinal clinical study, Khoury and Buchmann[69] evaluated the outcomes of three regenerative treatment protocols for peri-implantitis. Forty-one peri-implant defects were treated with flap surgery plus autogenous bone graft alone, autogenous bone graft plus nonresorbable membrane, or autogenous bone graft plus bioabsorbable barrier. After 3 years, significant changes in mean probing depth from baseline were noted in all three groups. Three-year radiographic evaluation showed a mean

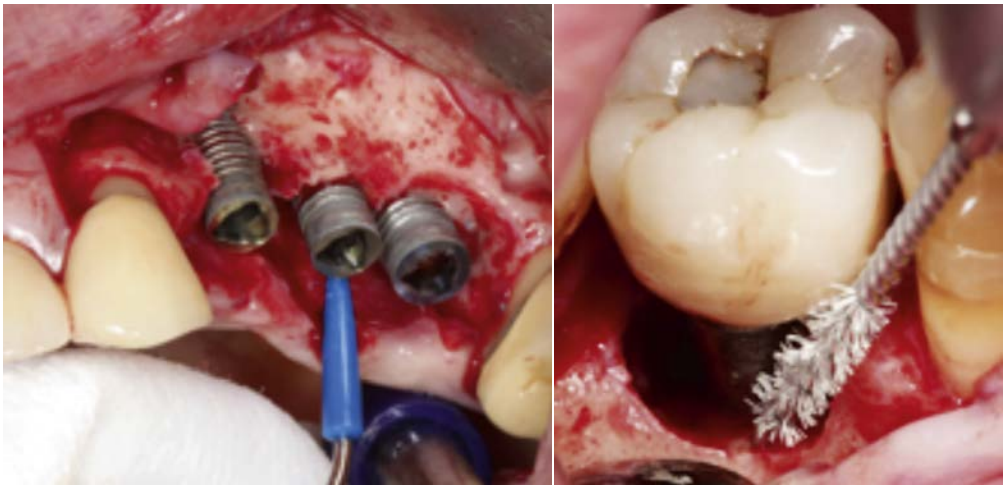

• **Figure 43-3** Open flap debridement with ultrasonic scaler and titanium brush.

bone gain in all treatment groups. Even though the differences among the three surgical treatment protocols were not significant, the treatment groups in which a barrier membrane was used exhibited more complications.

Lasers are now extremely popular for the treatment of peri-implantitis. The two most common are carbon dioxide (CO_2) and erbium-doped yttrium-aluminum-garnet (Er:YAG) lasers. The CO_2 laser is considered safe and may not negatively affect osteoblastic attachment to the implant surface.[70,71] The Er:YAG laser has bactericidal properties and can remove the biofilm without harming the implant surface.[71-73] Although some reports show promising preliminary results, long-term, controlled, comparative studies demonstrating their improved effectiveness over other methods of debridement and decontamination are generally lacking.[74-76]

Different bone graft materials have also been evaluated for the surgical treatment of peri-implantitis. Schwarz and colleagues[77,78] evaluated 6-month and 1-, 2-, and 4-year results of regenerative treatment of 22 peri-implantitis defects filled with a graft material in combination with a collagen membrane. The graft material was either a nanocrystalline hydroxyapatite or a xenograft. At 12 months, the mean PD was reduced from 6.9 mm to 4.9 mm, with a reduction of BOP from 80% to 36% in the hydroxyapatite group. In the xenograft group, the mean PD was reduced from 7.1 mm to 4.4 mm, with a reduction in the mean BOP from 78% to 29%. Higher mean probing depth reductions and clinical attachment level gains were reported at 4 years in the group treated with xenograft that was covered with a collagen membrane (Figure 43-4).

In addition to the techniques described in the nonsurgical approaches, techniques to modify the implant surface or implantoplasty are also documented. Romeo and co-workers[79,80] evaluated the clinical outcome of resective surgery and modification of surface topography (implantoplasty) with resective surgery alone for the treatment of peri-implantitis. The mean PD in the implantoplasty group decreased from 5.8 mm at baseline to 3.4 mm at 12 months, and the mean number of sites with positive BOP from 2.8 mm at baseline to 0.4 mm at 12 months. The mean recession in the implantoplasty group was increased from 0.5 mm to 2.3 mm. In the group treated with resective surgery alone, the mean PD had reduced from 6.5 mm to 5.9 mm and the mean number of sites with BOP had reduced from 2.9 at baseline to 2.7 at 12 months. The mean recession had increased from 0.2 mm to 1.4 mm. Two implants in the implantoplasty group were lost after 2 years because of mobility. The mean marginal bone level was unchanged 3 years after implantoplasty, whereas in the resective surgery group there was a mean bone loss of 1.4 mm at the mesial and 1.5 mm at the distal surfaces. Although commonly performed, results of regenerative procedures are not predictable.[81,82] It is also unclear if re-osseointegration is achieved, because it cannot be confirmed without histologic examination.

Future Directions

Even though implant dentistry has become a relatively successful treatment approach for partially and completely edentulous patients, complications continue to occur. Most implant-related complications are attributed to the failure of the osseointegration process and infection. To combat the inflammatory response from the presence of microbial biofilms, several innovative methods have been proposed. UV-mediated photofunctionalization of titanium modifies titanium implant surfaces from a hydrophobic to a superhydrophilic state and removes hydrocarbon contamination.[83] A recent report demonstrated that UV treatment of titanium surfaces can reduce attachment and monospecies biofilm formation of *Staphylococcus aureus* and *Streptococcus pyogenes*.[84] Photofunctionalization of the implant surface prior to insertion and its effect on oral bacterial attachment and biofilm formation was also evaluated.[85] UV-treated surfaces exhibited a significant reduction in

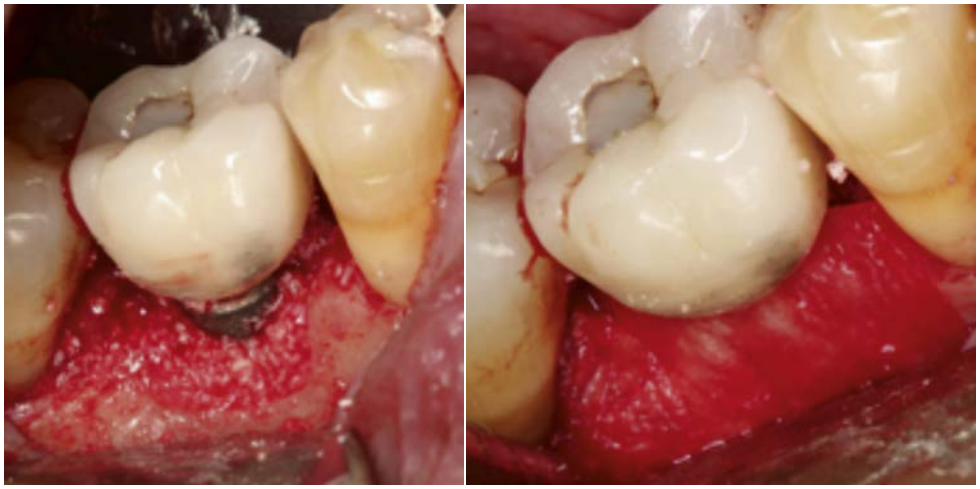

• **Figure 43-4** Peri-implantitis defect treated with xenograft and resorbable collagen membrane after decontamination.

bacterial attachment as well as subsequent biofilm formation compared to untreated ones. This treatment modality could provide additional support in the reduction of bacterial contamination for the treatment of peri-implantitis.

Nanomedicine and nanotechnology have also been evaluated for the treatment of peri-implantitis. In an experimental study,[86] the authors evaluated the antibacterial properties of silver nanoparticles deposited on titanium surfaces (Ti-nAg). Two species of bacteria, *S. aureus* and *Escherichia coli*, were used to test the antibacterial effect of the silver nanoparticles-treated surface. After a 24-hour incubation period, 94% of *S. aureus* and over 95% of *E. coli* had been killed, and the scanning electron microscopic examination of anti-adhesive efficacy showed that there were fewer bacteria attached to the Ti-nAg surface than to a control surface of untreated titanium. These data suggest that silver nanoparticle-modified titanium is a promising material that could be used as an implantable biomaterial with an antibacterial property.

Conclusions

Overall, treatment of peri-implantitis is extremely challenging, especially as patients have more medical risk factors, implant sites are more compromised with both hard and soft tissue deficiencies, prostheses are more complex and often have inadequate hygiene access, and implants are in function much longer. Focusing on prevention and early diagnosis of peri-implant diseases is an important strategy to prevent peri-implant mucositis from becoming peri-implantitis, increased severity of peri-implant bone destruction, and ultimate implant loss. Evaluating effective therapies can be problematic because research is in the early stages and mostly consists of case reports and series. In addition, combinations of multiple treatment protocols make identifying effective modalities almost impossible. As treatments become more complicated, where bone regeneration is used, results are often inconsistent and unpredictable. Evaluating outcomes of therapy also pose challenges, because objective measures are not well defined. Therefore, reaching a consensus to evaluate success of current therapies with clear outcome measures should be a priority to advance the field. Finally, continued focus on patient, dentist, and hygienist education is a key factor in prevention, diagnosis, and treatment of peri-implant disease and in maintaining implant health. Because its prevalence may continue to increase, peri-implantitis will be one of the major concerns facing clinicians practicing implant dentistry today.

References

1. Adell R, Lekholm U, Rockler B, Branemark PI: A 15-year study of osseointegrated implants in the treatment of the edentulous jaw, *Int J Oral Surg* 10:387, 1981.
2. Balshi TJ, Wolfinger GJ, Stein BE, Balshi SF: A long-term retrospective analysis of survival rates of implants in the mandible, *Int J Oral Maxillofac Implants* 30:1348, 2015.
3. Jimbo R, Albrektsson T: Long-term clinical success of minimally and moderately rough oral implants: a review of 71 studies with 5 years or more of follow-up, *Implant Dent* 24:62, 2015.
4. Moraschini V, Poubel LA, Ferreira VF, Barboza Edos S: Evaluation of survival and success rates of dental implants reported in longitudinal studies with a follow-up period of at least 10 years: a systematic review, *Int J Oral Maxillofac Surg* 44:377, 2015.
5. Roccuzzo M, Bonino L, Dalmasso P, Aglietta M: Long-term results of a three arms prospective cohort study on implants in periodontally compromised patients: 10-year data around sandblasted and acid-etched (SLA) surface, *Clin Oral Implants Res* 25:1105, 2014.
6. van Velzen FJ, Ofec R, Schulten EA, Ten Bruggenkate CM: 10-year survival rate and the incidence of peri-implant disease of 374 titanium dental implants with a SLA surface: a prospective cohort study in 177 fully and partially edentulous patients, *Clin Oral Implants Res* 26:1121, 2015.
7. Mozzati M, Gallesio G, Del Fabbro M: Long-term (9-12 years) outcomes of titanium implants with an oxidized surface: a retrospective investigation on 209 implants, *J Oral Implantol* 41:437, 2015.
8. Imburgia M, Del Fabbro M: Long-term retrospective clinical and radiographic follow-up of 205 Branemark System Mk III TiUnite implants submitted to either immediate or delayed loading, *Implant Dent* 24:533, 2015.
9. Albrektsson T, Zarb G, Worthington P, Eriksson AR: The long-term efficacy of currently used dental implants: a review and proposed criteria of success, *Int J Oral Maxillofac Implants* 1:11, 1986.
10. Becker ST, Beck-Broichsitter BE, Rossmann CM, et al.: Long-term survival of Straumann dental implants with TPS surfaces: a retrospective study with a follow-up of 12 to 23 years, *Clin Implant Dent Relat Res*, 2015 Mar 23. doi: 10.1111/cid.12334. Epub ahead of print.
11. Reference removed in pages.
12. Reference removed in pages.
13. Reference removed in pages.
14. Reference removed in pages.
15. Reference removed in pages.
16. Lindhe J, Meyle J: Group D of European Workshop on Periodontology: Peri-implant diseases: consensus report of the Sixth European Workshop on Periodontology, *J Clin Periodontol* 35:282, 2008.
17. Levignac J: (Periimplantation osteolysis—periimplantosis—periimplantitis), *Rev Fr Odontostomatol* 12:1251, 1965.
18. Mombelli A, van Oosten MA, Schurch Jr E, Land NP: The microbiota associated with successful or failing osseointegrated titanium implants, *Oral Microbiol Immunol* 2:145, 1987.
19. Albrektsson T, Isidor F: Consensus report of session IV. In Lang NPK, et al.: *Proceedings of the 1st European Workshop on Periodontology*, Switzerland, 1994, Quintessence, p 365.
20. Marcantonio C, Nicoli LG, Junior EM, Zandim-Barcelos DL: Prevalence and possible risk factors of peri-implantitis: a concept review, *J Contemp Dent Pract* 16:750, 2015.
21. Narendrakumar K, Kulkarni M, Addison O, et al.: Adherence of oral streptococci to nanostructured titanium surfaces, *Dent Mater* 31(12):1460–1468, 2015.
22. Lang NP, Berglundh T: Working Group 4 of Seventh European Workshop on Periodontology: Periimplant diseases: where are we now?—Consensus of the Seventh European Workshop on Periodontology, *J Clin Periodontol* 38(Suppl 11):178, 2011.
23. Renvert S, Roos-Jansaker AM, Claffey N: Non-surgical treatment of peri-implant mucositis and peri-implantitis: a literature review, *J Clin Periodontol* 35:305, 2008.

24. Vandeweghe S, Ferreira D, Vermeersch L, et al.: Long-term retrospective follow-up of turned and moderately rough implants in the edentulous jaw, *Clin Oral Implants Res*, 2015 Apr 9 doi: 10.1111/clr.12602. Epub ahead of print.
25. Atieh MA, Alsabeeha NH, Faggion Jr CM, Duncan WJ: The frequency of peri-implant diseases: a systematic review and meta-analysis, *J Periodontol* 84:1586, 2013.
26. Mombelli A, Muller N, Cionca N: The epidemiology of peri-implantitis, *Clin Oral Implants Res* 23(Suppl 6):67, 2012.
27. Zitzmann NU, Berglundh T: Definition and prevalence of peri-implant diseases, *J Clin Periodontol* 35:286, 2008.
28. Faveri M, Figueiredo LC, Shibli JA, et al.: Microbiological diversity of peri-implantitis biofilms, *Adv Exp Med Biol* 830:85, 2015.
29. Froum SJ, Rosen PS: A proposed classification for peri-implantitis, *Int J Periodontics Restorative Dent* 32:533, 2012.
30. Renvert S, Quirynen M: Risk indicators for peri-implantitis. A narrative review, *Clin Oral Implants Res* 26(Suppl 11):15, 2015.
31. Konstantinidis IK, Kotsakis GA, Gerdes S, Walter MH: Cross-sectional study on the prevalence and risk indicators of peri-implant diseases, *Eur J Oral Implantol* 8:75, 2015.
32. Saaby M, Karring E, Schou S, Isidor F: Factors influencing severity of peri-implantitis, *Clin Oral Implants Res*, 2014.
33. Newton JT, Asimakopoulou K: Managing oral hygiene as a risk factor for periodontal disease: a systematic review of psychological approaches to behaviour change for improved plaque control in periodontal management, *J Clin Periodontol* 42(Suppl 16):S36, 2015.
34. Moy PK, Medina D, Shetty V, Aghaloo TL: Dental implant failure rates and associated risk factors, *Int J Oral Maxillofac Implants* 20:569, 2005.
35. Kotsakis G, Zhang L, Gaillard P, et al.: Investigation of the association between cement-retention and prevalent peri-implant diseases: a cross-sectional study, *J Periodontol* 87(3):212–220, 2016.
36. Garcia-Delaney C, Sanchez-Garces MA, Figueiredo R, et al.: Clinical significance of interleukin-1 genotype in smoking patients as a predictor of peri-implantitis: A case-control study, *Med Oral Patol Oral Cir Bucal* 20:e737, 2015.
37. de Brandao ML, Vettore MV, Vidigal Jr GM: Peri-implant bone loss in cement- and screw-retained prostheses: systematic review and meta-analysis, *J Clin Periodontol* 40:287, 2013.
38. Peri-implant mucositis and peri-implantitis: a current understanding of their diagnoses and clinical implications, *J Periodontol* 84:436, 2013.
39. Pontoriero R, Tonelli MP, Carnevale G, et al.: Experimentally induced peri-implant mucositis. A clinical study in humans, *Clin Oral Implants Res* 5:254, 1994.
40. Belibasakis GN: Microbiological and immuno-pathological aspects of peri-implant diseases, *Arch Oral Biol* 59:66, 2014.
41. Rakic M, Grusovin MG, Canullo L: The microbiologic profile associated with peri-implantitis in humans: a systematic review, *Int J Oral Maxillofac Implants* 31(2):359–368, 2016.
42. Eick S, Ramseier CA, Rothenberger K, et al.: Microbiota at teeth and implants in partially edentulous patients. A 10-year retrospective study, *Clin Oral Implants Res* 27(2):218–225, 2016.
43. Heitz-Mayfield LJ, Lang NP: Comparative biology of chronic and aggressive periodontitis vs. peri-implantitis. *Periodontology*, 2000(53):167, 2010.
44. Canullo L, Penarrocha-Oltra D, Covani U, Rossetti PH: Microbiologic and clinical findings of implants in healthy condition and with peri-implantitis, *Int J Oral Maxillofac Implants* 30:834, 2015.
45. Pi-Anfruns J: Complications in implant dentistry, *Alpha Omegan* 107:8, 2014.
46. Klinge B, Flemming T, Cosyn J, et al.: The patient undergoing implant therapy. Summary and consensus statements. The 4th EAO Consensus Conference 2015, *Clin Oral Implants Res* 26(Suppl 11):64, 2015.
47. Jepsen S, Berglundh T, Genco R, et al.: Primary prevention of peri-implantitis: managing peri-implant mucositis, *J Clin Periodontol* 42(Suppl 16):S152, 2015.
48. Sousa V, Mardas N, Farias B, et al.: A systematic review of implant outcomes in treated periodontitis patients, *Clin Oral Implants Res*, 2015 Sep 18 doi: 10.1111/clr.12684. Epub ahead of print.
49. Costa FO, Takenaka-Martinez S, Cota LO, et al.: Peri-implant disease in subjects with and without preventive maintenance: a 5-year follow-up, *J Clin Periodontol* 39:173, 2012.
50. Algraffee H, Borumandi F, Cascarini L: Peri-implantitis, *Br J Oral Maxillofac Surg* 50:689, 2012.
51. Wilson Jr TG, Valderrama P, Rodrigues DB: The case for routine maintenance of dental implants, *J Periodontol* 85:657, 2014.
52. Salvi GE, Ramseier CA: Efficacy of patient-administered mechanical and/or chemical plaque control protocols in the management of peri-implant mucositis. A systematic review, *J Clin Periodontol* 42(Suppl 16):S187, 2015.
53. Corbella S, Del Fabbro M, Taschieri S, et al.: Clinical evaluation of an implant maintenance protocol for the prevention of peri-implant diseases in patients treated with immediately loaded full-arch rehabilitations, *Int J Dent Hyg* 9:216, 2011.
54. Tonetti MS, Chapple IL, Jepsen S, Sanz M: Primary and secondary prevention of periodontal and peri-implant diseases: Introduction to, and objectives of the 11th European Workshop on Periodontology consensus conference, *J Clin Periodontol* 42(Suppl 16):S1, 2015.
55. Swierkot K, Lottholz P, Flores-de-Jacoby L, Mengel R: Mucositis, peri-implantitis, implant success, and survival of implants in patients with treated generalized aggressive periodontitis: 3- to 16-year results of a prospective long-term cohort study, *J Periodontol* 83:1213, 2012.
56. Lang NP, Berglundh T, Heitz-Mayfield LJ, et al.: Consensus statements and recommended clinical procedures regarding implant survival and complications, *Int J Oral Maxillofac Implants* 19(Suppl):150, 2004.
57. Heitz-Mayfield LJ, Mombelli A: The therapy of peri-implantitis: a systematic review, *Int J Oral Maxillofac Implants* 29(Suppl):325, 2014.
58. Esposito M, Grusovin MG, Worthington HV: Interventions for replacing missing teeth: treatment of peri-implantitis, *Cochrane Database Syst Rev* 1:CD004970, 2012.
59. Lang NP, Mombelli A, Tonetti MS, et al.: Clinical trials on therapies for peri-implant infections, *Ann Periodontol* 2:343, 1997.
60. Heitz-Mayfield LJ, Lang NP: Antimicrobial treatment of peri-implant diseases, *Int J Oral Maxillofac Implants* 19(Suppl):128, 2004.
61. Buchter A, Meyer U, Kruse-Losler B, et al.: Sustained release of doxycycline for the treatment of peri-implantitis: randomised controlled trial, *Br J Oral Maxillofac Surg* 42:439, 2004.
62. Renvert S, Lessem J, Dahlen G, et al.: Topical minocycline microspheres versus topical chlorhexidine gel as an adjunct to mechanical debridement of incipient peri-implant infections: a randomized clinical trial, *J Clin Periodontol* 33:362, 2006.
63. Tang Z, Cao C, Sha Y, et al.: Effects of non-surgical treatment modalities on peri-implantitis, *Zhonghua Kou Qiang Yi Xue Za Zhi* 37:173, 2002.

64. Karring ES, Stavropoulos A, Ellegaard B, Karring T: Treatment of peri-implantitis by the Vector system, *Clin Oral Implants Res* 16:288, 2005.
65. Schwarz F, Sculean A, Rothamel D, et al.: Clinical evaluation of an Er:YAG laser for nonsurgical treatment of peri-implantitis: a pilot study, *Clin Oral Implants Res* 16:44, 2005.
66. Schwarz F, Becker K, Renvert S: Efficacy of air polishing for the non-surgical treatment of peri-implant diseases: a systematic review, *J Clin Periodontol* 42(10):951–959, 2015.
67. Machado MA, Stefani CM, Sallum EA, et al.: Treatment of ligature-induced peri-implantitis defects by regenerative procedures. Part II: A histometric study in dogs, *J Oral Sci* 42:163, 2000.
68. Schwarz F, Sahm N, Schwarz K, Becker J: Impact of defect configuration on the clinical outcome following surgical regenerative therapy of peri-implantitis, *J Clin Periodontol* 37:449, 2010.
69. Khoury F, Buchmann R: Surgical therapy of peri-implant disease: a 3-year follow-up study of cases treated with 3 different techniques of bone regeneration, *J Periodontol* 72:1498, 2001.
70. Kamel MS, Khosa A, Tawse-Smith A, Leichter J: The use of laser therapy for dental implant surface decontamination: a narrative review of in vitro studies, *Lasers Med Sci* 29:1977, 2014.
71. Romanos GE, Javed F, Delgado-Ruiz RA, Calvo-Guirado JL: Peri-implant diseases: a review of treatment interventions, *Dent Clin North Am* 59:157, 2015.
72. Kreisler M, Kohnen W, Marinello C, et al.: Bactericidal effect of the Er:YAG laser on dental implant surfaces: an in vitro study, *J Periodontol* 73:1292, 2002.
73. Takasaki AA, Aoki A, Mizutani K, et al.: Er:YAG laser therapy for peri-implant infection: a histological study, *Lasers Med Sci* 22:143, 2007.
74. Natto ZS, Aladmawy M, Levi Jr PA, Wang HL: Comparison of the efficacy of different types of lasers for the treatment of peri-implantitis: a systematic review, *Int J Oral Maxillofac Implants* 30:338, 2015.
75. Papadopoulos CA, Vouros I, Menexes G, Konstantinidis A: The utilization of a diode laser in the surgical treatment of peri-implantitis. A randomized clinical trial, *Clin Oral Investig* 19(8):1851–1860, 2015.
76. Yan M, Liu M, Wang M, et al.: The effects of Er:YAG on the treatment of peri-implantitis: a meta-analysis of randomized controlled trials, *Lasers Med Sci* 30(7):1843–1853, 2015.
77. Schwarz F, Sculean A, Bieling K, et al.: Two-year clinical results following treatment of peri-implantitis lesions using a nanocrystalline hydroxyapatite or a natural bone mineral in combination with a collagen membrane, *J Clin Periodontol* 35:80, 2008.
78. Schwarz F, Sahm N, Bieling K, Becker J: Surgical regenerative treatment of peri-implantitis lesions using a nanocrystalline hydroxyapatite or a natural bone mineral in combination with a collagen membrane: a four-year clinical follow-up report, *J Clin Periodontol* 36:807, 2009.
79. Romeo E, Ghisolfi M, Murgolo N, et al.: Therapy of peri-implantitis with resective surgery. A 3-year clinical trial on rough screw-shaped oral implants. Part I: clinical outcome, *Clin Oral Implants Res* 16:9, 2005.
80. Romeo E, Lops D, Chiapasco M, et al.: Therapy of peri-implantitis with resective surgery. A 3-year clinical trial on rough screw-shaped oral implants. Part II: radiographic outcome, *Clin Oral Implants Res* 18:179, 2007.
81. Chan HL, Lin GH, Suarez F, et al.: Surgical management of peri-implantitis: a systematic review and meta-analysis of treatment outcomes, *J Periodontol* 85:1027, 2014.
82. Froum SJ, Rosen PS: Reentry evaluation following treatment of peri-implantitis with a regenerative approach, *Int J Periodontics Restorative Dent* 34:47, 2014.
83. Tsukimura N, Yamada M, Iwasa F, et al.: Synergistic effects of UV photofunctionalization and micro-nano hybrid topography on the biological properties of titanium, *Biomaterials* 32:4358, 2011.
84. Yamada Y, Yamada M, Ueda T, Sakurai K: Reduction of biofilm formation on titanium surface with ultraviolet-C pre-irradiation, *J Biomater Appl* 29:161, 2013.
85. de Avila ED, Lima BP, Sekiya T, et al.: Effect of UV-photofunctionalization on oral bacterial attachment and biofilm formation to titanium implant material, *Biomaterials* 67:84, 2015.
86. Juan L, Zhimin Z, Anchun M, et al.: Deposition of silver nanoparticles on titanium surface for antibacterial effect, *Int J Nanomedicine* 5:261, 2010.

Index

A
A-delta nerve fiber, I-225
AAAASF. *See* American Association for Accreditation of Ambulatory Surgery Facilities (AAAASF)
AAAHC. *See* Accreditation Association for Ambulatory Health Care (AAAHC)
AAOMS. *See* American Association of Oral and Maxillofacial Surgeons (AAOMS)
Abbe flap, II-286, II-297–298, II-291f
Ablation, laser for, I-330, I-338f, III-352–355
ABMS. *See* American Board of Medical Specialties (ABMS)
Abrasion, exodontia and, I-301
Abutment
  anterior, decision tree for, I-637f
  cement-retained implant on, I-625f
  cementable, I-626f
  custom, I-630
  direct, I-626f
  gold, I-636
  Locator, I-657–658
  material choices, I-636–639
  posterior, decision tree, I-632f
  projection, in three-dimensional imaging, I-693–696, I-696f
  Snappy, I-626f
  stock, I-630, I-630f, I-634f
  temporary, immediate implant and, I-416–418
  titanium, I-636
  zirconia, I-625f, I-628, I-630f, I-636
Acantholysis, II-564
Acanthosis nigricans, III-668
Accelerated osteogenic orthodontics (AOO), III-247–248
  alternative options, III-261
  case study, III-251b–257b, III-259b–260b
  contraindications, III-250–261
  indications, III-250–261
  mandible, case study, III-251b–252b
  maxilla, case study, III-253b–257b
  orthodontic technique following, III-250
  orthognathic surgery with, III-259–261
  surgical technique, III-248–250
Accountant, for oral and maxillofacial surgical practice, I-63
Accreditation
  benefits, I-99–100
  definition, I-98–99
  outpatient surgery facility, I-96–101
Accreditation Association for Ambulatory Health Care (AAAHC), I-98, I-98t, I-100t
Accudent System, I-656f
ACE Distractor, I-539–540
Acellular dermal matrix, I-558, I-561f, III-611–612
Acetaminophen, I-232
  dosage, I-232t
  for temporomandibular joint disorders, II-870–871
Acetazolamide, II-207
ACGME. *See* American Council for Graduate Medical Education (ACGME)
Acinic cell carcinoma, II-498
Acinus, II-481
Acitretin, II-733
Acne, laser treatment, III-357–358
Acquired immunodeficiency syndrome (AIDS)
  lymphoepithelial cyst associated with, II-485
  osteoradionecrosis associated with, II-591f–594f
  parotid gland affected by, II-488
Acral lentiginous melanoma, II-692t, II-694f
Acrylic resin
  restoration with, I-597–599
  try-in, I-602f
  wraparound prosthesis, I-599f
Actinic keratitis, III-354
Actinic keratosis, II-719, II-723–724
  medical management, II-733–734
  photodynamic therapy for, II-734
  treatment, II-727
Actinobacillus actinomycetemcomitans, I-350
Actinomycin D, II-455
Active range of motion, II-806
Actonel. *See* Risedronate (Actonel)
Acute kidney injury
  preoperative evaluation of, I-158–159
  Rifle criteria for, I-153t
Acute suppurative parotitis, II-485–487
Acute suppurative sialadenitis, II-487
Acyclovir, II-553–556
Ad modum Brånemark technique, I-572–573, I-577, I-578f
ADA. *See* American Dental Association (ADA)
Addiction
  definition, II-952
  ethics and, I-12
  facial pain management and, II-952
  medical professional affected by, I-144
  opioid drug use and, I-228
  sexual, I-145
  treatment, I-145
Adenocarcinoma, polymorphous, II-503f
Adenoid cystic carcinoma, II-493t, II-498, II-500–501, II-759–760
Adenoidectomy, codeine warning, I-254
Adenoma
  monomorphic, II-493t
  pleomorphic, II-492–494, II-493t
Adenomatoid odontogenic tumor (AOT), II-368, II-394–397, III-744–745
Adipocyte, III-434, III-435f
Adipose tissue, III-429, III-434
Adolescent
  craniosynostosis care algorithm, III-677–678
  dentoalveolar injury, II-114
  heart rate, II-249–250
  neurologic abnormalities, III-284
  trauma outcomes, II-245
Adolescent internal condylar resorption, III-224–225
Adrenal insufficiency
  craniomaxillofacial trauma management and, II-3t
  preoperative evaluation of, I-158–159
Adrenergic system, local anesthesia and, I-179
Adrenocorticoid deficiency, I-159t
Adriamycin. *See* Doxorubicin (Adriamycin)
Advanced Beneficiary Notice (ABN), I-91
Advanced Trauma Life Support (ATLS), II-1, II-2b
  for dentoalveolar injury, II-115–116
  for gunshot patient, II-307, II-310–311
  for injured child, II-246
  for mandibular fracture, II-152
  midface fracture diagnosis and, II-212
  pediatric facial trauma evaluation with, II-232
Advil. *See* Ibuprofen (Advil, Motrin)
Aerodigestive tract, III-670–671
Afferent nerve fiber
  neurophysiology, II-942–943
  pain transmission, I-225
Affordable Care Act, I-95
Ageusia, definition, I-355t
Aging
  bone graft healing affected by, I-432
  forehead and brow ptosis in, III-395
  impairment caused by, I-146
  retirement and, I-140–141
Agonist-antagonist drugs, I-226
Agonist drugs, I-226
AHI. *See* Apnea-hypopnea index (AHI)
Airway
  adult, pediatric compared to, I-239–240, I-240f, II-249f
  assessment, II-9–10, I-213–214
  breathing
    circulation, disabilities, exposure (ABCDE), child trauma assessment with, II-246
    circulation (ABC), II-9
  in craniosynostosis care algorithm, III-671–672
  emergency equipment, I-245–247
  injuries affecting, II-11–12, II-11, II-11
  monitoring, I-167
  in nasal fracture, II-187
  obstruction, II-10
  patency, I-213–214
  pediatric, I-239–241, I-248–249, II-249f, II-258–260
  physical examination, II-10–11
  preanesthetic assessment, I-242
  preoperative evaluation, III-282–283
  upper, pediatric, I-239–240
Airway management
  advanced techniques, II-13–14
  in avulsive facial injury, II-282
  in craniomaxillofacial trauma, II-1–2, II-2f
  in craniosynostosis care algorithm, III-671–672
  for maxillofacial gunshot wound patient, II-308–309

This index contains all entries from Volume I, II, and III. Each entry lists the volume number first followed by the page number.
Page numbers followed by b, indicate boxes; f, figures; and t, tables.

Airway management *(Continued)*
in oculoauriculovertebral spectrum, III-692
pediatric, I-238, I-258–260
in pediatric trauma, II-248–249
surgical, II-14
for trauma patient, II-9–15
in Treacher Collins syndrome, III-705
Alar cinch, III-167–168
Alar-columellar relationship, III-370f
Alar width, III-368
Albumin, local anesthetics and, I-178
Alcohol use, oral cancer associated with, II-671
Aldrete scoring system, I-172–173, I-173t
Alendronate sodium (Fosamax), II-508t
Aleve. *See* Naproxen (Naprosyn, Aleve)
Alfentanil, I-197–198, I-199f
Algae, alloplastic implant with, I-440–441
Allele, II-603, II-606–607
Allergy
to dental cement, I-716
to local anesthesia, I-182–183
Allis clamp, III-77f
Allodynia
definition, I-355t, II-946t
neurosensory testing of, I-359
Allogenic, definition, I-437
Allogenic bone, I-439–440
demineralized, I-439
mineralized, I-439–440
Allograft, I-428–429
for burn injury, II-67
demineralized, I-439f
in esthetic contour graft, I-490
mineralized, I-440f
particulate, I-485f–487f, I-494f, I-500b
ridge augmentation and, I-483
stem cells combined with, I-439f
Alloplast
bone graft with, I-430–432
interpositional bone graft, I-527–528
Alloplast entubulation, I-372
Alloplastic, definition, I-437
Alloplastic bone graft, I-430–432, I-483–484
Aloe vera, II-67
Alopecia
in forehead and brow lift, III-425
in rhytidectomy, III-334
Alpha1-acid glycoprotein (AAG), I-178
Alpha-hydroxy acid, for chemical peel, III-443–444
Alprazolam (Xanax)
half-life, I-195t
protein binding, I-195t
for temporomandibular joint disorders, II-874t
Alveolar bone
classification, I-537
deficiency, I-526, I-538, I-538b
examination, in dentoalveolar injury, II-117
fracture, II-123t, II-133–137
healing, after trauma, II-138
injury treatment, II-133–137
Alveolar cleft, III-588, III-624f
Alveolar cleft lip, I-665, I-679–683
Alveolar distraction osteogenesis. *See* Distraction osteogenesis (DO), alveolar
Alveolar nerve, II-147
injury, I-368–369, I-377
bilateral sagittal split osteotomy and, I-378–379
coronectomy and, I-381–382
during exodontia, I-302
outcomes and conclusions, I-382–383
in sagittal split osteotomy, III-301–305
from third molar extraction, I-382–390
Alveolar nerve *(Continued)*
neurofibroma and, II-472
neuroma, I-317f
pediatric, I-259f
Alveolar osteitis, I-283
exodontia and, I-303
third molar extraction and, I-293–294
treatment, I-294
Alveolar process fracture, II-133–135
Alveolar repositioning osteotomy, I-529
Alveolar ridge
anatomy, II-670
augmentation, I-484, I-534
case study, I-500b–501b, I-503b
guidelines, I-538t, I-538b
horizontal, I-538–539
indications, I-537–538
vertical, I-538–539
capillary malformation in, II-538
defect, I-485f–490f, I-491–493, I-539
distraction, I-545f–546f
smile line and, I-588–589
squamous cell carcinoma, II-681–683
Alveolar socket, comminution, II-123t, II-133
Alveolar soft part sarcoma, II-644t, II-645–646, II-663–664
Alveolar split graft, I-528–529
Alveolar width, distraction osteogenesis and, I-529–532
Alveolus
augmentation, III-587
cleft, III-497, III-583
lack of, zygomatic implant for, I-570
reconstruction, III-589–592
three-dimensional image, I-691f
unrepaired, III-609–610
Alzheimer's disease, I-146
AMA. *See* American Medical Association (AMA)
Ameloblastic fibro-odontoma, II-451–453, III-745
Ameloblastic fibrodentinoma (AFD), II-453–454
Ameloblastic fibroma, II-449–451, III-745
Ameloblastic fibrosarcoma, II-454–455
Ameloblastic sarcoma, II-454–455
Ameloblastoma, II-401–424, III-744
anaplastic, II-421f
basal cell carcinoma compared to, II-401
clear cell, II-425, II-429
clinical forms, II-404–422
clinicopathologic considerations, II-402
cytologic malignant, II-420–422
dentigerous cyst and, II-345–347
extraosseous, surgical management, II-423–424
growth mechanism, II-404–422
intraosseous unicystic, II-423
magnetic resonance image of, III-742f
malignant, II-401, II-420–422
multicystic, II-404, II-407–409, II-410f–414f
pediatric, III-770f
peripheral, II-409–420, II-417f–418f, II-423–424
solid, II-404, II-407–409, II-415f–416f
surgical management, II-422–424
two-stage treatment, II-361
types of, II-402
unicystic, II-361, II-363f, II-404–407, II-408f–409f, III-744
American Academy of Pediatric Dentistry (AAPD), I-258
American Academy of Pediatrics (AAP), I-258
American Association for Accreditation of Ambulatory Surgery Facilities (AAAASF), I-98, I-98t, I-100t
American Association of Oral and Maxillofacial Surgeons (AAOMS), I-10
American Board of Medical Specialties (ABMS), I-1
American Cleft Palate-Craniofacial Association, III-491–492
American Council for Graduate Medical Education (ACGME), I-4–5
American Dental Association (ADA)
Code of Ethics, I-10
Principles of Ethics, I-9
recommendations on pediatric visits from, I-258
American Heart Association, I-181–182
American Joint Committee on Cancer (AJCC), II-693, II-698–699, II-702t, II-725–726
American Medical Association (AMA), I-9
American Society of Anesthesiologists (ASA), I-181–182, I-243
Amides, local anesthetics and, I-176–177
Amifostine, II-749, II-761
Amine, terminal, local anesthetics and, I-177
Aminoglycoside drugs, I-149t
Amitriptyline (Elavil)
for facial pain, II-955t
for fibromyalgia, II-970
for neuropathic pain, I-364
for temporomandibular joint disorders, II-873t
Amnesia, benzodiazepines and, I-192, I-194
Amoxicillin
for autogenous bone graft prophylaxis, I-451
for bite wound, II-62–63
AMPLE history (allergies, medications, pregnancy/past illnesses, last meal, events), II-10
Analgesia
cannabinoid, I-233
definition, I-211, II-946t
inpatient, I-234–235
ketamine for, I-206
nitrous oxide for, I-207
non-opioid, I-228–232, I-232t
nonsteroidal antiinflammatory drugs, I-228–230
patient-controlled, I-234–235
Analgesic drugs
compounded, I-363–364
for nerve injury, I-363–364
opioid, I-198–199, I-226–228
systemic, I-364–365
for temporomandibular joint disorders, II-870–871
Anaphylaxis
drugs associated with, I-252t
pediatric anesthesia and, I-252
Anatomic abutment, I-627f, I-634
Anchor
history of implants as, I-311
implant, complications, I-323
implant types as, I-313–316
miniplate, I-313–314
Anchor unit, I-312, I-312
Anchorage
direct, I-319, I-312, I-312
implant for, I-213
indirect, I-319, I-319, I-312
miniplate, I-314
miniscrew implant, I-314
orthodontic, I-312
Andreasen classification of dentoalveolar injury, II-120
Andrew's analysis, III-25
Anemia
evaluation, I-160f
preoperative evaluation, I-159
wound healing affected by, II-259

Anesthesia, II-9–15
ambulatory, I-191–210
of auricle, III-450f
BIS monitoring, I-171–172
choice of agents, I-218–219
combined infusions, I-219–220
complications, I-222–223
concepts, I-211–224
definition, I-355t
delivery techniques, I-218–219
depth of, I-171–172, I-217–218
drug pharmacology, I-191–210
electrocardiogram during, I-167
electronic dental, I-187–188
equipment, in oral and maxillofacial surgery, I-49
fluid administration, I-216–217
for forehead and brow lift, III-408
general, I-46–54, I-164–165
for nasal fracture reduction, II-179–180
for trauma patient, II-12–13
intraosseous, I-187
for Le Fort I osteotomy, III-161–162
levels, I-165t
for liposuction, III-431
local, I-176–190, I-232–233
chemistry of, I-176
complications of, I-182–184
drug-drug interaction in, I-181
duration of action of, I-178
duration of blockade of, I-178
efficacy, I-178
future of, I-187–188
history, I-176
for nasal fracture reduction, II-179–181
nerve injury caused by, I-376–377
pregnancy and, I-186
for rhinoplasty, III-377
systemic complications from, I-184–185
management, II-9–15
mandibular nerve block, II-950
monitoring, I-164, I-217–218
nerve block, I-178
outpatient, I-96
pediatric, I-238–256, I-258
alarms, I-245
complications, I-251–253
equipment, I-245–248
monitoring, I-244–245
preanesthetic assessment, I-242–244
recovery and discharge, I-253–254
room preparation, I-245–248
techniques, I-251
worksheet, I-246f
perioperative complications, I-251–253
pharmacology of drugs for, I-191–210
preoperative assessment for, I-212
pulse oximeter used during, I-168
recovery, I-221–222
for rhinoplasty, III-377
for rhytidectomy, III-329
risk management and, I-78, I-81–82
strategies, II-12–15
techniques, I-211–224
for trauma patient, II-9–15
tumescent, III-430
Anesthesia dolorosa, I-361
Anesthesia information system, I-172
Anesthesia nurse
position, I-50
role, I-53–54
Anesthesia record, I-172
Anesthetic drugs, local, I-176–190, I-232–233
allergy to, I-182–183
amide-linked, I-186
chemistry, I-176
Anesthetic drugs, local *(Continued)*
complications, I-182–184
drug-drug interaction, I-181
duration of action, I-178
duration of blockade, I-178
efficacy, I-178
ester-linked, I-185–186
extended release formulations for, I-187
for facial pain, II-956
future, I-187–188
history, I-176
injectable, I-179t
lipid solubility of, I-177t
long-acting, I-178
nerve injury associated with, I-183t, I-376–377
nerve injury caused by, II-81
onset time, I-178t
pediatric, I-258
pregnancy and, I-186
prolonged sensory alteration and, I-183–184
speed of onset, I-177
structure and properties, I-176–177
systemic complications, I-184–185
Anesthetic equipment, I-212–213
Aneurysmal bone cyst, II-467–468, II-751, III-752f–753f, III-852
Angiofibroma, juvenile nasopharyngeal, III-751, III-754f
Angiogenesis
bone healing and, I-427
in cancer progression, II-600
tumor progression, II-617–618
tumor-stroma interaction, II-618f
Angiography, of craniomaxillofacial pathologies, III-739
Angiosarcoma, II-644t, II-658–659
Angle, Edward H., III-44, III-1, III-4–5
Angle's classification, II-874
Anhydrase inhibitor drugs, II-207
Animal bite, II-61–67
Ankyloglossia, prominent lingual frenum as cause of, I-271
Ankylosing spondylitis, II-842
Ankylosis
bony, joint replacement for, II-931
condylar fracture associated with, II-270
Murphy's case series, II-767t
in pediatric patient, II-130–131
temporomandibular joint, II-137f–141f, III-209f–210f, III-932f
treatment history, II-767
Ann Arbor staging system, for lymphoma, II-708–709, II-714b
Annandale, Thomas, II-764
Anorganic bovine bone (ABB), bone graft with, I-429
Antagonist drugs, I-226
Anterior nasal spine, facial symmetry and, III-96
Anterolateral thigh flap, II-294, II-295f
Antiangiogenic drugs, II-509t
bone remodeling and, II-510
for cancer, II-514–515
drug holiday from, II-515
jaw osteonecrosis associated with, II-510
medication-related osteonecrosis of jaw associated with, II-514
for osteoporosis, II-514–515
Antibiotic drugs
anaphylaxis associated with, I-252t
for autogenous bone graft prophylaxis, I-451
Anticoagulant drugs
management, I-161f
preoperative management, I-161
Anticonvulsant drugs
for facial pain, II-956
for nerve injury, I-364
Antidepressant drugs
drug interaction with, I-181
for facial pain, II-955–956
for neuropathic pain, I-318–319
for temporomandibular joint disorders, II-872–873
Antifungal drugs, II-761
Antihistamine drugs, for temporomandibular joint disorders, II-874t
Antilingular eminence, III-88–89, III-89f
Antiresorptive associated osteonecrosis of the jaw (ARONJ), II-507
Antiresorptive drugs, II-507–508, II-508t
for cancer, II-514–515
medication-related osteonecrosis of jaw associated with, II-514
for osteoporosis, II-514–515
Antiviral drugs, II-556, II-761
Antrum of Highmore, I-509
Anxiety
management, I-234
pediatric, premedication for, I-248
Anxiolysis, benzodiazepines and, I-192–194
Anxiolytic drugs, for temporomandibular joint disorders, II-873
Apert syndrome, III-16, III-639–642, III-668–669, III-672, III-778
Apertognathia, III-172–173
Apexification procedure, II-130
Aphthous stomatitis, II-559–560
Aphthous ulcer, II-559
Apicocoronal anatomy, implant restoration and, I-391–392, I-395
Apicocoronal placement, I-396–397
Apicoectomy, laser, III-350
Apnea-hypopnea index (AHI), III-265–266
Apoptosis
evasion, cancer cell and, II-614–616
process, II-614–615
suppression, II-627–628
Aprotinin, anaphylaxis associated with, I-252t
Arachidonic acid, II-870
Arch bar, II-147, II-155
Arch form, I-173, III-595f
Arch provisional prosthesis, I-605–623
Arcus marginalis, III-397
Army Medical Department (AMEDD), I-24–26
Aromatic ring, I-176
ARONJ. *See* Antiresorptive associated osteonecrosis of the jaw (ARONJ)
Arteriovenous malformation, II-544–547, II-853
Artery(ies)
carotid, III-399
ear, III-448
facial, III-328, III-399
forehead, III-399
frontal sinus, II-230–231
maxillary, I-162f, III-510
nasal, II-176, III-365f
palatine, III-165
superficial temporal, III-399
Arthralgia, definition, II-946t
Arthritis
classification, II-836
connective tissue disease associated with, II-848
histopathogenesis, II-833
infectious, II-843–847
inflammatory, II-838–843
juvenile idiopathic, II-131, III-840–841
Lyme disease, II-846–847
metabolic, II-847–848
psoriatic, II-841–842
reactive, II-225, III-561–562
septic, II-843–847
temporomandibular joint, II-832–833, II-835–848

Arthritis *(Continued)*
temporomandibular joint replacement, II-929–931
traumatic, II-836
Arthrocentesis, temporomandibular joint, II-774, II-883–891
contraindications, II-884
double puncture, II-885–886
outcomes, II-888–889
single puncture, II-886
technique, II-884–888
Arthroplasty
arthroscopic, II-897
history, II-766–767
laser, III-358–359
Arthroscopy
arthroplasty, II-897
capsular release, II-897
complications, II-897–900
disc repositioning, II-897
equipment, II-894
inferolateral puncture technique, II-894
laser, III-358–359
lysis and lavage, II-896–897
operative, II-896–901
postoperative care, II-901
temporomandibular joint, II-774, II-892–903
anatomic considerations, II-892–893
complications, II-897–900
diagnostic uses, II-893
postoperative care, II-901
Arthrotomy
complications, II-918
in temporomandibular joint internal derangement surgery, II-910–918
Articaine (Septocaine), I-186
chemical neurotoxicity associated with, I-376
concentration, I-177t
duration of, I-179t
local anesthesia with, I-232–233
nerve injury associated with, I-183t
onset time, I-178t
Articular disc, II-778–779
displacement, II-769, II-792t–793t, II-797–798
illustration of, II-794f
osteoarthritis, II-837–838
in temporomandibular joint, II-815
in temporomandibular joint dysfunction, II-884
in temporomandibular joint internal derangement, II-910
Articular eminence, II-778
Articular fossa, II-778
Articulation
craniomandibular, II-777–778
in model surgery, III-49
temporomandibular joint, II-778, II-794
Articulator, in model surgery, III-50
Asenio, Dr. Oscar, III-516
Asenio technique for rotation and advancement flap, III-517–518, III-519f
Ashhurst, A.P.C, II-766
Aspiration
biopsy, II-331
for odontogenic tumor biopsy, II-393
in pediatric patient, I-253
prevention, in trauma patient, II-12
pulmonary, I-243t
Aspirin, I-232
dosage, I-232t
management, I-149t
preoperative management, I-161
rhytidectomy complications associated with, III-332
for temporomandibular joint disorders, II-870, II-871t
Assistant's stool, I-48
Associateship, I-41, I-44
Association of Medical Colleges (AAMC), I-4
Asthma
classification, I-153t
orthognathic surgery and, III-282
pediatric anesthesia and, I-244
preoperative evaluation and, I-152
severity classification, III-282t
vasoconstrictor drugs and, I-182b
Ativan. *See* Lorazepam (Ativan)
ATLS. *See* Advanced Trauma Life Support (ATLS)
Atracurium, anaphylaxis associated with, I-252t
Attachment
ball, I-654
Locator, I-654
Attenuation coefficient, in computed tomography, II-820–821
Attorney, for oral and maxillofacial surgical practice, I-63
Atypical facial pain, II-948
Atypical odontalgia, II-948–949
Auditory canal, II-96
Auricle
anesthesia, III-450f
cartilage, III-447–448
embryology, III-446–447
Auricular cartilage, III-447–448
Auriculocephalic angle, III-447f
Auscultation
chest, II-9
temporomandibular joint, II-808–809
in trauma patient, II-9
Autogenous graft
free, I-556
for temporomandibular joint surgery, II-772
Autograft, particulate bone for, I-452f
Autograft entubulation, I-371–372
Autoimmune disease, temporomandibular joint disorders and, III-225–226
Autologous, definition, I-437
Autologous bone, I-438
in sinus graft, I-465
Autologous fat transfer, in forehead and brow lift, III-419
Autonomy, principle of, I-9
Avance nerve graft, I-371
Avastin. *See* Bevacizumab (Avastin)
Aventyl. *See* Nortriptyline (Pamelor, Aventyl)
Avulsion
calcium hydroxide root canal fill, II-131
in dentoalveolar injury, II-124f, II-128–131
Axon, in nerve anatomy, II-77
Axonotmesis
causes of, II-70–71
description of, III-316
exodontia associated with, I-303
Azacitidine, II-625
Azaspirodecanedione, II-874t
Azathioprine, II-562

B

Baclofen (Lioresal), II-872t
Bacteremia, following exodontia, I-303
Bacteria
bone graft infected by, I-434
membrane contaminated with, I-482
parotitis from, II-485–486
peri-implantitis and, I-724
Bag-mask-valve device, I-13, II-245–247
Bag-mask ventilation, II-13, II-249
Ballistic missile
components, II-303
physics, II-305–307
soft tissue injury from, II-306
Ballistics, wound, II-304–305
Band of Büngner, II-77
Banker, for oral and maxillofacial surgical practice, I-63
Bar
attachments for, I-654
CAD-CAM, I-652–653, I-652f, I-658, I-661f
four-implant, I-650f
implants connected with, I-645–647, I-647f
milled, I-648–649, I-652–653
placement of, for overdenture, I-644f
Barbiturate drugs, I-200–203
action, I-201
clinical effects, I-202–203
discovery and development, I-200–201
metabolism, I-203
pharmacokinetics, I-203
side effects, I-203f
structure, I-201
Bardach, Janusz, III-535
Bardach palatoplasty, III-505, III-537, III-538f, III-611
Bariatric surgery, III-268
Barrier membrane, I-462–463
history, I-475
selection, I-480–483
in sinus augmentation, I-513
tent-pole technique, I-488f
Basal cell carcinoma, II-350, II-352–354, II-718–719, II-721f
ameloblastoma compared to, II-401
in basal cell nevus syndrome, II-367f
laser surgery for, I-343
radiation therapy for, II-734
treatment, II-727
types, II-718–719
Basal cell nevus syndrome, II-361–364, II-364t, II-366f–367f, II-718, II-732–733
Basic Life Support (BLS)
for gunshot patient, II-307
for pediatric patient, I-260
Basicranium, III-738
Battle sign, midface fracture associated with, II-216
Bauer retractor, III-88f
Beauty, definition of, III-13
Behavior, disruptive, I-143–146
Behavior guidance, I-272
Behavior therapy, for velopharyngeal dysfunction, III-579–580
Behavioral pain management, I-365
Behçet syndrome, II-560–561
classification, II-561
clinical features, II-560–561
treatment, II-561
Bell, William, III-5
Bell's palsy, II-100–101
Beneficence, principle of, I-9–10
Bennett movement, II-787
Benzocaine, I-185
Benzodiazepine drugs, I-191–197
clinical effects, I-192–195
development, I-191
discovery, I-191
half-life, I-195t
intravenous sedation with, I-220
for masticatory myalgia, II-969
metabolism, I-195–197
muscle relaxant effect, I-194
pharmacokinetics, I-195–197
side effect profile, I-193f
structure and activity, I-191–192
for temporomandibular joint disorders, II-873, II-874t
Benzodiazepine-gamma-aminobutyric acid - chloride ionophore complex, I-192f

Beta (ß) blocker drugs, drug interaction with, I-181
Beta (ß) tricalcium phosphate (ß-TCP), I-440–441
Betamethasone (Celestone), III-287t
  for facial pain, II-955t, II-957
  in orthognathic surgery, III-289
  in temporomandibular joint arthrocentesis, II-887
  for temporomandibular joint disorders, II-871t
Bevacizumab (Avastin), II-509t, II-511
Bicuspid
  supernumerary, I-268f
  transplantation, I-268
Bicycle, pediatric injury and death associated with, II-245
Bifid uvula, III-618–619
Bilateral cleft deformity, III-565
Bilateral coronal suture craniosynostosis, II-660
Bilateral sagittal split osteotomy (BSSO), I-354, III-367
  complications, III-79–80, III-144–145
  history, III-113–114, III-183
  for mandibular asymmetry, III-72b
  nerve injury from, I-378
  relapse after, III-116b, III-777–778
  unfavorable bony split, III-81–82
Billroth, Christian, III-534
Bioactive glass, I-440–441
Biologic, definition of, I-437
Biologic materials, implant with, I-441
Biological width
  immediate implant and, I-412–413
  for multiple implants, I-420–422
Biology, molecular, of cancer, II-599–642
Biomarker, in cancer diagnosis, II-622–624
Biomaterial, definition, I-437
Biomechanics, orthodontic, I-312, I-311–312
Biopsy
  aspiration, II-331
  definition, II-330
  excisional, II-724f
  frozen section, II-330–331
  fusiform, II-724f
  incisional, II-724f
  laser for, III-347
  for lymphoma diagnosis, II-707
  M-plasty, II-724f
  for melanoma diagnosis, II-692–693
  odontogenic myxoma, II-444
  odontogenic tumor, II-393
  punch, II-724
  for sarcoma diagnosis, II-646
  sentinel lymph node, II-697–698, II-730
  shave, II-723–724
  for skin cancer, II-723–725
  techniques, II-330, II-724f
Biphasic calcium phosphate (BCP), I-430–431
Birbeck granule, II-524–525
Bird-face deformity, III-113
BIS. *See* Bispectral index (BIS)
Bispectral analysis, for pediatric anesthesia monitoring, I-245
Bispectral index (BIS), I-217–218
  monitoring, I-171–172
  for pediatric anesthesia monitoring, I-245
Bisphosphonate drugs, II-507
  chemical structure, II-508f
  drug holiday from, II-514–515
  osteonecrosis associated with, I-304, II-507, II-509–511, II-514–515
  for osteoporosis, II-514
Bisphosphonate-related osteonecrosis (BRON), I-304, I-305t
Bite
  animal or human, wound from, II-61–67
  microbiology, II-62b
Bite-jig, III-31–35
Bite plane splint, temporomandibular joint, II-867–868
Bite registration, for model surgery, III-46
Bite wound, II-61–67
  antibiotic therapy, II-62b
  pediatric, II-278–279
Blair, Major Vilray P., I-24, III-113, III-492, III-1, III-4–5
Bleeding
  in forehead and brow lift, III-425
  impacted tooth removal and, I-292
  in orthognathic surgery, III-289
  postsurgical, I-281
  in rhinoplasty, III-383
Bleeding disorders, orthognathic surgery and, III-285
Bleomycin, II-714, II-756t–757t
Blepharoplasty, III-388–394
  brow lift compared to, III-407f, III-413f
  complications, III-393
  definition, III-388
  eyelid and orbital anatomy, III-388–389
  history, III-388
  laser, I-346, III-356
  postoperative care, III-393
  preoperative evaluation, III-389–391
  surgical technique, III-391–393
Blindness, herpetic infection as cause of, II-552
Blog, marketing and, I-104–105
Blood pressure
  errors in monitoring, I-165–166
  monitoring, I-165–166
  pediatric, I-239, II-249–250
Blood supply
  ear, III-448, III-449f
  to eyelid, III-391f
  to maxilla, III-161, III-162f
  to midface, II-214
  nasal, II-176–177, III-364, III-366f
  nasal septum, III-366f
Blood vessel(s)
  anomalies, II-534–549
  forehead, III-399–402
  rhytidectomy evaluation and, III-327–328
Blood volume, in pediatric trauma, II-250
BLS. *See* Basic Life Support (BLS)
Body composition, aging effects on, I-242
Body dysmorphic disorder (BDD), III-326, III-368, III-458
Body temperature, monitoring of, I-170
Bohr, Neils, III-336
Bolton discrepancy, III-196–197
Bone-anchored hearing aid, III-733
Bone density, immediate implant loading and, I-607
Bone flap. *See* Osteoperiosteal flap
Bone graft
  allogenic, I-437, I-439–440, I-440f
  allograft, I-427–429, I-490, I-500b
    ridge augmentation and, I-483
  alloplastic, I-427, I-430–432, I-440–441, I-483–484
  alveolar split, I-528–529
  augmentation procedures for, I-441–443, I-447–448
  autogenous, I-427–428, I-446–474
    advantages, I-446
    antibiotic prophylaxis, I-451
    block, I-461–462
    disadvantages, I-446
    donor sites, I-451–460
    guide bone regeneration and, I-483
Bone graft *(Continued)*
    for midface deficiency, III-602–605
    particulate bone for, I-452f
    patient preparation, I-451
    postoperative care, I-461
    sites for, I-428
  autologous, I-438
  for avulsive facial injury, II-287f
  barrier membrane for, I-462
  biological models, I-696–699
  block, I-428f, I-461–462, I-463f
  bone shaving for, I-448f
  cancellous, I-446–447, I-447f, I-462
  categories of, I-427
  circular block, I-451f, I-454f
  classification materials for, I-437–438
  for cleft lip and palate, I-619, III-679
  for cleft maxilla reconstruction, III-590–591, III-619
  cortical, I-446–447, I-447f, I-462
  corticocancellous, I-458
  in corticotomy surgery, III-248
  digital workflow protocols, I-688–710
  donor sites, I-451–460, I-704–706
  for ectodermal dysplasia, I-674–675
  esthetic contour, I-487–491
  in facial trauma reconstruction, II-284–285
  failure, I-441
  fixation screws, I-461–462
  flap closure, I-450f
  flap coverage, I-461
  for gunshot wound, I-667f
  histology, I-437–445
  iliac block, I-569–570
  iliac crest, I-673–674, II-297
  ilium as donor site, I-458–460
  implant placement, I-468
  implant restoration and, I-394
  interpositional, I-527–528
  in inverted L osteotomy, III-128f–130f
  in Le Fort I osteotomy, III-167
  local, I-451–452
  mandibular ramus as donor site, I-455–457
  mandibular symphysis, I-453–455
  materials for, I-426–436
  for maxilla cleft, III-584
  maxillary tuberosity as site, I-452–453
  for maxillomandibular defect, I-671–672
  for midface cleft reconstruction, III-602–605
  for midface fracture, II-220
  mobility of, I-434
  nerve injury associated with, II-84
  non-vascularized, I-671–672
  for orbital floor repair, II-231f
  for osteomyelitis, II-590
  in pediatric reconstruction, III-769
  peri-implantitis and, I-727
  placement, in biomedical model, I-701f
  preoperative evaluation, I-432, I-448–451
  recipient site, I-460–461
  rectangular block, I-454f
  remodeling, I-466–467
  resorption, I-466–467
  secondary, III-584
  simulation, I-700f
  sinus, I-464–465
  sinus-lift subantral, I-509–525
  space maintenance, I-483–484
  statistics on, I-426
  stereolithography for, I-696–699
  storage, I-447
  suboptimal healing of, I-432–434
  techniques and materials for, I-426–436
  techniques for, I-426–436

Bone graft *(Continued)*
three-dimensional imaging for, I-688–710
case study, I-688–696
simulation from, I-700f
tibia as donor site, I-457–458
titanium mesh technique, I-465
tuberosity block, I-452f
vascular compromise of, I-434
xenogeneic, I-437, I-441f, I-483
xenograft, I-429–430
Bone loss
bisphosphonate drugs for, II-507
grafting and, I-415–416
implant and, I-398–401
maxillary implant and, I-647–648
multiple implants and, I-401
smoking and, I-514
Bone marrow, stem cells from, I-438–439
Bone morphogenetic protein (BMP), I-427, II-586f–589f, III-591
in autogenous bone graft, I-446–447
bone growth and, I-441
as growth factor, I-431–432
space maintenance and, I-526–527
Bone remodeling
bisphosphonate drugs and, II-509–510
fixation screw and, II-164f
implant platform switching and, I-400
Bone spreader, in alveolar width osteotomy, I-529–531
Bone to implant contact (BIC), I-571
Bone transport
bifocal, III-217
dental implant in, III-218
in distraction osteogenesis, III-214–218
maxillary, III-218
multifocal, III-217
Bone tunnel, in forehead and brow lift, III-409f, III-415
Bone(s)
allogenic, I-428, I-439–440
alloplastic, I-440–441
aneurysmal cyst, III-751, III-752f–753f
augmentation
guided bone regeneration for, I-464
titanium mesh for, I-465–466
using guided bone regeneration, I-464
augmentation failure and, I-441, I-447–448
augmentation materials, I-437–438
augmentation procedures, I-441–443
augmentation techniques, I-438–441
autogenous, I-427
advantages, I-446
for cleft maxilla reconstruction, III-590
disadvantages, I-446
in sinus graft, I-465
autologous, I-438, I-465
biology, I-426–427, I-446–448
bundle, I-413–414
calcified, staining for visualization of, I-443f
cancellous, I-444f, I-446–447
bone graft with, I-427
ilium as donor site, I-458
from tibia, I-457–458
cortical, I-427, I-446–447
corticocancellous, ilium as donor site, I-458
craniofacial, III-628–629
crestal height, I-398–399
disease, II-508–509
facial
grafting of, I-415–416
in restored implant, I-411
forehead, III-396–397
fracture. *See* Fracture
Bone(s) *(Continued)*
frontal
fracture of, II-20–22
injury, II-230–243
surgical anatomy, II-230–231
growth
augmentation failure for, I-441
enhancing materials for, I-438
example of, I-442f
stem cells and, I-438–439
xenogeneic graft and, I-440
healing, I-257–258, II-426–427
heterotopic formation, II-858
injury, in dentoalveolar injury, II-123t
long-term changes, genioplasty and, III-104–105
midface, II-211
miniscrew implant and, I-315
nasal, II-175–176, III-367
necrosis, in osteomyelitis, II-575
orbital, II-18, II-19f
osteosarcoma, II-647–649
palatal, implant and, I-412
quality
immediate implant loading and, I-607
in maxilla, I-594
removal
for impacted molar extraction, I-287
in surgical extraction, I-280–281
resorption, I-643f
after graft, I-466–467
dentures and, I-642
spicule, I-305
squamous cell carcinoma, II-682
substitute materials for, I-437–438
temporal, II-815
for temporomandibular joint replacement, II-923
vascularized, II-286
xenogeneic, I-440
zygomatic, I-189, I-570–571
quad, I-570f
Boniva. *See* Ibandronate (Boniva)
Bony split, sagittal split osteotomy and, III-308–310
Bony wall, defect evaluation and, I-476
Book flap, I-528–529
Borrelia burgdorferi, II-846–847
Botox. *See* Botulinum neurotoxin (Botox)
Botryoid odontogenic cyst, II-365
Botulinum neurotoxin (Botox), I-319, III-365–377
adverse effects, III-442
contraindications, II-442, III-957
dilution table, III-440t
for facial pain, II-957
history, III-439–440
pharmacology, III-439–440
preparations, III-440
for temporomandibular joint disorders, II-872t
treatment technique, III-441–442
Botulism, III-439
Boundary violation, I-143–147
Bowman, Karl, II-769–770
Bowstring test, II-232–233
Boyne, Phillip, III-492, III-584
Brachycephaly, III-660, III-673
Brachytherapy, II-747–749
Bradycardia, pediatric, I-239, I-239t
BRAF inhibitor, II-701–702
Brain injury, II-254
Branchial arch syndrome, III-778f
Branchial cleft cyst, II-383–385
Brånemark, P. I., I-723
Brånemark fixture, for zygomatic implant, I-576f
Brånemark protocol, I-605
Breast cancer, malignant bone disease and, II-508
Breath sounds, in trauma patient, II-9
Breathing
assessment, in pediatric trauma, II-249
obstructed, facial cleft and, III-605–606
Brentuximab, II-714
Breslow melanoma classification, II-696t
BRON. *See* Bisphosphonate-related osteonecrosis (BRON)
Bronchospasm, in pediatric patient, I-252–253
Brophy, Truman, III-492
Broselow Emergency Pediatric Tape, I-245
Brow. *See* Eyebrow
Brown tumor, II-464–465
Brush biopsy, II-332, II-674–675
Bruxism, splint therapy for, II-868–869
BSSO. *See* Bilateral sagittal split osteotomy (BSSO)
Buccal bifurcation cyst, II-343, II-344f
Buccal nerve, II-75–76
Buccal plate
immediate implant and, I-410–411
remodeling, after immediate implant, I-413–414
thickness of, implant success and, I-413–414
Bucco-palatal dimension, I-413
Budgeting, for oral and maxillofacial surgical practice, I-67–68
Bullet
classification of, II-303
components, II-303
injury from, factors influencing degree of, II-307
movement, II-305, II-305f
soft tissue injury, II-306
types of, II-304
Bullous pemphigoid, II-563–564
Bundle bone, I-413–414
Bupivacaine, I-186
anaphylaxis associated with, I-252t
concentration, I-177t
duration of, I-179t
local anesthesia with, I-232–233
onset time, I-178t
potency of, I-176
systemic complications associated with, I-184
Bupivacaine liposome injectable suspension (Exparel), I-187
Buprenorphine (Buprenex), I-229t–230t
Burkitt lymphoma, II-710, II-713
Burn injury, II-67–68
Burn scar, laser surgery for, III-357–358
Burning mouth syndrome, II-949
Burnout, medical education and, I-6
Burn(s)
exodontia and, I-301
facial, II-67–68
management, II-67–68
Business management, of oral and maxillofacial surgical practice, I-58–72
Business model, for surgical practice, I-16–17
Buspirone (BuSpar), II-873, II-874t
Butorphanol (Stadol), I-229t–230t
Buy-sell agreement, I-60–61
BZD. *See* Benzodiazepine drugs

C

C corporation, I-58–59, I-59t
C nerve fiber, I-225
Cal bar stabilizing implant, I-573f
Calcified marine algae, alloplastic implant with, I-440–441
Calcifying epithelial odontogenic tumor (CEOT), II-398–401, II-424–425

Calcifying odontogenic cyst, II-368–371
Calcitonin, giant cell lesion treated with, II-462–463
Calcium hydroxide
  injury associated with, I-378
  root canal fill, II-131
Calcium phosphate
  alloplastic implant with, I-440–441
  for bone graft, I-483–484
Calcium sulfate, for bone graft, I-483–484
Caldwell-Luc procedure, I-295
Calhoun and Gibson method, chin position analysis with, III-460t–461t
Cancer. *See also* Carcinoma
  antiresorptive therapy for, II-514–515
  apoptosis and, II-615f
  biologically based treatment, II-626f
  chromosomal abnormalities, II-672
  diagnosis, II-622–624
  epithelial, II-600f, II-718–720
  genetic influence, II-602
  genomic sequencing, II-623
  head and neck, II-752–763
    epidemiology, II-752
    treatment, II-745–747
  histology, II-599–602
  incidence, II-599
  laryngeal, II-745t
  lip, II-735–737
  metastasis, II-619–621, II-620f
  molecular biology, II-599–642
  molecular diagnostics, II-622–624
  molecular therapeutics, II-624–629
  nasopharyngeal, II-744–745
  neovascularization, II-617–619
  nonepithelial, II-720
  nucleic acid dysregulation, II-606–609
  oncology principles, II-752–763
  oral
    deaths from, II-670
    diagnosis and evaluation, II-675
    epidemiology, II-671–675
    follow-up, II-684–685
    genetic factors, II-672–673
    nonsurgical management, II-677–679
    screening, II-673–674
    staging, II-675–677
    surgical management, II-679–683
  protein dysregulation, II-609–622
  radiation therapy, II-741–751
  salivary gland, II-759–760
  signal pathway altered by, II-602–622
  skin. *See* Skin cancer
  telomerase and, II-617f
  thyroid, radiation therapy for, II-742
  treatment, II-622–629, II-626f
Cancer cell
  apoptosis evasion, II-614–616
  biology, II-601–602
  chromosomal abnormalities, II-606–607
  differentiation, II-614
  DNA alterations in, II-606
  epigenetic alteration, II-609
  example, II-601f
  growth inhibitory signal and, II-612–614
  immortalization, II-616–617
  molecular changes, II-602f, II-621–622
  neovascularization, II-617–618
  nucleic acid alterations, II-609
  nucleotide sequence abnormalities, II-607–609
  release from growth signal requirement, II-617f
Cancer stem cell (CSC), II-599–600
Canine
  impacted, I-261–262, I-289–291
    excisional exposure of, I-263
    preoperative planning, I-289
    surgical technique, I-289–291
    treatment, I-262–269
  mandibular, impacted, I-291, I-291f
  maxillary
    extraction, I-277, I-278f
    impacted, I-289–291
    implant replacement, I-403
  transverse discrepancy, III-299
Cannabinoid drugs, I-363–364, I-364–365
Cannabis, I-233–234
Cant, occlusal, III-23
Canthopexy, transnasal, II-224
Canthotomy, lateral, II-194, II-196
Cantilever
  failure of, I-601f
  implant and, I-599–600, I-600f
Capecitabine, II-757t
Capillary malformation, II-538–539
Capnography, I-168–169
  circulatory system monitoring and, I-165
  normal morphology, I-170f
  for trauma patient assessment, II-9–10
Capnometry, for pediatric anesthesia monitoring, I-245
Capsaicin (Zostrix)
  for facial pain, II-955t
  for nerve injury, I-363
  topical, II-957–958
Capsule, temporomandibular joint, II-780
Carbamate, II-874t
Carbamazepine (Tegretol), I-364, II-956
Carbon dioxide (CO_2) laser. *See* Laser, carbon dioxide (CO_2)
Carbonic anhydrase inhibitor drugs, II-207
Carboplatin, II-755, II-757t
Carboxyhemoglobin, I-168
Carcinoembryonic antigen (CEA), II-623–624
Carcinogen, environmental, II-602
Carcinoma. *See also* Cancer.
  acinic cell, II-493t, II-498
  adenoid cystic, II-493t, II-498, II-500–501, II-759–760
  ameloblastic, II-401
  basal cell, II-718–719
  clear cell odontogenic, II-424–431
    clinicopathologic considerations, II-427–429
    differential diagnosis, II-427
  cutaneous, lymph node involvement, II-730
  epidermoid, II-493t
  head and neck
    chemotherapy for, II-755–756
    treatment, II-745–747
  hypopharyngeal, II-746t
  intraosseous odontogenic, II-431–435
  intraosseous odontogenic squamous cell, II-431f
  laser surgery for, I-343, III-354
  lip, II-735–737
  Merkel cell, II-720
  microcystic adnexal, II-719
  mucoepidermoid, II-492–493, II-493t, II-498, II-500–501, II-504t, II-759–760
  oropharyngeal, II-744t
  salivary duct, II-759–760
  sebaceous gland, II-720
  of skin appendages, II-719–720
  squamous cell. *See* Squamous cell carcinoma
  temporomandibular joint, II-848, II-857
  thyroglossal duct cyst associated with, II-383
  thyroid, radiation therapy for, II-742
Carcinoma in situ, II-599–600, II-600f
Cardiac arrest, in child, II-249
Cardiac assessment, preoperative, I-150f
Cardiac ischemia, II-950–951
Cardiac output
  definition, I-239
  pediatric, I-239, I-242
Cardiac risk index, I-150t
Cardiovascular complications
  endocarditis and, I-151t
  risk of, I-148–151
Cardiovascular disease, craniomaxillofacial trauma management and, II-3t
Cardiovascular system
  evaluation, for orthognathic surgery, III-280–282
  monitoring, during anesthesia, I-222
  pediatric, I-238–239
  preoperative evaluation of, I-138, III-148–151
  rhytidectomy evaluation and, III-327–328
Care
  access to, I-3
  continuous improvement of, I-3
Care plan, for craniomaxillofacial trauma, II-5–6
Caries
  exodontia for, I-275
  third molar removal and, I-284
Carisoprodol (Rela, Soma), II-872t
Carnegie stages, III-477f, III-478, III-479f–480f
Carney triad, II-644
Carnochan, John Murray, II-924
Carroll-Girard screw, II-193–194
Cartilage
  auricular, III-447–448
  for ear reconstruction, III-732
  graft, in cleft-nasal reconstruction, III-620
  Meckel, I-526
  nasal, II-175–178
  for temporomandibular joint replacement, II-924
Caspase cascade, II-615
CASS. *See* Computer-aided surgical simulation (CASS)
Cat, bite wound from, II-63
Catheter, intraosseous, I-247
Cauliflower ear deformity, II-57–58
Causalgia, II-946t, II-947
CDT. *See* Current Dental Terminology (CDT)
Cehpalosporin, for autogenous bone graft prophylaxis, I-451
Celebrex. *See* Celecoxib (Celebrex)
Celecoxib (Celebrex), I-232
  dosage, I-232t
  for facial pain, II-955t
  for temporomandibular joint disorders, II-871t
Celestone. *See* Betamethasone (Celestone)
Cell cycle clock, II-613f
Cell(s)
  apoptosis, II-614–616
  bone, I-446–447
  cancer, II-601–602, II-601f
  cycle control, II-613f
  dendritic, II-600–601
  division of, II-613f
  endothelial, II-257
  gene regulation of, II-603–606
  growth signal requirements, II-611f
  Hodgkin, II-709f
  natural killer, II-600–601
  normal division, II-612–613
  replication, II-616
  T, II-600–601
Cellulitis
  frontal sinus fracture associated with, II-243f
  lymphatic malformation associated with, II-539

Cement
acrylic urethane, I-715–716
allergic reaction to, I-716
clinical protocols for, I-717–720
complications, I-639
controlling flow of, I-713–714
corrosion from, I-716–717
effect of, on soft tissue, I-632
excess
avoidance of, I-639
issues associated with, I-711–712
implant, characteristics of, I-714
interactions, I-716
microbial growth and, I-715–716
orthozinc phosphate, I-715–716
peri-implant disease and, I-711
resin-based, I-715–716
selection, I-714–715
zinc oxide/eugenol, I-715–716
Cementable abutment, I-624–626, I-633–634
Cemento-osseous dysplasia, II-470–471
Cemento-ossifying fibroma, II-468–469
Cementoblastoma, II-438–439
Center for Medicare and Medicaid Services (CMS), I-87
Central deafferentation syndrome, I-361
Central giant cell granuloma, II-462–464, II-750–751, III-852
classification, II-463t
example, II-463f
Central nervous system (CNS), I-226
Centrax. *See* Prazepam (Verstran, Centrax)
Centric relation
inconsistent, of mandible, III-187–188
orthognathic surgery planning and, III-15
in temporomandibular joint disorders, II-875
Cephalometric analysis
for temporomandibular joint disorders, III-226
for velopharyngeal function, III-574–575
Cephalosporin, parotitis treated with, II-486–487
Cerebrospinal fluid (CSF), leakage, II-221, II-223
following midface fracture, II-226–227
frontal sinus fracture associated with, II-239–240, II-232, II-243
in pediatric facial trauma, II-241
in self-inflicted gunshot wound, II-323
Cerebrospinal fluid halo test, II-233f
Cerebrospinal fluid rhinorrhea, II-187, II-216, II-226–227
Cerebrovascular accident (CVA)
craniomaxillofacial trauma management and, II-3t
preoperative evaluation of, I-161
Certification. *See also* Accreditation
history of, I-96–97
Cervical injury
craniomaxillofacial fracture associated with, II-38
orthognathic surgery evaluation and, III-16–17
Cervical spine injury, II-11
Cervicofacial flap, II-290, II-293f
Cetuximab (Erbitux), II-673, II-747, II-756t–757t, II-759, II-759t
Champy, Maxime, II-63, III-162, III-6
Charnley, Sir John, II-298
Cheek, reconstruction, II-274–275
Chemical burn, endodontic materials associated with, I-378
Chemical injury
endodontic materials associated with, I-378
nerve injury associated with, II-87
Chemical peel, III-439–445
agents, III-443–444
complications, III-444
contraindications, III-443
history, III-442–443
procedure, III-444
Chemo-radiotherapy, for head and neck squamous cell carcinoma, II-753–754
Chemoprevention
for oral cancer, II-677
for skin cancer, II-732–733
Chemotherapy
for ameloblastic fibrosarcoma, II-455
concurrent radiation therapy with, II-747t
induction, for squamous cell carcinoma, II-754–756
for lymphoma, II-713
for melanoma, II-701
for metastatic head and neck cancer, II-755–756
for osteosarcoma, II-648–649
for rhabdomyosarcoma, III-760–762
for squamous cell carcinoma, II-753
Chemotherapy/radiation therapy (CRT)
induction chemotherapy combined with, II-755
for squamous cell carcinoma, II-753–754
Cherubism, II-466–467
Chest auscultation, in trauma patient, II-9
Chest wall, pediatric, I-240
Chewing sequence, II-787–788
Child. *See also* Infant
ablative defect reconstruction, III-763–769
airway management, I-238, II-241
ameloblastic fibro-odontoma in, II-452
ameloblastic fibroma in, II-449
anaphylaxis, I-252
anatomy and physiology, I-238–242, II-248t
anesthesia, I-238–256
complications, I-251–253
techniques, I-251
anesthesia worksheet, I-246f
anesthetic monitoring, I-244–245
assessment and management of injury, II-245–263
asthma, I-244
avulsive injury, II-274–275
axonal injury, II-251–252
bite wound, II-278–279
blood circulation, II-249–250
body composition, I-242
bradycardia in, I-239t
canine extraction for, I-262
cardiovascular conditions, III-280–281
cardiovascular system, I-238–239
codeine warning for, I-253–254
concussion, II-252
condylar fracture, II-270
craniofacial skeleton development, II-241–243
craniomaxillofacial pathology management, III-738–773
craniomaxillofacial surgery, III-627–644
craniomaxillofacial trauma, II-264–280
assessment, II-231–232
epidemiology, II-230–231
imaging, II-233–240
management, II-243
physical evaluation, II-232–233
craniosynostosis, III-646, III-671–677
demographics, I-257–258
dental development, I-258
dental extraction, I-260
dentoalveolar injury, II-270–271, II-114
dentoalveolar surgery, I-257–274
distraction osteogenesis, III-775
Child *(Continued)*
drug dosage for, I-250t
ear development in, III-446–447
endotracheal tube for, I-247
evaluation, for orthognathic surgery, III-280–281
Ewing sarcoma, II-662
facial fracture, II-35–38, II-38f
fear and anxiety in, premedication for, I-248
fracture management, II-243
glandular and ductal injury, II-272
growth and development, II-240
herpes simplex infection, II-555–556
impacted canine, I-261–262
impacted incisor, I-265
impacted molar, I-265–266
impacted premolar, I-265
impacted tooth, I-260–261
implant, I-269–270
infection, I-260
inhalation anesthesia, I-250–251
inhalation induction, I-220
injured, II-245–263
injury evaluation, II-246
injury patterns, II-260–261
injury prognosis, II-138–139
intracranial hemorrhage, II-252–254
intracranial pressure, III-645–646
intraoperative fluids for, I-248
intravenous access, I-247–248
kidney, I-241
local anesthesia complications, I-184
malignant hyperthermia, I-253
malignant tumor, III-757–763
mandibular fracture, II-270, II-167
mandibular hyperplasia, III-638
mechanism of injury, II-245
melanoma in, II-690
methemoglobinemia, I-185
midface fracture, II-270
nasal fracture in, II-269–270, II-186–187
nerve injury, II-272
neurologic status, II-247–248
obesity, II-259–260
operating room preparation, I-245–248
oral anatomy, I-258–260
orbital fracture, II-267–268
parotid gland abscess in, II-486–487
pharmacology, I-238–242
pharmacosedation, I-248–251
physiology, I-260
preanesthetic assessment, I-238, I-242–244
preoperative fasting, I-243
primary herpetic gingivostomatitis, II-552
primary tooth injury, II-131–133
protruding ear correction in, III-450
recovery and discharge, I-253–254
respiratory rate, II-249
respiratory system, I-239–241
rhabdomyosarcoma, II-654
sedation, I-212, I-238–256
seizure, post-traumatic, II-255–256
sinus development, II-241
skeletal fracture patterns, II-261
skull fracture, II-253
soft tissue injury, II-271–273
soft tissue physiology, II-256–257
soft tissue procedures, I-270–272
superficial wound, II-272
supernumerary teeth, I-266–268
temporomandibular joint replacement in, II-934
tension pneumothorax in, II-250f
thermoregulation, I-241–242
tissue recruitment, II-274–275
tooth avulsion, II-128

Child *(Continued)*
tooth transplantation, I-268–269
trauma, II-245–263
trauma outcomes, II-245
traumatic brain injury in, II-246–247, II-250–252
Treacher Collins syndrome, III-705–706
treatment challenges, I-272
upper respiratory infection, I-243–244
vital signs, I-239t
volume resuscitation for, II-250
wound healing, II-256–261
Child abuse
dentoalveolar injury associated with, II-114
facial injury from, II-231–232
trauma from, II-245, II-250–251
Child-Pugh Scoring System, I-156t
Chin
advancement, III-110f
augmentation
allograft, III-464b
alloplastic, III-463b
extraoral, III-464b
botulinum neurotoxin for, III-441
definciency, III-203f
deformity correction, with computer-aided surgical simulation, III-39
facial symmetry and, III-96
genioplasty, III-96–112
hyperplasia, III-306f
hypoplasia, III-309f
implant, III-104, III-321
in orthognathic surgery, III-28
position
analysis for, III-460t–461t
orthodontic treatment and, III-303t
small, cosmetic surgery, III-459b–463b
Chin wing osteotomy, III-319
Chlordiazepoxide (Librium)
discovery, I-191
structure, I-191f
for temporomandibular joint disorders, II-874t
Chlorhexidine
for autogenous bone graft prophylaxis, I-451
in mouthwash, II-551
Chlorhexidine gluconate, II-595
Chlorzoxazone (Paraflex), II-872t
Chondroblastoma, II-851–852
Chondrocramium, III-629–630
Chondrocyte
in cartilage, II-832
inflammation, II-833–835
joint function and, II-830
in osteoarthritis, II-838
synthesis by, II-831
Chondroma, II-475–476
Chondromalacia, II-837
Chondromatosis, synovial, II-796, II-798f, II-855–856
Chondrosarcoma, II-644t, II-649–651, II-856
classification, II-649–650
synovial, II-856
treatment, II-650–651
Christensen fossa implant, II-771
Christensen implant system, II-772–774
Chromatin
chromosome composed of, II-605f
gene activity and, II-603
Chromatolysis, II-72
Chromophore, I-328–329, III-339
carbon dioxide laser, I-331
diode laser, I-332
Chromosome
abnormalities
in cancer cells, II-606–607
oral cancer and, II-672
Chromosome *(Continued)*
alterations, II-607f, II-609f
composition, II-603, II-605f
deletion, II-607
Philadelphia, II-622–623
rearrangement, II-607
translocation, II-607, II-608f
Chronic bullous dermatosis of childhood, II-565
Chronic facial pain, II-941–961
cardiac origin, II-950–951
clinical examination, II-945–946
differential diagnosis, II-947–952
evaluation, II-944–947
pharmacotherapy, II-955t
surgical intervention, II-958
therapeutic injection, II-956–957
treatment, II-953–958
Chronic kidney disease, I-154t
preoperative evaluation of, I-152–155
stages, III-283t
Chronic obstructive pulmonary disease (COPD)
craniomaxillofacial trauma management and, II-3t
oral surgery and, I-151
orthognathic surgery and, III-282
preoperative evaluation of, I-151–152
Chronic obstructive sialoadenitis, II-490–492
Chymopapain, anaphylaxis associated with, I-252t
Cigarette smoking
airway patency and, I-215
autogenous bone graft failure, I-451
bone graft healing affected by, I-433
implant failure and, I-412
as mandibular surgery risk factor, III-297–298
oral cancer associated with, II-671
orthognathic surgery risk associated with, III-282–283
peri-implant disease associated with, I-723–724
preoperative evaluation and, I-152
rhytidectomy complications associated with, III-332
sinus augmentation and, I-514
Cinnamic aldehyde, II-550
Circulation
monitoring, I-169, I-244–245
pediatric, II-249–250
in pediatric trauma, II-250
Circulatory system, monitoring, I-165–167
Cisplatin, II-747, II-755, II-756t–757t
Claims professional, I-83
Clark melanoma classification, II-696t
Clark's rule, I-260–261
Clear cell
in ameloblastoma, II-402, II-425
in calcifying epithelial odontogenic tumor, II-399–400, II-424–425
in periodontal cyst, II-425f
Clear cell odontogenic carcinoma (CCOC), II-424–431, II-426f–427f
clinicopathologic considerations, II-427–429
differential diagnosis, II-427
with metastases, II-428f–430f
surgical management, II-429–431
Clear cell odontogenic tumor, II-425–427
Cleft deformity
bilateral, III-565
child feeding, III-494–496
classification, III-496f
complex, III-506–508
dentition abnormalities in, III-584–586
embryogenesis, III-493
genetics and etiology, III-493–494
management, III-491–512
obstructed breathing, III-605–606
Cleft deformity *(Continued)*
in oculoauriculovertebral spectrum, III-692
orofacial embryogenesis and, III-476–490
orthognathic surgery, III-596–608
prenatal counseling, III-494
reconstruction stages, III-610t
revision surgery, III-609–626
sites, III-486–489
treatment planning, III-496–497
unilateral, III-563–565
Cleft lip, I-679–683
bilateral, III-211f–212f, III-500–502, III-600b, III-605f–606f, III-621f–622f
bone grafting for, I-679
child feeding, III-494–496
configurations, III-495f
dentition abnormalities, III-584–586
etiology, III-513, III-561
genetics and etiology, III-493–494
genioplasty for, III-98
history of repair, III-491–493
implant and, I-680–683
incidence, I-561, III-665
infant orthopedic treatment, III-561–567
management, III-491–512
in oculoauriculovertebral spectrum, III-692
prenatal counseling, III-494
revision surgery, III-609–626
surgical techniques, III-514–515
timing of surgery, I-679
treatment planning, III-496–497
unilateral, III-499–500, III-600b, III-623f
repair, III-513–533
surgical techniques, III-514–515
Cleft lip repair, III-497–508, III-513–533
functional, III-525–526
midface growth, III-542–543
revision surgery, III-609–626
scar repair, III-620–622
secondary surgery, for scar revision, III-620–622
stages, III-610t
surgical techniques, III-514–515
timing, I-513–514, III-679
treatment planning, III-496–497
Cleft maxilla
bilateral, III-589–592
bone graft reconstruction, III-619
management, III-583–595
reconstruction, III-589–592
stabilization, III-606–607
surgical options, III-583–584
timing of grafting procedure, III-586–587
unilateral, III-589
Cleft palate, I-679–683
anatomy, III-535–536
bilateral, III-211f–212f, III-600b, III-621f–622f
bone grafting for, I-679
dentition abnormalities, III-584–586
etiology, III-561
fistula closure, III-611–612
genetics and etiology, III-493–494
genioplasty for, III-98
history of repair, III-491–493
implant and, I-680–683
incidence, III-561
infant orthopedic treatment, III-561–567
management, III-491–512
in oculoauriculovertebral spectrum, III-692
prenatal counseling, III-494
revision surgery, III-609–626
speech affected by, III-540–542, III-568–582
speech disorders, etiology, III-568–570
submucous, III-618–619
timing of surgery, I-679

Cleft palate *(Continued)*
treatment planning, III-496–497
unilateral, III-506f, III-600b
vocal dysfunction, III-572
Cleft palate repair, III-497–508, III-534–560
bone graft reconstruction, III-619
dental rehabilitation after, III-622–623
fistula, III-539–540
fistula closure, III-609–612
goals, III-610
history, III-534–535
midface growth, III-542–543
otologic and audiologic issues, III-540
revision surgery, III-609–626
secondary surgery, III-612–616
speech disorders and, III-568–582
stages, III-610t
surgical technique, III-536–539
timing of surgery, I-679
treatment planning, III-496–497
two-stage, III-548–549, III-551–552
Clindamycin
for autogenous bone graft prophylaxis, I-451
medication-related osteonecrosis treated with, II-516
parotitis treated with, II-486–487
postoperative infection treated with, I-303
Clinical examination
for implant overdentures, I-656–658
risk management and, I-76
Clinical margin, II-728
Clonazepam (Klonopin)
after nerve surgery, I-373
for facial pain, II-955t
for masticatory myalgia, II-969
for nerve injury, I-363
Clonidine, management, I-149t
Clopidogrel, I-161
Clostridium botulinum, III-439
Cloverleaf skull, III-669
CMS. *See* Center for Medicare and Medicaid Services (CMS)
CMS 1500 form, I-88
CNS. *See* Central nervous system (CNS)
Coagulation, laser for, I-330, I-335
Coagulation disorders
preoperative evaluation of, I-161
wound healing affected by, II-259
Coagulopathy, craniomaxillofacial trauma management and, II-3t
Cobalt chromium, framework with, I-599
Cocaine, I-176, I-185
Cocamidopropyl betaine, II-550–551
CODA. *See* Commission on Dental Accreditation (CODA)
Code of Ethics, American Dental Association (ADA), I-10
Code of Professional Conduct, AAOMS, I-9–10
Code set, for oral and maxillofacial surgery, I-89–90
Codeine, I-228
dose and potency, I-229t–230t
equianalgesic dosage, I-231t
for facial pain, II-953
FDA warning, I-253–254
for temporomandibular joint disorders, II-872t
Coding
evaluation and management, I-92–95
insurance, I-87–95
modifiers in, I-93–94
for pathology, I-92
radiology, I-94
for systemic diseases, I-94–95
for trauma, I-91–92
Cognitive-behavioral therapy, for temporomandibular joint disorders, II-968–969
Collagen
nerve anatomy and, II-77–78
in wound healing, II-257
Collagen matrix, I-558, I-560–561
Collagen membrane, I-462–463, I-485f–487f
natural, I-482
peri-implantitis treated with, I-727f
resorbable, I-482
Cologne Classification for Alveolar Ridge Defects, I-447–448
Columella
lengthening, III-500–501, III-505f
in rhinoplasty evaluation, III-369–370
Combitube, II-13–14
Commission on Dental Accreditation (CODA), I-5
accreditation of residency programs, I-8
Commission on Professional Conduct (CPC), I-9–10
Communication
empathy and, I-102
intraoffice, I-80–81
marketing through, I-134–136
in patient evaluation, I-120
with pediatric patient, I-257–258
personal, I-20
with postoperative patient, I-132
principles of, I-134–136
risk management and, I-80–81
in surgical practice, I-18
Community-based surgeon, I-12–13
Community service, I-132, I-126
Compensation, in oral and maxillofacial surgical practice, I-70–71, I-71t
Complex regional pain syndrome (CRPS), I-361b, I-362f, II-947–948
Composite model
in computer-aided surgical simulation, III-31–33
creation of, III-33f
frame of reference, III-33
orientation, III-36f
Comprehensive Accreditation Manual for Hospitals (CAMH), I-231b
Computed tomography (CT). *See also* Imaging
for bone graft preoperative evaluation, I-448–449, I-449f
computer-aided surgical simulation and, III-31
cone-beam, I-448–449, II-824–825
computer-aided surgical simulation and, III-31
for dentoalveolar injury, II-120
facial bone evaluated with, I-411
history, III-6–7
of impacted third molar, II-80f
of impacted tooth, I-261
for implant overdenture planning, I-656–657
for nerve imaging, II-79–80
palatofacial dimension measured with, I-413f
of temporomandibular joint, II-826f
for temporomandibular joint disorder, II-802
for temporomandibular joint reconstruction, III-223–226
three-dimensional imaging and, I-688
conventional linear, for temporomandibular joint, II-818–819
of craniomaxillofacial pathologies, III-738–739
of dentoalveolar injury, II-120
Computed tomography (CT) *(Continued)*
for facial nerve imaging, II-99–100
for facial pain, II-947
of frontal sinus fracture, II-241, II-232
image interpretation, II-17–20
of Le Fort fracture, II-217f
of lymphoma, II-711
of mandibular fracture, II-153
maxillofacial, II-20
of medication-related osteonecrosis of jaw, II-513f
for melanoma diagnosis, II-699
micro, I-443
of midface fracture, II-213, II-214f
multi-dectector, II-17
multidirectional, for temporomandibular joint, II-818–819
nasal fracture diagnosis with, II-178
of naso-orbito-ethmoid fracture, II-223
for nerve imaging, II-78–80
odontogenic tumor, II-392
for oral cancer evaluation, II-675
of osteomyelitis, II-586f–589f
of parotid gland tumor, II-493–494
for pediatric brain injury, II-251
pediatric trauma assessment with, II-247
salivary gland, II-481–483
of sarcoma, II-645
of skin cancer, II-725
of skull fracture, II-255f
temporomandibular joint, II-820–821
for temporomandibular joint disorder, II-802, II-820–821
of temporomandibular joint internal derangement, II-906
three-dimensional, I-207–208, II-688
computer-aided surgical simulation and, III-31–33, III-35
of frontal sinus fracture, II-234f
genioplasty planning with, III-101
for Le Fort I osteotomy, III-153–161, III-158f–160f
in Le Fort I segmental surgery, III-174, III-175f
for midface fracture, II-213, II-214f, II-227
of odontogenic tumor, II-392
trauma patient assessment with, II-5
of Treacher Collins syndrome, III-708f–709f, III-711f–712f
tuned-aperture, II-824
of zygomatic fracture, II-191, II-192f
for zygomatic implant, I-570–571
Computer, in oral and maxillofacial surgery, I-49
Computer-aided surgical simulation (CASS), III-31–34
accuracy, III-40–42
algorithm, III-32f
clinical implementation, III-34–40
cost-effectiveness, III-42
data processing, III-35–38
final symmetry in, III-39
for inverted L osteotomy, III-120
for mandibular deformity, III-39
for maxillary deformity, III-38–39
in orthognathic surgery, III-190
outcomes, III-40–42
preoperative records, III-34–35
surgical execution, III-39–40
surgical planning, III-38–39
for temporomandibular joint total replacement, III-229–232
Computer-controlled injection, I-187
Concomitant TMJ total joint replacement and orthognathic surgery (C-TJR-OS), III-222–245
case studies, III-235b, III-239b–240b

Concomitant TMJ total joint replacement and orthognathic surgery (C-TJR-OS) *(Continued)*
outcomes, III-238–242
surgical planning, III-229–232
surgical procedure, III-233–242
surgical sequence, III-232
traditional, III-228–229
Concussion
in dentoalveolar injury, II-127
pediatric, II-252
Condylar hyperplasia, II-145–147, III-850–851
Condylar resorption, adolescent internal, III-224–225
Condylar/subcondylar region, fracture of, II-28, II-31–34, II-36f
Condyle, II-779
aplasia, II-802f
arthritic, III-225f
computed tomography of, II-821
description of, II-794
displacement, in sagittal split ramus osteotomy, III-81
endoscopic approach, II-161–162
fracture, II-31–34, II-36f, II-149, II-165–166
head shapes, II-780f
imaging, II-816
internal derangement, II-813f
movement, II-795, II-796f
pediatric fracture, II-270
postoperative displacement, III-317
pseudocyst, II-852
replacement, II-923
resorption, III-145–146, III-148f–150f
in sagittal split ramus osteotomy, III-81
surgical access, III-740
in temporomandibular joint, II-815
in Treacher Collins syndrome, III-712–713
Condyle-disc complex, II-792t–793t, II-799f
Condylectomy, III-145–147
Condylotomy, II-917–918
Conflict of interest, management, I-3
Conflict resolution, in surgical practice, I-18–19
Congenital epulis, III-756–757
Congenital hemangioma, II-536–538
Congestive heart failure, oral surgery and, I-139
Connective tissue
ameloblastic fibroma, II-449–450
cementoblastoma, II-438–439
grafting of, I-415–416
myxoma, II-439
connective tissue disorders
arthritides associated with, II-848
temporomandibular joint disorders and, III-225–226
wound healing affected by, II-259
Consultant, use of, I-125–126, I-110–111
Consultation visit, for pediatric patient, I-257
Continuous passive motion, in temporomandibular joint, II-833–835
Continuous positive airway pressure (CPAP)
for obstructive sleep apnea, III-267
for pneumonitis, I-253
for velopharyngeal dysfunction, III-580
Converse, J. M., III-3–5
Convex profile, correction of, III-184
Copy abutment technique, I-718
Coral, alloplastic implant with, I-440–441
Cornelia de Lange syndrome, III-635f
Coronal suture craniosynostosis, III-654–657, III-658f–659f
Coronectomy, alveolar nerve injury and, I-381–382
Coronoid hyperplasia, III-150f–151f
Coronoid process
coronoidectomy, III-147
fracture, II-34, II-149
Coronoidectomy, III-147
Correct Coding Initiative (CCI), I-88
Corticosteroid drugs, I-233
for congenital hemangioma, II-537
for facial pain, II-957
giant cell lesion treated with, II-462–463
for lichen planus, II-559
for nerve injury, I-363
in orthognathic surgery, III-289
for pemphigoid, II-564
for temporomandibular joint disorders, II-870, II-871t
Corticotomy surgery
history, III-246–248
technique, III-248–250
Cortisone, equivalent dosage, III-287t
Cosmetic surgery. *See also* Rhytidectomy
case study, III-459b–463b
endoscopic facial, III-359
facial implant, III-458–475
forehead and brow lift, III-395–428
laser-assisted, I-343–347, III-355–358
marketing, I-130–132
problem patient, III-458
Costen, James, II-768
Costen's syndrome, II-768
Cottle test, III-371
COX. *See* Cyclooxygenase (COX)
Coxsackie virus, II-556–557
CPT. *See* Current Procedural Terminology (CPT)
Cranial vault, III-645
in craniosynostosis, III-673
distraction osteogenesis, III-780–781
dysmorphology, III-648–649, III-663f
sutures, III-646f
Cranio-orbito-zygomatic region, in Treacher Collins syndrome, III-706
Craniocerebral disproportion, III-673
Craniofacial disjunction, II-28
Craniofacial dysostosis, III-667
Craniofacial fibrous dysplasia, III-751–753, III-761f–762f
Craniofacial growth and development, III-738
Craniofacial management, in syndromic craniosynostosis, III-670–671
Craniofacial skeleton. *See* Skeleton, craniofacial
Craniofacial surgery
laser used in, I-351
in oculoauriculovertebral spectrum, III-696
Craniomandibular articulation, II-777–778
Craniomaxillofacial surgery
access, III-739–741
history, III-738
incisions, III-739–741
pediatric, III-627–644, III-738–773
Craniomaxillofacial tumor, III-739
endoscopic approaches, III-741
pathology, III-741–769
Cranioplasty, in craniosynostosis treatment, III-678
Craniosynostosis, III-630, III-631f, III-636, III-645–686
bilateral coronal suture, III-660
care algorithm, III-671–678
coronal suture, III-654–657, III-658f–659f
definition, III-645
diagnosis, III-647–648
distraction osteogenesis for, III-780–781
functional consequences, III-645–647
hydrocephalus in, III-646
lambdoid suture, III-659–660, III-664f
Craniosynostosis *(Continued)*
metopic suture, III-653–654, III-661f–662f
multiple-suture, III-646
neurodevelopmental effects, III-647
nonsyndromic, III-645–666
complications, III-650–651
diagnosis, III-647–648
forms of, III-653–660
treatment, III-648–660
ophthalmologic effects, III-647
sagittal suture, III-653–654
syndromes, III-667–686
care algorithm, III-671–678
craniofacial management, III-670–671
genetics, III-667–669
timing of surgery, III-670
timing of surgery, III-649–650
treatment complications, III-650–651
Craniotomy
craniosynostosis treatment and, III-648
frontal, II-241f
Cranium
growth, III-628–630, III-738
growth rate, III-629t
sutures, III-645
Cribriform plate, II-221, II-226–227
Cricothyroidotomy, II-15f, II-282
Cricothyrotomy, emergency, II-14–15
Crossing the Quality Chasm: A New Health System for the 21st Century, I-97
Crouzon syndrome, III-16, III-213f–214f, III-633f, III-639–642, III-668, III-672, III-778
Crown
cement-retained implant, I-625f, I-630f, I-632
cemented-screw-retained, I-720
copy abutment technique, I-718
damage to, during exodontia, I-298–299
discoloration, after injury, II-138–139
fracture, in dentoalveolar injury, II-123–125, II-124f
infraction, II-122–123
provisional, immediate implant and, I-416–418
swallowing of, during exodontia, I-302
zirconia, I-628
Crow's feet, botulinum neurotoxin for, III-441
CRPS. *See* Complex regional pain syndrome (CRPS)
Cryotherapy
for odontogenic keratocyst, II-356–357
for skin cancer, II-727–730
Curettage, for skin cancer, II-727
Current Dental Terminology (CDT), I-88–89
coding, I-87
Current Procedural Terminology (CPT), I-87–89
Curve of Spee
leveling, III-300
open bite treatment and, I-317
Cuspid, impacted, I-265f
CVA. *See* Cerebrovascular accident (CVA)
Cyanoacrylate, for superficial wound, II-272
Cyanosis, anesthesia associated with, I-168
Cyclin, cell division and, II-612–613
Cyclin D1, II-673
Cyclin-dependent kinase (CDK), II-627
Cyclobenzaprine (Flexeril)
for facial pain, II-955t
for masticatory myalgia, II-969
for temporomandibular joint disorders, II-872t
Cyclooxygenase (COX)
nonsteroidal antiinflammatory drugs and, I-228–230
for skin cancer, II-733–734
temporomandibular joint disorders and, II-870

Cyclooxygenase pathway, II-870f
Cyclophosphamide (Cytoxan), II-455, II-713, II-757t
Cyclopropane, I-207
Cyclovir, II-554
Cyst, II-338–390
  aneurysmal bone, II-467–468, II-751, III-752f–753f, III-852
  botryoid odontogenic, II-365
  branchial cleft, II-383–385
  buccal, II-343, II-344f
  calcifying odontogenic, II-368–371
  definition, II-338
  dentigerous, II-339–340, II-343–348, II-345f, II-355f
  dermoid, II-377, II-380f
  developmental, II-339t, II-343–371
  epidermoid, II-377
  ganglion, II-852
  gingival, II-365, II-424
  globulomaxillary, II-375–376
  inflammatory, II-339t
  of jaw, II-340b
  lateral periodontal, II-365, II-424
  lymphoepithelial, II-485
  maxillary, II-346f
  median mandibular, II-375
  median palatal, II-375
  mouth floor, II-380f
  mucous retention, laser for removal, III-349
  nasolabial, II-371–372, II-374f
  nasopalatine duct, II-372–375, II-376f–378f
  non-odontogenic, II-371–385
  odontogenic, II-338–343, II-347f, II-365–371
    intraosseous carcinoma from, II-433
    site of, II-340f
  palatine, II-375
  paradental, II-343
  parakeratotic, II-360f–361f
  parotid gland, II-485
  radicular, II-340–341, II-342f–343f
  residual, II-341–342
  salivary gland, II-483–485, II-493t
  surgical management, II-338
  synovial, II-852
  temporomandibular joint, II-850–856
  third molar removal and, I-284
  thyroglossal duct, II-378–383
  traumatic bone, II-852
  World Health Organization classification, II-339t
Cystic hygroma, II-539
Cytokine, joint function and, II-830–832
Cytologic malignant ameloblastoma, II-420–422, II-424
Cytology, exfoliative, II-331–332
Cytomegalovirus, parotid gland affected by, II-488
Cytoxan. *See* Cyclophosphamide (Cytoxan)

D

Dabrafenib, II-701–704
Dacarbazine, II-701, II-714
Dal Pont, Giorgio, III-62
Dalmane. *See* Flurazepam (Dalmane)
Dautrey, Jaque, III-6
Davis method, for otoplastic surgery, III-451–453, III-452f
Deafferentation pain syndrome, I-361
Debridement
  for gunshot wound, II-283, II-290
  for peri-implantitis, I-725–727
Decadron. *See* Dexamethasone (Decadron)
Decision making, in surgical practice, I-18
Decitabine, II-625
Decompression, for odontogenic keratocyst, II-357–361
Dedo classification of facial profiles, III-327t
Deep circumflex iliac artery flap, II-296
Defect
  acquired, I-665–679
    implant in, I-665–687
    pathology, I-666
    reconstruction, I-665–666
  alveolar ridge, I-485f–490f, I-491–493, I-501b
  concave, I-484
    bone graft and, I-477f
  configuration, guided bone regeneration and, I-476
  congenital, I-665–687
  dehiscence, I-499b
  fenestration, I-491, I-492f
  grafting options for, I-666
  maxillary, from failed implant, I-450f
  multiple tooth, I-476f
  peri-implant, I-493
  ridge, I-476
  single tooth, I-476f, I-478f
  site preparation, I-479
  socket, I-476
Deformation, definition, III-628t
Degenerative (osteo)arthritis, II-836–838
Degenerative joint disease, II-792t–793t, II-869
Dehydration, herpetic infection as cause of, II-555
Delaire craniofacial analysis, III-100f
Delaire philosophy, cleft lip repair and, III-514–515
Deltasone, for temporomandibular joint disorders, II-871t
Dementia, I-146, II-3t
Demineralized freeze-dried bone allograft (DFDBA), I-428–429
Demoral. *See* Meperidine (Demerol)
Dendritic cell, II-600–601
Denosumab (Xgeva, Prolia), II-463–464, II-508–510, II-508t
Dental arch form, I-595–596
Dental cement. *See* Cement
Dental education
  behavior in, I-6–9
  history, I-2
  oral and maxillofacial surgeon in, I-33–35
  professionalism in, I-4
  statistics, I-34
  teaching professionalism in, I-7–8
Dental history, for implant overdentures, I-656–658
Dental maintenance service organization (DMSO), I-40–41
Dental support organization, I-37
Dentigerous cyst, II-343–348, II-345f, II-355f
Dentition
  abnormality, in cleft lip and palate, III-584–586
  after cleft palate repair, III-622–623
  after orthognathic surgery, III-290–291
  eruption sequence of, I-259t
  permanent, injury prognosis, II-139–141
Dentoalveolar injury, II-114–145
  classification, II-121t
  crown-root fracture, II-125
  evaluation, II-115–117
  gingival, II-137
  incidence, II-114
  mucosal, II-137
  pediatric, II-270–271, II-114
  periodontal tissue injury, II-122t, II-127–131
  physical examination, II-117–119
  prevention, II-141
Dentoalveolar injury *(Continued)*
  prognosis, II-137–141
  radiographic examination, II-119–120
  root fracture, II-125–127
  splint therapy, II-135–137
  supporting bone injury in, II-123t
  treatment, II-120–122
Dentoalveolar surgery
  complications, I-298–310
  goals, I-257–258
  pediatric, I-257–274
Dentofacial deformity
  asymmetry and, III-279
  cervical spine abnormality associated with, III-16–17
  clinical evaluation, III-14–29
  combined maxillary and mandibular osteotomy for, III-184
  genioplasty, III-96
  Le Fort I osteotomy for, III-153
  orthognathic surgery for, III-278
  transverse discrepancy, III-173
Dentures
  base reinforcement, I-655
  bone resorption associated with, I-642
  CAD-CAM fabricated, I-619f, I-621f
  complete, I-594f
    example, I-606f
    implant-fixed, I-642–643
    implant overdentures compared to, I-641–642
    mandibular, I-608–614, I-641–642
    screw-retained, I-614
  fitting of, I-658
  overpartial, I-642f
  screw-retained, I-614
Deoxycholic acid, III-432
Deoxyribonucleic acid (DNA)
  alterations, in cancer cells, II-606
  cancer diagnosis and, II-622–623
  cancer treatment and, II-625
  damage to, cancer and, II-602
  function, II-603
  whole genomic sequencing, II-623
Dependence, facial pain management and, II-952
Depo-Medrol. *See* Methylprednisolone (Depo-Medrol)
Depression, facial pain and, II-944–945
Deproteinized bovine bone mineral (DBBM), I-429–430, I-490–491
Dermal filler, III-465b–467b, III-472b–473b
Dermatofibrosarcoma protuberans, II-644t, II-653–654, II-720–721
Dermoid cyst, II-377, II-380f
Desflurane (Suprane), I-207–208
Desipramine (Norpramin), II-873t
Desmethyldiazepam, I-196f
Desmoplastic fibroma, II-476–478
Desmoplastic melanoma, II-692t
Desyrel. *See* Trazodone (Desyrel)
Dexamethasone (Decadron), III-287t
  after nerve surgery, I-373
  for autogenous bone graft prophylaxis, I-451
  for facial pain, II-955t, II-957
  for lymphoma, II-713
  for nausea and vomiting, I-253
  in orthognathic surgery, III-289
  in temporomandibular joint arthrocentesis, II-887
  for temporomandibular joint disorders, II-871t
Dexmedetomidine, I-13, II-221
Dextran, I-252t

Diabetes mellitus
bone graft healing affected by, I-433
complications associated with, I-141
craniomaxillofacial trauma management and, II-3t
orthognathic surgery and, III-286–287
peri-implant disease associated with, I-723–724
preoperative evaluation of, I-157
wound healing affected by, II-258–259
Diagnostic techniques, II-329–337
Diagnostic wax-up, I-449f
Diatrizoate meglumine, II-483
Diazepam (Valium), I-195
anxiety management with, I-234
clinical effects, I-194
for facial pain, II-955t, II-956
half-life, I-195t
for masticatory myalgia, II-969
pharmacokinetics, I-204t
protein binding, I-195t
structure, I-196f
for temporomandibular joint disorders, II-873, II-874t
Diclofenac, I-232
dosage, I-232t
for temporomandibular joint disorders, II-871t
DICOM. *See* Digital Imaging and Communications in Medicine dataset (DICOM)
Didrone. *See* Etidronate (Didrone)
Didusch, J. F., III-476–477
Dieffenback, Johann, III-534
Diet, after orthognathic surgery, III-291
Differential diagnosis, risk management and, I-76
Diffuse axonal injury, II-251
Diffuse large B-cell lymphoma, II-708b, II-710
Diflunisal
dosage, I-232t
for temporomandibular joint disorders, II-871t
Digastric muscle, II-784–785
DiGeorge syndrome, III-493–494
Digital Imaging and Communications in Medicine dataset (DICOM), I-692–696
Dilaudid. *See* Hydromorphone (Dilaudid)
Dingman, Reed, II-769
Dingman mouth gag, III-543–544
Diphenhydramine, II-551, II-556
Diplopia, zygomatic fracture as cause of, II-203–204
Diprivan. *See* Propofol (Diprivan)
Direct Abutment, I-624–626, I-633–634
Disc displacement, temporomandibular joint reconstruction, III-224
Discectomy
auricular cartilage graft after, II-912–913
autogenous graft after, II-912
dermal graft after, II-913–914
temporalis myofascial flap, II-912
for temporomandibular joint internal derangement, II-911
Discharge notes, risk management and, I-78
Disciplinary action, I-6–9
Displacement, craniofacial, III-628–629
Disruption, definition, III-628t
Disseminated intravascular coagulation, infantile hemangioma associated with, II-534
Distraction histogenesis, III-775
Distraction osteogenesis (DO), I-196–221, III-526–554, III-774–785
advantages, III-775
alveolar, I-535
consolidation period, I-536–537
devices for, I-539
Distraction osteogenesis (DO) *(Continued)*
distraction period, I-536
example, I-539f–546f
fan-shaped, I-545–547, I-548f
guidelines, I-538b
horizontal, I-538–539, I-543
indications, I-537–539
latency period, I-536
mesiodistal, I-547–549, I-548f–551f
oblique, I-543–545
prerequisities, I-537f
protocol, I-535–537
three-dimensional, I-539–549
vertical, I-538–543
alveolar vertical, I-532
alveolar width, I-529–532
bifocal, III-217
biologic basis, III-775–776
bone transport, III-214–218
for cleft deformity, III-492–493
consolidation period, I-536–537
cranial vault, III-780–781
in craniosynostosis treatment, III-676–677
devices for, I-197, III-539
disadvantages, III-776
distraction rate, I-536
distraction rhythm, I-536
history, I-534–535, III-774–775, III-7–8
interdental, I-547
mandibular, III-147, III-637, III-776–778
for mandibular lengthening, III-202–208
for mandibular widening, III-196–202
maxillary, III-208–214, III-778
miniplate for, I-313
multifocal, III-217
nerve injury associated with, II-84
in oculoauriculovertebral spectrum, III-695–696
pediatric, III-637, III-768
postoperative care, III-202, III-206
protocol, I-535–537
relapse, III-777–778
for segmental defect, I-668
temporomandibular joint replacement and, II-934–935
three-dimensional alveolar, I-534–551
transport, I-547–549
in Treacher Collins syndrome, III-730
vertical, I-532
Diversity, in surgical practice, I-15–16
Divinyl ether, I-207
DMSO. *See* Dental maintenance service organization (DMSO)
DO. *See* Distraction osteogenesis (DO)
Docetaxel, II-755, II-756t–757t
Docking site, in distraction osteogenesis, III-214
Docking site surgery, III-217–218
Doconasol, II-553–554
Doctor's stool, I-47–48, I-48f
Documentation
claim form and, I-87–88
electronic health record, I-79
informed consent, I-77
of noncompliance, I-79–80
principles, I-87–88
risk management and, I-75–80
Dog, bite wounds from, II-61–62, II-62b
Dolder bar, I-648–649
Donor site
location, I-705f
for nerve graft, II-95
protocol for, I-704–706
Dose and potency, I-229t–230t
Double-opposing Z-plasty, III-536, III-542–543, III-610
limitations and complications, III-548
Double-opposing Z-plasty *(Continued)*
speech and, III-546–547
technique, III-543–546
Down syndrome
airway assessment in, I-243
orthognathic surgery and, III-286
Doxepin (Sinequan), II-873t
Doxorubicin (Adriamycin), II-455, II-713–714, II-757t
Doxycycline
for avulsed tooth, II-130
medication-related osteonecrosis treated with, II-516
peri-implantitis treated with, I-725–726
Drill, rotary, thermal trauma from, I-607
Droperidol, III-288
Drug-induced sleep endoscopy (DISE), III-265–266
Drugs. *See* Medication
Dry socket, I-283
exodontia and, I-303
third molar extraction and, I-293–294
treatment, I-294
DSO. *See* Dental support organization
Ductal stenosis, II-483
Duloxetine (Cymbalta)
for facial pain, II-955t
for neuropathic pain, I-364
Dynamic Abutment, I-638–639
Dysesthesia
definition, I-355t, II-946t
patient-reported, I-358
Dysmorphic disorder, I-106
Dysmorphology
cranio-orbital, III-636–637
definition, III-628t
Dysplasia
in cancer histology, II-599, II-600f
cemento-osseous, II-470–471
craniofacial fibrous, III-751–753, III-761f–762f
fibrous, II-470
florid cemento-osseous, II-471
focal cemento-osseous, II-471
periapical cemental, II-470–471
Dysplasia ablation, laser for, I-338f

E

E-plane, chin position analysis with, III-462f
Eagle's syndrome, II-951–952
Ear
blood supply, III-448, III-449f
deformities, III-448–450
in oculoauriculovertebral spectrum, III-695
in rhytidectomy, III-334–335
innervation, III-448, III-449f
laceration repair, II-276, II-235f
protruding, III-446–457
reconstruction
in oculoauriculovertebral spectrum, III-695–696
in Treacher Collins syndrome, III-732–733
surgical anatomy, III-447–448
surgical correction, III-450–453
in Treacher Collins syndrome, III-707
wound closure, II-57–58
Earlobe, protruding, surgical correction, III-453–455
Early implant loading (EIL), I-605–608
Eating disorders, craniomaxillofacial trauma management and, II-3t
Ecchymosis
frontal sinus fracture as cause of, II-231–232
midface fracture and, II-216
periorbital, skull fracture indicated by, II-254
postoperative, I-306f

ECG. *See* Electrocardiogram (ECG)
Ectasia, laser treatment, I-347
Ectodermal dysplasia, I-683–684
Ectropion, eyelid, II-203
Edatrexate, II-756t
Edema
  in mandibular surgery, III-314
  in orthognathic surgery, III-289–290
  in sagittal split ramus osteotomy, III-79
EEG. *See* Electroencephalogram (EEG)
Effexor XR. *See* Venlafaxine (Effexor XR)
Ehlers-Danlos syndrome, II-259
Einstein, Albert, III-336
Elavil. *See* Amitriptyline (Elavil)
Elderly patient
  benzodiazepine effects on, I-194
  bone graft healing in, I-432
Elective lymph node dissection, II-698
Electrocardiogram (ECG), I-166–167
Electrocautery, for skin cancer, II-727
Electrodesiccation, for skin cancer, II-727
Electroencephalogram (EEG)
  for pediatric anesthesia monitoring, I-245
  sedation monitoring and, I-171
Electromagnetic spectrum, III-337f
Electromyogram, for masticatory myalgia, II-964–966
Electromyography, II-103–104
Electron microscopy, II-335
Electroneurography, II-103–104
Electronic dental anesthesia (EDA), I-187–188
Electronic health record
  documentation with, I-79
  in VA system, I-32
Elevation
  of impacted third molar, I-288
  in simple extraction, I-276
Elevator, in simple extraction, I-276
Embolism, prevention, II-6
Embryo, Carnegie stages, III-477f, III-479f–480f
Embryogenesis
  cleft deformity and, III-493
  orofacial, III-476–490
Emergency care
  risk management in, I-77–78, I-81–82
  simulation of, I-212–213
Emergency equipment, for pediatric anesthesia, I-245
Emergency protocol, in oral and maxillofacial surgery, I-55
Emotional intelligence, I-144
Empathy, communication and, I-144
Emphysema, I-301
Employee
  family as, I-112
  hiring and firing, I-116–117, I-112–114, I-110
  interview, I-113
  as marketing asset, I-133–134
  salary and benefits, I-112
  superior, characteristics of, I-115–116, I-114, I-114
Employee relations, I-111–117, I-113
Enamel fracture, in dentoalveolar injury, II-123–124, II-124f
Enanthema, II-557
Encephalitis, herpetic, II-555
End-tidal CO_2, I-169
Endocannabinoid drugs, I-233
Endocarditis, III-281b
  cardiac conditions associated with, I-151t
  prophylaxis, I-151t
Endocrine system, preoperative evaluation of, I-142, III-286–287
Endodontics
  chemical burn from, I-378
  nerve injury associated with, I-87, II-377–378
  nerve trauma from, I-377
Endoneurium, in nerve anatomy, II-77–78
Endoscope
  example of, III-146f
  in forehead and brow lift, III-408–416
Endoscopy
  craniomaxillofacial tumor, III-741
  in forehead and brow lift, III-408–416
  for frontal sinus fracture, II-240
  in mandibular osteotomy, III-144–152
  for midface fracture repair, II-227
Endosseous cylinder, as anchor, I-313
Endothelial cell, wound healing and, II-257
Endotracheal intubation
  in laser surgery, III-343
  pediatric, I-239, II-248
Endotracheal tube, sizing, I-247
Enflurane (Ethrane), I-207
Enophthalmos, II-205–206, II-226
Enterovirus disease, II-556–557
Entropion, eyelid, II-203
Entubulation, for neural regeneration, II-96f
Environmental factors, in sarcoma etiology, II-644
Eosinophilic granuloma, II-523
Epidermal growth factor receptor (EGFR), II-607f, II-612, II-627
  in head and neck cancer, II-753f
  inhibitors, II-757–759, II-759t
  squamous cell carcinoma and, II-672–673
Epidermoid cyst, II-377
Epidermolysis bullosa, II-566–568
  clinical features, II-567
  treatment, II-567–568
Epignathus, III-756–757
Epilepsy, I-161
Epinephrine
  local anesthetics and, I-178–179
  maximum dosage, I-182t
  selectivity and potency, I-180t
  side effects, I-180–181
Epineurium
  internal neurolysis and, II-94
  in nerve anatomy, II-77–78
Epiphora, in midface fracture, II-226
Epistaxis
  midface fracture associated with, II-216
  nasal fracture as cause of, II-187
Epithelial cancer, II-718–720
Epithelial-mesenchymal transition, II-619–620
Epithelial odontogenic tumor, II-444–455
Epker, Bruce, III-5
Epstein-Barr virus, II-622–623
Epulis, congenital, III-756–757
Epulis fissuratum, III-349
Epworth Sleepiness Scale, III-265
Equal-appearing interval scale, III-574
Equipment
  anesthetic, I-212–213
  in oral and maxillofacial surgery, I-49
  for sitting position, I-46–50
Erbitux. *See* Cetuximab (Erbitux)
Erbium-doped yttrium-aluminum-garnet laser, peri-implantitis treated with, I-726–727
Erich arch bar, II-148f, II-153, II-155
Erickson Model Table, III-52, III-53f, III-54
Erlotinib, II-757, II-757t, II-759t
Ernst, Franz, III-535
Erythema chronicum migrans, II-846
Erythema multiforme, II-552–553, II-568
Erythrocyte sedimentation rate (ESR), II-840
Erythromycin, medication-related osteonecrosis treated with, II-516
Erythroplakia, laser treatment, I-336–338
Escherichia coli, peri-implantitis and, I-728
Esters, local anesthetics and, I-176–177
Esthetic Abutment, I-634
Esthetic contour graft, I-487–491, I-492f
Esthetic zone, implant planning and, I-449–450
Esthetics
  edentulous maxilla treatment planning and, I-592
  facial, III-13–14, III-16
Estrogen receptor, II-623–624
Ethics
  definition, I-9
  dilemmas, I-11–12
  professionalism and, I-1–13
Ethnicity, supernumerary teeth and, I-266–267
Etidocaine
  local anesthesia with, I-232–233
  onset time, I-178t
  systemic complications associated with, I-184
Etidronate (Didrone), II-508t
Etodolac
  dosage, I-232t
  for temporomandibular joint disorders, II-871t
Etomidate, II-13, II-192
Etoposide, II-714
Etretinate, II-733
Euclid, III-13
Eustachian tube
  cleft palate and, III-548
  dysfunction, III-568
Evaluation and management codes, I-92–95
Ewing sarcoma, II-644t, II-645–646, II-662–663, III-762–763
Exanthema, II-557
Exarticulation, in dentoalveolar injury, II-128–131
Exercise, aging and, I-140–141
Exercise therapy, for temporomandibular joint disorders, II-875–876
Exfoliative cytology, II-331–332
Exodontia
  basic and complex, I-275–297
  bone fracture and, I-307–308
  burns and abrasion during, I-301
  complications, I-298–308
  damage to adjacent structure during, I-298–299
  diagnosis, I-276
  flap design, I-280
  fracture and, I-307f
  hemorrhage, I-306–307
  indications, I-275–276
  infection following, I-303
  nerve injury during, I-302–303
  pain and swelling after, I-304
  patient positioning, I-276
  removal of wrong tooth, I-298
  soft tissue injury during, I-301
  treatment planning, I-276
  trismus after, I-304
Expander, maxillary, III-587
Exparel. *See* Bupivacaine liposome injectable suspension (Exparel)
Expert witness, surgeon as, I-10
External auditory canal, II-96
External neurolysis, II-93–94
Extra-oral vertical ramus osteotomy (EVRO), III-113
Extracellular matrix
  joint function and, II-830
  in temporomandibular joint disc repair, II-915

Extraction
flapless, implant success and, I-415–416
immediate implant after, I-410
of impacted canine, I-262
patient positioning, I-276
of pediatric canine, I-262
in pediatric patient, I-260
for primary tooth injury, II-132
simple, I-276–279
surgical, I-279–281
bone removal, I-280–281
complications, I-281–283
flap design, I-280
of impacted tooth, I-283–295
indications, I-280b
multi-rooted teeth, I-281
technique, I-286–288
third molar, I-283–286
Extranodal marginal zone B-cell lymphoma of mucosa associated lymphoid tissue, II-708b, II-710, II-711f
Eye
examination, in trauma patient, II-4, II-4f
herpetic infection involvement, II-552
muscles, II-204t
Eye injury, gunshot wound as cause of, II-311
Eyebrow
asymmetry, III-408
blood vessels, III-399–402
malposition, III-424
muscles, III-397f
muscles in, III-397–399
position, III-389–391
ptosis, III-395
Eyebrow lift, III-395–428
blepharoplasty compared to, III-407f, III-413f
complications, III-423–425
direct, III-418–419
eyebrow malposition following, III-424
mid-forehead, III-419
neurotoxin-assisted, III-421
postoperative care, III-422–423
preoperative assessment, III-405–408
techniques, III-408–419
transpalpebral/transblepharoplasty, III-419
tricophytic, III-419f
Eyelid
anatomy, III-388, III-390f
blood supply, III-391f
facial esthetics and, III-16
malposition, III-393
reconstruction, II-52
sebaceous gland carcinoma of, II-720
trauma repair, II-276–277
wound closure, II-51–52, II-54f
zygomatic fracture and, II-203
Eyewear, protective, for laser surgery, III-342, III-343f

F

Face. *See also* Midface
anteroposterior deficiency, III-98
asymmetric, case study, III-84b
avulsive injury, II-282
airway management, II-282
assessment, II-282
complications, II-300
management, II-282–283
pediatric, II-274–275
reconstruction, II-287f, II-296–297, II-283–300
rehabilitation, II-300
surgical management, II-265–266
balance, osteotomy and, III-184–185
bipartition osteotomy, III-677f
Face *(Continued)*
botulinum neurotoxin for enhancement, III-439–445
burn injury, II-67–68
buttresses of, II-212b
chemical peel, III-439–445
cleft
classification of, III-496f
complex, III-506–508
Dedo classification, III-327t
deformity, III-596–600
esthetic units, II-16, III-51f
esthetics, III-13–14
examination, in trauma patient, II-4
fracture, from gunshot wound, II-316
fracture patterns, II-20
growth abnormality, III-627–628
growth and development, III-738
imaging, II-18
implant, in cosmetic surgery, III-458–475
innervation, I-227f
lower, reconstruction, II-296–297
measurements, III-127t–128t
morphogenesis, III-476–486
osteotomy and facial proportions, III-184–185
paralysis, II-101t
pediatric fracture, II-35–38
pediatric trauma, II-264–280
plastic surgery, III-359
projection, osteotomy and, III-184–185
proportions, III-119f
racial variation in, III-25
reconstruction, in Treacher Collins syndrome, III-731–732
rhytidectomy evaluation, III-326–327
soft tissue injury, II-41–69
evaluation, II-41–42
postoperative care, II-60–61
subunits, II-51f
sunken, III-465b–467b
symmetry and proportion of, III-13–14, III-96, III-184–185
transplantation, gunshot wound treatment with, II-326
transverse asymmetry, III-98
upper, evaluation, III-16
upper third, rejuvenation, III-395
vertical deficiency, III-98
vertical excess, III-97–98
vertical support, II-211
Face height
long
case study, III-70b–71b
mandibular deficiency with, III-70b–71b
mandibular deficiency case study, III-65b
normal, mandibular deficiency and, III-65b
osteotomy and, III-184
short, mandibular deficiency with, III-68b–69b
short posterior
causes, III-118b
mandibular deficiency with, III-113–143
treatment planning, III-119–120
in Treacher Collins syndrome, III-706–707, III-724
Face-lift. *See* Rhytidectomy
Facebook, marketing and, I-139
Facebow record, for model surgery, III-46–47
Faceguard, dentoalveolar injury prevention with, II-141
Facial artery, rhytidectomy evaluation and, III-328
Facial artery musculomucosal flap, II-286–290, II-292f
Facial bone
grafting of, I-415–416
in restored implant, I-411
Facial cleft. *See* Cleft deformity
Facial nerve, III-400, III-402f
anatomy, II-96–99
Bell's palsy and, II-100–101
branching pattern, II-98f
description, II-70
extratemporal segment, II-98–99
identification of, II-161f
imaging, II-99–100
injury
classification, II-100, II-100t
clinical evaluation of, II-103–104
diagnosis and management, II-70–113
extratemporal, II-104–106
iatrogenic, II-102–103
infection as cause of, II-102
in mandibular fracture, II-168
outcomes, II-106
pediatric, II-272
in rhytidectomy, III-333–334
sagittal split osteotomy associated with, III-305–308
in sagittal split ramus osteotomy, III-80
from trauma, II-101–102
treatment, II-102, II-104–106
injury mechanism, II-100–103
intracranial segment, II-96–97
intratemporal segment, II-97–98
laceration, II-60
mastoid segment, II-97–98
microanatomy, II-77–78, II-99
paralysis of, from local anesthesia, I-184
parotidectomy and, II-495–496
rhytidectomy evaluation and, III-328
traumatic injury, II-101–102
tympanic segment, II-97
Facial profile, implant planning and, I-585–587
Facial resurfacing, III-355–356
Facial support, for implant, I-584–588
Facial surgery, laser-assisted, I-343–347
Facial wound, reconstruction following, I-665–666
Faciolingual anatomy, implant restoration and, I-392, I-395
Faciolingual placement, implant, I-397–398, I-398f
Failure to diagnose, I-82
Famciclovir, II-554, II-556
Farrior technique, for otoplastic surgery, III-453, III-455f
Fascia
in forehead, III-397–399
upper face, III-401f
FAST, pediatric trauma assessed with, II-246
Fasting
pediatric patient, I-243
preoperative, I-215–216
pulmonary aspiration and, I-243t
Fat, procurement, in fat transfer, III-436
Fat graft, III-433–437
in forehead and brow lift, III-419
in temporomandibular joint total reconstruction, III-238
Fat transfer
autologous, III-434, III-467b
complications, III-437
fat procurement, III-436
in forehead and brow lift, III-419
preoperative evaluation, III-434
techniques, III-429–438
Faulk-Effleston, Col. Jan, I-24
Fear, pediatric, premedication for, I-248
Feeding, infant, in craniosynostosis care algorithm, III-672
Felty syndrome, II-839

Fentanyl, I-200
dose and potency, I-229t–230t
equianalgesic dosage, I-231t
for facial pain, II-953
midazolam combined with, I-218
pediatric dosage, I-250t
for pediatric patient, I-249, I-251
structure, I-199f
synthesis, I-197–198
transdermal, II-954
Fibrin sealant, for frontal sinus fracture, II-238–240
Fibro-osseous lesion, II-468–471
Fibroblast
cancer-associated, II-600
tumor invasion and, II-620–621
wound healing and, II-257
Fibroma
ameloblastic, II-449–451, III-745
juvenile ossifying, III-751, III-755f–756f
nonossifying, II-854
odontogenic, II-435–438
differential diagnosis, II-437
management, II-438
ossifying, III-743f
Fibromatosis
juvenile aggressive, III-745–748
paragnathic, III-748f
Fibromyalgia
facial pain and, II-944–945
pharmacotherapy, II-955–956, II-970
Fibrosarcoma, II-644t, II-652–653, II-652f
ameloblastic, II-454–455
temporomandibular joint, II-934f
Fibrosis, temporomandibular joint replacement for, II-931
Fibrous dysplasia, II-470, II-853
Fibula free flap, II-294, II-296
Fiducial facebow, III-31–33, III-35
Field-of-view (FOV) device, I-692
Financial management, for oral and maxillofacial surgical practice, I-67–71
Fine needle aspiration biopsy, II-331, II-338
for lymphoma diagnosis, II-707
for parotid gland tumor, II-494
salivary gland, II-481–483
for sarcoma, II-646
Fire, laser surgery as cause of, III-342
Firearms
classification, II-303
deaths associated with, II-303
injuries from, I-307, II-665
pediatric injury and death from, II-245
types of, II-303–304
Fistula
in cleft palate repair, III-539–540
closure, III-609–612
in double-opposing Z-plasty, III-548
indications for repair, III-610–611
rate, after palatoplasty, III-610
timing of surgery, III-610–611
Fitzpatrick skin classification system, I-344, II-691, II-691t, II-723t
5-fluorouracil, II-733–734, II-747, II-754–755, II-756t–757t
Fixation
of alveolar fracture, II-134
for atrophic mandibular fracture, II-166–167
bioresorbable material, III-63–64
Champy's technique, II-162
for cleft maxilla stabilization, III-606
ear, III-452–453
endoscopic approach, II-161–162
external, II-155, II-156f
in forehead and brow lift, III-409, III-415
for genioplasty, III-104–105
Fixation *(Continued)*
intermaxillary, III-188
in Le Fort I osteotomy, III-166–167
for sagittal split ramus osteotomy, III-62–63
internal, II-162
intraoral/transbuccal approach, II-155–158
inverted L osteotomy and, III-119t
ivy loop, II-233f
lag screw, II-164
mandibular, history, II-146
materials for, II-162–164
maxillary, in Le Fort I osteotomy, III-167
maxillomandibular, II-153, II-155, II-270, II-280
for condylectomy, III-147
example of, II-148f
history, II-146
for mandibular osteotomy, III-145
open reduction and internal, II-147
osteosynthesis, in sagittal split ramus osteotomy, III-76–77
position screw technique, III-78f
resorbable materials in, III-79b
resorbable plate, II-162
resorbable screw, in sagittal split ramus osteotomy, III-77–79
rigid, II-162
for sagittal split ramus osteotomy, III-62–63
screw, III-7
semirigid, II-162
transcervical-retromandibular approach, II-160–161
transcervical-submandibular approach, II-158–160
transosseous wire, II-162
Fixation device
example of, II-318f
external, for gunshot wound, II-316–318
maxillomandibular, II-316
Fixation screw, I-461–462
case study, I-693
designs, II-164f
lag, II-164f
maxillomandibular, II-316
for mesh graft, I-465–466
passive bone, II-164f
placement, in biomedical model, I-701f
removal, I-468
Fixed restoration
arch form, I-595–596
case presentation, I-601–602
classification for, I-590
cost, I-596–597
denture conversion to, I-608–614
for edentulous maxilla, I-584–604
extraoral examination for, I-591–602
extraoral parameters for, I-586f
force placed on, I-594–595
implant distribution and placement, I-596
material selection, I-597–602
ridge form, I-595–596
screw-retained, I-614
treatment planning, I-592–597
Flap
Abbe, II-286, II-291f, II-297–298
anterolateral thigh free, II-294, II-295f
cervicofacial, II-290, II-293f
complications, II-300
deep circumflex iliac artery, II-296
design
bone augmentation and, I-460
for guided bone regeneration, I-476
for impacted tooth removal, I-286–287
in surgical extraction, I-280
Flap *(Continued)*
envelope, I-280, I-286
for eyelid laceration, II-51–52
facial artery musculomucosal, II-286–290, II-292f
fibula free, II-294
free, II-294–296
laceration, during exodontia, I-301
local, for avulsive facial injury, II-297–298, II-286–294
microvascular free, II-294–296
open-book, I-492f, I-494f
osteoperiosteal, I-526–554
paramedian forehead, II-290, II-292f
in pediatric ablative defect reconstruction, III-768
pericranial, II-241
radial forearm, II-294, II-295f
reconstructive, II-296b
reflection, in guided bone regeneration, I-480f
regional, for avulsive facial injury, II-286–294
for skin cancer repair, II-731–732
submental island, II-290–294
temporalis muscle, II-924, II-925f
temporalis myofascial, II-912
temporoparietal fascia, II-290, II-294f
trapezoidal, I-280
triangle, I-280
vascularized free, I-668–671
Flexeril. *See* Cyclobenzaprine (Flexeril)
Flickr, marketing and, I-105
Florid cemento-osseous dysplasia, II-471
Flow cytometry, II-335–336
Fluid
administration, I-216–217
intraoperative, for pediatric patient, I-248
perioperative, I-217
Fluid management, for pediatric patient, I-248
Flumazenil, I-197
discovery, I-191
half-life, I-195t
protein binding, I-195t
structure, I-196f
Fluoromethane, II-970
Fluorouracil, II-757t
Fluoxetine (Prozac), II-873t
Flurazepam (Dalmane), II-874t
Flurbiprofen, II-871t
Focal cemento-osseous dysplasia, II-471
Focused assessment by sonography for trauma (FAST), II-246
Follicular lymphoma, II-710
Follicular sac, II-437, II-437f, II-441–444
Food and Drug Administration (FDA), codeine warning from, I-253–254
Forced duction test, II-196, II-203, II-205f
Forceps
Ash, I-278f
cowhorn, I-279f
English, I-278f
extraction, I-277, I-278f
Hayton-Williams, II-217f
luxation, in simple extraction, I-277–278
No. 23, I-279f
No. 53, I-279f
No. 150, I-277, I-278f–279f
No. 151, I-277, I-278f–279f
No. 210, I-279f
No. 88 L/R, I-279f
rotation, I-278f
Rowe maxilla disimpaction, II-217f
Forehead
blood vessels, III-399–402
bone anatomy, III-396–397
lift, III-395–428
morphogenesis, III-476

Forehead *(Continued)*
muscles in, III-397–399, III-397f
nerves in, III-397f, III-399–402
ptosis, III-395
wound closure, II-50
Forehead and brow lift, III-395–428
adjunctive procedures, III-419–422
anatomic considerations, III-395–405
complications, III-423–425
coronal, III-416
endoscopic anatomy, III-402–405
endoscopic technique, III-408–416
esthetic considerations, III-395–405
mid-forehead, III-419
muscle and fascial anatomy, III-397–399
postoperative care, III-422–423
preoperative assessment, III-405–408
techniques, III-408–419
treatment approach, III-408–419
treatment goals, III-405–408
trichophytic and trichophylic, III-416–418
Forehead line, botulinum neurotoxin for, III-441
Foreign body
pediatric wound healing and, II-260
swallowing of, during exodontia, I-302
Fosamax. *See* Alendronate sodium (Fosamax)
Fospropofol, I-201, I-202f
Fox Plane, III-24
Fractional photothermolysis, III-339
Fracture
alveolar, II-120–121, II-133–137
alveolar process, II-133–135
angle, II-166, II-169f
blow-in, II-22
blowout, II-22
bone healing after, II-257–258
buccal plate, in sagittal split ramus osteotomy, III-82
buckle-type, II-261
complete, II-261
condylar, II-270, II-31–34, II-165–166
craniomaxillofacial, spine injury and, II-38
crown, II-123–125
crown-root, II-125
dentoalveolar, II-123t, II-149, II-233f
classification, II-120
pediatric, II-233f
treatment, II-120–122
exodontia and, I-307–308
facial, II-20
from gunshot wound, II-316
pediatric, II-230
following third molar extraction, I-307f
frontal bone, II-266–267, II-20–22
frontal sinus, II-230, II-21f, II-22t
classification, II-232–233
clinical evaluation, II-231–232
complications, II-241–243
endoscopic repair, II-240
images, II-234f
management, II-236
management algorithm, II-237
postoperative care, II-241
radiologic evaluation, II-232
surgical management, II-233–240
greenstick, II-261
Knight and North classification, II-27t
mandibular. *See* Mandibular fracture
Markowitz, II-221–223
maxillary, II-27–28, II-32f–33f, II-320f
maxillofacial, I-17, II-374–376
midface. *See* Midface fracture
nasal. *See* Nasal fracture
naso-orbito-ethmoid, II-213, II-220–225
classification, II-221–222
diagnosis, II-222–223
Fracture *(Continued)*
exposure, II-223–224
treatment, II-223
orbital, II-22
palatal, II-28, II-220
pediatric
blowout, II-268
facial, II-35–38
management, II-243
orbital, II-267–268
patterns of, II-261
sinus, II-266–267
skull, II-253
primary teeth, II-131–132
root, in dentoalveolar injury, II-125–127
septal, II-178–179
sinus, II-20f
skull
images, II-233f, II-232f
pediatric, II-253
socket wall, II-133
symphyseal, pediatric, II-270
temporal bone, facial nerve injury from, II-101–103
trapdoor, II-268
zygomatic. *See* Zygomatic fracture
Framework
case presentation, I-601–602
cobalt chromium, I-599
material selection for, I-597–602
zirconia, I-599–601, I-601f
zirconia titanium, I-601
Free autogenous graft, I-326, II-556
Free flap
non-vascularized, I-675
for osteoradionecrosis, II-596
vascularized, I-668–671, I-675
Free gingival graft, I-556, I-557f, I-560–561, I-562f
Freeze-dried bone allograft (FDBA), I-428–429
Frenectomy, I-270–271
for ankyloglossia release, I-271
laser, I-336f, III-348–349
lingual, I-271f
Frenotomy, I-270–271
Frenum
labial, surgery for, I-270–271
pediatric, procedures for, I-270
Fresh-frozen bone allograft (FFBA), I-428
Friedman Palate Position, III-266f
Friedman Staging System, III-267t
Frontal bone injury, II-266–267, II-230–243
Frontal sinus, II-20–22, II-22t
axial view, II-230
classification, II-232–233
clinical evaluation, II-231–232
comminution of, II-239f
coronal view, II-230f
fracture, II-20f
anterior wall, II-242
classification, II-232–233
complications, II-241
endoscopic repair, II-240
management algorithm, II-237
management of, II-236
pediatric, II-266–267
posterior wall, II-238–240
postoperative care, II-241
radiologic evaluation, II-232
surgical management, II-233–240
injury, II-230
management of, II-236
obliteration, II-236–238
radiologic evaluation, II-232
sagittal view, II-230
surgical anatomy, II-230–231
surgical management, II-233–240
Frost, Harold, III-247
Frozen section, II-330–331, II-393
Functional capacity, preoperative evaluation and, I-139
Functional cleft lip repair, III-525–526
principles, III-527–530
studies, III-530–531
surgical technique, III-527–528
Functional endoscopic sinus surgery, I-580, I-582f
Functional magnetic resonance imaging (fMRI), II-947
Functional matrix repair, III-525–531
Functional Outcomes of Sleep Questionnaire, III-265
Functional residual capacity (FRC)
age values, I-241t
pediatric, I-241, I-241t
Furlow double-opposing Z-plasty, III-505, III-546–547, III-610
example, III-507f
limitations and complications, III-548

G

Gabapentin (Neurotin)
for facial pain, II-955t, II-956
for nerve injury, I-364
Gabapentinoid drugs, I-233, I-364
Gait, in mandibular movement, II-806–808
Galetti articulator, III-49
Gamma (g)-aminobutyric acid (GABA)
action, I-191–192
discovery, I-191
Gamma (g)-aminobutyric acid - benzodiazepine receptor complex, I-192, I-194f
Ganglion cyst, temporomandibular joint affected by, II-852
Ganz-Rinaldi surgical protocol, I-705f–706f, I-706
Ganzer, Hugo, III-535
Gardner syndrome, II-464, II-475, II-476f, II-644
Garre osteomyelitis, II-858
Gas exchange, pediatric, II-249
Gastric emptying, anesthesia and, I-216
Gastroesophageal reflux disease (GERD), I-141, III-286
Gastrointestinal disease, preoperative management and, I-141–142
Gastrointestinal system
non-Hodgkin lymphoma, II-710
preoperative management and, I-141–142
GBR. *See* Guided bone regeneration (GBR)
Gefitinib, II-757, II-757t, II-759t
Gelatin, anaphylaxis associated with, I-252t
Gemcitabine, II-757t
Gender, pediatric trauma and, II-245
Gene
amplification, II-607, II-607f
cancer treatment based on, II-622, II-625
cell regulation, II-603–606
classification, II-603
epigenetic alteration, II-609
epigenetic control, II-605f
molecular paradigm, II-604f
Ras family, II-612
regions, II-603
sequencing, II-623
tumor suppressor, II-602–603, II-609, II-614, II-616
Gene expression
alterations, II-607, II-609
cancer diagnosis and, II-623
epigenetic alteration, II-609
epigenetic control, II-605f
molecular paradigm, II-603, II-604f
prevention, II-603

Gene therapy, for oral cancer, II-678–679
General partnership, I-58–59, I-59t
Genetics
  cancer development and, II-602
  cancer treatment based on, II-622, II-625
  cell regulation and, II-603–606
  in cleft deformity, III-493–494
  craniosynostosis syndromes, III-667–669
  melanoma and, II-690–691
  oral cancer and, II-672–673
  sequencing, II-623
  in Treacher Collins syndrome, III-703–705
Geniculate ganglion, II-97
Genioglossal advancement, III-268
Geniohyoid muscle, II-784
Genioplasty, III-96–112, III-319–321
  alloplastic, III-103–104
  bony changes, III-104–105
  chin position and, III-303t
  chin repositioning, III-108f
  complications, III-319–321
  in computer-aided surgical simulation, III-35–36
  facial orientation and, III-28
  fixation devices, III-104–105
  functional, III-96–97, III-101
  history, III-2
  indications, III-97–98
  mandibular widening with, III-201
  Michelet, III-101
  model surgery and, III-60
  neurosensory disturbance, III-320
  sagittal split, III-103, III-104f–105f
  sliding, III-101–103
  for small chin, III-463b
  surgery, III-101–104
  tissue analysis, III-98
  treatment planning, III-98–101
  vertical reduction, III-111f
  wound healing failure, III-320
Gerdy's tubercle, I-457–458
Ghost cell, II-370, II-372f–373f
Giant cell granuloma, II-462–464, II-750–751, III-852
  classification, II-463t
  example, II-463f
Giant cell tumor, II-464
Gingiva
  avulsive wound, II-137
  in dentoalveolar injury evaluation, II-117, II-123t
  in fixed restoration, I-589, I-590f
  hypertrophic, III-352
  injury treatment, II-137
  minimal display, treatment for, I-585f
  miniscrew implant and, I-316
Gingival cyst, II-365, II-424
Gingival graft, I-450–451, I-450f
Gingivectomy, laser, III-348–349
Gingivoperiosteoplasty, III-498, III-562, III-584
Gingivoplasty, laser, III-352
Glabella, III-395–396
  botulinum neurotoxin for, III-440
  horizontal line correction, III-411
  innervation, III-400
  muscles, III-404–405
Glandular odontogenic cyst, II-365–368, II-369f
Glasgow Coma Scale (GCS), II-9, II-247
Glenoid fossa, II-778, II-821
Globulomaxillary cyst, II-375–376
Glogau skin classification, I-343, II-723b
Glucocorticoid deficiency, I-159t
Glutamate, I-205
Glycolic acid, for chemical peel, III-443
Glycolysis, in cancer cell metabolism, II-601–602
Glycopyrrolate
  for autogenous bone graft prophylaxis, I-451
  for pediatric patient, I-251
Glycosaminoglycans, joint function and, II-830
Gold alloy
  for abutment, I-636
  for single anterior implant, I-630–631
Gold Humanism Foundation, I-4
Golden ratio, III-13, III-14f–15f
Goldenhar syndrome, III-687, III-689f, III-694f
Goldman tip, III-376
Goode's method, chin position analysis with, III-460t–461t
Goode's method of nasal projection, III-369
Gorlin-Goltz syndrome, II-361–364, II-364b
Gorlin syndrome, II-718
Gout, II-847–848
Graft
  auricular cartilage, II-912–913
  autogenous
    after discectomy, II-912
    for temporomandibular joint surgery, II-772
  bone. *See* Bone graft
  connective tissue, I-415–416
  costochondral, II-326
  dermal, II-913–914
  for ear laceration, II-58
  failed, temporomandibular joint replacement after, II-931
  free fibula, II-326
  free gingival, I-557f
  pediculated, I-556, I-560f
  peri-implant, I-415–416
  rib, in pediatric ablative defect reconstruction, III-766–767
  for skin cancer lesion repair, II-731–732
  soft tissue. *See* Soft tissue graft
  spreader, in rhinoplasty, III-371f
  techniques and materials for, I-426–436
  tip onlay, III-374
  umbrella, III-374
  vascularized interpositional, I-558
Granuloma
  central giant cell, II-750–751, III-852
  laser excision, III-349
Grayson nasoalveolar molding appliance, III-498
Greenstick fracture, II-261
Growth, definition, III-628t
Growth factor
  bone graft and, I-431–432
  cancer cell growth and, II-612
  cell division and, II-611f
  joint function and, II-830–832
  pain management and, II-959
  in temporomandibular joint arthrocentesis, II-888
Growth inhibitory signal, cancer cell growth and, II-612–614
Growth signal
  cell division and, II-611f
  release from, II-617f
GSW. *See* Gunshot wound (GSW)
GTR. *See* Guided tissue regeneration (GTR)
Guerrero, Caesar, III-5, III-7–8
Guided bone regeneration (GBR), I-462–464
  in alveolar distraction, I-538–539
  applications, I-484–493
  case study, I-499b–500b
  complications, I-464
  defect configuration and, I-476
  history, I-475
  horizontal augmentation, case study, I-502b
  horizontal bone augmentation, I-464
  implant placement, case study, I-495b, I-497b–498b
Guided bone regeneration (GBR) *(Continued)*
  implant simultaneous with, I-487–491
  incision design, I-476–479
  membrane selection, I-480–483
  multiple tooth, I-478f
  patient selection, I-476
  for peri-implant defect, I-493
  postoperative considerations, I-493–504
  principles, I-476–480
  single tooth, I-478f
  socket preservation, I-493
  soft tissue closure, I-479–480
  space maintenance, I-483–484, I-526–527
  titanium mesh in, I-484
  vertical augmentation, case study, I-501b–503b
  vertical bone augmentation, I-464
Guided tissue regeneration (GTR), I-475–508
Gunshot wound (GSW), II-282, II-284
  algorithm for treatment plan, II-312f
  assessment, II-308–309
  avulsive injury, I-665
  ballistics, II-304–305
  categories, II-305
  classification, II-304–305
  classification system, II-304–305
  complications associated with, II-300
  deaths associated with, II-303
  debridement, II-313–314
  facial injury from, II-282, II-294–296
  factors influencing degree of, II-307
  hemorrhage control, II-309
  high-energy, II-318–320
  low-velocity, II-316
  management diagram, II-312f
  mandibular fracture from, II-315–316
  maxillofacial, II-303–328
    assessment, II-308–309
    external fixator for, II-316–318
    reconstructive phase of treatment, II-324–326
    self-inflicted, II-320–323
    treatment, II-307–313, II-323–324
  neurologic evaluation, II-311
  ophthalmologic assessment, II-311
  reconstruction, I-667f
  self-inflicted, II-320–323
  soft tissue injury from, II-306
  surgical management, II-265–266
  trajectory patterns, II-283f
  treatment
    high-energy, II-318–320
    intermediate phase, II-323–324
    reconstructive phase, II-324–326
  treatment algorithm, II-312f
  treatment guidelines, II-313–314
Gutta percha, injury associated with, I-378

H

Hader bar, I-644f, I-646f, I-648f
Hair
  laser removal, I-349, III-358
  laser transplant, III-358
Halcion. *See* Triazolam (Halcion)
Hall, Richard John, I-176
Halothane (Fluothane), I-207
Halsted, William Stewart, I-176
Hand, foot, and mouth disease, II-556–557
Hand-Schuller-Christian disease, II-523
Handgun
  types of, II-303
  wound from, II-305–306
Hanks balanced salt solution, II-129–130
Hard palate
  anatomy, II-612–615, III-671
  repair, III-503, III-534

Hard palate *(Continued)*
squamous cell carcinoma, II-681–683
submucous cleft, III-618–619
surgical technique, III-537–539
two-stage repair, III-548–549, III-551–552
Hard tissue, peri-implant grafting and, I-415–416
Hargis, Harold, III-6
Harvest guide, I-705f
Hashimoto-Pritzker syndrome, II-523
Hashimoto thyroiditis, I-158, II-710
Hayes-Martin maneuver, II-158–160
Hayflick limit, II-616
Hayton-Williams forceps, II-217f
HBO. *See* Hyperbaric oxygen therapy (HBO)
HCPCS. *See* Healthcare Common Procedure Coding System (HCPCS)
Head and neck
abnormal shape, III-647–648
angiosarcoma, II-658
cancer
chemotherapy for, II-755–756
epidemiology, II-752
metastatic, II-755–756
oncology principles in, II-752–763
radiation therapy for, II-741–751
sites, II-742–745
treatment, II-745–747
chondrosarcoma, II-649
dissection, II-683
embryogenesis, III-478–480, III-481f–482f
fibrosarcoma, II-652
liposuction, III-429–438
lymphoma, II-707
malignant fibrous histiocytoma, II-651
melanoma, II-690
neurofibroma, III-755
non-Hodgkin lymphoma, II-710
non-melanoma skin cancer, II-717–740
in oculoauriculovertebral spectrum, III-690b
osteosarcoma, II-647
radiation therapy for, II-741–751
sarcoma, II-643, II-644t
skin cancer, II-721–725
soft tissue injury, II-41–42, II-41–69
squamous cell carcinoma, II-670–689, II-719, II-752
chemotherapy for, II-754–756
clinical trials, II-758t
risk factors, II-752
treatment, II-752–754
Headache
chronic, frontal sinus fracture as cause of, II-243
facial pain and, II-944–945
Healing cap, I-626f, I-634f
Health
behavioral, I-140–141
cognitive, I-141
Health care
access to, I-3
continuous improvement of, I-3
safety, I-96
Health history
preoperative evaluation and, I-138
risk management and, I-75–76
Health Insurance Portability and Accountability Act (HIPAA), I-85
Healthcare Common Procedure Coding System (HCPCS), I-87–89
Hearing, in craniosynostosis care algorithm, III-672
Hearing aid, bone-anchored, III-733
Hearing loss
in oculoauriculovertebral spectrum, III-696
in Treacher Collins syndrome, III-705, III-707, III-732–733
Heart disease, vasoconstrictor drugs and, I-182b
Heart failure
classes of, III-281t
oral surgery following, I-139
Heart murmur, pediatric, I-242
Heart rate, infant, II-249–250
Helicobacter pylori
lymphoma associated with, II-713
peptic ulcer disease associated with, I-140
Hemangioma
congenital, II-536–538
definition, II-534
infantile. *See* Infantile hemangioma (IH)
intraosseous, II-852–853
laser treatment, I-338, I-347
local anesthetics, III-356
management, II-537–538
resection, II-537–538
synovial, II-853
temporomandibular joint, II-852–853
as vascular anomaly, II-534
Hemangiopericytoma, II-644t, II-659–660
Hematologic disorders
orthognathic surgery and, III-284–285
wound healing affected by, II-259
Hematologic system, preoperative evaluation of, I-159–161
Hematoma
in blepharoplasty, III-393
epidural, II-252
local anesthetics and, I-184
in oculoauriculovertebral spectrum, III-688–690
otoplastic surgery and, III-455–456
postoperative, II-7f
in rhinoplasty, III-383
in rhytidectomy, III-332
septal, II-187
subdural, II-253–254
Hematoxylin and eosin (H&E) stain, II-331–332, II-692–693
Hemifacial microsomia, III-15–16, III-158f–160f
Hemimandibular elongation, III-17f–22f
Hemochromatosis, II-644
Hemoglobin, absorption spectrum, I-329f
Hemophilia, preoperative evaluation of, I-161
Hemorrhage
in gunshot wound patient, II-309
intracranial, II-252–254
intraoperative, I-306–307
in Le Fort I osteotomy, III-169
postoperative, I-306–307
in sagittal split osteotomy, III-82, III-310–313
subarachnoid, II-253
in vertical ramus osteotomy, III-314
Hemorrhagic bone cyst, II-852
Hemostasis
laser for, I-330
in orthognathic surgery, III-289
Hemostatic sponge, I-512–513
Henderson-Hasselbalch equation, I-177
Hendrickson classification of palatal fractures, II-216f
Heparin, preoperative management, I-161
Hepatic disease
preoperative evaluation of, I-141–142
preoperative management and, I-141–142
Hepatitis C, allograft material and, I-429
Heroin, synthesis, I-197–198
Herpangina, II-556–558
clinical findings, II-557
treatment, II-557–558
Herpes labialis, II-554–556
Herpes simplex virus infection, II-551–556
clinical features, II-552–553
diagnosis, II-553
diseases associated with, II-551–552
erythema multiforme associated with, II-568
pediatric, II-555–556
recurrent, II-554–555
secondary, II-553
systemic agents for, II-554
treatment, II-553–554
Herpes zoster, osteomyelitis and, II-582f–585f
Herpes zoster oticus, II-102
Herpetic encephalitis, II-555
Herpetic meningitis, II-555
Herpetiform aphthae, II-559
Heterotopic bone formation, II-858
High-reliability organization (HRO), I-97–98
Hinge articulator, III-49
Hip, bone harvested from, I-458–460
HIPAA. *See* Health Insurance Portability and Accountability Act (HIPAA)
Histamine release, opioid drugs associated with, I-199–200, I-201b
Histiocyte, definition, II-524–525
Histiocytosis, Langerhans cell, II-857
Histiocytosis X, II-523, II-525b
Histomorphometric analysis, I-443
History and physical examination (H&P), I-75–76
Hodgkin cell, II-709, II-709f
Hodgkin lymphoma, II-707, II-709
clinical staging, II-708b
radiation therapy for, II-741
survival rate, II-714
treatment, II-713–714
Holdaway method, chin position analysis with, III-460t–461t
Holoprosencephaly, III-487
Homeostasis, genetic regulation, II-603–604
Honesty, professionalism and, I-5
Horizontal alveolar transport osteogenesis, I-547–549
Hounsfield unit, II-820–821
House-Brackmann facial nerve grading scale, II-100, II-100t, II-103
H&P. *See* History and physical examination (H&P)
HRO. *See* High-reliability organization (HRO)
Hullihen, Simon, III-62, III-113, III-492, III-1
Human immunodeficiency virus (HIV)
allograft material and, I-429
lymphoepithelial cyst associated with, II-485
parotid gland affected by, II-488
Human papillomavirus (HPV), oral cancer associated with, II-672
Human resources
alternatives, I-67
in oral and maxillofacial surgical practice, I-65–67
Hunsuck, Ervin E., I-24
Hutchinson sign, II-552
Hyaluronic acid (HA), II-884, II-887
Hydrocephalus, III-646, III-672
Hydrocodone (Vicodin)
equianalgesic dosage, I-231t
for facial pain, II-953, II-955t
prescription, I-228
for temporomandibular joint disorders, II-872t
Hydrocortisone
equivalent dosage, III-287t
for temporomandibular joint disorders, II-871t
Hydrocortone, II-871t

Hydromorphone (Dilaudid)
dose and potency, I-229t–230t
pharmacokinetics, I-230t
synthesis, I-197–198
for temporomandibular joint disorders, II-872t
Hydroquinone, I-345
Hydroxyadriamycin, II-713
Hydroxyapatite
alloplastic implant with, I-440–441
for bone graft, I-483–484
bone graft with, I-430
Hydroxyurea, II-757t
Hydroxyzine (Vistaril), II-874t
Hyperalgesia, definition, I-355t, I-360, II-946t
Hyperbaric oxygen therapy (HBO), I-590, II-595, II-678
Hyperesthesia, definition, I-355t, II-946t
Hyperglycemia, complications associated with, I-141
Hyperkeratosis, laser treatment, I-336–338
Hypernasality, III-570
Hyperparathyroidism, II-464–466, II-465f
Hyperpathia, definition, I-355t, I-360
Hyperplasia
definition, III-628t
mandibular, III-638
Hypertension, intracranial, III-674–675
Hyperthyroidism, I-141, I-158, I-158t
Hypertrophy, definition, III-628t
Hypodontia, in cleft lip and palate, III-585
Hypoesthesia, definition, I-355t, II-946t
Hypoglossal nerve stimulation, III-269
Hypoglycemia, postoperative, I-216–217
Hypohidrotic ectodermal dysplasia, I-683
Hyponasality, III-570–571
Hypopharynx
carcinoma of, II-746t
radiation therapy for carcinoma of, II-744
Hypopigmentation, skin resurfacing and, I-345–346
Hypoplasia
mandibular, III-637–638
maxillary, III-638–642, III-639f, III-778
midface, III-630–632
Hypotension, rapid-onset, I-165
Hypothermia
perioperative, I-170
therapeutic, II-256
Hypothyroidism, I-141, I-158, I-158t
Hypoventilation, pediatric cardiac arrest and, II-249
Hypoxemia, anesthesia associated with, I-168

I

IAJ. *See* Implant-abutment junction (IAJ)
IAN. *See* Inferior alveolar nerve
Ibandronate (Boniva), II-508t
Ibuprofen (Advil, Motrin)
dosage, I-232t
for facial pain, II-954–955, II-955t
for masticatory myalgia, II-969
for nerve injury, I-363
preoperative, I-231
for temporomandibular joint disorders, II-871t
ICD-10 CM code set, I-89–92, I-90t
ICP. *See* Intracranial pressure (ICP)
Idiopathic bone cavity, II-852
Ifosfamide, II-757t
IH. *See* Infantile hemangioma (IH)
Iliac block graft, I-569–570
Iliac crest bone graft, I-437, I-458–459
for cleft maxilla reconstruction, III-590
complications, III-592
Ilium, as bone graft donor site, I-458–460
Ilizarov, Gavriel, III-247, III-774
Illness
progressive, I-146
short-term, I-145–146
Imaging. *See also* Computed tomography (CT); Magnetic resonance imaging (MRI)
avulsive facial injury, II-283
charge-coupled device, II-815–816
complementary metal oxide semi-conductor device, II-815–816
craniomaxillofacial pathology, III-738–739
dentoalveolar injury, II-119–120
digital, for temporomandibular joint, II-815–816
facial nerve, II-99–100
for facial pain, II-946–947
frontal sinus fracture, II-232
functional, II-825
fusion, II-826
head and neck skin cancer, II-721, II-725
interpretation, II-17–20
mandibular fracture, II-31, II-153
maxillofacial trauma, II-17–40
for melanoma diagnosis, II-699
midface fracture, II-213
naso-orbito-ethmoid fracture, II-223
odontogenic tumor, II-392–393
osteomyelitis, II-576
pediatric craniomaxillofacial trauma, II-233–240
pediatric facial fracture, II-38
pediatric trauma, II-246–247
photo-stimulable phosphor device, II-815–816
reverse Towne projection, II-816–817
salivary glands, II-481–483
sarcoma, II-645
submentovertex projection, II-817
temporomandibular joint, II-815–829
temporomandibular joint disorder, II-801–804
temporomandibular joint internal derangement, II-906–907
temporomandibular joint prosthetic reconstruction, III-223–226
three-dimensional, I-207–208, II-688–710
for anterior maxillary deficiency, I-688–696
history, III-7
midface fracture, II-213
sinus augmentation, I-705–706
temporomandibular joint, II-815, II-820, II-824–825
trigeminal nerve, II-78–81
zygomatic fracture, II-191–193
Imatinib, II-703–704
Imbrication, III-330
Imipramine (Tofranil), II-873t
Imiquimod, II-734
Immediate implant loading (IIL), I-605–623
advantages, I-606
case study, I-608–610
clinical findings for, I-606
digitally planned and converted technique, I-613–614
extraoral conversion technique, I-613
implant angulation, I-608
intraoral conversion technique, I-610–613
literature review, I-605–608
prosthetic principles, I-607
surgical and prosthetic principles, I-607–608
Immediate implant with immediate provisionalization (IIIP), I-410
advantages of, I-416
esthetic complications of, I-410–412
flapless procedure, I-412f
flapless procedure for, I-413–414
molar, I-418–420
surgical principles for, I-412–418
Immediate provisional restoration, I-416–418
Immune system
description, II-600–601
tumor invasion and, II-620–621
Immunoconjugate therapy, for cancer, II-625–626
Immunodeficiency
craniomaxillofacial trauma management and, II-3t
wound healing affected by, II-259
Immunofluorescence study, II-332
Immunoglobulin, in rheumatoid arthritis, II-839–840
Immunoglobulin A, in linear IgA disease, II-565
Immunohistochemistry, II-333–334
cancer diagnosis and, II-623–624
for melanoma diagnosis, II-694–695, II-695t
Immunostain, II-333f–335f
Immunotherapy, for oral cancer, II-678
Impairment
aging and, I-146
medical professional, I-106
physical and mental, I-143–147
Implant
in acquired and congenital defects, I-665–687
adjacent, I-420–422
adjacent teeth root position and, I-393
alignment, in implant overdentures, I-650–653
allogenic bone graft for, I-428–429
allograft, for chin augmentation, III-464b
alloplastic, I-440–441
for chin augmentation, III-463b
in oculoauriculovertebral spectrum, III-696
in rhinoplasty, III-380
for temporomandibular joint surgery, II-772
alveolar distraction and, I-539f–542f
apicocoronal, I-396–397
autogenous bone graft for, I-427–428, I-446–474
biological models, I-696–699
bone loss around, I-398–401
in bone transport, III-218
Cal bar stabilizing, I-573f
cantilever in, I-599–600, I-600f
case presentations, I-316–320
cement
clinical protocols, I-717–720
issues associated with, I-711–712
properties of, I-714
cement-retained single anterior, I-630–631
chin, III-96, III-104, III-321
in cleft palate repair, III-623
in cleft patient, I-680–683
clinical application, I-316–320
complications, I-323–324
connected, I-647–649
decision making process for, I-632–635
depth, cement margin site and, I-712–720
diameter, I-400
digital workflow protocols, I-688–710
for ectodermal dysplasia, I-675
esthetic
diagnosis, I-391–409
multiple implants and, I-401–405
treatment plan, I-391–409
extraoral, for chin augmentation, III-464b
facial, in cosmetic surgery, III-458–475
facial and lip support, I-584–588
failure, guided bone regeneration for, I-493, I-494f
failure rate of, smoking and, I-412
height, I-653
history, I-311
hyperbaric oxygen therapy, I-678

Implant *(Continued)*
immediate, I-410–425
angulation principles, I-608
buccal plate remodeling after, I-413–414
case study, I-608–610
denture conversion to, I-608–614
digitally planned and converted technique, I-613–614
esthetic complications of, I-410–412
extraoral conversion technique, I-613
intraoral conversion technique, I-610–613
mandibular, I-605–623
molar, I-418–420
multiple, I-420–422
positioning of, I-414–415
surgical and restorative principles for, I-412–418
individual *versus* connected, I-647–649
laser used in, I-340–341, III-349–350
lip, III-474b
location of, for overdentures, I-649–650
malar, III-468b–469b, III-470t
mandibular, I-605–623
maxillary anterior
esthetic zone evaluation, I-449–450
position of, I-414
microthreads at coronal aspect, I-399–400
miniplate, I-313–314
miniscrew, I-311
molar, I-418–420
multiple, I-401–405
neck design, I-399
nerve injury associated with, I-379–380, II-379–380
causes, I-379–380
repair, I-379–380
treatment, I-380
number of
for fixed prosthesis, I-594
illustration, I-647f
one-piece, I-400
osseointegration, I-678
patient condition, I-672–674
pediatric, I-269–270
placement, I-397f
in bone graft site, I-468
case study, I-498b
faciolingual, I-397–398, I-398f
mesiodistal, I-397
platform switching, I-400–401
pontic site development, I-404
position, I-396, I-397f, I-414–415
posterior, decision tree, I-632f
premaxillary, I-575
radiotherapy and, I-677–678
restorative aspects, I-711–722
screw-retained single anterior, I-631
screw *versus* cement, I-631–632, I-711
simultaneous with guided bone regeneration, I-487–491
case study, I-499b
single anterior, I-629–631, I-635
decision tree for, I-635, I-636f
single posterior, I-624–629, I-632–635
cement-retained, I-624–627
decision tree, I-632–635, I-632f
single tooth, I-478f, I-624–640
cement-retained, I-624–627
screw channel in, I-637–639
sinus augmentation simultaneous with, I-517f, I-519–520
sinus lift simultaneous with, I-519f
site development
case study, I-496b–497b
in guided bone regeneration, I-484–487
skeletally based, I-311–324
Implant *(Continued)*
smile line and, I-391–393
soft tissue attachment, I-712, I-713f
soft tissue interface, I-555, I-556f
splinted, I-647–649
surface characteristics, I-400
survival rates, I-672
temporal, in forehead and brow lift, III-421–422
temporomandibular joint, II-771
for temporomandibular joint disorders, II-770–771
tent-pole technique, I-485f–487f
three-dimensional alveolar distraction osteogenesis, I-534–551
three-dimensional imaging for, I-688–710
timing of, I-674–675
tooth position and, I-391–392
types, I-313–316, I-646
virtual planning of, I-611f
zygomatic. *See* Zygomatic implant
Implant-abutment junction (IAJ), I-400–401
Implant overdentures, I-641–664
base adaptation, I-654
base reinforcement, I-655
clinical procedures, I-656–658
complications, I-643–645
contact with ridge, I-654
controversy associated with, I-643–644
design principles, I-645–655
disadvantages, I-643
four-implant, I-656–658
implant alignment, I-650–653
implant-fixed dentures compared to, I-642–643
implant location, I-649–650
implant types for, I-646
loosening of retentive mechanism, I-644–645
mandibular, I-643–646
maxillary, I-646
natural tooth overdentures compared to, I-641–643
number of implants in, I-647f
occlusion, I-655
retentive mechanisms, I-654
three-implant, I-656–658
two-implant, I-645, I-656–658
Implant site, bony anatomy of, I-394–396
Improvised explosive device (IED), II-318, II-319f
Incisal edge, I-591–592
Incision
in alveolar distraction osteogenesis, I-535–536
for bone graft recipient site, I-460
capsular, II-909–910
coronal, for craniomaxillofacial surgery, III-739
craniomaxillofacial surgery, III-739–741
craniosynostosis surgery, III-670
double-opposing Z-plasty, III-544f
endaural, II-908–909
forehead and brow lift, III-408f
guided bone regeneration, I-476–479
impacted maxillary canine, I-290f
intracartilaginous, III-372, III-373f
Killian, III-372, III-373f
laser for, I-330
Le Fort I osteotomy, III-163
Lynch, II-184–185
mandibular movement for, II-787
open-book, I-478f
preauricular, II-908
rhinoplasty, III-371–372, III-377–381
sulcular, I-281f
temporomandibular joint internal derangement surgery, II-908–909
transfixion, III-373f
Incisor
fracture, II-126f
impacted, I-265
implant replacement, I-403
inclination, III-300, III-302f
maxillary
extraction, I-277
fracture, II-132f
implant for, I-420–422
primary, loss of, II-132
Indian Health Service, I-31
Indomethacin
dosage, I-232t
for temporomandibular joint disorders, II-871t
Infant
abnormal head shape, III-647–648
airway, I-239
body composition, I-242
chest wall, I-240
cleft lip and palate
management, III-491–512
presurgical orthopedic treatment, III-561–567
repair, III-503, III-513–533
treatment planning, III-496–497
cleft palate repair goals, III-610
cranial vault sutures, III-646f
craniosynostosis, care algorithm, III-671–675
endothelial tumor, II-534
gingival cyst of, II-365
heart rate, II-249–250
herpes simplex infection, II-555
lymphatic malformation in, II-539
rib cage, I-240f
thermoregulation, I-241–242
Treacher Collins syndrome, III-705–706
Infantile hemangioma (IH), II-534–536
anomalies associated with, II-536
incidence, II-535
management, II-537–538
PHACE association, II-536
phases, II-535
resection, II-537–538
steroid therapy for, II-537
Infection
after otoplastic surgery, III-456
allograft material and, I-429
bone graft healing affected by, I-433–434
facial nerve injury caused by, II-102
frontal sinus fracture associated with, II-241
herpes simplex virus, II-551–556
impacted molar removal and, I-292–293
lymphoma associated with, II-708–709
mandibular fracture and, II-168
in orthognathic surgery, III-290, III-315–316
pediatric, I-260
postsurgical, I-283, I-303
in rhinoplasty, III-383
in rhytidectomy, III-333–335
in sagittal split ramus osteotomy, III-82
salivary gland, II-485–488
sinus, I-579–581, I-581f
wound healing affected by, II-260
Infectious arthritis, II-843–847
Infective endocarditis, III-281b
Inferior alveolar nerve, II-74–75
in distraction osteogenesis, III-776–777
furcation, II-75t
imaging, II-78
injury, II-81
implant surgery as cause of, II-82
in intraoral vertical ramus osteotomy, III-91
in mandibular surgery, III-318
neurosensory testing for, II-88–90
in sagittal split ramus osteotomy, III-80, III-80b
third molar removal as cause of, II-82

Inferior alveolar nerve *(Continued)*
in mandibular fracture, II-168
in sagittal split osteotomy, III-301–305
surgical access, II-91–92, II-93f
Inferior alveolar nerve block (IANB), for pediatric patient, I-258
Inflammation
bone healing and, I-426–427
implant anchor and, I-323
salivary gland, II-485–488
Informed consent, I-62
documentation of, I-77
preoperative, for orthognathic surgery, III-280
professionalism and, I-2
risk management and, I-76–78
Infraction, crown, II-122–123
Infraorbital artery, I-510
Infraorbital nerve, II-76
injury, I-202, II-367–368
surgical access, II-91–92
Infraorbital paresthesia, II-202–203
Infraorbital rim, surgical approaches, II-196–199
Infratemporal fossa, displacement into, I-299–300
Infusion pump, I-218–219
Inhalation anesthesia, pediatric, I-250–251
Inhalation anesthetic drugs, I-206–208
action, I-207
clinical effects, I-207–208
induction, I-220
nitrous oxide, I-220
physical and chemical characteristics, I-207t
structure, I-207
Injection, local, nerve injury associated with, II-81
Injection device
computer-controlled, I-187
needleless, I-187
Injury
avulsive facial, II-282–302
complications, II-300–302
reconstruction, II-283–300, II-287–290f, II-296–297
rehabilitation, II-300
surgical management, II-283
axonal, II-251–252
blunt, pediatric, II-245
burn, II-67–68
cervical, craniomaxillofacial fracture and, II-38
dentoalveolar. *See* Dentoalveolar injury
facial
evaluation, II-41–42
pediatric, II-264–280
firearm-related, II-303, II-307
inhalation, airway affected by, II-11–12
intracranial, craniomaxillofacial fracture and, II-38
lacrimal, II-272–273
maxillofacial gunshot, II-303–328
assessment, II-308–309
treatment, II-307–314
mechanism
in craniomaxillofacial trauma, II-2
trauma patient assessment and, II-10
neurologic, pediatric, II-250–252
ocular, in midface trauma, II-213
pediatric, II-245–263
assessment, II-231–232
epidemiology, II-230–231
evaluation, II-246
patterns of, II-260–261
wound repair after, II-256–261
pediatric craniomaxillofacial, imaging, II-233–240
pediatric facial, physical evaluation, II-232–233
Injury *(Continued)*
shotgun, II-320
soft tissue, pediatric, II-271–273
thermal, airway affected by, II-11–12
zygomatic
complications associated with, II-202–207
treatment, II-193
Instagram, marketing and, I-105–106
Institute of Medicine (IOM), I-73, I-97
Instrumentation, for surgical removal of impacted tooth, I-286, I-286b
Insulin, oral surgery and, I-157t
Insulin growth factor (IGF), II-257–258, II-258t
Insurance, I-82, I-87–95
Insurance claim
incident *versus*, I-83
against oral and maxillofacial surgeon, I-82–83
Insurance contract, I-89
Integrin, II-619–620, II-629
Intensity-modulated radiation therapy, II-590, II-747–748
Interdental distraction osteogenesis (IDO), I-547
Interferon alfa-2b, II-701
Interleukin-1 (IL-1), II-831f, II-832–833, II-884
Interleukins
in temporomandibular joint dysfunction, II-884
in temporomandibular joint internal derangement, II-906
Intermaxillary fixation screw, II-147, II-148f
Internal auditory canal, II-96
Internal derangement (TMJ), II-813f, II-889, II-893–894
arthrotomy procedures, II-910–918
condylotomy for, II-917–918
diagnostic imaging, II-906–907
discectomy, II-911
pathogenesis, II-905–906
patient history, II-904–905
physical examination, II-904–905
postoperative therapies, II-918–919
preoperative therapies, II-907
stages, II-904, II-905b
surgery, II-904–922
surgical approaches, II-908–910
Wilkes classification, II-905b
wound closure, II-910
Internal neurolysis, II-94
International Association for Dental Traumatology (IADT), II-120
Internet
medical information on, I-80
oral and maxillofacial surgery marketing, I-102
Interpersonal relationships, surgical practice and, I-17–22
Interpositional bone graft, I-527–528
Interview
employee, I-113
key points, I-114b
Intracranial hypertension, III-674–675
Intracranial pressure (ICP)
in brachycephaly, III-660
in craniosynostosis, III-645–646, III-675
monitoring, in pediatric brain injury, II-254
in pediatric brain injury, II-252
Intraocular pressure, retrobulbar hemorrhage and, II-207
Intraoral vertical ramus osteotomy (IVRO), III-62–95
case study, III-84b, III-86b
complications, III-90–92
history, III-64
indications, III-83
limitations, III-83
surgical sequence, III-83–90
Intraosseous catheter, I-247
Intraosseous defect, in anterior maxilla, I-448f
Intraosseous hemangioma, II-852–853
Intraosseous odontogenic carcinoma (IOC), II-431–435, II-431f
clinicopathologic considerations, II-435
from epithelial odontogenic tumor, II-435
from odontogenic cyst, II-433
from odontogenic residue, II-433
outcomes, II-435
Intravelar veloplasty, III-535–536, III-538, III-539f, III-612–615
Intravenous access, pediatric, I-247–248
Intravenous agents, pharmacokinetics, I-204t
Intravenous line, in oral and maxillofacial surgery, I-50
Intubation
for airway patency, I-213–214
for pediatric trauma, II-248
Invasion-metastasis cascade, II-619
ION. *See* Infraorbital nerve
Ipilimumab, II-701, II-703–704
Irinotecan, II-757t
Irradiated cancellous allograft (ICA), I-429–430
Isocarboxazid, I-149t
Isoflurane (Forane), I-207–208
Isotretinoin, II-733
Isotretinoin (Accutane), III-355
Itinerant surgery, I-10, I-12
IVRO. *See* Intraoral vertical ramus osteotomy (IVRO)
Ivy, Robert H., I-24, II-146, III-492
Ivy loop fixation, II-146

J

Jaffe-Lichtenstein syndrome, II-470
Jaw
benign non-odontogenic lesion, II-462–480
cysts of, II-340b
exercises for, II-969f
Langerhans cell histiocytosis, II-524
lesions, II-462–480
medication-related osteonecrosis, II-507–522
clinical presentation, II-511–512
pathophysiology, II-509–510
research, II-517
risk factors, II-510–511
staging, II-512–513
treatment, II-514–517, II-516t
non-odontogenic developmental cyst, II-371–375
odontogenic myxoma, II-439–444
osteonecrosis, II-952
osteosarcoma, II-647
sarcoma, II-643–669
snapping, II-766–767
Jaw fracture, third molar removal and, I-285
Jaw recorder, I-657f
Jaws, examination, in dentoalveolar injury, II-117
JCAH. *See* Joint Commission on Accreditation of Hospitals (JCAH)
Jessner's solution, III-443
Joe Hall Morris external fixator, II-317, II-318f
The Joint Commission, I-96–98, I-98t–100t
Joint Commission on Accreditation of Hospitals (JCAH), I-96–97
Joint Commission on the Accreditation of Healthcare Organizations (JCAHO), I-228
Joint mobilization, for temporomandibular joint disorders, II-875
Joint sounds, temporomandibular joint, II-808–809
Justice, principle of, I-10
Juvenile aggressive fibromatosis, III-745–748

Juvenile idiopathic arthritis (JIA), II-131, III-840–841
example, III-137f–141f
temporomandibular joint total replacement, III-239b–240b, III-242
Juvenile nasopharyngeal angiofibroma, III-751, III-754f
Juvenile ossifying fibroma, II-469–470, III-751, III-755f–756f

K

K-wire, mandibular fixation with, II-316, II-317f
Kasabach-Merritt coagulopathy, II-534
Kazanjian, V. H., III-1–2, III-5
KCOT. *See* Keratocystic odontogenic tumor (KCOT)
Keloid, formation of, after otoplastic surgery, III-456
Keratinocyte, II-719
Keratoacanthoma, II-719
Keratoconjunctival herpes, II-555
Keratocyst, odontogenic, II-346–361
Keratocystic odontogenic tumor (KCOT), II-348–361
clinical features, II-350–352
in nevoid basal cell carcinoma syndrome, II-364–365
pathology, II-352–354
surgical management, II-356–361
ultrastructure, II-354
Keratosis, laser surgery for, I-343
Ketamine, I-203–206
action, I-205–206
adverse effects, I-206
BIS monitoring and, I-172
clinical effects, I-206
contraindications, I-206
general anesthesia with, II-13
intravenous sedation with, I-220
metabolism, I-206
for nerve injury, I-318
for neuropathic pain, I-323
for pediatric patient, I-249–251, I-250t
pharmacokinetics, I-204t, I-206
propofol combined with, I-219t
side effects, I-206
structure, I-205–206
topical, I-320–321
Ketoprofen
dosage, I-232t
for temporomandibular joint disorders, II-871t
Ketorolac
dosage, I-232t
preoperative, I-231
Kidney, pediatric, I-241
Kidney disease
preoperative evaluation of, I-140
stages, III-283t
Kiesselbach's plexus, III-366, III-366f
Kinetic energy, gunshot wound and, II-303–305
King-Denborough syndrome, I-253
Kleeblattschädel anomaly, III-669
Klonopin. *See* Clonazepam (Klonopin)
Knight and North fracture classification, II-27t
Koebner phenomenon, I-345–346, II-558
Köle, Heinrich, III-246
Kostecka, F., III-1
Kreins, Otto, III-535
Kybella. *See* Deoxycholic acid

L

L-lysine, II-555
Lacrimal apparatus, II-221
Lambdoid suture craniosynostosis, III-659–660, III-664f
Langerhans cell, II-524–530
Langerhans cell disease, II-464
Langerhans cell histiocytosis (LCH), II-523–533, II-857
classification, II-524t, II-525–526, II-526t, II-526b
clinical varieties, II-523–524
clonality, II-526–527
diagnosis, II-527–530
example, II-525f
histopathology, II-527
prognosis, II-527–530
treatment, II-527–530
Lanz, Otto, II-766, II-769f
Laryngeal mask airway (LMA), I-213–214, I-245–247
description and use, I-214–215
in maxillofacial trauma, II-14, II-14, II-14
sizes, I-247f
Laryngoscope, II-14
Laryngospasm
airway obstruction caused by, I-215
in pediatric patient, I-251–252
treatment, I-252
Larynx
chemotherapy/radiation therapy for carcinoma of, II-754
radiation therapy for carcinoma of, II-742–744, II-745t
Laser
ablation techniques, III-347, III-352–355
absorption, I-327, I-329f, III-340f
alexandrite, III-346
for aphthous ulcer, II-560
argon, III-344
in arthroscopy, II-897
benefits, I-333
blepharoplasty, I-346, III-356
carbon dioxide (CO_2), III-336, III-344
action, I-328–329
for blepharoplasty, III-356
disadvantages, I-333–334
for gingivectomy, III-348
for gingivoplasty, III-352
hard tissue surgery, I-329–330
implant surgery, I-340
incisional and excisional techniques, III-346–347
peri-implantitis treated with, I-727
for skin resurfacing, I-344
wavelength, I-331
components, I-327–328, I-328f, III-337
contact, III-347–348
copper vapor, III-345
cosmetic surgery with, I-343–347, III-355–358
in craniofacial surgery, I-351
diode, I-328–329
crown lengthening with, I-349
for implant surgery, I-341
for scaling and root planing, I-350
wavelength, I-331–332
disadvantages, I-333–334
emission, I-327, I-328f
endodontic treatment with, I-350
endoscopic surgery, III-358–359
erbium, I-333
erbium:chromium:YSGG, I-328–329
erbium:yttrium-aluminum-garnet (Er:YAG), I-328–330, I-333, I-345, III-355
implant surgery, I-340
skin resurfacing, I-344–345
excimer, III-345–346
exposure time, III-340
facial resurfacing with, III-355–356
facial surgery with, I-343–347
Laser *(Continued)*
flashlamp-pumped pulsed dye (FLPPD), III-345
in general dentistry, I-349–350
gingival tissue removal, I-349
hair removal, I-349
hair transplant and removal, III-358
history, III-336
holmium:yttrium-aluminum-garnet, I-341–342, III-359
holmium:yttrium-aluminum-garnet (Hol:YAG), III-345
human tissue affected by, I-328–329
implant care, III-349–350
implant surgery, I-340–341
incisional and excisional techniques, III-346–347
intraoral procedures, III-348–352
KTP, III-345
lesions treated with, I-347–349, III-352–354
light generation, I-327–331
low-level therapy, I-338–340, III-359–360
for lymphatic malformation, II-540
in maxillofacial surgery, III-336–363
mechanical design, III-339–341
microscopic surgery, III-358–359
neodymium:yttrium-aluminum-garnet (Nd:YAG), III-336, III-344–345
description and use, I-332–333
pigmented lesion, I-348, III-357
vascular lesion, I-347–348
nominal hazard zone, III-343
in oral surgery, I-327–353
peri-implantitis treated with, I-350, III-727
photocoagulation techniques, III-346
physics, I-327–331, III-336–337
pigmented lesion treated with, III-357
power, III-337
power density, I-330
Q-switched ruby, I-345, III-348–349
risk associated with, III-341
safety, I-334–335, III-341–344
scar revision, I-346, III-357–358
skin cancer treated with, I-343, II-727–728
skin resurfacing, I-343–344, I-344f
complications, I-345–346
contraindications, I-345
soft tissue, I-335–338
spot size, III-338
surgical technique, I-330, III-337–339, III-346
systems, III-344–346
tattoo treated with, I-348–349
temporomandibular joint surgery, I-341–343
tissue interaction, I-329f, III-339
types, III-339
uvulopalatoplasty, III-351–352
vaporization techniques, III-347
vascular lesion treated with, I-347–348
wavelength, I-331–333
wound healing, I-340, III-348
Laser-assisted uvulopalatoplasty (LAUPP), III-268, III-351–352
Laskin, Daniel, II-771
Lateral crural steal, III-374
Lateral periodontal cyst, II-365, II-424
Lateral pterygoid muscle, II-783–785
Lateral still cephalometry, III-574–575
Latex gloves, anaphylaxis associated with, I-252t
Latex sensitivity, III-284
Latham appliance, III-498, III-516, III-561–562
Law of Primacy, I-46
Lawsuit
frequency of, I-85
resolution, I-84
risk management and, I-83–84

LCH. *See* Langerhans cell histiocytosis (LCH)
Le Fort fracture, II-28, II-213–220
  anatomy, II-214
  diagnosis, II-215–217
  illustration, II-31f
  malunion, II-226
  for midface fractures, II-211–212, II-212f
  radiography of, II-217
  treatment, II-217–220
  type I, II-28, II-32f, II-212f
    description, II-212, II-215
    illustration, II-215f
    treatment, II-217–218
  type II, II-28, II-33f, II-212f
    description, II-212, II-215
    illustration, II-215f
    treatment, II-218
  type III, II-28, II-212f
    description of, II-212, II-215
    illustration, II-216f
    treatment, II-218–220
Le Fort I osteotomy, I-54–55, I-153–171, III-458, III-569–570, III-3
  anesthesia, III-161–162
  for cleft deformity, III-492–493
  complications, III-169–170
  in computer-aided surgical simulation, III-35–36, III-37f
  diagnosis, III-153–161
  history, III-153
  indications, III-153
  lip-to-tooth relationship in, III-24
  for lymphatic malformation, II-540–542
  maxillary hypoplasia and, III-638–639
  maxillary segmentation, III-165–166
  in maxillomandibular advancement, III-271f
  multi-piece, III-54–55
  in oculoauriculovertebral spectrum, III-696
  operative technique, III-161–168
  patient positioning, III-161–162
  planning, III-153–161
  segmental, III-172–182
  single-piece, III-54
  three-piece, III-176f
  in Treacher Collins syndrome, III-731
  two-segment, III-28–29
  for vertical maxillary excess, III-156f–157f
Le Fort I segmental surgery, III-172–182
  complications, III-178
  indications, III-172–173
  postoperative care, III-177–178
  presurgical preparation, III-173–174
  surgical technique, III-175–177
Le Fort III fracture, II-18
Le Fort III osteotomy, III-678f, III-4
  mandibular
    complications, III-144–145
    endoscopically assisted, III-144–152
    history, III-113–114, III-144, III-1–2
    with maxillary, III-183–195
    surgical technique, III-144–147
  mandibular ramus, III-62–95
  mandibular subapical, III-2
  maxillary, III-163–164
    history, III-2–3
    with mandibular, III-183–195
    in multiple segments, III-3
    three-piece, III-176f
  maxillary distraction and, III-208–212
  midface, III-4
  for midface cleft reconstruction, III-601
  nasal, III-164–165, III-378–380
  in oculoauriculovertebral spectrum, III-696
  relapse after sagittal split, III-116b
  sagittal split, II-86, III-113–114, III-144, III-204, III-2, III-4
Le Fort III osteotomy *(Continued)*
    complications, III-298–319
    nerve injury associated with, III-301–308
  sagittal split ramus, III-62–95
  septal, III-164–165
  sinus augmentation, I-514
  sliding genioplasty, III-102
  subcranial, III-678f
  symphysis widening, III-200
  vertical ramus, III-62–95, III-144–145
  vertical subcondylar ramus, III-313–314
  vomerine, III-164–165
  zygomatic fracture malunion, II-204–205
  zygomatic implant, I-574, I-576
LEAD system, I-539–540
Leadership, in oral and maxillofacial surgical practice, I-108
Lease agreement, I-61
Legacy, I-139
Legal documents, I-59–61
Legal entity
  comparison of, I-59t
  oral and maxillofacial surgical practice as, I-58–59
Legan's angle, chin position analysis with, III-460t–461t
Leiomyosarcoma, II-644t, II-645–646, II-656–658
Lentigo maligna melanoma, II-692t, II-693f
Lesion, II-338–390. *See also* Cyst
  aneurysmal bone cyst, II-467–468
  benign non-odontogenic, II-462–480
  central giant cell granuloma, II-462–464
  cherubism, II-466
  desmoplastic fibroma, II-476–478
  fibro-osseous, II-468–471
  giant cell
    classification, II-463t
    hyperparathyroidism and, II-464–465
  giant cell granuloma, II-462–464
  granular cell, III-756–757
  intraoral vascular, III-354–355
  jaw, II-849
  juvenile ossifying fibroma, II-469–470
  Langerhans cell histiocytosis, II-523
  laser for ablation, III-347
  laser for excision, I-336f, I-338, I-339f
  laser treatment, I-336–338, I-348–349, III-352–354
  malignant, III-354
  margin, II-728
  mouth floor, II-379f
  mucosal, laser for, I-336
  multinucleated giant cell, II-462–468
  neurofibroma, II-472
  odontogenic, II-391–392
  oral and maxillofacial region, II-338–390
  osteoblastoma, II-473–474
  osteochondroma, II-476
  parotid gland, II-485
  pigmented, laser treatment, I-348–349, III-357
  salivary gland, II-482
  skin, herpetic infection and, II-552
  vascular, laser treatment, I-347–348, III-356–357
Letterer-Siwe disease, II-523
Leukoplakia, laser treatment, I-336–338, III-352–353
Levonordefrin
  local anesthetics and, I-178–179
  maximum dosage of, I-182t
  selectivity and potency of, I-180t
Levorphanol (Levo-Dromoran)
  dose and potency, I-229t–230t
  for temporomandibular joint disorders, II-872t
Li-Fraumeni syndrome, II-644
Liability insurance, I-82
Librium. *See* Chlordiazepoxide (Librium)
Lichen planus, I-336–338, II-352, III-558–559
Lidocaine, I-186
  chemistry of, I-177f
  concentration, I-177t
  contraindications, II-555–556
  duration, I-179t
  local anesthesia with, I-232–233
  for nerve injury, I-316
  nerve injury associated with, I-183t
  onset time, I-178t
  potency, I-176
  side effects, I-180–181
Ligament(s)
  articular disc, II-778–779
  capsular, II-799–800
  extracapsular, in temporomandibular joint, II-780
  orbital, III-402, III-404f
  periodontal. *See* Periodontal ligament
  sphenomandibular, II-780–781
  stylomandibular, II-780–781
  temporomandibular joint, II-780–781, II-799–800
Light
  absorption of, III-336–337
  exposure, melanoma associated with, II-690–691
  laser emission of, III-337, III-338f
Lighting, for oral and maxillofacial surgery, I-48
Limited liability company, I-58–59, I-59t
Limited partnership, I-58
Linear IgA disease, II-565–566
Linezolid, parotitis treated with, II-486–487
Lingual frenum
  prominent, I-271f
  surgery, I-271–272
Lingual nerve, II-75, II-147
  furcation, II-75t
  injury, I-81–87, I-317f, II-367
    bilateral sagittal split osteotomy and, I-379
    during exodontia, I-302
    local anesthetic associated with, I-377
    outcomes and conclusions, I-382–383
    sagittal split osteotomy associated with, III-305
    in sagittal split ramus osteotomy, III-80
    from third molar extraction, I-380–382
  neuroma, II-94f
  relationship of, to mandible, II-76t
  retraction, I-381
  surgical access, II-92f
Lioresal. *See* Baclofen (Lioresal)
Lip
  botulinum neurotoxin for, III-441
  cancer, II-735–737
  competency, III-97f
  deformity, genioplasty for, III-98
  in dentoalveolar injury evaluation, II-117
  filler, III-472b–473b
  implant, III-474b
  maxillary incisor relationship, III-24
  reconstruction, II-297–298
  trauma repair, II-276
  wound closure, II-54–57
Lip adhesion, in cleft repair, III-498–499
Lip length, smile line and, I-588–591
Lip-lift technique, I-699–701, I-702f
Lip support
  classification, I-585
  derivation, I-587
  for implant, I-584–588
  maxilla positioning and, I-592
Lip-to-tooth relationship, III-24

Lipid solubility, local anesthetic drugs and, I-177t, I-178
Lipoadenoma, II-500–503
Lipophilic aromatic ring, I-176
Liposarcoma, II-644t, II-645–646, II-661
Liposuction, III-429–438
  complications, III-433
  postoperative care, III-433
  preoperative evaluation, III-430–431
  technique, III-431–432
Lithium, management, I-149t
Lithotripsy, laser, III-359
Little's area, III-366
Liver
  benzodiazepine metabolism in, I-195
  metabolic reactions of drugs, I-196t
  pediatric, I-241
Liver failure, craniomaxillofacial trauma management and, II-3t
LLLT. *See* Low-level laser therapy
LMA. *See* Laryngeal mask airway (LMA)
Loading, immediate implant, I-605–623
  denture conversion to, I-608–614
  success, I-606–607
  surgical and prosthetic principles, I-607–608
Local anesthetics. *See* Anesthetic drugs, local
Locator attachment, I-652f, I-654, I-656–658
Lonidamine, II-756t
Lorazepam (Ativan), I-197
  half-life, I-195t
  protein binding, I-195t
  structure, I-196f
  for temporomandibular joint disorders, II-874t
Lorenz, Walter, III-6
Loss of consciousness, pediatric trauma assessment and, II-246–247
Low-level laser therapy (LLLT), I-338–340, III-359–360
Luhr, Hans, III-63, III-183
Luminal. *See* Phenobarbital (Luminal)
Lung, pediatric, I-240–241
Luxation
  in dentoalveolar injury, II-124f, II-127
  extrusive, II-127
  intrusive, II-127–128
  lateral, II-127
Lyme disease, II-846–847
Lymph node
  biopsy, for melanoma diagnosis, II-697–698
  divisions, II-670
  groups, II-676t
  lymphoma, II-707
  oral cancer staging and, II-676t
  oral cancer survival rates, II-685f
  radiation therapy, II-742
  skin cancer involvement in, II-723, II-726, II-730–732
Lymphadenopathy, Langerhans cell histiocytosis and, II-527
Lymphangioma, II-539
Lymphatic malformation, II-539–542
Lymphoepithelial cyst, II-485
Lymphoepithelioma, II-744–745
Lymphoma, II-707–716
  angiocentric, II-710–711
  Ann Arbor staging system, II-708–709, II-714b
  B-cell, II-707, II-710
  diagnosis, II-707–709
  parotid gland, II-500
  post-transplant, II-711
  radiation therapy, II-741
  radiographic evaluation, II-711–712
  staging, II-708, II-714b
  survival rate, II-714
  T-cell, II-707, II-710
  treatment, II-713–714
Lymphonodular pharyngitis, II-556–557
Lynch incision, II-184–185
Lyrica. *See* Pregabalin (Lyrica)

M

Macrophage, wound healing and, II-257
Mafenide acetate, II-67
Magnetic resonance imaging (MRI). *See also* Imaging
  cervical spine injury assessment with, II-11
  craniomaxillofacial pathologies, III-738–739
  facial nerve imaging, II-99–100
  facial pain, II-947
  nerve imaging, II-80–81
  odontogenic tumor, II-392
  oral cancer evaluation, II-675
  parotid gland tumor, II-493–494
  pediatric brain injury, II-251f
  process, II-822
  salivary gland, II-481–483
  sarcoma, II-645
  skin cancer, II-725
  temporomandibular joint, II-821–824, II-823f
  temporomandibular joint disorder, II-802–804, II-820–824
  temporomandibular joint internal derangement, II-906
  temporomandibular joint reconstruction, III-223–224
Malformation, definition, III-628t
Malignancy
  in cancer progression, II-600f
  laser treatment, III-354
  maxillofacial region, II-590
  pediatric, III-757–763
Malignant ameloblastoma, II-401, II-420–422
Malignant fibrous histiocytoma, II-644t, II-645–646, II-651–652
Malignant hyperthermia (MH)
  in pediatric patient, I-253
  treatment, I-253
Malignant mixed tumor, II-493t
Mallampati classification, I-213t, I-242–243, III-283, III-283t
Mallampati test, I-213
Malocclusion
  class II, I-319, I-322, III-637
  class III, III-596
    correction of, I-320, III-184
    in maxillary hypoplasia, III-638–639
  in mandibular fracture treatment, II-168
  midface fracture as cause of, II-216
  severe, miniplate for, I-313
  in Treacher Collins syndrome, III-703, III-706, III-724
Malpractice insurance, I-82
MALT lymphoma, II-708b, II-710, II-711f, II-713
Managed care
  contracting, I-62
  marketing and, I-132–133, I-107
Management
  principles, I-134
  surgical practice, I-18
Mandible
  advancement, III-110f, III-147
  ameloblastoma in, II-402, II-412f–414f
  anatomic regions, II-149f
  anatomy, II-147–152
  aneurysmal bone cyst, II-467
  arteriovenous malformation, II-88f, II-547f
  asymmetric, III-72b
  atrophy, II-166
  blood supply, II-147
  bone graft, I-666–668
Mandible *(Continued)*
  bone harvested from, I-453–455
  cherubism, II-466–467
  condylar head shapes, II-780f
  condyle, II-794
  counterclockwise rotation, III-116–119
  cysts in, II-340f
  deformity correction, with computer-aided surgical simulation, III-39
  distraction osteogenesis, III-147, III-776–778
  examination, in trauma patient, II-4–5
  extraoral surgery, III-189
  fracture. *See* Mandibular fracture
  free movement, II-786–787
  growth rate, III-629t, III-632–635
  high-energy gunshot wound, II-318–320
  hyperplasia, III-638
  hypoplasia, III-637–638
  impacted molar, I-265–266
  inconsistent centric relation, III-187–188
  innervation, II-147
  keratocystic odontogenic tumor, II-350
  Langerhans cell histiocytosis, II-524
  lateral shift, II-787
  lengthening, III-202–208
    clinical indications, III-202–204
    in oculoauriculovertebral spectrum, III-695
  lingual nerve relationship to, II-76t
  malformation, in Treacher Collins syndrome, III-707–731
  masticatory movement, II-787–788
  mobilization, III-3–4
  morphogenesis, III-476–477
  movement, II-786–787, II-807
  myeloma, II-89f
  non-Hodgkin lymphoma, II-712
  odontogenic fibroma, II-436f
  odontogenic myxoma, II-440f–443f
  osteoblastoma, II-473–474
  osteomyelitis, II-89f
  osteosarcoma, II-647
  overdentures, I-643–644
  pediatric ablative defect reconstruction, III-766
  posterior, as bone graft donor site, I-455–457
  prognathic, III-83, III-84b, III-86b
  protrusion, II-787
  range of motion, II-16, III-805–806
  reconstruction, II-296–297, II-298f
    rib graft for, III-766–767
    in Treacher Collins syndrome, III-724–730
  relapse of advancement, III-637
  resection guide, I-675f–677f
  retrognathia, III-115f
  retrognathic, case study, III-86b
  retrusion, II-787
  segmental resection, I-666, I-668
  surgical access, III-740
  three-dimensional image, I-690–692
  transverse deficiency, III-196, III-200f
  in Treacher Collins syndrome, III-706–731
  vertical defect, I-539f–544f
  widening, III-196–202
    genioplasty with, III-201
    postoperative care, III-202
    surgical planning, III-197–199
Mandibular deficiency, III-300, III-301t, III-637–638
  case study, III-65b, III-68b–71b
  chin hyperplasia, III-306f
  chin hypoplasia, III-309f
  inverted L osteotomy, III-113–143
  with long face, case study, III-70b–71b
  treatment planning, III-119–120
Mandibular fossa, II-778

Mandibular fracture, II-28–35, II-37f, II-146–173
  angle fracture, II-166, II-169f
  atrophic, II-166–167
  biomechanics, II-149–151
  bone healing, II-151
  classification, II-148–151
  comminuted, II-319f
  complications, II-168
  condyle fracture, II-165–166
  controversy, II-165–167
  in dentoalveolar injury, II-123t
  displacement, II-151
  exodontia associated with, I-307
  favorable, II-149, II-150f
  following third molar removal, I-295
  gunshot wound, II-315–316
  hardware materials, II-162–164
  history of treatment, II-146–147
  imaging, II-153
  infection associated with, II-168
  multiple, II-35f
  muscular forces on, II-149
  nerve injury associated with, II-84–85, II-168
  open reduction, II-135f
  pathogenesis, II-147
  pathologic, II-34–35, II-37f
  patient assessment, II-152–153
  pattern and incidence, II-34f, II-151
  pediatric, II-270, II-35–38, II-38f, II-167
  stabilization, II-1–2
  tooth removal associated with, II-165
  treatment, II-153–164
    closed technique, II-153
    endoscopic approach, II-161–162
    intraoral/transbuccal approach, II-155–158
    open techniques, II-155
    transcervical-retromandibular approach, II-160–161
    transcervical-submandibular approach, II-158–160
  unfavorable, II-149, II-150f
Mandibular nerve block, nerve injury associated with, II-950
Mandibular osteotomy, III-62–95, III-144–152
  complications, III-144–145
  history, III-113–114, III-1–2
  mandibular osteotomy combined with, III-183–195
  subapical, III-2
  surgical technique, III-144–147
Mandibular ramus, as bone graft donor site, I-455–457
Mandibular region, bones of, II-18–20
Mandibular retrognathia, III-115f, III-776
Mandibular ridge
  bilateral atrophic, I-527f
  deficient, I-669f–670f
  triangular, three-implant prosthesis for, I-648f
Mandibular space, airway assessment and, I-243
Mandibular surgery, III-297–324
  complications, III-297, III-316–319
  hemorrhage in, III-310–313
  infection, III-315–316
  nerve injury in, III-300–301
  relapse following, III-317–318
  risk factors, III-297–298
  temporomandibular joint dysfunction associated with, III-317
Mandibular symphysis, as bone graft donor site, I-453–455
Mandibulofacial dysostosis, III-703
Mannitol, intraocular pressure treated with, II-207
Mantle cell lymphoma, II-710, II-713
Marfan syndrome, II-259
Margin
  in surgical excision, II-729–730
  tumor, II-728
Marginal bone loss, smoking and, I-514
Marie-Strümpell disease, II-842
Marine algae, alloplastic implant with, I-440–441
Marketing, I-102–136
  academic, I-107
  blog, I-104–105
  communication, I-134–136
  consultation, I-125–126
  cosmetic surgery, I-130–132
  definition, I-107
  employee hiring and firing, I-110
  Facebook, I-105
  Flickr, I-105
  four P's of, I-107
  image, I-118
  internal, I-126–127, I-131
  logo, I-118
  managed care, I-132–133
  materials, I-122–123
  to media outlet, I-128–129
  newsletter, I-127–128
  oral and maxillofacial surgical practice, I-64
  out-of-town patients, I-106
  patient waiting time and, I-120–121
  payment plans, I-129–130
  plan, I-117–136
  procedure-specific, I-126
  professional consultation, I-110–111
  Realself, I-106
  social media for, I-103–106
  synergy, I-123
  target market, I-122
  website for, I-103
  YouTube, I-105
Marketing plan, I-117–136
Markowitz classification, II-30f, II-222f
Markowitz fracture, II-221–223
Marsupialization, for odontogenic keratocyst, II-357–361
Massad impression tray, I-656f
Massad jaw disposable recorder, I-657f
Massage, for temporomandibular joint disorders, II-876
Masseter muscle, II-781–782, II-785
Mast cell, in neurofibroma, II-472
Mastication, mandibular movement for, II-787–788
Masticatory muscle
  evaluation, II-810
  pain, II-962
Maxilla
  advancement, III-106f–107f, III-596–598, III-600
  ameloblastoma, II-402, II-415f–416f
  anatomy, III-161
  aneurysmal bone cyst, II-467
  anterior deficiency, three-dimensional imaging for, I-688–696
  anterior teeth, positioning of, I-592
  aseptic necrosis, III-178
  atrophic subtotal, I-545f–546f
  bone-borne template, I-699–704, I-704f
  bone quality, I-594
  capillary malformation, II-538
  cherubism, II-466–467
  chondrosarcoma, II-649
  cleft, III-497
    bilateral, III-589–592
    history, III-583–584
    management, III-583–595
    reconstruction, III-589–592
    stabilization, III-606–607
Maxilla *(Continued)*
    surgical options, III-583–584
    timing of grafting procedure, III-586–587
    unilateral, III-589
  cyst, II-340f, II-346f
  deformity correction, with computer-aided surgical simulation, III-38–39
  dentigerous cyst, II-355f
  distraction osteogenesis, III-208–214, III-778
  double jaw surgery repositioning, III-53–55
  down-fracture, III-165, III-175–177, III-176f
  edentulous
    arch form in, I-595–596
    case presentation, I-601–602
    cost of restoration, I-596–597
    fixed restoration, I-584–604
    historic perspective, I-569–570
    prosthetic conversion technique, I-577–578
    ridge form in, I-595–596
    surgical options, I-573
    treatment planning, I-592–597
    zygomatic implant for, I-569–583
  examination, in trauma patient, II-4–5, II-6f
  fracture, II-15, II-32f–33f
    comminuted, II-320f
    in dentoalveolar injury, II-123t
    exodontia associated with, I-307
    pediatric, II-35–38, II-243
  growth rate, III-629t, III-630–632
  high-energy gunshot wound, II-318–320
  horizontal position, III-24–27
  hypoplasia, III-638–642, III-639f, III-778
  impacted canine, I-261–262
  implant in, example of, I-463f
  intraosseous defect, I-448f
  Langerhans cell histiocytosis, II-524
  midface fracture effect on, II-216
  mobilization, III-3–4
  morphogenesis, III-476–477
  non-Hodgkin lymphoma, II-712
  osteosarcoma, II-647
  reconstruction, I-299f, II-283–300, III-724–730
  repositioning, III-17f–22f
  resection guide, I-675f–677f
  roll orientation, III-23–24
  segmental bone defect, I-549f–551f
  segmental surgery, III-172
    complications, III-178
    postoperative care, III-177–178
    preparation, III-173–174
    technique, III-175–177
  segmentation, III-172
    in Le Fort I osteotomy, III-165–166
    in orthognathic surgery, III-28–29
  subluxation, II-768b
  three-dimensional image, I-690–692
  transverse deficiency, III-199f
  Treacher Collins syndrome, III-706, III-724–730
  v-shaped, III-197f
  vascular supply, III-161, III-162f
  vertical defect, I-547f, III-642
  vertical distraction osteogenesis, I-532
  yaw orientation, III-23
  zones, I-570f
Maxillary arch
  reconstruction, II-285–286
  thermoregulation, I-691f
  three-dimensional image, I-690–692
Maxillary artery, I-510
Maxillary cant, correction, III-137f–141f
Maxillary crest, load bearing function, I-571
Maxillary hypoplasia, Le Fort I osteotomy for, III-153
Maxillary obturator appliance, III-550–551, III-553–554

Maxillary osteotomy, III-163–164, III-183–195
Maxillary region, bones of, II-18
Maxillary sinus, I-509–510
  ameloblastoma, II-415f–416f
  augmentation
    graft materials, I-510–513
    preoperative evaluation, I-513–514
    pretreatment, I-510–513
  blood supply, I-510, I-510f
  cone-beam computed tomography evaluation, I-514
  displacement into, I-299
  drainage, I-581f
  infection, I-579–581
  injury, during exodontia, I-301–302
  pseudocyst, I-510
  radiographic evaluation, I-514
  vascular supply, I-510
Maxillary tuberosity, as bone graft donor site, I-452–453
Maxillofacial region
  cancer, II-742
  cysts, II-338–390
  herpes simplex infection, II-551–552
  lymphoma, II-707, II-712
  malignancy, II-590
  pathology, nerve injury associated with, II-87
  trauma, pediatric, II-264–280
  in Treacher Collins syndrome, III-706
  vascular anomalies, II-534–549
Maxillomandibular advancement (MMA)
  for obstructive sleep apnea, III-269–274
  outcomes, III-272–274
  postoperative care, III-272
  risks and complications, III-272
Maxillomandibular complex, counterclockwise rotation, III-116, III-121f–123f
Maxillomandibular fixation (MMF), II-316
  for condylectomy, III-147
  in Le Fort I osteotomy, III-166–167
  for Le Fort I segmental surgery, III-177–178
  for mandibular osteotomy, III-145
  in maxillomandibular advancement, III-271
  for pediatric condylar fracture, II-270
  for pediatric patient, II-280, II-270
  Risdon wire, II-270
Maxillomandibular region, in Treacher Collins syndrome, III-706
Maxillomandibular relationship, assessment, I-688–689
Maximal stimulation test, II-103–104
Mayo stand, I-49
McCune-Albright syndrome, II-470, III-751, III-753, III-757f–760f
McGill Pain Inventory, I-90, II-313
McKinney's point, III-328–329
Mechanical stress, joint function and, II-830
Mechanism of injury
  craniomaxillofacial trauma, II-2
  facial nerve, II-100–103
  pediatric, II-245
  trauma patient assessment, II-10
  trigeminal nerve injury, II-81–87
Mechlorethamine, II-714
Meckel's cartilage, I-526
Meclofenamate, II-871t
Media, marketing to, I-128–129, II-869–873
Medial pterygoid muscle, II-783, II-785
Median mandibular cyst, II-375
Median palatal cyst, II-375
Medical conditions, trauma management and, II-3t
Medical education
  behavior in, I-6–9
  history, I-2
  professionalism in, I-4
  teaching professionalism in, I-7–8
Medical Group Management Association (MGMA), I-125
Medical history
  craniomaxillofacial trauma assessment and, II-2–4
  for facial pain evaluation, II-944–945
Medical leave of absence, I-145
Medicare, I-89–91
Medication
  adjunct, I-233–234
  for cancer treatment, II-626–627
  for dental procedure, I-152t
  non-opioid analgesic, I-232
  osteonecrosis of jaw and, II-507–522
  pediatric dosage, I-250t
  pediatric response, I-242
  pharmacology, I-191–210
  preoperative evaluation, I-139
  selection, for sedation, I-212
  temporomandibular joint disorder, II-869–873
  topical, for skin cancer, II-733–734
Medication-related osteonecrosis of the jaw (MRONJ), II-507–522, II-952
  clinical presentation, II-511–512
  established, therapy for, II-515–517
  pathophysiology, II-509–510
  research, II-517
  risk factors, II-510–511
  risk minimization, II-514
  staging, II-512–513
  treatment, II-514–517, II-516t
Mefenamic acid, for temporomandibular joint disorders, II-871t
Megakaryocyte proliferation, I-160t
Melanin, absorption spectrum, I-329f
Melanocyte, II-357, III-702
Melanoma, II-690–706
  classification, II-696t
  clinical staging groups, II-699t
  diagnosis, II-692–697
  epidemiology, II-690
  etiology, II-690–692
  histologic features, II-696t
  incidence, II-690–692
  laser surgery for, I-343
  M classification, II-699t–700t
  management, II-697–698
  microinvasive, II-695
  mucosal malignant, II-702–704
  N classification, II-699t–700t
  nodular, II-693f
  oral, II-691f–692f, II-702–704
  pathologic staging, II-700t
  pediatric, II-690
  risk factors, II-691, II-691b
  in situ, II-695
  staging system, II-693, II-698–700
  statistics, II-691b
  subtypes, II-692t
  T classification, II-699t–700t
  treatment, II-700–702
Melanosome, III-357
Melanotic neuroectodermal tumor of infancy, III-757
Meloxicam, II-871t
Membrane
  bacterial contamination, I-482
  barrier, I-462–463, I-475
    selection, I-480–483
    in sinus augmentation, I-513
    tent-pole technique, I-488f
  collagen, I-462–463, I-482, I-485f–487f
  non-resorbable, I-481–482
  placement, I-479
  polytetrafluoroethylene, I-462–464, I-464f, I-480–482
Membrane *(Continued)*
  requirements, I-480
  resorbable, I-462–463, I-479, I-482–483
  selection, I-480–483
  socket preservation and, I-493
  space maintenance and, I-479
  synthetic, I-482
Meningitis
  frontal sinus fracture associated with, II-243
  herpetic, II-555
Mental health, patient, preoperative evaluation, III-286
Mental nerve
  in genioplasty, III-101, III-102f
  injury, during exodontia, I-302
  surgical access, II-91–92
Mentocervical angle, III-99
Menton point
  facial symmetry and, III-96
  ideal, III-100f
Meperidine (Demerol), I-199–200
  anaphylaxis associated with, I-252t
  dose and potency, I-229t–230t
  equianalgesic dosage, I-231t
  neurotoxicity, I-228
  pharmacokinetics, I-230t
  structure, I-199f
  synthesis, I-197–198
  for temporomandibular joint disorders, II-872t
Mepivacaine, I-186
  concentration, I-177t
  duration, I-179t
  local anesthesia with, I-232–233
  nerve injury associated with, I-183t
  onset time, I-178t
Meprobamate (Miltown), II-874t
Merkel cell carcinoma, II-720, II-734–735
Merrifield Z-angle, chin position analysis with, III-460t–461t
Mesenchymal odontogenic tumor, II-435–455
Mesiodistal placement, implant, I-397
Mesoneurium, in nerve anatomy, II-77–78
Messenger ribonucleic acid (mRNA), II-603, II-604f, II-623
Metabolic arthritis, II-847–848
Metabolic equivalent (MET)
  of activities, III-281t
  preoperative evaluation and, I-139, I-151t
Metabolism, monitoring, I-169
Metastasis
  cancer progression, II-600f
  cancer therapy and, II-629
  description, II-619–621
  diagram, II-620f
  perineural invasion and, II-722
  skin cancer, II-726
Methadone (Dolophine)
  dose and potency, I-229t–230t
  pharmacokinetics, I-230t
  for temporomandibular joint disorders, II-872t
Methemoglobin, I-168
Methemoglobinemia, I-185
Methocarbamol (Robaxin), II-872t
Methohexital, I-201–203
  distribution, I-205f
  pharmacokinetics, I-204t
Methotrexate, II-562, II-713, II-756t–757t
Methoxazepam, I-196f
Methylnaltrexone, I-198f
Methylparaben, I-176–177, I-182
Methylprednisolone (Depo-Medrol), III-287t
  after nerve surgery, I-373
  for facial pain, II-955t, II-957
  in orthognathic surgery, III-289
  in temporomandibular joint arthrocentesis, II-887

Metopic suture craniosynostosis, III-657–659, III-661f–662f
Metronidazole
  medication-related osteonecrosis treated with, II-516
  peri-implantitis treated with, I-725–726
  postoperative infection treated with, I-303
MH. *See* Malignant hyperthermia (MH)
Michelet genioplasty, III-101
Michel's solution, II-332
Micro-computed tomography, I-443
Microcystic adnexal carcinoma, II-719
Microneurosurgery
  contraindications, II-92t
  indications, II-90–91, II-92t
  outcomes, II-96
  for trigeminal nerve injury, II-91–96
Microsatellite instability (MSI), II-608–609
Microsomia
  craniofacial, III-636f
  hemifacial, III-158f–160f, III-638f
Microvascular free flap, II-294–296
Midazolam, I-195–196
  clinical effects, I-194
  fentanyl combined with, I-218
  half-life, I-195t
  pediatric dosage, I-250t, I-251
  pediatric premedication with, I-248–249
  pharmacokinetics, I-204t
  protein binding, I-195t
  structure, I-196f
Middorsum palatal stop, III-572
Midface
  anatomy, II-211
  blood supply, II-214
  bones, II-18
  in craniosynostosis, III-676
  description, II-211
  distraction osteogenesis for advancement, III-778
  growth, in cleft palate repair, III-542–543
  high-energy gunshot wound, II-318–320
  hypoplasia, III-630–632
  innervation, II-214
  pediatric injury patterns, II-260
  reconstruction, II-297–300
  surgical access, III-740
  in two-stage palatal repair, III-548–549
Midface deficiency, III-596
  bone graft, III-602–605
  orthognathic surgery, III-619
  presurgical evaluation, III-596–597
  psychosocial considerations, III-597
  surgical reconstruction, III-597–600
  timing of surgery, III-597
Midface fracture, II-211–229
  classification, II-211–213, II-215
  complications, II-225–227
  diagnosis, II-212–213, II-215–217
  endoscopic repair, II-227
  imaging, II-213
  Le Fort classification, II-213–220
  malunion, II-225–226
  pediatric, II-270
  treatment, II-217–220
Midline, facial, in orthognathic surgery, III-23
Migraine headache, facial pain and, II-944–945
Milk, avulsed tooth stored in, II-130
Millard, Ralph, III-492
Millard technique
  anatomical landmarks, III-516f
  cleft lip repair with, III-513–516
  markings and measurements, III-517f
  surgical procedures, III-516–519
  Tennison technique compared to, III-521–523, III-525
Miltown. *See* Meprobamate (Miltown)
Miniplate, I-313–314
  as anchor, I-313, I-311
  case presentation, I-318, I-319f
  clinical applications, I-316–318
  complications, I-323
  materials, I-320–323
  maxillary, placement of, I-322f
  open bite treated with, I-316–318, I-313
  placement, I-320–321
  screw fixation, I-313
  surgical placement, I-318
  surgical technique, I-320–323
Miniscrew implant (MSI), I-314–316, I-311
  adjunctive care, I-322
  as anchor, I-313
  bone considerations, I-315–316
  case presentations, I-318–319
  for class II malocclusion, I-322f
  complications, I-323
  design, I-315
  drill *versus* self-drill, I-316
  example of, I-315f
  for impacted second molar, I- 321f
  orthodontic loading, I-316
  placement angle, I-316, I-323
  placement technique, I-321–322
  self-drilling, I-321
  success rate, I-314
  torque, I-315
Minocycline HCL
  peri-implant disease treated with, I-725f
  peri-implantitis treated with, I-725–726
Mirror image routine, III-39, III-39f
Mitochondria, cancer diagnosis and, II-622–623
Mixed connective tissue disease, II-848
Mixed odontogenic tumor, II-444–455
Model, presurgical, III-44
Model for End Stage Liver Disease (MELD), I-141, I-156f
Modifiers, in coding, I-93–94
Mohs micrographic surgery, II-719–720, II-728–729, II-729b
  surgical excision *versus*, II-730
  surgical margin in, II-730
Molar
  displacement of, into submandibular space, I-300–301
  immediate implant for, I-418–420
  impacted, I-265–266, I-267f
  mandibular
    extraction, I-277–278
    sectioning and removal, I-281, I-282f
  maxillary
    extraction, I-277, I-279f
    sectioning and removal, I-281, I-283f
  second, impacted, I-319, I-321
  third
    caries, I-284
    cyst, II-343, II-345f
    displacement into infratemporal fossa, I-299–300
    dry socket after removal of, I-303
    eruption potential, I-286
    extraction complications, I-77
    impacted, I-80f, II-286–288
    incision for, I-287
    indications for removal, I-283–284
    infection following extraction, I-293
    injury from removal of, II-82
    nerve damage following extraction, I-294, I-380–382
    nerve damage treatment, I-382
    in orthognathic surgery, III-279
    pain following extraction, I-225
    postsurgical periodontal healing, I-295
Molar *(Continued)*
    sectioning for removal, I-287–288
    surgical extraction complications, I-293–295
    surgical technique for removal, I-286–288
    trigeminal nerve injury and, I-354
  transplantation, I-268
Molecular biology, II-336
  of cancer, II-599–642
  cancer treatment and, II-622–629
Monitored anesthesia care (MAC), I-213
Monitoring
  anesthesia, I-164
  blood pressure, I-165–166
  body temperature, I-170
  circulation, I-169
  history and evolution, I-165–173
  metabolism, I-169
  neuromuscular, I-170–171
  patient, I-164–175
  recovery, I-172–173
  respiration, I-169–170
  respiratory system, I-167–169
  sedation depth, I-171–172
Monoamine oxidase inhibitor drugs
  management, I-149t
  for temporomandibular joint disorders, II-872–873
Monroe-Kellie doctrine, II-252
Moose, Sanford, III-64, III-2
Morphine
  anaphylaxis associated with, I-252t
  discovery, I-197
  dose and potency, I-229t–230t
  equianalgesic dosage, I-231t
  for facial pain, II-953, II-954t
  pharmacokinetics, I-230t
  structure, I-198f
  for temporomandibular joint disorders, II-872t
Morris, Joe Hall, I-24
Morris, John, II-767–768
Motion, passive, in temporomandibular joint, II-833–835
Motor vehicle accident (MVA), II-10
  dentoalveolar injury from, II-114
  injury from, II-41–42
  pediatric injury and death from, II-245
Motrin. *See* Ibuprofen (Advil, Motrin)
Mouth floor
  anatomy, II-671
  cancer, II-679–680
  cyst, II-380f
  in dentoalveolar injury evaluation, II-117
  lesion, II-379f
Mouth rinse, steroid, II-551
Mouthguard, II-271
  dentoalveolar injury prevention, II-141
  types, II-141
Mouthwash
  oral hygiene and, II-551
  steroid, II-551
MRONJ. *See* Medication-related osteonecrosis of the jaw (MRONJ)
MSI. *See* Miniscrew implant (MSI)
Mucocele
  frontal sinus fracture as cause of, II-243
  laser for removal, I-337f, III-349
  salivary gland, II-483
Mucoepidermoid carcinoma, II-492–493, II-493t, II-498, II-500–501, II-504t, II-759–760
Mucoperiosteal flap
  for impacted maxillary canine, I-290f
  for impacted third molar, I-287f
  in surgical extraction, I-280

Mucosa
augmentation, I-558f
example, I-559f
keratinized, I-562f
with vestibular incision tunnel access, I-563
buccal, II-670
cancer, II-680–681
in dentoalveolar injury evaluation, II-117, II-123t
herpetic infection involvement, II-552–553
injury treatment, II-137
keratinized, I-555–557, I-559f
peri-implant, I-555–556
urinary bladder, for disc repair, II-915
Mucositis
oral, II-760–761
peri-implant, I-723
phases, II-761f
prevention, I-724–725
treatment, II-760–761
Mucous membrane pemphigoid, II-562–564
Mucous plug, in parotid gland, II-490
Mudd, Harvey, III-1
Muenke syndrome, III-668
Multiple myeloma, II-857
Mumps, II-487–488
Murphy, John, II-764–766, II-767t
Muscle relaxant drugs, I-234
for facial pain, II-956
for temporomandibular joint disorders, II-871–872, II-872t
Muscle(s)
digastric, II-784–785
exercises, for temporomandibular joint disorders, II-969
eye, II-204t
forehead, III-397f
geniohyoid, II-784
labiomental, III-97f
lateral pterygoid, II-783–785
mandibular, II-147, II-149
masseter, II-781–782, II-785
masticatory, II-794
evaluation, II-810
pain, II-962
medial pterygoid, II-783, II-785
mylohyoid, II-784–785
nasal, II-174–175, III-364, III-365f
ocular, midface fracture and, II-226
orbicularis, III-388–389, III-390f, III-398
pterygoid, II-783–784, II-795f, II-810
in secondary palate, III-612–615
soft palate, III-535–536
spasm, II-962, II-966b
temporalis, II-399, II-782–783, III-785
temporomandibular joint, II-781–784
actions, II-786b
disorders, II-962–972
evaluation, II-810
tenderness, II-963–964
velopharyngeal, III-614t
zygomatic, II-189
Musculoskeletal system, preoperative evaluation, III-285–286
Mustardé method, for otoplastic surgery, III-453, III-454f
Myalgia
central, II-967b
masticatory, II-962–963
clinical presentation, II-963–964
diagnosis, II-964–966
management, II-967b
pharmacotherapy, II-968–969
self-care program, II-968b
treatment, II-966–971
Mycoplasma pneumoniae, erythema multiforme associated with, II-568
Myelin, in nerve anatomy, II-77
Myeloma, multiple, II-857
Mylohyoid muscle, II-784–785
Myocardial infarction (MI), oral surgery following, I-139
Myofascial pain, II-962
clinical presentation, II-963–964
diagnostic tests, II-964–966
etiology, II-963
pathophysiology, II-963
pharmacotherapy, II-955–956, II-968–969
splint therapy for, II-868
treatment, II-966–971
trigger points, II-965f
Myofibroblast, II-600, II-620–621
Myositis, II-962, II-966b
Myospasm, II-794
Myxoma
odontogenic, II-439–444, III-745
differential diagnosis, II-441–444
management, II-444
soap bubble, III-746f

N

Naburnetone, II-871t
Nager syndrome, III-690, III-705, III-776
Nalbuphine (Nubain), I-229t–230t
Naloxone, I-198f, I-200
Naltrexone, I-198f
Nanomedicine, peri-implantitis treated with, I-728
Naprosyn. *See* Naproxen (Naprosyn, Aleve)
Naproxen (Naprosyn, Aleve)
dosage, I-232t
for facial pain, II-954–955, II-955t
for temporomandibular joint disorders, II-871t
Nasal air emission, III-571
Nasal complex
anatomy, II-174–177
blood supply, II-176–177
bony framework, II-175
fracture, II-174
hard tissue, II-175–176
innervation, II-177
lymphoma, II-712
pathogenesis, II-174–177
pediatric, II-186
Nasal deformity, revision surgery, III-620–622
Nasal dorsum, II-225
Nasal emission test, III-573
Nasal fracture, II-24–27, II-27f, II-174–188
algorithm for, II-181f
causes, II-174
classification of, II-178, II-179t
classification system, II-28t
closed reduction, II-180–182
complications, II-187
diagnosis and evaluation, II-177–178
dislocation with, II-176f
management, II-179–186
Markowitz classification, II-30f
nasal hump associated with, II-176f
open reduction, II-182–186
pediatric, II-269–270, II-35–38, II-186–187
treatment, II-178–186
Nasal region
bones of, II-18
fracture, II-24–27, II-27f
Nasal resonance, III-570
Nasal septum, II-175–176
blood supply, II-176, III-366f
composition, II-175
description, III-367
Nasal septum *(Continued)*
deviation, II-177–178
hematoma, II-187
open reduction, II-182–183
reduction of, in naso-orbito-ethmoid fracture, II-224–225
Nasal tip
control, in rhinoplasty, III-372–373
projection, III-373–375
rotation, III-375–376
shape, III-376–377
Nasal trumpet, I-54–55, I-56f
Nasal valve, II-175, III-370–371, III-371f
Nasalance, III-578
Nasendoscopy, for velopharyngeal function assessment, III-575–576
Naso-orbito-ethmoid (NOE) complex
anatomy, II-221
fracture, II-24–27, II-27f, II-29f–30f, II-30t, II-213, II-220–225
classification, II-221–222
diagnosis, II-222–223
exposure, II-223–224
in Le Fort type III fracture, II-218–219
pediatric, II-35–38
treatment, II-223
gunshot wound injury, II-323
injury to, II-5f
Markowitz classification of fracture, II-30f, II-222f, II-223
nasal fracture and, II-177–178
Nasoalveolar molding (NAM), III-562–565
Nasofacial angle, III-99
Nasofrontal duct (NFD), II-233, II-230–231
endoscopy of, II-240
in frontal sinus fracture, II-236–238, II-236
image of injury to, II-235f
Nasofrontal suture line, III-397
Nasolabial cyst, II-371–372, II-374f
Nasolabial fold, botulinum neurotoxin for, III-441
Nasolacrimal apparatus, II-221
Nasolacrimal duct, III-161f
Nasomaxillary buttress, II-211
Nasomental angle, III-99
Nasometry, III-541, III-578
Nasopalatine duct cyst, II-372–375, II-376f–378f
Nasopharyngoscopy, III-615
Nasopharynx
radiation therapy for carcinoma of, II-744–745, II-746t
surgical access, III-741
Natural head position (NHP), III-15
Nausea
anesthetic recovery and, I-222
in orthognathic surgery, III-288–289
in pediatric patient, I-253
postoperative, III-314
Neck. *See also* Head and neck
botulinum neurotoxin for, III-441
dissection, II-683
examination, for gunshot wound patient, II-311
lymphoma, II-709f
non-odontogenic developmental cyst, II-376–385
penetrating injury, II-60
range of motion, orthognathic surgery evaluation and, III-16–17
sarcoma, II-643, II-644t
zones of, II-310, II-310f
Needle breakage, local anesthetic injection and, I-184
Needleless injection, I-187
Needle(s), for wound closure, II-50t

Neoplasm
malignant, temporomandibular joint affected by, II-856–857
salivary gland, II-482, II-492, II-493t
Neovascularization, tumor, II-617–619, II-628
Nepotism, I-112
Nerve block
chemical, I-365
mandibular, nerve injury associated with, II-950
trigeminal, I-361–362
Nerve conduction, I-176
Nerve excitability test (NET), II-103–104
Nerve fiber
peripheral, neurophysiology, II-942–943
types of, local anesthesia and, I-179t
Nerve injury
acute, repair, I-375–376, I-379
agents for, I-363
axonal and cellular response, II-72–73
chronic, I-363–365
classification, I-355–356, II-72t, II-311
clinical measurement, I-357–362
clinical terms, I-355t
complex regional pain syndrome, I-361
computed tomography for, II-78–80
decompression, I-368–369
from dental procedure, II-949–950
diagnosis, I-357–362
endodontic, I-377–378
entubulation, I-371–372
during exodontia, I-302–303
facial, diagnosis and management, II-70–113
graft for, I-95, I-369–371
impacted tooth extraction and, I-294
implant, I-379–380
implant surgery as cause of, II-82–84, II-83f
internal neurolysis, I-372–373
in intraoral vertical ramus osteotomy, III-91
in inverted L osteotomy, III-124
local anesthetics associated with, I-183t, I-376–377
magnetic resonance imaging of, II-81
maxillofacial pathology as cause of, II-87
maxillofacial trauma, I-374–376
nerve redirection, I-373–374
neurectomy, I-373
neurosensory testing for, I-358f, I-358–360
nonsurgical treatment, I-362–365
orthognathic, I-86, II-378–379
in orthognathic surgery, III-316
outcomes and conclusions, I-382–383
pediatric, II-272
persistent postsurgical pain, I-374
post-traumatic, I-375
postsurgical management, I-373–374
recovery, I-360t, I-382–383
response to, I-356–357
in rhytidectomy, III-333–334
in sagittal split ramus osteotomy, III-79–80
secondary repair, I-376, I-379
Seddon-Sunderland classification, I-355–356, I-356t
surgical management, I-365–374, I-367, I-373–374
surgical repair cascade, I-368f, I-368
testing, II-87–90
third molar extraction, I-380–382
trigeminal. *See* Trigeminal nerve injury
vertical ramus osteotomy, III-314
wrapping for, I-371
Nerve Injury Recovery Scale (NIRS), I-360t
Nerve(s)
allogenic graft, I-371
alveolar, I-368–369
injury to, I-294
Nerve(s) *(Continued)*
neuroma, I-371f
pediatric, I-259f
auricular, III-400–402, III-448
blood supply, II-78
buccal, II-75–76
computed tomography of, II-78–80
cranial
magnetic resonance imaging of, II-80–81
pain transmission and, I-226
ear, III-448, III-449f
facial, III-400, III-401f–402f
anatomy, II-96–99
clinical evaluation, II-103–104
extratemporal injury, II-104–106
extratemporal segment, II-98–99
iatrogenic injury, II-102–103
imaging, II-99–100
infection, II-102
injury mechanism, II-100–103
injury treatment, II-104–106
intracranial segment, II-96–97
laceration, II-13–14
local anesthesia and paralysis, I-184
mandibular fracture, II-168
microanatomy, II-77–78, II-99
parotidectomy, II-495–496
rhytidectomy evaluation, III-328
surgical intervention outcomes, II-106
traumatic injury, II-101–102
fibrosis, I-369
forehead, III-397f, III-399–402
graft, I-95, II-369–371
allogenic, II-95–96
for facial nerve injury, II-104–105
hypoglossal, III-269
inferior alveolar, II-74–75
injury, II-300, III-81
in mandibular fracture, II-168
surgical access, II-91–92
infraorbital, I-76, II-367–368
lingual, I-367, II-76t, II-367
injury, II-81
surgical access, II-91–92
magnetic resonance imaging of, II-80–81
mandibular, II-147
mental, II-74–75
in genioplasty, III-101, III-102f
surgical access, II-91–92
microanatomy, II-77–78
nasal, II-177, III-367, III-368f
pain transmission, I-225
schematic representation, II-77f
spinal, pain transmission and, I-226
supraorbital, III-399–400
supratrochlear, III-400
trigeminal. *See* Trigeminal nerve
ultrasonography, II-81
vascular supply, II-78f
wrapping, I-371
Nervous system
opioid drugs effect, I-200f
pediatric, I-239
preoperative evaluation of, I-161, III-284
Neuralgia
definition, II-946t
hyperesthetic, I-361
hypoesthetic, I-361
Neuralgia-inducing cavitational osteonecrosis (NICO), II-948
Neurectomy, I-373
Neurilemmoma, II-472
Neuroanatomy, pain and, I-225–226
Neurocranium, III-629–630
Neurofibroma, II-472, II-474f, III-755
Neurofibromatosis, II-472, II-474f, III-753–756
Neurofibromatosis type I, II-644, II-660–661
Neurogenic sarcoma, II-660–661
Neurologic injury, pediatric, II-250–252
Neurolysis
external, II-93–94
internal, I-94, II-372–373
Neuroma
alveolar nerve, I-371f
example, II-73f
excision and restoration, II-94–95
lateral exophytic, II-73f
lingual nerve, II-94f
removal, II-94f
resection, I-369
trigeminal, I-370f
types of, II-73
Neuromuscular blockade, I-170–171
Neuromuscular system, monitoring, I-170–171
Neuron
trigeminal nerve, II-941–942
types of, local anesthesia and, I-179t
Neuropathic pain, definition, II-946t
Neuropathy
definition, II-946t
orthognathic, I-378–379
post-traumatic, I-375
Neuropraxia
cause of, II-70–71
description of, III-316
exodontia associated with, I-303
Neurorrhaphy
direct, II-94f
for facial nerve injury, II-104–105
for orthognathic trigeminal nerve injury, I-379
for trigeminal nerve, I-369
Neurosensory disturbance (NSD), III-316
Neurosensory testing, I-358–360, I-358f, II-315
algorithm for, II-92f
levels of, II-90
recording of, I-360
Neurotin. *See* Gabapentin (Neurotin)
Neurotmesis
description of, II-71–72, III-316
exodontia associated with, I-303
Neurotoxicity, chemical, I-376
Neurotoxin, in forehead and brow lift, III-421
Neurovascular bundle
injury, implant surgery as cause of, II-82
local anesthetics and injury to, I-183–184
Neutral head posture (NHP), III-33–34
Nevoid basal cell carcinoma syndrome, II-361–365, II-644
clinical features, II-350, II-364–365
pathologic features, II-352–354
Nevus flammeus neonatorum, II-538
Newborn
craniosynostosis algorithm of care, III-671–675
Treacher Collins syndrome, III-730
Newsletter, marketing with, I-127–128
Nexavar. *See* Sorafenib (Nexavar)
NFD. *See* Nasofrontal duct (NFD)
NHP. *See* Natural head position (NHP); Neutral head posture (NHP)
Nicotine
bone metabolism affected by, I-433
effects, I-215
as mandibular surgery risk factor, III-297–298
wound healing affected by, I-451
Nicotinic stomatitis, laser treatment, III-352
Nikolsky sign, II-563, II-565
Nitrate (NO_3), II-831
Nitric oxide (NO), II-832f, II-905–906
Nitric oxide synthase (NOS), II-831, II-833f
Nitrite (NO_2), II-831

Nitrous oxide (NO)
adverse effects, I-208
chondrocyte synthesis of, II-831
clinical effects, I-207–208
discovery, I-206–207
as inhalation agent, I-220
inhalation induction of, I-220
for pediatric patient, I-250
Node of Ranvier, II-77
Nodular melanoma, II-692t
Nominal hazard zone, III-343
Non-Hodgkin lymphoma, II-707, II-710
B-cell, II-710
clinical staging, II-708b
radiation therapy for, II-741
survival rate, II-714
T-cell, II-710
treatment, II-713–714
Non-malfeasance, principle of, I-9
Non-melanoma skin cancer (NMSC), II-717–740
clinical examination, II-722–725
epidemiology, II-718–721
epidemiology and etiology, II-717–718
imaging, II-725
incidence, II-717
lymph node involvement, II-730–732
medical management, II-732–735
metastasis, II-723
pathology, II-718–721
photodynamic therapy, II-734
recurrence, II-732–733
repair of wound, II-731–732
risk factors, II-717
screening, II-722–725
staging, II-725–727
surgical excision for, II-729–730
treatment, II-727–730
Non-odontogenic cyst, II-371–385
Noncompliance, risk management and, I-79–80
Noninvoluting congenital hemangioma (NICH), II-536–538, II-537f
Nonlipid reticuloendotheliosis, II-523
Nonossifying fibroma, II-854
Nonsteroidal antiinflammatory drugs (NSAID)
analgesia with, I-228–230
contraindications, I-230–231, I-233b
for facial pain, II-954–955, II-955t
peptic ulcer disease associated with, I-140
for reactive arthritis, II-562
rhytidectomy complications associated with, III-332
for skin cancer, II-733–734
for temporomandibular joint disorders, II-870, II-871t, II-968–969
Norepinephrine
local anesthetics and, I-178–179
selectivity and potency of, I-180t
Norpramin. *See* Desipramine (Norpramin)
Nortriptyline (Pamelor, Aventyl)
for fibromyalgia, II-970
for temporomandibular joint disorders, II-873t
Nose
anatomy, II-174–177, III-364–367
blood supply, II-176–177, III-364, III-366f
cartilage, II-175
cosmetic surgery, III-364
dissection, in functional cleft lip repair, III-529
examination, in trauma patient, II-4
facial esthetics and, III-16
floor, in orthognathic surgery, III-28
fracture of. *See* Nasal fracture
function, III-370–371
herpes simplex infection and, II-552
Nose *(Continued)*
innervation, II-177
morphogenesis, III-476
muscles, III-364, III-365f
nerve supply, III-367, III-368f
pathogenesis, II-174–177
pediatric, II-186
reconstruction, II-292f, II-297, II-299f, III-286
reshaping, in cleft lip repair, III-518–519
skin thickness, III-370
superficial musculoaponeurotic system, II-174–175
surface landmarks, III-384b
tip. *See* Nasal tip
trauma repair, pediatric, II-277–278
in Treacher Collins syndrome, III-731–733
wound closure, II-52–54, II-55f–56f
Nostril pinch test, III-573
Novocaine. *See* Procaine (Novocaine)
NST. *See* Neurosensory testing
Nubain. *See* Nalbuphine (Nubain)
Nuclear factor-kappa B, II-673
Nucleic acid
alterations, II-609
dysregulation, II-606–609
Nucleosome, II-605f
Nucleotide, mutations, II-610f
Nucleotide sequence abnormality, II-607–609, II-610f
Nurse, anesthesia. *See* Anesthesia nurse

O

OAVS. *See* Oculoauriculovertebral spectrum (OAVS)
Obesity
airway patency and, I-214
obstructive sleep apnea associated with, III-286
orthognathic surgery and, III-286
pediatric, II-259–260
wound healing affected by, II-259–260
Objectives Based Practice Transitions (OBT), I-42
Observer's Assessment of Alertness and Sedation Scale, I-217–218
Obstructive sleep apnea (OSA), I-185, III-214
accelerated osteogenic orthodontic procedure for, III-259b–260b
after pharyngeal flap procedure, III-618
in craniosynostosis, III-675
laser-assisted uvulopalatoplasty, III-351
nonsurgical treatment, III-267–268
orthognathic surgery, III-264–278
pathophysiology, III-264
patient evaluation, III-264–266, III-281
prevalence, III-264
surgical treatment, III-268
in Treacher Collins syndrome, III-730
treatment, III-266–274
Obturator appliance, III-550–551, III-553–554, III-579
Obwegeser, Hugo L., III-62, III-113, III-153, III-183, III-2–4
Occlusal plane
alteration, III-226–227
surgical decrease, III-227
Occlusal splint, II-865–869, II-867b
Occlusion
after orthognathic surgery, III-290–291
in computer-aided surgical simulation, III-35–36
final, for model surgery, III-49–50
implant overdentures, I-655
temporomandibular joint disorder management and, II-873–875
Occlusion *(Continued)*
in temporomandibular joint disorders, II-767–769
temporomandibular joint prosthetic reconstruction, III-226–227
temporomandibular joint replacement and, II-931–933
Ocular injury, zygomatic fracture associated with, II-191
Oculoauriculovertebral spectrum (OAVS), III-687–702
airway management, III-692
classification, III-690–691
cleft lip and palate, III-692
distraction osteogenesis, III-695
dysmorphology, III-687–690
ear reconstruction, III-695–696
mandibular lengthening, III-695
orthognathic surgery, III-696
pathogenesis, III-687–690
staged reconstruction, III-691–692
velopharyngeal insufficiency, III-692
Odontoameloblastoma, II-446–449
Odontogenesis
pediatric, I-258
process, II-338–339
Odontogenic cyst, II-338–343, II-347f, II-365–371
intraosseous carcinoma from, II-433
site of, II-340f
Odontogenic fibroma, II-435–438
differential diagnosis, II-437
management, II-438
Odontogenic keratocyst, II-345–361
pathology, II-356–361
surgical management, II-356–361
Odontogenic myxoma, II-439–444, III-745
differential diagnosis, II-441–444
management, II-444
Odontogenic residue, intraosseous carcinoma from, II-433
Odontogenic tumor, II-391–461, III-741–745
adenomatoid, II-394–397
biopsy, II-393
calcifying epithelial, II-398–401
classification, II-391–392
clinical considerations, II-392
definition, II-391
epithelial, II-394–435
imaging, II-392–393
mixed, II-444–455
squamous, II-397–398
surgical management, II-393–394
Odontoma, II-444–446, II-447f–448f, III-745
compound, I-269f
pediatric, I-268
Older patient. *See* Elderly patient
Oliver, Col. Robert T., I-24
OMENS classification system for oculoauriculovertebral spectrum, III-691b
OMS. *See* Oral and maxillofacial surgeon (OMS); Oral and maxillofacial surgery (OMS)
Oncocytoma, II-493t
Oncogene, II-602, II-612
apoptosis suppression and, II-627–628
in head and neck cancer, II-753f
Oncology
molecular biology, II-622–629
molecular diagnostics, II-622–624
molecular therapeutics, II-624–629
principles, in head and neck cancer management, II-752–763

Ondansetron, I-253, III-288
Open bite
  anterior, III-172–173
  case presentation, I-318, I-319f
  intraoral vertical ramus osteotomy for, III-86b
  miniplate anchor for, I-316–318, I-313
  skeletal anterior, miniplate anchor for, I-316–318
  in temporomandibular joint disorder, II-873–874
Open-book incision, I-478f
Open reduction and internal fixation (ORIF), II-147, II-166
Open reduction and semi-rigid fixation, II-166
Operating chair, I-46–47
Operative notes, risk management and, I-78
Operculectomy, laser, III-348–349
Ophthalmologic assessment, for gunshot wound, II-311
Opioid drugs, I-197–200
  action, I-198, I-200f
  addiction associated with, I-228
  adverse effects, I-228b
  analgesia, I-226–228
  anaphylaxis associated with, I-252t
  clinical effects, I-198–200
  commonly prescribed, I-227–228, I-229t–230t
  discovery, I-197–198
  effects, I-226
  equianalgesic dosage, I-231t
  for facial pain, II-953–954, II-954t
  for neuropathic pain, I-364
  receptors, I-198
  side effects, I-201b, I-226, I-228b
  structure, I-198
  for temporomandibular joint disorders, II-871, II-872t
Oral and maxillofacial surgeon (OMS)
  academic career, I-33–35
  addiction and, I-144
  in associateship, I-41, I-64–65
  boundary violations, I-143–147
  compensation plan, I-70–71, I-71t
  in Department of Veterans Affairs, I-31–33
  in DMSO, I-41
  as educator, I-15
  employment agreement for, I-60b
  exit planning, I-43–45
  as expert witness, I-10
  impairment of, I-143–147, I-145–147
  insurance claims against, I-82–83
  as leader, I-109, I-108
  as managing partner, I-64
  orthodontic concepts for, I-311–312
  in partnership, I-16, I-40
  pathologist interaction with, II-329–330
  patient relationship, I-20–21
  peer relationships, I-21
  practice entrance planning, I-39–42
  practice transition, I-39–45
  role, I-51–52
  in solo practice, I-16, I-40
  substance abuse by, I-144–145
  surgeon-scientist, I-35–37
  in U. S. Air Force, I-29–30
  in U. S. Army, I-24–26
  in U. S. Navy, I-26–29
  in U. S. Public Health Service, I-30–31
Oral and maxillofacial surgery (OMS)
  academic careers, I-33–35
  for accelerated orthodontic movement, III-246–263
  for ameloblastoma, II-422
  boundaries, I-143
  code sets, I-89–90
Oral and maxillofacial surgery (OMS) *(Continued)*
  complications, I-298–310
  cosmetic, facial implant in, III-458–475
  craniofacial, III-670–671
  craniomaxillofacial, III-627–644
  cyst, II-338–390
  dentoalveolar, complications, I-298–310
  double jaw, III-50–53, III-226–227
  emergency procedure, I-55
  ethics in, I-1–13
  facial wound, I-665
  Ganz-Rinaldi protocol, I-706f
  high-energy gunshot wound trauma, II-318–320
  history, I-96, III-1
  infection following, I-303
  interactions, II-329–337
  for keratocystic odontogenic tumor, II-356–361
  for labial frenum, I-270–271
  lasers in, I-327–363
  Le Fort I segmental, III-172–182
  lighting for, I-48
  maxillary, III-55
  maxillomandibular advancement, III-269–274
  melanoma, II-697, II-700
  model, III-44–61
  nasal fracture, II-179–186
  nerve injury, I-365–374
  neurological, II-90–91
  odontogenic tumor, II-391–461
  orthognathic. *See* Orthognathic surgery
  otoplastic, III-446–457
  pathology, II-329–337
  patient positioning, I-221
  pediatric, I-257–274
  postsurgical pain, I-374
  practice transition, I-39–45
  professionalism in, I-1–13
  reconstruction, I-283, II-283–284
  risk management, I-73–86
  segmental maxillary, III-172
  sitting position, I-46–57
    anesthesia administration, I-46–54
    equipment, I-46–50
  skin cancer, II-727–730
  squamous cell carcinoma, II-670–689
  support organizations, I-37
  team member locations, I-50
  techniques, II-329–337
  temporomandibular joint internal derangement, II-904–922
  third molar, complications, II-82
  training, I-1
  training programs, I-34
  trigeminal nerve injury, II-96
  two-jaw, III-23
  zygomatic arch fracture, II-201–202
  zygomatic fracture, II-190–194
Oral and maxillofacial surgical practice
  academic *versus* private, I-34, I-35b
  accounting, I-68
  advisor for, I-62–64
  alternatives to private practice, I-23–38
  articles of incorporation, I-59
  associateship, I-41, I-44
  benchmarking, I-64
  boundaries, I-143
  budgeting, I-67–68
  business management, I-58–72
  business model, I-16–17
  buy-in, I-44, I-61
  buy-out, I-41, I-44
  buy-sell agreement, I-60–61
  collection protocol, I-71
Oral and maxillofacial surgical practice *(Continued)*
  collection ratios, I-69–70
  communication in, I-18
  compensation plan, I-70–71
  compliance with regulations, I-67
  conflict resolution, I-18–19
  consultant for, I-125–126, I-110–111
  decision making, I-18
  deferred or incremental sale, I-41–42
  in Department of Veterans Affairs, I-31–33
  disruptive behavior, I-143–146
  diversity, I-15–16
  employee assessment, I-65
  employee relations, I-111–117
  employee retention, I-66–67
  employees, I-19–20
  employment agreement, I-60
  entrepreneurial model, I-16, I-19
  exit planning, I-43–45
  financial management, I-67–71
  financial trend analysis, I-69–70
  goals, I-14–16
  group practice, I-64
  hiring practices, I-65–66
  human resources, I-65–67
  insurance broker, I-63
  interpersonal relationships in, I-17–22
  leadership, I-109, I-108
  lease agreement, I-61
  legal documents, I-59–61
  legal entities, I-58–59
  management, I-18
  marketing, I-102–136, I-64
  medical errors in, I-97–98
  operating agreement, I-59
  options for entering, I-41–42
  organizational structure, I-64–67
  outpatient surgery facility, accreditation of, I-96–101
  overhead ratio, I-70
  partnership, I-16
  partnership model, I-16–18
  philosophical basis, I-14–22
  policy manual, I-116
  practice administrator, I-63–64
  profits, I-117, I-15
  quality assurance, I-62
  regulation, I-96
  revenue cycle, I-68–69
  risk management, I-61–62, I-73–86
  sale, I-44
  solo practice, I-64
  solo practice model, I-16–17
  succession planning, I-19
  transition, I-39–45
  in U. S. Air Force, I-29–30
  in U. S. Army, I-24–26
  in U. S. Navy, I-26–29
  in U. S. Public Health Service, I-30–31
  valuation, I-42
  vision in, I-109
Oral appliance, for obstructive sleep apnea, III-267
Oral cavity
  anatomy, II-670–671
  cancers, II-742
    diagnosis and evaluation, II-675
    follow-up, II-684–685
    nonsurgical management, II-677–679
    screening, II-673–674
    squamous cell, II-670–689
    staging, II-675–677
    surgical management, II-679–683
  lymphoma, II-707, II-712
  radiation therapy for, II-742t

Oral cavity *(Continued)*
subsites, II-670
tumor, III-740–741
Oral hygiene, salivary pellicle and, II-551
Oral mucosa
in dentoalveolar injury evaluation, II-117, II-123t
laser surgery on, I-335
lesion, I-336
Oral mucosal malignant melanoma, II-702–704
Oral teratoma, III-757
Orasone, II-871t
OraVerse. *See* Phentolamine (OraVerse)
Orbicularis muscle, III-388–389, III-390f, III-398
Orbit
fracture, pediatric, I-106
growth rate, III-629t, III-630
reconstruction
in oculoauriculovertebral spectrum, III-695
in Treacher Collins syndrome, III-713–715
retrobulbar hemorrhage and, II-206–207
Orbital cleft, III-507
Orbital compartment syndrome, II-206–207
Orbital floor
fracture, pediatric, II-268
surgical approaches to, II-196–199
Orbital ligament, III-402, III-404f
Orbital region
anatomy, II-190f
fracture, II-22
imaging, II-18
structure, II-19f
surgical approaches, II-196–199
Orbital rim, III-397
fixation, II-219f
in naso-orbito-ethmoid fracture, II-224
Orbital septum, III-388–389
Orbital wall, reconstruction, II-224
Orofacial embryogenesis, III-476–490
Orofacial region
innervation, I-227f
pain assessment, II-804–810, II-810b–811b
Oropharyngeal sphincter, III-535–536
Oropharynx, carcinoma
chemotherapy/radiation therapy for, II-754
radiation therapy, II-742, II-744t
Orthodontia, exodontia for, I-275
Orthodontic needs, third molar removal and, I-284
Orthodontic treatment
for impacted molar, I-266f
for pediatric impacted tooth, I-262, I-264
Orthodontics
accelerated osteogenic, III-247–248
after mandibular lengthening, III-206–208
anchorage, I-312, I-312
corticotomy-facilitated, III-246
following accelerated osteogenic procedure, III-250
goals, I-312
implant assisted, I-311–324
laser used in, I-350
miniplate, I-313–314
orthognathic surgery and, III-279–280
preoperative, III-299
skeletally based implant assisted, I-311–324
surgical, III-246
Orthognathic measurement
in double jaw surgery, III-52–53
for model surgery, III-46, III-48f
Orthognathic surgery
for accelerated orthodontic movement, III-246–263
accelerated osteogenic orthodontic procedure with, III-259–261
Orthognathic surgery *(Continued)*
airway evaluation, III-282–283
cleft, III-596–608
bone grafting in, III-602–605
presurgical evaluation, III-596–597
psychosocial considerations, III-597
timing of surgery, III-597
complications, III-297–298, III-316–319
computer-aided, III-31–34, III-190
dental rehabilitation needs in, III-20
dentofacial considerations, III-278–280
double-jaw, III-38, III-50–55
facial skeleton evaluation, III-16–20
hematologic evaluation, III-284–285
for hemimandibular elongation, III-17f–22f
history, III-1–2
infection, III-290, III-315–316
injury associated with, I-378–379
juvenile idiopathic arthritis and, III-131
laboratory testing, III-287–288
mandible-first, III-58–59
maxillary
multi-piece, III-56–58, III-58f
single-piece, III-55
maxillomandibular
planning for, III-21–29
stability, III-116–119
for midface deficiency, III-619
model, III-44–61
for asymmetric genioplasty, III-60f
genioplasty and, III-60
special considerations, III-60
musculoskeletal system evaluation, III-285–286
nerve injury associated with, II-86
nervous system evaluation in, III-284
oculoauriculovertebral spectrum, III-691, III-696
orthodontic considerations, III-279–280
patient evaluation, III-280–287
perioperative patient management, III-278–296
pitch orientation, III-27–28
postoperative management, III-288–292
relapse following, III-185, III-317–318
single-jaw, III-38
for sleep apnea, III-264–277
splint fabrication, III-50, III-55–59
stability after, III-185
temporomandibular joint replacement with, III-136
temporomandibular joint total reconstruction, III-222–245
in Treacher Collins syndrome, III-717f–722f
treatment planning, III-13–30
virtual, III-31–43
two-jaw, III-23, III-32f
venous thromboembolism in, III-298t
virtual treatment planning, III-31–43
Orthokeratin, II-354
Orthopantomogram, II-946
Orzel, II-757t
Os zygomaticum, I-571–573
OSA. *See* Obstructive sleep apnea (OSA)
Osseointegration, temporomandibular joint replacement and, II-927–928
Osseous crest, I-395
Ossifying fibroma, II-468–469, III-743f
juvenile, II-469–470
treatment, II-469
Osteoarthritis, II-835–838
facial pain and, II-944–945
splint therapy, II-869
temporomandibular joint, II-889
Osteoblast
in cancellous bone, I-427–428
staining for visualization of, I-442f
Osteoblastoma, II-472–474, II-475f
benign, II-854–855
cementoblastoma compared to, II-438
Osteochondroma, II-476, II-854
Osteochondromatosis, II-855–856
Osteoconduction
alloplastic implant and, I-440–441
bone growth and, I-439–440
definition, I-426, I-438
xenogeneic bone graft and, I-440
Osteogenesis
autologous stem cells and, I-438–439
bone growth and, I-438
definition, I-426, I-438
horizontal alveolar transport, I-547–549
Osteogenic, definition, I-438
Osteogenic distraction, for gunshot wound repair, II-326
Osteoid
bone healing and, I-426–427
staining for visualization of, I-443f
Osteoid osteoma, II-472–473, II-854
Osteoinduction
biologics and, I-441
definition, I-426, I-438
Osteoma, II-475, II-476f, II-854
Osteomyelitis, II-575–598
classification, II-575
clinical case, II-577f–585f
diagnosis, II-575
following exodontia, I-303
Garre, II-858
imaging, II-576
laboratory studies, II-575–576
management, II-576–590
mandibular, II-89f
temporomandibular joint affected by, II-858
Osteonecrosis
facial pain associated with, II-952
medication-related, II-507–522
clinical presentation, II-511–512
established, II-515–517
pathophysiology, II-509–510
research, II-517
risk factors, II-510–511
risk minimization, II-514
staging, II-512–513
treatment, II-514–517, II-516t
Osteoperiosteal flap, I-526–554
alveolar bone deficiency corrected with, I-526
free vascularized, I-668–671
space maintenance with, I-526–534
Osteoporosis, II-509
antiresorptive therapy for, II-514–515
osteonecrosis risk and, II-514
Osteoradionecrosis (ORN), I-304, II-575–598, II-749
clinical case, II-591f–594f
incidence, II-590
mandibular, II-34–35, II-37f
treatment, II-590–595
Osteosarcoma, II-644t, II-647–649, II-857
computed tomography of, II-646f
diagnosis, II-645–646
mandibular, II-645f
risk factors, II-647
treatment, II-647–648
Osteosynthesis
lines of, II-147f
in sagittal split ramus osteotomy, III-76–77
Osteotome, for sinus lift, I-520f
Osteotomy
alveolar, I-526–534
in alveolar distraction osteogenesis, I-536
alveolar repositioning, I-529
bilateral sagittal split, III-113–114

Osteotomy *(Continued)*
chin wing, III-319
combined maxillary and mandibular, III-183–195
case reports, III-191b
indications, III-184–186
mandible-first, III-187–189
maxilla-first, III-186–187
in computer-aided surgical simulation, III-35–36
craniosynostosis, III-650f, III-670
distraction osteogenesis following, III-775
extra-oral vertical ramus, III-113
facial bipartition, III-677f
horizontal ramus, III-204
implant transposition, I-529, I-530f
intraoral vertical ramus, III-62–95
history, III-64
indications, III-83
surgical sequence, III-83–90
inverted L, III-113–143
in combined maxillary and mandibular osteotomy, III-189
complications, III-124
indications, III-115–116
juvenile idiopathic arthritis and, III-131, III-137f–141f
modified, III-116f
nerve injury in, III-124
special considerations, III-131
stability, III-116–119, III-119t
surgical technique, III-120–124
virtual surgical plan, III-120, III-128f–130f
lateral nasal, III-164–165
Le Fort I, I-54–55, I-153–171, III-458, III-569–570, III-3
anesthesia, III-161–162
for cleft deformity, III-492–493
complications, III-169–170
in computer-aided surgical simulation, III-35–36, III-37f
diagnosis, III-153–161
history, III-153
indications, III-153
lip-to-tooth relationship in, III-24
for lymphatic malformation, II-540–542
maxillary hypoplasia and, III-638–639
maxillary segmentation, III-165–166
in maxillomandibular advancement, III-271f
multi-piece, III-54–55
in oculoauriculovertebral spectrum, III-696
operative technique, III-161–168
patient positioning, III-161–162
planning, III-153–161
segmental, III-172–182
single-piece, III-54
three-piece, III-176f
in Treacher Collins syndrome, III-731
two-segment, III-28–29
for vertical maxillary excess, III-156f–157f
Le Fort III, III-678f
mandibular
complications, III-144–145
endoscopically assisted, III-144–152
history, III-113–114, III-144, III-1–2
with maxillary, III-183–195
surgical technique, III-144–147
mandibular ramus, III-62–95
mandibular subapical, III-2
maxillary, III-163–164
history, III-2–3
with mandibular, III-183–195
in multiple segments, III-3
three-piece, III-176f

Osteotomy *(Continued)*
midface, III-4
for midface cleft reconstruction, III-601
nasal, III-164–165, III-378–380
in oculoauriculovertebral spectrum, III-696
relapse after sagittal split, III-116b
sagittal split, II-86, III-113–114, III-144, III-204, III-2, III-4
complications, III-298–319
nerve injury associated with, III-301–308
sagittal split ramus, III-62–95
septal, III-164–165
sinus augmentation, I-514
sliding genioplasty, III-102
symphysis widening, III-200
vertical ramus, III-62–95, III-144–145
vertical subcondylar ramus, III-313–314
vomerine, III-164–165
zygomatic fracture malunion, II-204–205
zygomatic implant, I-574, I-576
Otitis media, III-540, III-568–569
Otoplastic surgery, III-446–457
complications, III-455–456
Davis method, III-451–453, III-452f
Farrior technique, III-453, III-455f
Mustardé method, III-453, III-454f
protruding ear, III-450–453
protruding earlobe, III-453–455
techniques, III-450–453
Outpatient surgery facility, accreditation, I-96–101
Outpatient visit, coding for, I-92
Overbite, in temporomandibular joint disorder, II-873–874
Overdentures
controversy associated with, I-643–644
implant, I-641–664
maxillary long-bar, I-646f
natural tooth, I-641–643
two-implant, I-645
Overjet, in temporomandibular joint disorder, II-873–874
Oxaliplatin, II-757t
Oxazepam (Serax), I-196f, II-874t
Oxcarbazepine, I-369
Oxycodone (Percocet)
dose and potency, I-229t–230t
equianalgesic dosage, I-231t
for facial pain, II-953, II-955t
pharmacokinetics, I-230t
prescription, I-228
for temporomandibular joint disorders, II-872t
Oxygen
anesthetic recovery and, I-222
supplemental, for trauma patient, II-9–10
Oxygenation, monitoring, for pediatric patient, I-244
Oxyhemoglobin, I-168
Oxymorphone (Numorphan), I-229t–230t

P

Paclitaxel, II-757t
Pain
acute, management, I-234–235
behavioral pain management, I-365
central, definition, II-946t
central mechanisms, II-943–944
chronic facial, II-941–961
clinical examination, II-945–946
differential diagnosis, II-947–952
evaluation, II-944–947
management barriers, II-952–953
definition, I-225, II-946t
descriptors, II-946
facial, II-941–961

Pain *(Continued)*
cardiac origin, II-950–951
clinical examination, II-945–946
differential diagnosis, II-947–952
evaluation, II-944–947
management barriers, II-952–953
pharmacotherapy, II-955t
surgical intervention, II-958
therapeutic injection, II-956–957
treatment, II-953–958
as Fifth Vital Sign, I-234
following simple extraction, I-281
following surgical extraction, I-281
imaging, II-946–947
local anesthetic injection as cause of, I-184
management, I-225–237
myofascial, II-962
clinical presentation, II-963–964
diagnostic tests, II-964–966
splint therapy for, II-868
treatment, II-966–971
myogenous, II-791
nerve injury as cause of, II-90
neuropathic, I-233, I-360–362, II-946t
neurophysiology, II-941–943
orofacial
assessment, II-804–810, II-810b–811b
cardiac origin, II-950–951
temporomandibular joint disorder and, II-791
pathophysiology, I-225–226
patient assessment, I-234
patient perception, I-225
perioperative management, I-235f
peripheral mechanisms, II-942
postoperative, I-304
craniomaxillofacial trauma and, II-7
lasers and, I-340
management, I-225–237
postoperative management, I-235f
postsurgical, I-374
preoperative management, I-235f
sensory reeducation, I-365, I-366f
sympathetic mediated, I-361
temporomandibular joint, II-883
temporomandibular joint disorder, screening questionnaire for, II-804b–805b
third molar extraction and, I-293
Pain management
for chronic facial pain, II-941–961
future directions, II-958–959
in orthognathic surgery, III-288
for substance abuser patient, II-953
in temporomandibular joint disorder treatment, II-865
for temporomandibular joint disorders, II-970–971
Palatal bone, implant success and, I-412
Palatal fracture, II-28, II-220
Palate. *See also* Hard palate; Soft palate
free autogenous graft from, I-556
primary, III-502
secondary, III-502
soft tissue graft, I-556
squamous cell carcinoma, II-681–683
Palatine artery, III-165
Palatoplasty, III-505
Bardach, III-537, III-538f, III-611
fistula after, III-540
Furlow, III-546–548
speech and, III-540–542
two-flap, III-534, III-542, III-610
two-stage, III-548–549, III-551–552
Veau-Wardill-Kilner, III-538f, III-542
von Langenbeck, III-537f, III-542, III-611

Palpation, of temporomandibular joint, II-809
PALS. *See* Pediatric Advanced Life Support (PALS)
Pamelor. *See* Nortriptyline (Pamelor, Aventyl)
Pamidronate (Aredia), II-508, II-508t
Panoramic curve, I-688–689, I-689f
Panorex radiograph, I-570
Papanicolaou stain, II-331
Papaver somniferum, I-197
Papilla, interdental, implant and, I-401, I-402f
Papillary hyperplasia, laser treatment for, III-354
Papillomatosis, laser treatment for, III-354
Para-aminobenzoic acid (PABA), local anesthesia
  allergic reaction and, I-176–177, I-182, I-185
Paradental cyst, II-343
Paraflex. *See* Chlorzoxazone (Paraflex)
Parakeratin, II-352–354
Parakeratotic cyst, II-360f–361f
Paramedian forehead flap, II-290, II-292f
Paranasal sinus, lymphoma, II-712
Paraneoplastic pemphigus, II-564
Parasymphysis
  mandible, II-148
  widening, III-199–200
Parathyroid hormone (PTH)
  elevated, II-465–466
  hyperparathyroidism and, II-464
  osteonecrosis treated with, II-515–516
Parathyroid hormone-related protein (PTHrP), II-409, II-420
Parent
  of pediatric patient, I-257–258
  pediatric patient fear and anxiety and, I-248
Paresthesia
  after orthognathic surgery, III-291
  definition, I-355t, II-946t
  infraorbital, II-202–203
  local anesthetics and, I-183–184
  in osteomyelitis, II-575–576
Pargyline, I-149t
Parotid duct, laceration, II-58–60
Parotid gland
  benign tumor, II-494–496
  chronic obstructive sialoadenitis, II-491–492
  infection, II-485–486
  lesion, II-485
  malignant fibrous histiocytoma in, II-651
  nonsalivary tumor, II-500–503
  stone, II-490
  swelling, II-486f
  tumor, II-493–494, II-493t
  viral infection, II-487–488
Parotid sialocele, III-335
Parotidectomy, II-102–103, II-494–496
Parotitis, acute suppurative, II-485–487
Paroxetine hydrochloride (Paxil), II-873t
Paroxysmal positional vertigo (PPV), I-522
Partial pressure arterial oxygen (PaO_2), I-12
Partial pressure of CO_2, I-168–169
Partial pressure of oxygen (PaO_2), pediatric, I-241
Passive range of motion, II-806
Pathology. *See also* Surgical pathology
  coding for, I-92
  of dentigerous cyst, II-346–347
  of keratocystic odontogenic tumor, II-352–354
  oral and maxillofacial, II-329–337
  radicular cyst, II-341
  surgical interaction with, II-329–330
Patient
  agitated, I-55
  attitude, prosthesis choice and, I-643
  diabetic, anesthetic recovery, I-222
  informed consent, I-62
Patient *(Continued)*
  for orthognathic surgery, III-280
  risk management and, I-76–78
  lumbar support, I-54, I-56f
  monitoring, I-164–175
  noncompliance, I-79–80
  pain management, I-225–237
  pain perceived by, I-225
  payment history, I-129–130
  postoperative, communication with, I-132
  preoperative evaluation, I-148–163
  problematic, in cosmetic surgery, III-458
  rehydration, I-217
  sedation goals for, I-211–212
  selection
    for guided bone regeneration, I-476
    implant restoration and, I-391–393
    for zygomatic implant, I-570
  surgeon relationship with, I-20–21
  survey of, I-123–124
Patient confidentiality
  autonomy and, I-9
  professionalism and, I-3
Patient-controlled analgesia (PCA), I-234–235
Patient education, for peri-implant disease, I-725
Patient evaluation, I-119–120. *See also* Preoperative evaluation
  airway assessment and, I-213
  for blepharoplasty, III-389–391
  for craniofacial surgery, III-670
  for forehead and brow lift, III-405–408
  for liposuction, III-430–431
  for obstructive sleep apnea, III-264–266, III-281
  for orthognathic surgery, III-280–287
  for pain, I-234
  for rhinoplasty, III-367–368
  for rhytidectomy, III-325–327
  for soft tissue injury, II-41–42
  for temporomandibular joint prosthetic reconstruction, III-222–223
Patient health record, risk management and, I-75–80
Patient history
  airway assessment and, I-213
  for chronic facial pain evaluation, II-944
  craniomaxillofacial trauma assessment and, II-2–4
  for dentoalveolar injury evaluation, II-115–116
  for mandibular fracture evaluation, II-152–153
  preoperative evaluation and, I-138
  risk management and, I-75–76
  for temporomandibular joint disorder, II-801, II-904–905
  for temporomandibular joint internal derangement, II-904–905
  trauma management and, II-3t
  in trauma patient assessment, II-10
  zygomatic fracture assessment, II-190–191
Patient positioning, I-54
  anesthesia, I-221
  for exodontia, I-276
  for Le Fort I osteotomy, III-161–162
Patient preparation, for autogenous bone graft, I-451
Patient referral, I-122–123, I-122, I-81
Patient survey, I-123–124
Patient's rights, I-9
Paxil. *See* Paroxetine hydrochloride (Paxil)
Payment plan
  marketing and, I-129–130
  types of, I-129–130
Peck and Peck method, chin position analysis with, III-460t–461t
Peck graft, III-374
Pediatric Advanced Life Support (PALS), I-244, I-260
Pediatric Glasgow Coma Scale (PGCS), II-247, II-247t–248t
Pemphigoid, II-562–564
  clinical features, II-563
  treatment, II-564
Pemphigus, II-564–565
  clinical features, II-564–565
  treatment, II-565
Penciclovir, II-553–554
Penicillin
  anaphylaxis associated with, I-252t
  medication-related osteonecrosis treated with, II-516
  postoperative infection treated with, I-303
Pentazocine (Talwin)
  dose and potency, I-229t–230t
  for temporomandibular joint disorders, II-872t
Pentoxifylline, II-595–596
Peptic ulcer disease, I-141
Percocet. *See* Oxycodone (Percocet)
Peri-implant disease, I-711–730
  cement excess and, I-632, I-711
  laser treatment, III-350
  prevention, I-724–725
  risk factors, I-723–724
  scope, I-723
  treatment, I-725–727
Peri-implant inflammation, I-653f
Peri-implant mucositis, I-723
  prevention, I-724–725
  treatment, I-725–727
Peri-implantitis, I-723
  cement excess and, I-711
  definition, I-412–413
  example, I-712f
  laser treatment, I-340–341, III-350
  prevention, I-724–725
  risk factors, I-723–724
  scope, I-723
  treatment, I-725–727
Periadenitis mucosa necrotica recurrens, II-559
Periapical cemental dysplasia, II-470–471
Periapical root surgery, nerve injury caused by, II-87
Perichondritis, III-456
Pericoronitis
  third molar removal and, I-284
  treatment, I-284
Perineural invasion, tumor cell migration and, II-722
Perineurium, in nerve anatomy, II-77–78
Periodontal disease
  exodontia for, I-275
  third molar removal and, I-284
Periodontal ligament (PDL)
  bundle bone blood supply from, I-413–414
  healing, after trauma, II-137–138
  injury, II-122t
  luxation, II-127
  miniscrew implant and, I-315
  in simple extraction, I-276
Periodontal tissue, injury, II-127–131
Periodontally accelerated osteogenic orthodontics, III-247
Periodontitis
  exodontia for, I-275
  peri-implant disease associated with, I-723–724
Periodontium, biotype, I-393–405
Periorbital region, II-19f
Persistent idiopathic facial pain, II-948

Persistent postsurgical pain (PPSP), I-374
acute, I-374
chronic, I-374–375
management, I-375t
transition, I-374
Pfeiffer syndrome, III-669, III-672, III-778
PHACE vascular anomaly, II-536
Phantom bone disease, II-858
Pharmacologic prophylaxis, III-298
Pharmacosedation
general anesthesia and, I-248–251
pediatric, I-238–256
Pharyngeal cleft, II-383, II-383f
Pharyngeal flap procedure, III-616–618, III-616f
Pharyngeal structure, airway assessment and, I-243f
Pharyngeal wall, radiation therapy for carcinoma of, II-742
Pharyngoplasty, sphincter, III-579, III-617–618, III-617f
Pharynx, pediatric, I-240
Phencyclidine, I-203–204
Phenelzine, management, I-149t
Phenergan. *See* Promethazine (Phenergan)
Phenobarbital (Luminal), I-200–201, II-255–256
Phenol, for chemical peel, III-443–444
Phentolamine (OraVerse), I-188
Phenylephrine, selectivity and potency of, I-180t
Phenylpiperidine, structure, I-199f
Philadelphia chromosome, II-622–623
Photodynamic therapy, III-353
for oral cancer, II-677–678
for skin cancer, II-734
Photography, for model surgery, III-44–46
Physical examination
airway assessment with, II-10–11
for dentoalveolar injury evaluation, II-115–119
for mandibular fracture evaluation, II-152–153
for midface fracture diagnosis, II-212–213
for obstructive sleep apnea, III-265–266
oral cancer evaluation and, II-675
preoperative evaluation and, I-138
for rhytidectomy evaluation, III-326
risk management and, I-75–76
for skin cancer, II-722–725
for temporomandibular joint internal derangement, II-904–905
Physical therapy
after arthroscopy, II-901
after internal derangement surgery, II-918–919
for chronic facial pain, II-953
for temporomandibular joint disorders, II-875–877
Physicians' Charter, I-2, I-4
Pichler, Hans, III-113
Pierre Robin syndrome, III-547, III-776
Pigmented villonodular synovitis, II-855
Pindborg tumor, II-398
Pinterest, marketing and, I-105–106
Piroxicam
for masticatory myalgia, II-969
for temporomandibular joint disorders, II-871t
Pitch orientation
in computer-aided surgical simulation, III-38–39, III-120
model surgery and, III-44f
in orthognathic surgery, III-27–28
Pittsburgh Fistula Classification System, III-539–540, III-540f
Pivot splint, temporomandibular joint, II-867
Plagiocephaly, III-647
anterior, III-654–657
posterior, III-659–660
Plaque, control, II-551
Plasma, platelet-rich, I-460
Plasmatic inhibition, I-426–427
Plaster of Paris, alloplastic implant with, I-440–441
Plastic surgery, facial, laser used in, III-359
Plate
titanium, II-164
types of, II-164f
Platelet-derived growth factor (PDGF), I-257–258, I-258t, I-431–432, II-441
interpositional bone graft, I-527–528
Platelet-rich plasma, I-460, I-510–512
Platform switching, I-413
Pleomorphic adenoma, II-492–494, II-493t, II-500
Plication, III-330
Pneumonitis, continuous positive airway pressure for, I-253
Pocket mask, I-245–247
Pogonion position, III-28
Policy manual, I-116
Polyetheretherketone (PEEK), I-416–418
Polylactic acid/polyglycolic acid copolymer membrane, I-482–483
Polymethylmethacrylate (PMMA), I-416–418
Polymorphous low-grade adenocarcinoma, II-500–501, II-503f
Polysomnography, III-265
Polytetrafluoroethylene membrane, I-462–464, I-464f, I-480–482
Pontic site, development, I-404
Porcelain-fused metal (PFM), I-416–418, I-417f
Port-wine stain, II-538
Positioning. *See* Patient positioning
Positron emission tomography (PET)
cancer diagnosis, II-624
craniomaxillofacial pathologies, III-738–739
lymphoma, II-711–712
melanoma diagnosis, II-699
odontogenic tumor, II-392
oral cancer evaluation, II-675
temporomandibular joint, II-825
Post-transplant lymphoproliferative disorder, II-711
Post-traumatic seizure, II-255–256
Postanesthesia Discharge Scoring System, I-172–173
Posterior plagiocephaly, III-659–660
Posterior superior alveolar artery, I-510
Postoperative nausea and vomiting (PONV), III-288
Postoperative recovery, from anesthesia, I-221–222
Posttraumatic concussion syndrome, frontal sinus fracture associated with, II-243
Potassium ion, nerve conduction and, I-176
Powell and Humphreys method, chin position analysis with, III-460t–461t
Prazepam (Verstran, Centrax), II-874t
Prednisolone
equivalent dosage, III-287t
for temporomandibular joint disorders, II-871t
Prednisone
Bell's palsy treated with, II-101
for lymphoma, II-713
for pemphigus, II-565
for temporomandibular joint disorders, II-871t
Pregabalin (Lyrica), I-364, II-955t, II-956
Pregnancy
craniomaxillofacial trauma management and, II-3t
local anesthesia and, I-186
Premedication, for pediatric patient, I-248
Premolar
cyst at, II-343
impacted, I-265
mandibular
extraction, I-278f
impacted, I-291
maxillary
extraction, I-277
impacted, I-291, I-292f
roots, I-278f
Preoperative evaluation, I-148–163
airway assessment, I-213–214
anesthesia, I-212
asthma, I-139
cardiac assessment, I-150f
cardiac risk index, I-150t
cardiovascular, I-138
cerebrovascular accident, I-161
chronic obstructive pulmonary disease, I-139
coagulation disorders, I-161
components, I-138–139
endocrine system, I-142
exodontia, I-276
gastrointestinal disease, I-141–142
hematologic, I-159–161
nervous system, I-161
pulmonary system, I-139
renal disease, I-140–141
smoking, I-139
Preoperative fasting, I-215–216, I-243
Pressure-flow method, III-576–578
Pressure indicating paste (PIP), I-658
Presurgical infant orthopedics, III-561–562
Presurgical orthopedic appliance, III-498
Prilocaine, I-186
concentration, I-177t
duration of, I-179t
nerve injury associated with, I-183t
onset time, I-178t
Primary bone grafting, III-584
Primary herpes stomatitis, II-556
Primary herpetic gingivostomatitis, II-552, II-554
Primary intraosseous odontogenic carcinoma, II-431–432
Principles of Ethics, I-9
Procaine (Novocaine), I-185
chemistry, I-177f
history, I-176
onset time, I-178t
Procarbazine, II-714
Profecoxib, II-871t
Professional employment organization (PEO), I-67
Professional liability insurance, I-82
Professionalism
behaviors associated with, I-4
commitment to, I-3
definition, I-1–4
ethics and, I-1–13
framework for, I-5f
history of, in dentistry, I-2–4
Physicians' Charter description of, I-2
student evaluation and adherence to, I-4–6
teaching, I-4–5, I-7–8
unprofessional behavior, I-4
Proffit, William, III-5
Progress notes, risk management and, I-78–79
Proliferation phase, of bone healing, I-426–427
Prolonged sensory alteration, I-183–184
Promethazine (Phenergan), II-288, III-874t

Propacetamol, I-252t
Propofol (Diprivan), I-192, I-202–203
anaphylaxis associated with, I-252t
development, I-201
general anesthesia with, II-13
ketamine combined with, I-219t
pediatric dosage, I-250t
for pediatric patient, I-250–251
pharmacokinetics, I-204t, I-218–219
remifentanil combined with, I-219t
side effects, I-204f
structure, I-202f
Propofol infusion syndrome, I-203
Proportion
facial, osteotomy and, III-184–185
in facial esthetics, III-13–14
Propoxycaine, onset time, I-178t
Propranolol, for congenital hemangioma, II-537
Prostate-specific antigen (PSA), II-623–624
Prosthesis
angle of emergence, I-587–588
arch provisional, I-605–623
decision making process for, I-632–635
fixed
angle of emergence, I-587–588
case presentation, I-601–602
cost, I-596–597
denture conversion to, I-608–614
diagnosis for, I-584–591
edentulous maxilla, I-584–604
esthetics, I-592
extraoral examination, I-591–602
extraoral parameters, I-586f
force placed on, I-594–595
implant distribution and placement, I-596
implant-supported, I-608–614
material selection, I-597–602
number of implants, I-594
restorative classification, I-590
treatment planning, I-592–597
four-implant, I-649f
in immediate implant loading, I-607
overdenture, I-641
removable, I-461, I-592
retrievability, I-631–632
screw retention *versus* cement retention, I-631
six-implant, I-641f
for temporomandibular joint total reconstruction, III-228, III-229f, III-230–232, III-234f, III-242
three-implant, I-648f
two-implant, I-642f, I-654f
in zygomatic implant, I-581–582
Protamine, I-252t
Protein
cancer-associated, II-623–624
as cancer therapy target, II-625–626
cell structure and, II-605–606
dysregulation, II-609–622
gene expression and, II-604f
Protein binding, local anesthetic drugs and, I-178
Proteomic analysis, II-624
Proto-oncogene, II-602, II-612
Prozac. *See* Fluoxetine (Prozac)
Pseudo-tomogram, II-818, II-819f
Pseudocyst
definition, II-338
sinus, I-510
temporomandibular joint affected by, II-852
Pseudogout, II-847–848
Psoriatic arthritis, II-841–842
Pterygoid muscle, II-783–785, II-795f, II-810
Pterygomaxillary buttress, II-211
Pterygomaxillary disjunction, III-164
Ptosis, in craniosynostosis treatment, III-678
Public relations, for oral and maxillofacial surgical practice, I-64
Pulmonary complications
adolescent, III-282
prevalence of, I-139
Pulmonary system, preoperative evaluation of, I-139, III-282–283
Pulp
exposure, II-124
healing, after trauma, II-138
injury
in dentoalveolar injury, II-124
prognosis, II-138–139
treatment of, II-122–127
necrosis, after injury, II-140
Pulp testing, in dentoalveolar injury, II-118–119
Pulpitis, II-138–139
Pulse oximeter, II-12, II-168
Pulse oximetry
error rate, I-168
for pediatric anesthesia monitoring, I-245
Puncture wound, I-301
Pyriform rim, III-28
Pyrophosphate, II-550

Q

Quality assurance, I-62
Quantitative Sensory Test Recording and Neuropathic Mapping Form, I-359f
Quinolone, II-516

R

R-point, cell cycle and, II-612–613
Rabies, II-62b
Raccoon eye sign, II-216, II-254
Race, facial variation and, III-25
Radial forearm flap, II-294, II-295f
Radiation
emission, laser and, III-336–337
ionizing, non-melanoma skin cancer associated with, II-717
tissues damaged by, I-675–677
ultraviolet, skin cancer associated with, II-722–723
Radiation therapy, II-590, II-741–751
complications, II-749
concurrent chemoradiation *versus*, II-747t
definitive, II-745
dosage, II-741–742
fractionation, II-746–747
head and neck cancer, I-675–678
histologies, II-741–742
history, II-741
intensity-modulated, II-590, II-747–748
Langerhans cell histiocytosis, II-530
laryngeal, II-742–744
lymphoma, II-713
melanoma, II-700
nasopharyngeal, II-744–745, II-746t
oropharyngeal, II-742, II-744t
osteoradionecrosis prevention and, II-590
osteosarcoma, II-649
overview, II-741–745
postoperative, II-745–746
preoperative, II-745–746
rhabdomyosarcoma, III-760–762
side effects, II-749
skin cancer, II-734–735
systemic therapy with, II-747
techniques, II-747–749
third molar removal and, I-285
tissues damaged by, I-675–677
Radicular cyst, II-340–341, II-342f–343f
Radiofrequency ablation, II-540
Radiography
dentoalveolar injury, II-119–120
digital, III-6–7
impacted tooth, I-260–261, I-261f
insurance codes for, I-94
lymphoma, II-711–712
mandibular fracture, II-154f
midface fracture, II-217
model surgery, III-47–49
odontogenic tumor, II-392
osteomyelitis, II-586f–589f
panoramic, II-79f
for nerve imaging, II-78
for temporomandibular joint, II-817–818
Panorex, I-570
temporomandibular joint, II-815
temporomandibular joint disorder, II-801
three-dimensional, for temporomandibular joint, II-815
trauma patient assessment with, II-5
zygomatic fracture, II-191–193
Radiotherapy. *See* Radiation therapy
Ramsay Hunt syndrome, II-102
Ramus
fracture, II-34, II-149
osteotomy, in sagittal split ramus procedure, III-75f
reconstruction, in oculoauriculovertebral spectrum, III-692–695
Ramus/condylar unit (RCU), III-144
Range of motion
mandibular, II-805–806
temporomandibular joint, II-964
RANKL. *See* Receptor activator of nuclear factor-KB ligand (RANKL)
Ranula
laser for removal of, III-350
sublingual gland, II-483
Rapamune. *See* Sirolimus (Rapamune)
Rapidly involuting congenital hemangioma (RICH), II-536–538
Rathke's pouch, I-258
Rating site, marketing and, I-103–104
Reactive arthritis, II-225, III-561–562
clinical features, II-562
treatment, II-562
RealSelf, marketing and, I-106
Receptionist, as marketing asset, I-133
Receptor activator of nuclear factor-KB ligand (RANKL), II-507
Recombinant human bone morphogenetic protein-2 (rhBMP-2), I-458, I-510–512
Reconstruction
complications, II-276
flap options, II-296b
Ganz-Rinaldi surgical protocol, I-706f
implant placement timing, I-674–675
lip, II-297–298
mandibular, II-296–297, II-298f
maxillary, I-299f, II-283–300
nasal, II-297, II-299f
protocol for, I-704–706
scalp, II-298–300, II-301f
site-specific, II-296–297
Reconstruction plate, in inverted L osteotomy, III-128f–130f
Recovery
monitoring during, I-172–173
stages, I-172
Recurrent intracranial hypertension, III-674–675
Reed-Sternberg cell, II-707, II-709
Reflex sympathetic dystrophy, II-947
Refusal of treatment, I-77–78
Regenerative medicine, for temporomandibular joint disc repair, II-914–917

Regional acceleratory phenomenon, III-247
Registration, in computer-aided surgical simulation, III-31–33
Regulation, awareness of, I-85
Reiter syndrome, II-561–562, II-842–843
Rela. *See* Carisoprodol (Rela, Soma)
Relative value unit (RVU), I-88
Remifentanil, I-200
  advantages, I-220–221
  clearance, I-201f
  infusion duration, I-201f
  propofol combined with, I-219t
  structure, I-199f
  synthesis, I-197–198
Remodeling
  craniofacial, III-628–629
  definition, III-628t
Remodeling phase, of bone healing, I-426–427
Renal disease
  orthognathic surgery and, III-283–284
  pediatric, III-283
  physiologic disorders of, I-154t–155t
  preoperative evaluation of, I-140
Renal failure, I-154t–155t
  craniomaxillofacial trauma management and, II-3t
  preoperative management, I-155t
Renal system
  pediatric, I-241
  preoperative evaluation, III-283–284
Repositioning splint, temporomandibular joint, II-867
Rescue, from sedation, I-212–213
Residual cyst, II-341–342
Residual ridge form, I-595–596
Resonance, speech, in cleft palate, III-570–571
Resource-Based Relative Value Scale (RBRVS), I-88
Respiration
  age values, I-241t
  monitoring, I-169–170, I-222
  opioid drugs effect, I-199
  pediatric, I-241t
Respiratory failure, cervical spine injury associated with, II-11
Respiratory system
  cigarette smoking effects, I-215
  monitoring, I-167–169
  pediatric, I-239–241
Rest of Malassez, II-338–340
Rest of Serres, II-338–339
Resting skin tension lines (RSTL), II-724
Restoration
  cement-retained single anterior, I-630–631
  decision making process for, I-632–635
  fixed. *See* Fixed restoration
  retrievable, I-600, I-637
  screw-retained single, I-627–629
  screw-retained single anterior, I-631
  screw retention *versus* cement retention, I-631–632
  zirconia, I-628
Restoril. *See* Temazepam (Restoril)
Reticular formation, trigeminal nerve pathway and, II-942
Retinoblastoma, II-599, III-762–763
Retinoblastoma pathway, II-613
Retinoid medication, II-733
Retirement, I-138–142
  aging process, I-140–141
  balance in, I-138–139
  family and friends, I-139
  legacy, I-139
  recreation in, I-139
  spirituality, I-139
  work in, I-138
Retractor, Bauer, III-88f
Retrobulbar hemorrhage, II-206–207
Retromolar trigone, II-671, II-681–683
Reverse Towne projection, II-816–817
Reviews, marketing and, I-103–104
Rhabdomyosarcoma, II-644t, II-654–656, III-760–762, III-765f
  classification, II-655
  prognosis, II-655t
  spindle cell, II-657f
  treatment, II-655–656
  tumor-node-metastasis staging, II-655t
Rheumatoid arthritis, II-833, II-835, II-838–840
  facial pain and, II-944–945
  splint therapy for, II-869
  temporomandibular joint replacement for, II-930f
Rheumatoid factor, II-839–840
Rhinoplasty, III-364–387
  anesthesia, III-377
  case reports, III-384b–385b
  clinical evaluation, III-368–371
  closed, III-377–383
  complications, III-383–386
  consultation, III-367–368
  in craniosynostosis treatment, III-678
  incisions, III-371–372, III-377–381
  nasal function evaluation, III-370–371
  nasal tip control, III-372–373
  nasal tip rotation, III-375–376
  nasal tip shape, III-376–377
  open, II-186f, III-377–383
  patient evaluation, III-367–368
  postoperative care, III-383
  surgical technique, III-377–383
  in Treacher Collins syndrome, III-731
Rhytidectomy, III-325–335
  anatomic considerations, III-327–328
  anesthesia, III-329
  complications, III-332–333
  facial evaluation, III-326–327
  generations, III-326t
  infection following, III-333–335
  nerve injury, III-333–334
  patient evaluation, III-325–327
  patient marking, III-328–329
  postoperative care, III-331–332
  skin necrosis, III-333
  surgical technique, III-328–332
Rib
  adult *versus* infant, I-240f
  bone graft from, III-591
Rib graft, in pediatric ablative defect reconstruction, III-766–767
Ribonucleic acid (mRNA), messenger, cancer diagnosis and, II-623
Ribonucleic acid (RNA)
  function, II-603
  messenger, II-603, II-604f
Ribonucleic acid interference (RNAi), II-625
Rickett's divider, III-15f
Ridge, edentulous, III-60
Ridge augmentation, I-483
  in alveolar distraction, I-538–539
  example, I-488f
  three-dimensional, I-539
Ridge crest, prosthesis at, I-586f–587f
Ridge form, I-595f–596f
Rifle, injury from, II-303–304
Risedronate (Actonel), II-508t
Rish technique, chin position analysis with, III-460t–461t
Risk management, I-61–62
  anesthesia, I-78, I-81–82
  case studies, I-74–75
Risk management *(Continued)*
  communication with patient and, I-80–81
  definition, I-73–74
  documentation, I-75–80
  emergency preparedness, I-81–82
  failure to diagnose, I-82
  informed consent, I-76–78
  lawsuit, I-83–84
  mandibular surgery, III-297–298
  oral and maxillofacial surgery, I-73–86
  patient noncompliance, I-79–80
  patient referral, I-81
  patient refusal of treatment, I-77–78
  prevention and mitigation, I-74–82
  treatment plan, I-76
Risk manager, I-83
Rituximab, II-713
Robaxin. *See* Methocarbamol (Robaxin)
Rocker deformity, III-379–380
Rocuronium
  anaphylaxis associated with, I-252t
  general anesthesia with, II-13
  for laryngospasm, I-252
Roll orientation
  in computer-aided surgical simulation, III-38, III-120
  model surgery and, III-44f
  in orthognathic surgery, III-23–24
Root
  contact, miniscrew anchor failure and, I-323
  fracture, in dentoalveolar injury, II-124f, II-125–127
  miniscrew implant and, I-315
  position, implant restoration and, I-393
  reabsorption, third molar removal and, I-284–285
  residual, exodontia and, I-299
Root canal
  healing, after trauma, II-138
  nerve injury associated with, I-377, II-949–950
Root canal fill, calcium hydroxide for, II-131
Root membrane technique, I-420–422
Root submergence technique, I-420–422
Root tip
  displacement, I-299–301
  swallowing of, during exodontia, I-302
Rotary drill, thermal trauma from, I-607
Rotation and advancement flap technique, III-514–516
  Asenio technique, III-517–518
  nasal reshaping, III-518–519
  postoperative care, III-519
  surgical procedures, III-516–519
Roux, Philibert, III-534
Rowe maxilla disimpaction forceps, II-217f
Rule of tens, cleft lip repair and, III-513–514

S

S corporation, I-58–59, I-59t
Saddle nose, II-225
Saethre-Chotzen syndrome, III-631f, III-669
Safety, for pediatric anesthesia, I-238
Sagittal split genioplasty, III-103, III-104f–105f
Sagittal split osteotomy (SSO), III-62–95
  bilateral, III-64b
    indications for, III-64
    for mandibular asymmetry, III-72b
  chin position and, III-303t
  complications, III-79–80, III-298–319
  hemorrhage in, III-82, III-310–313
  history, III-144, III-183, III-4
  infection, III-82
  limitations, III-64–74
  nerve injury associated with, II-86, III-300–301, III-305–308, III-316–317

Sagittal split osteotomy (SSO) *(Continued)*
Obwegeser technique, III-63f
ramus, III-204
relapse after, III-82–83, III-116b, III-777–778
surgical sequence, III-74–79
in Treacher Collins syndrome, III-731
treatment planning, III-299
unfavorable bony split, III-81–82
Sagittal split ramus osteotomy (SSRO). *See* Sagittal split osteotomy (SSO)
Sagittal suture craniosynostosis, III-653–654
Salary and benefits, employee, I-112
Saliva
composition, II-481
formation, II-481
viscosity, II-482t
Salivary duct
carcinoma, II-759–760
obstruction, II-483
Salivary gland
cancer, II-759–760
cystic conditions, II-483–485
disease. *See* Salivary gland disease
imaging, II-481–483
infection, II-485–488
inflammatory conditions, II-485–488
lymphoepithelial cyst, II-485
lymphoma, II-712
neoplasms, II-493t
nonsalivary tumor, II-500–503
obstructive disease, II-488–492
pediatric injury, II-272
physiology, II-481
sialolithiasis, II-488–490
stones, III-359
tumor, II-492–503, II-493t, III-763
tumor stages, II-494t
types, II-482t
viral infection, II-487–488
Salivary gland disease, II-481–506
Salivary pellicle, II-550
Sarcoidosis, II-503
Sarcoma
alveolar soft part, II-663–664
ameloblastic, II-454–455
classification, II-643–644
definition, II-643
diagnosis, II-644–647
environmental factors, II-644
etiology, II-644
Ewing, II-662–663
head and neck, II-643, II-644t
incidence, II-643
jaw, II-643–669
neurogenic, II-644t, II-660–661
pediatric, II-654, III-760–763
radiation therapy, II-741–742
risk factors, II-644
synovial, II-661–662, II-856–857
temporomandibular joint, II-856
Saunders, William, I-24
Save-A-Tooth, II-130f
Scaling and root planing (SRP), I-350
Scalp
layers of, II-189–190
reconstruction, II-298–300, II-301f
wound closure, II-11
Scaphocephaly, III-653–654
Scar revision, laser surgery for, I-346, III-357–358
Scatter artifact, I-692–693
Schirmer test, II-103, III-392f
Schneiderian membrane, I-509–510
perforation, I-515–518
in zygomatic implant, I-574
Schultz, Louis, II-770
Schwann cell, II-472
nerve injury and, II-72
proliferation, II-73
trigeminal nerve anatomy and, II-77
Schwannoma, II-472, II-473f, II-660
Scientific knowledge, commitment of, I-3
Scleroderma, II-848
Sclerotherapy
for lymphatic malformation, II-539
for venous malformation, II-543
Screw channel, single implant and, I-637–639
Screw fixation, III-7
osteosynthesis, in sagittal split ramus osteotomy, III-76–77
position technique, III-78f
resorbable screws in, III-77–79, III-79b
Screw tent-pole technique, I-484
Scroll, nasal, III-367
Sebaceous gland carcinoma, II-720
Secondary intention healing
after biopsy, II-724
after Mohns procedure, II-730
after surgical excision, II-731
facial areas for, II-727, II-727f
for wounds, II-731–732
Secretory duct, II-481
Sedation
benzodiazepines and, I-192
BIS monitoring, I-171–172
bispectral index, I-217t
complications, I-222–223
deep, I-164, I-165t, I-211
depth, I-171–172
general, I-165t, I-211
goals, I-211–212
levels, I-165t, I-211
minimal, I-164, I-165t, I-211
moderate, I-164, I-165t, I-211
patient-controlled, I-219–220
pediatric, I-238–256
pediatric techniques, I-251
rescue, I-212–213
Sedative-hypnotic drugs, I-200–203
Seddon classification of nerve injury, II-70–73, II-71f
Seddon-Sunderland classification of nerve injury, I-311, I-355, I-356t
Seizure
epileptic, I-161
orthognathic surgery and, III-284
post-traumatic, II-255–256
Seizure disorder, craniomaxillofacial trauma management and, II-3t
Selective photothermolysis, III-339
Selective serotonin reuptake inhibitors (SSRI)
for facial pain, II-955–956
for fibromyalgia, II-970
for temporomandibular joint disorders, II-872–873
Selective transparency, in three-dimensional imaging, I-694f–695f
Self-inflicted gunshot wound (SIGSW), II-320–323
Sensation, altered, testing for, I-358f
Sensitization
chronic facial pain and, II-943
definition, I-355t
Sensory reeducation, I-365, I-366f
Sentinel lymph node biopsy, II-697–698, II-700, II-730
Sentinel vein, III-399
Septa
in maxillary sinus, I-509–510
orientation, I-511f–512f
Septocaine. *See* Articaine (Septocaine)
Septoplasty, III-380, III-382
Septorhinoplasty, II-180
Serax. *See* Oxazepam (Serax)
Seronegative spondylitis, II-842
Sertraline (Zoloft), II-873t
Sevoflurane (Ultane), I-207–208
inhalation induction of, I-220
mask induction with, I-251
for pediatric patient, I-251
Sexual addiction, I-145
Sexual harassment, I-113, I-111
Shaken baby syndrome, II-250–251
Shira, Maj. Gen. Robert B, I-24, III-4
Shock, in child, II-249–250
Shotgun
injury from, II-304, II-320
wound classification system, II-304
wound from, II-305–306
Sialadenitis
acute suppurative, II-487
chronic obstructive, II-490–492
Sialodochoplasty, II-679–680
Sialography
for chronic obstructive sialoadenitis, II-491–492
salivary gland, II-481–483
Sialolith
laser for excision of, I-336, III-350
location, II-488
parotid gland, II-490–492
submandibular gland, II-490
surgery, II-488
Sialolithiasis, II-488–490
Sicher, Harry, II-768–769
Sickle cell disease, I-159, III-285
Signal pathway, cancer and, II-602–622
Silver, Caroll, II-769–770
Silver sulfadiazine, II-67
Simon's method of nasal projection, III-369
Simulator, anesthetic, I-213
Sinequan. *See* Doxepin (Sinequan)
Single photon emission computed tomography (SPECT)
cancer diagnosis, II-624
facial pain, II-947
temporomandibular joint, II-825
Sinonasal tract
chondrosarcoma in, II-649
lymphoma, II-710
malignant fibrous histiocytoma in, II-651
Sinus
ameloblastoma, II-415f–416f
biology and anatomy, I-509–510
bone graft, I-464–465
floor, comminution of, II-239f
fracture, pediatric, II-266–267
frontal. *See* Frontal sinus
infection
management, I-579–581
sinus fracture as cause of, II-243
zygomatic implant associated with, I-581f
lateral approach, I-514–518
maxillary, I-509, I-510f
morphology, I-509–510
obliteration, II-236–238
paranasal, lymphoma, II-712
pediatric, II-241
pneumatization, I-509
pseudocyst, I-510
size, I-509
subantral surgery and graft, I-509–525
Sinus augmentation, I-464–465
complications, I-520–522
crestal approach, I-521f
Ganz-Rinaldi surgical protocol, I-705f–706f
graft materials, I-510–513
implant placement with, I-517f, I-519–520

Sinus augmentation *(Continued)*
indirect (transcrestal) approach, I-518–522, I-518f, I-521f
lateral approach, I-514–518, I-516f
perforation, I-515–518, I-518f, I-520–522
postoperative stage, I-522
preoperative evaluation, I-513–514
pretreatment, I-510–513
protocol, I-514–515
techniques, I-514–522
three-dimensional imaging for, I-705–706
transcrestal approach, I-518–522
Sinus graft, I-704–706
Sinus graft guide, I-705–706
Sinus lift
complications, I-520–522
implant simultaneous with, I-519f
indirect, I-519f
perforation, I-520–522
postoperative stage, I-522
for resorbed maxilla, I-569–570
techniques, I-514–522
Sinusitis, I-513–514
Sirolimus (Rapamune), II-509t
Sitting position
anesthesia administration, I-46–54
equipment, I-46–50
oral surgery from, I-46–57
Sjögren syndrome, II-483, II-503–504
lymphoma and, II-710, II-712
temporomandibular joint affected by, II-848
Skeleton
craniofacial, III-627–628, III-674f
concepts, III-628–629
dysmorphology, III-636
evaluation of growth, III-635
growth and development, III-629–635
growth discrepancy, III-627–628
injury, II-18
pediatric, II-241–243
craniomaxillofacial, distraction osteogenesis, III-774–785
facial
access, III-739
evaluation of, III-16–20
facial bipartition osteotomy, III-677f
growth and development, III-628–629
Skin
anatomy, II-722
nasal, II-174–177
nasal thickness, III-370
necrosis, III-333
types, II-722–723
wound closure, II-9–10
Skin cancer
biopsy, II-723–725
clinical examination, II-722–725
epithelial, II-718–720
head and neck, II-717–740
incidence, II-690
laser surgery for, I-343
lymph node involvement, II-730–732
medical management, II-732–735
metastasis, II-723
non-melanoma, II-717–740
nonepithelial, II-720
photodynamic therapy, II-734
radiation therapy, II-734–735
recurrence, II-732–733
repair of wound, II-731–732
risk factors, II-717
screening, II-722–725
staging, II-725–727
surgical excision, II-729–730
treatment, II-727–730
Skin creep, II-731
Skin lesion, hepatic infection and, II-552
Skin resurfacing
complications, I-345–346
contraindications, I-345
laser, I-343–344, I-344f
wound healing, I-345
Skull
basal view of, II-778f
cloverleaf, III-669
Kleeblattschädel, III-669
lateral view of, II-778f
surgical access, III-741
Skull fracture
images of, II-233f, II-232f
pediatric, II-253
Sleep apnea. *See* Obstructive sleep apnea (OSA)
Sleep study, III-265
Sliding genioplasty, III-101–103
SMARTlock Hybrid maxillomandibular fixation system, II-155
SMAS. *See* Superficial musculoaponeurotic system (SMAS)
Smile, favorable, orthognathic surgery and, III-26–27
Smile line, III-26–27
implant and, I-391–393, I-392f
lip length and, I-588–591
transition line and, I-570f
Smokeless tobacco, oral cancer risk and, II-671
Smoking. *See* Cigarette smoking
Snapping jaw, II-766–767
Snappy abutment, I-624–626, I-633–634
Snoring, treatment, III-351
SOAP. *See* Subjective objective assessment plan (SOAP)
Social media, oral and maxillofacial surgical practice marketing, I-103–106
Socket
after third molar removal, I-288
defect, I-476
immediate implant into, I-410
preservation
case study, I-495b, I-500b
in guided bone regeneration, I-493
in simple extraction, I-278–279
Socket shielding technique, I-420–422
Socket wall fracture, II-133
Sodium hypochlorite, injury associated with, I-378
Sodium ion channel
local anesthesia and, I-177
nerve conduction and, I-176
Sodium lauryl sulfate, II-550
Soft palate
anatomy, III-535, III-612–615
musculature, III-536f, III-612–615
radiation therapy for carcinoma of, II-742
repair, III-503, III-534
speech and, III-541
two-stage, III-548–549
surgical technique, III-536–537
Soft splint, temporomandibular joint, II-867
Soft tissue
attachment, to implant, I-712, I-713f
bone graft preoperative evaluation, I-450–451
cement retention effect, I-632
closure, in guided bone regeneration, I-479–480
dentoalveolar injury evaluation, II-117
emphysema, I-301
evaluation, in orthognathic surgery, III-16
examination, in trauma patient, II-4
facial wound and, I-666
fibrosarcoma, II-652
gunshot wound, II-306
Soft tissue *(Continued)*
implant interface, I-555
injury, II-256–257
burn, II-67–68
during exodontia, I-301
in osteotomy, III-312f
pediatric, II-271–273
postoperative care, II-14–15
treatment, II-137
in vertical ramus osteotomy, III-314
injury management, pediatric, II-271–273
laser interaction, III-339, III-341t
leiomyosarcoma, II-656
liposarcoma, II-661
matrix expansion technique, I-484
measurements, for genioplasty, III-99, III-99f
midface fracture effect, II-216
nasal, II-174–177
non-odontogenic developmental cyst, II-371–375
pediatric
injury patterns, II-260–261
procedures, I-270–272
wound healing, II-256–257
physiology, II-256–257
readaptation, in naso-orbito-ethmoid fracture, II-225
rhabdomyosarcoma, II-654
separation, in simple extraction, I-276
in Treacher Collins syndrome, III-706–707, III-731–732
wound closure, II-42–45
wound healing, II-256–257
zygomatic fracture complications and, II-203
Soft tissue augmentation, I-555–568
graft substitutes for, I-558–561
indications for, I-563
peri-implant, I-555–568, I-564f
peri-implant grafting and, I-415–416
periodontal, I-565f–566f
vestibular incision tunnel access for, I-561–563, I-565f–566f
Soft tissue graft
autogenous, I-556
pediculated, I-556–558
substitutes, I-558–561
vascularized interpositional, I-558, I-560f
Soft voice syndrome, III-572
Solar cheilitis, laser treatment, III-354
Sole proprietorship, I-58
Solvent-dehydrated allograft (SDA), I-429–430
Soma. *See* Carisoprodol (Rela, Soma)
Sorafenib (Nexavar), II-509t
Space maintenance
in guided bone regeneration, I-479, I-483–484
in metal and acrylic restoration, I-599f
in osteoperiosteal flap, I-526
osteoperiosteal flap for, I-526–534
strategy, I-526–532
Speech
articulation, III-571–572
characteristics, with cleft palate, III-570–572
cleft palate repair and, III-503, III-540–542
double-opposing Z-plasty and, III-546–547
evaluation, III-572–574
horizontal transition line and, I-591–592
intelligibility, III-571–572
normal development of, III-568–569
Speech disorders
in cleft palate, III-568–582
etiology, III-568–570
evaluation, III-572–574
Speech therapy, III-579–580
Speed of onset, of local anesthetics, I-177
Sphenomandibular ligament, II-780–781

Sphincter pharyngoplasty, III-617–618, III-617f
Spine injury
  cervical, II-11
  craniomaxillofacial fracture associated with, II-38
  orthognathic surgery evaluation, III-16–17
Splint
  acid-etch resin arch wire, II-135, II-136f
  bracket arch wire, II-136–137
  fabrication, III-51f
  intermediate
    fabrication of, III-55–59
    for mandible-first surgery, III-59f
  lingual, II-155
  in model surgery, III-50
  occlusal, III-177–178, III-187f
  in orthognathic surgery, III-290
  titanium trauma, II-136–137, II-137f
Splint therapy
  after internal derangement surgery, II-919
  alveolar fracture, II-134
  avulsed tooth, II-128–129
  dentoalveolar injury, II-135–137
  masticatory myalgia, II-967
  orthopedic intraoral, II-968
  primary tooth displacement, II-132
  techniques, II-135–137
  temporomandibular joint disorder, II-865–869, II-967–968
Spontaneous emission of radiation, III-336–337
Sports, dentoalveolar injury associated with, II-141
Spray and stretch technique, II-970
Squamous cell carcinoma, II-431f, II-498, II-499f, II-599, II-670–689, II-719
  buccal mucosa, II-680–681
  chemotherapy for, II-754–756
  diagnosis and evaluation, II-675
  epidemiology, II-671–675
  epidermal growth factor receptor inhibitors for, II-757–759
  follow-up, II-684–685
  genetic abnormalities associated with, II-672–673
  head and neck
    chemo-radiotherapy, II-753–754
    clinical trials, II-758t
    epidemiology, II-752
    treatment, II-752–754
  keratocystic odontogenic tumor, II-352–354
  laryngeal, chemotherapy/radiation therapy, II-754
  laser surgery, I-343
  lip, II-735–737
  lymph node involvement, II-730
  mouth floor, II-679–680
  nasopharyngeal, II-744–745
  nonsurgical management, II-677–679
  oncology principles in management of, II-752–763
  oropharygneal, chemotherapy/radiation therapy, II-754
  radiation fractionation scheme, II-746–747
  radiation therapy, II-734, II-741
  risk factors, II-671–672, II-752
  screening, II-673–674
  sites, II-742
  staging, II-675–677, II-726t
  surgical management, II-679–683
  tongue, II-681
  tonsillar fossa, II-743f
  treatment, II-727, II-752–754
Squamous odontogenic tumor (SOT), II-397–398
SRP. *See* Scaling and root planing (SRP)
SSRO. *See* Sagittal split osteotomy (SSO)
Stabilization splint, temporomandibular joint, II-866–867
Stadol. *See* Butorphanol (Stadol)
Staining
  histochemical, II-332
  immunoperoxidase, II-333
Stambaugh method, chin position analysis with, III-460t–461t
Staphylococcus aureus
  methicillin-resistant, II-486–487
  parotitis and, II-485–486
  peri-implantitis and, I-727–728
Stem cell
  autologous adult, I-438–439
  cancer, II-599–600
  in temporomandibular joint arthrocentesis, II-888
  transplantation, for lymphoma, II-713
Stem cell entubulation, I-372–373
Stereolithography, I-696–699
Stereotactic navigation system, II-227
Steroid drugs, I-233
  Bell's palsy treated with, II-101
  for congenital hemangioma, II-537
  equivalent dosages, III-287t
  in orthognathic surgery, III-287, III-289
  in temporomandibular joint arthrocentesis, II-887
Stethoscope, precordial/pretracheal, I-167–168
Stickler syndrome, III-493–494
Still disease, II-840
Stimulated emission of radiation, III-336–337
Stomatodynia, II-949
STOP BANG questionnaire, I-214t
Strain, repetitive, temporomandibular joint pain associated with, II-963, II-966b
Streeter, G. L., III-476–477
Streptococcus pyogenes, peri-implantitis and, I-727–728
Stroke. *See* Cerebrovascular accident (CVA)
Student, evaluation of, I-4–6
Sturge-Weber syndrome, II-538, II-538f
Stylomandibular ligament, II-780–781
Subarachnoid hemorrhage (SAH), II-253
Subjective objective assessment plan (SOAP), I-78–79
Sublingual gland
  cystic conditions, II-483–485
  nonsalivary tumor, II-500
  sialolithiasis, II-488
  tumor, II-493t
Subluxation, in dentoalveolar injury, II-127
Submandibular gland
  chronic obstructive sialadenitis, II-490
  excision, II-491f
  infection, II-487
  nonsalivary tumor, II-500
  sialolithiasis, II-488–490
  stone, II-490
  tumor, II-493t
Submandibular space, tooth displacement into, I-300–301
Submental island flap, II-290–294
Submucous cleft palate, III-618–619, III-692
Substance abuse, I-144–145
  craniomaxillofacial trauma management and, II-3t
  ethics and, I-12
  facial pain management and, II-953
Success, definition, I-14–17
Succinylcholine
  anaphylaxis associated with, I-252t
  general anesthesia with, II-13
  for laryngospasm, I-252
Sufentanil
  structure, I-199f
  synthesis, I-197–198
Sulindac, II-871t
Sunderland classification of nerve injury, I-71–72, II-71f, II-356t
Sunitinib (Sutent), II-509t, II-511
Superficial musculoaponeurotic system (SMAS), II-174–175, III-325, III-330, III-331f
Superficial spreading melanoma, II-692t
Supernumerary teeth, I-266–268
Suprane. *See* Desflurane (Suprane)
Surgeon. *See* Oral and maxillofacial surgeon (OMS)
Surgeon-scientist, oral and maxillofacial surgeon as, I-35–37
Surgery
  bariatric, III-268
  mandibular. *See* Mandibular surgery
  nasal, for obstructive sleep apnea, III-269
  oral. *See* Oral and maxillofacial surgery (OMS)
  orthognathic. *See* Orthognathic surgery
Surgical assistant, I-111
  position, I-50
  role, I-52–53
Surgical excision, II-729–730
  Mohs micrographic surgery *versus*, II-730
  repair after, II-731–732
  for skin cancer, II-729–730
Surgical guide
  custom tray from, I-615f
  in digital workflow protocol, I-688
  example, I-612f
  fabrication, I-699–704
  immediate implant loading and, I-607–608, I-611f
  resin pattern, I-704f
  three-dimensional imaging of, I-699–704
Surgical margin, II-728
Surgical pathology, II-329–337
  electron microscopy, II-335
  flow cytometry, II-335–336
  histochemical staining in, II-332
  immunofluorescence studies in, II-332
  immunohistochemistry in, II-333–334
  molecular biology in, II-336
Surgical practice. *See* Oral and maxillofacial surgical practice
Surgical repair cascade, nerve injury and, I-368, I-368f
Surgical resection
  arteriovenous malformation, II-547
  lymphatic malformation, II-539
  squamous cell carcinoma, II-753
  venous malformation, II-544
Surgically assisted rapid maxillary expansion (SARME), III-172
Surgically assisted rapid palatal expansion (SARPE), III-172–174, III-197
Sutent. *See* Sunitinib (Sutent)
Sutton disease, II-559
Suture
  absorbable, II-48t
  alar cinch, III-167–168
  ear laceration, II-57–60
  eyelid laceration, II-51–52
  lip laceration, II-54–57
  materials, II-42–44, II-46t
  nonabsorbable, II-49t
  selection, II-46t
  soft tissue injury, II-42–44
Swelling
  lasers and, I-340
  postsurgical, I-282, I-304
  third molar extraction and, I-293

Symmetry
esthetic implant restoration and, I-393f
facial, osteotomy and, III-184–185
in facial esthetics, III-13–14
final, in computer-aided surgical simulation, III-39
Sympathetic mediated pain, I-361
Sympathetic nervous system, pediatric, I-239
Symphysis
mandible, II-148
widening, III-199–200
Syndactyly, in Apert syndrome, III-669f
Synergy, in marketing, I-123
Synovial chondromatosis, II-796, II-798f, II-855–856
Synovial chondrosarcoma, II-856
Synovial fluid
arthritis effect on, II-835–836
in osteoarthritis, II-838
in temporomandibular joint dysfunction, II-884
temporomandibular joint inflammation and, II-832
temporomandibular joint internal derangement and, II-906
Synovial hemangioma, II-853
Synovial membrane, II-780
Synovial sarcoma, II-644t, II-661–662, II-856–857
Synovitis, II-837–838, II-855
Systemic disease, insurance codes for, I-94–95
Systemic lupus erythematosus (SLE), II-848

T

T cell, II-600–601
TAD. *See* Temporary anchorage device (TAD)
Talwin. *See* Pentazocine (Talwin)
Tattoo, laser treatment, I-348–349, III-357
TCS. *See* Treacher Collins syndrome (TCS)
Teeth. *See* Tooth
Teflon-Proplast implant, II-772
Tegretol. *See* Carbamazepine (Tegretol)
Telangiectasia
laser treatment, I-338
local anesthetics, I-347
Telecanthus, in naso-orbito-ethmoid fracture, II-221–222, II-224, II-226
Telephone ear deformity, III-456
Teletherapy, II-747–748
Telogen effluvium, III-418f, III-425
Telomerase, II-616–617, II-617f, II-628
Temazepam (Restoril)
structure, I-196f
for temporomandibular joint disorders, II-874t
Temozolomide, II-701
Temperature, monitoring, I-170
Temporal bone, in temporomandibular joint, II-815
Temporalis muscle, II-399, II-782–783, III-785
Temporalis muscle flap, II-924, II-925f
Temporary anchorage device (TAD), I-314–316, I-311
Temporomandibular joint (TMJ)
abnormal biomechanics, II-795–796
anatomy, II-766, II-794, II-892–893
ankylosing spondylitis effect on, II-842
ankylosis, II-209f–210f, II-767, II-769, III-932f
joint replacement for, II-931
arthritis, II-769, II-832–848, II-929–931
arthrocentesis, II-883–891
contraindications, II-884
double puncture, II-885–886
outcomes, II-888–889
single puncture, II-886
technique, II-884–888
Temporomandibular joint (TMJ) *(Continued)*
arthropathy, III-81, III-317
arthroscopy, II-892–903
complications, II-897–900
disc repositioning, II-897
lysis and lavage, II-896–897
postoperative care, II-901
articulation, II-794
auscultation, II-808–809
biomechanics, II-795
blood supply, II-784–785
capsule, II-780
computed tomography, II-818–821
cone beam computed tomography, II-824–825, II-826f
continuous passive motion, II-833–835
cross-sectional anatomy, II-402f, III-794f
cyst, II-850–856
development, II-777–778
disc derangement, II-813f, II-883
osteoarthritis associated with, II-837–838
repair, II-910
disc displacement, II-792t–793t, II-797–798, II-800f, II-807
disc perforation, I-342–343, II-910, II-914–917
dysfunction, in sagittal split ramus osteotomy, III-81
evaluation, II-805–809
function, II-777–790
functional imaging, II-825
fusion imaging, II-826
gait of movement, II-806–808
hemangioma, II-852–853
histology, II-778–785
hypermobility, I-342
imaging, II-815–829
immobilization, II-833–835
infectious arthritis effect on, II-843–847
inferior (lower) compartment, II-893
inflammation, II-832, II-858
inflammatory arthritis, II-929–931
innervation, II-784–785
internal derangement. *See* Internal derangement (TMJ)
joint adhesions, I-342
juvenile idiopathic arthritis effect on, II-131, III-840–841
laser-assisted surgery, I-341–343, III-358–359
lateral oblique view, II-817
ligaments, II-780–781
magnetic resonance imaging, II-821–824, II-823f
malignant neoplasms, II-856–857
metabolic arthritis effect on, II-847–848
metastatic carcinoma, II-857
movement, II-795
muscle disorders, II-962–972
clinical presentation, II-963–964
diagnostic tests, II-964–966
etiology and epidemiology, II-962–963
mechanisms, II-963
pathophysiology, II-963
pharmacotherapy, II-968–969
self-care for, II-968
treatment, II-966–971
muscles, II-781–784
actions, II-786b
combinations, II-786
evaluation of, II-810
in oculoauriculovertebral spectrum, III-690
osteoarthritis, II-836–838
osteochondroma, II-854
palpation, II-809
panoramic radiography, II-817–818, II-819f
parasagittal section, II-779f
Temporomandibular joint (TMJ) *(Continued)*
pathology, II-830–864, II-893–894
pathophysiology, II-830–835, II-884
pediatric, II-934
physiology, II-830–835
range of motion, II-797, II-805–806, II-964
reconstruction
in oculoauriculovertebral spectrum, III-692–695
orthognathic surgery and, III-222–245
replacement, II-923–940
alloplastic, II-924–929
autogenous, II-923–924
custom-made device for, II-928
distraction osteogenesis and, II-934–935
history, II-923–929
indications, II-929–933, II-933t
for loss of mandibular height, II-931–933
with orthognathic surgery, III-136
pediatric, II-934
reverse Towne projection, II-816–817
rheumatoid arthritis effect on, II-838–840
in sagittal split osteotomy, III-204
structure, II-777–790
subluxation, II-792t–793t, II-800f, II-807
submentovertex projection, II-817
superior (upper) compartment, II-893, II-895f
surgical anatomy, II-778–785
surgical trauma to, I-305–306
total prosthetic reconstruction
case studies, III-235b, III-239b–240b
imaging, III-223–226
magnetic resonance imaging, III-224
occlusal plane alteration, III-226–227
orthognathic surgery and, III-222–245
outcomes, III-238–242
patient evaluation, III-222–223
surgical procedure, III-233–242
virtual surgical planning, III-229–232
transcranial view, II-816, II-816f
transmaxillary view, II-816
traumatic arthritis, II-836
in Treacher Collins syndrome, III-707–731
tumors, II-848–858
ultrasonography, II-826
Temporomandibular joint disorder (TMD), II-764
abnormal biomechanics, II-795–796
algorithm for nonsurgical management, II-866f
arthritis, II-833–848, II-929–931
arthrocentesis for, II-883–891
double puncture, II-885–886
outcomes, II-888–889
single puncture, II-886
technique, II-884–888
arthroscopy for, II-892–903
assessment, II-791–814
background, II-791–796
cephalometric analysis, III-226
classification, II-905b
common features, II-791
computed tomography for, II-820–821
condylectomy, III-145–146
definition, II-791–796
diagnostic approach, II-792t–793t, II-812t
disc displacement, II-792t–793t, II-797–798, II-800f, II-807
imaging of, II-820
nonsurgical management, II-883
splint for, II-869
evaluation, II-801–804
evaluation form, II-810b–811b
exodontia and, I-306
genetic, II-858

Temporomandibular joint disorder (TMD) *(Continued)*
imaging, II-801–804
implant for, II-770–771
inflammatory, II-858
internal derangement. *See* Internal derangement (TMJ)
intracapsular adhesion, II-799–800
intracapsular pathofunctional, II-796–801
joint replacement, II-923–940
laser surgery, I-343
magnetic resonance imaging, II-821–824
metabolic, II-858
muscle disorders, II-962–972
clinical presentation, II-963–964
diagnostic tests, II-964–966
etiology and epidemiology, II-962–963
mechanisms, II-963
pathophysiology, II-963
pharmacotherapy, II-968–969
self-care for, II-968
treatment, II-966–971
nonsurgical management, II-865–883
nonsurgical therapy, II-770–771
occlusal management, II-873–875
occlusion role in, II-767–769
in oculoauriculovertebral spectrum, III-690
orofacial pain associated with, II-804–810
orthognathic surgery evaluation and, III-16
osteoarthritis, II-929–931
pathology, II-830–864
pathophysiology, II-884
pharmacotherapy, II-869–873
physical therapy, II-875–877
posterior teeth missing, II-874–875
risk management and, I-76
screening questionnaire, II-804b–805b
splint therapy, II-865–869
subluxation, II-792t–793t, II-800f, II-807
total prosthetic reconstruction, III-222–245
in Treacher Collins syndrome, III-707–731
treatment philosophies, II-865
Temporomandibular joint surgery
disc derangement, II-904–922
history, II-764–776
implants used in, II-770–771
laser-assisted, I-341–343
minimally invasive, II-774
open joint, II-772
total joint replacement, II-772–774
Temporomandibular ligament, II-780
Temporoparietal fascia flap, II-290, II-294f
Tendon, medial canthal, II-221–224
Tennison technique
cleft lip repair with, III-513–514, III-520–521
Millard technique compared to, III-521–523, III-525
outcomes, III-527f
surgical planning and markings, III-522–523
surgical technique, III-523–524
Tensile strength, II-831–833
Tension pneumothorax, pediatric trauma and, II-249, II-250f
Tent-pole technique, I-484, I-485f–487f
Tenting screw, I-484, I-488f, I-500b
bone graft support with, I-696f
case study, I-693
Teratoma, oral, III-757
Terminal amine, local anesthetics and, I-177
Termination, employee, I-116–117
Tessier, Paul, III-667, III-668f, III-4, III-6
Tessier cleft line, III-486, III-496f
Tetanus
prophylaxis, II-61t
wounds prone to, II-61t
Tetracaine, I-185–186
Tetracycline, nerve injury associated with, I-377
Thalamus, trigeminal nerve pathway and, II-942
Thalidomide, III-688, III-690
Thermal therapy, for temporomandibular joint disorders, II-876
Thermistor, I-170
Thermocouple, I-170
Thermoregulation, pediatric, I-241–242
Thiopental, I-200–201, I-252t
Third molar, extraction
complications, I-77
in orthognathic surgery, III-279
Third-party payer, I-87–95
Three-dimensional computerized scan, II-207–208
Three-dimensional printing, I-696–697, I-699f
Thrombocytopenia, I-160–161
Thromboembolism, III-298, III-299t
Thrombosis, II-6
Thyroglossal duct cyst, II-378–383
Thyroid cancer, radiation therapy for, II-742
Thyroid disease
orthognathic surgery and, III-287
preoperative evaluation of, I-152
vasoconstrictor drugs and, I-182b
Thyroid gland, thyroglossal duct cyst and, II-378
Thyroid storm, I-141
Thyromental distance, airway assessment and, I-213, I-243
Tibia, as bone graft donor site, I-457–458
Tidal volume
age values, I-241t
pediatric, I-241t
TiDesign abutment, I-627f, I-634
Tiludronate (Skelid), II-508t
Time-out, risk management and, I-78
Tissue
adipose, III-429, III-434
autogenous, for temporomandibular joint replacement, II-924
emphysema, I-301
expansion, in child, II-274–275
hard, pediatric surgery for, I-260–262
injury
classification of, II-121t
of face, head, and trunk, II-41–69
suture technique, II-42–44
laser interaction, I-329f, III-339, III-341t
laser light effects, I-328–329
laser surgery, I-335–338
mesenchymal, II-643
metastasis and, II-619–621
nasal, II-174–177
peri-implant grafting and, I-415–416
periodontal, injury to, II-122t, II-127–131
soft, laser surgery, I-335–338, I-349
Tissue engineering
for temporomandibular joint disc perforation, II-915
temporomandibular joint replacement and, II-935
Titanium
for abutment, I-636
dental cement interaction with, I-717
for fixation hardware, III-63
restoration with, I-597–599
for screw-retained restoration, I-627–628
for single anterior implant, I-630–631
Titanium bar
example, I-602f
fixation with, II-147
Titanium mesh, I-465–466, I-484
with bone graft, I-669f–670f
space maintenance and, I-526–527
Tizanidine (Zanaflex), II-955t, II-956
TMD. *See* Temporomandibular joint disorder (TMD)
TNM staging, for oral cancer, II-675–677
To Err is Human: Building a Safer Health System, I-73, I-97
Tobacco smoking. *See* Cigarette smoking
Tobacco use
as mandibular surgery risk factor, III-297–298
oral cancer associated with, II-671
squamous cell carcinoma and, II-752
Tocopherol, II-595–596
Tofranil. *See* Imipramine (Tofranil)
Tolerance, facial pain management and, II-952
Toluidine blue, cancer screening with, II-674
Tomography. *See* Computed tomography (CT)
Tongue
airway assessment and, I-242–243, I-243f
anatomy, II-671
avulsed, in gunshot wound, II-314f
cancer, II-681, II-682f
in dentoalveolar injury evaluation, II-117
interstitial brachytherapy implant, II-743f
lymphatic malformation of, II-540f–541f
reduction, III-269
squamous cell carcinoma, II-742
tumor, III-740–741
Tonsil
radiation therapy for carcinoma of, II-742
size, III-266f
Tonsillectomy
codeine warning, I-254
for sleep apnea, III-268
Tooth
aspiration, II-118f
avulsed
in dentoalveolar injury, II-120–121, II-128–131
storage, II-130
concussed, II-127
congenitally missing, I-679
damage to, during exodontia, I-298–299
deciduous, I-258
delivery, in simple extraction, I-278–279
development, I-258
dislodged, retrieval of, I-300
displacement
during exodontia, I-299–301
into submandibular space, I-300–301
erupted
removal, I-275–283
surgical complications, I-281–283
examination, in dentoalveolar injury, II-117
extraction, in pediatric patient, I-260
fracture
in dentoalveolar injury, II-123–124
during extraction, I-282f
third molar extraction and, I-293
impacted, I-283–295
angulation classification, I-286f
complications following extraction, I-293–295
contraindications for extraction, I-285–286
decision tree for, I-265f
distoangular, I-288f
flap design, I-286–287
horizontal, I-288f
mesioangular, I-288f
nerve damage following extraction, I-294
in older patient, I-285
in pediatric patient, I-260–261
removal, I-283–285
sectioning, I-287–288
socket care after removal, I-288
surgical extraction complications, I-293–295
surgical management, I-275–297

Tooth *(Continued)*
surgical technique, I-286–288
treatment, I-262–269
injury types, in dentoalveolar trauma, II-119f
luxation, II-127
maxillary, positioning of, I-592
mobility, in dentoalveolar injury, II-118
multi-rooted, removal, I-281
permanent
eruption sequence, I-259t
formation, I-258
injury prognosis, II-139–141
position, implant esthetics and, I-391–392
primary
dentoalveolar injury, II-124f
displacement, II-132–133
eruption sequence, I-259t
formation of, I-258
fracture, II-131–132
injury prognosis, II-138–139
injury treatment, II-131–133
removal of wrong, I-298
replanted, II-130–131, II-140–141
shape of, implant restoration and, I-393–405
soft tissue interface, I-556f
subluxation, II-127
supernumerary, I-266–268, III-585
swallowing of, during exodontia, I-302
transplantation
complications, I-269
pediatric, I-268–269
Tooth bud, I-258
Toothbrush
manual, II-551
sonic, II-551
Toothpaste, salivary pellicle affected by, II-550
Topiramax (Topamax), II-956
Total metabolic equivalent (MET), preoperative evaluation and, I-151t
"Town and gown" politics, I-12–13
Towne projection, II-816–817
Trachea, pediatric, I-240
Tracheostomy, III-268
TRACK PLUS system, I-539–540
Tramadol
action, I-228
equianalgesic dosage, I-231t
for fibromyalgia, II-970
for neuropathic pain, I-364
for temporomandibular joint disorders, II-872t
Trametinib, II-701
Transcription factor
cancer cell growth and, II-612
cell differentiation, II-614
Transcutaneous capnometry, for pediatric anesthesia monitoring, I-245
Transcutaneous electrical nerve stimulation (TENS)
electronic dental anesthesia and, I-187–188
for temporomandibular joint disorders, II-876–877
Transforming growth factor beta (TGF-ß), II-256–258, II-258t
Transition line
movement of, I-591
smile line and, I-570f
Transmission electron microscopy (TEM), II-335
Transnasal canthopexy, II-224
Transoral vertical ramus osteotomy (TOVRO), III-90f–91f
Transpalatal appliance (TPA), open bite treatment and, I-317
Transplantation
facial, II-326
lymphoma following, II-711
stem-cell, for lymphoma, II-713
tooth
complications, I-269
pediatric, I-268–269
Transtracheal jet ventilation, I-245–247
Transverse mandibular deficiency, III-196, III-199f–200f
surgical risk and, III-299
treatment, III-301t
Transverse maxillary deficiency, III-199f, III-299
Tranylcypromine, management, I-149t
Trauma
airway assessment, II-9–10
airway management, II-9–15
anesthesia management, II-12–15, II-9–15
arthritis caused by, II-836
avulsive facial, II-282–302
complications, II-300
reconstruction, II-283–300, II-287f, II-296–297
rehabilitation, II-300
blunt
head and neck, II-2
pediatric, II-245
coding and billing for, I-91–92
craniomaxillofacial, II-1–8
airway management, II-9–12, II-1–2
cervical spine injury associated with, II-11
clinical examination, II-4–5
imaging in, II-17–40
mechanism of injury, II-2
medical conditions affecting management of, II-3t
patient medical history and, II-2–4
postoperative management, II-7
preoperative care, II-6
treatment, II-5–6
defect caused by, I-665–679
dentoalveolar, II-114–145
necrosis associated with, II-515
osteonecrosis associated with, II-515
prevention, II-141
prognosis, II-137–141
radiographic examination, II-119–120
facial
evaluation, II-9–12
nerve injury associated with, II-949
statistics, II-1
facial nerve, II-101–102
from improvised explosive device, II-319f
initial and postoperative management, II-1–8
jaw osteonecrosis associated with, II-510–511
maxillofacial
assessment, II-1–2
imaging, II-17–40
nerve injury associated with, I-374–376, II-374–376
trigeminal nerve injury from, I-354–355
maxillofacial gunshot, II-303–328
assessment, II-308–309
treatment, II-307–314
nasal, algorithm for, II-181f
orbital, II-213
pediatric, II-264–280, II-245–263
assessment, II-231–232
costs, II-246
epidemiology, II-230–231, II-245–256
evaluation, II-246
imaging, II-233–240
neurologic status assessment for, II-247–248
outcomes, II-245
patterns, II-260–261
Trauma *(Continued)*
physical evaluation, II-232–233
wound repair after, II-256–261
pediatric craniomaxillofacial, II-264–280
risk factors, II-4
temporomandibular joint disorder from, II-800–801, II-963
Traumatic bone cyst, II-852
Traumatic brain injury (TBI)
intracranial pressure monitoring in, II-254
management, II-254–255
pediatric, II-246–247, II-250–252
hematoma in, II-252f
secondary brain damage, II-254
Traumatic optic neuropathy, II-204
Trazodone (Desyrel), II-873t
Treacher Collins syndrome (TCS), III-15–16, III-690, III-703–737, III-776
description, III-703
dysmorphology, III-706–707
ear reconstruction, III-732–733
facial growth, III-707
genetic markers, III-703–705
inheritance, III-703–705
maxillomandibular reconstruction, III-724–730
nasal reconstruction, III-731–733
newborn mandibular reconstruction, III-730
reconstruction, III-713–715
skeletal reconstruction, III-713
soft tissue reconstruction, III-731–732
testing, III-703–705
Treatment plan
cleft lip repair, III-496–497
cleft palate repair, III-496–497
concomitant temporomandibular joint replacement and orthognathic surgery, III-227–228
gunshot wound, II-318–320
implant overdentures, I-656–658
mandibular deficiency, III-119–120
mandibular distraction osteogenesis, III-776
orthognathic surgery, III-13–30
pediatric ablative defect reconstruction, III-765
risk management and, I-76–78
software, I-688
Trial, lawsuit settled by, I-84–85
Triamcinolone
equivalent dosage, III-287t
giant cell lesion treated with, II-462–463
Triangular flap technique, III-514, III-520–521
Triazolam (Halcion), I-196–197
half-life, I-195t
protein binding, I-195t
structure, I-196f
for temporomandibular joint disorders, II-874t
Tricalcium phosphate, I-430, I-483–484
Trichloroacetic acid, III-443
Tricyclic antidepressant drugs
for facial pain, II-955–956
for temporomandibular joint disorders, II-872–873
Trigeminal nerve, II-74f, II-941–942
anatomy, II-74–78
description, II-70
fibrosis, I-369
graft for, II-95
illustration, II-74f
imaging, II-78–81
lateral view, II-785f
magnetic resonance imaging, II-81
microanatomy, II-77–78
midface innervation by, II-214
nerve block of, I-318
neuroma, I-370f
orofacial innervation by, I-227f

Trigeminal nerve *(Continued)*
pain neurophysiology and, II-941–942
surgical principles and techniques, I-367
surgical repair, I-365–374
vascular supply, II-78f
Trigeminal nerve injury, I-354, II-354–390
behavior pain management for, I-365
bone graft as cause of, II-84
causes, I-354–357
chronic, I-363–365
classification, I-355–356
clinical terms, I-355t
diagnosis, I-354–357
diagnosis and management, II-70–113
endodontic, I-377–378
entubulation, I-371–372
graft for, I-369–371
implant, I-379–380
from local anesthetic, I-376
maxillofacial trauma associated with, I-374–376
microneurosurgery for, II-91–96
nerve block, I-361–362
neurorrhaphy, I-369
neurosensory testing for, I-358–360, I-358f, II-315
nonsurgical treatment, I-362–365
orthognathic, I-378–379
outcomes, II-96
outcomes and conclusions, I-382–383
patient-reported impaired functions, I-313–314
persistent postsurgical pain, I-357–358
postsurgical management, I-373–374
recovery, I-382–383
recovery scale, I-360t
response to, I-356–357
Seddon-Sunderland classification, I-355–356
surgical management, I-365–374, II-321–322
contraindications, I-366–367
indications, I-365–366
timing, I-366–367
surgical repair cascade, I-368f, I-368
third molar extraction, I-82, II-380–382
wrapping for, I-371
Trigeminal neuralgia, definition, I-355t
Trigger point
injection, II-970
myofascial pain and, II-962, II-965f
Trigonocephaly, III-657–659, III-661f–662f
Tripartite process, I-83–84
Trismus
local anesthetics and, I-184
postoperative, I-304
Trunk, soft tissue injury, II-41, II-41–42
Tube-shift technique, I-261f
Tuberculosis, parotitis associated with, II-486–487
Tuberosity
as donor site, I-563
free autogenous graft from, I-556
laser reduction, III-348–349
Tumescent anesthesia, III-430
Tumor
adenomatoid odontogenic, III-744–745
benign, temporomandibular joint, II-850–856
brown, II-464–465
calcifying odontogenic, II-368–371
chondroma, II-475–476
classification, II-599
craniofacial, III-738–739
craniomaxillofacial, pathology, III-741–769
desmoplastic fibroma, II-476–478
epithelial odontogenic, II-435
giant cell, II-464
growth, II-600
Tumor *(Continued)*
head and neck, II-721
hemangioma, II-534
hyperparathyroidism and, II-464
immunohistochemistry for diagnosis, II-333–334
of infancy, II-535
infantile endothelial, II-535
infantile hemangioma, II-534–536
keratocystic odontogenic, II-348–361
malignant, pediatric, III-757–763
malignant mixed, II-493t
mandibular, I-675f–677f
margin, II-728
maxillary, I-675f–677f
melanotic neuroectodermal, III-757
mesenchymal odontogenic, II-435–444
neovascularization, II-617–619, II-628
neurogenic, II-472
nonodontogenic, III-745–757
nonsalivary, II-500–503
odontogenic, II-391–461, III-741–745
odontogenic mixed, II-444–455
oral cavity, II-740–741, III-742t
osteoblastoma, II-473–474
osteochondroma, II-476
osteoma, II-475
parameningeal, III-760–762
parotid gland, II-494–496
pediatric, reconstruction, III-763–769
primary, in squamous cell carcinoma, II-679, II-726t
salivary gland, II-482, II-492–503, III-763
stroma, II-600
surgical pathology and management, II-391–461
targeted therapy based on, II-627–629
temporomandibular joint, II-848–858
third molar removal and, I-284
tongue, III-740–741
Warthin, II-482, II-493t, II-495
Tumor-associated macrophage (TAM), II-620–621
Tumor dormancy therapy, II-628
Tumor necrosis factor-alpha receptor (TNFR), II-614–615
Tumor-node-metastasis (TMN) staging
for rhabdomyosarcoma, II-655t
for skin cancer, II-725–726
Tumor suppressor gene, II-602–603, II-609, II-614
apoptosis suppression and, II-627–628
p16, II-616
p53, II-614, II-616, II-625
reduction of function, II-614
Tumorigenesis, II-599–601
apoptosis resistance, II-614
genetic events leading to, II-603
progression of, II-602
Tuned-aperture computed tomography (TACT), II-824
Turbinate, modification of, III-381
Twitter, marketing and, I-105–106
Two-flap palatoplasty, III-534, III-542

U

Ulcer
aphthous, III-354
herpetic, III-354
Ultane. *See* Sevoflurane (Ultane)
Ultrasonography
facial nerve imaging, II-100
nerve assessment, II-81
osteoradionecrosis, II-595–596
salivary gland, II-481–483
temporomandibular joint, II-826
Ultrasound
for osteoradionecrosis, II-595–596
for temporomandibular joint disorders, II-876
Ultraviolet light
exposure, melanoma associated with, II-690–691
skin cancer associated with, II-722–723
Ultraviolet radiation, skin cancer associated with, II-722–723
Umbrella graft, III-374
Underwood septa, I-509–510
Unilateral cleft deformity, III-563–565
United States Air Force, I-29–30
United States Army, I-24–26
United States Army Dental Corps, I-24–25
United States Navy, I-26–29
United States Public Health Service, I-30–31
Unprofessional behavior, I-4
causes, I-6
types of, I-7
Upper airway resistance syndrome, III-351
Upper respiratory infection (URI), pediatric anesthesia and, I-243–244
Uranoplasty, III-551
Urinary bladder mucosa, for temporomandibular joint disc repair, II-915
U.S. Food and Drug Administration (FDA), codeine warning from, I-253–254
Uvula, bifid, III-618–619
Uvulopalatopharyngoplasty (UPPP), III-268, III-351–352

V

VA. *See* Veterans Affairs (VA)
Vacuum-assisted closure device, II-732
Valacyclovir, II-554, II-556
Valdecoxib, II-871t
Van der Woude syndrome, III-493–494
Van Langenback, B. V., III-2
Vancomycin, parotitis treated with, II-486–487
Vaporization, laser for, I-330
Varicella zoster virus (VZV), II-102
Vascular anomaly
classification, II-535b
etiology, II-534
oral and maxillofacial, II-534–549
of oral and maxillofacial region, II-534–549
PHACE, II-536
Vascular endothelial growth factor (VEGF), II-257–258, II-618–619
Vascular malformation, II-534, II-538–547
definition, II-534
fast-flow, II-544–547
lymphatic malformation, II-539–542
slow-flow, II-538–544
venous malformation, II-543–544
Vascular system, rhytidectomy evaluation and, III-327–328
Vascularized interpositional graft, I-558, I-560f
Vasoconstrictor drugs, I-178–182
benefits, I-180
complications, I-182b
concentration, I-180
drug interactions, I-181
maximum dosage, I-181–182
selectivity and potency, I-180t
side effects, I-180–181
Vasodilation, opioids associated with, I-226
Vasopressor drugs, I-178–182
Veau, Victor, III-535
Veau-Wardill-Kilner palatoplasty, III-538f, III-541–542
Vein(s)
forehead, III-399
frontal sinus, II-230–231
jugular, rhytidectomy evaluation and, III-328

Vein(s) *(Continued)*
nasal, II-177
sentinel, III-399
Velopharyngeal dysfunction, III-540–541, III-568–569
alveolar anomaly, III-569
behavioral approaches, III-579–580
causes, III-569–570
consonants affected by, III-569t
dental anomaly, III-569
diagnosis, III-541
evaluation, III-572–578
management, III-578–580
secondary surgery, III-579, III-612–616
speech appliances, III-579
Velopharyngeal incompetence, III-540–541
Velopharyngeal insufficiency, III-497, III-540–541
after cleft palate repair, III-612–615
in oculoauriculovertebral spectrum, III-692
secondary surgery, III-615–616, III-618
surgical management, III-547, III-616–618
Velopharyngeal mechanism, III-612–615, III-614t
Velopharyngeal sphincter, III-607
Velopharynx
anatomy, III-535–536, III-536f
in cleft maxilla, III-607
Veloplasty, intravelar, III-535–536, III-538, III-539f, III-612–615
Velum, III-535, III-612–615
reconstruction, III-537
in two-stage palatal repair, III-549–550
Vemurafenib, II-701–704
Venlafaxine (Effexor XR), II-955t, II-956
Venous malformation, II-543–544
Venous thromboembolism (VTE), III-298, III-299t
Ventilation
age values, I-241t
bag-mask, II-13
monitoring, for pediatric patient, I-244
pediatric, I-241t
in trauma patient, II-9
Ventriculoperitoneal shunt, III-676
Veracity, principle of, I-10–11
Verrill sign, I-192–194
Verstran. *See* Prazepam (Verstran, Centrax)
Vertical distraction osteogenesis, I-532
Vertical maxillary excess (VME), III-153, III-156f–157f, III-642
Vesiculobullous disease, II-550–574
Vestibular incision subperiosteal tunnel access (VISTA), I-561–563, I-564f–566f
Vestibuloplasty, laser, III-350–351
Veterans Affairs (VA), oral and maxillofacial surgical practice in, I-31–33
Vicodin. *See* Hydrocodone (Vicodin)
Video nasendoscopy, III-575–576
Videofluoroscopy, III-575
Videolaryngoscope, II-14
Vinblastine, II-714, II-757t
Vincristine, II-455, II-713, II-756t
Vinorelbine, II-757t
Virtual surgical planning (VSP), III-114, III-173–174, III-174f
for inverted L osteotomy, III-120, III-128f–130f
in orthognathic surgery, III-190
protocol, III-120f
for temporomandibular joint total replacement, III-229–232
Virus, oral cancer associated with, II-672
Vision
in craniosynostosis care algorithm, III-672
craniosynostosis effects, III-647
Vision *(Continued)*
loss of, after head injury, II-204
in oral and maxillofacial surgical practice, I-109
in Treacher Collins syndrome, III-706
zygomatic injury repair and, II-193
Vistaril. *See* Hydroxyzine (Vistaril)
Vital capacity
age values, I-241t
pediatric, I-241t
Vital signs
by age, I-239t
anesthetic recovery and, I-222
pediatric, I-239t
in trauma patient assessment, II-10
Vitamin E, for mucositis, II-760–761
Vitek Teflon-Proplast implant, II-772
Vitiligo, skin resurfacing and, I-345–346
Voice, disorders, III-572
Vomiting
anesthetic recovery and, I-222
in pediatric patient, I-253
postoperative, III-314
Von Graefe, Carle, III-534
Von Langenbeck, Bernhard, III-534
Von Langenbeck palatoplasty, III-537f, III-542, III-611
Von Recklinghausen disease, III-753–755
Von Willebrand disease, I-161

W

Wakely, Cecil, II-769
Waldeyer ring, II-707, II-710, II-712
Walker, Robert V., III-5
Wallerian degeneration, II-72
Warburg effect, II-601–602
Ward, Sir Terence, II-771
Warfarin
management, I-149t
preoperative management, I-161
Warren, John, III-534
Warthin tumor, II-482, II-493t, II-495
Wassmund, Martin, III-113
Water, absorption spectrum, I-329f
Website
importance of, I-102
marketing, I-103
Webster's triangle, III-379–380
Werner syndrome, II-644
Westergren erythrocyte sedimentation rate, II-840
Wharton's duct, II-483–485
example, II-484f
sialolithiasis, II-488, II-490f
Whole genomic sequencing (WGS), II-623
Wickam striae, II-558
Wilcko, Thomas and William, III-246–247
Wilkes classification, of temporomandibular joint internal derangement, II-905b
Wolff's law, II-151–152
Wolford, Larry, III-5
Work-life balance, I-138–139
World Health Organization (WHO)
cyst classification from, II-339t
odontogenic tumor classification from, II-392
Wound
avulsive facial, II-282
management, II-286b
reconstruction, II-283–300
bite, II-278–279
closure, II-42–44
in internal derangement surgery, II-910
principles, II-10
in craniomaxillofacial trauma, II-2
deep, II-272
Wound *(Continued)*
dog bite, II-62b
ear, pediatric, II-276
facial, I-9, I-665–666, II-41
gunshot. *See* Gunshot wound (GSW)
nasal, pediatric, II-277–278
pediatric, II-272, II-272
puncture, I-301
superficial, pediatric, II-272
tetanus-prone, II-61t
Wound ballistics, II-304–305
Wound care
after orthognathic surgery, III-291–292
scar prevention and, II-234f
Wound closure
ear, II-57
eyelid, II-51–52, II-54f
facial nerve, II-60
forehead, II-50
in Le Fort I osteotomy, III-167–168
lip, II-12–14
nose, II-52–54, II-56f
parotid duct, II-12–13
postoperative care, II-60–61
scalp, II-50
suture materials, II-46t
suture selection, II-46t
Wound healing
barriers, II-258–260
cigarette smoking and, I-433, I-451
diabetes and, I-433
facial resurfacing, III-355–356
failure, in orthognathic surgery, III-320
growth factors in, I-431–432
infection and, I-260, II-433–434
inflammatory response, II-256–257
laser and, I-340
laser surgery, III-348
pediatric injury, II-256–261
principles, II-44–45
proliferative phase, II-257
remodeling phase, II-257
skin cancer, II-731–732
skin resurfacing, I-345
systemic factors and, II-259t
Wright-Giemsa stain, II-331

X

Xanax. *See* Alprazolam (Xanax)
Xenogenic, definition, I-437
Xenogenic collagen matrix (XCM), I-558, I-560–561, I-562f
Xenograft, I-429–430, I-437
bovine-derived, I-441f
materials, I-483
peri-implantitis treated with, I-727f
Xeroderma pigmentosum, II-732–733
Xerostomia
postradiation, II-483
radiation therapy associated with, II-749
in salivary gland disease, II-504
salivary pellicle affected by, II-551
in stomatodynia, II-949

Y

YAG laser. *See* Laser, erbium: yttrium-aluminum-garnet (Er:YAG)
Yaw orientation
in computer-aided surgical simulation, III-38–39, III-120
model surgery and, III-44f
in orthognathic surgery, III-23
YouTube, marketing and, I-105
Yttria-stabilized tetragonal zirconia polycrystal (Y-TZP), I-636

Z
Z-plasty
cleft repair with, III-505, III-507f
double-opposing, III-536, III-543
limitations and complications, III-548
speech and, III-546–547
technique, III-543–546
for labial frenum, I-270
in lingual frenectomy, I-271f
ZAGA classification, I-579f
Zanaflex. *See* Tizanidine (Zanaflex)
Zero-meridian of Gonzales-Ulloa, chin position analysis with, III-460t–461t
Zhao-Brånemark biomechanical analysis, for zygomatic implant, I-576f
Zide Quick Analysis of the Chin, III-460t–461t
Zinc chloride, II-551
Zirconia
for abutment, I-636
disadvantages, I-600
framework with, I-599–601, I-600f–601f
for screw-retained restoration, I-627–628
for single anterior implant, I-630–631
Zoledronic acid (Zometa), II-508t, II-510
Zoloft. *See* Sertraline (Zoloft)
Zone of adherence, III-397–398, III-402–404
Zostrix. *See* Capsaicin (Zostrix)
Zygoma
anatomy, II-189–190, II-190f
growth rate, III-629t, III-630
malunion, II-204–205
Zygoma *(Continued)*
processes of, II-189
reconstruction
in oculoauriculovertebral spectrum, III-695
in Treacher Collins syndrome, III-713–715
zygomatic arch and, II-200
Zygoma complex, II-27t
anatomy, II-189–190
fracture, II-27t
Zygomatic arch, II-189
cross section, III-402f
fracture, II-200–207
surgical approaches, II-199–202
Zygomatic complex, surgery, II-193–194
Zygomatic fracture, II-22–24, II-25f, II-27t, II-189–210
Carroll-Girard screw, II-193–194
complications, II-202–207
diplopia caused by, II-203–204
enophthalmos caused by, II-205–206
fixation, II-200
malunion, II-204–205, II-226
management, II-189–210
patient history, II-190–191
pediatric, II-243
physical examination for, II-190–191
radiography for, II-191–193
retrobulbar hemorrhage caused by, II-206–207
soft tissue complications, II-203
surgery, II-191–194
coronal approach, II-199–200
eyebrow approach, II-195–196
Zygomatic fracture *(Continued)*
lower eyelid approach, II-196
subciliary approach, II-197–198
subtarsal approach, II-198–199
transconjunctival approach, II-196–197
upper eyelid approach, II-194–195, II-195f
vestibular approach, II-194
treatment, II-193
Zygomatic implant, I-569–583, I-678–679
axis, I-573f
deformation under function, I-571–573
design, I-573
historical perspective, I-569–570
occlusal loading, I-572f
patient selection, I-570
postoperative care, I-578
preoperative considerations, I-573
prosthesis fabrication, I-581–582
prosthetic conversion technique, I-577–578
radiographic evaluation, I-570–571
sinus infection associated with, I-579–581
stress under load, I-572, I-572f
surgical complications, I-579–581
surgical options, I-573
surgical protocol, I-574–577
trajectory, I-572–573, I-576–577
Zygomatico-orbital reconstruction, in Treacher Collins syndrome, III-725f–729f
Zygomaticofrontal region, surgical approaches, II-194–196
Zygomaticomaxillary buttress, II-211
Zygomaticomaxillary complex, II-192f

This page intentionally left blank

ORAL AND MAXILLOFACIAL SURGERY

third edition

VOLUME 2

Trauma
Surgical Pathology
Temporomandibular Disorders

This page intentionally left blank

ORAL AND MAXILLOFACIAL SURGERY

third edition

VOLUME 2

Trauma
Surgical Pathology
Temporomandibular Disorders

VOLUME EDITOR

Raymond J. Fonseca, DMD
Private Practice
Oral and Maxillofacial Surgery
Asheville, North Carolina;
Clinical Professor, Department of Oral and Maxillofacial Surgery
University of North Carolina
Chapel Hill, North Carolina

SECTION EDITORS

Eric R. Carlson, DMD, MD, FACS
Raymond J. Fonseca, DMD
Gregory M. Ness, DDS, FACS

ELSEVIER

ELSEVIER

3251 Riverport Lane
St. Louis, Missouri 63043

ORAL AND MAXILLOFACIAL SURGERY, VOLUME 2, THIRD EDITION Set ISBN: 978-0-323-41499-9
Volume 1 ISBN: 978-0-323-41497-5
Volume 2 ISBN: 978-0-323-41496-8
Volume 3 ISBN: 978-0-323-41495-1

Copyright © 2018 by Elsevier, Inc. All rights reserved.

No part of this publication may be reproduced or transmitted in any form or by any means, electronic or mechanical, including photocopying, recording, or any information storage and retrieval system, without permission in writing from the publisher. Details on how to seek permission, further information about the Publisher's permissions policies and our arrangements with organizations such as the Copyright Clearance Center and the Copyright Licensing Agency, can be found at our website: www.elsevier.com/permissions.

This book and the individual contributions contained in it are protected under copyright by the Publisher (other than as may be noted herein).

Notices

Knowledge and best practice in this field are constantly changing. As new research and experience broaden our understanding, changes in research methods, professional practices, or medical treatment may become necessary.

Practitioners and researchers must always rely on their own experience and knowledge in evaluating and using any information, methods, compounds, or experiments described herein. In using such information or methods they should be mindful of their own safety and the safety of others, including parties for whom they have a professional responsibility.

With respect to any drug or pharmaceutical products identified, readers are advised to check the most current information provided (i) on procedures featured or (ii) by the manufacturer of each product to be administered, to verify the recommended dose or formula, the method and duration of administration, and contraindications. It is the responsibility of practitioners, relying on their own experience and knowledge of their patients, to make diagnoses, to determine dosages and the best treatment for each individual patient, and to take all appropriate safety precautions.

To the fullest extent of the law, neither the Publisher nor the authors, contributors, or editors, assume any liability for any injury and/or damage to persons or property as a matter of products liability, negligence or otherwise, or from any use or operation of any methods, products, instructions, or ideas contained in the material herein.

Previous editions copyrighted 2009 and 2000.

Library of Congress Cataloging-in-Publication Data

Names: Fonseca, Raymond J., editor.
Title: Oral and maxillofacial surgery.
Other titles: Oral and maxillofacial surgery (Fonseca)
Description: Third edition. | St. Louis, Missouri : Elsevier, [2018] |
Includes bibliographical references and indexes.
Identifiers: LCCN 2017002982| ISBN 9780323414999 (set : hardcover : alk. paper) | ISBN 9780323414975 (v. 1 : hardcover : alk. paper) | ISBN 9780323414968 (v. 2 : hardcover : alk. paper) | ISBN 9780323414951 (v. 3 : hardcover : alk. paper)
Subjects: | MESH: Oral Surgical Procedures | Face--surgery | Facial Bones--surgery | Maxilla--surgery
Classification: LCC RD523 | NLM WU 600 | DDC 617.5/2059--dc23 LC record available at https://lccn.loc.gov/2017002982

Senior Content Strategist: Jennifer Flynn-Briggs
Professional Content Development Manager: Jolynn Gower
Publishing Services Manager: Jeffrey Patterson
Senior Project Manager: Mary Pohlman
Design Direction: Ashley Miner

Printed in China.

Last digit is the print number: 9 8 7 6 5 4 3 2 1

ELSEVIER Book Aid International Working together to grow libraries in developing countries
www.elsevier.com • www.bookaid.org

I recognize Dr. Robert E. Marx, Dr. Edward T. Lally, and the late Dr. Joseph Ashman, the three teachers who taught me oral/head and neck tumor surgery, pathology, and anatomy. My career has been most gratifying due to the education provided to me by these exemplary individuals.

Eric R. Carlson

To Chester, Lady, Cheerio, Moxie, Domino, Sasha, Tuxedo, Chairman Meow, Zoey, Apollo, Ayla, Annabelle, and Atticus for enriching our lives.

Raymond J. Fonseca

As a resident I trained under Jerry Goldberg, whose practice was filled with patients suffering from TMJ disorders that few others welcomed. He would come back from early meetings of the American Society of Temporomandibular Joint Surgeons and tell tales of raucous debates over the cutting-edge knowledge, which he then passed on to us. I decided then that I wanted in on this field. When I interviewed for an academic job with Larry Peterson, he asked if I would be comfortable teaching residents to do TMJ surgery. I gave a qualified yes, and he said, "Then you will be our TMJ surgeon." And so it began. Nothing I have accomplished would have happened without the teaching, confidence, and support from these two great mentors, so I dedicate this work to Dr. Goldberg and to the memory of "Pete" Peterson.

Gregory M. Ness

In Memoriam

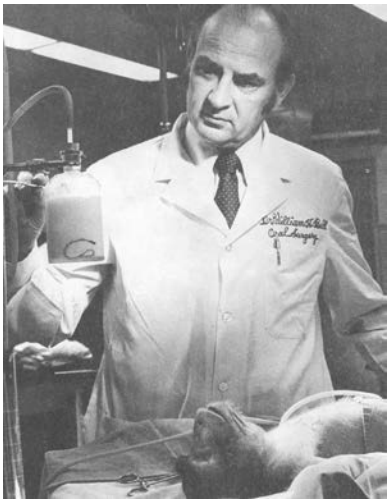

William H. Bell, DDS

We respectfully dedicate this edition of *Oral and Maxillofacial Surgery* to the memory of Dr. William "Bill" Harrison Bell. Matchless among his peers, Dr. Bell was an inimitable leader in surgery and medicine throughout his career.

In the early 1970s, Dr. Bell revolutionized oral and maxillofacial surgery through his landmark research on the biologic basis and clinical rationale for the Le Fort I osteotomy. In subsequent decades, he guided the hands of generations of surgeons, whether in academic medical centers across the world or through his meticulously detailed textbooks. It is a testament to Dr. Bell's always-passionate and always-persistent pursuit of excellence that his textbooks still remain contemporary decades after their publication.

While Dr. Bell was a revolutionary in our field, it is not simply in this spirit that we dedicate this book. Dr. Bell also served as an inspiration and mentor to us throughout our careers and lives, showing us always a readiness to inspire and a passion to change lives however he could. We are, quite simply, not alone in this feeling. It was this passion that compelled him to devote his life to improving patient care. It was this passion that affected so many others in our field. And it was this passion that also characterized so many areas of his vibrant and rich life—a life very well-lived.

It was an honor to learn from and know Bill. He was unwavering and uncompromising, and his love was unconditional. We know that the passion that burned in him to help others will continue to ignite the spirits of generations of surgeons to come. It will guide our hands and our actions as well.

Section Editors

Eric R. Carlson, DMD, MD, FACS
Professor and Kelly L. Krahwinkel Endowed Chairman
Director of Oral and Maxillofacial Surgery Residency Program
Director of Oral/Head and Neck Oncologic Surgery Fellowship Program
Department of Oral and Maxillofacial Surgery
University of Tennessee Medical Center
University of Tennessee Cancer Institute
Knoxville, Tennessee

Raymond J. Fonseca, DMD
Private Practice
Oral and Maxillofacial Surgery
Asheville, North Carolina;
Clinical Professor, Department of Oral and Maxillofacial Surgery
University of North Carolina
Chapel Hill, North Carolina

Gregory M. Ness, DDS, FACS
Professor—Clinical
Oral and Maxillofacial Surgery and Anesthesiology
The Ohio State University College of Dentistry
Columbus, Ohio

Contributors

Nabil A. Abaza, DMD, MS, PhD
Professor Emeritus
Department of Surgery
Drexel University School of Medicine
Philadelphia, Pennsylvania
Chapter 17: Cysts of the Oral and Maxillofacial Region

A. Omar Abubaker, DMD, PhD
Professor and Chairman
Oral and Maxillofacial Surgery
VCU Medical Center
Richmond, Virginia
Chapter 6: Diagnosis and Management of Dentoalveolar Injuries

Alejandro J. Almarza, PhD
Associate Professor of Oral Biology and Bioengineering
McGowan Institute of Regenerative Medicine
University of Pittsburgh
Pittsburgh, Pennsylvania
Chapter 42: Surgery for Internal Derangement of the Temporomandibular Joint

Mohammed Al-Obaidi, DMD, MD
Resident
Oral and Maxillofacial Surgery
UT Southwestern Medical Center
Dallas, Texas
Chapter 10: Diagnosis and Management of Midface Fractures

Brian Alpert, AB, DDS
Chairman and Professor of Oral and Maxillofacial Surgery
Surgical and Hospital Dentistry
University of Louisville School of Dentistry
Louisville, Kentucky
Chapter 25: Osteomyelitis and Osteoradionecrosis

Kevin Arce, DMD, MD, MCR
Assistant Professor of Surgery
Department of Surgery, Division of Oral and Maxillofacial Surgery
Mayo Clinic
Rochester, Minnesota
Chapter 27: Sarcomas of the Jaws

Wade Barker, DDS, MD
Resident
Department of Oral and Maxillofacial Surgery
Texas A&M College of Dentistry
Dallas, Texas
Chapter 14: Management of Avulsive Facial Injuries

William L. Barrett, MD
Director, University of Cincinnati Cancer Institute
Professor and Chairman, Department of Radiation Oncology
University of Cincinnati
Cincinnati, Ohio
Chapter 32: The Use of Radiation Therapy in Treatment of Head and Neck Cancer

Jeffrey D. Bennett, DMD
Chief, Oral and Maxillofacial Surgery
Roudebush VA Medical Center
Indianapolis, Indiana
Chapter 2: Airway and Anesthetic Management for the Traumatized Patient

Desmon Brown, DDS
Oral and Maxillofacial Surgery
Indiana University Health—Methodist Hospital
Indianapolis, Indiana
Chapter 11: Diagnosis and Management of Frontal Bone Injuries

John F. Caccamese, Jr., MD, DMD, FACS
Associate Professor and Vice Chairman
Oral and Maxillofacial Surgery
University of Maryland Dental School
Clinical Associate Professor, Pediatrics
Clinical Associate Professor, Otorhinolaryngology
University of Maryland School of Medicine
Co-director, Kernan Hospital and Greater Baltimore Cleft Teams
Baltimore, Maryland
Chapter 7: Diagnosis and Management of Mandible Fractures

Joshua A. Campbell, DDS
Assistant Professor
Department of Oral and Maxillofacial Surgery
University of Tennessee Graduate School of Medicine
Knoxville, Tennessee
Chapter 22: Langerhans Cell Histiocytosis

Eric R. Carlson, DMD, MD, FACS
Professor and Kelly L. Krahwinkel Endowed Chairman
Director of Oral and Maxillofacial Surgery Residency Program
Director of Oral/Head and Neck Oncologic Surgery Fellowship Program
Department of Oral and Maxillofacial Surgery
University of Tennessee Medical Center
University of Tennessee Cancer Institute
Knoxville, Tennessee
Chapter 22: Langerhans Cell Histiocytosis

James T. Castle, DDS, MS
Chairman
Oral and Maxillofacial Pathology
Naval Postgraduate Dental School
Bethesda, Maryland
Chapter 24: Vesiculobullous Diseases

Steven H. Cho, DDS
Assistant Clinical Professor of Dentistry
Oral and Maxillofacial Surgery
Columbia University College of Dental Medicine
New York, New York
Chapter 15: Treatment of Maxillofacial Gunshot Wound Injuries

William Chung, DDS, MD
Associate Professor
Oral and Maxillofacial Surgery
University of Pittsburgh Medical Center
Pittsburgh, Pennsylvania
Chapter 42: Surgery for Internal Derangement of the Temporomandibular Joint

Domenick P. Coletti, DDS, MD, FACS
Private Practice
Oral and Maxillofacial Surgery
Columbia, Maryland
Chapter 7: Diagnosis and Management of Mandible Fractures

Larry L. Cunningham, Jr., DDS, MD, FACS
Professor and Chief
Division of Oral and Maxillofacial Surgery
Interim Chair, Department of Oral Health Science
University of Kentucky College of Dentistry
Lexington, Kentucky
Chapter 9: Management of Zygomatic Fractures

Samir K. El-Mofty, DMD, MS, PhD
Professor, Pathology and Immunology
Professor, Otolaryngology—Head and Neck Surgery
Washington University
St. Louis, Missouri
Chapter 17: Cysts of the Oral and Maxillofacial Region

Kyle S. Ettinger, DDS, MD
Chief Resident
Division of Oral and Maxillofacial Surgery
Department of Surgery
Mayo Clinic and Mayo College of Medicine
Rochester, Minnesota
Chapter 27: Sarcomas of the Jaws

Tirbod Fattahi, DDS, MD, FACS
Chair and Associate Professor
Department of Oral and Maxillofacial Surgery
University of Florida, College of Medicine
Jacksonville, Florida
Chapter 11: Diagnosis and Management of Frontal Bone Injuries

Rui P. Fernandes, MD, DMD
Associate Professor
Surgery
University of Florida College of Medicine Jacksonville
Jacksonville, Florida
Chapter 20: Salivary Gland Disease

Elie M. Ferneini, DMD, MD, MHS, MB
Medical Director
Beau Visage Med Spa
Private Practice
Greater Waterbury OMS
Cheshire, Connecticut;
Assistant Clinical Professor, Division of Oral and Maxillofacial Surgery
University of Connecticut
Farmington, Connecticut
Chapter 2: Airway and Anesthetic Management for the Traumatized Patient

Christopher G. Fielding, DDS, MS
Naval Postgraduate Dental School
Professor
Oral and Maxillofacial Pathology
Uniformed Services University
Bethesda, Maryland
Chapter 24: Vesiculobullous Diseases

Phillip N. Freeman, MD, DMD, FACS
Oral and Maxillofacial Surgery
University of Texas Health Science Center Houston
Houston, Texas
Chapter 4: Soft Tissue Injuries of the Face, Head, and Trunk

James Fricton, DDS, MS
Professor Emeritus
Biological Sciences
University of Minnesota School of Dentistry
Senior Research Associate
HealthPartners Institute for Education and Research
HealthPartners
Minneapolis, Minnesota
Chapter 45: Temporomandibular Muscle Disorders: Diagnostic and Management Considerations

Kevin C. Gams, DDS
Chief Resident
Oral and Maxillofacial Surgery
University of Texas—Houston
Houston, Texas
Chapter 4: Soft Tissue Injuries of the Face, Head, and Trunk

Robert Gassner, MD, DMD, PhD, MBAe
Professor
Department of Cranio-maxillofacial and Oral Surgery
University Hospital of Innsbruck
Innsbruck, Austria
Chapter 35: Structure and Function of the Temporomandibular Joint
Chapter 38: Pathology of the Temporomandibular Joint

Ghali E. Ghali, DDS, MD
Professor and Chairman
Oral and Maxillofacial Surgery
Louisiana State University Health Sciences Center—Shreveport
Shreveport, Louisiana
Chapter 29: Melanoma

Lionel Gold, DDS
Chairman Emeritus
Director of Research
Thomas Jefferson University
Philadelphia, Pennsylvania
Chapter 18: Odontogenic Tumors: Surgical Pathology and Management

Wahid T. Hanna, MD
Private Practice
Hanna Cancer Associates
Professor of Medicine
Chief, Hematology/Oncology Division
University of Tennessee Medical Center
Knoxville, Tennessee
Chapter 33: Principles of Medical Oncology in the Management of Head and Neck Cancer

Sarah C. Harding, DMD
Department of Oral and Maxillofacial Surgery
Naval Station Norfolk—Branch Dental
Norfolk, Virginia
Chapter 8: Nasal Fractures

Gary M. Heir, DMD
Clinical Professor
Department of Diagnostic Sciences
Rutgers School of Dental Medicine
Newark, New Jersey
Chapter 36: Assessing Temporomandibular Disorders

John W. Hellstein, DDS, MS
Clinical Professor
Oral Pathology
University of Iowa
Iowa City, Iowa
Chapter 24: Vesiculobullous Diseases

Joseph I. Helman, DMD
C. J. Lyons Endowed Professor
Oral and Maxillofacial Surgery
University of Michigan
Ann Arbor, Michigan
Chapter 28: Squamous Cell Carcinoma of the Oral and Maxillofacial Region

Jon D. Holmes, DMD, MD, FACS, FICD
Private Practice
Clark Holmes Oral and Facial Surgery of Alabama
Birmingham, Alabama
Chapter 31: Non-melanoma Skin Cancer of the Head and Neck

Bruce B. Horswell, MD, DDS, MS
Director of FACES
Department of Surgery
Charleston Area Medical Center
Charleston, West Virginia
Chapter 12: Assessment and Management of the Injured Child
Chapter 13: Pediatric Craniomaxillofacial Trauma and Management

A. Thomas Indresano, DMD, FACD, FICD
The Dr. T. Galt and Lyn DeHaven Atwood Professor and Chairman
University of the Pacific
Dugoni School of Dentistry
Chief of Oral and Maxillofacial Surgery
Alameda Health System, Highland Hospital
Division of Oral and Maxillofacial Surgery
San Francisco, California
Chapter 39: Nonsurgical Management of Temporomandibular Joint Disorders
Chapter 41: Arthroscopy of the Temporomandibular Joint

Lewis C. Jones, DMD, MD
Assistant Professor
Oral and Maxillofacial Surgery
University of Louisville
Louisville, Kentucky
Chapter 13: Pediatric Craniomaxillofacial Trauma and Management

Deepak Kademani, DMD, MD, FACS
Associate Professor
Oral and Maxillofacial Surgery
University of Minnesota
Minneapolis, Minnesota
Chapter 30: Lymphoma

Dongsoo David Kim, DMD, MD
Associate Professor
Oral and Maxillofacial Surgery
Louisiana State University Health Sciences Center
Shreveport
Shreveport, Louisiana
Chapter 29: Melanoma

Antonia Kolokythas, DDS, MSc
Associate Professor
Oral and Maxillofacial Surgery
University of Illinois at Chicago
Chicago, Illinois
Chapter 5: Diagnosis and Management of Trigeminal and Facial Nerve Injuries

George Kushner, DMD, MD
Professor of Oral and Maxillofacial Surgery
University of Louisville
Louisville, Kentucky
Chapter 25: Osteomyelitis and Osteoradionecrosis

Hadas Lehman-Naaman, DMD, MSc
Senior Surgeon
Department of Oral and Maxillofacial Surgery
Hadassah Medical Center
Beit Zait, Israel
Chapter 44: Chronic Facial Pain: Evaluation, Differential Diagnosis, and Management Strategies

Michael R. Markiewicz, DDS, MPH, MD
Assistant Professor
Oral and Maxillofacial Surgery
University of Illinois at Chicago, Cancer Center
Feinberg School of Medicine
Northwestern University
Ann & Robert H. Lurie Children's Hospital
Chicago, Illinois
Chapter 20: Salivary Gland Disease

Damian Maxwell, MD, FACS
Pediatric General and Thoracic Surgery
Charleston Area Medical Center
Charleston, West Virginia;
Clinical Assistant Professor of General Surgery and Pediatric Surgery
West Virginia University
Morgantown, West Virginia
Chapter 12: Assessment and Management of the Injured Child

J. Michael McCoy, DDS
Professor, Oral and Maxillofacial Surgery
Professor, Pathology
Professor, Radiology
Medical Director, Hyperbaric Oxygen Therapy
University of Tennessee Graduate School of Medicine
Knoxville, Tennessee
Chapter 16: Oral and Maxillofacial Pathology: Available Diagnostic Techniques and Surgical Interactions

Avanti Mehrotra, MD
Humphrey Cancer Center
North Memorial Medical Center
Robbinsdale, Minnesota
Chapter 30: Lymphoma

Louis G. Mercuri, DDS, MS
Clinical Professor (Retired)
Surgery
Loyola University Stritch Medical School
Maywood, Illinois;
Consultant
Clinical Affairs
TMJ Concepts
Ventura, California
Chapter 43: Temporomandibular Joint Replacement

Michelle L. Mierzwa, MD
Assistant Professor
Radiation Oncology
University of Michigan Health System
Ann Arbor, Michigan
Chapter 32: The Use of Radiation Therapy in Treatment of Head and Neck Cancer

Andrew D. Miller, DMD, MD
Private Practice
Oral and Maxillofacial Surgery
Philadelphia, Pennsylvania
Chapter 17: Cysts of the Oral and Maxillofacial Region

Edward J. Miller, Jr., DMD
Private Practice
Oral and Maxillofacial Surgery
Staff OMS
New York Harbor VAMC
Clinical Instructor
NYUCD Oral and Maxillofacial Surgery
New York, New York
Chapter 15: Treatment of Maxillofacial Gunshot Wound Injuries

Michael Miloro, DMD, MD, FACS
Professor
Oral and Maxillofacial Surgery
University of Illinois
Chicago, Illinois
Chapter 5: Diagnosis and Management of Trigeminal and Facial Nerve Injuries

John B. Mulliken, MD
Plastic and Oral Surgery Department
Boston Children's Hospital
Boston, Massachusetts
Chapter 23: Vascular Anomalies of the Oral and Maxillofacial Region

Gregory M. Ness, DDS, FACS
Professor—Clinical
Oral and Maxillofacial Surgery and Anesthesiology
The Ohio State University College of Dentistry
Columbus, Ohio
Chapter 34: History of Temporomandibular Surgery
Chapter 45: Temporomandibular Muscle Disorders: Diagnostic and Management Considerations

Sami A. Nizam II, DMD, MD
Chief Resident
Rutgers Oral and Maxillofacial Surgery
Newark, New Jersey
Chapter 40: Arthrocentesis of the Temporomandibular Joint

Robert A. Ord, MD, DDS, MS
Professor and Chairman
Oral and Maxillofacial Surgery
University of Maryland
Baltimore, Maryland
Chapter 20: Salivary Gland Disease

Bonnie L. Padwa, DMD, MD
Oral Surgeon-in-Chief
Section of Oral and Maxillofacial Surgery
Boston Children's Hospital
Department of Plastic & Oral Surgery
Associate Professor in Oral & Maxillofacial Surgery
Harvard School of Dental Medicine
Boston, Massachusetts
Chapter 23: Vascular Anomalies of the Oral and Maxillofacial Region

Chan M. Park, DDS, MD, FACS
Residency Program Director
University of the Pacific/Highland Hospital
Oral and Maxillofacial Surgery Residency
Assistant Professor, Department of Oral and Maxillofacial Surgery
Arthur A. Dugoni School of Dentistry
University of the Pacific
San Francisco, California
Chapter 39: Nonsurgical Management of Temporomandibular Joint Disorders
Chapter 41: Arthroscopy of the Temporomandibular Joint

Ketan Patel, DDS, PhD
Attending Surgeon
Oral and Maxillofacial Surgery, Oral/Head and Neck Oncologic and Microvascular Surgery
North Memorial Medical Systems
Robbinsdale, Minnesota
Chapter 30: Lymphoma

Zachary S. Peacock, DMD, MD, FACS
Assistant Professor of Oral and Maxillofacial Surgery
Massachusetts General Hospital
Harvard School of Dental Medicine
Boston, Massachusetts
Chapter 3: Imaging in Maxillofacial Trauma

Anitha Potluri, BDS, DMD, MDSc
Assistant Professor and Director Oral and Maxillofacial Surgery
Diagnostic Sciences
University of Pittsburgh
School of Dental Medicine
Pittsburgh, Pennsylvania
Chapter 37: Imaging of the Temporomandibular Joint

Likith V. Reddy, DDS, MD, FACS
Associate Professor
Director of Residency Training
Oral and Maxillofacial Surgery
Texas A&M University College of Dentistry
Dallas, Texas
Chapter 8: Nasal Fractures
Chapter 14: Management of Avulsive Facial Injuries

Shravan Kumar Renapurkar, BDS, DMD
Assistant Professor
Oral and Maxillofacial Surgery
Virginia Commonwealth University
Richmond, Virginia
Chapter 6: Diagnosis and Management of Dentoalveolar Injuries

Salvatore L. Ruggiero, DMD, MD, FACS
New York Center for Orthognathic and Maxillofacial Surgery
Lake Success, New York;
Clinical Professor
Oral and Maxillofacial Surgery
Stony Brook School of Dental Medicine
Stony Brook, New York;
Clinical Professor
Hofstra LIJ—North Shore School of Medicine
Uniondale, New York
Chapter 21: Diagnosis and Management of Medication-related Osteonecrosis of the Jaw

MaryAnn (Ma'Ann) C. Sabino, DDS, PhD
Staff Surgeon
Oral and Maxillofacial Surgery
Hennepin County Medical Center
Adjunct Clinical Professor
Oral and Maxillofacial Surgery
University of Minnesota
Minneapolis, Minnesota
Chapter 44: Chronic Facial Pain: Evaluation, Differential Diagnosis, and Management Strategies

Salam O. Salman, DDS, MD
Assistant Professor
Oral and Maxillofacial Surgery
University of Florida—Jacksonville
Jacksonville, Florida
Chapter 9: Management of Zygomatic Fractures

Thomas Schlieve, DDS
Oral and Maxillofacial Surgery
University of Illinois—Chicago
Chicago, Illinois
Chapter 5: Diagnosis and Management of Trigeminal and Facial Nerve Injuries

Brian L. Schmidt, DDS, MD, PhD
Professor, Oral and Maxillofacial Surgery
Director, Bluestone Center for Clinical Research
New York University
New York, New York
Chapter 19: Benign Non-odontogenic Lesions of the Jaws

Rabie M. Shanti, DMD, MD
Fellow in Oral, Head and Neck Oncologic Surgery/Microvascular Reconstructive Surgery
Oral and Maxillofacial Surgery
Louisiana State University Health Sciences Center
Shreveport, Louisiana
Chapter 29: Melanoma

Janakiraman Subramanian, MD, MPH
Attending Physician
Medicine
Saint Luke's Hospital
Kansas City, Missouri
Chapter 33: Principles of Medical Oncology in the Management of Head and Neck Cancer

Srinivas Susarla, DMD, MD
Acting Instructor, Plastic Surgery
Acting Instructor, Oral and Maxillofacial Surgery
Seattle Children's Hospital/University of Washington
Seattle, Washington
Chapter 3: Imaging in Maxillofacial Trauma

James Q. Swift, DDS
Professor
Division of Oral and Maxillofacial Surgery
University of Minnesota
Minneapolis, Minnesota
Chapter 44: Chronic Facial Pain: Evaluation, Differential Diagnosis, and Management Strategies

Aditya Tadinada, DDS, MS, MDS
Director of Student Research and Assistant Program Director of the Residency Program
Oral and Maxillofacial Radiology
University of Connecticut
School of Dental Medicine
Farmington, Connecticut
Chapter 37: Imaging of the Temporomandibular Joint

Paul S. Tiwana, DDS, MD, MS, FACS
Sinn Chair and Professor of Oral & Maxillofacial Surgery and Neurological Surgery
Residency Program Director
UT Southwestern Medical School
Parkland Memorial Hospital
Dallas, Texas
Chapter 10: Diagnosis and Management of Midface Fractures

Randy Todd, DMD, MD, DMSc
Salem-Peabody Oral Surgery
Peabody, Massachusetts
Chapter 26: The Molecular Biology of Cancer

Trent L. Tucker, DDS, MD
Private Practice
Oral and Maxillofacial Surgery
Dayton, Ohio
Chapter 9: Management of Zygomatic Fractures

John S. Vorrasi, DDS
Associate Professor, Associate Program Director
Oral and Maxillofacial Surgery and Hospital Dentistry
Christiana Care Health System
Wilmington, Delaware
Chapter 7: Diagnosis and Management of Mandible Fractures

Brent B. Ward, DDS, MD
Associate Professor and Fellowship Program Director
Oral and Maxillofacial Surgery
University of Michigan
Ann Arbor, Michigan
Chapter 28: Squamous Cell Carcinoma of the Oral and Maxillofacial Region

Fayette C. Williams, DDS, MD, FACS
Clinical Faculty
Oral and Maxillofacial Surgery
John Peter Smith Hospital
Fort Worth, Texas
Chapter 31: Non-melanoma Skin Cancer of the Head and Neck

Thomas P. Williams, DDS, MD, FACS
Clinical Professor of Oral and Maxillofacial Surgery
University of Texas at Houston
Houston, Texas
Chapter 18: Odontogenic Tumors: Surgical Pathology and Management

James W. Wilson, DDS
Thomas M. Weil Professor in Oral and Maxillofacial Surgery
Professor and Vice Chair
Department of Oral & Maxillofacial Surgery
University of Texas Health School of Dentistry
Houston, Texas
Chapter 4: Soft Tissue Injuries of the Face, Head, and Trunk

Alison Y. Yeung, DDS, MD
Clinical Assistant Professor
Division of Oral and Maxillofacial Surgery
School of Dental Medicine
East Carolina University
Greenville, North Carolina
Chapter 1: Initial and Postoperative Management of the Craniomaxillofacial Trauma Patient

Vincent B. Ziccardi, DDS, MD, FACS
Professor, Chair and Residency Director
Oral and Maxillofacial Surgery
Rutgers School of Dental Medicine
Newark, New Jersey
Chapter 40: Arthrocentesis of the Temporomandibular Joint

Preface

We are excited to present the third edition of *Oral and Maxillofacial Surgery*. This three-volume text is the result of the collaboration of multiple contributors. The first edition, published in 2000, and the second edition, published in 2009, were very well-received. However, with all the advances in our profession, we felt it was time for a new edition. The section editors have done an excellent job recruiting the most knowledgeable individuals in their specific areas of expertise. The authors have submitted chapters that reflect the state of the art in their areas of responsibility.

This text is a comprehensive resource on oral and maxillofacial surgery. Every area in our specialty has been addressed. It defines the scope of the specialty. Every surgical procedure performed by an oral surgeon is covered in this text. This multi-volume text provides coverage of a wide range of issues related to surgical care, such as anesthesia, diagnostic imaging treatment planning, rehabilitation, physical therapy, and psychological considerations.

After an analysis of the changing field of oral and maxillofacial surgery, we strove to present a comprehensive, current book that covers the complete scope of our specialty. We hope that the reader appreciates and agrees with our efforts. We stated in the preface of the first edition that we hoped that our future attempts will present an even broader scope of oral and maxillofacial surgery. The fact that this edition has succeeded in that regard is a testament to the individuals who are constantly expanding the envelope.

Acknowledgments

The third edition of *Oral and Maxillofacial Surgery* is a team approach. The section editors—Eric R. Carlson and Gregory M. Ness (and myself)—were invaluable contributors to the success of this effort. They diligently pestered authors so that deadlines were almost met. This edition, like the last two, attempts to define the scope of oral and maxillofacial surgery and could not have come to fruition without these contributors.

Residents are the lifeblood of our specialty. Many have helped to contribute portions of chapters in this book. They have also provided us with friendship, dedication, intellectual stimulation, and humility, without which this book would not have been written.

Last, I would like to thank all the staff who helped to prepare these manuscripts and the editorial staff at Elsevier, who were so patient with our procrastination and meticulous in their development and editing of this book. Additionally, I would like to thank my staff—Laynee Adams, Sally Brown, Heather Early, Patty Martin, Sarah Merrill, Josie Ray, and Ashley Wood—who collectively and individually make my life so enjoyable.

Raymond J. Fonseca, DMD

Contents

VOLUME 2 CONTENTS

Trauma, Surgical Pathology, Temporomandibular Disorders

Volume Editor: Raymond J. Fonseca

Section 1: Trauma

1 **Initial and Postoperative Management of the Craniomaxillofacial Trauma Patient 1**
Alison Y. Yeung

2 **Airway and Anesthetic Management for the Traumatized Patient 9**
Elie M. Ferneini, Jeffrey D. Bennett

3 **Imaging in Maxillofacial Trauma 17**
Srinivas Susarla, Zachary S. Peacock

4 **Soft Tissue Injuries of the Face, Head, and Trunk 41**
Phillip N. Freeman, James W. Wilson, Kevin C. Gams

5 **Diagnosis and Management of Trigeminal and Facial Nerve Injuries 70**
Thomas Schlieve, Michael Miloro, Antonia Kolokythas

6 **Diagnosis and Management of Dentoalveolar Injuries 114**
Shravan Kumar Renapurkar, A. Omar Abubaker

7 **Diagnosis and Management of Mandible Fractures 146**
John S. Vorrasi, Domenick P. Coletti, John F. Caccamese, Jr.

8 **Nasal Fractures 174**
Likith V. Reddy, Sarah C. Harding

9 **Management of Zygomatic Fractures 189**
Trent L. Tucker, Salam O. Salman, Larry L. Cunningham, Jr.

10 **Diagnosis and Management of Midface Fractures 211**
Mohammed Al-Obaidi, Paul S. Tiwana

11 **Diagnosis and Management of Frontal Bone Injuries 230**
Tirbod Fattahi, Desmon Brown

12 **Assessment and Management of the Injured Child 245**
Bruce B. Horswell, Damian Maxwell

13 **Pediatric Craniomaxillofacial Trauma and Management 264**
Bruce B. Horswell, Lewis C. Jones

14 **Management of Avulsive Facial Injuries 282**
Likith V. Reddy, Wade Barker

15 **Treatment of Maxillofacial Gunshot Wound Injuries 303**
Edward J. Miller, Jr., Steven H. Cho

Section 2: Surgical Pathology

16 **Oral and Maxillofacial Pathology: Available Diagnostic Techniques and Surgical Interactions 329**
J. Michael McCoy

17 **Cysts of the Oral and Maxillofacial Region 338**
Nabil A. Abaza, Samir K. El-Mofty, Andrew D. Miller

18 **Odontogenic Tumors: Surgical Pathology and Management 391**
Lionel Gold, Thomas P. Williams

19 **Benign Non-odontogenic Lesions of the Jaws 462**
Brian L. Schmidt

20 **Salivary Gland Disease 481**
Michael R. Markiewicz, Rui P. Fernandes, Robert A. Ord

21 **Diagnosis and Management of Medication-related Osteonecrosis of the Jaw 507**
Salvatore L. Ruggiero

22 **Langerhans Cell Histiocytosis 523**
Eric R. Carlson, Joshua A. Campbell

23 **Vascular Anomalies of the Oral and Maxillofacial Region 534**
Bonnie L. Padwa, John B. Mulliken

24 **Vesiculobullous Diseases 550**
John W. Hellstein, Christopher G. Fielding, James T. Castle

25 **Osteomyelitis and Osteoradionecrosis 575**
Brian Alpert, George Kushner

26 **The Molecular Biology of Cancer 599**
Randy Todd

27 **Sarcomas of the Jaws 643**
Kyle S. Ettinger, Kevin Arce

28 **Squamous Cell Carcinoma of the Oral and Maxillofacial Region 670**
Brent B. Ward, Joseph I. Helman

29 **Melanoma 690**
Rabie M. Shanti, Dongsoo David Kim, Ghali E. Ghali

30 **Lymphoma 707**
Ketan Patel, Avanti Mehrotra, Deepak Kademani

31 **Non-melanoma Skin Cancer of the Head and Neck 717**
Fayette C. Williams, Jon D. Holmes

32 **The Use of Radiation Therapy in Treatment of Head and Neck Cancer 741**
William L. Barrett, Michelle L. Mierzwa

33 **Principles of Medical Oncology in the Management of Head and Neck Cancer 752**
Janakiraman Subramanian, Wahid T. Hanna

Section 3: Temporomandibular Disorders

34 **History of Temporomandibular Surgery 764**
Gregory M. Ness

35 **Structure and Function of the Temporomandibular Joint 777**
Robert Gassner

36 **Assessing Temporomandibular Disorders 791**
Gary M. Heir

37 **Imaging of the Temporomandibular Joint 815**
Anitha Potluri, Aditya Tadinada

38 **Pathology of the Temporomandibular Joint 830**
Robert Gassner

39 **Nonsurgical Management of Temporomandibular Joint Disorders 865**
A. Thomas Indresano, Chan M. Park

40 **Arthrocentesis of the Temporomandibular Joint 883**
Vincent B. Ziccardi, Sami A. Nizam II

41 **Arthroscopy of the Temporomandibular Joint 892**
A. Thomas Indresano, Chan M. Park

42 **Surgery for Internal Derangement of the Temporomandibular Joint 904**
William Chung, Alejandro J. Almarza

43 **Temporomandibular Joint Replacement 923**
Louis G. Mercuri

44 **Chronic Facial Pain: Evaluation, Differential Diagnosis, and Management Strategies 941**
James Q. Swift, MaryAnn (Ma'Ann) C. Sabino, Hadas Lehman-Naaman

45 **Temporomandibular Muscle Disorders: Diagnostic and Management Considerations 962**
James Fricton, Gregory M. Ness

1

Initial and Postoperative Management of the Craniomaxillofacial Trauma Patient

ALISON Y. YEUNG

Introduction

Trauma is the leading cause of mortality globally, and in the United States more than 3 million facial injuries occur each year, resulting in a large percentage of hospital admissions. Because more than 50% of patients with maxillofacial trauma have multisystem injuries as well, a thorough and efficient management strategy is crucial to optimize the care of the patient.

The goal in the management of the facial trauma patient is to restore function and esthetics while minimizing adverse events. The initial evaluation and management of the patient ensures that the appropriate treatment is rendered, whereas the focus in the postoperative setting is on an expeditious recovery with minimal complications. This chapter outlines some of the important principles in the care of the facial trauma patient in the perioperative setting. The subsequent chapters of this text will explore many of these principles in greater detail.

Initial Assessment

The creation of the Advanced Trauma Life Support (ATLS) course in 1978 provided a systematic approach to addressing the initial needs of the trauma patient. The principles outlined by ATLS (Box 1-1) should be applied to all trauma patients in the emergent setting, to quickly identify and treat any life-threatening injuries. However, it is rare for the oral and maxillofacial surgeon (OMS) to be the sole primary practitioner evaluating a trauma patient who presents to the hospital. A multidisciplinary approach to the management of the trauma patient has been adopted. In most situations, the trauma patient has been evaluated in the emergency room setting and the OMS is brought in as a consultant. This does not negate the need for a thorough understanding of the principles behind trauma care, as it allows the practitioner to be in sync with the efficient and effective methods of optimizing patient care in the hospital setting. In the case that the patient has been referred to you in the outpatient setting, it is important to ensure that all other systems have been evaluated and other systemic injuries have been addressed. If you are concerned that other injuries have not been thoroughly evaluated, a referral to the emergency room is warranted.

A thorough examination of the craniomaxillofacial region is typically achieved as a component of the secondary survey. However, the evaluation of head and neck injuries is tantamount to the management of a patent airway. As airway management is the first step of the primary survey in the ATLS process, it is imperative that the facial structures have stability to support patency. Hemorrhage should be controlled via compressive dressings or ligation of visible vessels. Care should be taken when packing materials or balloon catheters are placed to tamponade bleeding in the case of severe panfacial injuries involving the midface and naso-ethmoidal-orbital regions, as the cranial base can be entered and injury to the brain or orbital contents can occur. Dental prostheses, debris, and avulsed teeth should be removed to prevent aspiration or airway obstruction. Comminuted or severely displaced fractures of the mandible may result in an upper airway obstruction via the posterior displacement of the mandible and tongue base, especially when the patient is in the supine position. When integrity of the mandible is lost, increased laxity of the supporting musculature of the tongue and submental regions can obstruct the posterior oropharynx (Figure 1-1). Manual repositioning of the mandible and tongue can be helpful in relieving the obstruction, until a patent airway can be achieved by placement of

• Box 1-1 Principles of Advanced Trauma Life Support (ATLS)

1. Primary survey
   - Airway management with cervical spine protection
   - Breathing/Ventilation/Oxygenation
   - Circulation with hemorrhage control
   - Disability: Neurologic status
   - Exposure/Environmental control
2. Resuscitation and immediate intervention for life-threatening injuries
   - Normalization of vital functions
   - Imaging: AP CXR/pelvis, abdominal ultrasonography, C-spine
3. Secondary survey
   - Includes a full history and physical examination
   - Reassessment of vital signs
   - Indicated imaging obtained
   - Special procedures
4. Definitive care

AP, Anteroposterior; *CXR,* chest x-ray.

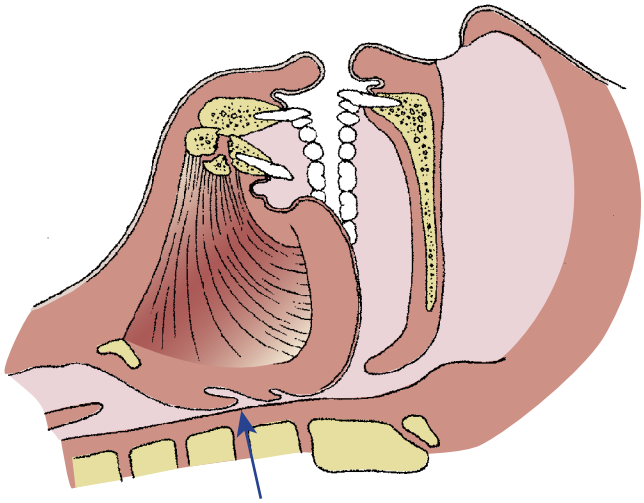

• Figure 1-1 Posterior displacement of tongue and occlusion of upper airway resulting from bilateral mandibular fractures. The *arrow* is indicating the occlusion of the posterior airway space as a result of posterior displacement of the tongue base, in association with bilateral mandible fractures. (From Hupp J, Tucker M, Ellis E: *Contemporary oral and maxillofacial surgery*, ed 6, St Louis, 2014, Mosby.)

an oral airway appliance or endotracheal intubation. The use of bridle wires to stabilize widely displaced mandibular fractures may be beneficial not only to assist in the management of a patent airway, but also to help decrease medullary bleeding as well as provide some pain relief to the patient.

The patient interview should identify the time and by what mechanism the trauma occurred. It should be ascertained whether or not the patient lost consciousness, as this can give an indication as to the degree of head trauma involved and the force sustained to create such injuries.

Mechanism of Injury

When managing trauma patients, having an understanding of the injuries sustained via various mechanisms can guide the evaluation of the patient and the rapid assessment of specific injuries. All wounds should be assessed for degree of contamination, and steps should be taken for appropriate antibacterial therapy.

Penetrating injuries result in a localized focused path of entry and exit of a sharp object. Penetrating wounds to the head and neck require a careful evaluation of the upper airway and vasculature, as direct injury to these structures can occur, in conjunction with facial bone fractures and expected soft tissue lacerations. Appropriate diagnostic studies, such as angiography or computed tomography (CT), should be completed to evaluate these anatomic structures.

Blunt trauma to the head and neck typically results in contusions and shearing forces that result in soft tissue lacerations as a result of tearing or avulsive injury. Wound margins may have extensive ecchymosis and, because of the nature of the injury, may require debridement and refining of the tissue edges to allow for improved adaptation of the margins and healing by primary intention. Facial fractures that occur as a result of blunt injury can be heavily comminuted.

Wounds resulting from gunshots follow a specific trajectory and damage pattern depending on the type of bullet and velocity. Wounds should be inspected for bullet fragments and debris that may have been fragmented and pulled into the wound. Surrounding tissue damage caused by burn injury and coagulative necrosis can have a delayed effect. Repeat evaluations should be performed to assess for progressive tissue damage.

Considerations Regarding the Medical History

A thorough understanding of the patient's preexisting medical conditions dictates the management of the patient in the perioperative period, but also allows the practitioner to better prevent postoperative medical complications, which can lead to prolonged hospital stays and increased resource utilization. Other known risk factors that tend to be commonly associated with the trauma patient can contribute to the complexity of managing craniofacial trauma.

A thorough review of the medical history, known drug allergies, and tetanus immunization should be performed, to anticipate any risks for intraoperative or postoperative complications. If the OMS becomes the primary admitting service, appropriate consultations should be considered to assist in the management of patients with complex medical conditions, such as internal medicine, infectious diseases, neurology/neurosurgery, or cardiology. The trauma literature has identified certain chronic medical conditions that have an increased risk for complications and mortality in the inpatient setting. A systematic review of data from the National Trauma Data Bank from 2002 to 2006 showed that preexisting chronic hepatic failure (cirrhosis), dialysis (end-stage renal disease), and anticoagulative therapies were risk factors for both complications and mortality. HIV/AIDS was a risk factor for the development of complications during the hospital stay. However, all other medical conditions require attention in the perioperative period to ensure patient safety. Table 1-1 outlines some common

TABLE 1-1 Common Systemic Medical Conditions and the Considerations that Should Be Made in the Management of Patients with These Conditions, in the Perioperative Setting

Medical Condition	Preoperative Considerations	Postoperative Considerations
Known cardiovascular disease (hypertension, angina/ACS, dysrhythmias, CAD, CHF, valvulopathy, etc.)	Cardiac risk assessment, plan for blood product replacement in the setting of expected high volume blood loss (maintain hemoglobin 7-8 g/dL), antiplatelet/anticoagulant reversal as needed	Consider continuous cardiac monitoring, maintain hemoglobin 7-8 g/dL
Diabetes mellitus	Cardiac and renal function should be evaluated, tight glycemic control, glycated hemoglobin value (glucose between 140 and 200 mg/dL)	Tight glycemic control, compromised immune function requiring considerations for antibacterial therapy, delayed healing, optimize nutrition
Renal failure	Be cautious in the setting of contrast use for imaging studies, renal adjustment for medication administration, evaluate for coagulopathy, consider consultation with renal service to manage the need for dialysis, evaluate nutritional status	Fluid status maintenance, renal adjustment for medication administration, be cautious with the use of nonsteroidal anti-inflammatory medications
Liver failure	Adjustment for medication administration, evaluate for coagulopathy and/or thrombocytopenia, OR positioning in the setting of ascites, evaluate nutritional status, consider consultation with medicine services for management assistance	Optimize nutrition, adjustment for medication administration as needed
Chronic obstructive pulmonary disease (COPD)	Optimize airways for the OR	Avoid prolonged ventilator assistance, aggressive chest physical therapy
Acquired/congenital coagulopathy or antiplatelet activity	Reversal/correction of coagulopathy or platelet dysfunction	Quick resumption of anticoagulant or antiplatelet therapy balanced with the concern for postoperative hemorrhage
Stroke	Antiplatelet or anticoagulant therapy reversal as needed, adjustment to OR positioning,	Aggressive chest physical therapy, consider consultation with neurology/neurosurgery services regarding the timeliness of resuming anticoagulant or antiplatelet therapy
Adrenal insufficiency	Supplemental steroid administration to prevent acute adrenal crisis, evaluate for electrolyte abnormalities	Tight glucose control in the setting of exogenous steroid administration
Immunodeficiency (HIV/AIDS), immune suppression (post-transplant)	Evaluate nutritional status, compromised immune function requiring antibacterial therapy, evaluate for thrombocytopenia, need for supplemental steroid therapy in the post-transplant patient	Delayed healing, tight glucose control in the setting of exogenous steroid administration
Dementia	Concerns in obtaining proper informed consent, evaluate nutritional status	Concerns for compliance
Substance abuse (alcohol/opiate), tobacco	Specific nutritional supplementation (thiamine, folate, multivitamin) for the alcohol dependent patient, consider prophylaxis to prevent acute substance withdrawal, administer nicotine patches as needed	Continue to monitor for withdrawal symptoms, delayed healing, optimize for early discharge, concerns for compliance
Psychiatric illness	Continue all psychiatric medications as previously prescribed	Concerns for compliance
Seizure disorder	Continue all antiepileptic medications, relative contraindication to maxillomandibular fixation	
Pregnancy	Positioning in the OR, OB/GYN consultation for continuous fetal heart monitoring	Avoid nonsteroidal anti-inflammatory medications, avoid medications with known teratogenic effects
Eating disorders	Assess for electrolyte abnormalities, dysrhythmias, evaluate nutritional status	Consider nutrition consultation

ACS, Acute coronary syndrome; *AIDS,* acquired immunodeficiency syndrome; *CAD,* coronary artery disease; *CHF,* congestive heart failure; *HIV,* human immunodeficiency virus; *OB/GYN,* obstetrics and gynecology; *OR,* operating room.

systemic illnesses and considerations that should be made in the management of the patient. All preexisting medications should be continued throughout the hospital stay. In some cases administration parameters should be delineated in the setting of medications that may affect cardiovascular stability.

Patients with chronic medical conditions have a tendency to be undernourished, which can affect healing in the postoperative period. Laboratory studies such as albumin and pre-albumin levels can help to assess nutritional status, and nutrition should be supplemented to optimize healing. Consultations with the nutrition services can be helpful in these settings.

Trauma can be a reoccurring disease process, and certain risk factors are associated with the repeat trauma patient. Alcohol and drug use have been estimated to be involved in as many as 50% to 70% of all trauma patients. The potential for acute substance withdrawal should be assessed based on quantity and frequency of use, and appropriate prophylactic measures should be taken to reduce the risk of the development of withdrawal. Alcohol has been found to affect platelet aggregation and can promote increased intraoperative bleeding. Although typically this bleeding is not profound, in the case of expected high-volume blood loss it could be a major factor.

Clinical Examination

The clinical examination of the craniomaxillofacial trauma patient should be performed in a thorough and efficient manner. Every practitioner should develop an algorithm that allows adequate and consistent evaluation of facial and oral structures. The clinical exam should dictate the need for any additional diagnostic studies, which should confirm or refute the clinical suspicion of fracture.

The scalp and soft tissue structures should be directly visualized for any lacerations or abrasions. In the case of patients placed in cervical spine precautions, the assistance of others should be solicited to roll the patient while maintaining proper spinal alignment so the back of the scalp can be examined thoroughly. The OMS should be mindful of the location of lacerations in relation to underlying fractures, as decisions regarding immediate versus delayed repair of the laceration may aid in definitive fracture repair.

If lacerations to ears are extensive or there are suspected fractures to the temporomandibular joints, the tympanic membranes should be evaluated via the use of an otoscope.

The eyes should be examined for lacerations to the eyelids and any penetrating injury to the globe. If lacerations involve the lid margin, an immediate ophthalmologic consultation should be obtained to evaluate the integrity of the canalicular structures. If any fat herniation is present, a globe injury should be suspected, and again an ophthalmologic consultation should be obtained. Pupillary abnormalities should be assessed, and documentation needs to be made if dilatory medications are used to aid the fundoscopic examination. Extraocular muscular function should be examined via range-of-motion and visual-field assessment to rule out the potential for muscle entrapment involving orbital wall defects (Figure 1-2). Measurements should be made of the interpupillary and intercanthal distances, to guide repairs in the setting of naso-orbito-ethmoid complex fractures (Figure 1-3).

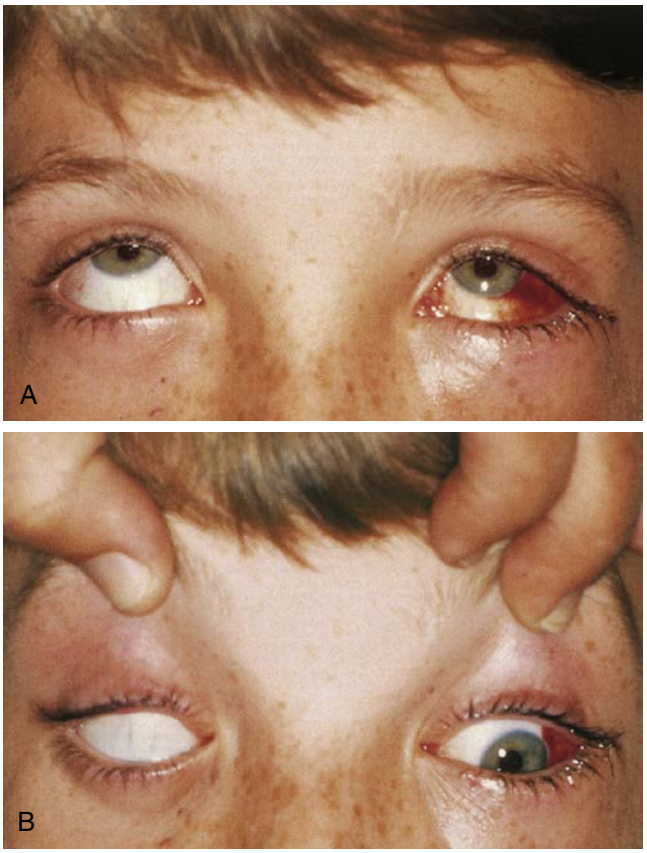

• **Figure 1-2** **A,** A 14-year-old patient with a left orbital floor fracture in upward gaze. **B,** Entrapment of inferior rectus muscle is the result of impingement in area of linear orbital floor fracture. In the down gaze, the patient is unable to rotate the left eye inferiorly, whereas the right eye is fully rotated inferiorly. (From Hupp J, Tucker M, Ellis E: *Contemporary oral and maxillofacial surgery*, ed 6, St Louis, 2014, Mosby.)

All facial structures should be palpated and manipulated for crepitus, mobility, or disruption of normal anatomic structures suggestive of bony fractures. Again, all suspected fractures should be confirmed against radiographic imaging.

The nasal bones should be directly palpated and the patency of the nasal airways should be evaluated. The nasal septum should be evaluated for laceration, perforations, and hematoma formation, as this could result in ischemic changes to the cartilaginous septum.

The intraoral examination should assess the dentition for fractured or avulsed teeth. The occlusion should be evaluated for any malocclusion, premature contacts, or disruption of the arch form. A determination should be made, based on discussions with the patient and the examination of occlusal wear patterns, regarding the patient's preexisting

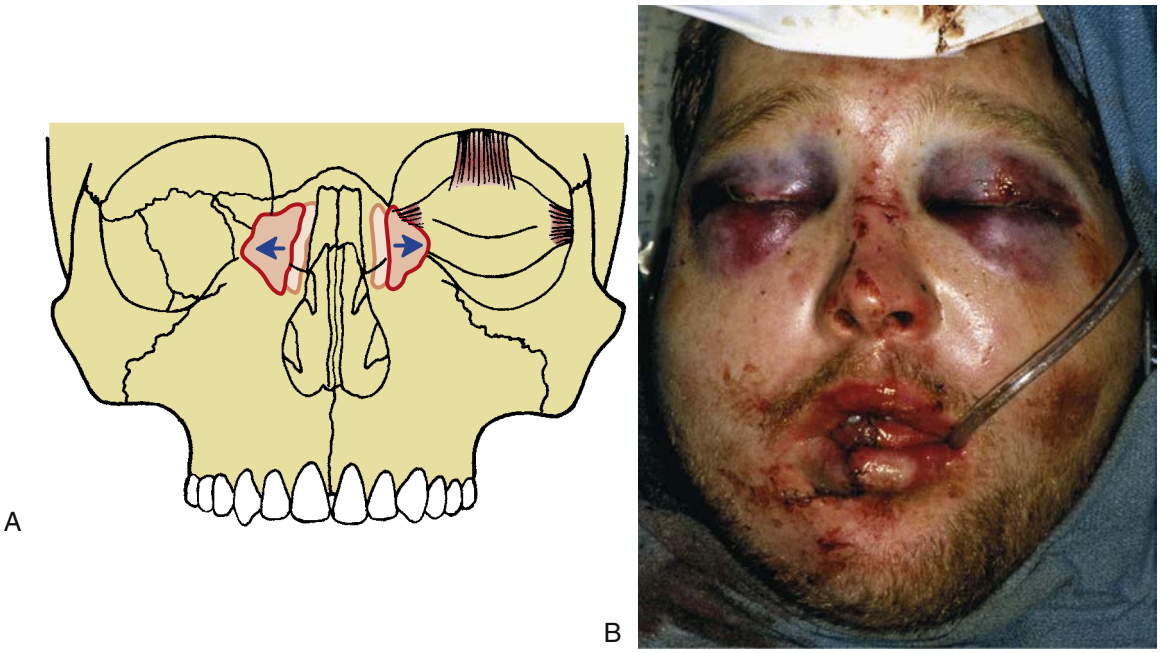

• **Figure 1-3** Injury to naso-orbito-ethmoid (NOE) complex, which resulted in the displacement of medial canthal ligaments and a widening of the intercanthal distance (i.e., traumatic telecanthus). **A,** Diagram of bony fractures and medial canthal ligament displacement. **B,** Clinical photograph. (From Hupp J, Tucker M, Ellis E: *Contemporary oral and maxillofacial surgery*, ed 6, St Louis, 2014, Mosby.)



• **Figure 1-4** Irregularity of plane of occlusion and laceration in gingiva and mucosa between the mandibular central incisors, indicating a likelihood of mandibular fracture in this area. (From Hupp J, Tucker M, Ellis E: *Contemporary oral and maxillofacial surgery*, ed 6, St Louis, 2014, Mosby.)

occlusal scheme. This will provide guidance during any fracture reduction surgery to create a reproducible occlusion. Gingival or mucosal lacerations, ecchymosis of the tissues of the floor of the mouth and vestibule, crepitus while palpating the vestibule, and areas of point tenderness could be suggestive of mandibular fractures (Figure 1-4). Crepitus and ecchymosis of the maxillary vestibule could be suggestive of a maxillary fracture at the Le Fort I level or a zygomaticomaxillary complex fracture. Bimanual palpation and manipulation of the maxilla and mandible should be performed to assess for gross mobility (Figure 1-5).

Diagnostic Studies

The medical history and clinical examination should identify the need for any additional studies. Laboratory values and radiographic imaging should be discussed and ordered in conjunction with those needed by other services. Typically a complete blood count with differential, hemoglobin and hematocrit, complete or basic metabolic panel, and coagulation studies are ordered for diagnostic and preoperative planning. Although plain films can be helpful, CT is considered the standard of care for imaging the facial bones. The exception in this author's opinion is the panoramic image, which provides valuable information when evaluating a mandibular fracture. Other imaging studies such as angiography and magnetic resonance imaging (MRI) may be useful in certain situations when the vessels or other soft tissue structures need to be evaluated.

Planning for Definitive Care

Once the patient has been thoroughly evaluated and the injuries requiring treatment have been identified, a definitive plan of care needs to be devised. In the case of isolated



• **Figure 1-5** Examination of maxilla for mobility. **A,** Firm pressure on the forehead is used to stabilize the patient's head. Pressure is placed on the maxilla in an attempt to elicit mobility. **B,** A stabilizing hand can also evaluate mobility in the area of nasal bones. (From Hupp J, Tucker M, Ellis E: *Contemporary oral and maxillofacial surgery*, ed 6, St Louis, 2014, Mosby.)

facial lacerations, a decision needs to be made if the repair can be effectively achieved in the emergency or inpatient room, or if the patient needs to be taken to the operating room. Patients whose situations require better lighting, aggressive hemostasis control, large volumes of local anesthetic, complex instrumentation, or a setting better suited for the sedated patient should be taken to the operating room.

In the case of multisystem injuries, the trauma patient may make multiple trips to the operating room. Discussions with other surgical services can allow for coordinated care, so that the risks associated with general anesthesia are kept to a minimum. Positioning and sterile draping can be coordinated to allow simultaneous access to the head and neck and other parts of the body. Communication with the anesthesia staff and trauma team should be clear if the patient will remain in maxillomandibular fixation in the postoperative period, as this may play a factor in airway management. Nasoendotracheal or submental intubation techniques or a tracheostomy will be necessary in the patient remaining in maxillomandibular fixation, and length of time of expected postoperative intubation will typically dictate the technique used.

Informed consent must be obtained from the patient when possible; however, in the trauma setting this may not be feasible. In cases that necessitate a power of attorney or other designated persons, adherence to specific hospital protocols is imperative.

Preventative Measures to Optimize Patient Care in the Preoperative Setting

Hospitalized patients are at risk for the development of various adverse events directly or indirectly associated with the condition that brought them to the hospital. Minimizing the potential for these events can reduce the length of the hospital stay as well as limiting resource utilization in all patients, especially those with multisystem traumatic injuries.

The use of H2 antagonists and proton pump inhibitors can decrease gastric acid production and risk for gastrointestinal bleeding. The increased stress on the body as well as varying parenteral nutrition can promote increased gastric acid production and the potential for peptic inflammation and ulceration.

Prevention of thrombosis and a subsequent embolic event in the trauma patient is imperative. While fractures of the long bones can promote fat emboli, the non-ambulatory state of many patients puts them at risk for the development of deep vein thrombi and possible pulmonary emboli. Sequential compression devices should be used in low-risk patients, and prophylactic anticoagulant therapy in those at greater risk.

Tight glycemic control has been found to positively affect outcomes in the hospitalized patient population. Studies have identified maintaining blood glucose levels between 140 and 200 mg/dL at all times can decrease the risk for adverse events.

Postoperative Management

The postoperative management of any patient should focus on expeditious discharge from the hospital. In the case of the craniomaxillofacial trauma patient, excluding recovery from other injuries, this typically revolves around the resolution of symptoms associated with general anesthesia and the reduction of postoperative complications.

Antibiotic therapy should be tailored for each patient, taking into consideration contamination of the surgical wounds and the integrity of the immune system, balanced with the concerns for the promotion of resistant bacteria and the development of *Clostridium difficile* colitis.

Encouraging ambulation postoperatively helps to decrease the risk of thrombosis, promotes voiding of the bladder, and aids in preventing pulmonary complications. Foley catheters used intraoperatively should be discontinued as soon as possible to promote ambulation and decrease the potential for urinary retention, especially in older male patients.

Aggressive incentive spirometry and chest therapy can help in resolving ventilator-associated atelectasis and decrease the risk of nosocomial pneumonia.

Pain in the postoperative period needs to be adequately managed to encourage a quick recovery. However, the use of intravenous medications can delay the discharge process. Transitioning the patient to oral forms of medication is important in discharge planning. Prolonged use of opioid medications has the adverse side effect of promoting constipation. With aggressive Valsalva maneuver while attempting to empty the bowels, there is an initial rise in blood pressure and stroke volume, followed by a decrease in venous return with increased intrathoracic pressure. The initial spike in stroke volume and blood pressure can promote postoperative complications associated with bleeding, such as retrobulbar hematoma formation following orbital floor repairs, or epistaxis following nasal bone reduction or other midface repairs (Figure 1-6). Administering stool softeners and laxatives in conjunction with opioid analgesics can reduce this potential and improve patient comfort.

Proper orders regarding wound care and suture removal should be provided to the nursing staff and to the patient on discharge. Wire cutters should be provided for patients placed in maxillomandibular fixation, to be carried with them at all times in the case of a medical emergency, and clear instructions should be provided on how to release the fixation if necessary.

Dietary restrictions, if any, should be specified for every patient and clearly delineated. All enteral and parenteral feeds should be resumed as soon as possible following surgery.

Instructions for follow-up should be clear and communicated to the patient and all services involved. All inpatient medications should be reviewed and confirmed against preadmission medications and any new medications required as a result of the hospital stay. Medication lists should be adjusted accordingly based on appropriate start and stop times designated by the prescribing service.

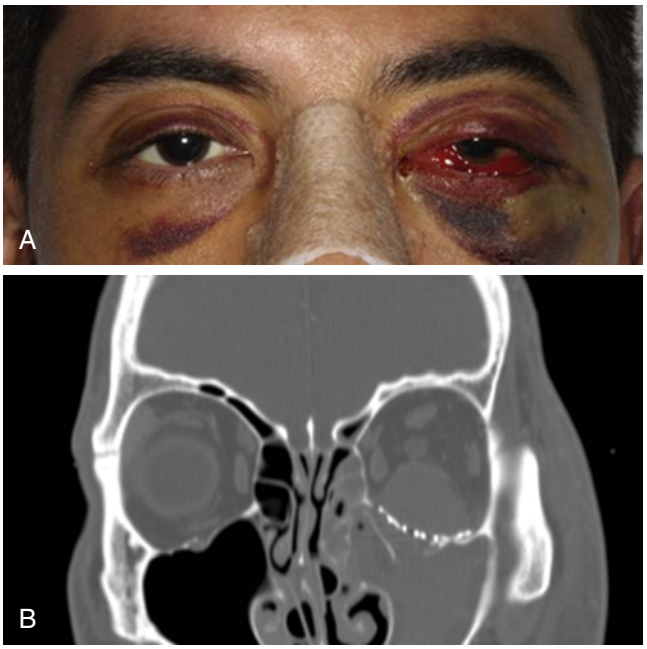

• **Figure 1-6** Postoperative hematoma formation in a patient 3 days following left orbital floor repair, who had been taking opioid pain medication for 7 days preoperatively. The patient reported straining and developing immediate sharp pain in the left eye. He reported to the emergency room, at which time evaluation noted a collection of blood in the left orbit. The hematoma was decompressed following release of the sutures used to repair the lateral canthotomy. The patient was evaluated by the ophthalmology service and had no residual visual or cosmetic defects. **A,** Proptosis associated with the left pupil. **B,** Hematoma associated with left orbital floor repair seen on coronal computed tomographic imaging.

Suggested Readings

ATLS Update: *Trauma reports*. http://search.proquest.com.jproxy.lib.ecu.edu/docview/758903580?accountid=10639, 2009.

Caccamese Jr JF, Coletti D: Peri-operative management of the craniomaxillofacial trauma patient. In Fonseca R, et al.: *Oral and maxillofacial surgery*, ed 2, St Louis, 2009, Elsevier.

Ceallaigh PO, et al.: Diagnosis and management of common maxillofacial injuries in the emergency department. Part 1: Advanced trauma life support, *Emerg Med J* 23:796–797, 2006.

Cowperthwaite MC, Burnett MG: Treatment course and outcomes following drug and alcohol-related traumatic injuries, *J Trauma Manag Outcomes* 5:3, 2011.

Gibson A, Boswell K: Facial trauma: challenges, controversies, and therapeutic options. In *Trauma reports*, 2011. http://search.proquest.com.jproxy.lib.ecu.edu/docview/857833925?accountid=10639.

Hupp J, Tucker M, Ellis E: *Contemporary oral and maxillofacial surgery*, ed 6, St Louis, 2014, Mosby. VitalBook file.

Motamedi MH, Dadgar E, Ebrahimi A, et al.: Pattern of maxillofacial fractures: a 5-year analysis of 8,818 patients, *J Trauma Acute Care Surg* 77:630, 2014.

Patel MS, et al.: The impact of select chronic diseases on outcomes after trauma: a study from the National Trauma Data Bank, *J Am Coll Surg* 212(1):96–104, 2011.

Perry M, Dancey A, Mireskandari K, et al.: Emergency care in facial trauma—a maxillofacial and ophthalmic perspective, *Injury* 36(8):875–896, 2005.

Perry M: Advanced Trauma Life Support (ATLS) and facial trauma: can one size fit all? *Int J Oral Maxillofac Surg* 37:209–214, 2008.

Shoko T, Shiraishi A, Kaji M, Otomo Y: Effect of pre-existing medical conditions on in-hospital mortality: analysis of 20,257 trauma patients in Japan, *J Am Coll Surg* 211:338, 2010.

The Internet Pathology Laboratory for Medical Education, The Internet Pathology Laboratory for Medical Education, Mercer University School of Medicine—Savannah: Firearms Tutorial. http://library.med.utah.edu/WebPath/TUTORIAL/GUNS/GUNINJ.html.

Thoren H, et al.: Occurrence and types of associated injuries in patients with fractures of the facial bones, *J Oral Maxillofac Surg* 68:805–810, 2010.

2

Airway and Anesthetic Management for the Traumatized Patient

ELIE M. FERNEINI, JEFFREY D. BENNETT

This chapter focuses on anesthetic and airway considerations in the management of the patient with oral and maxillofacial surgery injuries. This chapter emphasizes the basic principle of management as well as different pre-, intra-, and postoperative anesthetic strategies.

The Importance of the Airway in Maxillofacial Trauma

The maxillofacial trauma patient can present with impending airway compromise. During the initial assessment, the airway should be assessed for patency. Maxillofacial injuries can prevent the trauma surgeon from securing an airway. An airway obstruction can be due to a foreign body, mandibular injury, maxillary injury, tracheal injury, laryngeal injury, or tongue injury, which can be compounded by hemorrhage or edema resulting from injuries to these or associated structures. The trauma surgeon must evaluate the airway using a systematic approach. This will allow the accurate diagnosis of any life-threatening or minor injury.

During this assessment, great care must be taken to avoid excessive movement of the cervical spine. Patients with maxillofacial or head trauma should be presumed to have an unstable cervical spine injury. The patient's neck should not be rotated, hyperflexed, or hyperextended. In order to minimize iatrogenic injury, the patient's neck should be immobilized until a detailed cervical spine examination and complete cervical spine radiographic series are performed and a cervical spine injury has been ruled out.[1] There is no urgency to rule out a cervical spine injury in the newly injured unresponsive patient until the patient becomes fully cognizant and can subjectively respond to the assessment.

A common error in trauma management during the primary survey involves delay in securing the patient's airway. It is important for the trauma surgeon to be comfortable and competent at airway management.[2] Maxillofacial trauma can complicate airway management both in that[3] the injuries can compromise airway integrity, resulting in poor exchange or obstruction, and[4] the soft tissue or skeletal injury may make providing respiratory support difficult.

Initial Airway Assessment

Upon initial evaluation, the airway should be assessed to ascertain patency. Any airway obstruction can prevent securing a definitive airway. The well-established approach to the ABCs (airway, breathing, circulation) is the standard approach. Is the patient able to communicate verbally? Is the patient breathing spontaneously? Does the patient have adequate oxygenation? A negative response to any of these questions will require emergent intervention to secure adequate oxygenation and ventilation. The inability to obtain control of the airway can result in irreversible brain damage due to hypoxia in as little as 4 minutes. Severe head-injury patients with a Glasgow Coma Scale (GCS) score of 8 or less usually require the placement of a definitive airway.

Airway patency does not ensure adequate ventilation. Ventilation requires adequate gas exchange with adequate oxygenation with normal function of the lungs, diaphragm, and chest wall. A rapid assessment of these components is important. Performing a detailed and rapid thoracic lung exam can aid in this assessment. Chest auscultation and percussion can help in assessing the patency of oxygenation; auscultation is the most important technique in assessing air flow through the tracheobronchial tree. Breath sounds may be decreased when air flow is decreased (due to muscular weakness) or when the transmission of sound is poor (due to pleural effusion or pneumothorax). Additionally, the chest wall should be visually inspected to rule out any chest injuries. Conditions such as flail chest or massive hemothorax, as well as tension or open pneumothorax, can compromise ventilation and oxygenation and need immediate attention.

Every trauma patient should receive supplemental oxygen. Maintaining good oxygen saturation and preventing hypercarbia are key factors. A pulse oximeter is essential

in assessing adequate hemoglobin saturation. It is essential to put the pieces together, assessing visual inspection and data obtained from monitors, and integrating that information with the history of the event. This is illustrated by the potential for a false initial assessment for a patient who may have both normalappearing skin tone and oxygen saturation secondary to carbon monoxide exposure. Capnography could be helpful in monitoring the concentration or partial pressure of carbon dioxide (CO_2). It is usually presented as a graph of expiratory CO_2 plotted against time. The capnogram is a direct monitor of the inhaled and exhaled concentration or partial pressure of CO_2 and is actually an indirect monitor of the CO_2 partial pressure in the arterial blood.

Vital signs are an important part of the assessment. Hypotension is usually indicative of hypovolemia. In fact, hemorrhage is the most common cause of shock after injury. Almost all trauma patients have an element of hypovolemia, which is indicative of hemorrhagic shock. Cardiogenic shock due to myocardial dysfunction can occur in trauma patients, especially if they sustain blunt cardiac injury, cardiac tamponade, or myocardial infarction.[5] Skin color could be an important tool in assessing perfusion and oxygenation. Checking capillary refill is a useful tool. This is the rate at which blood refills empty capillaries. Capillary refill is prolonged if it is over 1.5 to 2 seconds. Prolonged capillary refill suggests diminished localized blood flow or dehydration.

History

As appropriate, each trauma patient should have a complete history and medical examination. In many acute trauma patients, history cannot be obtained from the patient. Prehospital personnel and family members may be helpful in providing some of this relevant information. The AMPLE history is a quick mnemonic to use in evaluating the trauma patient:

A: Allergies
M: Medications (currently used)
P: Pregnancy/Past illnesses
L: Last meal
E: Events/Environment related to the injury

Knowing about the past medical history (such as medical problems, medications, and allergies) is a key factor in successfully treating the trauma patient. A patient who is on a beta blocker can have a "normal" heart rate even in hypovolemic shock. Additionally, patients on anticoagulants are prone to severe bleeding and hemorrhage. With many elderly patients on anticoagulants, a neurologic hemorrhage must be ruled out in this patient population. Physiologic changes in the gravid patient present several potential challenges. There is the potential for airway compromise associated with an increased risk of aspiration, decreased functional residual volume, and increased difficulty in intubating the airway. There are hemodynamic changes that impact fluid management, as well as the pharmacokinetics and pharmacodynamics of anesthetic and emergency agents. Many anesthetic and emergency drugs can cross the placenta and have an adverse effect on the fetus.

The mechanism of injury can provide the trauma surgeon with pertinent information about the type of injuries sustained. Blunt injuries usually result from motor vehicle accidents (MVAs), falls, and occupation-related injuries. Important prehospital information to obtain from MVA patients includes seat belt usage, direction and type of impact, steering wheel deformation, and automobile damage. The mechanism of injury can usually predict the injury patterns. For example, rear impact in an MVA will probably result in cervical spine injury and/or soft tissue injury to the neck. Penetrating injuries are usually caused by stabbings and firearms. The extent of injury depends on the region of the body affected, the path of the penetrating object, and the organs in proximity to the injury, as well as the velocity of the missile.

Physical Examination

Airway patency can affect the ability to ventilate and intubate the patient. Part of a detailed trauma examination is to recognize the problem and manage it appropriately. Airway compromise may be partial or complete. Signs such as stridor, dyspnea, tachypnea, and dysphagia may be indicative of airway obstruction. Tachypnea, additionally, could be an early sign of airway or ventilatory compromise. The patient with an altered level of consciousness is at high risk of airway compromise and will require a secure airway.

1. Soft tissue: A detailed soft tissue examination must be performed. Significant tissue avulsions or injuries may result in an ability to secure a mask and provide ventilatory support.
2. Hemorrhage: Hemorrhage can lead to airway irritation, aspiration, and laryngospasm. Pressure packing may be needed to control the bleeding. If the bleeding does not stop, surgical exploration or interventional radiology might be indicated (especially in neck trauma). Hemorrhage can result in an expanding hematoma that can compromise airway integrity. Securing an airway either via intubation or tracheotomy may be required.
3. Skeleton
   (a) Mandibular fractures are common in trauma patients. Bilateral mandibular fractures can lead to a flail mandible. This can lead to an upper airway obstruction due to posterior movement of the tongue. Lying supine can further aggravate the obstruction. Airway adjuncts (e.g., nasopharyngeal airway) may assist in supporting and maintaining airway patency.
   (b) Trauma to the midface can result in injuries to the nasopharynx and oropharynx. These fractures could be associated with hemorrhage, dislodged teeth, or unstable segments (maxilla or midface), any of which could lead to airway compromise. Posterior and downward displacement of a Le Fort fracture can result in an open bite and difficulty with mask ventilation. Displacement of a Le Fort II/III fracture can result in obstruction of the nasopharynx.

(c) Nasal fractures can lead to posterior bleeding and aspiration and thus to nasopharyngeal obstruction. Nasal intubation is relatively contraindicated in midface fractures because of the risk of the endotracheal tube entering either the cranium or the orbit. A hematoma in the oropharynx or nasopharynx can lead to partial or complete airway obstruction. A nasal septal hematoma can lead to nasopharyngeal obstruction. An urgent surgical airway may be needed if endotracheal intubation is not possible.

4. Laryngeal trauma: Hoarseness can be associated with laryngeal trauma. Laryngeal trauma is associated with the triad of hoarseness, subcutaneous emphysema, and a palpable fracture. Patients with arytenoid injury are at higher risk of aspiration. Some of the symptoms of arytenoid injury include hoarseness, dysphagia, sore throat, dyspnea, vocal fatigue, loss of vocal control, and cough.[6] A flexible endoscopically guided intubation may be helpful in laryngeal trauma. Early diagnosis of tooth aspiration in the multi-trauma patient can be difficult because aspiration is rarely considered in the absence of an acute clinical presentation. Accounting for teeth is an important aspect of the maxillofacial exam.

Injuries Affecting the Airway: Cervical Spine Injury

Cervical spine injury must be presumed in any patient with maxillofacial or head trauma. The incidence of cervical injury in the presence of facial fractures has been reported to be 1% to 6%.[7-9] Cervical spine injuries tend to occur in patients between 15 and 45 years of age and are seen more commonly in males (7:3). The most common level of fracture is C2, whereas dislocations occur most commonly at the C5/6 and C6/7 levels.[10]

The exclusion of cervical spine injuries, or "clearance," requires the exclusion of both bony and ligamentous injuries. This usually calls for a combination of clinical assessment and radiologic investigation. Clinical clearance of cervical spine injury is difficult and unreliable in patients who are unconscious or have distracting injuries to other parts of the body.

Examination of the neck includes inspection, palpation, and auscultation. The standard three-view plain film series for a c-spine evaluation includes lateral, anteroposterior, and open-mouth view. The lateral cervical spine film must include the base of the occiput and the top of the first thoracic vertebra. The lateral view alone is inadequate and will miss up to 15% of cervical spine injuries. The lower cervical spine may be difficult to examine, and caudal traction on the arms should be used to improve visualization. If the lower cervical spine is not visualized, a computed tomography (CT) scan of the region is indicated.[11,12] Thin-cut (2-mm) axial CT scanning of specific bone windows, with sagittal and coronal reconstruction, should be used to evaluate abnormal, suspicious, or poorly visualized areas on plain radiology. With technically adequate studies and experienced interpretation, the combination of plain radiology and directed CT scanning provides a false-negative rate of less than 0.1%.[12] Magnetic resonance imaging (MRI) is the gold standard for clearing the cervical spine in a clinically suspicious or unresponsive trauma patient.[13] In most trauma centers, cervical fixation is usually maintained until the patient is awake and can respond to command.

The best method of immobilization is achieved with a combination of a rigid cervical collar, a cervical/head immobilizer, and a backboard.[14] Rigid cervical collars (by themselves) limit rotation and lateral movement only to 50% of normal and flexion and extension only to 30% of normal and do not provide adequate stabilization.

Respiratory complications are common with cervical spine injuries. The severity of respiratory failure depends on the level and severity of the injury. Complete dissection of the spinal cord above C3 will cause apnea and death, unless the patient receives immediate intubation and ventilatory support. For lesions between C3 and C5, the degree of respiratory failure is variable. The vital capacity can be reduced to 15% to 20% of normal. These patients are at risk of increasing diaphragmatic fatigue due to slowly progressive ascending injury resulting from cord swelling and edema. This usually leads to decompensation and retention of secretions on day 3 to 4 post injury. Intubation and ventilation is needed to prevent respiratory failure. Patients with high cervical spine lesions have increased bronchial secretions, possibly due to altered neuronal control of mucous glands. Injuries at C5 or below spare the phrenic nerve and diaphragmatic breathing. However, expiratory reserve may be impaired secondary to accessory muscle paresis.[15]

The decision to intubate depends on several factors, including:[16,17]

- Loss of innervation of the diaphragm (e.g., phrenic nerve injury)
- Fatigue of muscles of respiration
- Failure to clear secretions
- Failure to maintain a patent airway
- History of aspiration
- Presence of other injuries (e.g., head, maxillofacial, and/or chest injuries)
- Premorbid conditions, especially respiratory disease (chronic obstructive pulmonary disease) and/or obesity

Injuries Affecting the Airway: Cervical Airway Injury

Injuries to the cervical airway may result from blunt or penetrating trauma. The incidence is usually rare. Blunt trauma to the airway either from a direct blow to the cervical airway or from severe flexion/extension injuries may result in a thyroid or a cricoid cartilage fracture.[18]

Injuries Affecting the Airway: Thermal and Inhalation Injury

Thermal and/or inhalation injury to the airway must be suspected in any patient presenting with a history

of exposure to fire or smoke. Carbon monoxide (CO) toxicity is a major problem. CO does not cause direct injury to the lungs. Its toxic effect results from a displacement of oxygen from hemoglobin-binding sites, thereby decreasing the oxygen-carrying capacity of the blood. This causes a shift of the oxyhemoglobin dissociation curve to the left. This results in tissue hypoxia because the hemoglobin binds less oxygen for transport to the peripheral tissues and is less able to unload the oxygen to those tissues. CO reacts with myoglobin to further impair oxygen uptake by decreasing facilitated diffusion of oxygen into muscle. This leads to impaired tissue oxygen availability and delivery.[19,20] Cyanide causes tissue asphyxiation through the inhibition of intracellular cytochrome oxidase. It blocks the final step in oxidative phosphorylation and prevents mitochondrial oxygen use. The organs most affected to cellular hypoxia include the central nervous system and the heart.

Inhalation injury can occur with or without evidence of burns. Burns on the face and singed eyebrows and/or facial hair are indicative of smoke inhalation. Patients with respiratory injury present with many symptoms, including minor eye irritation, cough, dyspnea, hyperventilation, tachypnea, rales, wheezing, and facial burns. This can lead to acute respiratory failure. These symptoms usually present within 6 to 24 hours post injury.[19]

Pulse oximetry is an accurate technique to monitor oxygen saturation. However, it is falsely elevated by CO. One must not rely on pulse oximetry until the carboxyhemoglobin level has reached the reference range.

Additionally, arterial oxygen tension (partial pressure arterial oxygen [PaO_2]) does not accurately reflect the degree of CO poisoning or cellular hypoxia. The PaO_2 level reflects the oxygen dissolved in blood that is not altered by the hemoglobin-bound CO. Because dissolved oxygen makes up only a small fraction of arterial oxygen content, a PaO_2 level within the reference range may lead to serious underestimation of the decrement in tissue oxygen delivery and the degree of hypoxia at the cellular level that occurs when CO blocks the delivery of oxygen to the tissues. However, arterial blood gas (ABG) measurements are still useful.

Cyanide levels correlate closely with the level of exposure and toxicity. However, these levels may not be readily available. Many hospitals send out these tests, and results may take several days to a week. Persistent neurologic dysfunction unresponsive to use of supplemental oxygen, cardiac dysfunction, and severe lactic acidosis are usually indicative of cyanide intoxication. In a setting consistent with potential cyanide exposure, empiric therapy should be started.[19,20]

Both direct laryngoscopy and fiberoptic bronchoscopy are both diagnostic and therapeutic. Visualization of erythema, edema, ulceration, and soot deposition make bronchoscopy useful in evaluating the extent of injury to the tracheobronchial tree. Additionally, fiberoptic bronchoscopy can facilitate endotracheal tube placement.[21]

Anesthetic Strategies

The goal of triage is to classify patients into various categories, identifying the urgency of treatment. Traumatized patients are divided into two major categories:

- **Those patients who require airway control as part of the resuscitation.** These patients are usually apneic or have total or near-total airway obstruction. They are identified during the primary survey and will require establishment of a patent airway. Initially, the mouth must be inspected for the presence of any foreign material. Then administration of positive pressure ventilation by mask with 100% oxygen is performed. If ventilation is unsuccessful, placement of an oropharyngeal or nasopharyngeal airway may be used to facilitate mask ventilation. The surgeon must be aware of the potential complications of these airways. The oropharyngeal airway can induce gagging and coughing. This may lead to increased intracranial or intraocular pressure and/or vomiting. The nasopharyngeal airway can lead to epistaxis, and care must be used when using it in a patient with a base-of-skull fracture. If the patient cannot be effectively ventilated, laryngoscopy and intubation must be attempted. A LMA (laryngeal mask airway) or a Combitube (double-lumen airway) may be considered in these cases.
- **Those patients who require semi-elective airway control at some time during hospitalization for surgical management of the maxillofacial injury.** These patients usually require elective intubation or, in selected situations, a tracheostomy. Intubation or a surgical airway in this situation provides a patent airway, protects against aspiration of secretions, allows positive pressure ventilation, decreases anatomic dead space, and provides a potential emergency route for drug administration.

Basic Principles of Management

Prophylaxis Against Aspiration

Trauma patients are always considered to have full stomach. This is due to multiple reasons including:

- Ingestion of food or liquids before injury
- Swallowed blood from oral or nasal injury
- Delayed gastric emptying
- Administration of liquid contrast medium

Various actions are considered to prevent aspiration:

- Administer nonparticulate antacid prior to induction
- Cricoid pressure/Sellick maneuver applied continuously during airway management
- Rapid-sequence induction (RSI)
- Avoidance of ventilation between administration of medication and intubation
- Awake intubation with or without topical or anesthetic blocks to the upper airway

Induction of General Anesthesia

There is no ideal anesthetic drug for trauma patients with hemorrhagic shock. The key to safe anesthetic management

of these patients is to administer small incremental doses of whichever agents are selected. Titration of the general anesthetic is a key factor in preventing complications. Many agents are in our armamentarium for anesthetic planning. Some of the induction agents are propofol, etomidate, ketamine, and dexmedetomidine.

Propofol is an ideal general anesthetic agent used in induction. It has a rapid onset of action as well as fast recovery from its sedative-hypnotic effects. Propofol has antiemetic effects that may be beneficial, especially for a patient who may have maxillomandibular fixation. However, propofol has some unwanted side effects in trauma patients. It may potentiate profound hypotension due to its direct myocardial depression and decrease in systemic vascular resistance. These effects can be potentiated in the elderly or cardiac patient[22] and can be exacerbated in the hypovolemic trauma patient.

Etomidate is widely used in the trauma population because of its cardiovascular stability relative to other induction agents. In fact, etomidate provides advantages for induction of anesthesia in the setting of hemorrhagic shock. In a pig model of hemorrhagic shock, its pharmacodynamics and pharmacokinetics are minimally altered in contrast to other anesthetic drugs. However, etomidate may still produce profound hypotension due to its inhibition of catecholamine release. Additionally, it can cause adrenocortical suppression. Adrenal suppression was found to last 6 to 8 hours in patients following a single induction dose of etomidate, and more than 24 hours following etomidate infusion. However, the impact of single-dose etomidate on outcomes in critically ill patients remains unclear.[23,24]

Ketamine can be used for induction in trauma patients. It is most suitable in children who are hemodynamically unstable or hypovolemic.[25] Similar to propofol, ketamine is also helpful in asthmatic patients because of its bronchodilating properties. It can result in myocardial depression. In normal patients, the effects of catecholamine release usually will mask cardiac depression and result in tachycardia and hypertension. In patients with severe hemorrhagic shock, the cardiac depression may be unmasked. This will lead to cardiovascular collapse.[26,27]

Dexmedetomidine is an agonist of α_2-adrenergic receptors in certain parts of the brain. It is indicated for sedation of critically ill or trauma patients in an intensive care unit setting. Dexmedetomidine may also be used to provide sedation for an awake intubation. Clinically it provides sedation and analgesia. It does so with minimal respiratory compromise. Dexmedetomidine is administered via a slow bolus supplemented with a continuous infusion. It is not administered with incremental boluses because of concerns about peripheral α_2-receptor stimulation, with resulting hypotension and bradycardia. Intravenous infusion is commonly initiated with a 1 mcg/kg loading dose, administered over 10 minutes, followed by a maintenance infusion of 0.2 to 1.0 mcg/kg/hour.[28]

Succinylcholine remains the neuromuscular blocker with the fastest onset (30 seconds) and shortest duration of action. Therefore, it is the agent of choice for RSI. It is especially indicated in trauma patients presenting for an emergency procedure with a potentially full stomach or who have recently eaten.

However, succinylcholine may be contraindicated in selected trauma patients:

- Burn patients: Succinylcholine must be used cautiously in burn victims (after the first 24 hours) because of increased serum potassium. The rise in serum potassium that normally follows succinylcholine administration is markedly exaggerated in burned victims. The levels can reach as high as 13 mEq/L, resulting in ventricular tachycardia, fibrillation, and cardiac arrest.[29,30]
- Crush injury: Succinylcholine must be used cautiously in patients with crush injury. The injury to the muscular tissue secondary to the crush injury results in hyperkalemia, which can be compounded with the administration of succinylcholine.
- Ocular injury: Succinylcholine must be used cautiously in patients with intraocular trauma or ocular injury. It leads to increased intraocular pressure (IOP). The increased IOP occurs within 1 minute after injection, peaks at 2 to 4 minutes, and subsides by 6 minutes.[31]
- Intracranial injury: Succinylcholine results in increased intracranial pressure (ICP). In trauma patients with head injury, succinylcholine must be used cautiously. The risk must be weighed in each individual situation.

Rocuronium can be also used safely during RSI (1 mg/kg), with an onset of relaxation of 60 seconds. Unfortunately, at this dose the duration of action will be 1 to 2 hours.[32] Sugammadex is an agent for reversing the neuromuscular blockade caused by a nondepolarizing agent such as rocuronium. Its main advantage is reversal of neuromuscular blockade without relying on the inhibition of acetylcholinesterase. Its administration is therefore associated with much greater cardiovascular and autonomic stability than the traditional reversal agents. This agent is not yet available on the U.S. market.

Maintenance of anesthesia can be achieved with a combination of inhalation as well as intravenous agents.

Advanced Airway Techniques

The maxillofacial surgeon must be aware of the different available modalities to secure the airway. These include:

1. Two-handed mask ventilation: Bag-mask ventilation is the cornerstone of basic airway management. When a second person is available to provide ventilations by compressing the bag, a two-hand technique can be used. The surgeon creates opposing semicircles with the thumb and index finger of each hand to form a ring around the mask connector and hold the mask on the patient's face. Then, the mandible can be lifted with the remaining digits.[33]
2. Combitube: A Combitube, also known as a double-lumen airway, is a blind insertion airway device (BIAD) used in the prehospital and emergency setting. It is ideal to provide an airway for the trauma patient in respiratory

distress. The simplicity of placement is a major advantage over endotracheal intubation. However, this technique has some serious but rare complications, including aspiration, esophageal perforation, and facial nerve dysfunction.[34]

3. LMA: The laryngeal mask airway (LMA) is an easy way to ventilate a trauma patient (Figure 2-1). It is a supraglottic airway device and is a good alternative to bag-valve-mask ventilation (freeing the hands of the provider with the benefit of less gastric distention).[35] The LMA is actually placed into the back of the mouth following the curve of the tongue (Figure 2-2). The rate of complications is rare (0.15%). These complications include[36,37] aspiration of gastric contents, local irritation, pressure-induced lesions, facial nerve palsies, mild sympathetic response, obstruction, and laryngospasm.
4. The laryngoscope is a useful technique to visualize the vocal cords and the glottis (Figure 2-3).
5. Videolaryngoscope: The failure of direct laryngoscopy to provide an adequate view for tracheal intubation led to the development of videolaryngoscopy. The first camera screen laryngoscope was developed by Berall in 1998. Currently, there are several manufacturers of video laryngoscopes. These include the Glidescope, McGrath laryngoscope, Daiken Medical Coopdech C-scope vlp-100, and the Berci DCI laryngoscopes. These laryngoscopes employ a variety of features, such as a monitor on the handle and/or channels, to assist in guiding the endotracheal tube into the trachea. The superior performance of video laryngoscopy in airway management where cervical spine injury is suspected has raised the question of whether these scopes should replace direct laryngoscopy in routine airway management in the trauma patient.[38]
6. Retrograde intubation is another alternative to secure an airway in the trauma patient. Under local anesthesia, a cannula is inserted through the cricothyroid membrane into the trachea, and a guide wire is then passed through the needle upward through the vocal cords into the oral cavity. The wire is then used to guide an ET tube through the vocal cords.[39]



• **Figure 2-1** Laryngeal mask airway. (From Nemeth J, Maghraby N, Kazim S: Emergency airway management: the difficult airway, *Emerg Med Clin North Am* 30(2):401-420, 2012.)

Surgical Airways

Emergency airway management in the trauma patient often involves a combination of factors that increase the technical difficulty of intubation and increase patient risk. These factors include:

- Dynamically deteriorating clinical situation in the unstable patient
- Respiratory and ventilatory compromise
- Impaired ventilation and oxygenation
- Full stomach (increased risk of regurgitation, vomiting, aspiration)
- Increased secretions, blood, vomitus, and potential for foreign body
- Distorted anatomy

If intubation is not possible, a surgical airway is advised.

Emergency Cricothyrotomy

Emergency cricothyrotomy is one of the last-resort and potentially lifesaving procedures for maxillofacial trauma patients who cannot be intubated or ventilated.[40]

Traditionally, a surgical airway has been established by making an incision through the skin and the cricothyroid

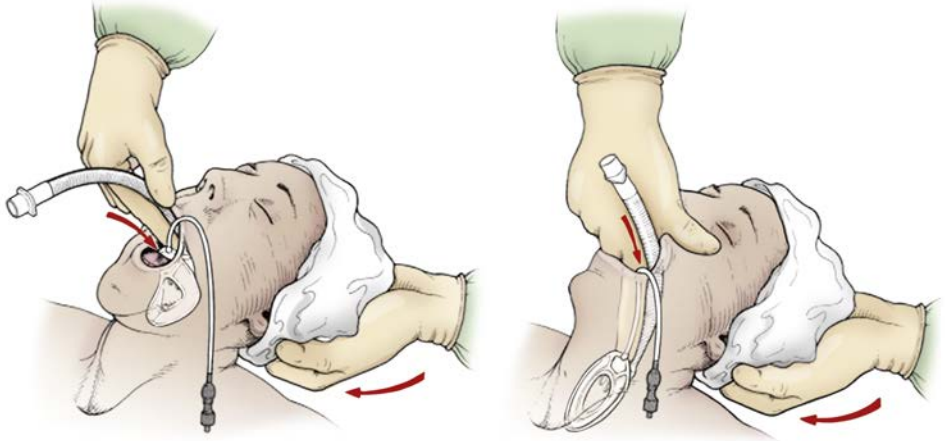

• **Figure 2-2** Proper placement of the laryngeal mask airway.

membrane into the tracheal lumen, through which an endotracheal tube is inserted.[41] This method potentially has some serious complications. Several investigators have modified this technique.[42] In recent years, a number of commercial kits that include all of the necessary equipment to establish a surgical airway have reached the market. The surgeon must be familiar with the kit used at his or her trauma center.

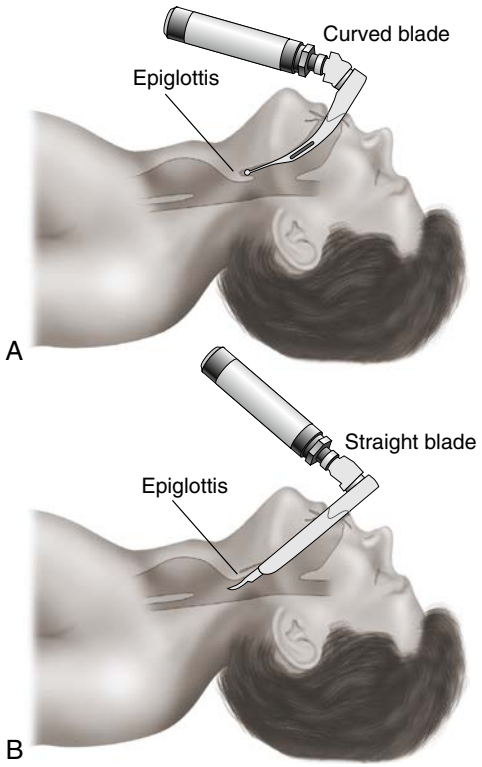

• **Figure 2-3** Proper position of the tip of the curved **(A)** and straight **(B)** blades. (From Fonseca RJ: *Oral and maxillofacial trauma*, ed 3, Philadelphia, 2005, Elsevier.)

An experienced surgeon with exact knowledge of the anatomy and technique must perform this procedure.

The basic steps to perform a cricothyrotomy include (Figure 2-4):

1. Hyperextend the neck.
2. Identify the groove between the cricoid and thyroid cartilages as well as the cricothyroid membrane.
3. Prep the area (with Betadine) and infiltrate with local anesthetic.
4. Incise through the skin vertically with a 1.5-cm cut. Then use blunt dissection ensuring that you can see the cricothyroid membrane.
5. With a No. 22 or No. 23 scalpel blade, stab through the membrane into the trachea.
6. Rotate the blade 90 degrees, then insert a curved artery forceps alongside the blade. Remove the blade and open the forceps side-to-side. This widens the space between the thyroid and cricoid cartilages.
7. Pass a thin introducer or a nasogastric tube into the trachea (if the access is very small).
8. Run a 4-6 endotracheal tube over the introducer and pass it into the trachea.
9. Remove the introducer, if used.

The tube can stay in place for up to 3 days.

In surgical cricothyrotomy, a scalpel is used to make a horizontal incision over the lower half of the cricothyroid membrane. The only absolute contraindication to surgical cricothyrotomy is age, although the exact age at which a surgical cricothyrotomy can be safely performed is controversial and has not been well defined. Various sources list lower age limits ranging from 5 to 12 years old.[43,44] Our recommendation is to use 12 years as the cutoff age. In patients below this cutoff age, needle cricothyrotomy is indicated because infants and children younger than 12 years usually have a smaller cricothyroid membrane as well as a more funnel-shaped, rostral, and compliant larynx.[45]

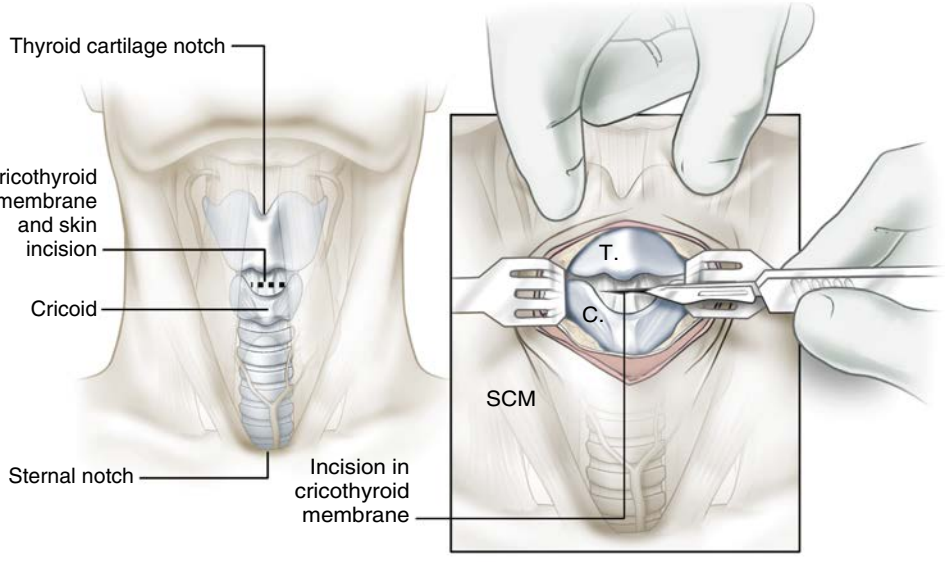

• **Figure 2-4** Cricothyroidotomy. (From Cummings C: *Otolaryngology*, ed 4, St Louis, 2005, Mosby.)

References

1. Aprahamian C, Thompson BM, Finger WA, et al.: Experimental cervical spine injury model: evaluation of airway management and splinting techniques, *Ann Emerg Med* 13(8):584–587, 1984.
2. Kunisaki SA, McCabe CJ: Initial evaluation and resuscitation: primary survey and immediate resuscitation. In Sheridan RL, editor: *The trauma handbook of the Massachusetts General Hospital*, Philadelphia, PA, 2004, Lippincott Williams & Wilkins, pp 71–88.
3. Hoyert DL, Heron MP, Murphy SL, Kung HC: Deaths: final data for 2003, *Natl Vital Stat Rep* 54(13):1–120, 2006.
4. Bonnie RJ, Fulco CE, Liverman CT: Magnitude and costs. In Bonnie RJ, Fulco CE, Liverman CT, editors: *Reducing the burden of injury, advancing prevention, and treatment*, Washington, DC, 1999, National Academy Press, pp 41–59.
5. American College of Surgeons Committee on Trauma: *Advanced trauma life support for doctors: Student course manual*, ed 8, Chicago, 2008, American College of Surgeons.
6. Stack Jr BC, Ridley MB: Arytenoid subluxation from blunt laryngeal trauma, *Am J Otolaryngol* 15(1):68–73, 1994.
7. Bayless P, Ray VG: Incidence of cervical spine injuries in association with blunt head trauma, *Am J Emerg Med* 7:139, 1989.
8. Beirne JC, Butler PE, Brady FA: Cervical spine injuries in patients with facial fractures: a 1 year prospective study, *Int J Oral Maxillofacial Surg* 24:26, 1995.
9. Davidson JSD, Birdsell DC: Cervical spine injury in patients with facial skeletal trauma, *J Trauma* 29:1276, 1989.
10. Ford P, Nolan J: Cervical spine injury and airway management, *Curr Opin Anaesthesiol* 15:193–201, 2002.
11. Clark CR, Igram CM, el-Khoury GY, et al.: Radiographic evaluation of cervical spine injuries, *Spine* 13:742–747, 1988.
12. Acheson MB, Livingston RR, Richardson ML, et al.: High-resolution CT scanning in the evaluation of cervical spine fracture: comparison with plain film examinations, *AJR Am J Roentgenol* 148:1179–1185, 1987.
13. Muchow RD, Resnick DK, Abdel MP, et al.: Magnetic resonance imaging (MRI) in the clearance of the cervical spine in blunt trauma: a meta-analysis, *J Trauma* 64(1):179–189, 2008.
14. Hastings RH, Marks JD: Airway management for trauma patients with potential cervical spine injuries, *Anesth Analg* 73:471, 1991.
15. Urdaneta F, Layon AJ: Respiratory complications in patients with traumatic cervical spine injuries: case report and review of the literature, *J Clin Anesth* 15(5):398–405, 2003.
16. Ball PA: Critical care of spinal injury, *Spine* 26:S27–S30, 2001.
17. Hambly PR, Martin B: Anaesthesia for chronic spinal cord lesions, *Anaesthesia* 53:273–289, 1998.
18. Mathison DJ, Grillo H: Laryngotracheal trauma, *Ann Thorac Surg* 43:254, 1987.
19. Rorison DG, McPherson SJ: Acute toxic inhalations, *Emerg Med Clin North Am* 10(2):409–435, 1992.
20. Weiss SM, Lakshminarayan S: Acute inhalation injury, *Clin Chest Med* 15(1):103–116, 1994.
21. Carr JA, Phillips BD, Bowling WM: The utility of bronchoscopy after inhalation injury complicated by pneumonia in burn patients: results from the National Burn Repository, *J Burn Care Res* 30(6):967–974, 2009.
22. Dundee JW, Robinson FP, McCollum JS, et al.: Sensitivity to propofol in the elderly, *Anaesthesia* 41:482, 1986.
23. Forman SA: Clinical and molecular pharmacology of etomidate, *Anesthesiology* 114(3):695–707, 2011.
24. Fragen RJ, Shanks CA, Molteni A, Avram MJ: Effects of etomidate on hormonal responses to surgical stress, *Anesthesiology* 61:652–656, 1984.
25. Waxman K, Shoemaker WC, Lipmann M: Cardiovascular effects of anesthetic induction with ketamine, *Anesth Analg* 59:355, 1980.
26. Dutton RP, McCunn M, Grissom TE: Anesthesia for trauma. In Miller RD, editor: *Miller's anesthesia*, ed 7, New York, 2009, Churchill Livingstone.
27. Grande CM, Stene JK, Bernhard WN: Airway management: considerations in the trauma patient, *Crit Care Clin* 6(1):37–59, 1990.
28. Dosing Guidelines for Precedex: http://www.precedex.com/wp-content/uploads/2010/02/Dosing_Guide.pdf.
29. Martyn J, Goldhill DR, Goudsouzian NG: Clinical pharmacology of muscle relaxants in patients with burns, *J Clin Pharmacol* 26(8):680–685, 1986.
30. Groner GA, Theye RA: Pathophysiology of hyperkalemia induced by succinylcholine, *Anesthesiology* 43:89–99, 1975.
31. Pandey K, Badola RP, Kumar S: Time course of intraocular hypertension produced by suxamethonium, *Br J Anaesth* 44:191–196, 1972.
32. Dutton RP: Trauma anesthesia. ASA refresher courses in anesthesiology, *American Society of Anesthiologists [homepage on the Internet]*, 2008. Available from http://journals.lww.com/asa-refresher/pages/results.
33. Komatsu R, Kasuya Y, Yogo H, et al.: Learning curves for bag-and-mask ventilation and orotracheal intubation: an application of the cumulative sum method, *Anesthesiology* 112:1525, 2010.
34. Vézina MC, Nicole PC, Trépanier CA, et al.: Retrospective study of complications associated with the Combitube, *Can J Anesth* 52(1), 2005. Supplement, pA12.
35. Miller RD: *Miller's anesthesia, ed 6*, Philadelphia, 2005, Elsevier Churchill Livingstone, pp 1625–1628.
36. Verghese C, Brimacombe JR: Survey of laryngeal mask airway usage in 11,910 patients: safety and efficacy for conventional and nonconventional usage, *Anesth Analg* 82(1):129–133, 1996.
37. Jeon YS, Choi JW, Jung HS, et al.: Effect of continuous cuff pressure regulator in general anaesthesia with laryngeal mask airway, *J Int Med Res* 39(5):1900–1907, 2011.
38. Agrò F, Barzoi G, Montecchia F: Tracheal intubation using a Macintosh laryngoscope or a GlideScope in 15 patients with cervical spine immobilization, *Br J Anaesth* 90(5):705–706, 2003.
39. Gupta B, McDonald JS, Brooks JH, et al.: Oral fiberoptic intubation over a retrograde guidewire, *Anesth Analg* 68:517–519, 1989.
40. Henderson JJ, Popat MT, Latto IP, et al.: Difficult Airway Society guidelines for management of the unanticipated difficult intubation, *Anaesthesia* 59(7):675–694, 2004.
41. American College of Surgeons, Committee on Trauma: Cricothyroidotomy, *Adv Trauma Life Support 58-61*, 2012.
42. Holmes JF, Panacek EA, Sakles JC, Brofeldt BT: Comparison of 2 cricothyrotomy techniques: standard method versus rapid 4-step technique, *Ann Emerg Med* 32(4):442–446, 1998.
43. Strange GR, Niederman LG: Surgical cricothyrotomy. In Henretig FM, King C, editors: *Textbook of pediatric emergency procedures*, Baltimore, 2008, Lippincott Williams & Wilkins, pp 331-338.
44. Brown CA, Walls RN: Airway. In Marx JA, Hockberger RS, Walls RM, editors: *Rosen's emergency medicine: concepts and clinical practice*, ed 8, vol 1, Philadelphia, 2014, Elsevier, pp 3-22.
45. Hebert RB, Bose S, Mace SE: Cricothyrotomy and percutaneous translaryngeal ventilation. In Roberts JR, editor: *Clinical procedures in emergency medicine*, ed 6, Philadelphia, 2014, Elsevier, pp 120-133.

3

Imaging in Maxillofacial Trauma

SRINIVAS SUSARLA, ZACHARY S. PEACOCK

Introduction

Imaging is a critical component of the diagnostic evaluation of a patient with craniomaxillofacial injuries. Although the history and physical examination remain the cornerstones of the initial assessment, two- and three-dimensional imaging techniques are adjuncts for diagnosis, treatment planning, follow-up evaluation, and outcome assessment.[1-11]

The interpretation of radiographic images from the traumatized face can be challenging, even for experienced practitioners. The face and cranium contain numerous critical structures, all confined into a relatively small volume. The superimposition of complex tissue layers over irregularly shaped osseous anatomy complicates the interpretation of plain radiographs. In this regard, the advent of computed tomography (CT) has significantly improved our ability to accurately diagnose, classify, and plan treatment for complex craniomaxillofacial injuries. For most patients with upper facial or midfacial injuries, multi-detector CT scanning (MDCT) is the standard for evaluation.[1,2,12-19] MDCT allows for visualization of the craniofacial skeleton in several planes (coronal, axial, sagittal), three-dimensional reformations, rapid image acquisition with limited requirements for patient positioning, and, more recently, advanced virtual treatment planning. Patients with a clinical examination concerning for mandibular or dental injury without concomitant midfacial or upper facial injury may, in certain circumstances, be adequately imaged by plain film techniques alone.[20-22]

In this chapter, we describe the detailed anatomy of the facial skeleton and predictable patterns of injury based on skeletal support structures, and offer a précis on radiographic identification of regional and complex injury patterns. Although management of specific facial fractures is discussed in detail elsewhere, indications for operative management are often based on a combination of clinical and radiographic findings. As such, this chapter briefly touches on common clinical findings and their correlation to radiographic findings, as well as implications for management.

Image Acquisition

Proper diagnosis of fractures of the maxillofacial skeleton requires high-resolution images, ideally formatted in the axial, sagittal, and coronal planes.[1-6] Over the past 15 years, there has been an increased emphasis on the use of three-dimensional reformations for diagnosis and management.[13-18] Standard parameters for scanning should include a narrow slice thickness (e.g., 0.625 mm on a 64-slice scanner), with the field of view extending from the vertex of the skull to the hyoid bone.[1,2] Axial reformations should be performed in both bone and soft tissue windows, with a maximum thickness of 1.25 mm. Coronal and sagittal reformations allow for further elucidation of displacement, angulation, and rotation and should be performed universally. The 0.625-mm source images are necessary for producing high-resolution three-dimensional reformations.[1-4]

In patients with isolated mandibular fractures without clinical suspicion for midfacial or upper facial injuries, two plain film views (e.g., panoramic radiograph with anterior-posterior radiograph) can be adequate. There are classically described plain film imaging techniques for specific mandibular fractures that can be used in the appropriate clinical context (see section on Mandibular Fractures for details).

Image Interpretation

Akin to clinical evaluation of the patient with facial injury, radiographic interpretation can be daunting, particularly for complex injuries. The clinician should take a systematic approach to interpreting the images and proceed in the same fashion with each patient. It is imperative that the clinician recognize that even "simple" injuries may have contre-coup components (e.g., mandibular body and contralateral body/subcondylar fractures). Similarly, one should

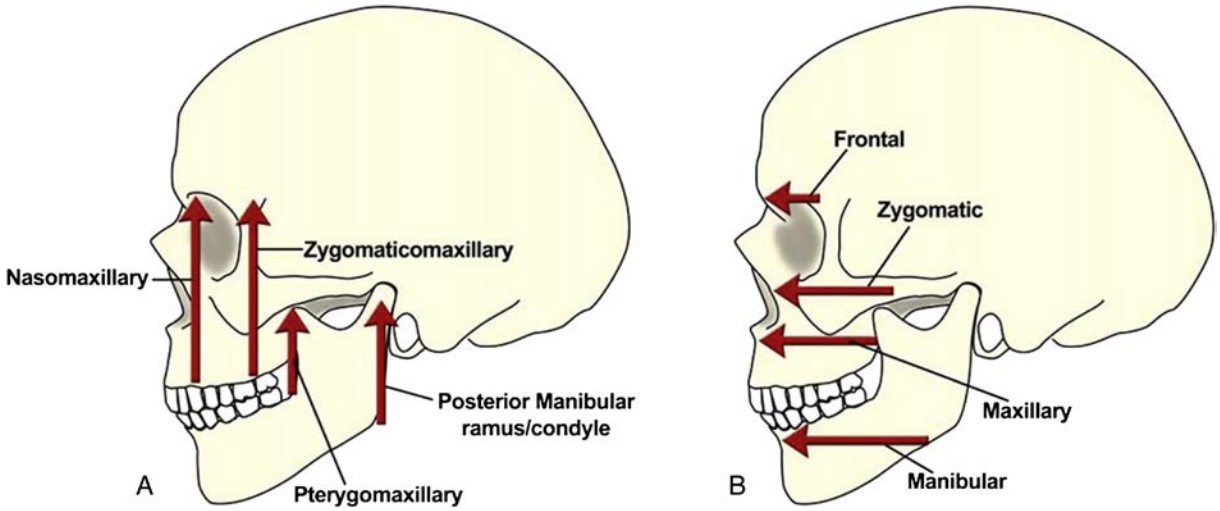

• **Figure 3-1** **A**, Vertical buttresses of the facial skeleton include the nasomaxillary, zygomaticomaxillary, pterygomaxillary, and condyle-ramus unit of the mandible. **B**, The frontal bone, zygomatic arch and body, maxilla and mandible make up the horizontal buttresses. (From Fonseca RJ, Barber HD, Powers MP, Frist DE, editors: *Oral and maxillofacial trauma*, ed 4, Philadelphia, 2013, Saunders.)

not be overwhelmed by a seemingly complex injury. A systematic evaluation ensures that no area is overlooked and that a full correlation between the physical findings and imaging occurs, regardless of the mechanism of injury or state of illness of the patient.

One proposed approach for interpreting such images is a "top to bottom" approach. For the purpose of image interpretation, the craniofacial skeleton can be organized into five distinct regions: (1) orbital, (2) nasal, (3) zygomatic, (4) maxillary, and (5) mandibular.[1,23,24] Maxillofacial injuries commonly involve several regions and several contiguous structures within regions. The facial skeleton is composed of several horizontal and vertical buttresses, which act to distribute force away from vital structures, leading to predictable patterns of injury. The horizontal buttresses of the face are the frontal, zygomatic, maxillary, and mandibular buttresses. These areas transmit anterior-posterior forces. The vertical buttresses of the face include the nasomaxillary, zygomaticomaxillary, pterygomaxillary, and mandibular ramus/condyle. Each region of the facial skeleton is supported by a combination of horizontal and vertical buttresses (Figure 3-1).

The orbital region includes the conical bony orbit and its contents (extraconal soft tissues, globe, extraocular muscles, nerves, vessels). The bony orbit proper is composed of seven constituent bones: the frontal, zygomatic, ethmoid, palatine, lacrimal, maxillary, and sphenoid (Figure 3-2). The external orbital skeleton (i.e., orbital rim) is primarily formed from the frontal bone, zygomatic bone, and maxilla. All seven bones contribute to the structure of the internal orbital skeleton, including the orbital roof, floor, and medial and lateral orbital walls. The orbit is horizontally supported by the frontal and zygomatic buttresses, as well as the supra- and infra orbital rims. It is supported vertically by the nasomaxillary and zygomaticomaxillary buttresses. This strong external framework of the external orbit prevents significant displacement of the osseous structures and affords significant protection to the globe and brain. Conversely, significant displacement of the orbital skeleton (e.g., displaced Le Fort III fracture) suggests a high-energy injury and should merit consideration for concomitant intracranial or cervical spine injury.

The nasal region is formed by the paired nasal bones, lacrimal bones, maxilla (frontal processes), nasal septum, and ethmoid sinuses. Horizontal support comes from the zygomatic buttress and the infraorbital rim. Vertical support comes from the nasomaxillary buttress and medial orbital wall.

The midface is primarily composed of the zygomatic and maxillary regions. The zygomatic region serves to connect the temporal, maxillary, and sphenoid bones and has a significant role in midfacial projection. Fractures of the zygoma will disrupt one or more of these connections. The zygomatic region is supported horizontally by the zygomatic arch, infraorbital rim, and zygomatic body. Vertical support is from the frontozygomatic pillar, lateral orbital rim, and zygomaticomaxillary buttress.

The maxillary region includes the maxilla proper, the maxillary alveolus (including the upper dental arch), and the hard palate (palatine process of the maxilla and the palatine bones). This region is supported horizontally by the maxillary buttress and vertically by the nasomaxillary, zygomaticomaxillary, and pterygomaxillary buttresses. Various patterns of Le Fort injuries will disrupt these buttresses.

The mandibular region is composed of the mandible proper and the mandibular alveolus. The mandible proper includes the temporomandibular joint and the cortical mandible. The mandibular alveolus includes the lower dental arch. The mandible is the only mobile portion of the facial skeleton, articulates with the skull base via the bilateral temporomandibular joints, and has no rigid connection

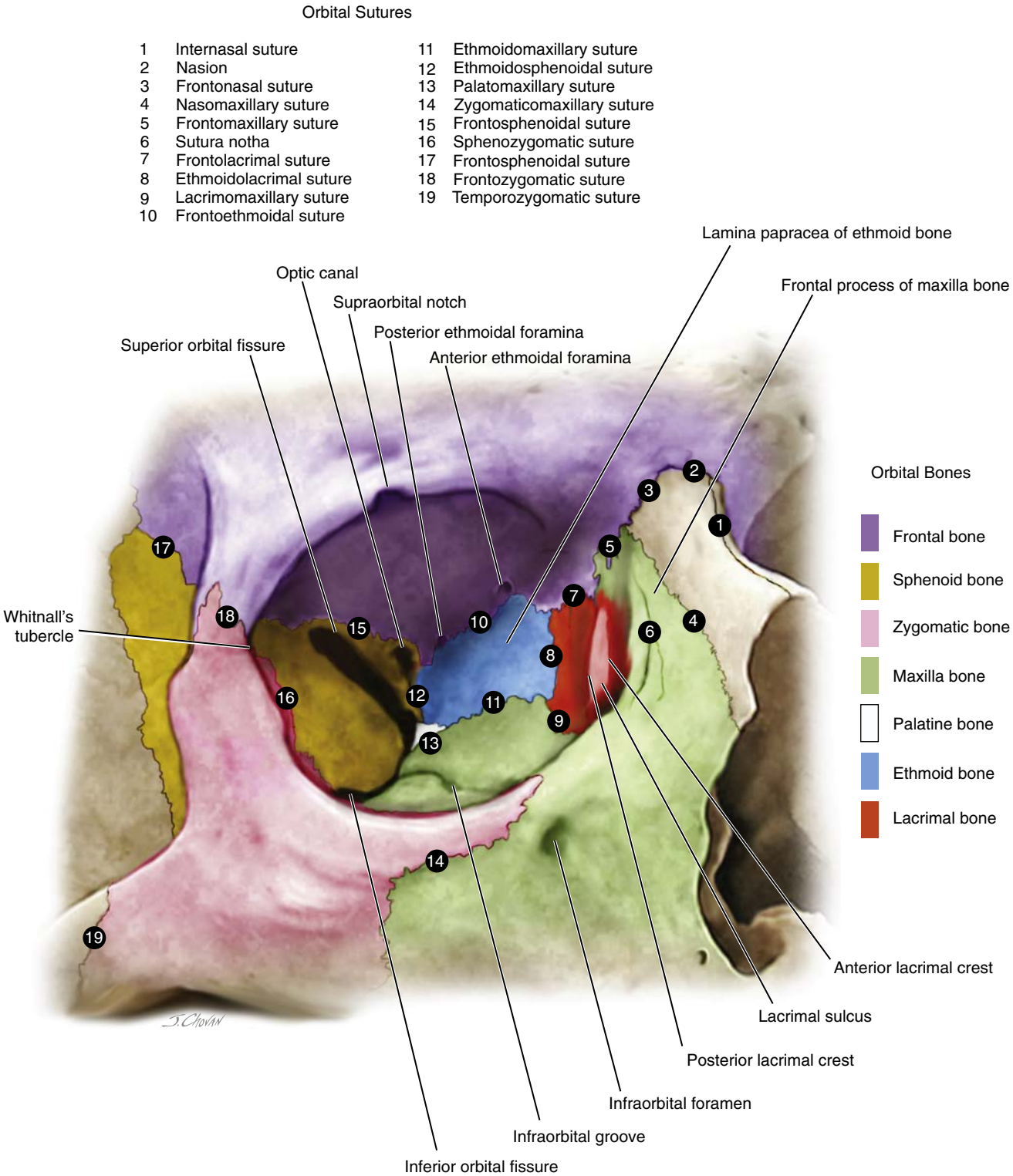

• **Figure 3-2** Seven bones make up the orbit and periorbital region. The orbital rims are part of the strong vertical and horizontal buttresses and include the frontal bone, zygoma, and maxilla. The internal orbit is composed of thin bones prone to fracture. Fractures that go through the orbital walls include orbital blow-out fractures, Le Fort II and III, and naso-orbitoethmoid fractures. (From Kademani D, Tiwana P, editors: *Atlas of oral and maxillofacial surgery*, ed 1, Philadelphia, 2015, Saunders.)

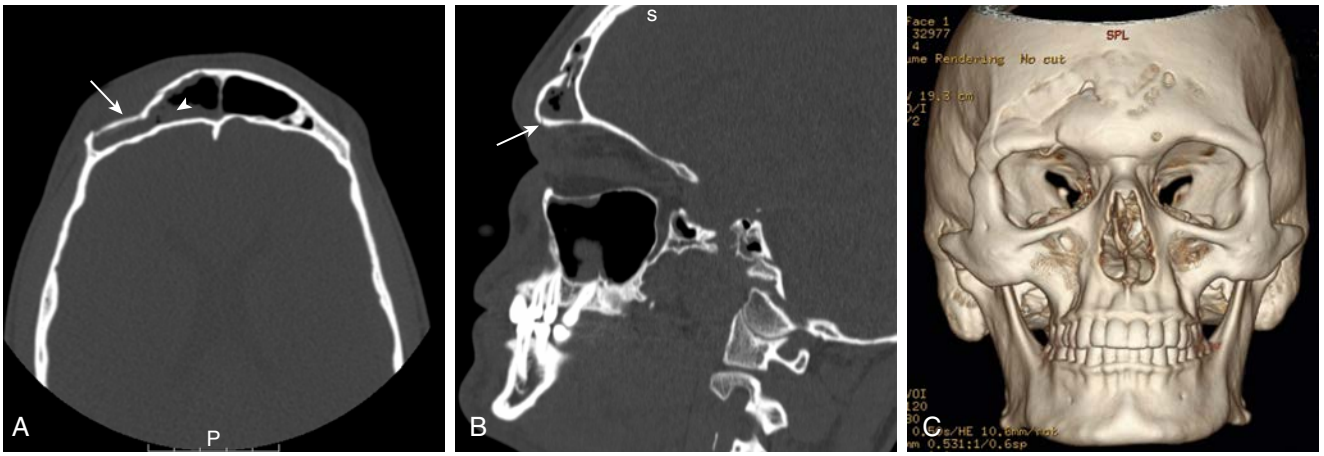

• **Figure 3-3** Frontal sinus fracture affecting anterior table only. **A**, Axial image shows depression of the anterior table (*arrow*) on the right side with fluid within the sinus (*arrowhead*). The posterior table is intact. **B**, Sagittal image demonstrates comminution of the anterior table extending to the superior orbital rim (*arrow*). **C**, Three-dimensional reformat shows the depression of the anterior table and extension to the orbital rim.

to the remainder of the craniofacial skeleton. The mandible is a self-contained unit, which has significant implications for injury patterns and management. The mandible is supported by the ramus/condyle unit vertically and the mandibular buttress horizontally.

A systematic approach to reading the maxillofacial CT is to start at the most superior portion of the scan and scroll through the axial slices from superior to inferior on the axial cuts.[1-5] For inexperienced clinicians, it is often helpful to have a pen and paper handy to document the fractures visualized on a particular view. Next, the clinician should scroll through the sagittal (lateral to medial) and coronal (anterior to posterior) views, again documenting the visualized fractures. With experience, one will be able to transpose fractures identified in one plane into the other two, assembling a three-dimensional construct of the injured skeleton. Finally, once the fracture inventory is assessed, the clinician should summarize the findings in terms of patterns of fractures rather than isolated elements of fractured bones. Descriptions in the latter format are cumbersome and unlikely to be helpful for clinical decision making.

Facial Fracture Patterns

The presence of anatomic buttresses within the facial skeleton not only is useful for segmentalizing the anatomy, but also can serve as a guide for predicting patterns of facial injury, based on the direction of force and magnitude of impact. The need for careful clinical evaluation and meticulous physical examination cannot be overemphasized. Seemingly small soft tissue injuries can often mask significant skeletal injury, due to the dispersal of forces along the facial buttresses. Similarly, massive soft tissue injuries often have significant underlying skeletal injuries that follow predictable patterns to disperse the force of injury away from the brain and spine.

Because facial fractures can and often do involve several contiguous bones or several regions of the facial skeleton, there is little utility in describing fractures on the basis of the bones involved (e.g., fracture of the anterior and posterior walls of the maxillary sinus, zygomatic arch, frontzygomatic suture, and orbital floor). Instead, the clinician should be familiar with patterns of injury and the bones involved (e.g., zygomaticomaxillary complex fracture). Familiarity with the typical pattern and location of facial fractures makes each evaluation more efficient and clinically useful.

Frontal Bone Fractures

Although the frontal bone is not typically considered a primary bone of the facial skeleton, it is often involved in patients sustaining high-energy head injuries and is managed by the specialist treating maxillofacial injuries (Figures 3-3 and 3-4).[25-28] The frontal bone forms the prominence of the forehead and contains the frontal sinus. The frontal sinus divides the frontal bone into an anterior portion (anterior table) and posterior portion (posterior table). The anterior table lies immediately adjacent to the soft tissue of the forehead, and an anterior table injury should be suspected in patients with forehead lacerations. Isolated injuries of the anterior table without deformity, however, are not generally serious and often can be managed non-operatively. On axial views, an air-fluid level within the frontal sinus is suggestive of a frontal sinus injury. Higher energy mechanisms often result in fractures of both the anterior and posterior tables, which are more serious because of potential involvement of the central nervous system. The communication between a nonsterile cavity (frontal sinus) and the intracranial space defines these injuries as compound fractures, requiring, at minimum, antibiotic

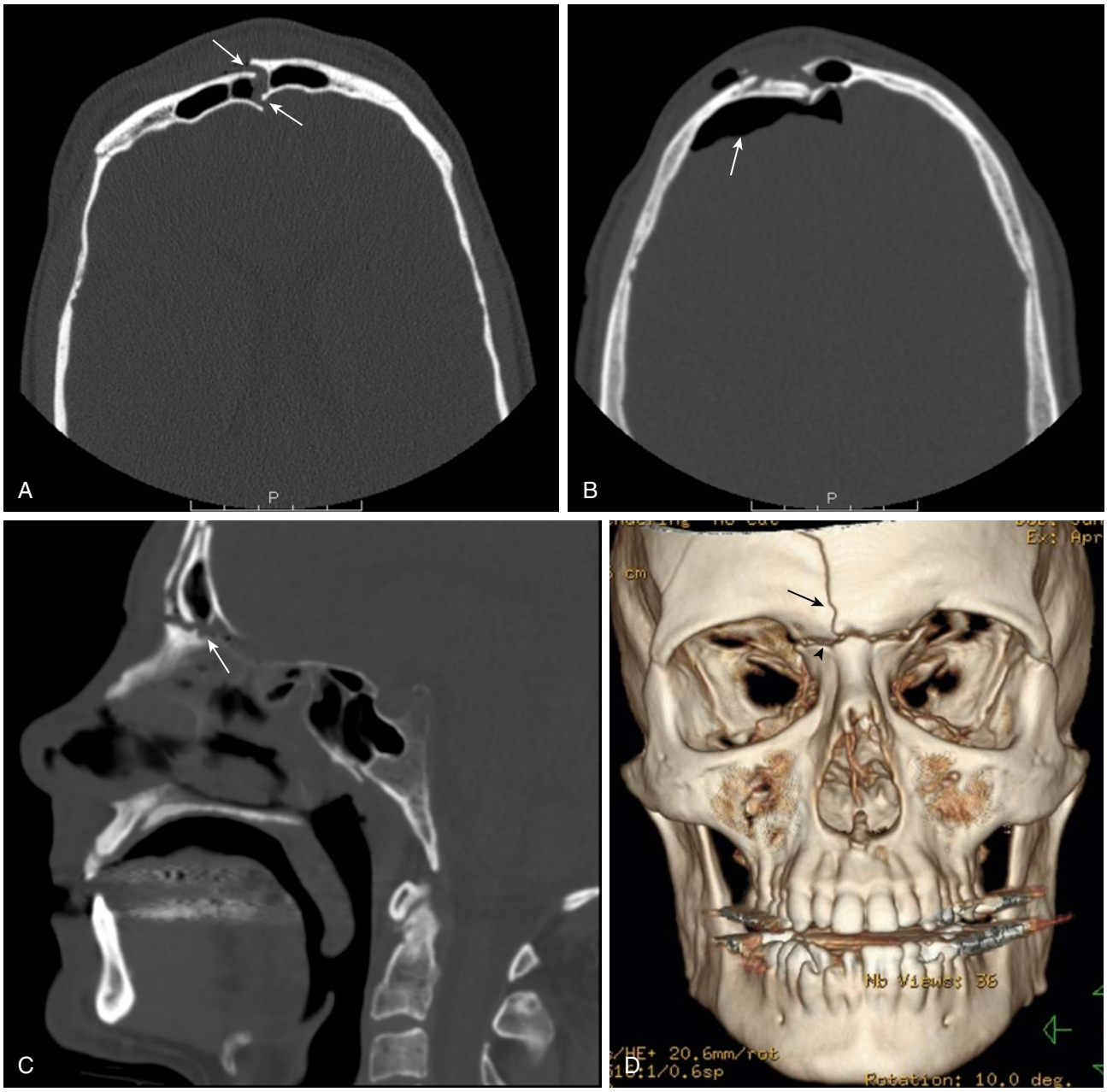

• **Figure 3-4** Frontal sinus fracture affecting both anterior and posterior tables. **A**, Axial image shows displacement of anterior and posterior tables (*arrows*) and **B**, pneumocephalus (*arrow*) behind a fractured posterior table. **C**, Sagittal image shows fracture through the anterior and posterior table at the start of the nasofrontal duct. **D**, Three-dimensional image showing displacement of the right frontal bone posteriorly (*arrow*) and the disruption at the inferior aspect of the frontal sinus and nasofrontal suture (*arrowhead*).

TABLE 3-1 Variations of Frontal Sinus Fractures and Clinical Significance

Type	Significance
Isolated anterior table	Displacement > width of anterior table requires open reduction
Posterior table fracture	Considered a compound skull fracture and may result in CSF leak. Antibiotic treatment typically required
Naso-frontal duct involvement	Requires operative intervention to obliterate sinus

treatment. In non-displaced fractures of the frontal sinus, pneumocephalus is a key finding indicative of posterior table involvement. Cerebrospinal fluid rhinorrhea suggests dural disruption, which may occur if the fracture extends along the floor of the anterior cranial fossa, through the cribriform plate. Limitation of extraocular movement, visual acuity changes, or forehead and upper eyelid ecchymosis are physical findings associated with frontal bone fractures involving the orbital roof.

An adequate description of a frontal sinus fracture should include the status of the anterior and posterior tables, as well as the patency of the nasofrontal duct (Table 3-1).[28] Isolated anterior table fractures often require open reduction if there is an aesthetic deformity or if the displacement is greater than the width of the anterior table. Fractures with posterior table involvement generally require neurosurgical consultation. Displaced posterior table fractures require open treatment, which may include cranialization of the frontal sinus. If the nasofrontal duct is obstructed/non-patent, the sinus should be obliterated.

Orbital Fractures

As mentioned previously, the orbit is composed of seven bones of varying size and shape and is rigidly connected to the frontal bone, cranial base, and midface. As such, fractures of the orbital skeleton may occur either in combination with other facial fractures (e.g., frontal sinus, zygomatic, nasal) or in isolation (e.g., orbital floor). Orbital fractures should be suspected in patients who sustain injuries to the forehead, zygoma, maxilla, or nose. Commonly used terminology for internal orbital fractures includes "blow-in" and "blow-out" injuries.

Blow-in fractures are those in which the orbital roof is displaced inferiorly into the orbit, usually from a direct blow to the supraorbital rim or via transmitted forces from a blow to the forehead. Such injuries may propagate posteriorly within the orbit, resulting in involvement of the orbital apex. Several critical cranial nerves (CN II, III, IV, V_1, and VI) travel through the orbital apex, and an orbital apex injury can manifest clinically as visual acuity changes, ophthalmoplegia, or corneal anesthesia.[29] Alternatively, edema or hematoma within the internal orbit can increase the intraorbital pressure, compromising the intraorbital neurovascular structures. Orbital roof injuries may also involve the anterior cranial fossa, and pneumocephalus may be seen on imaging.[29]

Blow-out fractures are those in which the orbital floor and/or medial wall are fractured and displaced into the surrounding air-filled spaces (i.e., the maxillary and ethmoid sinuses/nasal cavity) (Figure 3-5).[30-32] CT imaging in the axial, sagittal, and coronal planes is essential for accurate diagnosis, as axial cuts may miss orbital floor fractures and sagittal cuts may miss medial wall fractures. The appearance of the orbits should be symmetric, rounded, and smooth, with interruption in the cortex only at the bony articulations. By definition, the infraorbital rim is intact in a blow-out fracture. Theoretically, the force of the injury is transmitted to the internal orbit directly or indirectly via an increase in intraorbital volume, resulting in fracture of the thin medial wall or orbital floor. The contents of the orbit can herniate into the associated air-filled spaces.

Clinical indications for repair of orbital wall fractures are entrapment or enophthalmos. Herniation of extraocular muscle tissue (i.e., inferior or medial rectus muscles) may result in entrapment and limited extraocular movement (Figure 3-6). This occurs most commonly with small, narrow fractures, where the muscle can become impinged within the fracture.[1,2-31] An abrupt kink in the muscle is sometimes seen with such entrapment. Sagittal reformations are particularly helpful for visualizing entrapment of the inferior rectus in the orbital floor, and coronal reformations are useful for medial rectus entrapment in the medial wall. Larger fractures of the floor and medial wall generally do not result in entrapment but have a higher risk of subsequent enophthalmos.

Zygomatic Fractures

Direct blows to the prominence of the cheek or lateral midface can result in injury to the zygoma and its articulations.[33-35] Disruption of the articulations between the zygoma and the temporal, maxillary, and sphenoid bones are generally more common than intra-zygomatic fractures due to the density of the zygomatic body, although high-energy injury injures can lead to comminution of the zygoma (Figures 3-7 and 3-8). These injuries are commonly known as "zygoma," "zygomatic complex," or "zygomaticomaxillary complex" (ZMC) fractures. Diagnosis of ZMC fractures relies on accurate identification of the frontozygomatic, sphenozygomatic, zygomaticomaxillary, and temporozygomatic sutures. Diastasis at any of these articulations should raise suspicion for a ZMC fracture. Coronal and sagittal views afford evaluation of the orbital floor, which is often disrupted at the articulation of the zygoma with the maxilla and sphenoid.

Lateral blows to the face may result in isolated zygomatic arch fractures (Figure 3-9) that may result in a depression of the area anterior to the glenoid fossa. These can be seen on plain films such as the submentovertex or Waters' views, but are best seen on CT scan.

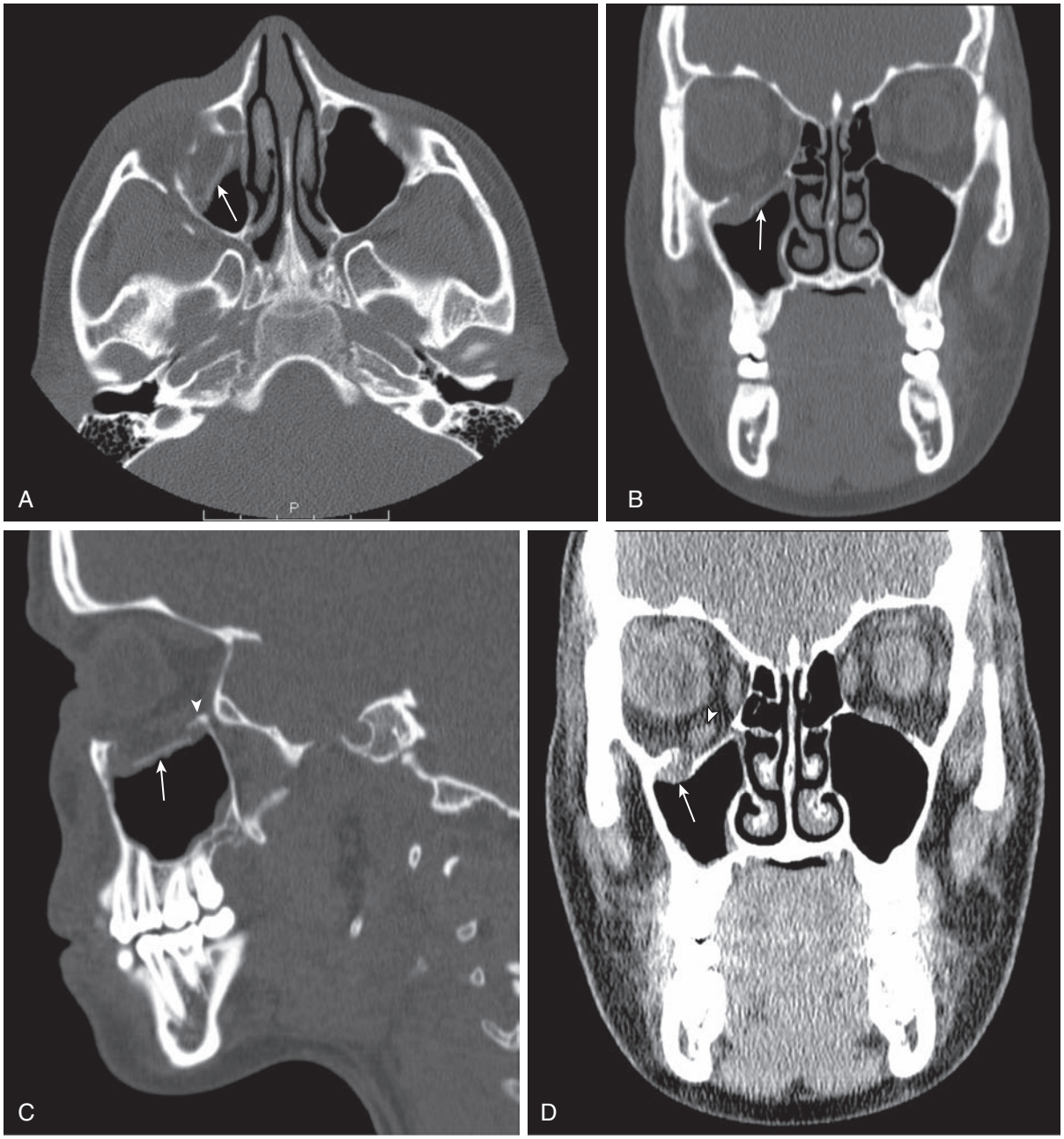

• **Figure 3-5** Orbital blow-out fracture. **A**, Axial views can often be unrevealing, but in this image a fragment of orbital floor is displaced into the sinus (*arrow*) along with orbital tissue. **B**, Coronal image shows downward displacement of the thin orbital floor (*arrow*). **C**, Sagittal image shows inferior displacement of the orbital floor into the maxillary sinus (*arrow*). A posterior shelf has been maintained (*arrowhead*). **D**, Coronal image with soft tissue window shows the displacement of orbital fat (*arrow*), but the inferior rectus remains in the orbit (*arrowhead*).

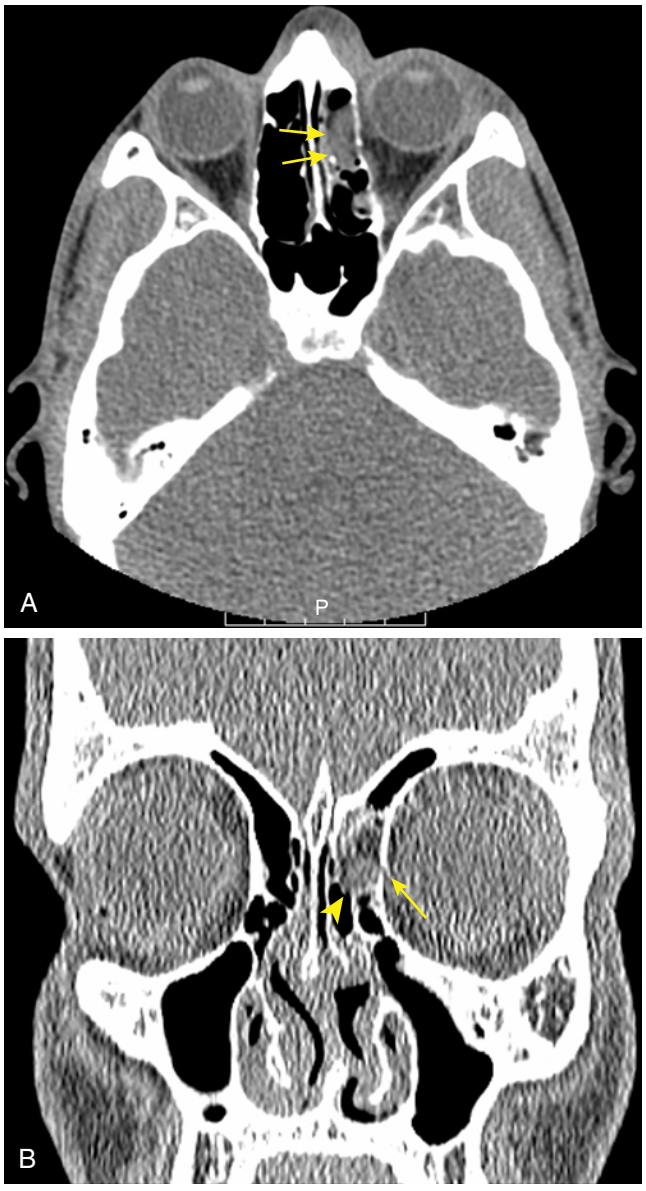

• **Figure 3-6** Fracture of the medial orbital wall with medial rectus entrapment. No lateral movement was possible with forced duction. **A**, Axial image (soft tissue window) shows entrapment of the medial rectus (*arrows*) through a minimally displace medial wall fracture (trapdoor). **B**, Coronal image (soft tissue window) shows a crack in the medial wall (*arrow*) with the entire medial rectus in the ethmoid sinus (*arrowhead*).

Clinical signs and symptoms of ZMC fractures include loss of cheek prominence, paresthesia in the infraorbital region, trismus with zygomatic arch involvement, and ocular findings if there is significant orbital floor involvement. Aesthetic deformities with displacement, trismus, extraocular muscle entrapment, visual acuity changes, or persistent infraorbital paresthesia secondary to impingement are indications for operative management.

ZMC fractures have long been classified according to the system of Knight and North (Table 3-2).[35] These surgeons used plain film images to classify ZMC fractures according to the vector of displacement and bony integrity of the zygoma proper. The system hierarchy was based on the stability following closed reduction, with type I fractures (non-displaced) being the most stable, types II and + V generally stable following reduction without fixation, and type III, IV, and VI fractures being the least stable and requiring some form of fixation. It is currently accepted that all displaced ZMC fractures require some form of reduction with or without fixation. More recent classification systems, based on CT imaging, have been useful in establishing the necessity for surgical treatment (see Table 3-2).[33]

Nasal/Naso-orbito-ethmoid Fractures

Fractures of the nasal region can be broadly classified into those that are isolated to the nasal bones proper and those that involve the naso-orbito-ethmoid (NOE) complex. Isolated nasal fractures are relatively common, because of the prominence of the nasal dorsum and its relatively weak bony support (Figure 3-10).[36-38] Patients presenting with isolated nasal fractures will often complain of perinasal swelling and tenderness. Signs include deformity over the nasal dorsum, epistaxis, nasal instability, or crepitus. For low-energy injuries, these features may be transient and there may be a delay in presentation; their absence does not exclude the possibility of nasal injury. As a corollary, old fractures of the nasal bones may appear similar to acute fractures on imaging. The absence of a recent history of trauma or signs of injury (edema, pain, crepitus, etc.) is inconsistent with an acute injury.

The majority of isolated nasal fractures occur as a result of force vectors directed from the lateral aspect.[48] Subsequently, displacement of the nasal bones typically occurs inferiorly and laterally, sometimes with displacement of the nasal septum or fracture of the frontal processes of the maxilla. Disruption of the anterior cartilaginous septum may be associated with fractures of the anterior nasal spine. A stratified classification scheme for nasal fractures has been proposed by Rohrich and Adams and may assist the clinician with management (Table 3-3).[37]

High-energy forces transmitted to the nasal region may result in NOE complex fractures (Figure 3-11). The NOE complex represents the bony union of the nasal and orbital regions and includes the nasal and ethmoid bones as well as the infraorbital rims and orbital floors. The history is typically consistent with a high-velocity or high-energy injury; concomitant intracranial or cervical spine injury should be exonerated. Although the typical clinical presentation is an amalgam of findings that can be seen with either nasal or orbital fractures, there are some specific clinical findings for NOE fractures. Telecanthus, an increase in the distance between the medial canthi, is mechanistically related to NOE fractures in that the medial canthal tendon is a critical anatomical component of the zone of injury. Injury to the medial canthal tendon may also manifest as a positive "bowstring" sign or "traction test." Other signs may include bilateral periorbital ecchymoses ("raccoon eyes," present with associated skull base fracture), epiphora (present with associated nasolacrimal system injury), or cerebrospinal fluid (CSF) rhinorrhea (nasofrontal duct injury).

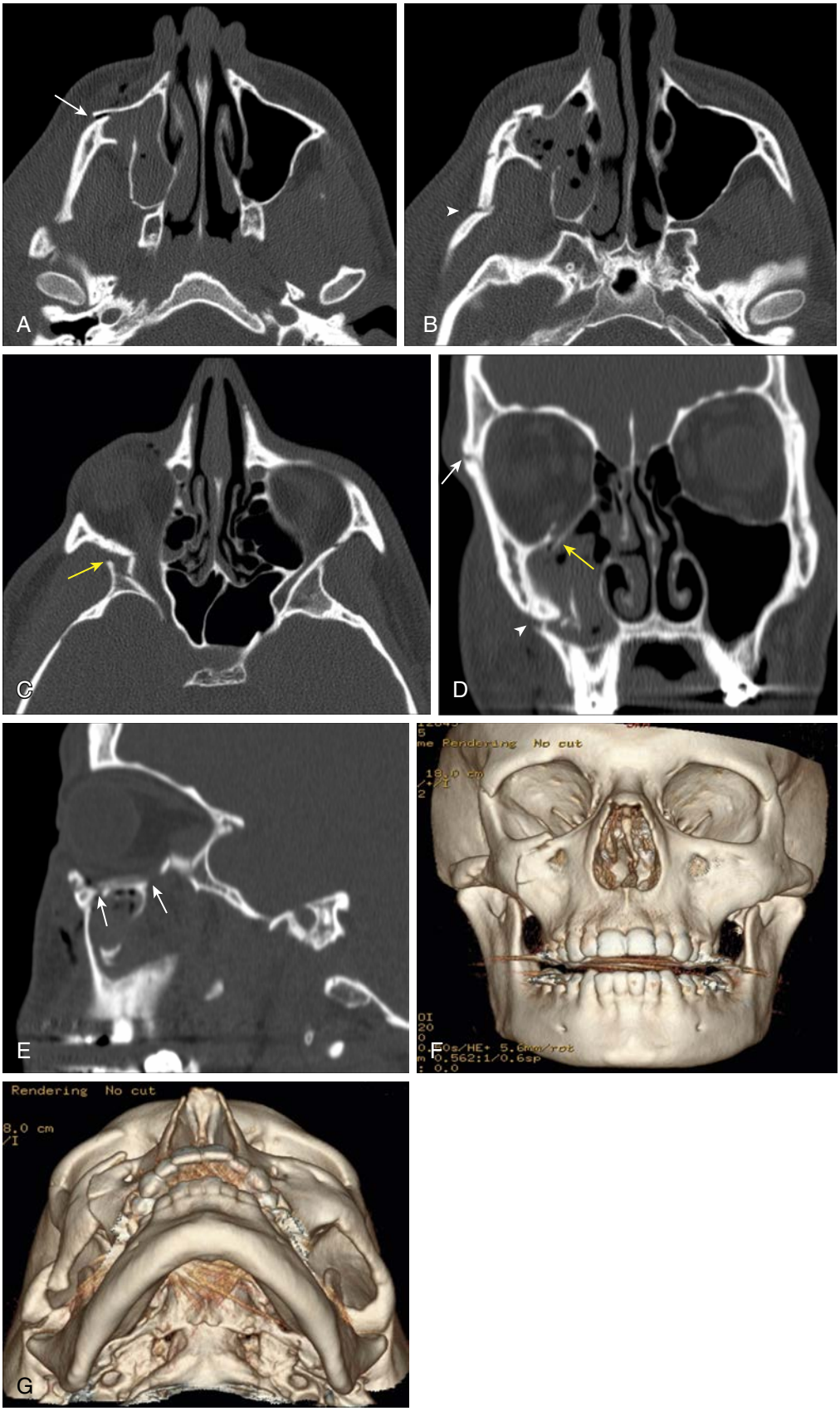

• **Figure 3-7** Zygomaticomaxillary complex fracture, Type B; Knight and North type IV. **A**-**C**, Axial images show fractures through the articulations of the zygoma: zygomaticomaxillary (*arrow*), zygomaticotemporal (*arrowheads*), and zygomaticosphenoid (*yellow arrow*). **D**, Coronal image shows a minimally displaced fracture through the zygomaticofrontal suture (*arrow*), zygomaticomaxillary buttress (*arrowhead*), and orbital floor (*yellow arrow*). **E**, Sagittal image shows the disruption of the orbital floor at the junction of the zygoma to the maxilla and sphenoid (*arrows*). **F-G**, Three-dimensional reformats highlight the medial rotation of the right zygoma and disruption at all four articulations.

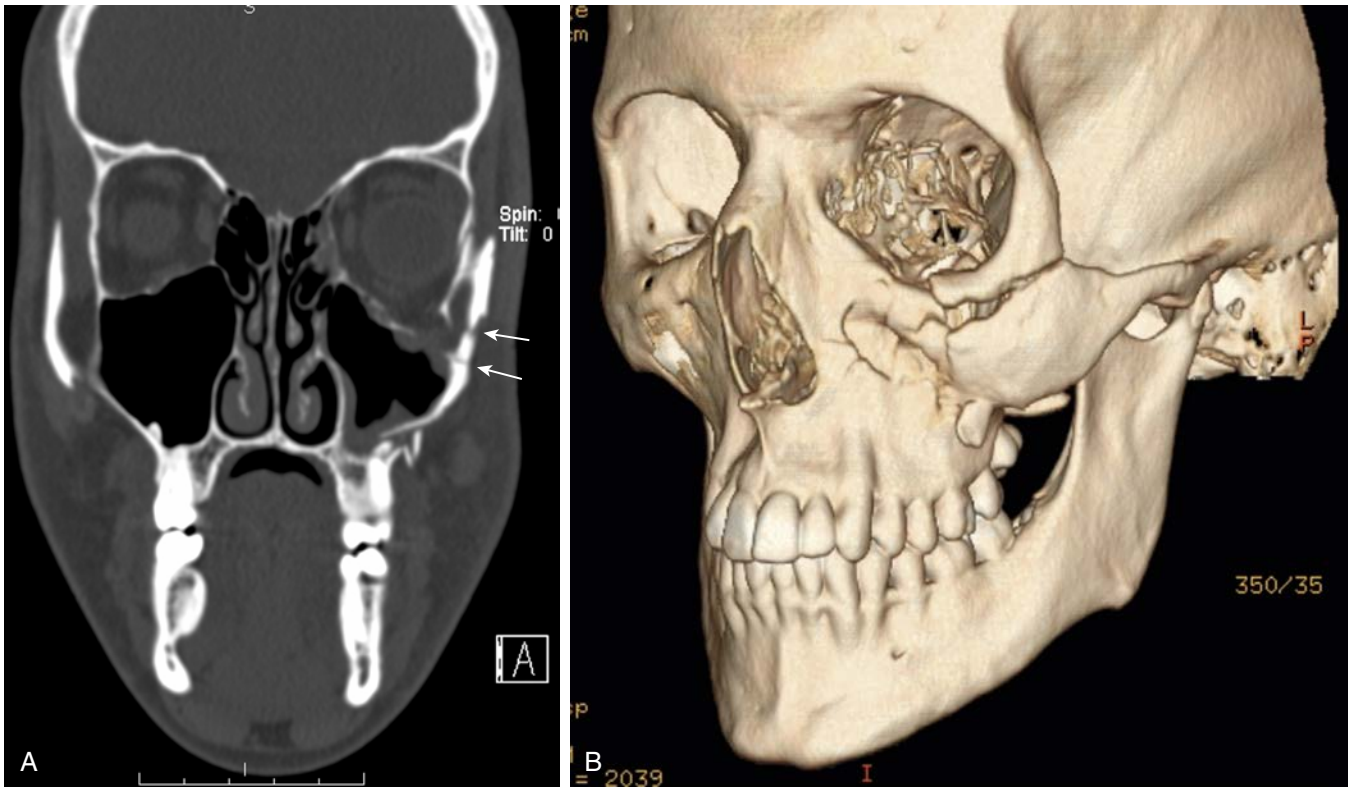

• **Figure 3-8** Comminuted zygomaticomaxillary complex fracture Type C; Knight and North type VI. **A**, Coronal image shows fractures within the body of the zygoma (*arrows*). **B**, Three-dimensional left three-quarter view shows the disruption of the zygomatic body and its articulation with the maxilla.

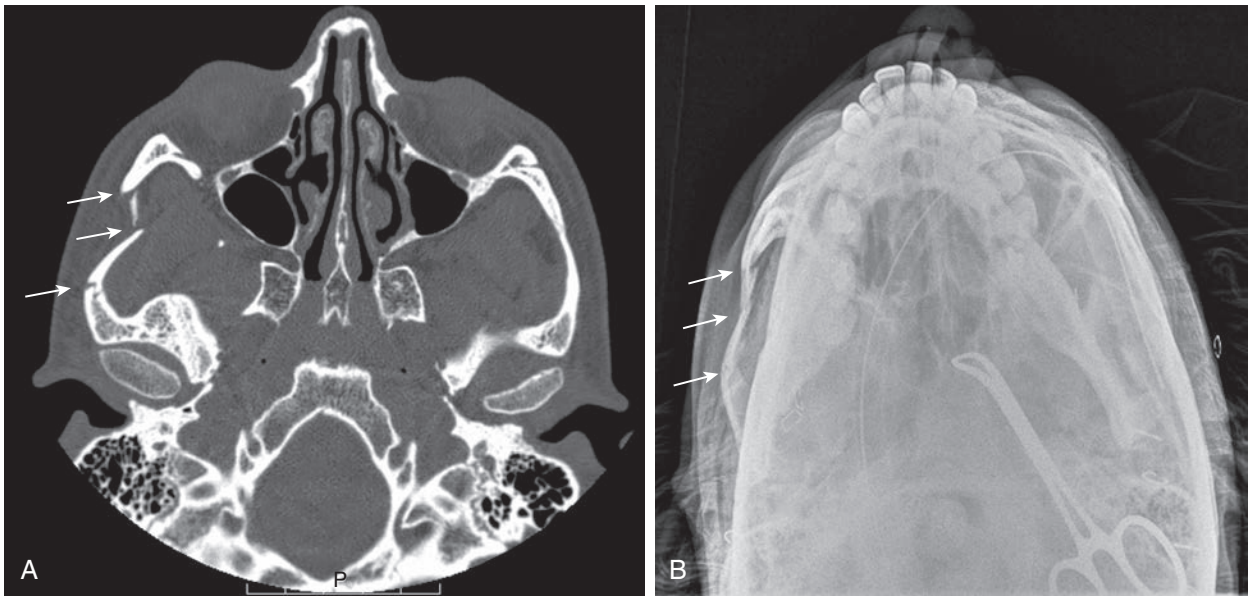

• **Figure 3-9** Zygomatic arch fracture. **A**, Axial image showing the classic three-fracture pattern (*arrows*) forming the letter M. **B**, Submentovertex plain film can also diagnose or determine adequacy of reduction after closed treatment. *Arrows* mark the fracture sites.

TABLE 3-2 Classification of Zygoma Complex Fractures

Type	Characteristics
A	Fracture limited to one zygomatic pillar: zygomatic arch, lateral orbital rim, or infraorbital rim
B	Fracture of all four zygomatic articulations with displacement
C	Multi-fragment fractures including comminution of the zygoma body

Knight and North Classification

Type	Description	Preferred Treatment
I	Non-displaced	Observation
II	Isolated arch	Observation or closed reduction
III	Depressed, non-rotated	Open reduction ± fixation
IV	Medially rotated	Open reduction ± fixation
V	Laterally rotated	Open reduction ± fixation
VI	Complex, comminuted	Open reduction + fixation

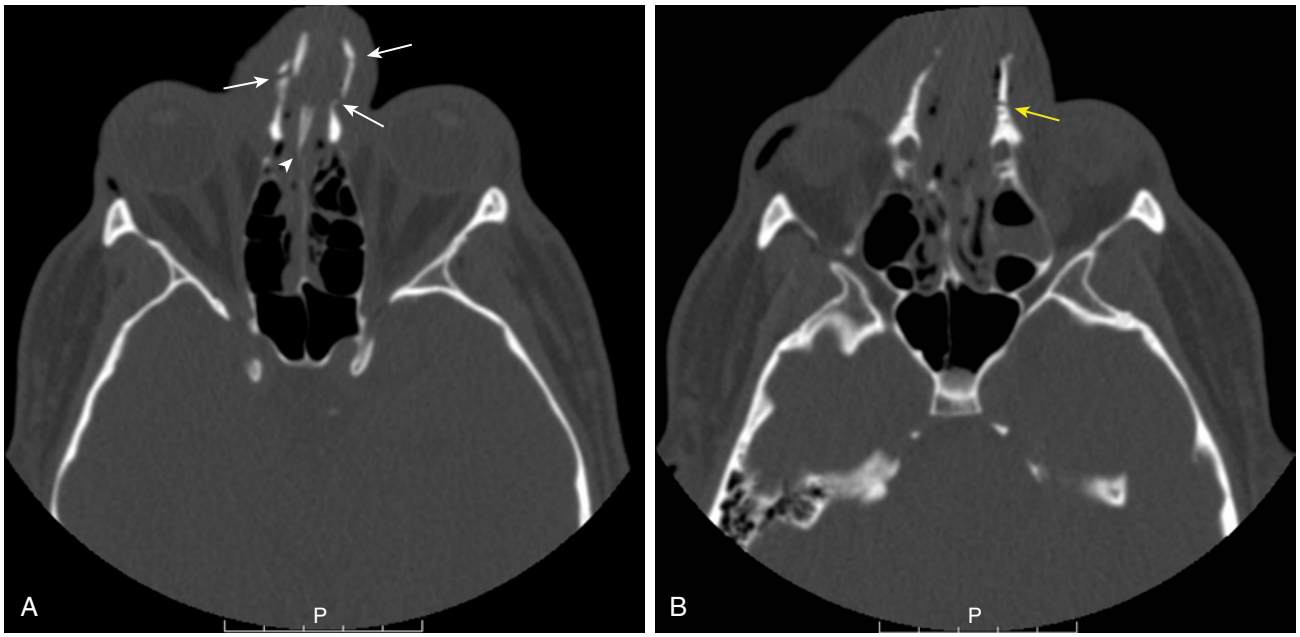

• **Figure 3-10** Nasal fractures. **A-B**, Axial images demonstrate comminution and displacement of the bilateral nasal bones (*arrows*) and through the perpendicular plate of the ethmoid (*arrowhead*). The left fracture occurred at the nasomaxillary suture (*yellow arrow*).

Markowitz and colleagues developed the most frequently used classification system for NOE fractures, based on the integrity of the medial canthal tendon (MCT) (Table 3-4, Figure 3-12).[39] Type I fractures involve a large central fragment with preserved attachment of the MCT; type II fractures involve comminuted fragments, but with a preserved MCT; type III fractures are the most severe (and difficult to treat), as they involve a comminuted NOE complex with MCT involvement.

Maxillary Fractures

Fractures of the maxilla are among the most well described injuries to the facial skeleton. Le Fort's seminal work on these injuries remains the foundation for modern diagnosis and management (Figure 3-13).[40] Clinical examination is typically notable for malocclusion and intraoral ecchymosis (commonly along the buccal mucosa or palate). Even non-displaced fractures can be

TABLE 3-3 Nasal Fracture Classification System

Type		Characteristics
I	Simple	Unilateral
II		Bilateral
III	Comminuted	Unilateral
		Bilateral
		Including frontal process of maxilla
IV	Complex	Associated with septal hematoma
		Associated with open nasal laceration
V		Associated with naso-orbito-ethmoid or midface fracture

uncomfortable for patients, and they may report a malocclusion even if an obvious malocclusion is not evident on examination.[23]

The Le Fort I-III level fractures are accepted as standard terminology for fractures of the maxilla alone, with involvement of the nasofrontal complex, or total craniofacial disjunction, respectively. The unifying feature of all levels of Le Fort fractures is fracture of the pterygoid plates.[41] A fracture of the pterygoid plates almost always indicates a fracture at one of the Le Fort levels.[1,41] Maxillary fractures may occur in isolation or with concomitant injury to the nasal, zygomatic, or orbital regions; may be unilateral or bilateral; and may be varied in severity (e.g., left-sided Le Fort I fracture with a right-sided Le Fort III fracture). As such, imaging of such suspected injuries requires careful assessment of the orbital, nasal, frontal, and zygomatic regions and assessment of laterality.

The Le Fort I fracture is a simple maxillary disjunction, separating the maxilla from its connection to the skull base, zygoma, and nasal septum (Figure 3-14). The classical fracture pattern will propagate from the pyriform rim and lateral nasal wall to the pterygomaxillary fissure, extending across the intervening bone by fracturing the anterior and posterior walls of the maxillary sinus. There is often a simultaneous fracture of the nasal septum. Clinically, the maxilla may be mobile, with the hard palate and alveolus mobile relative to the remainder of the midface.

The Le Fort II fracture is also known as a pyramidal fracture because the fracture lines may form a distinct triangular shape when viewed in the coronal plane (Figure 3-15). The Le Fort II pattern extends from the pterygoid plates superiorly and anteriorly, terminating at the nasofrontal suture. The intervening bony segments along the line of fracture are the lateral and anterior walls of the maxillary sinus, the orbital floor, and the medial orbital wall. Clinically, mobilization of the maxilla will result in tactile mobility at the nasofrontal suture.

"Craniofacial disjunction" is a synonym for the Le Fort III fracture. This is the most severe form of maxillary fracture, with a fracture line that propagates from the pterygoid plates superiorly to involve the zygomatic arch, lateral orbit, orbital floor, medial orbital wall, and nasal bones. As a result, the midfacial skeleton becomes separate from the skull base. Clinically, the mobilization of the maxilla will result in simultaneous mobilization of the lateral and inferior orbit.

A less common form of maxillary fracture that is independent of the Le Fort schema is the palatal fracture, or sagittal maxillary fracture.[42,43] In this fracture pattern, the fracture propagates along the sagittal or parasagittal planes of the hard palate, separating the maxilla into right and left symmetric segments or greater and lesser asymmetric segments. A malocclusion due to widening of the maxilla is often present. Associated fractures of the alveolar ridge, nasal septum, and maxillary sinus walls are common. Physical examination may be notable for missing or mobile teeth within a mobile alveolus. If there are teeth missing that were not otherwise known to be missing prior to injury and are not identifiable on clinical exam or facial imaging, a plain radiograph of the chest should be performed to exclude tooth aspiration.

Mandibular Fractures

The only mobile bone within the facial skeleton, the mandible is a complex, U-shaped structure with bilateral articulations with the skull base. With its prominent position in the lower face, the mandible is also among the most frequently fractured facial bones.[44-47] Almost half of all patients with maxillofacial injuries have a fracture of the mandible.[47] Given their frequency and the potential complexity of management, any clinician treating patients with maxillofacial injuries should be well-versed in the various radiographic methods for diagnosis of mandibular fractures. Although there is no universally accepted classification scheme for mandibular fractures, an adequate clinical description will include location, pattern, and displacement.

For the purposes of localization of zone of injury, there are six distinct regions of the mandible that are commonly fractured: the condyle/condylar neck, ramus, angle, body, symphysis/parasymphysis, and alveolus (Figure 3-16). The most common location for mandibular fractures is the mandibular body, defined as the region between the distal aspect of the mandibular canine and the distal aspect of the mandibular second molar.[44] The condylar/subcondylar region is the next most frequent, followed by the angle and symphysis/parasymphysis. Isolated injuries to the alveolus and coronoid process are relatively rare, with only the former readily apparent on clinical examination. The most often misdiagnosed or undiagnosed fractures are condylar fractures, particularly intracapsular fractures. This latter finding has important implications for management, as an undiagnosed and untreated intracapsular fracture can result in temporomandibular joint ankylosis.

Knowledge of mandibular biomechanics and fracture patterns is required to carefully evaluate imaging in a

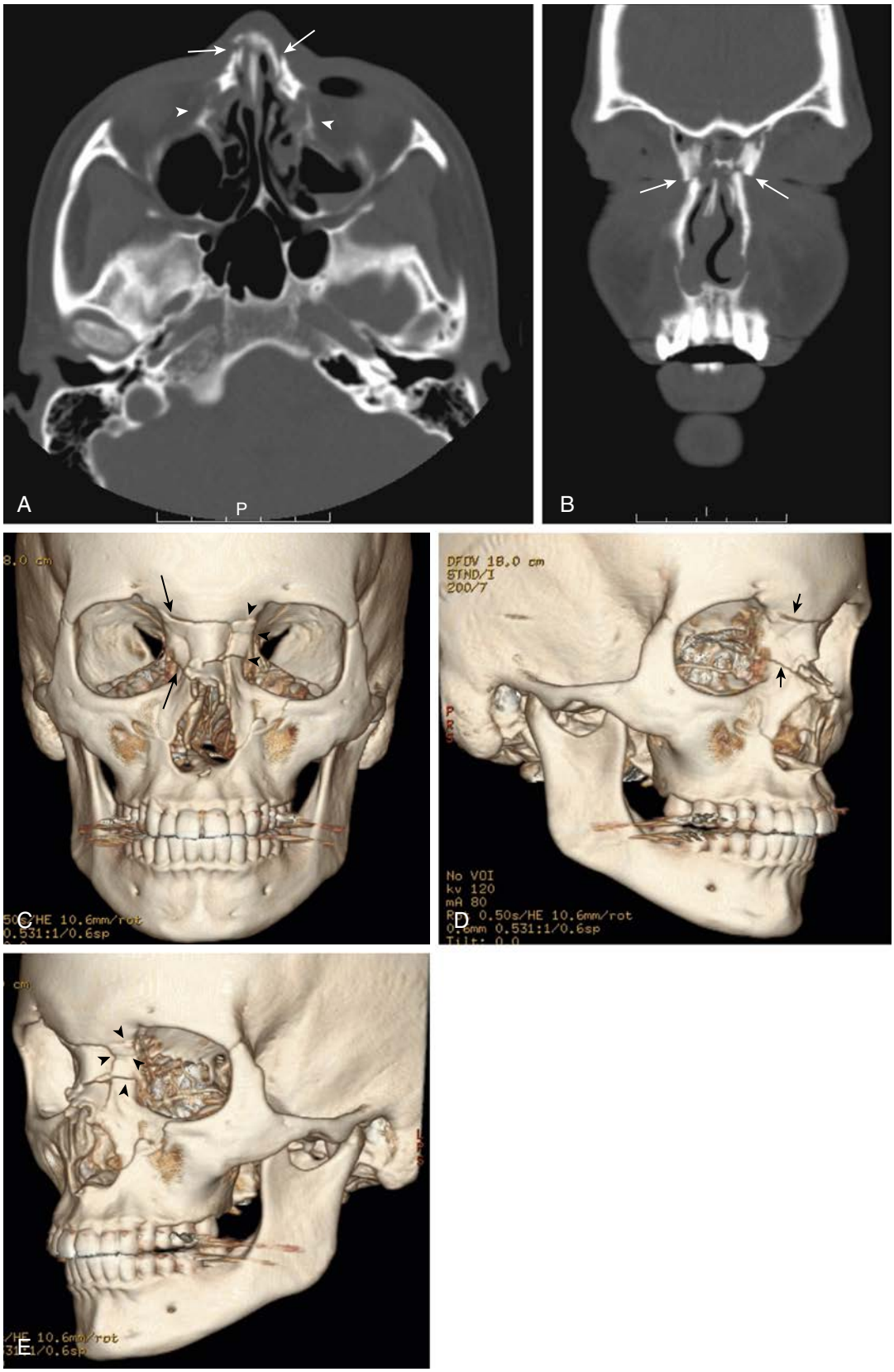

• **Figure 3-11** Naso-orbito-ethmoid (NOE) fracture: type I on right, type II on left. **A**, Axial view shows bilateral nasal bone fractures (*arrows*), disruption of the ethmoid sinus and medial wall of orbit (*arrowheads*). **B**, Coronal image displaying lateral displacement of the nasal processes of the maxilla with displacement laterally (*arrows*). **C**-**E**, Three-dimensional frontal (**C**), right (**D**), and left (**E**) lateral show the right-sided fractures (*arrows*) (type I) and comminution of the left side (*arrowheads*) (type II).

TABLE 3-4 Naso-orbito-ethmoid Classification System

Type	Characteristics
I	Single non-comminuted central fragment, no medial canthal tendon disruption
II	Comminution of central fragment, no medial canthal tendon disruption
III	Comminution of central fragment with medial canthal tendon disruption

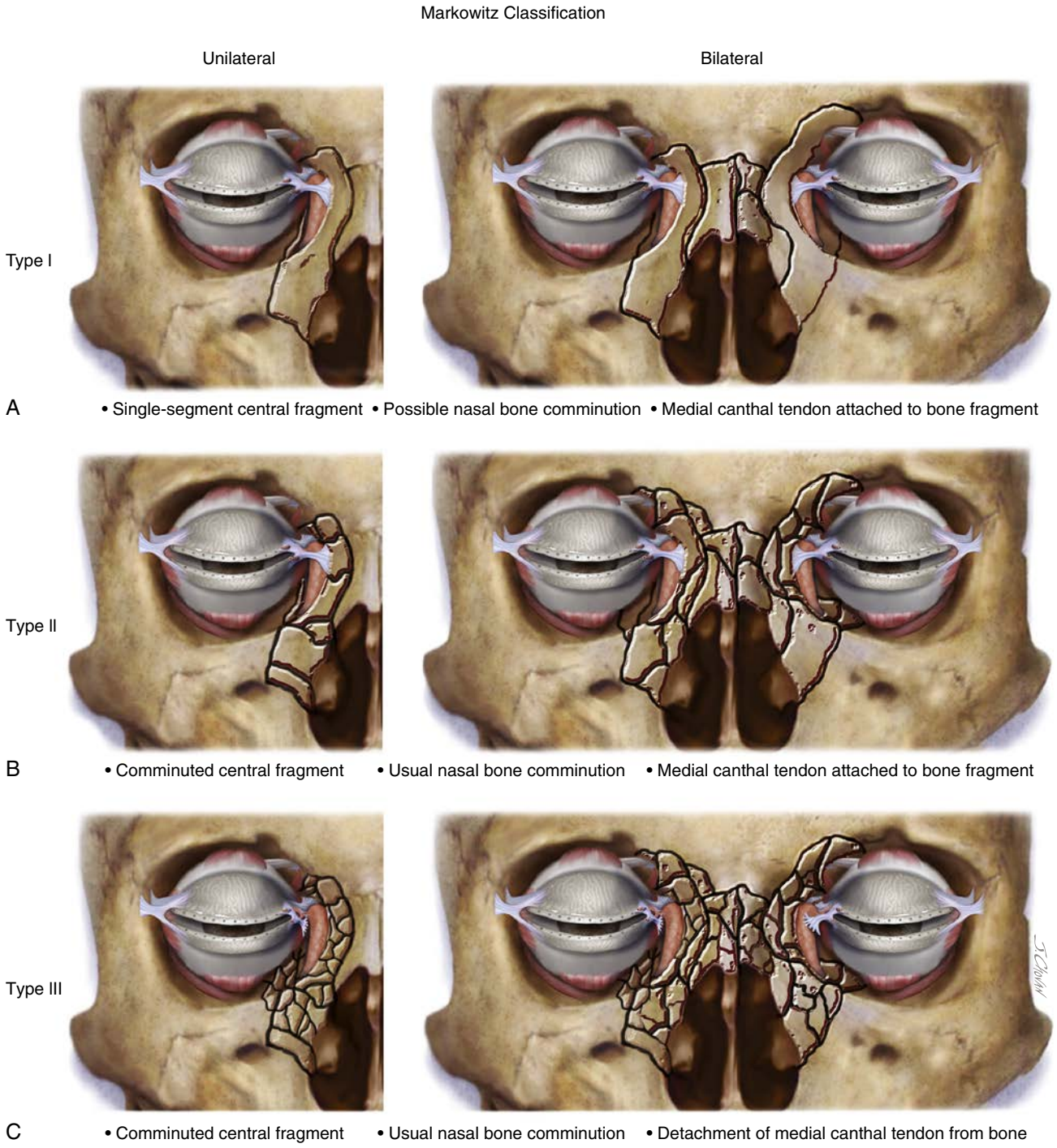

• **Figure 3-12** Naso-orbito-ethmoid (NOE) fractures can be classified into three types. **A**, Type I fractures have a large central fragment containing the medial canthal tendon (MCT). **B**, Type II fractures have comminution of the central fragment, but the MCT remains attached. **C**, Type III fractures have comminution and disruption of the attachment of the MCT. (From Kademani D, Tiwana P, editors: *Atlas of oral and maxillofacial surgery*, 1e, Philadelphia, 2015, Saunders.)

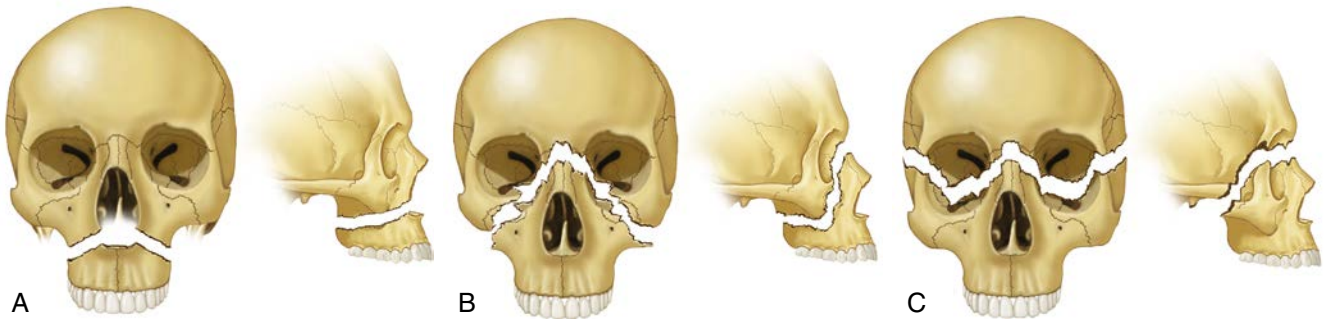

• **Figure 3-13** Le Fort fractures display classic fracture patterns along three levels. **A**, The Le Fort I fracture occurs along the anterior maxilla extending from the pyriform rims posteriorly through the maxillary sinus to the pterygoid plates. **B**, Le Fort II fractures are referred to as pyramidal when bilateral, as they extend from the nasofrontal suture through the medial orbital wall, floor, and infraorbital rim down to the pterygoid plates. **C**, Le Fort III fractures extend from the nasofrontal suture laterally and include the zygomas, resulting in a craniofacial dysjunction. (From Fonseca RJ, Barber HD, Powers MP, Frist DE, editors: *Oral and maxillofacial trauma*, 4e, Philadelphia, 2013, Saunders.)

patient with a suspected mandibular injury. Because of the U-shape of the mandible, forces applied to a single area of the bone will be transmitted along its contour proximally and distally. This often results in simultaneous fractures of the mandible and contre-coup injuries. Common patterns of fracture include fractures of the angle and contralateral body, bilateral angle fractures, and angle with contralateral subcondylar fractures.

From a biomechanical standpoint, fractures of the mandible are classified as favorable or unfavorable based on the relationship of the fracture trajectory relative to masticator muscle pull. Horizontally favorable fractures are those in which the fracture trajectory is perpendicular to the long axis of the masseter and medial pterygoid fibers. In this pattern, muscle pull will act to reduce the fracture. Horizontally unfavorable fractures are those in which the fracture orientation is parallel to the vector of muscle pull, resulting in displacement with muscle contraction. Vertically favorable fractures are those in which the fracture line, as viewed in the axial plane, is parallel to the medial pterygoid fibers. Unfavorable fractures will be oriented perpendicular to the medial pterygoid muscle fibers (or parallel to the lateral pterygoid fibers).

A rare pattern of injury that is of extreme clinical importance is the bilateral parasymphysis pattern, in which the genioglossus muscle attachment is in a single, centralized piece of bone, not attached to the remainder of the mandible. In this setting, the central segment is a "flail segment" that may allow for glossoptosis and airway embarrassment.

Although the majority of patients with facial injuries consistent with mandibular fractures will be imaged with MDCT, isolated mandibular fractures remain one area where plain film imaging may be adequate for diagnosis and management.[48] Regardless of the modality used for imaging, it is our practice to include a panoramic radiographic evaluation on all patients with mandibular injuries. There are two important reasons for this: (1) There are rare documented cases in which mandibular fractures were missed on facial CT due to the orientation of the fracture relative to the CT slice orientation, and (2) most patients with mandibular fractures will be followed with some form of imaging to assess healing for removal of fixation and/or resumption of regular dietary activities. With increasing concerns about cumulative radiation doses, plain film imaging is the modality of choice for following patients, and thus the initial assessment should include a plain film for baseline evaluation.

An isolated mandibular series is useful for imaging patients with a suspected mandibular fracture and no other facial fractures and can be particularly helpful if there is availability of panoramic radiography is available and a CT scan is not clinically necessary. The mandibular series consists of a Towne's view, bilateral oblique views, and posterior-anterior views of the mandible. The Towne's view (anterior-posterior) is an excellent method of visualizing the mandibular condyles/subcondylar region. Oblique views are generally adequate for visualizing the mandibular body, angles, and ramus. The posterior-anterior view is excellent for visualizing the symphysis and parasymphysis.

Condylar Fractures

Trauma to other parts of the mandible generally directs force toward the temporomandibular joint and often results in fractures of the condylar process or subcondylar region. Fractures to the area are divided into intra- and extracapsular fractures. Intracapsular fractures are more common in children and can be easily missed on plain films. Fractures that occur below the condylar head within the condylar neck down to the sigmoid notch are considered extracapsular or subcondylar. Unilateral subcondylar fractures often occur with contralateral angle or parasymphysis fractures. A blow to the chin may result in bilateral condylar fractures along with a fracture of the symphysis. The fractured condyles can be displaced in any direction but are often anteromedially displaced due to the pull of the lateral pterygoid muscle (Figure 3-17).

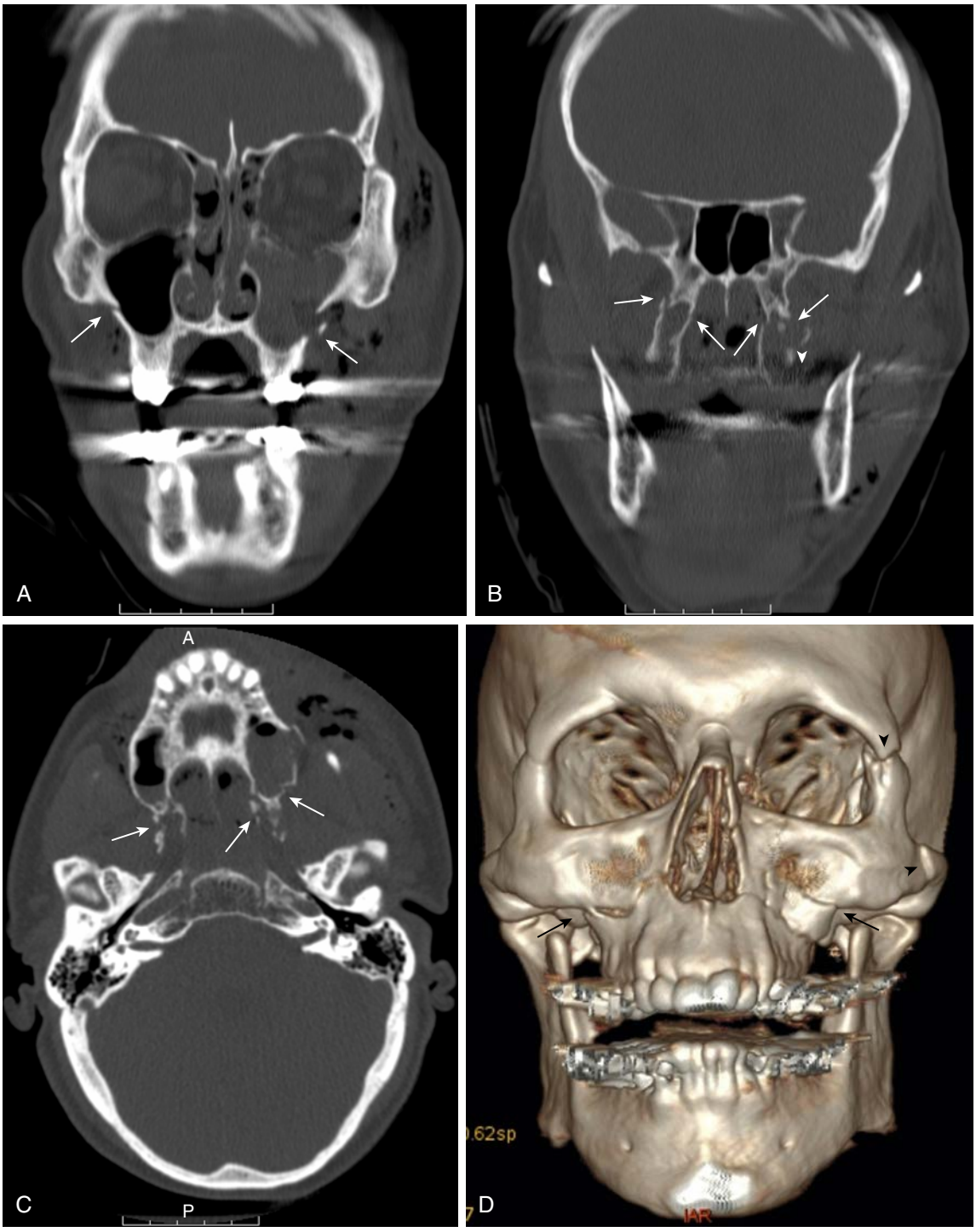

• **Figure 3-14** Le Fort I fracture. **A**, Coronal image shows bilateral fractures through the lateral wall of the maxillary sinuses just above the dentoalveolar segment of the maxilla (*arrows*). **B**-**C**, Coronal image (more posteriorly) and axial image show fractures through the bilateral pterygoid plates (*arrows*). **D**, Three-dimensional reformat showing the fractures extending from the pyriform apertures posteriorly toward the pterygoid plates (*arrows*). There is a concomitant zygomaticomaxillary fracture (*arrowheads*).



• **Figure 3-15** Le Fort II fracture. **A**-**C**, Coronal images moving anterior to posterior show fractures through the nasofrontal suture (*arrows*), pyramid-shaped combination of fracture (*lines*) through the orbital floor and lateral wall of the maxillary sinus, and pterygoid plates (*yellow arrows*). **D**, Axial image showing the pterygoid plate fractures (*arrows*).

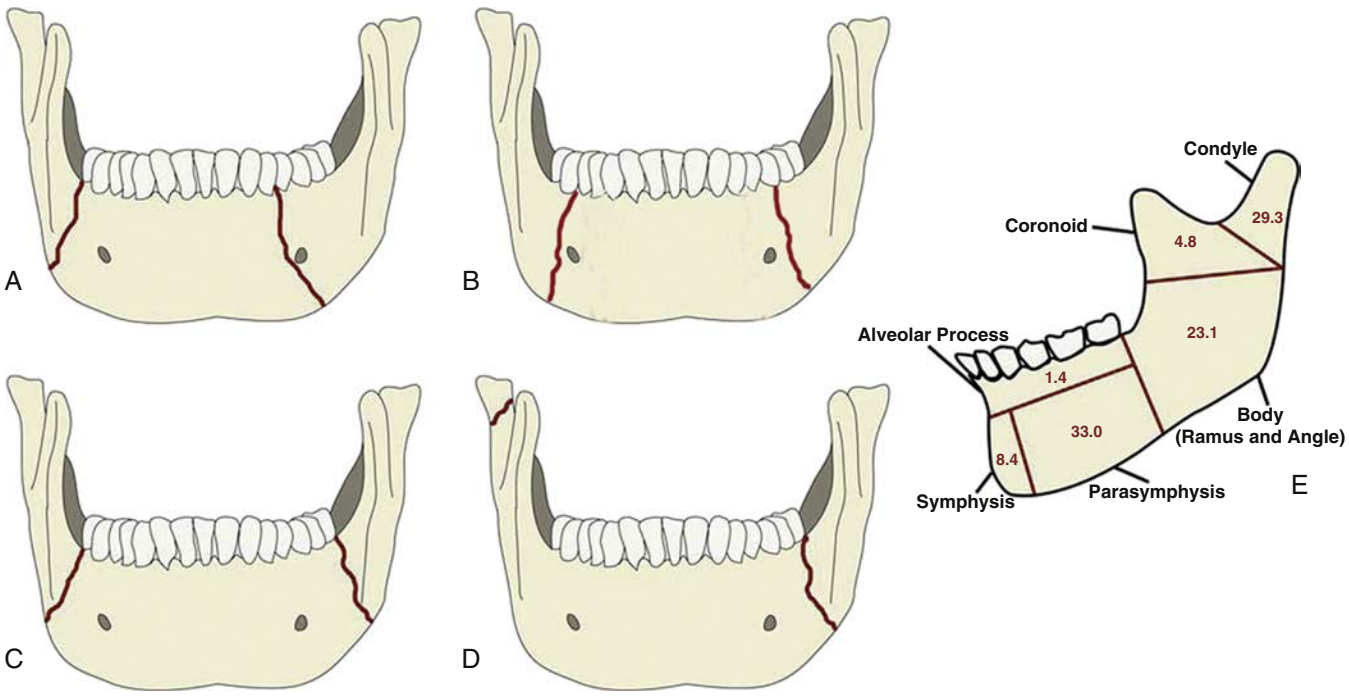

• **Figure 3-16** Pattern and incidence of mandibular fractures **A**, Parasymphysis and contralateral body. **B**-**C**, Bilateral body and angle fractures, respectively. **D**, Mandibulary body and contralateral condyle. **E**, Incidence (%) of fractures by location. (From Avery LL, Susarla SM, Novelline RA. Multidetector and three-dimensional CT evaluation of the patient with maxillofacial injury, *Radiol Clin North Am* 49(1):183-203, 2011.)

Plain films can demonstrate disruption of the posterior margin of the condylar neck or loss of vertical height of the condyle-ramus unit (see Figure 3-17, *A*). Intracapsular fractures can be missed and are best found via CT scan (Figure 3-18). Missed intracapsular fractures can have significant articular consequences, particularly in children.

Coronoid Process and Ramus Fractures

Fractures involving the coronoid process and/ramus are rare, accounting for less than 2% of mandibular fractures.[47] The coronoid is protected by the zygoma and arch, whereas the ramus is relatively dense compared to the adjacent subcondylar region and mandibular angle, which are far more commonly fractured.

Mandibular Angle Fractures

Fractures of the mandibular angle are among the most common mandibular fractures. Inherent weaknesses at the mandibular angle, such as the third molar, make the region prone to fracture with blows to the contralateral parasymphysis or ipsilateral mandibular body. The fracture usually extends superiorly from the retromolar region in the area of the third molar posteriorly toward the mandibular angle and is easily detected on plain films such as the panoramic radiograph or ipsilateral lateral oblique view.

Mandibular Body Fractures

A blow to the ipsilateral mandibular body commonly results in a fracture that traverses through existing teeth. This often results in a step-off the occlusion at the site of fracture and are generally considered compound fractures (Figure 3-19). Edentulous mandibles are particularly prone to mandibular body fractures (Figure 3-20) due to atrophy of the posterior mandibular alveolus with early loss of mandibular teeth.

Mandibular Symphysis Fractures

Mandibular symphysis and parasymphysis fractures occur in the areas between and including the mental foramina. Fractures in this area are often oblique and can be missed on a plain films. The clarity of the image of the mandibular parasymphysis in a panoramic radiograph is variable because of the narrow focal trough. A CT scan is often needed to appreciate the presence and direction of the fracture.

Pathologic Fractures

Mandibular fractures can result from inflammatory or neoplastic processes affecting the structure and integrity of the mandible. Osteoradionecrosis of the mandible can progress to the inferior border and result in a pathologic fracture (Figure 3-21, *A*). Weakening of the mandible after removal of deeply impacted mandibular third molars can lead to

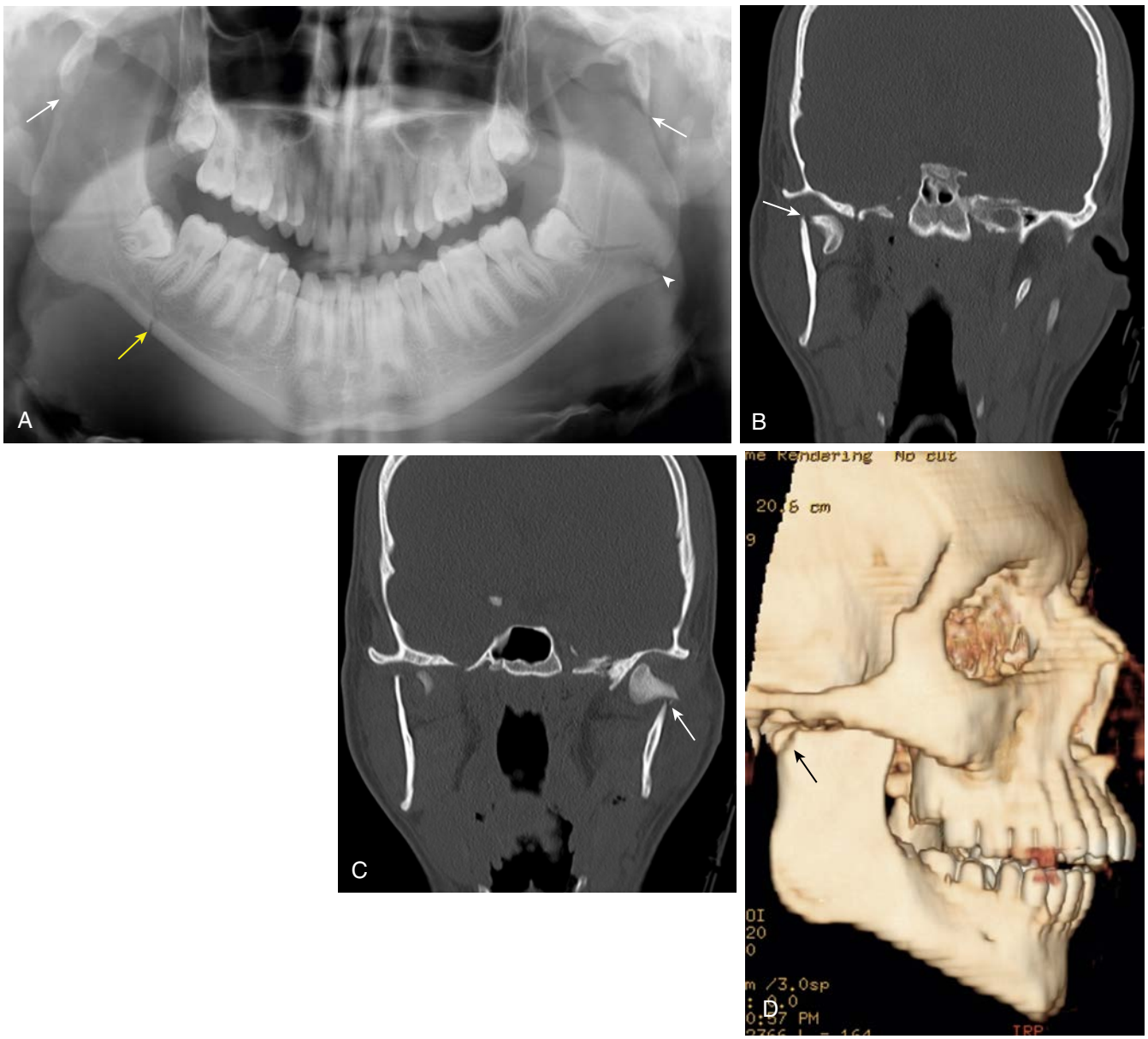

• **Figure 3-17** Multiple mandible fractures. **A**, Panoramic radiograph shows loss of continuity of the bilateral posterior ramus (*arrows*) indicating subcondylar fractures. Fractures are also seen of the left angle (*arrowhead*) through the impacted third molar and right body (*yellow arrow*). **B**, Coronal image shows high right subcondylar fracture with medial displacement of the condylar head out of the glenoid fossa (*arrow*). **C**, Coronal image shows low subcondylar fracture (*arrow*) also with medial displacement. **D**, Three-dimensional view highlights the high right subcondylar fracture with loss of ramus height (*arrow*).

pathologic fracture, particularly in those patients where the third molar makes up a large portion of the vertical height of the mandible (see Figure 3-21, *B*, *C*).

Pediatric Facial Fractures

Growth is a confounding variable in the biomechanics of the facial skeleton. The growing facial skeleton has different stress points than the mature facial skeleton, and patterns of fractures are consequently different in children compared to adults.[49-51] Nasal fractures are the most common type of facial fracture in children, but mandibular fractures remain the most frequent cause of hospitalization, as they almost always necessitate some form of treatment. The distribution of mass within the pediatric facial skeleton (prominent cranium, non-pneumatized sinuses within the maxilla) results in more frequent injuries to the condylar/subcondylar regions (Figure 3-22) of the mandible and the frontal bone/orbital roof, with less frequent injuries to the midface.[51,52] When midfacial injuries do occur, they do not follow the

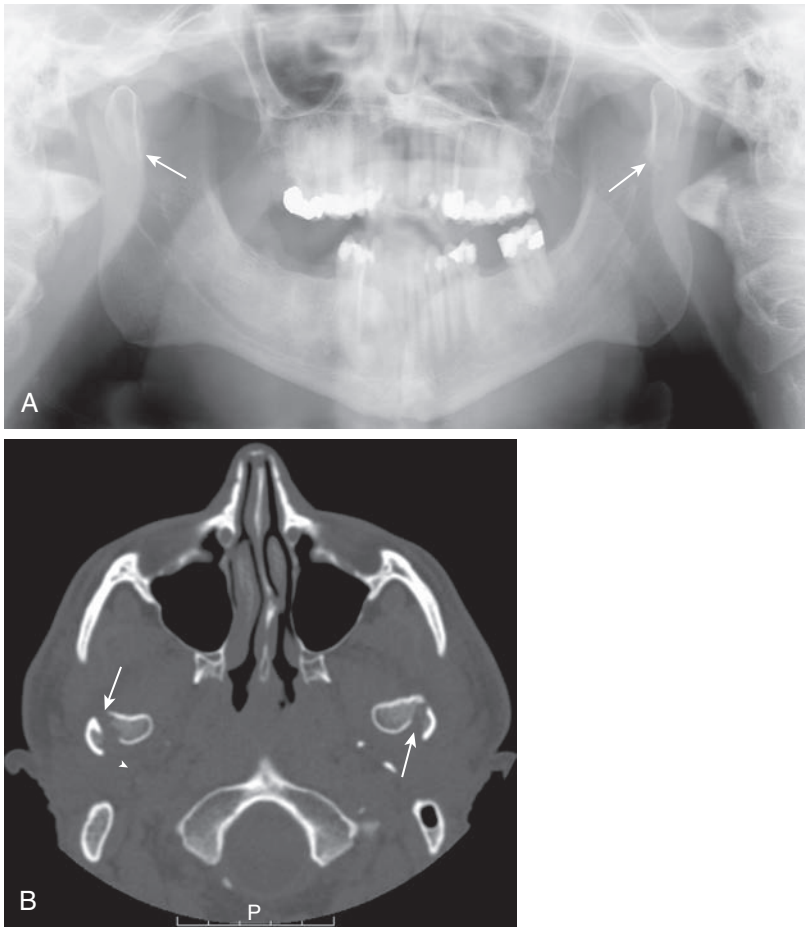

• **Figure 3-18** Bilateral mandibular condyle fractures (intracapsular). **A**, Panoramic radiograph shows disruption of the condylar head with displacement anterior to the articular eminences bilaterally (*arrows*). **B**, Axial image confirms intracapsular condylar fractures with displacement of the bilateral medial poles (*arrows*). The ramus heights are not substantially changed, and the malocclusion was subtle.

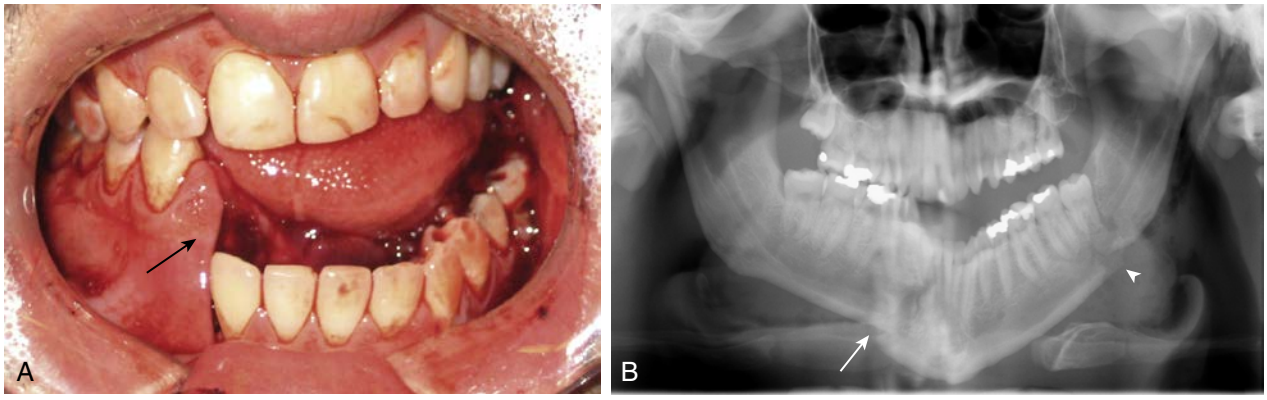

• **Figure 3-19** Mandibular body fracture. **A**, A stepoff in the occlusion (*arrow*) indicates a fracture between the teeth and represents a compound fracture. **B**, Panoramic radiograph demonstrating right mandibular body fracture (*arrow*) and left mandibular angle fracture (*arrowhead*).

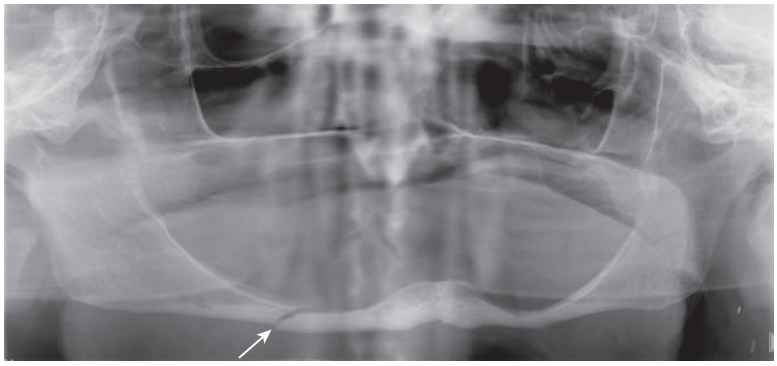

• **Figure 3-20** Fractures of edentulous mandibles typically occur in the region of the mandibular body (*arrow*) after longstanding edentulism of the posterior mandible.

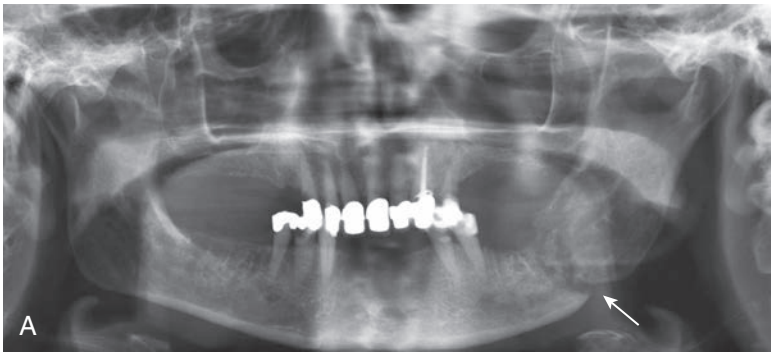

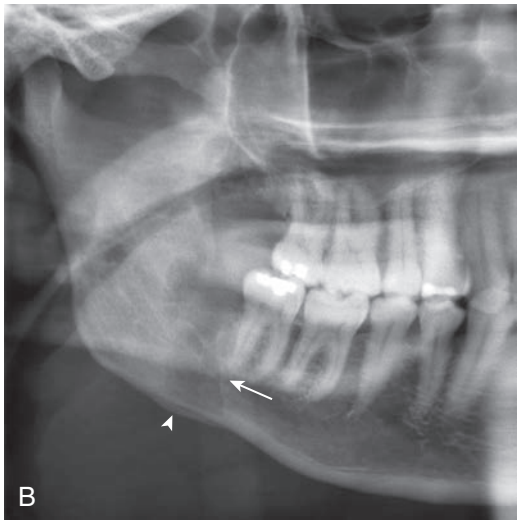

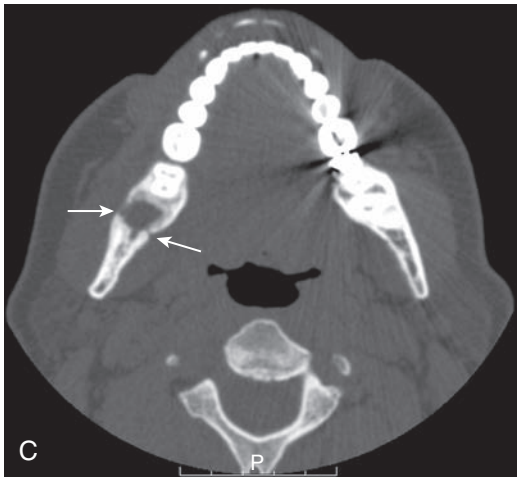

• **Figure 3-21** Pathologic fractures occur in compromised areas. **A**, Osteoradionecrosis has progressed to the inferior border and resulted in a pathologic fracture of the left mandibular body (*arrow*). **B**, After extraction of a deeply impacted third molar, the patient had persistent pain. A panoramic radiograph showed a linear radiolucency (*arrow*) and periosteal reaction (*arrowhead*). **C**, Axial CT image confirmed pathologic fracture through the third molar extraction socket (arrows).

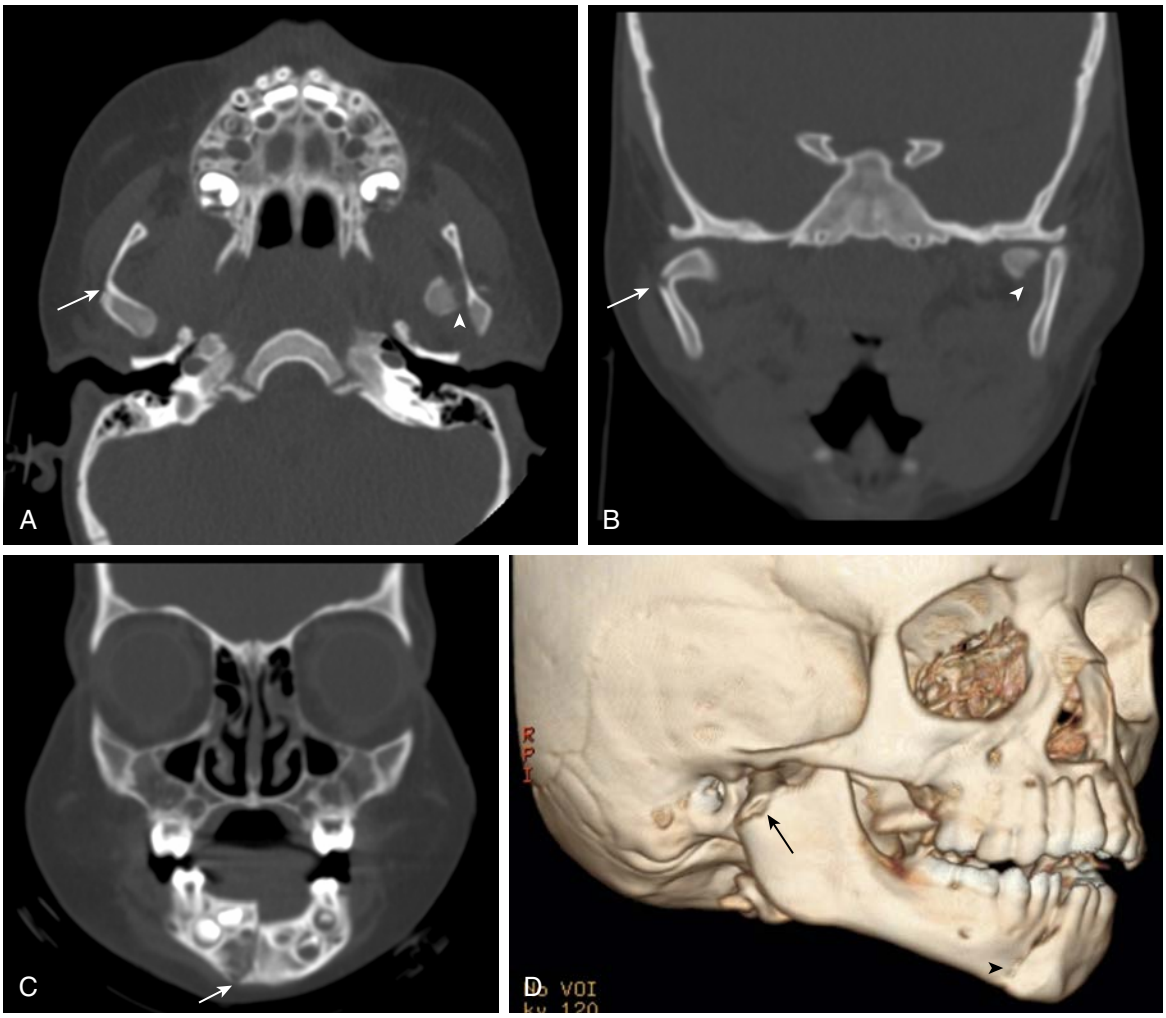

• **Figure 3-22** Pediatric mandibular fractures. **A-B,** Axial (**A**) and coronal (**B**) image shows right subcondylar fracture that is medially displaced with bending without displacement of the medial cortex (*arrows*) along with left intracapsular condyle fracture (*arrowheads*). **C**, Coronal image showing displaced symphysis fracture through tooth buds (*arrow*). **D**, Three-dimensional view of right subcondylar fracture (*arrow*) and symphysis fracture (*arrowhead*).

typical patterns described by Le Fort. Rather, they are more obliquely oriented across the zone of injury. Incomplete ossification of the facial skeleton results in bending in response to stress, with resultant greenstick or incomplete fractures.

Though there are reasonable concerns regarding the use of CT scans in children, CT imaging is the most accurate method of diagnosing facial fractures within this population. Clear discussions between the emergency personnel, surgeon, and radiologist are required to identify the most appropriate method of imaging for a particular injury presentation. Most institutions have diagnostic protocols for low-dose CT imaging for pediatric patients. Such protocols should be used whenever possible.

Children with facial injuries may, unfortunately, be victims of abuse.[49-51] If there is a suspicion of abuse, a skeletal survey to identify other injuries or old injuries in distant parts of the body is required and should be discussed with the radiologist.

Craniomaxillofacial Fractures with Associated Cervical Spine or Intracranial Injury

Among patients who present with facial trauma, 4% to 10% will have concomitant cervical spine injuries and up to 50% will have concomitant intracranial injuries.[53-56] Fractures of the frontal bone and orbital roof are associated with increased incidence of craniocervical injuries. Severe bilateral midfacial injuries are associated with skull-base injuries and death. Unilateral fractures of the nasal, orbital, zygomatic, and maxillary regions have been associated with skull-base fractures and intracranial injuries. Isolated mandibular fractures are associated with cervical spine injury. These associated patterns of injury should prompt the treating clinician to consider additional CT imaging of the cervical spine and head in patients who present with facial trauma.

Summary

Diagnostic imaging has a critical role in the management of facial trauma. Advances in imaging continue to improve the diagnosis and management of maxillofacial trauma.

References

1. Rhea JT, Rao PM, Novelline RA: Helical CT and three-dimensional CT of facial and orbital injury, *Radiol Clin North Am* 37(3): 489–513, 1999.
2. Avery LL, Susarla SM, Novelline RA: Multidetector and three-dimensional CT evaluation of the patient with maxillofacial injury, *Radiol Clin North Am* 49(1):183–203, 2011.
3. Patel R, Reid RR, Poon CS: Multidetector computed tomography of maxillofacial fractures: the key to high-impact radiological reporting, *Semin Ultrasound CT MR* 33(5):410–417, 2012.
4. Linnau KF, Stanley Jr RB, Hallam DK, et al.: Imaging of high-energy midfacial trauma: what the surgeon needs to know, *Eur J Radiol* 48(1):17–32, 2003.
5. Druelinger L, Guenther M, Marchand EG: Radiographic evaluation of the facial complex, *Emerg Med Clin North Am* 18(3):393–410, 2000.
6. Schuknecht B, Graetz K: Radiologic assessment of maxillofacial, mandibular, and skull base trauma, *Eur Radiol* 15(3):560–568, 2005.
7. Jarrahy R, Vo V, Goenjian HA, et al.: Diagnostic accuracy of maxillofacial trauma two-dimensional and three-dimensional computed tomographic scans: comparison of oral surgeons, head and neck surgeons, plastic surgeons, and neuroradiologists, *Plast Reconstr Surg* 127(6):2432–2440, 2011.
8. Holmgren EP, Dierks EJ, Homer LD, Potter BE: Facial computed tomography use in trauma patients who require a head computed tomogram, *J Oral Maxillofac Surg* 62(8):913–918, 2004.
9. Sitzman TJ, Hanson SE, Alsheik NH, et al.: Clinical criteria for obtaining maxillofacial computed tomographic scans in trauma patients, *Plast Reconstr Surg* 127(3):1270–1278, 2011.
10. Dos Santos DT, Costa e Silva AP, Vannier MW, Cavalcanti MG: Validity of multislice computerized tomography for diagnosis of maxillofacial fractures using an independent workstation, *Oral Surg Oral Med Oral Pathol Oral Radiol Endod* 98(6):715–720, 2004.
11. Scarfe WC: Imaging of maxillofacial trauma: evolutions and emerging revolutions, *Oral Surg Oral Med Oral Pathol Oral Radiol Endod* 100(2 Suppl):S75–S96, 2005.
12. Levy RA, Edwards WT, Meyer JR, et al.: Facial trauma and 3D reconstructive imaging: insufficiencies and correctives, *AJNR Am J Neuroradiol* 13:885, 1992.
13. Fox LA, Vannier MW, West OC, et al.: Diagnostic performance of CT, MPR and 3DCT imaging in maxillofacial trauma, *Comput Med Imaging Graph* 19:385, 1995.
14. Mayer JS, Wainwright DJ, Yeakley JW, et al.: The role of three-dimensional computed tomography in the management of maxillofacial trauma, *J Trauma* 28:1043, 1988.
15. Gillespie JE, Isherwood I, Barker GR, et al.: Three-dimensional reformation of computed tomography in the assessment of facial trauma, *Clin Radiol* 38:523, 1987.
16. Klenk G, Kovacs A: Do we need three-dimensional computed tomography in maxillofacial surgery? *J Craniofac Surg* 15(5):842–850, 2004.
17. Orentlicher G, Goldsmith D, Horowitz A: Applications of 3-dimensional virtual computerized tomography technology in oral and maxillofacial surgery: current therapy, *J Oral Maxillofac Surg* 68(8):1933–1959, 2010.
18. Pham AM, Rafii AA, Metzger MC, et al.: Computer modeling and intraoperative navigation in maxillofacial surgery, *Otolaryngol Head Neck Surg* 137(4):624–631, 2007.
19. Alder ME, Deahl ST, Matteson SR: Clinical usefulness of two-dimensional reformatted and three-dimensionally rendered computerized tomographic images: literature review and a survey of surgeons' opinions, *J Oral Maxillofac Surg* 53(4):375–386, 1995.
20. Yamaoka M, Furusawa K, Iguchi K: The assessment of fracture of the mandibular condyle by use of computerized tomography: incidence of sagittal split fracture, *Br J Oral Maxillofac Surg* 32:77, 1994.
21. Raustia AM, Pyhtinen J, Oikarinen KS, et al.: Conventional radiographic and computed tomographic findings in cases of fracture of the mandibular condylar process, *J Oral Maxillofac Surg* 48:1258, 1990.
22. Rehm CG, Ross SE: Diagnosis of unsuspected facial fractures on routine head computerized tomographic scans in the unconscious multiply injured patient, *J Oral Maxillofac Surg* 53:522, 1995.
23. Manson PN, Markowitz B, Mirvis S, et al.: Toward CT based facial fracture treatment, *Plast Reconstr Surg* 85:202, 1990.
24. Rodriguez ED, Bluebond-Langner R, Park JE, Manson PN: Preservation of contour in periorbital and midfacial craniofacial microsurgery: reconstruction of the soft-tissue elements and skeletal buttresses, *Plast Reconstr Surg* 121(5):1738–1747, 2008.
25. Strong EB, Pahlavan N, Saito D: Frontal sinus fractures: a 28-year retrospective review, *Otolaryngol Head Neck Surg* 135:774, 2006.
26. Tiwari P, Higuera S, Thornton J, et al.: The management of frontal sinus fractures, *J Oral Maxillofac Surg* 63:1354, 2005.
27. Fattahi T: Management of frontal sinus fractures. In Fonseca RJ, Marciani RD, Turvey TA, editors: *Oral and maxillofacial surgery*, vol. 2. St. Louis, 2009, Saunders, p 256–269.
28. Stanwix MG, Nam AJ, Manson PN, et al.: Critical computed tomographic diagnostic criteria for frontal sinus fractures, *J Oral Maxillofac Surg* 68(11):2714–2722, 2010.
29. Chirico PA, Mirvis SE, Kelman SE, et al.: Orbital "blow in" fractures: clinical and CT fractures, *J Comput Assist Tomogr* 13:1017, 1989.
30. Martello JY, Vasconez HC: Supraorbital roof fractures: a formidable entity with which to contend, *Ann Plast Surg* 38:223, 1997.
31. Pathria MN, Blaser SI: Diagnostic imaging of craniofacial fractures, *Radiol Clin North Am* 27:839, 1989.
32. Leone Jr CR: Periorbital trauma, *Int Ophthalmol Clin* 35:1, 1995.
33. Rohrich RJ, Hollier LH, Watumuli D: Optimizing the management of orbitozygomatic fractures, *Clin Plast Surg* 19:149, 1992.
34. Freeman LN, Selff SR, Aguilar GL, et al.: Selfcompression plates for orbital rim fractures, *Ophthal Plast Reconstr Surg* 7:198, 1991.
35. Knight JS, North JF: The classification of malar fractures: an analysis of displacement as a guide to treatment, *Br J Plast Surg* 13:325, 1961.
36. Reddy LV, Elhadi HM: Nasal fractures. In Fonseca RJ, Marciani RD, Turvey TA, editors: *Oral and maxillofacial surgery*, vol. 2. St. Louis, 2009, Saunders, p 270.
37. Rohrich RJ, Adams Jr WP: Nasal fracture management: minimizing secondary nasal deformities, *Plast Reconstr Surg* 106(2):266–273, 2000.
38. Supriya M, Clement WA, Ahsan F: Satisfaction with cosmesis following nasal manipulation: do previous fractures matter? *J Laryngol Otol* 120:749–52, 2006.
39. Markowitz BL, Manson PN, Sargent L, et al.: Management of the medial canthal tendon in nasoethmoid orbital fractures: the importance of the central fragment in classification and treatment, *Plast Reconstr Surg* 87(5):843–53, 1991.

40. LeFort R: E'tude experimentale sur les fractures de la machoire superieure, *Rev Chir* 23:208, 1901. [in French].
41. Rhea JT, Novelline RA: How to simplify the CT diagnosis of Le Fort fractures, *AJR Am J Roentgenol* 184(5):1700–1705, 2005.
42. Thompson R, Myer III CM: Sagittal palate fracture, *Ann Otol Rhinol Laryngol* 97(4 pt 1):432, 1988.
43. Hendrickson M, Clark N, Manson PN, et al.: Palatal fractures: classification, patterns, and treatment with rigid internal fixation, *Plast Reconstr Surg* 101(2):319–332, 1998.
44. Coletti DP, Caccamese Jr JF: Diagnosis and management of mandible fractures. In Fonseca RJ, Marciani RD, Turvey TA, editors: *Oral and maxillofacial surgery*, vol. 2. St. Louis, 2009, Saunders, p 139.
45. Assael LA: Clinical aspects of imaging in maxillofacial trauma, *Radiol Clin North Am* 31:209, 1993.
46. Avrahami E, Frishman E, Katz R: CT evaluation of otorrhagia associated with condylar fractures, *Clin Radiol* 49:877, 1994.
47. Ellis 3rd E, Moos KF, el-Attar A: Ten years of mandibular fractures: an analysis of 2,137 cases, *Oral Surg Oral Med Oral Pathol* 59(2):120–129, 1985.
48. Laine FJ, Conway WF, Laskin DM: Radiology of maxillofacial trauma, *Curr Probl Diagn Radiol* 22:145, 1993.
49. Kaban LB: Diagnosis and treatment of fractures of the facial bones in children 1943-1993, *J Oral Maxillofac Surg* 51(7):722–729, 1993 Jul.
50. Zimmermann CE, Troulis MJ, Kaban LB: Pediatric facial fractures: recent advances in prevention, diagnosis and management, *Int J Oral Maxillofac Surg* 35(1):2–13, 2006.
51. Haug RH, Foss J: Maxillofacial injuries in the pediatric patient, *Oral Surg Oral Med Oral Pathol Oral Radiol Endod* 90(2):126–134, 2000.
52. McGrath CJ, Egbert MA, Tong DC, et al.: Unusual presentations of injuries associated with the mandibular condyle in children, *Br J Oral Maxillofac Surg* 34:311, 1996.
53. Mithani SK, St-Hilaire H, Brooke BS, et al.: Predictable patterns of intracranial and cervical spine injury in craniomaxillofacial trauma: analysis of 4786 patients, *Plast Reconstr Surg* 123(4):1293–1301, 2009.
54. Elahi MM, Brar MS, Ahmed N, et al.: Cervical spine injury in association with craniomaxillofacial fractures, *Plast Reconstr Surg* 121(1):201–208, 2008.
55. Hills MW, Deane SA: Head injury and facial injury: is there an increased risk of cervical spine injury? *J Trauma* 34(4):549–553, 1993.
56. Kloss F, Laimer K, Hohlrieder M, et al.: Traumatic intracranial haemorrhage in conscious patients with facial fractures: a review of 1959 cases, *J Craniomaxillofac Surg* 36(7):372–377, 2008.

4

Soft Tissue Injuries of the Face, Head, and Trunk

PHILLIP N. FREEMAN, JAMES W. WILSON, KEVIN C. GAMS

Facial wounds are among the most commonly encountered problems in emergency departments (ED). Approximately one third of all lacerations occur in adults between the ages of 19 and 35 and predominantly in male patients, with approximately 50% occurring in the head and neck.[1-3] Injury patterns vary greatly, with trips and falls commonly causing isolated soft tissue injuries such as laceration and contusions mainly in children and the elderly.[4] Violence and motor vehicle accidents are among the most common causes of injury in individuals aged 15 to 50 years old.[3-5] Violence is most frequently by sharp injury from glass, knives, and wooden objects. In the United States motor vehicle collisions are the most prevalent cause of soft tissue damage to the face. More than 146,000 patients annually require hospital attention for facial soft tissue trauma.[6] Human and animal bites make up a small but significant percentage of soft tissue injuries. Burns, although infrequent compared to other wounds, also make up a small but significant percentage of facial wounds.

Initial Evaluation

Evaluation and management of trauma patients requires the advanced trauma life support (ATLS) protocol with a primary trauma survey followed by a secondary assessment for concomitant injuries.

A comprehensive head and neck exam should be performed to assess the extent of hard and soft tissue injury to determine the appropriate steps in management. All wounds should be evaluated for depth, size, and status of the wound for contusions, abrasions, crush injury, viability of the wound edges, and contamination. During the assessment period or during treatment of other injuries, the wounds should be kept moist with gauze soaked in saline until final management. Hemorrhage associated with most head and neck wounds may be substantial but can usually be controlled with local measures of pressure and ligation, or electrocautery when vessels are directly visible and can be isolated with a forceps. Persistent bleeding should be evaluated by direct pressure for inspection to prevent damage to other vital structures.

Injured and exposed structures should be identified, evaluated, and documented, with particular attention to cranial nerves V, VII, and XII. This is critical in the conscious patient and must be done prior to the use of any local or general anesthetic. A nerve stimulator may be helpful to stimulate the appropriate muscle groups in the nonparalyzed patient under general anesthetic. If a nerve has been damaged, appropriate microsurgical techniques should be used to attempt to restore continuity and ultimate function of the nerve. Always inquire about functional deficits that existed prior to the injury.

Parotid duct injuries should be suspected in any patient with lacerations extending from the pretragal region to the middle half of the upper lip. In patients with a suspected parotid duct injury, the duct should be cannulated intraorally at the level of the second maxillary molar and visualized through the wound. The authors' preference for cannulation is the use of a J-wire followed by an intracatheter placed over the J-wire. If ductal injury is poorly visualized in the wound, liquids such as propofol or methylene blue may be injected into the duct to assess the location of the injury.

Exposed cartilage that cannot be covered initially should be dressed with mafenide acetate (Sulfamylon) 5% or silver sulfadiazine cream. As well, neurovascular structures that cannot be covered should be dressed with nonadherent dressings such as Xeroform gauze or Adaptic gauze with or without bacitracin ointment. Abrasions and superficial burns can be dressed with Adaptic gauze and bacitracin. Deep wounds that cannot be closed can be dressed initially with hydrogel bandages, normal saline Kerlix dressings or iodoform gauze until definitive closure can be obtained. Eyelid avulsion wounds require immediate ophthalmic

antibiotic ointment and an occlusive eye shield to prevent exposure keratopathy.

In isolated soft tissue injuries emergent airway stabilization is rarely indicated. However, in patients with soft tissue injuries that need tracheostomy there is a high associated mortality (11.5%) and a significantly longer hospital stay than in patients with craniofacial fractures.[7] The difference is primarily attributed to neurologic injury, which requires delay of soft tissue repair until after the patient is stabilized. All patients should be assessed for concomitant intracranial, craniofacial, ophthalmologic, and cervical spine injuries. Documentation of the timing and mechanism of injury as well as postinjury signs and symptoms such as loss of consciousness, nausea, and vomiting should be used to guide assessment and management. Increased vascularity of most craniofacial structures limits the risk of infection relative to delays in treatment.[8,9] Time from injury to repair was initially thought to be associated with an increased risk of infection but recently has been shown to be not specifically related to incidence of infections. Berk, Osbourne, and Taylor found that wound age was of little concern in wounds located on the scalp and face.[8] Factors such as diabetes, wound contamination, length greater than 5 cm and location are important risk factors for wound infection.[8]

Improvements in decontamination by pressure irrigation over the past 30 years may have led to improved outcome.[10] It is also critically important to assess the mechanism of injury, as certain injuries that are associated with significant debris or wound contamination have been associated with increased incidence of infection. Impact crush injuries, for example, are as much as 100 times more susceptible to infection than are wounds caused by shear force.[11,12] Such wounds require pressure irrigation (< 15 psi) and debridement of all nonviable soft tissue to prevent postoperative infection. Also, photographs prior to injury are useful in identifying preexisting deformities and facial morphology.

Suture Technique and Suture Materials

Wound closure requires a variety of surgical techniques depending on the location of the wound, depth of the wound, anatomy of the wound margins, and presence of tissue edema.

Simple wound closure requires placement of sutures at the proper level in a trapezoidal fashion to create wound eversion. This principle applies to placement of subcutaneous sutures as well. Improper placement results in wound inversion (Figure 4-1). Multiple cutaneous suture techniques may be employed to accomplish the task of wound eversion as shown in Figure 4-2.

Simple wound closure that results in eversion and approximation of wound margins with subcuticular sutures

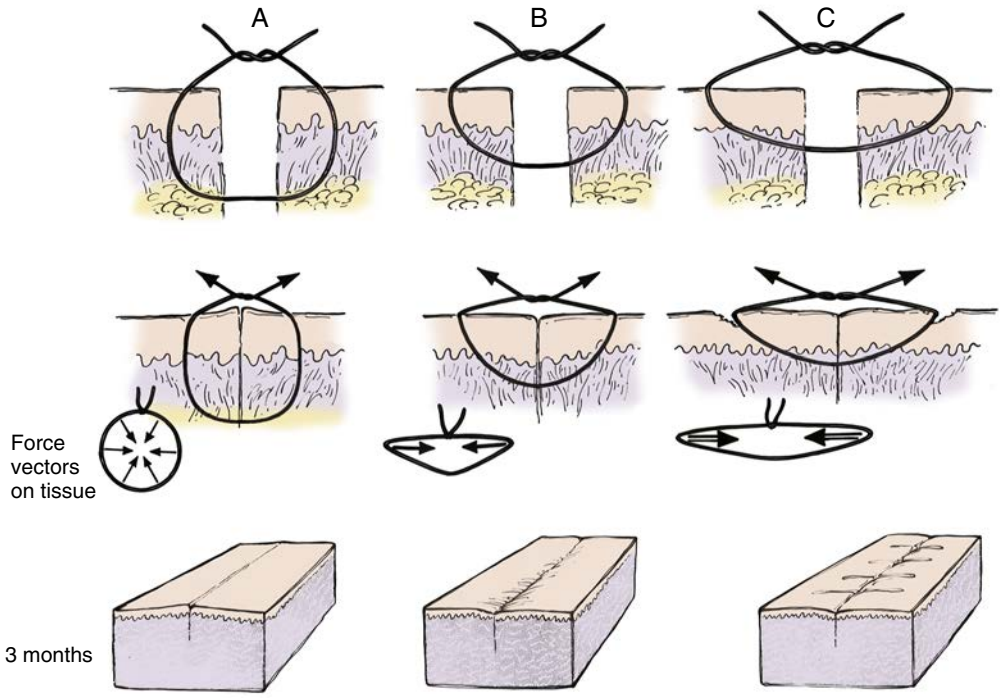

• **Figure 4-1** **A**, Proper placement of cutaneous suture showing equal distribution of tension along entire wound edge. Everted surgical would edges provide esthetic result. **B**, Improper placement of cutaneous suture with surgical bit too far from skin edge and too superficial. This creates vector forces that are greatest in a horizontal direction and produces inverted wound. **C**, Improper placement of cutaneous suture farther from skin edge with more superficial surgical bite. Force vectors on wound are greater in a horizontal direction and create more wound inversion. Additionally, permanent suture marks result in areas of pressure necrosis where wound closure tension is greatest. (From Sykes MJ, Byorth PJ: Suture needles and techniques for wound closure. In Baker SR, Swanson NA, editors: *Local flaps in facial reconstruction*, St. Louis, 1995, Mosby, p 56, Fig. 8, with permission.)

can be supported with paper tape for final closure, as seen in Figure 4-3. Paper tape alone may be used for closure of wounds that are superficial to the subcutaneous level, especially in pediatric patients.

In complex wounds, multilayered closure is required to eliminate dead space and provide wound eversion. This can be accomplished with either an interrupted suture or continuous suture technique as shown in Figure 4-4.

Closure of wounds with skin of unequal thickness requires placement of subcuticular sutures that maximize the cutaneous level and frequently requires modification of cutaneous suture placement (Figure 4-5). Staple closure may be used in a variety of circumstances but is most commonly used in the cutaneous closure of scalp. The proper placement of deep sutures and skin staples is demonstrated in Figure 4-6.

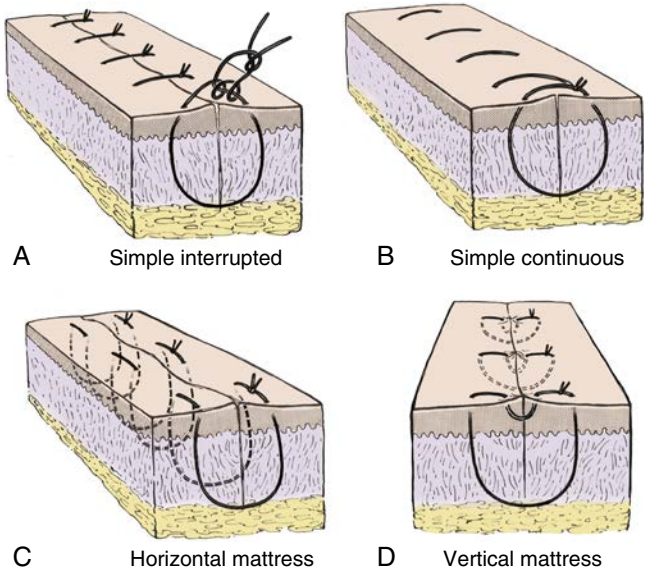

• **Figure 4-2** **A**, Simple interrupted suture. **B**, Simple continuous suture. **C**, Horizontal mattress suture. **D**, Vertical mattress suture. (From Sykes MJ, Byorth PJ: Suture needles and techniques for wound closure. In Baker SR, Swanson NA editors: *Local flaps in facial reconstruction*, St Louis, Mosby, 1995, p 57, Fig. 9, with permission.)

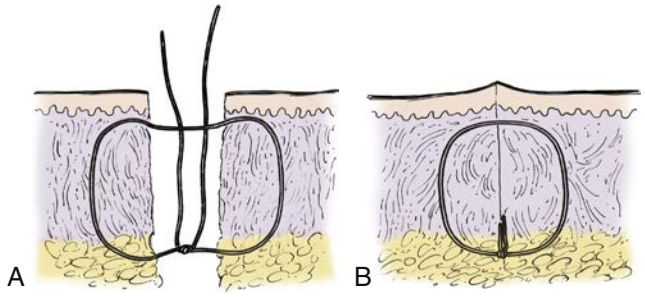

• **Figure 4-3** Schematic diagram of deep suture placement. Placement of deep sutures should eliminate dead space and accomplish wound edge approximation and eversion. (From Sykes MJ, Byorth PJ: Suture needles and techniques for wound closure. In Baker SR, Swanson NA editors: *Local flaps in facial reconstruction*, St Louis, Mosby, 1995, p 56, Fig. 7, with permission.)

Understanding suture ideal characteristics for both absorbable and nonabsorbable materials is important in selecting the proper suture. There is no ideal suture for all wounds, therefore taking into consideration the ideal characteristics of suture material is important for selection of each particular wound. Box 4-1 lists the ideal suture material characteristics.

Familiarity with suture material terminology gives the surgeon a better understanding of suture material characteristics. This enables the surgeon to choose the suture best suited for the purpose at hand. Table 4-1 lists suture terminology. An excellent regional guide for suture selection is in Table 4-2.

Suture materials are divided into natural fiber and synthetic fiber materials. Natural fibers are absorbable, although silk and cotton are extremely slow to be degraded over a period of several years and therefore considered to be nonabsorbable. Listed in Table 4-3 are natural materials and some of their characteristics, including tensile strength and absorption profile.

Synthetic fiber materials can be either absorbable or nonabsorbable. Absorbable synthetic fibers are polymers that degrade by hydrolysis and therefore cause less inflammation than natural fiber sutures. Listed in Table 4-4 are the absorbable synthetic suture materials and some of their characteristics, including tensile strength and absorption profile.

Synthetic nonabsorbable suture materials such as nylon and Prolene have long been the gold standard for cuticular closure. Nylon has a high level of elasticity and retains the

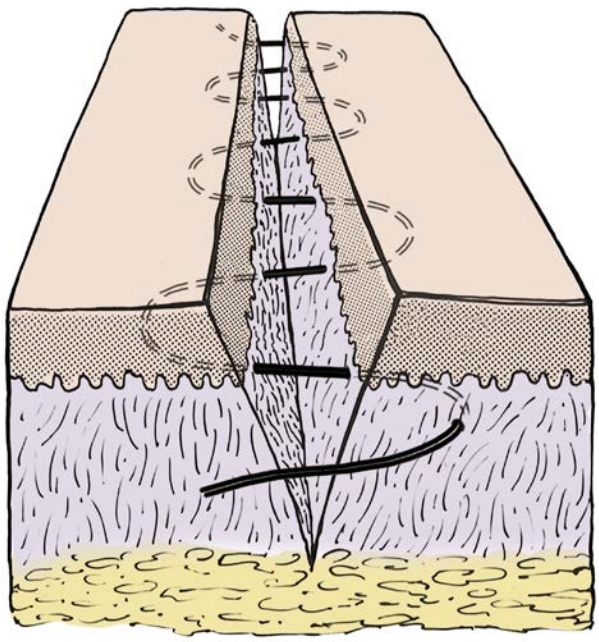

• **Figure 4-4** Intracuticular continuous suture. Cross-section of skin shows continuous suture at level of dermis to achieve maximal wound edge eversion. (From Sykes MJ, Byorth PJ: Suture needles and techniques for wound closure. In Baker SR, Swanson NA editors: *Local flaps in facial reconstruction*, St Louis, Mosby, 1995, p 58, Fig. 10, with permission.)

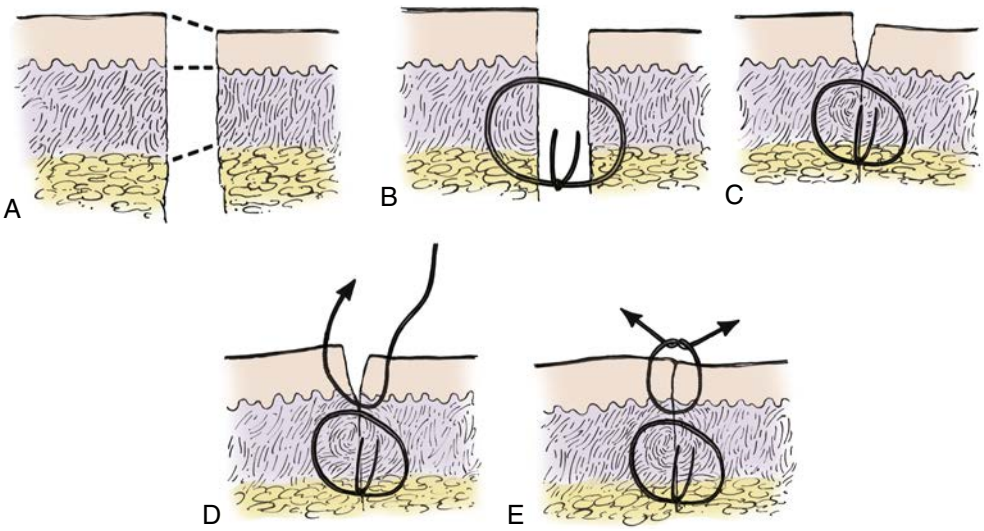

• **Figure 4-5** **A**, Schematic diagram illustrating two skin edges of unequal thickness. **B** and **C,** Placement of deep sutures in mismatched tissue to achieve maximal cutaneous alignment. Note suture is placed in dermis at deeper plane of thinner skin edge. **D** and **E,** Placement of cutaneous sutures in mismatched tissue to achieve maximal tissue eversion. (From Sykes MJ, Byorth PJ: Suture needles and techniques for wound closure. In Baker SR, Swanson NA editors: *Local flaps in facial reconstruction*, St Louis, Mosby, 1995, p 58, Fig. 11, with permission.)

most tensile strength of all synthetic materials. Prolene has the most pliability and knot-holding characteristic and is excellent for cuticular closure as well as vascular repair and approximation. Other synthetic suture materials have varied use as subcutaneous sutures for permanent holding characteristics. Table 4-5 lists the nonabsorbable synthetic suture materials and some of their characteristics.

Needle selection can be simplified into three categories: tapered, reverse cutting, and taper cutting. Further needle shapes are important for their particular utility and are divided based on their arc of curvature. Commonly used needles for wound closure include tapered for deep sutures and reverse cutting for skin closure. Tables 4-6 and 4-7 include needle types and shapes with their applications. Tissue sealants will be discussed in the section on postoperative wound care.

Principles of Wound Closure

Crikelair[14] listed the Halstedian fundamentals of surgical wound closure that apply to the management of any skin wound. These principles are: (1) place incisions to follow tension lines and natural folds in the skin; (2) handle tissue gently and debride only as much as necessary to ensure an adequately clean bed; (3) ensure complete hemostasis; (4) eliminate tension at the skin edges; (5) use fine sutures and remove them early; and (6) allow time for scars to mature before repeat intervention.

Wound closure requires a variety of surgical techniques for managing closure depending on the location of the wound, conformation of the wound (linear vs. curvilinear), depth of the wound, wound margins, and presence of abrasion, contusion, or avulsion. Isolated soft tissue wound closure should be performed as soon as possible, even with significant concomitant injuries. This approach has been shown to have improved postoperative esthetic outcomes.[14,15] Ideally, closure of facial soft tissue injuries should occur within the first 8 hours after injury. Soft tissue swelling associated with delay in wound closure can obscure anatomic landmarks and make primary closure more difficult. Closure in the ED requires meticulous cleaning of debris under nerve block with local anesthesia prior to closure.[16] Contraindications to primary closure in the ED include extensive lacerations, tissue closure that would result in significant tension, wounds that require complex tissue rearrangement, significant wound contamination, concomitant injuries that require general anesthesia (duct and nerve injuries), and inability to achieve adequate hemostasis or visualization in the ED setting. Wounds covering facial nerve or parotid duct injuries should be closed only after operative management of the deeper injury is complete.

Most lacerations can be treated using regional nerve blocks with small quantities of local anesthesia containing epinephrine and supplemented with 1:100,000 epinephrine solution where additional vasoconstriction is needed.[16] Pediatric patients who do not tolerate injection of local anesthesia may require conscious sedation for proper management of soft tissue injuries larger than 3 centimeters in length.

Optimizing wound healing through proper acute wound management involves removal of harmful debris/necrotic tissue, exploration for underlying injuries, control of bacterial burden, and multilayered closure. If wound contamination is present, wounds can be cleaned with a surgical antiseptic, preferably chlorhexidine gluconate.[17,18] Care must be taken not to scrub the wound because this can increase inflammation and result in poor esthetic outcome. Copious irrigation

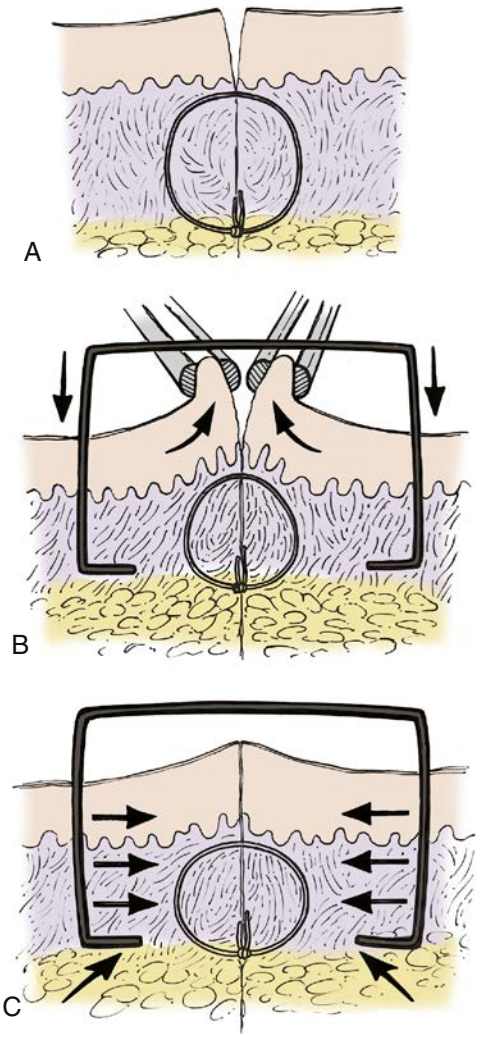

• **Figure 4-6** **A,** Deep tissue approximation required prior to placement of surgical staple. **B**, Tissue forceps approximating and everting skin edge during application of surgical staple. **C,** Appearance of surgical wound after appropriate placement of surgical staple. Note equal and well-distributed horizontal vector forces on tissue edge after appropriate placement. (From Sykes MJ, Byorth PJ: Suture needles and techniques for wound closure. In Baker SR, Swanson NA editors: *Local flaps in facial reconstruction*, St Louis, Mosby, 1995, p 59, Fig. 12, with permission.)

should be performed in all contaminated wounds and any wounds treated more than 6 hours after injury. Irrigation volumes of 50 to 100 mL per cm of laceration length have been reported to be appropriate for contaminated wounds. Clean, uncontaminated wounds treated early do not benefit from irrigation.[19] Pressure irrigation, which has been shown to improve decontamination of wounds, can be performed in the ED setting using a 35-cc syringe and an 18 gauge catheter. Longmire[21] found that pressures of 13 psi, generated by using a needle and syringe, were effective in reducing inflammation and infection when compared to irrigation using a bulb syringe associated with lower pressures. Pressures of 8-12 psi in the wound are believed to overcome the adhesive forces of the introduced bacterium.[20] After cleansing, all irregular wound edges and devitalized tissues should be debrided. In cases such as crush injuries where the extent of injury is unclear, tissues should be loosely approximated until the wound viability is assured.

• BOX 4-1 Ideal Suture Material Characteristics

- Minimal tissue injury
- Minimal tissue reaction
- Ease of handling
- High tensile strength
- Favorable absorption profile
- Resistance to infection

Marcus BC: Wound closure techniques. In Baker SR: *Local flaps in facial reconstruction,* ed 2, St Louis, 2007, Mosby.

Several key principles are necessary to achieve an optimal result when primarily closing traumatic wounds. First, a layered closure is critical to obliterate dead spaces and also to relieve tension on the epidermal layer. Deep closure can be accomplished with a variety of suture materials. Absorbable suture, generally 3-0 and 4-0, are appropriate for muscle layers, 4-0 or 5-0 absorbable sutures are appropriate for dermal closure, and 5-0 to 7-0 nonabsorbable monofilament sutures are used for skin layers. Cyanoacrylate tissue adhesive such as Dermabond (Ethicon) or use of Steri-Strips (3-M) are appropriate in pediatric patients with uncomplicated, clean lacerations as they have been shown to be time saving, cost effective, and are less painful for the patient.[21,22]

Ideally, definitive repair of bony and soft tissue injuries can be achieved in a single operation, as successive operations rarely improve functional outcomes.[23] In high-velocity or blast injuries, primary soft tissue closure is frequently not possible due to the need for multiple debridements. Clinically superior outcomes result from early soft tissue reconstruction, which prevents significant contracture and provides better coverage for later osseous reconstruction.[24] The presence of contamination has not been associated with an increase in perioperative or long-term complications, therefore contamination should not be considered a contraindication to this treatment approach.[25] Computed tomography angiography (CTA) is needed to evaluate recipient vessels for free flap reconstruction in patients with complex wounds. If palpable pulses are not appreciable and recipient vessels lie in the zone of injury, then CTA is the definitive method to evaluate vessel patency and integrity.

Management of Special Anatomic Units

The general principles apply to most facial lacerations, however, areas with specific facial anatomy require additional consideration. These areas include the esthetic units and subunits of the face (Figure 4-7) as well as the adjacent soft tissue needed for reconstruction. Scalp, although not considered an esthetic unit, also deserves special consideration due to the importance of its hair and the esthetic consequences from injuries.

TABLE 4-1 Suture Material: Definition of Terms

Absorbable Suture

Undergoes progressive loss of mass or volume (does not correlate with loss of tensile strength

Breaking Strength

Limit of tensile strength at which material (or tissue) failure occurs

Capillarity

Extent to which absorbed fluid is transferred along the strand

Elasticity

A measure of a suture's ability to regain its original form and length after deformation

Fluid Absorption

Ability to take up fluid after immersion

Knot Pull Tensile Strength

Breaking strength of a suture material, which can be 10% to 40% weaker after deformation by knot placement

Knot Strength

Amount of force necessary to cause a knot to slip, which is directly proportional to the coefficient of static friction and plasticity of a given material

Memory

A suture's inherent capability to return to or maintain its original gross morphologic shape; it is a function of elasticity, plasticity, and diameter

Nonabsorbable Suture

Undergoes no significant loss of mass or volume (does not correlate with retention of tensile strength

Plasticity

A measure of a suture's ability to deform without breaking and to maintain that new form after relief of the deforming force

Straight Pull Tensile Strength

Linear breaking strength of suture material

Suture Pullout Value

Limit of strength of a particular tissue as measured by the force applied to a loop of suture at which tissue failure occurs

Tensile Strength

A material or tissue's ability to resist deformation and breakage

Wound-Breaking Strength

Limit of tensile strength of a healing wound at which wound separation occurs

Coefficient of Friction

A numeric value that quantifies a material's surface characteristics that act to resist motion against another surface

Marcus BC: Wound closure techniques. In Baker SR: *Local flaps in facial reconstruction,* ed 2, St Louis, 2007, Mosby.

TABLE 4-2 A Regional Guide to Suture Selection

Region	Cutaneous Suture	Subcutaneous/ Fascia Suture	Comments
Eyelid and periorbital	#6-0, #7-0	#4-0, #5-0	Minimal tensile strength requirements Esthetic concerns at a premium
Nose and pinna	#5-0, #6-0	#4-0, #5-0	Small tensile strength requirements Esthetic concerns at a premium
Lip and vermilion	#6-0	#3-0, #4-0	Moderate tensile strength requirements due to highly active region Esthetic concerns at a premium
General facial and anterior neck	#5-0, #6-0 #4-0, #5-0	#3-0, #4-0	Moderate to high tensile strength requirements due to regional mobility Significant esthetic concerns
Nasal and oral mucosa	#3-0, #4-0	#3-0, #4-0	Moderate tensile strength needed due to tissue mobility May select based on ease or no need for removal No esthetic concern
Scalp and posterior neck	#3-0, #4-0	#2-0, #3-0	Tensile strength needed for moderate to heavy tissue and very mobile region Minimal esthetic concern
Superior trunk	#2-0, #3-0	#2-0, #3-0	Tensile strength needed for heavy tissue in a relatively mobile area
Major musculocutaneous flaps	#4-0, #5-0	#1-0, #2-0, #3-0	Maximal tensile strength needed because sutures are often under significant tension May require long-term tensile strength

Marcus BC: Wound closure techniques. In Baker SR: *Local flaps in facial reconstruction,* ed 2, St Louis, 2007, Mosby.

TABLE 4-3 **Natural Fiber Sutures**

Name	Source	Special Processing	Filament	Relative Tensile Strength*	Tensile Strength Profile†	Absorption Profile‡	Tissue Reaction	Ease of Use§
Absorbable								
Plain gut	Highly purified (nearly 100%)	None	Twisted	2	75% at 7 days	70 days proteolysis		
Chronic gut	Collagen derived from submucosa of sheep intestines or serosa of beef intestine	Chromium salt treatment resists breakdown Heat treated to speed up degradation	"virtual"	2	75% at 14 days 75% at 5 days	90 days proteolysis	5	4
Fast-absorbing gut			monofilament	2		60-70 days proteolysis		
Plain collagen	Beef achilles tendon	Chromium salt treatment	Twisted "virtual"		75% at 7 days 35% at 14 days	70 days proteolysis	4	3
Chronic collagen		Chromium salt treatment	monofilament			90 days proteolysis		
Nonabsorbable								
Silk	Silkworm	Coating with beeswax or silicone; dyed	Braided	1	Progressive loss over 1 year	Significant at 2 years proteolysis	4	1 (gold standard)
Cotton	Cotton seed		Twisted	1				2
Linen	Flax seed		Twisted	2				2
Surgical steel			Braided or monofilament	5	Significant loss only if kinked		1	5

*Relative tensile strength scale: 1 = least, 5 = greatest strength.
†Represents percentage of original dry, out of package tensile strength.
‡Represents relative tissue reaction: 1 = least, 5 = greatest reaction.
§Represents relative overall ease of use: 1 = easiest, 5 = most difficult.
Marcus BC: Wound closure techniques. In Baker SR: *Local flaps in facial reconstruction,* ed 2, St Louis, 2007, Mosby.

TABLE 4-4 **Absorbable Synthetic Sutures**

Name	Source	Special Processing	Filament	Relative Tensile Strength*	Tensile Strength Profile†	Absorption Profile	Tissue Reaction‡	Ease of Use§
Poliglecaprone 25 (Monocryl, Ethicon)	Synthetic copolymer glycolide and caprolate	Undyed	Monofilament	4 (1)	50-60% at 1 wk 20-30% at 2 wk 20% at 3 wk	90-120 days hydrolysis	2	1—very pliable elastic
Polydioxanone (PDSII, Ethicon)	Synthetic polymer polydioxanone	Undyed	Monofilament	4 (4)	70% at 3 wk 50% at 4 wk 25% at 6 wk	180-210 days hydrolysis	2	3
Polygalactin 910 (Vicryl, Ethicon)	Synthetic copolymer glycolide lactide	Dyed violet or undyed, coated galactin 370	Braid	4 (2)	65% at 2 wk 40% at 3 wk 8% at 4 wk	56-70 days hydrolysis	3	2
Polyglycolic acid (Dexons, Davis & Geck)	Synthetic polymer	Dyed or undyed, coated polycaprolate	Braid	4 (3)	65% at 1 wk 35% at 2 wk 5% at 4 wk	90-120 days hydrolysis	3	2
Polyglyconate (Maxon, Davis & Geck)	Synthetic polymer polytrimethylene carbonate	Dyed	Monofilament	4 (1)	75% at 2 wk 50% at 4 wk 25% at 6 wk	180-210 days hydrolysis	2	2

*Relative tensile strength scale: 1 = least, 5 = greatest strength.
†Represents percentage of original dry, out of package tensile strength.
‡Represents relative tissue reaction: 1 = least, 5 = greatest reaction.
§Represents relative overall ease of use: 1 = easiest, 5 = most difficult.
Marcus BC: Wound closure techniques. In Baker SR: *Local flaps in facial reconstruction,* ed 2, St Louis, 2007, Mosby.

TABLE 4-5 **Nonabsorbable Synthetic Sutures**

Name	Source	Special Processing	Filament	Relative Tensile Strength*	Tensile Strength Profile†	Absorption Profile	Tissue Reaction‡	Ease of Use§
Nylon Dermalon (Davis & Geck) Ethilon (Ethicon)	Synthetic polyamide	Clear or dyed	Monofilament	3	81% at 1 yr 72% at 2 yr 66% at 11 yr	Slow hydrolysis stable at 2 yr	2	2—low coefficient of friction
Nurolon (Ethicon) Surgilon (Davis & Geck)		Dyed, silicone coated	Braided	2	Same as above	Same as above	2†	1
Polybutester Novafi (Davis & Geck)	Synthetic copolymer polyglycol terephthate polytrithylene terephthate	Dyed blue	Monofilament	3	–	None	1	2—very elastic, very low coefficient of friction
Polyester Ticron (Davis & Geck) Ethibond extra (Ethicon)	Synthetic Dacron polyester	Dyed, silicone coated	Braided	3	–	None	2	2
Dacron (Davis & Geck) Mersilene (Ethicon)	Synthetic Dacron polyester	Dyed, uncoated	Braided	2	–	None	2	3
Polypropylene Prolene (Ethicon) Surgilene (Davis & Geck)	Synthetic polymer propylene	Dyed blue	Monofilament	2		None	1	3—very low coefficient of friction

*Relative tensile strength scale: 1 = least, 5 = greatest strength.
†Represents percentage of original dry, out of package tensile strength.
‡Represents relative tissue reaction: 1 = least, 5 = greatest reaction.
§Represents relative overall ease of use: 1 = easiest, 5 = most difficult.
Marcus BC: Wound closure techniques. In Baker SR: *Local flaps in facial reconstruction,* ed 2, St Louis, 2007, Mosby.

TABLE 4-6 Needle Point Types and Applications

	Type	Application
Taper	Aponeurosis Biliary tract Blood vessels Dura Fascia Gastrointestinal tract Muscle	Nerve Peritoneum Pleura Subcutaneous fat Urogenital tract
Conventional or reverse cutting	Dermis Ligament Nasal cavity Oral cavity Pharynx Skin Tendon	
Tapercut (tapered cutting point, very sharp)	Bronchus Dermis Ligament Nasal cavity Oral cavity Ovary Perichondrium	Periosteum Pharynx Sclerotic vessels Tendon Trachea Uterus

Marcus BC: Wound closure techniques. In Baker SR: *Local flaps in facial reconstruction,* ed 2, St Louis, 2007, Mosby.

TABLE 4-7 Needle Body Shapes and Applications

Shape	Application	
¼ circle	Eye Microsurgical	
⅜ circle	Aponeurosis Biliary tract Blood vessel Dura Eye Fascia Gastrointestinal tract Muscle Myocardium	Nerve Perichondrium Periosteum Peritoneum Pleura Tendon Urogenital tract
½ circle	Biliary tract Eye Gastrointestinal tract Muscle Nasal cavity Oral cavity Pelvis	Peritoneum Pharynx Pleura Respiratory tract Skin Subcutaneous fat Urogenital tract
⅝ circle	Cerebrovascular System Nasal cavity Oral cavity Pelvis	Urogenital tract
Compound curved ("J" shaped) Kieth (straight)	Cleft palate repair Eye Gastrointestinal tract Nasal cavity Oral cavity	Pharynx Skin Tendon Vessels

Marcus BC: Wound closure techniques. In Baker SR: *Local flaps in facial reconstruction,* ed 2, St Louis, 2007, Mosby.

Scalp

Scalp lacerations frequently bleed profusely due to the extensive blood supply and require good visualization to gain hemostasis. Head CT should be performed to rule out skull fractures prior to closure of scalp lacerations. Lacerations that are extensive are therefore better repaired in the operation room under more controlled conditions. Scalp lacerations with defects smaller that 3 cm can be closed primarily in most cases. Larger defects may require galea scoring to allow laxity for closure. Closure of the galea is important to achieve proper approximation of overlying soft tissue. Failure to close galea frequently results in a step defect in the scalp as illustrated in (Figure 4-8). Options for closure of larger defects in hair bearing areas include local rotational or advancement flaps, skin grafts provided pericranium is intact, burring the outer table when pericranium absence exposes bleeding bone to allow granulation tissue to form a vascular bed for skin grafting, and rotation of adjacent intact pericranium, galea, or temporoparietal fascia for a vascular base for skin graft coverage. This can later be followed with staged tissue expansion of the hair bearing areas for definitive scalp reconstruction. Pedicle flaps or free tissue transfer can be performed for large defects that cannot be managed solely with tissue expansion. Avulsion wounds of the scalp that are a result of blunt or shear forces have poor prognosis due to the vascular intimal damage that propagates proximal and distal within the vessels, and in such cases microscopic revascularization is generally unsuccessful. However, in large scalp avulsion injuries attempts should be made to revascularize when possible because reconstruction of hair bearing areas remain difficult without like tissue.

Forehead

Lacerations of the forehead should be comprehensively evaluated with special attention to cranial nerves V and VII. This is critical in the conscious patient and must be done prior to the use of any local anesthetic. Closure of wounds should follow the general principles described previously using conservative debridement and multiple layered closure. Avulsion defects that are smaller can be managed with rotational flaps or advancement local flaps based off the supraorbital or supratrochlear vessels. Larger tissue defects can be closed with split-thickness skin grafts followed by secondary tissue expansion for improved management of color and texture match with forehead skin. In cases where the entire esthetic unit is avulsed, skin grafting can result in an acceptable outcome without further treatment with distant flaps which often have poor color and texture match.

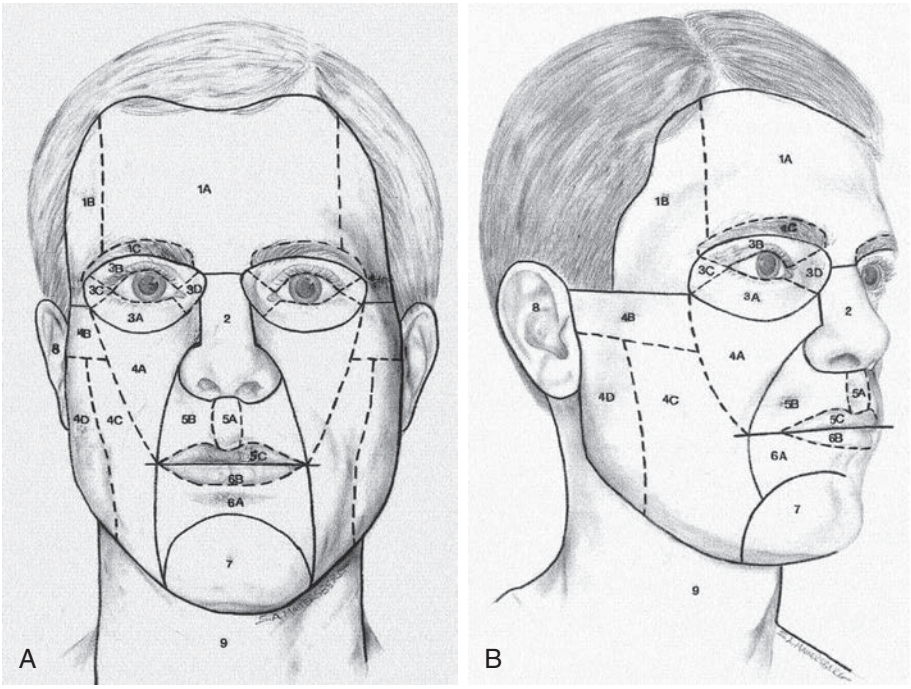

• **Figure 4-7** **A**, Frontal and **(B)** profile views of the esthetic units and subunits of the face. *1,* Forehead unit (*1A,* central subunit; *1B,* lateral subunit; *1C,* eyebrow subunit); *2,* nasal unit; *3,* eyelid units (*3A,* lower-lid unit; *3B,* upper-lid unit; *3C,* lateral canthal subunit; *3D,* medial canthal subunit); *4,* cheek unit (*4A,* medial subunit; *4B,* zygomatic subunit; *4C,* lateral subunit; *4D,* buccal subunit); *5,* upper-lip unit (*5A,* philtrum subunit; *5B,* lateral subunit; *5C,* mucosal subunit); *6,* lower-lip unit (*6A,* central subunit; *6B,* mucosal subunit); *7,* mental unit; *8,* auricular unit; *9,* neck unit. (From Fattahi TT. An overview of facial aesthetic units, *J Oral Maxillofac Surg* 61:1207–1211, 2003.)

Eyelid

Management of eyelid lacerations requires accurate identification of injury to all components of the eyelid. This involves upper lid, lower lid, medial canthus, lateral canthus, tarsal plates of upper and lower lid, levator aponeurosis, and lacrimal apparatus, as well as thickness of the injury and loss of tissue.[26] Timing of closure is not a critical factor owing to the excellent tissue vascularity in the periorbital area and in most cases a delay of 12 to 36 hours will not alter the outcome of the primary closure. Simple lacerations are closed anatomically in layers based on the tissues injured.[27] Closure materials include 5-0 and 6-0 plain gut for conjunctiva and orbicularis followed by 5-0 or 6-0 fast-absorbable plain gut or 6-0 nonabsorbable sutures for skin closure.

Lacerations of the lid margin and tarsal plate must be approximated anatomically and the lid margin everted with vertical mattress sutures using 6-0 silk to prevent notching (Figure 4-9). In lower lid lacerations anatomic approximation and support are important to prevent ectropion. The use of an orbicularis muscle sling sutured to lateral orbital rim using 5-0 Vicryl provides excellent support when laxity is present during repair. In upper lid lacerations levator aponeurosis integrity is important to establish to prevent postoperative ptosis. Presence of orbital fat implies a beach of the orbital septum indicating possible damage to the underlying levator palpebrae superioris muscle (Figure 4-10).



• **Figure 4-8** Poor outcome from scalp repair as a result of failure to close the galea in an anatomic closure.

When necessary, anatomic approximation of the aponeurosis with the tarsal plate can be performed with 6-0 or 7-0 polyglactin sutures placed central, medial, and lateral.[27] Medial lid lacerations require evaluation of the lacrimal ducts and canaliculi and appropriate ophthalmologic consultation for repair. Partial-thickness loss greater than



• **Figure 4-9** **A,**Through and through upper eyelid laceration managed with **(B)** closure of the palpebral conjunctiva using 6-0 plain gut with knot buried below conjunctiva. This is followed by tarsal plate repair with 6-0 polyglactin and skin closure with 6-0 polyprolene. Care must be taken to approximate margin anatomically and evert the gray margin using a horizontal mattress suture with 6-0 or 7-0 silk.

50% of either upper or lower lid requires full-thickness skin graft. Donor sites from the contralateral eyelid when adequate skin exists or postauricular (as opposed to retro auricular) full-thickness skin from the contralateral eyelid when available provide satisfactory match in thickness and color. Donor site deformities need to be prevented in both sites when using this technique. Local advancement flaps can be used in full-thickness tissue loss greater than one third of the upper lid in combination with lateral canthotomy and cantholysis. Greater loss of tissue may require myocutaneous flaps, whereas eyelid loss in excess of one half of the lid may require lid-sharing procedures of additional grafting, or both can be used for closure of defects up to 50% of the lid length (Figure 4-11). Avulsion injuries of eyelid can be repaired primarily if the horizontal length is less than one fourth of the upper lid or one half of the lower lid. Lower lid defects that are larger require lateral canthotomy and cantholysis or tarsal strip to allow for tension-free closure. A variety of single pedicle or bipedicle myocutaneous flaps from the apposing eyelid have been described for reconstruction of both upper and lower lid avulsion defects. Complete or near complete avulsion of upper and/or lower eyelid defects require switch flaps, composite flaps, cheek flaps, or forehead flaps. In complete upper and lower lid avulsion wounds it is critically important to protect the eye from further injury. Ophthalmic antibiotic ointment and protective shields should be employed for protection followed by early reconstruction. Establishment of medial and lateral canthus attachments is necessary to provide lid contour for globe protection.

Complete eyelid reconstruction can be achieved using microvascular transfer of dorsalis pedis with septal cartilage[28] or radial forearm flaps with palmaris longus tendon.[29] With severe injuries involving loss of the globe a complete prosthetic eye constructed by a maxillofacial prosthodontist is an excellent option and should be considered.

Lateral and medial canthus injuries occur frequently in lid injuries when lacerations in the adjacent area are full thickness. Repair requires primary canthopexy or canthoplasty when possible, but with more extensive injuries alternative repair may become necessary. Lateral canthus can be recreated with suture repair of the lower lid tarsus to the lateral orbit placed inside the rim. Medial canthus lacerations frequently involve the canaliculi or lacrimal apparatus and should be addressed with ophthalmologic consultation and the Jones dye test. A Jones I test can be performed using fluorescein dye placed in the eye and assessed for the presence of fluorescein in the nose after 5 minutes. If dye is present in the nose, a functional lacrimal apparatus is present. Without dye present, a Jones II test is performed by irrigating the nasolacrimal system with saline and having the patient expectorate the irrigation solution into a basin, where it is then checked for the presence of fluorescein. In the absence of a lacrimal apparatus injury, repair of the medial canthus is done with a method similar to that used in repair of Type III nasoorbitoethmoidal (NOE) injury.

Nose

Principles for repair of the nose are similar to those that apply to other special anatomic areas. With simple lacerations, anatomic approximation is performed using 5-0 chromic for mucosal lacerations and 5-0 or 6-0 nonabsorbable sutures for skin. The skin and soft tissues of the nasal tip and alar rim tend to be thick and relatively stiff, making primary closure of these regions more difficult. When cartilage lacerations are present, simple approximation with



• **Figure 4-10** Eyelid lacerations that appear innocuous with small skin loss as shown in **A** need to be explored as shown in **B**. As seen in **B**, there is a discontinuity of the levator aponeurosis and conjunctival laceration. Complete ophthalmologic exam needs to be performed before completion of repair. **C,** Completion of repair of the levator aponeurosis with 5-0 polydioxanone followed by repair of palpebral conjunctiva with 6-0 plain gut. This is followed by repair of the lid skin with advancement flap for final lid repair.



• **Figure 4-11** Complete loss of full-thickness lower lid as seen in **A**. Reconstruction with Hugh's tarsoconjunctival flap for posterior lamella and anterior lamella reconstructed with full-thickness skin graft from ipsilateral postauricular skin **(B).** Tarsoconjunctival flap is similar to an Abbey flap for lip reconstruction, however, division in inset is performed at 3 weeks.

monofilament absorbable sutures can prevent collapse of nasal ala and tip and improve esthetic outcome. The authors' have found that splinting significant lacerations that involve the alar margin and lower lateral cartilage with intranasal packs and external splints can reduce scar formation that results in external valve stenosis (Figure 4-12).

With tissue loss, successful reconstruction of soft tissue defects requires addressing all osseocartilaginous injuries or defects. Multiple algorithms have been devised for the evaluation and reconstruction of nasal defects.[30,31] Opinion varies with regard to reconstruction of the esthetic subunits of the nose. In the past, general consensus was that if a defect greater than 50% of a subunit is compromised, then the remainder should be excised so that the entire subunit can be reconstructed. Opinion is now shifting in favor of retaining as much of the anatomic structures of the nose and doing only esthetic subunits of the nose.[32] Partial-thickness defects over subunits with thinner skin can be closed using postauricular full-thickness skin grafts with reasonable esthetic outcome. Thicker skin defects of nasal tip and alae can be reconstructed with retroauricular full-thickness skin grafts; however, a better option is preauricular full-thickness grafts, which have better thickness and color match. With larger defects involving more than just tip, local and regional flaps such as dorsal nasal, cheek advancement, nasolabial, and paramedian forehead flaps are used for repair (Figure 4-13).

Extensive avulsion of soft tissue resulting from high-velocity projectiles or amputation from mechanical devices that cannot be closed with local or regional flaps requires bone graft and free flap reconstruction and often produces less than desirable esthetic results. In such cases, as with total avulsion of eyelid and ear defects, total nasal prosthetic reconstruction by a maxillofacial prosthodontist is an excellent option (Figure 4-14).

Lips

Anatomic landmarks are key to proper management of lip lacerations in restoring esthetics, motor function, and sensory function. Identification and marking of key landmarks such as the vermillion border, Cupid's bow, and commissure prior to injection of local anesthesia is important. Alignment of vermillion border is critical to the final esthetic outcome because the human eye can detect as little as 1 mm of discrepancy in vermillion continuity. Simple lacerations of the lips can be managed using the basic principles of wound closure. After thorough irrigation and wound debridement, closure of skin can be performed using 4-0 polyglactin or polydioxanone suture for deep tissue and intradermal approximation with 6-0 permanent monofilament skin sutures. If lip mucosa only is involved, irrigation and debridement is performed followed by closure with 3-0 or 4-0 chromic gut in a single layer fashion. Through and through lip lacerations should be closed from inside out. Following irrigation and debridement, mucosal closure can be performed with 3-0 or 4-0 chromic gut in a running locking fashion creating a watertight seal. If necessary, several interrupted sutures can be placed for proper anatomic alignment prior to placement of the running suture. Irrigation is performed extraorally to minimize oral bacterial contamination. Approximation of muscle with interrupted 3-0 or 4-0 polyglactin or polydioxanone is followed by intradermal approximation with 4-0 or 5-0 polyglactin or polydioxanone. Skin approximation should be accomplished with intradermal sutures to align the epidermis and prevent tension, followed by closure of skin with 6-0 cuticular sutures.



• **Figure 4-12** **A,** Complex nasal laceration with tacking suture used for temporary closure before definitive repair in the operating room. Repair requires minimal debridement and multiple layered anatomic closure. Extensive laceration with upper lateral cartilage avulsed from nasal bones, septum separated from upper lateral cartilages, septum fractured and separated from upper and lower lateral cartilages, and left lateral crus of lower lateral cartilage transected seen in **(B)**. Complete repair with suture repair of septum and lower lateral cartilage with 5-0 polydioxanone, transnasal repair of mucosa with 5-0 chromic, and layered closure of skin with 4-0 polygalactin and 5-0 polypropylene seen in **(C)**.

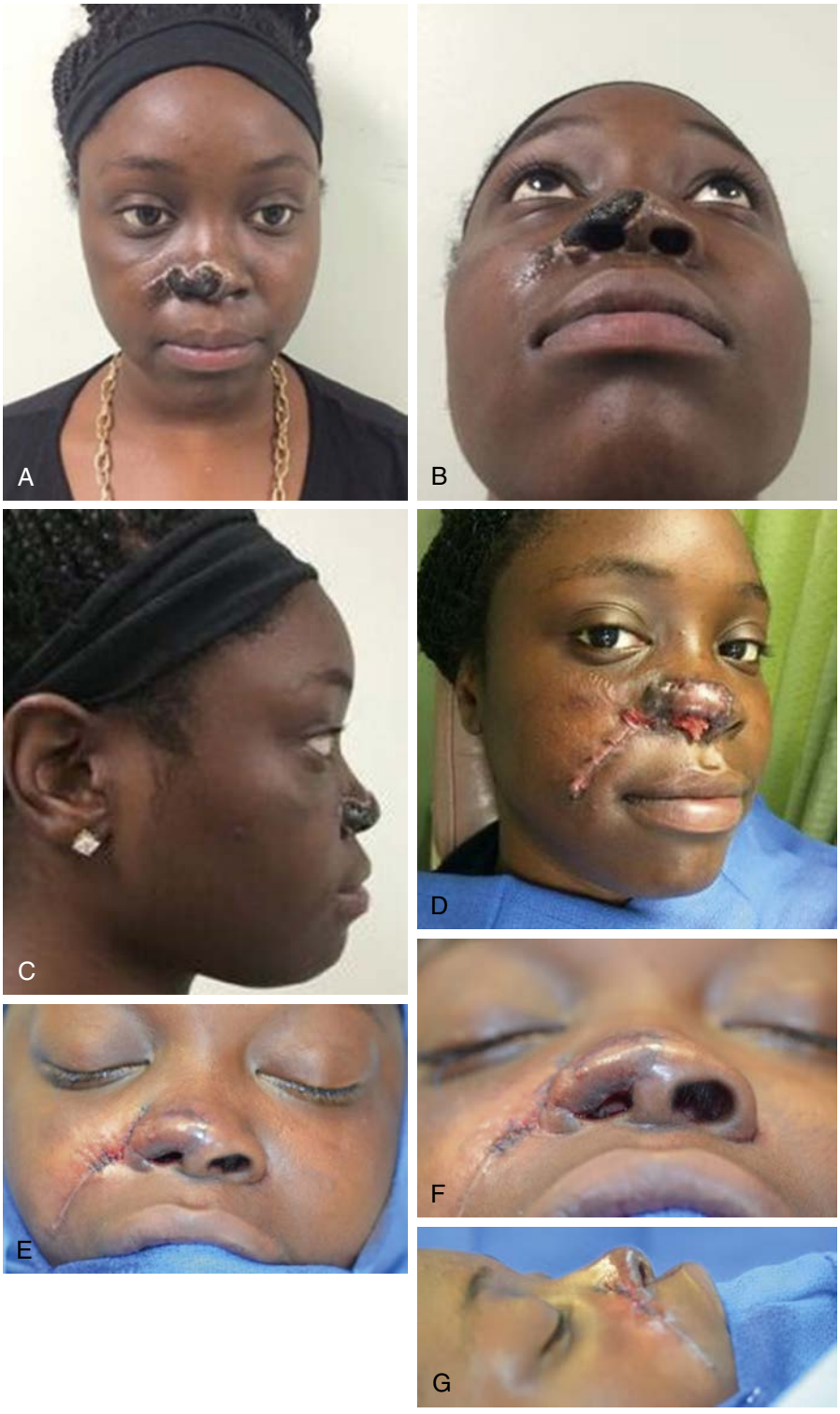

• **Figure 4-13** Composite loss of nasal tip involving portions of lateral crus, caudal septum, and nasal tip skin and mucosa **(A-C).** Patient at 1 week postoperative after reconstruction with nasolabial flap with auricular cartilage grafts from conchal bowl for medial and lateral crus reconstruction, and bipedical nasal mucosal flap for intranasal lining **(D).** Patient seen immediately postoperative following modification of the nasolabial flap inset to reestablish an esthetic nasofacial groove **(E-G).** Note the marked improvement of the nasolabial scar at 6 months.

Lip wounds may suggest significant tissue loss on first impression; however, by a careful approximation, it becomes apparent in many cases that most if not all of the tissue is present. When avulsion wounds exist in the lips it is important to assess the quantity of missing tissue. The lower lip is functionally more important than the upper lip because it maintains oral secretions and prevents drooling. The lower lip can tolerate up to one third loss of tissue and still be managed with primary closure. Upper lip avulsions are similar, with the exception of reestablishing normal Cupid's bow and philtral column anatomy. Esthetic outcome from upper lip loss is much less desirable than in the lower lip.



• **Figure 4-14** Patient with prosthetic nose following traumatic loss of all external nasal tissue.

Management of lip avulsion wounds can be accomplished with lip switch procedures such as the Abby-Elslander and reverse Abby-Elslander technique for defects of upper and lower lip, respectively. Lip switch procedures have major advantage in that lost tissue is replaced with like tissue. Bilateral and unilateral Karapanzic flaps can be employed for larger avulsion defects greater than one half the lip length, with the ultimate outcome dependent on the neurovascular supply of the lip for its functional maintenance.

In significant loss of upper and/or lower lip from large avulsion wounds such as gunshot wounds, it is often necessary to create lip tissue from distant free tissue transfer. Microvascular reconstruction with radial forearm and anterolateral thigh (ALT) can provide necessary tissue for lower lip with good outcome.[33,34]

Ears

Lacerations of the ear typically involve both skin and cartilage because of the thin nature of ear skin and its strong adherence to the underlying cartilage. As with all facial lacerations, the basic principles of wound management apply. Debridement of cartilage should be kept to a minimum because extensive cartilage removal results in significant deformities. Simple lacerations require skin closure only with skin adherence acting as a splinting mechanism. Permanent nonabsorbable sutures are used in most cases, but in young children and infants fast-absorbing gut is preferable.

Complex lacerations that lack support from cartilaginous injury require cartilage sutures. Absorbable monofilament 5-0 sutures such as PDS are preferable due to its absorption properties (Figure 4-15). Suture knots should be placed on the posterior of the cartilage repair, as knots on the anterior surface are visible and frequently become exposed. This is due to the tighter adherence of skin on the anterior surface versus the posterior skin. Following complex repair of ear



• **Figure 4-15** **A,** Complex forehead, lateral eyelid, cheek laceration, abrasion, contusion. Repair required copious irrigation, debridement of foreign material and nonviable severely contused cheek tissue with preservation of frontal branch of cranial nerve (CN) VII followed by multiple layered repair of soft tissue reapproximation with 5-0 polydyoxalene and multiple 6-0 prolene seen in **(B)**. Postoperative wound dressings included Bacitracin, adaptic gauze, 4-by-4 gauze, and Tegaderm occlusive bandage for management of the abrasion.

lacerations it is wise to apply a contouring bandage to provide support as well as prevent hematoma or serosa formation under the skin, which can result in a cauliflower ear deformity. The authors' preference for contour bandages is bacitracin-saturated cotton ball that can be placed into the contours of the ear from conchae to helical fold. Once the contours are filled, applications of 4-by-4 gauze front and back are placed followed by a mastoid bandage, as shown in Figure 4-16. The bandage is kept in place for 5 to 7 days.

Partial loss of ear skin can be repaired with split-thickness skin grafts taken from the contralateral ear postauricular skin. Adequate splinting to prevent hematoma and seroma is essential for survival of the graft (Figure 4-17). Lacerations that result in near avulsion should first be assessed for arterial inflow as well as venous outflow. In partial amputation with relatively large pedicle, the prognosis is good following conservative debridement and meticulous repair. If the pedicle is narrow, the chance of venous congestion is much higher. When outflow is inadequate, venous micro anastomosis is necessary. If unsuccessful, leech therapy can be used until adequate outflow channels are established (Figure 4-18). Pressure on the ear should be avoided during this period. As with complete avulsion of the scalp, mechanism of injury is a strong predictor of success. Injuries that are sharp avulsion have much better success of revascularization than those that are shearing and crushing in nature.

In complete traumatic loss of the ear excellent results can be obtained by implant-retained auricular prosthesis (Figure 4-19).



• **Figure 4-16** Mastoid bandage placement provides excellent support and compression over ear repairs and reconstructions. Bandage consists of cotton balls saturated in antibiotic ointment and placed in the contours of the ear anatomy followed by 4-by-4 gauze behind and covering the ear. This is followed by Kerlex wrapped as shown and tied in place over the forehead with suture or umbilical string.

Parotid Duct

Lacerations of the cheek that lie in a line from the tragus to the ipsilateral mid-upper lip and extend deep to the superficial muscular aponeurotic system (SMAS) need to be explored for parotid duct injuries and facial nerve injuries.[35]

Lacerations through parotid fascia in this area have high probability of duct injury. Cannulation of Stinson's duct, located adjacent to the first molar tooth, should be done and visualized in the open wound. Cannulation can most easily be performed with a J-wire and followed by a catheter placed over the J-wire. Injection of materials such as methylene blue or propofol allows documentation of duct injury. Direct visualization is difficult without adequate lighting and hemostasis, therefore this type of laceration repair should be done in the operating room. If duct laceration is within the hilum of the gland, stick tie suture ligation should be placed in the hilum, followed by ligation of the distal stump of the duct. If the ductal injury is more distal, anastomosis should be performed over the catheter with 8-0 nylon under microscopic or loop magnification. The catheter should be sutured in place intraorally and left

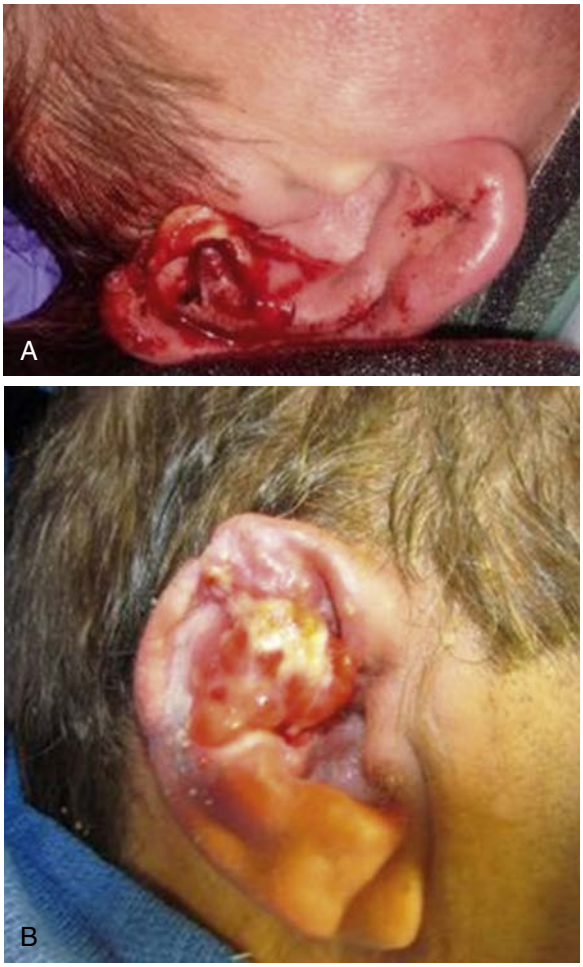

• **Figure 4-17** Ear partial skin avulsion seen in **(A)** before repair. Split-thickness skin graft reconstruction placed over pericondrium but without adequate splinting failed. The wound was allowed to granulate resulting in a cauliflower ear deformity seen in **(B).**



• **Figure 4-18** **A,** Near complete avulsion of ear. **B,** Superior pedicle with marginal blood supply after reattachment showing moderate cyanosis. **C,** Leech therapy applied to attempt for adequate venous outflow.

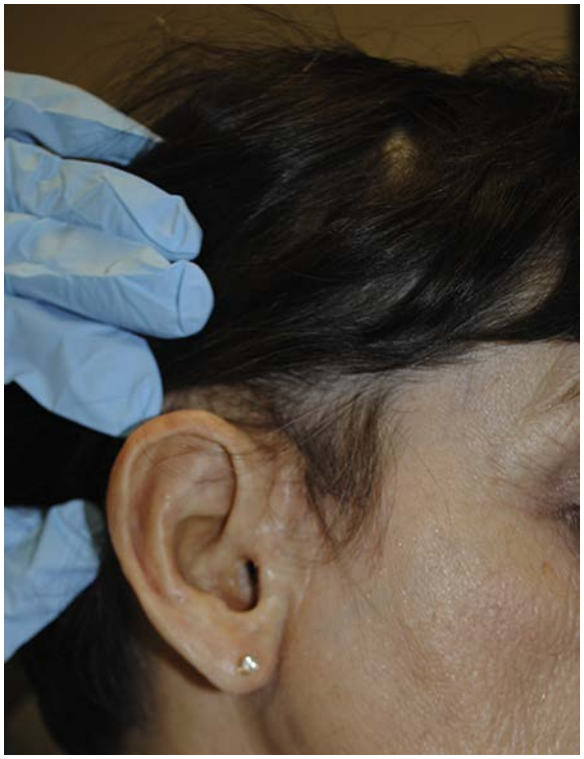

• **Figure 4-19** Excellent esthetic reconstruction with complete auricular prosthesis following total loss of auricle.

for a minimum of 2 weeks. Antibiotics and antisialogogues should be prescribed.

Sialocele is not uncommon with duct or gland injury. Initial management is with pressure dressing and antisialogogues.[36]

Facial Nerve

Laceration of the facial nerve can result from penetrating injuries to complex facial lacerations that involve structures deep to the SMAS (superficial musculoaponeurotic fascia). Complete examination of all branches of the facial nerve function should be performed on initial exam. If injury is proximal to the parotid gland, the main trunks of facial nerve may be involved and must be repaired. The use of local anesthesia should be delayed until the function of the facial nerve has been established. Injuries proximal to a vertical line drawn from the lateral canthus require exploration and repair. If anterior to the parotid gland, the branches of facial nerve are examined under loop magnification or operating microscope. The nerve stimulator is useful for identification of the distal segment within 48 hours of injury. After 48 to 72 hours, the distal nerve segments will no longer conduct the impulse.[37] Early microscopic epineural and perineural repairs with 9-0 or 10-0 nylon result in the best clinical outcomes and therefore should be the primary objective if facial nerve transection is identified. If both proximal and distal ends cannot be identified, suture tags should be placed for future exploration. (A more in-depth discussion is beyond this chapter and will be deferred.)



• **Figure 4-20** Penetrating neck injury dissecting in a subcutaneous level that extends for the mandibular border to below the level of the cricoid cartilage anteriorly and posterior to the sternocleidomastoid muscle. Computerized tomographic angiography was negative.

Neck

Penetrating injuries to the neck in the past have been classified according to the zone involved: zone I extends from the level of the clavicles and sternal notch to the cricoid cartilage, zone II extends from the cricoid cartilage to the angle of the mandible, and zone III extends from the angle of the mandible to the base of the skull. Injuries to the neck can involve deep structures affecting the vascular, respiratory, digestive, neurologic, endocrine, and skeletal structures. If injury of major vessels is suspected, computerized tomographic angiography (CTA) should be performed before exploration (Figure 4-20). Imaging triage can now accomplish what operative or selective evaluation could not: a safe and noninvasive evaluation of critical neck structures to identify or exclude injury based on trajectory, the key to penetrating injury management. A comprehensive physical examination combined with CTA is adequate for triage to effectively identify or exclude vascular and aerodigestive injury after penetrating neck trauma.[38]

Postoperative Care

Routine use of antibiotics should not necessarily be employed as a component of postoperative care in most facial lacerations; however, antibiotic prophylaxis is recommended in patients with prosthetic joints, patients at risk for endocarditis, patents receiving corticosteroid therapy,

TABLE 4-8 Characteristics of Tetanus-Prone Wounds

Clinical Features	Tetanus-Prone Wounds	Nontetanus-Prone Wounds
Age of wound	More than 6 hours	6 or fewer hours
Configuration	Stellate wound	Linear wound
Depth	More than 1 cm	1 cm or less
Mechanism of injury	Missile, crush, burn, or frostbite	Sharp surface (eg, knife)
Signs of infection	Present	Absent
Devitalized tissue	Present	Absent
Contaminants (dirt, feces, soil, saliva)	Present	Absent
Denervated or ischemic tissue or both	Present	Absent

From Edlich RF: Principles of emergency wound management, *Ann Emerg Med* 17(12):1284–1302, 1988, with permission.

and in immune compromised patients (e.g., diabetes mellitus, HIV, chemotherapy).[39] Other risk factors for infection include increased age, puncture wounds, impact wounds, presence of foreign bodies in the wound, heavy contamination, jagged wound edges, lacerations deeper than the subcutaneous layer, and wide gaping lacerations. These categories should strongly be considered for antibiotic therapy.[40-42] Through and through lacerations involving oral mucosa require clinical judgment. The choice of antibiotics should contain an active agent against staphylococci and β-hemolytic streptococci, such as a first-generation cephalosporin or penicillinase-resistant penicillin.[43] Wounds that have gross contamination and/or delay in time of wound closure should be considered for antibiotic therapy. A controlled study by Ichikawa found baseline wound infection rates that varied by degree of contamination: 2.6% in clean-contaminated, 5.8% in contaminated, and 20.8% in dirty wounds. Tetanus prophylaxis should be given according to the patient's immunization history (Tables 4-8 and 4-9).

Current CDC guidelines recommend a tetanus vaccine for wound management based on vaccination history and wound severity. All patients with an unknown vaccination history or who have received fewer than three doses should receive a tetanus diphtheria vaccine (Td). Inadequately vaccinated patients with anything other than a clean, minor wound should also receive tetanus immune globulin (TIG). Patients who have received three or more tetanus vaccines prior to the injury only need Td vaccination if their previous dose was more than 10 years ago for clean, minor wounds or 5 years for other wounds.

TABLE 4-9 Recommendations for Tetanus Prophylaxis

	DTP* (0.5 mL IM)	TIG (250 U IM)	TD¶ (0.5 mL IM)	TIG (250 U IM)
History of adsorbed tetanus toxoid (for children < 7 yr)				
Unknown or < 3 doses	Yes†	Yes‡	Yes†	Yes
3 or more doses	No¶	No	No¶	No

NOTE: All dog and cat wounds should be considered tetanus-prone wounds.
*Use diphtheria, tetanus (DT) if pertussis vaccine is contraindicated.
†The primary immunization series should be completed.
‡Administer in contralateral extremity.
¶Use diphtheria, tetanus, pertussis (DTP) for children <7 years old (DT if pertussis vaccine is contraindicated); TD is preferred to T if patient is ≥ 7 years old.
¶Yes, if > 5 years since last dose. (More frequent boosters are unnecessary and may accentuate side effects.)
§ Yes, if the routine immunization schedule has lapsed or if more than 5 years since last dose of tetanus toxoid.
IM, intramuscular; *TIG,* tetanus immune globin.
From American College of Emergency Physicians: Tetanus immunization recommendations for persons seven years of age or older, *Ann Emerg Med* 15:1111–1112, 1986; and American College of Emergency Physicians: Tetanus immunization recommendations for persons less than seven years old *Ann Emerg Med* 16:1181–1183, 1987, with permission.

Animal and Human Bites

Animal and human bite wounds are common and can cause significant morbidity and even mortality.[44] Types of bite wound injuries can be classified as abrasion, puncture, laceration, and avulsion. The majority of animal bite wounds are caused by dogs, with approximately 800,000 bite wounds per year in the United States, followed by cat wounds at 400,000 per year, and then human bite wounds[45,46] (Box 4-2). Appropriate wound management is the single most important factor in preventing infection in this patient population, and increasingly, dog bite wounds are a source of litigation due to improper management.[45,47]

Most dog bite wounds occur in children. The head and neck is the most common site of injury in children younger than 9 years old, whereas in children 10 years or older the

• BOX 4-2 Dog Bite Statistics

- 77.5 million dogs in the United States
- 4.5 million dog bites each year
- 1 in 5 bitten; 885,000 require medical attention
- Half of these are children:
  - Age 5 to 9 years; mostly boys
  - Face, head, and neck: 50% to 70%
- Adult victims, 5% to 15%: face, head, and neck
- In 2012, 27,000 underwent reconstructive surgery
- Most dog bites occur in or close to home and known to child/family

Gilchrist J, Sacks JJ, White D, Kresnow MJ: Dog bites: still a problem? *Inj Prev* 14(5):296-301, 2008; Centers for Disease Control and Prevention (CDC): Nonfatal dog bite-related injuries treated in hospital emergency departments—United States, 2001; *MMWR Morb Mortal Wkly Rep* 52(26):605-610, 2003.

TABLE 4-10 Retrospective Review of Bite Wounds for 2013 at Memorial Hermann Hospital TMC Houston, Texas

Soft Tissue Injuries	Total: 90	Hard Tissue Injuries	Total: 5
Face	31	Skull	1
Eye	18	Nasal	1
Lip	16	Dental	1
Scalp	11	Jaw	2
Nose	6		
Neck	5		
Ears	3		

extremities are the most commonly involved site[48] (Table 4-10). Dog bites occur most frequently in the victim's home and the dogs are most often known by the victim. Dog bite forces can vary considerably from 310 kPA to nearly 31,700 kPA in trained attack dogs.[49] Due to the high bite forces with these injuries, the possibility of underlying bony injury must not be overlooked.

Due to their rounded teeth and strong jaws, dog bite wounds are often crush-type injuries.[50] The wounds are most often polymicrobial with *Pasturella multocida*, *Pasturella canis*, *Streptococcus* species; *Staphylococcus* species and *Capnocytophagia canimorus* being the most commonly isolated pathogens[50] (Box 4-3). Amoxicillin/clavulanic acid (Augmentin) provides coverage for some penicillin-resistant *S. aureus* species and *Pasturella* species and is the preferred prophylactic antibiotic[49] (Box 4-4). Whether empirical prophylaxis is required for all bite wounds is unclear based on available literature; some authors argue for routine prophylaxis and others for prophylaxis in only high-risk cases.[51,52] Due to the rich vascular supply of facial tissue, immediate closure of bite wounds is typically safe even with old

• BOX 4-3 Microbiology of Bites

- Oral flora of dog and skin of human
- Common pathogens in order of prevalence:
  - *Pasturella multocida*: soft tissue inoculation, septic arthritis, osteomyelitis
  - Staphylococci
  - Streptococci
  - Anaerobic bacteria
  - Capnocytophaga: sepsis, meningitis

• BOX 4-4 Empiric Intravenous Antibiotic Therapy

Options for empiric gram-negative and anaerobic coverage include:

- Monotherapy with a beta-lactam/beta-lactamase inhibitor:
  - Ampicillin-sulbactam 3 g every 6 hours 50/mg/kg/dose (based on ampicillin component) every 6 hours
  - Piperacillin-tazobactam 4.5 g every 8 hours 125 mg/kg/dose (based on piperacillin component) every 8 hours
  - Ticarcillin-clavulanate 3.1 g every 4 hours 50 mg/kg/dose (based on ticarcillin component) every 4 hours
  - A third-generation cephalosporin in such as ceftriaxone 1 g IV every 24 hours

PLUS

- Metronidazole 500 mg IV every 8 hours (Metronidazole 10 mg/kg/dose every 8 hours)

OR

- A third-generation cephalosporin in such as ceftriaxone 100 mg/kg/dose every 24 hours

• Box 4-5 Rabies

- Neurotropic viruses: rhabdoviridae family
- Animal quarantine
- Rare in United States: 47 deaths from 1990 to 2005
- Geographic variation: U.S./Mexico border
- Wound care: Soap and water; povidone iodine, rabies vaccines; rabies immune globulin

injuries.[53] Grossly contaminated crush wounds with delayed presentation (> 24 hours) deserve careful consideration of primary versus delayed closure. Good lighting, sterile technique, thorough irrigation of wounds using tap water or normal saline, removal of foreign bodies, and debridement of tissue are the mainstays of wound management. Cultures are indicated only in grossly infected cases.[49] The CDC recommends observation of healthy animals for 10 days and human vaccination only if the animal shows symptoms of rabies. In unprovoked bites or animals demonstrating other rabid behavior immediate vaccination is recommended[54] (Box 4-5). Tetanus immune globulin and toxoid are recommended in bite victims who have had two or fewer primary immunizations. Tetanus toxoid alone is recommended in



• **Figure 4-21** Superficial dog bite wound management. Initial wound management includes copious irrigation with normal saline, when contaminated, followed by debridement of all nonviable tissue. Wound cultures are only necessary when wound is infected. In dog bite wounds, prophylaxis consists of oral amoxicillin clavulanate for 3 to 5 days and tetanus immune globulin and tetanus toxoid as listed in Tables 4-8 and 4-9. Primary closure can be performed in noninfected wounds.

patients who have completed the primary immunization series but have not received a booster within 5 years.[55]

Some differences but many similarities exist between cat and dog bite wounds. Cat bites are more likely to cause a puncture injury with deep penetration, leaving only a small opening through which fluids can drain.[49] For this reason, cat bites are associated with a twofold higher risk of infection than dog bites.[49,50] Bacteria commonly isolated from cat bite wounds include: *P. multocida, Bartonella henselae* (the causative organism of Cat-scratch disease), *Streptococcus*, and *Staphylococcus* species. Copious irrigation of wounds with normal saline or tap water is recommended along with primary closure in the majority of cases. As with dog bite wounds, Augmentin is the prophylactic antibiotic of choice with good coverage of the most common pathogens.[49] Clindamycin should not be used alone due to poor coverage of *Pasturella* species. Similar tetanus and rabies prophylactic measures are recommended.

Human bite wounds often compress the skin, but rarely cause avulsion injuries as in dog or cat bites. However, left untreated, open human bite wounds can cause significant morbidity.[49] The most common pathogens associated with human bites include *Streptococcus* and *Staphylococcus* species as well as anaerobic bacteria *Eikenella*, *Fusobacterium*, *Peptostreptococcus*, and *Prevotella*. The prophylactic antibiotic of choice is Augmentin. Clindamycin should not be employed due to poor coverage against *Eikenella* spp.

Several cases are presented to illustrate the nature and management of these bites. Superficial dog bite wound management includes copious irrigation with normal saline, close inspection, debridement of nonvital tissue, use of appropriate antibiotic therapy, application of rabies and tetanus toxoid protocol, and primary closure in noninfected wounds (Figure 4-21).

Complex dog bite wounds by their nature involve greater loss of tissue, larger surface area, and damage to underlying structures such as bone, glands, nerves, and muscle. Two concepts should be kept in mind for pediatric patients. First is to achieve closure of the wound with either approximation or skin grafts in order to minimize scar tissue (Figure 4-22). In this case extensive undermining was done, which resulted in excessive tension on the surface. Although there was dehiscence early, at 8 months there was appreciable improvement eliminating the need for revision. In addition, by not using aggressive flap procedures one keeps more options on the table for use at a later time.

Another concept for pediatric patients is that the soft tissue scars tend to grow with the patients. Individual judgment is needed to choose between early or late revision. Certainly, degree of disfigurement and psychological needs must be factored in. Figures 4-23 and 4-24 represent a case where wide scar bands occurred following reapproximation of tissue where excessive tissue was lost initially. At 1 year, a decision was made for excision of the scar with advance flap closure. The results 6 months later helped mitigate the patient's psychological distress.

In cases where there is extensive loss of tissue and late sequela will result in major deformities, local flaps, and in some cases free flap reconstruction, should be considered. Loss of major parts of special anatomic structures such as nose, eyelids, and ears requires such management. Early nasal reconstruction with local flaps such as nasolabial or axial pattern forehead flaps results in superior esthetic outcomes than when management is delayed. Axial pattern forehead flaps can provide coverage of tissue loss of multiple esthetic units (Figure 4-25), whereas nasolabial flaps are limited to isolated reconstruction for smaller areas. Eyelid avulsion wounds require early intervention in order to protect vision. In extensive avulsion wounds of both upper and lower eyelid, local cheek flaps similar to the Mustarde flap can be used for lower eyelid reconstruction. Axial pattern forehead flaps or radial forearm free flap reconstruction can be used for upper lid reconstruction (Figure 4-26), resulting in less scar contracture and improved esthetic appearance. The reader is encouraged to review multiple reconstructive options for complex avulsion wounds of special anatomic areas prior to deciding on which method will be the best.



• **Figure 4-22** Reapproximation of tissue. This case is an example of a complex wound with gaping margins and partial avulsion **(A)**. In this case, extensive wound undermining is done with tight closure **(B)**. Although dehiscence occurred at one year postoperative, it is much improved **(C, D).** An important concept for pediatric wounds is obtaining wound closure by whatever means necessary (undermining, or skin grafts) because of positive impact to reduce the amount of scarring.



• **Figure 4-23** Wound (**A**), immediate closure (**B**), and one year postoperative (**C**).



• **Figure 4-24** A, Scar excision at 12 months post operative. B, Wound closure under minimal tension after extensive undermining prior to closure. C, Appearance at 18 months postoperative without revisions. Use caution in determining timing for revision. Revision is necessary because of wide scar ban.



• **Figure 4-25** **A-B,** Dog bite avulsion wound of the nasal tip. **C-D,** forehead flap reconstruction. (Courtesy Phillip Freeman, DDS, MD)



• **Figure 4-26** Scalp-forehead flap reconstruction. (Courtesy Phillip Freeman, DDS, MD)

Facial Burns

Facial burns produce significant changes in the physical features that are central to the human being. Features of facial expression, communication, feeding, phonation, and special sensory altered by burns can change the patient's entire individual identity. Early evaluation and management is critical in order to maintain or restore facial features essential to identity. There are many types of burns caused by different mechanisms, such as thermal, radiation, chemical, or electrical. Burns can occur at temperatures above 48 °C and are time dependent. Burn injury is classified based on the level of the injury to the skin.

First-degree burns would be similar to a sunburn and can produce mild to moderate pain depending on the level of burn. First-degree burns affect only the epidermis, or outer layer of skin. The burn site is red, painful, dry, and with no blisters. Long-term tissue damage is rare and usually consists of an increase or decrease in the skin color.

Second-degree burns involve skin and superficial dermis and are referred to as "partial thickness." Second-degree burns involve the epidermis and part of the dermis layer of skin. The burn site appears red, blistered, and may be swollen and painful. Partial-thickness burns may be further divided into superficial and deep depending on the level. Typically, second-degree burns form fluid-filled blisters, which result in the separation of the epidermis and dermis and produce moderate to intense pain.

Third-degree burns refer to full-thickness skin and extend though the dermis into subcutaneous tissue and classically are insensate and pale to translucent in appearance. Third-degree burns destroy the epidermis and dermis. Third-degree burns may also damage the underlying bones, muscles, and tendons. There is no sensation in the area because the nerve endings are destroyed. Third-degree injuries are beyond the scope of this chapter and the reader is encouraged to review more comprehensive literature for details.

Because the face involves orifices with both respiratory and gastrointestinal tract epithelium, it is essential to evaluate all areas in the advanced trauma life support (ATLS) secondary survey. Airway evaluation should include observation for signs of singed nasal hair, nasal and oropharyngeal soot, erythema of the oropharynx, carbonaceous sputum, dysphonia, stridor, dyspnea, rhonchi, and wheezing. Initial arterial blood gas (ABGs) and chest x-ray (CXRs) should be done as a baseline. Fiberoptic evaluation of the airway should be performed and, if clinical signs and symptoms of the above are present, intubation should be performed for airway protection. Oropharyngeal exam may show similar findings of edema, erythema, or carbonaceous material with signs of dysphagia. Ophthalmology examination should be performed to evaluate for singed eyelash and brow hair, lid edema and blistering, conjunctival edema and injection, corneal exam, visual acuity, and funduscopic exam. Incidence of ocular injury in facial burns approaches 27%.[56,57]

Evaluation of ears, nose, and eyelids for deep partial-thickness and full-thickness burns dictates specific treatment protocol.

Management

Prevention of airway compromise and death caused by pulmonary injury from facial burns should be the first priority. Humidified 0_2 by face shield, elevation of head of bed, and suction for excess secretions should be initiated early. Simultaneous to pulmonary resuscitation, attention should be given to fluid resuscitation. Burn resuscitation is beyond the scope of this chapter and the reader is encouraged to review literature that deals with such.

In the acute phase, gentle debridement of loose skin and debris should be performed and antiseptic soap (TechniCare Surgical Scrub Care-Tech Laboratories, Inc.) should be used to clean and decontaminate the burned skin. Reduction in the bacterial count with antiseptic soap reduces the risk of conversion of burn wound depth from bacterial infection. The use of chlorhexidine gluconate offers optimum antisepsis, rapid onset of action, and broad spectrum coverage for gram-positive, gram-negative, and virucidal activity.[58]

The use of topical antimicrobials that control and limit burn wound antimicrobials ideally should be broad spectrum; should exhibit long duration, low toxicity, and good penetration; and should be inexpensive and easy to use. By providing good penetration and broad-spectrum coverage, topical antimicrobials prevent conversion of burn wounds from zone of stasis to zone of coagulation necrosis, thus reducing the need for debridement and subsequent grafting.

Topical agents commonly used are silver preparations such as silver sulfadiazine, silver nitrate, and Acticoat (Smith Nephew, Hull, UK). Mafenide acetate (Sulfamylon, Bertek Pharmaceuticals, Morgantown, WV), a sulfonamide, provides fast, deep penetration with excellent antimicrobial spectrum. Antibiotic preparations such as Neosporin, Polysporin, and Bacitracin are the most commonly used agents for superficial burns. Polysporin and Bacitracin in combination with enzymatic debriding agents provides clean burn wounds in partial-thickness burns and results in outcomes superior to those obtained by silver sulfadiazine.[59] However, the use of enzymatic debriding agents in facial burns remains controversial and produces variable results.[60] Multiple alternative methods have been described including amnion,[61] honey,[62,63] sucralfate,[63] beta glucans,[64] and aloe vera.[65] Aloe vera appears to accelerate the sound healing process in both first- and second-degree burns compared to traditional topical treatments. Cadaveric allografts appear to be a superior biologic dressing for superficial and deep partial-thickness burns when compared with traditional management with silver sulfadiazine.[66] Bioengineered skin substitutes have also been compared to traditional management and show similar efficacy.

Once wound closure is achieved, early rehabilitation is begun before scar formation demonstrates hypertrophy. Therapeutic intervention includes pressure garments, masks, and orthotic devices. Such pressure devices improve scar maturation and redistribution of collagen fibers. Compliance with such devices is the primary challenge in the rehabilitative phase; however, without adequate post-burn rehabilitation outcomes are universally less than desirable.

The most common form of facial compression is the use of a mask in combination with compression garments. Openings are made in the garment and mask for nasal obturators and oral commissure spreaders to give continuous pressure in this area. Garments and masks are worn for up to 1 year or more, with modifications made every 6 to 8 weeks to maintain adequate compression. Garments and masks are removed only for short periods for bathing, eating, oral hygiene, and exercise.

Recent developments in the management of burn scars with the use of fractionated CO_2 laser have shown promise in early outcomes. Further studies need to be conducted to compare the efficacy of different rehabilitative modalities.

References

1. Hussain K, Wijetunge DB, Grubnic S, Jackson IT: A comprehensive analysis of craniofacial trauma, *J Trauma* 36:34–47, 1994.
2. Singer AJ, Thode Jr HC, Hollander JE: National trends in ED lacerations between 1992 and 2002, *Am J Emerg Med* 24(2):183–188, 2006.
3. Ong TK, Dudley M: Craniofacial trauma presenting at an adult accident and emergency department with an emphasis on soft tissue injuries, *Injury* 30:357–363, 1999.
4. Chang LT, Tsai MC: Craniofacial injuries from slip, trip, and fall accidents of children, *J Trauma* 63:70–74, 2007.
5. Le BT, Dierks EJ, Ueeck BA, et al.: Maxillofacial injuries associated with domestic violence, *J Oral Maxillofac Surg* 59:1277–1283, 2001. discussion 1283–1284.
6. Hogg NJ, Stewart TC, Armstrong JE, Girotti MJ: Epidemiology of maxillofacial injuries at trauma hospitals in Ontario, Canada, between 1992 and 1997, *J Trauma* 49:425–432, 2000.
7. Hochberg J, Ardenghy M, Toledo S, et al.: Soft tissue injuries to face and neck: early assessment and repair, *World J Surg* 25:1023–1027, 2001.
8. Holmgren EP, Bagheri S, Bell RB, Bobek S, Dierks EJ: Utilization of tracheostomy in craniomaxillofacial trauma at a level-1 trauma center, *J Oral Maxillofac Surg* 65:2005–2010, 2007.
9. Dickinson JT, Jaquiss GW, Thompson JN: Soft tissue trauma, *Otolaryngol Clin North Am* 9:331–360, 1976.
10. Berk WA, Osbourne DD, Taylor DD: Evaluation of the "golden period" for wound repair: 204 cases from a third world emergency department, *Ann Emerg Med* 17:496–500, 1988.
11. Chatterjee JS: A critical review of irrigation techniques in acute wounds, *Int Wound J* 2(3):258–265, 2005.
12. Edlich RF: Principles of emergency wound management, *Ann Emerg Med* 17:1284, 1988.
13. Reference removed in pages..
14. Crikelair GF: Surgical approach to facial scarring, *JAMA* 172:140, 1960.
15. Benzil DL, Robotti E, Dagi TF, et al.: Early single-stage repair of complex craniofacial trauma, *Neurosurgery* 30:166–171, 1992. discussion 171–172.
16. Aveta A, Casati P: Soft tissue injuries of the face: early aesthetic reconstruction in polytrauma patients, *Ann Ital Chir* 79:415–417, 2008.
17. Zide BM, Swift R: How to block and tackle the face, *Plast Reconstruc Surg* 101(3):840–851, 1998.
18. Peterson AF, Rosenberg A, Alatary SD: Comparative evaluation of surgical scrub preparations, *Surg Gynecol Obstet* 146:63–65, 1978.
19. Paulson DS: Comparative evaluation of five surgical hand scrub preparations, *AORN J* 60(246):249–256, 1994.
20. Hollander JE, Richman PB, Werblud M, et al.: Irrigation in facial and scalp lacerations: does it alter outcome? *Ann Emerg Med* 31:73–77, 1998.
21. Longmire AW, Broom LA, Burch J: Wound infection following high-pressure syringe and needle irrigation, *Am J Emerg Med* 5(2):179–181, 1987.
22. Osmond MH, Klassen TP, Quinn JV: Economic comparison of a tissue adhesive and suturing in the repair of pediatric facial lacerations, *J Pediatr* 126:892–895, 1995.
23. Goktas N, Karcioglu O, Coskun F, et al.: Comparison of tissue adhesive and suturing in the repair of lacerations in the emergency department, *Eur J Emerg Med* 9:155–158, 2002.
24. Berthe JV, Pelc P, Jortay A, Coessens BC: Do multiple consecutive head and neck reconstructions improve the patients' functional outcome? *Acta Otorhinolaryngol Belg* 56:391–397, 2002.
25. Motamedi MH: Primary management of maxillofacial hard and soft tissue gunshot and shrapnel injuries, *J Oral Maxillofac Surg* 61:1390–1398, 2003.
26. Stanley Jr RB, Schwartz MS: Immediate reconstruction of contaminated central craniofacial injuries with free autogenous grafts, *Laryngoscope* 99:1011–1015, 1989.
27. Spinelli HM, Jelks GW: Periocular reconstruction: a systematic approach, *Plast Reconstr Surg* 91:1017–1024, 1993. discussion 1025–1026.
28. Chang EL, Rubin P: Management of complex eyelid lacerations, *Int Opthalmol Clin* 42(3):187–201, 2002.
29. Thai KN, Billmire DA, Yakuboff KP: Total eyelid reconstruction with free dorsalis pedis flap after deep facial burn, *Plast Reconstr Surg* 104:1048–1051, 1999.
30. Ueda K, Oba S, Okada M, et al.: Eyelid reconstruction with a composite radial forearm palmaris longus tendon flap, *J Plast Reconstr Aesthet Surg* 60:256–259, 2007.
31. Guo L, Pribaz JR, Pribaz JJ: Nasal reconstruction with local flaps: a simple algorithm for management of small defects, *Plast Reconstr Surg* 122:130e–139e, 2008.
32. Parrett BM, Pribaz JJ: An algorithm for treatment of nasal defects, *Clin Plast Surg* 36:407–420, 2009.
33. Rohrich RJ, Griffin JR, Ansari M, Beran SJ, Potter JK: Nasal reconstruction—beyond aesthetic subunits: a 15-year review of 1334 cases, *Plast Reconstr Surg* 114:1405–1416, 2004. discussion 1417–1419.
34. Jeng SF, Kuo YR, Wei FC, et al.: Total lower lip reconstruction with a composite radial forearm-palmaris longus tendon flap: a clinical series, *Plast Reconstruct Surg* 113(1):19–22, 2004.
35. Futran ND, Farwell DG, Smith RB, et al.: Definitive management of severe facial trauma utilizing free tissue transfer, *Otolaryngol Head Neck Surg* 132:75–85, 2005.
36. Van Sickels JE, Alexander JM: Parotid duct injuries, *Oral Surg Oral Med Oral Pathol* 52(4):364–367, 1981.
37. Rodriguez-Bruno K, Papel ID: Rhytidectomy: principles and practice emphasizing safety, *Facial Plast Surg* 27(1):098–111, 2011.
38. Bagheri SC, Khan A, Bell RB: Penetrating neck injuries, *Surg Clin N Am* 20(3):393–414, 2008.
39. Hollander JE, Singer AJ, Valentine SM, Shofer FS: Risk factors for infection in patients with traumatic lacerations, *Acad Emerg Med* 8:716–720, 2001.

40. Singer AJ, Hollander JE, Quinn JV: Evaluation and management of traumatic lacerations, *N Engl J Med* 337:1142–1148, 1997.
41. Nakamura Y, Daya M: Use of appropriate antimicrobials in wound management, *Emerg Med Clin North Am* 25:159–176, 2007.
42. Cruse PJ, Foord R: A five-year prospective study of 23,649 surgical wounds, *Arch Surg* 107:206–210, 1973.
43. Medel N, Panchal N, Ellis E: *Postoperative care of the facial laceration craniomaxillofacial trauma and reconstruction* 3(4):189–200, 2010.
44. Mchiek JN, Vergnes P, Bondonny JM: Treatment of facial dog bite injuries in children: a retrospective study, *J. Pediatr Surg* 35:580–583, 2000.
45. Lackmann GM, Draf W, Isselstein G, et al.: Surgical treatment of facial dog bite injuries in children, *J Craniomaxillofac Surg* 20:81–86, 1992.
46. Griego RD, Rosen T, Ornego IF, Wolf JE: Dog, cat and human bites: a review, *J Am Acad Dermatol* 33(6):1019–1029, 1995.
47. Marcy SM: Infections due to dog and cat bites, *Pediatr Infect Dis* 1(5):351–356, 1982.
48. Hon KL, Fu CC, Chor CM, et al.: Issues associated with dog bite injuries in children and adolescents assessed at the emergency department, *Pediatr Emerg Care* 23(7):445–449, 2007.
49. Morgan M, Palmer J: Dog bites, *BMJ* 334:413–417, 2007.
50. Aziz H, Rhee P, Pandit V, et al.: The current concepts in management of animal (dog, cat, snake, scorpion) and human bite wounds, *J Trauma Acute Care Surg* 78(3):641–648, 2015.
51. Dire DJ, Hogan DO, Riggs MW: A prospective evaluation of risk factors from dog bite wounds, *Acad Emerg Med* 3:258–265, 1994.
52. Cummings P: Antibiotics to prevent infection in patients with dog-bite wounds; a meta analysis of randomized trials, *Ann Emerg Med* 23:535–540, 1994.
53. Donkor P, Bankas DO: A study of primary closure of human bite injuries to the face, *J Oral Maxillofac Surg* 55:479–481, 1997.
54. Centers for Disease Control and Prevention: *Rabies: domestic animals*, April 29, 2016. Web.
55. Centers for Disease Control and Prevention: Tetanus http://www.cdc.gov.
56. Bagby SK: Acute management of facial burns, *Oral Maxillofacial Surg Clin N Am* 17(3):267–272, 2005.
57. Bouchard C, Morno K, Perkins J: Ocular complications of thermal injury: a 3-year retrospective, *J Trauma* 50(1):79–82, 2001.
58. Leon-Villapalos J, Jeschke MG, Herndon DN: Topical management of facial burns, *Burns* 34(7):903–911, 2008.
59. Soroff HS, Sasvary DH: Collagenase ointment and polymyxin B sulfate/Bacitracin spray versus silver sulfadiazine cream in partial-thickness burns: a pilot study, *J Burn Care Rehabil* 15:13–17, 1994.
60. Klasen HJ: A review on the nonoperative removal of necrotic tissue from burn wounds, *Burns* 26:207–222, 2000.
61. Branski LK, et al.: Amnion in the treatment of pediatric partial-thickness facial burns, *Burns* 34:393–399, 2008.
62. Bangroo AK: Honey dressing in pediatric burns, *J Indian Assoc Pediatr Surg* 10:172–175, 2005.
63. Banati A, et al.: Topical use of sucralfate cream in secondand third degree burns, *Burns* 27:465–469, 2001.
64. Delatte SJ, et al.: Effectiveness of beta-glucan collagen for treatment of partial thickness burns in children, *J Pediatr Surg* 36:113–118, 2001.
65. Maenthaisong R, et al.: The efficacy of aloe vera used for burn wound healing: a systematic review, *Burns* 33:713–718, 2007.
66. Horch RE, et al.: Treatment of second degree facial burns with allografts-preliminary results, *Burns* 31:597–602, 2005.

5

Diagnosis and Management of Trigeminal and Facial Nerve Injuries

THOMAS SCHLIEVE, MICHAEL MILORO, ANTONIA KOLOKYTHAS

Introduction

The face and perioral regions are among the body regions with the highest density of peripheral nerve receptors, and this feature makes neurologic disturbances less tolerable in the head and neck than other body parts. The 5th (trigeminal) and 7th (facial) cranial nerves innervate the vast majority of structures involved in sensation and function of the face. The trigeminal nerve is the largest cranial nerve, with three main divisions including the ophthalmic, maxillary, and mandibular branches. It is a mixed motor (special efferent and proprioceptive) and sensory (general afferent) peripheral nerve. Injury to the peripheral branches of the trigeminal nerve can be devastating because of the effects on speech, deglutition, mastication, and taste, as well as impact on social interactions. The facial nerve innervates the muscles of facial expression in addition to providing taste sensation and parasympathetic stimulation to the lacrimal, submandibular, and sublingual salivary glands. Damage therefore not only is cosmetically and functionally cataclysmic but has detrimental effects on psychological, social, and economic well-being.

Unfortunately, injury to the trigeminal and facial nerve can occur rather easily from trauma, infection, or pathology, or from commonly performed procedures in the maxillofacial region. Throughout their careers, oral and maxillofacial surgeons often encounter patients with trigeminal and/or facial nerve injuries and should be proficient in diagnosing and managing these cases appropriately because successful outcomes from nerve injuries are critically time-sensitive. In this chapter the following topics are presented: an overview of the anatomy of the trigeminal and facial nerve; a basic overview of peripheral nerve microanatomy to assist the reader's understanding of the events following injury and a nerve's regenerative properties; the available imaging modalities; several potential causes of nerve injury; and the neurosensory testing available for appropriate evaluation and classification of nerve injuries. Finally, the treatment of trigeminal and facial nerve injuries and the expected outcomes are discussed.

Classification of Nerve Injuries

Several complex cellular events occurring in and around the nerve structure are responsible for the response to trigeminal and facial nerve injury and are required for the regeneration and restoration of neurosensory function. Two nerve injury classification schemes, Seddon and Sunderland, are described and provide for a correlation between the clinical symptoms and the histologic changes observed within the nerve structure at the time of injury. Seddon's classification is based on the time between injury and recovery and the degree of recovery, whereas Sunderland places an emphasis on the specific histologic degree of damaged neural structures.

Seddon Classification System

The Seddon classification system includes three levels of nerve injury (Figure 5-1): neuropraxia, axonotmesis, and neurotmesis.[1] In neuropraxic injuries, the integrity of the axon is maintained, and the injury indicates a local conduction block from a transient anoxic event due to acute vascular interruption of the epineurial or endoneurial vasculature. Neuropraxia is usually the result of a mild nerve manipulation, traction, or compression injury and is characterized by a reversible conduction block, with a favorable outcome and complete recovery within days to weeks of the event. No axonal degeneration occurs in neuropraxic injuries, and damage is confined to the endoneurium only. Axonotmesis involves axonal damage, corresponds to degrees II-IV Sunderland injuries, demonstrates variable

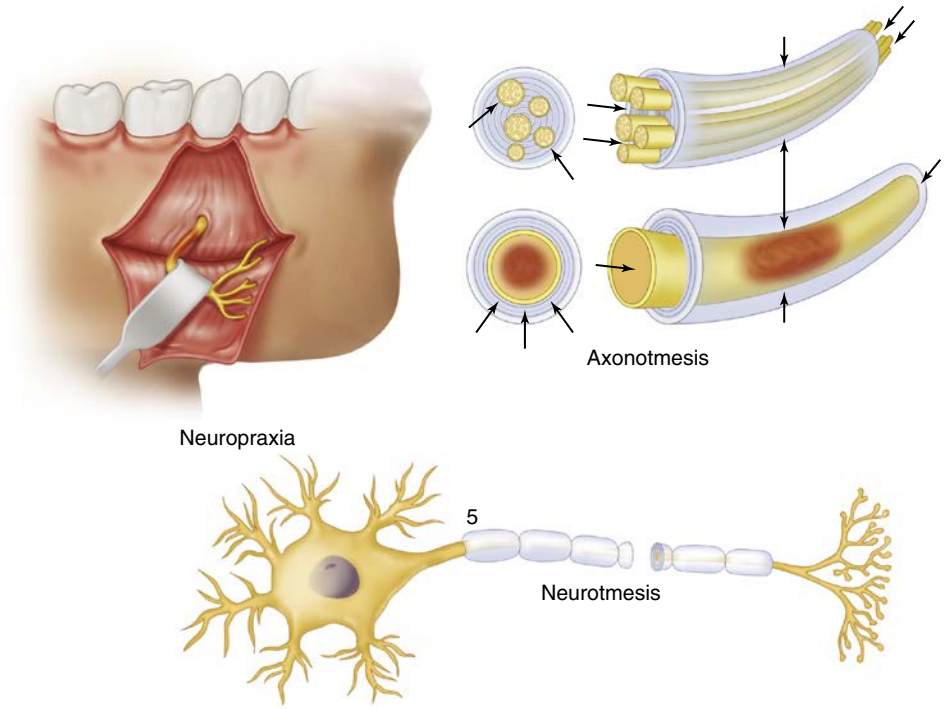

• **Figure 5-1** Seddon classification system including examples of neuropraxia with nerve stretching; axonotmesis with variable degrees of axonal injury; and neurotmesis with nerve transection. (From Fonseca RJ, Walker RV, Barber HD, et al: *Oral and maxillofacial trauma*, ed 4, St Louis, 2013, Saunders.)

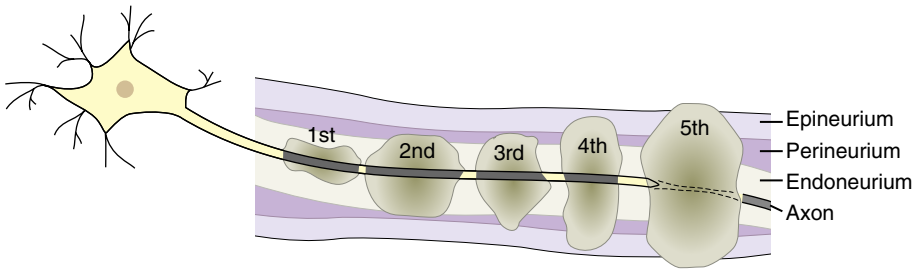

• **Figure 5-2** Sunderland classification system showing the five degrees of nerve injury with progressive injury beginning with damage confined within the endoneurium (1st degree injury) and extending outward to the perineurium (2nd degree), then through the perineurium (3rd degree), and to the epineurium (4th degree), and finally through the epineurium with discontinuity (5th degree). (From Fonseca RJ, Walker RV, Barber HD, et al: *Oral and maxillofacial trauma*, ed 4, St Louis, 2013, Saunders.)

degrees of demyelination and axonal injury, and therefore, spontaneous recovery varies significantly in this category of injuries. More details are provided in the following discussion of Sunderland's classification of nerve injuries. Finally, neurotmesis implies complete or near-complete nerve transection that includes epineurial discontinuity. Spontaneous recovery is unlikely, whereas neuroma formation is common.

Sunderland Classification System

Sunderland revised and further subclassified nerve injuries in 1951 and described a five-degree classification system (Sunderland's degree I-V nerve injury) based on histologic findings of the degree of nerve involvement[2] (Figure 5-2). A first-degree Sunderland injury is the same as Seddon's neuropraxia described earlier, and was further divided by Sunderland into three types based on severity and recovery time. First-degree Type I injury is the result of nerve manipulation that causes transient blood supply interruption that, once restored, allows for full sensory recovery after only a few hours. First-degree Type II injury involves intrafascicular edema formation, from fluid exudate or transudate, as a result of moderate traction or compression on the nerve. Sensory recovery follows edema resolution within a few days. First-degree Type III injury results from more aggressive nerve manipulation and may involve segmental demyelination with recovery requiring a few days to weeks.[3] Second-degree injuries involve axonal and myelin interruption with an intact endoneurium, epineurium, and perineurium, allowing for axonal regeneration. Recovery is a relatively slow process and may take up to 1 year for

TABLE 5-1 Classification of Nerve Injuries and Associated Findings

Injury Type	Histologic Findings	Response	Recovery Pattern	Recovery Rate	Treatment
First degree (Seddon neuropraxia)	Transient ischemia, anoxia, ± segmental demyelination, intrafascicular edema	Conduction block	Complete	Fast (hours to weeks)	None indicated
Second degree (Seddon axonotmesis)	Axon and myelin interruption (intact endoneurium, perineurium, & epineurium)	Wallerian degeneration distal to injury	Complete	Slow (weeks)	None indicated
Third degree	Injury involves endoneurium (intact perineurium & epineurium)	Wallerian degeneration and some degree of neuron cell death	Variable	Slow (weeks to months)	Nerve exploration may be considered
Fourth degree	Injury involves endoneurium and perineurium	Wallerian degeneration, neuron cell death, neuroma formation and intrafascicular fibrosis	None	Spontaneous recovery not likely	Microneurosurgery
Fifth degree (Seddon neurotmesis)	Complete nerve transection, continuity disruption	Wallerian degeneration, cell death neuroma, fibrosis	None	No spontaneous recovery possible	Microneurosurgery

complete return to normal sensation, but is possible because of the intact supporting connective tissue structures. These injuries are caused by traction or compression on the nerve. In third-degree injuries, the endoneurium is involved in the injury while the epineurium and perineurium remain intact. The usual etiologies are the same as for first- and second-degree injuries, and some spontaneous recovery is expected. Complete recovery is unlikely, and surgical exploration may be considered. Fourth-degree injuries caused by traction, compression, needle injection, or chemical injury lead to disruption of the endoneurium and perineurium, while the epineurium remains intact. These injuries are associated with a poor potential for spontaneous recovery and a high probability of neuroma formation and intraneural fibrosis. Surgical intervention is required for these injuries, especially if there is no improvement within 3 months following the injury. A fifth-degree injury in Sunderland's classification system corresponds to Seddon's neurotmesis. It implies nerve transection, avulsion, or laceration with complete disruption of all components of nerve organization with little to no chance of spontaneous recovery. Extensive fibrosis, neuroma formation, or neuropathic changes occur in these serious clinical situations, and microneurosurgery is indicated. In cases of witnessed nerve transection, immediate surgical intervention is warranted. Table 5-1 summarizes the types of injuries, corresponding histologic changes, responses, recovery pattern, rate of recovery, and recommended treatment.

Axonal and Cellular Response to Injury

Nerve injury involves several events and variable responses, but the basic process of nerve healing remains the same and involves a sequence of degeneration followed by regeneration.[4,5] Within hours of axonal injury, a series of events occur at the primary site of injury, as well as at the distal and proximal portions of the axon and the cell body. The changes within the cell body and the nerve fiber proximally depend on the proximity of the injury to the cell body as well as the severity of the injury. Within 6 hours of the injury, the metabolic rate of the cell body increases significantly. This results in edema and migration of the nucleus toward the periphery of the cell body, upregulation of the rough endoplasmic reticulum (Nissl substance), and increased protein synthesis. These events are collectively known as chromatolysis and represent the histologic correlation of RNA and protein synthesis, a programmed event intended to ensure cell survival that peaks within 14 to 21 days following acute injury.[6-14] Chromatolysis signals the proliferation of perineural glial cells that, along with macrophages, phagocytes, and Schwann cells, begins the cleanup process of cellular debris at the injury site.[4,5,15]

When the injury involves the axonal fibers (Sunderland II-V grade injuries), a series of molecular and cellular events occur, either simultaneously or consecutively, and collectively result in wallerian degeneration.[16] These events occur throughout the distal nerve trunk as well as the small portion of the proximal end close to the injury site. The distal portion of the axon becomes edematous, so its ends are sealed, while the myelin that surrounds the axon breaks down into droplets.[17] The debris is phagocytosed by Schwann cells with enhanced proliferation and activity levels as well as recruited macrophages. These events, which are a prerequisite for nerve regeneration to occur, are initiated within hours of the injury and are completed within 1 week following the nerve injury.[18-24] Neural degeneration occurs in both the distal and proximal nerve ends, so the final result is empty endoneurial tubes that act as conduits for nerve regeneration; these tubes are present up to the site of the injury.[17,21,25-27]

Proximally, the transected axon forms sprouts, or axonoplasmic extensions, that mimic the axon growth cones observed during embryonic neural development. Several substances produced by neural and supportive tissues are required, and these ultimately lead to the growth and regeneration of the axon toward its receptor target.[20,28-31] Each axon may have as many as 50 collateral axonal sprouts. The high proliferative activity of the Schwann cells noted during these phases is thought to be required for the production of new myelin that will host the new axon. This theory has been challenged by Yang and colleagues, who demonstrated that Schwann cell proliferation may not be an absolute requirement for nerve regeneration, but rather that this is achieved via existing Schwann cells that survive the insult but do not divide, and that the regeneration is axon-driven and axon-dependent, as opposed to a predominant Schwann cell influence.[19]

In any case, if these processes take place in the appropriate chronological order, spontaneous nerve regeneration will be achieved. In cases when there is interruption or unfavorable sequencing of these events, the outcome will be failure of reinnervation of target receptors and possible neuroma formation. Neuromas represent a disorganized mass of collagen fibers and nerve sprouts that are randomly oriented.[32-36] Neuromas can be of the following types: amputation (stump neuroma), neuroma-in-continuity (central or fusiform neuroma) (Figure 5-3), or lateral (lateral exophytic, or lateral adhesive neuroma) (Figure 5-4). Neuromas may be painful or asymptomatic, and histologic differentiation between the two clinical scenarios is not possible. What appears to distinguish the painful and non-painful neuromas is their neurophysiologic properties.[37-39] Last, consideration must be given to the mechanism of injury and the resultant nerve injury. For clean lacerations of the nerve, primary repair is usually indicated, but for avulsive-type injuries, a delayed primary repair is preferred. A delayed primary repair is typically performed at 21 days following the injury, as this allows time for the area of injury to become defined macroscopically, levels of neurotrophic and neurotropic factors are at their highest, and the nerve is most amenable to repair.

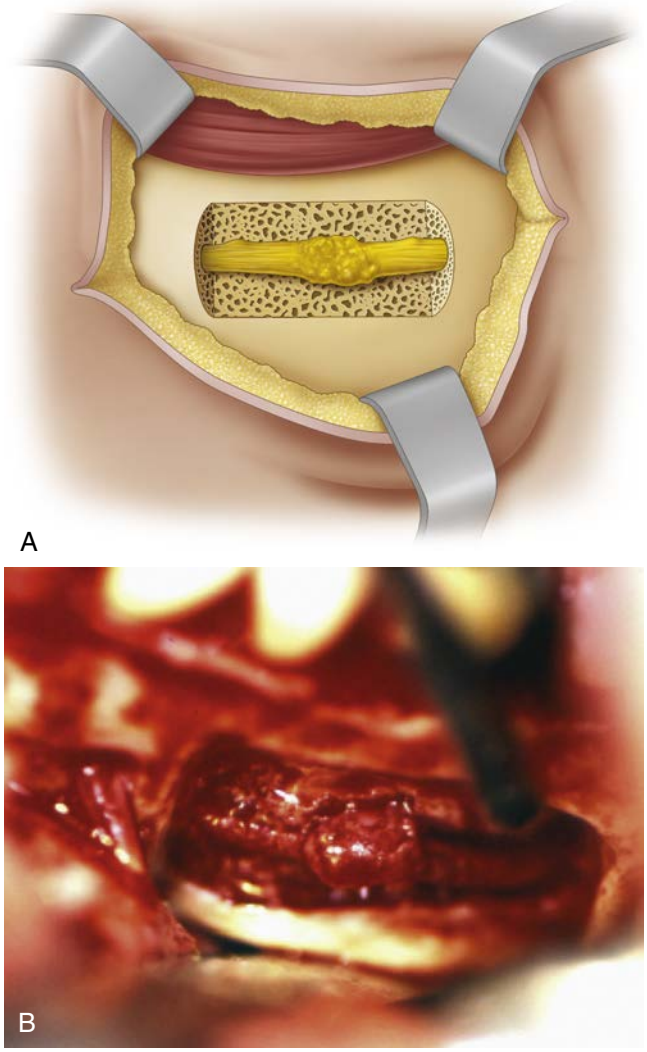

• **Figure 5-3** **A,** Diagram of a fusiform neuroma-in-continuity. **B,** Clinical example of an inferior alveolar nerve neuroma-in-continuity at the apex of a mandibular first molar following endodontic therapy with nerve injury. (From Fonseca RJ, Walker RV, Barber HD, et al: *Oral and maxillofacial trauma*, ed 4, St Louis, 2013, Saunders.)

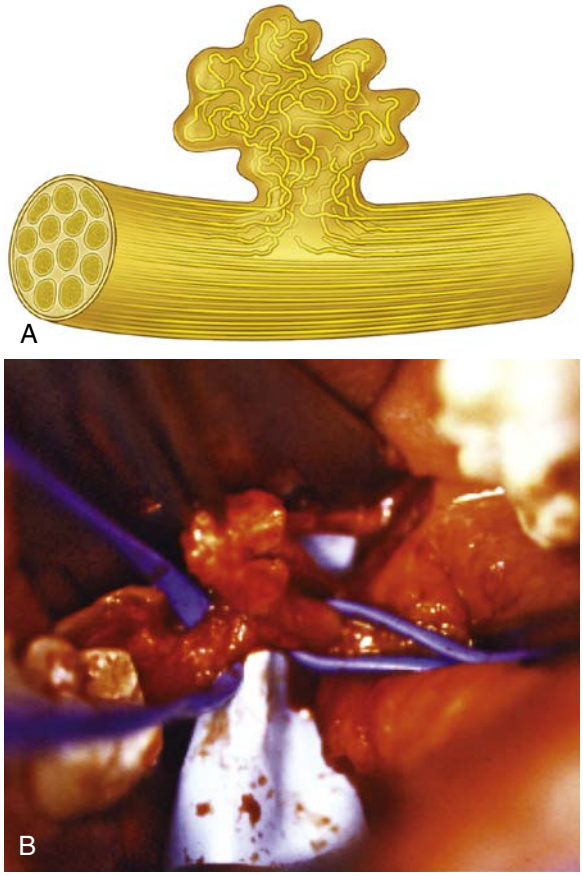

• **Figure 5-4** **A,** Diagram of a lateral exophytic neuroma. **B,** Clinical example of a lateral exophytic neuroma of the lingual nerve due to third molar removal. (From Fonseca RJ, Walker RV, Barber HD, et al: *Oral and maxillofacial trauma*, ed 4, St Louis, 2013, Saunders.)

Trigeminal Nerve Anatomy

Macroanatomy

Inferior Alveolar Nerve

The largest of the three branches of the mandibular division of the trigeminal nerve (V3) descends between the medial pterygoid muscle and the medial ramus and enters the mandible at the mandibular foramen (Figure 5-5). At the lingula (the bony landmark for the mandibular foramina along the medial surface of the ramus), the inferior alveolar nerve (IAN) has the greatest diameter of 2.4 ± 0.4 mm. At the mandibular foramen, the IAN diameter is 2.0 ± 1.1 mm. The mental nerve exits the mandible at the mental foramen, and the course of the bony canal appears to be fairly predictable.[40-42] Between the mandibular foramen, where the IAN enters the mandible, and the second premolar region, the IAN follows an S-shaped course. The nerve is most lateral in the third molar region and then approaches the lingual plate in the first molar region. In the premolar region, the IAN returns toward the buccal cortex before exiting the mandible through the mental foramen.

In their study of the mandibular canal, de Oliveira and colleagues analyzed the bi- and tridimensional position of the canal through multiplanar computed tomographic (CT) scan morphometric analysis and provided useful average distances of the canal to the buccal and lingual cortices, the inferior border, and the alveolar ridge. The locations of the mandible for the measurements were selected to represent areas of commonly performed maxillofacial procedures associated with high risk for nerve injury, specifically extraction of third molars, sagittal split osteotomy, and dental implant placement. The authors did not find significant differences between the right and left sides, whereas in edentulous patients the typical values were lower in females than in males, and in older patients (ages between 51 and 75 years) than in younger individuals (ages 25-50 years).[43]

According to Cutright and co-workers, the mental foramen was found to be apical to the second premolar in about 51% of the cases. It was noted that in whites the foramen was located between the premolars, whereas in blacks it was located distal to the second molar. In addition, the group noted small but significant differences between males and females for the three studied foramina (mental, infraorbital, and supraorbital).[44] In the sagittal plane, the course of the IAN in the mandible begins superiorly and lingually at the lingula, approximately 10 mm from the sigmoid notch, and it reaches its lowest point at the first molar-second premolar region, with the distance from the inferior border of the mandible of 7.5 mm ± 1.0 mm, where it splits into the incisive and mental nerve branches. The incisive dental branch continues forward toward the incisors, whereas the mental nerve ascends and loops backwards for a variable distance (3-7 mm) to exit at the mental foramina through the buccal cortex.[45,46]

Classically, the mental nerve is described as having two branches (range between one and four branches) with the largest being the labial branch running on the orbicularis oris

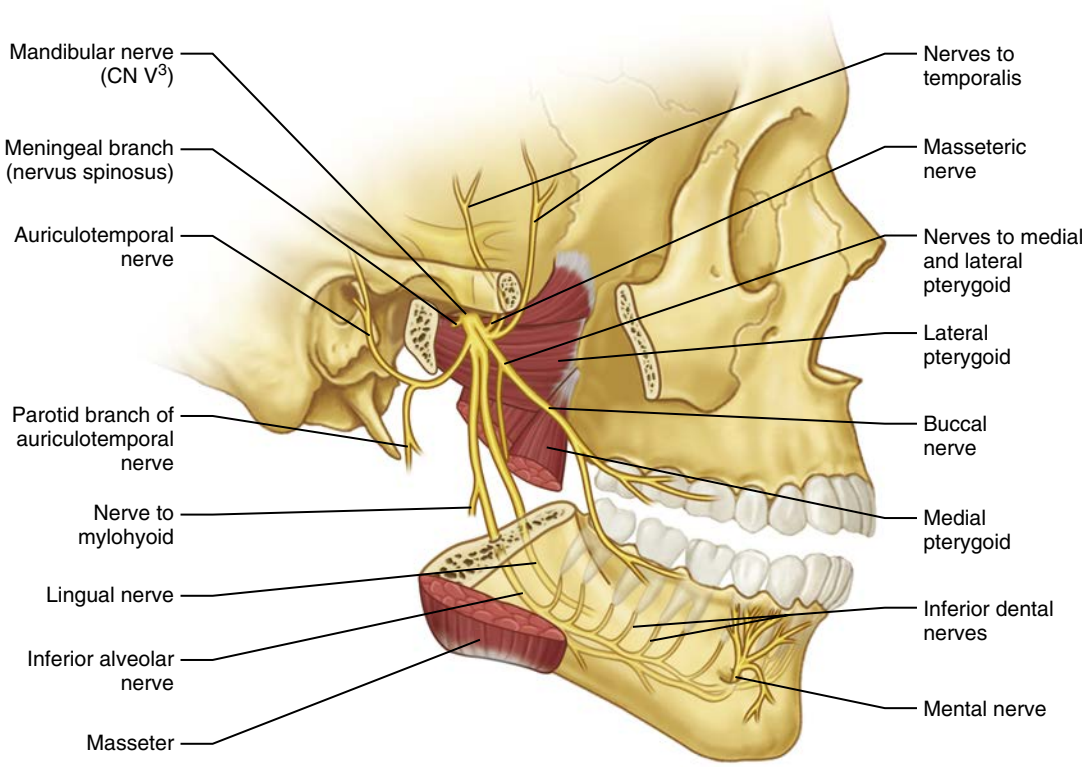

• **Figure 5-5** Regional anatomy demonstrating the peripheral trigeminal nerve system. (From Fonseca RJ, Walker RV, Barber HD, et al: *Oral and maxillofacial trauma*, ed 4, St Louis, 2013, Saunders.)

muscle fibers, and a smaller mucosal branch that runs posteriorly on the buccinator muscle fibers. The labial branch innervates the lip and chin mucosa and overlying skin, and it may re-enter the mandible to innervate the mandibular incisors and even cross the midline,[47] The mucosal branch innervates the buccal mucosa and gingiva of the mandible as far posteriorly as the first and second molar where cross innervation with the buccal nerve may occur. Throughout its course in the mandible, the IAN provides branches for innervation of the mandibular teeth.[48]

Lingual Nerve

The lingual nerve (LN) branches from the posterior division of the third division of the trigeminal nerve, medial to the lateral pterygoid muscle, and it is located medial to the IAN. It supplies sensory and special sensory function to the anterior two thirds of the ipsilateral tongue, floor of mouth, and lingual mandibular gingiva. The LN is joined by the chorda tympani as it passes through the pterygotympanic fissure, which provides taste (anterior two thirds of the tongue) and carries special visceral afferents (preganglionic parasympathetic fibers from the facial) to the submandibular and sublingual glands. Kim and associates, in their study of the topographic relationship of the LN and IAN at the infratemporal fossa and paralingual space in 32 cadaveric hemi-sectioned heads, noted four patterns of furcation between the two nerves in relationship to the sigmoid notch and the lingula (Table 5-2). In addition, the group measured the distance of the bifurcation to stable bony landmarks, including the foramen ovale and the hamulus. The bifurcation was identified to occur on average 14.3 mm (range: 7.8-24.1 mm) inferior to the foramen and 16.5 mm superior to the tip of the hamulus (range: 4.9-24.3 mm).[49] This variation in the bifurcation patterns between the IAN and the LN, as well as the collateral nerve branches at the retromolar region identified in 81.2% of the cases in the study by Kim and colleagues, is thought to contribute to the reported failure rate of mandibular anesthesia.[49,50]

TABLE 5-2 Types of Furcation of IAN and LN

Type of Furcation between IAN and LN	Level of Furcation between Sigmoid Notch and Lingula	Percentage per Type
Type I	Separation occurs above notch and inferior to otic ganglion	65.6% (21/32)
Type II	Separation occurs below notch and at superior half of distance between notch and lingula	28% (8/32)
Type III	Separation occurs below notch and at inferior half of distance between notch and lingula	3.1% (1/32)
Type IV	Separation occurs in a plexiform pattern	6.3% (2/32)

Kim SY, Hu Ks, Chung IH, et al: Topographic anatomy of the lingual nerve and variations in communication pattern of the mandibular nerve branches. *Surg Radiol Anat* 26:128-135, 2004.
IAN, Inferior alveolar nerve; *LN*, lingual nerve.

The LN then passes into the pterygomandibular space between the ramus and the medial pterygoid muscle, where it is surrounded by mesoneurial fat throughout its course. It enters the oral cavity over the superior pharyngeal constrictor, styloglossus, and mylohyoid muscles at the anterior border of the medial pterygoid muscle. As the nerve approaches the third molar region, it courses from a more lateral to a more medial position following the oblique flaring of the ramus. The exact location of the LN at the third molar region has been studied extensively, with some controversial findings between cadaveric studies, clinical observation during third molar surgery, and high-resolution magnetic resonance imaging, with regard to its proximity to the mandible.[51-58] Table 5-3 summarizes the reported distances and relationship of the nerve to the mandible at the third molar region. In this location, the nerve has a diameter between 2.0 and 5.0 mm and may be round, oval, kidney-bean shaped, elliptical, or ribbon-like in cross section, with a predominance of one shape versus another varying among the studies.[49,56,58]

At the second molar region, the LN crosses Wharton's duct from a lateral to medial direction traversing below the duct and hypoglossal nerve in the submandibular triangle. The nerve in this location gives off the preganglionic parasympathetic fibers (from the facial nerve) to the submandibular ganglion. These fibers are transected during submandibular gland excision so the gland can be released from the nerve. It has been reported that the risk of LN injury during submandibular gland excision or sialodochoplasty of the Wharton's duct ranges between 1.4% and 4.8%, and the nerve is in danger from both intraoral and extraoral approaches.[59-62]

After looping under Wharton's duct, the LN passes upward onto the genioglossus muscle and enters the oral tongue muscular substance. With the exception of one or two large branches that proceed toward the tip of the tongue, all other branches to the tongue and adjacent lingual mucosa and gingiva are of small diameter (generally no more than 1-2 mm). The larger branches provide the greatest density of innervation to the tip and medial portions of the anterior two thirds of the tongue, compared to the posterolateral, dorsal, and ventral portions, and this difference is developmentally driven.[63]

Buccal Nerve

The buccal nerve (BN) is a branch of the mandibular division of the trigeminal nerve that carries sensory fibers to the lower buccal sulcus, gingival, buccal, and cheek mucosa and may contribute to the cutaneous supply of the cheek. The nerve travels between the two portions of the lateral pterygoid muscle, beneath or through the lower part of the temporalis muscle deep to the mandible, then crosses over the external oblique ridge at the anterior border of the masseter muscle and merges with the same branch of the facial nerve. It is this

area where the nerve crosses over the external oblique ridge that places it at risk for injury, most commonly from third molar surgery. A rare variation that supports the IAN as the origin of the BN is described by Turner, Singh, and Jablonski and their colleagues, who identified the nerve exiting the mandible through a small foramen at the retromolar fossa.[64-67] As the nerve reaches the surface of the buccinator muscle, it divides into a superior division that supplies the muscle and an inferior division that provides the sensory innervation of the mucosa, as stated earlier.

Hendy and colleagues, in their study of the course and relationships of the BN in 20 cadaveric specimens, noted the following: The nerve was found to have 4 to 8 major branches with a mean number of 3 branches where it crosses the external oblique ridge. The nerve trunk was found to cross the ridge as close as 3 mm from its deepest concavity of the external oblique ridge in 70% (14 of 20) of specimens. In the remaining cases, the distance ranged between 7 and 12 mm below that point. The authors postulated that the nerve is at risk from incisions in this region even if these are placed as far away as 12 mm from the external oblique ridge. The variation of the branching patterns of the nerve, in addition to the high mechanosensory threshold noted on the buccal mucosa, may result either in a small area of damage or in the injury going unnoticed by the patient.[66,68,69]

Infraorbital Nerve

The infraorbital nerve (ION) is a major branch and the termination of the second division of the trigeminal nerve that emerges on the face via the infraorbital foramen. The foramen is on average 2.7 cm from the facial midline and 6 to 8 mm from the inferior orbital rim. In males the foramen is larger than in females, with some differences in the distances from the midline and infraorbital rim identified in anatomic studies.[44,70] In the study by Kazkayasi and co-workers, a single foramen was found in 90% of cases, two canals in 5%, and three canals in the remaining 5%. The shape of the canal was found to be oval in 30%, round in 40%, and semilunar in 30% of cases.[71] The ION enters the orbit via the inferior orbital fissure and transverses the orbital floor in the infraorbital canal (IOC) for 22 mm. The canal may not be complete, as the cortical thickness of its roof ranges between 0.1 and 6.0mm and thus the nerve may be exposed without a discrete superior bony wall. The combination of a groove and a canal is found in 50% of the cases, and the remainder demonstrate a complete canal.[71] Racial and gender variations have been reported in the location and shape of the foramen as well as the length of the canal.[70,72,73] After it exits the infraorbital foramen, four branches of the ION have been identified and correspond to the areas of the midface, nose, upper lip, and lower lid innervated by the nerve.[74] The ION is at risk for injury during approaches for reconstruction of the orbito-zygomatico-maxillary complex following traumatic events and during maxillary orthognathic surgery. Orthognathic-related injuries are typically transient and reversible, whereas sensory changes from entrapment of the nerve encountered in midface trauma may cause more problematic, long-term neurosensory changes.

TABLE 5-3 Distances and Relationship of Lingual Nerve (LN) to Mandible at the Third Molar Region

Authors Number of Nerves Method of Evaluation	Vertical Measurement (mm)	Horizontal Measurement (mm)	% of LN above Alveolar Crest	% of LN in Contact with Lingual Plate
Kiesselbach, Chamberlain:* 34 cadaveric and 256 in vivo nerves	2.28 ± 1.96	0.58 ± 0.9	17.6	62
Pogrel and Le:† 40 cadaveric nerves	8.32 ± 4.05	3.45 ± 1.48	15	0
Behnia et al:‡ 669 cadaveric nerves	3.01 ± 0.42	2.06 ± 1.10	14.05	23.27
Holzle and Wollfe:§ 68 cadaveric nerves	7.83 ± 1.65	0.86 ± 1.00	8.82	57.4
Karakas et al:‖ 21 cadaveric nerves	9.56 ± 5.28	4.19 ± 1.99	4.7	0
Miloro et al:¶ 20 in vivo nerves (HR-MRI)	2.75 ± 1.00	2.53 ± 0.67	10	25

*Kiesselbach JE, Chamberlain JG: Clinical and anatomic observations on the relationship of the lingual nerve to the mandibular third molar region, *J Oral Maxillofac Surg* 42:565-567, 1984.
†Pogrel MA, Le H: Etiology of lingual nerve injuries in the third molar region: a cadaver and histologic study, *J Oral Maxillofac Surg* 64:1790-1794, 2006.
‡Behnia H, Kheradvar A, Shahrokhi M: An anatomic study of the lingual nerve in the third molar region, *J Oral Maxillofac Surg* 58:649-651; discussion 652-653, 2000.
§Holzle FW, Wolff KD: Anatomic position of the lingual nerve in the mandibular third molar region with special consideration of an atrophied mandibular crest: an anatomical study, *Int J Oral Maxillofac Surg* 30:333-338, 2001.
‖Karakas P, Uzel M, Koebke J: The relationship of the lingual nerve to the third molar region using radiographic imaging, *Br Dent J* 203:29-31, 2007.
¶Miloro M, Halkias LE, Slone HW, Chakeres DW: Assessment of the lingual nerve in the third molar region using magnetic resonance imaging, *J Oral Maxillofac Surg* 55:134-137, 1997.

Microanatomy

The microanatomy of the trigeminal and facial nerves is the same, with sensory and motor nerves containing myelinated and unmyelinated fibers in a ratio of 1:4. The difference between the two types of fibers is the number of Schwann cells that surround each fiber with nodes of Ranvier that permit rapid saltatory nerve conduction (Figure 5-6). In the myelinated fiber, the ratio of nerve axons and Schwann cells is 1:1, whereas in the unmyelinated fiber the Schwann cell envelops several axons. The membrane, or basal lamina, created by the Schwann cell as it wraps around the axon, runs the entire length of the axon, is called a band of Büngner (laminar myelin sheath) and is crucial in the process of nerve regeneration. Although myelin may be destroyed during the nerve injury, the Schwann cells survive and play a major supportive role in nerve recovery and repair. The length of the axon surrounded by a single Schwann cell is known as the internode, and the small area (0.3 μm to 2.0 μm) between the internodes, where the axon is not myelinated, is known as a node of Ranvier. In each node of Ranvier, diffusion of ions occurs, resulting in nerve depolarization and repolarization. This allows for the conduction of nerve impulses along the nerve fiber. Conduction occurs only between the nodes of Ranvier (saltatory conduction) and is responsible for the rapid impulse transmission noted in myelinated nerve fibers (up to 150 m/s) compared to the nonmyelinated nerve fibers (2-2.5 m/s). Typically, unmyelinated axons are also smaller, with diameters ranging between 0.15 and 2.0 μm.

Collagen provides the framework that surrounds the nerve and creates the structural architecture within the nerve (Figure 5-7). The endoneurium is the first organization of fine collagen fibers around each nerve fiber axon. Several bundles of endoneurial groups, known as fascicles, are grouped together and surrounded by a second layer of collagen fibers (and mesothelial cells) called the perineurium. The outer layer of connective tissue supporting the nerve, along with some elastic fibers, creates the external epineurium or extrafascicular epineurium. Another layer of epineurium that invests the fascicles is known as internal epineurium. The epineurium makes up 50% of the cross-sectional area of

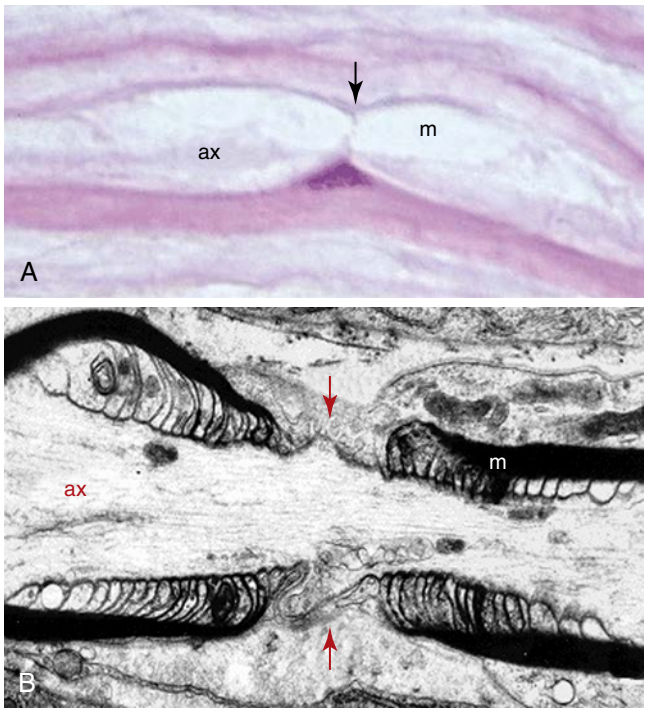

• **Figure 5-6** Hematoxylin and eosin **(A)** and silver stain **(B)** demonstrating the organization of a peripheral myelinated nerve in longitudinal section in the area of a node of Ranvier (*arrows*). *ax*, Axon; *m*, myelin. (From Fonseca RJ, Walker RV, Barber HD, et al: *Oral and maxillofacial trauma*, ed 4, St Louis, 2013, Saunders.)

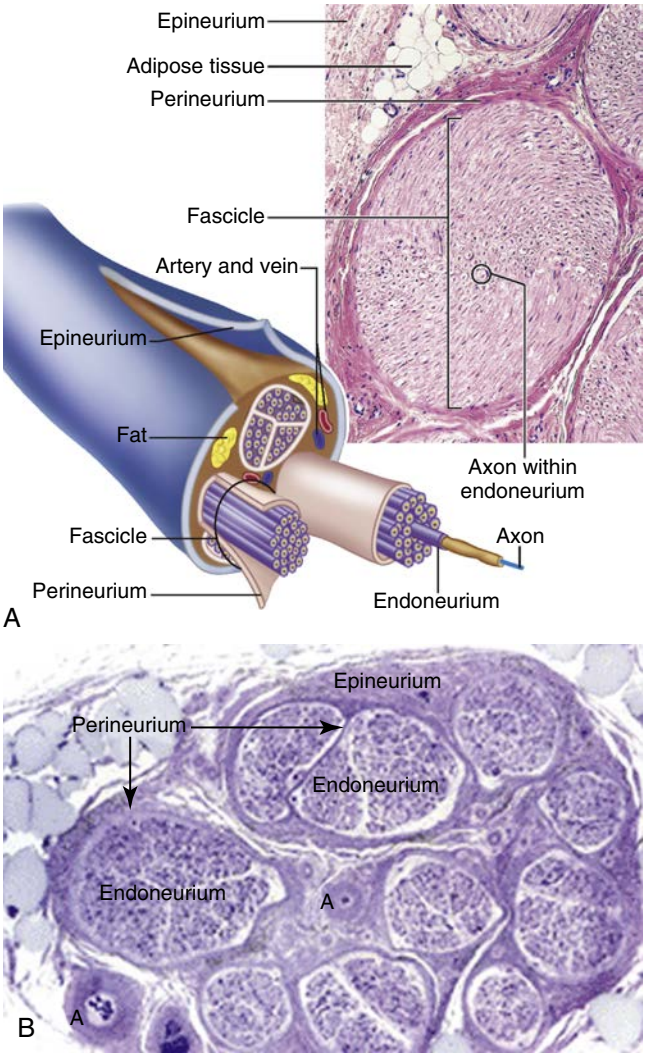

• **Figure 5-7** **A,** Schematic representation of nerve organization. **B,** Low power cross-section of polyfascicular nerve showing the organization of the nerve with individual nerve fibers surrounded by endoneurium, fascicles surrounded by perineurium, and the investing epineurium. The mesoneurium is visible surrounding the entire nerve sheath at the periphery, with adipose tissue (upper left). *A,* Perineurial and endoneurial blood vessels. (**A** from Patton K, Thibodeau G: *Anatomy and physiology*, ed 7, St. Louis, 2010, Mosby. **B** from Fonseca RJ, Walker RV, Barber HD, et al: *Oral and maxillofacial trauma*, ed 4, St Louis, 2013, Saunders.)

the nerve and provides some protection against compression. The final layer of connective tissue, which is continuous with the epineurium and surrounding tissue bed and is responsible for allowing some freedom of movement of the nerve, is known as the mesoneurium, or adventitia of the nerve.[75]

Peripheral nerves are often distinguished based on their fascicular pattern. A monofascicular pattern has only one large fascicle (an example is the chorda tympani); an oligofascicular pattern contains only a few fascicles (2 to 10; an example is the labial branch of the mental nerve); and a polyfascicular pattern has several different-sized fascicles, more than 10 in total (examples include the facial, IAN, lingual, and buccal nerves). The mean number of fascicles and the cross-sectional area of the trigeminal nerve branches decreases proceeding from proximal to distal nerve.[76-79]

A rich interconnecting vascular network of extrinsic and intrinsic systems provides blood supply for each neuron. The vessels reach the extrafascicular epineurium, via the vasa nervosum, after entering the mesoneurium and create a plexus that runs longitudinally at this level. The vessels continue their course toward the axon by passing in an oblique angle through the subsequent connective tissue layers and forming a longitudinally running plexus during their course at each level. This configuration allows for the individual fascicles to have their independent and rich blood supply analogous to an individual nerve fiber (Figure 5-8).[80,81] This passage of the vasculature between the layers of connective tissue may become an area of compromise within the intrafascicular layers. There are no associated draining lymphatics running with the vascular plexuses.

Trigeminal Nerve Imaging

Objective, noninvasive, radiologic imaging modalities in the preoperative assessment of the patient at risk for nerve injury, as well as a monitoring methods for post-injury and post-repair phases of neurosensory recovery, are highly desirable.[82] Radiologic assessment can be categorized with regard to the timing of the imaging period: that is, pre-injury, post-injury, and post-repair phases. Pre-injury assessment refers to the documentation of the in situ position of a nerve prior to any surgical intervention that places that nerve at risk for iatrogenic injury (e.g., third molar removal, tumor extirpation). Intraoperative monitoring of nerve function during a surgical procedure that involves a specific nerve may also be used, most commonly with functional study of nerve conduction and electrophysiologic status such as somatosensory evoked potentials (SSEP). Post-injury imaging is divided into a primary phase (i.e., following nerve injury and allowing for spontaneous neurosensory recovery without microneurosurgical intervention) and a secondary phase (i.e., following surgical nerve exploration and repair). Primary post-injury imaging may be clinically significant if it can correlate objective (radiologic) findings with subjective (clinical examination) findings, and thereby guide the need for surgical intervention, and possibly aid in treatment planning (i.e., the need for an interpositional nerve graft).

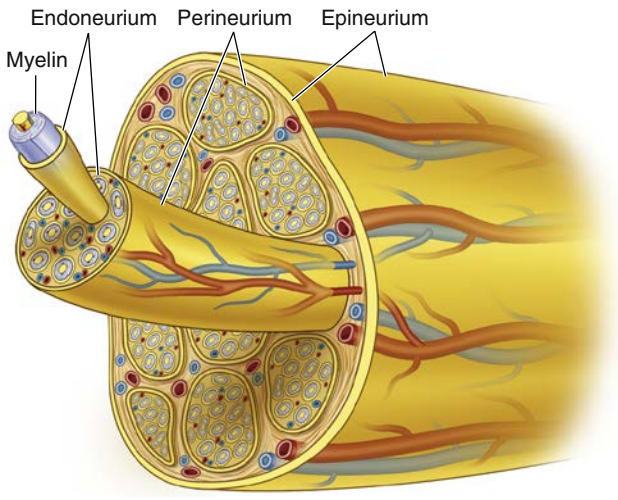

• **Figure 5-8** Schematic representation of vascular supply between the layers of the connective tissue surrounding the axon. *Red*, arteries; *blue*, veins; *yellow*, axons. (From Fonseca RJ, Walker RV, Barber HD, et al: *Oral and maxillofacial trauma*, ed 4, St Louis, 2013, Saunders.)

Panoramic Radiography

Preoperative assessment of the position of the inferior alveolar nerve during patient consultation has been routinely performed with the use of a panoramic radiograph. Obviously, information gained from this study is extremely limited because of the two-dimensional nature of the image, the variable magnification of the bony anatomy (for the inferior alveolar nerve), and the complete inability to visualize the position of the lingual nerve. Valuable information can be obtained from the panoramic radiograph as a stand-alone imaging modality in regard to the relationship of the IAN in the vertical plane, but not in the horizontal dimension. The most useful aspect of the panoramic radiograph is in assessing increased potential for inferior alveolar nerve injury during third-molar extraction based on the presence of several radiographic predictors[83,84] (Figure 5-9).

The post-surgery assessment of the nerve-injured patient usually includes a panoramic radiograph that may demonstrate a variety of clinically significant findings. The presence of a foreign body in the region of one or both nerves must be ruled out; these may include metallic foreign bodies from rotary instruments or amalgam particles from neighboring teeth, as well as retained tooth or root fragments following third-molar surgery. The presence of iatrogenic surgical disturbance of the nerves may be indicated by evidence of bone removal in proximity to the inferior alveolar neurovascular bundle or the lingual nerve (Figure 5-10). A panoramic radiograph or any other plain film is rarely used, however, to monitor progression following injury or repair.

Computed Tomography

The use of computed tomography (CT) in the assessment of nerve injuries is very limited. An evaluation of bone

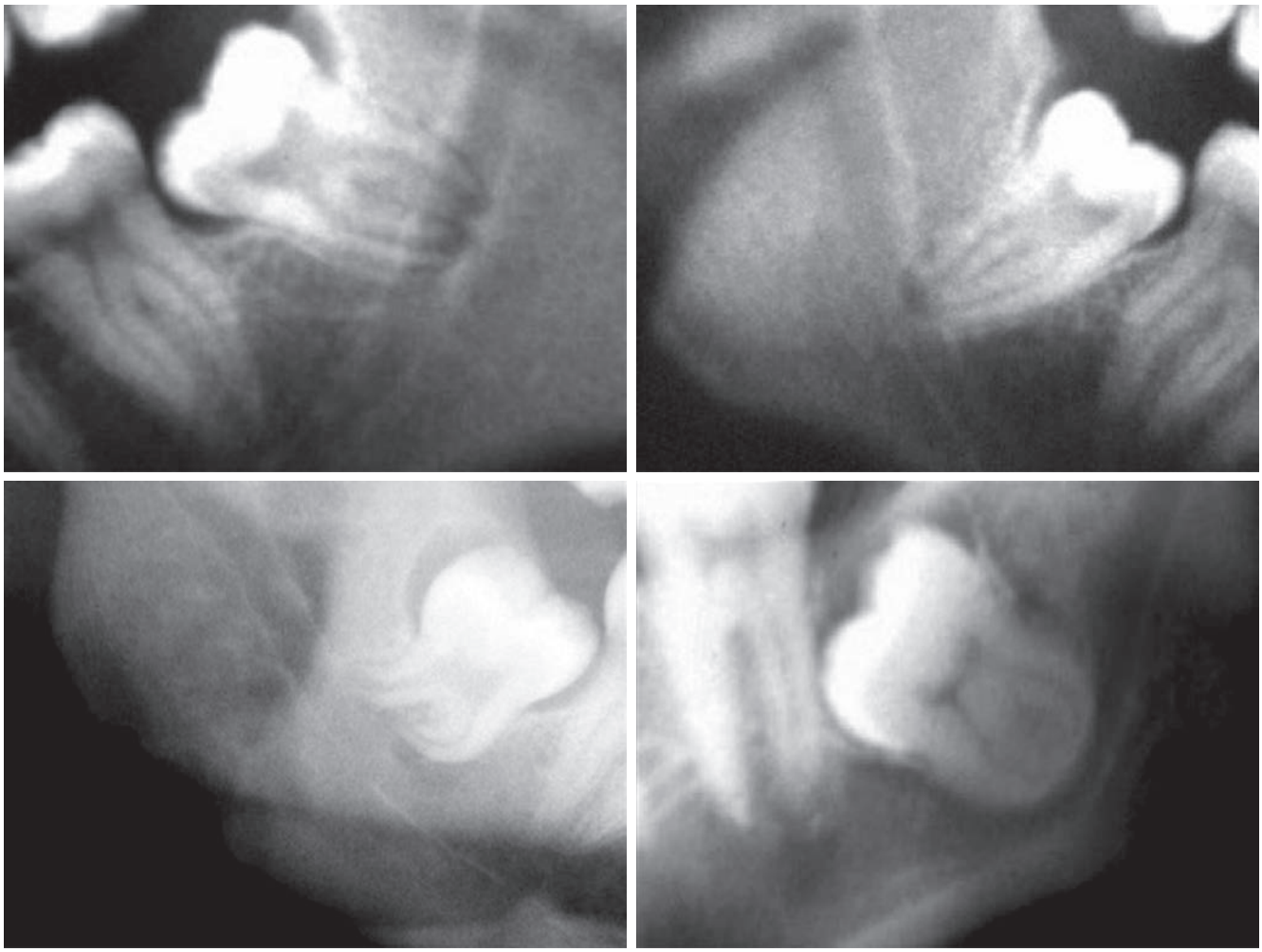

• **Figure 5-9** Panoramic radiographs showing examples of Rood radiographic predictors of root proximity to the inferior alveolar canal, including root darkening, root narrowing, root deflection, loss of the superior white line of the canal, and diversion of the canal. (From Fonseca RJ, Walker RV, Barber HD, et al: *Oral and maxillofacial trauma*, ed 4, St Louis, 2013, Saunders.)

window attenuation images may indicate violation of the cortical outline of the inferior alveolar canal, either from implant placement or following facial trauma involving the posterior mandible (Figure 5-11), but yields little information regarding the condition of the nerve or neurovascular bundle.[85] The use of soft tissue window images for the lingual or inferior alveolar nerves is compromised by very poor detail resolution that precludes its routine application in neural assessment. Furthermore, dental artifacts often impose severe limitations on obtaining accurate information regarding the position of the LN relative to the lingual cortex of the mandible in critical areas, even in the soft tissue windows and despite with the current high-resolution image acquisition.

In 1998 cone beam CT (CBCT) technology, until then used only in angiography, was employed in the United States as a potential imaging modality for the maxillomandibular complex. The use of CBCT for presurgical evaluation of an impacted mandibular third molar and its relationship to the IAN has gained popularity over CT scans and plain panoramic radiographs[86-90] (Figure 5-12).



• **Figure 5-10** Panorex following third molar removal showing the presence of preoperative radiographic predictors of root proximity to the canal, and evidence of the use of a drill distal to the crown of the extraction site in a patient with right lingual nerve injury.

The need for accurate imaging with the lowest possible dose of radiation (following the ALARA rule: as low as reasonably achievable) seems to be well satisfied with this technology. CBCT provides the desired three-dimensional representation of the anatomic location of interest with minimal distortion compared to traditional plain films and by simpler acquisition compared to CT systems.[91,92] Similar to the panoramic radiograph, CBCT can be used for preoperative risk assessment in various dentoalveolar procedures such as third-molar surgery or dental implants and pre-prosthetic surgery.[93-95] A major limitation remains the inability to visualize the lingual nerve, as no accurate soft tissue information can be obtained with use of CBCT.

Postoperative investigation of the surgical site for examination of the integrity of the IAN canal or presence of material, tooth or root fragments, within the canal could be superior and more reliable with CT or CBCT imaging than traditional panoramic imaging. Direct investigation of the integrity of the LN cannot be reliably performed with either modality because of the limitations discussed. Disruption of the lingual cortex of the mandible at the third-molar region that may be noted in a postoperative panoramic radiograph, and may imply trauma to the LN in the region, can be reviewed in more detail with CT or CBCT. Direct comparison of pre- and postsurgical images can be made and added to the information gathered from the clinical examination to potentially assist in the decision for need of exploration in the region.



• **Figure 5-11** Coronal CT scan through a mandibular body fracture showing canal involvement. (From Fonseca RJ, Walker RV, Barber HD, et al: *Oral and maxillofacial trauma*, ed 4, St Louis, 2013, Saunders.)

Magnetic Resonance Imaging

Magnetic resonance imaging (MRI) is the method of choice for visualization of all cranial nerves (CN), and each nerve segment can be seen and examined in detail with specific sequences. Because of the complexity of the course and surrounding anatomic structures, detailed examination of the CNs is possible only with careful planning and MRI technique selection. The imaging plane, coil selection, slice selection, in-plane resolution, and use of special techniques can be tailored based on the CN and the segment of interest so the highest quality image possible is obtained. The course of the lingual and inferior alveolar branches of the mandibular division, after it exits from foramen ovale, can be followed with high-resolution contrast-enhanced T-weighted (T1W) or T1W three-dimensional fast field echo (T1W 3D-FFE) sequences in the axial, coronal, and sagittal or parasagittal

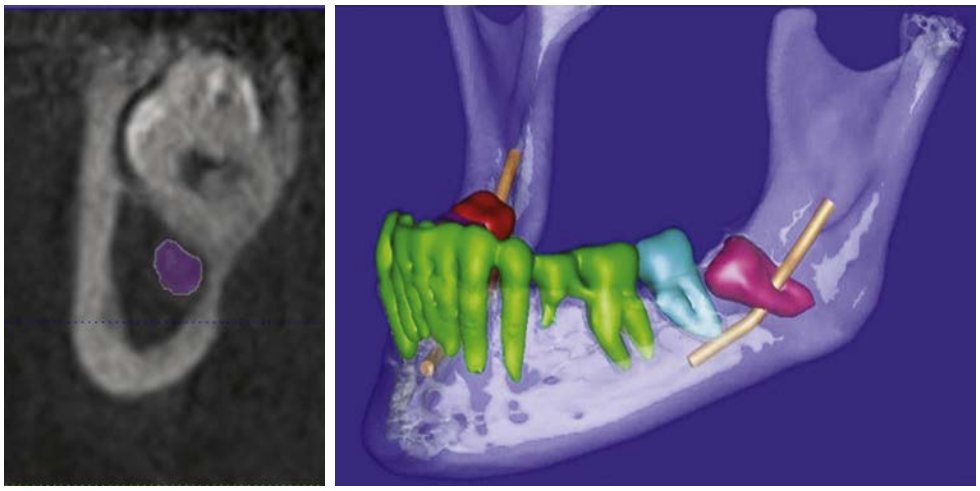

• **Figure 5-12** Cone-beam CT scan showing the proximity of the inferior alveolar canal to an impacted third molar, and 3D reconstruction of the scan to highlight the canal passing between the roots of the impacted third molar tooth. (From Fonseca RJ, Walker RV, Barber HD, et al: *Oral and maxillofacial trauma*, ed 4, St Louis, 2013, Saunders.)

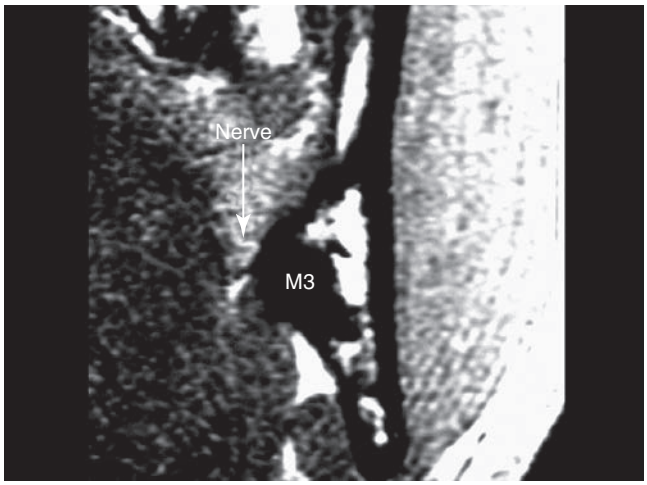

• **Figure 5-13** High-resolution MRI showing a kidney bean–shaped lingual nerve (*Nerve*) superior to the lingual crest, and in contact with the lingual plate in the third molar (*M3*) region. (From Fonseca RJ, Walker RV, Barber HD, et al: *Oral and maxillofacial trauma*, ed 4, St Louis, 2013, Saunders.)

planes.[96-100] MRI is the preferred imaging modality for examination of the status of the CNs in the presence of a disease process or injury.[97,101-104]

In an attempt to document the in situ position of the lingual nerve in the third molar region, high-resolution MRI has been studied. Ten patients (20 sides) of healthy adult volunteers without prior dental surgery were imaged using an MRI sequence that enabled visualization of the lingual nerve (Figure 5-13). This study documented that the lingual nerve position, while variable, was found to be superior to the lingual crest in 10% of cases, and in direct contact with the lingual plate in 25% of cases.[56]

The application of MRI in the assessment of the trigeminal nerve post-injury is in its early trial phases. Presumably, with improved resolution, a variety of anatomic changes in the nerve could be visualized. First, a change in nerve diameter may be visualized in cases of nerve injury with wallerian degeneration of the nerve segment distal to the site of injury with an acute or gradual decrease in nerve diameter. Second, an acute change in nerve position may be seen—for example, where the lingual nerve is retracted into the region of the third-molar socket with the formation of a lateral adhesive or exophytic neuromatous segment. Third, a change in nerve shape may be able to be visualized—for example, in the case of a fusiform neuroma-in-continuity, with a change in shape of the nerve for a certain distance with return to normal shape distal to the neuroma.[105]

The application of MRI to post-injury neural assessment is hindered by a variety of factors. The degree of image resolution and magnification significantly limits precise anatomic examination of the neural elements. The ability to image the internal architecture of neural anatomy will require dramatic improvements in resolution from currently available techniques. Also, while the lingual nerve lies within soft tissue and its course is unaccompanied, the inferior alveolar nerve lies within a cortical bony conduit and is joined by an artery and a vein throughout its course.

Ultrasonography

Several reports have described the use of ultrasound and high-resolution ultrasound technology mainly for assessment of peripheral nerve lesions. This real-time advanced technology with the high-resolution probes now available can offer compound imaging without radiation and in a relatively inexpensive manner. Although ultrasonography (US) has not been employed or investigated as a potential preoperative risk assessment tool for the trigeminal nerve, it has been demonstrated to be valuable in identification and safe advancement of the needle in brachial plexus and sciatic nerve blocks.[106]

Mechanisms of Injury to the Trigeminal Nerve

Several commonly performed procedures in the maxillofacial region are associated with potential injury to the terminal branches of the trigeminal nerve.

Local Anesthetic Injection

Injury to both the IAN and LN is possible during administration of mandibular block local anesthesia. Interestingly, prolonged sensory alterations are rare, considering the number of blocks administered daily by dental professionals. The ratio of injuries to injections has been estimated at between 1:26,762 to 1:160,571, although this may not represent the actual incidence because not all cases of sensory disturbances are reported.[107,108] Harn and Durham in 1990 reported an incidence of transient sensory disturbance of 3.62%, with only 1.8% incidence of long-duration changes (over 1 year).[109] The proposed mechanisms that result in this injury are multiple, the exact cause remains unclear, and there is no reliable way of avoiding these types of injuries. Direct penetration of the nerve by the needle, hematoma formation from vessel laceration, direct laceration of the nerve from a barb on the tip of the needle after repeated injections and needle contact with cortical bone, and chemical injury from intraneural injection are reasonable possibilities.[109-111] Direct toxicity of the local anesthetic solution (specifically 4% articaine and 4% prilocaine), especially when deposited within the confines of the epineurium, has been associated with cases of sensory changes after mandibular blocks.[112-115] Box 5-1 lists conclusions that can be made based on the current understanding of injection-related nerve injuries. These cases are usually associated with only a limited distribution of neurosensory alteration, reflecting the small number of fascicles insulted or involved in this type of injury.[116]

• BOX 5-1 Clinically Based Conclusions on Local Anesthesia-Related Nerve Injuries

1. Not predictable, possibly preventable
2. Painful response upon injection (electric-shock sensation) does not always accompany an injury
3. More common in female patients
4. More commonly result in dysesthesia than hypoesthesia
5. May follow a non-anatomic distribution (involvement of more than one division of the trigeminal nerve) due to segmental demyelination
6. More common with higher-concentration anesthetic solutions (e.g., 4% articaine)
7. Surgical exploration is not indicated due to nature and location of injury
8. Lingual nerve is more commonly affected than the inferior alveolar nerve
9. Spontaneous recovery usually occurs within 8 weeks of the injury
10. Less than one third of cases lasting longer than 8 weeks will recover fully
11. Pharmacologic management is indicated for unpleasant sensations (dysesthesia)

Third Molar Surgery

Complications associated with third molar removal are the most common cause of trigeminal nerve injury reported and can occur during any stage of the actual procedure (Figure 5-14) as well as during postoperative care.[117-121] The overall incidence of IAN injury during third molar surgery is estimated to be between 0.41% and 7.5%, resulting in temporary sensory changes in 2% to 6%, and permanent disturbances in 0.5% to 2% of cases. Stretching or manipulation of the lingual nerve from tissue retraction during third molar surgery is reported to cause temporary sensory disturbances at rates from 6.4% to as high as 15%, but less than 1% result in permanent changes.[116,122-128] Several risk factors associated with increased risk of IAN injury during this procedure have been discussed in the literature and include advanced age, female gender, tooth angulation, depth and type of impaction, integrity of the lingual cortex, complexity of the procedure, and surgeon experience.[129,130] Rood and Shehab in 1990 described seven radiographic predictors of potential proximity of a third-molar to the IAN on panoramic radiograph that may be helpful in the decision-making process regarding extraction versus more conservative approaches such as coronectomy or observation.[84] These radiographic predictors include darkening, deflection, or narrowing of the tooth root; diversion, narrowing, or interruption of the white line of the IAN canal; and a dark or bifid root apex. The most significant radiographic findings of potential nerve injury included root darkening, root deflection, and interruption of the white line of the IAN canal. It is important to note that subsequent studies have reported controversial findings, in both support and opposition of the value of these radiographic predictors in nerve injury (Figure 5-15).[131,132] In any case, these radiographic findings are neither highly sensitive nor specific for nerve injury.



• Figure 5-14 Diagram showing possible iatrogenic injury of the inferior alveolar nerve during extraction of a deeply impacted third molar. (From Hupp JR, Ellis E, Tucker MR: *Contemporary oral and maxillofacial surgery*, ed 5, St. Louis, 2008, Mosby.)

Dental Implant Surgery

With the wide utilization of dental implants for dental rehabilitation throughout the world, injury to the IAN is a fairly common occurrence with a 0% to 40% reported incidence of nerve injury due to implant placement, depending on location (Figure 5-16); and, patient management can be problematic.[133,134] The IAN, in particular, is at risk in the molar region as well as anterior to the mental foramen, especially in edentulous patients because of the associated alveolar ridge resorption. In addition, the surgeon should consider the anterior extension, or genu, of the neurovascular bundle beyond the foramen when placing dental implants in this region. These injures can result from surgical exposure, during preparation of the osteotomy site, or at the time of implant placement. Mechanical compression of the neurovascular bundle can result from overextension of and canal violation during the osteotomy. This can cause infracture of the cortex of the canal at the site and direct pressure on the IAN (Figure 5-17). Alternatively, bleeding within the canal from a laceration of the inferior alveolar vein or artery with an implant drill can cause pressure similar to a compartment syndrome. Finally, direct compression on the neurovascular bundle following restoration of the implant and mastication or prior clot formation and subsequent ectopic calcification may occur. Although extensive literature is available regarding the use of modern imaging modalities for treatment planning in implant dentistry, data are lacking on the most appropriate modality for nerve injury risk assessment, as discussed earlier.[42,134-139]

Management of these injuries is tailored individually based on the mechanism of injury and may involve implant removal as soon as such an event is recognized, or the use of pharmacologic therapy as indicated for dysesthesia. Immediate implant replacement with a shorter implant may be considered, but it is dependent on the exact cause of the trauma and the need or lack of need for nerve canal exploration as well as the timing and recognition of the occurrence.[117,134,140-143]

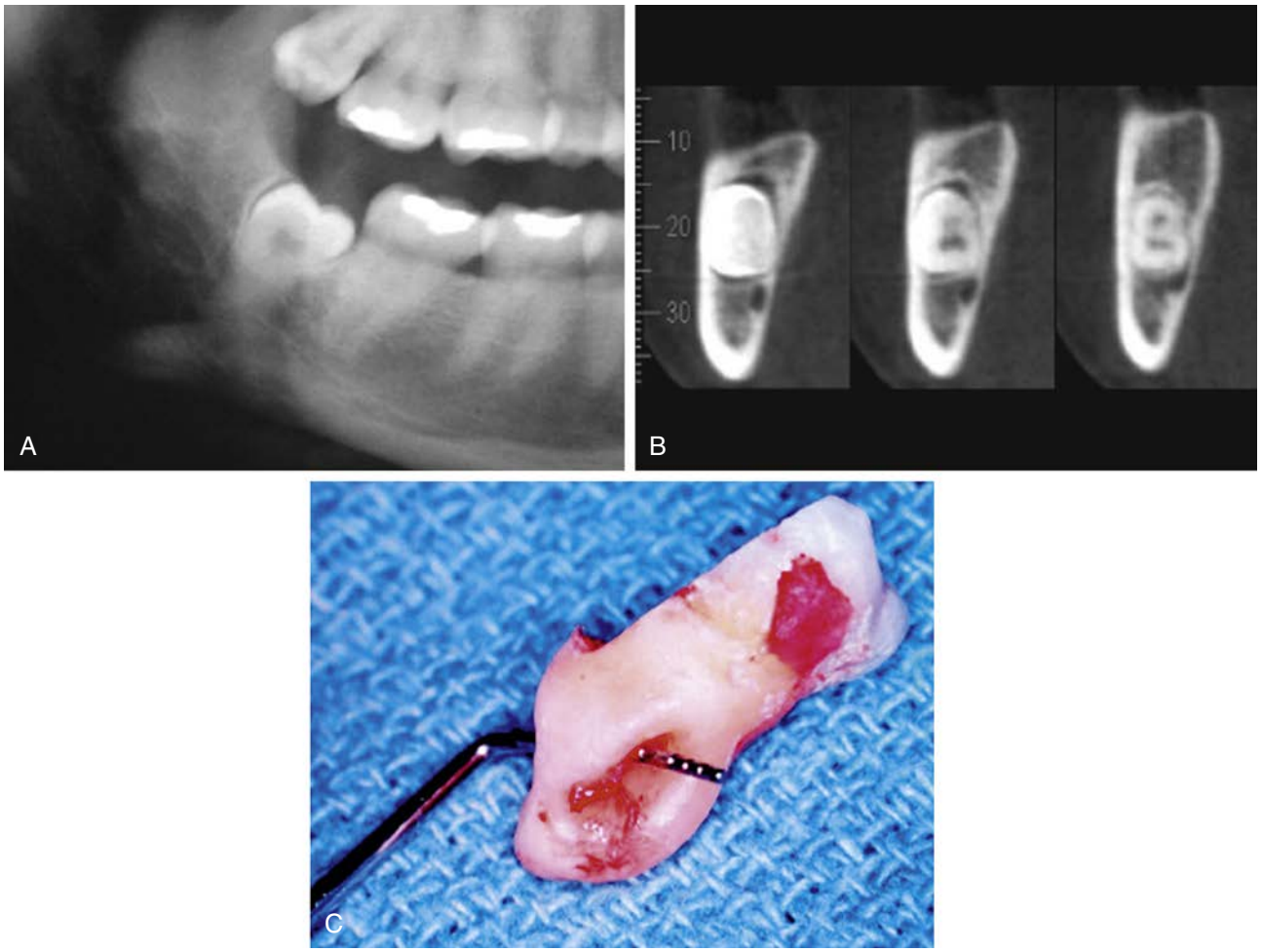

• **Figure 5-15** **A,** Panorex showing root proximity to the inferior alveolar canal. **B,** Cone-beam CT showing root proximity to the inferior alveolar canal. **C,** Third molar following removal with a periodontal probe showing the location of the inferior alveolar neurovascular bundle. Despite an attempt to section the tooth to avoid nerve injury, the nerve was transected during the extraction. (From Fonseca RJ, Walker RV, Barber HD, et al: *Oral and maxillofacial trauma*, ed 4, St Louis, 2013, Saunders.)

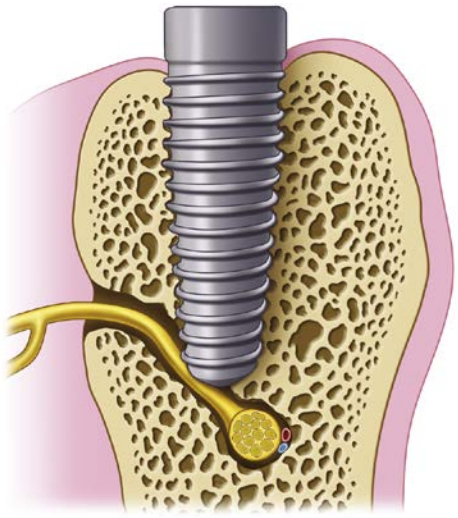

• **Figure 5-16** Diagram showing implant-related nerve injury that can occur when the implant is in proximity to the closed canal with possible bleeding, edema, and the development of a compartment syndrome that causes deleterious effects on the nerve even in the short term. (From Fonseca RJ, Walker RV, Barber HD, et al: *Oral and maxillofacial trauma*, ed 4, St Louis, 2013, Saunders.)



• **Figure 5-17** Panorex showing the distal implant placed within the confines of the inferior alveolar canal in a patient with inferior alveolar nerve paresthesia. (From Fonseca RJ, Walker RV, Barber HD, et al: *Oral and maxillofacial trauma*, ed 4, St Louis, 2013, Saunders.)

Procedures aimed at augmenting the alveolar bone height in the posterior mandible or improving the site to facilitate implant placement, such as bone grafting, distraction osteogenesis (DO), or IAN nerve lateralization carry their own risks for nerve injury. During bone harvesting from the mandibular ramus (Figure 5-18) or chin region (Figure 5-19), the IAN or mental nerves could be inadvertently injured, especially when a large area requires augmentation. When small, single tooth-sized grafts are harvested and appropriate preoperative radiographic examination of the area is undertaken, this risk appears to be minimal.[144] The same branches of the trigeminal nerve are at risk when securing autogenous or allogeneic bone graft material at the recipient site, either from direct compression of the nerve from the graft or from hardware (plates and screws) used to secure the graft in place. Distraction osteogenesis (DO), another method employed for alveolar ridge height augmentation, may lead to nerve injury, again either at the time of the osteotomy or directly from the device used for the distraction. The actual response of the IAN to the DO process has been studied in animal models, and it has been shown that several events occur at the cellular level, including activation and proliferation of Schwann cells as well as a limited degree of axonal degeneration and regeneration. The result is minor nerve injury that is reversible with no long-term sequelae.[145-147]



• **Figure 5-18** An example of a ramus graft procedure that places the inferior alveolar nerve at risk for injury due to its lateral location in this region of the mandible. (From Fonseca RJ, Walker RV, Barber HD, et al: *Oral and maxillofacial trauma*, ed 4, St Louis, 2013, Saunders.)

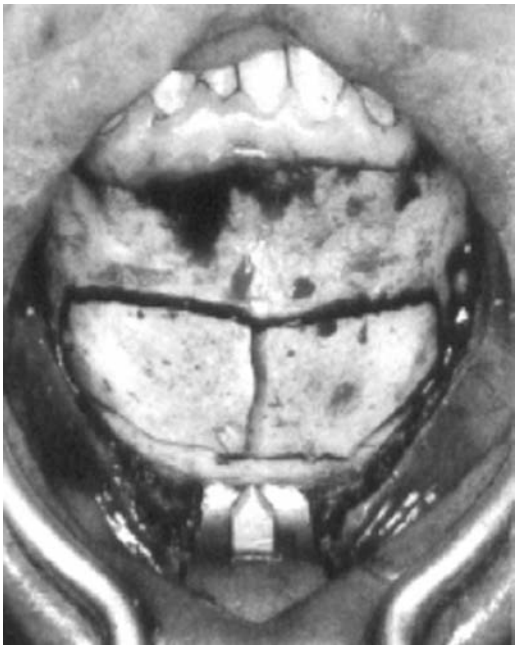

• **Figure 5-19** An example of a genial bone graft harvest that may sacrifice the incisive branch of the inferior alveolar nerve and result in paresthesia to the anterior mandible dentition. (From Fonseca RJ, Walker RV, Barber HD, et al: *Oral and maxillofacial trauma*, ed 4, St Louis, 2013, Saunders.)

Nerve lateralization for facilitation of implant placement is a viable option in select cases. With this approach, the lateral cortex of the mandible is removed and the IAN is exposed and lateralized so that implants of adequate length can be placed (Figure 5-20). The procedure inevitably causes some neural trauma, but the injury is "controlled," while the risk of compartment syndrome is eliminated along with risk of direct injury to the neurovascular bundle from the implant placement itself. The procedure is associated with a high incidence of neurosensory changes, some permanent, but with excellent implant stability, success, and high patient satisfaction.[148-154] If the nerve lateralization procedure requires release of the mental nerve from the mental foramen, then the incidence and degree of neurosensory dysfunction is increased over a transposition of the nerve posterior to, and not involving, the mental foramen. Recovery after nerve lateralization should be expected within 3 to 6 months, although up to 30% to 40% of patients, especially older individuals, may experience long-term neurosensory dysfunction.[154] The use of piezosurgery in a cadaveric study (10 sheep mandibles with 20 lateralizations) showed no disturbance of structures beyond the epineurium, and the overall degree of injury was found to be less than when the procedure was performed with conventional burrs.[155]

Maxillofacial Trauma

Maxillofacial trauma and surgery for the correction of facial injuries may result in disturbances of the peripheral branches of the trigeminal nerve in the vicinity of the traumatic injury. The overall incidence of neurosensory impairment has been reported to be 70.9%. In cases of nondisplaced fractures, the incidence was found to be 54.4%, while a significant increase was noted in displaced fractures of 88.2%. As expected, cases of direct injury had 100% neurologic impairment.[156] Fractures of the mandible may result in neurosensory alterations due to laceration, traction, or compression of the IAN from bony segment displacement (Figure 5-21) or treatment of the fracture with iatrogenic

injury to the nerve canal (Figure 5-22). Similarly, midface fractures or soft tissue trauma, lacerations, or avulsions may violate the infraorbital canal and damage the ION, leading to transient or permanent sensory alterations[156-159] (Figure 5-23). In a study by Kloss and colleagues, hypoesthesia of the ION was found in 10% of single, and 16% of multiple, midface fractures.[160]

Reduction of fractures with alignment of segments and removal of loose bony segments that impinge on the nerve will assist in spontaneous neurosensory recovery.

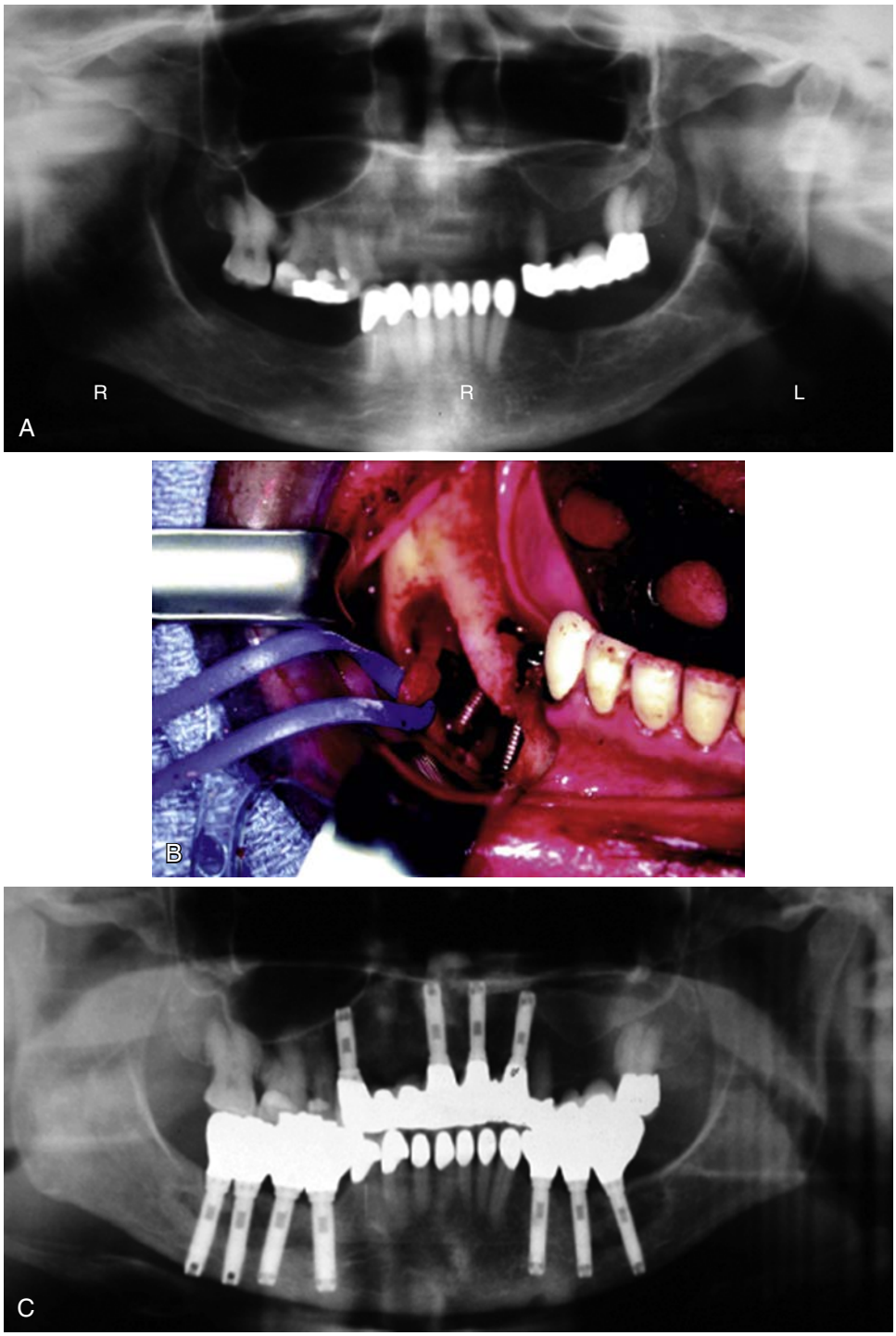

• **Figure 5-20** **A,** Panorex showing posterior mandibular edentulism with insufficient bone height above the canal and inadequate interocclusal clearance for implant placement. **B,** Nerve repositioning procedure results in a neuropraxic injury in a controlled fashion during implant placement. **C,** Panorex showing bilateral inferior alveolar nerve repositioning with restored implants that engage the superior and inferior borders of the posterior mandible for stability. (From Fonseca RJ, Walker RV, Barber HD, et al: *Oral and maxillofacial trauma*, ed 4, St Louis, 2013, Saunders.)

Unfortunately, treatment of facial fractures may cause further injury to branches of the trigeminal nerve due to nerve retraction or inadvertent placement of plates and screws.

Orthognathic Surgery

Neurosensory alterations are common sequelae of orthognathic surgery for correction of dentofacial deformities, especially mandibular procedures.[161] During sagittal split osteotomy (SSO), the IAN and LN can be injured at several locations and during the various steps of the procedure. These include during medial dissection at the lingula region, during the actual osteotomy procedure, or during mobilization or fixation of the segments. If the IAN is found to be located in the proximal segment after the osteotomy, then it may need to be mobilized, and this may cause further injury. The location of the IAN in relationship to the inferior border of the mandible, the ramus height, the dentofacial deformity to be corrected, and the patient's age and gender have all been associated with various incidences of neurosensory disturbances.[162-165] In addition, the incidence of neurosensory alterations during mandibular orthognathic surgery has been found to increase with intraoperative complications, most commonly unfavorable splits.[166] Furthermore, IAN sensory alterations appear to occur more frequently with additional procedures (e.g., genioplasty in addition to SSO), but these are transient, and spontaneous full recovery is usually reported within 6 to 12 months.[161,167,168] Interestingly, a substantial difference has been demonstrated between subjective and objective findings regarding sensory alterations after SSO with normal sensation reported in 73.7% of osteotomy sites, while objective testing revealed normal sensation in only 34.2% of cases.[169]

During maxillary or midface procedures, the ION is at risk for injury, most commonly due to soft tissue flap retraction rather than direct injury, and results in sensory changes of the upper lip, cheeks, lateral aspect of nose, and infraorbital region. Based on the nature of the injury (traction, compression, or pressure), full recovery is expected and usually achieved without intervention.[168] Segment fixation with plates and screws could theoretically cause direct injury to the ION or LN from bicortical screw overpenetration (Figure 5-24), but this is an event that is easily avoidable with adequate exposure, visualization, and protection of the nerve.



• **Figure 5-21** Panorex showing an open displaced unfavorable left mandible angle fracture. Note the displacement of the inferior alveolar canal. (From Fonseca RJ, Walker RV, Barber HD, et al: *Oral and maxillofacial trauma*, ed 4, St Louis, 2013, Saunders.)



• **Figure 5-22** Panorex showing fixation of a right mandibular body fracture with screws that penetrate the inferior alveolar canal in a patient with right inferior alveolar nerve dysesthesia. (From Fonseca RJ, Walker RV, Barber HD, et al: *Oral and maxillofacial trauma*, ed 4, St Louis, 2013, Saunders.)

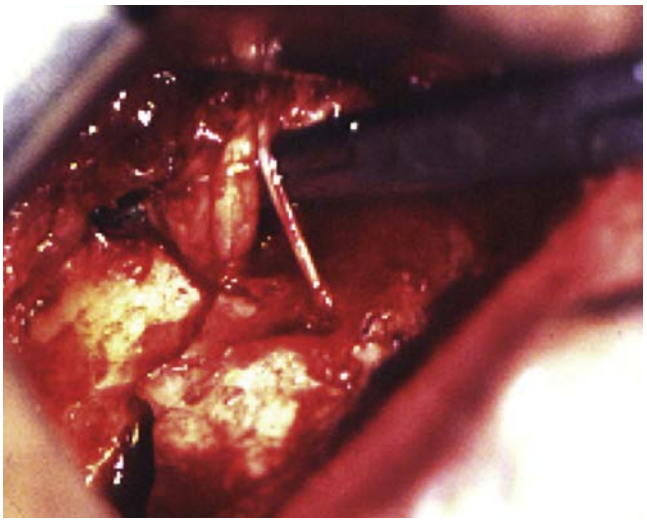

• **Figure 5-23** Intraoperative view of compression of the terminal branches of the right infraorbital nerve exiting from the infraorbital foramen in a patient with a displaced right zygomaticomaxillary complex fracture. (From Fonseca RJ, Walker RV, Barber HD, et al: *Oral and maxillofacial trauma*, ed 4, St Louis, 2013, Saunders.)

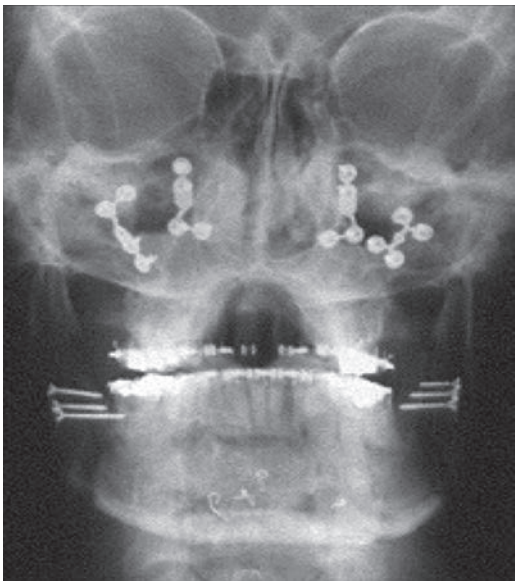

• **Figure 5-24** Posteroanterior skull film showing overpenetration of the bicortical screws used to stabilize the sagittal split osteotomies. This places the lingual nerve at risk for iatrogenic injury during orthognathic surgery. (From Fonseca RJ, Walker RV, Barber HD, et al: *Oral and maxillofacial trauma*, ed 4, St Louis, 2013, Saunders.)

Maxillofacial Pathology

Several odontogenic and non-odontogenic cysts and tumors may be found in the nerve-bearing segment of the mandible in intimate relationship with the IAN. These can result in displacement or encompassment of the canal (Figure 5-25). This also applies to tumors of the maxilla in the vicinity of the IOC. Benign pathology usually is not associated with neurosensory disturbances with the exception of neural or vascular tumors originating from the involved neurovascular bundle (Figure 5-26). On the contrary, malignant lesions usually will be associated with sensory changes, as is the case with specific pathology (e.g., adenoid cystic carcinoma with neurotropism), in cases of tumors with aggressive behavior, when the IAC is invaded by the tumor, or the tumor has caused a pathologic mandible fracture (Figure 5-27). Infectious processes are similarly associated with neurosensory changes if they involve nerve-bearing areas of the jaws but usually spontaneously resolve with resolution of the infection (Figure 5-28).

Treatment of maxillomandibular pathology often involves extensive bone and soft tissue resection that may include the IAN, mental nerve (MN), or ION and result in permanent anesthesia in the distribution of the corresponding resected nerve. On occasion, nerve pull-through procedures or utilization of adjuncts such as enucleation and curettage with cryotherapy, have been advocated for some tumors in an effort to minimize morbidity associated with alternative treatments and associated permanent neurosensory disturbances. These approaches remain somewhat controversial with regard to the associated risk of recurrence and can be in conflict with the basic oncologic principles for management of these tumors.[170-178]

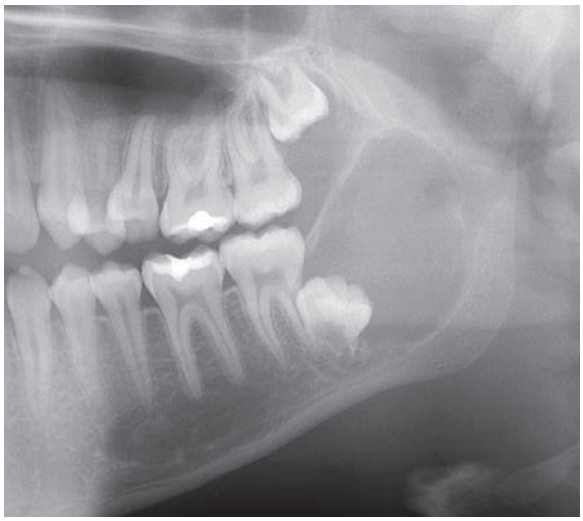

• **Figure 5-25** Panorex of a keratocystic odontogenic tumor causing displacement of the left inferior alveolar canal without paresthesia. (From Fonseca RJ, Walker RV, Barber HD, et al: *Oral and maxillofacial trauma*, ed 4, St Louis, 2013, Saunders.)

Endodontic and Chemical Injury

Endodontic therapy and periapical root surgery may place the IAN at risk for injury. The nerve may be injured by physical disruption with a file by overinstrumentation of the canal(s), by apicoectomy procedures, or by physical compression from extrusion of the filling materials used (Figure 5-29). The other mechanism of injury is that of chemical neurotoxicity, which may result from the use of certain root canal medicaments to treat the canal(s). These types of IAN injuries can be due to mechanical or chemical factors, or both, and can result in a foreign body reaction or granuloma formation in the canal that may impede spontaneous neurosensory recovery. Unfortunately, these injuries are difficult to manage, with variable success following microneurosurgery, and a large proportion of these injuries may manifest clinically as dysesthesia. For extrusion of potentially neurotoxic root canal filling materials into the IAC, prompt exploration, decompression, and debridement of the foreign material may be beneficial in preventing long-term sequelae.

In addition to root canal medicaments, many other chemical agents are potentially neurotoxic; these include tetracycline, Surgicel (oxidized cellulose), and prolonged exposure of the nerve to Carnoy's solution (a solution of ferric chloride, glacial acetic acid, chloroform, and ethanol).

Clinical Neurosensory Testing

The use of universally accepted terminology is crucial when discussing nerve injury, and it is imperative that the appropriate terms be used to describe and document each case for communication between clinicians, determination of management strategies, and medicolegal reasons (Box 5-2). In addition, a detailed description, including but not limited to nerve mapping and photographs of the region affected by

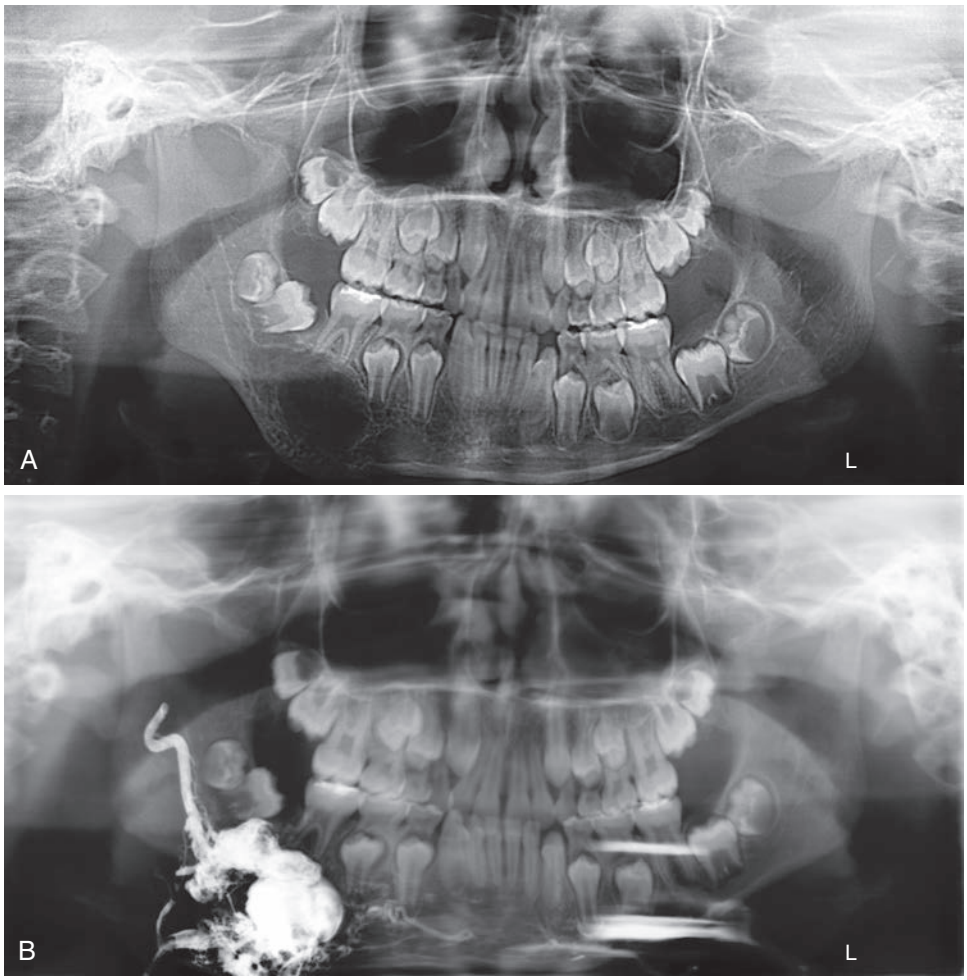

• **Figure 5-26** **A,** Panorex of an arteriovenous malformation of the right mandible involving the inferior alveolar canal. **B,** Panorex of the same patient following arteriography with embolization. (From Fonseca RJ, Walker RV, Barber HD, et al: *Oral and maxillofacial trauma*, ed 4, St Louis, 2013, Saunders.)

injury should be documented in each patient and used to quantify the initial presentation and, most importantly, to follow the progress of the area of involvement (Figure 5-30).

A detailed history and clinical examination along with objective testing that includes the use of specific neurosensory testing (NST), pain questionnaires, and visual analogue scales are crucial in the assessment of the patient who has sustained trauma to the trigeminal nerve. Attention to details regarding the onset of symptoms, events associated with the current complaints, and changes, including worsening or improvement, requires careful documentation and plays a critical role in the treatment decision-making process.[117,158,179,180] Descriptive terms used by the patient to qualify their symptoms need to be documented in the chart exactly as stated by the patient.

In a critical evaluation of the accuracy of NST to accurately diagnose trigeminal nerve injuries, Zuniga and co-workers demonstrated that for LN assessment, NST had superior sensitivity and specificity compared to examination of the IAN. In addition, IAN findings were associated with a high incidence of false-positive and false-negative results—23% and 40%, respectively.[181] This was subsequently supported in a recently published comparison between clinical NST and current perception thresholds.[182] NST should be performed in patients with neurosensory changes to determine the degree of sensory impairment, monitor recovery, and assist in decision making as to the need for surgical intervention. The clinical neurosensory testing protocol involves mechanoreceptive fiber testing performed first (two-point discrimination, static light touch, directional discrimination, and vibratory sense), followed by nociceptive fiber testing (pain stimuli and thermal discrimination). Testing should be performed in the same manner and sequence on each occasion, in a quiet, calm, comfortable environment with the patient in a semi-reclined position. It is important that the clinician explain in detail the tests that will be performed and assure the patient that there will be no pain involved. An uninvolved normal site should be used to establish a baseline control site and to demonstrate the tests about to be performed. Marking can be done directly on the patient's face with erasable markers, on photos obtained prior to testing, or on drawings on standard recording forms if available. If the marking is done directly on the face, the patient needs

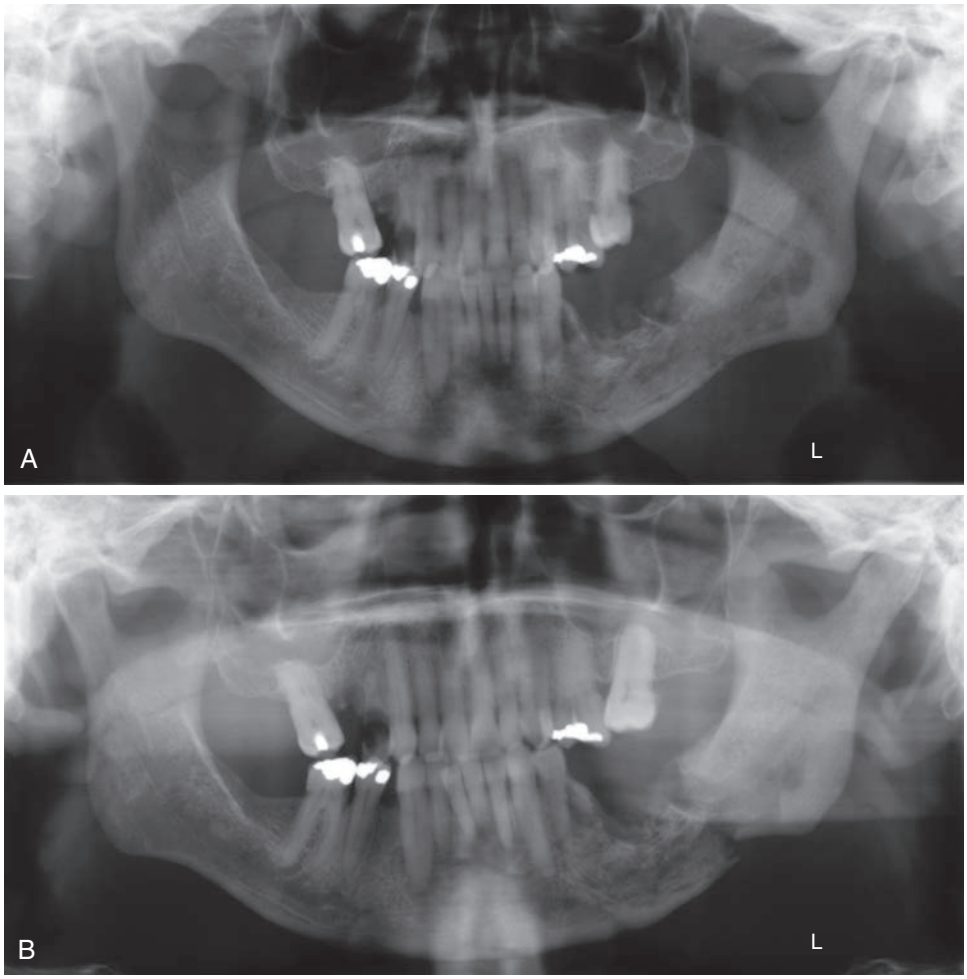

• **Figure 5-27** **A,** Panorex of multiple myeloma involvement of the left mandibular body. **B,** Panorex of the same patient with progression of the disease with a displaced unfavorable pathologic fracture of the left mandibular body with resultant inferior alveolar nerve paresthesia. (From Fonseca RJ, Walker RV, Barber HD, et al: *Oral and maxillofacial trauma*, ed 4, St Louis, 2013, Saunders.)

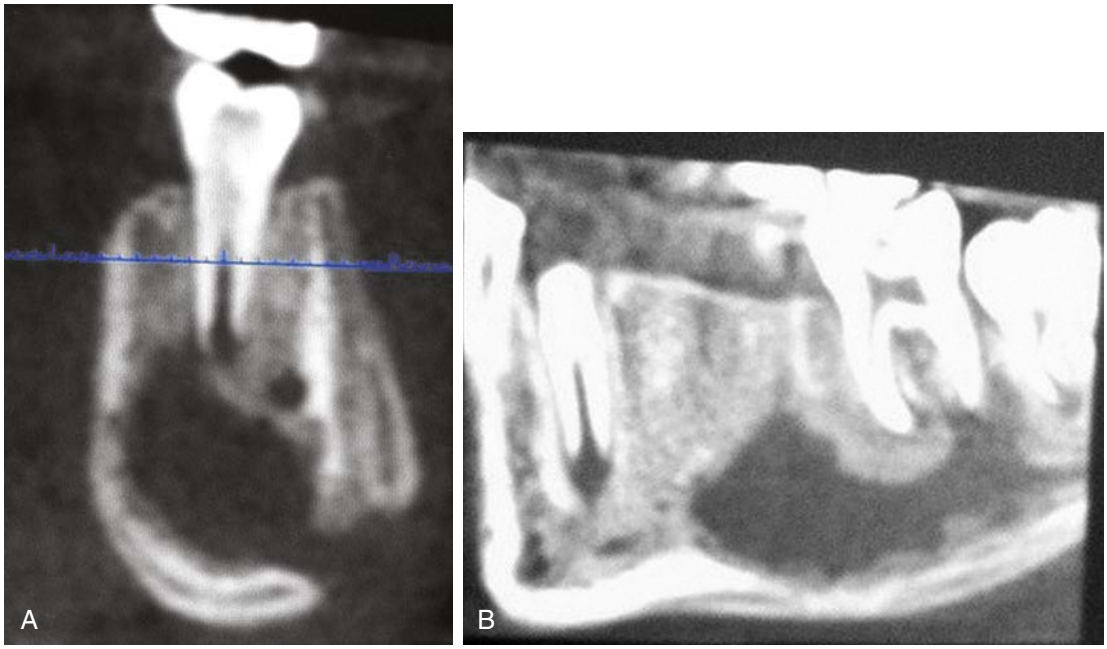

• **Figure 5-28** **A,** Coronal cone-beam CT (CBCT) showing Garre' osteomyelitis of the mandible with buccal cortical perforation and proliferative periostitis in a young patient involving the inferior alveolar canal with paresthesia. **B,** Sagittal CBCT of the same patient showing the extent of involvement of the Garre osteomyelitis throughout the marrow involving the inferior alveolar canal. (From Fonseca RJ, Walker RV, Barber HD, et al: *Oral and maxillofacial trauma*, ed 4, St Louis, 2013, Saunders.)

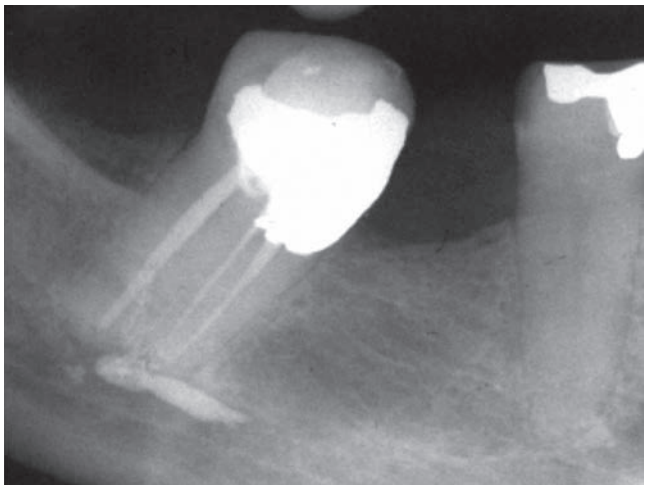

• **Figure 5-29** Periapical film showing root canal filling material within the inferior alveolar canal in a patient with inferior alveolar nerve dysesthesia. (From Fonseca RJ, Walker RV, Barber HD, et al: *Oral and maxillofacial trauma*, ed 4, St Louis, 2013, Saunders.)

• BOX 5-2 Select Terminology for Sensory Alterations

Allodynia: Pain due to a non-painful stimulus
Analgesia: Absence of pain from a painful stimulation
Anesthesia: Absence of any sensation from a painful or non-painful stimulation
Dysesthesia: Abnormal sensation, spontaneous or evoked, that is unpleasant
Hyperalgesia: Abnormal response to a painful stimulus
Hyperesthesia: Increased sensitivity to stimulation; excludes special senses
Hyperpathia: Increased reaction to a (repetitive) stimulus
Hypoalgesia: Diminished pain in response to a painful stimulus
Hypoesthesia: Decreased sensitivity to stimulation; excludes special senses
Neuralgia: Pain in the distribution of a nerve or nerves
Paresthesia: An abnormal sensation, spontaneous or evoked, that is not unpleasant

to be photographed, and all photos, drawings, and forms must be kept in the records for documentation purposes and for future reference and comparison.

The clinical neurosensory testing protocol (Figure 5-31) begins by outlining the area of sensory disturbance, using brush-stroke directional discrimination to differentiate between the normal and the affected area. Brush-stroke directional discrimination is performed with a camel-hair brush or a fine sable brush that is stroked across the affected area at a constant rate, and the patient is asked to indicate the direction of movement. The correct number of responses out of 10 is recorded. Static two-point discrimination is performed next using any device that allows for measurement between two points, and these tips should be blunt, not so sharp as to stimulate the nociceptive fibers. The closest distance at which the patient can discriminate two points versus one point at both the control and injured site is recorded. If the findings at this level of testing, brush stroke and two-point discrimination (Level A testing), are normal, no further testing is required. The patient injury can be classified as Sunderland first-degree injury. If the findings are abnormal at level A, testing proceeds to the next level. Level B testing involves contact detection and is performed with von-Frey hairs or Semmes-Weinstein monofilaments of several diameters reflecting the stiffness of the filament and the force required to deflect it on contact. The narrowest filament consistently detected by the patient is recorded for the control site and the involved site. Level A and B testing examines the integrity of the large myelinated A-alpha and A-beta fiber types. If Level B testing is normal, no further testing is required, and the patient is considered mildly impaired, representing a Sunderland second-degree injury. If findings are abnormal at Level B, then testing proceeds to the next level. This involves pinprick nociception and thermal discrimination, and it evaluates smaller myelinated A-delta fibers and unmyelinated C fibers. A 30-gauge needle, in the absence of a pressure-sensitive device, can be used for pinprick testing, with care not to cause injury to the skin or mucosa, and an all-or-none response may be recorded. For thermal discrimination, there are specialized Minnesota thermal discs or simpler options such as ice or hot water on a cotton swab. Suprathreshold thermal testing has been shown to be valuable in the assessment of iatrogenic injuries to the IAN and LN.[183] Normal responses at Level C testing imply a moderate impairment (Sunderland third-degree injury), whereas abnormal findings may be consistent with either severe impairment with an increased thermal threshold or a decreased nociceptive response (Sunderland fourth-degree injury) or lack of response to pinprick or temperature with complete anesthesia (Sunderland fifth-degree injury).[117]

Pain as a result of nerve injury can be assessed with a simple visual analogue scale or with a more complex McGill pain questionnaire. This can also be used for evaluation of altered sensation and is a useful tool for continuous monitoring of progress. Direct or indirect injury to the LN may cause taste alteration that can be a significant component of the patient's subjective complaints. Taste requires special testing that may involve the entire mouth or be localized; however, it is generally difficult to assess taste alterations, and there is poor correlation between degree of injury, alteration in taste, and response to surgical intervention.[117,184-187] Taste can be evaluated with 5% saccharose (sweet), 5% saline (salt), 5% citric acid (sour), and 0.5% quinine hydrochloride (bitter).[186]

Indications for Microneurosurgery

Careful patient assessment and collection of information from neurosensory testing are crucial in the decision-making process for treatment recommendations and the need for



• **Figure 5-30** Facial photographs with the areas of involvement marked are useful for monitoring progression. (From Fonseca RJ, Walker RV, Barber HD, et al: *Oral and maxillofacial trauma*, ed 4, St Louis, 2013, Saunders.)

surgical innervation (Table 5-4). With the exception of an observed nerve transection that requires immediate surgical repair, successful treatment of all other injuries requires a balance of timing to allow for potential spontaneous recovery without delaying timely microsurgical intervention. The complex events surrounding nerve injury with degeneration and regeneration distally, proximally, and centrally make timing of intervention critical when it is indicated.[188-191]

Clinical neurosensory testing, along with subjective findings, should guide and dictate appropriate treatment. When improvement is documented during periodic nerve testing, surgery is not yet indicated. Microneurosurgery is also not indicated in cases of central neuropathic pain, or most cases of dysesthesia or unpleasant sensations, and consideration should be given to pharmacologic management of these difficult clinical scenarios. If persistent paresthesia is documented in subsequent visits, then referral to a surgeon with expertise in microneurosurgery is prudent. Although several timing guidelines regarding surgical intervention exist, the scientific evidence to support them is limited.[192] It is generally accepted that prolonged delay may decrease the success of microneurosurgical repair. Regardless of the exact timing, indications for microneurosurgery include a witnessed nerve transection, no improvement of significant hypoesthesia (more than 50% compared to control site), the presence of a foreign body, neuroma formation, progressive worsening of hypoesthesia or dysesthesia, and intolerable subjective hypoesthesia.[193] Intervention for LN paresthesia should be considered earlier (1 to 3 months post injury) than for the IAN (3 to 6 months post injury), because the inferior alveolar canal provides a conduit to spontaneous nerve regeneration, whereas the LN lies in soft tissue. This may explain why IAN injuries have a higher rate of spontaneous recovery than LN injuries (Box 5-3). Some studies have indicated that no surgical intervention should be considered longer than 1 year post injury, because distal end organ neurotization is less likely, although others suggest that timing is less important and improvement can be achieved when microneurosurgery is performed after 12 months.[117,193]

Microneurosurgery for Trigeminal Nerve Injuries

Microneurosurgical procedures are best performed in the operating room under loop magnification or with use of an

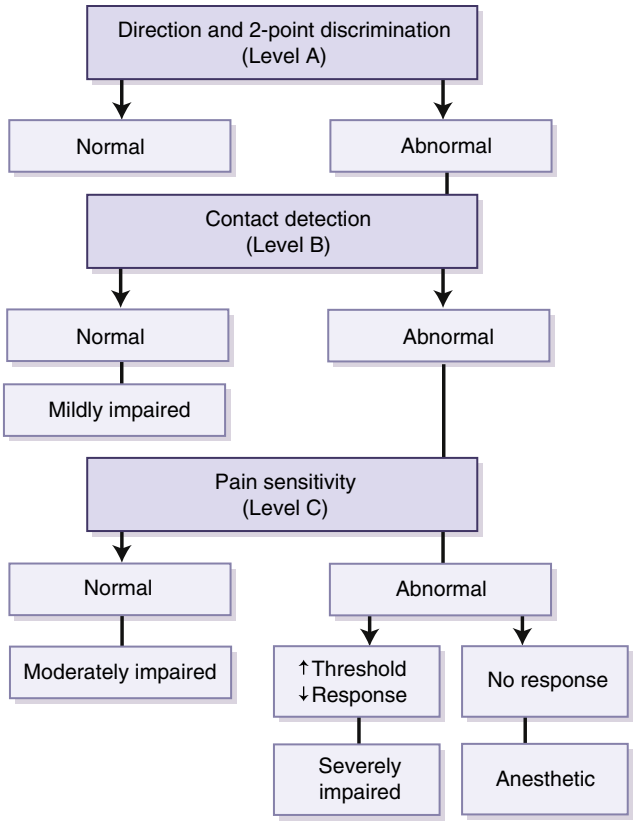

• **Figure 5-31** Clinical neurosensory testing algorithm. Level A testing (brush stroke direction and two-point discrimination) is done first, and if normal, the exam is normal (Sunderland 1st-degree injury). If Level A testing is abnormal, Level B testing with contact detection is performed, and if normal, the exam is mild impairment (Sunderland 2nd degree injury). If abnormal, Level C testing (pinprick and thermal discrimination) is done, and if normal, the exam is moderate impairment (Sunderland 3rd degree). If Level C is abnormal, then the patient is either severely impaired (Sunderland 4th degree) or, with no response to testing, is considered anesthetic (Sunderland 5th degree). (From Fonseca RJ, Walker RV, Barber HD, et al: *Oral and maxillofacial trauma*, ed 4, St Louis, 2013, Saunders.)

TABLE 5-4 Indications of and Contraindications for Microneurosurgery

Indications
Complete anesthesia
Less than 50% residual sensation (Sunderland III, IV, V)
No improvement within 3 months after injury
Observed nerve transection
Early dysesthesia (neuroma formation)
Intolerable subjective paresthesia
Contraindications
Continuing improvement in sensation
Late dysesthesia (especially IAN)
Central neuropathic pain
Complex regional pain syndrome
Trigeminal neuralgia
Atypical facial pain
Anesthesia dolorosa

• BOX 5-3 Recommended Time Frame for Microneurosurgery, When Indicated

Lingual nerve: 1-3 months after injury
Inferior alveolar nerve: 3-6 months after injury

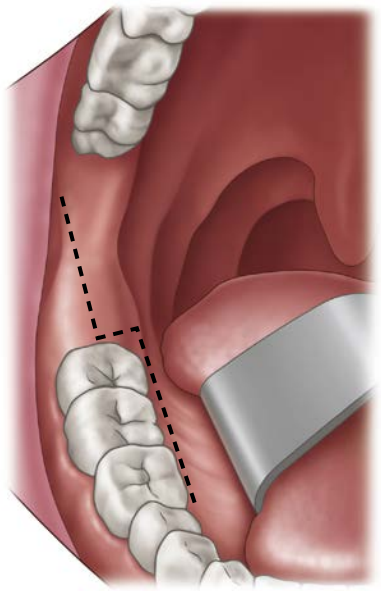

• **Figure 5-32** Diagram showing surgical access for lingual nerve repair using a lingual gingival sulcus approach with posterolateral extension. (From Fonseca RJ, Walker RV, Barber HD, et al: *Oral and maxillofacial trauma*, ed 4, St Louis, 2013, Saunders.)

operative microscope. Surgical exposure to assess the IAN, LN, MN, and ION can be easily performed via intraoral approaches, and in these cases surgical loop magnification maybe more practical than a microscope. There is a clear esthetic benefit from intraoral approaches, but these may be more challenging based on the site of the injury.[117] The more proximal the injury, the more challenging the access is; for example, a LN injury at the third molar region is more challenging to repair than an IAN in the mental foramen area. The individual patient anatomy, surgeon experience, mechanism of injury, and location of the injury are further considerations when deciding the most appropriate surgical approach.

The LN is approached intraorally via a paralingual or lingual gingival sulcus incision (Figure 5-32). The paralingual incision allows for small incision and direct visualization of the nerve, but it may be more challenging to identify the nerve stumps after transection because of retraction into the soft tissues. The latter approach involves a longer incision with anterior and posterior releases, but there is less risk of retraction of the nerve endings during dissection.[194] For the IAN (and MN), a vestibular incision with identification of the mental nerve and lateral decortication to expose a portion of the IAN is usually adequate to mobilize the mental nerve for repair. In cases of restricted mouth opening, an extraoral approach may be required. Once the mandible is accessed, the IAN is approached via lateral decortication

techniques (Figure 5-33).[195] Access to the ION can be accomplished transorally via a maxillary vestibular incision at the time of maxillary or zygomaticomaxillary complex fracture repair. Alternatively, a lower lid, transconjunctival, or subciliary incision may be more suitable and an osteotomy around the infraorbital canal may be required for nerve isolation.[76,194]

Dissection of the nerve from the surrounding tissue bed for inspection and further manipulation is the next step and is termed external neurolysis (EN). For the LN this may involve microdissection of the neurovascular bundle from surrounding scar tissue, whereas for the IAN it may imply the need for decortication of the IAC and lateralization of the IAN. Separation of the nerve from scar tissue that may be responsible for

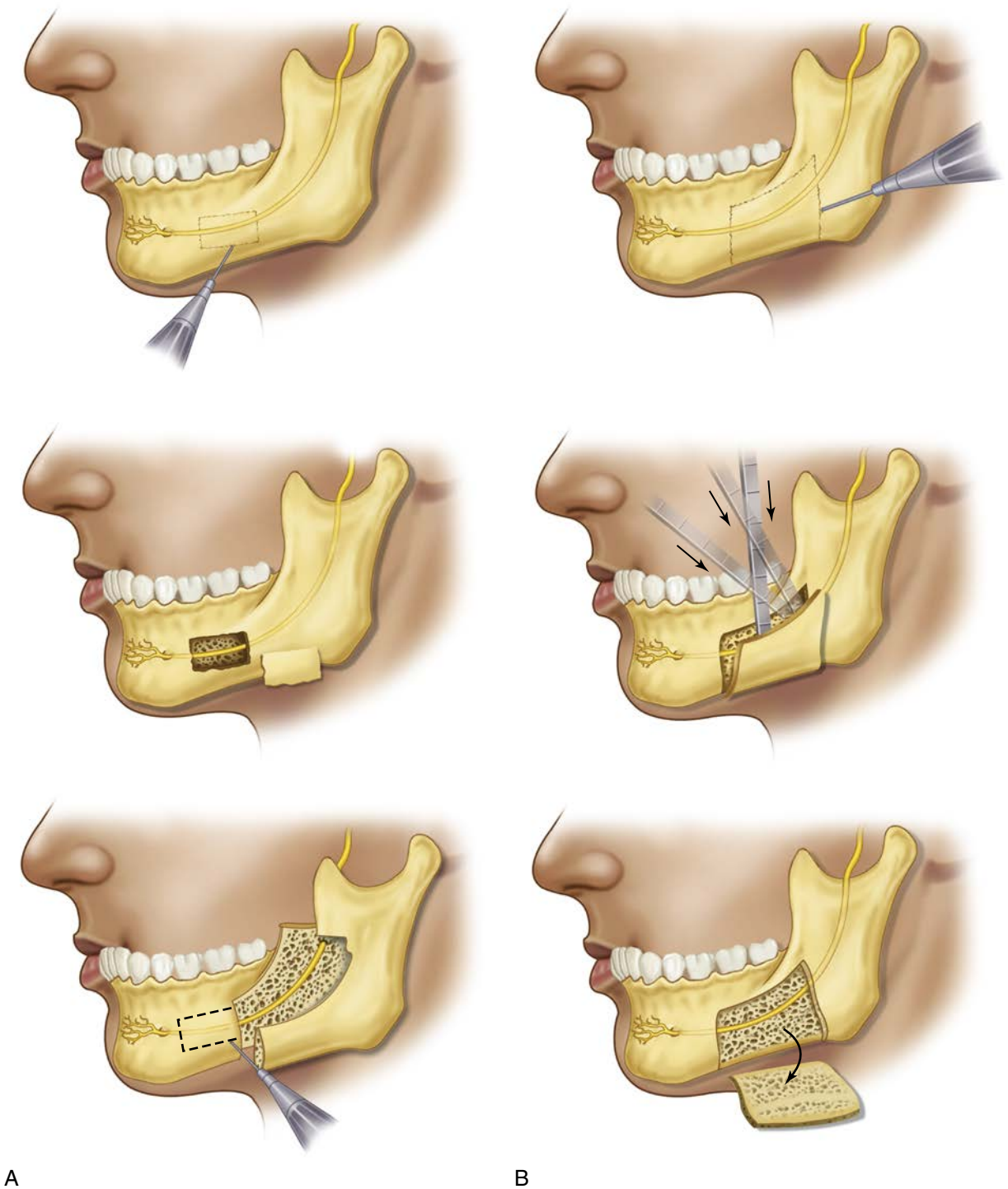

• **Figure 5-33** **A,** Diagram of techniques for inferior alveolar nerve access, including isolated decortication, or a sagittal split osteotomy, with extension to the mental foramen if necessary. **B,** Diagram of technique described by Miloro (see Ref. 195) for wide access to the inferior alveolar nerve via a complete lateral decortication window that may be replaced to protect the nerve repair site.

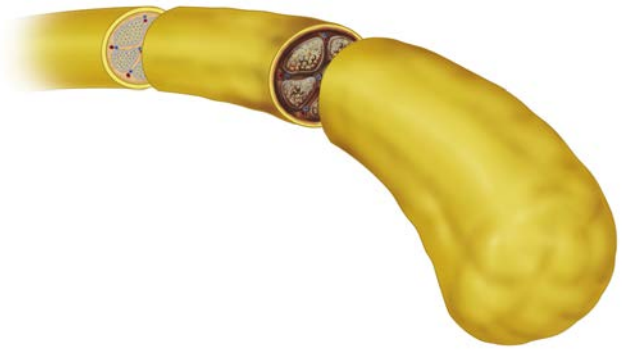

• **Figure 5-34** Diagram showing preparation of the nerve stump with serial 1.0 mm resections to remove scar tissue (neuroma) and ensure that normal healthy neural tissue is encountered prior to the neurorrhaphy procedure. Failure to debride the nerve stumps adequately will result in failure of neurosensory recovery. (From Fonseca RJ, Walker RV, Barber HD, et al: *Oral and maxillofacial trauma*, ed 4, St Louis, 2013, Saunders.)

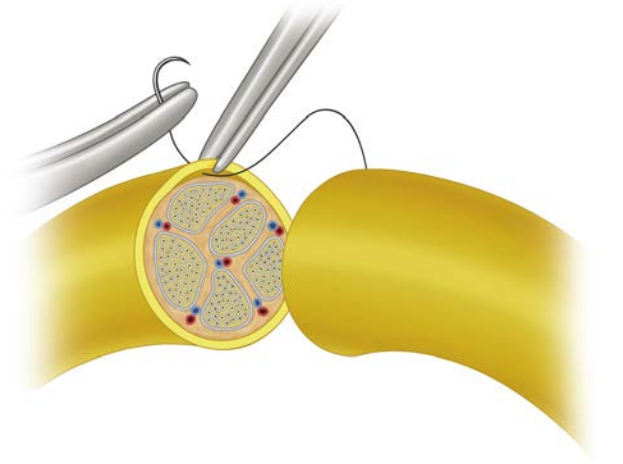

• **Figure 5-35** Diagram showing direct neurorrhaphy with epineurial sutures. (From Fonseca RJ, Walker RV, Barber HD, et al: *Oral and maxillofacial trauma*, ed 4, St Louis, 2013, Saunders.)

restriction or compression leading to a conduction block and prevention of spontaneous recovery may be all that is required. In cases of short duration of symptoms (less than 6 months) or if nerve compression from scarring is less than 25% of the nerve diameter without neuroma formation, EN may provide definitive treatment.[117,193,196,197] EN is performed under loop magnification; once completed, an examination of the nerve is performed and the need for additional intervention is determined. If foreign material or bone or tooth fragments are identified, they should be removed at this stage.

Several injuries may cause intraneural scarring that results in neurologic deficits while nerve continuity is maintained.[198] In such cases, internal neurolysis (IN) is indicated and requires opening the epineurium for fascicular examination. Because of the sparse amount of epineurium in the trigeminal nerve branches, this may lead to further fibrosis and iatrogenic scarring. Caution should be exercised when making the decision to proceed with IN, since it may cause worsening of the condition.[117] Several types of IN are described based on the exact tissue manipulation performed: epifascicular epineurotomy, epifascicular epineurectomy, and intrafascicular epineurectomy that are of progressive complexity, involve tissue removal, and are of questionable benefit for the trigeminal nerve system.[117,192,193]

In cases of neuroma formation, excision followed by restoration of nerve continuity is required. Careful examination of the nerve stumps to be anastomosed is crucial so that healthy nerve tissues are repaired, and scarred and necrotic nerve stumps are completely removed at 1.0-mm resection increments until normal tissue is encountered (Figure 5-34). For a direct neurorrhaphy, epineurial suturing with three or four 7.0 or 8.0 nonreactive sutures (nylon) is adequate for the trigeminal nerve (Figure 5-35).[199] Coaptation is the alignment of individual fascicles during direct repair, and this is difficult if not impossible with a polyfascicular nerve such as the trigeminal.[200,201] Nerve mobilization for tension-free closure is critical and may require dissection in proximal and distal directions (Figure 5-36) or,

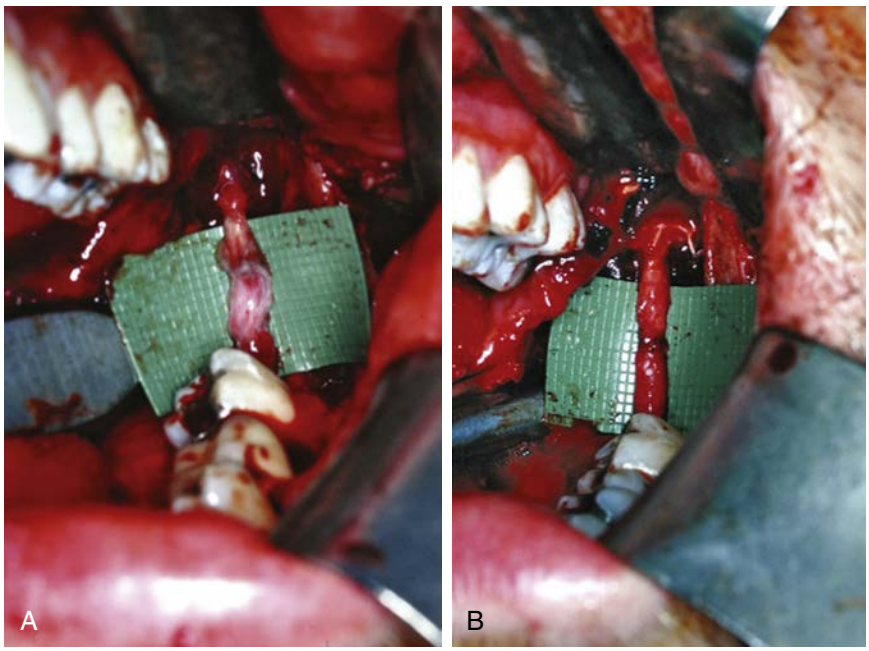

• **Figure 5-36** Clinical example of a left lingual nerve neuroma **(A),** and following resection of the neuroma and direct repair with epineurial sutures **(B)**. (From Fonseca RJ, Walker RV, Barber HD, et al: *Oral and maxillofacial trauma*, ed 4, St Louis, 2013, Saunders.)

additionally, in the case of the IAN, sacrifice of the terminal incisive branch to allow further release and mobilization of the IAN.[200]

Cases of nerve injury that result in nerve continuity defects or prevent primary tension-free repair will require indirect repair with interpositional grafting (Figure 5-37). Traumatic avulsive injuries, pathologic conditions involving the nerve, or extensive neuroma resection at the time of nerve repair are common reasons for these continuity defects of the nerve. When nerve mobilization is not adequate to allow tension-free primary repair, then interpositional grafts may be required. The donor site selection for a nerve graft depends on several factors that include diameter and fascicular pattern, correlation of neural function, and donor site morbidity. Usual donor sites for trigeminal nerve repair include the greater auricular and sural nerves because of ease of access and relatively low donor site morbidity with relatively tolerable anesthetic areas.[79,117,193,194,201] In fact, the sural nerve may be the preferred autogenous nerve graft because it matches most closely with the diameter and fascicular pattern of the trigeminal nerve system and it results in an area of minor donor site paresthesia (Figure 5-38).[202] The greater auricular nerve diameter is approximately 50% of the trigeminal nerve diameter, and therefore its usefulness may be limited to cable grafting (multiple grafts) for the trigeminal nerve. Additionally, the harvest would result in a facial scar as well as an area of deficit in the facial region that is less tolerable to patients than the donor site deficit of the lateral foot that results from sural nerve harvest.

Alternatively, several other materials may be used for indirect neurorrhaphy via entubulation techniques, including alloplastic tubes (Silastic, expanded polytetrafluoroethylene,

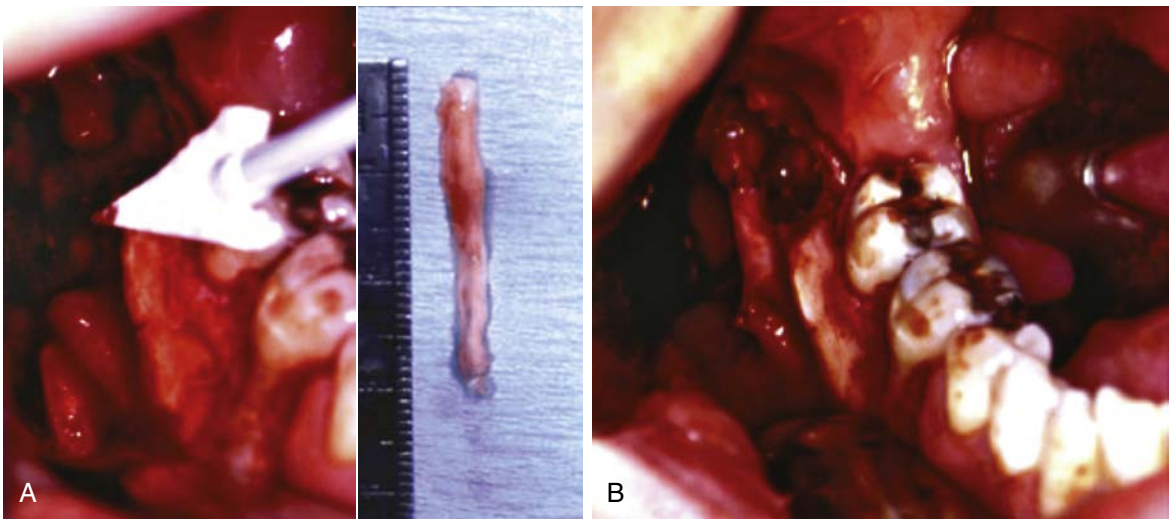

• **Figure 5-37** **A,** Clinical example of a discontinuity of the right inferior alveolar nerve following resection of a neuroma due to a third molar injury (*arrowhead Weck-Cel sponge*) (*left*). Autogenous sural nerve graft, 3 cm (*right*). **B,** Indirect graft repair of the right inferior alveolar nerve continuity defect using the autogenous sural nerve graft with epineurial sutures. (From Fonseca RJ, Walker RV, Barber HD, et al: *Oral and maxillofacial trauma*, ed 4, St Louis, 2013, Saunders.)

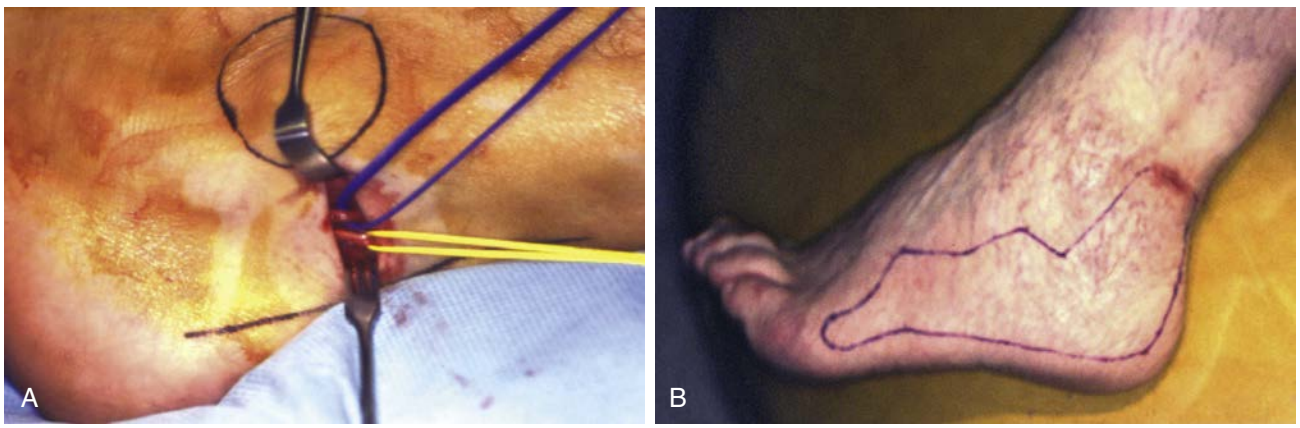

• **Figure 5-38** **A,** Clinical example of sural nerve harvest site posterior and superior to the lateral malleolus with identification of the lesser saphenous vein (anterior), and the sural nerve (posterior). **B,** Donor site deficit mapped with marker 1 week following sural nerve harvest. This area of paresthesia decreases significantly over time. (From Fonseca RJ, Walker RV, Barber HD, et al: *Oral and maxillofacial trauma*, ed 4, St Louis, 2013, Saunders.)

polyester, polyglycolic acid polymer), vein grafts,[203] and allogeneic nerve grafts (Figure 5-39). The use of alloplastic tubes is attractive because it eliminates donor site morbidity. Unfortunately, there has been no consistency in the reported clinical outcomes with these entubulation techniques, and therefore, this is not a standard technique for management of trigeminal nerve injuries with continuity defects. Vein grafting, on the other hand, has been successfully used for this purpose with results comparable to primary repairs in small defects of less than 5 mm.[204-209] Following surgical intervention, periodic follow-up with repeat NST to evaluate response to treatment is required, and sensory reeducation exercises may be used to augment spontaneous neurosensory recovery.

Outcomes of Trigeminal Nerve Injury and Surgical Intervention

Injuries to the peripheral branches of the trigeminal nerve may be associated with impairment of speech, taste, or mastication and impact on quality of life. Long-term effects of these injuries are not very well documented in the literature. In a recent effort to elucidate this subject, Pogrel and colleagues attempted to obtain information from patients several years following nerve injury via a telephone survey. Despite the poor 20% response rate, patients did report long-term difficulties with jobs, relationships, depression issues, speech, and eating problems. It was reported, however, that patients noted general improvement over time, with 8% describing complete recovery. It is unclear from this study if this represents true neurosensory recovery or adaptation to the altered status of the nerve, yet the authors were in support of surgical intervention when indicated.[188]

Based on the literature in this area, the success of microneurosurgical reconstruction of trigeminal nerve injuries could be estimated to be between 30% and 50%, for all degrees of injury and types of reconstruction, with higher success rates achieved when primary repair is performed.[117,210-212] However, gap repair with an autogenous sural nerve graft may provide a better outcome because the graft itself provides a rich source of Schwann cells and neurotropic and neurotrophic factors to an area of injury that can assist in the degeneration and regeneration process of neural recovery.[202] Factors contributing to the variability of reported success rates relate to inconsistencies in documentation and standardization as well as heterogeneity with regard to etiology of the injury, specific medical or surgical intervention, experience of the surgeon, timing of intervention, length of follow-up, neurosensory testing methods used, method of reporting results, and criteria used to evaluate and define a successful outcome. In a retrospective review of outcomes in 51 patients who underwent microneurosurgical intervention, the following observations were reported: (1) repairs performed less than 10 weeks (early repairs) from the injury appeared to do better than late ones; (2) improved sensation for both IAN and LN can be achieved with microneurosurgery in select cases; and (3) carefully selected patients do benefit from trigeminal nerve microneurosurgery.[210] There is a consensus that a need exists for more data in this area in the form of a prospective, randomized, multicenter clinical trial with standardization in diagnosis and management of trigeminal nerve injuries.



• **Figure 5-39** Diagram showing the principle of entubulation using a conduit to guide neural regeneration in cases of nerve discontinuity. (From Fonseca RJ, Walker RV, Barber HD, et al: *Oral and maxillofacial trauma*, ed 4, St Louis, 2013, Saunders.)

Facial Nerve Anatomy

Macroanatomy

The facial nerve contains approximately 10,000 fibers, of which 7000 are myelinated fibers innervating the facial musculature, with the remaining 3000 fibers providing sensation, taste, and parasympathetic secretomotor functions to the submandibular, sublingual, and lacrimal glands. The facial nerve is described as having three distinct segments: intracranial, intratemporal, and extratemporal. The intracranial segment is that portion of the nerve from the brainstem to the internal auditory canal (IAC). It is made up of two components, a motor root and nervus intermedius carrying sensory, preganglionic parasympathetic fibers, and special afferent sensory fibers. These two components join before becoming the intratemporal segment to form the common facial nerve. Within the caudal pons, motor fibers supplying the lower face cross to the contralateral motor nucleus. The majority of fibers supplying the musculature of the upper face also cross over to the contralateral motor nucleus; however, some fibers do not cross and continue to travel in the ipsilateral motor nucleus. The incomplete crossover of the fibers innervating the upper face results in forehead sparing, often indicative of a central etiology to facial paralysis. The nervus intermedius will provide sensation to the posterior concha and external auditory canal (EAC), taste sensation to the anterior two thirds of the tongue, and secretomotor innervation of the minor salivary, submandibular, sublingual, and lacrimal glands. The intracranial segment of the facial nerve is approximately 24 mm in length.[213,214]

Intracranial Segment

The intratemporal segment begins at the porus acusticus of the IAC and is divided into four portions as it travels to exit the stylomastoid foramen and become the extracranial portion. The first of four intratemporal segments is the meatal portion. This segment is 8 to 10 mm in length and extends from the porus acusticus of the IAC to the meatal foramen of the IAC.[213,214] Traveling in the anterior superior portion of

the IAC, the facial nerve is separated from the cochlear nerve anterior inferiorly by a horizontal segment of bone and the superior vestibular nerve posterior superiorly by a vertical segment of bone; it passes by the posterior inferiorly located inferior vestibular nerve. Running within the IAC is the anterior inferior cerebellar artery. A branch of this artery, the labyrinthine artery, supplies blood to this region of the facial nerve.[215]

Intratemporal Segment

The bony canal of the facial nerve begins the second segment of the intratemporal portion, the labyrinthine segment, which is the shortest segment (3-5 mm) and extends from the fundus to the geniculate ganglion. It is within this portion that the facial never runs through the narrowest portion of the IAC (0.68 mm) (Figure 5-40).[213] It is hypothesized this narrow canal is the culprit in facial nerve compression due to Bell's palsy and other causes of facial nerve edema. As the labyrinthine segment ends at the geniculate ganglion the facial nerve gives off its first branch, the greater superficial petrosal nerve (GSPN) (Figure 5-41). The GSPN carries preganglionic parasympathetic fibers from the superior salivatory nucleus to the pterygopalatine ganglion, where it synapses and postganglionic fibers join the maxillary branch of the trigeminal nerve to innervate the lacrimal gland and minor salivary glands of the nose and palate.[215]

The third segment of the intratemporal portion of the facial nerve, the tympanic segment, extends from the geniculate ganglion to the second genu (Figure 5-42). It begins with a 75-degree bend at the geniculate ganglion (first genu). This 8- to 11-mm segment passes superior and lateral to the oval window, inferior to the lateral semicircular canal, and then makes a second turn at a 95- to 125-degree angle (second genu) to become the mastoid segment. The tympanic segment has the highest rate of bony dehiscence (40% to 75%).[215,216]

The fourth and final segment of the intratemporal portion of the facial nerve, the mastoid segment, exits the temporal bone at the stylomastoid foramen approximately 10 to 14 mm from its origin at the second genu (Figure 5-43).[213,215] It gives off two branches, chorda tympani and the nerve to the stapedius muscle. Chorda tympani passes

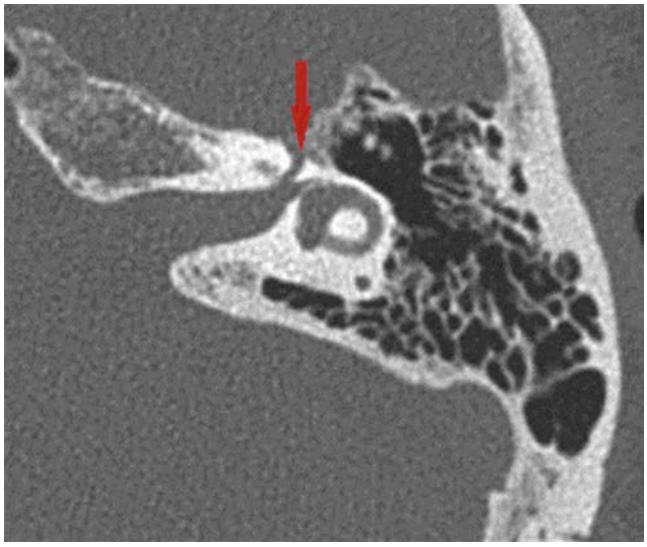

• **Figure 5-40** Labyrinthine segment (fallopian canal) of the intratemporal facial nerve segment (*red arrow*). Narrowest point in the course of the facial nerve canal.

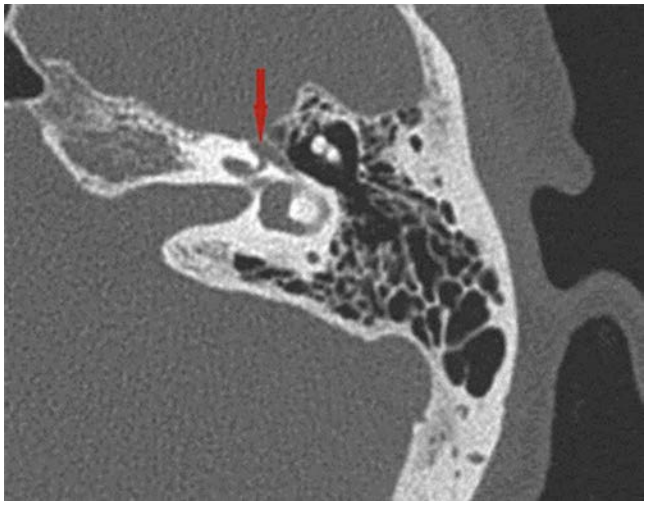

• **Figure 5-41** Geniculate ganglion (*red arrow*).



• **Figure 5-42** Tympanic segment of the intratemporal facial nerve segment (*red arrow*).

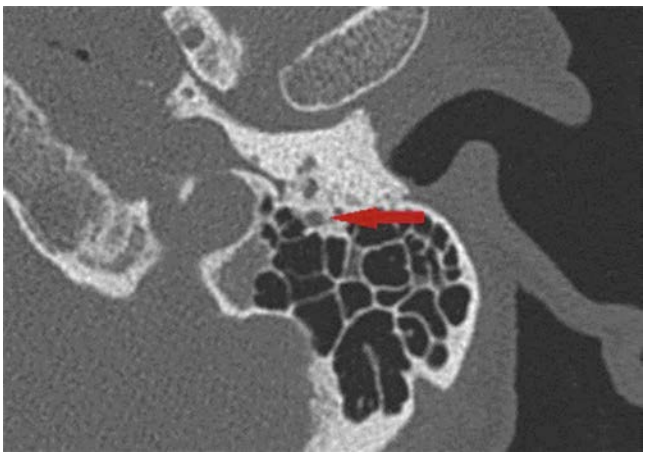

• **Figure 5-43** Mastoid segment of the intratemporal facial nerve segment (*red arrow*).

through the petrotympanic fissure and into the infratemporal fossa, where it joins the lingual branch of the trigeminal nerve before reaching the submandibular ganglion. Postganglionic fibers innervate the submandibular and sublingual glands as well as providing taste sensation to the anterior two thirds of the tongue.

Extratemporal Segment

The extratemporal segment of the facial nerve begins at the stylomastoid foramen, which is located posterolateral to the styloid process and anteromedial to the mastoid process. Before entering the substance of the parotid gland, the posterior auricular nerve and branches to the posterior belly of the digastric and stylohyoid muscle divide from the facial nerve. The posterior auricular branch divides into an auricular and occipital branch innervating the external auricular and occipital belly of the occipitofrontalis muscle, respectively. The facial nerve then travels between the digastric and stylohyoid muscles, superficial to the styloid process, and enters the substance of the parotid gland, dividing the parotid into a superficial and deep lobe. At an anatomic point located approximately 1.3 cm from the stylomastoid foramen, the pes anserinus (Latin: goose foot), the facial nerve divides into its two main branches, the temporofacial and cervicofacial.[217]

Various surgical landmarks are available to assist in locating the main trunk of the facial nerve. Prior to locating the nerve, exposure of several important anatomic landmarks should be completed. This includes exposure of the mastoid process, sternocleidomastoid, posterior belly of the digastric muscle, tympanic bone, and EAC. The main trunk of the facial nerve is located midway between the cartilaginous tragal pointer of the EAC and the posterior belly of the digastric muscle. It lies approximately 1.0 to 1.5 cm deep and slightly anterior and inferior to the tip of the external canal cartilage (tragal pointer). Additionally, the facial nerve is 1.0 cm deep to the medial attachment of the posterior belly of the digastric muscle to the mastoid. The tympanomastoid suture line is located approximately 6 to 8 mm lateral to the stylomastoid foramen. Additionally, as dissection proceeds, a branch from the occipital artery may be encountered. This artery lies in close proximity to the facial nerve trunk, and further dissection should be made with caution.[218,219] If the main trunk of the facial nerve cannot be located or its path traced proximally, retrograde dissection of one of the branches of the facial nerve may be necessary.

The temporofacial and cervicofacial trunks then divide into the final five branches of the facial nerve (temporal, zygomatic, buccal, marginal mandibular, and cervical) with various reported branching patterns and no predominant pattern (Figure 5-44).[220] The temporofacial trunk always gives rise to the temporal and zygomatic branches, whereas the cervicofacial trunk always gives rise to the marginal mandibular and cervical branches. The variation in branching patterns is due to the origin of the buccal branch as well as the presence of cross innervation. Cross innervation between the zygomatic and buccal branches is noted in

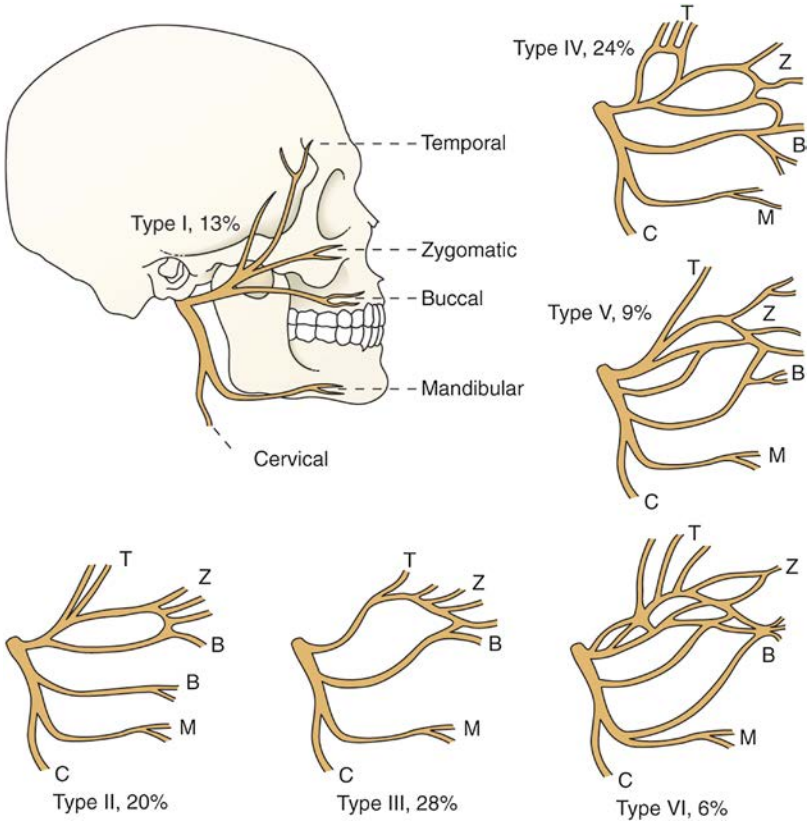

• **Figure 5-44** Variations in the branching pattern of the facial nerve. (From Townsend C, Beauchamp RD, Evers BM, et al: *Sabiston textbook of surgery*, ed 19, St Louis, 2013, Saunders.)

more than 70% of cases, whereas cross innervation between the temporal or marginal mandibular nerve to other facial nerve branches occurs in fewer than 15% of cases.[221]

The temporal branch of the facial nerve is described as crossing the zygomatic arch within or deep to the temporoparietal fascia approximately 0.8 to 3.5 cm anterior to the EAC and most commonly demonstrating two branches.[222] The course of the temporal branch has been noted to fall between two lines: a superior line connecting the upper tragus to the highest forehead crease, and an inferior line connecting the lower tragus to the lowest forehead crease.[223] In an axial high-resolution MRI study, Miloro and co-workers determined the mean distance from the most anterior aspect of the external acoustic meatus to the posterior ramus of the temporal branch was 2.12 ± 0.21 cm.[224] It innervates the frontalis, orbicularis oculi, corrugator supercilii and the anterior and superior auricular muscles. The temporal branch of the facial nerve also acts as the efferent limb of the corneal reflex.

The zygomatic branch of the facial nerve travels within the parotid gland until its exit approximately 30.71 mm (16.2-45.64 mm) anterior to the tragus and is located a mean vertical distance of 19.29 mm (5.7-28.72 mm) from a line connecting the lateral palpebral commissure and the tragus. It most commonly consists of two branches (69.7%) or three branches (25.8%). The nerve follows a path deep to the zygomaticus major and orbicularis oculi muscle and is located beneath the superficial fascia following its exit from the anterior border of the parotid. It innervates the medial head of the orbital portion of orbicularis oculi muscle, the depressor supercilii muscle, and the oblique head of the corrugator supercilii muscle.[225]

The buccal branch of the facial nerve exits at the anterior border of the parotid, generally noted to be 35 mm (21-53 mm) anterior to the tragus and along the transverse axis of the zygomatic arch, most often as a single branch located inferior and traveling parallel to the parotid duct. When multiple branches are noted exiting the parotid, the most common pattern is to have a branch superior and inferior to the parotid duct, with the superior portion crossing over the duct a variable distance from its emergence. In 100% of specimens, the entire course of the buccal branch of the facial nerve is below a line drawn from the tragus to ala nasi.[226,227] Innervation of the buccinator, levator labii superioris, risorius, levator labii superioris alaeque nasi, levator anguli oris, nasalis, orbicularis oris, depressor septi nasi, and procerus muscles is provided by the buccal branch of the facial nerve. For the majority of the paired facial muscles, innervation is from the deep aspect. The buccinator, levator anguli oris, and mentalis are the exceptions to this pattern.

The marginal mandibular branch of the facial nerve is located within or deep to the superficial layer of deep cervical fascia as it courses anteriorly and innervates the depressor labii inferioris, depressor anguli oris, and mentalis muscles. The location of this nerve in relation to adjacent structures has been extensively studied.[228-230] The marginal mandibular nerve is located above the inferior border of the mandible anterior to the facial artery in 100% of cases. Posterior to the facial artery, it is located above the inferior border in 81% of cases, and in the remaining 19% the marginal mandibular nerve is located up to 1.75 cm below the angle of the mandible with a reported average distance of 1.2 to,1.5 cm below the mandibular angle.[228-230] In addition, the marginal mandibular nerve is located superficial to the facial artery in 100% of cases. Cross innervation with other facial nerves is rare, and therefore injury to the marginal mandibular nerve causes permanent paralysis of innervated structures. The most common branching pattern is two or more with only 28% to 32% demonstrating a single branch-up until arborization near its termination.[228-230]

The cervical branch of the facial nerve innervates the platysma muscle and branches below the angle of the mandible in all cases. It can be reliably located 1 cm below a line connecting the mentum to mastoid about the position of the angle of the mandible.[231]

Microanatomy

The microanatomy of the facial nerve is consistent with that previously described in this chapter for the trigeminal nerve with few exceptions. The facial nerve is considered to be a polyfascicular nerve, although it does not begin to demonstrate true fascicular organization until the geniculate ganglion. Distal to this point, the number of fascicles increases in a proximal to distal fashion. The temporofacial trunk demonstrates on average 13 fascicles (2-29) and the cervicofacial trunk demonstrates an average of 16 fascicles (2-23) with an average fascicle diameter of 300 μm.[232] Within the substance of the parotid gland, the average facial nerve diameter ranges from 0.3 mm to 1.6 mm.[233] Similar to the trigeminal nerve branches, the mean number of fascicles and the cross-sectional area for the facial nerve branches decrease proceeding from proximal to distal nerve.[232]

Chorda tympani most commonly demonstrates a monofascicular pattern before its fusion with the lingual nerve 1 to 2 cm below the base of the skull and just above the lower border of the lateral pterygoid muscle.[78,234] At this point, the lingual nerve has been described as having both a monofascicular and oligofascicular pattern. Shortly after joining the lingual nerve, the fibers of chorda tympani are no longer recognizable as separate entities; the fibers join the lingual nerve fascicles. This explains the lack of gustatory recovery following repair of lingual nerve injuries at the level of the third molar.[78]

Facial Nerve Imaging

The choice of imaging modality in the evaluation of the facial nerve should take into account the location and suspected cause of injury. For suspected intracranial segment pathology or when the location of pathology is unknown, contrast-enhanced MRI is the preferred preliminary imaging. When pathology of the intratemporal segment is suspected, CT with thin cuts through the temporal bone is

indicated along with the addition of MRI, depending on the type of pathology suspected. For evaluation of the extracranial segment of the facial nerve, MRI is again preferred.[215]

Computed Tomography

CT is the preferred imaging modality for pathology of the intratemporal segment of the facial nerve. As mentioned previously, this segment extends from the porus acusticus of the IAC to the stylomastoid foramen and includes four segments: meatal, labyrinthine, tympanic, and mastoid. Dedicated high-resolution CT of the temporal bone with thin cuts (0.6 mm), helical mode acquisition, and contrast when neoplastic or vascular pathology are suspected is the imaging of choice.[235] If a tumor of the facial nerve is suspected, MRI should be obtained in addition to CT, as pathology of the facial nerve within its bony canal can only be inferred based on adjacent bony erosion evident on CT. High-resolution CT of the temporal bone can detect early erosion and destruction of the facial nerve canal in addition to providing important information regarding relationships to normal anatomic landmarks such as the ossicles that are not seen on MRI.[216] This information is crucial to preoperative planning in otologic surgery and leads to a decreased rate of iatrogenic facial nerve trauma.[216]

Magnetic Resonance Imaging

MRI is the preferred imaging modality for suspected neoplastic pathology and for the intracranial and extratemporal segments of the facial nerve. Its superior visualization of the soft tissues can identify perineural spread from parotid malignancy and enlargement of the facial nerve that can be missed with high-resolution temporal bone CT scanning.[214] The normal labyrinthine, cisternal, intracanalicular, and parotid segments of the facial nerve normally do not enhance, whereas the normal facial nerve will faintly enhance in the geniculate ganglion, tympanic, and mastoid segments on gadolinium contrast MRI imaging. Increased enhancement or asymmetric enhancement of these regions should prompt consideration of inflammatory or neoplastic processes. Once the facial nerve exits the stylomastoid foramen, it is best visualized with axial high-resolution T1-weighted images using a microscopic coil.[214]

Ultrasound

Ultrasound is rarely used in routine imaging of the facial nerve. However, there are several studies that have used ultrasound to evaluate the normal size of the facial nerve or prognosis of Bell's palsy based on nerve diameter.[233,236] In a prospective controlled trial, Lo and colleagues noted that a normal ultrasound diameter of the facial nerve on the affected side in Bell's palsy had a positive predictive value of 100% for recovery of facial nerve function, whereas an abnormal value had a negative predictive value of 77% for House-Brackmann Grade II or worse facial nerve function at 3 months.[236]

Classification of Facial Nerve Injury

Injuries to the trigeminal and facial nerve are both classified according to the previously described Seddon and Sunderland classification of nerve injury. In addition, the axonal and cellular response to injury is consistent between these two cranial nerves. Please see the section on classification of nerve injuries. In regard to facial nerve injury, an additional classification system, the House-Brackmann facial nerve function grading scale, is used (Table 5-5).[237] This scale is the official scale of the Facial Nerve Disorders Committee of the American Academy of Otolaryngology–Head and Neck Surgery (AAO-HNS. It consists of grades I through VI, with VI representing total paralysis. In patients with isolated injury to a single branch, the House-Brackmann scale is of limited use, and therefore more subjective notation of injury is utilized.

Mechanisms of Injury to the Facial Nerve

Bell's Palsy

Named for the Scottish anatomist who first described it, Charles Bell, facial paralysis due to Bell's palsy is an uncommon condition with an incidence ranging from 11.5 to 53.3 per 100,000 person years.[238] The condition can be found in the pediatric population; however, its incidence is higher with increasing age and in females across all age groups.

TABLE 5-5 House-Brackmann Facial Nerve Grading Scale

Grade	Description
I	Normal facial function
II	Mild Dysfunction—Slight weakness, slight synkinesis on close inspection. Moderate to good forehead function. Complete eye closure with minimal effort. Slight smile asymmetry with maximum effort. Normal symmetry and tone at rest.
III	Moderate Dysfunction—Obvious but not disfiguring difference between sides. Noticeable but not severe synkinesis. Slight to moderate forehead movement. Complete eye closure with effort. Strong but asymmetric smile with maximum effort. Normal symmetry and tone at rest.
IV	Moderately Severe Dysfunction—Obvious weakness and/or disfiguring asymmetry. Severe synkinesis. No forehead movement. Incomplete eye closure. Asymmetric smile with maximum effort. Normal symmetry and tone at rest.
V	Severe Dysfunction—Barely perceptible motion. Synkinesis usually absent. No forehead movement. Incomplete eye closure. Slight movement at the corner of mouth. Asymmetry at rest.
VI	Total Paralysis—No movement.

From House JW, Brackmann DE: Facial nerve grading system, *Otolaryngol Head Neck Surg* 93:146-147, 1985.

There is an increased risk in pregnancy and in patients with diabetes mellitus, hypertension, obesity, and prior upper respiratory infection (URI), with 60% reporting recent URI.[238] Although a viral etiology is suspected, the diagnosis of Bell's palsy is one of exclusion. Other causes of facial paralysis should be excluded through careful history and physical examination (Table 5-6). Imaging and laboratory testing are not routinely recommended in the evaluation of patients with new-onset Bell's palsy.[238] Despite being the most common cause of facial paralysis, the true etiology of Bell's palsy is not yet fully understood. Paralysis is thought to occur due to facial nerve edema and possible resulting compression of the vascular supply to the nerve as it travels through its bony canal, specifically within the labyrinthine segment.

Bell's palsy is defined by acute, unilateral facial nerve paresis or paralysis with progression to maximum severity within 72 hours and without an identifiable cause.[238] By definition, it involves all muscle groups of one side of the face. Signs of central nervous system disease, such as extremity weakness, and signs of ear or cerebellopontine angle disease, such as hearing loss, tinnitus, or vertigo, will be absent. Patients may complain of concurrent or prodromal ipsilateral pain about the face or ear as well as exposure eye keratopathy, xerostomia, taste disturbance, and hyperacusis.

Treatment of Bell's palsy is controversial.[239,240] Clinical practice guidelines from the AAO-HNS recommend treatment of all patients with suspected Bell's palsy with oral steroids within 72 hours of symptom onset.[26] Multiple studies including randomized, double-blind, placebo-controlled multicenter trials have been published.[241-243] The findings of these studies are in accordance with the clinical practice guidelines previously mentioned. Regardless of symptom severity, all patients benefited from early initiation of oral steroids. The evidence from these studies does not support the routine use of antivirals alone or in combination with prednisone; however, the AAO-HNS clinical practice guidelines leave the addition of oral antiviral therapy as an option due to low risk and weak data unable to exclude a small benefit.[238] Surgical decompression remains controversial, and no recommendation is provided by the AAO-HNS because of low-quality evidence and a small subset of patients with specific indications who may derive significant benefits from decompression surgery.[238,244-246] In a multicenter prospective trial, Gantz and associates demonstrated a benefit to early (within 2 weeks of symptom onset) surgical decompression of the facial nerve in a subset of patients demonstrated by electroneurography and electromyography to have a higher risk of poor return of facial function.[245] A Cochrane systematic review of available evidence published in 2013 concluded that there is only very low-quality evidence, and this is insufficient to decide whether surgical intervention is beneficial or harmful. However, they did state that further research is unlikely to be performed because of spontaneous recovery in most cases.[246] Regardless of treatment approach, patients should be referred to a facial nerve specialist if at any point during recovery they develop new or worsening neurologic findings, ocular symptoms, or have incomplete facial recovery at 3 months from onset of initial symptoms.[238]

Prognosis is best in those patients with incomplete paralysis; 94% will recover completely. Most patients will show some recovery without any intervention within 2 to 3 weeks of symptom onset and continue to improve until complete recovery at 3 to 4 months. However, without treatment, up to 30% will have incomplete recovery. If improvement is noted within 2 weeks, prognosis for complete recovery is best.[239,240] Of those who do not recover completely, sequelae are slight to mild in a large majority, with only 4% being described as having severe sequelae.[240] Possible sequelae include ageusia, facial spasm, facial pain, and corneal infection/abrasion. Additionally, patients can develop synkinesis, an involuntary muscular movement occurring simultaneously with voluntary movements. An example would be a patient who has movement of the corner of the mouth when attempting to close the ipsilateral eye.

TABLE 5-6 Etiology of Facial Paralysis

Congenital	Möbius syndrome, hemifacial microsomia, Goldenhar syndrome
Birth-Related	Trauma during delivery
Neurologic	Guillain-Barré, ischemic/hemorrhagic stroke, hypertension
Bell's Palsy	Herpes simplex virus, autoimmune reaction, ischemic neuropathy, microcirculatory failure of vasa nervorum, entrapment, idiopathic
Neoplasm	Central, parotid, and acoustic tumors
Hematologic	Leukemia, hemophilia
Infection	Otitis media, Lyme disease, Ramsay Hunt, herpes simplex, Epstein-Barr virus, mycoplasma, mastoiditis
Trauma	Temporal bone fracture, blunt or penetrating trauma to the extratemporal segment
Iatrogenic	Facial surgery, otologic surgery, brain surgery

Trauma

Traumatic injury to the facial nerve can occur at any point along its course from the brainstem to the muscles of facial expression or other target organs. Blunt and penetrating trauma can directly injure the facial nerve or cause injury to adjacent structures resulting in nerve transection, edema, vascular compromise, and ischemia. The second most common cause of facial nerve injury, traumatic injuries represent 15% of all cases of facial nerve paralysis, with the most common traumatic cause being temporal bone fracture. In total, 5% of trauma patients will sustain a temporal bone

fracture. There are two subtypes of temporal bone fracture, longitudinal and transverse, although in reality many fractures are a mixture of the two. The longitudinal fracture is the most common type (70-80%) and is classified by a fracture line along the long axis of the petrous temporal bone, which is also the path of least resistance to fracture propagation in the temporal bone.[247,248] It is generally caused by a direct blow to the temporoparietal region. Fortunately, longitudinal fractures are associated with facial nerve injury in only 10% to 20% of cases, with 94% returning to normal function. Transverse fractures are described as extending perpendicular to the long axis of the petrous bone, commonly from the jugular foramen or foramen magnum to the middle cranial fossa, and involving the bony labyrinth and/or geniculate ganglion. Because of labyrinth involvement, sensorineural hearing loss and vertigo are common. These fractures are associated with high-impact frontal or occipital trauma, and up to 50% of patients will have a facial nerve injury that does not return to normal function.[247,248] Prognosis is improved for patients who present with delayed-onset facial paralysis compared to those presenting with immediate-onset paralysis.

Physical exam should include a thorough head and neck exam noting any facial asymmetry, lacerations, bruising, or hematoma. Otoscopy should be completed to check for EAC lacerations, step-offs, hemotympanum, otorrhea, tympanic membrane (TM) perforation, and vertigo or a flaccid TM on pneumatic otoscopy. Fluid should be collected in cases of suspected cerebrospinal fluid (CSF) leak and sent for beta-2 transferrin testing. In addition to imaging with high-resolution dedicated CT of the temporal bones, facial nerve conduction testing with topographic and electrodiagnostic methods is advised. The specifics of these tests are discussed later.

Treatment of facial nerve injury due to temporal bone fracture is guided by clinical and facial nerve conduction examination. Surgical nerve decompression should be performed as soon as possible (within 1 month of injury) in patients with neural degeneration of the facial nerve that is >90% by facial nerve electrogram.[248-250] Complications of facial nerve decompression include dural tears, conductive and sensorineural hearing loss, loss of vestibular function, persistent CSF leak, meningitis, and injury to the anterior inferior cerebellar artery or its branches. The technique of nerve decompression and a complete discussion of its use is beyond the scope of this text; however, further information can be obtained from multiple sources.[248-253]

Facial nerve injury due to penetrating trauma and involving the extratemporal segment of the facial nerve requires prompt evaluation and management to avoid functional and cosmetic deficits. Injuries that are proximal to a line dropped from the lateral canthus are amenable to surgical repair. Injuries distal to this line are generally not repaired due to extensive nerve arborization and cross innervation. Additionally, individual facial muscle fibers can possess multiple motor endplates arising from different branches of the facial nerve. For these reasons, facial nerve dysfunction due to injury anterior to this perceived line is likely to recover spontaneously.[254] Repair of proximal injuries is discussed in detail in later sections of this chapter.

Infection

Facial nerve injury due to infection is the third most common cause of facial nerve injury, with the most common subset of patients presenting with herpes zoster oticus (Ramsay Hunt syndrome).[254] Other infectious causes of facial paralysis include Lyme disease, acute otitis media, chronic suppurative otitis media, malignant otitis externa, infected cholesteatoma, mastoiditis, tuberculous mastoiditis, human immunodeficiency virus, and parotitis.[255-262]

Herpes zoster oticus, also known as Ramsay Hunt syndrome, is due to reactivation of latent varicella zoster virus (VZV). It presents most often in patients over age 60, although it is an important cause of facial paralysis in children 6 to 15 years of age.[256] Patients describe a prodrome of symptoms similar to Bell's palsy, with pain in and around the ear followed by facial weakness. Those patients with Ramsay Hunt syndrome will then progress to develop facial paralysis, hearing loss, vertigo, and possibly facial numbness due to involvement of the trigeminal nerve. Seventy percent of patients will develop a rash around the ear with vesicle formation and crusting. Patients with Ramsay Hunt syndrome often have more severe paralysis at initial presentation, late neural denervation, and a less favorable recovery profile than Bell's palsy. Up to 50% of patients will have persistent facial weakness or other related symptoms despite adequate treatment with prednisone and antiviral medication.[256]

Iatrogenic

Iatrogenic injury of the facial nerve is a feared complication of many head and neck procedures. Facial nerve paralysis due to iatrogenic injury results in cosmetic and functional deficits, ocular complications, diminished quality of life, and, often, malpractice litigation.[263] Injury is most common following parotidectomy procedures due to frequent but necessary manipulation of the facial nerve during surgery. Often, these are neuropraxia-type injuries, and therefore recovery is expected within a few days to weeks of the inciting event. Temporary facial nerve dysfunction occurs in 20% to 40% of patients undergoing parotidectomy; however, the incidence of permanent injury is less than 4%.[264,265] To decrease the risk of facial nerve injury during parotidectomy, many surgeons use intraoperative nerve monitoring techniques, most commonly electromyography.[264] Studies have shown a reduced rate of temporary facial nerve paralysis and an unclear benefit regarding permanent injury when intraoperative nerve monitoring techniques are utilized. Because of the rarity of permanent paralysis, sufficiently large and statistically powered studies are lacking.[264] Injury of the facial nerve during otologic procedures is relatively uncommon, with an incidence of 0.6% to 3.7% in primary surgery and 4% to 10% in revision surgery. For otologic

surgery, data on intraoperative nerve monitoring techniques demonstrate a clear and cost-effective reduction in facial nerve injuries.[264,266,267] Another possible cause of iatrogenic facial nerve injury is during temporomandibular joint (TMJ) surgery. In a review of 102 patients evaluated for iatrogenic facial nerve injury at the Massachusetts Eye and Ear Infirmary Facial Nerve Center, oral and maxillofacial surgery procedures accounted for 40% of total injuries, with TMJ surgery responsible for 27% of total injuries. The temporal branch of the facial nerve was most likely to be injured during TMJ surgery.[267] Reports regarding the risk of facial nerve injury during temporomandibular joint surgery range from 2% to 25%.[268] Repair of mandibular trauma, especially when involving the condyle or subcondylar region, is associated with a risk of temporary facial nerve injury ranging from 8% to 48%, with the buccal branch or marginal mandibular branch most likely to be injured and permanent facial nerve injury an infrequent occurrence.[269-272] Risk factors for injury to the facial nerve included fracture location at the condylar neck, fracture dislocation, and operator inexperience (<3 years).[269] Recovery time ranged from 4 to 24 weeks, and in multiple case series, no permanent facial nerve injury has been reported.[269-272]

Clinical Evaluation of Facial Nerve Injury

The evaluation of facial nerve injury, as with trigeminal nerve injury, begins with a detailed history and physical examination. Patients presenting with facial paralysis should be questioned regarding timing of onset and associated symptoms such as pain, dizziness, changes in hearing, hyperacusis, tinnitus, changes in taste, extremity weakness, prior ear or facial surgery, tick bites or travel to endemic areas, dysphagia, dysarthria, and dry eyes. Patients with extremity weakness, forehead sparing, dysphagia, and dysarthria should be promptly evaluated for central lesions as a cause of their facial paralysis or weakness. The incomplete crossover of the fibers innervating the upper face results in forehead sparing, often indicative of a central etiology to facial paralysis. These patients will maintain the ability to wrinkle the forehead and raise the eyebrows. Additional evaluation and management of patients with central etiology to facial nerve injury is beyond the scope of this text. The clinical examination of patients with facial nerve injury should also include otoscopic examination, especially in cases of blunt traumatic injury, to evaluate for signs or symptoms of temporal bone fracture such as canal laceration, step-off, TM perforation, otorrhea, hemotympanum, or a flaccid TM or vertigo with pneumatic otoscopy. The House-Brackmann grading system should be used when applicable, as it is considered the standard by the AAO-HNS; however, it should be noted that when an extratemporal source of injury is suspected, such as with penetrating trauma to the face, this scale is of limited use, and a subjective description of facial function by the examining physician is appropriate.[237,238] If temporal bone fracture, or benign or malignant pathology is suspected, appropriate imaging should be ordered. For temporal bone fractures, high-resolution dedicated CT of the temporal bones is recommended. If pathology is suspected, MRI should be ordered to better evaluate soft tissues and perineural spread. Following the history and physical exam, facial nerve testing can be ordered when appropriate. Facial nerve testing can help to determine the site and severity of injury, as well as dictating treatment and prognosis.[273,274] In cases of penetrating injury to the extratemporal segment, and when the proximal and distal cut stumps of the facial nerve are identifiable and available for repair, immediate surgical repair by primary neurorrhaphy is advised and can proceed without additional facial nerve testing.[254] Dedicated facial nerve testing is divided into two categories, topographic testing and electrodiagnostic testing.

Topographic testing is used to determine the anatomic level of a peripheral lesion through a variety of tests. A Schirmer test is used to evaluate for lesions at or proximal to the geniculate ganglion. This test evaluates tear production; because the GSPN branches just prior to the geniculate ganglion, a lesion proximal to the geniculate ganglion would result in decreased tear production. In this test, filter paper is inserted into the eye and the degree of wetting of the paper after 5 minutes is recorded. A normal result is greater than 15 mm. Severe disease would be represented by less than 4 mm of wetting. When evaluating for facial nerve lesions, if the affected side shows less than half the amount of lacrimation seen on the unaffected side, the test is considered positive. An alternative, less invasive test involves the use of fluorescein eyedrops. Drops are placed into the eye, and drainage into the nose through the lacrimal duct is expected within 2 minutes. The utility of this test in evaluating for facial nerve injuries has not been explored, as most topographic testing is rarely used since the advent of high-resolution CT and MRI to localize lesions. Stapedius reflex testing can be utilized to evaluate for lesions proximal to the stapedius nerve. An audiologist uses impedance audiometry to record the presence or absence of stapedius muscle contraction to sound stimuli of 70 to 100 dB. An absence of this reflex or a reflex with less than half the amplitude indicates a nerve injury proximal to the branch point of the stapedius nerve within the mastoid segment of the intratemporal portion of the facial nerve. Finally, taste can be evaluated through electrogustometry. This test evaluates the function of chorda tympani and would also indicate presence of an injury within the mastoid segment.

Electrodiagnostic testing includes nerve excitability testing (NET), maximal stimulation testing (MST), electroneurography (ENoG), and electromyography (EMG). Electrodiagnostic testing provides more useful information regarding function and prognosis compared to topographic testing and is more commonly used in clinical practice. All of these tests except EMG require a normal contralateral facial nerve for comparison. In NET, a stimulating electrode is placed at the stylomastoid foramen. Current is applied and the face monitored by the operator for movement. The test is repeated on the opposite side, and a difference of 3.5 mA or greater is considered significant. In

contrast to NET, which measures the minimum current for contraction, MST uses a current that produces maximal contraction of the normal side. An electrode is placed over the stylomastoid foramen of the normal side, and the current that produces maximal contraction is measured. This current is then applied to the side of suspected injury, and the response is recorded as equal or decreased (mild, moderate, severe, absent). The MST has the advantage of a lower false-negative response rate, and patients with an absent response will have incomplete recovery of function in 100% of cases.[274] Although this test is subjective, an equal or mild decrease in response has been shown to have a favorable chance of recovery, whereas a severe decrease or absent response indicates advanced degeneration with a poor prognosis and suggests that surgical intervention with decompression may be indicated.[274-276] The most accurate diagnostic testing modality, ENoG, provides quantitative analysis of the extent of nerve degeneration and is most useful 3 to 21 days after injury.[275] It is performed by placing bipolar electrodes at the stylomastoid foramen and stimulating the facial nerve. The summation potential is then recorded by electrodes placed at the nasolabial groove. A percentage of the response on the normal side of the face is calculated, and the literature states a value greater than 90% degeneration as an indication for surgical decompression of the nerve. Values less than 90% indicated expected recovery of function in 80% to 100% of patients. Disadvantages to ENoG include patient discomfort, cost, and test-retest variability due to electrode positioning.[273,275,277,278] Last, electromyography can be used to assess muscle function. EMG is more useful 10 to 21 days or more following injury when fibrillations being to appear.[275] A needle electrode is inserted into the muscle and recordings are made during rest and voluntary contraction. Six to 12 weeks prior to the return of clinically evident facial nerve function, polyphasic reinnervation potentials can be measured.[273,275] Regarding extratemporal facial nerve trauma, these tests are most often used in the postoperative period to monitor for recovery or prior to surgery when nerve transection cannot be verified.

Treatment of Traumatic Extratemporal Facial Nerve Injuries

A discussion of the treatment of intratemporal facial nerve injuries is beyond the scope of this text; however, there are many injuries resources describing the indications, contraindications, and approaches for surgical treatment of intratemporal facial nerve injuries.[248-253]

Extratemporal facial nerve injuries encountered by the oral and maxillofacial surgeon are most commonly due to penetrating trauma or iatrogenic injury. In both cases, prompt recognition of injury and surgical repair are required. Early repair within 72 hours allows for nerve stimulation to identify cut distal nerve endings. After 72 hours, motor endplate depolarization is not possible, as neurotransmitter stores are depleted in the absence of antegrade axoplasmic transport.[279,280] Repair within 30 days has been shown to improve recovery of facial function.[214,281] Loupe or microscope magnification is recommended to assist in locating branches of the facial nerve and in visualizing healthy fascicles. When immediate repair is possible, the surgeon should access the facial nerve through existing lacerations or incisions (Figure 5-45). If delayed repair is carried out, a modified Blair incision is recommended. Following skin incision, dissection just below the superficial musculoaponeurotic system is carried out to create an anterior skin flap. Next, the main trunk of the facial nerve should be located using the landmarks previously described in this chapter (tragal pointer, tympanomastoid suture, attachment of posterior belly of the digastric) and the course of the facial nerve followed from proximal to distal until the site of injury is encountered. The superficial lobe of the parotid will require mobilization to identify more proximal branches; alternatively, a superficial parotidectomy may be performed to assist in tension-free repair and ease of identification. Once the area of trauma is reached (if using an existing laceration, full dissection of the facial nerve and the facial nerve trunk may not be necessary if the proximal and distal ends can be located), the facial nerve should be freed from any adhesions. Damage to Stensen's duct should be ruled out, as a salivary leak or sialocele may compromise the repair. Next, a colored background should be placed to improve visualization, and, if desired, microscopy can be used (Figures 5-46 and 5-47). The cut ends should be explored for 5 to 10 mm proximally and distally and electrical stimulation applied. A response with 0.05 mA indicates a good prognosis, and further exploration is not required. If a response is only obtained distally, further exposure is warranted prior to repair. A Victor-Meyer neurotomy instrument is then used to excise any neuroma or scarring until a normal-appearing fascicular pattern is noted. At this point, a determination should be made as to the need for any grafting or if primary neurorrhaphy can be completed. As a general rule, tension-free primary neurorrhaphy of the facial nerve can be performed if the defect is less than 17 mm.[214] The surgeon should always keep in mind that the most important



• **Figure 5-45** Severe facial soft tissue lacerations with injury to the facial nerve.

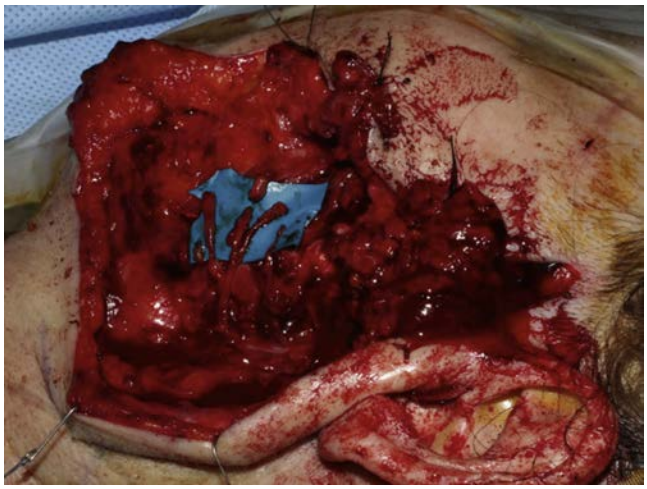

• **Figure 5-46** Proximal and distal ends of the facial nerve identified and isolated.

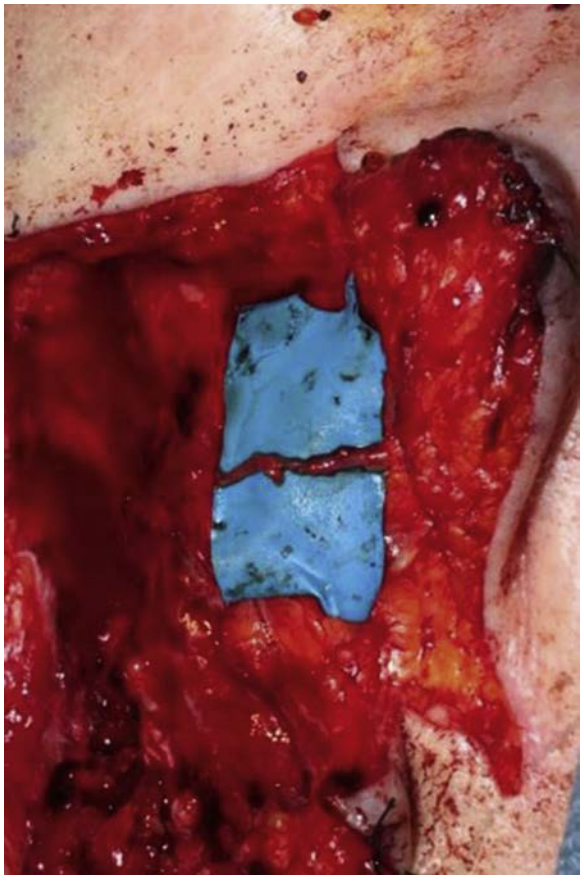

• **Figure 5-47** Repaired facial nerve.

prognostic factor for success is a tension-free coaptation of the nerve stumps.[214,282,283] If a tension-free repair cannot be completed, cable grafting, cross-facial nerve grafting, or crossover grafting should be considered. End-to-end anastomosis of the facial nerve is then performed with 8-0 or 9-0 nylon sutures as an epineural repair (see Figure 5-47). Most surgeons no longer perform perineural repair because of its increased technical difficulty and lack of demonstrated superiority over epineural techniques. Sutures should initially be placed 180 degrees to each other and should not be overtightened, as this can result in poor fascicle alignment and mushrooming. A loose approximation is preferred. Using the long ends to the already placed sutures, the nerve can be manipulated and rotated to allow placement of additional sutures as needed. Four sutures are typically all that is necessary to ensure alignment. The sutures are trimmed, and the wound is irrigated and closed in a layered fashion. In cases with significant gaps between the proximal and distal facial nerve stumps, superficial parotidectomy and mobilization of the branches of the parotid plexus can improve nerve mobility. Additional mobility can be obtained by decompression of the nerve from the mastoid and temporal portions of the intratemporal segment of the facial nerve by a neurotologist.[284]

When a tension-free repair is not possible, a cable (interposition) graft may be considered. Sources of allograft nerve include the greater auricular, sural, medial antebrachial, or lateral antebrachial cutaneous nerves. The greater auricular nerve is preferred because of its similar size to the facial nerve branches and location within the operative field in select cases. If more than 8 to 10 cm of graft is required, an alternative source such as the sural nerve will be necessary.[214] Facial nerve repair with a cable graft is similar to a direct repair, except that two sites of epineural suturing will be required.

If the proximal facial nerve stump is unavailable for repair, a cross-facial graft can be considered, using a contralateral facial nerve branch and nerve graft. This technique has the benefit of borrowing nerves with similar functions and can allow spontaneous and emotional facial expression without dyskinesis.[214,280] When smile reconstruction is desired, a buccal or zygomatic branch is identified and then stimulated to determine function. Multiple nerves are stimulated and mapped until a suitable donor with redundant functions is found. Use of a donor nerve that produces similar function as the injured side may decrease risk of synkinesis. A subcutaneous tunnel through the upper lip is then created to pass the graft from the normal donor side to the injured side, and tensionless epineural repair is performed on each side.[280]

An alternative technique is the nerve crossover or nerve transfer. This is most useful in cases where the contralateral facial nerve is unavailable or in the intermediate period following nerve injury, 3 weeks to 2 years. It requires an intact proximal donor nerve, intact distal facial nerve, and intact muscles of facial expression.[214,280] Possible donor nerves include the ipsilateral masseter branch of the trigeminal nerve and partial hypoglossal nerve. The ipsilateral masseter branch is advantageous because it can be used without the need for an intervening nerve graft and therefore will only have a single anastomosis. In addition, it has been noted that due to the close proximity between the facial and trigeminal nuclei in the pons, motor reeducation after this procedure is rapid. The ability to smile without active clenching has been reported in 66% to 82% of patients.[280] A partial hypoglossal donor is preferred over complete transection of the hypoglossal due to decreased morbidity. Patients with partial

transection have as little as 8% permanent tongue deficits, whereas the complete transection is associated with 100% deficit.[214,284] Patients who undergo this procedure will need significant biofeedback and motor sensory rehabilitation to learn voluntary control of movement, decrease synkinesis, and limit facial grimacing when chewing.[214]

Outcomes of Facial Nerve Injury and Surgical Intervention

Injury to the extratemporal branches of the facial nerve may be associated with impairment in facial expressions, eye protection, and oral competence, with additional effects on a patient's psychological, social, and economic well-being. The long-term effects of facial nerve injury are muscle denervation and atrophy. Immediate, primary repair of facial nerves has up to an 85% chance of acceptable recovery (House-Brackmann Grade I-III).[214,280-285] Cable grafting is associated with success rates of 54% to 80% (House-Brackmann Grade I-III), and recovery of function is first noticeable approximately 6 months after repair, with full recovery expected around 12 to 18 months following repair.[214,286-289] Cross-facial and crossover grafts are associated with success rates ranging from 25% to 82%, depending on the specific procedure performed and the definition of success, which is not standard across all studies.[214,280] In cross-facial grafting, noticeable facial movement is not evident until 9 to 12 months after surgery.[214] Factors that affect long-term results in facial nerve repair are patient age, chemotherapy or radiation treatment, nutrition status, time to repair, and underlying comorbidities such as diabetes mellitus.[214,284] When facial nerve repair and/or grafting techniques fail, static and dynamic reconstructive surgeries can be performed using static slings, regional muscle transfer, or free functional muscle transfer.[214,280]

References

1. Seddon HJ, Medawar PB, Smith H: Rate of regeneration of peripheral nerves in man, *J Physiol* 102:191–215, 1943.
2. Sunderland S: A classification of peripheral nerve injuries producing loss of function, *Brain* 74:491–516, 1951.
3. Sunderland S: Observations on the treatment of traumatic injuries of peripheral nerves, *Br J Surg* 35:36–42, 1947.
4. Stoll G, Muller HW: Nerve injury, axonal degeneration and neural regeneration: basic insights, *Brain Pathol* 9:313–325, 1999.
5. Muller HW, Stoll G: Nerve injury and regeneration: basic insights and therapeutic interventions, *Curr Opin Neurol* 11:557–562, 1998.
6. Hanz S, Fainzilber M: Retrograde signaling in injured nerve—the axon reaction revisited, *J Neurochem* 99:13–19, 2006.
7. Forman DS, Wood DK, DeSilva S: Rate of regeneration of sensory axons in transected rat sciatic nerve repaired with epineurial sutures, *J Neurol Sci* 44:55–59, 1979.
8. Bisby MA: Changes in the composition of labeled protein transported in motor axons during their regeneration, *J Neurobiol* 11:435–445, 1980.
9. McQuarrie IG: The effect of a conditioning lesion on the regeneration of motor axons, *Brain Res* 152:597–602, 1978.
10. McIntyre AK, Bradley K, Brock LG: Responses of motoneurons undergoing chromatolysis, *J Gen Physiol* 42:931–958, 1959.
11. Brody H, Rodbard S: Chromatolysis and vacuolation of specific diencephalic nuclei induced by acute pyrexia, *Am J Physiol* 196:33–35, 1959.
12. Lavelle A, Lavelle FW: Neuronal swelling and chromatolysis as influenced by the state of cell development, *Am J Anat* 102: 219–241, 1958.
13. Causey G, Stratmann CJ: Changes in the nucleic acid content of ganglion cells during chromatolysis and after stimulation, *Biochem J* 64:29–32, 1956.
14. Campbell B: Chromatolysis and the model of the neurone, *J Physiol* 124:28–29P, 1954.
15. McIlwain DL, Hoke VB: The role of the cytoskeleton in cell body enlargement, increased nuclear eccentricity and chromatolysis in axotomized spinal motor neurons, *BMC Neurosci* 6:19, 2005.
16. Terry RD, Harkin JC: Wallerian degeneration and regeneration of peripheral nerves, *Prog Neurobiol* 4:303–320, 1959.
17. Goodrum JF, Bouldin TW: The cell biology of myelin degeneration and regeneration in the peripheral nervous system, *J Neuropathol Exp Neurol* 55:943–953, 1996.
18. Nathaniel EJ, Pease DC: Regenerative changes in rat dorsal roots following Wallerian degeneration, *J Ultrastruct Res* 52:533–549, 1963.
19. Yang DP, et al.: Schwann cell proliferation during Wallerian degeneration is not necessary for regeneration and remyelination of the peripheral nerves: axon-dependent removal of newly generated Schwann cells by apoptosis, *Mol Cell Neurosci* 38:80–88, 2008.
20. Bajestan SN, et al.: Desert hedgehog-patched 2 expression in peripheral nerves during Wallerian degeneration and regeneration, *J Neurobiol* 66:243–255, 2006.
21. Fernandez E, et al.: Neurosurgery of the peripheral nervous system: injuries, degeneration, and regeneration of the peripheral nerves, *Surg Neurol* 48:446–447, 1997.
22. Mellick RS, Cavanagh JB: Changes in blood vessel permeability during degeneration and regeneration in peripheral nerves, *Brain* 91:141–160, 1968.
23. Mellick R, Cavanagh JB: The relation of the permeability of the vasa nervorum to degeneration and regeneration in peripheral nerves, *Proc Aust Assoc Neurol* 5:57–68, 1968.
24. Otsu A: Neurohistological researches of peripheral nerves of some pathological materials. (Degeneration and regeneration), *Acta Neuroveg (Wien)* 22:312–332, 1962.
25. Munger BL, Renehan WE: Degeneration and regeneration of peripheral nerve in the rat trigeminal system: III. Abnormal sensory reinnervation of rat guard hairs following nerve transection and crush, *J Comp Neurol* 283:169–176, 1989.
26. Stoll G, Jander S, Myers RR: Degeneration and regeneration of the peripheral nervous system: from Augustus Waller's observations to neuroinflammation, *J Peripher Nerv Syst* 7:13–27, 2002.
27. Wisniewski HM: Difference in the morphology of Wallerian degeneration in the central nervous system (CNS) and peripheral nervous system (PNS) and its effect on regeneration, *Birth Defects Orig Artic Ser* 19:389–395, 1983.
28. Szebenyi G, et al.: Fibroblast growth factor-2 promotes axon branching of cortical neurons by influencing morphology and behavior of the primary growth cone, *J Neurosci* 21:3932–3941, 2001.

29. Bomze HM, et al.: Spinal axon regeneration evoked by replacing two growth cone proteins in adult neurons, *Nat Neurosci* 4:38–43, 2001.
30. Buss A, et al.: Growth-modulating molecules are associated with invading Schwann cells and not astrocytes in human traumatic spinal cord injury, *Brain* 130(Pt 4):940–953, 2007.
31. Webber C, Zochodne D: The nerve regenerative microenvironment: early behavior and partnership of axons and Schwann cells. *Exp Neurol* 223:51–59.
32. Katenkamp D, Stiller D: Ultrastructure of perineurial cells during peripheral nerve regeneration. Electron microscopical investigations on the so-called amputation neuroma, *Exp Pathol (Jena)* 16:5–15, 1978.
33. Levickaya ES: [Structure of neuroma of central stump of peripheral nerve.], *Nevropatol Psikhiatriia* 18:68, 1949.
34. Mathews JG, Osterholm JL: Painful traumatic neuromas, *Surg Clin North Am* 52:1313–1324, 1972.
35. Gregg JM: Studies of traumatic neuralgia in the maxillofacial region: symptom complexes and response to microsurgery, *J Oral Maxillofac Surg* 48:135–140, 1990, discussion 141.
36. Gregg JM: Studies of traumatic neuralgias in the maxillofacial region: surgical pathology and neural mechanisms, *J Oral Maxillofac Surg* 48:228–237, 1990, discussion 238–239.
37. Meyer RA, et al.: Neural activity originating from a neuroma in the baboon, *Brain Res* 325:255–260, 1985.
38. Burchiel KJ, Russell LC: Effects of potassium channel-blocking agents on spontaneous discharges from neuromas in rats, *J Neurosurg* 63:246–249, 1985.
39. Korenman EM, Devor M: Ectopic adrenergic sensitivity in damaged peripheral nerve axons in the rat, *Exp Neurol* 72: 63–81, 1981.
40. Anderson LC, et al.: A review of the intraosseous course of the nerves of the mandible, *J Oral Implantol* 17:394–403, 1991.
41. Gowgiel JM: The position and course of the mandibular canal, *J Oral Implantol* 18:383–385, 1992.
42. Stella JP, Tharanon W: A precise radiographic method to determine the location of the inferior alveolar canal in the posterior edentulous mandible: implications for dental implants. Part 1: Technique, *Int J Oral Maxillofac Implants* 5:15–22, 1990.
43. de Oliveira Jr MRS, et al.: Morphometrical analysis of the human mandibular canal: a CT investigation, *Surg Radiol Anat* 33:345–352, 2011.
44. Cutright B, et al.: An anthropometric analysis of the key foramina for maxillofacial surgery, *J Oral Maxillofac Surg* 61:354–357, 2003.
45. Watanabe H, et al.: Mandible size and morphology determined with CT on a premise of dental implant operation, *Surg Radiol Anat* 32:343–349, 2009.
46. Rajchel J, Ellis 3rd E, Fonseca RJ: The anatomical location of the mandibular canal: its relationship to the sagittal ramus osteotomy, *Int J Adult Orthodon Orthognath Surg* 1:37–47, 1986.
47. Pogrel M, Smith R, Ahani R: Innervation of the mandibular incisors by the mental nerve, *J Oral Maxillofac Surg* 55: 961–963, 1997.
48. Alantar A, et al.: The lower labial branches of the mental nerve: anatomic variations and surgical relevance, *J Oral Maxillofac Surg* 58:415–418, 2000.
49. Kim SY, Ks Hu, Chung IH, et al.: Topographic anatomy of the lingual nerve and variations in communication pattern of the mandibular nerve branches, *Surg Radiol Anat* 26:128–135, 2004.
50. Blanton PL, Jeske AH: The key to profound local anesthesia: neuroanatomy, *J Am Dent Assoc* 134:753–760, 2003.
51. Erdogmus S, Govsa F, Celik S: Anatomic position of the lingual nerve in the mandibular third molar region as potential risk factors for nerve palsy, *J Craniofac Surg* 19:264–270, 2008.
52. Karakas P, Uzel M, Koebke J: The relationship of the lingual nerve to the third molar region using radiographic imaging, *Br Dent J* 203:29–31, 2007.
53. Pogrel MA, Le H: Etiology of lingual nerve injuries in the third molar region: a cadaver and histologic study, *J Oral Maxillofac Surg* 64:1790–1794, 2006.
54. Holzle FW, Wolff KD: Anatomic position of the lingual nerve in the mandibular third molar region with special consideration of an atrophied mandibular crest: an anatomical study, *Int J Oral Maxillofac Surg* 30:333–338, 2001.
55. Behnia H, Kheradvar A, Shahrokhi M: An anatomic study of the lingual nerve in the third molar region, *J Oral Maxillofac Surg* 58:649–651, 2000, discussion 652-653.
56. Miloro M, Halkias LE, Slone HW, Chakeres DW: Assessment of the lingual nerve in the third molar region using magnetic resonance imaging, *J Oral Maxillofac Surg* 55:134–137, 1997.
57. Pogrel MA, et al.: The relationship of the lingual nerve to the mandibular third molar region: an anatomic study, *J Oral Maxillofac Surg* 53:1178–1181, 1995.
58. Kiesselbach JE, Chamberlain JG: Clinical and anatomic observations on the relationship of the lingual nerve to the mandibular third molar region, *J Oral Maxillofac Surg* 42:565–567, 1984.
59. Skandalakis JE, Gray SW, Rowe Jr JS: Surgical anatomy of the submandibular triangle, *Am Surg* 45:590–596, 1979.
60. Berini-Aytes L, Gay-Escoda C: Morbidity associated with removal of the submandibular gland, *J Craniomaxillofac Surg* 20:216–219, 1992.
61. Goudal JY, Bertrand JC: [Complications of surgical treatment for submandibular calculi] (author's transl), *Rev Stomatol Chir Maxillofac* 80:349–350, 1979.
62. Milton CM, Thomas BM, Bickerton RC: Morbidity study of submandibular gland excision, *Ann R Coll Surg Engl* 68: 148–150, 1986.
63. Zahm DS, Munger BL: The innervation of the primate fungiform papilla—development, distribution and changes following selective ablation, *Brain Res* 356:147–186, 1985.
64. Singh S: Aberrant buccal nerve encountered at third molar surgery, *Oral Surg Oral Med Oral Pathol* 52:142, 1981.
65. Jablonski NG, et al.: Unusual origins of the buccal and mylohyoid nerves, *Oral Surg Oral Med Oral Pathol* 60:487–488, 1985.
66. Hendy CW, Smith KG, Robinson PP: Surgical anatomy of the buccal nerve, *Br J Oral Maxillofac Surg* 34:457–460, 1996.
67. Turner W: On some variations in the arrangements of the nerves of the human body, *Nat Hist Rev* 4:612–617, 1864.
68. Merrill RG: Prevention, treatment, and prognosis for nerve injury related to the difficult impaction, *Dent Clin North Am* 23:471–488, 1979.
69. Hendy CW, Robinson PP: The sensory distribution of the buccal nerve, *Br J Oral Maxillofac Surg* 32:384–386, 1994.
70. Aziz SR, Marchena JM, Puran A: Anatomic characteristics of the infraorbital foramen: a cadaver study, *J Oral Maxillofac Surg* 58:992–996, 2000.
71. Kazkayasi M, et al.: Microscopic anatomy of the infraorbital canal, nerve, and foramen, *Otolaryngol Head Neck Surg* 129:692–697, 2003.
72. Leo JT, Cassell MD, Bergman RA: Variation in human infraorbital nerve, canal and foramen, *Ann Anat* 177:93–95, 1995.
73. Hindy AM, Abdel-Raouf F: A study of infraorbital foramen, canal and nerve in adult Egyptians, *Egypt Dent J* 39:573–580, 1993.

74. Hu KS, et al.: Topographic distribution area of the infraorbital nerve, *Surg Radiol Anat* 29:383–388, 2007.
75. Friede RL, Bischhausen R: The organization of endoneural collagen in peripheral nerves as revealed with the scanning electron microscope, *J Neurol Sci* 38:83–88, 1978.
76. Mozsary PG, Middleton RA: Microsurgical reconstruction of the infraorbital nerves, *J Oral Maxillofac Surg* 41:697–700, 1983.
77. Svane TJ, et al.: Fascicular characteristics of the human inferior alveolar nerve, *J Oral Maxillofac Surg* 44:431–434, 1986.
78. Girod SC, et al.: The fascicular structure of the lingual nerve and the chorda tympani: an anatomic study, *J Oral Maxillofac Surg* 47:607–609, 1989.
79. Eppley BL, Snyders Jr RV: Microanatomic analysis of the trigeminal nerve and potential nerve graft donor sites, *J Oral Maxillofac Surg* 49:612–618, 1991.
80. Smoliar E, et al.: Microcirculatory bed of the human trigeminal nerve, *Anat Rec* 250:245–249, 1998.
81. Lundborg G: Intraneural microcirculation, *Orthop Clin North Am* 19:1–12, 1988.
82. Miloro M, Kolokythas A: Inferior alveolar and lingual nerve imaging, *Atlas Oral Maxillofac Surg Clin North Am* 19:35–46, 2011.
83. Sedaghatfar M, August MA, Dodson TB: Panoramic radiographic findings as predictors of inferior alveolar nerve exposure following third molar extraction, *J Oral Maxillofac Surg* 63:3–7, 2005.
84. Rood JP, Shehab BA: The radiological prediction of inferior alveolar nerve injury during third molar surgery, *Br J Oral Maxillofac Surg* 28:20–25, 1990.
85. Ganz SD: Conventional CT and cone beam CT for improved dental diagnostics and implant planning, *Dent Implantol Update* 16:89–95, 2005.
86. Suomalainen A, et al.: Reliability of CBCT and other radiographic methods in preoperative evaluation of lower third molars, *Oral Surg Oral Med Oral Pathol Oral Radiol Endod* 109:276–284, 2010.
87. Kositbowornchai S, et al.: Ability of two radiographic methods to identify the closeness between the mandibular third molar root and the inferior alveolar canal: a pilot study, *Dentomaxillofac Radiol* 39:79–84, 2010.
88. Nakayama K, et al.: Assessment of the relationship between impacted mandibular third molars and inferior alveolar nerve with dental 3-dimensional computed tomography, *J Oral Maxillofac Surg* 67:2587–2591, 2009.
89. Liu T, Xia B, Gu Z: Inferior alveolar canal course: a radiographic study, *Clin Oral Implants Res* 20:1212–1218, 2009.
90. Patel S, et al.: The potential applications of cone beam computed tomography in the management of endodontic problems, *Int Endod J* 40:818–830, 2007.
91. Roeder F, Wachtlin D, Schulze R: Necessity of 3D visualization for the removal of lower wisdom teeth: required sample size to prove non-inferiority of panoramic radiography compared to CBCT, *Clin Oral Investig* 16:699–706, 2012.
92. Ghaeminia H, et al.: Position of the impacted third molar in relation to the mandibular canal. Diagnostic accuracy of cone beam computed tomography compared with panoramic radiography, *Int J Oral Maxillofac Surg* 38:964–971, 2009.
93. Maloney K, et al.: Cone beam computed tomography and SimPlant materialize dental software versus direct measurement of the width and height of the posterior mandible: an anatomic study, *J Oral Maxillofac Surg* 69:1923–1929, 2011.
94. Worthington, P, Rubenstein J, Hatcher DC: The role of cone-beam computed tomography in the planning and placement of implants. *J Am Dent Assoc.* 141 Suppl 3:19S–24S.
95. Lofthag-Hansen S, Grondahl K, Ekestubbe A: Cone-beam CT for preoperative implant planning in the posterior mandible: visibility of anatomic landmarks, *Clin Implant Dent Relat Res* 11:246–255, 2009.
96. Aagaard BD, Maravilla KR, Kliot M: MR neurography. MR imaging of peripheral nerves, *Magn Reson Imaging Clin N Am* 6:179–194, 1998.
97. Cudlip SA, et al.: Magnetic resonance neurography of peripheral nerve following experimental crush injury, and correlation with functional deficit, *J Neurosurg* 96:755–759, 2002.
98. Grant GA, et al.: MR neurography: diagnostic utility in the surgical treatment of peripheral nerve disorders, *Neuroimaging Clin N Am* 14:115–133, 2004.
99. Hatipoglu HG, et al.: Comparison of FSE T2W and 3D FIESTA sequences in the evaluation of posterior fossa cranial nerves with MR cisternography, *Diagn Interv Radiol* 13:56–60, 2007.
100. Qian, J, Herrera JJ, Narayana PA: Neuronal and axonal degeneration in experimental spinal cord injury: in vivo proton magnetic resonance spectroscopy and histology, *J Neurotrauma* 27:599–610, 2010.
101. Filler AG, et al.: Application of magnetic resonance neurography in the evaluation of patients with peripheral nerve pathology, *J Neurosurg* 85:299–309, 1996.
102. Filler AG, Maravilla KR, Tsuruda JS: MR neurography and muscle MR imaging for image diagnosis of disorders affecting the peripheral nerves and musculature, *Neurol Clin* 22: 643–682, 2004. vi-vii.
103. Furuya Y, et al.: MRI of intracranial neurovascular compression, *J Comput Assist Tomogr* 16:503–505, 1992.
104. Rocca MA, Filippi M: Functional MRI in multiple sclerosis, *J Neuroimaging* 1(17 Suppl):36S–41S, 2007.
105. Parker GD, Harnsberger HR: Clinical-radiologic issues in perineural tumor spread of malignant diseases of the extracranial head and neck, *Radiographics* 11:383–399, 1991.
106. Graif M, et al.: Sciatic nerve: sonographic evaluation and anatomic-pathologic considerations, *Radiology* 181:405–408, 1991.
107. Renton T, et al.: Trigeminal nerve injuries in relation to the local anaesthesia in mandibular injections, *Br Dent J* 209:e15, 2010.
108. Pogrel MA: Summary of: Trigeminal nerve injuries in relation to the local anaesthesia in mandibular injections, *Br Dent J* 209:452–453, 2010.
109. Harn SD, Durham TM: Incidence of lingual nerve trauma and postinjection complications in conventional mandibular block anesthesia, *J Am Dent Assoc* 121:519–523, 1990.
110. Pogrel MA, Thamby S: Permanent nerve involvement resulting from inferior alveolar nerve blocks, *J Am Dent Assoc* 131: 901–907, 2000.
111. Stacy GC, Hajjar G: Barbed needle and inexplicable paresthesias and trismus after dental regional anesthesia, *Oral Surg Oral Med Oral Pathol* 77:585–588, 1994.
112. Pedlar J: Re: Prolonged paraesthesia following inferior alveolar nerve block using articaine, *Br J Oral Maxillofac Surg* 41:202, 2003.
113. Meechan JG: Re: Prolonged paraesthesia following inferior alveolar nerve block using articaine, *Br J Oral Maxillofac Surg* 41:201, 2003.

114. van Eeden SP, Patel MF: Re: prolonged paraesthesia following inferior alveolar nerve block using articaine, *Br J Oral Maxillofac Surg* 40:519–520, 2002.
115. Hillerup S, Jensen R: Nerve injury caused by mandibular block analgesia, *Int J Oral Maxillofac Surg* 35:437–443, 2006.
116. Miloro M: Microneurosurgery. In Miloro MG, Ghali GE, Lasen PE, Waite PD editors: *Peterson's principles of oral and maxillofacial surgery*, ed 4, Vol. 2. Hamilton, ON, 2004, BC Decker, Inc.
117. Katre C, et al.: Inferior alveolar nerve damage caused by bone wax in third molar surgery, *Int J Oral Maxillofac Surg* 39:511–513, 2010.
118. Pogrel MA, Thamby S: The etiology of altered sensation in the inferior alveolar, lingual, and mental nerves as a result of dental treatment, *J Calif Dent Assoc* 27(531):534–538, 1999.
119. Leist JC, et al.: Experimental topical tetracycline-induced neuritis in the rat, *J Oral Maxillofac Surg* 53:427–434, 1995.
120. Zuniga JR, Leist JC: Topical tetracycline-induced neuritis: a case report, *J Oral Maxillofac Surg* 53:196–199, 1995.
121. Williams M: Post-operative nerve damage and the removal of the mandibular third molar: a matter of common consent, *Br J Oral Maxillofac Surg* 34:386–388, 1996.
122. Pichler JW, Beirne OR: Lingual flap retraction and prevention of lingual nerve damage associated with third molar surgery: a systematic review of the literature, *Oral Surg Oral Med Oral Pathol Oral Radiol Endod* 91:395–401, 2001.
123. Shepherd JP: Lingual nerve retraction increases the risk of temporary lingual nerve damage during mandibular third molar surgery, *Evid Based Dent* 7:47, 2006.
124. Gomes AC, et al.: Lingual nerve damage after mandibular third molar surgery: a randomized clinical trial, *J Oral Maxillofac Surg* 63:1443–1446, 2005.
125. Loescher AR, Smith KG, Robinson PP: Nerve damage and third molar removal, *Dent Update* 30:375–380, 2003.
126. Valmaseda-Castellon E, Berini-Aytes L, Gay-Escoda C: Inferior alveolar nerve damage after lower third molar surgical extraction: a prospective study of 1117 surgical extractions, *Oral Surg Oral Med Oral Pathol Oral Radiol Endod* 92:377–383, 2001.
127. Valmaseda-Castellon E, Berini-Aytes L, Gay-Escoda C: Lingual nerve damage after third lower molar surgical extraction, *Oral Surg Oral Med Oral Pathol Oral Radiol Endod* 90:567–573, 2000.
128. Smith AC, et al.: Inferior alveolar nerve damage following removal of mandibular third molar teeth. A prospective study using panoramic radiography, *Aust Dent J* 42:149–152, 1997.
129. Rehman K, Webster K, Dover MS: Links between anaesthetic modality and nerve damage during lower third molar surgery, *Br Dent J* 193:43–45, 2002.
130. Brann CR, Brickley MR, Shepherd JP: Factors influencing nerve damage during lower third molar surgery, *Br Dent J* 186: 514–516, 1999.
131. Palma-Carrio C, et al.: Radiographic signs associated with inferior alveolar nerve damage following lower third molar extraction, *Med Oral Patol Oral Cir Bucal* 15:e886–e890, 2010.
132. Szalma J, et al.: The prognostic value of panoramic radiography of inferior alveolar nerve damage after mandibular third molar removal: retrospective study of 400 cases, *Oral Surg Oral Med Oral Pathol Oral Radiol Endod* 109:294–302, 2010.
133. Misch CE, Resnik R: Mandibular nerve neurosensory impairment after dental implant surgery: management and protocol, *Implant Dent* 19:378–386, 2010.
134. Greenstein G, Tarnow D: The mental foramen and nerve: clinical and anatomical factors related to dental implant placement: a literature review, *J Periodontol* 77:1933–1943, 2006.
135. Bartling R, Freeman K, Kraut RA: The incidence of altered sensation of the mental nerve after mandibular implant placement, *J Oral Maxillofac Surg* 57:1408–1412, 1999.
136. Burstein J, Mastin C, Le B: Avoiding injury to the inferior alveolar nerve by routine use of intraoperative radiographs during implant placement, *J Oral Implantol* 34:34–38, 2008.
137. Hegedus F, Diecidue RJ: Trigeminal nerve injuries after mandibular implant placement—practical knowledge for clinicians, *Int J Oral Maxillofac Implants* 21:111–116, 2006.
138. Worthington P: Injury to the inferior alveolar nerve during implant placement: a formula for protection of the patient and clinician, *Int J Oral Maxillofac Implants* 19:731–734, 2004.
139. Dao TT, Mellor A: Sensory disturbances associated with implant surgery, *Int J Prosthodont* 11:462–469, 1998.
140. Kraut RA, Chahal O: Management of patients with trigeminal nerve injuries after mandibular implant placement, *J Am Dent Assoc* 133:1351–1354, 2002.
141. Khawaja N, Renton T: Case studies on implant removal influencing the resolution of inferior alveolar nerve injury, *Br Dent J* 206:365–370, 2009.
142. Park JH, Lee SH, Kim ST: Pharmacologic management of trigeminal nerve injury pain after dental implant surgery, *Int J Prosthodont* 23:342–346, 2010.
143. Alhassani AA, AlGhamdi AS: Inferior alveolar nerve injury in implant dentistry: diagnosis, causes, prevention, and management, *J Oral Implantol* 36:401–407, 2010.
144. Nkenke E, et al.: Morbidity of harvesting of retromolar bone grafts: a prospective study, *Clin Oral Implants Res* 13:514–521, 2002.
145. Hu J, et al.: Response of Schwann cells in the inferior alveolar nerve to distraction osteogenesis: an ultrastructural and immunohistochemical study, *Int J Oral Maxillofac Surg* 32:318–324, 2003.
146. Wang XX, Wang X, Li ZL: Effects of mandibular distraction osteogenesis on the inferior alveolar nerve: an experimental study in monkeys, *Plast Reconstr Surg* 109:2373–2383, 2002.
147. Makarov MR, et al.: Evaluation of inferior alveolar nerve function during distraction osteogenesis in the dog, *J Oral Maxillofac Surg* 56:1417–1423, 1998. discussion 1424–1425.
148. Yoshimoto M, et al.: Microstructural and ultrastructural assessment of inferior alveolar nerve damage following nerve lateralization and implant placement: an experimental study in rabbits, *Int J Oral Maxillofac Implants* 24:859–865, 2009.
149. Yoshimoto M, et al.: A light and scanning electron microscopy study of bone healing following inferior alveolar nerve lateralization: an experimental study in rabbits, *Int J Oral Maxillofac Implants* 23:457–462, 2008.
150. Yoshimoto M, et al.: Bone healing after the inferior alveolar nerve lateralization: a histologic study in rabbits (Oryctolagus cuniculus), *J Oral Maxillofac Surg* 62(9 Suppl 2):131–135, 2004.
151. Peleg M, et al.: Lateralization of the inferior alveolar nerve with simultaneous implant placement: a modified technique, *Int J Oral Maxillofac Implants* 17:101–106, 2002.
152. Garg AK, Morales MJ: Lateralization of the inferior alveolar nerve with simultaneous implant placement: surgical techniques, *Pract Periodontics Aesthet Dent* 10:1197–1204, 1998.
153. Hirsch JM, Branemark PI: Fixture stability and nerve function after transposition and lateralization of the inferior alveolar nerve and fixture installation, *Br J Oral Maxillofac Surg* 33: 276–281, 1995.
154. Louis PJ: Inferior alveolar nerve repositioning, *Atlas Oral Maxillofac Surg Clin North Am* 9:93–128, 2001.

155. Metzger MC, et al.: Inferior alveolar nerve transposition—an in vitro comparison between piezosurgery and conventional bur use, *J Oral Implantol* 32:19–25, 2006.
156. Renzi G, et al.: Posttraumatic trigeminal nerve impairment: a prospective analysis of recovery patterns in a series of 103 consecutive facial fractures, *J Oral Maxillofac Surg* 62:1341–1346, 2004.
157. Westermark A, Jensen J, Sindet-Pedersen S: Zygomatic fractures and infraorbital nerve disturbances. Miniplate osteosynthesis vs. other treatment modalities, *Oral Surg Oral Diagn* 3:27–30, 1992.
158. Fogaca WC, Fereirra MC, Dellon AL: Infraorbital nerve injury associated with zygoma fractures: documentation with neurosensory testing, *Plast Reconstr Surg* 113:834–838, 2004.
159. Bagheri SC, et al.: Microsurgical repair of peripheral trigeminal nerve injuries from maxillofacial trauma, *J Oral Maxillofac Surg* 67:1791–1799, 2009.
160. Kloss FR, et al.: Complications related to midfacial fractures: operative versus non-surgical treatment, *Int J Oral Maxillofac Surg* 40:33–37, 2011.
161. Kim YK, Kim SG, Kim JH: Altered sensation after orthognathic surgery, *Int J Oral Maxillofac Surg*. 69:893–898, 2011.
162. Lemke RR, et al.: Neurosensory differences after wire and rigid fixation in patients with mandibular advancement, *J Oral Maxillofac Surg* 58:1354–1359, 2000. discussion 1359–1360.
163. Teerijoki-Oksa T, et al.: Risk factors of nerve injury during mandibular sagittal split osteotomy, *Int J Oral Maxillofac Surg* 31:33–39, 2002.
164. Van Sickels JE, et al.: Effects of age, amount of advancement, and genioplasty on neurosensory disturbance after a bilateral sagittal split osteotomy, *J Oral Maxillofac Surg* 60:1012–1017, 2002.
165. August M, et al.: Neurosensory deficit and functional impairment after sagittal ramus osteotomy: a long-term follow-up study, *J Oral Maxillofac Surg* 56:1231–1235, 1998. discussion 1236.
166. Yamauchi K, et al.: Risk factors for neurosensory disturbance after bilateral sagittal split osteotomy based on position of mandibular canal and morphology of mandibular angle, *J Oral Maxillofac Surg* 70(2):401–406, 2012.
167. Hua Z, et al.: [Nerve injury and neurosensory recovery following bilateral mandibular sagittal split osteotomy], *Zhonghua Zheng Xing Wai Ke Za Zhi* 18:291–293, 2002.
168. Karas ND, Boyd SB, Sinn DP: Recovery of neurosensory function following orthognathic surgery, *J Oral Maxillofac Surg* 48:124–134, 1990.
169. Coghlan KM, Irvine GH: Neurological damage after sagittal split osteotomy, *Int J Oral Maxillofac Surg* 15:369–371, 1986.
170. Gortzak RA, et al.: Growth characteristics of large mandibular ameloblastomas: report of 5 cases with implications for the approach to surgery, *Int J Oral Maxillofac Surg* 35:691–695, 2006.
171. Littler B: Conserving the inferior alveolar nerve during resection of the mandible, *Br J Oral Maxillofac Surg* 40:86–87, 2002.
172. Hatada K, et al.: Clinicostatistical study of ameloblastoma treatment, *Bull Tokyo Dent Coll* 42:87–95, 2001.
173. Chow HT, Teh LY: Sensory impairment after resection of the mandible: a case report of 10 cases, *J Oral Maxillofac Surg* 58:629–635, 2000.
174. Curi MM, Dib LL, Pinto DS: Management of solid ameloblastoma of the jaws with liquid nitrogen spray cryosurgery, *Oral Surg Oral Med Oral Pathol Oral Radiol Endod* 84:339–344, 1997.
175. Noma H, et al.: Repair of the mandibular nerve by autogenous grafting after partial resection of the mandible, *J Oral Maxillofac Surg* 44:30–36, 1986.
176. Wu TC, et al.: Ameloblastoma of the mandible treated by resection, preservation of the inferior alveolar nerve, and bone grafting, *J Oral Maxillofac Surg* 42:93–96, 1984.
177. Becker R: Continuity resection of the mandible with preservation of the mandibular nerve, *Br J Oral Surg* 8:45–50, 1970.
178. Sampson DE, Pogrel MA: Management of mandibular ameloblastoma: the clinical basis for a treatment algorithm, *J Oral Maxillofac Surg* 57:1074–1077, 1999. discussion 1078–1079.
179. Ghali GE, Epker BN: Clinical neurosensory testing: practical applications, *J Oral Maxillofac Surg* 47:1074–1078, 1989.
180. Kalladka M, et al.: Trigeminal nerve injury following accidental airbag deployment and assessment with quantitative sensory testing, *Cranio* 25:138–143, 2007.
181. Zuniga JR, et al.: The accuracy of clinical neurosensory testing for nerve injury diagnosis, *J Oral Maxillofac Surg* 56:2–8, 1998.
182. Ziccardi VB, Hullett JS, Gomes J: Physical neurosensory testing versus current perception threshold assessment in trigeminal nerve injuries related to dental treatment: a retrospective study, *Quintessence Int* 40:603–609, 2009.
183. Renton T, et al.: Quantitative thermosensory testing of the lingual and inferior alveolar nerves in health and after iatrogenic injury, *Br J Oral Maxillofac Surg* 41:36–42, 2003.
184. Morton RP, et al.: Patterns of sensory recovery in the lingual nerve after surgical trauma, *N Z Dent J* 101:53–57, 2005.
185. Scrivani SJ, et al.: Taste perception after lingual nerve repair, *J Oral Maxillofac Surg* 58:3–5, 2000. discussion 5–6.
186. Hillerup S, Hjorting-Hansen E, Reumert T: Repair of the lingual nerve after iatrogenic injury: a follow-up study of return of sensation and taste, *J Oral Maxillofac Surg* 52:1028–1031, 1994.
187. Blackburn CW: A method of assessment in cases of lingual nerve injury, *Br J Oral Maxillofac Surg* 28:238–245, 1990.
188. Pogrel MA, et al.: Long-term outcome of trigeminal nerve injuries related to dental treatment, *J Oral Maxillofac Surg* 69:2284–2288, 2011.
189. Dodson TB, Kaban LB: Recommendations for management of trigeminal nerve defects based on a critical appraisal of the literature, *J Oral Maxillofac Surg* 55:1380–1386, 1997. discussion 1387.
190. Gregg JM: Surgical management of inferior alveolar nerve injuries (Part II): The case for delayed management, *J Oral Maxillofac Surg* 53:1330–1333, 1995.
191. Donoff RB: Surgical management of inferior alveolar nerve injuries (Part I): The case for early repair, *J Oral Maxillofac Surg* 53:1327–1329, 1995.
192. Ziccardi VB, Steinberg MJ: Timing of trigeminal nerve microsurgery: a review of the literature, *J Oral Maxillofac Surg* 65:1341–1345, 2007.
193. Ziccardi VB, Zuniga JR: Traumatic injuries of the trigeminal nerve. In Fonseca RJ, Walker RV, Betts NJ, editors: *Oral and maxillofacial trauma*, ed 3, vol. 2. St Louis, 2005, Elsevier Saunders.
194. Meyer RA, Bagheri SC: Nerve injuries from mandibular third molar removal. *Atlas Oral Maxillofac Surg Clin North Am* 19:63–78, 2011.
195. Miloro M: Surgical access for inferior alveolar nerve repair, *J Oral Maxillofac Surg* 53:1224–1225, 1995.
196. Joshi A, Rood JP: External neurolysis of the lingual nerve, *Int J Oral Maxillofac Surg* 31:40–43, 2002.
197. Greenwood M, Corbett IP: Observations on the exploration and external neurolysis of injured inferior alveolar nerves, *Int J Oral Maxillofac Surg* 34:252–256, 2005.

198. Brown BA: Internal neurolysis in treatment of traumatic peripheral nerve lesions, *Calif Med* 110:460–462, 1969.
199. Meyer RA: Applications of microneurosurgery to the repair of trigeminal nerve injuries, *Oral Maxillofac Surg Clin N Am* 4:405–416, 1992.
200. Ziccardi VB, Assael LA: Mechanisms of trigeminal nerve injuries, *Atlas Oral Maxillofac Surg Clin North Am* 9:1–11, 2001.
201. Zuniga JR, LaBanc JP: Advances in microsurgical nerve repair, *J Oral Maxillofac Surg* 51(1 Suppl 1):62–68, 1993.
202. Miloro M, Stoner JA: Subjective outcomes following sural nerve harvest, *J Oral Maxillofac Surg* 63:1150–1154, 2005.
203. Miloro M: Discussion: The use of autogenous vein grafts for inferior alveolar nerve and lingual nerve reconstruction, *J Oral Maxillofac Surg* 59:988–993, 2001.
204. Pitta MC, et al.: Use of Gore-Tex tubing as a conduit for inferior alveolar and lingual nerve repair: experience with 6 cases, *J Oral Maxillofac Surg* 59:493–496, 2001. discussion 497.
205. Farole A, Jamal BT: A bioabsorbable collagen nerve cuff (NeuraGen) for repair of lingual and inferior alveolar nerve injuries: a case series, *J Oral Maxillofac Surg* 66:2058–2062, 2008.
206. Pogrel MA, Maghen A: The use of autogenous vein grafts for inferior alveolar and lingual nerve reconstruction, *J Oral Maxillofac Surg* 59:985–988, 2001. discussion 988–993.
207. Curtis NJ, et al.: Comparison of microsuture, interpositional nerve graft, and laser solder weld repair of the rat inferior alveolar nerve, *J Oral Maxillofac Surg* 69:e246–e255, 2011.
208. Jones RH: The use of vein grafts in the repair of the inferior alveolar nerve following surgery, *Aust Dent J* 55:207–213, 2010.
209. Jones RH: Repair of the trigeminal nerve: a review, *Aust Dent J* 55:112–119, 2010.
210. Pogrel MA: The results of microneurosurgery of the inferior alveolar and lingual nerve, *J Oral Maxillofac Surg* 60:485–489, 2002.
211. Smith KG, Robinson PP: An experimental study on the recovery of the lingual nerve after injury with or without repair, *Int J Oral Maxillofac Surg* 24:372–379, 1995.
212. Smith KG, Robinson PP: An experimental study of three methods of lingual nerve defect repair, *J Oral Maxillofac Surg* 53:1052–1062, 1995.
213. Feng Y, Zhang YQ, Liu M, et al.: Sectional anatomy aid for improvement of decompression surgery approach to vertical segment of facial nerve, *J Craniofac Surg* 23:906–908, 2012.
214. White H, Rosenthal E: Static and dynamic repairs of facial nerve injuries, *Oral Maxillofac Surg Clin N Am* 25:303–312, 2013.
215. Gupta S, Mends F, Hagiwara M, et al.: Imaging the facial nerve: a contemporary review, *Radiol Res Pract* 2013:248039, 2013.
216. Nager G, Proctor B: Anatomic variations and anomalies involving the facial canal, *Otolaryngol Clin N Am* 24:531–553, 1991.
217. Holsinger FC, Bui DT: Anatomy, function, and evaluation of the salivary glands. In Myers EN, Ferris RL, editors: *Salivary gland disorders*, Berlin, 2007, Springer, pp 1–16.
218. Granick MS, Hanna 3rd DC: Surgical management of salivary gland disease. In Grannick MS, Hanna 3rd DC, editors: *Management of salivary gland lesions*, Baltimore, 1992, Williams & Wilkins, pp 145–174.
219. Wang SJ, Eisele DW: Superficial parotidectomy. In Myers EN, Ferris RL, editors: *Salivary gland disorders*, Berlin, 2007, Springer, pp. 247–246.
220. Davis R, Anson B, Budinger J, Kurth L: Surgical anatomy of the facial nerve and parotid gland based upon a study of 350 cervicofacial halves, *Surg Gynecol Obstet* 102:385–412, 1956 Apr.
221. Gosain AK: Surgical anatomy of the facial nerve, *Clin Plast Surg* 22:241–251, 1995.
222. Al-Kayat A, Bramley P: A modified pre-auricular approach to the temporomandibular joint and malar arch, *Br J Oral Surg* 17:91–103, 1979.
223. Zani R, Fadul Jr R, Da Rocha MA, et al.: Facial nerve in rhytidoplasty: anatomic study of its trajectory in the overlying skin and the most common sites of injury, *Ann Plast Surg* 51:236–242, 2003.
224. Miloro M, Redlinger S, Pennington DM, Kolodge T: In situ location of the temporal branch of the facial nerve, *J Oral Maxillofac Surg* 65:2466–2469, 2007.
225. Saylam C, Ucerler H, Orhan M, Ozek C: Anatomic guides to precisely localize the zygomatic branches of the facial nerve, *J Craniofac Surg* 17:50–53, 2006.
226. Pogrel MA, Schmidt B, Ammar A: The relationship of the buccal branch of the facial nerve to the parotid duct, *J Oral Maxillofac Surg* 54:71–73, 1996.
227. Saylam C, Ucerler H, Orhan M, Ozek C: Anatomic landmarks of the buccal branches of the facial nerve, *Surg Radiol Anat* 28:462–467, 2006.
228. Dingman RO, Grabb WC: Surgical anatomy of the mandibular ramus of the facial nerve based on the dissection of 100 facial halves, *Plast Reconstr Surg Transplant Bull* 29:266–272, 1962.
229. Rodel R, Lang J: Peripheral branches of the facial nerve in the cheek and chin area: Anatomy and clinical consequences, *HNO* 44:572–576, 1996.
230. Batra AP, Mahajan A, Gupta K: Marginal mandibular branch of the facial nerve: an anatomical study, *Indian J Plast Surg* 43: 60–64, 2010.
231. Chowdhry S, Yoder EM, Cooperman RD, et al.: Locating the cervical motor branch of the facial nerve: anatomy and clinical application, *Plast Reconstr Surg* 126:875–879, 2010.
232. Captier G, Canovas F, Bonnel F, Seignarbieux F: Organization and microscopic anatomy of the adult human facial nerve: anatomical and histological basis for surgery, *Plast Reconstr Surg* 115:1457–1465, 2005.
233. Tawfik EA: Sonographic characteristics of the facial nerve in healthy volunteers, *Muscle Nerve* 52:767–771, 2015.
234. McManus LJ, Dawes PJ, Stringer MD: Clinical anatomy of the chorda tympani: a systematic review, *J Laryngol Otol* 125:1101–1108, 2011.
235. Mu X, Quan Y, Shao J, et al.: Enlarged geniculate ganglion fossa: CT sign of facial nerve canal fracture, *Acad Radiol* 19:971–976, 2012.
236. Lo Y, Fook-Chong S, Leoh T, et al.: High-resolution ultrasound in the evaluation and prognosis of Bell's palsy, *Eur J Neurol* 17:885–889, 2010.
237. House JW, Brackmann DE: Facial nerve grading system, *Otolaryngol Head Neck Surg* 93:146–147, 1985.
238. Baugh R, Basura G, Ishii L, et al.: Clinical practice guideline: Bell's Palsy executive summary, *Otolaryngol Head Neck Surg* 149:656–663, 2013.
239. Peitersen E: The natural history of Bell's palsy, *Am J Otol* 4:107–111, 1982.
240. Peitersen E: Bell's palsy: the spontaneous course of 2,500 peripheral facial nerve palsies of different etiologies, *Acta Otolaryngol Suppl*(549)4–30, 2002.
241. Berg T, Axelsson S, Engstrom M, et al.: The course of pain in Bell's palsy: treatment with prednisolone and valacyclovir, *Otol Neurotol* 30:842–846, 2009.
242. Engstrom M, Berg T, Stjernquist-Desatnik A, et al.: Prednisolone and valaciclovir in Bell's palsy: a randomised, double-blind, placebo-controlled, multicentre trial, *Lancet Neurol* 7:993–1000, 2008.

243. Axelsson S, Berg T, Jonsson L, et al.: Bell's palsy—the effect of prednisolone and/or valaciclovir versus placebo in relation to baseline severity in a randomised controlled trial, *Clin Otolaryngol* 37:283–290, 2012.
244. Mechelse K, Goor G, Huizing EH, et al.: Bell's palsy: prognostic criteria and evaluation of surgical decompression, *Lancet* 2:57–59, 1971.
245. Gantz BJ, Rubinstein JT, Gidley P, Woodworth GG: Surgical management of Bell's palsy, *Laryngoscope* 109:1177–1188, 1999.
246. McAllister K, Walker D, Donnan PT, Swan I: Surgical interventions for the early management of Bell's palsy, *Cochrane Database Syst Rev* 10:CD007468, 2013.
247. Chang CY, Cass SP: Management of facial nerve injury due to temporal bone trauma, *Am J Otol* 20:96–114, Jan 1999.
248. Liu Y, Han J, Zhou X, et al.: Surgical management of facial paralysis resulting from temporal bone fractures, *Acta Otolaryngol* 134:656–660, 2014.
249. Kim J, Moon IS, Shim DB, Lee WS: The effect of surgical timing on functional outcomes of traumatic facial nerve paralysis, *J Trauma* 68:924–929, 2010.
250. Fisch U: Current surgical treatment of intratemporal facial palsy, *Clin Plast Surg* 6:377–388, 1979.
251. Coker N: Traumatic intratemporal facial nerve injuries: management rationale for preservation of function, *Otolaryngol Head Neck Surg* 97:262–269, 1987.
252. Green JD: Surgical Management of Iatrogenic Facial Nerve Injuries, *Otolaryngol Head Neck Surg* 111:606–610, 1994.
253. Cvorovic L, Jovanovic MB, Markovic M, et al.: Management of complication from temporal bone fractures, *Eur Arch Otorhinolaryngol* 269:399–403, 2012.
254. Rovak JM, Tung TH, Mackinnon SE: The surgical management of facial nerve injury, *Semin Plast Surg* 18:23–30, 2004.
255. Makeham TP, Croxson GR, Coulson S: Infective causes of facial nerve paralysis, *Otol Neurotol* 28:100–103, 2007.
256. Robillard RB, Hilsinger Jr RL, Adour KK: Ramsay Hunt facial paralysis: clinical analyses of 185 patients, *Otolaryngol Head Neck Surg* 95:292–297, 1986.
257. Halperin JJ, Golightly M: Long Island Neuroborreliosis Collaborative Study Group. Lyme borreliosis in Bell's palsy, *Neurology* 42:1268–1270, 1992.
258. Cook SP, Macartney KK, Rose CD, et al.: Lyme disease and seventh nerve paralysis in children, *Am J Otolaryngol* 18:320–323, 1997.
259. Pollock RA, Brown LA: Facial paralysis in otitis media. In Graham MD, House WH, editors: *Disorders of the facial nerve*, New York, 1982, Raven Press, pp 221–224.
260. Farrugia EJ, Raza SA, Phillips JJ: Tuberculous otitis media: a case report, *J Laryngol Otol* 111:58–59, 1997.
261. Snider WD, Simpson DM, Nielson S: Neurological complications of acquired immunodeficiency syndrome: Analysis of 50 patients, *Ann Neurol* 14:403–418, 1983.
262. Telischi FF, Chandler JR, May M, Schaitkin BM: *The facial nerve—May's second edition*, New York, 2000, Thieme, pp 383–392.
263. Lydiatt DD: Medical malpractice and facial nerve paralysis, *Arch Otolaryngol Head Neck Surg* 129:50–53, 2003.
264. Eisele DW, Wang SJ, Orloff LA: Electrophysiologic facial nerve monitoring during parotidectomy, *Head Neck* 32:399–405, 2010.
265. Guntinas-Lichius O, Klussmann JP, Wittekindt C, Stennert E: Parotidectomy for benign disease at a university teaching hospital: outcome of 963 operations, *Laryngoscope* 116:534–540, 2006.
266. Wilson L, Lin E, Lalwani A: Cost-effectiveness of intraoperative facial nerve monitoring in middle ear or mastoid surgery, *Laryngoscope* 113:1736–1745, 2003.
267. Hohman MH, Bhama PK, Hadlock TA: Epidemiology of iatrogenic facial nerve injury: a decade of experience, *Laryngoscope* 124:260–265, 2014.
268. Hall MB, Brown RW, Lebowitz MS: Facial nerve injury during surgery of the temporomandibular joint: a comparison of two dissection techniques, *J Oral Maxillofac Surg* 43:20–23, 1985.
269. Shi D, Patil PM, Gupta R: Facial nerve injuries associated with the retromandibular transparotid approach for reduction and fixation of mandibular condyle fractures, *J Craniomaxillofac Surg* 43:402–407, 2015.
270. Downie JJ, Devlin MF, Carton AT, Hislop WS: Prospective study of morbidity associated with open reduction and internal fixation of the fractured condyle by the transparotid approach, *Br J Oral Maxillofac Surg* 47:370–373, 2009.
271. Yang L, Patil PM: The retromandibular transparotid approach to mandibular subcondylar fractures, *Int J Oral Maxillofac Surg* 41:494–499, 2012.
272. Ellis E, Dean J: Rigid fixation of mandibular condyle fractures, *Oral Surg Oral Med Oral Pathol* 76:6–15, 1993.
273. Gantz BJ, Gmuer AA, Holliday M, Fisch U: Electroneurographic evaluation of the facial nerve. Method and technical problems, *Ann Otol Rhinol Laryngol* 93(4 Pt 1):394–398, 1984.
274. May M, Harvey JE, Marovitz WF, Stroud M: The prognostic accuracy of the maximal stimulation test compared with that of the nerve excitability test in Bell's palsy, *Laryngoscope* 81:931–938, 1971.
275. Gantz BJ, Rubinstein JT, Gidley P, Woodworth GG: Surgical management of Bell's palsy, *Laryngoscope* 109:1177–1188, 1999.
276. Prim MP, De Diego JI, Sanz O: Prognostic factors in patients with idiopathic facial paralysis (Bell's palsy): a prospective study, *ORL J Otorhinolaryngol Relat Spec* 61:212–214, 1999.
277. Mancini P, De Seta D, Prosperini L, et al.: Prognostic factors of Bell's palsy: multivariate analysis of electrophysiological findings, *Laryngoscope* 124:2598–2605, 2014.
278. Takemoto N, Horii A, Sakata Y, Inohara H: Prognostic factors of peripheral facial palsy: multivariate analysis followed by receiver operating characteristic and Kaplan-Meier analyses, *Otol Neurotol* 32:1031–1036, 2011.
279. Watchmaker G, Mackinnon S: Nerve injury and repair. In Peimer C, editor: *Surgery of the hand and upper extremity*, New York, 1996, McGraw-Hill.
280. Warwick A, Tung T, Mackinnon S: Surgical management of facial nerve injuries. In Miloro M, editor: *Trigeminal nerve injuries*, New York, 2013, Springer.
281. Bascom DA, Schaitkin BM, May M, Klein S: Facial nerve repair: a retrospective review, *Facial Plast Surg* 16:309–313, 2000.
282. Millesi H: Nerve grafting, *Clin Plast Surg* 11:105–113, 1984 Jan.
283. Millesi H: Techniques for nerve grafting, *Hand Clin* 16:73–91, 2000.

284. Piza-Katzer H, Balogh B, Muzika-Herczeg E, Gardetto A: Secondary end-to-end repair of extensive facial nerve defects: surgical technique and postoperative functional results, *Head Neck* 26:770–777, 2004.
285. Hadlock TA, Greenfield LJ, Wernick-Robinson M, Cheney ML: Multimodality approach to management of the paralyzed face, *Laryngoscope* 116:1385–1389, 2006.
286. Gidley PW, Gantz BJ, Rubinstein JT: Facial nerve grafts: from cerebellopontine angle and beyond, *Am J Otol* 20:781–788, 1999.
287. Bozorg Grayeli A, Mosnier I, Julien N, et al.: Long-term functional outcome in facial nerve graft by fibrin glue in the temporal bone and cerebellopontine angle, *Eur Arch Otorhinolaryngol* 262:404–407, 2005.
288. Nakao Y, Piccirillo E, Falcioni M, et al.: Electromyographic evaluation of facial nerve damage in acoustic neuroma surgery, *Otol Neurotol* 22:554–557, 2001.
289. Malik TH, Kelly G, Ahmed A, et al.: A comparison of surgical techniques used in dynamic reanimation of the paralyzed face, *Otol Neurotol* 26:284–291, 2005.

6

Diagnosis and Management of Dentoalveolar Injuries

SHRAVAN KUMAR RENAPURKAR, A. OMAR ABUBAKER

Introduction

Injuries secondary to trauma are common in the facial region, and about 20% of these include injuries involving the dentoalveolar complex.[1,2] In the United States, traumatic dental injuries have been evidenced in approximately 1 of 4 adults and 1 of 6 adolescents.[3] These injuries could involve the tooth, surrounding soft tissues, and alveolar bone. In many of these patients, comprehensive management will require multidisciplinary care from various dental specialties including oral and maxillofacial surgery, restorative dentistry, prosthodontics, and orthodontics.

Isolated dentoalveolar injuries are common among children and adolescents, whereas those occurring concomitantly with other facial fractures are more common among young adults.[3-6] The reported prevalence of dentoalveolar injuries varies widely depending on factors such as age, cause of injury, country, environment, and gender. These injuries may be caused by motor vehicle accidents, motorcycles, bicycles, assaults, falls, sports, iatrogenic causes from intraoral procedures, and industrial accidents. Among preschool children and toddlers, dentoalveolar injuries are most often caused by falls, especially during the first year of life.[3,6,7] Boys have dental injury more commonly than girls.[6] A recent 12-year review estimated that across multiple studies spanning many countries, 71% to 92% of all dental trauma sustained in a lifetime occurs before the age of 19 years with a decrease in incidence after the age of 24 to 30 years.[3,7] Overall, the prevalence of dentoalveolar injuries among children with primary dentition is 11% to 30%, and among children with permanent dentition it is 5% to 20%. Boys also are affected almost twice as often as girls, with peak incidence at 2 to 4 years and 8 to 10 years.[7]

Many of these dentoalveolar injuries are underreported in trauma literature, as they are treated in an outpatient setting, in contrast to common pediatric facial fractures. The general prevalence of oral injury among pediatric patients is reported to be 5% of all facial fractures.[6]

Another cause of dentoalveolar and surrounding soft tissue injuries among children can be child abuse.[8-13] All 50 U.S. states have mandates for dentists and health care professionals to be able to identify and report child abuse and neglect.[8] When no obvious cause of the trauma is identifiable, child abuse may be suspected. In fact, roughly 50% of all physical injury associated with child abuse occurs in the head and neck region.[13] Finally, certain medical conditions may predispose a patient to dentoalveolar trauma, such as a history of uncontrolled seizures. Among children of school age, dentoalveolar injuries occur mostly on playgrounds and in bicycle accidents. In the teenage years, these injuries are most often caused by contact sports, motor vehicle accidents, and interpersonal violence. It has been stated that 33% of all traumatic dental injuries and up to 19% of injuries to the head and face are sports related.[14-16] Among adolescents with sports-related trauma, the incidence of dentoalveolar injuries is reported to be 36%.[16] Use of mouthguards has been strongly supported by the American Dental Association.[17] Extensive effort is spent on the fabrication of mouthguards, but there is no strong evidence in the literature to show their efficacy.[18] More recently the focus has been on preventive education and awareness among schools, sports authorities, and others. In addition, National Facial Protection Month, which occurs every April, has been successful in bringing attention to the prevention of sports-related injuries. This campaign has been promoted by the American Association of Oral and Maxillofacial Surgeons, as well as other dental organizations. (http://www.aaoms.org/media/april-is-national-facial-protection-month), (Figure 6-1).

Injuries to the dentoalveolar structures can present as an isolated injury or in association with multisystem injury as seen in motor vehicle accident victims. Dentoalveolar injuries

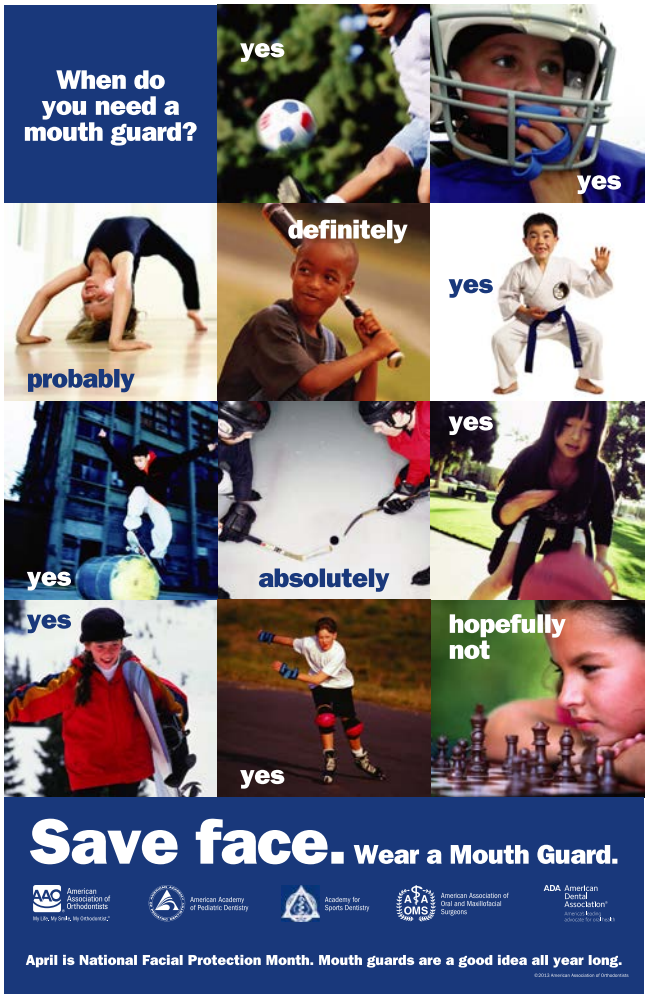

• **Figure 6-1** National Facial Protection Month in April annually has been a great way to educate patients about importance of prevention of sports-related orofacial injury.

can also result from direct trauma to the teeth or from indirect trauma from mandibular dentition forcibly closing against the maxillary dentition. If the injury is caused by direct trauma, the most likely teeth to sustain injury in both the primary and permanent dentition are the maxillary central incisors, because of their relatively exposed position**.** Large overjet, proclined incisors, and short upper lip predispose to increased incidence of dental trauma.[19] This occurs most commonly when these teeth are protruding, as in patients with Class II Division I malocclusion, an overjet greater than 5 mm, or in patients with insufficient lip closure.[20] These are followed in incidence by the upper and lower lateral incisors and the upper canines. Depending on the force of the impacted trauma, direct injury mechanisms can affect the upper or lower lip, occasionally causing laceration of the lip as well as dental or osseous alveolar fracture (Figure 6-2). Dentoalveolar injury from indirect trauma usually results from force applied to the chin, forcing the mandibular teeth against the maxillary dentition. The impact of this force often results in crown or crown-root fracture as well as condylar and/or mandibular symphysis fracture and anterior intraoral soft tissue and submental laceration (Figures 6-3 and 6-4).



• **Figure 6-2** Direct trauma to the lower lip causing a laceration in a child.

The nature of dentoalveolar injuries also varies with age, possibly because of the anatomic differences between the teeth and supporting structures of adults and pediatric patients. The lack of sinus pneumatization and higher ratio of cancellous to cortical bone, as well as the developing dentition within the facial skeleton, tend to increase the elasticity of the pediatric facial bones, making them less vulnerable to fractures. Trauma to the primary dentition most often affects the supporting structure (luxation and exarticulation), whereas trauma to the permanent dentition mostly affects the teeth themselves (causes crown fractures).[21] Only 10% of injuries to the primary dentition are crown or crown-root fractures. Seventy-five percent involve luxation or exarticulation of the tooth, compared to the incidence of mostly crown or crown-root fracture involvement in the permanent dentition.

The oral and maxillofacial surgeon (OMS) is often called to the emergency department to evaluate patients who sustain orofacial trauma. The first-aid treatment is regularly performed by an OMS, and subsequent dental and restorative management is performed in outpatient setting by other dental colleagues.

Evaluation of the Dentoalveolar Injury Patient

As with any other trauma patient, the evaluation process of a dentoalveolar trauma patient should include a thorough history and comprehensive physical examination, along with any necessary radiographic examination or other diagnostic procedures.

History and Physical Examination

A thorough and systematic evaluation and diagnosis must precede management of traumatic dental injuries. In general, primary evaluation of any trauma patient must be carried out based on Advanced Trauma Life Support (ATLS) guidelines.[22] Once the systemic stability of the patient is

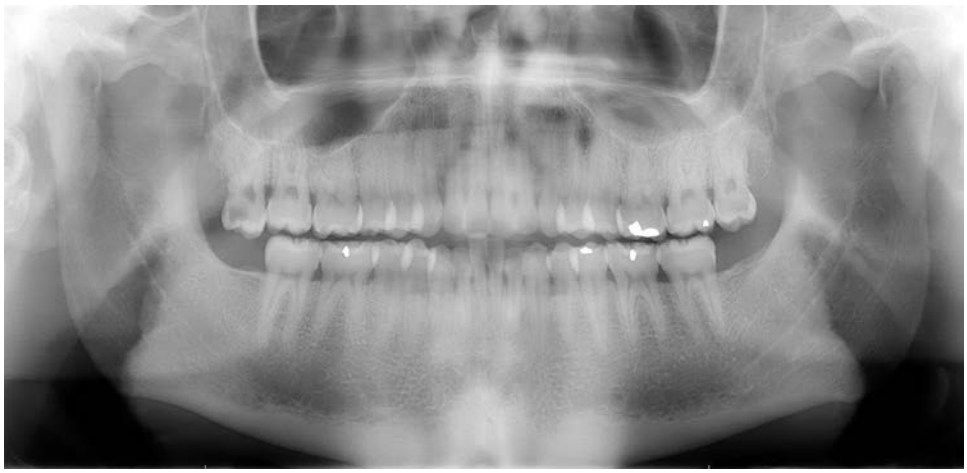

• **Figure 6-3** Mandibular anterior teeth luxated along with a concomitant subcondylar fracture. Dentoalveolar injuries can occur along with other facial bone fractures.

established, secondary evaluation is performed in a system wise fashion. Although dentoalveolar injuries, especially avulsive ones, are considered emergent, definitive repair of the dentoalveolar injury could be delayed until patient has been stabilized from a systemic standpoint. Results of the history and physical examination will dictate the need for diagnostic radiographs and/or special diagnostic tests such as pulp testing. Once a diagnosis is established based on clinical and radiographic evaluation, a treatment plan can be formulated. Because the length of time from injury until treatment is an important factor in determining the prognosis and outcome of dentoalveolar injury, the process of management should commence as soon as possible.[23]

History

Obtaining detailed history can provide invaluable information for the diagnosis and subsequent management of dentoalveolar injuries. However, the practitioner must keep in mind that children, in particular, do not often offer a reliable and detailed history, especially after a traumatic event. In this situation, one must depend on the accompanying adult or other eyewitnesses. The history obtained from patients with dentoalveolar injury should include the following information[24]:

1. Biographic and demographic data of the patient, including name, age, sex, race, address, and phone number.
2. The time interval between the injury and presentation. This is critical in ultimate prognosis of the teeth, especially in cases of avulsion or of tooth fracture with pulp exposure. The location of the incident or accident will help determine the degree of contamination of the wound and the indication for tetanus prophylaxis.
3. The mechanism of injury. This provides clues regarding the possibility of other injuries to suspect and evaluate via various imaging modalities. For example, a fall can cause injury to the maxillary anterior dentition, whereas a blow to the chin will often cause crown-root fractures of the premolar region with or without symphysis or condylar fractures. In children and women, if the reported mechanism of the injury does not correspond to the clinical presentation, the potential for abuse could be considered. In instances of abuse it is important that the clinician carefully document the clinical findings and the discussion with the patient and caregivers. Mechanism of injury also guides the clinician to suspect any occult injuries that may need further radiographic evaluation.
4. Information related to the event and its surroundings. This should also be recorded—for example, if any avulsed teeth, tissue, or fragments of teeth were noted at the site of the accident. Radiographic examination of the periapical tissues, chest, abdominal region, and perioral soft tissue is indicated when the preinjury dentition has



• **Figure 6-4** Gingival lacerations could be indicative of dentoalveolar fractures as well as underlying mandibular fractures.

changed in form or number. Management of partially or completely avulsed teeth by the patient should also be charted, including whether the teeth were replanted, or the storage medium used before presentation to the dentist or the emergency room. Medical events at the site of the accident are critical to note. Loss of consciousness, confusion, nausea, vomiting, or visual disturbances will indicate possible intracranial injury, which warrants neurologic evaluation. Patients who report persistence of these symptoms should be referred for emergent evaluation, and treatment of the dentoalveolar injury should be delayed until it is completed.

5. Subjective changes regarding dental occlusion as a result of the injury, which may indicate tooth displacement or dentoalveolar or jaw fractures.
6. A short medical and dental history to delineate any systemic or dental factors that can influence immediate and delayed treatment plans. Such factors include the presence of major systemic illness, especially those that may influence the treatment such as bleeding disorders and epilepsy. Also, knowledge of any previous oral and maxillofacial trauma may be helpful.

Physical Examination

An important aspect of the physical examination is the overall evaluation of the physical status of the patient. Historical findings will direct the examiner to anticipate injury patterns, thereby promoting a focused examination. As noted earlier, examination following the ATLS protocol will help identify or rule out systemic injuries in a systematic fashion. Abnormalities in vital signs may indicate intracranial injury, cervical spine injury, chest or abdominal injury, or even aspiration of an avulsed tooth. The mental status of the patient should also be assessed both by asking specific questions and by observing the patient's reaction and behavior during the history and examinations. Once a general examination is completed and a concomitant injury is ruled out, a thorough oral and maxillofacial examination is performed. Such examinations should include the following.[24]

Extraoral Soft Tissue Examinations

Lacerations, abrasions, and contusions of the face, chin, forehead, and scalp should be identified, and their depth, location, and proximity to vital structures should be established. The site of soft tissue trauma is a predictor of associated hard tissue injuries. Palpation of the temporomandibular joint and examination for range of jaw motion should be done to rule out condylar fracture.

Intraoral Soft Tissue Examination

Injuries of the oral mucosa, gingiva, lips, tongue, floor of the mouth, and cheek should be considered (see Figure 6-2). If present, such injuries should be carefully evaluated for the presence of foreign bodies, debris, and teeth or tooth fragments embedded within the tissue.[24,25] It may be necessary to debride the oral cavity of clots and debris and to stop active bleeding before completing a thorough examination.

Gingival lacerations (see Figure 6-4) are often indications of displacement of teeth, while bleeding from nonlacerated marginal gingiva often indicates periodontal ligament damage or mandibular fracture. It is important that all teeth be accounted for at this time. Missing teeth or pieces of teeth that have not been left at the scene of the accident should be considered to have been aspirated, swallowed, or displaced into the soft tissues, nasal cavity, or maxillary sinus (Figure 6-5).[24,26] Therefore, a radiographic examination of the head and neck, chest, and abdomen should be done to rule out presence of teeth or fragments into these tissues or organs.

Examination of the Jaws and Alveolar Bone

Fractures of the alveolar process protruding through the overlying mucosa are normally evident and readily detected by visual inspection. Mobility and crepitation of the palpated alveolar fracture segments confirms underlying bone injury when the overlying mucosa is not lacerated. Fractures of the jaw may be detected by presence of gross malocclusion, step-off deformities, pain, and mobility of the fractured segment to palpation. Bleeding from the gingival crevice of a tooth, vertical laceration of the attached mucosa, and submucosal ecchymosis of the floor of the mouth are other signs of jaw fracture.

Examination of the Teeth Structure

Direct examination of tooth structure is preceded by removing blood and debris from the teeth. Any infraction or fractures of the crowns should be noted. Infraction lines in the enamel can be detected by directing a light beam parallel to the long axis of the tooth. Crown fractures should be evaluated for extending into the dentin and the pulp. The size and location of pulp exposure should be recorded. Crown-root fractures in all quadrants should be evaluated as well. Changes in the color of a traumatized tooth and its translucency may indicate a pulp exposure. It is important to remember that indirect trauma leading to crown-root fractures in one quadrant is often accompanied by similar fractures in the ipsilateral opposing jaw.

Examination for Displacement of Teeth

Displacement of teeth as a result of dentoalveolar trauma can usually be readily detected by visual examination. Examination of the dental occlusion may also be helpful in detecting minor degrees of tooth movements. Although displacement of teeth as a result of dentoalveolar trauma can occur in any direction, the most common displacement is in a buccolingual direction (Figure 6-6). The direction and extent of displacement should be recorded. Lateral luxation and intrusion of teeth may present very minimal clinical symptoms because the teeth remain locked in this displaced

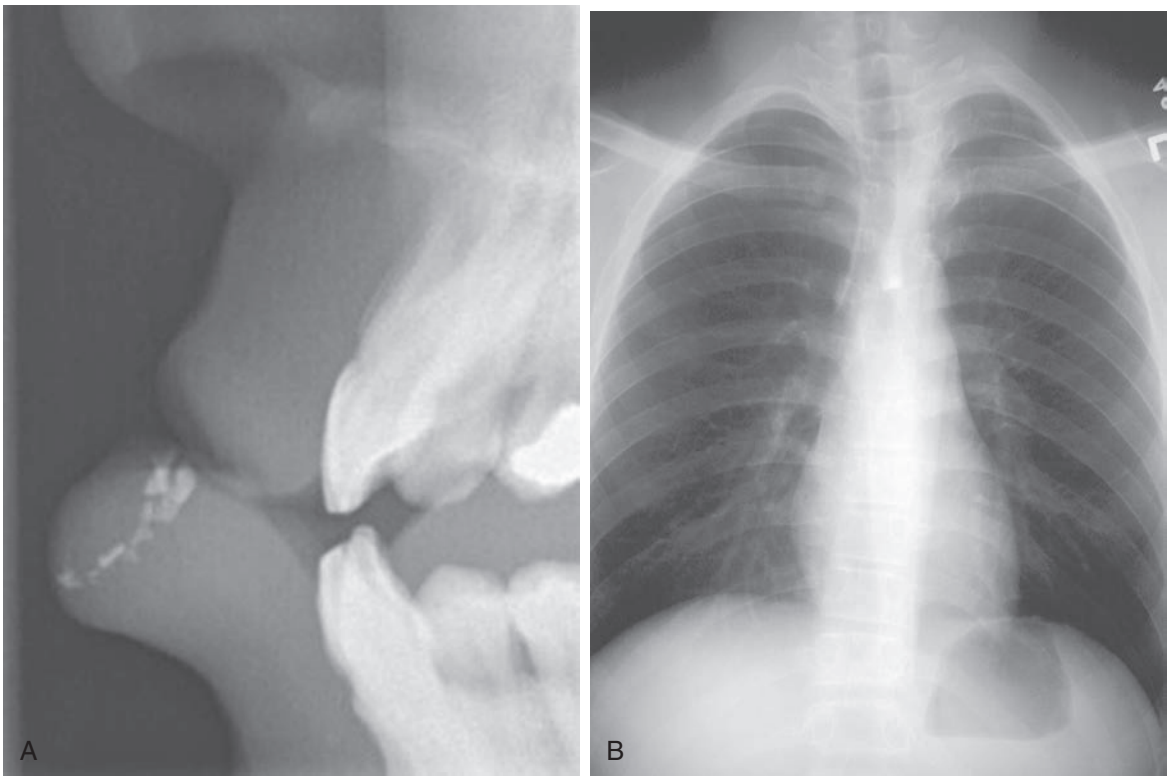

• **Figure 6-5 A,** Tooth fragments displaced into the lower lip. **B,** Chest radiograph showing aspirated tooth. Missing teeth or tooth fragments should be accounted for, and if they are not found, aspiration and displacement into surrounding tissues should be ruled out with imaging. (From Powers MP: Diagnosis and management of dentoalveolar injuries. In Fonseca JR, Walker RV, editors: *Oral and maxillofacial trauma*, ed 2, vol 1, Philadelphia, 1997, WB Saunders.)

position. Lingual and apical displacement of the apex of a primary tooth can interfere with its permanent successor.

Examination for Mobility of Teeth

All teeth should be tested for both horizontal and axial mobility by either manual palpation or use of a tongue blade. If a tooth does not appear to be displaced but is very mobile, a root fracture should be suspected. In such instances the location of the fracture usually determines the degree of mobility. When testing for mobility of one tooth, observing mobility of the adjacent teeth is suggestive of a dentoalveolar fracture.

Reaction to Percussion

Increased sensitivity to percussion in the absence of tooth displacement is indicative of injury to the periodontal ligament. This test can be performed by vertical and horizontal tapping of the tooth or gentle fingertip pressure when examining smaller children. A noninjured tooth should be used for control. Sound elicited by percussion, with the use of the handle of a mouth mirror, has been mentioned in the literature as providing diagnostic information.[24] An uninjured tooth will generally have a solid, metallic sound, whereas a luxated tooth will be dull. However, for this to be of any value, a quiet environment is required.



• **Figure 6-6** Buccal-palatal displacement of permanent maxillary central incisors is commonly seen.

Pulp Testing

Traumatized teeth could have paresthesia and altered neurologic response, and neural recovery takes longer than vascular regeneration.[24] Currently used tooth vitality tests register the conduction of stimuli to the sensory receptors of the dental pulp. This type of vitality testing is subjective and may be difficult to perform or

relatively unreliable in the acute setting following traumatic injury. Lack of cooperation and unreliability, especially among children, and false-negative results, which are common in acute injury, diminish the usefulness of pulp testing in the acute setting. Nonetheless, pulp testing several weeks later, after revascularization and nerve repair of the pulp, may be more accurate and should be performed before endodontic therapy. It can also be beneficial and important for planning treatment. Some of the methods used in pulp testing include electric pulp testing, thermal test using treated gutta-percha, ice, ethyl chloride, carbon dioxide snow, and dichlorodifluoromethane. The low sensitivity of some of these techniques led some to search for new methods of pulp testing. Laser Doppler flowmetry has been used in recent years as a more reliable method of assessing pulpal flow and vitality. Although promising, it still remains a sensitive and time-consuming technique and is not widely used because of cost and availability.[27] Even if unreliable, pulp testing should be performed at the earliest possible time after trauma as a baseline recording and then at regular intervals of 2, 4, and 6 to 8 weeks and then 6 and 12 months.[27]

Radiographic Examination

Radiographic examination is an essential part of evaluation that helps identify injuries affecting the root portion of the tooth and the periodontal ligament, as well as status of the bone. Such information includes presence of root fracture, root infraction, and root dislocation (Figure 6-7). Concomitant jaw fractures, preexisting periapical or periodontal disease, degree of extrusion or intrusion, and teeth or tooth fragments or foreign bodies lodged in the soft tissue can also be identified.[25,26] In children and young adults, radiographic examination serves to provide information regarding the extent of root development, size of the pulp chamber and root canal, and proximity of succedaneous teeth to the injured primary tooth. Choice of radiographs should be based on history and physical examination. Radiographic imaging of dentoalveolar trauma usually consists of more than one radiograph, including intraoral periapical, occlusal, and panoramic radiographs.[28] Correctly positioned periapical radiographs (central beam of x-ray parallel to the line of fracture) provide the most detailed information to adequately evaluate root fracture and dislocation of teeth. Often multiple views (ideally three radiographs) with two

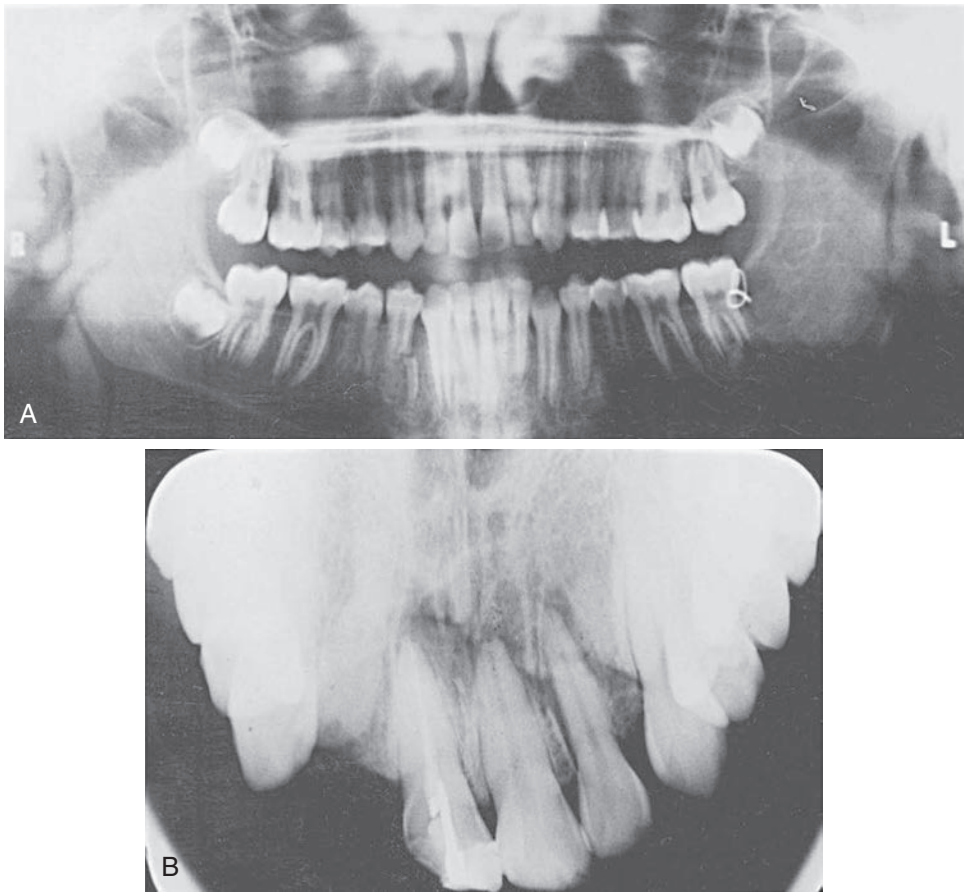

• **Figure 6-7** **A,** Panoramic radiographic examination for evaluation of dentoalveolar injury revealing a root fracture of the right mandibular first bicuspid. **B,** An occlusal radiograph showing a dentoalveolar fracture of the anterior maxilla. (From Abubaker AO, Papadopoulos H, Giglio JA: Diagnosis and management of dentoalveolar injuries. In Fonseca R, Marciani RD, Turvey TA, editors: *Oral and maxillofacial surgery*, ed 2, St Louis, 2009, Saunders.)

different vertical and three different horizontal angulations of the central beam may be necessary, especially to view root fractures. Periapical radiographs are also used postoperatively to confirm position of the root.

Occlusal radiographs are particularly useful to diagnose a root fracture, or lateral luxation with lingual displacement of the crown. Occlusal radiographs are also often made for patient comfort because they place minimal pressure on the traumatized area. They are also valuable in examining the floor of the mouth, tongue, cheek or lip lacerations for teeth or tooth fragments in the soft tissue. When occlusal radiographs or other x-ray exposure is used to examine soft tissue, a reduced radiographic exposure time is recommended.

Radiographically displaced teeth will appear as a widening of the periodontal ligament space or displacement of the lamina dura. Extruded teeth may appear as a periapical radiolucency compatible with the pattern and shape of the apical portion of the root. Lateral and extensive luxation of teeth will also appear as a widening of the periodontal ligaments. Intruded teeth often will show minimal radiographic findings or only a blurred or absent periodontal space.

If jaw fractures or fractures of the alveolar ridges are suspected, extraoral radiographs such as an orthopantomogram should be obtained. Although panoramic radiography can demonstrate fractures of the jaw, alveolar ridges, and teeth, it is best suited as a screening image for fractures of the condyle, subcondylar region, or angle or body of the mandible. The overlap of the vertebral column inhibits adequate visualization of maxillary and mandibular anterior dentition. Complex midface anatomy also limits the use of plain-film two-dimensional radiographs because of overlapping of structures. In these cases a three-dimensional (3D) imaging modality such as computed tomography (CT) or cone-beam CT (CBCT) is valuable in overcoming superimpositions while allowing a 3D evaluation. CT and CBCT both have good resolution, but CBCT have relatively less radiation exposure compared to a medical-grade CT scan. Imaging of soft tissue trauma may be better appreciated on a CT scan compared to a CBCT. Occasionally, access to or use of routine dental radiographs is limited, such as in a hospital setting and in children under the age of 2 years. CT scans have remained the gold standard for evaluation of facial bone fractures. With advent of CBCT and its availability and low cost in outpatient settings, it can be used a valuable tool in assigning both bony and dental structure injuries with higher definition and more accuracy to the nature of dentoalveolar injury.[30,31]

Classification of Dentoalveolar Fractures

Although historically there have been several classification systems in use for description of dentoalveolar trauma, each had its own advantages and disadvantages.[32-36] These systems are based on a variety of factors such as etiology, anatomy of injury, pathology, and therapy. The purpose of such classification is to provide a comprehensive and universal description of the injury for communication and treatment planning purposes. The most accepted and commonly used is Andreasen's modification of the WHO classification.[19,36,37]

Andreasen's classification[19] includes description of injuries to the teeth, supporting structures, gingiva, and oral mucosa, with some modifications to take into account anatomic, therapeutic, and prognostic considerations. This classification can be applied to both the permanent and primary dentition. In this classification system, dentoalveolar injuries are divided into four major categories: injuries to the dental tissues and pulp, to the periodontal tissues, to the supporting bone, and to the gingiva or oral mucosa. Descriptions and illustrations of the four categories are shown in Tables 6-1 through 6-4. Basic types of traumatic injuries to primary dentition are shown in Figure 6-8.[38]

Treatment of Dentoalveolar Injuries

General Considerations

An ideal outcome with treatment of dentoalveolar fractures would be to attain or preserve the premorbid functional state of teeth, bone, and gingiva; maintain esthetics; and optimize growth and development. Based on the Andreasen classification system and including the six luxation types and nine fracture types in both primary and permanent dentition, there could be 108 types or combinations of dental trauma entities. The complexity of diagnosis and management of dentoalveolar trauma has been perplexing to the clinician in making an evidence-based decision. The most recent IADT-recommended guidelines, updated in 2012, represent the best evidence based on the most current literature and expert opinion.[38] These guidelines are meant to help the clinician make acute management decisions with traumatic dental injury, but they do not substitute for comprehensive and detailed information on traumatic dental injury management as found in scientific literature and books. These guidelines have been made accessible online at http://www.dentaltraumaguide.org.

Factors to be considered in treatment planning include:

1. age of the patient;
2. cooperation of the patient;
3. primary, mixed or secondary dentition;
4. developmental state of the tooth;
5. classification and extent of the injury;
6. any concomitant bodily injuries or medical comorbidities;
7. restorability of the tooth based on decay and periodontal health; and
8. long-term restorative options.

Although every attempt should be made to preserve all of the dentoalveolar structures permanently, it is sometimes necessary to either sacrifice or only temporarily maintain teeth to facilitate future reconstruction, restoration, and rehabilitation. Therefore, deciding whether and when

TABLE 6-1 Injuries to Hard Dental Tissues and Pulp

Crown infraction	Incomplete fracture or crack of the enamel without loss of tooth substance	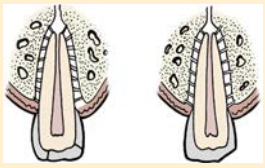
Uncomplicated crown fracture	A fracture confined to the enamel or involving the enamel and dentin without exposing the pulp	
Complicated crown fracture	Involves enamel and dentin with exposure of the pulp	
Uncomplicated crown-root fracture	Involves enamel, dentin, and cementum without exposure of the pulp	
Complicated crown-root fracture	Involves enamel, dentin, and cementum with exposure of the pulp	
Root fracture	Involves dentin, cementum, and the pulp	

Modified from Powers MP: Diagnosis and management of dentoalveolar injuries. In Fonseca JR, Walker RV, editors: *Oral and maxillofacial trauma*, ed 2, vol 1, Philadelphia, 1997, WB Saunders, p 333.

to remove teeth or bony segments at the initial phase of treatment should be done cautiously. Heroic attempts to maintain teeth that are otherwise unsalvageable for decay or periodontal reasons should be avoided unless they are being retained temporarily to preserve at-risk alveolar bone. Being able to maintain proper alveolar contour and bulk will often allow for a more satisfactory dental rehabilitation. Likewise, avulsed teeth that have an extremely poor prognosis when associated with alveolar fractures may be replanted for a period of time as both a means of properly reducing the fracture and as physiologic space maintainers. Such a tooth can always be removed at a later date. If root fractures are evident, clinically concomitant with alveolar fractures, the teeth are removed if it can be accomplished without compromising the alveolar segment. Otherwise, they are left in place for removal at a later date after the segment is healed. Root fractures, particularly apical third fractures, are often only discovered on postreduction radiographs taken in the dental office. These are managed in the same manner as if they had occurred without an alveolar fracture.

When dealing with alveolar fractures, debridement of bone should be conservative. The alveolar bones are highly vascular, and vitality may often be maintained by even a very small soft tissue pedicle. Therefore, an attempt should always be made to retain fragments that have soft tissue attachments. The avulsed tooth associated with an alveolar fracture may have to be rigidly splinted for 3 to 4 weeks instead of physiologically splinted for 7 to 10 days.

Use of antibiotics in dentoalveolar trauma is controversial, with limited evidence in the literature about its efficacy. Use should be at the discretion of the provider, who should

TABLE 6-2 Injuries to the Periodontal Tissues

Concussion	An injury to the tooth-supporting structures without abnormal loosening or displacement of the tooth, but with marked reaction to percussion	
Subluxation (loosening)	An injury to the tooth-supporting structures with abnormal loosening, but without displacement of the tooth	
Intrusive luxation (central dislocation)	Displacement of the tooth into the alveolar bone with comminution or fracture of the alveolar socket	
Extrusive luxation (peripheral dislocation, partial avulsion)	Partial displacement of the tooth out of the alveolar socket	
Lateral luxation	Displacement of the tooth in a direction other than axially, accompanied by a comminution or fracture of the alveolar socket	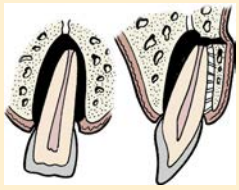
Retained root fracture	A fracture with retention of the root segment, but loss of the crown segment out of the socket	
Exarticulation (complete avulsion)	Complete displacement of a tooth out of the alveolar socket	

Modified from Powers MP: Diagnosis and management of dentoalveolar injuries. In Fonseca JR, Walker RV, editors: *Oral and maxillofacial trauma*, ed 2, vol 1, Philadelphia, 1997, WB Saunders, p 333.

consider other indications such as wound contamination, soft tissue trauma, and general medical status.[39]

The sequence of treatment of dentoalveolar fractures is an inside-to-outside approach that includes bone, teeth, and then soft tissue. Accordingly, underlying alveolar bone injuries are treated first, followed by placement or reduction of the teeth as they relate to the underlying bone, and then the soft tissues are repaired. Prioritizing treatment sequence in the presence of other more critical bodily injuries, especially in a hospital setting, may sometimes preclude optimal treatment of the dental injury. Compromises are often unavoidable for the overall good of the patient.

Treatment of Specific Types of Injuries to the Hard Dental Tissues and Pulp

Crown Infraction

An infraction is an incomplete crack in the enamel without any loss of tooth structure. These are asymptomatic; if tenderness is present, other injuries such as luxations or fractures should be suspected. The infraction can be sealed with composite resin to avoid discoloration, but otherwise no treatment is indicated. These injuries may be easily missed and may require direct transillumination to diagnose. Pulp

TABLE 6-3 Injuries to Supporting Bone

Comminution of the alveolar socket	Crushing and comminution of the alveolar socket occur, together with intrusive and lateral luxation	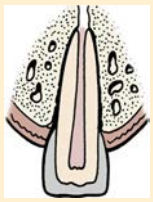
Fracture of the alveolar socket wall	Confined to the facial or lingual socket wall	
Fracture of the alveolar process	May or may not involve the alveolar socket	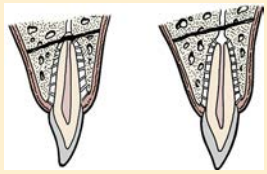
Fractures of the mandible or maxilla	Involves the base of the mandible or maxilla and often the alveolar process; may or may not involve the alveolar socket	

Modified from Powers MP: Diagnosis and management of dentoalveolar injuries. In Fonseca JR, Walker RV, editors: *Oral and maxillofacial trauma*, ed 2, vol 1, Philadelphia, 1997, WB Saunders, p 333.

TABLE 6-4 Injuries to the Gingiva or Oral Mucosa

Mucosal or gingival contusion	A bruise that is submucosal hemorrhage without mucosal break and usually produced by a blunt object
Mucosal or gingival abrasion	A superficial wound resulting in a raw, bleeding surface usually produced by rubbing or scraping of the mucosa
Mucosal or gingival laceration	Shallow or deep mucosal wound from a tear and usually produced by a sharp object

Modified from Powers MP: Diagnosis and management of dentoalveolar injuries. In Fonseca JR, Walker RV, editors: *Oral and maxillofacial trauma*, ed 2, vol 1, Philadelphia, 1997, WB Saunders, p 333.

vitality tests are not reliable at the time of injury. However, teeth with crown infraction should be evaluated periodically to monitor the status of the pulp to determine the need for or the nature of treatment at a later time. Prognosis for pulpal health is good except in cases of combination injuries with concomitant subluxation, intrusion, or concussion, which could be often overlooked in an acute setting.[39,40]

Crown Fractures

Enamel Fractures

The usual treatment for an enamel fracture is to smooth the sharp edges of the enamel or restore with composite and observe the tooth. The tooth fragment, if available, can also be bonded to the tooth. The accident impact force is not always proportional to the size of the fracture, and the pulp could later become necrotic; hence the need for periodic follow-up.

Enamel and Dentin Fractures

In permanent dentition, crown fractures account for 26% to 76% of all traumatic injuries seen in the dental office.[19] Radiographic and clinical examination is important to rule out tooth debris or fragments lodged in the soft tissue. Emergency treatment of enamel and dentin fractures is designed to reduce hyperemia and protect the pulp against any thermal stimuli or bacterial contamination. The tooth fragment, if available, can be bonded with bonding agents. A calcium hydroxide base should be placed on the exposed

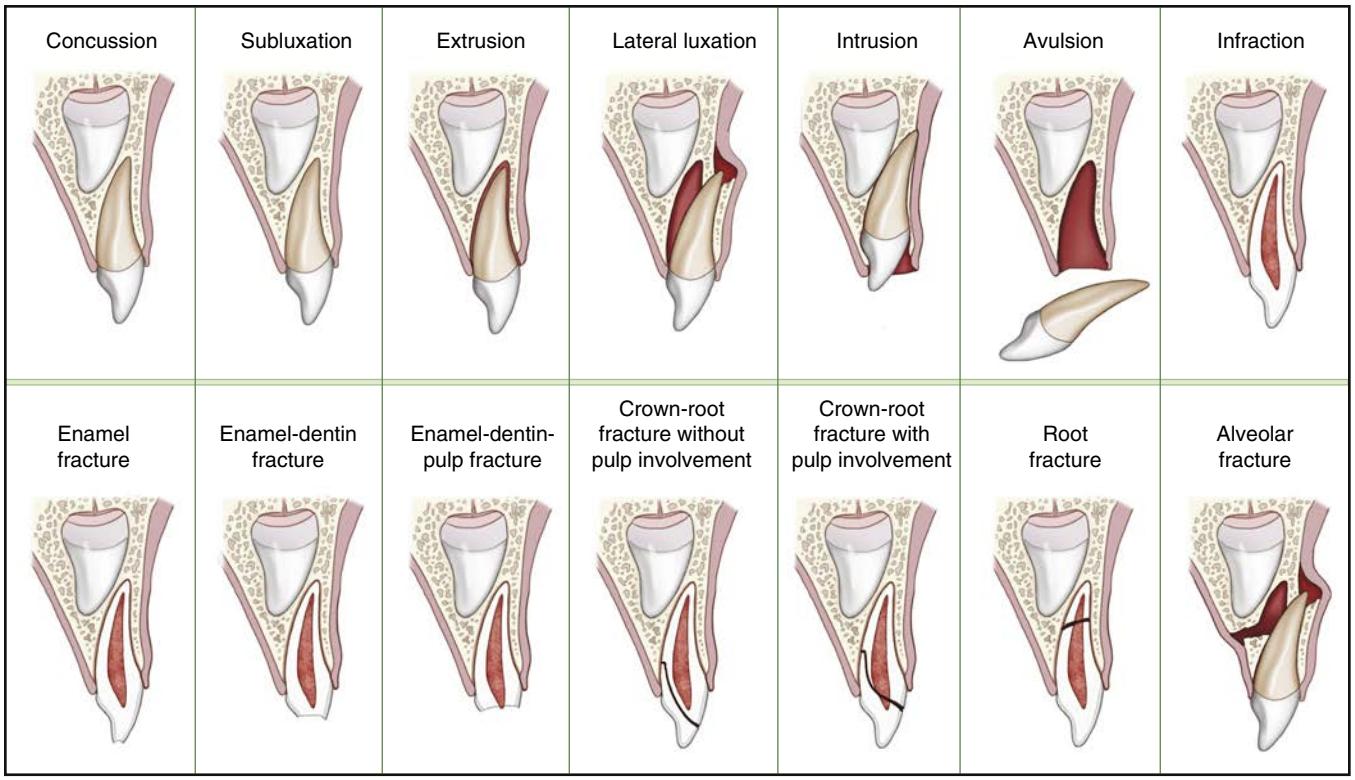

• **Figure 6-8** Injuries to primary teeth. (Modified from the *Dental trauma guide 2010*. International Association for Dental Traumatology.)

dentin, followed by an immediate temporary protective acid-etch resin restoration, especially if the remaining dentin is in close proximity to the pulp. Acid-etch resin restorations should hold the calcium hydroxide in place for a sufficient length of time ideally (6-8 weeks) to allow secondary dentin formation. A light cured glass ionomer liner/base, such as Vitrebond (3M Dental Products, St Paul, MN), can be used in place of calcium hydroxide. Resin restorations should restore the contact area, prevent movement of adjacent teeth into the fractured area, and provide sufficient incisal length to prevent the tooth from moving lingually.

Concurrently, restoring crown contour will prevent overeruption of the opposing tooth. Intermediate resin restorations also allow the tooth to be pulp-tested. After allowing for secondary dentin buildup, the final acid-etch resin restoration can be placed.

Enamel, Dentin, and Pulp

The aim of treatment in cases of pulp exposure should be to preserve a vital noninflamed pulp along with formation of a biologic hard-tissue barrier.[19] Factors to be considered in treatment planning include (1) age of the patient, (2) length of time elapsed since the injury occurred, (3) size of the pulp exposure, (4) condition of the pulp (vital or nonvital), and (5) the stage of root development.

Pulp Exposure with Vital Pulp

The prognosis is best for teeth with a vital pulp exposure if the fracture is treated as soon as possible.[41] A combination injury such as luxation and root fracture increases the chance of pulpal necrosis. In young patients with immature root apices as well as with completely formed root apices, pulp capping or pulpotomy is the treatment of choice. Pulp capping is indicated in cases where there has been a small area of pulp exposure, both in roots with immature and in those with mature apices, if the patient is seen within 24 hours after the injury. Calcium hydroxide (CH) or mineral trioxide aggregate (MTA) can be used in cervical pulpotomies or partial (Cvek) pulpotomies after removal of the superficial area of inflamed and hyperemic pulp. The direct pulp cap or pulpotomy is designed to allow a tooth with an open apex or recently formed apex to complete root development (apexogenesis) and physiologic dentin apposition. An intermediate protective restoration should be placed. A tooth with a vital pulp and incomplete root formation has the best recovery prognosis. Usually teeth that have cervical pulpotomies will ultimately need root canal therapy along with a post-and-core plus a crown.[41]

If the pulp exposure is large and/or if it has been present longer than 24 hours, root canal therapy is favored. Recent studies have shown MTA to be able to form a calcific bridge without inflammation in the pulp, whereas CH showed lesser calcification and presence of inflammation in the pulps capped. MTA is growing in popularity among clinicians for apexogenesis and apexification.[41]

Pulp Exposure with Nonvital Pulp

Root canal therapy should be performed if the pulp is necrotic and there is a mature apex. Apexification procedures

should be performed if there is a necrotic pulp with an immature apex.[41] The purpose of this procedure is to provide a calcific seal at the apex prior to condensing the gutta percha. This differs from apexogenesis in which completion of the root occurs. In the apexification technique, the canal is cleansed and a calcium hydroxide paste is placed in the canal (Figure 6-9). In 3 to 6 months, the tooth should be evaluated radiographically for a calcific bridge. If bridging has occurred, a root canal with gutta percha can be done. On occasion the apexification technique might take up to 18 months and the calcium hydroxide might have to be replaced every 3 to 6 months. In successful apexification treatment, teeth do not undergo physiologic dentin apposition and they are left with thin dentinal walls. If a tooth with a successful apexification technique is injured again, the tooth would be more susceptible to a cervical-third root fracture due to the thin dentinal walls.

Crown-Root Fracture

The treatment of crown-root fractures depends on several factors including the location of the fracture, the apical extent of the fracture, and whether the pulp is involved or not. Generally, emergency treatments for this type of fracture include temporary stabilization of the coronal fragment to the adjacent teeth and removal of these loose fragments before definitive treatment can be started sooner than later.[42] In fractures that are longitudinal and follow the long axis of the tooth or if the coronal fragment makes up more than one third of the clinical root, extraction is generally recommended. If the fracture line is above or slightly below the cervical margin, appropriate forms of conservative therapy can usually be employed to restore the tooth (Figure 6-10). Such therapies usually include crown-lengthening procedures or orthodontic elevation of the fracture site to provide for access for restorative margins. In young patients, treatment of this type of fracture is also influenced by whether the apex of the tooth is mature or immature. If the tooth is mature and restorable, endodontic treatment is indicated prior to restoration, whereas if the tooth is immature and the apex is open, a pulpotomy should be performed with a calcium hydroxide base and the tooth followed radiographically for closure of the apex. After such closure, definitive root canal therapy and permanent restoration can be completed.[40,42]

Root Fractures

Root fractures are relatively uncommon, with an incidence of 2.5% to 8% varying with age. They are found more commonly in adults, and they generally occur in teeth with complete root development, with the maxillary central incisor being the most common tooth.[44] Clinically, a root fracture is usually seen as an extruded tooth displaced lingually, making it difficult to differentiate from luxation injuries. Most root fractures occur in the apical and middle third and only rarely in the cervical third. Location of the root fracture plays a significant role in the prognosis of the tooth and hence in the treatment planning.[44]

Occlusal radiographs are useful for identifying the apical-third root fractures; periapical radiographs can identify root fractures at the middle and cervical thirds.

Radiographs taken immediately after an injury may not show a horizontal or diagonal root fracture. Intraoral periapical 90-degree film with central beam through the tooth can show a horizontal fracture more commonly in the cervical third of the root. In root fractures, separation of the

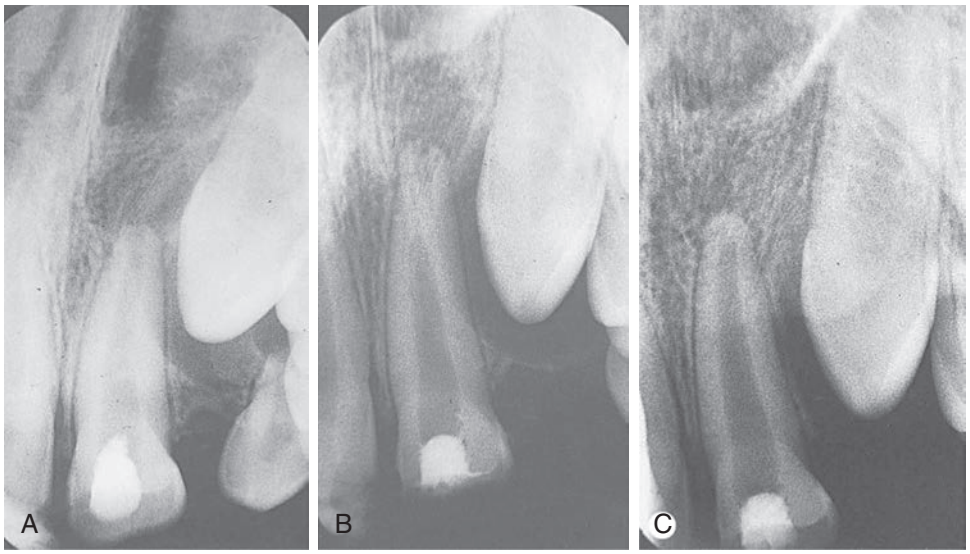

• **Figure 6-9** Periapical radiographs showing the results of the apexification procedure. **A,** A left central incisor necrotic tooth with an immature apex. **B,** The same incisor seen in Figure 6-8a after the placement of calcium hydroxide paste in the apex of the canal. **C,** Four months following treatment, note the radiopaque barrier that has formed at the apex. (From Abubaker AO, Papadopoulos H, Giglio JA: Diagnosis and management of dentoalveolar injuries. In Fonseca R, Marciani RD, Turvey TA, editors: *Oral and maxillofacial surgery*, ed 2, St Louis, 2009, Saunders.)

fragments must be substantial to appear on a radiograph. Only after a week or two, when hemorrhage, inflammation, and resorption have caused the fragments to separate, will the radiograph show the damage more conclusively. Diagonal root fractures are the most difficult to diagnose and are missed on intraoral periapical films. In suspected diagonal root fractures, a foreshortened (45-degree angulation) and an elongated (110-degree angulation) periapical film should be taken in addition to the standard 90-degree angulation.[40] Vertical root fractures in a labiolingual but not in a mesiodistal direction are easily discernible on a radiograph. Extraction is the treatment of choice in vertical root fractures because of nonrestorability.

Root fractures in the apical third without mobility require minimal treatment to avoid further trauma and improve the prognosis. The basic principle of treatment of root fractures with mobility consists of apposition of the fractured segments with flexible splinting for 4 weeks to 4 months for cervical-level root fractures. Splinting for 4 months is necessary because the repair of root fractures is similar to the repair of bone fractures, except slower.[41]

The treatment philosophy for cervical-third root fractures has changed significantly over the past decade. Extraction of the coronal part of the fracture followed by endodontic treatment was favored. Recent data have shown that—except for cervical-half root fractures, which are very close

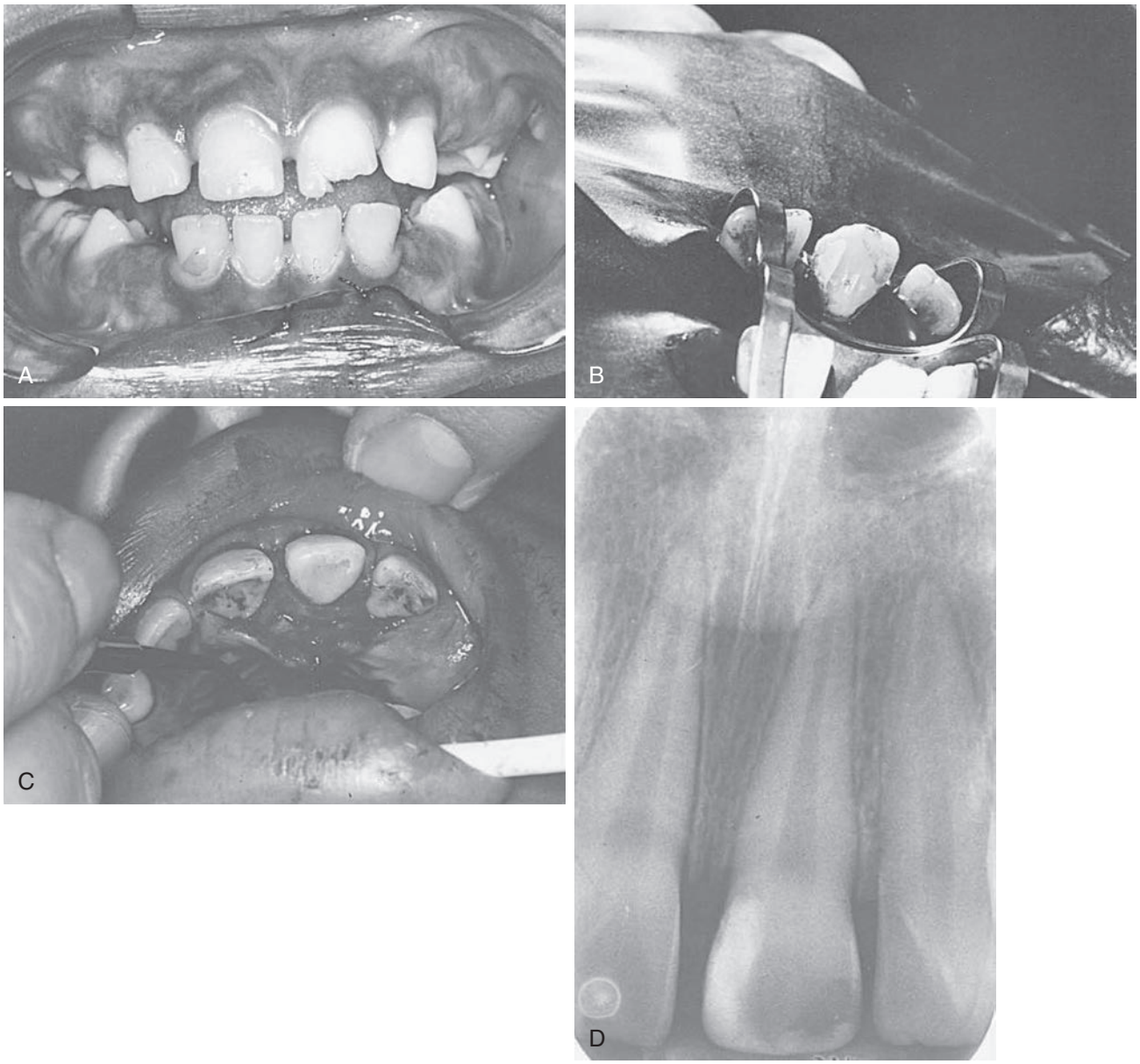

• **Figure 6-10** **A,** A fracture of the maxillary left permanent central incisor. **B,** Isolation of the tooth after flap surgery was done to see the extent of the fracture. **C,** The fracture restored with an acid-etch resin system. **D,** A periapical radiograph 1 year following treatment. (From Abubaker AO, Papadopoulos H, Giglio JA: Diagnosis and management of dentoalveolar injuries. In Fonseca R, Marciani RD, Turvey TA, editors: *Oral and maxillofacial surgery*, ed 2, St Louis, 2009, Saunders.)

to the gingival crevice—splinting and follow-up has helped the fractures heal with formation of hard tissues.[46] If pulp in the coronal segment undergoes necrosis, then orthodontic treatment of a cervical-third root fracture with removal of the coronal segment is considered.[47]

Root fractures can heal by four different modalities: (1) calcified tissue, (2) connective tissue, (3) bone and connective tissue, and (4) granulation tissue.[45] Healing by calcified tissue is usually seen in teeth with immature roots or in teeth with little or no fragment separation.[46] Radiographically, the segments are not rounded at the edges. In connective tissue healing, radiographically the segment edges are rounded, with partial or complete pulpal obliteration.[45] In healing with bone and connective tissue, each segment has its own periodontal ligament, and total calcific metamorphosis of both segments is a usual occurrence. In healing with granulation tissue, the teeth are usually loose, slightly extruded, and sensitive to percussion. The pulp in the coronal segment usually undergoes necrosis, whereas in the apical segment it is vital.

Monitoring is recommended for at least 1 year prior to determining the final pupal status in absence of other signs and symptoms.[40] Root canal therapy is withheld for apical and middle-third root fractures, until there is evidence of pulpal necrosis. Pulpal necrosis is usually seen only in the coronal segment. Increased separations of the segments with an adjacent radiolucency and tenderness to percussion are indications of pulpal necrosis. Endodontic treatment for root fractures consists of (1) pulpectomy of the coronal segment only, (2) pulpectomy of both segments, or (3) pulpectomy of the coronal segment with surgical removal of the apical segment.[48]

Treatment of Injuries to the Periodontal Tissues

Concussion

A concussed tooth is one that has received a traumatic insult but exhibits no evidence of mobility, displacement, or fracture. The tooth may be sensitive to percussion and/or exhibit symptoms of hyperemia. No treatment is recommended other than palliative therapy. If there are excessive masticatory forces on the injured tooth, taking the tooth out of function by relieving the occlusion may help. Concussed teeth may later develop a reaction to the trauma. The patient must be advised that additional treatment may be required and that the prognosis is guarded; however, the incidence of pulpal necrosis is low.[40,49]

Displacements

Displacements are classified as subluxation (loosening injury), luxation (labial, lingual, or lateral), intrusions, and extrusions (partial avulsions).

Subluxation

The tooth demonstrates tenderness to palpation with slight mobility but without evidence of displacement clinically and radiographically. No active treatment is usually necessary, but a flexible splint can be placed for up to 2 weeks for patient comfort. Patients have masticatory discomfort, which can be managed with a soft non-chew diet and relieving the occlusion. Continued observation of the tooth radiographically and by vitality testing during the follow-up period is essential. False-negative vitality tests are possible for up to 3 months, after which root canal therapy is usually necessary. This type of displacement injury has the best chance of the tooth remaining vital since the apical vessels are not displaced.

Extrusive Luxation

In extrusion injuries, the tooth is partially displaced from the socket, resulting in excessive mobility. Radiographic examination shows increased periodontal ligament space in the apical region. It should be repositioned in its original position using digital pressure and splinted with a flexible splint for 2 weeks. Continued clinical and radiographic observation is essential to identify pulpal necrosis and perform endodontic treatment. False-negative vitality tests are possible for up to 3 months.

Lateral Luxation

Lateral luxation is a complex injury that includes rupture or compression of the periodontal ligament (PDL), severance of the neurovascular bundle, and fracture of the alveolar walls around the tooth.[50] This causes lingual (most common), buccal, mesial, or distal displacement of the crown of the tooth. Such displacement is often painful, associated with large gingival laceration, and places the tooth in a "locked" position. The initial treatment of lateral luxation of the tooth is aimed at relieving the pain associated with this injury by repositioning and stabilizing the displaced tooth. This can usually be done by digitally manipulating the tooth to release the displaced root apex and repositioning the tooth into the proper alignment along with a flexible splint placement for 4 weeks. Repositioning of the tooth may require pressure application in the incisal direction to release the lock and return the root apex to its original location. These displacements should be followed closely to determine vitality. Such teeth may not respond normally to electric pulp testing for about 3 months. Follow-up examinations are therefore necessary, and depending on the stage of root development at the time of injury, endodontic therapy may be needed.

Intrusive Luxation

This results from apical displacement of the tooth into the alveolar bone. Intruded teeth are immobile with an ankylotic sound on percussion with minimal sensitivity. Stage of root development is a critical factor in treatment planning. In intruded permanent teeth with incomplete root development, spontaneous re-eruption is the first line of treatment (Figure 6-11). If there are no signs of re-eruption after a

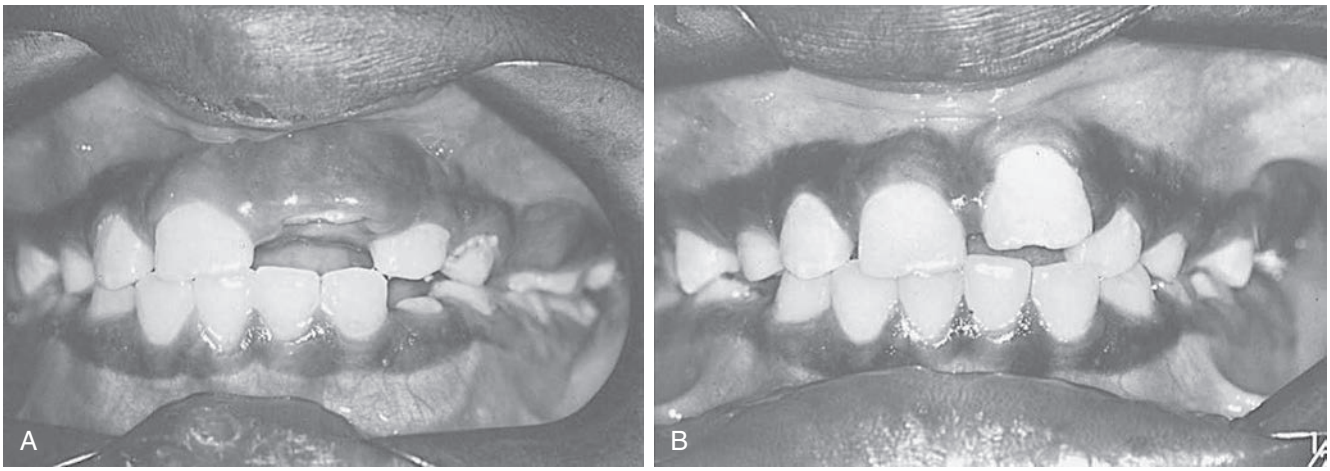

• **Figure 6-11 A,** Intrusion of a maxillary left permanent central incisor with an immature apex. **B,** Six months later the tooth has partially re-erupted. (From Abubaker AO, Papadopoulos H, Giglio JA: Diagnosis and management of dentoalveolar injuries. In Fonseca R, Marciani RD, Turvey TA, editors: *Oral and maxillofacial surgery*, ed 2, St Louis, 2009, Saunders.)

month, orthodontic repositioning may be required. If the intrusion is greater than 7 mm to begin with, orthodontic or surgical repositioning or a combination should be performed. Repositioning is followed by flexible splinting for 4 to 8 weeks. Orthodontic repositioning has been shown to have better marginal bone levels compared to surgical repositioning. Root canal therapy for re-erupted intruded teeth with an immature apex should only be done if signs of pulpal necrosis develop. Time is allowed for apexification prior to definitive endodontic treatment. In general, intruded teeth with immature root formation have a better prognosis with regard to pulpal necrosis.[51]

If the tooth has completed root development, allow spontaneous eruption only if displacement is less than 3 mm.[40] If there is no sign of spontaneous eruption in 2 to 4 weeks, orthodontic extrusion is recommended. In cases of severe displacement (>7 mm), surgical repositioning to its original position either by finger pressure or with forceps is performed, followed by flexible splint for 4 to 8 weeks. The incidence of pulpal necrosis in this type of injury in general is 88%; therefore endodontic therapy is initiated 10 to 14 days after the injury.[51] Inflammatory and/or replacement resorption can occur in approximately 48% of these teeth. The depth of intrusion has been found to be a factor in the development of root resorption, with intrusions of 1 to 3 mm having the lowest frequency.[51] For intruded teeth with completed root development, there is high likelihood of pulp necrosis. Calcium hydroxide can be placed as a temporary filling, followed by definitive endodontic treatment within 2 to 3 weeks.[40]

Exarticulation (Complete Avulsion)

Avulsion involves complete displacement of the tooth out of its socket. It may occur by itself or in conjunction with alveolar fractures and/or gingival lacerations. Children between 7 and 9 years of age are more often subject to avulsion because of the unsettled condition of the periodontal ligament and low mineralization of the alveolar bone caused by continued eruption of the teeth. Usually avulsion involves a single tooth, and the most frequently avulsed tooth is the maxillary central incisor. The chances of survival of the pulp and periodontal cells in a replanted tooth are highly dependent on the extra-alveolar time and handling of the avulsed tooth, which affect the pulp and periodontal reactions.[53] Treatment must be aimed at maintaining cellular viability, which can increase the chances of successful reattachment and decrease the chances of root resorption. The tooth's pH, osmolality, and cell metabolites can be physiologically maintained by various storage media. The periodontal ligament is usually restored in 3 to 4 weeks after a prompt replantation. After an extraoral dry time longer than 60 minutes, the periodontal ligament cells become nonviable.[54] The viability of the PDL can be assessed based on the extraoral dry time, storage media, and time of replantation. The treatment plan for avulsed teeth relies on maturity of the root apex and condition of the PDL cells.

Teeth that are nonrestorable because of extensive caries or severe periodontal disease should not be replanted, except for the temporary purpose of maintaining alveolus or esthetics until a definitive replacement is planned. In teeth with a closed apex and pulp that have been replanted prior to arrival or have a extraoral dry time of less than 60 minutes and have been stored in an appropriate storage medium, replantation should be performed, with a flexible splint for up to 2 weeks. Endodontic treatment should be performed on these teeth within the first 7 to 10 days before splint removal.[54] In teeth with a closed apex that have had more than 60 minutes of extraoral dry time, the PDL is likely nonviable. Splinting can still be performed, but the patient should be informed of the poor prognosis and increased probability of eventual loss of the tooth, likely due to replacement resorption. Flexible splinting is recommended for 4 weeks. Endodontic treatment on these teeth can be

performed either prior to replantation or within 7 to 10 days after replantation. In children and adolescents, ankylosed teeth with infra-positioning can be managed with decoronation. Patients and parents should be informed about the possibility of ankylosis and indications for decoronation.

In avulsed permanent teeth with open apex that were replanted before the patient's arrival or have an extraoral dry time of less than 60 minutes, the goal of replantation is possible revascularization of the pulp. On the other hand, if the extraoral dry time was greater than 60 minutes, the long-term prognosis is poor and hence the goal is restoring the tooth for esthetic/psychosocial/functional purpose. The ultimate outcome in these teeth is ankylosis or resorption. The time period of flexible splinting is similar to that for teeth with a closed apex: 2 weeks for early replantation and 4 weeks for delayed replantation.

The overall prognosis for replanted permanent teeth in terms of continued pulp vitality is very poor. However, replanted teeth are useful during the mixed dentition stage in children even if the long-term prognosis is poor, because alveolar bone support is maintained during maxillary growth. These replanted teeth also serve as a good esthetic space maintainer, even if it is for only a few years. The central incisor also provides guidance for the eruption of the lateral incisor into its position in the arch (Figure 6-12), as would the lateral incisor for the canine.

In general, the avulsed tooth should be gently rinsed under tap water before replantation; it should not be

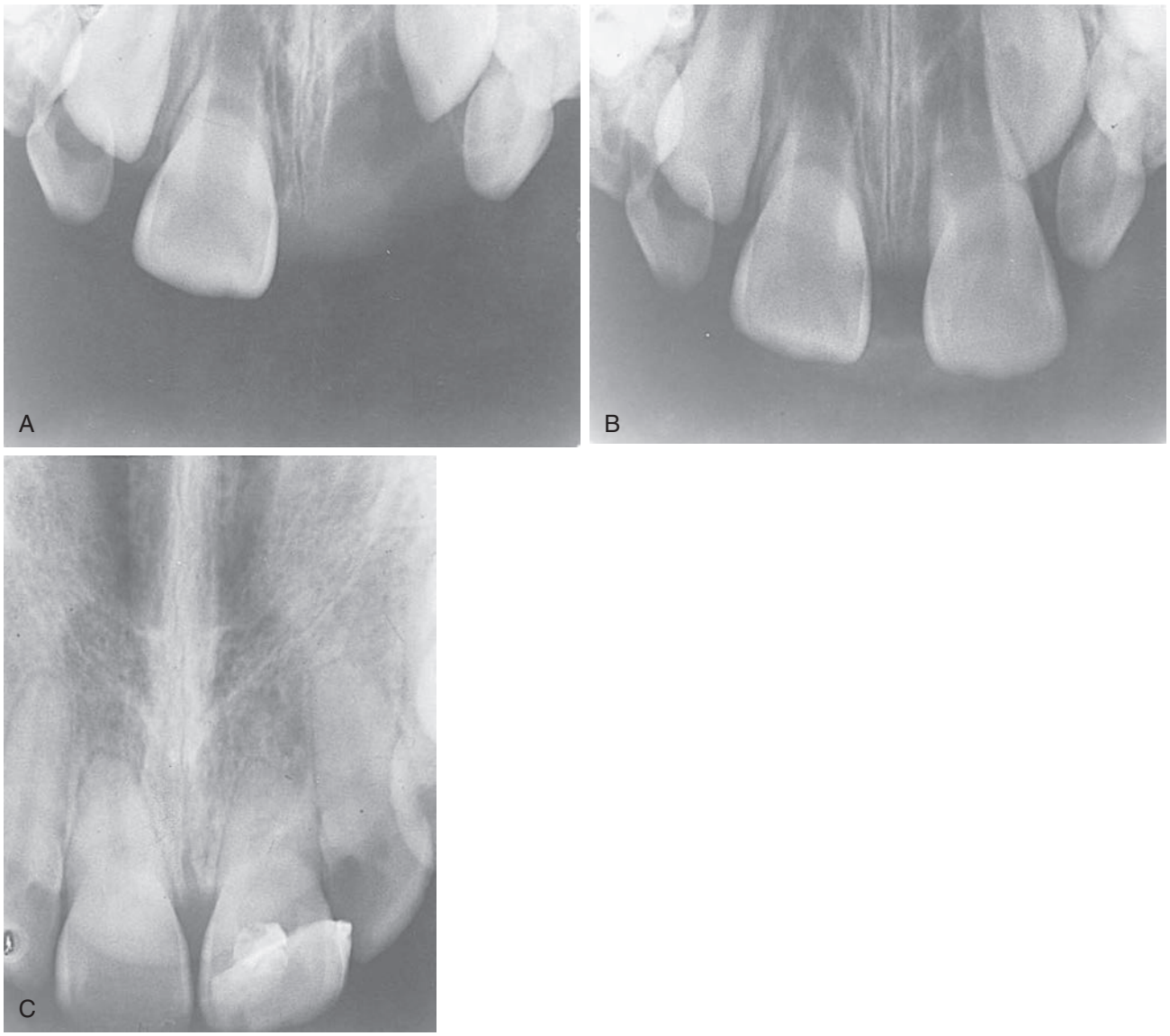

• **Figure 6-12** **A,** An occlusal radiograph of an avulsed immature maxillary left permanent central incisor prior to the eruption of the permanent lateral incisor. **B,** The tooth was replanted within 1 hour. The tooth has had the calcium hydroxide paste replaced every year. Seven years later the replanted tooth has served as guidance for the lateral incisor **(C).** (From Abubaker AO, Papadopoulos H, Giglio JA: Diagnosis and management of dentoalveolar injuries. In Fonseca R, Marciani RD, Turvey TA, editors: *Oral and maxillofacial surgery*, ed 2, St Louis, 2009, Saunders.)

scrubbed. If the tooth is maintained by soft tissue attachment, this attachment should not be removed. The objective is to maintain vital periodontal tissue and cementum. The tooth should be held in place either by finger pressure or by gently biting down on a handkerchief or washcloth until the patient is brought to the office or emergency room. If replantation is not possible, the tooth should be placed in the best transport medium available. The transport medium of choice is Hanks balanced salt solution (HBSS) or Viaspan.[55-57] Viaspan is used for transport organ storage. It has a pH of 7.4 with an osmolality of 320 mOsm, and vital cells were present at 7 days.[57] Hanks solution has a pH of 7.2 with an osmolality of 320 mOsm. Hanks can successfully preserve and reconstitute the periodontal ligament cells for at least 24 hours. Depleted cell metabolites can be replenished in Hanks solution.[58] Hanks solution is commercially available as Save-A-Tooth (3M Health Care) (Figure 6-13).

Milk, saliva, and saline are temporary storage media more readily available to the public; however, their effectiveness is very limited. Milk is a short-term storage medium (up to 6 hours) provided avulsed teeth are placed in it within 15 to 20 minutes. Milk only prevents cell death; it does not restore the cell's normal morphology and ability to differentiate and undergo mitosis. Milk has no ability to maintain viability after the cells have been dry stored for more than 20 minutes. Milk is a significantly better medium than saliva or water for preserving periodontal fibroblast viability and proliferative ability. If the tooth cannot be replanted immediately, it should be stored in milk if Hanks solution is not available. Storage of avulsed teeth in water or saliva should be avoided since they can damage the periodontal ligament cells and cause increased root resorption. Once teeth have been placed in Hanks solution, time is no longer as critical a factor.

Once the patient reaches the treatment facility, the tooth should be rinsed with saline. Any remaining periodontal ligament should not be removed. The alveolar socket should be debrided by saline irrigation without curettage. The blood clot should not be removed, because it will not interfere with positioning of the tooth or pulpal and periodontal healing. The tooth should be replanted and splinted as soon as possible. Manually compress the facial and lingual bony plate if spread apart. A radiograph should be taken to verify proper positioning of the replanted tooth. The need for tetanus prophylaxis should be evaluated. The value of antibiotic coverage for replanted teeth has not been clearly established by clinical studies, although experimental studies favor topical antibiotics. A 7- to 10-day course of amoxicillin is usually prescribed to prevent secondary infection from occurring and to promote wound healing.[53] The tooth should be taken out of occlusion, and the patient should not chew on it for the first month. When relieving the occlusion, reduction on the opposing teeth is preferable to avoid further pulpal injury. The patient should be instructed on gentle but thorough tooth brushing to prevent inflammation in the gingival crevice. Chlorhexidine rinses should be prescribed for gingival health, and analgesics for pain.



• **Figure 6-13** Save-A-Tooth containing Hanks balanced salt solution and a basket for placing the avulsed tooth.

Teeth with immature apices have a better prognosis than do teeth with mature apices. Immature teeth soaked in a doxycycline solution have a higher rate of pulpal revascularization than those not treated.[59] Tetracycline, in animal studies, has been also been shown to have antiresorptive properties.[60,61] If pathology is noted, thoroughly clean and fill the canal with calcium hydroxide (apexification procedure).

In 7 to 10 days the pulp should be removed and the canal filled with calcium hydroxide. The tooth can be obturated with gutta percha after 6 to 12 months of calcium hydroxide, provided there is no pathology present.

In teeth with an open or closed apex that have been extraoral for more than 60 minutes, endodontic treatment can be carried out prior to replantation or after. These teeth could be soaked in a 1% stannous fluoride solution for 5 minutes and in a 1 mg/20 mL doxycycline solution for 5 minutes. The antibiotic kills the bacteria that might remain on the root surface and has been shown in animal studies to synergize with the stannous fluoride to make the tooth more resistant to resorption.[62,63]

The two major reasons for failure of replanted teeth are inflammatory and replacement resorption (ankylosis). Inflammatory resorption is due to necrotic pulp, and replacement resorption is due to damage to the periodontal ligament. Andreasen and colleagues showed in a study on 400 replanted teeth that normal periodontal healing occurred in 24%, surface resorption in 5%, inflammatory resorption in 30%, and replacement resorption in 64% of cases.[64] Radiographically, the first signs of pulpal necrosis may be seen in 2 to 3 weeks, and inflammatory resorption could take 3 to 6 weeks up to 6 months. Inhibition of inflammatory resorption involves removal of necrotic tissue and filling the root canal with calcium hydroxide. Replacement resorption or ankylosis can be diagnosed clinically by percussion and immobility in 4-8 weeks, but radiographic evidence could take up to a year.[67] The extent of the injury, concomitant alveolar fractures, and age of the patient can affect the rate of progression of replacement resorption.[65,67] In younger patients, ankylosis alters the normal alveolar growth, resulting in infraocclusion of the replanted tooth.

There is no treatment for ankylosis as such, but to avoid extensive loss of alveolar bone from extraction of these teeth in younger children, decoronation, involving removal of the crown and the root canal filling so as to allow replacement of the remaining root with bone, has been the procedure of choice. This allows continued growth of alveolar bone coronal to the resorbing root.[68]

Radiographs should be taken in 2 weeks, 1, 2, 3, and 6 months, and then semiannually thereafter. The practitioner should also evaluate the unaffected adjacent teeth in displacement and avulsion injuries. Usually 50% of the supposedly unaffected adjacent teeth will undergo pulpal necrosis within 2 years from the time of injury. Finally, crown discoloration is common in replanted avulsed teeth.[69] This discoloration may later be treated by internal bleaching, veneers, or crowns.

Calcium Hydroxide Root Canal Fill

Inflammatory resorption usually occurs in teeth that have undergone severe displacement or avulsion. It appears to be related to pulpal necrosis. Removal of the necrotic pulp and the placement of calcium hydroxide in the canal appear to inhibit inflammatory resorption.[70-72] Calcium hydroxide should be used in avulsion and intrusion injuries and any luxation injury in which the tooth is displaced more than 3 to 5.0 mm. The procedure involves removal of the pulp and instrumenting the root canal thoroughly during the first or second week after the injury.[73] The canal should be filled with USP calcium hydroxide powder or Pulpdent (calcium hydroxide in aqueous methyl cellulose from Pulpdent Corp., Watertown, MA) (Figure 6-14). Filling the canal with calcium hydroxide at 1 to 2 weeks will allow initial repair of the periodontal ligament.[74] The powder may be inserted dry or made into a paste with either a local anesthetic solution, water, saline, camphorated monochlorophenol (CMCP). Because calcium hydroxide is a resorbable material, the canal should be recleansed and repacked with calcium hydroxide at 3-month intervals for a minimum of 1 year. There is no need to change the calcium hydroxide if it appears to occupy the root canal space adequately at the 3-month evaluation. If resorption is arrested or nonexistent, a gutta percha root canal can be done at the end of the year.

Treatment of Injuries to the Primary Teeth

Injuries involving primary dentition and injuries to children in general deserve special consideration. Difficulties with patient management due to lack of cooperation, as well as concern regarding underlying permanent dentition and the consequences, are some major factors affecting management. The treatment plan should aim at preventing or minimizing the injury to permanent dentition. Displacement injuries rather than fractures are more frequent in the primary dentition, in part because of the anatomic differences between a child and adult jaw in terms of bone mineralization and density. Most traumatic injuries to the primary teeth occur when the child is learning to walk, at 18 to 30 months old.[19,21,75]

Fractures of Primary Teeth

Fractures of primary teeth are less common than in the permanent dentition. Treatment of fractured primary teeth presents difficulties because of the small size of the tooth and the relatively large pulp chamber. In fractures involving enamel only, the sharp edges should be smoothed and the tooth observed. The same treatment can be provided for enamel and dentin (Class II) fracture. In severe or large fractures, calcium hydroxide/MTA and/or a light-cure glass ionomer liner/base (e.g., Vitrebond, 3M Dental Products) should be placed over the dentin followed by an acid-etch resin restoration[75,76] (see Figure 6-12). In primary teeth with fractures involving the pulp,

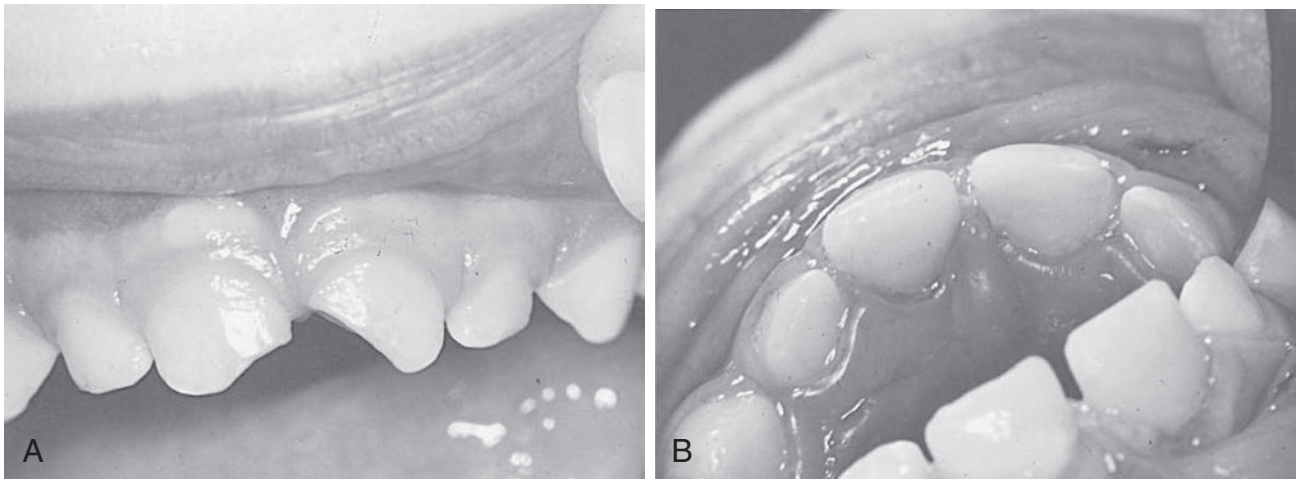

• **Figure 6-14** **A,** Mesioangular fractures of the maxillary primary central incisors. B, Acid-etch restorations placed using celluloid crown form. (From Abubaker AO, Papadopoulos H, Giglio JA: Diagnosis and management of dentoalveolar injuries. In Fonseca R, Marciani RD, Turvey TA, editors: *Oral and maxillofacial surgery*, ed 2, St Louis, 2009, Saunders.)

a calcium hydroxide partial pulpotomy should be performed, followed by a full-coverage restoration. Extraction of the involved tooth is the alternative option. Full coverage of all teeth that have pulpotomies or pulpectomies is necessary because the crown of the tooth is weak, usually unsupported, and is liable to fracture below the gingival attachment or crest of the alveolus.[75]

Root fractures are extremely rare. The most common root fracture occurs in the middle third of primary teeth (Figure 6-15). If the fracture is present in the apical third and the coronal segment exhibits no mobility, the tooth should be observed. If the fracture of the root occurs in the middle or cervical third, the coronal segment may be mobile and should be removed while the apical segment is left to resorb. The apical fragment should not be removed if injury to the developing permanent tooth is a possibility.[75]

If fistula, redness, or swelling appears, the tooth should be treated with pulpectomy or be removed. Teeth with zinc oxide and eugenol pulpectomies may not resorb normally and can cause displacement of underlying permanent teeth.[77] Pulpectomies should not be attempted on primary teeth with external resorption.

Displacements of Primary Teeth

Displacement injuries are more common in the primary dentition than in the permanent dentition. Primary teeth that have been subluxated do not need any acute treatment. They should be observed and the patient instructed about soft diet and oral hygiene measures. Treatment of displaced primary teeth depends on maturity of root formation, severity of displacement, and proximity or potential for injury to the permanent tooth bud. Laterally luxated teeth with the root apex displaced moderately in a labial direction with severe occlusal interference should be repositioned with digital pressure. Usually the tooth will snap back into position, and splinting may not be necessary. But depending on the patient's cooperation, a short period of splinting can be performed. Physiologic forces can be relied on to reposition the displaced tooth when the displacement is minimal and when there is no occlusal interference, as in the case of an anterior open bite. If the root apex is displaced into the permanent tooth, bud extraction is recommended. If a primary tooth is extruded, spontaneous realignment can happen in minimal extrusions (<3 mm) with immature root development. A tooth with a fully formed root with severe extrusion should be extracted.[75]

When a primary tooth is intruded, the practitioner should observe the tooth for re-eruption if the apex is displaced in a labial direction; otherwise, the tooth should be extracted (Figure 6-16). If the primary tooth has not started re-erupting within 4 to 8 weeks, it should be extracted. If acute inflammation and swelling, or inflammation of the gingiva and/or purulence from the gingival crevice, develop during the re-eruption phase, the tooth should be extracted. In primary teeth with alveolar fractures, the segment is repositioned and stabilized using a flexible splint for 4 weeks.

Replantation of primary teeth is not recommended. More importantly, the replacement of an avulsed primary tooth is contraindicated because of the increased probability of ankylosis, internal or external resorption, abscess formation, and alteration of the sequence or direction of eruption of the permanent tooth.

Premature loss of a primary incisor before the eruption of the primary canines usually results in arch perimeter loss. Primary incisors lost after the eruption of the primary canines usually result in space loss in crowded or nonspaced arches but not usually in spaced arches. However, adjacent teeth in the anterior segment can drift, which could cause an esthetic problem.

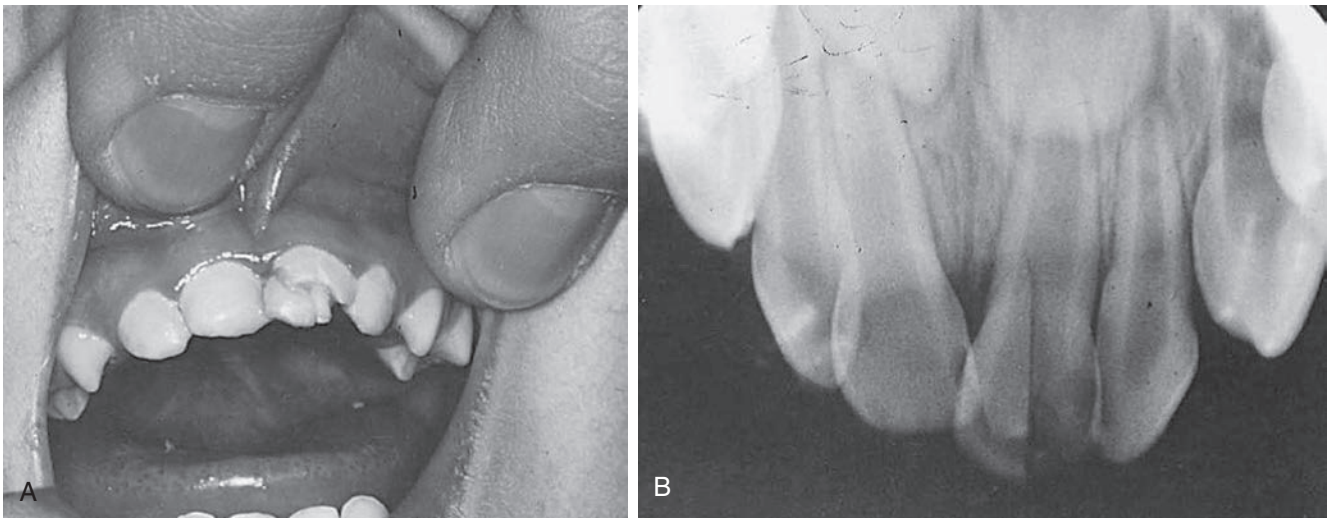

• **Figure 6-15** **A,** A vertical fracture of a maxillary left primary central incisor. **B,** An occlusal radiograph showing that the vertical fracture extends to the middle of the tooth. The tooth was later extracted. (From Abubaker AO, Papadopoulos H, Giglio JA: Diagnosis and management of dentoalveolar injuries. In Fonseca R, Marciani RD, Turvey TA, editors: *Oral and maxillofacial surgery*, ed 2, St Louis, 2009, Saunders.)

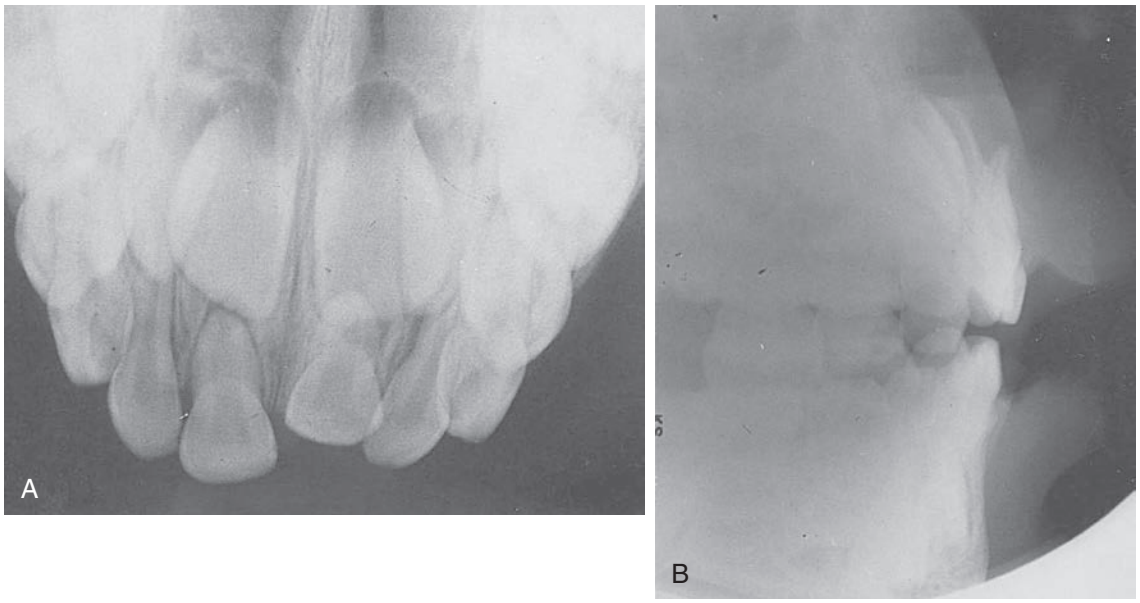

• **Figure 6-16** **A,** An occlusal radiograph showing an intruded maxillary primary central incisor. **B,** A lateral radiographic view showing the tooth displaced in a vestibular direction. (From Abubaker AO, Papadopoulos H, Giglio JA: Diagnosis and management of dentoalveolar injuries. In Fonseca R, Marciani RD, Turvey TA, editors: *Oral and maxillofacial surgery*, ed 2, St Louis, 2009, Saunders.)

Premature loss of primary incisors will not cause a delay or disruption in speech.[79-81] Parents are usually more concerned with the esthetics of the child. If the child had normal speech prior to the premature loss of the incisors, adaptation to the new environment should occur. In some cases, there may be some lisping until the eruption of the permanent incisors. Replacing the teeth with a prosthetic appliance, though not necessary for speech, will create a more normal oral environment that will foster the maintenance of previously normal speech.

A primary incisor removed before the age of 3 generally causes a delay in the eruption of the permanent successor; a primary incisor removed 1 to 2 years before its normal exfoliation time generally causes an acceleration in the eruption of the permanent successor. The eruption of the permanent successor often occurs in a more facial direction.[82]

Treatment of Injuries (Fractures) to the Supporting Bone

Fractures of the supporting bone can be divided into four types.[83]

Comminution of the Alveolar Socket

This type of fracture is usually associated with dental injuries such as lateral or intrusive displacement of teeth. Digital manipulation and repositioning of the displaced tooth is often adequate to reduce these fractures. Monitoring the pulpal status of the tooth and evidence of root resorption and ankylosis by routine follow-up is recommended.

Fractures of the Socket Wall

Fractures of the socket wall are often associated with dislocation of teeth with mobility of the buccal osseous plate and mucosal contusion. Reduction of these fractures after administration of local anesthesia can be achieved using simultaneous digital pressure over the apical area and at the lingual aspect of the crown. In case of comminuted fractures, loose fragments not attached to the periosteum should be removed and attempts to preserve the tooth should be made. After completion of the reduction, any mucosal laceration should be sutured, the involved teeth should be relieved from forces of traumatic occlusion, and the segment should be splinted for 4 weeks to allow for osseous healing. Because bone healing occurs relatively quickly in children, fixation often is unnecessary in this age group for primary dentition. The child should, however, be maintained on soft diet for 2 weeks and followed periodically to monitor pulp and tooth healing.

Fractures of the Alveolar Process

Alveolar process fractures may be isolated or may be seen in conjunction with other dental or facial injuries and with varying degrees of mucosal or gingival laceration. In most instances the fractured bony segment contains one or several teeth. These fractures occur most often in the anterior or premolar regions of children of oldest age group and adults.

The successful treatment of alveolar fractures is based on proper reduction and repositioning of the fractured segment using closed or open techniques followed by adequate stabilization to allow for osseous healing.[40] Closed reduction of dentoalveolar fractures may be accomplished with digital



• **Figure 6-17** **A,** Displaced dentoalveolar segment involving the maxillary anterior teeth. **B,** Closed reduction of dentoalveolar fractures using digital pressure on the alveolus and dental segment along with placement of a splint for stabilization.

pressure on the alveolus and dental segments (Figure 6-17). The segments then should be stabilized in place using either rigid splinting of the involved teeth or other forms of splinting techniques for 4 weeks. In children this period can be reduced to 3 weeks because of rapid healing.

Although alveolar fractures can usually be reduced and stabilized in proper position using closed methods, occasionally, to reduce the segment properly and achieve adequate stabilization, it is necessary to resort to open surgical techniques. Once the fracture is reduced, it can be stabilized or fixed in a variety of ways. In most instances, one arch fixation is adequate to provide stable fixation of simple alveolar fractures. However, a splint of bonded brackets or composite resin that fixes a wire to the teeth on either side of the fracture is superior to other forms of fixation with regard to hygiene and periodontal effects—although it may be impossible in instances where a procedure needs to be done in an emergency room or at bedside, without the necessary armamentarium, facilities, or cooperation to cleanse, dry, acid-etch, and bond brackets to composite resin. In these instances, an arch bar or a Risdon or Essig wire, either alone or supplemented with autopolymerizing acrylic resin, may be the best method of fixation. If necessary, this fixation may be changed to a more optimal splint at a later date.

Processed or autopolymerizing acrylic resin splints on the palatal, lingual, or occlusal coverage are also effective methods of fixation. However, they require impressions and models to construct and thus introduce a delay in the treatment. Fixation should be maintained for 4 to 6 weeks. Patients should maintain a soft diet. Open reduction is occasionally required, especially when the alveolar segment is significantly displaced or the roots of teeth or the bone in the segment interferes with proper repositioning of the segment. A vestibular incision is made apical to the fracture line and the segment pried into position using a sharp instrument such as periosteal elevator. Occasionally, an irregular area of spongy bone may inhibit the reduction. Proper alignment of the alveolus may require removal or contouring of the obstructing segment. Once the segment is satisfactorily repositioned and the proper occlusion is verified, the segment is fixed in place using transosseous wire or a small bone plate (Figure 6-18). Condemned teeth in an alveolar fracture segment should only be considered for extraction in the acute phase if they are poorly supported or infected. In general such extractions should be delayed until bone healing is complete to prevent inadvertent removal of the entire alveolar segment with the teeth during the extraction. Antibiotic coverage with penicillin, erythromycin, or clindamycin and the use of chlorhexidine oral rinse are recommended, especially in delayed treatment and extensive associated soft tissue lacerations. Tetanus booster is usually only indicated in wounds with dirt and road debris contamination. Careful follow-up of the involved teeth should be done to monitor the vitality of the tooth.

When an alveolar fracture occurs in conjunction with a jaw fracture, the treatment should be accomplished as soon as the patient's condition is stable. Generally, reduction of the fractures and maxillomandibular fixation with appropriate wiring techniques (arch bars, Risdon wiring, etc.) are required. This should be done as soon as possible to improve the prognosis of the dental and alveolar components. Additional maneuvers, such as open reduction of the jaw fractures, may be done later, if necessary.

Avulsed injuries of the alveolus are occasionally seen in conjunction with major facial injuries. The treatment is often dependent on the anatomic location of the avulsion and its relationship to other injuries, particularly fractures. In these instances, advancement of mucosal flaps is often used to cover exposed bone, particularly areas where there are fractures. Avulsions that result in nasal or maxillary sinus openings should be closed, if flaps can be advanced, so as not to compromise treatment of other injuries or preclude a more predictable closure by conventional means at a later date. The

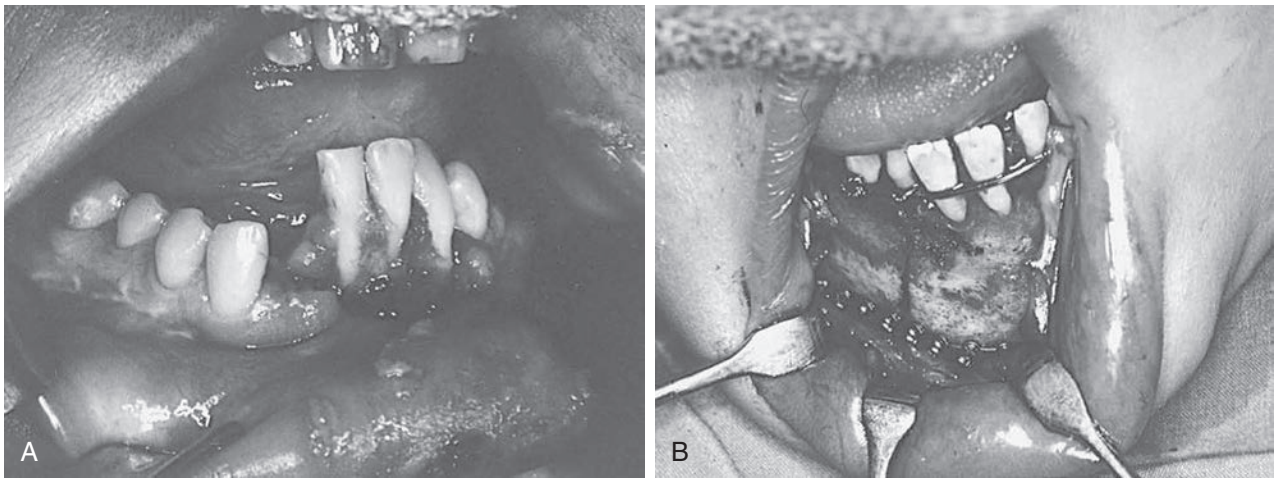

• **Figure 6-18** **A,** Open reduction of a displaced mandibular dentoalveolar fracture. **B,** A mucoperiosteal flap was elevated, the segment was satisfactorily reduced, the proper occlusion was verified, and the segment was fixed in place using arch wire and a small bone plate.

patient should be informed of the prognosis, especially as it applies to insurance coverage and possible litigation.

Splinting Techniques

Splinting is a form of fixation to stabilize the injured teeth in its normal anatomic position during the healing period. Importance of allowing physiologic mobility during this period of healing to avoid damage to the periodontal and pulpal healing is well known.[84-86] Requirements of an ideal splint would include:

1. Splint fabrication materials easily available in a dental office or emergency room,
2. Avoids or minimizes further trauma to the injured tooth or supporting structures,
3. Facilitates oral hygiene maintenance, avoids soft tissue irritation,
4. Stays passive and remains in its normal position throughout the immobilization period,
5. Allows physiologic movement of the tooth,
6. Does not interfere with the occlusion,
7. Allows easy access for endodontic treatment and pulp testing, and
8. Is easily removed in the dental office.

The splints that come closest to fulfilling these requirements are the acid-etch resin arch wire splint (Figure 6-19, *A*) and the orthodontic bracket arch wire splint (see Figure 6-17, *B*). These, of course, are difficult to apply when blood and saliva cannot be isolated from the field, such as in an emergency room.

A rigid splint increases the amount of external resorption and eventual early loss of the tooth.[87] For this reason, arch bars and other forms of interdental wiring are less than optimal. These types of splints also can cause orthodontic movement of the teeth, such as extrusion.

A splint should be left on for a minimal amount of time. Prolonged splinting will increase the risk of ankylosis. The optimal splinting period for a displaced or avulsed tooth is based on the type of dentoalveolar injury. Ideally, the splint should be maintained for 7 to 10 days because the gingival fibers are usually healed in 1 week, and this should provide adequate periodontal support. Alveolar bone fractures with replanted teeth may require a splint for 3 to 4 weeks, luxation may require a splint for 2 to 4 weeks, and root fractures require a splint for up to 12 weeks.

An acid-etch resin-only splint is easy to fabricate, but does not allow the teeth much mobility and is also fragile, resulting in fracture of the material. Newer multiphase resin materials (Protemp, Luxatemp) have been reported to provide semirigid splinting and retain the ease of application, oral hygiene, and patient acceptability. These do require the teeth to have fully erupted crowns with proper interproximal contact; otherwise the use of wire or fiber lines is unavoidable. A better splint is an acid-etch resin arch wire splint (see Figure 6-19, *A*).[86-88] This allows the tooth some mobility. Fiberglass instead of wires has been used in many cases, but the flexibility varies depending on the extension of the splint.[89] The wire is bent to conform to the facial surfaces of the teeth to be splinted. At least one tooth on either side of the displaced tooth or teeth must be included. The facial surfaces of all the teeth to be splinted are etched with phosphoric acid for 1 minute, after which they are washed and dried. The bonding agent is applied and a small amount of resin is placed in the middle of the facial surface over a small area. The arch wire is then passively placed in the resin. The resin material should not contact the gingiva because it will cause gingival inflammation. The practitioner must be sure that the displaced tooth is in its correct position. A radiograph should be taken to verify this after the splint is in place. The patient should be instructed in proper oral hygiene, stressing the importance of keeping the gingival crevice as well as the rest of the teeth clean.



• **Figure 6-19** **A,** An acid-etch resin arch wire splint. **B,** Luxation of maxillary permanent central incisors treated with an orthodontic bracket arch wire splint using ligature wires. **C,** Luxation of the maxillary permanent four incisors treated with an orthodontic bracket arch wire splint using AlastiK ligatures (3M) with banding of the permanent first molars for stabilization. (From Abubaker AO, Papadopoulos H, Giglio JA: Diagnosis and management of dentoalveolar injuries. In Fonseca R, Marciani RD, Turvey TA, editors: *Oral and maxillofacial surgery*, ed 2, St Louis, 2009, Saunders.)

When removing the splint, the wire can be cut between each tooth. The resin should not be removed because the replanted teeth are still loose and can be displaced. After the teeth are firmly attached in 2 to 3 months, the resin can be removed.

The orthodontic bracket arch wire splint is an excellent technique.[90,91] Acid-etch brackets are placed on the displaced tooth or teeth as well as on at least one sound tooth on either side of the displaced tooth. Sometimes it is necessary to extend this type of splint by banding the permanent first molars (see Figure 6-19, *C*). This can occur in the mixed dentition when permanent lateral incisors, canines, and/or premolars are absent or there is a deep overbite and additional teeth are necessary for stabilization. The arch wire can be either round or rectangular and is bent to conform to the facial surface of the teeth to be splinted. AlastiK (3M

Dental Products) ligatures are used to hold the arch wire to the brackets. The advantages of this splint over the acid-etch resin arch wire splint are that the practitioner can remove the elastic ligatures and the wire to check mobility of the displaced teeth. If there is excessive mobility, the splint can be replaced. New prefabricated splinting materials, such as the titanium trauma splint (TTS) with a rhomboid flat design, are being used because of ease of adaptability to the tooth (0.2-mm thickness) and increased patient comfort[92,93] (Figure 6-20).

It should be noted that a fairly high percentage of teeth involved in alveolar process fractures undergo pulpal necrosis and either internal or external resorption. This may occur even years later. The teeth must be carefully observed and endodontic intervention initiated at the appropriate time.

Treatment of Gingival and Mucosal Injuries

Injuries to the Gingiva and Mucosa

Intraoral soft tissue injuries to the gingiva and mucosa occur in the form of contusions, abrasions, lacerations, and avulsions. They are seen either alone or in conjunction with injuries to the teeth, facial bones, or alveolus.[94] Management in many instances depends on the presence or absence of injuries to these underlying structures as well as on periodontal considerations.

Contusions of the gingiva seldom require any active treatment other than appropriate oral hygiene to allow healing. These contusions are helpful in indicating possible underlying fractures of the bone and a need for further radiographic evaluation.[95] Underlying ecchymosis and/or hematoma will resolve with time without residual deformity.

Abrasions and lacerations of the oral soft tissue require thorough debridement and cleansing to remove all foreign bodies that could be potential sources of infection. Larger lacerations or avulsion injuries extending to the facial tissues should be considered for be treatment in the controlled setting of an operating room under general anesthesia. Careful oral hygiene and avoidance of thermally or chemically irritating food and drink allow for healing in a few days. Lacerations need to be repositioned without tension in correct anatomical position to avoid wound breakdown. Since the gingiva is highly vascular and necrosis is unusual, debridement when done should be extremely conservative. Antibiotic coverage and tetanus prophylaxis are considered on an individual basis depending on the extent of injury and degree of contamination of the wound. Evidence in the literature for routine use of antibiotics is limited, although most intraoral soft tissue wounds are considered contaminated by oral flora.[95] Hence the judgment for providing prophylactic antibiotics in absence of active infection is based on certain factors: degree of contamination of the wound, delay in debridement or repair, systemic indications due to immunocompromised status, and concomitant fractures. Current evidence shows benefit in use of preoperative and 24-hour postoperative antibiotics only. No benefit has been proven from prolonged use of postoperative antibiotics.[96,97]

Plain gut, chromic gut, or polyglycolic acid resorbable sutures in 3-0 or 4-0 sizes are commonly used to repair intraoral lacerations. Gut suture material is quite irritating, whereas polyglycolic acid suture is more difficult to tie and may take a long time to resorb. Less reactive nylon suture may annoy the patient by scratching the tongue, lip, or cheeks.

Avulsive wounds of the gingiva are infrequent and often are more apparent than real. After the wound is cleansed and the tissues are reassembled, presumed missing tissue may, in fact, be present. Management of an avulsive wound of the gingiva, in many respects, depends on the presence or absence of underlying injury to the alveolus or teeth. A gross alveolar fracture associated with a luxated or displaced tooth needs to be covered with soft tissue to promote healing of the fracture and/or retention of the tooth or teeth. Advancement soft tissue flaps to cover alveolar soft tissue defects will often be from non-keratinized alveolar mucosa rather than attached gingiva. Accordingly, small areas of avulsed attached gingiva, without underlying injuries, should be left to granulate and thus produce fixed gingiva, which is more periodontally desirable. Large areas of exposed bone should be covered whenever possible, even if it requires advancement of unattached gingiva.

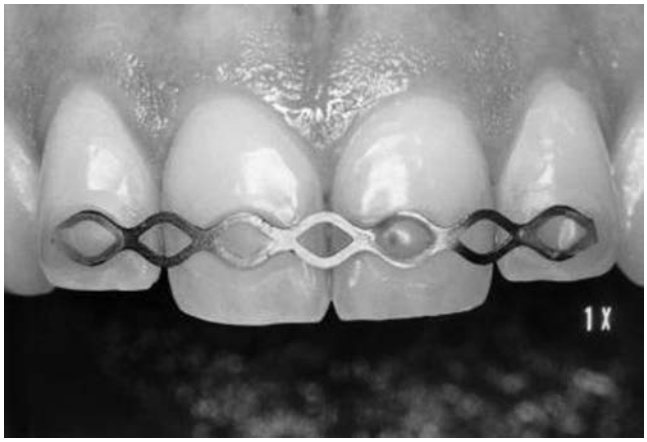

• **Figure 6-20** Titanium trauma splint.

Prognosis of Dentoalveolar Trauma

Reactions of Teeth/Surrounding Tissues to Trauma

The multiple types of dentoalveolar trauma and their combinations give rise to highly complex and variable healing scenarios. Knowledge of the basic reactions of the teeth and surrounding tissues to trauma is essential in rendering appropriate acute and follow-up care. Traumatized teeth and surrounding tissues often have an unpredictable course of healing. Ability to determine the ultimate outcome would help in fabricating the treatment plan. Basic reactions of dentoalveolar structures to trauma include healing

events related to alveolar bone, periodontal ligament (PDL), and the pulp tissue within mature and immature teeth.[98]

There are several basic healing patterns after trauma, based on events related to the tissue type involved in the injury. Alveolar bone healing events include those subsequent to acute bone loss and those secondary to ischemia and crushing. The chance of bone regeneration is good, especially in younger patients, owing to induction of bone from cells in PDL. Necrosis or loss of bone, either transient or permanent, happens more often in teeth with intrusion injuries that have mature roots.

Events related to PDL reaction can be divided into PDL loss facing the alveolar bone, loss of PDL facing the cementum, and PDL ischemia or contusion. PDL has good regenerative capacity when it is lost on the surface facing the alveolar bone. PDL loss facing the cementum and ischemic reaction lead to repair-related resorption or could result in ankylosis. Cementum tissue, when lost in cases of root fracture, is regenerated from the adjacent cementoblasts.[98]

Pulpal injuries can vary from direct pulp exposure to the oral cavity, exposure to PDL in root fractures, bacterial contamination secondary to invasion through the dentinal tubules, to partial or total severance at the apex during luxation injuries. Irrespective of the injury, there is a resultant neurovascular disturbance in the pulp to which it reacts, giving rise to responses ranging from secondary or tertiary dentin formation to inflammation, internal resorption, bone metaplasia, and infected or sterile necrosis. Response of the dentin-pulp complex varies depending on the type of injury, presence or absence of infection, root apex maturation, and origin of progenitor cells involved.

After pulp exposure from trauma, untreated exposure even after 1 week leads to superficial inflammation up to a depth of 2 mm.[99] In cases where capping is performed with a suitable material (calcium hydroxide or MTA), a hard tissue barrier is established. Healing starts with hemostasis, inflammation, proliferation, and remodeling. MTA is a promising new material for pulp capping, with reduced inflammation compared to calcium hydroxide.[100]

Luxation injuries, as discussed previously in this chapter, involve partial or total severance of neurovascular supply, resulting in ischemia. Wound healing starts at the apex and moves coronally and is significantly affected by the size of the apex. The recovery from pulpal severance includes either pulp revascularization or necrosis depending on the presence or absence of bacteria in the wound. In general the risk of pulp necrosis increases with the increase in root development. Revitalization is frequent in apical foramens larger than 1.0 mm in size, but infrequent below 0.3 mm. In teeth with a completely formed apex, in the absence of bacteria this sterile necrosis can persist asymptomatically for long periods of time. Tissue can be revascularized by ingrowth of mesenchymal cells. For example, in the case of PDL-derived progenitor cells, PDL tissue will be formed with cementum deposition on root canal walls. Dentin formation after revascularization is extensive, leading to pulpal obliteration.

Internal or root canal resorption is a rare occurrence. These are classified into root canal replacement resorption and root canal inflammatory resorption. Replacement resorption is characterized by an irregular radiolucency in the lumen of the canal. Histologically the replacement resorption is seen as a metaplasia of the pulp tissue into cancellous bone. This type of resorption usually does not progress and can be observed. Internal inflammatory resorption is characterized by an oval radiolucency that is seen histologically as transformation of pulp into granulation tissue, with giant cells in the granulation tissue resorbing the dentinal walls. Progress of this condition depends on interaction between necrotic and vital pulp, and root canal treatment is helpful if the condition is diagnosed early enough.

External resorption of the root in luxated or avulsed-replanted teeth is often the most difficult to predict. It is categorized into three types: inflammatory, surface, and replacement. Inflammatory external root resorption is related to the necrosis of pulp and is thought to be related to migration of bacteria thought he dentinal tubules into the PDL, causing inflammation and resorption.[101,102] Progressive resorption of tooth substance along with adjacent persistent alveolar radiolucency is a typical finding in inflammatory resorption. In surface resorption, the root surface shows lacunae repaired with cementum tissue. Surface resorption is self-limiting. Replacement resorption leads to ankylosis, resulting in direct union between root and bone. Disappearance of PDL space and progressive root resorption are characteristic radiographic signs.

Response to treatment and long-term success of treatment for dentoalveolar injuries are dependent on internal and external factors surrounding the individual case. Although treatment modalities can be planned and standardized, individual patient response and circumstances surrounding the treatment cannot be controlled. Factors influencing outcomes can be divided into intrinsic patient factors and extrinsic environmental factors. Patient-related factors include age, physical status, oral health including condition of the teeth and periodontium, habits of oral hygiene, mental and emotional status, and motivation to follow through with long-term follow-up examinations and necessary care. Important extrinsic factors affecting prognosis and treatment outcomes include nature of the injury, extent and severity of the injury, presence of concomitant trauma, and length of time from injury to definitive care.

Prognosis of Injury to the Primary Dentition

Primary teeth also show reactive responses in pulpal and PDL tissues. Initial reaction to trauma is pulpitis, characterized by pain and sensitivity to percussion and occurring as a result of vascular congestion.[77] This can lead to reversible or irreversible changes. Diagnosis of pulpal necrosis in primary dentition is challenging owing to unreliable pulp vitality testing.[103] Schröder found the frequency of pulpal

necrosis following luxation injuries to be similar to that for permanent teeth.[104] Color of the crown and associated radiographic indications are used to arrive at the conclusion of necrotic pulp. Discoloration of the crown following injury to primary teeth is frequently reversible, so color change should not be the sole criterion for pulpal therapy or extirpation. Hence, unlike permanent teeth, primary teeth that become discolored or darkened are not necessarily nonvital or necrotic. If the discoloration of the crown does not lighten within 3 weeks after the injury, and if radiographic signs of nonvitality including periapical radiolucency, nonobliteration of pulp, and lack of root formation are seen, pulpal necrosis is likely. A pink crown, however, usually signifies internal resorption, and the tooth should be removed. A yellowish, yellow-brown, or opaque discoloration is usually seen in traumatized primary anterior teeth that are visibly damaged. Radiographically, pulpal obliteration (calcific metamorphosis) is seen in primary teeth with a yellowish hue (Figure 6-21). The tooth usually remains vital. Primary teeth with calcific metamorphosis will usually resorb and exfoliate normally.[105]

A reversible grayish color will be seen in about 55% of the injuries to primary teeth. Studies have also shown that grayish discoloration was most often associated with pathology.[106,107] Periapical inflammation becomes evident 1 to 2 months after injury. Pulpectomy has been advocated in primary teeth with necrotic pulp.[108]

All displacement injuries to the primary teeth could potentially affect the associated developing permanent tooth buds, so careful follow-up evaluation for this sequela is required. Enamel hypoplasia in permanent dentition is the most common sequela after trauma to the primary dentition.[78] Pulp obliteration can happen in primary teeth as well, but no treatment is indicated, as these have been seen to resorb in a similar way to nontraumatized primary dentition. The crown of a tooth with pulp obliteration may show yellowish discoloration clinically, although this relationship is not diagnostic.[21] Inflammatory external or internal root resorption can occur in primary teeth and could potentially damage the developing permanent tooth buds. If any signs of resorption are noted, the teeth should be extracted.

Prognosis of Injuries to the Permanent and Developing Dentition

Isolated crown fractures involving only enamel and without associated injury to the periodontal ligament have a very good prognosis, more so if the root apex is open. The incidence of pulp necrosis is directly related to the degree of concomitant injury to the periodontium from combination of injuries. The overall incidence of necrosis irrespective of type of fracture or management is reported to be 1% to 6%. Exposed dentin may complicate the prognosis, because bacterial contamination of exposed dentinal tubules can result in infection. Both the length of time the dentin is exposed to the oral environment and the degree of dentin exposed are directly related to pulp survival. In one study, treatment for deep proximal fractures showed less chance of pulp necrosis (8%) compared to an untreated group (54%).[109] In complicated crown fractures exposing the pulp, both pulp capping and pulpotomy improve the chances of pulp survival. Pulpotomy had lower chances of resulting in pulp necrosis compared to pulp capping.[41]

The prognosis for pulpal healing after root fracture will depend on the extent of coronal fragment displacement and the stage of root development. Moreover, the location of a transverse root fracture does not affect pulp survival after injury. Repair of root fracture primarily depends on the degree of mobility and dislocation of the coronal segment and the stage of root development. Healing can occur regardless of fracture location, provided that proper reduction and fixation of the segment is accomplished.[110-113] The

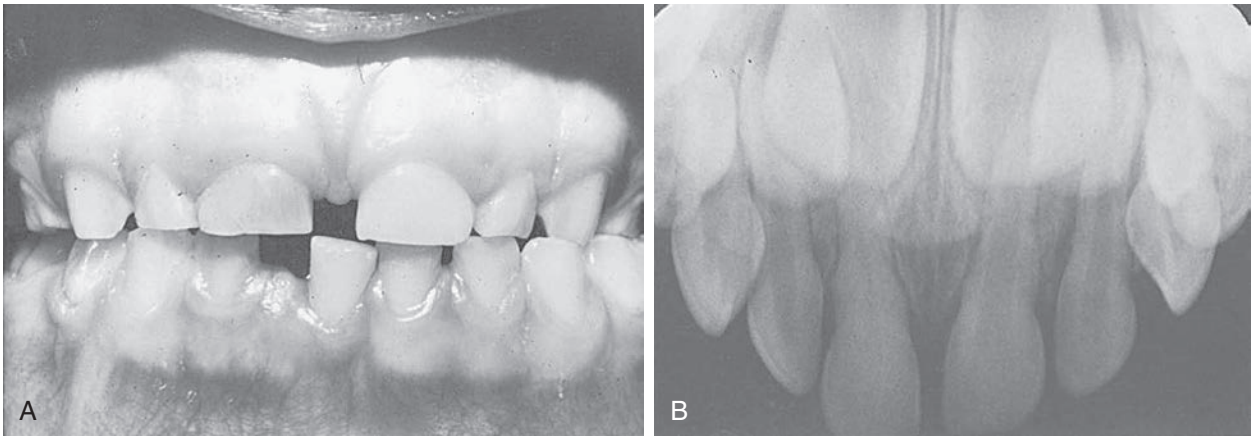

• **Figure 6-21** **A,** A previously traumatized right primary maxillary central incisor. Note the discoloration of the tooth associated with pulpal obliteration. **B**, An occlusal radiograph showing partial pulpal obliteration of a maxillary right primary central incisor (calcific metamorphosis). (From Abubaker AO, Papadopoulos H, Giglio JA: Diagnosis and management of dentoalveolar injuries. In Fonseca R, Marciani RD, Turvey TA, editors: *Oral and maxillofacial surgery*, ed 2, St Louis, 2009, Saunders.)

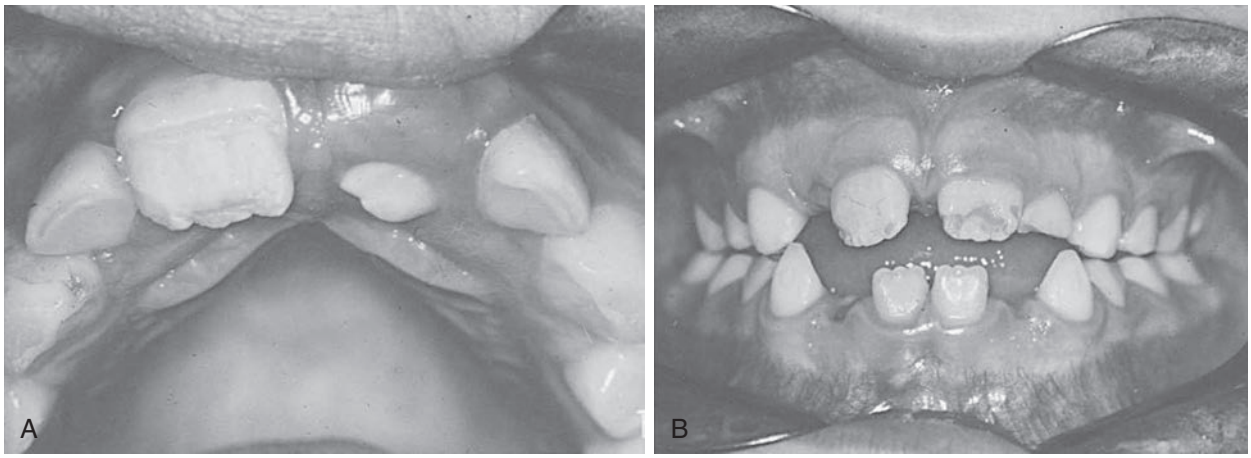

• **Figure 6-22 A,** Hypoplasia of the maxillary permanent central incisors resulting from displacement injuries to the primary teeth. The maxillary left primary central incisor had been intruded and the maxillary right primary central incisor had been luxated. Note the crown dilaceration of tooth left permanent maxillary central incisor due to intrusion of the primary incisor **(B).** (From Abubaker AO, Papadopoulos H, Giglio JA: Diagnosis and management of dentoalveolar injuries. In Fonseca R, Marciani RD, Turvey TA, editors: *Oral and maxillofacial surgery*, ed 2, St Louis, 2009, Saunders.)

incidence of pulp necrosis among permanent teeth with root fractures in general ranges between 20% and 55%.[114]

Although injuries to developing permanent teeth could result from proximity of the root apices of the primary teeth to the permanent tooth buds, damage to the permanent tooth buds most commonly occurs before the age of 3 years, when the permanent teeth are calcifying.[105] Intrusive and avulsion injuries at 2 years of age, occurring when the permanent tooth crown is about half formed, can result in permanent crown dilaceration. These teeth can erupt spontaneously or require surgical intervention to assist eruption.

Studies have shown a 50% (12%-69%) incidence of damage to the permanent tooth bud from displacement and avulsion injuries in the primary dentition.[78] Displacement and avulsion injuries may affect the developing permanent successor in the following way:

1. A white or yellow-brown discoloration with or without enamel hypoplasia (Figure 6-22, *A*)
2. Dilaceration of the crown (Figure 6-22, *B*) or root
3. Cessation of root development
4. Odontoma-like malformation
5. Sequestration of permanent tooth germs
6. Disturbance in eruption

The effect on the permanent tooth is dependent on its stage of development, the nature and the extent of the injury to the primary tooth, and the length of time the injury is allowed to exist in proximity to the developing tooth.[115,116] A very high frequency of disturbance in the development of permanent teeth is seen in intrusion (69%) and avulsion (52%), whereas extrusion (34%) and subluxation (27%) represent lower risks.[117,118] Any resulting infection from trauma poses another threat to the permanent teeth. Whether the various treatment modalities of removal, repositioning, pulpal therapy, or antibiotic therapy influence the prognosis of the injured primary tooth or its successor is not known.

Frequency of pulp necrosis after luxation injuries has been found to be between 15% and 59%. Key factors in determining the prognosis of these injuries are the type of luxation injury and the stage of root development at the time of injury. Teeth with mature root formation are at greatest risk of pulpal necrosis. Diagnosis of pulpal necrosis in permanent teeth after luxation injuries can vary from 6 months to up to 2 years because of difficulty in assessing radiographic signs of necrosis. Tenderness to percussion is found to be significantly related to presence of infection; however, sterile necrosis can be asymptomatic, and diagnosis is based on clinical parameters such as crown color, radiographic features, and pulpal sensitivity tests.

The greatest frequency of pulp necrosis is after intrusions, followed by lateral luxation and extrusions. In intrusive injuries, teeth with immature roots may be expected to spontaneously re-erupt over a period of several months and require little or no intervention.[52] Mature teeth are likely to undergo ankylosis if left in the intruded position. Endodontic treatment will be necessary but can be postponed until the tooth is in position.

Since the replanted tooth must revascularize the periodontal ligament, form a new periodontal fiber and gingival attachment, and finally revascularize and re-innervate the pulp, successful healing depends directly on the time from injury to replantation and the handling of the tooth (storage medium) prior to the replantation.[64-66] Consequently, avulsed immature teeth maintained in a physiologic medium before replantation will have the optimal prognosis for healing for up to 3 hours. Revascularization in replanted teeth with mature root apex is rare and mostly if carried out immediately after the avulsion. Root resorption, however, is the most frequent sequela after replantation. Factors shown to affect root resorption include length and type of extra-alveolar storage, stage of root development, and contamination of root surface. Three forms of postavulsion

root resorption have been identified.[119] Surface resorption appears to be transitional and a precursor to more severe resorption. Inflammatory resorption includes both the root surface and adjacent alveolar bone. Careful timing of root canal treatment (2 weeks post-replantation) can best arrest inflammatory resorption. Replacement resorption, which includes bony ankylosis, is the most severe form of resorptive response to avulsion and can lead to eventual loss of the tooth. Ankylosis can be usually detected in 4 to 8 weeks with a percussion test, but radiographic evidence may take up to a year. Avulsed teeth that have been replanted more than 60 minutes after the injury can be expected to eventually undergo replacement resorption. Prolonged splinting has been related to an increase in replacement resorption.

Finally, many patients with injuries of the dentoalveolar region, especially those that are avulsive, will benefit from a multidisciplinary approach to oral rehabilitation. Advances made in our specialty over the past 20 years in the areas of bone grafting, soft tissue grafting, and implantology have made the restoration of preinjury form and function the gold standard of care.

Prevention of Traumatic Dental Injury

The consequences of traumatic dental injuries are not just physical and esthetic, but psychosocial and economic as well.[6] Traumatic dental injuries are irreversible, and loss of tooth or supporting tissues could have permanent effects on the individual. Although much emphasis has been placed on various modes of prevention, including the role of mouthguards and faceguards, not all traumatic dental injuries are practically preventable, as most of them occur unexpectedly during daily activities.[120] Sports-related, iatrogenic, and fall-related injuries could possibly be prevented or reduced in severity. Contact sports have a higher incidence of dental and oral trauma based on the population and demographics, varying between 7% and 30%.[120-122] Certain preventive strategies include use of mouthguards, patient education, and modifying risky behavior. During sports and other activities in which there is a risk of falling or being hit by an object, wearing a faceguard or mouthguard still seems to be the only way to prevent or at least significantly reduce the seriousness of dental injuries. It has been reported that before the mandate to wear faceguards and mouthguards in U.S. high school football, facial and oral injuries constituted up to 50% of all reported football injuries. Subsequent to the mandate, a significant decrease was noted in reported injuries.[121] Currently, the U.S. National Collegiate Athletic Association requires mouthguards for four sports (ice hockey, lacrosse, field hockey, and football). However, the American Dental Association recommends the use of mouthguards in 29 sports/exercise activities.[122,123] Despite efforts to reduce the number of traumatic dental injuries, most current studies indicate that the overall incidence of dental trauma remains unchanged and is at a relatively high level for children and young adults. Knapik and colleagues[124] concluded from a systematic review of literature on effectiveness of mouthguards that the risk of orofacial sports injury was 1.6 to 1.9 times higher when mouthguards were not used. However, a review of this systematic review and meta-analysis shows that the studies included were of low level of evidence.[125] Hence, although mouthguards and faceguards do help reduce the incidence of sports-related injuries and those from other preventable etiologies, emphasis should be placed on education related to dental trauma and its first aid among children, teenagers, adults, and their caregivers. Controlling risks such as increased overjet or previous history of trauma in children that have been known to increase the incidence of dental trauma should be given priority.

Most of the literature on mouthguards has been focused on their fabrication and material properties rather than on their effectiveness. Mouthguards can be divided into three basic types on the basis of how they are manufactured and used[126]:

1. Stock prefabricated
2. Mouth-formed
3. Custom-made

Stock mouthguards carry the advantage of being readily available and inexpensive, and replacement is easy in case of loss. But these are not properly adapted to the dentoalveolar structures of the wearer and have to be held by occluding into them. These stock mouthguards have been reported to provide the least protection and carry the risk of falling out of the oral cavity before the impact of trauma, although there are no clinical studies to substantiate this claim.

Mouth-formed or self-adapted mouthguards (Figure 6-23) are a readily available and inexpensive alternative to custom-made mouth guards. They are two-layered, with a thick non-moldable outer layer and an inner resilient soft lining that is adapted by the wearer before use. The outer shell is adjusted to relieve the frenal attachments and flange depth, while the inner material is a layer of self-curing methyl methacrylate or silicone rubber. The other type of mouth-formed mouth guards are made of thermoplastic material that is again adapted by the user after warming the material to a set temperature while in the mouth. If adapted well, they can give a better fit than a stock mouthguard, but they carry the risk of thermal injury and improper adaptation that could potentially cause soft tissue injury.

Custom-made mouthguards (Figure 6-24) are fabricated in the laboratory on dental models of the individual's dentoalveolar structures. Many studies have shown better acceptance and comfort levels with these custom-fit mouthguards as opposed to stock and mouth-formed ones. Very few studies, however, offer clinical outcome data on the relative effectiveness of the various types of mouthguard, and the distinction is not clear and substantiated.

Use of faceguards and helmets has significantly reduced the incidence of facial injuries in certain contact sports.[121] One fact that has been noted among these youths is that although the number of oculofacial injuries has been reduced by faceguards, the number of spinal injuries has increased. More studies on their effectiveness and use are needed.



• **Figure 6-23** **A,** Boil and bite mouth guard placed in hot water and then adapted to the teeth and the palate **(B).** (From Bourguignon C, Sigurdsson A: Preventive strategies for traumatic dental injuries, *Dent Clin North Am* 53:729-749, 2009.)

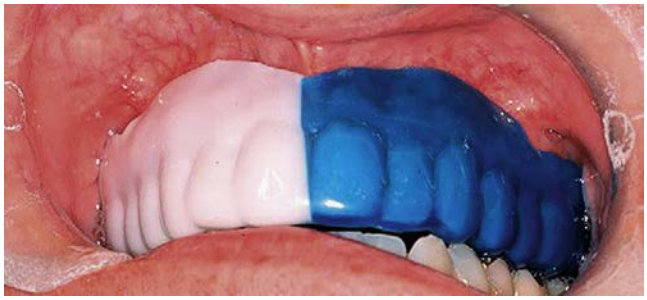

• **Figure 6-24** Custom-made mouth guards made from the dental models of a patient are more acceptable and comfortable. (From Bourguignon C, Sigurdsson A: Preventive strategies for traumatic dental injuries, *Dent Clin North Am* 53:729-749, 2009.)

Conclusions

Although dental traumatology has made significant advances, there still need for development of evidence-based practices. The lack of ethical basis for conducting large-scale, high-quality randomized controlled trials with dental trauma patients in distress is a significant obstacle to such studies. Although there have been a number of animal studies, which are a reasonable alternative, their application in humans is controversial. Most dental trauma occurs during everyday activities among children and adolescents, making them less likely to be prevented. More emphasis should be placed on educating patients, caregivers, and the general public about prompt management of dental trauma so as to reduce morbidity and long-term adverse consequences, which have physical, esthetic, emotional, psychosocial, and financial impact on the individual.

The successful launch of *Dental Trauma Guide* by the International Association for Dental Traumatology, based on the most recent literature evidence and expert opinion, is a substantial step in advancing the science. Ease of availability of information over the Internet and smartphones can help the clinician provide the best possible treatment option to the dental trauma patient. Large-scale clinical studies are needed on the effectiveness and long-term outcomes after successful management of dental trauma.

References

1. Macleod S, Rudd T: Update on the management of dentoalveolar trauma, *Curr Opin Otolaryngol Head Neck Surg* 20:318–324, 2012.
2. Iso-Kungas P, Tornwall J, Suominen AL, et al.: Dental injuries in pediatric patients with facial fractures are frequent and severe, *J Oral Maxillofac Surg* 70:396–400, 2012.
3. Glendor U: Epidemiology of traumatic dental injuries—a 12 year review of the literature, *Dent Traumatol* 24:603–611, 2008.
4. Ruslin M, Wolff J, Boffano P, et al.: Dental trauma in association with maxillofacial fractures: an epidemiological study, *Dent Traumatol* 31:318–323, 2015.
5. Andreasen J, Lauridsen E, Gerds T, Ahrensburg S: Dental Trauma Guide: a source of evidence-based treatment guidelines for dental trauma, *Dent Traumatol* 28:142–147, 2012.
6. Andersson L: Epidemiology of traumatic dental injuries, *J Endod* 39(3 Suppl):S2–S5, 2013.
7. Glendor U: Aetiology and risk factors related to traumatic dental injuries—a review of the literature, *Dent Traumatol* 25: 19–31, 2009.

8. Katner DR, Brown CE: Mandatory reporting of oral injuries indicating possible child abuse, *J Am Dent Assoc* 143: 1087–1092, 2012.
9. Welbury RR: Child physical abuse. In Andreasen JO, Andreasen FM, editors: *Textbook and color atlas of traumatic injuries to the teeth*, ed 3, Copenhagen, 1994, Munksgaard.
10. Hahn RA, Bilukha OO, Crosby A, et al.: First reports evaluating the effectiveness of strategies for preventing violence: early childhood home visitation. Findings from the Task Force on Community Preventive Services, *MMWR Recomm Rep* 52 (RR-14):1, 2003.
11. Child Welfare Information Gateway: *What is child abuse and neglect?* http://www.childwelfare.gov/pubs/factsheets/ whatiscan.pdf, 2008.
12. Needleman HL: Orofacial trauma in child abuse: types, prevalence, management, and the dental profession's involvement, *Pediatr Dent* 8:71, 1986.
13. Santos JF, Cavalcanti AL, Nunes KS, Silva EC: Primary identification of an abused child in dental office: a case report, *J Indian Soc Pedod Prev Dent* 25:191, 2007.
14. US Department of Health and Human Services: *Understanding and improving health and objectives for improving health*, ed 2, Washington, DC, 2000, U.S. Department of Health and Human Services, Healthy People 2010.
15. U.S. Department of Health and Human Services: *Oral health in America: a report of the surgeon general*, Rockville, MD, 2000, U.S. Department of Health and Human Services; National Institutes of Health, National Institute of Dental and Craniofacial Research.
16. Burt CW, Overpeck MD: Emergency visits for sports-related injuries, *Ann Emerg Med* 37:301–308, 2001.
17. ADA Council on Access: Prevention and Interprofessional Relations; ADA Council on Scientific Affairs, *J Am Dent Assoc* 137:1712–1720, 2006.
18. Sigurdsson A: Prevention of dental oral injuries. In Andreasen JO, Andreasen FM, Andersson L, editors: *Textbook and color atlas of traumatic injuries to the teeth*, ed 4, Oxford, 2007, Blackwell Munksgaard, p 814.
19. Glendor U, Marcenes W, Andreasen JO: Classification, epidemiology and etiology. In Andreasen JO, Andreasen FM, Andersson L, editors: *Textbook and color atlas of traumatic injuries to the teeth*, ed 4, Oxford, 2007, Blackwell Munksgaard, p 228.
20. Petti S: Over two hundred million injuries to anterior teeth attributable to large overjet: a meta-analysis, *Dent Traumatol* 31:1–8, 2015.
21. Flores MT, Holan G, Borum M, Andreasen JO: Injuries to the primary dentition. In Andreasen JO, Andreasen FM, Andersson L, editors: *Textbook and color atlas of traumatic injuries to the teeth*, ed 4, Oxford, 2007, Blackwell Munksgaard, pp 516–541.
22. American College of Surgeons: *Advanced trauma life support courses*, Chicago, 2004, American College of Surgeons.
23. Ritwik P, Massey C, Hagan J: Epidemiology and outcomes of dental trauma cases from an urban pediatric emergency department, *Dent Traumatol* 31:97–102, 2015.
24. Andreasen FM, Andreasen JO, Tsukiboshi M: Examination and diagnosis of dental injuries. In Andreasen JO, Andreasen FM, Andersson L, editors: *Textbook and color atlas of traumatic injuries to the teeth*, ed 4, Oxford, 2007, Blackwell Munksgaard.
25. Goodson A, Bhangoo P: The importance of thorough oral examination and the value of soft tissue radiography in the management of embedded tooth fragments, *Emerg Med J* 30:172, 2013.
26. Delap T, Dowllng P, McGilligan T, Vijaya-Sekaran S: Bilateral pulmonary aspiration of intact teeth following maxillofacial trauma, *Dent Traumatol* 15:190–192, 1999.
27. Levin L: Pulp and periradicular testing, *J Endodont* 39 (3 Suppl):S13–S19, 2013.
28. Kullman L, Al Sane M: Guidelines for dental radiography immediately after a dento-alveolar trauma, a systematic literature review, *Dent Traumatol* 28:193–199, 2012.
29. Reference deleted in page proof.
30. Cohenca M, Simon JH, Roges R, et al.: Clinical indications for digital imaging in dento-alveolar trauma. Part I: traumatic injuries, *Dent Traumatol* 23:95–104, 2007.
31. Cohenca N, Simon JH, Mathur A, Malfax JM: Clinical indications for digital imaging in dento-alveolar trauma. Part 2: root resorption, *Dent Traumatol* 23:105–113, 2007.
32. Ellis RG, Daury KW: *The classification and treatment of injuries to the teeth of children*, ed 5, Chicago, 1970, Year Book Medical.
33. Basrani E: *Fractures of the teeth*, Philadelphia, 1995, Lea & Febiger.
34. Ulfohn R: Casos insolitos de fracturas coronaries con curacion espontanae, *Rev Assoc Odontal Argent* 62:11, 1974.
35. Ingle JI, Frank AC, Natkin E, Nutting EE: Diagnosis and treatment of traumatic injuries and their sequelae. In Ingle JJ, Beveridge EE, editors: *Endodontics*, ed 2, Philadelphia, 1976, Lea & Febiger.
36. World Health Organization: *Application of the International Classification of Diseases and Stomatology, IDC-DA*, ed 2, Geneva, 1978, WHO.
37. Feliciano KMPC, de Franca Caldas Jr A: A systematic review of the diagnostic classifications of traumatic dental injuries, *Dent Traumatol* 22:71–76, 2006.
38. Andersson L: IADT guidelines for treatment of traumatic dental injuries, *Dent Traumatol* 28:1, 2012.
39. Lauridsen E, Hermann N, Gerds T, et al.: Pattern of traumatic dental injuries in the permanent dentition among children, adolescents, and adults, *Dent Traumatol* 28:358–363, 2012.
40. Diangelis A, Andreasen J, Ebeleseder K, et al.: International Association for Dental Traumatology guidelines for the management of traumatic dental injuries: 1. Fractures and luxations of permanent teeth, *Dent Traumatol* 28:2–12, 2012.
41. Cvek M: Endodontic management and use of calcium hydroxide in traumatized permanent teeth. In Andreasen JO, Andreasen FM, Andersson L, editors: *Textbook and color atlas of traumatic injuries to the teeth*, ed 4, Oxford, 2007, Blackwell Munksgaard.
42. Andreasen JO, et al.: Crown-root fractures. In Andreasen JO, Andreasen FM, Andersson L, editors: *Textbook and color atlas of traumatic injuries to the teeth*, ed 4, Oxford, 2007, Blackwell Munksgaard, pp 314–336.
43. Reference deleted in page proof.
44. Andreasen FM, Andreasen JO: Root fractures. In Andreasen JO, Andreasen FM, Andersson L, editors: *Textbook and color atlas of traumatic injuries to the teeth*, ed 4, Oxford, 2007, Blackwell Munksgaard, pp 337–371.
45. Andreasen J, Ahrensburg S, Tsilingaridis G: Root fractures: the influence of type of healing and location of fracture on tooth survival rates—an analysis of 492 cases, *Dent Traumatol* 28:404–409, 2012.
46. Cvek M, Tsilingaridis G, Andreasen J: Survival of 534 incisors after intra-alveolar root fracture in patients aged 7-17 years, *Dent Traumatol* 24:379–387, 2008.
47. Heithersay GS: Combined endodontic-orthodontic treatment of transverse root fractures in the region of the alveolar crest, *Oral Surg* 36:404, 1973.
48. Benenati FW, Simon JHS: Orthodontic root extrusion: its rationale and uses, *Gen Dent* 34:285, 1989.

49. Andreasen FM, Andreasen JO: Luxation injuries of permanent teeth: general findings. In Andreasen JO, Andreasen FM, Andersson L, editors: *Textbook and color atlas of traumatic injuries to the teeth*, ed 4, Oxford, 2007, Blackwell Munksgaard, pp 372–403.
50. Hecova H, Tzigkounakis V, Merglova V, Netolicky J: A retrospective study of 889 injured permanent teeth, *Dent Traumatol* 26:466–475, 2010.
51. Andreasen JO, Bakland LK, Matras R, Andreasen FM: Traumatic intrusion of permanent teeth. Part 2. A clinical study of the effect of preinjury and injury factors, such as sex, age, stage of root development, tooth location, and extent of injury including number of intruded teeth on 140 intruded permanent teeth, *Dent Traumatol* 22:90–98, 2006.
52. Andreasen FM, Andreasen JO: Intrusive luxation. In Andreasen JO, Andreasen FM, Andersson L, editors: *Textbook and color atlas of traumatic injuries to the teeth*, ed 4, Oxford, 2007, Blackwell Munksgaard, pp 428–443.
53. Andreasen FM, Andreasen JO: Avulsions. In Andreasen JO, Andreasen FM, Andersson L, editors: *Textbook and color atlas of traumatic injuries to the teeth*, ed 4, Oxford, 2007, Blackwell Munksgaard, pp 444–488.
54. Andersson L, Andreasen J, Day P, et al.: International Association for Dental Traumatology guidelines for the management of traumatic dental injuries: 2. Avulsion of permanent teeth, *Dent Traumatol* 28:88–96, 2012.
55. Sigalas E, Regan J, Kramer P, et al.: Survival of human periodontal ligament cells in media proposed for transport of avulsed teeth, *Dent Traumatol* 20:21–28, 2004.
56. Krasner P, Persen P: Preserving avulsed teeth for replantation, *J Am Dent Assoc* 123:80, 1992.
57. Trope M, Friedman S: Periodontal healing of replanted teeth stored in Viaspan, mild and Hanks balanced salt solution, *Endod Dent Traumatol* 8:183, 1992.
58. Hiltz J, Trope M: Vitality of human lip fibroblasts in milk, Hanks balanced salt solution and Viaspan storage media, *Endod Dent Traumatol* 7:69, 1991.
59. Cvek M, Cleaton-Jones P, Austin J, et al.: Effect of topical application of doxycycline on pulp revascularization and periodontal healing in reimplanted monkey incisors, *Endod Dent Traumatol* 6:170, 1990.
60. Sae-Lim V, Wang CY, Choi GW, Trope M: The effect of systemic tetracycline on resorption of dried replanted dogs teeth, *Endod Dent Traumatol* 14:127–132, 1998.
61. Sae-Lim V, Wang CY, Trope M: Effect of systemic tetracycline and amoxicillin on inflammatory root resorption of replanted dogs teeth, *Endod Dent Traumatol* 14:216–220, 1998.
62. Selvig KA, Bjorvatn K, Bogle GC, Wikesjo UME: Effect of stannous fluoride and tetracycline on periodontal repair after delayed tooth replantation in dogs, *Scand J Dent Res* 100:200, 1992.
63. Selvig JA, Bjorvatn K, Claffey N: Effect of stannous fluoride and tetracycline on repair after delayed replantation of root-planed teeth in dogs, *Acta Odontol Scand* 48:107, 1990.
64. Andreasen JO, Borum MK, Jacobsen HL, Andreasen FM: Replantation of 400 avulsed permanent incisors. 1. Diagnosis of healing complications, *Endod Dent Traumatol* 11:51–58, 1995.
65. Andreasen JO, Borum MK, Jacobsen HL, Andreasen FM: Replantation of 400 avulsed permanent incisors. 2. Factors related to pulpal healing, *Endod Dent Traumatol* 11:59–68, 1995.
66. Andreasen JO, Borum MK, Jacobsen HL, Andreasen FM: Replantation of 400 avulsed permanent incisors. 3. Factors related to root-growth, *Endod Dent Traumatol* 11:69–75, 1995.
67. Andreasen JO, Borum MK, Jacobsen HL, Andreasen FM: Replantation of 400 avulsed permanent incisors. 4. Factors related to periodontal-ligament healing, *Endod Dent Traumatol* 11:76–89, 1995.
68. Malmgren B, Malgren O: Orthodontic management of traumatized dentition. In Andreasen JO, Andreasen FM, Andersson L, editors: *Textbook and color atlas of traumatic injuries to the teeth*, ed 4, Oxford, 2007, Blackwell Munksgaard, pp. 669–715.
69. Pohl Y, Filippi A, Kirschner H: Results after replantation of avulsed permanent teeth. I. Endodontic considerations, *Dent Traumatol* 21:80–92, 2005.
70. Kerekes K, Heide S, Jacobsen I: Follow-up examination of endodontic treatment in traumatized juvenile incisors, *J Endod* 6:744, 1980.
71. Cvek M: Treatment of non-vital permanent incisors with calcium hydroxide. II. Effect on external root resorption in luxated teeth compared with effect of root filling with gutta percha. A follow-up, *Odontol Rev* 24:343, 1973.
72. Coccia CT: A clinical investigation of root resorption rates in replanted young permanent incisors: a five year study, *J Endod* 6:413, 1980.
73. Andreasen JO: The effect of pulp extirpation or root canal treatment on periodontal healing after replantation of permanent incisors in monkeys, *J Endod* 7:245, 1981.
74. Andreasen JO, Kristerson L: The effect of extra-alveolar root filling with calcium hydroxide on periodontal healing after replantation of permanent incisors in monkeys, *J Endod* 7:349, 1981.
75. Malmgren B, Andreasen J, Flores MT, et al.: International Association for Dental Traumatology guidelines for the management of traumatic dental injuries: 3. Injuries in the primary dentition, *Dent Traumatol* 28:174–182, 2012.
76. Waggoner WF: Restorative dentistry for the primary dentition. In Pinkham J, Casamassimo P, Fields H, editors: *Pediatric dentistry; infancy through adolescence*, ed 4, St Louis, 2005, Elsevier Saunders, pp 368–369.
77. McTigue DJ: Managing injuries to the primary dentition, *Dent Clin N Am* 53:627–638, 2009.
78. Lenzi M, Alexandria A, Ferreira D, Maia L: Does trauma in the primary dentition cause sequelae in permanent successors? A systematic review, *Dent Traumatol* 31:79–88, 2015.
79. Bankson N, Byrne M: The relationship between missing teeth and selected consonant sounds, *J Speech Hear Disord* 27:341, 1962.
80. Snow K: Articulation proficiency in relation to certain dental abnormalities, *J Speech Hear Disord* 26:209, 1961.
81. Mason RM: Communication disorders. In Stewart RE, Barber TK, Troutman KC, Wei SHY, editors: *Pediatric dentistry*, St Louis, 1982, CV Mosby.
82. Korf SR: The eruption of permanent central incisors following premature loss of their antecedents, *J Dent Child* 32:39, 1965.
83. Andreasen JO: Injuries to the supporting bone. In Andreasen JO, Andreasen FM, Andersson L, editors: *Textbook and color atlas of traumatic injuries to the teeth*, ed 4, Oxford, 2007, Blackwell Munksgaard, pp 489–515.
84. Oikarinen K: Tooth splinting: a review of the literature and consideration of the versatility of a wire-composite splint, *Endod Dent Traumatol* 6:237, 1990.
85. Oikarinen K: Comparison of the flexibility of various splinting methods for tooth fixation, *Int J Oral Maxillofac Surg* 17:125, 1988.

86. Oikarinen K, Andreasen JO, Andreasen FM: Rigidity of various fixation methods used as dental splints, *Endodont Dent Traumatol* 8:113, 1992.
87. Andreasen JO: The effect of splinting upon periodontal healing after replantation of permanent incisors in monkeys, *Acta Odont Scand* 33:313, 1975.
88. Ngassapa DN, Freihofer HM, Maltha J: The reaction of the periodontium to different types of splints, *Int J Oral Maxillofac Surg* 15:240, 1986.
89. Antrim DD: A functional splint for traumatized teeth, *J Endod* 8:328, 1982.
90. Hovland EJ, Gutmann JL: A traumatic stabilization for traumatized teeth, *J Endod* 2:390, 1976.
91. Macko DJ, Kazmierski MR: Stabilization of traumatized anterior teeth, *J Dent Child* 44:46, 1977.
92. Filippi A, von Arx T, Lussi A: Comfort and discomfort of dental trauma splints—a comparison of a new device (TTS) with three commonly used splinting techniques, *Dent Traumatol* 18:275, 2002.
93. von Arx T, Filippi A, Lussi A: Comparison of a new dental trauma splint device (TTS) with three commonly used splinting techniques, *Dent Traumatol* 17:266, 2001.
94. Gassner R, Tuli T, Hachl O, et al.: Cranio-maxillofacial trauma: a 10 year review of 9543 cases with 21067 injuries, *J Craniomaxillofac Surg* 31:51–61, 2003.
95. Andreasen JO, Andersson L: Soft tissue injuries. In Andreasen JO, Andreasen FM, Andersson L, editors: *Textbook and color atlas of traumatic injuries to the teeth*, ed 4, Oxford, 2007, Blackwell Munksgaard, pp 577–597.
96. Abubaker A: Use of prophylactic antibiotics in preventing infection of traumatic injuries, *Dent Clin North Am* 53:707–715, 2009.
97. Mark D, Granquist E: Are prophylactic oral antibiotics indicated for the treatment of intraoral wounds? *Ann Emerg Med* 52:368–372, 2008.
98. Andreasen J: Pulp and periodontal tissue repair—regeneration or tissue metaplasia after dental trauma. A review, *Dent Traumatol* 28:19–24, 2012.
99. Andreasen JO, Lovschall H: Response of oral tissues to trauma. In Andreasen JO, Andreasen FM, Andersson L, editors: *Textbook and color atlas of traumatic injuries to the teeth*, ed 4, Oxford, 2007, Blackwell Munksgaard, pp 62–113.
100. Pitt-Ford TR, Patel S: Technical equipment for assessment of dental pulp status, *Endod Top* 7:2, 2004.
101. Wedenberg C, Lindskog S: Experimental internal resorption in monkey teeth, *Endod Dent Traumatol* 1:221–227, 1985.
102. Andreasen FM, Kahler B: Pulpal response after acute dental injury in the permanent dentition: clinical implications—a review, *J Endodont* 41:299–308, 2015.
103. Kenwood M, Kim Seow W: Sequelae of trauma to the primary dentition, *J Pedod* 13:230–238, 1989.
104. Schröder U, Weenberg E, Granath LE: Traumatized primary incisors: follow-up program based on frequency of periapical osteitis related to tooth color, *Swed Dent J* 1:95–98, 1977.
105. Wilson CF: Management of trauma to the primary and developing teeth, *Dent Clin North Am* 39:133–167, 1995.
106. Croll TP, Pascon EA, Langeland K: Traumatically injured primary incisors: a clinical and histological study, *ASDC J Dent Child* 54:401–422, 1987.
107. Soxman JA, Nazif MM, Bouquot J: Pulpal pathology in relation to discoloration of primary anterior teeth, *ASDC J Dent Child* 51:282–284, 1984.
108. Johnson R: Traumatic dental injuries in children. Evaluation of traumatic dental injuries and treatment of injuries to primary teeth, *Update Pediatr Dent* 2:1-4, 6–7, 1989.
109. Ravn JJ: Follow up study of permanent incisors with enamel-dentin fractures after acute trauma, *Scand J Dent Res* 89:355–365, 1981. 1981.
110. Andreasen JO, Hjorting-Hansen E: Intra-alveolar root fractures: radiographic and histologic study of 50 cases, *J Oral Surg* 25:414, 1967.
111. Blackwood HJJ: Tissue repair in intra-alveolar root fractures, *Oral Surg* 12:360, 1959.
112. Jacobsen I: Root fractures in permanent anterior teeth with incomplete root formation, *Scand J Dent Res* 84:210, 1976.
113. Zachrisson BU, Jacobsen I: Long term prognosis of 66 permanent anterior teeth with root fracture, *Scand J Dent Res* 83:345, 1975.
114. Majorana A, Pasini S, Bardellini E, Keller E: Clinical and epidemiological study of traumatic root fractures, *Dent Traumatol* 18:77–80, 2002.
115. Andreasen JO, Sundstrom B, Ravn JJ: The effect of traumatic injuries to primary teeth on their permanent successors. A clinical and histologic study of 117 injured permanent teeth, *Scand J Dent Res* 79:219, 1971.
116. Andreasen JO, Ravn JJ: The effect of traumatic injuries to primary teeth on their permanent successors. II. A clinical and radiographic follow-up study of 213 injured teeth, *Scand J Dent Res* 79:284, 1971.
117. Andreasen JO, Ravn JJ: Enamel changes in permanent teeth after trauma to their primary predecessors, *Scand J Dent Res* 81:203, 1973.
118. Ravn JJ: Developmental disturbances in permanent teeth after exarticulation of their primary predecessors, *Scand J Dent Res* 83:131, 1975.
119. Tronstad L: Root resorption—etiology, terminology, and clinical manifestations, *Endodont Dent Traumatol* 4:241, 1988.
120. Sigurdsson A: Evidence-based review of prevention of dental injuries, *J Endodont* 39(3 Suppl):S88–S93, 2013.
121. Bourguignon C, Sigurdsson A: Preventive strategies for traumatic dental injuries, *Dent Clin North Am* 53:729–749, 2009.
122. National Collegiate Athletic Association: *Sports medicine handbook: Guideline 4c: Mouthguards*, Indianapolis, 2007, National Collegiate Athletic Association.
123. American Association for Health, Physical Education and Recreation, and American Dental Association (ADA): *Report of the Joint Commission on Mouth Protectors*, Chicago, 1960, American Dental Association.
124. Knapik J, Marshall S, Lee R, et al.: Mouthguards in sport activities: history, physical properties and injury prevention effectiveness, *Sports Med* 37:117–144, 2007.
125. Andreasen JO, Ahrensburg SS, Tendal B: Inappropriate use of meta-analysis in an evidence-based assessment of the clinical guidelines for replanted avulsed teeth: timing of pulp extirpation, splinting periods and prescription of systemic antibiotics, *Dent Traumatol* 26:451–452, 2010.
126. Tuna E, Ozel B: Factors affecting sports-related orofacial injuries and the importance of mouthguards, *Sports Med* 44:777–783, 2014.

7

Diagnosis and Management of Mandible Fractures

JOHN S. VORRASI, DOMENICK P. COLETTI, JOHN F. CACCAMESE JR.

Introduction

Mandible fractures constitute a significant proportion of facial trauma treated in both urban and rural hospitals. Treatment of facial fractures, specifically those involving the dentition, has been a core discipline for oral and maxillofacial surgeons around the world.

The evolution of mandible fracture treatment modalities has mirrored materials advancements with the development of rigid fixation and titanium metallurgy. Our specialty has moved away from the strict adaptation of commonly held orthopedic principles, instead modifying these ideas to better suit the unique demands of the maxillomandibular complex. The mandible is a complex bony structure involving unique cranial and dental articulations, a network of opposing and specialized muscles, and supporting functions of respiration, speech, deglutition, swallowing, and facial expression. Therefore, reconstructing the mandible and restoring function can have a significant impact for patients and can also present a challenge in the setting of high-velocity blunt or avulsive injury. With advancements in the treatment methods and armamentarium for fixation, we are able to piece together and stabilize fractures using a combination of rigid and semirigid fixation. Open reduction techniques allow early but graduated return to function without adding significant morbidity for the patient. Load-bearing titanium reconstruction plates are able to stabilize atrophic and comminuted mandible fractures, while endosseous dental implants are used to restore dental injuries.

The complexity of mandible fractures varies based on pattern, degree of comminution, displacement, and favorability. The AO/ASIF (Arbeitsgemeinschaft für Osteosynthesefragen/Association for the Study of Fixation) provides guidance and forms the basis for fracture fixation techniques to restore function and premorbid occlusion and avoid complications (such as nonunion, malunion, or infection). The principles assume an understanding of bony biology and wound healing that is critical to proper treatment planning.

History of Mandible Fractures

Mandible fracture treatment has been documented for thousands of years dating back to 1650 BC, as highlighted in ancient Egyptian scrolls.[1,2] Hippocrates was one of the first individuals to describe the concept of immobilization for mandible fractures, a problem that was previously considered a hopeless disease process.[3] Circumdental wires were successfully used to reduce and immobilize mandible fractures to aid in healing.

The 13th century brought about the concept of maxillomandibular fixation by using the stable jaw to reduce the fracture of the injured jaw. This added to the notion that recreating a proper occlusion should assist in reducing fractures to their appropriate anatomic position to heal.[4] The final publication of the use of occlusion and maxillomandibular fixation for stabilizing fractures was not to come for another 200 years.[5] Chopart subsequently designed a stabilization device mimicking a modern-day vise between which the mandibular occlusal surface and the external mandible border were placed in compression. Efforts toward more stable fixation took a leap forward at the turn of the 20th century as Gilmer described metal rods wired together that spanned the fractured site.[6] In 1846, Buck was the first surgeon of record to perform an open reduction.[7] He used an iron wire to fixate the fractured segments. Dr. Robert Ivy, a military oral and maxillofacial surgeon, built on Gilmer's lead to develop the "Ivy loop" technique, placing interproximal wires in the premolar regions of both arches to reduce the occlusion.[8] World Wars I and II brought further innovation and surgical progress to treatment of facial fractures. A distinct need for predictable and safe methods for fracture repair spawned surgical units on the front lines in Germany and France, but the mainstay of care was based on closed treatment.

Open reduction and internal fixation (ORIF) was not advocated until the mid-20th century because of fear of contamination of bone and hardware. There were few attempts to advance the management beyond bandages, maxillomandibular fixation, and Gunning-type splints until the 1960s, thanks to the research of two German surgeons, Luhr and Spiessl.[9,10] The concept of compression plates made of vitallium (cobalt-chrome-molybdenum) revolutionized the fixation concept and developed into the principles advocated by AO/ASIF. The field of orthopedics and orthopedic injuries guided the initiation of rigid fixation, but developments were hampered by bulky plates and significant morbidity (reoperation, nerve damage, large facial scars, etc.).

The introduction of miniplate fixation in the 1970s by Champy and Michelete[11,12] further reduced the morbidity of open reduction and recognized the mandible as a unique structure with dynamic musculature and movements that may help or hinder fracture healing. Based on lines of osteosynthesis, fractures without comminution, complex fragmentation, or comminution could be repaired using miniplates (Figure 7-1).

Intermaxillary fixation screws (IMFs) were introduced in the 1990s to further simplify the closed reduction technique and reduce the possibility of surgeon injuries because less wiring was now necessary (Figure 7-2).

Mandible fracture repair methods are continually evolving to optimize outcomes and minimize treatment. Recently a combination titanium arch bar with titanium bone screws introduced by Stryker allows multiple-vector, semirigid maxillomandibular fixation similar to Erich arch bars, but avoiding the tooth-borne forces. Resorbable plates using polymer materials are transitioning from cranial procedures to maxillofacial trauma, especially in the pediatric population. The biodegradable materials can maintain stability similar to miniplates in non—load-bearing areas (zygoma or midface fractures). Resorbable plates are also being used in nondisplaced angle fractures and pediatric mandible fractures as alternate means of fixation that eliminate the need for reoperative hardware removal.

Pathogenesis

In the United States, mandible fractures are largely the result of interpersonal violence, motor vehicle–related injuries, or accidents and falls.[13-15] Pathologic fractures and ballistic injuries are also seen, but with less frequency. Fortunately, with the advent of airbags and other traffic safety mandates, the incidence of motor vehicle–associated facial fractures has been reduced.[16] The populations most likely to be affected by facial fractures are male, younger than 35, in an urban setting, and of lower socioeconomic status.[17]

One of the largest retrospective studies, by Morris and colleagues in 2015, reviewed 4143 mandible fractures over a 17-year period.[18] The injury distribution by site was the angle (27.0%), symphysis (21.3%), condyle and subcondyle (18.4%), body (16.8%), multiple sites unspecified (7.1%), ramus (5.4%), alveolar border (2.9%), and coronoid (1.0%) (Figure 7-3). Injuries were typically the result of low-velocity blunt trauma. July and the summer months resulted in the highest number of mandible fractures, and 49.6% were single-site fractures.

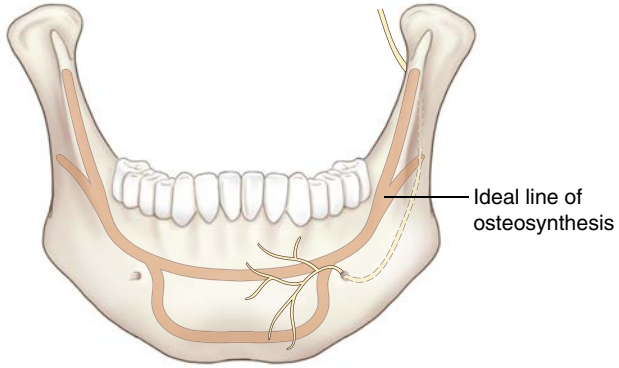

• **Figure 7-1** Champy's lines of osteosynthesis. (From Ricardo Cienfuegos, Carl-Peter Cornelius, Edward Ellis III, George Kushner: *Mandible fractures*. AO Foundation Online Resource, 2015.)

Anatomy

The mandible is one of the more complicated bones in the body in its mobility, growth, and function. The mandible has 13 muscle attachments. Within these are groups of jaw closers (temporalis, masseter, medial pterygoid), openers (digastric, lateral pterygoid), and glottic attachments (genioglossus and geniohyoid). The remaining muscles, such as the buccinator, platsyma, mentalis, mylohyoid, depressor labii inferiorius, and depressor anguli oris, can influence bone remodeling and displacement in fractures.

The temporomandibular joint (TMJ), the mandible's primary articulation with the cranial base, is a specialized system that allows two types of movement, including translation along the articular eminence and rotation within the glenoid fossa. The capsule, TMJ disc, and lateral ligaments support most of the TMJ movements. Deviation in opening or preauricular swelling may clinically indicate a TMJ injury or condyle fracture that should be investigated.

The major blood supply to the mandible develops along the inferior alveolar artery but transitions to the surrounding periosteum and muscle attachment as the body ages.[19] In the case of comminuted or atrophic mandible fractures, careful consideration of hardware location should target the highly vascular areas of the mandible (ramus and symphysis) and avoid sites with poor blood supply (the body).

The inferior alveolar nerve innervates one half of the mandibular dentition and exits at the mental foramen to supply the chin and lip soft tissue. The lingual nerve runs just inferior to the alveolus and supraperiosteal in the area of the third molar in most cases. Even with displaced fractures, this nerve rarely is injured. Nerve injuries associated with mandible fractures are discussed later in this chapter.

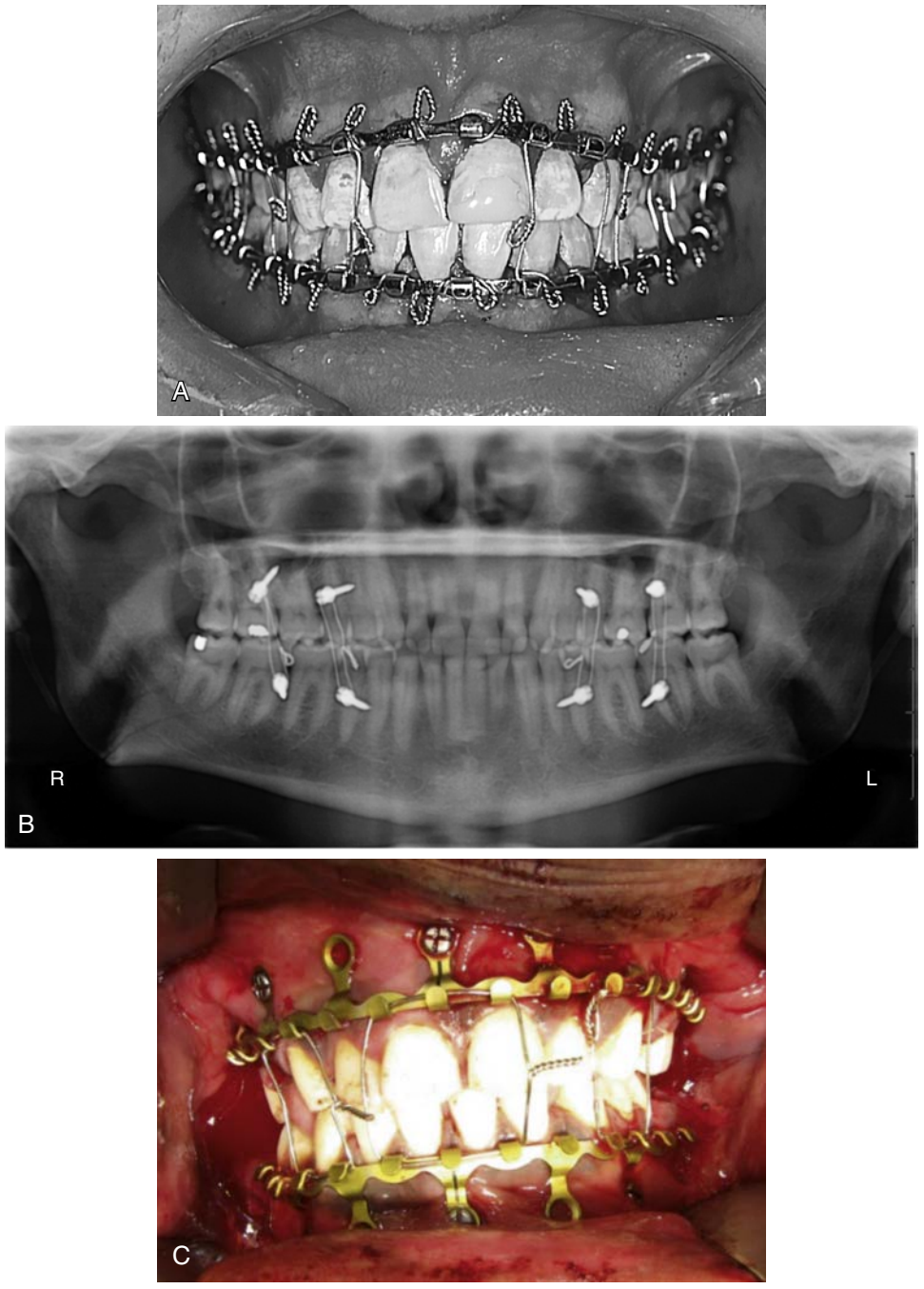

• **Figure 7-2** Intermaxillary or maxillomandibular fixation using **(A)** Erich arch bars or **(B)** IMF screws. **C,** hybrid system (Stryker CMF).

Fracture Classification

Fractures can be divided into several categories based on:
1. Location
2. Biomechanics
3. Fracture pattern

Location

The mandible is divided into anatomic subunits to better characterize the association of the dentition and associated muscle attachments with the injury.

- Symphysis: Occurring in the midline, between the central incisors.
- Parasymphysis: Area bound between vertical lines distal to the canines.
- Body: Area bound from the distal of the canine to the anterior border of the masseter muscle (the distal of the second molar).
- Angle: Area bound from the anterior border of the masseter (distal of second molar) to the posterior border of the masseter. Third molars, if present, are typically involved in angle fractures.

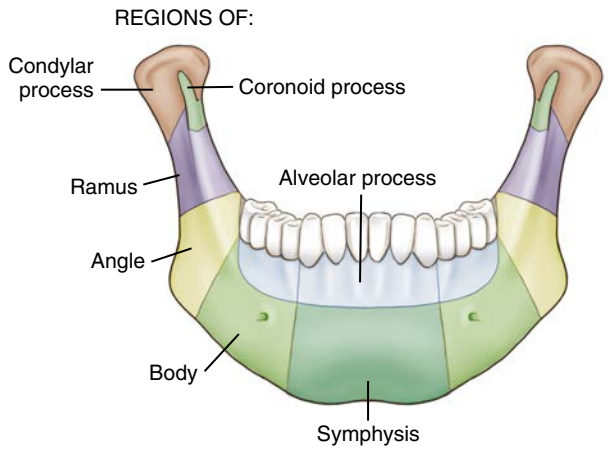

• **Figure 7-3** Fractures of the mandible according to anatomic region. (Adapted from Stevens M, Emam H: Mandibular body fractures. In Kademani D, Tiwana P, editors: *Atlas of oral and maxillofacial surgery*, Philadelphia, 2015, Saunders.)

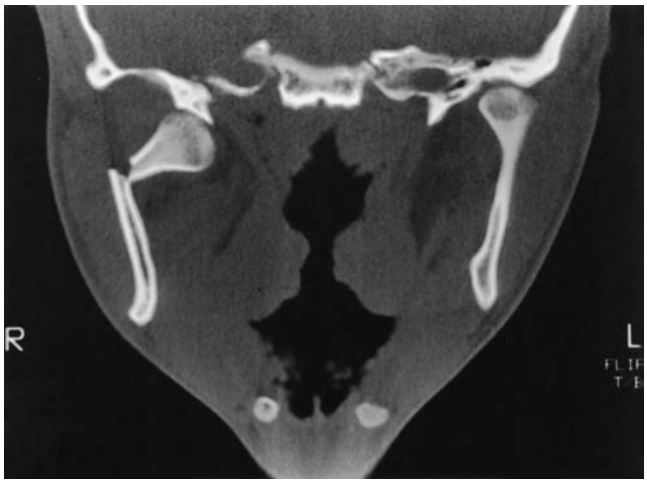

• **Figure 7-4** Computed tomography (CT) scan is ideal to assess condylar fracture position and displacement.

- Ramus: Area from the posterior border of the masseter to the height of the sigmoid notch. A "subcondylar fracture" is typically within the region of the ramus.
- Condyle:
  - *Intracapsular:* A fracture of the condylar head, which is bound by the capsule (Figure 7-4).
  - *Extracapsular/Condylar neck*: A fracture from the height of the sigmoid notch to the attachment of the capsule. These fractures can be further subdivided based on their distance from the sigmoid notch. A "high" fracture is at or just below the capsule and can denote difficulty in achieving fixation. A "low" fracture is near the notch and can be fixated by conventional means.
- Coronoid: The area of the coronoid process superior to the height of the sigmoid notch.
- Dentoalveolar: A fracture of the alveolar bone and supporting root structure; it does not involve the basal bone of the mandible.

The mental foramen, the third molar/angle area, and the mandibular canine sites are particularly susceptible to fracture due to the bone density at these locations. As a result, parasymphyseal and angle fractures constitute the majority of fracture sites. The coronoid process, however, is the least common mandible fracture site because of the protective effect of the zygomatic arch and masseter muscle shielding. Condylar process fractures are the most common fracture seen in the pediatric population and are termed intracapsular or extracapsular based on the association with the temporomandibular joint capsule. Mandibular body fractures are seen most commonly with in atrophic mandibles that have lost significant bone height and width due to changes associated with premature tooth loss and aging. The body of the mandible also has limited muscle attachments as opposed to the symphysis or ramus. Muscle attachments usually have a positive impact on bone density with regard to physiologic strain and blood supply. Last, dentoalveolar fractures without complete fracture of the mandible are a unique entity requiring reduction with reapproximation to the premorbid occlusion using Erich arch bars or dental splints affixed to the adjacent teeth.

Biomechanics

Understanding of the muscle attachments and the forces imposed on the mandible will aid the surgeon in management decisions. A mandible fracture has three forces acting on it: compression, tension, and torsion. These forces vary in magnitude depending on the location of the fracture. The muscles responsible for vertical displacement are the masseter, temporalis, and to a degree the medial pterygoid. Horizontal displacement can be caused by the lateral and medial pterygoid, and torsion by the mylohyoid, digastrics, and geniohyoid.

Displaced fractured segments are more or less well buttressed based on the vectors of muscle pull. A favorable fracture is one where the innate muscle forces have a tendency to reduce the fracture and thus contribute to buttressing. An unfavorable fracture is one in which the opposite is true, and the segments are displaced by muscle pull. This concept is most important when using closed reduction methods on fractures where the proximal segment of the fracture is wholly removed from the tooth-bearing mandible (condyle and angle fractures most typically) and the occlusion cannot be used to reduce both segments.

The favorability and unfavorability are described based on the plane of the films obtained; a "horizontally unfavorable" fracture is displacement noted on an orthopantomogram or Panorex (Figure 7-5). Conversely, a "vertically unfavorable" fracture is displacement noted on an anterior/posterior film. This can be confusing at times because the vectors of the muscle pull are opposite to the plane of the film. It is probably more important simply to denote whether or not a fracture is favorable or unfavorable. This feature of the fracture significantly affects the treatment plan. For example, the buttressing effect seen in some favorable fractures will make these more amenable to closed reduction and maxillomandibular fixation (MMF) (Figures 7-6 to 7-10). In contrast,

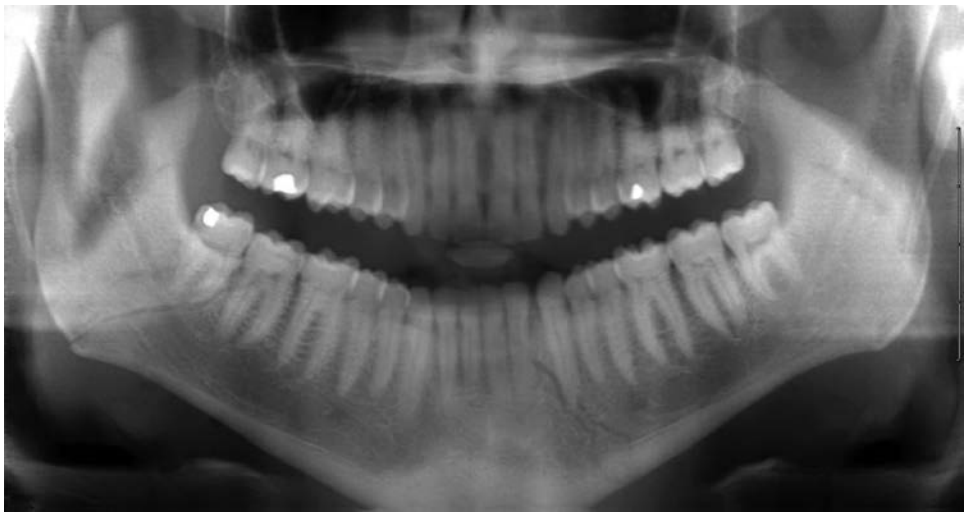

• **Figure 7-5** Panorex radiograph is an excellent modality for identifying mandible fractures. Radiograph shows a right body minimally displaced extending posteriorly to the angle of the mandible and left parasymphyseal fracture.

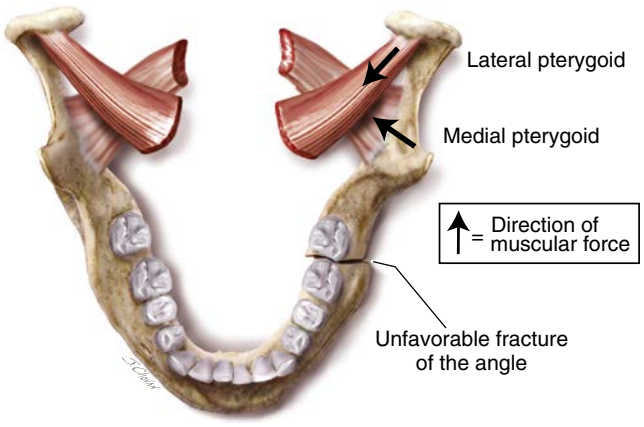

• **Figure 7-6** Horizontally unfavorable fracture.

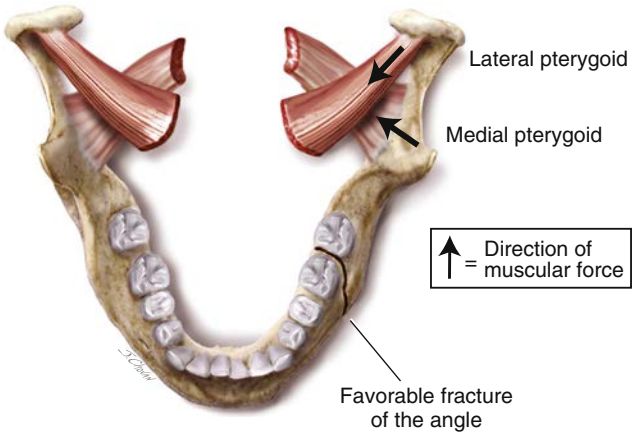

• **Figure 7-7** Horizontally favorable fracture.

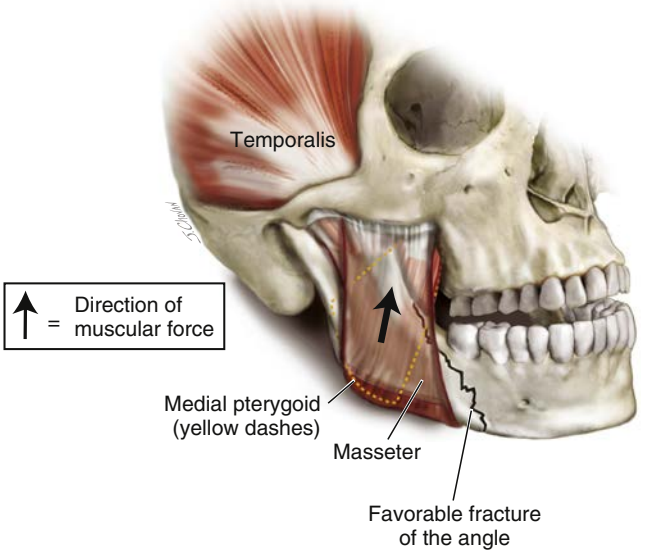

• **Figure 7-8** Vertically favorable fracture.

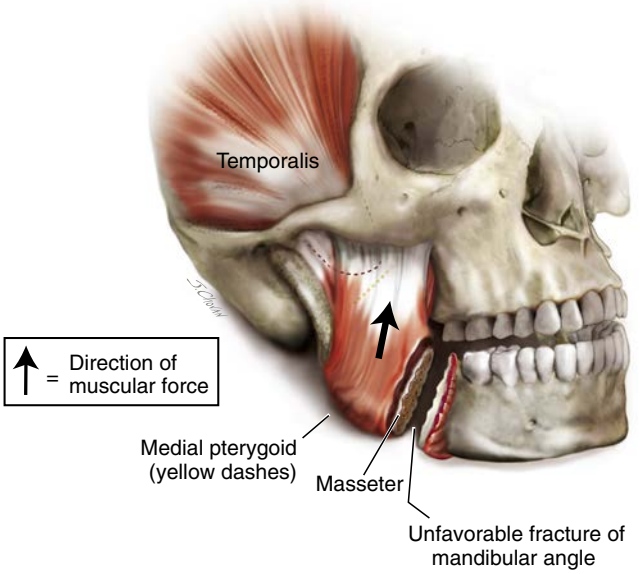

• **Figure 7-9** Vertically unfavorable fracture.

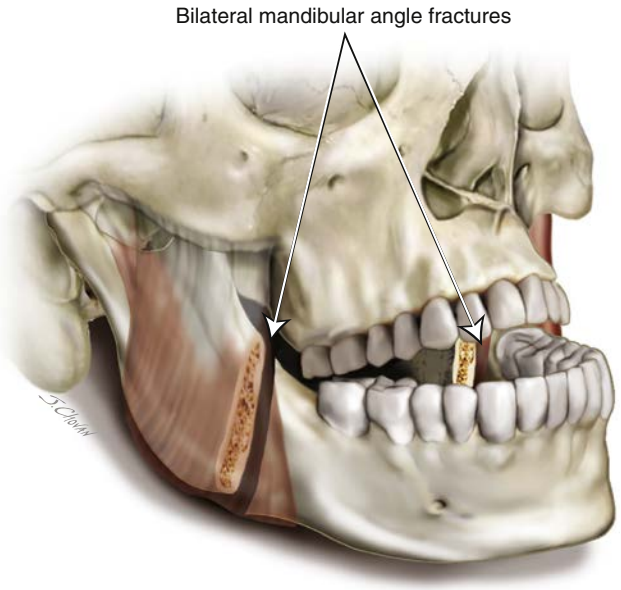

• **Figure 7-10** Bilateral mandible fractures can create posterior displacement of the distal segment due to glottic forces. This is termed the flail mandible and may have implications for the patient's airway.

unfavorable fractures are typically more amenable to open reduction and internal fixation for lack of buttressing. The routine use of computed tomography scans in maxillofacial trauma provides better diagnostic information in terms of favorable versus unfavorable compared with traditional radiographs.

Mandibular fracture displacement is defined as:

- Favorable (stable): When the fracture line and the vector of the muscle pull keep the fracture buttressed and appropriately reduced.
- Unfavorable (unstable): When the fracture line and the vector of the muscle pull cause displacement.

Similarly, a condyle fracture can be favorable or unfavorable biomechanically. Unfavorable fractures will be either displaced or dislocated. The decision to treat a condylar neck fracture open or closed can be greatly influenced by the degree of displacement or dislocation.

- Dislocated: Where the head of the condyle is dislocated from the glenoid fossa.
- Displaced: Where the head of the condyle remains in the glenoid fossa, but the neck of the condyle has been pulled out of alignment with the ramus. This can be in any direction, but most commonly is anteromedial because of the pull of the lateral pterygoid muscle.

Fracture Patterns

- Open (compound): A fracture that has communication with the external environment via skin, mucosa, or the periodontal ligament. Any fracture involving a tooth-bearing segment is an open fracture by definition.
- Closed (simple): A fracture that has no communication to the external environment.
- Comminuted: Multiple segments of bone that are shattered, crushed, or splintered.
- Greenstick/nondisplaced: The fracture is incomplete and/or only involves one cortex.
- Pathologic: Fracture occurring from preexisting disease that has structurally weakened the bone.
- Complex (complicated): Can be either a simple or compound fracture that is associated with significant adjacent soft tissue injury.
- Multiple: Two or more fractures within the same bone, but the fractures do not communicate with each other. A mandible will fracture in at least two locations approximately 50% of the time.[18]
- Atrophic: A fracture that occurs predictably at the body (often bilateral) due to mechanical weakening because of atrophy. An atrophic mandible is defined as an edentulous mandible that has 20 mm or less in height.
- Indirect: A fracture that occurs at a site distant from the area of impact—for example, the classic "guardsman fracture," involving bilateral condylar necks and the symphysis. The point of impact at the chin creates multiple fractures, a direct symphysis fracture and indirect condylar neck fractures.
- Impacted: A fracture that has segments "telescoped" on each other.

Open mandible fractures do not need to be treated with the same degree of urgency as our orthopedic colleagues would apply to open extremity fractures. Good outcomes can be expected with judicious and timely treatment, as well as with perioperative antibiotic use. In the case of open mandible fractures or mandible fractures involving tooth segments, perioperative antibiotics have been shown to be beneficial to reduce postoperative infections.[20,21] The same benefit has not been extended with the use of postoperative antibiotics.[22]

Fracture Biology

It is important for surgeons to understand the physiology of bone healing in addition to the biomechanics of facial bone function to best treat patients with any skeletal fracture. This is particularly helpful when determining the technique for fixation as well as the time allotted for the return of function. There are two processes by which a mandible fracture can heal; primary (direct) or secondary (indirect) bone healing. Either process will appropriately heal the mandible to a state that will withstand the biomechanical stress of function and form (Figures 7-11 and 7-12).

Primary healing occurs with direct contact of injured haversian systems that can remodel and form lamellar bone. The use of rigid fixation immobilizes and stabilizes well-buttressed segments to optimize contact healing without the formation of an intermediate callus. This type of healing more rapidly returns the fracture patient to the pre-injury state.

Secondary bone healing occurs with closed treatment of mandible fractures, such as when intermaxillary fixation is used for a favorable, minimally displaced angle fracture. During the healing process, a cascade of healing elements

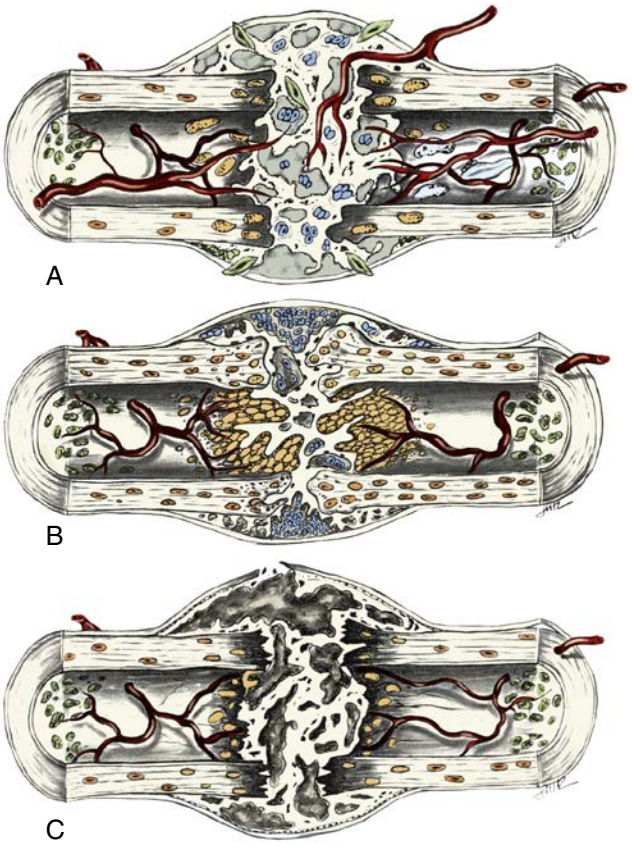

• **Figure 7-11** Early fracture with **(A)** hematoma; **(B)** fibrocartilage callus; **(C)** hard callus. This process is common with delayed healing or secondary healing.

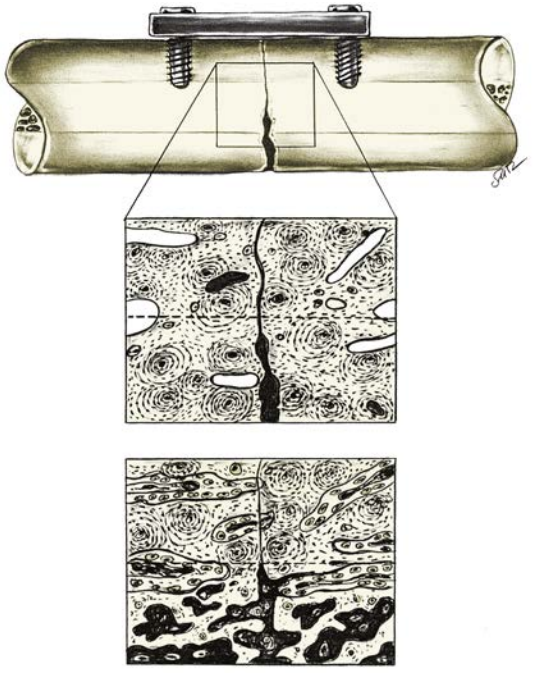

• **Figure 7-12** Primary (direct) bone healing on the superior portion closest to the plate due to close bone contact. Gap healing is the inferior portion as the bone is not in direct contact.

occupy the fracture site, beginning with hematoma formation and the subsequent inflammatory stage. This progresses into a soft callus and ends with remodeling. The periosteum and muscles place stresses on the fracture segments to create areas of apposition and resorption. This concept of mechanical stress dictating healing is Wolff's law.[23] If mechanical loading is placed on bone such as occurs with muscle pull, the bone will respond by remodeling and increasing in strength. This ultimately leads to equilibrium between stress and load. To achieve remodeling of the mandible to a full load-bearing state requires 4 to 6 months (less time than for long bones). The initial healing process, in order to return to normal function, typically takes an average of 4 to 6 weeks (depending on the type and severity of the fracture) and occurs in four stages.

- Inflammatory stage: The fracture causes a disruption of the vascular supply within the bone. Initially the fracture site hemorrhages, with the formation of a hematoma at the site. This is followed by an inflammatory process that involves the recruitment of macrophages, monocytes, neutrophils, and platelets. The vascular compromise initially causes necrosis of bone at the fractured edges, but a reparative process of angiogenesis ensues, as well as the formation of osteoprogenitor cells, mesenchymal cells, and fibroblasts.
- Cartilaginous stage: The initiation of a cartilaginous (soft) callus which is composed of fibrocartilaginous tissue. At the conclusion of this stage, the mobility across the fracture is eliminated.
- Bony callus stage: The conversion of the cartilaginous callus to a bony callus composed of immature woven bone, which typically occurs within 3 to 4 weeks of the injury. This is initiated by the conversion of chondrocytes to osteocytes, leading to the formation of endochondral bone.
- Remodeling stage: The return of the osseous tissue to its pre-injury state; continues for months following the injury. It is the final stage and results in the conversion of endochondral bone to mature lamellar bone.

Patient Assessment

Trauma centers evaluate and triage patients according to the principles of Advanced Trauma Life Support (ATLS). The primary survey is performed and the patient is stabilized. Soon thereafter, the secondary survey is conducted, including the craniomaxillofacial and neck examinations. Images can then be obtained based on suspicions brought about by clinical findings.

A history and physical exam are critical to managing head and neck injuries, and notes should be made concerning the mechanism of injury and loss of consciousness during the event. The physical exam should include an assessment from the skull to the clavicles for soft tissue injuries, ecchymosis, and asymmetries, as well as midline structures including the larynx and trachea. Neck zones I to III should be examined for penetrating trauma, crepitus, and hematoma.

The mandible and lower facial third should be examined and palpated for mobility, mucosal lacerations, fractured or avulsed teeth, malocclusion, bony steps or discontinuity, and any hematomas/ecchymosis of the floor of the mouth (Figures 7-13 and 7-14). The patient should be asked about paresthesia, anesthesia, or pain during the exam, and facial nerve integrity should be confirmed.

If a cervical collar is present, in-line stabilization should be used while the collar is removed for a thorough exam, so long as the patient is compliant. If a cervical spine injury is diagnosed, steps will have to be taken to immobilize the cervical spine during the definitive treatment of the facial fractures.



• **Figure 7-13** Step deformity seen with left mandibular body fracture.



• **Figure 7-14** Hematoma accompanying bilateral mandibular body fractures. The patient complained of progressive difficulty breathing and swallowing.

Imaging

The standard contemporary imaging modality is computed tomography (CT) to investigate maxillofacial trauma at the same time as other associated injuries. CT imaging highlights the bony structures better than other modalities, and three-dimensional reconstruction of the images can give the surgeon a comprehensive view of facial injuries. Level I trauma centers require access to CT capabilities, and the head/face/neck study can be included with a multisystem assessment when suspicion for injury exists. A mandible series of radiographs or a panoramic radiograph can also be ordered for centers without readily available CT. Right and left lateral oblique, panoramic, and reverse Townes views give the most thorough assessment of lower facial injury (Figure 7-15).

CT angiography can be used in the setting of blunt or penetrating neck trauma where vascular injury is suspected. Vascular injury to the common or internal carotid can influence the management of facial fractures if manipulation of the neck is contraindicated.

Treatment of Mandible Fractures

With all factors and possible implications considered, the treatment technique of mandible fractures is either open or closed. Technique decisions are based on the characteristics of the fracture as well as patient preference when appropriate. A Cochrane meta-analysis performed in 2013 by Nasser and colleagues was unable to recommend a single approach in the management of mandibular fractures without condylar involvement.[24]

Closed techniques use either tooth-borne or bone-borne stabilization to immobilize fracture segments to allow secondary healing. The keys to this technique are immobilization and approximation. This technique is reserved for patients who are capable of being placed into proper, premorbid occlusion, can be compliant, and possess no relative or absolute contraindication to a closed technique (seizure disorder, etc.). Whereas simple favorable fractures lend themselves to closed reduction and fixation, severe comminution of fractured segments may also be more appropriately treated using closed techniques to minimize devascularization of smaller bone fragments. There is evidence of cost effectiveness with closed reduction techniques, mostly due to materials and operative time.[25] The minimum time for adequate bony union is 4 to 6 weeks, but closed treatment can be extended to as long as 8 weeks with more severe facial injuries, comminution, or compromised patient healing capacity. The following appliances are commonly used for methods of maxillomandibular fixation:

Tooth-borne

- Erich arch bars
- Interdental wires (Ivy loops, eyelet wires, etc.)
- Lingual splint

Bone-borne

- Skeletal suspension wires



• **Figure 7-15** Radiographs such as these are less commonly used in major trauma centers but are useful in diagnosing mandible fractures. A mandible series showing a left angle fracture using **(A)** anteroposterior, **(B)** reverse Townes, and **(C)** lateral oblique views. **D,** A right mandibular body fracture is stabilized temporarily with a dental bridle wire. Typically this will be placed two teeth on either side of the fracture, if teeth are stable and present.

- External fixators
- Intermaxillary fixation (IMF) screws
- Hybrid systems (Stryker SMARTLock)

Erich arch bars have been the standard maxillomandibular fixation device for decades to render treatment in any number of settings: office, emergency room, or operating room. The stainless steel wire and arch bars are inexpensive compared to other methods of MMF. Arch bars are also excellent stabilizers for dentoalveolar fractures that may not be suitable for miniplates. The semirigid fixation adapts to neighboring teeth to reestablish intra-arch dimensions and contour. The arch bar can serve as a tension band to counter forces at the alveolar level while accompanying internal fixation techniques at the inferior border.

The arch bar does have several disadvantages: risk of operator or patient wire-related injury during placement, difficulty with patient hygiene, damage to the alveolar peridontium, and unintentional tooth movement or extrusion. Pediatric patients in the mixed dentition stage may be better served by other methods of closed treatment because of problems with arch bars engaging the height of contour and/or possible extrusion of deciduous teeth or underdeveloped permanent teeth. Depending on the state of developing tooth buds and the ability to use internal fixation, lingual splints, Ivy loops, eyelet wires, or skeletal suspension wires may be better options.

One of the more recent additions to the closed treatment/reduction armamentarium within the past several years has been the SMARTlock Hybrid MMF system (Stryker CMF, Kalamazoo, MI). The bone-borne titanium arch bar significantly reduces reliance on teeth for fixation techniques, similar to IMF screws but incorporates a full-arch distribution of forces similar to Erich arch bars.

The lingual splint is a technique with which the maxillofacial trauma surgeon should be familiar. It can be useful in the pediatric patient because of the challenges posed by mixed dentition. This phase precludes the use of internal fixation for the potential damage to tooth buds and potential for changes in growth. The lingual splint can be used in adult patients with a dentition that does not provide a stable base (i.e., partially edentulous) to reliably apply MMF. Obviously this will require impressions and casts of the maxilla and mandible. This may be difficult to obtain because of pain and trismus, and it may require the patient to undergo anesthesia. Impressions can also be made complicated by the presence of significant oral soft tissue injury and edema, or by the presence of an endotracheal tube. Before the fabrication of the lingual splint, the mandibular casts may need to be sectioned in order to reestablish an appropriate arch length and alignment. The splints can have arch bars incorporated into the acrylic and can be secured to remaining teeth/mandible with circumdental and skeletal wires.

External fixation has played a significant role in the treatment of comminuted mandible fractures and the atrophic mandible fracture for a number of years (Figure 7-16). Currently, however, the use of rigid fixation and microvascular reconstructive surgery has diminished its relevance. There are occasional instances where external fixation can be used as a bridging technique. In these situations, when the surgeon is waiting for the stabilization of soft tissue or recalcitrant infection, external fixation can be used to maintain the continuity defect and form. Once soft tissue stabilization is achieved, the definitive repair can be undertaken and the external fixation removed.

Open techniques have been revolutionized by advances in rigid fixation. Surgeons and patients appreciate an earlier return to function and avoidance of being "wired shut." Most mandible fracture segments can be accessed through oral and/or percutaneous (transbuccal) approaches. As a fracture's displacement or severity increases, the use of transcervical, retromandibular, or preauricular approaches may be warranted. Ramus and condyle fractures are typically accessed through neck and preauricular incisions; however, endoscopic approaches can be used as well.

Intraoral/Transbuccal approach (Figures 7-17 to 7-21)

1. Local anesthetic with epinephrine can be infiltrated throughout the field to aid in hemostasis.
2. An incision is made approximately 5 to 7 mm apical to the mucogingival junction. The incision is only through mucosa to aid in identification and preservation of mental nerve branches around the canine/premolar region. The foramen itself is typically located close to the apex of the second premolar; however, preoperative assessment and localization is helpful with a panoramic radiograph or CT scan. An alternative approach can be accomplished via sulcular incisions with generous releases. This approach will avoid vestibular scarring and localization of the mental nerve along its extrabony course, but might limit access and visualization for some fractures.
3. Anteriorly, the mentalis muscle is divided, leaving a cuff of muscle for closure, and posteriorly the buccinator is elevated from the mandible. A subperiosteal dissection is performed anteriorly or posteriorly using the blunt end of a periosteal to identify the mental foramen, which will help in nerve preservation.
4. The mental nerve and its branches should be identified and preserved. Skeletonization at its bony exit may be helpful for retraction and performed by incising along the periosteum overlying the nerve using a blade and tenotomy or iris scissors. If the fracture does involve the foramen, care must be taken to avoid unnecessary nerve injury during mobilization and reduction of the fracture.
5. Any granulation, clot, or fibrous soft tissue preventing proper reduction should be removed.
6. The fracture sites should be copiously irrigated to dilute microbial contamination.
7. Before fixation, all fractures should be accessed and mobilized as described.

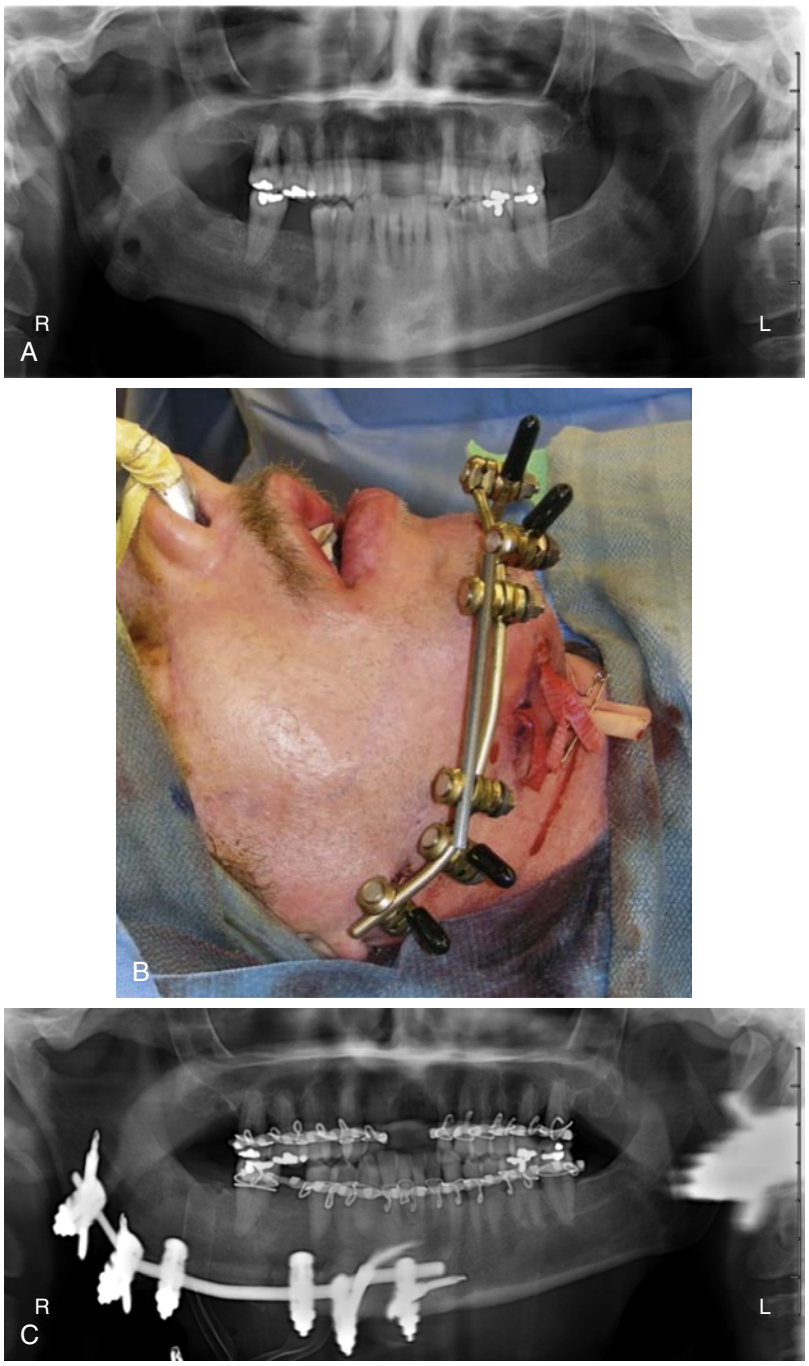

• **Figure 7-16** External fixation systems are an additional tool in the armamentarium for clinicians unable to immediately fixate segments in the setting of infection, nonunion, or noncompliance. **A,** This patient presented several weeks after sustaining a right parasymphyseal fracture with osteomyelitis and a submandibular space infection**. B,** Intraoperative photo of treatment as well as radiograph **(C)** showing fixation in place and Erich arch bars.

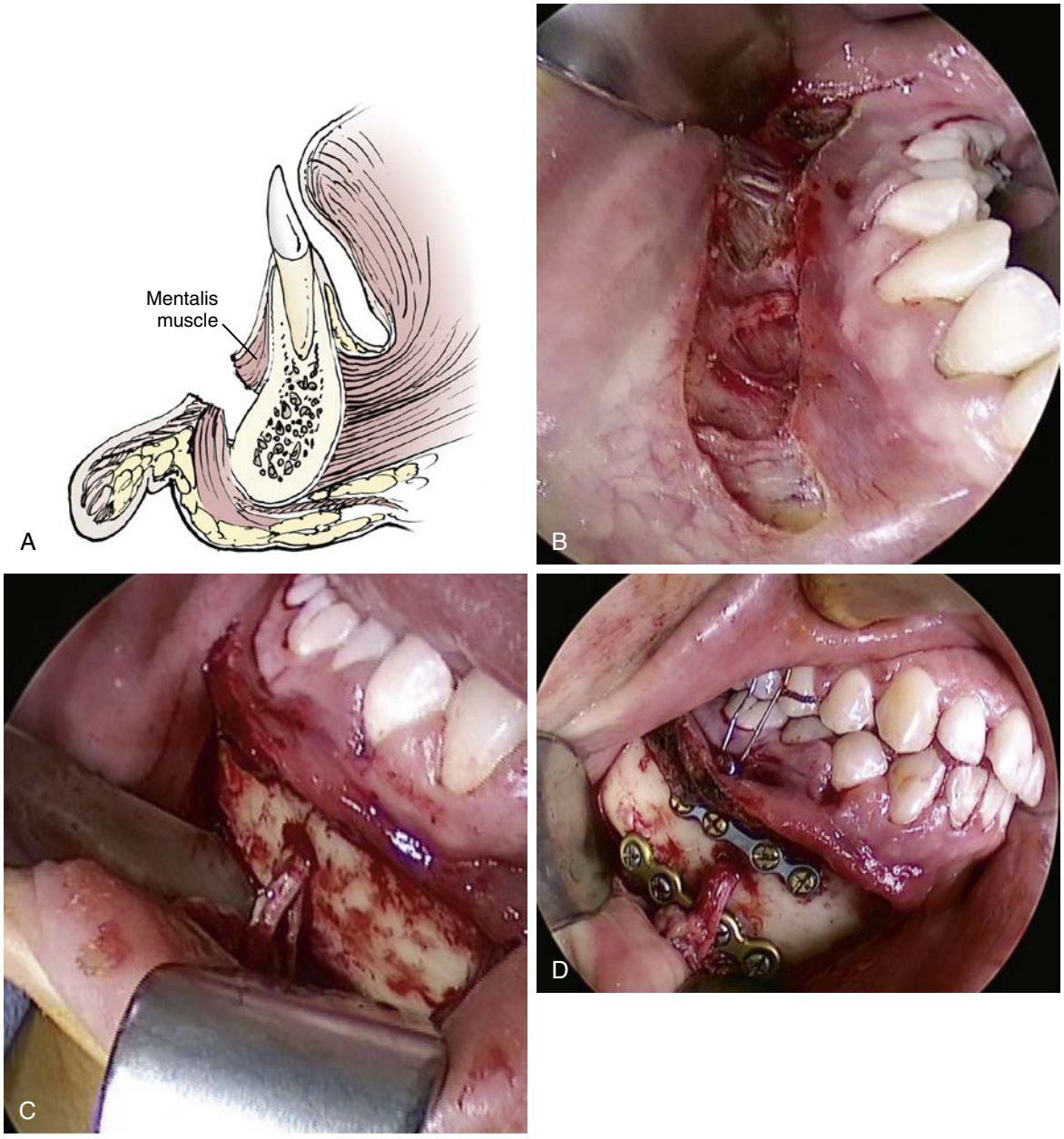

• **Figure 7-17** **A,** Path of dissection to the anterior mandible through mandibular vestibule. Mentalis muscle is incised and used later for layered closure. **B,** Access along the vestibule of the right mandible through mucosa, taking care to preserve the mental nerve. Similar vestibular access of the left angle fracture was completed. **C,** Identification, skeletonization, and protection of the mental nerve branches. IMF screw maxillomandibular fixation was used to reduce the fractures. **D,** Superior monocortical and inferior bicortical fixation is used to complete the fracture repair.

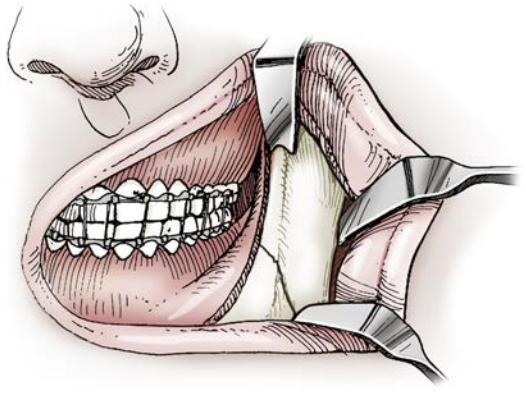

• **Figure 7-18** Transbuccal approach using subperiosteal dissection along ramus.

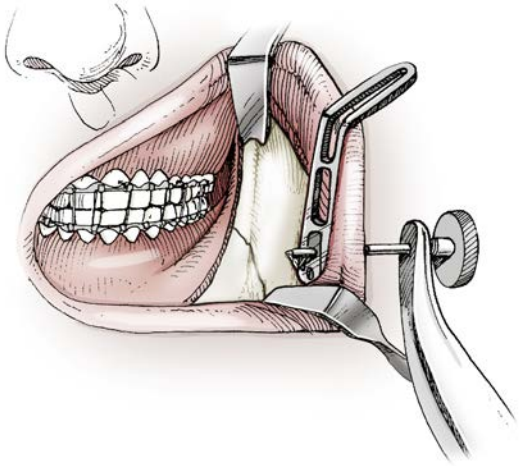

• **Figure 7-19** Transbuccal trocar in place with cheek retractor.

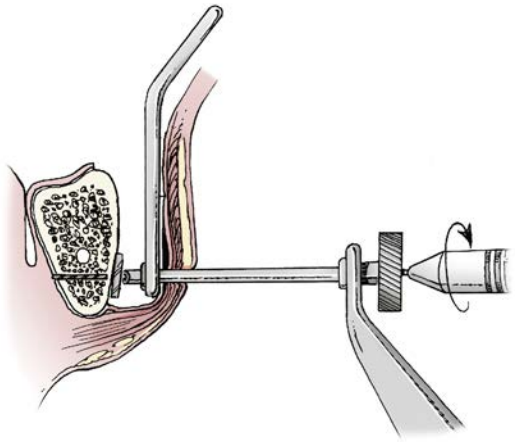

• **Figure 7-20** Preparation of inferior border bicortical plate fixation.

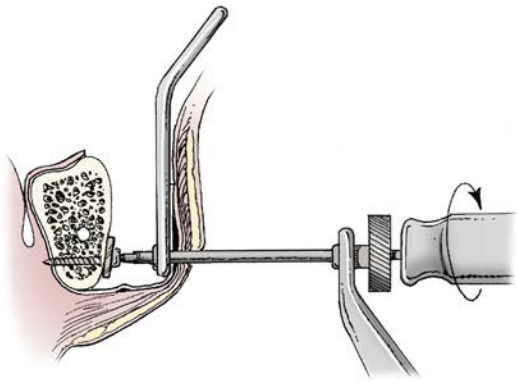

• **Figure 7-21** Bicortical screw placement based on accurate depth measurement to engage both cortices.

8. Fixation is then accomplished by any of several techniques. The authors prefer rigid fixation following AO/ASIF principles. Two-plate techniques place fixation along zones of tension and compression, typically a miniplate at the superior border and a fracture plate at the inferior border. Two-screw fixation is used on either side of the fracture with both plates for proper fixation. A single reconstruction plate (2.3 to 2.5 mm) at the inferior border can be used with three-screw fixation on either side of the fracture as an alternate technique. The authors prefer locking plates in the inferior border position.
9. A transbuccal puncture may be required to access more posterior body or angle plates (Figure 7-22). A cutaneous stab incision can be made through the cheek with a No. 15 blade overlying the portion of interest of the fracture. Blunt subcutaneous and trocar dissection is then carried out through the remainder of the cheek in order to manipulate the site for superior and inferior plate access both proximally and distally.
10. Resuspension of the mentalis muscle should be performed at closure to prevent a "witch's chin" deformity. Mucosa can then be closed using a continuous running 3-0 chromic gut suture.

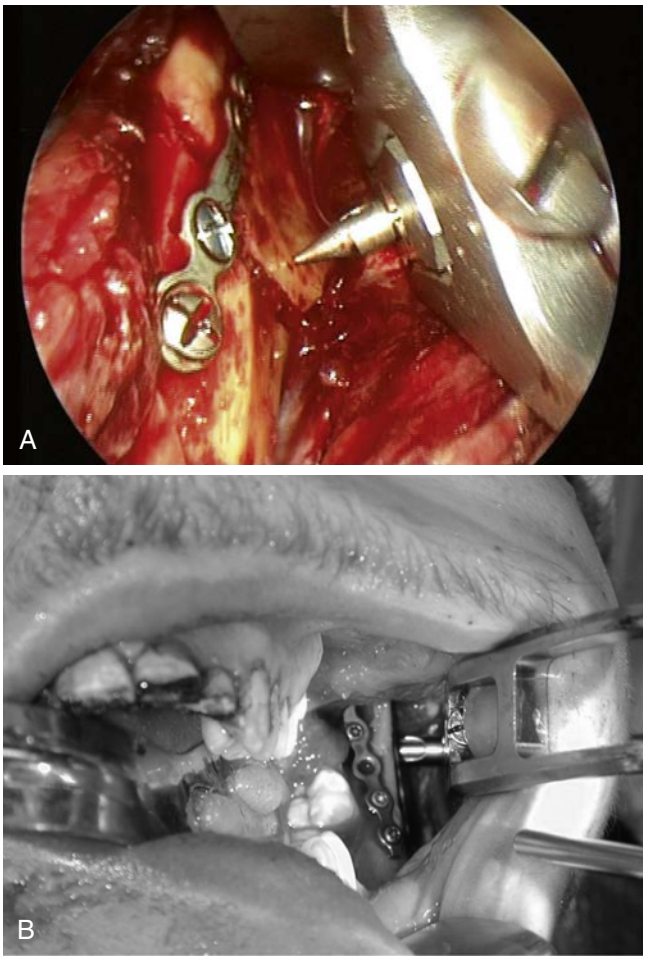

• **Figure 7-22** **A,** Transbuccal systems can be used for open reduction and internal fixation of angle and ramus fractures. The systems provide good posterior access and visualization of the fracture and fixation. **B,** Transbuccal approach to left angle.

Transcervical-Submandibular Approach (Figures 7-23 to 7-28)

A skin crease is identified approximately 2 cm (or more) below the inferior border of the mandible at the approximate area of the fracture with enough extension on either side to allow for the appropriate sized plate placement and necessary retraction. If the surgeon wishes to assess the facial nerve during the procedure, muscle relaxant should be avoided after intubation. The authors prefer a high apron incision and an anatomic approach where nerve monitoring is not used.

1. The skin, subcutaneous fat, and platsyma should be incised to identify the superficial layer of deep cervical fascia investing the submandibular gland. The marginal mandibular branch of the facial nerve will be deep to the platsyma and within the superficial layer of the deep cervical fascia.
2. The superficial fascia is divided at the inferior aspect of the submandibular gland, and a subcapsular dissection can be performed to protect the facial nerve. The facial vein can be divided at this point and retracted superiorly

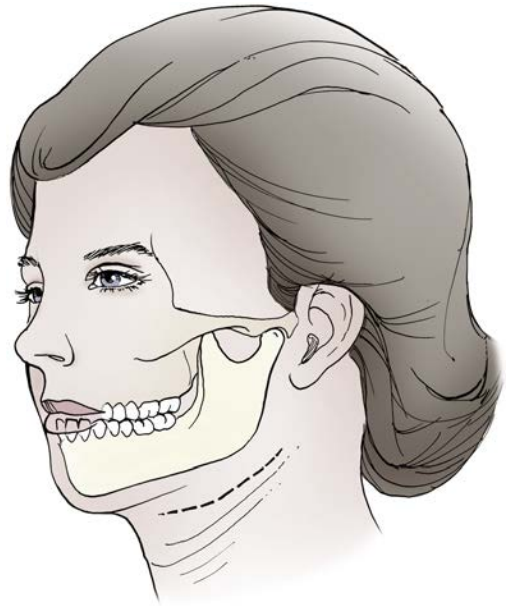

• **Figure 7-23** Extension of submandibular approach to the mandible using natural skin neck crease.

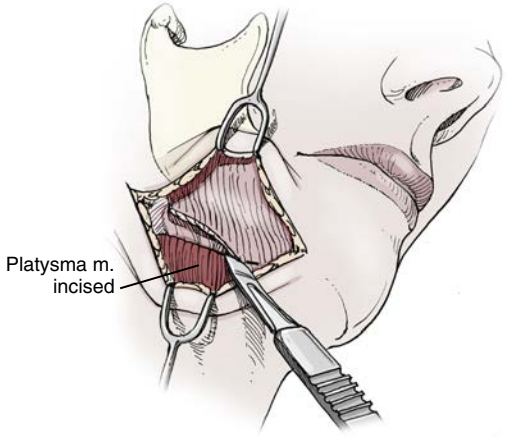

• **Figure 7-24** Incision through skin and platysma.

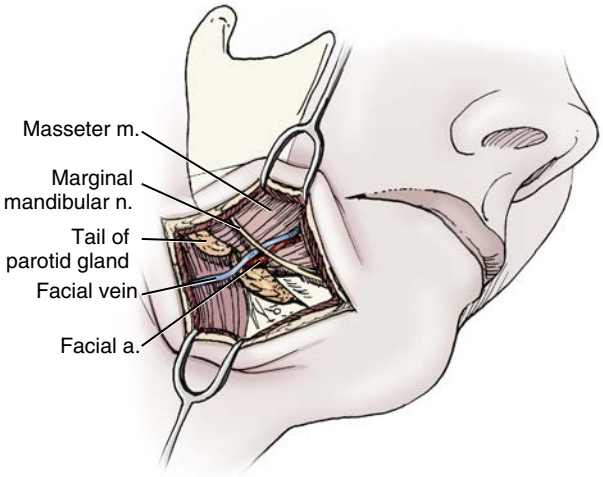

• **Figure 7-25** Dissection in subplatsymal plane to identify capsule of submandibular gland and facial vessels (artery and vein).

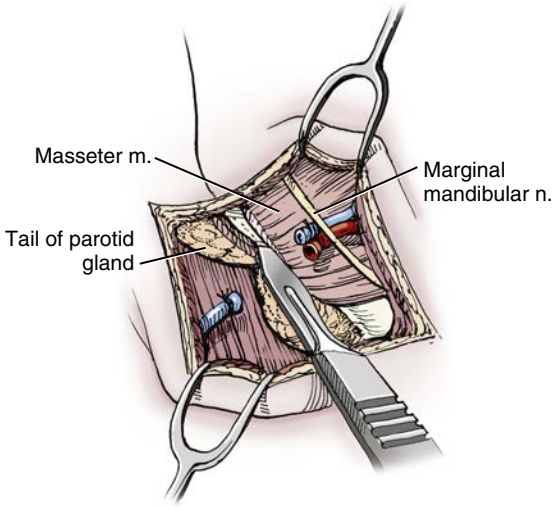

• **Figure 7-26** Division of the pterygomasseteric sling.

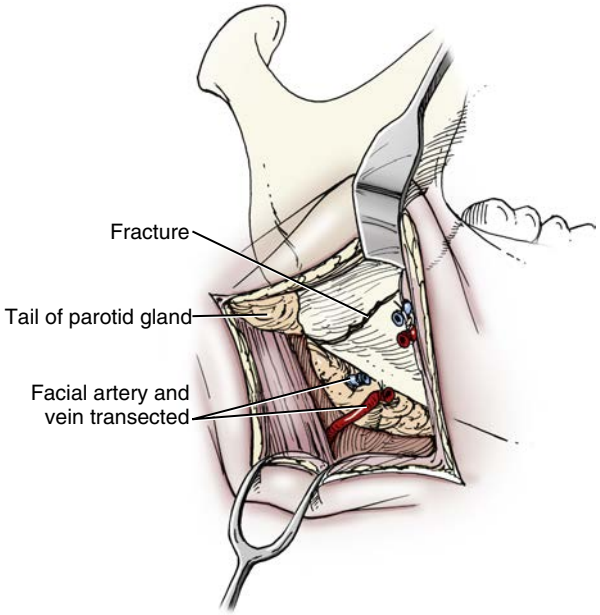

• **Figure 7-27** Identification of the fracture along a subperiosteal plane.

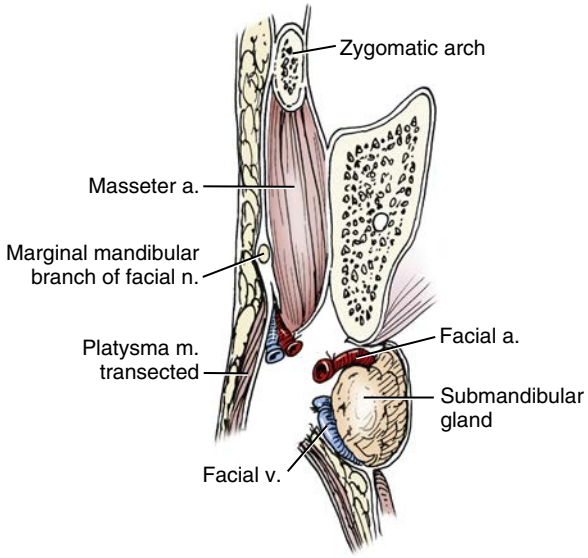

• **Figure 7-28** Coronal view of dissection planes.

to guide dissection and protect the facial nerve (Hayes-Martin maneuver). The facial artery should be identified near the posterior aspect of the gland and isolated/divided as necessitated by access. A cadaveric study by Dingman and Grabb identified the marginal mandibular branch of the facial nerve at most 1 cm below the inferior border of the mandible 81% of the time when posterior to the facial vessels. Anterior to the vessels, the marginal mandibular branches course inferior to the mandibular border only 19% of the time.[26] Nerve simulators can be used if there is any doubt or question of the tissue dissection.

3. Anterior to the gland and facial vessels, a plane of dissection deep to the superficial layer of deep cervical fascia should direct the surgeon to the anterior digastric muscle. This can be safely dissected superiorly to its insertion at the anterior mandible.
4. Using the Hayes-Martin technique of ligating and elevating the facial vein/artery, the facial nerve is protected for direct access to the inferior border of the mandible,[27] though often the anterior course of the facial artery/veins must be encountered and managed. The pterygomasseteric sling will be encountered and is incised as needed depending on location of the fracture. The periosteum is incised at the most inferior aspect of the mandible, and a subperiosteal dissection can be developed to identify the fractures.
5. Care should be taken to avoid any damage to the mental foramen while approaching and degloving the mandible from below.
6. Once the fractures have been identified, debrided, and mobilized, the patient can be placed into MMF. The fractures may need additional reduction and immobilization with reduction forceps prior to plating. Occlusion should be verified prior to final rigid fixation. ORIF principles are followed as described earlier.
7. Closure of the platsyma over a bulb suction round drain is recommended to manage dead space and prevent hematoma formation. Resorbable suture is used for platysma and deep dermal sutures. Skin can be closed with running nonresorbable monofilament or staples.

Transcervical-Retromandibular Approach (Figures 7-29 to 7-33)

A skin line several centimeters in length is marked paralleling the posterior border of the mandible 5 to 10 mm below the earlobe. The incision should be placed about 1 cm posterior to the ramus to allow elevation of the parotid gland.

1. Skin and subcutaneous fat are incised. Platysma may be encountered and should be incised as well. Identification of the superficial musculoaponeurotic system (SMAS) that invests the parotid gland and masseter and the anterior border of the sternocleidomastoid posteriorly will guide the dissection.
2. At this point two approaches are used, depending on the surgeon and level of fracture: the transparotid for higher condyle fractures, or the sub-parotid approach for lower ramus fractures.

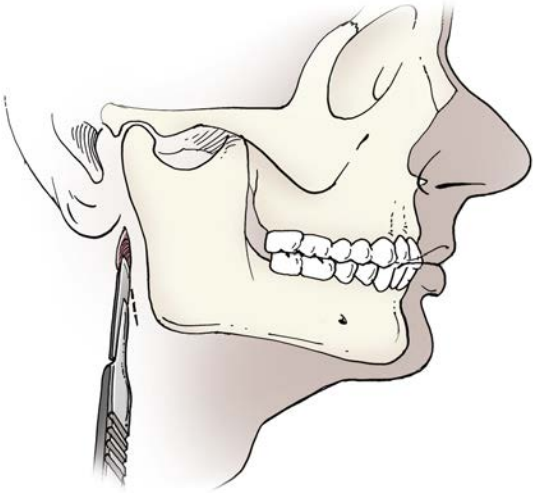

• **Figure 7-29** Retromandibular approach.

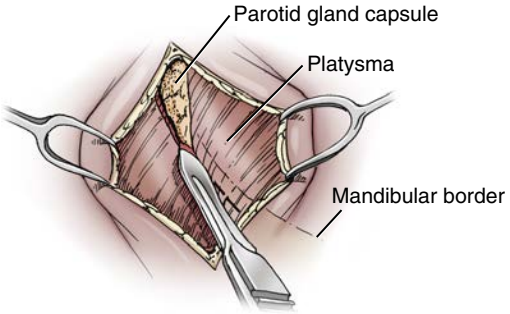

• **Figure 7-30** Incision through platysma muscle.

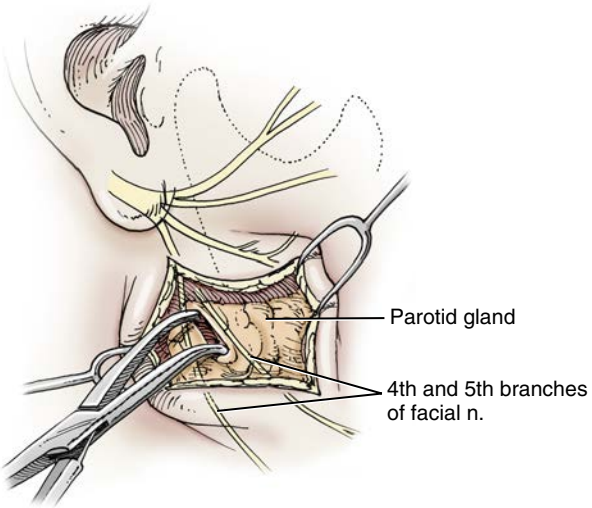

• **Figure 7-31** Dissection through the parotid bluntly to avoid facial nerve damage.

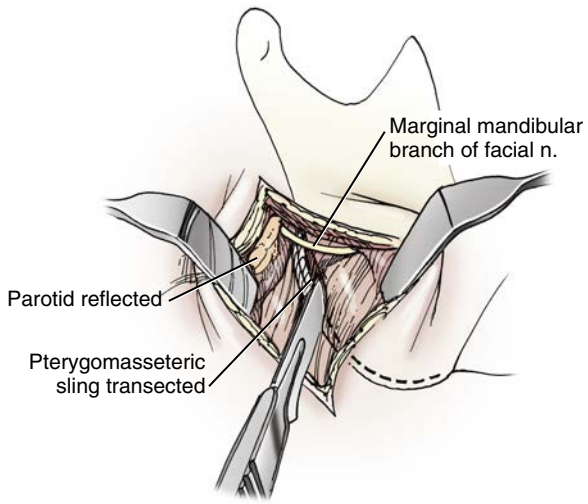

• **Figure 7-32** Incision through pterygomasseteric sling.

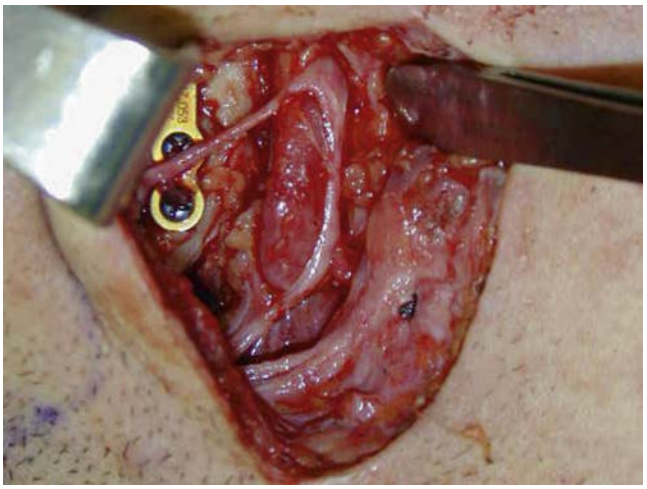

• **Figure 7-34** Identification of facial nerve branches (buccal and marginal mandibular).

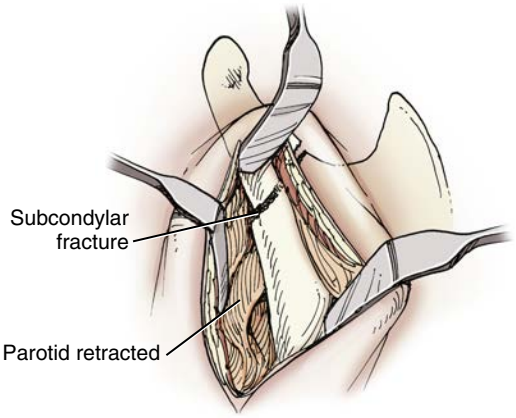

• **Figure 7-33** Exposure of condylar or mandible fracture in subperiosteal plane.

a. The transparotid directly divides the parotid capsule, and blunt dissection is used to dissect through the gland to the mandible. The buccal and marginal mandibular branches are routinely identified and retracted to access the condyle fracture (Figure 7-34). A nerve stimulator is used to verify branches of the facial nerve, and bipolar electrocautery is used for hemostasis. Transient facial nerve injury in the transparotid approach has been documented, but function usually returns by 6 months.[28] Careful retraction of the soft tissues enveloping facial nerve branches will limit the transient paralysis postoperatively.
b. The sub-parotid approach elevates the parotid superiorly to protect the facial nerve and provide access inferiorly along the posterior aspect of the mandibular angle. This approach is better suited for lower ramus fractures but can be elevated to expose up to the neck of the condyle. In this approach, the facial nerve is still susceptible to traction injury.

3. The masseter and periosteum should be incised and elevated to identify the posterior aspect of the mandible and associated fractures. Care should be taken to stay within the subperiosteal plane to avoid damage to the retromandibular vein.
4. If the sigmoid notch is encountered, a subperiosteal dissection should be maintained to avoid damaging the masseteric branch of the maxillary artery.
5. Fractures are mobilized, debrided, and reduced. Condyle fracture reduction should be reconfirmed after establishing MMF and accomplishing reduction of all other fractures. Occasionally segments of the condyle/condylar neck will be difficult to reduce with the patient in MMF.
6. Fixation should be applied as deemed appropriate. Several condyle-specific plates are currently available that are suited to the unique contours and space limitations of the anatomic region. Watertight closure of the parotid capsule using resorbable sutures will help prevent salivary leak. A round bulb suction drain can once again aid in the elimination of dead space and avoid seroma or hematoma formation. A pressure dressing can also aid in hemostasis and prevention of a salivary leak. Platysma is reapproximated and skin closed with running nonresorbable, monofilament suture.

Endoscopic Approach

Endoscopic approaches to the subcondylar and condylar region are used to minimize facial nerve damage as well as facial/neck scars. The approach uses a sagittal split/lateral mandibular vestibule access to manipulate segments and place miniplates. A less than 1 cm submandibular incision can be used with minimal dissection deep to the pterygomasseteric sling to place the endoscope. A 3- to 4-mm Storz endoscope can be used for the procedure. As previously mentioned, mobilization and reduction techniques should be carried out, but this time using direct endoscopic view and instrumentation. Right-angle drills and screwdrivers can be used to avoid percutaneous access higher on the face.

The technique requires considerable patience and typically will increase the surgical time by 1 to 2 hours.[29] The benefit is largely a reduction in facial scars when endoscopic approaches are compared to open access, along with decreased rate of facial nerve complications.[30] More details of endoscopic approaches to mandible fractures are presented in additional chapters.

Internal Fixation Techniques

The advancements in rigid internal fixation have revolutionized mandible and maxillofacial fracture treatment outcomes and hastened return to function. There are two broad categories of fixation methods:

- Semirigid fixation
- Rigid fixation

Semirigid fixation (with or without maxillomandibular fixation):

- Champy's technique (monocortical miniplate fixation)
- Resorbable plates
- Monocortical plate fixation (non-Champy)

Maxime Champy was a pioneer of semirigid fixation techniques.[12] Using the lines of osteosynthesis, based on his understanding of torsion, compression, and tension, miniplate semirigid fixation could be placed with proper buttressing to reduce the fractures and encourage primary healing within very specific parameters of wound management (Figure 7-35). This type of fracture fixation is best used with compliant patients who have well-buttressed fractures or along with a brief period of maxillomandibular fixation.

In pediatric patients, resorbable plates can add some rigidity to the reduction of a mandible fracture without the possibility of having to remove hardware due to translocation concerns. Poly-L-lactic or polyglycolic acid are major components of the current resorbable plating systems available. These constructs are reduced to water and carbon dioxide at about 8 to 18 months, depending on the polymer material composition. Most plating companies use a proprietary polymer with similar strength and resorption properties.[31] Resorbable plates should not be used as primary load-bearing plates, but several sources highlight their use with reduced or equivalent complication rates when compared with titanium plates and screws in well-buttressed fractures[32-34] (Figure 7-36). The cost and nature of the technique can be a deterrent for some surgeons.

Transosseous wire fixation has limited use in today's realm of miniplate and rigid fixation. Occasionally with comminuted fractures, smaller fragments can be transiently realigned with wire in preparation for placement of a reconstruction plate or more stable fixation.

Rigid fixation can use a number of techniques:

- Two-plate technique (superior monocortical tension-band and inferior border bicortical compression plate)
- Reconstruction plate
- Lag screw

The two-plate technique traditionally uses a superior tension band, low-profile/miniplate (or dental arch bar) to prevent fracture distraction at the alveolar process level, while a more rigid intermediate-profile plate is placed in the compression zone at the inferior border. The superior border plate is a monocortical plate respecting the local dental anatomy. The inferior border plate is fixated with bicortical screws to maintain rigidity, immobility, and fracture reduction.

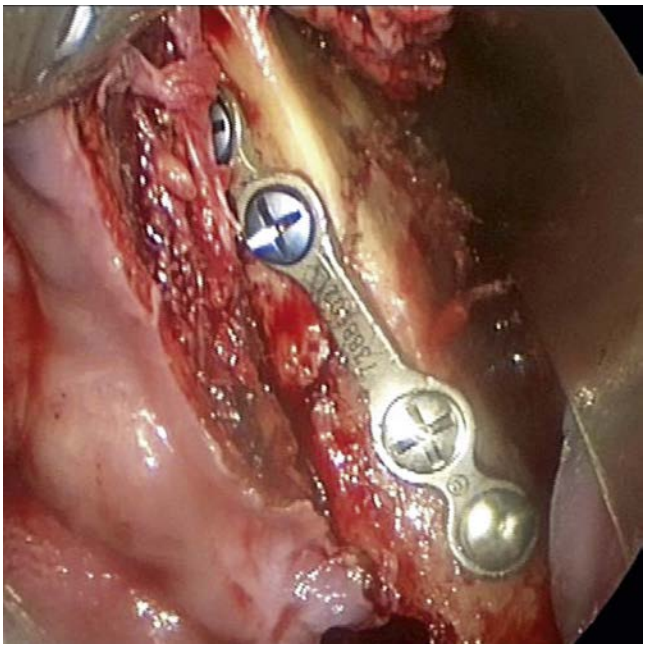

• **Figure 7-35** Favorable mandibular angle or ramus fractures may be amenable to Champy-style tension plates where compressive forces at the inferior border maintain fracture reduction. This obviates the need for transcervical or transbuccal approaches and the need for long-term maxillomandibular fixation.

A reconstruction plate is a rigid, higher-profile plate meant to temporarily restore form when a continuity defect is anticipated or when used to serve as the sole form of fixation. These plates are used for more load-bearing situations such as atrophic mandible fractures or continuity defects that require rigidity, flexion, and torsion strength (Figure 7-37).

Hardware Materials

Principles of orthopedic surgery in reduction and fixation were the initial concepts adopted and applied to mandible fractures. AO/ASIF introduced compression techniques to orthopedics in 1969, but required the additional modification of tension banding in the mandible to prevent displacement.[35,36] Compression plates have now largely fallen by the wayside. Contemporary plate manufacturers instead typically produce two kinds of fixation plates and screws: locking and nonlocking (bone plates). Depending on the scenario, either can be used with good results, so long as there is an understanding of the biomechanics and limitations of each device.

Nonlocking plates and screws do not have the capability of creating the single functional unit that a locking

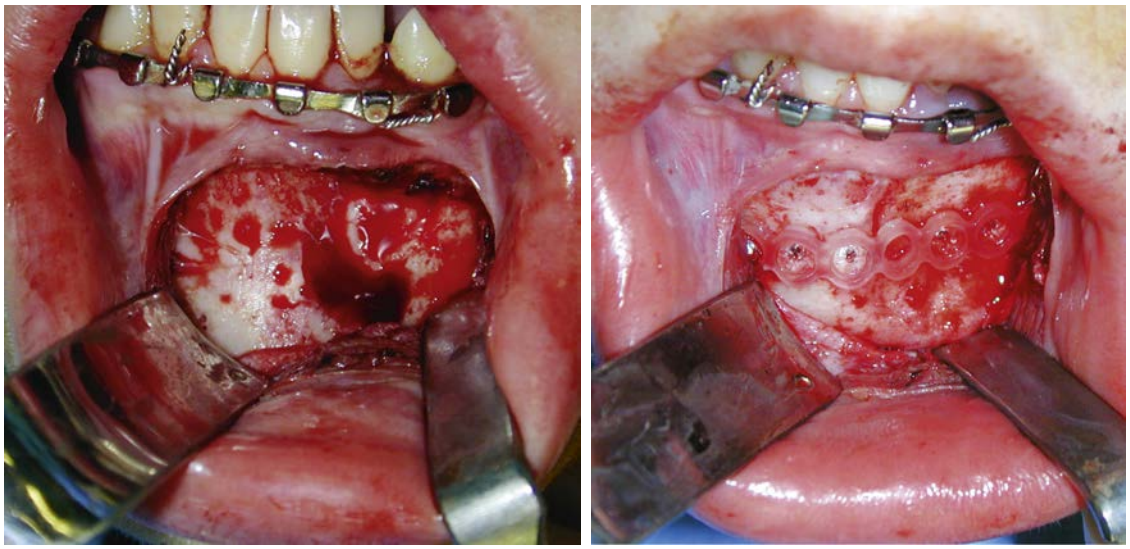

• **Figure 7-36** Resorbable systems can be used to treat pediatric fractures when there is concern that ongoing growth may result in translocation of hardware.

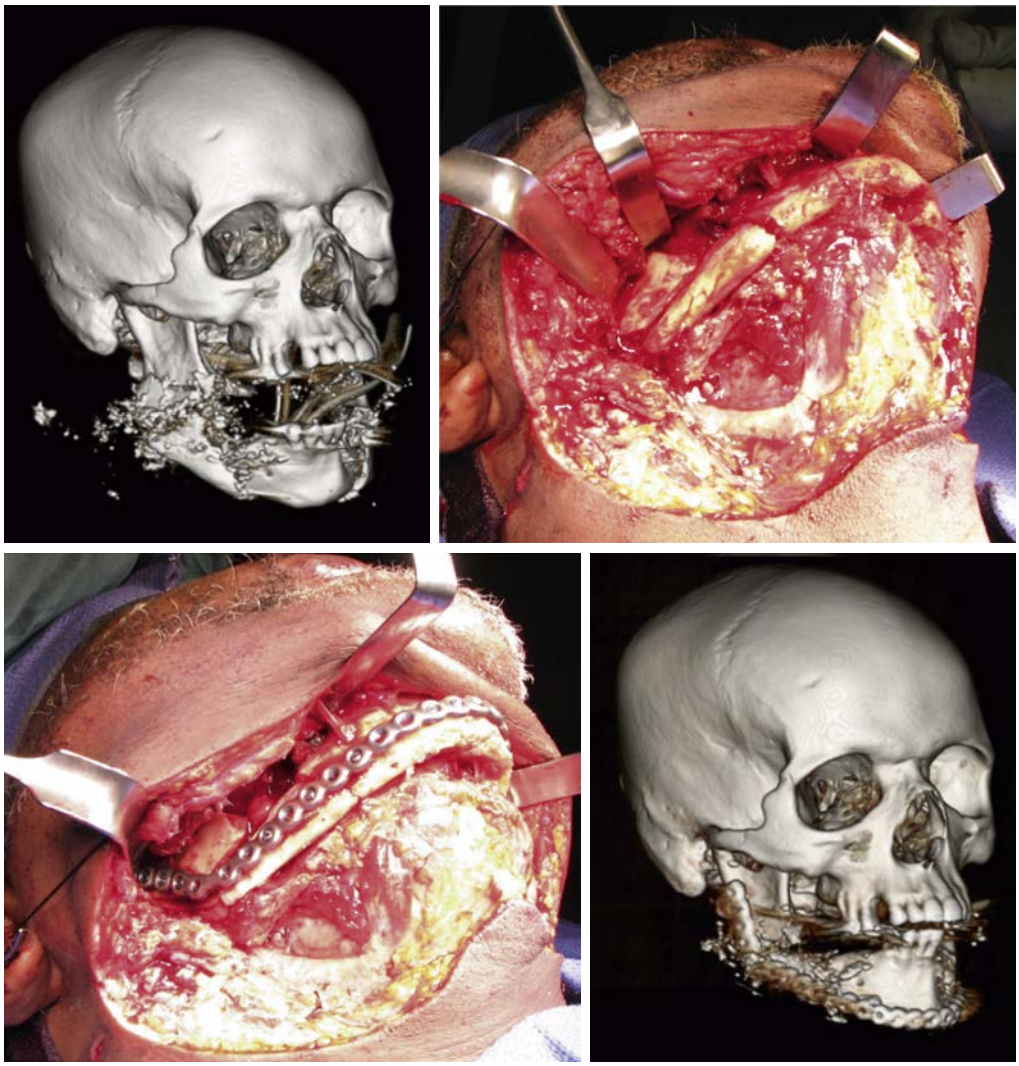

• **Figure 7-37** With severely comminuted mandible fractures, load-bearing fixation is used. This patient sustained a low-velocity gunshot wound to the mandible. Using virtual planning technology, a prefabricated titanium reconstruction plate was used to accurately reconstruct the lower jaw contour.

system does from the screw engaging the plate (Figures 7-38 to 7-40). Therefore, a compressive force is transmitted to the cortex once the screw is put to depth, which can compromise the vascularity of the bone adjacent to the plate, causing bone resorption. Additionally, the force transmitted from plate to bone can distract the fracture when plate position is not completely passive. The sum total of these two ill effects (hardware loosening and non-anatomic fracture reduction) can result in nonunion with low-load but persistent shear forces preventing bridging bone formation.

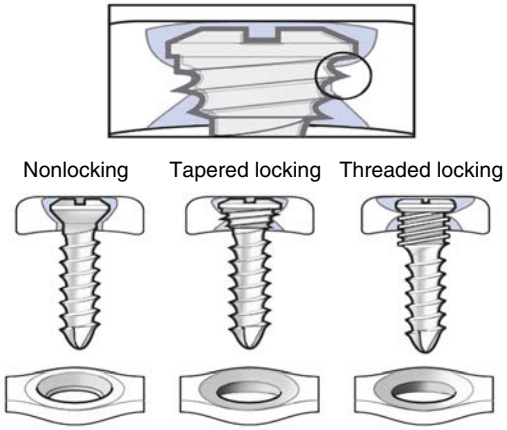

• **Figure 7-38** Plating and screw designs.

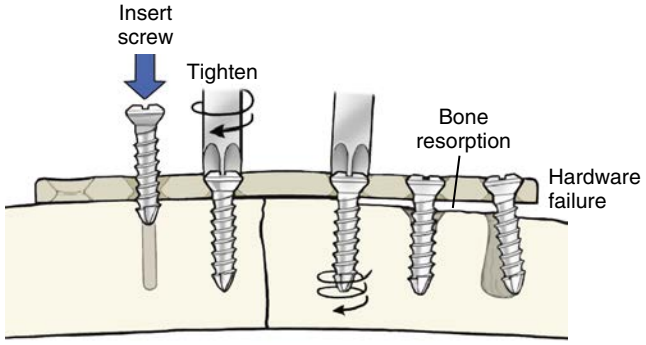

• **Figure 7-39** Bone resorption leading to hardware failure with nonlocking screws and plate.

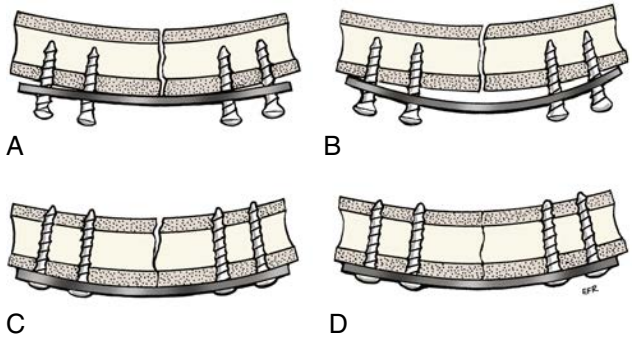

• **Figure 7-40** Plating situations: **A,** Underbent plate with gap healing. **B,** Lingual gap with tightened undercontoured plate. **C,** Overcontoured plate with gap. **D,** Tightened overcontoured plate with good bony reduction. (From Baker S, Dalrymple D, Betts NJ: Concepts and techniques of rigid fixation. In Fonseca RJ, Walker RV, editors: *Oral and maxillofacial trauma*, ed 2, vol 2, Philadelphia, 1997, WB Saunders.)

Locking plates and screws allow machine-placed threads in the screws to engage the plate and rigidly stabilize the entire unit without transmitting forces from the plate to the bone. This concept was initially introduced in 1987 as the titanium hollow-screw osteointegrated reconstruction plate (THORP).[37] A titanium plate was adapted to a fracture and positioned with hollow-bone screws. An expansion screw was then placed in the head of the bone screw to engage and lock the hollow screw into the titanium plate. The design was short-lived and replaced quickly by the contemporary locking screw that threads directly into the machined threads of the plate (thread-lock).[38] The locking plates allow for less precise adaptation of the plate to the bone without affecting the anatomic reduction of the segments. Other locking designs soon emerged (tapered-lock), each with advantages and disadvantages. There is limited evidence to show the locking design to be superior in terms of complications or surgical outcome when compared with nonlocking systems.[39]

The lag screw technique is a cost-effective rigid fixation method that applies a compressive force across reduced bony segments, maximizes bony buttressing, and eliminates the need for plate bending (Figures 7-41 and 7-42). The concept was first adapted from orthopedic surgery and applied to mandibular fixation in 1970 as a simple and effective mode of treatment.[40] This technique is ideally used in vertical well-buttressed fractures of the anterior mandible using two lag screws paralleling each other, and placed from opposite sides of the fracture. The lag technique prevents torsion and flexion of the mandible, maximizes fracture surface contact, and provides rigidity. The biomechanics of the technique compresses bony segments using a threaded hole in the opposite cortex and an unthreaded overdrilled portion of the cortex nearest the head of the screw. Countersinking of the screw head is optional for better contour. Screw stripping, shearing, fracture displacement, and instrument failure are inadvertent sequelae that can all occur using this technique.

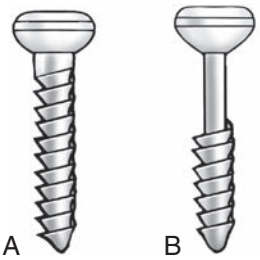

• **Figure 7-41** **A,** Passive bone screw. **B,** Lag screw with unthreaded superior section. (From Baker S, Dalrymple D, Betts NJ: Concepts and techniques of rigid fixation. In Fonseca RJ, Walker RV, editors: *Oral and maxillofacial trauma*, ed 2, vol 2, Philadelphia, 1997, WB Saunders.)

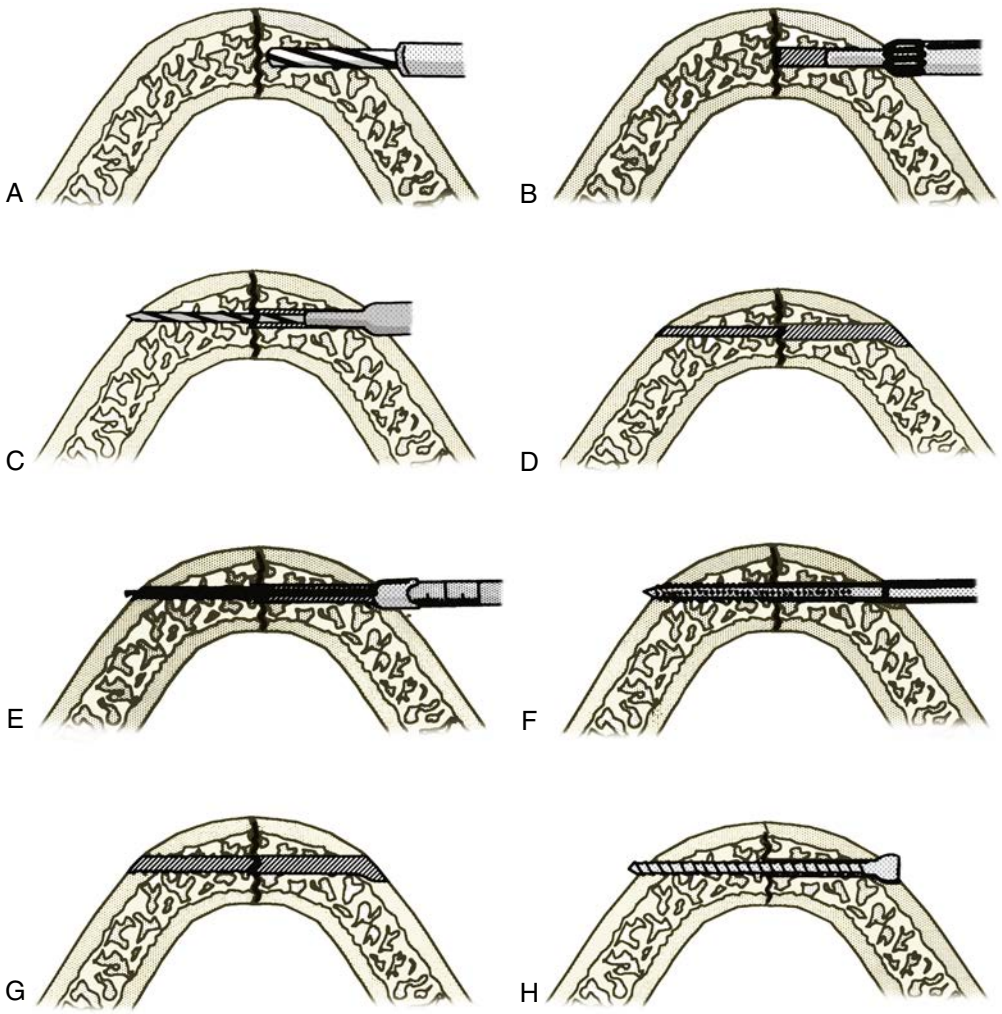

• **Figure 7-42** Protocol for lag screw placement for symphyseal fractures of the anterior mandible. **A,** Outer cortex wider diameter hole (2.7 mm) with **(B)** countersinking. **C,** 2.0-mm drill through opposing cortex through mandible. **D,** Resulting difference in proximal and distal segments of mandible based on 2.7-mm and 2.0-mm holes drilled. **E,** Depth gauge applied to assess fixation screw length. **F,** 2.0-mm tap then applied to distal segment. **G,** Screw threads present in proximal and distal segments. **H,** Lag screws inserted. Ideally a second screw would be applied in the opposite direction in an inferior and superior orientation. The lag screws would only engage the far cortex. (From Ellis E, Ghali GE: Lag screw fixation of anterior mandibular fractures, *J Oral Maxillofacial Surg* 49:13-21, 1991.)

Controversial Topics in Mandible Fracture Repair

Teeth in Line of Fracture

Most teeth involved in mandibular fractures do not require extraction, nor has any reduction in morbidity been demonstrated.[41,42] Indications for tooth removal include:

- Periapical pathology
- Active infection (acute or chronic)
- Interference with fracture reduction
- Root fracture

Some teeth in fracture sites can aid in buttressing fractures when maxillomandibular fixation is applied; however, recent literature has noted higher percentage of hardware failure when positioned over teeth in the line of the fracture[43] (Figure 7-43). If teeth become symptomatic, extractions can performed approximately 4 to 6 weeks after fracture union has been confirmed clinically and radiographically. Incision design, especially in angle fractures with planned removal of a third molar, should be tailored to promote primary closure over fracture sites and hardware.

Condyle Fractures

Fractures of the mandibular condyle can be within the TMJ capsule or extracapsular—at the neck/subcondylar. There is significant controversy surrounding the proper management of mandibular condyle fractures in the extracapsular classification. Several authors highlight better patient function and occlusion using open techniques.[44] The ultimate determining factor should be the ability to restore the occlusion



• **Figure 7-43** Panorex radiograph of left angle fracture splitting the lower left third molar. The tooth will require extraction to reduce postoperative complications.

and the patient's ability to function without pain. Details of condylar fractures including open and closed indications are discussed in a separate chapter.

Angle Fractures

Angle fractures are one of the most common fracture sites treated and are more likely to occur with an impacted third molar.[45] Managing the area is complicated by the distracting forces imposed by a network of muscle attachments (masseter, pterygoids, temporalis, and ligament attachments) and the inability to use tooth-borne stabilization of the superior border, such as an arch bar. Unfavorable angle fractures treated solely with maxillomandibular fixation may allow rotation of the proximal segment and subsequent malunion. The use of rigid fixation is currently advocated by many for the treatment of unfavorable displaced angle fractures, though Champy questioned the need for such treatment in nondisplaced or minimally displaced and favorable fractures. Using a single monocortical tension plate positioned on the external oblique ridge, semirigid fixation can be achieved to avoid neurovascular damage and damage to adjacent teeth, and to return function without maxillomandibular fixation.[12,46] In 1999, Ellis's prospective study reviewed eight methods for treating mandibular angle fractures. Transoral open reduction and semi-rigid fixation using the Champy technique yielded the lowest complication rate at 2.5%. Open reduction and rigid internal fixation (ORIF) paired with a transcervical approach and fixated with a reconstruction plate resulted in the next lowest rate of complication at 7.5%. Suffice it to say that there are many valid techniques used to treat angle fractures, and aside from the treatment of condylar injuries, angle fractures may generate the most differing opinions. There are several issues to consider when choosing a modality of treatment, including fracture buttressing, the need for tooth extraction, the presence of soft tissue injury, medical comorbidities, concomitant upper facial injuries, and patient compliance. Once the appropriate fixation method has been chosen, most fractures can be treated with a transbuccal/transoral technique. Transcervical approaches are warranted for unstable fractures and those where anatomic reduction is necessary.

Atrophic Mandible Fractures

Decreased osteogenesis, mandibular basal bone atrophy, and reduction in bone perfusion are common occurrences in elderly individuals. The inferior alveolar artery provides little predictable blood supply to the mandible with age, and instead, the lower jaw relies on periosteal and muscle attachment for vascularity.[19] Mandibular atrophy is evaluated based on the presence or absence of alveolar bone and varying amounts of basal bone height that may help guide treatment. Less than 1 cm of height is graded as severely atrophic and is at the highest risk for fracture.[47] The most susceptible portion of the mandible is in the saddle area of the mandibular body, where the bone tends to resorb to its lowest point of muscle attachment, the mylohyoid. Conservative techniques exist, including Gunning splints, circum-mandibular wires, and soft diets. These were advocated by the first Chalmers J. Lyons study in 1976.[48] However, the second Chalmers J. Lyons study in 1993 by Bruce and Ellis[49] suggested that rigid fixation should have a role in the treatment of atrophic edentulous mandible fractures and served to promote open approaches with rigid internal fixation (Figure 7-44).

Two primary management considerations include the placement of fixation where there is adequate blood supply to maintain healthy bone stock, and the use of a load-bearing reconstruction plate. With open approaches, periosteal detachment is inevitable but should be limited to the buccal tissues. Primary or secondary titanium reconstruction plates appropriate for the given fracture are then chosen and configured to span the fracture(s) with fixation screws placed in the symphysis and ramus. This should allow sufficient bone healing at the relatively less vascular fracture sites without concern for screw loosening while maintaining its load-bearing capability to restore function. With proper rigid technique, a lower rate of complications can be expected with open versus closed treatment.[50] Grafting can be undertaken

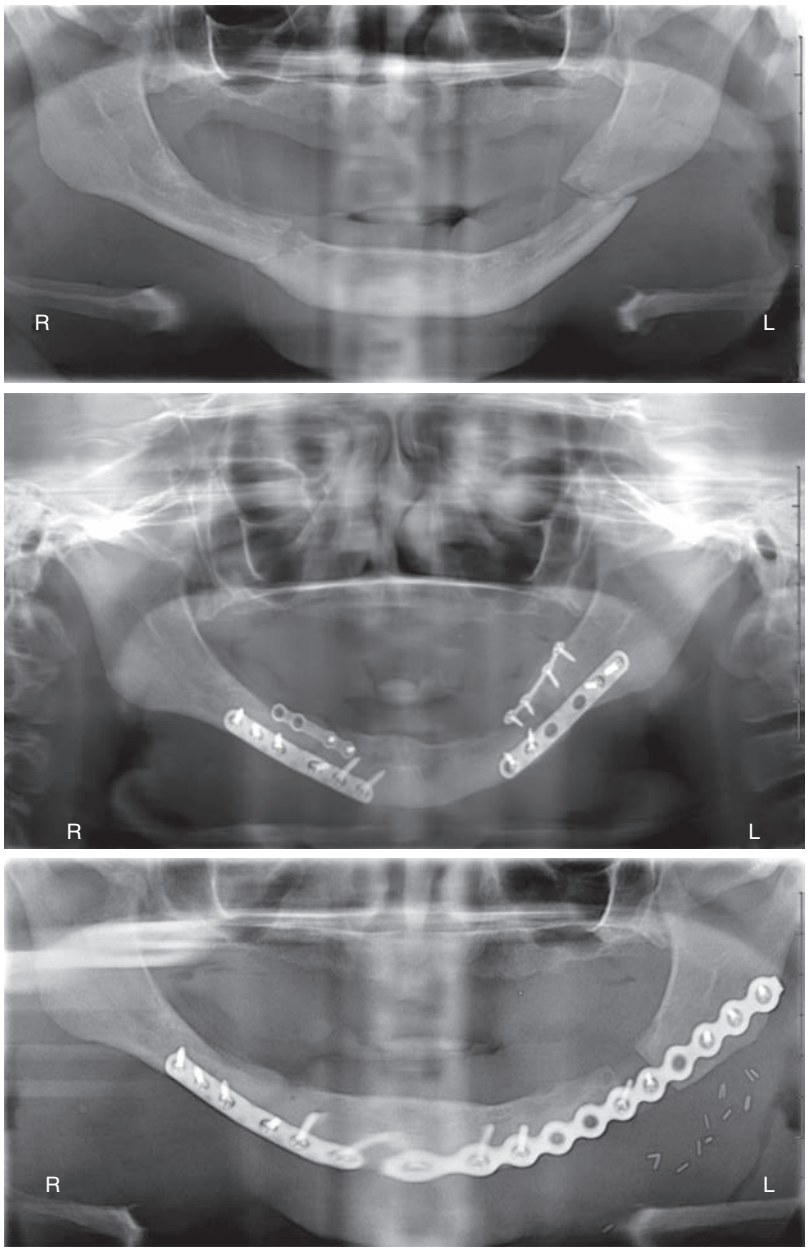

• **Figure 7-44** Inadequate fixation of a bilateral atrophic mandible fracture required reoperative fixation with a reconstruction plate and anterior iliac crest bone graft.

simultaneously with this form of rigid fixation in anticipation of dental rehabilitation.

Pediatric Mandible Fractures

The management of pediatric mandible fractures presents challenges unique to this age group. Treatment can be complicated by the presence of developing tooth buds, primary dental anatomy, and tooth loss experienced in the mixed dentition time frame. Nutrition and compliance are also distinctive considerations to this patient population. Greenstick fractures or monocortical fractures are more commonly observed because of the inherent flexibility of the mandible. The tenets of reduction and fixation are still important in this patient group, though the methods frequently differ. Controversies exist and revolve around the use of titanium versus restorable fixation as well as the necessity of plate removal when titanium is used.

Minor malocclusions are more forgiving in the primary and mixed dentition as differential tooth eruption can help to compensate for this in subsequent growing years. Condyle fractures are the most common mandibular fracture in the pediatric population.[51] The treatment of condyle fractures in children (<12 years old) is less controversial than in adults where the mainstay of treatment is closed or observational only. Damage to the growth center of the condyle can result in altered growth and facial asymmetry if not monitored. A more thorough review of pediatric mandible fractures is undertaken in another chapter.

Complications

Infection is the most common complication reported with mandibular fractures. With the advent of perioperative antibiotic therapy and plate-based fracture fixation, infection rates have been reduced compared to the wire osteosynthesis era, but still remain a challenge for even experienced surgeons. Sources quote infectious complications anywhere from 0.4% to 32% of all cases.[52] A study in 1975 examining pre-procedure antibiotic therapy for mandible fractures comparing closed and open techniques found a reduction in infection rate from 50% to 6%.[53] However, more contemporary evidence using randomized controlled studies has demonstrated less of an impact.[54,55] There is also a correlative relationship between postoperative infections and patients who are either immunocompromised or substance abusers.[56] Infections have also been associated with delayed fracture management, with evidence showing that increased time from injury to definitive treatment (greater than 72 hours) is correlated with a higher infection rate.[57] Surgical intervention is required for abscess drainage, debridement of infected tissue, and removal of any fibrous union. Koury and Ellis were able to treat infected mandibular fractures with placement of rigid reconstruction plates at the time of debridement.[58] Rigid fracture fixation is critical to allow normal bone healing and prevent any further complications at the site. Colonized hardware and biofilms are a concern; however, the majority of these fractures go on to heal with a stable union whether or not hardware eventually has to be removed (Figure 7-45). Clinical mobility, however, may indicate loose or infected hardware and nonunion that requires immediate surgical attention and consideration for closed treatment such as maxillomandibular fixation or external fixation. Long-term antibiotics via a peripherally inserted central venous catheter (PICC line) may be warranted for certain cases.

Malunion and malocclusion are the result of improper fracture alignment that occurs less frequently than infections. The literature sites a 0% to 4% occurrence in treated mandible fractures.[52] Improper reduction, insufficient mobilization, poor patient compliance, or improper fixation techniques can all lead to malunions (Figure 7-46). Transient malocclusion may present in 17% to 19% of cases after an open procedure, with only 0.5% to 3% requiring a secondary revision surgery.[59,60] Temporomandibular joint swelling/hemarthrosis/effusion and pterygomasseteric sling detachment may cause a transient postoperative malocclusion. Occlusal adjustments, orthodontics, or corrective jaw surgery may be suggested to patients with significant dysfunction or malunion following resolution of surgical edema. To prevent a malocclusion from occurring, proper reduction and fixation should be executed with careful attention to the occlusion intraoperatively. Panfacial trauma repair also requires attention to facial width and skull base articulation to accurately restore form and function (Figure 7-47). Family members and oral health care providers can assist with pictures or records of anterior open bites, asymmetries, or other dental abnormalities.

Nonunion/fibrous union is a usually result of fracture site mobility and the unstable formation of fibrovascular bridges. A hypoxic and inflammatory state may persist that prevents osteoprogenitor cells from functioning properly and repairing the defect. Fibrous ingrowth results in impaired bone filling capability. Nonunion has a reported overall incidence of approximately 3%.[61,62] Reoperation with debridement of the fibrous union is necessary along with removal of colonized or mobile hardware. In some cases, the retreatment may result in segmental defects that may require grafting. Rigid internal fixation should be employed if possible, or temporary external fixation/MMF may be used to help to stabilize the segments if recalcitrant infection is the cause.

Nerve damage is a rare permanent occurrence in mandible fractures. The inferior alveolar nerve (IAN) is the most commonly injured nerve and is housed in a cortical canal that runs through the ramus, angle, and body of the mandible, and exits its bony conduit at the mental foramen. The foramen is a consistent weak point in the mandible architecture that is frequently involved in the fracture line. Transient paresthesia is reported in about 11% to 59% of displaced fractures.[63,64] These injuries are predominately categorized as neuropraxias, where the nerve has been stretched or crushed. Traction injury can be a consequence of treatment for symphysis, parasymphysis, and body fractures. The degree of displacement can affect the severity of injury to the IAN, but it is rarely severed. Some sources report sensory deficits of the IAN distribution in as many as two thirds of fractures with displacement.[65] The degree of paresthesia should be carefully assessed before repair to evaluate the role of iatrogenic injury caused by manipulation, reduction, and placement of fixation. In situations of axonotmesis or neurotmesis (Sunderland IV or V) and preoperative anesthesia, surgical neurorrhaphy can improve sensory outcomes when performed at the time of mandibular fracture repair.[66] This is more often the case in severely displaced mandible fractures. Preoperative Sunderland I, II, or III nerve injuries do not require surgical repair and in fact may worsen with open fracture surgery.[67]

Facial nerve damage can be a result of access where a transcervical, retromandibular, or preauricular approach has been used. Significant dislocations of the condyle have been reported to cause facial nerve injury as well.[64]

Conclusion

Mandible fracture management is a complicated and evolving process aiming to restore form and function with early mobilization and minimal morbidity. The treatment choices depend on a wide array of variables, patient factors, and resources; however, the predictability of fixation with modern hardware and stabilization principles allows for consistently excellent outcomes.

Acknowledgment

The editors wish to thank Drs. John Caccamese and Dominic Coletti for their previous contributions to this chapter as well as Dr. Daniel Meara for patient cases.

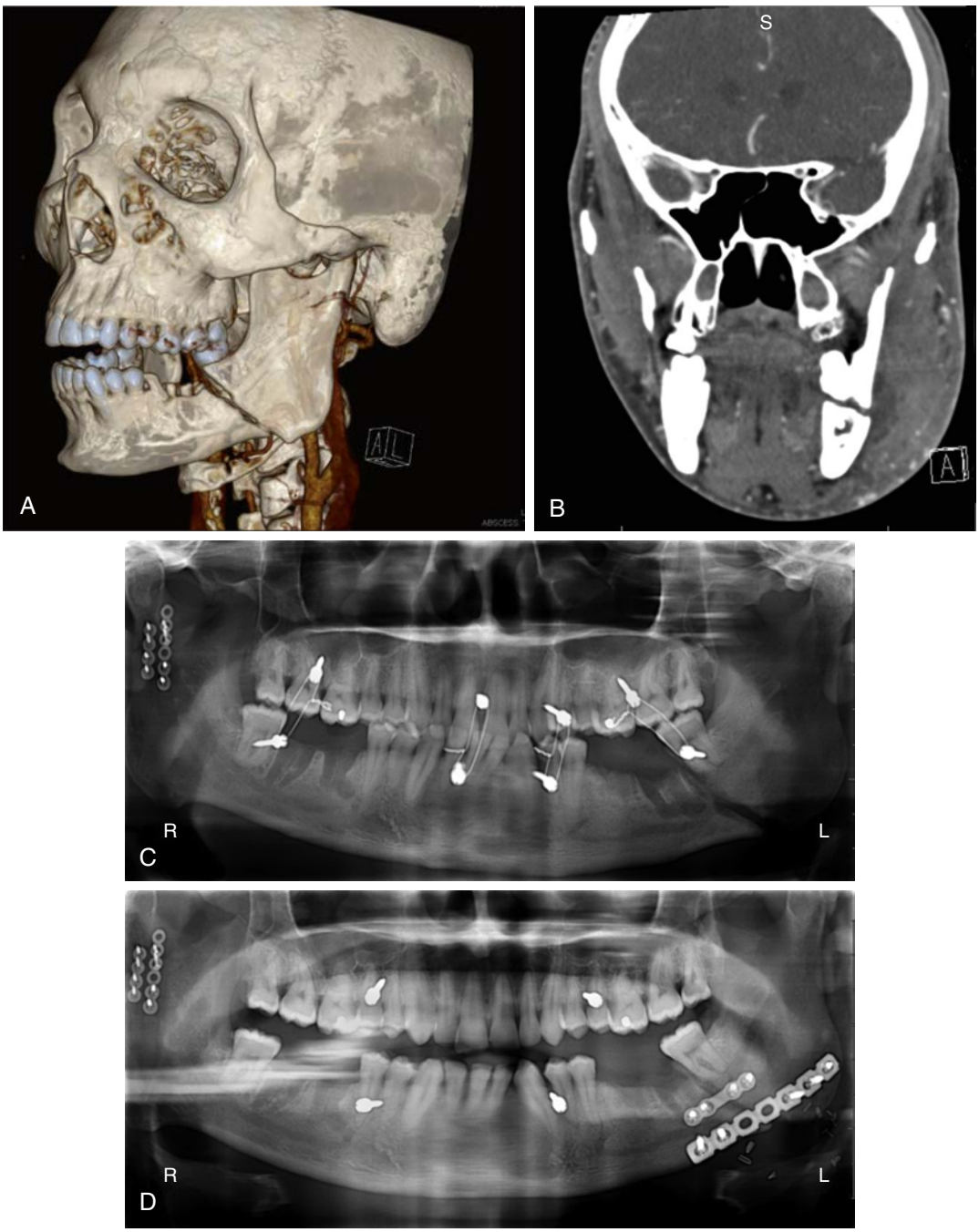

• **Figure 7-45** **A,** Delayed treatment of a left angle fracture resulted in multiple operative visits to clear a left submandibular and masseteric space infection as well as fixate the fracture. **B,** Computed tomography imaging of the left angle with associated infection. **C,** A concomitant left subcondylar fracture was plated using a retromandibular approach due to degree of displacement. **D,** Definitive treatment was delayed to clear left angle infection.

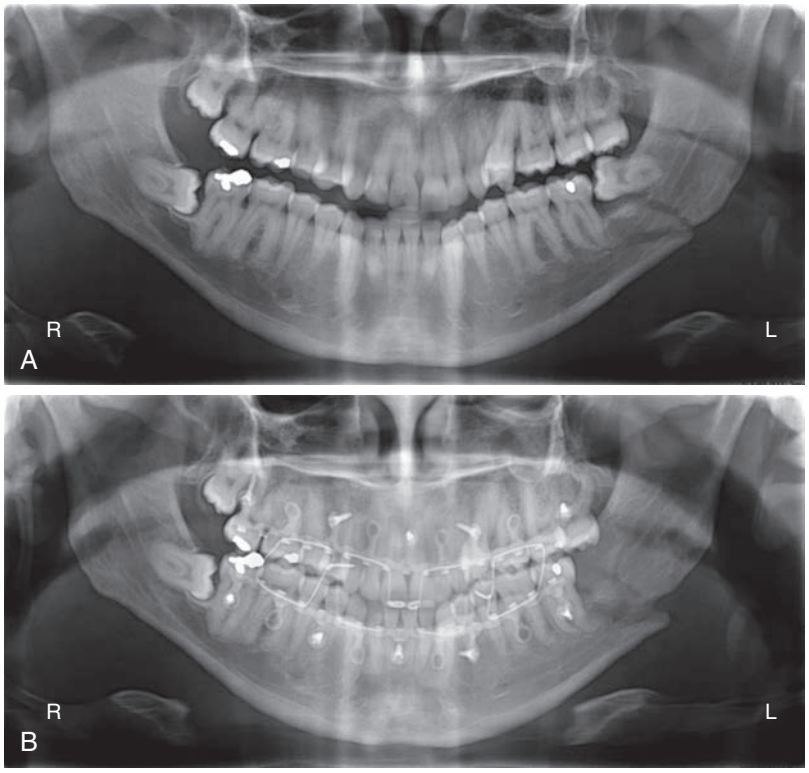

• **Figure 7-46** **A,** Closed reduction should be used with appropriate diagnosis and understanding of mandibular anatomy and muscle pull vectors. These images are the result of failure to diagnose and manage an unfavorable left angle fracture with attempted closed reduction and removal of horizontally impacted mandibular left third molar. **B,** Closed reduction attempted with rotation of the proximal segment due to muscle pull and lack of buttressing.

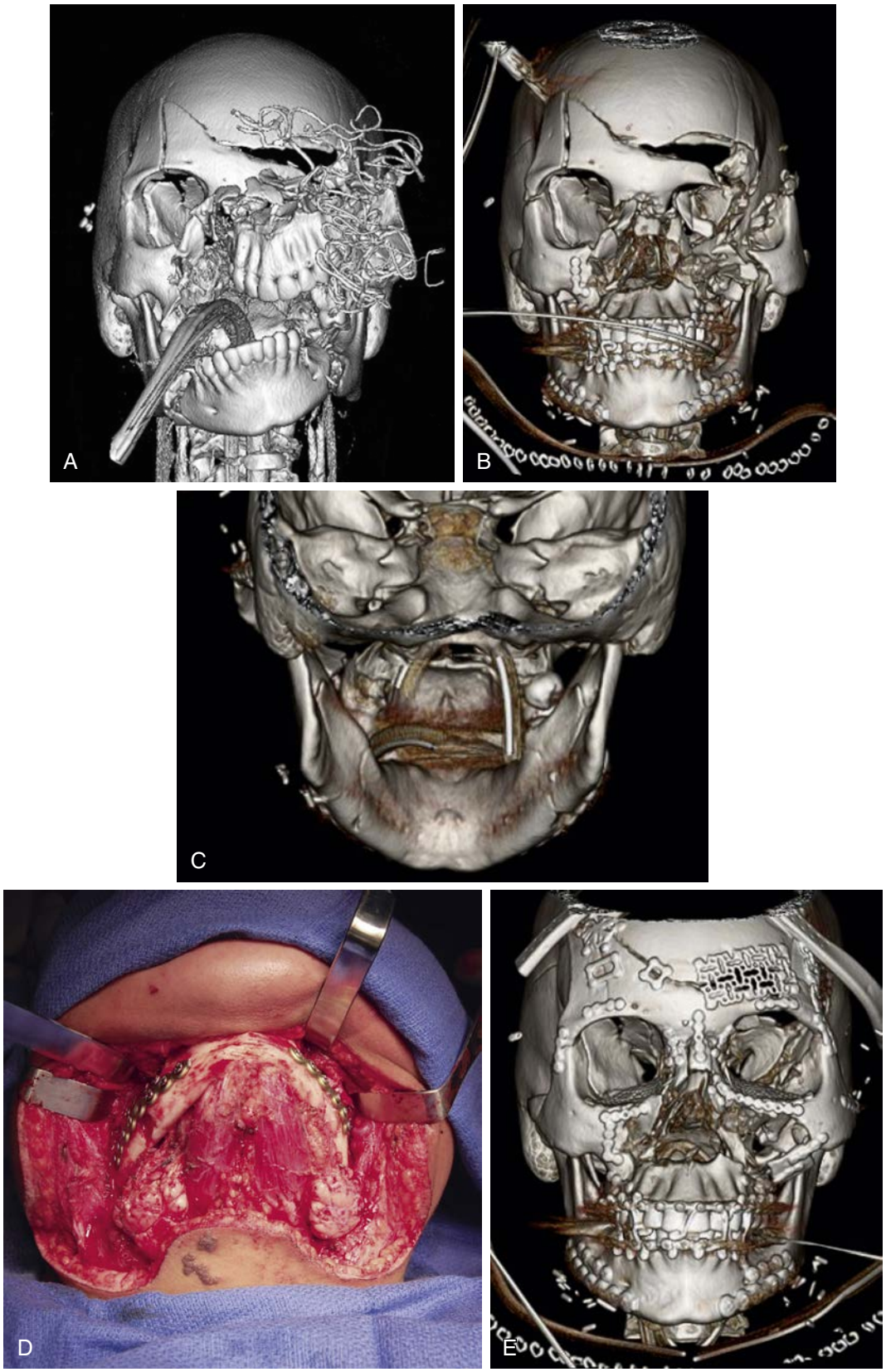

• **Figure 7-47** Patient was an unhelmeted passenger on an all-terrain vehicle that collided with a tree. **A,** There is severe comminution and displacement of facial fractures at the mid and upper face levels. Establishing an anatomically normal mandibular base is critical to the treatment of the remaining fractures. **B-C,** Staged repair was undertaken with tracheostomy, mandible fracture repair, and maxillary arch stabilization. Joint neurosurgical and upper facial repair ensued the following day. This allowed for the evaluation of the lower facial results. Note the excellent reduction of the mandible for purposes of establishing upper facial width. **D,** A transcervical approach allows the best visualization of the lingual and buccal cortices for anatomic reduction given the inability to use the maxillary dentition as a reference. **E,** Final result, largely built from the stable anatomic mandible and right midface.

References

1. *The Edwin Smith Surgical Papyrus (trans. Breasted JH)*, Chicago, 1930, University of Chicago Press.
2. Lipton JS: Oral surgery in ancient Egypt as reflected in the Edwin Smith Papyrus, *Bull Hist Dent* 30:108, 1982.
3. *Hippocrates: Oeuvres completes*, 1928 (English trans. Withington ET), Cambridge, MA.
4. Salicetti G: *Cyrurgia*, 1275.
5. Prevost N: *Translation of Salicetti's Cyrurgia*, Lyons, France, 1492.
6. Gilmer TL: Fractures of the inferior maxilla, *Ohio State J Dent Sci* 1(309), 1881-1882. 2:14,57, 112.
7. Buck G: Fracture of the lower jaw with replacement and interlocking of the fragments, *Annalist NY1* 245, 1846.
8. Ivy RH, Curtis L: *Fractures of the jaws*, Philadelphia, 1945, Lea & Febiger, pp 43–44.
9. Luhr HG: Zur stabilen Osteosynthese bei Unterkeiferfrakturen, *Dtsch Zahnarztl Z* 23:754, 1968.
10. Spiessl B: *New concepts in maxillofacial bone surgery*, Berlin, 1976, Springer.
11. Michelet FX, Deymes J, Dessus B: Osteosynthesis with miniaturized screwed plates in maxillofacial surgery, *J Maxillofac Surg* 1:79, 1973.
12. Champy M, Lodde JP, Schmitt R, et al.: Mandibular osteosynthesis by miniature screwed plates via a buccal approach, *J Maxillofac Surg* 6:14, 1978.
13. David L, Bisseck M, Defranzo A, et al.: Cost-based analysis of the treatment of mandibular fractures in a tertiary care center, *J Trauma* 55:514–517, 2003.
14. El-Degwi A, Mathog RH: Mandible fractures: medical and economic considerations, *Otolaryngol Head Neck Surg* 108:213–219, 1993.
15. Kruger G: *Textbook of oral and maxillofacial surgery*, St Louis, 1984, CV Mosby.
16. Mouzakes J, Koltai PJ, Kuhar S, et al.: The impact of airbags and seat belts on the incidence and severity of maxillofacial injuries in automobile accidents in New York State, *Arch Otolaryngol Head Neck Surg* 127:1189–1193, 2001.
17. Chrcanovic BR: Factors influencing the incidence of maxillofacial fractures, *Oral Maxillofac Surg* 16:3–17, 2012.
18. Morris C, Bebeau N, Brockhoff H, et al.: Mandibular fractures: an analysis of the epidemiology and patterns of injury in 4,143 fractures, *J Oral Maxillofac Surg* 73:951.e1–951.e12, 2015 May.
19. Bradley JC: Age changes in the vascular supply of the mandible, *Br Dent J* 132:142–144, 1972.
20. Greenberg RN, James RB, Marier RL, et al.: Microbiologic and antibiotic aspects of infections in the oral and maxillofacial region, *J Oral Maxillofac Surg* 37:873, 1979.
21. James RB, Fredrickson C, Kent J: Prospective study of mandibular fractures, *J Oral Maxillofac Surg* 31:275, 1981.
22. Miles BA, Potter JK, Ellis 3rd E: The efficacy of postoperative antibiotic regimens in the open treatment of mandibular fractures: a prospective randomized trial, *J Oral Maxillofac Surg* 64:576–582, 2006.
23. Forwood MR, Turner CH: Skeletal adaptations to mechanical usage, *Bone* 17:197s–205s, 1995.
24. Nasser M, Pandis N, Fleming PS, et al.: Interventions for the management of mandibular fractures, *Cochrane Database Syst Rev* (7):CD006087, 2013.
25. Schmidt B, Kearns G, Gordon N, Kaban L: A financial analysis of maxillomandibular fixation versus rigid internal fixation for treatment of mandibular fractures, *J Oral Maxillofac Surg* 58:1206–1210, 2000 Nov. discussion 1210–1211.
26. Dingman RO, Grabb WC: Surgical anatomy of the mandibular ramus of the facial nerve based on the dissection of 100 facial halves, *Plast Reconstruct Surg* 29:266, 1962.
27. Martin H: *Surgery of head and neck tumors*, New York, 1957, Hoeber-Harper, pp 119–130.
28. Girotto R, Mancini P, Balercia P: The retromandibular transparotid approach: our clinical experience, *J Craniomaxillofac Surg* 40:78–81, 2012.
29. Lauer G, Schmelzeisen R: Endoscope-assisted fixation of mandibular condylar process fractures, *J Oral Maxillofac Surg* 57: 36–39, 1999.
30. Ellis 3rd E, McFadden D, Simon P, Throckmorton G: Surgical complications with open treatment of mandibular condylar process fractures, *J Oral Maxillofac Surg* 58:950, 2000.
31. Ricalde P, Caccamese J, Norby C, et al.: Strength analysis of 6 resorbable implant systems: does heating affect the stress-strain curve?, *J Oral Maxillofac Surg* 66, 2493–2497, 2008.
32. Ferretti C: A prospective trial of poly-L-lactic/polyglycolic acid co-polymer plates and screws for internal fixation of mandibular fractures, *Int J Oral Maxillofac Surg* 37:242–248, 2008.
33. Laughlin RM, Block MS, Wilk R, et al.: Resorbable plates for the fixation of mandibular fractures: a prospective study, *J Oral Maxillofac Surg* 65:89–96, 2007.
34. Bayat M, Garajei A, Ghorbani K, Motamedi MH: Treatment of mandibular angle fractures using a single bioresorbable miniplate, *J Oral Maxillofac Surg* 68:1573–1577, 2010.
35. Muller ME, Allgower M, Willenegger H: *Technik der operativen Frakturenbehandlung*, Berlin, 1963, Springer.
36. Muller ME, Allgower M, Willenegger H: *Manuel der Osteosynthese: AO-Technik*, Berlin, 1969, Springer.
37. Raveh J, Vuillemin T, Ladrach K, et al.: Plate osteosynthesis of 367 mandibular fractures, *J Craniomaxillofac Surg* 15:244–253, 1987.
38. Herford A, Ellis E: Use of a locking reconstruction plate-screw system for mandibular surgery, *J Oral Maxillofac Surg* 56: 1261–1265, 1998.
39. Collins CP, Pirinjian-Leonard G, Tolas A, Alcalde R: A prospective randomized clinical trial comparing 2.0-mm locking plates to 2.0-mm standard plates in treatment of mandible fractures, *J Oral Maxillofac Surg* 62:1392–1395, 2004.
40. Brons R, Boering G: Fractures of the mandibular body treated by stable internal fixation: a preliminary report, *J Oral Surg* 28: 407–415, 1970.
41. Neal DC, Wagner W, Alpert B: Morbidity associated with teeth in the line of mandibular fractures, *J Oral Surg* 36:859, 1978.
42. Shetty V, Freymiller E: Teeth in the line of a fracture: a review, *J Oral Maxillofac Surg* 47:1303, 1989.
43. Gutta R, Tracy K, Johnson C, James L, Krishnan D, Marciani R: Outcomes of mandible fracture treatment at an academic tertiary hospital: a 5-year analysis, *J Oral Maxillofac Surg* 72:550–558, 2014.
44. Ellis E, Throckmorton G: Facial symmetry after closed and open treatment of fractures of the mandibular condyle process, *J Oral Maxillofac Surg* 58:719–728, 2000.
45. Fuselier JC, Ellis E, Dodson TB: Do mandibular third molars alter the risk of angle fractures? *J Oral Maxillofac Surg* 60: 514–518, 2002.
46. Ellis E: Treatment methods for fractures of the mandibular angle, *Int J Oral Maxillofac Surg* 28:243–252, 1999.
47. Luhr HG, Reidick T, Merten HA: Results of treatment of fractures of the atrophic edentulous mandible by compression plating: a retrospective evaluation of 84 consecutive cases, *J Oral Maxillofac Surg* 54:250–254, 1996.

48. Barber HD: Conservative management of the fractured atrophic edentulous mandible, *J Oral Maxillofac Surg* 59:789–791, 2001.
49. Bruce RA, Ellis 3rd E: The second Chalmers J. Lyons Academy study of fractures of the edentulous mandible, *J Oral Maxillofac Surg* 51:904–911, 1993.
50. Marciani RD: Invasive management of the fractured atrophic edentulous mandible, *J Oral Maxillofac Surg* 59:792–795, 2001.
51. Kaban LB, Mulliken MD, Murray JE: Facial fractures in children: an analysis of 122 fractures in 109 patients, *Plast Reconstr Surg* 59:15, 1977.
52. Koury M: Complications of mandibular fractures. In Kaban LB, Pogrel AAH, Perrot D, editors: *Complications in oral and maxillofacial surgery*, Philadelphia, 1997, WB Saunders, pp 121–146.
53. Zallen RD, Curry JT: A study of antibiotic usage in compound mandibular fractures, *J Oral Surg* 33:431–434, 1975.
54. Abubaker AO, Rollert MK: Postoperative antibiotic prophylaxis in mandibular fractures: a preliminary randomized, double-blind, and placebo-controlled clinical study, *J Oral Maxillofac Surg* 59:1415–1419, 2001.
55. Miles BA, Potter JK, Ellis 3rd E: The efficacy of postoperative antibiotic regimens in the open treatment of mandibular fractures: a prospective randomized trial, *J Oral Maxillofac Surg* 64, 576–82, 2006.
56. Senel FC, Jessen GS, Melo MD, Obeid G: Infection following treatment of mandible fractures: the role of immunosuppression and polysubstance abuse, *Oral Surg Oral Med Oral Pathol Oral Radiol Endod* 103:38–42, 2007.
57. Gazal G: Evaluation of the effectiveness of early or delayed treatment upon healing of mandibular fractures: a retrospective study, *Eur J Dent* 9:87–89, 2015.
58. Koury M, Ellis E: Rigid internal fixation for treatment of infected mandibular fractures, *J Oral Maxillofac Surg* 50:434–443, 1992.
59. Fordyce AM, Lalani Z, Songra AK, et al.: Intermaxillary fixation is not usually necessary to reduce mandibular fractures, *Br J Oral Maxillofac Surg* 37:52–57, 1999.
60. Renton TF, Wiesenfeld D: Mandibular fracture osteosynthesis: a comparison of three techniques, *Br J Oral Maxillofac Surg* 34:166–173, 1996.
61. Mathog RH, Boies Jr LR: Nonunion of the mandible, *Laryngoscope* 86:908–920, 1976.
62. Mathog RH, Toma V, Clayman L, Wolf S: Nonunion of the mandible: an analysis of contributing factors, *J Oral Maxillofac Surg* 58:746–752, 2000.
63. Izuka T, Lindquist C: Sensory disturbances associated with rigid internal fixation of mandibular fractures, *J Oral Maxillofac Surg* 49:1264, 1991.
64. Marchena JM, Padwa BL, Kaban LB: Sensory abnormalities associated with mandibular fractures: incidence and natural history, *J Oral Maxillofac Surg* 56:822–825, 1998.
65. Halpern LR, Kaban LB, Dodson TB: Perioperative neurosensory changes associated with treatment of mandibular fractures, *J Oral Maxillofac Surg* 62:576–581, 2004.
66. Zuniga JR: Advances in microsurgical nerve repair, *J Oral Maxillofac Surg* 51(Suppl I):62–68, 1993.
67. Bhagol A, Sungh V, Singhal R: *Management of mandibular fractures. A textbook of advanced oral and maxillofacial surgery.* Rijeka, Croatia, 2013, InTech.

8

Nasal Fractures

LIKITH V. REDDY, SARAH C. HARDING

Introduction

Fractures of the nose are the most common facial fractures because of its prominence in the face. Compared to any other facial bone, less energy is required to fracture the nasal complex.[1-3] These fractures frequently occur in conjunction with other facial fractures. The prevalence of nasal fractures is high and often unnoticed by both physicians and patients. Patients with nasal fractures typically present with some combination of deformity, tenderness, hemorrhage, edema, ecchymosis, instability, and crepitation (Figure 8-1). However, these features may not be present or may be transient.[4] Edema can mask underlying nasal deformity, crepitation, and instability; thus, many physicians and patients fail to pursue further diagnosis and appropriate treatment. If left untreated, a nasal fracture can result in unfavorable appearance and function, especially when the underlying structural integrity of bone and cartilage is lost. Nasal fractures are seen in all age groups, but this condition is seen commonly in young males, probably as a result of increased interpersonal violence in this age group.

Nasal fractures are caused by a variety of insults such as interpersonal violence, sports, motor vehicle accidents, and industrial injuries. Significant controversy exists about the treatment of nasal fractures. This is mainly in the timing of repair and the method employed—closed versus open approach. Untreated nasal fractures account for the high percentage of rhinoplasty and septoplasty procedures performed months to years after the initial trauma occurs. Nasal trauma can cause a dorsal hump deformity (Figure 8-2). Thus appropriate treatment should be rendered in a timely manner, before scarring and soft tissue changes occur. The incidence of post-traumatic nasal deformity requiring revision rhinoplasty ranges from 14% to 50%.[2] This shows that the initial approach to management of nasal fractures is suboptimal. Acute treatment of nasal fractures minimizes the amount of deformity, but the likelihood of additional treatment procedures should be considered.

Applied Anatomy and Pathogenesis

The nasal apparatus has a complex anatomy. Knowledge of this anatomy is of utmost importance in evaluation and management of nasal fractures. The nose occupies the middle third of the face and is attached at the top to the forehead; the free lower end of the nose is called the apex or tip. The upper part of the nose that is supported by the nasal bones is the bridge. The nasal bones and underlying cartilage are susceptible to fractures because the nose maintains a prominent position and central location on the face and because it has a low breaking strength. Patterns of fracture are known to vary with the momentum of the striking object and the density of the underlying bone.[5] As with other facial bones, younger patients tend to have larger nasoseptal fracture segments, whereas older patients are more likely to present with more comminuted fracture patterns[6] (Figure 8-3).

Skin and Soft Tissues

The skin of the nose can be divided into vertical thirds. It is generally thicker in males than in females, and major racial differences also exist. The upper third is fairly thick but tapers into a thinner mid-dorsal region. The inferior third regains the thickness of the upper third as a result of the more sebaceous nature of the skin in the nasal tip. The dorsal skin is usually the thinnest of the three sections of the nose. The difference in the skin thickness must be appreciated during dorsal reduction because minor imperfections or fractures in this area would be visible and perceptible. This would also make the dorsal area more susceptible to ecchymosis and lacerations with laterally directed forces on the nose. The skin thickness also varies between patients and must be considered during evaluation and treatment.

The nasal muscles are encountered deep to the skin and comprise four principal groups: the elevators, the depressors, the compressor, and the dilators. The elevators include the procerus and levator labii superioris alaeque nasi. The depressors are the alar nasalis and depressor septi nasi. The



• **Figure 8-1** Acute nasal fracture with deformity, swelling, ecchymosis, hemorrhage, and nasal laceration. **A,** Immediately; **(B)** 3 days post-injury.

compressor of the nose is the transverse nasalis, whereas the dilators are the dilator nares anterior and posterior. The muscles are interconnected by an aponeurosis termed the nasal superficial musculoaponeurotic system (SMAS). The internal nasal lining consists of squamous epithelium in the vestibule that transitions to pseudostratified ciliated columnar respiratory epithelium with abundant seromucous glands.

Hard Tissue Anatomy

Superiorly, the bony framework consists of the paired nasal bones attached to the frontal bone. Superolaterally, the nasal bones are connected to the lacrimal bones, and inferolaterally, they are attached to the ascending processes of the maxilla. Posterosuperiorly, the bony nasal septum is composed of the perpendicular plate of the ethmoid. Posteroinferiorly lies the vomer, which in part forms the choanal opening into the nasopharynx. The floor consists of the premaxilla and the palatine bones. The lateral nasal walls contain three pairs each of small, thin, shell-like bones: the superior, middle, and inferior conchae, which form the bony framework of the turbinates. Lateral to these curved structures lies the medial wall of the maxillary sinus. Inferior to the turbinates lies a space called a meatus, with names corresponding to the turbinate above (e.g., superior turbinate, superior meatus). The roof of the nose internally is formed by the cribriform plate of the ethmoid; posteroinferiorly to this structure, sloping down at an angle, is the bony face of the sphenoid sinus.

The nasal cartilages are paired upper lateral cartilages and lower lateral cartilages. These cartilages form the lower part of the internal skeleton of the nose. The nasal bones articulate with the upper lateral cartilages in a "lap" joint. The internal area or angle formed by the junction of the upper lateral cartilage with the nasal septum forms the internal nasal valve. This valve regulates nasal respiration.[7] The upper lateral cartilages are triangular in shape. The internal nasal valve comprises the narrowest portion of the nasal airway. This valve regulates nasal respiration, and an angle wider than 15 degrees is needed in this area for adequate nasal breathing. They are connected to the maxilla laterally and to the septum medially. Caudal to the upper lateral cartilages lie the lower lateral cartilages. The paired lower lateral cartilages swing out from medial attachments to the caudal septum in the midline, called the medial crura, and then to an intermediate crus area. They finally flare out superolaterally as the lateral crura. These cartilages are frequently mobile, unlike the upper lateral cartilages. The two medial crura of the lower lateral cartilage curve inferiorly down the midline to support the columella. The lateral crus of the lower lateral cartilage supports the ala during respiration. Adjacent sesamoid cartilages are variably found lateral to the lower lateral cartilages in the fibroareolar connective tissue.

The nasal septum forms the main vertical support of the nasal complex. It acts like a strut to support the nasal bones and upper and lower lateral cartilages in the midline. The nasal septum is made up of a bony component and a cartilaginous component. The vomer and perpendicular plate of the ethmoid form the bony component. The cartilaginous component is quadrangular in shape. The inferior aspect of the septum articulates with the crest or maxillary groove of the maxilla. This allows mobility of the septum but is also a



• **Figure 8-2** Dorsal deformity with nasal hump attributable to nasal fracture.

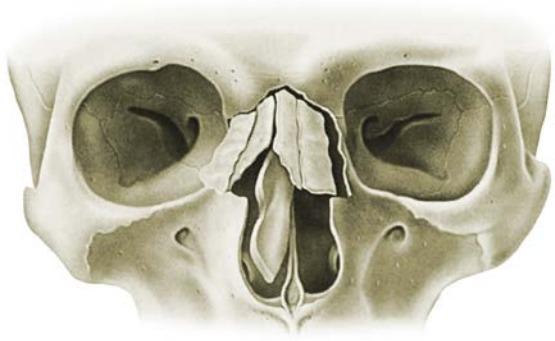

• **Figure 8-3** Artist's conception of nasal fracture with dislocation of nasal bones and septal cartilage.

common location for dislocation of the nasal septum during trauma. The septum articulates posteriorly with the sphenoid bone through the vomer.

Weak areas are noted in the cartilage framework and in the junctions of the upper lateral cartilages with the nasal bones and the septal cartilage at the maxillary crest. The weak areas account for an increase in the rate of fracture/dislocation after nasal trauma. A lateral force of only 16 to 66 kilopascals (kPa) and a greater frontal force of 114 to 312 kPa can displace the bony dorsum.[5] A large force in any direction can cause comminution of the nasal bones with an associated C-shaped deformity of the nasal septum. Murray and colleagues reported that almost any deviation of the fractured nasal bones involves a concomitant fracture of the septal cartilage. Cartilage fracture lines are often oriented vertically in the caudal septum and horizontally in the posterior portions.[5]

Lateral impact injuries are the most common type of nasal injury leading to fracture.[8] Lateral injury produces a depression of the ipsilateral nasal bone that usually involves the lower half of the bone, the nasal process of the maxilla, and a variable portion of the pyriform margin. Nasal fracture and displacement without septal fracture usually occur with weaker applied forces; however, with increased force, displacement of the bilateral nasal bones can be noted, and the septum is usually dislocated and fractured as well.[6]

Other injuries that are commonly associated with nasal fractures include midface injuries involving the frontal, ethmoid, and lacrimal bones; nasoorbitoethmoid (NOE) fractures; orbital wall fractures; cribriform plate fractures; frontal sinus fractures; and maxillary Le Fort I, II, and III fractures.

Blood Supply

The arterial supply to the nose is by (1) branches from the internal carotid, namely, the branches of the anterior and posterior ethmoid arteries from the ophthalmic artery; and (2) branches from the external carotid, namely, the sphenopalatine, greater palatine, superior labial, and angular arteries.

The external nose is supplied by the facial artery, which becomes the angular artery coursing over the superomedial aspect of the nose. The sellar and dorsal regions of the nose are supplied by the infraorbital artery, branches of the internal maxillary artery and ophthalmic arteries, and branches from the internal carotid system.

Internally, the lateral nasal wall is supplied by the sphenopalatine artery posteroinferiorly and by the anterior and posterior ethmoid arteries superiorly. The nasal septum also derives its blood supply from the sphenopalatine and anterior and posterior ethmoid arteries with the added contribution of the superior labial artery (anteriorly) and the greater palatine artery (posteriorly). The Kiesselbach plexus, or the Little area, represents a region in the anteroinferior third of the nasal septum where all three of the primary blood supply to the internal nose converge (Figure 8-4) and is commonly the source of anterior epistaxis.

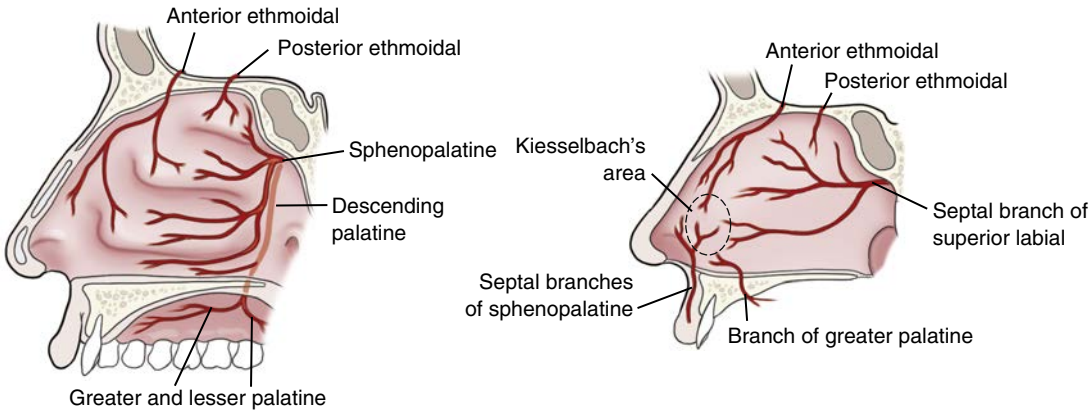

• **Figure 8-4** Blood supply to lateral and medial walls of nasal cavity.

Veins in the nose essentially follow the arterial pattern. They are significant for their direct communication with the cavernous sinus and for their lack of valves; these features potentiate the intracranial spread of infection. Even with the abundant blood supply of the nose, smoking does compromise postoperative healing.

Lymphatics arise from the superficial mucosa and drain posteriorly to the retropharyngeal nodes and anteriorly to the upper deep cervical nodes and/or submandibular glands.

Nerves

The sensory innervation to the nose is from the trigeminal nerve, whereas the motor supply to the nasal muscles is from the facial nerve. Sensory branches are from both the first and second divisions of the trigeminal nerve. Branches of the first division of cranial nerve V are the infratrochlear and external nasal branches of the anterior ethmoidal nerve. The supratrochlear nerve contributes slightly to the bridge of the nose. The infraorbital nerve supplies the inferolateral regions and the tip. The nasal septum is innervated by the anterior ethmoidal, nasopalatine, and maxillary nerves[1,7] (Figure 8-5).

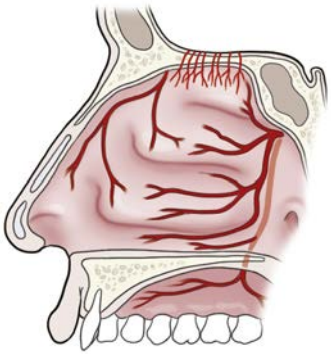

• **Figure 8-5** Innervation of lateral nasal wall.



• **Figure 8-6** Right-sided septal hematoma caused by septal fracture.

Diagnosis and Evaluation of Nasal Fractures

A thorough evaluation of nasal fractures is mandatory before embarking on any kind of treatment. Many of the post-traumatic nasal deformities are attributed to incomplete examination. History includes inquiring about the mechanism of injury, time elapsed, and previous nasal fractures or nasal surgery. Head injury must be ruled out first. Proper lighting, a nasal speculum, and a vasoconstrictor are required. History of epistaxis is important because it indicates mucosal injury. A complete examination of the nasoorbitoethmoid (NOE) complex and visual acuity is mandatory. Increased intercanthal distance (>30 mm) is a good indicator of a concomitant NOE complex fracture. Examination of other facial bones is undertaken to rule out other facial fractures. The nose is examined for gross deformity and external lacerations. Gentle palpation of the nasal bones provides an idea of the underlying mobility. Marked edema may mask an underlying nasal deformity. Review of old photographs or a driver's license can be very helpful. Intranasal examinations require a minimum of a nasal speculum. Rhinorockets or Afrin-soaked pledgets may be used for vasoconstriction. The examiner should look for mucosal lacerations and septal hematoma (Figure 8-6). A complete assessment of the nasal septum is the most important determinant of the outcome of nasal reduction. About 1% to 4% of the general population has some degree of septal deviation.[2,7] The entire septum is evaluated including dislocation of septal cartilage from the maxillary groove, and deviation

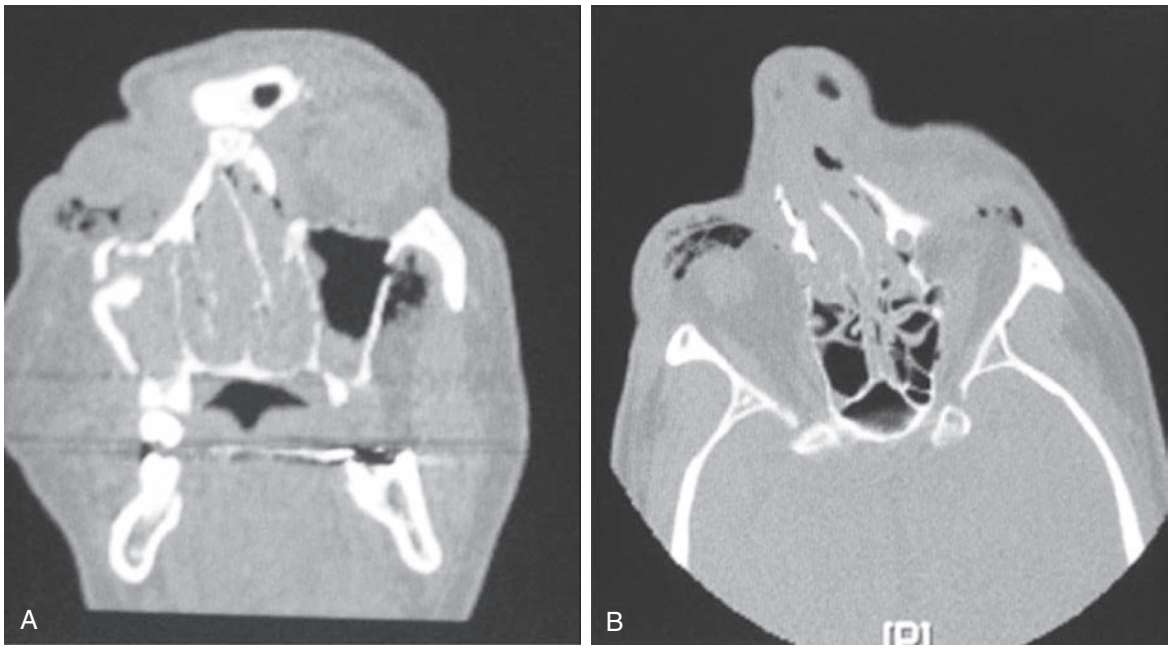

• **Figure 8-7** **A,** Coronal and **(B)** axial computed tomography scans showing nasal and septal fractures with other associated fractures.

or mobility is noted. Rohrich describes the pattern of fracture-dislocation of the septum in low-velocity injuries to be along the vomerine groove.[2]

High-velocity injuries tend to result in more extensive fractures of the quadrangular septal cartilage and perpendicular plate of the ethmoid. Following fracture, nasal bones unite in the direction of the deviated septum; therefore, proper alignment of the septum is the key to adequate nasal reduction.[2,9] Rohrich and colleagues developed a nasal fracture data sheet that is comprehensive of all the pertinent points to consider for minimizing further nasal fracture deformities.[2] They have also adopted a simple nasal fracture classification based on physical examination. They classify nasal fractures into simple, comminuted, complex (associated septal hematoma or open laceration), and associated NOE fractures.[2] Haug and Prather designed a different classification of nasal fracture based on the specific bones fractured.[10]

The use of computed tomography (CT) scans or plain films for the diagnosis and management of nasal fractures has been controversial; however, several small studies have shown that use of these modalities is neither cost-effective nor beneficial to the patient or physician. Nasal fractures are usually evident and can be verified by means of careful history-taking and physical examination. Rarely is the radiologic confirmation of these injuries needed.[1,7] This is because old fractures with bony deformities are very common and can be confused with new fractures.[1] Yabe and colleagues recommended routine preoperative and postoperative x-rays and CT scans, claiming that some slightly depressed nasal fractures are more easily diagnosed on lateral x-rays than on CT scans.[11] Nonetheless, patients determined by x-rays to have displaced nasal fractures are at a higher risk for long-term nasal deformity.[1,2,12] Although routine radiographs may be important from a medical/legal point of view, treatment is predicated on the basis of the physical examination alone. CT scans are indicated when a concomitant NOE or other facial fractures are suspected (Figure 8-7).

Although the use of plain images is not suggested, the preferred examination includes the acquisition of Waters' and lateral nasal views.

Classification of Nasal Fractures

Many different and often complex methods of classifying nasal-septal fractures have been proposed. However, the clinically pertinent understanding of a given nasal fracture lies in each individual patient's history. When predicting the amount of damage a patient may have sustained, attention should be given to the patient's age, the object that caused the fracture, and the force and direction of the object. The fracture patterns seen vary distinctly with the application of frontal and lateral forces. Lateral forces account for most nasal fractures. Most clinicians base their diagnosis and interventions on anatomic findings. Rohrich and Adams proposed a simple classification that might guide treatment[2] (Table 8-1).

Treatment of Nasal Fractures

Fractures of the nasal bones are the most site-specific bone injury of the facial skeleton. If left uncorrected, the loss of structural integrity and the soft tissue changes that follow may lead to both unfavorable appearance and poor function. Thus appropriate and timely treatment is warranted to

TABLE 8-1 Nasal Fracture Classification

Type	Description
I	Simple unilateral
II	Simple bilateral
III	Comminuted
a	Unilateral
b	Bilateral
c	Frontal process of maxilla
IV	Complex (nasal bone fractures with septal disruption)
a	Associated with septal hematoma
b	Associated with open nasal laceration
V	Associated NOE fracture/midface fracture

NOE, Nasoorbitoethmoid.

decrease morbidity in patients with these fractures. Because of the intimate associations of the bony and cartilaginous portions of the nose with the nasal septum, it is unusual to observe fractures to either structure without damage to the other. A common mistake in reduction of nasal fractures is to reduce the bony fracture without attention to the septum, which leads to progressive nasal obstruction as the septum heals with fibrous scar tissue. Septal fractures tend to activate interlocked stresses, and during the process of healing by fibrosis they may produce septal twisting of various configurations (C-shaped, S-shaped, or spurs) (Figure 8-8). Fracture lines are commonly vertical when located anteriorly and horizontal when located posteriorly.[13] Septal fractures also are frequently associated with a "telescoping" of the fractured edges, causing a retruded appearance of the cartilaginous portions of the nose.

Medical Management

Elevation of the head and use of cold compresses in the periorbital and nasal regions can be helpful while waiting for edema to subside. Even in the presence of significant edema, a nasal deformity often may be obvious. In a patient with no apparent abnormality at the initial visit, reassessment of the nose after the edema subsides may reveal findings necessitating repair. Surgical intervention may then be undertaken. Many patients who sustain nasal trauma present with profuse bleeding, which can usually be controlled with clot removal and the application of a topical vasoconstrictor. If this approach is unsuccessful, gauze packing, balloon catheterization, or other procedures may be required, but the ligation of vessels is rarely necessary. Nasal packing is the most common procedure performed to control bleeding after topical vasoconstrictors fail. Packing material is placed directly at the area of hemorrhage to supply pressure; however, bilateral packing is occasionally necessary to control bleeding from several areas. The packing is commonly removed in 2 to 5 days, and nasal reduction can be performed at the same time.



• **Figure 8-8** Septal deformity resulting from untreated nasal fracture.

Surgical Management

Injuries limited to the nasal soft tissues without concomitant nasal fracture are treated by debridement and closure. Landmarks of the nose are approximated first to prevent distortion, which may lead to a cosmetic deformity. Extra care is taken with through-and-through lacerations. In these situations the intranasal laceration is closed first using a resorbable suture, then cartilage is approximated, and finally skin is closed. Indications for repair of nasal fractures include abnormal nasal function, abnormal appearance, and presence of early post-injury complications. The preoperative evaluation should rule out nasofrontal and ethmoid fractures because these may require other types of surgical intervention. Injury to the nasofrontal duct, cribriform plate, or medial canthal ligaments must be recognized. Dorsal nasal reconstruction with rib graft or calvarial bone grafts is necessary in patients with severe nasal injuries, significant saddle-nose deformity, loss of dorsal projection, and shortened nasal length; the reconstruction must be discussed with the patient (Figure 8-9). These fractures are discussed in detail in Chapter 14.

There are three major considerations in the plan for reduction of a nasal fracture. The first consideration is whether to perform open reduction or closed reduction; the second is the use of local or general anesthesia; and the third is the timing of reduction. Considerable debate exists in the literature regarding reduction of nasal fractures. Although many studies advocate simple manipulation for reduction of nasal fractures, there is enough evidence to indicate that simple manipulation can and does result in significant post-traumatic nasal deformity. Crowther and O'Donoghue reported that only 9% of patients required septorhinoplasty as a result of inadequate simple manipulation.[12] Other authors cite a



• **Figure 8-9** **A,** Nasoorbitoethmoid (NOE) fracture with saddle-nose deformity, loss of dorsal projection, and shortened nasal length. **B,** NOE fracture reconstructed with calvarial bone graft.

higher percentage. Many studies suggest that all fractures be managed by simple manipulation while reserving open reduction for those cases that have failed simple manipulation. This would appear to be a more economical solution, but given the high incidence of post-traumatic nasal deformities requiring open septorhinoplasty, this might not be so. Nasal fractures cannot be approached in a cookbook fashion, but at the same time some form of an algorithmic approach is necessary. Another debate exists about the use of local versus general anesthesia. Historically, most studies found local anesthesia to be as effective as general anesthesia in the simple manipulation of nasal fractures. Cook and colleagues supported the use of local anesthesia, considering the many advantages of local anesthesia over general anesthesia.[14] However, Al-Moraissi and Ellis conducted a meta-analysis that demonstrated a statistically significant difference in patient satisfaction concerning nasal esthetics with treatment under general anesthesia when compared to treatment with local anesthesia alone. This resulted in decreased need for subsequent revision surgery.[15] Although it may be uncomfortable to undergo manipulation under local anesthesia, the advantages are obvious. Certainly the risks of general anesthesia cannot be ignored. However, it is certainly beneficial to consider initial treatment under general anesthesia for an accurate and controlled reduction when a septal fracture is present. Nasal fractures are best treated either immediately or after 7 to 10 days when all the edema has resolved. Most patients do not heal significantly before 3 weeks, and therefore closed reduction may be attempted any time in the first 2 to 3 weeks. After 3 weeks the fracture has healed such that it cannot be reduced easily and open reduction must be performed. Because of the maturing scar tissue and fibrosing cartilage, rhinoplasty must be delayed 3 to 6 months to obtain optimal results.

There are three options for treatment of nasal fractures: simple closed reduction, closed reduction with minimal septal work, or open septorhinoplasty. An algorithm developed by Rohrich and Adams serves as a good framework for decision making.[2] It should be used to supplement clinical impression, to minimize the incidence of post-traumatic deformity requiring revision septorhinoplasty (Figure 8-10). Mildly deviated fractures can be managed with closed reduction in the absence of moderate or severe septal deviation. Fractures with significant septal and nasal deviations with new dorsal hump deformity most likely require open reduction techniques that range from septoplasty or osteotomies to full septorhinoplasty.

Closed Reduction

The nose is anesthetized using 4% cocaine as an intranasal solution (maximum adult dose 8 mL) with 1:100,000 epinephrine-soaked pledgets. Afrin-soaked nasal pledgets can also be used if 4% cocaine is not available. This shrinks the nasal mucosa sufficiently to allow adequate intranasal examination. This is supplemented with external nasal field blocks using 2% lidocaine with 1:100,000 epinephrine along the nasal dorsum, lateral to the nasal pyramid, and at the base of the anterior septum. Transorally, infraorbital nerve blocks are performed. Injection in the greater palatine foramen achieves sphenopalatine blocks. This markedly reduces posterior nasal cavity bleeding and improves anesthesia. Transcutaneous infiltration bilaterally along the dorsum is helpful to anesthetize the infratrochlear nerve and the external nasal branch of the anterior ethmoidal nerve.

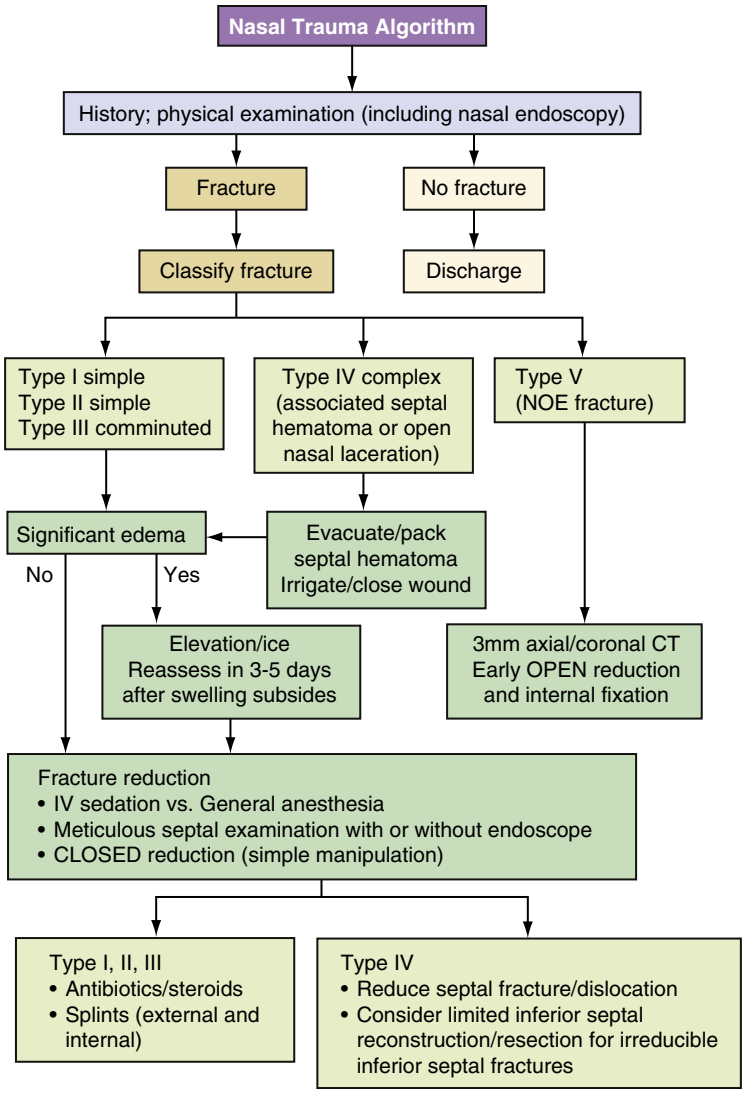

The pertinent points of emphasis in this algorithm are:
1. Swelling is allowed to resolve for proper reduction.
2. The septum is the key to management of nasal fractures.
3. All septal pathology must be identified.
4. Patients should be informed initially regarding the possibility of further nasal procedures.

• **Figure 8-10** Nasal trauma algorithm.

The internal nose is then anesthetized by submucosal intranasal injections along the inferior turbinates, dorsum, and nasal septum. If a transcolumellar incision is planned, injection at the base of the columella can be performed. Cook and colleagues have found external infiltrative anesthesia to the nasal dorsum to be as effective as and better tolerated than specific blocks to the infraorbital, external nasal, and infratrochlear nerves.[14] The minimum amount of local anesthesia should be injected to avoid additional distortion. Accuracy of placement is more important than the volume deposited. The surgeon should allow adequate time for the anesthesia to work before manipulation; otherwise, excessive bleeding will persist throughout the procedure.

The patient may be given oral or intravenous sedation to enhance the anesthesia. Even if general anesthesia is used, good local anesthesia is required to reduce bleeding. About 15 minutes should be allowed to maximize the vasoconstrictive property of the medication. After adequate anesthesia has been achieved, reexamination of the nose is performed.

Reduction of the bones is done first followed by reduction of the cartilages. This is accomplished by re-creating the fracture while molding with fingers. Few instruments are needed for fracture reduction. These include Asch and Walsham forceps, a large Kelly clamp with protective rubber tubing over the blades, Boies or Ballenger elevators, intranasal specula, and a head light. The majority of nasal fractures can be reduced by upward and outward forces with an instrument placed in the nose under the nasal bone. The instrument is inserted intranasally to a point 1 cm caudal to the nasofrontal angle. The depressed fragment is elevated

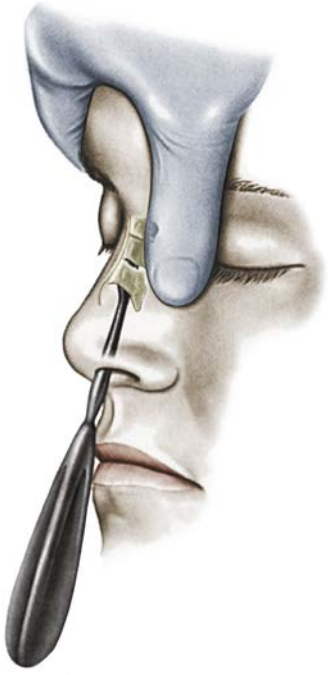

• **Figure 8-11** Lateral nasal wall fracture reduction with elevator.

by exerting force in the direction opposite to the fracturing force, usually anterolaterally. The reduction instrument is held with the dominant hand and the nasal bones are reduced in an anterior and superior direction perpendicular to the edge of the nasal bones. The less dominant hand is used to exert counterpressure to mold the bones and soft tissues against the forceps in an anteroinferior direction (Figure 8-11). If the opposite nasal bone is displaced laterally, that bone is moved medially to its normal position. The Asch or Walsham forceps may be used by inserting one blade in each nostril or by placing one blade in the nose under the nasal bone and the other blade on the overlying skin. Pressure should not be exerted too high in the nose (under the thick nasal bone near the nasofrontal suture) because this area is rarely fractured and manipulation can result in mucosal tears and subsequent bleeding. Reduction can usually be accomplished with the fragments remaining in position, but digital molding may be necessary in some patients. Septal alignment is the most important determining factor in preventing post-reduction deformity with loss of dorsal support and/or nasal obstruction. Reducing the nasal bone fragments first often reduces the septum simultaneously; if not, the Asch or Walsham forceps usually permit gentle elevation of the nasal pyramid while pressure is applied over the displaced septal region (Figure 8-12).

Once the septum is reduced into a satisfactory position, Doyle splints with an airway lumen are placed on either side of the septum. These are sutured to the septum using 3-0 silk or nylon trans-septal sutures. Care must be taken not to make the trans-septal sutures too tight; otherwise, pressure necrosis of the septum may result. Packing with antibiotic gauze or Merocel can be used to control hemorrhage, but most of the time this is unnecessary.[10] Packing is also used by some surgeons to prevent inward collapse of nasal bones.[16] The two main types of packing are the nonabsorbable polyvinyl acetate sponge (Merocel, Medtronic Inc., Minneapolis, MN) and the absorbable synthetic polyurethane foam (Nasopore Forte, Polyganics, Groningen, The Netherlands). Recent meta-analyses have suggested that Nasopore is better tolerated by patients due to ease of removal without the epistaxis encountered with removal of Merocel.[17-19] Last, external nasal splints are applied. The nasal skin is cleaned and degreased, and ½-inch Steri-Strips are applied. Either thermoplastic or metallic Denver splints can be used. Care must be taken not to disrupt the nasal bones when applying the splint. The splint should be used to cushion the nose; remind the patient to be careful with physical contact to the nose. Splints should not be used to maintain an unstable nasal reduction.[7] If there are concomitant maxillofacial fractures that require maxillomandibular fixation and the nose is packed, a tracheotomy might be needed.[7] Postoperative instructions, analgesics, and antibiotics are given to the patient. If Vaseline gauze nasal packs are used, they can be removed in 2 to 3 postoperative days. Nasal splints and Merocel sponges are typically removed in 7 to 10 days. If a Nasopore Forte sponge is used, it can easily be suctioned from the nose at this point with minimal pain. Fracture stability is checked at the 10-day postoperative visit, and if there is instability, the external splint should be replaced for another week; otherwise, it may be discarded. The patient is instructed to avoid physical contact to the nose, keep the head elevated, and apply ice packs for 24 hours. The patient is also cautioned not to wear glasses for 6 weeks. If glasses are needed, the patient can be instructed on how to tape the bridge of the glasses to the forehead to prevent undue pressure on the nose; otherwise, unattractive depression on the nasal bridge can occur. Patients are followed up at regular intervals for 6 weeks.

Because incomplete greenstick fractures of the septum and nasal bones can account for later deviations, Manson recommends that fracture lines be completed before reduction.[20] Some authors perform submucosal resection on C-shaped septal fractures (Figure 8-13). An aggressive submucous resection may cause a loss of nasal height and resultant dorsal nasal irregularities. A safer method is to attempt closed reduction and warn the patient of possible need for future rhinoplasty.[20] If the fracture cannot be reduced by closed reduction, the operation should be immediately converted to an open reduction. For this reason many authors advocate the use of the operating room for all closed reductions.

Open Reduction

The nose is anesthetized and prepared in a similar manner as in closed reduction. The operative procedure chosen is dictated by the patient's type of fracture-dislocation. Most cases needing open reduction are due to an interlocked segment of cartilage and/or bone. The goals of treatment of severely comminuted nasal fractures include narrowing of the nasal dorsum, maintenance of adequate nasal airway,

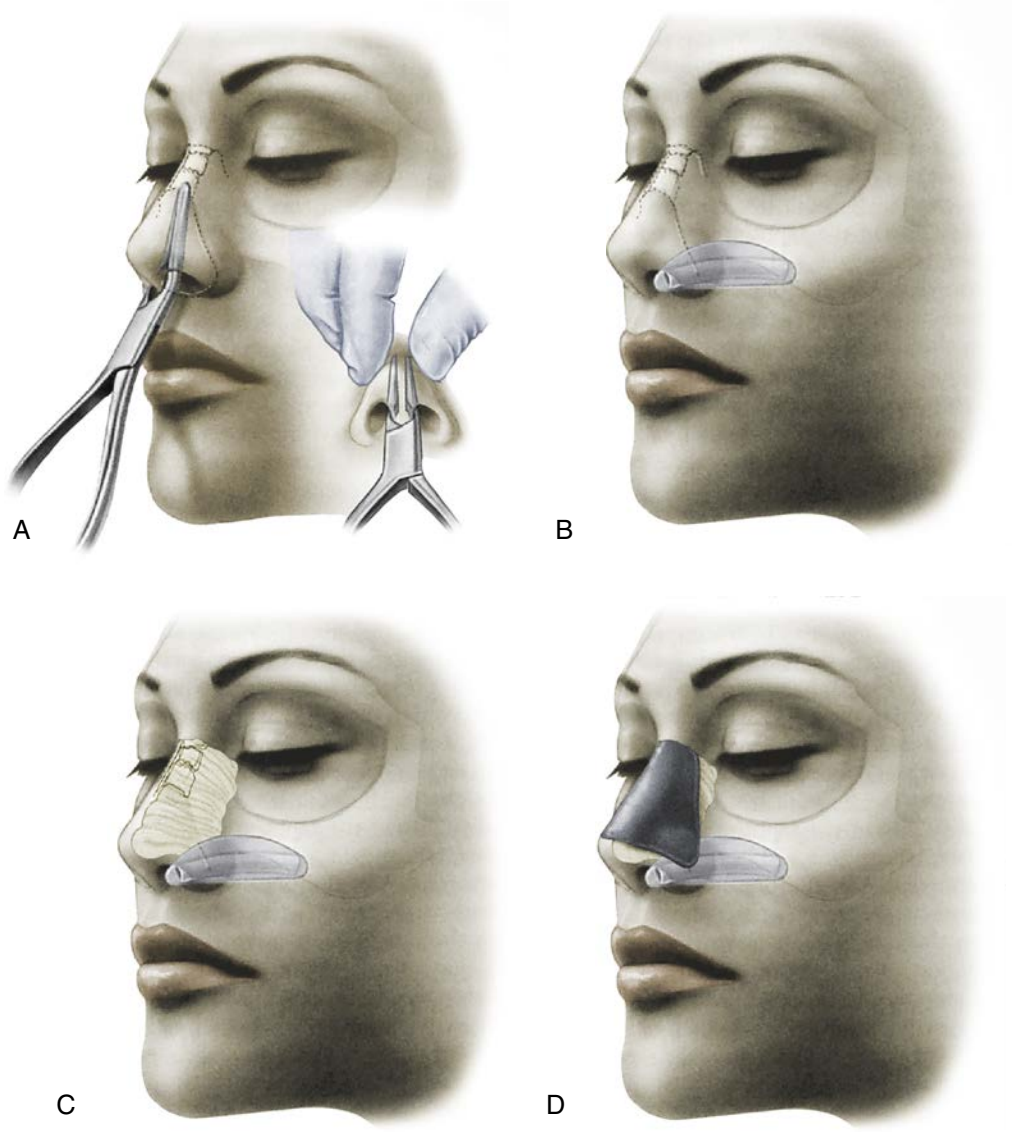

• **Figure 8-12** Methods of treatment of isolated nasal fractures. **A,** Asch forceps reducing fractures. **B,** Doyle splints in position. **C,** Gauze packing layered in nose. **D,** Denver splint in place. (Redrawn from Haug RH, Prather JL: The closed reduction of nasal fractures: an evaluation of two techniques, *J Oral Maxillofac Surg* 49:1291, 1991.)

and maintenance of projection of the nose.[21] Stability of reduction of nasal fractures is dictated by the nasal septum. Recurring nasal deformity usually arises from failure to centralize the displaced septal fracture during the initial surgery, rather than from release of internal stresses by microfractures.[22] The anterior portion of the septum is flexible and can be easily placed in the midline over the nasal spine at the time of manipulation while the posterior portion remains uncorrected (Figure 8-14). Subsequently, the stronger posterior portion will re-displace the anterior portion. It is not uncommon to find that a perfectly reduced nasal fracture has re-displaced by the time the nasal splints are removed.

The septum is approached through a hemi-transfixion incision on the side of dislocation (complete transfixion incisions predispose to lower tip height and introduce additional structural instability). Further access to the fracture line is gained through lateral intercartilaginous incisions (Figure 8-15). The dorsal skin is elevated off the upper lateral cartilages and the periosteum is elevated from the nasal bones. Pyriform aperture incisions provide access to the lateral fracture lines. Common findings are dislocation of the quadrangular cartilage off the maxillary crest, or a C-shaped fracture of septal cartilage and bone, as described by Murray and associates (Figure 8-16).[5]

The cartilaginous segments are exposed and reduced. Sometimes a segment of cartilage must be resected adjacent to the fracture. A Cottle elevator is used to excise small strips of cartilage, allowing the septum to swing like a "trapdoor" back into its normal position. A small chromic stay suture may be placed through the periosteum near the anterior nasal spine and the inferior portion of the cartilaginous septum to maintain its reduction. Often a displaced maxillary

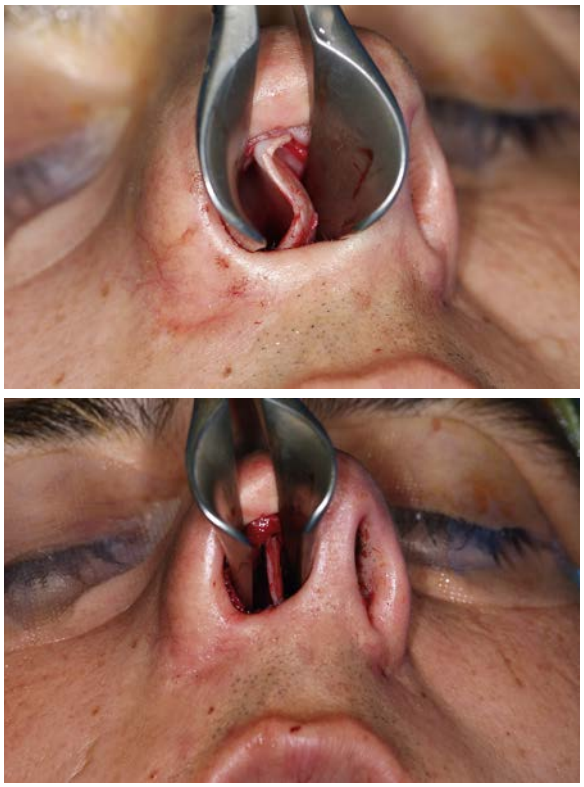

• **Figure 8-13** Submucosal septal resection for correction of septum.

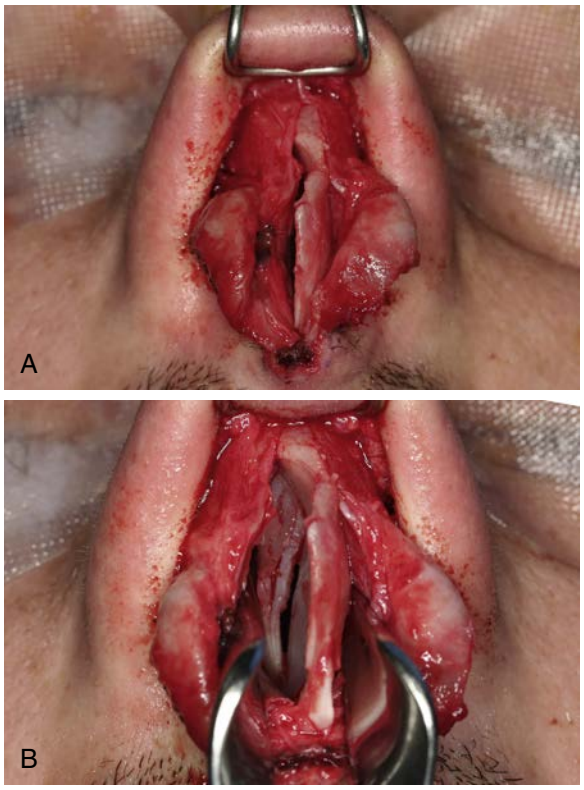

• **Figure 8-14** **A,** Demonstration of nasal septum with significant posterior deformity compared to the anterior deformity. **B,** Demonstration of fracture of posterior septum.

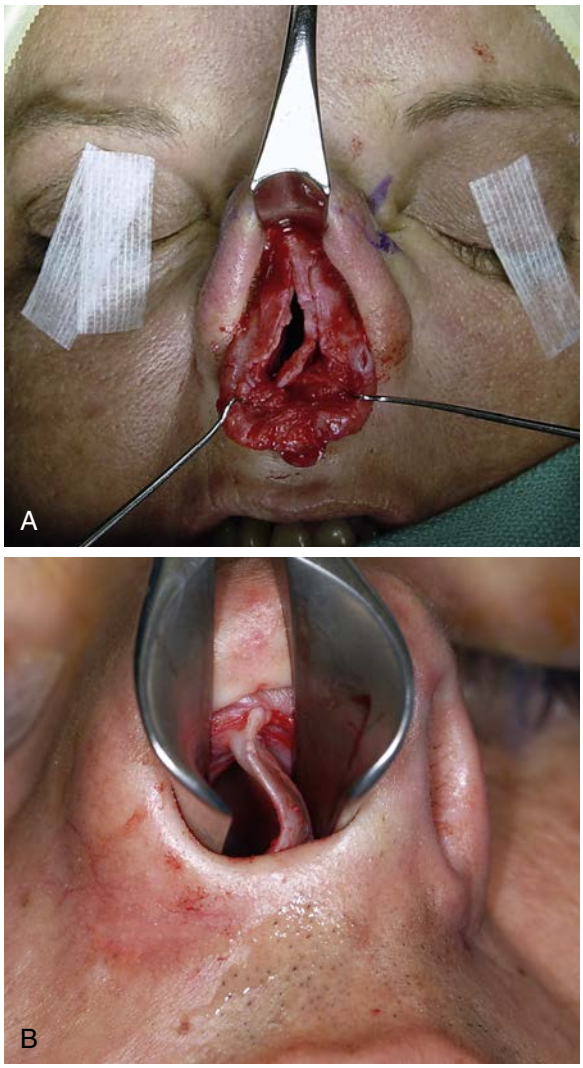

• **Figure 8-15** Exposure of septum. **A,** Dorsal approach by open rhinoplasty; **B,** transfixion incision.

crest must be removed entirely. Radical resection of cartilage or bone is avoided to preserve support and limit fibrosis and contracture. After septal surgery of this type, satisfactory reduction can almost always be accomplished.[20]

Open reduction is reserved for severe nasal fractures with or without an associated NOE complex fracture. Open reduction allows direct visualization of the fractures with more precise reduction. It also allows placement of grafts in areas of deficiency. Many surgeons defer open reduction to secondary corrective procedures or to cases that have failed closed reduction. In some cases early aggressive treatment may avert the need for secondary nasal revision. Open reduction can be done through a variety of approaches. An existing laceration gives an advantage to the surgeon. If necessary it may be minimally extended for better exposure. Standard closed rhinoplasty incisions allow improved access to reduction of the fragments. If more extensive exposure is required, then an open rhinoplasty approach provides the most exact and stable repair. This allows great exposure to the dorsum, septum, and tip region (Figure 8-17). Another

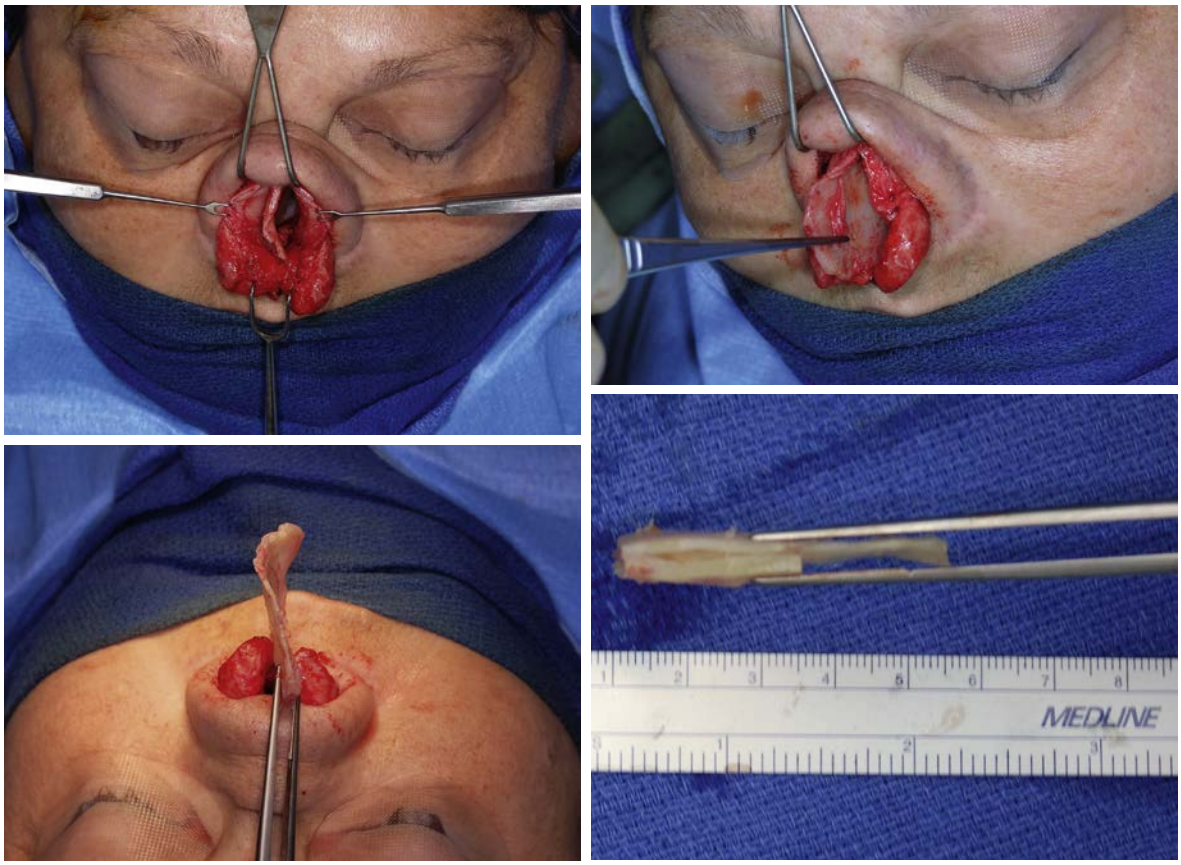

• **Figure 8-16** Correction of severe septal deformity; complete removal of cartilage and straightening on the table.

technique is the Lynch incision. This involves bilateral medial canthal incisions extended upward on either side along the medial orbital wall into the brow. This approach may be indicated when there is severe comminution associated with the NOE complex; this approach provides access to the nasal bridge and ethmoid sinuses, and laterally to the maxilla. When the two Lynch incisions are connected by an incision across the radix, this is called the open-sky approach or H incision. This approach provides great access for repair of multiple fractures under direct vision, but has fallen out of favor because facial aesthetics may be compromised. If there are preexisting lacerations, they may be used for part of the open-sky approach. The fourth approach is the coronal incision. It is mainly indicated when there are other associated fractures such as NOE, frontal sinus, or superior orbital rim. This approach allows great access to the entire forehead, NOE complex, and midface. If both maxilla and mandible need to be treated, a tracheotomy may be required.[2,7,12] If there are other maxillofacial fractures, the nose should be treated last to ensure adequate protection.[7]

Nasal repair, especially if the NOE complex is also involved, can be done through different techniques. Intranasal wiring can be used to correct traumatic telecanthus. Fine 26-gauge wires are used to connect through small holes drilled in the bone fragments.[23] The wire loop should include the medial canthal tendons on either side to ensure proper reduction of the telecanthus. Wire fixation can produce an accurate reduction, but it can also produce palpable sharp edges when the wires are twisted. The presence of wires can pose difficulty if subsequent revision rhinoplasty is considered. Some surgeons prefer slowly resorbing sutures in place of wires.[16] These are used in a figure-of-eight pattern to lock bone edges into close apposition. Miniplates can be used when there is severe comminution. Erosion of skin over the plate is possible, especially if eyeglasses are worn, but is generally uncommon. The advantage of plates over wires is that plates allow a better three-dimensional repair. Split-thickness free bone grafts can be used if a significant amount of bone is missing or unsalvageable.

If a coronal approach was used, then calvarial grafts can be easily obtained. Bone is harvested from the right parietal eminence. Soft tissue augmentation techniques can also be used to fill in soft tissue defects. Septal work is carried out in the fashion described previously. Septal hematoma is evacuated to prevent necrosis of the septum. Fractures of the septum usually occur in the quadrangular cartilage. If the fracture is too comminuted, the fragments are removed. Sound clinical judgment must be used in order to not compromise the support provided by the septum, leading to a saddle-nose deformity. Figure-of-eight sutures can be used to avoid overriding of the edges.

When the patient presenting with nasal fracture also has chronic nasal deformities from prior injury, the question arises as to whether to address those issues at the time of

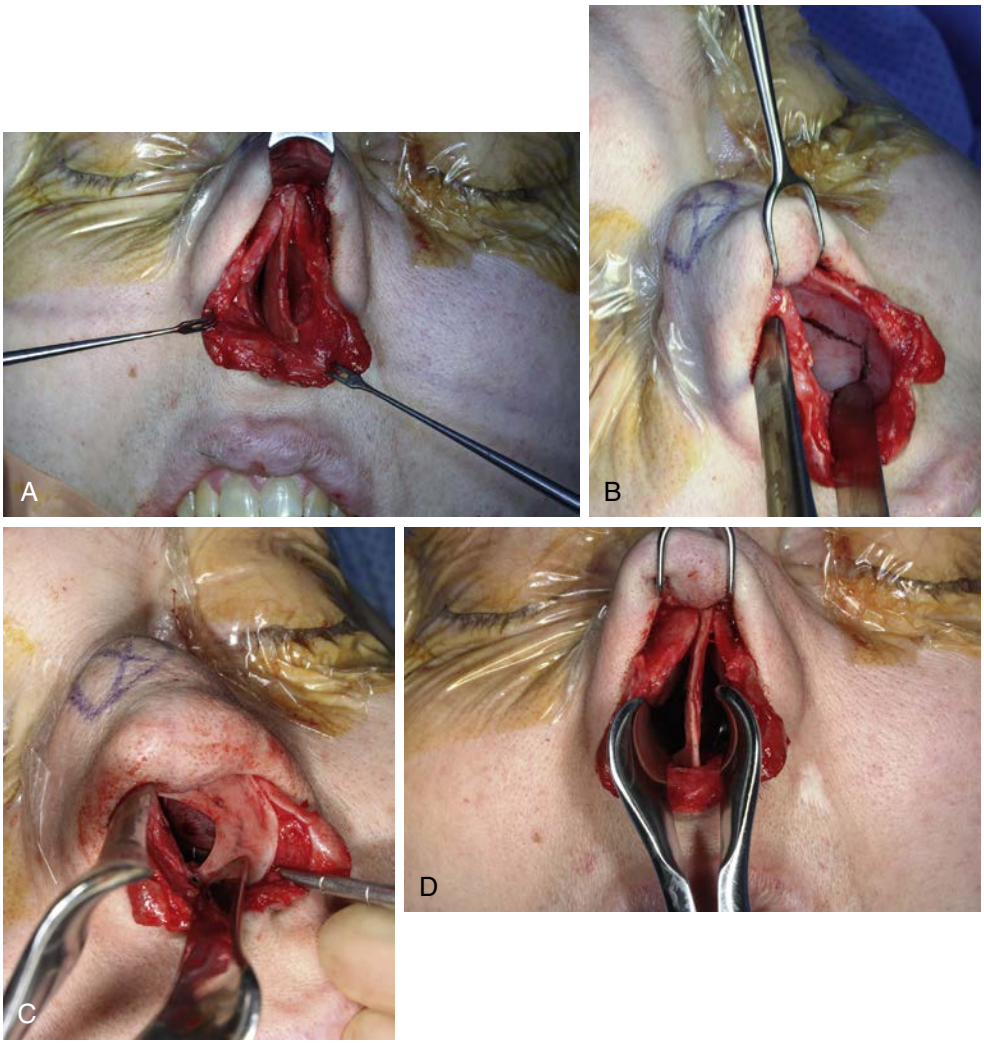

• **Figure 8-17** **A,** Open rhinoplasty with dorsal septal approach for exposure to the dorsum, septum, and tip region with precise correction of nasal septum. **B,** Marking for resection of deviated septum. **C,** Resection of deviated septum. **D,** Corrected septum.

nasal fracture reduction or delay them until later. Traditionally, nasal fracture reduction has been performed separately, with more refined septorhinoplasty being reserved until later. In carefully selected cases, extended septorhinoplasty may be performed during the nasal fracture reduction, especially in repair of the nasal septum. More refined procedures such as tip work are more effective when delayed until all the effects of edema and distortion are gone and the affected tissue has matured.

Nasal Fractures in Children

Many septal deformities in adults are due to minor trauma that occurred during childhood or as a newborn that went unrecognized. As the slight deviation matures, progressive nasal obstruction and deformity occur. A child's nose differs from that of an adult in several ways. Specifically, the underdeveloped nose has less frontal projection, is largely composed of cartilage, and possesses several growth centers. As a result, pediatric nasal trauma often presents a unique diagnostic and therapeutic dilemma. The immature nose is more likely to be associated with other fractures of the face because the nasal projection is much less prominent. Since the child's nose is more cartilaginous than its adult counterpart, it is easily compressible and absorbs little of the energy from the striking force as it passes across the face. The resultant edema spreads over the face and tends to disguise the extent of the nasal involvement in the pediatric age group.

The pediatric patient is likely to be uncooperative, and an exacting examination may not be possible. Extensive edema with facial trauma and the lack of rigidity of the nasal skeleton tend to produce a less than optimal situation for evaluation, even in the cooperative patient. The cartilaginous structures of the nose tend to buckle and twist with the trauma rather than to fracture.

Management of nasal fractures in children differs from that in adults in that general anesthesia is usually required. The prevailing method of managing pediatric nasal fractures is closed reduction. The nose with splayed nasal bones and no impactions can be reduced with bilateral digital

compression on the dorsum for 10 to 15 minutes. Often, nasal deviation to one side can also be reduced by digital compression on the side of the deviation. The cartilaginous elements do not move into place as readily, and when they are mobilized, they do not "snap" into place as do adult dislocations. The bony elements frequently are involved in a greenstick fracture and may be resistant to maintenance of the desired position. Although many nasal surgeons have advocated immediate repair of all septal deviations secondary to birth trauma, correction is necessary only in the case of nasal airway obstruction, as newborns are obligate nasal breathers.[24,25]

Nasal fractures can be associated with nasofacial disproportion, especially a long nose, in 21% of patients who were followed long-term. A long nose deformity was observed to develop during puberty, normally a time of rapid growth for the nose. These findings correlate with the three periods of nasal development: age 1 to 6 years (rapid growth), age 6 to 11 years (slow growth), and age 12 to 16 years (rapid growth).[26] Nasal surgery can be performed between the ages of 6 and 11 years when practical to potentially prevent nasofacial disproportion.

Complications of Nasal Fractures

Complications from nasal fractures include cosmetic deformity and airway obstruction. Problems arising from nasal fracture complications may be mitigated by adequately recognizing and treating the injury at the time it occurs. The complications can be broadly categorized into early and late.

Early Complications

Septal hematoma may develop either as a result of the injury or because of the repair, and is often bilateral. The fracture allows blood to pass into both mucoperichondrial planes, undrained. This may lead to fibrosis or to organization as a thick obstructive section of septal cartilage. If the hematoma is under excessive pressure, necrosis and perforation are likely results. Loss of septal support will cause collapse of the cartilaginous dorsum with a resultant saddle-nose deformity. If a hematoma is suspected, palpation for fluctuance may be done with cotton-tipped swabs followed by needle aspiration. Treatment is by horizontal incision at the base of the septum so as to produce dependent drainage. Bilateral hematomas are treated with a unilateral offset incision with preservation of the septum. Silastic splints, light packing, or mattress sutures for 2 to 3 days will prevent reaccumulation.

Edema, ecchymosis, and epistaxis usually resolve spontaneously. Intractable nasal hemorrhage, although rare, may necessitate ligation of the internal maxillary artery. Typically, compression with the balloon of a Foley catheter is adequate to tamponade the vessel for hemostasis. Infection is a rare complication, but antibiotic prophylactics should be used in immunocompromised patients and those who have hematomas. Cerebrospinal fluid rhinorrhea is associated with more severe trauma and indicates fracture of the posterior frontal sinus table or the cribriform plate. Laboratory diagnosis is easily made by glucose level measurements of the rhinorrhea and serum and the presence of beta-2 transferrin or beta-trace protein in the fluid. Though not as sensitive as laboratory testing, a quick evaluation of the fluid can be done with the halo test on a napkin at the bedside. Neurosurgery should be consulted and the patient observed closely for 6 weeks. Occasionally a lumbar drain or bone grafting may be necessary. Emphysema of the face and neck may also occur and usually resolves spontaneously with avoidance of increases in upper airway pressure.

Late Complications

Untreated hematomas of the nasal septum may become organized, resulting in subperichondrial fibrosis and thickening with partial nasal airway obstruction. The septum may be as thick as 1 cm, and in cases of repeated trauma the cartilaginous septum may be largely replaced with calcified or chondrified material. Submucosal resection of the thickened portion of the nasal septum may be required, and in some patients a partial turbinectomy may be advisable.

Synechiae may form between the septum and the turbinate in areas where soft tissue lacerations occur and the tissues are in contact. If bothersome, these may be treated by division followed by the placement of nonadherent, petrolatum-impregnated material between the cut surfaces for a period of 5 days. During this time, epithelialization occurs. Obstruction of the nasal vestibule may occur because of malunion of fractures of the pyriform margin or scar tissue contracture from loss of vestibular lining. Osteotomy of the bone fragments corrects the former; however, the contracture resulting from loss of soft tissue or scar contraction may require excision of scar, and replacement with skin or composite grafts within the nasal vestibule.

Residual osteitis is seen occasionally in compound fractures of the nose or in fractures associated with infected hematomas. Rarely, a portion of the bony nasal framework may be lost as a result of infection and may require late replacement with bone grafts. In these cases, appropriate debridement and antibiotics constitute the preferred regimen of treatment. Obstruction of the opening of the nasolacrimal duct leads to epiphora. Dacryocystorhinostomy may be needed for its correction.

Slight malunion of nasal fractures is common after closed reduction because the exact anatomic position of the fragments can be difficult to detect by palpation alone, especially in the presence of edema. Residual deviation also occurs because of release of "interlocked stresses" following fracture of the cartilage. If troublesome, the resulting external deformities may require reconstructive rhinoplasty.[2] Intraoperative imaging using a C-arm or O-arm for immediate evaluation of the reduction has been reported to result in fewer complications and decreased need for reoperation when used appropriately.[27]

References

1. Fonseca RJ: In *Oral and maxillofacial surgery*, vol. 3. Philadelphia, 2000, WB Saunders, pp 327–339.
2. Rohrich RJ, Adams Jr WP: Nasal fracture management: minimizing secondary nasal deformities, *Plast Reconstruct Surg* 106(2):266–273, 2000.
3. Supriya M, Clement WA, Ahsan F: Satisfaction with cosmesis following nasal manipulation: do previous fractures matter? *J Laryngol Otol* 120:749–752, 2006.
4. Tremolet de Villers Y, Schultz RC: Nasal fractures, *J Trauma* 15(4):319–327, 1975.
5. Murray JA, Maran AG, Mackenzie IJ, et al.: Open v closed reduction of the fractured nose, *Arch Otolaryngol* 110(12):797–802, 1984.
6. Cummings CW, Fredrickson JM, Harker LA, et al, editors: *Otolaryngology head and neck surgery*, ed 3, vol. 2. St Louis, 1998, Mosby-Year Book.
7. Fonseca RJ: *Oral and maxillofacial trauma*, ed 3, vol. 2. St Louis, 2005, Elsevier, pp 737–749.
8. Illum P, Kristensen S, Jorgensen K, et al.: Role of fixation in the treatment of nasal fractures, *Clin Otolaryngol* 8(3):191–195, 1983.
9. Verwoerd CD: Present day treatment of nasal fractures: closed versus open reduction, *Fac Plast Surg* 8(4):220–223, 1992.
10. Haug RH, Prather JL: The closed reduction of nasal fractures: an evaluation of two techniques, *J Oral Maxillofac Surg* 49: 1288–1292, 1991.
11. Yabe T, Ozawa T, Sakamoto M: Pre- and post operative X-ray and computed tomography evaluation in acute nasal fracture, *Ann Plast Surg* 53(6):547–552, 2004.
12. Crowther JA, O'Donoghue GM: The broken nose: does familiarity breed neglect? *Ann Roy Coll Surg Engl* 69:259–260, 1987.
13. Bailey BJ: Nasal fractures. In Bailey BJ, editor: *Head and neck surgery—otolaryngology*, vol. 1. Philadelphia, 1993, JB Lippincott.
14. Cook JA, Duncan R, McRae R, et al.: A randomized comparison of manipulation of the fractured nose under local and general anesthesia, *Clin Otolaryngol* 15:343–346, 1990.
15. Al-Moraissi EA, Ellis E: Local versus general anesthesia for the management of nasal bone fractures: a systematic review and meta-analysis, *J Oral Maxillofac Surg* 73:606–615, 2015.
16. Gunter JP, Rohrich RJ: Management of the deviated nose. The importance of septal reconstruction, *Clin Plast Surg* 15(1):43–55, 1988.
17. Jeong HS, Lee HK, Kim HS, et al.: A case-controlled, retrospective, comparative study on the use of biodegradable synthetic polyurethane foam versus polyvinyl acetate sponge after nasal fracture reduction, *Int J Oral Maxillofac Surg* 43:717–721, 2014.
18. Wang J, Cai C, Wang S: Merocel versus Nasopore for nasal packing: a meta-analysis of randomized controlled trials, *PLoS One* 9(4):e93959, 2014.
19. Yi CR, Kim YJ, Kim H, et al.: Comparison study of the use of absorbable and nonabsorbable materials as internal splints after closed reduction for nasal bone fracture, *Arch Plast Surg* 41: 350–354, 2014.
20. Manson PN: Facial injuries. In McCarthy JD, editor: *Plastic surgery*, vol. 2. Philadelphia, 1990, WB Saunders.
21. Renner GJ: Management of nasal fractures, *Otolaryngol Clin N Am* 24:195–213, 1991.
22. Harrison DH: Nasal injuries: their pathogenesis and treatment, *Br J Plast Surg* 32:57–64, 1979.
23. Kurihara K, Kim K: Open reduction and interfragment wire fixation of comminuted nasal fractures, *Ann Plast Surg* 24(2): 179–185, 1990.
24. McGraw-Wall BL: Facial fracture in children, *Fac Plast Surg* 7(3):198–205, 1990.
25. Stucker FJ, Bryarly RC, Shockley WW: Management of nasal trauma in children, *Arch Otolaryngol* 110(1):190–196, 1984.
26. Pollock RA: Nasal trauma. Pathomechanics and surgical management of acute injuries, *Adv Craniomaxillofac Fract Manag* 19(1):133–147, 1992.
27. Han DSY, Han YS, Park JH: A new approach to the treatment of nasal bone fracture: the clinical usefulness of closed reduction using a C-arm, *Plast Reconstruct Surg* 64:937–943, 2011.

9

Management of Zygomatic Fractures

TRENT L. TUCKER, SALAM O. SALMAN, LARRY L. CUNNINGHAM JR.

Introduction

Zygomatic fractures are common in facial trauma and, as is the case with other facial fractures, occur primarily among men in their third decade of life. Unpublished data from a recent 4-year retrospective chart review at the University of Kentucky resulted in finding 416 zygomaticomaxillary complex (ZMC) fractures and produced the following statistical data. The demographic data are similar to other review articles.[1-3] Fractures occur most commonly as the result of assaults (35.6%) or motor vehicle collisions (20.7%) with a mean age of 37.8 years (older than in other reviews). Anatomic incidence was found to be right orbital floor 37.3% and left orbital floor 34.9%, left ZMC 34.4% and right ZMC 24.5%, right arch 7.9% and left arch 6.7%; 4.8% were classified as panfacial fractures.

Displaced fractures of the zygoma cause obvious deformities of the midface related to the projection of the malar eminence, lateral projection of the arch, and position of the globe, which can affect vision. For these reasons, the appropriate diagnosis and treatment of these fractures are important for the functional and cosmetic outcome of facial trauma patients.

Anatomy

Because of its prominent position on the facial skeleton, the zygomatic bone is responsible for the anterior and lateral projection of the midface and thus is an important part of facial esthetics. Its outer (lateral) surface is convex; its inner (temporal) surface, concave. It is quadrilateral in shape and articulates with four other bones: maxilla, sphenoid, temporal, and frontal bones. Because it forms part of the lateral wall and floor of the orbit, fractures of the body of the zygoma usually involve fractures of the floor or the lateral wall of the orbit, or both (Figure 9-1).

The four processes of the zygoma are the frontal, maxillary, temporal, and sphenoid. The frontal process is sturdy; however, it narrows superiorly as it articulates with the zygomatic process of the frontal bone. It forms a large portion of the orbit and, together with the sphenoid bone, forms part of the orbital floor. The temporal process is narrow and thin. It articulates with the zygomatic process of the temporal bone, and together they make up the zygomatic arch. The body of the zygoma is sturdy, but its articulations are frequently the site of fracture.

Five muscles attach to the zygoma. The masseter muscle originates from its temporal surface; the zygomaticus major, the zygomaticus minor, and the levator labii superioris originate from its malar surface. The temporalis muscle and the temporalis fascia attach at the temporal process, specifically its posterolateral edge.

Two foramina arise from this bone. On the malar surface is the zygomaticofacial foramen, which provides exit to the nerve and vessels of the same name. The zygomaticotemporal foramen on its medial side transmits the zygomaticotemporal nerve and vessels.

From a frontal view, the ideal position of the zygomatic prominence is 10 mm lateral and 20 mm inferior to the lateral canthus. From a lateral perspective, the globe should be 1 mm anterior to the most prominent portion of the zygoma. Because these ideal measurements are not always found, an examination of the contralateral zygoma will determine the correct position of the injured zygoma in every patient who has no craniofacial anomalies.

For complex zygomatic fractures, multiple approaches are often needed for visualizing the fracture sites and applying internal fixation. The anatomy of the eyelids and scalp are briefly discussed here for later reference.

The upper eyelid consists of five distinct layers from skin to conjunctiva: the skin, the orbicularis oculi muscle, the orbital septum above or the levator palpebrae superioris aponeurosis below, the Müller muscle/tarsus complex, and the conjunctiva. The lower eyelid consists of at least four distinct layers: the skin and subcutaneous tissue, the orbicularis oculi muscle, the tarsus (upper 4 to 5 mm of the eyelid) or orbital septum, and the conjunctiva.

The layers of the scalp can be remembered with the simple mnemonic SCALP: s, skin; c, subcutaneous tissue;

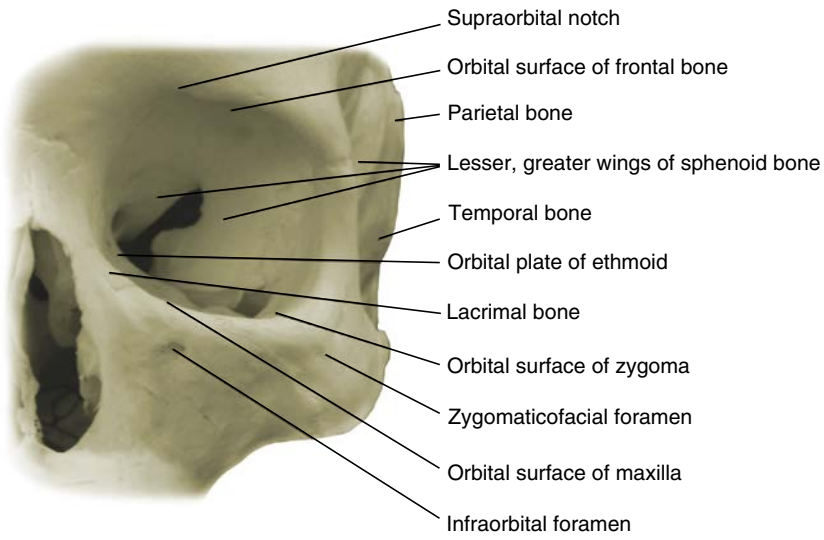

• **Figure 9-1** Bony anatomy of the orbit and zygoma.

a, muscularis aponeurotic; l, loose areolar connective tissue (subgaleal fascia or subaponeurotic plane); and p, pericranium (periosteum). The skin and subcutaneous tissue of the scalp are surgically inseparable, unlike these same structures elsewhere in the body. The musculoaponeurotic layer consists of the paired frontalis (epicranius) and occipitalis muscles, the auricular muscles, and a broad aponeurosis. The aponeurosis is the true galea and has two portions, an extensive intermediate aponeurosis between the frontalis and occipitalis muscles and a lateral extension into the temporoparietal region known as the temporoparietal fascia. The superficial temporal artery lies on or in this layer.

The subgaleal fascia is usually referred to as the loose areolar layer or the subaponeurotic plane. This layer cleaves readily, allowing the skin, subcutaneous tissue, and musculoaponeurotic layers to be stripped from the pericranium. The loose tissue of the subgaleal fascia allows free movement of the skin over the periosteum when the frontalis muscle is contracted. This fascial layer is used only for its ease of cleavage. Anteriorly the subgaleal fascia is continuous with the loose areolar layer deep to the orbicularis oculi muscles. Laterally the subgaleal fascia is attached to the frontal process of the zygoma and continues along the superior surface of the zygomatic arch, above the external auditory meatus, and over the mastoid process. The subgaleal fascia terminates as it fuses with the periosteum along the superior nuchal line. The pericranium is the periosteum of the skull and can be elevated from the skull, although it is more firmly attached along cranial sutures.

History and Physical Examination

The patient's medical history is always important, because many of these injuries will require operative intervention. As is often the case, medical and surgical problems may need to be managed in concert. The patient's mechanism of injury most often provides the initial indications of a possible zygomatic fracture.

Indications for surgery are cosmetic deformities and functional deficits[4] (Box 9-1). Because of the prominent

• BOX 9-1 Indications for Surgery

Depressed arch
Depressed malar eminence
Diplopia
Enophthalmos
Paresthesia in V2 distribution
Trismus

position of the zygoma on the face, zygomatic fractures can result in cosmetic deformities such as flattening of the malar eminence, widening or depression of the arch, orbital dystopia, or enophthalmos. These deformities can occur without severe impairment of function. However, fractures of the zygomatic arch can cause functional impairment by impinging on the temporalis muscle or obstructing the path of the coronoid and causing trismus. Zygomatic fractures impinging on the infraorbital nerve cause paresthesia or dysesthesia of the second division of the trigeminal nerve (V2). Disruption of the position of the globe can cause diplopia. Therefore, an examination of the orbit and the globe, including extraocular movements, an evaluation of the maxillary sinus, a determination of V2 sensation, and an examination of the range of motion of the mandible are essential in diagnosing zygomatic injuries (Figure 9-2).

Signs of zygomatic fracture are periorbital or maxillary vestibular ecchymosis, periorbital edema, flattened arch or malar prominence, deformity or displacement, trismus, displacement of palpebral fissure, enophthalmos, exophthalmos, chemosis, and conjunctival hemorrhage (see Figure 9-2; Figure 9-3), Symptoms that indicate zygomatic injury are pain, sensory deficit, crepitus from air emphysema, and diplopia.

Once the examination of the patient has been completed, the anatomic dislocation of the zygoma can best be evaluated by digital exploration. The patient should be in the cephalad position during the examination; the surgeon should compare the right and left sides simultaneously, beginning at the zygomaticofrontal suture and palpating

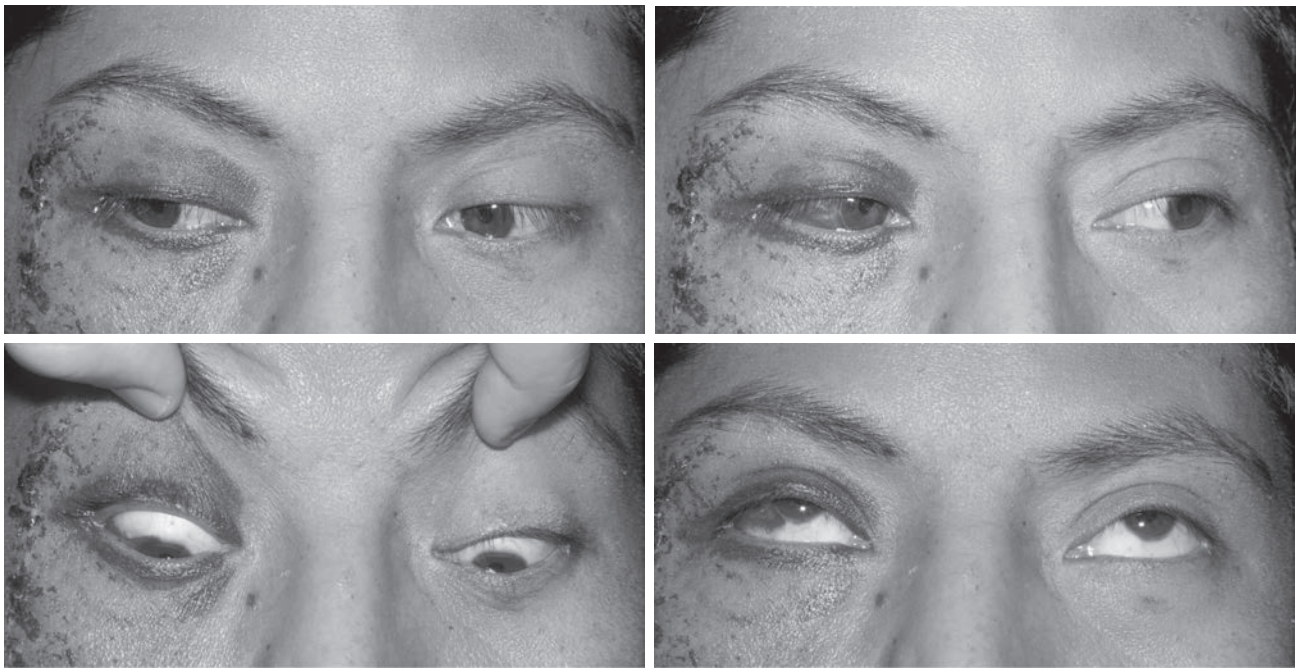

• **Figure 9-2** Extraocular movements. This patient shows no evidence of entrapment on exam. Note the subconjuctival hemorrhage of the patient's right eye.

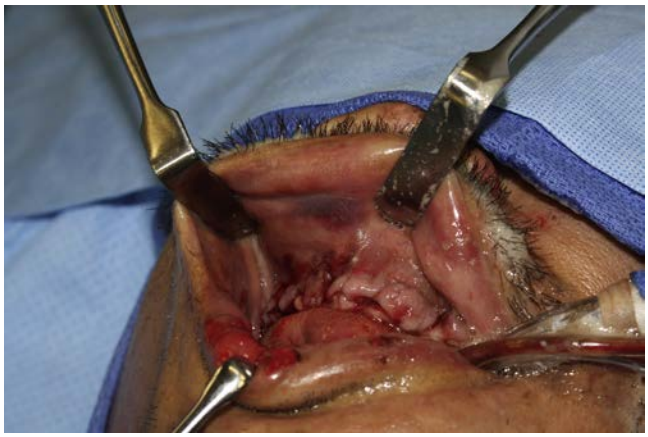

• **Figure 9-3** Vestibular ecchymosis associated with a zygomatic fracture. Avulsed maxillary dentition as well due to injury.

inferiorly and medially along the infraorbital rim. Then the zygomatic arch should be evaluated for dislocation, comminution, or pain. The buccal vestibule and antral wall should be palpated intraorally for detection of crepitus or bony disruption. Palpation is important because acute swelling after an injury can mask the displaced fracture (Figure 9-4).

Many surgeons consider an ophthalmologic examination an essential part of the examination for zygomatic fracture. Depending on the mechanism of injury, as many as 28% of patients with zygomatic injuries may have moderate to severe ocular injuries.[5-7]

Indications for Radiographs and Surgery

After the primary and secondary trauma survey, when life-threatening injuries have been ruled out or managed, radiographic imaging should be considered. Currently, computed tomography (CT) is the gold standard for diagnosing bony injuries of the face. Images (either direct or reformatted) should be obtained in the axial and coronal dimensions (Figure 9-5). With improvements in CT scan images, three-dimensional (3D) reconstruction images can provide greater visualization of displaced and fractures segments (Figure 9-6).

In the unlikely event that obtaining CT scans is impossible, plain radiography can be used. The images that should be obtained are a lateral skull view, a Waters (posteroanterior oblique) view, or a reverse Waters (anteroposterior oblique) view, and a submental vertex view of the skull. The Waters or posteroanterior view provides visualization of the inferior or lateral rims or both and of the orbital floors, as well as the maxillary sinuses. Often the zygomatic arch can also be visualized. If the patient cannot be placed in a supine or upright position, the modified or reverse Waters view (anteroposterior oblique) may be used. With this technique the structures are farther from the film; thus, the structures are not as well defined as in the classic Waters view. The lateral skull view provides detail about the paranasal sinuses and the presence of air intracranially.

CT scanning provides finely detailed views of the bony architecture and pinpoints even the smallest fractures. Because CT scanning uses less radiation and provides views more rapidly than plain radiography, it is now the procedure of choice. The best evaluation of suspected zygomatic and orbital fractures is provided by 1.5-mm slices in the axial plane (for information about the medial and lateral walls) and the coronal plane (for specific information about the orbital floor). Many scanners provide reconstructed coronal images, which are

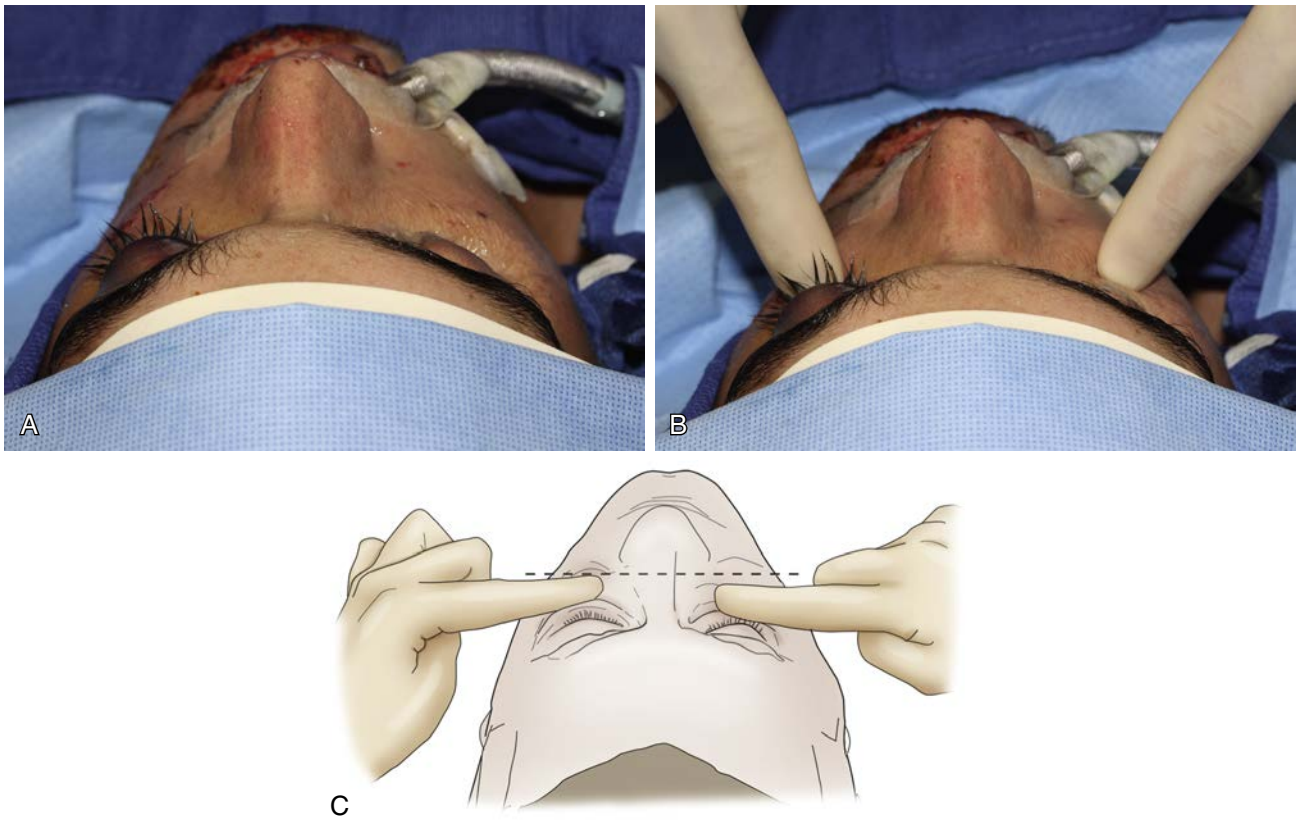

• **Figure 9-4** Facial swelling after trauma may mask a deformity that is easily palpated. **A,** Birdseye view demonstrating symmetric appearance due to edema. **B,** Palpating malar regions reveals depressed right zygomaticomaxillary complex (ZMC). **C,** Artist depiction of palpating depressed right ZMC.



• **Figure 9-5** **A,** Axial computed tomography (CT) scan image demonstrating fractured and displaced zygomaticomaxillary complex (ZMC). **B,** Coronal CT scan image demonstrating fractured and displaced ZMC.

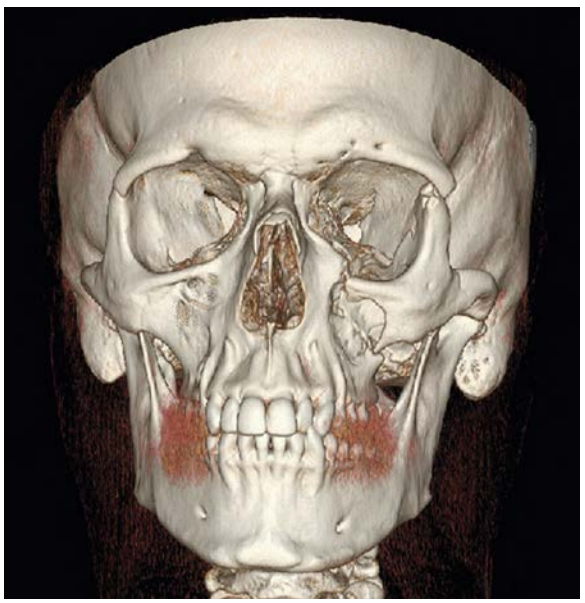

• **Figure 9-6** Three-dimensional reconstruction computed tomography scan image showing depressed zygomaticomaxillary complex fracture and increased orbital volume on the affected side.

usually adequate with axial slices of 1.5 mm or less. Sagittal images provide useful information about the posterior extent of a floor defect and the amount of posterior bone that remains. Sagittal scans are not routinely performed and must be specifically requested. Three-dimensional reconstructions can be created and are often useful for diagnosing and planning the treatment of complex fractures.

CT scanning also provides information about soft tissues. It can visualize orbital injuries such as a ruptured globe, dislocated lens, or vitreous hemorrhage and can demonstrate retrobulbar hemorrhage or disruption of the optic nerve. The extraocular muscles are clearly visible, and the clinical assessment of entrapped muscles can be confirmed. Preseptal and postseptal hematomas can also be differentiated.

Treatment

During the consideration of treatment for zygomatic injuries, the patient's interests should be paramount. The patient's age and medical history should be factored into the decision-making process. If, after being informed about the risks and benefits of surgery or observation, the patient elects surgery, the decision about how and when to treat can be addressed.

Fracture patterns are classified by anatomic location and by the pattern of segmentation and displacement seen on CT scans.[8-10] Fractures can be described as high-energy or low-energy injuries. A low-energy fracture typically results in mild to moderate displacement and is not comminuted. High-energy fractures often result in more severe displacement and comminution of the body of the zygoma. These injuries commonly require orbital reconstruction.[11]

The main reason not to treat zygomatic fractures surgically is the clinical absence of functional and esthetic compromise.[4,11] Another consideration is the degree of vision in the unaffected eye. Visceral and neurologic damage always takes precedence over a fractured facial bone. Although the risk to vision associated with the repair of a zygomatic fracture is low (<1%), it may be unwise to risk affecting the sight in the remaining functional eye.

Once the decision has been made to proceed with surgical treatment, the surgeon must decide when to operate. Waiting for residual edema to resolve, approximately 2 weeks, is usually acceptable. This delay allows time for adequately assessing and planning the case; in addition, findings associated with the injury manifest themselves during this time. Waiting longer than 2 weeks may complicate the surgical reduction of the fracture because early bone healing may begin during this time and may make osteotomy of the fracture site necessary. If soft tissue lacerations are present over the fracture sites, soft tissue fibrosis and contracture can make the soft tissue envelope more difficult to expand. Evidence of muscle entrapment on CT scan or on physical exam is an indication for immediate surgery. Pressure on the muscle from bone margins can lead to muscle necrosis and fibrosis, causing a permanent restriction of movement.

Surgical Approaches for Fractures of the Zygomatic Complex

The technique used to approach the facial skeleton depends on the individual fracture pattern and on the displacement of the fracture. For high-energy, comminuted fractures, or for multiple facial fractures, multiple approaches are necessary. For isolated zygomatic fractures, stable reduction can sometimes be achieved with less exposure. The order of the following approaches is based on the order in which they might be used for reducing an isolated, noncomminuted fracture of the zygoma (Figure 9-7).

Carroll-Girard Screw

The most direct approach in reducing a zygomatic fracture is to insert a Carroll-Girard screw. This T-shaped device has a handle at one end with a sharp screw portion perpendicular to it. This device must be placed into the body of the zygoma, thus requiring an incision directly over the malar prominence. This requirement is the main drawback of this approach; however, if the incision is performed properly, the scar is virtually invisible within 6 months. Alternatively, if



• **Figure 9-7** Exposure of zygomaticomaxillary buttress and infraorbital rim with placement fixation via preexisting laceration.

an infraorbital incision is used as an approach to the orbital rim, the screw can be placed through it. This screw is a useful device and provides traction in any direction. Some surgeons recommend placing this screw regardless of any other methods of reduction used (Figure 9-8).

Vestibular Approach

This technique can be used for a wide variety of midfacial procedures. It allows safe access to the entire facial surface of the midfacial skeleton, from the zygomatic arch to the infraorbital rim and the frontal process of the maxilla. With regard to zygomatic injuries specifically, this approach is required for visualization of the zygomaticomaxillary buttress. The greatest advantage of this approach is that the scar can be hidden. This rapid and simple approach is associated with few complications.

The path to the underlying facial skeleton is through mucosa, submucosa, facial muscles, and periosteum. The only important neurovascular structure encountered during this dissection is the infraorbital nerve, which is located approximately 7 to 10 mm inferior to the infraorbital rim and just medial to the zygomaticomaxillary suture.

After submucosal injection of a vasoconstrictor, the incision is placed approximately 3 to 5 mm superior to the mucogingival junction. This placement leaves a cuff of unattached mucosa at the inferior extent that must be closed at the end of the procedure. The incision extends as far posteriorly as is necessary for exposure, usually up to the first molar tooth. Whether the incision extends past the midline depends on whether the fractures are bilateral. The initial incision is perpendicular to the mucosa and then is angled perpendicular to the bone. The incision is carried through the periosteum, and a subperiosteal dissection is performed first anteriorly, then along the piriform aperture, and then posteriorly behind the zygomaticomaxillary buttress. Careful dissection at the buttress is advised so that the buccal fat pad is not exposed; such exposure is more of a nuisance than a complication of surgery.



• **Figure 9-8** Carroll-Gerard screw placement for manipulation of the body of the zygoma.

The unilateral maxillary vestibular incision is closed simply in one layer with a 3-0 resorbable suture. If a circumferential maxillary vestibular incision is made, the closure is more complex. An alar cinch with V-Y closure is performed, and the midline is then tacked; this technique creates a linear incision. The vestibule is then closed in a continuous fashion to the midline from both sides.

Approaches to the Zygomaticofrontal Region

When the fracture remains unreduced or unstable after a closed reduction and a vestibular approach have been attempted, the surgeon might then address the zygomaticofrontal region. It is not uncommon to find significant overlap of bone, with the inferior lateral orbital rim having been displaced medially and superiorly.

Lateral Canthotomy

If a lateral canthotomy is indicated (i.e., because exposure of the zygomaticofrontal suture is necessary), this is the initial incision. The initial incision is made with a No. 15 blade through the skin and dermis and proceeds for only approximately 1 cm. An anesthetic with a vasoconstrictor should then be administered under the conjunctiva and in the lateral canthotomy site as an aid to hemostasis. Administering the anesthetic after this incision helps avoid distortion of the tissue as the procedure progresses. The incision is completed with pointed scissors to the depth of the lateral orbital rim (7 to 10 mm). The layers that are incised are skin, orbicularis oculi muscle, orbital septum, lateral canthal tendon, and conjunctiva. Mobilizing the lower eyelid may require releasing the anterior limb of the lateral canthal tendon. Subperiosteal dissection is then continued on the lateral surface of the superior lateral orbital rim and is followed by reduction and placement of fixation.

Upper Eyelid Approach

The upper eyelid approach can also be used to access the lateral orbital rim, the lateral orbital wall, and the superior orbital rim. This approach is also known as the upper blepharoplasty, upper eyelid crease, and supratarsal fold approach. A natural skin crease in the upper eyelid excellently camouflages the scar. If there is no eyelid skin crease, a curvilinear incision should be along the supratarsal fold and should tail off laterally over the lateral orbital rim. Protection of the cornea is critical during surgery and can be achieved with a tarsorrhaphy or a corneal shield placed at the beginning of the procedure. When the location of the incision has been determined, the incision is made through the skin only. After the initial incision, a local anesthetic

with vasoconstrictor should be administered. Making the initial skin incision before administering the anesthetic is beneficial because distortion of the tissues after infiltration can make correct placement of the incision difficult. The incision should be placed at least 10 mm superior to the upper eyelid margin and 6 mm above the lateral canthus as it extends laterally (Figure 9-9).

The incision is made through the skin and the orbicularis oculi muscle. The vasculature of the muscle maintains the viability of the skin; elevating this vasculature with the skin creates a skin-muscle flap. This flap can be developed laterally, superiorly, and, if necessary, medially. Dissection continues superiorly just below the muscle and superficial to the orbital septum. Once the periosteum has been identified over the superior orbital rim, it is incised, and the periosteum is dissected up for exposure of the fracture. Care should be taken near the superior-lateral orbital rim, because the lacrimal fossa and gland are located just inside the rim.

After the fracture has been fixated, closure is performed in layers: periosteum, muscle, and skin.

Eyebrow Approach

This approach to the lateral orbital rim is straightforward and rapid and offers a relatively well-camouflaged scar. No important neurovascular structures are encountered during this approach. If the patient has undergone cosmetic eyebrow removal, or if exposure of the inferior lateral orbital rim is also necessary, the scars may be more apparent, and the extent of exposure may be limited.

This approach is rarely indicated; when it is, the eyebrow is not shaved. An incision of approximately 2 cm is made; the inferior extent of the incision should stop at the end of the eyebrow and parallel to the hair of the eyebrow so that no hair shafts are cut. The incision should not be extended inferiorly along the orbital rim, because such an extension may cross the lines of resting skin tension (Figure 9-10).

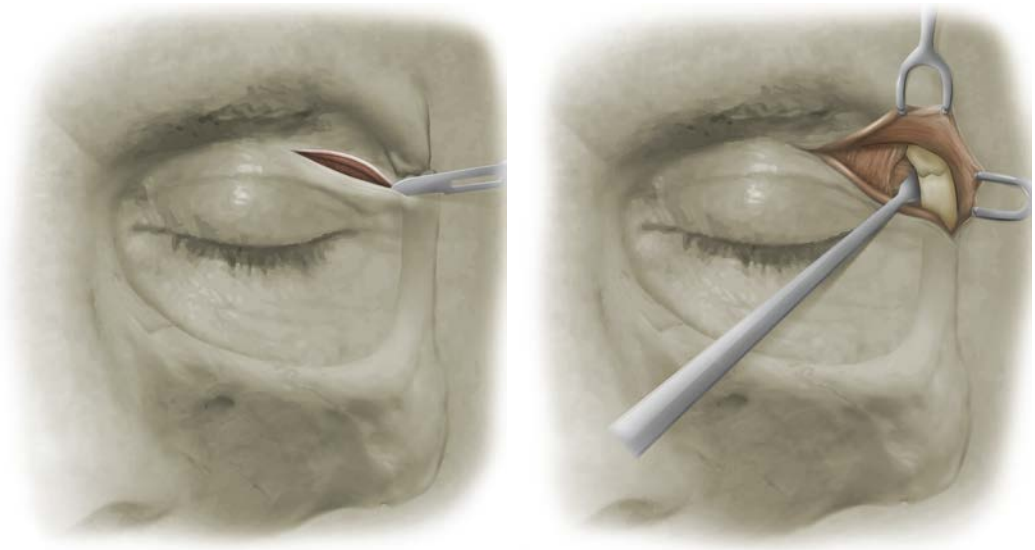

• **Figure 9-9** Placement of an upper eyelid incision for approaching the zygomaticofrontal suture.



• **Figure 9-10** Placement of a lateral brow incision for approaching the zygomaticofrontal suture.

Once undermining has been performed in a supraperiosteal plane, the skin is retracted over the area of interest and a periosteal incision is made. Dissection is performed in a subperiosteal plane, but again, access is limited. Closure is performed in a layered fashion.

Approaches to the Infraorbital Rim and the Orbital Floor

Lower Eyelid Approaches

Lower eyelid approaches provide excellent exposure of the inferior orbital rim, the floor of the orbit, the lateral orbit, and the inferior portion of the medial orbital rim and wall. Placing the incision in the thin skin of the eyelid and in the natural resting lines of the skin results in a scar that becomes inconspicuous with time; transconjunctival incisions are perhaps the best hidden. Several external incisions exist and are named according to the inferior or superior position at which they are placed on the skin and also according to the level at which the muscle is transected for exposure of the periosteum. The subciliary incision, also known as the infraciliary or blepharoplasty incision, is made just below the eyelashes. The subtarsal approach, also known as the mideyelid or skin crease approach, is made 4 to 7 mm below the eyelid margin (Figure 9-11).



• **Figure 9-11** Subciliary, subtarsal, and mid-lid approaches to the infraorbital rim and orbital floor.

Transconjunctival Approach

The transconjunctival approach can be used to expose the infraorbital rim and the floor of the orbit. However, when a lateral canthotomy is used in conjunction with this approach, exposure of the zygomaticofrontal suture and the lateral wall of the orbit can be obtained. Also with medial extension of the transconjunctival incision posterior to the caruncle (i.e., transcaruncular incision), the medial wall of the orbit can be exposed. Some authors separate the transconjunctival approach from the transconjunctival approach with medial extension (i.e., transcaruncular approach) and from the transconjunctival approach with lateral canthotomy extension. In this chapter, all of these are described under the transconjunctival approach.

The main advantage of this approach is that the scar is hidden; if a lateral canthotomy is used, an inconspicuous scar remains, usually in a skin crease. This approach is also rapid because it is not necessary to create a skin or a skin-muscle flap during dissection. With improper technique, the main disadvantage of this approach is entropion, which is more difficult to correct than the sequela of an improper skin incision (i.e., ectropion).

As is necessary with the previously described techniques, a forced duction test should be performed preoperatively and a corneal shield should be placed for protection. Two or three traction sutures, using 3-0 silk, can be placed into the lower eyelid approximately 5 mm inferior to the lid margin so that the tarsal plate is included in the suture.

The transconjunctival approach is begun by creating a small incision in the lateral conjunctiva with tenotomy scissors or with an electrocautery device. A subconjunctival plane is then bluntly dissected with the scissors, followed by completion of the conjunctival incision. This plane is easily found when this approach is combined with a lateral canthotomy. The incision is placed halfway between the inferior conjunctival fornix and the inferior margin of the tarsal plate. This incision can be placed as far medially as necessary as long as the lacrimal sac is not violated. This medial extension is called a transcaruncular incision because it was originally described as a 12- to 15-mm vertical incision through the conjunctiva and the lateral third of the caruncle. However, the incision can also be placed temporal to the caruncle. Either incision is carried superiorly through the conjunctiva to the level of the levator palpebrae aponeurosis, thereby exposing the underlying periorbita. Placing traction sutures in the vestibular conjunctiva can help hold the corneal shield in place and also help preserve the conjunctiva for closure at the end of the case (Figure 9-12).

After the incision has been made through the conjunctiva, the surgeon must decide whether to perform a preseptal or a retroseptal approach to the orbital rim. The advantages of the retroseptal approach are that it is more direct and may help avoid the scarring within the lower eyelid that is associated with the preseptal approach. However, with the retroseptal approach, periorbital fat will be encountered. Other than being bothersome throughout the case, no serious risk is associated with exposing this adipose tissue. With the retroseptal approach, the surgeon sharply incises the periorbita immediately posterior to the orbital rim, paying special attention to avoiding the lacrimal sac medially. This incision can be made with electrocautery or with a No. 15 blade. If a preseptal approach is used, blunt tenotomy scissors are used after the incision through the conjunctiva for dissection through the septum and the inferior lid retractor muscles. The dissection is continued anterior to the septum to the lower rim approximately 2 mm inferior to the superior border of the infraorbital rim. The periosteum is then incised sharply.

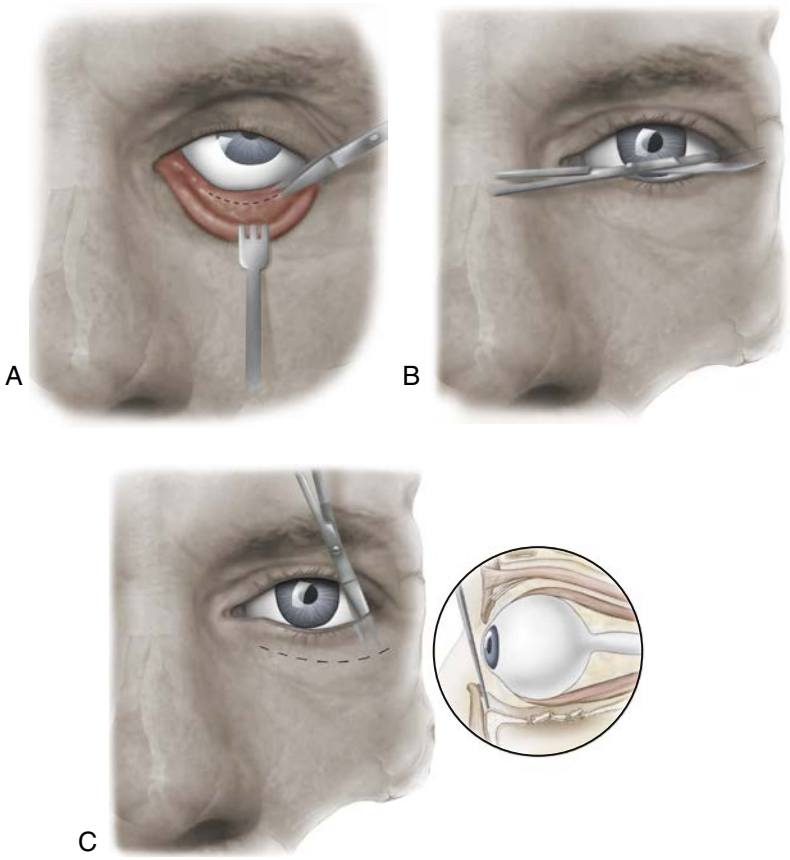

• **Figure 9-12** **A,** Location of the transconjunctival incision, inferior to the tarsal plate, and 3-4 mm superior to the conjunctival sulcus. **B,** Lateral canthal release. **C,** Blunt dissection to the orbital rim.

With both approaches, the periosteum can then be dissected off the anterior portion of the maxilla and zygoma, the orbital rim, and the orbital floor with periosteal elevators. Obviously, the extent of the dissection will be dictated by the initial exposure needed for identifying the fractures and determining the severity and location of the fractures (Figure 9-13).

These incisions should be closed in a layered fashion. If possible, the periosteum is closed with 4-0 resorbable suture. Closing the periosteum medially after a transcaruncular extension is quite difficult and is not essential. If a lateral canthotomy is performed, an inferior canthopexy suture should be inserted but not tied before the conjunctiva is closed. This technique allows open access for closure of the conjunctiva. A 4-0 long-lasting suture is used to reattach the lateral portion of the inferior tarsal plate to the residual superior portion of the lateral canthal tendon or to the fixed surrounding tissues. When the adequacy of this suture is assessed, the contralateral lateral canthus should be at a comparable level, and the lower lid should be adjacent to the globe. The surgeon should pull two ends of the suture to ensure that the suture is firmly attached to ligamentous tissue. The conjunctiva should be closed with 6-0 resorbable suture in a running fashion. If interrupted sutures are used to close the conjunctiva, the knots should be buried. After the conjunctiva has been closed, the canthopexy suture is tightened; this technique draws the lower eyelid into position. Subcutaneous and then 6-0 skin sutures are placed along the horizontal lateral canthotomy to complete the closure.

Subciliary Approach

This approach is begun by making a skin incision just below the eyelashes, 1 to 2 mm inferior to the lashes along the entire length of the eyelid. After the initial incision, local anesthetic with a vasoconstrictor should be administered in a manner similar to that described for the upper eyelid approach. Subcutaneous dissection is then performed 4 to 6 mm inferiorly along the entire extent of the incision.

Once the subcutaneous flap has been elevated, the incision is extended through the suborbicularis muscle, beginning at the lateral extent. The skin incision and the muscle incision are made at different levels so that hypertrophic scarring and exophthalmos can be avoided. This dissection is carried medially between the orbicularis oculi muscle and the orbital septum. An attachment of the orbicularis oculi muscle will remain; transecting this attachment inferior to the initial skin incision creates a "step" dissection. After the muscle has been transected, the orbital septum and periosteum will be exposed. The skin-muscle flap can be retracted inferiorly, and an incision can be made through the periosteum on the anterior surface of the maxilla and zygoma, 3 to 4 mm below or lateral to the orbital rim. Making the incision at this level avoids the insertion

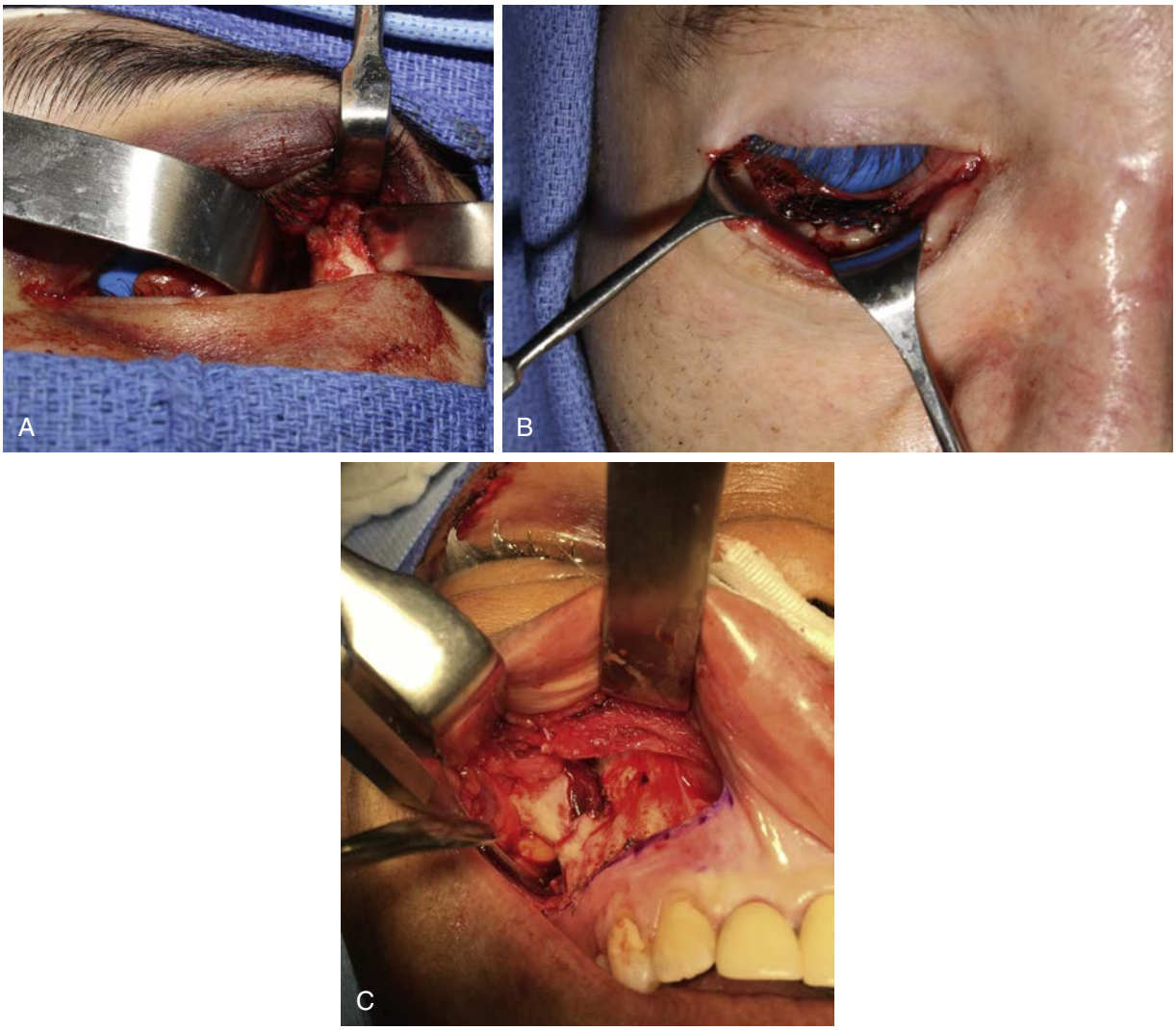

• **Figure 9-13** **A,** Exposure of the zygomaticofrontal fracture via a lateral canthotomy incision. **B,** Exposure of the infraorbital rim via a transconjunctival incision. **C,** Exposure of the zygomatic buttress via a maxillary vestibular incision.

of the orbital septum along the orbital margin and the infraorbital nerve, which is located approximately 5 to 7 mm inferior to the orbital rim.

With the sharp end of a periosteal elevator, a subperiosteal dissection can be performed along the anterior maxilla, the orbital rim, and, if necessary, along the orbital floor. If exposure of the lateral orbital rim is required, the incision can be extended 2 cm past the lateral canthus. This extension will allow access to the zygomaticofrontal suture and will not pose any threat of injury to the temporal branch of the facial nerve, which crosses the zygomatic arch 3 cm lateral to the lateral canthus. Supraperiosteal dissection is performed superior to the zygomaticofrontal suture. The skin, muscle, and superficial limb of the lateral canthus are retracted superiorly, thereby exposing the underlying periosteum. The initial infraorbital rim incision connects to an incision made in the periosteum on the lateral side of the lateral orbital rim.

Closure is performed in two layers, the periosteum and the skin. The periosteum can be closed with resorbable suture (Monocryl preferred), and the skin can be closed with a running 6-0 nonresorbable or fast-resorbing suture. If the extended incision is made, an isolated lateral canthopexy can be avoided as long as the periosteum is meticulously repositioned and sutured along the lateral orbital rim. A suspensory suture (Frost suture) placed in the lower eyelid can counteract skin and septal scarring, thus reducing the risk of lower lid shortening and ectropion. This suture may be left in place for several days or until gross edema has resolved. A suture is placed in the gray line of the lower lid and suspended in the forehead via an 18-gauge Angiocath with a vertical slit superiorly (Figure 9-14). Vision can be checked by opening the upper eyelid.

Subtarsal Approach

The subtarsal approach is very similar to the subciliary approach; the differences are described next. The skin incision is placed at the level of the inferior margin of the lower



• **Figure 9-14** Frost suture secured to the forehead using a 20-gauge Angiocath.

tarsus, in the subtarsal fold. Practically, it is made in the mideyelid in a natural eyelid crease. The benefits of this more inferiorly based incision are that it is less frequently associated with scleral show and ectropion. This incision will provide adequate access to the orbital floor and the inferior orbital rim. If extension of this incision is required, the incision will be carried laterally and inferiorly, following the natural skin resting lines. An extended incision and dissection lateral to the orbital rim, as in the subciliary incision, should not be used because of the lateral inferior position in which the incision would have to be made.

Unlike the subciliary incision, which is carried simply through skin, this incision is carried through both skin and orbicularis oculi muscle; it stops at the orbital septum. The skin-muscle flap is then dissected from the orbital septum inferiorly for approximately 4 mm. Retracting the skin-muscle flap will leave the orbital septum and periosteum exposed. The incision through the periosteum, the dissection of the orbit, and the closure are the same as those described for the subciliary approach.

Approaches to the Arch and the Zygomaticotemporal Suture

Coronal Approach

A versatile approach, the coronal approach can be used to access the upper third of the facial skeleton and the zygomatic arch. With respect to the zygomatic complex, the coronal approach is used for severely displaced and comminuted complex fractures that require access to and fixation of the zygomatic arch.

Once the need for a coronal incision has been determined, the location of the incision must be considered. Factors that must be included in determining the location of the incision are the patient's hairline and the amount of inferior access that is required for the procedure. The incision is usually placed along a line extending from one preauricular area to the other, several centimeters behind the hairline, or even more posteriorly for balding men. For most women and nonbalding men, the incision may be curved anteriorly at the vertex, paralleling but remaining 4 to 5 cm within the hairline. The amount of skeletal exposure depends on the inferior extent of the incisions, not on the anteroposterior location of the incision. When exposure of the zygomatic arch is unnecessary, extension of the coronal incision inferiorly to the level of the helix may be all that is needed. However, when exposure of the zygomatic arch is necessary, the coronal incision must be extended inferiorly to the level of the earlobe as a preauricular incision. Extending this incision will also allow access to the temporomandibular joint and the infraorbital rims.

Before the incision is made, a vasoconstrictor should be injected into the subgaleal plane for promoting hemostasis, and hydrodissection should be performed. After the vasoconstrictor has taken effect, cross-hatches should be made across the proposed site of the incision; these marks will assist in properly aligning the scalp at the end of the procedure. The initial portion of the incision is made with a No. 10 blade extending from one superior temporal line to the other through skin, subcutaneous tissue, and galea; this incision reveals the subgaleal plane of loose areolar connective tissue overlying the pericranium. Limiting the initial incision to the area between the superior temporal lines (i.e., from lateral orbit to lateral orbit) prevents the surgeon from incising through the temporalis fascia and into the temporalis muscle. The skin incision below the superior temporal line should be to the depth of the glistening superficial layer of temporalis fascia. An easy method of ensuring that the incision is made to the proper depth is to bluntly dissect with curved scissors in the subgaleal plane from above, toward the zygomatic arch, and incise to that depth. Once the initial incision has been completed, Raney clips or electrocautery can be used for achieving hemostasis.

Dissection can then be carried out anteriorly and laterally with finger dissection, blunt periosteal elevators, or back-cutting with a scalpel. Dissection continues anteriorly in the subgaleal fascial plane to a point 3 to 4 cm superior to the superior orbital rims or to the most superior extent of a frontal sinus fracture. Once this point has been reached, an incision is made through the periosteum from one superior temporal line to the other. Subperiosteal dissection continues to the supraorbital rims, and the lateral portion of the flap is dissected inferiorly atop the temporalis fascia.

Once the lateral portion of the flap has been elevated to within 3 to 4 cm of the body of the zygoma and the zygomatic arch and to the root of the arch, the superficial layer of temporalis fascia is incised at the root of the zygomatic arch, just in front of the ear. This incision continues anteriorly and superiorly at a 45-degree angle, joining the cross-forehead incision previously made through the pericranium at the superior temporal line. Incision through the superficial layer of the temporalis fascia reveals the superficial temporal fat pad and areolar tissue. Further dissection inferiorly within this layer provides a safe route of access to the zygomatic arch, because the temporal branch of the facial nerve

is always lateral to the superficial layer of the temporalis fascia. Once the superior surface of the zygomatic arch and the posterior border of the body of the zygoma have become palpable or visible, an incision is made through the periosteum along their superior surface. The incision progresses superiorly along the posterior border of the body of the zygoma and the orbital rim, ultimately meeting the cross-forehead horizontal incision through the pericranium.

As with the other approaches, with the coronal approach closure is layered. Closed suction drainage may be necessary with a 7-mm flat drain exiting the hair-bearing region of the scalp posterior to the incision. Suture resuspension of the soft tissues is necessary and can be accomplished with 3-0 resorbable sutures passed through the deep surface of the periosteum of the malar region and then suspended to the temporalis fascia or another stable structure. The periosteum around the lateral orbital rim is closed with 4-0 resorbable suture. The inferior edge of the superficial layer of the temporalis fascia is sutured approximately 1 cm superior to the superior edge of the incised fascia with running 3-0 long-lasting resorbable suture. Closing the horizontal periosteal incision across the forehead is not necessary. The scalp incision can be closed in two layers with 2-0 resorbable suture through the galea/subcutaneous tissues and with staples for the skin. The skin staples are removed in 10 days; the drain can usually be removed after 24 hours.

Fixation

Once the decision has been made to treat zygomatic injuries surgically, the need for fixation depends on the stability of the structures. Typically, low-energy injuries can be treated with open reduction alone, whereas high-energy injuries will require open reduction and internal fixation. An algorithm for fixation of noncomminuted fractures has been presented by Ellis and colleagues.[11] When the CT scan shows a displaced zygomatic fracture that is not comminuted and does not require orbital floor reconstruction, initial exposure should be obtained with a maxillary vestibular incision. If the fracture can be reduced and is stable, no fixation may be required; if the fracture is unstable after reduction, fixation should be placed. If the reduction remains unstable, exposure and fixation of the lateral orbital rim should be accomplished, followed by fixation of the infraorbital rim if necessary.

When evidence of a comminuted fracture exists, or when orbital floor reconstruction is anticipated, exposure of all fracture sites should be accomplished prior to placement of any fixation. This exposure would typically include an approach to the zygomaticofrontal region, infraorbital rim, and a maxillary vestibular incision. Fixation in each of these regions is usually necessary (Figures 9-15 and 9-16).

The Zygomatic Arch

In contrast to the zygoma, the arch is a relatively weak bone. It is laterally positioned and is a combination of two bones: the zygoma and the temporal bone. These two features,

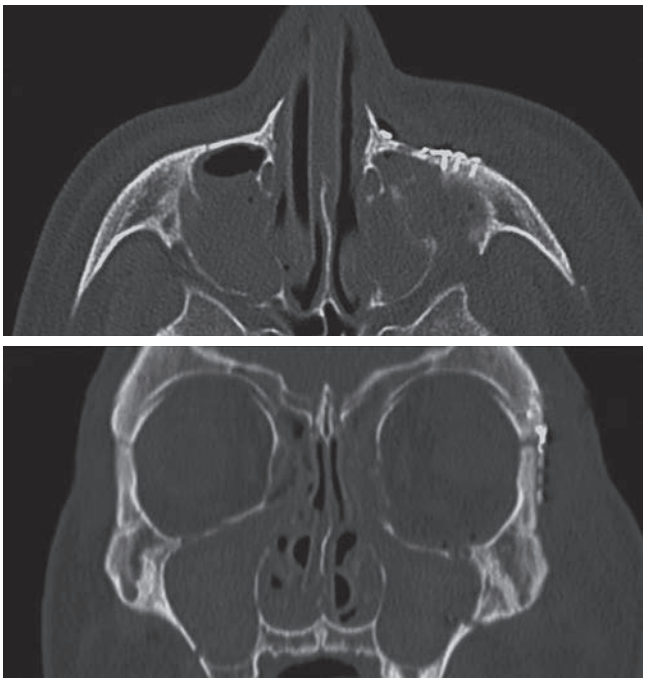

• **Figure 9-15** Axial and coronal computed tomography scans following reduction of zygoma.

lateral prominence and lack of strength, make fracture of the zygomatic arch a frequent occurrence. Such fractures may be of different types according to their cause. Isolated zygomatic arch fractures account for approximately 10% of all zygomatic fractures and are often the result of localized forces directed laterally with low impact (e.g., sports injuries and injuries caused by blows).[12,13] Fracture of the arch often occurs in combination with fractures of the zygomaticomaxillary complex and panfacial fractures.

Systems for classifying fractures of the zygomatic arch have been described by Knight and North, Manson, and more recently by Yamamoto and Ozyazgan and colleagues.[13-16] Ozyazgan divided zygomatic arch fractures into two groups based on radiological and clinical findings: type I isolated zygomatic arch fractures, localized in the zygomatic arch; and type II combined zygomatic arch fractures, in which the fracture in the arch was a component of a zygomatic bone fracture or of a Le Fort III level fracture.[13] The authors then subdivided these two main groups on the basis of the number of fracture lines: type I-A, two fractures; type I-B, more than two fractures; type II-A, one fracture; type II-B, multiple fractures. Yamamoto developed five types of isolated zygomatic arch fractures on the basis of the degree of displacement and the loss of bone contact at fracture lines as demonstrated by conventional axial radiographs, CT scans, or both.[16]

An isolated zygomatic arch fracture is not always discernible on examination because of overlying edema, but a fracture can usually be detected clinically by tenderness to palpation, depression in the region, and limited mouth opening. A severely depressed arch can limit mouth opening by preventing the coronoid process of the mandible

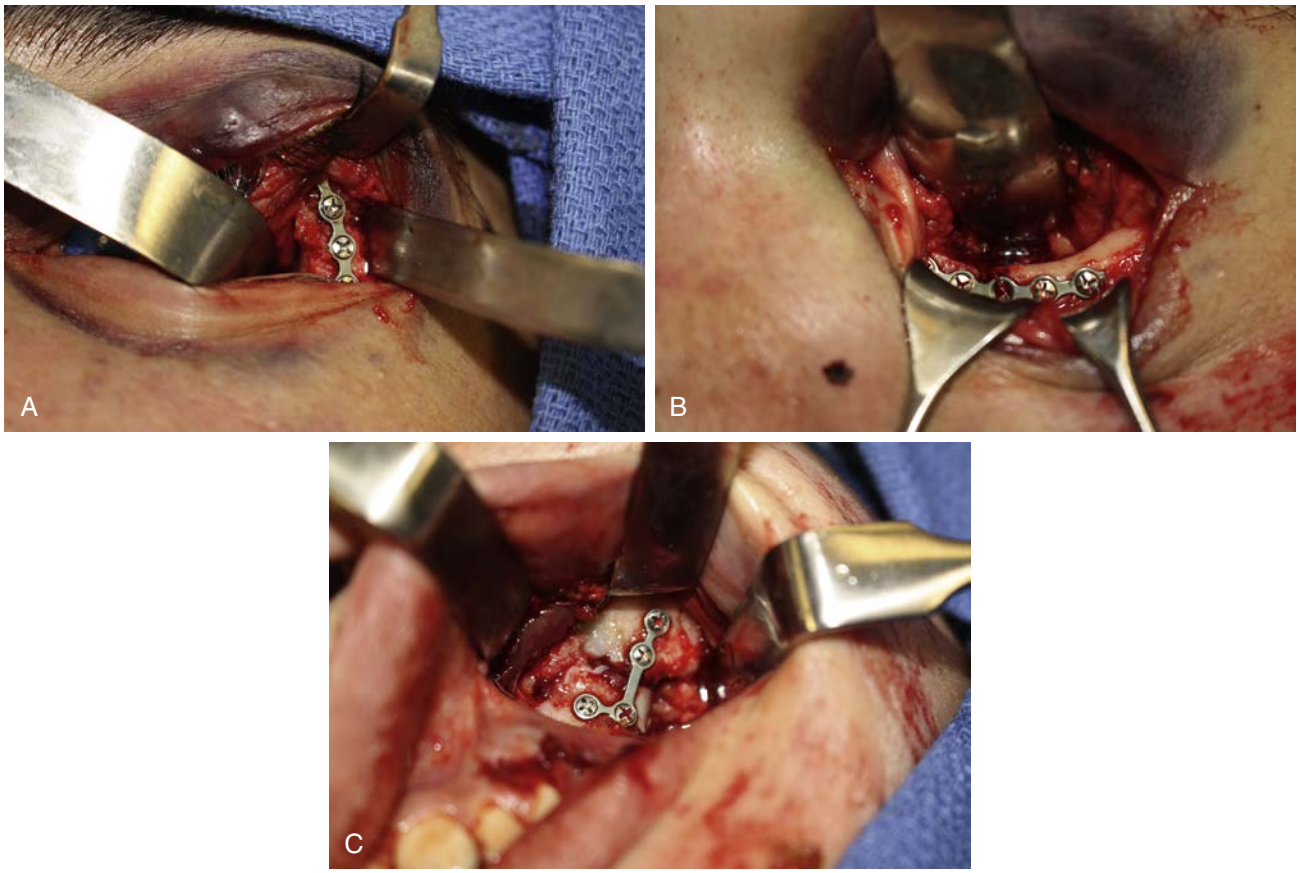

• **Figure 9-16** Fixation of fractures of the **(A)** zygomaticofrontal/lateral orbital rim, **(B)** infraorbital rim, and **(C)** maxillary buttress.

from moving forward during normal function or by trismus resulting from injury to the temporalis muscle.

The indications for treating zygomatic arch fractures are cosmetic and functional. If no cosmetic deformity and no functional deficit are apparent, the isolated fracture of the zygomatic arch can be observed without surgical treatment. However, if treatment is indicated, several techniques are available, including open reduction (coronal approach), intraoral elevation (Keen/vestibular approach), and extraoral elevation (Gillies method). The procedure should be carried out within 10 days; otherwise, early healing will make an anatomic reduction difficult.

Fixation of the isolated arch fracture is rarely required, but it may be necessary for type II fractures of the zygomatic arch. When the injury includes a severely displaced zygoma, the zygomatic arch will provide a point of reference for the reconstruction of the zygoma.[17] In such cases, fixation of the arch may be necessary.[18]

Existing lacerations, a hemicoronal incision, a coronal incision, or an extended preauricular surgical approach can be used for visualization of the zygomatic arch. The benefit of the coronal approach is that it enables visualization of the arch, superior orbital rim, and lateral orbital rim at the same time.

For arches that have not undergone fixation, numerous methods have been used to protect the arch from displacement during the healing period.[19-22] Ozyazgan and associates used an external splint made of a metal plate long enough to extend from the tragal region to the malar projection and shaped to fit the zygomatic arch.[13] This splint not only helped protect the unstable arch but also helped fixate the segment during healing.

Surgical Approaches to Isolated Zygomatic Arch Fractures

Two main approaches have been described for reducing isolated arch fractures: the temporal (Gillies) approach and the vestibular (Keen) approach.

Temporal (Gillies) Approach

The bifurcation of the superficial temporal artery usually lies 2.5 cm above and anterior to the helix of the ear. The Gillies incision begins at this area, passing through the skin and subcutaneous tissue and running at an angle from anterosuperior to posteroinferior, thereby avoiding this artery and its parietal and frontal branches. Sometimes the middle temporal vein may be encountered. The temporalis fascia is exposed above this bifurcation, and the dissection is continued to the layer deep to the temporalis fascia and superficial

to the muscle. An elevator is inserted into this plane, and the area is swept medial to the zygomatic arch and the infratemporal portion of the zygoma. Finally, the blade of a Rowe zygoma elevator is inserted, and pressure is exerted anteriorly and laterally until the fracture is reduced; often an audible click is heard when the zygoma locks into place. Care must be taken to ensure that the blade is not situated medial to the coronoid process. A sweeping action of the blade along the medial aspect of the zygomatic arch and onto and including the lateral aspect of the zygoma ensures a satisfactory reduction, which is confirmed by concomitant palpation of the reduction site by the nonoperating hand. The procedure is completed by closure of the incision in two layers. Most medially or inferiorly displaced zygomas respond to this maneuver (Figure 9-17).

Vestibular (Keen) Approach

The main advantage of this approach is that the procedure is carried out through an intraoral approach, thus sparing a skin incision. The approach is also more direct: less dissection is necessary, there is no risk to vessels during the dissection, and the angle of reduction is superior and lateral, a more ideal reduction vector for zygomas that lie medially and inferiorly.

When used for an isolated arch fracture, a limited incision of approximately 2 cm is made in the maxillary vestibule approximately 5 mm superior to the mucogingival junction but inferior to the zygomatic buttress (at the first molar). A periosteal elevator is introduced through the incision, and intimate contact with the lateral antral wall is maintained. This technique creates a subperiosteal dissection that exposes the infratemporal surfaces of the maxilla and zygoma. The medial surface of the zygomatic arch is dissected free, and the location of the coronoid process is ascertained. The flat blade of the Rowe elevator is gently introduced into the incision site and placed under the infratemporal surface of the zygomatic bone. With the surgeon's free hand placed over the operative site, the elevator is pulled superiorly and laterally. The blade is then swept laterally, medial to the zygomatic arch and lateral to the coronoid process. With a lateral pull along the fracture portion of the arch, followed by a sweeping and lateral force, the zygomatic arch component is reduced. A click can sometimes be heard as the zygoma, the arch, or both are reduced. The incision is closed with chromic or Vicryl suture.

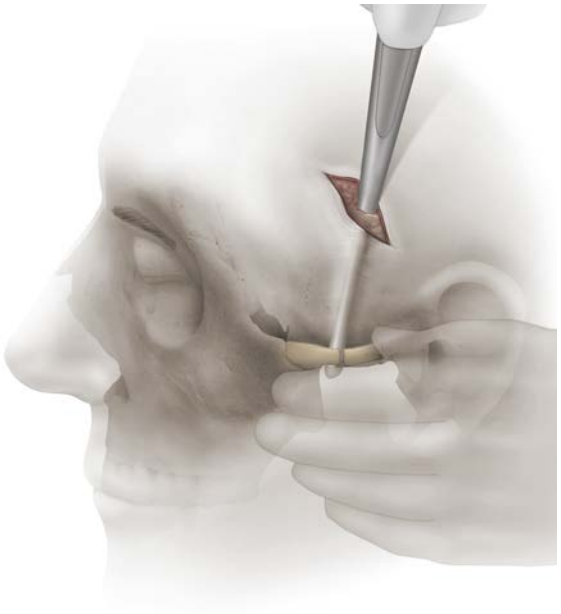

• **Figure 9-17** Gillies approach to the zygomatic arch.

Complications of Zygoma Injuries

Complications of fractures to the zygoma or the zygomatic arch are rare, but recognizing their signs and symptoms is important. These adverse events may occur early in the post-traumatic course or may manifest themselves late in the postoperative recovery period.

Infraorbital Paresthesia

After zygomatic injury, acute loss of sensory function of the infraorbital nerve is common and is the most frequently reported neurologic complication of zygomatic trauma.[23] The reason for this high incidence is its close proximity to the orbitozygomatic complex as it passes through the infraorbital fissure in the floor of the orbit to exit through the infraorbital foramen. Traumatic injury to the infraorbital nerve may be due to compression, edema, ischemia, or laceration.

During the immediate post-traumatic period, the incidence of sensory disturbances in association with fractures of the ZMC ranges from 18% to 94%.[9, 23-30] However, most patients with ZMC fractures will probably initially experience neurosensory deficits of the infraorbital nerve due to swelling or because the infraorbital foramen is in the fracture line.

Fractures whose repair requires open reduction and internal fixation are associated with a higher incidence of neurologic dysfunction. At the same time, however, recovery is faster when fractures are opened and fixated rather than reduced and not fixated.[23,28] The reason for this difference is presumably that anatomic reduction of the fracture relieves the pressure placed on the nerve, and fixation minimizes the potential for recurrence by keeping the bones in the correct anatomic position.

Because the infraorbital nerve can be damaged as it courses the floor of the orbit or, more commonly, as it exits from the infraorbital foramen, inspection during reduction is crucial. The surgeon should ensure that the nerve is not compressed during immobilization of the fractures and that the nerve is not compressed during reconstruction of the orbital floor.

Vriens and colleagues determined that certain fracture types are associated with a higher incidence of sensory

disturbance and thus with a different rate of return to normal sensation.[23] Overall, the long-term rate of complete sensory recovery of the infraorbital nerve is 64%; the return to normal sensation occurs on average within 15 weeks.

Once infraorbital nerve dysesthesia has been identified preoperatively, clinical neurosensory testing should be performed for establishing a baseline and should be repeated at each postoperative visit. The development of neuropathic pain warrants further investigation and intervention. Localization of nerve injury should be attempted. Infiltration of local anesthesia at the infraorbital foramen can help differentiate between neuroma formation within the infraorbital canal and neuroma formation distal to the foramen. Options for treatment include medications (e.g., amitriptyline, gabapentin), removal of bone plates, and nerve exploration.

Soft Tissue Complications

General complications that arise from the manipulation of soft tissue are numerous and can include dehiscence, hematoma or seroma, lymphedema, and scarring. With respect to the surgical approaches to the zygoma through the lower lid, other, more specific complications can arise, including vertical shortening of the lower lid, ectropion, and entropion.

If they become large enough, hematomas and seromas can be managed by decompression with a needle and a syringe. Lymphedema subsides over time, especially if the lower lid is supported in its proper position. Dehiscence of a wound may require nothing more than observation unless the defect becomes very large; in such cases the wound may require packing or, if indicated, resuturing.

Vertical shortening of the lower lid may occur when the scar contracts between the tarsal plate and the periosteum, thereby shortening the orbital septum. This complication can be prevented by providing superior support of the lower lid for several days (or until gross edema has resolved) after surgery. The simplest preventative method is the Frost suture.[31] This technique closes the eye, supports the lower lid, aids in the dissipation of lid edema, and allows postoperative examination of the globe and measurement of vision. Splinting of the lower eyelid by suturing antibiotic-laden, lubricated gauze to the lower eyelid after surgery has also been described.[32]

Ectropion and entropion are distressing problems, although most cases are self-limited. Ectropion is defined as the eversion of an edge or margin. Lower eyelid malpositions are graded mild when there is slight eversion of the cilia inferiorly with or without scleral show, moderate when the lid margin is everted with lower eyelid descent and scleral show, and severe when frank ectropion is present. Mild and moderate ectropion usually resolve over time with gentle massage of the lid. However, severe ectropion may require surgical correction.[33]

Specialized structures of the eyelids protect the eyes from exposure to the elements. Numerous oils, mucus, and tear glands are present within the tarsal-conjunctival mucous lining of the upper and lower eyelids. Blinking distributes this complex three-layer tear film over the surfaces of the eyes to protect them. Thus, chronic ectropion can result in exposure keratinization of the conjunctiva, which can contribute to ocular irritation and eventually lead to vision loss.

The incidence of ectropion in association with a transconjunctival approach to the infraorbital rim has been reported to range from zero to 6.7%.[34,35] When a subciliary approach is used, the incidence of ectropion ranges from 12% to 42%.[34,36-38]

Entropion is defined as an inversion or turning inward of an edge. It is usually symptomatic, with eye discomfort to the point of pain, tearing, photophobia, discharge, secondary infection, and various degrees of corneal surface breakdown (with visual loss). Occasionally, the lid is inverted so much that the lashes are tucked down into the fornix, but the eye is not particularly uncomfortable. Entropion that does not resolve spontaneously may require surgical correction.[33] However, frequent use of lubricating eye ointment and taping the lid into a relatively normal position may serve as effective temporary palliation.

Persistent Diplopia

Binocular diplopia is a common complication of zygoma fractures involving the orbit.[39] This complication may be temporary or may become permanent if not treated. When binocular diplopia is present initially after a zygomatic fracture, it is most likely due to edema or hematoma of one or more extraocular muscles or their nerves, as well as to intraorbital edema or hematoma. In such cases, resolution of diplopia after fracture treatment (if necessary) usually occurs spontaneously within 5 to 7 days (i.e., the time required for the initial edema or bleeding to disappear and resorb).

Diplopia can also be caused by muscle entrapment, but this cause is usually evident on clinical examination with a forced duction test or by simple examination of extraocular movements (Table 9-1). The forced duction test involves placing a drop of local anesthetic in the cul-de-sac of the lower lid, using a pair of toothed forceps to grasp the tendons of the appropriate rectus muscles and attempting to passively rotate the globe away from the restriction (Figure 9-18). Limitation of motion is not invariably an indication of entrapment; it can also be caused by orbital edema or hemorrhage. Conversely, the absence of resistance can indicate a neurologic deficit or a large nonrestrictive defect in the orbital floor. However, positive test results are much more likely with a "trap-door" injury. This cause of diplopia necessitates immediate exploration and reduction of herniated orbital tissue.

The cause of persistent diplopia is not known, but it has been postulated that post-traumatic fibrosis of the extraocular muscles results in residual diplopia after therapy.[40] The timing of treatment for diplopia is controversial. There is no debate that a displaced zygoma causing diplopia should be treated, nor is there controversy surrounding the need to reconstruct a large orbital floor defect with damage to the Lockwood ligament, which results in an inferior

TABLE 9-1 Eye Muscles with Their Actions and Innervation

Muscle	Origination	Insertion	Innervation	Function
Medial rectus	Margin of optic foramen	Sclera	CN III	Medial
Inferior rectus	Margin of optic foramen	Sclera	CN III	Inferior and medial rotation
Lateral rectus	Margin of optic foramen	Sclera	CN VI	Lateral
Superior rectus	Margin of optic foramen	Sclera	CN III	Upward and medial rotation of the eye
Superior oblique	Margin of optic foramen	Lateral/posterior globe	CN IV	Downward and lateral
Inferior oblique	Medial aspect of orbital floor	Inferior to the lateral rectus	CN III	Upward and lateral

repositioning of the globe. It is also commonly accepted that a trap-door injury or any physical restriction of movement should be corrected as early as possible.

The issue is whether to perform surgery on marginal cases when diplopia resolves slowly with simultaneous evidence of a cosmetic deformity. The possible resolution of diplopia can be hastened by the administration of steroids for 5 to 7 days; the use of this method can indicate whether the diplopia is caused by edema or by hemorrhage of the orbital muscle or fat.[41]

CT scans using 2-mm coronal cuts of the orbit demonstrate entrapment of the inferior rectus muscle and can aid in differentiating between contused and entrapped extraocular muscles. A contused muscle appears round on the scan; the normal muscle appears flat. In the case of possible muscle entrapment, the results of a forced duction test provide evidence of the need to explore the orbital floor.

Once the decision has been made to manage diplopia surgically, the goals are to prevent herniation of orbital contents, to provide a smooth orbital floor with or without an implant, and to reconstruct the floor or wall to mirror the contralateral side as closely as possible.

Traumatic Optic Neuropathy

Traumatic optic neuropathy is a rare but devastating cause of partial or complete loss of visual function after head injury. The incidence of traumatic optic neuropathy ranges from 2% to 20%.[6,12,39,42-49] It may manifest itself as conditions ranging from mild visual deficit to complete visual loss.

Injuries are classified as direct or indirect. Direct injuries, associated with penetrating injuries to the head, are typically caused by projectiles, stab wounds, or bone fragments. The prognosis for this type of injury is poor. Indirect injuries result from deforming forces applied to the bony orbit, or by motion of the globe, in which the optic nerve absorbs energy concentrated at the orbital apex. This type of injury occurs when there is no evidence of a penetrating wound and the patient has suffered blunt frontal trauma. The most common site of indirect injury is believed to be the intracanalicular segment of the nerve.[50] Recovery of vision following traumatic optic neuropathy resulting from indirect injury is more likely than for that resulting from direct injury, and visual recovery can occur with or without treatment.[51]

Assessment for traumatic optic neuropathy involves a detailed ocular examination, including pupillary size and response to light, visual acuity, and fundoscopic examination. The presence of a Marcus Gunn pupil (afferent pupillary defect) with normal results from a fundoscopic examination is diagnostic for afferent optic nerve injury.[52] The sluggish pupil in reaction to light is often characteristic of progressive optic nerve injury. Identifying malfunctioning pupils is important because the initial measurement of the relative afferent pupillary defect predicts the final visual outcome.[53,54] When the patient cannot perceive light, the visual prognosis is poor.[51,54,55]

In addition to the clinical examination, computed tomography is crucial in demarcating the location of the injury; it enables assessment of the optic nerve, the optic canal, and any intracranial lesions that may cause a deficit in vision.[56]

The appropriate treatment for patients with traumatic optic neuropathy remains controversial. Options include observation, corticosteroids administered at various doses, and decompression of the optic canal.[52,57-62] The International Optic Nerve Trauma Study found that 57% of patients receiving no treatment experienced improvement by three or more lines of visual acuity.[54] The occurrence of spontaneous improvement in many patients makes it difficult to assess the effectiveness of any treatment method, and some authors have reported no statistically significant improvement in outcome with steroid use.[63] Optic nerve decompression has been performed when no improvement is seen after medical management, if radiographic evidence of canal impingement exists, or if the patient has very poor vision.[64-66]

Malunion of Zygomatic Fractures

A malunion of the zygoma will often result in cosmetic deformity from a malposition of the malar eminence, as well as diplopia secondary to malposition of the globe (Figure 9-19). Correction of these problems can be attempted by either augmentation or osteotomy. The most commonly used materials



• **Figure 9-18** **A-B,** Forceps grasping the sclera above the inferior rectus attachment. **C-D,** Forced duction test showing unrestricted superior movement of the patient's eye.

for augmentation are Silastic, porous polyethylene, autogenous bone (calvarial), and hydroxyapatite-based materials. A corrective osteotomy should be performed as early as possible, before the fracture sites have healed and obscured the proper position of the fractured segments.

Two principal considerations are involved in addressing a malunion. If a functional deformity exists, a corrective osteotomy should be considered. An example of such a case is a malposed zygoma resulting in enophthalmos, diplopia, or both, or obstruction of the normal excursion of the coronoid process. If the deformity results in a cosmetic defect without a functional deficit, camouflaging the defect may be prudent. For example, if a malposed zygoma results in minimal zygomatic projection, an onlay graft using alloplastic or autogenous materials may be preferable to a corrective osteotomy.

Late-Onset Post-traumatic Enophthalmos

Enophthalmos is defined as recession of the globe within the orbit. Enophthalmos can result from an absolute reduction

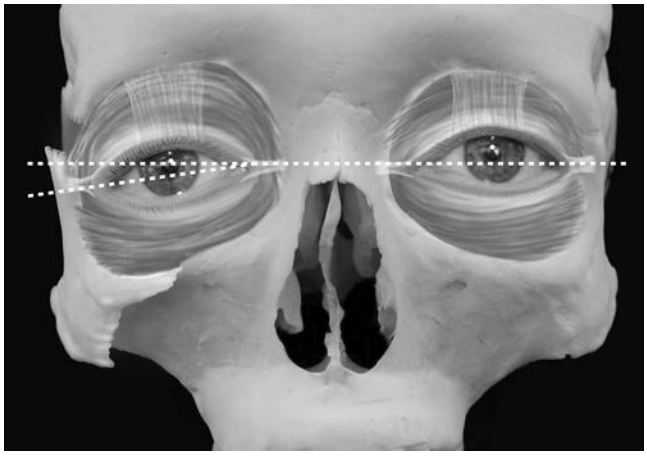

• **Figure 9-19** Illustration of orbital dystopia and malar eminence malposition related to zygoma position.

of orbital tissue, a relative reduction of tissue, or both. Factors such as scarring and atrophy of orbital soft tissue (i.e., fat) are considered absolute reductions of orbital tissue, whereas bony displacement resulting in displacement of orbital soft tissue is considered a relative reduction of tissue. Specifically, post-traumatic enophthalmos has been attributed to atrophy of orbital intermuscular fat, enlargement of the bony orbit, dislocation of the trochlea, cicatricial contraction of the retrobulbar tissues, unrepaired fractures of the orbital wall, and displacement of the orbital tissue.

Whitehouse and others have found that fat atrophy is not responsible for any alteration in orbital volume and is unchanged after trauma.[67,68] Rather, it has been determined that fat loss rather than fat atrophy plays the predominant role in traumatic enophthalmos. Orbital floor disruption in the face of an intact orbital periosteum (Lockwood ligament) does not result in displacement of the globe. Failure to reconstruct the orbital walls results in disruption of the orbital ligaments; such disruption causes the anterior support of the globe to be weakened and results in enophthalmos. Maxillofacial trauma resulting in enlargement of the orbital cavity, in combination with disruption of ligaments and intraconal compartments, is considered to be the principal cause of enophthalmos.[67,69-72] In summary, three basic mechanisms occur singly or in combination to cause post-traumatic enophthalmos: an increase in the size of the orbit, a decrease in orbital contents, and a disruption of the ligamentous structures of the globe.

Post-traumatic enophthalmos is relatively uncommon; it occurs in only 4% to 9% of patients with midfacial fractures. Patients with pure orbital blowout fractures or those who have residual enophthalmos after surgical reduction of simple fractures of the zygomatic complex are normally seen 3 to 4 weeks after the injury or the procedure, when the edema masking the enophthalmos has resolved and the residual defect has become apparent.[6,73] Enophthalmos may have functional consequences, including gaze-evoked diplopia, eyelid retraction, lagophthalmos, and exposure keratitis.

Physical findings suggestive of enophthalmos include a deeper eyelid sulcus, eyelid position, eyelid asymmetry, or smaller eye. Complete examination of the globe for gross injuries, changes in visual acuity, and decreases in extraocular muscle function with a forced duction test are essential. A exophthalmometer is used to determine the degree of enophthalmos. A measurable difference of 2 mm or less in the relative position of the globes is normal; a difference of 3 mm is usually detectable by others and is considered abnormal.[74,75] In addition, patients with measurements of less than 3 mm have been shown to be satisfied with their appearance.[76] Therefore, enophthalmos with a measurement of 3 mm or more is an indication for surgical repair.

Many researchers have attempted to relate the amount of enophthalmos to the degree of bony displacement.[77,78] Manson and associates carried out extensive studies evaluating globe position as determined by the content and relationship of intracoronal and extracoronal orbital fat.[69] They found that intracoronal fat found intramuscularly was separated from extracoronal fat by fine ligaments. Intracoronal fat is found almost exclusively posterior and proximal to the orbital wall, because that is the location of the extraocular muscles. Extracoronal fat is primarily found anteriorly. Most of the fat along the orbital floor is extracoronal and anterior to this axis. Its removal results in a supratarsal deficiency but no posterior displacement of the globe. However, because most of the lateral orbital wall is behind this axis, displacement of this osseous segment increases the orbital volume exponentially and creates excessive volume expansion within the orbit and resultant enophthalmos, as well as loss of intracoronal fat. Comminuted fractures of the lamina papyracea on the posterior floor also lie behind the global axis, which extends from the lateral orbital rim to the anterior portion of the lacrimal bone. Intracoronal fat is found primarily behind the axis, and its loss is also crucial to the development of enophthalmos. Therefore, enophthalmos results from an increase in bony orbital volume by displacement of the medial orbital wall, posterior floor, or lateral orbital wall and is less likely to be related to defects in the inferior orbital floor.

Enophthalmos is treated by decreasing the orbital volume with osteotomies, or increasing the volume of orbital tissue with bone grafts, cartilage grafts, or alloplastic implants. If the degree of enophthalmos is severe, a combination of these methods can be used.[79-85]

Retrobulbar Hemorrhage

Retrobulbar hemorrhage is an ophthalmologic emergency resulting in increased intraocular pressure with ophthalmic artery compromise and loss of vision due to retinal ischemia. The cause of retrobulbar hematoma is trauma, either iatrogenic or trauma in general.[86-91]

The anatomic boundaries of the orbit, its rigid bony walls, and its inflexible anterior limit (orbital septum and eyelids), combined with hemorrhage into the retrobulbar space, result in soft tissue expansion leading to anterior displacement of the globe and septum. As the elastic limits of the septum are reached and bleeding continues, the orbit

becomes a closed, nonyielding space. The orbital and intraocular pressures increase, and these pressures cause compression of orbital structures and ischemia of the globe and optic nerve; the ultimate result can be blindness.[86] This condition is known as orbital compartment syndrome.

When the orbital intraocular pressure is not dangerously high, the condition can be managed medically with topical treatments, systemic carbonic anhydrase inhibitors, and oral or intravenous osmotic agents. Intravenous acetazolamide 500 mg and hydrocortisone 100 mg can be administered; alternatively, a rapid infusion of 20% mannitol can be used. If vision does not improve rapidly, within 30 to 45 minutes, surgical measures should be considered.[86]

However, when orbital pressures are extremely high and profound visual compromise is obvious, medical measures are not sufficient to rapidly reduce the orbital pressure. In this situation, an emergent canthotomy and cantholysis are necessary. If decompression is carried out within 2 hours of the onset of symptoms, it is likely to be successful in avoiding permanent damage.[92,93] Ophthalmology consultation is strongly recommended.

Three-Dimensional Computerized Navigation

In recent years the imaging precision of three-dimensional (3D) computerized scans combined with advancements in computer software have allowed for more anatomic reduction of mid-face and orbital fractures. These 3D navigation and planning platforms have allowed for more accurate restoration of orbital volume, and the subsequent mitigation of complications such as enophthalmos, diplopia, and limitations on extraocular movements.[94]

Construction of a computerized 3D model is derived from thin slice (1-2 mm) CT or magnetic resonance images that are loaded in the computer software system.[94] The software then allows examination of the traumatic defect and planning of the surgical reduction. The goal of preoperative planning is to simulate the modifications that will take place operatively and provide the desired anatomically correct outcome.

The software allows for creation of a template for reconstructing the affected side by mirroring the contralateral side (if proper skeletal anatomic positioning is unaffected by the traumatic incident), thus aiding not only in preoperative virtual surgical planning, but also with intraoperative assessment of the reduction. In the case of bilaterally affected patients, more complex segmental manipulation of the model or subvolume CT reference file insertion must be used to achieve the desired template.[94]

Intraoperative navigation is accomplished by having the 3D computer model registered and calibrated such that the position of the patient on the operating table and the surgical instruments match in their positions displayed on the computer model in real time. This registration can be accomplished by establishing reference points on the CT scan, instruments, and patient (Figures 9-20 through 9-22).



• **Figure 9-20** Navigational system setup.



• **Figure 9-21** Navigational system locator and wand.

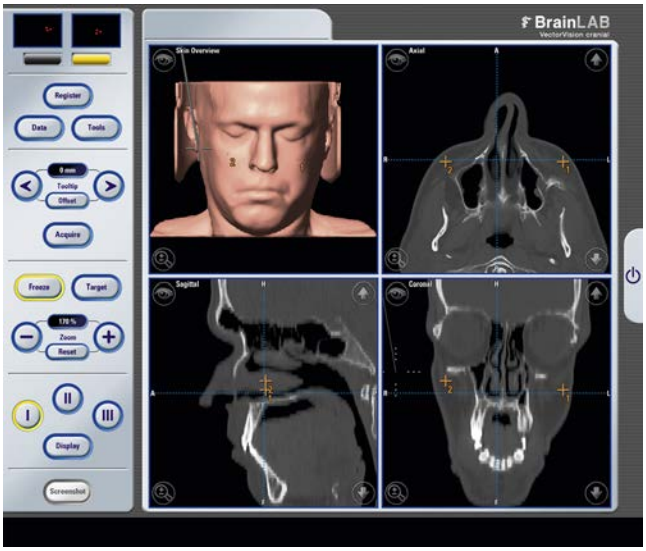

• **Figure 9-22** Screen shot of navigational display.

3D computerized navigation can be helpful in avoiding non-anatomic reductions, which can limit the need for secondary reconstructions and associated complications.[91] Although 3D computerized navigation is still in its infancy, excellent results are being produced with satisfactory reconstruction rates approaching 100% with navigation-guided procedures and 85.7% with computer-assisted 3D models, versus 74.3% with traditional surgery.[92]

Acknowledgment

The authors gratefully acknowledge Drs. Daniel Lew, John Birbe, and Matthew D'Addario, who contributed to previous editions of this chapter.

References

1. He D, et al.: Orbitozygomatic fractures with enophthalmos: analysis of 64 cases treated late, *J Oral Maxillofac Surg* 70(3): 562–576, 2012.
2. Dimitroulis G, Eyre J: A 7-year review of maxillofacial trauma in a central London hospital, *Br Dent J* 170(8):300–302, 1991.
3. Rallis G, et al.: Treating maxillofacial trauma for over half a century: how can we interpret the changing patterns in etiology and management? *Oral Surg Oral Med Oral Pathol Oral Radiol* 119(6):614–618, 2015.
4. Zachariades N, Mezitis M, Anagnostopoulos D: Changing trends in the treatment of zygomaticomaxillary complex fractures: a 12-year evaluation of methods used, *J Oral Maxillofac Surg* 56(10):1152–1156, 1998. discussion 1156–1157.
5. al-Qurainy IA, et al.: Midfacial fractures and the eye: the development of a system for detecting patients at risk of eye injury—a prospective evaluation, *Br J Oral Maxillofac Surg* 29(6):368–369, 1991.
6. al-Qurainy IA, et al.: The characteristics of midfacial fractures and the association with ocular injury: a prospective study, *Br J Oral Maxillofac Surg* 29(5):291–301, 1991.
7. al-Qurainy IA, et al.: Midfacial fractures and the eye: the development of a system for detecting patients at risk of eye injury, *Br J Oral Maxillofac Surg* 29(6):363–367, 1991.
8. Manson PN, et al.: Toward CT-based facial fracture treatment, *Plast Reconstr Surg* 85(2):202–212, 1990.
9. Zingg M, et al.: Treatment of 813 zygoma-lateral orbital complex fractures. New aspects, *Arch Otolaryngol Head Neck Surg* 117(6):611–620, 1991. discussion 621–622.
10. Gruss JS, et al.: The importance of the zygomatic arch in complex midfacial fracture repair and correction of posttraumatic orbitozygomatic deformities, *Plast Reconstr Surg* 85(6):878–890, 1990.
11. Ellis 3rd E, Kittidumkerng W: Analysis of treatment for isolated zygomaticomaxillary complex fractures, *J Oral Maxillofac Surg* 54(4):386–400, 1996. discussion 400–401.
12. Griffin Jr JE, Max DP, Frey BS: The use of the C-arm in reduction of isolated zygomatic arch fractures: a technical overview, *J Craniomaxillofac Trauma* 3(1):27–31, 1997.
13. Ozyazgan I, et al.: A new proposal of classification of zygomatic arch fractures, *J Oral Maxillofac Surg* 65(3):462–469, 2007.
14. Knight JS, North JF: The classification of malar fractures: an analysis of displacement as a guide to treatment, *Br J Plast Surg* 13:325–339, 1961.
15. Manson PN: Facial fractures. In McCarthy JG, editor: *Plastic surgery*, Philadelphia, 1990, WB Saunders, pp 867.
16. Yamamoto K, et al.: Clinical analysis of isolated zygomatic arch fractures, *J Oral Maxillofac Surg* 65(3):457–461, 2007.
17. Stanley Jr RB: The zygomatic arch as a guide to reconstruction of comminuted malar fractures, *Arch Otolaryngol Head Neck Surg* 115(12):1459–1462, 1989.
18. Stevens MR, Menis MA: Microscrew fixation of zygomatic arch fractures, *J Oral Maxillofac Surg* 51(10):1158–1159, 1993.
19. Guven O: Stabilisation of the delayed zygomatic arch fracture, *Int J Oral Maxillofac Surg* 16(4):445–447, 1987.
20. Lew DH, et al.: Simple fixation method for unstable zygomatic arch fracture using double Kirschner's wires, *Plast Reconstr Surg* 101(5):1351–1354, 1998.
21. Randall DA, Bernstein PE: Epistaxis balloon catheter stabilization of zygomatic arch fractures, *Ann Otol Rhinol Laryngol* 105(1):68–69, 1996.
22. Uglesic V, Virag M: A method of zygomatic arch stabilization, *Br J Oral Maxillofac Surg* 32(6):396–397, 1994.
23. Vriens JP, Moos KF: Morbidity of the infraorbital nerve following orbitozygomatic complex fractures, *J Craniomaxillofac Surg* 23(6):363–368, 1995.
24. De Man K, Bax WA: The influence of the mode of treatment of zygomatic bone fractures on the healing process of the infraorbital nerve, *Br J Oral Maxillofac Surg* 26(5):419–425, 1988.
25. Ellis 3rd E, A. el-Attar A, Moos KF: An analysis of 2,067 cases of zygomatico-orbital fracture, *J Oral Maxillofac Surg* 43(6): 417–428, 1985.
26. Jungell P, Lindqvist C: Paraesthesia of the infraorbital nerve following fracture of the zygomatic complex, *Int J Oral Maxillofac Surg* 16(3):363–367, 1987.
27. Lund K: Fractures of the zygoma: a follow-up study on 62 patients, *J Oral Surg* 29(8):557–560, 1971.
28. Taicher S, et al.: Recovery of the infraorbital nerve after zygomatic complex fractures: a preliminary study of different treatment methods, *Int J Oral Maxillofac Surg* 22(6):339–341, 1993.
29. Tajima S: Malar bone fractures: experimental fractures on the dried skull and clinical sensory disturbances, *J Maxillofac Surg* 5(2):150–156, 1977.
30. Wiesenbaugh Jr JM: Diagnostic evaluation of zygomatic complex fractures, *J Oral Surg* 28(3):204–208, 1970.
31. Murphy MT, Bradrick JP: Technique for fixation of the Frost suture, *J Oral Maxillofac Surg* 53(11):1360–1361, 1995.
32. Jothi S, Moe KS: Lower eyelid splinting: an alternative to the Frost suture, *Laryngoscope* 117(1):63–66, 2007.
33. Eliasoph I: Current techniques of entropion and ectropion correction, *Otolaryngol Clin North Am* 38(5):903–919, 2005.
34. Appling WD, Patrinely JR, Salzer TA: Transconjunctival approach vs subciliary skin-muscle flap approach for orbital fracture repair, *Arch Otolaryngol Head Neck Surg* 119(9):1000–1007, 1993.
35. Lorenz HP, Longaker MT, Kawamoto Jr HK: Primary and secondary orbit surgery: the transconjunctival approach, *Plast Reconstr Surg* 103(4):1124–1128, 1999.
36. Holtmann B, Wray RC, Little AG: A randomized comparison of four incisions for orbital fractures, *Plast Reconstr Surg* 67(6):731–737, 1981.
37. Lacy MF, Pospisil OA: Lower blepharoplasty post-orbicularis approach to the orbit—a prospective study, *Br J Oral Maxillofac Surg* 25(5):398–401, 1987.
38. Pospisil OA, Fernando TD: Review of the lower blepharoplasty incision as a surgical approach to zygomatic-orbital fractures, *Br J Oral Maxillofac Surg* 22(4):261–268, 1984.
39. Amrith S, et al.: Ophthalmic involvement in cranio-facial trauma, *J Craniomaxillofac Surg* 28(3):140–147, 2000.

40. Iliff N, et al.: Mechanisms of extraocular muscle injury in orbital fractures, *Plast Reconstr Surg* 103(3):787–799, 1999.
41. Millman AL, et al.: Steroids and orbital blowout fractures—a new systematic concept in medical management and surgical decision-making, *Adv Ophthalmic Plast Reconstr Surg* 6:291–300, 1987.
42. Ashar A, et al.: Blindness associated with midfacial fractures, *J Oral Maxillofac Surg* 56(10):1146–1150, 1998. discussion 1151.
43. Covington DS, et al.: Changing patterns in the epidemiology and treatment of zygoma fractures: 10-year review, *J Trauma* 37(2):243–248, 1994.
44. Gossman MD, Roberts DM, Barr CC: Ophthalmic aspects of orbital injury. A comprehensive diagnostic and management approach, *Clin Plast Surg* 19(1):71–85, 1992.
45. Gwyn PP, et al.: Facial fractures—associated injuries and complications, *Plast Reconstr Surg* 47(3):225–230, 1971.
46. Haug RH, Prather J, Indresano AT: An epidemiologic survey of facial fractures and concomitant injuries, *J Oral Maxillofac Surg* 48(9):926–932, 1990.
47. Holt GR, Holt JE: Incidence of eye injuries in facial fractures: an analysis of 727 cases, *Otolaryngol Head Neck Surg* 91(3):276–279, 1983.
48. Lim LH, et al.: Associated injuries in facial fractures: review of 839 patients, *Br J Plast Surg* 46(8):635–638, 1993.
49. Luce EA, Tubb TD, Moore AM: Review of 1,000 major facial fractures and associated injuries, *Plast Reconstr Surg* 63(1):26–30, 1979.
50. Ketchum LD, Ferris B, Masters FW: Blindness without direct injury to the globe: a complication of facial fractures, *Plast Reconstr Surg* 58(2):187–191, 1976.
51. Wang BH, et al.: Traumatic optic neuropathy: a review of 61 patients, *Plast Reconstr Surg* 107(7):1655–1664, 2001.
52. Spoor TC, et al.: Treatment of traumatic optic neuropathy with corticosteroids, *Am J Ophthalmol* 110(6):665–669, 1990.
53. Alford MA, Nerad JA, Carter KD: Predictive value of the initial quantified relative afferent pupillary defect in 19 consecutive patients with traumatic optic neuropathy, *Ophthal Plast Reconstr Surg* 17(5):323–327, 2001.
54. Levin LA, et al.: The treatment of traumatic optic neuropathy: the International Optic Nerve Trauma Study, *Ophthalmology* 106(7):1268–1277, 1999.
55. Levin LA, Baker RS: Management of traumatic optic neuropathy, *J Neuroophthalmol* 23(1):72–75, 2003.
56. Bun RJ, Vissink A, Bos RR: Traumatic superior orbital fissure syndrome: report of two cases, *J Oral Maxillofac Surg* 54(6):758–761, 1996.
57. Steinsapir KD: Treatment of traumatic optic neuropathy with high-dose corticosteroid, *J Neuroophthalmol* 26(1):65–67, 2006.
58. Yang WG, et al.: Outcome for traumatic optic neuropathy—surgical versus nonsurgical treatment, *Ann Plast Surg* 52(1):36–42, 2004.
59. Chen C, et al.: Endoscopic optic nerve decompression for traumatic optic neuropathy: an alternative, *Otolaryngol Head Neck Surg* 135(1):155–157, 2006.
60. Chen CT, et al.: Endoscopically assisted transconjunctival decompression of traumatic optic neuropathy, *J Craniofac Surg* 18(1): 19–26, 2007. discussion 27–28.
61. Chen HY, Tsai RK, Wang HZ: Intravenous methylprednisolone in treatment of traumatic optic neuropathy, *Kaohsiung J Med Sci* 14(9):577–583, 1998.
62. Spoor TC, et al.: Treatment of traumatic optic neuropathy with corticosteroids—correction, *Am J Ophthalmol* 111(4):526, 1991.
63. Entezari M, et al.: High-dose intravenous methylprednisolone in recent traumatic optic neuropathy; a randomized double-masked placebo-controlled clinical trial, *Graefes Arch Clin Exp Ophthalmol* 245(9):1267–1271, 2007.
64. Li KK, et al.: Extracranial optic nerve decompression: a 10-year review of 92 patients, *J Craniofac Surg* 10(5):454–459, 1999.
65. Li KK, et al.: Traumatic optic neuropathy: result in 45 consecutive surgically treated patients, *Otolaryngol Head Neck Surg* 120(1):5–11, 1999.
66. Thakar A, Mahapatra AK, Tandon DA: Delayed optic nerve decompression for indirect optic nerve injury, *Laryngoscope* 113(1):112–119, 2003.
67. Bite U, et al.: Orbital volume measurements in enophthalmos using three-dimensional CT imaging, *Plast Reconstr Surg* 75(4):502–508, 1985.
68. Whitehouse RW, et al.: Prediction of enophthalmos by computed tomography after "blow out" orbital fracture, *Br J Ophthalmol* 78(8):618–620, 1994.
69. Manson PN, et al.: Mechanisms of global support and posttraumatic enophthalmos: I. The anatomy of the ligament sling and its relation to intramuscular cone orbital fat, *Plast Reconstr Surg* 77(2):193–202, 1986.
70. Manson PN, et al.: Studies on enophthalmos: II. The measurement of orbital injuries and their treatment by quantitative computed tomography, *Plast Reconstr Surg* 77(2):203–214, 1986.
71. Parsons GS, Mathog RH: Orbital wall and volume relationships, *Arch Otolaryngol Head Neck Surg* 114(7):743–747, 1988.
72. Musch DC, Frueh BR, Landis JR: The reliability of Hertel exophthalmometry. Observer variation between physician and lay readers, *Ophthalmology* 92(9):1177–1180, 1985.
73. Ioannides C, et al.: Ocular injuries associated with fractures involving the orbit, *J Craniomaxillofac Surg* 16(4):157–159, 1988.
74. Migliori ME, Gladstone GJ: Determination of the normal range of exophthalmometric values for black and white adults, *Am J Ophthalmol* 98(4):438–442, 1984.
75. Koo L, Hatton MP, Rubin PA: When is enophthalmos "significant"? *Ophthal Plast Reconstr Surg* 22(4):274–277, 2006.
76. Putterman AM, Stevens T, Urist MJ: Nonsurgical management of blow-out fractures of the orbital floor, *Am J Ophthalmol* 77(2):232–239, 1974.
77. Cunningham LL, Peterson GP, Haug RH: The relationship between enophthalmos, linear displacement, and volume change in experimentally recreated orbital fractures, *J Oral Maxillofac Surg* 63(8):1169–1173, 2005.
78. Jin HR, et al.: Relationship between the extent of fracture and the degree of enophthalmos in isolated blowout fractures of the medial orbital wall, *J Oral Maxillofac Surg* 58(6):617–620, 2000. discussion 620–621.
79. Chowdhury K, Krause GE: Selection of materials for orbital floor reconstruction, *Arch Otolaryngol Head Neck Surg* 124(12): 1398–1401, 1998.
80. Choi JC, et al.: Porous polyethylene channel implants: a modified porous polyethylene sheet implant designed for repairs of large and complex orbital wall fractures, *Ophthal Plast Reconstr Surg* 15(1):56–66, 1999.
81. Kontio R, et al.: Effectiveness of operative treatment of internal orbital wall fracture with polydioxanone implant, *Int J Oral Maxillofac Surg* 30(4):278–285, 2001.
82. Tanag MA, et al.: Use of calcium phosphate cement paste in orbital volume augmentation, *Plast Reconstr Surg* 117(4): 1186–1193, 2006.

83. Gellrich NC, et al.: Computer-assisted secondary reconstruction of unilateral posttraumatic orbital deformity, *Plast Reconstr Surg* 110(6):1417–1429, 2002.
84. Chan CH, Spalton DJ, McGurk M: Quantitative volume replacement in the correction of post-traumatic enophthalmos, *Br J Oral Maxillofac Surg* 38(5):437–440, 2000.
85. Baumann A, et al.: Orbital floor reconstruction with an alloplastic resorbable polydioxanone sheet, *Int J Oral Maxillofac Surg* 31(4):367–373, 2002.
86. Ord RA: Post-operative retrobulbar haemorrhage and blindness complicating trauma surgery, *Br J Oral Surg* 19(3):202–207, 1981.
87. Ord RA, Awty MD, Pour S: Bilateral retrobulbar haemorrhage: a short case report, *Br J Oral Maxillofac Surg* 24(1):1–6, 1986.
88. Ord RA, El Attar A: Acute retrobulbar hemorrhage complicating a malar fracture, *J Oral Maxillofac Surg* 40(4):234–236, 1982.
89. Nicholson DH, Guzak SW: Visual loss complicating repair of orbital floor fractures, *Arch Ophthalmol* 86(4):369–375, 1971.
90. Lanigan DT, Romanchuk K, Olson CK: Ophthalmic complications associated with orthognathic surgery, *J Oral Maxillofac Surg* 51(5):480–494, 1993.
91. Thyne GM, Luyk NH: Zygomatic bone fractures complicated by retrobulbar haemorrhage, *N Z Dent J* 88(392):60–63, 1992.
92. Hislop WS, Dutton GN, Douglas PS: Treatment of retrobulbar haemorrhage in accident and emergency departments, *Br J Oral Maxillofac Surg* 34(4):289–292, 1996.
93. Hislop WS, Dutton GN: Retrobulbar haemorrhage: can blindness be prevented? *Injury* 25(10):663–665, 1994.
94. Schramm A, Gellrich N-C: Computer-assisted therapy in orbital and mid-facial reconstructions, *Int J Med Robotics Comput Assist Surg* 5:111–124, 2012.

10

Diagnosis and Management of Midface Fractures

MOHAMMED AL-OBAIDI, PAUL S. TIWANA

Introduction

The midface is the part of the facial skeleton spanning from the cranial base to the maxillary occlusal plane. This anatomic unit is important both functionally and cosmetically, as it provides support to the globes, sinuses, muscles of mastication and facial expression, and upper dentition. It therefore serves a supporting role in the physiologic function of the ocular, olfactory, respiratory, and digestive systems. Last, the human face remains our window to the world and is how others perceive us. Significant alterations of the form and function of the face secondary to trauma can leave a devastating impact on the daily life of the afflicted patient. Meticulous reduction and stabilization of these fractures is therefore a critical component of successful repair.

Although the epidemiology of facial fractures varies in the literature depending on the institution and population studied, general trends can be noted. Midface fractures occur more commonly in younger patients because this population subgroup is associated with frequent causes of injury: interpersonal violence, motor vehicle collisions, and sports-related trauma.[1-6] There is also a generally higher reported proportion of male patients.[2,4-7] Because of their centralized location within the facial skeleton, midface fractures often present in combination with other facial fractures or as part of panfacial injuries.

This chapter will discuss the diagnosis and management of midface fractures that affect the occlusion, that is, Le Fort type fractures, as well as naso-orbital-ethmoid (NOE) fractures. For the management of injuries such as isolated nasal fractures, zygomatic fractures, and orbital fractures, please see the relevant chapters in this text.

The authors wish to acknowledge Drs. Likith V. Reddy and Matthew Pagnotto for their previous contributions to this chapter.

Midface Anatomy

The midfacial skeleton is centered on the maxilla and its complex articulations with surrounding structures including the palatine, zygomatic, nasal, sphenoid, and ethmoid bones. The maxilla houses the bilateral maxillary sinuses, which expand in size from birth to adulthood and contribute to the inherent structural weakness of the region. The maxillary bones are integral in formation of the superior aspect of the oral cavity, the inferior and lateral walls of the nasal cavity, and the inferomedial aspects of the orbits. Therefore, most midface fractures involve the maxilla to some extent.

Critical to the management of injuries to the midface is understanding of the skeletal buttresses, vertical and horizontal pillars that provide support and protect vital structures from external forces[8-10] (Figure 10-1). The vertical support of the face is provided by the nasomaxillary (medial), the zygomaticomaxillary (lateral), and the pterygomaxillary (posterior) buttresses, which are most resistant to vertically directed forces. The horizontal buttresses—the supraorbital/frontal bar, infraorbital rims, the zygomas, and maxillary alveolus—are weaker but provide some resistance to horizontally directed forces. The weakest protection is available from the thin sagittal buttresses provided by the maxillary walls, palate, lateral nasal walls, and the nasal septum.[11] Areas of thin bone between this framework, as well as the paranasal sinuses, create anatomic sites of weakness that result in reasonably predictable fracture patterns.

Although the buttresses, just described, have been given varying names and definitions in the literature, it is critical to recognize their significance, as outlined in Box 10-1.[12]

Classification of Midface Fractures

Midface or middle third fractures include nasal fractures, orbital fractures, naso-orbital-ethmoid fractures, zygomatic and zygomaticomaxillary complex fractures, Le Fort fractures, palatal fractures, and maxillary dentoalveolar fractures.

Many classification schemes have been suggested for different midface fractures. The classic Le Fort system for maxillary fractures, first published in 1901, categorized fractures based on common patterns.[13] Rene Le Fort originally

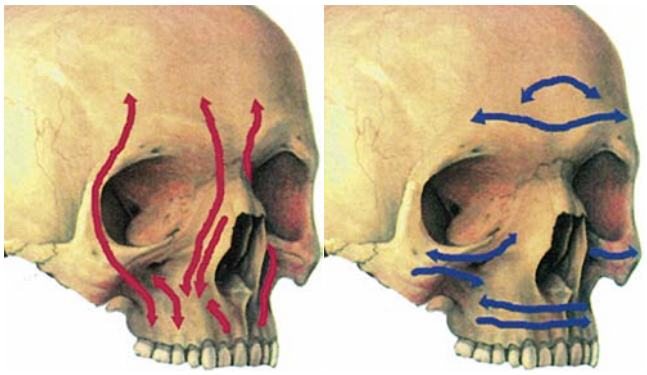

• **Figure 10-1** Classically depicted vertical *(left image)* and horizontal *(right image)* buttresses of the facial skeleton.

• Box 10-1 Buttresses of the Facial Skeleton: General Concepts

The buttress concept allows improved appreciation of facial structure.
Buttresses provide sufficient bone thickness to accommodate metal screw fixation.
All buttresses are linked directly or indirectly to the cranial base as a stable reference point.
Reduction of transverse buttresses restores facial profile and width; reduction of vertical buttresses restores facial height.
Reduction of the buttresses restores functional support to the teeth and globes.

Hopper RA, Salemy JD, Sze RW: Diagnosis of midface fractures with CT: what the surgeon needs to know, *RadioGraphics* 26:783-793, 2006.

studied these patterns on cadaver skulls subjected to external frontal forces and described three lines of least resistance or the "linea minoros resistentiae." These were subsequently adopted as the Le Fort I fracture, the Le Fort II fracture, and the Le Fort III fracture (Figure 10-2). Although this scheme has been prized as a simple and systematic method to diagnose and treat midface fractures, it is well recognized that most high-energy injuries today do not follow these patterns.

The Le Fort type I fracture pattern results from a force directed above the maxillary teeth, resulting in a separation of the palate. The Le Fort type II fracture pattern results from a force delivered at the level of the nasal bone, resulting in mobility and separation of the midface "pyramid." The Le Fort type III fracture pattern results from a force directed at the orbital level, resulting in a craniofacial dysjunction or separation of the entire middle third of the craniomaxillofacial skeleton from the skull base.

Other classification systems have been suggested to better describe midface fractures, citing the inadequacies of the Le Fort system. The system of Donat and colleagues is based on the facial vertical buttresses and horizontal beams and uses clinical and radiographic findings to describe the fracture pattern along 11 unilateral and 22 bilateral sites.[14] Although they have shown that this system can improve accurate diagnosis and communication, many surgeons find

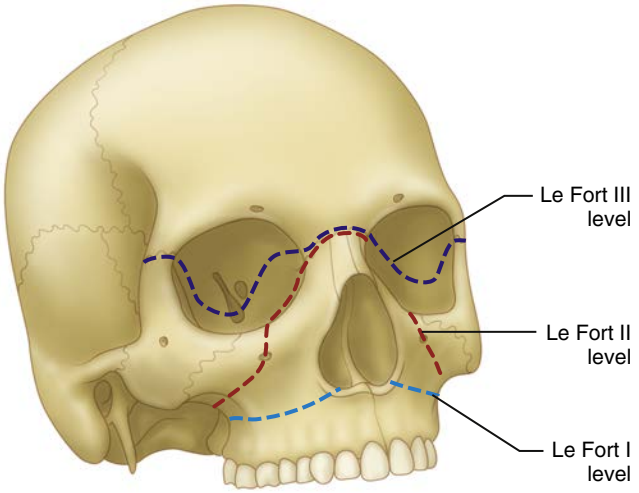

• **Figure 10-2** Le Fort classification of midface fractures. (From Baghaeri S: *Current therapy in oral and maxillofacial surgery*, St Louis, Mosby, 2012.)

it to be too complicated. Manson elaborated on the Le Fort classification by defining the level of highest fracture, the pattern of the segment of the maxilla carrying the dentition, and associated fractures.[15] Nevertheless, the original Le Fort classification system has to date remained the most popular and is discussed, along with palatal and naso-orbital-ethmoid fractures, in the following respective sections. Classification of other facial fractures is discussed in their respective chapters.

Diagnosis of Midface Fractures

Physical Examination

Initial evaluation of the severely injured midface begins with applying the principles of advanced trauma life support (ATLS). In assessing midfacial injuries in the emergency setting, the airway and cervical spine deserve particular attention. If the airway is compromised, a definitive airway must be established with intubation or surgical intervention. Care must be taken if endotracheal intubation is attempted, as cervical spine injuries occur in as many as 9.6% of patients with facial fractures.[16] Surgical tracheostomy or cricothyroidotomy is preferred if intubation cannot be achieved with in-line immobilization of the cervical spine.[17]

Once the patient is stabilized, assessment of the midface is carried out as part of the comprehensive facial examination. The complete facial examination is a systematic evaluation of all structures from the dura to the pleura and is beyond the scope of this chapter.

Thorough inspection of the face should be carried out and any areas of edema, ecchymosis, abrasions, lacerations, hemorrhage, and gross deformities noted and documented (Figure 10-3). Otorrhea or rhinorrhea should raise suspicion of cerebrospinal fluid (CSF) leakage, and packing should be avoided initially to prevent retrograde infection resulting in meningitis.

Palpation of the entire craniomaxillofacial skeleton is performed in a systematic manner to assess for step-offs,



• **Figure 10-3** Patient presenting after a motor vehicle crash. After the airway has been secured and the patient is stabilized, a full maxillofacial examination is completed. Note diffuse edema, ecchymoses, a large laceration, and a flat, rounded appearance, all suggestive of a severe midface fracture.

mobility, crepitus, or irregular segments. The surgeon begins palpation at the frontal bone and supraorbital rims and progresses downward along the facial skeleton, to evaluate the zygomas, maxilla, and mandible.

Attention should be paid to the periorbital regions, and a full ocular examination is performed. Extensive periorbital edema and ecchymosis are the first signs of orbital trauma. The globes should be evaluated for proptosis, extraocular muscle movement, and pupillary size and reactivity to light. Visual acuity and fundoscopic examination are also warranted. Ocular injury is commonly present in midface trauma patients. In one study of midface fractures with orbital injury, 90% of patients were found to have an ocular injury to some degree.[18] Patients with naso-orbital-ethmoid fractures are at significant risk of concomitant ocular injury and subsequent loss of vision, reported in 30% of patients in one series.[19] It is therefore prudent that all patients with facial fractures involving the orbit receive ophthalmologic evaluation.[18,19]

Evaluation of the lacrimal drainage apparatus and the medial canthal tendon are important parts of the evaluation for naso-orbital-ethmoid fractures. Detailed description of the bimanual examination and traction tests for the medial canthal tendon are presented in the NOE section below. Measuring the intercanthal distance is also an important part of assessing for naso-orbital-ethmoid fractures.

Evaluation of the maxilla for midface fractures is assessed by firmly grasping the pre-maxilla and attempting to displace it in three dimensions. Ecchymosis and laceration of the vestibule or palate are common findings with fractures of the maxilla. A malocclusion may be noted, and widening of the maxilla may be indicative of a palatal fracture.

Imaging

Prior to advancements in radiologic modalities, plain radiography was employed for assessing the midface. However, with current technology there is no longer a role for plain radiography in the evaluation of midface fractures. Computed tomography (CT) has become the modality of choice for evaluation of these injuries, and current multidetector CT techniques allow for excellent detection of fractures and patterns of injury[20] (Figure 10-4). Multiplanar high-resolution images are easily and quickly obtained and often can be reformatted to generate three-dimensional (3D) images. Thin cuts of 1.0 to 2.0 mm show adequate anatomic detail to demonstrate most facial fractures. Conversely, caution is advised when interpreting 5 mm or higher cut CTs, as fractures can be missed.

The role of 3D reformatted CT has been investigated. Previously it was reported to be inferior to 2D CT but useful in severe complex fractures.[21,22] With continued improvement in availability and technology, 3D CT is being used more often and is commonly employed in combination with 2D CT (Figure 10-5). However, because of artifact during the reformatting process, 3D CTs have decreased ability to detect nondisplaced fractures, inadequate soft tissue evaluation, and difficulty detecting deeper fractures.[23] Therefore, the authors recommend against relying solely on 3D CT images for diagnosis and treatment of midface fractures.

The use of magnetic resonance imaging (MRI) for the evaluation of facial fractures is not common, as bony trauma is better examined with CT. MRI can be used as an adjunctive modality when intracranial injury or unusual soft tissue injuries are suspected. MRI is also helpful for evaluation of cranial nerve deficits.[23] Similarly, ultrasound has not gained popularity in the acute facial trauma evaluation. Although it is noninvasive, inexpensive, safe, and fast, ultrasound will fail to demonstrate facial fractures with adequate accuracy. It has been employed, however, in certain clinical situations as an adjunct.[24]

Le Fort Fractures

Introduction

The Le Fort classification of midface fractures has been in use for over a century. Several additional attempts have been made to describe and classify midface fractures since that time.[14,15,25,26] However, this system remains the simplest and most widely recognized classification.

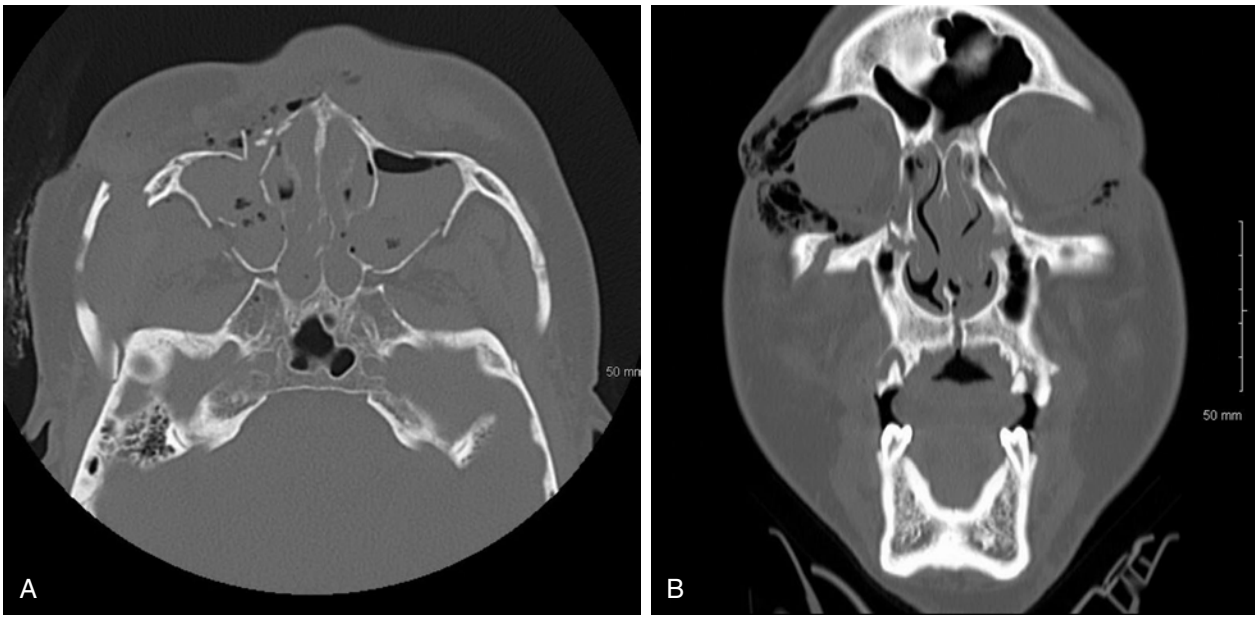

• **Figure 10-4** Two-dimensional computed tomographic images in **(A)** axial and **(B)** coronal views allow for accurate diagnosis of complex fractures. **A** is consistent with a left Le Fort II and right Le Fort III with a posteriorly impacted maxilla. **B** demonstrates a bilateral Le Fort II fracture with a concomitant sagittal palate fracture.

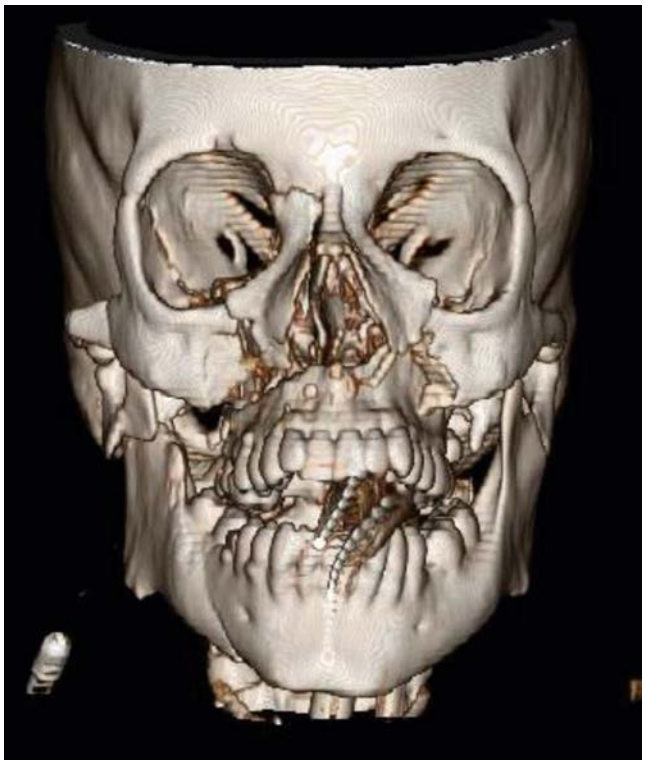

• **Figure 10-5** 3D CT reformatting shows excellent visualization of the pattern of injury and degree of displacement. This image depicts a complex midface fracture pattern with Le Fort I, II, and III levels.

Knowledge of the skeletal buttresses previously described and their involvement is a necessary part of the management of these fractures. Accurate diagnosis and identification of all fracture lines is important for the determination of stable and unstable bony landmarks. Furthermore, all Le Fort fractures affect the position of the maxillary alveolar ridge and thus affect the occlusion. Therefore, adequate management of Le Fort fractures centers around reestablishing the skeletal buttresses and the pre-injury occlusion.

Anatomy

Le Fort fractures involve several of the bones that make up the midface skeleton, including the maxilla, palatine bones, pterygoid plates of the sphenoid, zygomas, nasal bones, frontal bone, ethmoid, and vomer. As has been discussed earlier, the skeletal buttresses of the midface are often fractured and are key to achieving satisfactory results. These include the nasomaxillary, pterygomaxillary, and zygomaticomaxillary vertical buttresses, and the infraorbital rim, zygomas, and maxillary alveolar horizontal buttresses. Failure to reestablish these buttresses will invariably lead to inadequate midface height, width, and projection, resulting in a short, wide face.

The blood supply to the midface is provided mainly by the internal maxillary artery, a branch of the external carotid artery, with some contributions from the internal carotid artery via the ophthalmic artery and its branches—the anterior and posterior ethmoidal arteries. Branches of the maxillary artery include the descending palatine, sphenopalatine, infraorbital, and superior alveolar arteries.

Neurosensory supply is via the second division of the trigeminal nerve. This nerve exits the infraorbital foramen and supplies the lateral nasal, superior labial, and inferior palpebral regions as well as the labial mucosa and anterior teeth. The infraorbital neurovascular bundle is often encountered with adequate exposure and should be protected.

Classification

Maxillary midface fractures are most commonly classified by the Le Fort description. It is important to remember that patients often present with fractures of different levels, asymmetries, comminution, and additional facial fractures. Patients with more complex fractures are more likely to have coexisting secondary facial fractures and other traumatic injuries.

The Le Fort I fracture is a horizontal fracture caused by a force delivered above the apices of the maxillary teeth. It extends through the pyriform aperture of the nose anteriorly and the pterygoid plates posteriorly. It involves the lateral nasal wall (medial maxillary sinus wall) and the anterior and lateral maxillary sinus walls. Simply stated, a Le Fort I fracture is the separation of the palate from the rest of the maxilla (Figure 10-6).

The Le Fort II fracture is a pyramidal fracture that involves separation of the central midface from the cranial base. It extends from the pterygoid plates and zygomaticomaxillary suture through the infraorbital rims and ends at the nasofrontal suture (Figure 10-7). The zygomas and lateral aspects of the orbits are intact with Le Fort II fractures. Le Fort II fractures are usually indicative of a more severe injury and have been found to be significantly associated with intracranial injuries and increased mortality.[27]

The Le Fort III fracture is described as full craniofacial dysjunction, in which the entire midface is separated from the cranial base. Superiorly the fracture extends across the nasofrontal suture, the medial and lateral orbital walls, and the zygomaticofrontal sutures. Posteriorly it extends across the pterygoid plates and the posterior maxilla. Laterally it extends through the zygomatic arches (Figure 10-8). A pure Le Fort III fracture represented approximately 9% of midface fractures in one series.[28] Generally, the majority of Le Fort III fractures are a combination of Le Fort I, II, zygomaticomaxillary complex, and naso-orbital-ethmoid fractures. Additionally, Le Fort III fractures are also associated with serious intracranial injuries.[27]

For all Le Fort fractures, the nasal septum and palate may additionally be fractured. Palatal fractures have been classified by Hendrickson and colleagues as six types of fractures based on fracture pattern[29] (Figure 10-9):

Type I: alveolar
Type II: sagittal
Type III: parasagittal
Type IV: para-alveolar
Type V: comminuted/complex
Type VI: transverse

Type III fractures are the most encountered pattern as the parasagittal bone of the palate is thinner than the midsagittal buttress. Park and Ock presented an alternative scheme for classification of palatal fractures based on the required treatment plan.[30]



• **Figure 10-6** Le Fort I fracture. Note the fracture of the palate from the midface.

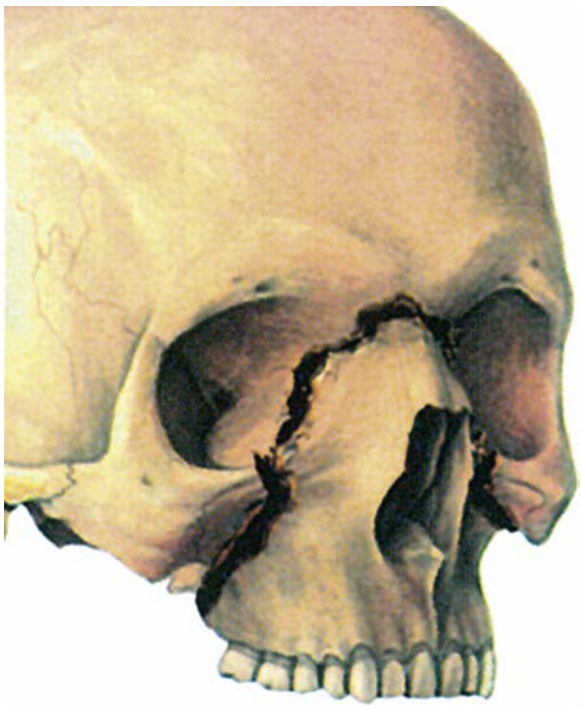

• **Figure 10-7** Le Fort II fracture. Note the pyramidal shape of the fractured maxillary segment.

Diagnosis

As with all facial traumatic injuries, a thorough clinical and radiographic examination is required. A systematic clinical evaluation of all portions of the face is carried out, with inspection and palpation of the facial skeleton and supportive structures. Edema, ecchymosis, abrasions, and lacerations should be noted. All bony projections and articulations should be palpated for any steps, mobility, or crepitus, which may indicate a fracture. An

ocular examination should assess visual acuity, pupil size and reactivity, and extraocular muscle movement. Extraocular muscle limitation and binocular diplopia may be indicative of an orbital fracture. Additional concomitant ocular injuries should be sought for, and findings such as monocular diplopia, hyphema, or anisocoria should raise suspicion for a globe injury. Most agree that patients with orbital trauma should have an ophthalmologic evaluation when possible.

Le Fort I fractures often have subtle clinical findings. Malocclusion and maxillary mobility are the most consistent findings. Muscle pull from the lateral and medial pterygoid muscles displaces the fractured maxilla backward and downward, which is clinically evident as an anterior open bite (Figure 10-10). Manual assessment of mobility involves placing an index finger and thumb posteriorly on the bony segment of the maxillary arch and attempting movement in three dimensions. Alternately, the thumb and index finger may grasp the anterior palate to attempt movement. Eliciting pain on palpation and on occlusion are also consistent findings. Palatal fractures can be assessed with manual attempts to transversely widen or collapse the maxillary arch. Palatal ecchymosis can also be indicative of a sagittal or parasagittal palatal fracture.

A Le Fort II fracture will usually be associated with more extensive soft tissue edema. Attention should be paid to the nasal bridge, the orbital rims, and the maxilla. Intraoral findings are similar to evaluation for a Le Fort I fracture. Additionally, mobility and step-offs may be encountered at the infraorbital rims and the nasal bridge, with overlying edema and ecchymosis. Bilateral periorbital edema and ecchymosis, known as "raccoon eye sign," is concerning for orbital fractures. Manipulation of the maxilla may elicit palpable mobility at the nasofrontal junction and infraorbital rims. Epistaxis is very common, and CSF rhinorrhea may be present when a dural tear at the skull base is involved. Hypoesthesia of the infraorbital nerve is also very common because of edema and direct trauma to the nerve.

Le Fort III fractures require a greater amount of force and therefore will be associated with additional cranial, orbital, and facial injuries. In addition to the findings described for Le Fort II fractures, Le Fort III fractures will elicit mobility at the zygomaticofrontal and nasofrontal sutures on manipulation of the maxilla. However, because of the frequent comminution and additional fracture patterns, this may not be present. Cranial base injury with CSF leakage from the nose (rhinorrhea) or ears (otorrhea) is assessed clinically, and any suspicious drainage should be tested with a simple halo test at bedside. This involves the use of a white paper towel to assess the spread of the dropped fluid. The more viscous blood will remain in the center, and CSF will spread more widely, creating a positive halo sign. Additional signs indicative of skull base fractures include "raccoon eyes" and Battle sign, which is ecchymosis overlying the mastoid process.



• **Figure 10-8** Le Fort III fracture. Note complete disarticulation of the facial skeleton from the skull base.

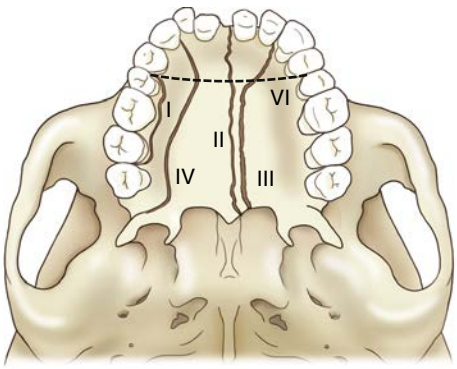

• **Figure 10-9** Hendrickson classification of palatal fractures.



• **Figure 10-10** Classic anterior open bite associated with a Le Fort fracture. Traumatic impaction of the maxilla and backward and downward pull of the pterygoid muscles contribute to this finding.

Radiographic examination for midface fractures is best accomplished with thin-cut (1.0 to 2.0 mm) CT with a minimum of axial and coronal sections. Additional information can sometimes be obtained from 3D CT reconstruction, which may aid in treatment planning. Attention should be paid to the skeletal buttresses and the posterior region of the maxilla and pterygoid plates (Figure 10-11).

A systematic clinical and radiographic evaluation of the facial skeleton allows the clinician to accurately diagnose Le Fort fractures. Often the patient has multiple fracture patterns and different fracture levels bilaterally. Treatment should not begin without adequate knowledge of the fracture diagnosis and classification.



• **Figure 10-11** Axial CT scan of a Le Fort III fracture demonstrating fractures through the pterygoid plates and the zygomatic arches bilaterally. All Le Fort fractures will demonstrate fractures at the posterior buttress through the posterior maxilla or pterygoid plates.

Treatment

General Considerations

Timing of repair of Le Fort fractures is somewhat controversial. Some surgeons have previously advocated early or immediate treatment. However, concomitant neurosurgical trauma and other injuries may come into play, and treatment is recommended once the patient is stabilized and edema from the initial insult has subsided. Nevertheless, ideal management is best performed within 10 to 14 days.[31,32] After this time period it may become exceedingly more difficult to adequately disimpact the maxilla and achieve optimal soft tissue drape.

Le Fort I Fractures

Treatment of an isolated Le Fort I fracture begins with adequate exposure via a maxillary vestibular incision and dissection of the fracture segments. Mobilization of the maxilla may be necessary, especially in the case of a delayed treatment. A Rowe maxillary disimpaction forceps or a Hayton-Williams forceps may be used to achieve adequate mobilization and reduction (Figure 10-12). A word of caution must be noted when using forceps to reduce midface fractures; the injudicious use of force when using these instruments can cause further fractures of the maxilla and skull base as well palatal and nasal mucosal tearing. Alternative instruments include Tessier maxillary mobilizers or a towel clamp in the anterior nasal spine region. The patient's occlusion is then reestablished by applying maxillomandibular fixation. At this point the maxillomandibular complex is positioned for fixation, with care taken to ensure the condyles are seated in the glenoid fossae and the vertical dimension of the face is correct. Once adequate position is achieved with the condyles seated, four-point rigid internal fixation is used to maintain the maxilla in a position to

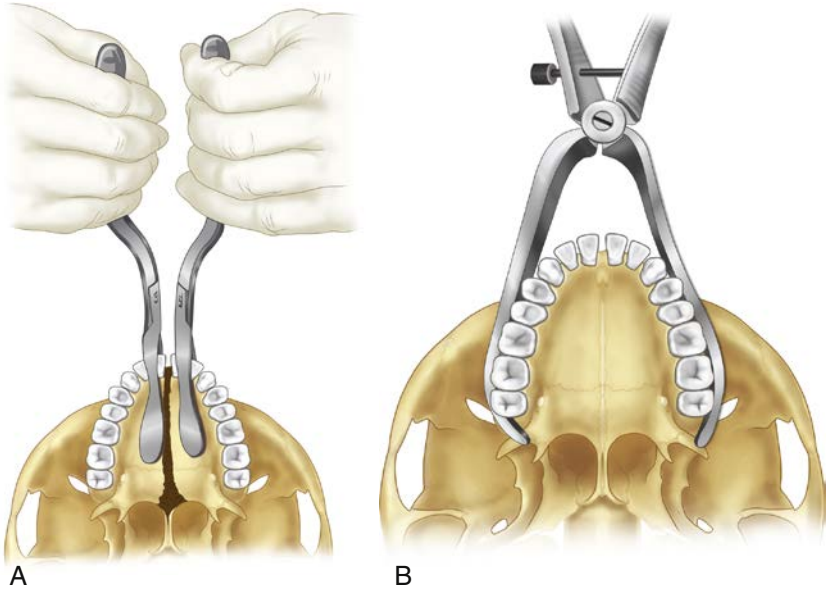

• **Figure 10-12** Disimpaction of the maxilla: **A,** Rowe maxilla disimpaction forceps. **B,** Hayton-Williams forceps. (From Fonseca RJ, Barber HD: *Oral and maxillofacial trauma*, ed 4, St Louis, Saunders, 2013.)

resist translational and rotational movement in all dimensions. Typically, miniplates are placed onto the zygomaticomaxillary buttresses and along the pyriform rim bilaterally (Figure 10-13). Maxillomandibular fixation can be released and the occlusion rechecked.

Although closed reduction with maxillomandibular fixation remains a viable treatment option, its postoperative course and recovery can be suboptimal from the patient's viewpoint. Rigid internal fixation allows for earlier function, improved nutrition, and more comfort.

Le Fort II Fractures

Treatment of Le Fort II fractures is best achieved with open reduction and internal fixation. Occasionally it is possible to achieve four-point fixation and stability with only an intraoral vestibular incision. However, for the majority of these fractures, displacement of fractures at the infraorbital rim, nasofrontal region, or orbital walls requires additional exposure through other incisions. A coronal incision is a viable option in cases where multiple sites of fixation are required, and provides the additional advantage of exposure of the cranial vault for graft harvest. Commonly access through the infraorbital rim is needed, and exposure can be achieved with any of several incisions including transconjunctival, subciliary, subtarsal or "mid-lid," and infraorbital incisions.

Once adequate exposure of the fracture lines is achieved, the maxilla is mobilized and maxillomandibular fixation is applied in a manner similar to the Le Fort I method. For a pure Le Fort II fracture, rigid internal fixation is achieved at the zygomaticomaxillary buttresses and the infraorbital rims (Figure 10-14). Additional points of fixation are needed based on the fracture pattern and comminution. When comminution limits the ability to reestablish vertical facial height using anatomic bony reduction, the surgeon fixates the maxilla at a position that allows approximately 2 mm of incisor show at repose.

Le Fort III Fractures

Le Fort III fractures require a more complicated surgical treatment. As stated previously, they are often found to coexist with other facial fractures and varying patterns of complexity and comminution. A Le Fort III fracture can be thought of

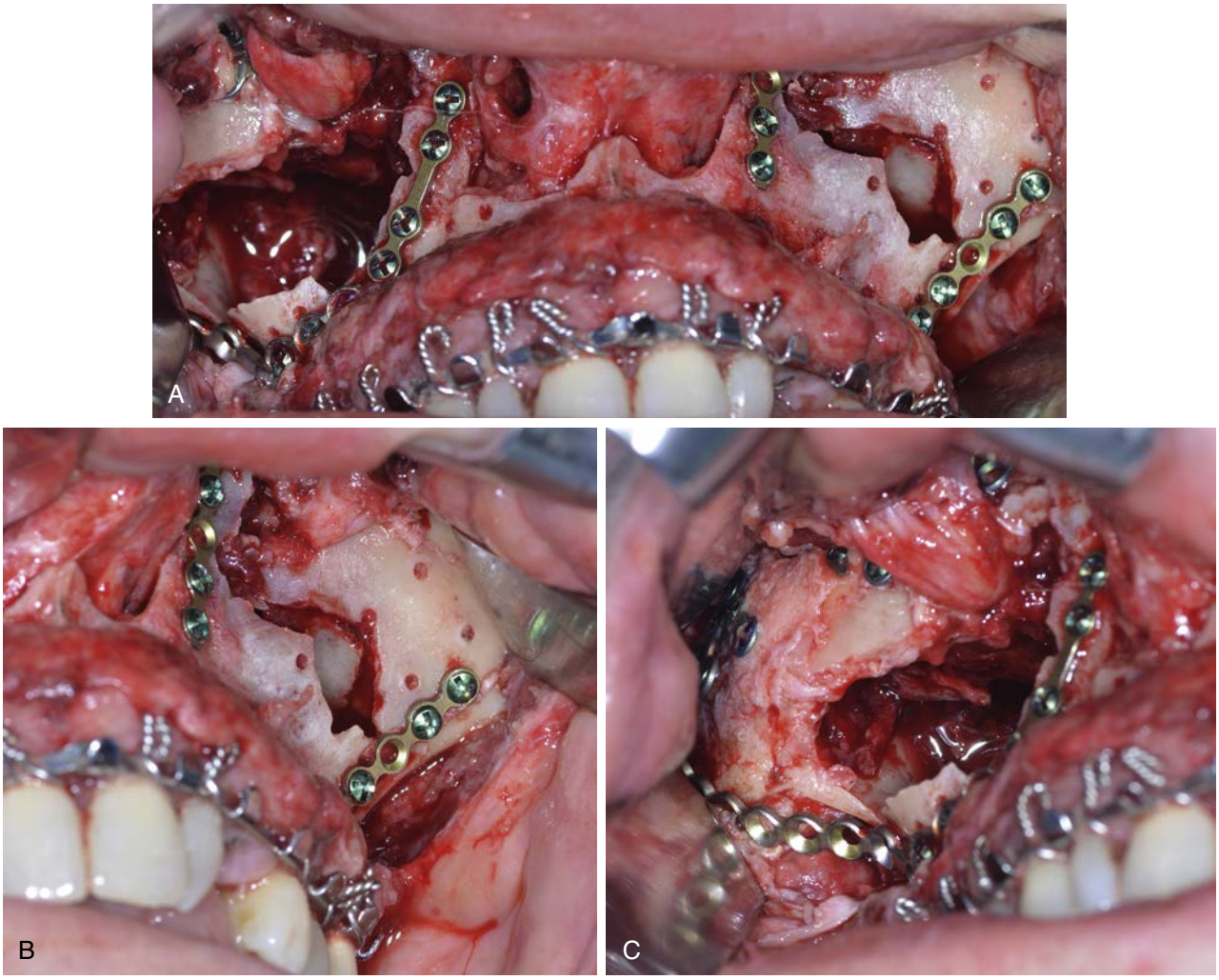

• **Figure 10-13** **A,** Four point rigid internal fixation for a Le Fort I fracture along the bilateral zygomaticomaxillary and nasomaxillary buttresses. Note significant comminution of the right maxillary sinus. **B,** Close-up of left side. **C,** Close-up of right side.

as a combination of bilateral Le Fort I/II, zygomatic, and naso-orbital-ethmoid fractures.[33] As such, the same principles apply to management of these fractures. Marciani and Gonty summarized the four factors contributing to successful management of complex craniomaxillofacial fractures. These are early definitive treatment; anatomic and functional repair of naso-orbital-ethmoid injuries; wide exposure of fractured segments; and anatomic repositioning and stable fixation in all planes.[34] A coronal incision is almost always necessary for adequate exposure for Le Fort III fractures (Figure 10-15).

Multiple treatment algorithms and sequences have been suggested for the treatment of complex panfacial fractures. Two main schools of thought are followed for the management of these injuries. The first was described by Gruss and colleagues, in which reconstruction proceeds from stable to unstable segments, that is, from the outer to the inner facial frame.[35,36] In this method, mandibular fractures are fixated last, obviating the need for open reduction and fixation of condylar process fractures. Fixation of the zygomatic (the "outer facial frame") fractures then proceeds from lateral to medial. The frontozygomatic and frontotemporal fractures are reduced and rigidly fixated, followed by the nasofrontal fractures. The maxilla is secured to the mandible with maxillomandibular fixation. This is followed by reconstruction of the nasal frame, the NOE segments, and the anterior maxillary buttresses. Finally, open reduction and fixation of symphyseal, body, and angle fractures of the mandible goes forward. Treatment is tailored for the individual patient and is based on a systematic evaluation of all fracture sites and wide exposure.

The second school of thought was introduced by Markowitz and expanded upon by Kelly and Manson.[37,38] They described a method whereby the width of the midface is first established at the NOE region, followed by an outward sequence of fixation ("inside-out"). The mandible was fixated, including open reduction of condyle fractures, before the final reduction of the midface was completed ("bottom-up"). The advances in rigid fixation over the past few decades have enabled surgeons to follow different methods and treatment sequences to achieve satisfactory results. It is

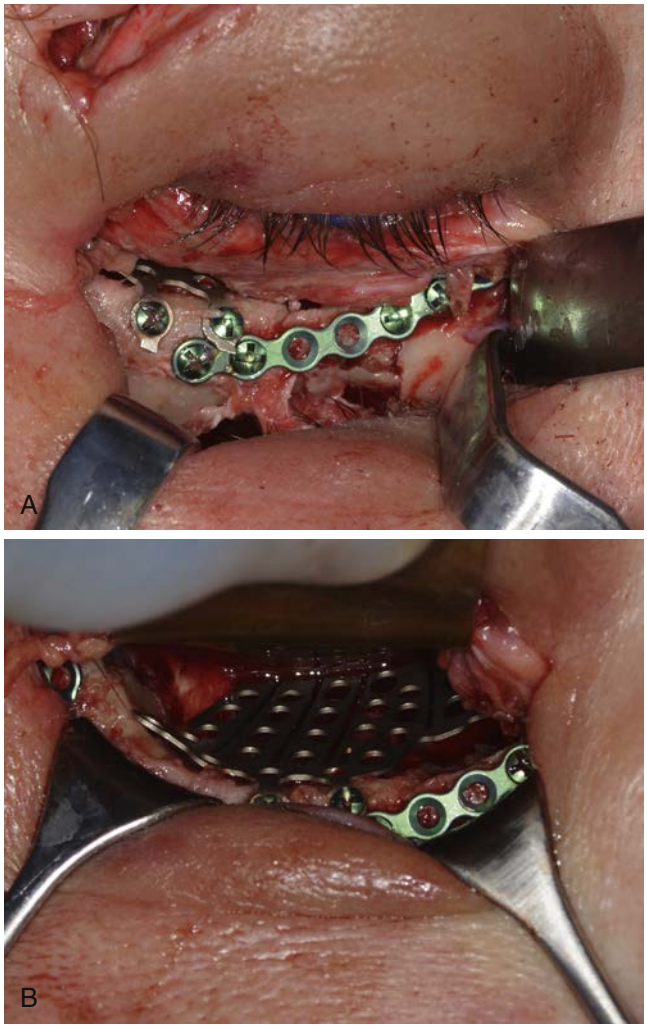

• **Figure 10-14** Rigid internal fixation of the inferior orbital rim (**A**). In this patient, a concomitant orbital floor blowout fracture required reconstruction with an orbital implant (**B**).

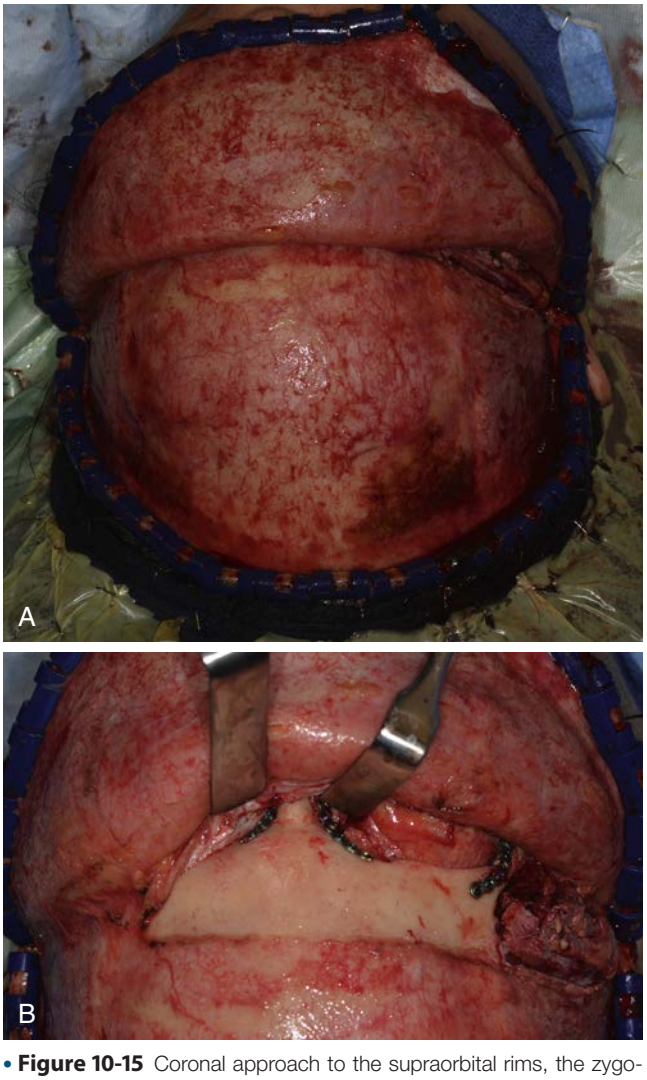

• **Figure 10-15** Coronal approach to the supraorbital rims, the zygomaticofrontal sutures, and the nasofrontal region. **A,** Elevation of the flap. **B,** Fixation of the bilateral nasofrontal and right zygomaticofrontal fractures. Note that the amount of exposure is dictated by the fracture pattern, and in this patient the left zygomaticofrontal suture was not exposed.

critical that the surgeon formulate a systematic treatment plan with the goals of reestablishing facial width, height, and projection, as well as the pre-injury occlusion.

With more severe fracture patterns and increased comminution, it is often necessary to use bone grafting procedures to reestablish the skeletal buttresses. Autogenous bone grafts remain the best option for facial reconstruction in trauma patients. Bone can be harvested from the calvarium, ribs, ilium, and intraorally from the mandible. Calvarial bone grafts are an excellent option as they are usually immediately available when a coronal flap has been elevated and can be used for various reconstruction purposes.

Palatal Fractures

Isolated palatal fractures are rare, and the presence of a sagittal palatal fracture usually indicates that a Le Fort fracture exists. Eight to 13% of Le Fort fractures are complicated by concomitant palatal fractures.[29,30] While the use of rigid internal fixation to repair a palatal fracture has been described in other specialties, its routine use is not indicated in oral and maxillofacial trauma surgery. Arguments against the use of rigid plate fixation include, first, the significant compromise in blood supply effected with mucosal stripping leading to bony necrosis; second, a substantial increase in the likelihood of an oral-nasal fistula; and last, the inability to simultaneously fixate the palate while maintaining maxillomandibular fixation, thereby automatically inducing error in reduction of the correct occlusion. Park and Ock reported rigid internal fixation of the palatal aspect in 33% of these fractures in a relatively small series.[30]

Occlusal splints can be extremely useful in reduction of palatal fractures. Preoperative impressions are taken and dental models are fabricated, with the splint fabricated after appropriate model surgery to reestablish the occlusion (Figure 10-16). If no mandibular fractures exist, the palatal fracture is reduced with the application of the occlusal splint, and maxillomandibular fixation is applied. Reduction and internal fixation of the Le Fort fractures is then carried out as previously described. If an occlusal splint is not possible, as in the rare case of the edentulous maxilla, anatomic reduction must be achieved, and consideration should be given to the use of a fixed denture-type splint or the use of rigid internal fixation of the palate. Pollock describes a method for achieving palatal vault fixation transmucosally, thus decreasing the risk of vascular compromise.[39]

Naso-Orbital-Ethmoid Fractures

Introduction

Injury to the naso-orbital-ethmoid region, referred to as the NOE fracture, poses a significant challenge in diagnosis and treatment.[31,40] It often involves comminuted segments and is associated with important anatomic landmarks, including the medial canthal tendon and the lacrimal apparatus. Furthermore, it is commonly associated with additional fractures as well as other traumatic injuries, including central nervous system injuries and CSF drainage.[19]

Mechanism and velocity of injury affect the variable patterns of NOE fractures seen, and these often occur with other midface fractures.[41] Ellis reported a 65% rate of concomitant Le Fort or frontal sinus fractures in his series of 26 patients with NOE injuries.[31] In order to achieve a satisfactory outcome, adequate surgical exposure and attention



• **Figure 10-16** Models taken for a patient with a sagittal palatal fracture. The left side model shows the posttraumatic dental arch. The maxillary model was cut at the site of fracture and the occlusion reestablished using an articulator and the mandibular cast. A surgical splint is fabricated from the postsurgical model on the right.

to the regional anatomy is required. Early repair is recommended, as poor cosmetic and functional results can ensue, including midface retrusion, blunted palpebral fissures, telecanthus, ocular dystopia, epiphora, nasal deformities, and cerebrospinal fistula formation.

Anatomy

The naso-orbital-ethmoid region is a complex intersection of the cranium, nose, orbit, and maxilla. The primary vertical support in the region is the frontomaxillary (nasomaxillary) buttress, which is made up of the internal angular process of the frontal bone, the frontal process of the maxilla, the lacrimal bone, and the ethmoid lamina papyracea bilaterally. This area is fragile and prone to comminution and displacement.[42] Two buttresses provide horizontal support to the region: the superior frontal bar along with the supraorbital rims, and inferiorly the infraorbital rims and zygomas.

The proximity of the cribriform plate of the ethmoid bone to these structures means that associated injury resulting in CSF leakage, pneumocephalus, or olfactory dysfunction is possible with these fractures. Two additional anatomic regions deserve mention, as they are especially important for the accurate diagnosis and management of NOE fractures: the medial canthal tendon and the nasolacrimal apparatus.

The medial canthal tendon is a complex fibrous extension of the tarsal plates and orbicularis oculi muscles (Figure 10-17). The tendon divides into anterior and posterior limbs, which each supply fibers to a third superior limb, which surrounds the lacrimal sac. The anterior limb attaches to the anterior lacrimal crest of the frontal process of the maxilla; it is fan-shaped, stronger, and functions to pull the medial commissure of the eyelid forward and downward.[43] The posterior limb attaches to the posterior lacrimal crest of the lacrimal bone; it is thinner and functions to maintain the eyelid position tangent to the globe. The superior limb attaches to the junction of the frontal process of the maxilla and the internal angular process of the frontal bone, superior to the lacrimal sac, and functions to pull the eyelid in a posterior and superior direction. The tensor tarsi, or Horner, muscle is intimately associated with posterior limb of the medial canthal tendon, functions to support the lacrimal apparatus, and plays an important role in tear flow.

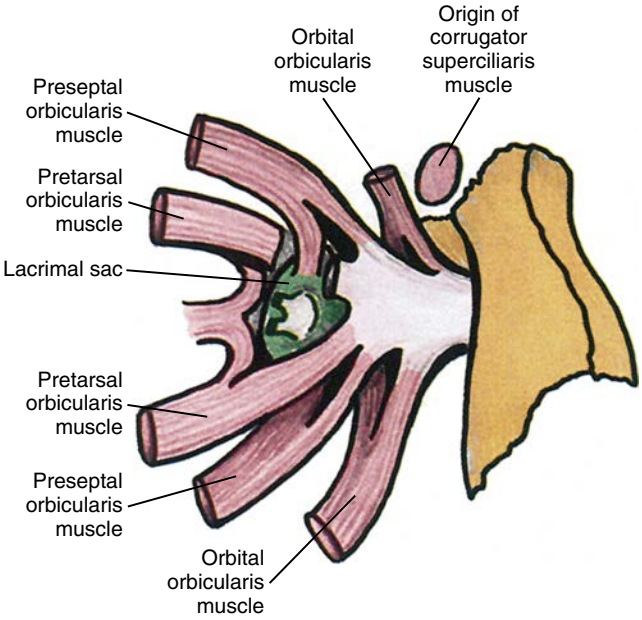

• **Figure 10-17** Anatomy of the medial canthal tendon.

Normal intercanthal distance, the distance spanning between the two medial canthal tendons, is 28 to 35 mm.[44,45] Disruption of the medial canthal tendon results in unopposed muscle pull of the orbicularis oculi muscle, which results in narrowing of the palpebral fissure and widening of the intercanthal distance, known as telecanthus. The presence and degree of medial canthal tendon displacement, whether from avulsion of attachment or mobility of a fractured bony segment, is paramount to accurate diagnosis and treatment of NOE fractures. Adequate reattachment and/or stabilization of the medial canthal tendon is necessary to prevent telecanthus, enophthalmos, and lacrimal system dysfunction.[45] Secondary, delayed reconstruction is extremely difficult.

The lacrimal apparatus is composed of the lacrimal gland in the superolateral aspect of the orbit and the drainage system medially. The lacrimal drainage apparatus consists of an upper and lower lacrimal canaliculus, which begins as a lacrimal punctum at the medial aspect of the eyelid margins, the lacrimal sac, and nasolacrimal duct. The upper and lower canaliculi join to form the common canaliculus prior to draining into the lacrimal sac located in the lacrimal fossa of the lacrimal bone. Tears drain into the lacrimal sac with the aid of the orbicularis oculi and Horner muscle function, and the nasolacrimal duct carries this flow from the sac to the inferior meatus of the nasal cavity. Dysfunction of the lacrimal drainage apparatus, whether from trauma or surgery, results in epiphora and must be evaluated perioperatively.

Classification

NOE fractures can be unilateral or bilateral, and their classification was classically described by Markowitz and colleagues in 1991.[46] This classification is based on the description of the central fragment, which is essentially the lower two thirds of the medial orbital rim, to which the medial canthal tendon attaches superiorly. Sargent more recently advocated the simplification of this previous scheme by classifying fractures as unilateral or bilateral, and as simple or complex/comminuted.[47]

A Markowitz type I NOE fracture involves the central fragment as a single segment, with the medial canthal tendon attached (Figure 10-18, *A*). This is the simplest form of the NOE fracture and may be unilateral or bilateral, with varying levels of displacement. If the fracture involves a single bilateral segment across the nasal bridge,

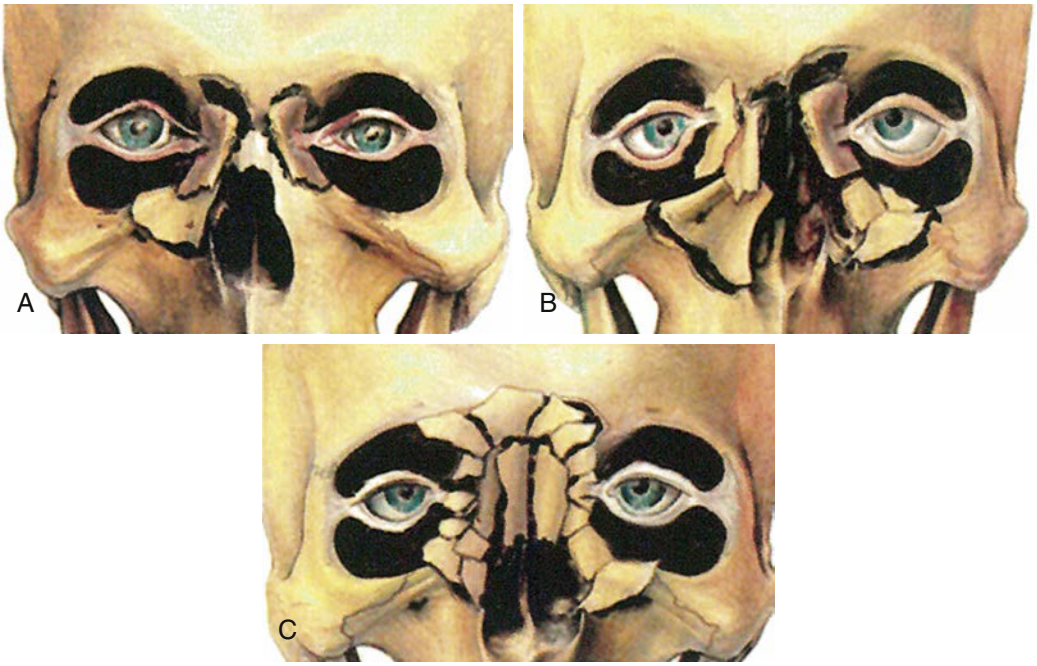

• **Figure 10-18** Markowitz classification of naso-orbital-ethmoid fractures. **A,** Type I; **B,** type II; **C,** type III.

telecanthus is not expected, and the fractures need only be fixated.

A Markowitz type II NOE fracture implies comminution of the central fragment with the medial canthal tendon remaining attached to a single osseous segment that is large enough to be reduced and fixated (see Figure 10-18, *B*).

A Markowitz type III NOE fracture is the most complex form of the fracture, which is defined as severe comminution of the central fragment with the medial canthal tendon being avulsed or remaining attached to a small osseous segment that cannot be fixated (see Figure 10-18, *C*). This dictates that transnasal wiring and possibly medial canthopexy be performed.

Diagnosis

Identification of NOE fractures is made by clinical and radiographic examinations. A thorough systematic maxillofacial trauma evaluation is carried out with visual inspection and manual palpation. Edema, ecchymosis, and lacerations are evaluated. Nasal projection, height, and mobility are evaluated. Flattening of the nasal dorsum, retrusion, and gross mobility are indicative of fractures in the region. The orbital rims are also palpated for any step-offs that would indicate fracture segments.

The intercanthal and interpupillary distance is measured to evaluate for telecanthus, taking into account the amount of edema present (Figure 10-19). An intercanthal distance of greater than 35 mm should raise suspicion of medial canthal tendon displacement, and greater than 40 mm is considered diagnostic.[48] Rounding of the medial canthal lake and epiphora are also supportive. Often it is helpful to obtain pre-injury photographs to compare to the clinical findings.[44]



• **Figure 10-19** Presentation of naso-orbital-ethmoid (NOE) injuries. This patient demonstrates the classic findings with NOE fractures, including telecanthus, flattening and widening of the nasal base, edema, ecchymosis, and signs of ocular injury such as subconjunctival hemorrhage.

The medial canthal tendon attachment can be evaluated externally with the "bowstring" or traction test. This is performed by applying lateral traction to the eyelids while palpating the medial canthal tendon attachment, with a positive test elicited with a palpable bowing of the fractured

segment. This can be difficult to assess in the acute setting when edema is present. The bimanual exam has been suggested to be a more sensitive test, using a Kelly clamp intranasally and a finger placed externally at the region of the medial canthal tendon. Lateral displacement of a fractured segment with the clamp will be palpated by the overlying finger.[49]

An intranasal examination is also necessary to evaluate the nasal septum, turbinates, and nasal mucosa. Any lacerations, hematomas, or active bleeding is evaluated. Clear rhinorrhea concerning for CSF leakage is indicative of involvement of the cribriform plate and skull base.

Radiographic evaluation for NOE fractures requires axial and coronal CT scans.[41] The extent of injury and comminution is best evaluated with 1.0- to 2.0-mm cuts (Figure 10-20). Three-dimensional CT reconstruction can be a valuable additional tool for assessment of comminution and fracture segments.

Clinical and radiographic examinations are used to make the diagnosis and further classify the fractures along with associated injuries, which directly dictate the type and extent of treatment.

Treatment

A systematic approach to the treatment of NOE fractures is recommended to avoid omitting any crucial steps in their management. This comprehensive treatment is best described as a series of eight steps first presented by Ellis: exposure, identifying the medial canthal tendon/tendon-bearing bone, reconstruction of the medial orbital rim, reconstruction of the medial orbital wall, transnasal canthopexy, reduction of septal fractures, nasal dorsum reconstruction/augmentation, and soft tissue readaptation.[31] Not all these steps are required for every fracture, but the surgeon should be cognizant of the importance of each one when needed. Most authorities recommend early treatment, as there is evidence that delayed primary treatment (later than 10-14 days) results in greater incidence of telecanthus and epiphora.[32,45,50]

Markowitz type I fractures are usually sufficiently managed by three-point rigid fixation of the central fragment (Figure 10-21). This is accomplished by reducing the segment and reestablishing the relationships of the nasofrontal junction to the nasal complex, the nasal complex to the maxillary buttress, and the nasal complex to the infraorbital rim. Medial canthal tendon disruption is rare in this type of fracture, and canthopexy is not usually indicated.

Markowitz type II fractures will involve more extensive comminution, but the medial canthal tendon will still be attached to a sizeable bony segment. Treatment here requires anatomic reduction of the comminuted bony fragments with intraosseous wiring or miniplates. This is followed by rigid fixation at the buttresses as described earlier. If the tendon-bearing osseous segment is rigidly fixated, no canthopexy is required.

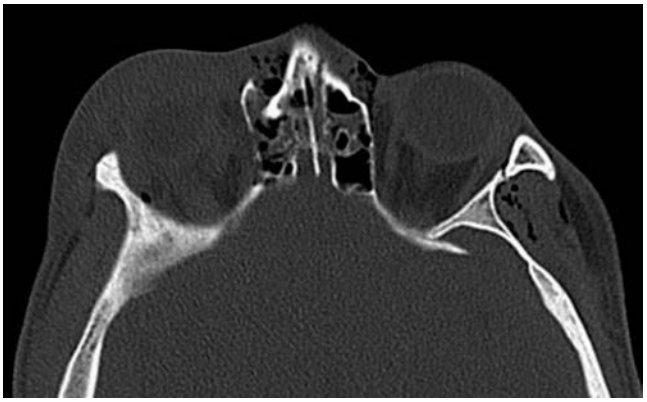

• **Figure 10-20** Axial computed tomography of a naso-orbital-ethmoid fracture demonstrates posteriorly impacted and comminuted nasal radix.

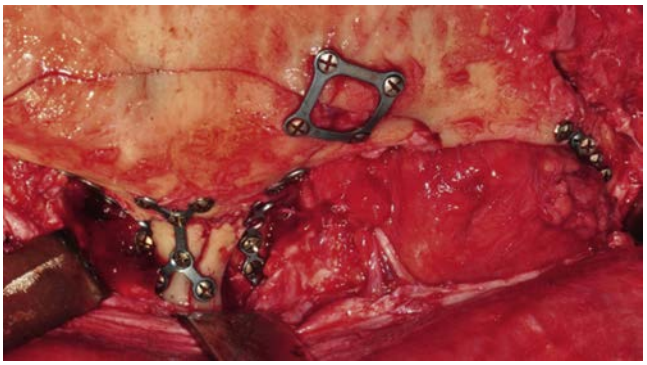

• **Figure 10-21** Three-point rigid fixation of bilateral single-segment naso-orbital-ethmoid fractures via a coronal incision. (From Fonseca RJ, Barber HD: *Oral and maxillofacial trauma*, ed 4, St Louis, Saunders, 2013.)

The type III Markowitz NOE fracture is the most difficult to treat because of the level of comminution and disruption of the medial canthal tendon. Transnasal wiring and canthopexy is usually necessary, as is nasal dorsum reconstruction. The principles of access and repair otherwise are similar, and close adherence to the eight steps presented here becomes more important in achieving a predictable outcome.

Exposure

Wide surgical exposure is required for adequate treatment of NOE fractures. Esthetic incisions are preferred, and therefore the coronal incision is used most frequently because of the combination of good cosmesis and wide exposure of the superior aspects of the fractures. Previously described incisions such as the gull-wing, open sky, or frontoethmoid (Lynch) incisions are avoided when possible because of the conspicuous location of their scars. Inferiorly, exposure of the central fragment is achieved with a lower eyelid incision. Finally, a maxillary vestibular incision is also often needed to expose the lower part of the nasomaxillary buttress for fixation. Another esthetic option that has been suggested for NOE fractures is the maxillary degloving approach.[51] A combination of a coronal incision, lower eyelid incision, and vestibular incision

is typically adequate for treatment of NOE fractures. The coronal flap should be dissected subperiosteally to expose the entire supraorbital rim from the frontozygomatic suture to the nasal bone. The supraorbital neurovascular bundle should be released from its notch or foramen to improve the ability to reflect the flap. Care should be taken to limit disruption of the lacrimal drainage system or strip any remaining medial canthal attachment from bone.

Identifying the Medial Canthal Tendon/ Tendon-bearing Bone

The medial canthal tendon must be identified in order to achieve a cosmetic result. This can be performed through the coronal flap exposure, or if necessary, through a separate skin stab incision placed 3 mm medial to the canthus. The medial canthal tendon is evaluated for complete avulsion or attachment to a bony segment. Regardless, it should be tagged with a braided suture or wire for later use in canthopexy.

Reduction/Reconstruction of the Medial Orbital Rim

Reconstructing the medial orbital rim and the central fragment is crucial to achieving adequate fixation and avoiding postoperative telecanthus. Rigid fixation with miniplates is used when the level of comminution allows for it. Transnasal wiring is used to medially reduce the canthal tendon-bearing bone segment. This is achieved by passing a 26- or 28-gauge wire through two holes drilled in the medial orbital wall, with at least one hole being posterior and superior to the lacrimal crest. This posterior vector is critical in preventing splaying or rotation of the osseous segment, with subsequent telecanthus (Figure 10-22). The wire is passed in a horizontal mattress fashion, and effort should be made to "over reduce" the medial orbital rims to reestablish the normal intercanthal distance and prevent a broad nasal dorsum.[48]

Reconstruction of the Medial Orbital Wall

Bony medial wall defects should be assessed preoperatively using CT images. If a significant medial orbital wall or orbital floor blowout fracture exists, this should be reconstructed to prevent postoperative sequelae such as enophthalmos, diplopia, and vertical dystopia.[52] The decision to reconstruct the medial orbital wall is guided by the surgeon's suspicion of a significant increase in orbital volume. The choice of reconstruction material is similar to uncomplicated orbital fractures and includes titanium mesh, alloplasts (such as porous polyethylene), and bone grafts harvested from the calvarium or ribs. Access is achieved through the previous surgical exposure, and the mesh or graft is secured to the orbital rim with rigid fixation.

Transnasal Canthopexy

Markowitz described a low 3% rate of medial canthal avulsion in patients with NOE fractures. Therefore, reduction and transnasal wiring of the tendon-bearing osseous segment is usually sufficient to prevent telecanthus when the tendon is intact. However, Merkx and colleagues reported a higher incidence of postoperative telecanthus when "indirect canthopexy" was performed through reduction and fixation of the tendon-bearing segment compared to a "direct technique" canthopexy.[45] If the medial canthal tendon is felt to be disrupted, or the comminution is too severe to reduce the tendon-bearing segment, then a transnasal medial canthopexy is indicated. This is accomplished by placing a 2- to 4-mm hole superior and posterior to the lacrimal crest along the medial orbital wall. The wire is passed transnasally with an awl and secured to the supraorbital rim on the contralateral side. It is important to achieve a superoposterior vector on the medial canthal tendon to prevent telecanthus and result in normal approximation of the lid to the globe. The position of the medial canthus must be evaluated often intraoperatively and compared to the contralateral canthus to ensure that symmetry and an adequate position are attained. If bilateral canthopexy is required, separate transnasal wires should be used, and the two should not be secured to each other. This avoids total loss of anatomic position if one side becomes loose postoperatively.[31]

Reduction of the Nasal Septum

The nasal septum is often fractured or displaced in NOE fractures. The goals of treatment should be to place the

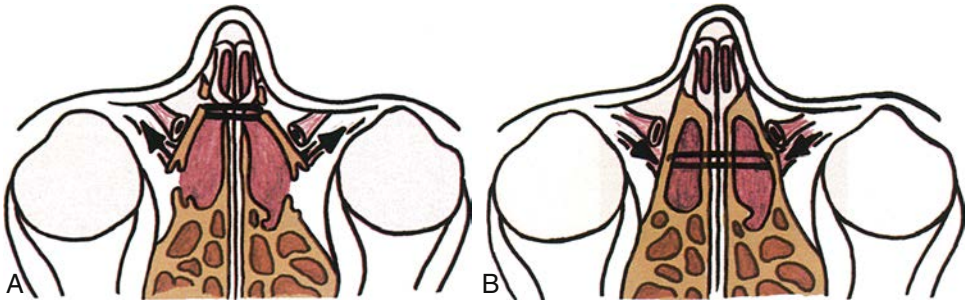

• **Figure 10-22** Transnasal wiring technique for naso-orbital-ethmoid fracture reduction. When the wire is passed in a vector anterior to the lacrimal crest **(A),** splaying of the posterior segment occurs and results in telecanthus. Posterior wire fixation **(B)** prevents this complication.

septum back into a midline position to prevent nasal airway compromise. As the bony dorsum will be reconstructed at the next step, no major reconstruction of the septum is warranted. Simple manipulation and the use of an Asch forceps is sufficient to apply anterior and superior force and bring the septum back into midline alignment.

Reconstruction/Augmentation of the Nasal Dorsum

Because of the nature of the NOE fracture, the nasal dorsum usually loses critical support from the bony and cartilaginous septum and nasal radix. Additionally, a flattened and retruded nasal dorsum (the "saddle" nose) worsens the appearance of telecanthus, whereas an overprojected dorsum may help mask a high intercanthal distance. For these reasons it is often necessary to reconstruct the nasal dorsum with the use of a cantilever dorsal bone graft. This can be obtained from calvarial bone nearby, or from other sources such as ribs, iliac crest, or the mandible.[53] The bone graft is an elongated sheet of cortical bone and is shaped to taper the two ends, which has been described as a "surfboard shape." The width of the graft is tailored to the gender, race, and facial proportions of the patient. The graft is secured to the frontal bone with rigid fixation (Figure 10-23). Additional nasal augmentation procedures may be needed depending on the status of the nasal cartilages. A columellar strut graft is sometimes indicated to improve nasal tip projection when this has been compromised. Markowitz used a columellar strut graft in approximately 20% of NOE fracture patients.

Readaptation of Soft Tissues

Poor adaption of the soft tissues into the medial naso-orbital "valley" region has been implicated in soft tissue thickening, which gives the appearance of increased intercanthal distance and widening of the nasal bridge. This can be ameliorated with meticulous draping of the soft tissues and adequate external splinting. A dorsal nasal splint such as a Denver splint may be used but often will not reach far enough posteriorly into the naso-orbital valley region. A thermoplastic splint (e.g., Aquaplast) is better suited, as it may be custom trimmed and molded down into these recesses. If severe comminution exists, external bolsters secured to each other with a transnasal wire are an excellent choice, with a variety of materials used and reported in the literature (Figure 10-24). Internal nasal splints such as Doyle splints are also used to support the nasal septum.

Complications

Complications associated with midface fractures increase with the severity and level of comminution of the injury. Before treatment, it is important to thoroughly document the concomitant injuries sustained from the traumatic event, such as nerve deficits, globe injuries, and hematomas.[2] Intraoperative complications may include excessive bleeding, nerve damage, and injuries to the cornea or globe. Postoperative complications are mainly related to inadequate reduction and fixation of fractures and associated structures. Resulting secondary deformities may be cosmetic, functional, or both and include facial asymmetry, enophthalmos, diplopia, telecanthus, epiphora, malocclusion, and mandibular hypomobility.[6,54] Additional postsurgical complications include infections, hematomas, and hypertrophic scarring.

Malunion

Malunion of a fracture occurs when it heals without reduction or with inadequate reduction. This creates a healed bone that is in incorrect anatomic alignment. The best way to avoid this complication is with timely treatment and

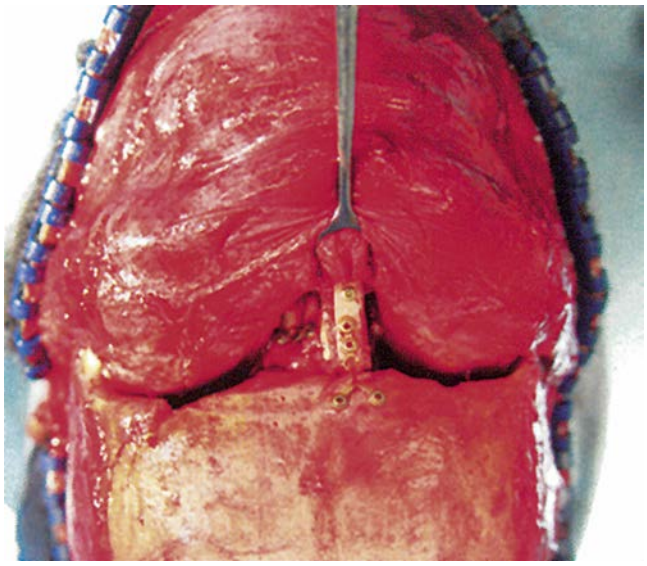

• **Figure 10-23** Nasal dorsum reconstruction with a dorsal bone graft via a coronal flap. (From Fonseca RJ, Marciani RD, Turvey TA: *Oral and maxillofacial surgery*, ed 2, St Louis, Saunders, 2008.)



• **Figure 10-24** Application of a rigid external nasal splint with transnasal wiring. (From Fonseca RJ, Marciani RD, Turvey TA: *Oral and maxillofacial surgery*, ed 2, St Louis, Saunders, 2008.)

meticulous surgical technique, as secondary correction of malunion becomes much more difficult.

Malunion of Le Fort fractures may result in malocclusion due to inadequate mobilization of the maxilla, inadequate intraoperative maxillomandibular fixation, and failure to seat the condyles in the glenoid fossae during fixation. It may also occur due to patient noncompliance with diet restrictions. Secondary corrections by performing a Le Fort I osteotomy and reestablishing the occlusion is usually sufficient. However, if a bony gap greater than 5 mm is noted after repositioning, placement of a bone graft should be considered.

Malunion of the zygoma or orbital walls may result in enophthalmos, hypophthalmos (hypoglobus), persistent diplopia, or cosmetic asymmetries.[54] The type of correction depends on the complication. Typically, functional problems are best treated with corrective osteotomies and bone grafting, whereas cosmetic deficiencies can be treated with augmentation with onlay autografts and alloplasts.

Enophthalmos

Several etiologies have been suggested for secondary deformities of the position of the globe, including fat atrophy, loss of suspensory ligament support, and increase in orbital volume due to inadequate reduction of fractures.[55] An early retrospective study concluded that the majority of orbital deformities were due to malposition of the zygoma.[56] The incidence of posttraumatic enophthalmos was reported to be 8% in one study.[18] Evaluation of secondary enophthalmos is best measured with CT scanning to assess the discrepancy between the volume of the orbital cavity and the orbital contents.[57] Treatment involves reconstruction of the orbit with implants or bone graft in order to restore the pre-injury orbital volume.

Telecanthus

Persistent telecanthus following NOE fracture repair is a difficult problem to correct. The incidence of postsurgical telecanthus was reported to be 14.1%.[5] In a study of 10 consecutive comminuted Markowitz type III NOE injuries, the mean postoperative intercanthal distance was 36 mm, and none of the patients had clinically detectable telecanthus. Merkx and colleagues reported on a series of 36 patients with NOE fractures, with significantly smaller intercanthal distance achieved with early primary repair of the fracture.[45] Furthermore, they noted better results when a "direct" technique using transnasal canthopexy was applied. Therefore it is clear that correct diagnosis and adequate reduction of the medial canthal tendons during the primary repair is critical to avoid this complication.

Epiphora

Epiphora, or tear overflow onto the face, can be caused by nasolacrimal drainage obstruction or ectropion of the lower eyelid. It is a known complication of nasolacrimal apparatus injury as it relates to midface fractures, especially naso-orbital-ethmoid fractures. Evaluation of the lacrimal canaliculi and nasolacrimal ducts with dyes and irrigation is controversial in the acute setting because of edema and inflammation, which increases the risk of iatrogenic injury.[50] An older study by Gruss and co-workers reported a low incidence of lacrimal dysfunction of 5% to 17.4%[58] and recommended deferring lacrimal apparatus repair initially.

In a more recent retrospective study of NOE fractures, posttraumatic epiphora due to dacryostenosis was noted in 27 of 58 patients (46.5%). Of those, 17 were permanent findings that required dacryocystorhinostomy to correct.[59] However, studies have demonstrated that early repair of NOE fractures significantly decreases the risk of developing epiphora.[45,58] The authors recommend treatment of the fracture and observation of the lacrimal apparatus in the postoperative period, with dacryocystorhinostomy reserved for persistent epiphora.

Ocular and Extraocular Muscle Complications

Complications related to globe injuries and extraocular muscle entrapments following midface fracture treatment have been reported. These can be related to isolated orbital fractures or more complex midface fracture patterns. Occasionally, reduction of the orbital components will entrap the extraocular muscles, and this can be avoided by fixating the orbital wall fracture after completed reduction and fixation of other fractures. Intraoperative forced duction examination before closing the soft tissues should confirm intact movements. Limitations in extraocular movements postoperatively are usually due to edema and local anesthesia. However, a forced duction test is required for persistent ophthalmoplegia to rule out true entrapment, and surgical exploration is performed to correct it.

Iatrogenic injuries to the globe, especially the cornea, are rare but have been reported. This is prevented by meticulous surgical technique and protection of the globe intraoperatively with corneal shields or suturing the eyelids. If an injury is suspected, urgent ophthalmologic evaluation is warranted. Common complaints include foreign body sensation and eye pain.

CSF Leakage

Cerebrospinal fluid rhinorrhea or otorrhea can be seen with high-impact injuries including Le Fort II, Le Fort III, and NOE fractures. The cribriform plate of the ethmoid bone is often fractured. Presence of CSF leakage is indicative of a dural tear. If suspected, diagnosis can be made with a bedside halo test or with formal laboratory testing with CSF-specific beta transferrin. Surgical repair of midface fractures can proceed, as reduction of the fractures will often assist in resolution of the leak. Herford and colleagues reported that 4 of 10 patients with severe NOE fractures had CSF leakage prior to treatment, and all resolved following open reduction and internal fixation.[53] When CSF rhinorrhea

or otorrhea is persistent for more than 3 to 4 weeks, surgical repair should be considered.[60] Antibiotic prophylaxis for meningitis is controversial and has been recommended by some authors. Additional precautions should be taken, including elevating the head of bed and avoiding straining, sneezing, and nose blowing.

Endoscopic Repair of Midface Fractures

The use of endoscopy for repair of craniomaxillofacial fractures has been a relatively recent endeavor. The lack of naturally occurring optical cavities in the maxillofacial region and the learning curve required to adopt new surgical techniques and armamentarium had previously deterred surgeons. Newer endoscopic technology and an increasing desire for minimally invasive surgical approaches have led to some advances in the field. Proponents cite decreased surgical access morbidity, smaller dissections, less conspicuous scars, decreased blood loss, and fewer complications of wide surgical access.[61]

Reported case series in the literature have now shown endoscopic surgical repair to be viable treatment options for mandibular condylar fractures, frontal sinus fractures, orbital floor fractures, and zygomatic arch fractures,[62-67] with reported success rates comparable to those of previous methods. Nevertheless, limited exposure remains a challenge, and increased operative times decrease its cost effectiveness. Wide application for routine midface fractures has not been adopted, but this technique may prove to be a powerful adjunct in maxillofacial surgery.

Summary and Future Advancements

Injuries to the midfacial skeleton present significant challenges to the maxillofacial trauma surgeon. Fractures of the midface are often the result of high-energy injuries and are often seen in the polytrauma patient. Concomitant neurologic and ocular injuries are frequently encountered and may delay or alter management. The anatomy is complex, and fracture patterns are highly variable and often comminuted. Complications are common, including secondary deformities related to malunion, malocclusion, ocular and canthal disturbances, and contour abnormalities. These are difficult to treat secondarily, and primary surgical repair is the best opportunity for success.

The ability to provide predictable successful treatment of midface fractures is predicated on knowledge of the complex anatomy, systematic physical and radiographic examination, accurate diagnosis, comprehensive treatment planning, and meticulous surgical technique. Central to the management of complicated injuries is the restoration of facial height, width, and projection, which is achieved by reestablishing the vertical and horizontal buttresses of the face. Additionally, the restoration of normal occlusion is a primary aspect of management of Le Fort maxillary fractures. Bone grafting should be used judiciously when significant bone loss and comminution has occurred, and the maxillofacial surgeon should be adept at these procedures.

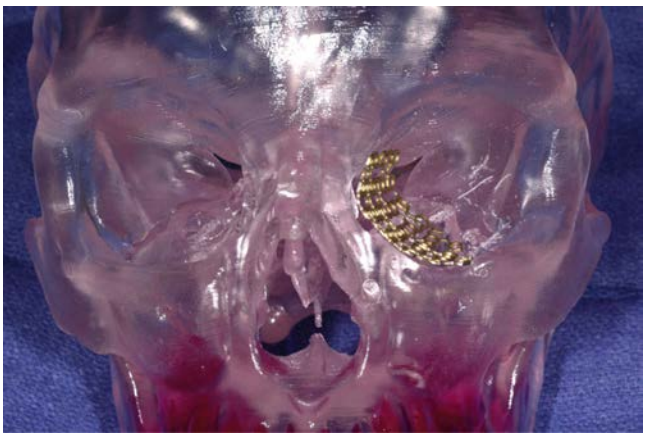

• **Figure 10-25** Stereolithographic model based on preoperative computed tomography, demonstrating the use of a preoperatively selected and bent reconstruction plate. (From Fonseca RJ, Barber HD: *Oral and maxillofacial trauma*, ed 4, St Louis, Saunders, 2013.)

Improvement in radiographic technology has increased the diagnostic capabilities of current CT imaging. More recent advancements have allowed for excellent 3D reconstruction of the facial skeleton, and the fabrication of stereolithographic models is steadily gaining popularity. These allow for excellent 3D treatment planning and are often used to fabricate pre-bent fixation plates prior to treatment, which decreases operative time (Figure 10-25). Virtual surgical planning is also being used more commonly for complex maxillofacial trauma and has promising applications.[68]

Finally, advancements in intraoperative stereotactic navigation systems and intraoperative CT imaging have become more commonplace. Navigation systems allow for precise manipulation and positioning of fracture segments into ideal alignment based on preoperative 3D scans.[69-71] Intraoperative CT and scanning is used to confirm adequate reduction and fixation immediately, allowing for corrections to take place and preventing the need for a second operation.[72] These techniques may prove to be especially important for secondary repair of posttraumatic deformities of the facial skeleton.

References

1. Iida S, Kogo M, Sugiura T, et al.: Retrospective analysis of 1502 patients with facial fractures, *Int J Oral Maxillofac Surg* 30: 286–290, 2001.
2. Kloss FR, Stigler RG, Brandstètter A, et al.: Complications related to midfacial fractures: operative versus non-surgical treatment, *Int J Oral Maxillofac Surg* 40:33–37, 2011.
3. Erdmann D, Follmar KE, DeBruijn M, et al.: A retrospective analysis of facial fracture etiologies, *Ann Plast Surg* 60:398–403, 2008.
4. Gassner R, Tuli T, Hèchl O, et al.: Cranio-maxillofacial trauma: a 10 year review of 9543 cases with 21067 injuries, *J Craniomaxillofac Surg* 31:51–61, 2003.
5. Kalavrezos ND, Graetz KW, Eyrich GK, et al.: Late sequelae after high midface trauma, *J Roy Coll Surg Edinb* 45:359–362, 2000.

6. O'Sullivan ST, Snyder BJ, Moore MH, et al.: Outcome measurement of the treatment of maxillary fractures: a prospective analysis of 100 consecutive cases, *Br J Plast Surg* 52:519–523, 1999.
7. Back CPN, McLean NR, Anderson PJ, et al.: The conservative management of facial fractures: indications and outcomes, *J Plast Reconstr Aesthet Surg* 60:146–151, 2007.
8. Manson PN, Hoopes JE, Su CT: Structural pillars of the facial skeleton: an approach to the management of Le Fort fractures, *Plast Reconstr Surg* 66:54, 1980.
9. Manson PN, Shack RB, Leonard LG, et al.: Sagittal fractures of the maxilla and palate, *Plast Reconstr Surg* 72:484, 1983.
10. Gruss JS, Mackinnon SE: Complex maxillary fractures: role of buttress reconstruction and immediate bone grafts, *Plast Reconstr Surg* 78:9–22, 1986.
11. Manson PN, Clark N, Robertson B, et al.: Subunit principles in midface fractures: the importance of sagittal buttresses, soft-tissue reductions, and sequencing treatment of segmental fractures, *Plast Reconstr Surg* 103:1287, 1999.
12. Hopper RA, Salemy JD, Sze RW: Diagnosis of midface fractures with CT: what the surgeon needs to know, *RadioGraphics* 26:783–793, 2006.
13. Le Fort R: Etude experimental sur les fractures de le machoire superieure, Parts I, II, III, *Rev Chir Paris* 23:201, 360, 479, 1901.
14. Donat TL, Endress C, Mathog RH: Facial fracture classification according to skeletal support mechanisms, *Arch Otolaryngol Head Neck Surg* 124:1306–1314, 1998.
15. Manson PN: Some thoughts on the classification and treatment of Le Fort fractures, *Ann Plast Surg* 17:356–363, 1986.
16. Mithani SK, St-Hilaire H, Brooke BS, et al.: Predictable patterns of intracranial and cervical spine injury in craniomaxillofacial trauma: analysis of 4786 patients, *Plast Reconstr Surg* 123:1293, 2009.
17. Crosby ET: Airway management in adults after cervical spine trauma, *Anesthesiology* 104:1293, 2006.
18. Al-Qurainy IA, Stassen LF, Dutton GN, et al.: The characteristics of midfacial fractures and the association with ocular injury: a prospective study, *Br J Oral Maxillofac Surg* 29:291, 1991.
19. Cruse CW, Blevins PK, Luce EA: Naso-ethmoid-orbital fractures, *J Trauma* 20:551, 1980.
20. Schuknecht B, Graetz K: Radiologic assessment of maxillofacial, mandibular, and skull base trauma, *Eur Radiol* 15:560, 2005.
21. Mayer JS, Wainwright DJ, Yeakley JW, et al.: The role of three-dimensional computed tomography in the management of maxillofacial trauma, *J Trauma* 28:1043, 1998.
22. Gillespie JE, Isherwood I, Barker GR, Quayle AA: Three-dimensional reformations of computed tomography in the assessment of facial trauma, *Clin Radiol* 38:523, 1987.
23. Mehta N, Butala P, Bernstein MP: The imaging of maxillofacial trauma and its pertinence to surgical intervention, *Radiol Clin North Am* 50(1):43–57, 2012.
24. Friedrich RE, Heiland M, Bartel-Friedrich S: Potentials of ultrasound in the diagnosis of midfacial fractures, *Clin Oral Invest* 7(4):226–229, 2003.
25. Marciani RD: Management of midface fractures: fifty years later, *J Oral Maxillofac Surg* 51(9):960–968, 1993.
26. Jackson IT: Classification and treatment of orbitozygomatic and orbitoethmoid fractures. The place of bone grafting and plate fixation, *Clin Plast Surg* 16:77–91, 1989.
27. Bellamy JL, Mundinger GS, Reddy SK, et al.: Le Fort II fractures are associated with death: a comparison of simple and complex midface fractures, *J Oral Maxillofac Surg* 71:1556–1562, 2013.
28. Cook HE, Rowe M: A retrospective study of 356 midfacial fractures occurring in 225 patients, *J Oral Maxillofac Surg* 48:574, 1990.
29. Hendrickson M, Clark N, Manson PN, et al.: Palatal fractures: classification, patterns, and treatment with rigid internal fixation, *Plast Reconstr Surg* 101:319, 1998.
30. Park S, Ock JJ: A new classification of palatal fracture and an algorithm to establish a treatment plan, *Plast Reconstr Surg* 107:1669, 2001.
31. Ellis 3rd E: Sequencing treatment for naso-orbito-ethmoid fractures, *J Oral Maxillofac Surg* 51:543, 1993.
32. Perry M: Maxillofacial trauma—developments, innovations and controversies, *Injury* 40:1252–1259, 2009.
33. McRae M, Frodel J: Midface fractures, *Facial Plast Surg* 16:107, 2000.
34. Marciani RD, Gonty AA: Principles of management of complex craniofacial trauma, *J Oral Maxillofac Surg* 51:535, 1993.
35. Gruss JS, Pollock RA, Phillips JH, Antonyshyn O: Combined injuries of the cranium and face, *Br J Plast Surg* 42:385, 1989.
36. Gruss JS, Bubak PJ, Egbert MA: Craniofacial fractures. An algorithm to optimize results, *Clin Plast Surg* 19:195, 1992.
37. Markowitz BL, Manson PN: Panfacial fractures: organization of treatment, *Clin Plast Surg* 16:105, 1989.
38. Kelly KJ, Manson PN, Vander Kolk CA, et al.: Sequencing LeFort fracture treatment (Organization of treatment for a panfacial fracture), *J Craniofac Surg* 1:168, 1990.
39. Pollock RA: The search for the ideal fixation of palatal fractures: innovative experience with a mini-locking plate, *Craniomaxillofac Trauma Reconstruction* 01:015, 2008.
40. Leipziger LS, Manson PN: Nasoethmoid orbital fractures. Current concepts and management principles, *Clin Plast Surg* 19:167, 1992.
41. Manson PN, Markowitz B, Mirvis S, et al.: Toward CT-based facial fracture treatment, *Plast Reconstr Surg* 85:202, 1990.
42. Gruss JS: Naso-ethmoid-orbital fractures: classification and role of primary bone grafting, *Plast Reconstr Surg* 75:303, 1985.
43. Jank S, Schuchter B, Emshoff R, et al.: Clinical signs of orbital wall fractures as a function of anatomic location, *Oral Surg Oral Med Oral Pathol Oral Radiol Endod* 96:149, 2003.
44. Tharanon W, Ellis 3rd E: A method to accurately determine the preinjury intercanthal distance, *J Oral Maxillofac Surg* 49:1023, 1991.
45. Merkx MA, Freihofer HPM, Borstlap WA, et al.: Effectiveness of primary correction of traumatic telecanthus, *Int J Oral Maxillofac Surg* 24:344–347, 1995.
46. Markowitz BL, Manson PN, Sargent L, et al.: Management of the medial canthal tendon in nasoethmoid orbital fractures: the importance of the central fragment in classification and treatment, *Plast Reconstr Surg* 87:843, 1991.
47. Sargent LA: Nasoethmoid orbital fractures: diagnosis and treatment, *Plast Reconstr Surg* 120:16S–31S, 2007.
48. Paskert JP, Manson PN, Iliff NT: Nasoethmoidal and orbital fractures, *Clin Plast Surg* 15:209, 1988.
49. Paskert JP, Manson PN: The bimanual examination for assessing instability in naso-orbitoethmoidal injuries, *Plast Reconstr Surg* 83:165, 1989.
50. Papadopoulos H, Salib NK: Management of naso-orbital-ethmoidal fractures, *Oral Maxillofac Surg Clin North Am* 21:221–225, 2009.
51. Cultrara A, Turk JB, Har-El G: Midfacial degloving approach for repair of naso-orbital-ethmoid and midfacial fractures, *Arch Fac Plast Surg* 6:133–135, 2004.
52. Manson PN, Grivas A, Rosenbaum A, et al.: Studies on enophthalmos: II. The measurement of orbital injuries and their treatment by quantitative computed tomography, *Plast Reconstr Surg* 77:203, 1986.

53. Herford AS, Ying T, Brown B: Outcomes of severely comminuted (type III) nasoorbitoethmoid fractures, *J Oral Maxillofac Surg* 63:1266, 2005.
54. Kochhar A, Byrne P: Surgical management of complex midfacial fractures, *Otolaryngol Clin North Am* 46(5):759–778, 2013.
55. Manson PN, Clifford CM, Su CT, et al.: Mechanisms of global support and posttraumatic enophthalmos: I. The anatomy of the ligament sling and its relation to intramuscular cone orbital fat, *Plast Reconstr Surg* 77:193, 1986.
56. Freihofer HP, van Damme PA: Secondary post-traumatic periorbital surgery. Incidence and results, *J Craniomaxillofac Surg* 15:183, 1987.
57. Bite U, Jackson IT, Forbes GS, Gehring DG: Orbital volume measurements in enophthalmos using three-dimensional CT imaging, *Plast Reconstr Surg* 75:502, 1985.
58. Gruss JS, Hurwitz JJ, Nik N, et al.: The pattern and incidence of nasolacrimal injury in naso-orbital-ethmoid fractures: the role of delayed assessment and dacryocystorhinostomy, *Br J Plast Surg* 38:116–121, 1985.
59. Becelli R, Renzi G, Mannino G, et al.: Posttraumatic obstruction of lacrimal pathways: a retrospective analysis of 58 consecutive naso-orbitoethmoid fractures, *J Craniofac Surg* 15:29–33, 2004.
60. Loew F, Pertuiset B, Chaumier EE, Jaksche H: Traumatic, spontaneous and postoperative CSF rhinorrhea, *Adv Tech Stand Neurosurg* 11:169, 1984.
61. Lee C, Czerwinski M: Applications of the endoscope in facial fracture management, *Semin Plast Surg* 22:29, 2008.
62. Chen CT, Chen YR: Endoscopically assisted repair of orbital floor fractures, *Plast Reconstr Surg* 108:2011–2018, 2001.
63. Strong EB: Endoscopic repair of orbital blow-out fractures, *Fac Plast Surg: FPS* 20:223–230, 2004.
64. Lai JP, Chen YR, Tung TC, et al.: Application of endoscope in zygomatic fracture repair, *Brit J Plast Surg* 53:100–105, 2000.
65. Mueller RV, Czerwinski M, Lee C, et al.: Condylar fracture repair: use of the endoscope to advance traditional treatment philosophy, *Fac Plast Surg Clin North Am* 14:1–9, 2006.
66. Krimmel M, Cornelius CP, Reinert S: Endoscopically assisted zygomatic fracture reduction and osteosynthesis revisited, *Int J Oral Maxillofac Surg* 31:485–488, 2002.
67. Chen DJ, Chen CT, Chen YR, et al.: Endoscopically assisted repair of frontal sinus fracture, *J Trauma Acute Care Surg* 55:378–382, 2003.
68. Balasundaram I, Al-Hadad I, Parmar S: Recent advances in reconstructive oral and maxillofacial surgery, *Br J Oral Maxillofac Surg* 50:695–705, 2012.
69. Markiewicz MR, Dierks EJ, Potter BE, Bell RB: Reliability of intraoperative navigation in restoring normal orbital dimensions, *J Oral Maxillofac Surg* 69:2833–2840, 2011.
70. Scolozzi P, Terzic A: "Mirroring" computational planning, navigation guidance system, and intraoperative mobile C-arm cone-beam computed tomography with flat-panel detector: a new rationale in primary and secondary treatment of midfacial fractures? *J Oral Maxillofac Surg* 69:1697, 2011.
71. Collyer J: Stereotactic navigation in oral and maxillofacial surgery, *Br J Oral Maxillofac Surg* 48:79, 2010.
72. Pohlenz P, Blessmann M, Blake F, et al.: Clinical indications and perspectives for intraoperative cone-beam computed tomography in oral and maxillofacial surgery, *Oral Surg Oral Med Oral Pathol Oral Radiol Endod* 103:412, 2007.

11

Diagnosis and Management of Frontal Bone Injuries

TIRBOD FATTAHI, DESMON BROWN

Introduction

Frontal bone injuries typically encompass frontal sinus injuries as well as supraorbital rim fractures. Often times, blunt or penetrating injures to the underlying brain are also encountered. The purpose of this chapter is to describe contemporary management of frontal sinus fractures and associated intracranial injuries.

Fractures of the frontal sinus or sinuses make up about 5% to 15% of all facial fractures in the adult patient.[1-3] This is a relatively low frequency of occurrence. However, there are a myriad short-term and long-term potential complications associated with this type of injury, which may involve not only the frontal sinuses, but more importantly the brain. Because of its potential for high morbidity and mortality, clinicians managing this type of injury must be able to address the acute injury appropriately as well as being cognizant of the potential complications and their inherent management.

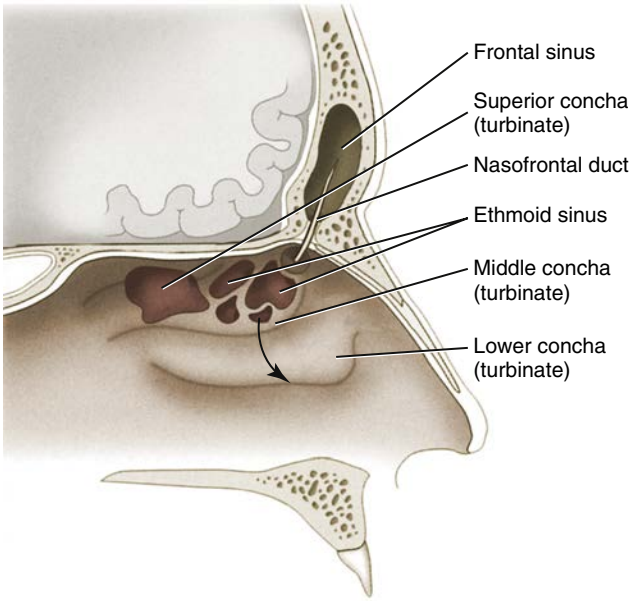

• **Figure 11-1** Sagittal view of the frontal sinus with the drainage pathway of the nasofrontal ducts.

The purpose of this chapter is to discuss surgical anatomy, radiographic and clinical evaluation of patients, classification of injuries, management of fractures, and complications associated with frontal sinus fractures.

Surgical Anatomy

The frontal sinus or sinuses are single or usually paired paranasal sinuses embedded within the frontal bar of the frontal bone (Figures 11-1, 11-2, and 11-3). They are outpouchings

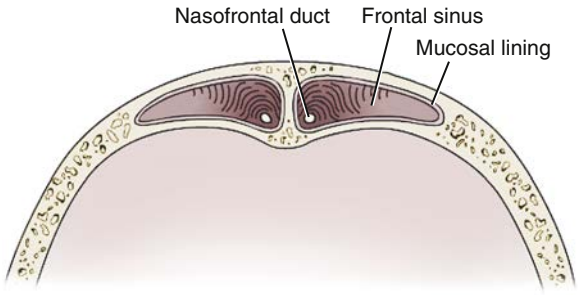

• **Figure 11-2** Axial view of the frontal sinus; note medial and posterior location of the nasofrontal ducts.

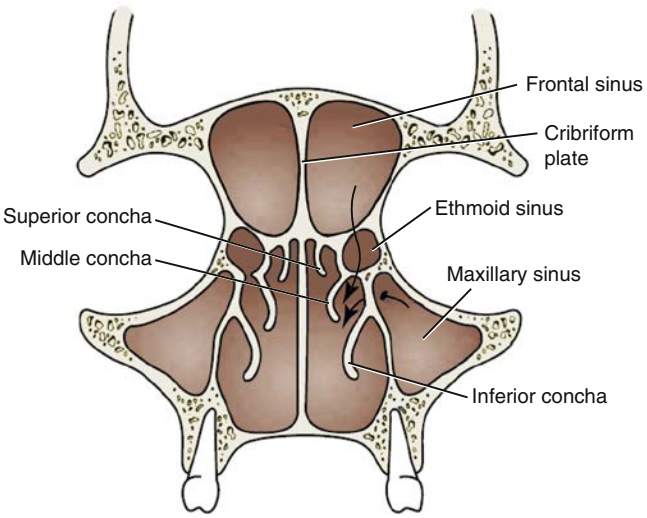

• **Figure 11-3** Coronal view of the frontal sinus.



• **Figure 11-4** **A,** Patient with blunt trauma to mid and upper face with deep laceration of the forehead. **B,** Further evaluation revealed displaced fracture of the left frontal sinus.

of the ethmoidal air cells with a typical size of 3.5 × 2.5 × 1.5 cm, although significant variations can occur. There usually exists a bony septum separating the right and left sinus. Initial pneumatization of the frontal sinus begins in the early stages of the second trimester, and radiographic evidence of the sinus can be seen by the age of 6 years.[4,5] The floor of the sinus forms a portion of the orbital roof; therefore, any medial orbital roof fractures may involve the frontal sinus. The posterior wall separates the anterior cranial fossa from the sinus. This wall is rather thin and can be fractured and displaced into the brain secondary to blunt trauma. Arterial blood supply to the sinus is via the supraorbital artery and the anterior ethmoidal arteries. The venous system mirrors that of the arterial system plus the diploic veins of the frontal bone, known as the veins of Breschet, and the superior sagittal sinuses. The physiology of the frontal sinus is similar to other paranasal sinuses of the face. Pseudostratified ciliated columnar respiratory epithelium lines the sinus. Mucin is cleared by the ciliary flow (rate of 250 cycles/min) and is drained from the sinus through the nasofrontal ducts (NFDs) located at the medial aspect of the floor into the middle meatus of the nose.[6,7] The location of the NFDs is clinically significant because trauma to the floor of the sinus or medial aspect of the sinus/orbital wall can injure the NFD.



• **Figure 11-5** Preoperative photograph of patient with frontal sinus trauma. Note periorbital edema and ecchymosis.

Clinical Evaluation

Patients with isolated frontal sinus fractures usually have periorbital ecchymosis and pain in the forehead region.[8] This finding in the presence of blunt trauma to the forehead along with lacerations in the region should raise the suspicion of frontal sinus fracture (Figures 11-4 and 11-5). Blunt or penetrating trauma to this region can also produce altered sensation of the forehead and scalp secondary to injury to the supraorbital and supratrochlear neurovascular bundles. If the patient is seen shortly after the injury, one might also appreciate a depression in the bony forehead. This finding is seldom seen because of soft tissue swelling. Crepitation might be palpable if evaluating such bony injuries. The

examiner should always be cognizant of other concomitant injuries such as intracranial bleeding and cervical injuries (Figures 11-6 and 11-7).

Evaluation of the nose for possible cerebrospinal fluid (CSF) is imperative in patients with frontal sinus fractures. If the posterior table of the sinus or the base of the skull in the region of the cribriform plate are fractured, the dura might be lacerated, causing leakage of CSF into the sinus and then into the middle meatus. Confirmation of the CSF from the nose can be done at bedside by performing the halo test or ring test. A small sample of the nasal drainage is placed on a cotton sheet; if a red central ring (blood) surrounded a by clear halo (CSF) is observed, one should suspect leakage of CSF (Figure 11-8). Other confirmatory tests include sending samples of the fluid to the laboratory for evaluation of chloride and glucose and the β2 transferrin test. CSF will usually have high chloride and low glucose concentration compared to serum.[9-11] Testing for presence of β2 transferrin, a protein marker found exclusively in CSF, aqueous humor, and endolymph, in the nasal drainage can be done via electrophoresis. It is important to remember that patients with frontal sinus trauma may also have associated orbital and naso-ethmoidal injuries. These injuries and their managements are discussed elsewhere in this book.



• **Figure 11-6** Significant frontal sinus trauma and simultaneous intracranial injury. Note intracranial bleed within the frontal lobe.

Radiologic Evaluation

The gold standard method of evaluation for frontal sinus fractures is computed tomography (CT).[12,13] This is also true of most mid and upper face trauma. Although multiple planes can be obtained, the two most useful planes of view are axial and coronal on a CT scan (Figures 11-9, 11-10, and 11-11). The ideal thickness of such a scan should be 1.0 mm. Generally no contrast is needed for evaluation of facial fractures, although intracranial bleeding usually requires addition of intravenous contrast to a CT scan. Axial views can give a clear view of the anterior and posterior table, as well as evidence of intracranial impingement. Coronal views can give clues to the status of the nasofrontal ducts, floor of the sinus, and involvement of other adjacent structures such as the orbital roofs. In cases of significant comminution, three-dimensional (3D) images can also be quite helpful (Figure 11-12).

Classification of Frontal Sinus Fractures

There have been numerous attempts at universal classification of fractures of the frontal sinus. For the most part, these

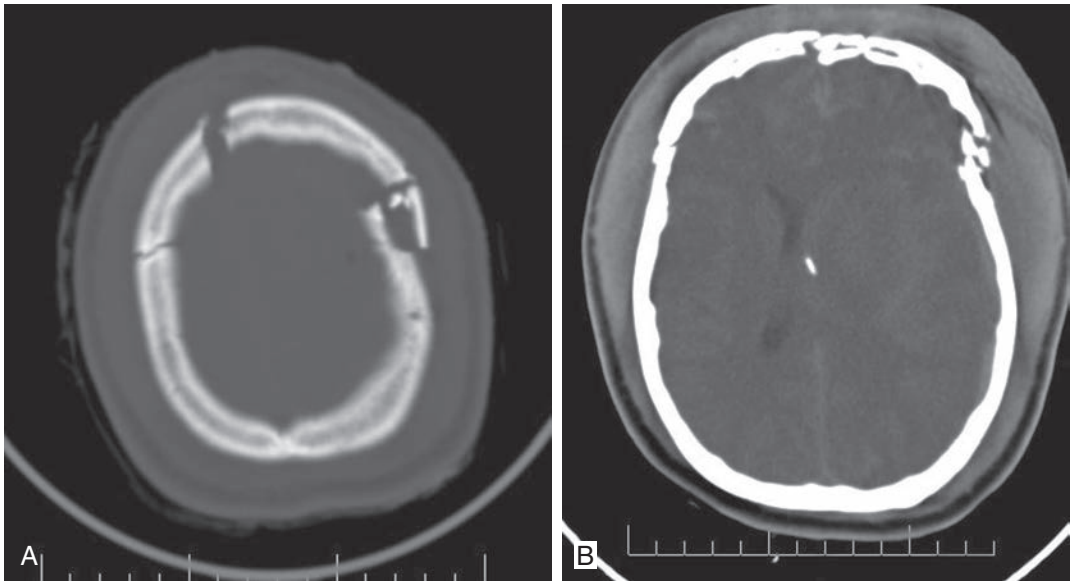

• **Figure 11-7** **A,** Significant skull fractures involving the frontal sinus and temporal regions. **B,** Note effacement of the lateral ventricle and intracranial contusion.

have added nothing other than confusion to the literature. The simplest and most basic classification of frontal sinus fractures is one that clearly describes three specific areas: the anterior table, the posterior table, and the status of the NFDs.[14-17]

An *isolated* anterior table fracture can be classified on the basis of its displacement. If the fracture involves a displacement greater than the width of the anterior table, it is considered a displaced fracture, and consideration should be given to surgical repair in order to prevent a cosmetic deformity (Figure 11-13). If the fracture displacement is not greater than the width of the anterior table, the fracture is classified as nondisplaced or minimally displaced. Classification of isolated anterior table fractures should also include involvement of one or both frontal sinuses (if there are two distinct sinuses).

An *isolated* posterior table fracture, although not as common, can also occur. The most common presentation of posterior table fracture is one with a concomitant anterior table fracture (Figure 11-14). The concern with these types of injuries is the possible intracranial involvement of the fracture. A posterior wall fracture can be comminuted, nondisplaced, or displaced intracranially. The last can cause significant brain injury.

Nasofrontal ducts should be considered injured if there are fractures along the floor of the sinus or the medial aspect of the orbital roofs (Figure 11-15). Intraoperative correlation is required in such cases.



• **Figure 11-8** Cerebrospinal fluid (CSF) halo test; blood in the middle and CSF along the periphery.

Surgical Management of Frontal Sinus Fractures

Access to the fractures is via a coronal (bitemporal) incision or through existing lacerations if long enough (Figures 11-16 and 11-17). Other incisions such as open sky and gull wing have been mentioned in the literature, although they are not aesthetically pleasing. The incision should extend between the preauricular regions in hair-bearing scalp in an irregular fashion (Figure 11-18). If there is receding hair, the incision can be moved posteriorly to ensure its placement within hair (Figure 11-19). The coronal flap is elevated in a subgaleal plane. The dissection can be carried in this plane until about 2 to 3 cm above the frontal sinus, at which point a subpericranial (subperiosteal) approach can be commenced.

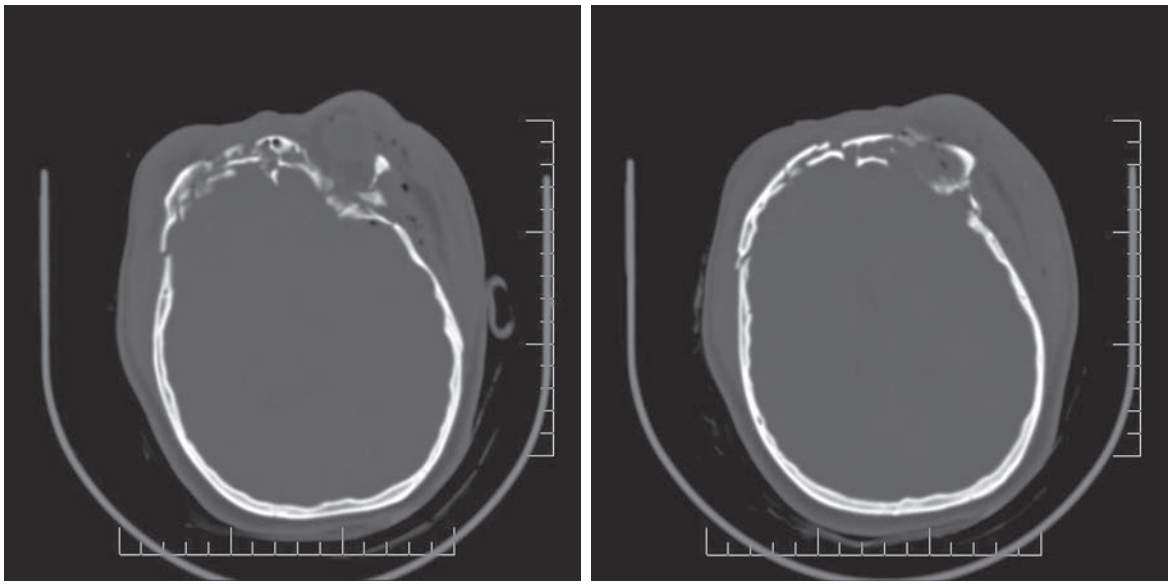

• **Figure 11-9** Axial computed tomography scan images depicting comminution of the anterior and posterior frontal sinus walls and lateral skull fracture.

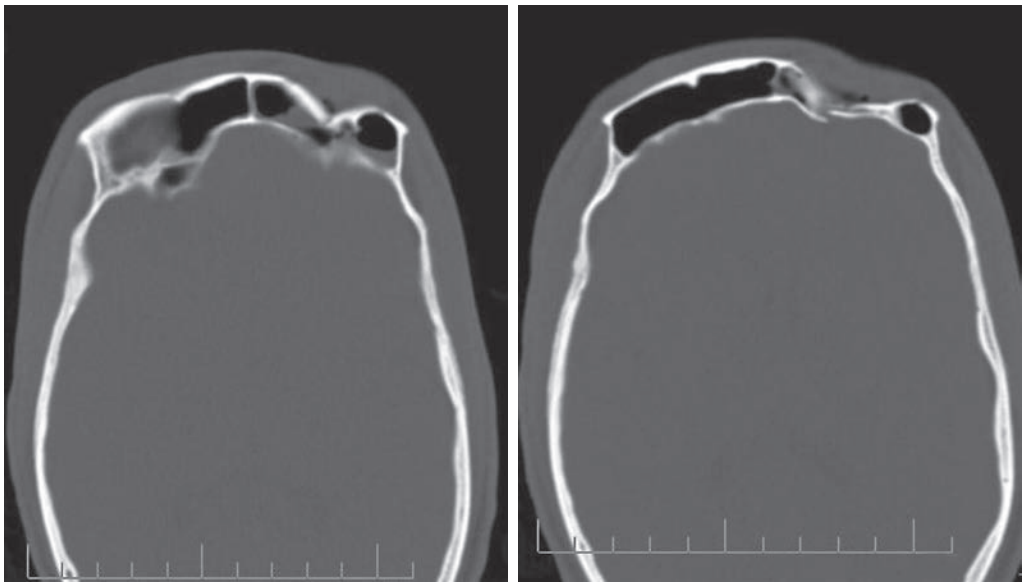

• **Figure 11-10** Axial computed tomography scan images demonstrating a displaced anterior and posterior table fracture of the left frontal sinus.

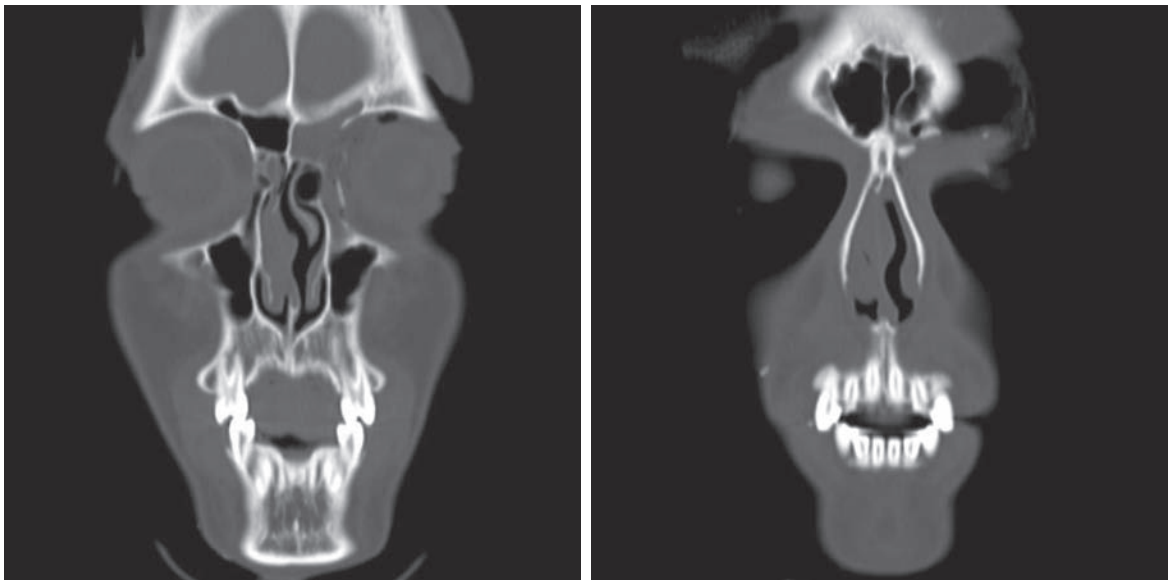

• **Figure 11-11** Coronal computed tomography scan images demonstrating left-sided frontal sinus fracture involving the floor of the sinus and orbital roof. This type of injury frequently involves the nasofrontal duct.

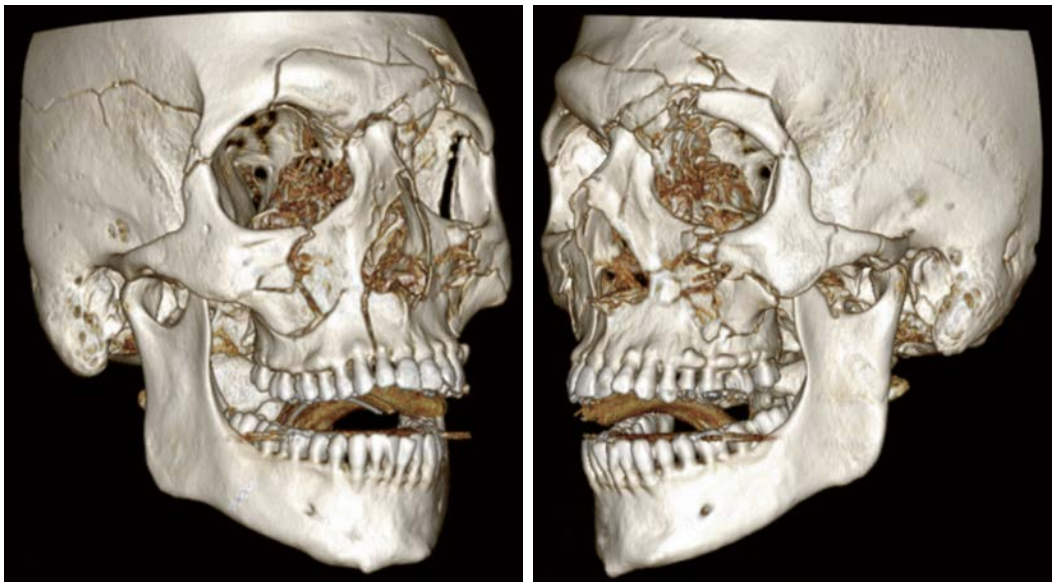

• **Figure 11-12** 3D reconstruction computed tomography depicting disruption of the frontal bar and midface trauma.

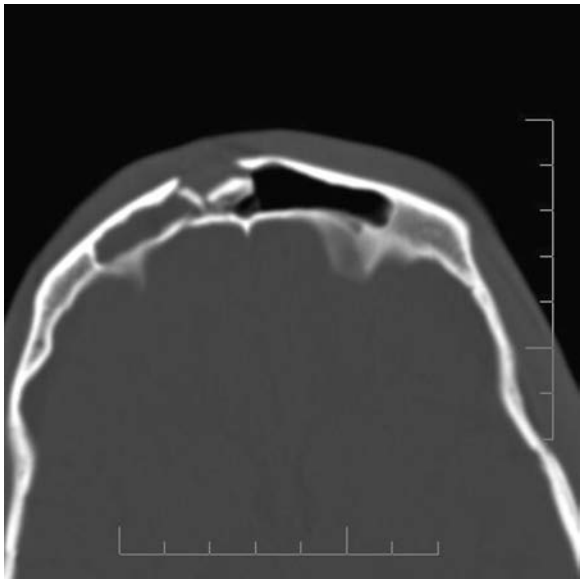

• **Figure 11-13** Axial image of a displaced anterior table fracture.

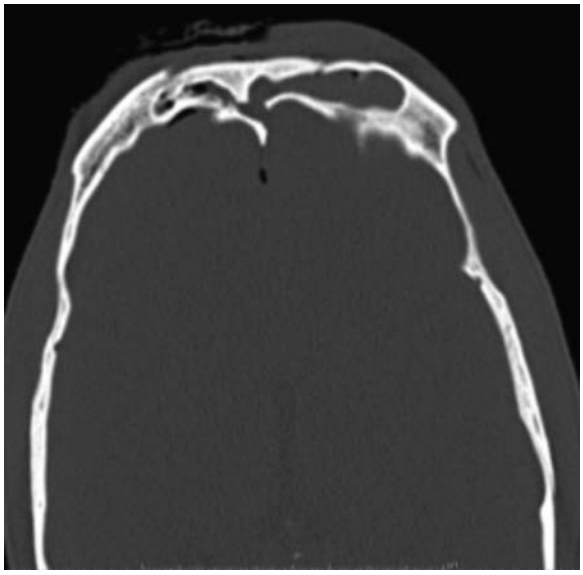

• **Figure 11-14** Axial image of fractures of anterior and posterior tables. This type of injury requires cranialization.

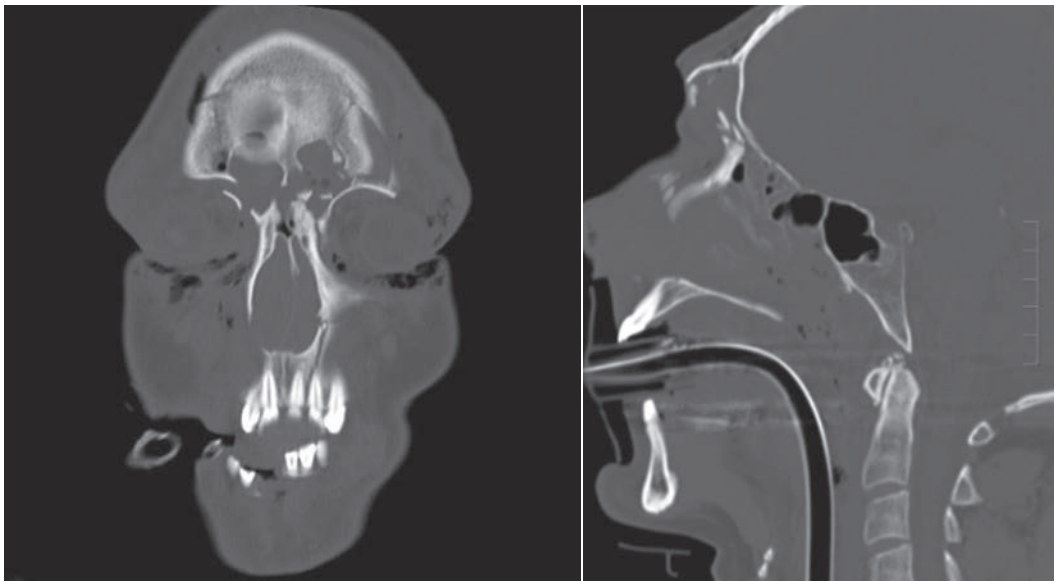

• **Figure 11-15** Coronal and sagittal views demonstrating high likelihood of injury to the nasofrontal ducts in the area of medial sinus floor.



• **Figure 11-16** Use of existing laceration to access left-sided frontal sinus fracture.

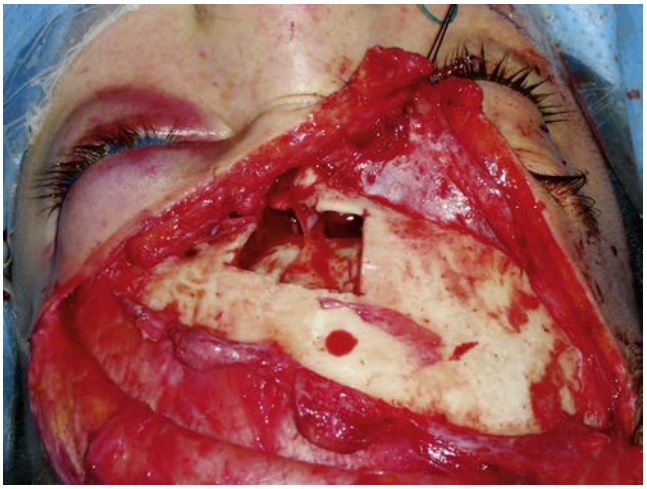

• **Figure 11-17** Extensive transverse laceration of the forehead with easy access to the frontal sinus. The fractured segments have been removed to gain access to the nasofrontal duct.



• **Figure 11-18** Irregular outline of a coronal incision in two different patients.



• **Figure 11-19** Note posteriorly placed incision *(arrows)* to ensure placement of the final scar within hair-bearing area in patients with receding hairline.

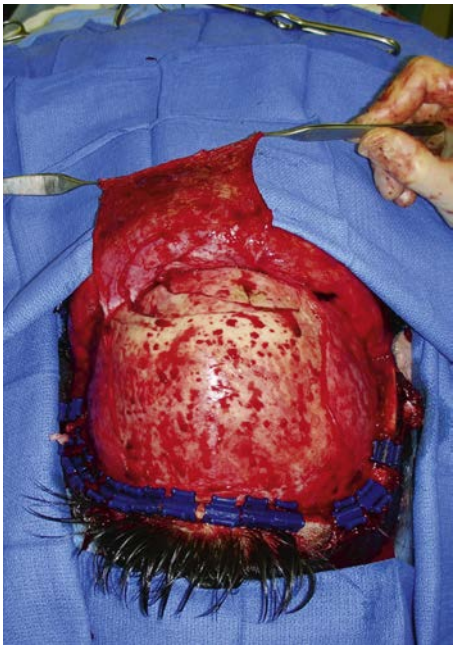

• **Figure 11-20** The coronal flap has been elevated in a subgaleal plane all the way anterior past the fractures. This allows elevation of a separate, pedicled vascularized pericranial flap (Adson pickups).

Alternatively, the dissection can be carried in a subgaleal plane all the way to the frontal bar; then a separate pericranial flap can be elevated which can be used as a vascular, pedicled flap to line the posterior wall or be used to obliterate the sinus (Figure 11-20).[18]

Once the fractures are visualized, treatment algorithms dictate how they should be addressed. Management of frontal sinus fractures is predicated on three anatomic structures: anterior table, posterior table, and NFDs (Figure 11-21). If the fracture is isolated to the anterior wall only without involvement of the NFDs or the posterior wall, but the displacement is greater than the width of the anterior table, the depressed segment is carefully reduced, and the fracture is fixated with titanium miniplates or resorbable plates (Figure 11-22). No further intervention is required. Nondisplaced or minimally displaced isolated anterior table fractures (less than the width of the anterior table) typically do not require surgical repair.

If the anterior wall and the NFDs are involved in the injury, then the decision must be made based on the health of the NFDs. The fractured anterior wall segments must be carefully removed and saved. If the status of the NFDs is uncertain, the patency of the ducts can then be confirmed by injecting a dye (methylene blue, fluorescein, or sterile milk) directly into the ducts at the base of the

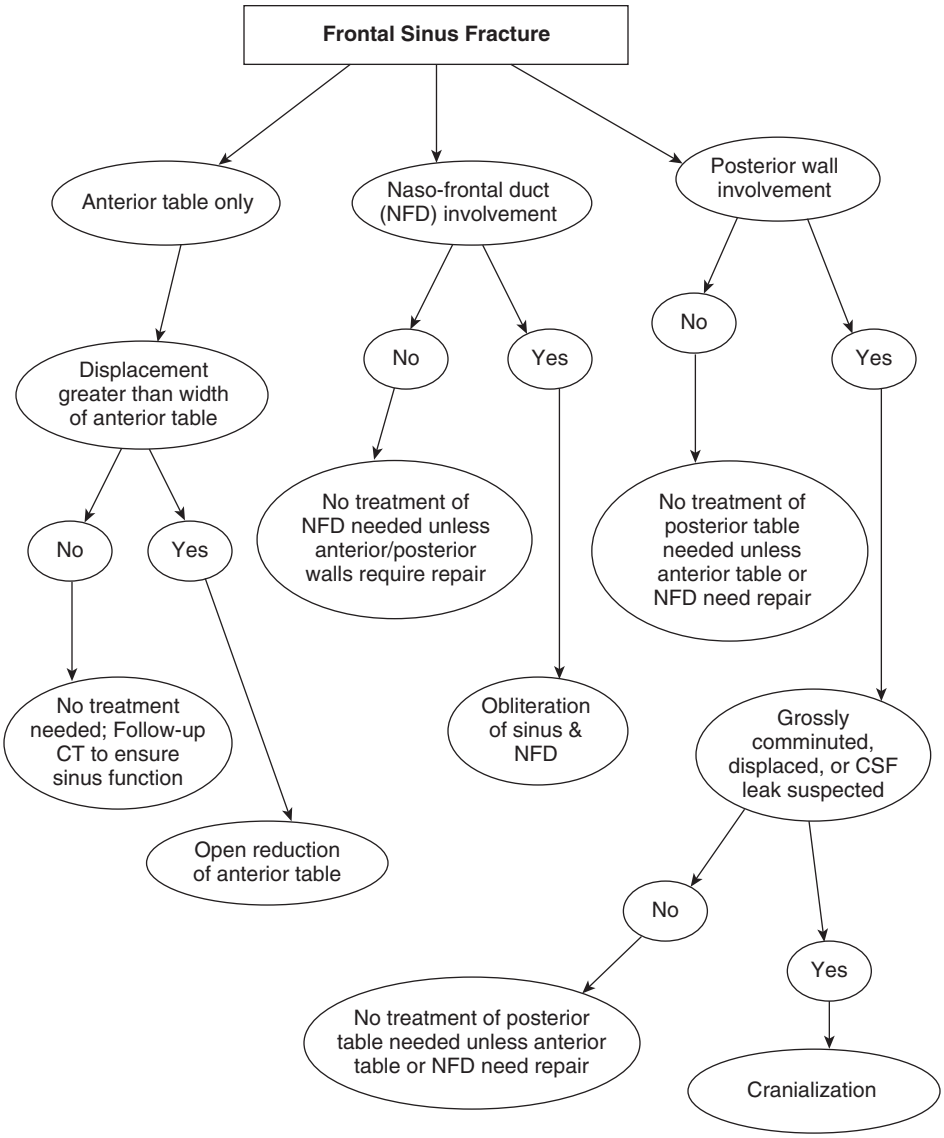

• **Figure 11-21** Simple algorithm for management of frontal sinus fractures.

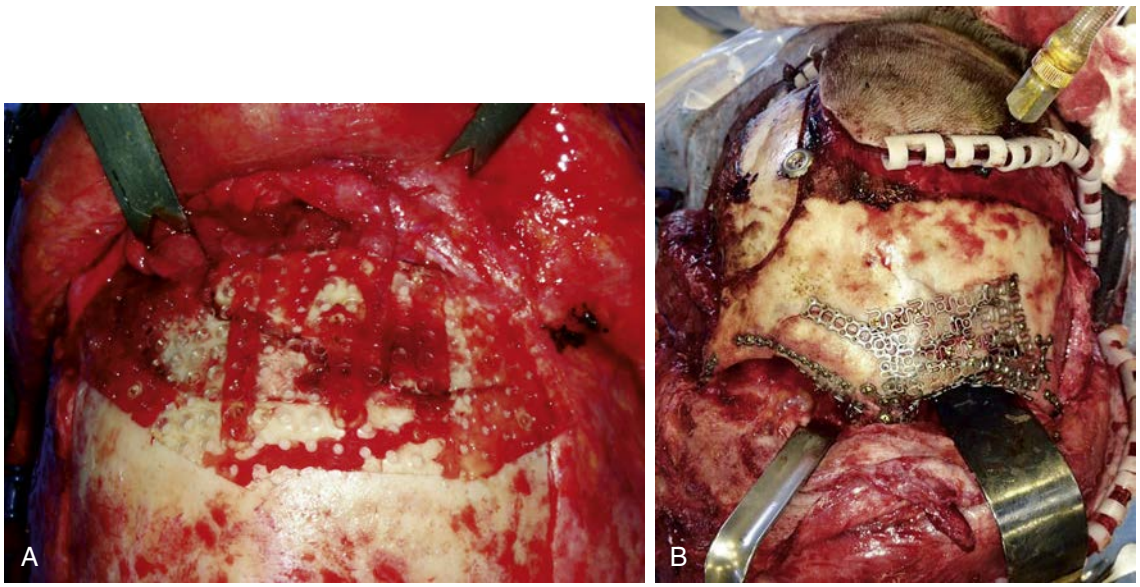

• **Figure 11-22** Reconstruction of the anterior table with resorbable mesh **(A)** and titanium **(B).**

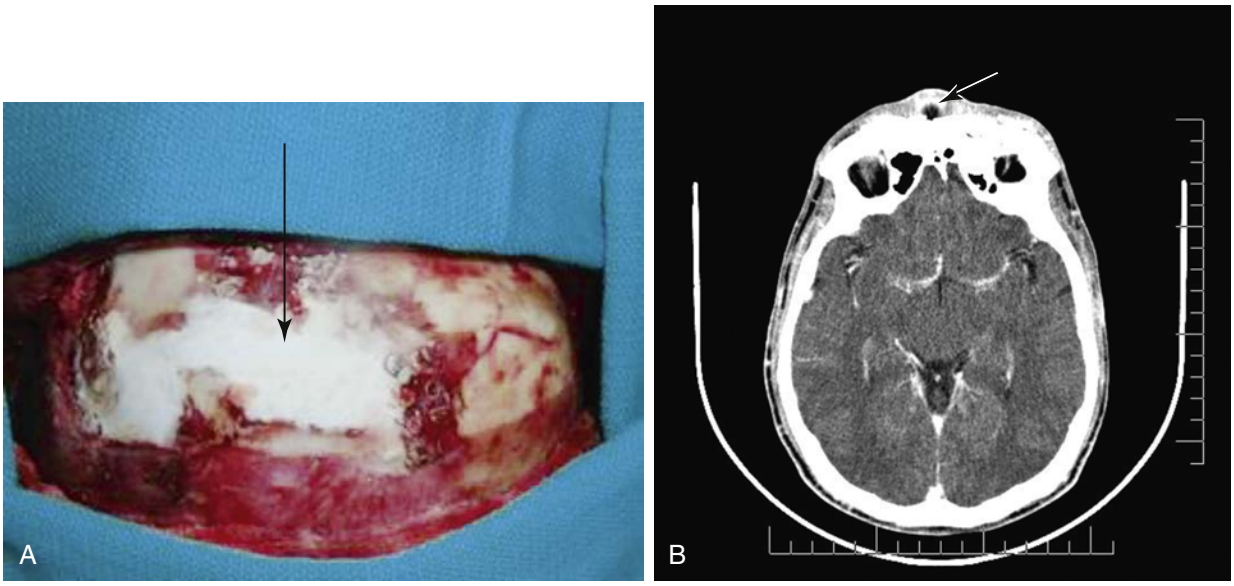

• **Figure 11-23** **A**, Intraoperative photo of patient with synthetic bone cement used for frontal sinus obliteration *(arrow)*. Two months later, the patient presented with a forehead abscess. **B**, Note abscess anterior to the sinus *(arrow)*. Patient required multiple debridements to remove necrotic bone and cement.

frontal sinus. If the dye is visualized in the middle meatus or in the nasopharynx, the NFDs are intact and do not require obliteration. If the NFDs are grossly involved in the fracture, or the results of dye injection are equivocal, the NFDs should be obliterated. [19,20] Obliteration of the NFDs renders the frontal sinus nonfunctional; therefore, the nasal cavity must be sealed from the sinus and the brain. This is done by removing any sinus lining from the opening of the NFDs and plugging the ducts with autogenous material such as fat, pericranium, temporalis muscle, fascia, or bone.[2,21] The sinus lining is removed with rotary instruments or sinus curettes. Oftentimes, sinus obliteration is done at the same time of NFD obliteration. Sinus obliteration is performed by removing all remnants of respiratory epithelium from the injured sinus. If the fractured anterior wall has been removed to facilitate access into the sinus, all sinus epithelium should be removed from it as well. The purpose of sinus obliteration is to close the dead space created by occluding the NFDs. It also offers one more layer of protection against retrograde nasal contaminants. Common materials used for sinus obliteration include abdominal fat, bone, and pedicled pericranial flap. Synthetic hydroxyapatite or bony cements should not be used to obliterate the entire sinus because of the high risk of infection secondary to lack of adequate vascularization (Figure 11-23).[2] The use of synthetic fibrin sealants has gained popularity in recent years in maxillofacial surgery.[22] Fibrin sealants essentially mimic the final two steps in the clotting cascade, forming a thin, sticky, gelatinous fibrin layer that can be sprayed onto an area. Fibrin sealants have been used in the management of frontal sinus fractures for occluding NFDs, for sinus obliteration, and in cases of posterior wall fractures by sealing the sinus from the dura and brain (Figure 11-24). Abdominal fat is, however, the most widely used material and is harvested from an infraumbilical, midline transverse incision 3 to 4 cm in length; alternatively, fat can be harvested from a 1-cm incision at the inferior portion of the umbilicus for a more aesthetic result. Blunt dissection superficial to the rectus fascia allows access to superficial abdominal fat, which can then be transplanted into the sinus. More than 60% of the transferred fat may be resorbed with time, so overfilling and gentle harvesting of the fat is important.[23-25] The authors' preferred method of obliteration is elevation of an extended pericranial flap; not only can this flap be used in obliteration of the sinus cavity, it can also be used to provide a layer of protection over dura in cases where cranialization is necessary.

Management of the posterior wall fractures probably poses the greatest risk of complications because of the potential for brain injury.[23-26] If a posterior wall fracture is present, irrespective of the presence of an anterior wall or NFD injury, the first question to ascertain is the determination of dural tears and CSF leaks. Most nondisplaced posterior wall fractures will not cause injury to the dura. On the other hand, grossly comminuted and displaced fragments of the posterior wall can in fact cause dural tears in the frontal lobe and initiate a CSF leak. If there is a nondisplaced posterior wall fracture, intraoperative evaluation is necessary to ensure absence of CSF leakage. CSF can be seen as a clear fluid leaving through the fractured segments of the posterior wall. If there is no CSF leakage, one can proceed as stated previously with any NFD injuries or anterior wall injuries. Fibrin sealants are an excellent option to seal any small fractures in the posterior wall. In cases of posterior wall displacement or gross comminution, significant dural tears can occur. Management of frontal sinus fractures with displaced or grossly comminuted posterior wall fractures requires a cranialization

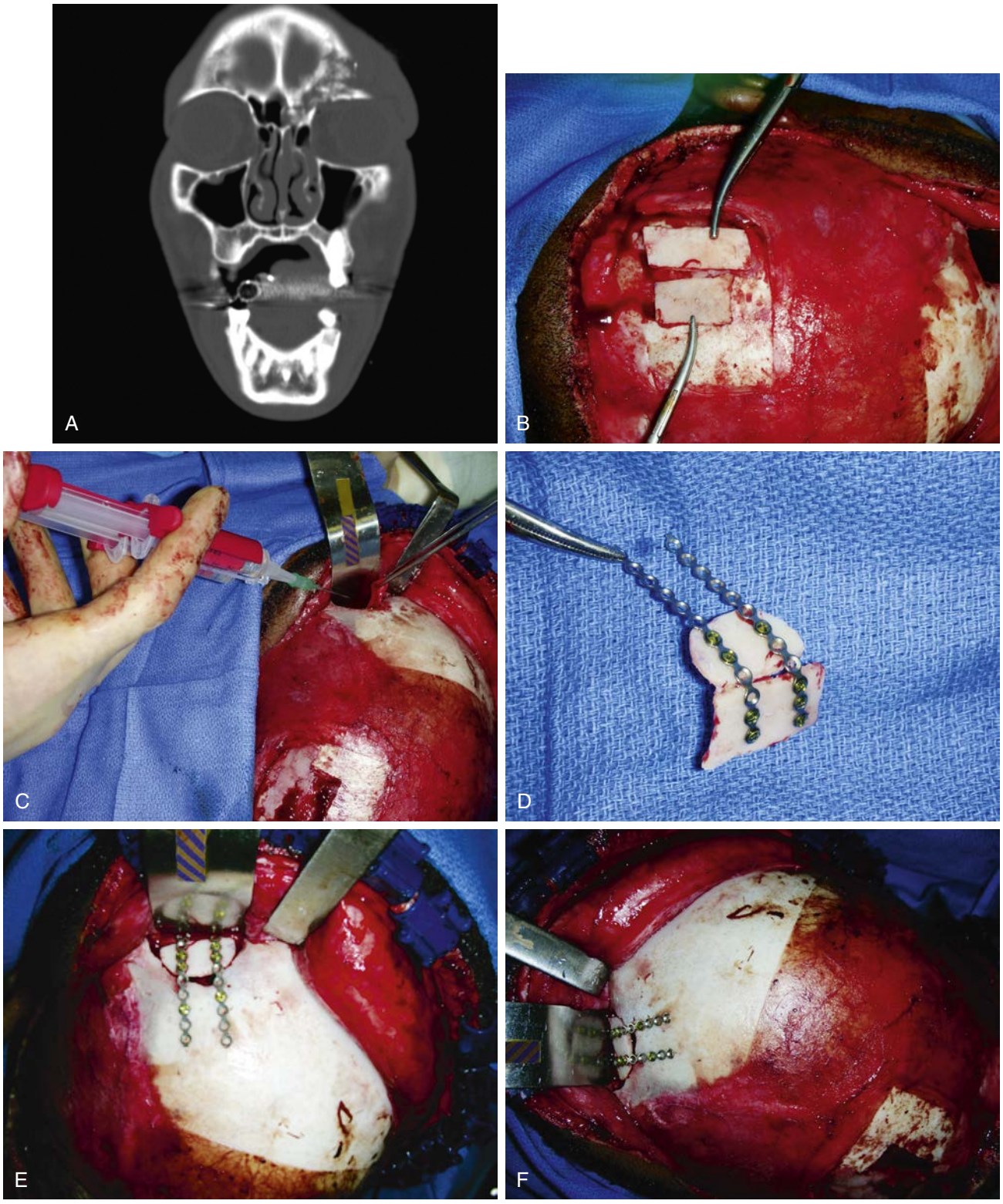

• **Figure 11-24** **A,** Comminution of the sinus floor with involvement of the anterior table and nasofrontal duct (NFD). **B,** Due to severe comminution, cranial struts were harvested to reconstruct the orbital roof and anterior sinus table. **C**, Application of fibrin sealant into the NFD and posterior wall. **D,** The harvested struts were plated to recreate an orbital roof and anterior sinus wall. **E-F,** Reconstructed area following securing of bone graft to the adjacent area.

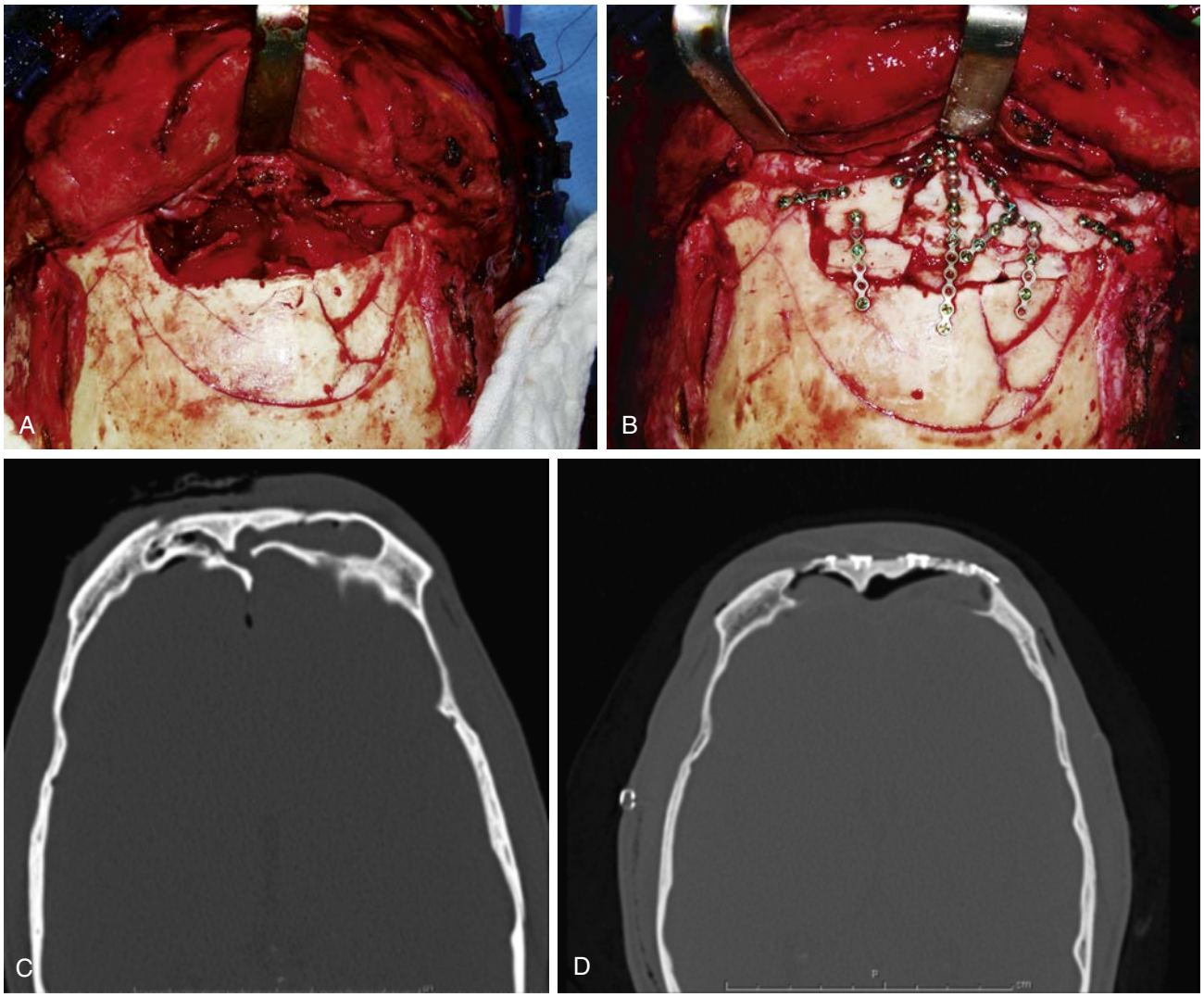

• **Figure 11-25** **A,** Anterior table and posterior table have been removed. Nasofrontal ducts are occluded. Sinus is cranialized. **B,** The anterior table has been reconstructed using plates and screws. **C-D,** Note removal of posterior wall and anterior movement of the frontal lobe following cranialization.

procedure. In this procedure, the entire damaged posterior wall is removed, all dural tears are repaired, and the frontal lobe is allowed to expand into the sinus (Figure 11-25). A formal frontal craniotomy may be required depending on the extent of dural injury (Figure 11-26).[27] In this procedure, the anterior cranial fossa is essentially increased. If cranialization is undertaken, the NFDs and the sinus must be obliterated as previously described. It is paramount to occlude the NFDs and completely separate the nasal cavity from the newly cranialized frontal sinus. Again, as previously mentioned, pericranial flaps can be quite useful in this mode of therapy.

In cases where gross comminution of the anterior wall renders its reconstruction difficult, one can use a large titanium mesh or obtain split calvarial bone to reconstruct the anterior wall.[28]

There are instances where the patient has two separate frontal sinuses separated by a thin bony septum. If only one side is injured, and there is no radiographic or clinical evidence of involvement of the other sinus, surgical repair should only be done to the injured sinus; the noninvolved sinus can continue to function as a normal paranasal sinus.

Endoscopic Repair

Newer technologic advances also play a role in the management of frontal sinus fractures. Isolated anterior table fractures can be treated with endoscopic assistance.[29-31] This technique is rather limited because it will not offer access into the sinus to evaluate the patency of the NFDs, although some authors have advocated performing a nasal endoscopy to evaluate the status of the NFDs at the time of repair of the anterior table. This is a useful technique where elevation of *large* bony fragments of the anterior wall is needed. Although it might be somewhat time consuming, it certainly obviates the need for a coronal incision and can reduce length of hospital stay postoperatively (Figure 11-27).

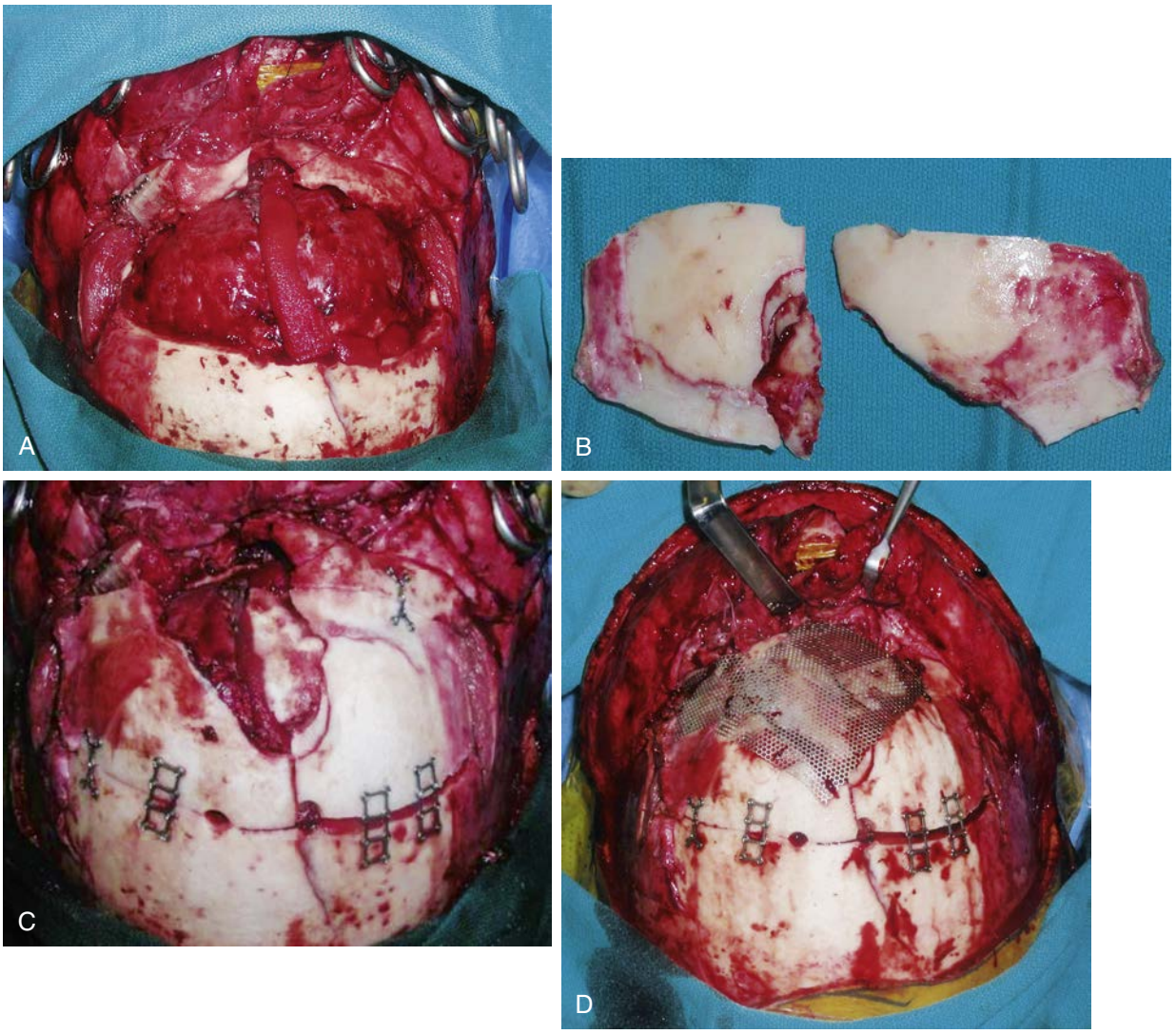

• **Figure 11-26** **A,** A frontal craniotomy to access large dural injury and intracranial bleed. The frontal sinus is fractured. **B,** Frontal bone is split into two pieces. **C,** Replacement of the frontal bone. The sinus has been cranialized. **D,** Large titanium mesh is placed to cover bony irregularities.

Postoperative Care

Patients with repaired frontal sinus fractures should receive perioperative antibiotics and be placed on sinus precautions. Length and choice of antibiotic therapy varies from institution to institution and is surgeon dependent. At least 24 hours of antibiotic therapy should be rendered to the patient. Sinus precautions should be continued for approximately 10 days. Physical activity should be avoided. Forehead sutures (if a forehead laceration was used during repair) should be removed in 5 days. Scalp sutures or staples should be removed in 10 to 14 days. A postoperative CT scan is recommended to assess the reconstruction of the sinus and to serve as a reference for future use. In cases where no surgery was rendered (e.g., nondisplaced fractures), a follow-up CT at 6 weeks is recommended to ensure proper aeration of the sinus.[32] Because certain postoperative complications can occur up to years later, frequent follow-up visits are recommended. This can be challenging at times because of the generally low compliance rate of patients with facial injuries.

Complications

There are two types of complications following frontal sinus fracture repair: acute and chronic.[4-6,33,34] Acute complications can occur within the first several weeks postoperatively and may include the following:

1. *Wound infection associated with the incision.* This may require local wound care, antibiotic therapy, and local debridement.
2. *Infection associated with the sinus (frontal bone osteomyelitis) and its new contents (abdominal fat, pericranial flap, etc.).* This more serious complication can be due to retrograde infection from the nose or formation of a blood clot within the sinus, which can foster an abscess. This is a serious matter and requires radiologic evaluation and

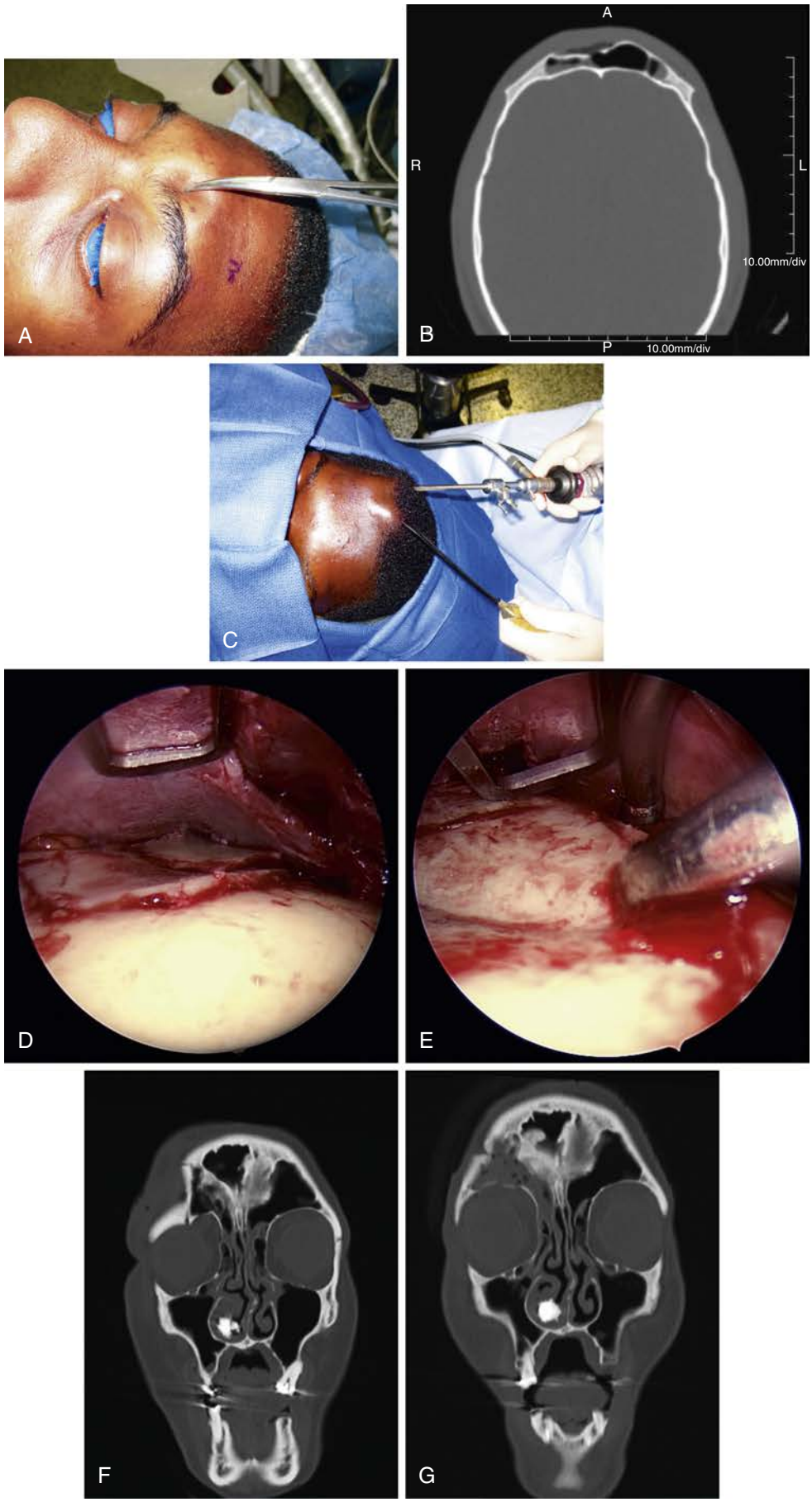

• **Figure 11-27** Anterior wall fracture.



• **Figure 11-28** Patient with postoperative cellulitis of the forehead 14 days following obliteration of the frontal sinus. Note areas of redness.



• **Figure 11-29** Hematoma formation following harvest of abdominal fat. Arrow points to umbilicus.

surgical intervention and debridement to prevent intracranial spread of infection (Figure 11-28).

3. *Complications associated with the donor site (abdomen).* If abdominal fat has been harvested, care must be taken to ensure a completely hemostatic donor site. Hematoma formation following abdominal fat harvest is rare, but must be treated with formal incision and drainage (Figure 11-29).
4. *Intracranial events such as meningitis and brain abscess.* This can be a direct extension of an abscess from within the sinus cavity with intracranial spread. It requires urgent medical and surgical intervention.
5. *CSF leaks.* Most CSF leaks associated with facial fractures cease following repair of the fracture. However, persistent CSF leaks following repair of frontal sinus fracture may require bed rest, elevation of the head, sinus precautions, or more invasive interventions such as lumbar drain or skull base surgery.

Chronic complications can occur up to years or decades postoperatively. These can include:

1. *Mucocele or mucopyocele formation.* This can occur if respiratory epithelium has not been fully removed from the NFDs or the sinus. Because the sinus may not be functioning (depending on the treatment rendered at the time of fracture repair), a mucocele may form. This can secondarily become infected (mucopyocele). Both entities need surgical intervention because they can enlarge, erode through adjacent bone, and spread intracranially.
2. *Cosmetic deformity.* If the anterior wall is not reconstructed properly or if the hardware is palpable, contour irregularities may occur. This usually necessitates a cranioplasty to augment and camouflage the contour deficit, or removal of the hardware. Contour irregularities can also occur following osteomyelitis of the frontal bone, which requires surgical debridement.
3. *Chronic headache and neurologic deficits.* Blunt trauma to the head may lead to posttraumatic concussion syndrome.[35] This can cause long-term headaches with no residual focal deficits. Other neurologic deformities include altered sensation of the forehead and scalp from the supratrochlear and supraorbital nerves, which might have been injured during the initial insult and/or surgery.

Management of postoperative complications, acute and chronic, requires a team approach including the surgeon, neurologist, and neurosurgeons. This ensures proper communication between practitioners and prompt management of potentially serious sequelae.

References

1. Sataloff RT, Sariego J, Myers DI, et al.: Surgical management of the frontal sinus, *Neurosurgery* 15:593, 1984.
2. Fattahi T, Johnson C: Steinberg B: Comparison of 2 preferred methods used for frontal sinus obliteration, *J Oral Maxillofac Surg* 63:487–491, 2005.
3. Luce E: Frontal sinus fractures: guidelines to management, *Plast Reconstr Surg* 80:500, 1987.
4. Cunningham LL, Haug RH: Management of frontal sinus and naso-orbitoethmoid complex fractures. In *Peterson's principles of oral and maxillofacial surgery*, Hamilton, ON, 2004, BC Decker.
5. Gonty AA, Marciani RD, Adornato DC: Management of frontal sinus fractures: A review of 33 cases, *J Oral Maxillofac Surg* 57:372, 1999.
6. Haug RH, Likavec MJ: Frontal sinus reconstruction, *Atlas Oral Maxillofac Surg Clin North Am* 2:65, 1994.
7. McLauglin RB, Rehl RM, Lanza DC: Clinically relevant frontal sinus anatomy and physiology, *Otolaryngol Clin North Am* 34:1, 2001.
8. Stevens M, Kline SN: Management of frontal sinus fractures, *J Craniomaxillofac Trauma* 1:29, 1995.
9. Brandt MT, Jenkins WS, Fattahi T, et al.: Cerebrospinal fluid: implications in oral and maxillofacial surgery, *J Oral Maxillofac Surg* 60:1049, 2002.
10. Giovanni G, Roccia F, Benech A, et al.: Analysis of 158 frontal sinus fractures: current surgical management and complications, *J Craniomaxillofac Surg* 28:133, 2000.

11. Yilmazlar S, Arslan E, Kocaeli H, et al.: Cerebrospinal fluid complicating skull base fractures: analysis of 81 cases, *Neurosurg Rev* 29:64, 2006.
12. Chen KT, Chen CT, Mardini S, et al.: Frontal sinus fractures: a treatment algorithm and assessment of outcomes based on 78 clinical cases, *Plast Reconstr Surg* 118:457, 2006.
13. Miglietta MA, Bernstein MP: CT evaluation of frontodiagonal skull base fracture, *J Trauma* 60:684, 2006.
14. Strong EB, Pahlavan N, Saito D: Frontal sinus fractures: a 28-year retrospective review, *Otolaryngol Head Neck Surg* 135:774, 2006.
15. Gossman DG, Archer SM, Arosarena O: Management of frontal sinus fractures: a review of 96 cases, *Laryngoscope* 116:1357, 2006.
16. Tiwari P, Higuera S, Thornton J, et al.: The management of frontal sinus fractures, *J Oral Maxillofac Surg* 63:1354, 2005.
17. Yavuzer S, Sari A, Kelly CP, et al.: Management of frontal sinus fractures, *Plast Reconstr Surg* 115(6), 79e-93e, 2005.
18. Donath A, Sindwani R: Frontal sinus cranialization using the pericranial flap: an added layer of protection, *Laryngoscope* 116:1585, 2006.
19. Harris L, Marano GD: McCorkle. Nasofrontal duct: CT in frontal sinus trauma, *Radiology* 165:195, 1987.
20. Stanley RB, Becker TS: Injuries of the nasofrontal orifices in frontal sinus fractures, *Laryngoscope* 97:728, 1987.
21. D'Addario M, Haug RH, Talwar RM: Biomaterials for use in frontal sinus obliteration, *J Long Term Eff Med Implants* 14:455, 2004.
22. Fattahi T, Mohan M, Caldwell GT: Clinical application of fibrin sealants, *J Oral Maxillofac Surg* 62:218, 2004.
23. El Khatib K, Danino A, Malka G: The frontal sinus: a culprit or a victim? A review of 40 cases, *J Craniomaxillofac Surg* 32:314, 2004.
24. Xie C, Mehendale N, Barrett D, et al.: 30-year retrospective review of frontal sinus fractures: The Charity hospital experience, *J Craniomaxillofac Trauma* 6:7, 2000.
25. Day TA, Meehan R, Stucker FJ, et al.: Management of frontal sinus fractures with posterior table involvement: a retrospective study, *J Craniomaxillofac Trauma* 4:6, 1998.
26. Manolidis S: Frontal sinus injuries: associated injuries and surgical management of 93 patients, *J Oral Maxillofac Surg* 62:882, 2004.
27. Piek J: Surgical treatment of complex traumatic frontobasal lesions: personal experience in 74 patients, *Neurosurg Focus* 9(1):e2, 2000.
28. Lakhani RS, Shibuya TY, Mathog RH, et al.: Titanium mesh repair of the severely comminuted frontal sinus fracture, *Arch Otolaryngol Head Neck Surg* 127:665, 2001.
29. Endoscopic-assisted reduction of anterior table frontal sinus fractures, *Laryngoscope* 116:1936, 2006.
30. Graham HD, Spring P: Endoscopic repair of frontal sinus fracture: case report, *J Craniomaxillofac Trauma* 2:52, 1996.
31. Smith TL, Han JK, Loehrl TA, et al.: Endoscopic management of the frontal sinus recess in frontal sinus fractures: a shift in the paradigm? *Laryngoscope* 112:784, 2002.
32. Swinson BD, Jerjes W, Thompson G: Current practice in the management of frontal sinus fractures, *J Laryngol Otol* 118:927, 2004.
33. Koudstaal MJ, Van Der Wal KG, Bijvoet HW, et al.: Post-trauma mucocele formation in the frontal sinus: a rationale of follow up, *Int J Oral Maxillofac Surg* 33:751, 2004.
34. Caroli E, Rocchi G, D'Andrea G, et al.: Management of the entered frontal sinus, *Neurosurg Rev* 27:286, 2004.
35. Willer B, Leddy JJ: Management of concussion and post-concussion syndrome, *Curr Treat Options Neurol* 8:415, 2006.

12

Assessment and Management of the Injured Child

BRUCE B. HORSWELL, DAMIAN MAXWELL

Epidemiology, Assessment, and Management of Pediatric Trauma

Introduction

Surgical care of infants and children has improved dramatically in the past four decades. One area of concern, however, remains in the area of pediatric trauma care. Worldwide, childhood injury remains a growing and costly problem. Every year approximately 875,000 children die from trauma, and nonfatal injuries directly and indirectly affect tens of millions of children globally.[1] As access to food and potable water improves and infectious diseases are more effectively controlled, injury remains a prolific killer and major cause of death in children. Trauma is the leading cause of morbidity and mortality among U.S. children, surpassing that of all other major causes combined.[1,2] On average, 12,000 children 0 to 18 years of age die each year in the United States from an unintentional injury.[3]

Mechanisms of Injury

The highest injury mortality rates for all death in children are due to unintentional injuries. Children aged 5 to 19 years die primarily from motor vehicle–related injuries, which peak during adolescence.[4,5] Bicycle-related accidents, inclusive of those involving motor vehicles, are still a significant problem for young and school-aged children.

Blunt injuries are more common than penetrating injuries in children, but penetrating injuries are more lethal. Despite a relative decline in penetrating injuries over the past 20 years, firearm-related deaths continue as one of the top three causes of death in American youth.[6-8] The reduction in injuries may be related to a concerted push by many health care organizations (American College of Surgeons, American Academy of Pediatrics, American Pediatric Surgery Association) to improve awareness and promote change in policy toward firearm possession and use. Similarly, education and environmental changes to promote behavior modification and ensure safety for children have all contributed to the reduction in firearm-related injury. Non-accidental trauma (child abuse) accounts for 5% to 10% of trauma-related injuries.[7] In summary, the leading cause of pediatric trauma mortality is from falls, and second is related to motor vehicle collisions.[8]

Gender

The death rate from injury for males is nearly twice that for females, and males had a higher mortality rate compared to females in all age groups. Boys are more likely to engage in high-risk behavior, which contributes to the gender difference in incidence.[9] Boys are also more prone to participate in contact sports and personal violence.

Outcomes

Data on outcomes for pediatric patients treated at dedicated pediatric trauma center versus non-dedicated centers have been conflicting. Both historical studies and contemporary investigations indicate that survivability and recovery is enhanced in hospitals that specialize in pediatric trauma rather than in non-specialized hospitals. Recent studies have shown that pediatric injury mortality is inversely proportional to the number of level 1 (highest designation by the ACS) pediatric trauma centers that regionally serve a population.[10-13] Conversely, injury-related mortality does not appear to differ when treating adolescents at adult trauma centers when compared to pediatric trauma centers.[14] Generally, outcomes improve at ACS-designated trauma centers, whether adult or pediatric, but verified level 1 pediatric trauma centers appear to have increased survivability and improved functional outcomes for infants and children.[10]

Costs

The financial burden related to childhood trauma is difficult to assess. One has to consider acute care medical costs, rehabilitation efforts, the loss of work or production, and the combination of these factors over a projected life span. The estimates, as depicted in Figure 12-1, are in the billions of dollars. These estimates take into account the loss of manpower in the workforce as well as the immediate and long-term costs to the individual and family/caregivers. Although children do tend to recover from injury faster than adults, their functional outcomes, if initially poor, are worse in the long term.[6] The indirect costs are immeasurable when considering the loss or chronic impairment of a child in the family or community.

Initial Evaluation

Assessment of the injured child differs from the care of adults in their unique injury patterns, physiologic responses, and management. Compared to adults, children have a smaller body mass to body surface area ratio and a less rigid skeleton protecting abdominal and thoracic structures. Energy transmitted through the body per unit volume, therefore, is much greater, leading to multi-system injury. The higher ratio of surface area to body mass also accounts for increased susceptibility of the pediatric patient to insensible fluid and heat loss, compounding the physiologic derangement in traumatic injury.[11]

Immediate action, whether in the field or at a medical facility, requires a systematic approach so that subtle, treatable injuries do not progress and become life-threatening. In 1979, Crowley defined the "Golden Hour," the first hour after a traumatic injury, as being critical for treatment to ensure optimal care for injured patients.[12] Dr. Alex, took it one step further when in 1994 at the Scudder Oration on Trauma of the American College of Surgeons (ACS), he referred to this early resuscitation period in young children as the "Platinum Half Hour."[13]

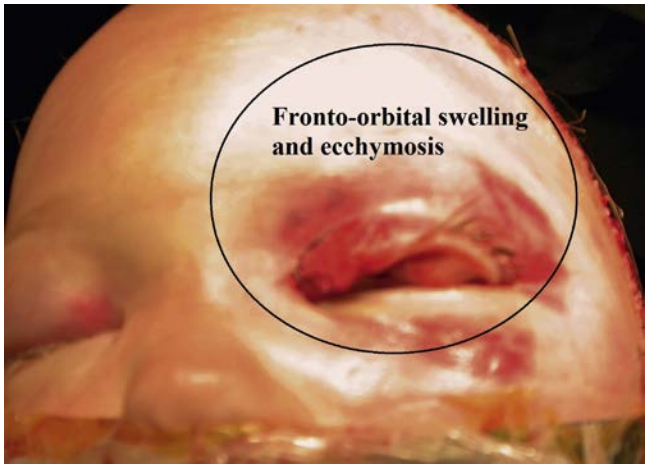

• **Figure 12-1** Child with head trauma and obvious peri-orbital bruising *(circle)*.

Several questions need to be answered during this critical time when confronted with these unknowns:

1. Is there an immediate threat to life?
2. Is this a single or multiple organ injury?
3. What is the most effective way to facilitate stabilization, workup, diagnosis, and therapy?

This approach involves the primary survey, a resuscitative phase, a secondary survey and definitive care as described by Advanced Trauma Life Support (ATLS) as advanced by the ACS.[14] The primary survey involves the identification of injuries related to control of the *airway*, ensuring adequate *breathing*, maintenance of *circulation*, assessing neurologic *disabilities*, and complete *exposure (ABCDEs)*, in that order but often simultaneously. This systematic progression addresses and corrects immediate threats to life *(ABCDs)* and assists in appropriate triage of the injured child. Adjunctive measures including urinary and naso-orogastric catheters should be placed where indicated and additional diagnostic measures that complete the initial evaluation include pulse oximetry measurement, intravenous (IV) access, electrocardiogram (ECG), radiographs, and focused assessment by sonography for trauma (FAST).[14-16]

Primary Survey—*ABCDEs*

- ***A***irway: clear, maintain and secure, protect cervical spine
- ***B***reathing: ventilate and oxygenate
- ***C***irculation: control bleeding, restore volume
- ***D***isability: Pediatric Glasgow Coma Scale (PGCS) and pupils
- ***E***xposure: disrobe, logroll, avoid hypothermia
- Foley catheter unless contraindicated
- Gastric tube unless contraindicated

Studies

Although a lateral c-spine, chest x-ray, and pelvic x-ray are still commonly ordered, their sensitivity to identify such injuries as pelvic fractures and cervical spine injuries are limited. The clinician should be cognizant that children's x-rays are not interpreted in the same manner as adult studies. Children may have significant spinal cord injury without radiographic abnormality (SCIWORA) or other bony injuries with what may appear to be normal x-rays.[11]

FAST is the evaluation of choice for the determination of significant amounts of fluid in the pediatric abdomen. It is especially useful in the hypotensive patient in whom the clinician wants to rule out intra-abdominal cavitary fluid. Its yield is often user dependent, but when performed by a trained surgeon, FAST is indispensable.[17]

Suspicion of traumatic brain injury should prompt the use of emergent non-contrasted computed tomography (CT) scan of the head. Children are at significant risk for intracranial injury and therefore should undergo imaging, particularly those children with signs of somnolence and decreased or changing mental status and/or irritability, focal neurologic findings, depressed skull fracture, bulging fontanel, seizure, worsening vomiting, and loss of consciousness

(LOC) for longer than 1 minute (see Figure 12-1).[15] Identifying reliably sensitive and specific clinical indicators has been difficult, however, because studies have found conflicting evidence regarding the significance of LOC, vomiting, seizures, and headache. Children younger than 2 years should be considered as a separate entity. Younger children are more difficult to assess clinically, are more easily injured even from short falls, have a higher incidence of asymptomatic or occult injuries, and more often are victims of non-accidental injury.[14,15] In addition to the predictors of intracranial injury found in older children, nonfrontal scalp hematomas (surrogate markers for skull fracture) were found to be predictors of intracranial injury, with larger hematomas in younger children of greater concern.[15] If the index of suspicion remains high for intracranial injuries, then CT should be performed (Figure 12-2).

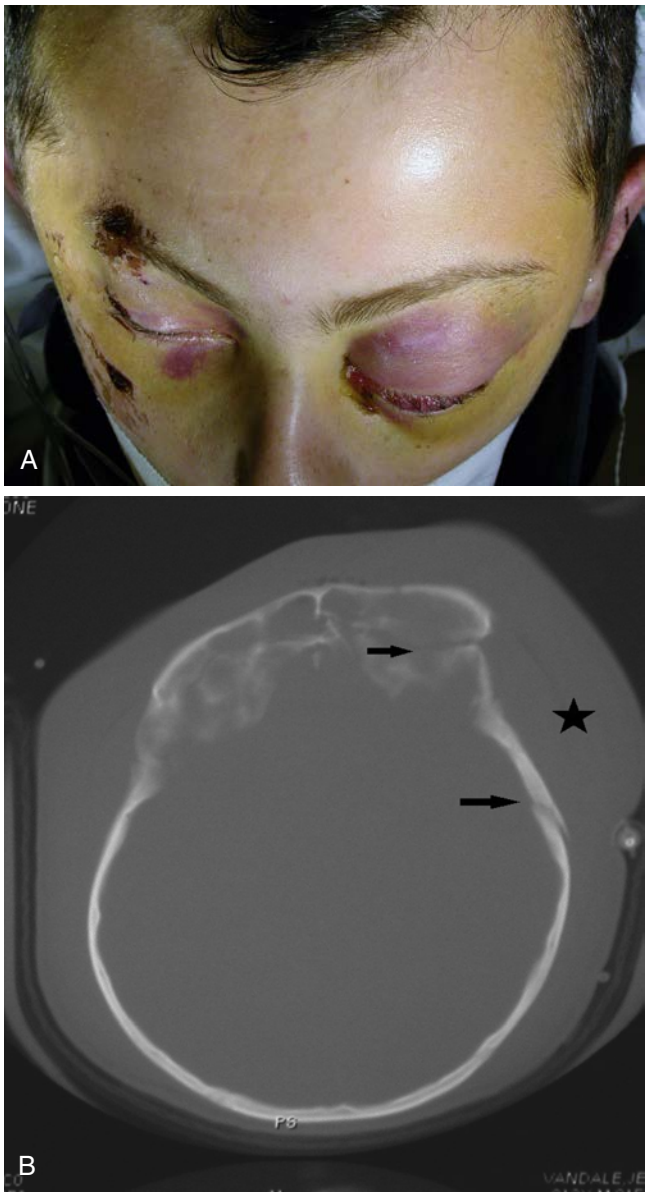

• **Figure 12-2** **A,** Child with large fronto-orbital hematoma and periorbital ecchymosis. **B,** Overlying scalp hematoma *(star)* and underlying cranial fractures *(arrows)* on computed tomography.

Indications for CT Head[11,14]

- Uncertain LOC or prolonged LOC
- Changing neurologic exam
- Bradycardia
- Signs of skull fracture
- Focal trauma, penetrating injury
- Bulging fontanel
- Signs of upper facial trauma
- Sedated or unreliable exam
- Seizures

Do not get CT in unstable, deteriorating child!

Criteria for Patients Who Can Reliably Forego Computed Tomography Imaging[14,16]

- Normal neurologic examination
- Normal mental status
- Normal behavior per caregiver
- No loss of consciousness (LOC)
- No vomiting
- No severe headache
- No evidence of skull fracture (for children <2 years, no nonfrontal scalp hematoma)
- No signs of basilar skull fracture (absent Battle, raccoon signs)
- No high-risk mechanism (fall greater than 3 feet in children <2 years, fall greater than 5 feet in older children, struck by high-impact object, ejection from motor vehicle, motor vehicle crash or auto pedestrian with death of another, auto-bike without helmet)
- No concern for non-accidental injury

Neurologic Status

Responsiveness is assessed with the alert, verbal, pain, unresponsive (AVPU) system and with the Glasgow Coma Scale (GCS) and its pediatric modification, the Pediatric Glasgow Coma Scale (PGCS) (Tables 12-1, 12-2, and 12-3).[17] The PGCS was developed for children younger than 5 years who have more limited communication skills. A total PGCS score of 13 to 15 represents minor injury, a score of 9 to 12 represents moderate injury, and a score lower than 8 represents severe injury.

Even with modifications, the GCS score has limitations in its use for infants and very young children. To date, however,

TABLE 12-1 Pediatric Glasgow Coma Scale: Eye Opening

Score	≥1 Year	0-1 Years
4	Opens eyes spontaneously	Opens eyes spontaneously
3	Opens eyes to a verbal command	Opens eyes to a shout
2	Opens eyes in response to pain	Opens eyes in response to pain
1	No response	No response

TABLE 12-2 Pediatric Glasgow Coma Scale: Best Motor Response

Score	≥1 Year	0-1 Years
6	Obeys command	N/A
5	Localizes pain	Localizes or withdraws to pain
4	Flexion withdrawal	Flexion withdrawal
3	Flexion abnormal (decorticate)	Flexion abnormal (decorticate)
2	Extension (decerebrate)	Extension (decerebrate)
1	No response	No response

TABLE 12-3 Pediatric Glasgow Coma Scale: Best Verbal Response

Score	>5 Years	2-5 Years	0-2 Years
5	Oriented, converses	Appropriate words	Cries appropriately
4	Disoriented but converses	Inappropriate words	Cries
3	Inappropriate words	Cries and/or screams	Cries and/or screams inappropriately
2	Incomprehensible sounds	Grunts	Grunts
1	No response	No response	No response

this is the best tool to facilitate communication between physicians and assess the neurologically injured child.[6,11,14]

Neurologic Disability

- Pupils: symmetry, reaction
- LOC: PGCS
- Track and trend PGCS as a vital sign
- Intubate for coma, PGCS ≤8
- Motor: strength, symmetry
- Abnormality/deterioration: call neurosurgeon
- Mild (PGCS 13-15): observe, consider CT for history of LOC
- Moderate (PGCS 9-12): admit, obtain CT, repeat CT 12-24 hr
- Severe (PGCS < 8): intubate, ventilate, obtain CT, repeat CT 12 to 24 hr

Resuscitation

Table 12-4 refers to some of the anatomic features that must be taken into consideration in the resuscitation of an injured child.

TABLE 12-4 Pediatric Anatomical and Clinical Relevance

Anatomical Distinctive	Clinical Relevance
Large body surface area, small body size	Greater forces of injury dealt to a small body and more organ exposure to injury
Large cranium to body proportion	Head trauma and increased cervical strain
Elastic skeleton	Less external trauma (i.e., fractures) with concealed internal injuries
Short pliable neck, large tongue	Difficult airway (uncuffed endotracheal tubes in very young)
Larynx anterior, short and cephalad with narrowest portion at cricoid	Increased risk of right bronchus intubation
Increased peripheral resistance and reflex tachycardia, less reserve	Rapid response to hypovolemia initially but also rapid cardiovascular decline with continued blood loss

At any point in the primary survey that a change occurs, the ABCDEs should be repeated to assess for deterioration. The evaluation of the injured child is a constant interplay between assessment and management as a dynamic process. Any child presenting after a major trauma should have supplemental oxygen and breathing supported. Respiratory distress and altered mental status are often the first signs of significant injury. In contrast to adult patients, tachycardia and hypotension are late signs of shock in the injured child.[11]

Airway

The pediatric airway has unique characteristics that must be considered to ensure a secure airway and optimize gas exchange. Because injured children do not usually present with preexisting pulmonary disease, serum oxygen saturation greater than 90% on room air is the objective hallmark of effective air exchange. Whenever this objective cannot be reached, one must consider parenchymal injury, pneumothorax, or aspiration. The most common reason to intubate an injured child is often to facilitate resuscitation from shock and/or coma.[6,16,18] Current trauma guidelines recommend immediate endotracheal intubation for patients with a PGCS <9 based on the high probability that such an altered level of consciousness is indicative of a brain injury of such severity that progressive cerebral edema is likely to occur.[18,19]

Airway management is complicated by a number of factors, including the urgency of situation with upper airway obstruction or preexisting hypoxia; uncertainty of cervical spine status; uncertainty regarding the airway because of the presence of blood, vomitus, or debris in the oral cavity or laryngopharyngeal injuries; a full stomach; intracranial hypertension; and uncertain volume status.[19]

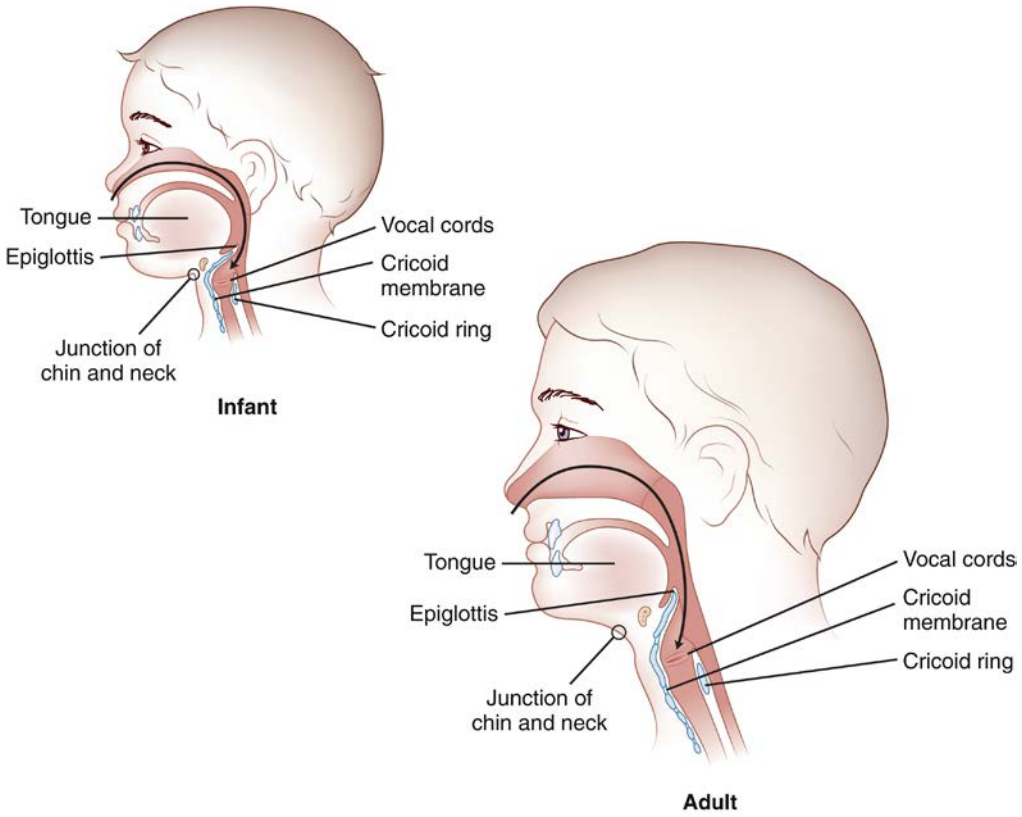

• **Figure 12-3** Diagram of adult and pediatric airways and distinctions. (From Auerbach PS, Cushing TA, Harris NS: *Auerbach's wilderness medicine,* ed 7, Philadelphia, 2016, Elsevier.)

The pediatric airway is small, short, and funnel shaped (Figure 12-3).[20] Its small diameter is the most important determinant of gas exchange, because small changes in diameter from edema or deformity can result in significant alterations in gas exchange. Children have large tongues relative to their oral cavities, which can easily occlude the oropharynx. Therefore, one should "align" the oral, pharyngeal, and laryngeal introits as much as possible to facilitate movement of air.[14] The disproportion between the cranium and the midface is inversely related to the age of the child. The larger occiput results in a tendency for the neck to flex, forcing the tongue posteriorly into the pharynx. The larynx is more anterior in the young child, and orienting the mid-face slightly superiorly and anteriorly (the "sniffing position") will protect the airway from collapse.[20] Once this is performed, simple bag-mask ventilation often allows for adequate gas exchange. If the decision is made to intubate the patient, a roll should also be placed under the shoulders to assist in maintaining this alignment while protecting the cervical spine at all times. When preparing to intubate a child with a severely compromised airway from head or neck trauma, neuromuscular blockade should be avoided unless immediate surgical airway personnel and equipment are on standby.[18,19] Surgical airways can be established first by cricothyroidotomy with a 14-gauge needle followed by a formal tracheostomy once the patient is stable.

Breathing

Normal respiratory rate in children is age dependent. Whereas an infant will breathe 60 times per minute, an older child will breathe 20 times per minute. It must be stressed that *hypoventilation and the associated respiratory acidosis is the most common etiology of cardiac arrest in children*. Adequate ventilation, combined with fluid resuscitation to maintain perfusion, remains the basis for resuscitation in the pediatric trauma patient.[14,20,21]

Tension pneumothorax is a clinical diagnosis based on the findings of respiratory distress, tachycardia, hypotension, tracheal deviation, absence of breath sounds, jugular venous distention, and cyanosis (Figure 12-4).[14] Treatment should not be delayed for radiographic confirmation. When tension pneumothorax is suspected, immediate needle decompression is required. This can be accomplished by percutaneously inserting a large-bore needle at the second intercostal space in the midclavicular line. Definitive chest tube placement can then be performed in the fifth intercostal space at the anterior axillary line.

Circulation

Children often maintain a normal blood pressure and heart rate until there is significant cardiovascular collapse due to their excellent physiologic reserve. The diagnosis of shock therefore is not always straightforward. The accepted ranges

of normal for vital signs vary with age. A normal heart rate for an infant can be as high as180 beats/minute, while a heart rate of >100 beats/minute for an adolescent would be considered tachycardia.[22] Less obvious signs of hypovolemia, such as decreased pulse pressure, mottled skin, cool extremities, and lethargy, can be clues of shock in the eyes of the experienced clinician.[14,21]

The first step in establishing circulation is to control any obvious bleeding with direct pressure. Blind clamping and application of tourniquets are discouraged. Initial intravenous access can usually be obtained by percutaneous methods in an upper extremity vein. This can often be technically challenging in the hypovolemic patient. If percutaneous access is unattainable, placement of a femoral vein line is often the next most appropriate step. If access cannot be gained, then surgical cut-down to the greater saphenous vein above the ankle is commonly used. When all else fails, intra-osseous access and infusion is required. Cannulation can often be facilitated by patented drills designed for this purpose and should be directed into the medullary cavity in the anteromedial aspect of the tibia, 2 to 3 cm distal to the tuberosity (away from the plateau), under sterile techniques. All medications that can be administered by IV for resuscitation can also be given through an intraosseous line but require saline flush.[1]

The child with significant trauma will require volume resuscitation, which begins with 20 to 40 mL/kg *warmed crystalloid* solution. Systolic blood pressure less than 70 mm Hg plus twice the age in years requires 40 to 60 mL/kg of crystalloids followed by 10 to 20 mL/kg warmed type-specific or O-negative packed red blood cells. This degree of instability usually results from greater than 30% to 35% loss of circulation blood volume, estimated at 80 to 90 mL/kg for children. The most likely site of such hemorrhage is the peritoneal cavity, and this can be confirmed quickly by surgeon-performed FAST examination and a chest x-ray.[6,11] Restoration of blood volume is most commonly achieved with type-specific blood, but in dire emergency O-negative blood may be used. One must continue to use O-negative blood for resuscitation if this was initially given. Because significant volumes of anti-A and anti-B antibody may be present in massive transfusions, it is not appropriate to change to type-specific blood after massive transfusion of O-negative blood.[6,16]

Neurologic

Traumatic brain injury (TBI) is an important cause of injury-related death and disability in children, accounting for over half of deaths. There is a bimodal distribution of TBI in children aged 0 to 4 years and adolescents.[4,23] TBI disproportionately affects males, accounting for the majority of hospital-related

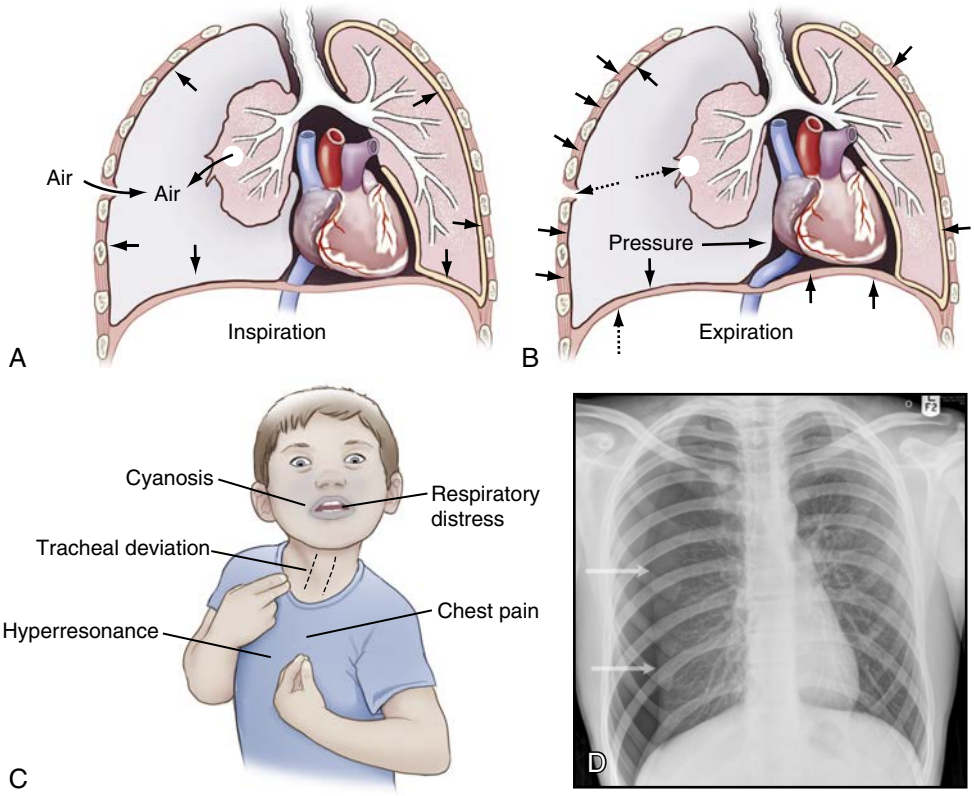

• **Figure 12-4** Tension pneumothorax with absent breath sounds, tracheal deviation away from injury, jugular distention, and cyanosis. (**D** From Kumar Thakur R, Mahomed A: Correlating radiology with thoracoscopic findings in a case of primary spontaneous pneumothorax in a child? *J Minim Invasive Surg Sci* 2(3):31-34, 2013.)

encounters and deaths from TBI in boys.[23] Non-accidental trauma (shaken baby syndrome or child abuse) should always be in the differential diagnosis in infants and young children.[24] Blunt or non-penetrating trauma occurs as the result of a direct impact on the brain and skull. These injuries often occur after a motor vehicle collision or fall and account for the vast majority of TBI in the United States.

Blunt head injury patterns vary, but regardless of classification, they typically result in damage to the underlying brain by either *coup or contrecoup forces* (Figure 12-5). Focal damage to the ipsilateral side of contact is termed coup and damage to the opposite side of the brain is termed contrecoup. The predominant contrecoup damage occurs on the side opposite the impact and is commonly accompanied by subdural hemorrhages and cortical contusion. The brain "bounces" off the skull, causing disruption of the overlying and very fine lattice-like surface meningeal vessels.[24]

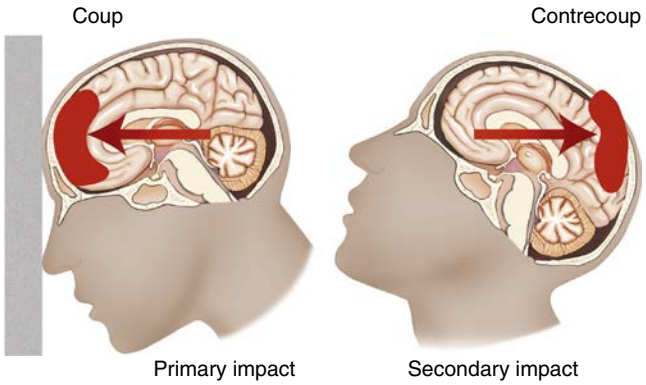

• **Figure 12-5** Whiplash and coup-contrecoup intracranial forces. The primary site of injury results from the brain thrust against the frontal area from sudden whiplash and/or striking an object forcefully. The secondary site of injury results from the brain being thrust backward after impact in a recoil motion. (Lewis SL, Dirksen SR, Heitkemper MM, Bucher L, Camera I: *Medical-surgical nursing: assessment and management of clinical problems,* ed 8, 2011, Elsevier.)

Penetrating injuries result in direct cerebral disruption of the underlying neuronal and vascular connections and indirect blast effect, especially in gunshot wounds. Penetrating injuries also carry a risk of increased infection due to the introduction of foreign material.

Axonal Injury

Axonal injury results from acceleration and deceleration forces or sudden rotation of the head and its "shearing" effects on the underlying neuronal structures. Axonal injury is often coupled with vascular injury. After several hours, physical separation of the axons occurs into proximal and distal segments. Mechanisms include blunt force, whiplash, and violent shaking. This shearing injury is classically observed as petechial hemorrhages in white matter and commonly referred to as diffuse axonal injury (DAI).[25] CT findings, although less sensitive than magnetic resonance imaging (MRI), may show punctate lesions <2 mm in the white matter, corpus callosum, and brainstem or vascular defects in diffusion-weighted images (Figure 12-6). Patients with DAI may spontaneously recover with transient loss of consciousness, or if severe, may be left with permanent neurologic defects or succumb to this potentially lethal injury. To date there are no effective treatments for DAI.

The benefit of routine *repeat* head CT scans in all brain-injured children admitted to the intensive care unit is of questionable value. One study of 173 patients demonstrated a 27% rate of CT-identified new lesions after initial CT, though no patients required operative intervention or

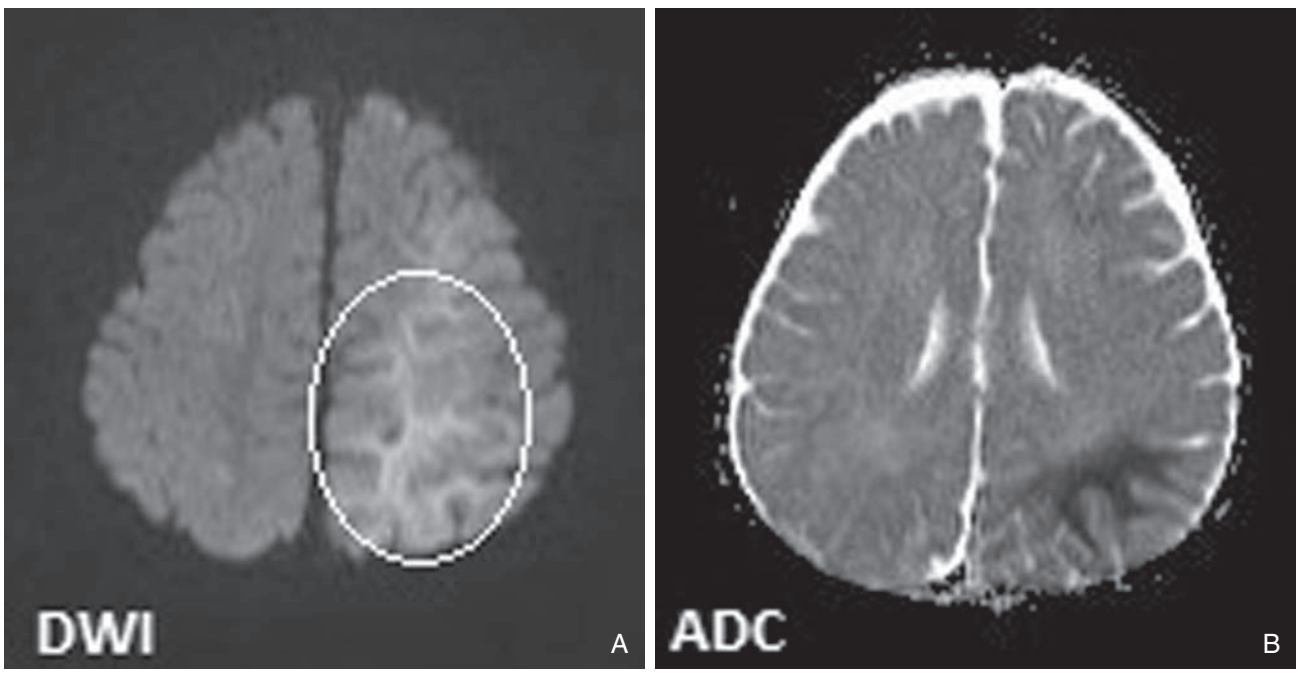

• **Figure 12-6** Magnetic resonance imaging diffusion-weighted image **(A)** with evidence of parenchymal edema and vascular flow defects **(B)** indicative of diffuse axonal injury.

change in care.[26] Another study of 63 children who had sustained TBI and were re-scanned 24 hours after their initial CT found a highly significant correlation between the children's GCS status and CT findings. The authors concluded that most patients with an unchanging or improving neurologic examination did not justify routine repeat head CT.[27]

Concussion

Concussion is often used to label the constellation of symptoms that occur after mild to moderate TBI when no pathologic lesion or process is identified. Generally speaking, concussion is a head injury resulting in altered mental status, with or without loss of consciousness. Classic symptoms include headache, nausea, vomiting, difficulty concentrating, retrograde and/or anterograde amnesia, and personality changes.[28] Complete recovery after concussion is common though unpredictable. Long-term consequences include impaired attention, cognition, depression, mood disorders, and emotional lability.[27,28]

The developing brain of a child has some structural differences when compared to the adult. The disproportionately large skull of an infant has to account for the rapid increase in size of the brain that takes place in the first 3 years of life.[28] The developing brain has incomplete synapse formation and neural arborization, which account for the impressive developmental cognition of a child as they mature. The subarachnoid space around the brain adds little protection from blunt trauma or applied shear forces. Studies have indicated that the smaller neural axis of infants and young children results in a less compliant pressure-volume relationship with an increased risk of intracranial hypertension, despite the space for expansion afforded by open sutures and fontanels.[29-31]

Monroe-Kellie Doctrine

Given that the cranium is a rigid, non-expansile container, the Monroe-Kellie doctrine states that the total volume of the intracranial contents will remain constant and any increase in the volume of one component must be at the expense of another.[32] Therefore, once a space-occupying lesion expands beyond the compliance of the other structures, the intracranial pressure (ICP) will begin to rise.[30-32] Expanding intracranial hemorrhages are classic examples of this phenomenon. Figure 12-7 demonstrates this intracranial phenomenon.

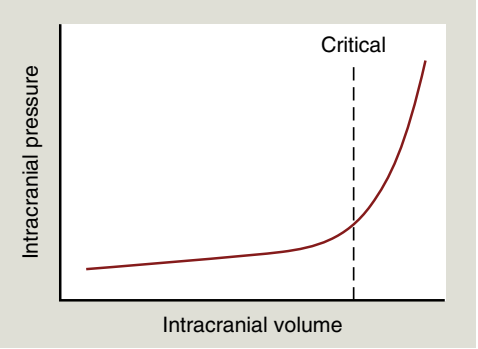

• **Figure 12-7** Intracranial volume (constant) = Brain + CSF + Blood + Mass lesion volumes Intracranial components are noncompressible; thus, once the cranial vault is filled, pressure (ICP) rises dramatically. Increasing ICP eventually leads to decreased cerebral blood flow. Expansile lesions or edematous brain will push CSF into the spinal canal or vascular spaces and herniation shortly follows.

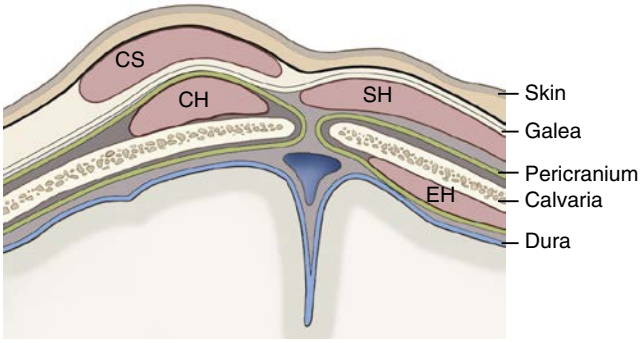

• **Figure 12-8** Diagram of subtypes of hematomas in traumatic brain injury in children. *CH,* Cephalohematoma; *CS,* caput succedaneum; *EH,* epidural hematoma; SH,subgaleal hematoma.

Intracranial Hemorrhage

Head trauma in children may result in both extra- and intra-cranial bleeding. Some overt presentations with obvious swelling, such as caput succedaneum or cephalohematomas from traumatic birth, are fairly benign, require no interventions and usually clear within days to weeks. Caput swellings are edematous scalp accumulations which cross the sutures, whereas cephalohematomas accumulate below the pericranium and are therefore confined by the sutural margins. Cephalohematomas are true hemorrhages and take longer to resolve. These are typified in Figure 12-8. Subgaleal hemorrhages are superficial to the skull, confined between the galea and pericranium, and generally are flatter and broader. More significant hemorrhages are those which occur intracranially from direct trauma to the head. Epidural hematomas are *extra*dural, and result from a disrupted artery with progressive expansion and a clear demarcation on CT imaging. Subdural hematomas are blood accumulations under the dura and have a more indistinct border.

Intracranial hemorrhages are classified as epidural, subdural, and subarachnoid hemorrhages. Figure 12-8 diagrammatically illustrates these particular lesions in TBI.

Epidural

Epidural hematoma typically results from disruption of the middle meningeal artery and is classically seen on CT as a lenticular or biconcave hypodense lesion (see Figure 12-9). The classic presentation of a "lucid interval" after TBI is less common in children than adults.[25,31] Typical symptoms include headache, lethargy, vomiting, irritability, confusion, and decreased level of consciousness. Progressive deterioration can result in seizures, hypertension, respiratory instability, pupillary changes, posturing, and cardiovascular compromise. Indications for evacuation can be size of lesion (>40 mL) or a neurologically deteriorating patient.[31]

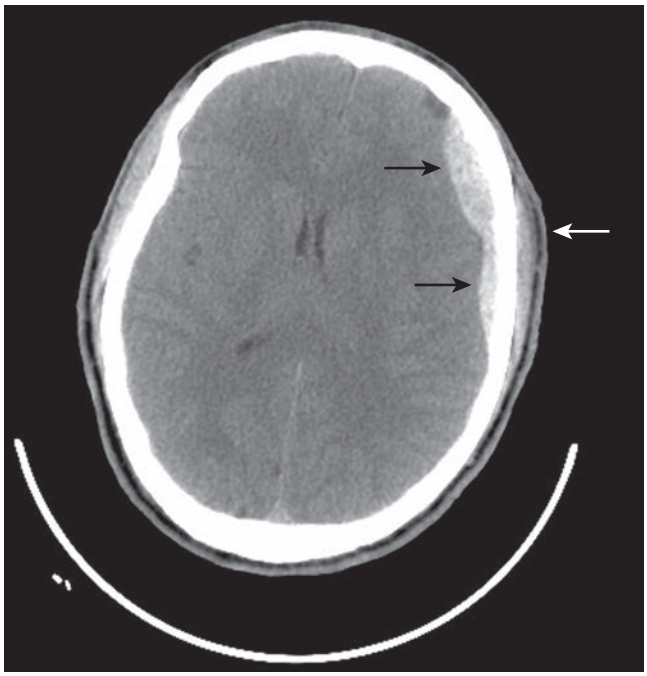

• **Figure 12-9** Axial computed tomography with contrast demonstrating epidural hematoma *(black arrows)* and classic lenticular or concave contour. Overlying scalp hematoma is noted *(white arrow)*.

Subdural

Subdural hemorrhages are classified as acute (<3 days), subacute (3-10 days) and chronic (>10 days). These crescent-shaped lesions on the surface of the brain follow the convexities and tend to encompass more of the hemisphere (Figure 12-10). These lesions are often associated with mass effect and cortical edema. Operative intervention is indicated when neurologic decompensation occurs in the presence of subdural hemorrhage and parenchymal injury.[25]

Acute subdural hematomas have a worse prognosis when compared to epidural hematomas because of the associated brain damage. In infants, it is possible to tap the subdural space at the level of the fontanel and produce rapid decompression. Patients with a midline shift greater than 5 mm should have prompt evacuation of clot and decompression via craniotomy.[31]

Subacute subdural hematoma can present in a similar fashion to acute hematoma but with signs of elevated ICP (frontal bossing, enlarged heads, dilated scalp veins, sunsetting eyes, papilledema, and bulging fontanels). The CT scan often shows isodense or hypodense fluid collections at the cerebral convexities. MRI studies may be helpful in diagnosing ongoing bleeding.[33] As with acute subdural hematomas, operative evacuation is often necessary.

Chronic subdural hematomas can cause symptomatic elevation of the ICP and may require intervention to manage increasing cranial expansion. Presentation is similar to those of a subacute subdural hematoma. Management options may include serial percutaneous CSF or hematoma drainage, limited craniotomies to drain and irrigate the subdural space, and subdural/peritoneal shunts.[31]



• **Figure 12-10** Axial computed tomography with contrast demonstrating subdural hematoma with irregularity that follows the contours of the cranial and cerebral surfaces *(arrows)* and encompasses more of the hemisphere.

Subarachnoid hemorrhages (SAH) are also common in children.[6] Subarachnoid bleeding in acutely traumatized children is common but rarely results in aneurysmal bleeding as seen in adults. This often occurs over the convexities of the brain affected by coup-contrecoup injuries, particularly over the frontotemporal poles. Traumatic SAH can also occur in the inter-hemispheric fissure and in the basilar cisterns and is secondary to disruption of the fine pia-arachnoid vessels. If associated with minor trauma, surgical intervention may not be warranted. However, evolving hydrocephalus may result during the chronic (resorptive) phase of subarachnoid hemorrhage, requiring ventricular shunting (Figure 12-11).

Skull fractures are commonly associated with head trauma in children (up to 21% reported).[9] CT is the diagnostic study of choice for skull fractures, which will allow simultaneous evaluation of the underlying parenchyma (Figure 12-12). The four major types of skull fractures are linear, depressed, diastatic, and those at the skull base.[34,35]

Linear skull fractures (simple "cracks") are the most common and should be followed closely for epidural hematoma. Depressed skull fractures indicate more forceful blunt trauma than linear fractures, and those that are greater than the bicortical thickness of the skull table and have dural tears require operative management.[35] Grossly displaced skull fractures are often associated with dural tears and parenchymal injury and therefore portend a

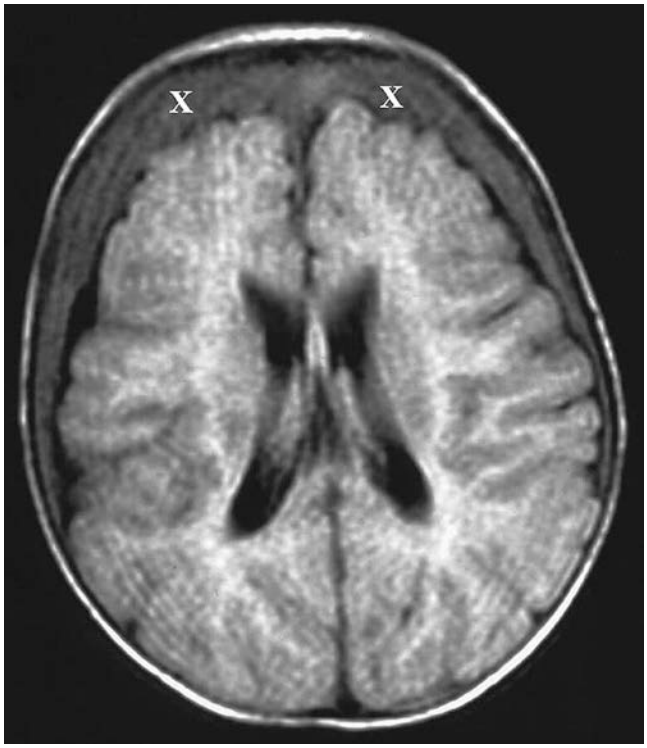

• **Figure 12-11** Resolved subarachnoid hemorrhage on magnetic resonance imaging in young child with residual hydrocephalus. (From Horswell BB, Istfan S: Child maltreatment, *Oral Maxillofac Surg Clin North Am* 24(3):511-517, 2012.)

worse prognosis. A majority of displaced skull fractures are open fractures. The distribution of fracture location is:

- 75% fronto-parietal
- 10% temporal
- 5% occipital
- 10% other or combined

Skull base fractures are uncommon in young children. Clinical signs of skull base fractures include raccoon eyes (periorbital ecchymosis) and Battle sign (mastoid ecchymosis) (Figure 12-13). Hemotympanum and oto-rhinorrhea are signs of basal skull fracture, and if this is noted, a cerebrospinal fluid (CSF) leak can be detected by the presence of β2-transferrin or CSF fluorescein dye study. Careful evaluation of cranial nerves I, III, VI, VII, and VIII, which traverse the skull base, should be undertaken. The low risk of meningitis in basilar skull fractures (2% to 9%) does not support the routine use of prophylactic antibiotics and may potentiate the development of resistant organisms.[36-38] On the other hand, children with a basilar skull fracture and a CSF leak should be considered for vaccination against *Streptococcus* pneumonia because of the risk of pneumococcal-associated meningitis.[39]

Secondary Brain Damage in TBI

The foundation of contemporary TBI management include thorough triage, resuscitation, emergent surgical evacuation of mass lesions, control of ICP, support of cerebral perfusion pressure (CPP), multimodal monitoring, and optimization of the neurovascular physiologic environment.[32-40] Secondary damage involves the progression of damage within the brain resulting from evolving edema, ischemia, and necrosis.[40,41] Hypotension and hypoxia can further exacerbate damage; therefore, elevated ICP or decreased CPP are to be avoided.

Keys to Avoiding Secondary Damage

- Establish baseline neurologic exam and repeat often (age-appropriate best verbal, motor, and pupils)
- Keep Pao_2 >80 mm Hg, Sao_2 >95%, $Paco_2$ 35-40 mm Hg
- Keep blood pressure in high-normal range
- Correct hypotension, hypoxia, hypoglycemia

ICP Monitoring in TBI

ICP monitoring should be considered for any child with a GCS score less than 8.[40] Cerebral perfusion pressure is considered the pressure gradient that is ultimately the driving force required for supplying cerebral metabolic needs. CPP is easily measured from ICP with the mathematical difference between the mean arterial pressure and ICP. Cerebral blood flow (CBF) is defined as the blood traversing through the cerebral circulation. In normal adults, CBF is 50 to 55 mL/100 g of brain tissue/minute. In children, CBF is relatively higher, corresponding to their age. However, cerebral autoregulation is often disrupted after severe TBI, thereby making CBF difficult to interpret and use.[41] Treatments are directed toward decreasing ICP and optimizing CPP. Pediatric TBI guidelines involve maintaining CPP between 40 and 65 mm Hg. There are no studies to support maintenance of CPP above any target threshold in infants or children in TBI to improve mortality or morbidity. However, a threshold below 40 mm Hg perfusion pressure appears to be associated with increased mortality; therefore, most treatment guidelines recommend a minimum CPP of 40 mm Hg.[42] ICP elevations above 20 mm Hg are not well tolerated and are associated with poor outcomes.[43,44] Sustained increased ICP may result in decreased cerebral perfusion and lead to subsequent herniation. Therefore, patients with sustained ICPs greater than 20 mm Hg should have intraventricular devices placed that effectively allow drainage of CSF and direct decrease of ICP.[19]

Ventilation should maintain a $PaCO_2$ of 35 to 40 mm Hg, as hypercapnia may cause significant increases in cerebral blood volume and flow. Hyperventilation can temporarily assist in reduction of ICP by causing cerebral vasoconstriction and thereby reducing cerebral blood flow if herniation is imminent; however, prophylactic hyperventilation to achieve a $PaCO_2$ <30 mm Hg should be avoided as it results in reduction of CBF and consequent ischemia. The clinical signs of herniation include nonreactive, dilated pupils, and Cushing triad (abnormal respiration, hypertension, and bradycardia).[45]

Management of TBI

Mannitol usage has fallen out of favor due to several side effects, including the rebound effect of secondary cerebral ischemia, serum electrolyte imbalance, and hypovolemia.

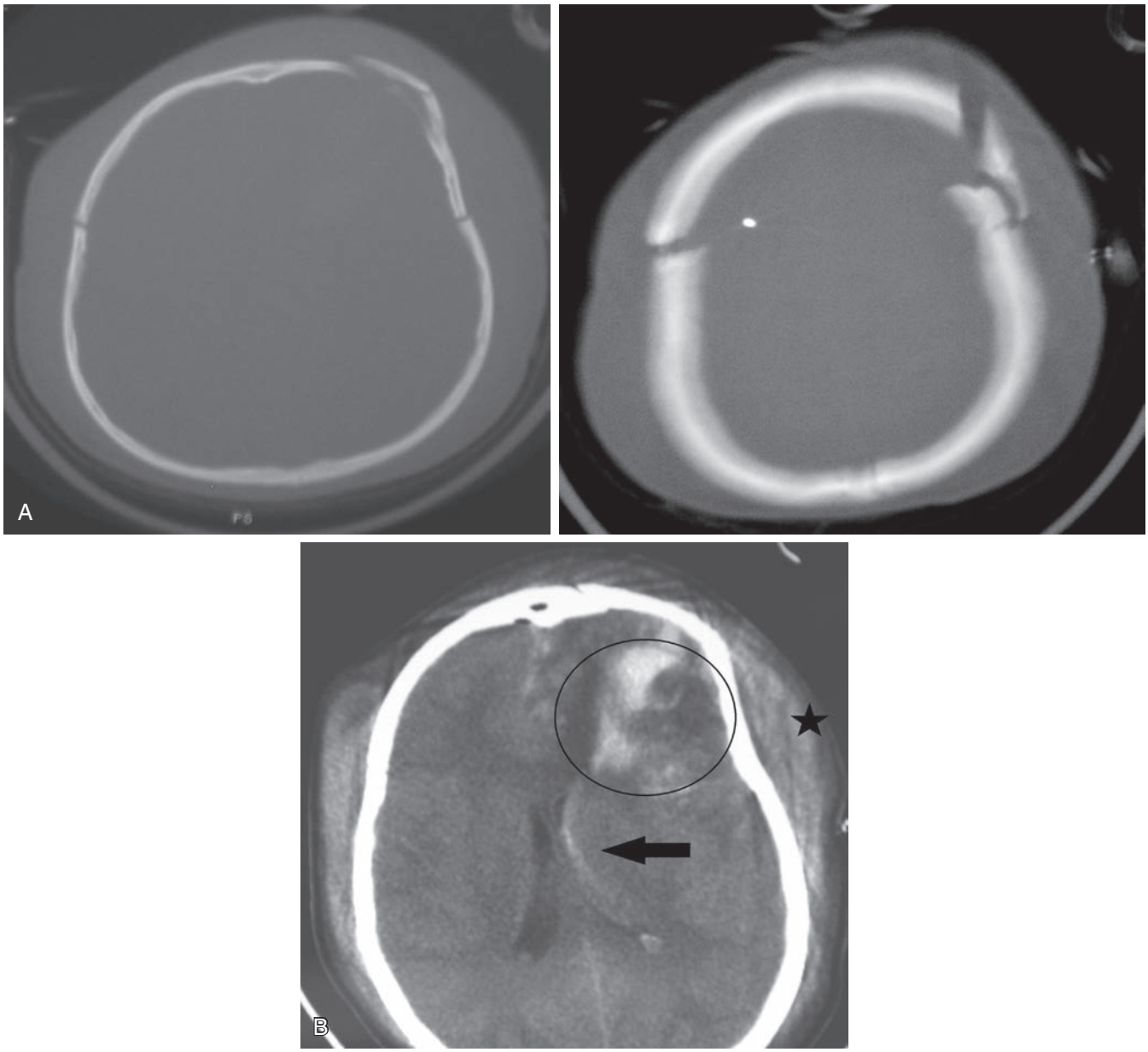

• **Figure 12-12** Computed tomographic *(CT)* images of pediatric skull fractures. **A,** Bone window CT demonstrating calvarial fractures. **B,** Brain window with contrast CT demonstrating scalp hematoma *(star)*, intraparenchymal hematoma *(circle)*, and edema with mass effect *(arrow)*.

Recent data suggest that 3% hypertonic saline should be used as the mainstay therapy to maintain serum sodium concentrations of 150 to 170 mEq/L and serum osmolarity of 360 mOsm/L, which is well tolerated in the pediatric patient with a head injury.[46,47] Hypertonic saline has also been reported to have several other potentially beneficial effects, including vasoregulatory, hemodynamic, neurochemical, and immunologic properties. Initial therapy should be 3 to 5 mL/kg or continuous infusion of 0.1 to 1.0 mL/kg/hr titrated to decreased ICP.[47]

Post-traumatic Seizures

When compared to the adult population, infants and small children are at an increased risk for post-traumatic seizures (PTS) due to increased excitability of the developing brain.[48] Post-traumatic seizures are the most common complication of TBI.[49] Non-accidental trauma is the strongest predictor for early post-traumatic seizures (EPTS), probably due to the repetitive nature of the injury over time.[50] Early post-traumatic seizures occur in 19% of children with TBI, usually manifest within 7 days of injury, and are typically self-limiting if the initial CT is normal.[46-48] Young age and non-accidental trauma are independent predictors for the development of seizures; therefore, prophylactic anticonvulsant therapy may be considered in the first week following severe TBI for those patients deemed at high risk for seizure activity (intra-parenchymal blood).[19] Treatment includes a loading dose of phenobarbital 15 to 20 mg/kg as a single dose with maintenance dose given 12 to 24 hours later at

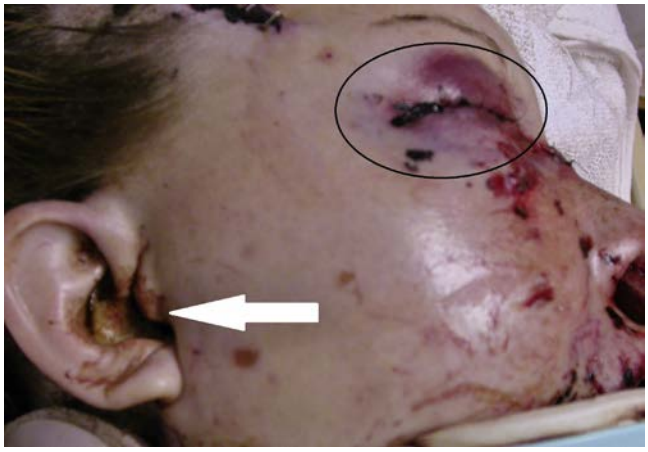

• **Figure 12-13** Skull base fractures (peri-orbital ecchymosis and mastoid swelling, *(circle)* with resultant cerebrospinal fluid pooling at the conchal bowl *(arrow)*.

5 mg/kg/day divided every 12 hours and subsequently titrated for therapeutic levels at 15 to 40 mcg/mL. No firm data in the pediatric literature suggest that these medications improve long-term outcomes or reduce the incidence of late post-traumatic seizures.[50,51]

Current data indicates that treatment with corticosteroids does not confer improved functional outcome, decrease mortality, or reduce increased ICP in children with TBI.[52] Given the lack of evidence and the potential harm from these medications, corticosteroids are not routinely recommended in the management of pediatric TBI.

It is estimated that 21% to 42% of children with severe TBI will develop refractory intracranial hypertension despite aggressive medical management.[51] Decompressive craniectomy, high-dose barbiturate therapy, hyperventilation, lumbar drain placement, and the use of moderate hypothermia should be considered in these patients.[52] Finally, therapeutic hypothermia may be considered as a second-line therapy; however, the benefits seen in animal models remains unsubstantiated in large randomized clinical studies in humans. Data extrapolated from the adult literature indicate that hyperthermia adversely affects TBI outcomes, and it may be advisable to consider *passive rewarming of the mild to moderately hypothermic* child with isolated head injury.

Summary

The assessment of the injured child remains a dynamic process with ever-changing variables and treatment strategies that continue to be refined with ongoing research. The principles described in this chapter are a guide to assist the clinician in the evaluation and management of the child with life-threatening injuries. Particular attention is given to the recognition and management of TBI in children, as this is key to reducing mortality and morbidity in this susceptible population. Guidelines are established to help orchestrate a clear and quick management scheme in the midst of a commonly chaotic trauma setting in the hope that clinicians can quickly identify, treat, and prevent ongoing injury.

Wound Repair in Children after Injury

Principles of Tissue Repair in Injury

Wound healing traverses a complex and connected process from a site of injury to a stable scar. The detailed and interrelated mechanisms of inflammation, coagulation, chemotaxis, phagocytosis, cellular recruitment and differentiation, growth factors, mediators and cytokine production, vascular ingrowth, and ultimate connective tissue organization proceeds along a multiple-level trajectory of cascading events. The biologic detail and data accompanying those events is monumental and beyond the scope of this chapter. However, it is necessary that the surgeon involved with the care of the injured child and the corresponding wounds understand basic tissue healing mechanisms and how they may be altered by adverse forces or, alternatively, harnessed to achieve a good outcome.

"Children are not small adults" is oft quoted regarding the care of children due to basic anatomic-physiologic differences and attendant strategies. This is particularly true for wound healing. Basic distinctions are observed and understood in wound healing for individuals as well as classes of patients, including children. Their stages, course, and trajectory in tissue repair are basically those of young healthy adults, but there are accelerated and exaggerated responses that should be recognized.

Although fetal wounds heal without scars because of a limited inflammatory response (amniotic bathing) and absence of transforming growth factor beta (TGF-β), postnatal tissue wounding takes on an accelerated and even more pronounced dynamic within days after birth.[53-55] This response accounts for the higher incidence of hypertrophic scarring in children after injury.[56,57] This can lead to a devastating effect on a child's well-being.[58]

Basic Soft Tissue Injury and Physiology

The complexity and degree of soft tissue disruption in children's injuries requires a basic understanding of connective tissue, epithelial, and osseous repair in children. Children heal at an accelerated and more pronounced rate than the adult patient. Generally speaking, children heal quickly but do so with more scarring, particularly in the dermis.[57-60]

Tissue repair begins seconds after injury with the coagulation cascade and formation of the platelet plug.[61-64] The coagulation cascade ends in the conversion of fibrinogen to fibrin and the formation of a gel (provisional) matrix that provides a primitive scaffold for subsequent events. The acute *inflammatory* response (hours to 2-3 days) soon follows with tissue leakage, cellular egress, and cytokine and factor release (Figure 12-14). Neutrophil and macrophage recruitment (monocyte precursors in circulation) accelerates and peaks at about 2 and 5 days, respectively, after injury; these cells contribute to the amplification of

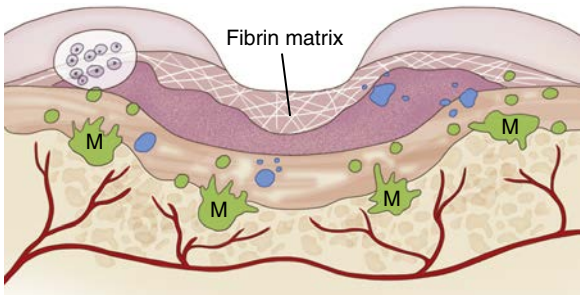

• **Figure 12-14** Diagram of reepithelialization with keratinocyte migration *(circle)* with macrophage *(M)* release of factors in response to cytokine signaling in the matrix gel and wound bed.

cytokine elaboration and release into the fibrin clot. Further, macrophages begin the simultaneous process of microbial phagocytosis, foreign body degradation, and processing matrix component breakdown products. Evidence suggests that neutrophilic predominance fades after day 3, and any significant presence in the wound thereafter may suggest impaired healing. Macrophages dominate the wound at the latter phase of inflammation and into the next phase of proliferation and are necessary for a stable, healing wound. It is important that no or little disruption of the provisional matrix occur, thus invoking more inflammation and delays in healing, which contributes to more scar formation.

After the inflammatory response, the *proliferative* phase ensues, with formation of a weakly arranged granulation tissue bed in the site of injury. This phase of wound healing generally proceeds from 4 to 21 days after injury. This granulation bed is composed of fibroblasts, macrophages, and endothelial cells that have been chemotactically attracted to or differentiated into building-block cells. Fibroblasts are the workhorse cells for building a more stable matrix with the cytokine-induced degradation of the initial fibrin matrix and formation of a collagen matrix. Into this matrix, fibroblasts produce collagen, principally type III collagen (types I, II, and III collagen are termed *fibrillar collagen*). Type III collagen predominates initially because of the hypervascular response in early repair. Fibrillar collagen dominates the early scar and will correspondingly increase in amount if the scar is not managed with reduction of tension and application of subtle pressure (wound support dressings, i.e., Silastic or hypoallergenic skin tapes). The degree to which this cascade of events proceeds and matures is variable, but as mentioned earlier, the process is more pronounced and faster in children.

The last and longest phase of wound healing is the *remodeling* phase, which proceeds up to 1 year after injury. This phase is characterized by wound contraction and collagen remodeling. Obviously the mechanisms during the first 21 days of wound healing that propelled such cellular activity and proliferation must be turned off to avoid an immature and unstable wound. These mechanisms are largely still unknown but probably work through contact inhibition of epithelial cells, fibroblast regression through molecular signaling, vascular maturity, and other environmental components. During remodeling, myofibroblasts in the surrounding tissue contract at the wound margins and reconstituted tissue to form a more densely compacted matrix. Remodeling involves formation of a more organized extracellular matrix, completed angiogenesis, and more mature collagen fibers (type I production from fibroblasts and breakdown of type III collagen) with elastin arranged in a tight, more parallel, and covalently bonded matrix.

Reepithelialization of damaged dermis begins within hours of injury with migration and proliferation of surrounding epithelial cells.[63] Immature keratinocytes, more prevalent in younger dermis that has not been exposed to injurious agents (aging process), release matrix metalloproteases and plasmin that assist in basement membrane disassociation and subsequent cell migration. Immature and burgeoning keratinocytes at the wound margin proceed onto the granulation bed (see Figure 12-14). This migration is promoted by growth factors, principally TGF-β which has a dual effect of promoting migration while also inhibiting proliferation, thus encouraging *horizontal* movement rather than the *vertical* hierarchy which exists in mature epidermis.[63,65,66] Once contact is made with opposing keratinocytes over the underlying matrix bed, this migration and proliferation stop, preventing overexpression of factors, cellular overgrowth, and hypertrophic scar formation.[64,65]

Soft tissue wound repair is a complex process that results in a mature scar. As repair proceeds, the wound gains strength, with about 20% tensile strength of unwounded tissue at 21 days, and attaining about 70% to 80% strength at the end of remodeling.[62] Younger children attain final wound integrity more quickly and to a higher degree of tissue strength compared to that in adults.

Bone Healing after Fracture

Initial injury at the site of fracture invokes the same acute inflammatory response as in soft tissue. There is an immediate vascular constriction to slow bleeding in concert with platelet clumping to form a platelet plug. Dilation then follows to allow neutrophils and platelets to spill into the developing clot. Platelet-mediated cytokines are released after degranulation within the organizing fibrin clot, including TGF-β, platelet-derived growth factor (PDGF), and vascular endothelial growth factor (VEGF).[67] These mediators effect the extravasation of plasma proteins into the maturing clot, enhancing further cellular recruitment and elaboration of other cytokines—interleukin (of several subtypes), tumor necrosis factor alpha, and PDGF. Principal among these cytokines is TGF-β, which exerts a wide response in the acceleration of the cascade of inflammatory events via rapid chemotaxis of neutrophils and monocytes to the site of injury. This process is accompanied by simultaneous vascular budding and neo-angiogenesis within the granulation matrix and scaffold of early organization.[68] These events occur within hours after injury and progress over the next 2 to 3 days after injury. Bone morphogenetic protein (BMP) belongs to the TGF-β superfamily and includes several subclasses of BMPs

TABLE 12-5 Growth Factors in Fracture Repair

Factor	Source	Function
TGF-B	Platelets, bone matrix	Stimulates proliferation of undifferentiated mesenchymal cells
BMP	Osteoprogenitor cells, osteoblasts, bone matrix	Promotes differentiation of committed mesenchymal cells into chondrocytes and osteoblasts
FGF	Macrophages, chondrocytes, osteoblasts	Mitogen for mesenchymal cells, chondrocytes, and osteoblasts
IGF	Bone matrix, osteoblasts, chondrocytes	Promotes proliferation and differentiation of osteoprogenitor cells
PDGF	Platelets, osteoblasts	Mitogen for mesenchymal cells and osteoblasts; macrophage chemotaxis

(2,4,6,7) which invoke osteoinduction through stimulating mesenchymal cells (in turn having been stimulated to become committed to bone production through TGF-β influence on *undifferentiated primitive* mesenchymal cells) to transform into osteoblasts.[67,69] Insulin growth factor (IGF, types 1 and 2) is the most abundant factor and has both paracrine and endocrine functions. It stimulates endochondral proliferation at the growth plates without maturation and also plays a role in intramembranous osseous healing. IGF-2 is potent and has wide-ranging influence on several target tissue cell types.[68,69] Table 12-5 lists several of the primary growth factors involved in fracture osseous repair.

Fracture Healing Mechanisms

Fracture healing is dictated by the location of the fracture, the health of the callus formed around the fracture, and the strain placed across the callus.[70] Systemic and local tissue factors play respective roles as defined later in this section. *Primary bone healing* takes place when bone fragments are firmly or closely abutting. This is essentially intramembranous bone healing and takes place in a stable fracture environment with little to no callus formation. Rapid vascular budding from the margins takes place with reestablished blood supply within a few days of injury. Endosteal activity is increased, osteoblasts stimulated, and haversian canals are directly remodeled in primary fracture healing.[71]

Increased strain, fragment mobility, and bony margin gap play a role in determining osseous healing by *secondary* means. Periosteal and soft tissue responses are key, there is initial hematoma formation which becomes the initial matrix, and growth factors are released to stimulate cellular differentiation and endothelial budding. An interval phase of *soft callus* formation of differentiated chondrocytes holds the fracture, but this can be easily disrupted by excessive forces, including surgery.[72] If stability exists, then osteoblastic differentiation and bone formation is encouraged, resulting in a *hard callus* of woven or immature bone. These intermediate and latter stages of secondary bone healing are respectively shortened in youthful bone (3-4 weeks) compared to that in adults (6-8 weeks), given equal forces applied across the site of injury.[72,73] Remodeling is a process of several weeks to months, attained earlier in children and modulated by external forces applied to the fracture site.

Barriers to Healing

Generally speaking, children heal well, and in the setting of a healthy child with favorable tissue profile and low bioburden (this will be reviewed later), a wound should predictably heal with little issue. It is important, however, to understand the chief mechanisms involved in tissue repair, which basically are similar in all age groups. Further, when unfavorable conditions are present, the surgeon must first recognize those conditions, then recruit appropriate systemic and exogenous adjuncts to turn the wound to an optimal healed state—minimal deformity and good function.

Systemic Factors

Most children are in good health, they do not have age-related damage to tissues, they are in prime cardiopulmonary condition and, for the most part, are nonsmokers and free of substance abuse. With that understood, the surgeon can expect wounds in a healthy child to heal fast and predictably.

There are some systemic factors that should be taken into consideration in a child with injuries.[74] Table 12-6 lists several disease states that can adversely affect wound healing. Children with any of these conditions may have altered or deficient responses to wound healing; therefore not only will the phases of tissue repair be prolonged, but a poorer wound more susceptible to breakdown or infection may be created. If poorly managed, deformity, chronicity, pain, and dysfunction may result with increased costs and burden of care.

Diabetes

It is well known that poorly controlled diabetes promotes increased demands on wounded tissue by poorly reducing the bio-burden of the wound. Bio-burden is that condition of a wound that has increased demands placed upon it for healing, principally due to the bacterial load in the wounded tissue, foreign body and microbial removal and the cellular response to accomplish it, microbial competition for oxygen and nutrients, and breakdown products that may further injure the resident cells and tissues, thus promoting an undesirable and prolonged inflammatory response and ultimately reducing wound integrity and strength. Diabetes further exacerbates the challenges to wound healing through insufficient vascular delivery of oxygen and

TABLE 12-6 Systemic Factors and Wound Healing

Diabetes	Poor tissue health; increased O_2 free radical damage, cellular dysfunction, leukocyte dysfunction in hyperglycemic state; increased microbial substrate
Immune altered states (including corticosteroids, NSAIDS)	Relative immune incompetence and poor resistance response; deficient chemotaxis; dysregulated cytokine, hormone, complement and factor production signaling
Connective tissue disorders (Ehlers-Danlos, Marfan, Werner)	Poor wound substrate production and matrix formation; altered fibroblast collagen production; weak scar
Malnutrition (vitamin deficiency, malabsorption)	Deficient collagen cross-linking; growth factor and collagen production deficiencies; altered chemotaxis, weakened cellular defense and poor inflammatory response
Hematologic (anemia, hemoglobinopathies, coagulopathies, factor deficiencies)	Poor oxygen delivery and off-loading; poor clot and provisional matrix formation; deficient cascade and cellular event sequences; hematoma formation and prone to wound breakdown
Obesity	Relative hypoperfusion in cutaneous and subcutaneous tissues; prone to hematoma, seroma formation; adipokines exert a general negative response on immune and inflammatory processes
Stress	Poor cell-mediated response; immune system dysregulation

After Percival SL, Hill KE, Williams DW et al: A review of the scientific evidence for biofilms in wounds. *Wound Repair Regen* 20(5):647-657, 2012.

nutrients. Leukocyte chemotaxis and the cellular ability to engulf and phagocytize microorganisms are weakened in the hyperglycemic state.

Immune Deficiency

Immune deficiency diseases and states are many and complex. Any altered ability of systemic host response to wounding, bacterial invasion, steps of provisional and mature matrix formulation (which the acute inflammatory and proliferative phases of wound healing are part of and build upon), and tissue collagen maturation will result in a poor wound state. Medications such as corticosteroids and nonsteroidal anti-inflammatory drugs (NSAIDs) suppress cellular wound response, fibroblast differentiation, and production of collagen, weaken collagen cross-linking, and reduce wound contraction and maturation.

Connective Tissue Disorders

Connective tissue disorders generally affect tissue proliferation and maturation, which will result in a poorly constructed wound with limited tensile strength. Principle diseases of connective tissue integrity are Ehlers-Danlos and Marfan syndromes. Thin, inelastic cutaneous tissue is more prone to injury, breakdown during healing, and prolonged healing. Malnutrition, principally protein and vitamin deficiencies, directly and adversely affect cellular metabolism through poor energy production, poor nutrient absorption, hypoalbuminemia (a decrease in the body's main serum-binding protein), and vascular fragility and compromise.

Hematologic Disorders

Hematologic disorders are varied in disease and expression. Anemic states have a direct consequence on wounded tissue if oxygen carrying capacity is diminished to the point that the high oxygen demands of injured tissue exceed supply. Wound healing stops, and the bio-burden necessarily increases. Usually mild anemia can be overcome with increased oxygen administration and iron administration if there is iron deficiency (this response is not immediate). Moderate to severe anemia or hemoglobinopathies, such as sickle cell anemia, will result in poor oxygen delivery to injured tissue. Usually, severe anemia will require a blood transfusion to overcome the deficiency state until the anemia is treated. Sickling of hemoglobin in sickle cell anemia requires immediate management with increased oxygen administration, warming the patient, hydration measures, and stopping stressors.

Coagulation disorders can also adversely affect wound healing. During the initial tissue response in injury, the coagulation cascade and platelet function must proceed normally to initiate and form a fibrin clot. It is within this primary matrix that the many events of inflammation and proliferation take place on the way to healing. Further, an expanding wound defect with poor clot formation or integrity will impede further healing processes, may contribute to increased bio-burden, and may inhibit endothelial formation in the granulation bed.

Obesity

Obesity is a problem in American youth; a significant portion of children presenting to the hospital with injury are obese (the Centers for Disease Control and Prevention estimates that about one third of all U.S. children are overweight or obese). Moderate obesity is defined as >40% above ideal body weight for age and sex, and moderate to severe obesity has a deleterious effect on tissue healing responses. Generally, poor healing in obesity relates to a corresponding vascular decrease in cutaneous and subcutaneous tissues with consequent diminished oxygen delivery to injured tissues. Adipokines are adipose cytokines that have modulating expression, chemical signaling, and impact on tissues through *pro-* and *anti-*inflammatory

mechanisms, as well as a key role in tissue insulin resistance. Evidence suggests that injured tissue has a prolonged inflammatory response due to the more predominant and forceful action of adipokine-mediated pro-inflammatory agents.

Local Factors

The health and integrity of the wound bed is significant for healing. Obviously, a breach in the soft tissue necessarily results in a change to the vascular network, may result in devitalized tissue, and introduces foreign body contaminants and bacteria into the wound. Each of these local barriers to healing will be reviewed.

Dermal Integrity

Intact skin and mucosa serve as the first host defense to disease and protects underlying tissues from exposure, dehydration, mechanical and biologic injury, and bacterial colonization. To the same degree of injurious breach of the dermis is a corresponding injury to underlying structures. Particularly exposed to contamination are the relatively avascular perifascial spaces, fat, and devitalized tissue. Gross contamination of these tissues necessitates thorough debridement and washout to promote the healing response. Tearing of the blood vessel network, particularly in the richly vascularized cutaneous tissues, results in relative tissue hypoxia in the wound bed and surrounding tissues. An abbreviated period of hypoxia follows every injury and serves to initiate the inflammatory response; however, prolonged tissue hypoxia will slow or halt the proliferative phase of healing.

Foreign Body

Accompanying the injurious insult may be the forceful introduction of particulate foreign bodies, contaminated liquids, or air. Further, nonviable bone fragments and soft tissue will also serve as a foreign body nidus that will increase the bio-burden of the wound and interfere with normal tissue healing by invoking a prolonged inflammatory response. Foreign bodies are quickly colonized by microorganisms, particularly gram-positive organisms such as staphylococci, which form a surface biofilm resistant to antimicrobial action. A 10^3 increase in minimal bactericidal levels has been determined necessary for most antibiotics in the face of a colonized foreign body contaminant.[73-75] Particulate matter such as road dirt, tar, and metallic substances can "stain" or tattoo the soft tissue, contributing to chronic inflammation, delayed healing, or an unsightly scar.

Infection

Any open wound has a bacterial load that may become problematic to healing. Microorganismal tissue loading can be characterized as[73,74]:

Contamination: bacterial presence without proliferation

Colonization: bacterial proliferation without signs or symptoms of infection

Critical colonization: progressive bacterial growth that is nearing the point of overwhelming tissue host defenses

Infection: Proliferation, invasion, and spread of bacteria beyond the wound margins with signs and symptoms of host response—swelling, erythema, pain, fever, purulence, leukocytosis, and tissue dysfunction (neural loss, joint immobility, thrombosis, etc.)

It is important to recognize that these various levels of bacterial loading in a wound will increase bio-burden and will tilt the wound toward delayed or ineffective healing.[76] Bacterial overgrowth (critical colonization or infection) results in production of free radicals injurious to healing tissue, cellular breakdown with release of proteases and enzymes, and the production of organismal toxins.[75] Management directives to include washout of contaminated or colonized wounds, or debridement (incision, drainage, and washout) of infected wounds, must be carried out to positively influence and promote healing. Even though "youthful health and vigor" are very important, the surgeon cannot entirely rely on them to supplant these management directives in the face of a contaminated problem wound with increased bio-burden.

Patterns of Injury in Children

Soft Tissue

Young children who sustain a force to the facial region distribute that force differently as compared to adults. The frontal-orbital region is a correspondingly larger and exposed area of children up to about 5 to 7 years of age before midface expansion takes place. Traumatic forces are more often delivered to this region and thus, traumatic brain injuries occur more commonly when the frontal-facial region is struck by blunt force.[15,24,76,77] Blows to the midface in younger children are to a smaller region of interrelated "soft" bones connected with wide sutures, buttressed by unerupted teeth, and set in the midst of absent or developing sinuses. There is a tendency to "bendiness" of the midface in children that will evenly distribute forces and result in more contusion and hematoma formation, and less fracture formation or displacement.[78-80] The very elastic soft tissue envelope of the facial skeleton gives way under blunt force, does not tear as easily as in adult soft tissues, but does result in respectively more significant hematoma formation and edema. The highly vascularized craniofacial tissues in children contribute to "exaggerated" swelling that can mimic or suggest more underlying injury than is actually present. These patterns of injury should not preclude the surgeon from keeping in mind that these forces will translate intracranially, as children are more apt to suffer TBI in the absence of fractures from upper facial blows than in the adult (due to the fragile interconnecting bridging veins and more loosely bound dural attachments).[15,16]

Traumatic forces directed to the lower face or neck in children can result in damage to the mandible and airway, respectively. Condylar fractures may not occur after a blow to the chin due to the elasticity of bone; however, intracapsular hematoma formation and microfracturing of the condylar surface may occur, which may have an effect on initial healing with increased fibrosis, scarring, and growth perturbations. Blows to the neck region may result in cartilaginous injury of the airway, and particular attention should be given to careful

assessment of the child early in management who has bruising and swelling around the neck.[20] Because of the higher location of the cricoid in children, this area can be damaged by blows to the submental and chin area. Actual tracheal or thyroid cartilage fracture is less common in young children compared to adolescents or adults; however, the small, easily collapsible airway in children combined with swelling will contribute to airway embarrassment very quickly and should be monitored.[18]

Skeletal

Fracture patterns in children are different than in adults due to thinner cortices, increased cortical elasticity, and relatively enlarged cancellous portion.[81] Bone in children has a lower modulus of elasticity, lower bending strength, and lower mineral content. The low bending strength induces more strain in pediatric bone than for the same stress on adult bone, which allows for greater energy absorption before ultimate failure and fracture. Several fracture mechanisms are recognized in orthopedics[81-83]:

- *Plastic deformation:* Blunt force applied to a bone results in microscopic weakening of the convex surface without translation to the concave surface. The surface morphology and contour may be changed, but a fracture does not take place. Mild deformations may be likened to a deep "bone bruise." Trabecular edema and intrabony architecture disruption of the cancellous portion may occur. Injury has occurred, but its effect may not be detected until growth has been adversely affected in later years. The mandibular condyle is especially susceptible to this mechanism of "non-fracture" injury. A more forceful or direct injury to the chin may result in a "*buckle-type fracture*," which is classically seen in long bones after compression forces are applied along the axis. There is compression fracture of the condylar surface and minor bulging of the condylar neck where trabecular compression has taken place. Active physiotherapy after a very short period (3-5 days) of immobilization is necessary for optimal healing in these fractures.

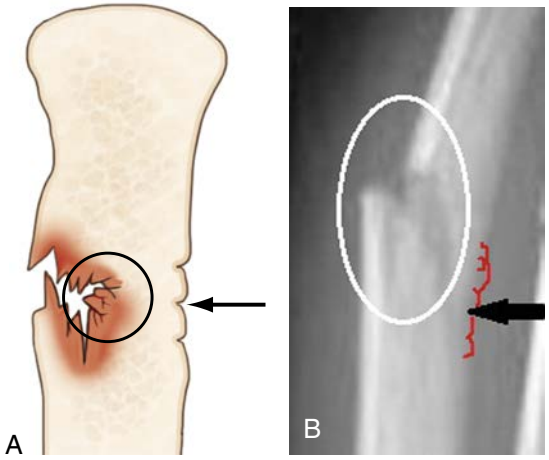

• **Figure 12-15** Diagram **(A)** and radiograph **(B)** of greenstick fractures, common in children. Force *(arrow)* is applied to the concave surface, which results in compression with buckling, but the convex *(*opposite, *circle)* surface tension is overcome and fractures.

- *Greenstick fracture:* A force is applied to a bone surface (concave) and the tensile resistance of the opposite or convex surface is overcome and fractures, but the concave surface remains intact though deformed or bent through compression (Figure 12-15). The thick, supple periosteum in children assists in keeping the pliable bones from completely fracturing and being displaced. Greenstick fractures are seen primarily in the mandible, but also nasal bones, zygomatic arch, and the thin calvaria of young children. Mechanical (applied) or resting (implied) immobilization for a period of 7 to 10 days followed by active physiotherapy is recommended, as tolerated and according to comfort levels of the child.
- *Complete fracture:* As the term implies, the force is excessive and results in complete bicortical bony separation, with or without fragment displacement. Complete fractures are generally detected on plain radiographs, though in children, some nondisplaced fractures may not become detectable until after a period of several days when initial fracture healing is underway.[83,84] Older children and adults suffer complete fractures more often than younger children due to increasing maturity and mineralization (brittleness) of bone and the significant forces they may be exposed to in accidents or assaults. Complete fractures require stable immobilization or fixation mechanics applied to the fracture to achieve satisfactory healing and avoid deformity and dysfunction.

Finally, loading and skull fracture characteristics, as noted in cranial trauma in infants and young children, suggest that skulls with patent sutures are subject to increased blunt force–induced TBI. This is due to higher strain in the calvarial surface and less absorptive capability of energy forces at the sutures.[84] This means that greater impact force is necessary to result in skull fracture, something to consider when examining an infant with a "low-fall" reported injury.

Summary

Wound healing in children is an accelerated and sometimes exaggerated response to the inflammatory mediators involved in injury and repair mechanisms. This often works to the advantage of young children—quick healing, faster recovery to function, and few long-term residual problems as compared to wound healing in older children or adults. Although these mechanisms of repair are advantageous and desirable, such responses to injury may result in overelaboration of collagen development, resulting in hypertrophic scars in complex soft tissue wounds. Excellent and early repair and wound support adjuvants are important in attaining a final scar and tissue state that is cosmetic, functional, and without long-term residual compromise of holistic health and psychological overtones. Healthy children will generally recover well from their injuries, provided expert surgical management and appropriate support resources are employed early on and throughout the healing period, and perhaps beyond.

References

1. Peden MM: *UNICEF, World Health Organization 2008 World Report on Childhood Injury Prevention*, Geneva, 2008, World Health Organization.
2. Centers for Disease Control and Prevention, National Center for Injury Prevention and Control: Web-based injury statistics query and reporting system (WISQARS). Department of Health and Human Services website. http://www.cdc.gov/ncipc/wisqars Accessed November 12, 2010.
3. National Center for Injury Prevention and Control: CDC Injury Fact Book. 2006 Centers for Disease Control and Prevention Atlanta. http://www.cdc.gov/ncipc/injuryfacts Accessed March 10, 2015.
4. Borse NN, Gilchrist J, Dellinger AM, et al.: CDC Childhood Injury Report: Patterns of unintentional injuries among 0-19 year olds in the United States, 2000-2006, *Atlanta*, 2008. Centers for Disease Control and Prevention, National Center for Injury Prevention and Control.
5. Centers for Disease Control and Prevention: Vital signs: unintentional injury deaths among persons aged 0-19 years—United States, 2000-2009, *Morbid Mortal Wkly Rep* 20(61):270–276, 2012.
6. Holcomb GW, Murphy JP, Ostile DJ, St. Peter SD, editors: *Ashcraft's pediatric surgery*, ed 6, Philadelphia, 2014, Elsevier, pp 177.
7. DiScala C: *National Pediatric Trauma Registry annual report. Tufts University Rehabilitation and Childhood Trauma Research and Training Center*, American College of Surgeons Trauma Data Bank, 2012.
8. Pediatric injuries annual report: *ACS National Trauma Data Bank*, 2012. https://www.facs.org Accessed May 15, 2015.
9. Cody BE, Mickalide AD: *Report to the nation: trends in unintentional childhood injury mortality, 1987-2000*, Washington, DC, 2003, National SAFE KIDS Campaign, pp 1–3.
10. Notrica DM, Weiss J, Garcia-Filion P, et al.: Pediatric trauma centers: correlation of ACS-verified trauma centers with CDC statewide pediatric mortality rates, *J Trauma Acute Care Surg* 73:566–572, 2012.
11. DeRoss AL, Vane DW: Early evaluation and resuscitation of the pediatric trauma patient, *Semin Pediatr Surg* 13:74–79, 2004.
12. Cowley RA: Foreword, *Am Surg* 45:77–78, 1979.
13. Haller JA: The surgical management of life-threatening injuries in children. 1994 ACS Scudder Oration on Trauma, *ACS Bull* 80:8–18, 1995.
14. *Advanced trauma life support for doctors*, ed 6, Chicago, 1997, American College of Surgeons Committee on Trauma.
15. Schunk JE, Schutzman SA: Pediatric head injury, *Pediatr Rev* 33:405–410, 2012.
16. Post AF, Boro T, Ecklund JM: Injury to the brain. In Moore EE, Feliciano DV, Mattox KL, editors: *Trauma*, ed 7, Chicago, 2013, McGraw-Hill Medical, pp 356–376.
17. Teasdale G, Jennett B: Assessment of coma and impaired consciousness: a practical scale, *Lancet* 2:81–84, 1974.
18. Davis DP, Peay J, Sise MJ, et al.: Prehospital airway and ventilation management: a trauma score and injury severity score-based analysis, *J Trauma* 69:294–301, 2010.
19. Bhalla T, Dewhirst E, Sawardekar A, et al.: Perioperative management of the pediatric patient with traumatic brain injury, *Paediatr Anaesth* 22(7):627–640, 2012.
20. Stone DJ, Gal TJ: Airway management. In Miller RD, editor: *Anesthesia*, Philadelphia, PA, 2000, Churchill Livingstone, pp 1414–1451.
21. Reis AG, Nadkarni V, Perondi MB, et al.: A prospective investigation into the epidemiology of in-hospital pediatric cardiopulmonary resuscitation using the international Utstein reporting style, *Pediatrics* 109:200–209, 2002.
22. Kincaid EH, Chang MC, Letton RW, et al.: Admission base deficit in pediatric trauma: a study using the national trauma data bank, *J Trauma* 51:332–335, 2001.
23. Langlois JA, Rutland-Brown W, Thomas KE: The incidence of traumatic brain injury among children in the United States: differences by race, *J Head Trauma Rehabil* 20:229–238, 2005.
24. Duhaime AC, Christian CW, Rorke LB, et al.: Non-accidental head injury in infants—the "shaken-baby syndrome", *N Engl J Med* 338:1822–1829, 1998.
25. Tabori U, Kornecki A, Sofer S, et al.: Repeat computed tomographic scan within 24-48 hours of admission in children with moderate and severe head trauma, *Crit Care Med* 28:840–844, 2000.
26. Da Silva PS, Reis ME, Aguiar VE: Value of repeat cranial computed tomography in pediatric patients sustaining moderate to severe traumatic brain injury, *J Trauma* 65:1293–1297, 2008.
27. Tieves KS, Goldstein J: Head injury and facial trauma. In Holcomb GW, Murphy JP, Ostlie DJ, St. Peter SD, editors: *Ashcraft's pediatric surgery*, ed 6, Philadelphia, 2014, Elsevier Health, pp 215–229.
28. Shapiro K, Marmarou A: Clinical applications of the pressure-volume index in treatment of pediatric head injuries, *J Neurosurg* 56:819–825, 1982.
29. Muizelaar JP, Marmarou A, DeSalles AA, et al.: Cerebral blood flow and metabolism in severely head-injured children. Part 1: Relationship with GCS score, outcome, ICP, and PVI, *J Neurosurg* 71:63–71, 1989.
30. Acra MJ: *Handbook of pediatric surgical critical care*, ed 1, Surgical Critical Care Task Force and the American Pediatric Surgical Association, 2013, pp 276–278.
31. Mokri B: The Monroe-Kellie hypothesis: applications in CSF volume depletion, *Neurology* 56(12):1746–1748, 2001.
32. McNeely PD, Atkinson JD, Saigal G, et al.: Subdural hematomas in infants with benign enlargement of the subarachnoid space, *Am J Neuroradiol* 27:1725–1728, 2006.
33. Ersohin Y, Mutluer S, Palali I, et al.: Pediatric depressed skull fractures: analysis of 530 cases, *Childs Nerv Syst* 12(6):323–328, 1996.
34. Steinbok P, Flodmark O, Martens D, et al.: Management of simple depressed skull fractures in children, *J Neurosurg* 66(4): 506–510, 1987.
35. Rathore MH: Do prophylactic antibiotics prevent meningitis after basilar skull fracture? *Pediatr Infect Dis J* 10:87–88, 1991.
36. Dagi TF, Meyer FB, Poletti CA: The incidence and prevention of meningitis after basilar skull fracture, *Am J Emerg Med* 1(3): 295–298, 1983.
37. Villalobos T, Arango C, Kubilis P, et al.: Antibiotic prophylaxis after basilar skull fractures: a meta-analysis, *Clin Infect Dis* 27(2):364–369, 1998.
38. Venetz I, Schopfer K, Muhlemann K: Paediatric, invasive pneumococcal disease in Switzerland, 1985-1994. Swiss Pneumococcal Study Group, *Int J Epidemiol* 27:1101–1104, 1998.
39. Adelson P, Bratton S, Carney N: Guidelines for the acute medical management of severe traumatic brain injury in infants, children and adolescents, *Pediatr Crit Care Med* 4:S1–S75, 2003.
40. Vavilala MS, Muangman S, Tontisirin N, et al.: Impaired cerebral autoregulation and 6-month outcome in children with severe traumatic brain injury: preliminary findings, *Dev Neurosci* 28:348–353, 2006.

41. Paulson OB, Strandgaard S, Edvinsson L: Cerebral autoregulation, *Cerebrovasc Brain Metab Rev* 2(2):161–192, 1990.
42. Pfenninger J, Kaiser G, Lutschg J, et al.: Treatment and outcome of the severely head injured child, *Intensive Care Med* 9(1):13–16, 1983.
43. Catala-Temprano A, Claret Teruel G, Cambra Lasaosa FJ, et al.: Intracranial pressure and cerebral perfusion pressure as risk factors in children with traumatic brain injuries, *J Neurosurg* 106:463–466, 2007.
44. Bratton SL, Chestnut RM, Ghajar J, et al.: Guidelines for the management of severe traumatic brain injury. VIII. Intracranial pressure thresholds, *J Neurotrauma* 24(Suppl 1):S55–S58, 2007.
45. Khanna S, Davis D, Peterson B, et al.: Use of hypertonic saline in the treatment of severe refractory posttraumatic intracranial hypertension in pediatric traumatic brain injury [see comment], *Crit Care Med* 28(4):1144–1151, 2000.
46. Morrow SE, Pearson M: Management strategies for severe closed head injuries in children, *Semin Pediatr Surg* 19(4):279–285, 2010.
47. Liesemer K, Bratton SL, Zebrack CM, et al.: Early post-traumatic seizures in moderate to severe pediatric traumatic brain injury: rates, risk factors, and clinical features, *J Neurotrauma* 28:755–762, 2011.
48. Annegers JF, Hauser WA, Coan SP, et al.: A population-based study of seizures after traumatic brain injuries, *N Engl J Med* 338:20–24, 1998.
49. Arango JI, Deibert CP, Brown D, et al.: Posttraumatic seizures in children with severe traumatic brain injury, *Childs Nerv Syst* 28(11):1925–1929, 2012.
50. Kochanek PM, Carney N, Adelson PD, et al.: Guidelines for the acute medical management of severe traumatic brain injury in infants, children, and adolescents. *Pediatr Crit Care Med* 13(Suppl 1):S1–S82, 2012.
51. Guresir E, Schuss P, Seifert V, et al.: Decompressive craniectomy in children: single-center series and systematic review, *Neurosurgery* 70(4):881–888, 2012.
52. Mackool RJ, Gittes GK, Longaker MT: Scarless healing. The fetal wound, *Clin Plast Surg* 25(3):357–365, Jul 1998.
53. Dang C, Ting K, Soo C, et al.: Fetal wound healing: current perspectives, *Clin Plast Surg* 30(1):13–23, 2003.
54. Penn JW, Grobbelaar AO, Rolfe KJ: The role of the TGF-β family in wound healing, burns and scarring: a review, *Int J Burns Trauma* 2(1):18–28, 2012.
55. Günter CI, Machens HG: New strategies in clinical care of skin wound healing, *Eur Surg Res* 49(1):16–23, 2012.
56. Gay S, Vijanto J, Raekallio J, et al.: Collagen types in early phases of wound healing in children, *Acta Chir Scand* 144(4):205–211, 1978.
57. Brown BC, McKenna SP, Siddhi K, et al.: The hidden cost of skin scars: quality of life after skin scarring, *J Plast Reconstr Aesthet Surg* 61(9):1049–1058, 2008.
58. Berman B, Viera MH, Amini S, et al.: Prevention and management of hypertrophic scars and keloids after burns in children, *J Craniofac Surg* 19(4):989–1006, 2008.
59. Gilpin DA, Barrow RE, Rutan RL, et al.: Recombinant human growth hormone accelerates wound healing in children with large cutaneous burns, *Ann Surg* 220(1):19–24, 1994.
60. Maxson S, Lopez EA, Yoo D, et al.: Concise review: role of mesenchymal stem cells in wound repair, *Stem Cells Transl Med* 1(2):142–149, 2012.
61. Gurtner GC: Wound healing: normal and abnormal. In CH Thorne RW, Beasley SJ, Aston SP, et al.: *Grabb and Smith's plastic surgery*, ed 6, Philadelphia, 2007, Wolters Kluwer, pp 15–22.
62. Garlick JA: Human skin-equivalent models of epidermal wound healing. In Rovee DT, Maibach HI, editors: *The epidermis in wound healing*, Boca Raton, FL, 2003, CRC Press, pp 5–13.
63. Reinke JM, Sorg H: Wound repair and regeneration, *Eur Surg Res* 49(1):35–43, 2012.
64. Goldman R. Growth factors and chronic wound healing: past, present and future. *Adv Skin Care* 17:24–25, 2204.
65. Hoeferlin LA, Huynh QK, Mietla JA, et al.: The lipid portion of activated platelet-rich plasma significantly contributes to its wound healing properties, *Adv Wound Care (New Rochelle)* 4(2):100–109, Feb 1 2015.
66. Marzona L, Pavolini B: Play and players in bone fracture healing match, *Clin Cases Bone Metab* 6(2):159–162, 2009.
67. Glowacki J: Angiogenesis in fracture repair, *Clin Orthop Relat Res* 355(Suppl):S82–S89, 1998.
68. Cho TJ, Gerstenfeld LC, Barnes GL, et al.: Cytokines and fracture healing, *Curr Opin Orthop* 12:403–408, 2001.
69. Le AX, Miclau T, Hu D, et al.: Molecular aspects of healing in stabilized and non-stabilized fractures, *J Orthop Res* 19(1):78–84, 2001.
70. Aiyer A: Fracture healing. www.orthobullets.com/basic-science/9009/fracture-healing Accessed May 18, 2015.
71. Wilkins KE: Principles of fracture remodeling in children, *Injury* 36(Suppl):S3–S11, 2005.
72. Rodriguez-Merchán EC: Pediatric skeletal trauma: a review and historical perspective, *Clin Orthop Relat Res* 432:8–13, 2005.
73. Galiano RD, Mustoe TA: Wound care. In CH Thorne RW, Beasley SJ, Aston SP, et al., editors: *Grabb and Smith's plastic surgery*, ed 6, Philadelphia, 2007, Wolters Kluwer, pp 23–32.
74. Percival SL, Hill KE, Williams DW, et al.: A review of the scientific evidence for biofilms in wounds, *Wound Repair Regen* 20(5):647–657, 2012.
75. Uçkay I, Pittet D, Vaudaux P: Foreign body infections due to Staphylococcus epidermidis, *Ann Med* 41(2):109–119, 2009.
76. Whatley WS, Allison DW, Chandra RK, et al.: Frontal sinus fractures in children, *Laryngoscope* 115(10):1741–1745, 2005.
77. Koltai PF, Rabkin D: Management of facial trauma in children, *Pediatr Clin North Am* 43:1253–1262, 1996.
78. Iatrou I, Theologie-Lygidakis N, Tzerbos FJ: Surgical protocols and outcome for the treatment of maxillofacial fractures in children: 9 years experience, *J Craniomaxillofac Surg* 38(7):511–516, 2010.
79. Gassner R, Tuli T, Hachl O, et al.: Craniomaxillofacial trauma in children: a review of 3385 cases with 6060 injuries in ten years, *J Oral Maxillofac Surg* 62:399–407, 2004.
80. Jenny C: Evaluating infants and young children with multiple fractures, *Pediatr Rev* 118(3):1299–1303, 2006.
81. Mabrey JD, Fitch RD: Plastic deformation in pediatric fractures: mechanism and treatment, *J Pediatr Orthop* 9(3):310–314, 1989.
82. Calmar EA, Vinci RJ: The anatomy and physiology of bone fractures and healing in children, *Clin Pediatr Emerg Med* 3(2): 85–93, 2002.
83. Della-Giustina K, Della-Giustina DA: Emergency department evaluation and treatment of pediatric orthopedic injuries, *Emerg Med Clin North Am* 17:895–922, 1999.
84. Coats B, Marguiles SS: Material properties of human infant skull and suture at high rates, *J Neurotrauma* 23(8):1222–1232, 2006.

13

Pediatric Craniomaxillofacial Trauma and Management

BRUCE B. HORSWELL, LEWIS C. JONES

Introduction

Facial injuries and fractures continue to increase in the United States despite advances in car seats, vehicle safety, and other accident prevention measures. A survey of pediatric emergency departments conducted by the National Trauma Registry from 2001 to 2005 showed that 4.6% of the nearly 300,000 pediatric trauma patients had facial fractures.[1] This does not include the many fractures (such as nasal bones) that do not present for formal evaluation or management. The Centers for Disease Control and Prevention (CDC) lists "unintentional injury" (abuse) as the leading cause of death for all pediatric patients more than 1 year of age for each of the past 10 years.[2] Despite efforts at prevention, trends continue to increase for injuries such as traumatic brain injury (TBI)—although TBI-related deaths have remained stable over the past decade (2001-2010), there has been an overall increase in the rates of TBI emergency department visits.[3] In the United States in a single year (2011), more than 650 children under the age of 12 years died and 148,000 were injured due to falls alone.[4] The cost of nonfatal injuries to the craniofacial region for children in 2012 alone was estimated by the CDC to be around $1.7 billion.[4]

Epidemiology and Trends

A recent study of trends in emergency department visits for pediatric facial fractures demonstrated that 75% of these patients were male and 72% were 15 to 21 years of age. The most common fractures were nasal and mandibular, which is consistent with other trauma database surveys.[1,5] Patterns of causes of facial fractures vary by gender and age. Facial fractures in girls are most often related to falls and motor vehicle collisions (MVCs), whereas in boys fractures are due more to firearms, recreation-related injuries, and assault. Children living in households with low annual income are more exposed to injury from firearms, violence, and MVCs.[5]

Injury in children follows a bimodal distribution with two spikes in incidence: toddler to 5 years, and adolescence. The etiologies for each group have remained the same over the past 2 decades; however, the incidence of facial injury has slowly increased, most likely due to children being left in improper care or engaging in risk-taking behavior.

Injuries associated with facial fractures are often serious because of the proximity of special organs, neurovascular structures, and the airway. It is prudent for the practitioner responsible for managing these injuries to be aware of these associations and perform a comprehensive workup before proceeding with management of the injuries. The surgeon needs to understand the development of the facial skeleton and its functional complexities during growth.

Assessment

History

The history of the accident includes the time, place, mechanism, others involved, and whether the event was witnessed; these aspects should be carefully elicited and recorded. Vaccination history needs to be documented and updated as necessary. If an animal was involved in the injury, such as a bite wound, the identification and location of the animal and need for possible quarantine must be determined. Rural injuries, particularly in livestock or poultry operations, are more prone to exposure to species-dependent pathogens, which will direct antibiotic regimens accordingly. Finally, the possibility of abuse needs to be ruled out. Mechanism of injury and the history must be reviewed, corroborated, reconciled, and reported if there is any suspicion of abuse. Oral and maxillofacial surgeons are in a key position to see children with facial injuries; therefore, they are held accountable to properly investigate and report any injury judged to be possibly initiated by abuse.

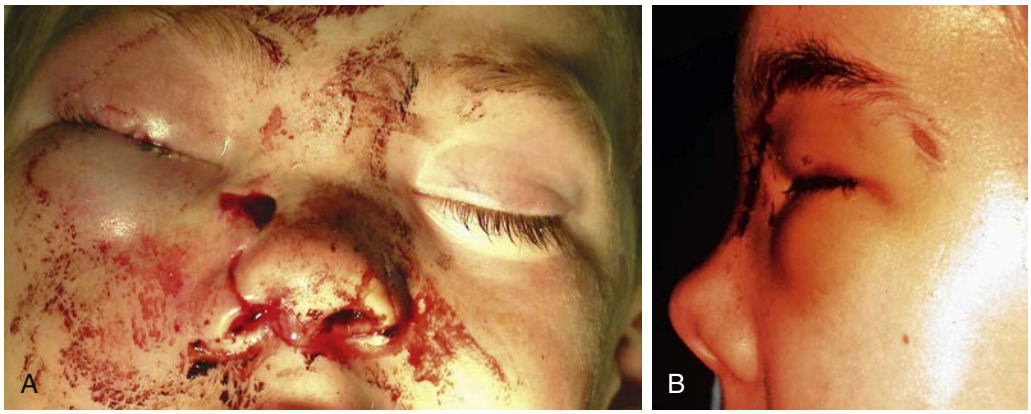

• **Figure 13-1** **A,** Significant naso-frontal swelling and pseudo-hypertelorism in a 3-year-old without fracture. **B,** Blunting of naso-frontal angle and loss of nasal projection suggests midface fracture with retro-impaction.

Physical Evaluation

Evaluation always begins with the Advanced Trauma Life Support (ATLS) protocol, which starts with an orderly and simultaneous approach to airway/breathing/circulation/deficits. With a secure airway and stable circulatory system, the mental status of the patient should be checked and rechecked appropriately for age and development (refer to Tables 12-1 through 12-3 in Chapter 12, Assessment and Management of the Injured Child). Charts with pictures that the child can name will allow for gross visual acuity verification. Extraocular movements can be verified by keeping the head still while an "attention holder," such as a colorful light or object, is moved in various directions to document ocular mobility and gaze. Repeat of these initial evaluations is necessary to closely ascertain neurologic status and detect any changes from the baseline that may indicate progression of injury.

Soft tissue injuries, including lacerations (particularly of the scalp), ecchymosis, abrasions, or avulsions may require attention to prevent ongoing blood loss. Injuries to the periorbital area should raise concerns for ocular trauma and may require evaluation by an ophthalmologist to rule out ocular damage. The nasolacrimal system should be evaluated, which may require general anesthesia for a comprehensive exam. In the uncooperative child, a complete exam will also include full evaluation of the nose to ensure no septal trauma and otoscopic examination of the ear canal and tympanic membrane. As with any exam, a consistent, repeatable, and systematic approach is the best way to identify injuries so they can be appropriately addressed.

Once the soft tissue exam is completed, methodical palpation beginning at the scalp and moving forward and down over the forehead and to the orbital rims and then inferior along the zygoma, maxilla, and mandible, including the preauricular region of the condyle, can help to identify fractures. Nasal saddle deformity and swelling over the nasofrontal region raise concern for naso-orbito-ethmoid (NOE) fractures. Nasal drainage is a concern for cerebrospinal fluid (CSF) leak as a result of dural tears and frontal sinus fractures. Loss of nasal projection and a blunted nasofrontal angle may indicate midface fracture with retrograde impaction; on the other hand, severe swelling of the nasal bridge can mimic hypertelorism (Figure 13-1), though there are no naso-orbital fractures. A "bowstring test" can help check stability of the medial canthal element; however, this can be difficult to assess in the awake, injured child. Symmetry of malar projection and flattening should be noted. Further, a down-slanting orbit (dystopia) may accompany significantly displaced zygomatic-orbital fractures. Jaw function is evaluated by checking for dental segment mobility, change in occlusion, deviation or pain with function, and bony irregularities. Guarding, pre-auricular swelling, tenderness, and deviation away from the injured side should alert the clinician to possible hemarthrosis, whereas deviation toward the side of injury usually indicates fracture displacement with foreshortening of the condylar-ramal segment. Dental status should be recorded as well as primary, mixed, or permanent dentition.

Radiographic Evaluation

Imaging is obtained to confirm suspicions generated on physical exam. Plain films in some instances are quite useful, such as a panoramic image for evaluation of dentition and mandible fractures, or submental vertex views that allow evaluation of the zygomatic arches. Computed tomography (CT) allows for a more detailed evaluation of the structures imaged, but does raise concern for cumulative doses for repetitive CT imaging in young children. New technology such as cone-beam CT helps to minimize the exposure while maximizing the data obtained from the exam. Finally, ultrasound can be used for soft tissue screening, such as hemarthroses, deep hematomas, and possible intracranial injury in the young child with open sutures. Ultimately, the clinician needs to determine the necessary imaging based on the physical exam.

Growth and Development

Airway and Sinuses

The airway and its associated sinuses develop throughout childhood and into adolescence. Changes that occur anatomically within the airway from infancy to adulthood

include the superior (or cephalad) positioning of the larynx in the infant (refer to Figure 12-3 in Chapter 12). An infant's larynx is at the level of C3-4 (cervical spine), which descends to C 4-5 in the adult. This cephalad positioning of the larynx affects visualization because of the proximity of the tongue base, which obscures the view of the vocal cords during direct laryngoscopy. The epiglottis also changes over time, beginning as a narrow, "omega"-shaped structure with an axis angled away from the trachea, then broadens during growth and flattens over time, as well as changing its axis to be parallel to the trachea. Finally, the narrowest point of the airway is at the glottis in the adult, but at the cricoid cartilage in an infant (subglottic).[6] These changes become relevant in the injured child who may require intubation or a surgical airway.

The paranasal sinuses develop throughout childhood and into adolescence. Studies based on CT scans demonstrate that the sinuses develop in the following order: ethmoid, maxillary, sphenoid, then frontal sinus.[7,8] They continue to develop into adolescence, with the ethmoid sinus completing its growth by the age of 12 years and the frontal sinus continuing to develop into late adolescence.[9] Injuries to the sinuses raise concern for post-injury obstruction. Obstruction of the duct or ostium can lead to obstruction, stasis, infections, chronic discomfort, and late mucocele development.

Injuries to the lower airway (oro- and hypopharynx) can manifest as dysphonia, dysphagia, and severe pain after injuries to the tongue, hyoid, or laryngeal cartilage. Speech is the result of a complex coordination of muscles and requires the harmonious relationship of lips, dentition, gnathic skeleton, tongue, velar mechanism, vocal cords, and airflow. Injury to any of these structures can result in decreased quality and production of speech.

Subglottic stenosis is one of the more problematic complications of prolonged intubation. In one prospective study of 120 children, there was an 11% incidence of subglottic stenosis in children intubated over 24 hours.[10]

Craniofacial Skeleton

The growth of the craniofacial skeleton is a complex dynamic of interrelated events that may be adversely affected by injury. The frontoparietal calvarium, nasomaxillary complex, zygomatic-orbital region, and mandibular corpus are formed principally through intramembranous ossification, while the non-calvarial parts of the occipital, sphenoid, and temporal bones and the mandibular condyle form through endochondral ossification. As these bones grow and develop, they mineralize, lose elasticity, and become less resistant to applied forces and fracture. An additional concern with pediatric fractures is the potential for disruption of normal growth vectors and "centers." The mandibular condyle (with its progressive endochondral growth and remodeling) and the nasal vault and septum (responsible for midface projection) may not respond to normal developmental influences of the expanding airway, oropharynx, and functional soft tissue envelope if severely injured.[11,12] The younger the child, the more deleterious injury is to growth vectors and mechanisms.

Increased periosteal activity in children can speed recovery through increased bone formation. This is often seen as a positive physiologic mechanism, but in intracapsular condylar fractures or injuries with hemarthrosis, inopportune bone formation can lead to ankylosis, immobility, and deformation. Further, prolonged maxillomandibular immobility in growing children can result in fibrous or pseudo-ankylosis.

Fracture Management

As with any fracture, the goals of treatment include restoration of form and function. The special considerations in children are those of future growth of the patient. Treatment (or improper treatment) may result in growth disturbance and gnathic compromise. Fixation devices may migrate during growth and later become problematic. The surgeon must decide on using open versus closed techniques, the type of fixation, grafts and adjuncts to healing, and timing of additional interventions. Therefore, it is important to understand the options available in order to address pediatric fractures appropriately and ensure restoration of form and function while minimizing growth disturbance.

Frontal Bone and Sinus Fractures

The incidence of frontal sinus fractures correlates with the development of the frontal sinus. The frontal sinus begins as an outgrowth of the nasal region that becomes radiographically evident at 4 to 5 years of age, achieves adult configuration by adolescence, and reaches full volume by the age of 20.[13] Concomitant intracranial injuries are more likely in children with frontal sinus fractures than in the adult, most likely because of the high forces required for fracture of the frontal bone.[14]

Frontal sinus fractures require repair when there is significant displacement of the frontal table that would result in cosmetic defects, retro-displacement of the posterior table, persistent CSF leak, or obstruction of the nasofrontal duct/outflow tract. Injuries without significant displacement of the anterior and/or posterior tables should be managed conservatively. This is accomplished with antibiotics (if there is a history of chronic sinusitis), decongestants as needed, head elevation, and sinus precautions. Long-term follow-up is necessary in order to detect early mucocele development. A follow-up screening CT of the paranasal sinuses at 4 to 6 months is recommended.

In cases requiring operative intervention, the repair should start with an approach that will result in a cosmetic scar—usually a coronal incision with wave incision design, or access gained through existing lacerations, though these may limit appropriate access. The fractured portions are removed and mucosa completely removed. The decision of how to treat the sinus (cranialization vs.

obliteration) should be determined by the state of the posterior table. Comminution of the posterior table, loss of dural integrity, and obvious CSF leak direct the surgeon to cranialization as the preferred treatment. Dural repair, grafting, and confirmation of cranial integrity are possible through complete removal of comminuted posterior table segments. If the posterior table is intact or with nondisplaced fractures and no CSF leak, obliteration of the sinus may be the treatment of choice. The outflow tract can be obliterated with fat, fascia, or pericranium. The author's preference is to use a pedicled pericranial flap (Figure 13-2, *A*) with fixation by tissue fibrin glue and obliteration with calvarial shavings or abdominal fat (see Figure 13-2, *B*). The outer table is then reconstructed with the use of resorbable mesh/plates/screws and harvested bone grafts if indicated. Small posterior drains and a firm dressing should be placed to prevent hematoma formation.

Complications include infection, persistent CSF leak, mucocele or mucopyelocele, meningitis, brain abscess, osteomyelitis, loss of tissue, and deformity. Concerning signs or symptoms of fever, progressive erythema or edema in the region, new-onset or worsening headache, or a change in neurologic status should prompt CT radiographic evaluation. Small and intermittent CSF leaks usually spontaneously resolve within several days.[13,15]

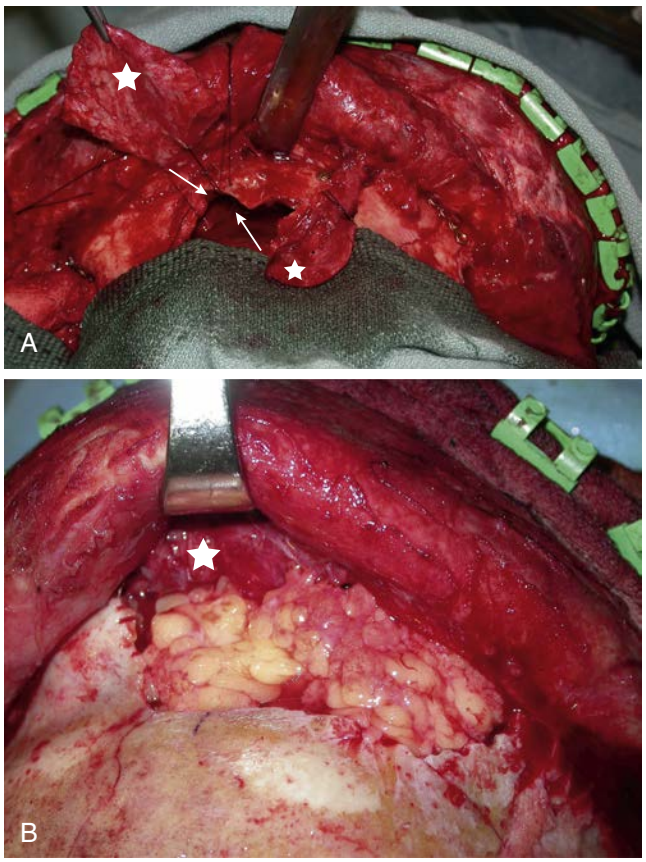

• **Figure 13-2** **A,** Pericranial flaps *(stars)* transferred into frontal recess over naso-frontal ducts *(arrows)*. **B,** Obliteration of frontal sinus with fat. *Star* indicates pericranial flap in place.

Finally, recent techniques using CT-guided technology and endoscopically assisted reduction of frontal sinus fractures have been described and, in cases with mild to moderate displacement of the frontal table, may allow reduction of fractures without significant scarring from access incisions.[15,16] Preservation of sinus integrity and physiology through appropriate surveillance and endoscopic management is now the preferred option in most frontal sinus fractures in children.

Orbital Fractures

Age plays a large role in the fracture pattern of the orbit when trauma is sustained to this region. A recent study of 312 pediatric patients over a 9-year period (4 months to 16 years of age) revealed results consistent with the anatomy and development of this region. Children less than 8 years of age were more likely to suffer orbital roof fractures (Figure 13-3), while those older than 8 years were more likely to suffer fractures of the orbital floor.[17] This correlates well with development of the orbit, which matures around the age of 7 years, as well as development of the maxillary sinus, which increases in volume and results in a larger surface area of the thin orbital floor and subsequent fracture.

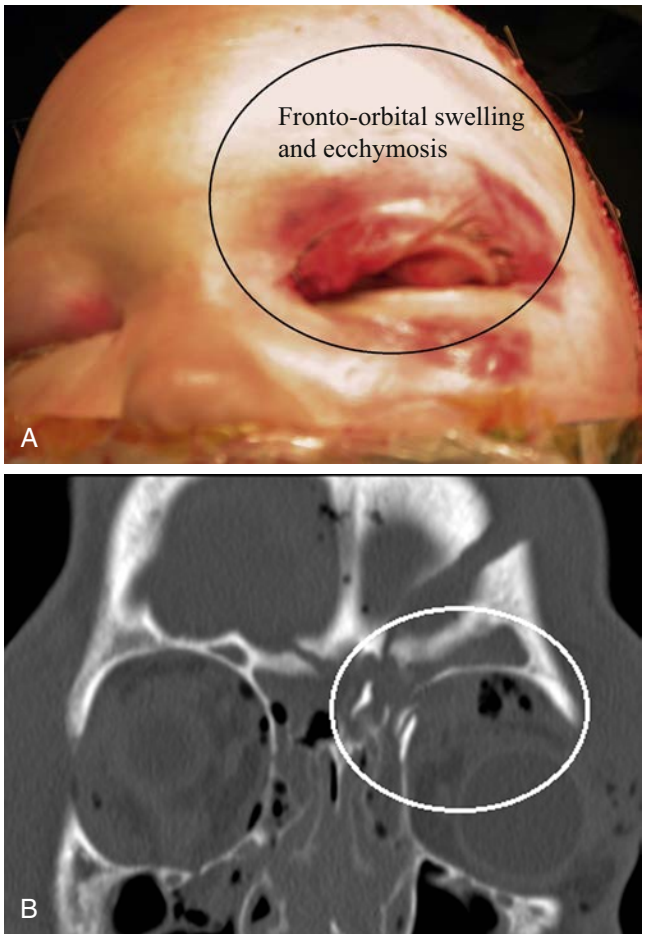

• **Figure 13-3** **A,** Five-year-old boy with significant orbital trauma from an ATV rollover. **B,** Frontal and orbital roof fractures *(circle)* in child.

Timing of repair of significant orbital floor fractures in children is crucial, as there are improved functional outcomes when these fractures are repaired early (within 48 hours).[17-20] Trapdoor fractures are more common in children due to the elasticity of the thin orbital bone; thus, the associated rectus musculature and periorbital fat become entrapped despite a lack of radiographic evidence of a bony defect (Figure 13-4).[19] A thorough ophthalmologic exam will reveal restriction of ocular movement with diplopia, often accompanied by nausea and vomiting.[19,20] The "white-eyed" blowout fracture with its lack of associated subconjunctival hemorrhage or chemosis is considered an urgent ophthalmologic condition that requires early surgical intervention before ischemia and necrosis of the entrapped tissue ensues.[21]



• **Figure 13-4** Blowout fracture of left orbit with soft tissue entrapment. Elevation of the eyes reveals the entrapped left periorbita that prevents elevation.

Fracture repair requires volume restoration of the orbit, periorbital content restoration, and forced-duction test to confirm a lack of entrapment. Autogenous tissue (costal cartilage/bone or calvarium) can be used in order to establish orbital restoration and integrity (Figure 13-5).

Intraoperative and acute complications of pediatric orbital floor fractures include oculocardiac reflex with profound bradycardia, persistent nausea, visual changes, and enophthalmos/exophthalmos. Delayed presentation of gaze restriction due to a pronounced inflammatory reaction to resorbable orbital mesh has been reported.[22,23]

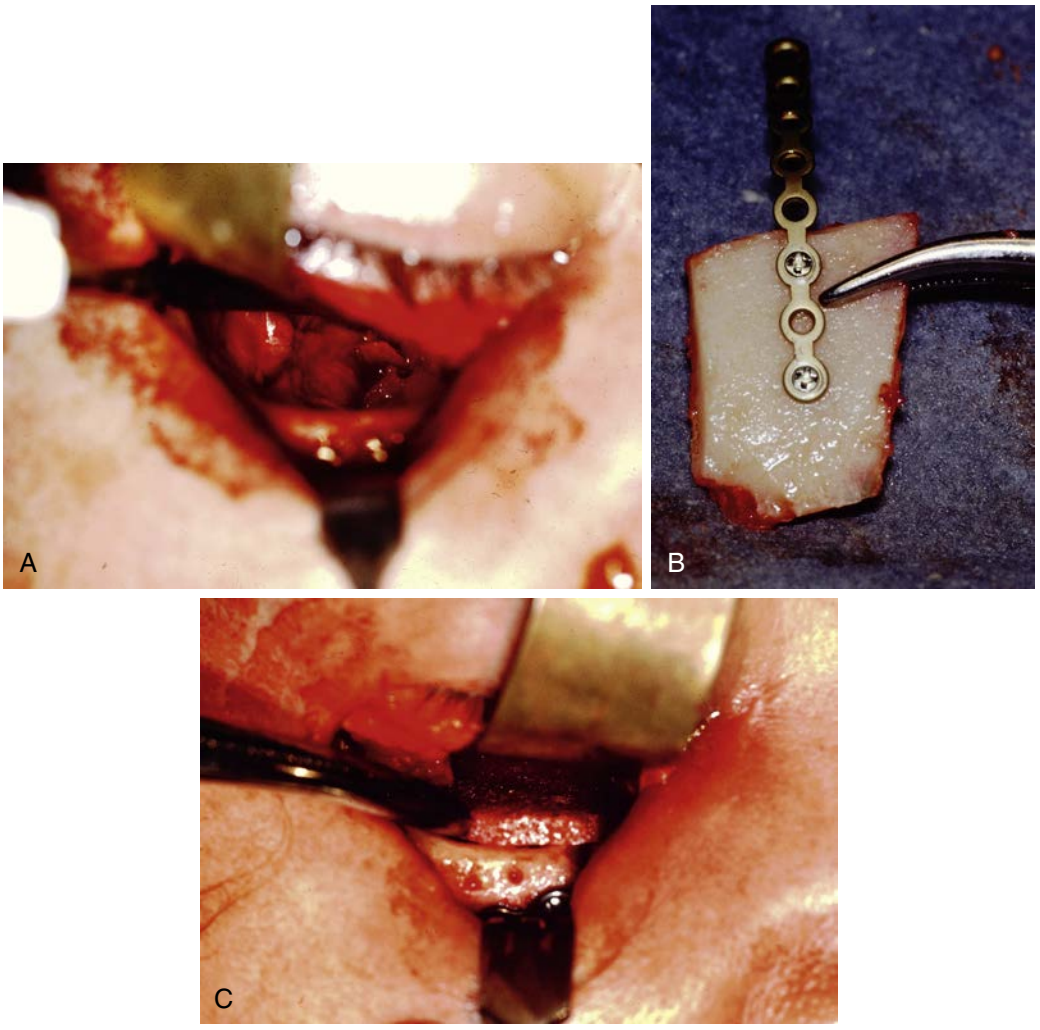

• **Figure 13-5** **A,** Operative photo of blowout fracture of the orbital floor. **B,** Calvarial bone graft adapted to fixation plate for orbital floor repair. **C,** Bone graft in orbital floor defect.

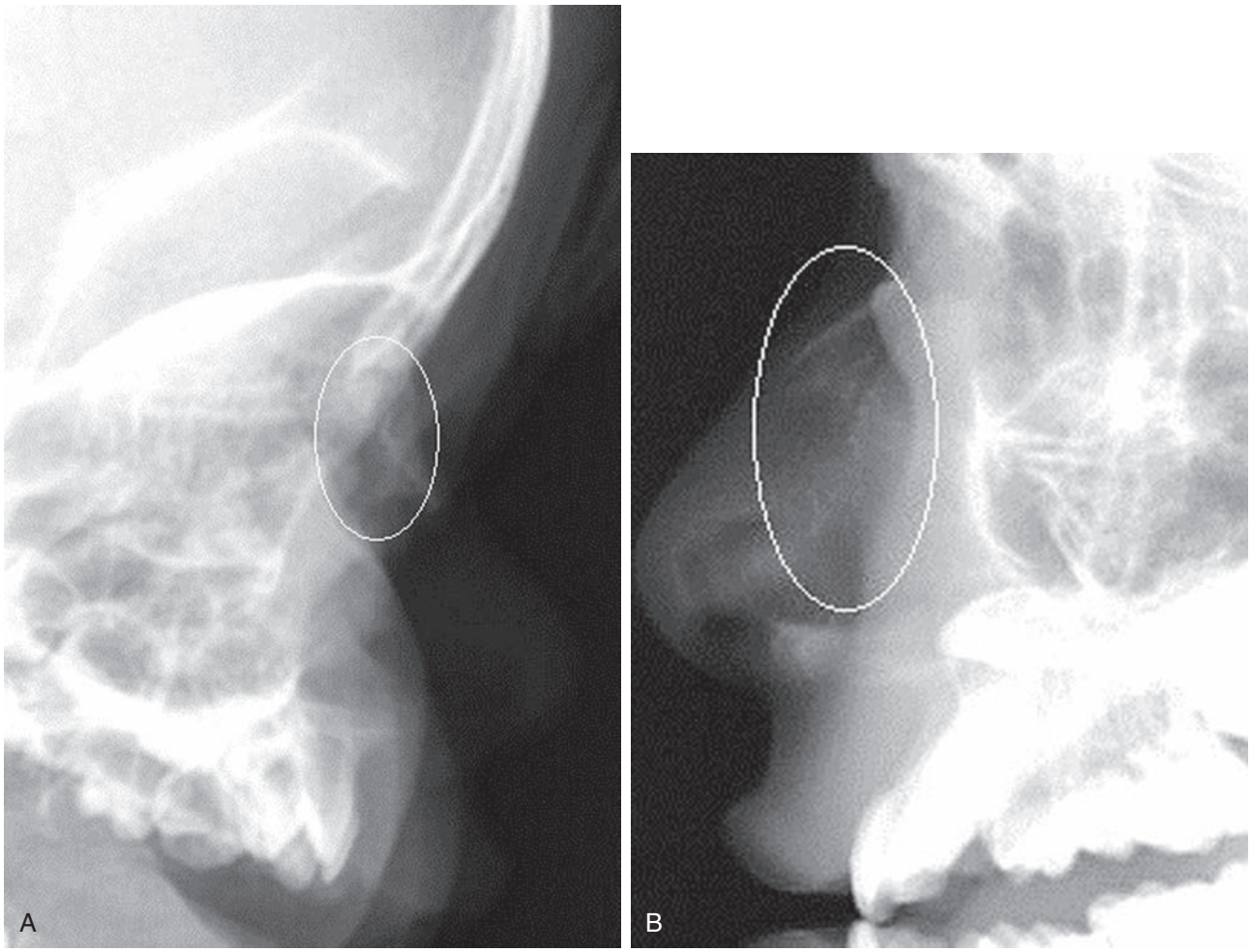

• **Figure 13-6** Plain radiograph image of a 1-year-old **(A)** and 10-year-old **(B).** Notice the wide naso-maxillary suture in the infant compared to the older child, which, in the setting of injury, may suggest a fracture.

Nasal Fractures

Nasal-septal fractures are among the most common injuries in children, yet are often underreported.[24-26] A recent retrospective study of more than 350 nasal bone fractures revealed that the most common causes were falls, sports incidents, interpersonal violence, and motor vehicle crashes.[27] Nasal injuries in the pediatric population differ in that the cartilaginous region and the immature bone are more pliable than in adults.[26] Deformation and greenstick fractures are more common as a result, which may be clinically evident initially after injury. The deformity resolves to some extent over the immediate post-injury period, though bony deformation may persist. A good indicator for possible surgical intervention is nasal airflow obstruction that does not resolve. Plain radiographs will detect grossly displaced fractures but not greenstick or minimally displaced fractures. Wide fronto-naso-maxillary sutures in young children are often misinterpreted as a "fracture" by some radiologists or emergency personnel and must be interpreted in light of the clinical presentation (Figure 13-6).[2]

Palpation of this region for step deformities or asymmetry is difficult if the child is uncooperative. Waiting for swelling to resolve, usually 3 to 5 days, to detect any residual deformity and careful assessment of nasal airflow are helpful to determine need for surgery. If clinical exam is not possible, then CT evaluation is recommended.

Treatment is best performed with closed reduction and a minimalist approach to avoid any future growth disturbances. Reduction should be performed within 7 days (or when swelling has resolved) of fracture as children will heal quickly and increased force may be necessary to obtain mobilization and reduction in order to overcome any deformation.[28]

When performing closed reduction, the surgeon should measure externally before placing the instrument intranasally to reduce the fracture. This will minimize the risk of placing the instrument unnecessarily deep in the nasal cavity with consequent nasofrontal or ethmoid air cell penetration. After reduction, careful evaluation for bleeding should be done; if there is prolonged oozing, temporary tamponade can be obtained with an astringent on a soft gauze strip. Once hemostasis has been confirmed, a conformable anatomic splint should be placed over the dorsum and secured to aid in protection. Postoperative complications include

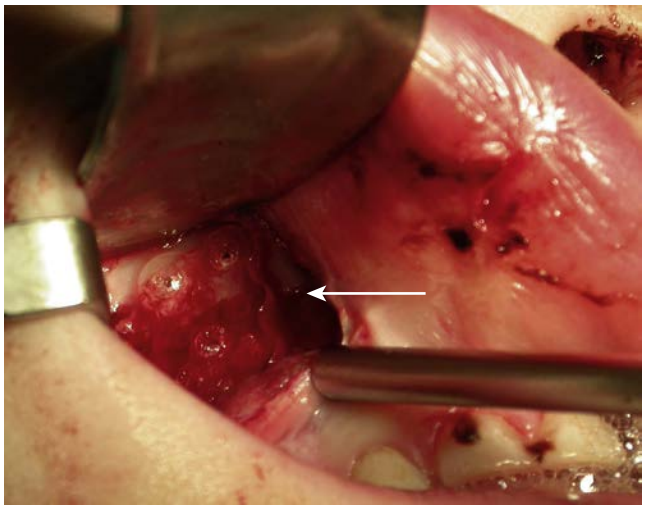

• **Figure 13-7** Operative photo of a resorbable plate at the zygomatic buttress *(arrow)*.

epistaxis, septal hematoma, obstruction, sinusitis, and need for reoperation due to inadequate reduction. Activities with the potential for contact, such as sports or recess, should be avoided for the first 6 weeks following a reduction unless full-face protection is provided.

Midface Fractures

Fractures of the zygoma and maxilla are uncommon in children compared to adults. An immature and more pliable facial skeleton with less prominent midface, small paranasal sinuses, and unerupted teeth (which act as intrabony "buttresses") affords some resistance to fracture forces, particularly in young children.[26,29] These fractures are often the result of sports injuries, motor vehicle collisions, and interpersonal violence.

Evaluation should include a full ophthalmologic exam. Loss of malar projection and symmetry, mandibular dysfunction due to zygomatic arch fracture, sensory changes, and orbital volume changes should be noted.

Patients with mixed or primary dentition may make it difficult to place conventional arch bars on the more bulbous primary teeth. In order to obtain intraoperative maxillomandibular fixation (MMF), a Risdon wire can be bonded to the teeth to achieve occlusion and closed reduction. If internal fixation is necessary, fracture repair can be accomplished with resorbable plates with judicious placement of monocortical screws (Figure 13-7).

Mandibular Fractures

Mandible fractures are among the most frequent facial bone fractures encountered, second to nasal fractures.[24,26,29-31] Mechanisms of injury include falls in younger children and vehicular crashes and sports injuries in adolescents. In young children the most common fracture of the mandible is the condyle, which then decreases in incidence with age.[32] Reports have suggested that up to 20% of condylar fractures are bilateral.[33-35] Fractures of the angle and body regions increase with age and with development of third molars.[36-38]

Treatment protocols should be categorized according to anatomic location of the fracture and developmental age. Young children have a great capacity for healing and remodeling; therefore, conservative management is preferred with simple MMF, whereas adolescents are treated similarly to adults.

Condylar Fractures

Intracapsular fractures are a concern for the development of ankylosis. Non-operative therapy with active physiotherapy is instituted as early as cooperation and comfort allow.[39] Evacuation of hemarthroses is not routinely performed in young children. Long-term follow-up with periodic radiographs to document condylar development and symmetry is prudent.

Treatment of condylar fractures is usually accomplished with a short period (5-7 days) of MMF in young children and longer periods (2 weeks) in pre-adolescents. Early mobilization and measured, prescribed physiotherapy encourage resolution of hematoma and edema and prevents muscular envelope contractures. Elastic or wire MMF may be used during the immobilization period and entirely depends on cooperation and airway status. A large prospective study with 61 patients under the age of 12 years showed no statistical difference in functional outcome between wire and elastic MMF.[40] As it is more easily tolerated and safer, elastic MMF for guided function should be implemented unless severe or complex comminution dictates strict rigid immobility.

Body and Symphyseal Fractures

Treatment of mandibular fractures with developing dentition in place is more complex for symphyseal, body, and angle fractures. The first step is establishing proper occlusal relationships with MMF. This can be challenging due to the short clinical crowns of primary and erupting teeth. Bonded Risdon wires provide dental fixation devices for establishing the occlusion. A single titanium or resorbable plate (double or strut plates) with monocortical screw fixation generally provides all the fragmentary stability required for primary osseous healing (Figure 13-8).[31,41,42] If the fracture appears to require additional stability, a short 1- to 2-week period of MMF will allow for adequate fracture healing prior to mobilization of the mandible.

Dentoalveolar Injuries

It is important to be familiar with dentoalveolar injuries, as they are common in children. Approximately one third of all cases are associated with adjacent facial soft tissue injuries.[43,44] Management of these injuries will depend on the associated injuries, numbers and class of teeth traumatized (primary vs. permanent), and condition of the supporting alveolar bone and muco-gingiva.[45]

The simplest of dentoalveolar injuries is that of the avulsed primary tooth. Primary teeth are not replanted,

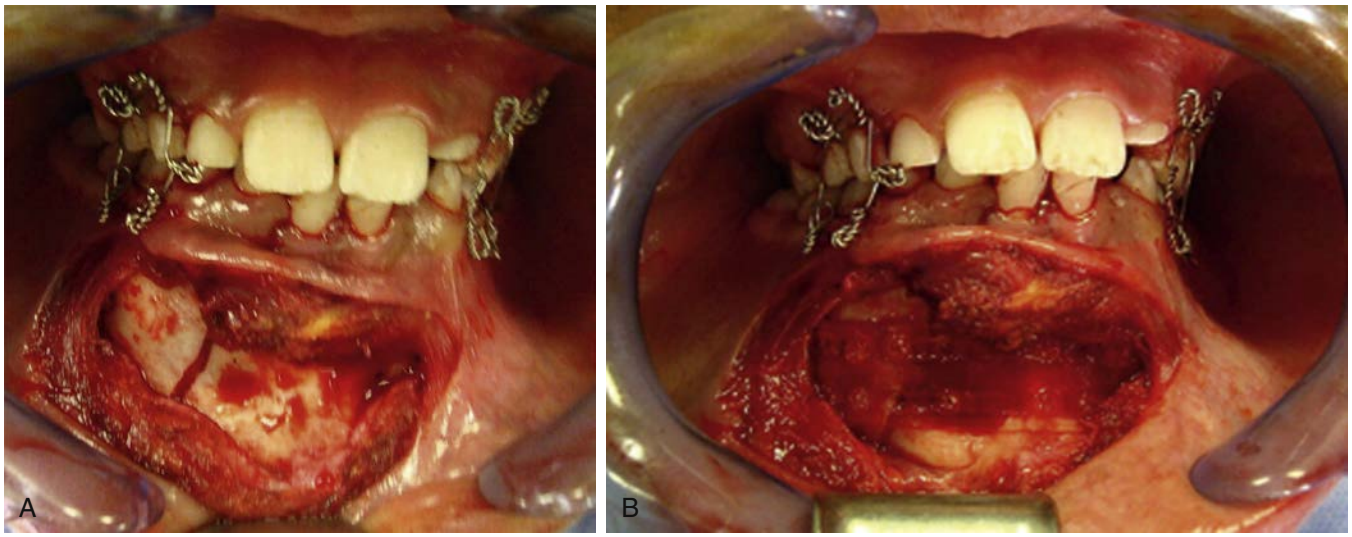

• **Figure 13-8** **A,** Ivy loop fixation prior to plate placement of parasymphysis fracture of the mandible. **B,** Single "ladder" type resorbable plate with monocortical screw fixation. (Source: Morris C, Kushner GM, Tiwana PS: Facial skeletal trauma in the growing patient, *Oral Maxillofac Surg Clin North Am* 24(3):351-364, 2012.)

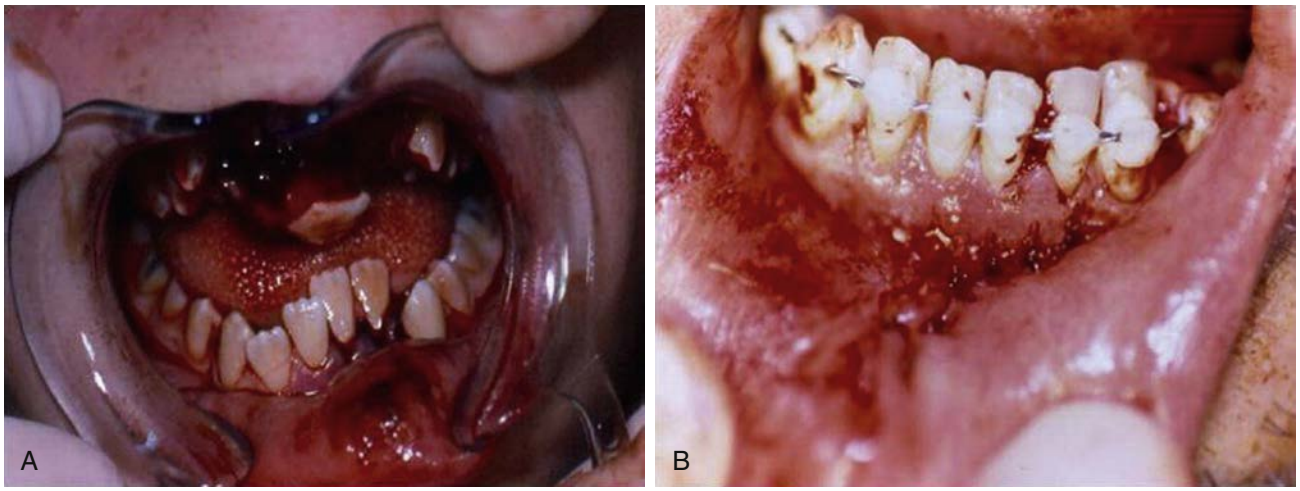

• **Figure 13-9** **A,** Dentoalveolar fractures with displaced teeth. **B,** Composite splint bonded in place. (Source: Morris C, Kushner GM, Tiwana PS: Facial skeletal trauma in the growing patient, *Oral Maxillofac Surg Clin North Am* 24(3):351-364, 2012.)

but space needs to be maintained for spatial eruption patterns to be preserved; therefore, referral to a pediatric dentist is recommended. The avulsed permanent tooth with an open apex and less than 1 hour ex situ should be replanted and splinted for 2 to 4 weeks while monitoring for revascularization versus necrosis, infection, or loss of attachment. A helpful website developed by the International Association of Dental Traumatology outlines all treatments for these injuries and is available at http://dentaltraumaguide.org.

Fractured dentoalveolar segments can be maintained with bonded wires (Figure 13-9), acrylic splints, or, if the bony segment is large enough, small fixation plates. Again, a conservative approach to these injuries in the young or mixed-dentition child is warranted.

Prevention of orofacial injuries in children is important. Mouthguards should be encouraged for any sport with the potential for contact-induced injuries to the oro-dental region. The mouthguard rule in collegiate sports was noted to decrease dental trauma from 280 events in 1970 to 55 in 1973 when the rule was first instituted.[46] Pediatric patients should be questioned as a matter of routine during well-child visits regarding the use of mouthguards and protective equipment in sports and recreation.

Soft Tissue Injuries and Management

The advent of sport vehicles, fast-paced recreational activities, risk-taking behavior in adolescents, and so forth have all translated into children more at risk for injury, particularly of the

facial region. Consequently, soft tissue injuries are common, particularly in the younger population. In order to address such injuries well, a careful examination process is warranted.

Inspection of facial soft tissue injuries in children should be performed in a controlled environment with parent or caregiver present and with adequate lighting and removal of extraneous noise or activities. Setting the stage for evaluation begins with a thorough review process with the caregiver and/or witness, done in a gentle but direct tone. This can be challenging in light of a severe soft tissue injury. Constant visual evaluation of the child, without the laying on of hands, allows for confirmation of patient stability, facial animation, and mental status changes.

Physical examination should note tissue margins, deficits and avulsions, possibility of retained foreign bodies, and damage to important underlying structures including salivary ducts, nerves, vessels, and/or muscle. The extent of the injury and age of the child will dictate the appropriate setting for treatment. Verification of vaccination status, especially tetanus currency, is recorded. A history of resistant or recurrent staphylococcal infections should prompt adequacy of previous treatment, by whom, and a nasal swab obtained to rule out staph colonization.

Superficial Wounds

Any wound, regardless of the depth or extent, requires thorough cleansing before closure. All debris must be removed, and tissue margins should be uniform and clean without foreign body discoloration. Superficial wounds with no missing tissue can usually be closed in a single layer. Often these wounds can be coapted with cyanoacrylate (tissue adhesive) if no tension exists at the wound margins. A prospective study by Singer and colleagues demonstrated similar cosmetic outcome with cyanoacrylate or standard closure with nonresorbable suture.[47] Placing adhesive near the eyes or lips in a restless child is to be discouraged. Several studies have also proven acceptable cosmetic outcome with the use of resorbable suture material.[48,49] Resorbable materials are preferable to extensive suture removal in a young child who may not tolerate suture removal in the ambulatory setting.

Deep Wounds

Deeper wounds require inspection for involvement of muscles, nerve, lacrimal system integrity, and salivary gland or ductal tissue injury (Figure 13-10, *A*). Most eyelid and lacrimal injuries will require sedation or general anesthesia for a proper evaluation in the young child. Facial nerve injury may be difficult to ascertain with extensive damage, swelling, and an uncooperative child. Animation may be recorded for later comparison during healing.

Judicious use of deeper, buried sutures to reduce tension and subcutaneous pull-out permanent sutures left for 2 to 3 weeks will significantly reduce tension, provide support to the healing wound, and reduce the number of cutaneous sutures required (see Figure 13-10, *B*). Liberal use of wound support tapes for 2 to 3 weeks postoperatively and then Silastic sheets (see Figure 13-10, *C*) for several weeks will reduce scarring.

Nerve Injuries

Generally, young children recover predictably from a nerve injury because of healthy neural tissues that exhibit pronounced axonal regeneration after contusion or transection. Sensory nerves that are injured in young children will predictably heal with return of normal dermatome sensory distribution. Adolescents with larger transected sensory nerves should be ideally repaired or given the option of repair, as one would with adult patients.

Injury to the facial nerve that occurs distal to a vertical line dropped from the lateral canthus is likely to undergo neural arborization and does not benefit from micro-neurosurgical reanastomosis. However, larger branches of the facial nerve proximal to this line do benefit from primary micro-neurosurgical repair.[50] Reapproximation of epineural tissue at the time of the initial repair is preferable and leads to the best possible outcomes. Reapproximation should be accomplished under magnification with 8-0 or 9-0 permanent suture.[51]

Glandular and Ductal Injuries

Lacerations of the salivary gland and ductal structures are managed differently depending on location. Intraparenchymal injury of the gland requires only closure of the capsule, a pressure dressing over the gland, and possibly a small dependent drain to prevent salivary accumulation.[52] Ducts (Wharton or Stenson) that are extraparenchymal and amenable to identification of proximal and distal stumps should be repaired with primary anastomosis over a stent that will be left in place for 2 to 4 weeks. Animal models have shown that reanastomosis should be performed with nonresorbable suture to minimize inflammation that accompanies degradation of suture material.[53] If the duct cannot be repaired, diversion of the proximal stump intraorally or tying off the proximal end and invoking an inflammatory sialadenitis with eventual ductal fibrosis and glandular involution can be performed.[54]

Complications of salivary gland repair include sialoceles that can usually be managed with repeated aspirations, antibiotics, and antisialogogues.[55] Established and recalcitrant parotid sialoceles, though uncommon in children, can also be managed with intraoral diversion for creation of a controlled intraoral fistula.[56]

Lacrimal Injuries

Disruption of the nasolacrimal canalicular system requires attention within 48 hours of injury to avoid very rapid scarring and ductal stenosis. The laceration traversing the canaliculus is identified with a Bowman probe or dilator (Figure 13-11, *A*) and irrigation attempted to confirm transection. Designed



• **Figure 13-10** Wound care to diminish hypertrophic scar formation. **A,** Dog bites to the face in a child at risk for hypertrophic scarring. **B,** Subcutaneous pull-out suture to maintain non-tension in the dermis during healing. **C,** Silastic sheets to maintain subtle pressure on the maturing scar to diminish hypertrophic scar formation.

Silastic tubes can then be placed at the time of the initial repair and left in place for several weeks (see Figure 13-11, *B*). Anchoring the distal tube ends intranasally with suture high in the nasal vestibule is key to prevent dislodgement. Antibiotic/anti-inflammatory ophthalmic agents are used for 1 to 2 weeks, and thereafter a simple wetting agent can be used to maintain hygiene and patency. The tubes are easily removed after several weeks of healing.[57] Associated eyelid wounds are then closed in the usual fashion, taking care to restore the anatomic lamellae of the eyelid. Complex eyelid and lacrimal wounds require loupe magnification or an operating microscope for adequate surgical management.

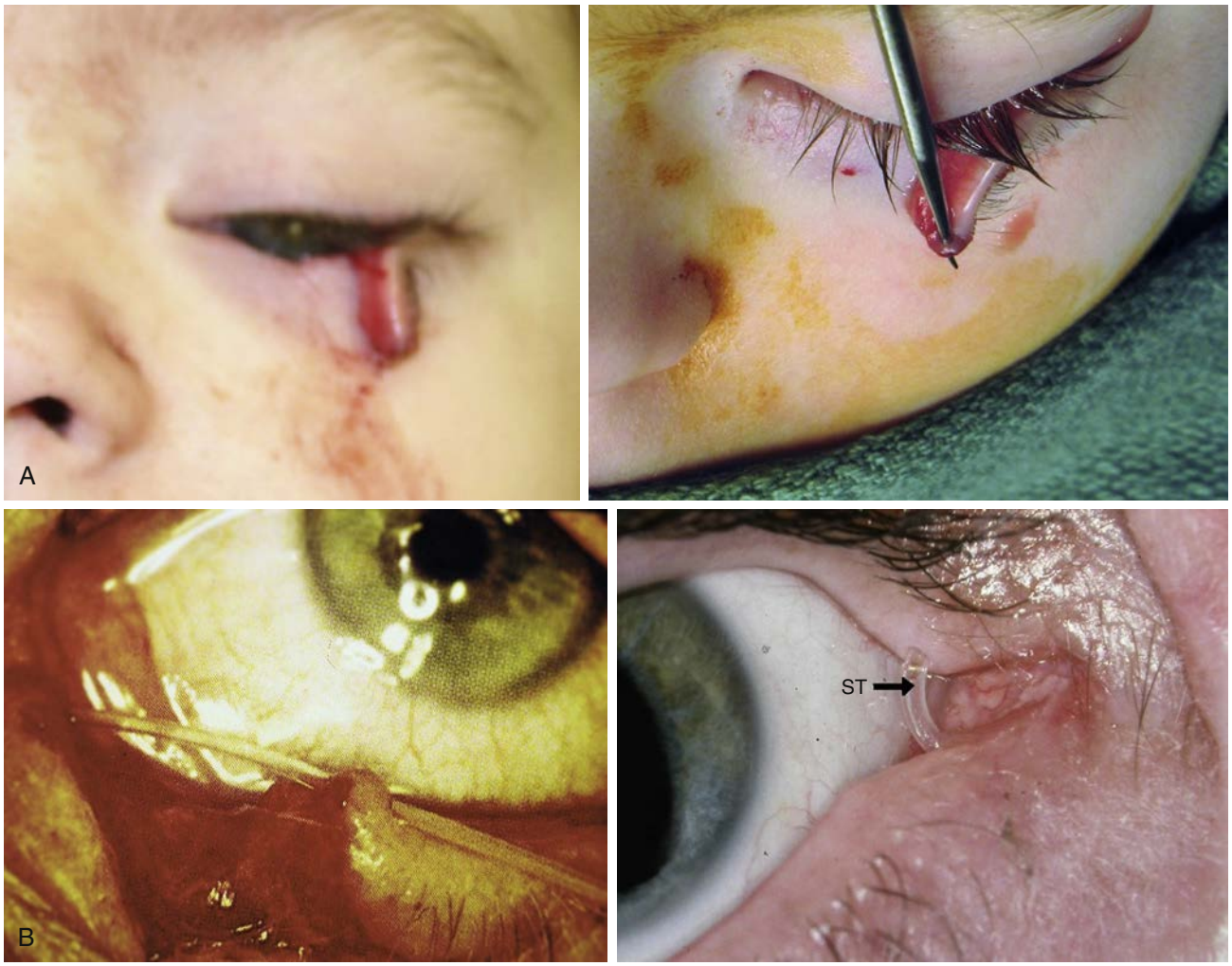

• **Figure 13-11** **A,** Lacrimal injury from torn lower eyelid. Avulsed lower eyelid at the medial canthal region involving the canaliculus with dilator probe in place. **B,** Lacrimal duct repair with prepared silicone tubes *(ST)* placed through upper and lower canaliculi, passed into the lacrimal sac and nasolacrimal duct.

Avulsive Injuries

Local Flaps

Loss of tissue in children always presents a challenge to the reconstructive surgeon because of the limited tissue depot in children as compared to the redundancy that exists in older patients. Depending on the location and defect size, local tissue rearrangement with rotational, interpolation or advancement flaps can be used for small to moderately sized defects.[58,59] Areas from which pedicled random pattern flaps can be raised to cover defects include the post-auricular, cervical, and lateral cheek with lateral canthotomy. Axial-pattern flaps include the glabellar (supratrochlear), submental (deep lingual), buccal myomucosal (facial), nasolabial (superior labial and angular), and lower lips/Abbé (inferior labial). Careful and conservative design for skin flaps in the facial region in children is paramount and should not be undertaken until the procedure has been thoroughly planned and reviewed with the parent and patient, if an older child. Placing new incisions to gain transposed tissue for defect fill on the young face should be limited and predictable. This concern has led to tissue recruitment through expansion.

Tissue Expansion

Tissue expansion allows for the use of similar-appearing skin to cover the defect, although disadvantages include the time involved in the staged operation and multiple office visits for serial saline injections.[60]

Tissue recruitment in children is generally limited to the scalp, forehead, and neck regions, as these areas lend to the nearby depot of similar tissue that can be expanded and transposed into the target site (Figure 13-12). Care must be exercised to place the access incision distant from the expander and target recipient site in order to avoid dehiscence and exposure of the reservoir. Exposure does not necessarily condemn the device, though its utility for further expansion is complete. For comfort and ease for access in children, the expander ports can be left externally to avoid



• **Figure 13-12** Tissue expansion. (Hogg NJV: Primary and secondary management of pediatric soft tissue injuries. *Oral Maxillofacial Surg Clin N Am* 24(3):374, 2012.)

percutaneous injections; there is no significant increase in infection rates with external ports. [61]

The biology of expanded tissues has been well studied, confirming that there is increased microvascularity to the expanded skin. This has a positive effect on tissue survival over that of acutely transposed tissue in a random-pattern flap. There is also an accompanying thickening of the overlying epidermis and simultaneous thinning of the dermis during the 2 to 3 weeks after expansion. Underlying muscle thins and atrophies but does rebound, whereas adipose tissue remains atrophied. Intraoperative on-table expansion can be used, especially in children, because of the better viscoelastic properties of youthful dermis. However, this does not recruit "new" tissue, but rather represents a stretching of the tissue as a "creep" mechanism.[62]

Expansion is performed on-table until overlying skin blanches; this resolves after several minutes. If not, then several milliliters of saline are removed until skin vascularity returns. Serial expansion then takes place every 2 weeks with 10 to 15 mL of saline injected in each expander or as comfort allows. Children usually tolerate expansion well if pre-injection ibuprofen or acetaminophen is administered 30 minutes before expansion. After the desired amount of tissue expansion has been attained (slightly overestimated amount of tissue), expander removal and flap rotation and inset is performed.

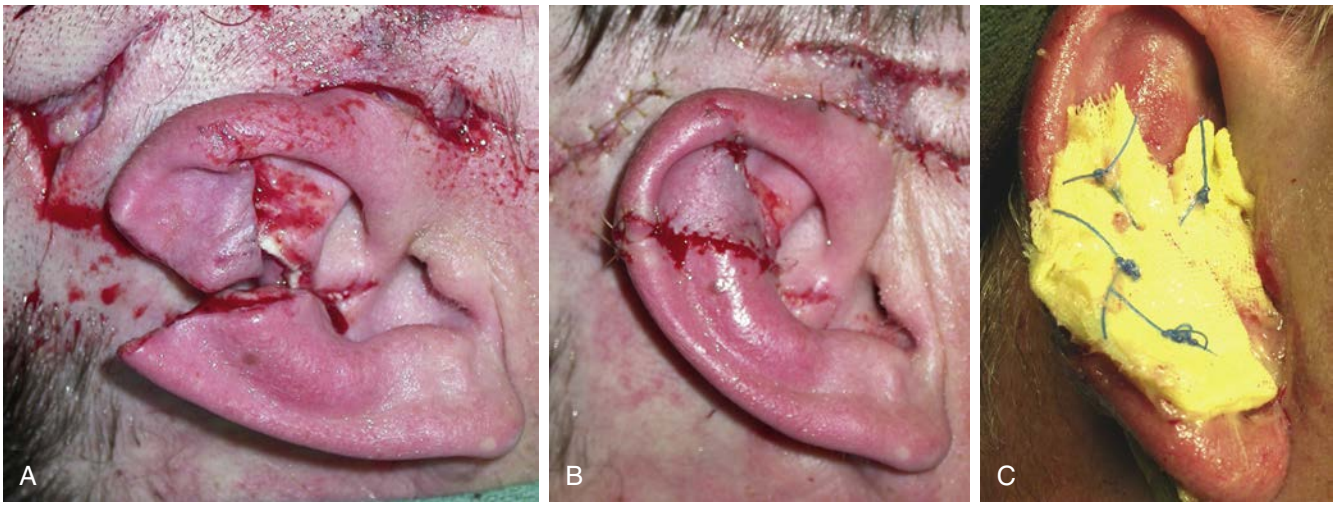

• **Figure 13-13** **A,** Complex ear laceration with torn cartilage. **B,** Repair of laceration. **C,** Bolster dressing to conform to ear anatomy and support tissues.

Special Regions

Lacerations of certain regions of the face require particular attention in repair due to the delicate aesthetic and specialized nature of the tissues. These regions include the ear, nose, eyelids, and lips. Knowledge and understanding of the related tissues and care given to proper anatomic restoration and tissue support will optimize healing. Cosmesis and function are paramount in these delicate regions and demand the surgeon's best effort to obtain physical, social, psychological, and emotional well-being after injury in the child.

Ear

Lacerations of the ear should be closed in a meticulous layered fashion to reapproximate the cartilaginous structures. Oversuturing the cartilage should be avoided, if possible, as the cartilage is soft, thin, and easily torn, especially in the young child. A tapered, non-cutting needle with either semipermanent or permanent suture (less inflammatory potential) is recommended.

Significant composite defects of the ear are approached in a staged fashion. Local soft tissue flaps and harvested cartilage from the opposite ear or rib are used for framework once the recipient site has been prepared and there are no signs of infection.

Complex, avulsive, or shredded ear wounds require support. Therefore, a lightly affixed bolster should be applied (Figure 13-13). The petrolatum-impregnated gauze dressings work well to conform to the ear contours, help discourage hematoma formation, and support neovascularization when the tissues are stabilized and protected. The outer helical skin is left exposed to verify vascularity and a large, fluff dressing placed for 3 to 5 days for protection while the child is sleeping or at play.

Lip

Children are apt to injure the lips from falls, sports contact, vehicular crashes, dog bites, assault, and play. Trauma to the lip region requires precise reapproximation of the orbicularis oris to restore function and avoid a postoperative furrow where a dehiscence of the muscle could develop if not properly repaired. This kind of defect is often seen in the cleft lip condition when there is imprecise muscle reconstruction. An optimal cosmetic result requires careful reapproximation of the vermilion border/white roll (indistinct at times in the lower lips of children); thus loupe magnification is usually necessary. If a significant portion of the lip and vermilion is missing, such as in a dog bite injury, then techniques such as an Abbé flap (lower lip pedicled flap to upper lip defect) should be considered for lip reconstruction. As the Abbé flap is based on the inferior labial artery, immediate reconstruction can take place in a contaminated bite wound. Division of the pedicle is done 2 to 3 weeks later.

It is also important in lip reconstruction to take measures to avoid loss of vestibular height, where possible, as once scar contracture has taken place, future tissue rearrangement and vestibuloplasty is much more challenging. Local buccal mucosal advancement flaps during the initial repair can often help to maintain vestibular height and depth.

Eyelids

Penetrating or complex orbital injuries should undergo CT evaluation before exploration and repair (Figure 13-14). The mechanism of injury may dictate the kind of injury encountered. Complex wounds to the eyelids can result in lid contracture, ectropion, entropion, trichiasis, blepharitis, exposure keratoconjunctivitis, and vision changes. Meticulous repair, usually in the operating room with a microscope, is required for extensive eyelid reconstruction. Preservation of all tissues is a goal, even if they are devitalized. Viable tissue should be maintained, carefully restored, and supported in order to maintain lid length, fornix depth, and healthy palpebral function. Devitalized or ischemic skin can be prepared and used as a free graft.

The lamellae of the upper (three compartments) and lower eyelids (two compartments) are restored or supported to the

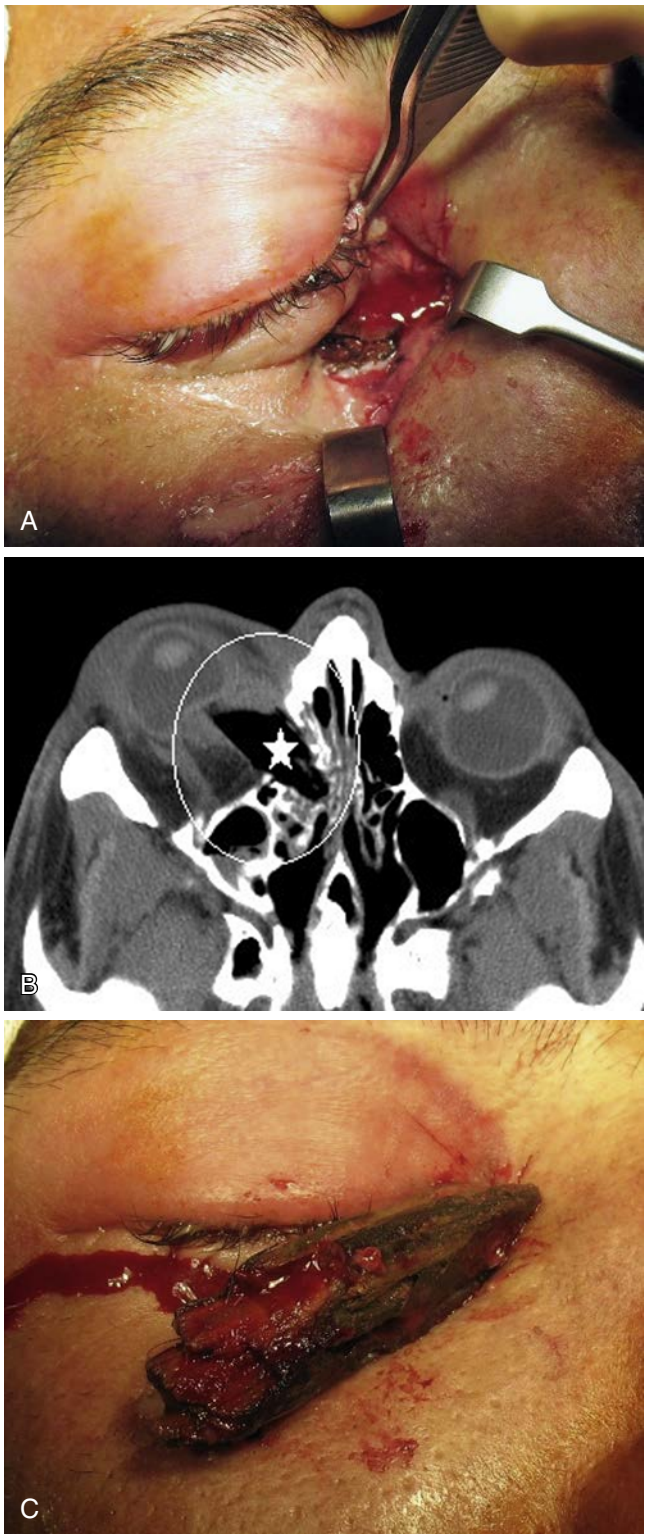

• **Figure 13-14** **A,** Penetrating orbital injury after being thrown from bike and striking tree. **B,** Axial CT demonstrating void *(encircled star)* on medial aspect. *Note* the deformation to globe from mass effect. **C,** Retrieval of foreign body from medial aspect of orbit.

optimum that can be achieved at the initial repair (Figures 13-15 and 13-16). Allowing healing to proceed in the midst of tissue loss or inadequate restoration invites lid contracture, which can be difficult to overcome later. Temporary tarsorrhaphy sutures should be placed at initial repair to suspend

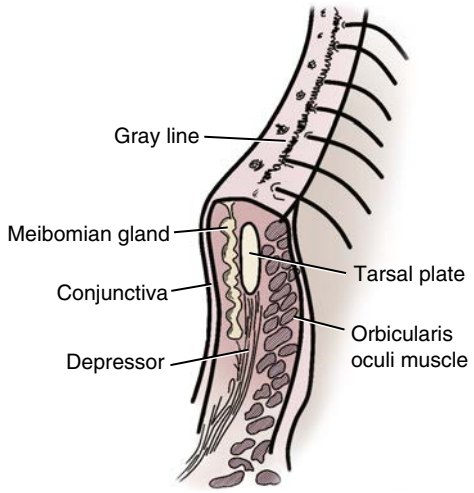

• **Figure 13-15** Diagram of basic eyelid anatomy and corresponding tissue compartments (lamellae). (With permission from Hogg NJV: Primary and secondary management of pediatric soft tissue injuries. *Oral Maxillofac Surg Clin N Am*, 24(3):368, 2012.)

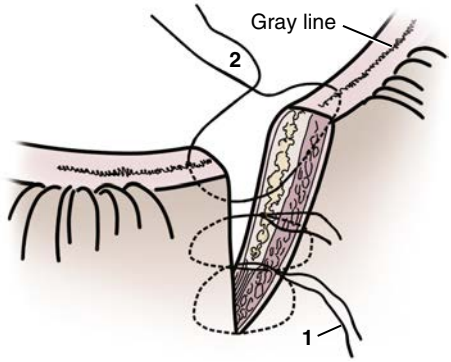

• **Figure 13-16** Diagrammatic repair of the lower eyelid. 1, Skin suture with tails left long. 2, Suture through gray line with tails left long and secured with skin tapes onto lower eyelid skin. (With permission from Hogg NJV: Primary and secondary management of pediatric soft tissue injuries. *Oral Maxillofac Surg Clin N Am*, 24(3):368, 2012.)

and support any eyelid that has a complex wound with tissue loss or has undergone grafting procedures (cartilage, mucosa, skin). Even young children seem to tolerate these stabilization sutures. Parents should be instructed on wound care, eye irrigation, and vigilance for postoperative infection. Temporary changes to the tear film, lid edema, and lacrimal stasis are to be explained and monitored. (Note: Lacrimal injuries are covered in the section "Deep Wounds.") Upper eyelid trauma with avulsive injury to the levator mechanism requires specialist repair, and referral is recommended.

Nose

Trauma to the nose, as with the ear, requires attention to various layers—vestibular skin and mucosa, cartilaginous elements, and overlying skin. The septal cartilage should be inspected to ensure that no septal hematoma exists that would require drainage and packing. Septal deviation, if significant, can be treated with closed reduction and placement of splints. Septal injury in children may result in growth disturbances;

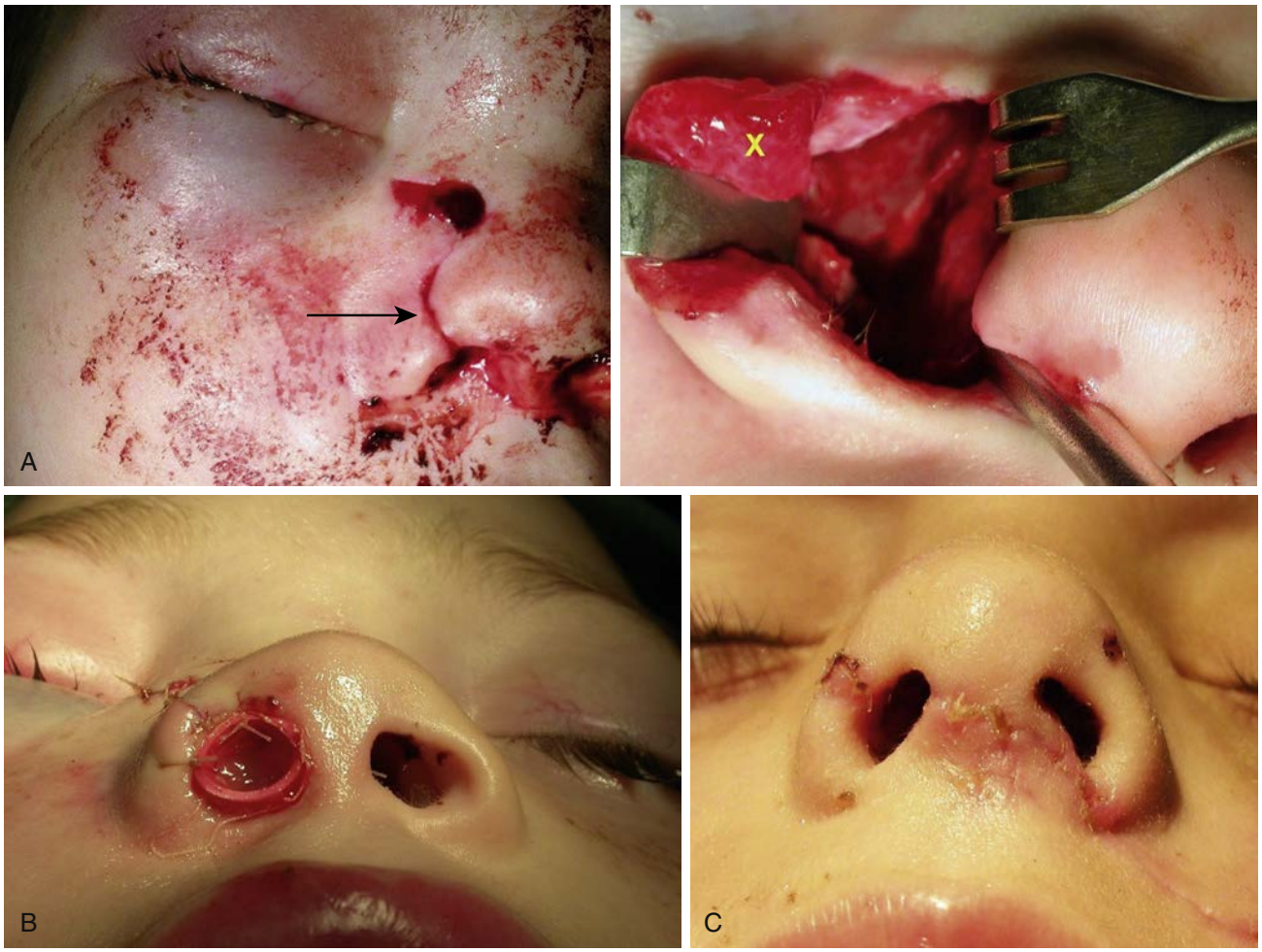

• **Figure 13-17** **A,** Complex nasal wound with circumferential laceration *(arrow)* and cartilage disruption *(X)*. **B,** Repair of full-thickness nasal wound with stent in place. **C,** Similar case of full-thickness nasal wound after stent removal at 2 weeks.

therefore a supportive nasal septal stent should be placed for 2 weeks if there are fractures, torn mucosa, or hematoma.

Layered closure begins intranasally with the mucosa and vestibular skin. Careful *alignment of the alar rim first* will help to sort through the intranasal soft tissue elements. Torn mucosa or vestibular skin can invaginate into the wound; thus, careful lifting and alignment and judicious (resorbable) suture placement will ensure that lining tissue is reestablished. A few inter-cartilaginous sutures to support the upper and lower lateral elements, if avulsed from their cephalad anchoring points, and intra-cartilaginous alignment of torn cartilage is carried out. An intranasal stent to discourage circumferential scarring and stenosis is placed for 2 to 3 weeks (Figure 13-17). Skin repair with small permanent or resorbable sutures completes the repair, and a supportive external dressing or splint is placed for protection purposes.

Bite Wounds

Children suffer over half of the animal (primarily dog) bites in the United States, and half of those bites will be to the head and neck region. Previously published data by the CDC demonstrated that the percentage of injuries to the head and neck region decreased with age with 65% in patients 0 to 4 years, 42% for ages 5 to 9 years, 20% for ages 10 to 14 years, and only 9% for patients over the age of 15 years.[62] Bite wounds to the head and neck are a compilation of crush, puncture, laceration, and avulsion tissue damage (Figure 13-18). Animal bite wounds contain the same oral pathogens as in humans in addition to *Pasteurella* spp and *Capnocytophaga* spp. Excellent vascularity of the head and neck decreases the risk of infection, though puncture wounds are more susceptible to infection.[63] Bites to the head by attack-dog breeds in children less than 3 years of age should prompt CT imaging to rule out skull penetration.

Verification of immunization status of the child is necessary, and if there is any doubt, then tetanus toxoid booster should be administered. Quarantine of the animal should be instituted through local law enforcement or the Humane Society. Treatment begins with thorough saline irrigation and debridement of any necrotic tissue and, if possible, attainment of primary closure.[64] Normal saline or a 1% povidone–iodine solution can be used as the



• **Figure 13-18** Avulsive bite wound with penetration to midface skeleton by a pit bull **(A)**. The nasomaxillary complex has been torn away from its base **(B)**.

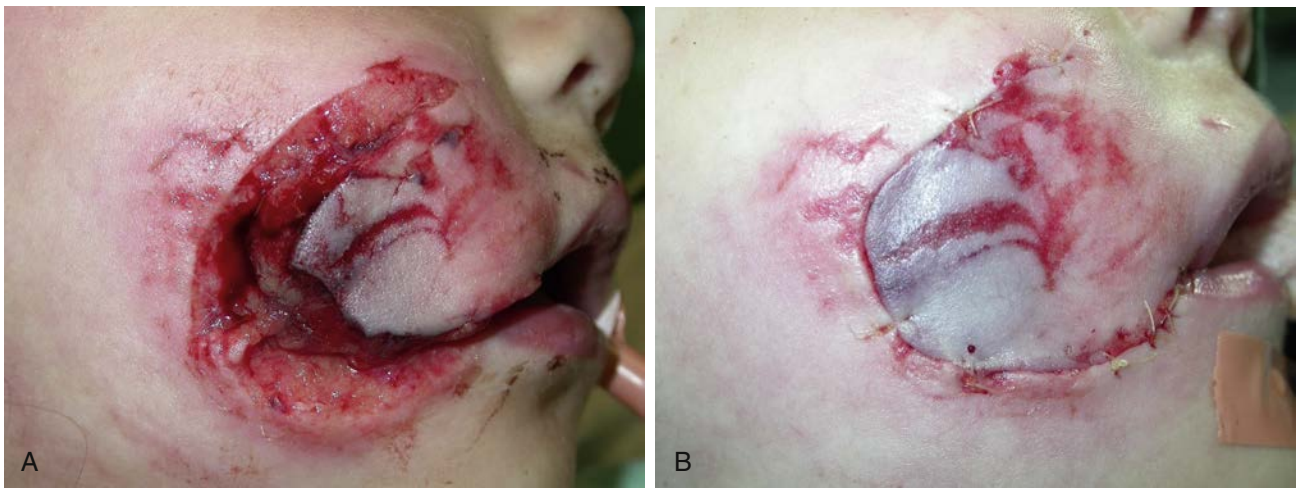

• **Figure 13-19** **A,** Avulsive dog bite to cheek in toddler. **B,** Repair of cheek wound from dog bite after selective debridement and washout.

irrigant with either a syringe catheter for puncture wounds or gentle lavage with bulb syringe for open wounds.[65-67] High-pressure irrigation (>20 psi) is not necessary and can be damaging to the more delicate injured tissues in children.

The debridement and removal of ragged or macerated margins with a sharp tissue scissors or blade will allow for an even, well-aligned closure (Figure 13-19). Deep tissue approximation is key to avoid hematoma and dead space infection. Dependent drainage with small drains can be placed to augment dead space obliteration.

Children should be placed on combination penicillin or extended cephalosporin antibiotics and then followed closely to ensure that there are no signs of infection. Parents or caregivers should be informed that an intense inflammatory response will follow at 2 to 3 days after a bite injury, but infection is typified by pain, discharge, fever, and elevated white count.

Summary

The child with significant injuries is always an emotionally charged and challenging event for the treating surgeon. Severe injuries must be quickly assessed, the child stabilized, wounded tissue maintained and supported, appropriate immunization and antibiotic status initiated, and plans made for comprehensive management of fractures and soft tissue wounds. During this initial assessment period, consistent serial evaluation of the child is undertaken in order to confirm neurologic and physiologic stability and rapid detection of any progressive bleeding, intracranial lesions, or compromised airway.

Careful attention to soft tissue health; meticulous handling of torn tissues; restoration of anatomic layers and margins; repair of injured ducts, nerves, and specialized tissues; and support to the reconstructed area will greatly optimize healing potential in the pediatric patient and reduce ultimate scarring and dysfunction. Long-term wound support and Silastic sheeting will improve scar cosmesis.

Children with facial fractures heal quickly because of increased osseous activity of the periosteum and endosteum, improved vascularity, and overall general systemic health. Most fractures can be fixated, if displaced, with minimal resorbable internal fixation, and simple jaw fractures easily managed with MMF. Young children should be mobilized from MMF within 7 to 10 days and begin active physiotherapy.

The pediatric trauma patient presents a specific set of challenges to the oral and maxillofacial surgeon. These challenges can be due to behavioral issues, growth and development factors and concerns, anatomic (skeletal) immaturity, unerupted teeth, family and compliance issues, and the future holistic well-being of an injured child. Every effort should be given to early and comprehensive surgical care of children with craniofacial injuries in order to obtain a satisfying and lasting cosmetic result.

References

1. Imahara SD, Hopper RA, Wang J, et al.: Patterns and outcomes of pediatric facial fractures in the United States: a survey of the National Trauma Data Bank, *J Am Coll Surg* 207:710–716, 2008.
2. Center for Disease Control and Prevention: Ten leading causes of death and injury. http://www.cdc.gov/injury/wisqars/leadingcauses.html Accessed April 15, 2015.
3. Center for Disease Control and Prevention: *Rates of TBI-related emergency department visits by age group-U.S*, . http://www.cdc.gov/traumaticbraininjury/data/rates_ed_byage.html, 2001-2010. Accessed April 15, 2015.
4. Center of Disease Control and Prevention. Protect the ones you love: Child injuries are preventable. National Action Plan for Child Injury Prevention. 2012. *www.cdc.gov/safechild*. Accessed February 15, 2016.
5. Allreddy V, Itty A, Maiorini E, et al.: Emergency department visits with facial fractures among children and adolescents: an analysis of profile and predictors of causes of injuries, *J Oral Maxillofac Surg* 72(9):1756–1765, 2014.
6. Litman RS, Fiadjoe JE, Stricker PA, Cote CJ: The pediatric airway. In Cote CJ, Lerman J, Anderson BJ, editors: *A practice of anesthesia in infants and children*, ed 5, Philadelphia, 2013, Saunders.
7. Shah RK, Dhingra JK, Carter BL, et al.: Paranasal sinus development, *Laryngoscope* 113(2):205–209, 2003.
8. Duerinckx AJ, Hall TR, Whyte AM, et al.: Paranasal sinuses in pediatric patients by MRI: normal development and preliminary findings in disease, *Eur J Radiol* 13:107–112, 1991.
9. Whatley WS, Allison DW, Chandra RK, et al.: Frontal sinus fractures in children, *Laryngoscope* 115(10):1741–1745, 2005.
10. Schweiger C, Marostica PJ, Smith MM, et al.: Incidence of postintubation subglottic stenosis in children: a prospective study, *J Laryngol Otol* 127(4):399–403, 2013.
11. Moss M, Bromberg BE, Song IG, et al.: The passive role of nasal septal cartilage in mid-facial growth, *Plast Reconstr Surg* 41(6):536–542, 1968.
12. Grymer LF, Gutierrez C, Stoksted P: The importance of nasal fractures during different growth periods of the nose, *J Laryngol Otol* 99(8):741–744, 1985.
13. Wright DL, Hoffman HT, Hoyt DB: Frontal sinus fracture in the pediatric population, *Laryngoscope* 102(11):1215–1219, 1992.
14. Nahum AM: The biomechanics of maxillofacial trauma, *Clin Plast Surg* 2(1):59–64, 1975.
15. Mensink G, Zweers A, van Merkesteyn JPR: Endoscopically assisted reduction of anterior table frontal sinus fractures, *J Craniomaxillofac Surg* 37(4):225–228, 2009.
16. Shumrick KA: Endoscopic management of frontal sinus fractures, *Facial Plast Surg Clin* 40(2):329–336, 2007.
17. Hink EM, Wei LA, Durairaj VD: Clinical features and treatment of pediatric orbit fractures, *Ophthal Plast Reconstr Surg* 30(2):124–131, 2014.
18. Gerbino G, Roccia F, Bianchi FA, Zavattero E: Surgical management of orbital trapdoor fracture in a pediatric population, *J Oral Maxillofac Surg* 68(6):1310–1316, 2010.
19. Cohen SM, Garrett CG: Pediatric orbital floor fractures: nausea/vomiting as signs of entrapment, *Otolaryngol Head Neck Surg* 129(1):43–47, 2003.
20. Wei LA, Durairaj VD: Pediatric orbital floor fractures, *J Am Assoc Pediatr Ophthal Strabismus* 15(2):173–180, 2011.
21. Parbhu KC, Galler KE, Li C, Mawn LA: Underestimation of soft tissue entrapment by computed tomography in orbital floor fractures in the pediatric population, *Ophthalmology* 115(9):1620–1625, 2008.
22. Joshi S, Kassira W, Thaller SR: Overview of pediatric orbital fractures, *J Craniofac Surg* 22(4):1330–1332, 2011.
23. Uygur S, Cukurluoglu O, Ozmen S, et al.: Resorbable mesh plate in the treatment of blow-out fracture might cause gaze restriction, *J Craniofac Surg* 20(1):71–72, 2009.
24. Kim SH, Lee SH, Cho PD: Analysis of 809 facial bone fractures in a pediatric and adolescent population, *Arch Plast Surg* 39(6):606–611, 2012.
25. Derosiers AE, Thaller SR: Pediatric nasal fractures: evaluation and management, *J Craniofac Surg* 22(4):1327–1329, 2011.
26. Zimmerman CE, Troulis MJ, Kaban LB: Pediatric facial fractures: recent advances in prevention, diagnosis and management, *Int J Oral Maxillofac Surg* 35(1):2–13, 2006.

27. Yilmaz MS, Guven M, Kayabasogly G, Varli AF: Efficacy of closed reduction for nasal fractures in children, *Br J Oral Maxillofac Surg* 51(8):e256–e258, 2013.
28. Koltai PJ, Rabkin D: Management of facial trauma in children, *Pediatr Clin North Am* 43:1253–1262, 1996.
29. Posnick JC, Wells M, Pron G: Pediatric facial fractures: evolving patterns of treatment, *J Oral Maxillofac Surg* 51(8):836–844, 1993.
30. Ferreira PC, Barbosa J, Braga JM, et al.: Pediatric facial fractures: a review of 2071 fractures, *Ann Plast Surg*, February 27, 2015. [Epub ahead of print].
31. Iatrou I, Theologie-Lygidakis N, Tzerbos FJ: Surgical protocols and outcome for the treatment of maxillofacial fractures in children: 9 years' experience, *J Craniomaxillofac Surg* 38(7):511–516, 2010.
32. Smith DM, Bykowski MR, Cray JJ, et al.: 215 mandible fractures in 120 children: demographics, treatment, outcomes, and early growth data, *Plast Reconstr Surg* 131(6):1348–1358, 2013.
33. Goth S, Sawatari Y, Peleg M: Management of pediatric mandible fractures, *J Craniofac Surg* 23(1):47–56, 2012.
34. Zhou HH, Han J, Li ZB: Conservative treatment of bilateral condylar fractures in children: case report and review of the literature, *Int J Pediatr Otorhinolaryngol* 78(9):1557–1562, 2014.
35. Norholt SE, Krishnan V, Sindet-Pedersen S, et al.: Pediatric condylar fractures, *J Oral Maxillofac Surg* 51:1302–1310, 1993.
36. Patil PM: Unerupted lower third molars and their influence on fractures of the mandibular angle and condyle, *Br J Oral Maxillofac Surg* 50(5):443–446, 2012.
37. Hanson BP, Cummings P, Rivara FP, John MT: The association of third molars with mandibular angle fractures: a meta-analysis, *J Can Dent Assoc* 70:39–43, 2004.
38. Lee JT, Dodson TB: The effect of mandibular third molar presence and position on the risk of an angle fracture, *J Oral Maxillofac Surg* 58(4):394–398, 2000.
39. Defabianis P: TMJ fractures in children and adolescents: treatment guidelines, *J Clin Pediatr Dent* 27:191–199, 2003.
40. Tabrizi R, Langner NJ, Zamiri B, et al.: Comparison of nonsurgical treatment options in pediatric condylar fractures: rigid intermaxillary fixation versus using guiding elastic therapy, *J Craniofac Surg* 24(3):e203–e206, 2013.
41. Li Z, David O, Li ZB: The use of resorbable plates in association with dental arch stabilization in the treatment of mandibular fractures in children, *J Craniomaxillofac Surg* 42(5):548–551, 2014.
42. Bell RB, Kindsfater CS: The use of biodegradable plates and screws to stabilize facial fractures, *J Oral Maxillofac Surg* 64(1):31–39, 2006.
43. Kumaraswamy SV, Madan N, Keerthi R, Singh DS: Pediatric injuries in maxillofacial trauma: a 5-year study, *J Oral Maxillofac Surg* 8(2):150–153, 2009.
44. Cavalcanti AL, Melo TR: Facial and oral injuries in Brazilian children aged 5-17 years: 5-year review, *Eur Arch Paediatr Dent* 9(2):102–104, 2008.
45. Ellis E: Soft tissue and dentoalveolar injuries. In Tucker MR, Hupp JR, Ellis E, editors: *Contemporary oral and maxillofacial surgery*, ed 6., Philadelphia, 2013, Elsevier, pp 470–490.
46. Reynolds JS, Reynolds MT, Powers MP: Diagnosis and management of dentoalveolar injuries. In Fonseca RJ, Barber HD, Powers MP, Frost DE, editors: *Oral and maxillofacial trauma*, ed 4, Philadelphia, 2012, Saunders.
47. Singer AJ, Hollander JE, et al.: Prospective randomized controlled trial of tissue adhesive vs standard wound closure techniques for laceration repair, *Acad Emerg Med* 5(2):94–99, 1998.
48. Couto JA, Sullivan JE, Greene AK: Facial wound closure in children using a 7-0 absorbable suture dressing, *J Craniofac Surg* 26(1):76–78, 2015.
49. Luck RP, Flood R, Eyal D, et al.: Cosmetic outcomes of absorbable suture in pediatric facial lacerations, *Pediatr Emerg Care* 24:137–142, 2009.
50. White H, Rosenthal E: Static and dynamic repairs of facial nerve injuries, *Oral Maxillofac Clin North Am* 25(2):303–312, 2013.
51. Colert S, Coombes D, Godden D, et al.: How do I manage an acute injury to the facial nerve? *Br J Oral Maxillofac Surg* 52(1):67–71, 2014.
52. Lazaridou M, Iliopoulos C, Antoniades K, et al.: Salivary gland trauma: a review of diagnosis and treatment, *Craniomaxillofac Trauma Reconstr* 5(4):189–196, 2012.
53. Dumpis J, Feldmane L: Experimental microsurgery of salivary ducts in dogs, *J Craniomaxillofac Surg* 29(1):56–62, 2001.
54. Van Sickels JE: Parotid duct injuries, *Oral Surg Oral Med Oral Pathol* 52(4):364–367, 1981.
55. Gordin EA, Daniero JJ, Krein H, et al.: Parotid gland trauma, *Facial Plast Surg* 26(6):504–510, 2010.
56. Donoso T, Comancic S, Argandoña J: Delayed treatment of parotid sialocele: a functional approach and review, *J Oral Maxillofac Surg* 73(2):284–290, 2015.
57. Long JA: Canalicular lacerations. In Long JA, Patel B, editors: *Surgical techniques in ophthalmology series: oculoplastic surgery*, Philadelphia, 2009, Saunders, p 89.
58. Herford AS: Early repair of avulsive facial wounds secondary to trauma using interpolation flaps, *J Oral Maxillofac Surg* 62(8):959–965, 2004.
59. Baker SR: Reconstruction of facial defects. In Cummings CW, Flint PW, Haughey BH, et al.: *Otolaryngology: head & neck surgery*, ed 5, Philadelphia, 2010, Mosby Elsevier.
60. Zimmerman A, et al.: Tissue expansion of the scalp in cranial and facial reconstruction, *Int J Oral Maxillofac Surg* 40(10):104–112, 2011.
61. Hoffmann JF: Tissue expansion in the head and neck, *Facial Plast Surg Clin North Am* 13(2):315–324, 2005.
62. Gilchrist J: Nonfatal dog bite-related injuries treated in hospital emergency departments in the US 2001, *MMWR Morbid Mortal Wkly Rep* 52(26):605–610, 2003.
63. Kountakis SE, Chamblee SA, Maillard AA, et al.: Animal bites to the head and neck, *Ear Nose Throat J* 77(3):216–220, 1998.
64. Mcheik JN, Vergnes P, Dondonny JM: Treatment of facial dog bite injuries in children: a retrospective study, *J Pediatr Surg* 35(4):580–583, 2000.
65. Morgan M, Palmer J: Dog bites, *BMJ* 334:413–417, 2007.
66. Dire DJ, Hogan DE, Riggs MW: A prospective evaluation of risk factors for infections from dog-bite wounds, *Acad Emerg Med* 1(3):258–266, 1994.
67. Stefanopoulos PK: Management of facial bite wounds, *Oral Maxillofac Surg Clin North Am* 21(2):247–257, 2009.

14

Management of Avulsive Facial Injuries

LIKITH V. REDDY, WADE BARKER

Avulsive facial injuries are a complex problem for even the most experienced surgeon. They can present with extensive loss of both hard and soft tissues. Gunshot wounds, including those that are self-inflicted, are the most common etiology of avulsive facial injuries. Other causes include motor vehicle collisions, industrial accidents, and animal bites. The goal of this chapter is to aid the treating surgeon and to familiarize the surgeon in training with the management goals, sequence, and surgical options available to reconstruct these patients. Goals of reconstruction include restoring function as well as improving facial projection, contours, and esthetics. The surgeon faced with the task of reconstructing patients with large avulsive tissue loss of the face needs to have an understanding of wound management, particularly wounds resulting from high energy transfer. It is imperative that the surgeon have a candid discussion with the patient and family before beginning reconstruction to establish reasonable expectations for the outcome and the number of procedures necessary. One of the less commonly understood and appreciated aspects of the care of these patients is the psychological component and the psychosocial implications of these devastating injuries. The limitations of the surgical intervention must be understood by the patient and family as well as by the surgical team. This important point should be brought to light during the early phases of treatment so that realistic goals and expectations can be set.

Wound Assessment

The predominant reason for large avulsive facial tissue defects at most Level I trauma centers is gunshot injuries. Clark and colleagues are credited with the most frequently used classification pattern for gunshot injuries to the facial skeleton.[1] They defined the following four patterns: the frontal cranium, the orbit, the lower midface, and the mandible. The resulting tissue damage from these patterns forms the zones of injuries. The zones are the central face, the lateral mandible, the lateral midface and orbit, and the lateral cranium and orbit (Figure 14-1). An understanding of ballistics is important because it helps the surgeon assess and understand the wound beyond what is clinically apparent. Gunshot wounds can be described as low or high energy based on the energy transfer characteristics between the missile and the tissue it encounters. High energy gun shot wounds and shotgun (pellet) wounds are the most likely to cause avulsive injuries of the face (Figure 14-2). Initially, the bullet crushes sufficient tissue to make an entrance wound through which the missile penetrates the underlying tissue, creating the zone known as the permanent cavity. Depending on the speed at which the bullet is traveling and the bullet's caliber, the walls of the permanent cavity may briefly radiate outward to form a temporary cavity.[2] The temporary cavity is a zone of radial tissue stretching secondary to expansile pressure changes in which tissue vascularity may be compromised. Because of this, secondary tissue necrosis may develop and the eventual wound may be larger than initially apparent.

Management

Initial Encounter

Airway

The initial assessment of patients with severe facial injuries should always center on assessing and securing the airway. Patients who have suffered significant facial avulsive tissue loss will often present with copious bleeding, and often debris in the airway. At the time of initial presentation in the trauma bay, these patients will often have a secured airway that was obtained in the field. In instances in which this has not occurred because of the complexity of the case, bleeding, and/or obscuration of the airway secondary to debris, the airway must be secured. The potential for cervical spine injuries must always be considered, and the neck should not be manipulated while securing the airway. If the conventional oral airway is not possible, a surgical airway should be obtained. The first and only airway that should be attempted in this situation is the cricothyroidotomy. This airway is simple and easy to obtain while requiring minimal dissection and limiting the potential for bleeding as with a tracheotomy. The cricothyroidotomy can later be converted to a tracheotomy in the operating room.

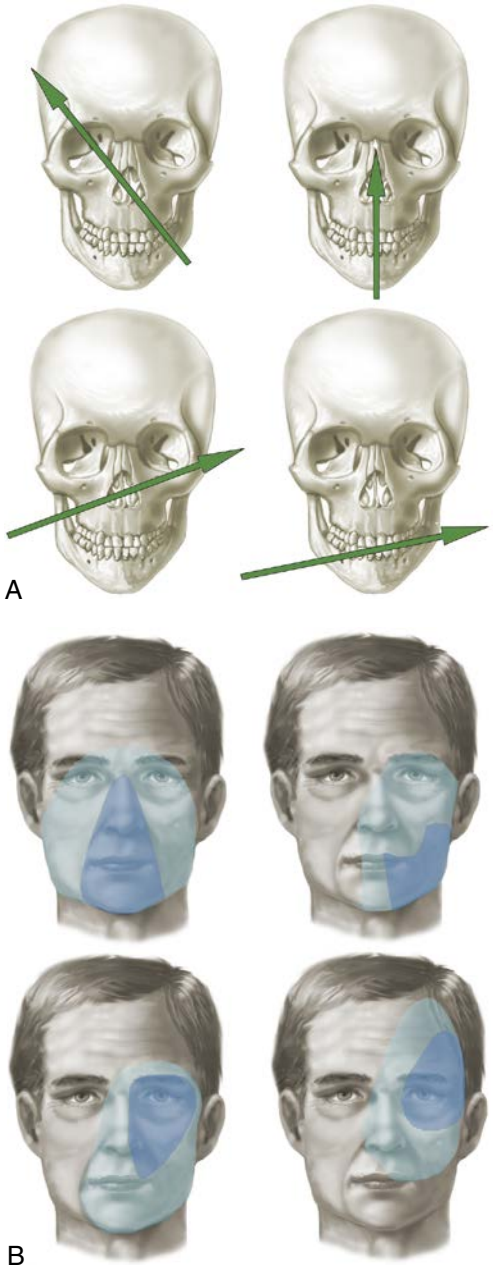

• **Figure 14-1 A,** Trajectory patterns of gunshot wound to the face. **B,** Corresponding zones of injuries. (Modified from Clark N, Birely B, Manson P et al: High-energy ballistic and avulsive facial injuries: classification, patterns, and an algorithm for primary reconstruction. *Plast Reconstr Surg* 98:583, 1996.)

Clinical Examination

Once the airway is secured, attention is diverted to the management of bleeding and other life- or limb-threatening conditions. Once the primary survey is completed, the maxillofacial specialist can then systematically and methodically assess the extent of the injuries, evaluating all of the injured structures as well as any missing tissues. Particular care is taken to assess nerve injuries and injuries to special structures such as the globe, salivary duct, and lacrimal duct (Figure 14-3). The assessment of the extent of hard tissue injury and loss is evaluated first clinically and then by diagnostic imaging.

Imaging

The vast majority of patients presenting to the emergency department with facial injuries will receive a computed tomography (CT) scan. The technological improvements in CT scanning now enable the clinician to immediately obtain very complex three-dimensional renderings of the facial skeleton that will aid in planning the surgical intervention.

Integration of three-dimensional scanning with CT angiography allows visualization of the regional vasculature, which can be assessed for injury or for potential sites of anastomosis in microvascular repair of the missing structures (Figure 14-4).

Surgical Management

Debridement

The conventional wisdom in management of gunshot wounds (GSWs) and other severe facial injuries with extensive tissue maceration is minimal surgical debridement. After the initial encounter and airway management and hemorrhage control, a very conservative surgical debridement is carried out. This initial debridement is performed on only obviously unsalvageable tissues, and care is taken to preserve as much viable soft tissue volume as possible. At the conclusion of the first debridement, establishment of occlusal relationships with arch bars may be done. The wound edges can be tacked to minimize desiccation of the exposed bone fragments where the tissue is not lost. The patient might need to be taken to the operating room for further limited debridement until the wound is declared adequately debrided. The additional goals during the phase of debridement includes creating a definitive airway as tracheostomy, closing of intracranial injuries, repair of ruptured globe injuries, and establishment and stabilization of occlusal relationships in remaining tooth-bearing segments. Aggressive debridement, particularly of skin margins and the tissues of the nose, palate, lips, and medial canthal areas, can complicate the choice of flap reconstruction or how a particular flap is inset. During the initial therapy, it is important to assess the extent of missing tissue, both hard and soft, and the surgical options available to reconstruct the defect. This includes the planning and need for potential local, regional, and/or distant flaps. This awareness will prevent the unwanted sacrifice of blood vessels that supply potential flaps or possible recipient vessels for later microvascular anastomosis. The end point for the debridement is the establishment of a healthy tissue bed for the eventual final reconstruction (Figure 14-5).

Reconstructive Concept

Historically, severe facial trauma often resulted in cosmetic and functional defects; however, advances in the science of reconstructive surgery and in the management of trauma patients have improved the morbidity associated with facial traumatic injuries. Current management reflects the evolution of both bony and soft tissue reconstruction principles and techniques. The functional units that are in the anterior

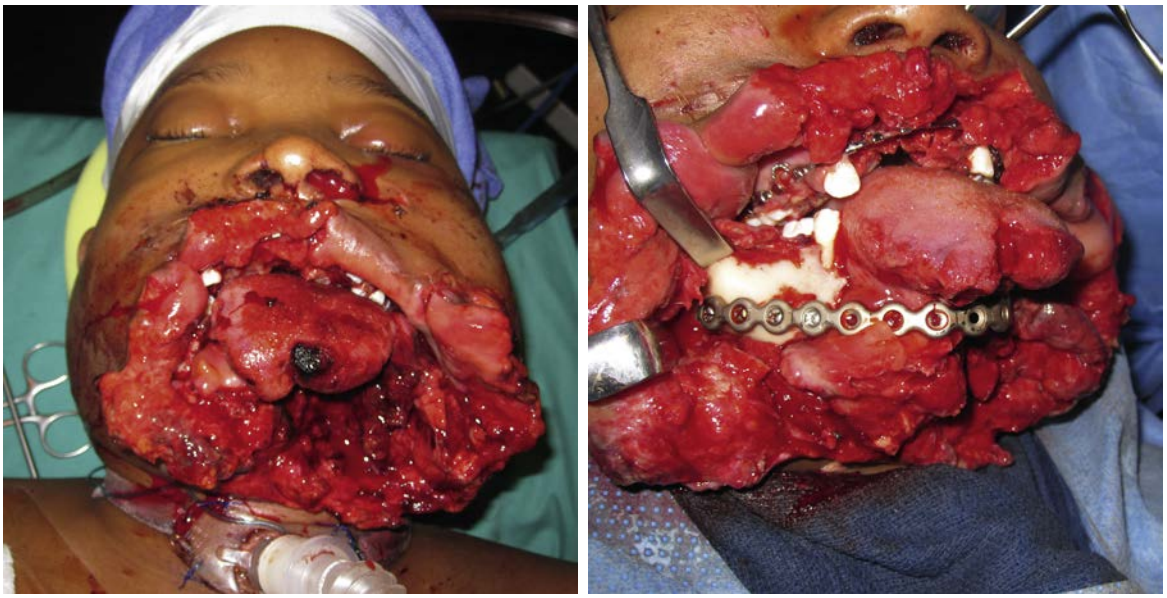

• **Figure 14-2** High energy transfer injury due to gun shot. (Missing tissues include lower lip, partial upper lip, cheek, anterior floor of the mouth and mandible wound demonstrating the missing tissues.)

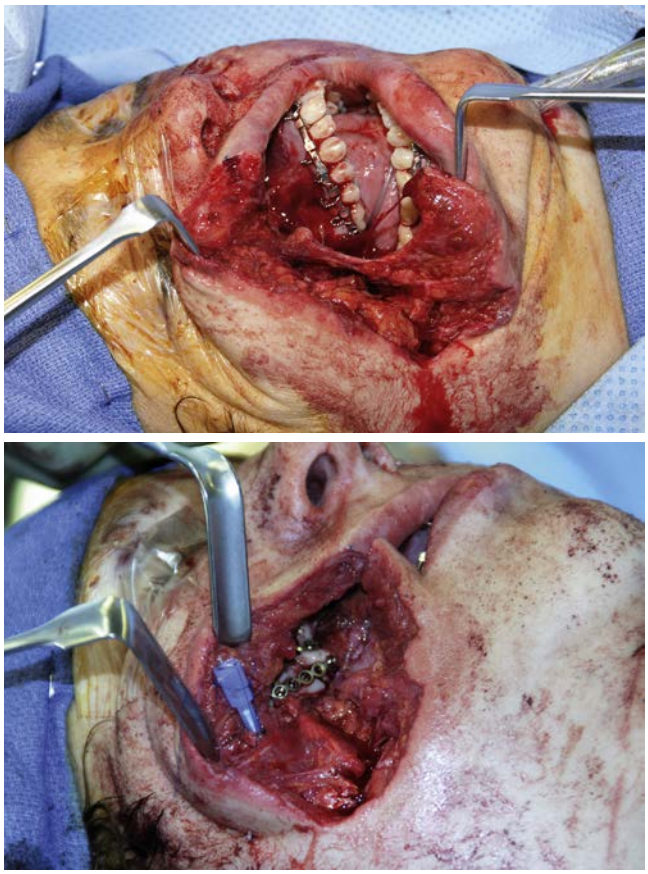

• **Figure 14-3** Injury due to a metallic projectile demonstrating Stensen duct injury and repair with cannulation, with skeletal repair.

face are the eyes, nose, and oral cavity. It is important preoperatively to evaluate the type of defect present and the anatomic location: a complete understanding of the function and esthetic relationship between normal face units. Often large avulsive wounds have adjacent facial bone fractures. The management of these wounds may best be approached in staged goals. The goals include restoration of the facial skeleton framework, definitive soft tissue reconstruction that might include free tissue transfer, and satisfactory soft tissue coverage of underlying bone for internal and external defects. This should include planning of dental and facial prosthetic rehabilitation in conjunction with flap selection, especially for the reconstruction of maxillary and mandibular defects.

A staged approach to the reconstruction of the severe facial trauma patient allows a systematic and ordered approach to avoid overlooking important steps in the treatment. The surgical management of these patients can be broken into reconstructive and rehabilitative phases (Box 14-1).

The current reconstructive phase should be performed as soon as reasonably possible after the injury to maintain soft tissue volume and minimize scar contracture. The principles include (1) wide access and exposure of fractures, (2) rigid internal fixation of fractures, (3) reconstruction of the underlying bone concurrently with the overlying soft tissue, (4) use of free bone grafts for midface when adequate nasal or oral lining tissue is present, and (5) selection of a free tissue transfer flap that minimizes the need for adjunctive reconstructive procedures. The best available soft tissue closure that does not cause significant distortion of the soft tissues is employed. It must be kept in mind that the surgeon will be returning soon during the definitive reconstruction; therefore, any rotation or advancement flaps performed to obtain skin closure should be done with an eye toward that procedure. The size of the oral stoma should not be compromised to facilitate closure. Access to the oral cavity for the placement of dental implants and prosthetic work must be maintained.

The bone of the periorbital area, forehead, and nasal dorsum bear minimal tension and are easier to contour

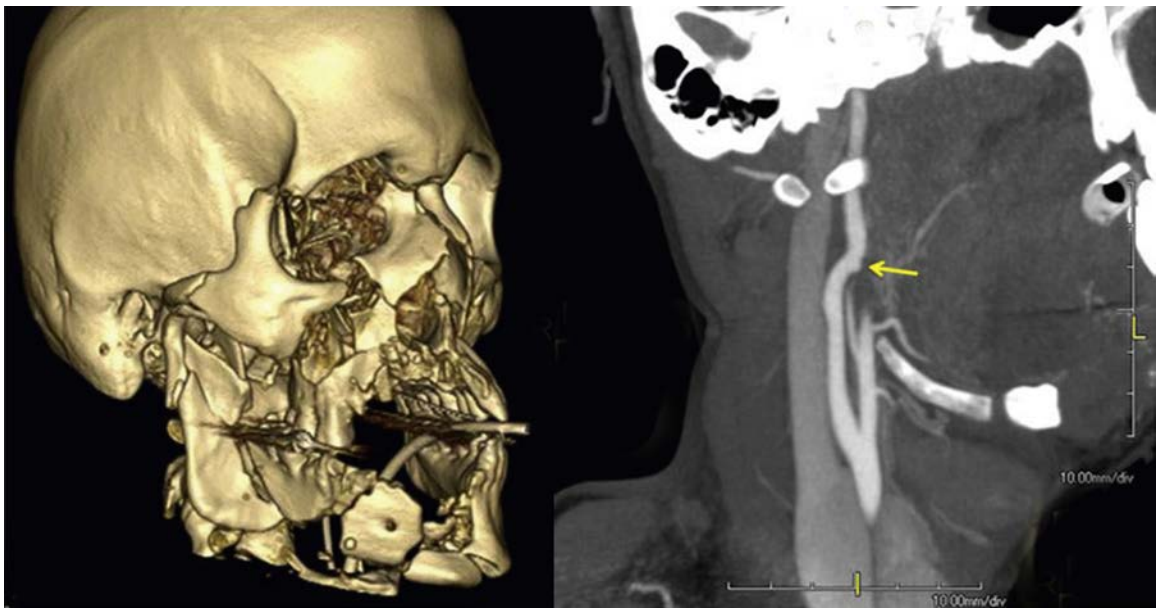

• **Figure 14-4** Computed tomographic angiography demonstrating the location of vascular patency and location of vascular injury.

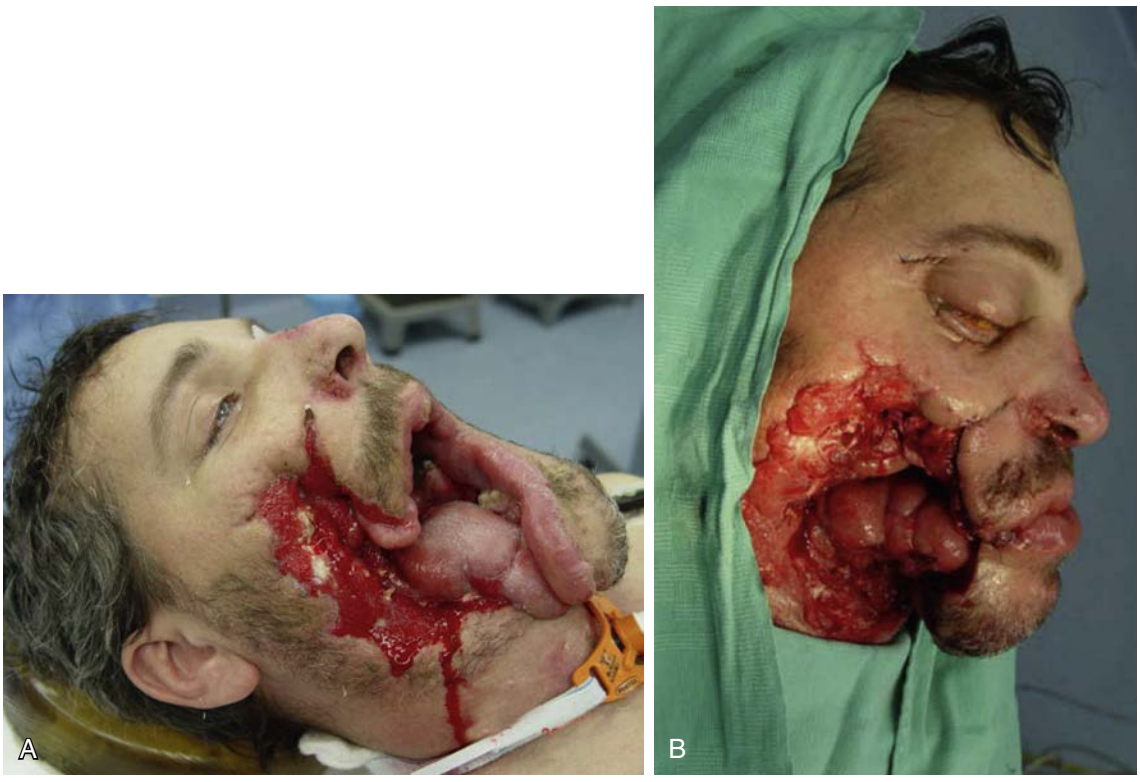

• **Figure 14-5** **A,** End point of debridement. **B,** Surgical debridement by 2 weeks show some early wound contracture.

with free bone grafts. Free bone grafts, especially cranial bone grafts, demonstrate excellent survival despite exposure to the sinonasal tract. If a small area of cranial bone graft is exposed within the sinonasal compartment, it usually gets covered with granulation tissue and mucosa with rigorous hygiene. The relatively thick cortical bone from this site facilitates rigid fixation, which is crucial to graft survival.

The reconstructive goals in the maxillary arch are to create a neo-alveolar ridge of stable bone that is suitable for prosthesis and close the palatal defect. This reconstruction should also provide replacement or support of facial soft

• BOX 14-1 Management of Avulsive Wounds

Both phases can be staged based on surgeon preferences, patient status, need for medical models, surgical guides, etc.

Reconstructive Phase

1. Debridement of foreign material and obviously nonviable tissue
2. Establishment of occlusal relationships
3 Extended access and exposure of fractures
4. Establishment of facial skeletal framework with internal fixation
5. Definitive free-bone graft reconstruction in areas with adequate soft tissue coverage
6. Reassess the missing tissue element. Selection of appropriate local and regional tissue flaps
7. Reconstruction of missing tissue elements with vascularized free-tissue transfer flap that includes underlying bone concurrently with the overlying soft tissue
8. Satisfactory soft tissue coverage of all underlying bone, internal, and external defects
9. Stenting of the facial soft tissue envelope such as internal nasal and NOE regions

Rehabilitative Phase

1. Dental and facial prosthetic rehabilitation
2. Major flap debulking and contouring as required
3. Aesthetic and functional refinement
4. Adjunctive cosmetic measures

NOE, Nasoorbitoethmoid.

tissues. The reconstructed maxillary arch is frequently flatter than the native maxillary alveolar arch; hence the denture will not be stable and will require dentition or osseointegrated implants for retention.

The use of vascularized bone to replace large segmental areas of the mandible is currently preferred and is often essential if the injury has destroyed or avulsed significant floor-of-mouth and chin soft tissue. Vascularized bone provides a rapid, dependable reconstruction, may be inset with its own vascularized soft tissue coverage, and survives the contaminated environment of the floor of the mouth. The exceptions to vascularized bone reconstruction of the mandible are cases in which there is an adequate remaining soft tissue overlying the mandible. Patients with only isolated oromandibular wounds can return to good function and adequate cosmesis. In patients with large central soft tissue defects involving maxilla, mandible, and nose, the reconstructive outcomes are far from satisfactory.

The selection of free tissue transfer is only limited by the patient's overall injuries, surgical limitations, and the imagination of the surgeon. The following options are some of the flaps most commonly used by the author and do not represent all the options available for head and neck reconstruction (Figure 14-6).

Local/Regional

Local flap options are often limited in cases of large soft tissue loss. One of the areas where this may not be the case is in the reconstruction of lip defects. Often, one of the lips is involved and the other is spared. This sparing allows for the use of the uninvolved lip as a donor site for the reconstruction of the affected lip. The other site is the forehead. The paramedian forehead flap may be used in the reconstruction of nasal defects, which can range from small defects to as large as total nasal coverage. Mucosal injuries are often allowed to heal by secondary intention. However, in cases in which significant bulk is missing, a good option is the use of the facial artery musculomucosal flap.

Abbe Flap

The Abbe flap has been in the armamentarium of maxillofacial surgeons for more than a century. It was first described by Abbe in 1898.[3] The flap is based on the superior and inferior labial arteries, which are branches of the facial artery. The utility of this flap cannot be overemphasized given its ability to replace like tissue with like tissue.[4] To improve the final aesthetic outcome, the defect may need to be extended to include the entire aesthetic subunit of the lip as described by Burget. When the defect is greater than half of a subunit, the full subunit should be excised. Extension of the wound is at times difficult to accomplish by the beginning surgeon because of fear of wasting tissues. This excision will allow for a better reconstruction by placing the incisions in a less conspicuous site. Once the defect is outlined, the width of the flap is decreased by approximately half, while maintaining a 1:1 ratio of the height of the flap. The ideal rotation of the flap is checked, and then the incision is begun on the contralateral side, away from the feeding labial artery. The incision is carried out to the full thickness up to about 1 cm of the remaining attachment of the artery and flap. At this point, careful dissection is undertaken to free as much of the muscle as possible to allow for proper arc of rotation, while still protecting the vascular pedicle. The skin is incised up to the vermilion without endangering the vascular pedicle, since it runs on the inner aspect of the lip.[5]

With the flap fully mobilized, the surgeon then begins the insetting by closing the mucosa, followed by muscular closure, and last skin closure. If this order of closure is not followed, the surgeon will be prevented or severely hindered from closing the mucosa once the muscular and skin closure is completed. The flap is allowed to develop collateral circulation for approximately 3 weeks or more before its release (Figure 14-7).

Facial Artery Musculomucosal Flap

The facial artery musculomucosal (FAMM) flap was first described by Pribaz and colleagues in 1992.[6] The flap is based on the facial artery and is an intraoral mucosal flap that can be used for a multitude of defects. The flap can be superiorly or inferiorly based and can rotate to reconstruct lip, cheek, floor of mouth, or palatal defects. The harvesting of the flap is first approached by using a portable Doppler probe intraorally to outline the path of the facial artery. Once the path is marked from the depth of the mandibular buccal vestibule to the maxillary vestibule, the width of the flap is marked. The intended defect size is limited to only 3 cm at its largest to

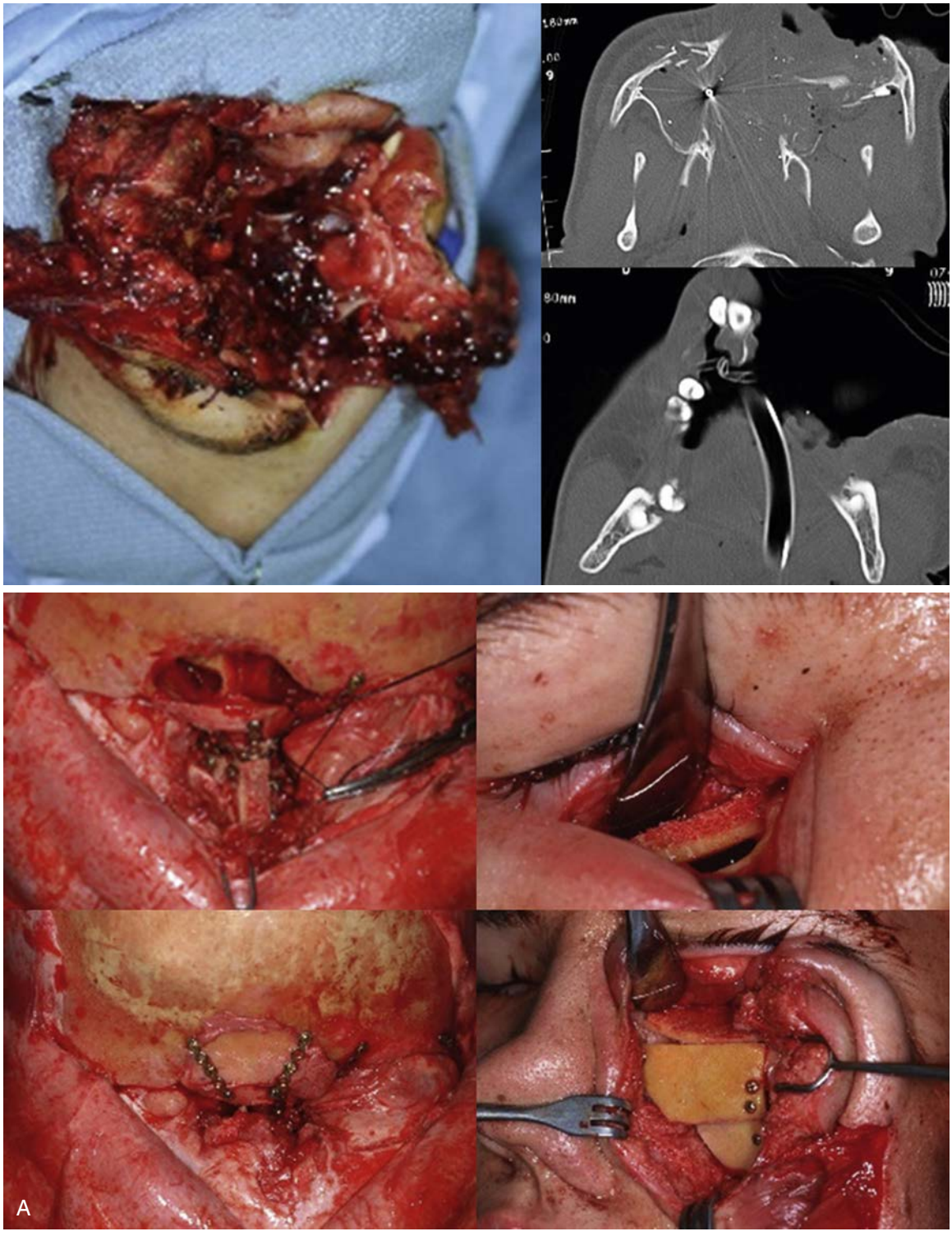

• **Figure 14-6** **A,** Surgical steps from bone graft—cranial bone grafts to nasal dorsum and midface, palate closure with temporalis flap, mandible reconstruction with osseocutaneous vascularized flap.

Continued

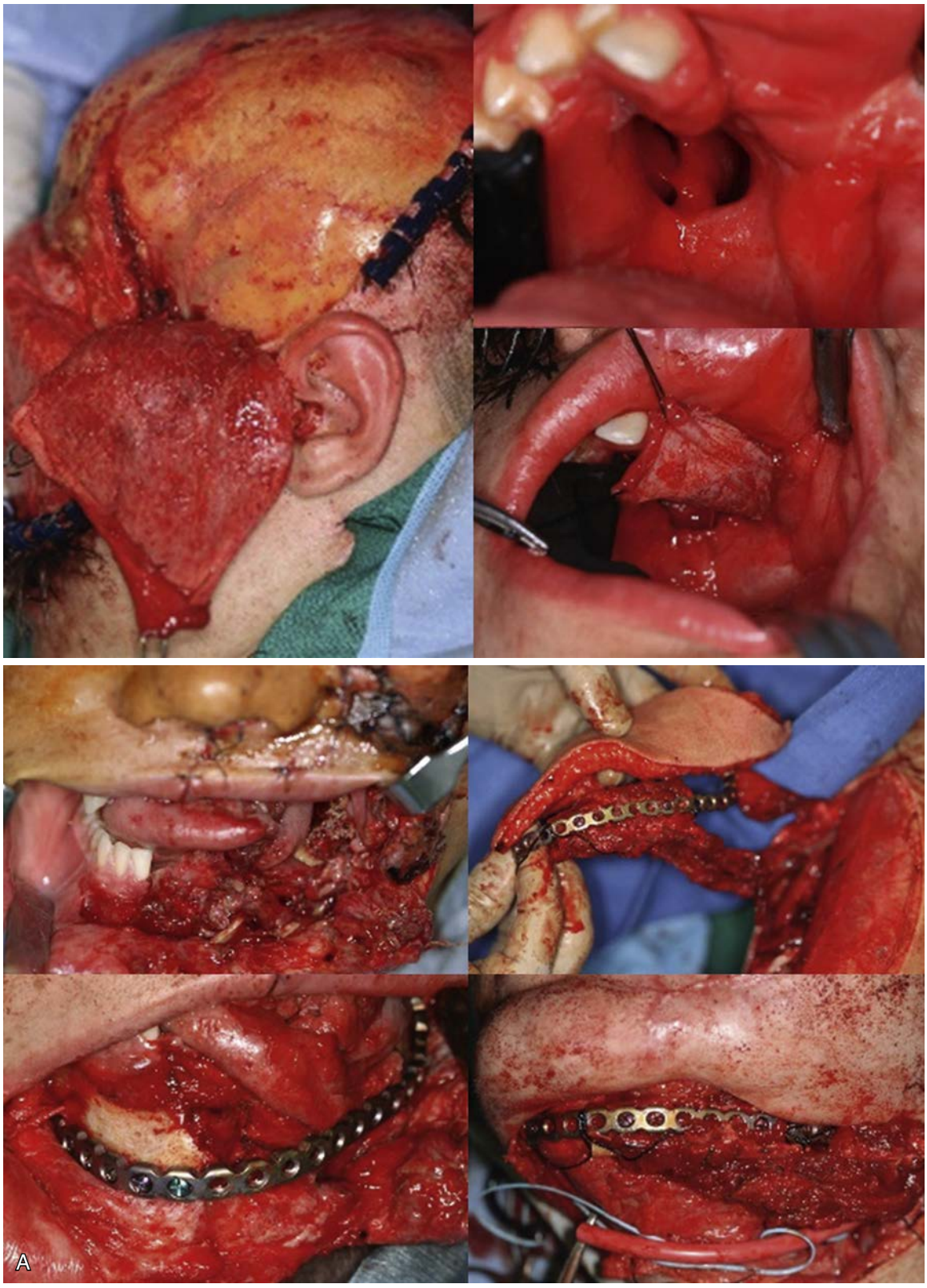

• **Figure 14-6, cont'd.**



• **Figure 14-6,** **B,** Rehabilitative phase demonstrating dental implants, prosthesis, debulking of the transferred tissue, and removal of the distant skin flap with adjacent tissue advancement after skin expansion.

Continued



• **Figure 14-6, cont'd.**

minimize scarring and postoperative trismus. The harvesting is done in a straightforward path by incising the marked flap past the buccinator muscle. The vessel is identified, ligated, and divided. Dissection is continued in the direction of the pedicle. Once the harvesting is completed, the donor site is closed in layers, and the flap is mobilized to the site to be reconstructed and is then inset (Figure 14-8).

Paramedian Forehead Flap

The paramedian forehead flap is one of the mainstay flaps for nasal reconstruction. This flap is most often used in the reconstruction of oncologic defects, but it can also be used for traumatic defects. The blood supply to the paramedian forehead flap is the supratrochlear artery. The design for this flap is most often based on a predetermined template. The author prefers to use the aluminum packaging of sutures as the material to outline the template for the defect. The template is transferred to the forehead region and the flap outline is marked. The elevation of the flap is in a subcutaneous plane until about 2 cm above the brow region. At this region the dissection is deepened to the periosteal plane and the flap dissection is completed. Rotation of the flap is checked to eliminate compression and kinking of the vascular pedicle (see Figure 14-3). The flap is then inset and, similar to other pedicled flaps, is allowed to develop collateral blood supply for about 3 weeks. It is then detached and the inset completed (Figure 14-9).

Cervicofacial Flap

The cervicofacial flap is a random flap that can be used to cover cheek defects and/or to bring like tissues to replace the skin component of previously transferred free flaps. The flap is marked from the area of the defect extending posterior and superior to the lateral canthal region. The incision is made to a level above the plane of the canthus and extended to the preauricular region, as with a rhytidectomy incision. The continuation of the incision in the neck is dependent on the extent of the defect to be closed. The incision can be extended to the chest region. The flap is then elevated in a subcutaneous plane and rotated to close the defect (Figure 14-10).

Temporoparietal Fascia Flap

The temporoparietal fascia flap is a thin, pliable flap that may be used for the reconstruction of several facial defects. This flap may also be harvested as an osteofascial flap.[7] Its utility is based on its ease of harvest and reach. It may be used to reconstruct defects of the midface, maxilla, buccal mucosa, floor of mouth, and mandible. Harvesting of the flap is first carried out by using Doppler to determine the path of the superficial temporal vessels. Once this is marked, a small strip of hair is shaved along the temporal region in the manner of a bi-temporal flap design. A thin flap is then elevated just below the level of the hair follicles. Care is taken to not injure the vasculature of the flap, which is found directly under the raised scalp flap. Once the desired length and width of the flap are exposed, the temporoparietal fascia is elevated off of the temporalis fascia and transferred to the desired location. When this flap is used for intraoral reconstruction, a skin graft is rarely needed because the flap will mucosalize (Figure 14-11). However, when used to provide coverage for facial defects, a skin graft may be used to improve the final cosmetic appearance.

Submental Island Flap

A recent addition to the armamentarium of the head and neck reconstructive surgeon is the submental artery flap. The first description of this flap was by Martin and colleagues in 1993.[10] The flap had little recognition and use in head and neck reconstructive surgery until Vural and Suen[11] described its usefulness for the reconstruction of various defects within the head and neck. The advantages of the submental island flap are its pliability and its excellent color match for facial reconstruction. As the name implies, the submental island flap is an axial flap based on the submental artery and its vena comitans. The design of the flap is somewhat limited by the amount of submental skin that can be harvested while still allowing primary closure of the defect. The width of the flap is determined by doing a pinch test and marking the area. The skin paddle is drawn and a subplatysmal flap is elevated around it. The skin is sutured to the underlying fascia to prevent shearing.



• **Figure 14-7** Abbe flap reconstruction for upper lip avulsion.

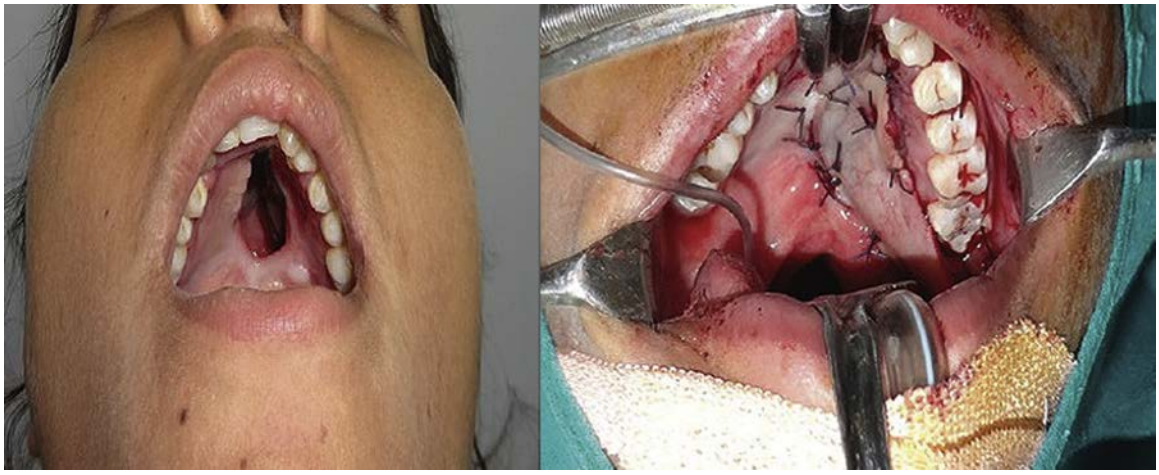

• **Figure 14-8** Facial artery musculomucosal (FAMM) flap for reconstruction of palatal defect.



• **Figure 14-9** Reconstruction of inadequately reconstructed and scarred nose due to previous motor vehicle collision. The reconstruction is demonstrated by paramedian forehead flap for nasal dorsum and the ala, previous scarred tissue used for columella and inner lining, and cartilage framework reconstructed with rib cartilage.



• **Figure 14-10** Cervicofacial rotational flap for avulsive skin defect.

Elevation of the flap is begun at the contralateral aspect of the pedicle. The anterior belly of the digastric is identified, and the elevation is carried superficial to its fascia. Once the perforating branches of the contralateral submental artery are encountered, they are ligated and divided. The ipsilateral anterior digastric is disinserted from the anterior mandible, and a portion of the muscle is raised with the flap. Dissection is then continued along the submental artery toward its detachment from the facial artery. All of the minor branches are ligated and divided. The elevation is completed after the

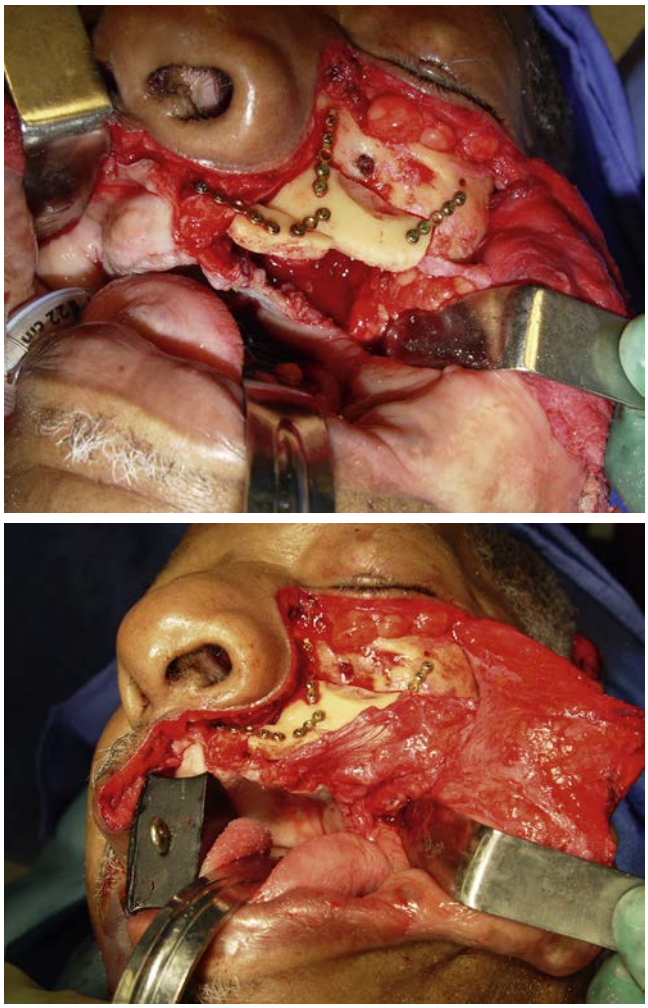

• **Figure 14-11** Temporoparietal fascia flap for correction of sinus lining, cheek, and palate region.

desired length of the vascular pedicle is dissected, allowing for a tension-free arc of rotation of the flap to cover the defect. This flap can be used to cover cheek defects and all intraoral defects, including defects in the maxilla.[12] The submental island flap may also be harvested as a reverse flow flap, in which case the perfusion will be dependent on the angular artery.[13] When used as a reverse flow flap, this flap may reach as high as the orbit, and thus can be used to cover orbital and periorbital defects.[14]

Microvascular Free Flaps

The use of free tissue transfer allows for the reconstruction of large avulsive tissue defects with one operation. Free tissue transfer has made it possible to transfer well-vascularized bone and soft tissue flaps into a hostile environment with excellent survival of the flap tissues or free bone grafts invested by the vascularized flap.[15] Many free flap options exist for the reconstruction of these defects. The choice of which flap to use should depend on the needs of the defect and the ability to contour and adapt the chosen flap to the defect site. Some of the disadvantages of these flaps are the second donor site, color mismatch, and long operative time. The following are some examples of commonly used free tissue flaps.

Radial Forearm Flap

The radial forearm flap was first described by Song and colleagues in 1982.[16] This flap revolutionized the field of microvascular surgery and in particular the use of this technique for head and neck reconstruction. The radial forearm free flap (RFFF) is now routinely used in most major medical centers for the reconstruction of head and neck soft tissue defects. The use of this flap has also been described as an osteocutaneous flap[17] for limited bony reconstruction of the head and neck, particularly of the midface. However, because of the possibility of a radius fracture, using this flap as an osteocutaneous flap is rarely considered. The RFFF is based on the radial artery, and its venous drainage is provided by the paired vena comitans or the cephalic vein (Figure 14-12). Preoperative assessment for the use of the RFFF is based on Allen's test, which is the assessment of the collateral circulation between the radial artery and the ulnar artery on the palmar arches.

The flap is elevated while taking care to maintain the paratenon covering the tendons to ensure adequate acceptance of the skin graft that is used to cover the donor site.

Fibula Free Flap

Since its description by Hidalgo[18] in 1989, the fibula free flap has truly become the "workhorse" flap for bony reconstruction in the head and neck, and in particular mandibular reconstruction. The fibula is a non-weight-bearing bone supplied by the peroneal artery. The peroneal artery sends perforators to the overlying skin. The length of the fibula is ideally suited for nearly all mandibular reconstruction, ranging from small to near-total reconstruction based on a single flap. The width and height of the flap are also well suited for mandibular and maxillary reconstruction because the flap will accept dental implants in a very predictable fashion, allowing not only for aesthetic reconstruction but also for functional reconstruction.

Anterolateral Thigh Free Flap

The use of the anterolateral thigh (ALT) flap in head and neck reconstruction continues to gain popularity in this country and has already become the preferred flap for small and large soft tissue defects in Asia. The ALT flap is one of the most commonly used perforator flaps for head and neck reconstruction. Wei and colleagues defined perforator flaps as those in which the source artery is deep and the branch that carries blood directly to fasciocutaneous tissue in its course to reach the skin passes through the overhanging muscular tissue without exclusively following the intermuscular septum.[19] The flap is based on the perforator branches from the descending branches of the lateral circumflex femoral artery and its vena comitans (Figure 14-13). In general, two to three perforators can be found to raise the flap. However, a single perforator can sustain an area of tissue as large as 22 cm^2.



• **Figure 14-12** Radial forearm flap for total upper lip and anterior premaxilla reconstruction.

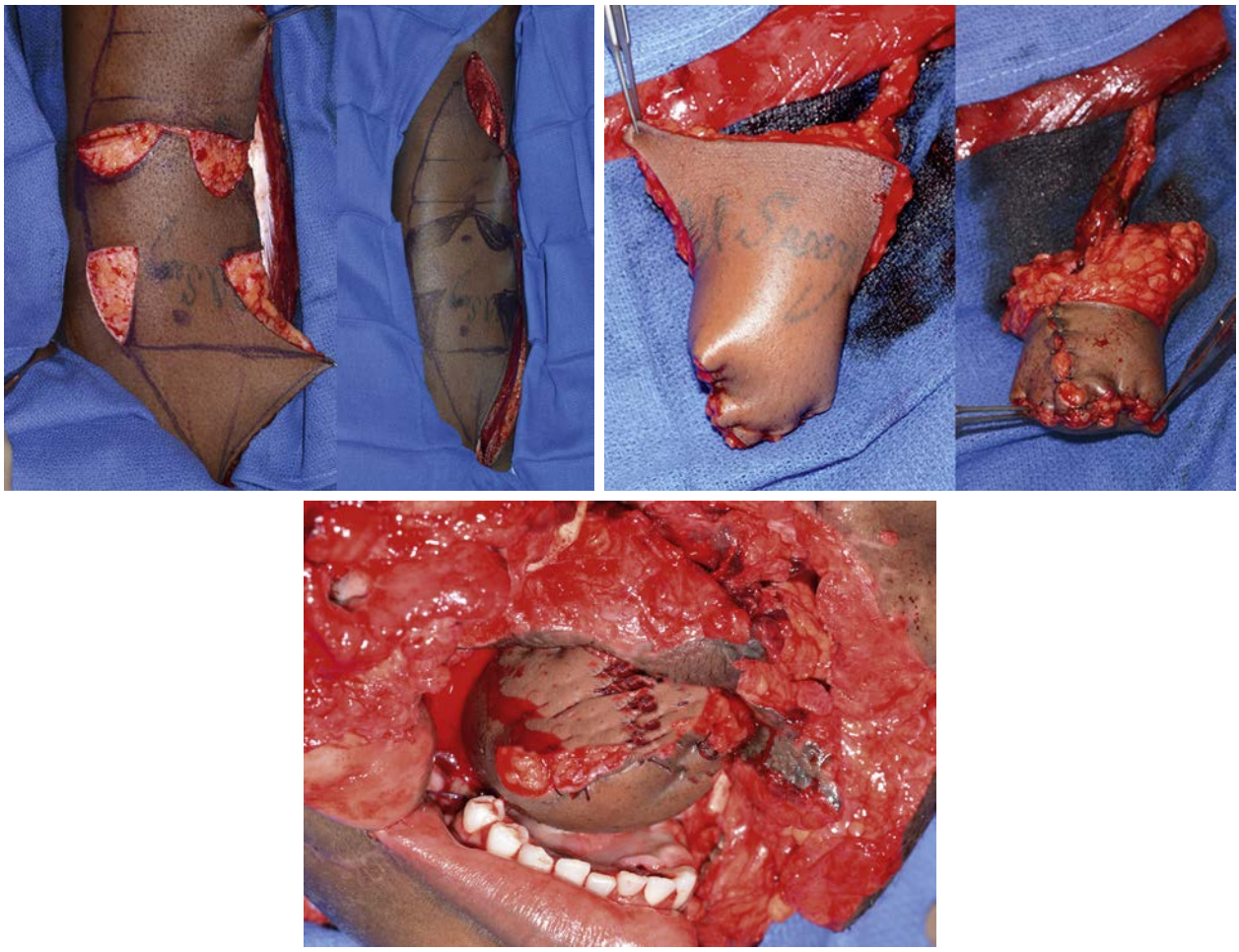

• **Figure 14-13** Anterolateral thigh flap for tongue reconstruction for self-inflicted gunshot wound.

• BOX 14-2 Reconstructive Flap Options for Site-Specific Defects

Lip
- Abbe flap (cross lip)
- Facial artery musculomucosal (FAMM)
- Radial forearm free flap (RFFF) with palmaris longus tendon
- Anterolateral thigh (ALT)

Nasal Tip
- Nasal flap
- Paramedian forehead
- Bilobed

Total Nasal Defects
- Paramedian forehead
- Prefabricated flap (RFFF)

Eyebrow
- Subcutaneous island pedicle flap
- Free scalp graft
- Pedicle superficial temporal artery scalp flap

Ear
- Reanastomosis of avulsed ear if adequate vessels remain
- Temporoparietal fascia flap coverage of rib

Cheek (Through-and-Through)
- Double island pectoralis major myocutaneous flap
- RFFF
- ALT
- Combination of free tissue and local
- Combination of one flap and skin graft of the exposed surface

Cheek
- Cervicofacial
- Submental island flap
- RFFF
- ALT

Scalp
- Rotation flaps
- Orticochea (banana peel) flap
- ALT
- RFFF
- Latissimus free flap

Maxillary Bone
- Bone graft with mesh retention
- RFFF osseocutaneous
- Fibula
- Deep circumflex iliac artery (DCIA)
- Scapula

Mandible
- Bone graft (anterior vs. posterior iliac crest)
- Fibula
- DCIA
- RFFF (osteocutaneous)

Deep Circumflex Iliac Artery Flap

The deep circumflex iliac artery (DCIA) flap is another popular option for free tissue transfer to restore the soft tissue and bony contours of the mandible. The DCIA is an ideal flap to restore the width and vertical dimension of the mandible and provide an appropriate bed for the placement of dental implants. The internal oblique muscle is harvested along with the iliac crest and is allowed to epithelialize to serve as soft tissue coverage for the graft intraorally. A skin paddle can also be taken with this flap. Disadvantages of this are the relatively short 4- to 5-cm vascular pedicle available, higher potential donor site morbidity, and sometimes bulk.[20] A vein graft may be taken if a longer pedicle is required.

Site-Specific Reconstruction

Because of the constraints of this chapter, a detailed description of a site-specific reconstructive algorithm is not possible. Refer to Box 14-2 for an overview of the author's preferred flap options for defects involving a variety of facial areas. The following is a description of reconstructive options for commonly injured sites.

Lower Face/Mandible

The reconstruction of mandibular defects can be a challenging problem because of the need to meet not only functional but also aesthetic requirements. The assessment of the type of reconstruction needed depends on the assessment of the integrity not only of the soft tissues in the neck but also, more critically, of intraoral soft tissues. The surgeon must determine the need for hard and soft tissue required to reconstruct the defect. Bone-only reconstruction is undertaken when there is adequate intraoral soft tissue and skin coverage in the neck. In this circumstance, the reconstructive option is dependent on the amount of missing bone. In most instances, if the size defect is less than 8 cm in length with good soft tissue bed and coverage, a nonvascularized graft may be used secondarily (Figure 14-14). The site of harvest for the graft is dependent on the surgeon's preference. The most commonly used site for such a defect size is the anterior iliac crest, given that the average amount of bone that can be harvested from this site is about 50 mL. If the defect is greater than 5 cm, the author prefers to use the fibula as an osseous-only flap. The fibula can be inset either with 2.0 mandibular plates or with a 2.4 mandibular reconstruction bar.

In situations in which the defect includes not only the bone but also the soft tissue, an osseocutaneous or osseomusculocutaneous fibula flap may be harvested to reconstruct the defect (Figure 14-15).

Other options to reconstruct these defects would include the use of scapular flap or the deep circumflex iliac artery (DCIA) flap. When only soft tissue is desired,

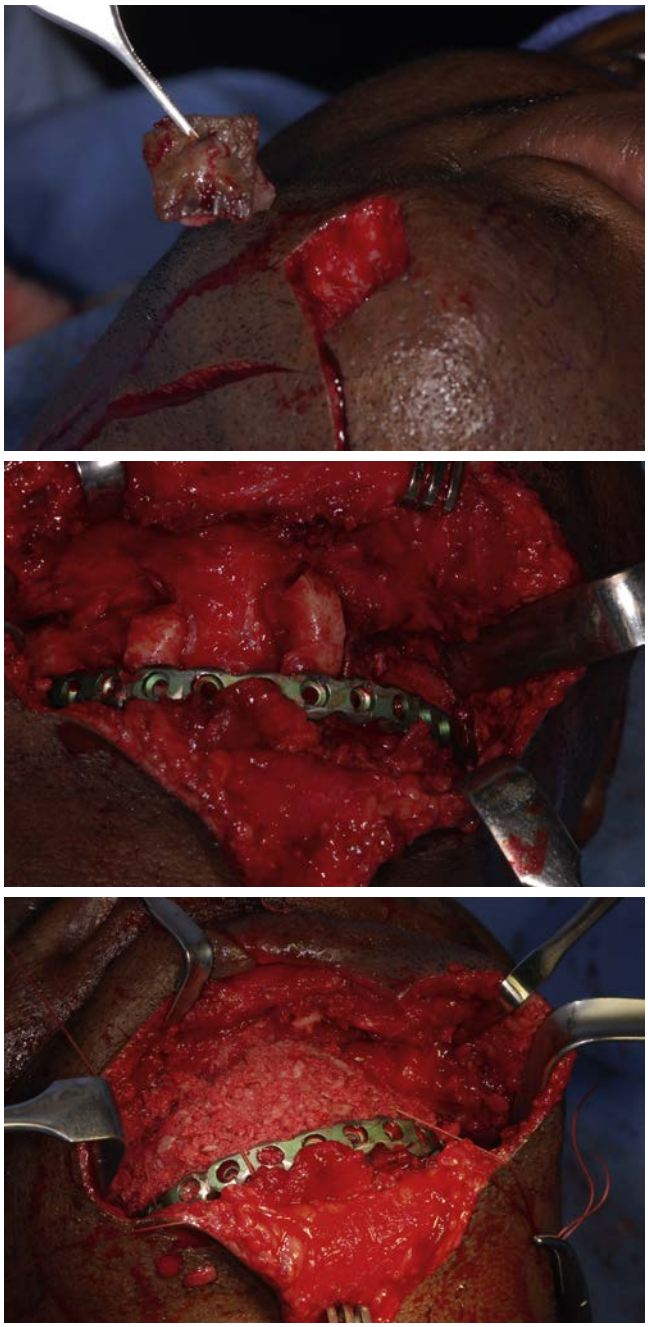

• **Figure 14-14** Reconstruction of mandible defect with iliac crest bone graft.

with the idea of performing delayed bony reconstruction, the surgeon may use the submental artery flap, the ALT flap, the RFFF, or any other soft tissue flap available that would cover the defect without prohibiting later reconstruction or unnecessarily causing problems to the patient.

Midface Defects

Avulsive defects of the midface may pose significant challenges to the surgeon and may cause significant psychological problems for the patient.

Nasal Defects

As a result of the central location of the nose within the facial structure, defects of this anatomic unit are very difficult to reconstruct and camouflage well. Nasal defects range from small soft tissue defects, which can be reconstructed with a skin graft, to total rhinectomy defects, which would necessitate extensive reconstruction with local flaps as well as microvascular tissue transfer. Small defects are often classified as those measuring less than 1.5 cm, and large defects are deemed to be those greater than 2.5 cm.[21] The cornerstone of nasal reconstruction depends on reestablishing the nasal lining and adequate nasal support (both bony and cartilaginous) and providing nasal skin coverage. The skin coverage of the nose should be based on the subunit principle as described by Burget and Menick.[22] Adjacent tissues are commonly used for the reconstruction of nasal lining. Examples of adjacent flaps used for the nasal lining are the nasolabial flaps in a turned-in fashion or a turned-in paranasal flap. In cases in which the septum is intact, the contralateral septal mucosa may be elevated and brought in through a small slit in the dorsal aspect of the cartilage, passed to the other side, and used as a lining. The cranial bone is often used as the ideal donor site for a bone graft to provide bridge support to the nasal dorsum. One of the advantages of this donor site is its accessibility when combined with a paramedian forehead flap. Reconstruction of defects of the skin is dependent on the size of the defect and the integrity of adjacent tissues. Various options are available for small ablative defects, ranging from the use of bilobed flaps, V-Y dorsonasal flaps, or skin island flaps to nasolabial flaps. Larger defects, including up to total loss of nasal skin, may be covered with the use of the paramedian forehead flap. If this is not available, then free tissue transfer may also be an option.[23,24] Free tissue transfer may range from a radial forearm flap to a prefabricated forearm or anterolateral thigh flap. In these cases, the entire nasal structure is fabricated at the donor site, and after completion of the staged prefabrication, the flap is harvested and transferred to the defect site.[25]

The complete reconstruction of extensive nasal defects is a staged process that may require up to four surgeries, with the last procedures being the thinning of the flap and final cosmetic touch-ups. The last surgeries often can be carried out using local anesthesia or light sedation.

Lip Defects

Like nasal injuries, lip defects can range from small to total. The approach used by the author when dealing with lip defects is dependent on the site (i.e., upper lip or lower lip). Defects of the upper lip that are less than 25% of the total upper lip length may be closed primarily without the need for reconstruction. Defects of the lower lip that are less than one-third total lip length may also be closed primarily without significant distortion of the lip and resultant microstomia. The flap for lip reconstruction most commonly used by the author is the Abbe flap. This flap may be used to reconstruct

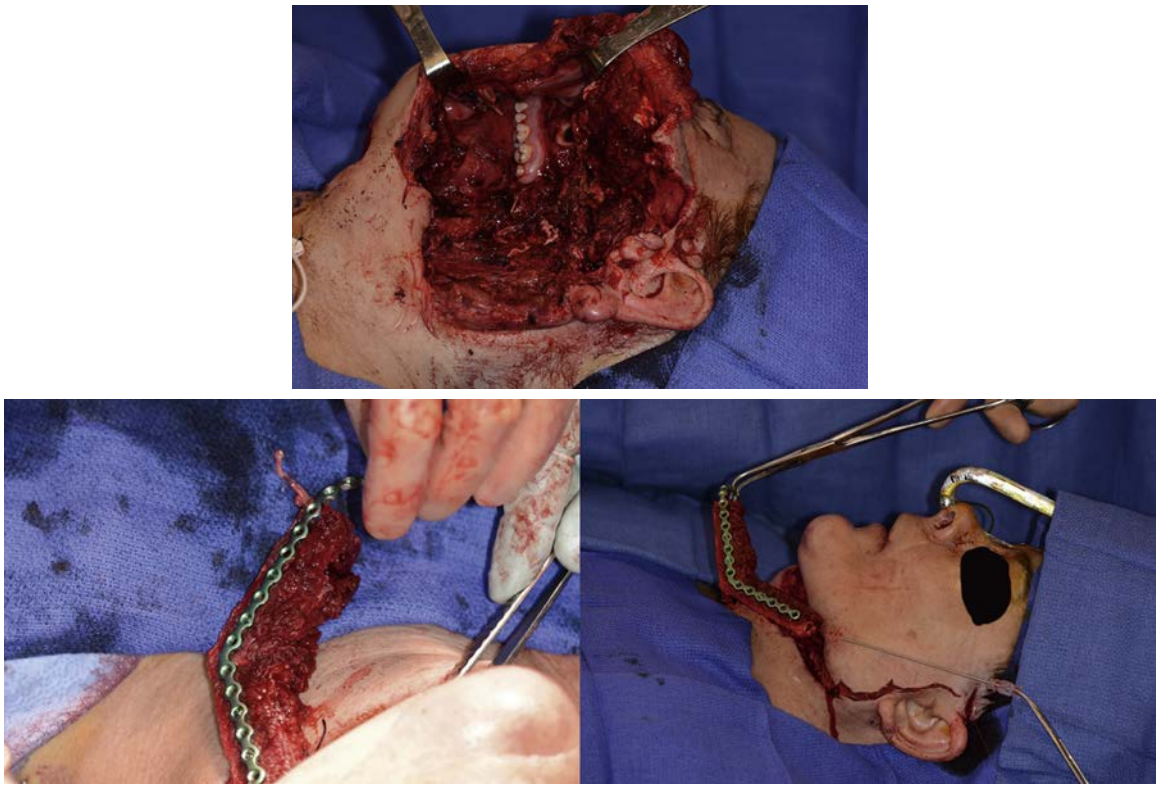

• **Figure 14-15** Fibula osseomusculocutaneous flap for mandible reconstruction.

either the lower or the upper lip. When defects of the lip are primarily centered on the mucosa or the vermilion, the FAMM flap may be used to reestablish thickness while providing the desired mucosal coverage.[26] A host of other local flaps have been described for reconstructing lip defects, but their description is beyond the scope of this chapter.

In cases of near-total or total lip loss, the option preferred by the author is microvascular tissue transfer. The most commonly employed free flap for total lip reconstruction is the radial forearm free flap with the palmaris longus tendon.[27,28] The ALT flap may also be used to reconstruct total lip and chin defects.[29] In cases in which total lip reconstruction is needed, the surgeon must anticipate sagging and thus use fascia or tendon to resuspend the lip and establish the commissure. Like the reconstruction of total nasal defects, the reconstruction of total lip defects is a multistage reconstruction, requiring replacement of the missing tissue followed by replacement of the lip vermilion and re-creation of the philtral ridges.

Cheek Defects

Injuries of the midface region have the potential to damage not only the soft tissue and the underlying bone but also the facial nerve and the parotid duct. When dealing with avulsive defects in the cheek, potential injuries to these structures must be assessed and, whenever possible, should be addressed. In the majority of cases, the defect is centered around missing skin and subcutaneous tissues. Significant loss of soft tissue of the cheek needs to be assessed for the amount of thickness needed. When the thickness is superficial but greater than what would be satisfactorily reconstructed with a skin graft, the cervicofacial flap may be employed. In cases in which the defect is through-and-through, several options would be available. A regional flap such as the pectoralis major flap may be used either as a double paddle or as a single paddle with skin grafting of the exposed muscle. The main drawback of these defects is that they are static reconstructions and the patient will have the sequela of loss of the facial nerve.

Large bony reconstruction of the midface may be provided by the use of the scapula free flap or the fibula flap. The fibula free flap is optimal for reconstruction for large bone and soft tissue defects of the midface region. The fibula flap is contoured to re-create the missing structure while the soft tissue component is used to bulk the missing soft tissue (Figure 14-16).

Scalp Defects

Scalp defects are often encountered in association with severe motor vehicular accidents, especially when the patient is ejected from the vehicle. These defects are often highly contaminated with road debris, and the extent of missing tissue is often difficult to assess in the trauma bay. These patients need to be brought to the operating room to have thorough irrigation of the site and assessment of the amount of missing tissue. The surgical options available

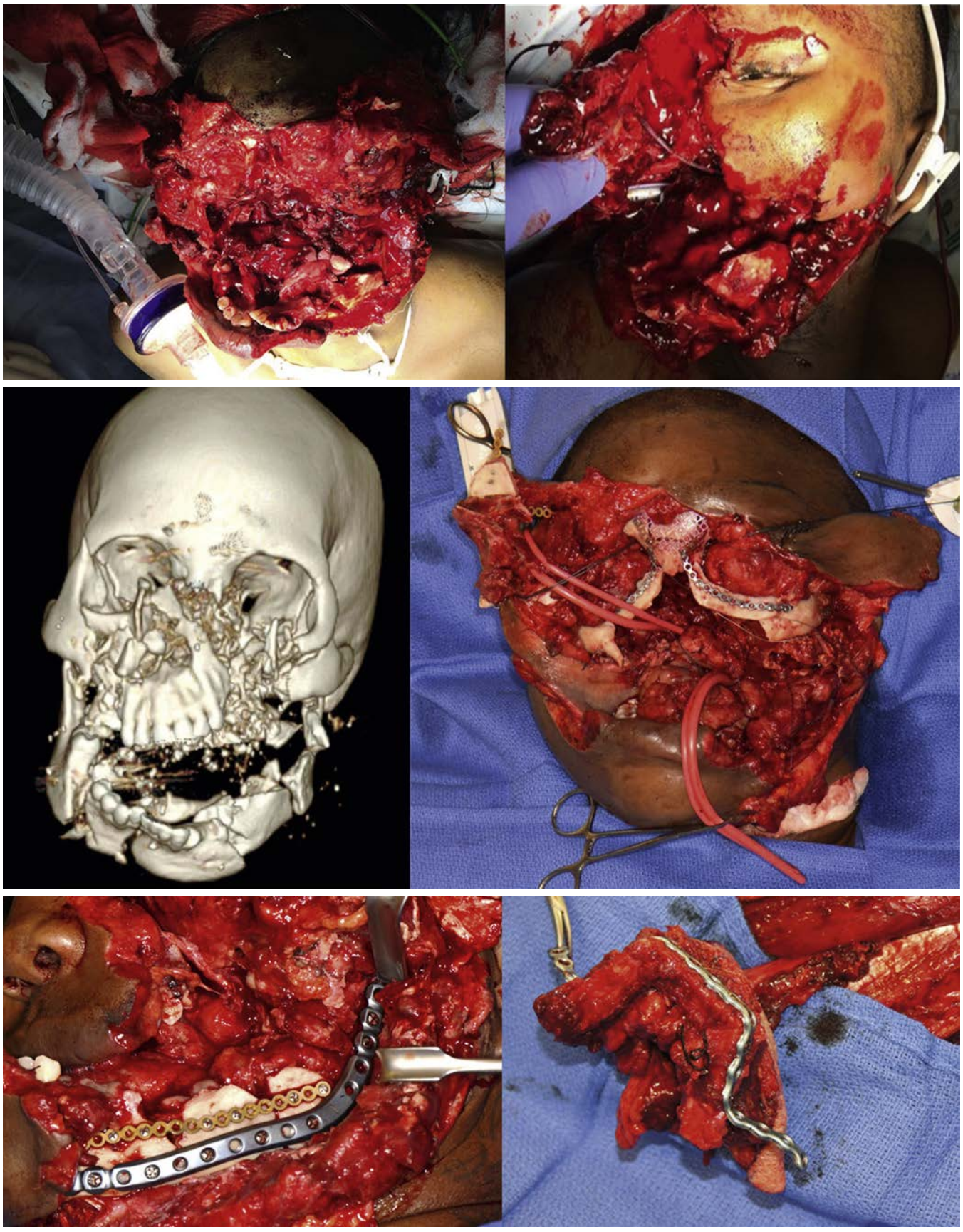

• **Figure 14-16** Reconstruction of nasal dorsum and orbits with cranial bone grafts, and the maxilla with osseomusculocutaneous flap.

Continued

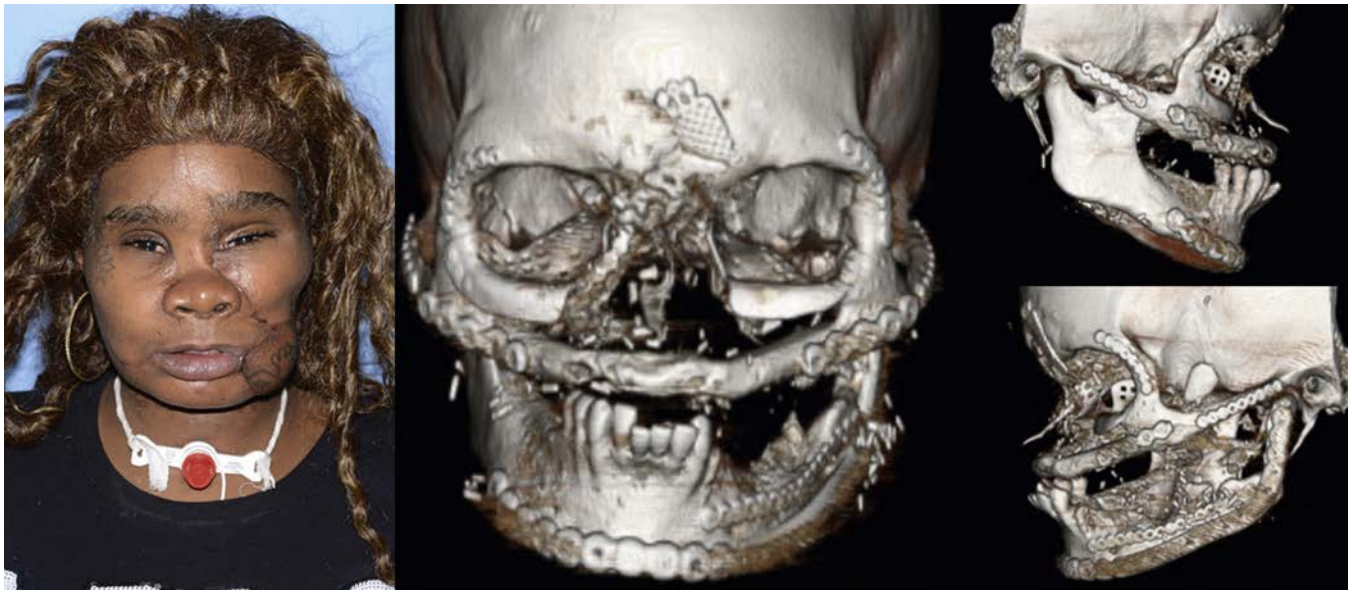

• **Figure 14-16, cont'd.**

range from a simple skin graft if the pericranium is intact to more complex options. Small defects can be closed with advancement of a pinwheel releasing flap. Moderate-sized defects may require a greater degree of rotation from the flaps (Figure 14-17). Once the flaps are elevated, the advancement is aided by scoring the pericranium. Large defects may be reconstructed with either the Orticochea three-flap technique or free tissue transfer. The free tissues commonly used in scalp reconstruction for large to total scalp defects are the ALT flap[30] and the latissimus dorsi flap.[31]

Aesthetic and Prosthetic Rehabilitation

Once the main surgical procedures have been completed, the final steps in reconstructing avulsive defects are debulking and serial excision surgeries. The goal of these procedures is to complete the reconstruction and allow the patient to return to daily activities. These procedures typically include prosthodontic reconstruction and facial aesthetic procedures (Figure 14-18). A team approach to the care of these patients cannot be overemphasized. The reconstruction of bony defects with free tissue transfer or with nonvascularized bone allows for the eventual placement of dental or other facial implants, while soft tissue reconstruction provides the platform for soft tissue prostheses such as eyes, ears, and noses (see Figure 14-16). The maxillofacial prosthodontist is charged with the task of making the prosthesis that bridges the limitations of surgical reconstruction.

Last, aesthetic surgical techniques, ranging from dermabrasion to scar revision, help to camouflage the scars and the transition between native tissues and transferred tissues. A thoughtful and systematic approach to the care of patients with large avulsive facial injuries positions the surgeon and the patient on the best possible path to the optimal outcome.

Complications

Complications related to the reconstruction can be grouped as functional or aesthetic. Functional complications range from flap vascular failure and infection to problems with vision, mastication, oral stoma competence, speech, and swallowing. Early institution of antibiotics, debridement of nonviable tissues and foreign matter from the wound, and stabilization of fractures will reduce the risk of serious infection. Gunshot wounds lead to progressive extensive soft tissue damage that can increase the risk of vessel thrombosis, particularly venous, if free tissue transfer reconstruction is performed too early. Return to the operating room after reconstruction for wound irrigation in suspect cases reduces the risk of free flap compromise and potential loss. All definitive bone grafts should be surrounded with vascularized tissue and rigidly fixated. Mucosal and flap closures in the floor of the mouth must be watertight. If infection does occur in the neck, prompt drainage and diversion away from the vascular pedicle should be undertaken. If the vascular pedicle is exposed to the infection, it should be covered with a regional myofascial flap. Nonvascularized bone reconstruction of the mandible should only be undertaken in a sterile wound with satisfactory soft tissue coverage available both internally and externally. The aesthetic complications include: poor nasal projection and shape, traumatic telecanthus, apparent asymmetry of the position of the eyes, and unsatisfactory facial contour due to underlying bone or overlying soft tissue irregularity.



• **Figure 14-17** Closure of scalp defects with scalp rotation flaps.

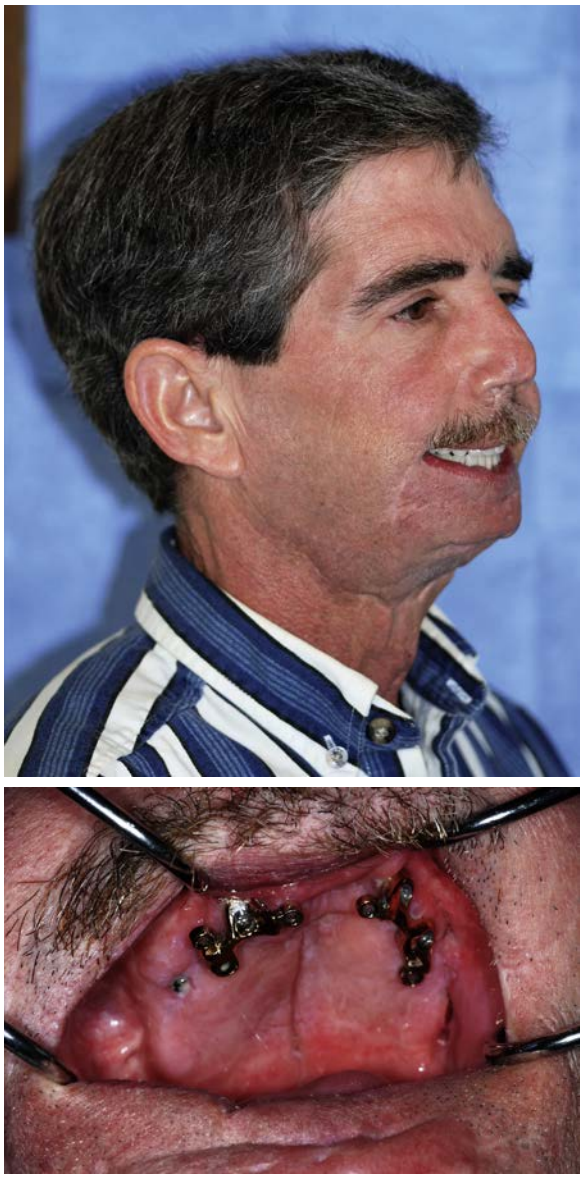

• **Figure 14-18** Prosthetic rehabilitation of reconstructive defects require dental implants due to flat alveolar ridges with no lip, alveolar transition.

References

1. Clark N, Birely B, Manson PN, et al.: High energy ballistic and avulsive facial injuries: classification, patterns, and an algorithm for primary reconstruction, *Plast Reconstr Surg* 98:583–601, 1996.
2. Eppley BL, Coleman JJ: Reconstruction of large hard and soft tissue loss of the face. In *Maxillofacial trauma and esthetic facial reconstruction*, New York, 2003, Churchill Livingstone, pp 384–414.
3. Abbe R: A new plastic operation for the relief of deformity due to double harelip, *Med Rec* 53:477–478, 1898.
4. Burget GC, Menick FJ: Aesthetic restoration of one half of the upper lip, *Plast Reconstr Surg* 78:583–593, 1986.
5. Schulte DL, Sherris DA, Kasperbauer JL: The anatomical basis of the Abbe flap, *Laryngoscope* 111:382–386, 2001.
6. Pribaz J, Stephens W, Crespo L, et al.: A new intraoral flap: facial artery musculomucosal (FAMM) flap, *Plast Reconstr Surg* 90(3):421–429, 1992.
7. Parhiscar A, Har-El G, Turk JB, et al.: Temporoparietal osteofascial flap for head and neck reconstruction, *J Oral Maxillofac Surg* 60(6):619–622, 2002.
8. Reference removed in page proof.
9. Reference removed in page proof.
10. Martin D, Pascal JF, Baudet J, et al.: The submental island flap: a new donor site. Anatomy and clinical application as a free or pedicled flap, *Plast Reconstr Surg* 92:867–873, 1993.
11. Vural E, Suen JY: The submental island flap in head and neck reconstruction, *Head Neck* 22:572–578, 2000.
12. Genden EM, Buchbinder D, Urken ML: The submental island flap for palatal reconstruction: a novel technique, *J Oral Maxillofac Surg* 62:387–390, 2004.
13. Kim JT, Kim SK, Koshima I, et al.: An anatomic study and clinical application of the reversed submental perforator-based island flap, *Plast Reconstr Surg* 109:2204–2210, 2002.
14. Karacal N, Ambarcioglu O, Topal U, et al.: Reverse-flow submental artery flap for periorbital soft tissue and socket reconstruction, *Head Neck* 28:40–45, 2006.
15. Gruss JS, Antonyshyn O, Phillips JH: Early definitive bone and soft-tissue reconstruction of major gunshot wounds to the face, *Plast Reconstr Surg* 87:436–450, 1991.
16. Song R, Gao Y, Song Y, et al.: The forearm flap, *Clin Plast Surg* 9(1):21–26, 1982.
17. Soutar DS, Scheker LR, Tanner NS, et al.: The radial forearm flap: a versatile method for intra-oral reconstruction, *Br J Plast Surg* 36(1):1–8, 1983.
18. Hidalgo DA: Fibula free flap: a new method of mandible reconstruction, *Plast Reconstr Surg* 84(1):71–79, 1989.
19. Wei FC, Jain V, Suominen S: Confusion among perforator flaps: what is a true perforator flap? *Plast Reconstr Surg* 107:874–876, 2001.
20. Rodriguez ED, Bluebond-Langner R, Martin M: Deep circumflex iliac artery free flap in mandible reconstruction, *Atlas Oral Maxillofac Surg Clin N Am* 14:151–159, 2006.
21. Yoon T, Benito-Ruiz J, Garcia-Diez E, et al.: Our algorithm for nasal reconstruction, *J Plast Reconstr Aesth Surg* 59:239–247, 2005.
22. Burget GC, Menick FJ: The subunit principle in nasal reconstruction, *Plast Reconstr Surg* 76:239–247, 1985.
23. Park SS: Reconstruction of nasal defects larger than 1.5 centimeters in diameter, *Laryngoscope* 110:1241–1250, 2000.
24. Winslow CP, Cook TA, Burke A, et al.: Total nasal reconstruction: utility of the free radial forearm fascial flap, *Arch Facial Plast Surg* 5:159–163, 2003.
25. Walton RL, Burget GC, Beahm EK: Microsurgical reconstruction of the nasal lining, *Plast Reconstr Surg* 115:1813–1829, 2005.
26. Pribaz JJ, Meara JG, Wright S, et al.: Lip and vermilion reconstruction with the facial artery musculomucosal flap, *Plast Reconstr Surg* 105:864–872, 2000.
27. Serletti JM, Tavin E, Moran SL, et al.: Total lower lip reconstruction with a sensate composite radial forearm-palmaris longus free flap and a tongue flap, *Plast Reconstr Surg* 99:559–561, 1997.
28. Jeng SF, Kuo YR, Wei FC, et al.: Total lower lip reconstruction with a composite radial forearm-palmaris longus tendon flap: a clinical series, *Plast Reconstr Surg* 113:19–23, 2004.
29. Yildirim S, Gideroglu K, Aydogdu E, et al.: Composite anterolateral thigh-fascia lata flap: a good alternative to radial forearm-palmaris longus flap for total lower lip reconstruction, *Plast Reconstr Surg* 117:2033–2041, 2006.
30. Zaretski A, Wei FC, Lin CH, et al.: Anterolateral thigh flap in head and neck reconstruction, *Semin Plast Surg* 20:64–72, 2006.
31. Lipa JE, Butler CE: Enhancing the outcome of free latissimus dorsi muscle flap reconstruction of scalp defects, *Head Neck* 26:46–53, 2004.

15

Treatment of Maxillofacial Gunshot Wound Injuries

EDWARD J. MILLER JR., STEVEN H. CHO

Gunshot wounds (GSWs) to the maxillofacial region continue to be a major public health concern in the United States. A thorough understanding of the scope of the problem and its specific relation to the surgeon treating these patients is essential. In the United States, the number of deaths per year due to injury by firearms is approximately 10.4 per 100,000. Causes of death due to firearm mortality include accidental discharge of firearm, suicide, assault by firearm, and firearm discharge of undetermined intent. Deaths from injury by firearms exclude deaths due to explosives and other causes indirectly related to firearms.[1]

Firearm-related injuries have declined 69% over the past two decades in the United States. The majority of these GSW injuries are nonfatal but do require hospitalization.[2,3] According to Kalesan and colleagues, there were 478,400 fatal and nonfatal firearms incidents in the United States in 2011, and 97.4% of these incidents were nonfatal. Overall, 75% of those injured required medical attention, and 80% of those requiring medical attention were hospitalized.[3] On average, there are 32 gun-related fatalities every day in the United States, and 140 are treated for a gun assault in an emergency room.[4] Of those injured, approximately 6% of GSWs involve the face, and male patients make up more than 80% of the population of GSW victims.[5]

Classification of Bullets and Firearms

Caliber is a term used by ammunition and firearm manufacturers in the United States to indicate the diameter of a bullet in hundredths of an inch or millimeters. A bullet that is 22 hundredths of an inch (.22) in diameter is called a 22-caliber or 9-mm bullet.[6] In general, the wounding power or lethal power of a projectile is proportional to the caliber. Any caliber of handgun or rifle can produce a lethal injury.[7] A cartridge is a single unit of ammunition consisting of the cartridge case, primer, and propellant with or without one or more projectiles. The cartridge designation typically includes a numerical value to indicate the approximate diameter of the bullet and will often include the manufacturer's name.[8]

Components of Ballistic Missiles

A round is one complete unit of ammunition. This includes the bullet, the cartridge case, the powder, and the primer.[9] The projectile or the bullet is the missile that is expelled and strikes the target. The accelerant, such as gunpowder or cordite that allows for expulsion of the projectile from the weapon, is the propellant. The primer is the device for igniting the propellant and sending the projectile on its flight. The container that packages the bullet, propellant, and primer as a single unit is the casing.[10]

Types of Firearms

There are three types of firearms: handguns, rifles, and shotguns.

The handgun is the smallest and the least powerful of all firearms. There are three common types of handguns: single-shot pistols, revolvers, and semiautomatic pistols. The single-shot pistol holds only a single round of ammunition and must be reloaded after each shot. Revolvers have a number of firing chambers in a revolving cylinder where each chamber in the cylinder is loaded with a single cartridge or charge. The semiautomatic can fire multiple shots, as many as 15 to 19 rounds. It uses the recoil generated by the fired cartridge to eject the empty cartridge case, load the next cartridge, and cock the hammer. Handgun injuries generally have a tendency to push away or stretch soft tissues including vessels or nerves, as opposed to creating avulsive wounds.[10]

A long gun is any firearm that is larger than a handgun with a barrel between 10 and 30 inches. The design of the long gun is intended for the user to hold and fire it using both hands. The long gun is generally held against the hip or the shoulder.

A rifle is named for the spiral fluting (rifling) carved into the inner surface of its barrel. This creates a self-stabilizing

spin to the single bullets it fires. Rifles, with long barrels and higher velocities, are very powerful and very accurate at long distances. They have the potential to destroy a large amount of tissue, as they are high-velocity, high–kinetic energy (KE) projectiles with the tendency to yaw, tumble, and fragment.[6,11]

Rifles, at distance, are similar to handguns because of low energy transfer. At close range, however, there is increased potential injury due to velocity and high energy transfer. Rifles have the capacity for high-speed automatic fire with a very small impact area. There is usually an exit wound, which may be stellate and larger than the entry wound. The existence of avulsive soft/hard tissue wounds and significant fragmentation of bone can be characteristic findings of rifle wounds.[10]

Shotguns are predominantly smoothbore firearms designed to fire a number of shots. Generally, the higher the shot number, the smaller the size of the pellets. The pellet sizes can range between 2 mm (#9 birdshot) used for small targets such as fowl and 8.4 mm (#00 double-aught buckshot) intended for larger game such as deer. A shotgun shell may contain one large projectile (called a slug) used for more powerful targets such as bear.[6,12]

Shotguns are similar in external appearance to rifles, but differ in the lack of rifling inside the barrel, which is the basis for their legal definition. Shotguns are classified according to gauge, which refers to the number of pellets (lead balls) that it would take to equal 1 pound when placed in a gun barrel of given diameter. This indicates the weight of the pellets fired by the weapon. A 12-gauge shotgun shoots pellets that weigh 1/12th of a pound each.[7]

Shotguns have a large impact area with considerably less range and accuracy. When a shotgun shell is fired, it breaks apart and the outer layers fall away, allowing pellets to separate radially, spread in a cluster, and become less aerodynamic as they pass through air. Pellets lose KE and velocity as they travel to the target; however, the larger impact area can compensate for reduced accuracy, overcoming the need for precision because the pellets spread during flight.[6]

Shotguns may cause minor to massive damage, depending on the range from the target and the size of the pellets fired. Shotgun wounds are unique because of the way the shotgun shells are constructed and the importance of range from gun to victim. Close-range wounds may involve massive tissue destruction and are equivalent to high-velocity GSWs. The pellets penetrate tissue and transfer kinetic energy to the victim, unlike other types of GSWs. Moreover, the pellets rarely exit the body. This means that all of the kinetic energy is transferred to the target tissue.[13]

Furthermore, there is a higher degree of contamination and presence of propelled gas and shock waves in shotgun injuries at close range. When the muzzle of the weapon is in contact with the target, the effect of gas that is discharged under pressure into the wound can be an additional source of tissue displacement, injury, and thermal burning.[8,10]

Two types of shotgun wound classification systems are described in the literature. Sherman and Parrish devised one classification system to describe shotgun wounds according to their distance. Specifically, their system was based on the number of yards/meters from muzzle to target. In type I wounds, the distance is greater than 7 yards, and such wounds tend to involve the subcutaneous tissue and deep fascia. (See Figure 15-21.) In type II wounds the distance is between 3 and 7 yards, and they show deeper pellet penetration of tissue. In type III wounds, the distance is less than 3 yards and these wounds have dramatic soft and hard tissue injuries and avulsion of tissue.[6,8] (See Figure 15-22.) Glazer and colleagues described the second classification system for shotgun wounds. Their system is based on pellet scatter. The pellet scatter in type I is within an area of 25 cm^2, type II 10 to 25 cm^2, and type III <10 cm^2.[6]

Wound Ballistics

Wound ballistics is the study of a missile's effect on living tissue. Knowledge of wound ballistics is essential to determine the extent and type of injury from a missile. Velocity has the largest impact on KE.[10,11] Both missile and tissue characteristics determine the nature of the wound. The degree of injury is primarily dependent on the mass and velocity of the missile.[14] In addition, the bullet's orientation and whether it fragments or deforms affect the nature of the wound. Understanding the mechanisms by which the projectile disrupts tissue provides more information for the surgeon evaluating and treating GSWs.[9,14]

The various types of bullets produce a variety of tissue injuries. Furthermore, similar bullets can also produce a wide variety of wounds that range from minor to lethal. The severity will vary depending on characteristics of the missile, the weapon, and the tissues struck. The bullets are shaped or composed differently for a variety of purposes. The "round-nose" bullet is blunted at the end. The "hollow-point" has a hole in the bullet that creates expansion when a target is struck, creating greater damage. In the "jacketed" bullet, the soft lead is surrounded by another metal, usually copper, that allows the bullet to penetrate a target more easily. The "wad cutter" has a flattened front end. The "semi-wad cutter" is an intermediate between round-nose and wad cutter. Tissue damage is dependent on the characteristics of the firearm firing the projectile (rifle vs. handgun); the nature of the projectile—for example, fully jacketed versus expanding bullet; and the attributes of the target tissue—for example, tissue elasticity.[11]

Wounds typically are classified as low-velocity (<1200 feet/second), medium velocity (<2000 feet/second), or high-velocity (>2000 feet/second).[5,7] The tissue injury is dependent on the efficiency of energy transfer; the projectile's physical characteristics, including deformation and fragmentation, KE, stability, entrance profile, and path traveled through the body; and the biologic characteristics of the tissues.[11] A velocity of 50 m/sec is required on impact to penetrate skin and 65 m/sec to fracture bone. However, any bullet is capable of inflicting serious or lethal injury if a vital structure (e.g., heart or brain) is involved.[14] In high-velocity

wounds there is more damage by production of shock waves and temporary cavitation in addition to laceration and crushing injury.[11,14]

Gunshot injuries are categorized as follows: (1) penetrating, where the missile strikes the victim without exiting the body; (2) perforating, with entrance and exit wounds without appreciable tissue loss; and (3) avulsive injuries, where there is an entrance and exit wound with an acute loss of tissue associated with the passage of the projectile out of the victim.[10]

The Physics of Ballistics

The motion of a projectile, from the instant of firing until impact at the target, is divided into three distinct phases: (1) internal ballistics is defined as the motion of a projectile while it is still in the gun, so it covers the time from the propellant's ignition until the projectile exits the gun barrel; (2) external ballistics deals with the phase of unpowered free flight of the projectile from the time it exits the gun until it reaches the target; and (3) terminal ballistics deals with the effect of the projectile on the target.[15]

There are three basic determinants of the external ballistics of the bullet: (1) mass of the bullet (the greater the mass of the bullet, the harder it is to propel with the same amount of gunpowder), (2) the amount of gunpowder in the cartridge (the larger the amount of gunpowder, the greater the explosion), and (3) the length of the barrel (the longer barrels, for example, the rifle, are able to attain significantly higher bullet velocities than handguns).[15]

Three key terminologies are important in understanding external ballistics: yaw, precession, and nutation. Yaw refers to the rotation of the nose of the bullet away from the line of flight. It is the deviation of a forward-moving aerodynamic object from its longitudinal axis (generally less than 1 to 2 degrees).[10] Precession is an angular force applied to a rotating object caused by its torque rotation of the bullet around the center of mass. Nutation refers to small circular movements at the bullet tip or the opposing force in a rotating object that gradually "normalize" along the longitudinal axis during projectile flight[7,10] (Figure 15-1).

A short, high-velocity bullet begins to yaw more severely and turn, and even rotate, upon entering tissue. This causes more tissue to be displaced, increases drag, and imparts more of the KE to the target. A longer, heavier bullet might have more KE at a longer range when it hits the target, but it may penetrate so well that it exits the target with much of its KE remaining.[11] Although these terms have practical applications in weaponry, the clinical significance in maxillofacial ballistic trauma is minimal.[10]

Three physical parameters have been used to explain and predict the damage caused by a bullet upon impact: KE, power, and momentum.[14] Once discharged from the weapon, the bullet's energy decreases throughout its flight. The bullet dissipates the remainder of its energy when it collides with a target.

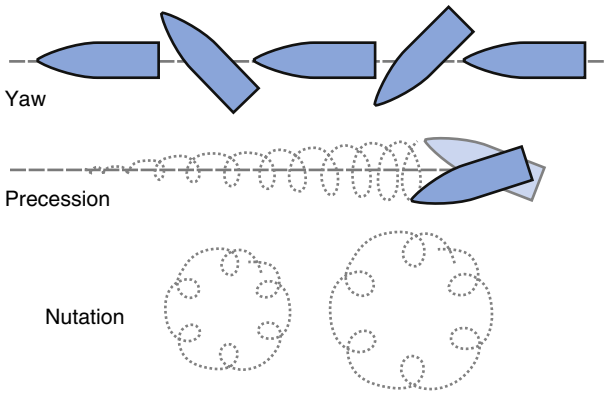

• **Figure 15-1** Movements of a bullet. The classic movements of yaw, precession, and nutation are diagrammed. (From Powers DB, Delo RI: Characteristics of ballistic and blast injuries. *Atlas Oral Maxillofac Surg Clin North Am* 21:15-24, 2013. Reprinted from U.S. Government Printing Office, *Emergency war surgery*, rev. 3, 2004.)

The projectile's wounding capacity is directly related to the amount of KE transferred to the tissue. Kinetic energy (KE) is equal to half the product of the mass (M) and velocity squared (V^2): $KE = \frac{1}{2}MV^2$. Doubling the mass doubles KE, but doubling the velocity quadruples KE.[5,11]

The total energy released to the target can be represented by:

$$\text{Change in KE} = \text{KE entry} - \text{KE exit}$$

Higher KE, which is increased by increasing bullet mass or velocity, has higher potential for wounding. However, if the exit KE is still high, then relatively minor tissue damage may result. A bullet that passes cleanly through the target and exits with significant velocity will not cause as much damage as a bullet with similar KE that completely decelerates and comes to rest within the target.[11]

A low-velocity bullet wound causes laceration and crushing of tissue. In addition to lacerating and crushing tissue, high-velocity bullet wounds cause cavitation and produce pressure and shock waves. There is rapid energy release upon penetration, and as energy is absorbed, the tissue starts to flow forward with the projectile. A large cavity is formed that may be 30 to 40 times the diameter of the bullet in a few milliseconds. The cavity produced is vapor filled, with a sub-atmospheric pressure, and is pulsatile in nature, expanding and collapsing repeatedly with decreasing amplitude. The target tissue comes to rest, leaving a permanent cavity.[14]

KE is not a predictor of injury. It reveals nothing about the magnitude, type, and location of tissue disruption or the forces that cause tissue disruption. One must determine if the mechanism of injury is predominantly one of crushing, such as a .71 caliber traveling 500 to 800 feet per second, or is predominantly tissue tearing from being displaced and stretched beyond its elastic limits by temporary cavitation, such as a .24 caliber traveling 3000 to 3300 feet per second.[14]

Handguns and shotguns are low to medium velocity. Tissue damage attributed to a low-velocity projectile is less

predictable. The bullet's tendency to deflect off the tissue results in bone and soft tissue damage. Some of the ballistic energy may be transferred to bone fragments, teeth, and dental prostheses, converting them to secondary projectiles that cause additional injuries. High-velocity GSWs are rarely seen in the emergency room because of the high fatality of such injuries.[5] Two major mechanisms of wounding occur: the crushing of the tissue struck by the projectile, forming a permanent cavity, and the radial stretching of the projectile path walls, forming a temporary cavity.[9]

Three tissue phenomena are noted upon impact: sonic wave formation, permanent cavitation, and temporary cavitation. There are two types of pressure waves produced by penetrating objects. The first wave is the sonic pressure wave or "shock wave" that precedes the projectile through tissue at the speed of sound (~4800 feet per second). The sonic pressure wave that was reported by Harvey in 1947, reaching pressure up to 117 atm and lasting only a few microseconds, forms a hemispherical arc ahead of the advancing bullet when a bullet enters soft tissue. No temporary cavity is formed with the sonic pressure wave, and it has no damaging effects on tissue. This is a finding confirmed by clinical experience with sonic pressure wave lithotripsy. In lithotripsy, the tissue receives sonic pressure waves two to three times greater than that produced by a supersonic rifle bullet, and as many as 2000 waves might be used during a single treatment of renal stones. These sonic waves do not significantly harm the surrounding tissues.[9,10,14]

A permanent cavity is created as the missile penetrates the wound and crushes the stricken tissue. The track made by the diameter of the bullet (cavity plus change in size through deformation) consists of crushed tissue and cellular debris. As the tissues recoil, hot gases dissipate, and soft tissue collapses inward, leaving a permanent cavity defect.[16] Adjacent to this track is the temporary cavity, a region in which the pressure wave created by the bullet causes outward stretching and shearing forces that produce tissue contusion.

The secondary pressure wave or the temporary cavity is created behind the path of the bullet, with pressures between 4 atm and sub-atmospheric pressure when the penetrating projectile strikes tissue. The wave radiates laterally away from the permanent cavity of the projectile path. This wave injures tissues such as muscle, vessels, and organs.[10] The maximal size of the temporary cavity occurs several milliseconds after the bullet has passed through the tissue[9] (Figure 15-2).

Bullets that display greater yaw will be associated with increased temporary cavitation. Velocity is another factor that increases the temporary cavity size. The higher the velocity of the bullet, the greater the KE, which may increase the temporary cavity by more than 10 times the caliber of the bullet in a few milliseconds[11,14] (Figure 15-3).

The effect and damage of the temporary cavitation can vary greatly depending on the elasticity of the injured tissue, the size of the cavity, and its anatomic location.[11,14] These forces can rupture blood vessels. The extracellular tissue matrix with collagen, reticular, and elastic fibers can also

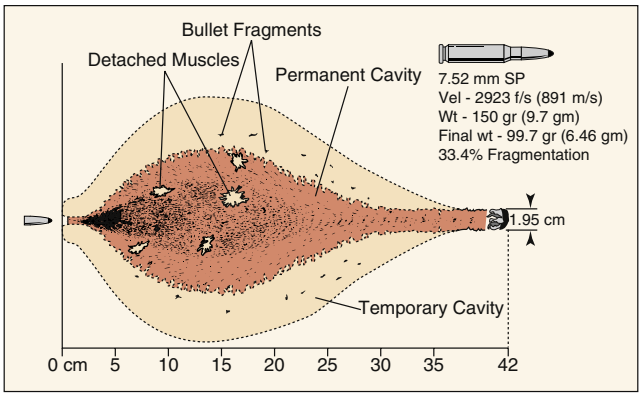

• **Figure 15-2** Cavity, soft-point bullet. As the bullet strikes the underlying structures, there is an almost instantaneous increase in temporary and permanent cavity. This occurs because the soft tip deforms and fragments. (From Powers DB, Delo RI: Maxillofacial ballistic and missile injuries. In Fonseca RJ, Barber HD, Walker RV, et al, editors: *Oral and maxillofacial trauma*, ed 4, St Louis, 2013, Saunders.)

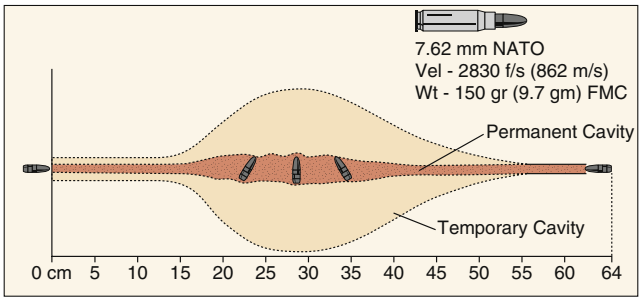

• **Figure 15-3** Cavity formation, high-velocity bullet. This figure depicts a 7.62-mm round from an M16 rifle. Note the relatively small permanent cavity and large temporary cavity. The bullet tumbles after 20 cm; thus in the maxillofacial area this bullet would not be very destructive if it traversed, for example, the bilateral buccal mucosa soft tissues. (From Powers DB, Delo RI: Maxillofacial ballistic and missile injuries. In Fonseca RJ, Barber HD, Walker RV, et al, editors: *Oral and maxillofacial trauma*, ed 4, St Louis, 2013, Saunders.)

be disrupted. At first, the projectile crushes structures along its track, similar to other forms of penetrating injury. Temporary cavitation, which follows the path of least resistance, causes shearing and compression, sometimes tearing structures or stretching inelastic tissue similar to blunt trauma.[14] Less elastic tissues (e.g., brain, liver, or spleen) fluid-filled organs (heart, bladder, gastrointestinal tract), and dense tissue (e.g., bone) may be severely damaged when they are contacted by a large temporary cavity. The cavity formed by most expanding handgun bullets is about 9 cm in diameter.[14] This 9-cm diameter cavity is likely to be absorbed in highly elastic tissues, such as the lung or muscle, which can easily accommodate the stretching created by the temporary cavity. These highly elastic tissues, therefore, are less affected or damaged by the formation of the temporary cavity.[9] In contrast to this, the temporary cavity has a very damaging effect on inelastic organs such as the liver, and in the cranial cavity, where the brain tissue is unable to move aside due to the restraint by the cranium. Thus, this 9-cm cavity will cause instant death.[14]

The following factors influence the degree of injury: yaw, deformation, and fragmentation of the bullet upon striking the target. The process of tumbling or yaw within the target significantly increases the destructive capacity of the projectile. When the yaw of the bullet is 90 degrees, the maximum effective diameter, the entire long axis of the bullet strikes the tissue and the amount crushed may be three times greater than that at zero degree yaw.[15] Two bullets of similar KE can have different wounding potentials. The ratio of bullet size to velocity also has a significant effect on tissue injury. A large, slow projectile tends to crush tissue in its path and creates little radial dispersion of energy (temporary cavity formation). A small, fast bullet tends to crush little tissue; however, it creates more transient radial tissue stretching.[15]

An expanding soft-point or hollow-point bullet causes more tissue disruption than a similar but non-expanding bullet.[14] Soft-point and hollow-point bullets deform into a mushroom shape, which increases the surface area and wound severity. If the mushroom diameter is 2.5 times the initial diameter of the bullet, the area of the tissue crushed is 6.25 times greater than for a non-deformed bullet. Bullet fragmentation increases the volume of tissue crushed by increasing the surface area of the bullet.[9] Bullets that fragment create much larger permanent cavities and cause extensive damage because of the production of secondary missiles.[14] Understanding the mechanism by which bullets disrupt tissue can help in evaluating and treating maxillofacial GSW victims' injuries and wounds. The nature of the wound is determined by both the missile and tissue characteristics. The elasticity and density of a tissue and the thickness of the body part wounded strongly affect the wound produced. The key factors in determining the wounding potential of a missile are mass, construction, tendency to fragment or yaw, and the missile's velocity. A bullet can cause more damage to tissue by fragmentation and yaw than by high velocity[9] (Figure 15-4).

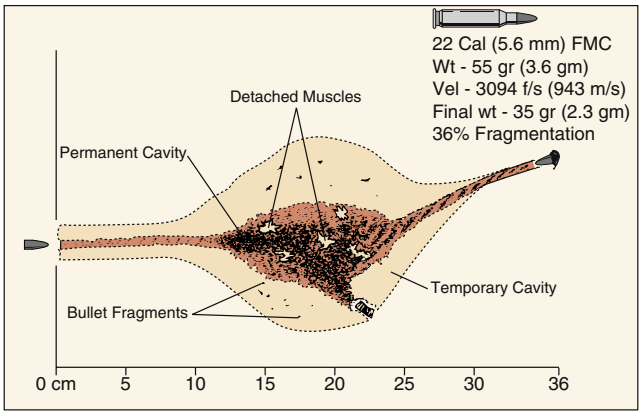

• **Figure 15-4** Cavity, small-caliber bullet. This figure depicts a small 22-caliber full-metal case round striking hard and soft tissues. The bullet deforms and creates both a large permanent cavity and another trajectory. Thus the wounding potential of a small-caliber bullet can be significant. (From Powers DB, Delo RI: Maxillofacial ballistic and missile injuries. In Fonseca RJ, Barber HD, Walker RV, et al, editors: *Oral and maxillofacial trauma*, ed 4, St Louis, 2013, Saunders.)

Treatment of Maxillofacial Gunshot Wound Injuries

Gunshot wounds to the maxillofacial region present the treating surgeon with a myriad of challenges. The highest priorities in treatment are the well-being of the GSW victim and excellent communication among all of the treating colleagues. The assigned trauma team members may vary depending on the needs of various acute care facilities. Nonetheless, a well-organized trauma team should be expected to evaluate all maxillofacial GSW patients. There are many components of care that happen concurrently when treating maxillofacial GSW victims. As primary assessment of the patient is occurring, there are acute issues that are a priority in treatment. The most urgent treatment needs for these patients are basic life support, including acute airway issues and all the components of shock management. These issues are treated concurrently and include the following:

1. Initial Treatment, GSW Maxillofacial Region—Treatment Sequence

1. Basic life support (BLS)
2. Advanced Trauma Life Support (ATLS)—primary and secondary survey/continuous patient resuscitation
3. Evaluation/treatment plan—trauma team
4. Ophthalmology/neurosurgery evaluation
5. Completion of head and neck exam and location of missiles
6. Initial procedures in operating room
7. Patient-specific therapy/surgery and further data collection; intravenous antibiotic therapy, including *Staphylococcus aureus* and *Streptococcus* coverage; admit to ICU or Close Observation Unit—monitor for expanding hematomas and airway compromise, obtain computed tomography (CT) of bony windows face and mandible, 0.5-mm cuts, reformat into 3D images and medical 3D modeling if needed.

2. Initial Treatment, GSW Maxillofacial Region—Treatment Sequence

The points previously listed specifically include these further components:

1. BLS:
   - 1A. Acute airway needs
   - 1B. Hemorrhage control intraorally, extraorally; removal of foreign bodies, initial stabilization of alveolar segments. Determine the amount of floor of the mouth and oropharyngeal swelling in acute ER setting and estimate short-term expected edema? Intubation? Surgical airway?[17]
2. ATLS: amount estimated blood loss, treatment of shock, hypovolemia, secondary evaluations.
3. Evaluation and treatment plan with trauma team—including plan to manage analysis of zones of the neck the missile traversed and associated damage, imaging

studies, immediate versus delayed operation, and anesthesia plan/consultation.
4. Early ophthalmologic assessment—visual acuity, retrobulbar hematoma, ophtho consult. Assess neurologic injury—open or closed intracranial injury, presence of cerebrospinal fluid (CSF), neurosurgical consultation.
5. Completion of head and neck exam and location of missiles:
   Including: evaluate cranial nerves, especially trigeminal and facial nerves, parotid flow—presence of saliva on the face? (See Figure 15-26.)
   Locate bullet fragment(s) —Follow flowchart figure for location of displaced missile (bullet). (See Figure 15-10, *C.*)
6. Initial procedures in operating room
7. Patient-specific therapy/surgery and further data collection

1A. Initial Assessment of the GSW Face Victim

Maxillofacial GSW victims presenting with cervical collars in place represent a challenge, as comfortable positions the patient can be placed in are limited by the concerns for a cervical spine injury. Moreover, the initial providers are often eager to manipulate the conscious patient's position. Patients maintaining their airway should only be repositioned with great caution as doing so may cause a rapid deterioration in their ability to maintain the airway. The conscious patient with an extensive GSW crossing one or more anatomic zones of the neck and maxillofacial region will often find a comfortable position to sustain life. Depending on the extent of the soft tissue damage to the face and airway, these patients will often be comfortable sitting up erect or positioned with the head forward. One may need to place the patient in the prone position for forward traction in order to keep the airway patent in the acute care setting.[18] These patients, whether sitting up, erect, or prone, can participate in maintaining their airway temporarily by maintaining traction on a suture tied to their anterior tongue. Very often these GSW patients have a soft tissue flap in their airway that may close their airway opening when they are repositioned against their will by a health care provider.[19] Similarly, patients with extensive mid-face comminution and floating maxillofacial segments may have compression of vascular components resulting in control of bleeding. These vessels can open again and cause hemorrhage when the segments are capriciously manipulated and result in loss of the airway in an otherwise conscious patient with a patent airway (Figure 15-5).



• **Figure 15-5** **A,** Sitting position. **B,** Semi-erect position. **C,** Prone position. Three different positions of the conscious maxillofacial gunshot-wound patient. They are all maintaining their own airways. These patients do not do well with sudden jostling or insistence that they reposition themselves. (Courtesy Dr. R. S. Sadda.)



• **Figure 15-6** Airway distress, zone III injury. Patient appears with posterior zone III wound extending across base of tongue. He has an obvious protruding tongue, excessive drooling, and an appearance of exhaustion with impending respiratory arrest. The urgency of this clinical appearance can be dismissed by the novice who is not impressed by any avulsive or displaced tissues as seen in many other injuries that have patent airways despite their gross appearance. This patient is treated with an urgent surgical airway if nasal intubation is not possible. (Courtesy Dr. R. S. Sadda.)

In addition to this, the clinical presentation of a prolapsed tongue in a maxillofacial GSW victim results in airway compromise secondary to a displaced anterior mandible fracture caused by the missile. This prolapsed tongue can be relieved by physically bringing the anterior mandibular segments, associated teeth, muscles and tongue forward by simple interdental wiring using 24- or 26-gauge stainless steel wire. This is done by grossly reducing the fracture, by connecting the traumatized, displaced anterior segments to the intact segments posterior to the fractures. This results in bringing all of the structures forward and thus the tongue away from the oropharynx.

An acute loss of the airway may result in the need for a rapid-sequence intubation or emergency airway in the ER setting. These situations are often met with chaos and may result in catastrophic results (Figure 15-6).

Many authors recommend a non-urgent surgical airway be placed in the OR setting where all hands and equipment are available to deal with any complications that may arise.[20] Furthermore, it is important for the consulting surgeon to be aware that many of the other practitioners evaluating the patient may not be accustomed to looking for tooth fragments and foreign bodies in the airway simply because they are not as experienced at finding foreign bodies in the various pouches and vestibules of the mouth or oropharynx. It is not uncommon to see a maxillofacial region GSW victim speaking fairly well although they have tooth fragments, whole teeth, and foreign bodies displaced throughout the airway. An early finding of any of these objects in the airway will help prevent laryngospasm, aspiration, pneumonia, and subsequent morbidity.

When the trauma team deems an acute surgical airway is necessary for an adult, the first choice is cricothyrotomy, followed by a conversion to a traditional tracheostomy in the OR under controlled conditions. The treatment of choice for an acutely needed surgical airway in a child is a tracheostomy.[20,21]

1B. Hemorrhage Control in the Acute Setting of the Maxillofacial GSW Victim

The surgical consultant is reminded to use universal precautions when examining these patients. These patients often present with bulky dressings, and unwrapping the dressings often reveals large, damaged vessels and exposes the health care providers to gross amounts of blood from pressurized areas. Immediate direct pressure is essential. Random clamping of tissues and vessels that have not been clearly isolated and identified is not recommended. This injudicious clamping may lead to permanent facial and trigeminal nerve injuries. Bulky moist pressure dressings are useful for a short time to stop arterial and venous bleeding.[18]

Mid-face bleeding that clinically appears to originate from the posterior nose or maxilla can be controlled by the use of 20 French Foley catheters carefully placed along the floor of the nose or the nasal remnants that are present and then inflated. The two Foley catheters usually require inflation with approximately 20 mL each of normal saline. They can then be secured together anteriorly to help maintain the posterior pressure and position of the catheter bulbs and thus curtail the bleeding. These catheters can be left in place until bleeding is curtailed or until angiography localizes and embolizes those vessels that may contribute to the hemorrhage.[22]

Foley catheters can also be used in deep wounds and the base of the skull, pterygoid plexus areas to help tamponade bleeding (Figure 15-7).

Floor of the mouth bleeding and bleeding from the base of the tongue can be controlled in the acute setting by a health care provider holding the tongue with his/her fingers and gauze or a suture through the tongue, and displacing it anteriorly to compress the vessels.

Exploration of any wound can easily be done with digital examination as well as a sterile cotton-tip applicator. This exploration will yield information on the path and structures the bullet may have encountered. Many of the maxillofacial GSW patients who have uncontrolled bleeding will need angiography to assess vascular damage and embolization of needed areas of the vascular tree, which is often a branch of the external carotid artery. Ligation of branches of the external carotid artery is not recommended, as collateral circulation will contribute to continuous bleeding. Complex multi-trauma patients also often develop massive complement release that can cause DIC (disseminated intravascular coagulation). This group of patients will also need transfusions of fresh frozen plasma (FFP) to provide coagulation factors.

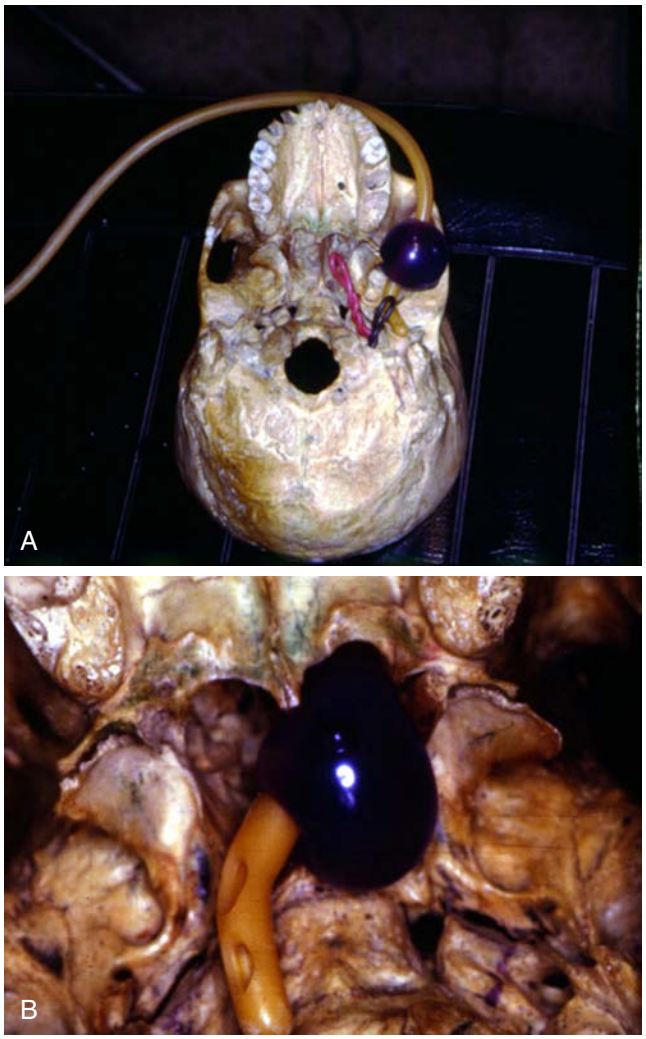

• **Figure 15-7** **A,** Base of skull Foley catheter and **(B)** posterior nasal Foley catheter. Foley catheters are useful in areas that have numerous vascular plexuses, such as the pterygoid plexus of veins in the infratemporal space and posterior nasal/maxilla regions, zone III locations. Foley catheters have been used to control bleeding temporarily in vascular injuries to the chest as well.

2. ATLS—Primary and Secondary Survey/ Continuous Patient Resuscitation and 3. Evaluation/Treatment Plan—Trauma Team

The clinical reality is that the components included in 2 and 3 happen simultaneously. Often a maxillofacial GSW victim presents to a smaller community hospital and is stabilized and consequently transferred to a Level I or Level II trauma facility for definitive care. Communication in these situations is essential to a good result for the patient. For example, the maxillofacial GSW patient may have a wound that entered the right maxilla and exited the left angle of the mandible. The patient is stable, and it appears there is no risk in transferring the patient to another facility for definitive care. This is an example of an occurrence that may be encountered in accepting a transfer of a maxillofacial GSW trauma patient. Incomplete information

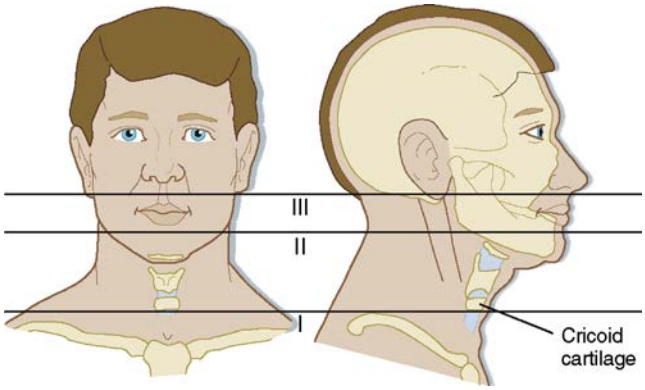

• **Figure 15-8** Zones of the neck. This is essential for the treating surgeon, as misdiagnoses can have poor outcomes for the patient. (From Adams J: *Emergency medicine*, ed 2, St Louis, 2013, Saunders.)

and communication of the areas the missile traversed and a thorough assessment of vascular or aerodigestive tract injury may lead to poor outcomes for these patients.

The zones of the neck that the missile traveled through should be documented and the information discussed with the treating trauma team. The management of penetrating neck trauma has changed over the past three decades from mandatory exploration of all wounds that penetrate the platysma muscle to selective nonoperative management of certain injury patterns.[23-25]

Historically the anatomic zones of the neck have been delineated into three areas known as zone I, zone II, and zone III (Figure 15-8). The anatomic zones and recommended studies are as follows:

- Zone I: Boundaries are between the clavicles and cricoid cartilage; contains lung, trachea, great vessels, esophagus, spinal cord, thoracic duct, cervical nerve trunks. Invasive studies recommended: angiography, bronchoscopy, esophagoscopy
- Zone II: Boundaries are between the cricoid cartilage and the angle of the mandible. Invasive studies recommended: none
- Zone III: Boundaries are from the angle of the mandible to the base of the skull. Invasive studies recommended: angiography, bronchoscopy, esophagoscopy

The recommended treatment for penetrating neck injuries to zone II has traditionally been exploration of the neck and wound.[23] Clinically many maxillofacial GSWs may cross more than one zone of the neck. In clinical assessment it is important to look, feel, and listen. The clinician should look at the zone or zones of the neck involved, assess the apparent depth of the wound, look for bubbling or bleeding, and assess for presence of a hematoma. The clinician should feel for subcutaneous emphysema and listen for bruits. One prospective study showed that physical examination is reliable for identifying those patients with penetrating injuries to the neck who require vascular or esophageal diagnostic studies.[23]

In 2014 Low and colleagues compared the external zone injury to the expected internal injury. Their sample had almost 50% GSWs to the anatomic zones I through III. They found that almost 27% of the wounds had internal

injuries that did not correlate with the anatomic zone they entered superficially. Their study shows that the anatomic location of the superficial injury may be of questionable use in guiding treatment. Low and co-workers emphasized that treatment should be guided by soft signs, hard signs, or no signs.[24]

Soft signs include:

1. Venous oozing
2. Non-expanding or non-pulsatile hematomas
3. Minor hemoptysis
4. Dysphonia
5. Dysphagia
6. Subcutaneous emphysema

Hard signs include:

1. Active hemorrhage
2. Expanding or pulsatile hematoma
3. Bruit or thrill in area of injury
4. Shock unresponsive to initial fluid resuscitation
5. Massive hemoptysis or hematemesis
6. Air bubbling through injury site

Their recommendation is to use multidetector computed tomographic angiography (MDCTA) and hard signs to make decisions as to when surgical intervention is needed. They found 90% of injured patients with hard signs had true injury.[24] The surgical consultant should communicate expediently with the trauma team to establish a comprehensive plan for acute and long-term treatment. Doppler ultrasound, a useful adjunct, has been shown to be impractical in evaluation of penetrating neck injuries as a result of the interpretation variability and the need for an experienced technician.[24]

Nevertheless, exploration of all neck wounds deep to the platysma muscle leads to a significant number of unnecessary operations and extra cost. However, the consequences of a missed injury are potentially high. To what extent clinical examination can be relied on, and which diagnostic adjuncts should be employed, remains a subject of some debate. The actual management plans will depend not only on the specific patient and the injury sustained, but also on available staffing, expertise, monitoring, and diagnostic modalities.[23-25] Furthermore, late effects of penetrating trauma to the head and neck vessels can result in pseudoaneurysms requiring treatment.[26]

4. Early Ophthalmologic Assessment and Neurosurgery Evaluation and Consultation

Eye injuries are not uncommon with GSWs to the maxillofacial region. The surgeon should be familiar with a basic screening for VA (visual acuity) and the presence of light perception. As a general rule, loss of the patient's ability to perceive a bright red object and perceive it instead as dark or crimson in color is an indication of developing optic nerve damage and vision loss. Early consultation with the ophthalmologic service early on is essential[27] (Figure 15-9). Neurosurgery consultation usually occurs early on in treatment and is done in coordination with the trauma team.



• **Figure 15-9** Ophthalmologic considerations. Patient presents with an anterior maxillofacial gunshot wound with no acute airway loss. Clinically he has significant periorbital ecchymosis. One of the priorities is to evaluate for retrobulbar hematoma: palpate the right eye for firm hardness in comparison to the left eye, feel for pulsations in the ecchymotic eye, visually inspect the amount of proptosis of the eye, and separate the lids to check for visual acuity. (Courtesy Dr. V. J. Perciaccante.)

5. Completion of Head and Neck Exam and Location of Missiles

Complete assessment of the wound and accounting for all bullet fragments is also essential in the treatment of maxillofacial GSW patients. Low-velocity wounds can be expected to have an entrance wound and often no exit wound. Furthermore, these GSW victims may have a bullet fragment traverse into the chest and/or below the diaphragm[28] (Figure 15-10).

The point of the algorithm is that when an exit wound is not found and plain film head and neck radiographs do not reveal the missile in local tissues, then another occurrence such as aspiration, ingestion, or embolization should be suspected. The diaphragm is the landmark dividing the chest from the abdomen. When the bullet fragment is located above the diaphragm, aspiration or embolization is suspected, and when it is found below the diaphragm in the gastric air bubble, we would suspect ingestion. Careful assessment and determination of the path of the bullet from the maxillofacial GSW victim is essential to comprehensive treatment.[28] Proper assessment, consultation, and communication with other members of the trauma team will help decrease morbidity for the patient.

6. Initial Procedures in the Operating Room and 7. Patient-specific Therapy/Surgery and Further Data Collection

Once the patient has been stabilized and is in the operating room with a secured airway, the wounds can be explored and initial treatment and debridement can be done. This part of the treatment plan—6 and 7—includes many elements.

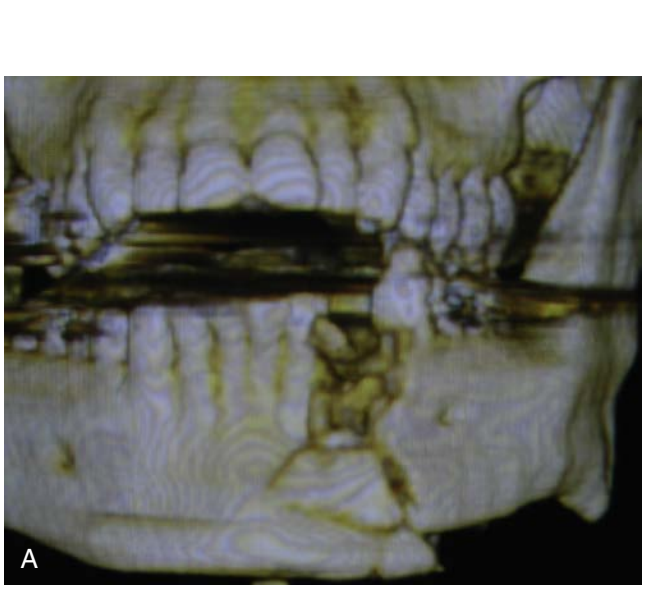

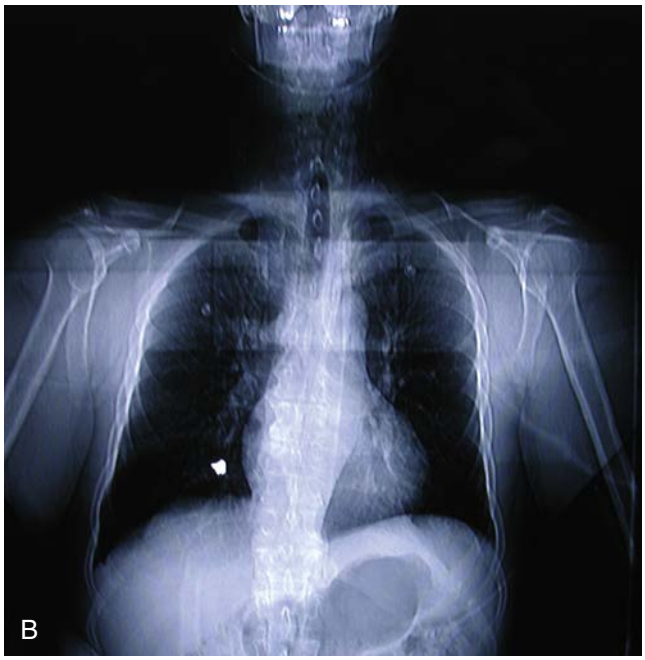

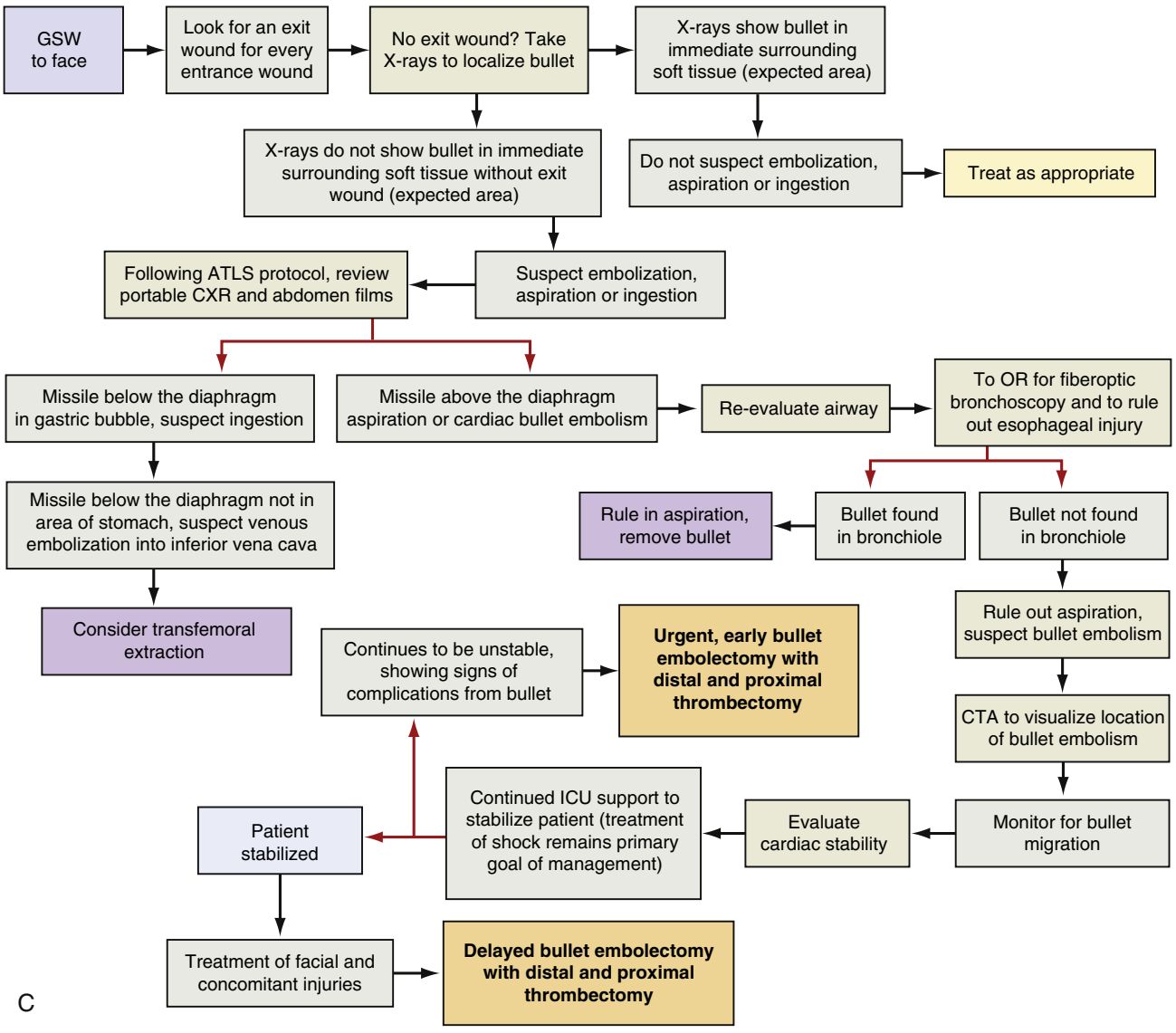

• **Figure 15-10** The patient had sustained a gunshot wound (GSW) to the anterior mandible **(A),** and the bullet traversed into the pulmonary artery to create a bullet embolus **(B). C,** Flowchart for bullet embolus. Diagram of management strategy for GSWs to the face involving retained missiles. (**B** From Jo C, Steed M, Perciaccante VJ: Bullet embolus to the pulmonary artery after gunshot wound to the face: case report and review of literature, *J Oral Maxillofac Surg* 68:504, 2010. **C** Courtesy Dr. V. J. Perciaccante.)

The treating surgical team at this point determines which techniques will be needed to eventually bring the patient to the reconstructive phase of treatment months later. There is a large difference between the planning and number of operations needed for the single, non-avulsive wound in Figure 15-13 versus the complex, avulsive wounds in Figure 15-15.

Primary Wound Treatment

Historically a great amount of time and energy was spent by treating surgeons on differentiating low-velocity GSWs from high-velocity GSWs. Contemporary treatment of GSW management is that the caliber of the projectile essentially makes little difference in the treatment of the patient.[29] Low-velocity bullet wounds from handguns (100-150) are often confined to the wound track. High-velocity bullet wounds (2000-3000) include missiles and assault rifle bullets. The most recent data and reporting of high-velocity wounds shows that tissue damage in excess of this projectile does not occur until approximately 15 cm into the body of the target. Thus, depending on the site of impact, this high-velocity projectile could exit the body before breakage and result in minimal tissue damage.[29,30] The high-energy wounds cause laceration and crush injuries to adjacent structures as well as have the potential to inflict injuries remote from the wound track. These high-energy wounds have an increased morbidity for the victim as they may involve kidneys, liver, and spleen.[29]

General Guidelines for Wound Treatment

Debridement of Wound

- Copious irrigation with warm, normal saline with bacitracin solution (4-6 L)
- Exploration of wounds under general anesthesia—unfolding and exploration
- Removal of any skin contaminants and road-rash-type debris that may cause permanent tattooing; may need to scrub skin[18]
- Assessment of regional neurovascular bundles, arteries, veins
- Assessment of parotid duct (see Figure 15-26)
- Assessment of nasolacrimal duct
- Early surgical debridement of devitalized tissue
- Removal only of bony fragments smaller than 1 cm, free floating, without periosteal attachment
- Use of Penrose drains—hematoma evacuation, delayed closure of wounds

Although a wound may initially appear to be avulsive, careful evaluation often reveals little or no tissue loss and thus primary closure is possible[31] (Figure 15-11).

However, when the avulsed facial soft tissue wound is large, it is preferable to suture the oral mucosa to the facial skin mucosa to decrease shrinkage.[18] Avulsed lower lip wounds also benefit from using the tongue as a source of soft tissue and muscle. The tongue is used as a tongue flap and sutured to the skin. The flap is checked for vascularity in 2 weeks by pinprick testing for bleeding and then separated, leaving the anterior tongue flap tissue to fill the avulsed lip defect (Figure 15-12).

Penrose drains are usually not needed for wounds treated and closed in the first 24 hours. Wounds treated after 24



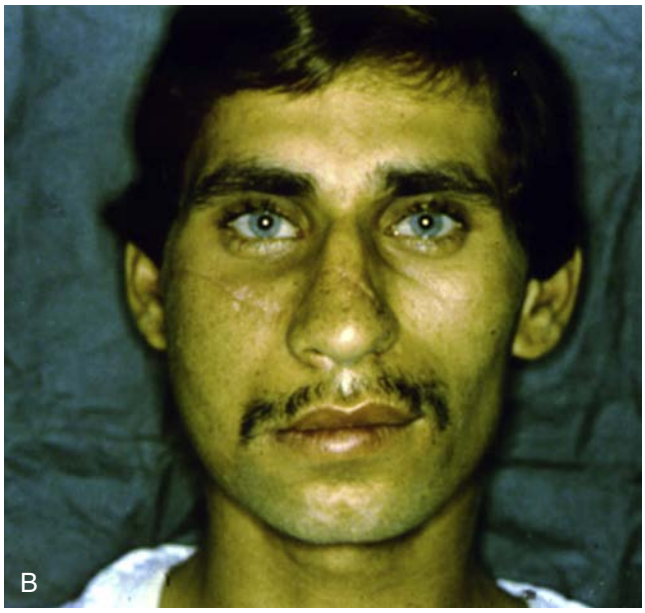

• **Figure 15-11** **A,** Open displaced wound. **B,** Wound, postoperative. The patient sustained a tangential wound that originally appears avulsive. Once the wound and flaps are explored, debrided and re-approximated in the operating room, it is obvious the nose and maxilla were grossly displaced to the right posterior face. This wound has a good prognosis, as the upper lip and nasal complex were intact as seen in the postoperative photo. These wounds benefit from suspension sutures. (Courtesy Dr. R. S. Sadda.)



• **Figure 15-12** Tongue to avulsed lower lip. These patients usually have advanced maxillofacial wounds requiring a tracheostomy. Use of a nasogastric tube (NGT) and NPO diet for a short period may be needed to allow the intraoral wounds to close. Use of the masticatory apparatus as soon as possible will contribute to healing and functional recovery. (Courtesy Dr. R. S. Sadda.)

hours are best treated by delayed closure and placement of a Penrose drain. Complex mandibular wounds that have extensive bony involvement and wounds involving the submandibular space will benefit from the placement of a Penrose drain.[7]

Wound edge debridement of nonviable tissue should preferably be limited to removing 1 to 2 mm of skin. This margin should be non-beveled. When needed, skin flaps can be mobilized by undermining the edges, permitting primary closure of the wound. When using this technique, the extent of undermining should be less than 5 cm, and deep subcutaneous sutures should be placed to reduce skin tension and premature opening of the healing wound. Rotational flaps can be cautiously used to close large, full-thickness soft tissue defects. The design of these flaps must be well planned. The rotational flap should not be brought from an area of the donor that appears unhealthy. Poor choices for donor flaps include dusky appearance and a flap edge that was part of the GSW cavitation. When soft tissue defects cannot be closed primarily using sterile fine mesh, moist gauze may be gently packed into the defect. The gauze is changed daily to successively smaller gauze as the wound begins to heal by secondary intention. A split-thickness graft can be used either initially or in a delayed fashion once the wound that has been packed with gauze begins to reepithelialize.[31]

Small pieces of bone fragments that are attached by periosteum should be left in place. These segments can be gently aligned with 0-chromic gut suture. In the maxilla when the anteromedial or lateral wall bone along with the underlying soft tissue is mobile and fractured, but the sinus drainage is patent, it is recommended to leave the Schneiderian membrane lining in place. Pseudopolyps will occur and then decrease in size, allowing the sinus mucosa to become continuous with the oral mucosa. This process will provide a more cleansable defect than having a split-thickness graft placed acutely to a denuded sinus wall.[18]

Nerve injury repair is done in a delayed process. When the ends of the trigeminal or facial nerve are found during debridement, a tag suture can be placed and the area revisited in a month to repair the defect. Open intraoral wounds will take several days to close. Once the wounds are closed, if the patient's neurologic status and swallowing are intact, they can advance to a liquid diet in addition to intravenous fluids. Extensive soft tissue losses and oral wounds are best treated with a nasogastric tube (NGT), such as a Dobhoff tube, for feedings while these wounds close.

Through-and-through wounds are treated by closure from inside first, then outside once hard tissues and fractures are initially reduced so as not to open closed wounds.[7]

Case Varieties and Management

Many practitioners will plan on definitive surgery for low-velocity, confined GSW's to the maxillofacial region. An example is shown in Figure 15-13, a low-velocity GSW to left lower face with a comminuted mandible fracture and no vascular injury. Such an injury can usually be treated in one or two surgeries.

These fractures can be treated in a multitude of ways. The rationale for open reduction via the simplification method should be discussed. The surgeon is faced with deciding how to stabilize and reduce mandible fractures that are extensively comminuted. Over the past several decades it has become increasingly common for surgeons to recommend open reduction and stable internal fixation using plates and/or screws.[32-41] The issue that is most concerning is that stripping comminuted bone may compromise an already compromised blood supply and result in further morbidity for the patient. Historically many of these surgeries resulted in significant osseous loss and morbidity. In fact, surgeons have recently shown that many of these fractures can do well with proper exposure and stabilization. Interestingly, Ellis and colleagues showed a 13.7% complication rate for open reduction of these types of fractures when there were more than five fragments. The complication rate for moderately and minimally comminuted fractures was 6.9% and 4.5%, respectively.[37] Their results showed a statistically significant relationship with non-occlusal complications ($P < 0.01$). Furthermore, the fractures treated with external pin fixation had a 23.5% complication rate, and those treated by open reduction and stable internal fixation had a complication rate of 17.1%.[37] The goal for this technique is open



• **Figure 15-13** **A,** Gunshot wound (GSW), zone III left face and jaw. Patient sustained a single GSW through the anterior face. entering anatomic neck zone III and causing a left comminuted mandible fracture. **B,** GSW, 3D, lateral mandible. **C,** GSW, left mandible. This is an axial computed tomographic view. No hard signs of vascular injury were noted on clinical exam. Note the presence of the impacted third molar in the comminuted fracture. Initial exam of this patient should pay special attention to airway edema and tongue swelling. **D,** Simplification and open reduction of fractures demonstrated. (Courtesy Dr. V. J. Perciaccante.)

reduction and internal fixation of the total comminuted fracture complex using a plate that is large enough to withstand functional forces.

The technique for open reduction of this comminuted mandible fracture from a GSW is as follows: First, the teeth are rigidly held together by any means the surgeon chooses. Second, the fractured comminuted mandible is accessed via a transcutaneous approach for large fractures. The key point in exposure of the comminuted segments is to maintain lingual periosteum wherever possible. The small segments are brought together using miniplates and lag screws.[33] This part of the treatment is the "simplification" of the fracture in preparation for the locking reconstruction plate. Small stainless steel wires are sometimes utilized as well to stabilize small segments of comminuted bone. (See Figure 15-13, *D*.) The locking reconstruction plate ideally should have three or four bicortical locking screws on each side of the most posterior fracture. The locking reconstruction plate allows several benefits in these cases. Essentially the locking reconstruction plate is similar to an external fixator in the sense that the large reconstruction plate or fixator bar is suspended from the fixation screws or locking implants locked into the reconstruction plate. Thus the plate is not being compressed onto the bone surface, but suspended from the fixation implants that are locked into the double lead threads of the locking plate. This design allows stabilization of the fracture with a plate that is not perfectly adapted to the mandibular bony contour. This is a big advantage, as adapting large reconstruction plates are difficult, and a great deal of experience and time are required to master the technique. The locking reconstruction plate has also been shown to cause less bony deterioration, as it does not compress itself on the bony surface and thus avoids some vascular compromise to the existing and healing bone.[41] Last, the locking screws are unlikely to cause inflammation when they are still present after bone resorbs around the screw because the screw is locked into the plate, unlike conventional AO techniques where the loose screw eventually causes bony

resorption and/or chronic inflammation. These reconstruction plates can be pre-bent preoperatively with the aid of virtual surgical planning and medical modeling. This process can save the surgeon a great deal of operative time.

Repair of Facial Fractures and Low-velocity GSW Injuries

The treating surgeon has many choices for fixation techniques to treat isolated mandibular fractures, avulsive injuries, or a combination of facial fractures all caused by maxillofacial GSWs. Fixation points for dentate segments traditionally include Erich arch bars and Ivy loops. These allow the surgeon to eventually establish maxillomandibular fixation (MMF) occlusion, the first step in the bottom-up method of repair of multiple facial fractures. Establishing accurate occlusion is also used in the inside-out method of facial fracture repair.

More recently, new fixation devices have been used for establishing MMF whether there are teeth present or absent, also known as edentulous segments. Surgeons with experience in rigid fixation or TADs (tissue-anchored devices), or IMF (intermaxillary fixation) screws may be more proficient with these techniques, or even the SMARTLock Hybrid fixation arch bar (an arch bar that is connected to rigid fixation screws; Stryker, Kalamazoo, MI) for the mandible or maxilla. These devices provide rigid fixation to bony structures rather than fixation to dental structures. Thus they provide fixation similar to skeletal wires without the complexities of using skeletal wire fixation. Also, skeletal wires may have tendency to stretch and need retightening of the skeletal wire as well as the maxillomandibular fixation (MMF) during the healing period to maintain stability of the bony segments. Skeletal fixation wiring includes circumzygomatic wires, zygomatic buttress wires, anterior nasal spine wires, pyriform rim wires, peri-alveolar wires, and circummandibular wires. The stainless steel wires used are usually 24-gauge wire for the skeletal fixation and 26-gauge wire for the interconnecting wire. These techniques of skeletal fixation are useful; however, it is unlikely that many institutions are consistently teaching these techniques. The treating surgeon must insist on excellent soft tissue mucosal care for all devices traversing the oral mucosa, as there is a potential for all of these devices to stimulate varying degrees of chronic tissue trauma, hyperplastic tissue, and patient discomfort at the sites of these devices. The peri-alveolar wire technique involves using a hollow spinal needle with a wire driver and air-controlled trigger release to drive the spinal needle through the alveolus. A stainless steel 24- to 26-gauge wire is placed through the hollow bore of the needle, the needle is removed, and then the wire is tightened over a hemostat to create a loop that can be used for fixation.

In addition to these techniques, the use of a 2-mm K-wire for stabilization of the bilateral mandibular interrami combined with circummandibular wires has been described by Shuker.[42] After routine irrigation and debridement, two holes are drilled using No. 6 round burs into the retromolar fossa at the level of the alveolar ridge. Shuker suggests that the maxilla be used as a guide for locating the retromolar fossa drilling sites in cases that have a severely disrupted mandibular arch. He recommends shaping the K-wire into a horseshoe anteriorly. The posterior of the K-wire is made about 1 cm wider to provide a springing action against the muscle pull medially. The ends of the wire are placed into the prepared holes and inserted about 1 cm deep. Proper seating may require gentle tapping to seat the K-wire correctly. He then uses 0.5-mm stainless steel circumferential wires suspended from the K-wire to the larger segments of the mandible. Shuker describes this technique as superior to an arch bar and a replacement for an external fixator because this K-wire device allows stabilization of the fractured body and rami segments of the mandible.[42] Application of the K-wire at the inferior border of the mandible is also useful for avulsive mandibular anterior wounds. In addition, the K-wire will provide a landmark for future dissection during reconstruction of the continuity defect (Figure 15-14).

Preparation of the correct curve of the K-wire is essential so the bilateral rami are not excessively splayed laterally. This technique is completed in a short time period and is very useful for initial treatment to allow the patient's soft tissue wounds to be supported by a correctly established three-dimensional structure. This technique is also gentle to the existing soft tissues. The radiograph in Figure 15-14 shows an example of a satisfactory placement of a K-wire in and a mandibular posterior comminuted mandibular fracture.

The K-wire technique has also been a useful and expedient treatment for large avulsive mandibular wounds as seen in Figure 15-15 (avulsive wound) and Figure 15-23 (large avulsive wound).

External Fixators for Maxillofacial GSW Injuries

There are generally two types of external fixators that are useful for maxillofacial GSW injuries. The technique is gentle to the soft tissues. Both fixators involve essentially the same primary adjustable metal splint. The primary splint is placed once the facial dimensions—anteroposterior, vertical, and transverse—have been realigned and the occlusion is fixed with any combination of intermaxillary fixation where possible. It is important to note that the bilateral rami will often be splayed laterally and will need to be properly reduced where possible to prevent posterior facial widening. This technique is obviously facilitated when there are condyles attached to the proximal segments. The bone screws can then be placed in preparation for the primary splint that will hold the mandible in place while the secondary splint is placed as either a metal device or an acrylic bar[43] (Figure 15-16).

Key points in using any external fixator include making sure that the surgeon has checked and familiarized himself

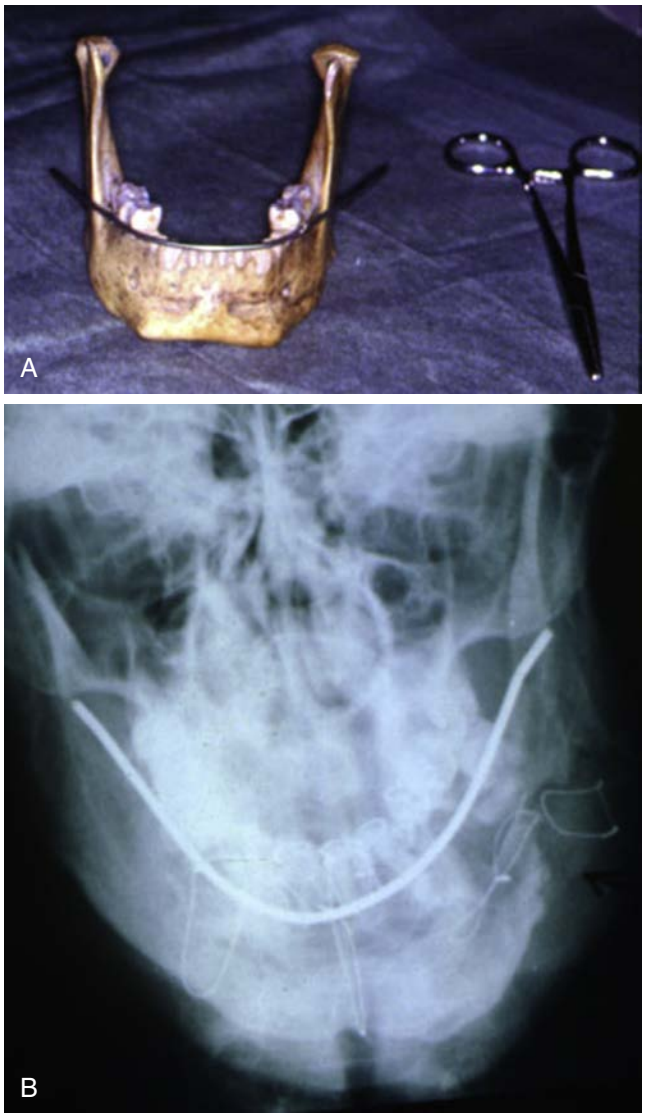

• **Figure 15-14** **A,** K-wire preparation. **B,** K-wire radiograph. (Courtesy Dr. R. S. Sadda.)

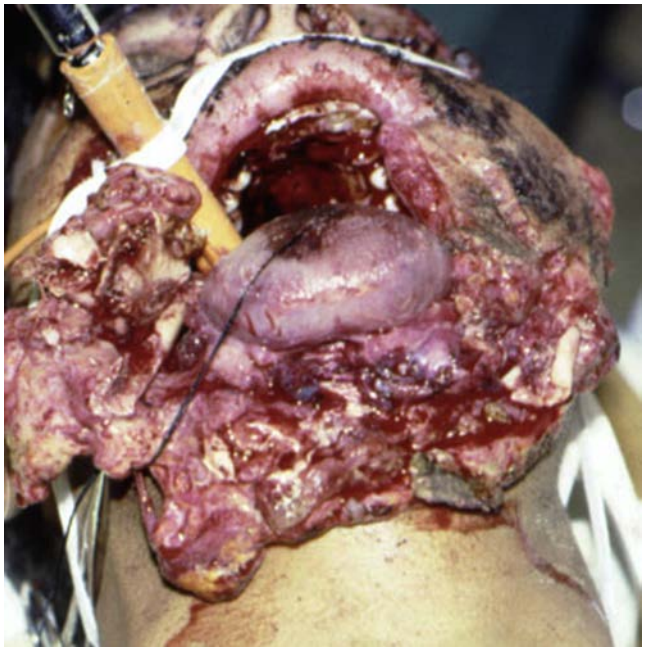

• **Figure 15-15** Avulsive wound and large avulsive wound (see Figure 15-23). Both are examples of large avulsive wounds, loss of mandibular bone, and soft tissue with mobile bilateral rami that benefit from repositioning and fixation. This technique is gentle on the soft tissues and does not require excessive stripping of the bilateral rami to place the K wire. (Courtesy Dr. R. S. Sadda.)

or herself with all of the necessary armamentarium to place the fixator. A preoperative trial run outside of the operating room manipulating the fixator parts and reviewing the set is recommended. Also, the novice surgeon will often place the primary splint on the superior part of the face rather than under the mandible. This is easily remedied by a simple realignment of the primary splint. The bone screws are different for the ramus and body of the mandible sites. The ramus bone screw has a broad flat base that tapers as it goes away from the bone contact. This allows the ramus bone, which is very flat and cortical, to engage a wide area of the bone screw, thereby preventing displacement. The mandibular body bone screws are narrow at the base and relatively parallel as they move away from the bony contact area. The mandibular body has more cancellous bone in most cases, and this allows more bony contact with a wider area of combined cancellous and cortical bone.[43]

Advantages of the Joe Hall Morris external fixator include the following:

1. Enables the surgeon to establish continuity in very comminuted fractures that are often difficult to reduce with rigid fixation.
2. Decreased surgical time for surgeons skilled in the use of acrylic.
3. Less metal hardware to manipulate as the secondary splint is acrylic.
4. Allows the surgeon to cut the acrylic bar weeks after surgery and "test" the continuity of the bony union. The acrylic can be replaced and the patient left in fixation for continued bony healing, or the surgeon may decide that clinically there is a fibrous union present, and then the patient can be prepped for debridement of the fibrous union and preferably placement of an autogenous iliac bone graft or tibial, cancellous bone graft.
5. Bone screws remain relatively stable to the acrylic bar in comparison to the metal second-stage attachments that often require regular tightening.

Potential disadvantages of the Joe Hall Morris external fixator include:

1. The technique may be cumbersome for the first-time user, especially in complex multi-segmented mandibular GSWs.
2. The fixator may be difficult for the patient to tolerate in warm climates.
3. Bone screws, when few in number, may loosen at the point of bone contact and cause loss of stability of reduced fractures.



• **Figure 15-16** **A,** External pin fixator metal. The metal here is for the second stage attached to the bone screws. Note the dressings of iodoform around the fixation screws. These screws often require repeated tightening during the healing phase. **B,** Joe Hall Morris fixator. Note the acrylic bar and the intraoperative procedure using dressings on top of the skin and under the acrylic bar to decrease any injury from the exothermic reaction of the setting acrylic.[43] **C,** Joe Hall Morris fixator. Fixator is successfully in place even in the setting of significant buccal facial swelling.[7] (**A** Courtesy Dr. V. J. Perciaccante; **B** from Morris JH, Hipp BR: Biphasic pin fixation. In Williams JL, editor: *Rowe and Williams' Maxillofacial Injuries,* Vol. 1, 2, New York, 1994, Churchill Livingstone, p. 337; **C** from Osborne TE, Bays RA: Pathophysiology and management of gunshot wounds to the face. In Fonseca RJ, Walker RV, editors: *Oral and maxillofacial trauma*, vol 2, Philadelphia, 1991, Saunders.)

4. Very often the novice surgeon will not manipulate the acrylic correctly over the threads of the fixation pins, and premature setting leads to a large block of wasted operative time during removal of excess acrylic from the bone-screw threaded heads with a burr. There is an inset area at the end of the antitorque wrench that allows the acrylic to be pushed off the top of the threads and thus ease placement for the fixation nut over the acrylic bar.[43]

Complex lower-face GSWs as seen in Figure 15-17 require a combination of techniques to treat the bony fractures. In this case, the patient sustained a zone III injury that resulted in a grossly displaced and comminuted right mandible fracture as well as a symphysis fracture. These fractures were treated by a metal external pin fixator on the right mandible and an open reduction of the anterior mandibular fracture with locking reconstruction plates.

Treatment Phases: Surgical Treatment of Mandible/Maxilla/Mid-face/Upper-face High-energy GSWs

Traditionally, high-energy GSWs to the face were commonly from rifles. Today, high-caliber handguns and IEDs (improvised explosive devices) are common causes of high-energy injuries. High-energy wounds pulverize soft tissues and bone (Figure 15-18).

Management of these complex maxillofacial injuries requires several considerations. Initial treatment is as previously discussed. These complex wounds are demanding because of tissue and bone loss. In addition to this, ophthalmologic and intracranial injuries are common with these complex injuries. Treatment planning for reconstructive procedures is facilitated by production of medical models.

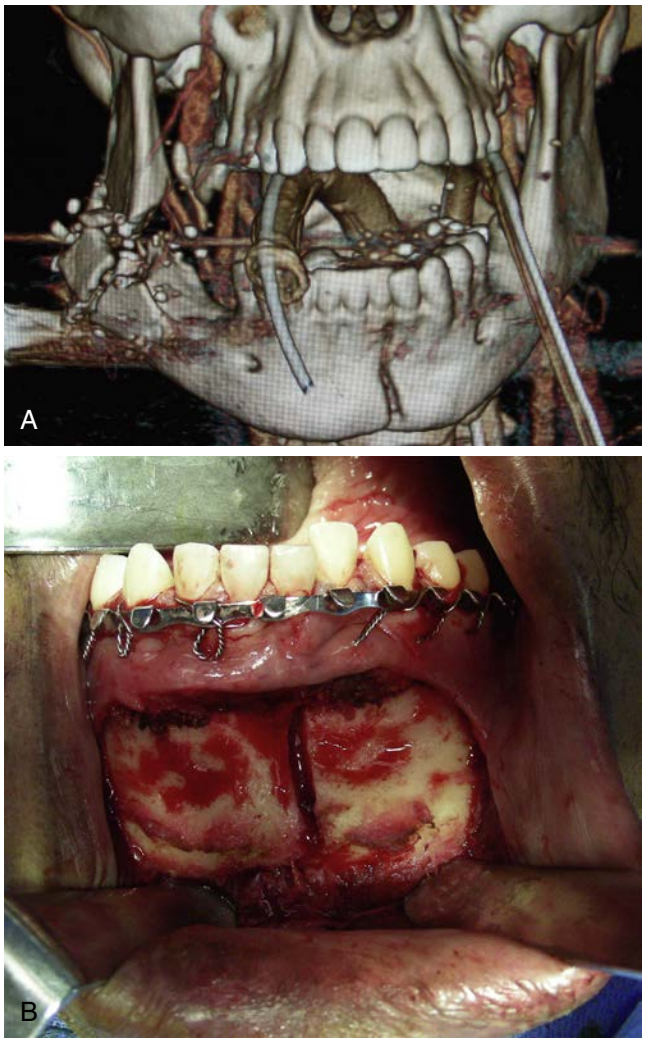

• **Figure 15-17** **A,** Comminuted mandible fractures. Anterior fracture seen as well in 3D reconstruction of computed tomography scan. Note gross flaring and displacement of right posterior mandible. The use of the external pin fixator metal (see Figure 15-16, *A*) allowed the area to be stabilized without gross periosteal stripping of the multiple comminuted segments to place a reconstruction plate. The fixator also allowed for some molding of the bony comminuted fracture that is also grossly flared laterally. This is likely not possible with a simple closed reduction. **B,** Anterior open reduction. Locking reconstruction plates were adapted and applied. This is often difficult in the anterior mandible, as the convexities of the symphysis may cause difficulty in adapting a reconstruction plate. This problem can be alleviated by some bony osteoplasty with a large pineapple-shaped burr to reduce the irregularities before adapting the reconstruction plate.



• **Figure 15-18** Characteristic facial injuries caused by an improvised explosive device (IED). Note concomitant burns, tissue loss, shrapnel injuries, ruptured right globe, and avulsed soft tissues. Only a small portion of the left side of the patient's lateral nasal complex was unaffected by this injury. (From Powers DB, Delo RI: Maxillofacial ballistic and missile injuries. In Fonseca RJ, Barber HD, Walker RV, et al, editors: *Oral and maxillofacial trauma*, ed 4, St Louis, 2013, Saunders.)

These models allow treatment planning conferences and measurements to be more efficient and accurate. The medical models can also be supplemented by 3D CT scanning and virtual surgical planning, such as is commonly done with orthognathic surgery planning and the treatment of dentofacial deformities.

Loss of mandible, lips, nose, and other midfacial tissues requires several tissues to reconstruct these defects. First, of utmost importance is the timing for grafting of onlay bone grafts; for example, calvarial grafts and costochondral grafts to the mid-face or mandible should be postponed until all salivary fistulas have been closed and all intraoral wounds have closed.[44] Contemporary treatment of these complex maxillofacial defects with microvascular free flaps and a skin paddle allows for coverage of the intraoral soft tissue defects and provides a stock of bone that is well perfused. Free flaps used in reconstruction of the hard palate include the scapular, fibular, radial forearm, rectus abdominis, iliac crest, and latissimus dorsi flap. These complex wounds often require many surgeries over several years. Tissue expansion has been used by many reconstructive surgeons and is often fraught with complications.[45]

Special considerations for these complex cases include preparing a problem list for each patient, diagramming all areas of craniofacial fractures and trauma, and a detailed anesthesia plan. Before a discussion with the anesthesia team, the surgical team should discuss with the trauma team the patient's current status, an updated history and physical, and a reasonable idea of how much surgery the patient can reasonably and safely tolerate. Many surgeons will stage complex injuries over several visits to the operating room. Surgical staging for this case may include, for example, placement of a tracheostomy and arch bars as the first surgery followed by definitive treatment of

injuries at another time. Of primary importance in all of these cases is management of the airway and possibilities of nasal intubation versus submental intubation versus tracheostomy. Once this information has been determined, the surgical team should make a detailed surgical plan and a list of needed equipment. One useful item for treating comminuted maxillary fractures is the formation of rigid occlusal surgical splints to establish occlusion and cross-arch stabilization in complex cases (Figure 15-19).

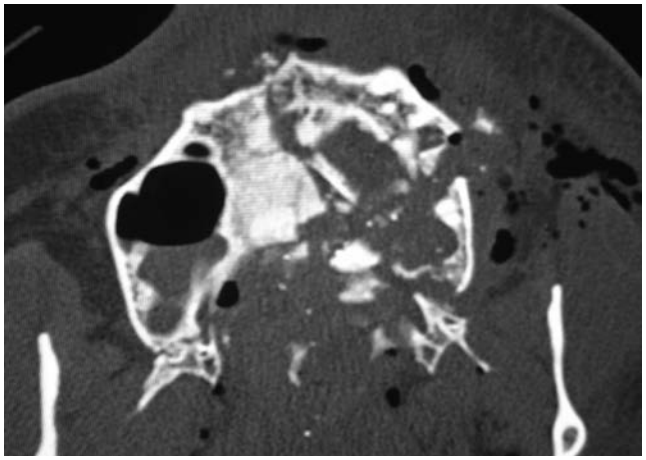

• **Figure 15-19** Comminuted maxillary fracture. When possible, impressions of the comminuted maxilla and mandible will assist in formation of a rigid surgical splint. These splints should have a palatal strap of acrylic that does not contact the soft tissue of the hard palate, and the splint should have buccal holes placed buccal to the contact points of the teeth. These holes will allow wire fixation of the splint to the arch bar.

Shotgun Injuries

To reiterate, these wounds have been classified into three types by Sherman and Parrish:

Type I: long-range, greater than 7 yards, penetration of subcutaneous tissue or deep fascia.

Type II: short range, 3 to 7 yards, penetration of body cavities.

Type III: point-blank range, less than 3 yards, extensive tissue destruction.[46]

(See Figures 15-20 and 15-21.)

Self-inflicted Gunshot Wounds

Maxillofacial GSWs attributed to shotguns have been shown to be suicide attempts in an estimated range of 20% to 76% of cases.[18,46,47] In 2000, the most common method of successful suicide was self-inflicted gunshot wounds (SIGSWs). Furthermore, more than 75% were SIGSWs to the head.[48] Surviving a SIGSW is relatively rare and makes up only 1% of all failed suicide attempts.[49] A poor prognosis for survival includes a Glasgow Coma Scale (GCS) of less than eight.[48,49]

Also, missiles traveling in a sagittal direction are less likely to be lethal as compared to those traveling in a coronal direction. Long-barreled firearms placed submentally may cause a hyperextension of the neck and thus a trajectory that does not enter intracranially. Furthermore, a handgun placed submentally may cause a jerk reflex that also hyperextends the neck and causes the trajectory to miss the intracranial structures.[1,13] Trauma to the periorbital region is a major concern and requires immediate ophthalmology

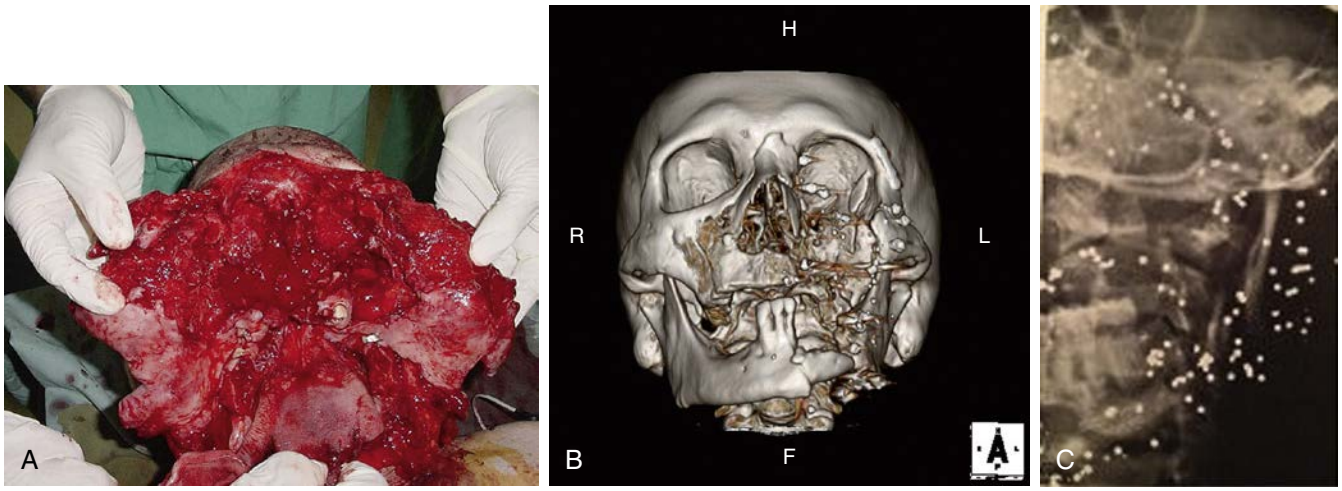

• **Figure 15-20** **A,** Self-inflicted shotgun wound in a suicide attempt. Note significant hard and soft tissue disruption and avulsion (Sherman and Parrish, Class III; Glezer, Class III). **B,** Three-dimensional reconstruction of computed tomography scan showing the degree of hard tissue loss experienced in a suicide attempt with a high-energy weapon. **C,** Class III shotgun wound, lateral plain film. Note hard tissue injury as well as concentrated shrapnel. (**B** From Powers DB, Delo RI: Maxillofacial ballistic and missile injuries. In Fonseca RJ, Barber HD, Walker RV, et al, editors: *Oral and maxillofacial trauma*, ed 4, St Louis, 2013, Saunders. **C** From Osborne TE, Bays RA: Pathophysiology and management of gunshot wounds to the face. In Fonseca RJ, Walker RV, editors: *Oral and maxillofacial trauma*, vol 2, Philadelphia, 1991, Saunders.)

examination; needed reconstructive procedures must be performed promptly. Many of these patients can be restored to functional vision despite the apparent devastation that may be seen during initial examination[50] (Figure 15-22).

These GSW victims sustain injuries that cause gaping wounds and extensive comminuted facial fractures. Shotgun wadding and pellets are often found scattered in the facial soft tissue wounds. In general, if a maxillofacial GSW victim arrives alive in the emergency room, there is a high survival rate in the absence of intracranial wounds.[29] These wounds will require several debridements until all nonviable tissue is removed and flap advancement or other techniques can be used to provide proper tissue bulk.[18]

The general treatment sequence for maxillofacial shotgun GSW injuries includes all of the previous listed treatments. In addition to these items, wadding and pellets just under the skin should be removed. Those that are deeply embedded should be left in place, as their

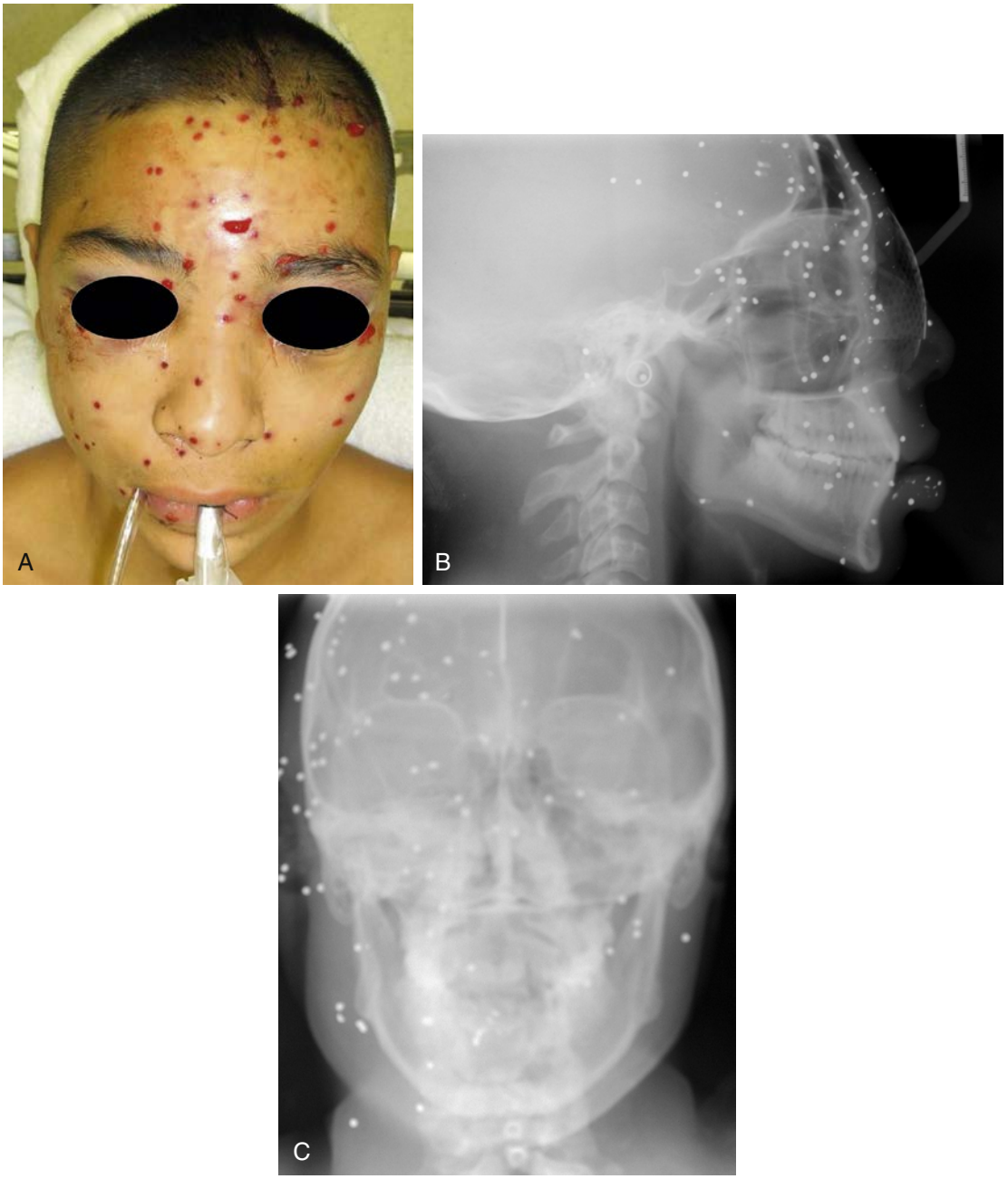

• **Figure 15-21** **A,** Characteristic facial appearance of a patient sustaining a shotgun wound from a distance. (Sherman and Parrish, class I; Glezer, class I). Note the presence of multiple punctate entry wounds, but no significant disruption of the facial features. **B** and **C,** Classic radiographic appearance of a patient sustaining a shotgun wound from a distance (Sherman and Parrish, class I; Glezer, class I). Note the presence of multiple shotgun pellets on the radiographs. (From Powers DB, Delo RI: Maxillofacial ballistic and missile injuries. In Fonseca RJ, Barber HD, Walker RV, et al, editors: *Oral and maxillofacial trauma*, ed 4, St Louis, 2013, Saunders.)

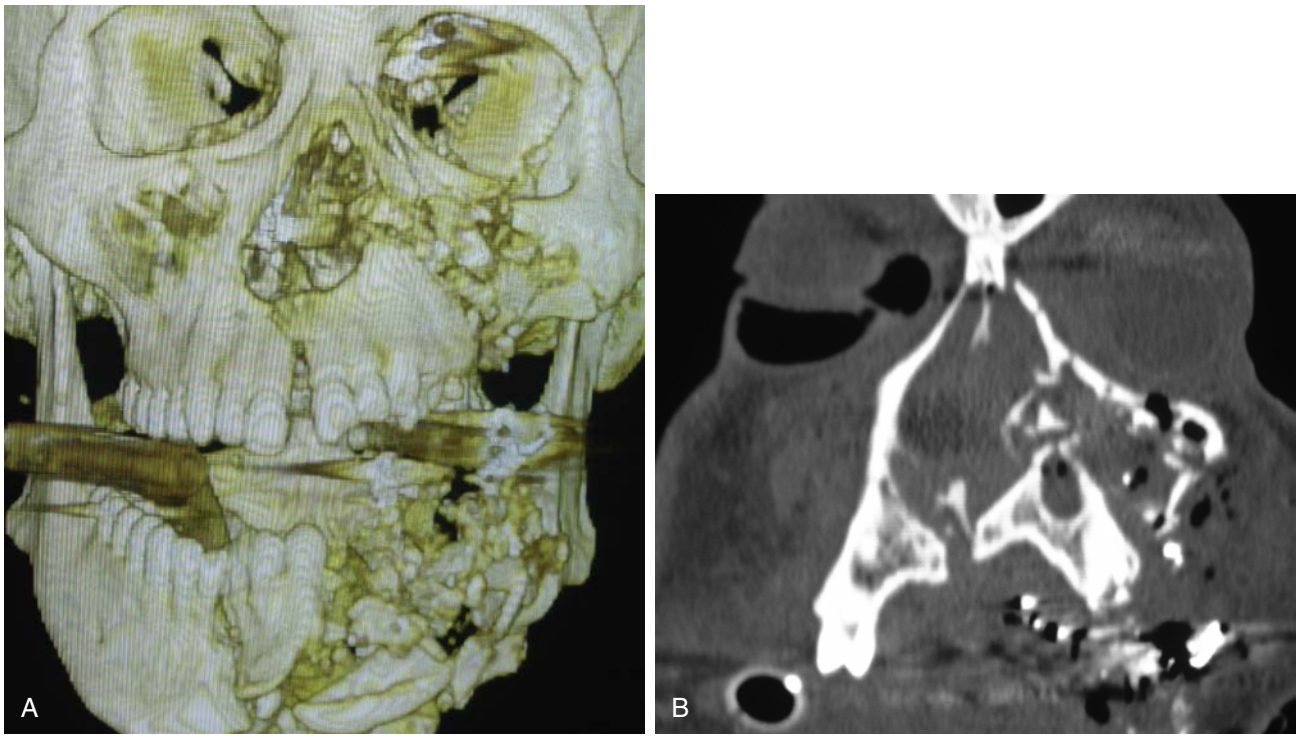

• **Figure 15-22** **A,** Self-inflicted gunshot wound (SIGSW), hemifacial and left frontal lobe. 3D reconstruction computed tomography: This patient sustained a comminuted mandible fracture, maxillary fracture, orbital fracture, and anterior cranial fossa trauma from a SIGSW. **B,** SIGSW coronal view CT.

removal may be destructive and cause iatrogenic injury. These wounds are not to be closed primarily in the early post-injury period, as abscess and soft tissue infection may occur. When there is an ensuing infection, it is treated by opening, draining, and debriding the wadding and pellets. Occasionally through-and-through drains may be needed for continuous irrigation of a grossly infected wound. Appropriately directed antibiotic treatment directed by culture and sensitivity results is prudent. Contemporary medicine suggests that the surgeon should adhere to a treatment protocol for judicious use and overuse of antibiotics.

A suicidal person who uses the shotgun in a submental position often blows off the anterior face and avoids intracranial injury. These patients will have excessive anteroposterior facial dimension loss due to bony and soft tissue destruction. Moreover, these cases will involve several surgeries before all of the nonviable soft tissue can be removed. These "second look" explorations help to avoid complications by using judicious, definitive debridement to avoid tissue loss and infection. The surgeon should not be focused on defining the areas of extent of damage at the first exploration, as sequential explorations will confirm the expectation that the wound is a high-energy injury by the obvious pattern of evolving tissue necrosis over time. This first look will also allow the surgeon to set the threshold for future re-exploration. Major issues are large losses of the mandibular and maxillary bone. One study showed that

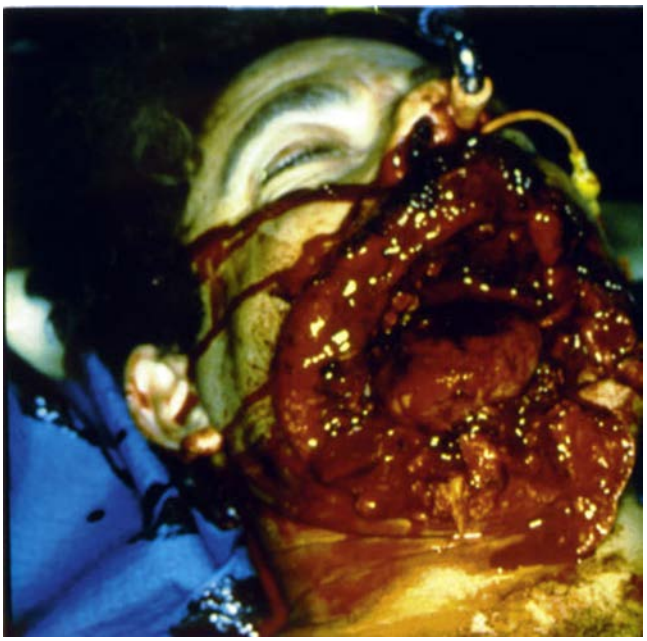

• **Figure 15-23** Large avulsive wound. This patient has gross soft tissue and bony loss of the lower face and mandible. Nasal intubation was possible to secure the patient's airway.

27% of the avulsive tissue loss in these injuries is the mandible[47] (Figure 15-23).

Debriding loose, non-periosteal attached bone, debriding and irrigating the wounds, and allowing for reduction and establishment of correct facial dimensions must be a

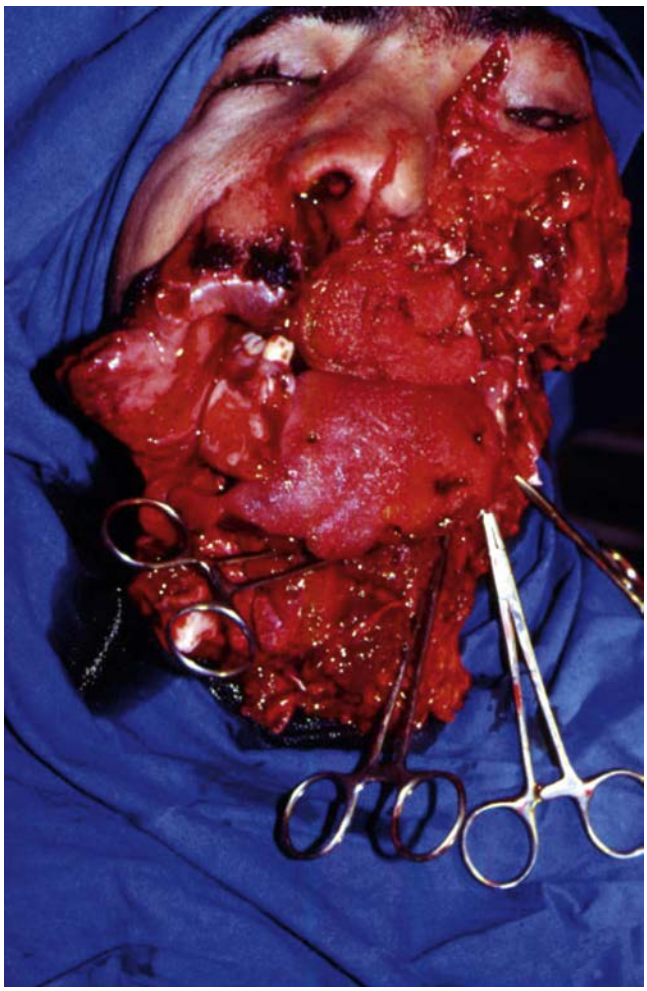

• **Figure 15-24** Avulsive flap. This is a complex gunshot wound to the maxillofacial region. The patient received a tracheostomy urgently. Gross displacement of the naso-orbito-ethmoid on initial exam is significant. Unfolding and evaluation in the operating room will likely reveal deeper damage extending to the frontal bone. Cerebrospinal fluid leaks are likely in these wounds. (Courtesy Dr. R. S. Sadda.)

priority.[18] If the mandible is involved with a major, multifragmented, comminuted mandible fracture (including damaged intraoral lining), approximately 35% of patients will have failed primary, immediate grafts and develop localized sepsis, persistent fistulae, wound breakdown, and graft loss. The key point many surgeons miss is that they underestimate the need for replacement of vascularized lining before nonvascularized bone grafting. Some surgeons also recommend post-grafting soft-tissue rest, a brief period of intermaxillary fixation, in patients with severe soft tissue injuries.[47]

These complex injuries often reveal deeper skull base injuries when the tissues are unfolded and explored in the operating room. For example, a complex deep injury may have obliterated bone extending into the anterior cranial fossa (Figure 15-24).

These injuries may present with cerebrospinal fluid (CSF) leaks due to damage through the cribriform plate. Neurosurgical consultation and surgical intervention by way of frontal bone bloc osteotomy and pericranial flaps are often used in conjunction with a lumbar drain to treat the CSF leak originating from damage to the dura at the cribriform plate and crista galli. The frontal bloc osteotomy gives the reconstructing surgeon the opportunity to use the inner table of the calvarium to harvest an inner cortex bone graft to reconstruct the nasal dorsum. Another key clinical pearl is that these complex naso-orbito-ethmoid (NOE) and deep fractures are best reconstructed in one surgery when possible—it is very difficult to reconstruct the adjacent structures in multiple sequential surgeries because of scarring and difficult access.

Reestablishing the intercanthal width in complex NOE trauma is difficult. These procedures require multiple surgical access incisions. Using C-shaped 2.0-mm flexible plates to connect structures high and low enables the surgeon to manipulate and narrow the radix area, thus correcting the traumatic telecanthus. Holton recommends a goal of 22 mm of bony reduction at the radix. The 22 mm, plus 5 mm on each side for the length of the medial canthal ligament, yields an intercanthal distance of 32 mm. The nasofrontal, nasolacrimal, and salivary ducts should be assessed and repaired as early as possible (Figure 15-25).

Furthermore, suspension of the facial muscles and tissues in the infraorbital region is done with suspension sutures. This technique uses a 1.2-mm titanium screw into the infraorbital rim to suspend and prevent sagging of the repaired issues.[51]

Intermediate Phase

A definite intermediate phase of treatment for maxillofacial GSWs may meld into the reconstructive phase. This is largely determined on an individual case basis. Regardless of the individual case, some of the components of the intermediate phase include supportive care and the prevention of complications. Supportive care includes nutritional needs and dealing with the challenges the maxillofacial GSW victim is faced with, including dysphonia, dysphagia, mucosal moisture changes, and neurosensory changes. Early function of these patients and use of the masticatory system enables increased blood flow and improved healing with increased presence of oxygen and nutrients to the healing tissues. Included with the masticatory function is maintenance of oral health, increased range of motion of the mandible, and decreased pain. Other supportive care includes ongoing psychological care, as many of these patients are victims of violence and frequently SIGSWs. In addition to this, ophthalmologic care must be continuous, as functional vision should be a priority. Neurologically improving the patient's cognitive function in those with brain injuries is essential. Many of these patients will require both occupational therapy and physical therapy for an extended amount of time.[7]

Prevention of complications includes monitoring for hemorrhage, infection, and further wound breakdown and

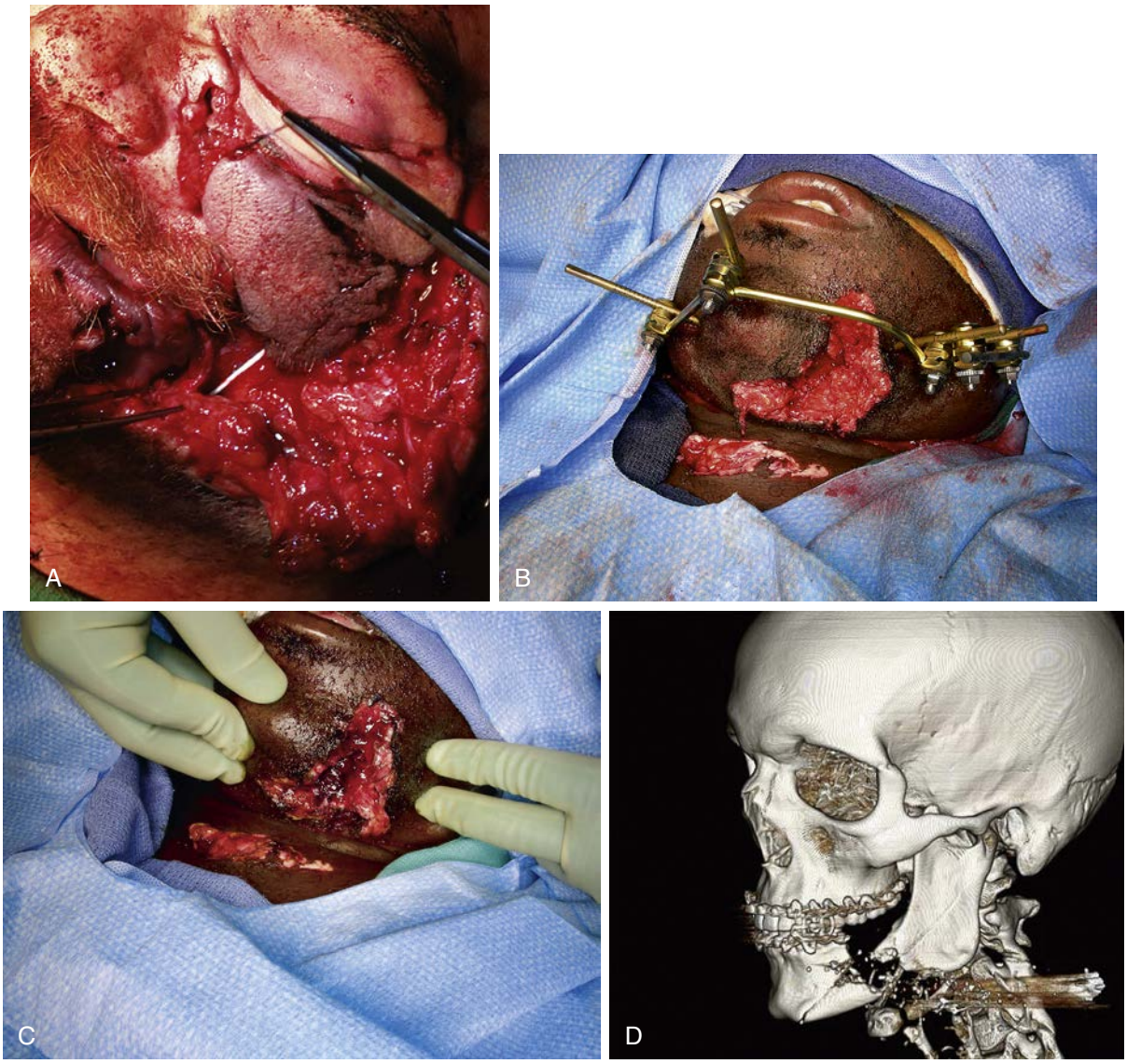

• **Figure 15-25** **A,** Cannulation of the severed parotid duct with Silastic tubing. All ballistic injuries to the craniomaxillofacial complex should undergo evaluation under some form of magnification for potential remnants of the salivary ducts and cranial nerves because primary repair is best accomplished at the time of initial injury. **B,** High-energy gunshot wound to the anterior mandible. Note the presence of soft tissue disruption and a second gunshot wound across the anterior neck, glancing off the surface epithelium and providing only superficial injury to the platysma. **C,** Initial stabilization of the patient was accomplished with an external fixator secondary to the presence of other life-threatening gunshot wounds that were sustained at the same time. The patient was subsequently treated with open reduction and internal fixation with a reconstruction plate and corticocancellous bone graft from the anterior ilium. **D,** Three-dimensional reconstruction of computed tomography (CT) scan indicating the degree of comminution and avulsive bone loss associated with this gunshot wound. The projectile can easily be identified at the bottom right of the CT scan. (From Powers DB, Delo RI: Maxillofacial ballistic and missile injuries. In Fonseca RJ, Barber HD, Walker RV, et al, editors: *Oral and maxillofacial trauma*, ed 4, St Louis, 2013, Saunders.)

bony sequestration. Wound care is essential, and for the patient who goes home with dressings, it is essential they receive immaculate wound care in a timely fashion.

Looking forward to the preparation for the reconstructive phase of treatment, it is essential that the patient's updated condition be continually documented, with consultations obtained as necessary. Imaging should be updated and medical models prepared as necessary. The overall goal is eventual reconstruction with adequate hard and soft tissues as well as a functioning dentition.

Reconstructive Phase

Traditionally the bony reconstructive phase for these wounds has been delayed several months, as nonvascularized grafts require watertight, sealed soft tissue margins. Continuity

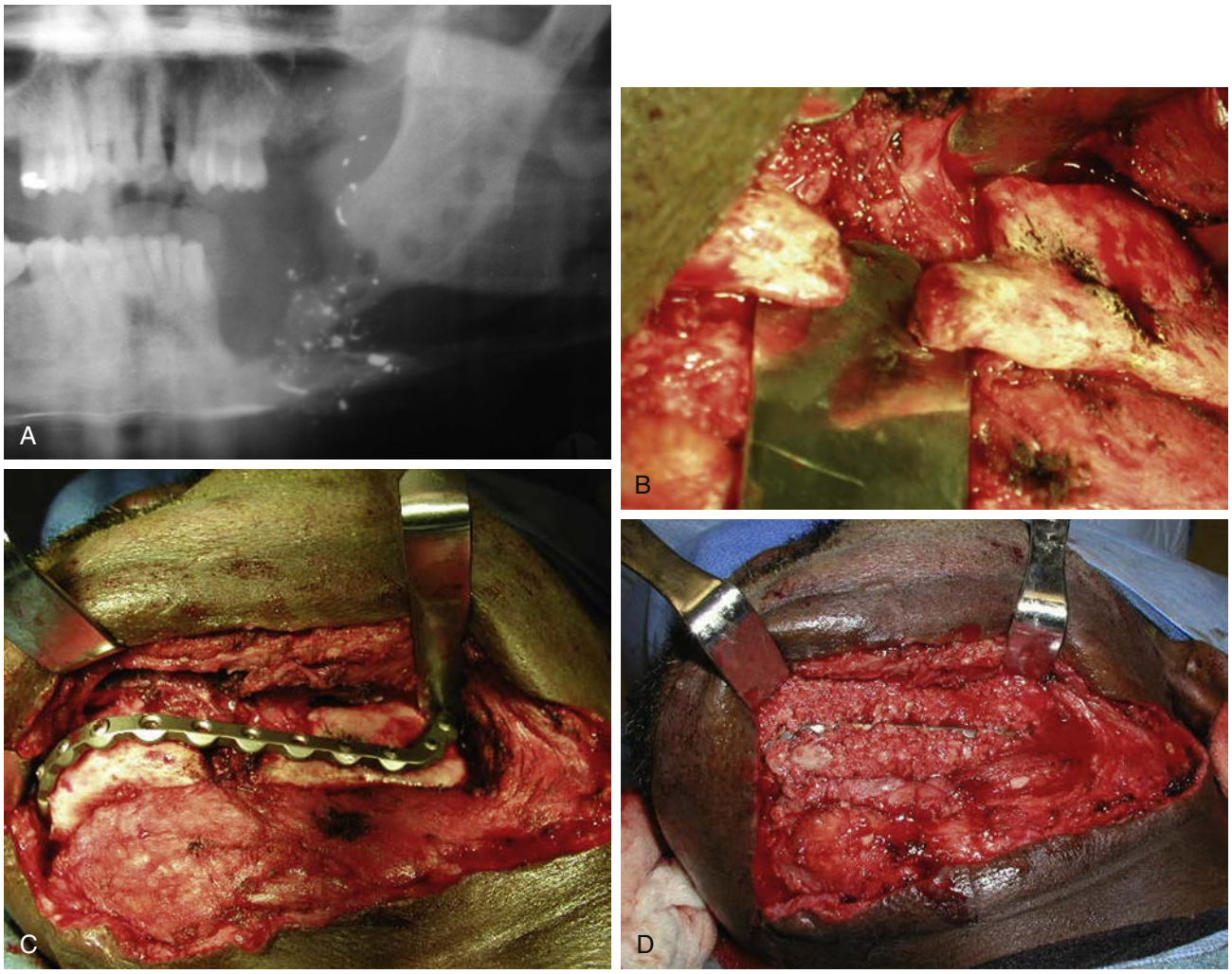

• **Figure 15-26** **A,** Panograph of post–gunshot wound defect. Continuity defect, left body mandible. Note shrapnel in wound and superior rotation of proximal ramus segment. Control of the proximal segment is easier once a coronoidectomy is completed on the ipsilateral side. **B,** After debridement. Note removal of all soft tissue from proximal and distal bony stumps. Copious irrigation with normal saline is done in preparation for the corticocancellous graft. **C,** Locking recon plate. Immobility of the graft is essential for bony healing. Alternative technique to recon plate: One should cautiously use the correct titanium mesh crib when restoring continuity defects. It is essential that the crib be rigid enough to prevent micromovement that may lead to a failed attempt at bony consolidation and thus not allow a bony union with the native mandibular stumps. **D,** Graft in situ. Note the overpacking of bone graft. This is a useful technique, as some resorption of the bony graft is expected. (Courtesy Dr. V. J. Perciaccante.)

and large defects are primarily grafted simultaneously when the overlying tissue is healthy.[52] To review, healthy tissue includes closed intraoral wounds, lack of infection, and lack of fistulae. The bone grafting material of choice is autogenous bone, as it revascularizes rapidly and is relatively resistant to infection. The tibial bone is recommended by many as the preferred site for harvesting copious amounts of marrow.[33] Many surgeons successfully use corticocancellous iliac grafting, both anterior and posterior, with a reconstruction plate or a titanium mesh crib for reconstruction of maxillofacial GSW continuity defects. These grafts will consolidate well in 6 months and allow reconstruction of the defect with dental implants and subsequently oral reconstruction. Many of these defects will also need soft tissue revision and vestibuloplasty as well as soft tissue grafting procedures because of inadequate firm tissue at the recipient dental implant site (Figure 15-26).

Key points in reconstruction of jaw injuries:

- Maturation of involved tissue should precede reconstruction or correction.
- Sufficient soft tissue cover, extra and intraoral, must be provided to permit adequate bone contour restoration. This is also called "lining" in many references written on GSW.
- Skin graft shrinkage will happen, and when the scar defect is released, it usually assumes proportions larger than initially visualized.
- Facial bone loss benefits from iliac grafting.
- Fixation and immobilization are essential for successful bone grafting.[18,47]

Each reconstruction case is managed on an individual basis. Mid-face and upper-face avulsive bony and soft tissue loss reconstruction will involve many surgeries over a span of time. Traditionally, reconstruction procedures have included calvarial grafts, costochondral grafts, iliac grafts, cranioplasty, and oculoplastic reconstructive surgeries.[47] Many injuries that will be planned for vascularized soft and hard tissue reconstruction may be reconstructed before the intraoral lining has completely healed, as providing soft tissue with the vascularized graft corrects for this problem. Also, defects involving the anterior of the mandible and defects larger than 10 cm often do well with vascularized osteocutaneous free fibula grafting. This technique allows a soft tissue paddle attached to a significant stock of bone to restore both bony and soft tissue defects. This bone can be used for immediate or delayed dental implant placement. When necessary, the free fibula can be used as a double barrel to provide additional height that mimics the shape of the mandibular alveolus. A reconstruction plate similar to the one used to stabilize the bilateral remaining mandible is used to attach the fibula graft. The graft is anchored with smaller diameter screws, placed monocortically, than fixation screws used to fixate the reconstruction plate to the existing native mandibular stumps. A combination of costochondral grafting attached to a rigid fixation reconstruction plate is possible, although it may be difficult to stabilize the soft costochondral graft. The costochondral graft is insufficient in bulk when used to restore the mandibular body region in combination with dental implant reconstruction.

A costochondral graft to restore the ramus and condylar segments has been used with a reconstruction plate. Also, a custom-made alloplastic implant has been employed, attaching a custom-made mandible seated into a custom-made fossa implant. A less commonly used technique to restore mandibular continuity in GSW defects is osteogenic distraction, also known as distraction osteogenesis. In 2005, Labbé and colleagues reported a series of 11 cases of mandibular continuity defects treated by osteogenic distraction.[53] On average their patients achieved nearly 8 cm of linear bone growth by way of the osteogenic distraction technique. Their recommendation is to use the trifocal technique. This technique involves one bone segment mobilized on each side, and thus two distracted foci and one consolidation focus. Osteogenic distraction can be used to reconstruct several different tissue types. In addition to bone elongation, it results in the formation of new skin, muscles, and subcutaneous tissues. All the tissues from skeleton to skin are elongated simultaneously without the inconvenience of skin expansion and with optimal aesthetic results. As distraction proceeds, the superficial tissues are elongated considerably more than the bone. This technique has disadvantages, such as the need for at least two surgeries. One surgery is for corticotomies and distractor placement, and the other is for at least removal of the distractor. At the time of distractor removal, a reconstruction plate and additional bone grafting may be needed. Very often the chin area requires additional grafting for esthetic purposes in these distraction cases. Another disadvantage can be the unsightly scars from the distractor fixation pins.[53]

Severe avulsive GSWs of the maxillofacial region have been treated with near-total face transplantation. One near-total face transplantation was done at the Cleveland Clinic in 2009. A 41-year-old woman had sustained a shotgun GSW to the maxillofacial region approximately 5 years prior to the face transplantation. Her injuries included severe damage to her mid-face, which included amputation of her nose, cheeks, upper lip, right globe, upper jaw, and maxillary alveolus and associated teeth. She was left with 20/200 vision in her left eye, and she had no function of smell because of a blocked nasal passage. Her main nutrition was by a percutaneous endoscopic gastrostomy tube. She had bony defects of her palate, maxilla, bilateral zygomas, bilateral orbits, and nasal bones. During a 5-year period she had more than 20 reconstructive surgeries. These surgeries still left her with a tremendous tridimensional defect of the craniofacial skeleton. It is estimated that soft tissue coverage of a full facial/scalp deficit would require more than 1200 cm^2 of autologous tissue provided in one flap. The largest autologous flap available from the human back by a scapular-parascapular flap is less than half of the total needed for a full facial/scalp defect. This patient successfully underwent the near-total face transplantation and did well. She was truly dedicated to engaging in the required physical therapy, speech therapy, and facial reanimation. As a result she was able to regain most of her missing facial functions of nasal breathing, sense of smell, drinking from a cup, eating solid foods, and speaking intelligibly. Sensory healing in the facial region provided a 7-mm two-point discrimination upon neurosensory testing.[54] Overall, this was an incredible accomplishment for a tremendous problem; however, this therapy was only made possible by an enormous effort of the patient, the appropriate location of a donor, the formation of an exceptional harvest and transplant team, an exceptional health care system/institution, and substantial funding. Perhaps this therapy will be used more in the future for other extremely complex craniofacial defects secondary to GSWs.[53]

References

1. Centers for Disease Control and Prevention: CDC's Web-based Injury Statistics Query And Reporting System (WISQARS). National Center for Health Statistics, Division of Vital Statistics, *Natl Vital Stat Rep* 64(2), 2015. Table 19.
2. Planty M, Truman JL: Bureau of Justice statistics, *firearm violence*, 1993-2001. http://www.bjs.gov/index.cfm?iid=4616&ty=pbdetail.
3. Kalesan B, French C, Fagan JA, et al.: Firearm-related hospitalizations and in-hospital mortality in the United States, 2000-2010, *Am J Epidemiol* 179(3):303–312, 2014.

4. Centers for Disease Control and Prevention: CDC's Web-based Injury Statistics Query And Reporting System, National Center for Injury Prevention and Control website. http://www/cdc.gov/injury/wisqaes/index.html.
5. Kaufman Y, Cole P, Hollier L: Contemporary issues in facial gunshot wound management, *J Craniofac Surg* 19(2):421, 2008.
6. Dufresne GW: Wound ballistics: recognizing wound potential. Part 1—characteristics of missiles and weapons, *Int J Trauma Nurs* 1(1):4, 1995.
7. Osborne TE, Bays RA: Pathophysiology and management of gunshot wounds to the face. In Fonseca RJ, Walker RV, editors: *Oral and maxillofacial trauma*, vol. 2. Philadelphia, 1991, Saunders.
8. Cunningham LL, Haug RH, Ford J: Firearm injuries to the maxillofacial region: an overview of current thoughts regarding demographics, pathophysiology, and management, *J Oral Maxillofac Surg* 61:932, 2003.
9. Hollerman JJ, Fackler ML, Coldwell DM, Ben-Menachem Y: Gunshot wounds: bullets, ballistics, and mechanisms of injuries, *Am J Roentgenol* 155(4):685, 1990.
10. Powers DB, Delo RI: Characteristics of ballistic and blast injuries, *Atlas Oral Maxillofac Surg Clin North Am* 21:15–24, 2013.
11. Bartlett CS: Clinical update: gunshot wound ballistics, *Clin Orthop Relat Res* 408:28, 2003.
12. Vayvada H, Menderes A, Yitmaz M, et al.: Management of close range, high-energy shotgun and rifle wounds to the face, *J Craniofac Surg* 16(5):794, 2005.
13. Kriet JD, Stanley Jr RB, Grady MS: Self-inflicted submental and transoral gunshot wounds that produce nonfatal brain injuries: management and prognosis, *J Neurosurg* 102(6):1029, 2005.
14. Fackler ML: Gunshot wound review, *Ann Emerg Med* 28(2):194, 1996.
15. Farjo LA, Miclau T: Ballistics and mechanisms of tissue wounding, *Injury* 28(Suppl 3):C12–C17, 1997.
16. Swift B, Rutty GN: The exploding bullet, *J Clin Pathol* 57(1):108, 2004.
17. Chen AY, Stewart MG, Raup G: Penetrating injuries of the face, *Otolaryngol Head Neck Surg* 115:464, 1996.
18. Spira M, Hardy B, Biggs TE, Gerow FJ: Shotgun injuries of the face, *Plast Reconstr Surg* 39:449, 1967.
19. Sadda RS: Maxillofacial war injuries during the Iraq-Iran War—an analysis of 300 cases, *Int J Oral Maxillofac Surg* 32:209–214, 2003.
20. Mohan R, Iyer R, Thaller S: Airway management in patients with facial trauma, *J Craniofac Surg* 20:21, 2009.
21. Holmgren EP, Bagheri S, Bell RB, et al.: Utilization of tracheostomy in craniomaxillofacial trauma at a level-1 trauma center, *J Oral Maxillofac Surg* 65:2007, 2005.
22. Rezende-Neto J, Marques AC, Guedes LJ, Teixera LC: Damage control principles applied to penetrating neck and mandibular injury, *J Trauma* 64:1142, 2008.
23. Demetriades D, Theodorou D, Cornwell E, et al.: Evaluation of penetrating injuries of the neck: prospective study of 223 patients, *World J Surg* 21:41, 1997.
24. Low GM, Inaba K, Choulias K, et al.: The use of the anatomic "zones: of the neck in the assessment of penetrating neck injury, *Am Surg* 80:970, 2014.
25. Brohi K: Penetrating neck injuries, trauma.org, 7:6 June 2002.
26. Pourdanesh F, Salehian M, Dehghan P, et al.: Pseudoaneurysm of the superficial temporal artery following penetrating trauma, *J Craniofac Surg* 24(4):e334, 2013.
27. Perry M, Dancey A, Mireskandari K, et al.: Emergency care in facial trauma—a maxillofacial and ophthalmic perspective, *Injury* 36:875, 2004.
28. Jo C, Steed M, Perciaccante VJ: Bullet embolus to the pulmonary artery after gunshot wound to the face: case report and review of literature, *J Oral Maxillofac Surg* 68:504, 2010.
29. Powers DB, Robertson OB: Ten common myths of ballistic injuries, *Oral Maxillofac Surg Clin North Am* 17:251, 2005.
30. Fackler ML: Civilian gunshot wounds and ballistics: dispelling the myths, *Emerg Med Clin North Am* 16:17, 1998.
31. Schultz RC: *Facial injuries*, Chicago, 1988, Year Book.
32. Herford AS, Ellis E: Use of a locking reconstruction bone plate/screw system for mandibular surgery, *J Oral Maxillofac Surg* 56:1261, 1998.
33. Alpert B, Tiwana PS, Kushner GM: Management of comminuted fractures of the mandible, *Oral Maxillofac Surg Clin North Am* 21:185, 2009.
34. Buchbinder D: Use of rigid internal fixation in the treatment of mandibular fractures, *Oral Maxillofac Surg Clin North Am* 2(1):41, 1990.
35. Smith BR, Johnson JV: Rigid fixation of comminuted mandibular fractures, *J Oral Maxillofac Surg* 51:1320, 1993.
36. Assael LA: Treatment of comminuted fractures of the mandible, *Atlas Oral Maxillofac Surg Clin North Am* 5(1), 1977.
37. Ellis III E, Muniz O, Anand K: Treatment considerations for comminuted mandibular fractures, *J Oral Maxillofac Surg* 61:861, 2003.
38. Finn RA: Treatment of comminuted mandibular fractures by closed reduction, *J Oral Maxillofac Surg* 54:320, 1996.
39. Smith BR, Teenier TJ: Treatment of comminuted mandibular fractures by open reduction and rigid internal fixation, *J Oral Maxillofac Surg* 54:328, 1996.
40. Spiessl B: Comminuted fractures. In *Internal fixation of the mandible*, Berlin, 1989, Springer.
41. Soderholm AI, Hallikainen D, Lindqvist C: Long-term stability of two different mandibular bridging systems, *Arch Otolaryngol Head Neck Surg* 119:1031, 1993.
42. Shuker ST: Interrami intraoral fixation technique for severe mandibular rifle fragmented bullet injury management, *J Craniofac Surg* 24:1168, 2013.
43. Morris JH, Hipp BR: Biphasic pin fixation. In Williams JL, editor: *Rowe and Williams' maxillofacial injuries*, Vol. 1. New York, 1994, Churchill Livingstone, pp 2.
44. Gruss JS, Antonyshyn O, Phillips JH: Early definitive bone and soft-tissue reconstruction of major gunshot wounds of the face, *Plast Reconstr Surg* 87:436, 1991.
45. Antonyshyn O, Gruss JS, Mackinnon SE, Zuker R: Complications of soft tissue expansion, *Br J Plast Surg* 41:239, 1988.
46. Sherman RT, Parrish RA: Management of shotgun injuries, *J Trauma* 3:76, 1963.
47. Clark N, Birely B, Manson PN, et al.: High-energy ballistic and avulsive facial injuries: classification, patterns, and an algorithm for primary reconstruction, *Plast Reconstr Surg* 98(4):583, 1996.
48. Beaman V, Annest JL, Mercy JS, et al.: Lethality of firearm-related injuries in the United States population, *Ann Emerg Med* 35(3):258, 2000.
49. Centers for Disease Control and Prevention: CDC's Web-based Injury Statistics Query And Reporting System, National Center for Injury Prevention and Control website. http://www/cdc.gov/injury/wisqaes/ Updated December 19, 2010.

50. Reddy AK, Baker MS, Sobel RK, et al.: Survivors of self-inflicted gunshot wounds to the head: characterization of ocular injuries and health care costs, *JAMA Ophthalmol* 132(6):730, 2014.
51. Holton J, Chung WL, Herford A: Trauma surgery, *J Oral Maxillofac Surg* 70(11 Suppl 3):e162–e203, 2012.
52. Spiessl B: Stable internal fixation. In Mathog RH, editor: *Maxillofacial trauma*, Baltimore, 1984, Williams & Wilkins.
53. Labbé D, Nicolas J, Kaluzinski E, et al.: Gunshot wounds: reconstruction of the lower face by osteogenic distraction, *Plast Reconstr Surg* 116(6):1596, 2005.
54. Siemionow MZ, Papay F, Djohan R, et al.: First U.S. near-total human face transplantation: a paradigm shift for massive complex injuries, *Plast Reconstr Surg* 125(10):111, 2010.

16

Oral and Maxillofacial Pathology: Available Diagnostic Techniques and Surgical Interactions

J. MICHAEL McCOY

Introduction

Surgical pathology is the specialty of medicine/dentistry that deals with the pathologic characteristics of hard and soft tissue removed from the living patient. The tissue removed includes not only the solid tissue seen in biopsy material, but also the cells seen in smears, aspirates, and tissue core biopsies. The surgical pathologist must be proficient in the evaluation of all types of cellular tissue. This includes normal as well as abnormal.

Unlike autopsy pathology, the decisions made by the surgical pathologist are often rapid and occasionally immediate. The rendered diagnosis frequently precedes the patient's treatment and, in many cases, influences or even dictates the exact nature of this treatment. In addition, the surgical pathologist also functions as a teacher or consultant. Such consultations should always benefit the patient as well as the clinician, even though the surgical pathologist works in a laboratory without true patient contact.

Historical Perspective

In times past, the surgical pathologist was situated in a division of surgery or at least closely affiliated with such a clinical department. Oftentimes, the examination of tissue removed from the living patient was relegated to the pathology resident. With such assignment came delays of pathology reports, and in some cases the report only stated "benign" or "malignant." Under such conditions the clinical surgeon's diagnoses and treatment recommendations were often much more appropriate than those of the undereducated and occasionally uninterested pathology resident. Even so, it was almost impossible to be a competent clinician and a skilled pathologist simultaneously. Yet, during these earlier times, there were those exceptional individuals who not only were skilled pathologists but, in addition, introduced numerous important contributions to their respective surgical disciplines.

In the first half of the 20th century, the technology of tissue fixation, staining procedures, and microscopic discrimination progressed rapidly. Immunostaining was initiated in the 1960s. Enzymatic immunochemistry and monoclonal antibody staining became widely used in the 1970s and 1980s. Both scanning and transmission electron microscopy were available for use in human tissue diagnostics in the 1960s. All of these techniques as well as many others allowed the surgical pathologist the ability to help recognize and categorize a multitude of human pathologic disease states.

Even though the title *surgical pathology* implies surgery, the surgical pathologist is actually closely related to all medical/surgical disciplines. These medical and/or dental professionals have the unique position of seeing both the beginning of a disease and the end point of many pathologic processes. The oral and maxillofacial surgical pathologist must have an extensive background in clinical medicine/surgery, but must also be quite thoroughly familiar with his or her own specialty. With the utilization of all the available diagnostic modalities comes the surgical pathologist's obligation to correctly discern among such testing methods, thus leading to a useful definitive diagnosis rather than just a myriad superfluous esoterica.

Surgeon/Pathologist Interaction

In order for any pathologic test to be *successful* (i.e., beneficial for the patient), the pathologist and the surgeon must communicate well. The importance of such a cohesive relationship cannot be stressed enough. It is imperative that each professional recognize the other's skills well enough that the

ultimate outcome will be exceptional patient care. Guided interaction should be the norm rather than the exception.[1]

A predicament that always appears to accompany laboratory analysis is a reasonable timetable for results. Several pathologic studies such as the frozen section must render an immediate diagnosis. Many others, such as the culture of an acid-fast bacillus, may take several weeks. During this longer time frame, the surgeon often becomes quite anxious, as these surgical clinicians are the ones who must ultimately deal with the patient and the related family. Realistic expectations should arise from prior reporting of earlier patient studies as well as turnaround times routinely published by the laboratory. The surgeon should always stay attuned to the needs of the pathologist. If the surgeon considers lymphoma as the diagnosis, tissue should routinely be submitted fresh for immunologic assays. Tissue that needs a bacterial or fungal culture should not be submitted in formalin. Technical advances must be followed closely by both the surgeon and the pathologist. In this way, such improper specimen handling will be discouraged.

Biopsy Techniques

A biopsy is defined as the removal of a small piece of tissue from a larger mass or tumor. This small fragment is then analyzed under a microscope in order to determine a specific diagnosis. The basic technique of tissue biopsy and its subsequent handling has undergone very few changes since its introduction many years ago. The handling, processing, and pathologic evaluation of this biopsy material are without a doubt the most important duties of the surgical pathologist. The surgeon should always remember that the pathologist cannot diagnose a specific disease entity if the biopsy material is not representative of that disease. Adequate biopsy material must be submitted, as interpretations of tiny tissue samples are quite often fraught with error. Small biopsy specimens taken with an electrocautery knife are often unsatisfactory because of the cellular cautery artifact seen under a microscope. If the patient presents with a large aggregate of lymph nodes, a biopsy of a peripheral node may not be as representative as one from the central portion of the mass. Biopsies removed from a tumor near an ulcerated area can frequently show only necrosis and inflammation. If a lesion is ulcerated, the biopsy should include both normal tissue and the ulcer. Although it is oftentimes not the ideal tissue fixative, 10% formalin is the fixative solution most often used today. The biopsied tissue should be placed immediately into this fixative and transported to the pathology laboratory within 24 hours.

The choice between an incisional or an excisional biopsy should be carefully considered before the biopsy procedure. The biopsy of an oral malignancy should not be of an excisional type, as such a procedure may leave no remaining visual landmarks of the original tumor. At the time of resection, the oncologic oral and maxillofacial surgeon may then be left with inadequate information regarding sufficient tumor margins.

Frozen Section

In the early 1900s, the frozen section, also known as the cryosection, was first discussed in the medical literature as a means to rapidly identify biopsy specimens. An instrument known as a freezing cryostat was later used to rapidly prepare biopsy material for the pathologist to evaluate. A reliable cryostat must be able to cut tissue specimens 5 to 10 μm in thickness after the tissue is flash-frozen to −20° to −30° C. The development of the freezing cryostat in the late 1950s led to the extensive use of the frozen section in today's hospital pathology departments. It was during this same latter time period that the frozen section was accepted as a valid diagnostic test.[2]

A frozen section should be accurate, rapid, and reliable. The use of this interpretive tissue assessment demands that the surgical oral and maxillofacial pathologist have a well-balanced clinical background as well as be proficient in the needed microscopic analysis. Before viewing the frozen tissue, the pathologist must be thoroughly briefed on the clinical nature of the patient's problem. While viewing the gross biopsied tissue, he or she should ask the surgeon's advice on the correct area of tissue to be microscopically examined. As often as not, complete sampling of large tissue specimens is limited because of time and equipment constraints. Consequently, judicious tissue sampling is of paramount importance. Similar, although not identical, problems arise in the sampling of smaller tissue biopsies. If at all possible, some of the biopsied tissue should be saved for permanent microscopic examination and only a tiny fragment used in the frozen section diagnosis. Once again, discussion of the case with the involved oral and maxillofacial surgeon can often create a tremendous difference in the ultimate outcome of the biopsy material.

The frozen section can be of great value to the oral and maxillofacial surgeon, but the surgeon and pathologist both should agree that such a test should only be used when the interpretation can provide information of immediate or ultimate value in the patient's management. A diagnostic frozen section generally should not be used if a more definitive surgery is contemplated at a later time. For such surgery, the classic biopsy using tissue fixation would be more appropriate. The surgeon should remember that the examination of frozen tissue is a great deal more difficult than examining properly fixed tissue. Examples of noncontroversial indications for the use of a frozen section during surgery include:

1. The diagnosis may influence immediate surgical management
2. The lesion is not accessible or the patient not amenable to preoperative biopsy
3. Preoperative biopsy attempted but was not successful
4. Staging of malignant neoplasms
5. Assessing the adequacy of excision
6. Procuring tissue for ancillary studies

The frozen section type of tissue examination should *not* be used in order to facilitate immediate discussion with the

patient or patient's family. One should always remember the fragilities of the frozen section's diagnostic abilities and thus the possibility of an inaccurate or incorrect immediate diagnosis.[3] In addition, it should be kept in mind that in this new age of medical care and its reimbursement, the frozen section not only raises the cost of the procedure but also increases the time the patient will be placed under a general anesthetic.

The surgeon and the pathologist should carefully consider all the viable options before considering the frozen section. At this time, the surgical pathologist should confirm the following conditions are met: (1) There is no risk of compromising the tissue specimen, (2) there is significant tissue for all ancillary studies, (3) there is a high probability of rendering the correct diagnosis, and (4) there is little risk of conveying incorrect diagnostic information. Then and only then should the frozen section examination proceed.

Aspiration Biopsy Techniques

The fine needle aspiration biopsy (FNA, FNAB) has enjoyed a clinical rebirth in the past 15 to 20 years. As an extremely cost-effective procedure, the FNA is now a commonly used method of diagnosis when dealing with neoplastic disease.[4] This procedure is performed not only by surgeons and pathologists, but also by many other medical/dental specialists such as internists, endocrinologists, and gastroenterologists. The recent advent of various imaging modalities such as computed tomography (CT) and ultrasound has stimulated radiologists to commonly perform FNA biopsies as well.

The crucial factor in the use of FNA is that, regardless of which medical or surgical specialist performs the procedure, he or she must be adequately trained in all aspects of lesion sampling and cell/smear preparation. Various stains of the cytopathology specimen are available, including routine hematoxylin and eosin (H&E), Papanicolaou (Pap), and Wright-Giemsa (Figure 16-1). In recent years, immunofluorescent and immunoperoxidase stains have proven to be quite useful in the determination of tumor origin (Figures 16-2 and 16-3). FNA can also provide tissue for use in flow cytometry or electron microscopy. If the aspirations are performed by a clinician, close communication with the cytopathologist is essential.[5]

Exfoliative Cytology

Oral exfoliative cytology has become extremely popular in the United States during the past 25 years. There is no doubt that the clinical brush biopsy technique and the Papanicolaou stain used by medical/dental generalists and specialists alike have resulted in the marked increase in the detection of early-stage oral/oropharyngeal cancers. This variation has also been successful because of the relatively long pre-invasive phase of oral squamous cell carcinoma.

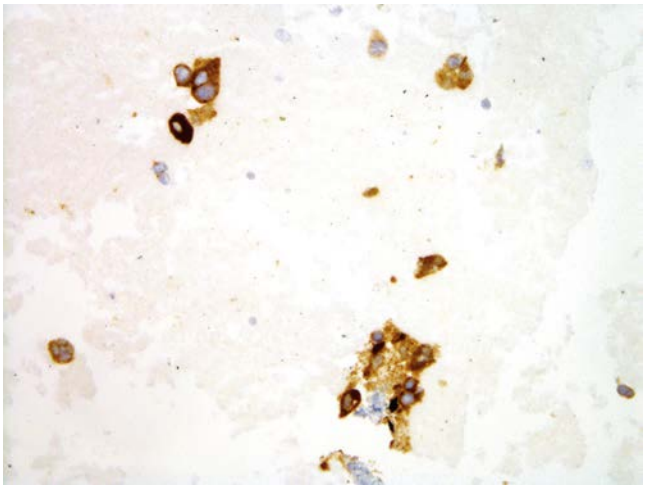

• **Figure 16-2** These same cells proved positive with a chromogranin immunostain that commonly stains neuroendocrine cells (400×, chromogranin).

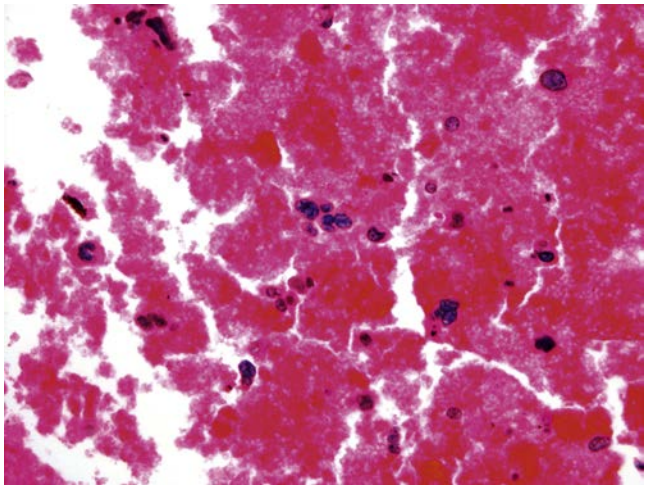

• **Figure 16-1** This represents a fine-needle aspiration (FNA) biopsy obtained from a patient with a solitary neck mass. Note the numerous cohesive islands of rather bland, monotonous, relatively round tumor cells (400×, Pap).

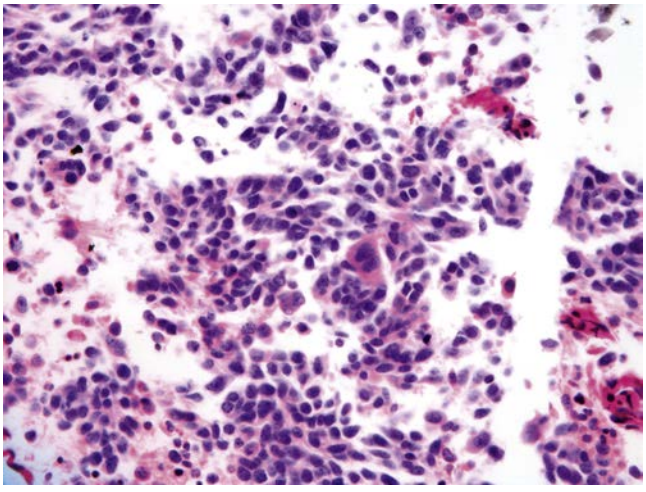

• **Figure 16-3** After review of the fine-needle aspiration seen in Figures 16-1 and 16-2, the primary tumor was found to be a carcinoid tumor of the small bowel as seen here, metastatic to the neck. Note the similarity of the small round cell population of both tumors (400×, H&E).

Some authorities believe that exfoliative cytology has little use in areas such as the oral cavity that are readily accessible for an open biopsy. It also makes little sense to use such a diagnostic technique as an oral screening tool in asymptomatic patients except under special circumstances. Still, evaluation of red, white, or mixed oral lesions using brush biopsy (cytologic) technique is a tool easily mastered by non-surgeons such as dentists, internists, or family medicine physicians.[6]

Even though the brush biopsy (cytologic) technique alone is not overly sensitive, when combined with nuclear DNA analysis, its sensitivity and specificity both can reach 98% to 100%. Cytology smears from all visible oral lesions are cheap, practical, noninvasive, painless, and safe screening methods for the detection of oral cancerous and precancerous lesions. When DNA image cytometry is added to the brush biopsy, this combined method is a very sensitive, highly specific, and reproducible tool for the identification of neoplastic cells in oral smears.

Special Histochemical Staining Techniques

The clinician often encounters the term *special stains* when discussing a specific case with a pathologist. He or she then wonders, "What is a *special* stain?" The *routine* or *usual* stain used in pathology laboratories today is the H&E. This specific stain has been used in surgical pathology for well over 150 years and has stood the test of time. Hematoxylin stains tissue a deep blue color while eosin staining produces a deep red. Depending on the exact tissue being studied, the majority of all cells will demonstrate an almost infinite number or combination of colors and/or patterns. These staining qualities are fairly reproducible regardless of the submitted tissue. Examples of such reproducibility include the facts that all sections of skeletal muscle will stain red with the H&E stain, while the nuclei of most cells will stain some hue of blue/black with the same stain.

It is unclear when and why the term *special* stains arose, but in the world of histology and pathology, this term refers to the empirical and histochemical staining techniques that have significantly contributed to both of these scientific fields beginning in the late 19th century. These stains are different from the usual or routinely used H&E stain. In other words, *special* stains are the stains other than either the H&E or immunoperoxidase stains that are used in pathology today. For the most part, these special stains are used for a single purpose only. Some of the more commonly used special stains are: (1) periodic acid–Schiff (PAS) and Grocott's methenamine silver (GMS) stains for fungi, (2) Gram stain for bacteria, (3) Congo Red stain for amyloid, and (4) the Fite stain for acid-fast bacilli (Figures 16-4 and 16-5).

Immunofluorescence Studies

Vesiculobullous or blistering diseases of the oral, nasal, and ocular mucosa are a very important group of immunologic maladies produced by pathologic autoantibodies directed against tissue sites located within or just below the mucosal surface. Direct immunofluorescent studies allow today's clinicians to better diagnosis, treat, and understand such clinical problems. The most commonly encountered of these ailments include benign mucous membrane pemphigoid, pemphigus vulgaris, linear IgA disease, epidermolysis bullosa, and other similar disease entities that occur within the mucosa of the oral and head and neck area.

Surgical oral and maxillofacial pathology laboratories use a special fluorescent microscope to examine mucosal biopsy material from patients demonstrating such clinical presentations (Figure 16-6). In order for mucosal tissue biopsies to be accurate, the oral and maxillofacial surgeon must be aware of the pathologist's special needs in such cases and thus collect the biopsy material in a specially prepared fixative and transport media known as Michel's solution. Each laboratory will have such material readily available for the clinician.

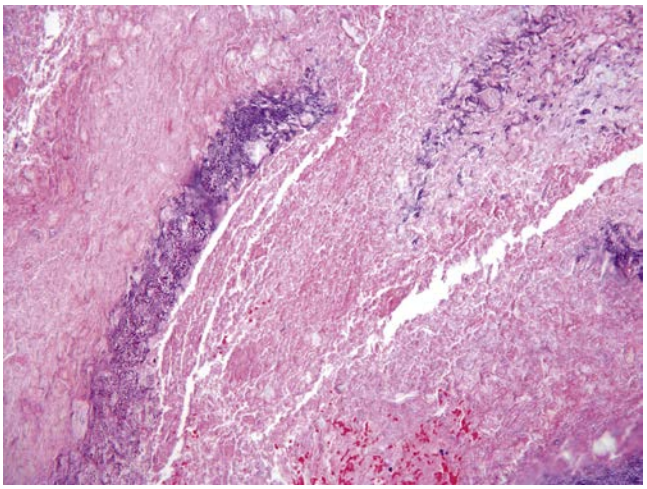

• **Figure 16-4** This biopsy material is from a large necrotic mass of the maxillary sinus clinically thought to be a mucocele. Note a few calcifications within the areas of necrosis (200×, H&E).

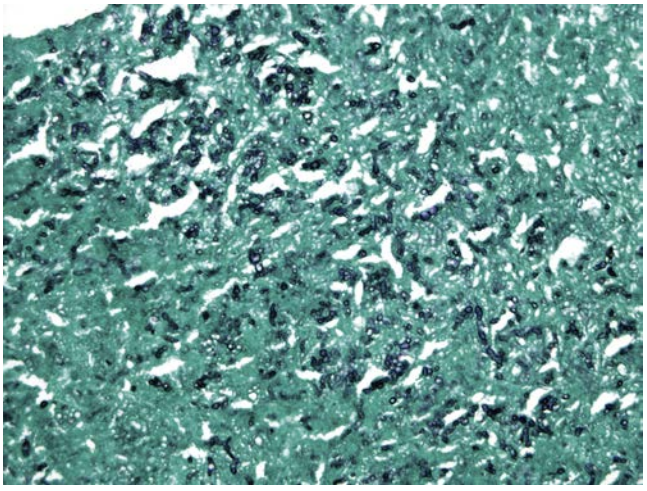

• **Figure 16-5** Special (non-immunohistochemistry) stain is of the sinus mass in Figure 16- 4. This GMS special stain demonstrates the septated hyphae of a fungus. In this case, *Aspergillus* was cultured from the surgical specimen (400×, GMS).

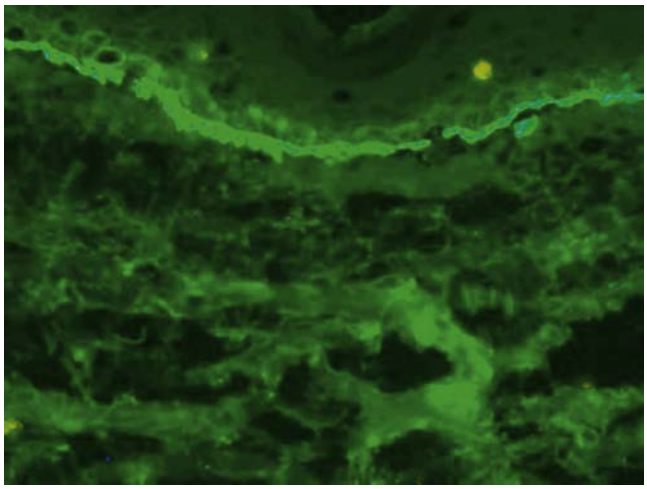

• **Figure 16-6** Seen is a direct immunofluorescent study of a biopsied gingival ulceration. Note the labeled IgG antibody deposited at the basement membrane area strongly suggesting benign mucous membrane pemphigoid (400×, Immunoglobin G-Immunofluorescent stain).

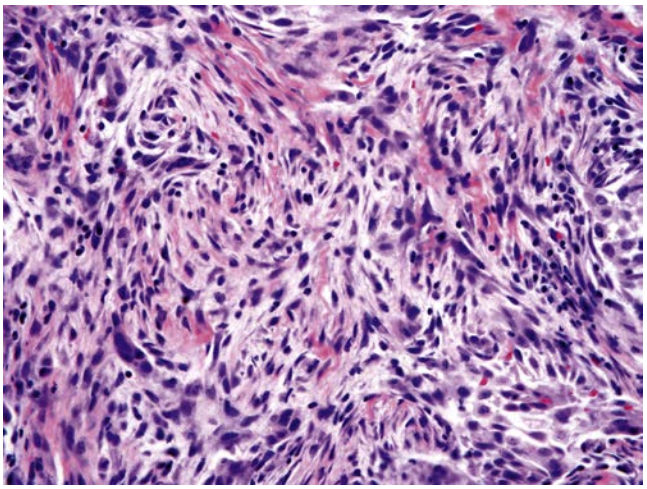

• **Figure 16-7** This biopsy demonstrates a poorly differentiated mass of tongue base. Note the spindle cells as well as the large multinucleated cells and the numerous atypical cell features. With routine H&E staining, this lesion could represent either a sarcoma or a carcinoma (400×, H&E).

Immunohistochemistry

For many years, surgical oral and maxillofacial pathologists have relied almost exclusively on their ability to characterize cell morphology under the light microscope. These same pathologists have long recognized the fallibility or imperfection of such methodology. More objective means of validating microscopic judgments have long been sought. Unique histochemical stains have been used for decades to depict specific cell arrangements and origins. These stains have been quite useful but lack the absolute ability to identify specific cell lineage or the biologic potential of individual cells. The use of immunohistochemistry (IHC) allows the identification of specific antigens associated with the pathologic cells. This methodology has allowed surgical pathology to become a much more objective science while still using the light microscope and the diagnostic rapidity that it possesses (Figures 16-7 and 16-8).

Immunoperoxidase stains came into relatively common use during the middle and late 1970s and even more so in the 1980s. Such stains have revolutionized the practice of diagnostic surgical pathology during this same time frame.[7] Immunoperoxidase or IHC stains are in fact a form of monoclonal antibodies, raised against specific proteins. These antibodies are then labeled with a marker that usually stains brown with a counterstain. There are many specific antibody kits available today, with new ones being produced almost monthly. Depending on the exact antibody being used and the biopsy tissue being examined, the pathologist can develop a working differential diagnosis or confirm an earlier impression by the use of these IHC stains (Figures 16-9 and 16-10).

The primary use of immunohistochemistry in surgical pathology is as a diagnostic tool to determine the cytologic lineage of tumor cells and thus, often, the primary site of the tumor itself (Figures 16-11 and 16-12). In recent times, this technique has demonstrated much success in selecting

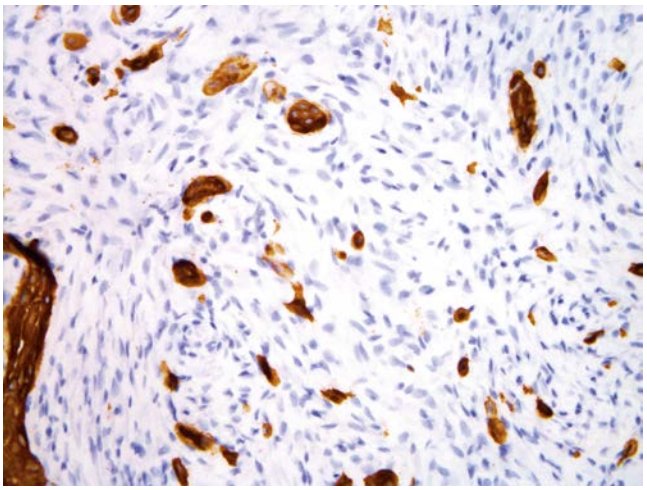

• **Figure 16-8** Seen is the same tongue base tumor as Figure 16-7 but now stained with a pancytokeratin (PanCK) immunostain. This lesion is now accurately characterized as a spindle cell carcinoma (400×, PanCK).

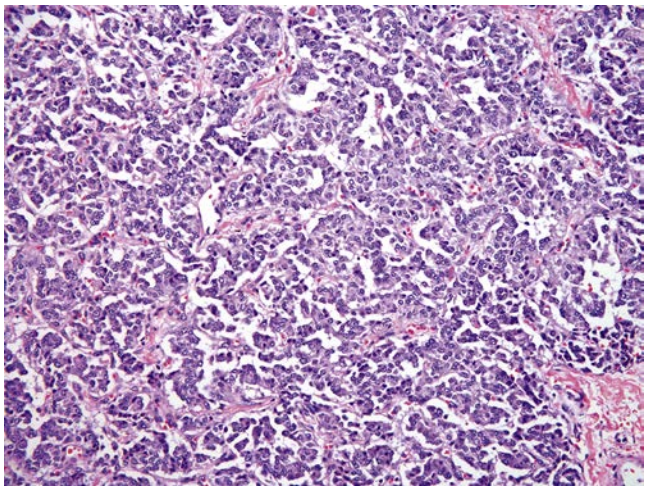

• **Figure 16-9** This biopsy is of a large deep neck mass near the carotid artery. Note the uniform cells suggestive of glandular origin (200×, H&E).

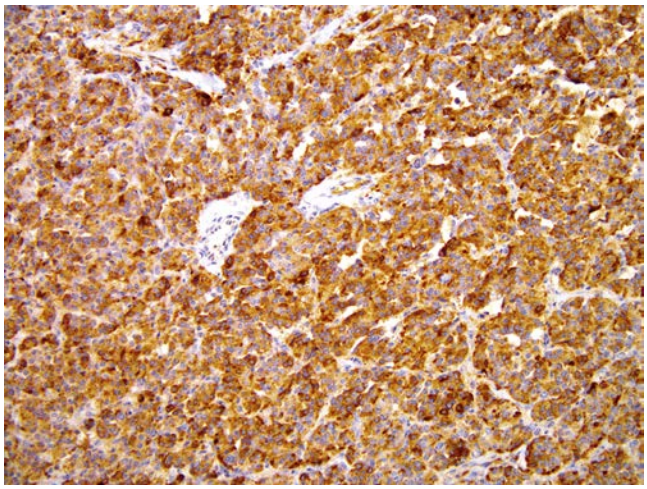

• **Figure 16-10** This represents a chromogranin immunostain of the neck mass seen in Figure 16-9. Note the uniform positive staining with this immunostain. Such findings are consistent with a lesion of neuroendocrine origin suggesting a paraganglioma—in this case, a carotid body tumor (200×, chromogranin).

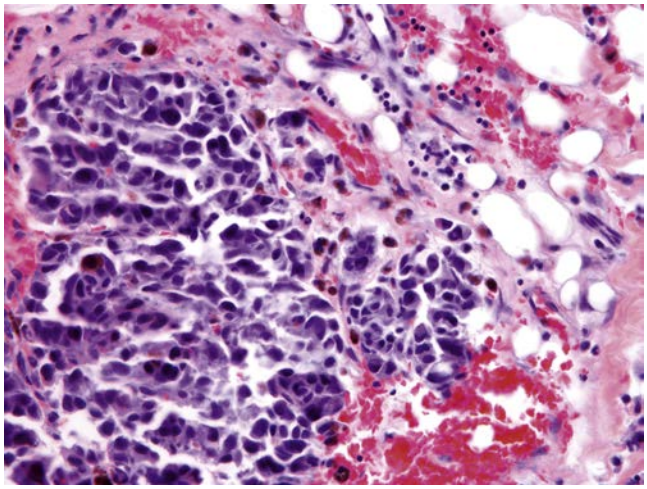

• **Figure 16-11** This biopsy is of a nodule in the skin just below the mandible. The malignant cells appear to be epithelial, but no history of oral/head and neck or skin cancer was ever identified (400×, H&E).

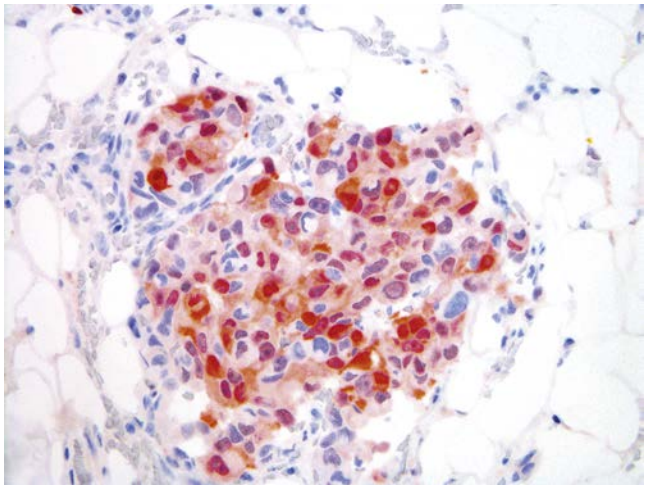

• **Figure 16-12** Represented is an IHC stain of specimen in Figure 16-11. In this case an S-100 stain was used to demonstrate melanin-producing cells; thus this patient's biopsy is now representative of a metastatic melanoma (400×, S-100).

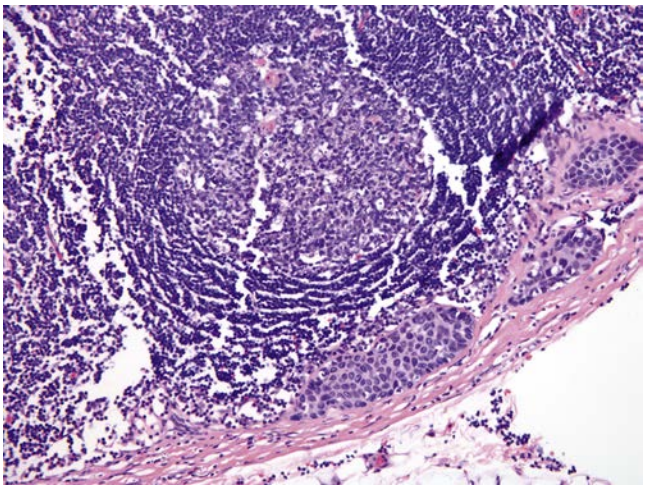

• **Figure 16-13** This is a cervical lymph node removed during a neck dissection in a T1N0M0 squamous cell carcinoma of the lateral tongue. Note the tiny island of unusual cells at the very periphery of a single small node (400×, H&E).

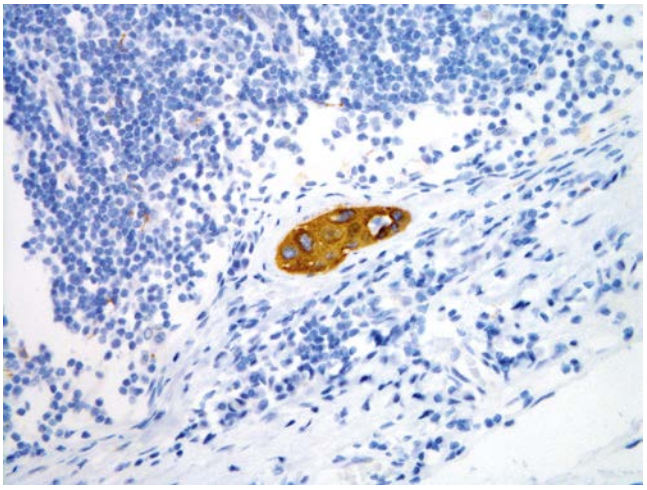

• **Figure 16-14** Seen here is the same node as in Figure 16-13 but now stained with a pancytokeratin (PanCK) immunostain that commonly stains squamous epithelial cells. Such staining allows the staging of this rather small tumor as a T1N1M0, thus altering the patient's therapeutic course and ultimate prognosis (400×, PanCK).

specific treatment regimens (Figures 16-13 and 16-14).[8] Another application of immunohistochemistry that is gaining popularity is its use as a predictor of disease progression and prognosis.[9] A working example of such ability is the p16 immunostain. Recent publications have established the p16 IHC stain as a faster and less expensive alternative to a papillomavirus polymerase chain reaction (HPV-PCR) in the identification of a high-grade papillomavirus. For this reason, the p16 immunostain is often used in the determination of a pathologic papillomavirus within the cells of specific oropharyngeal squamous cell carcinomas (Figures 16-15 and 16-16).[10]

It is a certainty that immunohistochemistry has the real potential to transform surgical pathology from a subjective art to an objective science, based principally on the microscopic recognition of immunostained cells.[11]

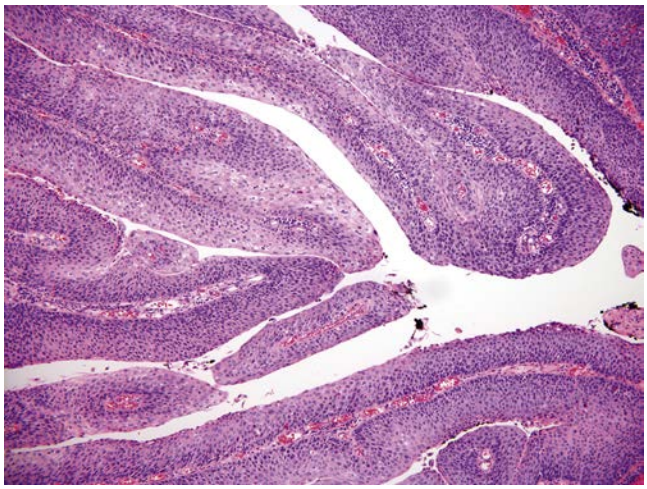

• **Figure 16-15** This biopsy specimen is from a soft palate lesion that clinically appears to represent a large and possibly very aggressive oral cancer. This biopsy is interpreted as a relatively rare papillary squamous cell carcinoma. Such lesions commonly denote an aggressive lesion with an extremely poor prognosis (200×, H&E).



• **Figure 16-16** This microphotograph represents a p16 immunostain of the lesion seen in Figure 16-15. Note that the entire tumor is composed of p16-positive cells. It is now recognized that such staining properties define the papillomavirus origin of this tumor and thus allow the patient's prognosis to become much more favorable (200×, p16).

Electron Microscopy

The use of transmission electron microscopy (TEM) as a diagnostic tool has commonly been replaced in surgical pathology by the application of immunohistochemistry and cytogenetics. TEM was very popular in the 1970s and early 1980s and was often used as an adjunctive diagnostic procedure to determine the cell of origin within many tumors of unknown derivation. Pathologists now have the option of choosing from a myriad ancillary diagnostic procedures to aid in the determination of such findings. These include immunohistochemistry, cytogenetics identification of specific reciprocal chromosome translocations, gene rearrangement studies, fluorescent in situ hybridization, and

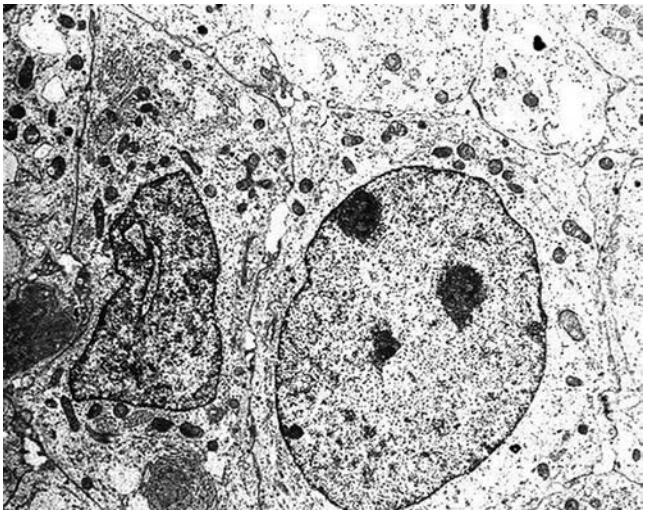

• **Figure 16-17** This photo represents a transmission electron micrograph (TEM) of the lesion seen in Figure 16-3. Note the very large nucleus and nucleolus of the tumor cell. Also view the intracellular filaments and desmosomes that characterize this lesion as a carcinoma rather than a sarcoma (6000×, TEM).

DNA-based polymerase chain reaction detection as well as electron microscopy. In more recent times, the surgical pathologist has found that immunohistochemistry as well as many others of these studies are incapable of solving all the diagnostic problems seen in tumor recognition and diagnosis. This realization in turn has caused a resurgence of interest in the use of TEM as a diagnostic tool.

Time and expense are very real constraints when using TEM. Initially, the diagnostic tissue must be fixed in a specific manner (buffered glutaraldehyde) so that the cell membrane and cytoplasmic organelles can be preserved. The tissue preparation and ultimate TEM examination usually take 3 to 4 days, which makes such diagnostic studies anything but routine. The surgical pathologist must be well-versed in the review of diagnostic electron microscopic features to take full advantage of the assets of TEM. Such studies have proven to be exceptional in certain lesions such as soft tissue tumors, Langerhans cell histiocytosis, and various undifferentiated neoplasms of the head and neck area (Figure 16-17).

Flow Cytometry

For over 15 years flow cytometry (FCM) has been used by the surgical pathologist to aid in the analysis of cellular DNA content as well as in the determination of specific cellular antigens.[12] Cell preparations from both cytology smears and surgical pathology specimens can be used by FCM processes.

FCM allows the detection of altered cell ploidy. It can also evaluate the excess or deficiency of chromosomal DNA within the cell. The methodology involves the measurement of the fluorescent intensity of cellular dyes that have been excited by a laser, usually of an argon-ion type. The dye-labeled cells pass in single file through a light beam. Thousands of such particles can be measured in a few seconds

depending on the flow rate. The collection of labeled particles of interest is then placed on a computer-generated histogram according to specific windows or gates. These graphs subsequently are interpreted by the surgical pathologist and presented to the clinician.

As stated previously, both tissue and cytologic cells are acceptable for FCM studies. Fresh tissue allows a much more accurate analysis, but processed tissue from paraffin blocks can also be used. Flow cytometric DNA ploidy has turned out to be a significant predictor for survival in oral squamous cell carcinoma. Only recently has FCM been identified for its contribution in assisting histopathology in the identification of potentially malignant salivary gland lesions.[13]

Molecular Biology

There have been tremendous advances in the field of molecular biology during the past 20 years. This knowledge has contributed immensely to our understanding of human disease. These advances have slowly become integrated into the practice of surgical pathology. Many methods are available to view molecular products and thus expand the traditional light microscopic analysis of tissue specimens. Some of the technologies available today include in situ hybridization, polymerase chain reaction, fluorescent in situ hybridization, and southern blot hybridization. At the present time, the use of such techniques has been limited primarily to large academic medical centers. There is no doubt that in time these laboratory principles will become available to all pathologists and thus can be used by all patient caregivers.

Once a diagnosis has been made, the surgical pathologist's next task is to provide the surgeon with information regarding the lesion's behavior, disease progression, and the ultimate prognosis of the particular disease state. The majority of molecular biologic tests help determine specific cellular factors or molecular abnormalities that have clinical relevance for treatment or prognosis. As an example, in cases of breast cancer, HER2-neu is frequently examined. Its presence is often a poor prognostic indicator. Another common use of molecular pathology is found within the field of gynecologic oncology. The number of human papillomavirus (HPV) genotypes is extensive, with more than 150 subtypes identified.[14] It has been determined that there are specific high-risk types (HPV 16, 18, 31, 45, and 56) that are associated with cervical cancer. Recently HPV was implicated in several squamous cell carcinomas of the head and neck. In addition, at present time, various oncogenes are recognized as having prognostic significance in cancer of the head and neck. Some of these include p53 (tumor suppressor gene products), bcl-2 (apoptosis inhibitor), Ki-67, and PCNA (cell proliferation markers). Only through the use of molecular biologic testing have these prognostic markers been identified. There is no doubt that as we learn more about the genetic events that determine biologic behavior, the list of these molecular markers will only increase.

Summary

By its very nature, surgical oral and maxillofacial pathology depends on the input of various clinicians. These dentists and physicians should be well aware of the abilities and limitations of our specialty. Surgical pathology is for the most part a very subjective specialty. As such, it relies on the interpretation of glass slides, gross tissue examination, laboratory studies, radiographs, and imaging studies as well as information from the supplied patient history. Unless the evaluation of all of this information is undertaken by the surgical pathologist, the microscopic evaluation may be in vain.

Presented are the majority of diagnostic methods available to the oral and maxillofacial surgical pathologist in his or her quest for diagnostic accuracy. A great number of oral and maxillofacial pathology cases do not need all of these available studies. In fact the majority need only a very few of them. Still, such methods are available today, and with the passage of time, even more sophisticated studies will become available. It is the hope of this author that the reader will now have a better understanding of the oral and maxillofacial surgical pathologist and as such avail themselves of the diagnostic skills of such a person.

References

1. Dumont T, Simon E, Garnier B, et al.: Contribution of the pathology examination in the operating theatre in patients with skin cancer: retrospective analysis of 388 patients, *Rev Stomatol Chir Maxillofac* 207:75–79, 2006.
2. Badoual C, Rousseau A, Heudes D, et al.: Evaluation of frozen section diagnosis in 721 parotid gland lesions, *Histopathology* 49:538–540, 2006.
3. LiVolsi VA, Baloch ZW: Use and abuse of frozen section in the diagnosis of follicular thyroid lesions, *Endocr Pathol* 16:285–293, 2005.
4. Mihashi H, Kawahara A, Kage M, et al.: Comparison of preoperative fine-needle aspiration cytology diagnosis and histopathologic diagnosis of salivary gland tumors, *Kurume Med J* 53:23–27, 2006.
5. Tan LG, Khoo ML: Accuracy of fine needle aspiration cytology and frozen section histopathology for lesions of major salivary gland, *Ann Acad Med Singapore* 35:242–248, 2006.
6. Poate TW, Buchanan JA, Hodgson TA, et al.: An audit of efficacy of the oral brush biopsy technique in specialist Oral Medicine unit, *Oral Oncol* 40:753–755, 2005.
7. Taylor CR, Levenson RM: Quantification of immunohistochemistry-issues concerning methods, utility and semi quantitative assessment II, *Histopathology* 49:411–424, 2006.

8. Myoung H, Kim MJ, Keem YJ, et al.: Correlation of proliferative marker (Ki-67 and PCNA) with survival and lymph node metastasis in oral squamous cell carcinoma: a clinical and histopathologic analysis of 113 patients, *Int J Oral Maxillofac Surg* 35:1005–1010, 2006.
9. El-Mofty SK, Patil S: Human papillomavirus (HPV)-related oropharyngeal nonkeratinizing squamous cell carcinoma: characterization of a distinct phenotype, *Oral Surg Oral Med Oral Pathol* 101:339–345, 2006.
10. Duncan L, Winkler M, Carlson E, et al.: p16 Immunohistochemistry can be used to detect human papillomavirus in oral cavity squamous cell carcinoma, *J Oral Maxillofac Surg* 71:1367–1375, 2013.
11. Asa SL: The role of immunohistochemical markers in the diagnosis of follicular-patterned lesions of the thyroid, *Endocr Pathol* 16:295–309, 2005.
12. Driemel O, Maier H, Kraft K, et al.: Flow cytometric DNA ploidy in salivary gland tumors, *Oncol Rep* 13:161–165, 2005.
13. Van Heerden WF, Raubenheimer EJ, Dreyer L: The role of DNA ploidy and Ki-67 in the grading of mucoepidermoid carcinomas, *Anticancer Res* 25(c3):2589–2592, 2005.
14. Pusztai L, Mazouni C, Anderson K, et al.: Molecular classification of breast cancer: limitations and potential, *Oncologist* 11:868–877, 2006.

17

Cysts of the Oral and Maxillofacial Region

NABIL A. ABAZA, SAMIR K. EL-MOFTY, ANDREW D. MILLER

Definitions

To thoroughly understand the biology of any lesion and, therefore, render the appropriate management, clear and accurate definitions are a prerequisite. This task may not be easily achieved for all the lesions discussed in this chapter.

For cysts of the oral and maxillofacial region, several terms need to be defined in order to provide both the treating surgeon and the patient with a clear understanding of the outcome and expectations.

Grossly, a cyst is a saclike mass or lesion containing luminal fluid or semi-fluid substances. By imaging, a cyst is a well-delineated area of different contrast to the surrounding tissue. A true cyst, however, is a histologic diagnosis in which the cyst wall is lined by epithelium regardless of its subtypes. The type and the biologic nature of the epithelium, however, have a significant impact on the lesion prognosis and recurrence rate. The major classifications have thus far been based on the origin of the epithelium—either from the processes of odontogenesis (odontogenic cysts) or from the embryogenesis of the head and neck region (non-odontogenic cysts). Frequently a lesion is described as cystic, which implies only a clinical or imaging feature; therefore the term is nonspecific. Occasionally the term *pseudocyst* may be used, which describes a collection of fluid or semi-solid material in a non-epithelialized tissue compartment that has been compressed to simulate the clinical cystic designation. For the purpose of this chapter, the specific definitions of odontogenic and non-odontogenic cysts are subsequently described in some detail.

General Surgical Considerations

In the surgical management of these cysts, it is critical that the physician submit any tissue that is surgically removed, regardless of the size, for microscopic examination by a pathologist familiar with the region. There is also an important role for fine-needle aspiration (FNA) biopsy in establishing the diagnosis of cysts of the oral and maxillofacial region.[1,2] The input of a cytopathologist is essential.

As this chapter details, most lesions under discussion are histologically benign, but the biologic behavior and recurrence rates differ from one cyst to the other. Therefore it is prudent that the treating oral and maxillofacial surgeon be aware of these differences. Then the patient and the surgeon can be on the same level of expectations, and repeated surgical intervention, if required, does not constitute misunderstanding. The initial surgical treatment and the subsequent follow-up of cysts of the oral and maxillofacial region depend on several factors:

1. The patient's age and overall health condition
2. Size and location of the cyst
3. Histologic diagnosis of the lesion gained by excisional, incisional, or FNA biopsies

Surgical procedures fall on a spectrum that includes marsupialization (unroofing of the cyst); enucleation; a two-stage surgery that consists of marsupialization with delayed enucleation thereafter; marginal or en bloc resection, with or without immediate reconstruction; and hemimaxillectomy or hemimandibulectomy, again with or without immediate reconstruction with grafting of bone and/or soft tissue. In all procedures, adjunct therapy including chemical cauterization, cryotherapy, or peripheral ostectomy with burrs has been reported, particularly if the diagnosed cyst is known to have a high recurrence rate. These surgical considerations are discussed in more detail in conjunction with individual lesions.

Odontogenic Cysts

Inflammatory

The process of odontogenesis is a unique histogenic and morphogenic phenomenon in human embryogenesis. After

complete formation of the two sets of dentition, deciduous and permanent, the embryogenic soft tissue remnants are widely accepted as the origin of both odontogenic cysts and tumors. The epithelial rests of Malassez and Serres, documented to be histologically present in the periodontal ligament and gingiva, respectively, are widely implicated in the pathogenesis of odontogenic cysts. The rests of Serres are remnants of the dental lamina, and the rests of Malassez are remnants of epithelium from the involution of the enamel organ.[3]

Table 17-1 summarizes suggested origins of these lesions. Currently there is no single classification that is universally accepted, and proposals for revisions are being made.[4-7] In 1992 the World Health Organization (WHO) classified cysts as developmental, including odontogenic, non-odontogenic, and inflammatory.[6] The WHO classification is shown in Box 17-1 and Figure 17-1. Briefly, developmental cysts are classified by the stage of odontogenesis from which they arise. The primordial cyst indicates that a proliferation of tissue occurred in the enamel organ before any calcification was initiated; therefore the cyst replaces a tooth, usually of the permanent dentition with no history of extraction. This is an old classification system that emerged before the understanding of the odontogenic keratocyst. Neville et al[8] concluded that a cyst clinically considered to represent a primordial cyst, in the older terminology, almost always is an odontogenic keratocyst microscopically.

The dentigerous cyst, a fairly common lesion, indicates proliferation of the remnants of the enamel organ after formation and calcification of a crown, most commonly the third molars and canines. This cyst can be around or lateral to the crown. The lateral periodontal cyst is epithelial proliferations lateral to the root of an erupted tooth, commonly a lower premolar. It is believed to result from proliferative activity of the periodontal rests of Malassez. The very common radicular or periapical cyst represents proliferation of epithelial remnants in the apex of a nonvital tooth, secondary to caries or trauma, and the subsequent inflammatory stimulation of the periapical tissues. Cysts that are present

TABLE 17-1 1985 WHO Classification of Cysts of the Jaws

Classification	Site	Suggested Origin
1. Developmental		
a. Odontogenic		
Odontogenic keratocyst	Usually mandibular angle or ramus	Dental lamina or tooth germ
Follicular cyst	Around crown of unerupted tooth	Follicle and reduced enamel epithelium
Eruption cyst	Around crown of unerupted tooth	Follicle and reduced enamel epithelium
Lateral periodontal cyst	Periodontal ligament	Dental lamina rests or reduced enamel epithelium
Gingival cyst of adults	Gingiva	Dental lamina rests or reduced enamel epithelium
Alveolar cyst of infants	Gum pads	Dental lamina
b. Non-odontogenic		
Nasopalatine duct cyst	Incisive canal and foramen	Oronasal duct epithelium
Nasolabial cyst	Soft tissues of buccal sulcus adjacent to upper canines	Nasolacrimal duct epithelium
Mid-palatal cyst of infants	Midline palate	Palatal process epithelium
2. Inflammatory		
Radicular cyst	Root apex	Rests of Malassez
Residual cyst	Edentulous alveolus	Rests of Malassez
Inflammatory lateral periodontal cyst	Periodontal ligament	Rests of Malassez
Paradontal cyst epithelium	Adjacent to partially erupted tooth involved by pericoronitis	Rests of Malassez or reduced enamel
Inflammatory epithelium	Follicle of unerupted permanent tooth below an infected deciduous tooth	Follicle and reduced enamel

Modified from Tinkler S: The jaws. In McGee JO, D'Isaacson PG, Wright NA, editors: *Oxford textbook of pathology: pathology of systems*, vol. 2a, Oxford, UK, 1992, Oxford University Press. Based on Main DMG: Epithelial jaw cysts: 10 years of the WHO classification, *J Oral Pathol* 14:1, 1985

after history of extraction of a tooth or the inadequate removal of associated soft tissue during a previous procedure are called residual cysts.

This chapter discusses in detail commonly encountered odontogenic cysts and, for completeness, briefly mentions less frequently encountered lesions.

• BOX 17-1 1992 WHO Classification of Cysts of the Jaws

Developmental

Odontogenic

Gingival cysts of infants (Epstein pearls)
Odontogenic keratocyst* (primordial cyst)
Dentigerous (follicular) cyst
Eruption cyst
Lateral periodontal cyst
Gingiva cyst of adults
Glandular odontogenic cyst; sialo-odontogenic cyst

Non-odontogenic

Nasopalatine duct (incisive canal) cyst
Nasolabial (nasoalveolar) cyst

Inflammatory

Radicular cyst
Apical and lateral cysts
Residual cyst
Paradental (inflammatory collateral, mandibular infected buccal) cyst

*WHO renamed odontogenic keratocyst to keratocystic odontogenic tumor in 2005.[24]

From Kramer IRH, Pindborg JJ, Shear M: *Histological typing of odontogenic tumors*, ed 2, Berlin, 1992, Springer.

Radicular Cyst

Clinical Features

Frequently referred to as a periapical cyst, it is the most common lesion encountered secondary to caries or trauma. Bacteria initiate inflammation in the pulp and the surrounding periapical tissues; the secreted chemical mediators of inflammation then induce proliferation of periapical soft tissues and stimulate osteoclastic activity. This inflammatory process also stimulates proliferation of the rest of Malassez, which is present in the periodontal ligament. As the proliferating islands of epithelium enlarge, their centers degenerate and/or liquefy, resulting in microcysts. The latter ultimately coalesce to form a fairly well-defined periapical bony rarefaction (Figure 17-2). If the offending tooth is not treated or extracted, the lesion continues to enlarge via the hyperosmolarity created by the cellular breakdown and the resulting osmotic gradient that favors the transudation of fluids into the lumen of the lesion.[8,9] There is long-standing discussion of the clinical, radiographic, and even histologic differentiation between the small periapical lesions—that is, whether they are radicular cysts or periapical granulomas. Several views have been expressed to differentiate the two lesions.[9] The authors believe this issue is of limited clinical value. Conceptually, if the tooth in question is salvageable, root canal, with or without apicoectomy, may be the treatment of choice. Follow-up is required to monitor the regression of the lesion. If the lesion continues to expand after root canal therapy or if the tooth is extracted, the lesion should be enucleated and submitted for microscopic examination.

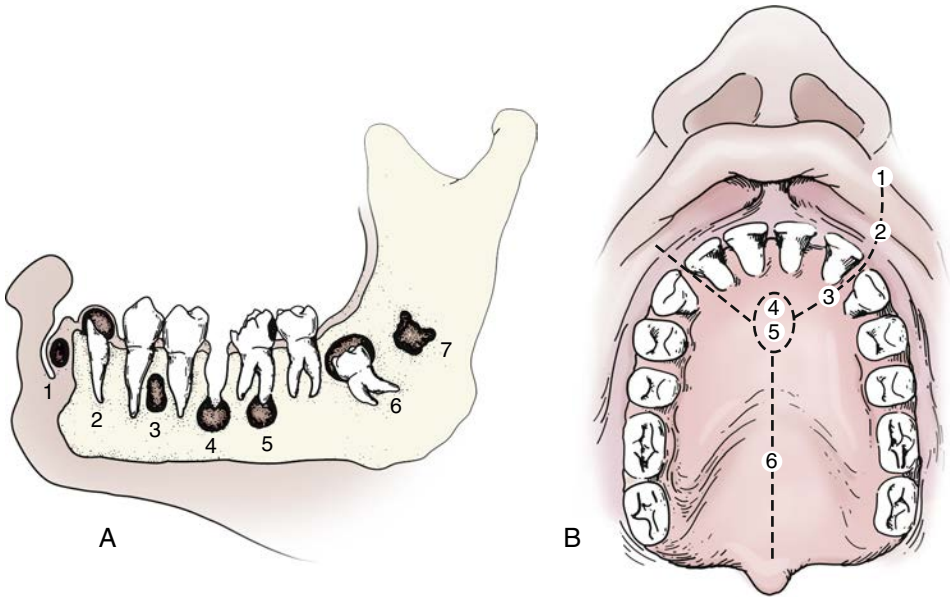

• **Figure 17-1** Diagrams of the site of odontogenic **(A)** and fissural (non-odontogenic) cysts **(B)** in the mandible and maxilla, respectively. **A**: *1,* gingival; *2,* eruption; *3,* lateral periodontal; *4,* residual; *5,* periapical (radicular); *6,* dentigerous; *7,* primordial. **B**: *1,* nasolabial cyst; *2,* nasoalveolar cyst; *3,* globulomaxillary cyst; *4,* nasopalatine cyst; *5,* cyst of palatine papilla; *6,* median palatal cyst. (From Batsakis JG: *Tumors of the head and neck; clinical and pathological considerations*, ed 2, Baltimore, 1979, Williams & Wilkins.)

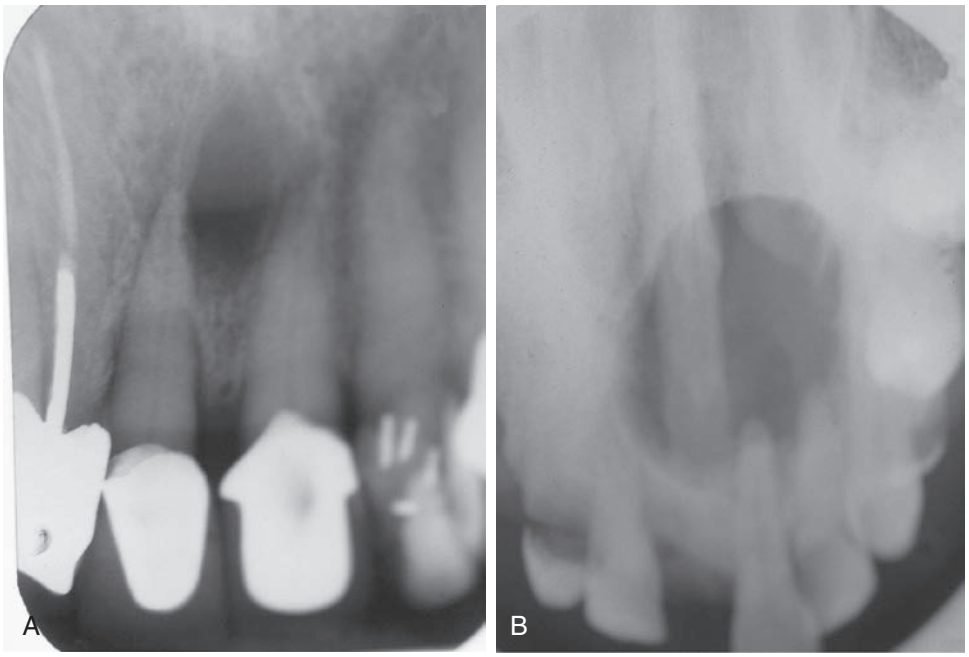

• **Figure 17-2** **A,** Periapical radiograph of maxillary anterior teeth showing a well delineated bony rarefaction at the apices of non-vital maxillary anterior teeth. **B,** An occlusal film of a radicular cyst of a traumatized maxillary central incisor. Differential diagnosis from incisive canal duct cyst is necessary.

Imaging Features

The apical radiolucency and the associated non-vital tooth are easily recognized by periapical radiographs. In large cysts, other plain films may be useful to delineate the lesion. In rare cases, a computed tomography (CT) scan may be useful. In all cases, the lesion is a well-delineated and corticated radiolucency that is confluent with the periodontal ligament of the associated tooth.

Pathologic Features

The radicular cyst is usually small, measuring 1 or 2 cm in diameter. However, on occasions, especially in patient populations with limited availability of oral health care, the cyst can attain several centimeters in diameter. The cyst contents are brown serosanguineous fluid with glistening cholesterol crystals commonly present. If the cyst has communicated with the oral cavity, the fluid may be suppurative.

Microscopically, the connective tissue wall varies in thickness and degree of inflammatory cell infiltrates (Figure 17-3, *A-C*). The epithelium is made of non-keratinized stratified squamous cells with varying thickness. In actively inflamed cysts, the epithelium is thicker with marked proliferation of the rete pegs into the cyst wall. Frequently, the epithelial lining is focally ulcerated. Histiocytes and foreign body giant cells are frequently present (see Figure 17-3, *D*). When the lesion drains into the oral cavity, the epithelial lining becomes attenuated and the cyst wall shows a marked decrease in the inflammatory cell infiltrate (see Figure 17-3, *E*). Cholesterol clefts and Rushton bodies are frequently seen. The origin of the latter has been debated and has yet to be settled.[5,6,9] These hyaline bodies can calcify and change the lesion's staining property from eosinophilic to basophilic.

Surgical Management

As previously mentioned, if the tooth in question is salvageable, root canal therapy with or without apicoectomy and retrograde filling is recommended. The progress of healing is then monitored. If the tooth is extracted, the lesion should be thoroughly enucleated. In small lesions, enucleation can be undertaken through the socket. In large cysts, an independent incision and bone removal are necessary to have adequate exposure of the lesion. Every attempt should be made to enucleate the lesion in total (Figure 17-4, *A*). A semilunar incision at the junction of the free and attached gingiva, with the curvature toward the crown of the tooth, is preferred, with care to extend the incision 5 to 10 mm beyond the anticipated resulting bony defect. The surgeon may elect to have the incision around the cervices of the teeth involved in the site. In the absence of exuberant acute inflammation and when the bony defect is significant, immediate bone grafting with autogenous or allogeneic material, or a mixture of the two, will enhance healing and facilitate early placement of an implant if the tooth in question has to be extracted (see Figure 17-4, *B*).

Residual Cyst

Clinical Features

Simply defined, a residual cyst is a retained radicular cyst or periapical tissues that are left behind after removal of an associated tooth.[6,8,10] History of extraction is important to help differentiate the lesion from primordial odontogenic keratocysts, which arise from epithelial elements of the enamel organ before any calcification (Figure 17-5, *A*).

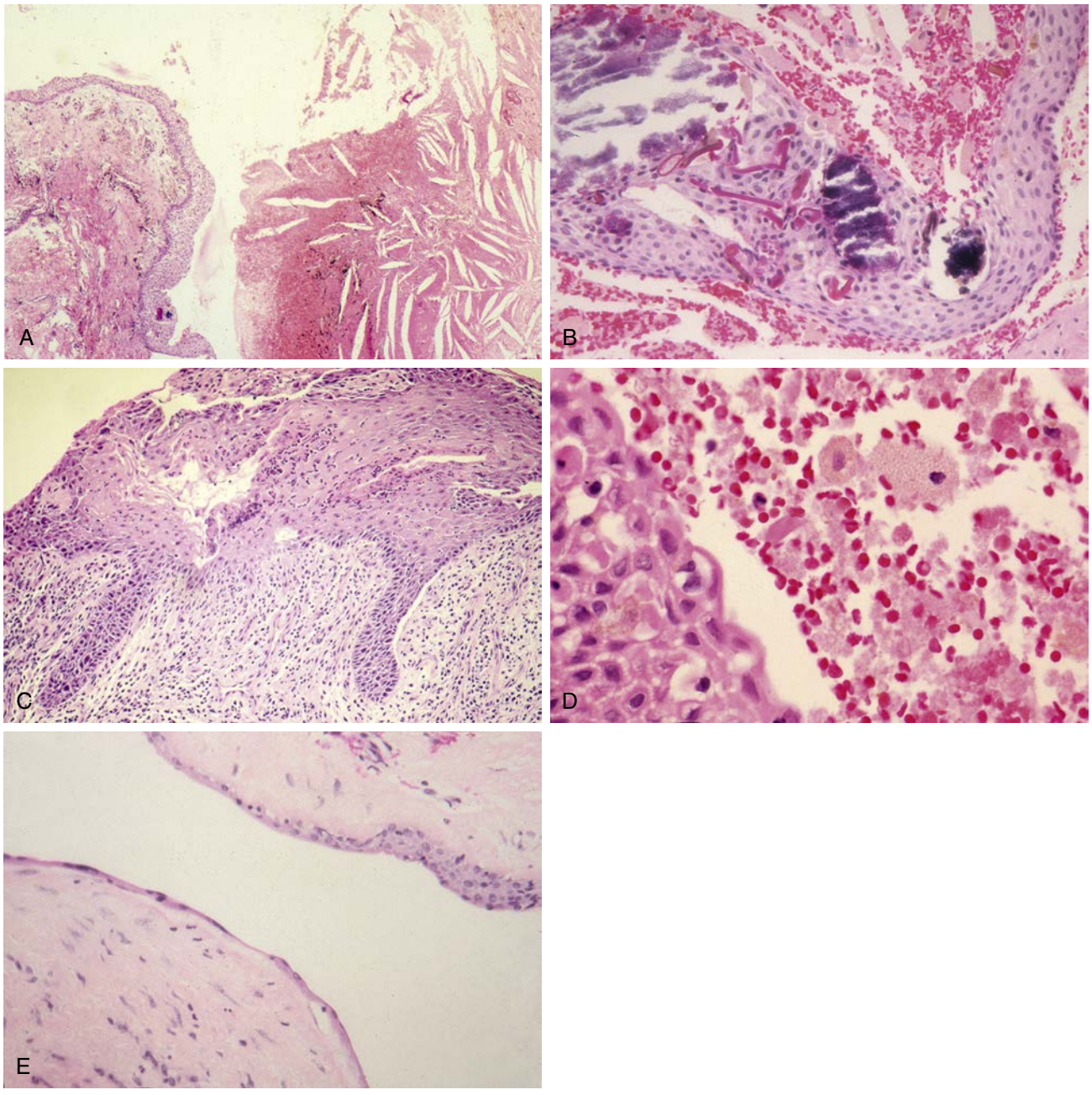

• **Figure 17-3** Photomicrographs of the radicular cyst showing **(A)** stratified squamous epithelium with cholesterol clefts **B,** Rushton bodies and calcification. **C,** Marked inflammatory cell infiltrate of the connective tissue wall with hyperplastic proliferation of the epithelial lining. **D,** Significant presence of histiocytes in the cyst lumen. **E,** Attenuated epithelial lining with obvious lack of inflammation when cyst drains to oral cavity.

Imaging Features

The cyst is usually small (1 to 3 cm in diameter) but may assume a large size if not treated (see Figure 17-5, *B* and *F*). The lesion is well delineated and may even be a corticated radiolucency.

Pathologic Features

The gross and microscopic features are similar to those of the radicular cyst. The degree of inflammation of the cyst capsule and its epithelial lining is variable. Presence of cholesterol clefts is common (see Figure 17-5, *D* and *E*).

Examination of the specimen is necessary not only to confirm the clinical diagnosis, but also to ensure that the lesion is not an aggressive keratocyst or other odontogenic tumor.

Surgical Management

Enucleation of the cyst is curative. Because ossification of the extraction socket has probably occurred, an independent incision is required. Routine follow-up radiographs reveal the healing progress.

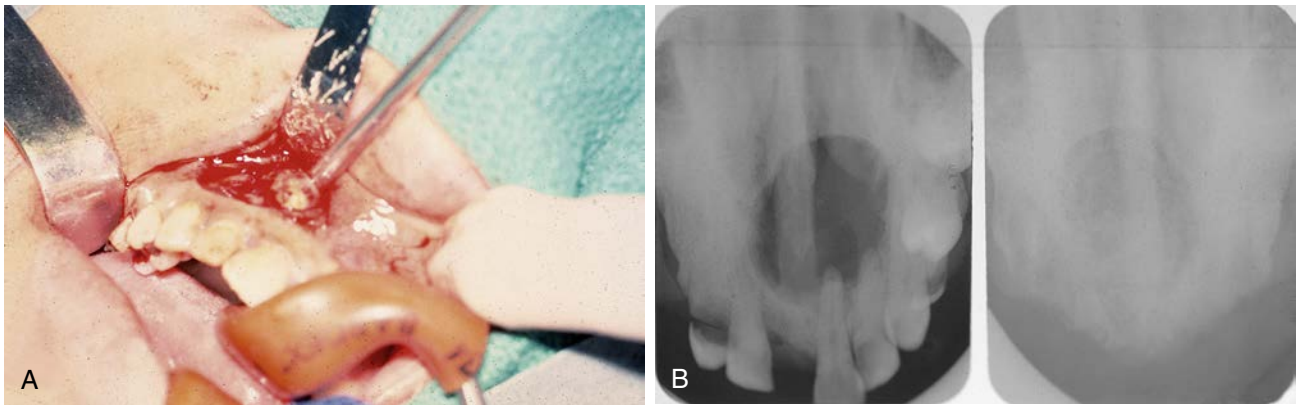

• **Figure 17-4** **A,** Enucleation of a maxillary radicular cyst in one piece. **B,** Two occlusal films; compare preoperative film shown in Figure 17-2, *B*, with postoperative film a few months after enucleation of cyst, extraction, and allogeneic bone grafting.

Paradental Cyst: Buccal Bifurcation Cyst

Overview

Paradental, buccal bifurcation, and mandibular infected buccal cysts are good examples of a lack of generally accepted and clear classification of cysts of the oral and maxillofacial region. The WHO classification describes a paradental cyst as an inflammatory collateral or mandibular infected buccal cyst.[4,6] The lesion is defined as a cyst near the cervical margin of the lateral aspect of a vital tooth, usually erupted mandibular molars (most commonly the third molars), with associated pericoronitis.[6] Other authors consider the paradental cyst as a variant of the dentigerous cyst.[9] Neville and colleagues[8] define the buccal bifurcation cyst as an uncommon inflammatory odontogenic cyst on the buccal aspect of the mandibular first molar, usually associated with enamel extensions into the bifurcation. These cysts are associated with the buccal surface of the mandibular molar in 5- to 11-year-old children.[6,8,11-13] The odontogenic epithelium in the superficial part of the periodontal ligament responds to the inflammatory stimulus and forms these lesions. Slight to moderate tenderness may be elicited. The histopathology of these lesions is nonspecific, with a cyst lining of non-keratinizing stratified squamous epithelium.[6,8,9] Inflammation is prominent. Extraction of associated third molars, particularly if not in function, and enucleation of the associated cyst are curative. In the buccal bifurcation lesion, enucleation without extraction of the associated tooth is adequate with reduction of the pocket depth and bone refill.[8,11-13] It has been reported that this cyst can resolve without surgery.[8,11]

Developmental

Dentigerous Cyst

Clinical Features

This is the second most commonly encountered odontogenic cyst in the oral and maxillofacial region. Frequently it is associated with third molars followed by maxillary canines. Lower premolars are also frequent sites (Figure 17-6, *D* and *E*). On a daily basis, oral and maxillofacial surgeons remove countless numbers of impacted teeth that have radiographic and gross evidence of cystic degeneration around part of or the whole crown of a tooth. The following question then arises: When do you call the lesion a dentigerous cyst versus an expanded follicle? Differentiation is clinically insignificant, although a lesion of 2.5 mm or larger has been reported as a requirement before a diagnosis of dentigerous cyst can be made.[14] The diagnosis is better supported by microscopic examination showing the cystic cavity to be lined by a confluent epithelial lining. A practical definition, therefore, is a lesion arising from the dental follicle of an unerupted or developing tooth with the latter projecting into the lumen. Depending on the location and the extent of the cystic degeneration in relationship to the crown of the associated tooth, the cyst can be described as central, lateral, or circumferential.[8] The degeneration of cells, with its subsequent hyperosmolarity and fluid transudation, has been theorized either to occur between the reduced enamel epithelium and the crown of the tooth or to be a result of the breakdown of the stellate reticulum, between the inner and outer enamel epithelium.[5,6,8,10] The cyst is usually small and may be discovered during routine radiographic examination of the jaw (see Figure 17-6, *A*). However, these cysts can assume large sizes and displace the associated impacted teeth to remote sites in the maxillofacial complex such as the ascending ramus in the mandible or the superior and posterior areas in the maxilla (see Figure 17-6, *B* and *C*). These large lesions can cause marked expansion of the cortices of the jaw with clinical evidence of their resorption evident by an "eggshell-crackling" or "frog-belly" phenomenon upon palpation. Root resorption of adjacent teeth does occur, but neurosensory deficits are not common. The cyst may be asymptomatic, but if it communicates with the oral cavity, it can become infected and pain is elicited. Painless facial swelling is also clinically apparent in larger lesions (see Figure 17-6, *F*).

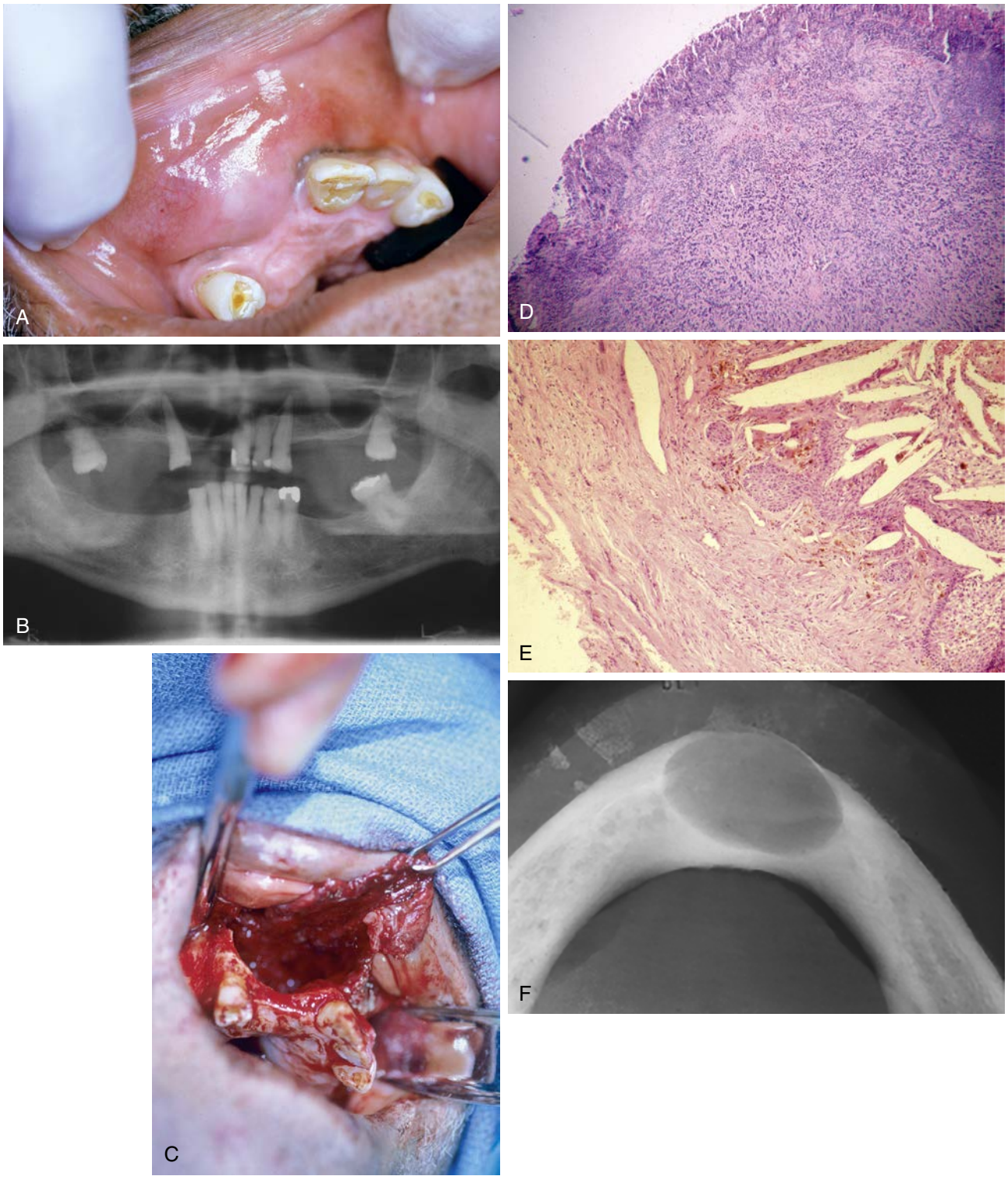

• **Figure 17-5** **A,** A residual right maxillary cyst with marked expansion in the buccal sulcus. **B,** Panogram from the same patient showing resorption of the roots of the adjacent teeth and a well-delineated radiolucency in the area of teeth #7 and #8. **C,** Cystectomy was performed by vestibular incision extending beyond the radiolucency, and cyst was enucleated. **D,** The cyst walls show significant inflammatory cell infiltrate. **E,** Focal presence of cholesterol clefts. **F,** An occlusal film from another patient shows a well-corticated radiolucency of a residual cyst in a 66-year-old woman.

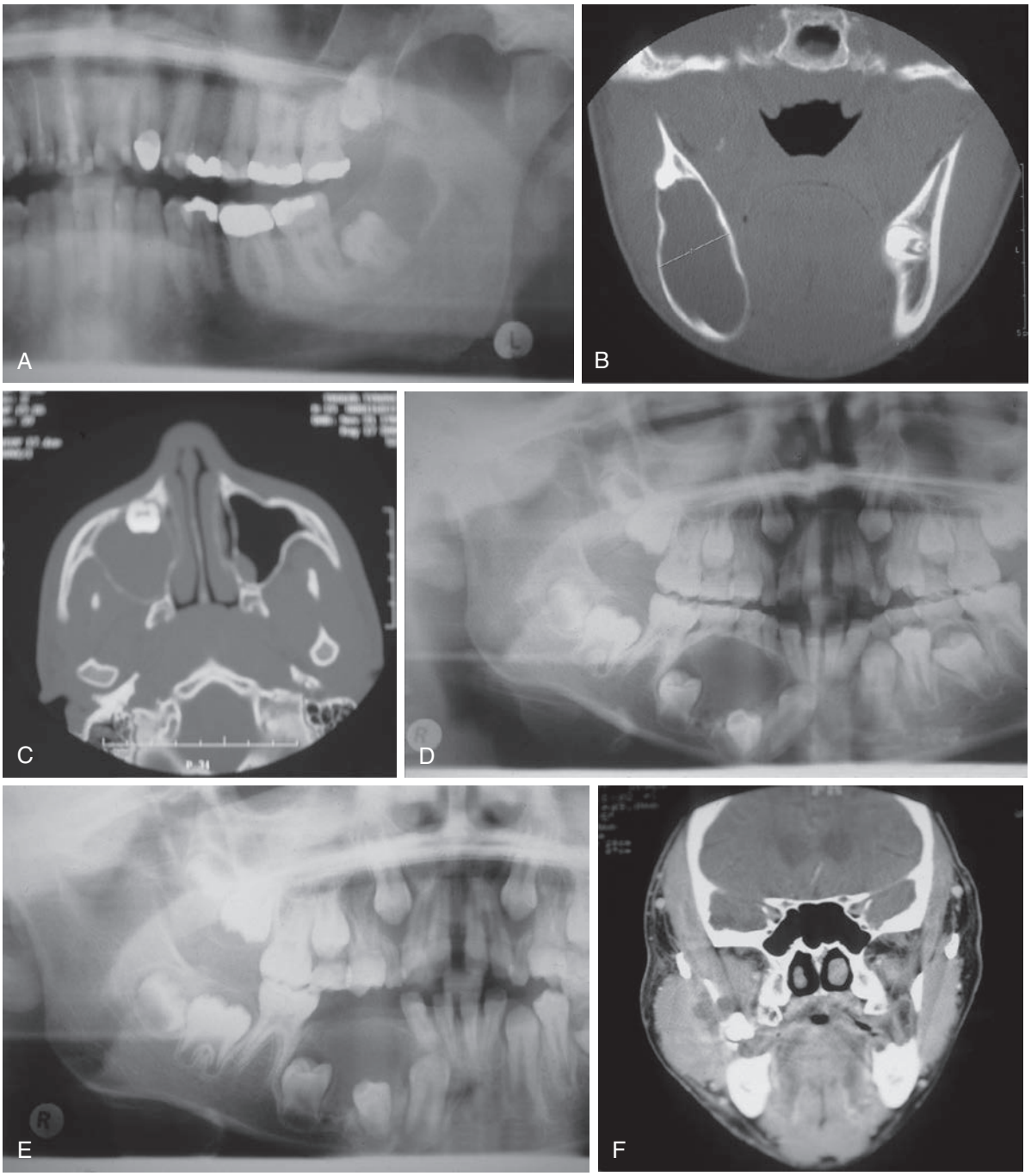

• **Figure 17-6 A,** Radiographs of clinically diagnosed dentigerous cysts commonly associated with impacted third molars. **B,** Displacing associated molar high into the ascending ramus of mandible. **C,** Superiorly in the infra-orbital region. **D-E,** Impeding eruption of right mandibular premolars in a 7-year-old boy (extraction of the deciduous teeth in the same patient and enucleation of the cyst to allow eruption of the impacted teeth is in progression). **F,** Cyst causing facial cellulitis when infected.

Imaging Features

A panogram is usually the first indication of the presence of the dentigerous cyst. It is usually adequate for the diagnosis of the lesion with typical presentation of a well-corticated radiolucency associated with the crown of an incompletely formed tooth (see Figures 17-6, *A*, and 17-10, *A*). The availability of CT scans with or without contrast has almost conclusively replaced the need for plain facial films in the diagnosis of large dentigerous cysts that significantly displace associated teeth and encroach on important adjacent structures. Coronal and axial cuts with or without contrast are important not only to delineate the extent of the cyst but also for planning the surgical approach (see Figure 17-6, *B* and *C*). It is critical to recall that clinical and imaging features are not diagnostic of a dentigerous cyst, despite being very suggestive. Among important lesions to consider are

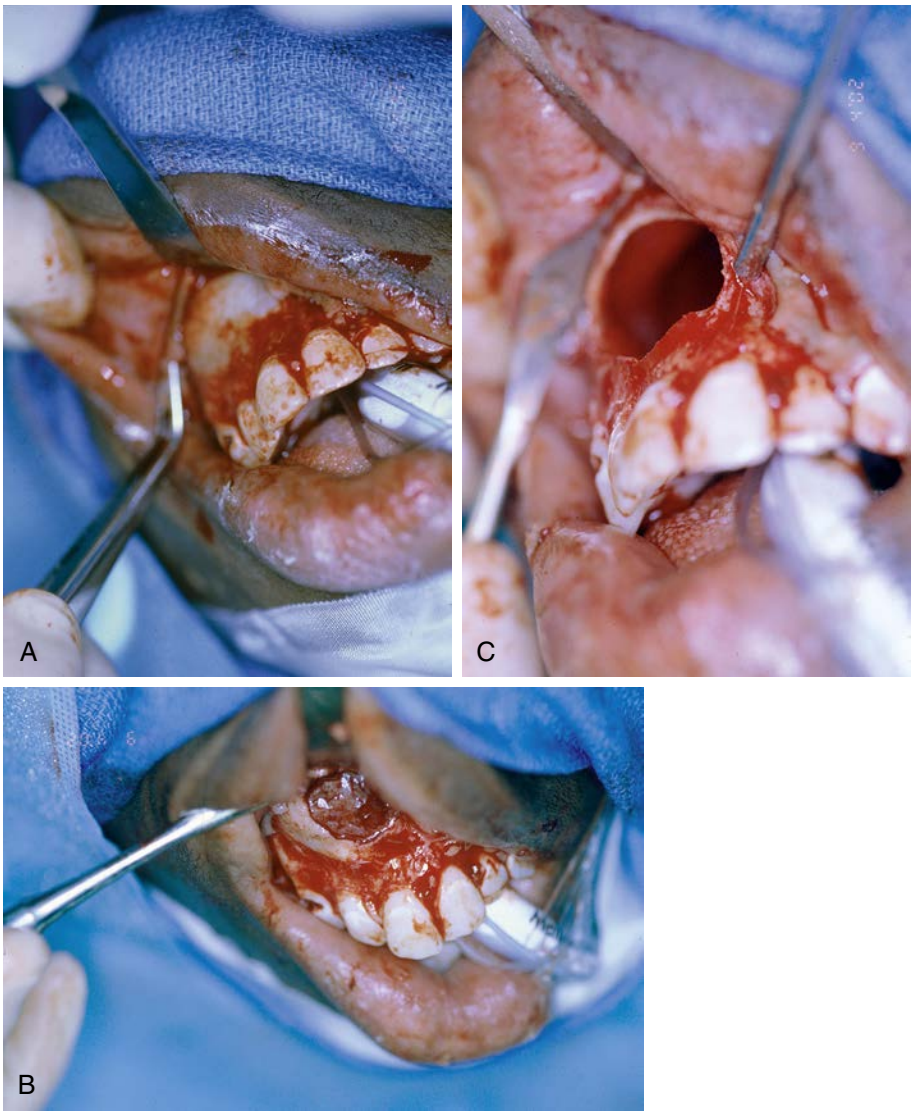

• **Figure 17-7** **A,** Photographs of a maxillary cyst causing significant buccal expansion and thinning of the bone cortex causing the clinical signs of "frog belly" and "eggshell crackling." **B,** Cyst wall apparent after removal of the residual thinned bone. **C,** Cyst bed after enucleation.

odontogenic keratocysts, unicystic ameloblastomas, and adenomatoid odontogenic tumors. The former two have a more aggressive biologic behavior. Dentigerous cysts lining epithelium retain some primordial odontogenic cells capable of ameloblastoma expression.[9] Therefore, dentigerous cysts are among the sources of ameloblastomas.[15] Odontogenic keratocyst, which is a histologic diagnosis, can present clinically and radiographically as dentigerous cyst. Therefore, in large cysts that radiographically appear to be dentigerous cysts, other differential diagnosis should be considered. A biopsy of the lesion is recommended either intraoperatively, by frozen section, or preoperatively, by incisional biopsy. The authors strongly believe in the value of intraoperative frozen section diagnosis and encourage its frequent use.

Pathologic Features

It is advisable to always aspirate a cystic lesion, particularly the expansible ones; examination of the aspirate is a good part of the diagnostic workup. We recommend critically evaluating the nature of the aspirate and, if needed, submitting it for cytopathologic examination. This simple step can be helpful in recognizing a vascular lesion, and cytopathology can strongly suggest the more aggressive odontogenic keratocyst.[1,2] Unless the dentigerous cyst is infected, the lesion contains straw-colored to brown fluid. When infected, the cyst contents would appear grossly suppurative. In noninfected lesions, the cyst wall is thin and attached to the cementoenamel junction of an associated tooth. Inflammation causes thickness of the cyst wall to varying degrees. The surgeon usually attempts to remove the cyst and the tooth from its bony bed in one piece (Figure 17-7, *A-C*). In large cysts in general, we have found that if intraoperatively the cyst is stuffed with gauze or other material after its enucleation and before it is placed in the fixative, this will help facilitate the selection of the part to be examined microscopically by the pathologist (Figure 17-8, *A*). Pathologists

favor sections from focally thickened wall or papillary projections into the lumen. This way a small early ameloblastoma or unicystic ameloblastoma arising from a dentigerous cyst would not be missed (see Figure 17-8, *B* and *C*). Usually the cyst consists of a thin connective tissue wall with minimal or no inflammatory cell infiltrate (Figure 17-9, *A* and *C*). The epithelial lining is stratified, non-keratinized epithelium, which is usually two to three cell layers thick with cuboidal basal cells (see Figure 17-9, *C*). If keratinization and other microscopic features of odontogenic keratocysts, as discussed previously, are present, the diagnosis is keratocyst rather than dentigerous cyst. It is important to remember that the dentigerous cyst epithelium is known to have the ability to differentiate into ciliated and mucus-secreting epithelium[16,17] (see Figure 17-9, *A-C*). Malignancies, including intraosseous mucoepidermoid carcinoma and carcinoma ex-dentigerous cyst, have been postulated to arise from the odontogenic epithelial cyst lining including dentigerous cyst.[18-22]

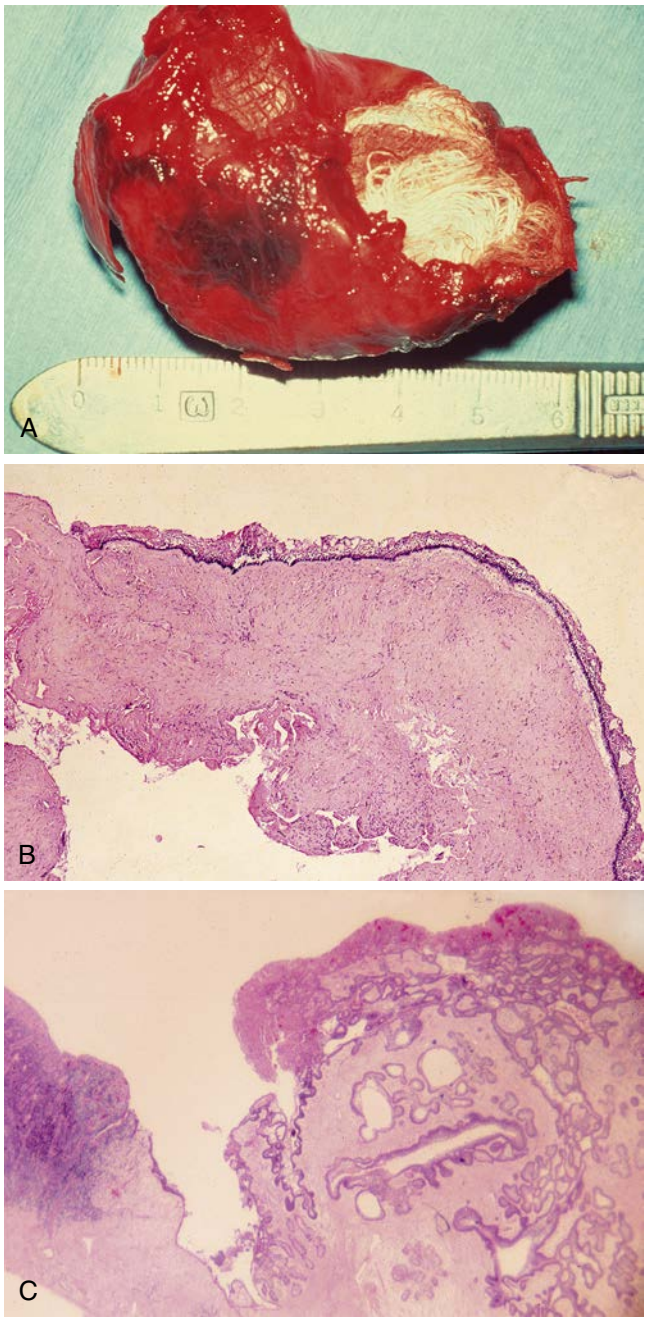

• **Figure 17-8** **A,** Photograph of an enucleated clinically diagnosed odontogenic cyst, intraoperatively filled with gauze to maintain its shape before fixation. **B,** Frozen section raised the issue of the possibility of early ameloblastoma because of this palisading basal cell layer and stellate-like epithelium. **C,** Permanent sections from the shape-maintained cyst facilitated sectioning of the focally thickened wall and the diagnosis of unicystic ameloblastoma.

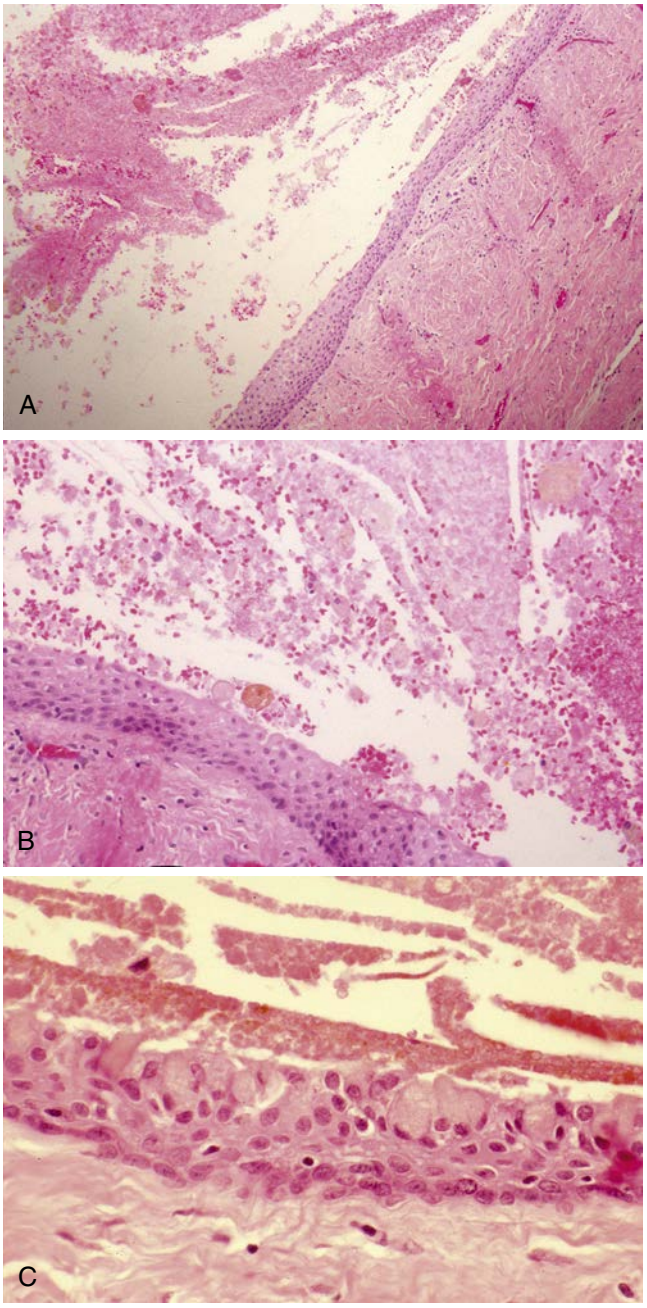

• **Figure 17-9** **A,** Photomicrographs of epithelial lining of a dentigerous cyst showing non-keratinizing stratified epithelium with no inflammation of the cyst wall. **B,** Cell contents are proteinaceous debris. **C,** Mucous metaplasia with frequent presence of "goblet" cells.

Surgical Management

Frequently, small dentigerous cysts associated with impacted teeth are totally enucleated during the surgical removal of these teeth (Figures 17-10, *A-C,* and 17-11). The majority of these cases are usually done in an outpatient setting, and it is critical that the cyst lining be submitted for histologic examination to rule out any unexpected metaplastic or proliferative changes. Although such changes may not necessarily change the performed surgical treatment, it should certainly change the follow-up protocol if the rendered diagnosis indicates a lesion with a history of significant recurrence rate such as an odontogenic keratocyst or ameloblastoma. On occasion, dentigerous cysts and their associated impacted teeth may require an extraoral approach and/or osteotomy in the mandible or a transantral maxillary approach in the maxilla (see Figure 17-6, *C*).

Keratocystic Odontogenic Tumor (Odontogenic Keratocyst)

Etiology

The keratocystic odontogenic tumor (KCOT) is a histologic diagnosis and can, therefore, clinically and radiographically present as any of several odontogenic cysts.[23] Because of its high recurrence rate and its aggressively destructive nature, it has been extensively studied. In 2005, the WHO reclassified the KCOT from a cystic to a neoplastic lesion, renaming the odontogenic keratocyst (OKC) to keratocystic odontogenic tumor. This change was based on several factors, including its high recurrence rate clinically, its histologic appearance, and the presence of tumor markers within the lesion. Specifically, the tumor markers associated with KCOTs include

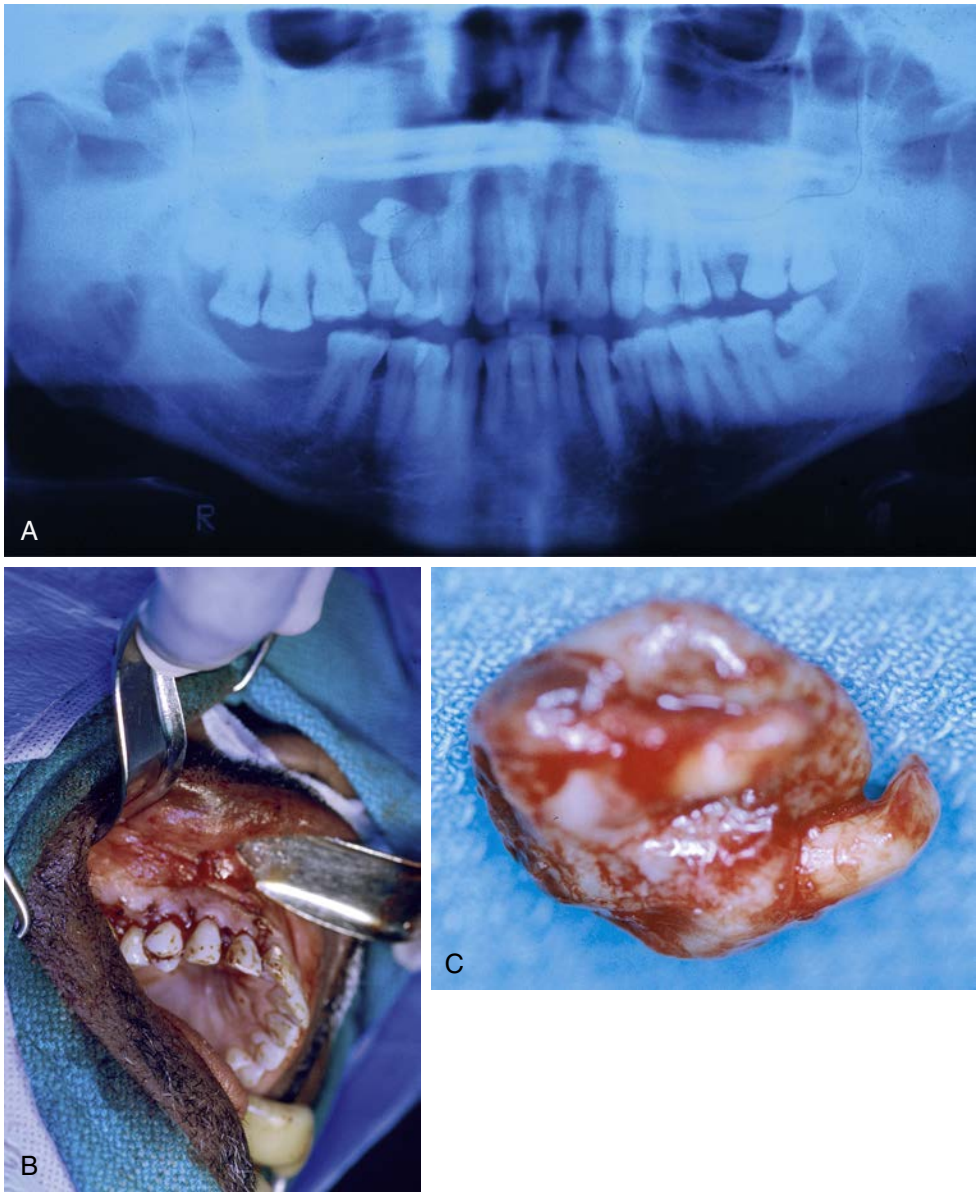

• **Figure 17-10** **A,** Panogram of a dentigerous cyst associated with an impacted right maxillary first premolar. **B,** Intraoral buccal sulcus incision and exposure of the cyst. **C,** The enucleated specimen with the associated tooth.

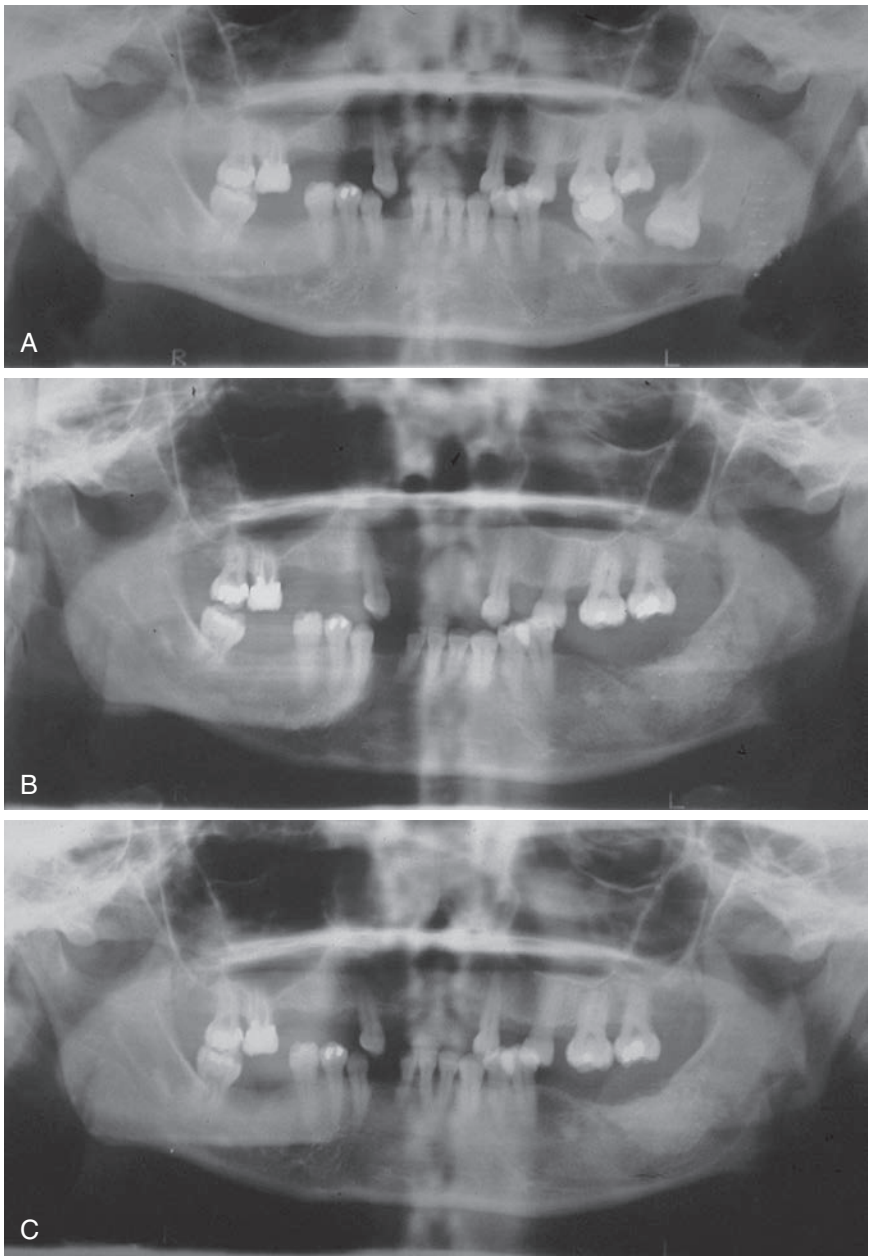

• **Figure 17-11** A series of preoperative panograms of a dentigerous cyst of the left angle of the mandible **(A),** allogeneic bone grafting several months postoperatively **(B),** and good consolidation of the bone graft 2 years after enucleation **(C).**

proliferating cell nuclear antigen (PCNA), matrix metalloproteinase (MMP) 2 and 9, p53 protein, Ki-67, and BCE2 sequence of the enzyme dihydrolipoyl acetyltransferase. The KCOT may histologically be subdivided into parakeratotic and orthokeratotic types, which are discussed in more detail later in the chapter. This reclassification by the WHO refers only to the parakeratinized version of the OKC, which leaves the orthokeratinized version under the grouping of other benign odontogenic cysts.[24,25]

Keratocystic odontogenic tumors have characteristic features that are unique compared to other cysts of the maxillofacial region. However, the origins of these unique lesions have long been a topic of debate. Whereas the primordium of the tooth was originally thought by many authors to be the origin of these cysts, it is now the dental lamina that is thought to be the most likely origin.[26] The basal cell layer of the oral epithelium is also thought to possibly play a role in the etiology of these cysts. At approximately the sixth week of gestation, the future alveolar processes of the mandible and maxilla begin to form invaginations. These invaginations are the beginning of the dental lamina, consisting of epithelium that remains connected to the overlying epithelial tissue until the tooth buds of the deciduous dentition begin to form. When this connection "loosens," it supports the theory that remnants of the epithelium remain in the gingiva. This would mean that when teeth erupt, they

would have to do so through these remnants. However, as pointed out by Stoelinga,[26] this is where the theory proves to be flawed, as these small microcysts that are often seen in this epithelium do not show the characteristic features of the typical KCOT. The dental lamina that extends to the lingual surface of the mandibular tooth buds and the palatal surface of the maxillary tooth buds, and eventually forms the permanent dentition, does not have a connection with the overlying epithelium. Therefore it is possible for these islands to be enclosed in bony crypts. Some of these cysts (for instance, lateral periodontal cysts) do have characteristics of KCOTs. Other potential causes, though unlikely, include a genetic trigger. The fact that KCOTs are often present with nevoid basal cell carcinoma syndrome could indicate this. A responsible gene has been located for this syndrome, and although it is unlikely to be the same gene that would play a role in solitary KCOTs, it does have a presentation that is quite similar.[26] No matter what the true origin may be, the dental lamina and basal cell layer, offshoots from the mucosa, have been repeatedly documented to be the areas in which KCOTs are attached to the oral mucosa.[27-29]

Clinical Features

Shear[30] found that over a period of 32 years in a sample of more than 2600 cysts of the jaw, KCOTs occurred in 255 patients and accounted for 292 cysts (11%). Keratocystic odontogenic tumors occur over a very wide age range, starting from the first decade of life to as late as the ninth. There seems to be a peak in the frequency in the second and third decades. The peak seems to be roughly a decade younger for females.[31] Data, however, have shown that KCOTs are found much more frequently in men than in women. This finding is even more pronounced in the black community. One study found the male to female ratio in the black community to be as high as 5:1.[32]

The most common site for keratocystic odontogenic tumors is by far the mandible. Findings ranging from 69% to 83% have been reported in the literature.[23,28,30,33-39] Approximately 50% of all KCOTs occur in the mandibular angle region. These can extend in any direction and become quite large and aggressive. There seems to be an increase in the number of KCOTs seen in the maxilla after the age of 50.[39] KCOTs that occur in regions other than the mandibular angle seem to be more related to systemic syndromes, especially those KCOTs that occur in the maxilla.[40,41] Common clinical findings associated with KCOTs are pain, swelling, and discharge (Figures 17-12, 17-13).

There also may occasionally be paresthesias of the lower lip if the inferior alveolar nerve has been impinged upon. Many patients are oblivious to the lesion until it is found on clinical and/or radiographic examination (see Figure 17-17, *A*). The cysts can vary greatly in size. Forssell[42] found that nearly half of all the KCOTs he studied were at least 40 mm in diameter, especially those that were in the ramus region of the mandible. Also, the larger these lesions become, the more likely they are to lead to displacement of teeth or other adjacent structures, such as the maxillary sinus (Figures 17-14, *A*, and 17-17, *C*). Some authors have reported very aggressive KCOTs that have penetrated into surrounding soft tissues.[43,44] Expansion has been reported to occur in up to 60% of cases.[36] Continuing investigation into their pathogenesis and optimal surgical management stems from the high recurrence rate. The incidence of recurrence for KCOTs has long been documented (see Figure 17-14). Recurrence rates ranging from less than 10% to more than 60% have been reported over the years.[30,36,37] As reported by several clinicians, there seems to be no definitive correlation between recurrence and patient age, location of the cyst, method of treatment, nature of cyst lining, or presence of cortical perforation, and whether or not the cyst was unilocular or multilocular.[33,35,45,46] However, others have found some correlation in recurrence rates with regard to location of the cyst.[32] Still others have also found there to be a correlation in regard to the type of procedure used to treat the original lesion as well as the type of cyst lining the original cyst.[47-49] Forssell and colleagues[50] found a significant recurrence rate in those patients whose KCOTs were found in conjunction with nevoid basal cell carcinoma syndrome. The reason for such a broad range of recurrences is yet unknown, but many theories have been suggested. Operative approach, improved clinical follow-up over 5 years, and improved intraoperative techniques are among the proposed factors related to the modulation of the recurrence rate (Figure 17-15).

With such a high potential for recurrence, the following question must be asked: Why do KCOTs tend to recur so often? The most obvious reason is incomplete enucleation of the original cyst. KCOTs have a tendency to occur in multiples. This may be due to the occurrence of satellite cysts, which if not removed surgically can lead to recurrence[30] (Figure 17-16, *A* and *B*). Second, KCOT linings tend to be very thin and fragile, which makes them much more difficult to remove completely than cysts with thick wall linings. This increases the potential of leaving part of the cyst wall behind when enucleating these cysts. This has been demonstrated by several investigators.[34,49,50]

For some time now, investigators have examined KCOTs having intrinsic growth potential.[51] It is now believed that patients with a predisposition to form keratocysts, particularly those with nevoid basal cell carcinoma, will always have the potential to form keratocysts as long as a dental lamina or its remnant is present.[52-54] Stoelinga and colleagues[27,55] have theorized that cysts arise from proliferation of basal cells of the oral mucosa, or hamartomas. They particularly thought this to be the case in the mandibular ramus and angle regions. They felt that when KCOTs were removed this mucosa should also be excised to help prevent recurrence. In any event, the exact cause for recurrences is not yet known, and very well may be multifactorial. To that extent, it has been suggested that KCOTs may be designated as benign neoplasms. This is supported by histologic, immunochemical, and genetic studies.[35,46,52-54]

As previously stated, the keratocysts can be divided into two distinct variations, namely orthokeratotic and

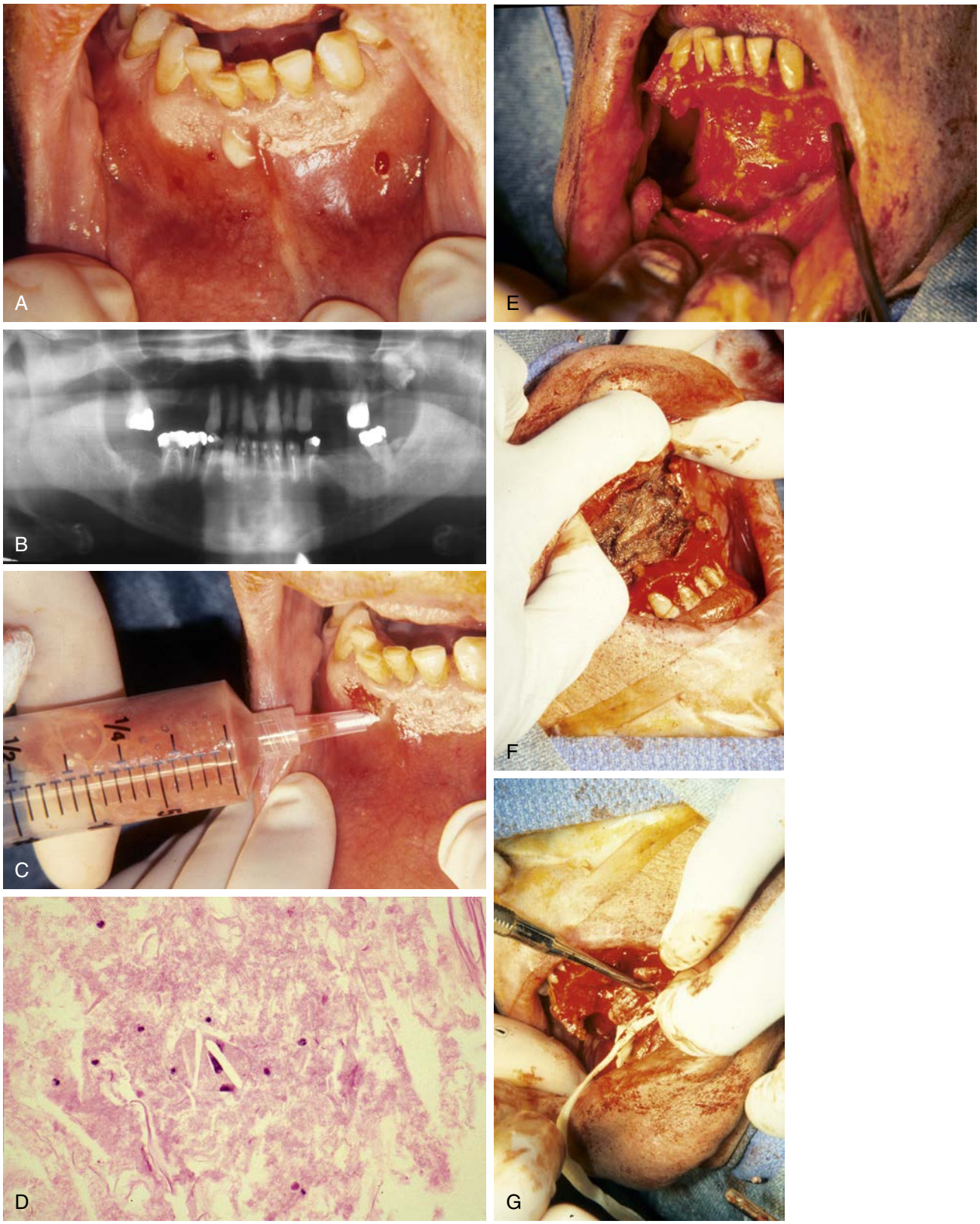

• **Figure 17-12** **A,** An 83-year-old man complained of pain and discharge from the anterior mandible. **B,** Panogram showed a large cyst that was difficult to diagnose. **C,** Aspiration was done and submitted for cytopathologic examination. **D,** Cytopathology suggested parakeratotic odontogenic cyst because of the scattered keratin debris and few scattered parakeratotic cells. **E-F,** The patient underwent cystectomy without extraction of any teeth along with chemical cauterization of the cyst bed and **(G)** iodoform packing. (Surgery performed by Otto Tidwell, DDS, Philadelphia.)

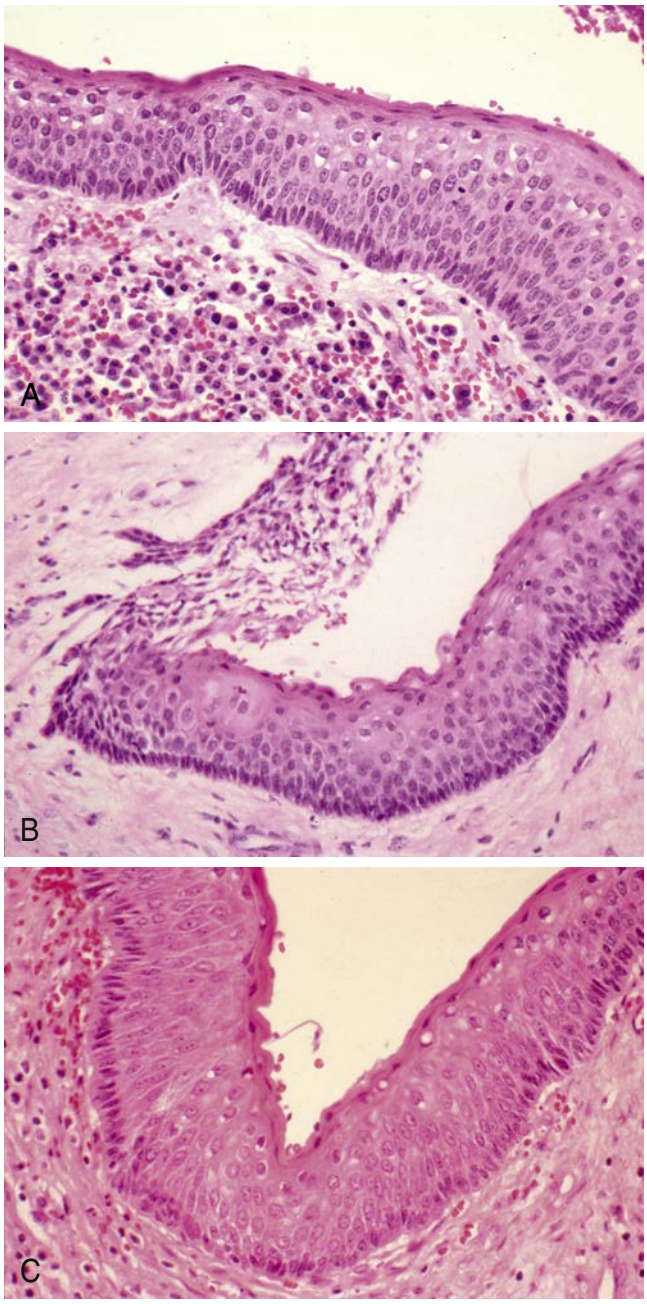

• **Figure 17-13** Photomicrographs from the patient illustrated in Figure 17-12. The histopathology is the classic picture of an odontogenic keratocyst. **A,** There is marked inflammatory cell infiltrate in the wall of the cyst with multilayered stratifying and parakeratotic luminal surface. **B,** Partial ulceration of the epithelial lining does occur, especially in infected cysts. **C,** The higher magnification shows the classic palisading of the columnar basal cells and corrugated luminal surface.

parakeratotic. The orthokeratotic lesions were first reported in literature by Schultz in 1927.[56] He described these as multilocular cysts. Wright[57] studied 60 cysts diagnosed as KCOTs, and found 13% of those lesions to be of the orthokeratinized variety. Approximately half of these lesions showed separation of the epithelium from the connective tissue. There also was no recurrence after 1 year of follow-up. He concluded that the orthokeratinized variety of KCOTs was a distinct biologic entity from their parakeratinized counterparts and showed a much lower potential for recurrence.[57] Recently, more evidence has shown that there is a distinct difference in the expression of keratin proteins (specifically, 10, 13, and 14) as well as collagen (types 1 and 3) when comparing parakeratotic and orthokeratotic KCOTs.[58]

It has also been suggested that *orthokeratinizing keratocyst* is an outdated term and the lesion should not be called keratocyst at all, but instead referred to as a cyst that produces keratin, recognizing its low propensity for recurrence and the distinct histologic difference between the two lesions in question.[9]

Imaging Features

Radiologic findings seen with KCOTs include lesions that appear either unilocular or multilocular on either traditional radiographic film or CT scan (see Figures 17-12, *B*, and 17-14, *A*; Figure 17-17, *A-C*). Scalloping may be seen with these lesions as well. On CT scan, expansion of the cortical bone may be more readily apparent than on plain film (see Figure 17-14, *A*). Also, cortical perforation can be determined on CT scan or magnetic resonance imaging (MRI), which can be a determining factor in treatment plans, as discussed later. In addition, KCOTs are typically found with unerupted teeth. This is especially true with initial lesion presentation, although lesions that recur will not have association with unerupted teeth. Naturally these imaging features are not diagnostic, but corticated scalloped margins with moderate expansion of the jaw are highly suggestive of KCOT (see Figure 17-17, *A*).

Pathologic Features

Undoubtedly, the most distinctive characteristic of the KCOT parakeratotic subtype is the presence of parakeratin (see Figures 17-13 and 17-16). It is so unusual that its presence along with other characteristic findings makes diagnosis usually obvious.[55] Histologic features include an epithelial lining of parakeratinized stratified squamous epithelium, ranging from 6 to 10 cell layers thick (see Figures 17-13 and 17-16). This epithelium also lacks rete pegs that create a flat interface between epithelium and connective tissue (see Figures 17-16, *B*, and 17-19, *D*). Small areas of orthokeratin may also be found, though this is rare. There is a well-delineated basal cell layer that is composed of columnar and cuboidal cells. Corrugation of the surface along with keratin in the lumen is also seen with parakeratinization (see Figure 17-16, *D*).[59] Although epithelial dysplasia has been described,[60] it is very rare; however, reports of squamous cell carcinoma have been published.[61-63] Mitoses are seen in both the basal and the parabasal regions of KCOTs. In 1970 Main[64] showed that the proliferation of cells in KCOTs was approximately four times that of non-odontogenic cysts and twice that of radicular cysts. In fact, it is more similar to that of ameloblastoma and the dental lamina. The wall of the KCOT is made up of a fibrous tissue that has mucopolysaccharides and normally has no evidence of inflammation (see Figure 17-14, *D*).

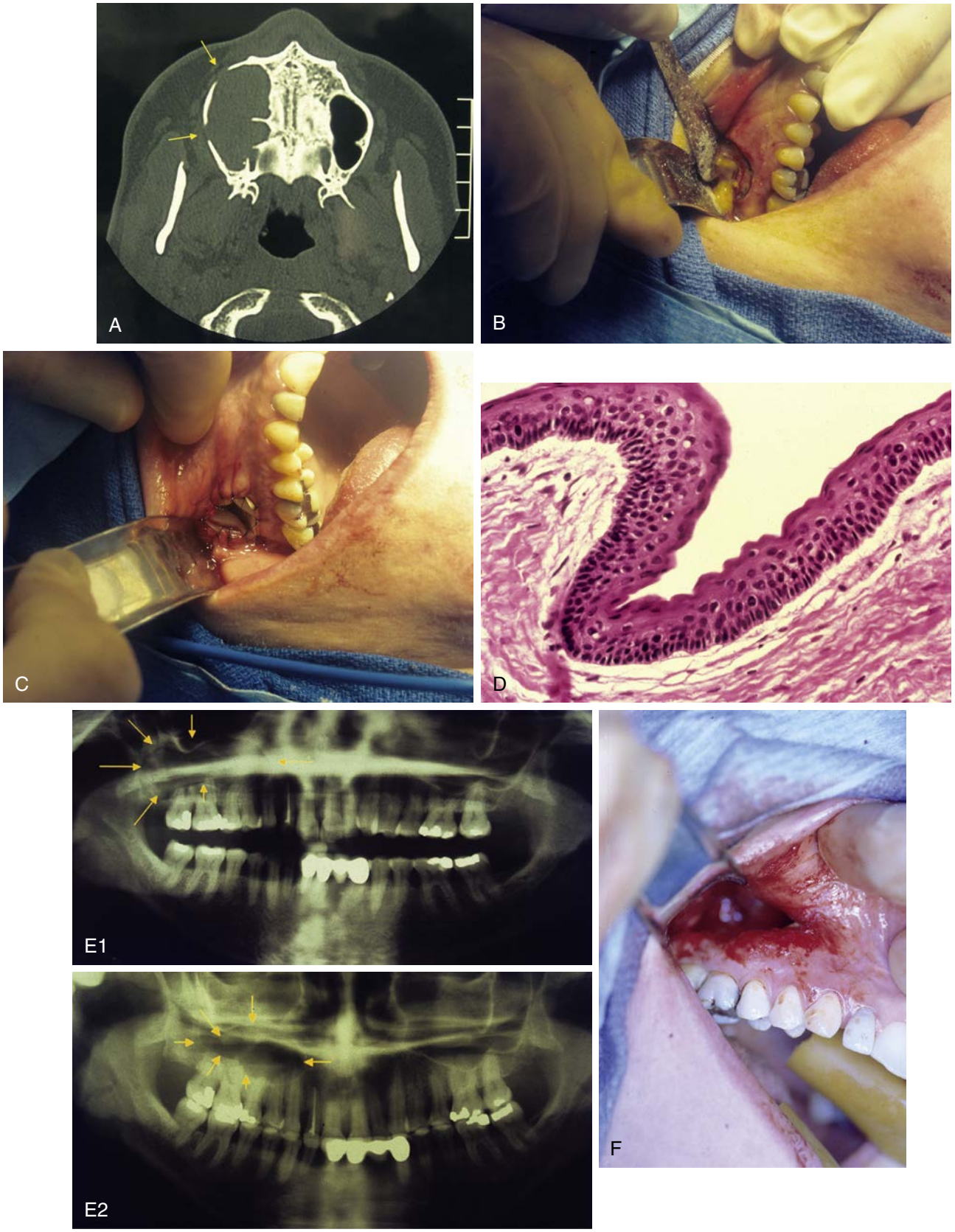

• **Figure 17-14** A 45-year-old woman with history of enucleated odontogenic keratocyst (OKC) in 1987 was seen with a recurring cyst initially seen in July 2003. **A,** Computed tomography scan of the recurring large cyst showed encroachment on the right maxillary sinus. **B,** A two-stage operation was done. Note the creamy contents of the cyst through the decompression site. **C,** A Penrose drain placed to maintain patency. **D,** The excised window showed classic OKC microscopic features. **E,** Original size of lesion shown by the *arrows* in *E1* panogram; 9 months later the cyst showed significant shrinkage (*arrows, E2* panogram).

Continued

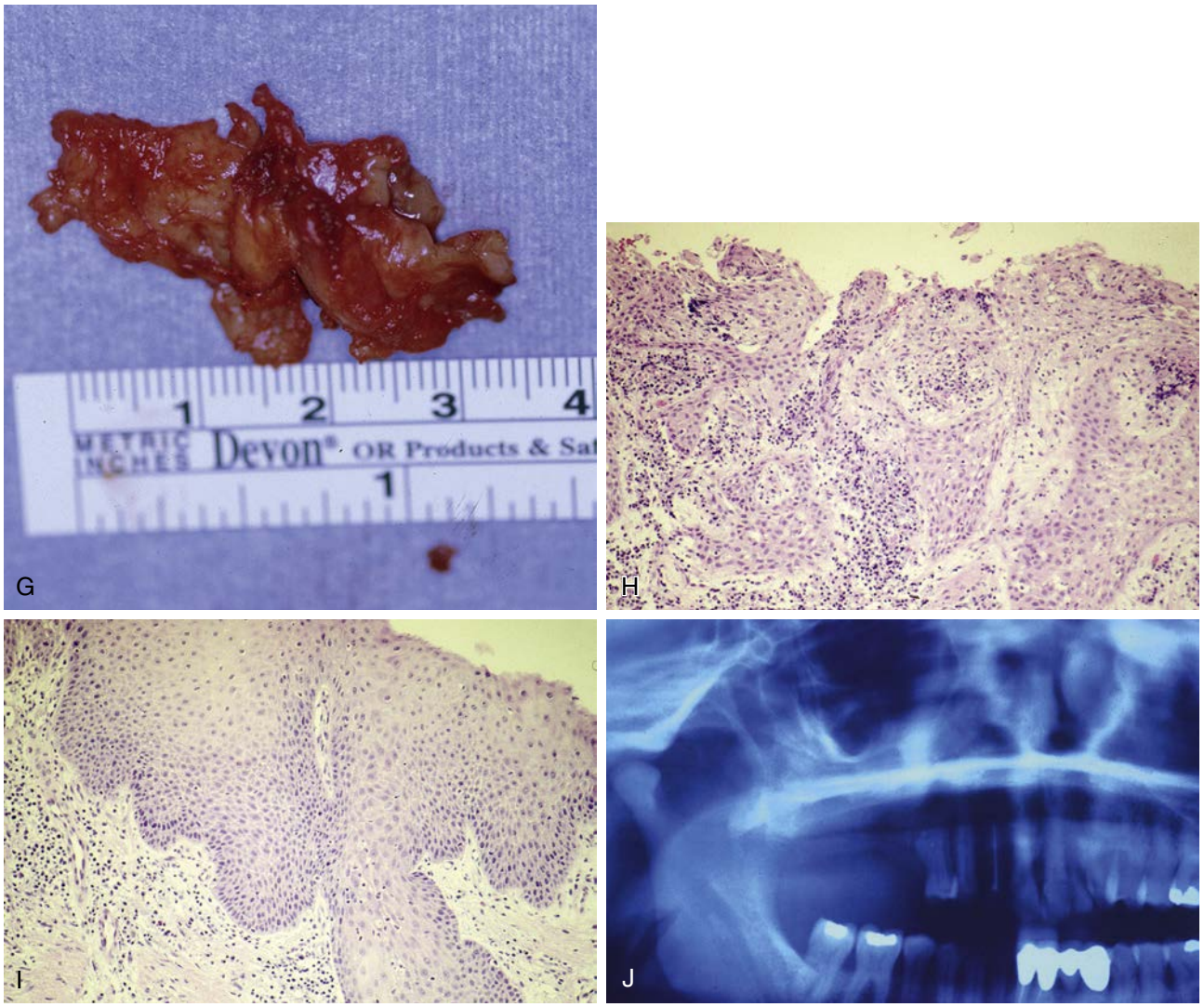

• **Figure 17-14, cont'd** **F-G,** The second stage was then performed with enucleation followed by cauterization by Carnoy solution and excision of the window margin. **H-I,** The resected specimen clearly showed the marked change of the epithelial lining to hyperplastic stratified squamous epithelium with intense inflammatory cell infiltrate of the cyst wall. **J,** Subsequent extraction of the maxillary molars was done, and the patient is currently free of recurrence as shown in the panogram taken in August 2005, revealing good bone healing.

There are instances in which KCOTs do in fact become infected and/or inflamed (see Figure 17-13, *A*). These lesions will have an even higher rate of proliferation than those that are not infected.[65] These lesions also show a tendency to change their epithelial lining to nonkeratinized[65,66] (see Figure 17-13, *B*). Satellite or "daughter" cysts may also be noted in the connective tissue wall of an OKC, but this is a more common finding when the KCOT occurs with nevoid basal cell carcinoma syndrome[67] (see Figure 17-16, *A* and *B*). Features unique to the orthokeratinized KCOT are an epithelium composed entirely of orthokeratinized stratified squamous epithelium two to three cell layers thick. There is obvious lack of palisading of the cuboidal basal cell layer, as characteristic of the parakeratotic variety. There are also no corrugations of the luminal surface, and there are abundant keratohyaline granules in superficial cells and pronounced orthokeratin in the lumen (Figure 17-18, *D* and *E*).[68]

Ultrastructure

Features seen in KCOTs include deep epithelial folds, desmosomal junctions, and tall columnar basal cells, which can show some variation. Glycogen is a usual component of the cytoplasm in KCOTs (see Figure 17-16, *C*). It has been suggested that there is an increase in glycogen levels when KCOTs are associated with nevoid basal cell carcinoma syndrome.[69] Wysocki and Sapp[70] showed that there were definitive differences between the parakeratinized and orthokeratinized KCOTs. They found that the morphology of the orthokeratotic version is more uniform and entirely covered in a layer of keratin. There is also an increase in tonofilaments as the cells mature. The granular cell layer consists of compacted degenerated cells that contain keratohyaline granules, with the luminal surface consisting of shreds of orthokeratin[68] (see Figure 17-18, *D*).

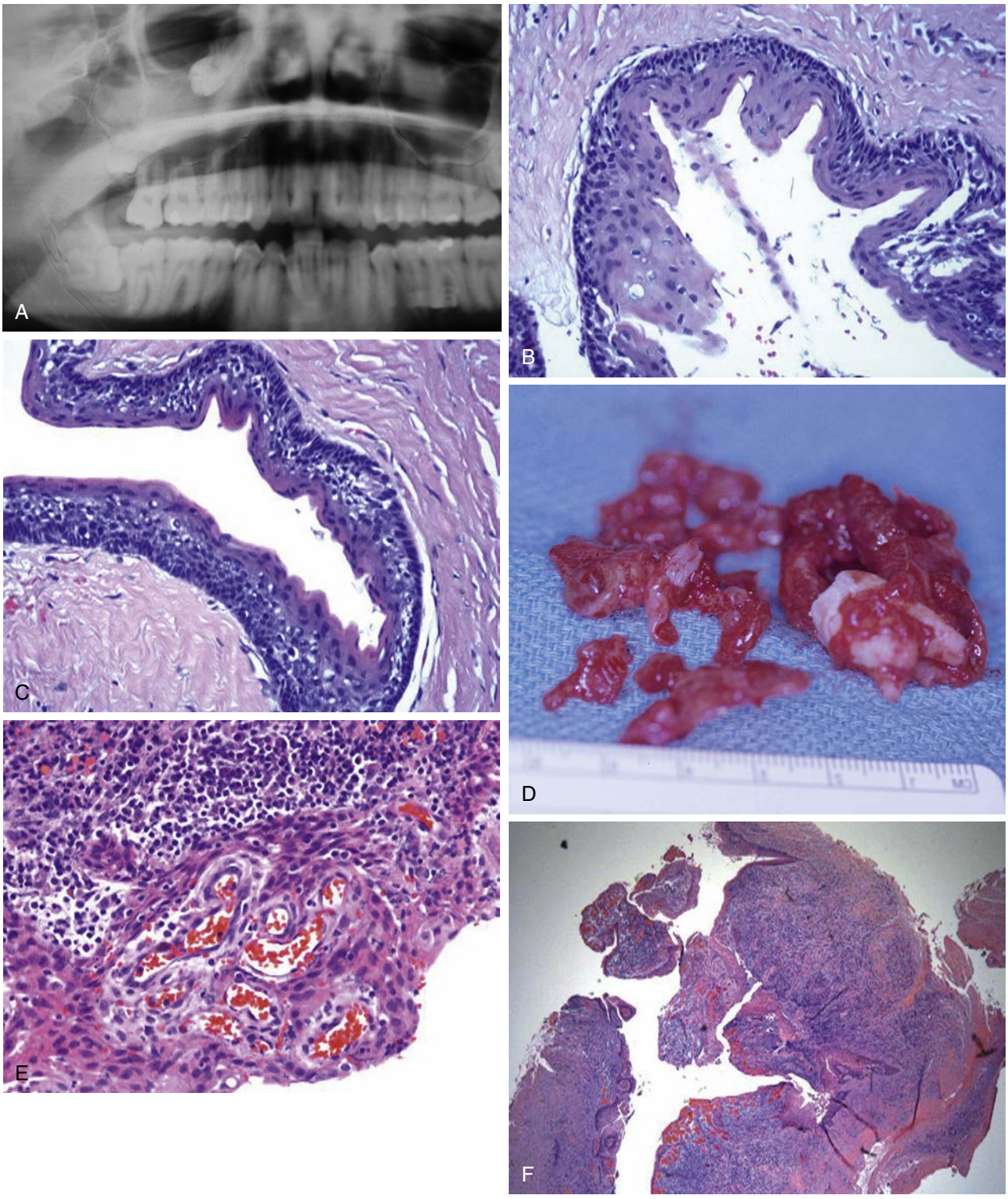

• **Figure 17-15** **A,** A 19-year-old man presented with impacted teeth and clinical diagnosis of dentigerous cyst of the right maxilla. Panogram showed the large cyst with the associated impacted molar. The computed tomographic scan (see Figure 17-6, *C*) and aspiration of keratin debris raised the possibility of odontogenic keratocyst (OKC). A two-stage procedure was undertaken. **B-C,** The histopathology showed classic features of OKC. **D,** Eight months after decompression, enucleation was performed. **E-F,** The cyst lining shows the marked microscopic changes with intense inflammation and stratified non-keratinizing stratified epithelium with marked hyperplastic proliferation and no classic features of OKC.

Surgical Management

The management of KCOT, the parakeratotic subtype, has evoked considerable discussions and raises several questions in regard to the optimal approach for its management (see Figures 17-12, 17-14, 17-17, and 17-18). Unfortunately, the issue is yet to be settled, and long-term studies are needed. There are many options and opinions for the surgical management of KCOTs. In 2006 Herb[71] contributed a thorough review of the literature of the treatment modalities of these lesions. Ghali and Connor,[72] in 2003, reviewed the surgical management of the KCOT. They reviewed the available treatment and concluded that debate still exists as to the most effective treatment for this lesion. They included enucleation and curettage, enucleation with peripheral ostectomy, complete resection, enucleation with cryotherapy or chemical adjunct therapy, and decompression and marsupialization as treatment modalities. Enucleation and curettage is considered the most conservative treatment option for KCOTs. However, the highest frequency of recurrence is seen with this method of treatment, and therefore it is no longer recommended by most authors as an appropriate initial therapy.[72] However, several studies have shown that KCOTs delivered in one piece reduce this risk. As discussed previously, the friability of the cyst lining often makes this difficult. Peripheral ostectomy is thought to be an adjunctive treatment option when a total resection can be avoided.[72] The thought process behind this technique is that as cysts grow in size, usually their borders will also increase in irregularity, making it harder to remove them in one single piece. At the very least, the surgeon should ensure that all bony margins are clear of cyst lining; this requires the surgeon to use an instrument, usually a rotary round burr, and remove the bony periphery of the cystic cavity. As described by Ghali and Connor,[72] the problem associated with this technique is that there is no way to determine the amount of bony removal that is sufficient. Methylene blue dye has been used to stain the periphery of the cyst cavity, but the depth of staining from methylene blue is not known. Osseous resection is frequently considered the most extensive form of treatment for KCOTs (Figure 17-19). However, some clinicians feel that a benign cyst does not warrant such an approach, whereas others have shown that it is consistently the only form of treatment that approaches, or has, a zero recurrence rate.[38,43,73,74] The reason for this success seems to stem from the fact that the entire lesion is removed en bloc along with the surrounding margin of bone, usually 1 cm.

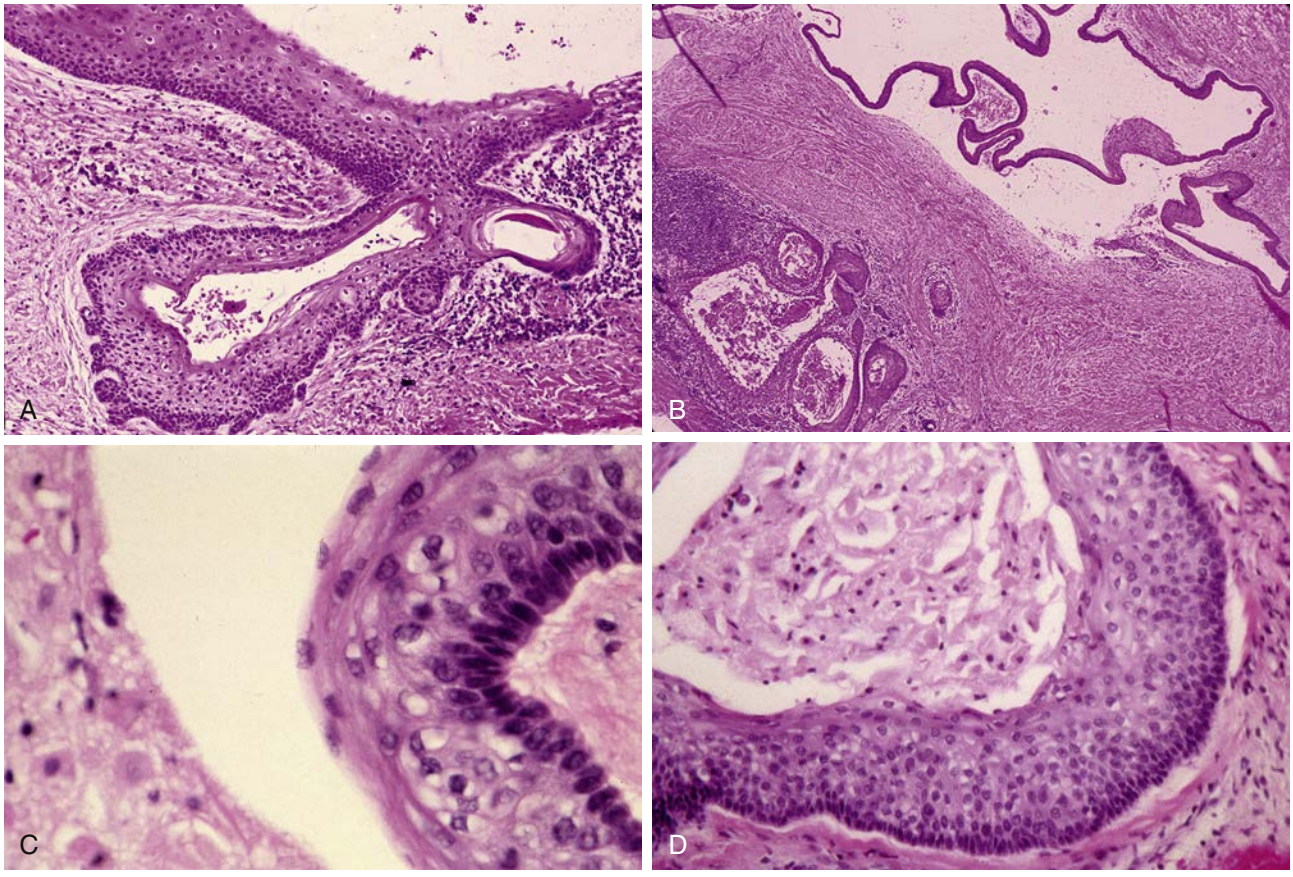

• **Figure 17-16** Other microscopic features of odontogenic keratocysts frequently present are **(A)** budding of the cyst lining into the connective tissue wall, flat epithelial and connective tissue interphase with fragmentation of the cyst lining, **(B)** formation of daughter cysts deep in the cyst wall, **(C)** subnuclear vacuolation of the columnar basal cells and clear cytoplasm (probably glycogen) of the suprabasal layers, and **(D)** exfoliation of parakeratotic cells in the lumen.

In cases with bony dehiscence, adjacent soft tissue can also be excised. For lesions occurring in the mandible superior to the inferior alveolar nerve canal, some authors have shown success with a marginal resection that spared the inferior border of the mandible.[75] Such large resections, however, do have drawbacks, including the need for future grafting, loss of nerve function, and cosmetic deformities. Use of cryotherapy is another form of treatment for managing odontogenic keratocysts.[76,77] The theory with this technique rests on the centuries-old belief that freezing can kill cells.[78] Freezing, however, does not destroy cells alone, as supercooling actually helps to preserve cells and, in fact, cooling will allow for survival of many tissues.[77,79,80] The technique of cryotherapy involves the formation of ice crystals, both intracellularly and extracellularly. This causes osmotic and electrolyte disturbances that ultimately lead to vascular stasis and then cell death by ischemic necrosis. The premise for using cryotherapy for the treatment of KCOTs rests in killing cells that cannot be seen by the naked eye. By freezing the bone that surrounds the cyst, the bone loses its vitality, presumably as would the cells within that bone. However, the bone does not lose its skeletal properties. After undergoing necrosis, the bone will then be re-formed by new cells in 2 to 3 weeks. Obviously this is a very appealing possibility in preventing the potential morbidity of resection. In addition to cryotherapy, Carnoy solution has been advocated for use in conjunction with surgical treatment.[81,82]

Other treatment options are decompression and marsupialization (see Figures 17-14 and 17-15). This is the process by which the overlying epithelium and bone are removed to essentially deroof the cyst; then, by keeping the hole open by various means, pressure within the cyst is relieved. It is important to realize, however, the difference between the two terms. Tucker and colleagues[83] clarify the

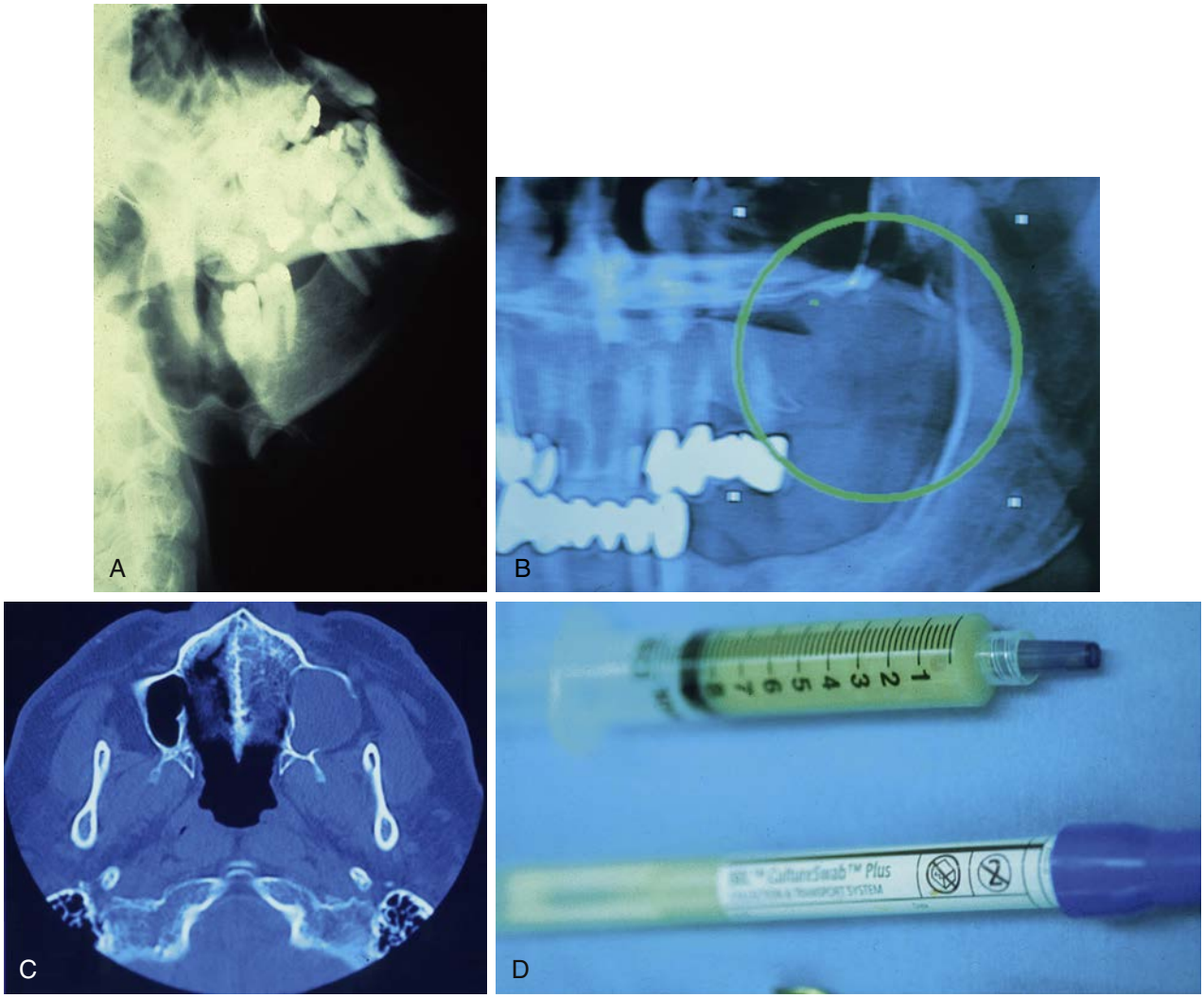

• **Figure 17-17** **A,** Characteristic but not pathognomonic radiographic features of odontogenic keratocyst (OKC) are well-corticated radiolucencies and minimal to moderate buccolingual expansion of common sites such as the angle and ascending ramus of the mandible. **B-C,** In large cases where extensive bone destruction occurred, there are no characteristic features as illustrated in the panogram and computed tomography scan of the same patient. **D,** However, aspiration of a significant amount of the creamy contents pointed toward OKC, which was proven microscopically.

Continued

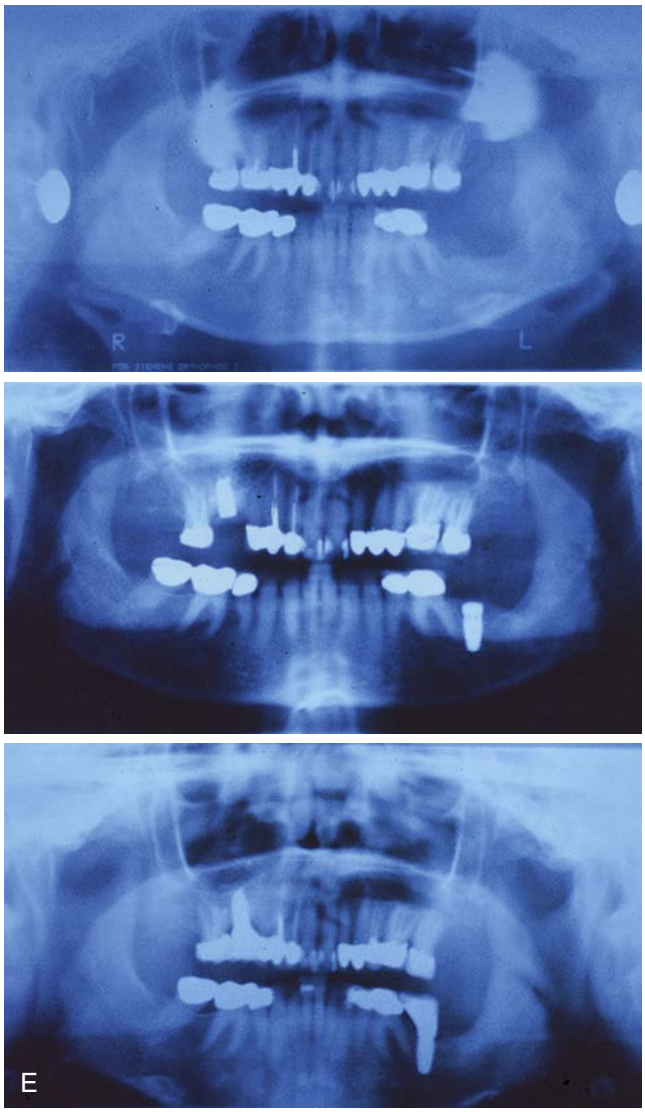



• **Figure 17-17, cont'd** **E-F,** A clinically diagnosed residual cyst proved to be OKC that had been enucleated. With subsequent bone grafting and implant placement, patient is free of recurrence 7 years after enucleation.

difference between the two procedures, despite the fact that both serve the same function and rely on the same principle of bone generation. Marsupialization is a one-stage definitive treatment, whereas decompression should be reserved for two-stage surgery of deroofing of the lesion followed several months later by cystectomy, with or without other adjunct therapy such as chemical cauterization or cryotherapy. There may be a role for marsupialization of large KCOTs; however, this modality of treatment has often resulted in mixed outcomes, especially in older patients.[84] The reported recurrence rate has ranged from 0%[84-87] to 100%.[85] Over the past few years, Pogrel and colleagues[84-88] have been advocating marsupialization and decompression as definitive treatment for KCOTs. However, in 2007 in a letter to the editor of the *Journal of Oral and Maxillofacial Surgery,* Pogrel issued a partial retraction to this concept.[89] He reported a recurrence rate of 12% in 42 of his cases with a maximum follow-up of 5 years. He stated that "in selected cases, decompression and marsupialization may be performed appropriately to decrease the size of the lesion, but once the lesion has been reduced in size sufficiently more definitive surgery is probably necessary"[89] (see Figures 17-14 and 17-15). Decompression has even been found to change the histologic makeup of the cysts themselves. Marker and colleagues[90] showed very good success in a large study of patients with KCOTs in which decompression was followed by cystectomy. They found that using a two-stage technique of decompression and then enucleation proved to be a very promising treatment option. The authors have had good results in the recent years with the two-stage decompression and enucleation technique and have applied it to multiple cases of KCOTs of various size. We have found the technique to be significant in reducing the size of cysts, which allows for easier enucleation and the ability to avoid

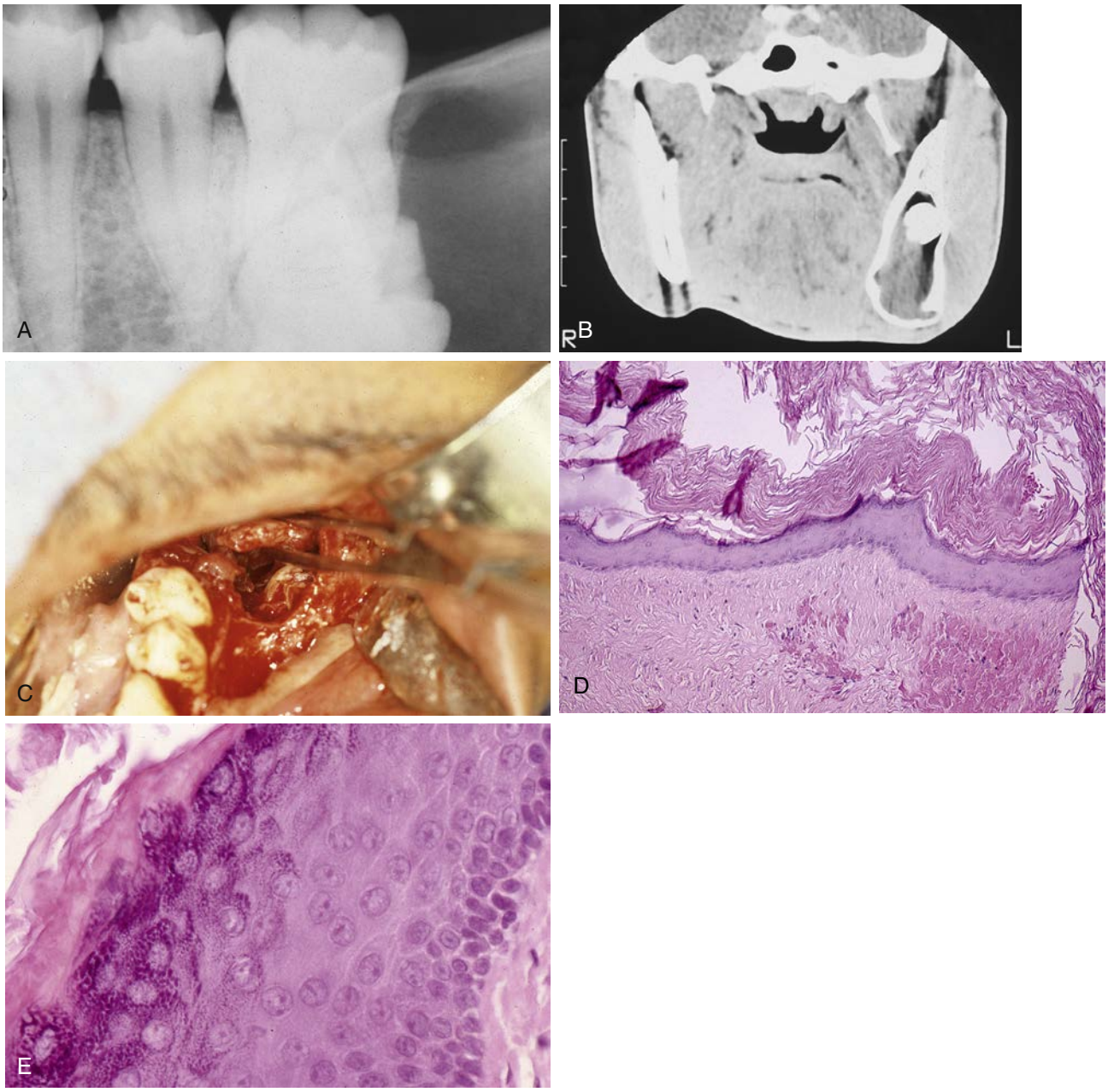

• **Figure 17-18** **A,** A routine periapical radiograph from a 26-year-old man shows a cyst with an associated second molar. **B,** A computed tomography scan revealed a well-corticated unicystic lesion with both impacted first and second molar. **C,** The cyst was enucleated. **D-E,** Histopathology shows stratified squamous epithelium with obvious lack of a columnar and palisading basal cells, marked keratohyaline granules in the superficial cells, and fibrillar keratin in the lumen. Diagnosis of orthokeratinized cyst was established.

large resections (see Figures 17-14 and 17-15). We have also had success when using this technique with recurrent KCOTs. For example, for a 45-year-old woman with recurrence of a maxillary KCOT, a decompression of approximately 9 months followed by enucleation and adjunct treatment with Carnoy solution was performed. The patient had no evidence of recurrence 3 years postoperatively (see Figure 17-14). As always, close and long-term follow-up is essential when treating the odontogenic keratocyst, regardless of the surgical modality used. The benefits of the use of the two-stage surgery approach far outweigh its drawbacks. Decreases in morbidity and fewer social consequences are the two most significant benefits. In summary, the available treatment modalities for KCOT are far from settled. There is no single approach that provides a cure with no or consistently low recurrence rates and simultaneously has limited morbidity. We therefore believe that all available surgical modalities, with the exception of marsupialization as the sole treatment, have a place in the armamentarium of the treating oral and maxillofacial surgeon. In small and bony

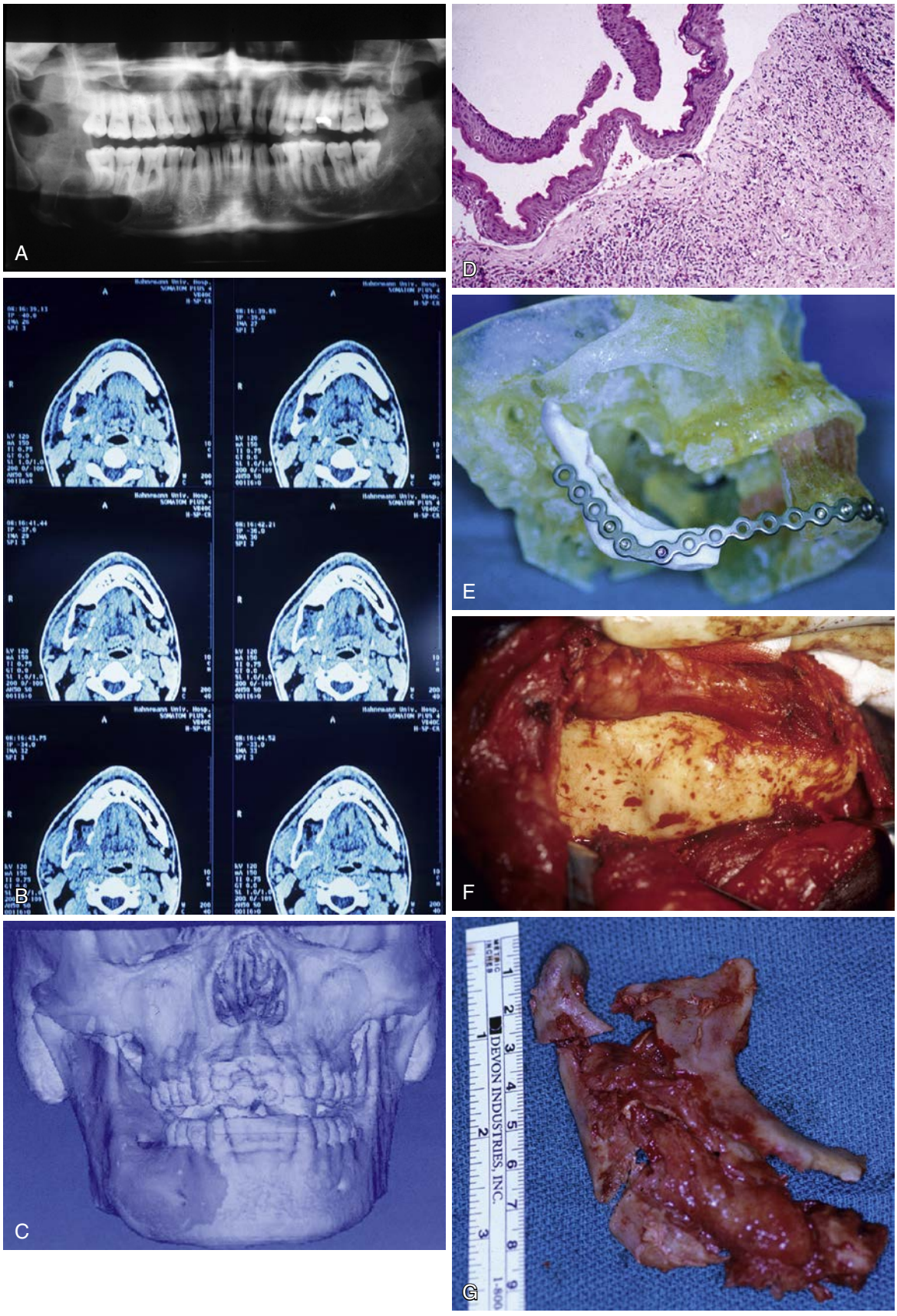

• **Figure 17-19** A 29-year-old man presented with chief complaint of recurrent pain and swelling for 2 years with no recommended management. A plain panogram **(A)** and 3D computed tomography scan **(B-C)** revealed a destructive lesion of left body and ascending ramus of mandible. **D,** An incisional biopsy led to a diagnosis of parakeratotic cyst. **E,** Preoperative planning was facilitated by stereolithographic model; the patient then underwent hemimandibulectomy with disarticulation. **F-G,** Intraoperatively, the resected specimen shows the expansion and destruction of bone.

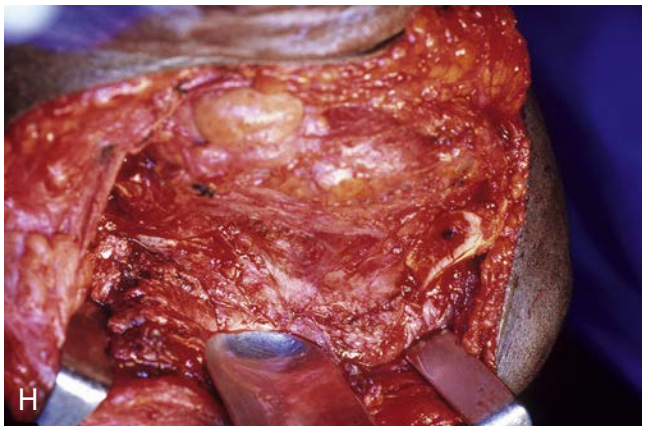

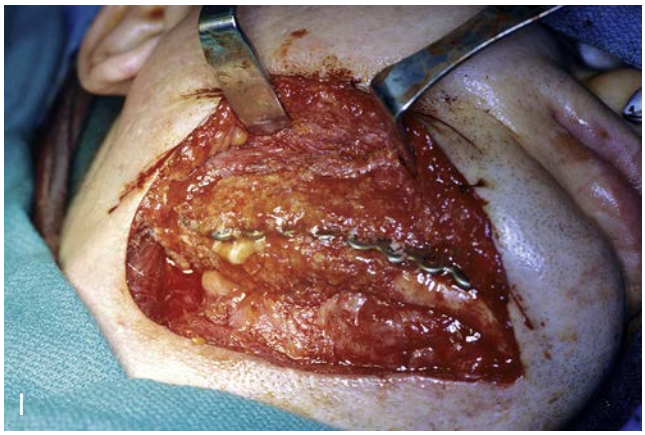

• **Figure 17-19, cont'd H-I,** The resected mandible was immediately reconstructed with reconstruction plate with attached metal joint, bone grafting, and plasma-rich platelets. (Surgery performed by Dr. Nabil Abaza and Steven Kaltman, DDS, MD, Fort Lauderdale, FL.)

contained lesions, we believe that cystectomy followed by other adjunct therapies—including chemical cauterization by Carnoy solution or 5% phenol, cryotherapy, or peripheral ostectomy, if practical—offers the optimal chance for good initial management of these lesions (see Figure 17-12). In large cysts, a two-stage procedure (decompression followed by cystectomy and also adjunct therapy) offers a sound approach.

This is particularly the case if there is bony dehiscence in the cyst bed. The bone regeneration and thickening of the cyst wall secondary to inflammation usually facilitate the enucleation of the cyst in one piece. The excision of the gingival tissue around the decompression site is also recommended. In large, particularly multi-loculated KCOTs and those that involve the superior position of the ascending ramus or the posterior maxilla, resection of the lesion with discontinuity defect may be the only sound surgical approach. Therefore hemimandibulectomy, with or without disarticulation, and hemimaxillectomy or partial maxillectomy should also be included in the surgeons' choices. Immediate or delayed reconstruction of the mandible or maxilla is then indicated (see Figure 17-19).

In addition to treatment of keratocystic odontogenic tumors, this two-stage treatment modality has proven successful for unicystic ameloblastomas. Although the topic of ameloblastoma is discussed in much greater detail in other chapters of this book, we have had excellent results with conservative two-stage treatment of unicystic ameloblastoma variants and have incorporated two cases into this section (Figures 17-20 and 17-21). This decompression treatment approach is limited to the unicystic variant of ameloblastomas and cannot be used for multicystic or solid ameloblastoma variants. The solid and multicystic ameloblastoma variants will require marginal resection with 1-cm bony margins around the radiographic limits of the lesion and one anatomic barrier.[91] Thus, CT scan imaging is mandatory during the treatment workup to confirm that the lesion is, in fact, unicystic in nature. Unicystic ameloblastomas typically occur in the third decade of life compared to the fourth for their multicystic and solid counterparts, which makes this conservative treatment modality more appropriate for the younger population typically affected by these lesions. Treatment of unicystic ameloblastomas using a two-stage decompression mandates good patient compliance and close follow-up. These patients must follow up frequently during the decompression period, in addition, to perform daily irrigation of the surgical site. The second-stage enucleation should be performed after decompression stage when there is sufficient bone to prevent damage to adjacent structures.[92] For the cases presented, a decompression stage of 9 months was successfully used.

Nevoid Basal Cell Carcinoma Syndrome

Overview

This syndrome is a genetic disorder with autosomal dominant inheritance, high penetrance, and variable expression.[93,94] In 1987 Gorlin[94] reviewed the syndrome history, tabulated the disease findings and their frequency, and commented on the naming of the syndrome. Historically, the syndrome was documented in two ancient Egyptian skeletons where multiple cysts, bifid ribs, relative shortening of the fourth metacarpal, and other skeletal findings were present.[95] In 1951 Binkley and Johnson[96] reported on a 30-year-old woman who had manifestations of the syndrome including numerous basal cell nevi, multiple jaw cysts with associated impacted teeth, and bifid ribs. The patient died from widespread metastases of an osteosarcoma of the jaw, apparently secondary to the irradiation therapy she received. Autopsy showed partial agenesis of the corpus callosum. The patient had a daughter who had many skin lesions as well, and these authors, therefore, speculated that the disease was genetic in origin. It was not until 1960, however, when Gorlin and Goltz[93] established the relationship of multiple basal cell epitheliomas, multiple jaw cysts, and bifid ribs, that the term *nevoid basal cell carcinoma syndrome* was coined. The syndrome also is frequently referred to as Gorlin-Goltz syndrome, Gorlin syndrome, and

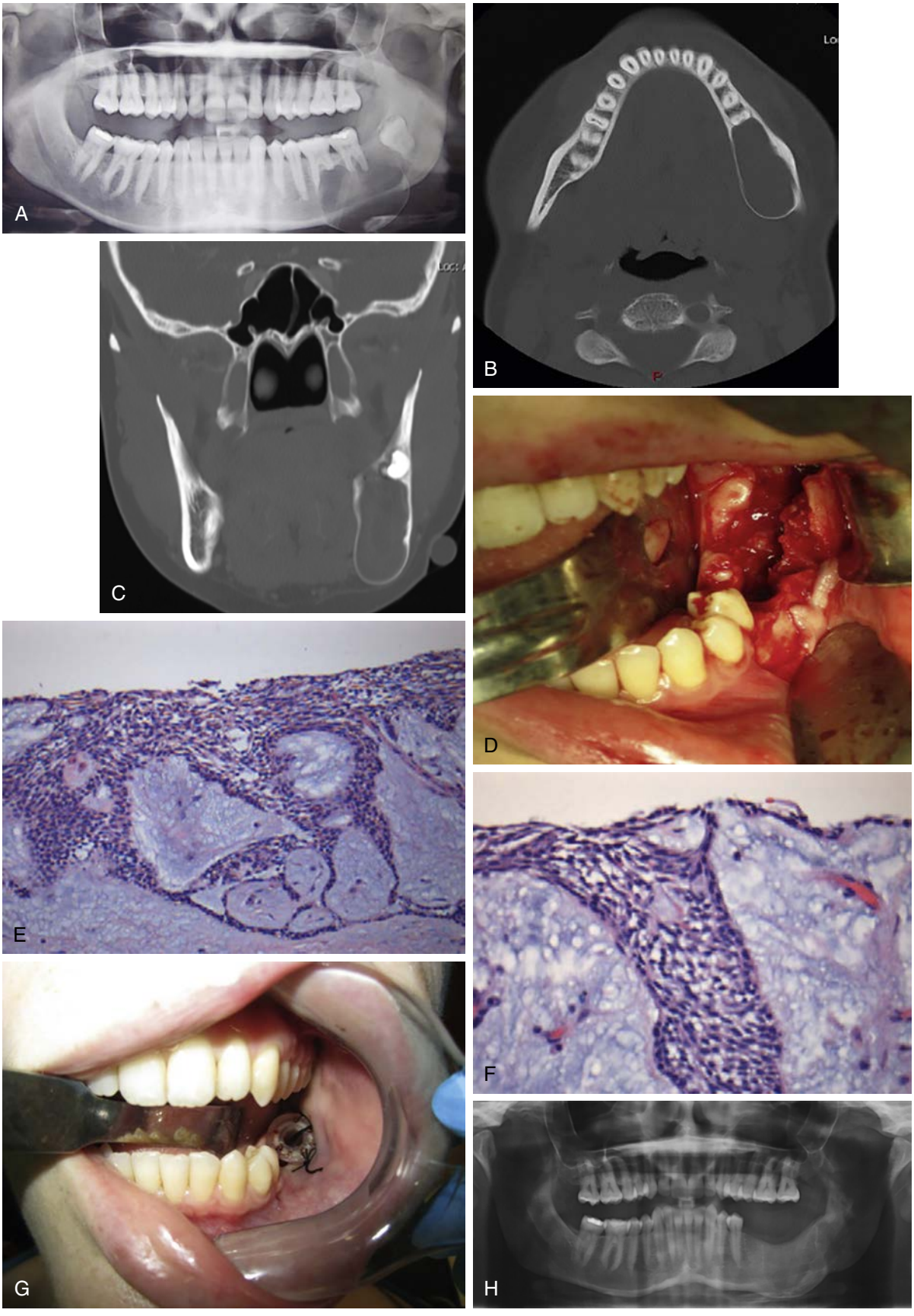

• **Figure 17-20** **A,** Radiograph of a 31-year-old woman with progressive left facial swelling. **B,** Axial and coronal computed tomography scan images **(C)** demonstrating the unilocular nature of the left mandibular cystic lesion. **D,** First-stage decompression surgery was completed. **E,** Low-power and **(F)** high-power photomicrographs of the ameloblastic epithelium show evidence of stellate reticulum and reverse polarization of the peripheral column cells. **G,** An acrylic button was placed during the 9-month decompression period, prior to second-stage enucleation. **H,** 1 year postoperative panogram shows good bone healing after second-stage enucleation. (Surgery performed by Dr. Nabil Abaza and Fizza Jaffery DMD, MD, Woodbury Heights, NJ.)

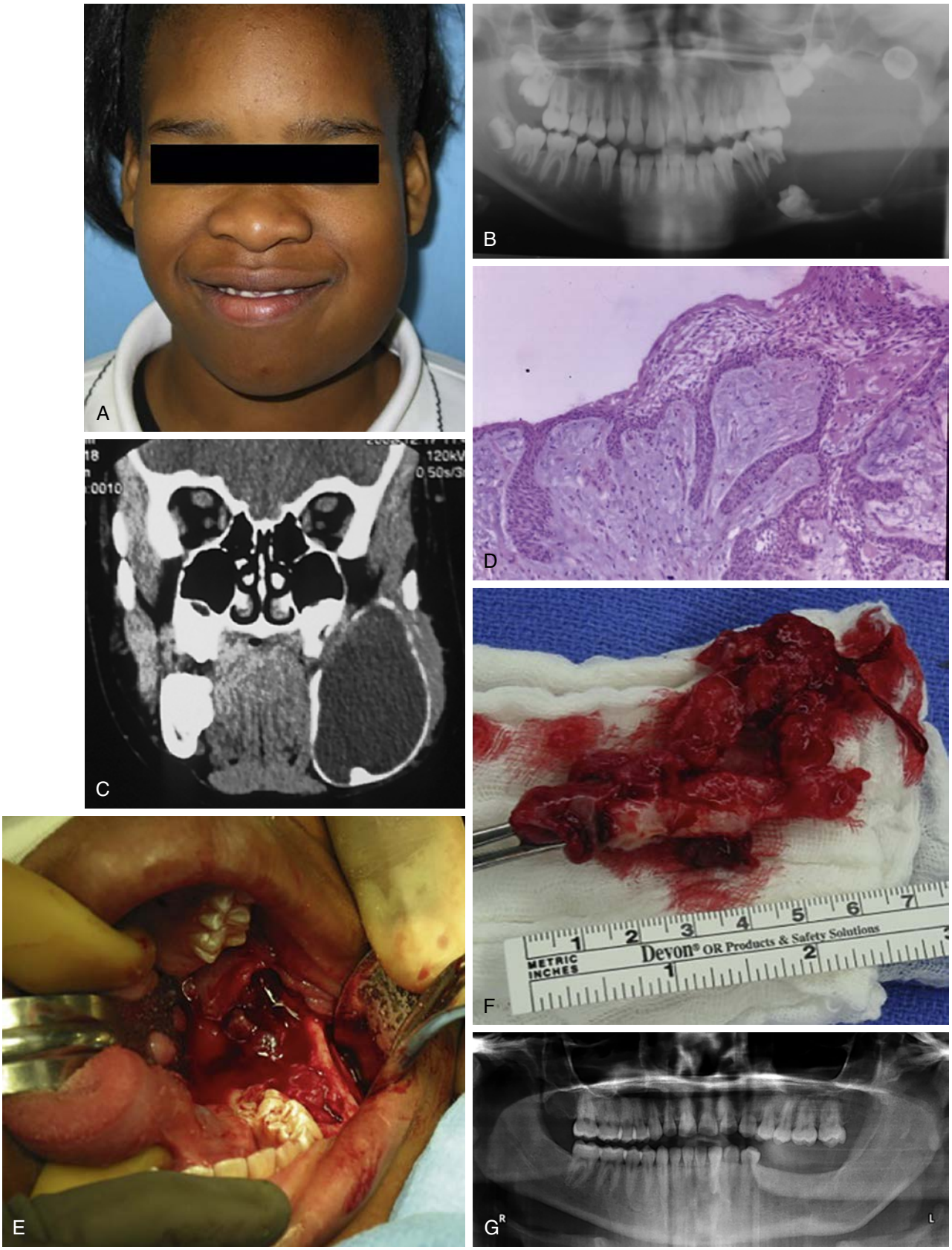

• **Figure 17-21** **A,** An 11-year-old girl presenting with left facial asymmetry. **B,** Panogram obtained at initial consultation and coronal computed tomography image **(C)** confirming unilocular nature of left mandibular lesion. **D,** Photomicrograph of the lesion showing ameloblastic epithelium with stellate reticulum, consistent with the diagnosis of unicystic ameloblastoma. **E-F,** Intraoperative images of the second-stage enucleation of the unicystic ameloblastoma after a 9-month period of decompression. **G,** 6-year postoperative panogram demonstrates successful treatment of the unicystic ameloblastoma without recurrence.

nevoid basal cell carcinoma syndrome (NBCCS) or the syndrome; dermatologists prefer the term *nevoid basal cell carcinoma syndrome*.[6,96,97] Gorlin[94] has expressed his opposition to eponyms because they say nothing about the syndrome.

Genetic studies have found the NBCCS gene to be mapped to chromosome 9, 9.622.3. It is proposed to function as a tumor suppressor by deletion of this region in many of the neoplasms related to the syndrome.[30,31] Tod and August[98] discussed molecular approaches to the diagnosis of sporadic and syndrome-associated KCOTs. The most studied marker is the *PTCH* gene, the human homolog of the *Drosophila* segment polarity gene, which is a tumor suppressor gene located on chromosome 9. These authors stated that the *PTCH* gene is a key regulator of the pluripotent hedgehog signaling network that is believed to have widespread consequences. Several congenital and neoplastic disorders are associated with gene mutations within this network.[98,99] Classic genetic and molecular studies have shown that the *PTCH* gene is mutated in patients with NBCC.[98]

• BOX 17-2 Features of Nevoid Basal Cell Carcinoma Syndrome

Cutaneous

Basal-cell epitheliomas
Milia
Palmar pits
Plantar pits
Epidermal cysts of skin
Subcutaneous calcifications
Cleft lip or palate
Polydactyly

Skeletal

Odontogenic keratocysts
Bifid ribs
Scoliosis
Mandibular prognathism
Increased calvarial diameter
Well-developed supraorbital rims
Spina bifida of cervical or thoracic spine
Hyperpneumatization of paranasal sinuses
Short fourth metacarpals
Marfanoid build

Ocular

Glaucoma
Cataracts
Coloboma of the iris
Hypertelorism
Strabismus
Nystagmus

Neurologic

Calcified falx cerebri
Mental retardation
Cerebral tumors
Agenesis of corpus callosum
Calcified tentorium cerebelli

Sexual

Undescended testes
Ovarian tumors
Hypogonadism

From Rogerson KC: Gorlin's syndrome: an update on diagnosis and management, *Oral Maxillofac Surg Clin North Am* 3:155, 1991.

Clinical Features

The clinical features of the syndrome are classically grouped within five categories: cutaneous, skeletal, ophthalmologic, neurologic, and sexual[100] (Box 17-2). The components of the syndrome are numerous with varying frequency (Table 17-2). The multiple odontogenic cysts and the basal cell nevi

TABLE 17-2 Components of Nevoid Basal Cell Carcinoma Syndrome and Their Frequency

I. Jaw and Skull	
1. Odontogenic keratocysts	>85%
2. Calcified falx cerebri	> 85%
3. Large calvaria	>60%
4. Large paranasal sinuses	>60%
5. Hypertelorism	>50%
6. Bridging of the sella turcica	>70%
7. Cleft lip and palate	<15%
II. Skin and Internal Organs	
1. Basal cell carcinomas	>70%
2. Milia/epidermoid cysts	>50%
3. Palmar-plantar pits	>50%
4. Calcified ovarian fibromas	>50%
5. Subcutaneous calcifications	<15%
6. Fetal rhabdomyomas	<15%
7. Ovarian fibrosarcomas	<15%
III. Axial Skeletal Abnormalities	
1. Rib abnormalities	>60%
2. Spina bifida	>50%
3. Kyphoscoliosis	>40%
4. Short fourth metacarpal	>25%
5. Lumbarization of sacrum	>40%
6. Pseudocysts of phalanges	>30%
IV. Central Nervous System	
1. Medulloblastomas	<2%
2. Congenital hydrocephalus	<3%
3. Mental deficiency	<3%
4. Craniopharyngiomas	<1%
5. Meningioma	<1%

From Marx RE, Stern D: Odontogenic and nonodontogenic cysts. In *Oral and maxillofacial pathology: a rationale for diagnosis and treatment*. Quintessence, 2003, Chicago, p 603.

constitute frequent and clinically significant expressions of the syndrome. The oral and maxillofacial pathologist and surgeon may be the first health care providers who diagnose or suspect the syndrome. They not only provide treatment for these patients, but also are obligated to consult other specialty providers because of the systemic nature of the syndrome. Genetic counseling of the patients and their families is strongly recommended. Some guidelines for the diagnosis are a family history, oral and complete skin examinations, radiographs of the jaw and chest, MRI of the brain, and also ultrasound of the pelvis in women. Keratocystic odontogenic tumors, usually multiple, occur with high frequency in the syndrome.[94] It is well established, however, that sporadic non–syndrome-associated cysts also occur.[23,94] The syndrome KCOTs are frequently multiple, and the patient is younger when the first lesion is diagnosed[9] (Figure 17-22). Shear[30] emphasizes that multiple cysts are not necessarily present at the time of the initial diagnosis, because cysts may develop afterward (see Figure 17-22, *C*). Basal cell carcinoma is a significant lesion in these patients[8,9] (Figure 17-23). Lesions begin during puberty or the second or third decade of life. They vary from flesh-colored papules to ulcerating plaques (see Figure 17-23, *A*). They are located most commonly in the midface area but also occur in non–sun-exposed sites. Among the skeletal abnormalities detailed in Boxes 17-1 and 17-2 and Table 17-2, the bifid ribs and calcification of the falx cerebri are most frequent (see Figure 17-22, B). The patient often has a characteristic face with frontal bossing, hypertelorism, and mild prognathism present.

Imaging and Pathologic Features

There are no special features to distinguish syndrome-associated from non–syndrome-associated KCOTs. The size varies depending on the time of diagnosis. The lesions can assume large size and can be unilocular or multilocular with significant displacement of associated teeth (see Figure 17-22, *A* and *B*).

The microscopic features are not pathognomonic for syndrome-associated cysts. The epithelial lining can be orthokeratinized or parakeratinized. The degree of inflammatory cell infiltrate depends on whether the lesion communicated with the oral cavity and became secondarily infected. Neville and colleagues[8] summarized the histopathologic characteristics of the syndrome cysts. These lesions tend to have more satellite cysts, solid islands of epithelial proliferations, and odontogenic epithelial rests within the fibrous capsule than do isolated keratocysts. The skin lesions in the syndrome exhibit a wide spectrum of histopathologic findings that range from benign adnexal basal cell lesions to aggressive, ulcerating basal cell carcinomas (see Figure 17-23; Figure 17-24).

Surgical Management

It is important to recognize that these patients must undergo multiple surgeries to excise current, recurring, or newly developing cysts. We treat these lesions like other KCOTs—by enucleation followed by adjunctive therapy if the size is small with no evidence of bony dehiscence. In large lesions we have been using the two-stage approach, with primary decompression followed by cystectomy and adjunct chemical cauterization, within a few months (see Figure 17-22).

Other Odontogenic Cysts

For the sake of completeness, the less frequently encountered odontogenic cysts are briefly discussed.

Gingival Cyst of Infants

This cyst occurs in infants a few hours to a few months old (Figure 17-25). Cysts appear as multiple, firm, white gingival nodules on the edentulous maxillary or mandibular ridges. They arise from proliferation of the dental lamina.[6,8] They usually involute, and no treatment is required except parent reassurance.[9]

Other inclusion cysts such as Epstein pearls and Bohn nodules are found in the midline of the palate or laterally on the hard and soft palate.[6,8,9]

Gingival Cyst of Adults

This is an uncommon lesion considered to be the soft tissue counterpart of the lateral periodontal cyst.[6,8,9] It is derived from the rests of Serres (the dental lamina) and has microscopic features similar to those of the lateral periodontal cyst.

Lateral Periodontal Cyst: Botryoid Odontogenic Cyst (BOC)

This is a rare odontogenic lesion that is derived from proliferation remnants of the dental lamina. It occurs generally in the mandible between premolar and cuspid teeth. Histologically it is lined with a thin band of stratified squamous non-keratinized epithelium that has clear focal plaques, because of their high glycogen content. It may be multiloculated, but its lining epithelium rarely shows keratinization.[101] A variant of the lateral periodontal cyst is the botryoid odontogenic cyst. The latter differs from the former in being radiographically and microscopically multilocular with numerous lobulations and thickened epithelial tufts resembling a grape cluster or botryoid.[9] It has a higher recurrence rate, probably because of the difficulty of its excision. Neville and colleagues[8] indicate that the term *lateral periodontal cyst* was used to describe any cyst developing along the lateral root surface, such as lateral radicular and odontogenic keratocysts. The lesion does have distinctive clinical and histopathologic features that differentiate it from other lesions that develop in the same location.[8,9]

Glandular Odontogenic Cyst

This is a relatively new entity and was initially referred to as a sialo-odontogenic cyst.[6,8,9] Most of these cysts occur in the anterior mandible, as seen in the panogram in Figure 17-26, *A*, of a 54 year-old man who was diagnosed with a glandular odontogenic cyst after incisional biopsy.

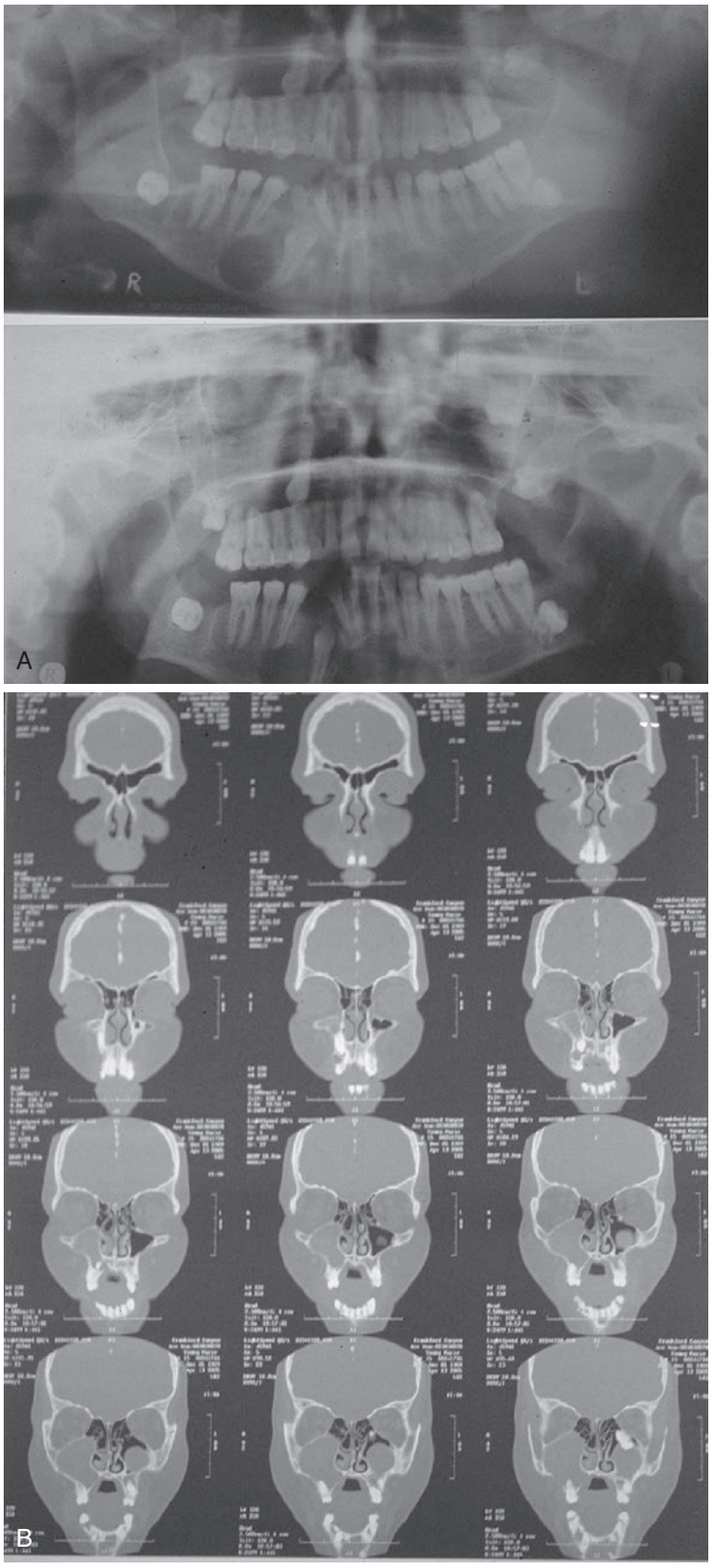

• **Figure 17-22** Frequent features of nevoid basal cell carcinoma syndrome includes multiple odontogenic keratocysts (OKCs) as illustrated in **(A)** a panogram and **(B)** computed tomography scan imaging **(B)** in a 16-year-old girl who has two siblings with jaw cysts. **A,** The patient initially seen with infection of anterior mandible; after clearing of the infection the cysts in this site were connected, decompression initiated to allow for the eruption of the lower right canine. The patient has had other procedures and continues to be under our care. **B,** Note the calcification of the falx cerebri.

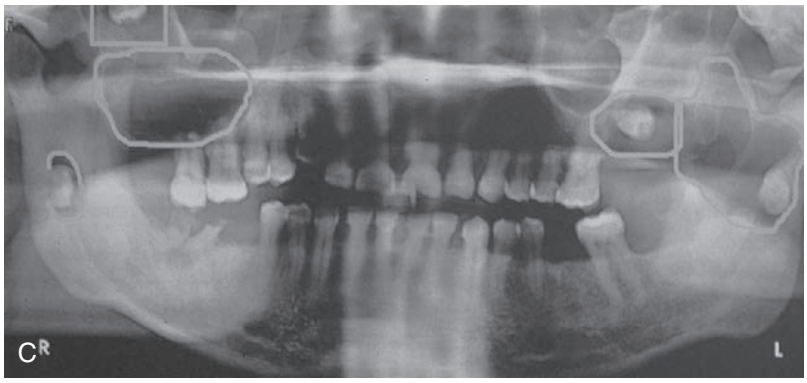

• **Figure 17-22, cont'd C,** Not all patients with multiple OKCs have the syndrome, as illustrated in a panogram of a 45-year-old man who has been recently seen with no apparent signs and symptoms of the syndrome.

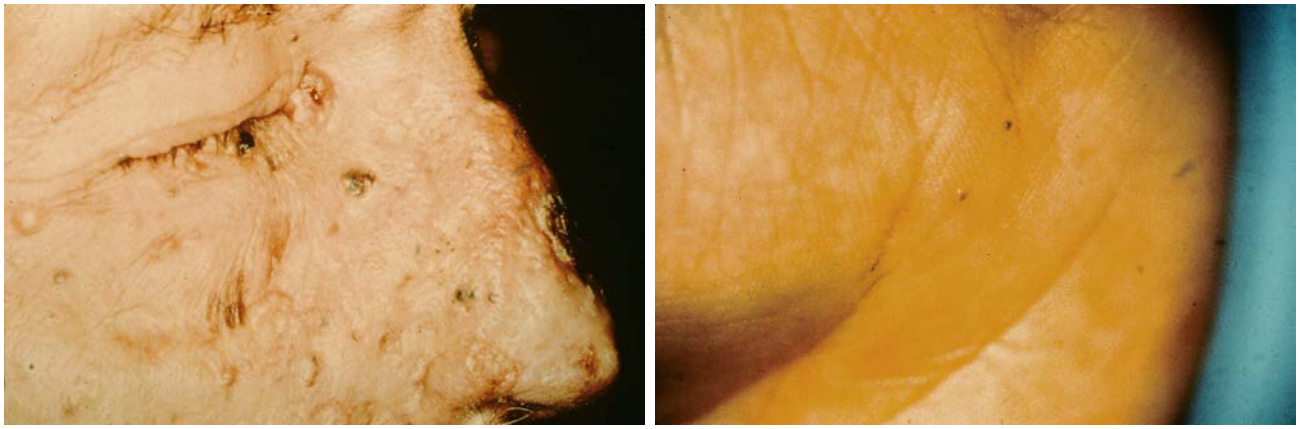

• **Figure 17-23** Basal cell carcinomas and palmar pitting are common and significant features of the syndrome.

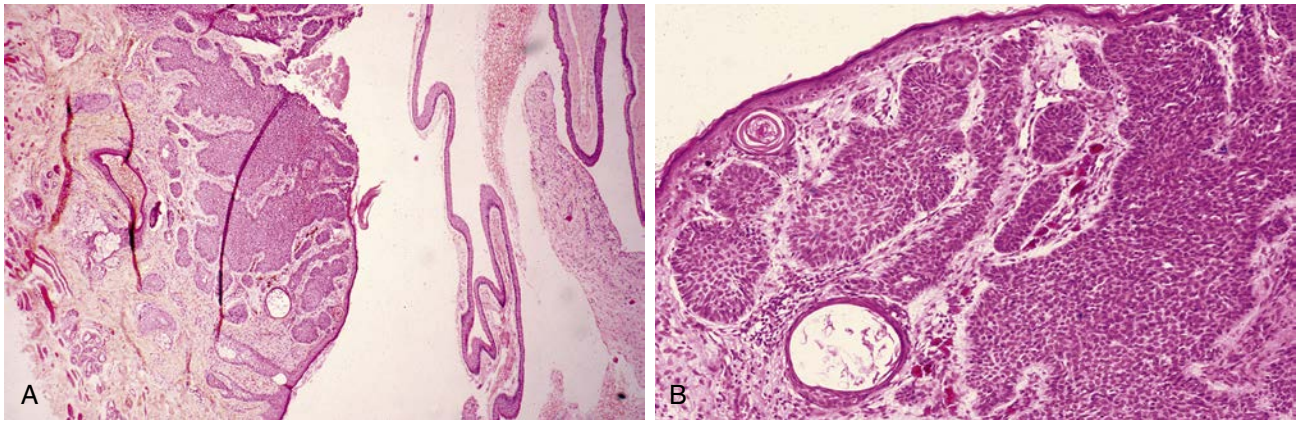

• **Figure 17-24 A,** A lower-power photomicrograph of odontogenic keratocyst and basal cell carcinoma from the same patient with nevoid basal cell carcinoma syndrome. **B,** Higher magnifications of multifocal basal cell carcinoma.

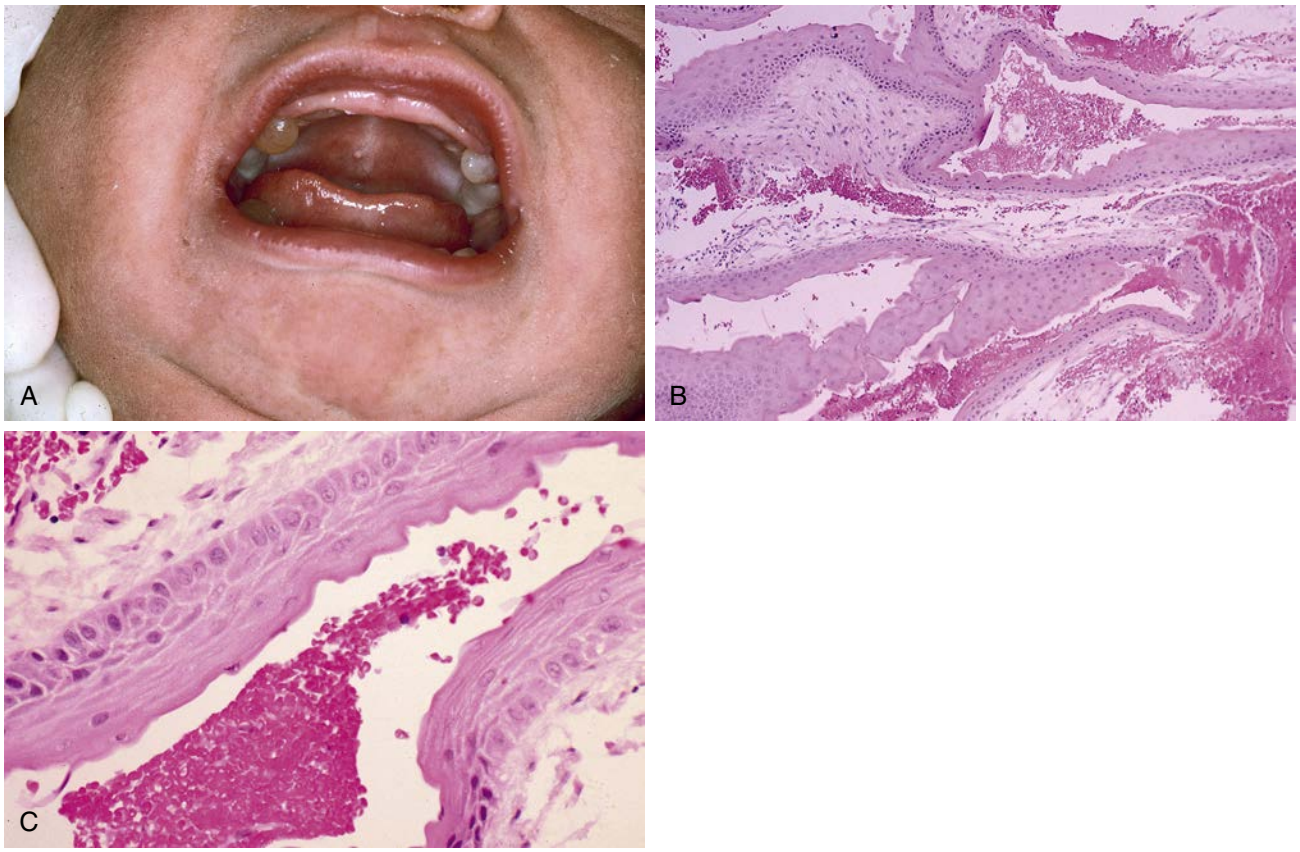

• **Figure 17-25** **A,** A 2-day-old baby boy with multiple cysts in the mandible and maxilla. Because of difficulty in nursing and the concern of the parents, the cysts were evacuated. **B-C,** Low and high magnification photomicrographs show a cyst lined with stratified parakeratotic squamous epithelium with surgical hemorrhage.

Radiographically, these lesions are multiloculated. Histologically, they are lined by nonkeratinized epithelium consisting of cuboidal cells, often with cilia at the luminal surface. The cyst has features that suggest a mucus-producing lesion. Gardner and Morency[102] and Kramer and colleagues[6] detailed the microscopic features of the cyst. The lining epithelium is cuboidal or columnar with crypts or cystlike spaces within the thickness of the epithelium. Histologic features of the cyst, such as mucous metaplasia, may overlap with other lesions (e.g., mucoepidermoid carcinoma and botryoid cyst). These lesions can also be quite aggressive and recur in up to 25% of cases.[102-104] In 2005 Kaplan and colleagues[103] reviewed 49 cases from the literature and added 7 new cases. These authors reasserted the aggressiveness of these lesions and reviewed the frequency of recurrences associated with the various available surgical modalities of treatment.[103] They recommended enucleation of small lesions and enucleation with peripheral ostectomy and resection for larger unilocular and multilocular lesions, respectively. Figure 17-26 shows treatment of a large, multilocular lesion with mandibular resection and immediate reconstruction. A two-stage surgery—decompression followed by a second-stage surgical therapy—is suggested for large lesions approaching vital structures. This approach to the lesion surgical management is similar to that for the odontogenic keratocyst and unicystic ameloblastoma, as presented in this chapter.

Calcifying Odontogenic Cyst/Tumor

Overview

In the oral and maxillofacial region, as in other anatomic sites, there are lesions that are cystic and defy a widespread acceptance in one classification or another. The calcifying odontogenic cyst (COC) and the adenomatoid odontogenic tumor (AOT) are among such lesions of interest to the oral and maxillofacial surgeon and pathologist. These two clinical entities are classified as tumors in the 1992 WHO classification of odontogenic tumors.[6] However, this view is not widely accepted. We discuss in detail the COC and tumor-related lesions. The AOT is presented elsewhere in this volume.

Clinical Features

The COC is an uncommon odontogenic lesion. In 1962 Gorlin and colleagues[105] identified the lesion as odontogenic and suggested it to be the counterpart of the cutaneous calcifying epithelioma of Malherbe, or pilomatricoma. In 1963 Gold[106] independently described three other cases. Pilomatricoma is a benign lesion that is hard and fixed to the skin but

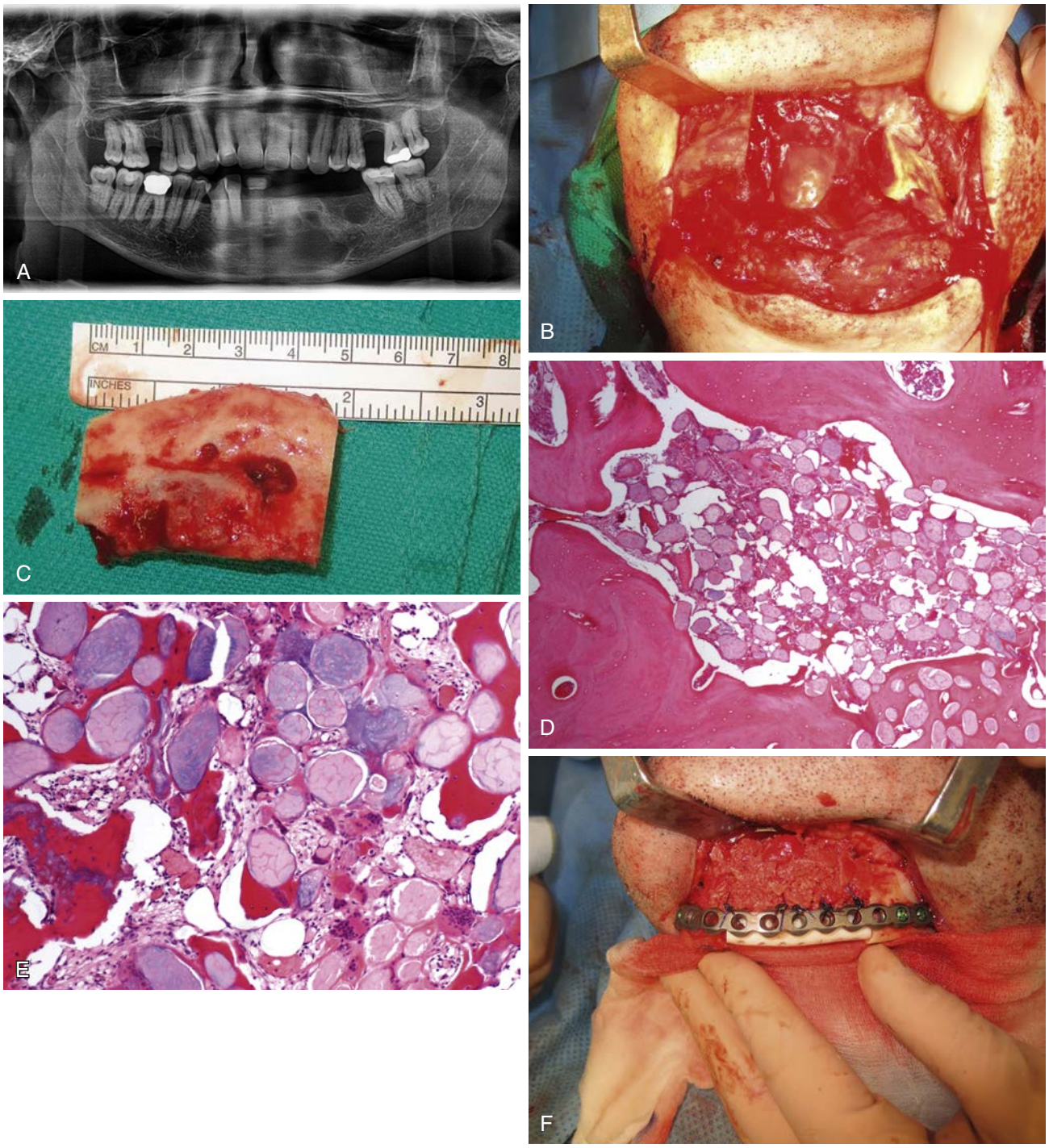

• **Figure 17-26** **A,** Panogram of a 54-year-old man presenting with buccal cortical expansion of the left mandibular parasymphyseal area. Incisional biopsy of the mandibular lesion revealed diagnosis of glandular odontogenic cyst. **B-C,** Surgical resection performed and specimen sent to pathology. **D,** Low-power photomicrograph of the glandular odontogenic cyst demonstrates the glandular structure of the lesion invading the bone. **E,** Higher-power magnification shows significant mucus production within the lesion, along with scattered giant cells. **F**, Immediate mandibular reconstruction performed with autogenous bone harvest using the posterior iliac crest. (Surgery performed by Joseph Kern, DDS, MD, Plymouth Meeting, PA; Fizza Jaffery, DMD, MD, Woodbury Heights, NJ; and Dr. Nabil Abaza. Photomicrographs were provided by Beth Mapow, DO, Drexel University Department of Pathology, Philadelphia.)

not the underlying tissue, and it occurs in the maxillofacial region in children, adolescents, and young adults. In analysis of a large series of the oral counterpart of pilomatricoma, the COC occurs, in descending order of frequency, as a central cystic lesion, which may be unilocular, multilocular, or associated with an odontoma; a peripheral cystic lesion on the gingiva or alveolar mucosa; or a peripheral or central solid growth or neoplasm.[107,108] Hong and colleagues[107] reviewed the published terms used to designate the lesion, and among the more frequently cited names are calcifying odontogenic cyst, keratinizing and calcifying odontogenic cyst, keratinizing ameloblastoma, calcifying ghost cell tumor, and cystic calcifying odontogenic tumor. These authors concluded that "the existence of numerous terms reflects a diverse histopathology and confusion about their nature as cysts, neoplasms, or hamartomas."[107] The second edition of the WHO classification of odontogenic lesions in 1992 includes the COC as an odontogenic tumor but indicates that most lesions appear non-neoplastic.[6] Praetorius and colleagues,[109] however, concluded that the spectrum of lesions designated as COC contains two different entities—a cyst and a neoplasm. The cystic entity was classified into three types and the neoplastic counterpart was termed dentinogenic ghost cell tumor.[43] Still others suggested more names such as dentino-ameloblastoma, epithelial odontogenic ghost cell tumor, calcifying ghost cell odontogenic tumor, and dentinogenic ghost cell odontogenic tumor as reviewed by Moleri and colleagues[108] in their reporting on the lesion in 2002. Gold's[106] original designation of the lesion as a keratinizing and calcifying odontogenic cyst accurately describes the lesion.[9,110] The tumor designation of this lesion arose from the solid pattern of growth. Furthermore, the tumor entity has been subcategorized into benign and malignant, based on the presence of malignant cytologic features; no metastasis has been reported.[6,111] The incidence of such malignant transformation is rare, but it has been documented.[111,112] It is of interest to recall that the skin pilomatricoma has malignant transformation to pilomatrix carcinoma in up to 9% of benign lesions.[113] Johnson and colleagues[110] suggested that in indisputably neoplastic cases, the lesion may be called ameloblastoma with COC or a ghost cell component. Hong and colleagues[107] have used the term *ameloblastoma ex-COC*. However, the following question remains: If the ghost cell component was absent, how would the lesion be diagnosed?

In summary, the COC is predominantly an intraosseous lesion, but it also appears extraosseously in around 12% to 20% of cases.[107] Maxillary and mandibular lesions have similar frequency and are diagnosed in patients in the second and third decade of life, younger if associated with an odontoma.[107,114] The extraosseous COC usually presents as a localized sessile or pedunculated mass on the gingiva.

Imaging Features

COCs are usually small lesions ranging from 2 to 4 cm in diameter, but they can attain large size with displacement of teeth and root resorption.[109,115] Most lesions are unilocular and cause saucerization of the bone, but some are multilocular. Irregular calcifications ranging from tiny flecks to large masses are usually scattered throughout the radiolucency.[68,108] The association with odontomas is well established.[107,115] With large lesions, thinning of the bone and encroachment on adjacent soft tissue can occur. In such cases and in suspected solid growth, a CT scan is advisable. The imaging features are nonspecific except perhaps the presence of scattered radiopacities that may shorten the differential diagnosis list.

Pathologic Features

The well-defined cystic lesion has a relatively thick connective tissue wall with an epithelial lining of variable thickness and morphology.[68,106,110,115] The basal cell layer is tall columnar or cuboidal, similar to ameloblasts, with the nuclei palisading away from the basement membrane (Figures 17-27, 17-28, *A-C*). Superficial to the basal cell layer is a multilayered epithelium resembling stellate reticulum. The hallmark of the lesion is the presence of "ghost cells" (see Figure 17-28, *A-C*). These cells display a progressively eosinophilic and granular cytoplasm and pyknotic nuclei and become swollen. The cells attain "ghostly" outlines, with only shadows of the cells and nuclear membranes faintly recognizable. These cells usually fuse and form extensive sheets that may fill the cyst lumen or herniate through the basement membrane into the connective tissue cyst wall. In the latter situation, foreign body–type granulomas are usually seen. The presence of these ghost cells is diagnostically helpful but is certainly not pathognomonic for the diagnosis of COC. Ghost cells are also present in odontomas, ameloblastomas, craniopharyngiomas, and pilomatricomas[107,116] (see Figure 17-28, *D*). The ghost cells usually fuse and form extensive sheets, and they may fill the cystic lumen.[108] Individually these cysts may undergo calcification or lose their cell outline and form sheetlike areas of calcification[106,110] (see Figure 17-28, *A*). The calcification has been reported to be dystrophic.[101,103,105] When the epithelium is in direct contact with the connective tissue, the calcification has been reported to contain dentinal tubules and, therefore, is occasionally referred to as dentinoid-like. COCs have been studied immunochemically and ultrastructurally.[68,111,117,118] Johnson and colleagues[110] found that the lining epithelial cells were strongly positive for cytokeratin, whereas full-blown and disintegrating ghost cells were unreactive.

Ultrastructure Features

Ultrastructurally, COCs in paraffin-embedded blocks have been examined previously by several authors.[68,117,118] The nature of the mature ghost cell remains unsettled. It has been claimed that they represent the product of normal or abnormal keratinization,[105,106] squamous metaplasia of odontogenic epithelium,[119] or abortive enamel or pre-enamel matrix formation.[120] The COC basal cells are cuboidal or low columnar in shape and are attached to neighboring cells by desmosomes and a lamina densa, which separates them from adjacent connective tissue by hemidesmosomes. Intracellular individual or small bundles of tonofilaments and a moderate number of regular organelles are present. The nucleus is

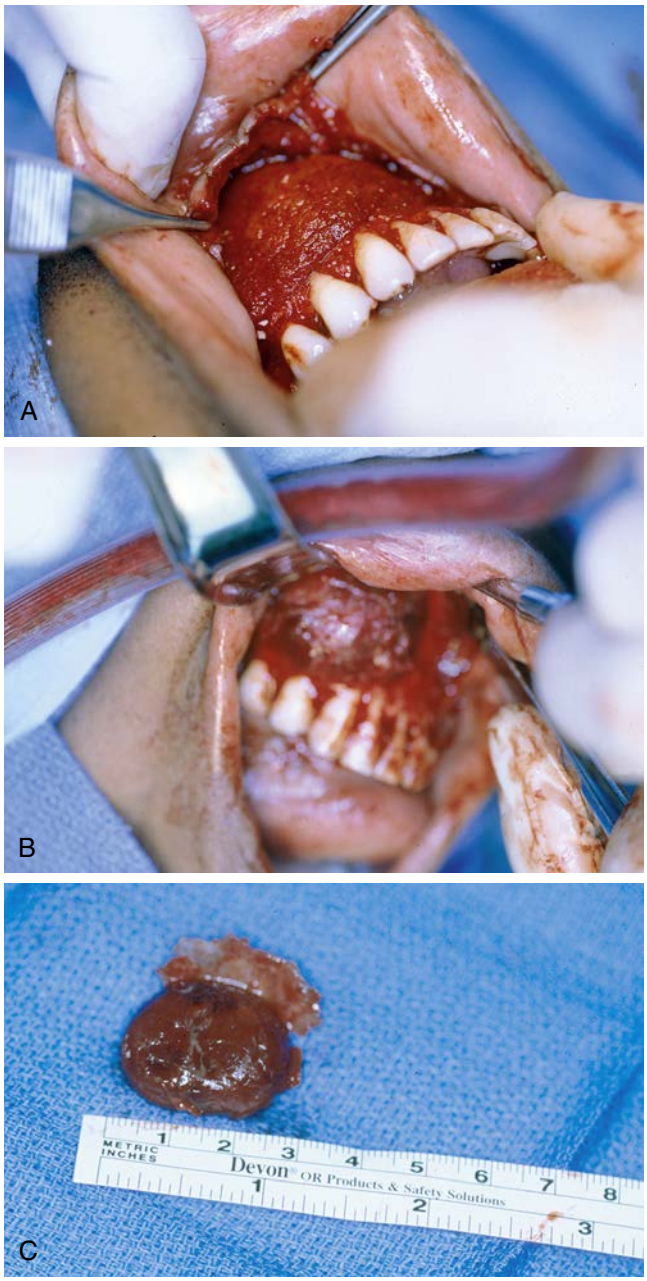

• **Figure 17-27** **A,** The calcifying odontogenic cyst (COC) is a well-delineated lesion that can cause cortical expansion and **(B-C)** is easily enucleated.

irregularly ovoid, with irregularly clumped chromatin. The stellate reticulum type cells are polygonal, with more desmosomal attachments to the neighboring cells. Their villus-like cytoplasmic projections into prominently expanded intercellular spaces are more frequent than those of the basal cells. The ghost cells are mostly anuclear and contain pyknotic nuclei or residues of chromatin in the negative nuclear zone.[68,117,118] The only organelles in their cytoplasm are very thick electron-dense fibrils of uniform size sharply defined against large empty spaces previously occupied by the nucleus (Figure 17-29, *A* and *B*). Small needlelike crystalloid structures are present in these cells. Fejerskov and Krogh[117] concluded from these observations that the COC keratinization pattern is not identical to that of the normal epidermis and oral mucosa. Chen and Miller[118] found similar ultrastructural features of ghost cells, in which the plasma membrane was thickened and irregularly disrupted, with disappearance of desmosomes and the villus-like projections seen in other cells. In addition, these two authors described another cell, the so-called hornified cell, which reacted like keratin with trichrome stain of 1-µm sections. By electron microscopy, however, these cells were composed of moderately densely packed and evenly distributed tonofilaments oriented in different directions with occasional residue of organelles (see Figure 17-29, *C*). Mineral crystals were deposited on bundles of tonofilaments of the ghost cells and the surrounding collagen fibers (see Figure 17-29, *D*). They concluded that mineralization of ghost or hornified cell residues is explained as dystrophic calcification. Kerebel and Kerebel,[119] in their light microscopy and scanning electron microscopy of ghost cells in complex odontoma, concluded that the tonofilaments in ghost cells are definitely not keratin, and the calcification must be considered a dystrophic process.

Surgical Management

For the more frequently encountered intraosseous calcifying odontogenic cysts, enucleation is adequate (see Figure 17-27). Few recurrences have been reported.[8,9,108,109] The peripheral lesions are cured by excision. In the rare large lesions, the COC is eradicated by enucleation or conservative excision.[8,9] If the COC is associated with microscopic features, besides the ghost cells, the diagnosis and treatment should naturally be geared toward the predominant histopathology.

Non-odontogenic Cysts

In the oral and maxillofacial region, several cysts do occur in line of fusion of the several zones of the jaw bone, the soft tissue associated with the maxillomandibular complex, and the neck. The stimulus for proliferation of the embryogenic remnants is still unclear. The more common lesions are discussed in some detail. For completeness, a summary of the less common cysts is also presented.

Non-odontogenic Developmental Cyst of the Jaw and the Associated Soft Tissue Complex

Nasolabial Cyst

Clinical Features

The nasolabial cyst was first described by Zuckerkandl in 1892[121] and was known as the nasoalveolar cyst.[122] The term *nasolabial* was coined by Rao[123] and is a more accurate description of the lesion than nasoalveolar.[122] In a review of 8000 cystic lesions of the oral cavity over a 10-year period, Allard[124] identified only 17 cases of these lesions. A report by Yuen and colleagues[122] in 2007 detailed the clinical features, diagnosis, and treatment of the lesions. The nasolabial cyst is, therefore, a rare entity; however, it has been suggested that its occurrence may be more common than previously

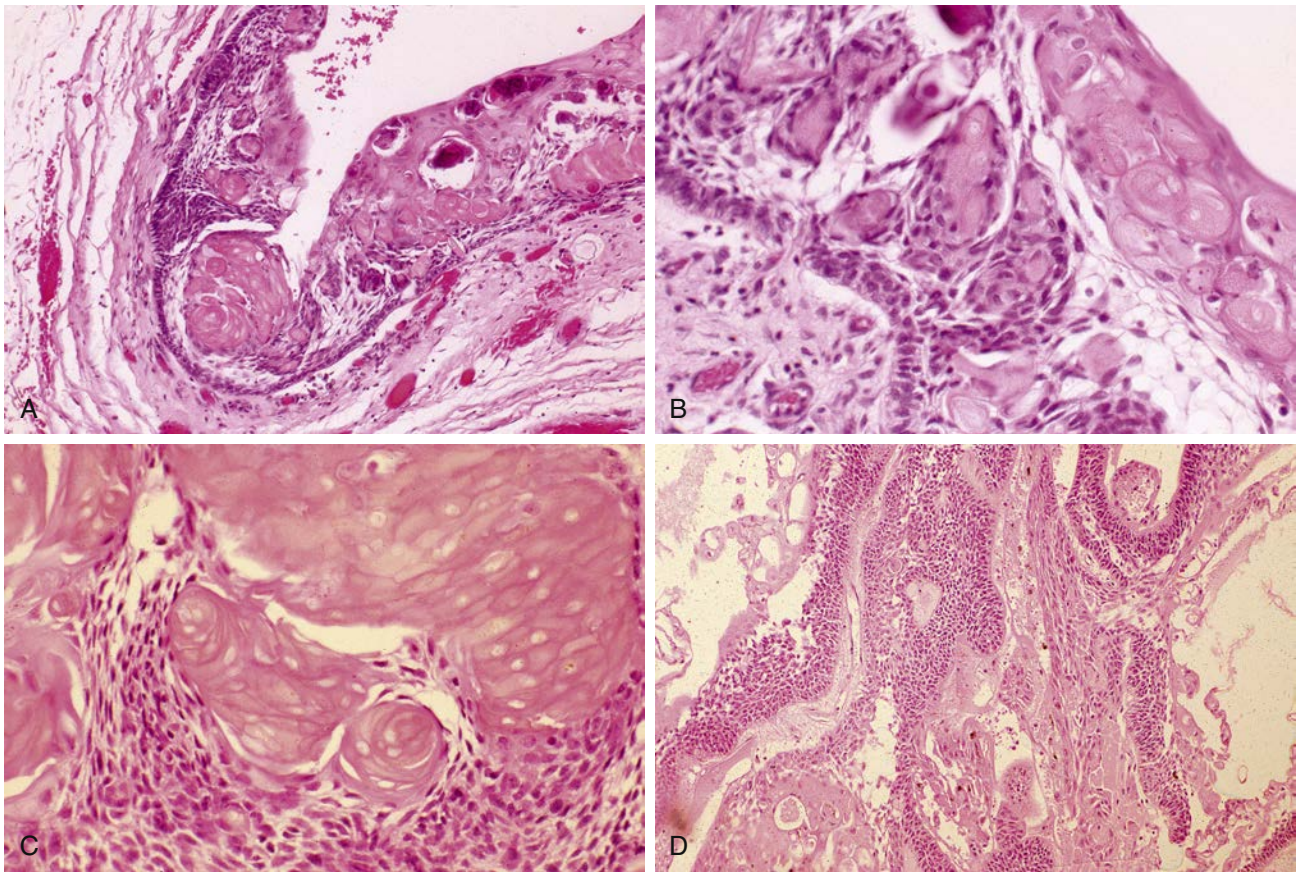

• **Figure 17-28** **A-C,** The cyst lining characteristically shows columnar basal cells, stellate reticulum-like supra-basal cells, microcalcification, and, above all, the "ghost" cells. **D,** These ghost cells are not pathognomonic for the calcifying odontogenic cyst, as they can be present in other lesions such as ameloblastoma.

thought.[122,125,126] Two theories have been proposed for the pathogenesis of nasolabial cysts.[122,124,127] The first suggests that the lesions are inclusion cysts arising from the epithelium that is retained in the mesenchyme after the fusion of the medial and lateral nasal processes. The second theory suggests that these cysts arise from proliferation of epithelial remnants from the nasolacrimal duct that extend between the lateral nasal process and the maxillary process.[124] These lesions may present as a nasal obstruction and deformity. They are smooth, fluctuant soft tissue masses between the upper lip and nasal aperture with obliteration of the nasolabial fold and elevation of the nasal ala.[122] Nasolabial cysts may grow in three possible directions: toward the nasolabial fold, toward the vestibule of the mouth, or toward the vestibule of the nose.[122,127] The lesion is best palpated bimanually intraorally or internasally.[122,127] Acute painful symptoms may develop secondary to infection. These symptoms should be differentiated from those caused by an odontogenic source. Rarely is the lesion bilateral (Figure 17-30, *A* and *B*).

Imaging Features

The nasolabial cyst is a soft tissue mass that is completely extraosseous. The radiographs may show bony rarefaction and deformity of the lateral and anterior edges of the nasal floor. There is rarely erosion of the maxilla.[126,127] MRI may show the cyst hypertense relative to cerebrospinal fluid (CSF) on T_1-weighted images, and isointense with CSF on T_2-weighted images.[128] Elaborate imaging is usually not necessary for proper diagnosis.

Pathologic Features

This soft tissue lesion usually contains mucoid and serous fluid, and if infected the contents are suppurative and hemorrhagic. The cyst capsule is a thick connective tissue capsule. The epithelial lining is pseudostratified epithelium, stratified squamous, and/or cuboidal epithelium with goblet cells.[93,122,127]

Surgical Management

Total excision of the cyst is curative, and care should be taken not to rupture the cyst. The surgical removal is accomplished by a sublabial incision in the buccal sulcus. If the nasal mucosa is breached, repair is not necessary.[122] Reepithelialization occurs with gentle packing of the vestibule (Figure 17-31, *A* and *B*).

Nasopalatine Duct Cyst

Clinical Features

This is a rare lesion but is the most common non-odontogenic cyst of the maxilla.[129,130] Swanson and colleagues[129] analyzed 334 cases that were diagnosed as incisive canal cyst, nasopalatine duct cyst, median palatine cyst, or cyst of the incisive papilla.

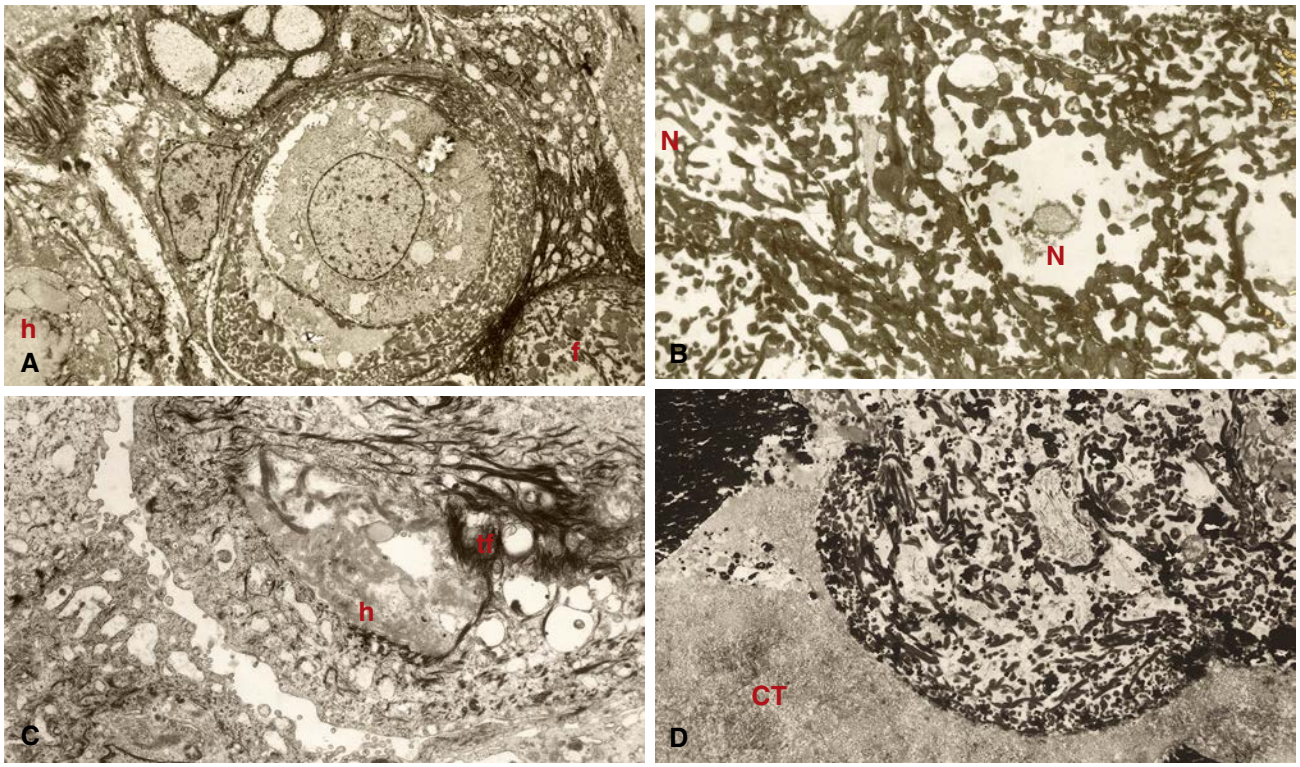

• **Figure 17-29** **A,** Ultrastructure examination shows degenerating cells *(center)* surrounded by ghost like cells that are mostly anuclear, with very thick electron-dense fibrils in their cytoplasm *(f)*. A part of a hornified cell *(h)* is seen (3750×). **B,** High magnification of ghostlike cells, showing the very thick electron-dense fibrils sharply defined against a large space previously occupied by the nucleus *(N)*. There is a disruption of the plasma membranes and disappearance of desmosomes (7500×). **C,** Hornified cell residue *(h)* densely packed with tonofilaments *(tf)* oriented in different directions and residue of organelles (7500×). **D,** Dense osmophilic calcification of denucleated ghost cell and the adjacent connective tissue *(CT)* (3750×). (From Abaza NA: Ultrastructural features and biologic aspects of odontogenic cysts and tumors: implications for surgical management. *Oral Maxillofac Surg Clin North Am* 6:523-577, 1994.)

These authors found the lesion to occur in the fourth and sixth decades of life, with slight male predilection. The lesions in this study had a 17-mm mean radiographic diameter with 75% of the lesions 20 mm or less in diameter; 70% of the cases studied were symptomatic. The cyst is thought to originate from epithelial remnants of the nasopalatine duct.[131,132] The stimulation of the epithelium to proliferate has been claimed to result from trauma, infection, or mucus retention.[9,129,131] Spontaneous cystic degeneration is also speculated because the lesions have been found in the human fetal incisive canal.[129,133] The entrapped epithelial remnants may be located at any site of the fusion of the two embryonic nasopalatine ducts from the median posterior palate to the soft tissue of the incisive papilla.[6] Therefore, cysts may occur in the posterior palatal midline, the incisive canal nasopalatine duct, or the soft tissue of the incisive papilla (palatine papilla). Because the incisive canal is several millimeters in vertical height, the cyst can present as either a labial or a palatal expansion, usually labial. When the cyst is large, both labial and palatal expansion is evident with fluid fluctuation present (Figures 17-32, 17-33, *A*, and 17-34, *A*). Diversion of the maxillary incisors is commonly present (Figure 17-34, *B* and *C*). Most of the lesions are small and asymptomatic (Figure 17-32, *A* and *B*).

Imaging Features

Imaging reveals a well-corticated lesion either round or heart shaped. A significant finding is that the radiolucency of the cyst is superimposed on the shadow of the periodontal membrane of the maxillary teeth. A feature that helps to clinically differentiate between this cyst and a periapical lesion (see Figure 17-34, *C* and *D*) is vitality testing of the associated teeth. Despite the availability of high-resolution imaging technology, a simple occlusal film may be very useful in the lesion diagnosis and in planning the surgical approach (see Figure 17-34, *D*). Small cysts should be differentiated from the normal radiographic diameter of the incisive canal, which has been stated to be 6 mm[131] (see Figure 17-32, *B*). With large cysts, perforation of overlying mucosa may occur, resulting in infection and pain. Large radicular cysts associated with infected maxillary incisors may be difficult to clinically differentiate from nasopalatine duct cysts.

Pathologic Features

The epithelial lining of the cyst may be squamous, pseudostratified ciliated, or a mixture of the two.[129,133] It has been reported the majority of the lining is mostly squamous epithelium.[129,134] This probably depends on the location



• **Figure 17-30 A,** Uncomplicated nasolabial cyst *(asterisk)* showing characteristic facial deformity with blunting of the nasolabial fold, elevation of the ala nasi, and protrusion of the upper lip *(arrow)*. **B,** A rare case of bilateral nasolabial cysts *(arrows)*. (From Yuen H-W et al: Nasolabial cysts: clinical features, diagnosis and treatment, *Br J Oral Maxillofac Surg* 45:293-297, 2007.)

of the initial epithelial proliferation either superiorly or inferiorly in the vertical height of the incisive canal (Figure 17-35). Frequently, mucus-secreting glands are seen (see Figure 17-35, *B*). Varying degrees of inflammatory cell infiltrate are present on the cyst wall (see Figure 17-35, *B*).

Surgical Management

Complete enucleation of the cyst is curative; recurrences are rare if completely excised. Recurrence rate has been reported to range from none to 11%.[129,135,136] The design of the surgical approach varies according to the location, labially or palatally, and the size of the lesion (see Figures 17-33 and 17-34). If the cyst is localized on the incisive papilla, a palatal mucoperiosteal flap around the crown of the maxillary teeth is used for excision of the lesion. In general, most nasopalatine duct cysts can be adequately approached by a labial incision around the cervices of the maxillary anterior teeth with an approximately 1-cm margin beyond the bony defect (see Figure 17-33). Once the flap is reflected, thinned bone is removed and the enucleation is accomplished. On occasion a second palatal flap may be necessary to free the cyst from both the labial and the palatal tissues, respectively. In large cysts that are markedly expanded palatally, a wide palatal approach may be required. A cervical incision from one maxillary first molar to the other is made (see Figure 17-34). Reflection of palatal mucosa is carefully undertaken, with care not to compromise the greater palatine blood vessels that are critical to the survival of the palatal tissue after cyst enucleation. Again it is important to recognize that the cyst may be adherent to the palatal mucosa. Therefore reflection of the palatal mucoperiosteum and enucleation of the cyst may need to be simultaneously performed. Plan of dissection should always favor removal of the cyst wall with care to maintain the integrity of the palatal mucosa. It is

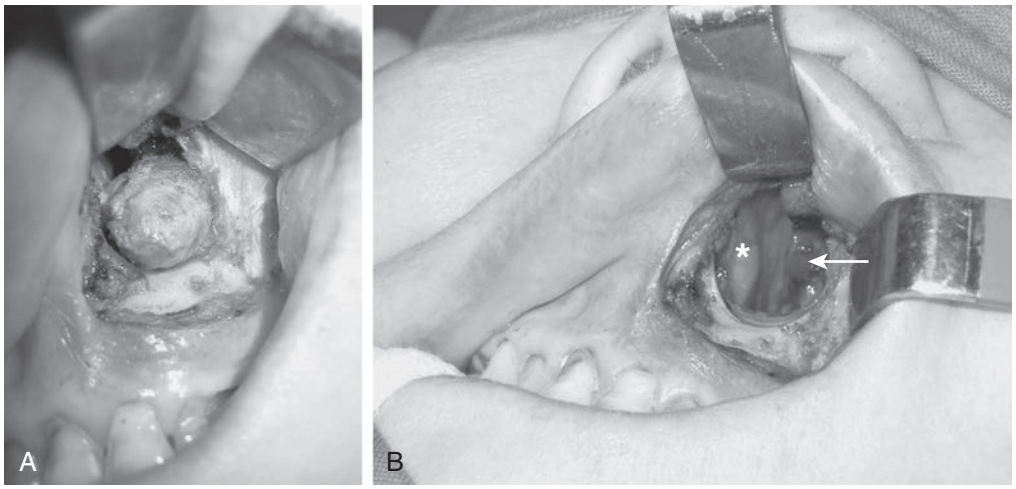

• **Figure 17-31 A,** Intraoperative view of left nasolabial cyst exposed through a sublabial incision. **B,** The buccal mucosa has been incised, elevated, and retracted. Intraoperative view of the resulting defect in the floor of the nasal vestibule when the nasal mucosa has been breached. The nasal septum *(asterisk)* and partially resected inferior turbinate *(arrow)* can be seen clearly. The defect is packed gently and allowed to granulate. (From Yuen HW et al: Nasolabial cysts: clinical features, diagnosis and treatment, *Br J Oral Maxillofac Surg* 45:293-297, 2007.)

always necessary to preoperatively fabricate a stent to support the palatal tissue and help prevent sagging of the palatal mucosa (see Figure 17-34, *F*). In large cases in which there is extensive bony destruction of the hard palate and the greater palatine vessels are compromised, sloughing of palatal mucosa may occur even if a complete palatal stent is used (see Figure 17-34, *H*). A secondary repair procedure will be required. Before reconstruction, it is advised to use the stent to avoid nasal phonation until the extent of the defect is stabilized. Depending on the size of the defect, rotating a palatal flap works well. In cases of extensive defects, palatal reconstruction by temporalis muscle[137] or tongue[138] flaps may be considered.

Other Non-odontogenic Cysts

Median Palatal (Palatine) Cyst

Classically the lesion was described as a fissural cyst from entrapped epithelium between the fused lateral shelves of the maxilla. The question arises whether such a lesion exists or whether it is a nasopalatine duct cyst arising from the posterior end of the migration tract of the two embryonic nasopalatine ducts.[8,9] The lesion is rare and usually present in young adults as a firm or fluctuant swelling of the palatal midline. The lesion may be symptomatic or asymptomatic and appears as a well-circumscribed radiolucency on an occlusal film. The cyst may be lined by squamous or respiratory epithelium. Complete excision is curative.



• **Figure 17-32 A,** An edentulous anterior maxilla of a patient with complaint of enlarged palatine papilla. **B,** Computed tomography scan revealed a small incisive canal cyst with evidence of palatine bone resorption.

Median Mandibular Cyst

Neville and colleagues[8] briefly discussed the questionable existence of this lesion and concluded that the lesion is probably odontogenic in origin.

Globulomaxillary Cyst

Embedded in the literature for years, this lesion was included in the 1971 WHO classification of histologic typing of odontogenic tumors[4] but removed in the second edition in 1992.[6] It was included as a fissural cyst secondary to proliferation of entrapped epithelium between the

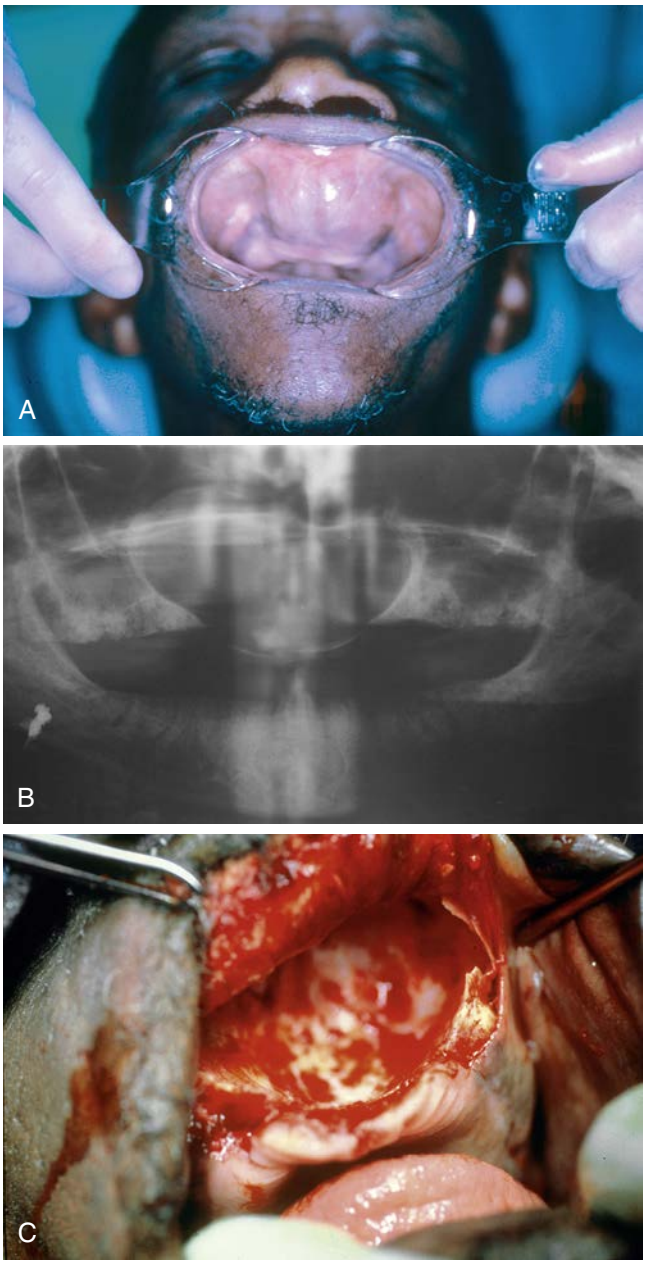

• **Figure 17-33 A,** A patient with large nasopalatine duct cyst that caused complete resorption of the buccal cortex. **B,** Panogram. **C,** The cyst was enucleated through a buccal approach.

globular portion of the medial nasal and maxillary processes. Because of lack of evidence to support the theory of embryogenic epithelial entrapment in the site, most authors dispute the presence of the lesion despite attempts to reclassify it as a fissural cyst.[8,9,139-141] The cyst most commonly appears as a radiolucency between the maxillary lateral and cuspid teeth, occasionally between central and lateral incisors. It is believed that it may represent an odontogenic keratocyst, a lateral periodontal cyst, a calcifying odontogenic cyst, or a periapical cyst that happens to occur in this region.[9,139,140,142] The histopathology reflects these diagnoses. Surgical enucleation is curative.

Non-odontogenic Developmental Cyst of the Neck

Developmental cysts are rare cystic malformations that commonly develop along embryonic fusion lines or from other embryonic remnants. In the neck the cysts may occur in the midline, such as in the cases of dermoid, epidermoid, and thyroglossal duct cysts; or they may present on the lateral aspect of the neck, as in the case of the branchial cleft cyst.[143-145]

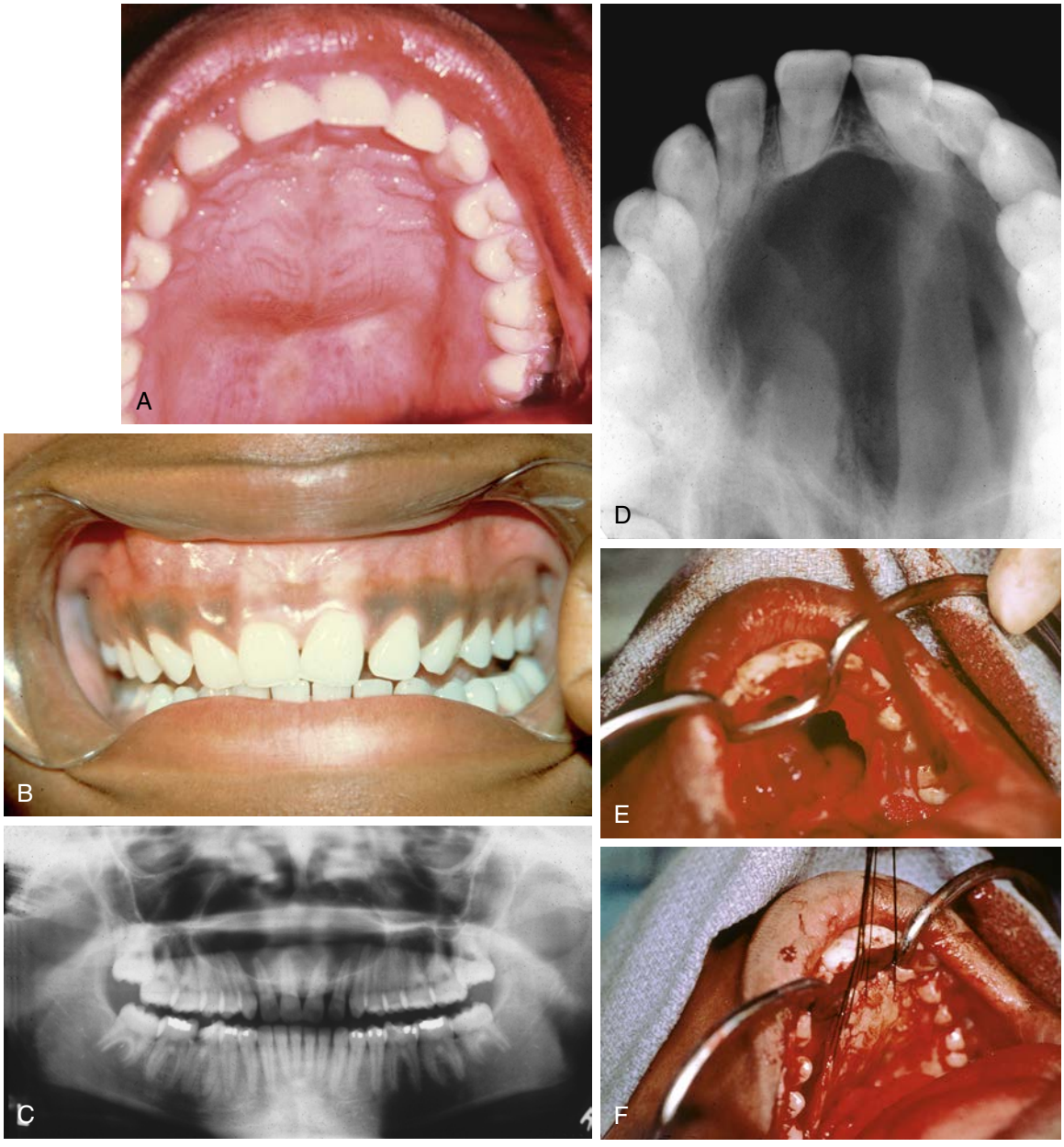

• **Figure 17-34** **A,** A 16-year-old girl seeking treatment for palatal swelling. **B,** The maxillary central incisors showed crown diversion. **C,** Panogram and upper occlusal films **(D)** show a large nasopalatine duct cyst. **E-F,** The cyst was enucleated palatally.

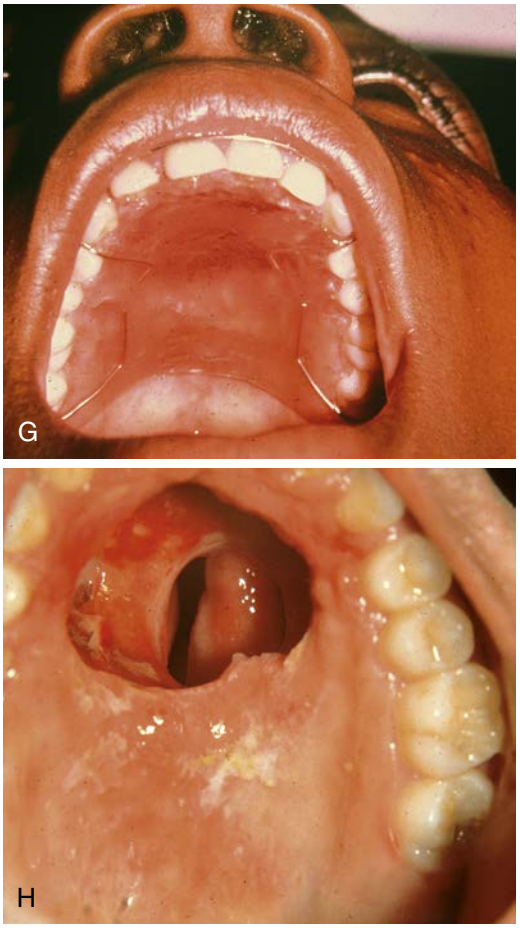

• **Figure 17-34, cont'd** **G,** The palatal mucosa was supported by a palatal splint. **H,** The mucosa partially dehisced, which was subsequently repaired. (Surgery performed by Barry Hendler, DDS, MD, Philadelphia, and Dr. Nabil Abaza.)

Dermoid and Epidermoid Cysts

Overview

The term *dermoid cyst* has been used to describe three histologically related, developmental keratinizing squamous epithelium lined cysts, namely, dermoid cyst, epidermoid cyst, and teratoid cyst.[145,146] An essential difference between dermoid cyst and epidermoid cyst is the presence of dermal appendages such as sebaceous glands and hair follicles within the wall of the former and the absence of these features in the latter. Teratoid cysts contain in their cyst walls structures derived from all three germinal layers, such as nervous, gastrointestinal, and respiratory tissues.[145,147,148] The teratoid cysts are extremely rare in the head and neck and are not discussed further.

Developmental epidermoid cysts should be distinguished from the more common keratinous cysts of the skin that are acquired and may arise as a result of cystic changes in hair follicles, as in the case of infundibular cysts.[147,149]

In reviews of a large number of dermoid cysts, only 7% occurred in the head and neck, with the periorbital lateral eyebrow area being the most common location.[150,151] The floor of the mouth is the second most common site; it accounts for 12% of all head and neck dermoid cysts,[150,152] followed by the tongue. In a review of 49 cases of pediatric dermoid cysts of the head and neck, Prayor and colleagues at the Mayo Clinic[153] found that 60% occurred periorbitally, 18% in the neck, 10% in the head (mainly scalp and forehead), 6% in the nose, and 4% in the ear.

Epidermoid cysts are rare and much less commonly encountered in the head and neck than dermoid cysts; most occur during infancy.[154]

Clinical Features

The cysts develop most commonly in children and young adults (Figure 17-36). They are frequently present at birth and are identified when large enough.[155,156] The most common clinical appearance of dermoid and epidermoid cysts of the neck is a midline suprahyoid-growing mass.[154] The mass is soft, mobile, and unattached to the overlying skin. Unlike thyroglossal duct cysts, the dermoids are not intimately associated with the hyoid bone and thus do not move on protrusion of the tongue.[157] The size of the cysts ranges from a few millimeters to 12 cm. Rapid increase in size may occur occasionally as a result of sinus formation, increased keratin desquamation, and sebum secretion during puberty and pregnancy.[154,158]

Dermoids of the neck usually arise from the floor of the mouth. Those arising inferior to the mylohyoid muscle cause a prominent submental swelling (Figure 17-37), whereas cysts developing between the geniohyoid and mylohyoid muscles in the sublingual space result in only a small external swelling.[159,160] Occasionally the cysts are displaced laterally into the submandibular space.[145,161]

Radiographically, dermoid cysts appear as a moderately thin-walled, unilocular mass. On CT scan the central cavity is usually filled with homogeneous, hypoattenuated fluid material. Discrete intracystic foci "marbles," with moderate hyperintensity, may be present. These structures result from coalescence of fat into small nodules within a fluid matrix.[162] This appearance is virtually pathognomonic of dermoid cysts in this location. Epidermoid cysts have fluid attenuation on CT scan and are hypointense on T_1-weighted images and hyperintense on T_2-weighted images, following the signal intensity of fluid.

Pathologic Features

Both dermoid and epidermoid cysts are lined with stratified squamous epithelium with keratin and/or a sebaceous material–filled cavity. However, in a true dermoid cyst the connective tissue wall shows variable dermal appendages, including sebaceous glands, hair follicles, and sweat glands[146,147,155] (Figure 17-38). The epithelial lining in either of the cysts may on occasion contain respiratory epithelium.[158]

Surgical Management

Complete surgical excision is the treatment of choice. Cysts occurring above the geniohyoid muscle can be removed through an intraoral approach. Cysts below that muscle and those below the mylohyoid muscle require an extraoral

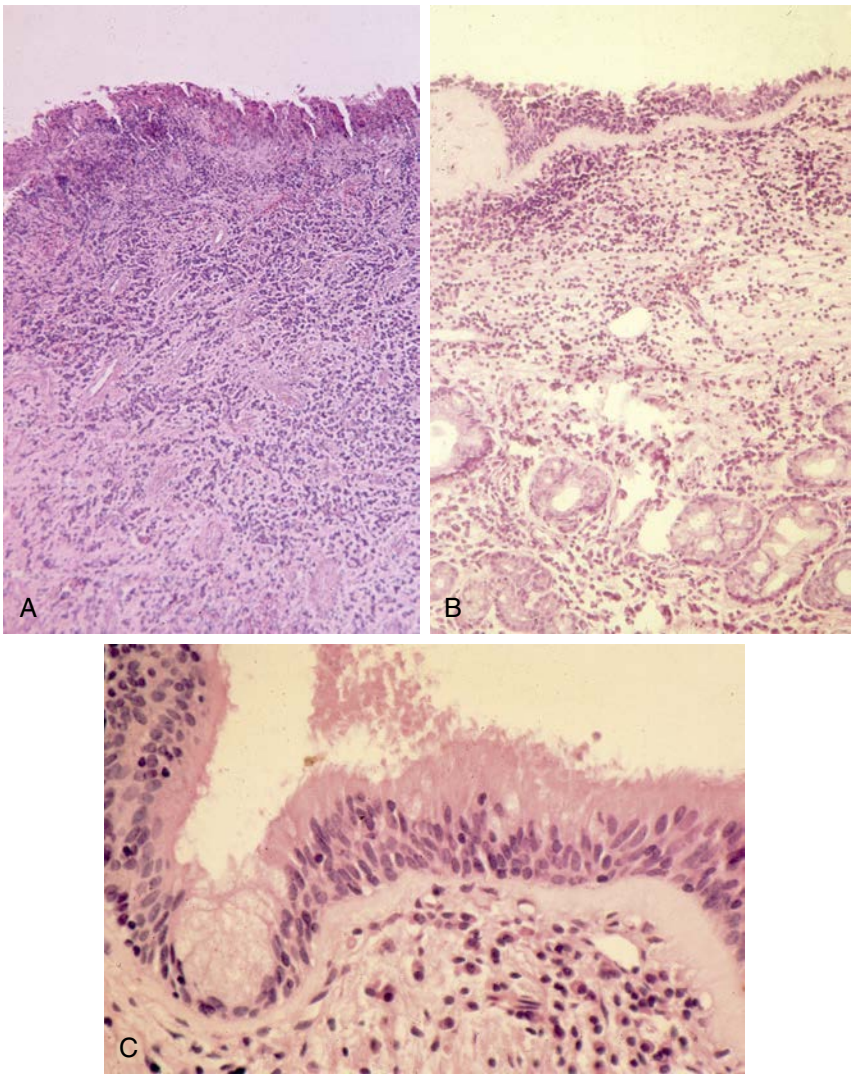

• **Figure 17-35** **A,** Photomicrographs of nasopalatine duct cyst lined by pseudostratified ciliated epithelium and inflammatory cell infiltrate of the wall. **B,** The wall focally contained mucous glands. **C,** Higher magnification clearly shows the ciliated epithelium.

approach.[150,163] According to Prayor and colleagues, among 49 pediatric patients only 1 patient had recurrence on follow-up.[153] Malignant transformation to squamous cell carcinoma has rarely been reported.[150]

Thyroglossal Duct Cyst

Overview

The thyroid gland develops as a median outgrowth from the floor of the primitive pharynx during the third week of fetal life. The thyroid primordium originates at the level of the foramen cecum, which in adults lies at the junction of the anterior two thirds and posterior one third of the tongue. The primitive thyroid descends through the mesoderm of the tongue and floor of the mouth and eventually passes anterior to the developing hyoid bone and laryngeal cartilage (Figure 17-39). The primitive gland reaches its final position in the anterior part of the neck by the seventh week of gestation.[143]

During migration, the anlage of the thyroid gland is connected to the tongue by a narrow tubular structure, the thyroglossal duct. This duct normally involutes by the eighth to tenth gestational week. The superior end of the canal persists as the foramen cecum of the tongue while the inferior end becomes the pyramidal lobe of the thyroid gland.[143,144] If any portion of the thyroglossal duct persists, cystic changes may occur as a result of secretion from the epithelial lining. Recurrent infections and inflammation may contribute to such events.[164]

Clinical Features

The thyroglossal duct cyst (TGDC) can develop at any age, but they are most commonly diagnosed in the first 2 decades of life. About 50% of cases occur before the age of 20 years.[165,166] In a review of 70 cases of TGDCs, the average age of presentation was 21.5 years.[165] There is no gender predilection.[164,166] However, a slight female bias with a

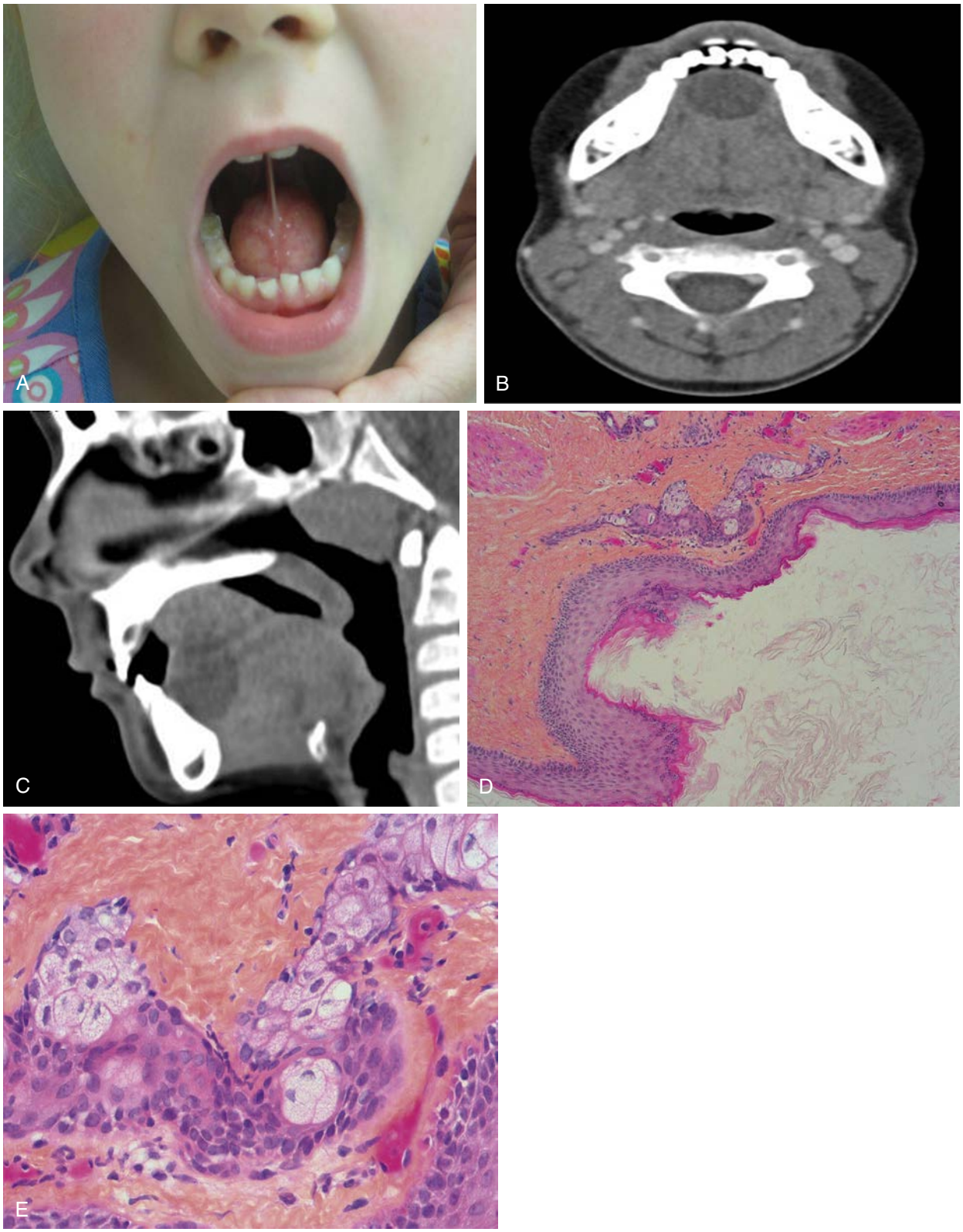

• **Figure 17-36** **A,** A 5-year-old girl presents with a midline floor of the mouth lesion. **B,** Axial, and sagittal computed tomography scan images **(C)** showing a well-circumscribed, hypodense lesion. **D,** Low-power photomicrograph showing stratified squamous epithelial lining of the dermoid cyst. **E,** High-power photomicrograph revealing sebaceous foci within the lesion. (Surgery performed by Joseph Kern DDS, MD, Plymouth Meeting, PA.)



• **Figure 17-37** Dermoid cyst of the floor of the mouth in an adult causing a prominent submental swelling.

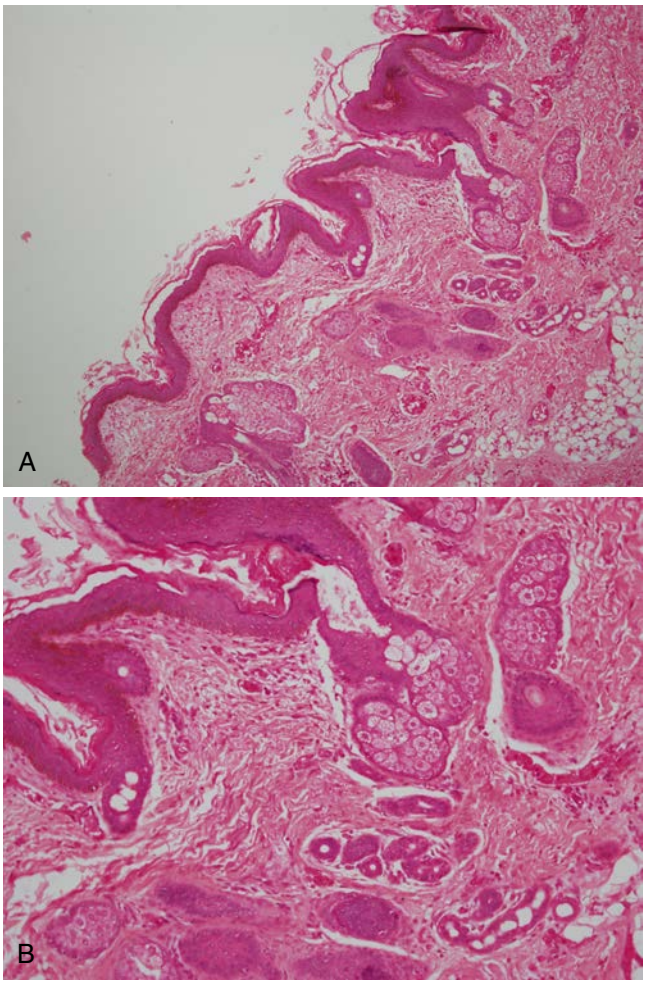

• **Figure 17-38** **A,** Dermoid cyst lined with stratified squamous epithelium. Dermal appendages are seen in the cyst wall, including hair follicles, sebaceous glands, and sweat glands. **B,** Higher magnification.

female-to-male ratio of 3:2 has been reported.[165] Rare cases of hereditary TGDC have been diagnosed. Typically, these cysts have an autosomal dominant pattern of transmission and occur in prepubertal girls.[167]

The majority of TGDCs are located in the midline or slightly off the midline. They are always within 2 cm of the midline.[168] Of those in a paramedian location, most will occur on the left, for reasons that are not well understood.[169] The cysts usually manifest as an enlarging painless fluctuant mass in a pediatric or young adult patient. The size of the cyst ranges from 0.5 to 6 cm in diameter, but most are between 1.5 and 3 cm.[170] Some cases may present with infection-related symptoms. These may improve by antibiotic treatment, but they frequently recur after completion of the antibiotic course.[170]

Approximately 80% of the cysts occur either at or below the level of the hyoid bone. The remaining 20% are located above that bone (Figure 17-40). In either case the cyst usually involves the hyoid bone (Figure 17-41). Rarely a TGDC may manifest as a mass in the floor of the mouth or tongue.[171-174] Characteristically the lesion moves upward on tongue protrusion, a reflection of the origin of the duct at the foramen cecum.[168,175]

Radiographically a TGDC appears in CT scans as a smooth, well-circumscribed mass anywhere along the vertical course of the vestigial thyroglossal duct; the mass has a thin wall and homogeneous attenuation[171] (Figure 17-42). With MRI the cyst has low signal intensity on T_1-weighted images and is hyperintense on T_2-weighted images, which reflects its fluid contents. The rim of the cyst is unenhancing unless inflammation is present.[159]

Pathologic Features

A TGDC contains colorless, viscous secretions. Microscopically the cyst is lined with pseudostratified columnar ciliated respiratory-type epithelium, or squamous epithelium[176-180] mucous glands may be present.[178] However, in our experience the latter finding is not common. Thyroid tissue is variably found in the wall of the cyst (Figure 17-43). The frequency of detection of glandular tissue depends on the diligence with which it is sought. It is variably reported for up to 62% of cases.[175,178,180-182] Using isotope scanning, Dische and Berg[182] found functioning thyroid tissue in one third of their patients with TGDC.

Surgical Management

Total surgical excision is the treatment of choice. Partial resection of the TGDC virtually always leads to recurrence. The recommended surgery is called the Sistrunk procedure. This operation involves en bloc excision of the entire thyroglossal

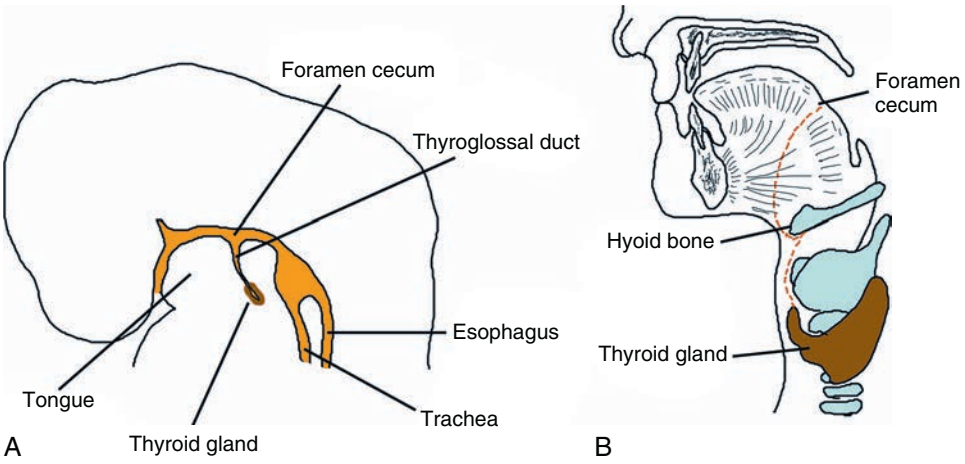

• **Figure 17-39** **A,** The primitive thyroid arises as an epithelial diverticulum at the level of the foramen cecum, in the midline of the pharynx. **B,** The *dashed red line* indicates the path of migration of the thyroid gland to its final position. (From August M, Faquin WC, Traulis M, Kaplan LB: Differentiation of odontogenic keratocysts from nonkeratinizing cysts by use of fine aspiration biopsy and cytokeratin-10 staining, *J Oral Maxillofac Surg* 58:935-940, 2000.)



• **Figure 17-40** **A,** Thyroglossal duct cyst located below the hyoid bone and **(B)** above the hyoid bone.

duct tract to the foramen cecum, as well as the central 1 to 2 cm of the hyoid bone. When this procedure is used, the rate of recurrence rarely exceeds 4% to 6%.[176,177,183,184] When the central part of the hyoid bone is not removed, a recurrence rate of 25% or more may be expected.[176] Incision and drainage of TGDC is not recommended.

Malignant changes in a TGDC are very rare, developing in less than 1% of patients.[185] They are more common in women by a margin of up to 2:1 and have been described in individuals from 6 to 84 years of age with an average of 39 years.[179,186,187] The most common carcinoma arising from TGDC is papillary thyroid carcinoma, developing in the ectopic thyroid tissue present in the cyst wall (Figure 17-44). It accounts for 80% to 90% of TGDC carcinoma, followed in frequency by squamous cell carcinoma at 5% (Figure 17-45) and follicular carcinoma at 3%.[179,181,186-189] Only two cases of concurrent papillary and squamous carcinomas in thyroglossal duct cysts have been reported.[190] One such case, but unreported, was diagnosed at our institution. Anaplastic thyroid carcinomas are extremely rare, and medullary carcinoma of the thyroid has never been seen in TGDC.[181,191] A majority of carcinomas arising in TGDCs are asymptomatic and are diagnosed only on microscopic examination of an excised, long-standing benign-appearing



• **Figure 17-41** Sagittal section in a cadaver showing thyroglossal duct cyst intimately associated with the hyoid bone.

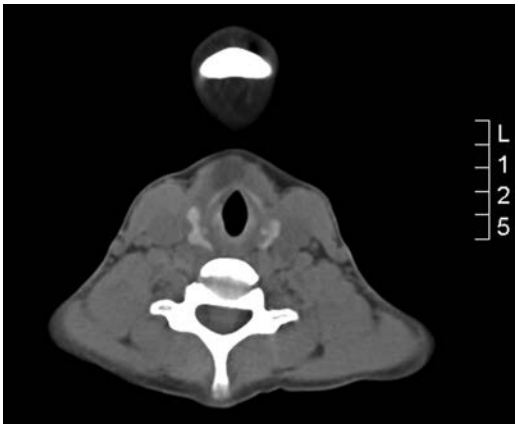

• **Figure 17-42** Axial computed tomography scan showing a thyroglossal duct cyst present anterior to the thyroid cartilage, at the midline and extending slightly to the right side.

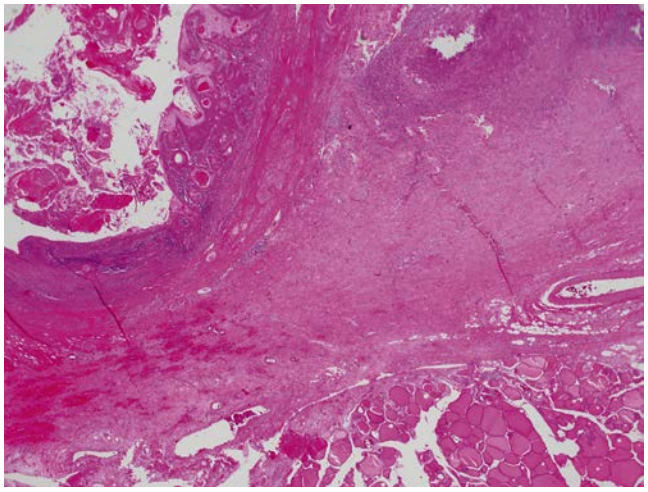

• **Figure 17-43** Thyroglossal duct cyst showing ciliated columnar epithelial lining. Thyroid follicles are present in the cyst wall.

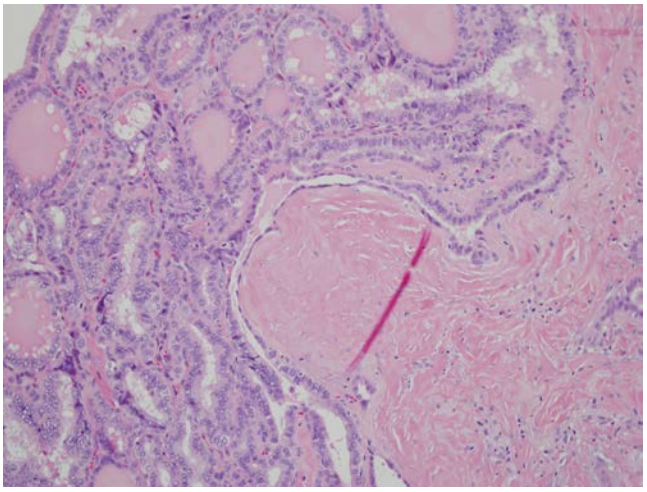

• **Figure 17-44** Papillary thyroid carcinoma arising in thyroglossal duct cyst. The epithelial cyst lining is seen at the upper left corner. The carcinoma in the cyst wall shows papillary and follicular growth patterns as well as characteristic nuclear features of papillary thyroid carcinoma.

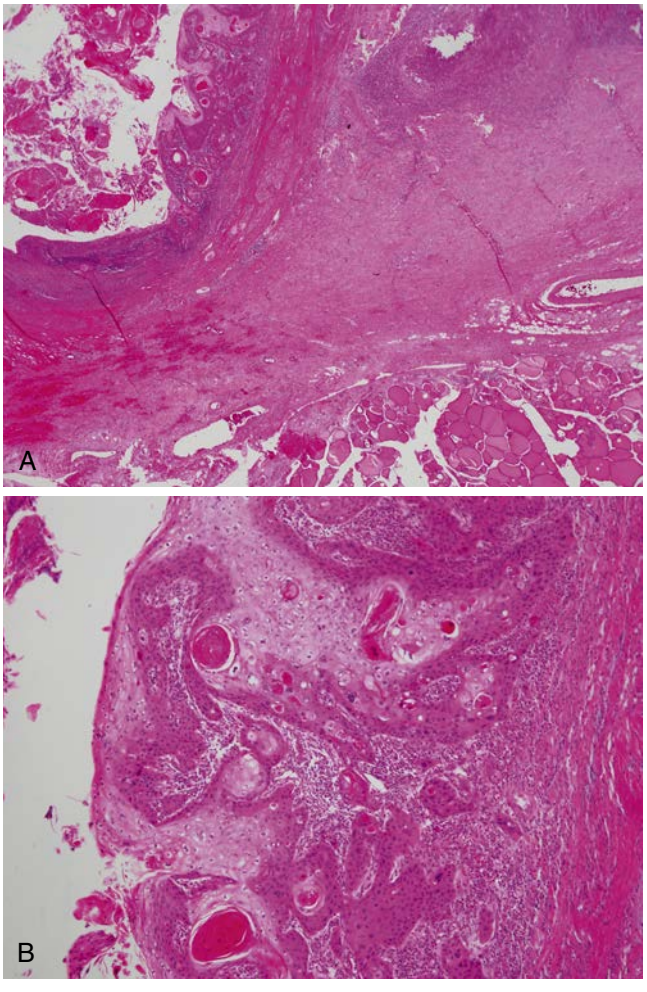

• **Figure 17-45** **A,** Invasive squamous cell carcinoma arising in thyroglossal duct cyst. **B,** Higher magnification.

cyst. Rarely, pain, sudden enlargement, hoarseness, airway compromise, or cervical lymphadenopathy may suggest malignant change.[192]

Radiographic examination may be useful in identifying malignancy. CT scans typically show dense, enhancing mural nodules (Figure 17-46). Additionally, in cases of papillary carcinomas, foci of calcification may be present.[193,194] FNA biopsy may confirm the diagnosis of malignancy. Microscopic examination reveals classical papillary thyroid carcinoma within the walls of the cyst. The tumor shows papillary and follicular features as a result of a combination of both growth patterns (see Figure 17-44). The tumor cells exhibit the classical cytologic features of papillary carcinoma of the thyroid, including large crowded nuclei, nuclear clearing, nuclear grooves, and pseudoinclusions. Psammoma bodies are seen in some of the cases.[192,194]

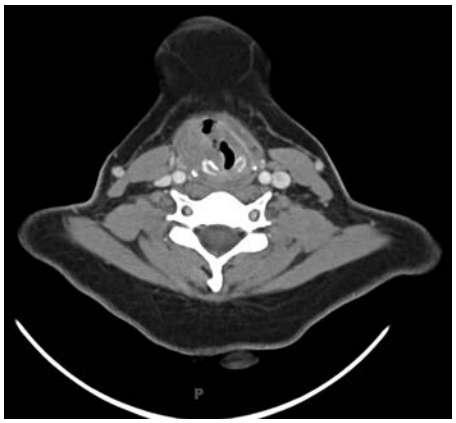

• **Figure 17-46** Axial computed tomography scan of squamous cell carcinoma arising in thyroglossal duct cyst. Enhancing soft tissue mass is seen in the wall of the cyst that involves the thyroid cartilage and extends into the endolaryngeal space.

Because carcinomas arising in TGDC are frequently coincidental, most are treated by the Sistrunk procedure described previously. In the absence of positive surgical margins or lymph node metastasis, no additional treatment is warranted. In the event of positive margins or lymph node involvement, wider resection of the lesion and neck dissection is indicated. Any associated thyroid gland disease should be evaluated and managed accordingly.[192,194]

It is generally agreed that the prognosis in the case of papillary carcinoma arising in TGDC is favorable and parallels that of primary papillary thyroid carcinoma. Local recurrence, metastasis, and death have rarely been reported.[186,189] However, squamous cell carcinoma arising in TGDC behaves more aggressively and may warrant more extensive surgery and possibly postoperative radiotherapy.[186,190,195]

Branchial Cleft Cyst

Overview

Four pharyngeal clefts separating the branchial arches are recognizable in the 5-week-old embryo (Figure 17-47). The dorsal part of the first cleft penetrates the underlying mesoderm and gives rise to the external auditory meatus. Active proliferation of the mesodermal tissue of the second arch causes it to overlap the third and fourth arches. Finally, it fuses with the epicardial ridge. The second, third, and fourth clefts lose contact with the outside and temporarily form an ectoderm-lined sinus, the cervical sinus (see Figure 17-47). With further development this sinus disappears entirely.[143,144]

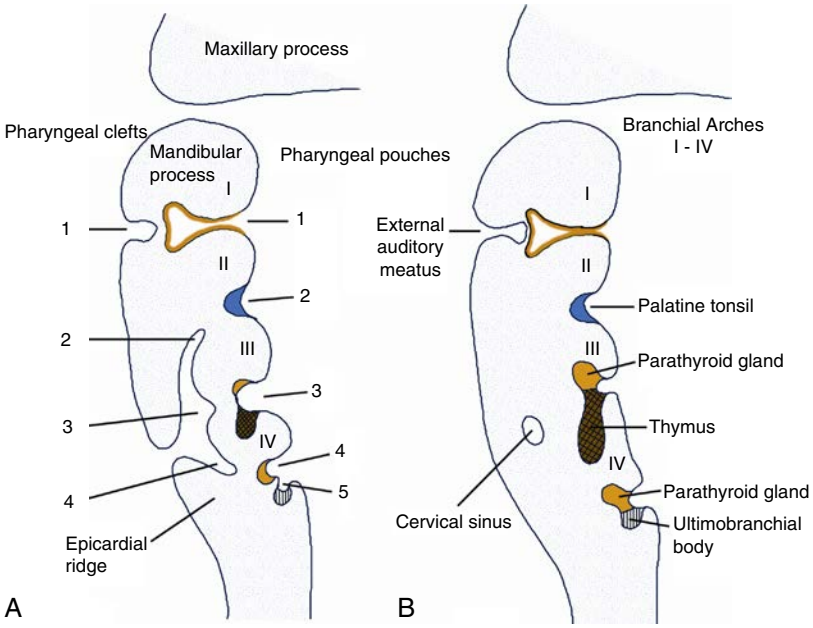

• **Figure 17-47** **A,** Schematic representation of the development of the pharyngeal clefts and pouches. The second arch grows over the third and fourth arches. **B,** Remnants of the second, third, and fourth pharyngeal clefts form the cervical sinus. (From Langman J: *Medical embryology,* Baltimore, 1984, Williams & Wilkins.)

Branchial cleft anomalies are believed to develop as a result of incomplete obliteration of the cervical sinus or from epithelial rests of the branchial clefts.[196] Abnormalities of the branchial clefts are usually cysts, sinuses, and fistulae. They occur primarily on the lateral side of the neck along the anterior border of the sternocleidomastoid (SCM) muscle, but may also be found in or around the parotid gland and external ear. The abnormalities are rarely bilateral and on occasion may be familial.[197-200] The lesions usually exist as an isolated phenomenon but on occasion may be associated with other defects such as patent ductus arteriosus, tear duct atresia, hearing abnormalities, and malformed auricles.[193-196]

In a review of 274 patients with branchial cleft anomalies, at the Mayo Clinic, the majority (75%) were cysts; 25% were fistulae.[201] Patients with branchial cleft cysts are usually older children or young adults, in contrast to patients with fistulae, who are usually infants or young children.[201,202]

The first branchial cleft cysts occur in the parotid gland as lymphoepithelial cysts. Those account for 5% of all branchial cleft defects and are most commonly seen in middle-age women.[203,204] Cysts arising from the third and fourth branchial clefts are extremely rare, with only a few cases reported. They occur in the posterior cervical space, usually in children and young adults.[196,205] The vast majority (95%) of branchial cleft anomalies arise from the second cleft, predominantly as cysts.[169] The following discussion addresses this entity, which will be referred to as branchial cleft cyst.

Clinical Features

The cysts are most commonly located in the submandibular space. However, because of the anatomic relationship of the second branchial cleft and the cervical sinus, they can occur anywhere along a line from the oropharyngeal tonsillar fossa to the supraclavicular region of the neck.[203] These cysts usually present as painless fluctuant masses in the lateral portion of the neck adjacent to the anteromedial border of the SCM muscle, at the mandibular angle[155,173,206] (Figure 17-48).

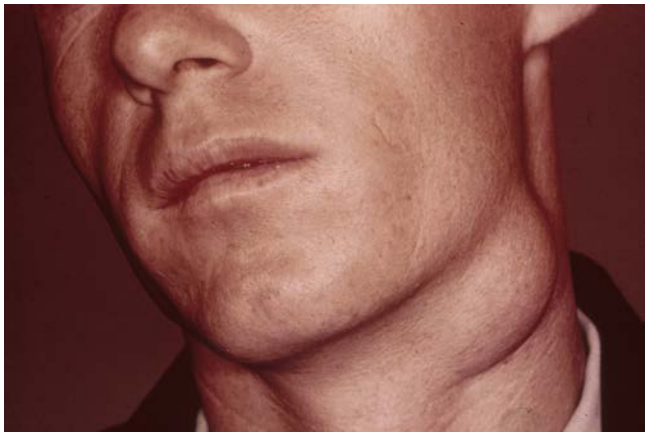

• **Figure 17-48** Branchial cleft cyst presenting as a mass in the submandibular area, adjacent to the anterior and medial borders of the sternocleidomastoid muscle.

The mass enlarges slowly over time and may become tender and painful if secondarily infected.[206] In a young patient, a history of recurrent inflammation in the region of the mandibular angle is highly suggestive of a branchial cleft cyst.

In CT scans these cysts are typically well-circumscribed, homogeneous, hypoattenuated masses surrounded by a uniformly thin wall[155] (Figure 17-49). Mural thickness may increase after infection. The typical location of the cysts from either CT scan or MRI imaging is at the anterior medial border of the SCM muscle lateral to the carotid space and at the posterior margin of the submandibular gland. The cyst typically displaces the SCM muscle posteriorly or posterolaterally, pushes the vessels of the carotid space medially or posteromedially, and displaces the submandibular gland anteriorly[173-203] (see Figure 17-49).

Pathologic Features

The cysts are usually unilocular and vary in size from 1 to 10 cm. They are usually filled with turbid yellowish fluid that may contain cholesterol crystals. Their walls are thin and lined with stratified squamous epithelium, in the majority of cases. Occasionally cysts may be lined with respiratory epithelium or combinations of both types of epithelium.[154,168,169,206] In almost all cases the epithelial lining overlays lymphoid tissues that may be diffuse or nodular with germinal centers and mantle zones[207] (Figure 17-50).

With repeated infection the wall may become fibrotic and the epithelium may then be partially replaced by granulation tissue or fibrous tissue.

Surgical Management

Complete surgical excision is indicated because of the frequency of secondary infections. In cases in which there is

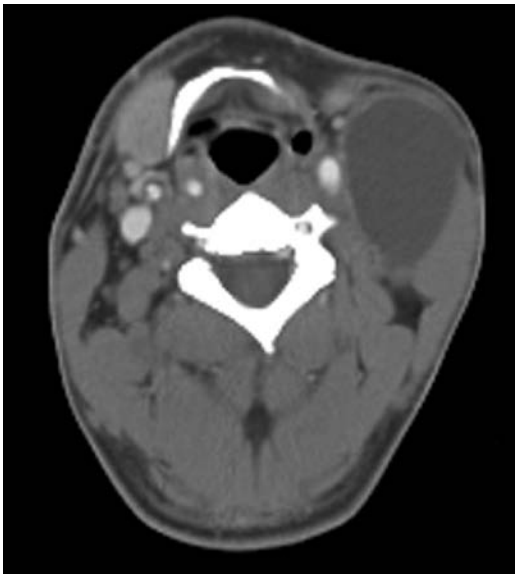

• **Figure 17-49** Axial computed tomography scan showing a large branchial cleft cyst that appears as a well-defined ovoid fluid-filled lesion in the left neck. The cyst is present between the submandibular gland, which is displaced interiorly, and the sternocleidomastoid muscle, which is displaced posterolaterally.

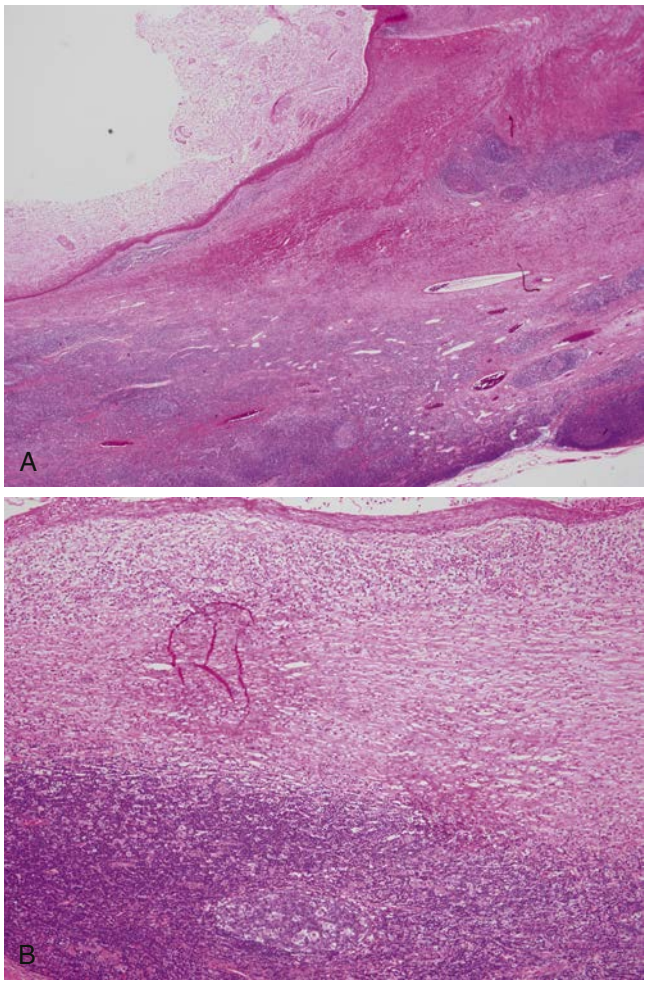

• **Figure 17-50** **A,** Branchial cleft cyst showing thin stratified squamous epithelium lining overlaying diffuse and nodular lymphoid tissue, with germinal centers, in the cyst wall. **B,** Higher magnification.

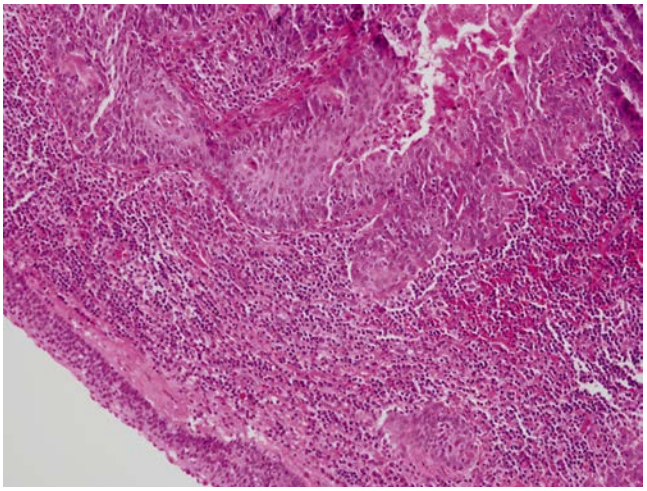

• **Figure 17-51** Branchial cleft carcinoma. Squamous cell carcinoma is present within the lymphoid tissue in the cyst wall. The cyst lining is benign stratified squamous epithelium.

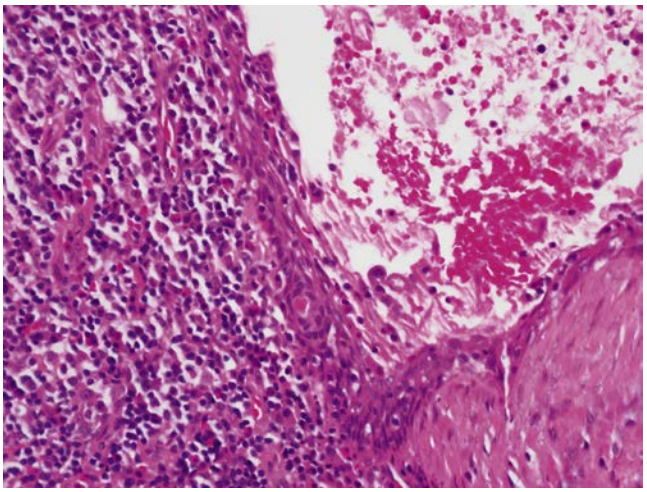

• **Figure 17-52** Cystic changes in metastatic oropharyngeal nonkeratinizing squamous cell carcinoma in a cervical lymph node. Basaloid epithelial cells with hyperchromatic nuclei form a thin lining of the cystic space.

significant inflammation, surgery may be delayed until it is resolved.[201] Patients who continue to have persistent branchial cleft remnants, with infectious episodes after repeated attempts at surgical excision, may benefit from functional neck dissection.[208]

A recurrence rate of 2.7% has been reported in a large review of cases. Higher recurrence rates were found in cases with a history of infection or previous surgical intervention.[208]

Malignant change in branchial cleft cysts (branchial cleft carcinoma) is extremely rare. In order to correctly make such a diagnosis, it is essential to be able to demonstrate carcinoma developing in the wall of a benign cyst (Figure 17-51). It is also important to rule out cystic changes in metastatic carcinoma in cervical lymph nodes. Such an event is particularly common in metastatic nonkeratinizing carcinomas of the oropharynx.

The lining epithelium in cystic lymph node metastasis may on occasion be very thin and deceptively bland. However, the cells tend to be more basaloid with darker nuclei as compared to the lining epithelial cells of branchial cleft cysts (Figure 17-52).[209] In the great majority of these metastases, human papillomavirus (HPV) can be identified by polymerase chain reaction (PCR) or in situ hybridization (ISH), and the cells react strongly and diffusely with p16 immunostain.[209,210] Thorough clinical evaluation may lead to detection of occult primary tumors, particularly in the tonsils and base of the tongue.

References

1. Abaza NA, Miloro M: Fine-needle aspiration in oral and maxillofacial diagnosis, *Oral Maxillofac Surg Clin North Am* 401–420, 1994.
2. August M, Faquin WC, Traulis M, Kaplan LB: Differentiation of odontogenic keratocysts from nonkeratinizing cysts by use of fine aspiration biopsy and cytokeratin-10 staining, *J Oral Maxillofac Surg* 58:935–940, 2000.

3. Ten Cate AR: Development of the tooth and its supporting tissues. In Ten Cate AR, editor: *Oral histology*, ed 3, St. Louis, 1989, Mosby, pp 57–79.
4. Pindborg JJ, Kramer IRH, Torlini H: *Histologic typing of odontogenic tumors, jaw cysts, and allied lesions*, Geneva, 1971, World Health Organization.
5. Verbin RS, Barnes L: Cysts and cyst-like lesions of the oral cavity, jaws and neck. In Barnes L, editor: *Surgical pathology of the head and neck*, New York, 1985, Marcel Dekker.
6. Kramer IRH, Pindborg JJ, Shear M: *Histological typing of odontogenic tumors*, ed 2, Berlin, 1992, Springer.
7. Phillipsen HP, Reichart PA: Revision of the 1992 edition of the WHO histological typing of odontogenic tumors: a suggestion, *J Oral Pathol Med* 31:253–258, 2002.
8. Neville BW, Damm DD, Allen CM, et al.: Developmental defects of the oral and maxillofacial region (Chapter 1); and Odontogenic cysts and tumors (Chapter 15). In *Oral and maxillofacial pathology,* ed 2, Philadelphia, 2002, WB Saunders, pp 589–639.
9. Marx KE, Stern D: *Odontogenic and nonodontogenic cysts.* In *Oral and maxillofacial pathology, a rationale for diagnosis and treatment*, Chicago, 2003, Quintessence, pp 573–633.
10. Gardner DD, Sapp JP, Wysocki GP: Odontogenic cysts of the jaws, *Bull Int Acad Pathol* 17:6–22, 1976.
11. Stafne EC: *Oral roentgenograph diagnosis*, Philadelphia, 1963, WB Saunders.
12. David LA, Sandor GKB, Stoneman DW: The buccal bifurcation cyst: is non-surgical treatment an option? *J Can Dent Assoc* 64:712–716, 1998.
13. Fowler CB, Brannon RB: The paradental cyst: a clinicopathologic study of six new cases and review of the literature, *J Oral Maxillofac Surg* 47:243–248, 1989.
14. Pompura JR, Sandor GKB, Stoneman DW: The buccal bifurcation cyst: a prospective study of treatment outcomes in 44 sites, *Oral Surg Oral Med Oral Pathol Oral Radiol Endod* 83:215–221, 1997.
15. Gold L: Biologic behavior of ameloblastoma, *Oral Maxillofac Clin North Am* 3:21–72, 1991.
16. Gorlin RJ: Potentialities of oral epithelium manifest by mandibular dentigerous cyst, *Oral Surg Oral Med Oral Pathol* 10:271, 1957.
17. Shear M: Secretory epithelium in the lining of dental cyst, *J Dent Assoc S Afr* 15:117, 1960.
18. Slater LJ: Odontogenic malignancies, *Oral Maxillofac Surg Clin North Am* 16(3):409–424, 2004.
19. Yasuoka T, Yonemoto K, Kato Y, et al.: Squamous cell carcinoma arising in a dentigerous cyst, *J Oral Maxillofac Surg* 58(8):900–905, 2000.
20. Johnson LM, Sapp JP, McIntire DN: Squamous cell carcinoma arising in a dentigerous cyst, *J Oral Maxillofac Surg* 52(9): 987–990, 1994.
21. Waldron CA, Koh ML: Central mucoepidermoid carcinoma of the jaws: report of four cases with analysis of the literature and discussion of the relationship to mucoepidermoid, sialoodontogenic and glandular odontogenic cysts, *J Oral Maxillofac Surg* 48(8):871–877, 1990.
22. Manojlovic S, Grgurevic J, Knezevic G, Kruslin B: Glandular odontogenic cyst: a case report and clinicopathologic analysis of the relationship to central mucoepidermoid carcinoma, *Head Neck* 19(3):227–231, 1997.
23. Brannon RB: The odontogenic keratocyst: a clinicopathologic study of 312 cases Part I. Clinical features, *Oral Surg Oral Med Oral Pathol* 42:54–72, 1976.
24. Philipsen HP: Keratocystic odontogenic tumor. In Barnes L, Everson JW, Reichart P, et al.: *World Health Organization classification of tumors: pathology and genetics of head and neck tumors*, Lyon, 2005, IARC Publishing, p 306.
25. Pogrel MA: The keratocystic odontogenic tumor, *Oral Maxillofac Surg Clin North Am* 25(1):21–30, 2013.
26. Stoelinga PJW: Etiology and pathogenesis of keratocyst, *Oral Maxillofac Surg Clin North Am* 15(3):317–324, 2003.
27. Stoelinga PJW: Long-term follow-up on keratocyst treated according to a defined protocol, *Int J Oral Maxillofac Surg* 30:14–25, 2001.
28. Voorsmit RACA: *The incredible keratocyst: a retrospective and prospective study*, Thesis, 1984, University of of Nijmegen.
29. Stoelinga PJW: Recurrences and multiplicity of cysts. In *Transactions of the Fourth International Conference on oral surgery*, 1973, pp 77–80.
30. Shear M: Odontogenic keratocysts; clinical features, *Oral Maxillofac Clin North Am* 15(3):335–345, 2003.
31. Oda D, Rivera V, Ghanee N, et al.: Odontogenic keratocyst: the northwestern USA experience, *J Contemp Dent Pract* 15:60–74, 2000.
32. Shear M: Odontogenic keratocyst (primordial cyst). In *Cysts of the oral regions,* ed 3, Oxford, UK, 1992, Butterworth-Heinemann, pp 4–45.
33. Vedtofte P, Precious F: Recurrence of the odontogenic keratocyst in relation to clinical and histological features: a 20-year follow-up study of 72 patients, *Int J Oral Surg* 8:412–420, 1979.
34. Forssell K: The primordial cyst: a clinical and radiographic study, *Proc Finn Dent Soc* 76:129–174, 1980.
35. Ahlfors E, Larsson A, Sjorgren S: The odontogenic keratocyst: a benign tumor? *J Oral Maxillofac Surg* 42:10–19, 1984.
36. Browne RM: The odontogenic keratocysts: clinical aspects, *Br Dent J* 128:225–231, 1970.
37. Hansen J: Keratocysts in the jaws. In Hudsted E, Hjorting-Hansen E, editors: *Oral surgery II (Transactions of the Second International Conference on oral surgery)*, Copenhagen, 1967, Munksgaard, pp 128, 134.
38. Hodgkinson DJ, Woods JE, Dahlin DC, Tolman DE: Keratocysts of the jaw: clinicopathologic study of 79 patients, *Cancer* 41:803–813, 1978.
39. Woolgar JA, Rippin JW, Browne RM: A comparative histological study of odontogenic keratocysts in basal cell nevus syndrome and control patients, *J Oral Pathol* 16:124–128, 1987.
40. Woolgar JA, Rippin JW, Browne RM: The odontogenic keratocyst and its occurrence in the nevoid basal cell carcinoma syndrome, *Oral Surg Oral Med Oral Pathol* 64:727–730, 1987.
41. Woolgar JA, Rippin JW, Browne RM: A comparative histological study of odontogenic keratocysts in basal cell nevus syndrome and control patients, *J Oral Maxillofac Surg* 16:75–80, 1987.
42. Forssell K: The primordial cyst: a clinical and radiographic study, *Proc Finn Dent Soc* 76:129–174, 1980.
43. Partridge M, Towers JF: The primordial cyst (odontogenic keratocyst): its tumor-like characteristics and behavior, *Br J Oral Maxillofac Surg* 25:271–279, 1987.
44. Emercon TG, Whitlock RIH, Jones JM: Involvement of soft tissues by odontogenic keratocyst (primordial cyst), *Br J Oral Surg* 9:181–185, 1972.
45. Browne RM: The odontogenic keratocyst: histological features and their correlation with clinical behavior, *Br Dent J* 131: 249–259, 1971.
46. Toller PA: Origin and growth of cysts of the jaws, *Ann Royal Coll Surg Engl* 40:306–336, 1967.

47. Niemeyer K, et al.: Behandlungsergebnisse and Langzeitbeobachtungen bei 62 Patienten mit Keratozysten, *Dtsch Zahnarztl Z* 40:637–640, 1985.
48. Voorsmit RACA, Stoelinga PJW, van Haelst UJGM: The management of keratocysts, *J Maxillofac Surg* 9:228–236, 1981.
49. Forssell K, Forssell H, Kahnberg KE: Recurrence of keratocysts: a long-term follow up study, *Int J Maxillofac Oral Surg* 17: 25–28, 1988.
50. Forssell K, Sorvari TE, Oksala E: An analysis of the recurrence of odontogenic keratocysts, *Proc Finn Dent Soc* 70:135–140, 1974.
51. Soskolne WA, Shear M: Observations on the pathogenesis of primordial cysts, *Br Dent J* 123:321–326, 1967.
52. Shear M: The aggressive nature of the odontogenic keratocysts: is it a benign neoplasm? A review. Part 1. Clinical and early experimental evidence of aggressive behavior, *Oral Oncol* 38:219–226, 2002.
53. Shear M: The aggressive nature of the odontogenic keratocyst: is it a benign neoplasm? A review Part 2. Proliferation and genetic studies, *Oral Oncol* 38:323–331, 2002.
54. Shear M: The aggressive nature of the odontogenic keratocyst: is it a benign neoplasm? A review Part 3. Immunocytochemistry of cytokeratin and other epithelial cell markers, *Oral Oncol* 38:407–415, 2002.
55. Stoelinga PJW: *Over kaak-kysten (Theis) Nijmegen:* University of Nijmegen, 1971.
56. Schultz L: Cysts of the maxillae and mandible, *J Am Dent Assoc* 14:1395–1402, 1927.
57. Wright JM: The odontogenic keratocyst: orthokeratinized variant, *Oral Sur Oral Med Oral Pathol* 51:609–618, 1981.
58. DaSilva MJ, De Sousa SO, Correa L, et al.: Immunohistochemical study of the orthokeratinized odontogenic keratocyst: a comparison with the odontogenic keratocyst, *Oral Surg Oral Med Oral Pathol Oral Rad Endod* 94:732–737, 2002.
59. Richard CKJ: Histology and ultrastructural features of the odontogenic keratocyst, *Oral Maxillofac Clin North Am* 15(3):325–333, 2003.
60. Rud J, Pindborg JJ: Odontogenic keratocysts: a follow-up study of 21 cases, *J Oral Surg* 27:323–330, 1969.
61. Moos KF, Rennie JS: Squamous cell carcinoma arising in a mandibular keratocyst in a patient with Gorlin's syndrome, *Br J Oral Maxillofac Surg* 25:280–284, 1987.
62. Minic AJ: Primary intraosseous squamous cell carcinoma arising in mandibular keratocyst, *Int J Oral Maxillofac Surg* 21:163–165, 1992.
63. Makowski GJ, McGuff S, Van Sickels JE: Squamous cell carcinoma in a maxillary odontodenic keratocyst, *J Oral Maxillofac Surg* 59:76–80, 2001.
64. Main DMG: Epithelial jaw cysts: a clinicopathological reappraisal, *Br J Oral Maxillofac Surg* 8:114–125, 1970.
65. Maeda Y, Hirota J, Yoneda K, et al.: Immunohistochemical study of jaw cysts: different existence of keratin in odontogenic and non-odontogenic epithelial linings, *J Oral Pathol Med* 19:289–294, 1990.
66. de Paula AM, Carvalhais JN, Domingues MG, et al.: Cell proliferation markers in the odontogenic keratocyst: effect of inflammation, *J Oral Pathol Med* 29:477–482, 2000.
67. Myoung H, Hong SP, Hong SD, et al.: Odontogenic keratocyst: review of 256 cases for recurrence and clinicopathologic parameters, *Oral Surg Oral Med Oral Pathol Oral Radiol Endod* 91:328–333, 2001.
68. Abaza NA: Ultrastructural features and biologic aspects of odontogenic cysts and tumors: implications for surgical management, *Oral Maxillofac Surg Clin North Am* 6:523–577, 1994.
69. Philipsen HP, Fejerskov O, Donatsky O, et al.: Ultrastructure of epithelial lining of keratocysts in nevoid basal cell carcinoma syndrome, *Int J Oral Surg* 5:71–81, 1976.
70. Wysocki GP, Sapp JP: Scanning and transmission electron microscopy of odontogenic keratocysts, *Oral Surg Oral Med Oral Pathol* 40:494–501, 1975.
71. Giuliani M, Grossi GB, Lazolo C, et al.: Conservative management of a large odontogenic keratocyst: report of a case and review of the literature, *J Oral Maxillofac Surg* 64:308–316, 2006.
72. Ghali GE, Connor MS: Surgical management of odontogenic keratocyst, *Oral Maxillofac Surg Clin North Am* 15(3):383–392, 2003.
73. Chuong R, Donoff RB, Guralnick W: The odontogenic keratocyst, *J Oral Maxillofac Surg* 40:797–802, 1982.
74. Bataineh AB, Al Quada MA: Treatment of mandibular odontogenic keratocysts, *Oral Surg Oral Med Oral Pathol Oral Radiol Endod* 86:42–47, 1998.
75. Poswillo DE: Cryosurgery in and around the oral cavity. In Taylor S, editor: *Recent advances in surgery*, London, 1973, Churchill-Livingstone, pp 69–101.
76. Schmidt BL, Pogrel MA: The use of enucleation and liquid nitrogen cryotherapy in the management of odontogenic keratocysts, *J Oral Maxillofac Surg* 59:720–725, 2001.
77. Farrant J: Mechanisms of cell damage during freezing and thawing and its prevention, *Nature* 205:1284–1287, 1965.
78. Schmidt BL: The use of liquid nitrogen and cryotherapy in the management of the odontogenic keratocyst, *Oral Maxillofac Clin North Am* 15(3):393–405, 2003.
79. Farrant J: Some mechanisms of freezing injury, *Proc Int Congr Cryosurg* 23–32, 1972.
80. Whittaker DK: Mechanisms of tissue destruction following cryosurgery, *Ann Roy Coll Surg Engl* 66(5):313–318, 1984.
81. Stoelinga PJW: Excision of the overlying, attached mucosa, in conjunction with cyst enucleation and treatment of the bony defect with Carnoy solution, *Oral Maxillofac Surg Clin North Am* 15(3):407–414, 2003.
82. Cutler EC, Zollinger R: Sclerosing solution in the treatment of cysts and fistulae, *Am J Surg* 19:411, 1933.
83. Tucker WM, Pleasants JE, MacComb WS: Decompression and secondary enucleation of a mandibular cyst: report of case, *J Oral Surg* 30:669, 1972.
84. Pogrel MA, Jordan RCK: Marsupialization as a definitive treatment for odontogenic keratocyst, *J Oral Maxillofac Surg* 62:651, 2004.
85. Voorsmit RACA: *The incredible keratocyst (doctoral dissertation)*, The Netherlands, 1984, University of Nijmegen, Nijmegen.
86. Pogrel MA: The history of odontogenic keratocyst, *Oral Maxillofac Surg* 15:311, 2003.
87. Pogrel MA: Decompression and marsupialization as a treatment for the odontogenic keratocyst. The odontogenic keratocyst, *Oral Maxillofac Surg Clin North Am* 15:415, 2003.
88. Pogrel MA: Treatment of keratocysts: the case for decompression and marsupialization, *J Oral Maxillofac Surg* 63:167–171, 2005.
89. Pogrel MA: Decompression and marsupialization as definitive treatment for keratocyst—a partial retraction, *J Oral Maxillofac Surg* 65:362–363, 2007.

90. Marker P, Brondum N, Clausen PP, et al.: Treatment of large odontogenic keratocysts by decompression and later cystectomy, *Oral Surg Oral Med Oral Pathol* 82:122–131, 1996.
91. Pogrel MA, Montes DM: Is there a role for enucleation in the management of ameloblastoma? *Int J Oral Maxillofac Surg* 38:807–812, 2009.
92. Gao L, et al.: Decompression as a treatment for odontogenic cystic lesions of the jaw, *J Oral Maxillofac Surg* 72(2):327–333, 2014.
93. Gorlin RJ, Goltz RW: Multiple nevoid basal cell epithelioma, jaw cysts and bifid rib: a syndrome, *New Engl J Med* 262:908–912, 1960.
94. Gorlin RJ: Nevoid basal-cell carcinoma syndrome, *Medicine* 66:98–113, 1987.
95. Santinoff MI, Wells C: Multiple basal cell naevus syndrome in ancient Egypt, *Med Hist* 13:294–297, 1969.
96. Binkley GW, Johnson HH: Epithelioma adenoids cysticum: basal cell neviagenesis of the corpus callosum and dental cysts, *Arch Dermatol Syphilol* 63:73–84, 1951.
97. Habif T: Pre malignant and malignant skin tumors. In *Clinical dermatology*, St Louis, 1990, Mosby, p 519.
98. Tod R, August M: Molecular approaches to the diagnosis of sporadic and nevoid basal cell carcinoma syndrome-associated odontogenic keratocysts, *Oral Maxillofac Surg Clin North Am* 15(3):447–461, 2003.
99. Cohen MMJ: Nevoid basal cell carcinoma syndrome: molecular biology and new hypothesis, *Int J Oral Maxillofac Surg* 28:216–223, 1999.
100. Rogerson KC: Gorlin's syndrome: an update on diagnosis and management, *Oral Maxillofac Surg Clin North Am* 3:155, 1991.
101. Gardner DG, Sapp JP, Wysocki GP: Odontogenic and "fissural" cysts of the jaws, *Pathol Annu* 13(pt 1):177–200, 1978.
102. Gardner DG, Morency R: The glandular odontogenic cyst: a rare lesion that tends to recur, *J Can Dent Assoc* 59:929–930, 1993.
103. Kaplan H, Gal G, Amair Y, et al.: Glandular odontogenic cyst: treatment and recurrence, *J Oral Maxillofac Surg* 63:435–441, 2005.
104. Noffke C, Raubenheimer EJ: The glandular odontogenic cyst: clinical and radiological features; review of literature and report of nine cases, *Dentomaxillofac Radiol* 31:333–338, 2002.
105. Gorlin RJ, Pindborg JJ, Clausen FP, et al.: The calcifying odontogenic cyst-a possible analogue of the calcifying epithelioma of Malherbe; an analysis of fifteen cases, *Oral Surg* 5:1235–1243, 1962.
106. Gold L: The keratinizing and calcifying odontogenic cyst, *Oral Surg* 16:1414–1424, 1963.
107. Hong PY, Ellis GL, Hartman KS: Calcifying odontogenic cyst: a review of ninety-two cases with reevaluation of their nature as cysts or neoplasm, the nature of ghost cells, and subclassification, *Oral Surg Oral Med Oral Pathol* 72:56–64, 1991.
108. Moleri AB, Moreira LC, Carvalbo JJ: Comparative morphology of seven new cases of calcifying odontogenic cysts, *J Oral Maxillofac Surg* 60:689–696, 2002.
109. Praetorius F, Hjorting-Hansen E, Gorlin RJ, et al.: Calcifying odontogenic cyst: range, variations and neoplastic potential, *Acta Odontol Scand* 39:227, 1981.
110. Johnson A, Fletcher M, Gold L, et al.: Calcifying odontogenic cyst: a clinicopathologic study of 57 cases with immunochemical evaluation for cytokeratin, *J Oral Maxillofac Surg* 55:679–683, 1997.
111. Ellis GL, Shmooklez BM: Aggressive (malignant) epithelial odontogenic ghost cell tumor, *Oral Surg Oral Med Oral Pathol* 61:471–478, 1986.
112. Ikemura K, Horie A, Tashiro H, et al.: Simultaneous occurrence of calcifying odontogenic cyst and its malignant transformation, *Cancer* 56:2861–2864, 1985.
113. Al-khateeb TH, Hamasha AAH: Pilomatricoma of the maxillofacial area in the northern regional Jordanian population: report of 31 cases, *J Oral Maxillofac Surg* 65:261–266, 2007.
114. Buchner A, Merill PW, Hansen LS, et al.: Peripheral (extraosseous) calcifying odontogenic cyst: a review of forty five cases, *Oral Surg* 72:65–70, 1991.
115. Buchner A: The central (intraosseous) calcifying odontogenic cyst: an analysis of 215 cases, *J Oral Maxillofac Surg* 49:330–339, 1991.
116. Regezi JA, Courtney RM, Kerr DA: Keratinization in odontogenic tumors, *Oral Surg Oral Med Oral Pathol* 39:447–455, 1975.
117. Fejerskov O, Krogh J: The calcifying ghost cell odontogenic tumor or the calcifying odontogenic cyst, *J Oral Pathol* 1:273–287, 1972.
118. Chen S, Miller AS: Ultrastructure of the keratinizing and calcifying odontogenic cyst, *Oral Surg* 39:769–780, 1975.
119. Kerebel B, Kerebel L: Ghost cells in complex odontoma: a light microscopic and SEM study, *Oral Surg* 59:371–378, 1985.
120. David R, Buchner A: Calcifying odontogenic cyst with intracellular amyloid-like material, *Oral Surg* 41:758–764, 1976.
121. Zuckerkandl E: *Normale und pathologische Anatomie der Nasenhohle*, Vienna, 1892, Braumuller, p 250.
122. Yuen H-W, et al.: Nasolabial cysts: clinical features, diagnosis and treatment, *Br J Oral Maxillofac Surg* 45:293–297, 2007.
123. Rao RV: Nasolabial cyst, *J Laryngal Otal* 69:352–354, 1955.
124. Allard RHB: Nasolabial cyst, review of the literature and report of seven cases, *Int J Oral Surg* 11:351–359, 1982.
125. Kuriloff DB: The nasolabial cyst-nasal hamartoma, *Otolaryngol Head Neck Surg* 96:268–272, 1987.
126. Choi JH, Cho JH, Kang HJ, et al.: Nasolabial cyst: a retrospective analysis of 18 cases, *Ear Nose Throat J* 81:94–96, 2002.
127. El-Din K, el-Hamd AA: Nasolabial cyst: a report of eight cases and a review of the literature, *J Laryngol Otol* 113:747–749, 1999.
128. Cure JK, Osuthorpe JD, Van Tassel P: MR of nasolabial cysts, *AJNR Am J Neuroradiol* 17:585–588, 1996.
129. Swanson KS, Kangars GE, Gunsolley JC: Nasopalatine duct cyst. An analysis of 334 cases, *Oral Maxillofac Surg* 49:268–271, 1991.
130. Anneroth G, Hall G, Stuge U: Nasopalatine duct cyst, *Int J Oral Maxillofac Surg* 15:572, 1986.
131. Roper-Hall HT: Cysts of developmental origin in the premaxillary region, with special reference to their diagnosis, *J Br Dent Assoc* 65:29, 1938.
132. Nortje CJ, Wood RE: The radiologic features of the nasopalatine duct cyst. An analysis of 46 cases, *Dentomaxillofac Radiol* 17:129, 1988.
133. Abrams AM, Howell FV, Bullock WK: Nasopalatine cysts, *Oral Surg Oral Med Oral Pathol* 16:306, 1963.
134. Allard RHB, VanDer Kwast WAM, Van Der Waal I: Nasopalatine duct cyst. Review of the literature and report of 22 cases, *Int J Oral Surg* 10:447, 1981.
135. Bodin I, Isacsson G, Julin P: Cysts of the nasopalatine duct, *Int J Oral Maxillofac Surg* 15:696, 1986.

136. Hedin M, Klanfeldt A, Persson G: Surgical treatment of nasopalatine duct cysts: a follow-up study, *Int J Oral Surg* 7:427, 1978.
137. Hoffez LB: Surgery for internal derangement of the temporomandibular joint. In Moloro M, editor: *Peterson's principles of oral and maxillofacial surgery*, vol. 2. Hamilton, ON, 2004, BC Decker, p 1007.
138. Herford AS, Ghali GE: Local and regional flaps. In Molero M, editor: *Peterson's principles of oral and maxillofacial surgery*, vol. 2. Hamilton, ON, 2004, BC Decker, p 775.
139. Christ TF: The globulomaxillary cyst: an embryologic misconception, *Oral Surg Oral Med Oral Pathol* 30:515–526, 1970.
140. Wysocki GP: The differential diagnosis of globulomaxillary radiolucencies, *Oral Surg Oral Med Oral Pathol* 51:281–286, 1981.
141. D'Silva NJ, Anderson L: Globulomaxillary cyst revisited, *Oral Surg Oral Med Oral Pathol* 76:182–184, 1993.
142. Wysocki GP, Goldblatt LI: The so-called "globulomaxillary cyst" is extinct, *Oral Surg Oral Med Oral Pathol* 76:185–186, 1993.
143. Moore K: *The developing human*, Philadelphia, 1988, Saunders.
144. Langman J: *Medical embryology*, Baltimore, 1984, Williams & Wilkins.
145. King RC, Smith BR, Burk JL: Dermoid cyst in the floor of the mouth. Review of the literature and case reports, *Oral Surg Oral Med Oral Pathol* 78(5):567–576, 1994.
146. Erich JB: Sebaceous, mucous, dermoid and epidermoid cysts, *Am J Surg* 44:672–677, 1940.
147. Mahmood S, Moody H: Dermoid, teratoma or choristoma? A rare lesion of the tongue in an adult, *Br J Oral Maxillofac Surg* 41(2):117–119, 2003.
148. Smirniotopoulos JG, Chiechi MV: Teratomas, dermoids, and epidermoids of the head and neck, *Radiographics* 15(6):1437–1455, 1995.
149. Boatman BW, Headington JT: Epidermoid and tricholemmal cyst. In Demis DI, editor: *Clinical dermatology,* Chapters 4-5, Philadelphia, 1996, Lippincott-Raven.
150. New G, Erich J: Dermoid cysts of the head and neck, *Surg Gynecol Obstet* 65:48–55, 1937.
151. New G: Congenital cysts of the tongue, the floor of the mouth, the pharynx and the larynx, *Arch Otolaryngol* 45:145–158, 1947.
152. Taylor BW, Erich JB, Dockerty MB: Dermoids of the head and neck, *Minn Med* 49(10):1535–1540, 1966.
153. Prayor SG, Lewis JE, Weaver AL, et al.: Pediatric dermoid cysts of the head and neck, *Otolaryngol Head Neck Surg* 132:938–942, 2005.
154. Som P: Cystic lesion of the neck, *Postgrad Radiol* 7:211–231, 1987.
155. Eppley BL, Bell MJ, Sclaroff A: Simultaneous occurrence of dermoid and heterotopic intestinal cysts in the floor of the mouth of a newborn, *J Oral Maxillofac Surg* 43(11):880–883, 1985.
156. Gibson Jr WS, Fenton NA: Congenital sublingual dermoid cyst, *Arch Otolaryngol* 108(11):745–748, 1982.
157. Park YW: Evaluation of neck masses in children, *Am Fam Physician* 51(8):1904–1912, 1995.
158. Seward GR: Dermoid cysts of the floor of the mouth, *Br J Oral Surg* 3(1):36–47, 1965.
159. Vogl TJ, Steger W, Ihrler S, et al.: Cystic masses in the floor of the mouth: value of MR imaging in planning surgery, *AJR Am J Roentgenol* 161(1):183–186, 1993.
160. Howell CJ: The sublingual dermoid cyst. Report of five cases and review of the literature, *Oral Surg Oral Med Oral Pathol* 59(6):578–580, 1985.
161. Ariyoshi Y, Shimahara M: Magnetic resonance imaging of a submental dermoid cyst: report of a case, *J Oral Maxillofac Surg* 61(4):507–510, 2003.
162. Hunter TB, Paplanus SH, Chernin MM, et al.: Dermoid cyst of the floor of the mouth: CT appearance, *AJR Am J Roentgenol* 141(6):1239–1240, 1983.
163. Chakravorty RC, Schatzki PF: Lateral sublingual dermoid, *Oral Surg Oral Med Oral Pathol* 39(6):862–866, 1975.
164. Allard RH: The thyroglossal cyst, *Head Neck Surg* 5(2):134–146, 1982.
165. Josephson GD, Spencer WR, Josephson JS: Thyroglossal duct cyst: the New York Eye and Ear Infirmary experience and a literature review, *Ear Nose Throat J* 77(8):642–644, 1998. 6–7, 51.
166. Katz AD, Hachigian M: Thyroglossal duct cysts. A thirty year experience with emphasis on occurrence in older patients, *Am J Surg* 155(6):741–744, 1988.
167. Greinwald Jr JH, Leichtman LG, Simko EJ: Hereditary thyroglossal duct cysts, *Arch Otolaryngol Head Neck Surg* 122(10):1094–1096, 1996.
168. Telander RL, Filston HC: Review of head and neck lesions in infancy and childhood, *Surg Clin North Am* 72(6):1429–1447, 1992.
169. Macdonald DM: Thyroglossal cysts and fistulae, *Int J Oral Surg* 3(5):342–346, 1974.
170. Deane SA, Telander RL: Surgery for thyroglossal duct and branchial cleft anomalies, *Am J Surg* 136(3):348–353, 1978.
171. Reede DL, Bergeron RT, Som PM: CT of thyroglossal duct cysts, *Radiology* 157(1):121–125, 1985.
172. Dolata J: Thyroglossal duct cyst in the mouth floor: an unusual location, *Otolaryngol Head Neck Surg* 110(6):580–583, 1994.
173. Miller MB, Rao VM, Tom BM: Cystic masses of the head and neck: pitfalls in CT and MR interpretation, *AJR Am J Roentgenol* 159(3):601–607, 1992.
174. Hawkins DB, Jacobsen BE, Klatt EC: Cysts of the thyroglossal duct, *Laryngoscope* 92(11):1254–1258, 1982.
175. Filston HC: Common lumps and bumps of the head and neck in infants and children, *Pediatr Ann* 18(3):180–186, 1989. 4, 6.
176. Ward GE, Hendrick JW, Chambers RG: Thyroglossal tract abnormalities, cysts and fistulas; report of 105 cases from the Johns Hopkins Hospital observed during the years 1926 to 1946, *Surg Gynecol Obstet* 89(6):727–734, 1949 (illustration).
177. Brown PM, Judd ES: Thyroglossal duct cysts and sinuses: results of radical (Sistrunk) operation, *Am J Surg* 102:494–501, 1961.
178. Sade J, Rosen G: Thyroglossal cysts and tracts. A histological and histochemical study, *Ann Otol Rhinol Laryngol* 77(1):139–145, 1968.
179. LiVolsi VA, Perzin KH, Savetsky L: Carcinoma arising in median ectopic thyroid (including thyroglossal duct tissue), *Cancer* 34(4):1303–1315, 1974.
180. el-Silimy OE, Bradley PJ: Thyroglossal tract anomalies, *Clin Otolaryngol Allied Sci* 10(6):329–334, 1985.
181. Lustmann J, Benoliel R, Zeltser R: Squamous cell carcinoma arising in a thyroglossal duct cyst in the tongue, *J Oral Maxillofac Surg* 47(1):81–85, 1989.
182. Dische S, Berg PK: An investigation of the thyroglossal tract using the radioisotope scan, *Clin Radiol* 14:298–303, 1963.

183. Hoffman MA, Schuster SR: Thyroglossal duct remnants in infants and children: reevaluation of histopathology and methods for resection, *Ann Otol Rhinol Laryngol* 97(5, pt 1):483–486, 1988.
184. Navas Molinero C, Sendra Tello J, Plaza Mayor G, et al.: Thyroglossal cyst: retrospective study of 58 cases. Results of the Sistrunk operation, *Acta Otorrinolaringol Esp* 51(4):340–347, 2000.
185. Heemskerk J, Stultiens GN, Tan I, et al.: Papillary carcinoma in a thyroglossal duct, *Acta Oncol* 45(3):332–334, 2006.
186. Renard TH, Choucair RJ, Stevenson WD, et al.: Carcinoma of the thyroglossal duct, *Surg Gynecol Obstet* 171(4):305–308, 1990.
187. Weiss SD, Orlich CC: Primary papillary carcinoma of a thyroglossal duct cyst: report of a case and literature review, *Br J Surg* 78(1):87–89, 1991.
188. Fernandez JF, Ordonez NG, Schultz PN, et al.: Thyroglossal duct carcinoma, *Surgery* 110(6):928–934, 1991, discussion 34-35.
189. Joseph TJ, Komorowski RA: Thyroglossal duct carcinoma, *Hum Pathol* 6(6):717–729, 1975.
190. Kwan WB, Liu FF, Banerjee D, et al.: Concurrent papillary and squamous carcinoma in a thyroglossal duct cyst: a case report, *Can J Surg* 39(4):328–332, 1996.
191. Nussbaum M, Buchwald RP, Ribner A, et al.: Anaplastic carcinoma arising from median ectopic thyroid (thyroglossal duct remnant), *Cancer* 48(12):2724–2728, 1981.
192. Page CP, Kemmerer WT, Haff RC, et al.: Thyroid carcinomas arising in thyroglossal ducts, *Ann Surg* 180(5):799–803, 1974.
193. Branstetter BF, Weissman JL, Kennedy TL, et al.: The CT appearance of thyroglossal duct carcinoma, *AJNR Am J Neuroradiol* 21(8):1547–1550, 2000.
194. Asakage T, Nara S, Yoshizumi T, et al.: Thyroglossal duct carcinoma: a case report, *Jpn J Clin Oncol* 27(5):340–342, 1997.
195. Yanagisawa K, Eisen RN, Sasaki CT: Squamous cell carcinoma arising in a thyroglossal duct cyst, *Arch Otolaryngol Head Neck Surg* 118(5):538–541, 1992.
196. Benson MT, Dalen K, Mancuso AA, et al.: Congenital anomalies of the branchial apparatus: embryology and pathologic anatomy, *Radiographics* 12(5):943–960, 1992.
197. Ford GR, Balakrishnan A, Evans JN, et al.: Branchial cleft and pouch anomalies, *J Laryngol Otol* 106(2):137–143, 1992.
198. Proctor B, Proctor C: Congenital lesions of the head and neck, *Otolaryngol Clin North Am* 3(2):221–248, 1970.
199. Buckingham JM, Lynn HB: Branchial cleft cysts and sinuses in children, *Mayo Clin Proc* 49(3):172–175, 1974.
200. Hunter AG: Inheritance of branchial sinuses and preauricular fistulae, *Teratology* 9(2):225–228, 1974.
201. Telander RL, Deane SA: Thyroglossal and branchial cleft cysts and sinuses, *Surg Clin North Am* 57(4):779–791, 1977.
202. Sedgwick CE, Walsh JF: Branchial cysts and fistulas; a study of seventy-five cases relative to clinical aspects and treatment, *Am J Surg* 83(1):3–8, 1952.
203. Harnsberger HR, Mancuso AA, Muraki AS, et al.: Branchial cleft anomalies and their mimics: computed tomographic evaluation, *Radiology* 152(3):739–748, 1984.
204. Faerber EN, Swartz JD: Imaging of neck masses in infants and children, *Crit Rev Diag Imag* 31(3-4):283–314, 1991.
205. Cote DN, Gianoli GJ: Fourth branchial cleft cysts, *Otolaryngol Head Neck Surg* 114(1):95–97, 1996.
206. Som PM, Sacher M, Lanzieri CF, et al.: Parenchymal cysts of the lower neck, *Radiology* 157(2):399–406, 1985.
207. Crocker J, Jenkins R: An immunohistochemical study of branchial cysts, *J Clin Pathol* 38(7):784–790, 1985.
208. Blackwell KE, Calcaterra TC: Functional neck dissection for treatment of recurrent branchial remnants, *Arch Otolaryngol Head Neck Surg* 120(4):417–421, 1994.
209. El-Mofty SK, Zhang MO, Davila RM: *Detection of HPV in metastatic squamous cell carcinoma in cervical lymph nodes: a tool for identification of the site of an occult head and neck primary (abstr 1016)*, San Diego, 2007, USCAP Annual Meeting.
210. El-Mofty SK, Patil S: Human papillomavirus (HPV)-related oropharyngeal nonkeratinizing squamous cell carcinoma: characterization of a distinct phenotype, *Oral Surg Oral Med Oral Pathol Oral Radiol Endod* 101(3):339–345, 2006.

18

Odontogenic Tumors: Surgical Pathology and Management

LIONEL GOLD, THOMAS P. WILLIAMS

Introduction

The embryologic events that initiate, control, and guide formation of human odontogenic structures take place through an intricate and finely regulated series of inductive interactions between epithelium and mesenchyme, which begin during the fifth and sixth weeks of intrauterine life and are completed about the sixteenth year after birth.[1,2] During this extended period, there is ample opportunity for developmental and growth mechanisms to fail in whole or in part, resulting in the formation of *malformations, hamartomas,* and *neoplasms,* collectively known as *odontogenic tumors*.

Odontogenic tumor, therefore, is an imprecise term that encompasses a wide spectrum of lesions and variants. Distinctions among these three forms of abnormalities may, in part, depend on the embryologic stage of initiation and the histologic and gross appearance of the lesion at the age of clinical discovery. Overlap and combinations among lesions are possible and do occur. A malformation, although neoplastically innocent, because of size and/or anatomic position may cause a functional disturbance or aesthetic liability; a hamartoma by continued growth may eventuate as a neoplasm; and a benign odontogenic cyst or usually self-limiting neoplasm may give rise to an aggressive or malignant neoplasm. Thus, an odontogenic lesion may require surgical management because of physical presence or biologic behavior. Biologic behavior, biologic activity, and growth potential are three interrelated effectors that determine a lesion's ability to harm the host.

Because histologic appearance and biologic behavior are not necessarily linked, assessment of the growth potential of an odontogenic lesion may be difficult. This is true particularly in the case of a "newly discovered" or rarely encountered entity of which long-term clinical experience has not been documented. Even in the instance of ameloblastoma, a lesion that has been recorded extensively for over a century, there are diametrically opposed management philosophies. In addition to so-called radical or conservative modalities, variations and combinations of treatment have been attempted.

The goal of treatment, of course, is eradication of a lesion with the least morbidity possible and the preservation or restoration of function. However, a common all-inclusive algorithm for the management of odontogenic tumors, as well as other maxillofacial jaw lesions, must await long-term treatment and outcome studies. The current basis for the decision whether, when, and how to manage a number of odontogenic lesions is contingent on individual clinical factors and assessment of the lesions' biologic behavior. Several odontogenic tumors have distinct histologic patterns, are well documented in case histories and case series studies, and have known outcome results; however, even among these lesions an occasional rogue lesion may exhibit unexpected biologic behavior.

Such activity may be regarded as chance vagary of the lesion but also may be due to unappreciated histologic or molecular variation with concomitant altered biologic behavior. Because histologic diversity may help to characterize odontogenic lesional behavior, it is prudent to consult an oral and maxillofacial pathologist for evaluation of odontogenic lesions. Presently most hospital pathology departments have an oral and maxillofacial pathologist on staff or routinely consult with them. This is to be expected and encouraged, because odontogenic tumors comprise a specialized area of pathology.

Classifications

It is interesting to read the earlier efforts at classification, especially by the British writers of the later 19th and early 20th centuries up to the 1930s, as they labored to clarify and classify odontogenic lesions.[3-6] The class name they adopted was *Odontomes,* under which the entire gamut of odontogenic lesions, as well as unrelated jaw lesions, were placed. In the United States, Ivy and Churchill[7] also made an effort to bring order to and reclassify odontogenic lesions. In 1946 Thoma and Goldman[8] published their classic paper, which

described a classification of odontogenic tumors based on the tissue cell of origin and eliminated many extraneous lesions from consideration. They recognized lesions derived primarily from epithelium, those predominantly from mesenchyme, and a mixed group in which both epithelial and mesenchymal tissues shared in the formation of a lesion. Their scheme, and particularly the case illustrations, demonstrated the inductive effects of one tissue (epithelium) on another (mesenchyme) in the pathogenesis of odontogenic tumors.

Several other revisions and refinements were made by Pindborg and Clausen[9] and by Gorlin and other colleagues,[10] who also proposed a classification based on the embryologic inductive interactions of the tissues on each other. These classifications provided a better means to view and catalog lesions in an orderly manner but did not give the surgeon insight into their biologic behavior. In a further departure, the World Health Organization (WHO) published a classification in 1971,[11] a revision in 1992,[12] and a further revision in 2005[13] with input from international groups of oral and maxillofacial pathologists, which is based on embryologic induction patterns (1992) but also categorizes odontogenic lesions into benign and malignant types (1971, 1992, 2005). The authors recognize the inherent difficulties in this or any classification that contains lesions of uncertain status as well as lesions for which behavioral information is still being accumulated. As is always the case, the latest efforts at histologic typing of odontogenic tumors have evoked reasonable suggestions and comments from several writers.[14-20] It is apparent that no classification is entirely satisfactory and that all have deficiencies. The order of presentation used in this chapter follows the traditional separation of lesions into epithelial, mesenchymal, and mixed types. In addition, an attempt is made to indicate a progression from the least to the most aggressive lesions. However, we emphasize again that known nonaggressive lesions may exhibit unexpected aggressive behavior.

General Clinical, Diagnostic, and Management Considerations

Clinical

Odontogenic tumors, as a group, are relatively uncommon; several are rare, and a few are very rare. Published occurrence reports of odontogenic tumors, expressed as percentage[3] of the total lesions in oral biopsy services of various institutions in the United States and countries throughout the world, reveal a low incidence. However, the percentage incidence of specific odontogenic tumors within the group appears to vary in different races and countries.[20,21] The clinical importance of odontogenic tumors is not measured by their numbers, but because some lesions are very destructive and surgical management involves the face, oral tissues, and jaws of both young and old patients. Correlation of clinical, radiographic, and histologic analyses is necessary to prevent over- or undertreatment.

There are no clinical signs, symptoms, or physical findings that permit diagnosis of specific odontogenic tumors. The age and sex of the patient and location characteristics of lesions are derived from pooled data compiled from the literature and unpublished cases. Such information is useful only when combined with other diagnostic features.

Imaging

Because most odontogenic tumors emanate from or involve the jaws, imaging modalities, including plain radiography (periapical, occlusal, panoramic), computed tomography (CT), CT three-dimensional (3D) reconstruction, computer-generated models, magnetic resonance imaging (MRI), and positron emission tomography (PET) scan CT, offer an unparalleled opportunity to view the tumor in relation to the jaws and adjacent soft tissues. Radiographic images do not provide pathognomonic identification of odontogenic lesions, because several odontogenic tumors as well as nonodontogenic lesions may share imaging characteristics. However, highly useful visual information can be gathered to study a lesion for presumptive differential diagnoses, selection of biopsy sites, and management decisions. A lesion's position, size, and shape; presence or absence of lesional calcifications; estimation of soft tissue volume in relation to calcified tissue, cyst formation, and impingement on or inclusion of vital anatomic structures; displacement of teeth or root resorption; and interface boundaries between lesion and host bone help the clinician to form a characterization of the tumor's activity and aggressiveness.

Odontogenic tumors are most often discovered by dental radiography (periapical, occlusal, or panoramic) as part of routine screening during a dental visit, examination of a patient with a specific complaint (e.g., pain or oral soft tissue or facial enlargement), or elective consultation (e.g., orthodontic or orthognathic surgery). The judgment of the clinician will determine the extent and types of imaging that are needed or most useful for the management of a specific case. Yet, in many instances, there is a tendency to use fewer imaging modalities than are desirable—which is usually later regretted, as imaging provides a valuable documentary and study tool.

Overall viewing of bone and soft tissue by consecutive anatomic "slices" and planes is provided by CT and MRI, respectively. The volume of the tumor and the interface margins between the tumor and surrounding bone and soft tissue is roughly revealed by PET-CT, obtained after injection of a glucose isotope conjugate metabolized by the tumor. The 3D CT (three-dimensional computerized tomogram) permits viewing the lesion in almost kaleidoscopic anatomic displays; the 3D CT generated model provides an excellent physical reproduction of the anatomic part and tumor. The model is useful for planning or carrying out a mock surgical

procedure and provides a mechanical frame on which to contour a reconstruction appliance.

Biopsy

Definitive diagnosis is established only after incisional, excisional, or intraoperative frozen section biopsy for histologic analysis. The specific biopsy technique is selected after careful assessment of the patient (age, physical health, and emotional status) and of the use of local, sedation, or general anesthesia to ensure patient cooperation, gain access to the lesion, and obtain sufficient tissue for study. An *incisional biopsy* performed several weeks before definitive management often precludes excision or frozen section diagnostic "surprises." Thus, time is gained to receive a soft or calcified tissue diagnosis, plan the surgical procedure, prepare and/or obtain special presurgical requirements, and fully discuss management with the patient or guardian. *Excisional biopsy* should be performed for completely calcified odontogenic lesions (i.e., malformations radiographically demonstrating only teeth or a cementum-like tissue) in which histologic diagnosis is not immediately essential; for physically impaired patients for whom several anesthetic or surgical exposures should be avoided; or for small lesions (approximately 1.0 to 1.5 cm in diameter) that can be excised completely and can reasonably be expected not to require further operation after histologic study. *Intraoperative frozen section* should be used to study questionable soft tissue encountered in areas not sampled by the incisional biopsy, and to examine the adequacy of the boundary between lesion and host bone and/or soft tissue in instances in which extensive resection is not planned. The preparation of a good frozen section is technique-sensitive and requires proper specimen orientation and avoidance of incorporated dense bone (which nicks the microtome blade and disrupts the tissue section).

The biopsy is an important procedure and must be planned and conducted carefully. Because of its key role in the diagnostic process, and later in the definitive surgical procedure, some aspects of the biopsy are discussed here in detail: (1) The lesion is approached, with radiographic guidance, by incision through intact crestal mucosa over intact bone, in order to preserve "noncontaminated" mucosal soft tissue that may be used for wound closure after a postbiopsy surgical procedure. (2) The lesion is aspirated through the intact bone to rule out a vascular lesion masquerading as an odontogenic tumor (other potential radiographic imitators of odontogenic tumors include aneurysmal bone cyst, giant cell lesion, and fibro-osseous disease). (3) Aspiration of cystic fluid neither confirms nor disproves the presence of a cystic odontogenic tumor; the fluid may or may not be retained for a cell-block preparation. (4) Entrance through the bone to the lesion should be selected and obtained without injury to nerves or teeth, if possible. (5) If the radiographs indicate variations in the lesion (solid, cystic, or calcified areas), a sufficient number of tissue samples should be removed for thorough histologic study, including tissue bordering the lesion–host bone interface. The specimens are incised for removal and not crushed with forceps or hemostats. (6) Before suture closure of the biopsy incision, if desirable, a nonresorbable tissue barrier can be placed over the bone entrance to the lesion to prevent fluid or lesional cell escape into noninvolved periosteum or mucosa.

The specimens are oriented and identified by marking the natural tissue surfaces with indelible ink of the same or a different color (i.e., to represent the biopsy sites such as anterior or posterior), spread flat with the tissue exudate side down on an absorbent surface (e.g., glove wrapper or filter paper), allowed to dry for about 3 to 4 minutes so that the specimen adheres to the carrier and does not curl, and placed into separate labeled containers. This technique permits the pathologist to identify and orient the frequently small tissue samples and prevents improper gross sectioning and poor histologic preparation.

The surgeon or assistant surgeon should complete the pathology laboratory form. This important function should not be assigned to others (e.g., circulating nurse), because accuracy cannot be assured later if questions concerning biopsy sites and histologic findings arise. The pathology laboratory form provides space for a brief history, clinical diagnosis, special instructions to the pathologist, and diagram of the lesion and lesional area to identify the orienting tissue ink marks. A radiograph (or good copy) of the lesion and anatomic site should accompany the specimen or be sent to the pathologist.

The histologic tissue slides should be reviewed by the surgeon alone or with the pathologist. Unusual, problematic, or unexpected findings should be discussed with the pathologist. After histologic study and diagnosis, the biologic activity of the lesion is estimated. An equivocal diagnosis or a choice among several diagnoses should initiate a review by other pathologists.

Management

The objectives of the surgical management of odontogenic tumors are the eradication of the lesion, preservation of normal tissue to the extent possible, and restoration of significant tissue loss, form, and function. All agree that the surgical procedure should be sufficient to the need; however, in many instances there is disagreement among surgeons and pathologists about the extent of surgery that specific tumors require. These differences of opinion are reflected in the literature and account for "conservative" or "radical" approaches to treatment that result from unanswered questions concerning the biologic activity of several odontogenic tumors.

Some surgeons maintain an almost mystical adherence to a conservative surgical approach, in the conviction that all odontogenic tumors are benign. This viewpoint amounts to a planned recurrence for some lesions. The basis for this opinion is the belief that a recurrence or recurrences (more properly, regrowth of residual lesion) can be managed by a simpler procedure that can avoid jaw resection. However,

one of the results of such an approach is the creation of a shotgun pattern of recurrence by which the lesion is spread throughout a larger area, thus compounding the surgical problem. Other surgeons are routinely aggressive in their approach to all odontogenic tumors, and so sacrifice more normal tissue than is necessary to ablate the lesion. The argument has been made that a well-planned and executed resection and reconstruction serves the patient physically and emotionally better than repeated surgical procedures.[22] The defense of or response to both positions lies in the continued accumulation and dissemination of accurate data and knowledge of odontogenic lesions. This can be achieved best by the surgeon and pathologist working together to correlate clinical, surgical, and histologic findings with biologic activity and clinical outcome. This effort would be aided greatly by the adoption of standardized, defined surgical excision terms acceptable to the entire surgical community.

One attempt to provide precisely defined excision terminology applicable to lesions in bone was offered by Gold and co-workers.[23] All excisions involving bone can best be described by the following designations: enucleation, curettage, marsupialization, recontouring, resection without continuity defect (Rs$^-$CD), resection with continuity defect (Rc$^-$CD), and disarticulation. All are definable.[23] Some may be used in combination, and three—Rs$^-$CD, Rc$^-$CD, and disarticulation—can be measured radiographically, grossly, and histologically. This terminology is employed in this chapter where germane. Certainly at present, there are no absolute standards of management for many odontogenic tumors. The treatment of several lesions continues to be debatable, and some suggestions for treatment made in this chapter may be in disagreement with the opinions of other writers.

Epithelial Odontogenic Tumors

Adenomatoid Odontogenic Tumor

The *adenomatoid odontogenic tumor* (AOT) has been known by a number of descriptive names since it was first reported[24] and later recognized as a distinct odontogenic lesion unrelated to ameloblastoma (Figure 18-1). Although it was considered to be a variant of ameloblastoma at one time, surgical and treatment outcome experience has borne out the benign, nonaggressive nature of this lesion. Variously known as adenoameloblastoma, ameloblastic adenomatoid tumor, glandular ameloblastoma, and adenomatoid ameloblastoma, as well as by other designations, the lesion has been extensively recorded in the literature.[25-27]

The acceptance of the more apt name adenomatoid odontogenic tumor[26] recognizes the unique and peculiar ductlike or tubelike histologic structures and odontogenic origin but removes the burden of ameloblastic stigmatization. The AOT can be considered a hamartoma with occasional neoplastic behavior.

Clinicopathologic Considerations

The adenomatoid odontogenic tumor is usually clinically evident during the latter part of the second decade; however, reported cases range in age between 4 and 80 years. There is a slight female over male incidence, an almost 2:1 site preference for maxilla over mandible, and a marked predilection for the anterior jaws (more than 85% of lesions appear anterior to the second premolar teeth).

The AOT has several radiographic appearances that may be considered typical but not pathognomonic. The lesion frequently appears as a well-circumscribed, pear-shaped radiolucency (stem portion toward the alveolar surface) lying between divergent roots of the canine and first premolar teeth (or between incisors or premolars); or as a unilocular, radiolucent lesion that is well circumscribed or bounded by a radiopaque margin, lateral to or containing an impacted tooth (similar to a follicular, dentigerous cyst, or occasionally a periodontal cyst) (Figure 18-2, *A-H*). Frequently, small, variously shaped faint or marked radiopaque particles (calcifications) may be distributed throughout the lesional space or are concentrated within a small area of a predominantly radiolucent lesion. Rarely, some lesions appear heavily calcified (see Figure 18-1, *A,B*). Root resorption occasionally occurs but is usually not severe (see Figure 18-1, *B*).

Histologically, the lesion is usually partially cystic and surrounded by a well-developed connective tissue capsule. The luminal surface is lined with a reduced odontogenic epithelium that leads to thickened mural proliferations of the AOT, which project into and partially or almost completely fill a cystic lumen with tumor lobules (see Figure 18-2, *F-H*). The characteristic AOT lesional tissue is composed of a profuse complex of rounded, rosette-like and stream-like aggregates of spindle-shaped odontogenic epithelial cells (see Figure 18-2, *G,H*), similar in size and shape to the stratum intermedium cells of the developing tooth germ (see Figure 18-1, *C*). Within the epithelial masses, some of the rounded and rosette forms appear to become hollow, assume ductlike or tubelike shapes, and are lined with a single layer of cuboidal or columnar epithelium (see Figure 18-1, *D*). Frequently, eosinophilic droplets (likened to enameloid products) are seen within the tubes or lying among the spindled epithelial masses (see Figure 18-1, *E,F*). To a greater or lesser degree, calcifications occur within the lumina of the ducts, scattered among the epithelial masses or in the stroma. These often appear as dystrophic irregular masses or have an annular shape, whereas occasional calcifications have a cementum or dentinlike appearance.

Several cases, personally studied, have demonstrated foci of clear cells within the adenomatoid cellular areas. However, such areas have not influenced treatment. Cases of combined AOT with calcifying epithelial odontogenic tumor (CEOT) have been reported.[28,29]

Management

Because of site, age, and imaging characteristics, lesions such as periodontal cyst, dentigerous cyst, calcifying odontogenic cyst (COC), CEOT, or desmoplastic ameloblastoma can be

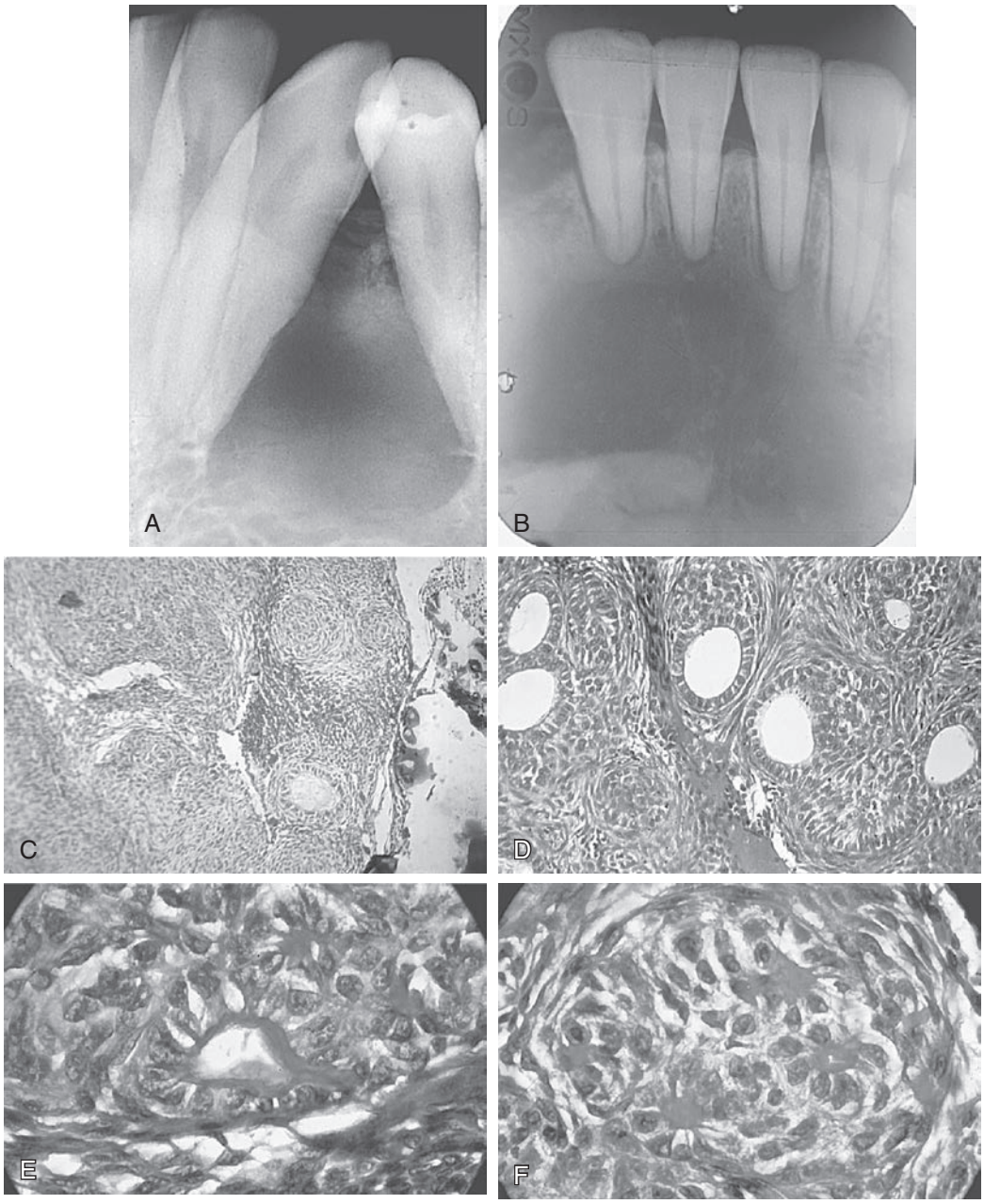

• **Figure 18-1** Adenomatoid odontogenic tumor (AOT). **A**, Radiograph of lesion in canine/premolar region shows wide divergence of tooth roots and pear-shaped radiolucency with intralesional calcifications. **B**, Nonpathognomonic radiograph of anterior mandibular AOT. Note blunting (resorption) of root tips, diffuse radiolucency, and intralesional calcification. **C**-**D**, Low- and medium-power photomicrographs of characteristic histologic morphology: profusely cellular epithelium, rosette-like masses, and ductlike configurations. **E**-**F**, High-power photomicrographs demonstrate ductlike and tubelike structures with an eosinophilic secretory product (possibly enameloid).

considered in the differential diagnosis. If sufficient suspicion exists that the lesion could be a CEOT or desmoplastic ameloblastoma, one or several biopsies of the lesion should be performed, because treatment varies.

The accumulated world experience with AOT, as reflected in 30 or more years of reports, depicts a lesion in which conservative management produces a uniformly excellent outcome without recurrence, except in one case. Takigami and co-workers[30] reported the case of a 49-year-old woman who had four recurrences of a maxillary AOT, which extended from the maxilla into the maxillary sinus, then extended to the posterior ethmoid and sphenoid sinuses, and finally extended intracranially into the middle fossa with destruction of the sella turcica, dorsum sellae, and anterior clinoid processes. A subtotal resection of the tumor was done.

In almost all instances, the lesion may be removed by surgical enucleation. After reflection of an ample mucosal flap and widened entrance through the usually thinned and expanded cortical bone, the connective tissue capsule of the lesion is encountered. Enucleation is achieved by separation

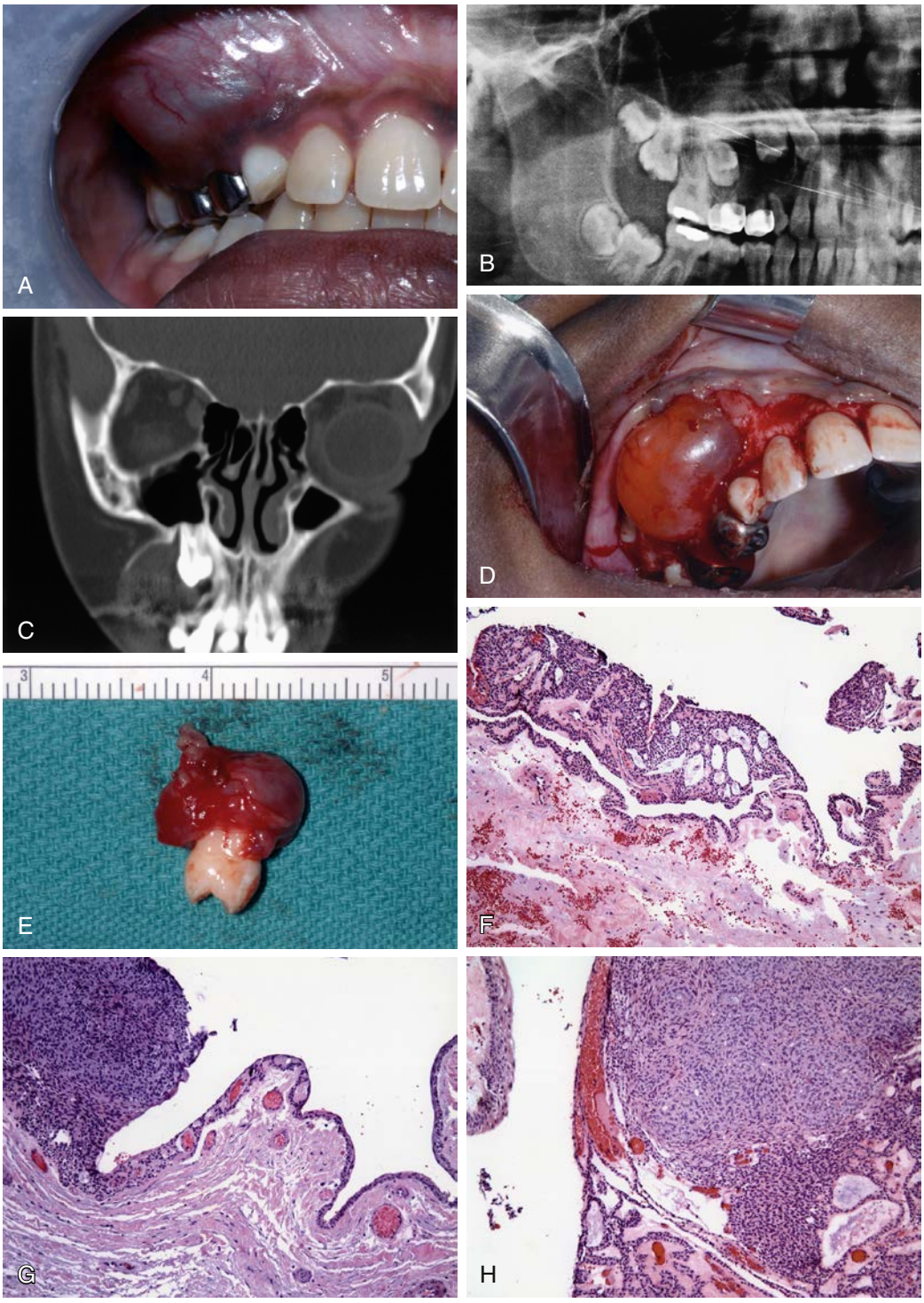

• **Figure 18-2** Cystic adenomatoid odontogenic tumor (AOT). **A,** An 11-year-old girl and her parents became aware of an enlarging swelling of her right cheek over a 2-month period. **B**-**C,** Panographic and CT radiographs revealed a 2.5 × 2.0 cm. radiolucent lesion in the anterior maxilla, containing severely displaced unerupted permanent teeth. **D,** A presumptive diagnosis of dentigerous cyst and/or AOT was made. At operation, a frozen section biopsy was diagnosed as a cyst with AOT. The lesion was dissected intact from the mucosa, aspirated, and enucleated. **E,** The specimen was thick-walled and contained the permanent first premolar tooth. The canine and second premolar were left in situ for eruption. **F**-**H,** Histologic sections showed characteristic cystic AOT morphology. (Case material courtesy Daniel Taub, DDS, MD, Thomas Jefferson University, Philadelphia.)

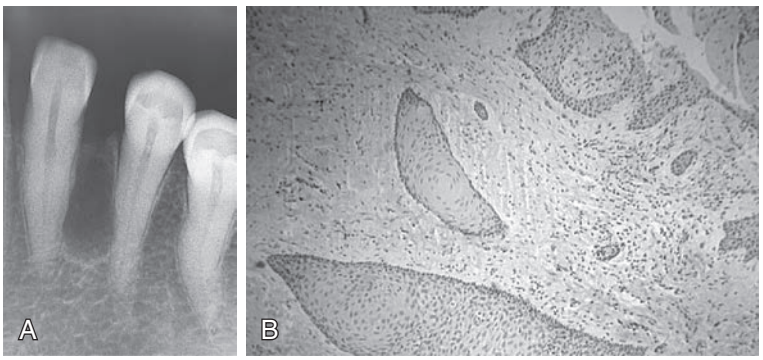

• **Figure 18-3** Squamous odontogenic cyst (SOT). **A,** Radiograph of mandibular periodontal cyst with SOT. **B,** Low-power photomicrograph demonstrates several large islands of benign squamous epithelium in the connective tissue wall of the cyst typical of cystic SOT.

of the lesion from bone without perforating the capsule. Portions of the capsule may be thinned or inflamed, permitting fragments of the lesion to escape the connective tissue envelope. Inspection, irrigation, and gentle curettage of the resultant cavity should remove any residual lesion. Primary closure of the wound with a cavity "filler" (e.g., oxidized cellulose, hydroxyapatite, or bone) can be performed. Teeth adjacent to the lesion may have divergently displaced roots (see Figure 18-1, *A*) as well as severely resorbed radicular bone. Such teeth should be removed if endodontic treatment and/or "bone fillers" cannot be provided. Impacted teeth in a follicular, dentigerous or periodontal cystic position can occasionally be salvaged for eruption if the lesion can be completely removed without injury to the teeth (see Figure 18-2, *A-H*).

Squamous Odontogenic Tumor

Squamous odontogenic tumor (SOT) was described and characterized by the collaboration of a small group of pathologists, each of whom had seen previously undescribed examples of the lesion (Figure 18-3).[31] SOT is a relatively rare, benign, but locally infiltrative and occasionally aggressive odontogenic epithelial lesion that appears to have hamartomatous and neoplastic characteristics. Since the initial description, a number of papers have amplified details of the clinical presentations and range of biologic activity of SOT.[31-36]

Clinicopathologic Considerations

The SOT is found over a wide age range from the second to the seventh decade, with most cases reported in young adults between 19 and 37 years of age. There does not appear to be a sex or race predilection. The mandible and maxilla are equally affected, and lesions are found singly or multicentrically in all areas of both jaws. The clinical symptoms vary with the circumstances of the individual lesion. Some tumors, within bone only, may be casually discovered by routine radiographs. When lesions occur in dentate areas, alveolar bone resorption around teeth causes mobility and pain. If cortical bone of the mandible or maxilla is penetrated by the lesion, the tumor infiltrates gingiva, occasionally the unattached alveolar mucosa, palatal soft tissue, and rarely the buccal mucosa. Lesions that involve the gingiva as well as alveolar bone, particularly if multicentric in both jaws, give a generalized impression of severe periodontal disease. Overtly aggressive maxillary tumors may infiltrate the maxillary sinus and nasal floor. An interesting study of familial SOTs in three siblings (two male, one female) has been reported.[37]

Radiographically, the SOTs, whether as single or multiple lesions of the mandible and maxilla, usually are seen as irregularly shaped or semicircular radiolucent areas with smooth sclerotic borders involving the superior area of the alveolus or roots of teeth. Some lesions are cystic or are associated with cysts and thus may radiographically appear as dentigerous, periodontal, or periapical in form (see Figure 18-3, *A*).

Histologic characteristics of solid and cystic tumors have been described. The typical solid lesion consists of numerous islands of squamous epithelium dispersed in a connective tissue stroma. The epithelial islands are variable in size, with irregularly shaped trabeculae that sometimes anastomose as well as rounded masses of benign stratified squamous epithelium with prominent intercellular bridges. The epithelial cells are uniform and without pleomorphism or nuclear hyperchromatism. The central areas of islands occasionally show foci of parakeratin or keratin, calcification, or cellular degeneration. Some epithelial nests show a cuboidal epithelial cell layer bordering the mature connective tissue stroma, whereas most rests have a compressed squamous cell layer lying against connective tissue (see Figure 18-3, *B*).

The cystic lesions contain many SOT islands in the connective tissue wall, either completely separated from the odontogenic epithelium lining the lumen or appearing to arise directly from the luminal epithelial lining. Doyle and colleagues[38] (in their study of three cases of SOT) included the first example of a cystic SOT, and Wright[39] (in an excellent study) reported five cystic SOT-like lesions. Hodgkinson and associates,[40] in a report of 79 odontogenic keratocysts, found a cyst that initially had been diagnosed and treated as a well-differentiated squamous cell carcinoma arising in a keratocyst. However, during preparation of their paper, the diagnosis was revised to SOT in the wall

of an odontogenic keratocyst. A case of putative carcinoma developing in a periodontal cyst, reported by Baker and colleagues,[41] appears on close inspection of the photomicrographs to be an example of SOT in a cyst wall. Van der Waal and co-workers[42] reported the case of a SOT-like lesion in bone, the radiograph of which was compatible with that of SOT islands admixed with epithelial islands resembling ameloblastoma. The published photomicrographs demonstrate why the authors were unable to reach a conclusion regarding the identity of the lesion. Similarly, the senior author (L.G.) treated a large posterior maxillary dentigerous cyst (radiographic diagnosis) that histologically revealed an odontogenic keratocystic epithelium lining the lumen, with numerous epithelial islands sharing SOT, ameloblastic, and keratocystic histologic characteristics in the cyst wall, and also emanating directly from the keratinizing epithelial lining of the lumen. A retrospective review of a number of lateral periodontal cysts from a study reported in 1973 revealed one that featured SOT-like islands in the cyst wall[43] (see Figure 18-3).

Management

There are no, or few, readily recognizable clinical or radiographic signs to presage a diagnosis of SOT. A definitive histologic diagnosis is made after biopsy, or histologic study of the excision specimen, if the lesion is removed without benefit of biopsy. The clinician with a strong index of suspicion may include SOT in the differential diagnosis, if lesions are multicentric in the mandible and/or maxilla, if there is gross alveolar bone involvement and bone loss around tooth roots, and if a generalized clinical picture of periodontal disease is present. However, if lesions are in bone and appear to be radiographically periodontal, dentigerous, or periapical cysts, there is no reason to suspect SOT.

Because SOT is benign but infiltrative, complete excision is required but should be tailored to the clinical and radiographic extent of the lesion. Lesions totally within bone can be removed by a combination of enucleation and curettage under frozen section guidance or can be resected without continuity defect if intact noninvolved bone margins can be established. Involved soft tissue overlying lesions that penetrate cortical bone should be included in the excision specimen, as should teeth within the lesional area.

SOTs in the form of cystic lesions (periodontal, dentigerous, or periapical) can be conservatively but completely excised by enucleation and/or curettage and require no further treatment unless histologic study reveals epithelial islands at the border or penetrating the connective tissue cyst wall at the bone interface. Prudence then dictates further excision to a histologically proven safe margin. According to Wright's report[39] of cystic SOTs, none has recurred, but there are no details offered of cyst wall–bone interface studies of the presence or absence of lesional tissue at the bone interface.

SOT exhibits a biologic behavioral pattern of aggression that appears unaccountable in strictly histologic terms; recurrences of incompletely excised lesions have been reported. Further, since SOT is rare, care must be exercised that the unexpected appearance of multiple islands of epithelium infiltrating the investing connective tissue of the lesion, and with occasional variable histologic characteristics, does not result in a mistaken diagnosis of ameloblastoma or squamous cell carcinoma, as has occurred; or conversely, an erroneous diagnosis of SOT instead of squamous cell carcinoma[44] (see Figure 18-22). A squamous cell carcinoma in a bone lesion has been reported in a patient who had multiple SOTs[45]; however, one could speculate whether the lesion was related to the SOT or was coincidental.

Calcifying Epithelial Odontogenic Tumor

Described in 1955 by Pindborg,[46] the *calcifying epithelial odontogenic tumor* (CEOT) also is known by the eponym *Pindborg tumor* (Figures 18-4 and 18-5). This seldom-occurring neoplasm[47] has distinctive histomorphologic features completely unlike those of ameloblastoma, to which it has been compared clinically. It is interesting that the 1946 Thoma and Goldman[8] report on the classification of odontogenic tumor shows photomicrographs of one of their cases (case 25) labeled adamantoblastoma, adenoid type (now called ameloblastoma) that is clearly recognizable as a calcifying epithelial odontogenic tumor, as is a 1948 case that Ivy[48] erroneously reported as ameloblastoma.

The number of published cases is not large, and the literature expresses conflicting opinions concerning the biologic behavior of CEOT. The lesion appears to occupy a position between hamartoma and aggressive neoplasm; however, there is no question that complete excision of the calcifying epithelial odontogenic tumor is required.

Clinicopathologic Considerations

The calcifying epithelial odontogenic tumor is clinically evident around the age of 40; however, reported cases show an age range between 13 and 80. There is no sex predilection. The mandible is the preferred site over the maxilla in an almost 3:1 ratio. The CEOT may occur in any area of the jaw, but the premolar/molar area appears to be favored. The CEOT is slow growing, locally aggressive, and without clinical signs until a clinically large mass is reached or incidental radiographs reveal the lesion.[46,47,49,50] Several extraosseous CEOTs in the anterior gingiva have been described.[51-54] In addition, CEOT in combination with AOT has been reported.[28,29]

A number of variable radiographic patterns are seen in CEOTs. The lesion may or may not be well circumscribed, mixed radiolucent-radiopaque, unilocular, or associated with an embedded or impacted tooth (see Figures 18-4 and 18-5). Infrequently, the lesion is multilocular with bony septae producing a "honeycomb" effect lacking well-defined margins (see Figure 18-4, *A*). Calcifications in the lesion appear as scattered, irregular radiopaque small or large particles. If the lesion is heavily calcified, a more dense radiopaque aggregation is produced. Thus, there is no radiographic pathognomonic appearance of the CEOT. Other lesions, such as myxoma, hemangioma, or ameloblastoma, may be suspected if the lesion is radiolucent; calcifying

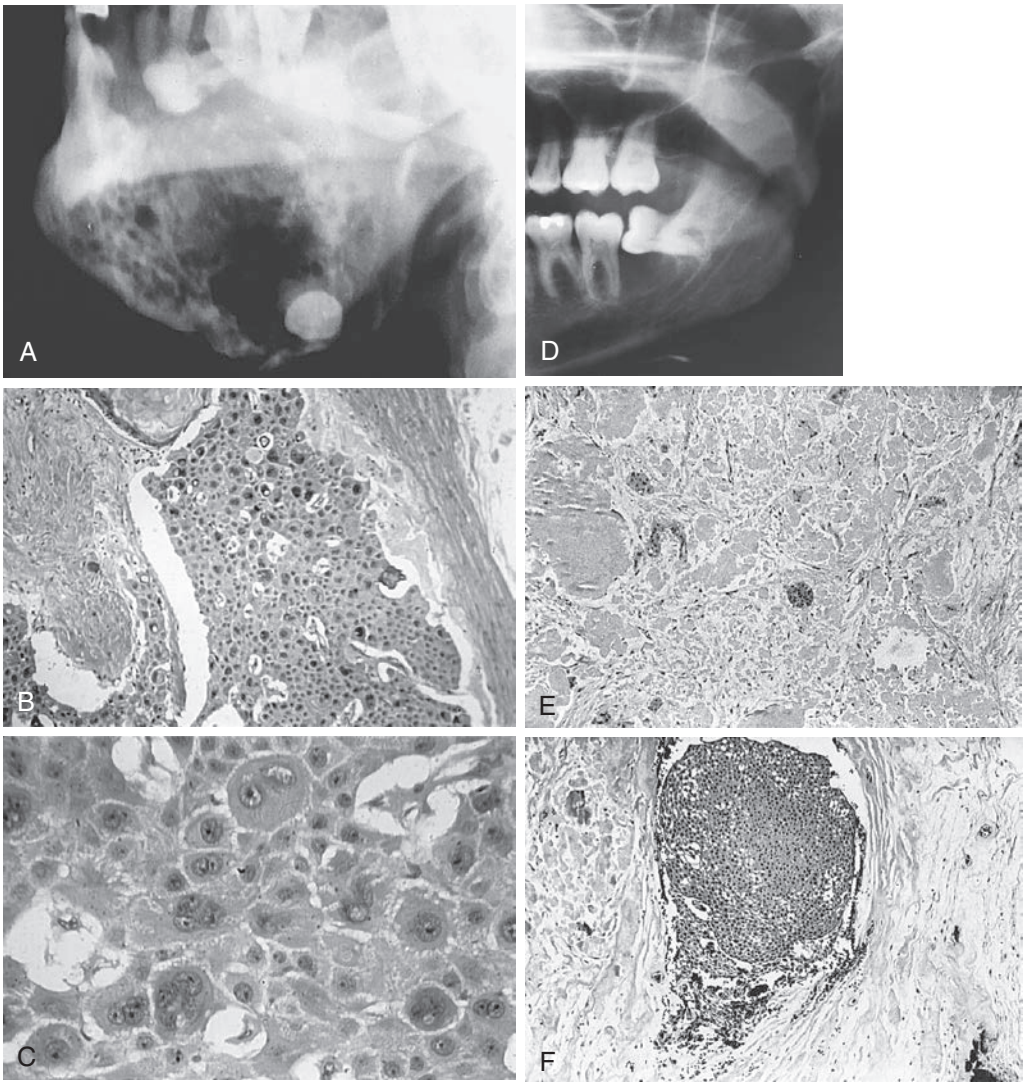

• **Figure 18-4** Calcifying epithelial odontogenic tumor (CEOT). **A,** Radiograph of extensive mandibular poorly circumscribed CEOT with multiple cribriform radiolucent areas and an impacted tooth. **B-C,** Low- and high-power photomicrographs illustrate "classic" CEOT histomorphology: large islands of squamous epithelium with prominent intercellular bridges and variously sized and shaped bizarre cells containing two and three nuclei. **D,** Radiograph of an impacted mandibular third molar in relation to an ill-defined soft tissue mass. The tooth was removed, and the lesion was excised by enucleation and curettage. **E-F,** Low- and medium-power photomicrographs of the soft tissue mass composed of extensive amorphous deposits of amyloid in a connective tissue stroma with scattered islands of odontogenic epithelium recognized as variant CEOT. (Case material **D-F** courtesy Dr. Mansoor Madani, Bala Cynwyd, PA.)

odontogenic cyst and AOT may be suspected if the lesion has radiopacities.

Histologically, the CEOT is characterized by a distinctive picture of trabeculae and/or sheets of large, eosinophilic-staining, squamoid-shaped epithelial cells, frequently with prominent intercellular bridges. The epithelial cells and their nuclei may vary greatly in shape and size. Some nuclei exhibit huge size and odd configurations with large, prominent nucleoli; binuclear and even trinuclear cells may be present. Although bizarre-looking cells are seen, the overall impression is not one of malignancy (see Figures 18-4, *B,C* and 18-5, *C*). The connective tissue stroma is usually inconspicuous between islands and sheets of epithelium. However, occupying the stroma in small areas of some lesions, or seeming to replace the stroma in large areas of other lesions, is a hyaline-like, homogeneous material identified as amyloid (see Figure 18-4, *E,F*).[55-57] Prominent or scattered calcifications, in concentric crenate-like shapes (Liesegang rings), may occur in the amyloid areas and, when present, account for the radiopacities seen in radiographs.

Several distinct histologic pattern variants have also been described, the most important of which include *clear cell* components. Prominent clear cell features in a CEOT appear to be associated with increased aggressiveness of the lesion according to several authors[58-60] (see later discussions of ameloblastoma with clear cells and clear cell odontogenic carcinoma). An excellent paper by Cheng and co-workers[61] discusses a case of CEOT with a conspicuous clear cell

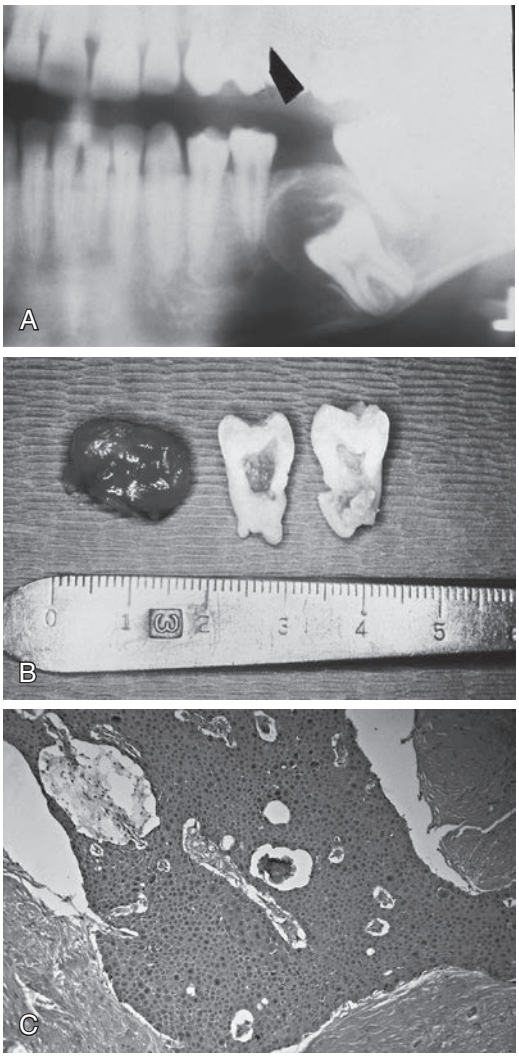

• **Figure 18-5** Calcifying epithelial odontogenic tumor (CEOT). **A,** A 16-year-old boy was referred for evaluation and treatment of an impacted mandibular first molar tooth in an apparent dentigerous cyst. The radiolucent lesion exhibited intralesional calcifications. **B,** The well-circumscribed lesion and tooth were surgically removed. **C,** A medium-power photomicrograph demonstrates classic histomorphology of CEOT. The patient has been followed for 13 years without recurrence.

component that also demonstrated marked cytologic atypia of the epithelial islands. Their case had intralesional vascular invasion, numerous mitotic figures, and an increased proliferating index marker (Ki-67) compared to a conventional CEOT. Despite such evidence, the authors did not regard the lesion to be malignant because demonstrable metastases were absent. They further cautioned that there were still insufficient case studies to confirm a generally aggressive behavior in all CEOTs containing clear cells. Yet, Hicks and co-workers[59], in their 1994 report, record an approximate 14% recurrence rate for conventional CEOT and a 22% recurrence rate for CEOT with clear cell component. The restriction placed by Cheng and colleagues[61] on their case is not justified. Their lesion is malignant with or without demonstrated metastasis.

Two more cases of malignant CEOT have been reported. In 1994, Basu and associates[62] detailed a case with marked nuclear and cellular atypia, perineural invasion around the inferior alveolar nerve, tumor cell invasion of vascular spaces, and metastasis to a submandibular lymph node. Veness and colleagues,[63] in 2001, presented a case of CEOT that recurred twice with increasing cellular atypia, cellular hyperplasia, and vascular invasion with metastasis to a cervical lymph node.

Management

The 1992 and 2005 World Health Organization (WHO) classification[12,13] of odontogenic tumors categorizes the CEOT as a benign, locally invasive neoplasm, but does not describe a recurrence rate (i.e. regrowth of residual lesion). Although Hicks and colleagues[59] describe recurrence percentages in their study (see above), a large body of management data has not been compiled, as it has for ameloblastoma, because of the relative scarcity of reported cases and lack of accurate long-term clinical follow-up evaluations.

Perhaps again, as with ameloblastoma, semantics may play a role in the WHO designation of CEOT as benign and locally aggressive. Locally aggressive CEOT does not appear sufficient to describe the aggressive ability of the maxillary lesion described by Bouchaert and co-workers[64] that involved the maxillary sinus, invaded the orbit and ethmoid sinus, and extended to the cranium with subsequent brain compression. Radiographically, lesions may appear well circumscribed or not well circumscribed, but clinically the tumor is infiltrative and not encapsulated.[65]

The surgical treatment of CEOT should be case specific and based on anatomic location and involvement (e.g., maxilla, mandible, pterygoid areas, nasoethmoidal-sinus region), lesion size (volume of jaw involved), clinical activity (penetration of cortical bone, periosteum, muscle, neural involvement), and histocytologic characteristics (neural or vascular infiltration, cellular atypia, marked clear cell presence, and mitotic index). As with any pathologic entity, an adequate number of incisional biopsies must be analyzed; extensive lesions should have multiple sites sampled. One must take into account that even the conventional histology of CEOT not infrequently presents a relatively bizarre microscopic appearance (especially to pathologists unfamiliar with this entity).

Enucleation with curettage is seldom a treatment option, except for very small lesions (i.e., 1.0 to 1.5 cm). Rs$^-$CD or Rc$^-$CD is more likely to result in cure. Obviously, if the lesion is suitable for resection without continuity defect, and an adequate margin of normal bone can be attained, Rs$^-$CD is the procedure of choice. Caution should be exercised with lesions containing aggregates of clear cells, since clear cell follicles and nests tend to be very infiltrative and may extend further into the marrow spaces in a "skip" manner (i.e., cell nests not anatomically contiguous) and are radiographically not well circumscribed (see Figure 18-21, *I,K*).

There are no studies yet that specifically address the issue of "safe" bone margins. Thus a margin of 1.5 to 2.0 cm

may be considered an adequate margin of normal bone, unless frozen sections indicate otherwise. Immediate or delayed reconstruction can be performed as described for ameloblastoma.

Ameloblastoma

The *ameloblastoma* has more than a 100-year history of recognition, reportage, and controversy. Although the most recorded lesion of the odontogenic series, it continues to evoke wide differences of opinion among pathologists and surgeons regarding its position in the neoplastic spectrum, biologic behavior, and management. Ameloblastoma has been described as "benign but locally invasive," "benign and locally invasive with a strong tendency to recur," and "locally malignant." Most opening statements of contemporary reports still quote older papers that depict ameloblastoma as a benign and rare or uncommon tumor. However, ameloblastoma is not rare or uncommon, as measured by present institutional statistics,[66] and its benignity is here denied.

The 1971 and 1992 WHO classifications[11,12] of odontogenic legions categorized conventional ameloblastoma (aka classic ameloblastoma) as a benign but locally invasive epithelial odontogenic neoplasm and also included a category of malignant epithelial odontogenic carcinomas in which *malignant ameloblastoma* and *ameloblastic carcinoma* are separately listed and defined. The WHO described *malignant ameloblastoma* as a neoplasm in which the metastatic lesion(s) continues to resemble conventional ameloblastoma (i.e., there are no microscopic differences between the metastatic lesion and the conventional ameloblastoma from which it emanates), whereas *ameloblastic carcinoma* is described as a malignant tumor in which the lesion demonstrates a spectrum of morphologic/cytologic/histologic characteristics of malignancy, and does or does not necessarily metastasize (see later section on Cytologic Malignant Ameloblastoma).

The WHO 1971 monograph[11] further proscribed that the designation malignant ameloblastoma should not be applied to ameloblastoma that endangers life by direct extension of the growth into vital structures. It appears that it is permissible to recognize a conventional ameloblastoma as malignant if it does metastasize, and to regard the same ameloblastoma as benign if it does not metastasize!

The senior author (L.G.)[17a] was not alone in objecting to this perplexing reasoning. Several writers[14-16] had previously faulted the narrow WHO definition of what constituted malignant ameloblastoma or ameloblastic carcinoma on several counts: (1) that a malignant lesion must produce metastases, (2) that the metastases must be histologically identical to the primary tumor, and (3) that the WHO definition is not consistent with malignancy as applied to other neoplasms. Yet, these authors did not reject the implausible WHO definitions, but accommodated to them with further refinements of the original WHO classification.

It is fitting here to quote several writers directly in order to help place this tumor in proper perspective. Willis[67] (a highly respected British pathologist) believed that clinicians have overemphasized the differentiation between benignancy and malignancy in order to gather prognostic information from pathologists regarding excised tumors. He believes that the question "Is this tumor innocent *or* malignant?" should be replaced by "*How* innocent or malignant is this tumor?" In a specific discussion of ameloblastoma, Willis[67] describes the lesion as "lowly malignant slowly growing" and further writes that "attempts to distinguish between benign and malignant ameloblastoma are futile; they are all malignant in that they are locally invasive and prone to recur." Carr and Halperin[68] in their paper on malignant ameloblastoma stated in their discussion: "Malignant and benign are poor terms when applied generally to this neoplasm, and the use of one instead of the other seems secondary to an understanding of how the tumor may behave and to an approach to treatment based on this understanding."

Consider the following description of the basal cell carcinoma, an acknowledged malignant tumor, offered by Gold[17a]: "slowly growing, infiltrative, capable of great destruction of soft tissue and bone, recurrent when not completely eradicated, capable of invading vital structures (orbit, skull, brain), seldom metastatic but capable of metastasis, presenting a number of histologic patterns, and arising from the epithelial skin surface and skin adnexa. If one substitutes oral epithelium for skin surface and dental lamina/enamel organ for skin adnexa, you are describing the known characteristics of the ameloblastoma." Thus, the ameloblastoma and the basal cell carcinoma share great similarity to each other in their histomorphology, growth, and infiltrative patterns.

If one takes into consideration that within the past 10 years the steadily increasing number of published reports in the world literature, in addition to the numerous previous accounts over many years that also have described "conventional" ameloblastomas that have metastasized, as well as morphologically and cytologically dysplastic ameloblastomas that have metastasized, one is forced to the conclusion that *conventional ameloblastoma is a de novo, low-grade, malignant basaloid tumor with a variable range of histologic patterns, clinical forms, and behavior.*

In 1999, Eversole[18] revised Elzay's[15] modification of the WHO classification of epithelial odontogenic tumors to produce his own version, which he (Eversole) considered more refined, but still not entirely satisfactory. Eversole's thoughtful paper approached but did not reach the essential conclusion that conventional ameloblastoma is a de novo malignancy. Neither did Philipsen and Reichart[19] in their 2002 paper, nor the authors of the 2005 WHO classification,[13] who continue to regard ameloblastoma under benign and malignant categories. None were able to concede the possibility that ameloblastoma is a de novo low-grade malignant lesion.

There are two incontrovertible characteristics that distinguish a malignant lesion: (1) the ability to invade and destroy tissue without regard to anatomic boundaries, and (2) the ability to metastasize. Ameloblastoma, whether in so-called

conventional or in markedly dysplastic form, qualifies by this definition as a malignancy. The recognition of the de novo malignant status of conventional ameloblastoma permits the progressive sequences from low-grade to high-grade cytologic malignancy to be seen as a continuum. It is possible then to eliminate the artificial and confusing terminology—malignant ameloblastoma and ameloblastic carcinoma—from the WHO classification; *ameloblastoma may be described also as a well-differentiated malignancy with or without metastases or poorly differentiated malignancy with or without metastases.*

The long-held traditional belief that ameloblastoma is benign, except in rare instances, will be difficult to reverse. It will require more than a casual alteration in mindset for pathologists and surgeons to accept what they have historically and traditionally regarded as a benign tumor should now be considered a malignancy. However, there are precedents for a change of status among a number of tumors when proof becomes evident, even if, as in the case of ameloblastoma, long delayed (see also morphogenesis of clear cell odontogenic tumor to malignant status in the section on clear cell odontogenic carcinoma). A change in perception is required that ameloblastoma, pari passu, is a de novo malignancy and is not a philosophic or nosologic exercise. It removes this lesion from untenable argumentation regarding its pathologic status. It is important to understand that conventional (classic) ameloblastoma, low-grade malignancy notwithstanding, is a dangerous lesion precisely because of its unpredictable behavior. This realization would have a salutary effect on the study and management of the lesion.

Clinicopathologic Considerations

The ameloblastoma is asymptomatic and remains undiscovered until lesional growth produces intraoral and/or external jaw swelling, tooth and dental occlusion disturbances, or incidental radiographic examination reveals a lesion. Paresthesia is an uncommon symptom and pain is rarely a presenting symptom unless the lesion causes root resorption and/or tooth mobility. Depending on the clinical form of the ameloblastoma, the age at which the lesion may become clinically evident is as early as the first decade or as late as the seventh. The lesion may occur in either jaw and in any area, but the sites of predilection are the posterior maxilla and the posterior molar-ramus region of the mandible. The mandible is the favored site over the maxilla by about a 4.5:1 ratio.

Radiographically, the ameloblastoma presents a unilocular or multilocular radiolucent appearance in several different forms and shapes. The apparent lesional edge may be distinct or indistinct. Small or large unilocular or multilocular lesions may contain unerupted deciduous or permanent teeth and give the appearance of a dentigerous cyst. Lesions in dentate areas cause root resorption and tooth displacement. Expansive distortions of normal mandibular or maxillary anatomic features commonly are caused by this lesion. Maxillary lesions often involve the maxillary antrum and change the normal radiolucency of the sinus to a more opacified appearance. One of the ameloblastoma variants—the desmoplastic ameloblastoma, most often found in the anterior maxilla or mandible—projects as a relatively radiopaque lesion because of the dense connective tissue content. The radiographic image of ameloblastoma is at most suggestive and not pathognomonic; other odontogenic and nonodontogenic lesions may simulate it (Figure 18-6, *A-H*).

Histologically, most ameloblastomas fall within two major morphologic configurations—the *follicular* and *plexiform* types. Combinations and variations of these two types, as well as other subtypes, are found even within the same lesion. The follicular type consists of small to large odontogenic epithelial nests (the follicles) and variously shaped and sized ameloblastomatous islands. The plexiform type consists of interlacing strands of narrow or wide odontogenic epithelial trabeculae. Both types have a columnar or cuboidal outer epithelial cell layer bordering the connective tissue stroma and enclosing the inner epithelial cells. The characteristic histologic signatures of the ameloblastoma are the orientation of the outer epithelial cell nuclei, which are positioned (polarized) away from the basement membrane (reverse polarity), and the frequent vesicular appearance of the outer cell cytoplasm abutting the basement membrane. In addition, the inner epithelial cells of the follicles are more or less loosely arranged as in a stellate reticulum, imitating the enamel organ architecture. Not infrequently, the strandular narrow configuration of the plexiform lesion has neither the outer epithelial cell nuclear orientation nor the appearance of inner cell stellate reticulum. A variety of subtypes are built around the basic morphologic characteristics. Compression of the stellate reticulum into a squamoid mass with squamous metaplasia and keratinization produces the *acanthomatous type*. The inner follicular and outer follicular cells may assume a basal cell appearance throughout the lesion, causing a striking histologic resemblance to basal-cell carcinoma, in which instance the *basal cell type* is noted. Other ameloblastoma variants also are well recognized such as *granular cell, desmoplastic, vascular,* and *spindle cell (sarcomatoid) types* (Figure 18-7).

Several rare subtypes have been reported, such as ameloblastoma with "ghost-cell" and keratinization as seen in the calcifying odontogenic cyst. More importantly, however, Waldron et al[16] have reported two cases containing clear cell strands and nests biphasically intermixed with follicular ameloblastoma as *clear cell ameloblastoma*. Both cases demonstrated marked cytologic atypia, and one was known to cause the patient's death by uncontrolled growth and metastasis (see later discussion of clear cell odontogenic carcinoma).[17a]

The supporting connective tissue stroma of multicystic and solid ameloblastoma, regardless of histologic subtype, varies from loose to dense, and from scant to plentiful. However, the solid and multicystic forms of the tumor do not produce an effective connective tissue capsule or evoke an encapsulating mechanism by surrounding bone or soft tissue (see Figure 18-7, *A-L*). The unicystic ameloblastoma, however, does have a peripheral connective tissue wall, which may be loose or dense and relatively thin or thick.[17a]

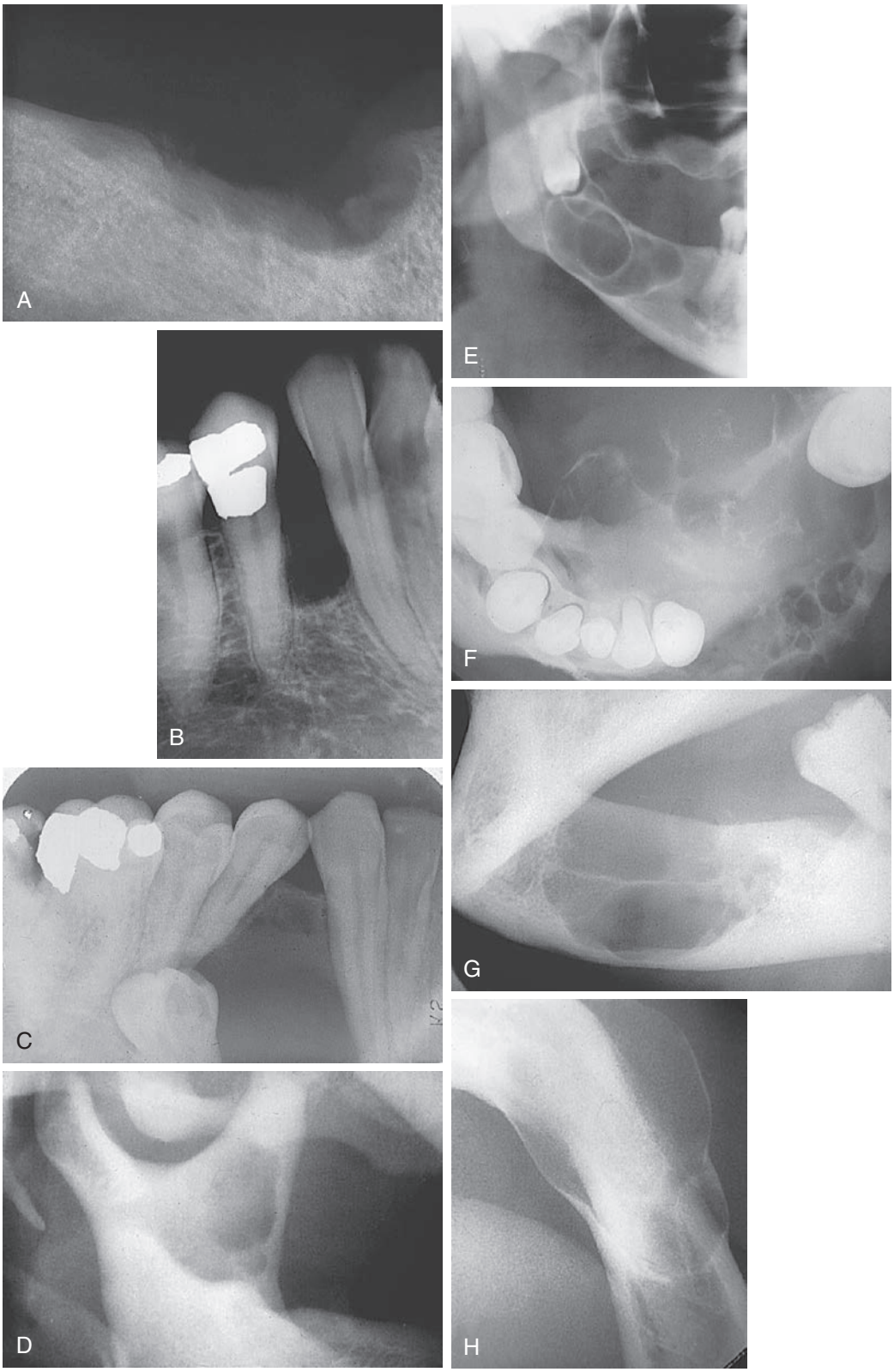

• **Figure 18-6** Ameloblastoma. Variations in radiographic appearance and location of ameloblastoma: **(A)** superficial alveolar crest, **(B)** periodontal cystlike, **(C)** dentigerous cystlike, **(D)** ramus, **(E-H)** multilocular.

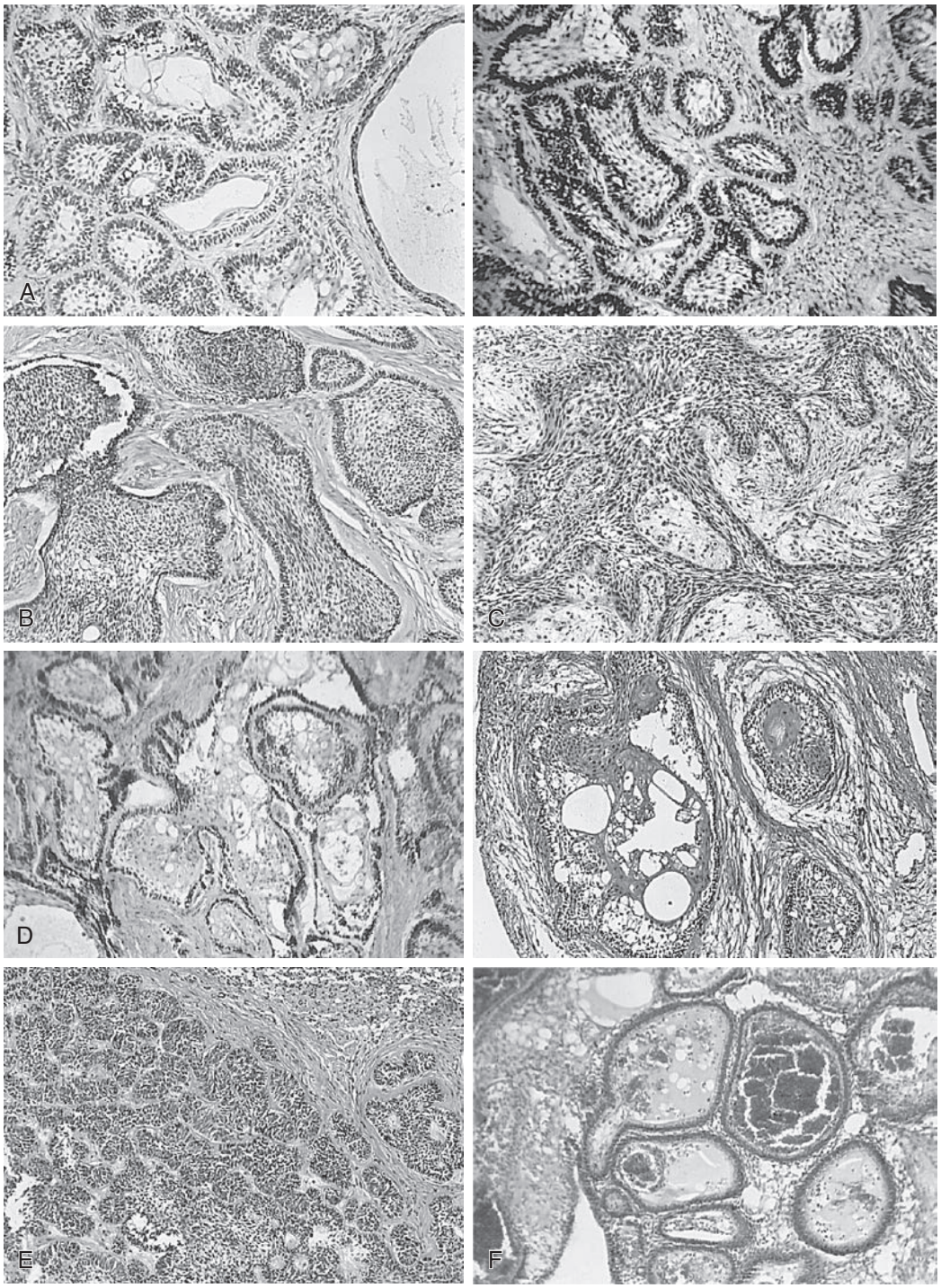

• **Figure 18-7** Ameloblastoma. Common and uncommon histologic patterns of ameloblastoma: **(A)** follicular (two examples are shown), **(B)** trabecular, **(C)** plexiform, **(D)** acanthomatous (two examples are shown), **(E)** basal cell, **(F)** vascular,

Clinical Forms and Mechanisms of Growth

Conventional ameloblastoma presents several clinical (physical) forms as well as histologic types; however, neither physical form nor histologic type is immutable, and combinations of form and type occur. The major intrabony (central) clinical forms are *unicystic* (unilocular) (Figures 18-8 to 18-11), *multicystic* (multilocular), and *solid* (Figures 18-12 to 18-14). The *peripheral* ameloblastoma is the visibly extraosseous soft tissue form of the lesion found in the gingiva and mucosa of the alveolar process (Figures 18-15 to 18-17).

Mixtures of histologic types of ameloblastoma in the original or in a recurrent lesion are not unusual; for example, a unicystic granular cell ameloblastoma, when recurrent years later, showed a multicystic follicular lesion,[69] and a large unicystic lesion simultaneously displayed elements of plexiform, granular cell, follicular, and acanthomatous types.[17a]

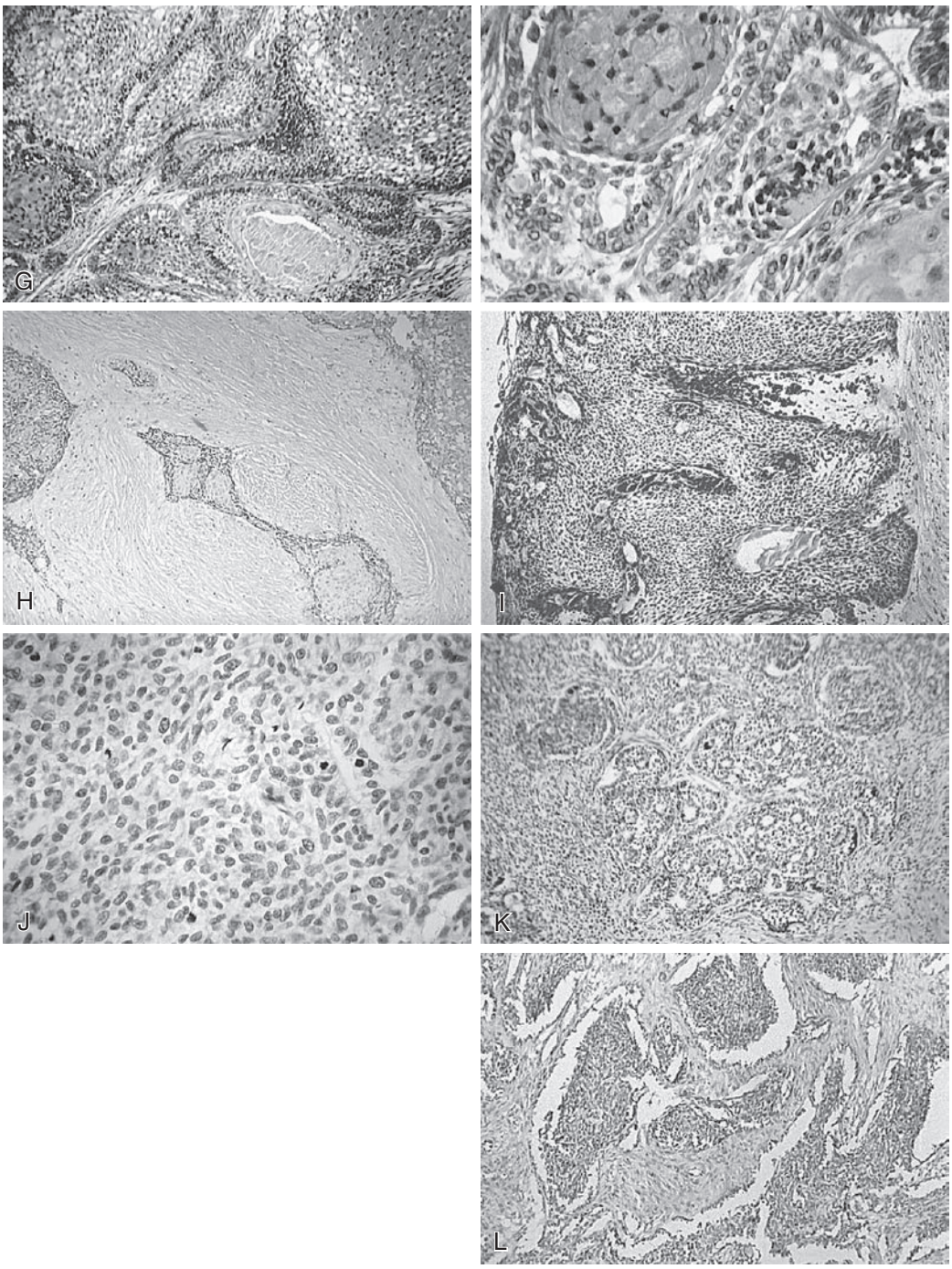

• **Figure 18-7, cont'd** **(G)** granular cell (low and high power are shown), **(H)** desmoplastic, **(I)** spindle cell (hyperplastic stellate reticulum), **(J)** hyperplastic stellate reticulum with mitoses, **(K)** undifferentiated, **(L)** anaplastic.

Unicystic Ameloblastoma

A *unicystic ameloblastoma* may form de novo or develop secondarily in an odontogenic keratocyst or dentigerous cyst.[70,71] The lesion may remain small, become large, or even develop into a multicystic form (see Figures 18-9, 18-11, and 18-13). Occasionally small satellite cysts, separated from the main cystic lesion, may be undetected clinically or radiographically.[72] Small or large unicystic lesions that contain unerupted (impacted) teeth, or those without unerupted teeth, are usually identified radiographically as a dentigerous cyst or odontogenic keratocyst. However, an often-overlooked radiologic feature of unicystic ameloblastoma involving a dentate area is the partial resorption of tooth roots (permanent or deciduous), a rare occurrence in dentigerous or odontogenic keratocyst.

The unicystic ameloblastoma exhibits two other notable clinical differences from the multicystic, solid, and peripheral forms, besides its physical shape. First, the lesion usually occurs in adolescents, teenagers, and young adults; and second, the lesion exhibits the previously described

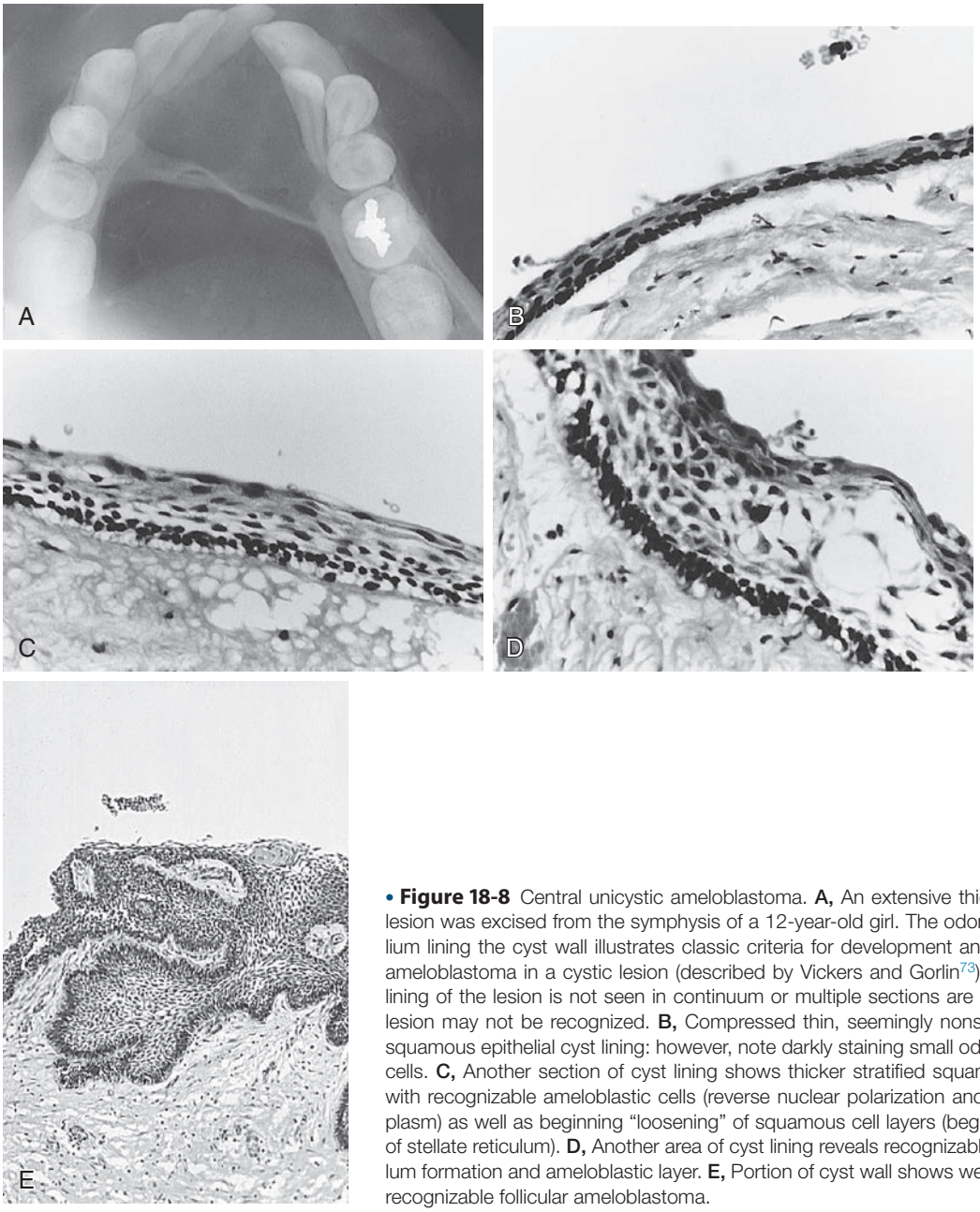

• **Figure 18-8** Central unicystic ameloblastoma. **A,** An extensive thick-walled cystic lesion was excised from the symphysis of a 12-year-old girl. The odontogenic epithelium lining the cyst wall illustrates classic criteria for development and recognition of ameloblastoma in a cystic lesion (described by Vickers and Gorlin[73]). If the epithelial lining of the lesion is not seen in continuum or multiple sections are not studied, the lesion may not be recognized. **B,** Compressed thin, seemingly nonspecific stratified squamous epithelial cyst lining: however, note darkly staining small odontogenic basal cells. **C,** Another section of cyst lining shows thicker stratified squamous epithelium with recognizable ameloblastic cells (reverse nuclear polarization and vesicular cytoplasm) as well as beginning "loosening" of squamous cell layers (beginning formation of stellate reticulum). **D,** Another area of cyst lining reveals recognizable stellate reticulum formation and ameloblastic layer. **E,** Portion of cyst wall shows well-formed, easily recognizable follicular ameloblastoma.

peripheral-encompassing connective tissue wall of varying thickness.

A diagnosis of unicystic ameloblastoma is influenced by several clinical and microscopic decisions: (a) The surgeon may elect to excise a cystic lesion, especially if not extensive, without a preceding biopsy. Thus, a microscopic diagnosis of unicystic ameloblastoma will be unexpected and will occasion further surgery or none, depending on a proper study of the excision specimen (see laboratory discussion [point d] later). (b) The surgeon may elect to biopsy an extensive cystic lesion; however, unless multiple sites are sampled, the diagnosis may not be made, because recognizable microscopic ameloblastic changes may not extend along the entire cyst lining. (c) A correct microscopic diagnosis will not be made if the hospital pathologist fails to recognize the sometimes subtle early or evolving ameloblastic changes described by Vickers and Gorlin[73] (see Figure 18-8) or misinterprets a plexiform ameloblastic lining as hyperplastic nonspecific epithelium (see Figure 18-10). (d) Gross sectioning of the unicystic specimen in the laboratory must be done in proper plane orientation so that histologic sections will reveal the ameloblastic proliferation in relation to the cyst lumen, lumen lining, and cyst wall. Recognition of the proliferative pattern of the unicystic ameloblastoma has clinical importance. Growth within the cyst cavity

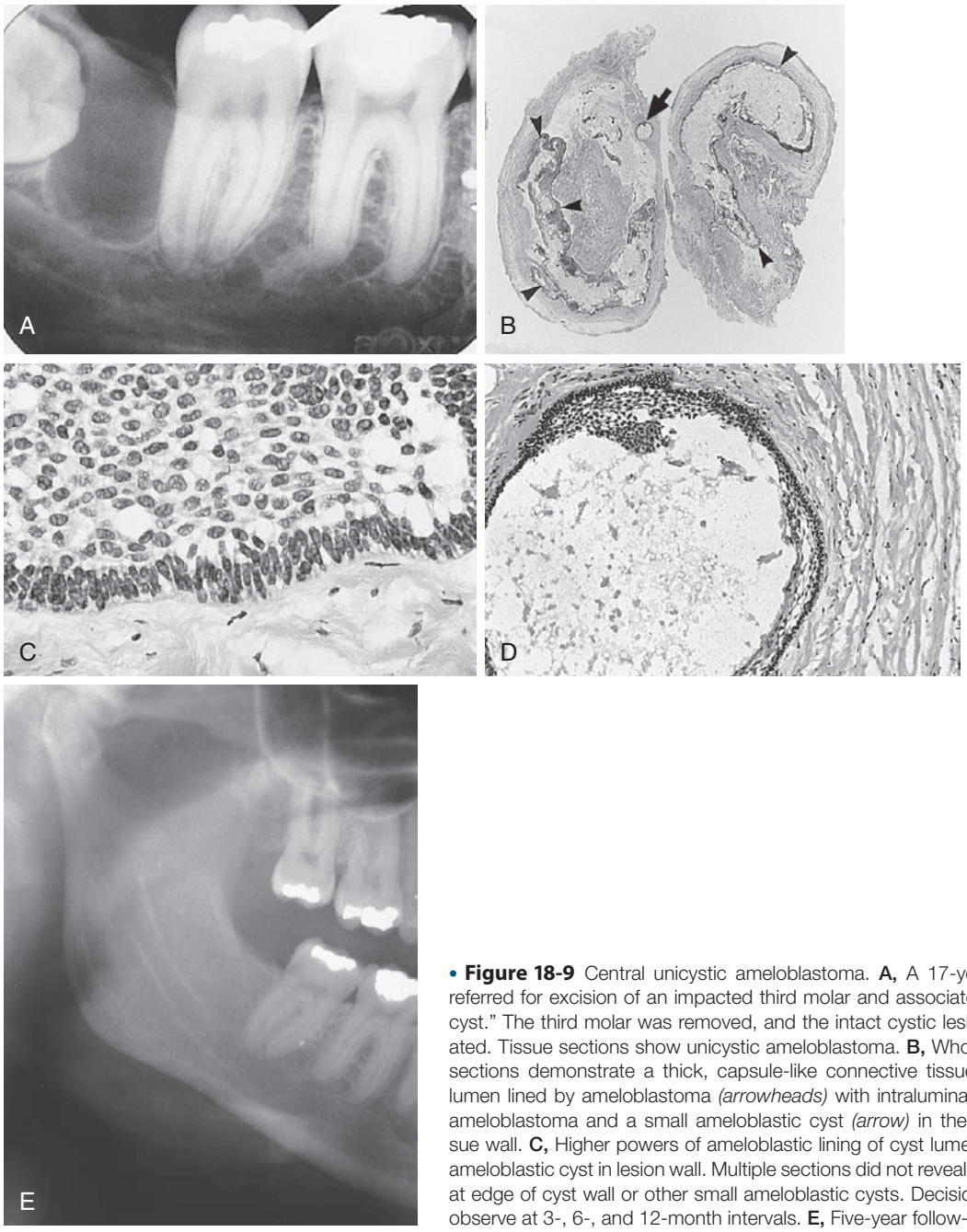

• **Figure 18-9** Central unicystic ameloblastoma. **A,** A 17-year-old girl was referred for excision of an impacted third molar and associated "dentigerous cyst." The third molar was removed, and the intact cystic lesion was enucleated. Tissue sections show unicystic ameloblastoma. **B,** Whole mount tissue sections demonstrate a thick, capsule-like connective tissue wall and cyst lumen lined by ameloblastoma *(arrowheads)* with intraluminal proliferation of ameloblastoma and a small ameloblastic cyst *(arrow)* in the connective tissue wall. **C,** Higher powers of ameloblastic lining of cyst lumen and **(D)** small ameloblastic cyst in lesion wall. Multiple sections did not reveal ameloblastoma at edge of cyst wall or other small ameloblastic cysts. Decision was made to observe at 3-, 6-, and 12-month intervals. **E,** Five-year follow-up panograph.

(intraluminal), growth along the cavity surface *(luminal),* or proliferation into the connective tissue of the cyst wall *(mural)*[74a] greatly affects treatment (see discussion under Management).

Solid and Multicystic Ameloblastomas

Solid and *multicystic ameloblastomas* may have similar origin in a field of neoplastic change (see Figures 18-12 and 18-13). Small foci of ameloblastoma spread out in a three-dimensional manner; the foci become masses and retain a solid form (see Figure 18-14) or make microcystic and/or macrocystic spaces lined by ameloblastic epithelium. Intraosseous ameloblastoma grows slowly but inexorably, by invasion of medullary spaces and resorption of cancellous and cortical (compact) bone. Ameloblastic epithelium or lesional connective tissue (stroma) is seen to directly abut resorbing trabecular bone, which still contains endosteal osteocytes and osteoblasts lining the side opposite to the resorbing trabecular surface. There rarely appears to be compensatory bone formation as a reaction to the presence of the tumor. Osteoclastic cellular activity is very rarely seen microscopically.[17a] The often cited "impenetrable barrier" of the compact (dense) bone of the

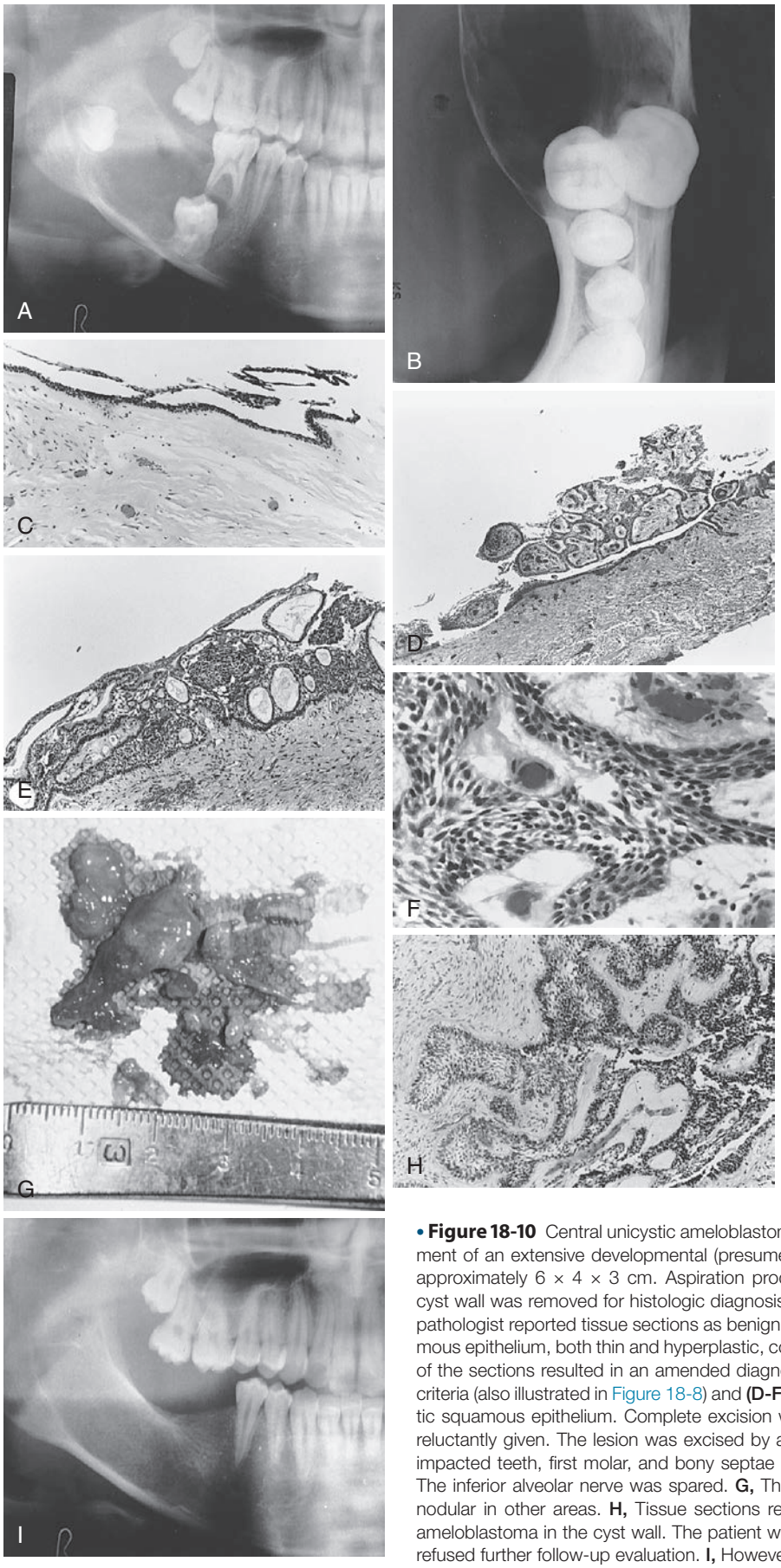

• **Figure 18-10** Central unicystic ameloblastoma. **A-B,** A 13-year-old boy was referred for treatment of an extensive developmental (presumed dentigerous) cyst of the mandible, measuring approximately 6 × 4 × 3 cm. Aspiration produced copious thin fluid. A large section of the cyst wall was removed for histologic diagnosis, and the lesion was marsupialized. The hospital pathologist reported tissue sections as benign fibroconnective tissue wall, focally lined by squamous epithelium, both thin and hyperplastic, consistent with dentigerous cyst. My routine review of the sections resulted in an amended diagnosis of unicystic ameloblastoma: **(C)** with classic criteria (also illustrated in Figure 18-8) and **(D-F)** with plexiform type misinterpreted as hyperplastic squamous epithelium. Complete excision was strongly advised, and parental consent was reluctantly given. The lesion was excised by a combination of enucleation and curettage. The impacted teeth, first molar, and bony septae projecting from the cortical walls were removed. The inferior alveolar nerve was spared. **G,** The cyst wall was thin in areas and thickened and nodular in other areas. **H,** Tissue sections revealed a combination of plexiform and follicular ameloblastoma in the cyst wall. The patient was followed periodically for 1 year, after which he refused further follow-up evaluation. **I,** However, the patient was seen 4 years later, because he was applying for health insurance.

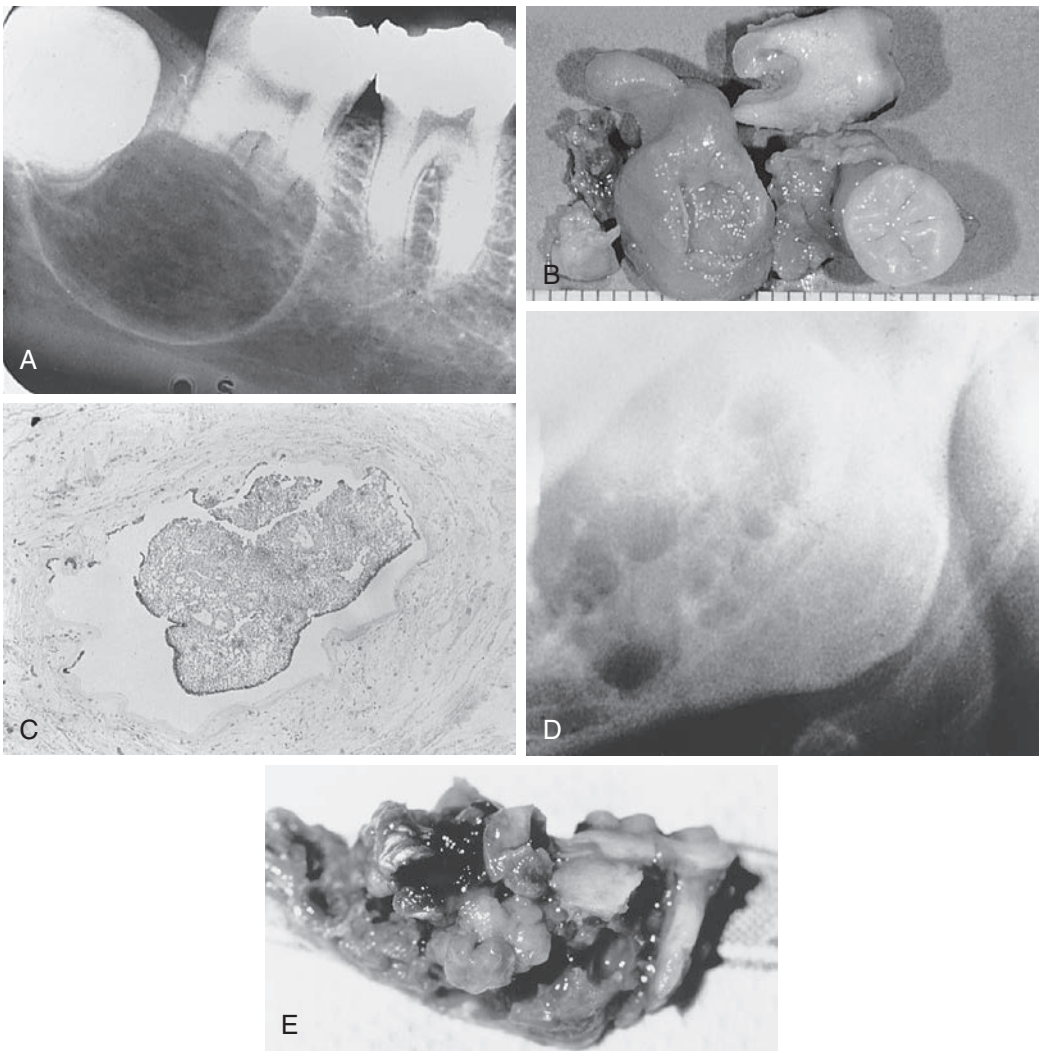

• **Figure 18-11** Recurrent central unicystic ameloblastoma. **A,** A 21-year-old man had excision of an impacted third molar, associated cyst, and second molar with root resorption. **B,** The gross specimen showed a fleshy, thick cystic structure attached to the impacted tooth and follicular sac. **C,** Tissue sections revealed a unicystic ameloblastoma with intraluminal ameloblastic proliferation and no apparent tumor in the cyst wall. **D,** Extensive recurrence 8 years later was treated by continuity resection and bone graft reconstruction. **E,** Gross specimen bisected to show recurrent ameloblastoma.

mandibular inferior border is mythical. The inferior border is resorbed by the tumor, sooner or later, dependent on the growth vectors of the lesion.[17a]

The pathophysiologic mechanism of the resorptive process is not yet completely known; however, contributing factors have emerged. In 1989, hypercalcemia was reported in two patients with metastasis of ameloblastoma to the lungs, thus suggesting evidence of an osteolytic humoral factor.[74b] A report published in 2004 by Abdelsayed and colleagues[75] found that a parathyroid hormone-related protein (PTHrP) was expressed by all lesions (100%) in a study of 30 unicystic and multicystic ameloblastomas. This local expression of PTHrP by tumor cells may readily provide a humoral cause of bone resorption and aggression by the tumor. Other genetic and molecular studies have contributed and will contribute to further understanding of this tumor.[76,77]

Peripheral Ameloblastoma

The *peripheral ameloblastoma* (by definition) is presumed to originate from residual or displaced odontogenic epithelial tissue in the gingiva or mucosal surface overlying the alveolar process (see Figures 18-15 and 18-16) and is the soft tissue counterpart of the intraosseous ameloblastoma, occurring on the gingival and mucosal covering of the alveolar process of the jaws.[78] The lesion may present a smooth sessile shape if the tumor is contained entirely within connective tissue well below the surface epithelium, and a warty or papillomatous shape if the lesion infiltrates the surface epithelium.[79,80] Like the intrabony ameloblastoma, *the peripheral ameloblastoma is not encapsulated but is strongly circumscribed by stromal connective tissue through which it can infiltrate surrounding mucosa as well as penetrate periosteum and involve bone*. The peripheral tumor has

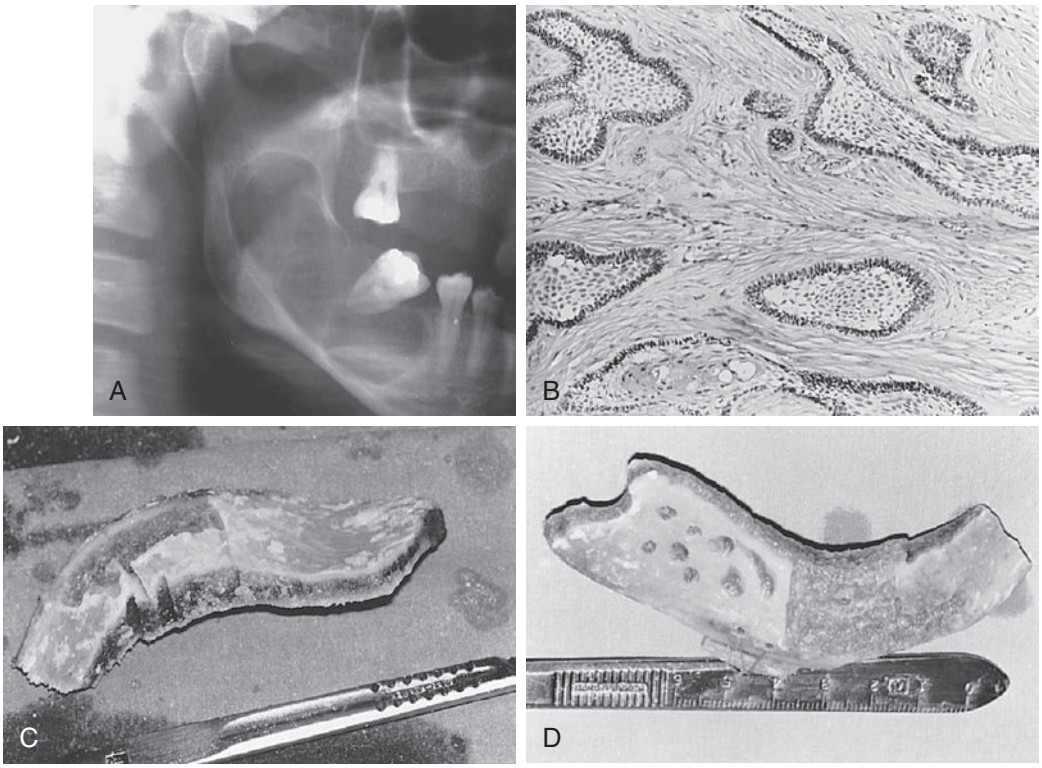

• **Figure 18-12** Central multicystic ameloblastoma of mandible. A 29-year-old woman was referred for diagnosis and treatment of intraoral and extraoral right facial swelling. The patient reported having intraoral drainage the previous day. Examination showed buccal and marked lingual mandibular expansion. The lingual surface was compressible, and the remaining molar tooth was mobile and displaced. **A,** Periapical, occlusal, and panographic films showed an extensive multicystic (multiseptated) radiolucent lesion with molar root resorption, buccal and lingual expansion, and cortical thinning. The molar was removed and biopsy specimens were taken through a crestal incision from the posterior, middle, and anterior cystic and solid lesional areas. **B,** Tissue sections revealed follicular ameloblastoma. Preoperative preparation included extraction of the maxillary right third molar and mandibular right first and second premolars; maxillary impression and model to fabricate a splint with incorporated arch bar; and cephalometric radiograph on which a mock resection of the involved mandible was done, from which to fashion a malleable lead pattern of the resected part to be used as a measurement guide for the bone graft. Two months after the patient was first seen, the operation was performed: (1) application of arch bar to remaining mandibular teeth reinforced with circummandibular wires, and application of maxillary splint to remaining upper teeth, reinforced with circumzygomatic arch wires; (2) intraoral buccal and lingual incisions to circumscribe narrowly and excise the healed previous gingival crestal incision biopsy site; (3) extension of crestal incision to ramus and to canine area for buccal and lingual subperiosteal reflection of mucosa for exposure and exploration to the inferior surface of mandibular body with extension of exploration to ramus coronoid notch area on buccal, release of temporal muscle to condyloid process with resection of process, and medial ramal exposure to lingula for visual inspection of cortical bone integrity; (4) the buccal and medial cortices of the body and ramus were intact, and the incision(s) were closed with running horizontal mattress and vertical interrupted sutures; (5) an extended submandibular extraoral incision was made from an area posterior to the angle to the area below the canine tooth, sharp and blunt dissection exposed the mandible to join the buccal and medial intraoral dissection (with care taken not to lacerate the oral mucosa or sutured mucosal incision), and the masseter and internal pterygoid muscles were incised and separated from the mandible; (6) the mandible was divided just posterior to the canine tooth to produce a continuity defect, then rotated laterally as blunt and sharp dissection continued superiorly along the ramus to expose the lateral condylar area, and medially to divide the inferior alveolar nerve from the mandibular branch as it entered the mandible at the lingula, with continued lateral rotation of the resected mandible, the lateral pterygoid muscles were exposed and cut at the insertion to the condyle and condylar neck, the lateral aspect of the condylar capsule was dissected and cut, and the resected specimen was disarticulated from the joint space and removed, leaving the temporomandibular joint (TMJ) disc intact and in place; **(C)** (7) a contralateral full-thickness (bicortical) extended anterior iliac crest graft was harvested to take advantage of the iliac curvature using the prepared lead pattern as a size and shape guide; **(D)** the graft was turned end over and reversed to simulate the curvature of the right side of the mandible, and sculpted, with preservation of cortical bone in the ramal and anterior areas for strength and ability to retain fixation wires, and decorticated in areas to permit rapid vascularization; (8) the cut end of the inferior border of the intact mandible and anterior end of the graft were prepared for a butt-and-inset step joint;

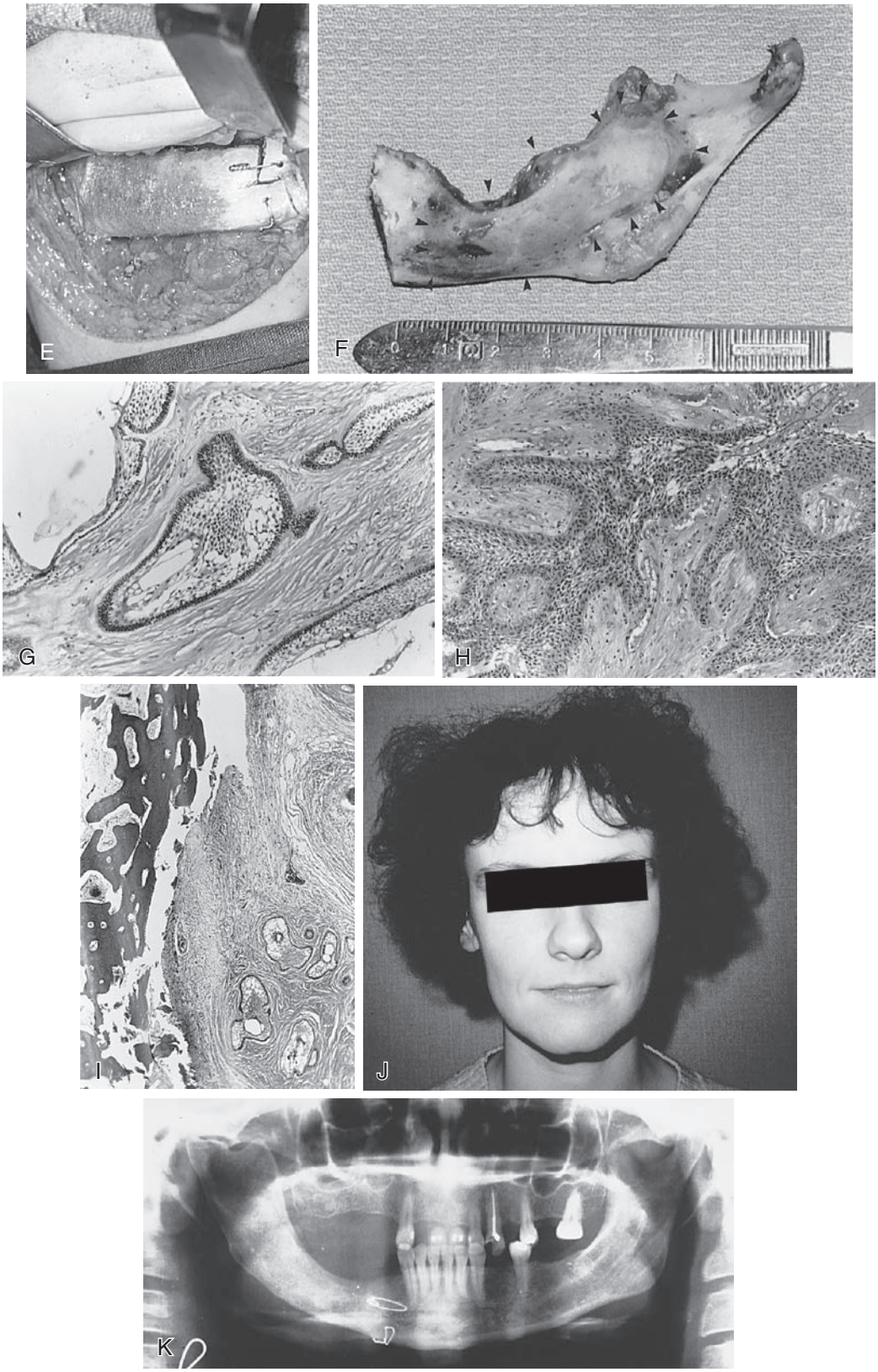

• **Figure 18-12, cont'd** **(E)** (9) intermaxillary fixation was secured, and the graft was inserted into the resection space in contact with the TMJ disc superiorly and fastened to the intact mandible with single horizontal and vertical wires. The masseter and internal pterygoid muscles were sutured in "sling" fashion around the graft angle, and the combined extraoral-intraoral periosteal and superficial tissues were firmly sutured in layers around the graft to provide tissue contact and eliminate "dead" space; no drain was inserted. **F,** Gross specimen, cross sections in the mental foramen area revealed a multicystic soft lesion filling interstices between buccal and medial cortices; the cortices were intact.**G-I,** Histologic sections showed follicular ameloblastoma with cyst formation and bone resorption. **J,** A clinical photograph 2 months postoperatively shows facial symmetry. A partial denture was constructed 10 months after the procedure; oral opening is satisfactory without mandibular deviation. **K,** A panographic film taken 10 years postoperatively.

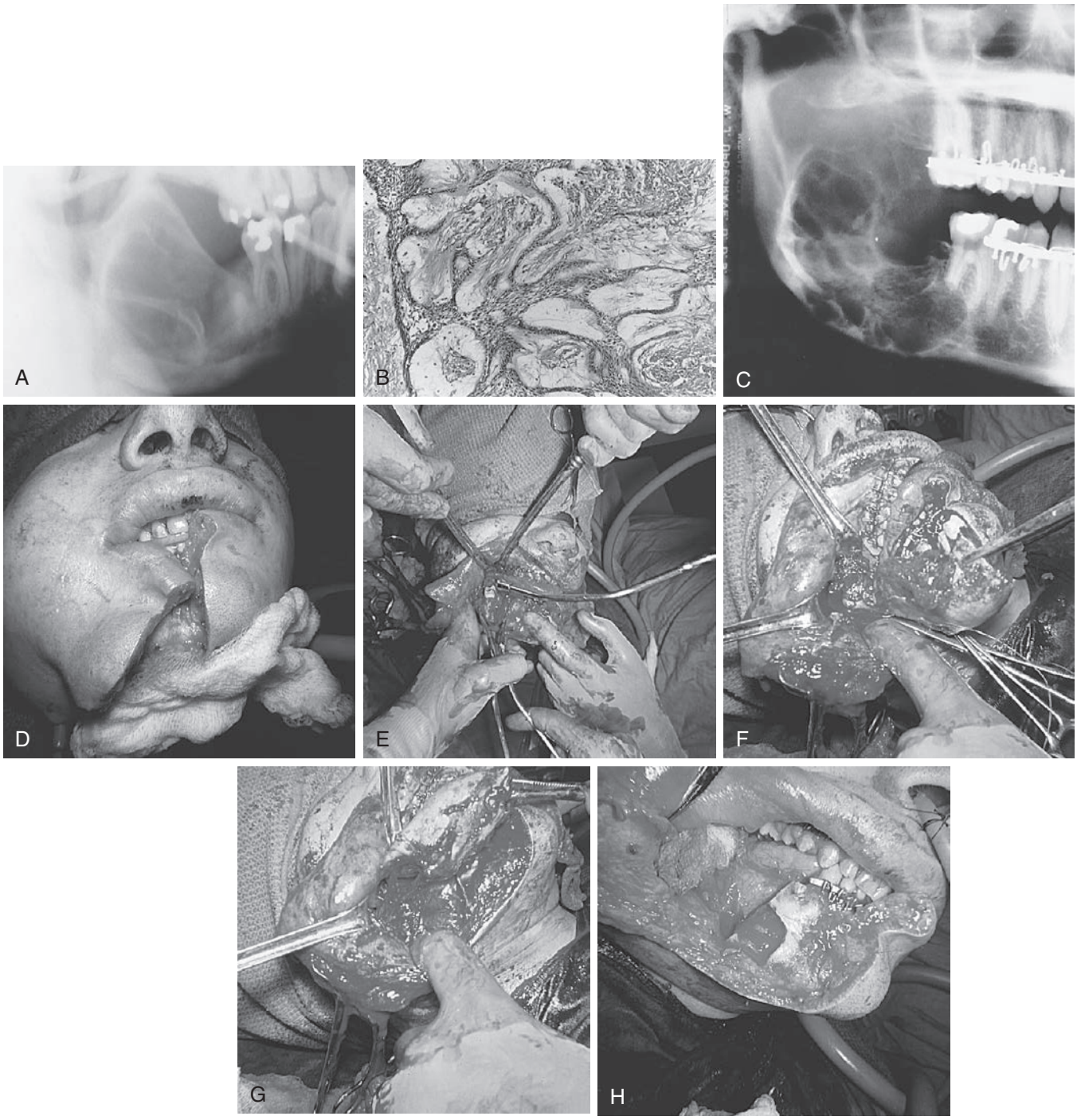

• **Figure 18-13** Central multicystic ameloblastoma of mandible. **A,** A 21-year-old man, operated on 3 years earlier for a "cyst" of the mandible, was referred for management of the lesion. **B,** A biopsy sample taken during the initial consultation and examination revealed a plexiform ameloblastoma. Preparation for the resection of the ameloblastoma began with application of mandibular and maxillary arch bars in the office, with further imaging including panographic, tomographic, and cephalometric radiographs. **C,** Note the conversion of a unicystic to a multicystic lesion. A malleable, thin lead pattern, later used for bone graft measurement, was fashioned from a mock resection performed on the cephalogram. Two units of autologous blood were banked for the procedure. A mandibular resection with continuity defect at the canine–first premolar interspace and disarticulation with preservation of the temporomandibular disc was performed. Because preoperative clinical and radiographic study determined that the lesion extended to the sigmoid notch and pterygoid areas with a significant extramandibular medial component, maximum access was required. Therefore, a combined extraoral and transoral approach utilizing a lip-splitting procedure was employed. A tracheostomy was done; the procedure included the following steps: **D,** The lower lip was vertically divided just past the midline with extension of the incision through the chin, in a slightly curvilinear manner, and continued submentally and submandibularly to the ramus area past the mandibular angle. **E**-**G,** The dissection was then carried out as detailed in Figure 18-12, but more supramandibularly to incorporate the extramandibular components of the lesion with muscle cover. **H,** The resected mandible was disarticulated, and a step was prepared in the intact mandible.

a basaloid pattern primarily, but frequently is mixed with follicular and acanthomatous elements, and in the absence of other subtypes appears identical to basal cell carcinoma.[81-83] Even a clear cell variant has been described.[84] Some lesions appear to emanate from surface epithelium or fuse with the surface (see Figure 18-16, *F*). Radiographs of the alveolar process contiguous with the lesion show varying involvement of the underlying bone and occasional resorption of adjacent tooth roots. The underlying bone is occasionally resorbed medial to the lesion or sometimes appears cupped out by a pressure phenomenon (see Figures 18-15 and 18-16). There is no certain knowledge that the lesion cannot simultaneously originate from bone and soft tissue and grow centrifugally rather than centripetally.

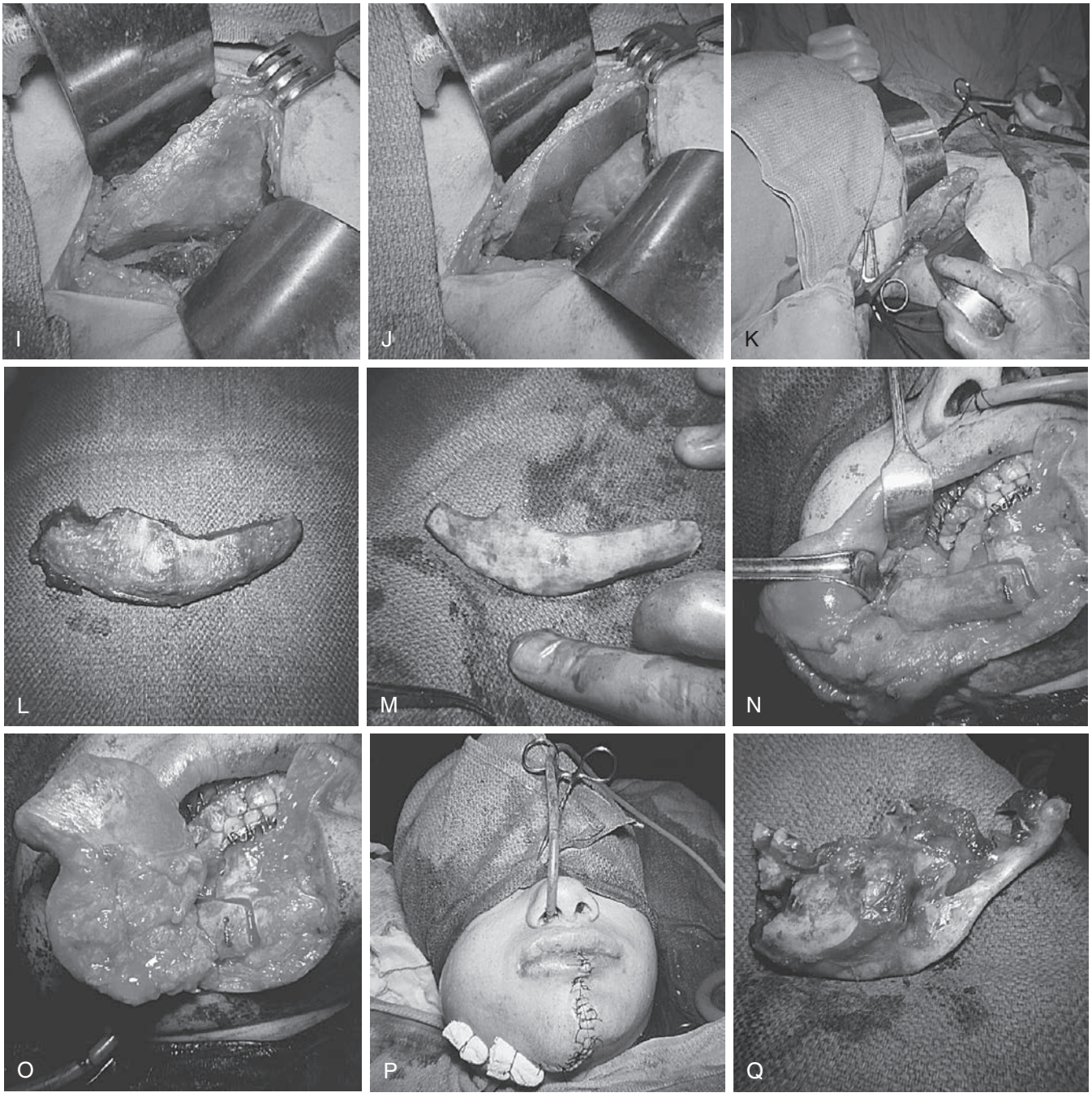

• **Figure 18-13, cont'd** **I-L,** A full-thickness (bicorticated) graft was harvested from the contralateral anterior iliac crest, using the lead pattern as a guide **(M)** and sculpted without decortication. **N,** The graft was placed into the intact mandibular step and against the temporomandibular disc and fixed to the mandible with a single vertical mattress wire. **O,** A drain was inserted, and the wound was firmly closed in multiple layers. **P,** Several "wrap-around" vertical mattress sutures were placed from the medial side to exit through the skin and were tied over bolsters to adapt the soft tissues more firmly around the graft. **Q,** The specimen as seen from the lingual (medial),

Continued

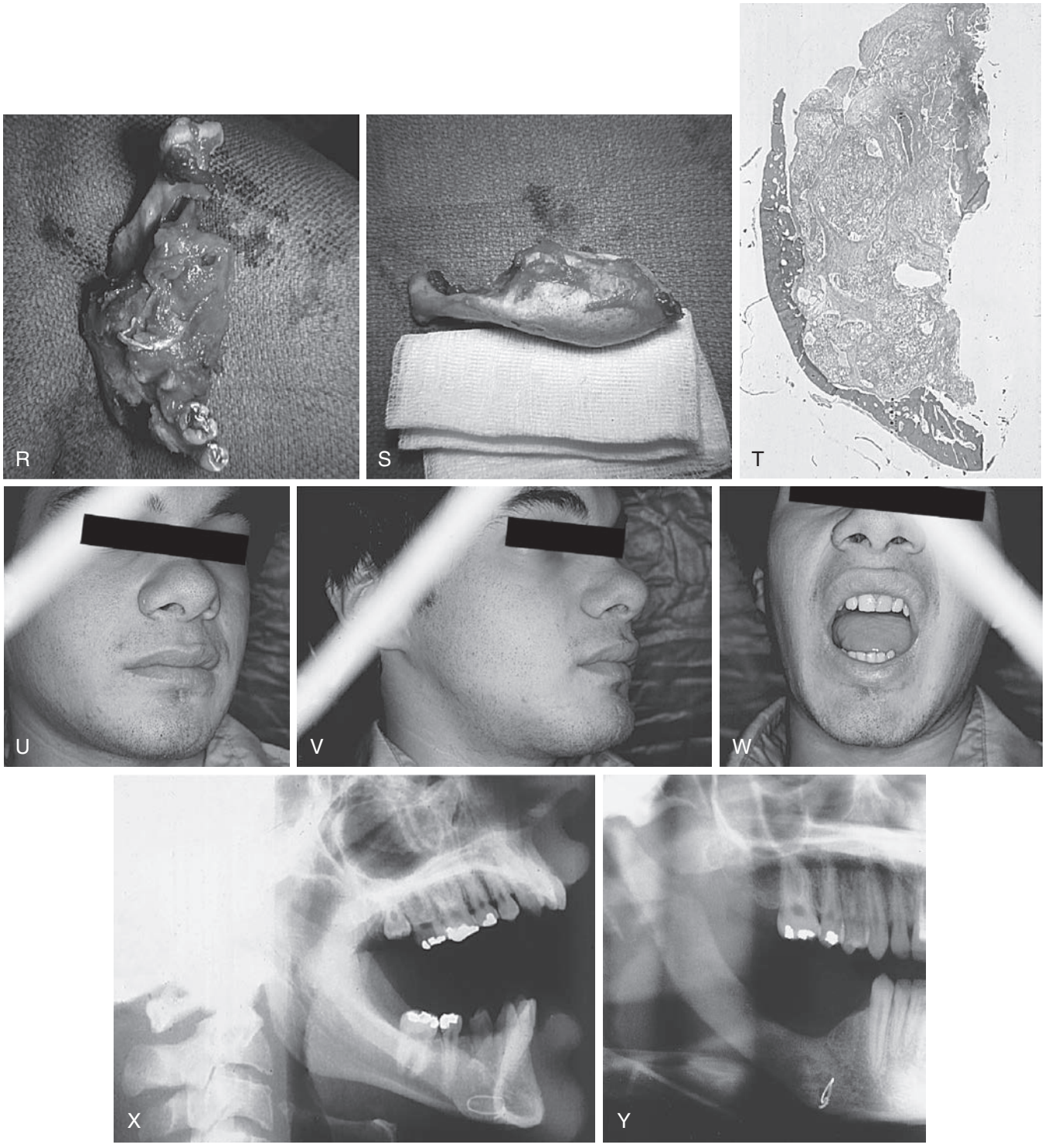

• **Figure 18-13, cont'd** **(R)** superior, and **(S)** buccal aspects (the soft tissue is removed to demonstrate classic gourd shape of the thinned expanded inferior border). **T,** Low-power photomicrograph of hemi-cross section taken through a portion of the specimen to demonstrate the solid and cystic tumor replacing the medullary spaces and resorbing cortical (compact) bone. The tumor was a predominantly solid lesion. **U-Y,** A good cosmetic and functional result was achieved. The patient was lost to follow-up evaluation after 9 months. (Patient left area and refused follow-up.)

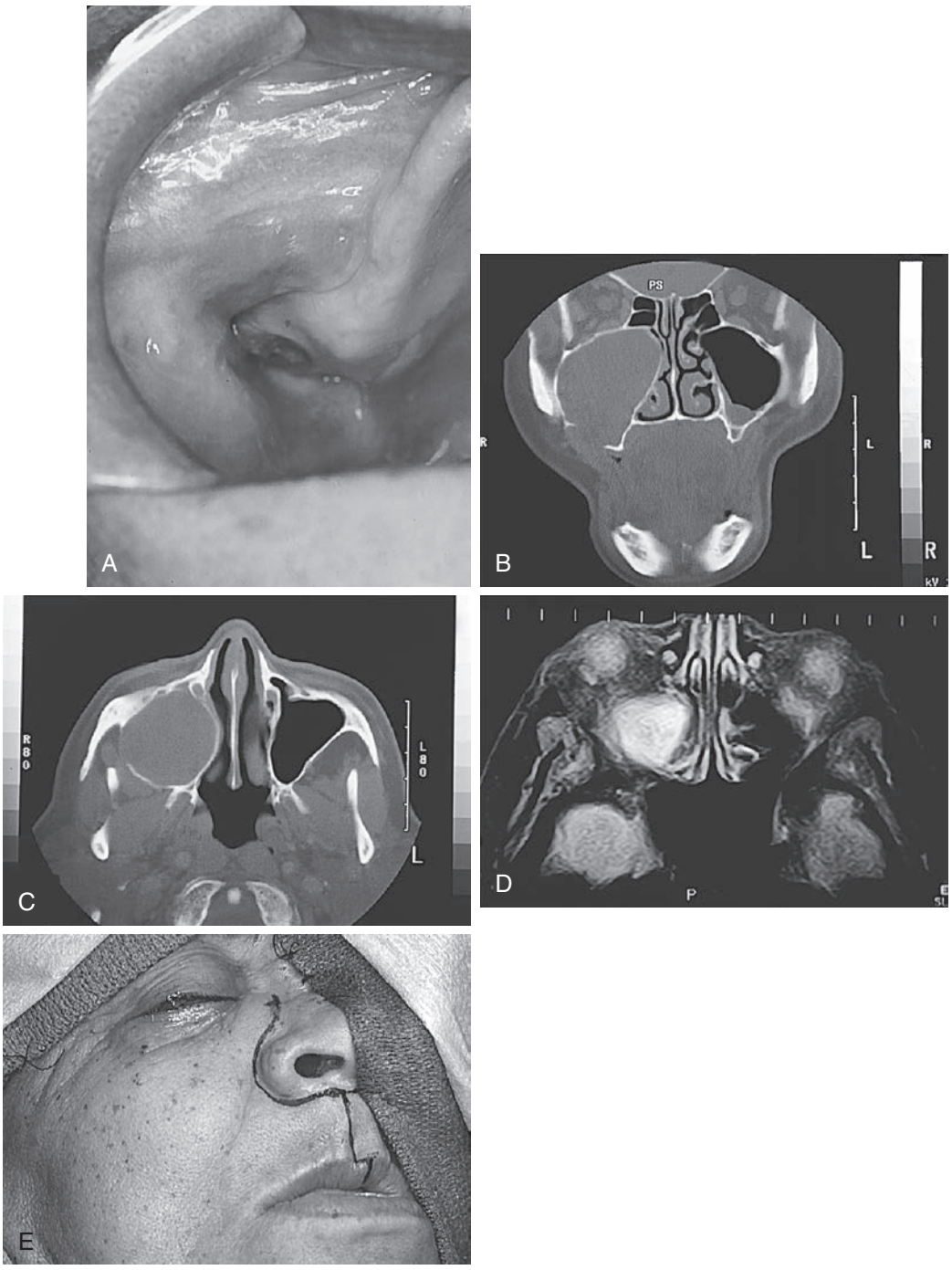

• **Figure 18-14** Solid ameloblastoma of the maxilla and maxillary sinus. A 77-year-old woman was referred for management of a previously biopsied follicular ameloblastoma of the right maxilla. **A,** The lesion expanded the buccal aspect of the maxilla and had resorbed the alveolar process and was palpable through the mucosa. The posterior biopsy site was ulcerated. **B-C,** Panographic, computed tomographic, and magnetic resonance imaging (MRI) revealed a circumscribed lesion occupying the maxilla and maxillary sinus, compressing the lateral nasal wall, involving the turbinates, and extending to the pterygoid plate. **D,** The infraorbital rim and floor of orbit and the ethmoid sinus were intact. The contrast MRI showed a solid lesion with suggestion of intralesional cystic spaces. **E,** A maxillectomy was performed, employing a Weber-Fergusson skin incision (without a horizontal infraorbital extension), combined with a transoral incision that spared uninvolved mucosa but included the biopsy site in the specimen.

Continued

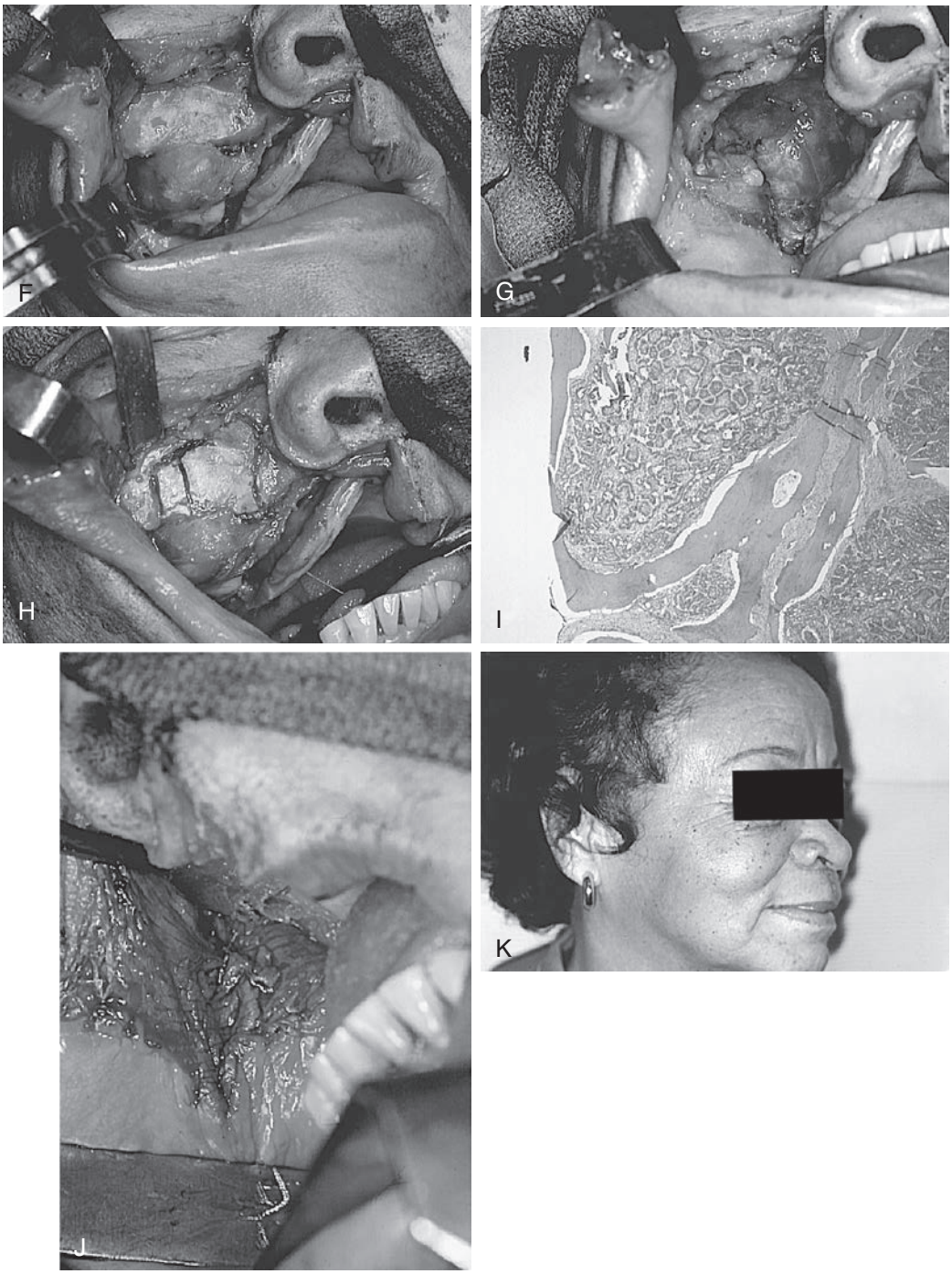

• **Figure 18-14, cont'd** **F-H,** The lesion had resorbed the posterior sinus wall but was **(I)** encased in remnants of the bone and circumscribing soft tissue. **J,** A meshed split-thickness skin graft was sutured to the inner raw surface of the facial flap and pterygoid area. Soft gauze, infiltrated with antibiotic ointment, was packed into the wound to obliterate space and support the skin graft. The pack was sutured in place across the palate. A temporary obturator was constructed within the mouth, and a permanent obturator was fabricated 2 months later. **K,** Facial appearance 2 months post operation.

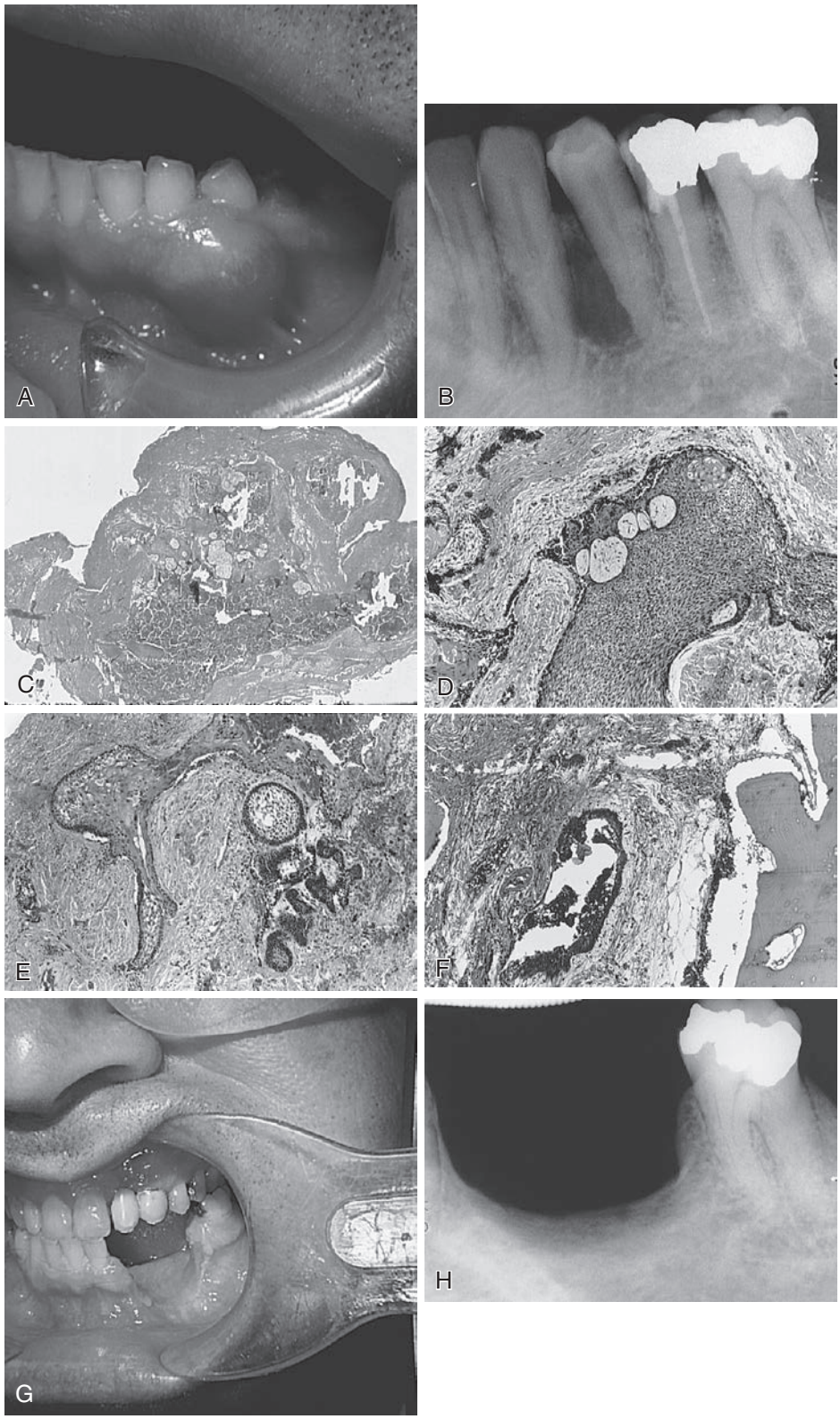

• **Figure 18-15** Peripheral ameloblastoma. **A,** A 46-year-old man was treated for a smooth-surfaced sessile 1.5 × 1.5 cm mass, involving the gingival and alveolar mucosa between the mandibular left canine and premolar teeth, that had been present for several years. **B,** Periapical, occlusal, and panographic radiographs showed a radiolucent lesion with irregular bone resorption, beginning root resorption, and possible extension to the lateral incisor. Block resection of the soft tissue mass, with deep curettage of the bone base, exposed the roots of the lateral incisor, canine, and first premolar teeth. **C**-**E,** Tissue (microscopic) sections showed a mixture of squamatoid, follicular, basaloid, and acanthomatous ameloblastic patterns. **F,** Microscopic sections of the bone bed revealed basaloid follicles adjacent to the bone. A resection without continuity defect of the tumor bed was done that incorporated the involved teeth and extended to a level below the tooth apices; residual tumor was not found. **G**-**H,** Clinical and radiographic examination 5 years later showed some bone regeneration with no recurrence.

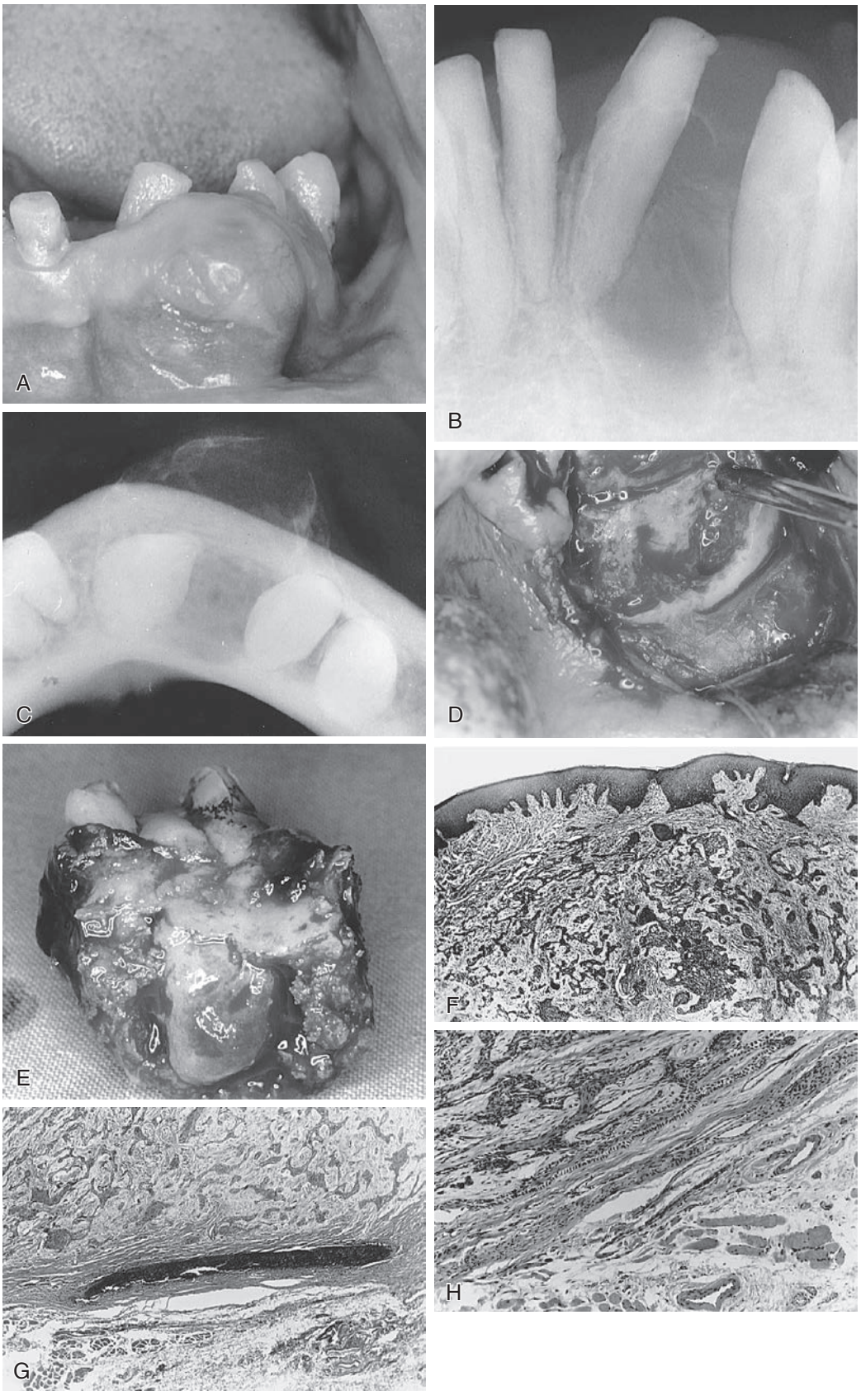

• **Figure 18-16** Peripheral ameloblastoma (possible central origin). **A,** A 55-year-old woman was referred for treatment of a smooth-surfaced, sessile mass, measuring 2.5 × 2.5 × 2.0 cm, involving the gingival and vestibular mucosa and covering the lateral incisor and canine that extended to the premolar. **B**-**C,** Periapical and occlusal radiographs showed a faintly septated radiolucent lesion causing separation of lateral incisor and canine teeth, with apparent thin bone covering a portion of the lesion's periphery. **D,** A block resection without continuity defect included the mass below the vestibular fornix and the three teeth, sparing the inferior lingual cortex. **E,** Specimen shown from the lingual and inferior surface. **F,** Tissue section of mucosal aspect reveals irregular large and small islands of mixed basaloid, acanthomatous, and occasional follicular ameloblastoma in a loose and dense stroma. **G,** The tumor abuts resorbing cortical bone and **(H)** periosteum separating tumor from muscle in the vestibule.

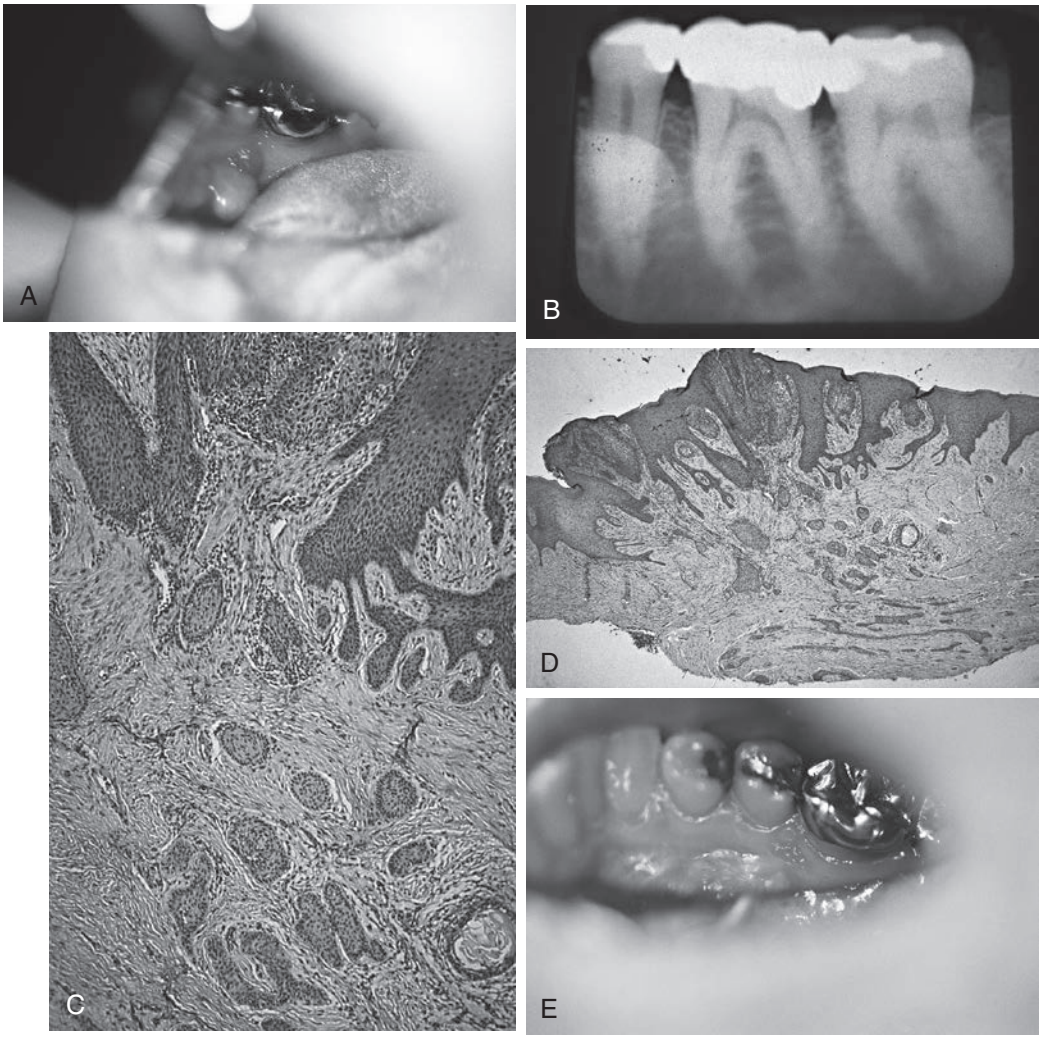

• **Figure 18-17** Recurrent peripheral ameloblastoma. **A,** A 55-year-old man was referred for evaluation and treatment of a 5-mm ovoid, reddish, slightly elevated lesion, with a pebbled surface on the lingual aspect of the gingival and alveolar mucosa, just superior to a mandibular torus. **B,** Panographic and periapical radiographs did not reveal bone involvement. The lesion was excised, and a microscopic diagnosis of peripheral ameloblastoma was made. **C,** Medium-power photomicrograph shows area of lesion in relation to surface gingival epithelium. The lesion recurred 8 months later and was re-excised with a 2-mm soft tissue margin, including the underlying periosteum. **D,** Scanning power photomicrograph demonstrates lesion at base of the tissue section. **E,** A second recurrence was seen within 3 months. The lesion was re-excised, again, with a perimeter of 5 mm of soft tissue and 3 mm of underlying bone (and the mandibular torus). There have been no recurrences (i.e., regrowth of residual tumor) in an 11-year follow-up period.

For a discussion of further potential links between peripheral ameloblastoma and intraosseous ameloblastoma, the reader is referred to papers by Ide et al[85] and Gold.[17a]

The peripheral ameloblastoma, because of its surface accessibility is the most readily managed of the ameloblastomas by relatively conservative surgery. However, growth characteristics such as tumor extension to the surface and medial and lateral infiltrating growth with circumscription but without true encapsulation must be taken into account. Recurrence, although uncommon, has been reported[78,79,83] (see Figure 18-17) (see discussion under Management).

Philipsen et al,[86] in a review of 160 cases of peripheral ameloblastoma culled from the world literature, identified 6 cases reported as malignant variants. These lesions were described as basal cell carcinoma[87] or squamous cell carcinoma.[88-90] One of the six cases was excluded (because of incomplete documentation) by Wettan et al[91] in a paper that also reviewed reported malignant peripheral ameloblastomas, and discussed their own cases of recurrent peripheral ameloblastoma with severe dysplasia.

In a letter to the editor in 2004, Ide and Kusama[92] discussed a paper published by them in 2001[93] of a maxillary peripheral ameloblastoma which "in spite of seemingly innocuous histology, showed unusual mitotic activity." The lesion was described as "partially malignant." In 2003, they studied an excised submandibular lymph node from the same patient, which was diagnosed as metastatic

well-differentiated peripheral ameloblastic carcinoma secondary to the original lesion. Ide and Kusama[92] now suggest that, in view of this retrospective diagnosis, mitotic activity in a peripheral ameloblastoma is possibly correlated with malignancy. They also find a corollary between the "conventional" appearance of peripheral ameloblastoma and "conventional" intraosseous ameloblastomas that have metastasized.

Their excellent discussion demonstrates the dilemma faced by pathologists who are reluctant to diagnose a lesion as malignant unless there is clear morphologic and cytologic evidence of malignancy, but also may represent an overly cautious desire not to over diagnose a lesion, which may influence a surgeon to perform what may be unwarranted, aggressive surgery.

Cytologic Malignant Ameloblastoma

As previously argued in the introduction to the section on ameloblastoma, the authors consider conventional ameloblastoma a low-grade de novo malignant tumor. Numerous reports document conventional ameloblastomas that aggressively invade adjacent and regional tissues as well as metastasize to the bronchopulmonary system, local and distant lymph nodes, and distant organs.[74b,94-100] Accounts suggest that nothing distinguishes some metastatic lesions from conventional ameloblastoma,[101-103] but several writers[17a,104,105] have commented that a number of photomicrographs reveal pronounced histologic dysplastic differences from conventional ameloblastoma that should have been recognized.

There is a tendency among some pathologists, once the histologic diagnosis of ameloblastoma is made, to dismiss the lesion from further consideration, since common knowledge holds that all ameloblastomas, of whatever subtype, behave in a similar manner. However, it is reasonable to expect that increased clinical aggression beyond the apparent slow progression of conventional ameloblastoma will be accompanied by histologic evidence of cytologic or gross atypia. It is probable that subtle morphologic histologic alterations are not recognized or are dismissed as unimportant, and obvious and blatant evidence of increased cellular atypia is regarded as "atypical," rather than an extension of the lesion's know biologic potential.

Subtle cytologic mutations can occur in ameloblastoma without physical or symptomatic awareness. *However, sudden, rapid, intraoral expansion of bone or soft tissue, and marked facial or cervical swelling, often accompanied by sensory loss and/or pain, may signal significant morphologic and cytologic changes in a lesion*. Imaging (panographic, CT, MRI) also may show extensive jaw bone destruction.

In unusual instances, clinical examination and imaging of maxillary lesions may reveal tumor masses, which extend into the maxillary sinus, nasoethmoidal, and pterygoid spaces or the skull base.[106,107] Mandibular lesions may infiltrate the floor of the mouth, parapharyngeal, and cervical regions.[108,109] *A clinically symptomatic patient may be the first sign of the presence of a de novo ameloblastic cytologic malignancy. However, more typically they will be patients who have been treated previously, sometimes years before, or have had numerous, intermittent unsuccessful procedures*.

In addition to imaging the primary jaw lesion when cytologic malignancy is proved or suspected, CT and PET examination should be extended to the chest, and bone scan to the skeletal system.[110] Isolated and multiple lung and pleural metastases as well as vertebral, hip, and other bone lesions may occur.[111] Metastases to brain, kidney,[112] and even myocardium[113] have been reported. Metastases to the skull, spine, lymph nodes, and distant organs do not occasion dispute concerning their metastatic credentials. However, metastasis to the lungs, often recorded as a favorite site, has raised the suggestion that aspiration occurred during a surgical procedure. Although implantation can and perhaps does occur, given the protective measures used to guard against aspiration, it must be a rare event measured against the numerous reports of metastases to the lungs. MacIntosh[114] has voiced the convincing argument that a common site of metastasis of oral salivary gland malignancy (e.g., mucoepidermoid carcinoma) is also to the lung, about which there has been no question of validity (Figure 18-18).

The histologic changes that accompany the progression from low-grade to high-grade malignancy range from relatively subtle to extreme atypia and produce marked deviation in epithelial cytologic characteristics as well as tissue pattern. Inner cell layers (such as stratum reticulum) become hypercellular and hyperchromatic and display mitotic activity with change in shape and size (often rounded with loss of polygonal shape). Masses of inner cells, no longer bound or restrained by an outer cell layer, infiltrate surrounding tissue as rounded or irregularly shaped islands. The peripheral (outer cell layer) cells also show atypia and hyperchromicity, change shape and size, lose nuclear polarity and identity as an outer cell layer, and proliferate as strands of undifferentiated carcinoma cells. Some lesions may retain segments of recognizable ameloblastic pattern or appear as undifferentiated carcinoma (see Figure 18-18).[17a] Clear cells may be present as islands and strands, or intermixed with squamous carcinomatous cells in irregularly shaped islands.[115]

An earlier discussion noted the production of a parathyroid hormone-related protein (PTHrP) by ameloblastic tumor cells in the local jaw lesion and a humoral factor in metastatic lesions in lung and bone, resulting in hypercalcemia.[75,76,94] An excellent study and case report by Cox and colleagues[116] demonstrates the relationship of PTHrP and hypercalcemia in a protracted case of ameloblastic carcinoma emanating from a conventional ameloblastoma (ex ameloblastoma) of the mandible. These findings suggest that *hypercalcemia may be a marker of metastatic disease in some instances, and that calcium levels should be routinely obtained*.

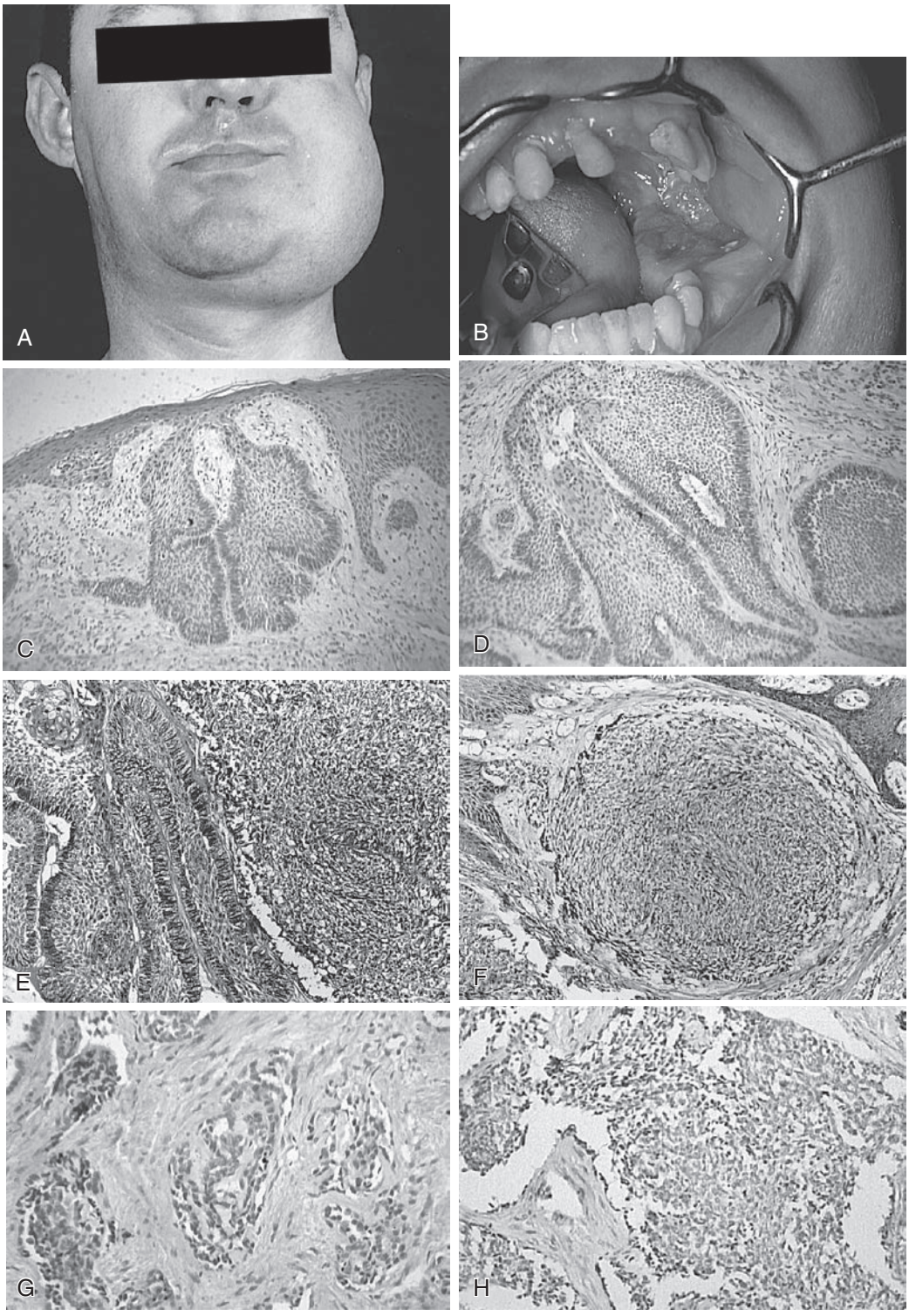

• **Figure 18-18** Central anaplastic ameloblastoma with metastases. A 32-year-old man was seen for a "lump on the left jaw" of 8 weeks' duration. The patient reported that he had had an "abscess in the jaw 15 years ago and never felt right since." **A-B,** Examination showed facial enlargement and an extensive intraoral lesion. Radiographs (unavailable) revealed almost complete replacement of the left mandible by a massive lesion. A biopsy was reported as anaplastic ameloblastoma. An extensive continuity resection of soft tissue and disarticulation of the mandible with neck dissection was done. Cervical lymph nodes were negative. The patient was hospitalized 6 months later in another hospital and died after 2 months. Pelvic and cervical vertebral metastases were proved at autopsy, but tissue slides of the metastatic lesions were never received. **C-H,** Photomicrographs of sections from the resection specimen demonstrate a spectrum of morphologic changes from areas of recognizable ameloblastoma to increasing anaplasia (undifferentiated carcinoma).

The cytologically malignant lesion that produces massive local disease or is combined with disseminated disease to organs and bone offers little to no possibility of salvage. Radiation and chemotherapy have had limited and temporary success[117,118] and are most suited, at this time, for palliation (not adjunctive therapy). Wide resection of the primary lesion and isolated metastatic lesions remains the best prospect for cure.

Management

The inability of the pathology community to resolve the continuing controversy surrounding the neoplastic classification of ameloblastoma has had a direct effect on surgeons' ability to deal unequivocally with this lesion. The pathologists who continue to deny low-grade malignant status to the tumor have hindered clinicians' understanding of the lesion's biologic behavior and potential, have given license to ineffective management, and must share with surgeons responsibility for the compromised treatment that some patients with ameloblastoma receive. Extensive knowledge of and clinical experience with ameloblastoma permit some general and specific principles of management to be enumerated. A recent paper by Carlson and Marx[119] is recommended for an excellent perspective on management.

General Principles

- Treatment must be guided by consideration of the behavior and potential of the tumor, the growth characteristics of the various physical forms, the anatomic site of occurrence, the clinical extent and size of the tumor, and the histologic assessment of the specific lesion.
- Unless precluded by the patient's physical and mental status and ability to withstand the surgical procedure and the postoperative recovery period, the goal of treatment is the total removal of the tumor by whatever surgical procedure or combination of procedures is necessary. *Less than complete excision is equivalent to planned recurrence (regrowth).*
- Present-day anesthesia, instrumentation, reconstructive surgical techniques, and materiel offer a number of choices for excellent functional and aesthetic restoration. Philosophic arguments about "radical" and "conservative" surgical approaches are irrelevant considerations, when weighed against the obligation to eradicate the lesion. The first procedure should be planned to be definitive and offer the best opportunity for cure, with the least psychological distress imposed on the patient.
- Curettage and enucleation of ameloblastoma, either separately or in combination, have resulted in recurrence (regrowth). The following recurrence rates of curetted lesions, compiled from relatively small series, are approximate and probably not completely accurate:
  - Intraosseous solid or multicystic lesions: 55% to 100%
  - Intraosseous unicystic lesions: 18% to 35%
  - Peripheral lesions: unknown, but occur
- Curettage as a primary or single surgical modality must be condemned. Curettage can disperse the tumor into uninvolved areas and make necessary subsequent procedures more tissue destructive. It is difficult to follow healing by radiographic examination of a lesion that has been treated by curettage, because recurrence may appear radiographically similar to formation of bone.
- Cancellous bone of the mandible and maxilla and cortical bone of the maxilla are readily infiltrated and resorbed by the tumor; the tumor spreads covertly through the bone.
- The dense cortical bone of the lateral and medial borders, as well as the inferior border and symphysis of the mandible, are temporary barriers. The dense bone of these sites can be and is invaded and destroyed by the tumor.
- The lesion microscopically infiltrates bone beyond the tumor-bone interface seen in imaging. Until anatomic and histologic studies prove the presumption incorrect, a safe margin of uninvolved bone is approximately 1.5 to 2 cm for solid and multicystic lesions, and 1 to 1.5 cm for unicystic and peripheral lesions.
- Resorption of cortical bone by the tumor permits growth into the periosteum; if the periosteum is penetrated, growth into surrounding muscle and soft tissue occurs.
- The peripheral connective tissue of ameloblastoma, whether dense or loose, may appear to circumscribe the lesion but cannot be considered a capsule. The tumor can and does grow into and through the peripheral connective tissue.
- Post-treatment patients should be followed for 15 to 20 years or longer.

Specific Principles

Intraosseous Solid, Multicystic, and Solid/Multicystic Ameloblastoma

- Mandibular excision, by block resection without continuity defect ($Rs^{-}CD$) or block resection with continuity defect ($Rc^{-}CD$), should be performed on lesions that, respectively, do not and lesions that do involve the superior-inferior diameter of the mandible, provided the general management principles (cited previously) are observed.
- The inferior alveolar nerve should be sacrificed if it lies within the lesion. If the surgical plan includes nerve grafting, it is best to perform the procedure at the time of resection whether bone reconstruction is immediate or delayed.[120]
- Resection should be exterior to a tumor-involved tissue plane (e.g., if cortical bone is resorbed and penetrated, the resection should include the periosteal layer of that area; if periosteum is infiltrated, the resection should include that portion of overlying muscle or mucosa).
- A thin inferior border of the mandible preserved in an Rs^{-}CD may fracture even if supported by a reconstruction plate placed to span and support the segment. Retention

of an inferior border less than 1 cm in thickness is not practical, and Rc-CD should be performed.
- Resection by sharp cutting instruments permits radiographic and histologic assessment of the resection margins. The technique of "grinding" bone away with a burr does not allow microscopic evaluation of the tumor-bone interface.
- Immediate reconstruction can be performed, by several techniques, if there is surgical, specimen radiographic, or intraoperative frozen section certainty of complete excision of the tumor. However, if there is uncertainty about the resection margins, reconstruction should be delayed until permanent tissue sections are studied.
- If sufficient uninvolved soft tissue is locally available to cover the resection bed, an autogenous free bone graft or bank allogeneic bone crib and patient marrow may be used with a reconstruction plate or wire fixation of the graft. Platelet-rich plasma[121] mixed into a particulate cortical/cancellous/marrow bone graft is an excellent binder and may promote bone formation.
- If insufficient soft tissue is locally available to cover the resection bed, a vascularized composite pedicle graft of bone and myocutaneous tissue can be used.
- Delayed reconstruction also may be employed in the instance of insufficient soft tissue at the resection site by application of a plate to maintain the resection space, and rotation of a vascularized regional myocutaneous flap. Bone grafting should immediately follow healing of the soft tissue bed, in order to prevent fracture of the reconstruction plate and subsequent infection.
- Maxillary lesions must be resected aggressively because of the ease with which the tumor can spread through the less dense cancellous and cortical bone, with access to the pterygoid region, sinuses, infratemporal space, and skull base.

Intraosseous Unicystic Ameloblastoma

- Most unicystic ameloblastomas are clinically and radiographically diagnosed initially as dentigerous cysts or odontogenic keratocysts and therefore are often treated without prior biopsy; the management selected (i.e., enucleation or marsupialization if the lesion is thought to be a cyst) is determined by patient-related clinical factors. Seldom is unicystic (mural) ameloblastoma considered in a differential diagnosis. Although often overlooked, an important radiographic diagnostic sign of a unicystic ameloblastoma is tooth root resorption in the lesional area. Cystic lesions such as dentigerous, calcifying odontogenic, and glandular odontogenic may also cause tooth root resorption, all of which should arouse sufficient suspicion to warrant performing a biopsy. Biopsy of a unicystic ameloblastoma does not guarantee correct diagnosis. The biopsy site may not include ameloblastic epithelium lining the lumen or within the cyst wall, and additionally the tissue sample may be misdiagnosed. Extensive unicystic lesions should be biopsied in several sites in an attempt to obviate selection of nondiagnostic areas.
- Careful radiographic examination can help determine whether small satellite cysts are present and are separated from the main cyst cavity by bony septae.
- The physical basis for attempted enucleation of a mural (unicystic) ameloblastoma is the integrity of the cyst wall: a property conferred by the density of the collagenous connective tissue and the ability to find a cleavage plane between the lesion and bone.
- Fragments of torn cyst wall that remain attached to bone and friable areas of cyst wall should be submitted for intraoperative frozen section to detect the presence or absence of ameloblastic foci.
- The absence of satellite cysts, physical integrity of the cyst wall, and negative intraoperative frozen section finding (i.e., absence of ameloblastic elements in the cyst wall adjacent to or abutting bone) are essential to a successful enucleation attempt.
- Curettage of the bone is discouraged because it may implant foci of ameloblastoma more deeply into bone. Adjunctive treatment of the bone tumor bed by chemical fixation with Carnoy solution[122] is of theoretical but unproven value, and cryosurgery gives inconstant benefit, as well as risk of sequestration or pathologic fracture.[123-126]
- If frozen sections or final microscopic sections of the tumor reveal foci of ameloblastoma within the cyst wall (so-called *mural* occurrence) at or near the bony tumor bed, it should be assumed that ameloblastoma is within adjacent bone. In such an instance, further management should be by Rs-CD or Rc-CD, depending on the extent of anatomic involvement. Reconstruction can follow in the same manner as outlined for intraosseous solid or multicystic lesions.
- *There is no surgical imperative that enucleation be the preferred management modality.* Indeed, there are some compelling reasons not to select enucleation, but to employ Rs-CD or Rc-CD with reconstruction from the outset. These are (1) a lesion so extensive as to result in pathologic fracture, soon or late, if enucleation alone is attempted; (2) the presence of small satellite cystic lesions (or invisible microscopic foci) in addition to primary lesions; (3) an intraoperative frozen section finding of ameloblastoma in the cyst wall at the cyst-bone interface; and (4) the ability to select a 1- to 1.5-cm resection margin distant to the radiographic lesion-bone interface, as a presumptive "safe" distance from the lesion.

Peripheral (Extraosseous) Ameloblastoma

- Peripheral ameloblastoma is seen as a sessile gingival and mucosal mass, with frequent separation of teeth in dentate areas, a smooth or warty (pebbled) surface, and a radiographic image that reveals the extent, if any, of alveolar bone involvement. Because there are no pathognomonic clinical characteristics, unless

a biopsy is performed, the lesion probably will be excised. Microscopic sections of the tumor will reveal the extent of involvement of surface mucosa, periosteum, and bone.
- With prior biopsy and identification of the lesion, Rs-CD should be done, with clinical and radiographic guidance, to excise a block containing the tumor, overlying mucosa, underlying periosteum, alveolar bone, and teeth. A 1- to 1.5-cm resection margin of clinically uninvolved soft tissue and bone should be included. Healing by wound dressing usually is sufficient.
- If the lesion has been removed without biopsy, and microscopic sections of the specimen reveal ameloblastoma at the excision margins, a secondary Rs-CD block centered on the previously excised area should be performed as described.

Cytologic Malignant Ameloblastoma

- A cytologically malignant ameloblastoma (CMA) will frequently exhibit a combination of characteristic features:
  - A history of a lesion treated previously (in instances years before) or multiple periodic operations without effective containment, except in instances of a de novo CMA.
  - Clinical signs of facial enlargement with sudden, rapid jaw and soft tissue expansion and symptoms of pain or sensory impairment in the jaw.
  - Past or present roentgenograms that reveal a lesion with indistinct borders merging with host bone and extensive destruction of cortical bone.
- Definitive diagnosis must be based on microscopic analysis of several biopsies taken from the lesion.
  - Tissue diagnosis should be performed by a pathologist familiar with the nuances of histologic atypia possible in ameloblastoma, as well as the spectrum of dysplastic changes displayed by CMA.
  - Fine-needle aspiration is not recommended as a biopsy technique and should not replace incisional biopsy of the primary lesion or metastatic sites.
- A positive diagnosis of CMA should initiate a roentgenographic survey for the presence of paragnathic tumor masses and metastases to regional lymph nodes, lung, and skeleton.
  - Metastatic lung and bone lesions may be present without clinical symptoms.
  - Serum hypercalcemia may indicate the presence of metastasis.
  - CT, MRI, PET-CT, and bone scan imaging are indicated for head, neck, chest, and skeletal survey.
- Physical and mental status permitting, and if surgically feasible, wide resection and reconstruction should be performed on the primary and metastatic lesions by a surgical team.
- Radiation and chemotherapy are questionable modalities for adjunctive treatment and should be reserved for palliation.

Clear Cell Odontogenic Carcinoma

A chronologic account of the recognition of the odontogenic "clear cell" from histologic curiosity to identification of its potential neoplastic and malignant behavior is interesting and instructive (Figures 18-19 to 18-21). The odontogenic epithelial cell, known as clear cell, has its origin in the embryonic oral ectoderm of the dental lamina. It was described by the early dental histologists as a basal cell whose cytoplasm did not stain in histologic preparations, because of a rich glycogen content, giving an empty appearance.[1] Pathologists through the years also have observed small and large islands of clear cells in follicular sacs and dentigerous cyst walls (in two reports,[127,128] the clear cell nests were erroneously described as sebaceous cells).

A study of epithelial nests in the human periodontal ligament by Reeve and Wentz[129] revealed three morphologic types, one of which consisted of large islands of clear cells, either densely packed or loosely arranged like a stellate reticulum, sometimes surrounded by a connective tissue capsule.

Clinical and histologic studies of the lateral periodontal cyst and gingival cyst by a number of investigators[43,130-132] showed the lesions to be unicystic or polycystic (also known as botryoid odontogenic cyst[133,134]), capable of recurrence,[135,136] and containing clear cells. Several reports pointed out the distinctive clear cell as one of the types of epithelium lining the cystic lumen and present in the connective tissue wall as nests, sheets, and lining of microcysts. Some periodontal cysts showed lumina lined by stratified squamous or cuboidal epithelium in combination with clear cell follicles or clusters (see Figure 18-19, *A-D*). One study[43] identified the neoplastic potential of the clear cell and helped clarify a case treated by the senior author (L.G.) in 1966, which had been classified as probably of odontogenic origin, and perhaps a variant of ameloblastoma, as an odontogenic tumor composed primarily of clear cells. This patient, after several Rs-CD and Rc-CD procedures, appeared to be cured in 1971 but later exhibited metastases to lung and ribs, survived for 18 years, and succumbed to the lesion now identified as clear cell odontogenic carcinoma (see Figure 18-21).

After the description of the classic CEOT as an entity by Pindborg in 1955,[46] CEOTs and variants were reported by a number of writers, including several who described CEOTs containing large areas of clear cells or composed chiefly of clear cells.[59,137-139] These tumors also were viewed as variants of the CEOT because the lesions contained areas of calcification and apparent amyloid (presumed collateral hallmark of CEOT). Greer and Richardson,[58] in a report titled "Clear Cell Calcifying Odontogenic Tumor Viewed Relative to the Pindborg Tumor," described a lesion composed entirely of clear cells except for a central radiopaque nidus. However, the authors, in this instance, expressed vexation with the assignment of the lesion to the CEOT category. They considered "unique tissue formations ill-used by compulsive subclassification." They knew the lesion was not primarily a Pindborg tumor and resented efforts to force it into that group. Their photomicrographs clearly demonstrated a clear

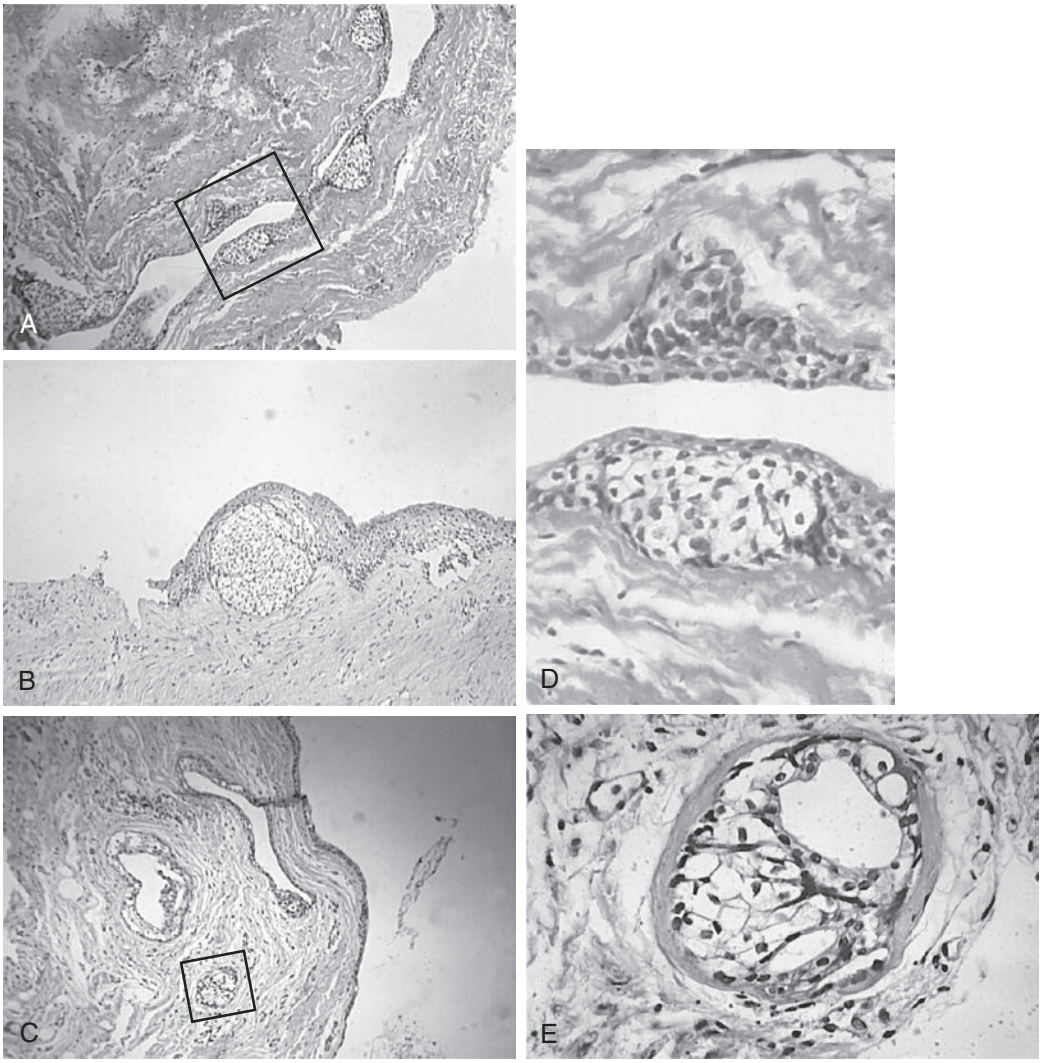

• **Figure 18-19** Periodontal cysts with clear cells. Photomicrographic patterns of clear cell follicles in the luminal lining and walls of several periodontal cysts. **A-C,** Low powers. **D,** High-power area of luminal lining in **(A). E,** High-power area of wall in **C**.

cell odontogenic tumor or carcinoma. Hicks and colleagues[59] reviewed the literature on clear cell variants of CEOT and presented an aggressive case example (see the previous section on CEOT).

Waldron and colleagues,[16] in a report characterizing *clear cell ameloblastoma* as an odontogenic carcinoma, described two cases of a malignant odontogenic neoplasm that exhibited a biphasic pattern of follicular ameloblastoma, with dysplastic follicular features and a very pronounced and prominent clear cell component. One patient apparently survived (6½ years of follow-up) and the other patient died of extensive and uncontrolled growth (infratemporal fossa, retro-orbital region, skull base, facial tissue) and cervical metastases. The authors regarded both lesions as malignant clear cell variants of ameloblastoma and took the occasion of their report to reexamine critically the neoplastic position of ameloblastoma and the WHO concept and classification of malignant odontogenic neoplasms.

A short report by Müller and Slootweg[140] discussing clear cell differentiation in an ameloblastoma described an anterior mandibular multilocular ameloblastoma in a 14-year-old boy, which in addition to typical follicular and plexiform patterns showed extensive fields of clear cell differentiation where normally stellate reticulum was expected. The tumor was treated by "conservative marginal resection with additional bone removal with burs." Examination 15 years later showed no recurrence. Because of this experience, the authors proposed to extend the family of ameloblastoma types to include a clear cell variant but cautioned that other nonodontogenic sources of clear cells must be ruled out (see later discussion).

In 1985, reports by Eversole and colleagues[141] and Hansen and colleagues[142] described and delineated the histochemical, ultrastructural, and clinical features of a rare, distinctive, aggressive odontogenic neoplasm, which they termed *clear cell odontogenic tumor* (CCOT). Although the lesions were aggressive, the authors were reluctant to characterize the CCOT as malignant, since none of the three cases evidenced regional or distant metastasis (parenthetically, between the time of Hansen and colleagues' original

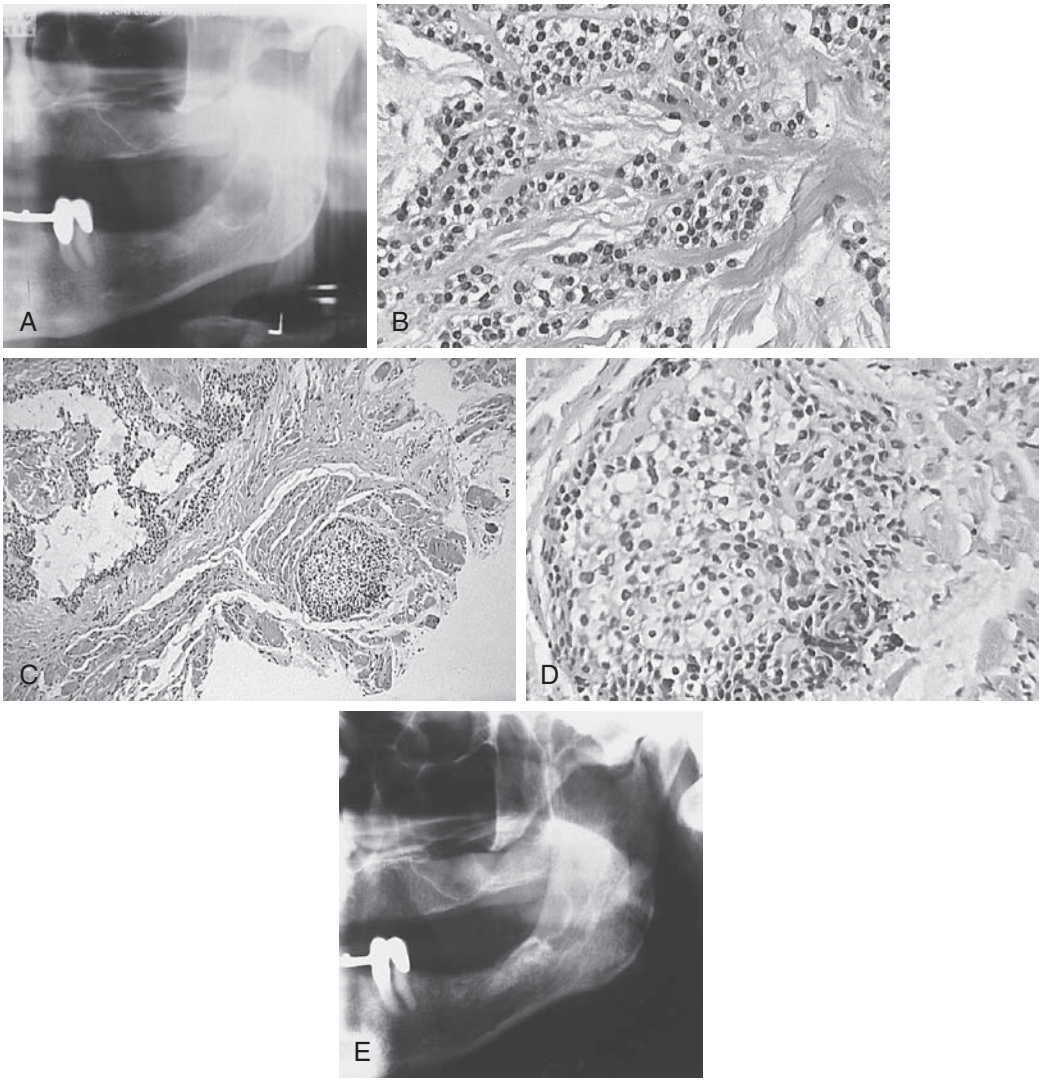

• **Figure 18-20** Clear cell odontogenic carcinoma with recurrence. A 59-year-old man complained of a nontender swelling in the left retromolar pad area of the mandible. **A,** A panograph revealed an approximate 3 × 2-cm radiolucent lesion with fairly well-defined margins. Aspiration did not produce aspirant; however, a solid "gritty" tissue was felt. The mandible was exposed by an intraoral mucoperiosteal flap distal and proximal to the mass; however, the buccal and lingual mucosa overlying the lesion was firmly attached and appeared infiltrated by tumor. The tumor mass with intact overlying mucosa was enucleated from the mandible. It was noted that the tumor had involved the mylohyoid muscle and anterior lateral pharyngeal wall. **B,** Tissue sections revealed a clear cell odontogenic carcinoma with muscle involvement: **(C)** low power; **(D)** high power. **E,** Fourteen years later the patient, then 73 years old, was seen again with evident recurrence. A biopsy again showed clear cell odontogenic carcinoma. Computed tomography demonstrated a 2-cm tumor mass in the superior medial retromolar region of the mandible with bone involvement. There was no evidence of lymph node metastasis. A combined extraoral-transoral approach (with lip incision) permitted good visualization of the mandible and the mucosa-covered tumor mass. A reconstruction plate was contoured, fitted, and screwed to the mandible, and then removed and set aside for later use. Continuity resection was completed with adequate distal and proximal bone margins. The specimen included the mucosal extension of the tumor. The plate was attached to the mandible and the oral and extraoral wounds were closed. The patient subsequently had mandibular reconstruction with a cadaveric mandible. Examination of the patient 1½ years after the surgery revealed no recurrence.

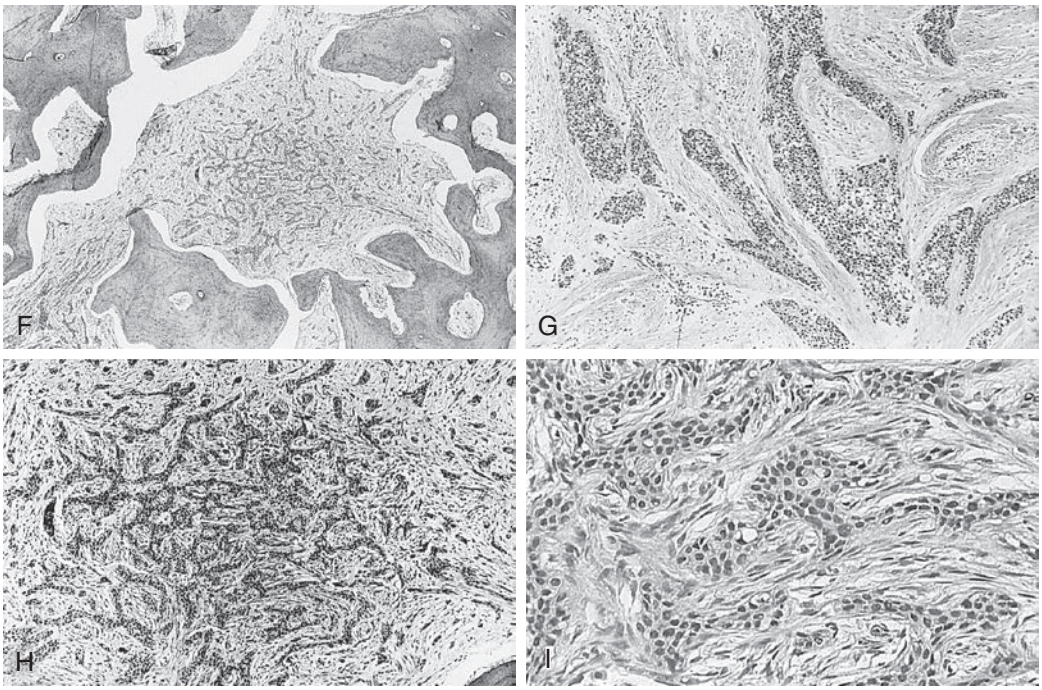

• **Figure 18-20, cont'd** Tissue sections of the resection specimen demonstrated greatly increased squamatization of the tumor (**F,** low power; **G,** high power) with decreased evidence of clear cells (**H,** low power; **I,** high power) as seen in the first excision 14 years previously. (Case material courtesy David J. Furman, DDS, Huntsville, AL, and Herman M. Teachey, MD, Huntsville, AL.)

1985 report[142] and Eversole and colleagues' 1995 report,[143] one of the three patients died of recurrent disease).

Within several years, however, Bang and co-workers,[144] Fan and colleagues,[145] Milles and associates,[146] and Eversole and co-workers[143] had published well-documented and illustrated cases that recorded local, regional, and distant malignant and metastatic behavior of the clear cell tumor and justified a change in designation from CCOT to *clear cell odontogenic carcinoma* (CCOC). This abbreviated account undoubtedly omits some who have contributed to the recognition of the neoplastic potential of the odontogenic clear cell (see discussion by Hansen,[142] who credited Rick with assigning a diagnosis of clear cell odontogenic carcinoma to a puzzling case presented in a 1981 seminar). Although an uncommon tumor, the CCOC probably has been unrecognized, misdiagnosed, and/or unreported in the past.

Clinicopathologic Considerations

The CCOC offers no distinctive clinical aids for differential diagnosis. The age of affected patients extends from the fourth to the eighth decade, with a markedly biased occurrence rate in women over men in an approximate 4:1 ratio. Almost 75% of lesions are found in the mandible and 25% in the maxilla. The anterior mandible is the site of predilection, followed by the body and angle regions. The anterior area also is favored in maxillary lesions. Radiographically, lesions show a radiolucent unilocular or multilocular appearance, with poorly defined irregular borders. Imaging reveals evident bone destruction in small or large lesions. Tooth root resorption is seen in areas of lesional involvement (see Figures 18-20, *A* and 18-21, *A*).

Presenting clinical symptoms and signs of the quiescent or slowly growing lesion are not diagnostic. Mild pain or discomfort may be experienced in the lesional region, with jaw enlargement and loosening of teeth in dentate areas of the lesion. Interestingly, none of the patients in the study by Eversole and co-workers[143] reported a sensory deficit.

Sudden and rapid jaw enlargement or massive swelling, without apparent provocation, usually signals overt, invasive, malignant behavior. Mandibular lesions may penetrate bone and infiltrate oral soft tissue and adjacent facial areas, including muscle and the cervical region.

Maxillary lesions may infiltrate and involve the nose, sinuses, orbit, adjacent zygomatic and facial bones, and skull base. Case reports illustrate cervical node metastasis as well as lung and liver metastases.

Some patients appear to have been successfully treated after local recurrence required further surgical procedures, and several appear to be living with disease. At least 5 patients have died of tumor—in some instances because of uncontrolled regional disease; in other instances patients have died after 7, 10, 18, or even 20 years with recurrent disease (see Figures 18-20 and 18-21).

Histologically, the clear cell odontogenic carcinoma is primarily and prominently composed of small and large nests and islands of clear cells—cells that are ovoid or round and have vacuolated clear cytoplasm, with small, round, often eccentric, pyknotic nuclei and distinct cytoplastic borders. The clear cells exhibit bimorphic as well as

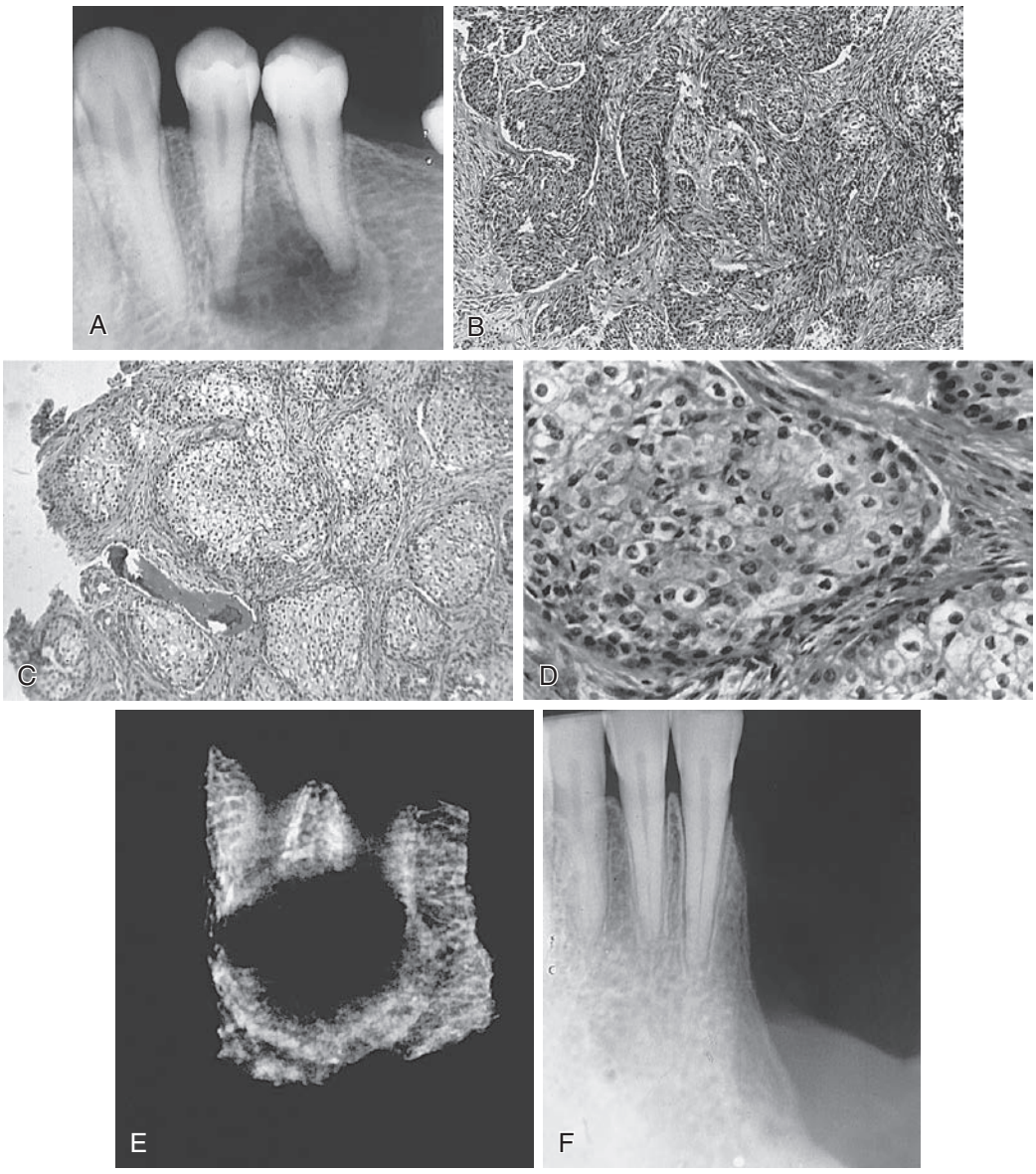

• **Figure 18-21** Clear cell odontogenic carcinoma with metastases. **A,** A 36-year-old woman was referred for treatment (May 1966) of a localized gingival swelling and radiolucent lesion in the left mandibular first and second premolar area. The lesion was enucleated and curetted, and the two teeth were extracted. It was noted that the bone walls were not smooth. A tissue diagnosis of ameloblastoma variant was made by the hospital pathologist. My interpretation conceded vague similarity to ameloblastoma but favored some form of odontogenic tumor with clear cells, specific entity not known. (A study of periodontal cysts in 1971 revealed clear cells similar to those of the tumor [see Figure 18-19].) **B,** Photomicrographs of the enucleated lesion demonstrated a biphasic tumor pattern of squamatoid islands admixed with clear cells **(C-D)** and a predominant pattern of clear cell follicles. **E**, Specimen radiograph of a limited resection without continuity defect performed within a month of the original procedure. The patient had frequent follow-up evaluation. **F,** Radiograph (Jan. 1967) of the anterior edge of the resection border showed no tumor.

polymorphic phases. Other tumor cells are polygonal and have cytoplasm with faint eosinophilia, and nuclei that are somewhat larger and vesicular. The bimorphic and polymorphic phases show strands, sometimes branching; more compressed and hyperchromatic appearing clear and squamoid cells; as well as squamous islands that are both innocuous and carcinomatous in appearance. Occasionally, clear cell islands exhibit reverse nuclear polarity and columnarization of peripheral cells lying against the basement membrane of the connective tissue stroma, similar to the peripheral cell arrangement of an ameloblastoma. The connective tissue stroma may be thin or somewhat dense and narrowly separate the islands of clear cells, or it may be more abundant in areas of the small nests and strands of tumor cells (see Figures 18-20 and 18-21).

The CCOC is seen to invade and resorb medullary and cortical bone as sheets and islands of tumor. Nests of clear

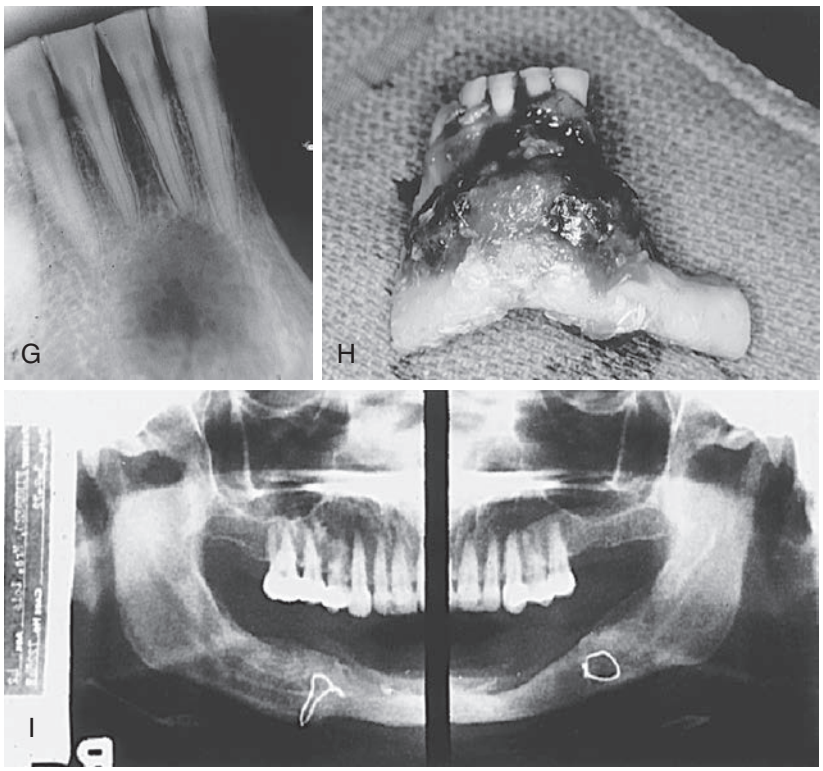

• **Figure 18-21, cont'd** **G,** Follow-up radiograph (Sept. 1967) showed anterior recurrence. A transoral resection (Nov. 1967) with continuity defect was performed from the mandibular right canine to the left second molar area (frozen sections of bone marrow curetted from the left resection end showed no tumor), with an immediate autogenous iliac crest graft. **H,** Specimen section, and **(I)** periodic panographs taken in 1972. Almost 9 years later (1976), a lung scan revealed a 1.5 × 2.0 cm tumor nodule in the left lung lingula and a lesion in the sixth rib. Rib resection was done and a course of chemotherapy was given.

Continued

cells infiltrate bone at some distance from the main tumor mass, as well as soft tissues after the bone barrier is breached.

Mitotic activity may or may not be present, either in the primary lesion or in the metastatic deposits. A diagnosis of malignancy is not dependent on the mitotic index of the tumor. CCOC is a de novo malignancy from onset.

The lesion called clear cell ameloblastoma is well illustrated in reports by Waldron and associates[16] and Müller and Slootweg.[140] In addition to the varied forms of clear cell islands previously described, conventional ameloblastic follicles incorporate clear cells that replace the stellate reticulum. The columnarization and reversed nuclear polarity of peripheral clear cells in some clear cell nests, the coexistence of clear cell islands and conventional ameloblastoma in the clear cell ameloblastoma, and histologically dysplastic ameloblastomatous configurations appear to point to a relationship between a "pure" CCOC and ameloblastoma. Is there a question of homology? Is CCOC a more embryologically dedifferentiated and virulent form of ameloblastoma, or is CCOC a distinct lesion that may, to an extent, neoplastically differentiate toward ameloblastoma? In either respect, it is apparent that the appearance of clear cells within a nominally conventional ameloblastoma confers further aggressive biologic behavior and metastatic capability.

Clear cell nests described in CEOTs[59,137-139] prompt similar questions. Is there a numerical percentage of clear cell islands in a CEOT necessary to convert a tumor from CEOT with clear cells to a CCOC with Pindborg features, and does the presence of calcifications and/or amyloid preclude a diagnosis of CCOC? There have not been sufficient cases with follow-up evaluation to answer these questions.

Discrimination between CCOC and other lesions containing or primarily composed of clear cells may present a differential diagnostic problem. The neoplasm may histologically resemble a number of clear cell adenocarcinomas of salivary gland origin,[147] squamous cell carcinoma with clear cells (also glycogen containing), or metastatic adenocarcinomas (e.g., kidney, ovary). The cells of CCOC demonstrate glycogen (strongly or weakly) in frozen sections with periodic acid-Schiff (PAS) and diastase digestion staining and are mucicarmine negative. Immunohistochemical staining variably discloses cytokeratin, epithelial membrane antigen, and S100 protein.[143]

Management

The preceding discussion is explicit: CCOC should be regarded as a de novo malignant odontogenic neoplasm, capable of uncontrolled local and regional growth and regional and distant metastases. The 1995 tabulation of CCOC cases by Eversole

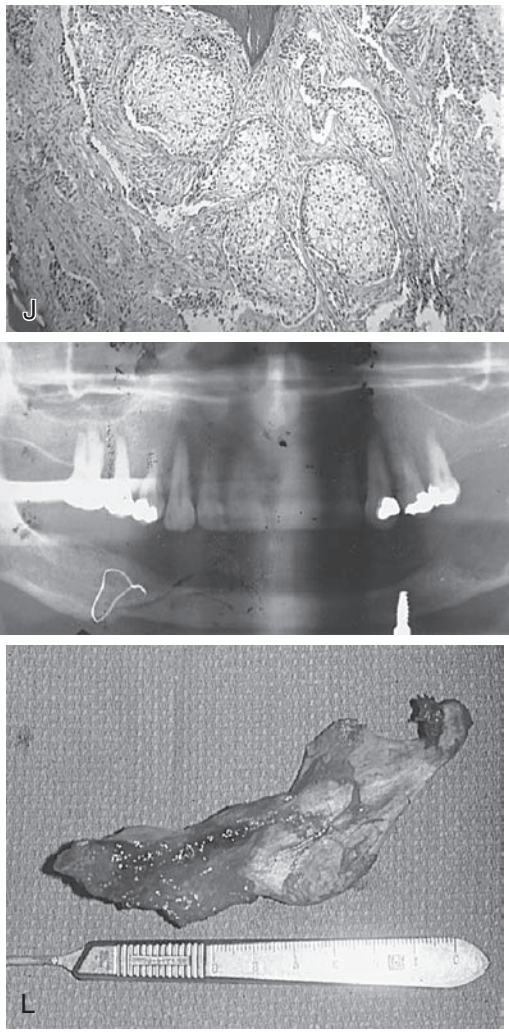

• **Figure 18-21, cont'd** **J,** Tissue sections from the rib demonstrated metastatic clear cell odontogenic carcinoma. **K,** Four months later clinical and radiographic examination revealed recurrence at the left (proximal) end of the graft. **L,** A left mandibular resection with continuity defect from the premolar area with disarticulation was done (Oct. 1976). No further reconstruction was considered. The patient's facial form was little affected, and the patient remained free of local tumor until her death 18 years after discovery of the oral lesion. The cause of death was considered to be progressive tumor disease and cardiac myopathy (autopsy was not performed).

and co-workers[143] showed, in addition to other details, that 4 of 14 patients died of disease within a 7- to 21-year follow-up period. A suggested management protocol is offered, supported by known characteristics and probable behavior of the lesion:

- Rule out metastatic disease and regional tumors that histologically simulate CCOC.
- Microscopic assessment of malignancy should not be based on the presence or absence of mitoses.
- CCOC, from the time of discovery, should be considered malignant and a potential metastasizing tumor.
- Ameloblastoma with microscopic evidence of ameloblastic atypia and a substantial clear cell component should be regarded as a CCOC.
- The position of CEOT with a substantial clear cell component has not yet been clearly established in the spectrum of CCOC lesions.[58-61] It appears best to regard such a lesion as malignant.
- The lesion must be resected aggressively.
- A definitive first surgical procedure offers the best opportunity for cure.
  - Resection should be guided by preoperative CT and/or MR imaging and intraoperative frozen section samples. *Tumor cell nests "wander" distant from the main mass of the lesion.*
  - Sacrifice neural structures in proximity to the lesion and soft tissue overlying cortical bone penetrated by the lesion.
  - Bone and soft tissue resection must maintain wide tumor-free margins in all dimensions to the extent, or beyond, that is recommended for ameloblastoma.

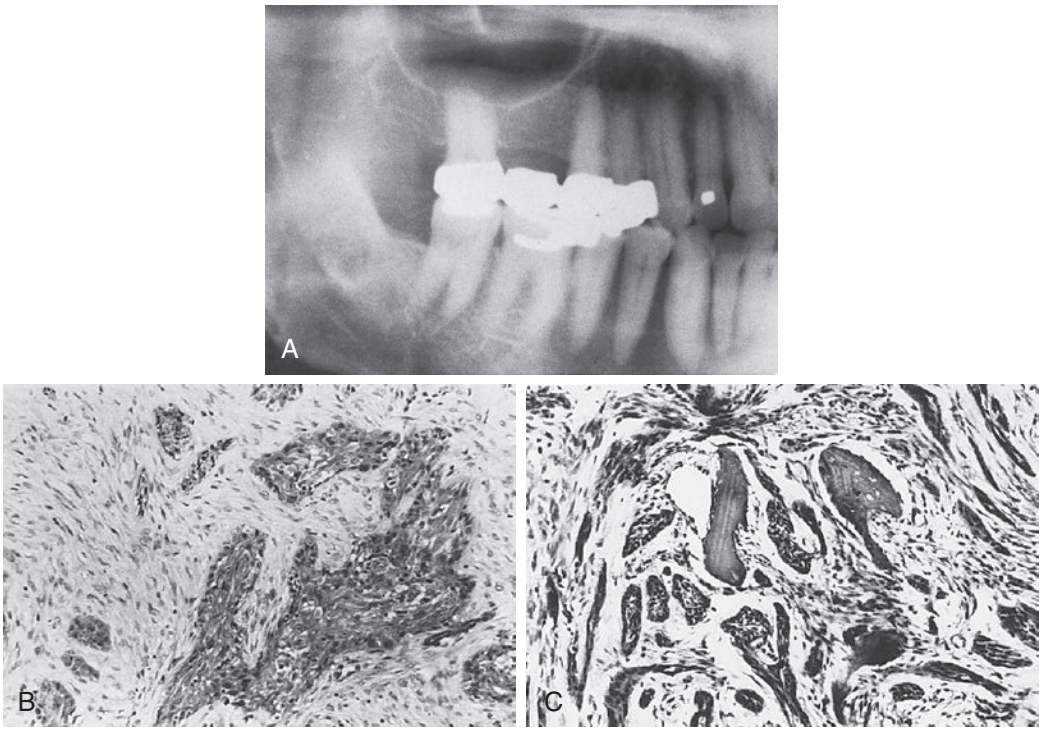

• **Figure 18-22** Intraosseous odontogenic squamous cell carcinoma. **A,** Panograph of a 67-year-old man who was seen by his dentist for a nonpainful, elevated, smooth mass in the right lateral mandibular canine-premolar alveolar ridge area. Under local anesthesia, five teeth were removed and the lesion was enucleated. **B,** A microscopic diagnosis of squamous odontogenic tumor was made. Eight months later, the patient was seen because of pain at the surgical site. A radiograph showed an ill-defined lesion. A biopsy was performed, and a microscopic diagnosis of acanthomatous ameloblastoma was given. The patient was referred to the University of Nebraska Medical Center, Department of Oral and Maxillofacial Surgery. On the basis of the biopsy report and radiographic appearance, a resection without continuity defect and immediate bone graft was performed. **C,** Tissue slides of the decalcified specimen showed cords and islands of epithelial cells with a hint of palisading, admixed with fragments of resorbed bone, consistent with a pattern of well-differentiated squamous cell carcinoma. A recommendation for mandibular resection and radical neck dissection was declined by the patient. Eleven months later, the patient complained of pain in the right mandible. A panograph showed a pathologic fracture and an ill-defined radiolucency. In the following month, numbness occurred in the right mandible. Examination showed a fungating mass in the anterior mandible. Bone scan revealed probable metastases in first lumbar vertebra, manubrium, second rib, and mandible. Combined chemotherapy and radiation therapy did not alter the progress of the disease. The patient died 38 months after first being seen. (From Ruskin JD, Cohen DM, Davis LF: Primary intraosseous carcinoma: report of two cases, *J Oral Maxillofac Surg* 46:425, 1988.)

- Follow-up and periodic visits should be scheduled every 3 months for the first year, every 6 months for the next 5 years, and yearly thereafter for more than 20 years.

Intraosseous Odontogenic Carcinoma

Intraosseous odontogenic carcinoma (IOC) is a malignant epithelial squamous cell tumor (squamous cell carcinoma) derived from odontogenic epithelium within the jaws (Figures 18-22 and 18-23). This definition explicitly excludes carcinomatous intraosseous involvement (invasion) of the jaws from nonodontogenic sources. The concept and proof of IOC has evolved over this century by publication of case reports, critical reviews, and analyses of case series, and by suggestions and arguments for an improved classification first enunciated by the WHO.[12] A number of writers have contributed greatly to this effort (including Shear,[148] Gardner,[149] Eversole and co-workers,[150] and Elzay[151]). The term primary intraosseous odontogenic carcinoma (PIOC) in the WHO classification indicates IOC derived from odontogenic rests only, excluding other IOCs derived from cysts or tumors; however, in Elzay's modification of the classification[151] PIOC represents the entire gamut of IOC lesions, which are then categorized into types and subtypes. Elzay's modification of the WHO classification was intended to permit closer scrutiny and study of cases of IOC. A further useful modification was presented by Waldron and Mustoe.[152] In its strictest sense the word *primary* implies the archetypical primordial odontogenic epithelial cell; however, even odontogenic rests represent an advanced

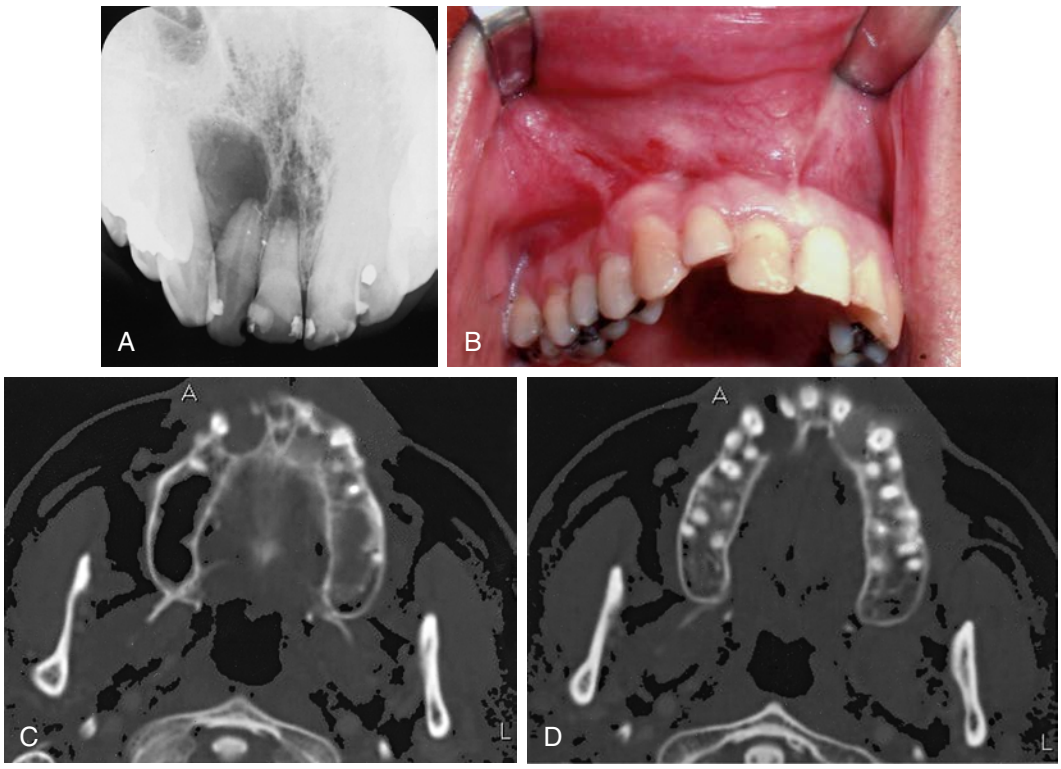

• **Figure 18-23** Intraosseous odontogenic squamous cell carcinoma with clear cells versus clear cell odontogenic carcinoma with squamatization. A 66-year-old man was seen in a practitioner's office complaining of "pain in his two upper front teeth with looseness of one for the past year." **A,** An occlusal radiograph showed a small periapical radiolucency over the carious maxillary right central incisor and a well-circumscribed significant radiolucent lesion between and above the diverging roots of the lateral incisor and canine teeth. The patient had a retrograde endodontic procedure and curettage on the central incisor and an incisional biopsy of the maxillary lesion, performed in the office (Jan. 2006). A microscopic report of "ameloblastoma with atypia" was received for the maxillary lesion, and acute and chronic inflammation for the periapical central incisor area. The patient was referred to Thomas Jefferson University, Department of Oral and Maxillofacial Surgery, for definitive treatment. **B,** Examination of the patient showed a modest, diffuse swelling with a slight central depression in the well-healed surgical site of the anterior maxilla, and a displaced right lateral incisor. The canine, lateral and central, exhibited decreased sensation on palpation. A restudy of the biopsy microscopic slides and further sectioning of the biopsy tissue block resulted in an amended diagnosis of odontogenic carcinoma. Panographic, computed tomographic, magnetic resonance, and positron emission tomography (PET) scan imaging did not reveal evidence of local or regional metastasis.**C**-**D,** The maxillary radiographs revealed labial and palatal cortical bone perforation, with a questionable overlying soft tissue component.

developmental progression. Therefore, further clarity can be achieved by elimination of the word *primary*. The senior author (L.G.) has previously expressed his opinion of the fallacies of the WHO classification as it relates to ameloblastoma in the preceding discussion of that lesion. This entire area still calls for clarification and simplification.

Reports published in the first half of this century considered IOC to be rare, but by the late 1990s the number of published reports showed that it is not rare but uncommon. In addition, extensive literature on IOC has accumulated, and critical analyses by writers have eliminated many reports for lack of convincing evidence; still a continual culling process has maintained many acceptable instances of IOC. Yet, even as more cases of IOC are presented, critical examination and proof of validity should continue to be demanded.

The sources of nonodontogenic carcinomas that invade the jaws are well known, and for obvious clinical reasons nonodontogenic carcinomas should be differentiated from intraosseous carcinoma of odontogenic origin. Nonodontogenic sources include carcinoma originating in the oral mucosa, maxillary sinus, nasal mucosa, submucosal salivary glands, intraosseous salivary gland inclusions, and metastasis from a distant primary site.

It should be noted that a surface mucosal carcinoma may arise in an unseen crypt or ulcer and directly invade underlying bone without apparent surface involvement, or a maxillary sinus carcinoma may involve the tooth-bearing segment of the maxilla before detection, and a submucosal salivary gland malignancy can invade bone without surface indication. Carcinomas from nonodontogenic sources may also be confused with odontogenic lesions (such as

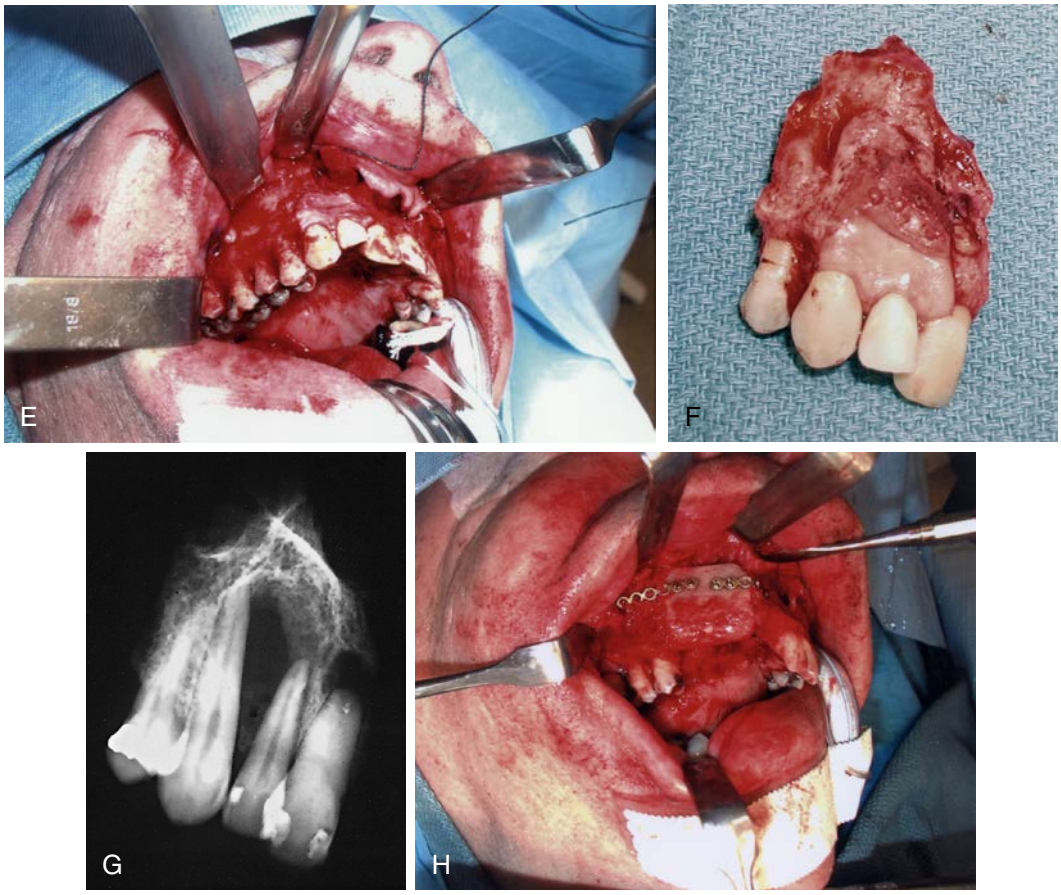

• **Figure 18-23, cont'd** **E,** A partial maxillary resection without continuity defect was performed (Mar. 2006). The resected specimen consisted of a block of the right anterior maxilla incorporating the right central incisor to the right first premolar and measured 5 cm from the teeth to the floor of the maxillary sinus, pyriform rim, and nasal spine. **F,** The specimen was 2 cm thick from anterior to posterior and included the palatal bone and periosteum. Soft tissue from all borders was taken for frozen sections, as well as peripheral bone for later sections. **G,** An intraoperative radiograph of the specimen was taken to help confirm adequate bone margins. **H,** The maxillary defect was reconstructed with an iliac crest cancellous bone block and iliac cortical bone chips overlaid with platelet-rich plasma and secured with small reconstruction bars. The soft tissue was generously undermined, permitting a tension-free closure.

Continued

histologic misinterpretation of adenoid cystic carcinoma for ameloblastoma or a maxillary sinus lesion that collides with a dentigerous cyst and thus obscures origin) or with metastatic lesions (which may simulate an odontogenic carcinoma).

After elimination of nonodontogenic sources of intraosseous carcinoma, a malignant epithelial neoplasm may be considered to have an odontogenic origin, principally originating in endosseous epithelial residue remaining after tooth development or in the epithelial lining of odontogenic cysts[153] and epithelial odontogenic neoplasms.

Intraosseous Carcinoma from Odontogenic Residue

IOC derived from endosseous epithelial "residue" by definition must include rests scattered in the medullary bone areas of the jaws, as well as those in the periodontal ligament and epithelial rests within follicular sacs. Proof of such origin may be difficult or impossible, since many lesions have a predominant squamous cell carcinoma pattern, not distinguishable from a surface mucosal source. If a lesion has odontogenic epithelial histologic characteristics in addition to a squamoid appearance, the possibility of a high-grade ameloblastoma cannot be excluded. As with all IOCs, careful clinical and radiographic documentation is necessary, especially since there is no histotypic appearance of IOC derived from epithelial rests.[40,152,153]

Intraosseous Carcinoma from Odontogenic Cysts

Numerous case reports have been published that describe origin from a variety of preexisting odontogenic cysts,[153] including dentigerous,[154-160] residual,[161,162] and keratocyst.[163,164] In addition to exclusion of carcinoma from nonodontogenic sources, photomicrographs must convincingly illustrate the histologic conversion of innocent epithelial cyst lining to a malignant epithelial lining or carcinomatous proliferation.

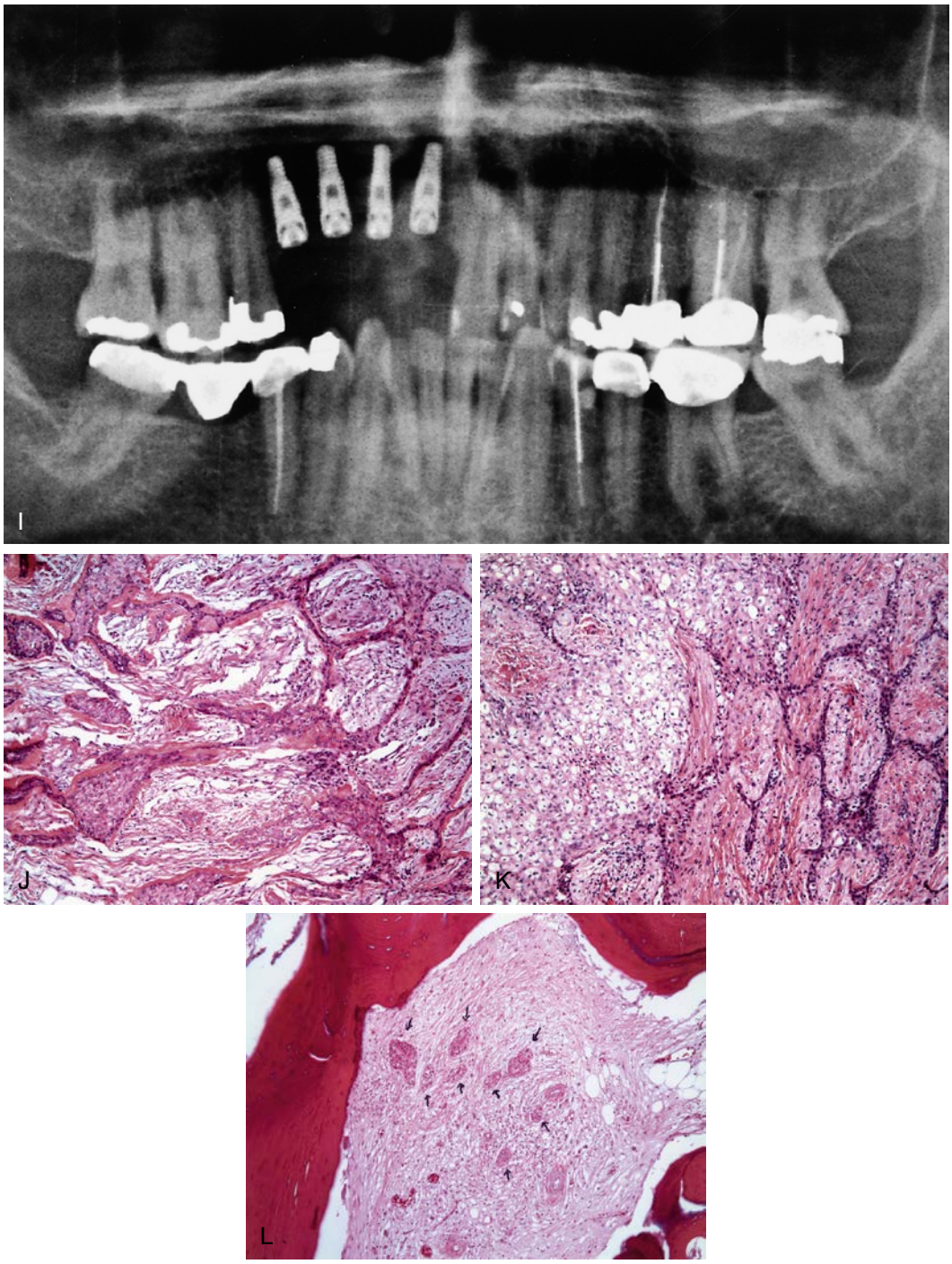

• **Figure 18-23, cont'd** **I,** Healing was uneventful, and implants were placed 6 months later. **J,** Gross sectioning of the specimen revealed a white-tan to red-brown, rounded, well-circumscribed tumor composed of numerous strands and nests of atypical squamous epithelium in a fibrous stroma and **(K)** large areas of clear cells admixed with squamous epithelial islands and strands also containing clear cells exhibiting mild atypia. The squamous epithelial strands are encased by homogeneous collagen. Scattered mitotic figures are present. **L,** Note small tumor nests in the bone separated from the main tumor mass. A cytokeratin stain (AE1/AE3) is especially positive in clear cell areas. These features support a diagnosis of intraosseous odontogenic squamous cell carcinoma with clear cells or clear cell odontogenic carcinoma with a squamatization. (Case material courtesy Robert J. Diecidue, DMD, MD, Thomas Jefferson University, Philadelphia.)

Intraosseous Carcinoma from Epithelial Odontogenic Tumors

All epithelial odontogenic tumors previously discussed in this chapter are theoretically capable of conversion to an IOC, and two should be considered IOCs from inception.

The *squamous odontogenic tumor* is a possible precursor of IOC. In one interesting, detailed report, an IOC was first histologically misinterpreted as squamous odontogenic tumor before clinical events led to a correct diagnosis.[44] Conversely, a squamous odontogenic tumor arising in a keratocyst was first incorrectly diagnosed as squamous cell carcinoma,[40] and a report of squamous cell carcinoma arising in a periodontal cyst is probably a cyst with SOT.[41]

In the discussion of *ameloblastoma*, the senior author (L.G.) expressed his opinion that ameloblastoma is a de novo low-grade malignancy, and that instances of conversion to a high-grade malignancy with metastasizing capability is not unexpected.

Since the 1980s the former clear cell odontogenic tumor, now properly termed *clear cell odontogenic carcinoma,* has demonstrated its position de novo as an IOC with metastasizing capability. The *clear cell ameloblastoma* described by Waldron and colleagues[16] combines odontogenic clear cells with ameloblastoma into a single IOC entity.

Malignant calcifying epithelial odontogenic tumors with and without a prominent clear cell presence have been documented.[61-63] Several malignant and metastasizing variants of *calcifying odontogenic cyst or tumor* have been reported under the names *odontogenic ghost cell tumor* and *ghost cell carcinoma.*[165-167]

Clinicopathologic Considerations and Outcome

The outcome of IOC is influenced by several factors—patient recalcitrance and refusal to be treated, time of discovery during the course of the lesion's development, correct (or incorrect) diagnosis, and definitiveness (or nondefinitiveness) of the initial surgical procedure appropriate for the clinical and histologic findings.

As a group, IOCs are found in older age groups, particularly in the sixth and seventh decades. Most studies show a higher occurrence in males than in females and in the mandible (particularly the posterior areas) rather than in the maxilla by a high ratio.

Signs, symptoms, and radiographic features are case specific. Patients may be seen with or without extraoral and/or intraoral swelling, or clinical evidence of metastasis. Pain is variably present. Edentulous patients may complain of inability to wear dentures because of pain or swelling. Paresthesia is an inconstant finding in mandibular lesions.

Radiographically, IOCs are radiolucent, sometimes suggestive, but not pathognomonic. They present a differing image dependent on the progression of the disease—from well-outlined radiolucencies to diffusely infiltrating lesions. IOCs that develop in odontogenic cysts may be innocuous in appearance.

Histologically, IOCs may not be suspected and may be a surprising microscopic finding after excision. All cystic lesions should be sectioned routinely to sample the entire lesion. This rule is demonstrated best by odontogenic cysts with IOCs that show "skip" areas of unaffected odontogenic epithelial lining alternating with areas of dysplastic to malignant epithelial lining, which may not be detected if insufficient sections are prepared. A report by Suei and co-workers is recommended for a discussion of diagnostic criteria.[168]

The outcomes of IOCs presented in published reports vary from apparent cure to protracted clinical course and fatal outcome, whereas some lesions are rapidly aggressive and lead to death with or without metastases. Cases demonstrate that conservative operations fail. An exception can be made for the instance of an odontogenic cyst in which only the epithelial lining shows malignant change, without involvement of the cyst wall. Early recognition and definitive oncologic procedures may result in successful management.

Mesenchymal Odontogenic Tumors

Odontogenic Fibroma

The WHO classifies *odontogenic fibroma as a benign, relatively rare connective tissue tumor that contains a variable amount of inactive odontogenic epithelium.*[11-13] The monograph's explanatory notes recognized that the parameters of the lesion were still evolving and that variants under this designation might, or might not, be acceptable in the future. Present convention finds it expedient to permit some flexibility in the histologic composition of odontogenic fibroma, especially since all agreed-upon types of the lesion pursue a benign behavioral course. The odontogenic fibroma is found intraosseously—*central odontogenic fibroma*—and extraosseously, on the gingiva—*peripheral odontogenic fibroma.*

Clinicopathologic Considerations

The infrequent occurrence of central odontogenic fibroma (Figure 18-24) is illustrated by Regezi's 1978 analysis[169] of 706 odontogenic tumors, which included 12 categories of lesions but did not record an odontogenic fibroma, and by Gorlin and co-workers' 1963 classification and extensive discussion[170] of odontogenic tumors, which also omitted the lesion. However, in 1970 Gorlin's discussion of odontogenic tumors[171] included the odontogenic fibroma and provided a succinct description of the lesion. The intraosseous lesion is not inconsequential and, despite benign behavior, may be responsible for significant tissue destruction.

Central Odontogenic Fibroma

The clinical features and analysis of a large series of central odontogenic fibroma[172-176] show a wide age range at identification from 14 to 72 years, with a mean of approximately 37 years. There appears to be a striking female occurrence and predilection for the maxilla, anterior to the first molar. Most lesions are asymptomatic and are discovered by radiograph; however, occasional clinical enlargement and root resorption produce discomfort.

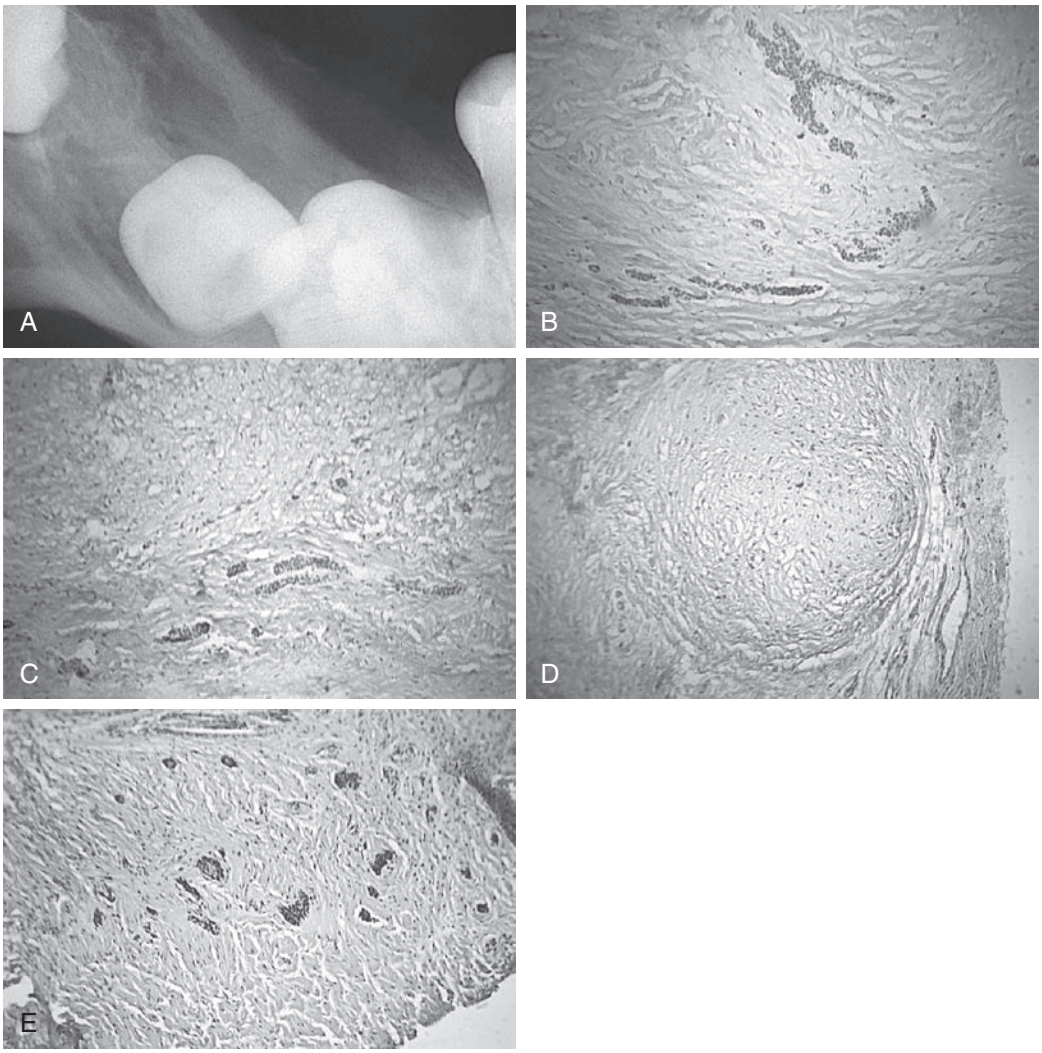

• **Figure 18-24** Central odontogenic fibroma of mandible. A 13-year-old girl was seen for a gingival enlargement and noneruption of mandibular right first and second molar teeth. **A,** Radiographs showed the two molars and the developing third molar to be displaced and enveloped by a poorly delineated soft tissue lesion. A somewhat gelatinous soft tissue mass was excised by a combination of enucleation and curettage, and the three teeth were removed. The first and second molars appeared malformed. **B**-**C,** Tissue sections revealed slightly varying morphologic characteristics of myxoid-appearing connective tissue with scattered strands of odontogenic epithelium and odontogenic epithelial rosettes, **(D)** several whorled areas of myxomatous connective tissue surrounded by denser connective tissue, and **(E)** peripherally more dense collagenous tissue containing scattered small epithelial rosettes. The lesion was not encapsulated.

Radiographically, odontogenic fibroma is generally radiolucent and multilocular, although unilocular lesions are not unusual. The lesion may have a well-defined sclerotic outline or an ill-defined nonsclerotic border that merges into surrounding bone as if infiltration is occurring. Lesions in dentate areas are frequently associated with the roots of teeth and may cause extensive root resorption or root divergence (see Figure 18-24, *A*). Several large lesions have been associated with unerupted third molars, and infrequently, radiopacities may be seen in a lesion.

The histologic composition of odontogenic fibroma varies and is perhaps a reflection of the histologic sources of the lesion. Origins in the dental papilla, follicular sac, and periodontal membrane have all been proposed and indeed may be a reasonable explanation for the different histologic patterns encountered in the lesion.

The connective tissue stroma may exhibit a whorling or interlacing dense collagen matrix and a hypocellular or fairly cellular uniform fibroblast population, or may show a somewhat loose fibrillar or myxoid background. The odontogenic epithelial component is scattered throughout the connective tissue as narrow islands, strands, or cords of cuboidal or slightly polygonal cells. Most notable is the obvious passivity of the epithelium, which lacks an ameloblastic appearance. Very occasionally an inductive-like hyalinization effect is seen in the connective tissue around some epithelial islands, and even cementum-bone-like or dentinoid-like calcification. Some lesions have a sparse odontogenic epithelial population,

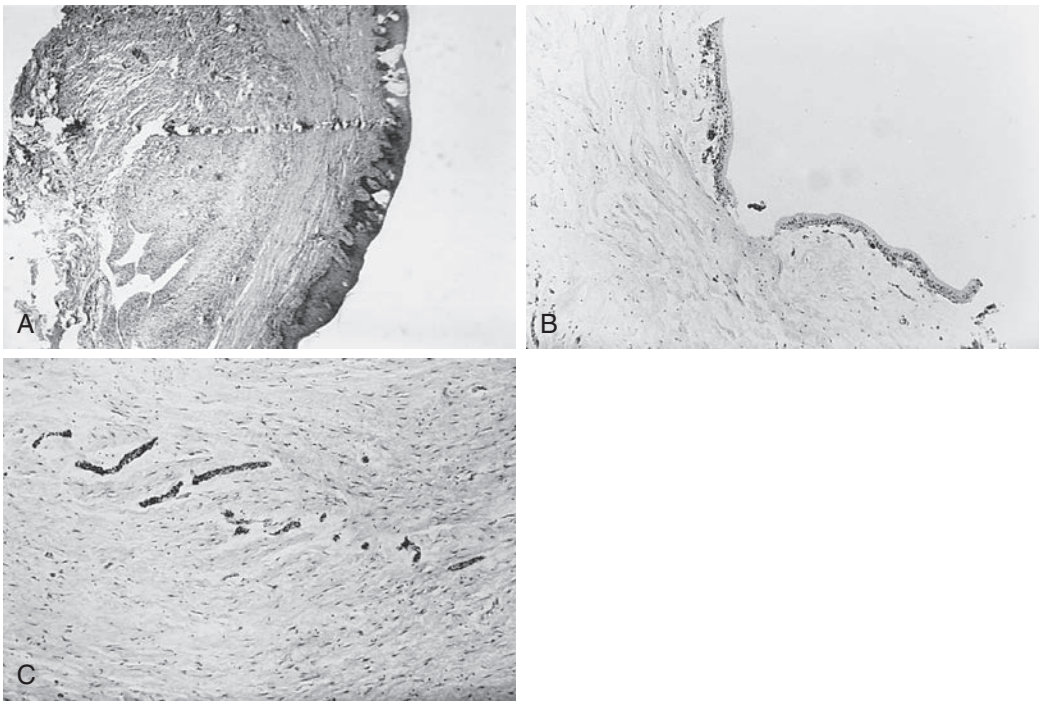

• **Figure 18-25** Follicular sac. Hyperplastic myxomatous or fibromyxomatous tissue of follicular sacs may be misinterpreted occasionally as odontogenic fibroma or myxoma. Radiographs and clinical findings should be submitted to the pathologist to prevent such an occurrence. **A,** Follicular tissue and overlying mucosa excised with a rudimentary supernumerary tooth from the anterior palate of an infant. Enlarged follicular sac removed during surgical exposure of an impacted maxillary canine. **B,** Note reduced enamel epithelium that covered the canine crown, **(C)** along with larger mass of the follicular sac containing scattered odontogenic epithelial rests.

whereas others show a profuse odontogenic epithelial proliferation, to a degree that overshadows the connective tissue. The odontogenic fibroma is not encapsulated, and the intraosseous lesion either is circumscribed or merges with the surrounding bone (see Figure 18-24, *B-E*).

Peripheral Odontogenic Fibroma

The peripheral odontogenic fibroma mirrors the central lesion in histologic appearance. However, a compilation of case reports and studies[143,169-180] shows that the extraosseous lesion is found more frequently in the mandible than in the maxilla and affects males and females almost equally. There is a wide age range of occurrence from the first to the eighth decade. Most lesions are found anterior to the second premolar and measure between 1 cm and 3 cm in diameter. The lesions are always on the attached gingiva, are pedunculated or sessile, and have a normal gingival color. Large lesions may displace teeth but do not usually involve the underlying bone. Radiographs reveal calcification in the peripheral lesion more often than in the central lesion. It is probable that the gingival lesion described as *odontogenic epithelial hamartoma*[181] is an exuberant expression of peripheral odontogenic fibroma.

Differential Diagnosis

The hallmark of the odontogenic fibroma continues to be the presence of inactive odontogenic epithelium, whether sparse or profuse, in a connective tissue stroma, which varies from dense to loose. The production of a small amount of a cementum-like or dentin-like calcification does not mitigate against this diagnosis. Two thoughtful reports by Gardner,[182,183] in 1980 and 1982, sought to resolve some of the conflicting opinions regarding the histologic composition of odontogenic fibroma. He proposed that two forms of the lesion be recognized—a *simple central* or *simple peripheral type* and a WHO *central* or WHO *peripheral type.* However, most recent writers believe that these designations are unnecessary additions to the nomenclature.

Diagnostic distinction should be made between odontogenic fibroma and other central connective tissue lesions that do not contain epithelium, such as desmoplastic fibroma and myxoma, both of which are more aggressive than odontogenic fibroma. The ameloblastic fibroma does contain odontogenic epithelium in addition to an active fibromyxoid connective tissue stroma; however, the epithelium in this odontogenic mixed tumor is an active and proliferative component that histologically simulates an ameloblastic or dental lamina appearance. The ameloblastic fibroma is also more aggressive than odontogenic fibroma. The follicular sac surrounding the crown of an unerupted tooth also contains both odontogenic epithelium and connective tissue and, if hyperplastic, may be misinterpreted as an odontogenic fibroma or myxoma, a not infrequent error (Figure 18-25).

Management

Odontogenic fibroma is a benign lesion, small or extensive, and probably has finite growth potential. However, recurrences or, in most instances, regrowth of residual lesions have been reported for both central and peripheral forms.[173,180,184] It is also possible that in very rare instances, central odontogenic fibroma may exhibit marked infiltrative behavior similar to that of fibrosarcoma.[173] Thus, each lesion must be carefully assessed histologically.

Central Odontogenic Fibroma

Excision is dependent on the clinical extent and anatomic involvement of the individual lesion. Most lesions can be managed by a combination of enucleation and curettage. Rarely is a resection procedure required. If the tumor incorporates the mandibular neurovascular bundle, an attempt should be made to preserve it. Teeth in the lesional area should be removed.

Peripheral Odontogenic Fibroma

The lesion should be excised to the interface with bone and a modest perimeter of uninvolved tissue. Teeth that are obviously incorporated in the tumor should be removed.

Cementoblastoma

Cementoma is the time-honored designation for connective tissue lesions of the jaws that produce cementum-like or osteocementum-like calcifications. It has long been recognized that the term *cementoma* encompasses several pathologic entities that overlap and bear histologic similarities to each other but should be separated on clinicopathologic bases.[171,185] As often occurs, lesions that have similarities and are extensively studied and recorded over time generate a confusing array of terms until some acceptable consensus is achieved to bring order to seemingly disparate pathologic processes (e.g., cementoma, periapical cemental dysplasia, florid osseous dysplasia, multiple cemento-ossifying fibroma, gigantiform cementoma, cementifying fibroma, and chronic sclerosing osteomyelitis). Presently it is accepted by most oral and maxillofacial pathologists that such lesions fall within the classification of fibro-osseous diseases, which may be subclassified into three subsets—craniofacial fibrous dysplasia, ossifying fibroma, and cemento-osseous dysplasia.[186,187] The lesion called cementifying fibroma, and formerly classified as an odontogenic tumor, is now considered a member of this group and is considered to be an expression of the benign neoplastic ossifying fibroma. It has been seen that calcifications histologically similar to cementum or osteocementum are found also in fibro-osseous lesions of the paranasal sinus area and craniofacial bones and, therefore, may originate from the endosteal connective tissue of medullary bone as well as connective tissue of the odontogenic apparatus. The fibro-osseous lesions of ossifying fibroma and cemento-osseous dysplasia are not considered here. The cementum-forming odontogenic tumor is considered.

The cementoblastoma (also called true cementoma) is an uncommon, perhaps rare, odontogenic tumor of connective tissue forming cementum-like calcification, fused to a tooth root.

Clinicopathologic Considerations

The cementoblastoma occurs with almost equal frequency in the mandible or maxilla, and always in the premolar or molar region. Most cases are found within the second decade, and without a gender predilection. The lesion tends to grow slowly by expansion and eventually produces a clinical enlargement that sometimes resorbs the lateral and medial cortical bone. Discomfort or pain is a not-uncommon clinical symptom. Palpation of the tooth involved in the lesion, or palpation of the hard lesion underlying the mucosa, is painful. Paresthesia is not present, and the affected tooth is frequently vital.[188,189] Lesions range in size from 0.5 cm to 5.5 cm in diameter and may involve the maxillary sinus and orbital floor.[190]

Radiographically, the cementoblastoma presents a well-defined round or oval calcified mass attached to the root of a tooth, which may show obvious resorption. The central area of the lesion may be uniformly dense or slightly mottled, and the more peripheral calcified regions may exhibit a radial distribution. The border of the lesion is usually radiolucent and sharply demarcates the lesion from the surrounding medullary bone[189,191]

Histologically, a dense cemental or osteocemental mass, with numerous reversal lines, forms a calcified mosaic pattern and occupies the central areas of the lesion. Entrapped cells are sparsely scattered within the cementum. At the edges of the dense calcified masses, an active vascular fibroblastic connective tissue stroma, with little collagen and dilated thin-walled vessels, forms large hyperchromatic cementoblasts that line the cementoid (osteoid) seams of the calcifying trabeculae; multinucleated giant cells lie in trabecular lacunae and appear to be simultaneously remodeling the trabeculae. The outermost peripheral trabeculae are not well mineralized and adjoin a narrow border of fibrous connective tissue that separates the lesion from the adjacent medullary bone. The lesional areas that fuse directly with the resorbing dentin of the root replace the periodontal ligament at the junction and may even invade the pulpal tissue[188,189,191-193]

The cementoblastoma parallels the histologic characteristics of the *osteoblastoma* and may represent the cemental analogue of that endosteal bone tumor.[194] Both lesions share an active vascular calcifying tissue and are differentiated by the radiographic and cemental appearance of the former and the obvious bone trabeculae of the latter. Differentiation between osteoblastoma and *osteoid osteoma* is based on the latter's more cortical position, small size, and histologic and radiographic features of a small central soft tissue nidus surrounded by sclerotic bone.

Management

The number of reports in the literature that strictly define the cementoblastoma according to age, site, clinical symptoms,

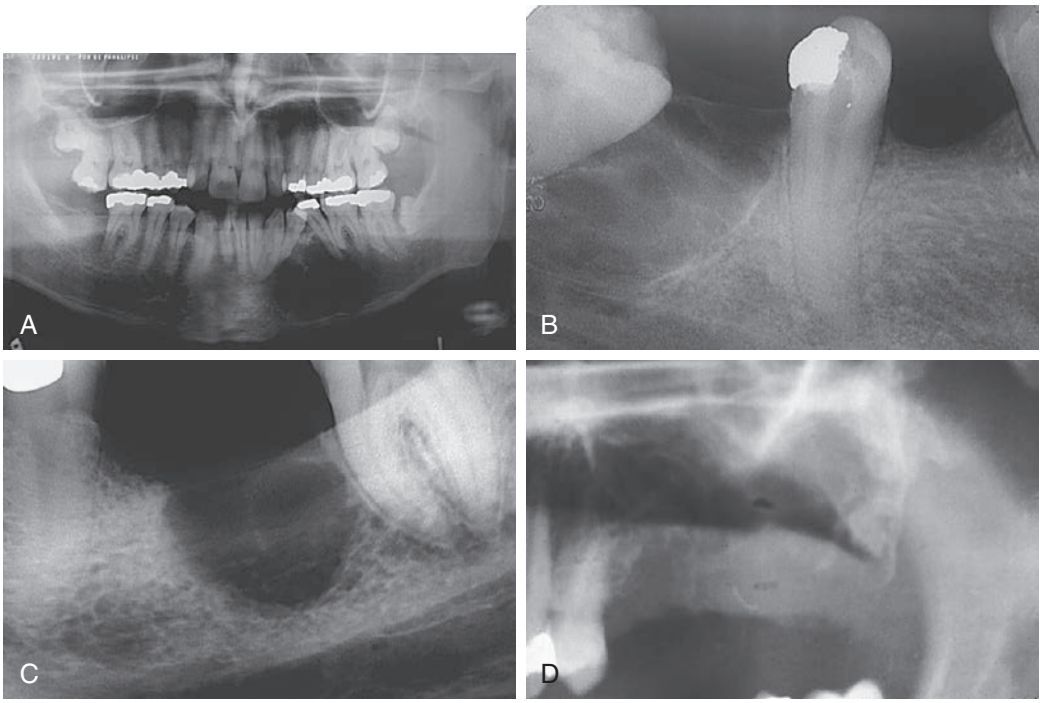

• **Figure 18-26** Odontogenic myxoma. **A-C,** Several radiographic patterns seen in odontogenic myxoma of the mandible and **(D)** maxilla with sinus involvement.

radiographic identification, and histologic appearance testify to its apparent slow growth and benign nature. The size of the lesion varies but is usually between 1 cm and 3 cm in diameter and is almost always separated from surrounding bone by a surgically discernible capsule-like connective tissue, permitting enucleation after exposure of the lesion. Larger lesions can be cut into segments for enucleation; however, the tooth attached to the lesion is firmly fused and in almost all instances must be or should be removed with the lesion. In one interesting report, including a 4-year follow-up period,[195a] endodontics with preservation of the tooth and excision of the lesion was successfully performed. Complete enucleation of the lesion and curettage of surrounding bone constitute sufficient treatment, and recurrence is not expected. However, a recent paper by Brannon et al[195b] reviewed a large series of cementoblastomas and the literature with emphasis on recurrence. In 35 cases for which they had follow-up data, 13 (37.1%) had recurrence. Their study showed that recurrence (regrowth of residual lesion) is a consequence of incomplete removal.

Because of the presence of areas of active osteoid (i.e., cementoid) formation by large hyperchromatic and pleomorphic cells, histologic misinterpretation of or doubt about the benign nature of the lesion is possible if all clinical and radiographic data are not appreciated. The occasional "sunburst" radiographic appearance of the lesion in an axial projection produced by the radial calcifying trabeculae may hide the defining sharp border.[189] This should not be mistaken as radiographic evidence of osteosarcoma and, conversely, should not be ignored by the surgeon if further study is warranted.

Odontogenic Myxoma

The *myxoma (odontogenic myxoma, myxofibroma) of the jaws is a benign, usually slow-growing, infiltrative tumor of connective tissue* (Figures 18-26 to 18-28). It is presumptively odontogenic in origin because almost all cases have been found in the jaws, and its histologic appearance most closely simulates that of the mesenchymal tissue of the follicular sac or dental papilla. Most authors believe the lesion is exclusively found in tooth-bearing areas of the jaws.[196] However, a few cases have been seen in nontooth areas of the jaws.[197] A report of three cases of extragnathic fibromyxomas, only one of which had accompanying photomicrographs, was not convincing.[198] Extensive literature (well over 200 reported cases) indicates that the lesion is neither common nor rare.[199]

Clinicopathologic Considerations

The lesion occurs in both the maxilla and the mandible, with a slight preponderance in the mandible. Myxoma tends to be unilateral, but lesions may extend past the midline (mandibular lesions more frequently than maxillary lesions). There is a slightly more frequent occurrence in females than in males and a very wide age range, from 11 months[200] to the seventh decade. However, most lesions are clinically detected within the second to sixth decade. The occurrence in children may be higher than previously believed.[201]

Radiographically, most lesions are multilocular, whether small or extensive; however, unilocular lesions have been reported. Some myxomas radiographically resemble dentigerous cysts if an unerupted tooth has been "trapped" within the

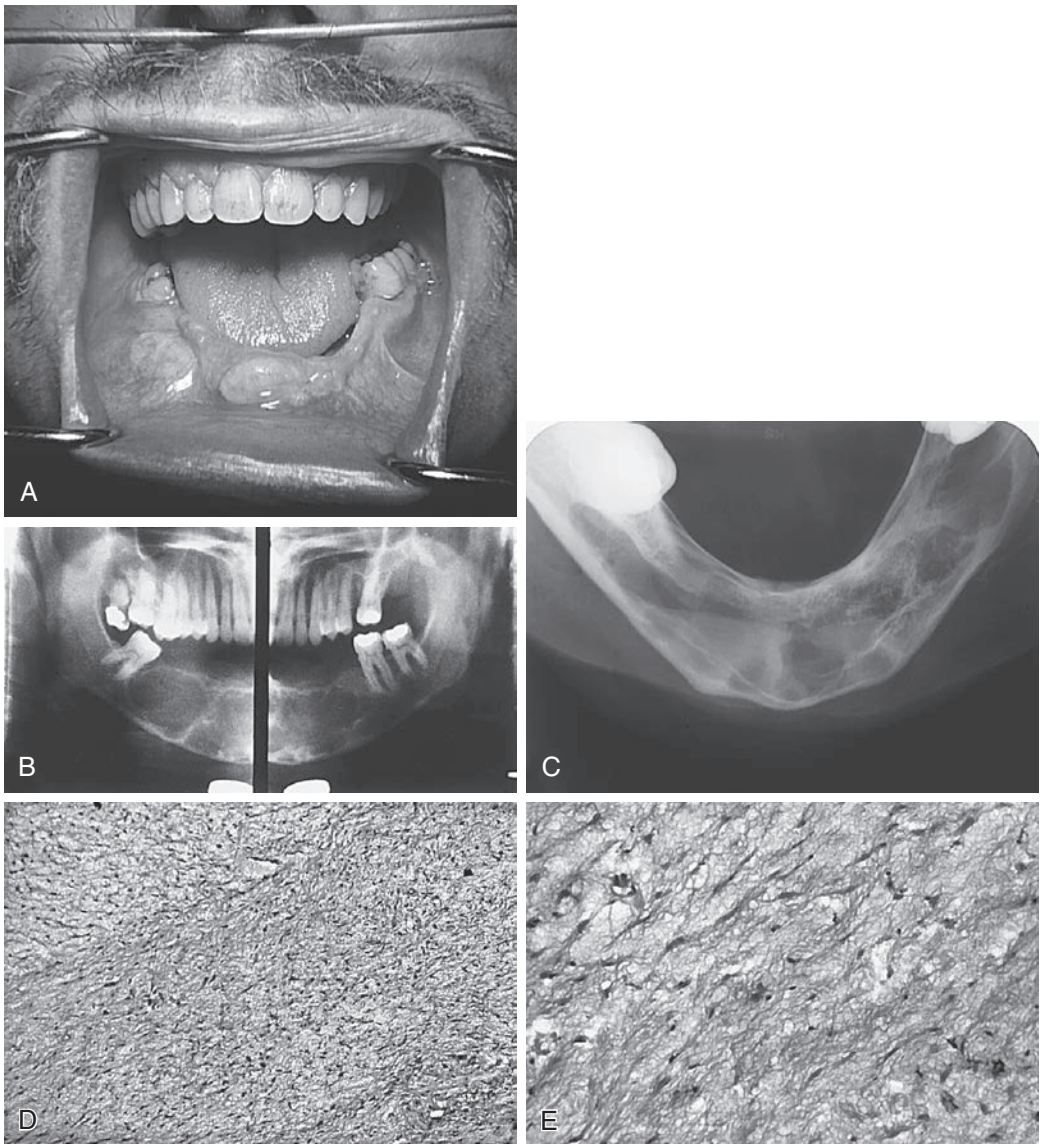

• **Figure 18-27** Odontogenic myxoma of mandible. **A-C,** A 44-year-old man was referred for treatment of an extensive multilocular mandibular lesion. **D-E,** The lesion had been excised 6 years earlier with a histologic diagnosis of odontogenic myxoma and was now recurrent and greatly increased in size. A repeat biopsy confirmed the diagnosis.

lesion. The myxoma may displace teeth or rarely resorb tooth roots if the lesion involves dentate areas.[202] The lesion may be entirely radiolucent or have a "soap bubble," "honeycomb," or striated appearance described as similar to that of the strings of a tennis racket. The radiographic image is not pathognomonic and may simulate a number of diverse lesions such as ameloblastoma and hemangioma, as well as others. *The radiograph may indicate a lesion-bone boundary more circumscribed than is actually present* (see Figure 18-26, *A-D*).

Histologically, myxoma is characterized by stellate, angular, or rounded mesenchymal (fibroblast-like) cells with long protoplasmic processes in a mucoid stroma, staining heavily basophilic with hematoxylin and eosin. Fibrillar strands of reticulin and occasional well-formed collagen fibers permeate the mucopolysaccharide ground substance, which histochemically consists of hyaluronic acid and chondroitin sulfate. Some myxomas produce sufficient stromal collagen to justify a histologic designation of myxofibroma. Rarely, odontogenic epithelial rests may be encountered in the lesion. Mitosis is not a feature of myxoma. Although some radiographs of the lesion may give the appearance of circumscription or well-defined margins, few lesions demonstrate histologic evidence of encapsulation,[203] and most should be regarded as not encapsulated. Small loculi of tumor infiltrate the marrow and resorb medullary bone in a three-dimensional manner in advance of the main lesional mass. Bone resorption takes place in the absence of osteoclasts, and the tumor directly abuts the bone. Large or small lesions can resorb cortical bone and penetrate periosteum (see Figure 18-28, *O*). Thus, the lesion may be directly contiguous with overlying gingiva or alveolar mucosa. There often appears to be a surgical plane between myxoma and

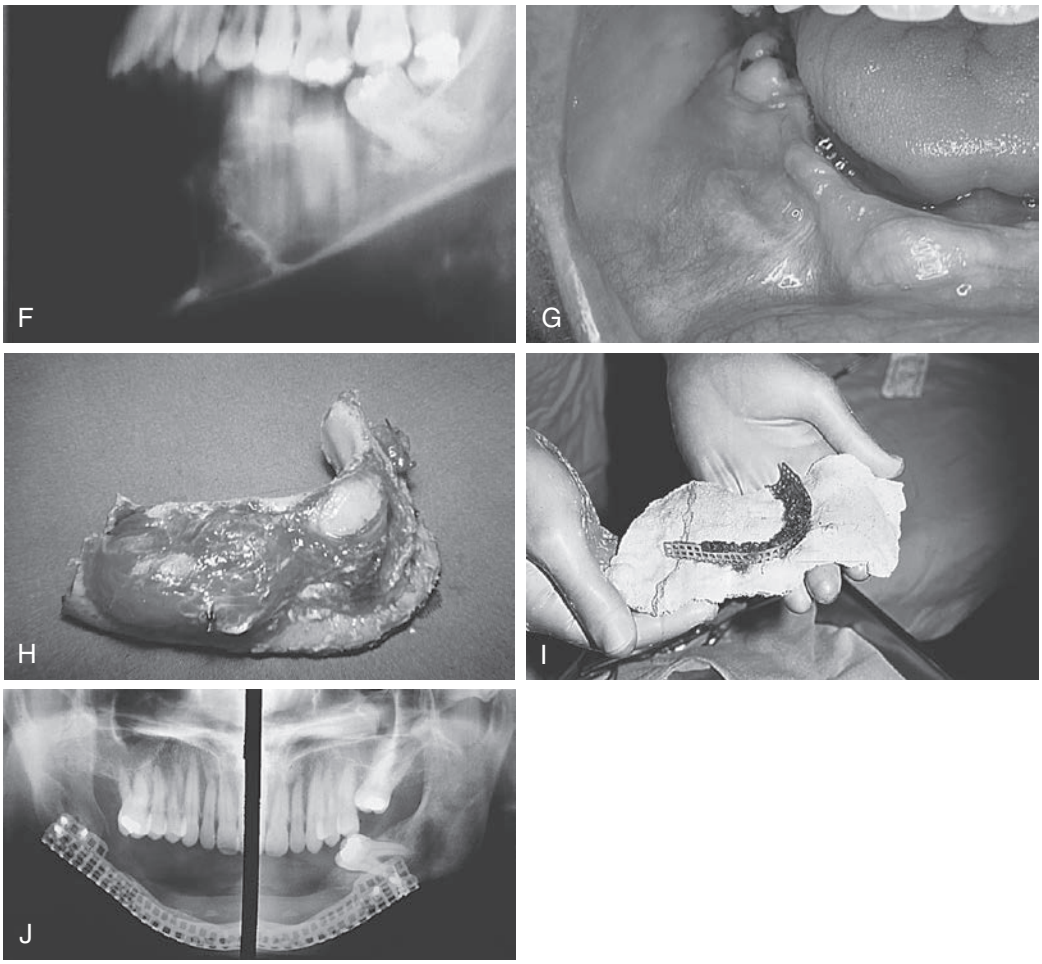

• **Figure 18-27, cont'd** **F,** A tomogram demonstrated buccal and labial cortical bone resorption. **G,** The tumor was palpable immediately beneath the gingival and vestibular mucosa; note indentation of tumor mass by maxillary teeth. **H,** A transoral resection with continuity defect from right to left third molar areas and immediate reconstruction with iliac crest bone graft was performed. The inferior alveolar nerve was sacrificed, with preservation of almost all gingival and alveolar mucosa. Within 4 days a *Pseudomonas* species infection occurred, causing loss of graft. Aggressive antibiotic and local treatment resulted in complete healing of the tumor bed and soft tissues. Mandibular spatial position was maintained by a Hall Morris appliance. **I,** Six months later, continuity was successfully established by an extraoral approach using a titanium crib filled with autogenous iliac cortical bone chips and cancellous marrow. **J,** Panograph 3 years after surgery.

adjacent soft tissue, unless inflammation and/or ulceration in the area promotes intermixing of lesion and soft tissue at the juncture (see Figures 18-27 and 18-28).

Clinically, myxoma increases in size slowly and is asymptomatic and may not be diagnosed until an extensive lesion produces swelling or the lesion is discovered in radiographs. Tooth movement is not common and does not cause patient complaint.[204] In dentate areas the lesion may extend into interradicular areas, and in edentulous areas the lesion may expand toward the occlusal surface and interfere with occlusion. Maxillary myxomas may infiltrate into and occupy the maxillary sinus and cause nasal obstruction and even exophthalmos.[199]

Differential Diagnosis

There are no means to distinguish myxoma radiographically from a host of odontogenic or nonodontogenic lesions. However, histologically, few lesions may be misinterpreted as myxoma. Those odontogenic lesions that contain a marked epithelial presence such as ameloblastoma or ameloblastic fibroma offer no challenge, and odontogenic fibroma usually contains sufficient epithelium to be readily differentiated. It is possible for myxofibroma to be so heavily collagenized or for desmoplastic fibroma or neurofibroma[205] to contain enough myxomatous areas to create diagnostic doubt, but this is highly unusual. The absence of marked mitotic activity mitigates against a sarcomatous lesion, such as malignant fibrous histiocytoma, but does not exclude the possibility. More commonly, a hyperplastic follicular sac or a pulpal "bulb" separated from the developing root of an unerupted tooth is misinterpreted as myxoma (see Figure 18-25). Soft tissue mucinosis or myxomas of oral soft tissue are not discussed here and bear no relation to central

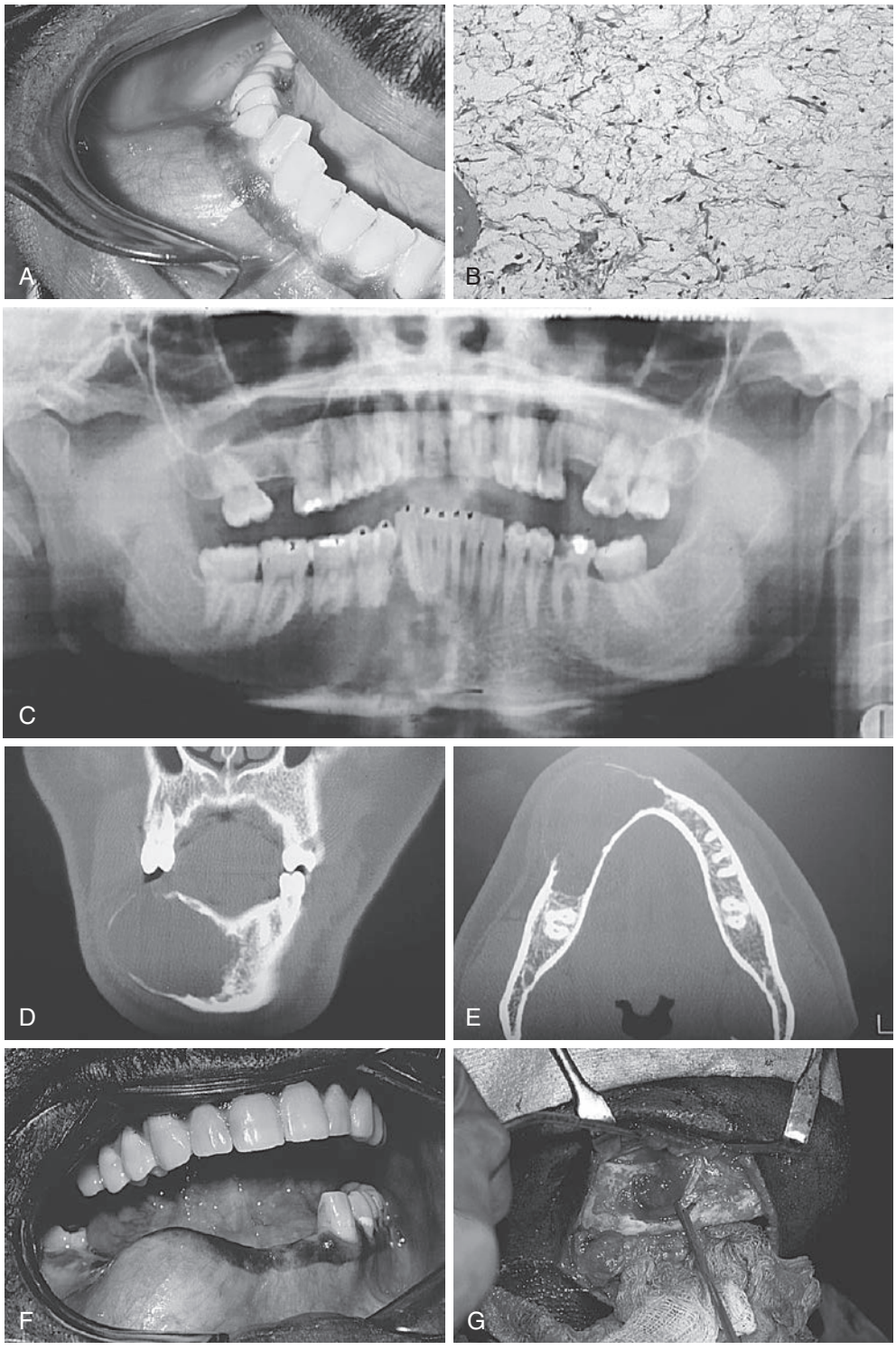

• **Figure 18-28** Odontogenic myxoma of mandible. **A,** A 36-year-old man requested treatment for his mandibular tumor, biopsied and histologically diagnosed as odontogenic myxoma 2 years previously at another institution. Resection and bone graft reconstruction had been recommended; however, the patient, fearful of the procedure, refused. Increase in the size of the lesion prompted the patient to seek treatment. **B,** The previous tissue slides were requested, and the diagnosis was confirmed. **C**-**E,** Imaging revealed the tumor extent. Teeth proximal and distal to the lesion as well as within the lesional area were extracted to permit soft tissue healing for attempted retention of mucosal tissue. **F,** Further oral expansion of the lesion occurred during the 3½-month healing period. An extraoral approach with continuity resection and immediate bone graft was planned, as well as preservation of the inferior alveolar neurovascular bundle and mental nerve (if possible). Maxillary and mandibular fracture bars were placed. The lesion was approached from the inferior border of the mandible (the inferior border was seen to be involved by tumor). The mental nerve was seen coursing superiorly over the tumor mass and was dissected free and preserved, with sacrifice of the anterior incisive extension. **G,** The lesion was displaced superiorly and the mandibular canal was decorticated, unroofing the inferior alveolar neurovascular bundle to a point well proximal to the angle extent of the lesion; the neurovascular bundle was lifted free and protected. A reconstruction bar (plate) was sized and bent to conform to the inferior border of the symphysis and right body, and to extend past the proximal (angle area) and distal (left body) resection margins.

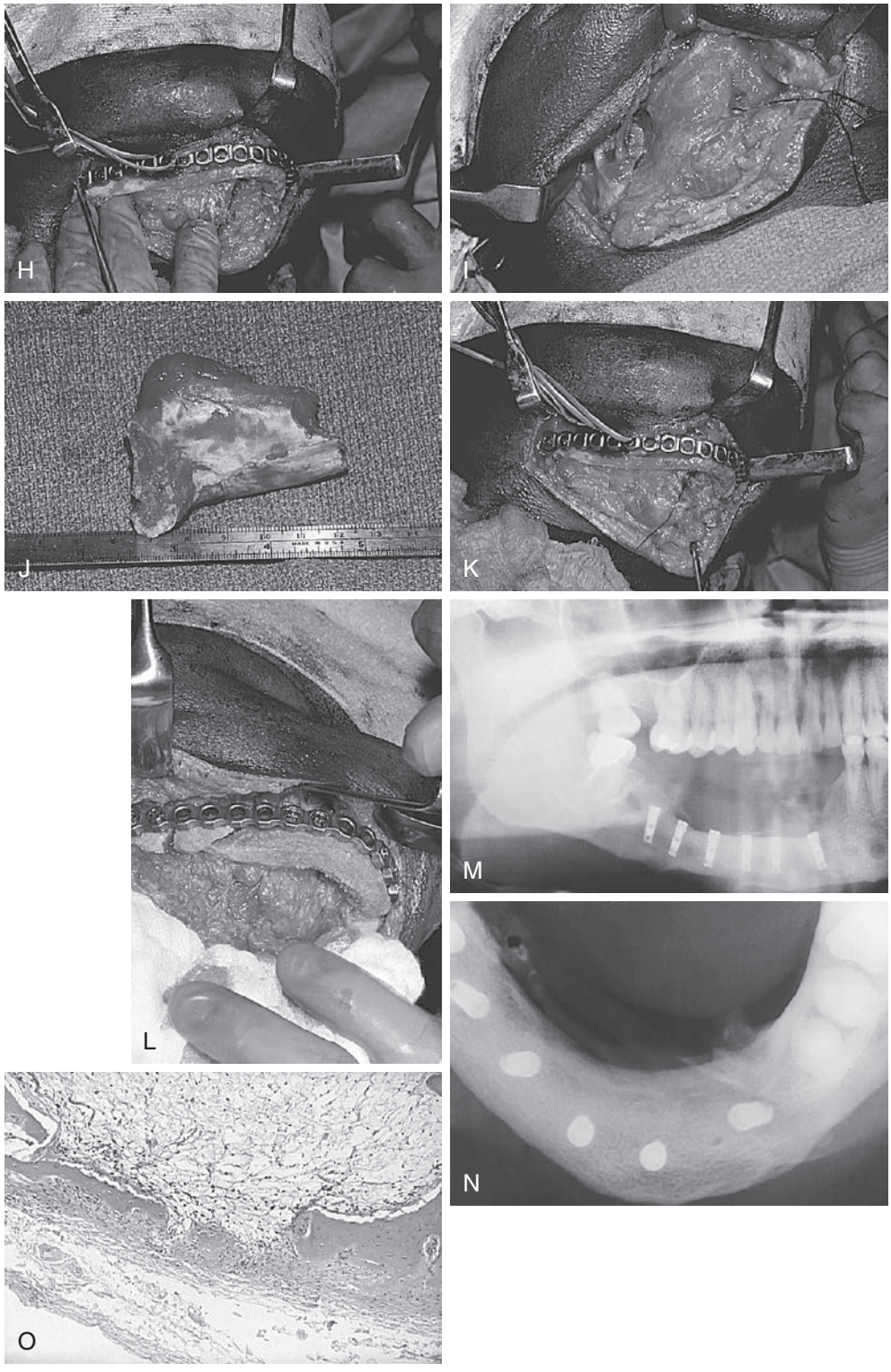

• **Figure 18-28, cont'd** **H,** The plate was fixed to the mandible by screws past the intended resection margins, and then unscrewed and set aside (the screw holes marked the sites of reattachment of the plate to preserve the spatial contour of the mandible). Superior dissection over the tumor mass was attempted to free the tumor from the overlying gingiva without perforation into the oral cavity; however, this proved impossible from the inferior approach, and a gingival laceration occurred. The oral cavity was entered and an extended incision was made through the gingival crest mucosa, permitting visual dissection of the lesion, freeing mucosa and isolating the tumor. **I,** The continuity resection was completed, and **(J)** the specimen was removed (viewed from lingual surface). The laceration was repaired, and the oral incision was sutured in a "watertight" fashion. Intermaxillary fixation wires were placed. **K,** The reconstruction plate was reattached with additional screws, and the detached extrinsic tongue muscles were sutured to the plate. The wound was closed in layers and a drain placed. **L,** Ten months later a full-thickness iliac crest graft was taken, sculpted, and placed through an extraoral approach. The graft consolidated in 9 months. The reconstruction plate was removed transorally, and six titanium implants were placed for a prosthesis. **M-N,** Two-year postoperative panograph reveals good bone repair and bulk. **O,** Photomicrograph of specimen: tumor interface with mandibular inferior border. Note resorption of mandibular inferior border cortex.

myxoma. Grossly, the myxoma is readily identified by its gelatinous texture and shiny appearance.

Management

Despite the voluminous literature on myxoma, accurate reports of long-term follow-up evaluation or statistical analysis of the efficacy of various treatment modalities are not available. It is generally known that recurrences (i.e., regrowth), early or late, are seen more often in lesions treated by curettage and/or enucleation than in lesions surgically resected. The key to successful treatment, and avoidance of recurrence, is appreciation of the infiltrative behavior of the myxoma. Although benign, the lesion does not exhibit limited growth potential; enlargement in all dimensions continues. The following management protocol, which is employed by the writers, is offered:

- Biopsy performed in a central area of the lesion and at the radiographic lesion-host bone interface histologically identifies the lesion, establishes the physical characteristics of the tumor (i.e., whether one is dealing with a loose gelatinous, mucoid mass or a lesion with more firm consistency), and determines the presence of a circumscribing border and, most importantly, the infiltrative characteristics at the lesion-bone interface. Entry to the lesion should be through a noninflamed, nonulcerated crestal area to prevent "contamination" of mucosal tissue subsequently required for closure in the definitive procedure.
- Attempts to excise by enucleation and curettage should be restricted to unilocular lesions of no more than 1 cm to 2 cm in diameter, accompanied by vigorous and purposeful curettage of the surrounding bone bed. Rapid histologic sections help determine, but do not necessarily prove, that the entire lesion has been removed. Hypothetically, lesions that contain more collagen than those that are predominantly mucoid have a greater probability of successful enucleation and curettage. Chemical cauterization (e.g., Carnoy solution) of the tumor bed may be of value. Teeth and alveolar processes at the edge or within the radiographic and clinical limits of the lesion should be removed. Grinding of the tumor bed by burrs does not permit histologic examination of the lesion-bone interface. Histologic evidence of tumor at the interface should initiate plans for reoperation within a 3- to 4-month period with excision of bone perimeters for further histologic analysis.
- Extensive lesions should be excised by Rs-CD or Rc-CD, including a perimeter margin of tumor-free bone. An unproven recommendation of a 1-cm margin is suggested but should be confirmed by histologic analysis of the specimen. The decision to perform an Rs-CD or Rc-CD is dependent on the anatomic extent of the lesion. If Rs-CD is likely to result in incomplete excision or pathologic fracture, Rc-CD should be performed.
- The neurovascular bundle of the mandible should not be sacrificed routinely, even in lesions that require Rc-CD. The mandibular canal may be intact, or relatively intact, providing protection for the inferior alveolar nerve. The canal can be unroofed and the neurovascular bundle exposed and examined throughout the length of the lesion. If the bundle is obviously permeated or hopelessly involved by tumor, it should be included in the resection. In the instance of a more collagenized (myxofibromatous) lesion, the bundle may be displaced rather than incorporated and, if separable from the tumor, can be preserved.
- The decision for immediate or delayed reconstruction is dependent on the clinical and/or histologic certainty of complete excision of the tumor and the tissue requirements for reconstruction (as outlined in management of ameloblastoma).

Mixed (Epithelial/Mesenchymal) Odontogenic Tumors

The group of lesions known as mixed odontogenic tumors display a wide range of inductive interactions between odontogenic epithelium and odontogenic ectomesenchyme. The lesions produced demonstrate a spectrum that includes anomalies, hamartomas, and benign and malignant neoplasms.

The interrelationships among the members of this group have been a subject of continuing debate and commentary in the literature.[206-211] There is still difference of opinion regarding whether some lesions are hamartomas or neoplasms, whether some should be considered extensions of an existing lesion or separate entities, and whether there is a developmental continuum expressed by members of the group.

It is readily appreciated that a calcified anomaly *(odontoma)* must begin as a soft tissue lesion, but it is not known whether an observed soft tissue lesion *(ameloblastic fibroma)* will progress through developmental stages *(ameloblastoma fibro-odontoma)* and mature to a harmless calcified state or whether both ameloblastic fibroma and ameloblastic fibro-odontoma will continue to expand as a hamartoma or neoplasm.

It is probable that all the possibilities may occur; however, there are no histologic means to predict the biologic behavior of a specific lesion. From the surgical perspective, although most mixed odontogenic lesions exhibit benign behavior and should be treated conservatively, management is based on the clinical circumstance of the specific lesion at the time of discovery. For the most part, and for the purposes of this discussion, the lesions are presented as traditionally defined without further regard to their probable interrelationships. However, in the discussion of *odontoameloblastoma* and *ameloblastic fibrodentinoma* some special notice is taken of the delineation of these lesions.

Odontoma

The odontoma is radiographically and histologically recognizable in two forms—*compound odontoma* and *complex*

odontoma (Figure 18-29). Both are the end products of the anomalous completion or incompletion of tooth formation by odontogenic epithelium and odontogenic ectomesenchyme. The compound odontoma usually consists of formed calcified toothlike structures or miniature teeth, and the complex odontoma is a disorderly and haphazard arrangement of calcified dental structures.

Clinicopathologic Considerations

The odontoma is considered to be the most common odontogenic lesion and occurs in both jaws, with a slight prevalence difference between the complex (more common in the mandible) and the compound (more common in the maxilla).[171] Most compound odontomas are seen in the anterior jaw, whereas complex odontomas are seen most often in the posterior jaw, particularly in the third molar region.[169] There is an insignificant gender difference.

Although the age range is between the first and seventh decades, most odontomas are discovered in the first and second decades. The lesions remain asymptomatic and are clinically revealed by routine radiographs or by radiographs taken because of the persistence of a deciduous tooth, noneruption of a permanent tooth, or, in some instances, alveolar bone or jaw enlargement.

Radiographically, mature lesions are readily distinguished. A compound odontoma is seen as a packet of malformed or dwarfed teeth or toothlike forms surrounded by a narrow radiolucent zone, sometimes overlying or alongside an unerupted tooth or between the roots of a deciduous tooth, preventing eruption of the underlying permanent tooth. The complex odontoma may be a small, large, or smooth ovoid, densely radiopaque mass, frequently overlying a displaced unerupted tooth, often surrounded by a thin radiolucent zone.

The forming odontoma radiographically reflects the stage of development at the time of discovery. Thus, complete radiolucency is possible when the lesion is initiated, extending to the later appearance of calcified structures as the odontoma "matures." Occasionally, large well-circumscribed cystlike lesions show a mixed radiolucent/radiopaque image, with irregularly shaped calcified complex odontomatous masses surrounded by radiolucent areas.

Grossly and histologically, the compound odontoma is usually found within a connective tissue capsule. The lesion is composed of anatomically distinct, small, well-formed or distorted teeth with enamel, dentin, pulp, and cementum. The complex odontoma lacks anatomic organization and consists of calcified dental tissue in bizarre combinations, often bound together in a mass of cementum, also frequently surrounded by a thin connective tissue capsule. Histologic differentiation between the two types is not always possible since combinations occur (see Figure 18-29). Occasionally, the lumen of a calcifying odontogenic cyst contains complex odontomatous masses[212,213] (Figure 18-30).

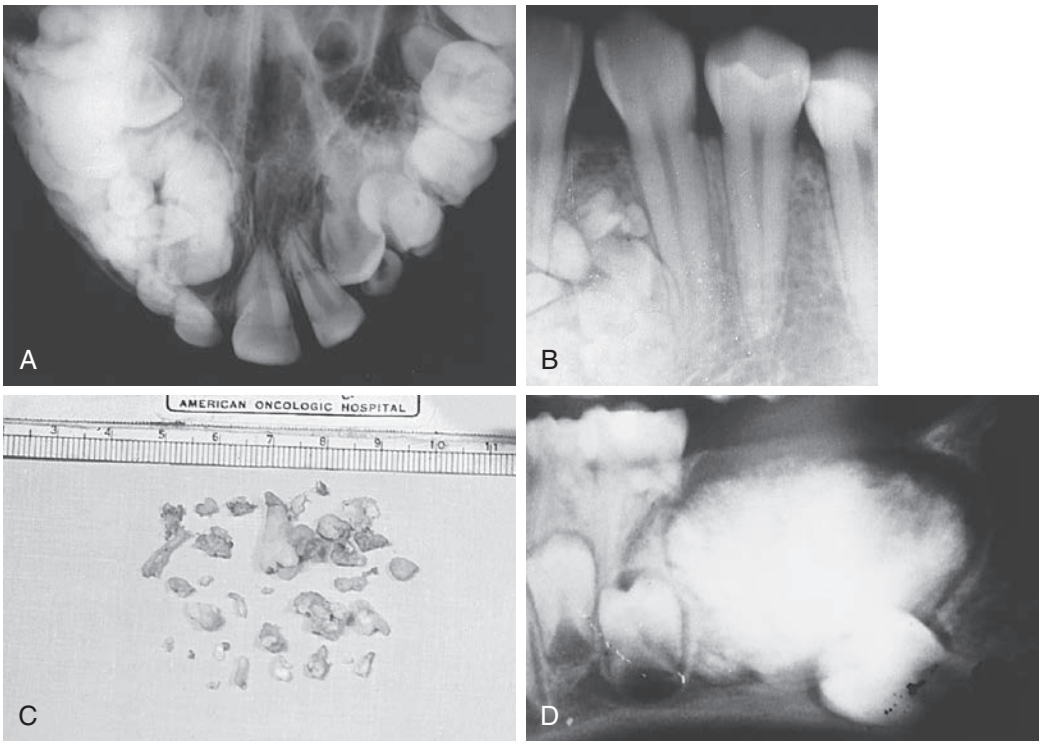

• **Figure 18-29** Compound and complex odontoma. **A-B,** Radiographs of compound odontoma demonstrate readily identified malformed and miniature teeth. **C,** Individual dwarfed teeth and toothlike forms from a specimen of a maxillary compound odontoma. **D,** Radiograph of complex odontoma shows densely radiopaque calcified mass.

Continued

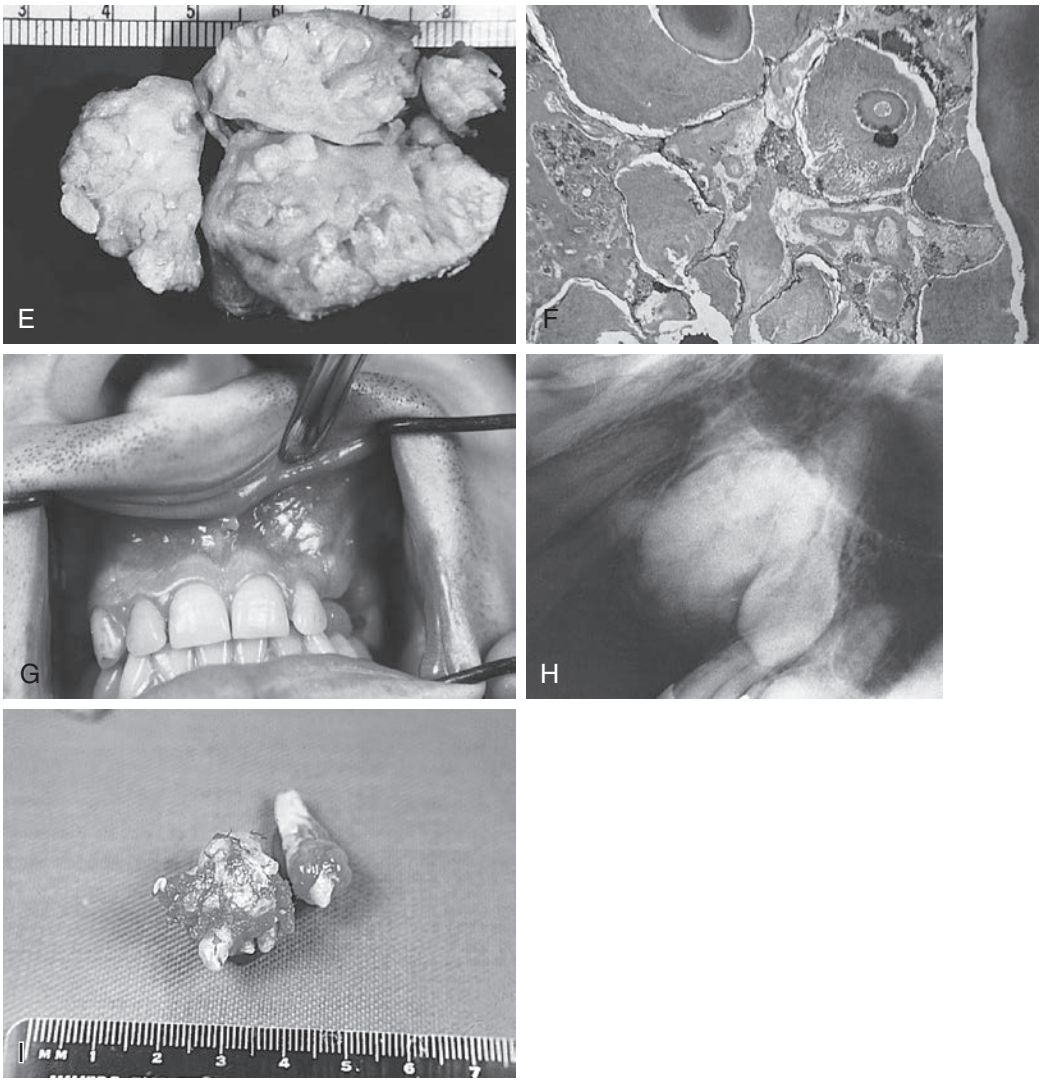

• **Figure 18-29, cont'd** **E,** Specimen photograph of a large complex odontoma reveals toothlike forms embedded in a mass of dentin and cementum. **F,** Photomicrograph of a still "maturing" complex odontoma. **G-I,** Clinical appearance and radiographic and gross specimens of a complex-compound odontoma enucleated from the anterior maxilla of an 18-year-old man.

Management

- The completely calcified complex or compound odontoma is biologically inert and need not be removed if the clinical diagnosis is secure and no useful purpose would be served by removal. However, there are several reasons for excision of a lesion: (1) because of patient concern about the diagnosis, once informed of the lesion's presence; (2) to permit the possible eruption of a tooth blocked by an odontoma, in a clinically favorable position; and (3) to establish a diagnosis between a complex odontoma and other radiographically opaque lesions such as cementoblastoma, or large lesions containing a mixture of radiolucent and radiopaque areas that might represent ossifying fibroma or an odontogenic neoplasm (e.g., CEOT, odontoameloblastoma).
- Both compound and complex odontomas are approached through intraoral mucosal incisions and adequate removal of overlying bone to expose the lesion. Compound odontomas are enucleated if the capsule is intact, or the individual tooth forms are carefully removed if the capsule is disrupted. Small complex odontomas are enucleated in the same manner. However, large or huge complex odontomas should be cut into segments for removal, in order to conserve normal bone and to prevent jaw fracture that can result if excessive elevative force is applied in areas of the lesion that lack encapsulation and may be fused to surrounding bone. The odontoma is not a recurrent lesion if calcified and completely excised; however, unnoticed remaining formative odontogenic soft tissue may continue to produce odontomatous calcified tissue.

Odontoameloblastoma

The *odontoameloblastoma* (formerly called *ameloblastic odontoma*) is defined by the WHO[11] as "a very rare neoplasm,

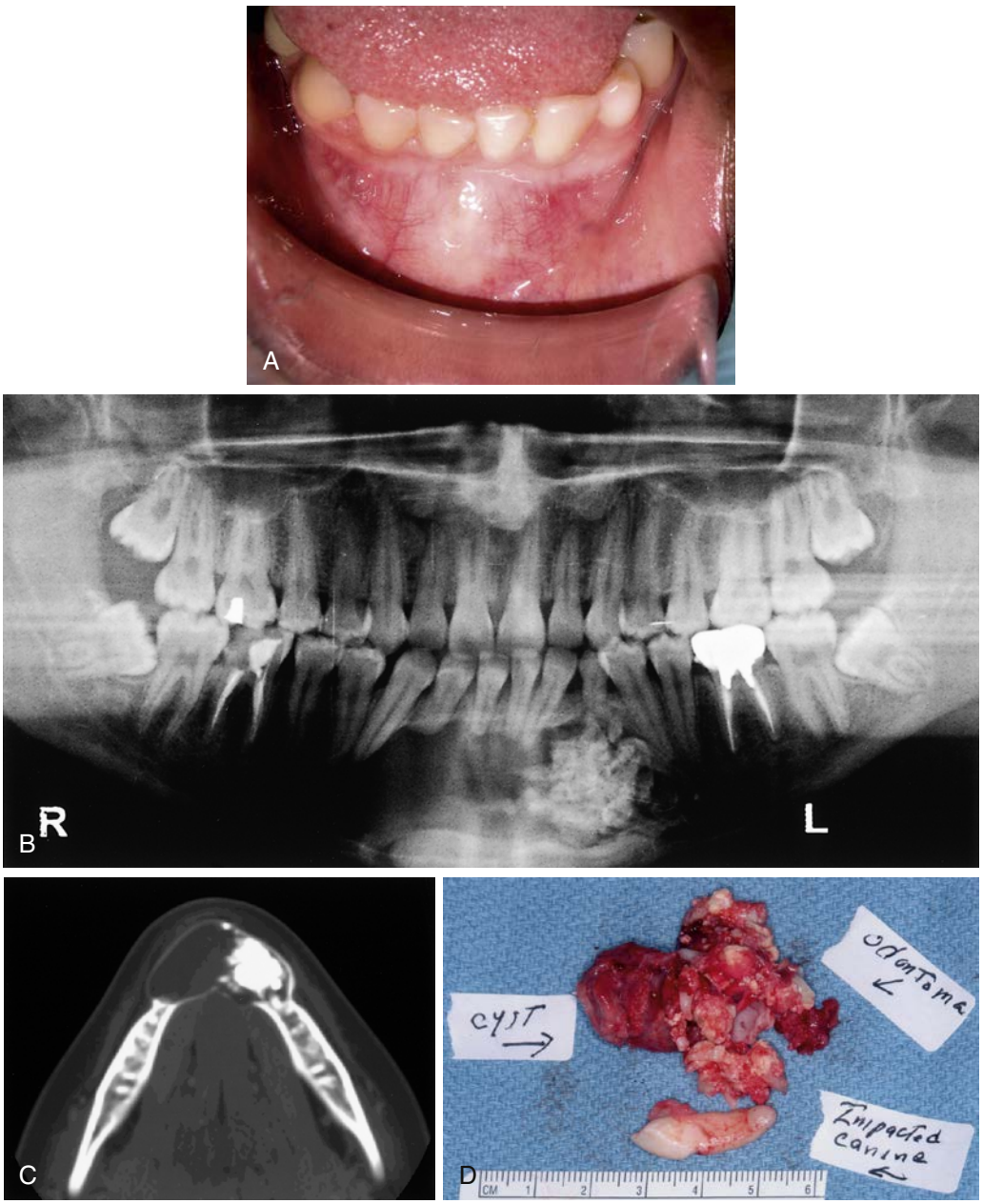

• **Figure 18-30** Calcifying odontogenic cyst with complex odontoma. An 18-year-old woman was referred because of an enlarging anterior mandibular swelling and displaced teeth preventing mouth closure. **A,** The swelling was painless and gradually increased in size over a year. **B**-**C,** Panographic and computed tomographic radiographs revealed a 6.5 × 3.0 cm radiolucent lesion occupying the mandibular symphysis, displacing the right first premolar to the left first premolar teeth, and causing slight root-end resorption of the four anterior teeth. Lying within the extensive radiolucency was a complex odontomatous mass measuring 2.5 × 2.5 cm. The partially resorbed left deciduous canine tooth was in situ, and the permanent left canine was horizontally displaced to the inferior mandibular border. An incisional biopsy of the cyst wall was reported as calcifying odontogenic cyst (also known as keratinizing and calcifying odontogenic cyst). Before the definitive procedure, the displaced teeth were endodontically treated. The lesion was excised under general anesthesia. The cyst and odontoma were removed by enucleation and curettage. **D,** The cyst wall was both thick and thin in areas, with care taken to remove the entire cyst wall and odontoma. The mental nerve was protected and preserved. Reconstruction was immediately accomplished by adaptation of a thin reconstruction bar secured to the mandible.

Continued

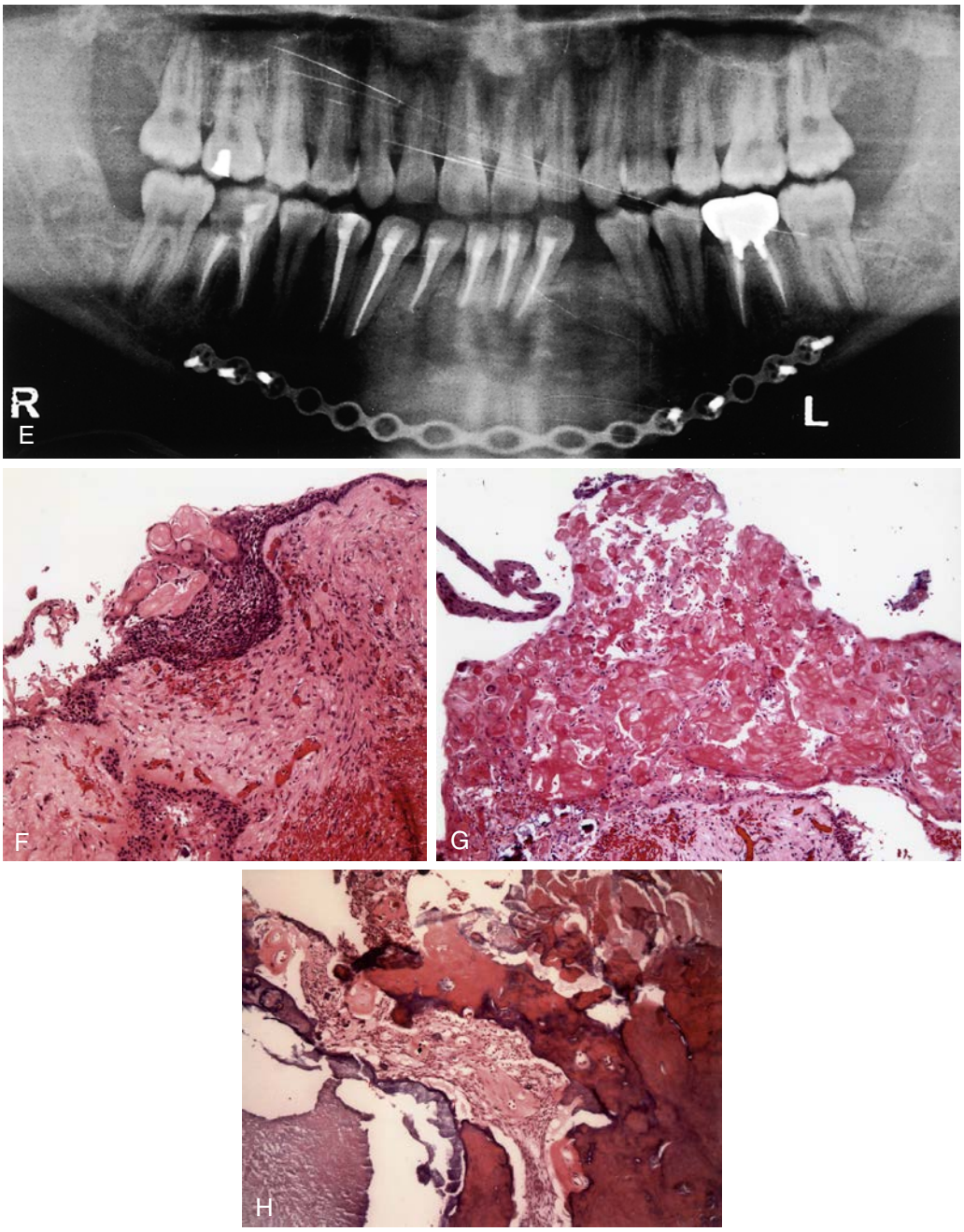

• **Figure 18-30, cont'd** **E,** A mixture of iliac crest bone marrow aspirate, allogeneic bone, patient cortical bone chips, and platelet-rich plasma was implanted in the surgical defect. The wound was closed primarily. **F,** Histologic sections of the specimen showed a calcifying and keratinizing odontogenic cyst. **G,** High power of "ghost cells" in calcifying odontogenic cyst lining. **H,** Area of accompanying complex odontoma. (Case material courtesy Daniel Taub, DDS, MD, Thomas Jefferson University, Philadelphia.)

which includes odontogenic ectomesenchyme, in addition to odontogenic epithelium, that resembles an ameloblastoma both in structure and in behavior. Because of the presence of the odontogenic ectomesenchyme, inductive changes take place leading to formation of dentin and enamel in parts of the tumor" (see Figure 18-34 and comments on ameloblastic fibrodentinoma). This definition is supported by several writers, but with slightly differing connotations and emphasis. Gorlin[171] and Frissell and Shafer[214] believe the odontoameloblastoma is a "tumor in which there is simultaneous occurrence of ameloblastoma and a complex or compound odontoma within the same tumor." Regezi and Sciubba[185] state that the odontoameloblastoma is a rare variant that is essentially an ameloblastoma in which there is focal differentiation into an odontoma. However, Gorlin[171] also states that the lesion is not invasive, thus introducing a confusing contradiction regarding the ameloblastic credentials of the lesion he describes as odontoameloblastoma. Several oral

pathology texts recommend that odontoameloblastoma be treated as an ameloblastoma. However, with almost no exception, this recommendation has not been followed in the cases published under the designation of odontoameloblastoma or ameloblastic odontoma. Most such cases have been evaluated by Slootweg[209] in an extensive analysis of mixed odontogenic tumors, and in his opinion they are either ameloblastic fibro-odontomas or complex odontomas. This opinion is supported on several bases by the present writers after careful review of a number of published cases[215-224] and other cases not cited.

The published lesions, whether small, large, or extensive, are radiographically well circumscribed, appearing as radiopaque centrally, surrounded by a radiolucent zone, or containing irregular small or large radiopaque masses interspersed with radiolucent areas, and usually surrounded by a sclerotic bone margin. None appeared to give a radiographic impression of infiltration. All were conservatively excised by enucleation and/or curettage. Only a few showed recurrent growth, which could be explained by continued growth of overlooked residual lesion (as has also been described for ameloblastic fibro-odontoma). In one case, the excised regrowth demonstrated further formation of odontomatous structures.

Histologic descriptions and photomicrographs (one case did not offer a photomicrograph) of the ameloblastic elements did not describe or illustrate impressive amounts of ameloblastic tissue. All of the ameloblastomatous tissue was contained within the lesions, many of which were encapsulated. None qualified as a legitimate example of ameloblastoma that would justify aggressive treatment.

Clinicopathologic Considerations

Several cases[8,214,224] appeared to fulfill the criteria for odontoameloblastoma; however, these also did not greatly differ radiographically, or to any extent clinically, from the cases already discussed. Radiographically, they were similarly well circumscribed and contained similar opacified (calcified) odontomatous masses. The age of occurrence was mainly in the first and second decades, with a male predilection. The lesions usually occupied the posterior regions of both jaws and clinically produced expansion of the jaws. The distinguishing characteristic was that the ameloblastic elements appeared to be well-differentiated follicular or plexiform masses and islands, in more than casual amounts and distributed throughout the lesion. Only one report[217] specifically addressed an infiltrative-like quality of the lesion in one area.

Management

Almost all the acceptable cases of odontoameloblastoma described here were initially treated conservatively, including recurrences. The extensive maxillary lesion described by La Briola and colleagues[224] was initially managed by hemimaxillectomy, and the twice-recurrent lesion of Frissell and Shafer[214] was conclusively managed by Rs-CD. Conservative excision appears to be the prudent initial management selection.

- Lesions that are primarily radiopaque and circumscribed by sclerotic bone should be excised by enucleation and careful curettage.
- Lesions that contain significant areas of radiolucency, in addition to calcified odontomatous masses, should be biopsied in several areas.
  - Histologic assessment of the biopsy determines the presence or absence of a capsule and the quantity and distribution of ameloblastic elements.
  - If a capsule is present, the lesion should be excised by enucleation and careful curettage.
  - If a capsule is not present, the lesion should be excised by enucleation and careful curettage or at most Rs-CD.
- Histologic analysis of the specimen determines whether a further surgical procedure is indicated. Rarely is Rc-CD justified. However, clinical features, imaging, and anatomic involvement must be taken into account in the management of the specific lesion.

Ameloblastic Fibroma

The *ameloblastic fibroma is a benign mixed odontogenic tumor in which odontogenic epithelium and odontogenic ectomesenchyme proliferate as a combined soft tissue neoplasm, without the formation of calcified tooth structures* (Figure 18-31). Although it is statistically rare, the accumulation of published cases has permitted analysis of the clinical parameters of the lesion.[209,211,225] It is probable that ameloblastic fibroma is a true neoplasm of embryonic tissue.

Clinicopathologic Considerations

As with other members of the mixed odontogenic group, ameloblastic fibroma typically is found in the first 2 decades. The median age is 14 or 15 years, with a range of discovery up to 40 years. The youngest case thus far reported occurred in a 7-week-old infant.[226] Males and females are equally affected. The lesion occurs in both jaws; however, the mandible, particularly the third molar area, is the site of predilection.

Radiographically, ameloblastic fibroma projects a radiolucent, unilocular image, usually well delineated and frequently with a radiopaque (sclerotic) border. Ameloblastic fibroma is often associated with unerupted teeth and may resemble a dentigerous cyst. Small lesions tend to be unilocular, whereas large or extensive lesions assume a multilocular configuration, with variation in size from 1 cm to 8 cm. There are no pathognomonic radiographic clues to the lesion's identity. The only frequent clinical sign is enlargement of the affected jaw, rarely accompanied by pain. The expanding lesion may cause tooth movement, but rarely tooth root resorption.

Histologically, ameloblastic fibroma is composed of a cell-rich mesenchymal-appearing connective tissue in which odontogenic epithelium is prominently displayed and dispersed throughout the lesion. The connective tissue simulates the pattern of the dental papilla, with rounded or angulated embryonic-appearing fibroblasts. In most areas of the lesion, little or no collagen appears, and the stroma has a fibromyxoid appearance. The odontogenic epithelium is present as narrow variously shaped cords, straight or curved strands, and branching configurations of cuboidal or columnar cells. The strands frequently expand into terminal club shapes that demonstrate

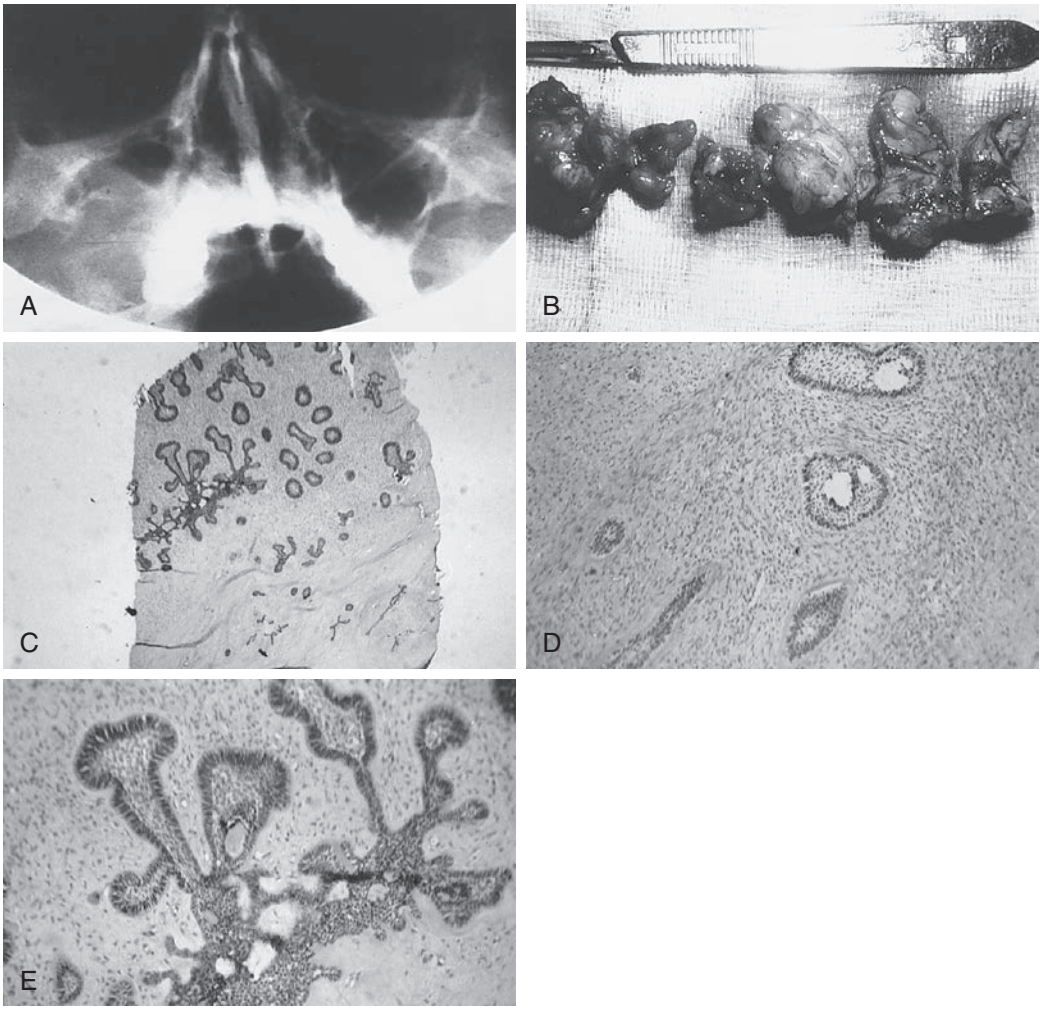

• **Figure 18-31** Ameloblastic fibroma. **A,** An extensive lesion of the right maxilla and maxillary sinus was excised by enucleation and curettage from a 27-year-old woman. **B,** The gross specimen demonstrates a lobular pattern. Tissue sections show ameloblastic configurations within a hypercellular and hypocellular fibromyxoid connective tissue. Note slight inductive effect bordering some ameloblastic strands (**C,** low power; **D**-**E,** medium power).

classic ameloblastic configuration with a central stellate reticulum appearance and peripheral columnar cells with reversed nuclear polarity. Small islands of ameloblastic cells may show a typical follicular appearance and cystic change. The microscopic patterns of odontogenic epithelium and the mesenchymal connective tissue may vary in large lesions to produce proportional differences between the two tissue components. Not infrequently, hyalinization of mesenchymal tissue is observed around the epithelial islands to indicate an inductive effect; however, induction does not proceed past this initial step. Frequently a connective tissue capsule is present.

The growth pattern of ameloblastic fibroma occurs usually by smooth expansion within the jaws, producing cortical bone thinning or occasional resorption. Several surgical descriptions, however, report that "finger-like projections of the tumor extend into the bone."[227]

Management

Ameloblastic fibroma has been traditionally managed by a conservative surgical approach, unless the extreme size of a lesion (i.e., 7 to 8 cm) has dictated the anatomic need for resection procedures (either Rs$^-$CD or Rc$^-$CD). Several case presentations[228-231] as well as Trodahl's analysis[225] report recurrences. The recurrence rate of 43.5% in Trodahl's 1972 study appears alarmingly high when compared to Zallen and co-workers' study[232] of published cases, which shows a recurrence rate of 18%. Examination of case surgical details indicates that recurrences are probably regrowth of residual tumor, not unexpected in an embryonal-type neoplasm. In Trodahl's series, 92% of the lesions were initially treated by excision (the term not further defined), enucleation, or curettage. The few recurrences reported in the literature on ameloblastic fibroma show that the recurrence exhibits the same histologic features as seen in the specimen of the initial excision, and a few demonstrated further maturation toward odontoma formation. One recurrence[229] showed acanthomatous changes in ameloblastic elements and a marked increase in collagen content. *It should be noted that a common history in the literature on ameloblastic fibrosarcoma shows that approximately 45% of the sarcomatous lesions evolve from ameloblastic fibromas that have been incompletely excised or not treated.*

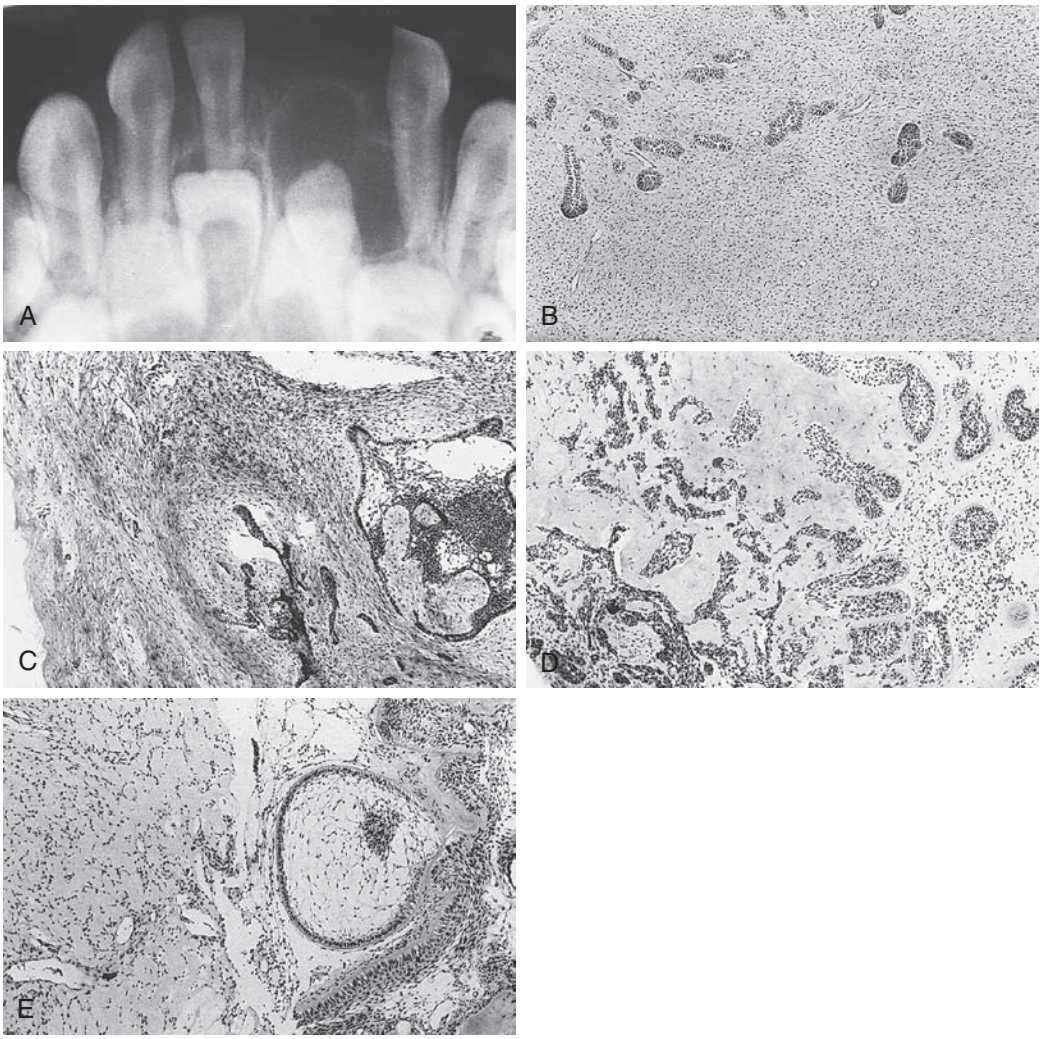

• **Figure 18-32** Ameloblastic fibro-odontoma. **A,** Periapical radiograph of lesion in the anterior mandible of a 2½-year-old child. The lesion produced a labial bulge and measured approximately 2 cm in diameter. The lesion was excised by enucleation and curettage. **B,** Photomicrographs demonstrate a soft tissue mass of cellular fibromyxoid connective tissue in which areas display ameloblastic strands and islands, some of which are surrounded by acellular zones of collagen, compatible with ameloblastic fibroma. **C,** Other areas of the lesion demonstrate hyperplastic masses of ameloblastic epithelium. **D,** However, extensive hyalinization of the connective tissue by the inductive effect of the ameloblastic-like epithelium, as well as **(E)** the presence of an enamel organ and amelogenic epithelium, presage future probable formation of an odontoma. (Case material courtesy Dr. Joseph C. Piotrowski, Toms River, NJ.)

- Most, if not all, recurrences probably result from incomplete excision; however, a conservative first approach to management is acceptable if the lesion is encapsulated.
- The presence or absence of encapsulation should be established during the first stages of the surgical procedure. Despite encapsulation, some lesions may have loculi of the tumor that escape detection and excision.
- Enucleation and curettage result in successful excision of unilocular, encapsulated lesions. Careful histologic study of multiple sections of different regions of the lesion should be carried out to detect areas of atypical change in the mesenchymal tissue.
- Extensive or multilocular lesions are more definitively managed by Rs$^-$CD or Rc$^-$CD from the outset, if surgically indicated.
- Huge lesions require Rc$^-$CD and bone graft if anatomic integrity of the jaw is so compromised that pathologic fracture may result from extirpative surgery.
- Studies of cases indicated that approximately 45% of ameloblastic fibrosarcomas evolve from untreated or incompletely treated ameloblastic fibroma (see discussion of odontogenic sarcoma).
- Long-term clinical and radiographic follow-up evaluation is required; 10 years is not an unreasonable period.

Ameloblastic Fibro-odontoma

The ameloblastic fibro-odontoma is a benign mixed odontogenic tumor that appears to be a histologic combination of ameloblastic fibroma and forming complex odontoma (Figures 18-32 and 18-33). The lesion has the expansile

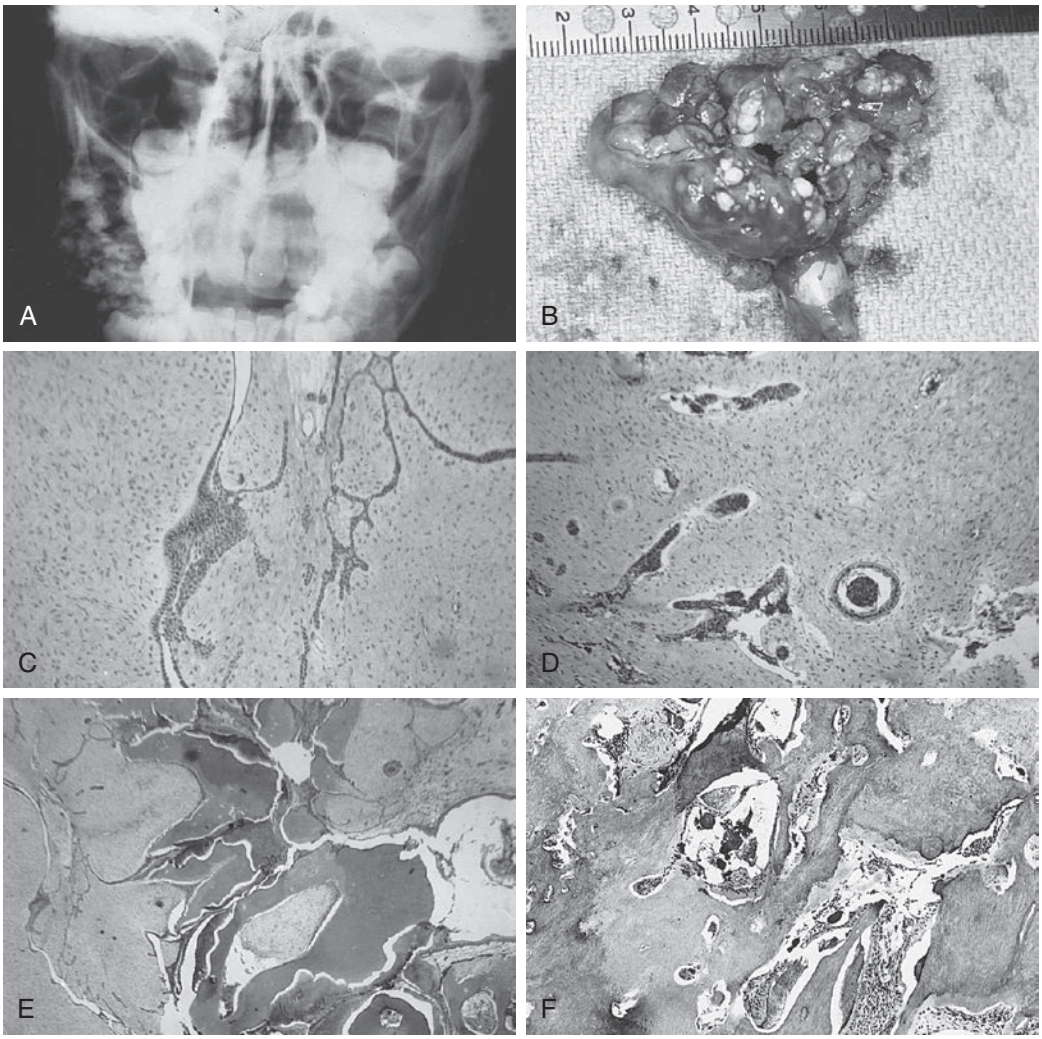

• **Figure 18-33** Ameloblastic fibro-odontoma. **A,** Posteroanterior radiograph of an extensive lesion in the ramus and posterior-mid body of the right side of the mandible in an 11-year-old girl. The lesion was excised by enucleation and curettage. **B,** The specimen shows partial encapsulation with calcified dental tissues and toothlike masses embedded in the lobular soft tissue. **C-D,** Photomicrographs demonstrate regions of the lesion: Peripheral areas show ameloblastic fibroma-like proliferations, while adjoining areas demonstrate formation of malformed teeth **(E-F)** and calcifying compound and complex odontomatous masses.

growth potential of the former and the inductive capability of the latter.

Clinicopathologic Considerations

As with other mixed odontogenic tumors, the lesion is typically found in children in the first and second decades, with a male-to-female ratio of approximately 3:1. The lesion is reported to occur with equal frequency in both jaws in one series[209] and preponderantly in the mandible in another series of cases[233] with the site of predilection in the premolar-molar region. Jaw enlargement is often present without clinical symptoms.

Radiographically, the tumor is unilocular or multilocular, with well-defined sclerotic borders, and is seen as a mixed radiopaque-radiolucent large or extensive lesion. The tumor is frequently associated with unerupted teeth or in place of absent teeth. Lesions may vary in the proportion and distribution of radiolucent (soft tissue) and radiopaque (calcified) areas.

Histologically, regions of the tumor demonstrate the same composition of tissue elements as in ameloblastic fibromacords and strands of odontogenic epithelium dispersed in a cell-rich mesenchymal tissue, but also admixed with areas in which odontogenic epithelium and the mesenchymal tissue form dental papillae and enamel organs. Enamel matrix and dentin are produced in bizarre forms and combinations as in a complex or compound odontoma. The tumor is well circumscribed or surrounded by a connective tissue capsule that separates the lesion from bone.

Management

The noninvasive and expansile characteristics of ameloblastic fibro-odontoma, in addition to encapsulation or well-defined circumscription, permit conservative excision by

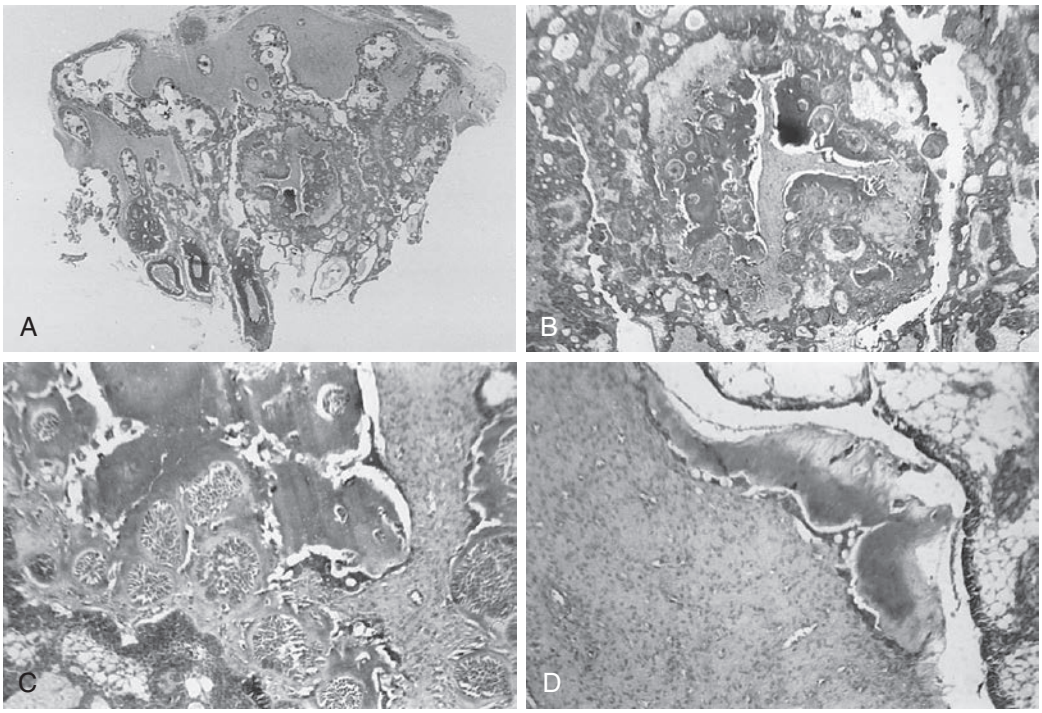

• **Figure 18-34** Ameloblastic fibrodentinoma. Tissue sections found in a review of archival files of the biopsy department revealed an ameloblastic fibrodentinoma, the case details of which are unknown. The histologic morphology and topography of the lesion suggest that a designation of odontoameloblastoma could also be acceptable (see text discussion). **A,** Microscopic sections had been prepared thicker than usual microtome cut. Scanning microscope demonstrates a partially encapsulated lesion whose mesenchymal connective tissue stroma contains a significant and prominent proliferation of ameloblastic epithelium in cords, strands, and islands surrounded by areas of forming dentinoid, partially calcified dentinoid, or cementoid masses and toothlike forms. **B,** The relationship of the dentinoid to the pulplike mesenchymal tissue and ameloblastic elements is seen in low power. **C,** Medium power shows mesenchymal, calcifying dentinoid, and ameloblastic elements. **D,** High power illustrates tubular dentinoid and odontoblast-like cells between mesenchyme and dentinoid, as well as ameloblastic aggregates exterior to the dentinoid.

enucleation. However, bosselated projections or lobular areas of the tumor must be carefully removed; recurrence is probable if residual lesion remains. Huge tumors[233,234] require resection (Rs-CD or Rc-CD) as indicated by the site, extent, and anatomic involvement of the lesion. It should be noted that Howell and Burkes[235] reported a case of ameloblastic fibro-odontoma that converted to ameloblastic sarcoma.

Ameloblastic Fibrodentinoma

The *ameloblastic fibrodentinoma* (AFD), formerly dentinoma, is a rare, benign odontogenic mixed tumor and is probably a variant of ameloblastic fibroma or ameloblastic fibro-odontoma, in which odontogenic mesenchyme is induced to form dentin or a dentin-like product by the odontogenic epithelium (Figure 18-34). Like ameloblastic fibro-odontoma, AFD is generally considered to be a hamartoma rather than a neoplasm; and, similar to ameloblastic fibro-odontoma, AFD can exhibit considerable growth potential. Although the designation ameloblastic fibrodentinoma is named in the index (with two page listings) of the *Tumors and Cysts of the Jaw* atlas by Sciubba and colleagues,[236] the lesion is not discussed in the text. The WHO 1992 and 2005 classification of odontogenic tumors[12,13] does list the lesion. The senior author's (L.G.) experience with the ameloblastic fibrodentinoma is limited to the discovery and study of an old archival case shown in Figure 18-34. The lesion exhibited a considerable quantity of conventional ameloblastic epithelium in relation to forming dentin, dentinoid, and several toothlike forms. I chose to call the lesion ameloblastic fibrodentinoma, but probably odontoameloblastoma or ameloblastic fibro-odontoma also would have been suitable.

The recognition of ameloblastic fibrodentinoma as an entity (and not as a taxonomic oddity) is still being examined, and despite numerous papers in the literature, the lesion may eventually be merged into ameloblastic fibro-odontoma. A paper by Philipsen, Reichart, and Praetorius is recommended for review.[237]

Clinicopathologic Considerations

A review of the literature by Ulmansky and colleagues[238] revealed 33 cases recorded between 1936 and 1993. The lesion is found more commonly in the mandible than the maxilla (3:1), and in males more often than females (2:1).

AFD has a wider age range of occurrence than other members of the mixed odontogenic tumor group. Lesions have been clinically discovered in patients from 4 to 60 years of age, with the usual age below 30. Lesions in children are associated with unerupted or missing deciduous teeth and are usually found in the anterior jaw, whereas lesions in adults, involving permanent teeth, show a preference for the posterior regions of the jaw.

The lesions are asymptomatic and are clinically noted because of swelling or enlargement of the jaws. Most often failure of deciduous[239] or permanent teeth to erupt, in the presence of jaw enlargement, draws a patient to the attention of a practitioner, with subsequent discovery of a lesion in radiographic examination.

Radiographically, AFD may be small or extensive,[240] unilocular or multilocular, and most often has well-defined borders. Radiopaque material may be dispersed throughout a lesion, whereas other instances of AFD are predominantly radiolucent.[241] Unerupted deciduous or permanent teeth are often seen to be deeply situated in a lesion[242]; occasionally, heavily opacified lesions are found in edentulous areas of adults.

Histologically, AFD is seen in several configurations within a basic lesional format of ameloblastic fibroma—strands and islands of odontogenic epithelium proliferating in a mesenchymal, cellular, papilla-like connective tissue. In hematoxylin- and eosin-stained sections, the mesenchymal tissue may appear hypocellular, eosinophilic, and hyalinized in areas in which the odontogenic epithelium is embedded. Other foci may show islands of proliferating odontogenic epithelium surrounded by cell-free mesenchyme, whereas the peripheral epithelial cells of other islands take on an ameloblastic appearance and induce dentinoid matrix in the interface area with the mesenchyme. Various stages of induction of dentin may be demonstrated, resulting in lesions that display dentinoid, osteodentin, and, rarely, tubular dentin.[243] The dentin may be infrequently and poorly mineralized; however, Manning and Browne[244] have recorded an example of a large mineralized AFD.

Management

Complete excision of AFD, as recommended for ameloblastic fibroma and ameloblastic fibro-odontoma, is necessary because residual lesion has the capacity to grow. The form of excision is case dependent—enucleation if possible, with Rs-CD and Rc-CD as an option if the surgical circumstance requires or warrants.

Ameloblastic Fibrosarcoma/Ameloblastic Sarcoma

Ameloblastic fibrosarcoma (AFS) or *ameloblastic sarcoma* is "*a neoplasm with a similar structure to ameloblastic fibroma, but in which the ectomesenchymal component shows the features of sarcoma*." This definition in the WHO[11] classification has not been superseded. The WHO explanatory note further cautions that the term should be applied only to neoplasms in which mesenchymal tissue, but not the odontogenic epithelium (ameloblastic elements), appears malignant.

An AFS in which dentinoid or osteodentin is induced or an AFS in which both dentin and enamel are produced have been, respectively, termed *ameloblastic dentinosarcoma* and *ameloblastic odontosarcoma*.[245] However, several authors[246-248] believe that the variant presence of dentinoid or an odontomatous mass does not influence or alter the course of the lesion, and therefore the terms serve no useful purpose and should be discontinued.[248]

A survey of AFS in 1977 recorded 22 lesions,[235] and another survey in 1995 accounted for 51 lesions,[250] more than double the number of reported cases within 18 years. Despite the apparent rarity of AFS, numerous published case reports[235,245,246,249-253] and detailed reviews[235,247,248] have fully documented the clinical and histologic range of this neoplasm.

Clinicopathologic Considerations

Approximately 45% of AFS lesions present clinical, radiographic, and histologic evidence of origin in ameloblastic fibroma, ameloblastic fibro-odontoma, or odontoameloblastoma, thus accounting for an average age of 21 years for patients whose AFS appears to arise de novo, and an average age of 33 years for patients in whom conversion from a preexisting benign mixed odontogenic tumor (an indication of a time-related process) occurred.

There is a modest gender preference for male over female (1.5:1) and a marked predilection for the mandible over the maxilla (4:1), with most lesions appearing in the posterior areas of both jaws.

The outstanding clinical signs and symptoms were swelling and pain in almost all cases; however, paresthesia was uncommon. Mobility of teeth and an intraoral tumor mass occurred in some instances (particularly those in which massive lesions were present). Many cases exhibited a moderate growth rate over several years, succeeded by rapid growth that forced patients to seek treatment.

Radiographs demonstrate a radiolucent, multilocular appearance, with either well-defined or irregular borders. However, lesions that are very large at the time of clinical discovery show marked areas of bone destruction and indistinct margins, with thinning, expansion, or disruption of the cortex. Maxillary lesions may extend into the maxillary sinus, with destruction of the sinus walls. Root resorption and tooth displacement are inconstant features. Lesions that contain dentinoid or odontomatous tissue usually show radiopaque foci.

Histologically, as in ameloblastic fibroma, the ameloblastic cords, trabeculae, and islands in AFS do not show increased evidence of malignancy; however, the mesenchymal tissue demonstrates marked change from the dental papilla appearance and exhibits features of malignancy—hypercellularity, pleomorphism, hyperchromasia, and increased as well as abnormal mitoses.

The mesenchymal elements of the ameloblastic fibroma, per se, may present a disquieting, sometimes

chaotic appearance, but changes in size, shape, staining intensity, and mitotic activity of the cells are usually absent. Careful search of histologic sections of some ameloblastic fibromas may reveal foci of increased cellularity and changes in size and shape of mesenchymal cells. Such areas may or may not be significant in a lesion's conversion to malignancy.

In ameloblastic fibroma, many ameloblastic islands are surrounded by a clear or hyalinized zone (in which dentinoid may develop) peripheral to which is the mesenchymal stroma. In contrast to this appearance, in AFS the clear zones lessen or vanish, and the malignant stromal cells directly encircle the ameloblastic islands.

Cases that document repeated recurrences show that recurrence often is accompanied by increased cellularity and increasingly anaplastic cells, bizarre mitoses, and formation of tumor giant cells. In some recurrent lesions the ameloblastic elements notably diminished with each recurrence, and in a few cases they totally disappeared, signaling the lesion's complete conversion into fibrosarcoma. Similarly, dentinoid induced in some ameloblastic fibromas also tended to disappear completely as lesions converted to AFS. It is an interesting hypothesis that perhaps the ameloblastic epithelium and ectomesenchyme of the ameloblastic fibroma exert a reciprocal benignifying effect on each other, but when a malignant process intervenes, the ameloblastic epithelium loses not only control, but also presence.

In a study by Muller and colleagues[249] the DNA content of mesenchymal cells in AFS in comparison with ameloblastic fibroma was measured to see whether a correlation existed between histologic features and DNA ploidy. If so, DNA content could help provide an objective measurement to assess clinical behavior in addition to histologic grading. The study did not demonstrate such a correlation.

Management and Outcome

The earlier reports of AFS tended to depict the lesion in a somewhat casual manner, despite the recognition of the malignant histologic characteristics. It was mistakenly believed that local removal of the tumor was sufficient.

Leider and associates[247] in their 1972 survey found they could not correlate clinical behavior with microscopic characteristics. They believed that despite the histologic features of an anaplastic mesenchymal tumor, the lesion behaved as a low-grade fibrosarcoma. They recognized that most cases of AFS arose from malignant change in ameloblastic fibroma and that repeated recurrences led to uncontrollable disease and death. Altini and co-workers[248] in their 1985 study characterized the biologic behavior of AFS as locally aggressive rather than regionally or distantly metastatic. Both of these studies gave relatively ambiguous recommendations for "surgical excision" or "resection." Muller and colleagues[249] in their 1995 survey recommended surgical management as dictated by the clinical extent of disease. It is clear from a review of case histories that AFS has a range of biologic behavior from low-grade fibrosarcoma to high-grade fibrosarcoma.

Chemotherapy has been used in two instances in an attempt to manage recurrent extensive ameloblastic fibrosarcoma. In the first case, details of which were reported by Goldstein and associates[251] in 1976 and by Howell and Burkes[235] in 1977 (same case), a 37-year-old man had a lesion in the mandibular premolar region recognized in 1954 but treated during a 10-year period from 1960 to 1970. Initial treatments included multiple curettements over 5 years; recurrences were treated by partial resections, followed by radical resections; subsequent recurrences were treated by further resection, until massive soft tissue involvement made further surgery impossible. Chemotherapy was initiated with daily oral cyclophosphamide (Cytoxan) and weekly intravenous actinomycin D and vincristine. Clinical success with no evidence of disease for 1 year was achieved, after which a small recurrence was again treated by the chemotherapeutic regimen with a further 1-year disease free state. A small malignant melanoma was then found and excised. However, pulmonary and cerebral metastases of the melanoma occurred, and the patient died. In the second case, reported by Park and co-workers,[253] a 17-year-old boy had an exophytic intraoral lesion and a destructive lesion of the mandible and associated soft tissue. Biopsy revealed ameloblastic fibrosarcoma. Composite resection and immediate reconstruction were performed, followed by adjuvant chemotherapy with cyclophosphamide, doxorubicin (Adriamycin), and vincristine. Three months later facial recurrence was seen. Radiation was initiated without response, and the patient died. In the first case multiple diagnoses were made over the years—dentigerous cyst, ameloblastic fibro-odontoma, and finally AFS—apparently signifying a conversion; in the second case, the lesion appeared to be de novo AFS.

- Histologically, tissue analysis of ameloblastic fibroma, particularly recurrent lesions, may be difficult or lead to misdiagnosis. Multiple sections from all areas of the tumor should be studied; over- or underdiagnosis is possible.
- The potential for malignant change in ameloblastic fibroma is sufficient indication for aggressive initial resection by Rs-CD or Rc-CD. Approximately 45% of AFS is secondary to malignant change in ameloblastic fibroma.
- A total of 20% to 23% of AFS cases eventuate in death of the patient as a result of uncontrollable extension of the disease.
- Metastasis is not a usual feature of AFS behavior but has been reported.
- Early diagnosis and initial aggressive resection by Rs-CD or Rc-CD of de novo or secondary AFS is mandatory. Adjuvant chemotherapy may be indicated in massive lesions.
- Long-term clinical and radiographic follow-up evaluation of at least 10 years is necessary.

Acknowledgment

The authors wish to express their gratitude to Karen Perkins for the preparation of this manuscript.

References

1. Orban BJ: *Oral histology and embryology*, ed 4, St Louis, 1957, CV Mosby.
2. Popoff SN, Marks SC: The regulation of skeletal modeling and remodeling in the jaws, *Oral Maxillofac Surg Clin N Am* 9(4):563, 1997.
3. Sutton JB: Odontomes, *Trans Odont Soc Great Br* 20:32, 1888.
4. Gabell DF, James WW, Payne JL: *Report on odontomes, the Committee Appointed by British Dental Association*, London, 1914, John Bale, Sons & Danielson.
5. Pitts AT: Some reflections on the nature of odontomes, *Br Dent J* 54:217, 1933.
6. Tratman EK: Odontomes and their relationship to each other, *Br Dent J* 66:580, 1939.
7. Ivy RH, Churchill HR: The need of a standardized surgical and pathological classification of the tumors and anomalies of dental origin, *Proc Am Assoc Dent Schools* 7:240, 1930.
8. Thoma KH, Goldman HM: Odontogenic tumors: a classification based on observation of the epithelial, mesenchymal, and mixed varieties, *Am J Pathol* 22:433, 1946.
9. Pindborg JJ, Clausen F: Classification of odontogenic tumors: a suggestion, *Acta Odontol Scand* 16:203, 1958.
10. Gorlin RJ, Chaudhry AP, Pindborg JJ: Odontogenic tumors-classification, histopathology and clinical behavior in man and domesticated animals, *Cancer* 14:73, 1961.
11. Pindborg JJ, Kramer IRH: *Histological typing of odontogenic tumors, jaw cysts, and allied lesions*, Geneva, 1971, World Health Organization. no. 5.
12. Kramer IRH, Pindborg JJ, Shear M: *Histological typing of odontogenic tumors*, ed 2, Berlin, 1992, World Health Organization, Springer.
13. Barnes L, Eveson JW, Reichert P, et al.: *WHO Classification of Tumors, pathology & genetics. In Head and neck tumors*, Lyon, France, 2005, IARC Press, p 283.
14. Slootweg PJ, Müller H: Malignant ameloblastoma or ameloblastic carcinoma, *Oral Surg* 54:299, 1982.
15. Elzay RP: Primary intraosseous carcinoma of the jaws: review and update of odontogenic carcinomas, *Oral Surg* 54:299, 1982.
16. Waldron CA, Small IA, Silverman H: Clear cell ameloblastoma: an odontogenic carcinoma, *J Oral Surg* 43:707, 1985.

17a. Gold L: Biologic behavior of ameloblastoma, *Oral Maxillofac Surg Clin N Am* 3:21, 1991.

17b. Müller H, Slootweg PJ: The growth characteristics of multilocular ameloblastoma, *J Maxillofac Surg* 13:224, 1985.

18. Eversole LR: Malignant epithelial odontogenic tumors, *Sem Diagn Pathol* 16:317, 1999.
19. Philipsen HP, Reichart PA: Revision of the 1992-edition of the WHO histological typing of odontogenic tumors. A suggestion, *J Oral Pathol Med* 31:253, 2002.
20. Mosqueda-Taylor A, Ledesma-Montes C, Caballero-Sandoval S, et al.: Odontogenic tumors in Mexico: a collaborative retrospective study of 349 cases, *Oral Surg Oral Med Oral Pathol* 84:672, 1997.
21. Chidzonga MM, Lopez Perez VM: Portilla Alvarez AL: Ameloblastoma: the Zimbabwean experience over 10 years, *Oral Surg Oral Med Oral Pathol* 82:38, 1996.
22. Shatkin S, Hoffmeister FS: Ameloblastoma: a rational approach to therapy, *Oral Surg* 20:421, 1965.
23. Gold L, Upton GW, Marx RE: Standardized surgical terminology for the excision of lesions in bone: an argument for accuracy in reporting, *J Oral Maxillofac Surg* 49:1214, 1991.
24. Stafne EC: Epithelial tumors associated with developmental cysts of the maxilla: report of 3 cases, *Oral Surg Oral Med Oral Pathol* 1:887, 1948.
25. Das AE, Cooper WK, Medak H: Adenoameloblastoma: report of a case, *J Oral Surg* 22:434, 1964.
26. Philipsen HP, Birn H: The adenomatoid odontogenic tumor: ameloblastic adenomatoid tumor or adenoameloblastoma, *Acta Pathol Microbiol Scand* 75:375, 1969.
27. Philipsen HP, Reichert P, Zhang K, et al.: Adenomatoid odontogenic tumor: biologic profile based on 499 cases, *J Oral Pathol Med* 20:149, 1991.
28. Damm DD, White DM, Drummond JF, et al.: Combined epithelial odontogenic tumor: adenomatoid odontogenic tumor and calcifying epithelial odontogenic tumor, *Oral Surg Oral Med Oral Pathol* 55:487, 1983.
29. Bingham RA, Adrian JC: Combined epithelial odontogenic tumor-adenomatoid odontogenic tumor and calcifying epithelial odontogenic tumor: report of a case, *J Oral Maxillofac Surg* 44:574, 1986.
30. Takigami M, Uede T, Imazumi T, et al.: A case of adenomatoid odontogenic tumor with intracranial extension, *Neurol Surg (Jpn)* 16:775, 1988.
31. Pullon P, Shafer W, Elzay R, et al.: Squamous odontogenic tumor, *Oral Surg* 40:616, 1975.
32. McNeil J, Price H, Stoken N: Squamous odontogenic tumor: report of a case, *J Oral Surg* 38:466, 1980.
33. Carr RJ, Carlton DM, Marks RB: Squamous odontogenic tumor: report of a case, *J Oral Surg* 39:297, 1981.
34. Goldblatt L, Brannon R, Ellis G: Squamous odontogenic tumor, *Oral Surg Oral Med Oral Pathol* 54:187, 1982.
35. Kristensen S, Andersen J, Jacobsen P: Squamous odontogenic tumor, *J Laryngol Otol* 99:191, 1985.
36. Mills WP, Davila MA, Beutenmuler ER, et al.: Squamous odontogenic tumor, *Oral Surg* 61:557, 1986.
37. Leider A, Jonker A, Cook H: Multicentric familial squamous odontogenic tumor, *Oral Surg Oral Med Oral Pathol* 68:175, 1989.
38. Doyle JL, Grodjesk JE, Dolinsky HB, et al.: Squamous odontogenic tumor: report of three cases, *J Oral Surg* 35:994, 1977.
39. Wright JM: Squamous odontogenic tumor-like proliferations in odontogenic cysts, *Oral Surg* 47:354, 1979.
40. Hodgkinson DJ, Wood JE, Dahlin DC, et al.: Keratocysts of the jaws, *Cancer* 41:803, 1978.
41. Baker RD, D'Onofrio ED, Corio RL, et al.: Squamous cell carcinoma arising in a lateral periodontal cyst, *Oral Surg Oral Med Oral Pathol* 47:495, 1979.
42. Van der Waal I, de Rjcke T, Van der Kwast W: Possible squamous odontogenic tumor: report of a case, *J Oral Surg* 38:460, 1980.
43. Gold L, Sliwkowski AS: Lateral periodontal cysts: a clinical and histologic study. In Kay LW, editor: *Transactions of the IV International Conference on Oral Surgery*, Amsterdam, 1971, Munksgaard, p 85. 1973.
44. Ruskin JD, Cohen DM, Davis LF: Primary intraosseous carcinoma: report of two cases, *J Oral Maxillofac Surg* 46:425, 1988.
45. Norris L, Baghaei-Rod M, Maloney P, et al.: Bilateral maxillary squamous odontogenic tumors and the malignant transformation of a mandibular radiolucent lesion, *J Oral Maxillofac Surg* 42:827, 1984.

46. Pindborg JJ: Calcifying epithelial odontogenic tumor, *Acta Pathol Microbiol Scand Suppl* 111:71, 1955.
47. Philipsen HP, Reichert PA: Calcifying epithelial odontogenic tumor: biologic profile based on 181 cases from the literature, *Oral Oncol* 36:17, 2000.
48. Ivy RH: Unusual case of ameloblastoma of mandible: resection followed by restoration of continuity by iliac bone graft, *Oral Surg* 1:1074, 1948.
49. Solomon MP, Vuletin JC, Pertschuck DO, et al.: Calcifying epithelial odontogenic tumor, *Oral Surg Oral Med Oral Pathol* 40:522, 1975.
50. Stinson PG, Luna MA, Butler JJ: Seventeen-year history of calcifying epithelial odontogenic (Pindborg) tumor, *Oral Surg Oral Med Oral Pathol* 25:204, 1968.
51. Patterson JT, Martin TJ, DeJean CK, et al.: Extraosseous calcifying odontogenic tumor, *Oral Surg Oral Med Oral Pathol* 27:363, 1969.
52. Wertheimer FW, Zielinski RJ, Wesley RK: Extraosseous calcifying epithelial odontogenic tumor (Pindborg tumor), *Int J Oral Surg* 6:266, 1977.
53. Houton GD, Fowler CH: Extraosseous calcifying epithelial odontogenic tumor: report of two cases and review of the literature, *Oral Surg Oral Med Oral Pathol* 83:577, 1997.
54. Orsini G, Favia G, Piattelli A: Peripheral clear cell calcifying epithelial odontogenic tumor: report of a case, *J Periodontal* 71:1177, 2000.
55. Vickers RA, Dahlia DC, Gorlin RI: Amyloid-containing odontogenic tumors, *Oral Surg Oral Med Oral Pathol* 20:476, 1965.
56. Ranlov P, Pindborg JJ: The amyloid nature of the homogenous substance in the calcifying epithelial odontogenic tumor, *Acta Pathol Microbiol Scand* 168:169, 1966.
57. Gardner DG, Michaels I, Liepa E: Calcifying epithelial odontogenic tumor: an amyloid-producing neoplasm, *Oral Surg Oral Med Oral Pathol* 26:812, 1968.
58. Greer RO, Richardson JF: Clear-cell calcifying odontogenic tumor viewed relative to the Pindborg tumor, *Oral Surg Oral Med Oral Pathol* 42:775, 1976.
59. Hicks MJ, Flaitz CM, Wong ME, et al.: Clear cell variant of calcifying epithelial odontogenic tumor: case report and review of the literature, *Head Neck* 16:272, 1994.
60. Schmidt-Westhausen A, Philipsen HP, Reichert PA: Clear cell calcifying epithelial odontogenic tumor: a case report, *Int J Oral Maxillofac Surg* 21:47, 1992.
61. Cheng Y-SL, Wright JM, Walstad WR, et al.: Calcifying epithelial odontogenic tumor showing microscopic features of potential malignant behavior, *Oral Surg Oral Med Oral Pathol* 93:287, 2002.
62. Basu MK, Matthews JB, Sear AJ, et al.: Calcifying epithelial odontogenic tumor: a case showing features of malignancy, *J Oral Pathol* 13:310, 1984.
63. Veness MJ, Morgan G, Collins AP, et al.: Calcifying epithelial odontogenic (Pindborg) tumor with malignant transformation and metastatic spread, *Head Neck* 23:692, 2001.
64. Bouchaert MM, Raubenheimer EJ, Jacobs FJ: Calcifying epithelial odontogenic tumor with intracranial extension; report of a case and review of the literature, *Oral Surg Oral Med Oral Pathol* 90:656, 2000.
65. Airu L, Zhen L, Jian S: Calcifying epithelial odontogenic tumors, *J Oral Pathol* 11:399, 1982.
66. Jing W, Xuan M, Lin Y, Wu L, et al.: Odontogenic tumors: a retrospective study of 1642 cases in a Chinese population, *Int J Oral Maxillofac Surg* 36:20, 2007.
67. Willis RA: *Pathology of tumors*, St Louis, 1948, CV Mosby, pp. 1, 19, 106, 258, and 308.
68. Carr RF, Halperin V: Malignant ameloblastomas from 1953 to 1966: review of the literature and report of a case, *Oral Surg* 26:514, 1968.
69. Abaza NA, Gold L, Lally E: Granular cell odontogenic cyst: a unicystic ameloblastoma with late recurrence as follicular ameloblastoma, *J Oral Surg* 47:168, 1989.
70. Robinson L, Martinez MG: Unicystic ameloblastoma: a prognostically distinct entity, *Cancer* 40:2278, 1977.
71. Ackerman GL, Altini M, Shear M: The unicystic ameloblastoma: a clinicopathologic study of 57 cases, *J Oral Pathol* 17:541, 1988.
72. Leider AS, Eversole LR, Barkin ME: Cystic ameloblastoma: a clinicopathologic analysis, *Oral Surg* 60:624, 1985.
73. Vickers RA, Gorlin RJ: Ameloblastoma: delineation of early histopathologic features of neoplasia, *Cancer* 26:1699, 1970.

74a. Sheteyer A, Lustman J, Lewin-Epstein J: The mural ameloblastoma: a review of the literature, *J Oral Surg* 36:866, 1978.

74b. Harada K, Suda S, Kayano T, et al.: Ameloblastoma with metastasis to the lung and associated hypercalcemia, *J Oral Surg* 47:1083, 1989.

75. Abdelsayed RA, Vartanian RK, Smith KK, et al.: Parathyroid hormone-related protein (PTHrP) expression in ameloblastoma, *Oral Surg Oral Med Oral Pathol* 97:208, 2004.
76. Kumamoto H, Ooya K: Expression of parathyroid hormone-related protein (PTHrP), osteoclasts differentiation factor (ODF)/receptor activator of nuclear factor-KB ligand (RANKL) and osteoclastogenesis inhibitory factor (OCIF)/osteoprotegerin (OPG) in ameloblastomas, *J Oral Pathol Med* 33:46, 2004.
77. Kumamoto H: Molecular pathology of odontogenic tumors, *J Oral Pathol Med* 35:65, 2006.
78. Gardner DG: Peripheral ameloblastoma. A study of 21 cases, including 5 reported as basal cell carcinoma of the gingiva, *Cancer* 39:1625, 1977.
79. Wertheimer FW, Stroud DE: Peripheral ameloblastoma in a papilloma with recurrence: report of a case, *J Oral Surg* 30:47, 1972.
80. Kaneko Y, Ueno S: Peripheral ameloblastoma resembling a papilloma: report of a case, *J Oral Surg* 44:737, 1986.
81. Peters RA, Gingrass RP, Reyer CN, et al.: Basal cell carcinoma of the oral cavity: report of a case, *J Oral Surg* 30:63, 1972.
82. Waldron CA: Comment: basal cell carcinoma of the oral cavity—report of a case, *J Oral Surg* 30:63, 1972.
83. Simpson HE: Basal cell carcinoma and peripheral ameloblastoma, *Oral Surg* 38:233, 1974.
84. Ng KH, Siar CH: Peripheral ameloblastoma with clear cell differentiation, *Oral Surg* 70:210, 1990.
85. Ide F, Kaoru K, Tanaka A, Sakashita H: Peripheral ameloblastoma is not a hamartoma but rather more of a neoplasm, *Oral Oncol* 38:318, 2002.
86. Philipsen HP, Reichart PA, Nikai H, et al.: Peripheral ameloblastoma: biologic profile based on 160 cases from the literature, *Oral Oncol* 37:17, 2001.
87. Edmondson HD, Browne RM, Potts AJC: Intraoral basal cell carcinoma, *Brit J Oral Surg* 20:239, 1982.
88. McClatchey KD, Sullivan MJ, Paugh DR: Peripheral ameloblastic carcinoma: a case report of a rare neoplasm, *J Otolaryngol* 18:109, 1989.
89. Califano L, Maremonti P, Boscairio A, et al.: Peripheral ameloblastoma: report of a case with malignant aspect, *Br J Oral Maxillofac Surg* 34:240, 1996.

90. Baden E, Doyle JL, Petriella V: Malignant transformation of peripheral ameloblastoma, *Oral Surg Oral Med Oral Pathol* 75:214, 1993.
91. Wettan HL, Patella PA, Freedman PD: Peripheral ameloblastoma: review of the literature and report of recurrence as severe dysplasia, *J Oral Maxillofac Surg* 59:811, 2001.
92. Ide F, Kusama K: Letter to the editor: difficulty in predicting biologic behavior of peripheral ameloblastoma, *Oral Oncol* 40:651, 2004.
93. Tajima Y, Kuroda-Kawasaki M, Ohno J, et al.: Peripheral ameloblastoma with potentially malignant features: report of a case with special regard to its keratin profile, *J Oral Pathol Med* 30:494, 2001.
94. Cranin NA, Bennett J, Solomon M: Massive granular cell ameloblastoma with metastasis: report of a case, *J Oral Surg* 45:800, 1987.
95. Dahlgren SE, Eckström C, Mossberg B: Mandibular ameloblastoma with pulmonary and mediastinal lymph node metastasis, *Acta Otolaryngol* 72:220, 1971.
96. Gall JA: Ameloblastoma of the mandible with pulmonary metastasis, *Oncology* 32:118, 1975.
97. Herceg SJ, Harding RL: Malignant ameloblastoma with pulmonary metastasis: report of a case and review of the literature, *Plast Reconstr Surg* 49:456, 1972.
98. Ikemura K, Tashiro H, Fujino H, et al.: Ameloblastoma of the mandible with metastasis to the lungs and lymph nodes, *Cancer* 29:930, 1972.
99. Lee RD, White WL, Totten RS: Ameloblastoma with distant metastases, *Arch Pathol* 68:23, 1959.
100. Sugimiura M, Yamauchi T, Yashikawa K, et al.: Malignant ameloblastoma with metastasis to the lumbar vertebrae—report of a case, *J Oral Surg* 27:350, 1969.
101. Takewchi S, Kobayashi K, Minakawa T, et al.: Metastatic ameloblastoma of the skull, *Surg Neurol* 15:182, 1981.
102. Ueda M, Kaneda T, Imaizumi M, et al.: Mandibular ameloblastoma with metastasis to the lungs and lymph nodes: a case report and review of the literature, *J Oral Surg* 47: 623, 1989.
103. Henderson JM, Sonnet JR, Schlesinger C, Ord RA: Pulmonary metastasis of ameloblastoma. Case report and review of the literature, *Oral Surg Oral Med Oral Pathol* 88:170, 1999.
104. Corio RD, Goldblatt LI, Edwards PA: Ameloblastic carcinoma: a clinicopathologic study and assessment of eight cases, *Oral Surg* 64:570, 1987.
105. Waldrom CA: Comment: malignant ameloblastoma with metastasis to the lumbar vertebrae—report of a case, *J Oral Surg* 27:356, 1969.
106. Dhir K, Sciubba J, Tufano RP: Ameloblastic carcinoma of the maxilla, *Oral Oncol* 39:736, 2003.
107. Sastre J, Muñoz M, Naval L, Adrados M: Ameloblastic carcinoma of the maxilla: report of a case, *J Oral Maxillofac Surg* 60:102, 2002.
108. Önerci M, Yilmaz T, Doğan R, Sungur A: Pulmonary metastasectomy in the treatment of recurrent ameloblastoma of the maxilla and mandible: a case report, *Eur Arch Otolarynol* 258:251, 2001.
109. Verneuil A, Sapp P, Huang C, Abemayor E: Malignant ameloblastoma: classification, diagnostic and therapeutic challenges, *Am J Otolaryngol* 23:44, 2002.
110. Datta R, Winston JS, Diaz-Reyes G, et al.: Ameloblastic carcinoma: report of an aggressive case with multiple bony metastases, *Am J Otalaryngol* 24:64, 2003.
111. Nguyen BD: Malignant ameloblastoma with thoracic vertebral metastasis: PET/CT and MR imaging, *Clin Nucl Med* 30:450, 2005.
112. Hayakawa K, Hayashi E, Aoyagi T, et al.: Metastatic malignant ameloblastoma of the kidneys, *Int J Urol* 11:424, 2004.
113. Zwahlen RA, Vogt P, Fischer FS, Gratz KW: Case report: myocardial metastasis of a maxillary malignant ameloblastoma, *J Oral Maxillofac Surg* 61:731, 2003.
114. MacIntosh RB: Aggressive surgical management of ameloblastoma, *Oral Maxillofac Surg Clin N Am* 3:73, 1991.
115. Hall JM, Weathers DR, Unni KK: Ameloblastic carcinoma: an analysis of 14 cases, *Oral Surg Oral Med Oral Pathol* 103:799, 2007.
116. Cox DP, Muller S, Carlson GW, Murray D: Ameloblastic carcinoma ex. ameloblastoma of the mandible with malignancy-associated hypercalcemia, *Oral Surg Oral Med Oral Pathol* 90:716, 2000.
117. Ciment LM, Ciment AJ: Malignant ameloblastoma metastatic to the lungs 29 years after primary resection: a case report, *Chest* 121:1359, 2000.
118. Grünwald V, Le Banc S, Karstens JH, et al.: Metastatic malignant ameloblastoma responding to chemotherapy with paclitaxel and carboplatin, *Ann Oncol* 12:1489, 2001.
119. Carlson ER, Marx RE: The ameloblastoma: primary, curative surgical management, *J Oral Maxillofac Surg* 64:484, 2006.
120. LaBanc JP: Inferior alveolar nerve repair after treatment of benign cysts and tumors of the mandible, *Oral Maxillofac Surg Clin N Am* 3:209, 1991.
121. Marx RE: Platelet-rich plasma: a source of multiple autologous growth factors for bone grafts. In *Tissue engineering*, Chapter 4, Chicago, 1999, Quintessence Publishing, p 71.
122. Voorsmit RACA: *The incredible keratocyst: a retrospective and prospective study*, Naarden, The Netherlands, 1984, Los Printers, p 315.
123. Bradley PF: Modern trends in cryosurgery of bone in the maxillofacial region, *Int J Oral Surg* 7:405, 1978.
124. Fisher AD, Williams DF, Bradley PF: The effect of cryosurgery on the strength of bone, *Br J Oral Surg* 15:215, 1977.
125. Pogrel MA: The use of liquid nitrogen cryotherapy in the management of locally aggressive bone lesions, *J Oral Maxillofac Surg* 51:269, 1993.
126. Salmassy DA, Pogrel MA: Liquid nitrogen cryosurgery and immediate bone grafting in the management of aggressive primary jaw lesions, *J Oral Maxillofac Surg* 55:784, 1995.
127. Gorlin RJ: Potentialities of oral epithelium manifest by mandibular dentigerous cysts, *Oral Surg Oral Med Oral Pathol* 10:271, 1957.
128. Spouge JD: Sebaceous metaplasia in the oral cavity occurring in association with dentigerous cyst epithelium, *Oral Surg Oral Med Oral Pathol* 21:492, 1966.
129. Reeve CM, Wentz FM: The prevalence, morphology, and distribution of epithelial rests in the human periodontal ligament, *Oral Surg Oral Med Oral Pathol* 15:785, 1962.
130. Standish SM, Shafer WG: The lateral periodontal cyst, *J Periodontal* 29:27, 1958.
131. Bhaskar SN: Gingival cyst and the keratinizing ameloblastoma, *Oral Surg Oral Med Oral Pathol* 19:79, 1965.
132. Wysocki GP, Brannon RB, Gardner DC, et al.: Histogenesis of the lateral periodontal cyst of the adult, *Oral Surg* 50:327, 1980.
133. Weathers DR, Waldron CA: Unusual multilocular cysts of the jaws (botryoid odontogenic cysts), *Oral Surg* 36:235, 1973.
134. Kaugers GE: Botryoid odontogenic cyst, *Oral Surg* 62:555, 1986.

135. Greer RO, Johnson M: Botryoid odontogenic cyst: clinicopathologic analysis of ten cases with three recurrences, *J Oral Maxillofac Surg* 46:574, 1988.
136. Phelan JA, Kritchman D, Fusco-Ramer M, et al.: Recurrent botryoid odontogenic cyst (lateral periodontal cyst), *Oral Surg* 66:345, 1988.
137. Abrams AM, Howell FV: Calcifying epithelial odontogenic tumor: report of 4 cases, *J Am Dent Assoc* 74:1231, 1967.
138. Krolls SO, Pindborg JJ: Calcifying epithelial odontogenic tumor, *Arch Pathol* 98:206, 1974.
139. Smith RA, Roman RS, Hansen LS, et al.: The calcifying epithelial odontogenic tumor, *J Oral Surg* 35:160, 1977.
140. Müller H, Slootweg P: Clear cell differentiation in an ameloblastoma, *J Maxillofac Surg* 14:158, 1986.
141. Eversole LR, Belton C, Hansen LS: Clear cell odontogenic tumor: histochemical and ultrastructural features, *J Oral Pathol* 14:603, 1985.
142. Hansen LS, Eversole LR, Green TL, et al.: Clear cell odontogenic tumor: a new histologic variant with aggressive potential, *Head Neck Surg* 8:115, 1985.
143. Eversole LR, Duffey DC, Powell NB: Clear cell odontogenic carcinoma: a clinicopathologic analysis, *Arch Otolaryngol Head Neck Surg* 121:685, 1995.
144. Bang G, Koppang HS, Hansen LS, et al.: Clear cell odontogenic carcinoma-report of three cases with pulmonary and lymph node metastasis, *J Oral Pathol Med* 18:113, 1989.
145. Fan J, Kubota E, Imamura H, et al.: Clear cell odontogenic carcinoma—a case report with massive erosion of neighboring organs and lymph node metastasis, *Oral Surg Oral Med Oral Pathol* 74:768, 1992.
146. Milles M, Dogle JL, Mesa M, et al.: Clear cell odontogenic carcinoma with lymph node metastasis, *Oral Surg Oral Med Oral Pathol* 76:82, 1993.
147. Batsakis JG: Clear cell tumors of salivary glands, *Ann Otol Rhinol Laryngol* 89:196, 1980.
148. Shear M: Primary intra-alveolar epidermoid carcinoma of the jaw, *J Pathol* 97:645, 1969.
149. Gardner A: The odontogenic cyst as a potential carcinoma—a clinicopathologic appraisal, *J Am Dent Assoc* 78:746, 1969.
150. Eversole LR, Sabes WR, Rovin S: Aggressive growth and neoplastic potential of odontogenic cysts with special reference to central epidermoid and mucoepidermoid carcinomas, *Cancer* 35:270, 1975.
151. Elzay RP: Primary intraosseous carcinoma of the jaws. Review and update of odontogenic carcinomas, *Oral Surg* 54:299, 1982.
152. Waldron CA, Mustoe TA: Primary intraosseous carcinoma of the mandible with probable origin in an odontogenic cyst, *Oral Surg Oral Med Oral Pathol* 67:716, 1989.
153. Kay LW, Kramer IR: Squamous cell carcinoma arising in dental cyst, *Oral Surg Oral Med Oral Pathol* 15:970, 1962.
154. Kramer HS, Scribner JH: Squamous cell carcinoma arising in a dentigerous cyst, *Oral Surg Oral Med Oral Pathol* 19:555, 1965.
155. Lee KW, Loke SJ: Squamous cell carcinoma arising in a dentigerous cyst, *Cancer* 20:2241, 1967.
156. Chretien PB, Carpenter DF, White NS, et al.: Squamous carcinoma arising in a dentigerous cyst: presentation of a fatal case and review of four previously reported cases, *Oral Surg* 30:809, 1970.
157. Berenholz L, Gottlieb RD, Cho SY, et al.: Squamous cell carcinoma arising in a dentigerous cyst, *Ear Nose Throat J* 67:764, 1988.
158. Maxymiw WG, Wood RE: Carcinoma arising in a dentigerous cyst: a case report and review of the literature, *J Oral Maxillofac Surg* 49:639, 1991.
159. Johnson LM, Sapp JP, McIntire DN: Squamous cell carcinoma arising in a dentigerous cyst, *J Oral Maxillofac Surg* 52:987, 1994.
160. Manganaro AM, Cross SE, Startzell JM: Carcinoma arising in a dentigerous cyst with neck metastases, *Head Neck* 19(5):436, 1997.
161. Browne RM, Gough NG: Malignant change in the epithelium lining odontogenic cysts, *Cancer* 29:1199, 1972.
162. Martinelli C, Melhado RM, Callastini EA: Squamous cell carcinoma in a residual mandibular cyst, *Oral Surg* 44:274, 1977.
163. Areen RG, McClatche KD, Baker HL: Squamous cell carcinoma developing in an odontogenic keratocyst, *Arch Otolaryngol* 107:568, 1981.
164. Minic AJ: Primary intraosseous squamous cell carcinoma arising in a mandibular keratocyst, *Int J Oral Maxillofac Surg* 21:163, 1992.
165. Ikemura K, Horie A, Tashiro H, et al.: Simultaneous occurrence of a calcifying odontogenic cyst and its malignant transformation, *Cancer* 56:2861, 1985.
166. Ellis GL, Shmookler BM: Aggressive (malignant) epithelial odontogenic ghost cell tumor, *Oral Surg Oral Med Oral Pathol* 61:471, 1986.
167. Grodjesk JC, Dolinsky HB, Schneider LC, et al.: Odontogenic ghost cell carcinoma, *Oral Surg Oral Med Oral Pathol* 63:576, 1987.
168. Suei Y, Tanimoto K, Taguchi A, et al.: Primary intraosseous carcinoma—a review of the literature and diagnostic criteria, *J Oral Maxillofac Surg* 52:580, 1994.
169. Regezi JA, Kerr DA, Courtney RM: Odontogenic tumors: analysis of 706 cases, *J Oral Surg* 36:771, 1978.
170. Gorlin RJ, Meskin LH, Brodey R: Odontogenic tumors in man and animals: pathologic classification and clinical behavior—a review, *Ann NY Acad Sci* 108:722, 1963.
171. Gorlin RJ: Odontogenic tumors. In ed 6, Gorlin RJ, Goldman HM, editors: *Thoma's oral pathology*, vol. 1. St Louis, 1970, CV Mosby.
172. Handlers JP, Abrams AM, Melrose RJ, et al.: Central odontogenic fibroma: clinicopathologic features of 19 cases and review of the literature, *J Oral Maxillofac Surg* 49:46, 1991.
173. Doyle JL, Lamster IB, Baden E: Odontogenic fibroma of the complex (WHO) type: report of six cases, *J Oral Maxillofac Surg* 43:666, 1985.
174. Dahl EC, Wolfson SH, Haugen JC: Central odontogenic fibroma: review of literature and report of cases, *J Oral Surg* 39:120, 1981.
175. Dunlap CL, Barker BF: Central odontogenic fibroma of the WHO type, *Oral Surg* 57:390, 1984.
176. Mallow RD, Spatz SS, Zubrow HJ, et al.: Odontogenic fibroma with calcification, *Oral Surg Oral Med Oral Pathol* 22:564, 1966.
177. Farman AG: The peripheral odontogenic fibroma, *Oral Surg* 40:82, 1975.
178. Buchner A: Peripheral odontogenic fibroma—report of five cases, *J Craniomaxillofac Surg* 17:134, 1989.
179. de Viller Slabbert H: Altini M: Peripheral odontogenic fibroma: a clinicopathologic study, *Oral Surg Oral Med Oral Pathol* 72:86, 1991.
180. Daley TD, Wysocki GP: Peripheral odontogenic fibroma, *Oral Surg Oral Med Oral Pathol* 78:329, 1994.

181. Baden E, Moskow BS, Moskow R: Odontogenic gingival epithelial hamartoma, *J Oral Surg* 26:614, 1968.
182. Gardner DG: The central odontogenic fibroma—an attempt at clarification, *Oral Surg* 50:425, 1980.
183. Gardner DG: The peripheral odontogenic fibroma: an attempt at clarification, *Oral Surg* 54:40, 1982.
184. Heimdal A, Isacsson G, Nisson L: Recurrent central odontogenic fibroma, *Oral Surg* 50:140, 1980.
185. Regezi JA, Sciubba J: *Oral pathology*, ed 2, Philadelphia, 1993, Saunders. Chapter 11.
186. Eversole LR: Craniofacial fibrous dysplasia and ossifying fibroma in surgical pathology: fibro-osseous disease, *Oral Maxillofac Surg Clin N Am* 9:625, 1997.
187. Melrose RJ: The clinico-pathologic spectrum of cemento-osseous dysplasia in surgical pathology: fibro-osseous diseases, *Oral Maxillofac Surg Clin N Am* 9:643, 1997.
188. Abrams AM, Kirby JW, Melrose RJ: Cementoblastoma—a clinical-pathologic study of seven new cases, *Oral Surg* 38:394, 1974.
189. Sciubba JJ, Fantasia JE, Kahn LB: Tumors and cysts of the jaw. Armed Forces Institute of Pathology, Fascicle 29:109-112, 2001.
190. Berwick JE, Mayni GF, Berkland ME: Benign cementoblastoma: a case report, *J Oral Maxillofac Surg* 48:208, 1990.
191. Fujita S, Takahashi H, Okabe H, et al.: A case of benign cementoblastoma, *Oral Surg Oral Med Oral Pathol* 68:64, 1989.
192. Wertheimer FW, Driscoll EJ, Stanley HR: "True" (attached) cementoma with root canal involvement: report of a case, *Oral Surg Oral Med Oral Pathol* 14:630, 1961.
193. Corio RL, Crawford BE, Schaberg SJ: Benign cementoblastoma, *Oral Surg* 41:524, 1976.
194. Larsson A, Forsberg O, Sjögren S: Benign cementoblastoma, cementum analogue of benign osteoblastoma, *J Oral Surg* 36:299, 1978.
195a. Goerig AC, Fay JT, King E: Endodontic treatment of a cementoblastoma: report of a case, *Oral Surg* 58:113, 1984.
195b. Brannon RB, Fowler CB, Carpenter WM, et al.: Cementoblastoma: an innocuous neoplasm? A clinicopathologic study of 44 cases and review of the literature with special emphasis on recurrence, *Oral Surg Oral Med Oral Pathol* 93:311, 2002.
196. Dahlin DC: *Bone tumors: general aspects and data on 3987 cases*, ed 2, Springfield, IL, 1967, Charles C. Thomas.
197. Colburn JF, Epker BN: Myxoma of the mandibular condyle—surgical excision with immediate reconstruction, *J Oral Surg* 33:351, 1975.
198. Marcove RC, Kambolis C, Bullogh PG, et al.: Fibromyxoma of bone: a report of 3 cases, *Cancer* 17:1209, 1964.
199. Farman AG, Nortjé CT, Grotepass FW, et al.: Myxofibroma of the jaws, *Br J Oral Surg* 15:3, 1977–1978.
200. James DR, Lucas VS: Maxillary myxoma in a child of 11 months, *J Craniomaxillofac Surg* 15:42, 1987.
201. Keszler A, Dominguez FV, Giannunzio G: Myxoma in childhood: an analysis of 10 cases, *J Oral Maxillofac Surg* 53:518, 1995.
202. Barros RE, Dominguez FV, Cabrini RL: Myxoma of the jaws, *Oral Surg Oral Med Oral Pathol* 27:225, 1969.
203. Bojrab DG, Topazian RG: Large myxoma of the mandible, *J Oral Surg* 29:371, 1971.
204. Zimmerman DC, Dahlin DC: Myxomatous tumors of the jaws, *Oral Surg Oral Med Oral Pathol* 11:1069, 1958.
205. Slootweg PJ, Wittkampf ARM: Myxoma of the jaws, *J Maxillofac Surg* 14:46, 1986.
206. Hooker SP: Ameloblastic odontoma—an analysis of twenty-six cases (abstract), *Oral Surg* 24:375, 1967.
207. Spouge JD: Odontogenic tumors, *Oral Surg Oral Med Oral Pathol* 24:392, 1967.
208. Eversole LR, Tomich CE, Cherrick HM: Histogenesis of odontogenic tumors, *Oral Surg* 32:569, 1971.
209. Slootweg PJ: An analysis of the interrelationship of the mixed odontogenic tumors—ameloblastic fibroma, ameloblastic fibro-odontoma, and the odontoma, *Oral Surg* 51:266, 1981.
210. Gardner DG: The mixed odontogenic tumors, *Oral Surg* 58:166, 1984.
211. Hansen LS, Ficarra G: Mixed odontogenic tumors—an analysis of 23 new cases, *Head Neck Surg* 10:330, 1988.
212. Gorlin RJ, Pindborg JS, Clausen FP, et al.: The calcifying odontogenic cyst—a possible analogue of the cutaneous calcifying epithelioma of Malherbe. An analysis of 15 cases, *Oral Surg Oral Med Oral Pathol* 15:1235, 1962.
213. Gold L: The keratinizing and calcifying odontogenic cyst, *Oral Surg Oral Med Oral Pathol* 16:1414, 1963.
214. Frissell CT, Shafer WG: Ameloblastic odontoma, *Oral Surg* 6:1129, 1953.
215. Silva CA: Odontoameloblastoma, *Oral Surg* 9:545, 1959.
216. Forsberg A, Lagergren C, Märtensson G: Ameloblastic odontoma: report of a case, *Oral Surg Oral Med Oral Pathol* 14:726, 1961.
217. Caruso WR, Itkin A: Ameloblastic odontoma: report of a case, *Oral Surg Oral Med Oral Pathol* 16:582, 1963.
218. Choukas NC, Toto PD: Ameloblastic odontoma, *Oral Surg Oral Med Oral Pathol* 17:10, 1964.
219. Olech E, Alvares O: Ameloblastic odontoma, *Oral Surg Oral Med Oral Pathol* 23:487, 1967.
220. Jacobson PH, Quinn JH: Ameloblastic odontoma: report of 3 cases, *Oral Surg Oral Med Oral Pathol* 26:829, 1968.
221. Dutta A: Ameloblastic odontoma, *Oral Surg* 29:827, 1970.
222. Worley RD, McKee PE: Ameloblastic odontoma. Report of case, *J Oral Surg* 30:764, 1972.
223. Kaugars GE, Zussmann HW: Ameloblastic odontoma, *Oral Surg* 71:371, 1991.
224. La Briola JD, Steiner M, Bernstein ML, et al.: Odontoameloblastoma, *J Oral Surg* 38:139, 1980.
225. Trodahl JN: Ameloblastic fibroma: a survey of cases from the Armed Forces Institute of Pathology, *Oral Surg* 33:547, 1972.
226. Mosley EL, Russell D, Noren S, et al.: Ameloblastic fibroma in a 7-week-old infant—a case report and review of the literature, *J Oral Maxillofac Surg* 56:368, 1998.
227. Grenfell JW, Maris AM: Ameloblastic fibroma: report of a case, *Oral Surg Oral Med Oral Pathol* 21:403, 1966.
228. Tanaka S, Mitsui Y, Mizuno Y, et al.: Recurrent ameloblastic fibroma, *Oral Surg* 33:944, 1972.
229. Carr RF, Halperin V, Wood C, et al.: Recurrent ameloblastic fibroma, *Oral Surg* 29:85, 1970.
230. Sawyer DR, Nwoku AL, Mosadomi A: Recurrent ameloblastic fibroma, *Oral Surg* 53:19, 1982.
231. Monteil RA, Le Bas V, Favot C, et al.: Stereologic analysis of histologic parameters of a twice-recurrent ameloblastic fibroma, *Oral Surg* 61:168, 1986.
232. Zallen RD, Preskar MH, McClary SA: Ameloblastic fibroma, *J Oral Maxillofac Surg* 40:513, 1982.
233. Miller AS, Lopez A-CF, Pullon PA, et al.: Ameloblastic fibro-odontoma: report of seven cases, *Oral Surg* 41:354, 1976.
234. Piette EMG, Tideman H, Wu PC: Massive maxillary ameloblastic fibro-odontoma—case report with surgical management, *J Oral Maxillofac Surg* 48:526, 1990.

235. Howell RM, Burkes Jr EJ: Malignant transformation of ameloblastic fibro-odontoma to ameloblastic fibrosarcoma, *Oral Surg* 43:391, 1977.
236. Sciubba JJ, Fantasia JE, Kahn LB: *Tumors and cysts of the jaw*, Washington, DC, 2001, Armed Forces Institute of Pathology.
237. Philipsen HP, Reichart PA, Praetorius F: Mixed odontogenic tumors and odontomas. Considerations on interrelationship, *Oral Oncol* 33:86, 1997.
238. Ulmansky M, Bodner L, Praetorious F, et al.: Ameloblastic fibrodentinoma—report on two new cases, *J Oral Maxillofac Surg* 52:980, 1994.
239. Azaz B, Ulmansky M, Lewin-Epstein J: Dentinoma—report of a case, *Oral Surg Oral Med Oral Pathol* 24:659, 1967.
240. Akal ÜK, Günham Ö, Güler M: Ameloblastic fibrodentinoma: report of two cases, *Int J Oral Maxillofac Surg* 26:455, 1997.
241. Anker AH, Radden BG: Dentinoma of the mandible, *Oral Surg Oral Med Oral Pathol* 67:731, 1989.
242. Lukinmaa P-L, Hietanen J, Laitinen JM, et al.: Mandibular dentinoma, *J Oral Maxillofac Surg* 45:60, 1987.
243. Gulman S, Adams RJ, Boggiano JJ: "Dentinoma" of the mandible, *Oral Surg* 34:921, 1976.
244. Manning GL, Browne RM: Dentinoma, *Br Dent J* 128:178, 1970.
245. Pindborg JJ: Ameloblastic sarcoma in the maxilla: report of a case, *Cancer* 13:917, 1960.
246. Cina MT, Dahlin DC, Gores RJ: Ameloblastic sarcoma: report of two cases, *Oral Surg Oral Med Oral Pathol* 15:695, 1962.
247. Leider AS, Nelson JF, Trodahl JN: Ameloblastic fibrosarcoma of the jaws, *Oral Surg* 33:559, 1972.
248. Altini M, Thompson SH, Lownie JF, et al.: Ameloblastic sarcoma of the mandible, *J Oral Maxillofac Surg* 43:789, 1985.
249. Muller RM, Parker DC, Kapadia SB, et al.: Ameloblastic fibrosarcoma of the jaws, *Oral Surg Oral Med Oral Pathol* 79:459, 1995.
250. Cataldo E, Nathanson N, Shklar G: Ameloblastic sarcoma of the mandible, *Oral Surg Oral Med Oral Pathol* 16:953, 1965.
251. Goldstein G, Parker FP, Fitzhugh GS: Ameloblastic sarcoma. Pathogenesis and treatment with chemotherapy, *Cancer* 37:1673, 1976.
252. Takeda V, Kaneko R, Suzuki A: Ameloblastic fibrosarcoma in the maxilla, malignant transformation of ameloblastic fibroma, *Virchows Arch* 404:253, 1984.
253. Park HR, Shin KB, Sol MY: A highly malignant ameloblastic fibrosarcoma, *Oral Surg Oral Med Oral Pathol* 79:478, 1995.

19

Benign Non-odontogenic Lesions of the Jaws

BRIAN L. SCHMIDT

Lesions Containing Multinucleated Giant Cells

Jaw lesions that microscopically contain giant cells include the giant cell granuloma, the giant cell tumor, hyperparathyroidism, cherubism, and the aneurysmal bone cyst. All of these jaw lesions are identical histologically and must be distinguished based on clinical, radiographic, and biochemical means.

Central Giant Cell Granuloma

The central giant cell granuloma represents a benign proliferation of fibroblasts and multinucleated giant cells. Despite early references to the lesion as a "giant cell reparative granuloma," progression is likely without treatment.[1,2] The precise nature of the central giant cell granuloma remains speculative. It has been suggested that it may be an inflammatory lesion, a reactive lesion, a neoplasm, or an endocrine lesion. The proliferating cell in this lesion is the fibroblast, which is believed to produce cytokines, resulting in the recruitment of monocytes, which subsequently transform into multinucleated giant cells. Immunohistochemistry has shown the giant cells to be osteoclasts.[3] There is also debate on whether the central giant cell granuloma is unique to the jaws or whether it represents a continuum of the same disease process as giant cell tumors affecting the long bones, which are discussed later in this chapter.

Central giant cell granulomas of the jaws are most often found in children and young adults, with up to 75% of cases occurring before 30 years of age. Females are affected twice as frequently as males. The lesion most often occurs anterior to the first permanent molar teeth. The mandible is affected three times more frequently than the maxilla, and the lesion may be seen to cross the midline. There are two types of central giant cell granulomas based on biologic behavior and radiographic features. Chuong, Kaban, and colleagues formalized a classification system that also provides a guide for treatment.[4] The aggressive form has three of the following criteria: greater than 5 cm, rapid growth, root resorption, tooth displacement, cortical bone thinning, cortical bone perforation, and recurrence after curettage (Table 19-1; Figure 19-1).

A giant cell lesion that is larger than 5 cm and/or recurs after curettage is aggressive based on these characteristics alone. The nonaggressive lesion is asymptomatic, grows slowly, and does not produce cortical perforation or root resorption. Presently, there are no molecular methods of differentiating the aggressive form from the nonaggressive type, and the clinician is dependent on the history, physical examination, plain radiographs, and computed tomography with contrast. Radiographically, central giant cell granulomas may present as a unilocular or multilocular radiolucency that is usually well delineated.

Histologically, the central giant cell granuloma contains few to many multinucleated giant cells in a background of fibroblasts with varying amounts of collagen. The multinucleated giant cells are often focally aggregated; however, they may be evenly distributed. Hemosiderin-laden macrophages and extravasated erythrocytes are commonly seen. Foci of osteoid may be seen, particularly at the periphery of the lesion. These histopathologic features are similar, if not identical, to those seen in the brown tumor of hyperparathyroidism and cherubism.

Treatment regimens have varied over the past two decades, and a single effective treatment strategy for lesions does not exist. For years surgical curettage has been the treatment of choice; however, curettage alone is associated with a 30% to 70% recurrence rate for aggressive lesions.[5] The lack of a single effective treatment is the consequence of varied biologic behavior among central giant cell granulomas. Treatment regimens should be guided by the classification of the lesion as either

TABLE 19-1 Criteria for Classifying Giant Cell Lesions of the Jaws

	Aggressive	Nonaggressive
Lesion size	≥5 cm	<5 cm
Rapid growth	Yes	No
Root resorption	Often	No
Tooth displacement	Often	No
Cortical bone perforation	Often	No
Recurrence after curettage	Yes	No

Adapted from Chuong R, Kaban LB, Kozakewich H, Perez-Atayde A: Central giant cell lesions of the jaws: a clinicopathologic study, *J Oral Maxillofac Surg* 44: 708-713, 1986.

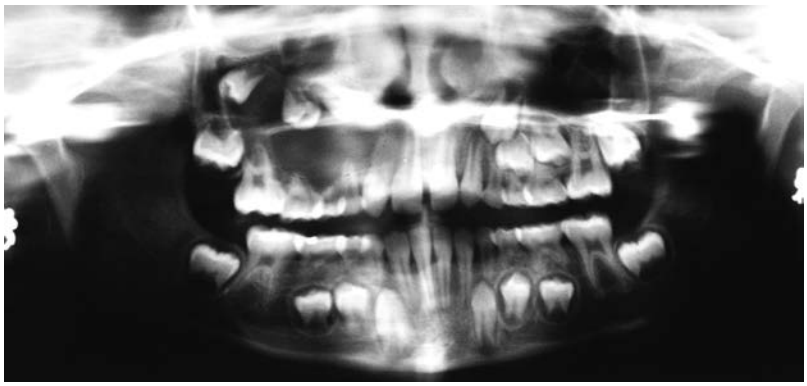

• **Figure 19-1** Central giant cell granuloma. The lesion involves the right maxilla in a 9-year-old girl with root resorption and tooth displacement.

aggressive or nonaggressive. For an aggressive giant cell lesion, resection with histologically clear margins is generally effective treatment.[4] Recurrence risk and the fact that with large lesions even conservative curettage may be associated with the loss of teeth, damage to the inferior alveolar nerve, and sinus and nasal implications has led to the development of several nonsurgical and adjuvant treatments. The first nonsurgical treatment proposed was intralesional corticosteroid injections.[6] Weekly injections of triamcinolone for 6 weeks have been shown to induce partial and in some cases complete resolution of the lesions.[6-9] The mechanism of action for steroid treatment of giant cell lesions remains unknown. In 1993, Harris reported on the management of aggressive central giant cell granulomas with subcutaneous calcitonin injections.[10] Human calcitonin 0.5 mg (100 IU) was administered subcutaneously for 1 year. Subsequent reports by Pogrel, who administered calcitonin for approximately 18 months, have confirmed the efficacy of this method (Figure 19-2).[11-13]

A double-blind placebo-controlled study evaluating the efficacy of calcitonin in the management of the central giant cell granuloma found no difference between calcitonin and placebo.[14] The mode of action of calcitonin remains speculative; however, some of the giant cells in these lesions have been shown to have calcitonin receptors.[13] Thus, the therapeutic effect of calcitonin may be mediated through inhibition of osteoclastogenesis. In 1999, Kaban and colleagues reported on the management of an aggressive giant cell lesion with interferon alpha-2a following two failed resections. Alpha-interferon given by subcutaneous injection following enucleation has clearly documented efficacy.[5,15] The lesion is enucleated with preservation of teeth and the inferior alveolar nerve. One to 2 days following enucleation, interferon alpha-2b is started at a dose of 3,000,000 units/m^2 injected subcutaneously per day. Interferon treatment is continued for 6 months or until there is evidence of complete regeneration of the defect based on a computed tomography (CT) scan. The rationale for this therapy is that the antiangiogenic action of the alpha-interferon will suppress the angiogenic component of the lesion, resulting in resolution. For aggressive giant cell lesions, two likely effective treatment regimens are resection with histologically clear margins or the combination of enucleation followed by interferon therapy. In most cases surgery is still required after the alpha-interferon treatment; however, it may be less radical, and there may be a reduced recurrence rate.

Denosumab (Xgeva, Amgen, Thousand Oaks, CA; Prolia, Bioscience Technology, Rockaway, NJ) is a human monoclonal antibody that binds receptor activator of nuclear factor-κB ligand (RANKL). Denosumab is FDA

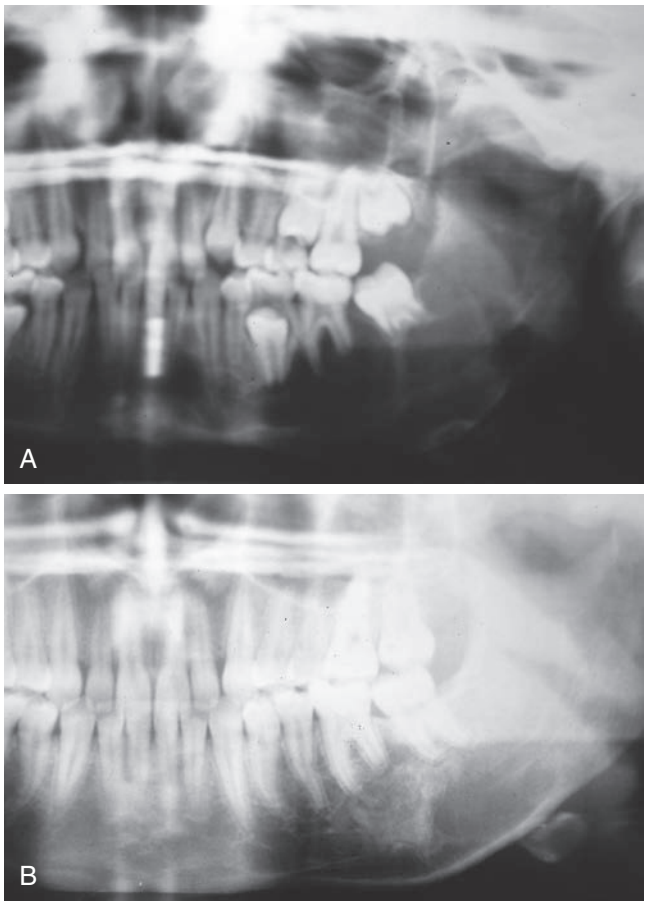

• **Figure 19-2** Central giant cell granuloma treated with calcitonin. **A,** Left mandibular lesion in a 9 year-old. **B,** Significant resolution after 18 months of calcitonin with continued root development of the lower left second molar and eruption of the lower left second premolar. (**A** from Pogrel MA: Calcitonin therapy for central giant cell granuloma. *J Oral Maxillofac Surg* 61:651, 2003. **B** Courtesy Dr. M. Anthony Pogrel.)

approved and has been used for treatment of osteoporosis in postmenopausal women. Experience with denosumab in the management of central giant cell granuloma is limited; however, the drug shows promise in reducing lesion size.[16]

Giant Cell Tumor

The giant cell tumor normally found in long bones is an aggressive lesion that some believe is a variant of low-grade osteosarcoma. This tumor is generally believed to be an entity that is separate from the central giant cell granuloma of the jaws, although, according to some authorities it rarely occurs in the jaws. Histologically, it is very similar to the central giant cell granuloma, although the giant cells are larger with more nuclei and are more evenly distributed, the stroma is more cellular, and there may be areas of necrosis. However, in any particular case it may be difficult to make a distinction. The recurrence rate of giant cell tumors in long bones following curettage is higher than for central giant cell granulomas of the jaws, leading some authorities to advocate resection.

Hyperparathyroidism

Hyperparathyroidism is characterized by the overproduction of parathyroid hormone (PTH). Primary hyperparathyroidism (HPT) is the uncontrolled production of PTH as the result of a parathyroid adenoma, hyperplasia, or rarely an adenocarcinoma. Primary HPT is most commonly seen in postmenopausal women, with a female-male ratio of 3:1. Secondary hyperparathyroidism occurs in response to hypocalcemia, most often as a result of chronic renal failure. In both forms of hyperparathyroidism, excess PTH levels stimulate osteoclast-mediated bone resorption, which may produce a focal bone lesion known as a brown tumor of hyperparathyroidism. The lesion derives its name from the color of the tissue as seen on surgical exploration, which is a result of erythrocyte extravasation and hemosiderin deposition within the lesion, as well as fibrous replacement of the bone marrow.

Like the central giant cell granuloma, the brown tumor of hyperparathyroidism lesion appears radiographically as a well-defined unilocular or multilocular radiolucency. Loss of the lamina dura occurs in about 80% of patients with hyperparathyroidism who present with brown tumors and helps to distinguish jaw lesions due to hyperparathyroidism and lesions representing primary jaw tumors.[17] Loss of the radiopaque lamina dura gives a characteristic "floating teeth" appearance to dental films (Figure 19-3). The changes in bone observed with hyperparathyroidism include mild bone pain without radiologic findings, mild osteopenia, or osteitis fibrosa cystica, which is characterized by a constellation of severe changes, including diffuse subperiosteal resorption, multiple bone cysts, and brown tumors. The most common sites of brown tumors are the ribs, clavicles, pelvic girdle, and mandible. When a brown tumor occurs in the mandible, patients complain of localized jaw pain and swelling, bleeding from the gums, and loose teeth. The maxilla is an uncommon site for brown tumors.

The radiographic differential diagnosis of multiple mandibular radiolucencies includes brown tumors and other clinical entities that have distinct histologic appearances, such as Langerhans cell disease (which can also cause loss of lamina dura on dental films), primary or metastatic cancers, multiple odontogenic keratocysts as part of nevoid basal cell carcinoma syndrome, ossifying fibromas, and jaw osteomas of Gardner syndrome.

Before the advent of inexpensive assays for calcium and phosphorus in the 1950s and 1960s, brown tumors were commonly seen as the presenting symptom of hyperparathyroidism.[17] However, with current widespread screening for calcium and phosphorus abnormalities, as well as parathyroid hormone, most cases of hyperparathyroidism are detected in asymptomatic patients. Before the diagnosis of primary hyperparathyroidism is made, hyperparathyroidism secondary to renal failure should be ruled out. In the case of secondary hyperparathyroidism, appropriate laboratory values will demonstrate impaired renal function and hypocalcemia. A 24-hour urinary calcium level should be

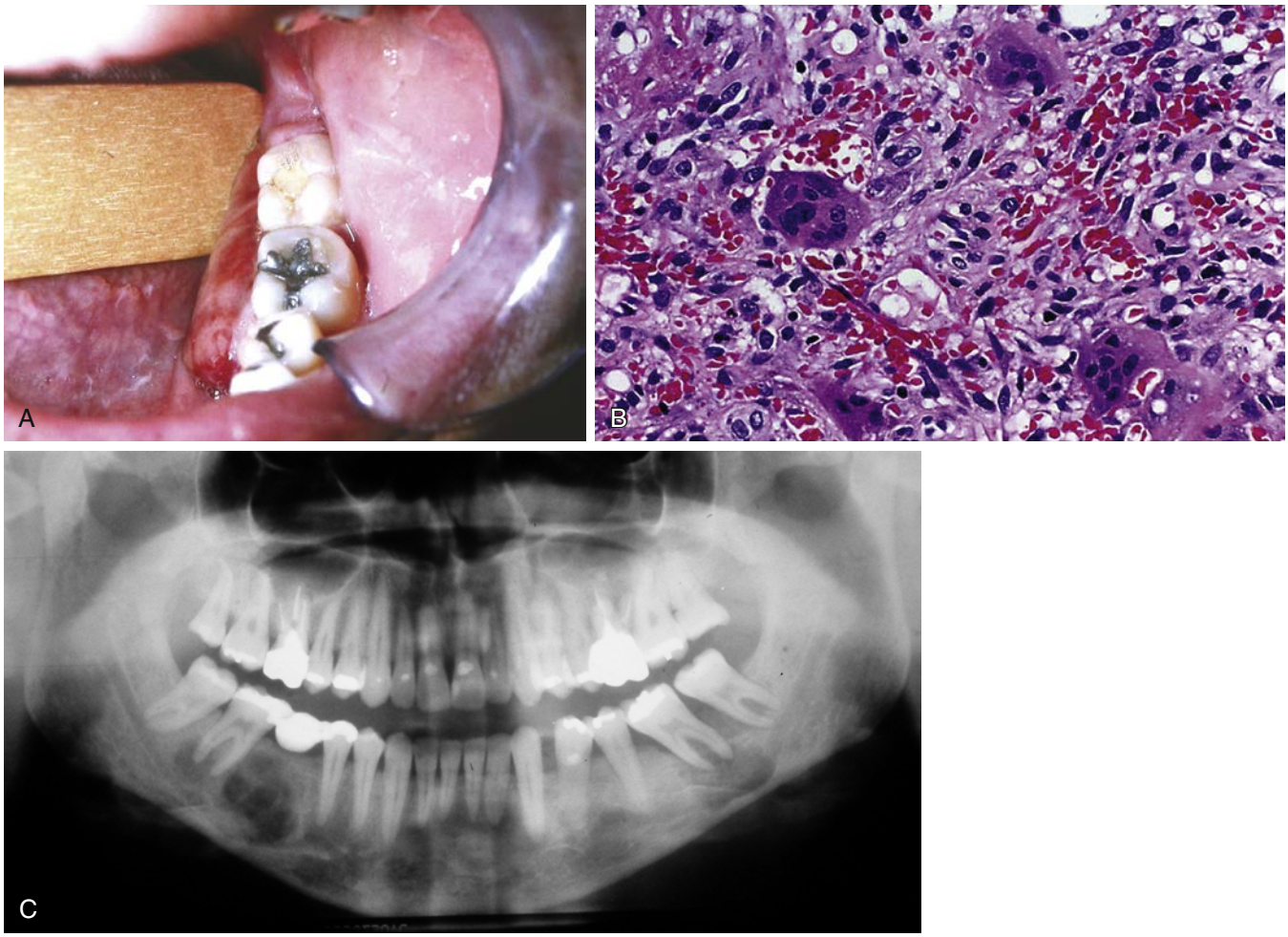

• **Figure 19-3** Hyperparathyroidism. **A,** Left mandibular gingival lesion in a 30-year-old woman with hyperparathyroidism. The associated mandibular molars were mobile. **B,** A biopsy of the gingival lesion revealed spindle-shaped fibroblastic cells, extravasated red blood cells, and giant cells in varying shape and distribution. **C,** The panoramic radiograph demonstrated multiple radiolucencies in the mandible.

measured to rule out benign familial hypocalciuric hypercalcemia, a hereditary condition that leads to hyperparathyroidism because of low renal sensitivity to parathyroid hormone. As opposed to patients with primary hyperparathyroidism, patients with benign familial hypocalciuric hypercalcemia do not benefit from parathyroidectomy.[18] Brown tumors can be seen in primary hyperparathyroidism or in secondary hyperparathyroidism related to renal failure. Because there are a number of familial hyperparathyroidism syndromes, a family history should be elicited. Hyperparathyroidism can occur as part of a multiple endocrine syndrome (multiple endocrine neoplasia type 1 or 2A) or as the hyperparathyroidism–jaw tumor syndrome. Hyperparathyroidism–jaw tumor syndrome is an autosomal dominant disease that is characterized by either adenoma or carcinoma (in 10%-15% of patients) of the parathyroid, fibro-osseous lesions of the jaws, renal cysts, and tumors. Eighty percent of patients with the syndrome will present with hyperparathyroidism.[19] Hyperparathyroidism–jaw tumor syndrome was recently shown to be caused by a mutation in tumor-suppresser gene *HRPT2* (also known as *CDC73*).[19,20] This tumor suppressor gene encodes a protein parafibromin.[19] *CDC73* mutations have dominant germline gene behavior and variable penetration. The jaw tumors of this syndrome, interestingly, are not giant cell tumors and thus occur by a mechanism distinct from hyperparathyroidism. Forty percent of patients with the syndrome will develop jaw tumors, including ossifying fibromas, that are distinct from the brown tumors secondary to hyperparathyroidism.

Histologically, the giant cell lesions associated with hyperparathyroidism are characterized by proliferation of spindle-shaped fibroblastic cells, extravasated red blood cells from hemorrhage, hemosiderin deposits, and trabeculae of new bone formation. CD68-positive giant cells can be present in varying shape, distribution, and number and are consistent with increased osteoclast activity.

Patients with primary hyperparathyroidism will be hypercalcemic, with associated signs and symptoms including fatigue, weakness, memory loss, depression, renal symptoms (polyuria, polydipsia, renal stones), constipation, abdominal pain, and pancreatitis. In contrast, those with secondary hyperparathyroidism will be hypocalcemic and

those with central giant cell granulomas will have normal serum calcium levels. Elevated serum PTH levels are associated with both forms of hyperparathyroidism. Normal PTH levels are found in association with central giant cell granulomas. Therefore, serum calcium and PTH levels should be obtained in patients with giant cell lesions in order to exclude hyperparathyroidism. If a diagnosis of hyperparathyroidism is confirmed, treatment must be aimed at the cause (parathyroidectomy). Brown tumors of primary hyperparathyroidism are treated with surgical removal of the abnormal parathyroid tissue and normalization of parathyroid hormone levels. Typically the brown tumors will regress after the hyperparathyroidism has been successfully corrected.[17,21,22] Surgical excision of the brown tumor itself is generally not recommended. Complete healing of the affected bone, however, can be delayed as much as 5 years with conservative management.[23] Thus, surgical resection of lesions that are large, symptomatic, or at risk for pathologic fracture might be indicated.

Cherubism

Cherubism is a rare hereditary condition characterized by painless, bilateral, symmetrical expansion of the embryologic mandible and maxilla. It was first described in 1933, when it was named familial multilocular cystic disease of the jaws.[24] It follows an autosomal dominant pattern of inheritance with 100% penetrance in males, 50-75% penetrance in females, and variable expressivity. There is a 2-to-1 male predominance. Sporadic cases have also been reported in up to 40% of cases. The genetic defect has been mapped to chromosome 4p16.3,[25,26] which encodes the binding protein SH3BP2.[27-29] Recently, work with murine genetic models has suggested that infection and activated macrophages might be driving development and progression of cherubism.[30]

The lesions of cherubism commonly begin to manifest as painless, bilateral, symmetric expansion of the jaws between 2 and 5 years of age (Figure 19-4), although milder forms may not be detected until a later age. The lesions are confined to the mandible and maxilla and the remaining facial bones are not involved. The regions most often affected are the mandibular angle, ascending ramus, retromolar region, and maxillary tuberosity; however, in severe cases the entire mandible and maxilla may become involved with resultant difficulties with speech and chewing. Middle conchal expansion with maxillary involvement might manifest as difficulty with nasal breathing. Most cases involve the mandible only. On palpation, the affected areas of the jaws are hard. The mandibular condyles are always spared. With involvement of the maxillary contribution to the orbital floor, the globes may be displaced upward, resulting in scleral show. With eyes that appear to be turned upward and a round face, children with a severe form of this condition appear like cherubs depicted in Renaissance paintings. Interference of the developing teeth can lead to missing, malformed, or impacted teeth.



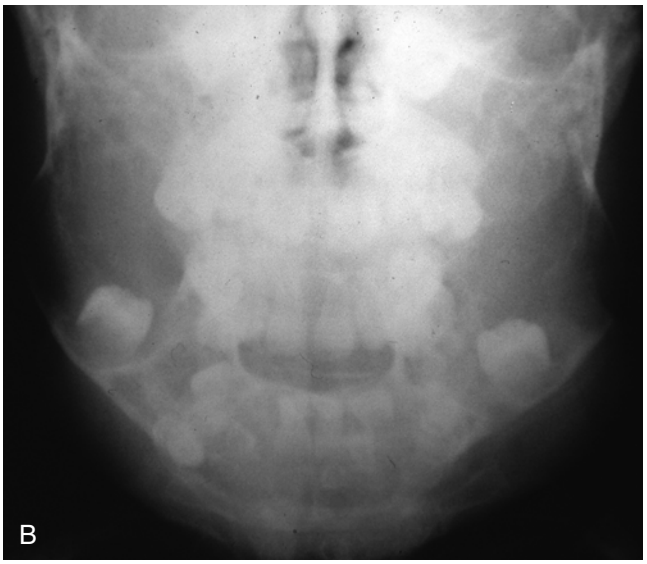

• **Figure 19-4** Cherubism. **A,** Frontal view of a 5-year-old boy with bilateral facial expansion. **B,** Radiolucencies in the mandible bilaterally with sparing of the condyles. (Courtesy Dr. M. Anthony Pogrel.)

Radiographically, the involved bones show multilocular radiolucencies with thin and expanded cortices. There may be premature exfoliation of primary teeth as well as unerupted and displaced permanent teeth on the radiograph. The mandibular condyles will appear normal on radiographs. Histologically, the lesions resemble the central giant cell granuloma. However, some lesions will exhibit eosinophilic perivascular cuffing of collagen surrounding small capillaries throughout the lesion, allowing for differentiation between the two lesions.

The lesions of cherubism tend to enlarge until puberty, at which time they begin to regress. In the majority of cases near-complete resolution of the facial expansion occurs by 30 years of age. Therefore, treatment is usually conservative,

allowing natural regression to occur. If surgical recontouring of expanded bone is necessary, it is best to defer it until after puberty. During childhood and early adolescence, treatment should be directed toward facilitating the eruption of teeth. Despite the histologic similarity of cherubism to central giant cell granuloma, calcitonin has no efficacy in the management of the lesions associated with cherubism.[31]

Aneurysmal Bone Cyst

The aneurysmal bone cyst is a pseudocyst characterized by blood-filled spaces in a connective tissue stroma containing multinucleated giant cells. The lesion was first described by Jaffe and Lichtenstein in 1942.[32] Jaw involvement was first reported in 1958.[33] The lesion occurs most commonly in the long bones and vertebrae. Within the craniofacial complex, it is most common in the mandible, followed by the maxilla. The etiology and pathogenesis of the lesion remain unknown, although the lesion is generally regarded as reactive. Controversy remains over whether the lesion occurs as a primary entity or results from the development of a dilated vascular bed in a preexisting intrabony lesion. Molecular evidence now exists that supports the theory that vascular injury is important in the development of this lesion.[34] There is also controversy as to whether the aneurysmal bone cyst is a distinct entity or whether the lesion is a form of the central giant cell lesion. In the jaws, the aneurysmal bone cyst occurs with other bone disease 22% of the time.[35]

Aneurysmal bone cysts can occur at any age; however, the peak incidence occurs within the second decade of life, with most occurring prior to 30 years of age. There is a slight female predilection. Mandibular and maxillary lesions most frequently occur in the molar regions. Patients often present with facial swelling that may develop fairly rapidly and can be associated with pain; however, often the lesions are asymptomatic (Figure 19-5). The lesion usually appears radiographically as a multilocular radiolucency,

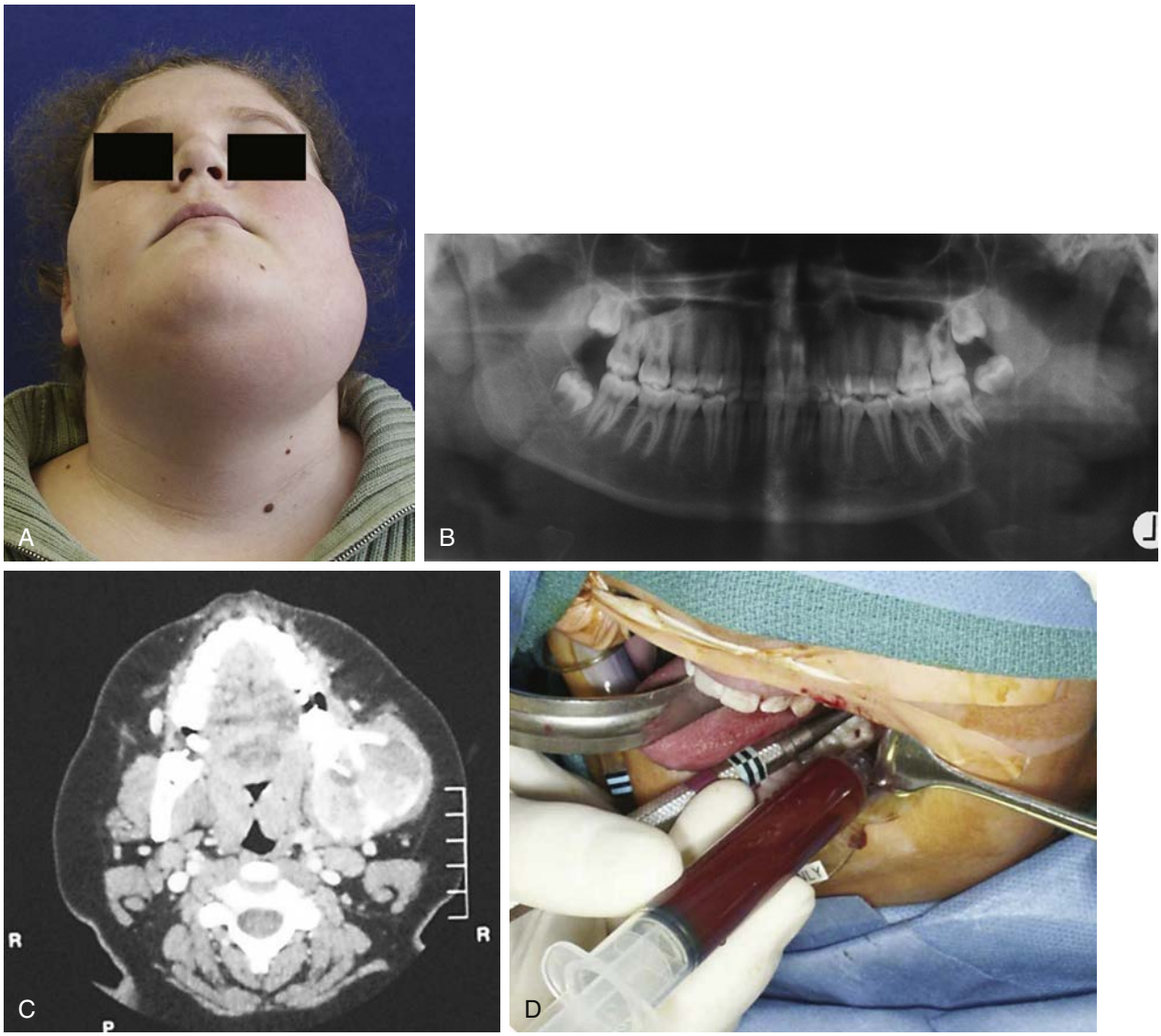

• **Figure 19-5** Aneurysmal bone cyst. **A,** A 13-year-old girl with a rapidly expanding mandibular angle mass over the course of 3 weeks. **B,** Panoramic radiograph revealed expansile, destructive lesion. **C,** Axial CT demonstrating cortical expansion and thinning. **D,** At the time of surgical resection the lesion was filled with blood.

Continued

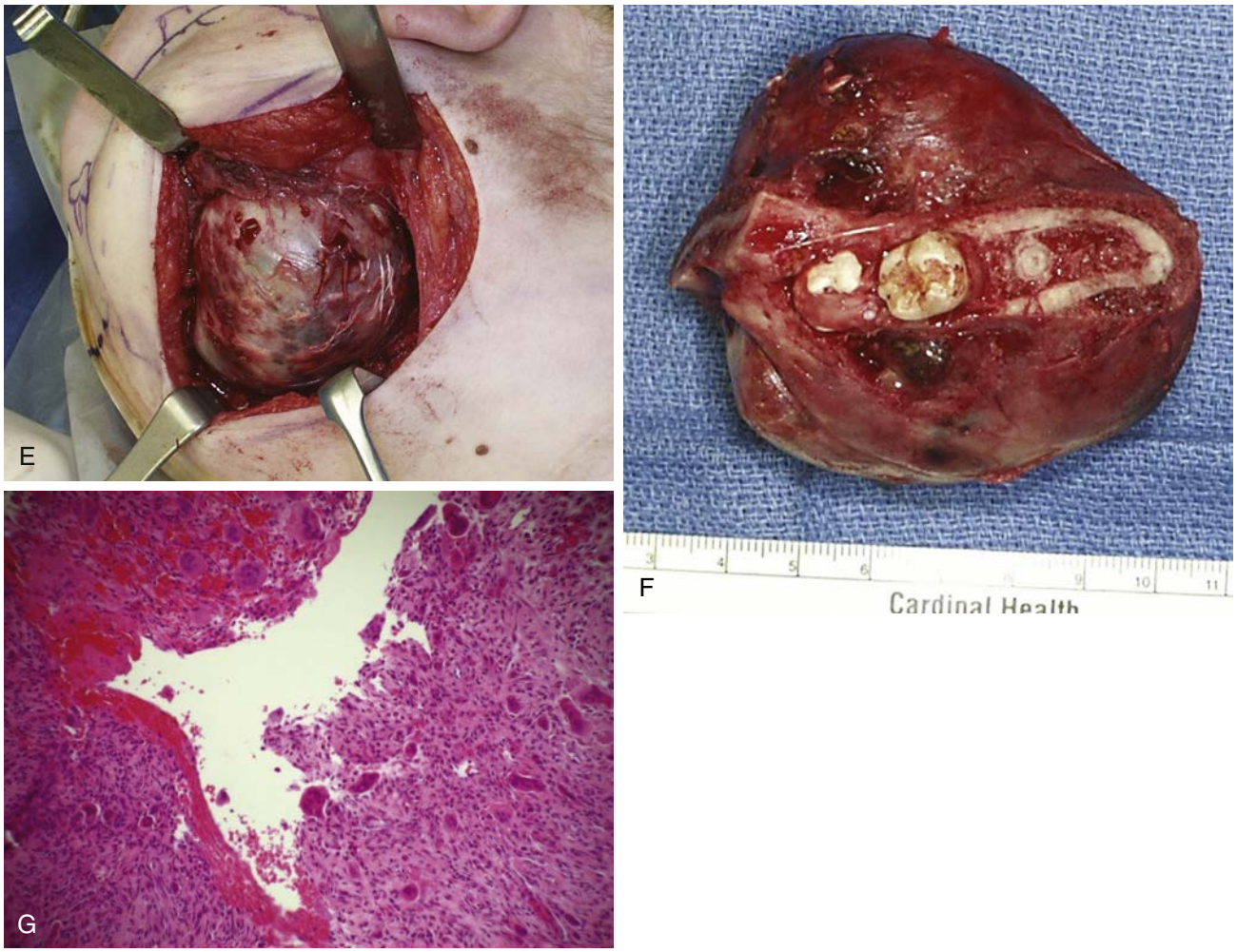

Figure 19-5, cont'd **E,** Lesion at time of resection. **F,** Resected lesion. **G,** Histology shows a cellular connective tissue stroma admixed with multinucleated giant cells and extravasated red blood cells. A prominent sinusoidal space is seen.

giving it a "soap bubble" appearance; however, lesions can appear unilocular. The cortex can be expanded, thinned, or destroyed.[36] Microscopically, sinusoidal blood-filled spaces of varying size are seen. These spaces are not lined by endothelium, but are surrounded by a fibrous connective tissue stroma with variable numbers of multinucleated giant cells that typically line the cystic spaces. The stromal cells consist of fibroblasts, myofibroblasts, osteoblasts, and histiocytes.[37] Osteoid and woven bone can often be seen within the lesion.

Treatment for aneurysmal bone cysts should be based on the biologic behavior of the lesion. Treatment options include enucleation, curettage, curettage with cryotherapy, and resection. In the long bones, curettage alone has been associated with a recurrence rate in the range of 50%.[38] The combination of curettage and cryotherapy is associated with a decreased rate of recurrence.[39,40] Although some authors feel that maxillofacial aneurysmal bone cysts are associated with a relatively high recurrence rate, curettage remains the treatment of choice. For lesions that are rapidly growing, resection is often necessary. At the time of surgery, lesional tissue appears like a "blood-soaked sponge." Although lesions are often blood-filled, significant hemorrhage is usually not encountered.

Fibro-osseous Lesions

Ossifying Fibroma (Cemento-ossifying Fibroma)

The ossifying fibroma is a neoplasm that belongs to a group of lesions referred to as benign fibro-osseous lesions. These lesions are characterized by the replacement of normal bone by fibrous tissue and varying amounts of newly formed bone and/or cementum-like material. Because of their histologic similarities, ossifying fibroma, fibrous dysplasia, and cemento-osseous dysplasia are classified together as benign fibro-osseous lesions. The World Health Organization in 2005 classified these three groups of lesions in the group of bone-related lesions.[41] The diagnosis of benign fibro-osseous lesions and further differentiation of the lesions within this group is based on clinical, radiographic, and histopathologic correlation. Chromosomal abnormalities have been identified in the ossifying



• **Figure 19-6** Ossifying fibroma. Panoramic radiograph demonstrating well-demarcated radiolucent-radiopaque lesion.

fibroma[42-44]; however, the molecular mechanisms that underlie the development of this tumor remain unknown. Histologically, the ossifying fibroma is characterized by spindle-shaped fibroblasts within a background of fibrous connective tissue. Bony spheroids are distributed throughout the lesion. Lesions with similar clinical presentation and clinical behavior that contain spheroidal bone have been designated cementifying fibroma or cementoossifying fibroma.

Ossifying fibromas typically present as a painless, slow-growing, and expansile lesion. Although they occur over a wide age range, most cases occur in the third and fourth decades of life. There is definite female predilection. They are felt to be confined to the jaws and craniofacial complex. The mandible, particularly the premolar-molar region, is affected more commonly than the maxilla. Rare multicentric and/or familial ossifying fibromas have been reported.[45,46]

Radiographically the ossifying fibroma is typically a well-defined radiolucency with a variable degree of internal calcification, depending on the maturity of the lesion (Figure 19-6). The borders are usually smooth and may be sclerotic. Root displacement and, less commonly, root resorption may be seen. Histologically, they are composed of a fibrous stroma with bony trabeculae and/or cementum-like spherules evenly distributed throughout the stroma (Figure 19-7).The microscopic appearance may be indistinguishable from fibrous dysplasia.

The recommended treatment of ossifying fibromas is complete surgical excision and will depend on the location and size of the lesion. The smaller lesions characteristically shell out from the surrounding bone with ease (Figure 19-8). Reported rates of recurrence have ranged from less than 1% to 63%.[47-55] Involved teeth with evidence of resorption should be removed with the lesion. In light of the potential for recurrence, some authors advocate more extensive surgery for larger, more aggressive lesions and lesions involving the craniofacial bones.[49,56,57] If resection is planned, it is important to consider that ossifying fibromas do not display an infiltrative pattern into bone and therefore require smaller margins (approximately 5 mm) than the 1 cm typically required for an ameloblastoma, odontogenic myxoma, or calcifying epithelial odontogenic tumor.

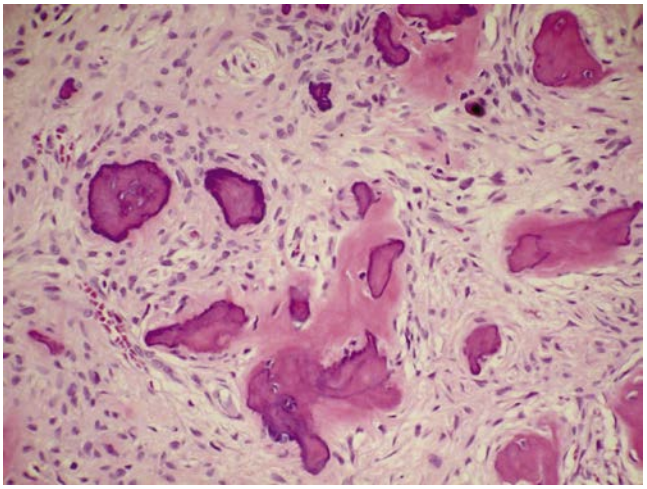

• **Figure 19-7** Ossifying fibroma. Cellular fibroblastic tissue with areas of calcification with osteoid differentiation.

Juvenile Ossifying Fibroma (Juvenile Aggressive Ossifying Fibroma; Juvenile Active Ossifying Fibroma)

The juvenile ossifying fibroma is considered by many to be a unique lesion because of its reported tendency to occur in children and adolescents, its more complex histologic features, and its tendency for more aggressive growth. However, there is no general agreement among pathologists with respect to the proper terminology, histopathologic features, or criteria for separating these lesions from the conventional ossifying fibroma.[58] Histologically the lesions are typically characterized by many spindled cells with a small amount of intervening collagen and osteoid. A rearrangement of the long arm of chromosome 12 that includes the genes *MDM2* and *RASAL1* might drive juvenile ossifying fibroma and might serve as a diagnostic and predictive marker for aggressive behavior.[59]

The lesions are typically observed in patients younger than 15, rapidly increase in size, and generally do not

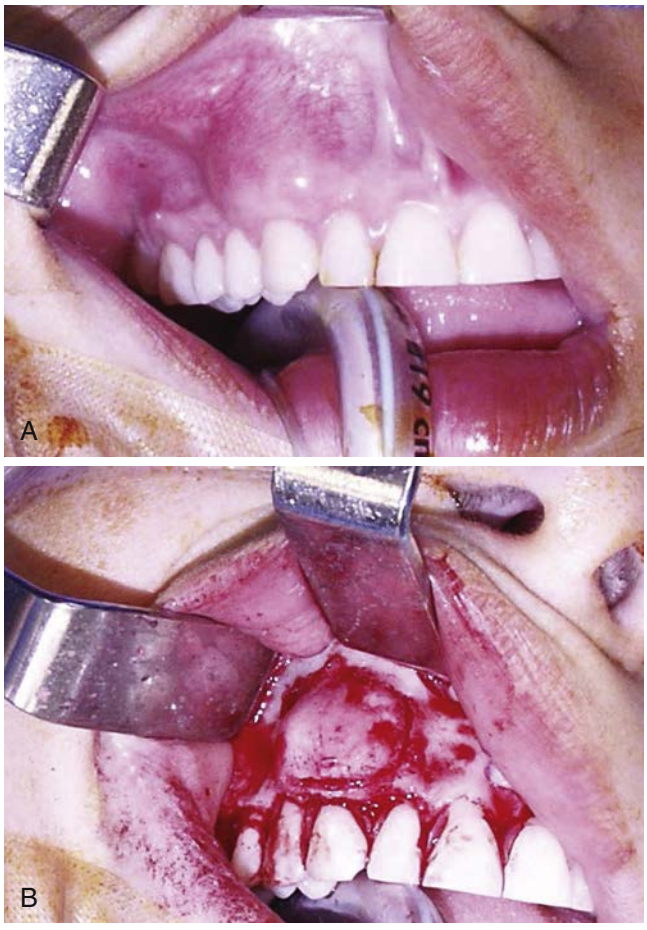

• **Figure 19-8** Ossifying fibroma. **A,** Well-demarcated maxillary expansion with intact mucosa. **B,** Because lesion was small and well demarcated, it was treated with enucleation. The lesion easily shelled out.

produce pain or paresthesia. In comparison to ossifying fibroma, the mandible is much less commonly involved. The maxilla, paranasal sinuses, orbit, and frontal and ethmoid bones are more commonly affected. Because of these sites of involvement, patients can present with nasal obstruction, proptosis, and exopthalmos.[60] Two variants of the juvenile ossifying fibroma have been described. These are the trabecular variant[61] and the psammomatoid variant.[62] The trabecular variant has strands of immature cellular osteoid within the lesion and usually occurs in childhood with a slight maxillary predilection. The psammomatoid variant has small spherical ossicles surrounded by osteoid rims within the lesion. It occurs over a wider age range than the trabecular variant and usually affects the orbit or paranasal sinuses.

Although considered more aggressive than the more common ossifying fibroma that generally occurs at a later age, aggressive excision is recommended for the juvenile ossifying fibroma if the lesion is recognized early, is well confined within the bone, and is accessible to meticulous technique. Recurrence rates of 20% to 58% have been reported.[58] Clinical behavior such as rapid growth might require more aggressive management including resection with 5-mm margins (Figure 19-9).

Fibrous Dysplasia

Patients with fibrous dysplasia exhibit slow, asymptomatic enlargement of either one (monostotic) or multiple bones (polyostotic). The bone enlargement is due to replacement of medullary bone with a fibrous connective tissue proliferation containing variable amounts of osseous matrix that do not mature to lamellar bone. The etiology of fibrous dysplasia is unknown; however, the presence of an activating mutation of Gs alpha gene in osteoblastic progenitor cells has been proposed to lead to increased proliferation and abnormal differentiation of bone.[63] Fibrous dysplasia can present as a component of multiple syndromes. The combination of polyostotic fibrous dysplasia, café-au-lait macules, and endocrine abnormalities including precocious sexual development, acromegaly, hyperthyroidism, hyperparathyroidism, and hyperprolactinemia is McCune-Albright syndrome. The combination of cutaneous melanotic pigmentation and multiple skeletal lesions consisting of fibrous dysplasia is known as Jaffe-Lichtenstein syndrome.

Monostotic fibrous dysplasia commonly involves the jaws, skull, long bones, pelvis, and ribs. Jaw involvement involves the maxilla more commonly than the mandible; the premolar region is most commonly involved in the former and the body region in the latter. Patients usually notice slow, asymptomatic enlargement. Whereas displacement of teeth commonly occurs, mobility of teeth is uncommon. A key clinical and radiographic feature for diagnosing fibrous dysplasia is the lack of a clear margin between the affected bone and the normal bone. The histologic features of fibrous dysplasia consist of fibroblasts within a background of collagen.

Treatment for fibrous dysplasia is necessary only when patients develop functional or cosmetic disturbances due to the bone expansion and should be delayed until adulthood if possible. Lesion expansion will typically stabilize after puberty. A skeletal survey can be used to determine whether the patient has polyostotic or monostotic fibrous dysplasia. Clinical and radiographic examination can be used to follow the extent and progression of disease. When the maxilla or mandible is affected, bone recontouring can be performed transorally. Resection has been recommended in cases where hearing or vision was threatened; however, prophylactic decompression is not recommended.[64]

Cemento-osseous Dysplasias

Periapical cemental dysplasia, focal cemento-osseous dysplasia, and florid osseous dysplasia make up the group of lesions known as cemento-osseous dysplasias.

Periapical Cemental Dysplasia

This lesion primarily affects the anterior mandibular region of middle-aged black women. The teeth involved are vital. Patients are generally asymptomatic, and the lesions are generally discovered on routine radiographic examination. The lesions typically start as radiolucencies involving the apices

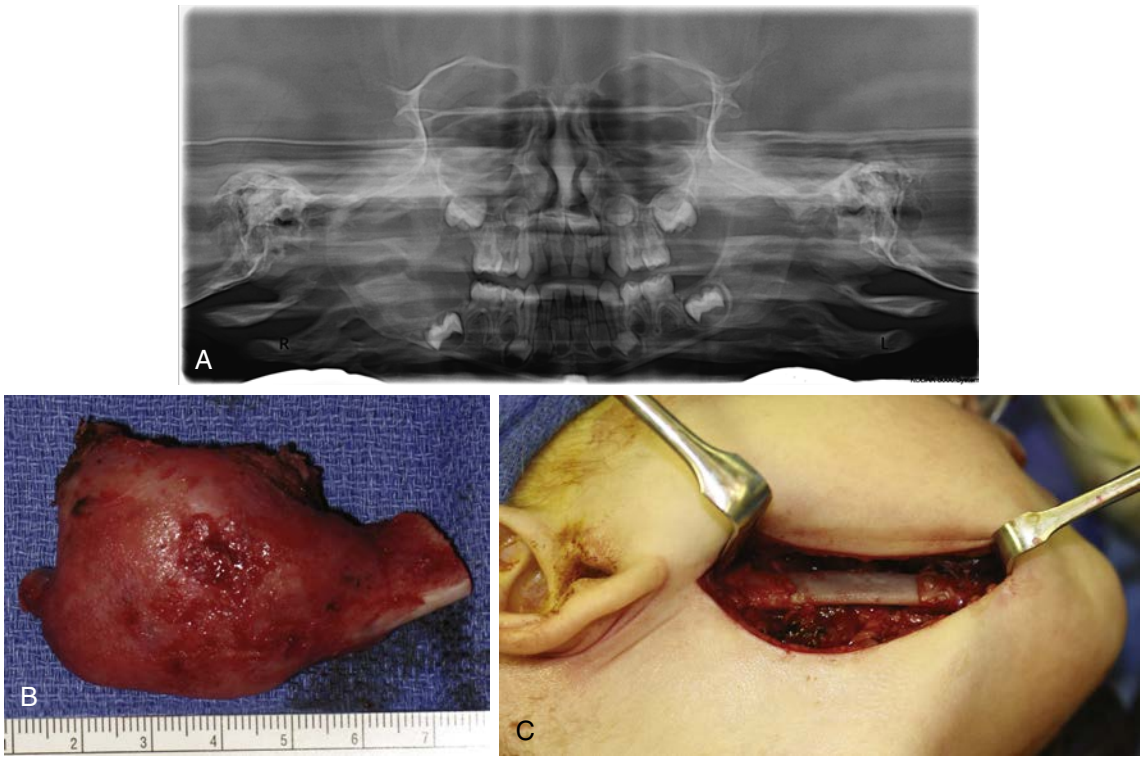

• **Figure 19-9** Juvenile ossifying fibroma. **A,** Panoramic radiograph of rapidly expanding right mandibular lesion in a 3-year-old girl. **B,** Aggressive clinical behavior dictates resection. The lesion is well demarcated with adjacent mandible grossly normal. **C,** Reconstruction with costochondral graft and resorbable mesh.

of the mandibular incisors. With time the lesions produce a radiolucent-radiopaque pattern with a progressive increase in radiopacity. Ultimately the radiolucent-radiopaque pattern stabilizes on radiographs. The diagnosis can be made based on clinical and radiographic features, and a biopsy is not required. When biopsied the tissue generally consists of cells in a background of collagen that contains a variable amount of cementum or osseous-like tissue. The amount of calcified tissue increases with time. No treatment is required for periapical cemental dysplasia.

Florid Cemento-osseous Dysplasia

Florid cemento-osseous dysplasia is similar to periapical cemental dysplasia but involves all portions of the mandible and in some cases the maxilla (Figure 19-10). Similar to periapical cemental dysplasia, this disease process typically involves middle-aged black women. Also similar to periapical cemental dysplasia, the lesions present as a mixed pattern on radiographs. The lesions are typically asymptomatic. Surgical trauma in the form of a biopsy, tooth extraction, or poorly fitting dentures can lead to a chronically draining site that does not heal and can progress to osteomyelitis. The histologic features will parallel those of periapical cemental dysplasia, except that florid cemento-osseous dysplasia often contains large sclerotic, acellular collections of cementum-like material.

The diagnosis should be made on the basis of clinical and radiographic examination. Biopsy and tooth extraction should be avoided. Development of osteomyelitis in the setting of florid osseous dysplasia should be managed in similar fashion to osteomyelitis. Debridement of symptomatic areas might be required.



• **Figure 19-10** Florid cemento-osseous dysplasia. (Courtesy Dr. M. Anthony Pogrel.)

Focal Cemento-osseous Dysplasia

Focal cemento-osseous dysplasia is a localized form of cemento-osseous dysplasia. Either the mandible or maxilla can be affected, with the posterior mandible being the most common site. Involved areas are generally less than 2 cm. Women are more commonly affected than men. Both white and black patients can be affected. Lesions are generally asymptomatic and identified on routine radiographs. Diagnosis is made on the radiographs, and biopsy is generally not required. Treatment is necessary only if symptoms require removal of the involved tooth and localized debridement. Lesions can develop in multiple sites consistent with florid osseous dysplasia.

Neurogenic Tumors

Schwannoma (Neurilemmoma)

The schwannoma is a slow-growing, benign tumor arising from Schwann cells of the nerve sheath (neurilemma). As this encapsulated tumor enlarges, it pushes the involved nerve aside without enveloping it. It most commonly occurs in the soft tissues of the head and neck, as well as the flexor surfaces of the upper and lower extremities. Intraosseous lesions are rare; however, the mandible is the most common site of occurrence for central lesions, and maxillary lesions have been reported. Lesions may occur over a wide age range but are most common in young adults. Bony lesions may be asymptomatic or produce expansion, pain, paresthesia, tooth mobility, and/or tooth displacement.

The usual radiographic appearance is that of a well-defined, unilocular radiolucency with a thin, sclerotic border. Histologically, this is an encapsulated spindle-cell tumor that consists of variable amounts of two types of tissue, Antoni A and Antoni B. Antoni A tissue consists of spindle cells organized in palisaded whorls and waves around central acellular, eosinophilic areas termed Verocay bodies. Antoni B tissue consists of spindle cells randomly arranged within a loose, myxomatous stroma. The tumor is strongly S-100 protein positive.

Intraosseous schwannomas can be treated by enucleation and curettage. When the lesion arises from an identifiable nerve, such as the inferior alveolar nerve, it can be excised from the nerve while preserving nerve integrity (Figure 19-11, *A*). Recurrences are rare.

Neurofibroma

Neurofibromas arise from a mixture of cell types, including Schwann cells and perineural fibroblasts. They may occur as solitary lesions or in association with neurofibromatosis. Solitary lesions are much more common than those associated with neurofibromatosis (Figure 19-12). Neurofibromatosis is an autosomal dominant condition in which 50% of cases result from spontaneous mutation. Two types of this genetic disorder exist, neurofibromatosis type 1 (von Recklinghausen disease of the skin) (Figure 19-13) and neurofibromatosis type 2 (central neurofibromatosis). Neurofibromatosis types 1 and 2 are genetically and clinically distinct. Of patients with neurofibromatosis type 1, 95% show autosomal dominant missense or nonsense mutations, small insertions or deletions, large-scale deletions, or chromosomal translocations affecting the *NF1* gene located on 17q11.2.[65] Type 1 neurofibromatosis has variable disease manifestations. Tissues of neural crest origin are affected.

Neurofibromatosis type 1 can be diagnosed when two or more of the following exist:

1. Six or more café-au-lait spots greater than 5 mm in diameter in prepubertal patients and greater than 15 mm in postpubertal patients
2. One plexiform neurofibroma or two or more neurofibromas of any type
3. Two or more pigmented iris hamartomas (Lisch nodules)
4. Inguinal or axillary freckling
5. Optic nerve glioma
6. A distinct osseous lesion such as dysplasia of the greater wing of the sphenoid or pseudoarthrosis
7. A first-degree relative with neurofibromatosis type 1

Type 2 can be diagnosed when one or more of the following findings are present:

1. Bilateral cranial nerve VIII schwannomas (acoustic neuromas)
2. A first-degree relative with neurofibromatosis type 2 and either a single cranial nerve VIII mass or any of the following findings: schwannoma, neurofibroma, meningioma, glioma, or juvenile posterior subcapsular lens opacity

Although most commonly reported in soft tissues, neurofibromas do occur in bone and have been reported in association with the inferior alveolar nerve. Pain or paresthesia may result from lesions of the inferior alveolar nerve. Patients may also present with cortical expansion. Intraosseous lesions may produce a well-demarcated or poorly defined unilocular or multilocular radiolucency. Adjacent soft tissue neurofibromas may produce cortical erosion. Solitary neurofibromas and those found in association with neurofibromatosis share the same microscopic features. The tumor is composed of spindle-shaped cells with fusiform or wavy nuclei in a delicate connective tissue matrix. It is not encapsulated and may blend with the adjacent connective tissues. Mast cells are characteristically scattered throughout the lesion. A histologic subtype known as a plexiform neurofibroma is highly characteristic of neurofibromatosis.

The normally recommended treatment of solitary lesions following biopsy is localized excision with a 1-cm margin if possible. As opposed to the schwannoma, the involved nerve cannot be preserved because the neurofibroma arises from within the nerve. The lesions are often vascular, and extensive blood loss has been reported from surgical management of mandibular lesions; thus some authors have advocated mandibular resection. Radiation therapy is not recommended. The number of neurofibromas that can occur with neurofibromatosis type 1 makes complete surgical therapy impractical. In these cases, surgery is reserved for lesions that are large, symptomatic, and/or compromise function. Malignant transformation to neurogenic sarcoma occurs in 5% to 15% of neurofibromas associated with neurofibromatosis. Malignant transformation is felt not to occur with solitary lesions.

Other Tumors

Osteoid Osteoma

The osteoid osteoma is thought to be a benign neoplasm with unclear etiology. The osteoid osteoma and osteoblastoma are histologically identical, and the latter can be considered a larger version of the former. They are distinguished from one another primarily by size, differences in sites of occurrence, and associated symptoms. The osteoid osteoma is smaller than 2 cm; occurs most frequently in the femur, tibia, and phalanges; and presents with nocturnal pain that

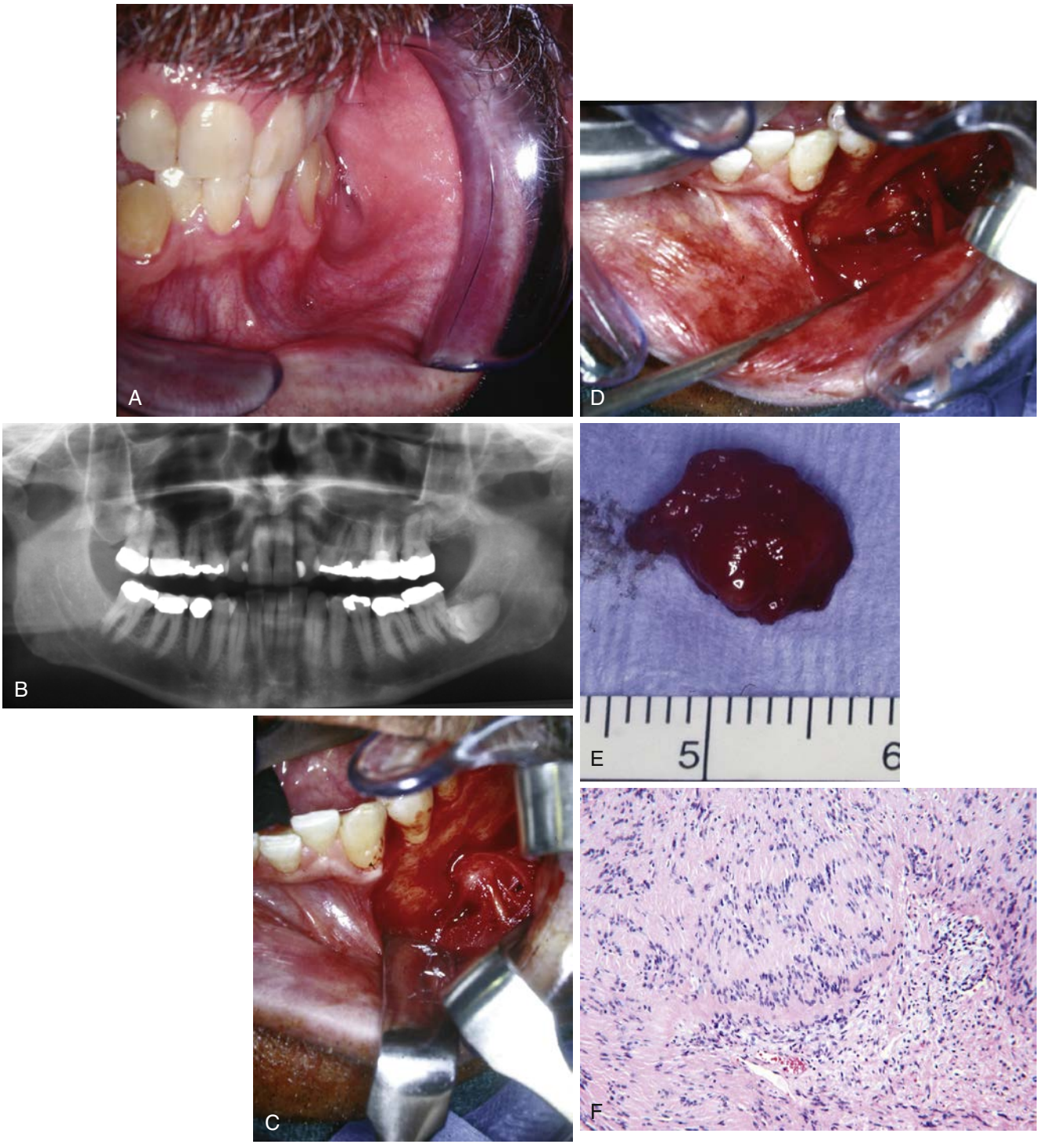

• **Figure 19-11** Schwannoma. **A,** A mass is present at the site of the mental nerve foramen between the first and second bicuspids. **B,** Panoramic radiograph revealed an expansile lesion within the inferior alveolar nerve canal. **C,** A mass associated with the mental nerve was identified on exploration. **D,** The mass was resected with preservation of the main branch of the mental nerve. Only a single branch of the mental nerve required resection, and this branch could be repaired primarily. **E,** Resected mass. **F,** Histology demonstrated palisaded Schwann cell nuclei around acellular zones forming Verocay bodies.

is alleviated by aspirin. Most cases occur in the second decade, with 85% to 90% occurring before 30 years of age. There is a 2-to-1 male predilection. The osteoid osteoma very rarely occurs in the jaws. Its characteristic radiographic feature is a zone of reactive sclerosis surrounding the lesion.

Osteoblastoma

The osteoblastoma is greater than 2 cm in diameter, occurring most frequently in the vertebrae and long bones of the extremities. The craniofacial skeleton is the site of

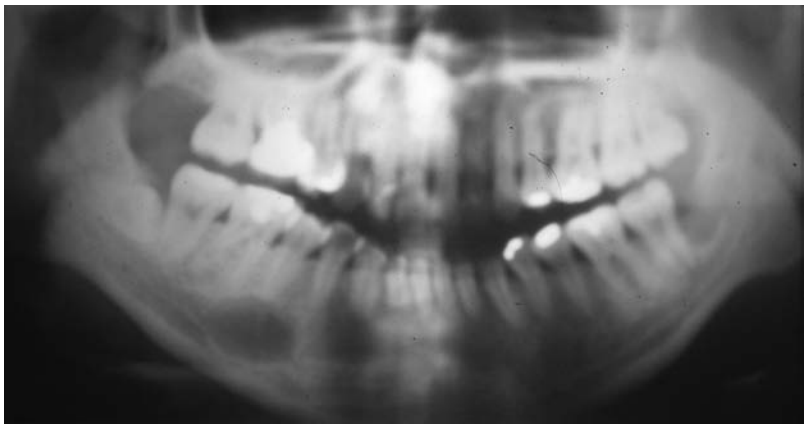

• **Figure 19-12** Neurofibroma. Solitary lesion involving right inferior alveolar nerve. (Courtesy Dr. M. Anthony Pogrel.)



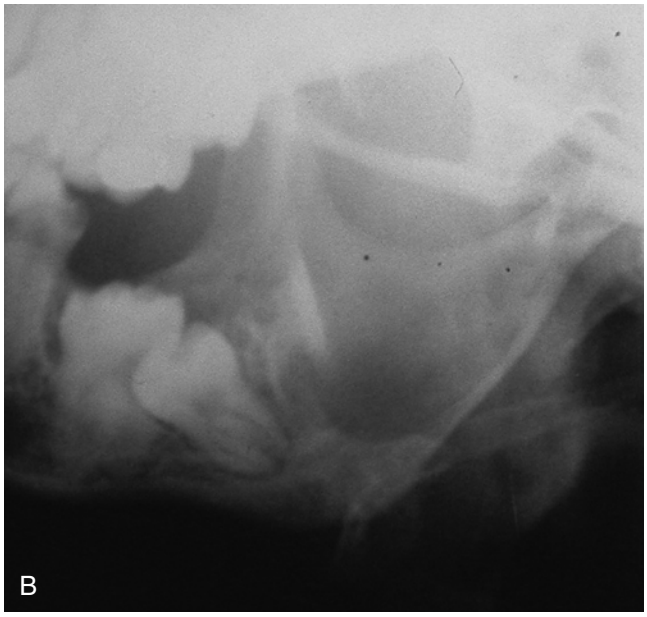

• **Figure 19-13** Neurofibromatosis type I. Patient with combination of café-au-lait spots and neurofibroma. **A,** Multiple café-au-lait spots. **B,** Neurofibroma involving inferior alveolar nerve. (Courtesy Dr. M. Anthony Pogrel.)

involvement in 15% of osteoblastomas. The mandible is the most commonly affected site in the head and neck. Within the jaws, the posterior tooth-bearing portion is the area most often involved; however, the condyle and the coronoid process are generally spared.[66] Clinically, the osteoblastoma often develops relatively rapidly, producing swelling and pain in patients less than 30 years of age, and men are twice as commonly affected as women.[67] Osteoblastomas in younger patients can be considerably more aggressive. Paresthesia should alert the clinician to the possibility of an osteosarcoma. In contrast to osteoid osteomas, the pain is not typically nocturnal and it does not respond as well to aspirin. Enlarged lesions are typically painful on palpation.

Radiographically, these lesions are usually well defined with a mixed radiolucent-radiopaque pattern (Figure 19-14). In contrast to the osteoid osteoma where sclerotic bone surrounds the lesion, a thin radiolucent rim typically surrounds the variably calcified osteoblastoma. Slower growing osteoblastomas might demonstrate a sclerotic border on plain radiographs. Histologically, irregular trabeculae of osteoid and immature bone are seen within a cellular, richly fibrovascular stroma. The osteoid trabeculae, which exhibit varying degrees of calcification, are surrounded by prominent osteoblasts, which are large, hyperchromatic, and uniform. Osteoclasts may be adjacent to the bone, and irregular reversal lines are often present. In some cases, histologic differentiation between osteoblastoma and low-grade osteosarcoma may be difficult.

Treatment of the osteoblastoma is generally confined to conservative surgical resection with a 5-mm margin. There have been reports of some lesions regressing after incomplete excision or biopsy.[68] Recurrences are rare, but have been reported particularly when surgical access is restricted given the location. Recurrent osteoblastomas should be treated with en bloc resection.[69] Rare examples of malignant transformation have been reported.[70,71] However, because of the possible difficulty in differentiating some osteoblastomas from osteosarcomas, some of these may represent an incorrect initial diagnosis. There is no role for radiation therapy.



• **Figure 19-14** Osteoblastoma. Well-defined mixed radiolucent-radiopaque lesion involving the left posterior mandible (Booth PW, Schendel SA, Hausamen JE (editors): *Maxillofacial surgery,* Vol 1, ed 2, 2007, Churchill Livingstone.)

Osteoma

Osteomas are benign tumors composed of mature compact or cancellous bone. They are distinguished from the common palatal and mandibular tori as well as buccal exostoses despite identical histopathology. Tori and buccal exostoses are felt to be of developmental or reactive origin and not true neoplasms. Osteomas may arise from the surface of bone (periosteal osteoma), or they may be located in the medullary bone (endosteal osteoma).

Osteomas may arise in the paranasal sinuses, skull bones, and facial bones, including the maxilla and mandible. The craniofacial and jaw bones are the most commonly affected of all bones.[72] The mandible or maxilla can be involved. Periosteal osteomas are most likely to affect the angle portion of the mandible. Maxillary sinus involvement can present as ophthalmologic symptoms, headaches, or sinusitis. They most commonly develop in young adults but can be identified in any age. Osteomas are usually solitary, except in cases of Gardner syndrome. Periosteal osteomas most often present as slow-growing, painless, discrete bony masses. Endosteal osteomas are usually asymptomatic and noted on routine radiographs. Radiographically, osteomas appear as well-circumscribed, sclerotic masses. There are two histologic variants. One variant consists of normal-appearing, dense, compact bone with sparse marrow tissue. The other form consists of lamellar trabeculae of cancellous bone with fibrofatty marrow. Osteoblastic activity is often prominent.

Gardner syndrome is a rare autosomal-dominant condition first reported in the early 1950s.[73] Patients with Gardner syndrome have different combinations and display a variable onset of the triad of skin and soft tissue tumors, benign osteomas, impacted permanent and supernumerary teeth, odontomas, and congenital hypertrophy of the retinal pigmented epithelium (CHRPE).[74,75] Osteomas are reported in 50% of patients. The genetic defect has been mapped to 5q21 where the familial adenomatous polyposis (APC) gene resides[76-78] The gene encodes a 2843-amino acid polypeptide.[77] The majority of patients have an incomplete manifestation of the syndrome. The most clinically important aspect of the syndrome is the high rate of malignant transformation of bowel polyps into invasive adenocarcinoma. In fact, the malignant transformation rate is 50% by age 30. As a result, patients with an established diagnosis of Gardner syndrome typically undergo a prophylactic colectomy. Patients with multiple osteomas should undergo investigation for Gardner syndrome. Osteomas in association with Gardner syndrome are frequently seen at the mandibular angles as well as other facial bones and long bones (Figure 19-15). It is important to note that the development of osteomas precedes the other manifestations of the syndrome.

Histologically osteomas can consist of mature lamellar bone or cancellous bone with abundant fibrofatty marrow between bone trabeculae. Radiographically osteomas show as well-circumscribed, densely sclerotic, and radiopaque; a sclerotic border can be present. Endosteal osteomas are generally identified on routine radiographic examination.

Osteomas can be managed based on clinical behavior. Small, asymptomatic cases may be followed clinically and radiographically. If an osteoma is deforming or causing pain, it can be treated by local excision. An endosteal osteoma can be treated with enucleation. Periosteal osteomas can often be osteotomized from the mandible along a cleavage plane. Recurrences following excision are very rare.

Chondroma

Chondromas are benign tumors composed of mature hyaline cartilage. They most commonly occur in the bones of the hands and feet, with very rare occurrences in the craniofacial complex. Within the maxillofacial region, they can involve

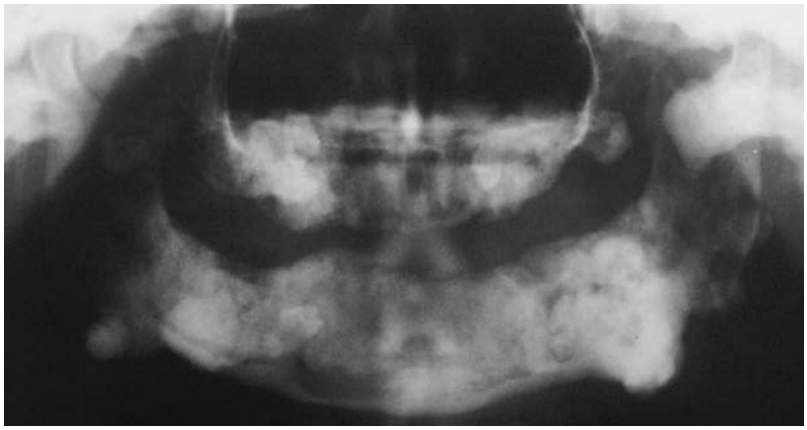

• **Figure 19-15** Mandibular and maxillary osteomas in patient with Gardner syndrome. (Courtesy Dr. M. Anthony Pogrel.)

the nasal septum and anterior maxilla, as well as the mandibular condyle, coronoid process, body, and symphysis.

Chondromas typically presents as a painless, slowly progressive swelling. They usually appear before 50 years of age. There is no sex predilection. Radiographically, they appear as a unilocular or multilocular radiolucency, which may have internal foci of calcification. The lesions are composed of well-defined lobules of mature hyaline cartilage containing small chondrocytes with regular nuclei. The microscopic distinction between a benign chondroma and low-grade chondrosarcoma is very difficult. Considering the rarity with which chondromas occur in the craniofacial complex, the difficulty in differentiating between a chondroma and a low-grade chondrosarcoma, and the aggressive nature of chondrosarcomas, one should question the diagnosis of a benign chondroma in the jaws.

In order to avoid the potential risk of undertreating a malignancy, some authors consider chondromas of the jaws as potentially malignant and manage them accordingly.[79] These authors recommend wide surgical resection with 1-cm margins. If the lesion recurs following more conservative surgical treatment, the lesion should certainly be considered a low-grade chondrosarcoma and treated with wide surgical resection.

Osteochondroma

Osteochondroma is the most common benign tumor of bone, but rarely affects the oral and maxillofacial region.[80] It represents a hamartomatous process affecting endochondral bones and is cartilage-capped bony protrusion on the external surface of bone. The lesion represents an osteocartilaginous exostosis and can affect the mandibular condyle and coronoid process, as well as the posterior maxilla, maxillary sinus, and zygomatic arch. The etiology is unclear. Stress in the region of tendinous insertion might affect cells with cartilaginous potential. Such stress could lead to the formation of these tumors at the insertion of the temporalis muscle into the coronoid process and at the insertion of the lateral pterygoid muscle into the condyle.[81] Men are twice as commonly affected as women and are usually in their 20s at the time of diagnosis; however, patients with craniofacial osteochondromas are slightly older. Because the osteochondroma often produces an exophytic growth from the mandibular condyle, symptoms can consist of difficulty with jaw opening, unilateral posterior open bite, chin deviation, and facial asymmetry.

On radiographs the osteochondroma shows up as a well-defined radiopacity with a cortical outline and a central trabecular pattern. The cartilaginous portion might not be visible on radiographs. Osteochondromas of the condyle generally extend anterior from the condyle and follow the course of the lateral pterygoid muscle. Lesions affecting the coronoid project superiorly along the course of the temporalis muscle. The histologic features demonstrate both cartilaginous and bone features. The surface portion consists of hyaline cartilage and associated perichondrium. The region adjacent to bone demonstrates endochondral ossification. Deep to the area of endochondral ossification, there is medullary bone that blends with the underlying normal medullary bone.

Treatment of the osteochondroma is generally based on the patient's symptoms. Involvement of the condyle and surrounding muscles can produce difficulty opening, jaw deviation, and pain. In such cases, condylar resection with immediate costochondral reconstruction is recommended. Conservative condylar resection with articular disc repositioning has been described.[81] Involvement of the coronoid process can be addressed with coronoid process resection.

Desmoplastic Fibroma

The desmoplastic fibroma is a rare, benign, locally aggressive tumor of bone that is considered to be the osseous counterpart of soft tissue fibromatosis.[82] The etiology and pathogenesis of this lesion remain unknown, although genetic, endocrine, and traumatic factors have been suggested. The tumor affects extracranial bones including the long bone and the pelvis; however, the mandible has been considered the most common site of involvement.

The lesion usually occurs in children and young adults, with over 80% being discovered before 30 years of age.

Within the jaws, the posterior mandible body-angle-ramus is the area most frequently involved. Patients most often present with a painless, slow-growing, firm swelling of the affected jaw (Figure 19-16).[83,84] Rapid growth can occur with invasion into adjacent soft tissues.

Radiographically, the lesion typically produces a large radiolucency, which may be unilocular or multilocular. The margins may be well or poorly defined. Cortical perforation and root resorption may be seen. Microscopically, the lesion is composed of interlacing bundles and whorled aggregates of

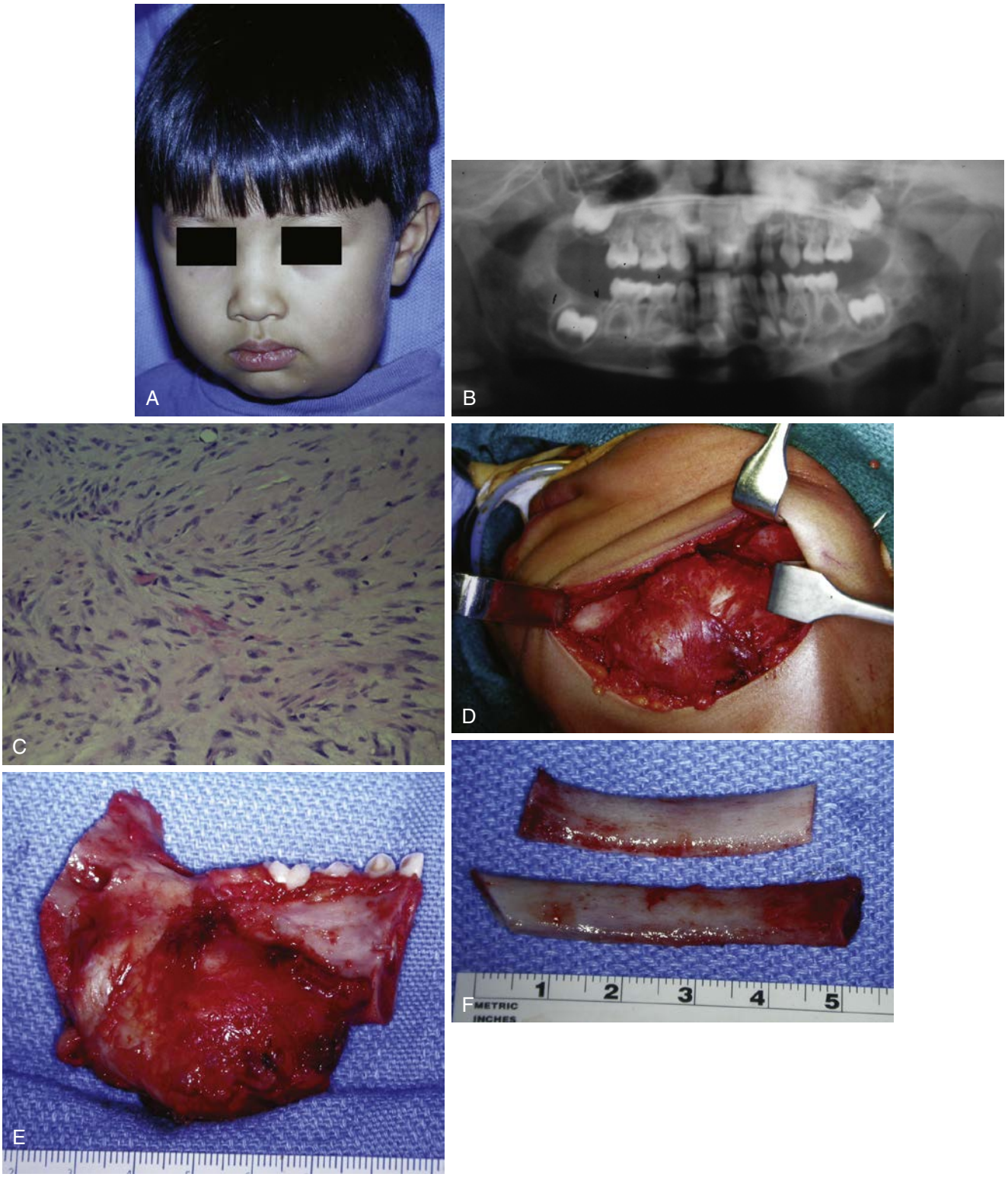

• **Figure 19-16** Desmoplastic fibroma. **A,** A 4-year-old boy with a rapidly expanding left mandibular angle mass. **B,** Panoramic radiograph revealed destructive, expansile lesion. **C,** A haphazard arrangement of spindle-shaped fibroblasts in a collagenous stroma. **D,** Aggressive clinical behavior dictated resection. Expansile, destructive mass at angle of mandible pushing into adjacent soft tissue. **E,** Resected mass. **F,** Costochondral grafts for immediate reconstruction.

Continued

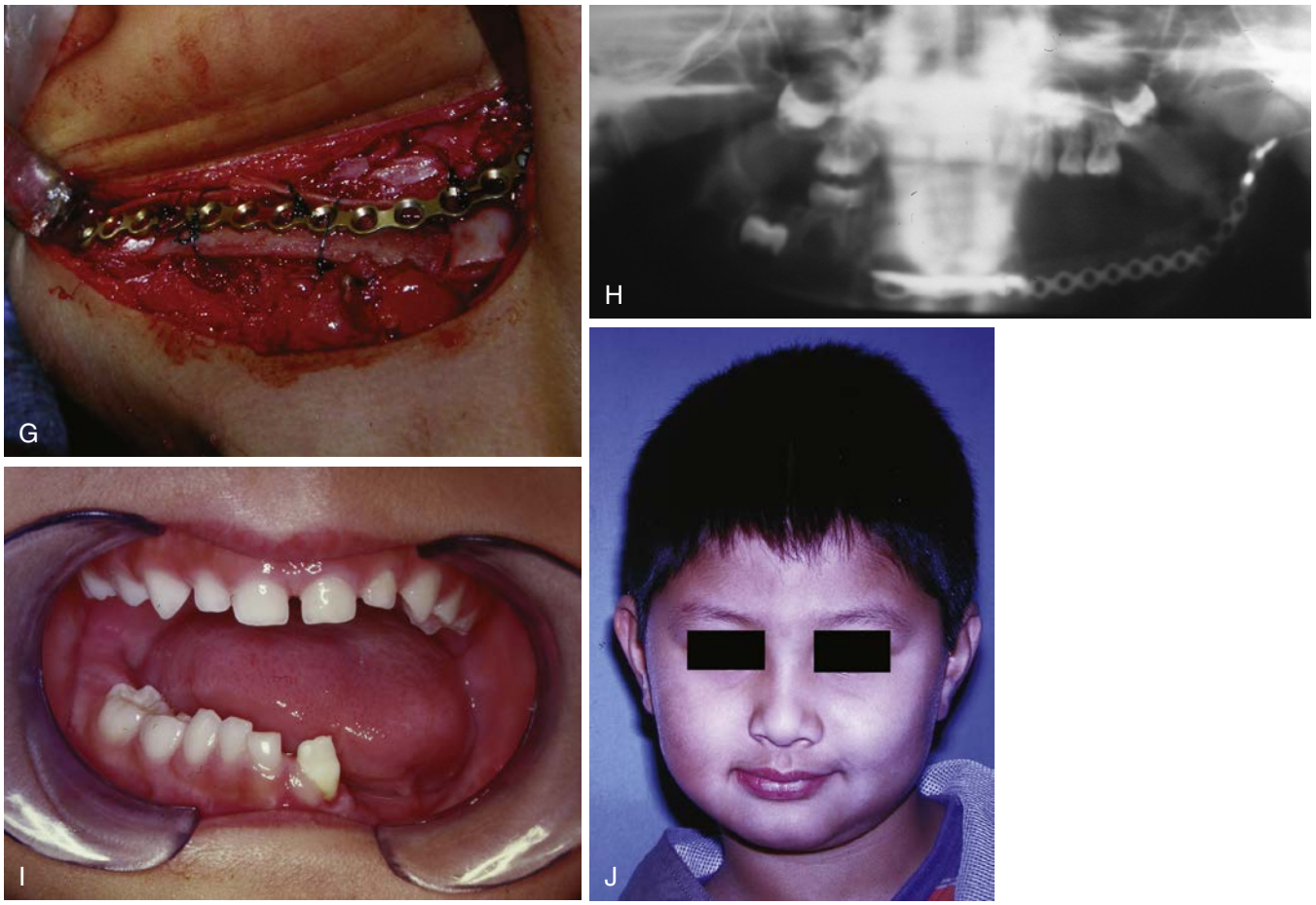

Figure 19-16, cont'd **G,** Reconstructed mandible with two ribs. **H,** Panoramic radiograph 4 years later. **I,** Symmetric mandibular opening. **J,** Normal facial contour with no evidence of recurrence. (Courtesy Dr. M. Anthony Pogrel.)

densely collagenous tissue with spindled and elongated fibroblasts. The degree of cellularity may vary from one area of the lesion to another. Cellular atypia, anaplasia, and mitotic figures are not seen. This lesion does not produce bone.

Recurrence rates following conservative surgical treatment, such as curettage and local excision, are high, whereas lesions treated by resection with wide margins do not tend to recur.[85,86] Recurrence is more commonly seen with lesions that erode bone and invade adjacent tissues.[82] Thus, despite a benign histology, the desmoplastic fibroma should be treated aggressively with resection. Radiation[87] and chemotherapy[88,89] have been recommended for lesions involving vital structures and those located in areas where resection would be debilitating; however, surgical resection is the treatment of choice in terms of tumor control and minimizing disruption of normal growth.

References

1. Bernier JL, Cahn LR: The peripheral giant cell reparative granuloma, *J Am Dent Assoc* 49:141, 1954.
2. Jaffe HL: Giant-cell reparative granuloma, traumatic bone cyst, and fibrous (fibro-osseous) dysplasia of the jawbones, *Oral Surg Oral Med Oral Pathol* 6:159, 1953.
3. Flanagan AM, Nui B, Tinkler SM, et al.: The multinucleate cells in giant cell granulomas of the jaw are osteoclasts, *Cancer* 62:1139, 1988.
4. Chuong R, Kaban LB, Kozakewich H, Perez-Atayde A: Central giant cell lesions of the jaws: a clinicopathologic study, *J Oral Maxillofac Surg* 44:708, 1986.
5. Kaban LB, Troulis MJ, Ebb D, et al.: Antiangiogenic therapy with interferon alpha for giant cell lesions of the jaws, *J Oral Maxillofac Surg* 60:1103, 2002.
6. Jacoway J, Howell FV, Terry BC: Central giant cell granuloma: an alternative to surgical therapy, *Oral Surg Oral Med Oral Pathol* 66:572, 1988.
7. Carlos R, Sedano HO: Intralesional corticosteroids as an alternative treatment for central giant cell granuloma, *Oral Surg Oral Med Oral Pathol Oral Radiol Endod* 93:161, 2002.
8. Kermer C, Millesi W, Watzke IM: Local injection of corticosteroids for central giant cell granuloma. A case report, *Int J Oral Maxillofac Surg* 23:366, 1994.
9. Terry BJJ: Management of central giant cell lesions: an alternative to surgical therapy, *Oral Maxillofac Surg Clin North Am* 6:579, 1994.
10. Harris M: Central giant cell granulomas of the jaws regress with calcitonin therapy, *Br J Oral Maxillofac Surg* 31:89, 1993.
11. O'Regan EM, Gibb DH, Odell EW: Rapid growth of giant cell granuloma in pregnancy treated with calcitonin, *Oral Surg Oral Med Oral Pathol Oral Radiol Endod* 92:532, 2001.

12. Pogrel MA: Calcitonin therapy for central giant cell granuloma, *J Oral Maxillofac Surg* 61:649, 2003.
13. Pogrel MA, Regezi JA, Harris ST, Goldring SR: Calcitonin treatment for central giant cell granulomas of the mandible: report of two cases, *J Oral Maxillofac Surg* 57:848, 1999.
14. de Lange J, van den Akker HP, Veldhuijzen van Zanten GO, et al.: a randomized double-blind placebo-controlled study, *Int J Oral Maxillofac Surg* 35:791, 2006.
15. Kaban LB, Mulliken JB, Ezekowitz RA, et al.: Antiangiogenic therapy of a recurrent giant cell tumor of the mandible with interferon alfa-2a, *Pediatrics* 103:1145, 1999.
16. Naidu A, Malmquist MP, Denham CA, Schow SR: Management of central giant cell granuloma with subcutaneous denosumab therapy, *J Oral Maxillofac Surg* 72:2469, 2014.
17. Rosenberg EH, Guralnick WC: Hyperparathyroidism: a review of 220 proved cases, with a special emphasis on findings in the jaws, *Oral Surg Oral Med Oral Pathol* 15(suppl 2):84, 1962.
18. Kebebew E, Clark OH: Parathyroid adenoma, hyperplasia, and carcinoma: localization, technical details of primary neck exploration, and treatment of hypercalcemic crisis, *Surg Oncol Clin N Am* 7:721, 1998.
19. Carpten JD, Robbins CM, Villablanca A, et al.: HRPT2, encoding parafibromin, is mutated in hyperparathyroidism-jaw tumor syndrome, *Nat Genet* 32:676, 2002.
20. Parfitt J, Harris M, Wright JM, Kalamchi S: Tumor suppressor gene mutation in a patient with a history of hyperparathyroidism-jaw tumor syndrome and healed generalized osteitis fibrosa cystica: a case report and genetic pathophysiology review, *J Oral Maxillofac Surg* 73:194 e1, 2015.
21. Guney E, Yigitbasi OG, Bayram F, et al.: Brown tumor of the maxilla associated with primary hyperparathyroidism, *Auris Nasus Larynx* 28:369, 2001.
22. Keyser JS, Postma GN: Brown tumor of the mandible, *Am J Otolaryngol* 17:407, 1996.
23. Kennett S, Pollick H: Jaw lesions in familial hyperparathyroidism, *Oral Surg Oral Med Oral Pathol* 31:502, 1971.
24. Jones WA: Familial multi-locular cystic disease of the jaws, *Am J Cancer* 17:946, 1933.
25. Mangion J, Rahman N, Edkins S, et al.: The gene for cherubism maps to chromosome 4p16.3, *Am J Hum Genet* 65:151, 1999.
26. Tiziani V, Reichenberger E, Buzzo CL, et al.: The gene for cherubism maps to chromosome 4p16, *Am J Hum Genet* 65:158, 1999.
27. Imai Y, Kanno K, Moriya T, et al.: A missense mutation in the SH3BP2 gene on chromosome 4p16.3 found in a case of nonfamilial cherubism, *Cleft Palate Craniofac J* 40:632, 2003.
28. Lo B, Faiyaz-Ul-Haque M, Kennedy S, et al.: Novel mutation in the gene encoding c-Abl-binding protein SH3BP2 causes cherubism, *Am J Med Genet A* 121:37, 2003.
29. Ueki Y, Tiziani V, Santanna C, et al.: Mutations in the gene encoding c-Abl-binding protein SH3BP2 cause cherubism, *Nat Genet* 28:125, 2001.
30. Prod'Homme V, Boyer L, Dubois N, et al.: Cherubism allele heterozygosity amplifies microbe-induced inflammatory responses in murine macrophages, *J Clin Invest* 125:1396, 2015.
31. Southgate J, Sarma U, Townend JV, et al.: Study of the cell biology and biochemistry of cherubism, *J Clin Pathol* 51:831, 1998.
32. Jaffe HL, Lichtenstein L: Solitary unicameral bone cyst, with emphasis on the roentgen picture, the pathologic appearance and the pathogenesis, *Arch Surg* 44:1004, 1942.
33. Bernier JL, Bhaskar SN: Aneurysmal bone cysts of the mandible, *Oral Surg Oral Med Oral Pathol* 11:1018, 1958.
34. Shinde A, Mehlman CT, Collins MH: Aneurysmal bone cysts express vascular markers, *Pediatr Dev Pathol* 9:38, 2006.
35. Robinson PD: Aneurysmal bone cyst: a hybrid lesion? *Br J Oral Maxillofac Surg* 23:220, 1985.
36. Motamedi MH, Yazdi E: Aneurysmal bone cyst of the jaws: analysis of 11 cases, *J Oral Maxillofac Surg* 52:471, 1994.
37. Aho HJ, Aho AJ, Einola S: Aneurysmal bone cyst, a study of ultrastructure and malignant transformation, *Virchows Arch A Pathol Anat Histol* 395:169, 1982.
38. Biesecker JL, Marcove RC, Huvos AG, Mike V: Aneurysmal bone cysts. A clinicopathologic study of 66 cases, *Cancer* 26:615, 1970.
39. Marcove RC, Sheth DS, Takemoto S, Healey JH: The treatment of aneurysmal bone cyst, *Clin Orthop Relat Res* 157, 1995.
40. Motamedi MH, Behroozian A, Azizi T, et al.: Assessment of 120 maxillofacial aneurysmal bone cysts: a nationwide quest to understand this enigma, *J Oral Maxillofac Surg* 72:1523, 2014.
41. Barnes L, Eveson JW, Reichart P, Sidransky D: *World Health Organization classification of tumors. Pathology and genetics head and neck tumors*, Lyon, France, 2005, IARC Press.
42. Dal Cin P, Sciot R, Fossion E, et al.: Chromosome abnormalities in cementifying fibroma, *Cancer Genet Cytogenet* 71:170, 1993.
43. Gollin SM, Storto PD, Malone PS, et al.: Cytogenetic abnormalities in an ossifying fibroma from a patient with bilateral retinoblastoma, *Genes Chromosomes Cancer* 4:146, 1992.
44. Parham DM, Bridge JA, Lukacs JL, et al.: Cytogenetic distinction among benign fibro-osseous lesions of bone in children and adolescents: value of karyotypic findings in differential diagnosis, *Pediatr Dev Pathol* 7:148, 2004.
45. Canger EM, Celenk P, Kayipmaz S, et al.: Familial ossifying fibromas: report of two cases, *J Oral Sci* 46:61, 2004.
46. Yih WY, Pederson GT, Bartley Jr MH: Multiple familial ossifying fibromas: relationship to other osseous lesions of the jaws, *Oral Surg Oral Med Oral Pathol* 68:754, 1989.
47. Boysen ME, Olving JH, Vatne K, Koppang HS: Fibro-osseous lesions of the cranio-facial bones, *J Laryngol Otol* 93:793, 1979.
48. Dehner LP: Tumors of the mandible and maxilla in children. I. Clinicopathologic study of 46 histologically benign lesions, *Cancer* 31:364, 1973.
49. Eversole LR, Leider AS, Nelson K: Ossifying fibroma: a clinicopathologic study of sixty-four cases, *Oral Surg Oral Med Oral Pathol* 60:505, 1985.
50. Hamner 3rd JE, Scofield HH, Cornyn J: Benign fibro-osseous jaw lesions of periodontal membrane origin. An analysis of 249 cases, *Cancer* 22:861, 1968.
51. Sciubba JJ, Younai F: Ossifying fibroma of the mandible and maxilla: review of 18 cases, *J Oral Pathol Med* 18:315, 1989.
52. Smith AG, Zavaleta A: Osteoma, ossifying fibroma, and fibrous dysplasia of facial and cranial bones, *AMA Arch Pathol* 54:507, 1952.
53. Sweet RM, Bryarly RC, Kornblut AD, Corio RL: Recurrent cementifying fibroma of the jaws, *Laryngoscope* 91:1137, 1981.
54. Waldron CA, Giansanti JS: Benign fibro-osseous lesions of the jaws: a clinical-radiologic-histologic review of sixty-five cases. II. Benign fibro-osseous lesions of periodontal ligament origin, *Oral Surg Oral Med Oral Pathol* 35:340, 1973.
55. Zachariades N, Vairaktaris E, Papanicolaou S, et al.: Ossifying fibroma of the jaws. Review of the literature and report of 16 cases, *Int J Oral Surg* 13:1, 1984.
56. Commins DJ, Tolley NS, Milford CA: Fibrous dysplasia and ossifying fibroma of the paranasal sinuses, *J Laryngol Otol* 112:964, 1998.
57. Said-al-Naief NA, Surwillo E: Florid osseous dysplasia of the mandible: report of a case, *Compend Contin Educ Dent* 20:1017, 1999.

58. Brannon RB, Fowler CB: Benign fibro-osseous lesions: a review of current concepts, *Adv Anat Pathol* 8:126, 2001.
59. Tabareau-Delalande F, Collin C, Gomez-Brouchet A, et al.: Chromosome 12 long arm rearrangement covering MDM2 and RASAL1 is associated with aggressive craniofacial juvenile ossifying fibroma and extracranial psammomatoid fibro-osseous lesions, *Mod Pathol* 28:48, 2015.
60. Wenig BM, Vinh TN, Smirniotopoulos JG, et al.: Aggressive psammomatoid ossifying fibromas of the sinonasal region: a clinicopathologic study of a distinct group of fibro-osseous lesions, *Cancer* 76:1155, 1995.
61. Kramer IR: The World Health Organization: histological typing of odontogenic tumours: an introduction to the second edition, *J Dent Assoc S Afr* 47:208, 1992.
62. Johnson LC, Yousefi M, Vinh TN, et al.: Juvenile active ossifying fibroma. Its nature, dynamics and origin, *Acta Otolaryngol Suppl* 488:1, 1991.
63. Shenker A, Weinstein LS, Sweet DE, Spiegel AM: An activating Gs alpha mutation is present in fibrous dysplasia of bone in the McCune-Albright syndrome, *J Clin Endocrinol Metab* 79:750, 1994.
64. Lee JS, FitzGibbon E, Butman JA, et al.: Normal vision despite narrowing of the optic canal in fibrous dysplasia, *N Engl J Med* 347:1670, 2002.
65. Messiaen LM, Callens T, Mortier G, et al.: Exhaustive mutation analysis of the NF1 gene allows identification of 95% of mutations and reveals a high frequency of unusual splicing defects, *Hum Mutat* 15:541, 2000.
66. Shatz A, Calderon S, Mintz S: Benign osteoblastoma of the mandible, *Oral Surg Oral Med Oral Pathol* 61:189, 1986.
67. Smith RA, Hansen LS, Resnick D, Chan W: Comparison of the osteoblastoma in gnathic and extragnathic sites, *Oral Surg Oral Med Oral Pathol* 54:285, 1982.
68. Eisenbud L, Kahn LB, Friedman E: Benign osteoblastoma of the mandible: fifteen year follow-up showing spontaneous regression after biopsy, *J Oral Maxillofac Surg* 45:53, 1987.
69. Colm SJ, Abrams MB, Waldron CA: Recurrent osteoblastoma of the mandible: report of a case, *J Oral Maxillofac Surg* 46:881, 1988.
70. Benoist M: Experience with 220 cases of mandibular reconstruction, *J Maxillofac Surg* 6:40, 1978.
71. Ohkubo T, Hernandez JC, Ooya K, Krutchkoff DJ: "Aggressive" osteoblastoma of the maxilla, *Oral Surg Oral Med Oral Pathol* 68:69, 1989.
72. Kaplan I, Calderon S, Buchner A: Peripheral osteoma of the mandible: a study of 10 new cases and analysis of the literature, *J Oral Maxillofac Surg* 52:467, 1994.
73. Gardner EJ, Richards RC: Multiple cutaneous and subcutaneous lesions occurring simultaneously with hereditary polyposis and osteomatosis, *Am J Hum Genet* 5:139, 1953.
74. Carl W, Sullivan MA: Dental abnormalities and bone lesions associated with familial adenomatous polyposis: report of cases, *J Am Dent Assoc* 119:137, 1989.
75. Traboulsi EI, Krush AJ, Gardner EJ, et al.: Prevalence and importance of pigmented ocular fundus lesions in Gardner's syndrome, *N Engl J Med* 316:661, 1987.
76. Bodmer WF, Bailey CJ, Bodmer J, et al.: Localization of the gene for familial adenomatous polyposis on chromosome 5, *Nature* 328:614, 1987.
77. Groden J, Thliveris A, Samowitz W, et al.: Identification and characterization of the familial adenomatous polyposis coli gene, *Cell* 66:589, 1991.
78. Nishisho I, Nakamura Y, Miyoshi Y, et al.: Mutations of chromosome 5q21 genes in FAP and colorectal cancer patients, *Science* 253:665, 1991.
79. Hackney FL, Aragon SB, Aufdemorte TB, et al.: Chondrosarcoma of the jaws: clinical findings, histopathology, and treatment, *Oral Surg Oral Med Oral Pathol* 71:139, 1991.
80. Karras SC, Wolford LM, Cottrell DA: Concurrent osteochondroma of the mandibular condyle and ipsilateral cranial base resulting in temporomandibular joint ankylosis: report of a case and review of the literature, *J Oral Maxillofac Surg* 54:640, 1996.
81. Wolford LM, Mehra P, Franco P: Use of conservative condylectomy for treatment of osteochondroma of the mandibular condyle, *J Oral Maxillofac Surg* 60:262, 2002.
82. Vally IM, Altini M: Fibromatoses of the oral and paraoral soft tissues and jaws. Review of the literature and report of 12 new cases, *Oral Surg Oral Med Oral Pathol* 69:191, 1990.
83. Bertoni F, Present D, Marchetti C, et al.: Desmoplastic fibroma of the jaw: the experience of the Istituto Beretta, *Oral Surg Oral Med Oral Pathol* 61:179, 1986.
84. Hopkins KM, Huttula CS, Kahn MA, Albright JE: Desmoplastic fibroma of the mandible: review and report of two cases, *J Oral Maxillofac Surg* 54:1249, 1996.
85. Bohm P, Krober S, Greschniok A, et al.: Desmoplastic fibroma of the bone. A report of two patients, review of the literature, and therapeutic implications, *Cancer* 78:1011, 1996.
86. Kwon PH, Horswell BB, Gatto DJ: Desmoplastic fibroma of the jaws: surgical management and review of the literature, *Head Neck* 11:67, 1989.
87. Sanfilippo NJ, Wang GJ, Larner JM: Desmoplastic fibroma: a role for radiotherapy? *South Med J* 88:1267, 1995.
88. Ayala AG, Ro JY, Goepfert H, et al.: Desmoid fibromatosis: a clinicopathologic study of 25 children, *Semin Diagn Pathol* 3:138, 1986.
89. Goepfert H, Cangir A, Ayala AG, Eftekhari F: Chemotherapy of locally aggressive head and neck tumors in the pediatric age group. Desmoid fibromatosis and nasopharyngeal angiofibroma, *Am J Surg* 144:437, 1982.

20

Salivary Gland Disease

MICHAEL R. MARKIEWICZ, RUI P. FERNANDES, ROBERT A. ORD

Introduction

The salivary glands in humans are divided into the paired major glands (parotid, submandibular, and sublingual) and 750 to 900 minor salivary glands. These glands function to produce saliva, which serves as a lubricant aiding in swallowing, an emulgent aiding in the enzymatic breakdown of food, a taste mediator, and a manufacturer of hormones and hormone-like substances. It also assists in immunologic function by assisting in the excretion of endogenous and exogenous antibodies, assists in bacterial defense, and has cleansing properties.[1-4] Saliva is composed of a mixture of electrolytes and macromolecules, and its secretion is tightly modulated by the autonomic nervous system, humoral factors, and disease states. A variety of disease processes that affect these glands may come to the attention of oral and maxillofacial surgeons. These can be broadly classified into cystic, inflammatory, obstructive, and neoplastic diseases and may include systemic diseases that involve the salivary glands.

Salivary Gland Physiology

The three basic subunits of salivary gland tissue include the acinus, the secretory duct (which is composed of intercalated and striated ducts), and the collecting duct with the acinus and proximal secretory duct comprising the "secretory end piece." The parotid and submandibular glands have a single elongated large caliber collecting duct with a few branching interlobular ducts, which are in turn connected to several intralobular ducts. These ducts transport saliva from several acini. Acini are classified as serous, mucous, or mixed. The parotid gland is made up of mostly serous, the submandibular gland is mixed between serous and mucous, and the sublingual and minor salivary glands are mostly mucous-type acini (Table 20-1).[5]

Saliva is formed via active transport in the secretory unit (acinus and secretory duct) and is under the control of complex neuronal and hormonal signals. The acinus is responsible for fluid generation. The secretion then transverses the ductal system, which is impermeable to water. Sodium (Na^+) and chloride (Cl^-) is reabsorbed, and potassium (K^+) and bicarbonate (HCO_3^-) is secreted. When entering the mouth, saliva is hypotonic (approximately 25 mEq/L NaCl). Fluid transport in salivary glands is primarily osmotic and responds to transepithelial salt gradients. Three mechanisms of primary fluid secretion have been proposed but are beyond the scope of this chapter.[6,7] Macromolecules are added to saliva by secretory granules of the acinar and ductal cells, which are under autonomic nervous system stimulation—primarily the salivary center of the medulla.[8] The rate of flow of saliva is highly variable and usually stabilizes by the age of 15 years. However, it is affected by systemic and iatrogenic processes such as radiation therapy.[9,10] Normal unstimulated and stimulated salivary flow is approximately 0.1 to 0.3 mL/min and 0.2 to 7 mL/min, respectively, with stimulated saliva flow comprising approximately 80% to 90% of daily average saliva production.[5,11] In the unstimulated state, the submandibular gland account for 71% of saliva production, whereas the parotid and sublingual glands produce 25% and 3% to 4%, respectively. In the stimulated state, the parotid gland supplies two thirds of salivary production.[12]

Acidic and sour-tasting foods increase saliva flow, whereas sweet foods decrease flow.[13,14] Other stimulants of salivary flow include chewing, gustatory, and olfactory stimuli. Increase in saliva flow in response to mastication is thought to be regulated by receptors in the mucosa, muscles of mastication, and temporomandibular joint.[15] Other factors that regulate salivary flow include circadian rhythm, mood, medications, and systemic disease.[16]

Imaging of the Salivary Glands

Not all disorders of the salivary gland require imaging as part of their workup. The purpose of imaging should be to aid in pathologic diagnosis, fine-needle aspiration, localizing a lesion, and staging. Modalities for salivary gland imaging include magnetic resonance imaging (MRI), computed tomography (CT), ultrasound (US), and sialography. Fine-needle aspiration (FNA) may be performed under US guidance to aid in diagnosis. Whereas the quality of MRI, US, magnetic resonance (MR) sialography, and CT has

TABLE 20-1 Acini Type and Saliva Viscosities by Salivary Gland Type

Salivary Gland	Acinar Type	Viscosity	Whole Unstimulated Daily Saliva (%)
Parotid	Serous	Watery	25
Submandibular	Mixed	Semiviscous	71
Sublingual	Mucous	Viscous	3 to 4
Minor	Mucous	Viscous	Trace

From Mandel ID: Sialochemistry in diseases and clinical situations affecting salivary glands, *Crit Rev Clin Lab Sci* 12:321, 1980.

increased significantly, there has been minimal advancement in conventional sialography.

Cross-sectional imaging techniques such as CT and MRI have the additional benefit of evaluating surrounding tissue planes, the extent of salivary gland tumors, and associated lymphadenopathy, vascular spread, neural spread, and bony invasion. Diseases such as sialolithiasis should usually be evaluated via CT to identify calcification associated with an obstructive stone. The chance of malignancy increases as the size of the salivary gland decreases, with 50% to 80%, 40% to 60%, and 30% to 40% of minor salivary, submandibular gland, and parotid gland tumors being malignant, respectively. Of benign lesions, 80% will be pleomorphic adenoma. Whereas lesions with smooth borders are likely benign, lesions with less demarcated borders and those that infiltrate adjacent structures are likely malignant. In general, CT should be used to evaluate inflammatory disease, whereas MRI should be used to evaluated neoplastic processes. The use of nuclear medicine imaging for salivary gland disease is not discussed here.

Computed Tomography

CT is most useful when evaluating calcific lesions and inflammatory conditions of the salivary glands.[17] This is preferred when evaluating calcifications and bony anatomy. The use of intravenous iodinated contrast increases the sensitivity for evaluating salivary soft tissue pathology, and also its extent and spread, by delineating the fat planes of the neck, which aids in differential diagnosis. Though the sensitivity of CT for detecting head and neck lesions approaches 100%, its drawbacks are that it is often poor at distinguishing benign and malignant lesions. In addition, CT may be poor at discriminating between spread to adjacent tissue and at identifying early-onset Sjögren syndrome and benign lymphoepithelial lesions associated with acquired immunodeficiency syndrome (AIDS). MRI may be better at identifying these lesions.

Magnetic Resonance Imaging

MRI is the modality of choice for identifying salivary gland neoplasms because of its ability to finely delineate various soft tissues in a high-quality manner. Most lesions will be identifiable on T1-weighted images. Benign lesions will be well defined. Pleomorphic adenomas, the most common salivary gland tumor, will have low T1 and high T2 signal intensities and solid enhancement on fat, as well as suppressed T1-weighted images after intravenous (IV) gadolinium. Warthin tumors will be seen in the lower portion of the parotid gland and as a heterogeneous signal on T2-weighted images, with bright T2 signals in the areas of cyst formation. The presence of multiple lesions is suggestive of Warthin tumor. The nodularity of the cyst will help differentiate from other cystic lesions. In addition, up to 10% of patients will present with bilateral Warthin tumors.[18] The addition of post-contrast imaging on fat-saturated sequences makes salivary lesions and their adjacent soft tissues more easily identifiable. Following fat saturation, structures that were previously hyperintense on T1-weighted images become hypointense, making the soft tissue mass well delineated within the gland. IV gadolinium contrast may further define salivary lesions, and enhancement about the meninges, within the foramina of the skull base, or within the marrow of the mandible or maxilla would all suggest spread of tumor along these structures. MRI is also best for delineating spread a long the pterygopalatine fossa, stylomastoid foramen and cranial nerve V2, foramen ovale and CN V3, foramen rotundum and CN V2, and the vidian canal and associated nerve. A possible malignant result or irregular borders on FNA should be further evaluated with MRI, as should all submandibular and sublingual gland tumors given the high incidence of malignancy and perineural spread associated with these structures. Malignant neoplasms will usually display a low to intermediate signal on T1WI and T2WI and ill-defined or irregular borders. Mucoepidermoid carcinoma may look like pleomorphic adenoma when small because of its smooth wall. It may contain calcifications and mucinous cysts that appear with high signal on T1- and T2-weighted images. Adenoid cystic carcinoma is the second most common malignancy overall and the most common one found in the submandibular and sublingual glands, with the solid form appearing low in signal on T2-weighted images and the cribriform or tubular subtype appearing high in signal on T2-weighted images. Because of the high incidence of perineural spread with this tumor, the cranial nerves and skull base must be evaluated.

Ultrasound

Ultrasound for salivary gland tumors is used with much more frequency in Europe than in North America.[19] It works in the absence of ionizing radiation and is especially useful in children. For an experienced ultrasonographer, US may identify and characterize a lesion's location. Normal salivary tissue appears homogenous and hyperechoic compared to adjacent muscles. Higher fat content increases the echogenicity and suppresses US waves, limiting the assessment of deep anatomic structures. Malignant lymph nodes will appear as lacking a fatty hilum, more round, and with

an abnormal peripheral vascularity on Doppler US. Benign lesions will usually appear hyperechoic with smooth borders. Warthin tumors will often contain internal anechoic cystic hypervascular areas, whereas pleomorphic adenomas display lobulated contours and occasional internal calcifications. Malignancies will often have irregular borders and shape and be hypoechoic, containing a heterogeneous internal structure and hypervascular internal cysts.

Fine-Needle Aspiration

FNA is a procedure that often relies on US guidance. However, for lesions such as mobile and superficial palpable masses of the parotid gland, US may not be necessary. CT guidance may also be helpful for deeper lesions. The use of US guidance has been shown to increase diagnostic accuracy when compared to FNA without guidance.[20] In addition to making FNA more accurate, US allows the clinician to evaluate the characteristics of a lesion, such as borders and invasion to adjacent anatomic structures. With a cytopathologist present to confirm that enough material is obtained, aspiration with a 22-gauge needle is often adequate for obtaining enough diagnostic material.[21] A meta-analysis by Schmidt and colleagues of 64 parotid lesion FNA samples (N = 6169) showed a sensitivity of 80%, specificity of 97%, and positive predictive value of 90% for differentiating benign from malignant parotid lesions.[22]

Sialography

Sialography is used to visualize the intraglandular ductal system of the major salivary glands. MR sialography is very useful in evaluating the intra- and extraglandular ductal systems in conditions such as postradiation xerostomia, ductal stenosis, and Sjögren syndrome.[23] However, with the advent of serum markers such as SS-A and SS-B for Sjögren syndrome and the advances in CT and MRI, conventional sialography has become an inferior imaging modality. Sialography is contraindicated in patients with iodine contrast allergies or acute sialadenitis. To perform sialography, a blunt-tipped sialographic cannula attached to tubing is used to access the duct. Lacrimal duct dilators may be necessary to cannulate and dilate the papilla. Diatrizoate meglumine, a water-soluble contrast agent, provides excellent contrast opacification of the ductal architecture with no reported adverse effects with duct perforation. MR sialography was first reported by Lomas and colleagues in 1996[24] and produces high-resolution images of the major salivary glands displaying obstructions and duct caliber changes. MR sialography may be used in patients with contrast allergies.

Cystic Conditions

Minor Salivary Glands

The mucocele is the most common cystic lesion of the minor salivary glands. The vast majority represent extravasation phenomena and have no epithelial lining. The most common site is the lower lip in young people, and the etiology is usually minor trauma. Up to 20% of these lesions may represent true retention cysts secondary to obstruction or microliths.[25] These occur in older patients and may affect any site where minor salivary glands occur.

Treatment of this condition is directed toward the underlying gland. Although the mucocele may spontaneously rupture or be "drained" by the patient (occasionally leading to complete resolution following scarring) simple removal of the "cyst" leads to recurrence of the mucocele. A vertical incision over the lesion with removal of the underlying minor salivary gland is almost always curative. A critical aspect is to remove the underlying salivary glands associated with the "cyst." In cases in which recurrence has been a problem, a CO_2 laser can be used to cauterize the surgical bed and any underlying salivary tissue. The wound is left open to heal by secondary epithelialization.

Sublingual Gland

Ranulas are essentially mucoceles that arise from the floor of the mouth secondary to obstruction of the salivary ducts of the sublingual glands and, like simple mucoceles, are caused by traumatic injury to the sublingual gland or its ducts.[26] The ranula is so named for its resemblance to a frog's belly (*rana* and *ranula* mean "frog" and "little frog," respectively, in Latin). This appearance is due to the accumulation of saliva beneath the thin mucous membrane of the floor of the mouth. The majority of these lesions result from extravasation of saliva secondary to trauma. However, their occurrence in young children may indicate dysgenetic development of the sublingual gland duct system. Penetration through a dehiscence of the mylohyoid can allow the lesion to occur in the upper neck as a "plunging" ranula[27] (Figure 20-1). Management of the lesion has been the subject of controversy and can be performed in a variety of ways, which is thoroughly discussed in a definitive paper by Catone.[28] Treatment may be delayed for up to 6 months, because some may resolve spontaneously.[26] Management options include simple excision of the ranula with or without the associated sublingual gland via an intraoral approach, transcervical excision, marsupialization, laser therapy, robotic surgery, and sclerotherapy, versus injection of material into the ranula and excision.[29-34] Imaging is not usually necessary to confirm diagnosis. On ultrasound ranulas will appear as hypoechoic cystic masses with internal echoes. CT or MRI may be helpful in identifying localizing ranulas, though they may appear like well-circumscribed low attenuated masses, similar to dermoid cysts—another common neck mass in children.

However, it is our belief that the only satisfactory method of treatment is excision of the sublingual gland. Initially, Wharton's duct is cannulated so that it can be identified and protected during the dissection (Figure 20-2). Although lacrimal probes are traditionally used, cannulation may be difficult in the presence of swelling. The use of endodontic

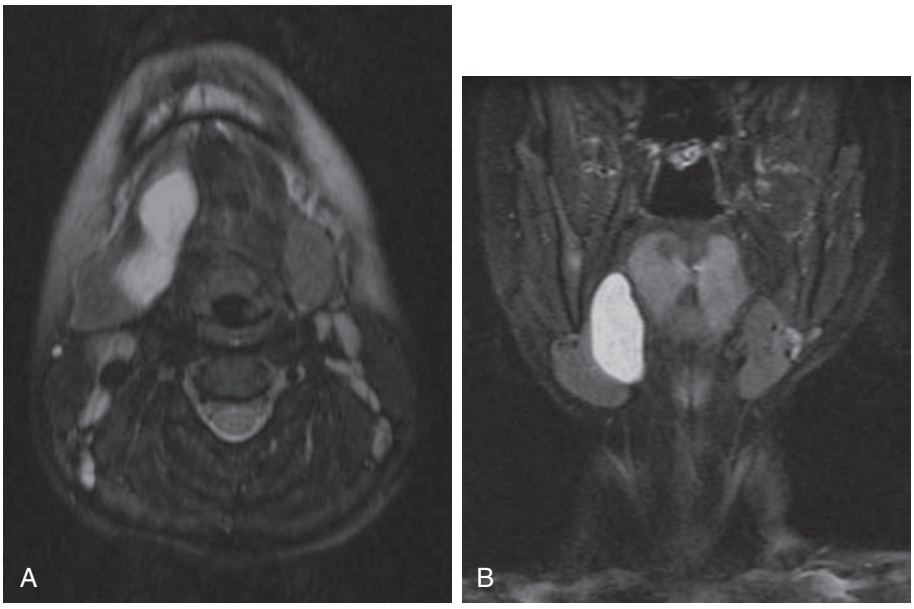

• **Figure 20-1** Axial **(A)** and coronal views **(B)** of magnetic resonance imaging scan of a young boy with a plunging ranula; note the extension of the ranula through the mylohyoid muscle to reach the neck.

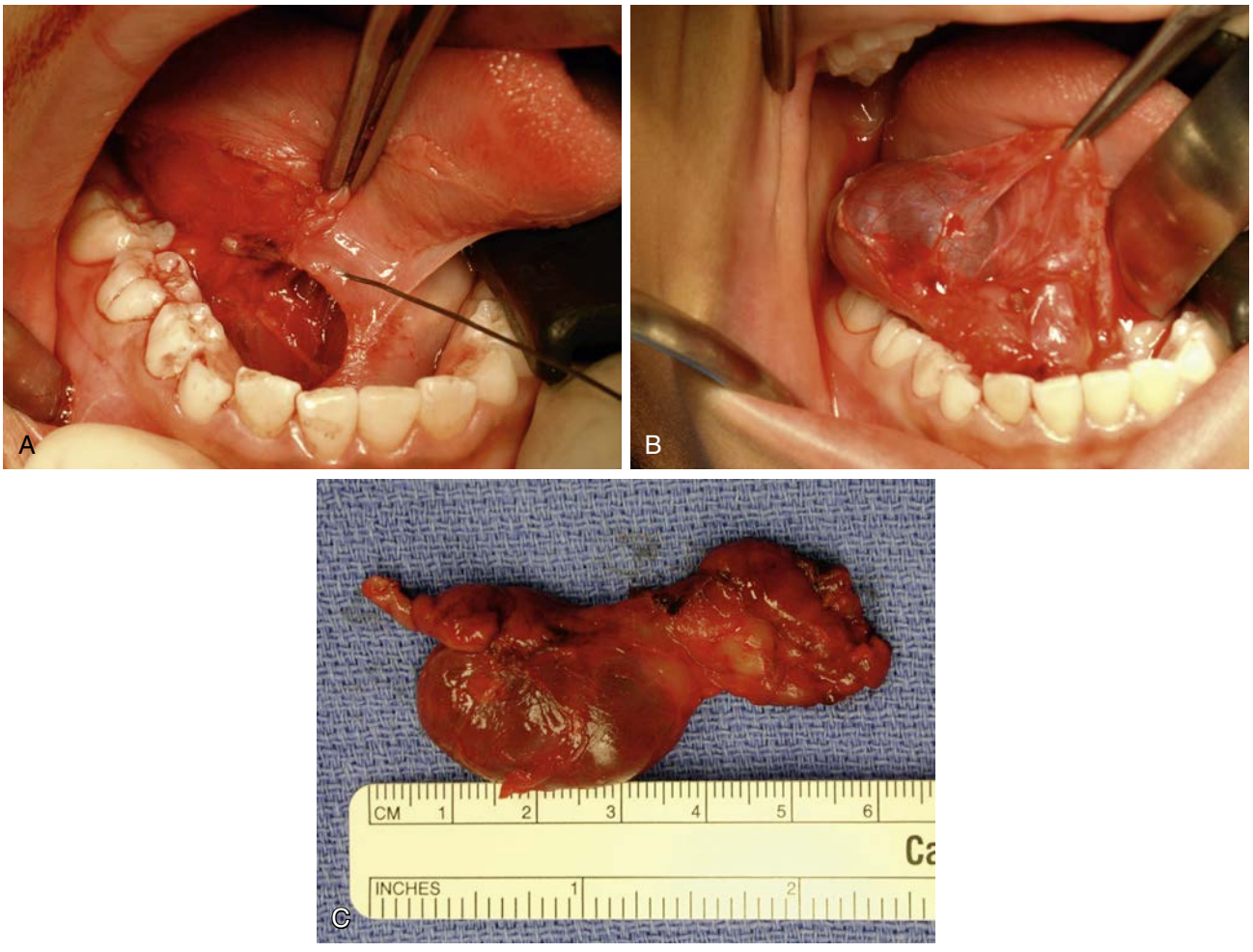

• **Figure 20-2** Cannulation of Wharton's duct to facilitate the identification of the duct during dissection. Mucosal retention sutures may be used to aid in retraction and exposure **(A).** The sublingual gland and associated ranula are then dissected and exposed, **(B)** and removed **(C).**

gutta-percha points may facilitate initial identification and dilation of the duct. An incision is made in the mucosa overlying the duct and along the floor of the mouth, leaving enough tissue for easy closure. The gland is dissected from anterior to posterior, protecting the submandibular duct and obtaining hemostasis as the dissection proceeds. At the posterior edge of the gland, care is taken to identify and preserve the lingual nerve as it passes under Wharton's duct. The posterior border of the sublingual gland may be intimately associated with the oral extension of the submandibular gland, and sharp dissection may be required to separate the two glands—often this border is not discernible. Hemostasis should be ensured before closure. For plunging ranulas, either an intraoral or a transcervical approach may be used, depending on their size, with a transcervical approach being reserved for recurrences and those with a large pseudocyst where dependent drain placement is advantageous.[30-34]

Submandibular Gland

True cysts of the submandibular gland are extremely rare and will not be discussed.

Parotid Gland

There are a number of true cystic lesions that affect the parotid gland, including hereditary polycystic disease,[35] parotid duct cysts, retention cysts, and lymphoepithelial cysts.[36] The lymphoepithelial cyst is the only common entity.

Lymphoepithelial cysts occur as solitary masses within the parotid gland that are clinically indistinguishable from parotid tumors. Also known as branchial cleft cysts, they are usually developmental in nature and histologically are composed of a squamous or pseudostratified epithelial lining surrounded by lymphoid tissue. Even when imaging reveals a cystic lesion, a cystic tumor, such as a pleomorphic adenoma, mucoepidermoid carcinoma, or Warthin tumor, cannot be excluded. The parotid lymphoepithelial cyst resembles the branchiogenic cyst histologically, but its histogenesis is thought to be due to inflammation causing proliferation of epithelial remnants within parotid lymph nodes.[37] This theory has received additional support in recent years by the recognition of multiple bilateral lymphoepithelial cysts of the parotid gland as a manifestation of acquired immunodeficiency syndrome (AIDS)[38] (Figure 20-3).

In the case of a solitary lesion of the lateral lobe of the parotid gland, superficial parotidectomy with preservation of the facial nerve is recommended. Patients infected with human immunodeficiency virus (HIV) may have bilateral occurrence of multiple lymphoepithelial cysts—bilateral parotidectomy may be beneficial for cosmetic reasons.

Inflammatory/Reactive Conditions

The salivary glands can be affected by a variety of infectious processes, either bacterial or viral. In many cases of chronic

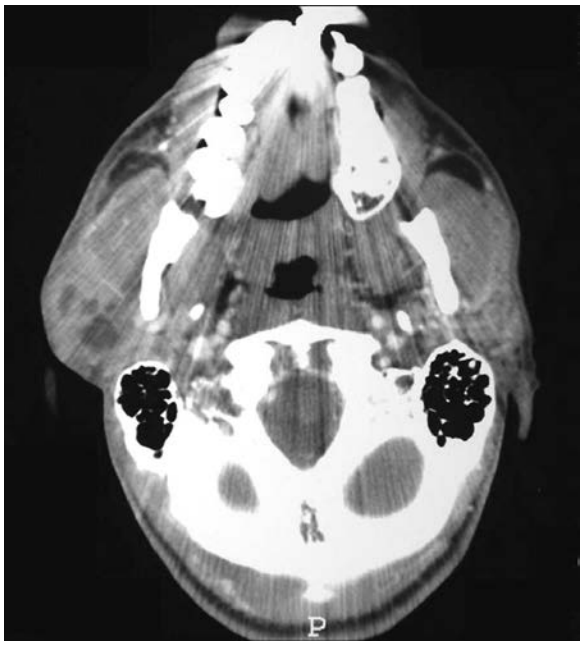

• **Figure 20-3** Patient with bilateral lymphoepithelial cyst of the parotid gland. Right greater than left.

and recurrent infections, underlying problems, such as sialoliths or ductal abnormalities, are major etiologic factors. These conditions are reviewed in the section on obstructive diseases. This section is restricted to acute infection of the salivary glands. The parotid gland is most often affected by these conditions when compared to the other major salivary glands. Radioiodine-induced sialadenitis is not discussed in this chapter.

Acute Suppurative Parotitis

Of the major salivary glands, the parotid gland is by far the most susceptible to infection. This is likely because it is mostly serous in nature, and serous saliva, when compared with mucinous saliva, lacks immunoglobulin A antibodies, lysosomes, and sialic acid—which have antimicrobial properties. In addition, saliva from the submandibular and sublingual glands contains high-molecular-weight glycoproteins that competitively inhibit bacterial attachment to the epithelial cells of the salivary ducts. A patient with acute suppurative parotitis may have symptoms and clinical findings of painful peri–parotid gland swelling, fever, redness, and purulent discharge from Stensen's duct (Figure 20-4). The condition is usually associated with an ascending infection from the oral cavity, with the causative organism being usually being *Staphylococcus aureus* and anaerobic bacteria.[39] Predominant anaerobes include anaerobic gram-negative bacilli (i.e., pigmented *Prevotella* and *Porphyromonas*); *Fusobacterium* spp.; and *Peptostreptococcus* spp. In addition to these, *Streptococcus* spp. and aerobic and facultative gram-negative bacilli (including *Escherichia coli*) have been reported. Organisms less frequently seen include *Haemophilus influenzae, Treponema pallidum, Bartonella henselae,* and *Eikenella corrodens. Mycobacterium tuberculosis* and atypical

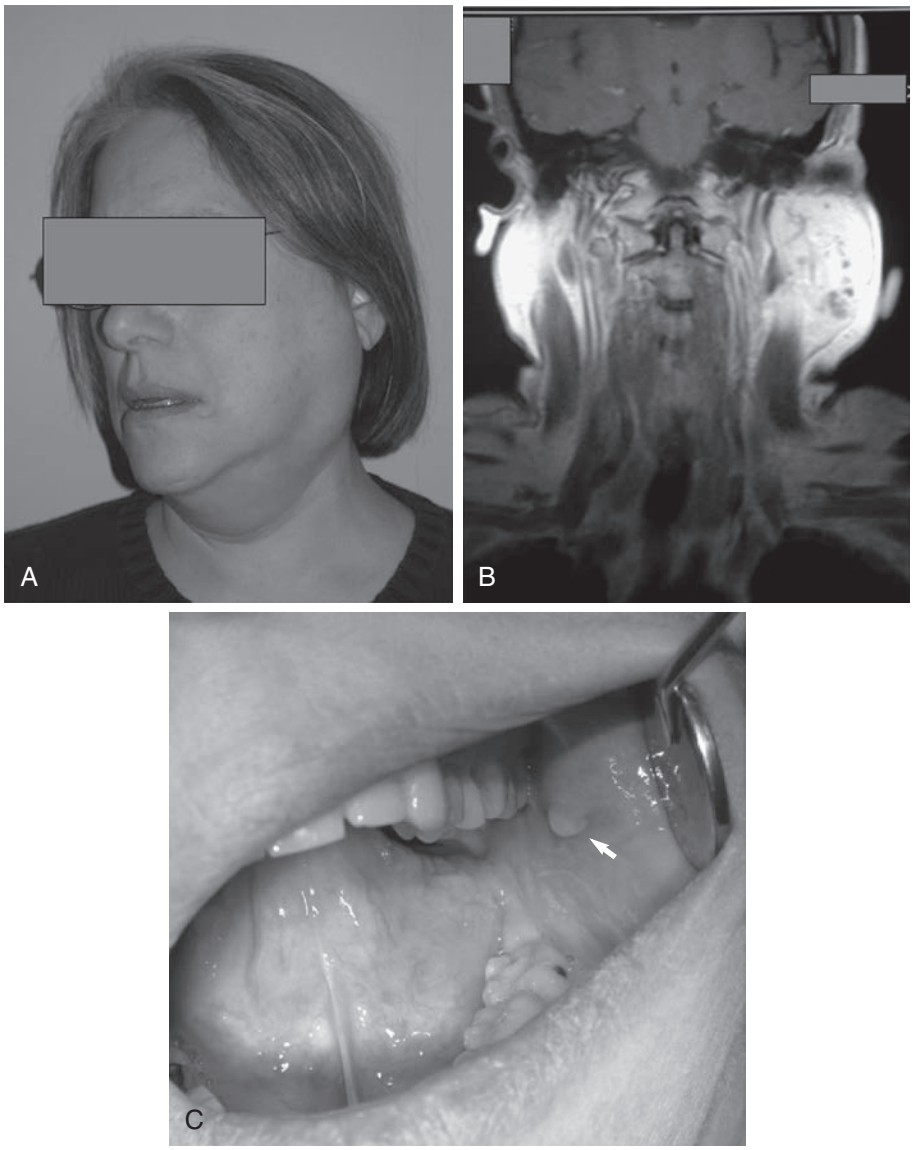

• **Figure 20-4** **A,** Patient with sudden onset of painful parotid gland swelling. **B,** Magnetic resonance imaging of the parotid glands reveals diffuse left parotid gland swelling. **C,** Purulent discharge at Stensen's duct is noted after massage of the parotid gland *(arrow)*.

mycobacteria are rare causes of infection. The choice of antibiotics should be guided by identification of the etiologic agent—which again is usually *S. aureus* in nature. In hospitalized and immunocompromised patients, aerobic and facultative gram-negative bacilli are increasingly seen.[40] Most cases are associated with systemic disease-causing cachexia or dehydration (e.g., uremia, diabetes, liver failure, or hypothyroidism). In the past, the condition was a more common postoperative complication, probably as a result of poor fluid management. In healthy patients, a stone or other underlying local condition should be suspected. Samples for culture and sensitivity testing are obtained by digitally milking the gland when possible, and appropriate antibiotics that are well absorbed by salivary glands are prescribed. Supportive measures (e.g., fluid replacement and analgesics) should be instituted as well as sugar-free sour "candy" to encourage drainage.[13,14] If acute abscess formation occurs (Figure 20-5), surgical drainage is required. Incisions should be placed parallel to facial nerve branches to prevent injury. A preauricular incision with blunt dissection into the abscess using a small hemostat results in a more cosmetic scar and prevents facial nerve damage.

In infants and children, abscesses in the parotid region are usually due to hematogenous spread of bacteria to parotid lymph nodes. Subsequent suppuration and breakdown of nodes cause an abscess that requires drainage. Tuberculosis is another rare cause of parotitis. The infection may be confined to the parotid lymph nodes or may affect the salivary gland parenchyma. Staphylococci is the leading etiologic agent in adult and neonatal suppurative parotitis and usually resistant to penicillin but responsive to aminoglycosides or a third-generation cephalosporin.[41] Intravenous ampicillin/sulbactam or clindamycin are advised while awaiting cultures and sensitivities in order to cover for the



• **Figure 20-5** Computed tomography scan showing parotid abscess with peripheral ring enhancement.

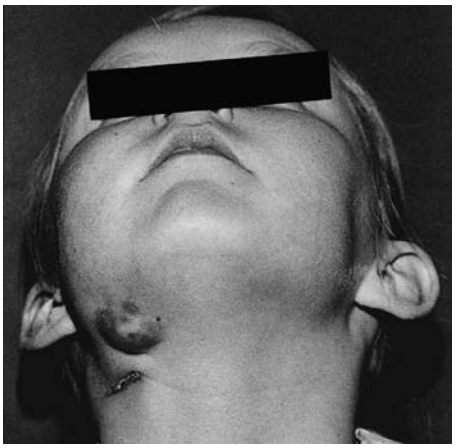

• **Figure 20-6** Ten-year-old girl with *Mycobacterium avium-intracellulare* infection of the parotid nodes, which were removed by a superficial parotidectomy. Swelling now involves the submandibular nodes.

most common pathogens.[42] However, when methicillin-resistant *Staphylococcus aureus* is identified as the causative bacterium, unless sensitive to clindamycin, intravenous vancomycin or linezolid are advised. In pediatric patients, cervical lymphadenitis associated with atypical mycobacteria may rarely affect the parotid lymph nodes[43] (Figure 20-6).

Acute Suppurative Sialadenitis of the Submandibular Gland

Acute suppurative infection of the submandibular gland occurs less often than that of the parotid gland and is usually associated with sialolithiasis within Wharton's duct. Management, however, is the same as for the parotid gland, with caution not to confuse this presentation with that of submandibular space infection from an odontogenic source, which is much more common (Figure 20-7).



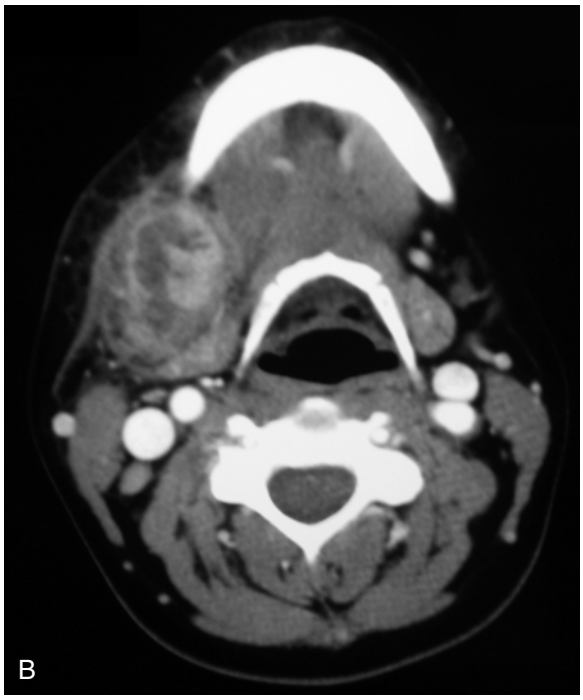

• **Figure 20-7** **A,** Young female patient with a large right submandibular swelling, malaise, fever, and leukocytosis. **B,** Computed tomography scan reveals ring enhancement and diffuse swelling of the submandibular gland.

Viral Infections of the Parotid Gland

Mumps

Before the institution of routine immunization with measles-mumps-rubella (MMR) vaccine, mumps was extremely prevalent in children aged 2 to 14 years and was also known as epidemic parotitis. True mumps is caused by the mumps paramyxovirus, but a similar clinical disease can also occur with Coxsackie virus A and echovirus. The virus is spread by droplet infection and in 75% of cases affects both parotid glands. Painful parotid gland swelling may last 2 weeks. Other organs (e.g., testes, ovaries, breasts, and pancreas)

may be affected, and in adult men, orchitis may lead to sterility. Meningoencephalitis can also occur, which may damage the auditory nerve. Management focuses on the relief of symptoms with analgesics, supportive intravenous fluid therapy, and appropriate consultation for possible encephalitis, meningitis, nephritis, myocarditis, and pancreatitis. [44]

HIV

As previously mentioned, 3% to 6% of patients with AIDS may exhibit bilateral lymphoepithelial cysts, which often may be the first indicator of HIV infection.[36] In addition, in children with AIDS, bilateral parotid gland swelling as a result of lymphocytic infiltration is often seen. In the long term, lymphoma involving the parotid gland may develop in HIV patients (see the section on tumors).[36,45]

Cytomegalovirus

This systemic viral illness is particularly frequent in immunosuppressed patients (e.g., those with bone marrow transplants, on chemotherapy, or with HIV).[46] When cytomegalovirus is suspected, the patient should be isolated from pregnant women to prevent fetal infection with teratogenic effects.[47] Cytomegalovirus infection may occur in an identical fashion to infectious mononucleosis, and interestingly, viral parotitis may also occur in Epstein-Barr viral infections. Other causes of salivary gland infection include granulomatous infections (tuberculous mycobacterial disease vs. nontuberculous mycobacterial disease vs. actinomycosis), cat-scratch disease, toxoplasmosis, and parasitic infections. Other non-infectious inflammatory diseases of the salivary glands include Sjögren syndrome, sarcoidosis, Kimura disease, and Rosai-Dorfman disease.[48]

Obstructive Disease

Although the major condition considered under the heading of obstructive disease is sialolithiasis, mucous plugs, strictures, and duct ectasia may also cause obstruction and give rise to chronic sialoadenitis. Obstructive disease is clinically most relevant in the submandibular and parotid glands. The mechanism for salivary stone formation is related to the same three factors that cause cholelithiasis and renolithiasis: stasis, infection, and alteration of the duct constituents. Desquamated epithelial cells, microorganisms, and salivary duct–derived lysosomes and mitochondria-like structures may be the matrix that forms prior to calcium in the duct.[49] Furthermore, the submandibular gland is the most common gland for sialolithiasis. This is thought to be due to the alkaline pH and high mucin and calcium content of saliva in Wharton's duct, as well as the anatomic characteristics of this duct, which include a long ascending trajectory that circumvents the posterior border of the mylohyoid muscle, possibly contributing to salivary gravitational flow stasis and, perhaps, to calcium precipitation. Decreased salivary flow is further diminished after sialolith formation and salivary gland infection leading to the formation of intraductal sludge and recurrent salivary gland infections and/or recurrent sialolith formation usually necessitating sialadenectomy.

Sialolithiasis

Minor Salivary Glands

Although this is an unusual condition, it is well reported in the literature.[50] The microliths usually are of no clinical significance.

Sublingual Gland

According to Rauch's extensive review of 1200 cases of salivary calculi in the German literature, 7% of salivary stones are found in the sublingual gland.[51] These may cause obstruction of the sublingual gland or problems in Wharton's duct.

Submandibular Gland

As mentioned previously the majority of sialoliths (approximately 85%) occur in the submandibular gland, probably as a result of mucous saliva produced by this gland.[52] These stones usually occur in adults and may be asymptomatic. However, when they reach a suitable size to obstruct the duct lumen, patients experience pain and swelling of the gland, particularly in relation to meals. Secondary infection often supervenes with fever, redness, and purulent discharge from the duct. Eighty-five percent of submandibular stones are radiopaque and can be well visualized on plain films. Approximately 50% of stones will be found in the duct distal to the edge of the mylohyoid muscle and are best seen in an occlusal radiograph. The remaining 50% are found below the mylohyoid or at the hilum of the gland and can be seen on lateral oblique or panoramic radiographs (Figure 20-8). Occasionally, stones are radiolucent and can be visualized only as filling defects on sialography.

Although some stones pass spontaneously or following duct dilation, most require surgical removal. The classic reports by Seward[53-55] describe the principles of surgical management. Stones, particularly those at the orifice or in the distal half of this duct, are removed transorally via sialodochoplasty (Figure 20-9). A suture is passed around the duct posterior to the stone and is used as a traction suture to occlude the duct and prevent the stone from being displaced posteriorly during surgery. A vertical incision is made over the stone, and the duct is opened to allow the stone to be delivered. The duct is irrigated to remove microliths, and the duct edges are sutured to the oral mucosa to form a new orifice. Opening the duct in a vertical manner allows marsupialization of the orifice and prevents stricture.

The further posteriorly the stone occurs, the more technically difficult it is to remove it from a transoral approach because the duct lies deeper and access to it is poor. Once the stone is at the level of the edge of the mylohyoid, removal of the submandibular gland is safer and more certain. An incision is made in a skin crease approximately two finger-widths below the inferior border of the mandible. A dissection taken is taken in the subplatysmal plane, and the inferior border of the gland is identified. An intracapsular

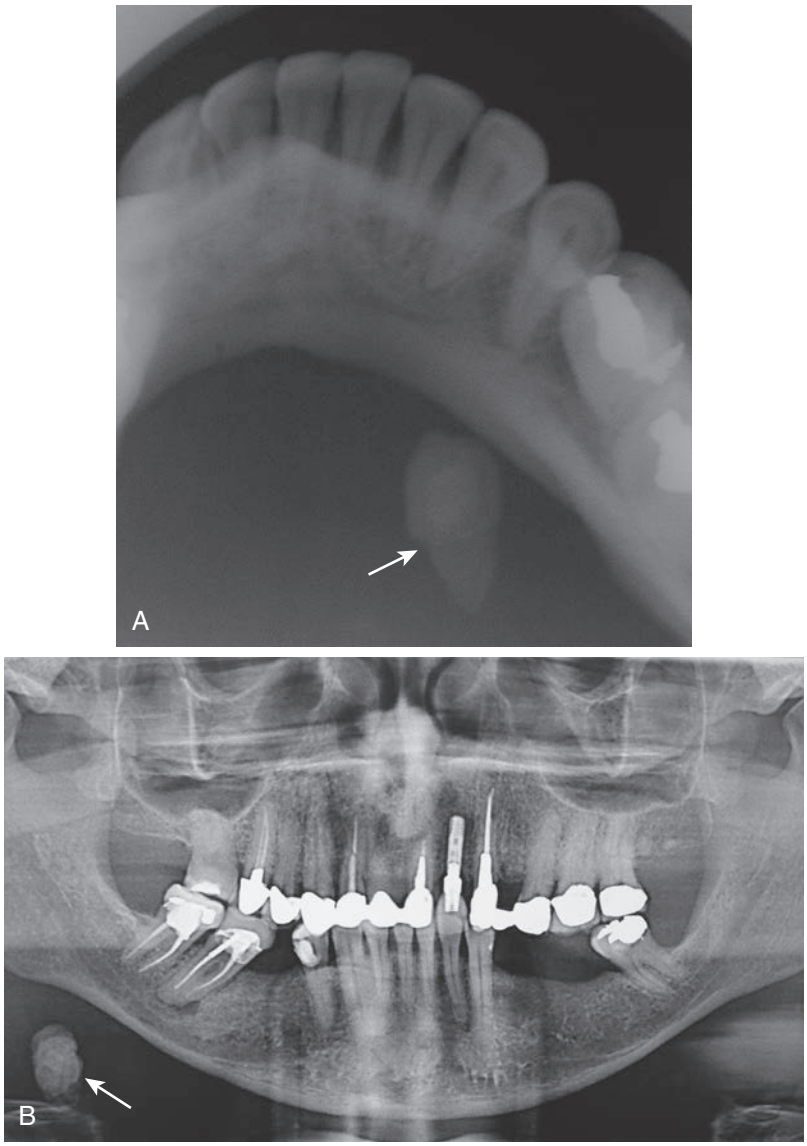

• **Figure 20-8** **A,** Occlusal radiograph shows a large right submandibular sialolith in the distal end of Wharton's duct *(arrow)*. **B,** Panoramic radiograph revealing a large right submandibular sialolith at a level below the mylohyoid, near the hilum of the gland *(arrow)*.

dissection is performed, staying close to the surface of the gland, mobilizing the overlying fascia and capsule of the gland superiorly to protect the marginal mandibular branch of the facial nerve. The inferior and posterior borders of the gland are mobilized rapidly with a combination of blunt and sharp dissection. The inferior border of the gland is followed anteriorly to allow the anterior pole of the gland to be mobilized from the mylohyoid muscle. In cases of chronic recurrent obstruction and sialoadenitis, scarring and adhesions may make dissection more difficult. Once the anterior pole is free, the gland can be retracted posteriorly to expose the posterior edge of the mylohyoid muscle. The muscle is retracted to visualize the lingual nerve and Wharton's duct. The nerve connection from the lingual nerve to the gland is cut, and the duct is carefully dissected from the nerve. While using traction on the gland, the duct is dissected as far forward into the floor of the mouth as possible and then ligated and sectioned to prevent leaving any residual stones (Figure 20-10).[49] The facial artery or vein may be ligated during dissection, but this is often not necessary with careful intracapsular dissection unless the vessel passes directly through the gland. Coagulation or ligation of branches from these vessels to the gland should be meticulous, and care should be taken to ensure complete hemostasis before closure. A suction drain is routinely used overnight.

Although as much of the submandibular duct as possible is removed, a small remnant remains because it is often difficult to distinguish between the submandibular and sublingual glands. Because of the secretions from the sublingual gland entering Wharton's duct, further calculi may form in this remnant, and some authors advocate removing the entire duct by dissecting and freeing the anterior third when the submandibular gland and its proximal duct are removed (as previously described).[49] However, this allows



• **Figure 20-9** **A,** Transoral surgical removal of a stone in the distal portion of Wharton's duct. **B,** Specimen.

communication between the mouth and the neck, and the surgery is no longer considered to be a "clean" case. In addition, sectioning of the sublingual ducts may lead to subsequent ranula formation.

Three approaches to submandibular stones that avoid the use of surgery are catheters, endoscopy,[56] and lithotripsy[57]—laser, basket, or grasper.[58] Very small Foley-type catheters (Fogarty catheters) are passed beyond the stone, the balloon is inflated, and the catheter is removed, retrieving the stone. Miniature endoscopes allow direct visualization of stones and their removal with forceps or baskets.[13,58] Although lithotripsy has been used extensively for renal calculi, its use for salivary stones is less well reported. Extracorporeal lithotripsy has been reported to leave residual lithiasis in 40% to 50% of cases.[59] For this reason, endoscopic lithotripsy has been advocated to give improved results. With a combination of laser or pneumoblastic fragmentation and forceps extraction, 15 of 18 patients (83%) were successfully treated. However, 12 of 39 patients (31%) were unable to have successful endoscopic cannulation.[59]

Parotid Gland

Parotid stones account for 10% of salivary stones, and the majority (85% to 90%) are radiolucent.[60] Most of these are mucous plugs, which are covered in the section on chronic obstructive sialoadenitis. True calcified stones are unusual, and virtually all are found in the duct, rather than the hilum or the gland. Their presentation is similar to that of submandibular stones, with symptoms of pain and swelling, particularly while eating. Dental radiographs held in the cheek may be useful for the diagnosis of calcified stones,[61] and sialograms are beneficial for the diagnosis of radiolucent stones.

Stones at the distal end of the duct or at Stensen's papilla are dealt with as described for submandibular stones occurring at the duct orifice. Once the stone is located posterior to the point where Stensen's duct turns around the masseter, it is no longer accessible from a transoral approach (Figure 20-11). In these cases, an extraoral approach may be chosen. Although some authors advocate an incision that is parallel to the branches of the facial nerve, this runs perpendicular to the relaxed skin tension lines. Alternatively, an incision can be made in the line of a skin crease (through skin *only*), with subsequent dissection parallel to the facial nerve branches.[62] Once the stones are removed, the duct is repaired over a plastic cannula, which is left in place for 6 weeks to act as a stent. An alternative approach to stones in the proximal duct at the hilum of the gland is a parotidectomy incision, raising a skin flap superficial to the parotid capsule and identifying the duct anteriorly as it leaves the gland. This approach results in excellent cosmesis and allows direct visualization of branches of the facial nerve.

Chronic Obstructive Sialoadenitis

Submandibular Gland

In the submandibular gland, obstruction is virtually always secondary to stone formation. If removal of the stone does not cure the condition, the gland should be excised as described earlier.

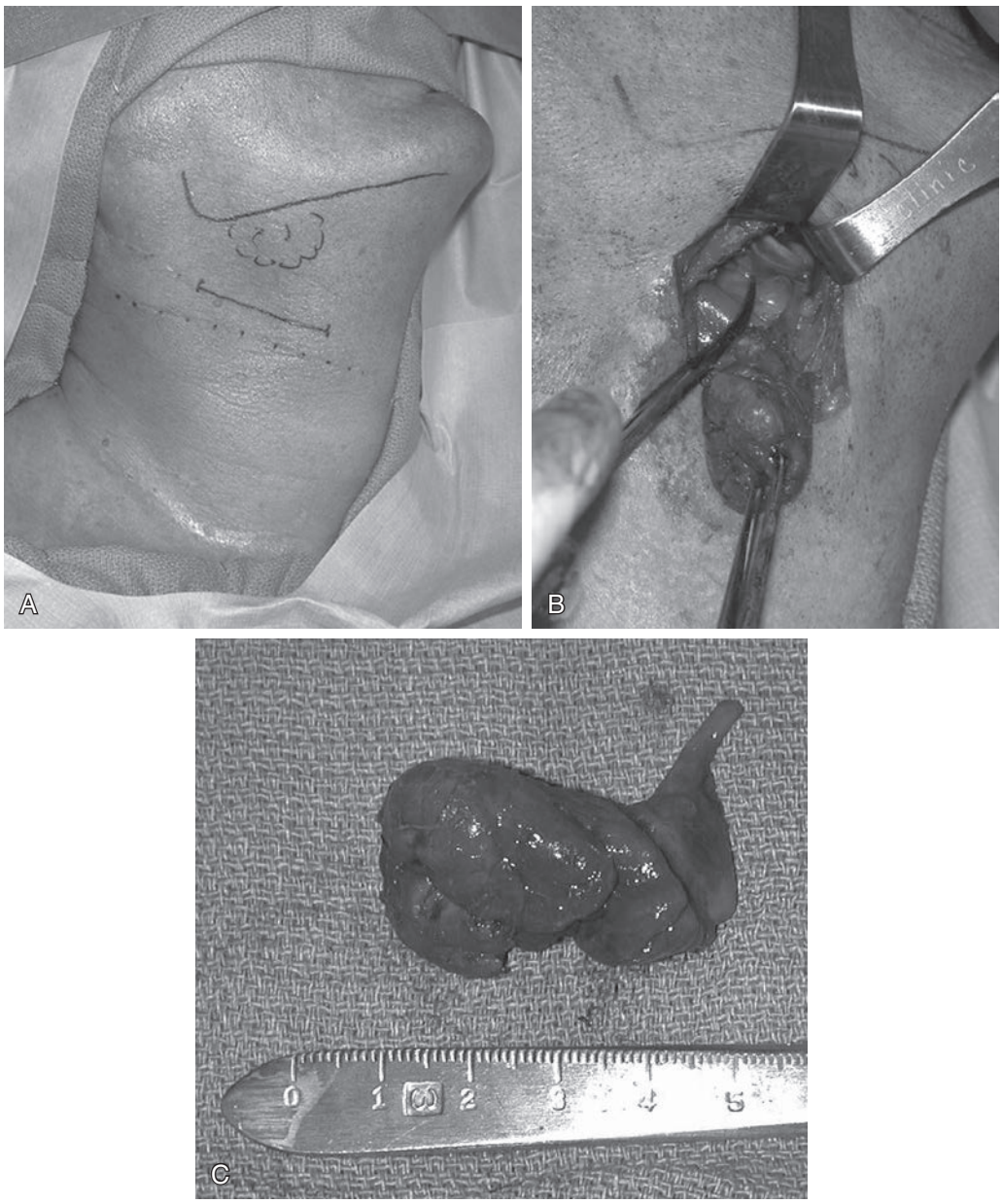

• **Figure 20-10** **A,** Marking for submandibular gland excision. The authors prefer to hide the incision within a neck crease whenever possible while staying two fingerbreadths below the inferior border of the mandible. **B,** With the dissection completed, the only remaining attachment is the duct. **C,** The specimen is removed. Note the extension of the duct.

Parotid Gland

In the parotid gland, recurrent swelling, pain, and purulence are not always associated with an identifiable sialolith. In addition, there is a subgroup of children whose disease appears to run a different course from that of adults. The history is recurrent unilateral parotid gland swelling, often present for many years. The swelling is not always painful and may be accompanied by a salty taste. Initial treatment after history and examination is conservative. The patient is instructed to massage the swollen gland to "milk" out saliva and is placed on antibiotics, particularly when the saliva is purulent or "snowstorm" in appearance.

A sialogram is essential in all cases as both a diagnostic and a therapeutic tool. If a stone or mucous plug is identified, this can be treated as suggested previously.[63] Likewise, a stricture (usually as a result of trauma or a stone that has been passed) can be treated by dilation or repair of the duct. In most cases, the changes seen within the duct are nonspecific inflammation, then sialectasis, followed by dilation and segmentation of the duct. This proceeds to increased dilation of the duct with gross destruction of the salivary gland structure and the branching duct system (Figure 20-12). Most patients, even at relatively late stages, are helped by sialography, which probably relieves obstructive symptoms by its mechanical irrigation and dilation

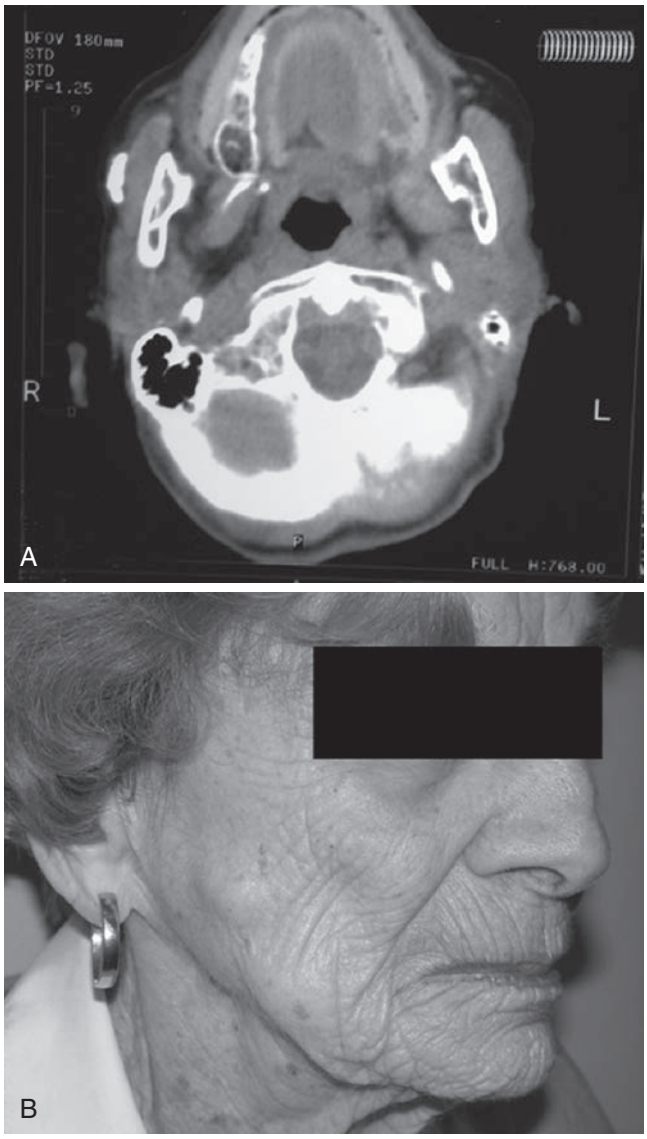

• **Figure 20-11** **A,** Computed tomography scan of a large right parotid duct stone. **B,** Clinical image showing the elevation of the skin caused by the stone.

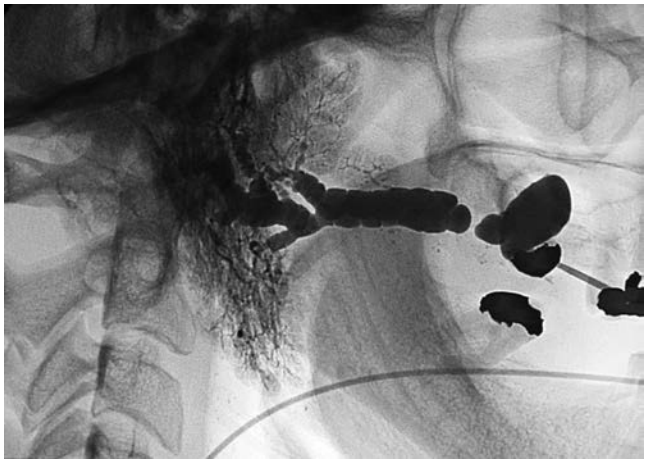

• **Figure 20-12** Parotid sialogram showing significant dilation of the duct in a long-standing sialoadenitis.

of the ducts. In many cases, symptomatic treatment with massage, antibiotics, and duct dilation is sufficient. Those patients who are improved by sialography and then relapse can have their ducts cannulated and irrigated with antibiotic solution or steroids. A minority of patients (less than 10%) will continue to complain of symptoms and will require parotidectomy. This operation is technically challenging because of scarring and fibrosis, which make facial nerve dissection difficult. The senior author undertakes superficial parotidectomy with the removal of Stensen's duct and the accessory gland. The deep lobe is usually not removed, although some authorities advocate total parotidectomy.

The senior author does not agree with ligating Stensen's duct for this condition. This leads to cystic dilation of the distal portion of the duct and makes subsequent parotidectomy very demanding. Another treatment that has been advocated is the sectioning of the tympanic nerve (nerve of Jacobson), a branch of the glossopharyngeal nerve in the middle ear. Although this prevents parotid secretion, the effect is only temporary. The complete pathogenesis of this condition is unknown and probably represents a combination of infection, inflammation, obstruction, and possible congenital duct abnormalities.

In children, the sialogram normally shows punctate sialectasis. However, the disease usually does not progress as it does in adults. Conservative therapy is essential because virtually all children obtain resolution of their symptoms after puberty.[64]

Tumors

All the salivary glands may be involved by tumors arising from salivary acinar or ductal cells. Two predominant theories have been proposed with regards to salivary gland neoplasms: (1) the multicellular theory, which suggests that each type of neoplasm originates from a distinctive cell type—that is, Warthin and oncocytic cell tumors arise from acinar cells, and mixed tumors arise from intercalated duct and myoepithelial cells[65,66]; and (2) the bicellular reserve cell theory, which suggests that the origin of the various types of salivary neoplasms can be traced to the basal cells of either the excretory or the intercalated duct, and either of these two types of cells can act as a reserve cell with the potential for differentiation into a variety of epithelial cells.[67] Radiation[68] and viral exposure,[69] as well as genetics, have been shown to be associated with benign salivary gland neoplasms. [70]

The most common neoplasm of the salivary glands is the pleomorphic adenoma (Table 20-2).[71] The majority of tumors (70%) occur in the parotid gland; 22% arise in the minor glands, 8% stem from the submandibular glands, and 1% in the sublingual glands. Although three-fourths of parotid and over half of submandibular neoplasms are benign, 85% of minor salivary gland tumors are malignant. This is based on data on 2807 subjects from Memorial Sloan-Kettering over a 35-year period. In total, benign neoplasms constituted 55% (1529) of all salivary gland neoplasms,

with the pleomorphic adenoma constituting 45% (n = 1280) of all salivary neoplasms, and 84% of all benign neoplasms. A study by Eveson and Cawson found that of 2410 salivary gland tumors,[72] 73% occurred in the parotid gland, with 15% of those being malignant; however, 14% occurred in minor salivary glands, with 46% being malignant. Eleven percent were submandibular gland tumors with 37% being malignant, whereas sublingual gland tumors made up 0.3% of all salivary gland tumors with 86% being malignant. Warthin tumor was the second most common benign tumor with a 12% incidence. In addition, tumors arising from nonsalivary tissue and the lymph nodes are found in the parotid glands. Malignant neoplasms of the salivary glands represent approximately 3% of all head and neck cancers. [71] Less than 5% of all salivary gland tumors occur in children; however, when they do, they are mostly malignant. [73]

TABLE 20-2 Distribution of 2807 Salivary Neoplasms

Histology	No. of Patients	%
Pleomorphic adenoma	1274	45.4
Warthin tumor	183	6.5
Benign cyst	29	1.0
Lymphoepithelial lesion	17	0.6
Oncocytoma	20	0.7
Monomorphic adenoma	6	0.2
Mucoepidermoid carcinoma	439	15.7
Adenoid cystic carcinoma	281	10.0
Adenocarcinoma	225	8.0
Malignant mixed tumor	161	5.7
Acinic cell carcinoma	84	3.0
Epidermoid carcinoma	53	1.9
Other (anaplastic)	35	1.3
Total	2807	100.0

From Spiro RH: Salivary neoplasms: overview of a 35-year experience with 2807 patients, *Head Neck Surg* 8:177-184, 1986.

The most common salivary gland malignancy is mucoepidermoid carcinoma, comprising approximately 34% of salivary gland malignancies, followed by adenoid cystic carcinoma, adenocarcinoma, malignant mixed tumor, acinic cell carcinoma, and squamous cell (epidermoid) carcinoma, making up 22%, 18%, 13%, 7%, and 4%, respectively.[71-74] When a tumor is present, the ratio of malignant to benign tumors increases from parotid, submandibular, minor and sublingual glands, respectively (Table 20-3). Salivary gland malignancies should be staged appropriately (Table 20-4).

Parotid Gland

The majority of parotid tumors are benign and occur in the superficial lobe. Parotid tumors may also occur in the accessory gland. An accessory parotid gland occurs in approximately 21% of human subjects. It is located anterior to the main parotid gland, usually just above Stensen's duct and connected by its own duct to the latter. Any lesions that can occur in the main parotid gland can also arise in an accessory parotid gland[75] (Figure 20-13).

Most benign and malignant salivary gland tumors are slow growing and are frequently present for months or even years before a patient seeks treatment. They can reach a considerable size. The usual clinical presentation is a painless ovoid mass in the parotid region that is discrete and not fixed to either skin or deep structures. Pain is usually associated with malignancy. Signs that are associated with malignancy include facial nerve palsy, skin ulceration, and cervical lymphadenopathy. However, less than a third of malignant lesions display any of these signs, and clinical differentiation between benign and malignant lesions is usually impossible. Patients should be asked about a history of skin cancer, because melanoma can metastasize to the parotid gland. Although sialography classically shows the "ball in hand" sign for parotid masses, it is no longer used for identifying tumors. CT scanning and MRI are the modalities of choice, although they are of little help for superficial lobe tumors. Both imaging modalities are useful for deep lobe tumors, particularly to demonstrate involvement of the lateral pharyngeal space by the 1% to 2% of deep lobe tumors that "dumbbell" through the stylomandibular canal formed by the membrane between the mandible and stylomandibular

TABLE 20-3 Relationship between Site of Primary Tumor and Malignancy

Site	Numbers	% Frequency	% Malignancy
Parotid	1756	72.9	14.7
Submandibular	257	10.7	37
Sublingual	7	0.3	85.7
Minor glands	336	14	46.4
Unknown	54	2.2	NA

From Eveson JW, Cawson RA: Salivary gland tumours. A review of 2410 cases with particular reference to histological types, site, age and sex distribution, *J Pathol* 146:51-58, 1985.

TABLE 20-4 Stages of Salivary Gland Malignancies

Stage	T	N	M
I	T1	N0	M0
II	T2	N0	M0
III	T3	N0	M0
	T1	N1	M0
	T2	N1	M0
	T3	N1	M0
IVA	T4a	N0	M0
	T4a	N1	M0
	T1	N2	M0
	T2	N2	M0
	T3	N2	M0
	T4a	N2	M0
IVB	T4b	Any N	M0
	Any T	N3	M0
IVC	Any T	Any N	M1

From AJCC: Major salivary glands (parotid, submandibular, and sublingual). In Edge SB, Byrd DR, Compton CC, et al, editors: *AJCC cancer staging manual*, ed 7, New York, 2010, Springer, pp 79-86.

ligament. These tumors may originate from the deep or superficial lobe; however, in either case they may extend to the parapharyngeal space, displacing the oropharyngeal wall medially.

Furthermore, the parapharyngeal space can be divided into pre-styloid (anterolateral) and post-styloid (posteromedial) compartments by a fascial layer that extends from the styloid process to the tensor veli palatini. Deep-lobe parotid tumors involving the pre-styloid compartment of the parapharyngeal space may present as a submucosal bulging mass in the oropharynx and/or nasopharynx that distorts the soft palate or obstructs the eustachian tube. Tumors of the post-styloid compartment may show disability of cranial nerves IX and X (decreased gag reflex, aspiration); cranial nerve X alone, which would manifest as asymmetric palate elevation, hoarseness, and dysphagia; and cranial nerve XI, which would manifest as weakness of the trapezius muscle. An affected cranial nerve XII would manifest as atrophy and paresis of the tongue.

In addition, MRI studies have claimed to distinguish pleomorphic adenomas from malignant tumors on the basis of T1 and T2 characteristics. Because 80% of tumors are benign and 80% of these are pleomorphic adenomas, parotid tumors without signs of malignancy are initially approached as if they were pleomorphic adenomas. The pleomorphic adenoma has a false capsule, and if this is ruptured, the spilled tumor cells can seed and lead to recurrence. Therefore an open biopsy of parotid tumors is contraindicated. Fine-needle aspiration biopsy (FNAB) may be used for preoperative diagnosis. However, the surgeon's confidence in the diagnosis will depend on the competence of the cytologist, because the diagnosis of salivary tumors can be extremely confusing. At the time of surgery, frozen sections carry the same risk of seeding as an open biopsy, and they are notoriously unreliable in the diagnosis of malignant salivary tumors. The most common malignant tumor of the parotid gland is the mucoepidermoid carcinoma.

Benign Tumors

Pleomorphic adenoma is the most common tumor found in the parotid region. It is slow growing, may become very large, and is found in all age groups. It is named pleomorphic, or "mixed tumor," because it possesses histologic characteristics of both epithelia and mesenchymal components. Approximately 90% of pleomorphic adenomas arise superficial to the facial nerve. The nature of its false capsule with "buds" of tumor growing into it makes enucleation an illogical operation. The surgical approach adopted should remove the tumor in its entirety with a surrounding cuff of normal tissue. These surgical principles should also be applied to other benign tumors of the parotid gland. In a superficial lobe tumor, this is best achieved with a superficial parotidectomy (lateral lobectomy), which remains the basic operation in parotid surgery (Figure 20-14). The facial nerve is preserved. In deep lobe tumors, a total parotidectomy is required. This is a more technically demanding operation because of the confined space between the mandible and mastoid, the presence of the external carotid artery, and the need to protect the facial nerve. Following a superficial parotidectomy in which the superficial lobe is pedicled inferiorly to the deep lobe, the tumor is delivered inferiorly after the facial nerve is lifted away. It is rarely possible to obtain a good cuff of normal tissue around deep lobe tumors. In some cases of retromandibular tumors lying deep to the mandible, anterior dislocation of the mandible or osteotomy of the vertical ramus may be required. In large lateral pharyngeal space tumors, blind enucleation should be avoided, and various mandibular osteotomies have been described to access these neoplasms.[76] In the past, the senior author performed the double mandibular osteotomy described by Attia and colleagues.[77] However, we have recently changed our approach to a non–lip-splitting double mandibular osteotomy to preserve cosmesis, while still obtaining excellent exposure of the tumor (Figure 20-15).

Recurrent pleomorphic adenomas may be unifocal or multifocal, but in general they are rare. Multifocal lesions may involve the skin, muscle, and facial nerve and require en-bloc resection as for a malignant tumor. Recent publications suggest a limited role for radiation therapy in multifocal recurrence.[78] True malignant change is rare and usually occurs in a long-standing benign pleomorphic adenoma. The prognosis and treatment depend on the type of malignancy present and whether the tumor has extracapsular

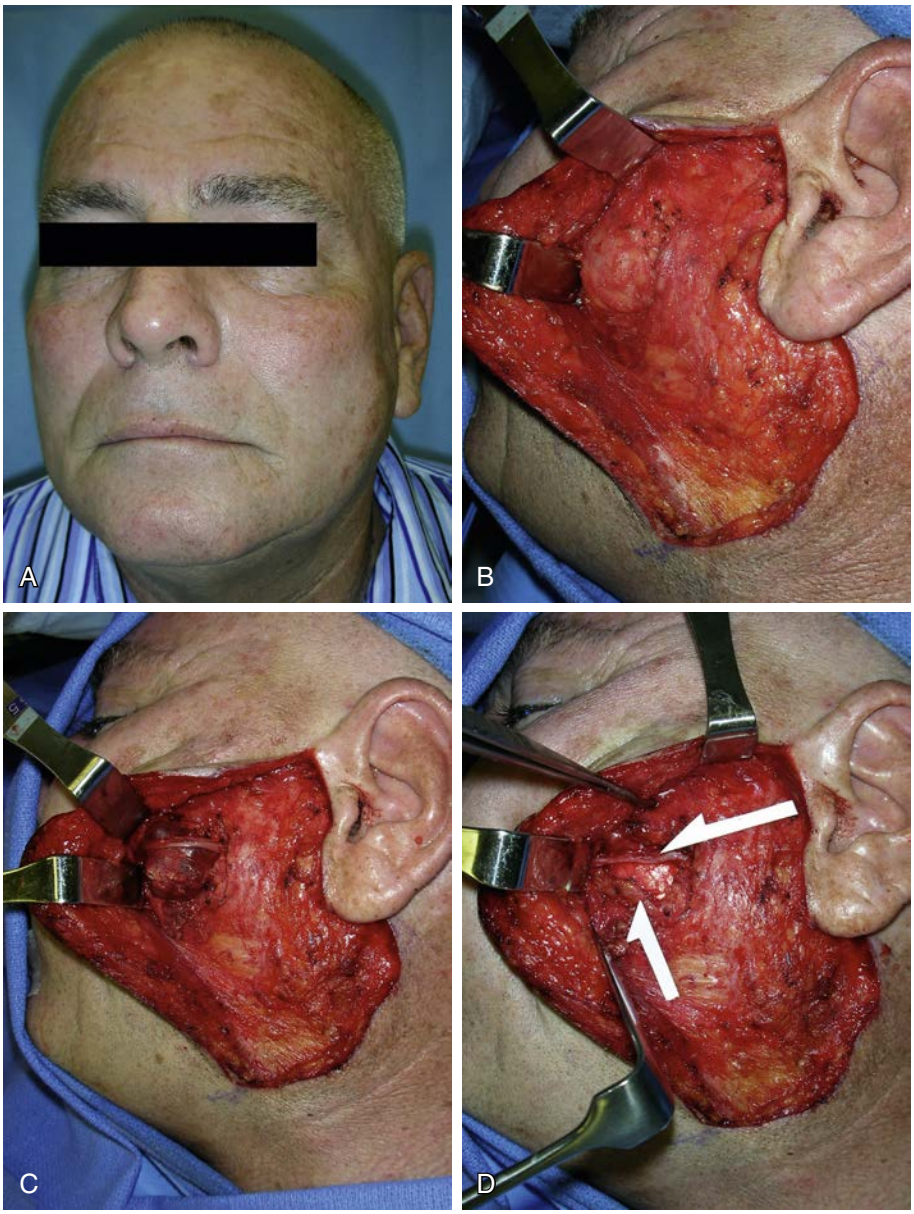

• **Figure 20-13** **A,** Patient with enlarging cheek mass over past 2 years; preoperative image revealed an anterior parotid mass, and fine-needle aspiration was consistent with a pleomorphic adenoma of the accessory parotid gland. **B,** Flap elevated to reveal the lesion. **C,** Further dissection and exposure of the buccal branch of the facial nerve traveling directly over the tumor. **D,** Completed dissection. Note the position of the nerve *(superior arrow)* in relation to the duct *(inferior arrow)*.

spread. Congenital tumors include the hemangioma, vascular and lymphatic malformations, and sialoblastoma.

Warthin tumor is the other common benign parotid tumor and the second most common benign salivary gland neoplasm, which can be multiple and bilateral.[79] Warthin tumor is also known as papillary cystadenoma lymphomatosum or adenolymphoma. Bilateral Warthin tumors occur in 10% of cases and may be simultaneous, have a male preponderance, and are associated with cigarette smoking.[80] These "tumors" may just be reactive proliferation of salivary duct tissue in lymph nodes, and some authorities advocate no surgery if the diagnosis can be made definitively by FNAB. Other less common benign neoplasms include myoepithelioma, basal cell adenoma, sclerosing polycystic adenosis, and keratocystoma.

Briefly, for parotidectomy, a skin incision is placed in the preauricular crease, then extended to the root of the helix and inferiorly around the lobule of the ear over the mastoid tip, then slightly forward into natural skin crease of the neck (modified Blair). Alternatively, a facelift incision may be used starting just on or inside the tragus, with a posterior hairline extension versus the cervical extension of the modified Blair. A skin flap is then elevated superior to the parotid fascia in the preauricular region, and in the subplatysmal plane once in the neck. The great auricular nerve and external jugular vein are identified just over

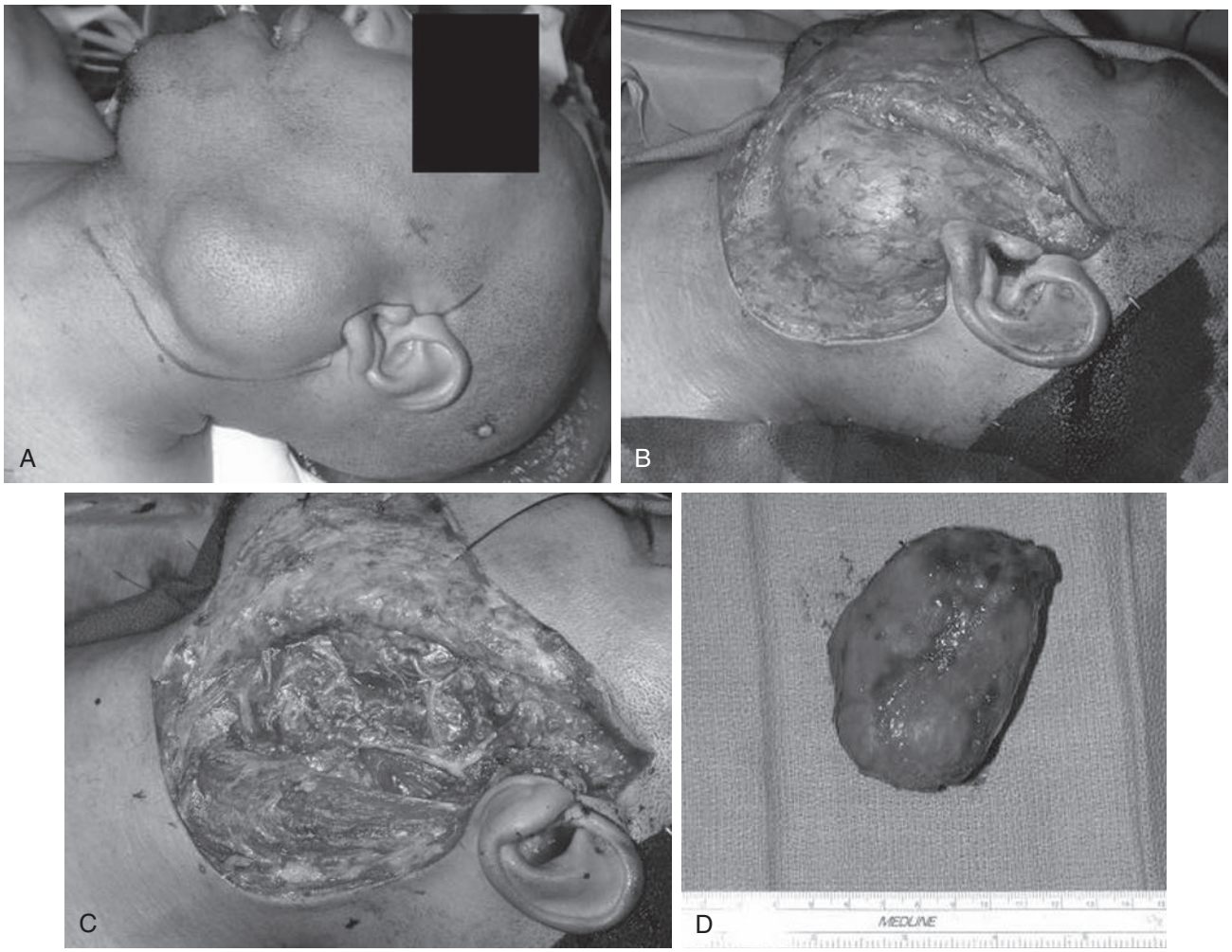

• **Figure 20-14** **A,** A modified Blair incision is marked. Care is made not to extend the incision too far posterior to the lobule of the ear, especially in smokers, so as to prevent ischemia of the flap. **B,** Flap is elevated up, exposing the tumor. **C,** Completed superficial parotidectomy. Note the facial nerve. **D**, Excised specimen.

the sternocleidomastoid (SCM) muscle—these are usually divided to free the tail of the parotid off the SCM. The posterior belly of the digastric muscle is exposed proximal to its attachment to the mastoid bone. The fascia between the parotid gland and the cartilaginous external auditory canal is carefully dissected while retracting the parotid gland anteriorly. Key landmarks to identify the main trunk of the facial nerve are the tragal pointer and attachment of the posterior belly of the digastric muscle to the mastoid bone. The nerve will usually be found between these two landmarks. Usually the nerve can be found approximately 1 to 1.5 cm deep and inferior to the tragal pointer. The third landmark is the tympanomastoid suture, which can be found medial to the main trunk of the nerve. The main trunk of the facial nerve is usually 6 to 8 mm deep to the tympanomastoid suture line. If tumor lies over the main trunk of the nerve, one or more peripheral branches can be identified distally and traced back proximally to the main trunk. [81] The marginal mandibular branch may be identified below the lower border of the mandible, as it crosses the superficial branch to the facial vessels just beneath the deep cervical fascia, or the buccal branch may be identified just beneath the parotidomasseteric fascia, coursing parallel to the parotid duct. In a cadaver study by Rea and colleagues, the main trunk of the facial nerve was found 5.5 ± 2.1mm from the posterior belly of the digastric muscle, 6.9 ± 1.8 mm from the tragal pointer, 10.9 ± 1.7 mm from the junction between the bony and cartilaginous ear canal and 2.5 ± 0.4 mm from the tympanomastoid suture, making the tympanomastoid suture the most reliable landmark.[82] Once the facial nerve is identified, the overlying tissue is carefully dissected and elevated from the upper and lower divisions and off their divisions (branching at the pes anserinus). When total parotidectomy is indicated, the facial nerve and its branches are carefully dissected from the deep parotid tissue. The deep lobe is then delivered carefully and atraumatically. The nerve may need to be sacrificed when involved. Excision of parapharyngeal space salivary gland tumors is usually done as an external approach. When tumors are located in the superior aspect of the parapharyngeal space approaching the eustachian tube and skull base, a mandibulotomy is often needed for access.

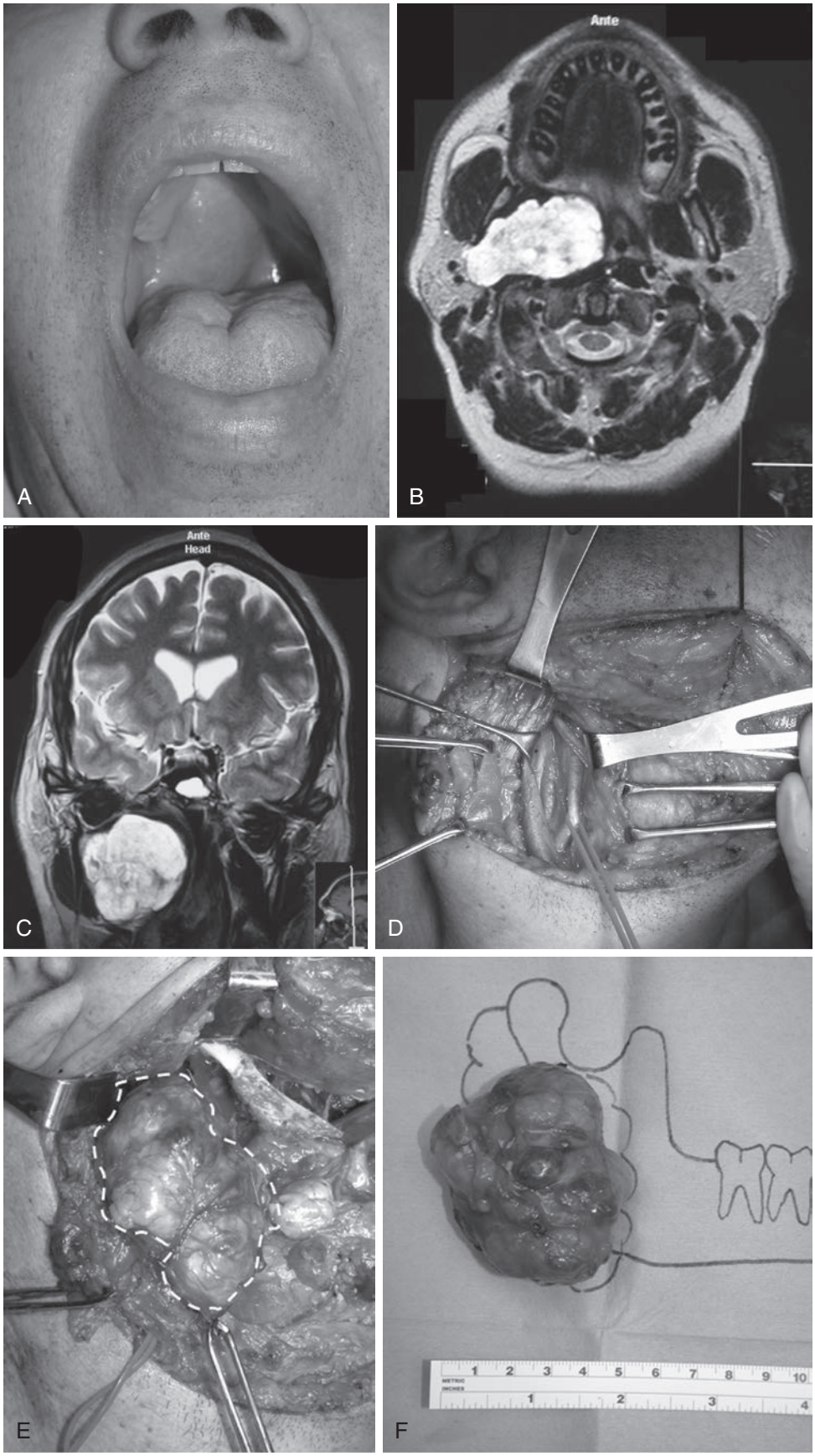

• **Figure 20-15** **A,** Patient with complaints of difficulty swallowing secondary to increasing mass on the right lateral pharyngeal region. **B,** Axial magnetic resonance image of lateral pharyngeal space pleomorphic adenoma. **C,** Coronal view of same lesion. **D,** Exposure of the great vessels and placement of vessel loops for control of bleeding in case of hemorrhage during tumor dissection. **E,** Outline of the tumor as it is being delivered. The approach is facilitated by performing a double mandibular swing osteotomy. One osteotomy is performed at the subsigmoid area as a vertical subsigmoid osteotomy, and the other is performed anterior to the mental foramen. In performing this double osteotomy, the lip innervation is preserved while maintaining aesthetics by not performing a lip split. **F,** Delivered specimen.

Continued



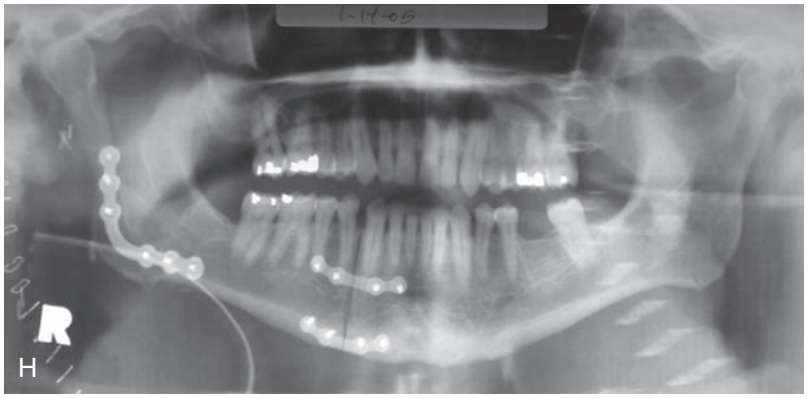

• **Figure 20-15, cont'd** **G,** Closure of the neck after excision of the lateral pharyngeal tumor. Note that the incision is kept well below the chin, and a lip-splitting incision is avoided. **H,** Postoperative panoramic radiograph of the double mandibular osteotomy.

Low-Grade Malignant Tumors

The two most common low-grade malignancies are acinic cell carcinoma and low-grade mucoepidermoid carcinoma. Acinic cell carcinoma can be bilateral in 8% of cases. Mucoepidermoid carcinoma is the most common salivary cancer in children. Both of these tumors rarely metastasize to cervical nodes but are prone to local recurrence. Unless the facial nerve is involved, they should be treated similarly to a pleomorphic adenoma.

High-Grade Malignant Tumors

Adenoid cystic carcinoma is slow growing, but as a result of its infiltrative nature, perineural spread, and hematogenous metastasis, it behaves like a high-grade tumor over a long period. Five-year survival is less important than 10- or 15-year survival. Cervical metastases are found in only 20% of cases, so elective neck dissection is not advocated for the neck with no positive nodes. Wide local excision with parotidectomy, sacrificing skin, muscle, facial nerve, and bone when indicated, is the treatment of choice. Most authorities advocate adjuvant wide-field radiation therapy.

Squamous carcinoma, high-grade mucoepidermoid carcinoma, and the high-grade adenocarcinomas (e.g., comedo ductal adenocarcinoma) are aggressive cancers with a poor prognosis. These neoplasms require excision with wide margins and in-continuity neck dissection. Depending on the involvement of other sites, skin, muscle, bone, and the facial nerve may require sacrifice. A recent publication advocates preserving the facial nerve, even in high-grade malignant tumors, unless the nerve is directly involved[83] (Figure 20-16). Adjuvant radiation therapy is indicated for all these tumors. The prognosis depends on the stage at presentation, involvement of the nerve, and histologic diagnosis. There is some evidence that fast neutron radiation therapy may be more effective against salivary cancers than photon therapy.

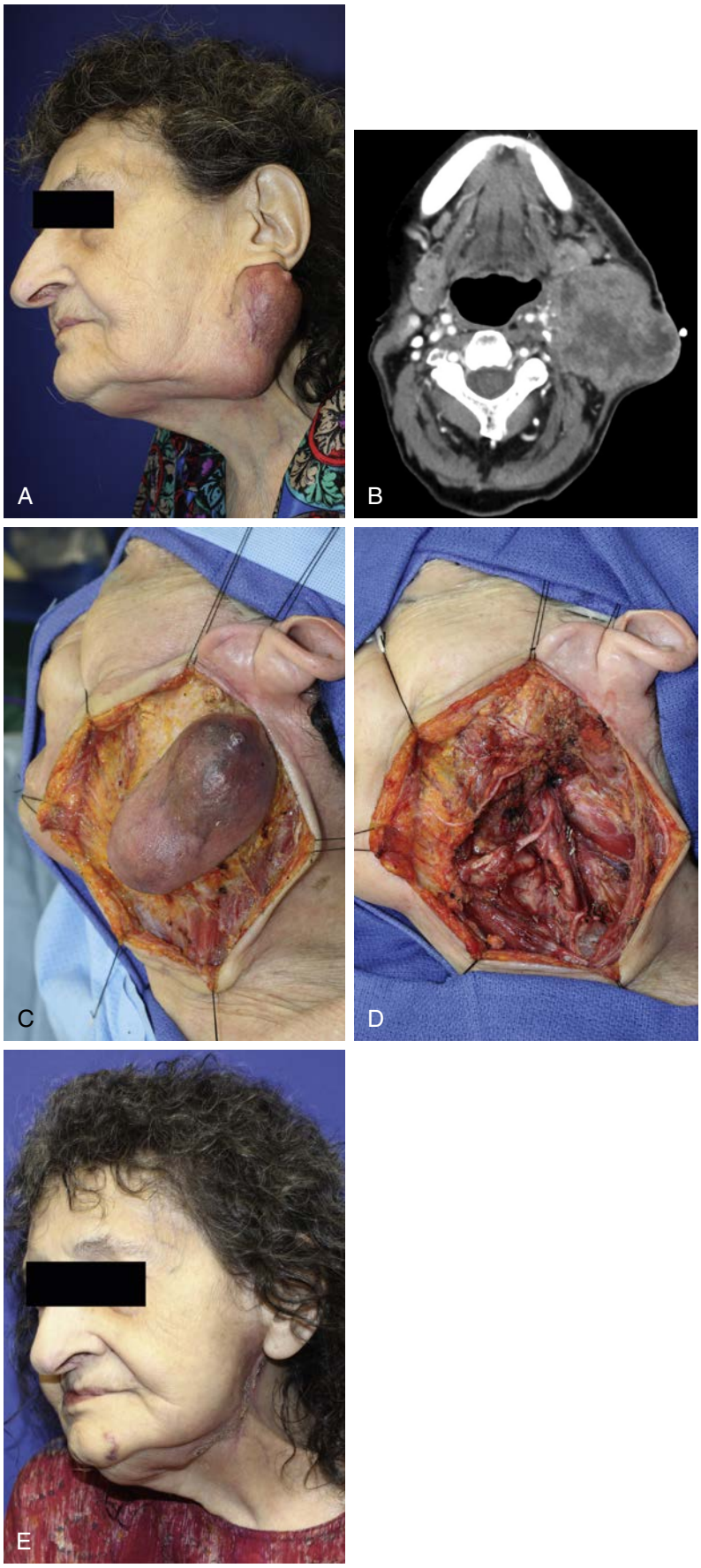

• **Figure 20-16** **A,** Patient with squamous cell carcinoma of the parotid gland and involvement of the overlying skin. **B,** Axial view of contrast computed tomography of the neck, with contrast demonstrating a large tumor involving the deep parotid lobe and lateral pharyngeal space. **C,** Elevation of skin flap to incorporate a selective neck dissection with the parotidectomy and overlying compromised skin. **D,** Completed neck dissection and parotidectomy. **E,** Oblique view of the patient 3 months after surgery.

Nonsalivary Tumors

Tumors in the parotid gland may have a nonsalivary origin or arise from lymph nodes within the parotid gland. Tumors of nonsalivary origin are particularly common in children, with vascular malformations, particularly those of venous and lymphatic vessels, constituting 50% to 90% of all parotid tumors in the pediatric population. Treatment depends on their size and composition and whether they are high or low flow. Many require no active therapy, but surgery with or without embolization, compression, and multiple hemostatic sutures has been used. In rapidly growing hemangiomas, steroid therapy or interferon-α may be helpful. Another common parotid lesion in children and adults is the plexiform neurofibroma.

Lymph nodes within the parotid gland may be involved by metastatic skin cancer, particularly squamous cell carcinoma or melanoma. The scalp, eyelids, and neck should always be examined in a patient with a parotid mass.

Lymphomas are not uncommon in the parotid region. These may involve the lymph nodes or the substance of the gland. There is an increased incidence in patients with AIDS and also in patients with Sjögren syndrome. A sudden increase in the size of the parotid gland in a patient with Sjögren syndrome should always be regarded as a possible lymphomatous change.

Submandibular Gland

Fifty percent of tumors of the submandibular gland are malignant. A pleomorphic adenoma is the most common benign tumor, and adenoid cystic carcinoma is the most common malignant tumor of the submandibular gland. Clinically, these lesions appear as a submandibular mass that can be palpated bimanually in the submandibular triangle, which distinguishes the mass from a cervical node. Skin tethering, cervical lymphadenopathy, fixation to the mandible, and involvement of facial, lingual, or hypoglossal nerves are signs of malignancy. CT and MRI are helpful, and FNAB may give a histologic diagnosis. Other submandibular gland entities acting like tumor include chronic sclerosing sialadenitis (Kuttner tumor).

Benign tumors may be excised with extracapsular dissection and excision of the submandibular gland (Figure 20-17). The most common malignant tumor of the submandibular gland is the adenoid cystic carcinoma. Malignant tumors have a poor prognosis because of late diagnosis and early involvement of the marginal mandibular branch of the facial nerve, which would manifest as weakness of the lower lip, or change in sensation of the tongue from involvement of the lingual nerve. Frequently the mass is diagnosed as inflammatory and excised without a proper oncologic approach. Neck dissection is usually carried out with en-bloc excision of the submandibular triangle, including the mandible if it is involved. The neck dissection may be selective or a modified radical, depending on the stage of nodal disease. Radiation therapy is usually required postoperatively for malignant tumors.

Sublingual Gland

Tumors of the sublingual gland are rare (1% to 2% of all salivary gland tumors), but 90% of these tumors are malignant. The authors have yet to see a benign tumor in this region. The lesions usually occur as a hard, painless mass of the sublingual gland. Pain is indicative of perineural spread. These tumors can rapidly involve the lingual nerve, the body of the mandible, and the musculature of the tongue. Prognosis depends on the stage and microscopic diagnosis of the tumor. CT scanning or MRI is helpful in the workup, and a transoral biopsy is indicated. To obtain adequate margins, mandibulotomy and lip split are usually required, so a supraomohyoid neck dissection is undertaken in most cases. Obviously, involvement of the mandible or the lingual nerve or the presence of metastatic nodes dictates a composite resection with possible radical neck dissection or a modified radical neck dissection and postoperative radiation therapy.

Minor Salivary Glands

Approximately 750 minor salivary glands are found in the oral cavity, nasal cavity, paranasal sinuses, and pharynx. Pleomorphic adenomas may arise from minor salivary glands, with the most common site being the palate, followed by the upper lip. Pleomorphic adenoma of the lower lip is uncommon,[84] whereas it is the most common benign tumor of the lacrimal gland.[85] The majority of these glands are found at the junction of the hard and soft palate, which is the most common site for minor salivary gland tumors. In the palate, 50% of these tumors are malignant, whereas 85% to 90% are malignant in the tongue, and only 20% are malignant in the upper lip.[83] Other benign tumors of the upper lip minor salivary glands include the canalicular adenoma and lipoadenoma.

Lipoadenoma

The diagnostic workup is similar to that for salivary tumors at other sites. CT scanning is best for bony involvement in palatal lesions, and MRI is better to display soft tissue invasion or perineural spread. A transoral biopsy should be undertaken at the center of the tumor and should include overlying mucosa. The most common benign tumor is a pleomorphic adenoma. Malignant tumors are divided into low-grade and high-grade lesions. A pleomorphic adenoma is treated by local excision with 0.5- to 1-cm margins. Enucleation will lead to recurrence. Except in the case of larger neglected tumors, reconstruction may be by primary or secondary healing or include the use of local flaps. Bony excision is usually not required because a pleomorphic adenoma does not invade bone, although it may cause pressure resorption (Figure 20-18).

The most common malignant tumor of the minor salivary glands is the adenoid cystic carcinoma, except those

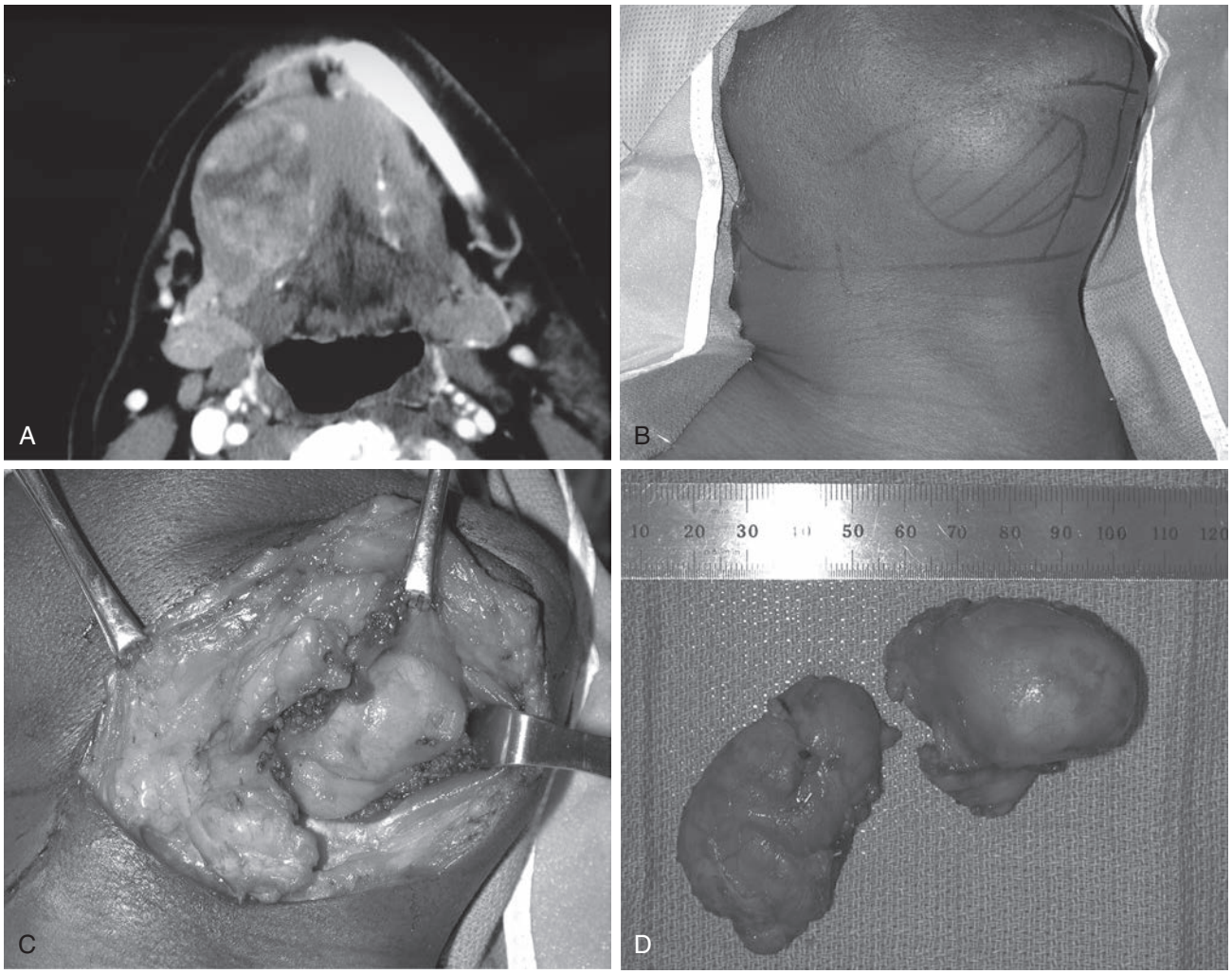

• **Figure 20-17** **A,** Computed tomography scan of a patient with pleomorphic adenoma of the submandibular gland proven by fine-needle aspiration biopsy. **B,** Intraoperative markings. Note the clearly apparent right submandibular swelling. **C,** Intraoperative dissection and exposure of the tumor. **D,** Resected specimen.

that arise in the nasal cavity and paranasal sinuses, in which case adenocarcinoma was the most common type. Low-grade malignant tumors include low-grade mucoepidermoid carcinoma, polymorphous low-grade adenocarcinoma (PLGA), and clear cell carcinoma. The first two tumors are particularly common. These lesions are all characterized by local invasion and infiltration; however, cervical node metastasis or distant metastasis is very rare. Surgery should involve wide local excision with clear margins because local recurrence is the major problem (Figure 20-19). Low-grade mucoepidermoid carcinoma is the most common malignant minor salivary gland tumor in the senior author's series, although older series report adenoid cystic carcinoma as the most prevalent. Low-grade mucoepidermoid carcinoma is frequently cystic because of its many mucous cells and has a propensity for involving the retromolar trigone. It may also occur in children. PLGA is being diagnosed more often as pathologists became more aware of its existence. It may mimic a pleomorphic adenoma and adenoid cystic carcinoma from a microscopic standpoint. Recurrences can occur after many years, mandating long-term follow-up. Perineural spread is not uncommon, but it does not appear to adversely affect prognosis, as is the case for adenoid cystic carcinoma. Clear cell salivary carcinoma must be distinguished from clear cell variants of other salivary tumors, odontogenic tumors, and renal cell metastases. These tumors generally behave in a low-grade fashion.

Although adenoid cystic carcinoma is slow growing, its relentless infiltration and invasion and its tendency to spread along perineural spaces make this a high-grade malignancy with a poor prognosis over a 10- to 20-year follow-up period. The tumor rarely metastasizes to lymph nodes, but hematogenous spread to lung, bone, and liver is common (Figure 20-20). These metastases are slow growing

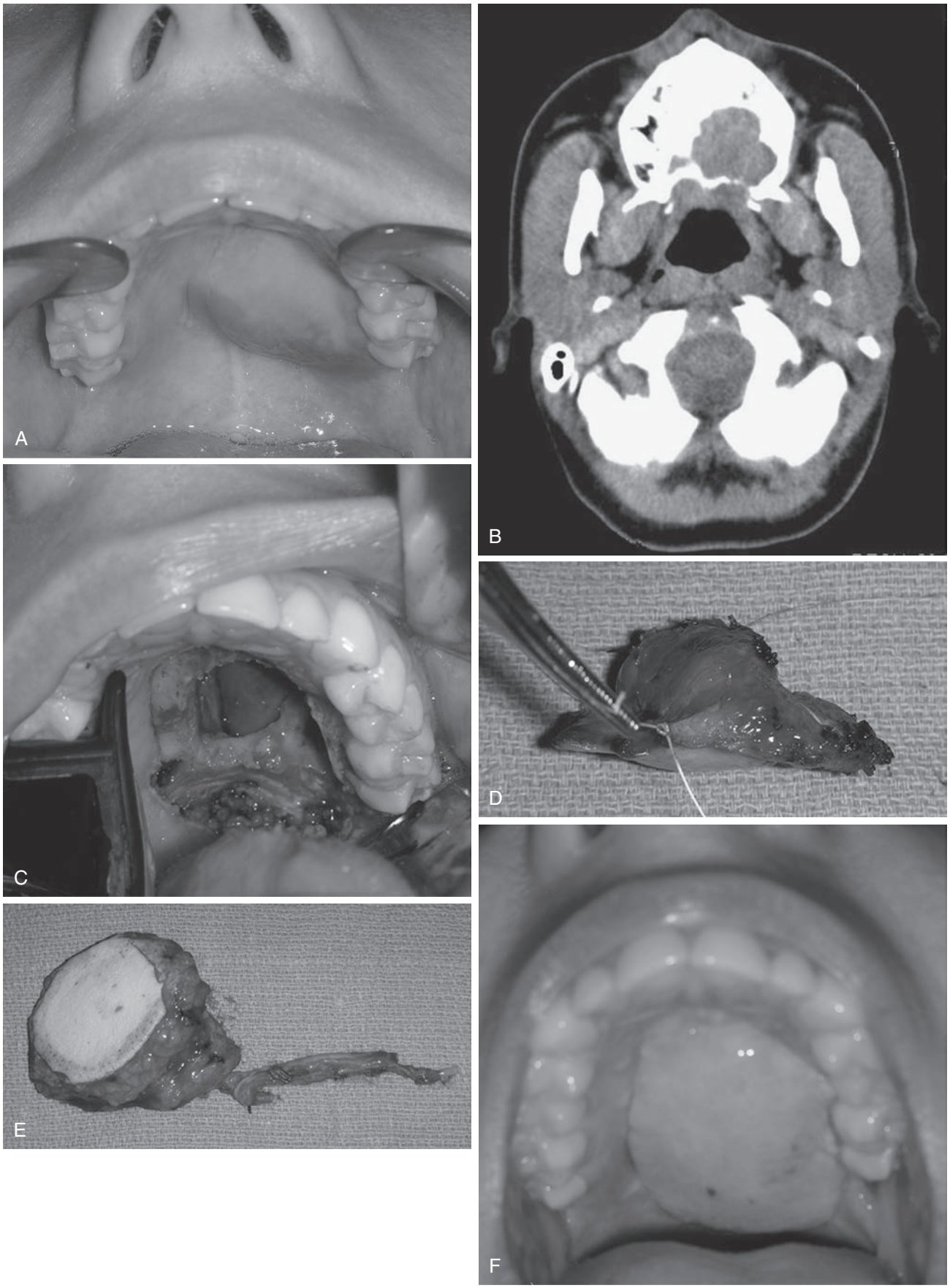

• **Figure 20-18** **A,** Young patient with a large minor salivary gland pleomorphic adenoma in the hard palate. **B,** Computed tomography scan reveals large pressure resorption of the bony hard palate with communication into the maxillary sinus (coronal not shown). **C,** Appearance of the resected bed. Note the large bony defect with extension into the maxillary sinus and nasal cavity. **D,** Resected specimen. **E,** Harvested anterior lateral thigh free flap to reconstruct the defect. **F,** View of the reconstructed palate 2 months postoperatively. No debulking procedure has been done. Patient has good speech and no communication with the sinus or nasal cavity.

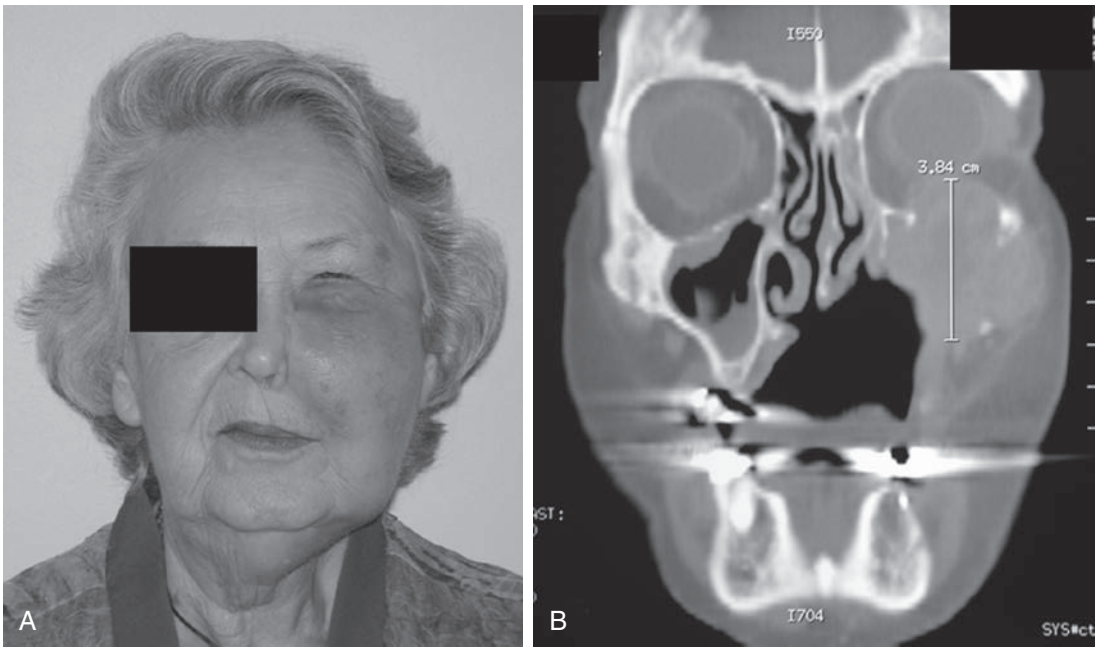

• **Figure 20-19** **A,** Patient with a large recurrent polymorphous low-grade adenocarcinoma of the left maxilla, extending to the cheek and invading the orbit. **B,** Computed tomography scan revealing the extent of recurrence and orbital invasion.

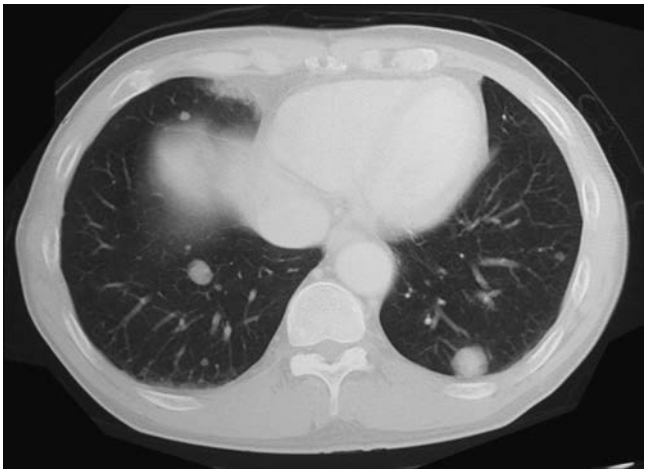

• **Figure 20-20** Patient with previously resected adenoid cystic carcinoma of the retromolar region now with metastatic adenoid cystic carcinoma to the lungs, the so-called cannon balls.

and compatible with many years of survival. In the palate and maxillary sinus, involvement of the greater palatine nerves can lead to early orbital, skull base, and brain involvement. Histologic typing is important in determining prognosis; canalicular tumors have the best prognosis in terms of survival, cribriform tumors have an intermediate prognosis, and solid tumors with necrosis have a very poor prognosis. The presence of perineural spread is an indicator of increased local recurrence and distant metastases. Radical resection with wide margins (identifying major nerves and following them with frozen section) is the recommended treatment. Adjuvant radical radiation therapy given with high fractionation and wide fields is usually recommended. Distant metastases are frequently slow growing and, when symptomless, do not usually require therapy. However, excision of solitary or symptomatic pulmonary or brain metastases has been advocated. There is no good evidence that chemotherapy is beneficial.

High-grade mucoepidermoid carcinoma behaves similarly to squamous cell carcinoma, which it may closely resemble microscopically (Table 20-5). This tumor frequently metastasizes early to lymph nodes and is regarded as relatively radioresistant. Radical surgery with 1- to 2-cm margins and neck dissection, as indicated, is usually followed by radiation therapy. However, these patients frequently succumb to distant metastases.

Salivary Diseases Associated with Systemic Disease

There are a number of systemic diseases, usually causing swelling or xerostomia, that may involve the salivary glands.

Sarcoidosis may have swelling of the parotid gland and occasional facial nerve palsy. Involvement of the lacrimal gland, uveal tract, and parotid gland (known as Heerfordt uveoparotitis) is also a manifestation of sarcoidosis.

Bilateral swelling of the major salivary glands is also an accompaniment of many endocrine diseases (e.g., thyroid disease, diabetes) and metabolic conditions (e.g., alcoholism). This condition is called sialosis.

There are a number of diseases characterized by bilateral swelling of the major salivary glands, dry eyes, and xerostomia. The best known is Sjögren syndrome, in which the patient also suffers from a collagen autoimmune disease, most commonly rheumatoid arthritis. Diagnosis is based on

TABLE 20-5 Grading System for Mucoepidermoid Carcinoma

Parameter (Auclair)	Point Value
Cystic component	+2
Neural invasion	+2
≥4 mitoses/10 hpf	+3
Necrosis	+3
Anaplasia	+4
Grade	**Point Score**
Low (1)	0-4
Intermediate (2)	5-6
High (3)	≥7

Parameter (Brandwein)	Point Value
Cystic component <25%	+2
Tumor front invades in small nests and islands	+2
Pronounced nuclear atypia	+2
Lymphatic and/or vascular invasion	+3
Neural invasion	+3
Necrosis	+3
Four or more mitoses/10 hpf	+3
Bony invasion	+3
Grade	**Point Score**
Low (1)	0
Intermediate	2-3
High (3)	≥4

hpf, High-power field.
From Auclair PL, Goode RK, Ellis GL: Mucoepidermoid carcinoma of intraoral salivary glands. Evaluation and application of grading criteria in 143 cases, *Cancer* 69:2021-2030, 1992; Brandwein MS, Ivanov K, Wallace DI et al: Mucoepidermoid carcinoma: a clinicopathologic study of 80 patients with special reference to histological grading, *Am J Surg Pathol* 25:835-845, 2001.

history and examination, but may be confirmed by special tests, including antibody profiles (anti-SS-A and anti-SS-B antibodies) and a salivary gland biopsy to confirm the presence of lymphocytic infiltration. Although the common site for a biopsy is the lip (involving the removal of three to four minor salivary glands), a parotid gland biopsy is recommended by some authorities.[86] Treatment is symptomatic, with artificial tears and saliva and the use of fluoride trays with regular dental follow-up. If the parotid glands become very enlarged, they may be removed for improved cosmesis. However, this is difficult surgery because of the fibrosis and microabscesses present. Rapid growth of any gland should alert the surgeon to the possibility of lymphomatous change.

Lymphomas may occur in the parotid gland without antecedent Sjögren syndrome or AIDS. In children with AIDS, bilateral lymphocytic infiltration of the major glands may be seen.

Xerostomia is a symptom associated with a variety of underlying disease states, including endocrine and metabolic disorders and psychiatric disease. The clinician should always obtain a list of the patient's medications because sedatives, antidepressants, and antihypertensives are among the common groups of drugs that may cause xerostomia.

References

1. Chambers MS, Garden AS, Kies MS, Martin JW: Radiation-induced xerostomia in patients with head and neck cancer: pathogenesis, impact on quality of life, and management, *Head Neck* 26(9):796–807, 2004.
2. Tabak LA: In defense of the oral cavity: structure, biosynthesis, and function of salivary mucins, *Annu Rev Physiol* 57:547–564, 1995.
3. Mandel ID: The role of saliva in maintaining oral homeostasis, *J Am Dent Assoc* 119(2):298–304, 1989.
4. Klapper CE, Volker JF: The influence of impaired salivary function on dental caries in the Syrian hamster, *J Dent Res* 32(2):219–223, 1953.
5. Mandel ID: Sialochemistry in diseases and clinical situations affecting salivary glands, *Crit Rev Clin Lab Sci* 12(4):321–366, 1980.
6. Turner RJ: Mechanisms of fluid secretion by salivary glands, *Ann NY Acad Sci* 694:24–35, 1993.
7. Baum BJ: Principles of saliva secretion, *Ann NY Acad Sci* 694:17–23, 1993.
8. Garrett JR: Recent advances in physiology of salivary glands, *Br Med Bull* 31(2):152–155, 1975.
9. Humphrey SP, Williamson RT: A review of saliva: normal composition, flow, and function, *J Prosthet Dent* 85(2):162–169, 2001.
10. Ship JA, Fox PC, Baum BJ: How much saliva is enough? "Normal" function defined, *J Am Dent Assoc* 122(3):63–69, 1991.
11. Arglebe C: Biochemistry of human saliva, *Adv Otorhinolaryngol* 26:97–234, 1981.
12. Edgar WM: Saliva: its secretion, composition and functions, *Br Dent J* 172(8):305–312, 1992.
13. Epstein LH, Paluch R, Coleman KJ: Differences in salivation to repeated food cues in obese and nonobese women, *Psychosom Med* 58(2):160–164, 1996.
14. Epstein LH, Paluch R, Smith JD, Sayette M: Allocation of attentional resources during habituation to food cues, *Psychophysiology* 34(1):59–64, 1997.
15. Anderson DJ, Hector MP: Periodontal mechanoreceptors and parotid secretion in animals and man, *J Dent Res* 66(2):518–523, 1987.
16. Leibovitz A, Plotnikov G, Habot B, et al.: Saliva secretion and oral flora in prolonged nasogastric tube-fed elderly patients, *Isr Med Assoc J* 5(5):329–332, 2003.
17. Silvers AR, Som PM: Salivary glands, *Radiol Clin North Am* 36(5):941–966, 1998. vi.
18. Christe A, Waldherr C, Hallett R, et al.: MR imaging of parotid tumors: typical lesion characteristics in MR imaging improve discrimination between benign and malignant disease, *AJNR Am J Neuroradiol* 32(7):1202–1207, 2011.
19. Yousem DM, Kraut MA, Chalian AA: Major salivary gland imaging, *Radiology* 216(1):19–29, 2000.

20. Robinson IA, Cozens NJ: Does a joint ultrasound guided cytology clinic optimize the cytological evaluation of head and neck masses? *Clin Radiol* 54(5):312–316, 1999.
21. Sherman PM, Yousem DM, Loevner LA: CT-guided aspirations in the head and neck: assessment of the first 216 cases, *AJNR Am J Neuroradiol* 25(9):1603–1607, 2004.
22. Schmidt RL, Hall BJ, Wilson AR, Layfield LJ: A systematic review and meta-analysis of the diagnostic accuracy of fine-needle aspiration cytology for parotid gland lesions, *Am J Clin Pathol* 136(1):45–59, 2011.
23. Karaca Erdogan N, Altay C, Ozenler N, et al.: Magnetic resonance sialography findings of submandibular ducts imaging, *BioMed Res Int* 2013:417052, 2013.
24. Lomas DJ, Carroll NR, Johnson G, et al.: MR sialography. Work in progress, *Radiology* 200(1):129–133, 1996.
25. Harrison JD: Salivary mucoceles, *Oral Surg Oral Med Oral Pathol* 39(2):268–278, 1975.
26. Lesperance MM: When do ranulas require a cervical approach? *Laryngoscope* 123(8):1826–1827, 2013.
27. McClatchey KD, Appelblatt NH, Zarbo RJ, Merrel DM: Plunging ranula, *Oral Surg Oral Med Oral Pathol* 57(4):408–412, 1984.
28. Catone GA: Sublingual gland mucous escape: pseudocysts of the oro-cervical region, *Oral Maxillofac Surg Clin N Am* 7:431–478, 1995.
29. de Santana Santos T, Martins VB, Frota R, Karam FK: Excision of ranula using injection of hydrocolloid dental impression material, *J Craniofac Surg* 24(5):1859–1860, 2013.
30. Yang Y, Hong K: Surgical results of the intraoral approach for plunging ranula, *Acta Otolaryngol* 134(2):201–205, 2014.
31. Garofalo S, Mussa A, Mostert M, et al.: Successful medical treatment for ranula in children, *Oral Surg Oral Med Oral Pathol Oral Radiol* 117(4):e289–297, 2014.
32. Zola M: Laser for treatment of ranula, *J Oral Maxillofac Surg* 65(6):1271, 2007.
33. Takagi S, Mizukawa N, Kimura T, Asaumi JI: Treatment of a plunging ranula with fenestration and continuous pressure, *Br J Oral Maxillofac Surg* 41(6):410–413, 2003.
34. McGurk M: Management of the ranula, *J Oral Maxillofac Surg* 65(1):115–116, 2007.
35. Petersson F: Sclerosing polycystic adenosis of salivary glands: a review with some emphasis on intraductal epithelial proliferations, *Head Neck Pathol* 7(Suppl 1):S97–106, 2013.
36. Sujatha D, Babitha K, Prasad RS, Pai A: Parotid lymphoepithelial cysts in human immunodeficiency virus: a review, *J Laryngol Otol* 127(11):1046–1049, 2013.
37. Fujibayashi T, Itoh H: Lymphoepithelial (so-called branchial) cyst within the parotid gland. Report of a case and review of the literature, *Int J Oral Surg* 10(4):283–292, 1981.
38. Kirshenbaum KJ, Nadimpalli SR, Friedman M, et al.: Benign lymphoepithelial parotid tumors in AIDS patients: CT and MR findings in nine cases, *AJNR Am J Neuroradiol* 12(2):271–274, 1991.
39. Brook I: The bacteriology of salivary gland infections, *Oral Maxillofac Surg Clin N Am* 21(3):269–274, 2009.
40. Brook I, Frazier EH, Thompson DH: Aerobic and anaerobic microbiology of acute suppurative parotitis, *Laryngoscope* 101(2):170–172, 1991.
41. Ismail EA, Seoudi TM, Al-Amir M, Al-Esnawy AA: Neonatal suppurative parotitis over the last 4 decades: report of three new cases and review, *Pediatr Int* 55(1):60–64, 2013.
42. Donovan ST, Rohman GT, Selph JP, et al.: Methicillin-resistant Staphylococcus aureus as a cause of neonatal suppurative parotitis: a report of two cases and review of the literature, *Ear Nose Throat J* 92(6):269–271, 2013.
43. Mitchell DA, Ord RA: Atypical mycobacterial infection presenting as a parotid mass in a child, *J Craniomaxillofac Surg* 16(5):221–223, 1988.
44. Kabakus N, Aydinoglu H, Yekeler H, Arslan IN: Fatal mumps nephritis and myocarditis, *J Trop Pediatr* 45(6):358–360, 1999.
45. Mandel L, Surattanont F: Bilateral parotid swelling: a review, *Oral Surg Oral Med Oral Pathol Oral Radiol Endod* 93(3):221–237, 2002.
46. Van Vooren JP, Farber CM, Daelemans P, et al.: Acute Sjogren-like syndrome as the first manifestation of a generalized CMV infection in a patient with AIDS, *J Laryngol Otol* 109(11):1113–1114, 1995.
47. Ornoy A, Tenenbaum A: Pregnancy outcome following infections by coxsackie, echo, measles, mumps, hepatitis, polio and encephalitis viruses, *Reprod Toxicol* 21(4):446–457, 2006.
48. Kruse AL, Gengler C, Gratz KW, Obwegeser JA: Extranodal manifestation of Rosai-Dorfman disease without involvement of lymph nodes, *J Craniofac Surg* 21(6):1733–1736, 2010.
49. Markiewicz MR, Margarone 3rd JE, Tapia JL, Aguirre A: Sialolithiasis in a residual Wharton's duct after excision of a submandibular salivary gland, *J Laryngol Otol* 121(2):182–185, 2007.
50. Jensen JL, Howell FV, Rick GM, Correll RW: Minor salivary gland calculi. A clinicopathologic study of forty-seven new cases, *Oral Surg Oral Med Oral Pathol* 47(1):44–50, 1979.
51. Rauch S: *Die Speicheldrusen des Menschen*, Stuttgart, 1959, Thieme.
52. Lustmann J, Regev E, Melamed Y: Sialolithiasis. A survey on 245 patients and a review of the literature, *Int J Oral Maxillofac Surg* 19(3):135–138, 1990.
53. Seward GR: Anatomic surgery for salivary calculi. II. Calculi in the anterior part of the submandibular duct, *Oral Surg Oral Med Oral Pathol* 25(3):287–293, 1968.
54. Seward GR: Anatomic surgery for salivary calculi. 3. Calculi in the posterior part of the submandibular duct, *Oral Surg Oral Med Oral Pathol* 25(4):525–531, 1968.
55. Seward GR: Anatomic surgery for salivary calculi. IV. Calculi in the intraglandular part of the submandibular duct, *Oral Surg Oral Med Oral Pathol* 25(5):670–678, 1968.
56. Nahlieli O, Baruchin AM: Sialoendoscopy: three years' experience as a diagnostic and treatment modality, *J Oral Maxillofac Surg* 55(9):912–918, 1997, discussion 919–920.
57. Iro H, Schneider HT, Fodra C, et al.: Shockwave lithotripsy of salivary duct stones, *Lancet* 339(8805):1333–1336, 1992.
58. Papadaki ME, McCain JP, Kim K, et al.: Interventional sialoendoscopy: early clinical results, *J Oral Maxillofac Surg* 66(5):954–962, 2008.
59. Arzoz E, Santiago A, Esnal F, Palomero R: Endoscopic intracorporeal lithotripsy for sialolithiasis, *J Oral Maxillofac Surg* 54(7):847–850, 1996, discussion 851–852.
60. Iro H, Zenk J, Escudier MP, et al.: Outcome of minimally invasive management of salivary calculi in 4,691 patients, *Laryngoscope* 119(2):263–268, 2009.
61. Suleiman SI, Hobsley M: Radiological appearances of parotid duct calculi, *Br J Surg* 67(12):879–880, 1980.
62. Oh HK, Park HJ, Oh JS, et al.: Transcutaneous approach for the removal of parotid gland stones, *J Craniofac Surg* 25(6):2196–2198, 2014.
63. Wang S, Marchal F, Zou Z, et al.: Classification and management of chronic sialadenitis of the parotid gland, *J Oral Rehabil* 36(1):2–8, 2009.

64. Leake DL, Krakowiak FJ, Leake RC: Suppurative parotitis in children, *Oral Surg Oral Med Oral Pathol* 31(2):174–179, 1971.
65. Levin RJ, Bradley MK: Neuroectodermal antigens persist in benign and malignant salivary gland tumor cultures, *Arch Otolaryngol Head Neck Surg* 122(5):551–557, 1996, discussion 557–558.
66. Dardick I, Byard RW, Carnegie JA: A review of the proliferative capacity of major salivary glands and the relationship to current concepts of neoplasia in salivary glands, *Oral Surg Oral Med Oral Pathol* 69(1):53–67, 1990.
67. Batsakis JG, Luna MA, el-Naggar AK: Basaloid monomorphic adenomas, *Ann Otol Rhinol Laryngol* 100(8):687–690, 1991.
68. Modan B, Chetrit A, Alfandary E, et al.: Increased risk of salivary gland tumors after low-dose irradiation, *Laryngoscope* 108(7):1095–1097, 1998.
69. Tsai CC, Chen CL, Hsu HC: Expression of Epstein-Barr virus in carcinomas of major salivary glands: a strong association with lymphoepithelioma-like carcinoma, *Hum Pathol* 27(3):258–262, 1996.
70. Liu J, Shao C, Tan ML, et al.: Molecular biology of adenoid cystic carcinoma, *Head Neck* 34(11):1665–1677, 2012.
71. Spiro RH: Salivary neoplasms: overview of a 35-year experience with 2,807 patients, *Head Neck Surg* 8(3):177–184, 1986.
72. Eveson JW, Cawson RA: Salivary gland tumours. A review of 2410 cases with particular reference to histological types, site, age and sex distribution, *J Pathol* 146(1):51–58, 1985.
73. Pinkston JA, Cole P: Incidence rates of salivary gland tumors: results from a population-based study, *Otolaryngol Head Neck Surg* 120(6):834–840, 1999.
74. Hunter RM, Davis BW, Gray Jr GF, Rosenfeld L: Primary malignant tumors of salivary gland origin. A 52-year review, *Am Surg* 49(2):82–89, 1983.
75. Polayes IM, Rankow RM: Cysts, masses, and tumors of the accessory parotid gland, *Plast Reconstr Surg* 64(1):17–23, 1979.
76. Flood TR, Hislop WS: A modified surgical approach for parapharyngeal space tumours: use of the inverted "L" osteotomy, *Br J Oral Maxillofac Surg* 29(2):82–86, 1991.
77. Attia EL, Bentley KC, Head T, Mulder D: A new external approach to the pterygomaxillary fossa and parapharyngeal space, *Head Neck Surg* 6(4):884–891, 1984.
78. Renehan A, Gleave EN, McGurk M: An analysis of the treatment of 114 patients with recurrent pleomorphic adenomas of the parotid gland, *Am J Surg* 172(6):710–714, 1996.
79. Lefor AT, Ord RA: Multiple synchronous bilateral Warthin's tumors of the parotid glands with pleomorphic adenoma. Case report and review of the literature, *Oral Surg Oral Med Oral Pathol* 76(3):319–324, 1993.
80. Pinkston JA, Cole P: Cigarette smoking and Warthin's tumor, *Am J Epidemiol* 144(2):183–187, 1996.
81. O'Regan B, Bharadwaj G: Tumour recurrence after surgical removal of parotid pleomorphic salivary adenoma using a retrograde facial nerve dissection technique, *Br J Oral Maxillofac Surg* 50(5):417–419, 2012.
82. Rea PM, McGarry G, Shaw-Dunn J: The precision of four commonly used surgical landmarks for locating the facial nerve in anterograde parotidectomy in humans, *Ann Anat* 192(1):27–32, 2010.
83. Ord RA: Surgical management of parotid disease, *Atlas Oral Maxillofac Surg Clin North Am* 6(1):1–28, 1998.
84. Jansisyanont P, Blanchaert Jr RH, Ord RA: Intraoral minor salivary gland neoplasm: a single institution experience of 80 cases, *Int J Oral Maxillofac Surg* 31(3):257–261, 2002.
85. Cates CA, Manners RM, Rose GE: Pleomorphic adenoma of the lacrimal gland in a 10 year old girl, *Br J Ophthalmol* 86(2):249–250, 2002.
86. Marx RE: Incisional parotid biopsy for diagnosis of systemic disease, *Oral Maxillofac Surg Clin N Am* 7:505–518, 1995.

21

Diagnosis and Management of Medication-related Osteonecrosis of the Jaw

SALVATORE L. RUGGIERO

Introduction

Antiresorptive medications such as bisphosphonates and more recently the receptor activator of nuclear factor-κB ligand (RANKL) inhibitors are a class of agents used to treat osteoporosis and the complications associated with malignant bone metastases. Despite these benefits, osteonecrosis of the jaws is recognized as a significant complication in a subset of patients receiving these drugs. Based on a growing number of case reports and institutional reviews, antiresorptive therapy may cause exposed and necrotic bone that is isolated to the jaw. This complication usually presents following simple dentoalveolar surgery. The pathogenesis for this complication appears to be related to the profound inhibition of osteoclast function and bone remodeling. The emergence of jaw necrosis in bisphosphonate-naive patients receiving monoclonal therapy with RANKL inhibitors[1-4] prompted the American Dental Association to introduce the more generic term ARONJ (antiresorptive associated osteonecrosis of the jaw).[5] MRONJ (medication-related osteonecrosis of the jaw) is the most recent nomenclature change, proposed in the 2014 position paper of the American Association of Oral and Maxillofacial Surgeons (AAOMS).[6] This modification was considered necessary in order to address the growing number of osteonecrosis cases affecting the jaws that were associated with antiangiogenic therapies.

In this chapter we review the clinical indications for antiresorptive therapy and certain antineoplastic agents along with the osteonecrosis risks associated with their long-term use. Diagnostic strategies, risk stratification and guidelines for staging and management of patients with established MRONJ are also reviewed.

Antiresorptive Agents: What Are They and How Do They Work?

Bisphosphonates were developed in the 19th century, but were first investigated in the 1960s for use in disorders of bone metabolism. Their nonmedical use included water softening in irrigation systems used in orange groves.[7] The initial rationale for their use in clinical practice was centered on their potential for preventing the dissolution of hydroxyapatite, the principal bone mineral, and hence arresting bone loss.

All bisphosphonates are non-metabolized synthetic analogues of pyrophosphate. There are a variety of bisphosphonates that are approved for clinical use in the United States. They are segregated based on potency and route of administration (Table 21-1). Bisphosphonates bind avidly to exposed bone mineral around resorbing osteoclasts, resulting in very high levels of bisphosphonate in the resorption lacunae. Because bisphosphonates are not metabolized, these high concentrations are maintained within bone for long periods of time. Bisphosphonates are then internalized by the osteoclast, causing disruption of osteoclast-mediated bone resorption at various levels.[8] At the tissue level, bisphosphonates will inhibit bone resorption and decrease bone turnover as assessed by biochemical markers. The degree to which these compounds will also alter bone formation is related to their effects on bone turnover, which is closely coupled to bone formation. On a cellular level, the bisphosphonates target the osteoclasts and may inhibit their function in several ways: (1) inhibition of osteoclast recruitment,[9] (2) reduction of osteoclast life span,[10] and (3) inhibition of osteoclastic activity at the bone surface.[11] At a molecular level it has been postulated that bisphosphonates modulate osteoclast function by interacting with a cell surface receptor or an intracellular enzyme.[12]

TABLE 21-1 Antiresorptive Medications

Generic Name	Brand Name (Delivery)	RAP*
Etidronate	Didrone (PO)	1
Tiludronate	Skelid (PO)	10
Alendronate sodium	Fosamax (PO)	1,000
Risedronate	Actonel (PO)	5,000
Ibandronate	Boniva (PO/IV)	10,000
Zoledronic acid	Zometa (IV)	100,000
Pamidronate	Aredia (IV)	100
Denosumab	Xgeva (IV), Prolia (PO)	Similar to zoledronic acid

*Relative antiresorptive potency.

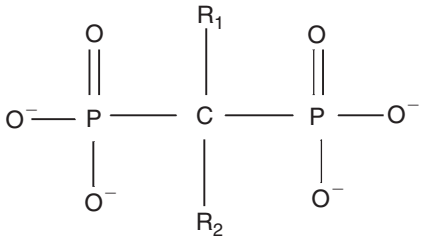

• **Figure 21-1** Chemical structure of the basic bisphosphonate molecule.

Each bisphosphonate has a different R1 or R2 side chain attached to the central carbon atom (Figure 21-1). The R1 side chain determines affinity for bone, whereas the R2 side chain is responsible for potency and antiresorptive properties. In general, side chains that contain a nitrogen atom are more potent than the non-nitrogen bisphosphonates. Etidronate, tiludronate, and clondronate are older-generation bisphosphonates that do not contain nitrogen. Once internalized by the osteoclast, these agents inhibit adenosine triphosphate–dependent intracellular enzymes that result in cellular apoptosis. The next generation of bisphosphonates contained a nitrogen side group characterized by a primary amine (alendronate and pamidronate) or a tertiary amine (risedronate and ibandronate). Zoledronic acid, the most potent bisphosphonate, is a tertiary amine that is part of a ring structure. The nitrogen-containing bisphosphonates inhibit the activity of the enzyme farnesyl diphosphate synthase in the mevalonate pathway, which blocks the phenylation of small signaling proteins (GTPases) that are required for osteoclast function and survival.

Bisphosphonates also have demonstrated effects unrelated to osteoclast inhibition. Pamidronate has been associated with an acute-phase reaction characterized by fever and transient changes in various cytokine levels such as interleukin-6, tumor necrosis factor-alpha, C-reactive protein, and elastase.[13] More importantly, pamidronate was reported to significantly depress bone blood flow in rats.[14,15] The mechanism of this effect may be attributable to a complex interaction of pamidronate with growth hormone and insulin-like growth factor 1, both of which are thought to play a role in the regulation of blood circulation in bones. Bisphosphonates can also inhibit endothelial cell function in vitro and in vivo.[16] Those cells treated with bisphosphonates demonstrated decreased proliferation, an increased rate of apoptosis, and a decrease in capillary-tube formation. In that same study, there was a marked reduction in the number of blood vessels in pagetic bone marrow after bisphosphonate treatment when compared to pretreatment biopsies. Bisphosphonates have also demonstrated potent antiangiogenic properties due to their ability to significantly decrease circulating levels of vascular endothelial growth factor (VEGF) in breast cancer patients with bone metastases.[17] Wood and colleagues[18] demonstrated the antiangiogenic properties of bisphosphonates on several levels: (1) potent inhibition of vessel sprouting in a chick embryo model, and (2) potent inhibition of angiogenesis induced by subcutaneous implants impregnated with bFGF in a murine model. These antiangiogenic properties have generated interest in the potential of bisphosphonates as antitumor agents.[19,20]

Denosumab (Prolia, Xgeva) is a novel antiresorptive agent that exists as a fully humanized antibody against RANKL. This receptor activator is a cytokine that is important for the formation, function, and survival of osteoclasts.[21] Denosumab prevents the interaction of RANKL with its receptor (RANK) on osteoclast and osteoclast precursors, resulting in profound inhibition of osteoclast function and osteoclast-mediated bone resorption. Interestingly, these agents do not bind to bone, and their effects on bone remodeling are reversible within 6 months of treatment cessation.

Antiresorptive and Antiangiogenic Therapy in Clinical Practice

The complications associated with metastatic bone disease, osteoporosis, and Paget disease are related to perturbations in osteoclast function. Therefore, it is not surprising that antiresorptives, which are potent inhibitors of osteoclast function, have demonstrated clinical efficacy in these diseases.

Malignant Bone Disease

Annually, about 1 million women worldwide will develop breast cancer.[22] Of those progressing to advanced disease, close to 70% will develop bone metastases.[23,24]

The efficacy of intravenous bisphosphonates and RANKL inhibitors in reducing bone pain, hypercalcemia, and skeletal complications has been extensively documented in patients with advanced breast cancer, multiple myeloma, and prostate cancer.[1,25-36] This has resulted in widespread use of antiresorptives in medical oncology practices. Myeloma-related lytic disease is now understood to be

TABLE 21-2 Antiangiogenic Medications Associated with Osteonecrosis of the Jaw

Drug	Drug Class
Bevacizumab (Avastin)	Monoclonal antibody
Sunitinib (Sutent)	Tyrosine kinase inhibitor
Sorafenib (Nexavar)	Tyrosine kinase inhibitor
Sirolimus (Rapamune)	Mammalian target of rapamycin pathway

secondary to increased osteoclastic activity and impaired osteoblastic activity. Myeloma cells are known to secrete both stimulators of osteoclast activation such as RANKL and soluble molecules such as dickkopf 1 (DKK) that inhibit osteoblastic activity.[37] Bisphosphonates and RANKL inhibitors suppress osteoclast function and therefore block the formation of "punched-out" lytic bony lesions and consequent manifestations of lytic bony disease.

Thus antiresorptives are frequently administered to patients with osteolytic metastases, especially if there is risk for significant morbidity. Based on clinical practice guidelines established by the American Society of Clinical Oncology, the use of antiresorptives is considered the standard of care for treatment of: (1) moderate to severe hypercalcemia associated with malignancy and (2) metastatic osteolytic lesions associated with breast cancer and multiple myeloma in conjunction with antineoplastic chemotherapeutic agents.[38,39] In patients with osteolytic metastases, oral bisphosphonate therapy is not as efficacious as the intravenous form in preventing skeletal complications and therefore is not indicated for patients with cancer.

Tumor formation and propagation often requires the formation of new blood vessels. This process of angiogenesis requires binding of signaling molecules such as VEGF, which then promotes growth, migration, and differentiation of vascular endothelial cells. Angiogenesis inhibitors (tyrosine kinase inhibitors and monoclonal antibody targeting VEGF) function by interfering with the formation of new blood vessels by binding to various signaling molecules, disrupting the angiogenesis-signaling cascade. These classes of medications have demonstrated efficacy in the treatment of a variety of neuroendocrine and gastrointestinal tumors (Table 21-2). Recently, these novel chemotherapeutic regimens have been associated with the development of jaw necrosis. Several case series have reported jaw necrosis in patients receiving combination therapy (antiangiogenic medication and an antiresorptive) and when an antiangiogenic drug is used as a single agent.[40-45]

Osteoporosis

Osteoporosis, a disease that is characterized by increased skeletal fragility and low bone mineral density, is responsible for more than 1.5 million fractures in postmenopausal women each year at an annual cost of $18 billion.[46] It is estimated that 35% of postmenopausal Caucasian American women have some degree of osteoporosis in the hip, spine, or forearm and that 40% of these women will experience some type of osteoporotic fracture.[47] This is in contrast to men over the age of 50, of whom only 13% are estimated to have an osteoporotic fracture.[47] Although bone quality cannot be measured directly, bone mineral density is a relatively easy parameter to measure. Osteoporosis is characterized clinically by the T score, which represents the number of standard deviations the bone mineral density is above or below the normal mean bone density of a young Caucasian individual.

As a potent suppressor of osteoclast activity, bisphosphonates slow the remodeling process and increase bone mineral density, thereby reducing the risk of fracture in women with osteopenia and osteoporosis.[48,49] All bisphosphonates currently approved for osteoporosis treatment have been shown to significantly reduce the risk of osteoporotic fractures. Alendronate has been shown to prevent bone loss at the spine and hip in menopausal women and reduce fractures at these sites by approximately 50%.[50-52] In a large prospective trial, risedronate produced a 30% reduction in hip fractures.[53,54] Because of their proven clinical efficacy, bisphosphonates are considered first-line therapy in the treatment of osteoporosis and are the most widely prescribed antiresorptive agent.

As an inhibitor of RANKL expression, denosumab is also a potent inhibitor of osteoclast function and has also been demonstrated to reduce the risk of osteoporotic fractures.

A significant reduction in the risk of vertebral, nonvertebral, and hip fractures in osteoporotic patients was reported when denosumab administered subcutaneously on a biannual schedule.[55-57]

Medication-related Osteonecrosis of the Jaw

Pathophysiology

Since 2003 numerous reports have highlighted the adverse effect profile of this class of agents, including the development of osteonecrosis of the jaw in patients treated with bisphosphonates.[58-65] Since its discovery, numerous animal and in vitro studies have shed some light on the potential mechanisms for MRONJ and have generated several hypotheses regarding the etiopathogenesis of this medication-related complication.

The most popular and researched hypothesis focuses on the inhibition of osteoclast-mediated bone remodeling. The profound inhibition of osteoclast function can also inhibit normal bone turnover to such an extent that local microdamage from normal mechanical loading or injury (tooth extraction) cannot be repaired. This position is supported by several studies that have demonstrated bone necrosis isolated to the alveolar component of the jaw in animal models exposed to bisphosphonates.[66-68]

Denosumab is an antiresorptive agent that exists as a fully humanized antibody against RANKL. As such, it is a

profound inhibitor of osteoclast function and bone remodeling. Interestingly, these agents do not bind to bone, and their effects on bone remodeling are reversible within 6 months of treatment cessation. Recent case reports[2-4] and large-scale clinical trials[1] have shown that osteonecrosis of the jaw (ONJ) occurs in patients treated with denosumab. These findings strongly suggest that suppression of osteoclast-mediated bone remodeling, a common feature of both denosumab and the bisphosphonates, is likely a key factor in the pathogenesis of ONJ.

Local inflammation and infection within the bone and adjacent soft tissue is also considered to be an important aspect of this process.[69,70] Bacteria in the form of biofilms have been demonstrated to exist on many necrotic bone specimens.[71,72] Unlike the typical planktonic bacteria, these polymicrobial bacterial colonies form a dense polysaccharide matrix that effectively isolates them from circulating or topical antimicrobial medications. This may be responsible for the recalcitrant infections that are common in patients with stage 2 and 3 disease. Bisphosphonates have also been demonstrated to interact with macrophages and other immune-modulating cells, causing a blunted response to local infection.[73,74]

Alternatively, the antiangiogenic properties of certain bisphosphonates (not denosumab) may affect the local bone blood supply, contributing to the apparent ischemic changes noted in the affected patients' jawbones. This has been supported by reports of bisphosphonate-induced inhibition of angiogenesis in culture and animal tumor models[16,18] and long-term suppression of VEGF levels in cancer patients.[17,75] Furthermore, a growing number of reports describe jaw necrosis in cancer patients receiving antiangiogenic medications.[40,43,76] However, these findings are opposed by other animal studies in which bisphosphonates had no effect on angiogenesis associated with endochondral ossification[77] or at regions of bisphosphonate-induced matrix necrosis.[66]

Direct mucosal toxicity from high bisphosphonate concentrations in the bone has also been considered as the primary etiology for bone exposure and necrosis.[78-80] This is based on culture data in which high concentration of bisphosphonate were found to be toxic to oral mucosal cells. In order to recapitulate this effect in vivo, the oral mucosa would need to be exposed to high concentrations of bisphosphonate for a prolonged period of time. This situation can theoretically occur at surgical sites or regions of inflammation where there is a local reduction in pH and a release of bisphosphonate from the bone.[81] However, the clinical scenario where ONJ presents spontaneously in the non-dentate region of the jaw does not fit this hypothesis well.

Because only a minority of patients receiving antiresorptives develop bone necrosis, it is also conceivable that individual genetic variations in drug metabolism or skeletal homeostasis may confer susceptibility or resistance to developing MRONJ. Several pharmacogenetic studies have established a potential relationship between MRONJ and certain single nucleotide polymorphisms (SNPs) occurring at a gene location associated with bone metabolism and disease.[82-84] In these genomic studies, patients with SNPs that were associated with perturbations in bone density, collagen formation, and bone turnover were noted to have an elevated risk of developing MRONJ. In one study an SNP associated with activity of farnesyl diphosphate synthase, the enzyme that is specifically targeted by bisphosphonates, was linked to a higher risk of jaw necrosis.[83] These findings provide additional support for the existence of a germline sensitivity to bisphosphonates.

It appears likely that the etiology of MRONJ is the result of a multifactorial process, with intense inhibition of bone remodeling being the central initiating event. The apparent selective involvement of the maxilla and mandible may be a reflection of the unique environment of the oral cavity. Typically, healing of an open bony wound (e.g., extraction socket) in the presence of normal oral microflora occurs quickly and without complication. However, when the healing potential or the vascular supply of the jaw is compromised by either tumoricidal radiation doses or some other agent(s) or pathologic process, then minor injury or disease in these sites increases the risk for osteonecrosis and osteomyelitis.

Risk Factors

Jaw necrosis occurs as a drug-related complication following medical therapy for both malignant and non-malignant disease. The most common indication for antiresorptive therapy is for the treatment of disorders of bone turnover (osteopenia and osteoporosis). In this group the reported risk of MRONJ has been consistently low. This is based on population survey studies that have estimated the risk of ONJ associated with oral bisphosphonate use. These survey studies report a risk level that ranges from 0.00038% to 0.1%.[85-88]

In the setting of intravenous zoledronate therapy for the treatment of malignant disease, the risk of MRONJ is 50 to 100 times higher, with a range of 0.7% to 6.7%.[89,90] The risk of MRONJ in cancer patients receiving RANKL inhibitors is similar to that in patients receiving zoledronate therapy and ranges from 0.7% to 1.9%.[1,25,27,91,92]

Osteonecrosis of the jaw has also been reported in patients receiving antiangiogenic therapy for a spectrum of malignant diseases. Guarneri and colleagues reported a risk of 0.2% but noted that the risk may be higher (0.9%) in patients who are receiving zoledronate as well.[93] Several case reports have also been published, describing jaw necrosis in patients receiving antiangiogenic medications in conjunction with zoledronate and also in patients who are bisphosphonate naïve.[40,41,43,76]

Several retrospective and prospective studies have identified other potential risk factors associated with the development of MRONJ in patients at risk.[94-98] In the majority of MRONJ cases, dentoalveolar trauma is the most prevalent and consistent risk factor.[90,96,99,100] In case-control and longitudinal studies, cancer patients receiving zoledronate who had tooth extractions had a 16- to 33-fold increase in

ONJ risk.[90,101] Based on the best level of current evidence, the estimate of ONJ risk for extraction patients receiving IV bisphosphonates ranges from 1.6% to 14.8%.[102-104] A prospective study by Kunchur and colleagues reported a MRONJ risk estimate of 0.5% for extraction patients who were receiving oral bisphosphonates.[105] An increased risk of necrosis has also been reported in denture wearers.[106] In one study of more than 1600 cancer patients receiving IV bisphosphonate therapy, denture use was associated with a twofold increase in MRONJ risk.[90]

Patients with a history of inflammatory dental disease, such as periodontal disease or periapical pathology, were also at an increased risk for developing MRONJ.[104,107,108] Saad and co-workers reported that pre-existing inflammatory dental disease was associated with MRONJ in 50% of the cases in their series.[100] This underscores the importance of maintaining good oral health and avoiding extractions in this population.

The duration of antiresorptive therapy also appears to be related to jaw necrosis, with longer treatment regimens associated with a greater risk of developing disease.[94,107] Several prospective studies have reported an escalation of MRONJ risk as the duration of exposure increased in cancer patients receiving either zoledronate or denosumab.[27,100]

The PROBE study reported a similar trend in osteoporosis patients receiving oral bisphosphonates, where the prevalence of ONJ increased from 0% at baseline to 0.21% after 4 years of exposure.[85,87] Though MRONJ is found in both sexes, the literature reports more cases in females than males, which is likely a reflection of the large number of cases reported in breast cancer patients and patients with osteoporosis.

In 2005 the Food and Drug Administration (FDA) responded to the growing number of MRONJ cases by issuing broad drug class warning of this complication for all bisphosphonates. More recently, the FDA has issued an ONJ advisory for the antiangiogenic medications bevacizumab and sunitinib.[109,110] This has also prompted a change in clinical practice. With the benefit of bisphosphonate therapy beyond 5 years coming into question for patients with osteoporosis[111] and the growing concern about long-term suppression of bone turnover,[112] some clinicians have emphasized the importance of a drug holiday. In a consensus statement from the Mayo Clinic, the use of bisphosphonates in the treatment of multiple myeloma was modified to limit the exposure of intravenous bisphosphonates and minimize the potential for MRONJ.[113]

The usefulness of an antiresorptive drug holiday to minimize MRONJ risk or to expedite the healing of existing MRONJ lesions continues to be a point of controversy across several disciplines. Despite the lack of evidence, position papers from various professional associations have advocated for the use of a drug holiday for those patients at highest risk.[5,114,115] In 2011 the FDA failed to find any meaningful data that would guide decision making regarding a drug holiday.[85] Although the AAOMS position paper in 2014 acknowledged the current lack of data to support or refute a drug holiday, they continue to support this approach, citing a theoretical benefit for those patients at risk.[6] This theoretical benefit is based on bone physiology, the pharmacokinetics of bisphosphonates, and their effect on local osteoclasts.[116]

Clinical Presentation

The patient history and clinical examination are the most sensitive diagnostic tools for this condition. A diagnosis of MRONJ should be considered if a patient presents with all of the following criteria[6]:

1. Current or previous treatment with antiresorptive and/or antiangiogenic agents
2. Exposed bone or bone that can be probed through an intraoral or extraoral fistula(e) in the maxillofacial region that has persisted for more than 8 weeks; and
3. No history of radiation therapy to the jaws or obvious metastatic disease to the jaws.

Areas of exposed and necrotic bone may remain asymptomatic for weeks, months, or years and may result in pain or exposed maxillary or mandibular bone. The size of the affected area can range from a non-healing extraction site to necrosis and exposure of the entire jaw.

These lesions are most frequently symptomatic when surrounding tissues become inflamed or there is clinical evidence of exposed bone. Signs and symptoms that may occur before the development of clinically detectable osteonecrosis include pain, tooth mobility, mucosal swelling, erythema, and ulceration. These may occur spontaneously or more commonly at the site of prior dentoalveolar surgery. Intraoral and extraoral fistulae may develop when necrotic jawbone becomes secondarily infected (Figure 21-2). Some



• **Figure 21-2** Stage 2 medication-related osteonecrosis of the jaw with an area of exposed alveolar bone and a draining intraoral fistula.



• **Figure 21-3** Panoramic radiograph of a patient with stage 3 medication-related osteonecrosis of the jaw. There is a non-healing extraction site with a sclerotic lamina dura and osteolysis extending to the inferior border of the left mandible.

patients may also present with complaints of altered sensation in the affected area as the neurovascular bundle becomes compressed from the inflamed surrounding bone. Chronic maxillary sinusitis secondary to osteonecrosis with or without an oral-antral fistula can be the presenting symptom in patients with maxillary involvement. It has been observed that lesions are found more commonly in the mandible than the maxilla (3:1 ratio); however, simultaneous areas of necrosis in the maxilla and mandible have also been reported.[100]

Radiographic changes are typically not evident until there is significant bone involvement or demineralization. Therefore, panoramic and periapical radiographs may not reveal significant changes in the early stages of osteonecrosis. Little or no ossification at a previous extraction site may represent an early radiographic sign. Early or late radiographic changes may mimic classic periapical pathology or osteomyelitis or, in cancer patients, may raise the suspicion of primary (myeloma) or metastatic bone disease. When there is extensive bone involvement, regions of mottled bone or sequestrum similar to that of diffuse osteomyelitis are noted. Widening of the periodontal ligament space may also be noted radiographically. In more advanced cases, osteosclerosis of the bone may be noted radiographically, especially osteosclerotic lamina dura (Figure 21-3).

The findings on computed tomography (CT) are also nonspecific, but this modality is significantly more sensitive to changes in bone mineralization and therefore is more likely to demonstrate areas of focal sclerosis, thickened lamina dura, early sequestrum formation, and presence of reactive periosteal bone (Figure 21-4).[117]

CT images have also proved to be more accurate delineating the extent of disease, which is very helpful for surgical treatment planning.[118,119] Technetium-99 bone scanning is a highly sensitive imaging modality for the identification of inflammation, which is commonly present in patients with established MRONJ. The utility of bone scintigraphy in patients at risk of MRONJ has received growing attention following reports of increased tracer uptake in regions of the jaws that subsequently developed necrosis.[120,121] Although nuclear imaging has limited value in patients with existing disease because of its poor specificity, its use as a predictive tool in patients with preclinical disease (stage 0) appears to have some level of theoretical benefit and therefore requires continued evaluation. Magnetic resonance imaging (MRI) is also a highly sensitive imaging modality for the presence of osseous edema and inflammation and is often used to identify the early acute phase of osteomyelitis. The imaging characteristics of MRI in patients with MRONJ have been described[122,123]; however, because of its low level of specificity. MRI has limited predictive value for detecting early disease. The use of positron emission tomography (PET) has also been reported in MRONJ patients with established disease. However, because of a low level of sensitivity, specificity, and accuracy, this imaging modality has limited diagnostic value.[124]

Staging

The presentation and symptomatology of MRONJ can vary in patients despite similar disease processes, drug dosing regimens and treatment duration. A clinical staging system has been developed in order to more accurately categorize patients with MRONJ, direct rational treatment guidelines and collect data to assess the prognosis in patients who have been exposed to antiresorptive (IV or oral) and antiangiogenic medications (Table 21-3).[6]

Patients who are considered *at risk* have no evidence of exposed or necrotic bone but have been exposed to either antiresorptive or antiangiogenic medications. The potency of the antiresorptive used, the duration of exposure, and dentoalveolar surgery are consistent factors in assessing ONJ risk. The risk associated with targeted antiangiogenic cancer therapies is also associated with jaw necrosis, but further studies are needed to assess risk stratification.

A stage 0 (non-exposed bone variant) category was created to identify "at-risk" patients with nonspecific clinical signs and symptoms such as pain, abscess formation, altered sensory functions or osteosclerosis on radiographic exam but no clinical evidence of necrosis or exposed bone. Several

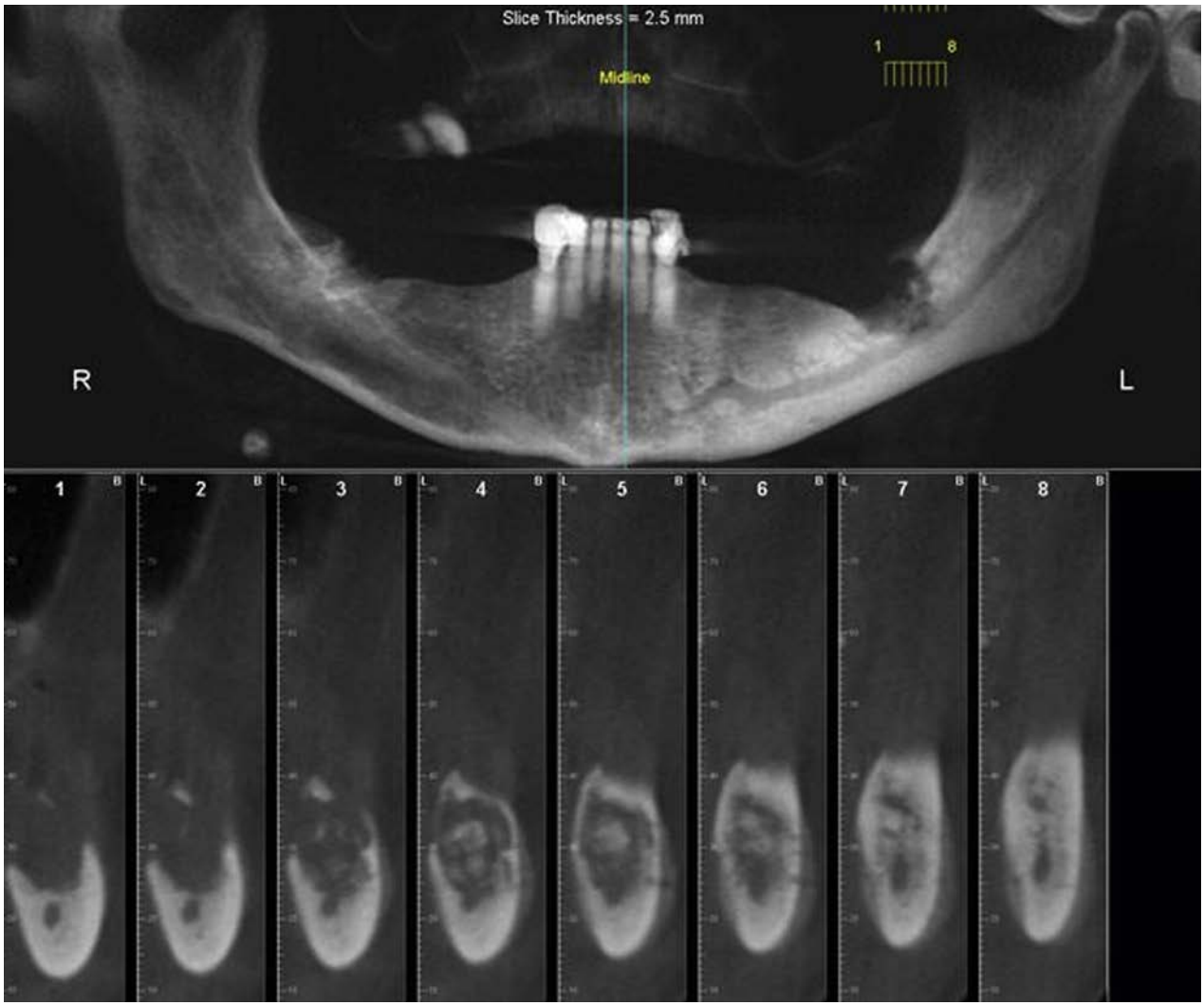

• **Figure 21-4** Cone-beam computed tomography scan of the left mandible demonstrating osteosclerosis and sequestration of the left mandibular body at a non-healing extraction site. There is also reactive periosteal bone formation at the lateral cortical bone surface.

TABLE 21-3 MRONJ Staging

At Risk Category	No apparent exposed/necrotic bone in patients who have been treated with an antiresorptive or antiangiogenic medications
Stage 0	No clinical evidence of exposed bone. Nonspecific clinical findings, radiographic changes or symptoms
Stage 1	Exposed/necrotic bone or fistulas that probe to bone in patients who are asymptomatic and have no evidence of infection
Stage 2	Exposed/necrotic bone or fistulas that probe to bone with infection as evidenced by pain and erythema in the region of the exposed bone with or without purulent drainage
Stage 3	Exposed/necrotic bone or fistulas that probe to bone in patients with pain, infection, and one or more of the following: pathologic fracture, extra-oral fistula, oral antral or oral nasal communication or osteolysis extending beyond the alveolar bone

case studies have reported that up to 50% of patients with stage 0 have progressed to stage 1, 2, or 3.[121,125]

Patients with *stage 1* disease have exposed bone or bone that can be probed but are asymptomatic. There is no evidence of significant adjacent or regional soft tissue inflammatory swelling or infection. *Stage 2* disease is characterized by exposed bone or bone that can be probed with associated pain, adjacent or regional soft tissue inflammatory swelling, or secondary infection. Patients with *stage 3* disease have exposed bone or bone that can be probed in association with pain, adjacent or regional soft tissue inflammatory swellings or secondary infections in addition to one or more of the following findings:

1. Exposed necrotic bone extending beyond the region of alveolar bone, that is, inferior border and ramus in the mandible, maxillary sinus, and zygoma in the maxilla
2. Pathologic fracture
3. Extraoral fistula
4. Oral antral/oral nasal communication
5. Osteolysis extending to the inferior border of the mandible or sinus floor

Treatment Guidelines

The goal of treatment for patients at risk of developing MRONJ or who have active disease is to preserve the quality of life by controlling pain, managing infection, and preventing the development of new areas of necrosis. Although eliminating all areas of necrosis is sometimes impossible, patients can remain asymptomatic with treatment intervention. The management strategy for these patients will vary according to their risk of developing MRONJ or their stage of disease. Consideration must also be given to patients who are about to initiate antiresorptive or antiangiogenic therapy and therefore assume a level of risk at a future point in time. The degree of risk will depend on the type of drug and the duration of exposure. Guidelines for prophylactic management or treatment have been structured to address three distinct clinical scenarios: (1) patients who are about to initiate antiresorptive or antiangiogenic therapy for cancer or osteoporosis, (2) asymptomatic patients receiving antiresorptive or antiangiogenic therapy for cancer or osteoporosis, and (3) patients with established MRONJ.

Patients Who Are About to Initiate Antiresorptive or Antiangiogenic Therapy

The treatment objective for cancer patients who are about to initiate antiresorptive or antiangiogenic therapy is to minimize the risk of developing MRONJ. Although a small percentage of patients receiving these medications develop osteonecrosis of the jaw spontaneously, the majority of affected patients experience this complication following some type of dentoalveolar surgery. Therefore, efforts to optimize dental health and avoid future extractions should be the main goal in patients who will receive these medications. In the clinical setting of cancer therapy, initiation of antiresorptive or antiangiogenic therapy should be delayed, if possible, until the dental health is optimized. This decision must be made in conjunction with the treating physician, dentist, and other specialists involved in the care of the patient. The time-tested dental care protocols instituted to prevent osteoradionecrosis in radiated cancer patients serve as an appropriate model for patients at high risk for MRONJ. Nonrestorable teeth and those with a poor prognosis should be extracted. Other elective dentoalveolar surgery should also be completed at this time. Based on our understanding of osteoradionecrosis, it appears advisable that antiresorptive or antiangiogenic therapy be delayed at least 2 to 3 weeks to ensure that adequate osseous and soft tissue healing has occurred. Dental prophylaxis and caries control are critical to maintaining functionally sound teeth and must be continued throughout therapy. Patients with full or partial dentures should be examined for areas of mucosal trauma, especially along the lingual flange region. The use of early dental screenings and preventative dental therapies has been demonstrated to lower the risk and frequency of MRONJ.[100,126-129]

The likelihood of MRONJ developing in the osteoporosis patient is significantly lower than in the cancer patient. Moreover, the duration of antiresorptive medication exposure required to develop ONJ is much greater in the noncancer setting. Therefore, patients who are about to begin antiresorptive therapy for osteoporosis are at no immediate risk. However, considering that most osteoporosis patients will require antiresorptive treatment that extends beyond 4 years, they should be informed at the initiation of therapy of the impending risk of MRONJ and the importance of maintaining optimal dental health.

Asymptomatic Patients Receiving Antiresorptive/Antiangiogenic Therapy for Osteoporosis or Cancer

Osteoporosis patients receiving oral bisphosphonates are at a much-reduced risk of developing MRONJ, given limited bioavailability and reduced potency of the oral medication. Nonetheless, numerous cases of MRONJ have been reported in patients exposed to oral bisphosphonates. Population survey studies estimate the risk of ONJ associated with oral bisphosphonate to range from 0.00038% to 0.1%.[85-88] Similar to patients exposed to intravenous bisphosphonates, the duration of oral bisphosphonates therapy appears to be an important factor, with most cases of MRONJ occurring after 4 years of exposure.[85] Therefore, no alteration or delay in the planned dentoalveolar surgery is typically necessary for patients who have received antiresorptive therapy for less than 4 years. Shortened exposure times and an elevated risk of MRONJ may exist for patients with comorbid risk factors such as corticosteroid or antiangiogenic therapy.[100,108]

For those osteoporosis patients who have taken bisphosphonates for more than 4 years (or less if other comorbid conditions exist), discontinuation of the medication for 2 months before oral surgery may reduce the risk. The bisphosphonate can be restarted once osseous healing has occurred. The rationale for this approach is based on a pharmacokinetic and bone physiology studies that examine the interaction of antiresorptive medications with the surrounding bone and the bone remodeling cells (osteoclast, osteoblasts, and osteocytes).[116,130] Although the risk of MRONJ associated with denosumab therapy in osteoporosis patients has been considered equivalent to that with bisphosphonates, prospective population studies similar to those conducted for bisphosphonates are needed to accurately assess the risk of anti-RANKL treatment in the setting of osteoporosis.

Although limited supportive data exist for such a strategy (level 5 evidence), several professional societies including the American Association of Oral and Maxillofacial Surgeons have advocated the use of a drug holiday for those patients at highest risk due to the theoretical benefit that may exist.[5,6,114]

Efforts to assess risk by measuring fluctuations in bone turnover markers are problematic and remain controversial.[105,131-135] The rationale for this approach is based the knowledge that markers for bone remodeling will increase

within months following withdrawal of oral bisphosphonate medications, thereby suggesting that osteoclastic function and bone remodeling are normalizing.[136,137] However, these markers are a reflection of total bone turnover throughout the entire skeleton and are not specific for bone remodeling within the unique environment of the maxilla or mandible. From a more practical perspective, using bone turnover markers to estimate the level of bone turnover suppression is only meaningful when compared to baseline, pretreatment levels, and these are rarely obtained in clinical practice.

Cancer patients receiving *intravenous* bisphosphonate therapy, subcutaneous denosumab therapy, or antiangiogenic drugs are at risk of developing MRONJ following dentoalveolar surgery. The estimates of cumulative incidence of MRONJ for cancer patients receiving IV bisphosphonates ranges from 0.7% to 6.7%, which was 50 to 100 times higher than placebo groups.[90,138] For cancer patients receiving subcutaneous denosumab, the risk of MRONJ was similar to zoledronate therapy and ranged from 0.7% to 1.9%.[1,25,27,91,92] The risk of MRONJ associated with antiangiogenic therapy (with or without concomitant antiresorptive therapy) ranged from 0.2% to 0.9%.[93]

Dentoalveolar trauma remains as a major contributing factor to the development of necrosis. In some studies, patients receiving intravenous bisphosphonates and undergoing dentoalveolar surgery were significantly more likely to develop MRONJ than patients who did not have dentoalveolar surgery.[90,107] Therefore, maintaining good oral hygiene and dental care is critical in preventing dental disease that may require dentoalveolar surgery. In general, procedures that involve direct osseous injury should be avoided. Nonsurgical endodontic therapy is the preferred treatment for teeth that are symptomatic. Patients with symptomatic nonrestorable teeth that would otherwise require extraction may be treated by removal of the crown and performing endodontic treatment of the remaining roots.[139-141] Similarly, placement of dental implants or any type of periodontal flap surgery that would expose or injure bone should be avoided in these patients.

The use of a drug holiday for cancer patients receiving IV bisphosphonates or antiangiogenic therapy remains controversial with limited data to support or refute such a practice. However, in an animal study, improved healing of induced MRONJ lesions was noted when denosumab was terminated. The same healing benefit was not identified in those animals receiving IV bisphosphonate therapy.[142]

It is critical that all patients who are receiving antiresorptive or antiangiogenic treatment be educated as to the importance of dental hygiene and regular dental evaluations. Patients should be specifically instructed to report any pain, swelling, or exposed bone that would either predict or characterize MRONJ. Multiple studies have demonstrated the efficacy of dental screenings and prophylactic dental treatment in lowering the risk of MRONJ. These include prospective studies that have reported significant reductions in the incidence of MRONJ when preventative dental measures are instituted before and during drug therapy.[100,126-129] It is equally important that general dentists and the dental specialist become knowledgeable about this complication so that dental treatment and procedures that are not associated with a risk of MRONJ can be delivered and oral health maintained.

Patients with Established MRONJ

The main goal of therapy for patients with established MRONJ is to maintain or preserve the quality of life while supporting the oncologic or osteoporotic treatment. This can be achieved by controlling pain and the secondary infection that is common for most of these patients. It is also important to prevent the extension of existing areas of necrosis and the development of new lesions. Patients with an established diagnosis of MRONJ are certainly at higher risk of developing osteonecrosis following any type of dentoalveolar surgery. Therefore the guidelines for dental treatment and oral surgery mentioned in the previous section certainly apply to this group of patients and are important in preventing the development of new areas of jaw necrosis. It is important that patients with established MRONJ avoid elective dentoalveolar surgical procedures (i.e., extractions and implant surgery), because these surgical sites are the most likely to result in new areas of exposed necrotic bone.

The treatment algorithms for MRONJ are based on a compilation of clinical data and treatment experiences from multiple cases series.[63,64,143,144] There are a limited number of prospective studies evaluating management strategies that include long-term outcomes.

Earlier strategies for treating these patients with exposed bone were similar to those for osteomyelitis or osteoradionecrosis and were associated with a variable degree of success. This might be due, in part, to the difficulty in obtaining a surgical margin that remains viable. More recent studies have reported successful treatment outcomes with operative therapies (resection, sequestrectomy)[145-151] and nonoperative therapies (systemic and local antimicrobial treatment).[103,146,152-154] In addition to cases of advanced disease (stage 3), surgical treatment should be considered for stage 2 disease when nonoperative therapies have failed to control infection or pain.

The efficacy of hyperbaric oxygen (HBO) therapy as a treatment adjunct has been studied in a prospective randomized controlled trial. The study was underpowered and failed to demonstrate that HBO improved gingival coverage of exposed bone to a statistically significant degree.[155] The use of other adjunct therapies such as platelet-rich plasma,[156] low-level irradiation therapy,[157] pentoxifylline/α-tocopherol.[158] and bone morphogenetic protein[159] has been described, but only in small case series. Therefore additional prospective controlled studies are warranted to establish the efficacy of these treatments.

The use of parathyroid hormone (PTH) appears to be the most promising nonoperative therapy for MRONJ. Recombinant human PTH or teriparatide is the only anabolic agent approved in the United States for use in humans for the treatment of osteoporosis. Daily PTH injections

stimulate enhanced bone formation through positive effects on osteoblast life span and direct stimulation of quiescent bone lining cells.[160] PTH also has potent anti-inflammatory effect within bone marrow and can enhance soft tissue healing and collagen formation.[161,162] In several case reports, the use of systemic low-dose PTH was successful in resolving an area of necrosis when other modalities of treatment had failed.[163,164] In each case, when combined with other standard treatment strategies, PTH therapy resulted in a relatively rapid resolution of the exposed bone. In a recent prospective, placebo-controlled study of 40 patients, low-dose systemic PTH in conjunction with vitamin D and oral calcium was associated with greater resolution of periodontal bone defects and accelerated intraoral osseous healing.[165] In a small animal study, PTH was shown to enhance bone healing in compromised bone wounds that were exposed to bisphosphonates.[166] Although systemic PTH is currently contraindicated in patients with osteolytic bone metastases, these promising findings may have real applicability for ONJ cases in the non-cancer setting. If these agents can be delivered locally to the regions of necrosis, the concern about enhanced medullary cellular proliferation in the cancer patient may be ameliorated.

For patients with established MRONJ, regardless of disease stage, exposed, necrotic bone that is a constant source of soft tissue irritation should be removed or recontoured without exposing adjacent bone so that soft tissue healing can be optimized. Loose segments of bony sequestrum should be removed without exposing uninvolved bone. The extraction of grossly mobile or symptomatic teeth within exposed, necrotic bone should be considered, because it is unlikely that the extraction will exacerbate the established necrotic process.

Stage-specific treatment strategies have been proposed for the management of necrotic bone (Table 21-4).[6] By definition, patients with stage 1 MRONJ are asymptomatic and have no clinical evidence of infection. These patients may benefit from the use of oral antimicrobial rinses such as chlorhexidine 0.12%. Surgical treatment is not required unless areas of exposed bone are a physical irritant to the surrounding soft tissue. In that instance surface recontouring of the exposed bone is helpful. Surveillance of these regions of jaw necrosis is important to detect the early signs and symptoms of disease progression. These patients should be examined every 3 to 4 months.

Patients with stage 2 MRONJ will have exposed necrotic bone that is painful and associated with a local infection. The disruption in the bone remodeling process has now resulted in regions of necrotic bone, possibly with biofilm formation, that are now secondarily infected. These patients benefit from the use of oral antimicrobial rinses in combination with antibiotic therapy. If reliable culture data are obtainable, they can be used to direct the appropriate antibiotic regimen. In general, most of the isolated microbes have been sensitive to the penicillin group of antibiotics. Quinolones, metronidazole, clindamycin, doxycycline, and erythromycin have been used with success in patients who are allergic to penicillin. In refractory cases, patients may require surgical therapy in combination with oral or intravenous antibiotic therapy. In special circumstances where patients with multiple myeloma are being considered for stem cell transplantation, the maintenance of an "infection-free" oral environment is important. However, despite aggressive therapy, some patients will have persistent infection and exposed bone. The risks and benefits of proceeding with the transplantation in this setting must be considered on a case-by-case basis.

Patients with stage 3 disease are the most challenging. These patients typically have pain and infection that affects their quality of life (Figure 21-5). The large burden of necrotic bone that results in fistulization, pathologic

TABLE 21-4 Stage-specific MRONJ Treatment Recommendations

At Risk Category	No surgical or medical treatment indicated Patient education and routine dental care
Stage 0	Systemic management including pain medication and systemic antibiotics
Stage 1	Antibacterial mouth rinse Clinical follow-up on a quarterly basis Patient education and review of indications for continued antiresorptive/antiangiogenic therapy
Stage 2	Oral antibacterial mouth rinse Symptomatic treatment with oral antibiotics and pain medication debridements to remove mobile sequestrum or to relieve soft tissue irritation
Stage 3	Antibacterial mouth rinse Antibiotic therapy and pain control Surgical debridement/resection for longer term palliation of infection and pain



• **Figure 21-5** Extensive extraoral fistula in a patient with stage 3 medication-related osteonecrosis of the jaw.

fracture, or extensive sinusitis is typically refractory to antibiotic therapy (Figure 21-6). At this stage, aggressive surgical management is indicated so that palliation or resolution of acute infection and pain can be achieved. Persistent regions of exposed bone may remain or develop at the periphery of the resection/debridement because of the generalized effects of antiresorptives and the compromised bone healing throughout the jaw. For patients with mandibular necrosis that is associated with a pathologic fracture or osteolysis extending to the inferior border, segmental resection is indicated. Immediate reconstruction with nonvascularized or vascularized bone has been reported,[167-169] but the potential for necrotic bone to develop or persist at the margins of the recipient site remains a persistent concern with this approach. Stabilization of the residual mandibular segments with a reconstruction plate is a viable alternative, but patients should be aware of the potential for hardware failure at the margin of the resection (Figure 21-7). Soft tissue coverage of the hardware and surrounding bone should be accomplished with local or distant flaps.

Patients with stage 3 maxillary disease, characterized by large areas of exposed bone with facial swelling and/or sinusitis, will often require a maxillary resection. In cases where chronic sinusitis exists, resection of the infected maxillary alveolar bone with creation of an oral antral communication will serve to reduce or eliminate the infected bone and provide immediate and long-term drainage of the sinus. Reconstruction of maxillary defects can be immediate or delayed with fabrication of a partial denture or maxillary obturator. Surgical management of maxillary disease seems to follow a more predictably successful course postoperatively than patients who have had marginal or segmental resections of the mandible. This may be due in part to the vascularity of maxillary bones.

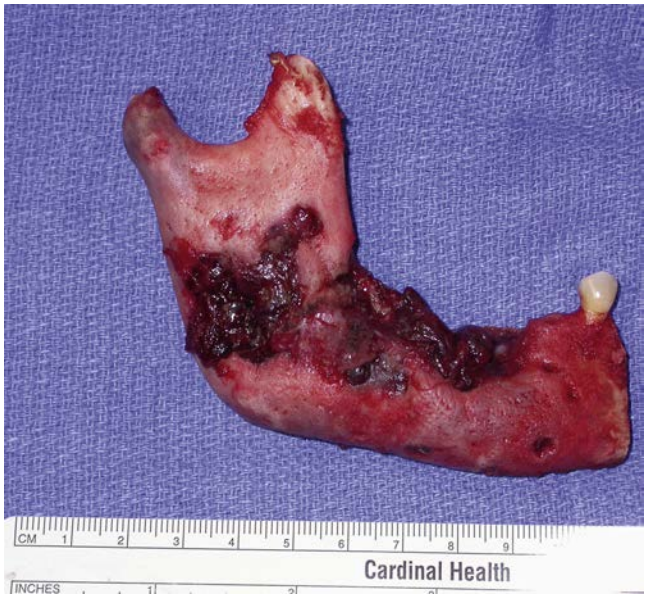

• **Figure 21-6** Necrotic right mandible from a patient with stage 3 medication-related osteonecrosis of the jaw.

Future Research

Medication-related osteonecrosis of the jaw is a well-recognized complication of antiresorptive and antiangiogenic therapy that can have serious dental and medical consequences for patients with cancer and osteoporosis. However, the efficacy of these medications in treating and preventing the significant skeletal complications associated with osteoporosis and bone metastases has had a major positive impact on quality of life for most patients. Basic science research, including animal and human studies that were funded through various government and private institutions, have provided significant advances in our understanding of this disease process since it was first described in 2004. The development of a valid animal model has provided additional insight into the pathophysiology of MRONJ and has established a framework for future translational research. Future studies can now focus on confirming the efficacy of existing guidelines related to prevention, operative and nonoperative therapies, and risk assessment and reduction strategies. The efficacy of novel targeted therapies for the treatment of various cancers has been established, but jaw necrosis has also emerged as a complication within this cohort of patients. Clinical and animal studies are now warranted to further clarify how these agents, which have no effect on bone remodeling, can result in jaw necrosis.

As our understanding of the etiopathogenesis of MRONJ continues to evolve, health care providers will be able to make more accurate judgments about risk, prognosis, treatment selection, and outcome.

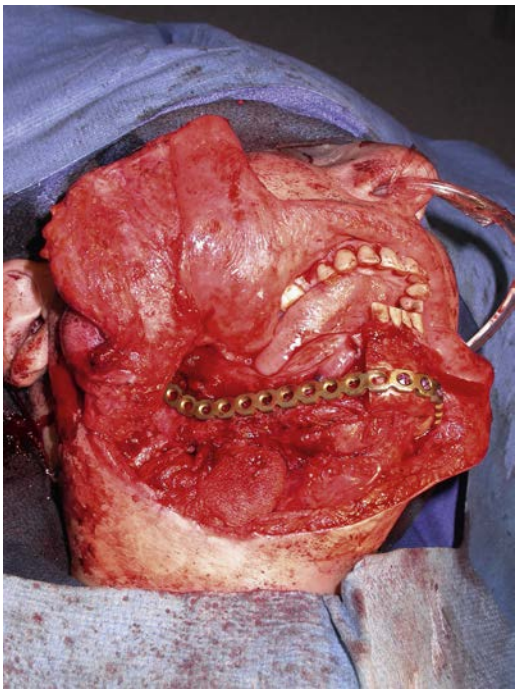

• **Figure 21-7** Intraoperative view of a hemi-mandibulectomy procedure and immediate reconstruction with a plate in a patient with stage 3 medication-related osteonecrosis of the jaw.

References

1. Stopeck A, Body J, Fujiwara Y: Denosumab versus zoledronic acid for the treatment of breast cancer patients with bone metastases: results of a randomized phase 3 study, *Eur J Cancer Suppl* 7(2), 2009.
2. Aghaloo T, Felsenfeld A, Tetradis S: Osteonecrosis of the jaw in a patient on denosumab, *J Oral Maxillofac Surg* 68:959–963, 2010.
3. Taylor K, Middlefell L, Mizen K: Osteonecrosis of the jaws induced by anti-RANK ligand therapy, *Br J Oral Maxillofacial Surg* 48:221–223, 2010.
4. Diz P, Lopez-Cedrun J, Arenaz J, Scully C: Denosumab-related osteonecrosis of the jaw, *J Am Dent Assoc* 143(9):981–984, 2012.
5. Hellstein J, Adler R, Edwards B, Jacobsen P, et al.: Managing the care of patients receiving antiresorptive therapy for prevention and treatment of osteoporosis, *J Am Dent Assoc* 142(11):1243–1251, 2011.
6. Ruggiero S, Dodson T, Fantasia J, et al.: American Association of Oral and Maxillofacial Surgeons paper on medication-related osteonecrosis of the jaw—2014 update, *J Oral Maxillofac Surg* 72:1938–1956, 2014.
7. Blomen L: *History of bisphosphonates: Discovery and history of the non-medical uses of bisphosphonates*, Amsterdam, 1995, Elsevier Science.
8. Rodan G, Fleisch H: Bisphosphonates: mechanisms of action, *J Clin Invest* 97:2692–2696, 1996.
9. Hughes D, MacDonald B, Russell R, et al.: Inhibition of osteoclast-like cell formation by bisphosphonates in long-term cultures of human bone marrow, *J Clin Invest* 83:1930–1935, 1989.
10. Hughes D, Wright K, Uy H: Bisphosphonates promote apoptosis in murine osteoclasts in vitro and in vivo, *J Bone Miner Res* 10:1478–1487, 1995.
11. Murakami H, Takahashi N, Sasaki T, et al.: A possible mechanism of the specific action of bisphosphonates on osteoclasts: tiludronate preferentially affects polarized osteoclasts having ruffled borders, *Bone* 17:137–144, 1995.
12. Sahni M, Guenther H, H F, et al.: Bisphosphonates act on rat bone resorption through the mediation of osteoblasts, *J Clin Invest* 91:2004–2011, 1993.
13. Thiebaud H, Sauty A, Burckhardt P, et al.: An in vitro and in vivo study of cytokines in the acute-phase response associated with bisphosphonates, *Calcif Tissue Int* 61:386–392, 1997.
14. Kapitola J, Zak J: Effect of pamidronate on bone blood flow in oophorectomized rats, *Physiol Res* 47:237–240, 1998.
15. Kapitola J, Zak J, Lacinova Z, et al.: Effect of growth hormone and pamidronate on bone blood flow, bone mineral and IGF-I levels in the rat, *Physiol Res* 49(Suppl 1):S101–106, 2000.
16. Fournier P, Boissier S, Filleur S, et al.: Bisphosphonates inhibit angiogenesis in vitro and testosterone-stimulated vascular regrowth in the ventral prostate in castrated rats, *Cancer Res* 62:6538–6544, 2002.
17. Santini D, Vincenzi B, Avvisati G: Pamidronate induces modifications of circulating angiogenic factors in cancer patients, *Clin Cancer Res* 8:1080–1084, 2002.
18. Wood J, Bonjean K, Ruetz S: Novel antiangiogenic effects of the bisphosphonate compound zoledronic acid, *J Pharm Exp Ther* 302:1055–1061, 2002.
19. Gnant M, Mlineritsch B, Schippinger W, et al.: Endocrine therapy plus zoledronic acid in premenopausal breast cancer, *N Engl J Med* 360:679–691, 2009.
20. Hiraga T, Williams P, Ueda A, et al.: Zoledronic acid inhibits visceral metastases in the 4T1/luc mouse breast cancer model, *Clin Cancer Res* 10:4559–4567, 2004.
21. Boyle WJ, Simonet WS, Lacey DL: Osteoclast differentiation and activation, *Nature* 423(6937):337–342, 2003.
22. Ferlay J, Bray F, Pisani P, et al.: GLOBOCAN 2000: cancer incidence, mortality and prevalence worldwide, version 1.0. IARC CancerBase No. 5, *IARC CancerBase No. 5.Lyon: IARC-Press*, 2001.
23. Coleman R: Skeletal complications of malignancy, *Cancer* 80(suppl 8):1588, 1997.
24. Coleman R: Metastatic bone disease clinical features, pathophysiology and treatment strategies, *Cancer Treat Rev* 27:176, 2001.
25. Fizazi K, Carducci M, Smith M, et al.: Denosumab versus zoledronic acid for the treatment of bone metastases in men with castration-resistant prostate cancer: a randomized, double-blind study, *Lancet* 377:813–822, 2011.
26. Fizazi K, Lipton A, Mariette X, et al.: Randomized phase II trial of denosumab in patients with bone metastases from prostate cancer, breast cancer, or other neoplasms after intravenous bisphosphonates, *J Clin Oncol* 27(10):1564–1571, 2009.
27. Henry D, Costa L, Goldwasser F, et al.: A double-blind, randomized study of denosumab versus zoledronic acid for the treatment of bone metastases in patients with advanced cancer (excluding breast and prostate) or multiple myeloma, *J Clin Oncol* 29:1125, 2011.
28. Lipton A, Fizazi K, Stopeck A, et al.: Superiority of denosumab to zoledronic acid for prevention of skeletal-related events: a combined analysis of 3 pivotal, randomised, phase 3 trials, *Eur J Cancer* 48:3082–3092, 2012.
29. Berensen J, Lichtenstein A, Porter L: Efficacy of pamidronate in reducing skeletal events in patients with advanced multiple myeloma, *N Engl J Med* 334:484–493, 1996.
30. Berensen J, Lichtenstein A, Porter L: Long term pamidronate treatment of advanced multiple myeloma patients reduces skeletal events, *J Clin Oncol* 16:593–597, 1998.
31. Conte P, Coleman R: Bisphosphonates in the treatment of skeletal metastases, *Semin Oncol* 31:59–63, 2004.
32. Hortobagyi G, Theriualt R, Lipton A: Long-term prevention of skeletal complications of metastatic breast cancer with pamidronate, *J Clin Oncol* 16:2038–2043, 1998.
33. Michaelson M, Smith M: Bisphosphonates for the treatment and prevention of bone metastases, *J Clin Oncol* 23:8219–8224, 2005.
34. Theriualt R, Lipton A, Hortobagyi O: Pamidronate reduces skeletal morbidity in women with advanced breast cancer and lytic lesions: a randomized placebo-controlled trial, *J Clin Oncol* 17:846, 1999.
35. Hortobagyi G, Theriualt R, Porter L: Efficacy of pamidronate in reducing skeletal complications in patients with breast cancer and lytic bone metastasis, *N Engl J Med* 335:1785–1792, 1996.
36. van Holten-Verzantvoort A, Kroon H, Bijvoet O: Palliative pamidronate treatment in patients with bone metastases from breast cancer, *J Clin Oncol* 11:491–498, 1993.
37. Glass D, Patel M, Karsenty G: A new insight into the formation of osteolytic lesions in multiple myeloma, *N Engl J Med* 349:2479–2480, 2003.
38. Berenson J, Hillner B, Kyle R, et al.: American Society of Clinical Oncology clinical practice guidelines: the role of bisphosphonates in multiple myeloma, *J Clin Oncol* 20:3719–3736, 2002.

39. Hillner B, Ingle J, Berenson J: American Society of Clinical Oncology guideline on the role of bisphosphonates in breast cancer, *J Clin Oncol* 18:1378–1391, 2000.
40. Ayllon J, Launay-Vacher J, Medioni J, et al.: Osteonecrosis of the jaw under bisphosphonate and antiangiogenic therapies: cumulative toxicity profile? [Letter to the editor], *Ann Oncol* 20:600–601, 2009.
41. Beuselinck B, Wolter P, Karadimou A, et al.: Concomitant oral tyrosine kinase inhibitors and bisphosphonates in advanced renal cell carcinoma with bone metastases, *Br J Cancer* 107:1665–1671, 2012.
42. Bozas G, Roy A, Ramasany V, et al.: Osteonecrosis of the jaw after a single bisphosphonate infusion in a patient with metastatic renal cell cancer treated with sunitinib, *Onkologie* 33:321–323, 2010.
43. Christodoulou C, Pervena A, Klovas G, et al.: Combination of bisphosphonates and antiangiogenic factors induces osteonecrosis of the jaw more frequently than bisphosphonates alone, *Oncology* 76:209, 2009.
44. Hofert S, Eufinger H: Sunitinib may raise the risk of bisphosphonate related osteonecrosis of the jaw: presentation of three cases, *Oral Surg Oral Med Oral Pathol Oral Radiol Endod* 110:463–469, 2010.
45. Smidt-Hansen T, Folkmar T, Fode K, et al.: Combination of zoledronic acid and targeted therapy is active but may induce osteonecrosis of the jaw in patients with metastatic renal cell carcinoma, *J Oral Maxillofac Surg* 71:1532, 2013.
46. Gabriel S, Tosteson A, Leibson C: Direct medical costs attributable to osteoporotic fractures, *Osteoporos Int* 13(323-330), 2002.
47. Office of the Surgeon General (US): *Bone health and osteoporosis: a report of the Surgeon General*, Rockville, MD, 2004, Office of the Surgeon General (US).
48. Chestnut C, Majumdar S, Gardner J: Assessment of bone quality, quantity and turnover with multiple methodologies at multiple skeletal sites, *Adv Exp Med Biol* 496:95–97, 2001.
49. Guyatt G, Cranney A, Griffith L: Summary of meta-analysis of therapies for postmenopausal osteoporosis and the relationship between bone density and fractures, *Endocrinol Metab Clin North Am*(659-679)31, 2002.
50. Black D, Cummings S, Karpf D: Randomized trial of effect of alendronate on risk of fracture in women with existing vertebral fractures, *Lancet* 348:1535–1541, 1996.
51. Hosking D, Chilvers C, Christiansen C: Prevention of bone loss with alendronate in postmenopausal women under 60 years of age. Early Postmenopausal Intervention Cohort Study Group, *N Engl J Med* 338:485–492, 1998.
52. Ravin P, Bidstrup M, Wasnick R: Alendronate and estrogen-progestin in the long-term prevention of bone loss: four-year results from the early postmenopausal intervention cohort study randomized, controlled trial, *Ann Intern Med* 131:935–942, 1999.
53. McClung M, Geusens P, Miller P: Effect of risedronate on the risk of hip fracture in elderly women, *N Engl J Med* 344:333–340, 2001.
54. Miller P, Roux C, McClung M: Risedronate reduces hip fractures in patients with low femoral neck bone mineral density, *Arthritis Rheum* 42(Suppl 9):S287, 1999.
55. Cummings S, Martin J, McClung M, Siris E: Denosumab for the prevention of fractures in postmenopausal women with osteoporosis, *N Engl J Med* 361(8):756–765, 2009.
56. Papapoulos S, Chapurlat R, Libanati C, et al.: Five years of denosumab exposure in women with postmenopausal osteoporosis: results from the first two years of the FREEDOM extension, *J Bone Miner Res* 27(3):694–701, 2012.
57. McClung M, Lewiecki M, Cohen S, et al.: Denosumab in postmenopausal women with low bone mineral density, *N Engl J Med* 354:821–831, 2006.
58. Bilezikian J: Osteonecrosis of the jaw—do bisphosphonates pose a risk? *N Engl J Med* 355:2278–2281, 2006.
59. Gibbs S, O'Grady J, Seymour J: Bisphosphonate-induced osteonecrosis of the jaws requires early detection and intervention, *Med J Aust* 183:549–550, 2005.
60. Marx R, Sawatari Y, Fortin M: Bisphosphonate-induced exposed bone (Osteonecrosis\Osteopetrosis) of the jaws: risk factors, recognition, prevention and treatment, *J Oral Maxillofac Surg* 63:1567–1575, 2005.
61. Mehrotra B, Ruggiero S: Bisphosphonate related osteonecrosis (BRON) of the jaw: single institutional update [Abstract], *Blood* 106:291, 2005.
62. Migliorati C, Schubert M, Petersen D: Bisphosphonate-associated osteonecrosis of mandibular and maxillary bone. An emerging oral complication of supportive cancer therapy, *Cancer* 104:83–93, 2005.
63. Ruggiero S, Fantasia J, Carlson E: Bisphosphonate-related osteonecrosis of the jaw: background and guidelines for diagnosis, staging and management, *Oral Surg Oral Med Oral Pathol Oral Radiol Endod* 102:433–441, 2006.
64. Ruggiero S, Mehrotra B, Rosenberg T: Osteonecrosis of the jaws associated with the use of bisphosphonates: a review of 63 cases, *J Oral Maxillofac Surg* 62:527–534, 2004.
65. Vannucchi A, Ficarra G, Antonioli E: Osteonecrosis of the jaw associated with zoledronate therapy in a patient with multiple myeloma, *Br Hematol* 128:738–740, 2005.
66. Allen M, Burr D: Mandible matrix necrosis in beagle dogs following 3 years of daily oral bisphosphonate treatment, *J Oral Maxillofac Surg* 66:987–994, 2008.
67. Allen M, Kubek D, Burr D, Ruggiero S: Compromised osseous healing of dental extraction sites in zoledronic acid-treated dogs, *Osteoporos Int* 22(693):702, 2011.
68. Burr D, Allen M: Mandibular necrosis in beagle dogs treated with bisphosphonates, *Orthodont Craniofac Res* 12:221–228, 2009.
69. Katsarelis H, Shah N, Dhariwal D: Infection and medication-related osteonecrosis of the jaw, *J Dent Res* 94:534–539, 2015.
70. Kos M, Brusco D, Kuebler J, Engelke W: Clinical comparison of patients with osteonecrosis of the jaws, with and without a history of bisphosphonates administration, *Int J Oral Maxillofac Surg* 39(11):1097–1102, 2010.
71. Sedghizadeh P, Kumar S, Gorur A, et al.: Identification of microbial biofilms in osteonecrosis of the jaws secondary to bisphosphonate therapy, *J Oral Maxillofac Surg* 66:767–775, 2008.
72. Kumar S, Gorur A, Schaudinn C, et al.: The role of microbial biofilms in osteonecrosis of the jaw associated with bisphosphonate therapy, *Curr Osteoporos Rep* 8:40–48, 2010.
73. Pazianas M: Osteonecrosis of the jaw and the role of macrophages, *J Natl Cancer Inst* 103(3):232–240, 2011.
74. Reid IR, Cornish J: Epidemiology and pathogenesis of osteonecrosis of the jaw, *Nat Rev Rheumatol* 8:90–96, 2012.
75. Santini D, Vincenzi B, Dicuonzo G, et al.: Zoledronic acid induces significant and long-lasting modifications of circulating angiogenic factors in cancer patients, *Clin Cancer Res* 9:2893, 2003.

76. Brunello A, Saia G, Bedogni A, et al.: Worsening of osteonecrosis of the jaw during treatment with sunitinib in a patient with metastatic renal cell carcinoma, *Bone* 44:173, 2009.
77. Deckers M, Van Beek E, Van Der Pluijm G, et al.: Dissociation of angiogenesis and osteoclastogenesis during endochondral bone formation in neonatal mice, *J Bone Miner Res* 17:998, 2002.
78. Landesberg R, Cozin M, Cremers S, et al.: Inhibition of oral mucosal cell wound healing by bisphosphonates, *J Oral Maxillofac Surg* 66:839–847, 2008.
79. Kim R, Lee R, Williams D, Bae S, et al.: Bisphosphonates induce senescence in normal human keratinocytes, *J Dent Res* 90(6):810–816, 2011.
80. Schellar E, Baldwin C, Kuo S, et al.: Bisphosphonates inhibit expression of p63 by oral keratinocytes, *J Dent Res* 90(7):894–899, 2011.
81. Otto S, Pautke C, Opelz C, et al.: Osteonecrosis of the jaw: effect of BP type, local concentration, and acid milieu on the pathomechanism, *J Oral Maxillofac Surg* 68:2837–2845, 2010.
82. Katz J, Gong Y, Salmasinia D, et al.: Genetic polymorphisms and other risk factors associated with bisphosphonate induced osteonecrosis of the jaw, *Int J Oral Maxillofac Surg* 40(6):605–611, 2011.
83. Marini F, Tonelli P, Cavalli L, et al.: Pharmacogenetics of bisphosphonate-associated osteonecrosis of the jaw, *Front Biosci* E3:364–370, 2011.
84. Nicoletti P, Cartsos V, Palaska P, et al.: Genomewide pharmacogenetics of bisphosphonate-induced osteonecrosis of the jaw: the role of RBMS3, *Int J Oral Maxillofac Surg* 17:279–287, 2012.
85. Briefing information for the September 9, 2011: Joint Meeting of the Reproductive Health Drugs Advisory Committee and the Drug Safety and Risk Management Advisory Committee, 2011. http://www.fda.gov/AdvisoryCommittees/CommitteesMeetingMaterials/Drugs/DrugSafetyandRiskManagementAdvisoryCommittee/ucm270957.htm.
86. Felsenberg D, Hoffmeister B: Necrosis of the jaw after high-dose bisphosphonate therapy, *Dtsch Arztebl* 103:3078, 2006.
87. Lo J, O'Ryan F, Gordon N, et al.: Prevalence of osteoporosis of the jaw in patients with oral bisphosphonate exposure, *J Oral Maxillofac Surg* 68:243, 2010.
88. Malden N, Beltes C, Lopes V: Dental extractions and bisphosphonates: the assessment, consent and management, a proposed algorithm, *Br Dent J* 206(2):93–98, 2009.
89. Coleman R, Marshall H, Cameron D, Dodwell D, et al.: Breast-cancer adjuvant therapy with zoledronic acid, *N Engl J Med*, 2011.
90. Vahtsevanos K, Kyrgidis A, Verrou E: Longitudinal cohort study of risk factors in cancer patients with bisphosphonate-related osteonecrosis of the jaw, *J Clin Oncol* 27, 2009.
91. Qi W, Tang L, He A, et al.: Risk of osteonecrosis of the jaw in cancer patients receiving denosumab: a meta-analysis of seven randomized controlled trials, *Int J Clin Oncol* 19:403, 2013.
92. Scagliotti G, Hirsh V, Siena S, et al.: Overall survival improvement in patients with lung cancer and bone metastases treated with denosumab versus zoledronic acid: subgroup analysis from a randomized phase 3 study, *J Thorac Oncol* 7:1823, 2012.
93. Guarneri V, Miles D, Robert N, et al.: Bevacizumab and osteonecrosis of the jaw: incidence and association with bisphosphonate therapy in three large prospective trials in advanced breast cancer, *Breast Cancer Res Treat* 122:181–188, 2010.
94. Badros A, Weikel D, Salama A: Osteonecrosis of the jaw in multiple myeloma patients: clinical features and risk factors, *J Clin Oncol* 24:945–952, 2006.
95. Dimopoulos M, Kastritis E, Moulopoulos L: The incidence of osteonecrosis of the jaw in patients with multiple myeloma who receive bisphosphonates depends on the type of bisphosphonate [Abstract], *Blood* 106:637, 2005.
96. Durie B, Katz M, Crowley J: Osteonecrosis of the jaw and bisphosphonates [Letter], *N Engl J Med* 353:99, 2005.
97. Pozzi S, Marcheselli R, Sacchi S: Analysis of frequency and risk factors for developing bisphosphonate associated necrosis of the jaw [Abstract], *Blood* 106:5057, 2005.
98. Tossi P, Zamagni E, Cangini D: Bisphosphonates and osteonecrosis of the jaws: incidence in a homogeneous series of patients with newly diagnosed multiple myeloma treated with zoledronic acid [Abstract], *Blood* 106:3461, 2005.
99. Fehm T, Beck V, Banys M, et al.: Bisphosphonate-related osteonecrosis of the jaws: incidence and risk factors in patients with breast cancer and gynecological malignancies, *Gynecol Oncol* 112:605–609, 2009.
100. Saad F, Brown JE, Van Poznak C, et al.: Incidence, risk factors, and outcomes of osteonecrosis of the jaw: integrated analysis from three blinded active-controlled phase III trials in cancer patients with bone metastases, *Ann Oncol* 23(5):1341–1347, 2012.
101. Kyrgidis A, Tzellos T, Toulis K, et al.: An evidence-based review of risk reductive strategies for osteonecrosis of the jaws among cancer patients, *Curr Clin Pharmacol* 8:124–134, 2013.
102. Mozzati M, Arata V, Gallesio G: Tooth extraction in patients on zoledronic acid therapy, *Oral Oncol* 48(9):817–821, Sep 2012.
103. Scoletta M, Arduino P, Dalmasso P, et al.: Treatment outcomes in patients with bisphosphonate-related osteonecrosis of the jaws: a prospective study, *Oral Surg Oral Med Oral Pathol Oral Radiol Endod* 110:46–53, 2010.
104. Yamazaki T, Yamori M, Ishizaki T, et al.: Increased incidence of osteonecrosis of the jaw after tooth extraction in patients treated with bisphosphonates: a cohort study, *Int J Oral Maxillofac Surg* 41(11):1397–1403, 2012.
105. Kunchur R, Need A, Hughes T, Goss A: Clinical investigation of C-terminal cross-linking telopeptide test in prevention and management of bisphosphonate-associated osteonecrosis of the jaws, *J Oral Maxillofac Surg* 67:1167–1173, 2009.
106. Kyrgidis A, Vahtsevanos K, Koloutsos G: Bisphosphonate-related osteonecrosis of the jaws: a case controlled study of risk factors in breast cancer patients, *J Clin Oncol* 26, 2008.
107. Hoff A, Toth B, Altundag K: Osteonecrosis of the jaw in patients receiving intravenous bisphosphonate therapy, *J Clin Oncol* 24:8528, 2006.
108. Tsao C, Darby I, Ebeling PR, et al.: Oral health risk factors for bisphosphonate-associated jaw osteonecrosis, *J Oral Maxillofac Surg* 71:1360, 2013.
109. United States. Food and Drug Administration: Avastin (bevacizumab) safety information. http://www.fda.gov/Safety/MedWatch/SafetyInformation/ucm275758.htm.
110. United States. Food and Drug Administration: Sutent (sunitinib malate) capsules safety information. http://www.fda.gov/safety/medwatch/safetyinformation/ucm224050.htm.
111. Ott S: Long-term safety of bisphosphonates [Editorial], *J Clin Endocrinol Metab* 90:1897–1899, 2005.
112. Odvina C, Zerwekh J, Sudhaker R: Severely suppressed bone turnover: a potential complication of alendronate therapy, *J Clin Endocrinol Metab* 90:1294–1301, 2005.

113. Lacy M, Dispenzieri A, Gertz M: Mayo clinic consensus statement for the use of bisphosphonates in multiple myeloma, *Mayo Clin Proc* 81:1047–1053, 2006.
114. Khan H, Morrison A, Hanlet D, et al.: International consensus on the diagnosis and management of osteonecrosis of the jaw, *J Bone Miner Res* 30:3–23, 2015.
115. Ruggiero S, Dodson T, Assael L, et al.: American Association of Oral and Maxillofacial Surgeons position paper on bisphosphonate-related osteonecrosis of the jaws: 2009 update, *J Oral Maxillofac Surg* 67:2–12, 2009.
116. Damm D, Jones D: Bisphosphonate-related osteonecrosis of the jaws: a potential alternative to drug holidays, *Pharmacotherapeutics* 33–37, 2013.
117. Bianchi S, Scoletta M, Cassione F, et al.: Computerized tomographic findings in bisphosphonate-associated osteonecrosis of the jaw in patients with cancer, *Oral Surg Oral Med Oral Pathol Oral Radiol Endod* 104:249–258, 2007.
118. Treister N, Friedland B, Woo S: Use of cone-beam computerized tomography for evaluation of bisphosphonate-associated osteonecrosis of the jaws, *Oral Surg Oral Med Oral Pathol Oral Radiol Endod* 109:753–764, 2010.
119. Arce K, Assael L, Weissman J, Markiewicz M: Image findings in bisphosphonate-related osteonecrosis of the jaws, *J Oral Maxillofac Surg* 67(Suppl 1):75–84, 2009.
120. Chiandussi S, Biasotto M, Cavalli F, et al.: Clinical and diagnostic imaging of bisphosphonate-associated osteonecrosis of the jaws, *Dentomaxillofac Radiol* 35:236–243, 2006.
121. O'Ryan F, Khoury S, Liao W, Han M: Intravenous bisphosphonate-related osteonecrosis of the jaw: bone scintigraphy as an early indicator, *J Oral Maxillofac Surg* 67:1363–1372, 2009.
122. Bedogni A, Blandamura S, Lokmic Z, et al.: Bisphosphonate-associated jawbone osteonecrosis: a correlation between imaging techniques and histopathology, *Oral Surg Oral Med Oral Pathol Oral Radiol Endod* 105(3):358–364, 2008.
123. Garcia-Ferrer L, Bagan JV, Martinez-Sanjuan V, et al.: MRI of mandibular osteonecrosis secondary to bisphosphonates, *AJR Am J Roentgenol* 190(4):949–955, 2008.
124. Belcher R, Boyette J, Pierson T, et al.: What is the role of positron emission tomography in osteonecrosis of the jaws? *J Oral Maxillofac Surg* 72(2):306–310, 2014.
125. Fedele S, Porter S, D'Aiuto F, et al.: Nonexposed variant of bisphosphonate-associated osteonecrosis of the jaw: a case series, *Am J Med* 123:1060–1064, 2010.
126. Bonacina R, Mariani U, Villa F, et al.: Preventive strategies and clinical implications for bisphosphonate-related osteonecrosis of the jaw: a review of 282 patients, *J Can Dent Assoc* 77:147, 2011.
127. Dimopoulus M, Kastritis E, Bamia C, et al.: Reduction of osteonecrosis of the jaw (ONJ) after implementation of preventive measures in patients with multiple myeloma treated with zoledronic acid, *Ann Oncol* 20:117, 2009.
128. Ripamonti C, Maniezzo M, Campa T, et al.: Decrease occurrence of osteonecrosis of the jaw after implementation of dental preventive measures in solid tumor patients with bone metastases treated with bisphosphonates. The experience of the National Cancer Institute of Milan, *Ann Oncol* 20:137–145, 2009.
129. Vandone AM, Donadio M, Mozzati M, et al.: Impact of dental care in the prevention of bisphosphonate-associated osteonecrosis of the jaw: a single-center clinical experience, *Ann Oncol* 23(1):193–200, 2012.
130. Bone H, Hosking D, Devogelaer J, et al.: Ten years' experience with alendronate for osteoporosis in postmenopausal women, *N Engl J Med* 350:1189–1199, 2004.
131. Bagan J, Jimenez Y, Gomez D, Sirera R: Collagen telopeptide (serum CTX) and its relationship with size and number of lesions in osteonecrosis of the jaws in cancer patients on intravenous bisphosphonates, *Oral Oncol* 44:1088–1089, 2008.
132. Kwon Y, Kim D, Obe J, Yoo J: Correlation between serum C-terminal cross-linking telopeptide of type 1 collagen and staging of oral bisphosphonate-related osteonecrosis of the jaws, *J Oral Maxillofac Surg* 67:2644–2648, 2009.
133. Lehrer S, Montazem A, Ramanathan L, et al.: Normal serum bone markers in bisphosphonate-induced osteonecrosis of the jaws, *Oral Surg Oral Med Oral Pathol Oral Radiol Endod* 106:389–391, 2008.
134. Marx R, Cillo J, Ulloa J: Oral bisphosphonate-induced osteonecrosis: risk factors, prediction of risk using serum CTX testing, prevention, and treatment, *J Oral Maxillofac Surg* 65:2397–2410, 2007.
135. Hutcheson A, Cheng A, Kunchar R, et al.: A C-terminal cross-linking telopeptide test–based protocol for patients on oral bisphosphonates requiring extraction: a prospective single-center controlled study, *J Oral Maxillofac Surg* 72(8):1456–1462, 2014.
136. Rosen H, Moses A, Garber J, et al.: Serum CTX: A new marker of bone resorption that shows treatment effect more often than other markers because of low coefficient of variability and large changes with bisphosphonate therapy, *Calcif Tissue Int* 66:100–103, 2000.
137. Rosen H, Moses A, Garber J, et al.: Utility of biochemical markers of bone turnover in the follow-up of patients treated with bisphosphonates, *Calcif Tissue Int* 63:363–368, 1998.
138. Coleman R, Woodward E, Brown J, et al.: Safety of zoledronic acid and incidence of osteonecrosis of the jaw (ONJ) during adjuvant therapy in a randomised phase III trial (AZURE: BIG 01-04) for women with stage II/III breast cancer, *Breast Cancer Res Treat* 127:429, 2011.
139. American Association of Endodontists: *Endodontic implications of bisphosphonate-associated osteonecrosis of the jaws*, Chicago, 2010, American Association of Endodontists, p 4.
140. Katz H: Endodontic implications of bisphosphonate-associated osteonecrosis of the jaws: a report of three cases, *J Endodontol* 31:831–834, 2005.
141. Sarathy A, Bourgeois S, Goodell G: Bisphosphonate-associated osteonecrosis of the jaws and endodontic treatment: two case reports, *J Endodontol* 31:759–763, 2005.
142. de Molon R, Shimamoto H, Bezouglaia O: OPG-Fc but not zoledronic acid discontinuation reverses osteonecrosis of the jaws (ONJ) in mice, *J Bone Miner Res* 30:1627–1640, 2015.
143. Marx R: Pamidronate (Aredia) and zoledronate (Zometa) induced vascular necrosis of the jaws: a growing epidemic, *J Oral Maxillofac Surg* 61:1115–1117, 2003.
144. Ruggiero S: Guidelines for the diagnosis of bisphosphonate related osteonecrosis of the jaw (BRONJ), *Clin Cases Miner Bone Metab* 4:1–6, 2007.
145. Carlson E, Basile J: The role of surgical resection in the management of bisphosphonate-related osteonecrosis of the jaws, *J Oral Maxillofac Surg* 67(Suppl 1):85–95, 2009.
146. Eckardt A, Lemound J, Lindhorst D, et al.: Surgical management of bisphosphonate-related osteonecrosis of the jaw in oncologic patients: a challenging problem, *Anticancer Res* 31:2313–2318, 2011.
147. Graziani F, Vescovi P, Campisi G, et al.: Resective surgical approach shows a high performance in the management of advanced cases of bisphosphonate-related osteonecrosis of the jaws: a retrospective survey of 347 cases, *J Oral Maxillofac Surg* 70:2501, 2012.

148. Mucke T, Koschinski J, Deppe H, et al.: Outcome of treatment and parameters influencing recurrence in patients with bisphosphonate-related osteonecrosis of the jaws, *J Cancer Res Oncol*, 2010.
149. Stanton DC, Balasanian E: Outcome of surgical management of bisphosphonate-related osteonecrosis of the jaws: review of 33 surgical cases, *J Oral Maxillofac Surg* 67(5):943–950, 2009.
150. Stockman P, Vairaktaris E, Wehrhan F, et al.: Osteotomy and primary wound closure in bisphosphonate-associated osteonecrosis of the jaw: a prospective clinical study with 12 months follow-up, *Support Cancer Care* 18:449–460, 2009.
151. Williamson RA: Surgical management of bisphosphonate induced osteonecrosis of the jaws, *Int J Oral Maxillofac Surg* 39(3):251–255, Mar 2010.
152. Saussez S, Javadian R, Hupin C, et al.: Bisphosphonate-related osteonecrosis of the jaw and its associated risk factors: a Belgian case series, *Laryngoscope* 119(2):323–329, 2009.
153. Van den Wyngaert T, Claeys T, et al.: Initial experience with conservative treatment in cancer patients with osteonecrosis of the jaw (ONJ) and predictors of outcome, *Ann Oncol* 20(2):331–336, 2009.
154. Wutzl A, Biedermann E, Wanschitz F, et al.: Treatment results of bisphosphonate-related osteonecrosis of the jaws, *Head Neck* 30(9):1224–1230, 2008.
155. Freiberger JJ, Padilla-Burgos R, McGraw T, et al.: What is the role of hyperbaric oxygen in the management of bisphosphonate-related osteonecrosis of the jaw: a randomized controlled trial of hyperbaric oxygen as an adjunct to surgery and antibiotics, *J Oral Maxillofac Surg* 70(7):1573–1583, 2012.
156. Lee C, David T, Nishime M: Use of platelet-rich plasma in the management of oral bisphosphonate-associated osteonecrosis of the jaw: a report of 2 cases, *J Oral Implantol* 32:371–382, 2007.
157. Vescovi P, Merigo E, Manfredi M, et al.: Nd:YAG laser biostimulation in the treatment of bisphosphonate associated osteonecrosis of the jaw: clinical experience in 28 cases, *Photomed Laser Surg* 26:37–46, 2008.
158. Epstein M, Wicknick F, Epstein J, et al.: Management of bisphosphonate-associated osteonecrosis: pentoxifylline and tocopherol in addition to antimicrobial therapy. An initial case series, *Oral Surg Oral Med Oral Pathol Oral Radiol Endod* 110:593–596, 2010.
159. Gerard DA, Carlson ER, Gotcher JE, Pickett DO: Early inhibitory effects of zoledronic acid in tooth extraction sockets in dogs are negated by recombinant human bone morphogenetic protein, *J Oral Maxillofac Surg* 72(1):61–66, 2014.
160. Neer R, Arnaud C, Zanchetta J: Effect of parathyroid hormone (1-34) on fractures and bone mineral density in postmenopausal women with osteoporosis, *N Engl J Med* 344:1434–1441, 2001.
161. Kuroshima S, Kovacic BL, Kozloff KM, et al.: Intra-oral PTH administration promotes tooth extraction socket healing, *J Dent Res* 92(6):553–559, 2013.
162. Serhan C: Pro-resolving lipid mediators are leads for resolution physiology, *Nature* 510:92–101, Jun 5 2014.
163. Harper R, Fung E: Resolution of bisphosphonate-associated osteonecrosis of the mandible: possible application for intermittent low-dose parathyroid hormone [rhPTH(1-340)], *J Oral Maxillofac Surg* 65:573–580, 2007.
164. Cheung A, Seeman E: Teriparatide therapy for alendronate-associated osteonecrosis of the jaw, *N Engl J Med* 363:2473–2474, 2010.
165. Bashutski JD, Eber RM, Kinney JS, et al.: Teriparatide and osseous regeneration in the oral cavity, *N Engl J Med* 363(25):2396–2405, 2010.
166. Kuroshima S, PF E, McCauley L, et al.: Early effects of parathyroid hormone on bisphosphonate/steroid-associated compromised osseous wound healing, *Osteoporos Int* 25:1141, 2014.
167. Engroff SL, Kim DD: Treating bisphosphonate osteonecrosis of the jaws: is there a role for resection and vascularized reconstruction? *J Oral Maxillofac Surg* 65(11):2374–2385, 2007.
168. Ferrari S, Bianchi B, Savi A, et al.: Fibula free flap with endosseous implants for reconstructing a resected mandible in bisphosphonate osteonecrosis, *J Oral Maxillofac Surg* 66(5):999–1003, 2008.
169. Seth R, Futran ND, Alam DS, Knott PD: Outcomes of vascularized bone graft reconstruction of the mandible in bisphosphonate-related osteonecrosis of the jaws, *Laryngoscope* 120(11):2165–2171, 2010.

22

Langerhans Cell Histiocytosis

ERIC R. CARLSON, JOSHUA A. CAMPBELL

The group of diseases collectively known as Langerhans cell histiocytosis (LCH) includes entities formerly referred to as histiocytosis X, eosinophilic granuloma, Letterer-Siwe disease, Hand-Schuller-Christian disease, Hashimoto-Pritzker syndrome, self-healing histiocytosis, pure cutaneous histiocytosis, Langerhans cell granulomatosis, type II histiocytosis, and the generic term nonlipid reticuloendotheliosis. The common feature of these diseases is the proliferation of clonal CD1a-positive immature dendritic cells (LCH cells) in the skin, bone, lymph nodes, and other organs. Langerhans cell histiocytosis is a rare disease that affects 5 children per million population and about 1 to 2 adults per million population.[1] It is predominantly a disease of children: More than 50% of affected individuals are younger than 15 years of age, with an average age of presentation of 25 years.[2] The peak incidence is between 1 and 4 years. The prevalence of LCH seems to be higher among whites than other races.[2]

The first case of LCH was described by Dr. Thomas Smith in 1865 in a 4-year-old patient with punched-out lesions of the calvarium.[1,3,4] The skull defects were originally thought to be congenital based on drawings, as x-ray was not developed until 1895. The child died 1 month later of respiratory complications related to whooping cough. Hand-Schuller-Christian disease was independently described by Hand in 1893, Schuller in 1915, and Christian in 1920 in patients with exophthalmos, polyuria, and skull defects.[1-3] The disease was initially attributed to tuberculosis infection. Letterer-Siwe disease was described by Letterer in 1924 and Siwe in 1933 as an acute disorder of the reticuloendothelial system in two young children.[1-3] This disease was characterized by marked hepatosplenomegaly, lymphadenopathy, bone tumors, anemia, and hyperplasia of nonlipidized histiocytes. Eosinophilic granuloma of bone was first described by Mignon in 1930 as a granulomatous bone lesion in an adolescent male.[1,3,4]

In 1940 Lichtenstein and Jaffe described a case of a solitary bone lesion of the femur in a 4-year-old girl that did not suggest any classified disease of bone, either inflammatory or neoplastic.[5] This case was also notably composed of sheet-like collections of histiocytes. Earlier reports suggested the possibility of myeloma with prevalence of eosinophilic cells or osteomyelitis with an eosinophilic reaction.[5] The authors decided that the lesion represented neither a myeloma nor an osteomyelitis, as had been suggested by others, but rather some type of granuloma. This notwithstanding, the lesion did not fit into any of the recognized granuloma categories. Moreover, they proposed that the granuloma existed in response to a virus. The name *eosinophilic granuloma of bone* was applied because of the preponderance of eosinophils, although the authors fully recognized that the basic cells were histiocytes. The authors pointed out those specific clinical features that might lead one to suspect the presence of eosinophilic granuloma of bone even before surgical intervention is attempted. Among these were the occurrence of the lesion in a child or a very young adult; a short history of painful localized swelling of only several weeks' duration; radiographic evidence of a rarefied and destructive bone lesion, especially in the calvarium, but also in the ribs or in a long bone, and with perforation of the cortex; and perhaps a palpable soft tissue mass overlying the affected bone. Jaffe and Lichtenstein were quick to point out that these features may lead the clinician to suspect malignant disease, specifically a Ewing sarcoma.[6]

Jaffe and Lichtenstein also reported the realization that multiple bone lesions may be encountered, and of the same kind as the solitary lesions.[6] They therefore recommended that even in cases in which there was supposedly only a solitary lesion in bone, additional lesions that may be present should be searched for radiographically. This radiographic investigation is now known as a skeletal survey. Aside from the known focus of LCH, a negative skeletal survey in combination with no suspicion for visceral involvement means that a patient has single-system unifocal LCH, as will be discussed.

The clinical varieties of LCH range from a curable solitary destructive lesion of bone to a lethal leukemia-like disorder that primarily affects infants.[7] The clinically evident pathology in LCH is broadly divided into two categories: direct involvement with the disease (i.e., bone or organ lesions) and secondary consequences resulting from permanent damage by the primary disease (i.e., exophthalmos, diabetes insipidus, fractures, and loss of teeth).[8] In addition, in anatomic terms, LCH is classified as a single-system (SS)

TABLE 22-1 Contemporary Anatomic Classification of Langerhans Cell Histiocytosis (LCH)

Classification System	Organ/System Involvement
Single-system LCH (SS-LCH)	Bone: unifocal or multifocal Skin Lymph node Lungs Hypothalamic-pituitary/CNS Other (thymus, thyroid)
Multisystem LCH (MS-LCH)	2 or more organs with or without risk organs Risk organs = bone marrow, spleen, liver, lung

versus multisystem (MS) and unifocal versus multifocal disease (Table 22-1). MS disease is classified into two groups depending on whether risk organs (RO), namely, the liver, lungs, spleen, and bone marrow, are involved. SS disease, RO-negative MS disease, and RO-positive MS disease are almost equivalent to eosinophilic granuloma, Hand-Schuller-Christian disease, and Letterer-Siwe disease, respectively.[9] The cause of LCH is unknown, with many researchers debating whether LCH represents a reactive immune condition or a malignancy. The identification of activating *BRAF* gene mutations strongly supports the hypothesis that LCH is a neoplastic process.[10,11]

Langerhans cell histiocytosis affects the head and neck region quite commonly, particularly the skull and jaws.[1] It has been estimated that the head and neck region is involved in approximately 90% of cases.[12] In addition, osteolytic bone lesions are a common manifestation of single-system LCH in adults.[2] With jaw involvement, 90% of patients are younger than 40 years of age, with a mean of 19 years.[1] Unifocal involvement of the jaws represents about 50% of maxillofacial LCH, with multifocal, single-system disease and multifocal multisystem disease equally accounting for the other 50%. The mandible is involved approximately three times more commonly than the maxilla. The posterior region of the jaws is more commonly involved than the anterior region. Early disease in the oral and maxillofacial region is manifested by lytic lesions of the jaws, often seen as localized, punched-out radiolucencies with no calcification and no sign of sclerosis or reaction at the borders[13] (Figure 22-1). The most common symptom is pain, although a mass may also be a presenting symptom.[14] With advanced disease, there may be severe alveolar bone resorption, producing the appearance of "teeth floating in air" (Figure 22-2). Interestingly, isolated mucosal lesions occurring in the absence of osseous lesions have been reported.[15] As discussed in detail in this chapter, the extent of the disease process often dictates the specific form of surgical therapy for a single-system unifocal LCH of the jaws in terms of whether an enucleation and curettage or a resection of the affected jaw is indicated. Prompt diagnosis of disease is essential to providing curative surgical therapy with little or no deformity. Thus the surgeon should consider LCH on a differential diagnosis of lucent lesions of the jaws, especially in patients younger than 40 years of age.



• **Figure 22-1** This panoramic radiograph demonstrates a unifocal site of Langerhans cell histiocytosis of the left mandible.

The Langerhans Cell

The term *histiocyte* refers to two groups of immune cells, macrophages and dendritic cells. The Langerhans cell is a mononuclear cell of bone marrow origin that belongs to the dendritic cell family. It can be generated from peripheral blood monocytes by the action of granulocyte-macrophage colony-stimulating factor and tumor necrosis factor-a (TFN-α). The normal Langerhans cell is recognized to be an important antigen-presenting cell in the skin that represents the most peripheral extension of the immune system. Langerhans cells are normally found in mucosa, lymph nodes, and bone marrow. With the uptake of antigen, these cells migrate to afferent lymphatic channels and travel to paracortical zones in regional lymph nodes. Once there, the endocytosed antigens are presented to naïve helper T cells. Langerhans cells have not proven to be clonal.[1] In 1868, Paul Langerhans, a 21-year-old medical student at the University of Berlin under the mentorship of Professor Virchow, described the cell that bears his name.[16] His initial impression was that the cell was a nerve receptor cell because of its stellate, dendritic appearance. Only in later years did Langerhans realize that his original supposition was incorrect. In 1961 Birbeck and colleagues[17] described the organelle that has become the unique label of the cell. Interestingly, there are stages of the cell's development when the Birbeck granule is not identified. Typically, two characteristics are observed in Langerhans cells. The first is the presence of Birbeck granules. These intracellular structures are rod-shaped with a



• **Figure 22-2** An advanced case of Langerhans cell histiocytosis of the bilateral mandible manifested by "teeth floating in air." This patient proved to have multifocal, single-system disease. The second deposit of eosinophilic granuloma was found in the fibula.

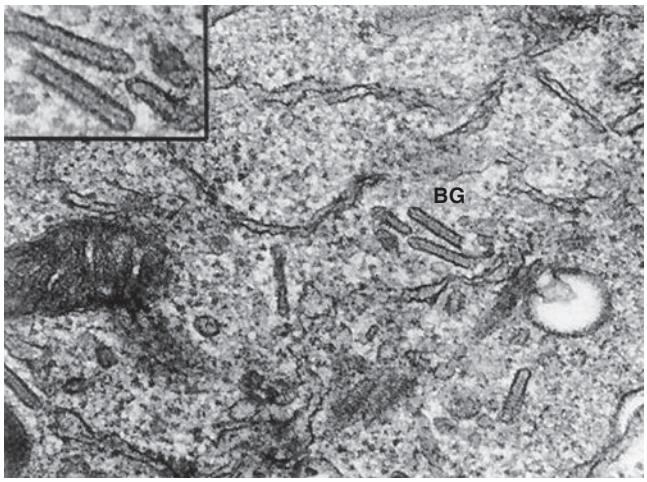

• **Figure 22-3** An electron micrograph demonstrating a characteristic Birbeck granule *(BG)* found in Langerhans cell histiocytosis. Original magnification 50,000×. Inset = original magnification 100,000×.

ballooning at one end that resembles a tennis racket. Under electron microscopy, the Birbeck granule (Figure 22-3) consists of a bilayered membrane. They can also be observed to develop as invaginations of the cell membrane. These findings resulted in a hypothesis that the granules represented the cellular response to an antigen being presented on this cell, and therefore reflect the normal function of Langerhans cells. One theory with respect to the pathogenesis of LCH, therefore, is that immunologic stimulation of this normal antigen-presenting cell may continue in an uncontrolled manner, and that this results in proliferation and accumulation of these cells.[8] The second characteristic of Langerhans cells, which is diagnostic of the pathology, is that they stain strongly positive for the presence of CD1a on their surfaces. This property is highly characteristic of Langerhans cells, but not of other cells of histiocytic origin.

• BOX 22-1 Classification of Histiocytosis X

Histiocytosis X, localized to bone (eosinophilic granuloma, solitary or multiple
Histiocytosis X, disseminated, acute, or subacute (Letterer-Siwe syndrome)
- With destructive skeletal lesions (eosinophilic granuloma)
- With transition to chronic phase (Schuller-Christian disease)

Histiocytosis X, disseminated, chronic (Schuller-Christian syndrome)
- With destructive skeletal lesions (eosinophilic granuloma)
- With early extraskeletal lesions (indicate sites) resembling eosinophilic granuloma
- With acute or subacute exacerbations (Letterer-Siwe disease)
- With involvement predominantly of bone, lungs, pituitary, and/or brain, skin, mucous membranes (oral, anal, genital), liver or lymph nodes, etc. (in varying combinations, as the case may be)

After Lichtenstein L: Histiocytosis X. Integration of eosinophilic granuloma of bone, "Letterer-Siwe disease" and "Schuller-Christian disease" as related manifestations of a single nosologic entity, *Arch Pathol* 55:84-102, 1953.

Classification of Langerhans Cell Histiocytosis

In 1953 Lichtenstein[18] lamented that his 1944 paper did not offer acceptable nomenclature for his discovery published in 1940. He believed that some designation built around histiocytosis was appropriate, because this term had the reference to an inflammatory proliferative reaction and it was the one feature common to all of the various pathologic expressions of the disease. Lichtenstein considered and discarded the designation *idiopathic histiocytosis* because it lacked specificity, in that it might apply as well to lesions of sarcoidosis, for example. As such, he presented "histiocytosis X" for the disease under consideration[18] and suggested the classification seen in Box 22-1 in

1953. The designation *histiocytosis X* was proposed for reasons of brevity as well as to imply the need to search for the specific etiologic agent. In 1953 Lichtenstein reorganized his thoughts on histiocytosis X and proposed a simpler classification in his landmark paper, as seen in Box 22-2. This classification is widely accepted in the 21st century, although under the designation *Langerhans cell histiocytosis*. A Writing Group of the Histiocyte Society was developed that developed a classification as a standard for diagnosis and patient management in cases of Langerhans cell histiocytosis.[19,20] Their initial publication reinforced the correct nomenclature for this disease process as Langerhans cell histiocytosis rather than histiocytosis X as had previously been designated. The most current method of categorization of LCH is based on risk stratification of affected individuals into recommended treatment protocols formulated by the Histiocyte Society[21] (Table 22-2). Unifocal disease involves a single disease system with a single site of involvement. There is a good prognosis in this group, and older children and adults are typically affected. Multifocal single-system disease most commonly affects young children and is present when several lesions are identified in a single organ system. Bone is most commonly involved, and this represents multifocal eosinophilic granuloma. The prognosis is intermediate. Multifocal multisystem disease carries the worst prognosis, where multiple lesions are found in more than one organ group. Commonly affected organ systems include bone, skin, liver, spleen, and lymph nodes. Children younger than 2 years of age represent the majority of patients in this group.

• BOX 22-2 Modern Classification of Langerhans Cell Histiocytosis

Monostotic or polyostotic eosinophilic granuloma of bone: Solitary or multiple bone lesions without visceral involvement.

Chronic disseminated histiocytosis: A disease involving bone, skin, and viscera. This is referred to as Hand-Schuller-Christian disease and may involve a triad consisting of punched-out calvarial lesions, exophthalmos, and diabetes insipidus.

Acute disseminated histiocytosis: A disease with prominent cutaneous, visceral, and bone marrow involvement occurring mainly in infants. This is referred to as Letterer-Siwe disease.

After Lichtenstein L: Histiocytosis X. Integration of eosinophilic granuloma of bone, "Letterer-Siwe disease" and "Schuller-Christian disease" as related manifestations of a single nosologic entity, *Arch Pathol* 55:84-102, 1953.

Clonality of Langerhans Cell Histiocytosis

For decades, it had been thought that LCH was a reactive proliferation rather than a neoplastic process, at least in part due to the dearth or absence of mitotic figures.[22] Moreover, the issue of clonality of the lesion was questioned. A distinguishing feature of a neoplasm is its origin from a single clone of cells, whereas a reactive process is generally considered polyclonal. As such, work has been revealed that has identified the clonality of LCH. Willman and colleagues[7] studied 10 female patients with various forms of LCH whose ages ranged from 3 months to 25 years. Molecular analysis revealed evidence of clonal cells in 9 of the 10 patients in whom results could be interpreted with confidence. It is notable that all three forms of LCH exhibited a clonal pattern. The authors concluded their study by stating that LCH is probably a clonal neoplastic disorder with highly variable biologic behavior. This notwithstanding, other authors contend that LCH represents a reactive process, similar to sarcoidosis.[16] Closer examination of the authors' comments, however, reveals that they indicate that a benign neoplastic process cannot be completely ruled out in the light of current knowledge. Further, they state that there is no evidence that LCH is a malignant neoplastic process based on their experience of 238 cases over a 50-year period.[16] Although there are rare malignancies featuring cells with Langerhans cell phenotype, malignant LCH is not recognized.[23] Malignant disorders of histiocytes are quite rare, with fewer than seven cases per year reported in the literature.[21] The malignant histiocytic disorders include the monocyte-related leukemias and

TABLE 22-2 Current Classification of Langerhans Cell Histiocytosis Formulated by the Histiocyte Society

Classification	Anatomic Distribution	Features
Unifocal disease (eosinophilic granuloma)	Single-system disease with single site of involvement	• Most commonly bone • Older children and adults • Good prognosis
Multifocal single-system disease (Hand-Schuller-Christian disease)	Multiple sites of involvement in single organ system	• Most commonly bone • Young children • Intermediate prognosis
Multifocal multisystem disease (Letterer-Siwe disease)	Multiple involved sites in more than one organ system	• Most commonly bone, skin, liver, spleen, and lymph nodes • Children younger than 2 years of age and infants • Poor prognosis

After Hicks J, Flaitz CM: Langerhans cell histiocytosis: current insights in a molecular age with emphasis on clinical oral and maxillofacial pathology practice, *Oral Surg Oral Med Oral Pathol Oral Radiol Endod* 100:542-566, 2005; Favara BE, Feller AC: Contemporary classification of histiocytic disorders, *Med Pediatr Oncol* 29:157-166, 1997.

other malignancies; the dendritic cell–related histiocytic sarcomas; and the macrophage-related histiocytic sarcomas.[21] In the final analysis, LCH is an obscure disease that ranges from a highly curable lesion resembling an inflammatory process to a highly lethal multisystem process. Whether LCH represents a reactive or neoplastic process still remains unclear, although treatment is regimented and highly effective in many cases.

Histopathology of Langerhans Cell Histiocytosis

For many years the definitive diagnosis of LCH was impaired by the lack of an agreed-upon set of diagnostic criteria.[8] The diagnostic criteria for LCH, which are histopathologic, are standardized and include the presence of CD1a cell surface staining or the finding of Birbeck granules in lesional cells for definitive diagnosis. A presumptive diagnosis made with less rigid criteria is no longer appropriate.

The basic lesion of LCH is formed by collections of pathologic Langerhans cells (PLCs), indeterminate cells, interdigitating cells, and macrophages accompanied by T lymphocytes with variable numbers of multinucleated giant histiocytes and eosinophils[24] (Figure 22-4). The hallmark of the lesion is the PLC, which is cytologically benign and resembles the normal Langerhans cell described previously, but is not morphologically dendritic.[24] Despite the activated state of Langerhans cell histiocytes, their ability to carry out antigen presentation is absent or rarely observed.[1] These cells do not have the ability to migrate from the lesional tissue, and along with inflammatory cells, they recruit other cells to the lesion. Additional diagnostic characteristics of the pathologic Langerhans cells include nuclei that are deeply indented and elongated on light microscopy, and cytoplasm that is pale and abundant.[25] Specific organ sites involved with LCH include bone, skin, and lymph nodes, among others. Osseous lesions are present in most cases of LCH, either as a solitary focus or as part of multisystem disease. There is a predilection for hematopoietically active medullary sites, the skull being most frequently involved. Other common locations are the femur, pelvis, tibia, scapula, jaw, humerus, vertebrae, and ribs. The small bones of the hands and feet are uncommonly involved. Histologically, osteoclast-like multinucleated giant histiocytes with bone destruction, necrosis, hemorrhage, and eosinophilic abscesses may be present. Skin involvement is present in more than 80% of patients with disseminated disease and in 30% of patients with less extensive multisystem disease.[24] Isolated cutaneous involvement may occur.[24] Skin of the head and neck region, trunk, groin, and extremities are common sites of involvement, with a diversity of clinical appearances. Seborrhea-like papular scaling eruptions, petechial and purpuric lesions, and papular xanthoma-like lesions may be noted. Histologically, diffuse bandlike or multifocal nodular aggregates of pathologic Langerhans cells in the papillary dermis are accompanied by violations of the epidermal-dermal interface and occasionally epidermal ulcerations.

Lymphadenopathy may be the sole manifestation of LCH. It may occur in occur in multisystem disease, or it may be a focal process associated with adjacent bone or skin disease. Cervical lymph nodes are most often involved, followed by inguinal, axillary, mediastinal, and retroperitoneal sites. Histologically, lymph node involvement is characterized by the presence of PLCs and related dendritic cells, macrophages, multinucleated giant histiocytes, T lymphocytes, and eosinophils.

Diagnosis, Treatment, and Prognosis of Langerhans Cell Histiocytosis of the Oral and Maxillofacial Region

A patient with LCH of the oral and maxillofacial region typically presents with pain and swelling (Figure 22-5).

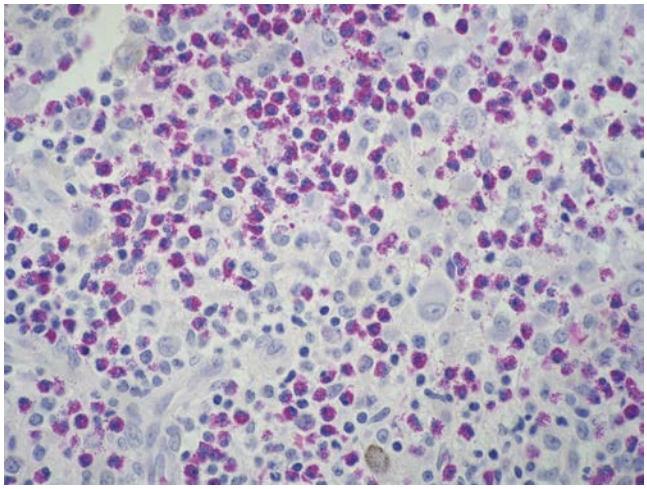

• **Figure 22-4** Characteristic histopathology of Langerhans cell histiocytosis. A preponderance of eosinophils and histiocytes is noted. Hematoxylin and eosin, original magnification 100×.



• **Figure 22-5** A 13-year-old boy with a painless swelling of 16 days duration at the time of presentation.



• **Figure 22-6** The panoramic radiograph of the patient in Figure 22-5 shows an ill-defined and destructive radiolucency of the right mandible ramus.

In the case of advanced disease, "teeth floating in air" may be noted radiographically. A panoramic radiograph will most commonly depict a destructive, ill-defined osteolytic process of the mandible (Figure 22-6). A differential diagnosis of osteomyelitis and benign or malignant tumor might be established. Because 75% of patients are younger than 20 years of age,[1,13] however, eosinophilic granuloma should be placed formidably on the differential diagnosis. This notwithstanding, an incisional biopsy is an essential step in the workup because of the varied number and classification of possible diagnoses. Histopathologic examination of representative tissue in the osteolytic lesion is paramount for diagnosis, and the specimen must be examined by a pathologist familiar with the microscopic features of LCH. Examination with hematoxylin and eosin stains, supplemented with confirmatory S-100 and CD1a immunohistochemistry, forms the basis for definitive diagnosis (Figure 22-7). Electron microscopy may be employed, searching for characteristic Birbeck granules, but is not essential for diagnosis. Once a diagnosis of LCH has been established, it is important to classify and stage the disease process. To this end, a skeletal survey must be undertaken to search for other skeletal lesions (Figure 22-8). This will permit distinguishing unifocal versus multifocal disease. In years past, a radionuclide bone survey was commonly obtained to identify skeletal involvement. Parker and colleagues[26] compared the results of radionuclide studies and a plain skeletal series in 18 patients with untreated Langerhans cell histiocytosis. They concluded that radiographic skeletal survey is more sensitive than radionuclide studies in detecting the skeletal lesions of this disease process. It might also be useful to reexamine the patient's history

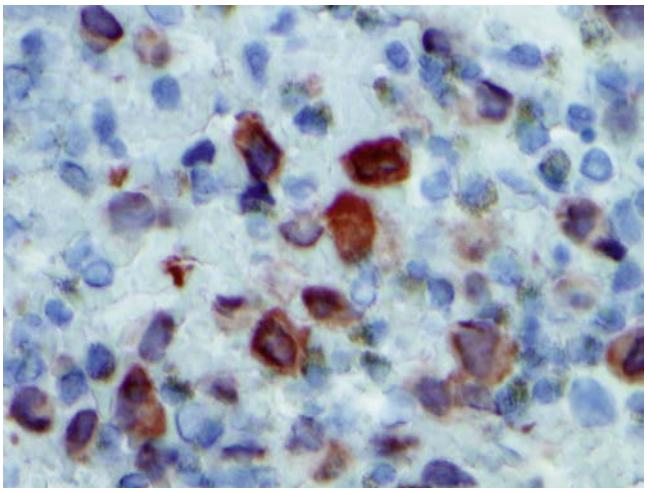

• **Figure 22-7** CD1a immunohistochemistry of a case of Langerhans cell histiocytosis showing strong positivity. Such a result is confirmatory for this diagnosis.

and physical examination to search for signs suggestive of disseminated involvement. Reevaluation of the patient for a subtle exophthalmos or historical symptoms of polyuria might lead to a diagnosis of Hand-Schuller-Christian disease that would be treated very differently from a solitary eosinophilic granuloma of the jaws. Additional laboratory studies should include complete blood count (CBC), platelet count, liver function tests (aspartate transaminase [AST], alanine transaminase [ALT], alkaline phosphatase, bilirubin, total protein and albumin), coagulation studies (prothrombin time [PT], partial thromboplastin time [PTT], and fibrinogen), chest radiographs if not included in the skeletal survey,

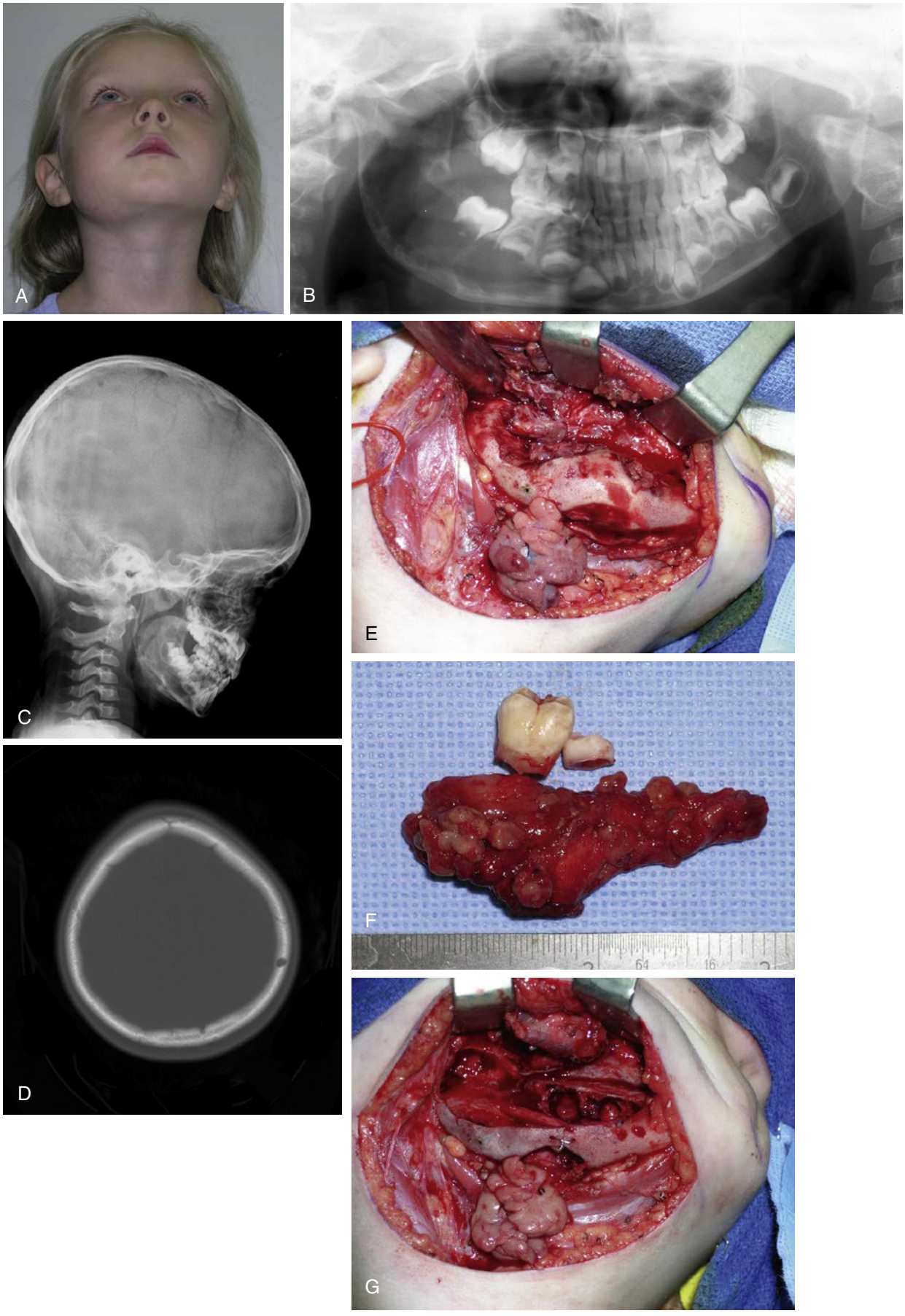

• **Figure 22-8** **A,** A 4-year-old girl with a 6-week history of right facial swelling. **B,** Panoramic radiograph demonstrates a destructive radiolucency of the right mandibular body and ramus. Incisional biopsy revealed Langerhans cell histiocytosis. **C,** A skeletal survey was obtained that demonstrated a second lesion in the left parietal bone. **D,** A head computed tomographic scan was also obtained that demonstrated this lesion. The patient was therefore classified as multifocal, single-system disease. She underwent enucleation and curettage of her mandibular lesion **(E-G),** followed by postoperative chemotherapy.

and urine osmolality measurement after overnight water deprivation.[20]

The diagnostic value of ^{18}F-fluorodeoxyglucose positron emission tomography (^{18}FDG PET) and magnetic resonance imaging (MRI) in LCH has been investigated for primary staging and disease follow-up.[27] One study compared 21 ^{18}FDG PET scans with 21 MRI scans in 15 patients with biopsy-proven histiocytosis. Six patients had unifocal disease, 4 had single-system multifocal disease, and 5 had multisystem disease. Primary criteria for the lesion-based analysis were contrast enhancement for MRI and standardized uptake value (SUV) greater than the mean SUV of the right lobe of the liver for PET. The sensitivity and specificity of PET were 67% and 76% and of MRI were 81% and 47%, respectively. This retrospective analysis suggested a pivotal role of ^{18}FDG PET in lesion follow-up after chemotherapy. MRI showed a higher sensitivity for primary staging of LCH, evaluation of brain involvement, and biopsy planning. The authors concluded that combined MRI/PET analysis improved sensitivity by decreasing the false-negative rate during primary staging, indicating a future role of simultaneous whole-body PET/MRI for primary investigation of LCH.

From an oral and maxillofacial surgery standpoint, the initial workup of a patient with LCH is performed with the possibility of *ruling in* a unifocal focus of eosinophilic granuloma. Surgery for a single focus of eosinophilic granuloma of the head and neck region is a preferred method of treatment and is highly curative. Curettage is most commonly employed for accessible and relatively small lesions where sufficient bone remains to permit bony regeneration (Figure 22-9). When disease is extensive, a segmental resection may be required and preferable (Figure 22-10). The use of radiation therapy may play a role in the management of lesions that recur after surgery, and in the management of lesions in surgically inaccessible areas. It has been recommended that the dose of radiation be under 1000 cGy, and preferably in the range of 550 to 600 cGy.[28] With unifocal bone disease, local excision with or without radiation therapy has led to more than 95% disease-free survival. Relapse has been found to occur in about 10% of cases.[1] Howarth and colleagues presented 314 patients with LCH, including 342 osseous lesions in 188 patients.[29] Of these osseous deposits, 121 (35.4%) were in the skull and jaws. Of the 211 relapses observed in these 314 patients, the median time from the end of initial treatment to relapse was 12 months.[29] Lieberman and co-workers reported that patients with eosinophilic granuloma do not die of their disease.[16] Multifocal bone disease may have similar surgical treatment with or without the addition of chemotherapy. Relapses are more common in multifocal disease than in unifocal disease and are noted in approximately 76% of cases.[1] Approximately 3% of patients die of their disease. Treatment of multifocal multisystem disease employs the combination of surgery, chemotherapy, and radiation therapy. A large percentage of patients (95%) develop relapses.[1] One in six patients with multifocal multisystem disease will die of their disease. Azreen and colleagues[12] have pointed out that the prognosis of this disease is closely related to the age at disease onset; involvement of high-risk organs including the bone marrow, lungs, liver, and spleen; and response to initial therapy that should be assessed at 6 to 12 weeks following chemotherapy. Children younger than 2 years have a higher mortality rate than older children and adults. The presence of organ dysfunction and multi-organ involvement are poor prognostic signs. Clearly, patients showing response to initial chemotherapy have a better prognosis.

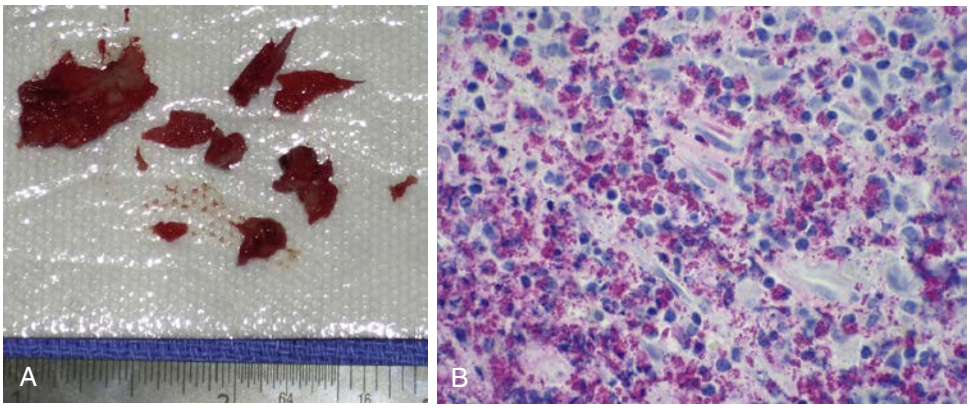

• **Figure 22-9** Surgical treatment of the patient in Figures 22-5 and 22-6. **A,** An incisional biopsy was obtained that led to a diagnosis of LCH. **B,** A full workup, including a skeletal survey, failed to disclose other lesions, thereby indicating the patient had unifocal disease. (H&E, original magnification 100 ×.) An enucleation and curettage of this lesion was performed

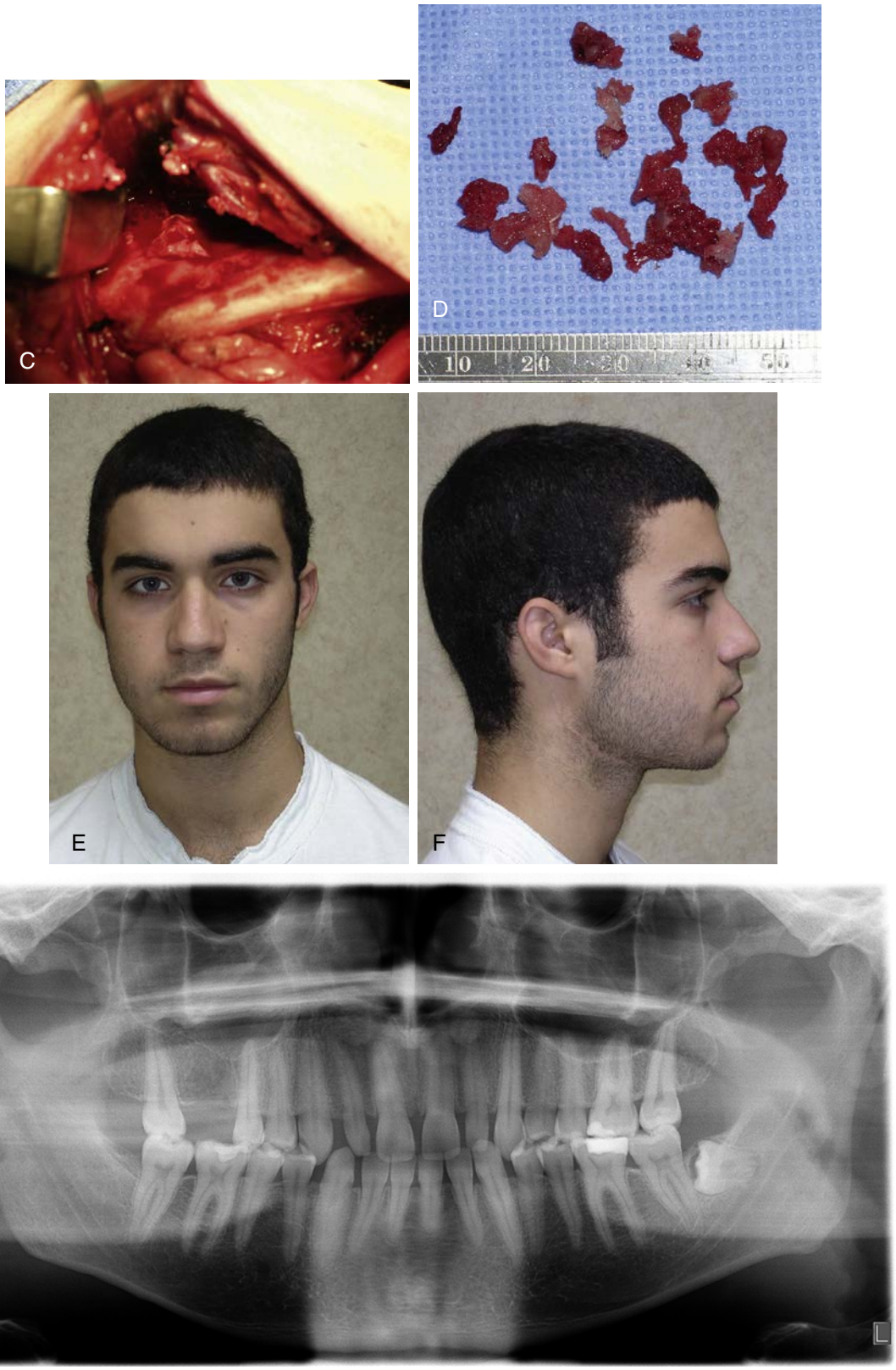

• **Figure 22-9, cont'd (C-D).** At 2½ years after surgery, he showed no clinical signs of recurrent disease **(E-F),** and no radiographic signs of disease at 10 years after surgery **(G).**

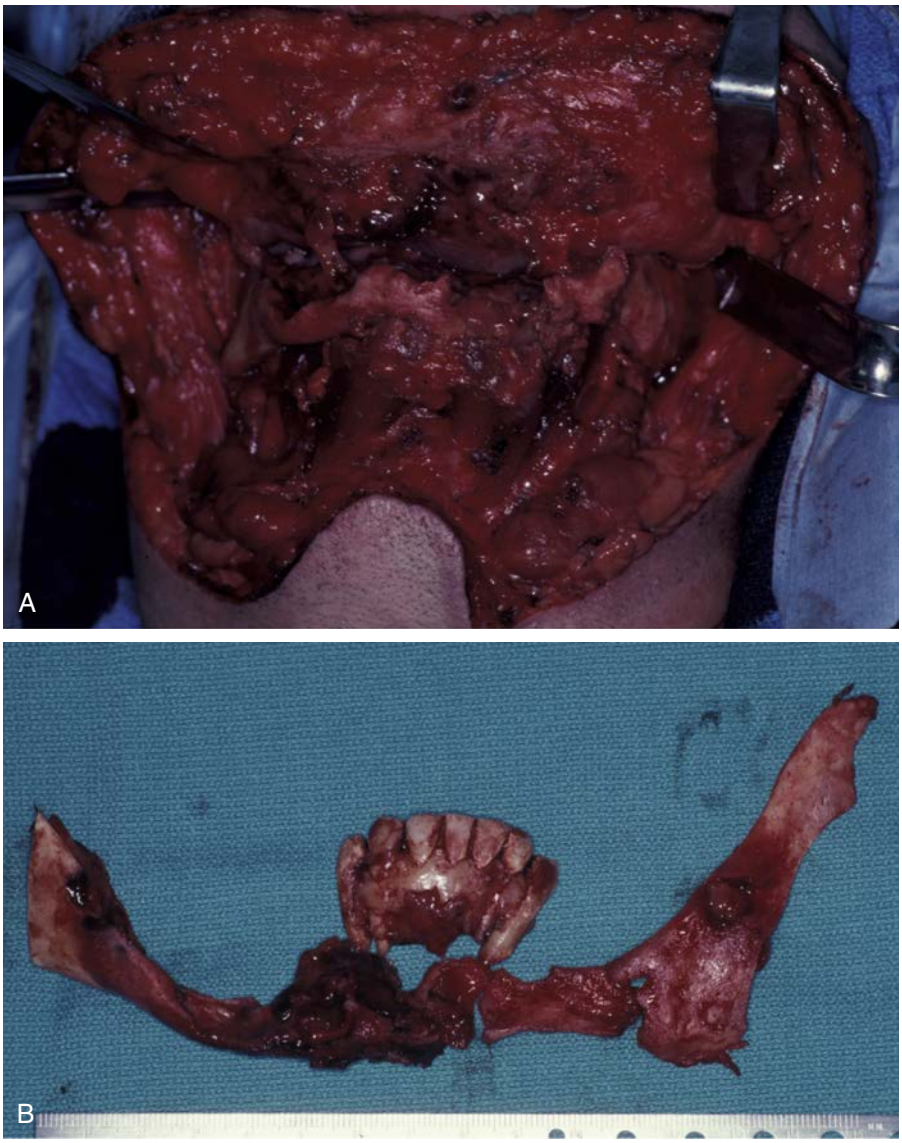

• **Figure 22-10** The surgery **(A)** for the patient whose panoramic radiograph is noted in Figure 22-2. Because of the advanced nature of his disease, a segmental resection was required **(B)**.

References

1. Hicks J, Flaitz CM: Langerhans cell histiocytosis: current insights in a molecular age with emphasis on clinical oral and maxillofacial pathology practice, *Oral Surg Oral Med Oral Pathol Oral Radiol Endod* 100:542–566, 2005.
2. Chiong C, Jayachandra S, Eslick GD, et al.: A rare case of Langerhans cell histiocytosis of the skull in an adult: a systematic review, *Rare Tumors* 5:e38, 2013.
3. Leonidas JC, Guelfgaut M, Valderrama E: Langerhans cell histiocytosis, *Lancet* 361:1293–1295, 2003.
4. Coppes-Zantinga A, Egeler RM: The Langerhans cell histiocytosis X files revealed, *Br J Hematol* 116:3–9, 2002.
5. Lichtenstein L, Jaffe HL: Eosinophilic granuloma of bone. With report of a case, *Am J Pathol* 16:595–604, 1940.
6. Jaffe HL, Lichtenstein L: Eosinophilic granuloma of bone. A condition affecting one, several or many bones, but apparently limited to the skeleton, and representing the mildest clinical expression of the peculiar inflammatory histiocytosis also underlying Letterer-Siwe disease and Schuller-Christian disease, *Arch Pathol* 37:99–118, 1944.
7. Willman CL, Busque L, Griffity BB, et al.: Langerhans cell histiocytosis (histiocytosis X)—a clonal proliferative disease, *N Engl J Med* 331:154–160, 1994.
8. Ladisch S: Langerhans cell histiocytosis, *Curr Opin Hematol* 5:54–58, 1998.
9. Morimoto A, Oh Y, Shioda Y, et al.: Recent advances in Langerhans cell histiocytosis, *Pediatr Int* 56:451–161, 2014.
10. Grana N: Langerhans cell histiocytosis, *Cancer Control* 4: 328–334, 2014.
11. Badalian-Very G, Vergilio J, Degar BA, et al.: Recurrent BRAF mutations in Langerhans cell histiocytosis, *Blood* 116: 1919–1923, 2010.
12. Azreen AB, Kwan CVY, Prepagaren N: Langerhans cell histiocytosis of maxillary sinus, *Med J Malaysia* 67:627–628, 2012.
13. Eckardt A, Schultze A: maxillofacial manifestations of Langerhans cell histiocytosis: a clinical and therapeutic analysis of 10 patients, *Oral Oncol* 39:687–694, 2003.

14. Alessi DM, Marceri D: Histiocytosis X of the head and neck in a pediatric population, *Arch Otolaryngol Head Neck Surg* 118:945–948, 1992.
15. Kacher JE, Philipone E: Clinical pathologic conference case 2: Langerhans cell histiocytosis, *Head Neck Pathol* 5:273–275, 2011.
16. Lieberman PH, Jones CR, Steinman RM, et al.: Langerhans cell (eosinophilic) granulomatosis. A clinicopathologic study encompassing 50 years, *Am J Surg Pathol* 20:519–552, 1996.
17. Birbeck MS, Breathnach AS, Everall JD: An electron microscope study of basal melanocytes and high-level clear cells (Langerhans cells) in vitiligo, *J Invest Dermatol* 31:51–64, 1961.
18. Lichtenstein L, Histiocytosis X: Integration of eosinophilic granuloma of bone, "Letterer-Siwe disease" and "Schuller-Christian disease" as related manifestations of a single nosologic entity, *Arch Pathol* 55:84–102, 1953.
19. Writing Group of the Histiocyte Society: Histiocyte syndromes in children, *Lancet* 1:208–209, 1987.
20. Clinical Writing Group of the Histiocyte Society: Histiocytosis syndromes in children II. Approach to the clinical and laboratory evaluation of children with Langerhans cell histiocytosis, *Med Pediatr Oncol* 17:492–495, 1989.
21. Favara BE, Feller AC: Contemporary classification of histiocytic disorders, *Med Pediatr Oncol* 29:157–166, 1997.
22. Egeler RM, D'Anglo GJ: Langerhans cell histiocytosis, *J Pediatr* 127:1–11, 1995.
23. Carlson ER, August M, Ruggiero SL: Locally aggressive benign processes of the oral and maxillofacial region, *Select Read Oral Maxillofac Surg* 12:1–52, 2004.
24. Schmitz L, Favara BE: Nosology and pathology of Langerhans cell histiocytosis, *Hematol Oncol Clin North Am* 12:221–246, 1998.
25. Merchant SN, Nadol JB: Otologic manifestations of systemic disease. In Cummings CW, editor: *Cumming's otolaryngology head and neck surgery, 4e*, Philadelphia, 2005, Elsevier Mosby, pp 2881–2905.
26. Parker BR, Pinckney L, Etcubannas E: Relative efficacy of radiographic and radionuclide bone surveys in the detection of the skeletal lesions of histiocytosis X, *Radiology* 134:377–380, 1980.
27. Mueller WP, Melzer HI, Schmid I, et al.: The diagnostic value of 18-FDG PET and MRI in paediatric histiocytosis, *Eur J Nucl Med Mol Imaging* 40:356–363, 2013.
28. Smith DG, Nesbit ME, D'Angelo GJ, Levitt SH, Histiocytosis X: Role of radiation therapy in management with special reference to dose levels employed, *Radiology* 106:419–422, 1973.
29. Howarth DM, Gilchrist GS, Mullan BP, et al.: Langerhans cell histiocytosis. Diagnosis, natural history, management, and outcome, *Cancer* 85:2278–2290, 1999.

23

Vascular Anomalies of the Oral and Maxillofacial Region

BONNIE L. PADWA, JOHN B. MULLIKEN

The rapidly evolving field of vascular anomalies combines the expertise of several surgical, radiologic, and medical specialists. In the past, the field was obscured by a cloud of confusing descriptive and histologic words. Improper terminology and classifications led to incorrect diagnosis, inappropriate treatment, and ill-conceived research endeavors. Vascular anomalies were often called "hemangioma" and specified by adjectives such as "capillary," "strawberry," "cavernous," "central," "venous," and so forth. Unfortunately, the generic label "hemangioma" was applied to many types of vascular lesions, both congenital and acquired, with different etiologies and clinical presentations.

In 1982 Mulliken and Glowacki analyzed the cellular features of the various vascular lesions seen in infancy and childhood and correlated their findings with physical examination and natural history.[1] They concluded that, on the basis of cellular kinetics, there are two major types of vascular anomalies: infantile hemangioma (IH) and vascular malformations. In 1996 the International Society for the Study of Vascular Anomalies adopted an expanded schema by categorizing vascular anomalies into *tumors* and *malformations*.[2] In modern medical usage, the Greek nominative suffix "-oma" refers to a lesion that arises by upregulated cellular growth. Hence, the word *hemangioma* denotes a benign vascular tumor, almost exclusively occurring in infancy. There are other vascular tumors with borderline or intermediate malignant features specified as hemangioendotheliomas. The least common are malignant vascular tumors, angiosarcomas, and lymphangiosarcomas.

Vascular malformations arise as the result of abnormal embryonic development. They are subdivided anatomically and rheologically into *slow-flow* lesions (i.e., capillary malformation [CM], lymphatic malformation [LM], and venous malformation [VM]) and *fast-flow* lesions (i.e., arterial malformations, such as aneurysm, ectasia, stenosis, fistula, and arteriovenous malformation [AVM]) (Box 23-1).

More than 90% of vascular anomalies can be differentiated by history and physical examination.[3] About one third of IHs are nascent at birth; two thirds appear postnatally. Rapid growth in early infancy is the defining feature. In contrast, many vascular malformations are noted at birth, and they expand commensurately with the child. Radiologic examination, ultrasonography (US), and magnetic resonance imaging (MRI) are commonly used to confirm the clinical diagnosis, document the extent and flow characteristics, and search for other vascular lesions. A biopsy is mandatory if there is equivocation about the clinical or radiologic diagnosis.

Histologically, hemangiomas demonstrate endothelial hyperplasia and glucose transporter-1 protein (GLUT1) immunopositivity, whereas vascular malformations have slow endothelial turnover and are GLUT1 negative.[4]

There are no specific hematologic abnormalities associated with IHs. Slow-flow vascular malformations, specifically venous and lymphaticovenous types, exhibit stasis, causing localized and disseminated intravascular coagulopathy.

IHs rarely cause skeletal hypertrophy or deformation of nearby bone by a mass effect, whereas slow-flow vascular malformations can cause bony deformation, and fast-flow lesions typically cause osteolysis.[5]

Since the single case report in 1940, the double eponym Kasabach-Merritt has been used to include profound thrombocytopenia, petechiae, and bleeding in association with a "giant hemangioma."[6] Unfortunately, the eponym continues to be commonly applied to the disseminated intravascular coagulopathy seen with slow-flow anomalies. Kasabach-Merritt coagulopathy is not a syndrome; rather, it is a phenomenon that occurs only with more invasive vascular tumors, kaposiform hemangioendothelioma (KHE), and tufted angioma (TA).[7,8]

Infantile Hemangioma

The term *hemangioma* should be restricted to the endothelial tumor of infancy that displays a unique biologic behavior of rapid growth and slow regression.

• BOX 23-1 Binary Classification of Vascular Anomalies, According to the International Society for the Study of Vascular Anomalies

Tumors
Hemangioma
Hemangioendotheliomas
Angiosarcoma
Miscellaneous
Malformations
Slow flow
  Capillary
  Lymphatic
  Venous
Fast flow
  Arterial
Combined

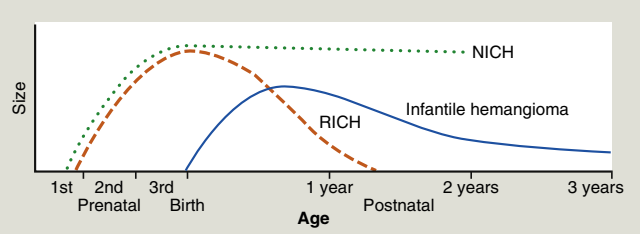

• Figure 23-1 Life cycle of common infantile hemangioma, as well as rapidly involuting infantile hemangioma *(RICH)* and noninvoluting infantile hemangioma *(NICH)*. (From Mulliken JB, Enjolras O: Congenital hemangiomas and infantile hemangioma: missing links, *J Am Acad Dermatol* 50:875-882, 2004.)



• Figure 23-2 Ulcerated hemangioma of the lower lip and tongue in a 3-month-old. *Note* the macular appearance of the tongue hemangioma.

This most common tumor of infancy occurs in 4% to 10% of Caucasian infants[9]; it is less frequent in dark-skinned infants. By age 1 year, approximately 10% to 12% of Caucasian children have a hemangioma. Females are more affected with a gender ratio of 2.4:1. Hemangiomas occur most frequently in the head and neck region (60%).[3] There is an increased incidence of 23% in premature infants weighing less than 1200 g.[10] Eighty percent of cutaneous hemangiomas are single, and 20% are multiple. Multiple cutaneous lesions often are associated with hemangiomas in other organ systems, especially liver, brain, gastrointestinal tract, and rarely in the lung.[9]

The typical infantile hemangioma (IH) is usually not evident at birth, although in 30% of patients, there may be a precursor lesion, such as a small macular red spot, pale area, telangiectasia, or ecchymotic lesion.[3] IHs appear during the first to fourth weeks of life and are followed by rapid postnatal growth, peaking by 5 to 6 months (proliferating phase). After the first year, the IH stabilizes and for a time grows at the same rate as the child, and then slowly regresses (involuting phase). Proliferation and involution are not distinct stages in the life cycle; rather, proliferation continues as involution slowly begins to predominate. As the hemangioma regresses, it becomes softer and its erythematous color changes to a gray hue. Complete resolution (involuted phase) occurs in more than 50% of children by age 5 and in more than 70% by the age of 7, with continued improvement until ages 10 to 12 (Figure 23-1). After involution is complete, there may be redundant atrophic skin, yellow discoloration or scarred patches if there was previous ulceration, residual fibrofatty tissue, and telangiectasia (Figure 23-2).[11]

The three phases of the IH's life cycle can be distinguished clinically, microscopically, and immunohistochemically.[12] In the proliferating phase, the tumor is composed of plump, rapidly dividing endothelial cells that form tightly packed sinusoidal channels. The endothelial cells express phenotypic markers of activated and mature endothelium.[12] Angiogenic proteins (e.g., basic fibroblast growth factor [bFGF] and vascular endothelial growth factor [VEGF]) and enzymes involved in remodeling of extracellular matrix (e.g., type IV collagenase and high-molecular-weight matrix metalloproteinases) are prominent in proliferating hemangiomas and diminish to normal levels during regression.[13,14] In the involuting phase, there is decreasing endothelial proliferation, increasing apoptosis, preponderance of stromal cells (e.g., mast cells, fibroblasts, and macrophages) and the first evidence of fibrofatty replacement of the tumor.[15] After regression is complete, all that remains are a few tiny capillary-like feeding vessels (encased in multilaminated basement membrane) and draining veins surrounded by islands of fibrofatty tissue admixed with dense collagen and reticular fibers.

If the tumor grows in the superficial dermis, the skin becomes raised, crimson in color, and firm and rubbery



• **Figure 23-3** **A,** Rapidly involuting infantile hemangioma on chin of newborn. Raised with red-violaceous color. **B,** Ten months later, lesion has nearly resolved.

to palpation. However, if the hemangioma develops in the lower dermis and subcutis, the lesion may appear slightly raised with a bluish hue or the overlying skin can be smooth and of normal color. These deeper lesions, once labeled "cavernous hemangiomas," often are not detected until 3 to 4 months of age. Both superficial and deep lesions are firm to palpation and exhibit the characteristic to-and-fro murmur on continuous-wave Doppler examination.[16] During the proliferative phase, they can become ulcerated and infected.[17] Multifocal hemangiomas can involve visceral organs (e.g., liver, gastrointestinal tract, brain, and lung) and, if large, can divert significant intravascular volume, resulting in high-output cardiac failure.[18]

Associated Malformative Anomalies

IHs in the head and neck can arise in association with structural anomalies, which are not necessarily vascular in nature. This was not well appreciated until these various malformations were compiled as the acronym PHACE: **P**osterior fossa anomalies, **H**emangioma of the face, **A**rterial abnormalities, **C**ardiac defects and coarctation, and **E**ye anomalies.[19,20] PHACE association occurs in a spectrum; the female preponderance is 9:1, higher than in isolated IH. The facial hemangioma typically manifests at birth as a diffuse (regional) reticular stain in the frontal and maxillary areas that tends to become plaquelike and pebbly. If the cheek and mandibular areas are involved ("beard distribution"), there also may be an obstructing laryngeal (subglottic) hemangioma. PHACE-associated anomalies also can occur with focal and multifocal hemangiomas. PHACE association should be promptly diagnosed by MRI or magnetic resonance angiography (MRA). Vascular anomalies include persistent embryonic intracranial and extracranial arteries, hypoplasia or absence of the ipsilateral carotid or vertebral vessels, aneurysmal dilatation of the carotid artery, and coarctation and right-sided aortic arch. Cerebrovascular occlusive changes, resembling moyamoya disease, can develop in these infants.[21] Seizure and stroke, secondary to cerebral infarction, can occur in infancy, and progressive stenosis and tortuosity can cause neurologic sequelae in childhood and adolescence.[22,23] The original acronymic designation PHACE did not include the possibility of sternal nonunion or supraumbilical raphe; these were included later by adding S to make PHACES.[20,24]

Congenital Hemangioma

There are rare vascular tumors that occur fully grown at birth and do not exhibit the expected postnatal course and life cycle of the common IH. These are defined as *congenital* hemangiomas, and there are two subtypes: rapidly involuting congenital hemangioma (RICH) and the noninvoluting congenital hemangioma (NICH) (see Figure 23-1). Both RICHs and NICHs have an equal sex ratio. RICH is raised with a characteristic red-violaceous color, central telangiectasias, and frequently with a peripheral pale halo (Figure 23-3). There may be superficial ulceration, central



• **Figure 23-4** Noninvoluting infantile hemangioma on the mandibular border of a 5-year-old. Well-circumscribed macule, coarse telangiectasias, and prominent to-and-fro murmur on handheld Doppler examination.

nodularity, or scar. Rapid arteriovenous shunting can simulate an AVM. Transient thrombocytopenia can also occur; however, the hematologic profile is more that of consumptive coagulopathy (i.e., it is not a Kasabach-Merritt phenomenon). Platelet levels rise rapidly as the tumor regresses. RICH commonly occurs on the trunk and extremities, but also in the head and neck and the liver. RICH involutes rapidly during the first few weeks or months of life.[25]

NICHs are typically ovoid, macular, or slightly raised; light gray in color with prominent coarse telangiectasias; and warm on palpation (Figure 23-4).[26] There is a predisposition for the mandibular border.[26] An NICH is typically a well-circumscribed lesion, averaging 5 to 6 cm in diameter.[27] An NICH is usually not diagnosed until later in childhood because it was mistaken for common IH or presumed to be a small AVM. NICH can occur as a large lesion in the cervical and occipital areas. Sometimes lesions in this location expand during adolescence and exhibit polypoid excrescences.

RICHs and NICHs have overlapping radiologic and histologic features with IHs; however, curiously, neither type of congenital tumor immunostains for glucose transporter-1 protein (GLUT1).[27] This raises the question of whether these congenital hemangiomas are variations in the hemangiomatous spectrum or entirely different tumors that arise in fetal life. There are more similarities than dissimilarities between IHs, RICHs, and NICHs. Furthermore, RICHs and NICHs can coexist with IHs.[11]

Management

Observation and waiting for involution is appropriate for small hemangiomas that cause no harm or disfigurement. Spontaneous ulceration has been reported to occur in up to 20% of cutaneous hemangiomas[28]; this most frequently involves lesions on the lips, perineum, anogenital area, and extremities (see Figure 23-2). An ulcerated hemangioma can become infected or destroy a lip, nose, or eyelid. For small superficial ulcerations, treatment includes cleansing with application of hydrated petrolatum dressing or a topical antibiotic.[29] Scarring is worse in ulcerated areas compared with nonulcerated areas following regression. There is some evidence to suggest that pulsed dye laser therapy can be effective for ulcerated hemangiomas.[30] Nevertheless, pulsed dye laser therapy for proliferating and early involuting hemangiomas is not indicated because the laser cannot penetrate deep enough into the tumor to be effective.[31] Laser application during proliferation of the hemangioma can cause ulceration, hypopigmentation, and scarring.[31,32] Laser therapy does not alter the life cycle of the hemangioma. A pulsed dye laser is effective for photocoagulation of the residual telangiectasias that persist after involution.

Pharmacologic therapy is indicated if a hemangioma causes destruction, distortion, or obstruction—for example, a proliferating hemangioma producing subglottic narrowing and distortion of the growing cornea, resulting in astigmatic amblyopia or blockage of the visual axis, causing deprivation amblyopia and failure to develop binocular vision. Subglottic hemangioma can be life threatening. The symptoms are hoarseness and biphasic stridor, generally manifesting between 4 and 12 weeks of age. Approximately 50% of these infants have a cutaneous hemangioma in a beardlike distribution.[33] A tracheostomy may be necessary if the lesions are large or unresponsive to pharmacologic therapy. Other alternatives include a carbon-dioxide laser (for unilateral lesions) and open resection.[34]

Intralesional steroids are useful for small lesions on the face (less than 2 cm in diameter).[35] Systemic steroids and propranolol (a beta-blocker[36]) should be used only in infants with a hemangioma that (1) is rapidly growing and seriously distorting facial features; (2) is causing recurrent bleeding, ulceration, or infection; and (3) is impinging on critical anatomic structures.[37] Endangering and life-threatening complications, such as high-output cardiac failure with a large tumor or multiple intrahepatic tumors, occur in 10% of hemangiomas.[38] The responsiveness to corticosteroids, the first-line treatment, is as high as 85%, with stabilization of growth or accelerated regression.[39] Indications for second-line therapy (vincristine) are failure of response to corticosteroids/propranolol, contraindications to prolonged systemic corticosteroids, and complications of corticosteroids or propranolol.

Resection is a consideration in all three phases of the hemangioma life cycle. Indications for excision in infancy include obstruction of a vital structure, recurrent bleeding, and ulceration. Resection during early involution can be carried out if excision is inevitable because of postulceration scarring, expanded skin, or high possibility of fibrofatty residuum and if the scar is easily concealed or if staged excision will be necessary. Indications for resection during late childhood include damaged skin, excess skin, abnormal contour (fibrofatty residuum), distortion, and loss of tissue.[40] Resection of a facial hemangioma, in any of the phases of its life cycle, requires careful planning. The

conventional method is excision in a lenticular format with linear closure in the axis of the relaxed cutaneous tension lines, either as a single or staged procedure. This technique is applicable in some locations, such as the lips, eyelids, neck, and sometimes the scalp. Most hemangiomas are spherical, and lenticular excision (to minimize "dog ears") causes central tension that flattens a convex area, such as the cheek or forehead, or may cause distortion of nearby structures. Hemangiomas act as a tissue expander; therefore circular excision and purse-string closure should always be the first consideration. This technique converts a circular lesion into a small circular or ellipsoid scar. Thereafter, a second excision can be either circular or lenticular. The result is the smallest possible scar with minimal distortion of surrounding structures.[41]

RICH often leaves behind loose skin and prominent draining veins. Resection may be indicated in an end-stage RICH. NICH can be resected, and diagnosis is established; usually the indication is cosmetic.

Vascular Malformations

Vascular malformations are localized abnormally formed lymphatic or blood vessels. Present at birth, some vascular malformations are obvious, whereas others manifest later in life. They grow commensurately with the patient. Malformations are divided by the preponderant vessel type and the rheologic characteristics (i.e., flow [slow- or fast-flow]). The malformation may be a single vessel type or a combination of anomalous channels, often with soft tissue and skeletal overgrowth in an extremity. Combined vascular anomalies in the head and neck region are lymphaticovenous (LVM) and arteriovenous (AVM).

US is helpful in distinguishing lymphatic, venous, and arteriovenous malformations.[16] MRI is the gold standard to determine the type and extent of the lesion; gadolinium is given as a contrast agent for enhancement.

Slow-Flow Vascular Malformations

Capillary Malformation

A capillary malformation (CM) occurs at birth as a macular pink stain that blanches with pressure. It is also known by the 19th-century term "port-wine stain." CM should not be confused with *nevus flammeus neonatorum* ("stork bite" or "angel kiss"), a common fading birthmark located on the forehead, eyelids, and nuchal region. CM has an equal sex ratio, and the incidence is 0.3%.[42] They can occur anywhere on the body and can be localized or extensive. Facial CMs often occur in a dermatomal distribution: 45% are restricted to one of the three trigeminal dermatomes, whereas 55% overlap sensory dermatomes, cross the midline, or occur bilaterally (Figure 23-5).[43]

Histologically, a CM is characterized by ectasia of capillary-to-venular sized vessels in the upper dermis. Facial CMs tend to gradually darken to an intense red hue during young adulthood and to a deep purple during middle age. The skin thickens and becomes raised and studded with nodular fibrovascular lesions, giving the appearance of cobblestones. Often there is associated soft tissue, gingival, and skeletal overgrowth in the area of the stain. This typically occurs in the maxilla and particularly the alveolar ridge, although the malformation does not involve the bone (see Figure 23-5). Patients with a CM of the alveolar ridge frequently develop gingival overgrowth, and pyogenic granulomas are common. To prevent these lesions, patients should practice good oral hygiene and receive regular dental cleaning. Operative procedures in the oral cavity, such as gingivectomy, extractions, and osteotomies, can be done without concern for excessive bleeding in the presence of a CM.



• **Figure 23-5** Sixteen-year-old boy with extensive bilateral facial capillary malformation in V_1, V_2, V_3 (Sturge-Weber syndrome); note soft tissue, gingival, and skeletal overgrowth in the area of the stain. Bony enlargement involves the maxilla and mandible and particularly the alveolar ridge.

Although most CMs occur sporadically, if they are located in the upper face, Sturge-Weber syndrome should be considered. Sturge-Weber syndrome is defined as a CM in the V1 ± V2 trigeminal areas associated with leptomeningeal capillary and venous anomalies and vascular lesions of the ocular choroid. The leptomeningeal vascular lesions can cause refractory seizures, contralateral hemiplegia, and variably delayed motor and cognitive development. Anomalous choroidal vascularity can result in retinal detachment, glaucoma, and blindness.[44] Patients with Sturge-Weber syndrome can have an extensive facial CM and stains on the trunk and extremities. Some patients exhibit major maxillary and/or mandibular overgrowth with evidence of vascular changes in bone. CMs can rarely be a red flag of an underlying structural anomaly. Midline occipital CMs can overlie ectopic meninges or an encephalocoele.[45] CMs over the cervical or lumbar spine may be a clue to occult spinal dysraphism.



• **Figure 23-6** Infant with lymphatic malformation (LM) in floor of mouth, elevating tongue. LMs in this position must be differentiated from a ranula.

Management

A pulsed dye laser is standard treatment; photocoagulation might prevent fibrovascular overgrowth ("cobblestoning"). Significant lightening of the CM occurs in approximately 80% of patients. Multiple sessions are generally required and often need to be repeated several years later.[46,47]

If there is cutaneous overgrowth despite laser treatment, staged excision and skin grafting should be considered.[48] The most common operation for a facial CM is contour resection for labial hypertrophy. Orthognathic correction may be indicated for occlusal canting caused by asymmetrical maxillary overgrowth or mandibular prognathism.

Lymphatic Malformation

Lymphatic anomalies occur in diverse forms, from isolated tiny mucosal or cutaneous blebs to large channel or multilocular lesions. Lymphatic malformations (LMs) are characterized as microcystic ("lymphangioma") or macrocystic ("cystic hygroma") or combined forms. LMs in the head and neck region occur in the neck, cheek, and cervicofacial region, extending into the mediastinum, and, less commonly, in the orbit (Figure 23-6).[49]

An LM in the forehead and periorbital tissues causes swelling of the supraorbital area and upper eyelid and usually proptosis as a result of intraorbital involvement.[50] Facial LMs appear as unilateral or bilateral hypertrophy, macrocheilia, and macrotia. LMs in the tongue and oral floor cause macroglossia with dark-stained vesicles on the dorsal surface. Cervicofacial LMs are associated with overgrowth of the mandibular body and resulting open bite and anterior crossbite (Figure 23-7).[49]

Prenatal US will detect relatively large lesions as early as the second trimester.[51] Most LMs are noted at birth or within the first year of life. Tracheostomy in a neonate may be needed to secure the airway in the presence of an extensive cervical LM that involves the supraglottic region (pharynx). Two major complications are infection and intralesional bleeding. LMs enlarge commensurate with the child's growth, but can suddenly expand as a result of cellulitis, often occurring along with an upper respiratory infection. The inflamed tissue is typically tense, warm, and erythematous and can lead to airway obstruction if there is involvement of the floor of the mouth and tongue. LMs can also expand as a result of an intralesional hemorrhage from small vessels within the malformation and present as oozing from mucosal and cutaneous vesicles.[52]

Management

Recurrent cellulitis may be caused by periodic seeding with common oral microorganisms. Infections should be treated promptly with broad-spectrum antibiotics continued for weeks rather than days.[49] Intravenous antibiotic administration is necessary if oral treatment fails or if there are signs of respiratory compromise. Antibiotic prophylaxis is controversial, but can be effective in diminishing the infective episodes. Meticulous oral hygiene along with regular dental cleaning every 4 months is recommended to minimize gingival inflammation. Many patients have multiple dental caries leading to premature tooth loss, which is usually related to the inability of the patient or dentist to access teeth for cleaning and restoration.[49] Teeth can be extracted without concern for bleeding.

Sclerotherapy is effective primary treatment of macrocystic disease or secondarily for recurrent cysts following partial extirpation.[53] Doxycycline, sodium tetradecyl sulfate, OK-432, absolute ethanol, and bleomycin have all been used as sclerosing agents.[54-57] The success of sclerotherapy in treating patients with LMs has made this modality preferable to resection, whenever possible.[58]

Resection of a large macrocystic LM is appealing, but it is often incomplete, and persistent swelling is predictable.[53] Staged excision, limiting each procedure to a defined anatomic area, is recommended for a diffuse microcystic LM.

Repeated resection in the same area becomes increasingly difficult. Nerve damage is more likely with each procedure because dense scar tissue distorts the usual anatomic location of nerves, especially the facial, hypoglossal, lingual, phrenic, and spinal accessory nerves.[49] The possibility of intraoperative nerve damage cannot be overemphasized. Facial nerve weakness only adds to the deformity in these patients, who are often already disfigured. Bilateral hypoglossal nerve loss is a devastating complication of repeated excision. An annoying problem after resection is the appearance of vesicles in the scar; this is the result of transection and regeneration of anomalous lymphatic channels.[49] Persistent edema of the face or neck can also adversely affect the postoperative result. A custom-made elastic compression garment should be worn after a major facial resection in an effort to minimize swelling.

Total resection may be possible for the child with an isolated LM of the dorsal tongue. Reduction for macroglossia



• **Figure 23-7** **A,** Child with lymphatic malformation (LM) of tongue and floor of mouth. Lingual movement diminished by fibrosis from previous episodes of infection, bleeding, and sclerotherapy. **B,** Cervicofacial LM is typically associated with overgrowth of mandibular body with resulting open bite and anterior crossbite. **C,** LM in tongue with blood-filled vesicles on dorsal surface; these are aggravated by trauma or infection.

is indicated for persistent protrusion or to allow for correction of a malocclusion.[49,53] The timing of resection is based on functional and emotional issues. Lingual reduction alone will not obviate a tracheostomy or decannulation. This requires removal of the lesion from the floor of the mouth via a cervical incision. Transoral resection of the floor of the mouth and tongue base should be avoided because of the high likelihood of postoperative functional problems. Debulking an enlarged and protruding tongue to return it to the oral cavity can have a negative impact on speech and feeding secondary to insufficient functional lingual mass.[53] Many patients have speech problems that are related to the intraoral bulk of the lesion, reduced lingual mobility, tooth loss, palatal immobility, and poor oral competence.[49,53]

Bleeding vesicles on the lingual dorsum are often aggravated by trauma or infection.[53] The bleeding is typically a daily oozing that can be a minor annoyance, but can also cause chronic blood loss and anemia.

Vesicles of the mucous membranes and dorsal tongue can be treated by laser (carbon dioxide, yttrium-aluminum-garnet [Nd:YAG], or potassium titanyl phosphate), or radiofrequency ablation.[46] Radiofrequency ablation is similar to laser photocoagulation. Most patients require a combination of these modalities to adequately treat LM of the lingual base and floor of the mouth.[49,53] Embolization can control bleeding from these vesicles.[53]

Cervicofacial LMs can be disfiguring, not only because of soft tissue hypertrophy, but as a result of bony enlargement and malocclusion. Most patients with a cervicofacial LM have progressive mandibular overgrowth and prognathism, class III malocclusion, a steep mandibular plane angle, effacement of the gonial angle, and anterior open bite (Figure 23-8).[49] Orthognathic procedures can be undertaken

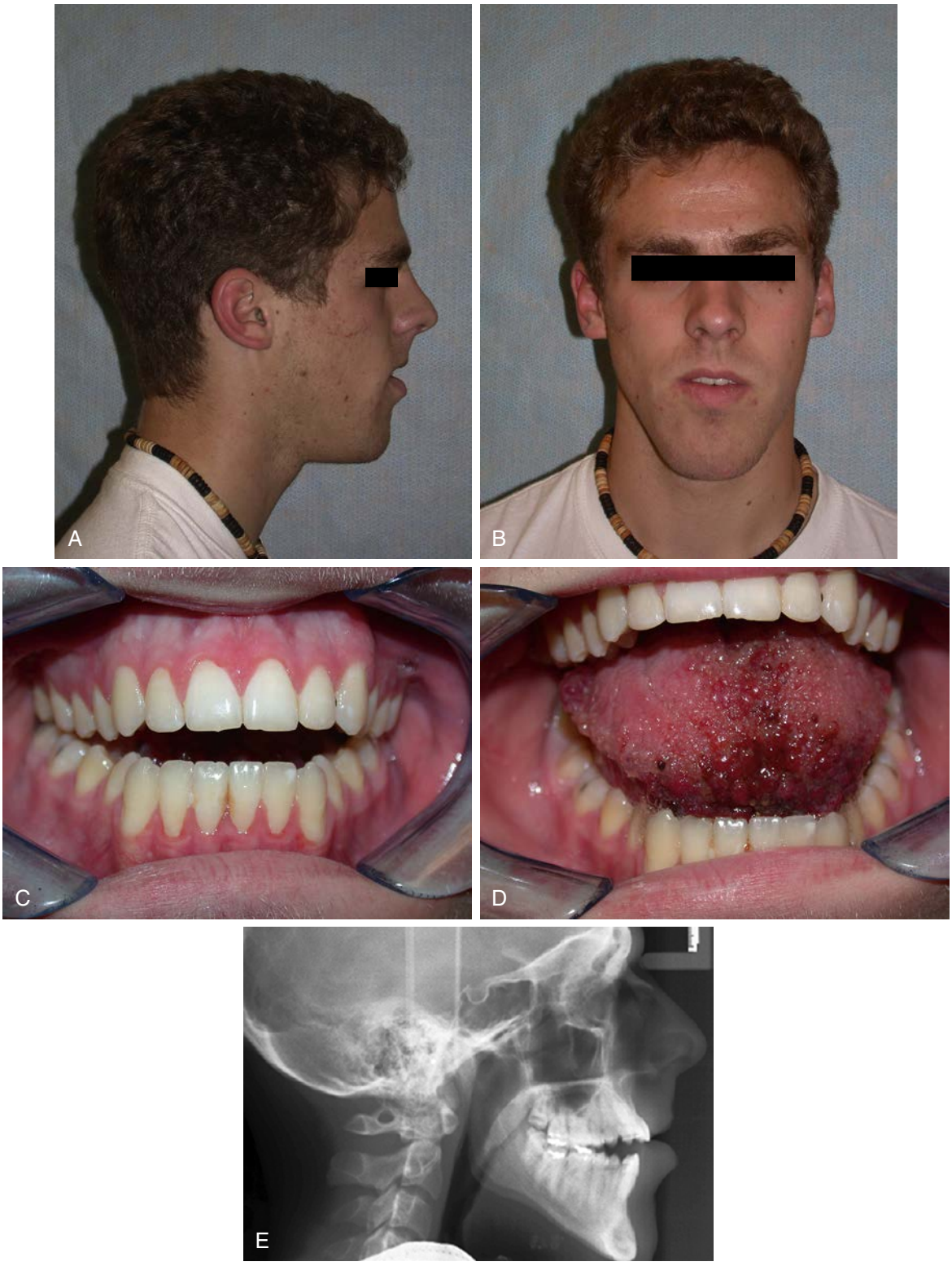

• **Figure 23-8** **A,** Frontal and **(B)** lateral photographs of 18-year-old man with lymphatic malformation of floor of mouth and tongue. Note long lower face height. **C,** Anterior open bite and **D,** blood-filled vesicles on dorsal tongue. **E,** Lateral cephalogram demonstrates steep mandibular plane and anterior open bite.



• **Figure 23-9** **A,** Frontal and **(B)** lateral photographs of patient in Figure 23-8 1 year after Le Fort I osteotomy shows improved lower face height. **C,** Anterior open bite has been closed. **D,** Lateral cephalogram demonstrates normalized occlusal planes.

at the appropriate age only after lingual size and position is acceptable. Orthognathic operations should ideally be postponed until lower jaw growth is complete; however, severe deformity with functional impairment can be so devastating that early osteotomy may be indicated (Figure 23-9). Le Fort I osteotomy and mandibular anterior segmental osteotomy allow for correction of the sagittal discrepancy and closure of the open bite without compromising the posterior airway space. Similarly, an ostectomy at the angle of the mandible with counterclockwise rotation of the mandibular body allows for correction of the steep mandibular plane and anterior open bite.[49]

Preoperative treatment is unnecessary for extractions, resection, or osteotomy, but the airway must be considered and managed accordingly. In addressing the mandibular deformity, it is important to remember the competing goals of improving jaw position without impinging on the airway.[53]

Judicious use of antibiotics is necessary in the perioperative period. Antibiotics should be administered for 2 to 3 weeks postoperatively, rather than just for days.



• **Figure 23-10** Small venous malformation of buccal mucosa can easily be treated in office with injection of sclerosing agent. Consider ultrasound or magnetic resonance imaging (with gadolinium) before treatment to determine size and extent of lesion.

Venous Malformation

Venous malformations (VMs) are the most common type of vascular malformation. These lesions have erroneously been referred to as "cavernous hemangiomas." They are not tumors, because they do not demonstrate endothelial proliferation unless there is intravascular clotting and fibrovascular growth. They are developmental abnormalities of veins composed of thin-walled, dilated channels of variable size and mural thickness with normal endothelial lining and deficient smooth muscle.[9] Venous lesions are blue-purple in color, soft, compressible, and nonpulsatile (Figure 23-10). VMs generally occur in skin, subcutis, and submucosa, but can involve muscle, viscera, and the central nervous system. Most VMs are solitary. Multifocal forms occur and should raise suspicion that there is a hereditary basis. Causative genes are known for cerebral cavernous malformation *(KRIT1),*[59] cutaneomucosal VM *(TIE2),*[60] and glomuvenous malformation (GVM) *(glomulin)*. GVM is the most common familial type of VM and can have macular lesions in infancy with expansion to plaquelike or nodular facial lesions. *TIE2* mutations are multiple focal lesions, often located in mucous membranes and the tongue.[61] Blue rubber bleb nevus syndrome is familial, although the gene has not been identified. These venous lesions can involve the face and oral cavity, but typically are located on the trunk, palms and soles, and gastrointestinal tract.

Venous anomalies usually grow in proportion to the child, but enlargement can occur with trauma or may coincide with puberty and pregnancy.[62] VMs characteristically expand with a Valsalva maneuver, when the patient bends over with the head in a dependent position, or with jugular vein compression.[51] Phlebothrombosis is common within venous anomalies because of stasis, and recurrent localized pain, distention, and tenderness are frequent presenting complaints. Phleboliths can be palpated or seen on plain radiographs and on all MRI sequences.[52]

VMs can cause progressive distortion of facial features (Figure 23-11). Patients with an extensive VM or LVM generally involve the overlying soft tissue and commonly cause skeletal alteration and hypertrophy without intraosseous involvement.[63] There are, however, rare instances of VMs within the facial bones. The most common intraosseous craniofacial location is the mandible, followed by the maxilla.[63] They are rarely found in the frontal, zygomatic, and nasal bones. Unfortunately, these lesions have been called "central" or "intraosseous" hemangiomas in the literature. Oral VMs can cause malocclusion as a result of the mass effect on the dentoalveolus.[51] VMs in the buccal mucosa can also involve the gingiva, tongue, palate, and oropharynx, but rarely interfere with speech and feeding.[51] VMs in the pharynx may compress and deviate the upper airway, leading to obstructive sleep apnea that is usually insidious in onset.[51]

The anatomic location and extent of the VM is best visualized by MRI with contrast. Stasis in large or extensive venous anomalies is frequently associated with a low-grade localized or generalized intravascular coagulopathy.[51] International normalized ratio and prothrombin time are often within normal limits, whereas fibrin split products and D-dimers are elevated, with concomitant decreased fibrinogen and platelet levels. It is important to correct coagulopathy preoperatively; even dental extraction in the presence of gingival venous lesions can result in a life-threatening hemorrhage. Indications for therapy include appearance, pain, and functional problems.[51] The primary therapeutic modalities are sclerotherapy, surgical resection, or a combined approach.[51]

Management

A patient with a large VM can be managed nonoperatively by giving daily aspirin (81 mg) to help prevent thrombosis and control the associated pain. Sclerotherapy is the mainstay of treatment and involves injection of an agent into the anomalous channels, resulting in endovascular destruction, clotting, and obliteration.[64] Small varicosities of mucosa and skin can easily be treated in the office with a local injection of 1% sodium tetradecyl sulfate (see Figure 23-10). However, an experienced interventional radiologist is trained to treat large VMs under general anesthesia and fluoroscopy (Figure 23-12).[51]

Direct injection of a sclerosing agent, such as sodium tetradecyl sulfate (3%) or absolute ethanol, into the anomaly is sometimes performed with the arterial inflow and venous outflow occluded during the procedure.[65,66] Multiple sclerotherapeutic sessions are often necessary to shrink a lesion because of the perverse tendency for recanalization. The success rate for sclerotherapy has been reported to be 76%; possible complications include blistering, full-thickness cutaneous and/or mucosal necrosis, and nerve injury.[67]



• **Figure 23-11** **A-B,** Fifteen-year-old girl with extensive cervicofacial venous anomaly that involves glottis, floor of mouth, tongue, anterior neck, chin, and lower lip. **C,** She has an anterior open bite secondary to vertical mandibular growth and tongue position with deformation of anterior maxilla.

Intralesional photocoagulation with the Nd:YAG (1064 nm) laser has been used successfully to treat deep VMs of the oral cavity.[68]

Resection without preoperative sclerotherapy is indicated only for small, solitary lesions or VMs in anatomic sites that are dangerous to sclerose (e.g., around major nerves).

Resection should be carried out after completion of sclerotherapy when there are no remaining large venous channels. Bleeding is controlled with compression. An extraction socket can be sutured tightly and/or the wound packed, the head wrapped, coagulopathy reversed, the patient kept intubated, and hypotension maintained. Resection is indicated to reduce bulk and to improve contour and function. Total excision of the venous anomaly is the therapeutic goal, but is not usually achievable because of the extent of the lesion and its location in relation to vital anatomic structures. In this case only subtotal or contour resection is possible. Subtotal resection is likely to be followed by expansion of the remaining malformed venous channels.

Orthognathic surgery can be undertaken safely, but should be done with preoperative treatment of localized coagulopathy, protection of the airway with a tracheostomy for extensive involvement of the oral cavity and glottis, and the use of preoperative sclerotherapy (Figure 23-13).

Fast-Flow Vascular Malformations

Arteriovenous Malformation

An AVM is composed of abnormal communications between arteries and veins without the normal intervening capillary bed. An AVM may result from an error of vascular development between the fourth and sixth weeks of gestation. Causative mutations for familial AVMs include *RASA1* for capillary malformation–arteriovenous malformation[69] (CM-AVM) and *PTEN* for *PTEN*-associated vascular anomaly.[70]



• **Figure 23-12** **A-B,** Multiple sclerotherapy sessions diminished size of venous malformation. **C,** Dentition has been leveled and aligned in preparation for orthognathic surgery. **D,** Lateral cephalogram shows dentoalveolar maxillary protrusion, vertical mandibular excess, and multiple phleboliths.

Expansion of an AVM is the result of increased blood flow through the lesion and subsequent tortuosity of adjacent feeding arteries and dilation of veins (collateralization and recruitment).[71] Recent evidence supports the theory that vasculogenesis may be involved in the enlargement of arteriovenous malformations. Hypoxia in the nidus may cause recruitment of endothelial progenitor cells, because ischemia is a potent stimulator of vasculogenesis.

AVMs are present at birth, but they may not be clinically evident or are misdiagnosed as a CM or hemangioma.[51] They rarely expand in infancy or early childhood; more typically, they grow proportionately starting in late childhood. Usually, years go by before they pose a threat to the patient as the signs and symptoms of their fast-flow nature become obvious. Nevertheless, rapid expansion can occur following local trauma, attempted excision or ligation, or hormonal changes associated with puberty or pregnancy.[72]

AVMs of the head and neck are less common than slow-flow anomalies (capillary, lymphatic, and venous malformations). Primary skeletal involvement occurs in the tooth-bearing bones, which are invariably expanded by the malformation.[72] AVMs in the maxilla and mandible constitute 4% and 5%, respectively, of all craniofacial AVMs (Figure 23-14).[72] AVMs of the jaws may be asymptomatic or present as a pulsatile swelling, localized throbbing pain, toothache or earache, or unexpected hemorrhage following dental extraction or exfoliation. A loose tooth in a bleeding socket should be treated with extreme caution.

Bleeding can be fatal. The most effective measure is immediate packing and pressure. Preoperative embolization before extraction of teeth is useful to help control bleeding. The typical radiographic findings are an ill-defined radiolucency or a well-defined multilocular lesion.



• **Figure 23-13** **A-B,** One year following Le Fort I osteotomy to close anterior open bite and further sclerotherapy. Temporary tracheostomy to protect airway after sclerotherapy and surgical correction has been removed. **C,** Final occlusion after orthodontic appliances removed is stable. **D,** Lateral cephalogram shows improved jaw relations.

The Schobinger clinical staging system for AVMs, introduced at the 1990 meeting of the International Workshop for the Study of Vascular Anomalies, is useful for documenting the presentation and evolution.[71] Stage I (quiescence) is characterized by a cutaneous blush, warmth, and arteriovenous shunting by Doppler examination. Stage II (expansion) is similar but with enlargement, pulsations, bruit, thrill, and tense and/or tortuous veins. Stage III exhibits dystrophic skin changes, ulceration, tissue necrosis, bleeding, and persistent pain. Cardiac failure (decompensation) constitutes progression to stage IV.

AVMs can remain stable for years in stage I. A bruit is of little significance unless it increases in intensity. The onset of pain, pruritus, or enlargement heralds likely progression to the next stage of ulceration and hemorrhage. Once pain, ulceration, or bleeding become established, progression is inevitable unless the lesion is treated.[73]

Clinical diagnosis is confirmed by US and color Doppler examination. MRI and/or MRA define the extent of soft tissue involvement.[74] Angiography shows variable degrees of arterial dilatation and tortuosity, arteriovenous shunting, and dilated draining veins. Angiography is rarely performed unless intervention is planned under the same anesthetic.

Management

The mainstays of AVM management are embolization, sclerotherapy, surgical resection, and reconstruction.[75] Intervention is indicated for complications, such as repeated hemorrhage, persistent pain, ischemic ulceration, or cardiac failure. The therapeutic strategy for these

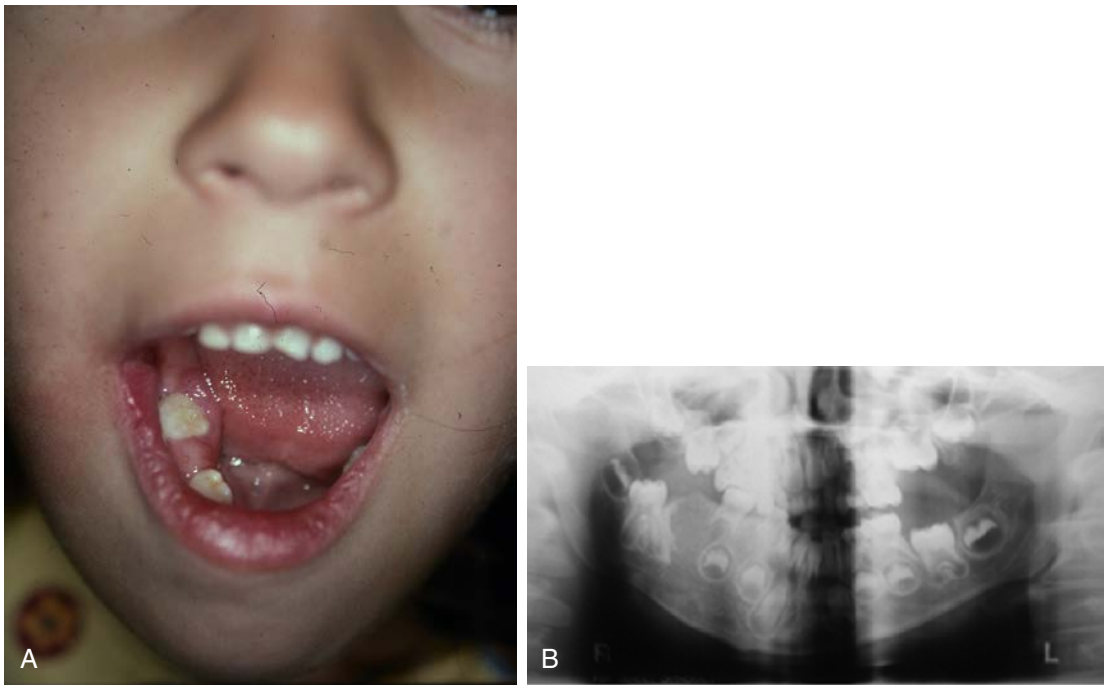

• **Figure 23-14** **A,** Six-year-old with arteriovenous malformation (AVM) of mandible diagnosed after frightening hemorrhage following exfoliation of primary molar. **B,** Panoramic radiograph shows AVM of right mandible and bony overgrowth.

lesions is selective embolization and sclerotherapy with or without resection. Embolization involves placement of coils or glue by either accessing the malformation from a proximal arterial or retrograde venous approach or by direct transosseous puncture.[76,77] Sclerotherapy involves direct puncture of the nidus to permit local arterial and venous occlusion.

Endovascular treatment can be palliative or preoperative, but almost never curative.[78,79] For extensive or inaccessible lesions, endovascular therapy can be used as the primary treatment. However, this is regarded as only for temporary control; in time, recanalization and reexpansion usually occur. Embolization can be used to relieve symptoms, reduce frequency of bleeding episodes, and diminish the size of the AVM.[51]

Preoperative endovascular therapy is used to diminish blood loss during the operation and facilitate extirpation.[51] Usually the resection is planned 48 to 72 hours after endovascular occlusion. Although it is preferable to totally resect an AVM, this is often not feasible because of the extent of the lesion, or inaccessibility may preclude total removal. Determining whether the resection is complete can be problematic because of troubles in delineating the limits of the malformation. Venous runoff, difficulty controlling blood loss, absence of tissue planes, and the need to preserve blood supply to neighboring structures make complete extirpation challenging. The most useful guidelines are intraoperative Doppler examination and the bleeding pattern of tissue at the resection margin; frozen sections are not particularly helpful.[73] For AVMs of the jaw, endovascular treatment represents the therapy of choice in these sometimes life-threatening lesions. Surgery, often leading to facial mutilation and necessitating massive reconstruction, should be avoided, at least as the initial therapy.[80]

Combined treatment is used for localized early stage (I and II) and for painful or rapidly enlarging lesions (stage III and IV). Intervention for an extensive stage I to II AVM is controversial because one cannot predict when and if they will progress, resection will likely be incomplete, and the deformity produced may be worse than that created by the AVM.[73] Resection of a stage I AVM should be considered only if it can be easily accomplished without causing major deformity, particularly in a young patient. There is no indication for proximal ligation or embolization of feeding vessels, which causes only recruitment of flow from nearby arteries to supply the nidus and denies access for embolization.

Kohout and colleagues reported an overall control rate of 60% for AVMs in the head and neck region, defined as radiographic absence of the lesion.[72] Control for small malformations was 69% with excision only and 62% for extensive malformations with combined embolization and resection. The control rate was 75% for stage I, 67% for stage II, and 48% for stage III malformations. Outcome was not affected significantly by age at treatment, sex, Schobinger stage, or treatment method. Mean follow-up was 4.6 years. Treatment failures are due to persistence of the lesion because of the surgeon's inability to appreciate the extent of the lesion during resection, impossibility of complete resection because of involvement of vital structures, and a second nidus that was not seen on initial radiographic examination.[51,73]

Summary

Treatment of patients with vascular anomalies requires an interdisciplinary team and translational research efforts. This combined approach will provide insight into the molecular basis of these disorders and a deeper understanding of vascular morphogenesis. In the future, this emerging knowledge will contribute to novel ways to treat vascular anomalies and to regulate pathologic angiogenesis.[81]

References

1. Mulliken JB, Glowacki J: Hemangiomas and vascular malformations in infants and children: a classification based on endothelial characteristics, *Plast Reconstr Surg* 69:412–422, 1982.
2. Enjolras O, Mulliken JB: Vascular tumors and vascular malformations (new issues), *Adv Dermatol* 13:375–423, 1997.
3. Finn MC, Glowacki J, Mulliken JB: Congenital vascular lesions: clinical application of a new classification, *J Pediatr Surg* 18:894–900, 1983.
4. North PE, et al.: GLUT1: a newly discovered immunohistochemical marker for juvenile hemangiomas, *Hum Pathol* 31: 11–22, 2000.
5. Boyd JB, et al.: Skeletal changes associated with vascular malformations, *Plast Reconstr Surg* 74:789–797, 1984.
6. Kasabach HH, Merritt KK: Capillary hemangioma with extensive purpura, *Am J Dis Child* 59:1063, 1940.
7. Sarkar M, et al.: Thrombocytopenic coagulopathy (Kasabach-Merritt phenomenon) is associated with kaposiform hemangioendothelioma and not with common infantile hemangioma, *Plast Reconstr Surg* 100:1377–1386, 1997.
8. Enjolras O, et al.: Infants with Kasabach-Merritt syndrome do not have "true" hemangiomas, *J Pediatr* 130:631–640, 1997.
9. Marler JJ, Mulliken JB: Current management of hemangiomas and vascular malformations, *Clin Plast Surg* 32:99–116, 2005.
10. Amir J, et al.: Strawberry hemangioma in preterm infants, *Pediatr Dermatol* 3:331–332, 1986.
11. Mulliken JB, Enjolras O: Congenital hemangiomas and infantile hemangioma: missing links, *J Am Acad Dermatol* 50:875–882, 2004.
12. Takahashi K, et al.: Cellular markers that distinguish the phases of hemangioma during infancy and childhood, *J Clin Invest* 93:2357–2364, 1994.
13. Gonzalez-Crussi F, Reyes-Mugica M: Cellular hemangiomas (hemangioendotheliomas) in infants. Light microscopic, immunohistochemical, and ultrastructural observations, *Am J Surg Pathol* 15:769–778, 1991.
14. Marler JJ, et al.: Increased expression of urinary matrix metalloproteinases parallels the extent and activity of vascular anomalies, *Pediatr* 116:38–45, 2005.
15. Razon MJ, et al.: Increased apoptosis coincides with onset of involution in infantile hemangioma, *Microcirculation* 5:189–195, 1998.
16. Paltiel HJ, et al.: Soft-tissue vascular anomalies: utility of US for diagnosis, *Radiology* 214:747–754, 2000.
17. Kane WJ, et al.: Significant hemangiomas and vascular malformation of the head and neck: clinical management and treatment outcomes, *Ann Plast Surg* 35:133–143, 1995.
18. Boon LM, et al.: Hepatic vascular anomalies in infancy: a twenty-seven-year experience, *J Pediatr* 129:346–354, 1996.
19. Frieden IJ, Reese V, Cohen D: PHACE syndrome. The association of posterior fossa brain malformations, hemangiomas, arterial anomalies, coarctation of the aorta and cardiac defects, and eye abnormalities, *Arch Dermatol* 132:307–311, 1996.
20. Metry DW, et al.: The many faces of PHACE syndrome, *J Pediatr* 139:117–123, 2001.
21. Burrows PE, et al.: Cerebral vasculopathy and neurologic sequelae in infants with cervicofacial hemangioma: report of eight patients, *Radiology* 207:601–607, 1998.
22. Drolet BA, et al.: Early stroke and cerebral vasculopathy in children with facial hemangiomas and PHACE association, *Pediatrics* 117:959–964, 2006.
23. Bhattacharya JJ, et al.: PHACES syndrome: a review of eight previously unreported cases with late arterial occlusions, *Neuroradiology* 46:227–233, 2004.
24. Gorlin RJ, et al.: Marked female predilection in some syndromes associated with facial hemangiomas, *Am J Med Genetics* 52:130–135, 1994.
25. Boon LM, Enjolras O, Mulliken JB: Congenital hemangioma: evidence of accelerated involution, *J Pediatr* 128:329–335, 1996.
26. Enjolras O, et al.: Non-involuting hemangioma: a rare cutaneous vascular anomaly, *Plast Reconstr Surg* 107:1647–1654, 2001.
27. Berenguer B, et al.: Rapidly involuting congenital hemangioma: clinical and histopathologic features, *Pediatr Dev Pathol* 6:495–510, 2003.
28. Achauer BM, Chang CJ: Vander Kam VM: Management of hemangioma of infancy: review of 245 patients, *Plast Reconstr Surg* 99:1301–1308, 1997.
29. Kim HJ, Colombo M, Frieden JJ: Ulcerated hemangiomas: clinical characteristics and response to therapy, *J Am Acad Dermatol* 44:962–972, 2001.
30. David LR, Malek MM, Argenta LC: Efficacy of pulse dye laser therapy for the treatment of ulcerated haemangiomas: a review of 78 patients, *Br J Plast Surg* 56:317–327, 2003.
31. Batta K, et al.: Randomised controlled study of early pulsed dye laser treatment of uncomplicated childhood haemangiomas; results of a 1-year analysis, *Lancet* 360:521–527, 2002.
32. Witman PM, et al.: Complications following pulsed dye laser treatment of superficial hemangiomas, *Lasers Surg Med* 38:116–123, 2006.
33. Orlow SJ, Isakoff MS, Blei F: Increased risk of symptomatic hemangiomas of the airway in association with cutaneous hemangiomas in a "beard" distribution, *J Pediatr* 131:643–646, 1997.
34. Rahbar R, et al.: The biology and management of subglottic hemangioma: past, present, future, *Laryngoscope* 114:1880–1891, 2004.
35. Chen MT, Yeong EK, Horng SY: Intralesional corticosteroid therapy in proliferating head and neck hemangiomas: a review of 155 cases, *J Pediatr Surg* 35:420–423, 2000.
36. Léauté-Labrèze C, Dumas de la Roque E, Hubiche T, et al.: Propranolol for severe hemangiomas of infancy, *N Engl J Med* 358:2649–2651, 2008.
37. Bennett ML, et al.: Oral corticosteroid use is effective for cutaneous hemangiomas: an evidence-based evaluation, *Arch Dermatol* 137:1208–1213, 2001.
38. Enjolras O, Gelbert F: Superficial hemangiomas: associations and management, *Pediatr Dermatol* 14:173–179, 1997.

39. Bennett ML, et al.: Oral corticosteroid use is effective for cutaneous hemangiomas: an evidence-based evaluation, *Arch Dermatol* 137:1208–1213, 2001.
40. Mulliken JB: Management of hemangiomas (special symposium), *Pediatr Dermatol* 14:60–62, 1997.
41. Mulliken JB, Rogers GF, Marler JJ: Circular excision of hemangioma and purse-string closure: the smallest possible scar, *Plast Reconstr Surg* 109:1544–1554, 2002.
42. Jacobs AH, Walton RG: The incidence of birthmarks in the neonate, *Pediatrics* 58:218–222, 1976.
43. Enjolras O, Riché MC, Merland JJ: Facial port-wine stains and Sturge-Weber syndrome, *Pediatrics* 76:48–51, 1985.
44. Thomas-Sohl KA, Vaslow DF, Maria BL: Sturge-Weber syndrome: a review, *Pediatr Neurol* 30:303–310, 2004.
45. Rogers GF, Mulliken JB, Kozakewich HP: Heterotopic neural nodules of the scalp, *Plast Reconstr Surg* 115:376–382, 2005.
46. Pence B, Aybey B, Ergenekon G: Outcomes of 532 nm frequency-doubled Nd:YAG laser use in the treatment of port-wine stains, *Dermatol Surg* 31:509–517, 2005.
47. Lanigan SW, Taibjee SM: Recent advances in laser treatment of port-wine stains, *Br J Dermatol* 151:527–533, 2004.
48. Clodius L: Surgery for the facial port-wine stain: technique and results, *Ann Plast Surg* 16:457–471, 1986.
49. Padwa BL, et al.: Cervicofacial lymphatic malformation: clinical course, surgical intervention, and pathogenesis of skeletal hypertrophy, *Plast Reconstr Surg* 95:951–960, 1995.
50. Greene AK, et al.: Periorbital lymphatic malformation: clinical course and management in 42 patients, *Plast Reconstr Surg* 115:22–30, 2005.
51. Marler JJ, et al.: Prenatal diagnosis of vascular anomalies, *J Pediatr Surg* 37:318–326, 2002.
52. Ninh T, Ninh T: Cystic hygroma in children: report of 126 cases, *J Pediatr Surg* 9:191, 1974.
53. Edwards PD, et al.: Lymphatic malformation of the lingual base and oral floor, *Plast Reconstr Surg* 115:1906–1915, 2005.
54. Okada A, et al.: Injection of bleomycin as a primary therapy of cystic lymphangioma, *J Pediatr Surg* 27:440–443, 1992.
55. Greinwald JJ, et al.: Treatment of lymphangiomas in children: an update of Picibanil (OK-432) sclerotherapy, *Otolaryngol Head Neck Surg* 121:381–387, 1999.
56. Lee BB, et al.: Current concepts in lymphatic malformation, *Vasc Endovasc Surg* 39:67–81, 2005.
57. Molitch HI, et al.: Percutaneous sclerotherapy of lymphangiomas, *Radiology* 194:343–347, 1995.
58. Kim KH, et al.: Sclerotherapy for congenital lesions in the head and neck, *Otolaryngol Head Neck Surg* 131:307–316, 2004.
59. Gunel M, et al.: A founder mutation as a cause of cerebral cavernous malformation in Hispanic Americans, *N Engl J Med* 334:946–951, 1996.
60. Vikkula M, et al.: Vascular dysmorphogenesis caused by an activating mutation in the receptor tyrosine kinase TIE2, *Cell* 87:1181–1190, 1996.
61. Boon LM, et al.: Glomuvenous malformation (glomangioma) and venous malformation: distinct clinicopathologic and genetic entities, *Arch Dermatol* 140:971–976, 2004.
62. Kaban LB, Mulliken JB: Vascular anomalies of the maxillofacial region, *J Oral Maxillofac Surg* 44:203–213, 1986.
63. Boyd JB, et al.: Skeletal changes associated with vascular malformations, *Plast Reconstr Surg* 74:789, 1984.
64. Hein KD, et al.: Venous malformations of skeletal muscle, *Plast Reconstr Surg* 110:1625–1635, 2002.
65. Siniluoto TM, et al.: Percutaneous sclerotherapy of venous malformations of the head and neck using sodium tetradecyl sulphate (Sotradecol), *Scand J Plast Reconstr Surg Hand Surg* 31:145–150, 1997.
66. Lee BB, et al.: Advanced management of venous malformation with ethanol sclerotherapy: mid-term results, *J Vasc Surg* 37:533–538, 2003.
67. Berenguer B, et al.: Sclerotherapy of craniofacial venous malformations: complications and results, *Plast Reconstr Surg* 104:1–11, 1999.
68. Chang CJ, Fisher DM, Chen YR: Intralesional photocoagulation of vascular anomalies of the tongue, *Br J Plast Surg* 52:178–181, 1999.
69. Eerola I, Boon LM, Mulliken JB, et al.: Capillary malformation-arteriovenous malformation: a new clinical and genetic disorder caused by RASA1 mutations, *Am J Hum Genet* 73:1240–1249, 2003.
70. Tan WH, Baris HN, Burrows PE, et al.: The spectrum of vascular anomalies in patients with PTEN mutations: implications for diagnosis and management, *J Med Genet* 44:594–602, 2007.
71. Mulliken JB: Vascular anomalies. In Aston SJ, Beasley RW, Thorne CHM, editors: *Grabb and Smith's plastic surgery*, Philadelphia, 1997, Lippincott-Raven.
72. Kohout MP, et al.: Arteriovenous malformations of the head and neck: natural history and management, *Plast Reconstr Surg* 102:643–654, 1998.
73. Mulliken JB, Young AE: *Vascular birthmarks: hemangiomas and malformations*, Philadelphia, 1988, Saunders.
74. Gold L, et al.: Characterization of maxillofacial soft tissue vascular anomalies by ultrasound and color Doppler imaging: an adjuvant to computed tomography and magnetic resonance imaging, *J Oral Maxillofac Surg* 61:19–31, 2003.
75. Shapiro NL, et al.: Osseous craniofacial arteriovenous malformations in the pediatric population, *Arch Otolaryngol Head Neck Surg* 123:101–105, 1997.
76. Fan X, et al.: Direct-puncture embolization of intraosseous arteriovenous malformation of jaws, *J Oral Maxillofac Surg* 60:890–896, 2002.
77. Kademani D, et al.: An alternative approach to maxillofacial arteriovenous malformations with transosseous direct puncture embolization, *Oral Surg Oral Med Oral Pathol Oral Radiol Endod* 97:701–706, 2004.
78. Persky MS, Yoo HJ, Berenstein A: Management of vascular malformations of the mandible and maxilla, *Laryngoscope* 113:1885–1892, 2003.
79. Liu D, Ma XC: Clinical study of embolization of arteriovenous malformation in the oral and maxillofacial region, *Chin J Dent Res* 3:63–70, 2000.
80. Rodesch G, et al.: Arteriovenous malformations of the dental arcades. The place of endovascular therapy: results in 12 cases are presented, *J Craniomaxillofac Surg* 26:306–313, 1998.
81. Vikkula M, et al.: Molecular basis of vascular anomalies, *Trends Cardiovasc Med* 8:281–292, 1998.

24

Vesiculobullous Diseases

JOHN W. HELLSTEIN, CHRISTOPHER G. FIELDING, JAMES T. CASTLE

Introduction

This group of diseases is classified broadly under the terms vesiculobullous or vesiculoulcerative disorders. The group includes causes from a number of often unrelated problems, including infectious diseases, genetic diseases, acquired diseases, as well as idiopathic and autoimmune diseases. Clinically, they generally produce some discomfort to the patient, with variability in duration and severity. However, some foundation therapeutic paradigms apply to all these diseases regardless of cause. In addition, some of these diseases are managed rather than cured. Thus control of low-level disease processes is often a key to long-term patient care. In our clinical oral and maxillofacial pathology referral practice, it is not uncommon for many of our referrals to have been treated with the appropriate medications, but the referring clinician did not consider overall maintenance of an intact oral mucosal surface along with the salivary pellicle. In addition, simply educating the patient about the expected disease course and prognosis is often essential.

These foundation principles, which are discussed in this chapter, are not therapeutic in and of themselves. It is best to think of them as providing the best scenario for therapeutic regimens to be most effective. The desired effect is less potent medications, less complicated regimens, and more time between exacerbations.

- Decrease all possible irritants
- Avoid mucosal irritants such as pyrophosphates, cinnamon, menthols, and phenols
- Avoid destruction of "salivary pellicle"
  - Especially avoid sodium lauryl sulfate (SLS)
  - Also minimize ethanol
- Maintain and build salivary pellicle
  - Counteract xerostomic agents as much as possible
  - Hydration
  - Prescribe cholinergics or buffered citrate
- Manage bugs
  - Bacteria
  - Fungi

Oral health care products are notorious for having potential irritants incorporated right into the product. Pyrophosphates are one of the more common irritants in mouth rinses and toothpastes. They are actually seen in the majority of toothpastes. Pyrophosphates act several ways including to help potentiate the sodium lauryl sulfate and to decrease the possibility of mineralization. In those with irritated oral mucosae, they cannot be considered helpful. In addition, pyrophosphates are not very pleasant tasting, so they are generally masked with the use of cinnamic aldehyde or other strong flavoring agents. Cinnamic aldehyde in particular creates sensitivity reactions in some patients, but especially in those with mucositis, it is at least considered not helpful. In the mouth rinse category, menthol and camphors are not uncommon ingredients. Again, these essential oils all have some antibacterial effect but can also act as an irritant.

Maintenance of the salivary pellicle is one of the most essential aspects of protecting the mucosa. The salivary pellicle is the first barrier preventing antigenic presentation to the immune system. In addition, the salivary pellicle acts as a deflector for minor trauma secondary to mastication, habits, and oral health care. Sodium lauryl sulfate removes the salivary pellicle very efficiently. Sodium lauryl sulfate is in a number of oral health care products and, most notably, in every toothpaste that foams. Each time the salivary pellicle is removed, the patient's saliva must re-form it. Again, in a normal patient this is not a major complication, but in the patient with some sort of mucositis, it is best to have the mucosa protected as much and as long as possible. Ethanol also removes the salivary pellicle to a certain extent. Therefore minimization of ethanol-containing mouth washes is also desirable.

Of special note regarding toothpaste that is free of sodium lauryl sulfate is the fact that major distributors are constantly changing formulations. Some formulations are switched to an alternate surfactant named cocamidopropyl betaine. This is still a surfactant, and although studies need to be performed as to whether this is as damaging to the salivary pellicle as sodium lauryl sulfate, there is little doubt

that it does have some effect. Many previous brands such as Biotene, Tom's of Maine, Sensodyne, and Rembrandt have all been purchased by larger companies. Ingredient lists of brands all require close perusal because of the transient nature of some of the formulations. But, as of this writing in 2015, finding a well-known name brand without a surfactant in the formulation is extraordinarily difficult. The former go-to brands just named are no longer predictably surfactant free. In addition, finding one with no other irritant such as polyphosphates/pyrophosphates is extraordinarily difficult.

In a number of patients, xerostomia is what minimizes the effectiveness and production of the salivary pellicle. This is often due to multiple medicines that the patient is taking. Xerostomic medications include antidepressants, antianxiety agents, antihypertensives, and antihistamines, just to name a few. All are drying agents. If the patient is not taking an anticholinergic type of medication (i.e., bladder control medication), salivary flow can be stimulated with medications such as pilocarpine or cevimeline. However, it is very common to have some sort of anticholinergic in the patient history. For these patients, the only solution may be buffered malic tablets which are sold under the brand name of SalivaSure (Scandinavian Formulas, Sellersville PA). Even simpler and more basic is instructing the patient on proper hydration.

Good oral hygiene is also very important. It is appropriate to think of oral hygiene as managing the "bugs." For this, alcohol-free chlorhexidine or 2% zinc chloride mouth rinses may be less irritating for some patients. But finding the alcohol-free chlorhexidine can be problematic, and there is some loss of antimicrobial efficacy. When a patient is using any chlorhexidine product, it should be emphasized that fluoride within toothpastes can deactivate the chlorhexidine. Patients should wait 20 to 30 minutes after brushing before rinsing with the chlorhexidine.

Simply encouraging good plaque control through proper toothbrushing and actually instructing them to *avoid* commercial mouthwashes is often effective in at least minimizing possible confounding oral hygiene elements working against the therapeutic regimen. Often the patient's mucosal surfaces adjacent to the teeth and are very tender which makes it difficult to properly brush. Patients are often able to better manage a sonic type of toothbrush (as opposed to a manual toothbrush) to minimize trauma and maximize oral health. Although there is certainly movement associated with the sonic toothbrushes, these are somewhat better than the shearing action that can occur with many of the rotary-type electric toothbrushes. Manual toothbrushes are often just too difficult to control and always traumatize the adjacent mucosa. If manual toothbrushes are used, soft bristles are mandatory, and even softer bristles for sensitive patients are also available. They are often marketed with descriptors such as "supersoft for sensitive care."

A special note: When treatment is discussed in the various disease categories to follow, the reader will note the absence of some regimens with which they may be familiar. Specifically concoctions known variously as magic mouth rinse, special mouth rinse, or miracle mouth rinse will not be recommended. A quick note as to why this is omitted follows.

Many clinicians have used such rinses, perhaps even successfully. However, in my experience on numerous referrals, there is usually no place for such concoctions. The typical formulations for these prescriptions are as follows:

- Magic rinse, special rinse, and miracle rinse (all generally the same thing, may be known by other names regionally)
  - Nystatin 12,500 units/mL
  - Diphenhydramine 1.25 mg/mL
  - Hydrocortisone 0.25 mg/mL

Do these concentrations make any sense?

- Normal nystatin 100,000/mL
  - 12,500 units/mL represents an eightfold decrease
- 7.5 mg total dose of diphenhydramine is low
  - Probably acts as a topical anesthetic, not as an antihistamine
- Hydrocortisone 25 mg/mL
  - 10-fold decrease from Dexamethasone 0.5 mg/5 mL
  - 20-fold decrease from 0.1% triamcinolone acetonide

Please note the concentrations just outlined. They simply do not make any sense. If you think the patient needs steroids, use a potent enough steroid to do the work. If the patient needs an antifungal, why go with a concentration of an antifungal that is 8 times less than the mildest antifungal that we would ever prescribe? If you want a topical anesthetic effect, why would we choose diphenhydramine? If we want to use diphenhydramine, why wouldn't we just use it by itself in a more potent concentration or use viscous lidocaine if the patient is old enough? So in short, if you believe antifungals are needed, prescribe a proper antifungal. If you think they need an anti-inflammatory, prescribe a potent enough steroid to do the job. If they need some topical anesthetic, think about the potency of topical anesthetic that would be appropriate for the age group being treated.

When steroid rinses or systemic steroids are used, candidal overgrowth is a common complication. In practice, it is generally useful to give forewarning to the patient about the possibility of candidal overgrowth and to alert them to what to expect. But don't empirically start antifungals on every patient. It is generally best to communicate this possibility to the patient or give a patient handout to cover this possibility. Anecdotally, candidal overgrowth probably occurs in only 25% or less of patients, and therefore antifungals are not necessary in most patients. Increasing age and immune status would predict increasing possibilities for thrush. With that said, some clinicians may prefer to go ahead and use adjunctive antifungal therapy when employing steroids.

Herpes Simplex Virus Infections

The herpes family is a family of DNA viruses that includes a diverse group of viruses ranging from herpes simplex 1



• **Figure 24-1** Primary herpes, adult case with punched-out papilla and buccal mucosa lesions.



• **Figure 24-2** Primary herpes, adult case with intact vesicle and marginal gingivitis.

through herpes type 8. Diseases caused by or associated with the herpes family include but are not limited to chicken pox, shingles, genital herpes, "cold sores," chronic fatigue syndrome, Kaposi sarcoma, lymphoproliferative diseases/lymphomas, and mononucleosis.[1-9] Herpes simplex 2 infections can also occur in the oral region. For simplicity, the oral and maxillofacial region herpetic infections (both primary and secondary) in this chapter for clinical purposes will be considered to be herpes simplex 1 because therapy and prognosis are the same for herpes simplex 2. Serum antibody conversion of patients exposed to herpes simplex 1 has decreased somewhat over the decades, at least in the Western world. Currently, in the United States, people in upper socioeconomic strata have a serum antibody conversion rate of only 50% to 60%. On the other hand, in undeveloped third world countries, the rate by adulthood may be as high as 95%.[10-15] When considering serum conversion rates, the main thing to remember is that a large number of Americans coming into your practice may indeed present with primary herpetic gingivostomatitis at *any* age.

Herpes simplex virus has been implicated in causing various immune-mediated reactions, most notably erythema multiforme.[16] Also, although secondary herpetic recurrences often create lesions, the lesions are not necessary for viral shedding. Viral shedding can occur intermittently without lesions in a significant subsample of people who have been exposed to the virus (Figures 24-1 and 24-2).

Clinical Features

As any oral and maxillofacial surgeon knows, the two expressions of herpes simplex 1 are in the form of primary and secondary infections.

Primary Herpetic Gingivostomatitis

In primary infections, the patients are generally children; however, as mentioned before, because of the relatively low serum antibody conversion rate in the United States, a primary infection may be diagnosed at any age. In addition, people who are immunosuppressed can have multiple recurrent episodes of primary herpetic-like lesions. In primary herpetic gingivostomatitis, the lesions can occur on any of the oral mucosal surfaces, regardless of whether they are "keratinized" or "nonkeratinized." Classically, the interdental papillae will be "punched out." Also, it is unusual for the lesions to be localized on only one type of mucosal surface or to be unilateral. Therefore, a clinical diagnosis of primary herpes should be entertained only in the presence of bilateral disease affecting both keratinized and nonkeratinized mucosa. The onset of the lesions should be rather rapid and sudden, generally over the course of 24 to 48 hours. There is often cervical lymphadenopathy as well as an elevated temperature. If lesions involve the skin, this may portend a more severe disease course than if only the oral mucosal surfaces are involved.[1,13,17-22]

Of particular note in skin lesions (whether lesions are primary or secondary): *involvement of the tip of the nose or in areas of V_1 distribution is an ophthalmologic emergency!* This presentation is known as Hutchinson sign. If present, it could portend herpetic involvement of the eye, which can result in blindness. Indeed, herpetic infections are one of the leading causes of acquired blindness in childhood.[23,24]

Both skin and oral mucosal lesions generally start out as small vesicular lesions that rapidly coalesce into irregularly shaped ulcers. The individual ulcers are often surrounded by an erythematous halo. The halo region can vary in width and erythematous nature depending on size and location. The primary outbreak can involve circumoral skin, the vermilion border, the oral mucosa, the oropharynx, and pharyngeal tonsillitis, although other surfaces are possible. The most difficult problem with primary herpes is management of pediatric patients in their various developmental groups. This is covered at length in a separate section (Figures 24-3 and 24-4).



• **Figure 24-3** Recurrent herpes labialis with various stages of lesions.



• **Figure 24-4** Recurrent herpes of palate.

Secondary Herpes

On the oral mucosa, secondary herpes will uniquely involve the keratinized oral mucosal surfaces. This is in stark contrast to the distribution of aphthous type ulcers. The keratinized surfaces of the oral mucosa are the hard palate, dorsum of tongue, gingivae and lip vermilion (centered outside the wet line). In classic cases of recurrent herpes, a prodrome will present itself prior to vesicle formation. The prodrome usually starts out as a feeling of fullness, with or without tingling. Generally, within the next 24 to 48 hours, vesicles will appear. As with primary herpes, these small 1- to 3-mm vesicles will often coalesce. In recurrent herpes the lesions are often unilateral, though occasional multifocal bilateral expressions may occur. These bilateral occurrences are generally associated with some immunosuppression. Individual lesions generally last 7 to 10 days.

Reasons for recurrences are many. Triggering agents include trauma, drying, light exposure, and altered immune status. The number of Americans with a history of secondary herpes varies by report but is probably in the range of a quarter to one third of the population.[25]

Histopathology

The virus primarily reacts within the nucleus to create changes within the nuclei of the epithelial cells. This is generally observed as a chromatin pattern that is altered to create peripheralized chromatin granules with central clearing. The nuclei are often multiple, and each nucleus may also be enlarged, with the definition of the nucleolus impossible to discern. These nuclear changes have often been termed ballooning degeneration, and multinucleation is a common focal feature. The degeneration of the cells also results in loss of cohesiveness of the squamous cells. This results in free-floating acantholytic cells, commonly called Tzanck cells.

Diagnosis

The diagnosis of both primary and secondary herpes is generally clinical. The need for a biopsy is rare. Occasionally there may be some confusion between primary herpetic gingivostomatitis and erythema multiforme. Though culture can be performed in such cases, results generally take up to 48 hours. An additional complicating factor is that viral shedding can occur in people with erythema multiforme who originally had a subclinical case of primary herpetic gingivostomatitis. In acute cases the clinical acumen of the clinician will allow for proper diagnosis. The more difficult cases are those in immunosuppressed patients when lesions persist for long periods of time or do not conform to the 7- to 10-day period of immunocompetent patients. In these patients biopsy, cytology, or culture might be helpful. In some cases where there is some clinical doubt and an intact vesicle is present, puncturing of the vesicle with immediate retrieval of cells for cytologic evaluation can be helpful. However, this is usually more for curiosity than for obtaining a definitive diagnosis prior to therapy.[13,17,19]

Treatment and Prognosis

We begin with a short treatment regimen that will cover the great majority of adult patients. These treatments are rather straightforward, although many options exist. Management of the pediatric patient is more complicated and often requires consultation.

Premise #1

Topical antivirals are *not* usually a first-line therapy for secondary herpetic lesions in our clinical practice. There are some studies that show a reduction in the length of the lesions of half a day to 1 day or more, with some resultant decrease in discomfort. The literature is generally clear that topical agents help less predictably than the systemic therapies. With that said, when looking at many of these studies there may be subgroups of patients who do respond to topical therapy. For instance, in some studies the half-day to 1-day reduction was actually because 5% to 10% of the

patients never developed a vesicle after application of the topical agent at the prodrome. Therefore, the reduction in some reports was partially due to a small subset of patients. This appears to happen with many of these topical agents. It is possible that some patients misinterpreted what they perceived as a prodrome and would never have developed lesions. It seems prudent to use the topical agents only if the patient already knows that they are a member of that small subset of patients who generally benefit from topical agents. These topical agents are relatively expensive, and sometimes cost of the course of topical therapy is almost the same as that of the systemic therapy. If used, the general efficacy of topical agents may be as follows: penciclovir > acyclovir cream > acyclovir ointment > doconasol.[26-31]

Premise #2

Although, like the topical preparations, L-lysine may be beneficial in a subset of patients, this is not a first-line therapy. In some patients it may act best as a prophylactic agent, although scientific proof of this remains sketchy. Regardless, it must be the systemic version of L-lysine and not the topical version. The systemic version at least has the possibility of substituting into the protein synthesis of the viral replication.[32-34]

Premise #3

In primary herpetic gingivostomatitis, the major clinical problem to address will be maintenance of hydration. "Tilt tests," vascular rebound, decrease in diaper changes, skin turgor, and other methods for hydration evaluation are highly recommended in patients with primary herpetic gingivostomatitis. These methods will be further elucidated in the section on pediatric management.

Premise #4

Of the systemic medications, the a cyclovir family of drugs offer the best evidence of efficacy. Famciclovir, penciclovir, valacyclovir, and acyclovir all can alter the systemic course of the disease, whether it is primary or secondary. However, they are best given within 24 to 48 hours of prodromal onset.

Premise #5

After the 48- to 72-hour window, therapy is generally limited to managing the pain/discomfort and hydration problems the patient is experiencing.

Premise #6

Systemic medications as outlined next appear most efficacious, although valacyclovir, famciclovir, and acyclovir are very similar by class.

Systemic Agents for Herpes Simplex in the Non-immunosuppressed Patient

Cyclovir Antiviral Family

For all members of this antiviral family, use with caution in patients with renal or hepatic disease. Also consider patient's hydration status. Headache and/or nausea are dose-related side effects and may occur in about one of six patients.

Primary HSV

RX: Acyclovir 400 mg
Disp: 50 tablets
Sig: 400 mg 5 times daily for *10 days*

Recurrent HSV

RX: Acyclovir 400 mg
Disp: 25 tablets
Sig: 400 mg 5 times daily for *5 days*

Acyclovir for Herpes Labialis

Duration of pain and time to complete healing is unaffected with doses of 400 mg three times daily
Increasing dose to 400 mg five times daily decreases duration of pain by 36% and time to loss of crust by 27%
Only effective if initiated very early in recurrence
Valacyclovir is the authors' preferred drug for recurrent herpes—a prodrug of acyclovir that is 3 to 5 times more bioavailable than acyclovir
It is FDA pregnancy category B and has not been approved in prepubertal patients

Suggested prescriptions for adult immunocompetent patients follow.

Primary HSV

RX: Valacyclovir 1 g caplets
Disp: 20 caplets
Sig: 1 gram twice per day for *10 days*

Recurrent HSV Labialis

RX: Valacyclovir 1 g caplets
Disp: 6 caplets
Sig: 2 g immediately at prodrome, then 2 g more 12 hours later. Save last two caplets to use for next outbreak. (The goal is to always have an initial dose available even if the pharmacy is closed.)
RX: Famciclovir 500 mg caplets
Disp: 6 caplets
Sig: 3 caplets immediately at prodrome. Save 3 caplets to use for next outbreak. (The goal is to always have an initial dose available even if the pharmacy is closed.)

Prophylaxis for Recurrent HSV Infections (Immunocompetent Patients)

Long-term prophylaxis is indicated if patients have at least 6 or more herpetic outbreaks per year
Reassess need every 6 to 12 months
There is some concern for developing viral resistance; therefore long-term management should often be by an infectious disease specialist.

RX: Acyclovir 400 mg (Zovirax, generic)
Disp: 60 tablets

Sig: Take 1 tablet every 12 hours. Must be given in divided doses. Prophylactic doses between 400 and 1000 mg/day reduce the frequency of herpes labialis by 50% to 78%.

RX: Valacyclovir 500 mg (Valtrex)
Disp: 30 caplets
Sig: Take 1 caplet daily

This is an alternative regimen for patients with more than 9 episodes per year

It does not appear to have large advantage over acyclovir 400 mg twice daily and is more expensive

OTC: L-Lysine 500 mg Tablets

Review of clinical trials shows lysine *may* have a preventive value in doses of at least 1,000 mg/day. It is contraindicated with renal or hepatic impairment. Dietary supplements are not regulated for purity or efficacy. Topical lysine does not seem to have any predictable benefit.

Pediatric Herpes

Treatment of herpes in the pediatric age groups can be very difficult. Because of the wide range of how primary herpes infections affect the infant age group, the major challenge in primary herpetic gingivostomatitis is deciding when therapeutic intervention is necessary. This is a key teaching point. If observed at the right time, it may be easily diagnosed as primary herpes, but intervention is not always necessary. Generally intervention is necessary if the patient becomes dehydrated or if the lesion extends out of the immediate perioral region. There are various definitions for "outside the perioral region." A good rule of thumb is that if the herpetic lesions extend past the nasolabial fold, onto the nose, or below the chin onto the inferior surface of the chin, referral to a physician is indicated. Along with dehydration, these are general signs that a patient's infection may be more severe than most.[18,20-22,26,27,35-37]

Pediatric treatment groups are broadly divided into four subdivisions: infancy ages 0 to 2, preschool ages 2 to 6, elementary school ages 6 to 12, and adolescent ages 12 to 18. Each of these groups present unique challenges and therapeutic differences. The 0 to 2 age group will not be discussed in detail. In this group, systemic therapy should always be in conjunction with the pediatrician or pediatric infectious disease physician.

In severe cases, the earlier that the infection is encountered and seen to pass the immediate perioral region, the more concern there should be. Referral or cooperative therapy in conjunction with the patient's pediatrician is often a must in these cases. The major concern in any age group, but particularly in infancy, is the possibility of either herpetic encephalitis or herpetic meningitis. Self-inoculation to involve additional sensory ganglia, especially during the initial infection, is of great concern. Keratoconjunctival extension is particularly problematic. Keratoconjunctival herpes can acutely result in blindness or possibly result in major problems later in life due to recurrences along that nerve region. Extension to involve the fingers is referred to as herpetic whitlow. Infections of the fingertip and their recurrent lesions can be very debilitating, especially in adulthood. Person-to-person spread of the viral particles is also of increased concern in these cases.[37-39]

Evaluation of infants especially and children under 6 must center on the patient's hydration status and to a lesser extent their nutritional intake. Evaluation of the hydrated state of the young child and infant is complicated because of the extreme adaptability of a young person's vascular system.

In general, assessment for dehydration is best made using skin turgor, breathing rate, and capillary refill time. Capillary refill time is best determined by pressing on the ball of the fingertip. Normal color should be established by 2 seconds; 1.5 to 2.0 seconds is borderline acceptable. Turgor is measured by pinching a small skin fold on the lateral abdominal wall at the level of the umbilicus. The fold should be promptly released and the time it takes to return to normal form measured. Clear norms are not established, and results are depicted as immediate, slightly delayed, and delayed. The clinician should test multiple "normal" children to get a feel for this reaction. Last, the respirations should be assessed from a distance, preferably as the child is in the waiting area.[40] Respiratory cutoffs that indicate elevated rates are greater than 60/min in children younger than 2 months, greater than 50/min for infants 2 to 12 months, and greater than 40 for children older than 12 months.[41]

These three tests used together are probably the best objective method for evaluating dehydration. However, experienced clinicians can observe clues for dehydration such as chalky or dry skin and by observing the general affect of the patient.

In the preschool child, the risk of meningitis and encephalitis is reduced in comparison to the infant but remain a concern.[42] This risk continues to decrease with age. In contrast, the malaise associated with primary infections seems to increase with age. In all age groups, the risk of infecting other members of the family, which can cause recurrent lesions or primary infections, should not be underestimated. Likewise, daycare center settings are hotbeds for possible infectious outbreaks. The younger the child, the greater the chance for oral fomite transfer to occur.[37] The patient should be kept away from daycare centers as long as any open ulcers are present and generally 48 hours after these lesions have completely crusted. This is not a perfect system, because viral shedding can continue within the saliva for days or weeks afterwards and intermittently for the rest of the patient's life.

Treatment of systemic infections centers around maintenance of hydration and nutritional intake with symptomatic relief, pain management, and reduction of the patient's fever if present. Traditionally pain management with topical anesthetics has centered around coating agents. In the past, viscous lidocaine was a popular ingredient in the various mixes. It cannot be overemphasized that this has changed. Currently the use of viscous lidocaine in children less than 7 or 8 years old is contraindicated, and in some communities,

use could be considered malpractice. This is due to the toxic sensitivity associated with the viscous lidocaine and may be related as much to the patient's weight as to his or her age. In short, the patient can experience a methemoglobin anemia or cardiac arrhythmia, and without immediate intervention, multiple patients have died.[43]

Although this is a rare reaction, and use of viscous lidocaine in the dental practice is relatively common even in children under age 8, this is a changing paradigm in pediatric care, and lidocaine should be avoided at all costs. For this reason the recommended topical anesthetic coating is diphenhydramine hydrochloride 12.5 mg per 5 mL syrup mixed 1:1 with Mylanta or Kaopectate. When dispensed, the diphenhydramine generally comes in a 4-ounce (118-mL) bottle, so the total mixture may be 8 ounces (336 mL) and the patient is to rinse with 1 teaspoon every 4 hours for 2 minutes. Although the patient can swish and spit, it is also acceptable to swish and swallow. Children under age 4 often cannot swish and spit. If the child cannot rinse, the use of a cotton tipped applicator to swab the inside of the mouth is sometimes helpful. It is best to reserve the topical coating agents for children over the age of 2. Some adolescents or patients in the preteen age group may like the effect of topical anesthetics. For these patients there is also some hesitance to use viscous lidocaine 2% solutions. Over-the-counter preparations such as Chloraseptic or Orajel may provide sufficient relief. Benzocaine has also been associated with methemoglobinemia, and some caution with its use is also advised.

In these older children over age 12, new topical coating agents such as Gelclair may be beneficial. The key aspect on when use of Gelclair is appropriate is whether the patient can faithfully expectorate or not. This is used by rinsing and spitting every 3 to 4 hours. This is a better coating agent than the previously described 50/50 mix of diphenhydramine and Mylanta, and many patients have expressed a preference for this material when supplied. The mainstay of treatments of all of this age group centers on the use of acyclovir or valacyclovir and when to use these medications.

In most cases systemic antivirals should only be used if the infection is encountered in the first 48 to 72 hours. Antivirals should always be used whenever the primary gingival stomatitis extends past the previously mentioned perioral region. In the 48- to 72-hour window, the clinician will need to use best judgment on how the child is being affected by the infection and whether intervention is necessary.

In all pediatric dosage regimens, the normal dose of acyclovir is 20 mg/kg. Acyclovir may be used in all four age groups. The maximum dose of acyclovir peaks at 800 mg. Valacyclovir and famciclovir have also been used. The famciclovir package insert lists two studies of subjects 18 years of age or older. Famciclovir has been used in the adolescent group off-label; however, it is probably best to keep it simple and use either acyclovir or valacyclovir in the groups discussed in this review. Valacyclovir has been approved for use in children age 12 or older. Studies have been conducted on children less than 12 years of age. In these studies, group dosages of approximately 30 mg/kg have been safely used. Valacyclovir is a prodrug of acyclovir and is eliminated the same way as acyclovir. The one complication of valacyclovir of major importance is that it is contraindicated in patients who are immunocompromised. This limitation has generally been for patients who are on the bone marrow transplant ward or have HIV infection. Although not necessarily replicated, one study did show a higher incidence of thrombocytopenic purpura in these specific patients.[44,45]

In general, valacyclovir is approved for use for herpes labialis only in children 12 or over. Off-label for herpes labialis and primary herpes stomatitis in children younger than 12 is best considered in consultation. There are no suspensions of valacyclovir, although the caplets could be reduced to powder and then compounded into a 25 mg/mL or 50 mg/mL suspension. Some compounding pharmacies have used Orasweet as a flavoring agent to counter the very bitter taste of valacyclovir, but if this is a concern about the patient's ability to swallow a tablet, then probably the patient should receive the acyclovir rather than the valacyclovir. Acyclovir comes in varying strengths. The suspension is a 200 mg/5 mL suspension. The appropriate volume should be dispensed. The directions should read to take the appropriate numbers of milliliters, which should be calculated at 20 mg/kg. This will be taken in four divided doses with a maximum dosage of 50 mg/kg per day.[27,36,46]

Herpes gingival stomatitis remains a complicated disease to control. It is extremely common, with 60% of the population having been exposed to the virus by age 21. There are many factors in the recurrence rate as well as the exposure causes, but the most important aspect of treatment is a proper diagnosis and assessment of the patient to decide whether systemic therapy or symptomatic therapy is the best approach for that particular patient.

Herpangina

Herpangina is a disease that generally occurs in epidemic fashion throughout the world. Some of the most well-documented epidemics occurred throughout areas of eastern Asia, most notably Taiwan and Japan.[47-52] Although herpangina is the disease discussed primarily in this section, perhaps the best way to think of this group of diseases is under the heading of *enterovirus diseases*. This group includes herpangina, and hand, foot, and mouth disease, as well as acute lymphonodular pharyngitis. These diseases probably vary only in clinical phenotypic presentation and have great overlap in the actual virus that acts as a causative agent in each.[53]

The enteroviruses are complicated by historical inconsistencies in nomenclature as well as evolvement of the classification system itself. The enteroviruses are a subset of the picornavirus family. As such they are, of course, RNA viruses. The Coxsackie virus species were first described by a laboratory in Coxsackie, New York. The echovirus species were first named because investigators believed that the

members of this family were not pathogenic in humans. As such, the "echo" in echovirus originally stood for enteric cytopathogenic human orphan virus. However, time has shown us that they are indeed pathogenic. Other branches of the enterovirus are rhinovirus, poliovirus, aphthovirus, cardiovirus, and hepatovirus categories. In addition, there are some unclassified members of the family. Recently discovered members of the family have generally been named simply as numbered enteroviruses beginning with enterovirus 68 and now including members or proposals through enterovirus 73. Of these recently described enteroviruses, enterovirus 71 is particular important clinically, as will be discussed later.[54]

The coxsackievirus family is generally divided into Coxsackie A and Coxsackie B groups. In the Coxsackie A group there are a total of 23 types, although the numbers range from A1 to A24 with no A23. The Coxsackie B group consists of six members with B1 to B6 represented. The echoviruses are numbered 1 to 34 although two numbers are not represented, for a total of 32 (Figure 24-5).

Clinical Findings

These diseases are generally classified under the exanthemas. Exanthemas are represented by such common diseases as measles, rubella, and roseola, to name a few. When lesions involve the oral mucosa, the term is *enanthema*. In the past it was feasible to memorize for test-taking purposes which enteroviruses could possibly cause herpangina. Now with 21 different members of the family having been associated with herpangina, it is best to just think in generalities. The most common types associated with herpangina are within the Coxsackie A group.[48,51,55] Of most clinical significance, though, is the possibility that enterovirus 71 may cause herpangina. Enterovirus 71 can cause severe symptoms and has resulted in a number of reported deaths. Complications of enterovirus 71 and occasionally other members of the enterovirus group include meningitis, pulmonary edema, paralysis, and severe central nervous system symptoms.[55-59] In these more severe cases, the fever tends to be more elevated for a longer period of time and general presentation of the symptoms is also more severe. Thus the clinician is warned that in cases of hand, foot, and mouth disease; herpangina; or lymphonodular pharyngitis, if the systemic symptoms appear to be severe, further delineation of the viral subtype may be warranted. Viral subtyping can be performed on stool samples as well as by culture and subsequent analysis. Fortunately, these severe manifestations are rare, and in the common presentation the diagnosis is made through simple clinical observation. With that said, serologic and culture tests may be performed.



• **Figure 24-5** Herpangina lesion on the palate of an adult patient.

The oral ulcers of herpangina are one of the first presenting signs of the disease. The oral ulcers generally present as only a handful of vesicles. The vesicles are often fragile and surrounded by a small region of erythematous change. The individual vesicles are generally small and on the order of 2 to 4 mm. The ulcers are almost always confined to the soft palate, faucial pillars, and tonsillar bed of the palatine tonsils. In the clinical setting of hand, foot, and mouth disease, the vesicles are not limited to the posterior portion of the oral cavity and may occur on other anterior surfaces. In addition, there are often more numerous vesicles, on the order of 15 to 25. In addition to the oral mucosa, in hand, foot, and mouth disease, either the hands or feet should also be involved.[53]

Following the oral vesicles, flulike symptoms will quickly ensue over and persist over several days. Though these systemic symptoms resolve, if they are severe or long lasting, again consideration of enterovirus 71 complications could be very important. Flulike symptom examples include cough, malaise, lymphadenopathy, nausea, rhinorrhea, muscle ache, and diarrhea.

Histopathology

As reported by Neville and colleagues, the histopathologic features, if biopsied, are nonspecific, with disruption of the epithelium. Inflammatory cells as well as intracellular and intercellular edema are also noted. The vesicle itself tends to be intraepithelial.[53]

Treatment

As mentioned previously, the disease is generally self-limiting, with no need for therapeutic intervention. Supportive care for the various symptoms is often necessary. These generally center around use of antipyretics, antiemetics, antidiarrheals, and analgesics. As with herpes, assessment of the patient's hydration status is important, and proper instructions for hydration should be established. Referral to an infectious disease consultant, pulmonary specialist, pediatrician, or primary care provider may be necessary in many cases. Isolation of the patient to prevent epidemic spread of the disease is necessary. Transmission can be by respiratory droplet or saliva in the acute phase, though the oral-fecal route of transmission is probably the most common method in epidemics. Therefore good hygiene practices and isolation of the patient are advised. Epidemics are most common in crowded

conditions, with the summer months and early fall being the most common times of year.[47,54,60-64]

Lichen Planus

Lichen planus is a relatively common inflammatory mucocutaneous disease with a distinct morphology affecting approximately 1% of the general population. It commonly affects middle-aged adults with a slight predominance in women.[65] Oral lesions can be seen alone or in combination with cutaneous disease. In contrast to skin involvement, oral lichen planus tends to be more persistent and refractory to treatment. Whether oral lichen planus constitutes a premalignant lesion remains controversial. A relatively low incidence of malignant change in oral lichen planus has been reported in some serial studies and is usually confined to patients with less common erosive or atrophic forms of oral lichen planus[64,66,67] (Figure 24-6).

Etiology

The pathophysiology of lichen planus is not fully understood. It is thought to be an autoimmune-mediated disease triggered by antigenic alterations on the cell surface of the basal layer of the epithelium. Langerhans cells act as antigen-presenting cells to T lymphocytes, stimulating their proliferation, with subsequent epithelial changes in a mechanism similar to that for allergic contact dermatitis.[68] Although many cases of lichen planus are idiopathic, some cases are linked to the use of medications, dental restorative materials, and, in some populations, infection with the hepatitis C virus.[69-72] The association of certain medications and oral lichenoid lesions has been well described.[73-76]

Clinical Features

Cutaneous lesions seen in lichen planus include violaceous polygonal papules and plaques. Upon closer examination, a delicate reticulated pattern of white scale known as Wickam striae is observed. Some have described the classic cutaneous lesions of lichen planus as pruritic, polygonal, planar (flat-topped), purple papules and plaques. The flexor surfaces of extremities are commonly involved and dystrophic changes in the nail beds can sometimes be seen. Lesions may erupt on surfaces exposed to trauma in a response known as the Koebner phenomenon.[65] This tissue response to trauma can also be seen in oral lichen planus.[77]

Reticular and erosive lichen planus are the two main forms of oral lichen planus, and it is not uncommon for patients to present with a combination of both forms. Reticulated oral lichen planus is the most common form and generally presents as asymptomatic delicate interlacing white striae found in a bilateral distribution. The buccal mucosa is the most common site of involvement, followed by the tongue, gingiva, and lips. An uncommon variant of reticulated oral lichen planus, known as plaque-type lichen planus, is sometimes found on the dorsal surface of the tongue and on the buccal mucosa and can clinically resemble leukoplakia.[64,78-80]

Erosive oral lichen planus presents as irregular centrally ulcerated atrophic and erythematous lesions, often with fine white lacelike striae at the periphery. Erosive lichen planus tends to be a multifocal process, with the degree and morphology of the erythematous and ulcerated lesions changing over time. Bullous and atrophic oral lichen planus are believed to represent variants of erosive lichen planus. Typically, symptomatic patients with erosive lichen planus complain of a painful burning sensation that can be debilitating and exacerbated by diet. Erosive lichen planus is sometimes limited to the gingiva and can present clinically as a painful desquamative gingivitis.[81-83] In some patients, a characteristic erosive gingival and genital involvement has been described in a syndrome complex referred to as the vulvovaginal-gingival syndrome.[84]

Histopathology and Laboratory Studies

Although the clinical presentation of reticulated oral lichen planus can sometimes be characteristic for the disease, biopsy is recommended to confirm the clinical diagnosis and, in erosive lichen planus,[64,85] can be essential in excluding other inflammatory and neoplastic diseases.[81] The histopathologic features of idiopathic lichen planus are characteristic, but not specific, as other lichenoid lesions can show similar features on light microscopy. Microscopic examination typically shows an intense bandlike lymphocytic infiltrate at the epithelial/connective tissue interface with vacuolar degeneration of the basilar epithelial layer. Varying degrees of hyperkeratosis of the surface epithelium is seen and the spinous layer can be hyperplastic, ulcerated or atrophic depending on the clinical form of oral lichen planus. Scattered degenerating keratinocytes or colloid bodies can sometimes be found within the deeper epithelial layers. Direct immunofluorescence studies can be helpful in differentiating erosive lichen planus from other vesiculobullous diseases.[86] Skin patch testing is sometimes performed in suspected cases of lichenoid contact lesions.[87] Hepatitis C testing is recommended for newly diagnosed cases of oral lichen planus in some populations.[71,72,88]



• **Figure 24-6** Erosive lichen planus of the buccal mucosa.

Treatment

Patients with asymptomatic reticular lichen planus usually require no additional treatment other than periodic clinical follow-up once the diagnosis is established. Topical and systemic corticosteroids used alone or in combination are the most widely accepted therapy for erosive and symptomatic cases of oral lichen planus. Short-term use of systemic corticosteroids can be effective in the initial control of the disease or in cases refractory to topical therapy, but their inherent toxicity limits their use in the treatment of chronic disease. Other innovative therapies used in recalcitrant cases include the use of tacrolimus, retinoids, and immunosuppressant and cytotoxic drug therapy. Concomitant antifungal therapy is useful in reducing the incidence of candidiasis during corticosteroid and other immunosuppressant therapy.[77,85,89-91]

Aphthous Stomatitis

Recurrent oral aphthous ulcerations are often a frustrating, lifelong curse for patients and practitioners alike, as no single treatment modality is totally curative and no clearly defined etiology has been identified. Commonly referred to as canker sores, these painful oral ulcers present in three clinical variations: minor, major, and herpetiform lesions. In most studies, 20% of the population is affected, with a higher prevalence seen in whites younger than 40 years of age and with females outnumbering males.[92] In addition to genetic and familial factors, environmental and stress-related influences have been implicated as a cause for recurrent aphthous stomatitis.

Many factors are believed to initiate aphthous stomatitis, including medications such as Cox-2 inhibitors, nonsteroidal anti-inflammatory drugs (NSAIDs), and antidepressants.[93] Anxiety or stress, hormonal changes, allergies, nutritional deficiencies, and antigen exposure that produces a hypersensitivity reaction as a result of minor trauma or bacterial infiltration are all factors in the development of aphthous lesions.[93-95] A tendency toward a familial inheritance pattern has also been observed[96] (Figure 24-7).

Clinical Features

The vast majority of patients, 80%, present with minor aphthous ulcers that do not reach a size greater than 1 cm and affect the nonkeratinized areas of the oral mucosa, specifically the buccal and labial mucosa, ventral tongue, anterior floor of the mouth, and vestibular fold. The lesional process starts with an initial painful sensation to a localized mucosal area that becomes erythematous and progresses to a quickly disappearing blister. This blistered area will then transform to an ulceration with an intense burning sensation that is surrounded by an erythematous halo and covered by a thin yellow-white layer of fibrin. These painful ulcers present as solitary lesions, although multiple sites can be involved at one time. These lesions heal spontaneously in 10 to 14 days.[93]

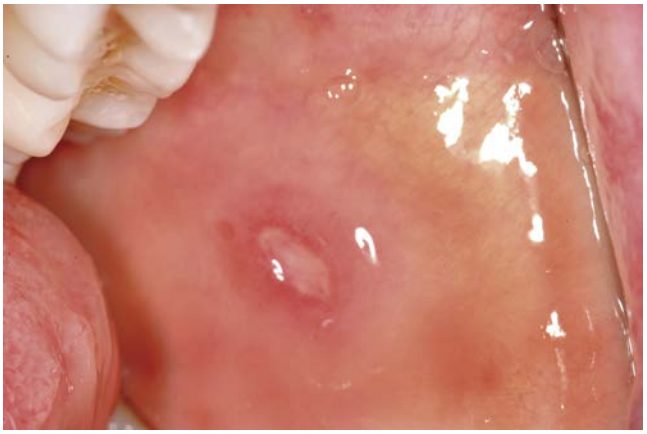

• **Figure 24-7** Aphthous minor ulcer of the mucosa.

The variant major aphthous ulcer, also termed periadenitis mucosa necrotica recurrens or Sutton disease, is seen in less than 10% of cases and are larger ulcers reaching 1 cm or greater in diameter. These ulcers show an irregular area of circumscription as well as a raised erythematous border surrounding a crater-like depression. These ulcers can form singularly, in multiples, and have been found to coalesce, forming larger lesions. Weeks or months may be necessary for these lesions to heal, and scarring may also be a resultant component.[94,95,97]

The third variant, herpetiform aphthae, are so named for their resemblance to recurrent herpes simplex, although no correlation has been noted between the processes. Recurrent herpes simplex typically affects the keratinized mucosa, whereas recurrent aphthous stomatitis avoids the keratinized mucosa. Successive crops of dozens of painful, pinpoint ulcers 1 to 3 mm in size appearing on the nonkeratinized mucosa characterize this variant.[93] These lesions heal in 7 to 10 days and normally without scarring.

Clinicians should remember that oral aphthae could also represent an initial sign of a more ominous systemic malady, in which case deeper investigation or a referral opinion should be sought. The ulcers of recurrent aphthous stomatitis should be distinguished from herpetic gingivostomatitis, herpes simplex, erythema multiforme, pemphigus, pemphigoid, Reiter syndrome, and Crohn disease.[98]

Histopathology

Histopathologic features are non-contributory. Biopsy is rarely indicated except possibly in lesions that persist for longer than 3 weeks. If biopsied, the features will be that of a nonspecific ulcer.

Treatment

Treatment, which is usually palliative, centers around the pain experienced with the ulcers and their subsequent

effect on daily life of the patient. A reduction in the number and duration of outbreaks and the promotion of healing are necessary treatment goals. Use of a twice-daily rinse of 0.12% chlorhexidine rinse (Peridex, Periogard)[97,99] as well as topical corticosteroids such as 1% triamcinolone paste (Adcortyl or Kenalog in Orobase)[94] have been shown to enhance healing. Topical gels of 0.05% fluocinonide, 0.05% clobetasol, or 0.05% amlexanox[98] have also proven beneficial in the treatment of mild cases of recurrent ulcers. Data demonstrating greater efficacy of systemic steroids rather than topical corticosteroids are lacking and there is a risk of adverse side effects such as hypertension and hyperglycemia. Therefore systemic use of steroids should be usually considered in consultation with verification of clinical diagnosis.[97]

Low-energy laser treatment has also been shown to be effective against recurrent aphthous ulcerations for immediate relief of pain and a possible reduction in the healing period. A CO_2 laser at a wavelength of 10.6 nm, continuous wave at 1.0-1.5 and placed on the ulcer in a circular motion over Elmex gel for 5 seconds, proved effective for immediate pain relief.[100,101] Additionally, a Nd:YAG laser with a 320-µm fiber optic cable set to 2 W and 20 pulses per second was shown to achieve long-lasting pain relief in recurrent lesions.[101]

Behçet Syndrome

Behçet disease has been known since ancient times. A description by Hippocrates reportedly describes the disease process well. In the 1930s, a Turkish dermatologist by the name of Behçet delineated the disease for the modern clinician. It should not be unexpected that a Turkish dermatologist and an ancient Greek physician saw enough of these patients to think that the disease warranted delineation. The disease itself is generally considered most likely in patients from countries along the ancient Silk Road that ran from China to the Mediterranean and then finally by ship to Greece and Italy. This is the famous trade route that Marco Polo is credited with opening. Though not 100%, people with HLA-B51 tend to be more prone to the disease. The anecdotal assumption is that the genetics associated with this HLA genotype successfully traveled the route along with tea, silk, and other goods.[102-107]

Once thought to be a spondyloarthropathy, today it is considered a vasculitis.[108] Other co-factors include immunodysregulation, antigenic reactions, and alteration in healing and repair, as well as possible viral or bacterial co-factors.[109,110] The disease is most important to oral surgeons in that these patients often present as aphthous ulcer patients who are very difficult to manage with standard therapies. In addition, the oral manifestations of the disease are usually the first sign of the disease. In considering Behçet's disease in a differential diagnosis list, it must be remembered that the other diagnostic signs of the disease may not be present during its first stages.

Clinical Features

Though the disease can present in childhood,[111,112] most patients first present as young adults or in middle age. As reported by Marshall, in Turkey the incidence may be as high as 420 per 100,000 people, with Japan having approximately 20 per 100,000 and the United States having 1 to 2 cases per 100,000.[113] The disease is extremely uncommon among African Americans and has not been reported in Native Americans. The actual time needed to establish the diagnosis of Behçet disease is often quite lengthy and difficult. This is due to the irregular presentation patterns as well as the often progressive and intermittent nature of the disease process. Patients tend to have exacerbations with varying lengths of remission.[102,103]

The aphthous-like ulcers present in Behçet disease can take up any of the three standard forms of aphthae. These include herpetiform aphthae, minor aphthae, and major aphthae. In general, the aphthae tend to come in crops rather than as single lesions. In addition, the lesions are often in areas not usually associated with aphthous ulcers. (As reviewed in the aphthous section, the most common locations for aphthae are the ventral surfaces of the tongue, floor of mouth, buccal mucosae, and labial mucosae.) In Behçet disease the ulcers are often in the oral pharynx, with the soft palate and tonsillar pillars being common sites of involvement. The ulcers themselves, though they may be small and herpetiform as previously mentioned, are often rather jagged along the periphery rather than being the uniform circular form of standard aphthous ulcers. The central area of ulceration is crater from as in normal aphthae though the surrounding erythematous halo is often more extensive than standard aphthae.[114-116] In this author's experience (JWH), the most common presentation for Behçet patient is that the ulcers also tend to last somewhat longer than the standard 10 to 14 days of regular aphthae. Thus, they tend to act more like aphthous major with multiple lesions and lengthened duration.

Systemically, Behçet disease can affect multiple parts of the body, although in contrast to most vasculitides, the kidneys usually seem to escape.[117] The clinician should remember that, like the oral lesions, the disease in other body regions tends to go through remissions and exacerbations with a variable periodicity.

As alluded to earlier, the actual process of establishing a definitive diagnosis of Behçet disease gets quite complicated because of variability and stage of presentation. In the international classification outlined next, recurrent aphthous ulcers are not just a major criterion but actually a mandatory criterion. For this reason other classification systems have evolved that allow for the possibility of not having oral involvement. It seems unlikely that an oral surgeon would

be called on to diagnose Behçet in a patient with no oral symptomatology or signs. For this reason only the international classification system is given. The interested reader could delve further into other classification systems.[17-20]

International Criteria for Classification of Behçet Disease

Obligatory criterion:

- Recurrent oral ulcerations
  - Including: minor aphthous, major aphthous or herpetiform ulceration. (Ulcers should be observed by a physician/dentist or judged to be reliable by patient history)
  - Ulcers should recur at least three times in one 12-month period

Plus two of the following:

- Recurrent genital ulceration
  - Recurrent genital aphthous ulceration or scarring—especially in males. (Ulcers should be observed by a physician or judged to be reliable by patient history)
- Eye lesions
  - Including: anterior uveitis, posterior uveitis, cells in vitreous on slit lamp examination ***or*** retinal vasculitis as observed by ophthalmologist
- Skin lesions
  - Including: erythema-nodosum-like lesions (observed or judged to be reliable by patient history), pseudofolliculitis, papulopustular lesions ***or*** acneiform nodules consistent with Behçet observed by a physician and in post-adolescent patients not receiving corticosteroids
- Positive pathergy test
  - Defined as an erythematous papule, >2 mm, at the prick site 48 h after the application of a sterile needle, 20-22 gauge, which obliquely penetrated avascular skin to a depth of 5 mm, and is read by a physician at 48 hours[17]

The other systems involved besides the eyes, skin, and genitalia include the joints, central nervous system, pulmonary system, and gastrointestinal systems.[118-120] When trying to confirm the diagnosis in an evolving clinical setting, consultation with multiple physicians is likely. Dermatologists, rheumatologists, and ophthalmologists are likely consultant sources. Some clinicians may not be familiar with what has been called the pathergy test. In this test a 20- to 22-gauge sterile needle is inserted into the forearm to a depth of 5 mm. The area is observed 48 hours after the needle penetration, and if there is a papule larger than 2 mm at the site of the needle stick, the test is said to be positive. The problems with this test include that in some populations there is less likelihood of positivity. For instance, positivity in Americans would be rather unlikely, whereas in a person of Turkish origin, a positive pathergy would be much more likely.[121] There also appears to be some difference based on how well the area overlying the needle stick was cleaned before the test. If the area is cleansed first, the rate of positivity goes down! If examined histopathologically, the area shows neutrophilic infiltrates with some perivascular aggregates. For the oral health care provider, the bottom line is that, if Behçet disease is considered in the differential diagnosis because of some suspicion of systemic involvement, appropriate referral should be accomplished.

Some of the more unusual complications associated with Behçet include central nervous system involvement. Such involvement can be severe, with psychoses, meningitis, and convulsions having been reported. However, the neurologic problems are generally a very late-stage presentation.[110,122-124] On the other hand, ocular involvement with the possibility of subsequent blindness does reveal the need for a thorough ophthalmologic consult in cases where Behçet disease is likely.[110,125]

A note must be made here concerning the need for referrals. Aphthous stomatitis is a very common disease. It certainly is not necessary to refer all cases aphthous with recurrences in people having more than three recurrences in 1 year to a specialist for further evaluation. The need for referral should be based on eliciting positive responses to skin, genital, ocular, or joint signs or symptoms.

Histopathology

Usually the oral ulcerations are similar enough to aphthous ulcers that a biopsy is not considered necessary and therefore not performed. In the few cases where a biopsy has been taken, the ulceration is nonspecific. Some deep myovasculitis may be seen, but this is also seen in other types of oral ulcerative diseases and is nonspecific. The only time biopsy is usually performed is in the case of longstanding lesions (longer than 2 to 3 weeks) and where possible granulomatosis disease is needed.[126]

Treatment

As mentioned previously, the main treatment paradigm associated with Behçet is to get adequate referral to a variety of health care providers and try to establish a definitive diagnosis. The actual treatment of the oral ulcerations centers around the same therapeutic regimes as used for aphthous stomatitis.

Reactive Arthritis (Reiter Syndrome)

Reiter syndrome, also referred to as reactive arthritis, is a rheumatic disease belonging to a category of seronegative spondyloarthropathies. Use of the designation *Reiter syndrome* is becoming more and more discouraged because of Dr. Reiter's involvement with the Nazi party during World War II.[127] A peripheral arthritis with characteristic extra-articular manifestations is the hallmark of this disease. In its classic description, a triad of arthritis, conjunctivitis, and non-gonococcal urethritis is seen, although this constellation of features is not found in all cases of Reiter syndrome. Reactive arthritis is an acute arthritis resulting from an

extra-articular infection that is usually venereal or enteric in origin. Peak onset is seen between 15 and 35 years of age with a significant male predilection seen in postvenereal disease.[128-131]

Etiology

Reactive arthritis is an autoimmune phenomenon triggered following urogenital or enteric infections generally seen in genetically susceptible individuals expressing the human leukocyte antigen (HLA)-B27.[132,133] Enteric bacterial infections associated with reactive arthritis include *Salmonella, Shigella, Campylobacter,* and *Yersinia* species, whereas *Chlamydia trachomatis* accounts for most of the reported postvenereal cases.[134] Additionally, an association of reactive arthritis and human immunodeficiency virus infection has been described.[135]

Clinical Features

Clinical symptoms of reactive arthritis usually begin 1 to 4 weeks after infection.[128,130,131,136,137] Peripheral articular involvement lasting longer than 1 month is a key symptom. Articular swelling, pain, and involvement of soft tissue similar to rheumatoid arthritis is seen, but unlike rheumatoid arthritis, it is asymmetrical in distribution and commonly oligoarticular. Lower back pain secondary to sacroiliitis is a common clinical feature. Inflammation of tendinous insertions of bone, particularly the Achilles and patellar insertions, can be a distinctive feature of reactive arthritis. Dactylitis in the form of "sausage digits" can also be observed.[128,129,138]

A spectrum of mucocutaneous lesions is associated with reactive arthritis. Balanitis circinata—shallow erythematous ulcerations at the meatus and on the glans penis—are sometimes seen. Painful hyperkeratotic plaques with an erythematous base known as keratoderma blennorrhagica can be seen on plantar and palmar surfaces. Although oral lesions are reported in less than 20% of cases, oral findings include serpiginous plaques on the tongue resembling geographic tongue, as well as diffuse erythematous papules and ulcerations of the oral mucosa.[128,129,139]

A urethritis with a nonpurulent discharge is a common finding. Prostatitis, cervicitis, and vulvovaginitis are other urogenital manifestations that may be encountered. Conjunctivitis is a common ocular finding and usually manifests before the onset of arthritis.[128-130]

Histopathology and Laboratory Studies

No single laboratory or imaging finding is diagnostic of reactive arthritis, as the diagnosis is based on clinical data. Although a positive HLA-B27 result is not specific of the disease, haplotyping can be used to diagnose reactive arthritis and can be particularly helpful in atypical cases lacking extra-articular findings. Documentation of bacterial infection through microbiologic examination of smears and cultures of the urethral or cervical discharge must be considered. Tests for *Chlamydia* species should be performed in suspected cases of reactive arthritis, and HIV testing should be considered. Tests for rheumatoid factor and antinuclear antibodies are negative.[128-130] Early in the course of the disease, radiographic findings are generally unremarkable. In chronic severe disease, periosteal reaction at tendon insertion sites can often be observed, as well as sacroiliitis and syndesmophyte formation.[140] Hematoxylin and eosin findings are non-contributory and reveal only a nonspecific ulcer.

Treatment

Curative treatment for reactive arthritis does not presently exist. Most patients have a self-limited clinical course and require only symptomatic and supportive care. NSAIDs are the mainstay in treating the musculoskeletal symptoms seen in reactive arthritis. Occasionally, intra-articular injections of corticosteroids or systemic steroids are prescribed in patients with poor response to NSAIDs. Cytotoxic therapy using methotrexate or azathioprine has been proposed in treating severe cases of reactive arthritis. Urethritis is usually treated with tetracyclines or broad-spectrum antibiotics because of the frequency of coexisting infections; however, the treatment of urethritis has not been shown to modify the clinical course of reactive arthritis.[128-130] The disease may be associated with chronic recurrent ocular inflammation that requires systemic therapy to control the inflammation and to prevent progressive visual loss.[141] The clinical course of reactive arthritis may be prolonged, with acute exacerbations and remissions occurring for weeks to months. An estimated recurrence rate of approximately 15% has been reported.[131,142]

Pemphigoid

The all-inclusive term *pemphigoid* refers to a group of chronic autoimmune disorders characterized by subepithelial blistering lesions involving mucosal surfaces and/or the skin. Mucous membrane pemphigoid is the preferred term when the condition is primarily mucosal. This condition has been commonly referred to in medical and dental literature as benign mucous membrane pemphigoid, cicatricial pemphigoid, oral pemphigoid, and ocular pemphigoid, which are not completely accurate terms. When the condition primarily involves the skin, bullous pemphigoid is the preferred term.

Mucous membrane pemphigoid affects 2 to 5 patients per 100,000 with more than 85% showing oral involvement. The most commonly affected areas are the oral cavity (90%) and eyes (65%), with the nose, nasopharynx, larynx, and skin (20%-30%) involved less often.[143] It affects women approximately 2:1 over men and presents at a mean age of onset over 50 years of age.[144,145] Although cases have been reported, the disease is extremely infrequent in children.[146]

Bullous pemphigoid, the most common autoimmune blistering disease, is considered a separate entity from mucous membrane pemphigoid.[147] Men are affected at the same rate as women, and both are generally elderly adults when the disease presents. The disease has been characterized as self-limiting but can last from a few months up to 10 years with considerable morbidity.[147] Lesions are located predominantly on flexural surfaces of the extremities, lower abdomen, groin, axillae, and less commonly, the head and neck areas.[148-150]

It has been suggested that an environmental factor, specifically a virus or drug, combined with genetic susceptibility leads to the development of autoantibodies to an antigen within the mucosal or skin basement membrane zone.[145] The use of ibuprofen, amoxicillin, captopril, clonidine, furosemide, and indomethacin, among others, has been reported to induce lesions of pemphigoid.[151] There is a defect in immune regulation, and autoantibodies, usually IgG but also IgA, are formed against components of the basement membrane zone. Numerous inflammatory mediators entice acute and chronic inflammatory cells to the basement membrane zone, where enzymes aid in the separation of the epithelium from the underlying tissues[152] (Figures 24-8 and 24-9).



• **Figure 24-8** Pemphigoid ulcers of the gingiva.



• **Figure 24-9** Pemphigoid with Nikolsky sign.

Clinical Features

Mucous membrane pemphigoid is characterized by the development of a recurring vesicle or bulla which evolves to become an erosion or ulcer affecting the mucous membranes of the body. Healing may result in scarring of the affected area. The mucous membranes lining the mouth, specifically the gingiva, buccal mucosa, and palate, are most commonly affected,[145] with the initial sign being generalized erythema and edema, which can then progress to sloughing of the mucosal epithelium in large sheets or strands. Often the gingiva will appear quite erythematous and tender, leading to sloughing, referred to as desquamative gingivitis. Patients are symptomatic and have a chief complaint of oral pain due to mucosal ulceration and desquamation. Lesions of the tongue, soft palate, uvula, and lips prove difficult to treat because of repeated trauma.[145]

Extraoral involvement of mucous membrane pemphigoid includes inflammation or erosions forming on the conjunctiva. Ocular symptoms may include burning or grittiness in the eye, increased pressure within the eye (glaucoma), abnormal inward turning of the eyelid (entropion), and abnormal inward turning of the eyelashes (trichiasis), potentially causing irritation of the corneal surface. Symblepharon formation is a major concern for corneal damage and resultant scarring, which can lead to blindness. A symblepharon is formed by scarring and adhesion of the bulbar to the palpebral conjunctiva.[151]

Bullous pemphigoid consists of taut blisters that arise on normal or erythematous skin, often with pronounced pruritus. Pruritic urticarial plaques that progressively become more edematous, often for a long period of time before bulla formation, have been noted in two thirds of patients.[147] The bullae then rupture to leave an eroded base that does not extend further and are therefore Nikolsky sign negative. In contrast to mucous membrane pemphigoid, oral lesions are uncommon at presentation but can be seen as the disease progresses in 10% to 40% of patients.[153-155]

Histopathology

When a patient is suspected of having either mucous membrane pemphigoid or bullous pemphigoid, a biopsy should be obtained for routine light microscopy as well as for direct immunofluorescent (DIF) studies. Histopathologic examination shows a subepithelial cleft whereby intact surface epithelium is separating from the underlying supporting tissues in combination with a mixed inflammatory infiltrate. A biopsy sample of perilesional tissue placed in an isotonic medium such as Michel's solution, which does not allow degradation of the vital tissue components, should be used for DIF. In 80% to 100% of patients, DIF will show a linear

band at the basement membrane zone with IgG and C3 as well as IgA to a significantly lesser degree.[145,156] Studies using indirect immunofluorescent techniques on a patient's serum have had unpredictable results in mucous membrane pemphigoid patients, although IgG basement membrane zone antibodies are seen in 70% of patients with bullous pemphigoid.[156]

Treatment

Patients with mild oral disease, including desquamative gingivitis, can be treated twice daily with gel-based topical corticosteroids such as 0.05% fluocinonide, clobetasol propionate, or betamethasone dipropionate[137,142,145,152,157-159] that should be in contact with the tissues for at least 30 minutes. An adhesive base such as Orabase or vacuum-formed latex trays holding the gel or ointment in contact with the tissues are suggested modalities. Both bullous pemphigoid and mucous membrane pemphigoid patients benefit from topical corticosteroid applications as well as intralesional corticosteroid injections of triamcinolone acetonide 5 to 10 mg/mL every 2 to 4 weeks. Intralesional treatment has shown prompt healing for stubborn lesions. Daily application of topical tacrolimus 0.1% showed resolution and prevented progression of lesions.[160] Dapsone has been considered the drug of choice, although it does not come without adverse side effects such as hemolysis, methemoglobinemia, and hepatotoxicity. The usual effective dose is between 100 and 200 mg/day. Minocycline in dosages between 50 and 100 mg/day has been shown to be effective through its anti-inflammatory and anticollagenase activity but also is known for inducing nausea, photosensitivity, and hyperpigmentation.[152,161] Azathioprine, 1 to 2 mg/kg/day, or cyclophosphamide, 0.5 to 5 mg/kg/day, can be used to treat these diseases, but neither is usually sufficient alone, and side effects such as bone marrow suppression are possible.[146] Their use is in a steroid-sparing role, although initial treatment usually includes concomitant prednisone dosing of at least 40 mg/day. An isolated case of stubborn mucous membrane pemphigoid showed rapid resolution following treatment with infliximab at a dosage of 5 mg/kg at 2 and 6 weeks with maintenance doses every 8 weeks.[162]

Pemphigus

Pemphigus encompasses a group of autoimmune diseases that exhibit as blistering conditions of the skin and/or mucosal membranes. Included in this group is pemphigus vulgaris, pemphigus foliaceus, pemphigus vegetans, pemphigus erythematosus, and paraneoplastic pemphigus—although pemphigus vulgaris, vegetans, and paraneoplastic pemphigus are the only forms where oral cavity involvement is common. Paraneoplastic pemphigus has been characterized as a separate disease process due to an underlying lymphoproliferative neoplasm.[163] Pemphigus affects the skin and oral mucosa but also the mucosa of the nose, conjunctiva, esophagus, pharynx, and larynx.[164] The vast majority of

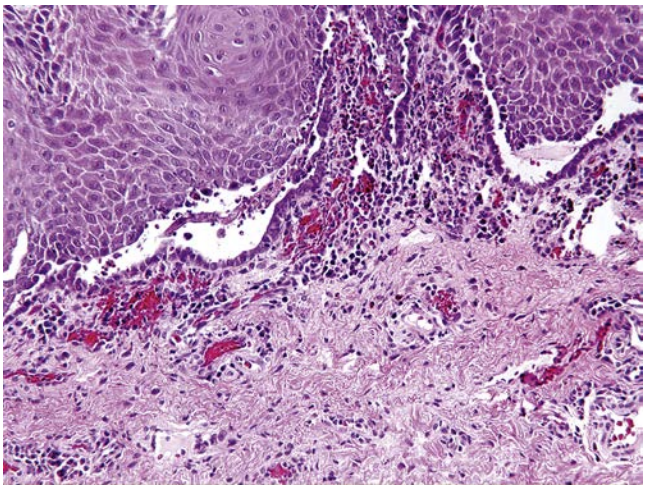

• **Figure 24-10** Photomicrograph of pemphigus.

cases, 90%, present as pemphigus vulgaris, whereas 7% present with pemphigus foliaceus.[165] Incidence rates vary from country to country, but one to six cases per million people per year is the norm.[166] Women equal men in incidence rates with the fifth decade being the mean age of presentation. Ashkenazi Jews and persons of Mediterranean origin have been shown to be especially at risk for pemphigus.[167] As pemphigus vulgaris exhibits an initial mucosal manifestation before cutaneous aspects, the dentist is of paramount importance for initial diagnosis.

Keratinocytes of the skin and mucosa are anchored to the underlying connective tissue as well as one another through multiple mechanisms that include desmosomes. In pemphigus, an autoimmune process disrupts this attachment whereby immunoglobulin G (IgG) but occasionally IgA, IgM, and complement protein C3 are directed against structural proteins desmoglein 1 and 3, leading to epithelial breakdown[163,168] known as acantholysis. Desmoglein 1 is found throughout all layers of the skin but is only minimally present in mucous membranes, whereas desmoglein 3 is found in the two or three deepest layers of the epidermis and is predominantly expressed throughout mucous membranes.[168] As a result, some patients develop mucosal lesions without skin blisters due to circulating antibodies against desmoglein 3 and low titers against desmoglein 1. The preserved function of desmoglein 1 in the skin prevents the development of cutaneous lesions while impaired desmoglein 3 function causes acantholysis in the oral cavity.[168]

Various drugs can act as triggers for the formation of bullae and include penicillamine, rifampicin, and angiotensin-converting enzyme (ACE) inhibitors such as captopril.[164] Other factors can exacerbate pemphigus, such as dental work, radiographs, exposure to sun, stress, and trauma[163] (Figure 24-10).

Clinical Features

Pemphigus vulgaris is the most common form of pemphigus and runs a chronic course with 80% of cases originating

in the oral cavity[163,169] causing fragile blisters which rupture to result in irregularly arranged surface erosions and ulcerations which are quite painful. The palate, buccal mucosa, labial mucosa, gingiva, and ventral tongue are the most common presenting intraoral sites. The lesions of pemphigus vulgaris are slow to heal if, at all. Therefore, with persistent lesions in which viral, bacterial, and fungal causes can be ruled out, pemphigus vulgaris should be considered. Within 6 months of an initial diagnosis of pemphigus vulgaris, 99% of cases also show cutaneous involvement, mainly of the scalp, face, and upper torso[163,169] whereby flaccid blisters filled with a clear fluid arise to leave an eroded base once they are ruptured.

For patients with lesions suspicious for pemphigus vulgaris, a clinical procedure can be performed on normal-appearing gingiva or skin near an existing lesion whereby firm rubbing pressure is exerted which elicits bulla formation. This is termed a positive Nikolsky sign and is highly suggestive for pemphigus, but it is not specific for this diagnosis and may be absent entirely.

Like pemphigus vulgaris, in more than half of cases, pemphigus vegetans initially shows oral lesions months before the formation of cutaneous lesions, although all cases eventually manifest with oral lesions.[152,170] The groin and axilla are also common clinical locations. This rare variant of pemphigus vulgaris is characterized initially by pustules (Hallopeau type) or flaccid bullous lesions that transform into erosions (Neumann type). These pustules or bullae subsequently develop into hyperpigmented vegetative plaques with pustules and hypertrophic granulation tissue at the periphery.[152] An additional characteristic feature of pemphigus vegetans is a cerebriform tongue characterized by a pattern of sulci and gyri on the dorsal surface. Patients with the Hallopeau type have a relatively benign disease with a prolonged remission period, whereas patients with the Neumann type have a course similar to that of pemphigus vulgaris.[171]

Histopathology and Laboratory Findings

As the differential is large and varying, including lichen planus, pemphigoid, epidermolysis bullosa, linear IgA disease, lupus erythematosus, and graft-versus-host disease, among others, additional testing might be required. A biopsy immersed in 10% neutral buffered formalin for routine histologic examination is of paramount diagnostic utility, but DIF of the tissue received in a medium such as Michel solution that does not allow degradation of the vital tissue components is an important adjunct tool. Immunoglobulins, complement, and fibrin are preserved in Michel solution, which is a transport medium that also maintains isotonicity and a pH of 7.0 to 7.2. An assay of the patient's serum can also be performed using indirect immunofluorescence studies in a search for circulating autoantibodies. Immunofluorescence will show a classic "fishnet" pattern within the epithelium. On hematoxylin and eosin staining, the split will be above the basement membrane, with acantholytic "Tzanck" cells being a common feature focally.

Treatment

The goal of treatment is control of the immediate disease activity with continued maintenance at the lowest drug levels possible to prevent new lesions. Although topical corticosteroid application may suffice for a while, oral prednisone at 20 to 40 mg/day initially and escalating to 120 mg/day or more is the universal approach until disease activity is controlled. Long-term use of potent steroids may have deleterious effects, including mucosal atrophy and irritation, secondary candidiasis, poor wound healing, hypertension, hyperglycemia, adrenal suppression, osteoporosis, weight gain, fat redistribution, and increased risk of infection.[172-176]

Plasmapheresis in conjunction with cytotoxic drugs such as azathioprine or cyclophosphamide is effective at decreasing circulating concentrations of pathogenic pemphigus antibodies, but this method is increasingly being replaced by administration of intravenous immunoglobulin to achieve the same result.[177] Additional drugs used as adjuvants to reduce the dose of corticosteroid therapy include immunosuppressants such as cyclosporine and methotrexate, anti-inflammatory drugs such as dapsone and colchicine, and antimalarials such as hydroxychloroquine. Mycophenolate mofetil, a drug used for prevention of rejection in renal allogeneic transplants, has also been shown to provide effective treatment through B-lymphocyte suppression, all with minimal side effects.[176,177]

Linear IgA Disease

Linear IgA disease is an uncommon autoimmune vesiculobullous disease that can involve both cutaneous and mucosal surfaces. Linear IgA disease is characterized by subepidermal blistering with a linear homogenous deposition of IgA antibodies along the basement membrane zone as seen in direct immunofluorescence studies.[178] Originally considered a form of dermatitis herpetiformis, linear IgA disease is now considered a distinct entity.[179,180] Linear IgA disease has a bimodal age of onset with a slight female predilection and usually presents before 5 years of age in children and after 30 years of age in adults.[181,182] In children the disease has been referred to as *chronic bullous dermatosis of childhood*.[182]

Etiology

Idiopathic linear IgA disease is caused by a linear deposition of IgA antibodies at the basement membrane leading to neutrophil chemotaxis and complement activation, which causes a lack of adhesion at the dermal-epidermal interface that eventuates in blister formation. Different target antigens at the dermal-epidermal junction have been described in linear IgA disease, and the mechanism

of the loss of self-tolerance to these target antigens is unknown.[183]

Drug-induced linear IgA disease has been well documented. Although the list of implicated medications continues to grow, historically vancomycin has been a major offending drug. Drug-induced linear IgA disease is more commonly seen in the older population, as this group is often being treated for multiple medical conditions.[184]

Linear IgA disease has been reported in association with various infectious and neoplastic diseases, but their causal role in stimulating linear IgA disease has yet to be defined.[185] Unlike dermatitis herpetiformis, a gluten-sensitive enteropathy is generally not associated with linear IgA disease.[181,186]

Clinical Features

Cutaneous lesions of linear IgA disease consist of groups of clear or hemorrhagic vesicles and bullae arranged in annular or herpetiform configurations resembling a *cluster of jewels* and are highly characteristic of the disease. In children the lesions are typically found on the lower abdomen and around the perineum; in adults the lesions are typically found on the trunk and on the extensor surfaces of limbs.[181,182] Ocular involvement in the form of symblepharon formation from the scarring of ruptured conjunctival bullae can occur.[187]

Oral lesions have been reported in more than 50% of cases and can sometimes dominate the clinical presentation. Oral manifestations of linear IgA disease can precede cutaneous involvement, thereby complicating the clinical diagnosis. Oral ulcerations and erosions resulting from ruptured intraoral vesicles and bullae are a common oral manifestation and can be a source of significant morbidity in patients with linear IgA disease. In contrast to cutaneous lesions, mucosal lesions usually heal with scarring. The gingival and buccal mucosa is frequently involved. When the gingiva is involved, it frequently will manifest clinically as a desquamative gingivitis. An erosive cheilitis is seen when the lip vermilion is involved.[184,188-194]

Histopathology and Laboratory Studies

In addition to tissue biopsy for standard hematoxylin and eosin stained tissue microscopy, immunofluorescence studies are critical for the diagnosis of linear IgA disease, as clinically linear IgA disease exhibits a phenotype that resembles or overlaps other vesiculobullous diseases.[179,189,195] Direct immunofluorescence of perilesional and adjacent clinically normal tissue will show a homogenous linear deposition of IgA antibodies at the basement membrane zone. A linear deposition of C_3 may also be seen, and a subset of patients with linear IgA disease will exhibit both IgA and IgG deposition at the basement membrane zone.[178,180,183,188,194] Approximately 30% to 50% of patients with linear IgA disease will demonstrate circulating serum antibodies on indirect immunofluorescence studies, but these circulating antibody titers are typically low.[179,196] Tzanck smears of bullae fluid may be helpful to rule out a herpes viral infection.

Treatment

Linear IgA disease is a chronic disease characterized by periods of exacerbation and remission. Consultation with dermatology and ophthalmology is important in the ultimate clinical management of patients with linear IgA disease. Most cases respond to dapsone or sulfapyridine; however, oral lesions can prove to be more persistent and difficult to clear. A combination of dapsone and prednisone may help in controlling mucosal disease.[189,190,194,195,197]

Epidermolysis Bullosa

Epidermolysis bullosa is actually a group of diseases. The genetic delineation for this disease group continues to evolve, although it is fairly well defined at this point. However, the clinical aspects of the various diseases also carry great importance in establishing a diagnosis, and therefore dermatologists continue to group them on a clinical basis as well as a genetic basis. The hereditary categories are grouped into the simplex, hemidesmosomal, junctional, and dystrophic varieties. Some clinical types have yet to be defined genetically. In addition, there is an autoimmune-mediated category called epidermolysis bullosa acquisita.[198-203] This category will be considered separately, as there are better treatment modalities for this group of patients.[204-207]

In the simplex form, the splitting actually occurs within the epithelium. This is unique among the varieties of epidermolysis bullosa. The genetic defect associated with epidermolysis bullosa simplex relate to genes coding for keratins 5 or 14. These keratins are essential links in establishing the structural integrity of squamous cells. The simplex group may be inherited and subcategorized by genetic criteria and/or by clinical picture. The signs and symptoms associated with the simplex varieties are rather mild compared to the other varieties.[201]

In the hemidesmosomal category and with the other varieties, the splitting will occur at the basement membrane. The hemidesmosomal designation is somewhat new. In the past, many of these were classified as the non-Herlitz type of junctional epidermolysis bullosa. Hemidesmosomal epidermolysis bullosa is generally a somewhat more severe form than the simplex. Genetic defects have to do with type XVII collagen, integrin a6β4, and pectin.[200]

In the junctional varieties the genetic defect is in lamin a3, e3, and gamma 2. The Herlitz type is particularly devastating and often lethal in the neonatal period. There is still a non-Herlitz type of junction epidermolysis bullosa subtype, and this type does often allow for life into adulthood.[200]

In the dystrophic category, the defect is in the *production* of type VII collagen. There is some variability in the severity of the clinical disease, which may be accounted for by the differing chromosomal defects affecting type VII collagen production.

Simplex, hemidesmosomal, and dystrophic categories have both autosomal dominant and autosomal recessive inheritance patterns. If separated from the hemidesmosomal designation, the junctional variety is only transmitted by an autosomal recessive mode.[208]

The epidermolysis bullosa acquisita subgroup may be most unfamiliar to the reader. This is an autoimmune disorder that is acquired much later in life than the typical presentation of other epidermolysis bullosa patients. In the subgroup there are antibodies to collagen type VII. The autoimmune disruption of the type VII collagen results in loss of attachment at the base of the membrane and can result in severe signs and symptoms.[209]

Clinical Features

In the simplex variety, the symptoms are less severe, and thus patients may be diagnosed somewhat later in life. The classical junctional variety of the disease comes in two different varieties. One is termed the Herlitz type and the other the non-Herlitz form. Both of these are autosomal recessive. The Herlitz type is often lethal within the first year of life. The non-Herlitz form is milder and patients may have a normal life span. The hemidesmosomal variants were often classified originally under the designation of non-Herlitz type of junctional epidermolysis bullosa. In any of the patients with longer life span, scarring at points of contact is not unusual. Often the scarring is so severe as to result in loss of eyelashes, fingernail dystrophy, focal alopecia with scarring, eyelash and oral mucosal ulceration, and gingival attachment loss. One of the most characteristic deformities has been termed the "mitten" deformity and is the consequence of sequential loss of digits and may progress to loss of the entire hand or foot. In the dystrophic types of epidermolysis bullosa, the disease is not as life threatening as the Herlitz type of junctional epidermolysis bullosa. That is not to say that the disease cannot be disabling and often cause severe problems with significant scarring and loss of function.[210-214]

Oral mucosa involvement is generally seen as gingival erythema and recession. Loss of gingival attachment may progress, with resultant tooth mobility and tooth loss. There may be some scarring in the buccal mucosal vestibule with resulting loss of vestibular height.[212-215]

Histopathology

Splitting in the epidermolysis bullosa simplex group will be within the stratum spinosum. Splitting in all other categories is at the basement membrane. Electron microscopy may sometimes be helpful in discerning some of these diseases from each other. However, the usefulness of electron microscopy has diminished with the advent of genetic testing. In any of the genetic diseases, immunofluorescent studies will not be helpful. However, in the epidermolysis bullosa acquisita cases, immunofluorescence will be positive. Various immunoglobulins and complement can be seen in epidermolysis bullosa acquisita patients. If performed, the immunofluorescence pattern is linear and very similar to findings in cicatricial pemphigoid. However, the immunofluorescence may not be seen on both sides of the split. In epidermolysis bullosa acquisita, the immunofluorescent pattern may be more prominent on the connective tissue side.[25]

Treatment and Prognosis

The main dental problems associated with these patients have to do with gingival trauma secondary to mastication and oral hygiene. A soft food diet and minimization of oral trauma secondary to oral hygiene should be stressed. Plaque can be particularly irritating to the gingival surfaces. Therefore there is the quandary of balancing the trauma secondary to oral hygiene procedures with the plaque buildup if oral hygiene is not properly performed. This is often a fine line that is difficult to consistently control. In addition, enamel defects may be severe enough to necessitate coronal coverage.[199,213,216-222]

The dental practitioner should avoid trauma to the mucosal surfaces as much as possible. If the patient becomes edentulous, wearing standard dentures may be problematic due to the pressure and shearing affect of the dentures.[215] There has been one successful report of the use of dental implant–supported prostheses in patients with epidermolysis bullosa.[223] Our clinical experiences have also shown implants to be possible.

Several clinical notes are important. First and foremost is that if crown and bridge procedures are going to be performed, leaving the margins "high and dry" seems to be much preferred. The irritation associated with subgingival margins has been seen to result in increased irritation and rapid gingival attachment loss. Also of possible concern is use of gingival packing material, which may be problematic in these patients. The clinician should also be aware of possible air emphysemas in these patients. This would be caused by high-speed air-driven handpieces. These handpieces can also create widespread positive Nikolsky sign due to the air pressure generated by the handpieces and dissecting through the tissues. Although this may not be avoidable, awareness of the problem may decrease the effect.

Other preventive dental regimens should also be instituted. Proper fluoridation should be provided to these patients to minimize dental caries and therefore the need for dental care. There have also been increased reports of squamous cell carcinoma of the skin in patients with the recessive dystrophic form of the disease. The dental practitioner should strive to achieve the least traumatic methods of dental health care delivery possible. This would include lubrication of the lips and perioral tissues and use of the rubber dam whenever practical.[25]

In the epidermolysis bullosa acquisita form, immunemodulating and anti-inflammatory agents may be used in the oral cavity. These include but are not limited to steroid rinses, tacrolimus, pimecrolimus, dapsone, and

cyclosporine. In the future, gene therapy may be appropriate for some of these diseases; of particular current interest are those dystrophic types associated with a single defect and type VII collagen.[204,208,224-227]

Erythema Multiforme

Erythema multiforme is an acute self-limiting hypersensitivity reaction of variable severity that is characterized by targetoid skin eruptions with or without mucous membrane involvement. Once considered a disease spectrum that included Stevens-Johnson syndrome and toxic epidermal necrolysis, erythema multiforme is now considered by many investigators to be a distinct entity.[228-230] Additionally, erythema multiforme is sometimes subclassified as erythema multiforme minor or major based on the involvement of cutaneous surfaces alone or in combination with mucous membranes.[231,232] Erythema multiforme affects males more often than females and is seen over a wide age range, with a peak incidence in the second through fourth decades of life.[233]

Etiology

Although the exact pathophysiology of erythema multiforme is not completely understood, it appears to involve a cell-mediated hypersensitivity reaction triggered by a variety of stimuli including viruses, bacteria, or drugs.[228-230,232,233] Herpes simplex virus is the most commonly described triggering agent, accounting for over 50% of cases.[228,229,234,235] *Mycoplasma pneumoniae* is another commonly reported etiology, especially in children. In many cases, a triggering stimulus cannot be elucidated. Although vaccine- and drug-related erythema multiforme have been reported, drugs are a more common triggering agent for Stevens-Johnson syndrome and toxic epidermal necrolysis.[228] Recurrent cases of erythema multiforme are often secondary to herpes simplex virus reactivation, even when the viral reactivation may be subclinical.[235]

Clinical Features

Mild prodromal symptoms consisting of fever, malaise, headache, and joint pain can be found in some cases of erythema multiforme and herald the onset of skin lesions. Cutaneous lesions present as sudden-onset, symmetrically distributed, red to dusky edematous macules or papules that spread peripherally and can fuse into patches. The lesions favor palmar and plantar surfaces, extensor surfaces of extremities, and the face. Characteristic targetoid or iris lesions consisting of concentric circular erythematous rings are commonly found on distal extremities.[228,230,233,236] The oral cavity is commonly involved when mucous membranes are affected. Oral lesions begin as erythematous patches that coalesce into diffuse shallow ulcerations and erosions. A necrotic pseudomembranous exudate covers the ulcerated mucosa that may mimic candidiasis. Hemorrhagic crusting of the lip vermilion is not uncommon.[232-235] In contrast to cutaneous lesions, the diffuse ulcerations in the oral cavity are painful, and patients can become dehydrated because of lack of fluid intake.[198,200,232,234] In the absence of skin lesions, the mucosal lesion of erythema multiforme can present a diagnostic challenge.[232,234,237-240]

Histopathology and Laboratory Studies

No specific laboratory tests are currently available for the diagnosis of erythema multiforme, and the diagnosis is usually driven by the clinical presentation. However, ancillary laboratory studies can be helpful in the management of these patients. In severe cases, complete blood count usually reveals moderate leukocytosis with atypical lymphocytes. Electrolyte values may be abnormal with severe skin and mucous membrane involvement, and these values are useful to guide volume and electrolyte replacement therapy. The sedimentation rate is usually elevated but is nonspecific. Cultures are indicated in severe cases where secondary infection is a concern and should be obtained from blood, sputum, and mucosal lesions. Herpes simplex virus antigens can sometimes be detected by immunofluorescence studies. Biopsy of skin lesions shows mononuclear perivascular infiltrates and edema with subepidermal bullae formation with necrosis of overlying keratinocytes. Direct and indirect immunofluorescence studies of biopsy material are not diagnostically useful but may be important to exclude other vesiculobullous diseases.[233,234,236,241]

Treatment

Most cases of erythema multiforme are self-limiting, with lesions subsequently resolving within 2 to 3 weeks. Supportive and palliative care using analgesics, soothing mouth rinses, and electrolyte replacement therapy when indicated are appropriate. Antibiotic therapy is initiated when clinical evidence of secondary infection exists.[233,241] The use of corticosteroids in the treatment of erythema multiforme is controversial, and they should be used only with caution.[230,242] Prophylactic oral acyclovir or valacyclovir is effective in decreasing the frequency and severity of recurrent herpes and herpes-associated erythema multiforme.[230,243]

References

1. Birek C: Herpesvirus-induced diseases: oral manifestations and current treatment options, *J Calif Dent Assoc* 28(12):911–921, 2000.
2. Flaitz CM, Jin YT, Hicks MJ, et al.: Kaposi's sarcoma-associated herpesvirus-like DNA sequences (KSHV/HHV-8) in oral AIDS–Kaposi's sarcoma: a PCR and clinicopathologic study, *Oral Surg Oral Med Oral Pathol Oral Radiol Endod* 83(2):259–264, 1997.
3. Harris NL: Epstein-Barr virus in lymphoma. Protagonist or passenger?, [editorial; comment] *Am J Clin Pathol* 98:278–281, 1992.
4. Kempf W, Adams V, Pfaltz M, et al.: Human herpesvirus type 6 and cytomegalovirus in AIDS-associated Kaposi's sarcoma: no evidence for an etiological association, *Hum Pathol* 26(8): 914–919, 1995.

5. Lozada-Nur F, Robinson J, Regezi JA: Oral hairy leukoplakia in nonimmunosuppressed patients. Report of four cases, *Oral Surg Oral Med Oral Pathol* 78(5):599–602, 1994.
6. Muecke M, Amedee RG: Herpes zoster oticus: diagnosis and management, *J LA State Med Soc* 145(8):333–335, 1993.
7. Santucci M, Gallo O, Calzolari A, et al.: Detection of Epstein-Barr viral genome in tumor cells of Warthin's tumor of parotid gland, *Am J Clin Pathol* 100:662–665, 1993.
8. Tsai CC, Chen CL, Hsu HC: Expression of Epstein-Barr virus in carcinomas of major salivary glands: a strong association with lymphoepithelioma-like carcinoma, *Hum Pathol* 27(3):258–262, 1996.
9. Wong KF, Chan JK, Lo ES, et al.: A study of the possible etiologic association of Epstein-Barr virus with reactive hemophagocytic syndrome in Hong Kong Chinese, *Hum Pathol* 27(11):1239–1242, 1996.
10. Xu F, Sternberg MR, Kottiri BJ, et al.: Trends in herpes simplex virus type 1 and type 2 seroprevalence in the United States, *JAMA* 296(8):964–973, 2006.
11. Cunningham AL, Taylor R, Taylor J, et al.: Prevalence of infection with herpes simplex virus types 1 and 2 in Australia: a nationwide population based survey, *Sex Transm Infect* 82(2):164–168, 2006.
12. Kasubi MJ, Nilsen A, Marsden HS, et al.: Prevalence of antibodies against herpes simplex virus types 1 and 2 in children and young people in an urban region in Tanzania, *J Clin Microbiol* 44(8):2801–2807, 2006.
13. Birek C, Ficarra G: The diagnosis and management of oral herpes simplex infection, *Curr Infect Dis Rep* 8(3):181–188, 2006.
14. Hellenbrand W, Thierfelder W, Muller-Pebody B, et al.: Seroprevalence of herpes simplex virus type 1 (HSV-1) and type 2 (HSV-2) in former East and West Germany, 1997-1998, *Eur J Clin Microbiol Infect Dis* 24(2):131–135, 2005.
15. Schillinger JA, Xu F, Sternberg MR, et al.: National seroprevalence and trends in herpes simplex virus type 1 in the United States, 1976-1994, *Sex Transm Dis* 31(12):753–760, 2004.
16. Orton PW, Huff JC, Tonnesen MG, et al.: Detection of a herpes simplex viral antigen in skin lesions of erythema multiforme, *Ann Intern Med* 101(1):48–50, 1984.
17. Amir J: Clinical aspects and antiviral therapy in primary herpetic gingivostomatitis, *Paediatr Drugs* 3(8):593–597, 2001.
18. Amir J, Harel L, Smetana Z, et al.: The natural history of primary herpes simplex type 1 gingivostomatitis in children, *Pediatr Dermatol* 16(4):259–263, 1999.
19. Chauvin PJ, Ajar AH: Acute herpetic gingivostomatitis in adults: a review of 13 cases, including diagnosis and management, *J Can Dent Assoc* 68(4):247–251, 2002.
20. Frenkel LM: Herpes simplex virus infections in adolescents, *Adolesc Med* 6(1):65–78, 1995.
21. Holbrook WP, Gudmundsson GT, Ragnarsson KT: Herpetic gingivostomatitis in otherwise healthy adolescents and young adults, *Acta Odontol Scand* 59(3):113–115, 2001.
22. King DL, Steinhauer W, Garcia-Godoy F, et al.: Herpetic gingivostomatitis and teething difficulty in infants, *Pediatr Dent* 14(2):82–85, 1992.
23. Zaal MJ, Volker-Dieben HJ, D'Amaro J: Prognostic value of Hutchinson's sign in acute herpes zoster ophthalmicus, *Graefes Arch Clin Exp Ophthalmol* 241(3):187–191, 2003.
24. Tomkinson A, Roblin DG, Brown MJ: Hutchinson's sign and its importance in rhinology, *Rhinology* 33(3):180–182, 1995.
25. Neville BW, Damm DD, Allen CM, et al.: *Oral and maxillofacial pathology*, 2e, Philadelphia, 2002, Saunders.
26. McKeough MB, Spruance SL: Comparison of new topical treatments for herpes labialis: efficacy of penciclovir cream, acyclovir cream, and n-docosanol cream against experimental cutaneous herpes simplex virus type 1 infection, *Arch Dermatol* 137(9):1153–1158, 2001.
27. Miller CS, Cunningham LL, Lindroth JE, et al.: The efficacy of valacyclovir in preventing recurrent herpes simplex virus infections associated with dental procedures, *J Am Dent Assoc* 135(9):1311–1318, 2004.
28. Spruance SL, Nett R, Marbury T, et al.: Acyclovir cream for treatment of herpes simplex labialis: results of two randomized, double-blind, vehicle-controlled, multicenter clinical trials, *Antimicrob Agents Chemother* 46(7):2238–2243, 2002.
29. Spruance SL, Hill J: Clinical significance of antiviral therapy for episodic treatment of herpes labialis: exploratory analyses of the combined data from two valaciclovir trials, *J Antimicrob Chemother* 53(5):703–707, 2004.
30. Spruance SL: N-docosanol (Abreva) for herpes labialis: problems and questions, *J Am Acad Dermatol* 47(3):457–458, 2002.
31. Spruance SL, Kriesel JD: Treatment of herpes simplex labialis, *Herpes* 9(3):64–69, 2002.
32. Milman N, Scheibel J, Jessen O: Lysine prophylaxis in recurrent herpes simplex labialis: a double-blind, controlled crossover study, *Acta Derm Venereol* 60(1):85–87, 1980.
33. Milman N, Scheibel J, Jessen O: Failure of lysine treatment in recurrent herpes simplex labialis, *Lancet* 2(8096):942, 1978.
34. Elish D, Singh F, Weinberg JM: Therapeutic options for herpes labialis: experimental and natural therapies, *Cutis* 76(1):38–40, 2005.
35. Amir J, Harel L, Smetana Z, et al.: Treatment of herpes simplex gingivostomatitis with aciclovir in children: a randomised double blind placebo controlled study, *BMJ* 314(7097):1800–1803, 1997.
36. Dekker CL, Prober CG: Pediatric uses of valacyclovir, penciclovir and famciclovir, *Pediatr Infect Dis J* 20(11):1079–1081, 2001.
37. Schmitt DL, Johnson DW, Henderson FW: Herpes simplex type 1 infections in group day care, *Pediatr Infect Dis J* 10(10):729–734, 1991.
38. Cengizlier R, Uysal G, Guven A, et al.: Herpetic finger infection, *Cutis* 69(4):291–292, 2002.
39. Gill MJ, Arlette J, Buchan K: Herpes simplex virus infection of the hand. A profile of 79 cases, *Am J Med* 84(1):89–93, 1988.
40. Steiner MJ, DeWalt DA, Byerley JS: Is this child dehydrated? *JAMA* 291(22):2746–2754, 2004.
41. Margolis P, Gadomski A: The rational clinical examination. Does this infant have pneumonia? *JAMA* 279(4):308–313, 1998.
42. Ito T, Watanabe A, Akabane J: Acute disseminated encephalomyelitis developed after acute herpetic gingivostomatitis, *Tohoku J Exp Med* 192(2):151–155, 2000.
43. Puczynski MS, Ow EP, Rust C: Cardiopulmonary arrest due to misuse of viscous lidocaine, *Arch Otolaryngol* 111(11):768–769, 1985.
44. Rivaud E, Massiani MA, Vincent F, et al.: Valacyclovir hydrochloride therapy and thrombotic thrombocytopenic purpura in an HIV-infected patient, *Arch Intern Med* 160(11):1705–1706, 2000.
45. Bell WR, Chulay JD, Feinberg JE: Manifestations resembling thrombotic microangiopathy in patients with advanced human immunodeficiency virus (HIV) disease in a cytomegalovirus prophylaxis trial (ACTG 204), *Medicine (Baltimore)* 76(5):369–380, 1997.
46. Grose C, Wiedeman J: Generic acyclovir vs. famciclovir and valacyclovir, *Pediatr Infect Dis J* 16(9):838–841, 1997.

47. Shah VA, Chong CY, Chan KP, et al.: Clinical characteristics of an outbreak of hand, foot and mouth disease in Singapore, *Ann Acad Med Singapore* 32(3):381–387, 2003.
48. Urashima M, Shindo N, Okabe N: Seasonal models of herpangina and hand-foot-mouth disease to simulate annual fluctuations in urban warming in Tokyo, *Jpn J Infect Dis* 56(2):48–53, 2003.
49. Chang LY, King CC, Hsu KH, et al.: Risk factors of enterovirus 71 infection and associated hand, foot, and mouth disease/herpangina in children during an epidemic in Taiwan, *Pediatrics* 109(6):e88, 2002.
50. Lin TY, Chang LY, Hsia SH, et al.: The 1998 enterovirus 71 outbreak in Taiwan: pathogenesis and management, *Clin Infect Dis* 34(Suppl 2):S52–S57, 2002.
51. Yamadera S, Yamashita K, Kato N, et al.: Herpangina surveillance in Japan, 1982-1989. A report of the national epidemiological surveillance of infectious agents in Japan, *Jpn J Med Sci Biol* 44(1):29–39, 1991.
52. Nakamura Y, Yanagawa H, Nagai M: Epidemic patterns of infectious diseases from the results of the surveillance of infectious diseases in Japan, *Pediatr Infect Dis J* 7(4):262–266, 1988.
53. Neville B, et al.: Viral infections. In Neville BW, editor: *Oral and maxillofacial pathology*, ed 3, St. Louis, 2009, Saunders/Elsevier, pp 257–258.
54. Miller MJ: Summary of current nomenclature, taxonomy, and classification of various microbial agents. Viral taxonomy, *Clin Infect Dis* 16(5):612–613, 1993.
55. Nakayama T, Urano T, Osano M, et al.: Outbreak of herpangina associated with Coxsackievirus B3 infection, *Pediatr Infect Dis J* 8(8):495–498, 1989.
56. Chang LY, Lin TY, Huang YC, et al.: Comparison of enterovirus 71 and coxsackie-virus A16 clinical illnesses during the Taiwan enterovirus epidemic, 1998, *Pediatr Infect Dis J* 18(12):1092–1096, 1999.
57. Hsiung GD, Wang JR: Enterovirus infections with special reference to enterovirus 71, *J Microbiol Immunol Infect* 33(1):1–8, 2000.
58. Kung CM, King CC, Lee CN, et al.: Differences in replication capacity between enterovirus 71 isolates obtained from patients with encephalitis and those obtained from patients with herpangina in Taiwan, *J Med Virol* 79(1):60–68, 2007.
59. Landry ML, Fonseca SN, Cohen S, et al.: Fatal enterovirus type 71 infection: rapid detection and diagnostic pitfalls, *Pediatr Infect Dis J* 14(12):1095–1100, 1995.
60. Scott LA, Stone MS: Viral exanthems, *Dermatol Online J* 9(3):4, 2003.
61. Lopez-Sanchez A, Guijarro GB, Hernandez VG: Human repercussions of foot and mouth disease and other similar viral diseases, *Med Oral* 8(1):26–32, 2003.
62. Hosoya M, Ishiko H, Shimada Y, et al.: Diagnosis of group A coxsackieviral infection using polymerase chain reaction, *Arch Dis Child* 87(4):316–319, 2002.
63. Marks MI: Coxsackieviruses in human disease, *Am Fam Physician* 12(5):88–91, 1975.
64. Casparis S, Borm JM, Tektas S, et al.: Oral lichen planus (OLP), oral lichenoid lesions (OLL), oral dysplasia, and oral cancer: retrospective analysis of clinicopathological data from 2002-2011, *Oral Maxillofac Surg* 19(2):149–156, 2015.
65. Lehman JS, Tollefson MM, Gibson LE: Lichen planus, *Int J Dermatol* 48(7):682–694, 2009.
66. Eisen D: The clinical features, malignant potential, and systemic associations of oral lichen planus: a study of 723 patients, *J Am Acad Dermatol* 46(2):207–214, 2002.
67. Segura S, Rozas-Munoz E, Toll A, et al.: Evaluation of MYC status in oral lichen planus in patients with progression to oral squamous cell carcinoma, *Br J Dermatol* 169(1):106–114, 2013.
68. Cobos-Fuentes MJ, Martinez-Sahuquillo-Marquez A, Gallardo-Castillo I, et al.: Oral lichenoid lesions related to contact with dental materials: a literature review, *Med Oral Patol Cirurg Bucal* 14(10):e514–e520, 2009.
69. Carrozzo M: Oral diseases associated with hepatitis C virus infection. Part 2: lichen planus and other diseases, *Oral Dis* 14(3):217–228, 2008.
70. Gandolfo S, Carbone M, Carrozzo M, et al.: Oral lichen planus and hepatitis C virus (HCV) infection: is there a relationship? A report of 10 cases, *J Oral Pathol Med* 23:119–122, 1994.
71. Lodi G, Pellicano R, Carrozzo M: Hepatitis C virus infection and lichen planus: a systematic review with meta-analysis, *Oral Dis* 16(7):601–612, 2010.
72. Maticic M: Lichen planus in hepatitis C virus infection: an early marker that may save lives, *Acta Dermatovenerol Alp Pannonica Adriat* 16(1):3–6, 2007.
73. Fessa C, Lim P, Kossard S, et al.: Lichen planus-like drug eruptions due to beta-blockers: a case report and literature review, *Am J Clin Dermatol* 13(6):417–421, 2012.
74. McCartan BE, McCreary CE: Oral lichenoid drug eruptions, *Oral Dis* 3(2):58–63, 1997.
75. McCartan BE, McCreary CE, Healy CM: Studies of drug-induced lichenoid reactions: criteria for case selection, *Oral Dis* 9(4):163–164, 2003.
76. Rice PJ, Hamburger J: Oral lichenoid drug eruptions: their recognition and management, *Dent Update* 29(9):442–447, 2002.
77. Farhi D, Dupin N: Pathophysiology, etiologic factors, and clinical management of oral lichen planus, part I: facts and controversies, *Clin Dermatol* 28(1):100–108, 2010.
78. Muller S: Oral manifestations of dermatologic disease: a focus on lichenoid lesions, *Head Neck Pathol* 5(1):36–40, 2011.
79. Schlosser BJ: Lichen planus and lichenoid reactions of the oral mucosa, *Dermatol Ther* 23(3):251–267, 2010.
80. Scully C, Carrozzo M: Oral mucosal disease: Lichen planus, *Br J Oral Maxillofac Surg* 46(1):15–21, 2008.
81. Azizi A, Rezaee M: Comparison of periodontal status in gingival oral lichen planus patients and healthy subjects, *Dermatol Res Pract* 2012:561232, 2012.
82. Gagari E, Damoulis PD: Desquamative gingivitis as a manifestation of chronic mucocutaneous disease, *J Dtsch Dermatol Ges* 9(3):184–188, 2011.
83. Stone SJ, Heasman PA, Staines KS, et al.: The impact of structured plaque control for patients with gingival manifestations of oral lichen planus: a randomized controlled study, *J Clin Periodontol*, 42(4):356–362, 2015.
84. Eisen D: The vulvovaginal-gingival syndrome of lichen planus. The clinical characteristics of 22 patients, *Arch Dermatol* 130(11):1379–1382, 1994.
85. Usatine RP, Tinitigan M: Diagnosis and treatment of lichen planus, *Am Fam Physician* 84(1):53–60, 2011.
86. Robertson WD, Wray D: Immunohistochemical study of oral keratoses including lichen planus, *J Oral Pathol Med* 22:180–182, 1993.
87. Al-Hashimi I, Schifter M, Lockhart PB, et al.: Oral lichen planus and oral lichenoid lesions: diagnostic and therapeutic considerations, *Oral Surg Oral Med Oral Pathol Oral Radiol Endod* 103(Suppl):S25.e21-12, 2007.

88. Shengyuan L, Songpo Y, Wen W, et al.: Hepatitis C virus and lichen planus: a reciprocal association determined by a meta-analysis, *Arch Dermatol* 145(9):1040–1047, 2009.
89. Lopez-Jornet P, Camacho-Alonso F, Salazar-Sanchez N: Topical tacrolimus and pimecrolimus in the treatment of oral lichen planus: an update, *J Oral Pathol Med* 39(3):201–205, 2010.
90. Asch S, Goldenberg G: Systemic treatment of cutaneous lichen planus: an update, *Cutis* 87(3):129–134, 2011.
91. Zhang J, Zhou G, Du GF, et al.: Biologics, an alternative therapeutic approach for oral lichen planus, *J Oral Pathol Med* 40(7):521–524, 2011.
92. Messadi DV, Younai F: Aphthous ulcers, *Dermatol Ther* 23(3):281–290, 2010.
93. Zunt SL: Recurrent aphthous stomatitis, *Dermatol Clin* 21(1):33–39, 2003.
94. Scully C: Clinical practice. Aphthous ulceration, *N Engl J Med* 355(2):165–172, 2006.
95. Scully C, Porter S: Oral mucosal disease: recurrent aphthous stomatitis, *Br J Oral Maxillofac Surg* 46(3):198–206, 2008.
96. Miller MF, Garfunkel AA, Ram CA, et al.: The inheritance of recurrent aphthous stomatitis. Observations on susceptibility, *Oral Surg Oral Med Oral Pathol* 49(5):409–412, 1980.
97. Belenguer-Guallar I, Jimenez-Soriano Y, Claramunt-Lozano A: Treatment of recurrent aphthous stomatitis. A literature review, *J Clin Exp Dent* 6(2):e168–e174, 2014.
98. Casiglia JM: Recurrent aphthous stomatitis: etiology, diagnosis, and treatment, *Gen Dent* 50(2):157–166, 2002.
99. Hunter L, Addy M: Chlorhexidine gluconate mouthwash in the management of minor aphthous ulceration. A double-blind, placebo-controlled cross-over trial, *Br Dent J* 162(3):106–110, 1987.
100. Aggarwal H, Singh MP, Nahar P, et al.: Efficacy of low-level laser therapy in treatment of recurrent aphthous ulcers—a sham controlled, split mouth follow up study, *J Clin Diagn Res* 8(2):218–221, 2014.
101. Albrektson M, Hedstrom L, Bergh H: Recurrent aphthous stomatitis and pain management with low-level laser therapy: a randomized controlled trial, *Oral Surg Oral Med Oral Pathol Oral Radiol* 117(5):590–594, 2014.
102. Al-Mutawa SA, Hegab SM: Behçet's disease, *Clin Exp Med* 4(3):103–131, 2004.
103. Al-Otaibi LM, Porter SR, Poate TW: Behçet's disease: a review, *J Dent Res* 84(3):209–222, 2005.
104. Alekberova ZS, Madanat VI, Polianskaia IS, et al.: The HLA-B5 immunogenetic marker in Behçet's disease, *Ter Arkh* 65(5):12–14, 1993.
105. Bonfioli AA, Orefice F: Behçet's disease, *Semin Ophthalmol* 20(3):199–206, 2005.
106. Houman MH, Ben GI, Lamloum M, et al.: Esophageal involvement in Behçet's disease, *Yonsei Med J* 43(4):457–460, 2002.
107. Lee LA: Behçet disease, *Semin Cutan Med Surg* 20(1):53–57, 2001.
108. Onder M, Gurer MA: Behçet's disease: an enigmatic vasculitis, *Clin Dermatol* 17(5):571–576, 1999.
109. Hegab S, Al-Mutawa S: Immunopathogenesis of Behçet's disease, *Clin Immunol* 96(3):174–186, 2000.
110. Onder M, Gurer MA: The multiple faces of Behçet's disease and its aetiological factors, *J Eur Acad Dermatol Venereol* 15(2):126–136, 2001.
111. Bahabri SA, al-Mazyed A, al-Balaa S, et al.: Juvenile Behçet's disease in Arab children, *Clin Exp Rheumatol* 14(3):331–335, 1996.
112. Tugal-Tutkun I, Urgancioglu M: Childhood-onset uveitis in Behçet disease: a descriptive study of 36 cases, *Am J Ophthalmol* 136(6):1114–1119, 2003.
113. Marshall SE: Behçet's disease, *Best Pract Res Clin Rheumatol* 18(3):291–311, 2004.
114. Helm TN, Camisa C, Allen C, et al.: Clinical features of Behçet's disease. Report of four cases, *Oral Surg Oral Med Oral Pathol* 72(1):30–34, 1991.
115. Rapidis AD, Langdon JD, Patel MF: Recurrent oral and oculogenital ulcerations (Behçet's syndrome), *Oral Surg Oral Med Oral Pathol* 41(4):457–466, 1976.
116. Rigby AS, Chamberlain MA, Bhakta B: Behçet's disease, *Baillieres Clin Rheumatol* 9(2):375–395, 1995.
117. Zahiri K, Hachim K, Zamd A, et al.: Renal involvement in Behçet's disease. About six cases, *Rev Med Interne* 24(1):4–10, 2003.
118. Chang HK, Kim SY: Survey and validation of the criteria for Behçet's disease recently used in Korea: a suggestion for modification of the International Study Group criteria, *J Korean Med Sci* 18(1):88–92, 2003.
119. Lee S: Diagnostic criteria of Behçet's disease: problems and suggestions, *Yonsei Med J* 38(6):365–369, 1997.
120. O'Neill TW, Rigby AS, Silman AJ, et al.: Validation of the International Study Group criteria for Behçet's disease, *Br J Rheumatol* 33(2):115–117, 1994.
121. Barnes CG: Behçet's syndrome—classification criteria, *Ann Med Interne (Paris)* 150(6):477–482, 1999.
122. Akbulut L, Gur G, Bodur H, et al.: Peripheral neuropathy in Behçet disease: an electroneurophysiological study, *Clin Rheumatol*, 26(8):1240–1244, 2007.
123. Saip S, Siva A, Altintas A, et al.: Headache in Behçet's syndrome, *Headache* 45(7):911–919, 2005.
124. Al-Fahad SA, Al-Araji AH: Neuro-Behçet's disease in Iraq: a study of 40 patients, *J Neurol Sci* 170(2):105–111, 1999.
125. Tugal-Tutkun I, Onal S, tan-Yaycioglu R, et al.: Uveitis in Behçet disease: an analysis of 880 patients, *Am J Ophthalmol* 138(3):373–380, 2004.
126. Houman MH, Ben GI, Khiari BSI, et al.: Deep vein thrombosis in Behçet's disease, *Clin Exp Rheumatol* 19(5 Suppl 24):S48–S50, 2001.
127. Altman LK: Experts re-examine Dr. Reiter, his syndrome and his Nazi past, *New York Times* F7:12, 2000.
128. Amor B: Reiter's syndrome. Diagnosis and clinical features, *Rheum Dis Clin North Am* 24(4):677–695, 1998.
129. Barth WF, Segal K: Reactive arthritis (Reiter's syndrome), *Am Fam Physician* 60(2):499–503, 507, 1999.
130. Hughes RA, Keat AC: Reiter's syndrome and reactive arthritis: a current view, *Semin Arthritis Rheum* 24(3):190–210, 1994.
131. Leirisalo-Repo M: Reactive arthritis, *Scand J Rheumatol* 34(4):251–259, 2005.
132. Leirisalo-Repo M: Inflammation in HLA-B27-associated diseases, *Scand J Rheumatol Suppl* 87:140–147, 1990, discussion 147.
133. Reveille JD: HLA-B27 and the seronegative spondyloarthropathies, *Am J Med Sci* 316(4):239–249, 1998.
134. Leirisalo-Repo M, Hannu T, Mattila L: Microbial factors in spondyloarthropathies: insights from population studies, *Curr Opin Rheumatol* 15(4):408–412, 2003.
135. Altman EM, Centeno LV, Mahal M, et al.: AIDS-associated Reiter's syndrome, *Ann Allergy* 72(4):307–316, 1994.
136. Leirisalo-Repo M: Early arthritis and infection, *Curr Opin Rheumatol* 17(4):433–439, 2005.

137. Yu DT: Pathogenesis of reactive arthritis, *Intern Med (Tokyo)* 38(2):97–101, 1999.
138. Willkens RF, Arnett FC, Bitter T, et al.: Reiter's syndrome. Evaluation of preliminary criteria for definite disease, *Arthritis Rheum* 24(6):844–849, 1981.
139. Martin DH, Mroczkowski TF: Dermatologic manifestations of sexually transmitted diseases other than HIV, *Infect Dis Clin North Am* 8(3):533–582, 1994.
140. Klecker RJ, Weissman BN: Imaging features of psoriatic arthritis and Reiter's syndrome, *Semin Musculoskelet Radiol* 7(2):115–126, 2003.
141. Kiss S, Letko E, Qamruddin S, et al.: Long-term progression, prognosis, and treatment of patients with recurrent ocular manifestations of Reiter's syndrome, *Ophthalmology* 110(9):1764–1769, 2003.
142. Fox R, Calin A, Gerber RC, et al.: The chronicity of symptoms and disability in Reiter's syndrome. An analysis of 131 consecutive patients, *Ann Intern Med* 91(2):190–193, 1979.
143. Eschle-Meniconi ME, Ahmad SR, Foster CS: Mucous membrane pemphigoid: an update, *Curr Opin Ophthalmol* 16(5):303–307, 2005.
144. Ahmed AR, Kurgis BS, Rogers 3rd RS: Cicatricial pemphigoid, *J Am Acad Dermatol* 24(6 Pt 1):987–1001, 1991.
145. Fleming TE, Korman NJ: Cicatricial pemphigoid, *J Am Acad Dermatol* 43(4):571–591, 2000, quiz 591–594.
146. Bagan J, Lo Muzio L, Scully C: Mucosal disease series. Number III. Mucous membrane pemphigoid, *Oral Dis* 11(4):197–218, 2005.
147. Walsh SR, Hogg D, Mydlarski PR: Bullous pemphigoid: from bench to bedside, *Drugs* 65(7):905–926, 2005.
148. Alonso-Llamazares J, Rogers 3rd RS, Oursler JR, et al.: Bullous pemphigoid presenting as generalized pruritus: observations in six patients, *Int J Dermatol* 37(7):508–514, 1998.
149. Di Zenzo G, Della Torre R, Zambruno G, et al.: Bullous pemphigoid: from the clinic to the bench, *Clin Dermatol* 30(1):3–16, 2012.
150. Di Zenzo G, Marazza G, Borradori L: Bullous pemphigoid: physiopathology, clinical features and management, *Adv Dermatol* 23:257–288, 2007.
151. Vassileva S: Drug-induced pemphigoid: bullous and cicatricial, *Clin Dermatol* 16(3):379–387, 1998.
152. Sollecito TP, Parisi E: Mucous membrane pemphigoid, *Dent Clin North Am* 49(1):91–106, 2005.
153. Ruocco E, Wolf R, Caccavale S, et al.: Bullous pemphigoid: associations and management guidelines: facts and controversies, *Clin Dermatol* 31(4):400–412, 2013.
154. Southwell B, Riaz F, Khachemoune A: Bullous pemphigoid: a short review, *Dermatol Nurs* 21(6):322–326, 2009.
155. Ujiie H, Shibaki A, Nishie W, et al.: What's new in bullous pemphigoid, *J Dermatol* 37(3):194–204, 2010.
156. Kershenovich R, Hodak E, Mimouni D: Diagnosis and classification of pemphigus and bullous pemphigoid, *Autoimmun Rev* 13(4-5):477–481, 2014.
157. Daniel BS, Borradori L, Hall 3rd RP, et al.: Evidence-based management of bullous pemphigoid, *Dermatol Clin* 29(4):613–620, 2011.
158. Kirtschig G, Middleton P, Bennett C, et al.: Interventions for bullous pemphigoid, *Cochrane Database Syst Rev*(10), 2010. Cd002292.
159. Knudson RM, Kalaaji AN, Bruce AJ: The management of mucous membrane pemphigoid and pemphigus, *Dermatol Ther* 23(3):268–280, 2010.
160. Gunther C, Wozel G, Meurer M, et al.: Topical tacrolimus treatment for cicatricial pemphigoid, *J Am Acad Dermatol* 50(2):325–326, 2004.
161. Gurcan HM, Ahmed AR: Efficacy of dapsone in the treatment of pemphigus and pemphigoid: analysis of current data, *Am J Clin Dermatol* 10(6):383–396, 2009.
162. Heffernan MP, Bentley DD: Successful treatment of mucous membrane pemphigoid with infliximab, *Arch Dermatol* 142(10):1268–1270, 2006.
163. Bystryn JC, Rudolph JL: Pemphigus, *Lancet* 366(9479):61–73, 2005.
164. Black M, Mignogna MD, Scully C: Number II. Pemphigus vulgaris, *Oral Dis* 11(3):119–130, 2005.
165. Chams-Davatchi C, Valikhani M, Daneshpazhooh M, et al.: Pemphigus: analysis of 1209 cases, *Int J Dermatol* 44(6):470–476, 2005.
166. Woldegiorgis S, Swerlick RA: Pemphigus in the southeastern United States, *South Med J* 94(7):694–698, 2001.
167. Pisanti S, Sharav Y, Kaufman E, et al.: Pemphigus vulgaris: incidence in Jews of different ethnic groups, according to age, sex, and initial lesion, *Oral Surg Oral Med Oral Pathol* 38(3):382–387, 1974.
168. Ettlin DA: Pemphigus. *Dent Clin North Am* 49(1):107–125, 2005.
169. Ben Lagha N, Poulesquen V, Roujeau JC, et al.: Pemphigus vulgaris: a case-based update, *J Can Dent Assoc* 71(9):667–672, 2005.
170. Markopoulos AK, Antoniades DZ, Zaraboukas T: Pemphigus vegetans of the oral cavity, *Int J Dermatol* 45(4):425–428, 2006.
171. Ahmed AR, Blose DA: Pemphigus vegetans. Neumann type and Hallopeau type, *Int J Dermatol* 23(2):135–141, 1984.
172. Ahmed AR, Gurcan HM: Use of intravenous immunoglobulin therapy during pregnancy in patients with pemphigus vulgaris, *J Eur Acad Dermatol Venereol* 25(9):1073–1079, 2011.
173. Ahmed AR, Shetty S: A comprehensive analysis of treatment outcomes in patients with pemphigus vulgaris treated with rituximab, *Autoimmun Rev* 14(4):323–331, 2015.
174. Ahmed AR, Spigelman Z, Cavacini LA, et al.: Treatment of pemphigus vulgaris with rituximab and intravenous immune globulin, *N Engl J Med* 355(17):1772–1779, 2006.
175. Bystryn JC, Rudolph JL: IVI g treatment of pemphigus: how it works and how to use it, *J Invest Dermatol* 125(6):1093–1098, 2005.
176. Enk AH, Knop J: Mycophenolate is effective in the treatment of pemphigus vulgaris, *Arch Dermatol* 135(1):54–56, 1999.
177. Bystryn JC, Habib N: Treatment options in pemphigus, *G Ital Dermatol Venereol* 144(4):351–361, 2009.
178. Flotte TJ, Olbricht SM, Collins AB, et al.: Immunopathologic studies of adult linear IgA bullous dermatosis, *Arch Pathol Lab Med* 109(5):457–459, 1985.
179. Smith EP, Zone JJ: Dermatitis herpetiformis and linear IgA bullous dermatosis, *Dermatol Clin* 11(3):511–526, 1993.
180. Wilson BD, Beutner EH, Kumar V, et al.: Linear IgA bullous dermatosis. An immunologically defined disease, *Int J Dermatol* 24(9):569–574, 1985.
181. Chorzelski TP, Jablonska S, Maciejowska E: Linear IgA bullous dermatosis of adults, *Clin Dermatol* 9(3):383–392, 1991.
182. Jablonska S: The therapies for linear IgA bullous dermatosis of childhood, *Pediatr Dermatol* 16(5):415, 1999.
183. Wojnarowska F, Bhogal BS, Black MM: Chronic bullous disease of childhood and linear IgA disease of adults are IgA1-mediated diseases, *Br J Dermatol* 131(2):201–204, 1994.

184. Femiano F, Scully C, Gombos F: Linear IgA dermatosis induced by a new angiotensin-converting enzyme inhibitor, *Oral Surg Oral Med Oral Pathol Oral Radiol Endod* 95(2): 169–173, 2003.
185. Godfrey K, Wojnarowska F, Leonard J: Linear IgA disease of adults: association with lymphoproliferative malignancy and possible role of other triggering factors, *Br J Dermatol* 123(4):447–452, 1990.
186. Leonard JN, Griffiths CE, Powles AV, et al.: Experience with a gluten free diet in the treatment of linear IgA disease, *Acta Dermatovenereol* 67(2):145–148, 1987.
187. Laforest C, Huilgol SC, Casson R, et al.: Autoimmune bullous diseases: ocular manifestations and management, *Drugs* 65(13):1767–1779, 2005.
188. Sanchez AR, Rogers 3rd RS, Kupp LI, et al.: Desquamative gingivitis associated with IgG/IgA pemphigoid presents a challenging diagnosis and treatment: a case report, *J Periodontol* 75(12):1714–1719, 2004.
189. Weinberg MA, Insler MS, Campen RB: Mucocutaneous features of autoimmune blistering diseases, *Oral Surg Oral Med Oral Pathol Oral Radiol Endod* 84(5):517–534, 1997.
190. Chan LS, Regezi JA, Cooper KD: Oral manifestations of linear IgA disease, *J Am Acad Dermatol* 22(2 Pt 2):362–365, 1990.
191. Cohen LM, Ugent RB: Linear IgA bullous dermatosis occurring after carbamazepine, *J Am Acad Dermatol* 46(2 Suppl Case Reports):S32–S33, 2002.
192. del Valle AE, Martinez-Sahuquillo A, Padron JR, et al.: Two cases of linear IgA disease with clinical manifestations limited to the gingiva, *J Periodontol* 74(6):879–882, 2003.
193. O'Regan E, Bane A, Flint S, et al.: Linear IgA disease presenting as desquamative gingivitis: a pattern poorly recognized in medicine, *Arch Otolaryngol Head Neck Surg* 130(4):469–472, 2004.
194. Bickle K, Roark TR, Hsu S: Autoimmune bullous dermatoses: a review, *Am Fam Physician* 65(9):1861–1870, 2002.
195. Cohen DM, Bhattacharyya I, Zunt SL, et al.: Linear IgA disease histopathologically and clinically masquerading as lichen planus, *Oral Surg Oral Med Oral Pathol Oral Radiol Endod* 88(2):196–201, 1999.
196. Flotte TJ, Baird LG: Immunoglobulin light and heavy chain isotypes in skin diseases: restricted distribution in bullous pemphigoid and linear IgA bullous dermatosis, *J Immunol (Baltimore)* 136(2):491–496, 1986.
197. Chan LS, Cooper KD: Interferon alfa for linear IgA bullous dermatosis, *Lancet* 340(8816):425, 1992.
198. Mitsuhashi Y, Hashimoto I: Genetic abnormalities and clinical classification of epidermolysis bullosa, *Arch Dermatol Res* 295(Suppl 1):S29–S33, 2003.
199. Pfendner E, Rouan F, Uitto J: Progress in epidermolysis bullosa: the phenotypic spectrum of plectin mutations, *Exp Dermatol* 14(4):241–249, 2005.
200. Solovan C, Ciolan M, Olariu L: The biomolecular and ultrastructural basis of epidermolysis bullosa, *Acta Dermatovenerol Alp Pannonica Adriat* 14(4):127–135, 2005.
201. Uitto J, Richard G: Progress in epidermolysis bullosa: genetic classification and clinical implications, *Am J Med Genet C Semin Med Genet* 131C(1):61–74, 2004.
202. Varki R, Sadowski S, Pfendner E, et al.: Epidermolysis bullosa. I. Molecular genetics of the junctional and hemidesmosomal variants, *J Med Genet* 43(8):641–652, 2006.
203. Woodley DT, Chen M: Epidermolysis bullosa: then and now, *J Am Acad Dermatol* 51(1 Suppl):S55–S57, 2004.
204. Cunningham BB, Kirchmann TT, Woodley D: Colchicine for epidermolysis bullosa acquisita, *J Am Acad Dermatol* 34(5):781–784, 1996.
205. Hallel-Halevy D, Nadelman C, Chen M, et al.: Epidermolysis bullosa acquisita: update and review, *Clin Dermatol* 19(6):712–718, 2001.
206. Miller JL, Stricklin GP, Fine JD, et al.: Remission of severe epidermolysis bullosa acquisita induced by extracorporeal photochemotherapy, *Br J Dermatol* 133(3):467–471, 1995.
207. Wakelin SH, Bhogal B, Black MM, et al.: Epidermolysis bullosa acquisita associated with epidermal-binding circulating antibodies, *Br J Dermatol* 136(4):604–609, 1997.
208. Trent JT, Kirsner RS: Epidermolysis bullosa: identification and treatment, *Adv Skin Wound Care* 16(6):284–290, 2003.
209. Dar NR, Hameed A, Khan AA: Epidermolysis bullosa acquisita, *J Pak Med Assoc* 47(7):192–194, 1997.
210. Silva LC, Cruz RA, bou-Id LR, et al.: Clinical evaluation of patients with epidermolysis bullosa: review of the literature and case reports, *Spec Care Dent* 24(1):22–27, 2004.
211. Laimer M, Lanschuetzer CM, Diem A, et al.: Herlitz junctional epidermolysis bullosa, *Dermatol Clin* 28(1):55–60, 2010.
212. Feijoo JF, Bugallo J, Limeres J, et al.: Inherited epidermolysis bullosa: an update and suggested dental care considerations, *J Am Dent Assoc* 142(9):1017–1025, 2011.
213. Kramer SM, Serrano MC, Zillmann G, et al.: Oral health care for patients with epidermolysis bullosa—best clinical practice guidelines, *Int J Paediatr Dent* 22(Suppl 1):1–35, 2012.
214. Stavropoulos F, Abramowicz S: Management of the oral surgery patient diagnosed with epidermolysis bullosa: report of 3 cases and review of the literature, *J Oral Maxillofac Surg* 66(3):554–559, 2008.
215. Pekiner FN, Yucelten D, Ozbayrak S, et al.: Oral-clinical findings and management of epidermolysis bullosa, *J Clin Pediatr Dent* 30(1):59–65, 2005.
216. Chen M, Kim GH, Prakash L, et al.: Epidermolysis bullosa acquisita: autoimmunity to anchoring fibril collagen, *Autoimmunity* 45(1):91–101, 2012.
217. Fine JD, Bruckner-Tuderman L, Eady RA, et al.: Inherited epidermolysis bullosa: updated recommendations on diagnosis and classification, *J Am Acad Dermatol* 70(6):1103–1126, 2014.
218. Fine JD, Eady RA, Bauer EA, et al.: The classification of inherited epidermolysis bullosa (EB): Report of the Third International Consensus Meeting on Diagnosis and Classification of EB, *J Am Acad Dermatol* 58(6):931–950, 2008.
219. Hsu CK, Wang SP, Lee JY, et al.: Treatment of hereditary epidermolysis bullosa: updates and future prospects, *Am J Clin Dermatol* 15(1):1–6, 2014.
220. Kim JH, Lee SE, Kim SC: Successful treatment of epidermolysis bullosa acquisita with rituximab therapy, *J Dermatol* 39(5): 477–479, 2012.
221. Langan SM, Williams HC: A systematic review of randomized controlled trials of treatments for inherited forms of epidermolysis bullosa, *Clin Exp Dermatol* 34(1):20–25, 2009.
222. Petrova A, Ilic D, McGrath JA: Stem cell therapies for recessive dystrophic epidermolysis bullosa, *Br J Dermatol* 163(6):1149–1156, 2010.
223. Penarrocha-Diago M, Serrano C, Sanchis JM, et al.: Placement of endosseous implants in patients with oral epidermolysis bullosa, *Oral Surg Oral Med Oral Pathol Oral Radiol Endod* 90(5):587–590, 2000.

224. Mohr C, Sunderkotter C, Hildebrand A, et al.: Successful treatment of epidermolysis bullosa acquisita using intravenous immunoglobulins, *Br J Dermatol* 132(5):824–826, 1995.
225. Robinowitz BN, Towery DS, Meyers SW, et al.: Successful treatment of epidermolysis bullosa acquisita with mesalazine [letter], *Br J Dermatol* 137(1):154–155, 1997.
226. Schmidt E, Hunzelmann N, Zillikens D, et al.: Rituximab in refractory autoimmune bullous diseases, *Clin Exp Dermatol* 31(4):503–508, 2006.
227. Woodley DT, Keene DR, Atha T, et al.: Injection of recombinant human type VII collagen restores collagen function in dystrophic epidermolysis bullosa, *Nat Med* 10(7):693–695, 2004.
228. Assier H, Bastuji-Garin S, Revuz J, et al.: Erythema multiforme with mucous membrane involvement and Stevens-Johnson syndrome are clinically different disorders with distinct causes, *Arch Dermatol* 131(5):539–543, 1995.
229. Auquier-Dunant A, Mockenhaupt M, Naldi L, et al.: Correlations between clinical patterns and causes of erythema multiforme majus, Stevens-Johnson syndrome, and toxic epidermal necrolysis: results of an international prospective study, *Arch Dermatol* 138(8):1019–1024, 2002.
230. Williams PM, Conklin RJ: Erythema multiforme: a review and contrast from Stevens-Johnson syndrome/toxic epidermal necrolysis, *Dent Clin North Am* 49(1):67–76, 2005.
231. Bastuji-Garin S, Rzany B, Stern RS, et al.: Clinical classification of cases of toxic epidermal necrolysis, Stevens-Johnson syndrome, and erythema multiforme, *Arch Dermatol* 129(1):92–96, 1993.
232. Farthing P, Bagan JV, Scully C: Mucosal disease series. Number IV. Erythema multiforme, *Oral Dis* 11(5):261–267, 2005.
233. Lamoreux MR, Sternbach MR, Hsu WT: Erythema multiforme, *Am Fam Physician* 74(11):1883–1888, 2006.
234. Ayangco L, Rogers 3rd RS: Oral manifestations of erythema multiforme, *Dermatol Clin* 21(1):195–205, 2003.
235. Huff JC: Erythema multiforme and latent herpes simplex infection, *Semin Dermatol* 11(3):207–210, 1992.
236. Katta R: Taking aim at erythema multiforme. How to spot target lesions and less typical presentations, *Postgrad Med* 107(1):87–90, 2000.
237. Al-Johani KA, Fedele S, Porter SR: Erythema multiforme and related disorders, *Oral Surg Oral Med Oral Pathol Oral Radiol Endod* 103(5):642–654, 2007.
238. Schneider G, Kachroo S, Jones N, et al.: A systematic review of validated methods for identifying erythema multiforme major/minor/not otherwise specified, Stevens-Johnson syndrome, or toxic epidermal necrolysis using administrative and claims data, *Pharmacoepidemiol Drug Safety* 21(Suppl 1):236–239, 2012.
239. Sokumbi O, Wetter DA: Clinical features, diagnosis, and treatment of erythema multiforme: a review for the practicing dermatologist, *Int J Dermatol* 51(8):889–902, 2012.
240. Sinha A, Chander J, Natarajan S: Erythema multiforme presenting as chronic oral ulceration due to unrecognised herpes simplex virus infection, *Clin Exp Dermatol* 31(5):737–738, 2006.
241. Leaute-Labreze C, Lamireau T, Chawki D, et al.: Diagnosis, classification, and management of erythema multiforme and Stevens-Johnson syndrome, *Arch Dis Child* 83(4):347–352, 2000.
242. Yeung AK, Goldman RD: Use of steroids for erythema multiforme in children, *Can Fam Physician* 51:1481–1483, 2005.
243. Tatnall FM, Schofield JK, Leigh IM: A double-blind, placebo-controlled trial of continuous acyclovir therapy in recurrent erythema multiforme, *Br J Dermatol* 132(2):267–270, 1995.

25

Osteomyelitis and Osteoradionecrosis

BRIAN ALPERT, GEORGE KUSHNER

Osteomyelitis

Osteomyelitis and osteoradionecrosis are diseases of bone characterized by necrosis of the bone secondary to bacterial invasion. In the case of osteomyelitis, infectious agents overcome host resistance and progressively involve the marrow, compromising blood supply—resulting in necrosis and ultimate sequestration. For osteoradionecrosis (ORN), the bone is already compromised by a radiation-induced avascular necrosis. With its diminished endosteal and periosteal blood supply, it easily succumbs to this bacterial insult and its sequelae. In the case of osteomyelitis, the endosteal and periosteal blood supply at least began intact. In ORN, it may already be fatally compromised.

Classification

Osteomyelitis can be defined or classified in a variety of ways.[1-5] It can be classified by presentation: acute, suppurative, chronic, non-suppurative, sclerosing, and so on. It can be defined by type of infected organism involved: luetic, tubercular, actinomycotic, staphylococcal, fungal, herpetic, and so on. We find Hudson's classification[5] most useful, as he defines it by acute or chronic and identifies the various types within this classification. A detailed description of the various types of osteomyelitis and their presentations is beyond the scope of this chapter; we will leave this to the various pathology texts and monographs.

Diagnosis

Classic acute osteomyelitis with swelling, fever, adenopathy, leukocytosis, loose teeth, paresthesia, multiple draining fistulas, and so forth is today a third-world presentation rarely seen in developed countries, presumably because of antibiotic use and more optimal dental care. Such cases were classically managed with removal of the etiology—the infected teeth—and exposure of and decortication of the jaw (sequestrectomy and saucerization) via extraoral approach to allow vascular periosteum to contact the exposed marrow. This was followed by irrigations and antibiotic therapy.

In the developed world, the presentation is more subtle but still with swelling, pain, temperature elevation, adenopathy, leukocytosis, and drainage. The hallmark symptom to distinguish osteomyelitis from long-term or chronic dentoalveolar abscess is often paresthesia. Although at one time this was fairly rare, the incidence is certainly on the rise, presumably due to antibiotic resistance or immune deficiency or suppression. At any rate, we are seeing more now. All too commonly, the scenario of toothache, root canal treatment, extraction, infected socket followed by management with multiple debridements, IV antibiotic regimens, drains, and so on, with continued progressive involvement of more bone, intensifying paresthesia, and, ultimately, pathologic fracture is seen. That is the point when patients are seen in a tertiary medical center.

Microbiology

Osteomyelitis of the long bones has been generally associated with a staphylococcal etiology.[6] Osteomyelitis of the jaw is more likely due to streptococcal and anaerobic bacteria.[7] Most of these infections are mixed and often difficult to define because of contamination from oral flora. Gram stains are often useful in showing various bacterial types as well as the presence of fungi. Proper culture and sensitivities and bone batteries on excised sequestra, although useful in theory, are often unrewarding in actual use.

Laboratory Studies

Laboratory studies would obviously reveal leukocytosis and elevation of the erythrocyte sedimentation rate as well as C-reactive protein. These, of course, are indicators of inflammation and are hardly specific for osteomyelitis; yet they can be used to follow progression of the disease.[8] The absence of these indicators when it seems that all the

hallmarks of osteomyelitis are present should suggest the possibility of neoplasm.

Imaging

Today modern imaging has further defined both what we see and what we do with computed tomographic (CT) images demonstrating circumferential involvement not amenable to the traditional sequestrectomy and saucerization and lateral decortication but requiring full-thickness resection (Figure 25-1).

Panoramic imaging can give an idea, but changes in the bone with a classic "moth-eaten" appearance are late and only reflect demineralization of the cortex. The CT scan will give a much truer picture circumferentially of the cortical erosion so that one can more truly see the extent of the disease. Nuclear medicine in the form of technetium-99, gallium-67, or indium-111 can be used to highlight areas of increased bony activity as well as differentiate areas of infection from other etiologies. Magnetic resonance imaging is said to be useful in identifying earlier stages of osteomyelitis by noting the loss of marrow signal.[9]

Management

Over the past almost 50 years, management has involved sequestrectomy and saucerization—opening up the involved area, removing the sequestrum, and decorticating to allow periosteal and vascular contact in addition to intravenous antibiotics appropriate for the culture and sensitivity.[5] If, as was all too often the case, this was unsuccessful and led to pathologic fracture, skeletal pin fixation was used to maintain mandibular continuity. For a time it was fashionable to place antibiotic-impregnated beads into the defect.[10,11] Reconstruction was accomplished following resolution of the infection and complete healing of the oral wound (Figure 25-2).

Later, reconstruction plate (an internal fixator) replaced the skeletal pins. Later yet, primary reconstruction was done at the time of resection. The current management involves resection with inferior alveolar nerve preservation and primary reconstruction with either autogenous bone graft or tissue engineering, a treatment that has dramatically shortened the course of this condition (Figures 25-3, 25-4, and 25-5).[8]

Medical Management

In almost 50 years in tertiary care medical centers, we have never seen a case of mandibular osteomyelitis managed successfully with antibiotics either alone or with "minor surgery." It just does not happen. Perhaps if we were to see condylar osteomyelitis in a neonate—a classic presentation in the first half of the 20th century—antibiotics alone might suffice, but not in adults and certainly not when there is nonvital bone needing to be debrided. This is not to say that chronic disease states such as diabetes should not be optimized. Likewise, antibiotic therapy is certainly a useful adjunct.

Discussion and Personal Perspectives

There are some fundamental truths regarding osteomyelitis and its management.

1. The presenting symptoms and appearance of osteomyelitis and cancer—primary or metastatic—is often indistinguishable (radiographic appearance, paresthesia, etc.). Tumor must be ruled out.[8]
2. Bone devitalized by infection, the hallmark of which is the "moth-eaten" appearance, must be resorbed by the body (a long process), exfoliated, or surgically removed.
3. The soft tissue is not infected, the bone is—thus there is no reason to delay definitive reconstruction.
4. The resected area does not require tumor resection protocol (in continuity), so there is no reason not to attempt preservation of the inferior alveolar neurovascular bundle by resecting the dead bone in pieces. Although the patient may already suffer from paresthesia, a hallmark symptom of mandibular osteomyelitis, one should still try to facilitate recovery of sensation.

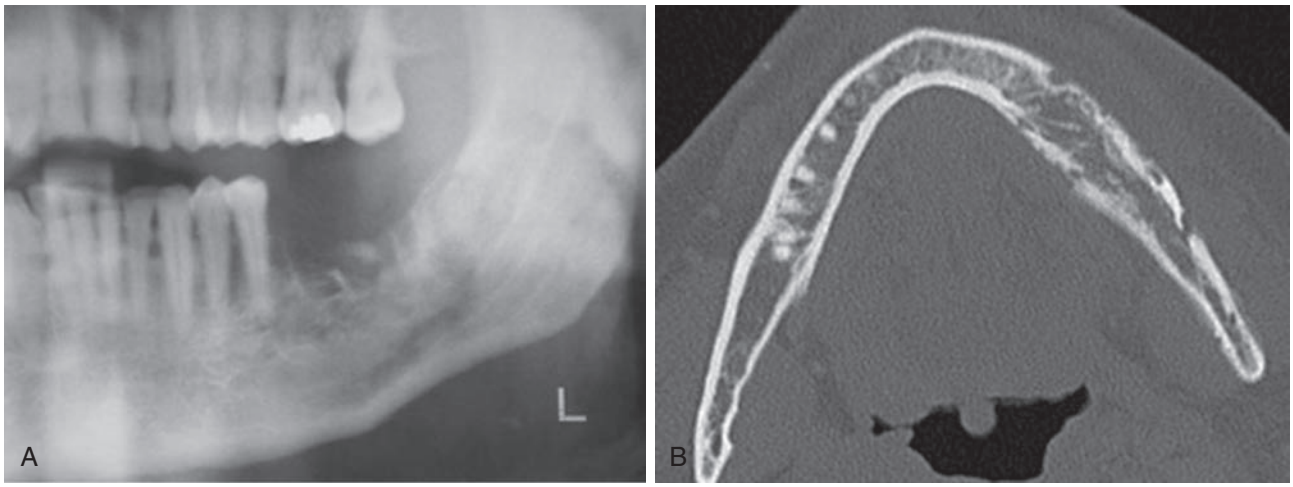

• **Figure 25-1** Panoramic **(A)** and computed tomography (CT) **(B)** images of same jaw demonstrating circumferential involvement seen on CT but not appreciated on panoramic radiograph.

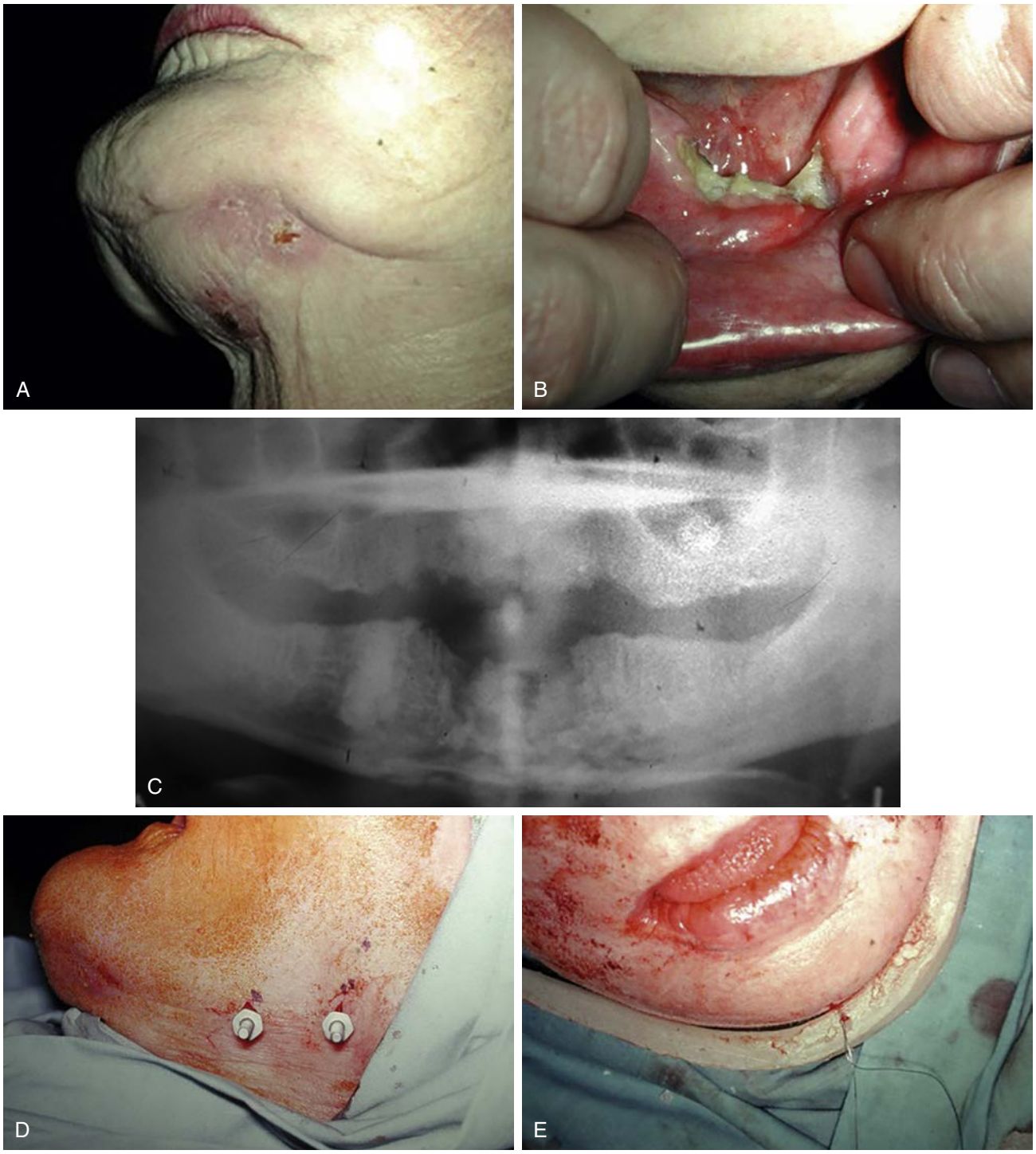

• **Figure 25-2** 55-year-old woman referred by her dentist for treatment of osteomyelitis. She had her remaining six anterior teeth removed 6 weeks prior, followed by exposed bone, multiple debridements, and recently, draining extraoral fistulae **(A)** and obvious nonviable bone **(B).** Panoramic radiograph **(C)** revealed extensive osteomyelitis. Resection of the involved bone was planned. Skeletal pins **(D)** and an external acrylic bar **(E)** were applied. The anterior mandible was resected via an intraoral approach

Continued

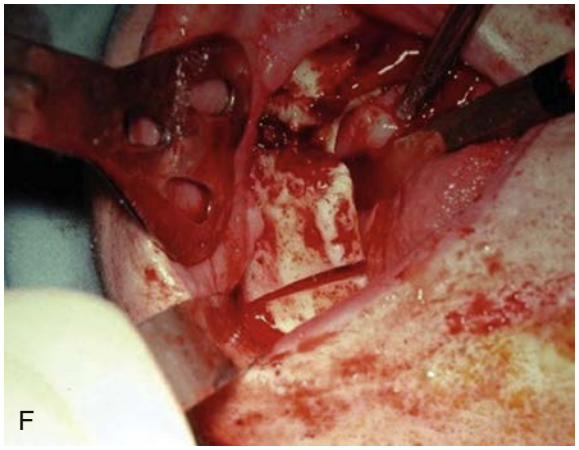



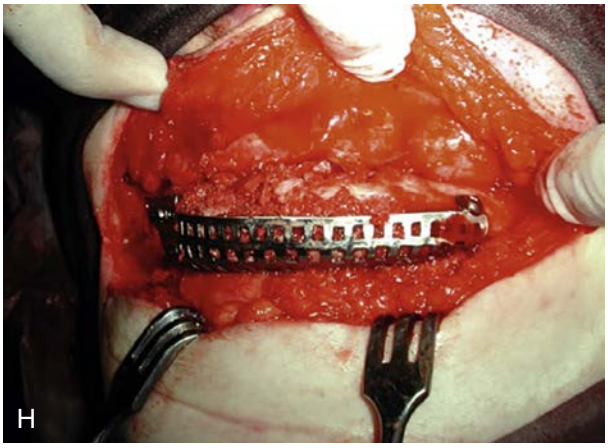

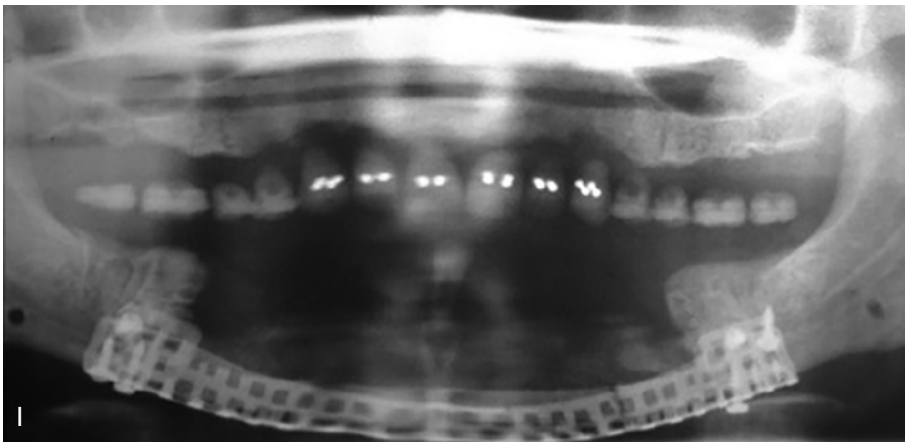

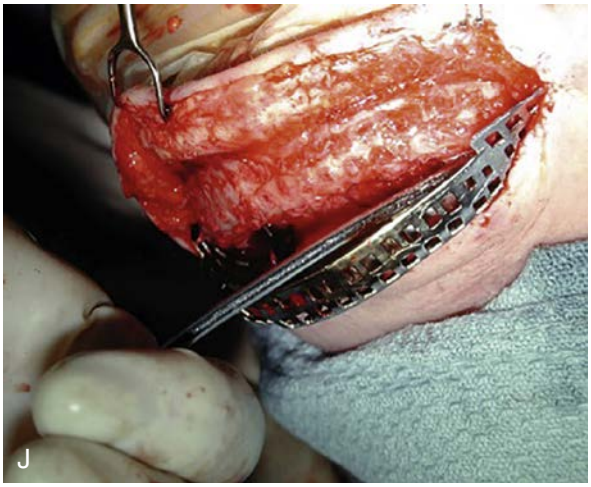

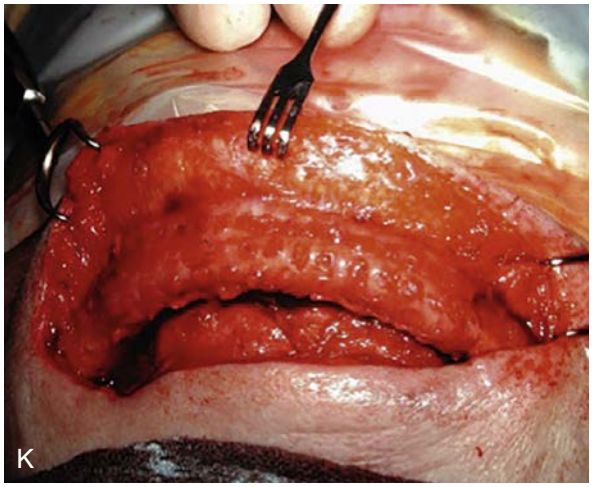

• **Figure 25-2, cont'd** **(F, G).** Following healing of the intraoral wound and closure of fistulae, the anterior mandible was reconstructed with "mesh and mush" via an extraoral approach **(H).** Panoramic radiograph **(I)** demonstrates the reconstruction. Four months later, the mesh was removed **(J)** leaving a nicely reconstructed anterior mandible **(K).**

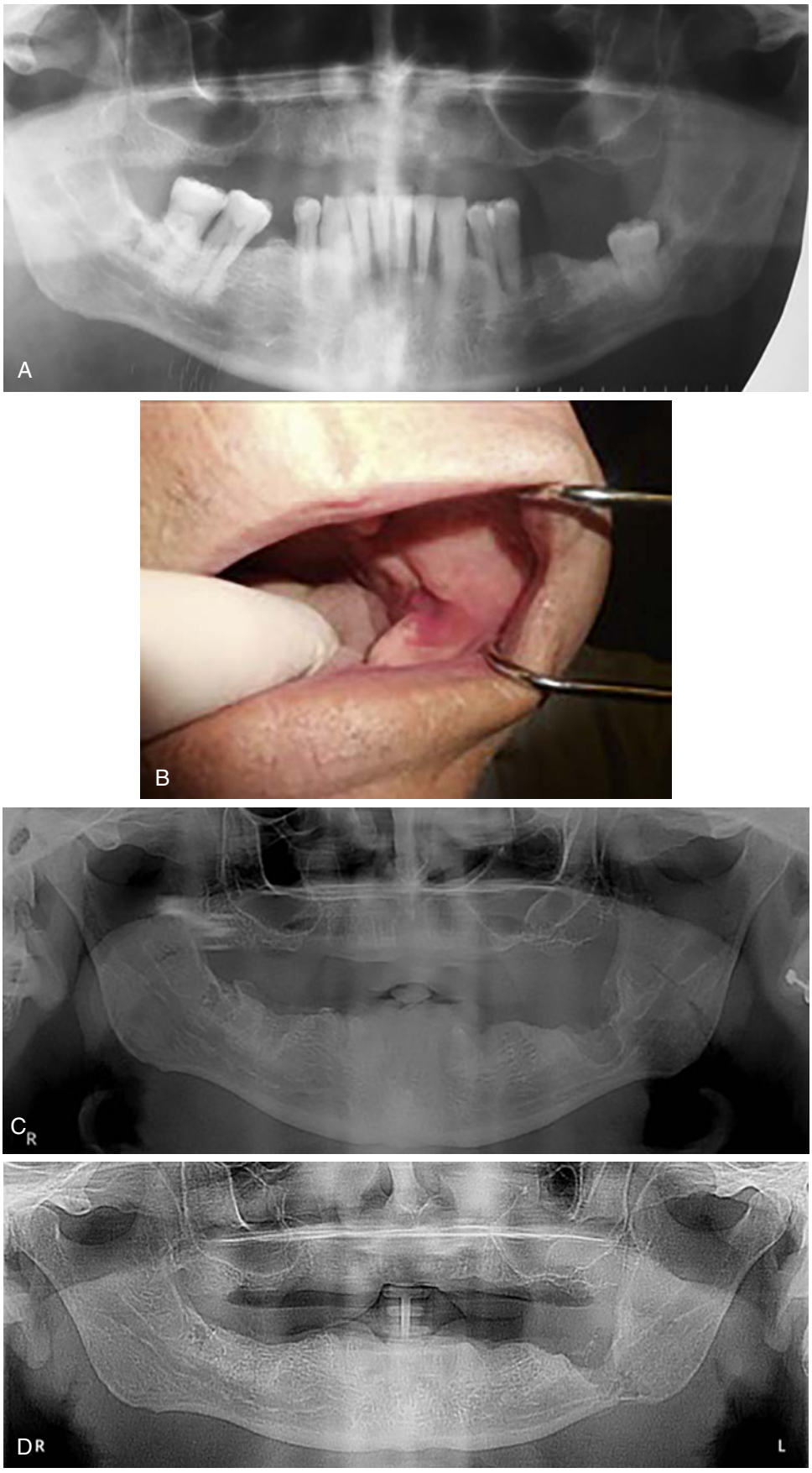

• **Figure 25-3** Panoramic image of a 73-year-old man prior to removal of remaining teeth in preparation for a denture **(A).** The #17 wound failed to heal **(B)** leading to progressive bone loss and pathologic fracture **(C-E).** Extraoral exposure

Continued

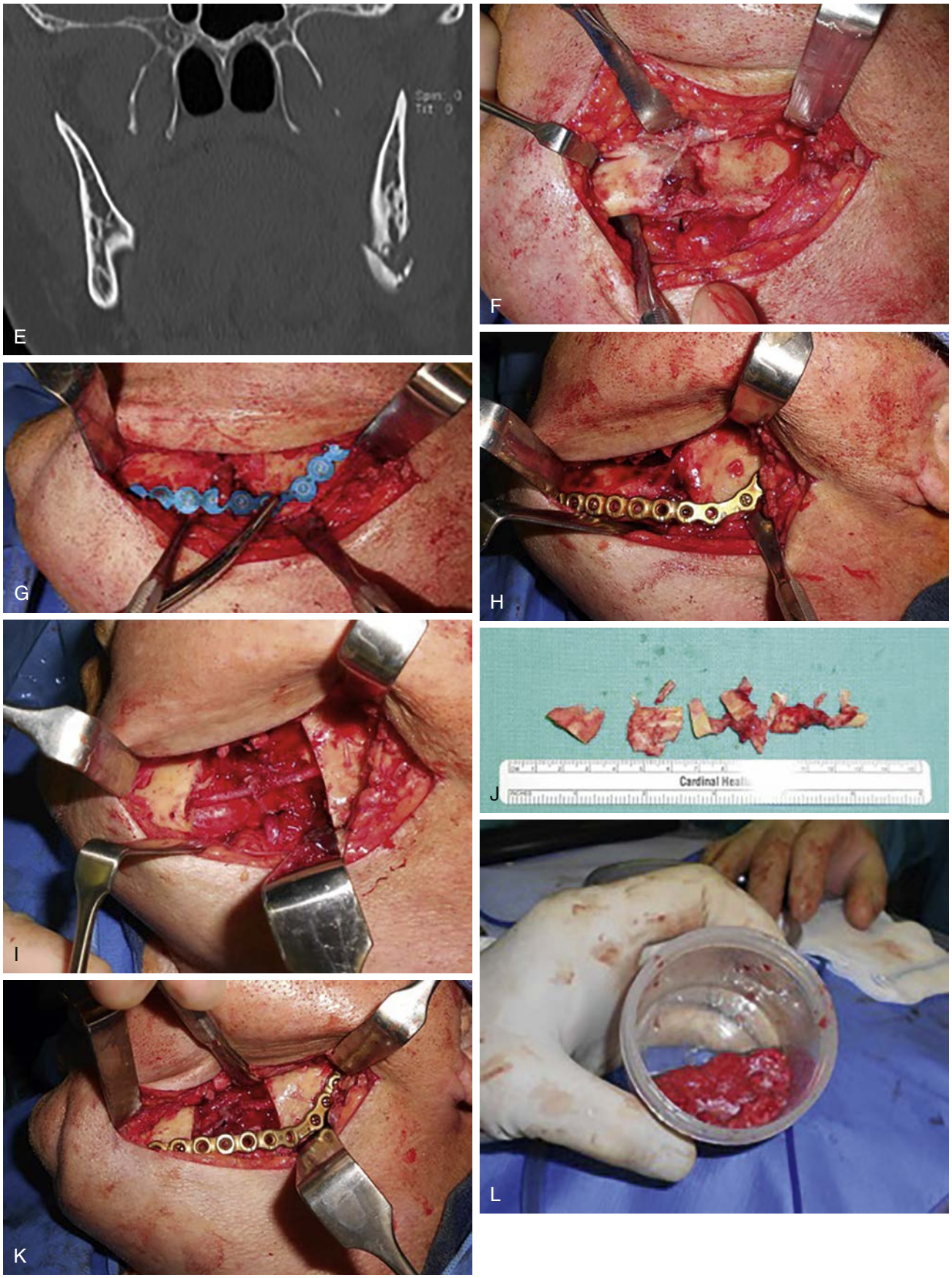

• **Figure 25-3, cont'd** **(F)** revealed the extent of destruction. A template was applied **(G)** allowing adaptation of a reconstruction plate **(H)** temporarily prior to resection of the area of osteomyelitis with neurovascular bundle preservation **(I).** Note that the bone was not resected in continuity **(J).** The reconstruction plate was adapted **(K)** and the oral wound closed in two layers. A particulate graft was harvested from the tibia **(L),** compressed in a modified large bone bore syringe



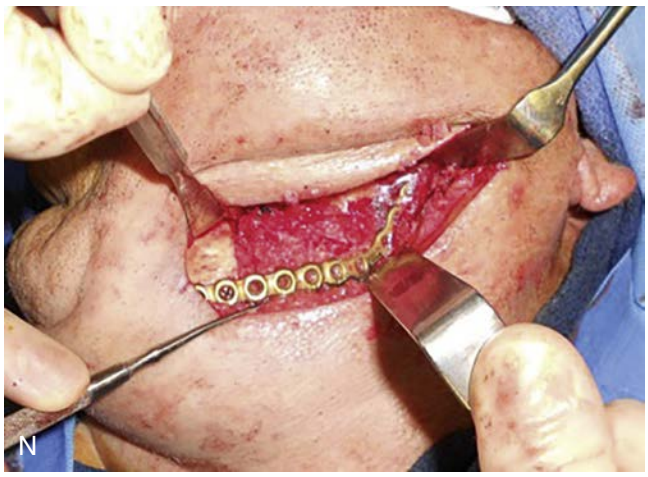



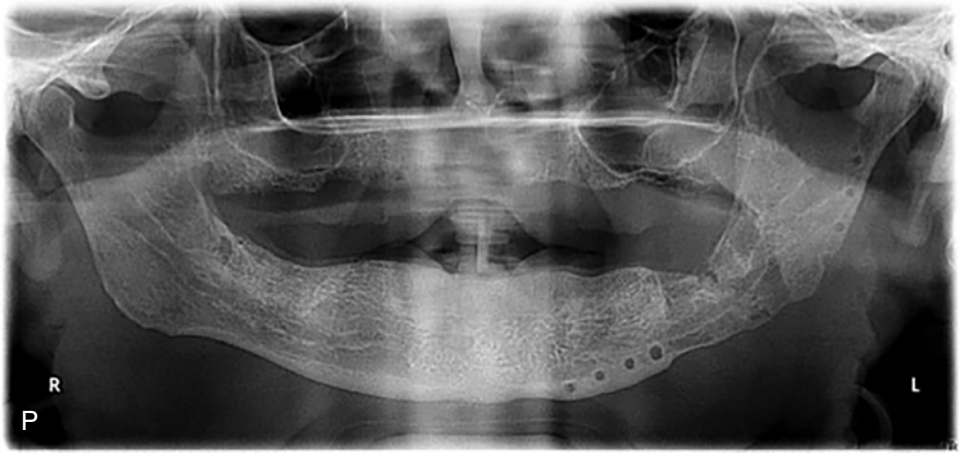

• **Figure 25-3, cont'd** **(M),** and placed into the defect **(N).** Immediate postoperative three-dimensional computed tomography **(O)** demonstrates the resection and reconstruction. Panoramic x-ray at 7 months, following removal of the reconstruction plate, demonstrates bone fill **(P).** Note the formation of a new mandibular canal in the grafted section.



• **Figure 25-4** A 72-year-old man following a 3-month history of herpes zoster of V-3. The skin eruptions have resolved **(A)** but there is exposed alveolus **(B)** and a pathologic fracture evident **(C).** The exposed alveolus was lifted off **(D, E)** revealing a bed of granulation tissue present

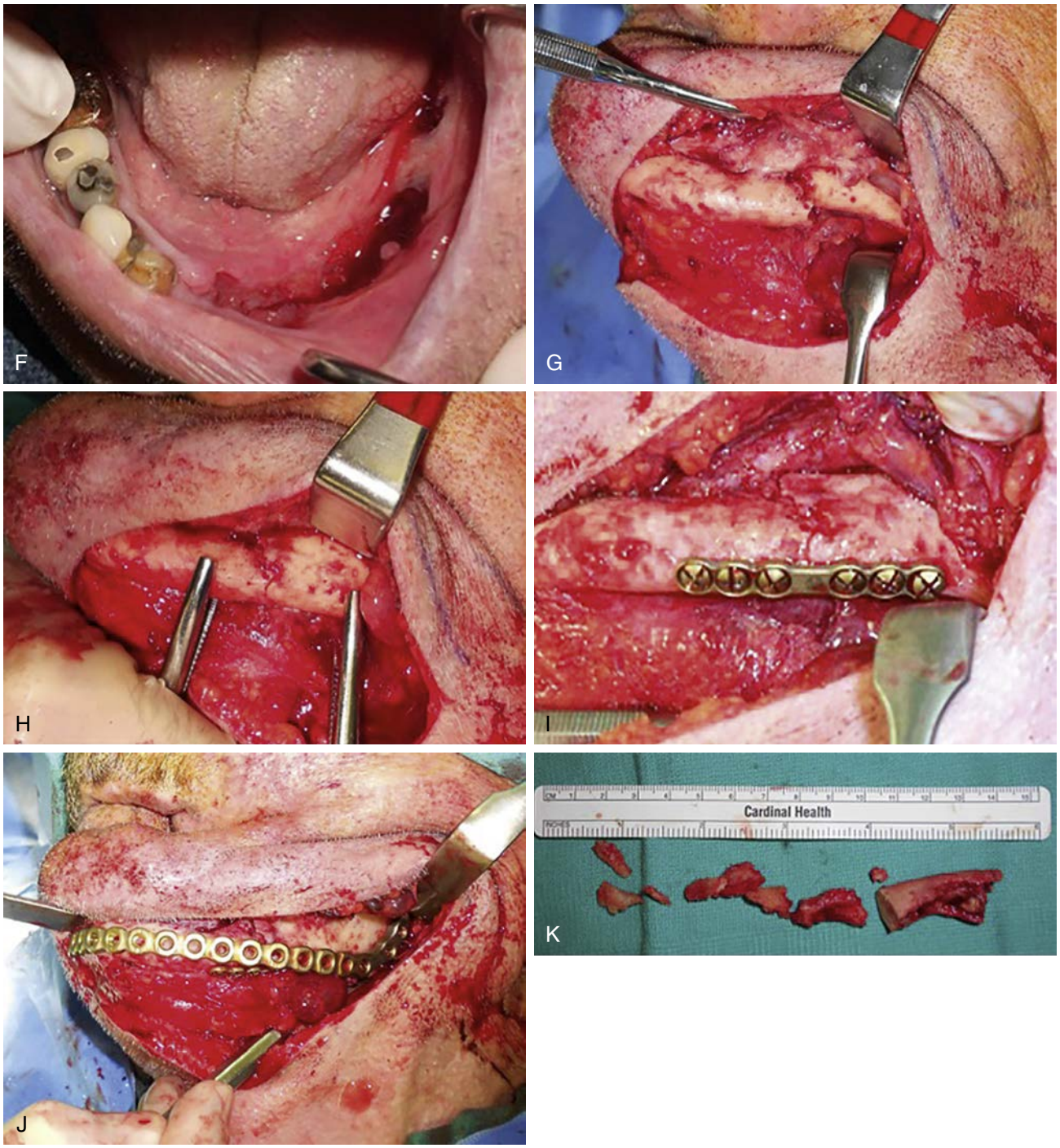

• **Figure 25-4, cont'd** **(F).** Exposure through the neck revealed the fracture **(G),** which was reduced **(H)** and temporarily stabilized with an inferior border miniplate **(I).** A locking reconstruction plate (LRP) was fitted and temporarily applied **(J).** The area of osteomyelitis was now resected in pieces **(K)** with

Continued

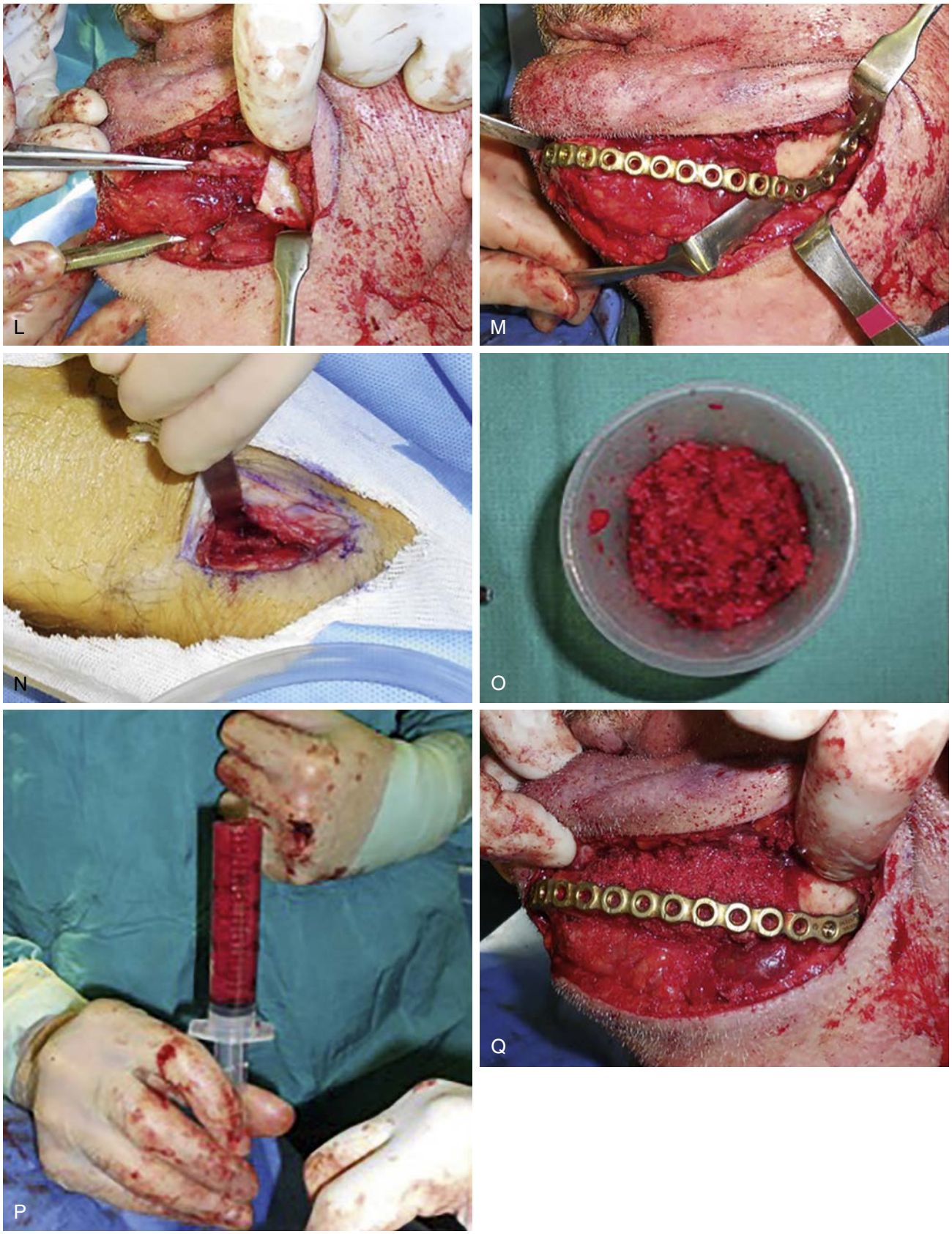

• **Figure 25-4, cont'd** preservation of the inferior alveolar neurovascular bundle **(L).** The LRP was reapplied and fixed with multiple screws **(M),** and the oral wound was closed. A particulate marrow graft was harvested from the tibia **(N, O)**, compressed with a modified large-bore syringe **(P),** and placed in the defect **(Q).**

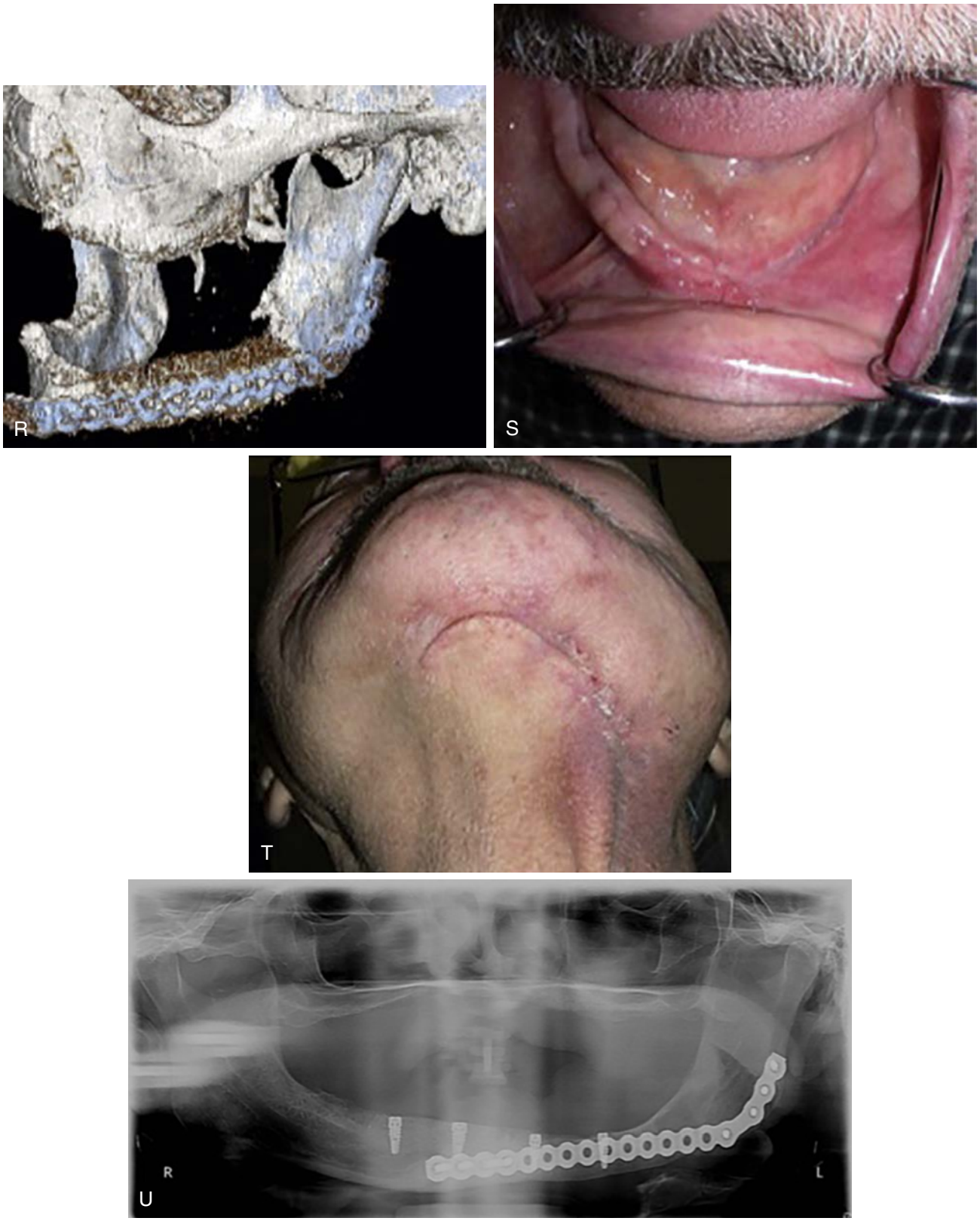

• **Figure 25-4, cont'd** Three-dimensional computed tomography **(R)** demonstrates the reconstruction. Healed oral **(S)** and neck **(T)** wounds and the panoramic radiograph at 6 months **(U)** following dental implant placement (two in grafted area).

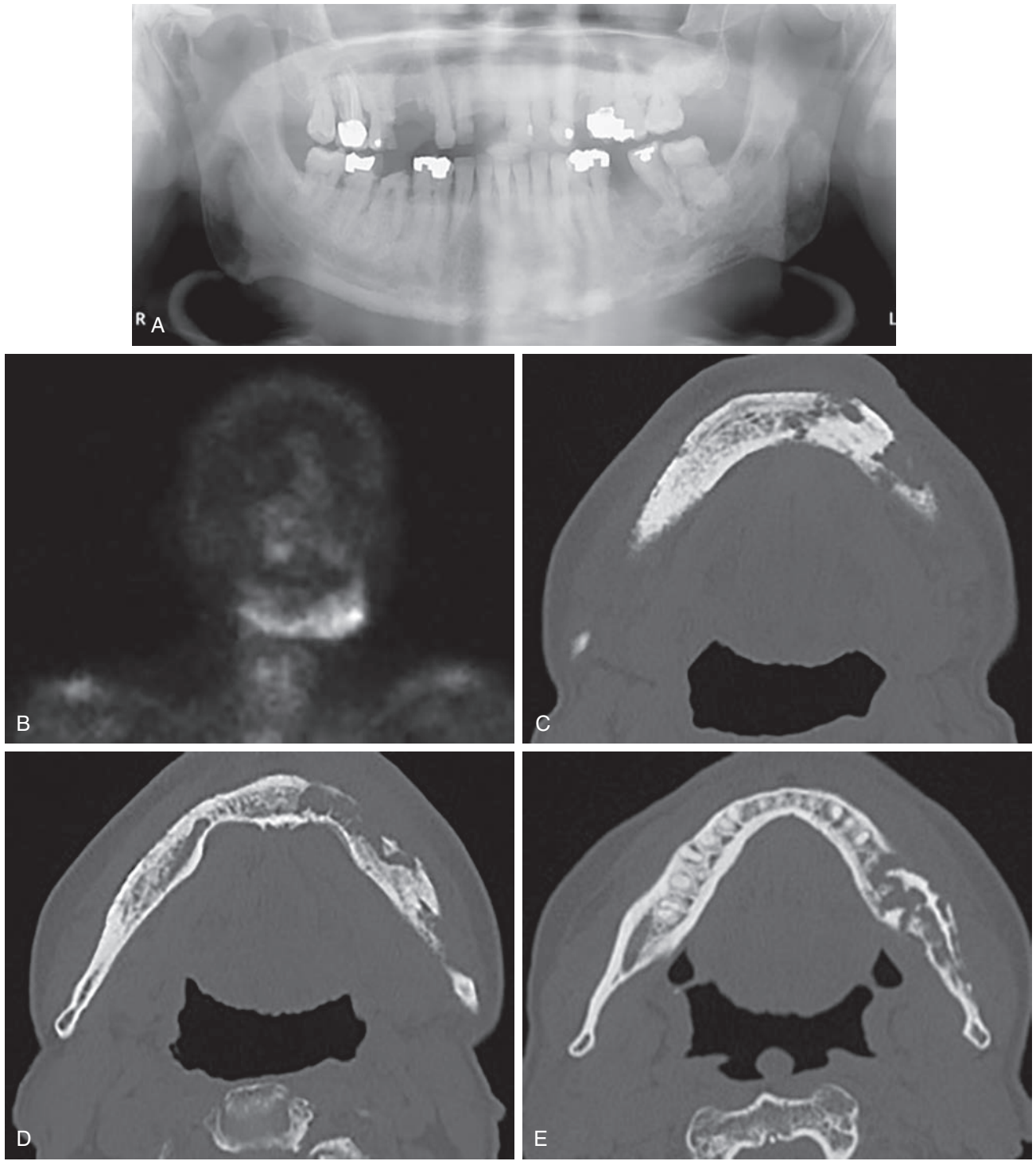

• **Figure 25-5** Panoramic radiograph **(A)** of a 75-year-old diabetic man with a 3-month history of pain, swelling, intraoral drainage, and paresthesia of his left mental distribution. Technetium-99 scan **(B)** demonstrated "hot" left mandible. Computed tomography scans **(C-E)** demonstrate moth-eaten appearance. An intraoral biopsy was consistent with osteomyelitis. It was scheduled for resection with neurovascular bundle preservation and immediate reconstruction.





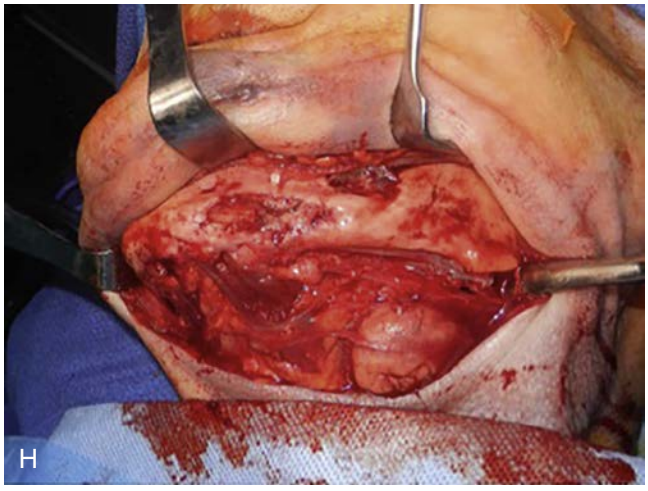



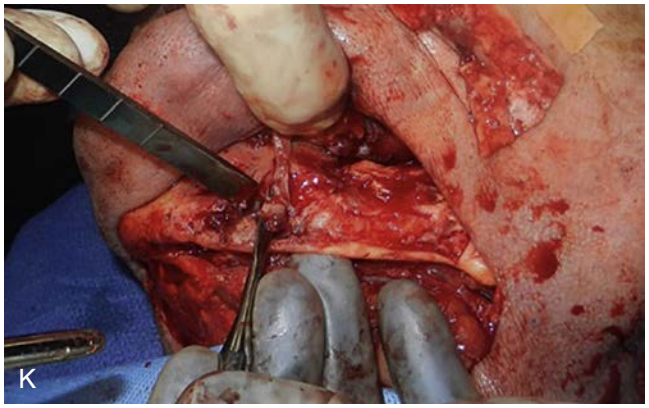



• **Figure 25-5, cont'd** In preparation, a stereolithic model of his mandible was obtained **(F, G)** to aid in locking reconstruction plate (LRP) adaptation in advance of surgery. An approach through the neck **(H)** reveals the destruction. The preadapted LRP was temporarily applied **(I)** and then removed. Lines of outer cortical osteotomies were made **(J),** the outer cortex removed, and the neurovascular bundle dissected free **(K).**

Continued

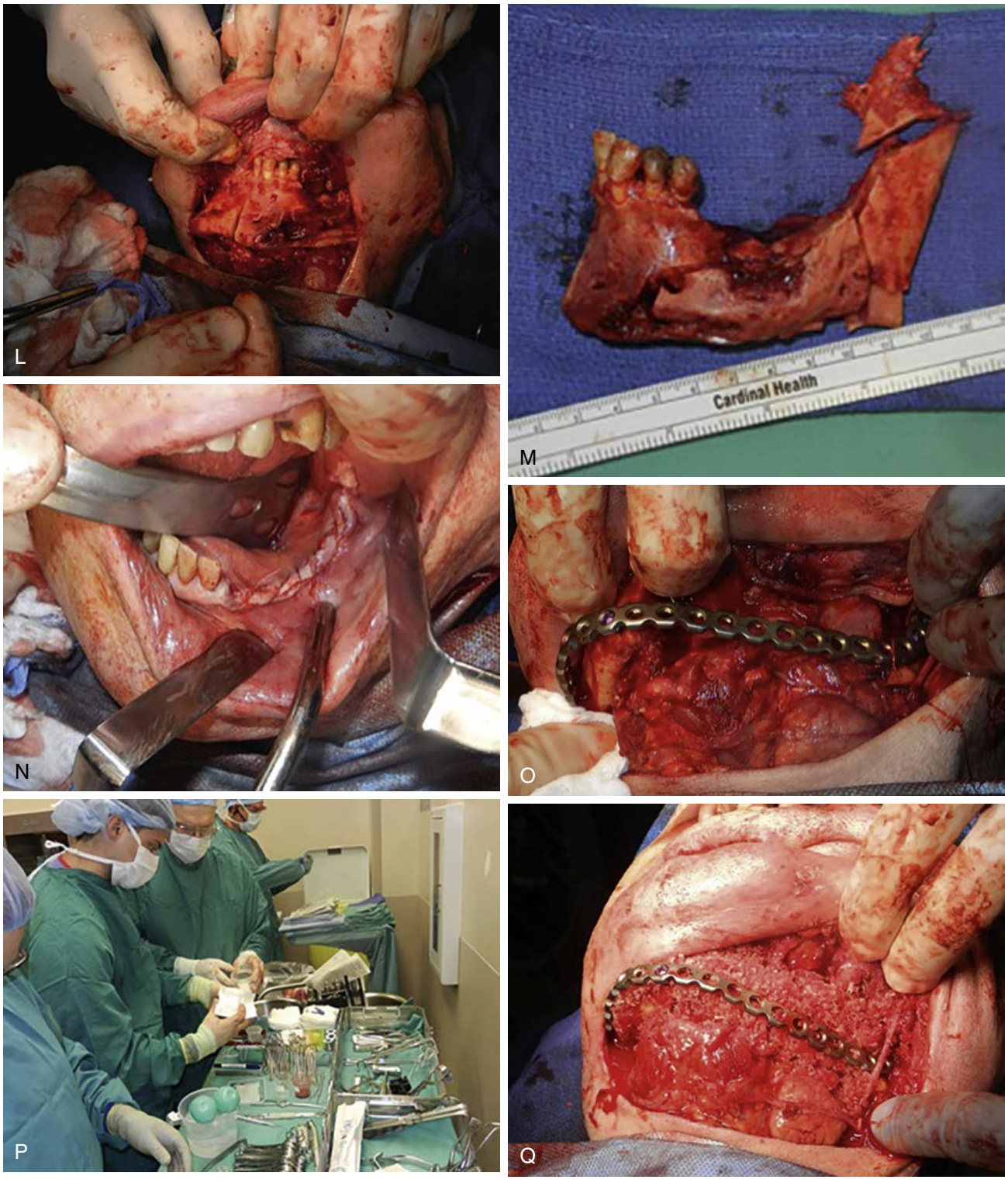

• **Figure 25-5, cont'd** The anterior osteotomy was completed **(L)** and the specimen delivered **(M).** Two-layer intraoral closure was accomplished **(N)** following application of the LRP **(O).** In view of the size of the defect to be grafted, it was decided to utilize a combination of particulate marrow from the tibia, bone morphogenetic protein (BMP), and freeze-dried allograft held together with platelet-rich plasma. **P**, Graft preparation on the back table. The mixture was packed into the defect **(Q)** and the wound closed.



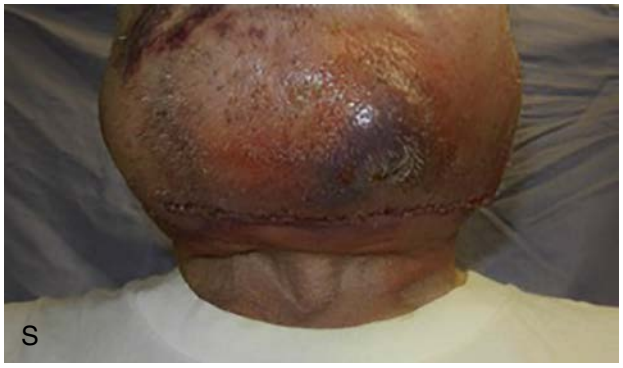









• **Figure 25-5, cont'd** The use of BMP is noted for impressive edema **(R, S)** which ultimately resolves. Two-year follow-up **(T-W)** reveals good bone formation, facial form, and complete oral healing.

5. Infected mandibular fractures are not true osteomyelitis with fever, leukocytosis, adenopathy, and so on. They are areas of dead bone that need to be resorbed or removed for healing to take place. They are treated by rigid internal fixation, debridement, and primary reconstruction as well.[12]
6. A word on graft systems when there is oral contamination: Modern implant dentistry and the use of transoral bone grafts in support thereof have changed the way we view bone grafts.

For reconstruction of significant segmental defects with through-and-through exposure, an adequate tension-free oral closure with healthy tissue is necessary. Likewise, block grafts or costochondral grafts, which are slower to revascularize, should be avoided because if they become exposed in the mouth to wound breakdown, the entire graft may be lost. Particulate marrow grafts are more quickly revascularized, so that if the intraoral wound breaks down only a few flakes are lost.

In cases where there is inadequate healthy tissue for tension-free oral closure (most unusual in mandibular osteomyelitis) or the patient is immunocompromised, delayed reconstruction should be considered (Figure 25-6).

Osteoradionecrosis

Malignancies of the maxillofacial region continue to plague our patients and often occupy a large portion of our practices. In 2014, more than 41,000 new cases of malignancies in the oral cavity and pharynx were diagnosed in the United States.[13] Treatment of these malignancies involves surgery, chemotherapy, radiation therapy, or a combination of these modalities. Radiation therapy plays a valuable role in treatment of maxillofacial malignancies, but it also has well-known and very real complications. Short-term complications include mucositis, altered taste, and xerostomia. Longer-term complications include radiation fibrosis of the muscles of mastication, which leads to trismus. Radiation caries are also commonly seen with longstanding xerostomia.[14] The most dreaded complication of radiation therapy to the jaws is the development of osteoradionecrosis (ORN).

Osteoradionecrosis is defined by exposed bone through the oral mucosa that persists for greater than 3 months in the radiated field. There should be no other contributing factors such as bisphosphonate therapy. The definition of osteoradionecrosis has been modified, as early ORN has radiographic changes that are visible before the clinical symptoms of exposed bone arise.[15] The incidence of ORN is variable, ranging from a low of 2% to a high of 40%.[16] Osteoradionecrosis is more common and predominantly seen in the mandible (Figures 25-7, 25-8, and 25-9). Despite considerable efforts, no universally accepted treatment protocol has been determined. Osteoradionecrosis is commonly caused by dental procedures, such as extractions, in the radiated field. Any oral surgical procedure involving manipulation of bone can be a causative factor in the development of ORN. Poorly fitting dental prostheses that cause sore spots (mucosal breakdown) have also been identified as an etiology of ORN. Spontaneous ORN has been reported in the radiated field without an identifiable etiology.

Osteoradionecrosis has been well studied and there is extensive literature devoted to the subject. Marx, in the early 1980s, developed a theory that radiation caused hypoxia, hypocellularity, and hypovascularity. This triad could lead to osteoradionecrosis of the jaws.[17]

Marx theorized the main etiology was hypoxia in both hard and soft tissues, which led to the use of hyperbaric oxygen (HBO) in managing osteoradionecrosis. Recent advances have brought forth new explanations for ORN, such as the radiation-induced fibroatrophic theory. Impaired healing results from endothelial cell injury, release of cytokines, and abnormal fibroblast activity.[16] Clinicians will gain a better understanding of this complex disease process as research and evidence-based science improves.

Prevention of osteoradionecrosis can be very important in the overall care of the patient. Once the diagnosis of malignancy has been established and radiation therapy has been planned, the patient should be referred for dental evaluation, preferably by a dentist who is accustomed to treating oncology patients. There are established guidelines for dental management of the cancer patient during all aspects of radiation therapy treatment.[14] Emphasis is placed on removing potential sources of infection before radiation therapy has been initiated. Teeth with poor prognoses related to periodontics, endodontics, or restorability should be extracted before radiation therapy, and adequate time for the soft tissue healing is preferred. Dental prostheses should be inspected for potential irritation areas. Dentate patients undergoing radiation therapy to the jaws should be evaluated for fluoride carriers, as the caries index generally rises secondary to xerostomia. All patients receiving radiation therapy to the jaws should be counseled with regard to its effects on soft tissues (mucositis and pain) and the importance of oral hygiene and dental care during and after treatment.[14] The principle is to minimize invasive dentistry after radiation therapy has been delivered to the jaws. Dental extractions in the post radiation therapy period have a higher incidence of developing osteoradionecrosis.[18]

Advances in radiation therapy have also improved care for the oncology patients. Intensity-modulated radiation therapy (IMRT) allows for high doses of radiation to be given directly to the tumor and lower doses to the surrounding normal tissues. The overall effect is tumoricidal doses to the cancer and decreased radiation exposure to the jawbones, soft tissues, and salivary glands.[14] The lower dose of radiation to the surrounding tissues allows for decreased xerostomia, and the increased salivary flow equates to a lower chance of radiation caries. The lower incidence of radiation caries can mean fewer dental extractions in the radiated field and a lower chance of osteoradionecrosis.

Despite the advances in managing osteoradionecrosis, there is no universally accepted treatment protocol. Early-stage ORN, with small areas of exposed bone, can be managed conservatively with observation and chlorhexidine







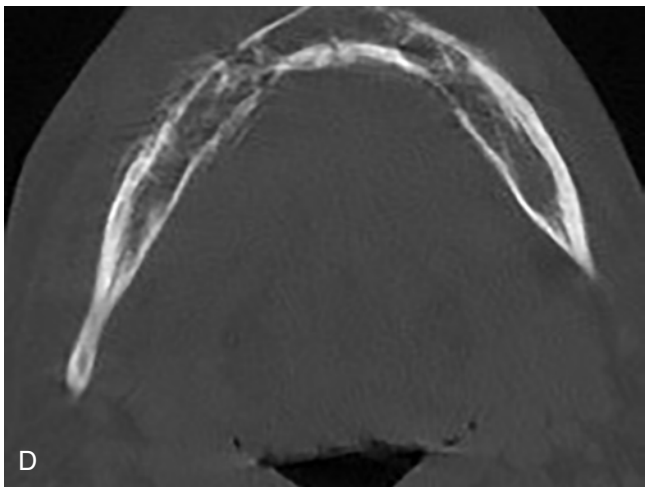



• **Figure 25-6** A 45-year-old man afflicted with AIDS **(A).** Three months prior he had undergone removal of three teeth and excision of mandibular tori in preparation for a mandibular removable partial denture. Incision and drainage was performed multiple times, along with minor sequestrectomies and multiple courses of intravenous antibiotics. He now presents with draining oral wounds **(B)** and moth-eaten appearance on panoramic radiograph **(C).** The computed tomographic (CT) scan **(D)** reveals the process to be bilateral. A phase I biphasic appliance **(E)** was applied and the mandible resected from right posterior

Continued





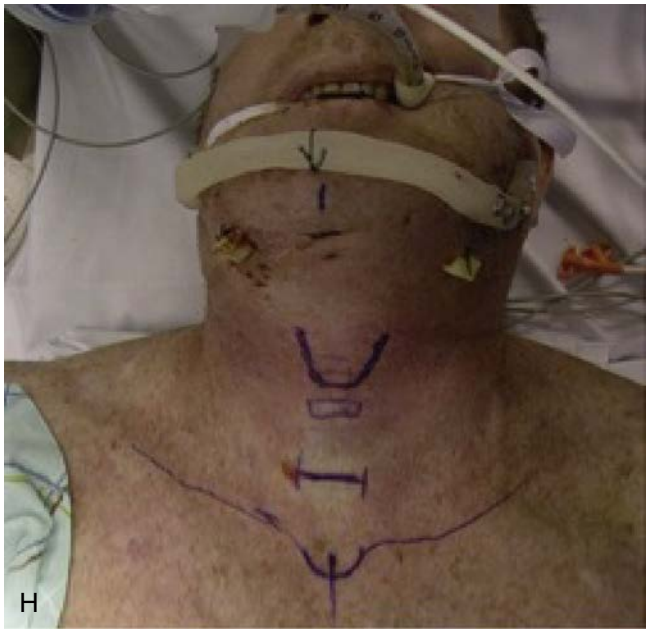

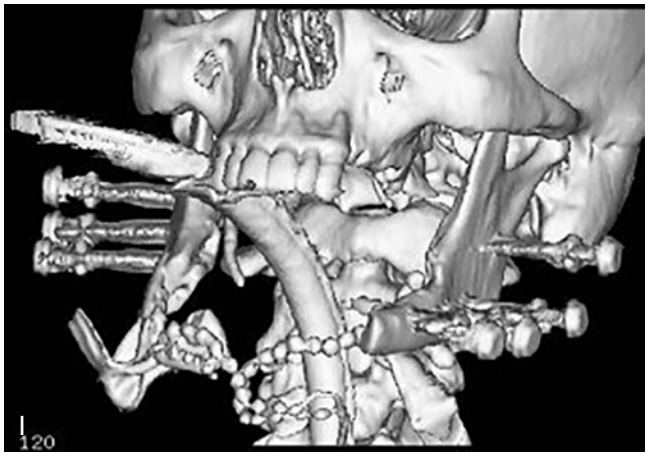





• **Figure 25-6, cont'd** body to left second molar region **(F).** The phase I biphase was converted to phase II by placing an acrylic bar **(G, H).** The three-dimensional (3D) CT **(I)** demonstrates the skeletal view of the defect and remaining jaw. Note the antibiotic bead chain in place. A fungal etiology for the osteomyelitis was discovered in the resected specimen. The patient was not considered to be a suitable for a free fibula reconstruction by two separate microvascular surgeons although his CD4 count was in the 950 range. Reconstruction was accomplished with a combination of tibia **(J, K)**

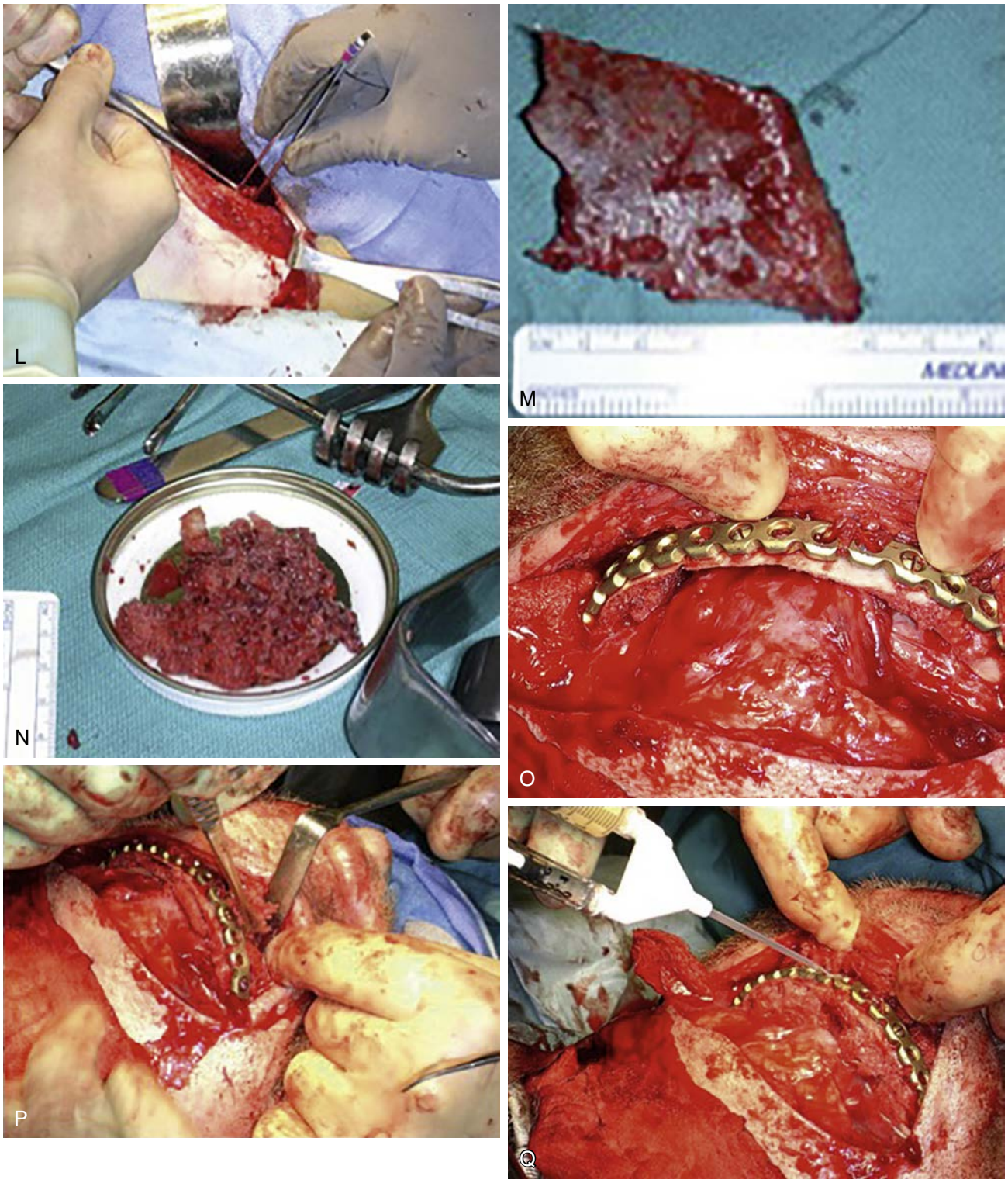

• **Figure 25-6, cont'd** and iliac crest **(L-N).** Three separate teams harvested the grafts and performed the mandibular reconstruction with a locking reconstruction plate and a combination of corticocancellous strips and particulate marrow **(O-Q).**

Continued

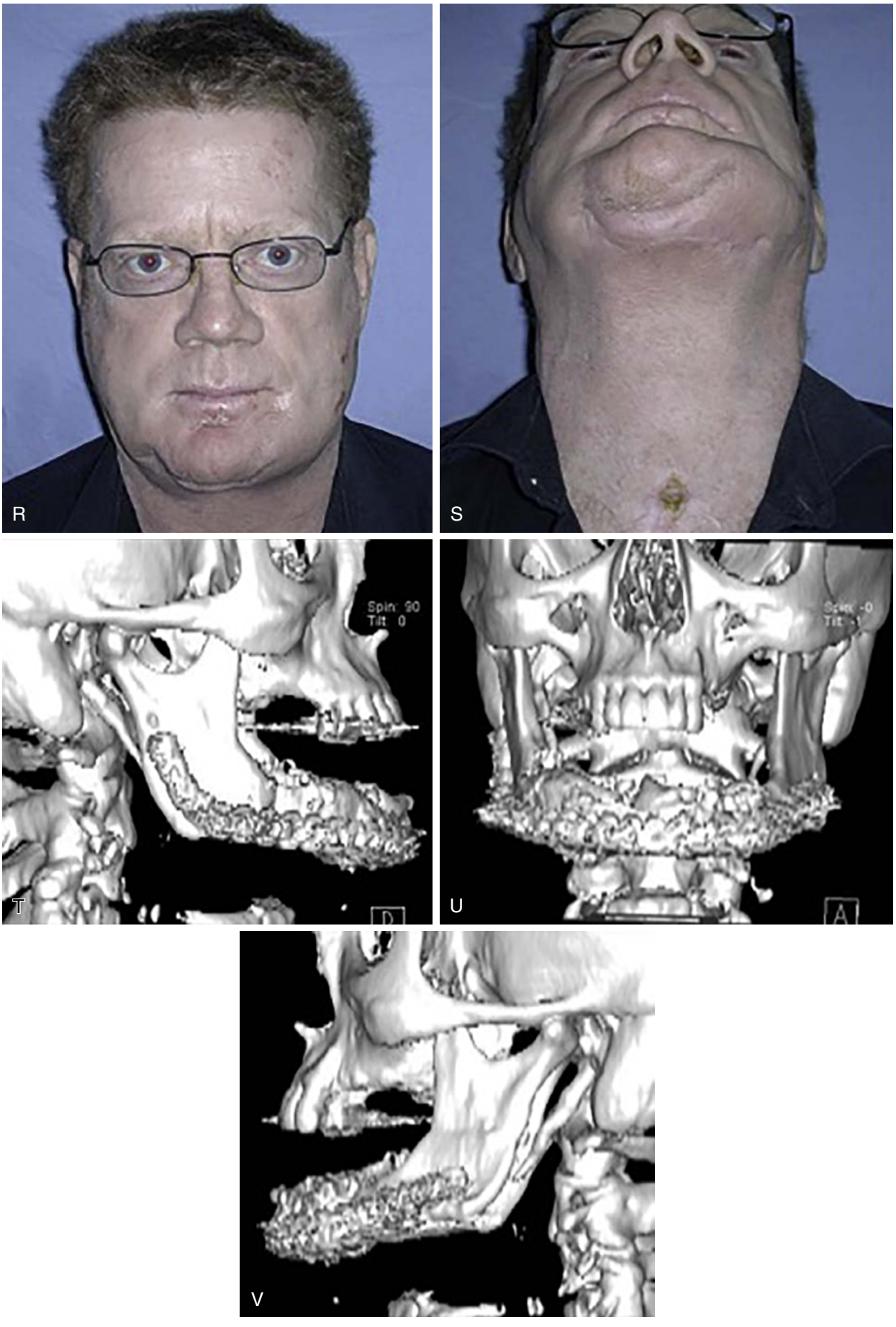

• **Figure 25-6, cont'd** He healed uneventfully **(R, S).** 3D CTs **(T-V)** demonstrate the mandibular reconstruction.

gluconate rinses. Early-stage ORN often has very few clinical symptoms other than intraoral exposed bone. Sharp bony edges can be smoothed or gently debrided. Antibiotic therapy is generally saved for acute episodes or "flare-ups." The patient should be counseled to stop smoking and maintain good oral hygiene.

Mid-stage ORN has larger areas of exposed bone and more extensive disease. Often this will present with symptoms of pain and swelling. Sequestrectomy or debridement of necrotic bone becomes increasingly indicated. Chlorhexidine gluconate rinses and systemic antibiotics play a larger role in patient management. HBO can play a role in the management of osteoradionecrosis. During HBO therapy, patients breathe 100% oxygen at pressures of 2 to 3 atm. The patient's tissue oxygen levels increase, and the overall effect is better wound healing. HBO treatment can be used in a variety of conditions other than osteoradionecrosis to augment wound healing. Marx's HBO protocol calls for both preoperative and postoperative HBO sessions in conjunction with the surgical intervention. HBO has also been recommended for extraction of teeth in the radiated field, often as seen with radiation caries, in an attempt to decrease or eliminate the chance of osteoradionecrosis. HBO treatments are given as daily treatment sessions of approximately 2 hours over a 30- to 40-day time period.[17] The HBO treatment protocol can be both time-consuming and expensive for the patient. HBO has conflicting scientific evidence of efficacy in the treatment of osteoradionecrosis. There are numerous conflicting studies in the literature. The debate continues today, with no universally accepted treatment protocol.



• **Figure 25-7** Clinical photograph of early osteoradionecrosis of anterior mandible after dental extractions in the radiated field.



• **Figure 25-8** Clinical photograph of more extensive osteoradionecrosis of anterior mandible after dental extractions in the radiated field.

Other treatment modalities have been advocated for the management of ORN. Ultrasound has been used to treat earlier stages of ORN. Ultrasound increases angiogenesis and stimulates wound healing and has been used to treat other chronic wound problems in the human body.[19] Pentoxifylline and tocopherol have been proposed in the management of ORN. Pentoxifylline is a vasodilator that increases blood flow to the area of healing. Tocopherol or vitamin E scavenges oxygen radicals. Patients were given daily doses of these medications over a period of time, often months. Healing of ORN was seen in the study group.[20,21] Additional research needs to be performed to confirm these results. Platelet-rich plasma has also been used to treat osteoradionecrosis. It has added growth factors that augment soft tissue healing[22] and has been throughout the body to aid in healing of both hard and soft tissue. A universally accepted



• **Figure 25-9** Panoramic radiograph of same patient. Notice lytic bony changes in the anterior mandible.

treatment protocol has yet to be scientifically validated and generally adopted.

Late-stage ORN is very often debilitating. Chronic pain, invasion into adjacent anatomic areas, extraoral fistulae, and pathologic fractures are commonly seen. The late-stage presentation of ORN is often treated with resection of the involved tissues (Figures 25-10 and 25-11). Options for reconstruction can include no reconstruction, local tissues such as myocutaneous flaps, or distant flaps with their own blood supply. The advent and increasing popularity of "free flaps" and microvascular surgery techniques that bring flaps with their own blood supply to the radiated (hypoxic) field has been a huge advancement in this field. Hidalgo first described the osteocutaneous free fibula flap in 1988.[14,23] The fibula is the most commonly used donor site for microvascular reconstruction in the maxillofacial region (Figures 25-12, 25-13, and 25-14). The fibula provides adequate bone and a soft tissue flap to reconstruct both hard and soft tissue defects. It can be osteotomized to curve and follow facial contour. Dental implants are possible in the fibula to support dental rehabilitation in these patients (Figure 25-15). The fibula has been a reliable free flap with an excellent survival rate of 95%.[14,24] Nonvascularized grafts have traditionally not performed as well in the radiated field. Other options for microvascular reconstruction in the maxillofacial region include the iliac crest, scapula, and distal radius. Microvascular surgeons are becoming very creative in their reconstructive efforts to restore patients to their premorbid state. The future of designer flaps that are crafted for very specific needs holds great promise for the patients.

Radiation therapy provides a vital role in the treatment of oral and maxillofacial malignancies. The most dreaded complication of radiation to the jawbones is osteoradionecrosis. Clinicians forge onward to prevent and treat this complication, which has caused significant morbidity and even mortality in our patient population. Despite our best efforts, a definitive and universally accepted protocol to manage the devastating effects of osteoradionecrosis has yet to be found. However, the future is still very bright and hopeful for our maxillofacial oncology patients.



• **Figure 25-10** Panoramic radiograph of a patient with osteoradionecrosis in left mandibular body and angle region. Note lytic bony changes and pathologic fracture.



• **Figure 25-11** Resection of osteoradionecrosis in left mandibular body and angle region with *no* reconstruction. Patient was medically compromised and could not tolerate extensive surgery.



• **Figure 25-12** Panoramic radiograph of patient after dental extraction in radiated field of left posterior mandible.

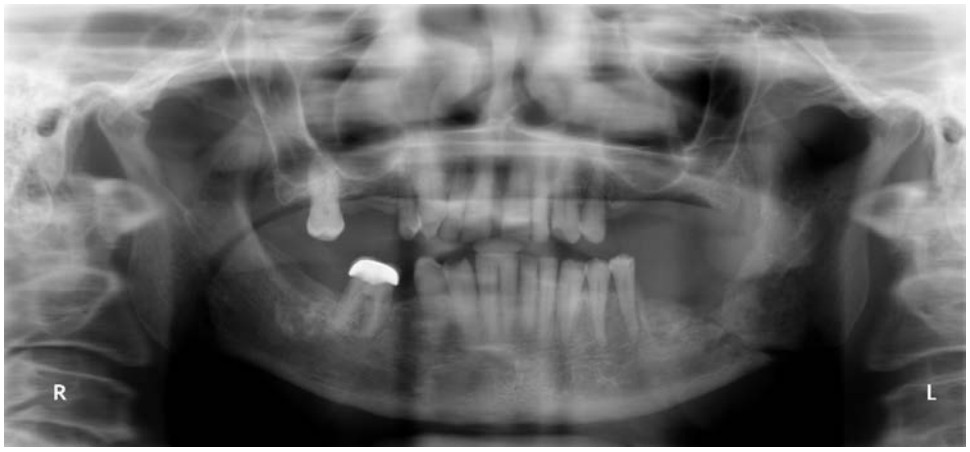

• **Figure 25-13** Subsequent panoramic radiograph of same patient with osteoradionecrosis and pathologic fracture left posterior mandible.

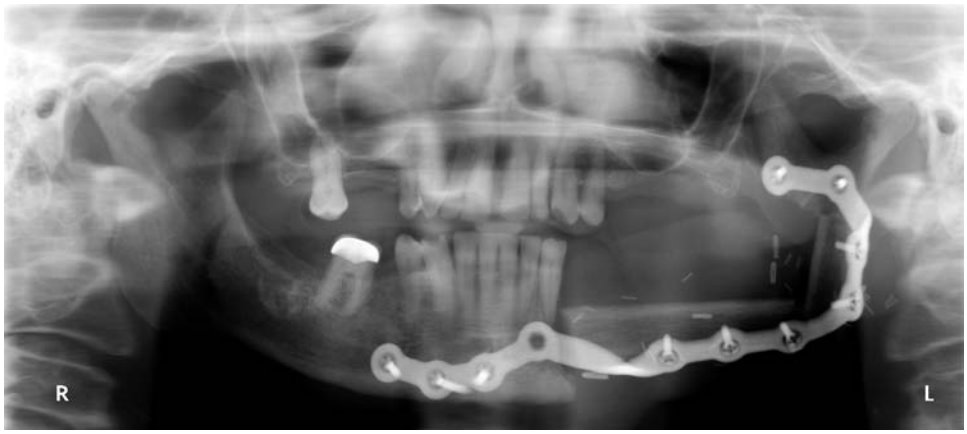

• **Figure 25-14** Panoramic radiograph showing resection of osteoradionecrotic left mandibular body with microvascular fibula free flap reconstruction and rigid internal fixation.

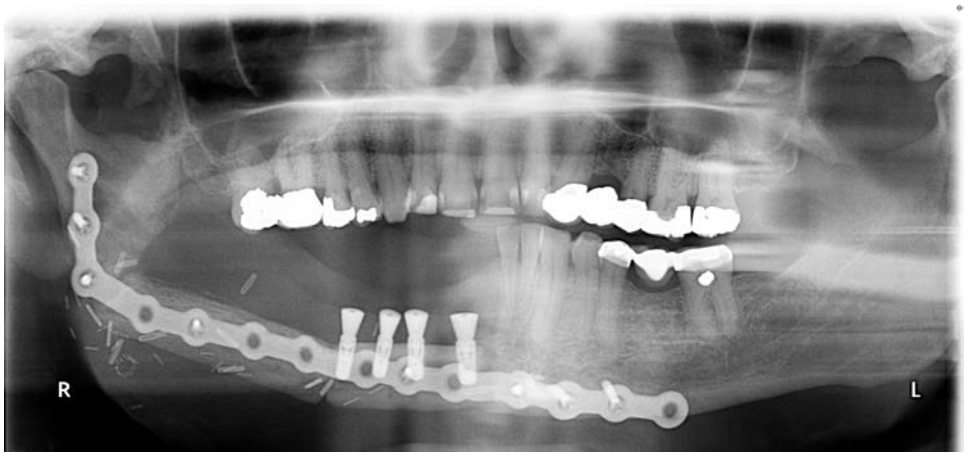

• **Figure 25-15** Panoramic radiograph showing implant placement in fibula free flap for subsequent dental implant rehabilitation.

References

1. Cierny G, Mader J, Pennick J: A clinical staging system for osteomyelitis, *Contemp Orthop* 10–17, 1985.
2. Lew DP, Waldvogel FA: Osteomyelitis, *N Eng J Med* 336:999–1007, 1997.
3. Topazian RG: Oteomyelitis of the jaws. In Topazian G, Goldbert H, Hupp JR, editors: *Oral and maxillofacial infections*, ed 4, Philadelphia, 2002, Saunders.
4. Vighagool A, Calhoun J, Mader J, et al.: Therapy of bone and joint infections, *Hosp Formul* 28–66, 1993.
5. Hudson JW: Osteomyelitis and osteoradionecrosis. In Fonseca RJ, editor: *Oral and maxillofacial surgery*, vol. 5. Philadelphia, 2000, Saunders.
6. Waldvogel FA, Papageorgiou PS: Osteomyelitis: the past decade, *N Engl J Med* 303–360, 1980.
7. Schulster GS: Microbiology of the orofacial region. In Topazian G, Goldbert H, Hupp JR, editors: *Oral and maxillofacial infections*, ed 4, Philadelphia, 2002, Saunders.
8. Kushner GM, Alpert B: Osteomyelitis and osteoradionecrosis. In Milori M, Ghali G, Larsen PE, Waite PD, editors: *Peterson's principles of oral and maxillofacial surgery*, ed 3, vol. 1. Shelton, CT, 2012, People's Medical Publishing House, pp 861–874.
9. Schuknecht B, Carls F, et al.: Mandibular osteomyelitis: evaluation and staging in 18 patients using magnetic resonance imaging, computed tomography and conventional radiographs, *J Craniomaxillofac Surg* 25(1):25–26, 1997.
10. Chisholm B, Lew D, Sadasvian I: The use of tobramycin in impregnated polymethylmethacrylate beads in the treatment of osteomyelitis of the mandible, *J Oral Maxillofac Surg* 51:444, 1993.
11. Grime P, Bowerman J, Weller P: Gentamicin impregnated PMA beads in the treatment of chronic osteomyelitis of the mandible, *Br J Oral Maxillofac Surg* 28:367, 1990.
12. Benson PD, Marshall M, Engelstad M, et al.: The use of immediate bone grafting in reconstruction of clinically infected mandibular fractures—bone grafts in the presence of pus, *J Oral Maxillofacial Surg* 64:122–126, 2006.
13. American Cancer Society: *Cancer facts and figures, 2013*. http://www.cancer.org/acs/groups/content/@epidemiologysurveilance/documents/acspc-036845.pdf.
14. Chrcanovic B, Reher P, et al.: Osteoradionecrosis of the jaws—a current overview—Part 2: dental management and therapeutic options for treatment, *Oral Maxillofac Surg* 14:81–95, 2010.
15. Deshpande S, Thakur M, et al.: Osteoradionecrosis of the mandible: through a radiologist's eyes, *Clin Radiol* 70:197–205, 2015.
16. Odell K, Uttam S: Osteoradionecrosis, *Oral Maxillofacial Surg Clin N Am* 23:455–464, 2011.
17. Marx R: Osteoradionecrosis: a new concept in its pathophysiology, *J Oral Maxillofac Surg* 41:283–288, 1983.
18. Reuther T, Schuster T, et al.: Osteoradionecrosis of the jaws as a side effect of radiotherapy of head and neck tumor patients: a report of a thirty year retrospective review, *Int J Oral Maxillofac Surg* 32:289–295, 2003.
19. Rice N, Polyzois I, et al.: The management of osteoradionecrosis of the jaws: a review, *Surgeon* 13(2):101–109, 2015.
20. Hayashi M, Pellecer M, et al.: The efficacy of pentoxifylline/tocopherol in the treatment of osteoradionecrosis, *Spec Care Dent* 35(6):268–271, 2015.
21. Bohn J, Schussel J, et al.: Tissue repair in osteoradionecrosis using pentoxifylline and tocopherol—report of three cases, *Oral Maxillofac Surg* 20(1):97–101, 2016.
22. Gallesio G, Del Fabbro M, et al.: Conservative treatment with plasma rich in growth factors: Endoret for osteoradionecrosis, *J Craniofac Surg* 26:731–736, 2015.
23. Hidalgo D: Fibula free flap: a new method of mandibular reconstruction, *Plast Reconstr Surg* 84:71–79, 1989.
24. Chaine A, Pitak-Amnop P, et al.: Post-operative complications of fibular free flaps mandibular reconstruction: an analysis of 25 consecutive cases, *Oral Surg Oral Med Oral Pathol* 108:488–495, 2009.

26

The Molecular Biology of Cancer

RANDY TODD

Introduction

Understanding the molecular biology of cancer is an essential step toward developing a rational approach for the diagnosis and treatment of the oncology patient. Fundamentally, cancer results from a collection of molecular errors that confer increasingly abnormal proliferative and invasive behaviors. Alterations of regulatory molecules lead to a limited expansion of a single cell until the next mutation occurs, and that new mutation, in turn, gives rise to a clonal outgrowth with even greater proliferative potential.[1,2] Therefore, as the cancer cell "evolves," it gains the ability to take advantage of and outcompete its normal neighbors. These changes that define the malignant cell are being investigated as valuable targets to better diagnose and treat cancer patients.[3] This chapter provides a broad overview of the types of molecular alterations that govern cancer cell behavior and discusses some of the approaches using these observations as diagnostic and therapeutic targets.

Cancer remains the second leading cause of death in the United States and kills one in five persons in developed countries.[4] Tumors are classified into two broad groups: solid and hematopoietic.[5] Solid tumors are further divided based on their tissue of origin: epithelial (carcinomas), mesenchymal (sarcomas), or neuroectodermal. The disease is also frequently divided into inherited and sporadic forms. Inherited malignancies occur in the pediatric patient population and/or present earlier than their sporadic counterparts. For example, there are inherited and sporadic forms of retinoblastoma, an eye tumor.[6] Inherited retinoblastoma shows a family predilection and presents early as multiple tumors in both eyes. Sporadic retinoblastoma occur in patients without a family history of the disease, presents in one eye, and occurs at a later stage in life. Therefore, in addition to chemical carcinogens, radiation and viruses, age and genetic background are key risk factors in developing the disease. All five of these risk factors share a common characteristic of altered DNA structure and function. Epidemiologic studies suggest that 80% to 90% of cancers arise from an accumulation of DNA-damaging environmental exposures over time.[7] The histopathologic stages observed during tumorigenesis also reflect the time-dependent accumulation of environmental and inherited genetic damage.[8]

Cancer Histology

Rather than arising de novo, cancers develop through a progression of histologic changes characterized by a breakdown of tissue architecture that is followed by local and distant invasion into surrounding "normal" tissue.[5] For example, squamous cell carcinomas begin as hyperplasia or a thickening of the epithelium (Figure 26-1, *A*). However, cell division is confined to the basal layer of the epithelium, and the more superficial layers remain ordered and show differentiation (see Figure 26-1). As tumor progression continues, the epithelium becomes dysplastic. Cell division is observed above the basal layer, and the structure of the epithelium loses its order. Dysplasia is further categorized as mild, moderate, or severe, based on how superficial cellular atypia occurs within the epithelium. Left alone, dysplasia can remain harmless or can even regress spontaneously. Carcinoma in situ presents with disordered cell division and tissue structure, as well as cells having structural characteristics of cancer cells. However, as the name implies, carcinoma in situ is restricted by the basal membrane and does not invade the surrounding structures. Squamous carcinoma is characterized by underlying connective tissue invasion. Cancers are further graded by their level of differentiation (well, moderately, or poorly differentiated). Following local invasion of the underlying stroma and surrounding normal structures, the cancer metastasizes.

Although it is tempting to think of cancers as a homogeneous cell population, emerging evidence indicates that even early tumors may already contain distinct clonal subpopulations. This heterogeneity is likely due to cancer stem cells (CSCs).[9-11] CSCs are functionally defined by their efficiency in seeding new tumors in mice.[12] Like stem cells in normal tissues, CSCs self-renew and spawn derivatives. Therefore, the plasticity of CSCs allows formation of functionally distinct cell populations. Diversity of cell

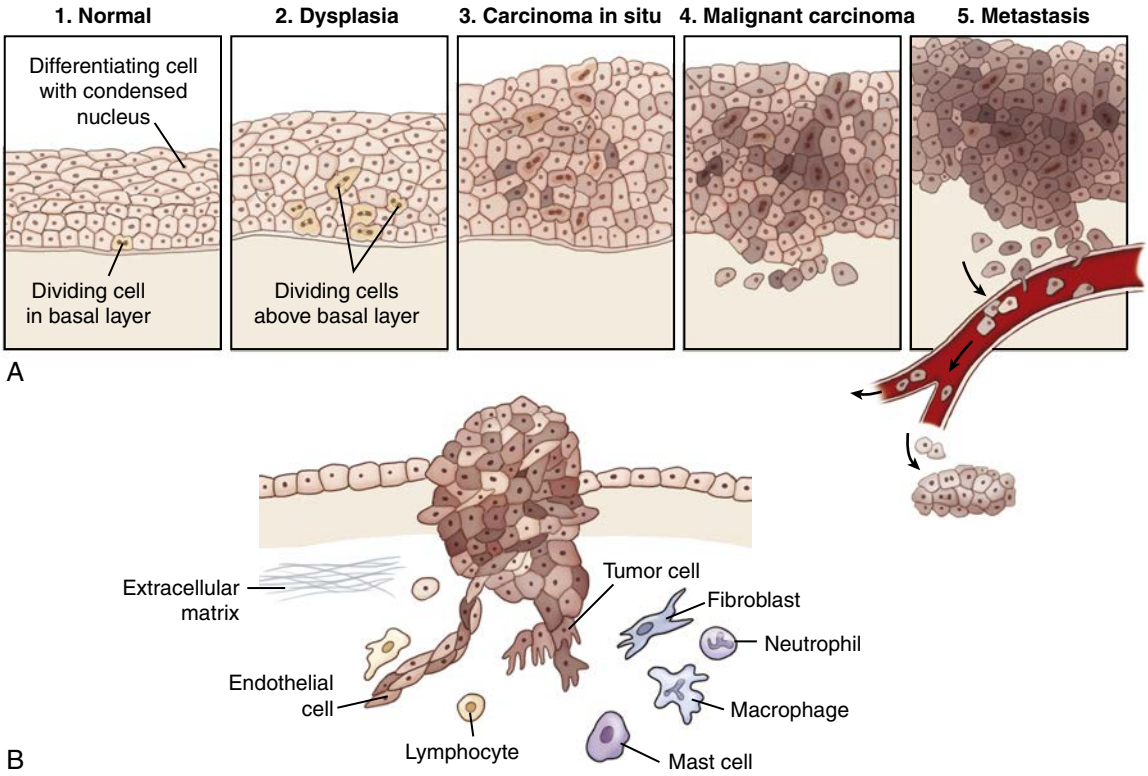

• **Figure 26-1 A,** Epithelial cancer progression. Malignancies arise through a series of histopathologic changes. *1,* In normal epithelium, cell division occurs in the basal layer while the more superficial layers show increasing degrees of differentiation. *2,* Dysplastic epithelium shows cell division above the basal layer. In addition, cellular changes characteristic of cancer cells are also observed. Degrees of dysplasia (mild, moderate, severe) are based on the relative thickness of these changes. *3,* Carcinoma in situ is characterized by malignant changes in the full thickness of the epithelium. However, the basement membrane is intact in both dysplasias and carcinoma in situ. *4,* Carcinoma shows disruption of the basement membrane and invasion of cancer cells into the stroma. *5,* Metastasis is the transfer of disease from one organ to another not directly connected with it. **B,** The cancer stroma. Cellular alterations in the stroma invaded by cancer, once believed to be a protective response, may actually support tumor progression and metastasis.

subpopulations allow each clonal group to contribute to the growth of the tumor by either conferring a specific contribution or offering complementary capabilities between cell types.[13] To add to the complexity of the anatomy of cancer tissue, the tumor stroma is believed to make important contributions to tumorigenesis.

Several important stromal changes occur during cancer progression (see Figure 26-1, *B*). Recent research has focused not only on the cancer cell, but the cell types found within the "normal" stroma.[14] In essence, the tumor has an organ-like complexity.[9] A microenvironment exists in which the cancer cells interact with tumor-associated fibroblasts, endothelial cells, and immune cells.[15]

The most abundant cell type in the tumor stroma are cancer-associated fibroblasts.[16] Fibroblast proliferation is often referred to as "desmoplasia" and is recognized as a wound response to the cancer.[17] The predominant cell type in this stromal reaction is the myofibroblast, named for the morphologic characteristics of its large, spindle-like shape, indented nuclei, and stress fibers.[18] Myofibroblasts are rare in healthy tissue but are commonly found in chronic wounds. The desmoplastic stroma associated with myofibroblasts is believed to support tumor proliferation, metastasis/invasion, and angiogenesis.[9]

Angiogenesis is an essential requirement for a tumor mass to grow larger than about 1 mm^3. Only 1 in 600 of these in situ malignancies achieves the blood supply necessary to become a clinically detectable tumor.[19,20] Rather than invading and appropriating existing vascular beds, tumors recruit and stimulate endothelial cells to construct a tumor-specific blood supply.[19,20] In fact, vascular density has been used to follow a primary tumor toward its malignant end point.[21] Endothelial cells and pericytes are important components of tumor-associated vasculature. Although a great deal has been elucidated regarding tumor neovascularization (discussed later), relatively little is known about the lymphatic endothelial cells that form the channels required for the metastatic spread of many cancers.[9] Pericytes are specialized mesenchymal cells that are related to smooth muscle. In addition to the support of and collaboration with endothelial cells, pericytes may serve as a barrier to cancer cell intravasation.[22]

A pronounced inflammatory infiltrate is present in the stroma.[23,24] Diverse evidence exists whether the

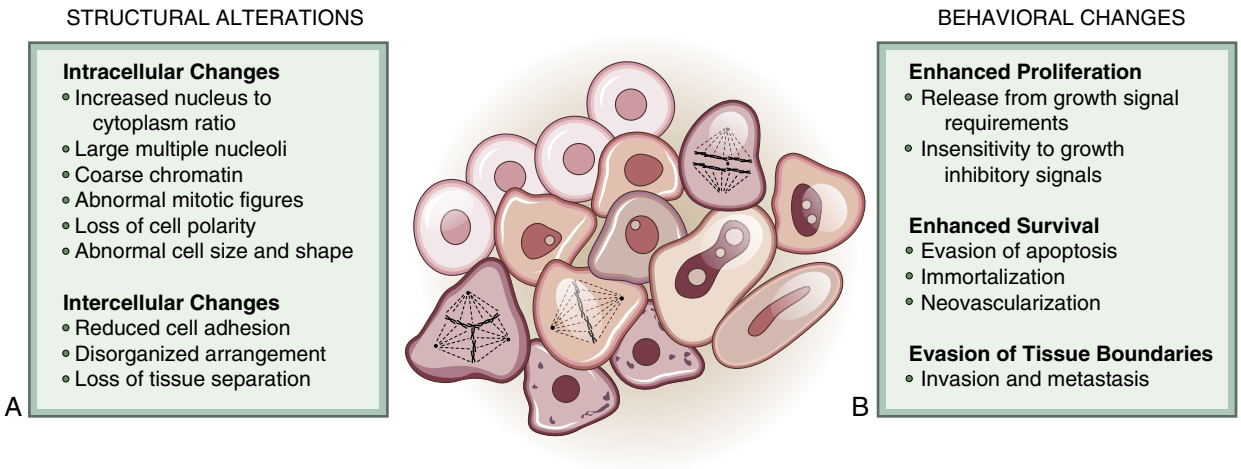

• **Figure 26-2** The cancer cell. In addition to changes in the tissue architecture during cancer progression, the cancer cell accumulates several alterations. **A,** Structural alterations of the cancer cell appear both internally (such as increased nucleus:cytoplasmic ratio and abnormal mitotic figures) and with relation to other cells in the tissue (such as reduced cellular adhesion and loss of polarity). **B,** Important behavioral changes in the cancer cell can be broadly categorized in rapid proliferation (release from growth factor requirements and insensitivity to growth inhibitory signals), enhanced survival (evasion of apoptosis and immortalization), and evasion of tissue boundaries (invasion and metastasis).

tumor-associated inflammatory cells inhibit or promote tumor growth.[9] Likely, both concepts are true. Because immunosuppressed individuals experience elevated levels of certain cancers, it is believed that the immune system surveys and eliminates cancer cells.[25] Although a comprehensive overview of tumor immunology is beyond the scope of this chapter, for summary purposes it can be broadly subdivided into the innate and adaptive immune systems.[26,27] The innate immune system, consisting of macrophages, dendritic cells, and cytotoxic T cells/natural killer (NK) cells, detects and kills cancer cells. Monocytes are recruited early and are later differentiated into macrophages.[28] Cytotoxic T cells recognize and attack cells with tumor-associated antigens (TAAs), releasing factors that inactivate cytotoxic T cells and recruiting regulatory T cells (which also inactivate cytotoxic T cells).[29,30] Dendritic cells are important antigen-presenting cells that can also suppress angiogenesis. However, cancer cells can evade immunosurveillance by downregulating TAAs. The adaptive immune system consists of T and B lymphocytes, key stimulators of both the cytotoxic and humoral anti-tumor responses. However, not only can the immune response be suppressed by cancer cells, but some studies indicate that factors produced by immunocytes can support cancer progression.[31] The contribution to and/or inhibition of tumorigenesis by these stromal cell types is an active area of investigation that will be discussed further. In addition to an accumulation and progression of tissue changes, the cancer cell itself shows important alterations from its normal counterparts.

Cancer Cell Biology

Cancer cells have several structural and behavioral differences from normal cells[5] (Figure 26-2, *A*). Structurally, cancer cells show varying degrees of anaplasia (or degree of differentiation). Both the cytoplasm and nucleus are pleomorphic. Malignant cells may be either much larger or smaller than their normal counterparts. Typically, cancer cells show a loss of cell adhesion between cells and loss of polarity with respect to the overall tissue architecture. The nuclei of cancer cells typically are disproportionally larger (with respect to the cytoplasm) and more dense (or hyperchromatic). Large nucleoli also appear, suggesting high synthetic activity. Normal mitotic spindles are replaced in malignant cells by atypical mitotic figures with tripolar, quadripolar, or multipolar spindles.

In cell culture and in vivo, cancer cells show key behavioral alterations that are often reflected in the structural changes[9] (see Figure 26-2, *B*), Cancer cells often proliferate rapidly and in an uncontrolled manner. In addition, cellular controls leading to apoptosis or cell death are often abrogated. Malignant cells lack the ability to terminally differentiate. Evasion of apoptosis, senescence, and terminal differentiation leads to enhanced cell survival. Most importantly, cancer cells invade the local stroma and induce changes such as angiogenesis. Many malignant cells eventually achieve the ability to metastasize.

Fueling these malignant phenotypes is a metabolic switch in cancer cells (referred to as the "Warburg effect") to glycolysis as the primary energy source.[32-34] To compensate for the lower efficiency for generating energy, cancer cells increase glucose intake (a phenotype that is exploited in positron emission tomography [PET], where radiolabeled glucose is used as a reporter).[9,35] Despite its inefficiencies, the Warburg effect has selective advantages for cancer cells. Byproducts of glycolysis can fuel biosynthetic pathways that generate nucleosides and amino acids.[9] Furthermore, lactate secreted from glucose-dependent cancer cells can be used

by better-oxygenated cancer cells as fuel.[36] In fact, the same molecular determinants governing malignant cell phenotypes also contribute to the metabolic changes within the cancer cell to support these phenotypes.[9]

In summary, time and exposure to environmental carcinogens lead to the cellular and histologic progression observed during malignant transformation. It is widely believed that these risk factors lead to an accumulation of underlying genetic alterations that drive the structural and functional traits characteristic of the cancer cell. Molecular biology has provided important insights into the causes of cancer progression. In the next section, the nature of cancer-associated molecular alterations in cancer cells is examined in the context of their influence on cancer behavior.

Signal Pathways Are Altered by Cancer-Associated Molecular Changes

Several observations support a multistage progression during tumorigenesis.[8,37] Epidemiologic studies examining age-specific mortality rates for different forms of human cancer predict that multiple alterations are required for the genesis and outgrowth of clinically detectable tumors. Clinical and histologic detection of "premalignant" lesions and their underlying microscopic changes also suggests that multiple pathways are involved in cancer development. In addition, behavioral differences (such as treatment response) between clinically and histologically identical lesions suggest that distinct subcellular or molecular pathways may be abrogated to account for the observed difference.

Several lines of evidence indicate that the multiple molecular events lead to cancer development are genetic in nature. In the early 20th century, Boveri suggested that chromosomal imbalances lead to cancer development.[38] This observation was supported by the study of inherited pediatric tumors and identification of damaged chromosomes in cancer cells. Furthermore, chromosomal DNA damage was linked to cancer formation. DNA repair defects were linked to ultraviolet (UV) light-induced skin cancers. Muller and Auerbach demonstrated the mutagenic potential of ionizing radiation and chemical carcinogens, respectively. Statistical analysis of human tumor incidence and natural history in sporadic and inherited human tumors suggested that between 7 and 10 genetic events were required in human tumorigenesis (Figure 26-3). These genetic events were thought to be in two broad categories: oncogenes and tumor suppressor genes.

Oncogenes, or altered growth genes that promote cancer formation (proto-oncogenes), were identified early in molecular investigations in the origins of human cancer.[38] Rous suggested that a retrovirus that caused sarcomas in chickens contained a specific oncogenic sequence. Duesberg and Vogt confirmed that a genetic element induced the chicken sarcoma, and Bishop and Varmus identified the specific v-Src oncogene. Weinberg later identified the first human oncogene using nonviral human tumor cells.

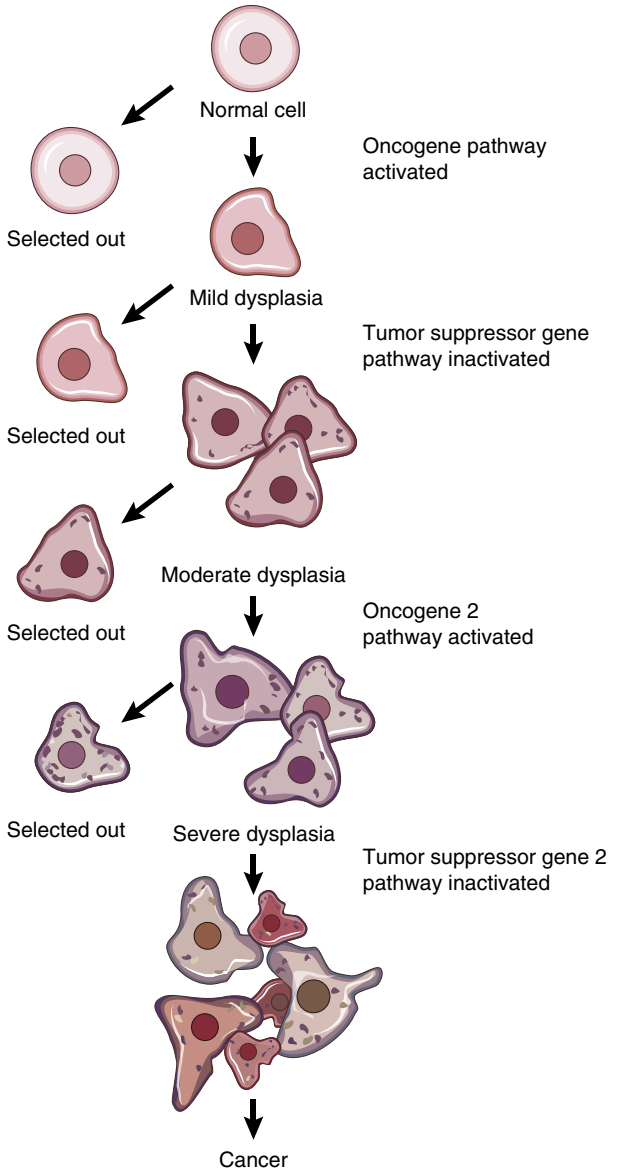

• **Figure 26-3** Accumulation of molecular changes in the cancer cell. The cancer cell is a product of a Darwinian selection process. The cancer cell undergoes alterations in molecular pathways that confer a behavioral advantage, causing cells without these changes to be selected out. These molecular alterations principally consist of overactivity of tumor-promoting (oncogene) pathways or inactivation of tumor suppressor pathways.

Because oncogenes could be experimentally added to normal cells to induce a malignant phenotype, oncogenes were initially easier to study.

Tumor suppressor genes, or genetic elements that suppress tumorigenesis, were also postulated early in cancer research.[39] At the cellular level, cancer is a recessive phenotype: normal cellular activity can suppress malignant transformation. Experimentally, fusion of cancer cells with normal cells resulted in a hybrid cell with normal cell characteristics, suggesting that normal cells had one or more elements that could suppress cancer formation.[40] Later, the addition of specific normal chromosomes to certain cancer cells was found to have the same effect.[41,42] Using statistical

analysis of inherited tumors, Knudson compared the difference between the natural history of inherited versus sporadic cancers and suggested a "two-hit" hypothesis in which both copies of a tumor suppressor gene had to be inactivated for cancer formation.[42] Familial cancers, which arose earlier, occurred in patients who inherited a damaged gene copy, thereby reducing the time leading to the inactivation of both copies.[43] This "two-hit" hypothesis was supported experimentally after the identification of the first tumor suppressor gene.[44] The retinoblastoma (Rb) gene was cloned by Friend from the pediatric eye tumor (discussed earlier) with a biphasic clinical appearance. In patients who presented early with retinoblastoma (usually in both eyes), a damaged copy of the gene was found to be inherited. In patients with the sporadic form of the disease (usually affecting one eye and presenting later), both inherited copies of the Rb gene were normal.[45,46]

Although an accumulation of genetic events is widely believed to lead to tumorigenesis, the nature and identification of those events continues to be refined. Cell behavior is governed by various molecular pathways. With each oncogene pathway that becomes activated and each tumor suppressor gene pathway that becomes inactivated, the cell acquiring these changes clonally expands because of a behavioral selective advantage over its neighbors. Disruption of these molecular pathways occurs when genetic alterations lead to abnormal numbers and/or function of the protein elements that govern cell structure and behavior. Therefore, in order to understand how cells become malignant, it is important to first understand the nature of gene regulation and how it is altered during human cancer development.

Gene Regulation of Cell Function: A Primer

How do genetic alterations lead to cancer cell behavior? Although cellular homeostasis is regulated at many levels, the core of basic cancer research is based on the disruption of the molecular paradigm of gene expression (Figure 26-4). Genes (or coding regions of DNA) are transcribed into messenger RNA (mRNA) that is later translated into proteins. The gene products, proteins, govern much of the structure/function of the cell and are the true determinants of the malignant phenotype.[47] Therefore, to understand the molecular biology of cancer, it is important to understand its key elements: DNA, mRNA, and proteins associated with the malignant phenotype.

DNA (or *d*eoxyribo*n*ucleic *a*cid) is an essential molecule in human health and disease. The 23 pairs of human chromosomes are composed of DNA and protein. Within chromosomal DNA, there are approximately 23,000 paired genes. Therefore, there are two copies of each gene, a DNA region that carries the structural and functional blueprint of the cell.[48] The paired, homologous regions of DNA are called alleles. *Every* cell contains *every* gene that encodes *every* structural and functional detail of an organism. Genes are grouped into two broad classes: housekeeping genes and tissue-specific genes. Housekeeping genes account for the majority of gene activity and control baseline cell function and structure. Tissue-specific genes are responsible for specific characteristics of differentiated cell types. Whereas about 10,000 to 15,000 housekeeping genes are expressed, fewer than 1000 tissue-specific genes are active in any given cell type.[49] Therefore, a significant portion of genes in a differentiated cell remain inactive. This diversity of genetic activity is the essence of both morphologic and physiologic differences between cell and tissue types.

Genes have three fundamental regions that help govern which sequences are expressed: the enhancer/promoter region, the coding region and the termination region.[50] The gene promoter/enhancer region, which is bound by transcription factors, determines the activity of a gene. Some genes are constituently active; others respond to specific internal/external stimuli. The termination region stops that activity. The coding region contains the message that is transcribed into RNA and subsequently translated into protein. The message translated is based on the order of the nucleotides: adenine, thymine, guanine, and cytosine. The order of these nucleotides is highly regulated. Although there is a redundancy in the code that allows for a limited number of specific changes, nucleotide insertions, deletions, or exchanges can have far-reaching effects (which are discussed later). To prevent nucleotide sequence changes, DNA mismatch repair genes provide an important mechanism to protect the integrity of the code.[51]

In addition to direct regulation of gene activity, genes are controlled by epigenetic factors.[52,53] The conformation of chromosomal DNA regulates the ability of genes to be expressed (Figure 26-5). Chromosomal DNA packaged with histone proteins is called chromatin.[54] Dense chromatin prevents gene expression; open chromatin allows gene activity.[55,56] The two best-understood means of epigenetic control of gene expression are DNA methylation and histone modification.[57] Modification of the nucleotides cytosine and guanine with a methyl group can silence gene activity, whereas removal of the groups can activate gene expression. In addition, modification of histones (a protein family associated with chromosomal DNA) though acetylation, methylation, and phosphorylation is another important control of gene activity. These modifications to DNA and histone change the conformation of the chromosome, leading to dense (low gene expression) and open (high gene expression) chromatin (see Figure 26-5, *B*). Therefore, gene regulation is both genetic (or controlled by the promoter/enhancer gene region) and epigenetic (or gene expression control based on chromatin structural conformation near the gene).

The genetic message encoded in DNA is carried by an intermediary molecule, messenger RNA (*r*ibo*n*ucleic *a*cid) or mRNA, from the nucleus to the cytoplasm (see Figure 26-4, *B*) Outside the nucleus, the message is transcribed into protein. Amounts of mRNA are regulated by two primary mechanisms. First, gene activity and post-transcriptional processing influence how much or how little mRNA is produced. Second, the structure and stability of the mRNA molecule

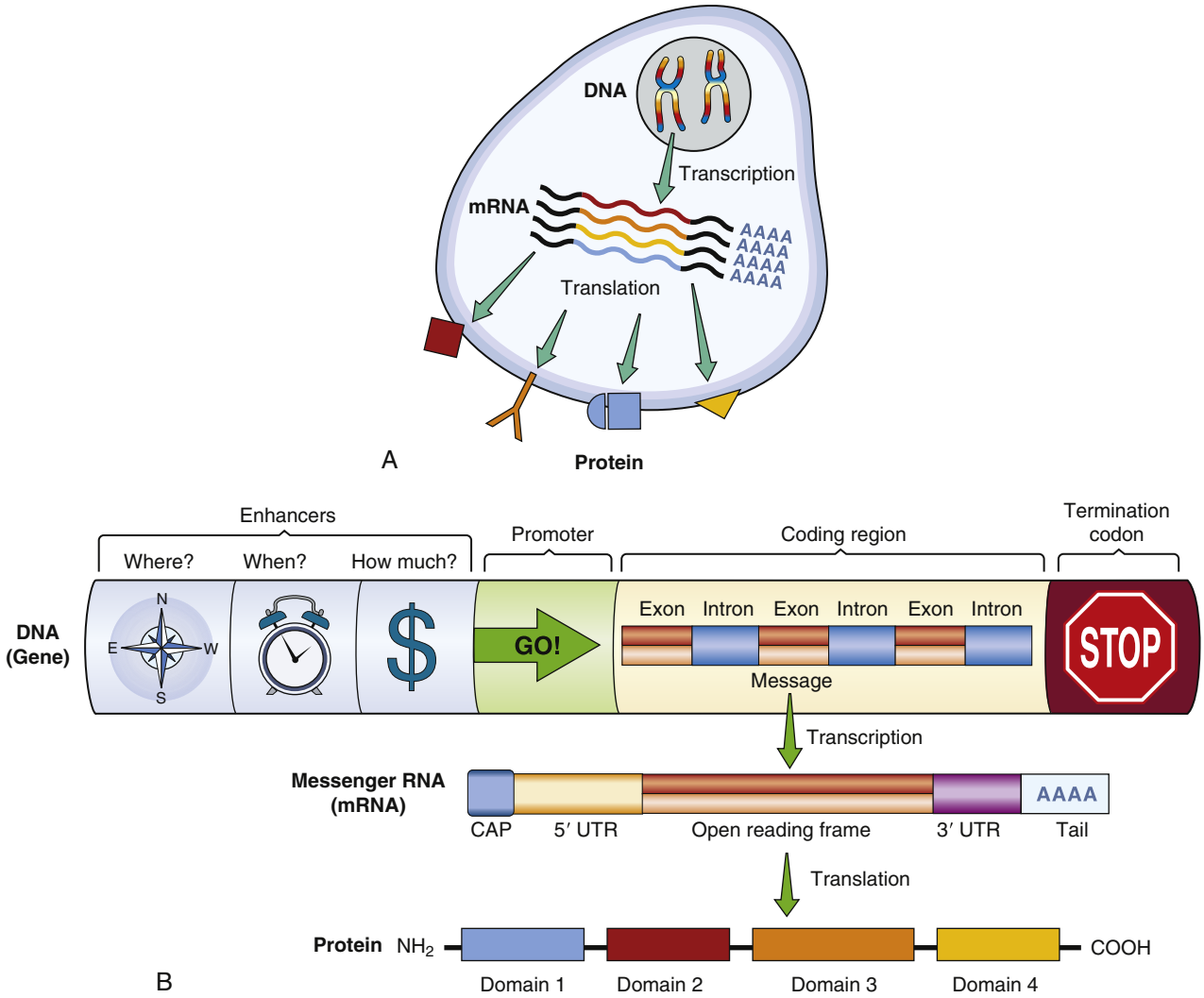

• **Figure 26-4** The molecular paradigm of gene expression. **A,** The cellular location of gene activity. Genes are coding areas found in the DNA of chromosomes. They are transcribed into messenger RNA, which moves from the nucleus into the cytoplasm to be translated into protein. Proteins can be ligands, receptors, secondary messengers, transcription factors, and so on. **B,** Schematic of gene expression. The gene is composed of four primary regions: enhancers (which guide where, when, and how much a gene is expressed), a promoter (which initiates gene transcription), the coding region (which contain the message in regions called exons separated by "spacer" DNA called introns), and a termination codon. The messenger RNA is transcribed and processed from the gene. The message for the new protein is in the open reading frame. The flanking regions (5′ and 3′ untranslated regions) are regulatory regions that govern the transcript stability and translation efficiency. A 5′ cap aids in translation and helps protect the transcript. A polyadenylated (poly A+) tail also helps protect many transcripts from degradation. DNA and RNA are nucleic acids (DNA has thymine, whereas RNA has uracil; both have adenine, guanine, and cytosine). Protein is a chain of amino acids (three nucleic acids encode one amino acid). Domains are distinct functional areas of the protein determined by the amino acid sequence, chemical modifications, and structural conformation of the molecule. *UTR,* Untranslated region.

regulate how much transcript is available for protein production. Messenger RNAs have three primary domains. The open reading frame (or region carrying the protein coding sequence) is flanked by 5′ and 3′ untranslated regions (UTRs). The UTRs play a key role in stability and translation. Many (but not all) mRNAs are further protected by a 5′ cap and poly-adenylated tail that retard transcript degradation. By varying the speed by which mRNA is degraded and/or translated, the cell has another means of regulating itself independently of gene activity. Furthermore, micro RNAs (miRNAs), usually 22 nucleotides in length, can bind mRNA. Thus, miRNA binding further epigenetically alters transcriptional activity by degrading mRNA or prevention of translation.[58] Genes that regulate cell homeostasis ("housekeeping" genes) are often constituently active, whereas genes responding to a stimulus, such as proliferation, undergo increases and decreases in cellular levels. Like DNA, mRNA does not affect cell structure or function directly.

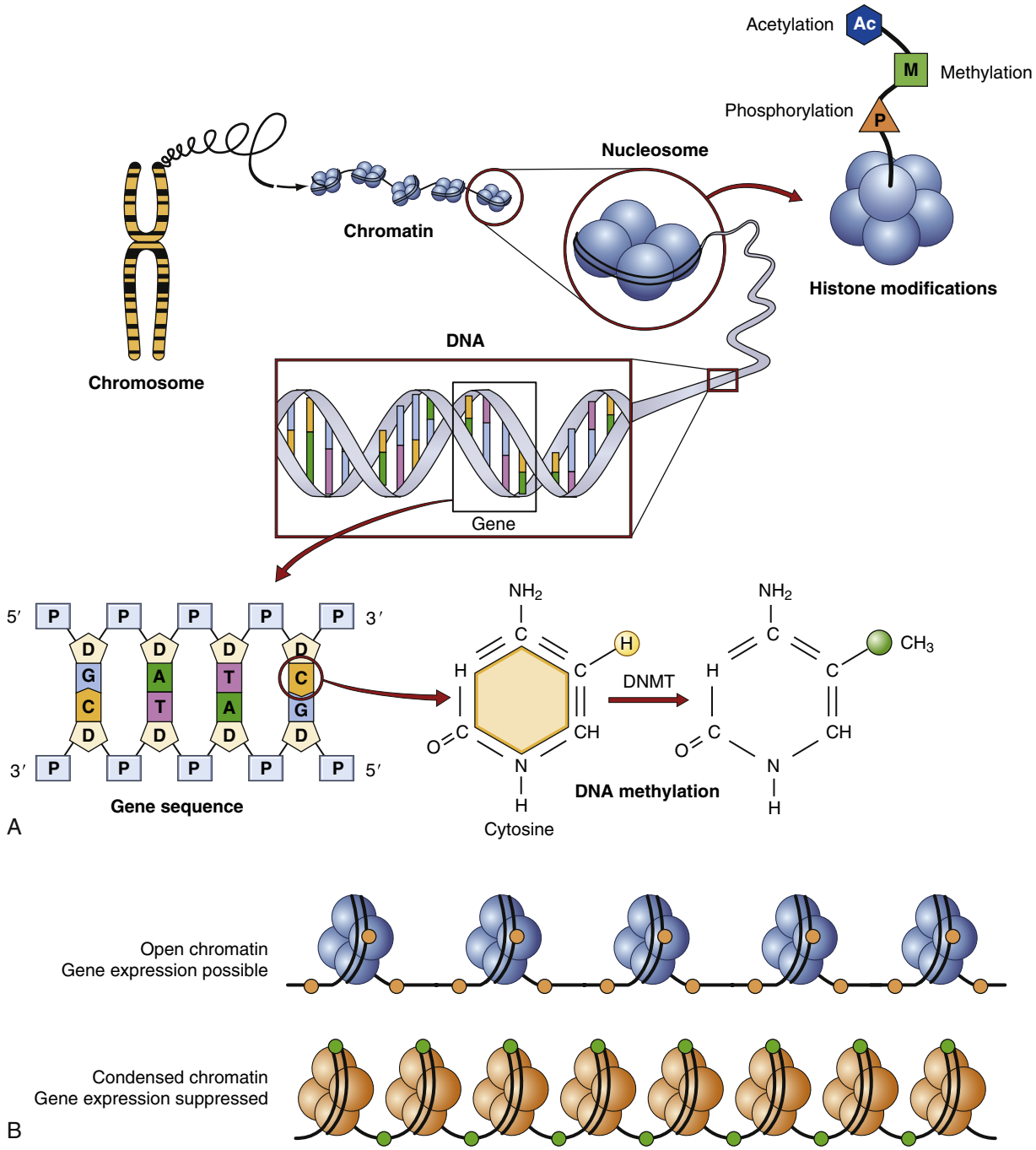

• **Figure 26-5** Epigenetic control of gene expression. **A,** Epigenetic modifications. Human chromosomes are composed of chromatin, DNA wrapped around histone protein octomers. Each DNA-histone octomer complex is termed a nucleosome. The nucleosome can be modified and epigenetically controlled at two sites. The DNA can be methylated at the 5-position of cytosine. The histone can be modified through acetylation, methylation, and/or phosphorylation. **B,** Mechanism of epigenetic control of gene expression. Modification of histones and DNA cause reversible modifications in chromatin organization. Genes are expressed when the chromatin is open. Acetylated histone *(blue)* and de-methylated cytosine *(yellow)* lead to open chromatin. Gene expression is suppressed when the chromatin is condensed. Methylated cytosines *(green)* and deacylated histones lead to condensation of the chromatin. *DNMT,* DNA methyltransferase.

Proteins are responsible for many important structural and functional properties of a cell (see Figure 26-4). Each of three nucleotides in the DNA/mRNA coding region is translated into a single amino acid that is added to the protein chain. Proteins often contain several functional groups called domains. For example, the cell surface protein epidermal growth factor receptor contains a ligand binding domain, a transmembrane domain, and a tyrosine kinase domain (to stimulate intracellular signaling).[59] In addition to the presence and amount of protein synthesis, protein

function is further regulated by chemical and conformational modifications that allow the cell even finer (and more rapid) means of regulation.[49] Proteins can be activated by enzymatic cleavage of inactive precursor molecules. Extracellular proteins are frequently modified by glycosylation, or the addition of complex sugar molecules. Intracellular proteins, especially those associated with signal transduction, undergo the phosphorylation of specific amino acids (serine, threonine, or tyrosine). Acetylation is also a major form of chemical modification of proteins. Environmental changes, such as a change in pH, can profoundly affect protein structure and function. Last, protein function can be modulated by feedback inhibition.[49]

Taken together, the constituents of the DNA→mRNA→protein molecular paradigm shows a remarkable amount of efficiency and flexibility. Although the cell contains an estimated 23,000 to 40,000 genes, mRNA and protein processing actually can generate an estimated 1 million separate proteins.[60] Modulation of gene expression exerts a more powerful, albeit slower, response to the cell's needs than protein metabolic and feedback inhibition functions.[49] In addition to structural building blocks, proteins also govern regulatory pathways as ligands, receptors, secondary (or intracellular) messengers, and transcription factors. Proteins act in cascades or pathways. Frequently, proteins producing similar effects within these pathways lead to redundancies that protect and maintain the cellular function governed by the pathway. In short, at each step of the paradigm (DNA→mRNA→protein), cell structure and function can be regulated and modified.

The molecular basis of many human diseases, including cancer, results from perturbations in this genetic paradigm. Therefore, discovery of "disease genes" for conditions such as Alzheimer disease, cystic fibrosis, or breast cancer is an important but preliminary step toward unraveling the molecular basis of the disease pathogenesis. Molecular alterations leading to the aberrant behavior of the cancer cell can be categorized as nucleic acid (DNA/mRNA) and protein alterations. Changes in DNA structure and function (gene expression) lead to important qualitative and quantitative protein alterations that ultimately result in the structural and behavioral characteristics of the cancer cell.

Nucleic Acid Dysregulation in Human Cancer

Complex biologic and biochemical mechanisms protect the integrity of DNA; therefore, there is a low rate of mutagenesis in normal cells. Some genetic diversity must occur to allow for evolution; however, rapid or uncontrolled genomic alterations can lead to cancer or cell death. Biologically, tissue architecture protects stem cells (believed to be the originating cell type of human cancers) from genetic damage.[61] Biochemically, an array of enzymes and low molecular weight molecules neutralizes mutagens before causing any genetic alterations. However, each cell type still undergoes low but significant mutation rates due to a variety of chemically reactive molecules.[62] Cancer-associated DNA alterations come in two major groups. First, large-scale chromosomal abnormalities can affect multiple genes and signal pathways. Second, nucleotide sequence alterations affect specific genes. Cancer-associated mRNA changes result from either large or small-scale DNA alterations, as well as perturbations in other post-transcriptional regulatory mechanisms.

Genomic Instability Leads to DNA Alterations in Cancer Cells

Because most cancer cells are observed to show at least some DNA alteration, many investigators believe a certain level of genomic instability allows the cancer cell to sustain the necessary genetic damage to lead to the malignant transformation.[63-66] Variability in development and progression between tumors suggests that tumors may differ in their proclivity to accumulate the necessary genetic alterations. Cancer cell genetic alterations can occur at a frequency as high as 100 times that of their non-transformed counterparts.[67] Therefore, in addition to selective pressures on cancer cells, genetic alterations leading to cancer behavior may be due to a failure to survey and repair DNA damage, as well as enhanced sensitivity to mutagens.[65,68,69] "Caretakers" of genome integrity can be arranged into three broad categories: (1) DNA damage detection and repair mechanisms, (2) direct DNA damage molecules, and (3) inhibitors of DNA mutagens.[9,70-72] Genomic instability can be progressive or episodic. Progressive instability results from an inherited defect that leads to new mutations with each successive cell generation. In progressive genomic instability, DNA alterations tend to be widespread in the genome.[73-75] Episodic instability leads to specific DNA alterations that occur in cells that do not inherit a defect in genomic homeostasis.[75] Rather, episodic instability is triggered by a selective pressure, such as oxidative stress. Both large-scale chromosomal alterations and small-scale nucleotide sequence alterations might result from either type of genomic instability during tumorigenesis.[76-78]

Chromosomal Abnormalities in Cancer Cells

Most human cancers show quantitative (aneuploidy) or qualitative (structural) chromosomal abnormalities.[79] Numerical chromosome changes involve either the entire chromosome or one of the DNA alleles (or pairs). Allelic changes often result in the duplication of the remaining allele.[80] Cells within various tissues tend to share the same numerical chromosomal alterations and can lose a significant number of alleles (25% to 50%) during malignant transformation. These alterations may be due to progressive instability through inheritance of mutations to DNA damage repair genes such as MMR and p53.[81-85] Several other events can lead to numerical chromosomal alterations in aneuploid cancer cells. Abnormalities in the number and/or function of the chromosomal centrosome due to STK 15 kinase or p53 inactivation can lead to aneuploidy.[81] Alteration of mitotic spindle checkpoints, such as hMAD2 in breast cancer, can lead to abnormal segregation

of chromosomes during cell division.[86,87] Last, inactivation of genes that respond to DNA damage, such as p53 ATM or BRCA1/2, can also lead to replication of an altered DNA number.[85,88,89] In addition to numerical chromosomal alterations, three forms of chromosomal structural alteration may be critical for malignant progression: gene amplification, rearrangement/translocation, and deletion.

Gene amplification is the repeated duplication of a certain chromosomal region, often 50- to 100-fold[38] (Figure 26-6). There are two distinct structural alterations that lead to amplification. Double minutes are small pieces of chromosome that lack a centromere.[90] They cannot be inherited but are maintained by selective pressures. Homogeneous staining regions are double minutes that are incorporated into the genome and are inherited. Increased gene copy number can lead to overexpression of that gene.[91] Amplification is believed to occur late in tumor development and has been linked with resistance to chemotherapeutic agents.[92,93] Both double minutes and homogeneous staining regions are frequently observed in chemotherapy-resistant tumors and are believed to harbor genes that confer a selective advantage to the cancer cell.

Chromosomal rearrangements such as translocations have been well described in human cancers[38] (Figure 26-7). Translocations are a transfer of part of one chromosome to another.[94] Translocations are considered reciprocal if two chromosomes trade material. Like gene amplification, translocations can lead to cancer-associated alterations of gene expression.[95] In Burkitt lymphoma, reciprocal translocation of the Myc proto-oncogene to an immunoglobulin promoter in B cells leads to an elevated expression of Myc.[96,97] Therefore, unlike gene amplification, which increases gene expression by increasing template number, this example of reciprocal translocation leads to increased gene expression by changing the transcriptional regulatory apparatus. The Philadelphia chromosome (a translocation from chromosome 9 to chromosome 22) is an important marker for chronic myelogenous leukemia.[98] Rather than alter the expression level of the genes at this locus, a fusion gene product, BCR-ABL, results. Activation of both oncoproteins is important to tumor progression.

Chromosomal deletions are believed to be an important mechanism of inherited loss of tumor suppressor gene loci[38] (Figure 26-8). Following the sporadic or inherited deletion of one allele, the second can be inactivated by either mutation or epigenetic "silencing" (which is discussed later) in a "two-hit" fashion. In colorectal cancer, deletions of important suppressor gene loci at chromosome 5 (APC), 17 (p53), and 18 (DCC) are important molecular events leading to malignant progression.[99-101] Although translocations and deletions are often linked to genes that promote malignant transformation, chromosomal deletions are primarily associated with loss of genes that suppress cancer formation.

Nucleotide Sequence Abnormalities in Cancer Cells

Rather than large-scale changes in chromosomal DNA, nucleotide sequence alterations affect individual genes.[102-104]

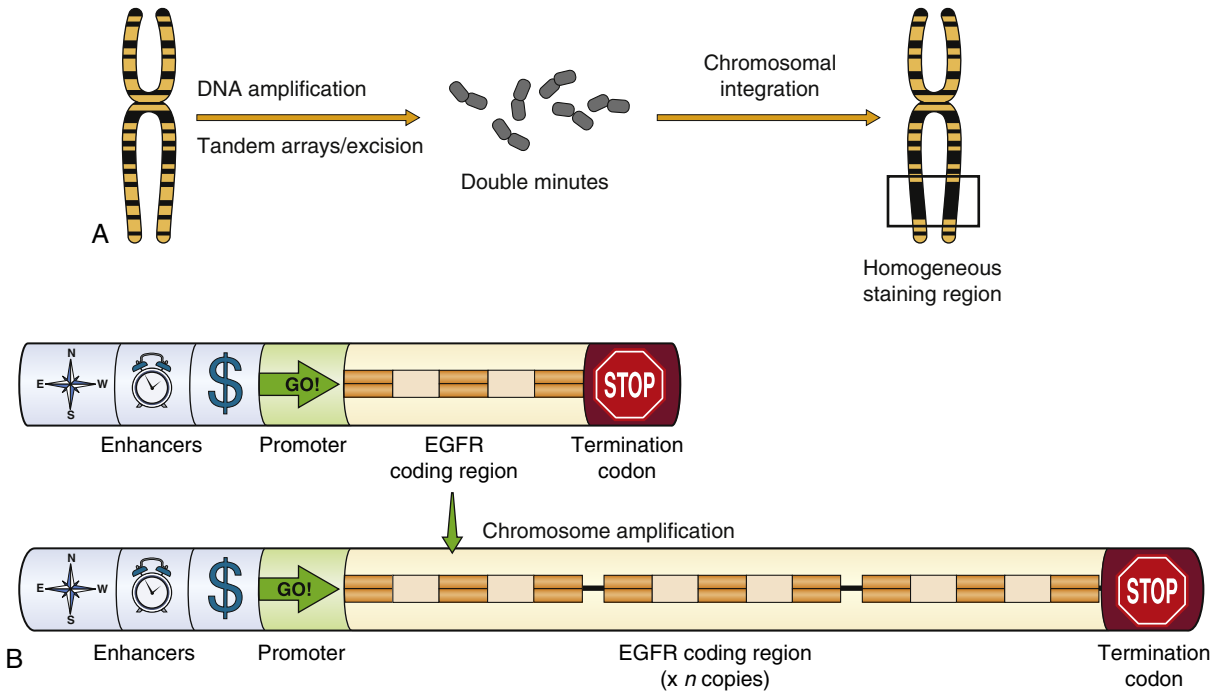

• **Figure 26-6** Cancer-associated chromosomal alterations: gene amplification. **A,** Amplified DNA in tandem arrays is excised as double minutes or reintegrated as homogeneous staining regions. **B,** Cancer-associated gene amplification of a gene such as the epidermal growth factor receptor *(EGFR)* occurs when multiple copies of the same gene come under the control of the same promoter, thereby increasing the number of transcript copies and protein products.

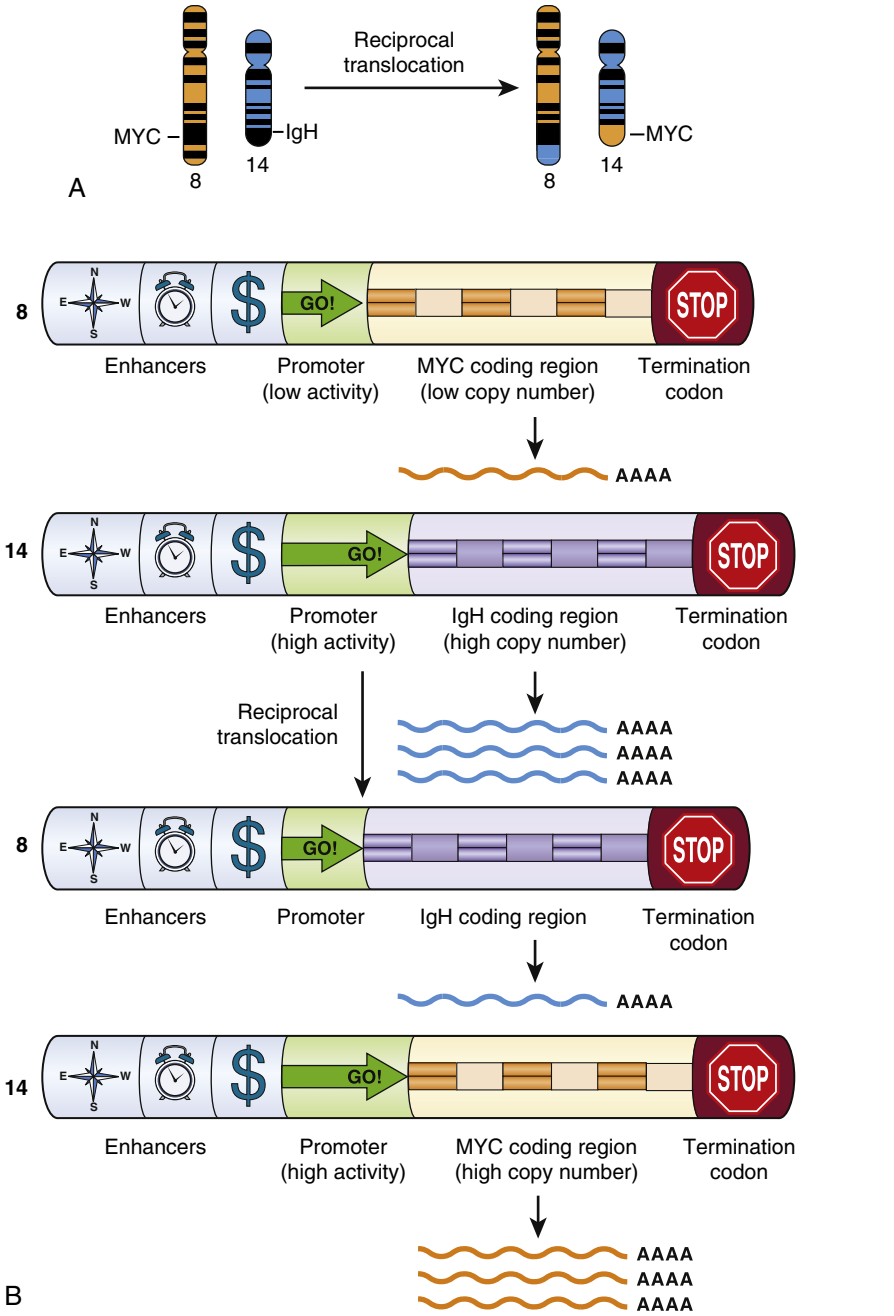

• **Figure 26-7** Cancer-associated chromosomal alterations: translocation. **A,** An exchange of a portion of chromosome 8 containing the Myc gene with that of a segment of chromosome 14 leads to the Myc gene being attached to a highly active immunoglobulin promoter. **B,** The consequence of the reciprocal translocation is that the Myc gene activity is increased because it is now under the control of a more active promoter.

These alterations usually involve a single nucleotide change or insertion/deletion of nucleotides[105] (Figure 26-9). Changes in a single nucleotide (point mutation) can lead to a missense mutation (changing an amino acid) or nonsense mutation (stopping protein synthesis). Inserting and deleting nucleotides are both classified as frameshift mutations because the numerical change in nucleotides shifts how the message is read, leading to a completely altered amino acid sequence. This altered amino acid sequence can lead to profound changes in protein function.[105] A common nucleotide alteration observed in cancer cells is microsatellite instability.

Microsatellite instability (MSI) in cancer cells refers to insertion or deletion of nucleotides in simple repeated sequences that are normally found in DNA.[103] Microsatellites are repeats of four (or more) nucleotides and appear as numerous and randomly distributed regions throughout the chromosomal DNA.[106] The frequency of microsatellite alteration depends, in part, on the type of repeated sequence (mononucleotide repeat, dinucleotide repeat), length (larger

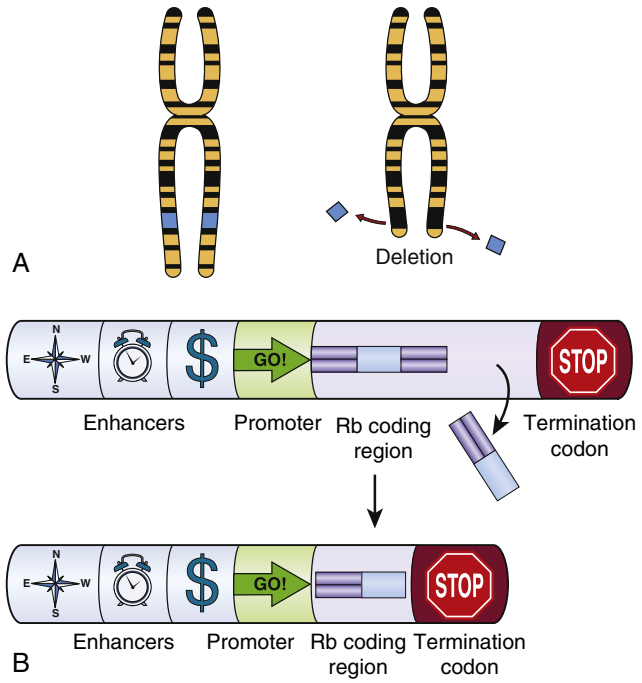

• **Figure 26-8** Cancer-associated chromosomal alterations: deletion. **A,** Portions of a chromosome (or even entire chromosomes) can be lost as a result of genomic instability. **B,** The consequences of the deletion can be the loss of a copy of an important suppressor gene such as Rb. Subsequent mutation of the second copy can lead to loss of its suppressor activity.

alleles are more frequently altered), location of the sequence, and the type of alteration in DNA repair.[107-109] Alteration of mismatch repair genes such as hMSH1/2/3, hPMS1/2, and hMLH3 is associated with an increased frequency of MSI.[110-119] MMR-deficient cancer calls can show about a 100-fold increase in MSI over MMR-proficient cancer cells.[120] Microsatellite alteration leads to frameshift mutations in important proteins regulating normal cellular homeostasis, such as TGFβRII, BAX, APC, and IGFIIR.

Epigenetic Alteration of Gene Expression in Cancer Cells

Tumor suppressor gene inactivation and oncogene activation can occur through epigenetic manipulation of gene expression.[121,122] The "two-hit" hypothesis (where a tumor suppressor gene functional loss is due to a sequential loss of both alleles) typically refers to mutation or deletion of each gene copy. However, a similar effect can be achieved in cancer cells through epigenetic gene inactivation.[123,124] Hypermethylation of one or both copies of genes encoding important cell adhesion molecules and growth regulatory proteins can lead to loss of gene expression. In addition, DNA hypomethylation can lead to chromosomal instability and oncogene activation.[125-127] Epigenetic alteration of gene expression has been observed in several cancers, including colorectal cancer (MLH1), renal cell carcinoma (VHL), p16/CNKN2A (head and neck cancer), and BRCA1 (breast cancer).[128-131] Epigenetic gene expression alteration is an important target for cancer therapy that is discussed later.

Summary and Consequences of Cancer Cell Nucleic Acid Alterations

In summary, cancer arises from an accumulation of inherited or environmentally triggered genetic (and epigenetic) alterations. Genes become overactive or silenced by large-scale genetic changes such as chromosome number (aneuploidy) and structure (amplification, rearrangement, deletion) or small-scale genetic changes such as nucleotide point mutation, insertion, or deletion. Gene expression is also affected by epigenetic or conformational changes due to nucleotide or histone modifications. These large- and small-scale alterations, in turn, create quantitative and/or qualitative changes in the encoded mRNAs. Ultimately, the changes in the transcripts lead to either increases/decreases in protein amount or a change (overactivity or suppression) in protein function. These proteins perform crucial roles in normal cellular homeostatic pathways. Abrogation of these pathways leads to the cancer cell behavior that confers a selective advantage over their normal cellular counterparts.

Protein Dysregulation: How Genetic Alterations Lead to Cancer

When genes are activated, the products of their expression are proteins. Therefore, when gene expression is quantitatively and/or qualitatively altered, the same changes to the protein product can occur. Proteins govern many of the structural and functional characteristics of the cell and are often categorized by their cellular location and function (Figure 26-10, *A*). In the context of cancer biology, deregulated proteins that support malignant traits are often referred to as oncoproteins; those that inhibit the malignant phenotype are termed tumor suppressor proteins (often referred to as "gatekeepers"). Extracellular proteins refer either to molecules that provide a structural and regulatory framework for the cell or to soluble factors that can provide signals locally or from a distance. Cell surface proteins can be part of the extracellular matrix or specific surface receptors that carry an extracellular message internally. Secondary messengers are factors in an intracellular network that signal a cell to respond to stimuli. Part of that response can be to signal transcription factors to upregulate or downregulate gene activity. The activated genes can lead to a strong, pluripotent response. Not only do proteins form response pathways, but also they can create networks of pathways. In other words, activation or inactivation of a factor in one pathway can influence the function of several other pathways. These pathway networks may influence a single or several cell traits.[49]

By changing the amount and/or function of a protein, an entire protein pathway or pathway network can become deregulated.[132,133] For example, a cancer cell might carry a gene mutation that leads to production of a growth factor receptor that is activated without needing to be bound to a growth factor. The result is the stimulation of a network of pathways leading to cell proliferation, even though all the other proteins in the pathway are "normal." Accelerated

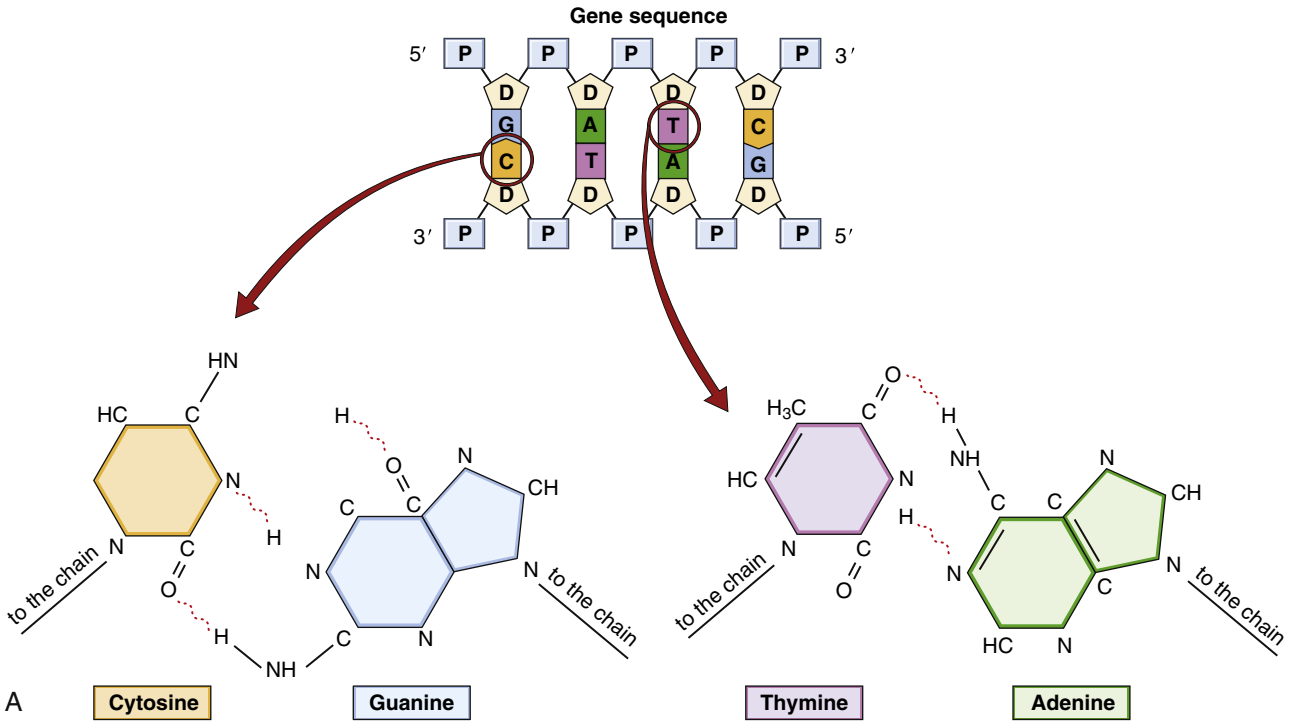

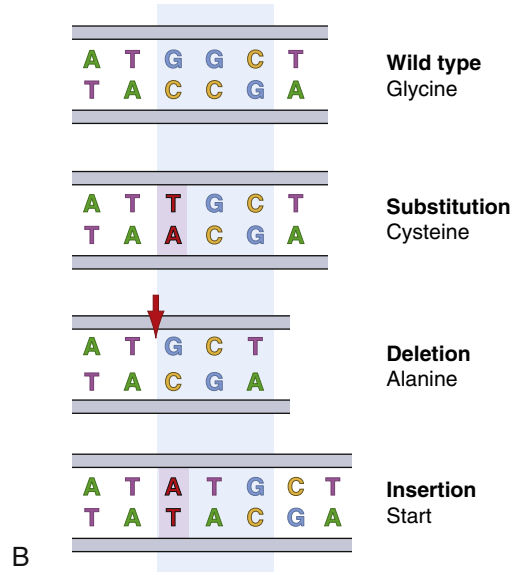

• **Figure 26-9** Nucleotide sequence mutations. **A,** The nucleotide is the fundamental component of DNA. The components of the nucleotide are phosphorus *(P)*, sugar (deoxyribose, *D*), and four nucleotides cytosine *(C)*, guanine *(G)*, thymine *(T)*, and adenine *(A)*. The two DNA strands have complementary nucleotide sequences based on pairings between G:C and T:A. **B,** DNA sequence changes can result in profound protein alterations. Each three nucleotides encode a single amino acid in the polypeptide chain. For example, GGC is eventually translated as glycine. A G→T substitution changes the code to the amino acid cysteine (TGC). Deletion of G leads to a shift in how the sequence is read; therefore, the peptide chain starts with alanine (rather than glycine) and each amino acid thereafter is incorrect because of the sequence frameshift. Likewise, addition of a nucleotide leads to a frameshift. Instead of glycine, a start codon (ATG) is generated, creating a new (and different) polypeptide chain. A frameshift can also lead to a mistaken stop codon that will prematurely terminate the synthesis of the amino acid chain.

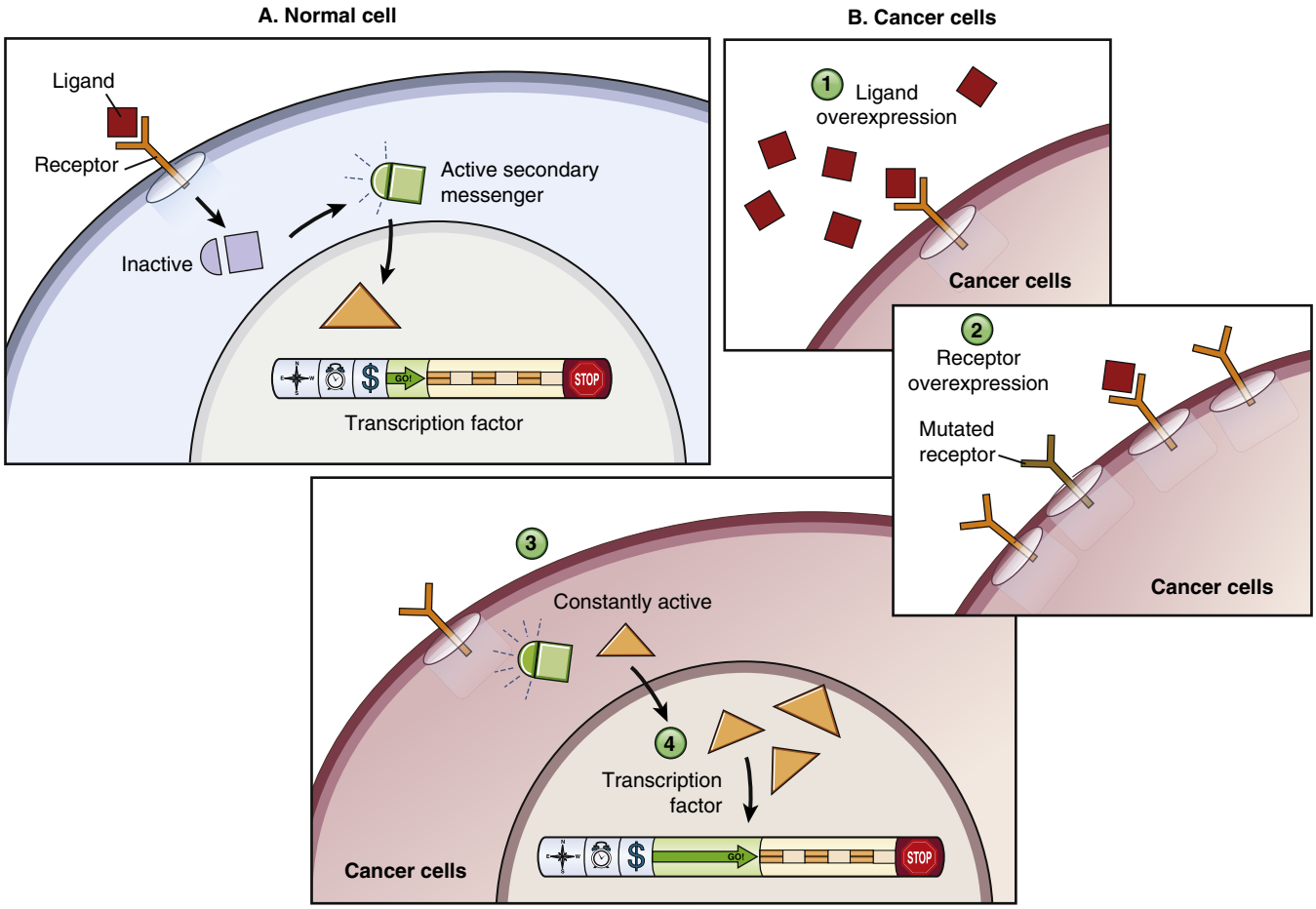

• **Figure 26-10** Release from growth signal requirements. **A,** The signal transduction pathway. Many proteins serve to transmit signals to allow the cell to respond to stimuli. Signals for cell division often are triggered by an extracellular ligand such as a growth factor (GF). Binding of the growth factor receptor (GFR) initiates the activation of secondary messengers that conduct the message from the cell surface throughout the cytoplasm and to the nucleus. Activation of transcription factors can initiate programmed cellular responses. **B,** Growth signal requirements can be negated by alteration of any component of the pathway. *1,* Overexpression or autostimulation produced by cancer cells can eliminate the need to wait for other cellular sources to provide a stimulus. *2-4,* Overexpression or mutation of GFRs, secondary messengers, or transcription factors can make the cancer cell more sensitive to growth stimulation, or mutated forms might remain constituently activated.

proliferation confers a selective advantage on the cancer cell over its neighbors. The cancer cell proliferates without needing to be stimulated by the appropriate ligand; the normal cell must wait for the proper signal(s).[134] In addition, accelerated activity might lead to other genetic mistakes that could generate other mutations to support genetic growth. Several traits are believed to confer selective advantages that form the hallmarks of cancer cell biology.[9]

Several important regulatory pathways are abrogated to allow cancer cells to outcompete their normal neighbors. Molecular alterations at the DNA, mRNA, and/or protein levels disrupt key networks that regulate normal cell appearance and behavior, thereby leading to the common cancer cell traits. However, because different cells may be regulated by different molecules and the alteration of any single molecule within a pathway or network may lead to the same malignant trait, no single molecular alteration is responsible for cancer (or even a single cancer trait) within all malignancies.[134,135] Important molecular growth controls that are deregulated in the process include release from growth signal requirements, insensitivity to inhibitory signals, evasion of apoptosis, immortalization, neovascularization, and metastasis.[9]

Release from Growth Signal Requirement

Hyperactivation of proliferative or mitogenic pathways is a key trait of cancer cells.[15,136] The release of cancer cells from normal growth controls is largely achieved by the overactivity of growth-promoting networks and inactivation of growth-inhibiting networks (discussed in the next section). Normal cells depend on diffusible factors, extracellular matrix molecules, and cell-cell adhesion molecules as growth signals. Therefore, the growth signal starts at the cell surface, is transmitted through the cell membrane, and stimulates intracellular cascades that control the signal response. Without the proper growth signals, normal cells do not divide or remain in a quiescent state.

There are four fundamental mechanisms through which a cancer cell becomes autonomous from growth signal requirements (see Figure 26-10, *B*). First, extracellular growth signals can be altered.[137] A well-described example is autocrine stimulation, a positive feedback loop by which the cancer cell produces its own growth factors.[138] The result is that the cancer cell is no longer dependent on growth factors from the microenvironment to stimulate cell division. Overexpression of growth factors, such as platelet-derived growth factor and transforming growth factor alpha (TGF-α), is also common in solid tumors.[139-141] Alternatively, the tumor stroma can supply mitogenic factors.[16]

Second, cell surface receptors can be altered quantitatively or qualitatively. In normal cells, cell surface receptors have extracellular ligand-binding domains, transmembrane domains, and intracellular domains that transmit the growth signal by phosphorylating target molecules at specific amino acids (primarily tyrosine or serine/threonine).[59,142-144] Overexpression of growth factor receptors, such as the epidermal growth factor receptor and HER2/neu receptor, leads to a hypersensitivity to growth factors in the microenvironment.[145] Receptors also can be truncated, leaving the domains responsible for cellular stimulation active without either the requirement of ligand binding or the ability to inhibit stimulation.[146] In addition, cancer cells can change the receptors on the cell surface to those that promote cell growth. Frequently, cancer cells alter integrins, cell surface molecules that transmit signals from the extracellular matrix.[147-149]

Third, cancer cells may have altered secondary messenger pathways, molecular messengers that receive and process messages from stimulated cell surface receptors.[150,151] Signals generated by receptor-ligand binding are sent through the cytosol and to the nucleus by secondary messengers. A growth signal can be accentuated by disrupting negative feedback mechanisms that inhibit cell proliferation.[9] These pathways have many members and can be altered by changing the structure or function of any one of its members. For example, the SOS-Ras-Raf-MAPK pathway is altered in many tumors.[9,152,153] In normal cells, Ras is activated by binding to GTP.[38] This is mediated by guanine nucleotide exchange factors (GEF) and inhibited by guanine activating proteins (GAP). In cancer cells, Ras can be activated by overactivity of GEF or inactivation of GAP.[154] Other important secondary messenger pathways include the JAK/STAT, Wnt-catenin, and PTEN regulatory loops.[155-157] Ultimately, abrogated secondary messenger pathways can lead to activation of cell proliferation programs.

Fourth, overexpression of transcription factors or expression of mutated transcription factors can activate immediate-early and delayed growth programs in conjunction with or independent of upstream stimulation. For example, overexpression of the transcription factor Myc contributes to deregulated cell growth (and is associated with poor prognosis) in many human cancers (the molecular mechanism is discussed in the next section).[158,159] As a transcription factor, Myc controls the expression of several proliferation-related genes necessary to sustain a response to a growth signal.[160,161] Overexpression of transcription factors such as Myc overrides inhibition of gene expression activation by outcompeting transcription inhibitors (such as Mad and Max).[162,163]

What is the selective advantage of growth signal independence for the cancer cell? Rapid cell division helps replace normal cells with other cancer cells within a tissue. In addition, rapid cell division can result in more DNA mutations by decreasing the time in which it is possible to detect and repair replication errors. Therefore, other genes might be mutated, leading to the deregulation of other networks and acquisition of new cancer cell traits. Proto-oncogenes refer to genes that encode for growth-promoting proteins in a normal cell. Oncogenes refer to altered (mutated) proto-oncogenes (normal growth stimulatory genes) that lead to this self-sufficiency from growth signals. These mutations can be both large-scale and small-scale chromosomal alterations. EGFR can be overexpressed through gene amplification or activated through a gene deletion.[164] The Ras gene family is altered by a point mutation leading to an amino acid change. This single amino acid substitution results in GEF overactivity and constituent Ras activity.[165] In some cases, epigenetic forces such as DNA methylation also have a role in oncogene activation.[166] Although hyperactivity of growth-promoting pathways clearly is important to cancer development, the intensity of oncogenic signaling depends on disabling growth-inhibitory and apoptotic pathways.

Insensitivity to Growth Inhibitory Signals

To maintain homeostasis in normal tissues, growth-inhibitory signals modulate and block growth-promoting signals.[136,167,168] These signals (or ligands) also bind cell surface receptors that trigger intracellular secondary messengers and activate transcription factors. Growth-inhibitory signals are either soluble or adherent to adjacent extracellular matrix or neighboring cells. These "gatekeeper" proteins, encoded by tumor suppressor genes, are inactivated during tumorigenesis, leading to a loss of extracellular and intracellular controls to cell division.[136]

Normal cell division is regulated by a complex molecular circuit often referred to as the cell cycle clock.[169] Specific checkpoints in the cell cycle clock are governed by changing the levels of cyclins, a family of regulatory proteins of serine-threonine kinases (known as cyclin-dependent kinases).[170] The levels of cyclins rise and fall depending on the cell cycle stage. Accumulation and destruction of these cyclins ensure that each checkpoint in the cell cycle occurs in its proper order at its proper time. The four checkpoints in the cell cycle clock are G1 (gap 1), S (DNA synthesis phase), G2, and M (mitosis) (Figure 26-11). External signals, such as extracellular mitogenic signals, influence the decision of a cell to replicate in the G1 phase; the progression through the remaining phases of the cell cycle is independent of external signals once the cell division regulatory apparatus passes the restriction point (or R-point).[169] Cyclins D and E are most directly under mitogenic control and G1; the

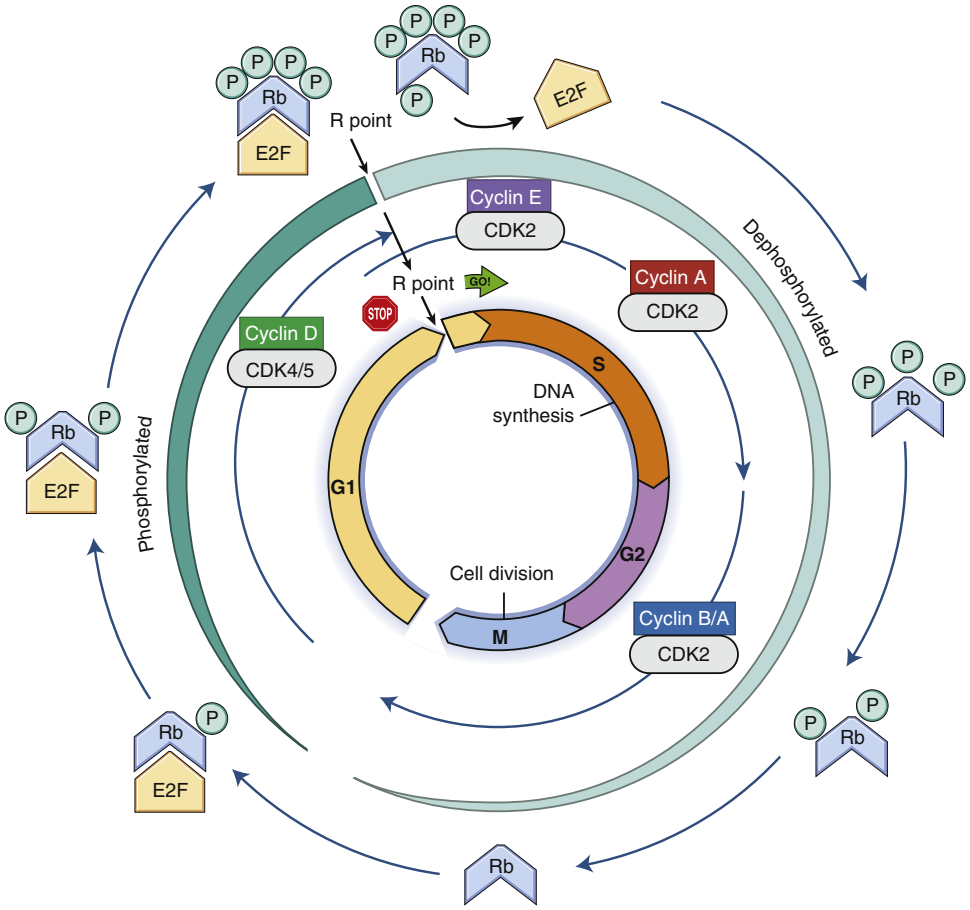

• **Figure 26-11** Rb-mediated control of the cell cycle. The molecular regulators that govern cell division are referred collectively as the "cell cycle clock." A cell can choose between a quiescent (no cell division or G_0) and proliferative (cell division) state based on upstream signal transduction pathways triggered by transforming growth factor beta (TGF-β), integrins, the microenvironment, tyrosine kinase receptors, and G-proteins. The cell cycle is divided into four phases: G1 (or gap 1), S (DNA synthesis), G2, and M (mitosis or cell division). In G1, the cell is responsive to upstream signals promoting and inhibiting cell division. Restriction or R point is the moment in G1 where the cell decides to commit irreversibly to cell division. The cell cycle phases are controlled by the pairing/activation of cyclins with cyclin-dependent kinases (CDKs). Rb is hypophosphorylated during G1 until the cell progresses through R-point. Subsequently, Rb becomes progressively more phosphorylated until the M/G1 transition (it then becomes dephosphorylated). Rb is an inhibitor of cell division. Phosphorylation inactivates Rb and allows cell division. The cyclin-CDK complexes phosphorylate Rb, thereby guaranteeing that cell division is completed. In cancer, mutation/deletion of the Rb gene, Rb promoter methylation, or Rb sequestration by tumor viruses perpetually inactivates Rb control of R-point, thereby eliminating an important restriction of cell division.

remaining cyclins (A and B) regulate the remaining cell cycle phases.[168,171-173] The key regulatory point in G1 between cell division (entrance into the cell cycle) versus differentiation/senescence (cell cycle block) is the R-point.[174-177] Therefore, a critical step to achieve unconstrained proliferation in tumorigenesis is to deregulate the proteins that govern R-point.

Most signals that regulate cell division at R-point modulate the retinoblastoma (pRb) pathway.[178-183] G1-phase moves irreversibly to S-phase based on the activity of the transcription factor E2F. pRb inhibits proliferation by binding/inactivating E2F transcription factors. E2Fs control genes necessary for cell division.[184] When phosphorylated, pRb can no longer bind E2F; therefore, cells progress through R-point into S-phase. In normal cells, pRb is dephosphorylated by antigrowth signals, such as transforming growth factor beta (TGF-β), and the pRb-E2F complex blocks cell cycle progression from G1 to S.[185] Cell proliferation occurs when cyclin D (complexed with either cdk4 or cdk6) and cyclin E (with cdk2) phosphorylate pRb, overcoming its inhibitory effects on the cell cycle by causing E2F to be released.[186-190]

In cancer cells, pRb activity often is blocked or lost, leading to a loss of R-point regulation and uncontrolled cell proliferation.[178] In some tumors, such as retinoblastomas, osteosarcomas, and small-cell lung carcinomas, pRb is inactivated directly through gene mutation/deletion or promoter methylation.[9] Viruses, such as the human papillomavirus in cervical cancers, also produce proteins that bind and inactivate the pRb protein.[191,192] However, like

the SOS-Ras-Raf-MAPK pathway, the pRb circuit more often is inactivated by disrupting other members of the pathway.[9,193] For example, cancer cells might lose TGF-β responsiveness through downregulation of the receptor or production of dysfunctional receptors.[194,195] Intermediary messengers in the pathway, such as Smad4 and $p15^{INK4B}$, also might be mutated. In breast cancers, cyclin D1 is overexpressed, causing hyperphosphorylation of pRb.[196,197] Therefore, inactivation of any member of the pRb pathway can lead to the same trait of uncontrolled proliferation that is characteristic of cancer cells. In addition, oncoproteins that can deregulate cell differentiation can affect pRb cell cycle regulation. Hypophosphorylated pRb is required to halt cell division to allow differentiation.[198] Oncoproteins such as Myc inhibit cell differentiation in human cancers by overriding pRb's control of cell division.

In the differentiated state, cells are controlled by internal programming (rather than external anti-mitogenic signals) that blocks reentry into the cell cycle.[163] Differentiated cells contribute to tissue function (in contrast to nondifferentiated cells), which supports tissue renewal by replacing lost cells. Cancer cells often vary in their degree of differentiation. The significance and underlying mechanism of cellular differentiation is poorly understood. At the molecular level, two transcription factors, Max and Mad, bind and stimulate genes involved in differentiation.[158] Normal proliferating cells produce Myc, which binds preferentially to Max, allowing the expression of proliferation genes.[199] In cancer cells, Myc is overproduced, leading to displacement of Mad for Myc and a switch from differentiation programs to proliferation gene programs. As mentioned earlier, Myc is overexpressed in Burkitt lymphoma.[159] The coding region of the Myc gene is translocated or swapped to the highly active promoter of an immunoglobulin gene in B cells. Normally, the immunoglobulin gene/gene promoter is very active in B cells and the Myc gene/gene promoter is not. By replacing the immunoglobulin coding region with Myc, the affected B cell fails to perform its differentiated task (to produce immunoglobulins), instead overproducing Myc, which leads to increased proliferation. Increased Myc protein binds to and sequesters transcription factors that promote differentiation and bind to/activate the promoters of proliferation genes. Therefore, Myc overexpression not only accelerates growth promoters (as addressed in the previous section) but inhibits growth suppression (through differentiation).[200]

What is the selective advantage to the cancer cell of inhibiting growth suppressors? The genetic basis of the loss of inhibitor or "gatekeeper" protein function probably is more common in human cancers than oncogene activation but is experimentally more difficult to identify because it is a negative phenotype (or an event no longer present in a cancer cell). Dozens of tumor suppressors that inhibit cell proliferation through a variety of mechanisms have been identified in a wide range of human cancers.[9] Classically, the inhibitor proteins are completely inactivated. By the strictest definition of tumor suppressor genes, a chromosomal loss of heterozygosity (LOH) must be identified in many different tumors, where one allele (often due to a deletion) and an inactivating mutation is identified in the second gene copy.[201] However, the expression of the second copy of many tumor suppressor genes may be inactivated by promoter methylation.[202] In addition, tumor suppressor gene function can be reduced by other mechanisms. The function neurofibromatosis-1 gene (NF-1) product is reduced through haploinsufficiency, or the loss of only one gene copy.[203] Growth suppressors such as PTEN phosphatase are inactivated by promoter methylation.[157] The tumor suppressor gene p53 is inactivated in some cancers through a dominant negative mechanism. A mutation in one copy of the p53 gene leads to a mutant protein that binds and eliminates the normal or wild-type protein product of the unaffected gene. Loss of p53 function is one of the most common molecular events in human cancer, and the biologic consequences are far-reaching, especially with respect to apoptosis.[204] In short, virtually every cancer involves some genetic and/or epigenetic perturbation of cell cycle regulation/the Rb pathway. Furthermore, in human cancers, inactivation of the growth inhibitors is likely a more common and important event leading to uncontrolled proliferation than is overactivity of oncoproteins.

Evasion of Apoptosis

Thus far, the protein products (ligands, receptors, secondary messengers, and transcription factors) of proto-oncogenes and tumor suppressor genes have been discussed in the context of pro-mitogenic and anti-mitogenic regulators. However, there are key regulators abrogated in tumorigenesis that control a cell's exit from the cell cycle.[205,206] Cells leaving the cell cycle (like differentiated cells) are termed quiescent or post-mitotic. Quiescent cells can reenter the cell cycle. Post-mitotic cells undergo several processes including terminal differentiation, senescence, or apoptosis.[207,208]

Resistance to apoptosis is a critical hallmark of cancer cells.[9,209] Tissue homeostasis balances renewal (through cell division) against attrition (through cell death). Apoptosis (deriving from the Greek term for the falling of petals from a flower or leaves from a tree) is a genetically programmed cell death that is triggered from either internal or external signals, such as growth factor withdrawal, ionizing radiation, chemotherapy cytokine exposure, high calcium concentrations, nitric oxide, or oxidative stress[210,211] (Figure 26-12). Once initiated, apoptotic cascades systematically dismantle a cell to a condensed mass of its sum parts that is engulfed by neighboring phagocytic cells. Left in place, apoptosis eliminates the "precancer" cells that have begun the succession of genetic changes conferring growth advantages by detecting, among other things, DNA damage and oncogene activation. Like the cell cycle, apoptosis is regulated by pro- and anti-apoptosis pathways; therefore, apoptosis is tightly regulated and a function of the severity of the stimulus rather than simply the specificity or a single apoptotic stimulus.[209]

The process of apoptosis proceeds through three phases: initiation phase, effector phase, and degradation

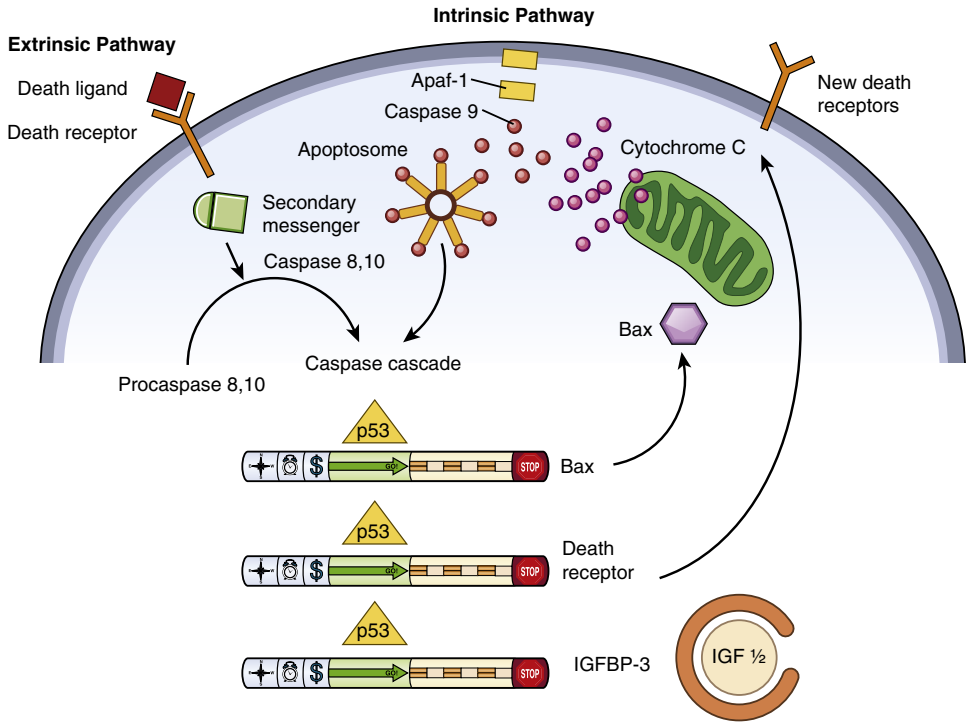

• **Figure 26-12** Apoptosis and cancer. Initiation of apoptosis occurs with extrinsic and intrinsic pathways. *Above:* Extrinsic pathways *(left)* are triggered by death ligand–receptor binding and secondary messenger activation that leads to cleavage of procaspases 8 and 10 to activated caspases. The intrinsic pathway begins with cytochrome C release from the mitochondria. Apaf-1 combines with cytochrome C and caspase 9 to form the apoptosome, which also activates the executioner caspases. *Below:* p53 activates several pro-apoptotic gene programs. Cell death receptor genes are activated to make the cell more sensitive to additional cell death signals. IGF-binding protein-3 (IGFBP-3) is activated. IGFBP-2 sequesters IGF 1/2 and blocks their anti-apoptotic activities. p53 also upregulates Bax, the pro-apoptotic protein that contributes to cytochrome C release.

phase.[210,211] The initiation phase triggers apoptosis and is governed by the extrinsic pathway (receptor-mediated) and intrinsic pathway (mitochondria-dependent).[212,213] The extrinsic pathway is initiated by extracellular ligands that bind to the tumor necrosis factor-alpha receptor (TNFR) superfamily.[214-219] Ligand-receptor binding leads to activation of the secondary messengers: death domain adaptor proteins FADD and TRADD.[220-222] However, there are other extracellular ligands/pathways that prevent apoptosis. For example, colony stimulating factors block hematopoietic stem cells from undergoing apoptosis. These secondary messengers lead to caspase (8 and 10) activation through a death-inducing signaling complex (DISC).[220-222] The intrinsic pathway (which responds to intracellular stress, such as DNA damage, growth factor withdrawal, and some chemotherapeutic drugs) results in increased mitochondrial membrane permeability and release of cytochrome C (which causes apoptosome formation and caspase [3 and 9] activation).[212,223-227] The Bcl-2 family (including Bcl-x_L, Bcl-w, Mcl-1, and A1) inhibits apoptosis by stabilizing the mitochondrial membrane and preventing cytochrome C release through binding (and suppressing) proapoptotic proteins such as Bax and Bak.[228-231]

The effector phase leads to the activation of the caspase cascades that control destruction of the cell. Caspases are a family of 14 proteases that function in two groups: initiator and effector caspases.[223,232] Therefore, caspases do not act simultaneously, but as a cascade. Although structurally similar, caspases are very specific in their substrates, and that specificity allows them to function in a highly orchestrated manner, controlling the specific stages of cellular breakdown (degradation phase).[233,234] Although both the extrinsic and intrinsic pathways of the initiation phase trigger different initiator caspase activation, the caspase cascades tend to converge at the effector caspases.[235] An important family of caspase inhibitors, the inhibitors of apoptosis (IAPs), play a central regulatory role in blocking apoptosis initiated either by the extrinsic or intrinsic pathways.[236,237]

The final stage, the degradation phase, results in the byproducts of the cellular suicide.[210] The cell nucleus fragments, and double-stranded DNA is broken down into nucleosomal segments. The cytoplasm condenses and protrusions appear in the cell membrane. Finally, the cell collapses into membrane-bound apoptotic bodies that are ultimately engulfed by phagocytes. The entire process spans between 30 minutes and 2 hours.

What is the selective advantage for the cancer cell with an inactive apoptosis program? Escape from apoptosis allows for unstable cell populations, (that normally would be eliminated) a key survival advantage, that provides the

opportunity to generate increasingly aggressive clones.[238] Dysregulation of a variety of protein factors in apoptosis pathways can lead to apoptosis escape. Receptors of the TNFR superfamily are mutated and/or downregulated in several lymphoid and solid tumors. Bcl-2 is overexpressed in over half of non-Hodgkin lymphomas.[238,239] IAPs have been shown to be overexpressed in breast, colon, and pancreatic cancers.[240-243] The nuclear factor κB (NFκB), an important transcription factor in apoptosis, is frequently deregulated in lymphomas.[244] However, perhaps the most important and best-described molecular event leading to apoptosis is the deregulation of p53.

The p53 tumor suppressor gene regulates many functions, including growth arrest and DNA repair, senescence, terminal differentiation, and apoptosis.[245] The function of p53 is lost in 50% of all cancers.[246,247] More than 85% of p53 mutations result in a single amino acid substitution. Under normal conditions, p53 is short-lived and appears in small amounts unless otherwise stimulated.[248] p53 is controlled by regulators such as Mdm2 and $p19^{ARF}$ that increase p53 levels in response to DNA damage, UV radiation, ionizing radiation, oncogene signaling, hypoxia, and transcriptional abnormalities.[246,249-251] Wild-type p53 upregulates Bax, Apaf-1, and caspase 9, upstream regulators of the intrinsic apoptotic pathway. In cancer cells, the mutant p53 binds and inactivates the wild-type p53 in a dominant negative fashion. In addition, mutant p53 is not subject to the same control by regulators such as Mdm2 as is wild-type p53.[249,252] Loss of p53 function supports malignant progression by allowing cells harboring aggressive mutations to clonally expand, preventing a halt to cell growth and allowing a rapidly growing cell population to expand uninhibited by hypoxia.[211]

Recently, other genetic programs for cell death have emerged that are subverted by cancer cells. Autophagy, a response to stresses such as nutrient deficiency, leads to organelle breakdown.[209,253] Catabolites from the organelles are then used to support the cancer cell's energy demands. Cell stress–induced signals, such as PI1-kinase, AKT, and mTOR kinases, that attempt to induce apoptosis are also upstream regulators of autophagy. Stress induction of autophagy allows the cancer cell to survive by achieving a dormant state. Necrosis is another genetically based program that paradoxically benefits cancer cells.[209] Pro-inflammatory signals produced by the breakdown of necrotic cells attract inflammatory cells through bioactive mediators such as IL-1α.[27] The inflammatory cells, in return, produce cytokines such as growth factors that promote cancer cell growth. In addition to evading and/or taking advantage of pathways meant to eliminate genetically damaged cells, cancer cells must override other internal cellular programs that limit replicative potential.

Immortalization

After a fixed number of doublings, a cell senesces or stops proliferating. In cell culture, limited replicative potential is referred to as the Hayflick limit.[254] Unlike the traits discussed earlier, senescence is largely independent of environmental cues.[255-257] The number of times that a normal cell can replicate is based on the length of its telomeres (from the Greek *telos* meaning "end" and *meros* meaning "part"), serving as a generational clock.[9] These protective G-rich DNA-protein terminal ends of the chromosomes prevent fusion with other chromosomes[258] (Figure 26-13, *A*). Because of inefficiencies in the enzyme that copies DNA, each time a cell replicates, it loses a portion of its telomere.[259] Complete loss of the telomere cap threatens a cell's genetic stability, as the uncapped chromosomal ends can fuse and subsequently rebreak to bind with other chromosomal ends (see later discussion).[260] Therefore, to prevent DNA replication errors, the cell reaches a crisis and stops undergoing mitosis. Other triggers of senescence include oncogene activation (Ras, BRAF), DNA replication stress, and cellular insult (DNA damage, high oxygen levels).[261]

The cancer cell avoids the consequences of crisis and achieves a limitless replicative potential or immortalization.[262-264] Two molecular primary events allow a cancer cell to overcome senescence/crisis and become immortal. First, a defective apoptotic pathway must exist; otherwise, the chromosomal damage generated during crisis would lead to the autodestruction of the cell.[263] The loss of the protective telomere cap leads results in prolonged breakage/fusion/bridge (BFB) cycles, allowing chromosomes to stick to one another[265] (see Figure 26-13, *B*). The loss of a single telomere can result in ongoing genomic instability involving multiple chromosomes, leading to rearrangements commonly associated with human cancer. BFBs lead to aneuploidy, abnormal chromosome number and structure due to amplifications, rearrangements, and deletions.[266,267] Gatekeeper pathways, such as p53 and p16, must be abrogated, or the cell would undergo senescence.[261] DNA damage, dysfunctional telomeres, and genotoxic stress activate p53/p21 gene expression that leads to growth arrest. Mutant p53 prevents the arrest. Oncogene activation and cellular stress induce p16, an upstream regulator of pRb. Activation of pRb leads to chromatin reorganization and E2F target gene repression. Unlike the p53 pathway, once the pRb pathway is activated, it cannot be reversed. By avoiding senescence, these cells can undergo mutations of other oncogenes and tumor suppressor genes.

For cells to clonally expand long enough to accumulate enough mutations to become malignant, a second critical step must be achieved for immortalization: abrogation of the generational clock through renewal of the telomere.[267] Most immortal cells maintain their telomeres using two strategies.[268] First, an enzyme called telomerase can add DNA to the ends of chromosomes.[269] Telomerase is absent in non-immortalized cells in vitro as well as most premalignant tissue in vivo. However, 85% to 90% of immortalized cells, including cancer cells, have abundant telomerase activity. Recently, telomerase has been found to support malignant transformation through telomere-independent pathways, such as Wnt pathway signal amplification, apoptosis evasion, and enhancement of cell proliferation.[270,271]

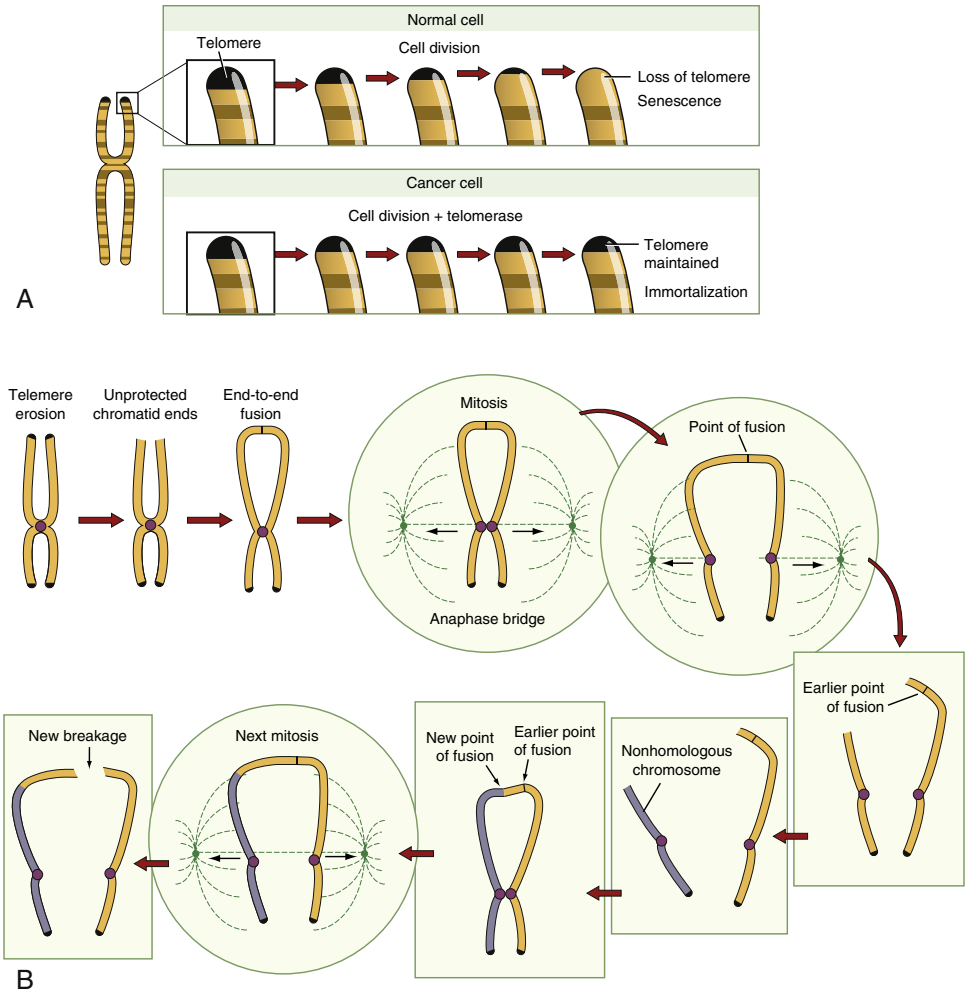

• **Figure 26-13** Telomerase and cancer. **A,** Telomerase function. In normal cells, a fraction of the chromosomal telomere is lost with each cell division. When the entire telomere is lost, the cell undergoes senescence. Cancer cells produce telomerase, an enzyme that maintains the telomere, thereby allowing progeny of the precancer/cancer cells to divide indefinitely. **B,** Chromosome rearrangement through breakage/fusion/bridge (BFB) cycles. Chromosomes with eroded telomeres can fuse end-to-end. When the chromosomes separate in mitosis, an asymmetric break can occur in the DNA. A different (nonhomologous) chromosome can fuse with the new DNA end. In the next mitosis, chromosomal rearrangement occurs.

Second, the remaining 10% to 15% of immortalized cells use a mechanism termed ALT (alternative lengthening of telomeres), which maintains the telomere by swapping sequences between chromosomes.[260,272]

What is the selective advantage of immortalization for the cancer cell? Accumulation of genetic events leading to malignant phenotypes requires clonal expansion beyond the replicative limit of normal cells.[267] Furthermore, a clinical cancer is composed of a large number of cells. A tumor is first visible by imaging at 10^8 cells, first palpable at 10^9 cells, and lethal at 10^{12} cells. Both intracellular and extracellular mechanisms leading to attrition prevent sufficient clonal expansion through immortalization, a release from senescence.[9] The telomerase/ALT pathways undermine the generational clock that halts proliferation.[210] Abrogation of the apoptotic pathways allows expansion of these clones carrying altered DNA. Immortalization is a difficult trait to achieve (approximately 1 in 10 million "precancer" cells acquires the trait) and a critical hallmark for a precancerous/cancer cell to obtain.[37]

Whereas immortalization is triggered independently of environmental cues, tumorigenesis can be supported by stromal cells (which are genomically stable) undergoing senescence.[16] Senescent fibroblasts can change the microenvironment of precancer and cancer cells that supports growth and tumor progression. Senescent fibroblasts disrupt the functional and morphologic differentiation of epithelial cells by altering the extracellular matrix and secreting growth factors that induce a supportive environment for tumor progression. Furthermore, a mass of cancer cells without replicative restraint requires a robust nutritional supply.

Neovascularization

New blood vessel formation or angiogenesis is a pivotal process in human health and disease.[273] Angiogenesis plays

a crucial role during development, particularly organogenesis.[274] In adults, angiogenesis occurs primarily during wound healing, reproductive functions, or the development of compensatory collateral blood vessels for oxygen/nutrient-deprived tissue. During tumor progression, angiogenesis is a critical and growth-limiting step.[21] The growing tumor mass is supported by enhanced cell proliferation, blockage of senescence, and escape from apoptosis. However, the ability of the tumor mass to expand is profoundly limited by the risk of outstripping its nutrient supply. Nutrients can diffuse three to four cell lengths (or approximately 100 μm) from a capillary.[275] Cells, even cancer cells, beyond that distance die. Therefore, the generation of a vascular network to feed the tumor is critical. Without a sufficient vascular supply to provide nutrients and oxygen to the rapidly dividing cancer cells, a tumor would grow little more than 2 mm in diameter.[276] Cancer cells must acquire the ability to create new vessels or their progression is limited severely. Accordingly, cells in premalignant or incipient lesions must be able to undergo neovascularization to progress to larger neoplasias.

There are two phases in tumor neovascularization. In the prevascular phase (the "angiogenic switch"), cancer cells accumulate changes that support vessel growth to meet the metabolic demands of the growing tumor.[277] Only 1 in 600 incipient tumor masses develops this switch. In the vascular phase, the tumor undergoes rapid growth and metastasis.[19] Angiogenesis arises from a collaboration of cancer cell signaling, matrix support/modification, and endothelial cell proliferation.[278] The process is regulated by pathways that support and inhibit endothelial cell growth. In most normal situations, the homeostatic balance is tipped in favor of angiogenesis inhibition.[21] In addition to increased production of pro-angiogenesis factors, tumor neovascularization is achieved by reduced activity of anti-angiogenic pathways.[279]

Pro-angiogenesis pathways involve a complex interaction between the cancer cells and underlying stroma[280,281] (Figure 26-14). Fibroblast growth factors sustain tumor angiogenesis when constituently overexpressed by cancer cells.[282,283] Vascular endothelial growth factors (VEGFs) are also expressed by cancer cells in response to hypoxia and oncogene signaling.[284] Of the approximately 200 human cancers, about 60% overexpress VEGF.[275] Much of the VEGF released is sequestered by the extracellular matrix (ECM) and becomes inactivated.[285,286] Therefore, the cancer cells must recruit myeloid cells (macrophages and mast cells) that, in turn, secreted matrix metalloproteinases (MMPs) that degrade the ECM and release VEGF.[287] There are gradations of the angiogenic switch that stimulates

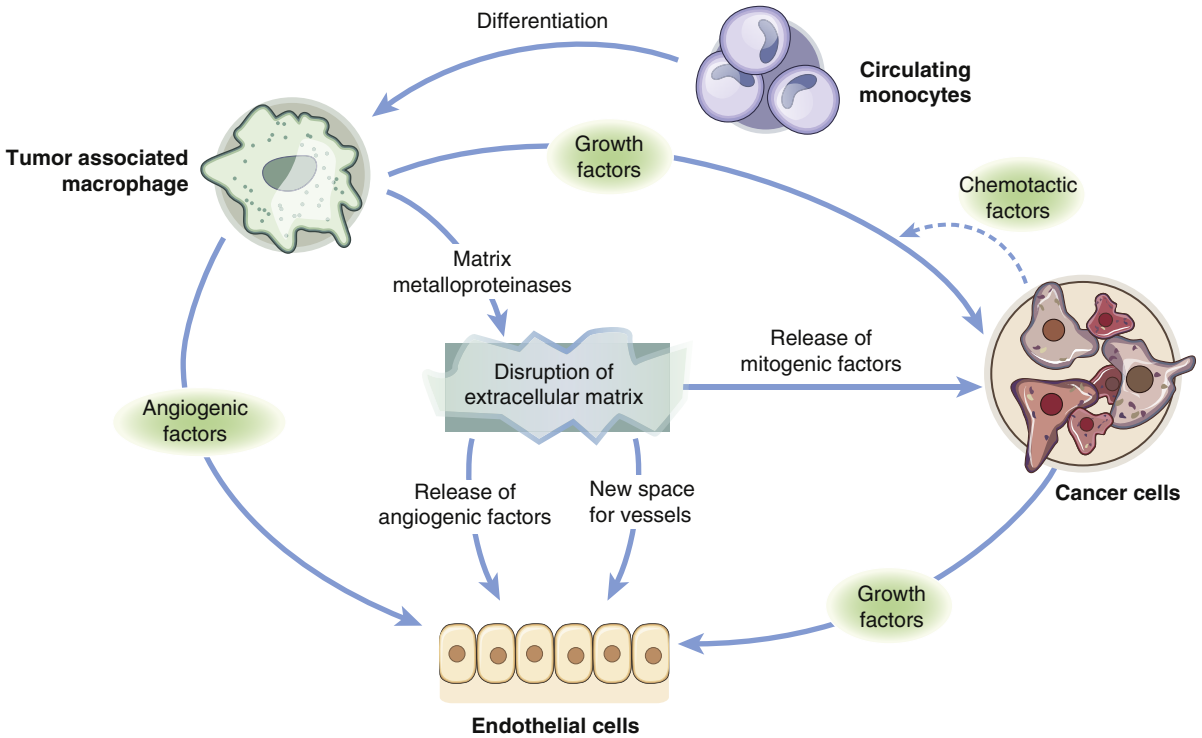

• **Figure 26-14** Tumor-stroma interactions in angiogenesis. To meet the metabolic needs of the growing tumor mass, cancer cells must establish a dialogue with cells within the underlying stroma. For example, cancer cells secrete chemotactic factors, such as MCP-1, which recruit/differentiate circulating monocytes into macrophages. The macrophages "talk back" by generating directly and indirectly (through degradation of the extracellular matrix [ECM]) mitogenic factors for the tumor cell. In addition, the macrophage also supports tumor neovascularization by secreting angiogenic factors (such as vascular endothelial growth factor [VEGF]), liberating angiogenic factors from the ECM and remodeling the stromal matrix in order to support new vessel formation. Stromal fibroblasts, the inflammatory infiltrate, and other cell types also participate in heterotypic interactions that support both tumor growth and angiogenesis.

tumor neovascularization.[9] Some tumors are highly vascularized, whereas others are associated with largely avascular stroma. How intensely the pro-angiogenic factors tip vascular homeostasis probably depends on both the biology of the cancer cells (such as activation of dominant oncogenes like Ras) and inductive signals produced by the stroma (such as by immune inflammatory cells). Other important angiogenic factors include angiogenin, TGF-α, TGF-β1, RhoA/Rho Kinase, and platelet-derived growth factor (PDGF).[288,289]

Antiangiogenic pathways also involve the interplay between malignant cells and "normal" stromal cells. For example, after being secreted by a variety of cells into the ECM, thrombospondin-1 (TSP-1) forms a homotrimer that binds to CD-36 and halts endothelial cell proliferation.[290] TSP-1 also binds the pro-apoptosis Fas receptor that is displayed on proliferating (but not nonproliferating, mature) endothelial cells.[291] Both p53 and Myc function downregulate angiogenesis inhibitors, such as TSP-1.[292] Angiogenesis inhibitors have been found to be products of the proteolytic cleavage of structural proteins within the ECM or factors released in the circulation.[293] Endogenous matrix anti-angiogenesis factors include endostatin, anastellin, and arrestin; non-matrix vascular inhibitors include interferon-α, interleukin-1β/-12/-18, angiostatin, antithrombin III, TIMP-2, and vasostatin.[293] In health, these factors limit angiogenesis to a transitory event during wound healing. Circulating anti-angiogenic factors may serve as an intrinsic barrier to expansion of incipient neoplasias.[9]

There are six mechanisms leading to tumor neovascularization.[275,294,295] First, sprouting angiogenesis involves the proliferation and migration of endothelial cells from preexisting blood vessels.[294] Overproduction of VEGF induces endothelial cell proliferation and increases extracellular matrix degradation permissive for endothelial cell migration.[296] Second, intussusceptive vascular growth may account for 50% of tumor neovascularization.[297-299] Rather than sprouting, intussusception involves the partition of adjacent vessels. Therefore, angiogenesis can be achieved rapidly and with more metabolic economy because no endothelial cell proliferation is needed. Intussusception is supported by TGF-β, cell adhesion molecules, VEGF and PDGF. Third, angioblast recruitment, precursors to endothelial cells, can contribute to tumor neovascularization.[300,301] Again, VEGF induces MMP9, mobilizing progenitor cells and inducing differentiation to mature endothelial cells. Fourth, cooption occurs in certain tumors such as gliomas.[302] Ang 2 is activated and induces endothelial cell apoptosis, leading to hypoxia.[275] VEGF production is induced by the hypoxia, and sprouting angiogenesis is induced. Fifth, mosaic cell formation, accounting for approximately 15% of tumor neovascularization, are vessels lined with both endothelial cells and tumor cells.[303-305] Angiogenic factors such as FGF2, VEGF, and MMP2 lead to increases in basement membrane degradation and permeability. Last, vascular mimicry occurs, where vessels are formed that are lined with laminin instead of endothelial cells.[280]

In short, the ability of the tumor cell to induce a supporting vasculature confers a major selective advantage. Although a cancer cell might accumulate the molecular machinery for deregulated growth, clonal expansion cannot occur without the nutritional support to fuel the metabolic requirements. Furthermore, tumor neovascularization is important for the spread of the primary tumor to other anatomic sites. And, like the molecular events supporting metastatic spread, tumor neovascularization depends on an interplay between the genomically unstable cancer cells and genomically stable cells in the underlying stroma.

Tissue Invasion and Metastases

Rather any molecular or biochemical marker, invasion of neoplastic cells into surrounding "normal" tissues is the key event that separates malignant from benign tumors.[306] Metastasis, the cause of approximately 90% of cancer deaths, is the transfer of disease from one organ or tissue to another not directly connected with it.[307] The cellular processes observed in the histopathology of metastasis are beginning to be understood at the molecular level. Like tumor neovascularization, metastasis is the result not only of intrinsic genetic changes in the cancer cell, but of a series of complex alterations with the tumor microenvironment.[9]

Metastasis follows a series of rate-limiting histopathologic steps often referred to as the invasion-metastasis cascade.[307-309] After the cancer cell detaches from the primary tumor and invades the host stroma, it intravasates into either lymphatic or blood vessels, spreads to the capillary bed of distant organs and extravasates from the capillary lumen back into the stroma. The metastatic cell then proliferates in the receptive organ parenchyma. Having undergone further genetic selection, the metastatic cell has proliferative, survival, migratory, and invasive abilities beyond those of its malignant counterparts. Hence, the molecular alterations intrinsic to the metastatic cell confer, in part, the ability to activate the tumor microenvironment to undergo changes at the primary and secondary sites to support invasion and metastasis.[306,309]

Tumor invasion is initiated by fundamental changes to the cancer cell. Referred to as the epithelial-mesenchymal transition (EMT), the cancer cell undergoes functional and anatomic changes that shed static phenotypes in favor of those that promote detachment and mobility (Figure 26-15).[9,310-312] Several phenotypes are lost in EMT cells, including intermediate filament expression, cell polarity, differentiation gene programs, and E-cadherin expression (a key regulator of adhesion junctions linking the cell's cytoskeleton to neighboring cells).[313-316] In turn, the EMT cell acquires several traits, including a fibroblast-like shape, increased mobility, upregulation of transcriptional programs supporting stem cell–like phenotypes, and expression of N-cadherin.[317] Several pleiotropically acting transcription factors have been implicated in supporting the stem cell–like properties and driving malignant progression toward metastasis, including Snail-1/-2, Slug, Twist, Zeb-1/-2, Goosecord, and E12/E47.[9,318-322] In addition to loss

of static cell adhesion molecules, the invading cancer cells have acquired other traits that support motility. [323] Factors that induce locomotion in cancer cells include HGF, scatter factor, and EGF.[324,325] Activation of Rho, small ras-like GTPase molecules, also transforms cell shape, adhesion, and motility.[326,327] The invading cells generate lamellipodia, extensions of their cytoplasm/cell membrane toward the direction of movement.[328,329] Cell surface proteases degrade the ECM at the edge. During this process, new adhesion molecules are formed while others along the trailing edge are released. Last, space needs to be made into which the invading cancer cell will travel. At the lead edge of the cancer cell, MT1-MMP cleaves proenzymes such as pro-MMP2, collagen type IV (in the basement membrane), and collagen type I (in the ECM).[330] Furthermore, the cancer cell secretes factors, such as epithelial growth factor, to induce fibroblasts and endothelial cells in the stroma to synthesize metalloproteinases that degrade the basement membrane and extracellular matrix.[315,331] Disruptions of the basement membrane and extracellular matrix allow the tumor cell to transmigrate into the stroma and intravasate into blood or lymphatic vessels. A key family of molecules altered in this process is the integrins.[332-334] Integrins, cell surface receptors linking the extracellular matrix to the cell's cytoskeleton, regulate signaling cascades that modulate proliferation, survival, polarity, mobility, and differentiation.[335] Activation of oncogenes and loss of tumor suppressor gene function in cancer cells not only allow the cells to survive and proliferate in the absence of normal cell-matrix adhesion, but often cause the cancer cells to overexpress the integrin subunits that promote migration and metastasis.[336-338] In addition, integrins can recruit metalloproteases to degrade the extracellular matrix, supporting cancer cell migration and invasion into the stroma.[339] Although the EMT changes in the cancer cell are critical for invasion through the basement membrane, as well as intravasation into and extravasation out of the endothelial lumen, the EMT phenotype would be impossible without support from the tumor-associated reactive stroma.[340]

Cancer and stromal cells generate growth factors, cytokines, and chemokines that mutually benefit each other and support metastasis (see Figure 26-15). Key stromal cells include the endothelium, fibroblasts, and the immune system. Angiogenesis was reviewed in the previous section. The tumor-associated vasculature not only provides the nutritional support for the expanding tumor mass, but

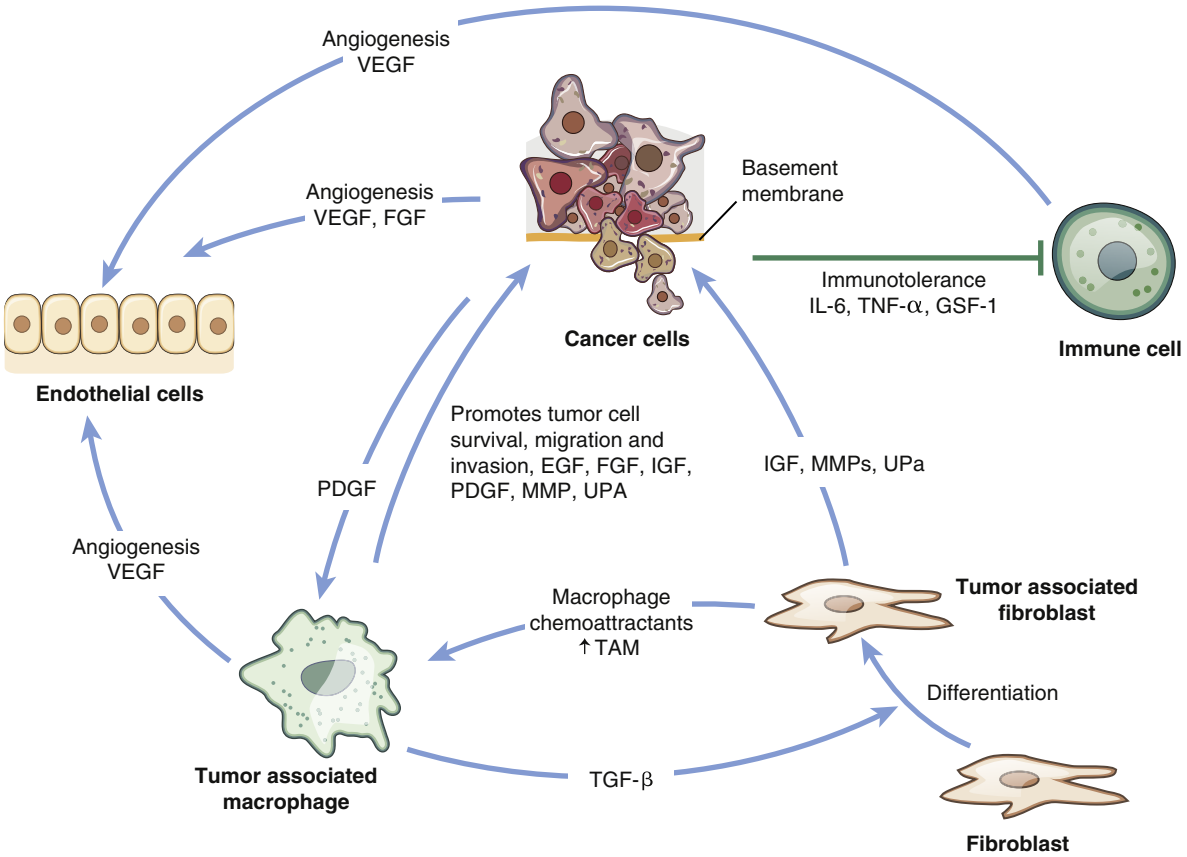

• **Figure 26-15** Invasion and metastasis. Interactions between the cancer cell and the tumor stroma support invasion and metastasis through secreted ligands. The cancer cell secretes cytokines that cause tumor-associated macrophages (TAMs) to secrete TGF-β (that, in turn, causes fibroblasts to differentiate into myofibroblasts. Cancer cells also secrete factors that suppress the immune system. The myofibroblasts and TAMs, in turn, secrete ligands that promote tumor survival, invasion, and metastasis. Cancer cells, myofibroblasts, and TAMs all secrete factors that support angiogenesis.

also offers a valuable channel of escape.[15,274,341] The neovasculature augments the contact area between the tumor mass and potential escape routes (for the tumor cell with the intrinsic invasive properties) and has a distinct morphology (large, tortuous, and leaky vessels due to an incomplete pericyte lining and fragmented basement membrane) that is compatible for tumor cell intravasation. Stromal fibroblasts transdifferentiate into myofibroblasts shortly before tumor invasion.[342-344] Myofibroblasts promote invasion and metastasis by secreting factors that degrade the basement membrane and extracellular matrix (by secreting serine proteases, promoting angiogenesis, and stimulating cancer cell proliferation).[345,346] Last, the immune system, although it clearly surveys for and kills cancer cells, paradoxically can promote tumor invasion and metastasis.[347] For example, tumor-associated macrophages (TAMs), differentiated from monocytes at sites of tumor invasion, are attracted to the invasive edge by cytokines such as IL-4 and CSF-1.[348,349] TAMs can repress tumor growth and progression by killing cancer cells and presenting tumor antigens to other members of the immune system.[350,351] However, TAMs also secrete factors that promote tumor cell proliferation and support angiogenesis.[352-355] In summary, the stroma's contribution to invasion and metastasis is multifactorial and essential. The stroma secretes numerous factors that support the EMT phenotype, including TGF-β, TNF-α, EGF, HGF, Wnt, and IGF. TGF-β's activity promoting cell stasis is inactivated when the Rb pathway is lost (an event common to most cancer cells); therefore, TGF-β stimulates cell proliferation and secretion of lytic proteins.[356-359] MMPs secreted by fibroblasts, mast cells, and macrophages dissolve the ECM, providing space for cancer to invade and release of growth factors to support growth. MMP-9 supports local invasion, as well as intra- and extravasation, by dissolving collagen IV, V, XI, XIV, laminin, and fibrinogen.[15] Vascular endothelium is believed to have organ-site specific "docking" molecules supporting the tropism of cancers to certain sites.[360]

Cancer dissemination occurs in many forms.[9] A mesenchymal type of invasion describes the EMT program of cell spread.[361,362] Collective invasion refers to cancer cells pushing directly into adjacent tissue but rarely metastasizing. Cancer cells showing amoeboid invasive patterns use cell plasticity to insinuate themselves through cell matrices rather than clearing a path.[363] Cells disseminating remotely from the primary tumor initially reverse the EMT program. In the mesenchymal-epithelial transition (MET), circulating cancer cells extravasate into a stroma ill-prepared to support cancer growth.[364] With no cytokines, MMPs, and so on to support invasion, the cancer cell reverts to a more static cellular program (return of a basement membrane, cell polarity, certain differentiated cell structure/functions) that forms nests of cells (<2 mm) called micrometastases.[365] The molecular mechanisms governing suppression of micrometastatic growth, the switch from dormancy of micrometastases to metastases, and the success of metastatic spread are poorly understood. Adaptation of the micrometastatic colonies to the microenvironment of the end-organ parenchyma is probably highly inefficient.[309] In fact, dissemination may be a much earlier step in tumorigenesis than previously believed: The successful adaptation of a micrometastatic colony to its environment may simply require so much time it appears to be a late event.[9] Furthermore, the mechanisms of metastatic tropism are also incompletely understood.[366] Like the mechanisms of invasion, the factors supporting metastatic colonization likely will be a combination of cancer cell metastatic gene signatures and permissive biologic programs specific to individual organs.[9]

Putting It All Together: How Molecular Changes Govern a Cancer Cell

The cancer cell has undergone a Darwinian selection that has conferred cellular characteristics that allow it to exploit and outcompete its normal neighbors.[367] There are several hallmarks of cancer cell behavior.[9] The cancer cell proliferates in the absence of normal growth signals and without the normal inhibitory controls. Therefore, the cancer cell can out-replicate its normal counterpart. In addition, senescence and apoptosis, normal traits that cease cell division and lead to elimination of defective cells, are evaded in cancer cells. Rapid cell division, immortality, and apoptosis evasion all enhance a cancer cell's chance of undergoing more mutations that may result in greater selective advantage. However, intracellular traits leading to an expanding tumor mass are insufficient alone to result in a clinically detectable tumor mass. Cancer cells must undergo an "angiogenic switch" that allows them to feed this growth by exploiting normal stromal cells to generate a neovascular network. In turn, that vascular network not only provides nutrients to allow the tumor mass to expand but is an essential step in allowing the cancer to invade beyond the local stroma to other anatomic sites: metastasis.[9]

These cancer cell traits are controlled by complicated regulatory pathway networks subverted by critical errors accumulated during tumorigenesis.[38] The networks are composed of cooperating and competing pathways that stimulate or suppress cell behaviors. Each pathway contains proteins: cell surface ligands/receptors, secondary messengers, and transcription factors. Normal regulatory functions of pathways are abrogated by abnormalities in these proteins. Enhanced protein activity can be due to such mechanisms as overproduction, overactivity, or presence at an ectopic site/time. Reduced protein activity can be the result of absence of protein production or dominant negative suppression of wild-type function by a mutant protein counterpart.

In the previous section, the mechanisms leading to altered protein activity were reviewed. Large- and small-scale changes in chromosomal structure (or epigenetic alteration of gene activity) lead to a qualitative and/or quantitative change in gene expression and protein production. Changes in genomic stability/DNA repair enhance and accelerate these critical genetic changes that lead to cancer. Furthermore, epigenetic events, as well as signals from the

tumor microenvironment, also affect cancer cell behavior. This understanding of the cumulative factors that govern malignant cell behavior is the basis for creating a rational, individualized clinical approach to the diagnosis and management of the oncology patient.

How Molecular Biology Can Affect Clinical Oncology: Toward the Rational Treatment of Cancer

A 2004 survey of the cancer literature revealed almost 300 genes that have been implicated in the genesis of human cancers.[368] Identifying and understanding the molecular events governing the behavior of the cancer cell will, it is hoped, lead to a more precise diagnosis of the disease and a better-targeted (and less toxic), individualized therapeutic protocol.[369,370] Clearly, a comprehensive review of molecularly based diagnostic and therapeutic agents is beyond the scope of this chapter. However, based on the themes reviewed here, we can survey some of the approaches by which molecular biology may transform clinical oncology.

Molecular Diagnostics in Oncology

Understanding the biology leading to cancer progression can lead to a more sensitive and precise diagnosis of the disease.[371,372] At present, the majority of cancers are diagnosed using light microscopy and clinical parameters, such as the TNM classification.[5] Molecular markers offer the potential of identifying divergent cellular behavior in histologically and clinically identical lesions.[368] There are many potential benefits to these biologically based markers[373] (Figure 26-16). Disease susceptibility will be better assessed with respect to cancer predisposition, influence of environmental factors, risk, and prevention. Cancer diagnosis can be improved both through better early diagnosis and through more precise disease stratification.[374] Conventional and alternative treatment should be more easily selected by better predicting therapeutic response and alternatives.[369] Last, aftercare of the cancer patient will be improved by better disease monitoring, predicting/mitigating treatment side effects and preventing disease recurrence.[60] At present, these changes are detectable not only in biopsy tissue, but body fluids (saliva, aspirates/lavage samples, urine, and stool).[375,376] Several requirements will need to be met for these new cancer biomarkers to serve as the basis of an efficient screening program.[377] Most importantly, these biomarkers will need to have a high sensitivity and specificity, especially with low disease volume such as early-stage or precursor lesions.[378] The tests must be easy and minimally invasive, as well as cheap, rapid, reproducible, and cost-effective.

DNA is a promising target for new cancer markers. DNA is a stable molecule and readily detected by a number of robust methods.[48] However, DNA alterations do not always directly contribute to the cancer phenotype. At present, several DNA-based approaches are being explored. Both gross (chromosome translocation, deletion, and amplification) and fine (mutation, microsatellite instability, and single nucleotide polymorphisms [SNP]) alterations are being tested. Perhaps the most famous example is the chromosomal translocation known as the Philadelphia chromosome, a hallmark in the diagnosis of chronic myelogenous leukemia.[379] Double minutes/gene amplification have been shown as a reproducible marker of poor prognosis.[90] For example, Myc amplification is strongly correlated with stage III and IV neuroblastomas, known to have a 10% to 30% 2-year survival.[380] Chromosome number was shown to be a more powerful predictor of the transformation of

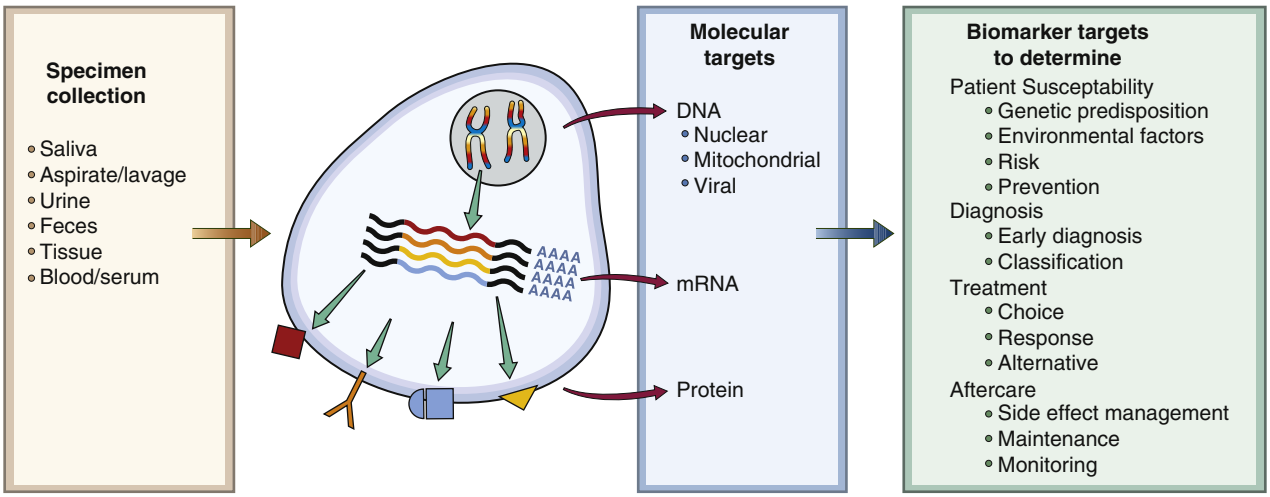

• **Figure 26-16** Molecular diagnosis in oncology. Our understanding of the molecular basis of cancer will translate into improved diagnosis in the cancer patient. Advances in collection techniques now allow molecular targets to be detected in a myriad patient specimens. Marker panels based on DNA, mRNA, and protein targets will generate molecular "signatures" of an oncology patient's disease. Based on the diagnostic signature, important determinations can be made regarding susceptibility, diagnosis, treatment, and aftercare that is individualized to the patient.

"premalignant" oral lesions than was histologic assessment of the degree of dysplasia.[381] Mutations in the p53 gene are being used not only for cancer detection, but in the prediction of prognosis and assessment of resection margins.[382] Promoter methylation studies are identifying cancer-associated functional changes in the gene.[383] SNP and methylation studies of various metabolic enzymes, such as glutathione-S-transferase, have been used to explore cancer risk.[375] Last, in addition to human nuclear DNA, mitochondrial and viral DNA are being tested as potential cancer markers. Mitochondria, organelles that contain DNA separate from nuclear DNA, are sensitive to carcinogens and, therefore, readily undergo mutation.[384] Because each cell carries hundreds of copies of the same mitochondrial gene, and all copies of that gene undergo mutation, alterations in mitochondrial DNA are easier to detect than are changes in nuclear DNA. The Epstein-Barr virus (EBV) is being explored as a biomarker for nasopharyngeal carcinomas. EBV DNA is being used to assess tumor burden, monitor for recurrence/metastasis, and predict prognosis.[375,385]

The full potential of DNA as a diagnostic target is being realized through whole genomic sequencing (WGS), a means of analyzing chromosomal changes throughout the entire cancer cell DNA.[386] These advances have been realized through improved automated sequencing that has reduced costs by a factor of 10 billion while increasing experimental efficiency by 10 millionfold since the early automated sequencers of the 1980s.[387] WGS has identified important targets, such as BRAF, isolated important mechanisms of cancer chromosomal rearrangements (chromothripsis), and generated genomic signatures, such as CONEXIC in human melanomas, that aid in tumor diagnosis.[388-390] To more effectively target a personalized diagnostic approach, various high-throughput technologies are being employed to assess DNA copy number (comparative genomic hybridization, digital karyotyping, representational oligonucleotide microarrays, SNP arrays, and molecular inversion probes deep sequencing), and mutation detection (in addition to WGS, mass spectroscopy, and next-generation sequencing).[391] High-throughput epigenetic profiling, using both methylation and acetylation arrays, is also available.[392,393] Although DNA biomarkers have proven most useful in determining cancer predisposition, recent advances in mRNA analysis may provide another robust means of diagnosing/classifying cancers.

Messenger RNA is a more difficult biomarker to target because it is often rapidly degraded and therefore more difficult to isolate/identify from patient specimens. With improved detection techniques, mRNA has been found more easily in biopsy specimens and all body fluids.[375] More importantly, emerging methods of high-throughput analyses (and statistical analysis to interpret the data) have led to advances in mRNA-based cancer diagnosis based on mRNA splicing form detection and gene expression profiling.[394] Both exon junction arrays and genomic tiling arrays are available but expensive and of limited diagnostic application.[391] Using microarray analysis for gene expression profiling, investigators have been able to separate and identify histologically identical but clinically (and prognostically) distinct malignancies, including lymphoma subtypes and pediatric "blue cell" tumors.[395] Investigators are using primarily three different strategies to correlate gene expression "signatures" to the clinical behavior of cancer.[396] The simplest approach is to correlate gene expression patterns to known clinical features that have an impact on outcome, such as local invasion, node status or metastasis. For example, investigators have been able to establish expression profiles from normal colonic epithelium; adenomas; Dukes-B, -C, and -D adenocarcinomas; and liver metastases.[397] Another approach is to identify gene expression profiles that correlate with treatment response. For example, a signature of 21 genes was identified to predict which breast cancers would be refractory to tamoxifen treatment.[398,399] Last, expression profiles are being tested that identify long-term prognosis/relapse. For example, a 70-gene signature was identified that correlated with recurrence within 5 years in patients with node-negative breast cancers that was able to identify 90% of the poor-outcome patients.[400] This poor prognosis signature was developed into a molecular diagnostic test (MammaPrint; Agendia, Amsterdam).[401] Similar tests, such as the 76-transcript Rotterdam signature or the 21-transcript Oncotype DX assay (Genomic Health, Redwood City, CA), identify distal recurrence in node-negative, estrogen receptor–positive breast cancer patients.[402] The early promise of high-throughput analysis of gene expression has prompted investigators to suggest that a "cancer chip" eventually might be used to individualize the diagnosis, treatment, and post-therapeutic monitoring of the cancer patient.[403] However, before high-throughput analysis of gene expression profiles reaches the bedside, a standardization of intra- and inter-laboratory methods and statistical analysis has to be established. In addition, specimen acquisition methods, handling, and experimental "noise" must be resolved.[396] In short, mRNA, although a biologically fragile molecule, may serve as a more precise method of identifying cancer-related gene activity and a valuable surrogate measure of protein production/activity.

Today, cancer-associated proteins are the most commonly used tumor biomarker and have met with limited success. Because of transcriptional regulation and post-translational modifications, it has been estimated that the 23,000 to 40,000 genes have the potential to produce about 1 million different proteins.[60,391] Although this might provide a greater pool of candidate biomarkers, protein identification is a technically more cumbersome process than nucleic acid identification. Most of the cancer-related protein markers to date suffer not only from the difficulties discussed earlier of using a single marker approach, but also from biologic limitations related to protein biochemistry. For example, the presence or absence of the estrogen receptor (ER) in breast cancers is part of every diagnostic workup of a breast cancer patient to determine candidacy for endocrine therapy. The gold standard to assess ER status is immunohistochemistry (IHC). Although major diagnostic

decisions depend on the results of ER IHC, the reliability of the test is far from perfect.[404] Overall, the existing assay has a positive predictive value of 30% to 60%. Sample fixation, antigen retrieval, and staining techniques differ among laboratories.[405] Interpretation of the data varies due to reading variability between pathologists and image analysis settings. The prostate-specific antigen (PSA) is a routine test for prostate cancer screening, although more than one third of patients who have an elevated PSA level have benign disease.[406] Moreover, PSA sensitivity and specificity depend on the amount of protein produced by the cancer cell, the amount of tumor mass, and covariables such as inflammation and tissue manipulation.[377] Similarly, the carcinoembryonic antigen (CEA), used to monitor disease progression and therapeutic response of colorectal cancers, is expressed in only a fraction of cancers.[375] Similarly, the use of tumor markers such as CEA, Ca 72-4, or Ca 19-9 to detect stage I gastric cancer is successful in less than 25% of cases.[377] For many other cancers, there are no tissue-specific markers. To better the clinical application of protein biomarkers, investigators have combined known protein biomarkers with assays for proliferation-related gene expression.[404] In addition, new high-throughput analyses, such as mass spectroscopy–based techniques, are identifying multiple, novel protein biomarkers.

Rather than target a single protein, proteomic analysis surveys the entire complement of polypeptides in a cancer cell.[407] Traditional western blotting, IHC, and enzyme-linked immunosorbent assays can be used to assess only a limited number of proteins and are unable to map signal transduction events.[391] Furthermore, post-translational modifications of the cancer proteins can be examined (such as phosphorylation, ubiquitination, glycosylation, methylation, and acetylation). Proteomic analysis is primarily performed using an approach based on 2D gel electrophoresis, reverse-phase protein array, or mass spectroscopy.[164,408-410] For example, the proteomics of the cancer cell has been examined to identify biomarkers used for screening, surveillance, and prognosis in colorectal cancer.[411] Proteomic analysis the "secretome," extracellular proteins excreted into the tumor microenvironment, has been applied to a variety of human cancers (lung, breast, prostate, colorectal, and pancreatic) to better understand the tumor microenvironment and identify circulating biomarkers.[412] To date, identification of robust biomarkers using proteomics has proven elusive.[413]

Last, target proteins and the functions they govern are being used to advance diagnostic imaging.[392] Smart contrast agents, such as conjugated gadolinium that binds to proteins associated with apoptosis, are showing promise as earlier indicators of therapeutic response.[414] Positron emission tomography (PET) and single photon-emission computed tomography (SPECT) target tumor metabolism and protein function to differentiate between normal and malignant tissue, especially for cases of detection and surveillance in Hodgkin disease, non-Hodgkin lymphoma, and head and neck, lung, and pancreatic cancers.[415,416]

In summary, multiple DNA, mRNA, and protein cancer-related biomarkers are being identified. The molecular assessment of the cancer patient will likely involve multiple markers and possibly multiple types of biomarkers (DNA, mRNA, protein).[377] Several challenges remain for biomarker research. While many target markers and pathways have been identified, continued research is necessary to identify novel molecules and order the priority of those identified. Identification of these targets is complicated by the biologic variability of patient samples due to factors such as age, sex, exercise, diet, and circadian rhythm.[60] Cancer biomarkers likely will vary not only between cancer types and subtypes, but also with respect to the time point of disease progression.[417,418] Therefore, a biomarker important in early detection might not be useful to identify chemoresistance. There needs to be more standardization in sample handling, analysis, and statistical analysis.[164] Last, the current methods need to be simplified, more robust, more affordable, and amenable to automation/high-throughput analysis. Several collaborative efforts are underway to meet the challenges of molecular oncology. For example, to categorize molecular profiles of various tumors and identify common events, the National Cancer Institute has collaborated with the National Human Genome Research Institute to undertake the Cancer Genome Atlas (http://cancergenome.nih.gov). The Memorial Sloan Kettering Cancer Center's cBioPortal for Cancer Genomics (http://www.bioportal.ort/publicportal/) is another resource for identifying cancer-related molecular pathways. Meeting the technical, economic, and ethical challenges of translating these molecular findings into clinical practice is being facilitated by groups such as the Institute of Medicine Roundtable on Translating Genome-based Research for Health (http://iom.edu/Reports.aspx) and the Genetics and Public Policy Center at Johns Hopkins University (http://www.dnapolicy.org/). Clearly, a cross-disciplinary effort (including DNA/mRNA/protein high-throughput analysis, systems biology/bioinformatics, health policy/ethicists, and so on) will be necessary to convert the multidimensional data sets into useful biomarkers to advance the management of the cancer patient.[391] Ultimately, the technical challenges raised by biomarker research are surmountable. Standardization of sample handling/processing, as well as analysis and interpretation, are technically achievable obstacles. The use of cancer-related biomarker panels will likely yield easy, cheap, minimally invasive, reproducible, and rapid results with a high sensitivity and specificity. These cancer-related molecular events will also lead to target-specific therapeutic options.

Molecular Therapeutics in Oncology

Although better assessment of the cancer patient through the use of biomarkers might improve the efficacy of current tumor therapies, the molecular differences between normal and cancer cells can be exploited to supplement current treatment protocols and to develop novel, target-specific approaches.[9,419,420] Designer treatments based on

cancer-related molecular changes represent an important improvement over the majority of cancer therapies today that distinguish poorly between the biology of normal cells/tissues and those that are malignant cells.[421] Although a comprehensive review of the current clinical trials of these new biologic targets is beyond the scope of this chapter, it is helpful to consider the rational treatment of cancer in two broad categories. First, it is important to understand the strategies used to target cancer-related molecular changes: DNA alterations, changes in gene expression, and aberrant protein products. Second, rather than simply attacking the cancer cell, investigators are targeting specific cancer cell behaviors: uncontrolled cell proliferation, evasion of apoptosis, tumor neovascularization, and invasion/metastasis.

Strategies of Cancer-Related Molecular Therapeutics

Earlier in this chapter, the molecular alterations leading to cancer cell behaviors were reviewed. Large and small genomic alterations (as well as epigenetic mechanisms) lead to quantitative or qualitative changes in gene expression and protein production. Therefore, it is helpful to consider cancer-related therapeutic strategies based on how the cancer cell deviates from the normal DNA→mRNA→protein paradigm.

DNA-based strategies attempt to override genetic alterations accumulated during cancer progression (Figure 26-17).[422,423] New genetic material is introduced into cancer cells to either directly replace damaged genes or counteract the biologic effects of that genetic damage. Approaches include direct loss or gain of gene function, as well as cancer cell–clearing immune activation, drug resistance gene inactivation, augmentations of DNA repair enzyme activity, angiogenesis inhibition, or enzymatic destruction of viral/cancer genetic material.[422,424,425] Genes are introduced into cancer cells using microorganism and nanocarrier methods. Microorganism vectors include viruses (retroviruses, adenoviruses, and adeno-associated viruses), bacteria, yeast, and parasites.[426] Nanocarrier methods include nanotechnologic methods, including polymerid and magnetic nanoparticles, dendrimers, lipid-based carriers (liposomes/micelles), and carbon nanotubes.[427] Although several different target genes and methods of gene delivery are under investigation, perhaps the most studied is adenovirus p53 gene therapy.[428,429] Mutation of the p53 gene occurs in over 50% of all cancers. Functional loss of the p53 protein contributes to uncontrolled cell proliferation and escape from apoptosis.[430] Therefore, the addition of a normal p53 gene should restore important growth arrest and apoptosis in the cancer cell. The most successful method of p53 gene delivery is the adenovirus, though retroviruses and other nonviral carriers have also been successfully used.[431,432] Infection of the cancer cell by the p53 adenovirus allows delivery of the normal p53 gene to the cancer cell genome. Not only has restoration of p53 function led to reduction of the tumor mass, but, because important growth arrest and apoptosis controls are reactivated, transfer of the tumor suppressor gene in combination with conventional DNA-damaging treatments restores sensitivity to radiation and chemotherapy.[428,433] Several important limitations of this approach remain, including efficient gene delivery and gene regulation. In addition to introducing genetic material to restore "normal" gene expression, cancer therapeutic strategies are targeting restoration of native gene activity.

Cancer-related gene expression is another potent target in molecular cancer therapeutics. Two major approaches are RNA interference (RNAi) of gene expression and reversal of epigenetic gene silencing.[434-437] RNAi is an emerging approach that checks gene expression.[438] Short interfering RNA (siRNA) can be introduced into cells directly using nanocarriers such as liposomes or produced in the cells by introducing DNA-based vector systems.[439] A target of RNAi-based approaches, Bcl-2 and related proteins are overexpressed in a wide variety of cancers.[440,441] Like p53, Bcl-2 is an important regulator of apoptosis. The siRNAs bind complementary portions of the overexpressed Bcl-2 mRNA, leading to degradation of the transcript and effectively silencing the oncogene.[442] Limitations of the RNAi approach to be addressed include chemical modification of siRNAs to increase stability, improved tissue targeting, and selection of siRNA design.[438,439] The last aspect is important because the siRNA must be able to target the cancer-related gene expression but have enough flexibility that different mutations of the same gene will not render the approach ineffective. In addition to RNAi approaches, treatments that inhibit DNA methylation and histone acetylation can reactivate epigenetically silenced genes (or silence epigenetically activated genes).[437] Drugs such as azacitidine and decitabine have been shown to have therapeutic potential in myelodysplastic syndromes, hematologic malignancies, and solid tumors.[443,444] Therefore, rather than replacing structurally damaged DNA (such as using an adenovirus to deliver normal p53), low molecular weight drugs restore DNA function/gene activity of important, structurally intact, but chemically inhibited tumor suppressor genes (and other regulatory genes) to induce growth arrest and apoptosis in the cancer cell.

Gene product (or protein) targeting can be subcategorized into two approaches: monoclonal antibodies and low molecular weight drugs (see Figure 26-17) Anticancer agents targeting cell surface or extracellular space proteins are usually antibody-based.[445,446] Enzymes with catalytic clefts and pathways relying on protein-protein binding are usually targeted by low molecular weight drugs. Thus oncoprotein ligands, receptors, secondary messengers, and transcription factors are all potential therapeutic targets.[447-450]

Cancer-specific protein changes provide a means of differentiating normal from malignant tissue.[451] Cell surface and extracellular matrix proteins are excellent targets for unconjugated antibody and immunoconjugate therapy.[452] Several mechanisms of action have been described using unconjugated antibodies.[445] Strategies include using antibodies to (1) crosslink cell surface receptors and initiate apoptotic signaling, (2) coat cancer cells and initiate an

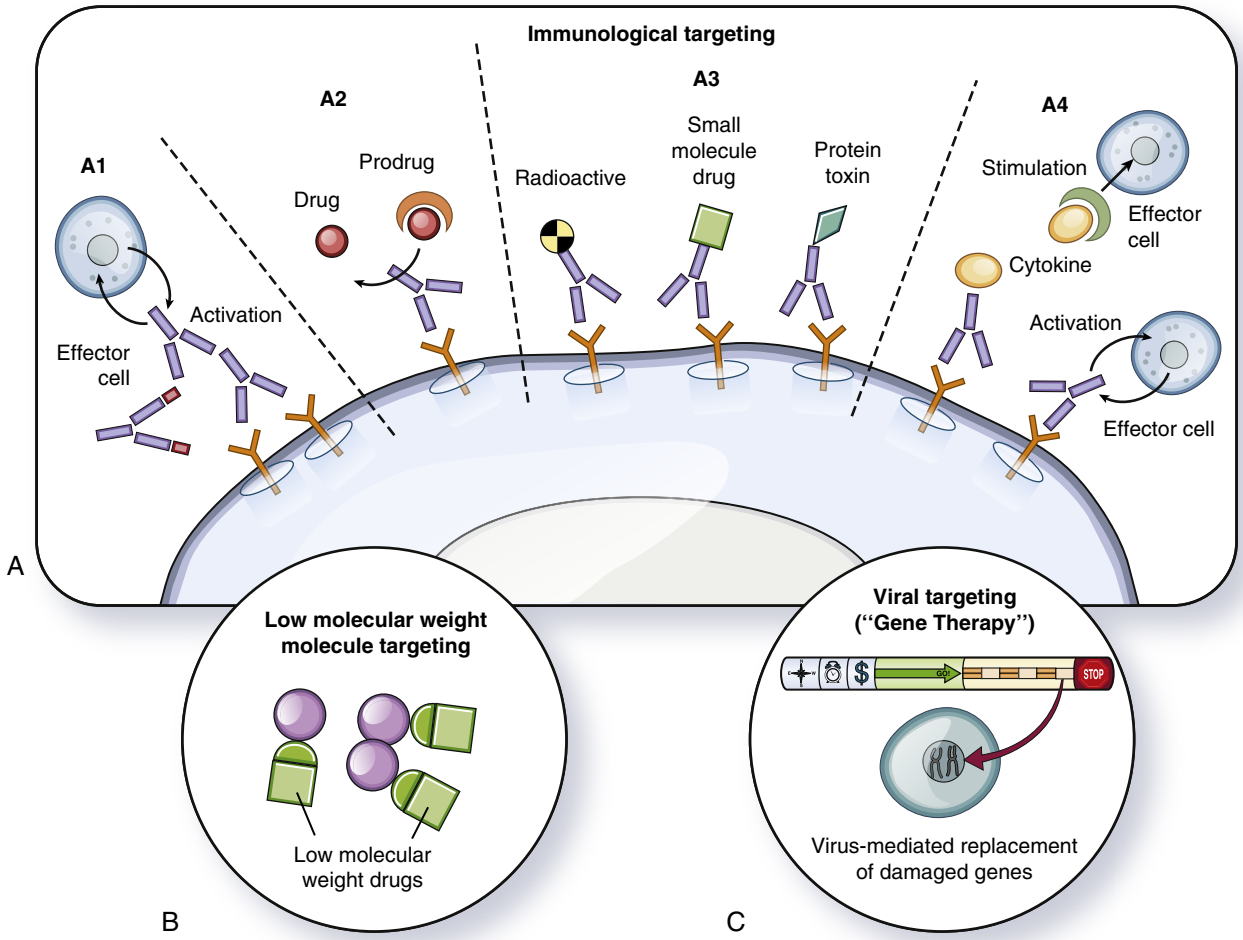

• **Figure 26-17** Biologically based cancer treatments. Several treatment strategies are under investigation. Cancer-associated molecular alterations are combated at the cell surface using antibodies and low molecular weight drugs. Intracellular alterations are targeted using low molecular weight drugs and transmembrane carriers (such as viruses). **A,** Several antibody-based approaches are under investigation, including *(A1)* growth/survival receptor blocking, *(A2)* delivery of pro-enzyme/drug therapy, *(A3)* targeting cytotoxic effectors, such as radionuclides, small-molecule drugs, and toxins, and *(A4)* stimulation of the immune system. **B,** Low molecular weight drugs have been successful in blocking the kinase activity of activated receptors and their secondary messengers such as Ras. **C,** Gene therapy has been explored to restore the function of damaged genes, such as p53, thereby inhibiting cancer cell proliferation and enhancing apoptosis. In addition, pharmacologic agents that interfere with epigenetic gene expression modulation and RNAi targeting cancer-associated gene expression are important nucleic acid–based anticancer approaches (*not shown*).

immune response, (3) activate the caspase cascade, and (4) neutralize ligands (such as angiogenic growth factors).[453] Specific targeting of immunoconjugates has the potential of reaching high concentrations at the tumor site without the dose-limiting side effects of nontargeted systemic therapies.[454,455] Cytotoxic payloads conjugated to antibodies include radionuclides (yttrium-90, iodine-131), small chemotherapeutic drugs (doxorubicin, calicheamicin), toxins (ricin, gelonin, diphtheria toxin), immunostimulatory cytokines (IL-2, IL-12, GM-CSF), and liposomes carrying anticancer drugs (paclitaxel, vincristine, siRNA).[455] In general, unconjugated antibody and immunoconjugate therapy is well tolerated with a minimum of side effects.[456] However, there can be some bystander tissue damage with some of the antibody strategies, such as radionuclide immunoconjugate therapy.[457,458] Other limitations on clinical success include immunogenicity, insufficient tumor localization/tissue penetration, and failure to trigger the intended biologic effect.[459] Like other biologically based approaches (such as adenovirus p53 gene therapy), the ability of antibody therapy to restore/sensitize apoptotic pathways makes this strategy an attractive adjuvant to chemotherapy and radiation therapy to augment their antitumor effects.

Low molecular weight drugs target intracellular enzymatic activity and protein-protein interactions.[460,461] The greatest number of these agents target signal transduction pathways

governing growth- and survival-promoting kinases. Ras, a proto-oncogene mutated in 30% of all tumors, is dependent on farnesylation for activity.[462,463] Inhibitors of farnesyl protein transferase (the tricyclic SCH66336 and the methylquinolone R115777) are being investigated as potential anti-Ras therapeutic agents in a wide variety of solid tumors. Imatinib mesylate, a drug that interferes with the abnormal Bcr-Abl tyrosine kinase fusion protein, has been approved to treat patients with chronic myelogenous leukemia in blast crisis.[464] Synthetic inhibitors, such as ZD1839, erlotinib (OSI-774, Tarceva), tyrostin, lavenditin, and quinazoline, are being investigated to block tyrosine kinase overactivity of oncogenes.[465-467] In addition to some of the low molecular weight drugs targeting the major tumor cell phenotypes addressed in the following section, other drugs in clinical development address such diverse events as tumor metabolism, histone deacylation, demethylation, and DNA repair.[468-470]

Virtually every molecular change is being explored as a potential diagnostic and therapeutic target: large and small chromosomal changes, gene expression alterations, as well as gene products.[3] Oncoproteins and growth suppressor proteins, including extracellular ligands, cell surface receptors, secondary messengers, and transcription factors, serve as a means to combat malignant tissue while sparing normal tissue. Greater success of these approaches likely will be achieved as they are grouped in the context of combating individual cancer traits.

Targeted Therapy Based on Tumor Behavior

Cancer is a multistep process due to the accumulation of multiple genetic alterations. These molecular alterations govern cellular characteristics evolved during tumorigenesis in a Darwinian selection process. Therefore, a cancer "cure" will necessitate multiple biologic targets that affect many of the behavioral hallmarks of the cancer cell: uncontrolled proliferation, evasion of growth arrest/apoptosis, neovascularization, and metastasis.[471,472]

Uncontrolled proliferation exhibited by cancer cells is a primary target for biologically based cancer therapeutics. The majority of oncogenes and tumor suppressor genes are components of signal transduction pathways that govern cell division.[9] Cancer-associated ligands, ligand receptors, secondary messengers, and transcription factors have all been explored as therapeutic targets.[449,450] For example, EGFR pathways are commonly altered in a wide variety of cancers and have been aggressively investigated.[473,474] Overexpressed and mutated (and constituently activated) receptors are being targeted using monoclonal antibody-based strategies (trastuzumab, ertumaxomab) and by blocking transmission of the tyrosine kinase-mediated signal transduction pathway (erlotinib, gefitinib, afatinib).[473-475] The goal of EGFR-targeted therapeutics and similar strategies is to modulate uncontrolled upstream stimulation of the cell cycle.[468-470] Additional approaches are being explored to specifically control the cell cycle clock.

The inactivation of CDK inhibitors (such as p16INK4a and p27kip1), as well as tumor suppressors (such as p53 and pRb), results in the uncontrolled cell proliferation of cancer cells through the constitutive activation of CDK-cyclin complexes.[476,477] Limiting the cancer cell's ability to cycle would not only check tumor growth but might also lead to reduction of the mass through induction of apoptotic pathways.[478] A variety of gene expression inhibitors, low molecular weight agents, biologically active peptides, monoclonal antibodies, and gene therapy approaches have been employed to exploit this cancer behavior.[479,480] One promising approach is the development of CDK inhibitors (CDKi) as novel antitumor agents.[481,482] Many of these compounds target either the catalytic CDK subunit or regulatory pathways that govern CDK activity.[480,483] Flavopiridol, a protein kinase inhibitor, appears to be a potent CDKi by binding and directly inhibiting CDK-1, -2, -4 and -6.[482,484,485] In addition, flavopiridol induces apoptosis by activating the MAPK pathway and inhibiting anti-apoptotic molecules such as Bcl-2 and IAP. CDKi is also being investigated as an adjuvant to current chemotherapeutic protocols.[480] Resistance to current chemotherapeutic agents is due, in part, to the ability of the cancer cell to manipulate cell cycle position to allow repair and avoid apoptosis.[486] By proper timing of the appropriate CDKi, the chemotherapeutic agent can more effectively kill the cancer cell.[480,487] Newer generation CDKis, such as dinaciclib, appear to be even more potent and have a wider therapeutic window/more selective effects than flavopiridol.[484]

Following arrest of cancer cell cycling, other biologically based chemotherapeutic agents might lead to cancer cell killing (apoptosis) or growth arrest (differentiation, senescence). The suppression of apoptosis in cancer cells is not only a fundamental mechanism of tumor formation and progression, but a means of resistance to therapy.[488-490] Like uncontrolled proliferation, many of the oncogenes and tumor suppressor genes identified in human cancers are important regulators of apoptosis.[491] Also, like the targets of uncontrolled proliferation, many types of biologically based therapies are under investigation. Current chemotherapeutic agents depend not only on the cell cycle, but on intact apoptotic programs.[492] At present, chemotherapy induces apoptosis in a general manner, rather than targeting cancer cells only.[493] Therefore, novel apoptosis-based agents need not only to target cancer cells, but to protect normal cells against dose-limiting side effects of chemotherapy or radiation. An example of normal cell survival factors includes G-CSF, a growth factor that counteracts depletion of neutrophils by enhancing proliferation of hematopoietic stem cell proliferation and differentiation.[494,495] In addition to protecting normal tissues from damage, several molecularly based approaches are based on our knowledge of the defects in the apoptotic pathway. Apoptosis-inducing ligands and cell surface receptors, such as the TRAIL signaling pathway, have been targeted using soluble recombinant proteins and antagonistic antibodies.[496-498] Defects in the p53 pathway have been targeted using adenovirus gene therapy.[428,499-501] Low molecular weight agents act directly against p53, such as PRIMA-1, and p53 inhibitors, such as MDM2.[252,502-504]

Inhibitors of apoptosis, such as the Bcl-2 and IAP gene families, have been targeted using RNAi and small peptides, such as BH3 mimetics ABT-737 and ABT-263, that block protein-protein binding.[439,505] Like biologically based approaches to uncontrolled proliferation, targeting of cancer-specific genetic lesions that lead to evasion of apoptosis requires identifying which molecular events may selectively modulate the cancer cell without adverse effects on other cell types or organ systems.

An alternative approach to lead cancer cells to exit the cell cycle is to induce differentiation or senescence.[506,507] Although the bulk of cancer therapy is based on cancer cell killing or resection, a new concept for cancer therapy is termed "tumor dormancy therapy."[508] The goal of this approach is to prolong patient survival time while retaining quality of life. Several differentiation-inducing therapeutic agents are under investigation, including nerve growth factor, trans-retinoic acid, dimethyl sulfoxide, peroxisome proliferator–activated receptor-gamma, 12-0-tetradecanoylphorbol 13-acetate, hexamethylene-bis-acetamide, TGF-β, butyric acid, cAMP, and vesnarinone.[507] Senescence-based therapies can be divided into replicative senescence and premature senescence approaches.[509,510] Replicative senescence, the process leading to growth rate decline in normal metabolically active cells, is primarily subverted by telomerase activity, an event present in 85% to 90% of cancer cells.[510-512] Telomerase inhibition strategies include natural/chemical inhibitors (GRN163L, β-rubromycin, and oleic acid), small molecule inhibitors (such as Vx-001), antisense oligonucleotides (such as GRN 163L), immunotherapies (such as GRVAC1 and GV1001), and gene therapies.[513-516] G-quadruplex stabilizers, such as tankyrase, have also been investigated.[517] Premature senescence, also referred to as oncogene-induced senescence, is targeted using selective microRNA expression epigenetic modifications or stress conditions to influence cell growth arrest through pathway mediators such as p21(Waf1/Cip1/Sdi1).[510,518,519] Likewise, several telomerase inhibitors, such as MST-312, have been shown to induce senescence.[520] Pathways that govern cell differentiation and senescence are much less defined (and likely more variable) than those that govern proliferation and apoptosis. A chief concern in both approaches is a transient or incomplete therapy-induced response.[261] Biologically based therapeutics targeting proliferation, apoptosis, differentiation, and senescence all target cancer cell biology. Therapeutic strategies targeting other cancer cell behaviors, such as neovascularization and metastasis, often target non-neoplastic cells as well to control cancer growth.

Tumor neovascularization is a primary target of biologically based cancer therapy.[275,521] Angiogenesis-targeted therapy has been used in cytotoxic and cytostatic ("tumor dormancy therapy") strategies.[522] Both the cancer cell and stromal cells can be targeted. Therapies focusing on the cancer cell offer the advantage of attacking tumor-specific molecular alterations; however, the genomically unstable cancer cell is also prone to evolving a therapy-resistant phenotype.[522] Stromal cells (principally endothelial cells) are genomically stable and therefore less likely to develop resistance. However, caution must be taken not to target gene activity that is necessary to maintain normal physiologic activity in healthy organ systems that require angiogenesis. Inhibition of tumor neovascularization has been achieved primarily using agents that affect endothelial cells directly. This strategy arrests endothelial cell proliferation (and vessel growth) and promotes tumor-associated endothelial cell death.[523,524] In addition, endothelial cell progenitor recruitment is blocked. Targeting the endothelial cells reduces the overall bulk of the tumor-associated vascular work, normalizing the chaotic pattern and abnormal architecture.[21] The overall therapeutic effect reduces the delivery of nutrients to the metabolically active cancer cells and improves the delivery of conventional chemotherapeutic agents. However, endothelial cell-related mechanisms can be overcome by tumor-secreted VEGF and survival factors. The endothelial cells can also be protected by other stromal cells or rendered irrelevant by vascular mimicry or cooptation.

In addition to endothelial cells, stromal cells targeted in anti-angiogenic therapy include mural cells, fibroblasts, and hematopoietic cells.[522] Inhibition of PDGF pathways reduces differentiation of progenitor cell pools into endothelial cells, as well as destabilizing smooth muscle cells that might cover and protect endothelial cells.[140] Furthermore, fibroblast recruitment of progenitor cells is inhibited. Last, chemokine antagonist inhibition of signaling from inflammatory infiltrate (specifically, IL-8) reduces the recruitment, differentiation, and cytokine production of mature leukocytes. This strategy also has important treatment implications for metastasis.[525] However, there is much redundancy in chemokine signaling, and inhibition of specific signals often results in overexpression of others.

Cancer cell–related anti-angiogenic therapy consists of both conventional (chemotherapy, radiation) and biologically based treatments.[526] Even some anti-angiogenic therapy is cytotoxic to cancer cells by interfering with survival pathways and enhancing sensitivity to treatments.[275] The result of a decreased tumor mass is a reduction of pro-angiogenic factors and decompression of the existing vasculature (thereby improving drug delivery).[21] However, cancer cells frequently will upregulate other pro-angiogenesis factors or, because of their genomic instability, select clones that adapt to the more unfavorable microenvironment.[522] The primary classes of anti-angiogenic therapeutic agents are monoclonal antibodies and small molecule tyrosine kinase inhibitors. Leading examples of monoclonal antibody therapeutic agents include bevacizumab (anti-VEGFR-1/2), cetuximab (anti-EBFR), and panitumumab (anti-EGFR).[527-529] Small molecule tyrosine kinase inhibitors include erlotinib (EGFR), sorafenib (VEGFR-1/2/3, PDGFR-β?and Raf-1), and sunitinib (VEGFR-1/2/3, PDGFR-β?and RET).[530] Other anti-angiogenic strategies are emerging.[531] Rapamycin and other mTOR inhibitors block the PI2/AKT pathway.[532] Bortezomib, a proteasome inhibitor, attacks the cancer cell directly.[533] Thalidomide and zoledronate possess

immunomodulatory, anti-inflammatory, and anti-angiogenic properties.[534,535] Endostatin and combretastatin A4 induce apoptosis in endothelial cells. Interferon-α inhibits bFGF and VEGF.[536]

In short, anti-angiogenesis therapy can be used alone to inhibit tumor growth (and thereby manage it as a chronic disease) or in combination with other conventional cancer therapies to enhance their efficacy.[537] Success of anti-angiogenesis therapy will depend on targeting multiple molecules/cell types and exploring strategies to delay, minimize, or even avoid resistance.[341,538] Last, novel agents will need to be identified that only affect cancer-associated neovascularization without affecting quiescent vessels in healthy organs.[539]

Like tumor neovascularization, metastasis progresses because of a synergy between cancer cells and stromal cells. However, the underlying biology of metastasis remains poorly understood.[9] Many current biologically based therapies targeting metastasis use strategies that address other malignant phenotypes, including neovascularization. For example, therapy targeting cancer cell phenotypes such as uncontrolled proliferation also affects key molecular events governing metastasis. Monoclonal antibodies targeting the EGFR 2 (HER2 or HER2/neu) are effective as an adjuvant and as treatment for metastatic breast cancer.[540] Furthermore, low molecular weight tyrosine kinase inhibitors have also proven to be effective anti-metastatic agents, especially for central nervous system metastases that are refractory to available chemotherapeutic agents.[541] Emerging targets of cancer invasion/metastasis include the HGF-c-MET signaling axis and the integrins. Aberrant expression of c-MET is widely associated with cancer invasion and metastasis.[542,543] Therapeutics designed to block HGF-MET binding include competitive HGF analogues (NK4); truncated, soluble forms of MET that serve as decoys; and monoclonal antibodies (rilotumumab, onartuzumab).[544,545] Small synthetic MET kinase inhibitors targeting the ATP binding site or an inactivating loop binding site have also entered clinical trials.[546,547] Last, attenuation of the MET signal via plant-derived polyphenols is under exploration.[548]

Therapeutic targets of metastasis affect not only cancer cells, but stromal cells as well. Integrins, a family of cell adhesion molecules that help transmit signals from the extracellular matrix into the cell, are important mediators of cell proliferation, and angiogenesis, as well as invasion and metastasis.[549] E-cadherin (discussed earlier in this chapter) is an important integrin involved in suppression of cancer metastasis. Integrins are believed to be involved in several steps of the metastatic cascade, including invasion through the basement membrane into the stromal connective tissue, dissemination of the cancer cell from the primary tumor, intravasation, lymphatic/blood stream transport, extravasation, and proliferation of the cancer cell at the secondary site.[147] Like antibodies, integrin antagonists have easy access to the cell surface.[550,551] Integrin antagonists act as competitive inhibitors, as allosteric inhibitors (changing the integrins' conformation into a less active form), or via antibody-mediated functional blocking (likely through both competitive and allosteric inhibition).[552,553] Other integrin-mediated anti-metastatic strategies include downregulating integrin gene expression using low molecular weight drugs or constructing integrins with compounds toxic to the cancer cell in a manner similar to immunoconjugates discussed earlier.[554,555] Biologically-based therapeutic agents based on metastasis-specific molecular alterations will require more experimentation to reveal their efficacy and limitations. Like angiogenesis-based therapies, agents targeting metastasis are being successfully employed as adjuvants to existing chemotherapy protocols. Although these combinations may not cure cancer, they may prolong patient survival and convert cancer to a chronic, manageable disease.[556-559]

As the molecular alterations leading to cancer are being defined, each change identified can serve as a means to better diagnose and treat the disease.[3] Panels of biomarkers can now be used to determine a molecular signature of cancer activity. In addition, cancer-associated molecular alterations can be used to develop designer drugs that can better address the biology of the disease in an individualized manner. Currently, these novel therapeutic strategies, alone or as adjuvants to current chemotherapeutic protocols, can improve patient survival and allow cancer to be treated as a chronic disease. Development and evaluation of novel anticancer agents are being facilitated by initiatives such as NCI's Cancer Therapy Evaluation Program (http://ctep.cancer.gov/default.htm) and NCI Experimental Therapeutics program (http://next.cancer.gov). In the future, combinations of these biologically based agents may lead to new cancer cures.

Summary and Future Directions

Advances in molecular biology are already having an impact on clinical oncology. Alterations of DNA structure, gene expression, and protein function ultimately disrupt key regulatory pathways and pathway networks. As these molecular alterations are accumulated, the cancer cell acquires important traits that confer a selective advantage over its normal neighbors. These cancer-associated behaviors include deregulated cell proliferation, evasion of apoptosis, neovascularization, and metastasis. Identification of the molecular alterations underlying these cancer cellular characteristics not only provides insights into the biology of the disease but highlights critical targets that may improve the diagnosis and treatment of the oncology patient. Though there are many achievements in the more than 30-year history of molecular oncology, several challenges remain for the future. New molecular alterations continue to be identified. Challenges remain to prioritize their biologic importance and determine the feasibility of translating this knowledge from the bench to the bedside. In the future, high-throughput analysis of cancer-related alterations may allow cancers to be categorized by their molecular makeup rather than clinical parameters such as tissue of origin or size. Identification of the biomarkers indicative of the malignant phenotype

will allow us to predict clinical behavior long before conventional microscopic or imaging techniques. However, challenges remain in standardization of specimen collection, interpretation of results, and identification of a rapid, inexpensive, robust, and technically feasible protocol for a clinical setting. In the future, DNA-mRNA-protein marker panels may determine risk/prevention, diagnosis, treatment choice, and monitoring of the cancer patient. Last, cancer-associated molecular changes are also providing important therapeutic targets. However, challenges remain regarding dose/timing, delivery, and treatment duration. In the future, molecularly based designer drugs may augment or replace conventional therapeutic strategies, reducing cancer to a manageable, chronic disease.

References

1. Cairns J: Mutation selection and the natural history of cancer, *Nature* 255:197–200, 1975.
2. Fialkow P: Clonal origin of human tumors, *Annu Rev Med* 30:135–143, 1979.
3. Collins FS, Varmus H: A new initiative on precision medicine, *N Engl J Med* 372:793–795, 2015.
4. Jernal A, Center N, DeSantis C, Ward E: Global patterns of cancer incidence and mortality rates and trends, *Cancer Epidemiol Biomarkers Prev* 19:1893–1907, 2010.
5. Robbins S, Cotran R, Kumar V: *Neoplasia. Pathologic Basis of Disease*, Philadelphia, 1984, Saunders.
6. Benavente CA, Dyer MA: Genetics and epigenetics of human retinoblastoma, *Annu Rev Pathol* 10:547–562, 2015.
7. Wilson S, Jones L, Coussens C, Hanna K, editors: *Cancer and the Environment: Gene-Environment Interaction*, Washington, DC, 2002, National Academy Press.
8. Vogelstein B, Kinzler K: Cancer genes and the pathways they control, *Nat Med* 10:789–799, 2004.
9. Hanahan D, Weinberg R: Hallmarks of cancer: the next generation, *Cell* 144:646–674, 2011.
10. Cabrera MC, Hollingsworth RE, Hurt EM: Cancer stem cell plasticity and tumor hierarchy, *World J Stem Cells* 7:27–36, 2015.
11. Chang AI, Schwertschkow AH, Nolta JA, Wu J: Involvement of mesenchymal stem cells in cancer progression and metastases, *Curr Cancer Drug Targets* 15:88–98, 2015.
12. Cho RW, Clarke MF: Recent advances in cancer stem cells, *Curr Opin Genet Dev* 18:48–53, 2008.
13. Jung A, Brabletz T, Kirchner T: The migrating cancer stem cells model—a conceptual explanation of malignant tumour progression, *Ernst Schering Found Symp Proc* 109–124, 2006.
14. Eid JE, Garcia CB: Reprogramming of mesenchymal stem cells by oncogenes, *Semin Cancer Biol* 32:18–31, 2015.
15. Catalano V, Turdo A, Di Franco S, et al.: Tumor and its microenvironment: a synergistic interplay, *Semin Cancer Biol* 23:522–532, 2013.
16. Bhowmick N, Neilson E, Moses H: Stromal fibroblasts in cancer initiation and progression, *Nature* 432:332–337, 2004.
17. Dvorak H: Tumors: wounds that do not heal. Similarities between tumor stroma generation and wound healing, *N Engl J Med* 315:1650–1659, 1986.
18. Micke P, Ostman A: Exploring the tumour environment: cancer-associated fibroblasts as targets in cancer therapy, *Expert Opin Ther Targets* 9:1217–1233, 2005.
19. Folkman J, Kalluri R: Cancer without disease, *Nature* 427:787, 2004.
20. Hanahan D, Folkman J: Patterns and emerging mechanisms of the angiogenic switch during tumorigenesis, *Cell* 86:149–153, 1996.
21. Auguste P, Lemiere S, Larrieu-Lahargue F, Bikfalvi A: Molecular mechanisms of tumor vascularization, *Crit Rev Oncol* 54:53–61, 2005.
22. Raza A, Franklin MJ, Dudek AZ: Pericytes and vessel maturation during tumor angiogenesis and metastasis, *Am J Hematol* 85:593–598, 2010.
23. Ling S, Feng T, Jia K, et al.: Inflammation to cancer: the molecular biology in the pancreas (Review), *Oncol Lett* 7:1747–1754, 2014.
24. Mei Z, Liu Y, Liu C, et al.: Tumour-infiltrating inflammation and prognosis in colorectal cancer: systematic review and meta-analysis, *Br J Cancer* 110:1595–1605, 2014.
25. Penn I: Depressed immunity and the development of cancer, *Cancer Detect Prevent* 18:241–252, 1994.
26. Wang E, Panelli M, Monsurro V, Marincola F: A global approach to tumor immunology, *Cell Mol Immunol* 1:256–265, 2004.
27. Grivennikiv SL, Greten FR, Karin M: Immunity, inflammation, and cancer, *Cell* 140:883–899, 2010.
28. Bingle L, Brown N, Lewis C: The role of tumour-associated macrophages in tumour progression: implications for new anticancer therapies, *J Pathol* 196:254–265, 2002.
29. Dranoff G: Cytokines in cancer pathogenesis and cancer therapy, *Nat Rev Cancer* 4:11–22, 2004.
30. Dunn G, Bruce A, Ikeda H: Cancer immunoediting: from immunosurveillance to tumor escape, *Nat Immunol* 3:991–998, 2002.
31. Frisch M, Biggar R, Engels E, Goedert J: Association of cancer with AIDS-related immunosuppression in adults, *JAMA* 285:1736–1745, 2001.
32. Warburg O: On respiratory impairment in cancer cells, *Science* 124:269–270, 1956.
33. Mikawa T, Leonart ME, Takaori-Kondo A, et al.: Dysregulated glycolysis as an oncogenic event, *Cell Mol Life Sci* 72:1881–1892, 2015.
34. Gonzalez CD, Alvarez S, Ropolo A, et al.: Autophagy, Warburg, and Warburg reverse effects in human cancer, *Biomed Res Int*, http://dx.doi.org/10.1155/2014/926729.
35. Jones RG, Thompson CB: Tumor suppressors and cell metabolism: a recipe for cancer growth, *Genes Dev* 23:537–548, 2009.
36. Kennedy KM, Dwhirst MW: Tumor metabolism of lactate: the influence and therapeutic potential for MCT and CD147 regulation, *Future Oncol* 6:127–148, 2010.
37. Hanahan D, Weinberg R: The hallmarks of cancer, *Cell* 100:57–70, 2000.
38. Todd R, Munger K: Oncogenes. In Cooper DN, editor: *Nature Encyclopedia of the Human Genome*, London, 2003, Nature Publishing, pp 435–442.
39. Scherr C: Principles of tumor suppression, *Cell* 116:235–246, 2004.
40. Harris H, Miller O, Klein G, Worst P, Tachibana T: Suppression of malignancy by cell fusion, *Nature* 223:363–368, 1969.
41. Stanbridge E, Flandermeyer R, Daniels D, Nelson-Rees WA: Specific chromosome loss associated with the expression of tumorigenicity in human cell hybrids, *Somatic Cell Mol Genet* 7:699–712, 1976.
42. Vogelstein B, Kinzler K: *The Genetic Basis of Human Cancer*, New York, 1998, McGraw-Hill.

43. Fearon E: Human cancer syndromes, *Science* 215:252–259, 1997.
44. Knudson A: Mutation and cancer: statistical analysis of retinoblastoma, *Proc Natl Acad Sci USA* 68:820–823, 1971.
45. Friend S, Bernards R, Rogelj S, et al.: A human DNA segment with properties of the gene that predisposes to retinoblastoma and osteosarcoma, *Nature* 323:643–646, 1986.
46. Friend S, Horowitz J, Gerber M, et al.: Deletions of a DNA sequence in retinoblastomas and mesenchymal tumors: organization of the sequence and its encoded protein, *Proc Natl Acad Sci USA* 84:9059–9063, 1987.
47. Ornstein D, Petricoin E: Proteomics to diagnose human tumors and provide prognostic information, *Oncology* 18:521–532, 2004.
48. Todd R, Donoff R, Wong D: The chromosome: cytogenetic analysis and its clinical application, *J Oral Maxillofac Surg* 58:1036–1041, 2000.
49. Pardee A: Regulatory molecular biology, *Cell Cycle (Georgetown, Tex)* 5:1–6, 2006.
50. Kim Y, Flynn T, Donoff R, Wong D, Todd R: The gene: the polymerase chain reaction (PCR) and its clinical application, *J Oral Maxillofac Surg* 60:808–815, 2002.
51. Chao E, Lipkin S: Molecular models for the tissue specificity of DNA mismatch repair-deficient carcinogenesis, *Nucl Acid Res* 34:840–852, 2006.
52. Baylin S: DNA methylation and gene silencing in cancer, *Nat Clin Pract Oncol* 2(Suppl 1):S4–S11, 2005.
53. Rodenhiser D, Mann M: Epigenetics and human disease: translating basic biology into clinical applications, *CMAJ* 174:341–348, 2006.
54. Peterson C, Laniel M: Histones and histone modifications, *Curr Biol* 14:R546–R551, 2004.
55. Rountree M, Bachman K, Herman J: DNA methylation, chromatin inheritance, and cancer, *Oncogene* 20:3156–3165, 2001.
56. Rodriguez-Paredes M, Esteller M: Cancer epigenetics reaches mainstream oncology, *Nat Med* 17:330–339, 2011.
57. Sadakierska-Chudy A, Kostrzewa RM, Filip M: A comprehensive view of the epigenetic landscape part I: DNA methylation, passive and active DNA demethylation pathways and histone variants, *Neurotox Res* 27:84–97, 2015.
58. Kala R, Peek G, Hardy T, Tollefsbol T: MicroRNAs: an emerging science in cancer epigenetics, *J Clin Bioinform* 3:6–13, 2013.
59. Todd R, Wong D: Epidermal growth factor receptor (EGFR) biology and human oral cancer, *Histol Histopathol* 14:491–500, 1999.
60. Kolch W, Mischak H, Pitt A: The molecular make-up of a tumour: proteomics in cancer research, *Clin Sci* 108:369–383, 2005.
61. Jordan C, Guzman M, Noble M: Cancer stem cells, *N Engl J Med* 355:1253–1261, 2006.
62. Hoeijmakers J: Genome maintenance mechanisms for preventing cancer, *Nature* 41:366–374, 2001.
63. Macheret M, Halazonetis TD: DNA replication stress as a hallmark of cancer, *Annu Rev Pathol* 10:425–448, 2015.
64. Abbas T, Keaton MA, Dutta A: Genomic instability in cancer, *Cold Spring Harb Perspect Biol* 5:199–208, 2013.
65. Negrini S, Gorgoulis VG, Halazonetis TD: Genomic instability—an evolving hallmark of cancer, *Nat Rev Mol Cell Biol* 11:220–228, 2010.
66. Shen Z: Genomic instability and cancer: an introduction, *J Mol Cell Biol* 3:1–3, 2011.
67. Glaab W, Tindall K: Mutation rate at the hprt locus in human cancer cell lines with specific mismatch repair-gene defects, *Carcinogenesis* 18:1–8, 1997.
68. Jackson SP, Bartek J: The DNA-damage response in human biology and disease, *Nature* 461:1071–1078, 2009.
69. Salk JJ, Fox EJ, Loeb LA: Mutational heterogeneity in human cancers: origin and consequences, *Annu Rev Pathol* 5:51–75, 2010.
70. Kinzler KW, Vogelstein B: Cancer-susceptibility genes. Gatekeepers and caretakers, *Nature* 386:761–763, 1997.
71. Donley N, Thayer MJ: DNA replication timing, genome stability and cancer: late and/or delayed DNA replication timing is associated with increased genomic instability, *Semin Cancer Biol* 23:80–89, 2013.
72. Iyama T, Wilson 3rd DM: DNA repair mechanisms in dividing and non-dividing cells, *DNA Rep* 12:620–636, 2013.
73. Aaltonen L, Peltomaki P, Leach F, et al.: Clues to the pathogenesis of familial colorectal cancer, *Science* 260:812–816, 1993.
74. Aaltonen L, Peltomaki P, Mecklin J, et al.: Replication errors in benign and malignant tumors from hereditary nonpolyposis colorectal cancer patients, *Cancer Res* 54:1645–1648, 1994.
75. Rosenberg S, Thulin C, Harris R: Transient and heritable mutators in adaptive evolution in the lab and in nature, *Genetics* 148:1559–1566, 1998.
76. Feig D, Reid T, Loeb L: Reactive oxygen species in tumorigenesis, *Cancer Res* 54:1890s–1894s, 1994.
77. Jackson A, Chen R, Loeb L: Induction of genomic instability by oxidative DNA damage, *Proc Natl Acad Sci USA* 95:12468–12473, 1998.
78. Sieber O, Heinimann K, Tomlinson I: Genomic instability—the engine of tumorigenesis? *Nat Rev Cancer* 3:701–708, 2003.
79. Meltzer P, Kallioniemi A, Trent J: Chromosome alterations in human solid tumors. In Scrivner C, Beaudet A, Sly W, Valle D, editors: *The Metabolic and Molecular Bases of Inherited Disease*, New York, 2001, McGraw-Hill, pp 575–596.
80. Vogelstein B, Fearon E, Kern S, et al.: Allelotype of colorectal carcinomas, *Science* 244:207–211, 1989.
81. Coleman W, Tsongalis G: Molecular mechanisms of human carcinogenesis. In Bignold L, editor: *Cancer: Cell Structures, Carcinogens and Genomic Instability*, Switzerland, 2000, Birkauser.
82. Ghadimi B, Sackett D, Difilippantonio M, et al.: Centrosome amplification and instability occurs exclusively in aneuploid, but not in diploid colorectal cancer cell lines, and correlates with numerical chromosomal aberrations, *Genes Chromosomes Cancer* 27:183–190, 2000.
83. Kastan M, Kuerbitz S: Control of G1 arrest after DNA damage, *Environ Health Prospect* 101:55–58, 1993.
84. Lengauer C, Kinzler K, Vogelstein B: Genetic instability in colorectal cancers, *Nature* 386:623–627, 1997.
85. Kastan M, Onyekwere O, Sidransky D, Vogelstein B, Craig R: Participation of the p53 protein in the cellular response to DNA damage, *Cancer Res* 51:6304–6311, 1991.
86. Bharadwaj R, Yu H: The spindle checkpoint, aneuploidy, and cancer, *Oncogene* 23:2016–2027, 2004.
87. Li Y, Benezra R: Identification of a human mitotic checkpoint gene: hsMAD2, *Science* 274:246–248, 1996.
88. Canman C, Lim D: The role of ATM in damage responses and cancer, *Oncogene* 17:3301–3308, 1998.
89. Zhang H, Tombline G, Weber B: BRCA1, BRCA2, and DNA damage response: collision or collusion, *Cell* 92:433–436, 1998.
90. Gebhart E: Double minutes, cytogenetic equivalents of gene amplification, in human neoplasia—a review, *Clin Transl Oncol* 7:477–485, 2005.
91. Nowell PC, Croce CM: Chromosomal approaches to the molecular basis of neoplasia, *Symp Fund Cancer Res* 39:17–29, 1986.

92. Hogarty M, Brodeur G: Gene amplification in human cancers: biological and clinical significance. In Scrivner C, Beaudet A, Sly W, Valle D, editors: *The Metabolic and Molecular Bases of Inherited Disease*, New York, 2001, McGraw-Hill, pp 597–610.
93. Zahreddine H, Borden KL: Mechanisms and insights into drug resistance in cancer, *Front Pharm* 4:28, 2013.
94. Jividen K, Li H: Chimeric RNAs generated by intergenic splicing in normal and cancer cells, *Gene Chrom Cancer* 53:963–971, 2014.
95. Roukos V, Misteli T: The biogenesis of chromosome translocations, *Nat Cell Biol* 16:293–300, 2014.
96. Dalla-Favera R, Martinotti S, Gallo R, Erickson J, Croce C: Translocation and rearrangements of the c-myc oncogene in human undifferentiated B-cell lymphomas, *Science* 219:963–967, 1983.
97. Ott G, Rosenwald A, Campo E: Understanding MYC driven aggressive B-cell lymphomas: pathogenesis and classification, *Blood* 122:3884–3891, 2013.
98. Naka K, Hoshii T, Tadokoro Y, Hirao A: Molecular pathology of tumor-initiating cells: lessons from Philadelphia chromosome-positive leukemia, *Pathol Int* 61:501–508, 2011.
99. Baker S, Preisinger A, Jessup J, Paraskeva C, Kinzler K, Vogelstein B: p53 gene mutations occur in combination with 17p allelic deletions as late events in colorectal carcinogenesis, *Cancer Res* 50:7717–7722, 1990.
100. Fearon E, Cho K, Nigro J, et al.: Identification of a chromosome 18q gene that is altered in colorectal cancers, *Science* 247:49–56, 1990.
101. Kinzler K, Nilbert M, Su L, et al.: Identification of FAP locus genes from chromosome 5q21, *Science* 253:661–665, 1991.
102. Arana ME, Kunkel TA: Mutator phenotypes due to DNA replication infidelity, *Semin Cancer Biol* 20:304–311, 2010.
103. Kim JC, Mirkin SM: The balancing act of DNA repeat expansions, *Curr Opin Genet Dev* 23:280–288, 2013.
104. Preston BD, Albertson TM, Herr AJ: DNA replication fidelity and cancer, *Semin Cancer Biol* 20:281–293, 2010.
105. Kim Y, Donoff R, Wong D, Todd R: The nucleotide: DNA sequencing and its clinical application, *J Oral Maxillofac Surg* 60:924–930, 2002.
106. Watson MM, Berg M, Soreide K: Prevalence and implications of elevated microsatellite alterations at selected tetranucleotides in cancer, *Br J Cancer* 111:823–827, 2014.
107. Honchel R, Halling K, Thibodeau S: Genomic instability in neoplasia, *Semin Cell Biol* 6:45–52, 1995.
108. Thibodeau S, French A, Cunningham J, et al.: Microsatellite instability in colorectal cancer: different mutator phenotypes and the principal involvement of hMLH1, *Cancer Res* 58:1713–1718, 1998.
109. Yamada N, Castro A, Farber R: Variation in the extent of microsatellite instability in human cell lines with defects in different mismatch repair genes, *Mutagen* 18:277–282, 2003.
110. Bronner C, Baker S, Morrison P, et al.: Mutation in the DNA mismatch repair gene homologue jMLH1 is associated with hereditary non-polyposis colon cancer, *Nature* 368:258–261, 1994.
111. Fishel R, Lesco M, Rao M, et al.: The human mutator gene homolog MSH2 and its association with hereditary nonpolyposis colon cancer, *Cell* 75:1027–1038, 1993.
112. Jirieny J, Nystrom-Lahti M: Mismatch repair defects in cancer, *Curr Opin Genet Dev* 10:157–161, 2000.
113. Leach F, Nicolaides N, Papadopoulos N, et al.: Mutations of a mutS homolog in hereditary non-polyposis colorectal cancer, *Cell* 75:1215–1225, 1993.
114. Lipkin S, Wang V, Jacoby R, et al.: MLH3: a DNA mismatch repair gene associated with mammalian microsatellite instability, *Nat Genet* 24:27–35, 2000.
115. Nicolaides N, Papadopoulos N, Liu B, et al.: Mutations of two PMS homologues in hereditary nonpolyposis colon cancer, *Nature* 371:75–80, 1994.
116. Palombo F, Gallinari P, Iaccarino I, et al.: Mutations of GTBP in genetically unstable cells, *Science* 268:1912–1914, 1995.
117. Papadopoulos N, Nicolaides N, Liu B, et al.: Mutations of GTBP in genetically unstable cells, *Science* 268:1915–1917, 1995.
118. Papadopoulos N, Nicolaides N, Wei Y, et al.: Mutation of a mutL homolog in hereditary colon cancer, *Science* 263:1625–1629, 1994.
119. Umar A, Risinger J, Glaab W, Tindall K, Barrett J, Kunkel T: Functional overlap in mismatch repair by human MSH3 and MSH6, *Genetics* 148:1637–1646, 1998.
120. Hanford M, Rushton B, Gowen L, Farber R: Microsatellite mutation rates in cancer cell lines deficient or proficient in mismatch repair, *Oncogene* 16:2389–2393, 1998.
121. Wongtrakoongate P: Epigenetic therapy of cancer stem and progenitor cells by targeting DNA methylation machineries, *World J Stem Cell* 7:137–148, 2015.
122. Toyota M, Suzuki H: Epigenetic drivers of genetic alterations, *Adv Genet* 70:309–323, 2010.
123. Esteller M: CpG island hypermethylation and tumor suppressor genes: a booming present, a brighter future, *Oncogene* 21:5427–5440, 2002.
124. Wajed SA, Laird PW, DeMeester TR: DNA methylation: an alternative pathway to cancer, *Ann Surg* 234:10–20, 2001.
125. Akhavan-Niaki H, Samadani AA: DNA methylation and cancer development: molecular mechanism, *Cell Biochem Biophys* 67:501–513, 2013.
126. Das PM, Singal R: DNA methylation and cancer, *J Clin Oncol* 22:4632–4642, 2004.
127. Esteller M, Herman JG: Cancer as an epigenetic disease: DNA methylation and chromatin alterations in human tumours, *J Pathol* 196:1–7, 2002.
128. Hitchins MP, Rapkins RW, Kwok CT, et al.: Dominantly inherited constitutional epigenetic silencing of MLH1 in a cancer-affected family is linked to a single nucleotide variant within the 5′UTR, *Cancer Cell* 20:200–213, 2011.
129. Kiss NB, Muth A, Andreasson A, et al.: Acquired hypermethylation of the P16INK4A promoter in abdominal paraganglioma: relation to adverse tumor phenotype and predisposing mutation, *Endocr Relat Cancer* 20:65–78, 2013.
130. Naushad SM, Reddy CA, Kumaraswami K, et al.: Impact of hyperhomocysteinemia on breast cancer initiation and progression: epigenetic perspective, *Cell Biochem Biophys* 68:397–406, 2013.
131. Vanharanta S, Shu W, Brenet F, et al.: Epigenetic expansion of VHL-HIF signal output drives multiorgan metastasis in renal cancer, *Nat Med* 19:50–56, 2013.
132. Hunter T: Oncoprotein networks, *Cell* 88:333–334, 1997.
133. Hunter T: Signaling-2000 and beyond, *Cell* 100:113–127, 2000.
134. McCormick F: Signalling networks that cause cancer, *Trends Cell Biol* 9:M53–M56, 1999.
135. Yarden Y, Sliwkowski M: Untangling the signalling network, *Nat Rev Mol Cell Biol* 2:127–137, 2001.
136. Lee EY, Muller WJ: Oncogenes and tumor suppressor genes, *Cold Spring Harb Perspect Biol* 2:a003236, 2010.

137. Black PC, Dinney CP: Growth factors and receptors as prognostic markers in urothelial carcinoma, *Curr Urol Rep* 9:55–61, 2008.
138. Witsch E, Sela M, Yarden Y: Roles for growth factors in cancer progression, *Physiology* 25:85–101, 2010.
139. Cross M, Dexter T: Growth factors in development, transformation and tumorigenesis, *Cell* 64:271–280, 1991.
140. Ostman A: PDGF receptors-mediators of autocrine tumor growth and regulators of tumor vasculature and stroma, *Cytokine Growth Factor Rev* 15:275–286, 2003.
141. Heldin CH: Autocrine PDGF stimulation in malignancies, *Ups J Med Sci* 117:83–91, 2012.
142. Grandal MV, Madshus IH: Epidermal growth factor receptor and cancer: control of oncogenic signalling by endocytosis, *J Cell Mol Med* 12:1527–1534, 2008.
143. Schlessinger J: Ligand-induced, receptor-mediated dimerization and activation of EGF receptor, *Cell* 110:669–672, 2002.
144. Yaffe M: Phosphotyrosine-binding domains in signal transduction, *Nat Rev Mol Cell Biol* 3:177–186, 2002.
145. Fu X, Osborne CK, Schiff R: Biology and therapeutic potential of PI3K signaling in ER+/HER2-negative breast cancer, *Breast (Edinb)*(Suppl 2)S12–S18, 2013.
146. Lemmon MA, Schlessinger J: Cell signalling by receptor tyrosine kinases, *Cell* 141:117–134, 2010.
147. Eble J, Haier J: Integrins in cancer treatment, *Curr Cancer Drug Targets* 6:561–571, 2006.
148. Weber GF, Bjerke MA, DeSimone DW: Integrins and cadherins join forces to form adhesive networks, *J Cell Sci* 124:1183–1193, 2011.
149. Epifano C, Perez-Moreno M: Crossroads of integrins and cadherins in epithelia and stroma remodeling, *Cell Adhes Migrat* 6:261–273, 2012.
150. Blume-Jensen P, Hunter T: Oncogenic kinase signalling, *Nature* 411:355–365, 2001.
151. Brognard J, Hunter T: Protein kinase signalling networks in cancer, *Curr Opin Genet Dev* 21:4–11, 2011.
152. Chang L, Karin M: Mammalian MAP kinase signalling cascades, *Nature* 41:37–40, 2001.
153. Brown MD, Sacks DB: Protein scaffolds in MAP kinase signaling, *Cell Signal* 21:462–469, 2009.
154. Prior IA, Hancock JF: Ras trafficking, localization and compartmentalized signalling, *Semin Cell Dev Biol* 23:145–153, 2012.
155. Katoh M: WNT/PCP signaling pathway and human cancer (review), *Oncol Rep* 14:1583–1588, 2005.
156. O'Shea JJ, Holland SM, Staudt LM: JAKs and STATs in immunity, immunodeficiency, and cancer, *N Engl J Med* 368:161–170, 2013.
157. Jiang BH, Liu LZ: PI3K/PTEN signaling in angiogenesis and tumorigenesis, *Adv Cancer Res* 102:19–65, 2009.
158. Marcu K, Bossone S, Patel A: myc function and regulation, *Annu Rev Biochem* 61:809–860, 1992.
159. Smith SM, Anastasi J, Cohen KS, Godley LA: The impact of MYC expression in lymphoma biology: beyond Burkitt lymphoma, *Blood Cell Mol Dis* 45:317–323, 2010.
160. Herkert B, Eilers M: Transcriptional repression: the dark side of myc, *Gene Cancer* 1:580–586, 2010.
161. Soucek L, Evan GI: The ups and downs of Myc biology, *Curr Opin Genet Dev* 20:91–95, 2010.
162. Amati B, Brooks M, Levy N, Littlewood T, Evan G, Land H: Oncogenic activity of the c-Myc protein requires dimerization with Max, *Cell* 72:233–245, 1993.
163. Maddika S, Ande SR, Panigrahi S, et al.: Cell survival, cell death and cell cycle pathways are interconnected: implications for cancer therapy, *Drug Resist Updates* 10:13–29, 2007.
164. Kolch W, Mischak H, Chalmers M, Pitt A, Marshall A: Clinical proteomics: a question of technology, *Rapid Commun Mass Spectrom* 18:2365–2366, 2004.
165. Malumbres M, Barbacid M: RAS oncogenes: the first thirty years, *Nat Rev Cancer* 3:459–465, 2003.
166. Cui X, Lu Z, Kurosawa A, et al.: Both CpG methylation and activation-induced deaminase are required for the fragility of the human bcl-2 major breakpoint region: implications for the timing of the breaks in the t(14;18) translocation, *Mol Cell Biol* 33:947–957, 2013.
167. Blanpain C: Tracing the cellular origin of cancer, *Nat Cell Biol* 15:126–134, 2013.
168. Malumbres M, Barbacid M: To cycle or not to cycle: a critical decision in cancer, *Nat Rev Cancer* 1:222–231, 2001.
169. Vermeulen K, Van Bockstaele DR, Berneman ZN: The cell cycle: a review of regulation, deregulation and therapeutic targets in cancer, *Cell Prolif* 36:131–149, 2003.
170. Musgrove E: Cyclins: roles in mitogenic signaling and oncogenic transformation, *Growth Fact* 24:13–19, 2006.
171. Pestell RG: New roles of cyclin D1, *Am J Pathol* 183:3–9, 2013.
172. Zalzali H, Harajly M, Abdul-Latif L, et al.: Temporally distinct roles for tumor suppressor pathways in cell cycle arrest and cellular senescence in Cyclin D1-driven tumor, *Mol Cancer* 11:28, 2012.
173. Witkiewicz AK, Knudsen KE, Dicker AP, Knudsen ES: The meaning of p16(ink4a) expression in tumors: functional significance, clinical associations and future developments, *Cell Cycle* 10:2497–2503, 2011.
174. Chandler H, Peters G: Stressing the cell cycle in senescence and aging, *Curr Opin Cell Biol* 25:765–771, 2013.
175. Massague J: How cells read TGF-b signals, *Nat Rev Mol Cell Biol* 1:298–307, 2000.
176. Sherr C, Roberts J: CDK inhibitors: Positive and negative regulators of G1 phase progression, *Genes Dev* 13:1501–1512, 1999.
177. Rayess H, Wang MB, Srivatsan ES: Cellular senescence and tumor suppressor gene p16, *Int J Cancer* 130:1715–1725, 2012.
178. Classon M, Harlow E: The retinoblastoma tumour suppression in development and cancer, *Nat Rev Cancer* 2:910–917, 2002.
179. Dick FA, Rubin SM: Molecular mechanisms underlying RB protein function, *Nat Rev Mol Cell Biol* 14:297–306, 2013.
180. Henley SA, Dick FA: The retinoblastoma family of proteins and their regulatory functions in the mammalian cell division cycle, *Cell Div* 7:10, 2012.
181. Lui H: New roles for the RB tumor suppressor protein, *Curr Opin Genet Dev* 14:55–64, 2004.
182. Manning AL, Dyson NJ: RB: mitotic implications of a tumour suppressor, *Nat Rev Cancer* 12:220–226, 2012.
183. Poznic M: Retinoblastoma protein: a central processing unit, *J Biosci* 34:305–312, 2009.
184. Dyson N: The regulation of E2F by pRB-family proteins, *Genes Dev* 12:2245–2262, 1998.
185. Chen HZ, Tsai SY, Leone G: Emerging roles of E2Fs in cancer: an exit from cell cycle control, *Nat Rev Cancer* 9:785–797, 2009.
186. Baker SJ, Reddy EP: CDK4: a key player in the cell cycle, development, and cancer, *Gene Cancer* 3:658–669, 2012.
187. Fisher RP: The CDK Network: Linking cycles of cell division and gene expression, *Gene Cancer* 3:731–738, 2012.
188. Harbour J, Luo R, Dei Santi A: Cdk phosphorylation triggers sequential intramolecular interactions that progressively block Rb functions as cells move through G1, *Cell* 98:859–869, 1999.

189. Paternot S, Bockstaele L, Bisteau X, Kooken H, Coulonval K, Roger PP: Rb inactivation in cell cycle and cancer: the puzzle of highly regulated activating phosphorylation of CDK4 versus constitutively active CDK-activating kinase, *Cell Cycle* 9:689–699, 2010.
190. Suryadinata R, Sadowski M, Sarcevic B: Control of cell cycle progression by phosphorylation of cyclin-dependent kinase (CDK) substrates, *Biosci Rep* 30:243–255, 2010.
191. Bellacchio E, Paggi MG: Understanding the targeting of the RB family proteins by viral oncoproteins to defeat their oncogenic machinery, *J Cell Physiol* 228:285–291, 2013.
192. Nevins J: E2F: a link between the Rb tumor suppressor protein and viral oncoproteins, *Science* 258:424–429, 1992.
193. Malumbres M, Perez De Castro I, Hernandez M: Cellular response to oncogenic ras involves induction of the Cdk4 and Cdk6 inhibitor p15(INK4b), *Mol Cell Biol* 20:2915–2925, 2000.
194. Drabsch Y, ten Dijke P: TGF-β signalling and its role in cancer progression and metastasis, *Cancer Metastasis Rev* 31:553–568, 2012.
195. Massague J: TGF-beta signalling in context, *Nat Rev Mol Cell Biol* 13:616–630, 2012.
196. Sherr C: The INK4a/ARF network in tumour suppression, *Nat Rev Mol Cell Biol* 2:731–737, 2001.
197. Kamato D, Burch ML, Piva TJ, et al.: Transforming growth factor-beta signalling: role and consequences of Smad linker region phosphorylation, *Cell Signal* 25:2017–2024, 2013.
198. Buchkovich K, Duffy L, Harlow E: The retinoblastoma protein is phosphorylated during specific phases of the cell cycle, *Cell* 58:1097–1105, 1989.
199. Eisenman R: Deconstructing Myc, *Genes Dev* 15:2023–2030, 2001.
200. Shortt J, Johnstone RW: Oncogenes in cell survival and cell death, *Cold Spring Harb Perspect Biol* 4, 2012.
201. Cichowski K, Jacks T: NF1 tumor suppressor gene function: narrowing the GAP, *Cell* 104:593–604, 2001.
202. Wang S, Wang Z: Epigenetic aberrant methylation of tumor suppressor genes in small cell lung cancer, *J Thorac Dis* 5:532–537, 2013.
203. Jouhilahti EM, Peltonen S, Heape AM, Peltonen J: The pathoetiology of neurofibromatosis 1, *Am J Pathol* 178:1932–1939, 2011.
204. Brown CJ, Lain S, Verma CS, Fersht AR, Lane DP: Awakening guardian angels: drugging the p53 pathway, *Nat Rev Cancer* 9:862–873, 2009.
205. Heijink AM, Krajewska M, van Vugt MA: The DNA damage response during mitosis, *Mutat Res* 750:45–55, 2013.
206. Topham CH, Taylor SS: Mitosis and apoptosis: how is the balance set? *Curr Opin Cell Biol* 25:780–785, 2013.
207. Larsson LG: Oncogene- and tumor suppressor gene-mediated suppression of cellular senescence, *Semin Cancer Biol* 21:367–376, 2011.
208. McDuff FK, Turner SD: Jailbreak: oncogene-induced senescence and its evasion, *Cell Signal* 23:6–13, 2011.
209. Ouyang L, Shi Z, Zhao S, et al.: Programmed cell death pathways in cancer: a review of apoptosis, autophagy and programmed necrosis, *Cell Prolif* 45:487–498, 2012.
210. Cheung H, Arora V, Korneluk R: Abnormalities of cell structures in tumors: apoptosis in tumors. In Bignold L, editor: *Cancer: cell structures, carcinogens and genomic instability*, Switzerland, 2006, Birkauser, pp 201–221.
211. Fadeel B, Orrenius S: Apoptosis: a basic biological phenomenon with wide-ranging implications in human disease, *J Intern Med* 258:479–517, 2005.
212. Danial N, Korsmeyer S: Cell death: critical control points, *Cell* 116:205–219, 2004.
213. Lindsay J, Esposti MD, Gilmore AP: Bcl-2 proteins and mitochondria—specificity in membrane targeting for death, *Biochim Biophys Acta* 1813:532–539, 2011.
214. Ashkenazi A, Dixit V: Death receptors: signaling and modulation, *Science* 281:1305–1308, 1998.
215. Gonzalvez F, Ashkenazi A: New insights into apoptosis signaling by Apo2L/TRAIL, *Oncogene* 29:4752–4765, 2010.
216. Goodel D: The molecular perspective: tumor necrosis factor, *Oncology* 11:83–84, 2006.
217. Palacios C, Yerbes R, Sanchez-Perez T, et al.: The long and winding road to cancer treatment: the trail system, *Curr Pharm Des* 20:2819–2833, 2013.
218. Sayers TJ: Targeting the extrinsic apoptosis signaling pathway for cancer therapy, *Cancer Immunol Immunother* 60:1173–1180, 2011.
219. Strasser A, O'Connor L, Dixit V: Apoptosis signaling, *Annu Rev Biochem* 69:217–245, 2000.
220. Boldin M, et al.: A novel protein that interacts with the death domain of Fas/APO-1 contains a sequence motif related to the death domain, *J Biol Chem* 270:7795–7798, 1995.
221. Chinnaiyan A, O'Rourke K, Tewari M, Dixit V: FADD a novel death domain-containing protein, interacts with the death domain of Fas and initiates apoptosis, *Cell* 81:505–512, 1995.
222. Kischkel F, Hellbardt S, Behrmann I, et al.: Cytotoxicity-dependent APO-1 (Fas/CE95)-associated proteins from a death-inducing signaling complex (DISC) with the receptor, *EMBO J* 14:5579–5588, 1995.
223. Fiandalo MV, Kyprianou N: Caspase control: protagonists of cancer cell apoptosis, *Exp Oncol* 34:165–175, 2012.
224. Kulikov AV, Shilov ES, Mufazalov IA, et al.: Cytochrome c: the Achilles' heel in apoptosis, *Cell Mol Life Sci* 69:1787–1797, 2012.
225. Lavrik IN, Krammer PH: Regulation of CD95/Fas signaling at the DISC, *Cell Death Differ* 19:36–41, 2012.
226. Saelens X, Festjens N, Vande Walle L, et al.: Toxic proteins released from mitochondria in cell death, *Oncogene* 23:2861–2874, 2004.
227. Scorrano L, Oakes S, Opferman J, et al.: BAX and BAK regulation of endoplasmic reticulum Ca^{2+}: a control point for apoptosis, *Science* 300:135–139, 2003.
228. Distelhorst C, Shore G: Bcl-2 and calcium: controversy beneath the surface, *Oncogene* 23:2875–2880, 2004.
229. Droin N, Green D: Role of Bcl-2 family members in immunity and disease, *Biochim Biophys Acta* 1644:179–188, 2004.
230. Kirkin V, Jos S, Zornig M: The role of Bcl-2 family members in tumorigenesis, *Biochim Biophys Acta* 1644:229–249, 2004.
231. Kontos CK, Christodoulou MI, Scorilas A: Apoptosis-related BCL2-family members: key players in chemotherapy, *Anticancer Agents Med Chem* 14:353–374, 2013.
232. Thornberry N, Lazebnik Y: Caspases: enemies within, *Science* 281:1312–1326, 1998.
233. Hengartner M: The biochemistry of apoptosis, *Nature* 407:770–776, 2000.
234. Thornberry N, Rano T, Peterson E: A combinatorial approach defines specificities of members of the caspase family and granzyme B. Functional relationships established for key mediators of apoptosis, *J Biol Chem* 272:17907–17911, 1997.

235. Shalini S, Dorstyn L, Dawar S, Kumar S: Old, new and emerging functions of caspases, *Cell Death Differ* 22:526–539, 2015.
236. Salvesen G, Duckett C: IAP proteins: blocking death's door, *Nat Rev Mol Cell Biol* 3:401–410, 2002.
237. Silke J, Meier P: Inhibitor of apoptosis (IAP) proteins-modulators of cell death and inflammation, *Cold Spring Harb Perspect Biol* 5, 2013.
238. Igney F, Krammer P: Death and anti-death: tumour resistance to apoptosis, *Nat Rev Cancer* 2:277–288, 2002.
239. Reed J: Dysregulation of apoptosis in cancer, *J Clin Oncol* 17:2941–2953, 1999.
240. Silke J, Vucic D: IAP family of cell death and signaling regulators, *Methods Enzymol* 545:35–65, 2014.
241. Sasaki H, Sheng Y, Kotsuji F, Tsang B: Down-regulation of X-linked inhibitor of apoptosis protein induces apoptosis in chemoresistant human ovarian cancer cells, *Cancer Res* 60:5659–5666, 2000.
242. Schimmer A, Welsh K, Pinilla C, et al.: Small-molecule antagonists of apoptosis suppressor XIAP exhibit broad antitumor activity, *Cancer Cell* 5:25–35, 2004.
243. Yang L, Caao Z, Yan H, Wood W: Coexistence of high levels of apoptotic signaling and inhibitor of apoptosis proteins in human tumor cells: implication for cancer specific therapy, *Cancer Res* 6815–6824, 2003.
244. Shen HM, Tergaonkar V: NFkappaB signaling in carcinogenesis and as a potential molecular target for cancer therapy, *Apoptosis* 14:348–363, 2009.
245. Speidel D: The role of DNA damage responses in p53 biology, *Arch Toxicol* 89:501–517, 2015.
246. Haupt S, Haupt Y: Improving cancer therapy through p53 management, *Cell Cycle* 3:912–916, 2004.
247. Vogelstein B, Kinzler K: p53 function and dysfunction, *Cell* 70:523–526, 1992.
248. Slee E, O'Connor D, Lu X: To die or not to die: how does p53 decide? *Oncogene* 23:2809–2818, 2004.
249. Golubovskaya VM, Cance WG: Targeting the p53 Pathway, *Surg Oncol Clin N Am* 22:747–764, 2013.
250. Mrozek A, Petrowsky H, Sturm I, et al.: Combined p53/Bax mutation results in extremely poor prognosis in gastric carcinoma with low microsatellite instability, *Cell Death Differ* 10:461–467, 2003.
251. Soengas M, Alarcon R, Yoshida H: Apaf-1 and caspase-9 in p53-dependent apoptosis and tumor inhibition, *Science* 284:156–159, 1999.
252. Nag S, Qin J, Srivenugopal KS, Wang M, Zhang R: The MDM2-p53 pathway revisited, *J Biomed Res* 27:254–271, 2013.
253. Czarny P, Pawlowska E, Bialkowska-Warzecha J, et al.: Autophagy in DNA damage response, *Int J Mol Sci* 16:2641–2662, 2015.
254. Hayflick L: The limited in vitro life-time of human diploid cell strains, *Exp Cell Res* 37:614–636, 1965.
255. Salama R, Sadaie M, Hoare M, Narita M: Cellular senescence and its effector programs, *Genes Dev* 28:99–114, 2014.
256. Savage SA: Human telomeres and telomere biology disorders, *Prog Mol Biol Translat Sci* 125:41–66, 2014.
257. Stepanenko AA, Kavsan VM: Immortalization and malignant transformation of eukaryotic cells, *Tsitol Genet* 46:36–75, 2012.
258. Shay J, Zou Y, Hiyama E, Wright W: Telomerase and cancer, *Hum Mol Genet* 10:677–685, 2001.
259. Shay JW, Wright WE: Senescence and immortalization: role of telomeres and telomerase, *Carcinogen* 26:867–874, 2005.
260. Cheung AL, Deng W: Telomere dysfunction, genome instability and cancer, *Front Biosci* 13:2075–2090, 2008.
261. Mooi W, Peeper D: Oncogene-induced cell senescence—halting on the road to cancer, *N Engl J Med* 355:1037–1046, 2006.
262. Reddel RR: Telomere maintenance mechanisms in cancer: clinical implications, *Curr Pharm Des* 20:6361–6374, 2014.
263. Lleonart ME, Artero-Castro A, Kondoh H: Senescence induction; a possible cancer therapy, *Mol Cancer* 8:3, 2009.
264. Stewart S, Weinberg R: Telomerase and human tumorigenesis, *Semin Cancer Biol* 10:300–406, 2000.
265. Cristofalo V, Lorenzini A, Allen R: Replicative senescence: a critical review, *Mech Ageing Dev* 125:827–848, 2004.
266. Lundblad V: Genome instability: McClintock revisited, *Curr Biol* 11:R957–R960, 2001.
267. Raynaud CM, Sabatier L, Philipot O, et al.: Telomere length, telomeric proteins and genomic instability during the multistep carcinogenic process, *Crit Rev Oncol Hematol* 66:99–117, 2008.
268. Mathon N, Lloyd A: Cell senescence and cancer, *Nat Rev Cancer* 1:203–213, 2001.
269. Xu L, Li S, Stohr BA: The role of telomere biology in cancer, *Annu Rev Pathol* 8:49–78, 2013.
270. Kang HJ, Choi YS, Hong SB, et al.: Ectopic expression of the catalytic subunit of telomerase protects against brain injury resulting from ischemia and NMDA-induced neurotoxicity, *J Neurosci* 24:1280–1287, 2004.
271. Park JI, Venteicher AS, Hong JY, et al.: Telomerase modulates Wnt signalling by association with target gene chromatin, *Nature* 460:66–72, 2009.
272. Gocha AR, Harris J, Groden J: Alternative mechanisms of telomere lengthening: permissive mutations, DNA repair proteins and tumorigenic progression, *Mutat Res* 743-744:142–150, 2013.
273. Furuya M, Nishiyama M, Kasuya Y, Kimura S, Ishikura H: Pathophysiology of tumor neovascularization, *Vasc Health Risk Manag* 1:277–290, 2005.
274. Samples J, Willis M, Klauber-Demore N: Targeting angiogenesis and the tumor microenvironment, *Surg Oncol Clin North Am* 22:629–639, 2013.
275. Folkman J: Angiogenesis, *Annu Rev Med* 57:1–18, 2006.
276. Gimbrone MJ, Leapman S, Cotran R: Tumor dormancy in vivo by prevention of neovascularization, *J Exp Med* 136:261–276, 1972.
277. Bergers G, Benjamin L: Tumorigenesis and the angiogenic switch, *Nat Rev Cancer* 3:401–410, 2003.
278. Jung YD, Ahmad SA, Liu W, et al.: The role of the microenvironment and intercellular cross-talk in tumor angiogenesis, *Semin Cancer Biol* 12:105–112, 2002.
279. Folkman J, Kalluri R: Tumor angiogenesis. In Kufe D, Pollock R, Weichselbaum R, editors: *Cancer medicine*, Hamilton, ON, 2003, BC Decker, pp 161–194.
280. Maniotis A, Foldberg R, Hess A: Vascular channel formation by human melanoma cells in vivo and in vitro: vasculogenic mimicry, *Am J Pathol* 155:739–752, 1999.
281. Tlsty T: Stromal cell can contribute oncogenic signals, *Semin Cancer Biol* 11:97–104, 2001.
282. Presta M, Dell'Era P, Mitola S, et al.: Fibroblast growth factor/fibroblast growth factor receptor system in angiogenesis, *Cytokine Growth Fact Rev* 16:159–178, 2005.
283. Baeriswyl V, Christofori G: The antiogenic switch in carcinogenesis, *Semin Cancer Biol* 19:329–337, 2009.

284. Pradeep CR, Sunila ES, Kuttan G: Expression of vascular endothelial growth factor (VEGF) and VEGF receptors in tumor angiogenesis and malignancies, *Integ Cancer Ther* 4:315–321, 2005.
285. Claesson-Welsh L, Welsh M: VEGFA and tumour angiogenesis, *J Intern Med* 273:114–127, 2013.
286. Nyberg P, Salo T, Kalluri R: Tumor microenvironment and angiogenesis, *Front Biosci* 13:6537–6553, 2008.
287. Furuya M, Yonemitsu Y: Cancer neovascularization and proinflammatory microenvironments, *Curr Cancer Drug Targets* 8:253–265, 2008.
288. Chen W, Mao K, Liu Z, Dinh-Xuan AT: The role of the RhoA/Rho kinase pathway in angiogenesis and its potential value in prostate cancer (Review), *Oncol Lett* 8:1907–1911, 2014.
289. Keeley EC, Mehrad B, Strieter RM: Chemokines as mediators of tumor angiogenesis and neovascularization, *Exp Cell Res* 317:685–690, 2011.
290. Lawler PR, Lawler J: Molecular basis for the regulation of angiogenesis by thrombospondin-1 and -2, *Cold Spring Harb Perspect Med* 2:a006627, 2012.
291. Volpert OV, Zaichuk T, Zhou W, et al.: Inducer-stimulated Fas targets activated endothelium for destruction by anti-angiogenic thrombospondin-1 and pigment epithelium-derived factor, *Nat Med* 8:349–357, 2002.
292. Giuriato S, Ryeom S, Fan AC, et al.: Sustained regression of tumors upon MYC inactivation requires p53 or thrombospondin-1 to reverse the angiogenic switch, *Proc Natl Acad Sci USA* 103:16266–16271, 2006.
293. Nyberg P, Xie L, Kalluri R: Endogenous inhibitors of angiogenesis, *Cancer Res* 65:3967–3979, 2005.
294. Carmeliet P: Mechanisms of angiogenesis and arteriogenesis, *Nat Med* 6:389–396, 2000.
295. Kushner EJ, Bautch VL: Building blood vessels in development and disease, *Curr Opin Hematol* 20:231–236, 2013.
296. Ng Y-S, Krilleke D, Shima D: VEGF function in vascular pathogenesis, *Exp Cell Res* 312:527–537, 2006.
297. Djonov V, Andres A, Ziemiechi A: Vascular remodelling during the normal and malignant life cycle of the mammary gland, *Microsc Res Tech* 52:182–189, 2001.
298. Djonov V, Kurz H, Burri P: Optimality in the developing vascular system: branching remodeling by means of intussusception as an efficient adaptation mechanism, *Dev Dyn* 224:391–402, 2002.
299. Patan S, Munn L, Jain R: Intussesceptive microvascular growth in a human colon adenocarcinoma xenograft: a novel mechanism of tumor angiogenesis, *Microvasc Res* 51:260–272, 1996.
300. Moore M: Putting the neo into neoangiogenesis, *J Clin Invest* 109:313–315, 2002.
301. Rafii S: Circulating endothelial precursors: mystery, reality, and promise, *J Clin Invest* 105:17–19, 2000.
302. Holash J, Maisonpierre P, Compton D: Vessel cooption, regression, and growth in tumors mediated by angiopoietins and VEGF, *Science* 284:1994–1998, 1999.
303. Chang Y, di Tomaso E, McDonald D, Jones R, Jain R, Munn L: Mosaic blood vessels in tumors: frequency of cancer cells in contact with flowing blood, *Proc Natl Acad Sci USA* 97:14608–14613, 2000.
304. Folkman J: Can mosaic tumor vessels facilitate molecular diagnosis of cancer? *Proc Natl Acad Sci USA* 98:398–400, 2001.
305. Prause J, Jensen O: Scanning electron microscopy of frozen-cracked, dry-cracked and enzyme-digested tissue of human malignant choroidal melanomas, *Graefes Arch Klin Exp Ophthamol* 212:212–225, 1980.
306. Comoglio P, Trusolino L: Invasive growth: from development to metastasis, *J Clin Invest* 109:857–862, 2002.
307. Wittekend C, Neid M: Cancer invasion and metastasis, *Oncology* 69:14–16, 2005.
308. Chambers A, Groom A, MacDonald I: Dissemination and growth of cancer cells in metastatic sites, *Nat Rev Cancer* 2:563–572, 2002.
309. Talmadge JE, Fidler IJ: AACR centennial series: the biology of cancer metastasis: historical perspective, *Cancer Res* 70:5649–5669, 2010.
310. Li L, Li W: Epithelial-mesenchymal transition in human cancer: Comprehensive reprogramming of metabolism, epigenetics, and differentiation, *Pharmacol Ther* 150:33–46, 2015.
311. Klymkowsky MW, Savagner P: Epithelial-mesenchymal transition: a cancer researcher's conceptual friend and foe, *Am J Pathol* 174:1588–1593, 2009.
312. Polyak K, Weinberg RA: Transitions between epithelial and mesenchymal states: acquisition of malignant and stem cell traits, *Nat Rev Cancer* 9:265–273, 2009.
313. Berx G, van Roy F: Involvement of members of the cadherin superfamily in cancer, *Cold Spring Harb Perspect Biol* 1:a003129, 2009.
314. Cavallaro U, Christofori G: Cell adhesion and signalling by cadherins and Ig-CAMs in cancer, *Nat Rev Cancer* 4:839–849, 2004.
315. Kopfstein L, Christofori G: Metastasis: cell-autonomous mechanisms versus contributions by the tumor microenvironment, *Cell Mol Life Sci* 63:449–468, 2006.
316. Perl A, Wilgenbus P, Dahl U, Semb H, Christofori G: A causal role for E-cadherin in the transition from adenoma to carcinoma, *Nature* 392:190–193, 1998.
317. Mani SA, Guo W, Liao MJ, et al.: The epithelial-mesenchymal transition generates cells with properties of stem cells, *Cell* 133:704–715, 2008.
318. Gonzalez DM, Medici D: Signaling mechanisms of the epithelial-mesenchymal transition, *Sci Signal* 7, 2014. re8.
319. Micalizzi DS, Farabaugh SM, Ford HL: Epithelial-mesenchymal transition in cancer: parallels between normal development and tumor progression, *J Mammary Gland Biol Neoplasia* 15:117–134, 2010.
320. Schmalhofer O, Brabletz S, Brabletz T: E-cadherin, beta-catenin, and ZEB1 in malignant progression of cancer, *Cancer Metastasis Rev* 28:151–166, 2009.
321. Taube JH, Herschkowitz JI, Komurov K, et al.: Core epithelial-to-mesenchymal transition interactome gene-expression signature is associated with claudin-low and metaplastic breast cancer subtypes, *Proc Natl Acad Sci USA* 107:15449–15454, 2010.
322. Yang J, Mani SA, Weinberg RA: Exploring a new twist on tumor metastasis, *Cancer Res* 66:4549–4552, 2006.
323. Thiery JP, Acloque H, Huang RY, Nieto MA: Epithelial-mesenchymal transitions in development and disease, *Cell* 139:871–890, 2009.
324. Mizuno S, Nakamura T: HGF-MET cascade, a key target for inhibiting cancer metastasis: the impact of NK4 discovery on cancer biology and therapeutics, *Int J Mol Sci* 14:888–919, 2013.
325. Wu Y, Antony S, Meitzler JL, Doroshow JH: Molecular mechanisms underlying chronic inflammation-associated cancers, *Cancer Lett* 345:164–173, 2013.
326. Alan JK, Lundquist EA: Mutationally activated Rho GTPases in cancer, *Small GTPases* 4:159–163, 2013.
327. Amin E, Dubey BN, Zhang SC, et al.: Rho-kinase: regulation, (dys)function, and inhibition, *Biol Chem* 394:1399–1410, 2013.

328. Klemke RL: Trespassing cancer cells: "fingerprinting" invasive protrusions reveals metastatic culprits, *Curr Opin Cell Biol* 24:662–669, 2012.
329. Yilmaz M, Christofori G: Mechanisms of motility in metastasizing cells, *Mol Cancer Res* 8:629–642, 2010.
330. Willis AL, Sabeh F, Li XY, Weiss SJ: Extracellular matrix determinants and the regulation of cancer cell invasion stratagems, *J Microsc* 251:250–260, 2013.
331. Lindsey S, Langhans SA: Crosstalk of oncogenic signaling pathways during epithelial-mesenchymal transition, *Front Oncol* 4:358, 2014.
332. Guo W, Giancotti F: Integrin signalling during tumor progression, *Nat Rev Mol Cell Biol* 5:816–826, 2004.
333. Hood J, Cheresh D: Role of integrins in cell invasion and migration, *Nat Rev Cancer* 2:91–100, 2002.
334. Hynes R: Integrins: bidirectional, allosteric signalling machines, *Cell* 110:673–687, 2002.
335. Ganguly KK, Pal S, Moulik S, Chatterjee A: Integrins and metastasis, *Cell Adhes Migrat* 7:251–261, 2013.
336. Gingras M, Roussel E, Bruner J, Branch C, Moser R: Comparison of cell adhesion molecule expression between glioblastoma multiforme and autologous normal brain tissue, *J Neuroimmunol* 57:143–153, 1995.
337. Natali P, Hamby C, Felding-Habermann B, Liang B, Nicotra M, DiFilippo F: Clinical significance of alpha(v)beta3 integrin and intercellular adhesion molecule-1 expression in cutaneous malignant melanoma lesions, *Cancer Res* 57:1554–1560, 1997.
338. Rolli M, Fransvea E, Pilch J, Saven A, Felding-Habermann B: Activated integrin alphabeta3 cooperates with metalloproteinase MMP-9 in regulating migration of metastatic breast cancer cells, *Proc Natl Acad Sci USA* 100:9482–9947, 2003.
339. Yue J, Zhang K, Chen J: Role of integrins in regulating proteases to mediate extracellular matrix remodeling, *Cancer Microenviron* 5:275–283, 2012.
340. Stivarou T, Patsavoudi E: Extracellular molecules involved in cancer cell invasion, *Cancers* 7:238–265, 2015.
341. Carmeliet P, Jain R: Angiogenesis in cancer and other diseases, *Nature* 407:249–257, 2000.
342. De Wever O, Mareel M: Role of tissue stroma in cancer cell invasion, *J Pathol* 200:429–447, 2003.
343. Orimo A, PB G, Sgroi D, Arenzana-Seisdendos F, Delaunay T, Naeem R: Stromal fibroblasts present in invasive human breast carcinomas promote tumor growth and angiogenesis through elevated SDF-1/CXCL12 secretion, *Cell* 121:335–348, 2005.
344. Walsh DA: Pathophysiological mechanisms of angiogenesis, *Adv Clin Chem* 44:187–221, 2007.
345. Byun JS, Gardner K: Wounds that will not heal: pervasive cellular reprogramming in cancer, *Am J Pathol* 182:1055–1064, 2013.
346. Ellenbaas B, Weinberg R: Heterotypic signaling between epithelial tumor cells and fibroblasts in carcinoma formation, *Exp Cell Res* 264:169–184, 2001.
347. Coussens L, Werb Z: Inflammation and cancer, *Nature* 420:860–867, 2002.
348. Jinushi M, Komohara Y: Tumor-associated macrophages as an emerging target against tumors: creating a new path from bench to bedside, *Biochim Biophys Acta* 1855:123–130, 2015.
349. Eljaszewicz A, Wiese M, Helmin-Basa A, et al.: Collaborating with the enemy: function of macrophages in the development of neoplastic disease, *Med Inflam* 2013:831387, 2013.
350. Balkwill F: Tumor necrosis factor or tumor promoting factor? *Cytokine Growth Factor Rev* 13:135–141, 2002.
351. Gabrilovich D, Chen H, Girgis K, Cunningham H, Meny G, Nadaf S: Production of vascular endothelial growth factor by human tumors inhibits the functional maturation of dendritic cells, *Nat Med* 2:1096–1103, 1996.
352. Cursiefen C, Chen L, Borges L, Jackson D, Cao J, Radziejewski C: VEGF-A stimulates lymphangiogenesis and humangiogenesis in inflammatory neovascularization via macrophage recruitment, *J Clin Invest* 113:1040–1050, 2004.
353. Maruyama K, Ii M, Cursiefen C, Jackson D, Keino H, Tomita M: Inflammation-induced lymphangiogenesis in the cornea arises from CD11b-positive macrophages, *J Clin Invest* 115:2363–2372, 2005.
354. Owen JL, Mohamadzadeh M: Macrophages and chemokines as mediators of angiogenesis, *Front Physiol* 4:159, 2013.
355. Schoppmann S, Birner P, Stockl J, Kalt R, Ullrich R, Caucig C: Tumor-associated macrophages express lymphatic endothelial growth factors and are related to peritumoral lymphangiogenesis, *Am J Pathol* 161:947–956, 2002.
356. Hao NB, Lu MH, Fan YH, Cao YL, Zhang ZR, Yang SM: Macrophages in tumor microenvironments and the progression of tumors, *Clin Dev Immunol* 2012:948098, 2012.
357. Viola A, Sarukhan A, Bronte V, Molon B: The pros and cons of chemokines in tumor immunology, *Trend Immunol* 33:496–504, 2012.
358. Creighton CJ, Gibbons DL, Kurie JM: The role of epithelial-mesenchymal transition programming in invasion and metastasis: a clinical perspective, *Cancer Manage Res* 5:187–195, 2013.
359. Perrot CY, Javelaud D, Mauviel A: Insights into the transforming *growth fact*or-beta signaling pathway in cutaneous melanoma, *Ann Dermatol* 25:135–144, 2013.
360. Garcia-Roman J, Zentella-Dehesa A: Vascular permeability changes involved in tumor metastasis, *Cancer Lett* 335:259–269, 2013.
361. Friedl P, Wolf K: Tube travel: the role of proteases in individual and collective cancer cell invasion, *Cancer Res* 68:7247–7249, 2008.
362. Friedl P, Wolf K: Plasticity of cell migration: a multiscale tuning model, *J Cell Biol* 188:11–19, 2010.
363. Madsen CD, Sahai E: Cancer dissemination—lessons from leukocytes, *Dev Cell* 19:13–26, 2010.
364. Franco-Chuaire ML, Magda Carolina SC, Chuaire-Noack L: Epithelial-mesenchymal transition (EMT): principles and clinical impact in cancer therapy, *Invest Clin* 54:186–205, 2013.
365. Ahmad A, Hart IR: Biology of tumor micrometastasis, *J Hematother* 5:525–535, 1996.
366. Yang J, Lam DH, Goh SS, et al.: Tumor tropism of intravenously injected human-induced pluripotent stem cell-derived neural stem cells and their gene therapy application in a metastatic breast cancer model, *Stem Cells* 30:1021–1029, 2012.
367. Purushotham AD, Sullivan R: Darwin, medicine and cancer, *Ann Oncol* 21:199–203, 2010.
368. Weinberg R: *The biology of cancer*, New York, 2006, Garland Science.
369. Dietel M, Sers C: Personalized medicine and development of targeted therapies: The upcoming challenge for diagnostic molecular pathology. A review, *Virchows Arch* 448:744–755, 2006.
370. Duffy MJ, Crown J: Companion biomarkers: paving the pathway to personalized treatment for cancer, *Clin Chem* 59:1447–1456, 2013.
371. Diamandis M, White NM, Yousef GM: Personalized medicine: marking a new epoch in cancer patient management, *Mol Cancer Res* 8:1175–1187, 2010.

372. Cortes J, Calvo E, Vivancos A, Perez-Garcia J, Recio JA, Seoane J: New approach to cancer therapy based on a molecularly defined cancer classification, *Cancer* 64:70–74, 2014.
373. Dietel M, Johrens K, Laffert M, et al.: Predictive molecular pathology and its role in targeted cancer therapy: a review focussing on clinical relevance, *Cancer Gene Ther* 20:211–221, 2013.
374. Moschos SA: Genomic biomarkers for patient selection and stratification: the cancer paradigm, *Bioanalysis* 4:2499–2511, 2012.
375. Sidranski D: Emerging molecular markers of cancer, *Nat Rev Cancer* 2:210–219, 2002.
376. Yoshizawa JM, Schafer CA, Schafer JJ, et al.: Salivary biomarkers: toward future clinical and diagnostic utilities, *Clin Microbiol Rev* 26:781–791, 2013.
377. Ebert M, Corc M, Malfertheiner P, Rocken C: Advances, challenges, and limitations in serum-proteome-based cancer diagnosis, *J Proteome Res* 5:19–25, 2006.
378. Taube S, Jacobson J, TG L: Cancer diagnostics: decision criteria for marker utilization in the clinic, *Am J Pharmacogenomics* 5:357–364, 2005.
379. Tefferi A, Dewald G, Litzow M, et al.: Chronic myeloid leukemia: current application of cytogenetics and molecular testing for diagnosis and treatment, *Mayo Clin Proc* 80:390–402, 2005.
380. Schwab M, Amler L: Amplification of cellular oncogenes: a predictor of clinical outcome in human cancer, *Genes Chromosomes Cancer* 1:181–193, 1990.
381. Sudbo J, Kildal W, Risberg B, Koppang H, Danielsen H, Reith A: DNA content as a prognostic marker in patients with oral leukoplakia, *N Engl J Med* 344:1270–1278, 2001.
382. Sherr C, McCormick F: The RB and p53 pathways in cancer, *Cancer Cell* 2:103–112, 2002.
383. Jones P, Baylin S: The fundamental role of epigenetic change in cancer, *Nat Rev Cancer* 3:415–428, 2002.
384. Santos C, Martinez M, Lima M, Hao YJ, Simoes N, Montiel R: Mitochondrial DNA mutations in cancer: a review, *Curr Top Med Chem* 8:1351–1366, 2008.
385. Han BL, Xu XY, Zhang CZ, et al.: Systematic review on Epstein-Barr virus (EBV) DNA in diagnosis of nasopharyngeal carcinoma in Asian populations. Asian Pac, *J Cancer Prevent* 13:2577–2581, 2012.
386. Watson IR, Takahashi K, Futreal PA, Chin L: Emerging patterns of somatic mutations in cancer, *Nat Rev Genet* 14:703–718, 2013.
387. Idris SF, Ahmad SS, Scott MA, Vassiliou GS, Hadfield J: The role of high-throughput technologies in clinical cancer genomics, *Expert Rev Mol Diagn* 13:167–181, 2013.
388. Dutton-Regester K, Hayward NK: Whole genome and exome sequencing of melanoma: a step toward personalized targeted therapy, *Adv Pharmacol* 65:399–435, 2012.
389. Inaki K, Liu ET: Structural mutations in cancer: mechanistic and functional insights, *Trends Genet* 28:550–559, 2012.
390. Dutton-Regester K, Hayward NK: Reviewing the somatic genetics of melanoma: from current to future analytical approaches, *Pig Cell Melanoma Res* 25:144–154, 2012.
391. Gonzalez-Angulo AM, Hennessy BT, Mills GB: Future of personalized medicine in oncology: a systems biology approach, *J Clin Oncol* 28:2777–2783, 2010.
392. Tang J, Xiong Y, Zhou HH, Chen XP: DNA methylation and personalized medicine, *J Clin Pharm Ther* 39:621–627, 2014.
393. Pasic MD, Samaan S, Yousef GM: Genomic medicine: new frontiers and new challenges, *Clin Chem* 59:158–167, 2013.
394. Li X, Quigg RJ, Zhou J, Gu W, Nagesh Rao P, Reed EF: Clinical utility of microarrays: current status, existing challenges and future outlook, *Curr Genomics* 9:466–474, 2008.
395. Golub T, Slonim D, Tamayo P, et al.: Molecular classification of cancer: class discovery and class prediction by gene expression monitoring, *Science* 286:531–537, 1999.
396. Buckhaults P: Gene expression determinants of clinical outcome, *Curr Opin Oncol* 18:57–61, 2006.
397. Kwong K, Bloom G, Yang I, et al.: Synchronous global assessment of gene and protein expression in colorectal cancer progression, *Genomics* 86:142–158, 2005.
398. Roukos DH, Murray S, Briasoulis E: Molecular genetic tools shape a roadmap towards a more accurate prognostic prediction and personalized management of cancer, *Cancer Biol Ther* 6:308–312, 2007.
399. Paik S, Shak S, Tang G, et al.: A multigene assay to predict recurrence of tamoxifen-treated, node-negative breast cancer, *N Engl J Med* 351:2817–2826, 2004.
400. van de Vijver M, He Y, van't Veer L, et al.: A gene-expression signature as a predictor of survival in breast cancer, *N Engl J Med* 415:530–536, 2002.
401. Eroles P, Bosch A, Perez-Fidalgo JA, Lluch A: Molecular biology in breast cancer: intrinsic subtypes and signaling pathways, *Cancer Treat Rev* 38:698–707, 2012.
402. Markopoulos C: Overview of the use of Oncotype DX as an additional treatment decision tool in early breast cancer, *Expert Rev Anticancer Ther* 13:179–194, 2013.
403. Ramaswamy S, Golub T: DNA microarrays in clinical oncology, *J Clin Oncol* 20:1932–1941, 2002.
404. Pusztai L, Mazouni C, Anderson K, Wu Y, Symmans W: Molecular classification of breast cancer: limitations and potential, *Oncologist* 11:868–877, 2006.
405. Rhodes A: Quality assurance in immunohistochemistry, *Am J Pathol* 27:1284–1285, 2003.
406. Bratt O, Lilja H: Serum markers in prostate cancer detection, *Curr Opin Urol* 25:59–64, 2015.
407. Ellis MJ, Gillette M, Carr SA, et al.: Connecting genomic alterations to cancer biology with proteomics: the NCI clinical proteomic tumor analysis consortium, *Cancer Disc* 3:1108–1112, 2013.
408. Gallagher RI, Espina V: Reverse phase protein arrays: mapping the path towards personalized medicine, *Mol Diagn Ther* 18:619–630, 2014.
409. Masuda M, Yamada T: Signaling pathway profiling by reverse-phase protein array for personalized cancer medicine, *Biochim Biophys Acta*, pii: S1570–9639(14) 00274, 2014.
410. Cutillas PR: Role of phosphoproteomics in the development of personalized cancer therapies, *Proteomics Clin Appl* 9:383–395, 2015.
411. de Wit M, Fijneman RJ, Verheul HM, Meijer GA, Jimenez CR: Proteomics in colorectal cancer translational research: biomarker discovery for clinical applications, *Clin Biochem* 46:466–479, 2013.
412. Makridakis M, Vlahou A: Secretome proteomics for discovery of cancer biomarkers, *J Proteomics* 73:2291–2305, 2010.
413. Pavlou MP, Diamandis EP: The cancer cell secretome: a good source for discovering biomarkers? *J Proteomics* 73:1896–1906, 2010.
414. Murahari MS, Yergeri MC: Identification and usage of fluorescent probes as nanoparticle contrast agents in detecting cancer, *Curr Pharm Des* 19:4622–4640, 2013.

415. Clark AS, McDonald E, Lynch MC, Mankoff D: Using nuclear medicine imaging in clinical practice: update on PET to guide treatment of patients with metastatic breast cancer, *Oncology* 28:424–430, 2014.
416. Avram AM: Radioiodine scintigraphy with SPECT/CT: an important diagnostic tool for thyroid cancer staging and risk stratification, *J Nucl Med* 53:754–764, 2012.
417. Catenacci DV: Next-generation clinical trials: novel strategies to address the challenge of tumor molecular heterogeneity, *Mol Oncol* 9:967–996, 2015.
418. Samuel N, Hudson TJ: Translating genomics to the clinic: implications of cancer heterogeneity, *Clin Chem* 59:127–137, 2013.
419. Stevens EA, Rodriguez CP: Genomic medicine and targeted therapy for solid tumors, *J Surg Oncol* 111:38–42, 2015.
420. Chabner B, Roberts TJ: Chemotherapy and the war on cancer, *Nat Rev Cancer* 5:65–72, 2005.
421. Sawyers C: Targeted cancer therapy, *Nature* 432:204–207, 2004.
422. Ortiz R, Melguizo C, Prados J, et al.: New gene therapy strategies for cancer treatment: a review of recent patents, *Recent Pat Anticancer Drug Discov* 7:297–312, 2012.
423. Thomas F, Desmedt C, Aftimos P, Awada A: Impact of tumor sequencing on the use of anticancer drugs, *Curr Opinion Oncol* 26:347–356, 2014.
424. Liu S: Epigenetics advancing personalized nanomedicine in cancer therapy, *Adv Drug Del Rev* 64:1532–1543, 2012.
425. Kelley MR, Fishel ML: DNA repair proteins as molecular targets for cancer therapeutics, *Anticancer Agents Med Chem* 8:417–425, 2008.
426. Mohit E, Rafati S: Biological delivery approaches for gene therapy: strategies to potentiate efficacy and enhance specificity, *Mol Immunol* 56:599–611, 2013.
427. Bolhassani A, Javanzad S, Saleh T, et al.: Polymeric nanoparticles: potent vectors for vaccine delivery targeting cancer and infectious diseases, *Hum Vaccine Immunother* 10:321–332, 2014.
428. Roth J: Adenovirus p53 gene therapy, *Expert Opin Biol Ther* 6:55–61, 2006.
429. Tazawa H, Kagawa S, Fujiwara T: Advances in adenovirus-mediated p53 cancer gene therapy, *Expert Opin Biol Ther* 13:1569–1583, 2013.
430. Burns T, El-Diery W: The p53 pathway and apoptosis, *J Cell Physiol* 181:231–239, 1999.
431. Fujiwara T, Cai D, Georges R, et al.: Therapeutic effect of a retroviral wild-type p53 expression vector in an orthotopic lung cancer model, *J Natl Cancer Inst* 86:1437–1438, 1994.
432. Zhang W, Fang X, Mazur W, French B, Georges R, Roth J: High-efficiency gene transfer and high-level expression of wild-type p53 in human lung cancer cells mediated by recombinant adenovirus, *Cancer Gene Ther* 1:5–13, 1994.
433. Giaccia AJ: Molecular radiobiology: the state of the art, *J Clin Oncol* 32:2871–2878, 2014.
434. Farooqi AA, Rehman ZU, Muntane J: Antisense therapeutics in oncology: current status, *Onco Targets Ther* 7:2035–2042, 2014.
435. Li Z, Rana TM: Therapeutic targeting of microRNAs: current status and future challenges, *Nat Rev Drug Disc* 13:622–638, 2014.
436. Morris K: Therapeutic potential of siRNA-mediated transcriptional gene silencing, *Biotechniques*(Suppl)7–13, 2006.
437. Gallinari P, Di Marco S, Jones P, et al.: HDACs, histone deacetylation and gene transcription: from molecular biology to cancer therapeutics, *Cell Res* 17:195–211, 2007.
438. Bernards R: Exploring the uses of RNAi—gene knockdown and the Nobel prize, *N Engl J Med* 355:2391–2394, 2006.
439. Mocellin S, Costa R, Nitti D: RNA interference: ready to silence cancer? *J Mol Med* 84:4–15, 2006.
440. Adams J, Cory S: The Bcl-2 protein family: arbiters of cell survival, *Science* 249:1322–1326, 1998.
441. Thorsen SB, Obad S, Jensen NF, Stenvang J, Kauppinen S: The therapeutic potential of microRNAs in cancer, *Cancer J* 18:275–284, 2012.
442. Cioca D, Aoki Y, Kiyosawa K: RNA interference is a functional pathway with therapeutic potential in human myeloid leukemia cell lines, *Cancer Gene Ther* 10:125–133, 2003.
443. Aparicio A, Weber J: Review of the clinical experience with 5-azacytidine and 5-aza-2′-deoxycitidine in solid tumors, *Curr Opin Investig Drugs* 3:627–633, 2002.
444. Luebbert M: DNA methylation inhibitors in the treatment of leukemias, myelodysplastic syndromes and hemoglobinopathies: clinical results and possible mechanisms of action, *Curr Top Microbiol Immunol* 249:135–164, 2000.
445. van de Watering FC, Rijpkema M, Robillard M, et al.: Pretargeted imaging and radioimmunotherapy of cancer using antibodies and bioorthogonal chemistry, *Front Med* 1:44, 2014.
446. Sliwkowski MX, Mellman I: Antibody therapeutics in cancer, *Science* 341:1192–1198, 2013.
447. Dorer DE, Nettelbeck DM: Targeting cancer by transcriptional control in cancer gene therapy and viral oncolysis, *Adv Drug Deliv Rev* 61:554–571, 2009.
448. Tsai CJ, Nussinov R: The molecular basis of targeting protein kinases in cancer therapeutics, *Semin Cancer Biol* 23:235–242, 2013.
449. Libermann TA, Zerbini LF: Targeting transcription factors for cancer gene therapy, *Curr Gene Ther* 6:17–33, 2006.
450. Zhang Z, Li M, Rayburn ER, Hill DL, Zhang R, Wang H: Oncogenes as novel targets for cancer therapy (part II): intermediate signaling molecules, *Am J Pharmacogenomics* 5:247–257, 2005.
451. Harris M: Monoclonal antibodies as therapeutic agents for cancer, *Lancet Oncol* 5:293–302, 2004.
452. Allen T: Ligand-targeted therapeutics in anticancer therapy, *Nat Rev Cancer* 2:750–763, 2002.
453. Zangemeister-Wittke U: Antibodies for targeted cancer therapy-technical aspects and clinical perspectives, *Pathobiology* 72:279–286, 2005.
454. Alewine C, Hassan R, Pastan I: Advances in anticancer immunotoxin therapy, *Oncologist* 20:176–185, 2015.
455. Sharkey R, Goldenberg D: Targeted therapy of cancer: new prospectives for antibodies and immunoconjugates, *CA Cancer J Clin* 56:226–243, 2006.
456. Pereira PM, Korsak B, Sarmento B, et al.: Antibodies armed with photosensitizers: from chemical synthesis to photobiological applications, *Org Biomol Chem* 13:2518–2529, 2015.
457. Weber JS: Current perspectives on immunotherapy, *Semin Oncol* 41(Suppl 5):S14–S29, 2014.
458. Jain R: Transport of molecules, particles, and cells in solid tumors, *Annu Rev Biomed Eng* 1:241–263, 1999.
459. Presta L: Engineering antibodies for therapy, *Curr Pharm Biotechnol* 3:237–256, 2002.
460. Yang J, Kopecek J: Macromolecular therapeutics, *J Control Release* 190:288–303, 2014.
461. Gibbs J: Mechanism-based target identification and drug discovery in cancer research, *Science* 287:1969–1973, 2000.

462. Brunner R, Hahn S, Gupta A: Farnesyltransferase inhibitors: an overview of the results of preclinical and clinical investigations, *Cancer Res* 63:5656–5658, 2003.
463. Downward J: Targeting Ras signalling pathways in cancer therapy, *Nat Rev Cancer* 3:11–22, 2003.
464. Salesse S, Verfaillie C: Bcr/Abl: from molecular mechanisms of leukemia induction to treatment of chronic myelogenous leukemia, *Oncogene* 21:8547–8559, 2002.
465. Sawyers C: Opportunities and challenges in the development of kinase inhibitor therapy for cancer, *Genes Dev* 17:2998–3010, 2003.
466. Shawver L, Slamon D, Ullrich R: Smart drugs: tyrosine kinase inhibitors in cancer therapy, *Cancer Cell* 1:117–123, 2002.
467. Zwick E, Bange J, Ullrich R: Receptor tyrosine kinases as targets for anticancer drugs, *Trends Mol Med* 8:16–23, 2002.
468. Lin R, Zhou X, Huang W, et al.: Acetylation control of cancer cell metabolism, *Curr Pharm Des* 20:2627–2633, 2014.
469. Nam SO, Yotsumoto F, Miyata K, et al.: Possible therapeutic targets among the molecules involved in the Warburg effect in tumor cells, *Anticancer Res* 33:2855–2860, 2013.
470. Ocana A, Pandiella A: Personalized therapies in the cancer "omics" era, *Mol Cancer* 9:202, 2010.
471. De Palma M, Hanahan D: The biology of personalized cancer medicine: facing individual complexities underlying hallmark capabilities, *Mol Oncol* 6:111–127, 2012.
472. Du W, Elemento O: Cancer systems biology: embracing complexity to develop better anticancer therapeutic strategies, *Oncogene* 34:3215–3225, 2015.
473. Dhomen NS, Mariadason J, Tebbutt N, Scott AM: Therapeutic targeting of the epidermal growth factor receptor in human cancer, *Crit Rev Oncol* 17:31–50, 2012.
474. Vecchione L, Jacobs B, Normanno N, Ciardiello F, Tejpar S: EGFR-targeted therapy, *Exp Cell Res* 317:2765–2771, 2011.
475. Villalobo A, Garcia-Palmero I, Stateva SR, Jellali K: Targeting the calmodulin-regulated ErbB/Grb7 signaling axis in cancer therapy, *J Pharm Pharmaceut Sci* 16:177–189, 2013.
476. Asghar U, Witkiewicz AK, Turner NC, Knudsen ES: The history and future of targeting cyclin-dependent kinases in cancer therapy, *Nat Rev Drug Disc* 14:130–146, 2015.
477. Wesierska-Gadek J, Maurer M, Zulehner N, Komina O: Whether to target single or multiple CDKs for therapy? That is the question, *J Cell Physiol* 226:341–349, 2011.
478. Diaz-Moralli S, Tarrado-Castellarnau M, Miranda A, Cascante M: Targeting cell cycle regulation in cancer therapy, *Pharmacol Ther* 138:255–271, 2013.
479. Itoh Y, Suzuki T, Miyata N: Small-molecular modulators of cancer-associated epigenetic mechanisms, *Mol Biosyst* 9:873–896, 2013.
480. Schwartz G, Shah M: Targeting the cell cycle: a new approach to cancer therapy, *J Clin Oncol* 23:9408–9421, 2005.
481. Senderowicz A: Cyclin-dependent kinases as targets for cancer therapy. In Giaccone G, Schilsky R, Sondel P, editors: *Cancer chemotherapy and biological response modifiers*, New York, 2002, Elsevier Science, pp 169–188.
482. Wang LM, Ren DM: Flavopiridol, the first cyclin-dependent kinase inhibitor: recent advances in combination chemotherapy, *Mini Rev Med Chem* 10:1058–1070, 2010.
483. Bruyere C, Meijer L: Targeting cyclin-dependent kinases in anti-neoplastic therapy, *Curr Opin Cell Biol* 25:772–779, 2013.
484. Blachly JS, Byrd JC: Emerging drug profile: cyclin-dependent kinase inhibitors, *Leuk Lymphoma* 54:2133–2143, 2013.
485. Esposito L, Indovina P, Magnotti F, Conti D, Giordano A: Anticancer therapeutic strategies based on CDK inhibitors, *Curr Pharm Des* 19:5327–5332, 2013.
486. Shah M, Schwartz G: Cell cycle mediated drug resistance: An emerging concept in cancer therapy, *Clin Cancer Res* 7:2168–2181, 2001.
487. Motwani M, Delohery T, Schwartz G: Sequential dependent enhancement of caspase activation and apoptosis by flavopiridol on paclitaxel-treated human gastric and breast cancer cells, *Clin Cancer Res* 5:1876–1883, 1999.
488. Burz C, Berindan-Neagoe I, Balacescu O, Irimie A: Apoptosis in cancer: key molecular signaling pathways and therapy targets, *Acta Oncol* 48:811–821, 2009.
489. Jia LT, Chen SY, Yang AG: Cancer gene therapy targeting cellular apoptosis machinery, *Cancer Treat Rev* 38:868–876, 2012.
490. Melet A, Song K, Bucur O, Jagani Z, Grassian AR, Khosravi-Far R: Apoptotic pathways in tumor progression and therapy, *Adv Exp Med Biol* 615:47–79, 2008.
491. Koff JL, Ramachandiran S, Bernal-Mizrachi L: A time to kill: targeting apoptosis in cancer, *Int J Mol Sci* 16:2942–2955, 2015.
492. Lopez-Beltran A, Maclennan GT, de la Haba-Rodriguez J, Montironi R, Cheng L: Research advances in apoptosis-mediated cancer therapy: a review. Analytical and quantitative cytology and histology, *Int Acad Cytol* 29:71–78, 2007.
493. Brown J, Attardi L: The role of apoptosis in cancer development and treatment response, *Nat Rev Cancer* 5:231–237, 2005.
494. Altznauer F, Martinelli S, Yousefi S, et al.: Inflammation-associated cell cycle-independent block of apoptosis by survivin in terminally differentiated neutrophils, *J Exp Med* 199:1343–1354, 2004.
495. Dibbert B, Weber M, Nikolaizik W, et al.: Cytokine-mediated Bax deficiency and consequent delayed neutrophil apoptosis: a general mechanism to accumulate effector cells in inflammation, *Proc Natl Acad Sci USA* 96:13330–13335, 1999.
496. Prasad S, Kim JH, Gupta SC, Aggarwal BB: Targeting death receptors for TRAIL by agents designed by Mother, *Nature. Trends Pharm Sci* 35:520–536, 2014.
497. Bellail AC, Qi L, Mulligan P, Chhabra V, Hao C: TRAIL agonists on clinical trials for cancer therapy: the promises and the challenges, *Rev Recent Clin Trials* 4:34–41, 2009.
498. Elrod HA, Sun SY: Modulation of death receptors by cancer therapeutic agents, *Cancer Biol Ther* 7:163–173, 2008.
499. Zawacka-Pankau J, Selivanova G: Pharmacological reactivation of p53 as a strategy to treat cancer, *J Intern Med* 277:248–259, 2015.
500. Hall P, McCluggage W: Assessing p53 in clinical contexts: unlearned lessons and new perspectives, *J Pathol* 208:1–6, 2006.
501. Hasty P, Christy BA: p53 as an intervention target for cancer and aging, *Pathobiol Aging Age Rel Dis* 3, 2013 http://dx.doi.org/10.3402/pba.v3i0.22702.
502. Bykov V, Issaeva N, Shilov A, et al.: Restoration of the tumor suppressor function to mutant p53 by a low-molecular-weight compound, *Nat Med* 8:282–288, 2002.
503. Vassilev L, Vu B, Graves B, et al.: In vivo activation of the p53 pathway by small-molecule antagonists of MDM2, *Science* 303:844–848, 2004.
504. Wade M, Li YC, Wahl GM: MDM2, MDMX and p53 in oncogenesis and cancer therapy, *Nat Rev Cancer* 13:83–96, 2013.
505. Billard C: BH3 mimetics: status of the field and new developments, *Mol Cancer Ther* 12:1691–1700, 2013.
506. Dimri G: What has senescence got to do with cancer? *Cancer Cell* 7:505–512, 2005.
507. Kawamata H, Tachibana M, Fujimori T, Imai Y: Differentiation-inducing therapy for solid tumors, *Curr Pharm Des* 11:379–385, 2005.

508. Uhr J, Scheuermann R, Street N, Vitetta E: Cancer dormancy: opportunities for new therapeutic approaches, *Nat Med* 3:505–509, 1997.
509. Acosta JC, Gil J: Senescence: a new weapon for cancer therapy, *Trends Cell Biol* 22:211–219, 2012.
510. Vargas J, Feltes BC, Poloni Jde F, Lenz G, Bonatto D: Senescence; an endogenous anticancer mechanism, *Front Biosci* 17:2616–2643, 2012.
511. Gomez DL, Farina HG, Gomez DE: Telomerase regulation: A key to inhibition? (Review), *Int J Oncol* 43:1351–1356, 2013.
512. Roh JI, Sung YH, Lee HW: Clinical implications of antitelomeric drugs with respect to the nontelomeric functions of telomerase in cancer, *Onco Targets Ther* 6:1161–1166, 2013.
513. Agrawal A, Dang S, Gabrani R: Recent patents on anti-telomerase cancer therapy, *Recent Pat Anticancer Drug Discov* 7:102–117, 2012.
514. Mizushina Y, Takeuchi T, Sugawara F, Yoshida H: Anti-cancer targeting telomerase inhibitors: beta-rubromycin and oleic acid, *Mini Rev Med Chem* 12:1135–1143, 2012.
515. Roth A, Harley CB, Baerlocher GM: Imetelstat (GRN163L)—telomerase-based cancer therapy, *Rec Results Cancer Res* 184:221–234, 2010.
516. Ruden M, Puri N: Novel anticancer therapeutics targeting telomerase, *Cancer Treat Rev* 39:444–456, 2013.
517. Chen H, Li Y, Tollefsbol TO: Strategies targeting telomerase inhibition, *Mol Biotechnol* 41:194–199, 2009.
518. Cmielova J, Rezacova M: p21Cip1/Waf1 protein and its function based on a subcellular localization, *J Cell Biochem* 112:3502–3506, 2011.
519. Roninson IB: Tumor cell senescence in cancer treatment, *Cancer Res* 63:2705–2715, 2003.
520. Seimiya H, Oh-hara T, Suzuki T, et al.: Telomere shortening and growth of human cancer cells by novel synthetic telomerase inhibitors, MST-312, MST-295, and MST-199, *Mol Cancer Ther* 1:657–665, 2002.
521. Wang Z, Dabrosin C, Yin X, et al.: Broad targeting of angiogenesis for cancer prevention and therapy, *Semin Cancer Biol* 35(suppl):S224–S243, 2015.
522. Carmeliet P: Angiogenesis in life, disease and medicine, *Nature* 438:932–936, 2005.
523. Jain R: Normalization of tumor vasculature: an emerging concept in antiantiogenic therapy, *Science* 307:58–62, 2005.
524. Kerbel R, Kamen B: The anti-angiogenic basis of metronomic chemotherapy, *Nat Rev Cancer* 4:423–436, 2004.
525. De Palma M, Venneri M, Galli R, et al.: Tie2 identifies a hematopoietic lineage of proangiogenic monocytes required for tumor vessel formation and a mesenchymal population of pericyte progenitors, *Cancer Cell* 8:211–226, 2005.
526. Maity A, Bernhard EJ: Modulating tumor vasculature through signaling inhibition to improve cytotoxic therapy, *Cancer Res* 70:2141–2145, 2010.
527. Bellou S, Pentheroudakis G, Murphy C, Fotsis T: Anti-angiogenesis in cancer therapy: Hercules and hydra, *Cancer Lett* 338:219–228, 2013.
528. Hsu JY, Wakelee HA: Monoclonal antibodies targeting vascular endothelial growth factor: current status and future challenges in cancer therapy, *BioDrugs* 23:289–304, 2009.
529. Rogosin S, Sandler AB: Beyond bevacizumab: antiangiogenic agents, *Clin Lung Cancer* 13:326–333, 2012.
530. Adjei AA: Novel small-molecule inhibitors of the vascular endothelial growth factor receptor, *Clin Lung Cancer* 8(Suppl 2):S74–S78, 2007.
531. Samant RS, Shevde LA: Recent advances in anti-angiogenic therapy of cancer, *Oncotarget* 2:122–134, 2011.
532. Frost P, Berlanger E, Mysore V, et al.: Mammalian target of rapamycin inhibitors induce tumor cell apoptosis in vivo primarily by inhibiting VEGF expression and angiogenesis, *J Oncol* 2013:897025, 2013.
533. Shen M, Schmitt S, Buac D, Dou QP: Targeting the ubiquitin-proteasome system for cancer therapy, *Expert Opin Ther Targets* 17:1091–1108, 2013.
534. D'Amato RJ, Loughnan MS, Flynn E, Folkman J: Thalidomide is an inhibitor of angiogenesis, *Proc Natl Acad Sci USA* 91:4082–4085, 1994.
535. Metcalf S, Pandha HS, Morgan R: Antiangiogenic effects of zoledronate on cancer neovasculature, *Future Oncol* 7:1325–1333, 2011.
536. Abdollahi A, Hlatky L, Huber PE: Endostatin: the logic of anti-angiogenic therapy, *Drug Resist Updates* 8:59–74, 2005.
537. Gacche RN, Meshram RJ: Angiogenic factors as potential drug target: efficacy and limitations of anti-angiogenic therapy, *Biochim Biophys Acta* 1846:161–179, 2014.
538. Abdollahi A, Folkman J: Evading tumor evasion: current concepts and perspectives of anti-angiogenic cancer therapy, *Drug Resist Updates* 13:16–28, 2010.
539. Boehm S, Rothermundt C, Hess D, Joerger M: Antiangiogenic drugs in oncology: a focus on drug safety and the elderly—a mini-review, *Gerontology* 56:303–309, 2010.
540. Shtiegman K, Kochupurakkal B, Ben-Basat Y, Yarden Y: Epidermal growth factor receptor. In Perry M, editor: *Cancer: genetic aberrations and underlying signal pathways*, Alexandria VA, 2005, American Society of Clinical Oncology, pp 689–707.
541. Geyer C, Forster J, Lindquist D, et al.: Lapatinib plus capecitabine for HER2-positive advanced breast cancer, *N Engl J Med* 355:2733–2743, 2006.
542. Parikh RA, Wang P, Beumer JH, Chu E, Appleman LJ: The potential roles of hepatocyte growth factor (HGF)-MET pathway inhibitors in cancer treatment, *Onco Targets Ther* 7:969–983, 2014.
543. Cecchi F, Rabe DC, Bottaro DP: Targeting the HGF/Met signalling pathway in cancer, *Eur J Cancer* 46:1260–1270, 2010.
544. Vigna E, Comoglio PM: Targeting the oncogenic Met receptor by antibodies and gene therapy, *Oncogene* 34:1883–1889, 2015.
545. Yap TA, Sandhu SK, Alam SM, de Bono JS: HGF/c-MET targeted therapeutics: novel strategies for cancer medicine, *Curr Drug Targets* 12:2045–2058, 2011.
546. Cecchi F, Rabe DC, Bottaro DP: Targeting the HGF/Met signaling pathway in cancer therapy, *Expert Opin Ther Targets* 16:553–572, 2012.
547. Scagliotti GV, Novello S, von Pawel J: The emerging role of MET/HGF inhibitors in oncology, *Cancer Treat Rev* 39:793–801, 2013.
548. Steffan JJ, Coleman DT, Cardelli JA: The HGF-met signaling axis: emerging themes and targets of inhibition, *Curr Protein Pept Sci* 12:12–22, 2011.
549. Jin H, Varner J: Integrins: roles in cancer development and as treatment targets, *Br J Cancer* 90:561–565, 2004.
550. Curley G, Blum H, Humphries M: Integrin antagonists, *Cell Mol Life Sci* 56:427–441, 1999.
551. Rust W, Carper S, Plopper G: The promise of integrins as effective targets for anticancer agents, *J Biomed Biotechnol* 2:124–130, 2002.
552. Posey J, Khazaeli M, DelGrosso A, et al.: A pilot trial of Vitaxin, a humanized anti-vitronectin receptor (anti avb3) antibody, in patients with metastatic cancer, *Cancer Biother Radiopharm* 16:125–132, 2001.

553. Trikha M, Zhou Z, Nemeth J, et al.: CNTO95, a fully human monoclonal antibody that inhibits av integrins, has antitumor and antiangiogenic activity in vivo, *Int J Cancer* 110:326–335, 2004.
554. Funahashi Y, Sugi N, Semba T, et al.: Sulfonamide derivative, E7820, is a unique angiogenesis inhibitor suppressing an expression of integrin alpha2 subunit on endothelium, *Cancer Res* 62:6116–6123, 2002.
555. Li J, Li J, Holmes L, et al.: Fusion protein from RGD peptide and Fc fragment of mouse immunoglobin G inhibits angiogenesis in tumor, *Cancer Gene Ther* 11:363–370, 2004.
556. Miller K, Chap L, Holmes F, et al.: Randomized phase III trial of capecitabine compared with bevacizumab plus capecitabine in patients with previously treated metastatic breast cancer, *J Clin Oncol* 23:792–799, 2005.
557. Muss H: Targeted therapy for metastatic breast cancer, *N Engl J Med* 355:2783–2785, 2006.
558. Piccart-Gebhart M, Procter M, Leyland-Jones B, et al.: Trastuzumab after adjuvant chemotherapy in HER2-positive breast cancer, *N Engl J Med* 353:1659–1672, 2005.
559. Romond E, Perez E, Bryant J, et al.: Trastuzumab plus adjuvant chemotherapy for operable HER2-positive breast cancer, *N Engl J Med* 353:1673–1684, 2005.

27

Sarcomas of the Jaws

KYLE S. ETTINGER, KEVIN ARCE

Introduction

Sarcomas represent a rare and diverse group of malignant neoplasms that derive histogenetically from tissues with mesenchymal origin. This is distinct from malignant neoplasms of epithelial origin, which are classified as carcinomas. Terminally differentiated tissues of mesenchymal origin include bone, cartilage, fibrous tissue, muscle, vascular tissue, neural tissue, and adipose tissue. Among the various tissue types, approximately 80% of all sarcomas originate from soft tissue components, whereas the remaining 20% comprise neoplasms originating from bone and cartilaginous lineages.[1] Collectively, sarcomas are exceedingly rare neoplasms, and as a group they constitute less than 1% of all cancer diagnoses in the United States.[2,3] When considering the specific anatomic subsite of the head and neck, sarcomas represent only 1% of all primary head and neck malignancies.[4,5] Furthermore, primary sarcomas of the head and neck represent only 2% to 15% of all adult sarcoma diagnoses.[5,6] However, in pediatric populations, up to 35% of all sarcomas will arise within the head and neck region.[7]

Classification

Sarcomas can be classified according to a multitude of criteria, including the previously mentioned tissue of origin, the histologic grade of the neoplasm, and the anatomic subsite within the head and neck from which the tumor arises. Each of these features provides valuable information regarding prognosis and can also be useful for developing treatment plans, as well as determining the need for adjuvant or neoadjuvant therapy. For most sarcoma subtypes, there is little to no controversy as to which tissue type the sarcoma derives from. However, for some sarcomas, it remains unclear as to which tissue type serves as the progenitor for the neoplasm. Immunohistochemistry and the advent of new molecular oncology markers have aided in the ability to definitively classify sarcomas; however, as many as 20% of sarcomas will remain unclassified following pathologic review.[8] The specific subtypes of head and neck sarcomas as well as their respective tissue of origin are listed in Table 27-1.

The histologic grade of head and neck sarcomas is a reliable predictor of prognosis and consequently is a designated component of the American Joint Committee on Cancer (AJCC) staging system. By definition osteosarcomas, malignant fibrous histiocytomas (MFHs), rhabdomyosarcomas, angiosarcomas, synovial sarcomas, and Ewing sarcomas are all considered to be high-grade neoplasms,[1,9,10] whereas dermatofibrosarcoma protuberans, desmoid tumors, and atypical lipomatous tumors are all considered low grade.[4,11] Additionally, there are a number of sarcomas that require their own individualized histologic grading systems, including chondrosarcomas, fibrosarcomas, leiomyosarcomas, liposarcomas, neurogenic sarcomas, and hemangiopericytomas.[12] The prognostic importance of histologic grade for sarcomas is reflected in the near-100% 5-year survival rates for patients with grade 1 sarcomas reported in one series, whereas patients with grade 2 and 3 sarcomas experienced 5-year survival rates of only 64%.[13] Furthermore, high histologic tumor grade has also been shown to be associated with increased rates of local recurrence and increased rates of distant failure, as well as decreased rates of disease-specific survival.[14]

Classifying sarcomas based on the anatomic subsite within the head and neck has also proven to be useful in terms of prognosticating outcomes and guiding treatment decisions. Tumor location and proximity to other anatomic structures in the head and neck can influence the aggressiveness of surgical interventions, especially when considering the anticipated morbidity and functional deficits that are incurred postoperatively. Although negative margin status remains a critically important aspect of operative intervention for head and neck sarcomas,[1,4,6,9,15] unacceptable morbidity following surgical resection can often serve as a basis for consideration of non-operative treatment modalities, particularly in cases of pediatric head and neck sarcomas. The use of microvascular free tissue transfer in reconstruction of

TABLE 27-1 Histologic Subtypes of Head and Neck Sarcomas According to Tissues of Origin

- Bone
  - Osteosarcoma
- Cartilaginous
  - Chondrosarcoma
- Fibrous
  - Malignant fibrous histiocytoma
  - Fibrosarcoma
  - Dermatofibrosarcoma protuberans
- Muscular
  - Rhabdomyosarcoma
  - Leiomyosarcoma
- Vascular
  - Angiosarcoma
  - Hemangiopericytoma
- Neural
  - Neurogenic sarcoma
- Adipose
  - Liposarcoma
- Histogenesis Unclear
  - Synovial sarcoma
  - Ewing sarcoma
  - Alveolar soft part sarcoma
- Unclassified

oncologic defects has enabled much more complex surgical resections to be planned and executed for head and neck sarcomas; however, high-grade tumors in unresectable locations can still preclude the use of surgery for primary disease control. Ultimately, when considering all anatomic sites, the presence of a sarcoma within the head and neck is a poor prognostic factor in and of itself. When compared to other anatomic sites, sarcomas arising within the head and neck are associated with the highest rates of local recurrence and the poorest disease-specific survival.[14,15]

Etiology of Sarcomas

Although sarcomas can certainly occur de novo in patients without any known risk factors, there are a multitude of known genetic and environmental risk factors predisposing to the development of sarcomas. Li-Fraumeni syndrome, neurofibromatosis type I, Gardner syndrome, nevoid basal cell carcinoma syndrome, Carney triad, heredity hemochromatosis, and Werner syndrome have all been linked to the presence of sarcomas.[16-18] Li-Fraumeni syndrome is an autosomal dominant disorder involving mutation of the p53 tumor suppressor gene. Affected individuals suffer from breast cancer, soft tissue sarcomas, central nervous system malignancies, leukemia, and adrenocortical carcinomas.[16,18] Neurofibromatosis type I is an autosomal dominant disorder involving mutation of a gene on chromosome 17 responsible for controlling cell division.[17] Patients affected by this disorder are predisposed to increased rates of childhood rhabdomyosarcomas, liposarcomas, and fibrosarcomas in addition to neurogenic sarcomas, which tend to develop in adulthood.[18] Gardner syndrome represents an autosomal dominant disorder involving mutation in the adenomatous polyposis coli (APC) gene. These patients experience a multitude of benign and malignant neoplastic processes including osteomas, epidermal cysts, fibromas, lipomas, desmoid tumors, and hundreds of adenomatous colorectal polyps which inevitably progress to colorectal cancer, as well as an array of extracolonic malignancies involving the duodenum, thyroid, pancreas, stomach, central nervous system, liver, and adrenal glands. Nevoid basal cell carcinoma syndrome, an autosomal dominant disorder involving mutation in the PTCH1 gene on chromosome 9, has been linked with development of rhabdomyosarcomas and fibrosarcomas.[19] Carney triad, a specific subtype of multiple endocrine neoplasia (MEN) syndrome, is characterized by the presence of three classically associated tumors: gastric epithelioid leiomyosarcoma, pulmonary chondroma, and extra-adrenal paraganglioma.[20] Hereditary hemochromatosis is an autosomal recessive disorder involving mutation in the HFE gene leading to increased intestinal absorption of iron and has been associated with sarcomas of the liver.[21,22] Werner syndrome is a rare autosomal recessive disorder involving a mutation in the WRN gene, which is responsible for encoding a DNA helicase and a DNA exonuclease.[23] The syndrome is characterized by the appearance of premature aging, and it is associated with a significantly increased susceptibility to the development of soft tissue sarcomas.[23]

Numerous environmental factors have also been suggested as causative agents in the development of sarcomas. External beam radiation therapy,[24] exposure to various radioisotopes,[18] high-intensity electromagnetic fields,[25] phenoxyacetic acid–based herbicides,[26] Agent Orange,[26] dioxin,[26] polyvinyl chlorides,[18] thorium oxide (Thorotrast),[18] and inorganic arsenic[18] have all been implicated in the formation of sarcomas. Prenatal exposure to cocaine and marijuana has been shown to be associated with an up to fivefold increased risk of developing pediatric rhabdomyosarcoma.[27] The use of smokeless tobacco products has also been shown to correlate with increased risk of developing sarcomas of the upper aerodigestive tract, and this risk is further intensified by concomitant cigarette use.[28]

Although multiple genetic and environmental factors have been found to be associated with the development of head and neck sarcomas, the vast majority will not be attributable to any specific exposure or underlying genetic syndrome. The relative rarity of these tumors as a whole also makes it exceedingly difficult to accurately determine relative risk values across populations for different exposure types. Ultimately, for most patients afflicted with sarcomas of the head and neck, the true etiologic cause is likely the end result of a complex interplay occurring between environmental factors and some level of an underlying baseline genetic predisposition.

Diagnosis

The clinical presentation of head and neck sarcomas can be highly variable depending on the specific area of involvement and the proximity to surrounding anatomic structures. Tumors involving the nasal cavity or paranasal sinuses may present with nasal obstruction, orbital proptosis, diplopia, or recurrent epistaxis. Sarcomas involving the ear and lateral

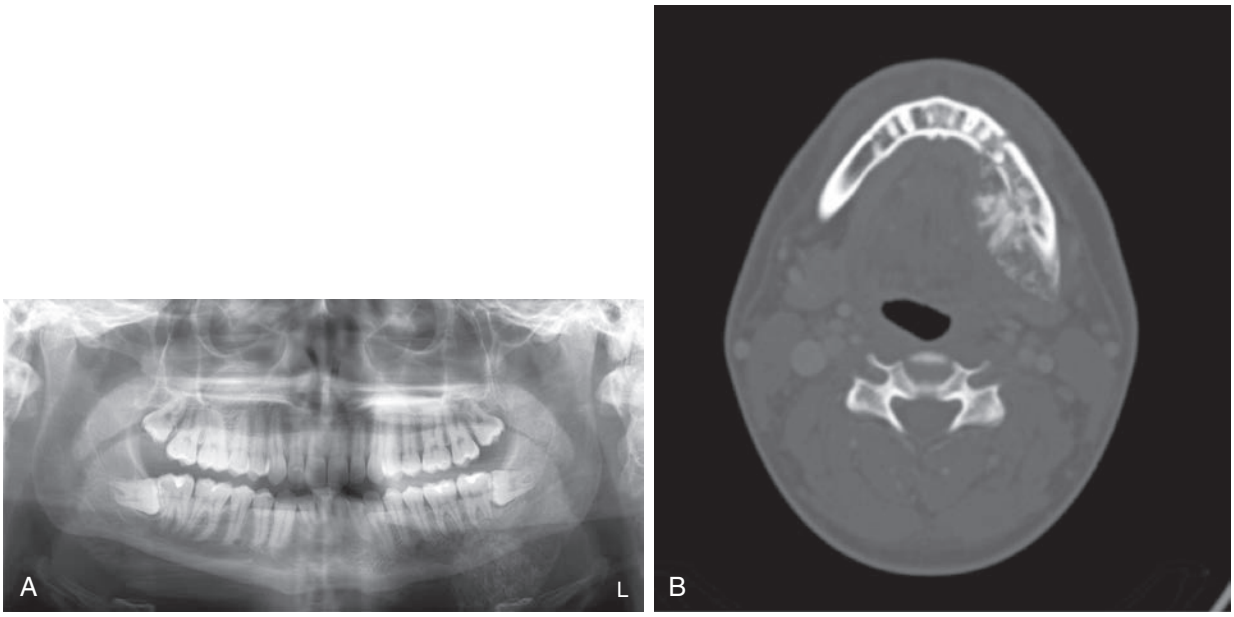

• **Figure 27-1** High-grade chondroblastic osteosarcoma of the right mandible in a 21-year-old male. Panoramic x-ray **(A)** and axial computed tomography scan **(B)** demonstrate periosteal reaction and radial spicules with "sunburst" appearance.

skull base can present with possible facial paralysis, hearing deficits, otalgia, or equilibrium disturbances. Tumors that involve the oral cavity can present with odontalgia, tooth mobility, paresthesias, and facial asymmetry. Involvement of the neck can result in impingement of neurovascular structures leading to dysphagia, hoarseness, and in rare instances even dyspnea. However, despite the widely variable presentations of head and neck sarcomas a common, but not necessarily specific, unifying symptom seen in up to 80% of sarcoma patients is the presence of a painless expansile mass.[4]

Thorough physical examination, although always a requisite, can occasionally be somewhat limited in terms of fruitfulness depending on tumor location. Accordingly, advanced imaging studies are vital adjuncts to the physical examination when evaluating for the presence of head and neck sarcomas. Advanced imaging modalities are able to much more accurately determine the exact size and location of a lesion and can also provide valuable information regarding bony invasion, intracranial extension, and regional nodal involvement. In virtually all instances, obtaining a high-resolution computed tomography (CT) scan or magnetic resonance imaging (MRI) will be indicated before consideration of definitive treatment planning. Specific advantages of CT scanning over MRI include reduced time required for image capture, diminished problems with motion artifact, increased sensitivity for osseous lesions, and an overall reduced higher soft tissue resolution (enabling better interrogation of perineural invasion, dural involvement, bone marrow extension, orbital invasion, etc.), lack of radiation exposure, and identification classic of T1- versus T2-weighted image changes associated with specific sarcoma types and can aid in pre-pathologic tumor characterization.

It is important to note that certain histologic subtypes of sarcomas tend to demonstrate classic radiographic findings on either CT or MRI, which if present, can be extremely useful from both a treatment planning and a diagnostic standpoint. For example, osteosarcomas are well known to demonstrate a hallmark periosteal "sunburst" reaction that can be visualized on plain radiographs as well as on CT imaging (Figure 27-1). Osteosarcomas can also present with findings of significant osseous destruction, peripheral soft tissue calcifications, and evidence of new or abnormal bone formation (Figures 27-2 and 27-3). Extraskeletal Ewing sarcomas will typically appear as hypodense lesions with evidence of irregular enhancement when visualized with CT imaging. Ewing sarcomas will also typically show evidence of significant muscle and subcutaneous tissue infiltration. On MRI imaging, Ewing sarcomas will typically present as a hypointense lesion on T1-weighted imaging, which will then appear hyperintense on T2-weighted projections. MRI evaluation of liposarcomas reveals a hyperintense T1-weighted signal and only modest signals on T2-weighted imaging. Alveolar soft-part sarcomas tend to show a hyperintense signaling on both T1- and T2-weighted images. Comparatively, malignant fibrous histiocytomas typically exhibit an isointense T1-weighted signal and a hyperintense T2-weighted signal. CT imaging of malignant fibrous histiocytomas also typically reveals evidence of significant bone destruction, local expansion, and extensive bone remodeling. Leiomyosarcomas can appear as non-enhancing masses with areas of cystic necrosis when visualized on CT. However, these lesions should be distinguished from

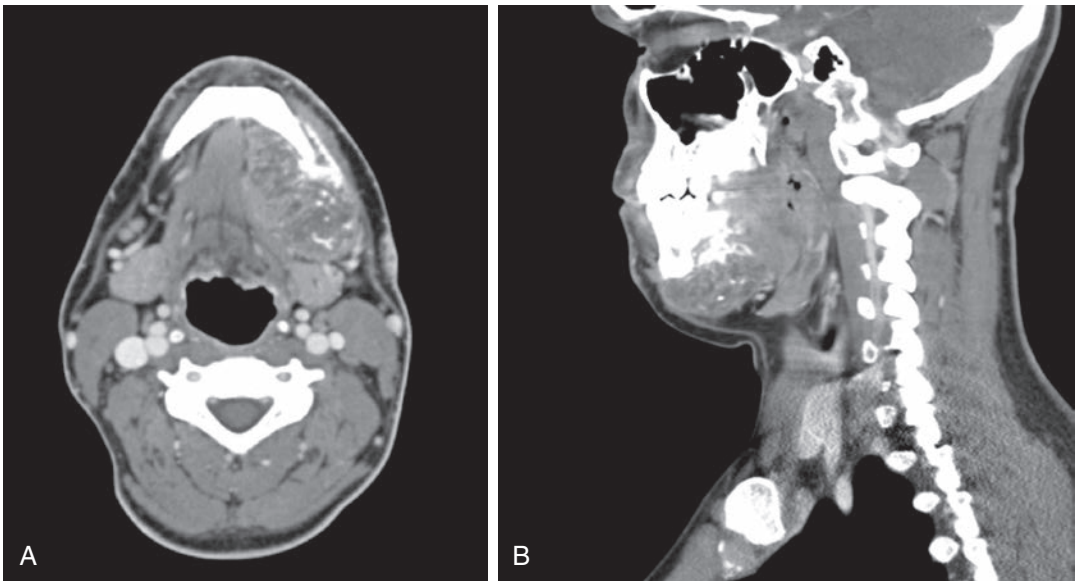

• **Figure 27-2** Axial **(A)** and sagittal computed tomography **(B)** scan demonstrating a large, heterogeneous mass with internal osteoid mineralization and cortical destruction involving the left mandible with mass effect on the adjacent musculature.

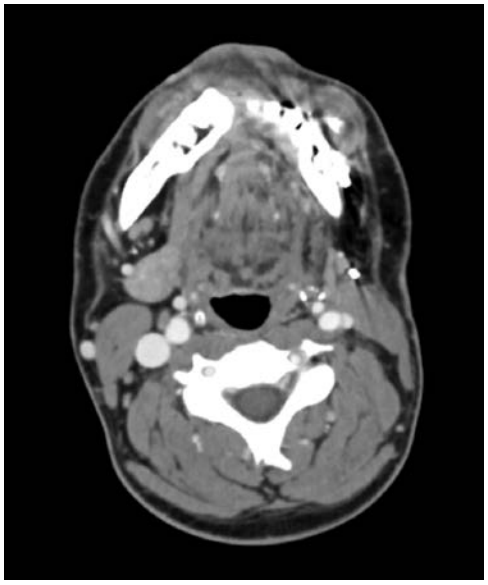

• **Figure 27-3** Metastatic, recurrent high-grade osteosarcoma presenting as a soft tissue mass with internal calcification adjacent to the left mandible.

hemangiopericytomas, which can also demonstrate areas of cystic necrosis, but will also typically present with speckled calcification and an intense hypervascular enhancement.[26]

Although all of the aforementioned imaging findings are useful for assisting with diagnosis, none of the findings alone are sufficient for diagnosis. Furthermore, the "classic" imaging hallmarks of specific sarcoma subtypes are not always evident, and heterogeneity of sarcomas on advanced imaging is not an unexpected finding.[29] Accordingly, tissue biopsy will always be required before a definitive diagnosis can be rendered. Generally imaging should always be performed before procurement of a biopsy specimen in order to reduce any postsurgical inflammatory changes that may obscure image quality or alter the innate imaging characteristics of the lesion itself. Options for diagnostic biopsy of a presumed head and neck sarcoma include fine-needle aspiration (FNA), core needle biopsy, or an open incisional biopsy. FNAs are often chosen for suspected sarcomas of the parotid, neck, or parapharyngeal spaces. Conversely, transmucosal incisional biopsies are often appropriate for most tumors involving the oral or nasal cavities; however, the surgeon must be conscious not to inadvertently "seed" the tumor into uninvolved areas when performing the biopsy itself. Regardless of whatever option is chosen, the surgeon must also be cognizant of the potential advantages and disadvantages of each technique and the eventual implications for accurate diagnosis. For example, a complete surgical resection of a tumor involving the parotid, neck, or parapharyngeal space is preferable to an attempt at open biopsy if the initial FNA was equivocal in order to prevent contamination of uninvolved areas. Furthermore, the surgeon must also be mindful of the specific expertise and preferences of the pathologists working at his or her institution, as not all pathologists will be as skilled or adept at rendering an appropriate diagnoses from a biopsy modality with which they are less familiar. Ideally, if suspicion for head and neck sarcoma is high, the specimen should be sent to a pathologist who is experienced in interpretation of sarcoma histology, as an inaccurate diagnosis could have catastrophic implications for both the patient and provider. One should not overlook the importance of second opinions from outside facilities if there remains any doubt or question over the histologic diagnosis. However, given the relative rarity of head and neck sarcomas, identification of centers with such specific expertise can sometimes prove to be difficult.

Finally, once a histologic diagnosis of a head and neck sarcoma has been rendered, it is exceedingly important to further investigate for the presence of distant metastases. The most commonly involved site of distant metastasis for all head and neck sarcomas is the lungs.[26] Accordingly, chest imaging should be obtained and can be limited to plain films for low-grade lesions; however, high-grade tumors will necessitate more advanced CT imaging.[30] Positron emission tomography (PET) is also useful in identifying the presence of distant metastases both at the time of initial diagnosis and during interval surveillance following primary tumor management.[31]

Osteosarcoma

Osteosarcomas, also commonly termed osteogenic sarcomas, represent the most common nonhematopoietic primary malignant neoplasm of bone, and they are known to occur anywhere in the body.[32-34] The majority of osteosarcomas will present in the long bones of adolescent patients with a particular predilection for the long bones around the knee.[26,35] Appendicular osteosarcomas typically demonstrate a bimodal age distribution, with most occurring between the ages of 10 and 20 years, and a smaller subset occurring in adults more than 50 years of age. Specific involvement of head and neck subsites is an uncommon occurrence, with less than 10% of all primary osteosarcomas arising within the head and neck region.[26,35-37] However, osteosarcomas do represent one of the most common histologic subtypes of sarcoma presenting within the head and neck, and they account for approximately 10% to 15% of all sarcoma diagnoses within this anatomic area.[38] The average age of diagnosis for patients with primary head and neck osteosarcoma is typically within the third and fourth decades of life, which exceeds the age of patients diagnosed with long bone osteosarcoma by approximately 10 to 15 years.[26] Although osteosarcomas can occur de novo, they are also well known to arise secondarily from multiple known risk factors. Previous history of head and neck radiation or chemotherapy for another tumor,[39-41] syndromic conditions (Rothmund-Thompson syndrome, Li-Fraumeni syndrome),[8,42-44] bone dysplasias (Paget disease, fibrous dysplasia, enchondromatosis),[8] chronic osteomyelitis,[45] trauma,[45] and transformation from a preexisting benign tumor[46] have all been described to be associated with the development of osteosarcomas.

The majority of patients with osteosarcoma will present with a rapidly growing, painless mass; however, some patients can experience symptoms for a protracted period of time, suggesting that some osteosarcomas can be slow growing (Figure 27-4). Average duration of symptoms before initial diagnosis typically ranges between 2 and 6 months.[35,47,48] Osteosarcomas frequently involve the maxilla and the mandible, and approximately 50% of osteosarcomas will originate from either of these two structures (Figure 27-5).[26] The most frequently reported site of mandibular involvement is the posterior body and horizontal portion of the mandibular ramus, whereas maxillary lesions typically present in the inferior portions of the maxilla, including the alveolar ridge, sinus floor, and palatine processes.[8] Accordingly, loosening of teeth, pain, paresthesias, and nasal obstruction are not uncommon findings.



• **Figure 27-4** 34-year-old man with a 6-week history of rapidly enlarging palatal mass.

Histologically, osteosarcomas of the head and neck are indistinguishable from osteosarcomas involving the appendicular skeleton.[49] The primary characteristic of all osteosarcomas is the production of an osteoid matrix, which will appear as an eosinophilic hyalinized material on hematoxylin and eosin staining. The osteoid is also typically surrounded by a rim of osteoblasts and is interspersed with spindle-shaped stromal cells that will display varying degrees of anaplasia and mitotic activity.[32,50] There are a total of seven histologic subtypes of osteosarcomas: osteoblastic, chondroblastic, fibroblastic, small cell, giant cell, telangiectatic, and parosteal. The osteoblastic, chondroblastic, and fibroblastic variants represent the three most common subtypes.[8] Because chondroblastic osteosarcomas can closely resemble the histologic patterns seen in chondrosarcomas, the identification of bone formation within the tumor is essential to distinguishing the former from the latter. For specific variants of osteosarcoma, the clinical behavior of the lesion can occasionally be correlated with the specific histologic subtype. For example, telangiectatic osteosarcomas are known to be highly aggressive tumors, whereas parosteal osteosarcomas are considered to be low-grade neoplasms and are associated with a more favorable prognosis.[51,52] Additionally, the chondroblastic subtype has been proposed to be associated with poorer survival outcomes, whereas the fibroblastic variant is reported to have the most favorable prognosis.[48] However, histologic subtype has failed to demonstrate a statistically significant impact on survival in the largest reported series of head and neck osteosarcomas.[48,53]

Although the optimal treatment protocol for head and neck osteosarcomas remains controversial, complete surgical resection of the tumor with negative margins remains the singular unifying theme in all purported regimens (Figure 27-6). Surgical resection achieving negative margins remains the single most important aspect in the treatment of osteosarcoma, and numerous studies have demonstrated

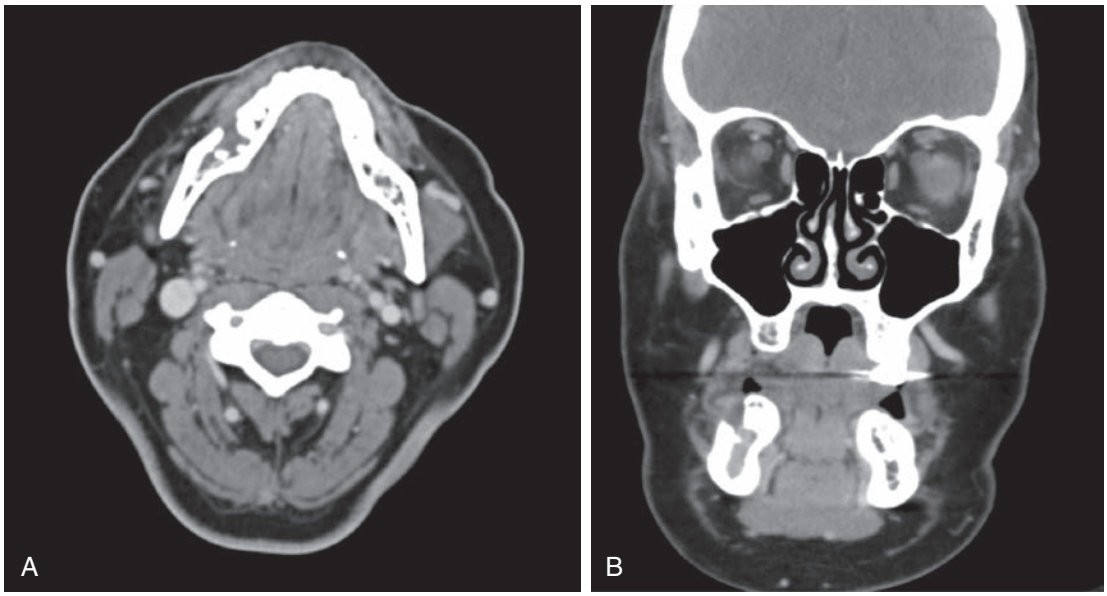

• **Figure 27-5** 47-year-old woman with low-grade osteosarcoma of the right mandible body. Axial **(A)** and coronal **(B)** computed tomography scans demonstrate a well-marginated, cortical defect.

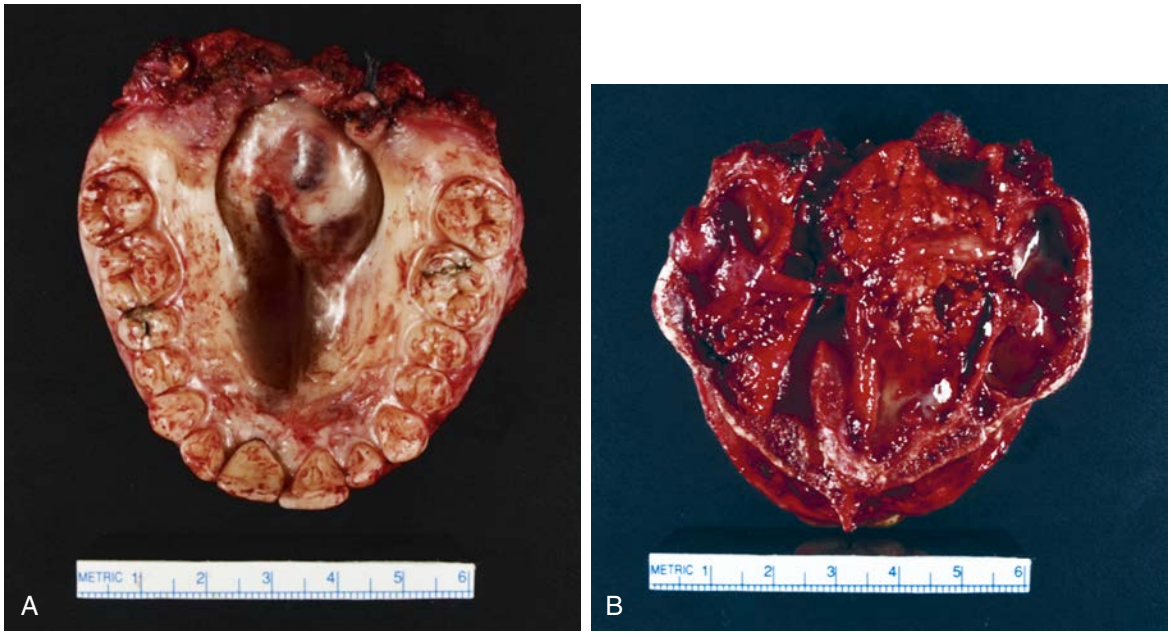

• **Figure 27-6** Bilateral infrastructure partial maxillectomy for treatment of palate chondroblastic osteosarcoma after neo-adjuvant chemotherapy. **A,** Maxillectomy specimen palatal view. **B,** Maxillectomy specimen superior view. Tumor invades through palatal bone.

significant reduction in local disease control and survival rates when nonsurgical treatment modalities are selected.[45,47,54] Elective neck dissection for the treatment of osteosarcoma is unnecessary, as regional spread of osteosarcomas to cervical lymph nodes is exceedingly uncommon.[26] However, selective neck dissection should be performed if there is frank clinical or radiographic evidence of nodal involvement or if there is direct extension of the primary tumor into the soft tissues of the neck.

Chemotherapy and radiotherapy have also both been used as neoadjuvant and adjuvant treatment modalities in combination with surgical resection.[38,45,49,54,55] The use of neoadjuvant chemotherapy carries the advantage of preemptively evaluating the response to various chemotherapeutic agents and can aid in the eventual selection of optimal adjuvant regimens. The chemotherapeutic drugs presently in use to treat osteosarcoma include high-dose methotrexate with leucovorin rescue, adriamycin, cisplatin, ifosfamide, and

cyclophosphamide.[8] The rationale for use of chemotherapy regimens is predominantly directed toward destruction of pulmonary micrometastases, which are present in as many as 80% of appendicular osteosarcomas at the time of diagnosis.[56] However, only 7% to 17% of patients with head and neck osteosarcomas will go on to develop distant metastases (most commonly to the lung and brain),[49,54] and therefore the use of chemotherapy in this patient population may potentially hold less utility. Nevertheless, systemic neoadjuvant chemotherapy has been shown to correlate with initial improvements in disease-free survival as well as overall survival rates for head and neck osteosarcomas.[49,54,57]

The use of radiation therapy as an adjuvant modality in the treatment of head and neck osteosarcoma has become increasingly frequent, particularly in cases of high-grade tumors or large lesions, and in patients with close or positive surgical margins.[45,47,54] Surgical margin status seems to be the predominant factor in the decision to use radiation therapy, as obtaining clear margins for head and neck osteosarcomas can often prove to be more difficult when compared to lesions involving the appendicular skeleton.[47] A consensus regarding the benefit of radiation therapy for head and neck osteosarcoma has not definitively been reached, as some report no survival benefit from either external beam radiation or brachytherapy,[49] whereas others report improved local control, disease-specific survival, and overall survival in patients with positive or close margins following surgery.[58] Nevertheless, the use of radiation therapy must also be weighed against the known risks of developing a post-irradiation osteosarcoma, which is associated with significant morbidity and unfavorable outcomes.[26]

Despite the ongoing controversy regarding the optimal treatment regimen for head and neck osteosarcomas, the overall survival rates remain exceedingly poor. Overall 2-year survival rates are reported to be 53% to 66%,[49,54] and 5-year survival rates are 42% to 55%.[47,49,54] Disease-free survival at 5-year follow-up is achieved for only 25% to 30% of all patients.[47,54] A number of prognostic factors for head and neck osteosarcomas have been repeatedly identified within the literature. Surgical margin status is widely known to correlate significantly with both local disease control and overall survival rates. The presence of a positive margin has been shown to dramatically reduce the 5-year survival rates from 75% in patients with negative margins, to a mere 35% where negative margins are not achieved.[47,49] Recurrent osteosarcomas as well as post-irradiation osteosarcomas are also known to have a significantly worse prognosis.[49] Conversely, osteosarcomas of the maxilla and mandible portend higher survival rates given a greater likelihood for complete resection when compared to other extragnathic head and neck locations.[55]

In conclusion, osteosarcomas of the head and neck represent extremely rare neoplasms, although they are one of the most common subtypes of sarcomas presenting within the head and neck. They represent extremely aggressive tumors and by definition are considered high-grade malignancies. Although optimal treatment regimens have not definitively been established, complete surgical resection with negative margins (Figure 27-7) remains a cornerstone of multimodal treatment strategies that can dramatically affect local disease control and overall survival rates.

Chondrosarcoma

Chondrosarcomas are rare neoplasms, which, not unlike osteosarcomas, are more commonly found affecting appendicular skeleton and have specific predilection for the extremities, pelvis, and long bones.[59] Presentation within the head and neck is uncommon, with only 5% to 10% of all chondrosarcomas occurring within this region of the body.[60] Additionally, chondrosarcomas constitute less than 10% of all head and neck sarcoma diagnoses overall.[60] These neoplasms are exceedingly uncommon in pediatric populations, and there are only a handful of case reports and case series available in the literature.[61] Owing to the relative rarity of chondrosarcomas, the typical age of presentation reported is widely variable, with some suggesting onset within the third and fourth decades of life,[62] whereas others report peak presentation within the fifth to seventh decades.[61] No male or female predominance has been demonstrated within the available literature of reported cases.[26]

The most commonly affected subsite within the head and neck is the sinonasal tract, with approximately 50% of head and neck chondrosarcomas occurring within this region.[60,62,63] Other commonly affected head and neck sites are the mandible and the larynx, which combine for the majority of the remaining chondrosarcomas diagnosed within the head and neck region.[62-64] The typical presenting symptoms of chondrosarcomas are largely dependent on the specific subsite affected; however, the most common presentation is that of a painless mass or swelling. Relative to osteosarcomas, pain is a less frequently reported complaint with chondrosarcomas. Large chondrosarcomas involving the sinonasal tract or maxilla can cause nasal obstruction, sinusitis, epistaxis, and loosening of teeth. Proptosis, photophobia, or even visual loss can also occur if there is extensive orbital invasion.[61]

Histologically, chondrosarcomas are composed of a chondroid matrix with lacunar formation and varying degrees of chondrocyte maturation and cellularity. Four distinct histologic variants of chondrosarcomas have been identified: clear cell, dedifferentiated, myxoid, and mesenchymal.[65] The mesenchymal and myxoid variants constitute the majority of head and neck cases.[8] As previously mentioned, chondroblastic osteosarcomas can be easily confused with the histologic presentation of chondrosarcomas, and the presence of bone formation is a requisite for distinguishing the former from the latter. Immunohistochemical markers are also useful in confirming the diagnosis of chondrosarcoma, as these neoplasms generally express positivity for vimentin, CD99, S-100, and Sox-9.[60] Histologic grading of chondrosarcomas is unique from the standard WHO four-grade system for all cancers excluding lymphomas and leukemias (Grade 1: Well Differentiated; Grade 2:

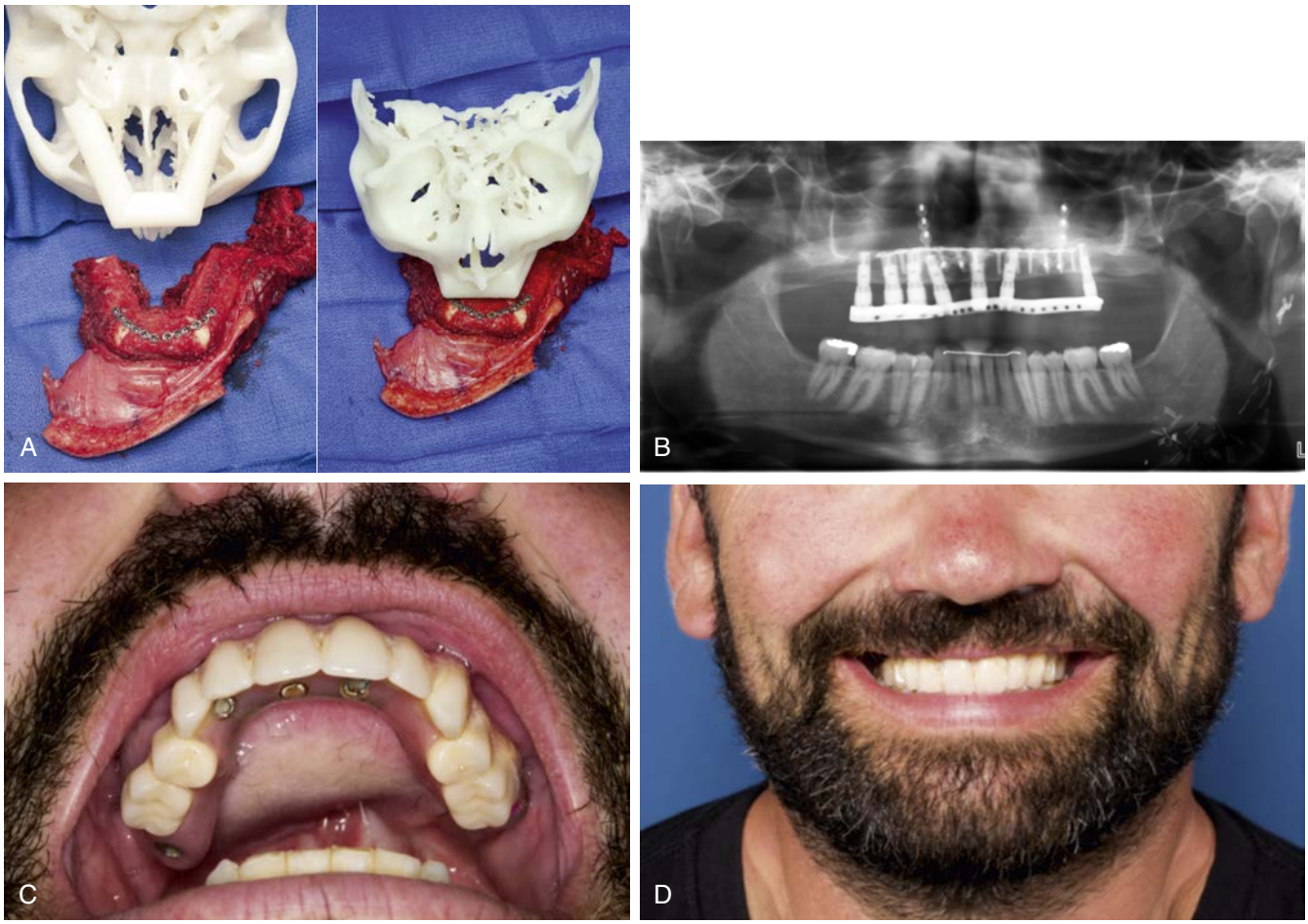

• **Figure 27-7** Bilateral infrastructure maxillectomy and immediate reconstruction with a free fibula flap **(A)** and secondary endosseous implant reconstruction of the neomaxilla **(B).** The interim maxillary prosthesis serves as a tissue conformer **(C)** and provides good function and aesthetics **(D).**

Moderately Differentiated; Grade 3: Poorly Differentiated; Grade 4: Undifferentiated).[66] Chondrosarcomas are instead histologically classified into three grades based on tumor characteristics including nuclear size, staining pattern, mitotic activity, and degree of cellularity. Histologic grading is an important prognostic indicator for chondrosarcomas, as increasing histologic grade portends a more aggressive clinical behavior of the neoplasm, an increased risk of distant metastasis, and an overall poorer prognosis.[65,67] Grade 1 chondrosarcomas are moderately cellular with abundant hyaline cartilage matrix. Chondrocytes are small with either round nuclei or binucleate in morphology, and mitotic figures are absent from all microscopic fields.[67,68] Grade 2 chondrosarcomas are typified by increased cellularity and a reduced proportion of chondroid matrix. Chondrocytes demonstrate enlarged nuclei, which can appear vesicular or hyperchromatic. Mitotic figures will be present; however, they will be widely scattered throughout the specimen.[67,68] Grade 3 chondrosarcomas are typically highly cellular and show absent or sparse chondroid matrix. Chondrocytes will exhibit obvious nuclear pleomorphism, and mitoses are easily detectable. The vast majority of chondrosarcomas arising within the head and neck are histologic grades 1 or 2, with grade 3 tumors being much more uncommon.[17]

Treatment of head and neck chondrosarcoma involves complete surgical excision including all involved structures in an attempt to attain negative margins. Regional nodal metastases are exceedingly uncommon, and elective neck dissection is generally not required unless there is direct invasion of the tumor into the neck structures or there is frank clinical or radiographic evidence of regional nodal involvement.[26] However, local recurrence is common and direct invasion into vital structures of the head and neck represents the leading cause of disease-related deaths.[69] Approximately 10% to 30% of patients will go on to develop distant metastases, most commonly to the lungs; however, this is typically in association with recurrent or uncontrolled local disease.[59,60,64] Radiation and chemotherapy have both been used as adjuvant therapies in the treatment of chondrosarcoma,[8,61] but the benefits of these modalities have yet to be demonstrated by any non-randomized or randomized prospective studies.[8] Traditionally radiation and chemotherapy were reserved for the treatment of locally advanced disease or unresectable tumors, in spite of the widely held

belief that chondrosarcomas are in fact radiotherapy- and chemotherapy-resistant neoplasms.[8,61] Nevertheless, some authors report a radioresponsiveness for chondrosarcomas,[70-72] although higher radiation doses (>65 Gy) are typically required for effect.[8] More recently, proton beam therapy has also been suggested as an adjunctive modality in the treatment of head and neck chondrosarcoma in order to reduce the morbidity associated with external beam radiation therapy.[73-75] However, the reports of proton beam therapy for the treatment of chondrosarcoma are limited to a few case studies, and evidence is presently insufficient to recommend its widespread use.

The overall 5-year survival rate for head and neck chondrosarcomas is reported to be 77.6%, and 5-year disease-specific survival is reported to be 87.2%.[65] The observed 10-year survival and 10-year disease-specific survival is reported as 64.3% and 70.6%, respectively.[65] Factors that have been identified to correlate with a poorer prognosis include tumors with high histologic grade and the presence of regional or distant disease at the time of diagnosis.[65] Additionally, 5-year disease-specific survival rates were also found to be poorer in mesenchymal and myxoid histologic variants of chondrosarcoma when compared with conventional chondrosarcomas.[65]

In conclusion, chondrosarcomas represent exceedingly rare neoplasms within the head and neck. The clinical behavior of the tumor and overall prognosis are closely tied to the histologic grade of the lesion, with higher histologic grades being associated with increased risk of distant metastasis as well as poorer prognosis. Treatment of chondrosarcomas is surgical, with complete excision and negative margins being the ultimate goal. The use of radiation, chemotherapy, and more recently proton beam therapy have all been reported in the treatment of chondrosarcoma; however, insufficient evidence currently exists to recommend use of these modalities as a standard of care.

Malignant Fibrous Histiocytoma

Malignant fibrous histiocytomas (MFHs) are soft tissue sarcomas deriving from fibrous tissue, and they represent the most commonly diagnosed sarcoma within the head and neck region.[8,26] MFHs also represent one of the most common varieties of soft tissue sarcomas when all anatomic subsites are considered; however, head and neck MFHs comprise only 3% to 10% of all diagnosed cases.[8,26] MFHs most commonly present in the fifth and six decades of life. They have a 2:1 male-to-female predominance, with a tendency for earlier age of presentation in women than in men.[8] Previous history of exposure to ionizing radiation is strongly associated with the development of MFHs, and many cases involving the head and neck occur in the wake of previous radiation therapy for squamous cell carcinomas or lymphomas.[76,77]

Similar to many other head and neck sarcomas, the most common presentation of MFH is that of a painless swelling;[78] additional symptoms will be dependent on the specific area and anatomic structures involved. The most commonly involved subsites within the head and neck include the sinonasal tract, the upper aerodigestive system, and the parotid gland, with relatively equal distribution among these three areas.[79,80] Typically, MFHs will present in either a submucosal or subcutaneous location; however, the tumors can also arise centrally in bone as well.[26] Multifocal presentations have been reported, but this is extremely uncommon.[26,78] Approximately one third of cases will go on to develop distant metastases, most commonly involving the lungs, liver, and bone.[8]

Histologically MFHs are composed of spindle-shaped fibroblastic cells admixed with mononuclear histiocytic cells in a storiform pattern with interspersed multinucleated giant cells. A total of five different histologic variants have been identified: inflammatory, giant cell, myxoid, storiform-pleomorphic, and angiomatous.[8] The storiform-pleomorphic variant is the most common.[8] Histologic features of MFHs can closely resemble those of a multitude of other neoplastic processes, including anaplastic lymphomas, pleomorphic leiomyosarcomas, pleomorphic liposarcomas, malignant melanomas, anaplastic carcinomas, malignant peripheral nerve sheath tumors, malignant gliomas, and gliosarcomas.[8,81] Accordingly, thorough histologic review by pathologists experienced in the diagnosis of head and neck sarcomas is of paramount importance. Positivity for a number of immunohistochemical markers including vimentin, α1-antichyemotrypsin, and Ki-67 can also be useful if diagnosis is in question. Tumor immunonegativity for S-100 and cytokeratins can also facilitate distinction of MFHs from other types of neoplastic processes.[8] Historically, histiocytic markers such as CD68, α1-chymotrypsin, and factor XIII were previously used to identify MFHs; however, these markers have fallen out of favor, given the nonspecific nature of their immunoreactivity.[82]

Surgical resection with generous margins is the primary treatment modality for MFHs. Given the relative infrequency of regional metastasis, elective lymphadenectomy is generally not indicated.[8,26,83] Postoperative radiation is typically recommended for unresectable tumors and tumors with close or positive margins.[78,83] However, adjuvant radiation therapy has been shown in some series to impart superior local disease control regardless of margin status for MFHs of the head and neck, as well as other anatomic subsites.[84,85] Adjuvant chemotherapy in the treatment of MFH has typically been implemented in the setting of metastatic disease. Adjuvant chemotherapy trials for MFH have demonstrated significant improvement in local recurrence-free survival, distant recurrence-free survival, and overall recurrence-free interval; however, these trials have also failed to show a significant overall survival advantage.[86]

Overall 5-year survival rates for head and neck MFHs are reported to be approximately 40% in larger series; the reported 5-year survival rates range from 19% to 75%.[1,26,78] Local recurrence occurs in approximately 20% of patients, and most disease-related deaths are secondary to distant metastases, most commonly involving the lungs.[78] Positive

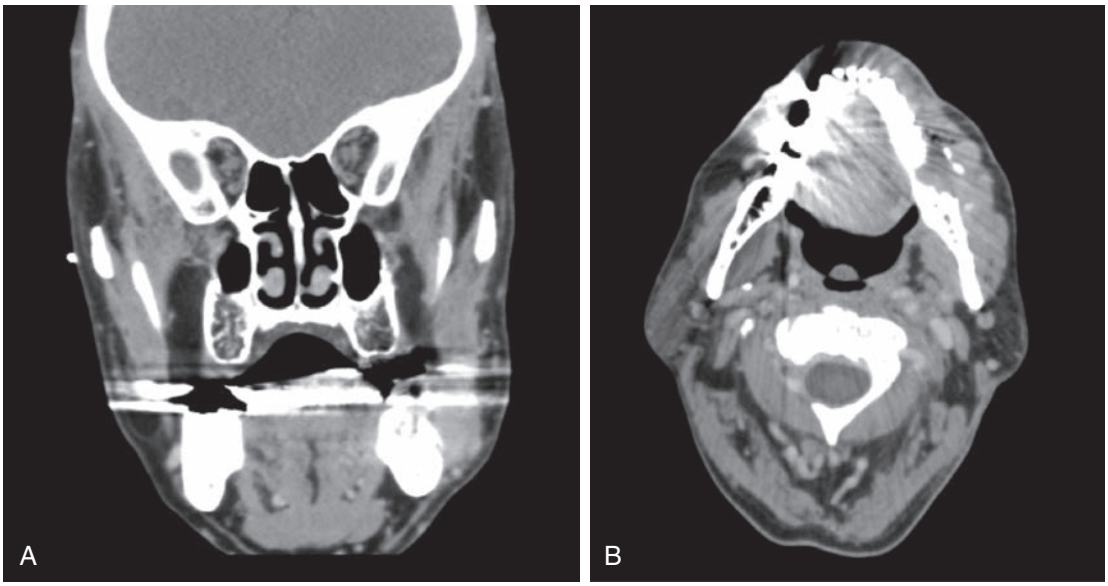

• **Figure 27-8** Fibrosarcoma left perimandibular region in the setting of previous radiation therapy for treatment of nasopharyngeal carcinoma. Coronal **(A)** and axial **(B)** computed tomography scans demonstrate a mass in the left perimandibular region with calcification and mandibular cortical destruction.

margin status, tumor size greater than 5 cm, tumors originating in bone, high histologic grade, and specific involvement of the head and neck are all prognostic factors adversely affecting outcome and survival.[78,87,88]

In summary, MFHs represent the most common variety of soft tissue sarcoma and are the most common sarcoma diagnosed within the head and neck region. They typically affect older adults and are strongly associated with prior exposure to head and neck radiation. Histologically, these tumors can resemble a number of other malignancies, and review by an experienced pathologist is critical. Immunohistochemistry can be a used as a diagnostic adjunct if the histologic diagnosis is in question. Treatment is surgical, with adjuvant radiation indicated for close or positive margin status. Elective neck dissection is typically unnecessary given the low propensity for regional metastasis.

Fibrosarcoma

Fibrosarcomas represent a very common variant of soft tissue sarcoma; however, only 5% of fibrosarcomas occur within the head and neck region.[89] The majority of fibrosarcomas will occur in the fourth or fifth decade of life,[90,91] yet the tumors are also known to occur in young adults and children. Prior head and neck radiation exposure is a well-known risk factor for the development of fibrosarcomas, and approximately 10% of patients with fibrosarcomas of the head and neck will have this history (Figure 27-8).[81,90,91] Most reported series on head and neck fibrosarcoma also suggest a slight male predominance.[81,90,91]

The most common presenting symptom of fibrosarcomas is the presence of a painless expanding mass, as fibrosarcomas typically need to reach a relatively large size before inducing symptoms of pain. Fibrosarcomas most commonly occur on the face, scalp, or neck; however, cases have also been documented involving the nose and paranasal sinuses.[26,81,90,91] On CT imaging, fibrosarcomas typically appear as isodense tumors and are only mildly enhancing following contrast administration.[92] MRI imaging demonstrates low to intermediate signal intensity on all sequences and only mild to moderate enhancement with gadolinium contrast.[92]

Histologically, fibrosarcomas demonstrate fascicles of spindle-shaped cells that are classically arranged in a herringbone pattern.[92] The spindle cells typically exhibit scant cytoplasm and relatively homogenous size and shape, as well as prominent hyperchromatic nucleoli.[92] Mitotic figures are typically seen; however, they can be variable in number across specimens. Poorly differentiated tumors typically show less organized cellular architecture, and the fibroblastic cells can have a more round or ovoid appearance. Less differentiated tumors will also demonstrate less collagen production than well-differentiated tumors.

Treatment of fibrosarcomas involves wide surgical excision for tumors that demonstrate low-grade histology (Figure 27-9). Negative surgical margins are critical, as local recurrence is the primary mode of treatment failure and eventual death.[90] High-grade tumors, large tumors, or tumors with positive surgical margins are indicated for adjuvant chemotherapy or radiation therapy.[8,81,90] Neck dissection is indicated only in patients with clinically positive cervical lymph nodes, and elective treatment of the neck is not required on a routine basis.[91]

Prognosis for fibrosarcoma is relatively favorable when compared to other types of head sarcomas. Overall 5-year survival rates are reported to range from 62% to 82%

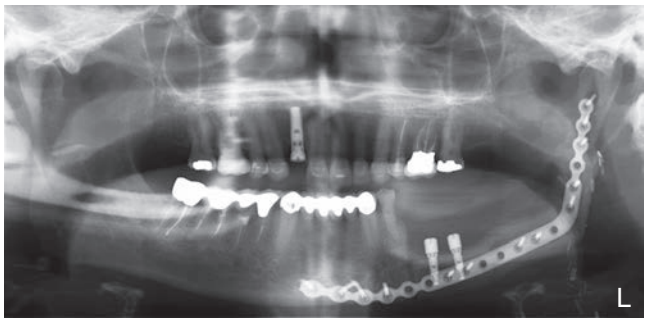

• **Figure 27-9** Composite resection and immediate reconstruction of left mandible for treatment of low-grade fibrosarcoma.

with 5-year disease-free survival rates ranging from 32% to 57%.[1,4,9,81,90,91] However, there is a high propensity for local recurrence, as this occurs in approximately 31% to 62% of patients.[26] Distant metastases are reported to occur in 12% to 21% of patients and most commonly involve the lungs.[81,90,91] Distant metastases have been reported to occur even after multiple decades,[89] highlighting the importance of long-term follow-up. Prognostic factors associated with improved outcomes include lesions with low-grade histology, tumors less than 5 cm in diameter, and negative surgical margin status.[9,81,89-91] High-grade tumors portend a poor prognosis irrespective of margin status, and multimodal therapy is typically recommended despite a lack of evidence for improved survival with multimodal strategies.[26,81]

In summary, fibrosarcomas are a relatively common subtype of soft tissue sarcoma that most frequently involves the extremities and are a very rare entity within the head and neck region. A history of head and neck radiation exposure is a well-documented risk factor for the development of fibrosarcomas. Treatment of low-grade, small fibrosarcomas is effectively carried out with wide surgical excision alone. Strong consideration for multimodal therapy involving surgery and postoperative adjuvant therapies should be given for high-grade lesions and large tumors. Generally, the prognosis for fibrosarcomas is favorable when compared to other types of head and neck sarcomas, yet local recurrence remains a significant problem.

Dermatofibrosarcoma Protuberans

Dermatofibrosarcoma protuberans represents a rare low-grade cutaneous sarcoma that most commonly arises on the skin of the trunk and extremities.[93] Dermatofibrosarcoma protuberans constitutes less than 5% of all soft tissue sarcoma diagnoses and only 4% to 10% of all head and neck sarcomas.[1,4,15,90,91] The typical age of occurrence is in the early to mid-adult life, with a mean age of presentation of 31 years.[26,94] The tumors are known to occur in children, and congenital cases have also been described, yet these are exceedingly rare occurrences.[95,96] Men are more commonly affected; the male-to-female ratio is reported to be 7:3.[94,97]

Clinically, the tumors present as painless, raised, sclerotic plaques or nodules on the skin and typically possess a blanchable reddish-blue color.[26] The most commonly affected subsite within the head and neck is the scalp, with the face and neck combining as the next most common locations of tumor origination.[98-100] Dermatofibrosarcoma protuberans typically begin as a single plaque that will demonstrate a slow, locally infiltrative growth over a period of several years.[94,95] In more advanced stages, multiple satellite nodules can coalesce to form a larger protuberant mass, hence the name dermatofibrosarcoma *protuberans*.[11] Because of the slow-growing and indolent nature of the lesions, dermatofibrosarcoma protuberans can easily be misdiagnosed as keloids, basal cell carcinomas, or even scleroderma.[11] Dermatofibrosarcoma protuberans is known to occur most commonly in areas of healthy skin, but also has been reported to arise in areas of repeated trauma including vaccination sites, irradiated skin, and scars.[95] Ultrasonography of these lesions typically demonstrates hypoechoic or mixed echoic tumor with Doppler flow patterns involving either the entire tumor or just in the periphery of the lesion.[92] On CT, the tumors appear isodense to hypodense and can show moderate peripheral enhancement if concomitant central necrosis is present.[92] On MRI, the lesions will appear hypointense to isointense relative to adjacent muscle on T1-weighted imaging, whereas T2-weighted imaging generally demonstrates an isointense to hyperintense signal relative to muscle.[92]

Histologically, dermatofibrosarcoma protuberans typically occurs within the subcutaneous soft tissues, in a plane superficial to the superficial fascia of the skin. Origination deep to the superficial fascia is also reported, albeit much less commonly.[92] On hematoxylin and eosin staining, dermatofibrosarcoma protuberans appears as a conglomeration of monomorphic spindle cells arranged in a storiform pattern embedded in variable amounts of fibrous stroma. The spindle cells are typically monotonous, with bland tapered nuclei and sparse mitotic figures.[92] Immunopositivity for the otherwise nonspecific CD34 marker represents the most valuable diagnostic immunohistochemical finding; however, additional immunostaining for factor XIIIa may also be required to distinguish dermatofibrosarcoma protuberans from dermatofibromas.[101]

Treatment of dermatofibrosarcoma protuberans is ideally carried out with wide surgical resection with histologically negative margins, as these tumors have extremely high recurrence rates, but very low metastatic potential.[26,95] The adequacy of surgical resection remains the most important factor in patient outcome, as local recurrence rates are reported to be as high as 20% to 55%.[5,11,97-100] Obtaining negative margins at the time of surgery is often complicated by the multiple projections into the surrounding tissues that are characteristically present with dermatofibrosarcoma protuberans.[11,95,99] It has been reported that even obtaining 5-cm margins around the macroscopic tumor at the time of surgery can still leave residual disease in 5% of patients.[102] Accordingly, Mohs micrographic surgery is often recommended in order to ensure adequacy of resection margins while not simultaneously compromising functional or

esthetic outcomes with overzealous excision.[95,97,103] The use of adjuvant radiation therapy has been described and is typically reserved for recurrent lesions, positive margin status, or in cases where wider excision is not possible due to anatomic limitations.[104,105]

Prognosis for patients with dermatofibrosarcoma protuberans is quite good, particularly if truly negative margin status is achieved with the initial resection. Overall 5-year survival rates are reported to approach 100% with truly negative margins.[1,4,99] However, the head and neck represents a relatively common site for tumor recurrence relative to other sites within the body,[95] which possibly reflects a tendency of surgeons to obtain narrower margins given the anatomic constraints inherent to this area.

In summary, dermatofibrosarcoma protuberans represent rare low-grade malignancies that are uncommon within the head and neck region. Clinically, the tumors can resemble a number of other pathologic conditions, given their propensity for indolent but locally invasive growth. Treatment is via complete surgical excision with negative margins whenever possible, and the use of Mohs micrographic surgery holds specific utility for tumors involving the head and neck region. Complete surgical resection with truly negative margins portends an extremely favorable prognosis; however, these tumors have a very high potential for local recurrence with inadequate resection.

Rhabdomyosarcoma

Rhabdomyosarcomas (RMSs) are soft tissue sarcomas that most commonly affect children and adolescents, with only rare presentation in adult populations.[8] RMSs comprise approximately 4% to 8% of all pediatric cancer diagnoses, and they represent the most common type of sarcoma affecting children.[106-108] Collectively, rhabdomyosarcomas constitute up to one fourth of all head and neck sarcoma diagnoses,[1,4,9,84,106] and of these 90% will occur in children.[106,109] When considering all anatomic subsites within the body, approximately 40% of rhabdomyosarcomas occur within the head and neck (Figure 27-10).[106,109] Males and females appear to be equally affected, with some studies suggesting only very slight male predominance.[107-109] A limited number of epidemiologic studies suggest a higher incidence of pediatric RMS in patients exposed to radiation in utero,[110] in children from low socioeconomic status,[111] and in children of mothers using cocaine and marijuana during pregnancy.[27]

Accurate diagnosis of RMS necessitates both a thorough clinical and radiographic examination by the astute clinician; however, specific interrogation of the neck is also of paramount importance, as head and neck RMSs are well known to metastasize to the regional cervical lymph nodes.[107,112] Additional investigation for distant metastases is also indicated given the reported 9% to 23% of patients harboring distant disease at the time of diagnosis.[26,108,112] Of the relatively few cases diagnosed in adult patients, the most common anatomic subsite involved is the sinonasal tract.[107,108] In pediatric patients the orbit is most commonly involved, followed by the nasopharynx, paranasal sinuses, ear, oral cavity, neck, parotid gland, and facial soft tissues.[113] The constellation of presenting symptoms for head and neck RMS are variable and dependent on the anatomic subsite involved. However, the most commonly reported symptoms in children include nasal obstruction, rhinorrhea, recurrent otitis media, and orbital proptosis.[114]

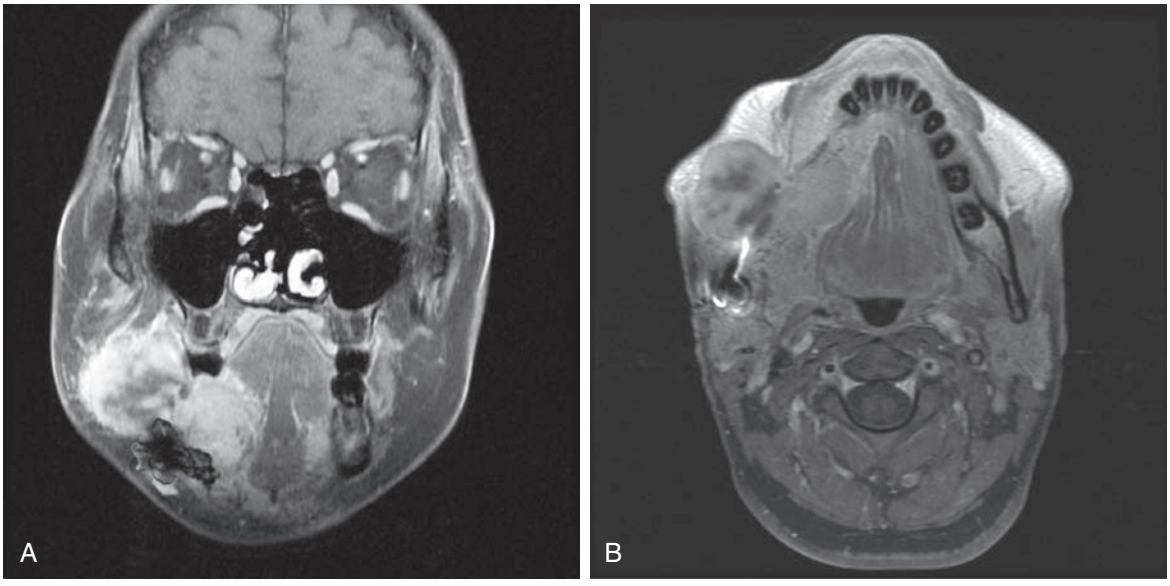

• **Figure 27-10** Coronal **(A)** and axial T1-weighted magnetic resonance imaging **(B)** showing a large spindle cell rhabdomyosarcoma involving the right masticator space, buccal space, maxilla, mandible, and floor of the mouth.

Histologically, RMSs are categorized according to the International Classification of Rhabdomyosarcoma (ICR) system devised by the Intergroup Rhabdomyosarcoma Study Group (IRSG). The most recent iteration of the ICR divides RMSs into five distinct subtypes based on cellularity, spindle cell morphology, stroma characteristics, growth patterns, and correlative immunohistochemical studies. The five currently recognized histologic subtypes of RMSs include embryonal, botryoid, spindle cell, alveolar, and undifferentiated. [115] The botryoid and spindle cell RMSs both represent less common variants of the embryonal subtype. Appropriate histologic classification of RMSs is of critical importance, as the various histologic subtypes are each associated with widely differing prognoses (Table 27-2). In pediatric patients younger than 10 years, embryonal subtype is the most commonly diagnosed RMS, whereas in patients older than 10 years, alveolar RMSs become the most common diagnosis.[8] However, embryonal RMSs represents the most common type of RMS presenting within the head and neck region overall.[26,107]

In children, head and neck RMSs are also classified based their site of origin: orbital, parameningeal, or non-parameningeal.[116] Parameningeal sites include the middle ear, nasal cavity, paranasal sinuses, nasopharynx, and infratemporal fossa. Non-parameningeal sites are defined as the scalp, parotid gland, oral cavity, oropharynx, hypopharynx, larynx, thyroid/parathyroid, and neck.[116] Because the anatomic site of origin correlates with prognosis, the three head and neck origin sites are also incorporated into a pretreatment tumor-node-metastasis (TNM) staging for RMSs (Table 27-3).[116,117] The IRSG also uses surgicopathologic criteria in pediatric patients (local extension, regional metastasis, distant metastases, amount of residual tumor following resection) in order to appropriately stage RMSs into various IRS Clinical Groups (Table 27-4).[116,117] Coupled together, these two staging systems enable providers to tailor therapy options based on the severity of a patient's specific disease burden as well as their relative prognosis following the initial surgical resection. The work of the IRSG along with cooperation from other collaborative cancer study groups, including the more recently formed Children's Oncology Group (COG) and Children's Oncology Group Soft Tissue Sarcoma (COG-STS), has allowed for improved staging, more accurate risk stratification, and better assessment of long-term comparisons between treatment various regimens.[8,26] Accordingly, dramatic advancements have been made in the treatment of pediatric RMSs, which have subsequently led to improvement in survival rates from roughly 25% in the early 1970s to 71% in 2001.[8,113]

Treatment of all RMSs is based on the principle of "risk-adapted therapy," which takes into account the various staging and prognostic classification schemes delineated by the IRSG in order to appropriately target therapy to the specific disease severity. Complete surgical resection remains the cornerstone of therapy for most patients; however, complete resection of head and neck RMSs can be precluded by unacceptable functional or cosmetic outcomes and involvement of vital anatomic structures.[26] Accordingly, a multimodal approach involving radiation therapy

TABLE 27-2 Prognosis of Rhabdomyosarcomas Based on Histologic Subtype

Superior Prognosis

Botryoid rhabdomyosarcoma
Spindle cell rhabdomyosarcoma

Intermediate Prognosis

Embryonal rhabdomyosarcoma

Poor Prognosis

Alveolar rhabdomyosarcoma
Undifferentiated sarcoma

TABLE 27-3 Tumor-Node-Metastasis (TNM) Staging for Rhabdomyosarcomas

Stage	Site	Tumor Size	Nodal Involvement	Presence of Metastases
I	Orbit Head and Neck Genitourinary (non-bladder, non-prostate)	<5 cm or >5 cm	N0, N1, NX	M0
II	Bladder/prostate Extremity, trunk Parameningeal Other	<5 cm	N0, NX	M0
III	Bladder/prostate Extremity, trunk Parameningeal Other	>5 cm	N1, N0, NX	M0
IV	All sites	<5 cm or >5 cm	Any N	M1

N0, no regional nodal metastases; N1, regional nodal metastases; NX, unknown nodal status; M0, no distant metastases; M1, distant metastases

TABLE 27-4 Intergroup Rhabdomyosarcoma Study (IRS) Clinical Groups of Rhabdomyosarcoma

Group I

Localized disease, completely removed
a. Confined to muscle or organ of origin
b. Infiltration outside of organ or muscle of origin; regional nodes not involved

Group II

Total gross resection with evidence of regional spread
a. Grossly resected tumor with microscopic residual disease
b. Regional disease with involved nodes, completely resected with no microscopic residual disease
c. Regional disease with involved nodes, grossly resected, but with evidence of microscopic residual and/or histologic involvement of the most distal regional node in the dissection

Group III

Incomplete resection, or biopsy with presence of gross disease

Group IV

Distant metastasis

and multi-agent chemotherapy is often implemented for RMSs involving head and neck subsites (Figure 27-11). A multitude of chemotherapeutics are currently used to treat RMSs, including vincristine, dactinomycin, doxorubicin, ifosfamide, etoposide, cyclophosphamide, actinomycin-D, topotecan, irinotecan, cixutumumab, and temozolomide.[8] The specific type of multimodal management differs based on site of origin for head and neck RMSs. Orbital RMSs are unique in that surgical resection does not confer any survival benefit over radiation and chemotherapy.[118] Accordingly, combined chemo-radiation therapy is the preferred modality given the significant morbidity caused by loss of an eye, and orbital exenteration is generally reserved for cases of recurrent disease.[117] Parameningeal RMSs are also generally less amenable to surgical resection given a greater likelihood of incomplete resection, significant risk to major cranial nerves, and greater disfigurement of the facial skeleton.[119] Consequently, limited surgical resection coupled with combined radiation and chemotherapy confers the least amount of morbidity while still maintaining adequate survival rates.[119] Treatment of non-parameningeal RMSs involves surgical resection and chemotherapy (typically vincristine and dactinomycin, with or without cyclophosphamide), with or without radiation therapy.[120] With this regimen more than 80% of patients with parameningeal RMSs are expected to be cured of their disease, and elective cervical lymph node dissection is generally unnecessary.[120] Surgery is often also useful as a "second-look" procedure wherein patients deemed to be partial responders to adjuvant therapies can subsequently be reclassified as complete responders based on results of post-treatment biopsies.[119]

Given the efforts of collaborative international study groups such as the IRSG, COG, and COG-STS, prognoses for head and neck RMSs have dramatically improved over the past 5 decades. The 5-year survival rates for parameningeal head and neck RMSs are reported to be 50% to 70%, whereas 5-year survival rates for non-parameningeal sites are reported to be 70% to 80%.[121] This is to be taken in distinction to the pre-1970s 5-year survival rates for head and neck RMS of 25%.[121] The 5-year overall survival rates for pediatric RMSs at all sites are currently 89%, 86%, 69%, and 30% for stage I, II, III, and IV tumors respectively.[7,26] Because of the rarity of RMSs in adults, survival data for non-pediatric RMS are limited. However, outcomes for adult RMSs are reported to be much poorer, with 5-year survival rates reaching only 30%.[8,26] A number of prognostic factors have been identified to correlate with a worse prognosis for head and neck RMSs, including older age at diagnosis, local invasiveness, presence of metastases at diagnosis, regional nodal involvement, unresectability, tumor size, tumor grade, and alveolar histologic subtype.[106,108,109,122,123]

In summary, RMSs represent the most common type of sarcoma presenting in pediatric populations and constitute approximately 25% of all head and neck sarcoma diagnoses. Five distinct histologic subtypes are currently recognized, and each subtype is associated with a different prognosis. Staging of RMSs involves both a modified pretreatment TNM staging system and a Clinical Group stage—both of which are extremely important in prognosticating outcomes and tailoring treatment regimens. Multimodal therapy involving combinations of surgery, radiation, and chemotherapy has produced significant survival improvements for pediatric RMSs over the past 50 years due to intense research and clinical protocols designed to optimize treatment strategies. Nevertheless, adult patients and some subsets of pediatric patients still suffer from exceedingly abysmal prognoses in spite of the recent advancements.

Leiomyosarcoma

Leiomyosarcomas are rare soft tissue sarcomas that are believed to originate from either smooth muscle cells or pluripotent undifferentiated mesenchymal stem cells.[124] Leiomyosarcomas most commonly arise in the uterus, digestive tract, and retroperitoneal fossa. Leiomyosarcomas of the head and neck are exceedingly rare, with around 100 cases reported within the literature.[125] Leiomyosarcomas also represent the least common type of soft tissue sarcoma originating in the head and neck region, as they accounting for only 5% of all head and neck sarcoma diagnoses.[1,4,9,84] Patients with head and neck leiomyosarcoma most commonly present within the fifth to sixth decade of life, and no gender predilection has been reported.[9]

Diagnosis of head and neck leiomyosarcoma does not differ significantly from the diagnosis of other types of head and neck sarcomas, as appropriate clinical and radiographic examinations are requisite before obtaining a definitive tissue diagnosis. However, additional imaging investigations

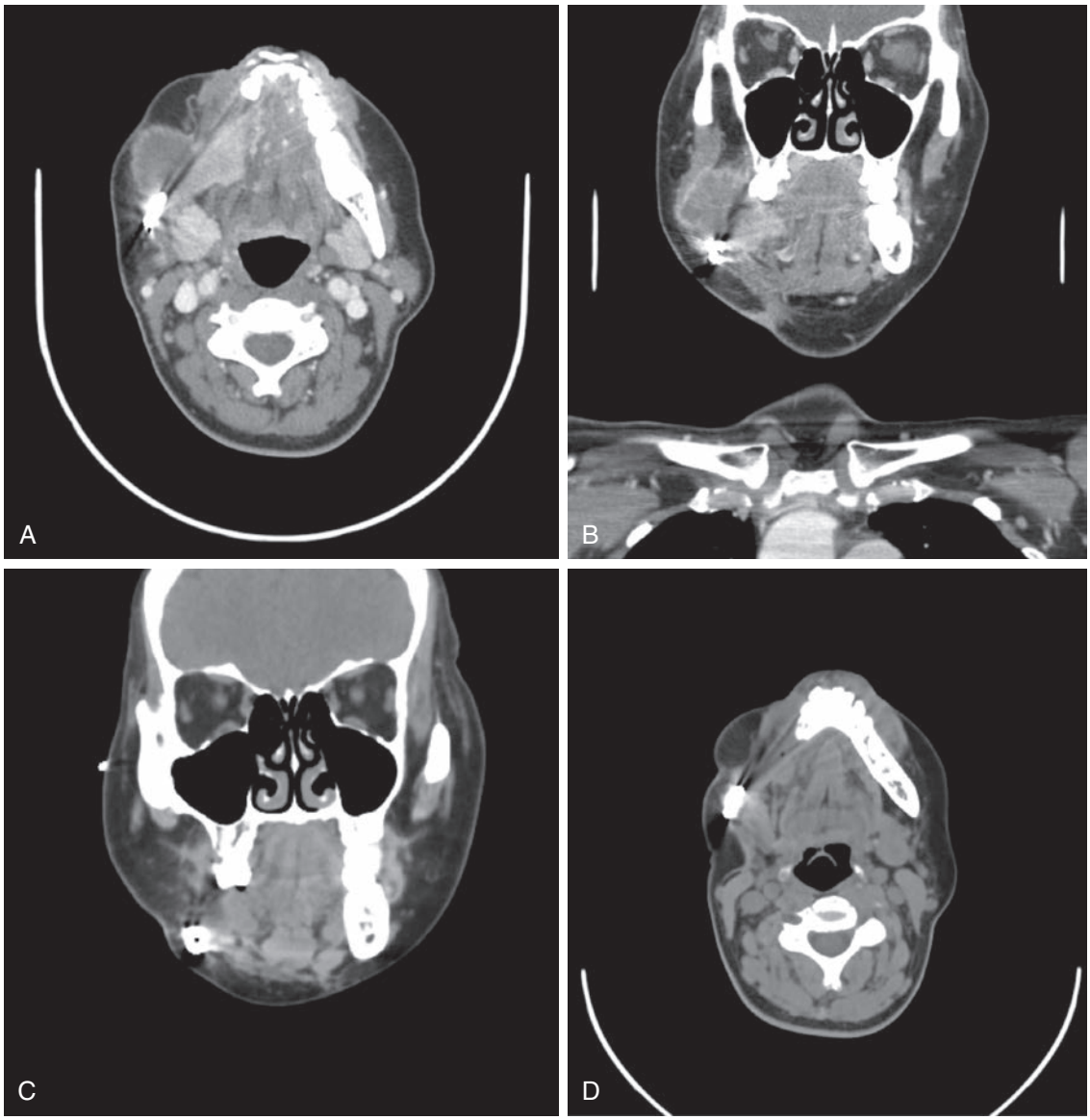

• **Figure 27-11** Axial **(A)** and coronal **(B)** computed tomography (CT) scans demonstrating the presence of a spindle cell rhabdomyosarcoma with associated increased surgical morbidity in order to obtain negative surgical margins. Good treatment response to multimodal treatment consisting of radiation therapy and four cycles of ifosfamide and doxorubicin as demonstrated in coronal **(C)** and axial **(D)** CT scans.

including chest films or CT, abdominal ultrasound, abdominal CT, or radioisotope bone scans may also be warranted given the possibility of a secondary head and neck leiomyosarcoma arising from a metastatic gastrointestinal or genitourinary primary.[126] The most common site of presentation for primary head and neck leiomyosarcomas is the neck, which constitutes approximately 30% to 50% of all tumors presenting within this region.[4,84] Other commonly reported head and neck subsites include the oral cavity, scalp, and jaws.[127] Involvement of the sinonasal tract parapharyngeal spaces is much less common, although a limited number of cases have been reported.[127-129]

Histologic examination of leiomyosarcomas reveals fascicles of spindle-shaped cells with abundant eosinophilic fibrillary cytoplasm. Nuclei are often oval to elongated (cigar-shaped) and can appear hyperchromatic with varying degrees of atypia and pleomorphism.[126] Mitotic figures will typically be scattered throughout multiple fields and can vary in number from infrequent to abundant.[126] Immunohistochemical analysis typically shows positivity for one or more of the following markers: desmin, muscle-specific actin, smooth muscle myosin, vimentin, and smooth muscle actin.[126,129]

Treatment of leiomyosarcomas is best accomplished with complete surgical excision with negative margins when possible. The success of the initial surgical management is of paramount importance, as this has been found to be a notable prognostic factor in terms of outcome and likelihood of

local recurrence.[124,126,130] Adjuvant radiation and chemotherapy are employed in the treatment of leiomyosarcomas; however, they are generally reserved for cases of residual disease following surgery, for inoperable tumors, or for palliative treatment.[128] Elective neck dissection is unnecessary given the extremely low propensity for regional nodal metastases. Local recurrence is known to occur in approximately 45% of cases and likely represents an underlying inadequacy of the initial surgical treatment.[124,130] Distant metastases are also common and are reported to occur in approximately 17% to 35% of patients.[26]

Prognosis for head and neck leiomyosarcomas is variable, owing to the relative rarity of this sarcoma subtype within the head and neck region. Overall survival rates for tumors involving the oral cavity and sinonasal tract are reported to range from 32% to 43%,[124,130] whereas larger scale series report survival rates as high as 70%.[9,84] Prognostic factors that are likely to correlate with worse outcomes include high histologic grade,[9] local tumor extension,[128] residual disease following surgical resection,[26] and posterior anatomic locations (infratemporal fossa, pterygoid plates, mandibular condyle).[126]

In summary, leiomyosarcomas are exceedingly uncommon tumors within the head and neck and account for only 5% of all head and neck sarcoma diagnoses overall. Diagnostic evaluation of head and neck leiomyosarcomas should also include evaluation of the gastrointestinal and genitourinary systems, given the possibility for metastatic disease presenting within the head and neck. Treatment of leiomyosarcomas is optimally carried out via complete surgical excision, as residual disease predisposes to recurrence and is correlated with poorer overall survival.

Angiosarcoma

Angiosarcomas are extremely rare malignant endothelial cell tumors of lymphatic or vascular origin.[8] Collectively angiosarcomas represent less than 1% of all soft tissue sarcoma diagnoses; however, they make up approximately 15% of sarcoma diagnoses within the head and neck region.[1,4,131] Approximately 50% of all angiosarcomas will occur within the head and neck when all anatomic locations are considered.[132-135] The typical age of onset is after the fifth decade of life, and individuals younger than 50 years of age are rarely affected.[132,133,136,137] Caucasians are much more commonly affected than African Americans, and there is a 2:1 male to female predominance.[8,133,134] Several environmental and genetic risk factors have been implicated in the development of head and neck angiosarcomas, including previous history of head and neck radiation, chronic lymphedema, Milroy syndrome, vinyl chloride, arsenic, anabolic steroids, BRCA1 mutation, BRCA2 mutation, neurofibromatosis type I, Maffucci syndrome, and Klippel-Trénaunay syndrome.[138]

Clinically, most angiosarcomas will present as violaceous bruise-like macules and plaques, and correct diagnosis is often delayed because of their mimicry of other dermatologic conditions. Typically, the tumor will be present for a number of months before more ominous symptoms of bleeding, ulceration, and pain occur.[132,133] Additionally, some angiosarcomas lack the characteristic vascular appearance and assume a more nodular form that lead to misdiagnosis as folliculitis, benign vascular formations, malignant melanoma, Merkel cell carcinoma, or basal cell carcinoma.[26] The most common locations for head and neck angiosarcomas are the face and scalp,[8,26] and coupled with its predilection for Caucasian individuals, this has led some to suggest a potential etiologic correlation with sun exposure—although this has never been clearly demonstrated within the literature. At the time of diagnosis, approximately one third of patients will present with multifocal head and neck lesions; however, only 10% of patients will exhibit regional cervical metastases.[26] The presence of distant metastases at the time of diagnosis occurs in approximately 20% to 45% of patients, and the most commonly involved site is the lungs.[8,132,133,135,137] Tissue diagnosis is most appropriately obtained through the use of incisional biopsy, given the most typical location of the lesion on the skin of the face and scalp. Excisional biopsies are generally not preferred, as an inadequate initial excision could lead to disruption of the macroscopic tumor margins and would eventually complicate a future and more definitive surgical resection.[6,30]

Histologically, angiosarcomas are composed of an infiltrative proliferation of endothelium-lined blood vessels forming anastomosing channels and dilated sinusoids. The malignant endothelial cells appear hyperchromatic and demonstrate varying levels of atypia. Neoplastic cellular proliferation into the lumina of the vascular spaces is also characteristic.[26] Immunopositivity for CD31, CD34, factor VIII, and von Willebrand factor is noted in up to 60% to 80% of cases and can help to facilitate appropriate histologic diagnosis.[132,139]

The optimal treatment of head and neck angiosarcomas has not yet been clearly delineated owing to the relative rarity of the neoplasm and its universally dismal prognosis.[26] Because of the propensity for these neoplasms to exhibit rapid subcutaneous spread over large areas, the ability to achieve negative margin status is dramatically impaired and local recurrence is an almost universal clinical hallmark of the disease.[134,137] Even with the use of fresh frozen–section analysis at the time of the initial surgery, obtaining truly negative margins remains unlikely. This is exemplified by the finding that negative margin status was not correlated with overall patient survival in several studies.[140,141] Accordingly, adjuvant wide-field radiation therapy has been used with increasing frequency, and it has been shown to improve both survival rates and local disease control when administered in combination with chemotherapy.[8,132,133,137] Some investigators have also suggested that definitive radiation therapy without surgical resection plus or minus chemotherapy may even offer adequate primary local disease control.[133,142-144]

Prognosis for patients affected by angiosarcomas of the head and neck remains exceedingly poor, as 5-year survival

rates range from only 12% to 33% overall.[133,134,137] Complete resection of all macroscopic disease before initiation of adjuvant radiation therapy has been associated with improved rates of local disease control,[144] and lesions less than 10 cm in diameter have also been associated with a more favorable prognosis.[133,134] Interestingly, the histologic grade of angiosarcomas has never been shown to correlate with survival, which is an atypical characteristic relative to virtually all other types of head and neck sarcomas.[26] Overall, angiosarcomas behave like aggressive high-grade malignancies and typically cause death via distant metastases.[26,132-134,144]

In conclusion, angiosarcomas are extremely rare sarcomas that are uncommon overall, but have a high propensity for presenting within the head and neck when they do occur. Angiosarcomas most commonly affect older Caucasian males and are associated with a number of genetic and environmental risk factors. Appropriate clinical diagnosis can be delayed by relatively innocuous clinical appearance of the lesions, and they can be easily confused with a number of other dermatologic conditions. Optimal treatment regimens for angiosarcomas have yet to be established; however, most recent evidence suggests utility in combination multimodal therapy involving surgery, radiation, and chemotherapy. Unfortunately, even attaining negative margin status at the time of surgery does not affect survival, and patients have an almost universally dismal prognosis overall.

Hemangiopericytoma

Hemangiopericytomas represent rare vascular sarcomas that originate from the pericytes of Zimmermann, which are cells that encircle capillary endothelium and function as baroreceptors within the capillary walls.[145] Literature on this rare neoplasm is scant and is predominantly made up of case reports and small case series.[146] The majority of hemangiopericytomas originate in the pelvis, retroperitoneum, and lower extremities; however, approximately 25% present within the head and neck.[145] Hemangiopericytomas can present over a wide age range, and the peak incidence occurs between the third and fifth decades of life.[145] No gender predilection has been observed based on reported cases, and no etiologic risk factors have been identified.[26,146]

The most common clinical presentation of hemangiopericytomas is that of a soft, slow-growing, painless mass.[147,148] Accordingly, these tumors can easily be mistaken for lipomas or other benign neoplasms, leading to a delay in proper diagnosis.[147,148] However, despite being described as an indolent tumor, local invasion with destruction of adjacent anatomic structures and metastatic spread are also common features of this sarcoma.[149] The most frequently involved head and neck subsite is the sinonasal tract,[145-147] and tumors in this region can produce various symptoms including nasal obstruction, epistaxis, pain, headache, and visual disturbance.[145,146] CT imaging of hemangiopericytomas typically reveals a noncalcified soft tissue mass displacing adjacent structures and occasionally eroding bone. Contrast-enhanced CT imaging will typically highlight the vascular nature of these lesions,[145] and angiography can be used for large tumors in order to delineate the anatomy of the vascular supply.[146] Preoperative arterial embolization can also be used to help minimize blood loss prior to the primary surgical resection.[146]

Histologically, hemangiopericytomas are typically well-circumscribed tumors composed of tightly packed cells surrounding endothelium-lined vascular channels.[145] The cytoplasm of the tumor cells is typically sparse, with indistinct borders, and the nuclei often appear vesicular or ovoid in shape.[145] The vascular channels within the tumors typically demonstrate irregular branching that results in a characteristic "staghorn" or "antler-like" appearance.

Treatment of hemangiopericytoma is ideally carried out through complete surgical resection with negative margins. Local recurrence as well as distant metastasis is reported to occur frequently after surgical resection; however, head and neck hemangiopericytomas have less propensity for distant spread than do tumors originating in other anatomic regions.[147] Long-term follow-up of patients is required, as the mean time to recurrence is 46 months following initial treatment, and recurrence has been reported to occur up to 17 years following primary management.[146] Elective cervical lymphadenectomy is unnecessary, as regional lymph node involvement has not been observed.[145] The use of adjuvant radiation and chemotherapy remains largely untested.[26] However, patients undergoing adjuvant radiation therapy following incomplete surgical resection have demonstrated a non-statistically significant increase in disease-free survival and a statistically significant decrease in rate of recurrence in a limited number series.[146] The use of radiotherapy alone as the primary treatment modality has been shown to correlate with higher rates of recurrence as well as tumor-related death.[146]

Accurately establishing prognosis for head and neck hemangiopericytomas is hindered by the limited number of cases available within the literature, as well as by a relative lack of adequate observational follow-up—although 10-year survival rates have been reported to reach as high as 70%.[145,146] When all anatomic subsites are considered, the overall survival rates for hemangiopericytomas range from 40% to 76%.[84,145-147,149] However, local recurrence rates for head and neck hemangiopericytomas are reported to reach as high as 40%, and metastatic disease develops in 15% of cases—typically involving the lungs, liver, and bone.[145] A number of negative prognostic factors affecting survival have been identified, including presence of tumor necrosis, high histologic grade, more than four mitotic figures per high-power field, and tumor size greater than 6.5 cm.[146]

In summary, hemangiopericytomas represent extremely rare vascular sarcomas that most commonly involve the sinonasal tract within the head and neck. They are locally aggressive and typically have a high rate of local recurrence, particularly in cases of incomplete surgical resection. Treatment is predominantly surgical, although there is some early

evidence that adjuvant radiation therapy can delay time to recurrence in cases of residual disease after resection. Accurate assessment of prognosis for head and neck hemangiopericytomas is severely limited by the neoplasm's propensity for delayed recurrence and inadequate durations of follow-up for many of the reported cases within the literature.

Neurogenic Sarcoma

Neurogenic sarcomas are rare soft tissue sarcomas that are known by a multitude of different names including neurofibrosarcomas, malignant neurofibromas, malignant peripheral nerve sheath tumors, malignant neurilemmomas, and malignant schwannomas.[150-152] Neurogenic sarcomas make up roughly 5% to 10% of all soft tissue sarcoma diagnoses;[153] however, up to 20% of these tumors will present within the head and neck.[154] Considering only head and neck subsites, neurogenic sarcomas represent 5% to 15% of all sarcomas diagnosed within this region.[4,6,9,15,84,131] Neurogenic sarcomas predominantly affect adults and occur over a wide age range (fourth to sixth decades of life) with a roughly equal sex predilection.[150,151,154,155] They are known to occur de novo, from a preexisting neurofibroma, or more rarely, they can also arise from a preexisting schwannoma.[155] Neurogenic sarcomas also possess an extremely strong association with neurofibromatosis type I (NF1), as well as a weaker association with neurofibromatosis type II (NF2).[152,154] Patients affected by NF1 have an approximately 4600 times greater risk of developing neurogenic sarcomas relative to individuals of the general population, and approximately 50% of all neurogenic sarcomas occur in patients with NF1.[154] Furthermore, approximately 10% of neurogenic sarcomas are also associated with previous history of radiation exposure, either therapeutic or environmental.[155]

The most common clinical presentation of neurogenic sarcomas is that of a painless enlarging neck mass, although a neuropathy within the distribution of the nerve of origin is also a common presenting symptom.[150] Neurogenic sarcomas are highly aggressive and are known to grow rapidly along nerves with infiltration of surrounding tissues.[153] MRI is most commonly used to delineate the extensiveness of these tumors, and concomitant CT imaging is also useful to assess for any evidence of osseous invasion.[153,156] Imaging findings commonly reported for neurogenic sarcomas include heterogeneous contrast enhancement, contour irregularity, and evidence of tumor necrosis.[152,153,156] Unfortunately, the aforementioned imaging findings are not specific enough to allow neurogenic sarcomas to be distinguished from other types of benign or malignant nerve sheath tumors; ultimate diagnosis requires analysis of a tissue specimen.[153,156]

Histologically, the specific "cell of origin" for neurogenic sarcomas has yet to be definitively established, although it is postulated that these tumors may arise from neural crest cells.[155] The accurate diagnosis of neurogenic sarcomas is also significantly impeded by the absence of specific morphologic, immunohistochemical, and molecular criteria for these lesions.[155] Typical histologic features include fascicles of atypical spindle-shaped cells in a palisading arrangement, nuclear atypia, bizarre giant cells, mitotic figures, and necrosis.[156] However, the histologic patterns seen within neurogenic sarcomas can also closely resemble findings seen within other spindle cell neoplasms such as malignant fibrous histiocytoma, fibrosarcoma, leiomyosarcoma, angiosarcoma, and even malignant melanoma.[150,155,156] Immunohistochemically, there are no diagnostic markers specific to neurogenic sarcomas, as S-100, CD34, TLE1, nestin, Sox10, and HMGA2 all exhibit variable expression by these tumors.[155] Accordingly, accurate diagnosis requires good correlation with clinical history, presence of NF1/NF2 diagnoses, and exclusion of similar neoplasms by a combination of immunohistochemistry and molecular genetic analysis.[155] Histologic identification of a nerve trunk or evidence of a preexisting neurofibroma or schwannoma from which the tumor originates can also facilitate the diagnosis.[150]

Treatment of neurogenic sarcomas involves wide local excision; however, the resectability of the tumor can be limited by the neuroanatomic extension of the lesion.[91,150,151] Every attempt should be made to obtain negative margins at both the proximal and distal extension of the originating nerve, as positive margin status correlates with poor outcomes.[151,154] Resection of adjacent anatomic structures may also be required, given the lack of true capsules surrounding these tumors and their propensity for local tissue invasion.[157] Elective neck dissection is unnecessary, given the rarity of regional nodal involvement seen with neurogenic sarcomas.[150,151,154,157] The role of adjuvant therapies has been widely reported within the literature because of the neurogenic sarcoma's propensity for local recurrence;[150,151] however, the utility of adjuvant therapies remains unclear given the tumor's limited sensitivity to both radiation and chemotherapy.[155]

The prognosis for neurogenic sarcomas is relatively poor, with overall 5-year survival rates reported to range from 47% to 61% and 10-year survival rates ranging from 35% to 24%.[9,131,157] Approximately 40% of patients will develop local recurrence, and one third of patients will go on to develop distant metastases, most commonly to the lungs and bone.[150,151,155] Factors associated with poor prognosis include tumors larger than 5 cm, positive surgical margins at the time of resection, higher histologic grade, mitotic index greater than 6/10 per high-power field, and tumors associated with NF1.[9,154,155,157]

In summary, neurogenic sarcomas represent rare soft tissue sarcomas within the head and neck region. They possess a strong association with the presence of NF1 and are also weakly associated with both NF2 and a previous history of ionizing radiation exposure. They are highly aggressive neoplasms with a propensity for both local recurrence and distant metastases. Accurate diagnosis is challenging due to the histologic features shared by a number of other neoplastic processes and a relative lack of distinguishing immunohistochemical markers. Treatment is predominantly via surgical resection with full attempt at obtaining negative

margins. The role of adjuvant therapies remains controversial, although they are recommended by numerous authors. Prognosis remains relatively poor overall owing to the propensity for local recurrence and metastatic spread.

Liposarcoma

Liposarcomas represent a relatively common type of soft tissue sarcoma and account for approximately 35% to 45% of all soft tissue sarcoma diagnoses.[158] Most liposarcomas originate in the lower extremities or retroperitoneum.[15,159] Liposarcomas of the head and neck are exceedingly rare, with only 2% of liposarcomas presenting in this region.[8] Liposarcomas most commonly present in adults in the fifth to sixth decades of life with a median age at diagnosis of 51 years.[158,160] Males are more commonly affected, with a 5:3 male-to-female ratio.[160] Known etiologic risk factors for liposarcoma include neurofibromatosis type I (NF1), history of soft tissue trauma, and previous history of radiation exposure.[8]

Diagnosis of head and neck liposarcoma does not differ significantly from diagnosis of other types of sarcomas originating within the head and neck region. The upper aerodigestive tract (oral cavity, oropharynx, hypopharynx, and larynx) is the most commonly involved head and neck subsite, representing approximately 50% of liposarcoma cases.[160-164] The upper aerodigestive tract is followed closely by the neck, which is responsible for approximately one third of the remaining head and neck liposarcoma cases.[160-164] Presenting symptoms will depend on the specific anatomic area involved but can include dysphagia, dyspnea, airway obstruction, and hoarseness, given the common involvement of the upper aerodigestive tract. As is the case for numerous other types of head and neck sarcomas, the most commonly reported presenting symptom is that of a painless expansile mass.[158]

Histologically, liposarcomas are characterized by vacuolated lipoblasts with pleomorphic nuclei and varying levels of hyperchromatic stroma. Four distinct histologic variants have been described: well-differentiated, myxoid, pleomorphic, and round cell.[165] Liposarcomas are also categorized into low-grade and high-grade tumors depending on the specific histologic variant seen. Well-differentiated and myxoid variants are classically low-grade lesions, whereas pleomorphic and round cell variants represent high-grade tumors.[165] Appropriate histologic classification is important in the management of liposarcomas, as the histologic grade of the lesion predicts tumor behavior and also affects the overall prognosis.[8,158,160,161]

Treatment of liposarcomas involves complete surgical resection of the tumor whenever possible, as local recurrence represents the main pattern of treatment failure.[26] Regional metastases are exceedingly rare, and therefore elective management of the neck is typically not indicated.[163] Adjuvant radiation therapy has been shown to reduce rates of local recurrence; however, it does not seem to affect overall survival.[8] Nevertheless, adjuvant radiation therapy is often recommended for close or positive margins or in patients with unfavorable histologic variants (pleomorphic or round cell subtypes).[163]

Prognosis for head and neck liposarcomas remains variable depending on histologic grade. The overall 5-year survival rate for patients with well-differentiated liposarcomas is reported to be 100%, whereas survival rates for the myxoid variant are reported to range from 60% to 73%.[158,160,166] Patients with the pleomorphic variant can expect 5-year survival rates of 42%, whereas the round cell variant possess the most dismal prognosis with expected 5-year survival rates of 0%.[160] Histologic grade also portends the likelihood of experiencing distant metastases, as well-differentiated variants virtually never metastasize and the myxoid variant is known to occasionally spread to nonpulmonary sites.[26] Pleomorphic and round cell variants also demonstrate a propensity for distant metastases; however, these variants most commonly involve the lungs.[160,161] It has been reported that tumors involving the oral cavity, pharynx, and neck appear to have a worse prognosis than lesions involving the scalp and face;[160] however, more recent series have reported contradictory findings.[158] Interestingly, tumor size does not appear to affect survival for head and neck liposarcomas.[160,161]

In summary, liposarcomas represent one of the most common forms of soft tissue sarcoma; however, it is exceedingly uncommon for them to present within the head and neck region. They most commonly affect older males, and the most common site of involvement within the head and neck is the upper aerodigestive tract. Appropriate histologic diagnosis and accurate assessment of histologic grade are of paramount importance, as this not only predicts prognosis, but also can aid in identifying patients who require more aggressive forms of treatment. Complete surgical resection remains the gold standard treatment for all histologic variants of liposarcomas, and adjuvant radiation therapy is typically indicated in cases of high-grade neoplasms or when clear surgical margins are not obtained. Long-term follow-up with appropriate serial imaging studies is indicated based on the histologic variant of the resected tumor and the respective propensity for distant metastases.

Synovial Sarcoma

Synovial sarcoma is a relatively common soft tissue sarcoma that represents approximately 10% of all soft tissue sarcoma diagnoses.[167] However, head and neck synovial sarcoma is extremely rare, with less than 6% of all reported cases occurring within the head and neck region.[168,169] Furthermore, synovial sarcomas make up only 3% to 5% of all head and neck sarcoma diagnoses.[170] The majority of synovial sarcomas occur in the lower extremities, which account for approximately 70% of all cases.[170] Although para-articular locations for synovial sarcomas are common, these tumors rarely involve or originate from a true synovial structure.[170,171] Rather, their true cellular origin is believed to be from pluripotent mesenchymal cells, and their name is

actually derived from the tumor's histologic resemblance to normal synovial membrane.[170-172] Head and neck synovial sarcomas have a median age at diagnosis of approximately 32 years; however, they have been reported to occur over an exceedingly wide range of ages (4 to 76 years).[169] There is a slight male predominance based on the roughly 100 cases of head and neck synovial sarcoma reported within the literature.[169,173]

Diagnosis of synovial sarcoma can be challenging, as the tumors can occasionally be slow growing, have variable size presentation, and can also appear benign on imaging studies.[169] Accordingly, synovial sarcomas have been reported to be one of the most commonly misdiagnosed soft tissue malignancies.[169] Over 90% of synovial sarcomas contain a specific balanced translocation between the X chromosome and chromosome 18, t(x;18)(p11.2;q11.2), and identification of this translocation can greatly facilitate the appropriate diagnosis.[171] The most commonly involved head and neck subsites for synovial sarcomas include the hypopharynx and parapharyngeal spaces; however, they have also been reported to occur in the tonsils, tongue, and orofacial soft tissues.[167] The most commonly reported presenting symptom is that of a painless slow-growing expansile mass;[171,173] however, additional symptoms, including pain, dysphagia, dyspnea, paresthesias, limited mandibular opening, and migraine headaches, have also been reported.[169,170]

Histologically, synovial sarcomas are composed of two morphologically distinct, but histogenetically related cell types: epithelioid cells and spindle cells.[169,172] A biphasic form is noted when both cell types are present histologically; however, monophasic forms composed of only one of the two cell types can also occur.[169,172] Depending on the predominance of the two cell types and the degree of differentiation, synovial sarcomas form a continuous spectrum of histologic variants including biphasic, monophasic fibrous, monophasic epithelial, and poorly differentiated (round cell).[169] The biphasic form is most readily diagnosed; however, the monophasic forms represent a greater diagnostic challenge, and immunohistochemical analysis is often required to distinguish monophasic synovial sarcomas from other types of spindle-cell neoplasms.[167] Immunopositivity for vimentin, cytokeratin, and EMA is rarely identified in other neoplasms, and with combined positivity for CD99 and Bc12, a definitive diagnosis of monophasic synovial sarcoma can be rendered.[167] Nevertheless, it is also recommended to corroborate diagnosis with negative immunostaining for S-100 and SMA to rule out neurogenic or smooth-muscle derived sarcomas.[167]

Treatment of synovial sarcomas is primarily based on wide surgical resection in an attempt to achieve negative margins.[167,172,173] Given the rarity of regional nodal metastasis, elective management of the neck is not indicated on a routine basis.[167] Numerous reports also suggest the utility of postoperative radiation and chemotherapy; however, given the relative rarity of head and neck synovial sarcoma, optimal management protocols have yet to be established.[169,171-173] Some evidence exists that postoperative adjuvant radiation therapy may have a positive impact on both local control and overall survival rates; however, future longitudinal prospective investigations will be required in order to fully validate these results.[169]

Prognosis for synovial sarcomas is not well delineated owing to the relative rarity of this tumor within the head and neck region. Reported 5-year survival rates vary widely depending on the study and range from 36% to 81%.[169,172,173] Head and neck synovial sarcomas are well known to exhibit very high rates of distant metastatic spread, most commonly involving the lungs, and this represents the leading cause of death for this sarcoma.[172,173] Prognostic factors that have been reported to correlate with unfavorable outcomes include tumor size larger than 5 cm, positive margins, non-calcifying tumors, and monophasic variants.[169,173-175]

In summary, synovial sarcomas are common soft tissue sarcomas that rarely present within the head and neck region. Their histogenetic origin remains unclear, although it is proposed that they derive from pluripotent mesenchymal cells. They commonly arise from para-articular regions within the extremities; however, they do not originate from true synovium and can be found in complete isolation from synovial structures. Histologic diagnosis is greatly aided by the use of immunohistochemistry, particularly in the case of monophasic tumors. Optimal treatment strategies have yet to be developed; however, wide surgical resection followed by adjuvant radiation therapy has been suggested to improve local recurrence rates and possibly survival.

Ewing Sarcoma

Ewing sarcomas represent the second most common primary malignant bone cancer in children and adults (following osteosarcoma), and these sarcomas account for roughly 10% of all malignant osseous tumors.[176,177] Ewing sarcomas most commonly arise in the pelvis or long bones of the lower extremities, and involvement of the head and neck is exceedingly rare.[176,178,179] In fact, Ewing sarcomas of the head and neck represent only 1% to 4% of all reported cases.[176,179] Ewing sarcomas most commonly affect children and young adults, with the peak incidence occurring during the teenage years.[176-180] No gender predilection has been observed based on reported cases.[177,178,180]

The most common presenting symptom for patients with head and neck Ewing sarcoma is that of a rapidly growing expansile mass.[177,179-181] Associated symptomatology depends on the anatomic area of involvement; however, pain, paresthesias, and visual disturbances have all been reported as common complaints.[176,181] The most commonly involved head and neck subsites are the maxilla and mandible, followed closely by the skull.[177,179,181] A number of other areas, including the orbit, scalp, sinonasal tract, paravertebral areas, and neck have all been reported as less common sites of origination.[177,178,180]

Histologically, Ewing sarcomas are composed of small, round hyperchromatic cells with scant cytoplasm, well-delineated uniform nuclei, and indistinct cellular borders.[181] The tumor cells are often arranged in broad sheets with fibrovascular septa separating the tumor into lobular domains. Analogous to synovial sarcomas, the exact histogenesis of Ewing sarcomas remains unclear, yet there is increasing evidence to support a neuroectodermal origin.[176,179-181] Over 90% of Ewing sarcomas share a chromosomal translocation commonly found in primitive neuroectodermal tumors, (t:12;22)(q;24:12), and identification of this translocation greatly facilitates diagnosis in cases with equivocal histology.[181] Immunohistochemical analysis revealing positivity for FLI1 and CD99 can also be used to confirm the diagnosis of Ewing sarcoma.[181]

Treatment of head and neck Ewing sarcomas is greatly aided by the well-known chemo- and radiosensitivity of these tumors.[179] However, reports describing outcomes for head and neck Ewing sarcomas are limited given the relative rarity of tumors within this region, and many management decisions are extrapolated from investigations evaluating Ewing sarcomas of the appendicular skeleton.[179] Nevertheless, the largest studies on head and neck Ewing sarcomas from the Intergroup Ewing sarcoma Study (IESS) have demonstrated that combination neoadjuvant chemotherapy regimens coupled with surgical resection have greatly improved survival rates in patients with localized disease.[177] Accordingly, wide surgical resection in conjunction with chemotherapy remains a cornerstone of treatment for head and neck Ewing sarcomas.[181] The use of radiation therapy for head and neck Ewing sarcoma remains somewhat controversial; however, its use is widely recommended for cases of large unresectable tumors where operative morbidity would be significant or in cases of residual disease following initial surgical resection.[176,178,179,181] Opponents of radiation therapy as primary treatment for head and neck Ewing sarcoma cite the well-documented risk of inducing secondary post-radiation malignancy, as well as the inevitable radiation-induced disturbance of facial growth centers in children and adolescents.[179,181]

Prognosis for Ewing sarcomas at all anatomic sites has been dramatically improved over the past 20 years with the use of multimodal therapy, and 5-year survival rates, once 10%, are currently 50% to 70% overall.[179,181] Prognosis for head and neck Ewing sarcomas remains less well defined owing to the rarity of this lesion within this region; however, some evidence suggests that patients may actually fare better with head and neck tumors when compared to other anatomic sites.[178] Head and neck Ewing sarcomas are noted to be less likely to present with distant metastases at the time of diagnosis; however, it remains unclear whether this is the result of tumor biology or higher likelihood of earlier diagnosis when compared to other anatomic areas.[179] Ultimately, local tumor control remains a mainstay of improving survival and reducing rates of distant metastases, as patients with residual disease following surgical resection suffer from a significantly worse prognosis.[178]

In conclusion, Ewing sarcomas are the second most common primary malignant bone cancer in children and adults; however, they are extremely uncommon within the head and neck region. They most commonly affect children and young adults, and they most typically arise from the gnathic structures within the head and neck. Their histogenetic origins have not been fully delineated, yet the most currently favored hypothesis is that of a neuroectodermal lineage. Treatment primarily involves multidrug neoadjuvant chemotherapy followed by surgical resection; however, radiation therapy continues to be investigated in both definitive and adjuvant applications. Overall prognosis for head and neck Ewing sarcomas is likely more favorable than for tumors arising in other locations; however, the rarity of these sarcomas precludes accurate assessments of true prognosis.

Alveolar Soft Part Sarcoma

Alveolar soft part sarcoma (ASPS) is a soft tissue sarcoma of uncertain histogenetic origin that makes up less than 1% of all soft tissue sarcoma diagnoses.[182] ASPSs most commonly occur in the tissues in the upper and lower extremities of adolescents and young adults, with a notable predilection for females—particularly in younger age groups.[183-186] Peak incidence is reported to occur between the ages of 15 and 35 years.[183] Involvement of the head and neck subsites is exceedingly uncommon owing to the overall rarity of this neoplasm; however, approximately 25% of all ASPSs will occur within the head and neck region.[185-187]

Clinically, ASPSs are usually slow-growing neoplasms with minimal features that would suggest a malignant process.[183] ASPSs also are noted for exhibiting very indolent clinical courses even in patients with underlying metastatic disease at the time of diagnosis.[182] The most common clinical presentation of ASPS is that of a painless, slow growing mass, and the most commonly involved head and neck subsites are the orbit and the tongue.[184-186,188] MRI of ASPS does reveal a characteristic high-intensity signaling on both T1- and T2-weighted images that can help to distinguish this neoplasm from other types of soft tissue sarcomas, which are typically isointense and hyperintense on T1- and T2-weighted images, respectively.[189]

Histologically, ASPS has a pseudovascular appearance with clusters of large polygonal tumor cells containing eosinophilic cytoplasm and one to multiple vesicular nuclei.[185] Tumor cell nests are typically separated by vascular channels and fibrous septa that create an alveolar pattern.[183] As previously mentioned, the tissue of origin for ASPS has not been definitively classified; however, myogenic and neural crest origin remain the two leading hypotheses. More credence has been lent to the myogenic theory given the results of more recent immunohistochemical characterization. ASPS typically demonstrates immunopositivity for both vimentin

and desmin, while conversely showing immunonegativity for EMA, cytokeratins, chromogranin A, synaptophysin, S-100, HMB45, and Melan-A.[183,185] Another defining feature of ASPS is the presence of cytoplasmic crystals containing PAS-positive and diastase-resistant material that are either rhomboid or rod-like in appearance. This finding is present in over 80% of reported cases.[185,188]

Given the relative rarity of ASPS, optimal treatment recommendations have largely been extrapolated from therapies established for other soft tissue sarcomas.[26,185] There is general agreement that the primary treatment modality is wide surgical resection with no need for elective neck dissection given the very low rates of regional metastasis.[185,186,188,190] The role of radiation therapy remains controversial, as earlier studies demonstrated no significant benefit with adjuvant radiation therapy; however, more recent studies have demonstrated significant improvements in rates of local control following primary surgical resection.[185] Given the extremely high propensity for distant metastatic spread seen with ASPS, recommendations for adjuvant chemotherapy have been previously proposed, yet multiple studies have demonstrated extremely poor responsiveness to multiple cytotoxic agents.[185] Nevertheless, given the highly vascular composition of ASPS, newer antiangiogenic agents, such as bevacizumab, sunitinib malate, and cediranib have shown some early promise in clinical trials for both primary and metastatic ASPS.[185]

Long-term prognosis for ASPS remains exceedingly poor, owing in large part to high rates of distant metastases, which are present in up to 65% of patients at the time of diagnosis.[191] The most common sites of metastatic spread are the lungs, followed by the bones, brain, and lymph nodes.[186] Overall 5-year survival rates with adequate primary surgical resection are reported to be as high as 65%; however, these rates drop to 38% at 10 years and 15% at 20 years, which highlights the inevitable impact of local recurrence and metastatic spread.[186] Prognostic factors affecting survival are difficult to establish given the rarity of ASPS in the head and neck region; however, large tumor size and more advanced AJCC stage have been suggested to correlate with reduced rates of survival.[185]

In summary, ASPS is an extremely rare soft tissue sarcoma that makes up less than 1% of all sarcoma diagnoses overall. Its overall rarity makes head and neck presentations uncommon; however, up to 25% of ASPS occur in head and neck subsites—particularly in pediatric and adolescent populations. Accurate diagnosis is critical, as these tumors often do not exhibit clinical features of malignancy, and the presence of metastatic dissemination at the time of diagnosis is common. Optimal treatment strategies have yet to be developed, although wide surgical resection remains a cornerstone of management. More recent studies suggest the utility of adjuvant radiation therapy in improving local disease control, and newer antiangiogenic agents are currently in trials for both primary and metastatic ASPS. Overall, the prognosis for ASPS remains poor given the high rates of distant metastasis.

References

1. Wanebo HJ, Koness RJ, MacFarlane JK, et al.: Head and neck sarcoma: report of the Head and Neck Sarcoma Registry. Society of Head and Neck Surgeons Committee on Research, *Head Neck* 14(1):1–7, 1992.
2. Landis SH, Murray T, Bolden S, Wingo PA: Cancer statistics, 1999, *CA Cancer J Clin* 49(1):8–31, 1999.
3. Jemal A, Thomas A, Murray T, Thun M: Cancer statistics, 2002, *CA Cancer J Clin* 52(1):23–47, 2002.
4. Weber RS, Benjamin RS, Peters LJ, Ro JY, Achon O, Goepfert H: Soft tissue sarcomas of the head and neck in adolescents and adults, *Am J Surg* 152(4):386–392, 1986.
5. Brockstein B: Management of sarcomas of the head and neck, *Curr Oncol Rep* 6(4):321–327, 2004.
6. Kraus DH, Dubner S, Harrison LB, et al.: Prognostic factors for recurrence and survival in head and neck soft tissue sarcomas, *Cancer Jul 15* 74(2):697–702, 1994.
7. Lawrence Jr W, Anderson JR, Gehan EA, Maurer H: Pretreatment TNM staging of childhood rhabdomyosarcoma: a report of the Intergroup Rhabdomyosarcoma Study Group. Children's Cancer Study Group. Pediatric Oncology Group, *Cancer* 80(6):1165–1170, 1997.
8. O'Neill JP, Bilsky MH, Kraus D: Head and neck sarcomas: epidemiology, pathology, and management, *Neurosurg Clin N Am* 24(1):67–78, 2013.
9. Farhood AI, Hajdu SI, Shiu MH, Strong EW: Soft tissue sarcomas of the head and neck in adults, *Am J Surg* 160(4):365–369, 1990.
10. Lawrence Jr W: Operative management of soft tissue sarcomas: impact of anatomic site, *Semin Surg Oncol* 10(5):340–346, 1994.
11. Laskin WB: Dermatofibrosarcoma protuberans, *CA Cancer J Clin* 42(2):116–125, 1992.
12. Sturgis EM, Potter BO: Sarcomas of the head and neck region, *Curr Opin Oncol* 15(3):239–252, 2003.
13. Willers H, Hug EB, Spiro IJ, Efird JT, Rosenberg AE, Wang CC: Adult soft tissue sarcomas of the head and neck treated by radiation and surgery or radiation alone: patterns of failure and prognostic factors, *Int J Radiat Oncol Biol Phys* 33(3):585–593, 1995.
14. Cakir S, Dincbas FO, Uzel O, Koca SS, Okkan S: Multivariate analysis of prognostic factors in 75 patients with soft tissue sarcoma, *Radiother Oncol* 37(1):10–16, 1995.
15. Le Vay J, O'Sullivan B, Catton C, et al.: An assessment of prognostic factors in soft-tissue sarcoma of the head and neck, *Arch Otolaryngol Head Neck Surg* 120(9):981–986, 1994.
16. Malkin D, Li FP, Strong LC, et al.: Germ line p53 mutations in a familial syndrome of breast cancer, sarcomas, and other neoplasms, *Science* 250(4985):1233–1238, 1990.
17. Viskochil D, White R, Cawthon R: The neurofibromatosis type 1 gene, *Annu Rev Neurosci* 16:183–205, 1993.
18. Zahm SH, Fraumeni Jr JF: The epidemiology of soft tissue sarcoma, *Semin Oncol* 24(5):504–514, Oct 1997.
19. Farndon PA, Del Mastro RG, Evans DG, Kilpatrick MW: Location of gene for Gorlin syndrome, *Lancet Mar 7* 339(8793):581–582, 1992.
20. Carney JA: The triad of gastric epithelioid leiomyosarcoma, pulmonary chondroma, and functioning extra-adrenal paraganglioma: a five-year review, *Medicine (Baltimore)* 62(3):159–169, 1983.
21. Maynard JH, Fone DJ: Haemochromatosis with osteogenic sarcoma in the liver, *Med J Aust* 2(25):1260–1263, 1969.

22. Sussman EB, Nydick I, Gray GF: Hemangioendothelial sarcoma of the liver and hemochromatosis, *Arch Pathol* 97(1):39–42, 1974.
23. Hsu JJ, Kamath-Loeb AS, Glick E, et al.: Werner syndrome gene variants in human sarcomas, *Mol Carcinog* 49(2):166–174, 2010.
24. Mark RJ, Poen J, Tran LM, Fu YS, Selch MT, Parker RG: Post-irradiation sarcomas. A single-institution study and review of the literature, *Cancer* 73(10):2653–2662, 1994.
25. Tynes T, Andersen A, Langmark F: Incidence of cancer in Norwegian workers potentially exposed to electromagnetic fields, *Am J Epidemiol* 136(1):81–88, 1992.
26. Potter BO, Sturgis EM: Sarcomas of the head and neck, *Surg Oncol Clin N Am* 12(2):379–417, 2003.
27. Grufferman S, Schwartz AG, Ruymann FB, Maurer HM: Parents' use of cocaine and marijuana and increased risk of rhabdomyosarcoma in their children, *Cancer Causes Control* 4(3):217–224, 1993.
28. Zahm SH, Heineman EF, Vaught JB: Soft tissue sarcoma and tobacco use: data from a prospective cohort study of United States veterans, *Cancer Causes Control* 3(4):371–376, 1992.
29. Patel SC, Silbergleit R, Talati SJ: Sarcomas of the head and neck, *Top Magn Reson Imaging* 10(6):362–375, 1999.
30. Arca MJ, Sondak VK, Chang AE: Diagnostic procedures and pretreatment evaluation of soft tissue sarcomas, *Semin Surg Oncol* 10(5):323–331, 1994.
31. Al-Ibraheem A, Buck AK, Benz MR, et al.: (18)F-fluorodeoxyglucose positron emission tomography/computed tomography for the detection of recurrent bone and soft tissue sarcoma, *Cancer* 119(6):1227–1234, 2013.
32. Clark JL, Unni KK, Dahlin DC, Devine KD: Osteosarcoma of the jaw, *Cancer* 51(12):2311–2316, 1983.
33. Dahlin DC, Unni KK: Osteosarcoma of bone and its important recognizable varieties, *Am J Surg Pathol* 1(1):61–72, 1977.
34. Unni KK, Dahlin DC, McLeod RA, Pritchard DJ: Intraosseous well-differentiated osteosarcoma, *Cancer* 40(3):1337–1347, 1977.
35. Gadwal SR, Gannon FH, Fanburg-Smith JC, Becoskie EM, Thompson LD: Primary osteosarcoma of the head and neck in pediatric patients: a clinicopathologic study of 22 cases with a review of the literature, *Cancer* 91(3):598–605, 2001.
36. Delgado R, Maafs E, Alfeiran A, et al.: Osteosarcoma of the jaw, *Head Neck* 16(3):246–252, 1994.
37. Tanzawa H, Uchiyama S, Sato K: Statistical observation of osteosarcoma of the maxillofacial region in Japan. Analysis of 114 Japanese cases reported between 1930 and 1989, *Oral Surg Oral Med Oral Pathol* 72(4):444–448, 1991.
38. Bielack SS, Kempf-Bielack B, Delling G, et al.: Prognostic factors in high-grade osteosarcoma of the extremities or trunk: an analysis of 1,702 patients treated on neoadjuvant cooperative osteosarcoma study group protocols, *J Clin Oncol* 20(3):776–790, 2002.
39. Arlen M, Shan IC, Higinbotham N, Huvos AJ: Osteogenic sarcoma of head and neck induced by radiation therapy, *N Y State J Med* 72(8):929–934, 1972.
40. LiVolsi VA: Osteogenic sarcoma of the maxilla, *Arch Otolaryngol* 103(8):485–488, 1977.
41. Maes P, Brichard B, Vermylen C, Cornu G, Ninane J: Primary and secondary osteosarcoma of the face: a rare childhood malignancy, *Med Pediatr Oncol* 30(3):170–174, 1998.
42. Cumin I, Cohen JY, David A, Mechinaud F, Avet-Loiseau H, Harousseau JL: Rothmund-Thomson syndrome and osteosarcoma, *Med Pediatr Oncol* 26(6):414–416, 1996.
43. Green JS, Rickett AB: Rothmund-Thomson syndrome complicated by osteosarcoma, *Pediatr Radiol* 28(1):48–50, 1998.
44. Gardner GM, Steiniger JR: Family cancer syndrome: a study of the kindred of a man with osteogenic sarcoma of the mandible, *Laryngoscope* 100(12):1259–1263, 1990.
45. Oda D, Bavisotto LM, Schmidt RA, et al.: Head and neck osteosarcoma at the University of Washington, *Head Neck* 19(6):513–523, 1997.
46. Bundgaard T, Frost-Jensen V, Buhl L: Sarcomatous change in a previously benign osteofibroma in the maxillary sinus, *Arch Otorhinolaryngol* 245(1):22–24, 1988.
47. Daw NC, Mahmoud HH, Meyer WH, et al.: Bone sarcomas of the head and neck in children: the St Jude Children's Research Hospital experience, *Cancer* 88(9):2172–2180, 2000.
48. Laskar S, Basu A, Muckaden MA, et al.: Osteosarcoma of the head and neck region: lessons learned from a single-institution experience of 50 patients, *Head Neck* 30(8):1020–1026, 2008.
49. Ha PK, Eisele DW, Frassica FJ, Zahurak ML, McCarthy EF: Osteosarcoma of the head and neck: a review of the Johns Hopkins experience, *Laryngoscope* 109(6):964–969, 1999.
50. Lewis M, Perl A, Som PM, et al.: Osteogenic sarcoma of the jaw. A clinicopathologic review of 12 patients, *Arch Otolaryngol Head Neck Surg* 123(2):169–174, 1997.
51. Roca AN, Smith Jr JL, Jing BS: Osteosarcoma and parosteal osteogenic sarcoma of the maxilla and mandible: study of 20 cases, *Am J Clin Pathol* 54(4):625–636, 1970.
52. Chan CW, Kung TM, Ma L: Telangiectatic osteosarcoma of the mandible, *Cancer* 58(9):2110–2115, 1986.
53. Garrington GE, Scofield HH, Cornyn J, Hooker SP: Osteosarcoma of the jaws. Analysis of 56 cases, *Cancer* 20(3):377–391, 1967.
54. Mark RJ, Sercarz JA, Tran L, et al.: Osteogenic sarcoma of the head and neck. The UCLA experience, *Arch Otolaryngol Head Neck Surg* 117(7):761–766, 1991.
55. Kassir RR, Rassekh CH, Kinsella JB, et al.: Osteosarcoma of the head and neck: meta-analysis of nonrandomized studies, *Laryngoscope* 107(1):56–61, 1997.
56. Jaffe N: Osteosarcoma: review of the past, impact on the future. The American experience, *Cancer Treat Res* 152:239–262, 2009.
57. Smeele LE, Kostense PJ, van der Waal I, Snow GB: Effect of chemotherapy on survival of craniofacial osteosarcoma: a systematic review of 201 patients, *J Clin Oncol* 15(1):363–367, 1997.
58. Guadagnolo BA, Zagars GK, Raymond AK, et al.: Osteosarcoma of the jaw/craniofacial region: outcomes after multimodality treatment, *Cancer* 115(14):3262–3270, 2009.
59. Browne JD: Management of nonepidermoid cancer of the larynx, *Otolaryngol Clin North Am* 30(2):215–229, 1997.
60. Farrell ML, Gluckman JL, Biddinger P: Tracheal chondrosarcoma: a case report, *Head Neck* 20(6):568–572, 1998.
61. Gadwal SR, Fanburg-Smith JC, Gannon FH, Thompson LD: Primary chondrosarcoma of the head and neck in pediatric patients: a clinicopathologic study of 14 cases with a review of the literature, *Cancer* 88(9):2181–2188, 2000.
62. Burkey BB, Hoffman HT, Baker SR, Thornton AF, McClatchey KD: Chondrosarcoma of the head and neck, *Laryngoscope* 100(12):1301–1305, 1990.
63. Mark RJ, Tran LM, Sercarz J, Fu YS, Calcaterra TC, Parker RG: Chondrosarcoma of the head and neck. The UCLA experience, 1955-1988, *Am J Clin Oncol* 16(3):232–237, 1993.

64. Ruark DS, Schlehaider UK, Shah JP: Chondrosarcomas of the head and neck, *World J Surg* 16(5):1010–1015, 1992, discussion 1015–1016.
65. Koch BB, Karnell LH, Hoffman HT, et al.: National cancer database report on chondrosarcoma of the head and neck, *Head Neck* 22(4):408–425, 2000.
66. Hoffman HT, Karnell LH, Funk GF, Robinson RA, Menck HR: The National Cancer Data Base report on cancer of the head and neck, *Arch Otolaryngol Head Neck Surg* 124(9):951–962, 1998.
67. Pring ME, Weber KL, Unni KK, Sim FH: Chondrosarcoma of the pelvis. A review of sixty-four cases, *J Bone Joint Surg Am* 83-A(11):1630–1642, 2001.
68. Angelini A, Guerra G, Mavrogenis AF, Pala E, Picci P, Ruggieri P: Clinical outcome of central conventional chondrosarcoma, *J Surg Oncol* 106(8):929–937, 2012.
69. Rapidis AD, Archondakis G, Anteriotis D, Skouteris CA: Chondrosarcomas of the skull base: review of the literature and report of two cases, *J Craniomaxillofac Surg* 25(6):322–327, 1997.
70. Harwood AR, Cummings BJ, Fitzpatrick PJ: Radiotherapy for unusual tumors of the head and neck, *J Otolaryngol* 13(6):391–394, 1984.
71. McNaney D, Lindberg RD, Ayala AG, et al.: Fifteen year radiotherapy experience with chondrosarcoma of bone, *Int J Radiat Oncol Biol Phys* 8(2):187–190, 1982.
72. Krochak R, Harwood AR, Cummings BJ, Quirt IC: Results of radical radiation for chondrosarcoma of bone, *Radiother Oncol* 1(2):109–115, 1983.
73. Noel G, Habrand JL, Jauffret E, et al.: Radiation therapy for chordoma and chondrosarcoma of the skull base and the cervical spine. Prognostic factors and patterns of failure, *Strahlenther Onkol* 179(4):241–248, 2003.
74. Noel G, Feuvret L, Ferrand R, et al.: Radiotherapeutic factors in the management of cervical-basal chordomas and chondrosarcomas, *Neurosurgery* 55(6):1252–1260, 2004, discussion 1260–1252.
75. Rosenberg AE, Nielsen GP, Keel SB, et al.: Chondrosarcoma of the base of the skull: a clinicopathologic study of 200 cases with emphasis on its distinction from chordoma, *Am J Surg Pathol* 23(11):1370–1378, 1999.
76. Zagars GK, Ballo MT, Pisters PW, et al.: Prognostic factors for patients with localized soft-tissue sarcoma treated with conservation surgery and radiation therapy: an analysis of 1225 patients, *Cancer* 97(10):2530–2543, 2003.
77. Patel SG, See AC, Williamson PA, Archer DJ, Evans PH: Radiation induced sarcoma of the head and neck, *Head Neck* 21(4):346–354, 1999.
78. Blitzer A, Lawson W, Zak FG, et al.: Clinical-pathological determinants in prognosis of fibrous histiocytomas of head and neck, *Laryngoscope* 91(12):2053–2070, 1981.
79. Fell W, Housini I, Marple B: Radiation-induced malignant fibrous histiocytoma of the head and neck, *Otolaryngol Head Neck Surg* 118(4):529–531, 1998.
80. Singh B, Shaha A, Har-El G: Malignant fibrous histiocytoma of the head and neck, *J Craniomaxillofac Surg* 21(6):262–265, 1993.
81. Frankenthaler R, Ayala AG, Hartwick RW, Goepfert H: Fibrosarcoma of the head and neck, *Laryngoscope* 100(8):799–802, 1990.
82. Satomi T, Watanabe M, Kaneko T, Matsubayashi J, Nagao T, Chiba H: Radiation-induced malignant fibrous histiocytoma of the maxilla, *Odontology* 99(2):203–208, 2011.
83. Barnes L, Kanbour A: Malignant fibrous histiocytoma of the head and neck. A report of 12 cases, *Arch Otolaryngol Head Neck Surg* 114(10):1149–1156, 1988.
84. Tran LM, Mark R, Meier R, Calcaterra TC, Parker RG: Sarcomas of the head and neck. Prognostic factors and treatment strategies, *Cancer* 70(1):169–177, 1992.
85. Fagundes HM, Lai PP, Dehner LP, et al.: Postoperative radiotherapy for malignant fibrous histiocytoma, *Int J Radiat Oncol Biol Phys* 23(3):615–619, 1992.
86. Adjuvant chemotherapy for localised resectable soft-tissue sarcoma of adults: meta-analysis of individual data. Sarcoma Meta-analysis Collaboration, *Lancet* 350(9092):1647–1654, 1997.
87. Clark DW, Moore BA, Patel SR, Guadagnolo BA, Roberts DB, Sturgis EM: Malignant fibrous histiocytoma of the head and neck region, *Head Neck* 33(3):303–308, 2011.
88. Oda Y, Tamiya S, Oshiro Y, et al.: Reassessment and clinicopathological prognostic factors of malignant fibrous histiocytoma of soft parts, *Pathol Int* 52(9):595–606, 2002.
89. Scott SM, Reiman HM, Pritchard DJ, Ilstrup DM: Soft tissue fibrosarcoma. A clinicopathologic study of 132 cases, *Cancer* 64(4):925–931, 1989.
90. Mark RJ, Sercarz JA, Tran L, Selch M, Calcaterra TC: Fibrosarcoma of the head and neck. The UCLA experience, *Arch Otolaryngol Head Neck Surg* 117(4):396–401, 1991.
91. Greager JA, Reichard K, Campana JP, Das Gupta TK: Fibrosarcoma of the head and neck, *Am J Surg* 167(4):437–439, 1994.
92. Hourani R, Taslakian B, Shabb NS, et al.: Fibroblastic and myofibroblastic tumors of the head and neck: comprehensive imaging-based review with pathologic correlation, *Eur J Radiol* 84(2):250–260, 2015.
93. Snow SN, Gordon EM, Larson PO, et al.: Dermatofibrosarcoma protuberans: a report on 29 patients treated by Mohs micrographic surgery with long-term follow-up and review of the literature, *Cancer* 101(1):28–38, 2004.
94. Hegde U, Shetty SK, Sreeshyla HS, Doddawada VG: Dermatofibrosarcoma protuberans—a recurrent lesion with unusual presentation in the parotid region, *J Clin Diagn Res* 8(3):130–131, 2014.
95. Paradisi A, Abeni D, Rusciani A, et al.: Dermatofibrosarcoma protuberans: wide local excision vs. Mohs micrographic surgery, *Cancer Treat Rev* 34(8):728–736, 2008.
96. Taylor HB, Helwig EB: Dermatofibrosarcoma protuberans. A study of 115 cases, *Cancer* 15:717–725, 1962.
97. Vandeweyer E, Seyeidi JV, Deraemaecker R: Dermatofibrosarcoma protuberans of the upper lip: an overview and a case report, *Eur J Surg Oncol* 23(3):275–277, 1997.
98. Gayner SM, Lewis JE, McCaffrey TV: Effect of resection margins on dermatofibrosarcoma protuberans of the head and neck, *Arch Otolaryngol Head Neck Surg* 123(4):430–433, 1997.
99. Mark RJ, Bailet JW, Tran LM, et al.: Dermatofibrosarcoma protuberans of the head and neck. A report of 16 cases, *Arch Otolaryngol Head Neck Surg* 119(8):891–896, 1993.
100. Rich JD, Zbylski JR, LaRossa DD: Dermatofibrosarcoma protuberans of the head and neck, *Am Surg* 46(4):208–215, 1980.
101. Wick MR, Ritter JH, Lind AC, Swanson PE: The pathological distinction between "deep penetrating" dermatofibroma and dermatofibrosarcoma protuberans, *Semin Cutan Med Surg* 18(1):91–98, 1999.

102. Ratner D, Thomas CO, Johnson TM, et al.: Mohs micrographic surgery for the treatment of dermatofibrosarcoma protuberans. Results of a multiinstitutional series with an analysis of the extent of microscopic spread, *J Am Acad Dermatol* 37(4):600–613, 1997.
103. Parker TL, Zitelli JA: Surgical margins for excision of dermatofibrosarcoma protuberans, *J Am Acad Dermatol* 32(2 Pt 1):233–236, 1995.
104. Ballo MT, Zagars GK, Pisters P, Pollack A: The role of radiation therapy in the management of dermatofibrosarcoma protuberans, *Int J Radiat Oncol Biol Phys* 40(4):823–827, 1998.
105. Suit H, Spiro I, Mankin HJ, Efird J, Rosenberg AE: Radiation in management of patients with dermatofibrosarcoma protuberans, *J Clin Oncol* 14(8):2365–2369, 1996.
106. Callender TA, Weber RS, Janjan N, et al.: Rhabdomyosarcoma of the nose and paranasal sinuses in adults and children, *Otolaryngol Head Neck Surg* 112(2):252–257, 1995.
107. el-Naggar AK, Batsakis JG, Ordonez NG, et al.: Rhabdomyosarcoma of the adult head and neck: a clinicopathological and DNA ploidy study, *J Laryngol Otol* 107(8):716–720, 1993.
108. Nayar RC, Prudhomme F, Parise Jr O, et al.: Rhabdomyosarcoma of the head and neck in adults: a study of 26 patients, *Laryngoscope* 103(12):1362–1366, 1993.
109. La Quaglia MP, Heller G, Ghavimi F, et al.: The effect of age at diagnosis on outcome in rhabdomyosarcoma, *Cancer* 73(1):109–117, 1994.
110. Grufferman S, Ruymann F, Ognjanovic S, Erhardt EB, Maurer HM: Prenatal X-ray exposure and rhabdomyosarcoma in children: a report from the children's oncology group, *Cancer Epidemiol Biomarkers Prev* 18(4):1271–1276, 2009.
111. Grufferman S, Wang HH, DeLong ER, et al.: Environmental factors in the etiology of rhabdomyosarcoma in childhood, *J Natl Cancer Inst* 68(1):107–113, 1982.
112. Kraus DH, Saenz NC, Gollamudi S, et al.: Pediatric rhabdomyosarcoma of the head and neck, *Am J Surg* 174(5):556–560, 1997.
113. Malempati S, Hawkins DS: Rhabdomyosarcoma: review of the Children's Oncology Group (COG) Soft-Tissue Sarcoma Committee experience and rationale for current COG studies, *Pediatr Blood Cancer* 59(1):5–10, 2012.
114. Anderson GJ, Tom LW, Womer RB, et al.: Rhabdomyosarcoma of the head and neck in children, *Arch Otolaryngol Head Neck Surg* 116(4):428–431, 1990.
115. Qualman SJ, Coffin CM, Newton WA, et al.: Intergroup Rhabdomyosarcoma Study: update for pathologists, *Pediatr Dev Pathol* 1(6):550–561, 1998.
116. Dagher R, Helman L: Rhabdomyosarcoma: an overview, *Oncologist* 4(1):34–44, 1999.
117. Neville HL, Raney RB, Andrassy RJ, Cooley DA: Multidisciplinary management of pediatric soft-tissue sarcoma, *Oncology (Williston Park)* 14(10):1471–1481, 2000, discussion 1482-1476, 1489-1490.
118. Maurer HM, Beltangady M, Gehan EA, et al.: The Intergroup Rhabdomyosarcoma Study—I. A final report, *Cancer* 61(2):209–220, 1988.
119. Daya H, Chan HS, Sirkin W, Forte V: Pediatric rhabdomyosarcoma of the head and neck: is there a place for surgical management? *Arch Otolaryngol Head Neck Surg* 126(4):468–472, 2000.
120. Pappo AS, Meza JL, Donaldson SS, et al.: Treatment of localized nonorbital, nonparameningeal head and neck rhabdomyosarcoma: lessons learned from intergroup rhabdomyosarcoma studies III and IV, *J Clin Oncol* 21(4):638–645, 2003.
121. Crist W, Gehan EA, Ragab AH, et al.: The Third Intergroup Rhabdomyosarcoma Study, *J Clin Oncol* 13(3):610–630, 1995.
122. Raney RB, Anderson JR, Barr FG, et al.: Rhabdomyosarcoma and undifferentiated sarcoma in the first two decades of life: a selective review of intergroup rhabdomyosarcoma study group experience and rationale for Intergroup Rhabdomyosarcoma Study V, *J Pediatr Hematol Oncol* 23(4):215–220, 2001.
123. Rodary C, Gehan EA, Flamant F, et al.: Prognostic factors in 951 nonmetastatic rhabdomyosarcoma in children: a report from the International Rhabdomyosarcoma Workshop, *Med Pediatr Oncol* 19(2):89–95, 1991.
124. Izumi K, Maeda T, Cheng J, Saku T: Primary leiomyosarcoma of the maxilla with regional lymph node metastasis. Report of a case and review of the literature, *Oral Surg Oral Med Oral Pathol Oral Radiol Endod* 80(3):310–319, 1995.
125. Gavriel H, Yeheskeli E, Hermann G, Eviatar E: Leiomyosarcoma of the parapharyngeal space: a very rare entity, *Ear Nose Throat J* 93(7):E5–8, 2014.
126. Vilos GA, Rapidis AD, Lagogiannis GD, Apostolidis C: Leiomyosarcomas of the oral tissues: clinicopathologic analysis of 50 cases, *J Oral Maxillofac Surg* 63(10):1461–1477, 2005.
127. Marioni G, Bertino G, Mariuzzi L, et al.: Laryngeal leiomyosarcoma, *J Laryngol Otol* 114(5):398–401, 2000.
128. Fusconi M, Magliulo G, Della Rocca C, et al.: Leiomyosarcoma of the sinonasal tract: a case report and literature review, *Am J Otolaryngol* 23(2):108–111, 2002.
129. Akcam T, Oysul K, Birkent H, Gerek M, Yetiser S: Leiomyosarcoma of the head and neck: report of two cases and review of the literature, *Auris Nasus Larynx* 32(2):209–212, 2005.
130. Kuruvilla A, Wenig BM, Humphrey DM, Heffner DK: Leiomyosarcoma of the sinonasal tract. A clinicopathologic study of nine cases, *Arch Otolaryngol Head Neck Surg* 116(11):1278–1286, 1990.
131. Freedman AM, Reiman HM, Woods JE: Soft-tissue sarcomas of the head and neck, *Am J Surg* 158(4):367–372, 1989.
132. Aust MR, Olsen KD, Lewis JE, et al.: Angiosarcomas of the head and neck: clinical and pathologic characteristics, *Ann Otol Rhinol Laryngol* 106(11):943–951, 1997.
133. Holden CA, Spittle MF, Jones EW: Angiosarcoma of the face and scalp, prognosis and treatment, *Cancer* 59(5):1046–1057, 1987.
134. Lydiatt WM, Shaha AR, Shah JP: Angiosarcoma of the head and neck, *Am J Surg* 168(5):451–454, 1994.
135. Maddox JC, Evans HL: Angiosarcoma of skin and soft tissue: a study of forty-four cases, *Cancer* 48(8):1907–1921, 1981.
136. Albores-Saavedra J, Schwartz AM, Henson DE, et al.: Cutaneous angiosarcoma. Analysis of 434 cases from the Surveillance, Epidemiology, and End Results Program, 1973-2007, *Ann Diagn Pathol* 15(2):93–97, 2011.
137. Mark RJ, Tran LM, Sercarz J, et al.: Angiosarcoma of the head and neck. The UCLA experience 1955 through 1990, *Arch Otolaryngol Head Neck Surg* 119(9):973–978, 1993.
138. Young RJ, Brown NJ, Reed MW, et al.: Angiosarcoma, *Lancet Oncol* 11(10):983–991, 2010.
139. Loudon JA, Billy ML, DeYoung BR, Allen CM: Angiosarcoma of the mandible: a case report and review of the literature, *Oral Surg Oral Med Oral Pathol Oral Radiol Endod* 89(4):471–476, 2000.

140. Guadagnolo BA, Zagars GK, Araujo D, et al.: Outcomes after definitive treatment for cutaneous angiosarcoma of the face and scalp, *Head Neck* 33(5):661–667, 2011.
141. Pawlik TM, Paulino AF, McGinn CJ, et al.: Cutaneous angiosarcoma of the scalp: a multidisciplinary approach, *Cancer* 98(8):1716–1726, 2003.
142. Ohguri T, Imada H, Nomoto S, et al.: Angiosarcoma of the scalp treated with curative radiotherapy plus recombinant interleukin-2 immunotherapy, *Int J Radiat Oncol Biol Phys* 61(5):1446–1453, 2005.
143. Sasaki R, Soejima T, Kishi K, et al.: Angiosarcoma treated with radiotherapy: impact of tumor type and size on outcome, *Int J Radiat Oncol Biol Phys* 52(4):1032–1040, 2002.
144. Morrison WH, Byers RM, Garden AS, et al.: Cutaneous angiosarcoma of the head and neck. A therapeutic dilemma, *Cancer* 76(2):319–327, 1995.
145. Gillman G, Pavlovich JB: Sinonasal hemangiopericytoma, *Otolaryngol Head Neck Surg* 131(6):1012–1013, 2004.
146. Duval M, Hwang E, Kilty SJ: Systematic review of treatment and prognosis of sinonasal hemangiopericytoma, *Head Neck* 35(8):1205–1210, 2013.
147. Batsakis JG, Jacobs JB, Templeton AC: Hemangiopericytoma of the nasal cavity: electron-optic study and clinical correlations, *J Laryngol Otol* 97(4):361–368, 1983.
148. Daniels RL, Haller JR, Harnsberger HR: Hemangiopericytoma of the masticator space, *Ann Otol Rhinol Laryngol* 105(2):162–165, 1996.
149. Koscielny S, Brauer B, Forster G: Hemangiopericytoma: a rare head and neck tumor, *Eur Arch Otorhinolaryngol* 260(8):450–453, 2003.
150. Bailet JW, Abemayor E, Andrews JC, et al.: Malignant nerve sheath tumors of the head and neck: a combined experience from two university hospitals, *Laryngoscope* 101(10):1044–1049, 1991.
151. Hoffmann DF, Everts EC, Smith JD, Kyriakopoulos DD, Kessler S: Malignant nerve sheath tumors of the head and neck, *Otolaryngol Head Neck Surg* 99(3):309–314, 1988.
152. Voorhies J, Hattab EM, Cohen-Gadol AA: Malignant peripheral nerve sheath tumor of the abducens nerve and a review of the literature, *World Neurosurg* 80(5), 654, 2013.
153. Ziadi A, Saliba I: Malignant peripheral nerve sheath tumor of intracranial nerve: a case series review, *Auris Nasus Larynx* 37(5):539–545, 2010.
154. Ducatman BS, Scheithauer BW, Piepgras DG, et al.: Malignant peripheral nerve sheath tumors. A clinicopathologic study of 120 cases, *Cancer* 57(10):2006–2021, 1986.
155. Thway K, Fisher C: Malignant peripheral nerve sheath tumor: pathology and genetics, *Ann Diagn Pathol* 18(2):109–116, 2014.
156. Hu SW, Lin WC, Tsai HJ, Chien SH, Tsai KB: Immunoprofiles in malignant peripheral nerve sheath tumor: three case reports and literature review, *Kaohsiung J Med Sci* 22(3):135–142, 2006.
157. Greager JA, Reichard KW, Campana JP, DasGupta TK: Malignant schwannoma of the head and neck, *Am J Surg* 163(4):440–442, 1992.
158. Davis EC, Ballo MT, Luna MA, et al.: Liposarcoma of the head and neck: The University of Texas M. D. Anderson Cancer Center experience, *Head Neck* 31(1):28–36, 2009.
159. Russell WO, Cohen J, Enzinger F, et al.: A clinical and pathological staging system for soft tissue sarcomas, *Cancer* 40(4):1562–1570, 1977.
160. Golledge J, Fisher C, Rhys-Evans PH: Head and neck liposarcoma, *Cancer* 76(6):1051–1058, 1995.
161. McCulloch TM, Makielski KH, McNutt MA: Head and neck liposarcoma. A histopathologic reevaluation of reported cases, *Arch Otolaryngol Head Neck Surg* 118(10):1045–1049, 1992.
162. Saunders JR, Jaques DA, Casterline PF, et al.: Liposarcomas of the head and neck: a review of the literature and addition of four cases, *Cancer* 43(1):162–168, 1979.
163. Stewart MG, Schwartz MR, Alford BR: Atypical and malignant lipomatous lesions of the head and neck, *Arch Otolaryngol Head Neck Surg* 120(10):1151–1155, 1994.
164. Dahl EC, Hammond HL, Sequeira E: Liposarcomas of the head and neck, *J Oral Maxillofac Surg* 40(10):674–677, 1982.
165. Enzinger FM, Winslow DJ: Liposarcoma. A study of 103 cases, *Virchows Arch Pathol Anat Physiol Klin Med* 335:367–388, 1962.
166. Wenig BM, Weiss SW, Gnepp DR: Laryngeal and hypopharyngeal liposarcoma. A clinicopathologic study of 10 cases with a comparison to soft-tissue counterparts, *Am J Surg Pathol* 14(2):134–141, 1990.
167. Khalili M, Eshghyar N, Ensani F, Shakib PA: Synovial sarcoma of the mandible, *J Res Med Sci* 17(11):1082–1085, 2012.
168. Park JK, Ham SY, Hwang JC, et al.: Synovial sarcoma of the head and neck: a case of predominantly cystic mass, *AJNR Am J Neuroradiol* 25(6):1103–1105, 2004.
169. Wushou A, Miao XC: Tumor size predicts prognosis of head and neck synovial cell sarcoma, *Oncol Lett* 9(1):381–386, 2015.
170. Wushou A, Zhao YJ, Shao ZM: Synovial sarcoma of the infratemporal fossa: a case report, *Oncol Lett* 8(5):2165–2170, 2014.
171. Cihak RA, Lydiatt WM, Lydiatt DD, Bridge JA: Synovial sarcoma of the head and neck: chromosomal translation (X;18) as a diagnostic aid, *Head Neck* 19(6):549–553, 1997.
172. Carrillo R, Rodriguez-Peralto JL, Batsakis JG: Synovial sarcomas of the head and neck, *Ann Otol Rhinol Laryngol* 101(4):367–370, 1992.
173. Bukachevsky RP, Pincus RL, Shechtman FG, et al.: Synovial sarcoma of the head and neck, *Head Neck* 14(1):44–48, 1992.
174. Amble FR, Olsen KD, Nascimento AG, Foote RL: Head and neck synovial cell sarcoma, *Otolaryngol Head Neck Surg* 107(5):631–637, 1992.
175. Miloro M, Quinn PD, Stewart JC: Monophasic spindle cell synovial sarcoma of the head and neck: report of two cases an review of the literature, *J Oral Maxillofac Surg* 52(3):309–313, 1994.
176. Qureshi SS, Kembhavi S, Bhagat M, et al.: Primary non-metastatic Ewing sarcoma of the jaw in children: results of surgical resection and primary reconstruction, *J Surg Oncol* 110(6):689–695, 2014.
177. Sneige N, Batsakis JG: Ewing's sarcoma of bone and soft tissues, *Ann Otol Rhinol Laryngol* 98(5 Pt 1):400–402, 1989.
178. Raney RB, Asmar L, Newton Jr WA, et al.: Ewing's sarcoma of soft tissues in childhood: a report from the Intergroup Rhabdomyosarcoma Study, 1972 to 1991, *J Clin Oncol* 15(2):574–582, 1997.
179. Whaley JT, Indelicato DJ, Morris CG, et al.: Ewing tumors of the head and neck, *Am J Clin Oncol* 33(4):321–326, 2010.
180. Batsakis JG, Mackay B, el-Naggar AK: Ewing's sarcoma and peripheral primitive neuroectodermal tumor: an interim report, *Ann Otol Rhinol Laryngol* 105(10):838–843, 1996.

181. Solomon LW, Frustino JL, Loree TR, et al.: Ewing sarcoma of the mandibular condyle: multidisciplinary management optimizes outcome, *Head Neck* 30(3):405–410, 2008.
182. Lieberman PH, Brennan MF, Kimmel M, et al.: Alveolar soft-part sarcoma. A clinico-pathologic study of half a century, *Cancer* 63(1):1–13, 1989.
183. Yigitbasi OG, Guney E, Kontas O, et al.: Alveolar soft part sarcoma: report of a case occurring in the sinonasal region, *Int J Pediatr Otorhinolaryngol* 68(10):1333–1337, 2004.
184. do Nascimento Souza KC, Faria PR, et al.: Oral alveolar soft-part sarcoma: review of literature and case report with immunohistochemistry study for prognostic markers, *Oral Surg Oral Med Oral Pathol Oral Radiol Endod* 99(1):64–70, 2005.
185. Mullins BT, Hackman T: Adult alveolar soft part sarcoma of the head and neck: a report of two cases and literature review, *Case Rep Oncol Med* 2014:597291, 2014.
186. Kanhere HA, Pai PS, Neeli SI, et al.: Alveolar soft part sarcoma of the head and neck, *Int J Oral Maxillofac Surg* 34(3):268–272, 2005.
187. Eley KA, Afzal T, Shah KA, Watt-Smith SR: Alveolar soft-part sarcoma of the tongue: report of a case and review of the literature, *Int J Oral Maxillofac Surg* 39(8):824–826, 2010.
188. Hunter BC, Devaney KO, Ferlito A, Rinaldo A: Alveolar soft part sarcoma of the head and neck region, *Ann Otol Rhinol Laryngol* 107(9 Pt 1):810–814, 1998.
189. Iwamoto Y, Morimoto N, Chuman H, Shinohara N, Sugioka Y: The role of MR imaging in the diagnosis of alveolar soft part sarcoma: a report of 10 cases, *Skeletal Radiol* 24(4):267–270, 1995.
190. Batsakis JG: Alveolar soft-part sarcoma, *Ann Otol Rhinol Laryngol* 97(3 Pt 1):328–329, 1988.
191. Portera Jr CA, Ho V, Patel SR, et al.: Alveolar soft part sarcoma: clinical course and patterns of metastasis in 70 patients treated at a single institution, *Cancer* 91(3):585–591, 2001.

28

Squamous Cell Carcinoma of the Oral and Maxillofacial Region

BRENT B. WARD, JOSEPH I. HELMAN

Introduction

Oral cavity and oropharyngeal cancer account for more than 7000 deaths annually, with an annual incidence of more than 30,000 new cases within the United States.[1] Worldwide it is the sixth most common malignancy, with incidence varying greatly among different geographic locations. Its prevalence can range from countries with rates similar to those in the United States, to countries such as India, where death from oral cavity cancer is one of the top three forms of cancer death. Even within the U.S. population, a fivefold difference in mortality is seen among states, likely a result of differences in ethnic and socioeconomic factors as well as the use of tobacco products.[2] Despite improvements in treatment, long-term survival rates are relatively unchanged over the past 30 years. For the oral and maxillofacial surgeon, an understanding of this disease and its impact on society, as well as the surgeon's role in identification and treatment, is imperative.

Anatomy

The oral cavity extends from the vermilion border of the lips to an imaginary coronal plane at the junction of the hard and soft palates and the circumvallate papilla. There are seven anatomic subsites included within the oral cavity: lips, buccal mucosa, lower and upper alveolar ridges, hard palate, floor of mouth, tongue (anterior two thirds), and the retromolar trigone. Subsite variation in cancer incidence, lymph node drainage, and overall prognosis exists.

Lymph node basins that drain the oral cavity are divided into five groups based on anatomically defined structures.

- Level I—includes the submental nodes bounded by the anterior bellies of the digastric muscles and the hyoid bone as well as the submandibular group bounded by the body of the mandible and the posterior bellies of the digastric muscles bilaterally.
- Level II—includes the upper jugular lymph nodes extending from the base of the skull to the level of the carotid artery bifurcation. The anterior border is the lateral aspect of the sternohyoid muscle, with the posterior border of the sternocleidomastoid (SCM) muscle serving as the posterior border of the level. Level II is also subdivided into levels IIA (inferior medial) and IIB (superior lateral) by the spinal accessory nerve.
- Level III—includes nodes located adjacent to the middle third of the internal jugular vein from the carotid bifurcation to the omohyoid muscle, with the same anterior and posterior boundaries as level II.
- Level IV—includes the lower jugular group, inferior to the omohyoid and superior to the clavicle, with the same anterior and posterior boundaries as levels II and III.
- Level V—includes nodes anterior to the anterior border of the trapezius and posterior to the posterior border of the SCM. The inferior border of this level is the clavicle.

Buccal Mucosa

The buccal mucosa includes all mucous membranes lateral to the alveolar sulcus from the lips anteriorly to the retromolar trigone and pterygomandibular raphe posteriorly. Lymphatic drainage from these sites is primarily to levels I and II in the neck. It should be noted that cancer of the buccal mucosa can perforate beyond the buccinator muscle to the buccal fat and subcutaneous tissues, which may drain to the periparotid lymph nodes.

Alveolar Ridge

The alveolar ridges include the maxillary and mandibular alveolar processes and the overlying mucosa. On the maxilla, this extends from the buccal sulcus to the hard palate. In the mandible, the alveolar ridge extends from the buccal sulcus to the free mucosa of the floor of the mouth. Lymphatic drainage from the upper and lower buccal aspects is to the submandibular and submental (level I) nodes. The lingual aspects of the upper and lower alveolar ridges are to the submandibular (level I), superior deep jugular (level II), and retropharyngeal nodes.

Floor of the Mouth

The floor of the mouth extends from the lower alveolar ridge to the ventral surface of the tongue. Its posterior limit is the anterior tonsillar pillar. The floor of the mouth has both superficial and deep drainage systems that drain to the submandibular nodes (level I) and to levels I, II, and III, respectively. Crossover drainage to the contralateral side has been demonstrated in anterior portions of both the deep and superficial systems.

Retromolar Trigone

The retromolar trigone (RMT) is the triangular region overlying the ascending ramus of the mandible. The base is formed by the last tooth in the arch with the apex at the maxillary tuberosity. Medial and lateral borders are formed by the anterior tonsillar pillar and the buccal mucosa. The mucosa in this region is tightly adherent, leading to early bony invasion. Lymphatic drainage is primarily to the superior deep jugular (level II) nodes, with some drainage from this region to the periparotid and retropharyngeal nodes.

Hard Palate

The hard palate extends from the superior alveolar ridge to the palatine bones posteriorly. Tumors in this region may access additional sites through the incisive and greater palatine foramina. Drainage from the palate is primarily to levels I and II.

Tongue

The anterior two thirds of the tongue (mobile tongue) anterior to the circumvallate papillae is included in the oral cavity, whereas the base is a part of the oropharynx. Six paired muscles form the mobile tongue. Lymphatic drainage is extensive and has been divided into anterior, lateral, central, and posterior groups. The primary basins include levels I, II, and III. More anterior lymphatic channels drain first to submental nodes, which further drain to lower jugulo-omohyoid nodes. The posterior compartments drain primarily to upper jugulodigastric nodes. As with the floor of the mouth, communication across the midline exists.

Epidemiology

Risk Factors

Tobacco

Large, well-designed, population-based studies affirm the correlation between tobacco use and the risk of oral cavity cancer.[3,4] Tobacco smoking is an independent risk factor; compared to nonsmokers, smokers are six to eight times more likely to develop oral cavity cancer.[5] This is especially true for women, who are twice as likely as men to develop oral cancer given the same amount of tobacco consumption.[6] More than 300 chemicals in tobacco smoke have been identified as contributing to carcinogenesis.[7] It is thought that exposure to these carcinogens leads to malignant transformation of cells. Smoking cessation is effective in reducing risk, though not in its complete elimination. Individuals who refrained from smoking 1 to 9 years showed a 30% reduction of risk, with a 50% reduction for individuals abstaining from smoking more than 9 years.[3]

Outside of cigarettes, both pipe and cigar smoking increase the risk for the development of oral cancer. The role of smokeless tobaccos within the United States has long been accepted to increase cancer risk, especially gingival and buccal cancers. A North Carolina–based study from 1986 showed a fourfold increase in risk in women users of smokeless tobacco.[8] Recently some have disputed the results of this study, claiming a lack of causation. Bouquot and Meckstroth reviewed statistics from West Virginia (the state with the highest per capita consumption of smokeless tobacco) in regard to incidence and mortality of oral and pharyngeal cancer, concluding that rates were less than the national average.[9] Accortt and colleagues categorized 6779 subjects 45 to 75 years of age. In their study, exclusive use of smokeless tobacco was not shown to increase incidence of oral cancer in males or females. No synergistic effects were observed between smoking tobacco and smokeless tobacco.[10] The use of smokeless tobacco, however, has been correlated with other cancer risk factors, with a recommendation for educating these patients regarding their overall cancer risk.[11] It is likely that the debate over causation for smokeless tobacco and oral cancer will continue, and patients should be aware at present that risks may exist.

Other forms of chewed tobacco have been shown as independent risk factors for oral cancer. Likely the most prominent is use of tobacco and betel nut in parts of India and Southeast Asia. In one study the incidence of oral cavity cancer was 123-fold higher for individuals who smoke and chew betel nut.[12] These data imply that 40% to 50% of all cases of oral cavity cancer in this geographic region occur in individuals with this habit.

Alcohol

The relationship between alcohol and cancer is clear for hard liquor and high-level alcohol consumers, but less well-defined in other risk groups. Approximately 75% of all patients who develop oral cancer do consume alcohol at some level.[13] One Swedish-based study of more than 1300 individuals showed moderate alcohol intake alone (<10 g/day) did not increase risk significantly, but high intake (>50 g) was an independent risk factor with a relative risk of 5.5. In addition, alcohol in conjunction with smoking was synergistic, with a relative risk of 22.1 compared to a relative risk of 6.5 from smoking alone.[14] In another study looking at extreme alcohol consumers, the risk for cancer from alcohol has been found to be greater than that from smoking alone.[15] Alcohol may predispose to cancer in any location in the oral cavity and is thought to possibly contribute more highly to dependent sites such as the floor of the mouth and lower buccal vestibule.

Viruses

A number of human viruses have been suggested as etiologic agents for oral cavity cancer through their transformation of human DNA. Herpes simplex virus type 1 (HSV-1) and human papillomaviruses (HPVs) have been reported by various authors. An association between HSV-1 and smoking with oral cancer development was suggested using immunologic parameters.[16] Animal model studies using HSV-1 in rats have been suggestive as well.[17]

Although the role of HPV in oropharyngeal cancer has been established, the role of HPV in oral cavity cancer at present is controversial. HPV-6 and HPV-16 have been most commonly implicated using polymerase chain reaction (PCR) assays of human tissue. In one study, HPV-16 was found to be present in tumor at a rate five times that of normal mucosa.[18] Additionally, in one study, oral squamous cell carcinoma cases were reported to have the presence of HPV.[19] Studies reporting on 5-year survival have revealed an improved prognosis for patients with and without nodal disease who have HPV-16-positive tumors compared to those who lack HPV.[20] Despite these positive studies, a number of institutions have reported minimal or no association between HPV and the oral cavity. Furthermore, a causative role has not been clearly established, and questions have been raised regarding possible contamination of specimens and faulty analysis.[21,22] At present, HPV's role in cancer development of the oral cavity remains unclear.

Other Factors

Although causation has not been established, a number of other factors are found in higher degrees among patients with oral cavity cancer. Nutritional deficiency including iron and vitamins A, C, and E has been documented. A number of well-designed studies have suggested the protective benefits of diets high in total vegetable and fruit intake as well as fiber found in green vegetables.[23,24] In a U.S.-based case-control study of second primary cancers, the risk of developing a second primary was 40% to 60% lower among those individuals with the highest levels of intake for total vegetables, demonstrating the protective nature of this diet.[25]

Patients with oral cancer are found to have higher degrees of oral disease including periodontal disease and caries.[26] Although association is present, no direct causation can be attributed.

Genetic Abnormalities and Clinical Implications

Chromosomal Abnormalities and Genetic Instability

Chromosomal abnormalities resulting from severe DNA damage have been extensively documented in head and neck squamous cell carcinoma (HNSCC).[27,28] Abnormalities include both losses and gains in genetic material on chromosomes 3, 4, 7, 8, 9, 11, 13, 17, 18, and 19. Evidence suggests that some chromosomal alterations may be linked to malignant progression. For example, changes at 3p and/or 9p with any other chromosomal abnormality were associated with a 33-fold increase in risk of cancer.[29]

Genetic instability includes microsatellite alterations and loss of heterozygosity. Microsatellites are highly polymorphic tandem repeat sequences of DNA that can be examined following amplification by polymerase chain reaction. Loss of heterozygosity (LOH) results from loss of one parent's contribution to part of the cell's genome. Both microsatellites and LOH are common findings in cancer. Microsatellites have been successfully used as tumor markers in a large number of malignancies including oral cancer.[30] Using 52 known tumor-associated alterations in tumors compared to normal tissue in the same patient demonstrated 29% of patients to have at least one microsatellite marker present in tumor.[31] Sidransky and colleagues examined microsatellite markers or loss of heterozygosity in 21 patients and showed that 18 (86%) demonstrated LOH and 5 had both LOH and microsatellite alteration. Malignant progression has also been documented through microsatellite changes.[32] From a clinical perspective, tetranucleotide microsatellite instability has been tested at surgical margins for recurrence prediction.[33]

p53 (TP53 *Gene*)

TP53 is located on the short arm of chromosome 17 at 17p13.1. It functions primarily to produce arrest of the cell cycle for DNA repair. Ultimately, if repair is unsuccessful, p53 is one of the leading signals causing cells to engage in programmed cell death, or apoptosis, via a number of complex cellular signaling pathways.[34,35] Mutations to *TP53* are one of the most frequent abnormalities in HNSCC cell lines and tissue specimens, variably reported in 30% to 75% of tumors.[36,37] Prognostic significance of p53 mutation has been reported. For example, node-negative oral squamous cell carcinoma patients with p53 overexpression were found to have poorer survival.[38]

Epidermal Growth Factor Receptor

Epidermal growth factor receptor (EGFR) has been frequently found to be overexpressed in HNSCC. EGFR is a receptor tyrosine kinase that can be bound by ligands including EGF (epidermal growth factor) and transforming growth factor-alpha (TGF-α). Activation of EGFR leads to changes in a number of pathways including *RAS* and *STAT* for regulation of cell growth. EGFR mRNA is overexpressed in 92% of HNSCC, with evidence of increased expression in advanced-stage and poorly differentiated tumors.[39] A number of studies have additionally documented the association of EGFR upregulation as an independent predictor for decreased disease-free survival.[40,41] In addition, higher levels of EGFR have been noted in the oral cavity and pharynx compared to other HNSCC sites.[42] Overexpression is the result of both decreased receptor downregulation and increased mRNA synthesis. Association between EGFR activation and matrix metalloproteinase (MMP) has been suggested, lending evidence to EGFR's role in invasion and metastasis.[43]

A number of therapeutic strategies are in various stages of development to specifically target this receptor. Gefitinib (Iressa), a small-molecule EGFR-selective inhibitor of tyrosine kinase activity that blocks EGF autophosphorylation and activation, has shown limited success primarily because of its side effects and a lack of increase in patient survival. Preclinical models under current investigation include anti-EGFR variable regions VHH (nanobodies), immunoliposomes created with Fab′ fragments, and antisense or small interference RNA to EGFR.

In March 2006 the Food and Drug Administration approved Erbitux (cetuximab) for head and neck cancer as the first treatment in 45 years to increase survival when combined with radiotherapy for unresectable disease. Its approval followed trials that confirmed a survival advantage to patients with locoregionally advanced disease who underwent radiation therapy with cetuximab versus radiation alone.[44]

Nuclear Factor-Kappa B

Nuclear factor-kappa B (NF-κB) is a transcription factor for inflammatory and immune response that serves as a cytokine modulator.[45] In the normal cellular environment it remains in the cytoplasm tightly associated with protein inhibitors (I-κBs). With activation, I-κBs are phosphorylated and ubiquitinated with subsequent proteosomal degradation, freeing NF-κB as a heterodimer of p65 and p50 subunits for nuclear translocation and gene activation. NF-κB is activated by a number of carcinogens and tumor promoters as well as the tumor necrosis factor (TNF) superfamily.[46] Immunohistochemistry of biopsy specimens demonstrates that oral cancer expresses higher levels of NF-κB in comparison to normal and dysplastic tissue.[47] Downregulation of NF-κB has been attempted using nonsteroidal anti-inflammatory drugs, which have been shown effective in vitro.[48] To date no conclusive evidence to support this treatment exists in HNSCC.

Cyclin D1

Cyclin D1 is a regulatory protein that drives cells through the cell cycle. In HNSCC, cyclin D1 gene amplification has been recognized in 26% to 68% of cases.[49,50] The presence of cyclin D1 overexpression has been correlated with increased nodal involvement and decreased overall and tumor-free survival.[51,52]

Screening for Cancer

Five-year survival of oral cavity cancer is inversely related to tumor size, the presence of nodal involvement, and distant metastasis. Detection in early stages has been shown to dramatically affect survival rates and is the most important variable leading to disease-free survival.[53,54] Survival by stage for the oral cavity, reported by the American Joint Committee on Cancer, based on 1985 to 1991 data, is as follows: stage I, 65% to 70%; stage II, 50% to 55%; stage III, 38% to 44%; stage IV, 24% to 28%. Although these numbers are somewhat lower than the currently reported statistics, their trend stands true. Given this reality, the desire for early diagnosis in order to increase survival has continued as a favorable objective. Overall, the success of the oral screening exam has been variably reported, with sensitivities ranging from 57% to 61% and with a specificity of 98%.[55-59] In 1965 Sandler reported success with visual inspection alone, in which 70 of 287 carcinomas and 20 of 28 carcinomas in situ were thought to be benign on clinical exam. Campaigns to enhance public and professional awareness are ongoing as a result of a number of studies that demonstrate both to be lacking.[56,57] In addition, the desire for an early detection screening tool has led to the creation of adjuncts to the physical exam. At present, no accepted screening test is available, and current guidelines from the American Cancer Society recommend only routine clinical examination of the oral cavity in association with the health maintenance exam. A number of limitations exist in the early detection paradigm that are worthy of limited exploration, given the confines of this chapter.

Holmes and Dierks et al[58] shed light on early detection in the United States, reporting their patient referral patterns for oral and oropharyngeal cancer. Fifty-one patients were reviewed with the conclusion that symptomatic and symptom-free detection was most likely to be accomplished by a professional who was a regional specialist (routinely working in the oral cavity).[58] Half of all patients who initially visited a non-regional specialist did not receive a biopsy or referral at their first visit, regardless of the fact that they presented with later clinical and pathologically staged disease, compared to those examined by a regional specialist. Because the majority of the regional specialists in the report were primary care dentists, it is important to consider the access of these professionals to the general public for the purposes of screening.

The 2003 *National Health Care Disparities Report*[59] suggests that fewer than 50% of all individuals more than 45 years of age see a dentist on an annual basis. By age 65 the estimated number is 42.6%. Outpatient visits to physicians for these same age groups are 77% and 89%, respectively.[59] When these statistics are combined with the data from Holmes and colleagues,[58] it is clear that barriers exist in access to the individuals most capable of early detection. If organized screening is to be effective, it is likely that both provider and public awareness will need to be increased and access to care barriers addressed.

Until recently, no prospective data existed to validate mass screening for early detection of oral cavity cancer. In 2005 results from Kerala, India, offered the first support through prospective evaluation of more than 191,000 patients.[62] In the intervention group, visual examination was completed at 3-year intervals over a 10-year time period. The control group received no screening exams but did receive standard care. For those who developed cancer during the time of the study, the stage of disease in the intervention group was lower—41% stage I and II compared to 23% in the control, which was statistically significant. Overall 5-year survival

was 50% in the intervention group compared to 34% in the control, which was again statistically significant. Mortality was decreased in the intervention group 21% overall, 22% for high-risk women, and 43% for high-risk men, with only the high-risk men group being statistically significant. Methodologic weaknesses in the study have caused some to raise concerns, as well as the fact that neither cost analysis nor harm from false-positive or false-negative exams are addressed.[63]

Diagnostic Adjuncts

Because no true screening test other than oral exam exists at present, a number of adjuncts have been developed in an attempt to increase the sensitivity and specificity of the oral screening exam. These tests range from those with established records of utility to those recently introduced to the market for use.

Toluidine Blue

Toluidine blue is a metachromatic vital dye that binds nuclei with a high DNA or RNA content, such as may occur in precancerous (dysplastic) or cancerous lesions (Figures 28-1 and 28-2). Its use as an adjunct to the physical exam for cancer screening has been documented over the past three decades with numerous reports in the literature. The sensitivity for toluidine blue screening has been reported to be 100% for lesions histologically consistent with invasive squamous cell carcinoma. In one study of 87 total lesions, sensitivity for invasive cancer was 100% (18/18); dysplasia revealed a less predictive result at 80% (29/39). The authors noted an advantage for toluidine blue as a screening tool because of the fact that a number of lesions not clinically visible before its application were discovered. Toluidine blue is limited by its specificity, which in this study was reported as 54%.[60] Mashberg reported the ability to increase overall specificity with a two-wash technique in which positive results were followed by removal of irritants and repeat evaluation in 2 weeks. Using this technique, he and his colleagues were able to raise specificities into the 90s.[61,64] Onofre and colleagues[64a] reported on their experience with 50 lesions in which sensitivity was 100% for carcinoma and carcinoma in situ. Dysplasia overall had a sensitivity of 50% with 3/6 mild dysplasias positive but 0/2 moderate dysplasias with uptake. Overall the specificity again was low at 67%. In the hands of the knowledgeable user, toluidine blue may offer an advantage over clinical examination alone. As a mass screening device, the lack of specificity results in a large number of false positives. In these cases clinical judgment would be required to decide whether or not biopsy or other diagnostic tests would be indicated.

OralCDx (Brush Biopsy)

The brush biopsy was first reported via a multi-institutional randomized prospective trial in 1999.[65] Unlike cytology, which has been shown ineffective for diagnosis of oral cavity cancer, this technique uses a brush, which has the capacity to procure a transepithelial specimen for microscopic evaluation of individual cells. The procedure is relatively painless and can be easily accomplished in a clinical setting. The results of the test are reported as positive, negative, and atypical. In the original report using 945 enrolled patients, a sensitivity of 100% was reported for 131 atypical and positive results, all of which revealed malignant or dysplastic lesions on histopathology. Specificity for positive results was reported as 100% and 92.9% for atypical results, with 14 of 196 total benign lesions testing atypical on brush biopsy. In addition, 4.5% of innocuous lesions that would not have been biopsied before brush were subjected after positive or atypical brush results and found to be malignant or dysplastic. A number of limitations to this study have been subsequently explored, which raise concerns for this technique. Because of institutional review board (IRB) restrictions and patient loss, 618 patients were never subjected to biopsy, which could have significantly altered the results. In clinical practice, concerns have been raised over the possibility of false-negative results, although the examples used in the



• **Figure 28-1** Squamous cell carcinoma of lateral tongue.



• **Figure 28-2** Squamous cell carcinoma of lateral tongue stained with toluidine blue.

only publication to raise these issues are of questionable appropriateness for a brush biopsy technique.[66] Likely of greater clinical impact is the lower than expected positive predictive value of 38%, with 150 of 243 patients with positive or atypical results on brush being negative on scalpel biopsy. Two studies reported in *Oral Oncology* in September 2004 highlight the continued debate of this technique. Poate et al[68] reported on 112 patients with an overall sensitivity for dysplasia or cancer of 71.4% and a specificity of 32%. The positive predictive value of a positive or atypical result was 44% with a negative predictive value of 60%.[68] In the same publication, Scheifele et al reported on 103 patients studied with OralCDx in which brush biopsy positive for dysplasia and cancer showed a sensitivity of 92% and a specificity of 94%.[69] Although some have argued that these results are superior to accepted screening tools in other body sites, such comparisons are unwarranted given significant differences in disease epidemiology and alternative screening methodologies for each disease.

Because clinical oral examination alone suffers in sensitivity but not in specificity and screening tests suffer from the opposite, a combination of these techniques in trained individuals may offer an advantage. Clinical judgment is necessary not only for conducting an appropriate visual examination but also for making determinations of which lesions to immediately subject to biopsy and in which lesions an adjunct may be helpful, based on the pretest probability of the patient and the specific adjunct characteristics relating to sensitivity and specificity. It is highly likely that additional tests will continue to be developed and used (e.g., VisiLite plus, VELscope, Microlux/DL). It is imperative that practitioners become proficient in evaluating the utility of screening tools and diagnostic adjuncts, because these instruments may be of benefit to their patient population. Evaluating test characteristics using the concepts of pretest probability, sensitivity, and specificity is critical to the practice of oral and maxillofacial surgery, now and in the future, in which an increasing number of diagnostic adjuncts are likely to become available. Science, and not marketing, should guide clinical practice.

Diagnosis and Pretreatment Evaluation

Patients with cancer of the oral cavity should undergo an extensive evaluation before treatment, including a complete history and physical examination, dental evaluation, and serologic and radiographic evaluations, as well as flexible endoscopy or operative direct laryngoscopy plus or minus esophagoscopy and bronchoscopy when clinically indicated. Physical examination includes notation of the size, location, and appearance of the primary lesion as well as clinical evidence of tumor spread to adjacent structures, such as trismus denoting muscle involvement and paresthesias denoting neurologic involvement. Specifically related to neural spread, otalgia may indicate involvement of the ninth and tenth cranial nerves, whereas hypoesthesia of the lingual, infraorbital, and inferior alveolar nerves may denote fifth cranial nerve involvement. Palpation is used to gain an understanding of potential depth of invasion, which should be confirmed histologically given its impact on treatment decisions. The neck must always be palpated in order to assess the potential for lymph node involvement for staging and treatment planning.

Global evaluation of the patient should include an assessment for determination of the patient's ability to tolerate treatment, which will most often involve surgical management. Outside of co-morbid medical conditions, it should be realized that weight loss caused by malnutrition and dehydration is a common finding in patients with later stages of disease.

A number of imaging techniques can be helpful in visualization of the complete extension of the primary tumor and of any nodal disease. Computed tomography (CT) imaging is most commonly employed for this purpose, allowing imaging of the primary tumor as well as an assessment of peritumoral invasion of structures, including bone of the mandible, maxilla, and palate. In addition, CT can simultaneously assess the potential involvement of lymph node basins. Alternatively, magnetic resonance imaging (MRI) may be employed and will provide greater detail of soft tissue for lesions, such as those confined to the tongue. MRI is also superior in cases in which a large number of dental restorations are likely to create CT artifact, which will obscure the view of the primary lesion.

Positron emission tomography (PET) continues to be studied in regard to its utility in the initial evaluation of confirmed oral cavity cancer, but to date, evidence for its superiority to the traditional techniques is limited. In addition, the higher cost of this technology is a limiting factor. Ultrasound has been used for screening of nodal disease, although it is not widely considered the diagnostic modality of choice. Imaging of the chest is indicated either through standard x-ray or by CT scan if warranted.

Staging

Clinical staging of oral cavity cancer uses the TNM staging system from the American Joint Committee on Cancer (AJCC) (Table 28-1). This system is based on the information gained from physical examination and imaging studies to categorize patients. Staging is important for effective communication among professionals, as well as for increased standardization in prognosis assessment. T stage refers to the size of the primary tumor, which may be measured intraorally and correlated with the radiographic evaluation for confirmation of final dimensions. N denotes nodal involvement of adjacent lymph node basins of the neck assessed by palpation and diagnostic imaging. M refers to evidence of distant metastasis. Staging then follows a logical progression in which higher stage patients have more aggressive disease and therefore decreased survival. It must be recognized that all factors known to affect survival are not taken into account by this system, including factors on histologic examination (such as perineural and perivascular

TABLE 28-1 Description of the Different Lymph Node Groups in Neck Dissections

Levels	Lymph Node Groups	Boundaries	Comments	Primary Tumor Site
IA	Submental	Superior: symphysis of mandible Lateral: anterior bellies of digastric muscles Inferior: body of hyoid bone	Only submental lymph nodes belong to this level	Lower lip, anterior part of oral cavity, floor of mouth, anterior portion of alveolar part of mandible
IB	Submandibular	Superior: body of mandible Anterior: anterior belly of digastric muscle Posterior: stylohyoid muscle Inferior: posterior belly of digastric muscle	When metastases are present in this level, submandibular gland is also usually removed during neck dissection	Oral cavity, anterior portion of nasal cavity, soft tissues of face, submandibular gland
IIA	Upper jugular (subdivided into two sublevels)	Superior: skull base Anterior: stylohyoid muscle Posterior: accessory nerve Inferior: horizontal plane defined by inferior body of hyoid bone	Lymph nodes around internal jugular vein in this region located anterior to accessory nerve belong to this level	Oropharynx (including retromolar region, soft palate, tonsils), thyroid gland, parotid gland
IIB		Superior: skull base Anterior: accessory nerve Posterior: lateral border of sternocleidomastoid muscle Inferior: horizontal plane defined by inferior body of hyoid bone	Lymph nodes around internal jugular vein in this region located posterior to accessory nerve belong to this level	Oral cavity, nasal cavity, oropharynx (including retromolar region, soft palate, tonsils), nasopharynx, hypopharynx, parotid gland
III	Middle jugular	Superior: horizontal plane defined by inferior body of hyoid bone Anterior: medial border of sternocleidomastoid muscle Posterior: lateral border of sternocleidomastoid muscle, branches of cervical plexus Inferior: horizontal plane defined by inferior border of cricoid cartilage	These lymph nodes are located around internal jugular vein in this region	Oral cavity, oropharynx, nasopharynx, hypopharynx, larynx, thyroid gland
IV	Lower jugular	Superior: horizontal plane defined by inferior border of cricoid cartilage Anterior: medial border of sternocleidomastoid muscle Posterior: lateral border of sternocleidomastoid muscle, branches of cervical plexus Inferior: clavicle	These lymph nodes are located around internal jugular vein in this region; Virchow's nodes, significant for gastric cancer, also belong to this level	Hypopharynx, thyroid gland, larynx, cervical esophagus, stomach
VA	Posterior triangle (subdivided into two sublevels; demarcation line is horizontal plane defined by inferior border of cricoid cartilage)	Superior: apex of convergence of sternocleidomastoid and trapezius muscles Anterior: lateral border of sternocleidomastoid muscle, branches of cervical plexus Posterior: trapezius muscle Inferior: horizontal plane defined by inferior border of cricoid cartilage	Lymph nodes along lower portion of accessory nerve	Nasopharynx, oropharynx, skin of posterior neck, skin of scalp
VB		Superior: horizontal plane defined by inferior border of cricoid cartilage Anterior: lateral border of sternocleidomastoid muscle, branches of cervical plexus Posterior: anterior border of trapezius muscle Inferior: clavicle	Lymph nodes along transverse artery and other supraclavicular nodes, except Virchow's nodes	Thyroid gland
VI	Anterior compartment	Superior: hyoid bone Lateral: common carotid arteries Inferior: suprasternal notch	This group includes pretracheal, prelaryngeal, precricoid, and perithyroidal lymph nodes and nodes along recurrent laryngeal nerves	Thyroid gland, glottic, subglottic larynx, apex of piriform sinus, cervical esophagus

From Subramanian S, Chiesa F, Lyubaev V et al: The evolution of surgery in the management of neck metastasis, *Acta Otorhinolaryngol Ital* 26:309-316, 2006.

invasion or nodal extracapsular spread), immune and nutritional status, and patient co-morbidities. As our knowledge continues to increase regarding factors affecting survival, it is likely that the staging system will continue to evolve.

Nonsurgical Management

Alternatives and adjuncts to the surgical management of squamous cell cancer and prevention of recurrence in the oral cavity exist. Outside of radiation and chemotherapy, these modalities are for the most part investigational. Still, it is hoped that the future treatment of oral cancer will evolve, and alternatives to surgery may include a combination of these current alternatives. The need for continued advances cannot be overstated in a disease for which the death rate has been basically unchanged for nearly half a century. In addition, treatment of advanced cases of head and neck cancer carries with it significant morbidity. Difficulties with swallowing and speech frequently may lead to need for permanent tracheotomy and percutaneous feeding tubes. In the face of this morbidity, classic radical therapy has been called into question as the importance of quality of life has taken precedence over quantity of life. Still, the ultimate goal of treatment in any patient is cure, if possible. An additional question arises when considering alternative therapies in regard to their applicability for earlier stage cancers where surgical management is not as deforming and morbidities from the alternatives may carry more morbidity than traditional surgical management.

Patients guided by their health care professional must understand the options in order to make appropriate decisions for treatment. As modalities other than surgery continue to evolve, the optimal choices for treatment may change; those involved in this process must keep up to date with ongoing advances in this area. At the present time, decisions regarding treatment options must take into consideration the location and size of the primary tumor, the status of regional lymph nodes, the status of distant metastatic disease, and the overall health status of the patient.

Chemoprevention

Research in the area of chemoprevention has been ongoing since the 1970s with the goal of identifying agents that are efficacious at preventing SCCHN with limited toxicity.[70] Currently, more than 2000 agents have been shown to have chemopreventive activity while being studied in a variety of in vitro and in vivo systems.[71] Of these agents, retinoids, in particular 13-*cis*-retinoic acid (13-cRA), have been the most extensively studied. The term retinoids refers to vitamin A and a number of its natural and synthetic derivatives. In vitro studies have demonstrated the ability of retinoids to inhibit malignant transformation of cells subjected to tumor promoters that would otherwise lead to tumorigenesis.

Clinical trials of these agents have revolved around two goals: preventing premalignant lesions from transforming into malignancy and prevention of secondary tumors in patients with treated disease. The effects of 13-cRA were studied in a randomized trial using 44 patients with oral leukoplakias.[67] Patients received 1 to 2 mg/kg/day doses or placebo for a total of 3 months with 6 months of follow-up. Complete or partial remission was obtained in 67% of the treatment group versus 10% in the placebo group, with a statistical significance $p = .0002$. Although the results were promising, two important limitations of the study were noted: (1) Toxic effects of the dosage given included skin dryness with peeling and facial erythema, conjunctivitis, and hypertriglyceridemia. Although these toxicities were tolerated for the 3-month period, it was noted that they would likely not be tolerable over extended periods of time. (2) A note was made of several early relapses within the successfully treated group, raising the question of a need for long-term treatment regimens, which would not likely be tolerated.

Subsequent studies to answer this dilemma have used treatment regimens with initial induction doses of 1 to 2 mg/kg/day with low-dose (0.05 mg/kg/day) maintenance. One-year follow-up results on these patients have been promising in regard to toxicity and efficacy.[72]

In the area of chemoprevention of second primary tumors and field cancerization, a number of studies have been completed. In one study patients with HNSCC received radiotherapy or surgical management followed by high-dose 13-cRA (100 mg/m^2/day) for 1 year after treatment.[73] This dose was decreased by half in 53% of patients, who could not tolerate the side effects of the medication. With a median follow-up of 55 months, the treated patients had 14% second primary rate versus 31% in the untreated group ($p = .04$). Important to note in their study was the lack of statistically significant effect on primary tumor recurrence or survival rates.

Future research in this important area involves the identification of appropriate targets for chemoprevention with high efficacy and low toxicity. Ongoing studies are underway using the tools of molecular genetics in attempting to identify candidates for which available chemoprevention may be indicated.[74] At present the retinoids remain an area of greatest promise. Ongoing research enhancing our understanding of the mechanism of action of retinoids will further assist in the creation of targeted chemopreventive agents.

Photodynamic Therapy

Photodynamic therapy (PDT) has been actively investigated in clinical trials since the late 1980s, treating a large number of tumors including HNSCC. PDT uses a photosensitizing agent designed to selectively target the neoplastic cells with subsequent activation and killing of the target. Necrosis of the tumor is thought to involve vascular collapse associated with the generation of free oxygen radical production.[75] Advantages of this technique include selective targeting of neoplastic cells (by unknown mechanisms) and the ability to use this tool in conjunction with established regimens of

surgery, chemotherapy, and radiation therapy. A number of new photosensitizers are currently under study, with Photofrin being the most widely used agent at the present time. The treatment regimen consists of intravenous injection of Photofrin with laser photoactivation 48 hours later using 630-nm wavelength light. A major limitation of treatment with this wavelength is the penetration depth in tissue of only 0.5 to 1 cm. In addition, a side effect of treatment with Photofrin is photosensitivity, which may last up to 6 weeks. Newer agents under study attempt to minimize these limitations.

The results of treatment for early SCCHN in the oral cavity appear promising. In 2006 Biel[77] reported on 15 years of experience with the use of photodynamic therapy in which 183 oral cavity squamous carcinomas were treated. In addition, literature is reviewed from 505 reported cases of Cis, T1, and T2 lesions of the oral cavity, larynx, pharynx, and nasopharynx; 89.1% of these patients achieved complete clinical response.[77]

Fan et al reported the use of *meta*-(tetrahydroxyphenyl) chlorine (mTHPC), a second-generation photosensitizer, in 19 patients with histologically confirmed oral cancer.[78] The six single-lesion T1 and T2 patients were cleared with one treatment. Three of 6 T4 lesions were reported cleared as well. Lesions in patients with field cancerization changes were not as successful, with only 9 of 14 T1 and T2 lesions cleared, with 4 requiring additional treatments. The mean follow-up of patients in this study was 63 weeks. Copper and colleagues reported on 25 patients receiving mTHPC for T1 (63%), T2 (28%), and multiple primary tumors (8%).[79] The complete remission rate with 37 months follow-up was 95% for T1 lesions and 57% for T2 lesions. All cases with recurrent disease were salvaged with standard surgery and/or radiotherapy. Five of the patients at the time of salvage were positive for lymph node metastasis.

Photodynamic therapy presents significant advantages in the limitation of morbidity associated with treatment of HNSCC. At present, data exist in support of this modality for treatment of early-stage disease. Photodynamic therapy may be used in conjunction with other modalities. Continued documentation of long-term follow-up and also controlled clinical trials are needed to elucidate its ultimate role.

Immunotherapy

Active immunotherapy (administration of agents external to the patient) and passive immunotherapy (administration of agents originally obtained from the patient) continue to be studied extensively in regard to a variety of malignant tumors. Development of tumor vaccines that incorporate defined epitopes from the cancer cells as well as attempts to globally stimulate the immune system provide plausible avenues for ultimate treatment, or as an adjunct to treatment, of HNSCC. The requirements for this therapy to work include the following: (1) identification of tumor-specific antigens; (2) activation of antigen processing cells (APCs) to present antigens via major histocompatibility complex (MHC) to T cells; (3) directed T cells activated by APCs capable of recognizing tumor; and (4) lysis of tumor cells by activated T cells.

The tools of molecular biology have recently allowed the identification of many tumor-associated antigens.[80] These tumor antigens can be processed by APCs and presented to T cells, which do indeed infiltrate into tumor. Haeffner and colleagues demonstrated T cell recognition of antigen by the existence of activated tumor-infiltrating lymphocytes in squamous cell carcinoma after presentation of antigen.[76] Unfortunately, although evidence of activation was present, tumor lysis did not occur. One possible explanation for this is the finding that HNSCC often produces significant quantities of immunosuppressive cytokines, resulting in the inability to complete the T-cell mediated lysis.

One possible answer to this dilemma involves the boosting of the immune system through a variety of mechanisms. Studies using interferon-α, interleukin-2, tumor necrosis factor, and other immunomodulators have been conducted. Attempts have been made to administer these agents intralesionally, intralymphatically, and systemically. A study representative of many variations on this theme reported a phase II trial with neoadjuvant immunotherapy for oral squamous cell carcinoma. Interleukin-2 injection occurred in 19 patients, with 2 complete, 2 major (>50%), and 4 minor (>30% but <50%) responses. The overall response rate was 42%.[81]

With respect to SCCHN, immunotherapy at present remains investigational in nature and in need of additional controlled clinical trials to define its place in treatment modalities. SCCHN does possess the elements needed for treatment via modulation of the immune system, and immunotherapy in some fashion may likely play a role in the treatment of this disease as our understanding of the processes involved evolves.

Gene Therapy

Gene therapy is defined as the transfer of genetic material for treating human disease. This definition encompasses the transfer of new genetic material as well as the modulation of existing genes. The first report of a fully successful gene therapy treatment occurred in 2000 with the treatment of a child with severe combined immunodeficiency.[82] Gene therapy has the potential to treat HNSCC, which is known to involve multiple genetic "hits" in its transformation process from a normal cell to malignancy. At the present time, direct injection into tumor is a requirement for gene therapy in tumor treatment, making local HNSCC an acceptable target.

As reviewed by Xi and Grandis,[83] several general strategies are used in cancer treatment with gene therapy: addition of a tumor-suppressor gene (gene addition therapy), deletion of a defective tumor gene (gene excision therapy), downregulation of the expression of genes that stimulate tumor growth (antisense RNA), enhancement of immune surveillance (immunotherapy), activation of prodrugs that

have a chemotherapeutic effect ("suicide" gene therapy), introduction of viruses that destroy tumor cells as part of the replication cycle, delivery of drug resistance gene(s) to normal tissue for protection from chemotherapy, and introduction of genes to inhibit tumor angiogenesis.

Genetic material must be packaged and delivered in a vector to its target site. The ideal vector, not yet achieved, would specifically target the desired cells, deliver a precise amount of desired genetic material, and show no toxicity. Vectors currently in use are considered either viral or nonviral in nature. Viral vectors at the present time include adenovirus, adeno-associated virus, retroviruses, lentiviruses, herpesvirus, and hybrids of these. The nonviral vectors include the use of liposomes and naked DNA with chemical and physical transfection techniques. Of the present techniques available, one that appears particularly promising involves the creation of a recombinant adenovirus that selectively replicates and kills cells that are deficient in p53.

At the present time, gene therapy is a new investigational approach to the treatment of HNSCC. In the future, cancer-based gene therapy could be combined with known effective approaches to attempt to decrease tumor bulk and therefore the morbidity associated with treatment. As our understanding of the genetics of cancer and our ability to externally control those genes increases, HNSCC will be an attractive target for implementation of protocols for treatment. At the present time phase I, II, and III trials are underway in order to establish and delineate the role of gene therapy in the treatment of HNSCC.

Surgical Management

The Primary Tumor

The word *carcinoma* (*karkinos:* "crab") is attributed to the father of medicine, Hippocrates (460-370 BC), who noticed that blood vessels around non–ulcer-forming and ulcer-forming tumors looked like the claws of a crab. Hippocrates, and later Galen (129-199 AD), maintained that cancer was generated by a "humoral" etiology caused by an excess of "black bile." As a result of their theory, they did not believe in the surgical management of malignant tumors, but Galen performed several cancer resections, recommending excision through surrounding healthy tissue.[84] Galen also described how tumor growth developed again even after the scar healed. Intuitively, he presented the basic concepts of surgical resection with negative margins, and the potential for tumor recurrence. The skeptical approach toward surgery was maintained through many centuries, until 1845, when Lebert described cancer cells and recommended surgical excision for the treatment of breast cancer.[85]

Surgery is presently the most common treatment modality in the management of squamous cell carcinomas (SCCa) of the oral and maxillofacial region. Alternative therapeutic options should be considered based on such factors as the medical condition of the patient, tumor stage, and prognosis.

Basic principles of surgical oncology are applied: resection with curative intent of the primary tumor with *at least* 1 cm of negative surgical margins. In specific situations, patients who have unresectable tumors undergo surgery with palliative intent.

Several factors are significant in the incidence of local recurrence and overall survival rates: positive surgical margins, perineural invasion, bone invasion, pattern of invasion, lymphocytic response, vascular invasion, extracapsular extension, and tumor (T) size.[86-94]

Cancer of the Floor of the Mouth

Excision of T1 lesions of the floor of the mouth (FOM) can usually be performed through a transoral approach, and the area can be reconstructed with a split-thickness skin graft. Neck dissections may be required based on the depth of invasion of the cancer. Because of the variety of immediate surrounding tissues, this type of cancer may involve the salivary ducts of the submandibular and sublingual glands, the tongue, or the mandibular alveolar ridge (Figure 28-3).

A retrospective study of 63 specimens of FOM squamous cell carcinoma with inclusion of the sublingual salivary gland was conducted.[87] Seventeen cases (27%) had histopathologic sublingual gland invasion. Clinically, this was evident at the time of surgery in 15 patients (88%). Microscopic invasion into the sublingual gland without macroscopic evidence was present in only 4.2% of patients. The findings of the study support a wide local excision of early-stage superficial SCCa of the FOM without obtaining significant benefit by excising the sublingual gland unless there is macroscopic evidence of invasion, significant tumor depth, or an advanced T stage.

If the submandibular duct is in the area of the lesion and if a neck dissection is not planned, a sialodochoplasty would be indicated. A potential complication would be an obstructive sialoadenitis caused by scarring at the site of the repositioned duct. The use of sialodochoplasty in this clinical setting is supported by a study on outcomes of repositioning and



• **Figure 28-3** Squamous cell carcinoma of the floor of the mouth with extension into the ventral surface of the tongue.

cannulation of the submandibular duct after excision of floor of mouth cancer. The study identified an incidence of postoperative neck swelling in only 15% of patients within the first 25 postoperative months, concluding that sialodochoplasty is a sound procedure that does not compromise the cancer resection.[88] In T1N0M0 lesions, the reported incidence of occult metastasis has been 21% while it is 62% in T2N0M0 SCCa of the FOM.[9] Regardless of the T stage, Spiro and colleagues[89] suggested that tumor thickness (more than 2-mm depth of invasion having more incidence of cervical metastasis), rather than tumor staging, may be a better way to select oral cancer patients who are likely to benefit from elective neck dissections.

Disease-specific cumulative 5-year survival for patients with FOM cancer has been reported to be 76%, with 95% survival rate for stage I, 86% for stage II, 82% for stage III, and 52% for stage IV (Figure 28-4).[9]

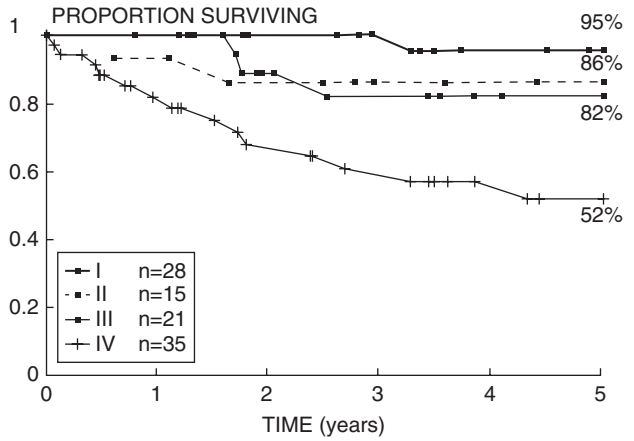

• **Figure 28-4** Disease-specific survival by pathologic group stage. (From Hicks WL, Loree TR, Carcia RI et al: Squamous cell carcinoma of the floor of mouth: a 20 year review. *Head and Neck* 19:400-405, 1997.)



• **Figure 28-5** Verrucous carcinoma of the buccal mucosa.

Cancer of the Buccal Mucosa

The incidence of squamous cell carcinomas of the buccal mucosa (Figures 28-5 and 28-6) in western countries is mostly related to the use of tobacco, with an overall low incidence of 10% of all oral cancers. In Southeast Asia (especially in India) the incidence of SCCa has been correlated with the chewing of a combination of tobacco, betel nut, and lime with an estimated prevalence of more than 40% of oral cancers in this geographical region.

In a retrospective review of 121 previously untreated patients with SCCa of the buccal mucosa, the locoregional recurrence was 57% for all patients, with 80% occurring in the primary site alone.[90] Even patients with T1 and T2 lesions who received surgery only had a recurrence rate of 41%. Patients with T3-T4 lesions had better long-term locoregional



• **Figure 28-6** Invasive squamous cell carcinoma of the buccal mucosa and lower vestibule with gingival extension.

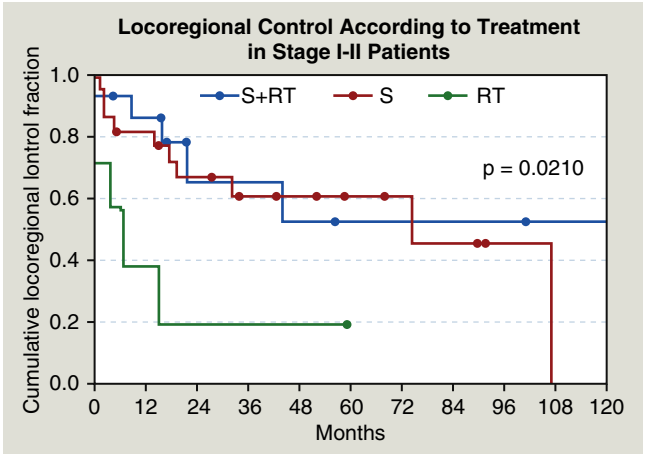

• **Figure 28-7** Locoregional control curve for patients with buccal mucosa cancer stage I-II disease. The 5-year locoregional control rates for S, RT, and S+RT groups are 60.7%, 19.1%, and 52.2%, respectively (p = 0.0210). *S*, Surgery alone; *RT*, radiotherapy; *S+RT*, surgery followed by postoperative radiotherapy. (From Lin CS, Jen YM, Cheng MF et al: Squamous cell carcinoma of the buccal mucosa: an aggressive cancer requiring multimodality treatment, *Head Neck* 28[2]:150-157, 2006.)

control and survival rates when treated by a combination of surgery and radiotherapy than when treated by either modality alone (Figure 28-7). Patients with buccal mucosa SCCa have a worse stage-for-stage survival rate than do patients with any other cancerous sites in the oral cavity. The presence of regional metastasis has a significant effect on survival rates. In a study conducted at the M.D. Anderson Cancer Center, the 5-year survival rate for patients with positive neck nodes was 43% versus 70% when the neck was negative[91] (Figure 28-8).

As a result of the reported high recurrence rate and potential poor prognosis of carcinomas of the buccal mucosa,[92] multimodality combinations of surgery and radiation with or without chemosensitizers are recommended for patients with this type of lesion. Nair and co-workers reported an 85% 3-year disease-free survival rate for stage I and 63% for stage II when the primary modality of treatment was radiotherapy with either interstitial radium needles or external beam.[93] Most publications provide better outcomes with a combination of surgery and postoperative radiation in more advanced stages.

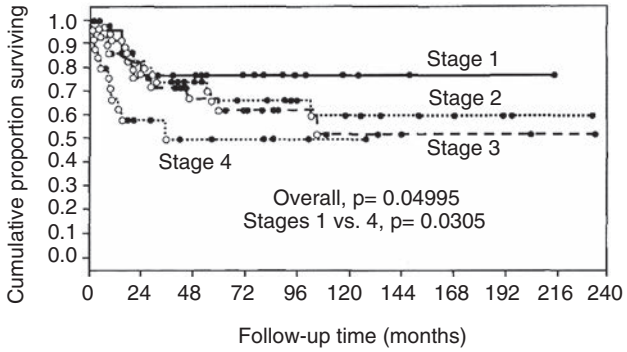

• **Figure 28-8** Effect of disease stage on survival in buccal mucosa cancer. The impact of disease stage is shown here on a Kaplan-Meier plot. For patients with stage I, II, III, and IV disease, 5-year survival rates were 78%, 66%, 62%, and 50%, respectively. (From Diaz EM Jr, Holsinger FC, Zuniga ER et al: Squamous cell carcinoma of the buccal mucosa: one institution's experience with 119 previously untreated patients, *Head Neck* 25[4]:267-273, 2003.)

Cancer of the Tongue

Likely to be the most common oral cancer, SCCa of the tongue (Figure 28-9) accounts for about 20% of all oral and pharyngeal cancers, including lip cancer.[94]

Epidemiologic data show an increased incidence in younger adults ages 20 to 44[95] with some suggestive evidence of higher locoregional failure in the younger patients.[96] In a recent article, the overall survival rate has been correlated with tumor grade and tumor size, with no difference in survival rates between patients with tongue cancer and patients with cancer in other sites of the oral cavity[97] (Figure 28-10). Neck metastasis of early (T1-T2) squamous cell carcinoma of the tongue was correlated with tumor thickness, muscle invasion, poorly differentiated tumors, infiltrating-type invasion front, presence of perineural invasion, and presence of angiolymphatic invasion.[98]

While positive cervical lymphatic metastasis has always been documented as having a very negative effect on survival, a retrospective analysis of 266 patients comparing clinical versus pathologic lymph node staging demonstrated statistically significant survival differences in pathologic lymph node stages as well.[99]

In the past decade, significant data has been added to the literature in the management of base-of-tongue cancer by Transoral Robotic Surgery (TORS).

A recent review of articles on the subject from 2000 to 2014 by Helman and associates concluded that TORS has a positive role in oropharyngeal cancer by decreased morbidity, length of stay and total intubation time.[99a] Prospective studies are being conducted comparing TORS to non-robotic approaches in oropharyngeal carcinomas.

Squamous Cell Carcinoma of the Retromolar Trigone, Alveolar Ridge, and Palate

The gingival tissues on the alveolar ridge or the retromolar trigone are in very close proximity to the underlying periosteum, and significant difficulties have been encountered

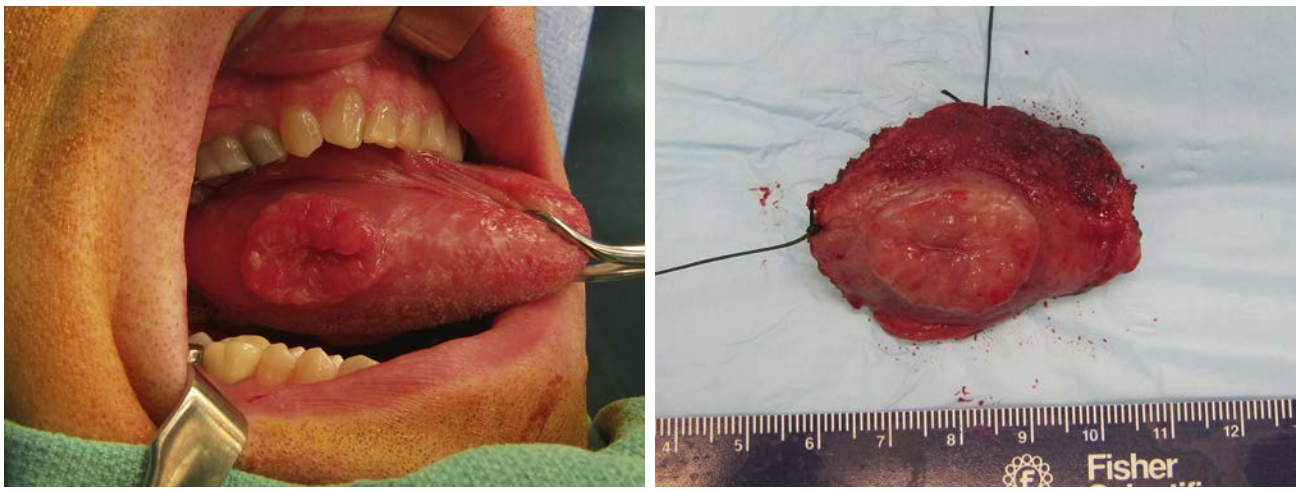

• **Figure 28-9** Squamous cell carcinoma of the tongue.

trying to identify bony invasion. Computed tomography has been useful in the diagnosis of bone involvement, but inaccurate. A study by Lane and colleagues[100] found an incidence of 50% mandibular invasion in retromolar SCCa that was not identified radiographically by CT in 27% of the patients. The effectiveness of skeletal scintigraphy is of relative value as well. Tsuchimochi and co-workers[101] described accumulation of technetium-99m methylene diphosphonate in areas of the mandible invaded by cancer. Bone scans have increased uptake in areas of osteoblastic activity; therefore the radioisotope concentrates in the immature bone surrounding the tumor as well as in the reactive periosteum in adjacent contact with the tumor, making this test highly sensitive but nonspecific with a potential false-positive result. Magnetic resonance imaging has a reported accuracy of 87% in establishing the involvement of the mandibular bone marrow, even in the absence of discontinuity of the cortical bone.[102]

A comparison between different imaging modalities and direct inspection after periosteal stripping was conducted by Brown and associates.[103] The results showed that orthopantomograms, CT, and periosteal stripping with direct inspection underpredicted the width and depth of bony invasion, whereas bone scans and MRI overestimated it.

Diagnosis of tumor extension into bone is critical to render proper treatment. Genden et al[104] recommended a panoramic radiograph and CT scan for all tumors of the retromolar trigone. In patients with trismus, extensive soft tissue involvement, or sensory disturbance, an additional MRI would be indicated.

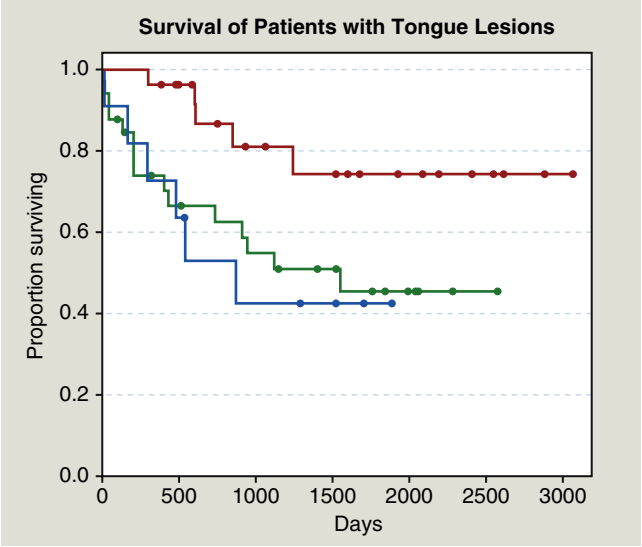

• **Figure 28-10** Disease-free survival of tongue cancer with respect to tumor grade. Kaplan-Meier curve illustrating the disease-free probabilities with respect to tumor grade. Grade 1 is shown at the top as a *red* line, grade 2 at the bottom as a *green* line, and in the middle is grade 3 as a *blue* line. (From Friedlander PL, Schantz SP, Shaha AR et al: Squamous cell carcinoma of the tongue in young patients: a matched-pair analysis, *Head Neck* 20[5]:363-368, 1998.)

The treatment plan would include a bone resection in most cases. If the tumor approaches the periosteum, a marginal resection would be indicated to achieve tumor clearance and appropriate clean margins. When the cancer has early cortical mandibular invasion, conservation surgery preserving some mandibular continuity has been shown to be a valid option without evidence of disease 2 years after treatment in 78% of patients with T1, 73.1% of T2, 63.5% of T3, and 33.3% of T4.[105]

When the preoperative assessment is positive for involvement into the marrow space, a segmental resection is indicated. I. A. McGregor and colleagues[106] reported a readily available route of cancer spread through the porous alveolar ridge in edentulous patients. Of 46 nonirradiated mandibles (10 partially dentated and 36 edentulous), 41 were invaded through the alveolar ridge. They also found that perineural spread through the inferior alveolar nerve was a regular occurrence after bony invasion reached the mandibular canal.

A. D. McGregor and associates suggested that a more aggressive pattern of invasion through cortical bone was present in previously irradiated mandibles.[107] The pattern of invasion in 16 irradiated mandibles was more variable with multiple foci of tumor present in areas where the tumor was adjacent to the bone, implying the need for more radical resections in post-irradiated mandibles with tumor.

Boyle and Strong[108] recommended the following contraindications to marginal resections of the mandible:

1. Gross involvement of the cortical or cancellous bone of the mandible
2. Inability to preserve the inferior alveolar artery
3. Significant resorption of the mandible, suggesting very thin and weak residual bone
4. A previously irradiated mandible
5. Cancer abutting the mandible on more than two surfaces

Regarding contraindication 2, if the consideration to perform a radical resection because of the inability to preserve the inferior alveolar artery is based on evidence for direct invasion into the canal, then there is no doubt of the need to perform a segmental mandibulectomy and even evaluate the nerve margins for perineural spread.

On the other hand, the rationale is clouded if the justification for a segmental resection is based on the concern for vascular supply to the mandible as a result of the inability to preserve the inferior alveolar artery. If the canal was not infiltrated and there is no evidence of deep invasion, the mandible may remain viable through periosteal blood supply, even after sacrificing the inferior alveolar vessels.

Carcinomas of the hard palate and upper alveolus are uncommon. Alveolectomy, palatectomy, and infrastructure maxillectomy are the procedures of choice for this specific location.[109] Whereas squamous cell carcinomas still represent more than 50% of the malignant lesions of the hard palate, minor salivary gland tumors represent from one third to almost one half of the pathology in this location.[110,111]

The management of the neck in gingival and alveolar cancer has become a controversial issue that may require prospective data in order to establish a treatment strategy.

Soo and co-workers[112] reported an incidence of 14% neck metastasis at the time of diagnosis of maxillary gingival carcinoma. Overholt and colleagues[113] reported 13% neck metastasis at the time of diagnosis of palatal carcinoma.

More recent data from Simental and associates[114] have shown a much higher incidence of occult neck metastasis when patients with negative nodes at the time of presentation eventually developed neck metastasis despite control of their primary cancer. Only 7.6% of the patients in their group had clinically positive neck disease at the time of the initial evaluation, but an additional 27% of patients had cervical failures at the site of first failure for a total of 34.6%. Similar data were published by Zwetyenga et al,[115] with a 28% incidence of positive lymph node(s) in advanced upper gingival and hard palate cancer. Additional data from Toronto, showed similar results with occult nodal metastases of 26% of patients clinically staged as N0.[115a] Montes and Schmidt demonstrated that the aggregate of all patients with different stages of oral maxillary squamous cell carcinoma, 42.9% of the patients manifested disease to the cervical lymph nodes.[115b]

The accumulated experience in the management of the negative neck in cancer of this location supports surgical intervention through a selective neck dissection.

Types of Neck Dissection

Several clinical and pathologic characteristics have been described as predictive factors for oral cancer metastasis to regional cervical nodes. The radical neck dissection, initially described by Jawdynski in 1888[116] and later published and systematized by Crile in 1906[117] and advocated by Martin in 1951,[118] is the main treatment modality in the management of tumor metastasis to the lymph nodes of the neck.

In 1963 Suarez[119] and later in 1967, Bocca[120] published a technique preserving the spinal accessory nerve, sternocleidomastoid muscle, and internal jugular vein, achieving a similar degree of regional control while avoiding the morbidity associated with the removal of these three structures.

In 1972 Lindberg[121] described the distribution of cervical metastasis in relation to the primary tumor after reviewing 2004 patients with SCCa of the head and neck. This finding, later validated in additional studies by Shah[122] and Byers and colleagues,[123] led to the implementation of selective neck dissections for patients with clinically negative necks or for very selected patients with positive necks. Outstanding and detailed reviews of the historic evolution of neck dissections have been published by Ferlito and colleagues[124] and Subramanian and associates.[125]

In 2001 the American Head and Neck Society proposed an update for the classification of neck dissections.[126] The different levels of the cervical lymph nodes and the new classification of neck dissections are represented in detail within Tables 28-1 and 28-2. The classification of 1991 differs only in the description of selective neck dissections (SNDs) (Figure 28-11), which are now described as SND with the use of parentheses to denote the levels or sublevels removed.

Despite performance of a neck dissection, the presence of extracapsular spread and soft tissue deposits of cancer diminishes the survival rates significantly. The presence of cervical lymph node metastasis reduced the 5-year survival rate by 50%, while extracapsular spread or soft tissue deposits of cancer roughly decreased the survival rate by an additional 50% (Figures 28-12 and 28-13).[127]

Since the early 1990s, sentinel lymph node biopsy has been used mostly for breast cancer and melanoma.[128,129] The technique involves the histologic sampling of the lymph node that drains a radioisotope after it is injected at the site of the primary tumor. A review by Devaney and colleagues concludes that a negative sentinel node biopsy does not necessarily exclude the presence of other positive cervical lymph nodes.[130] Therefore this technique should still be considered an investigational procedure until further data are available.

TABLE 28-2 Types of Neck Dissections

Surgery	Structures Removed
Radical neck dissection	Lymph node levels I-V, sternocleidomastoid muscle, internal jugular vein, and accessory nerve
Extended neck dissection	Lymph node levels I-V, sternocleidomastoid muscle, internal jugular vein, and accessory nerve plus at least one lymphatic or nonlymphatic structure not sacrificed during radical neck dissection (parapharyngeal nodes, superior mediastinal nodes, perifacial nodes, carotid artery, hypoglossal nerve, vagus nerve, paraspinal muscles, etc.)
Modified radical neck dissection	Radical neck dissection minus at least one of the three major structures (namely, sternocleidomastoid muscle, internal jugular vein, or accessory nerve); the structure preserved should be specifically named
Selective neck dissection	At least one of the six lymph node levels/sublevels preserved; none of the structures (namely, sternocleidomastoid muscle, internal jugular vein, and accessory nerve) are sacrificed (the removed levels or sublevels should be mentioned within parentheses: I-III, II-VI, VI, etc.)

From Subramanian S, Chiesa F, Lyubaev V et al: The evolution of surgery in the management of neck metastasis, *Acta Otorhinolaryngol Ital* 26:309-316, 2006.

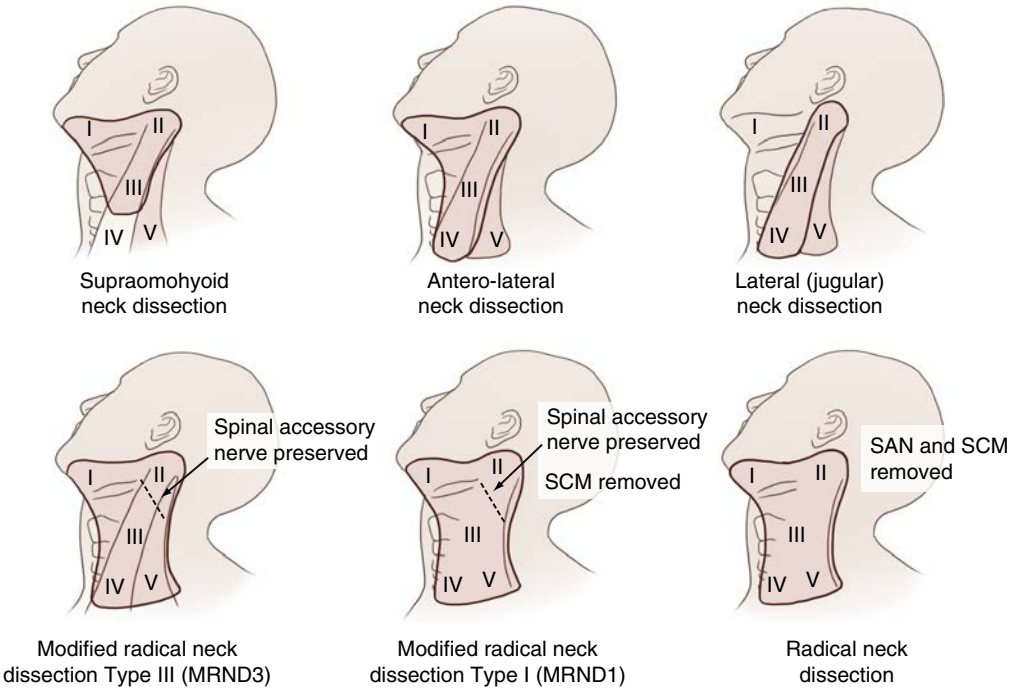

A

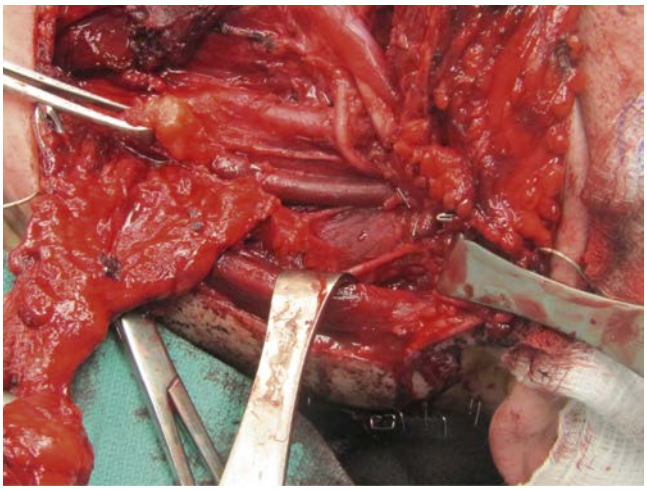

B

• **Figure 28-11** **(A)** Types of neck dissections according to the classification of 1991. **(B)** The retractors are holding the sternocleidomastoid muscle and exposing the spinal accessory nerve which is the boundary between Level 2A and 2B. Above the Army-Navy retractors one can identify the internal jugular vein and the carotid artery with the cranial nerve X in between the two vessels and the cranial nerve XII crossing the bifurcation of the carotid artery. (Courtesy Shah J: Patterns of cervical lymph node metastasis from squamous cell carcinomas of the upper aerodigestive tract, *Am J Surg* 160:405-409, 1990.)

Follow-up

Long-term follow-up of patients after treatment for SCCa of the oral cavity is critical. Appointments should be scheduled based on individual risk of recurrence and the development of second primary tumors. Furthermore, follow-up is dictated by the need for additional treatments associated with morbidity from the surgery and the necessity of providing social and psychological support. These visits should include an annual chest radiograph and measurement of liver enzymes as well as thyroid function tests in patients who have received radiation to the lower neck.

The American Head and Neck Society recommends the following follow-up regimen:

- First year post-treatment: 1 to 3 months
- Second year: 2 to 4 months
- Third year: 3 to 6 months
- Fourth and fifth years: 4 to 6 months
- Beyond 5 years: 12 months

A recent British study on practices of 50 units revealed that all patients were followed monthly for the first year, with 90% having visits every 2 months during the second year. Although variations occurred during the third and fourth years, by the fifth year 6-month visits

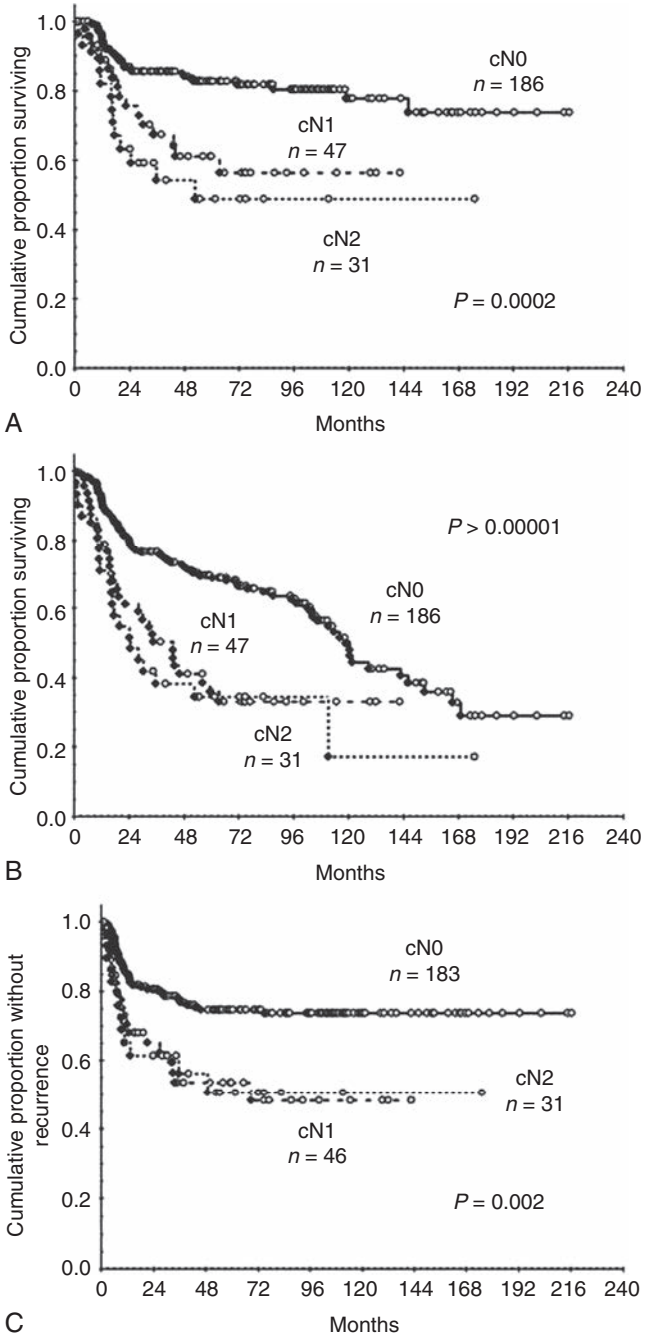

• **Figure 28-12** Impact of clinical lymph node stage on **(A)** disease-specific survival, **(B)** overall survival, and **(C)** disease-free interval for patients with squamous cell carcinoma of the oral tongue who received neck dissection. Closed symbols died of disease **(A-B)** and recurrent disease **(C).** Open symbols censored. (Courtesy Greenberg JS, El Naggar AK, Mo V, et al: Disparity in pathologic and clinical lymph node staging in oral tongue carcinoma. Implication for therapeutic decision making, *Cancer* 98[3]:508-515, 2003.)

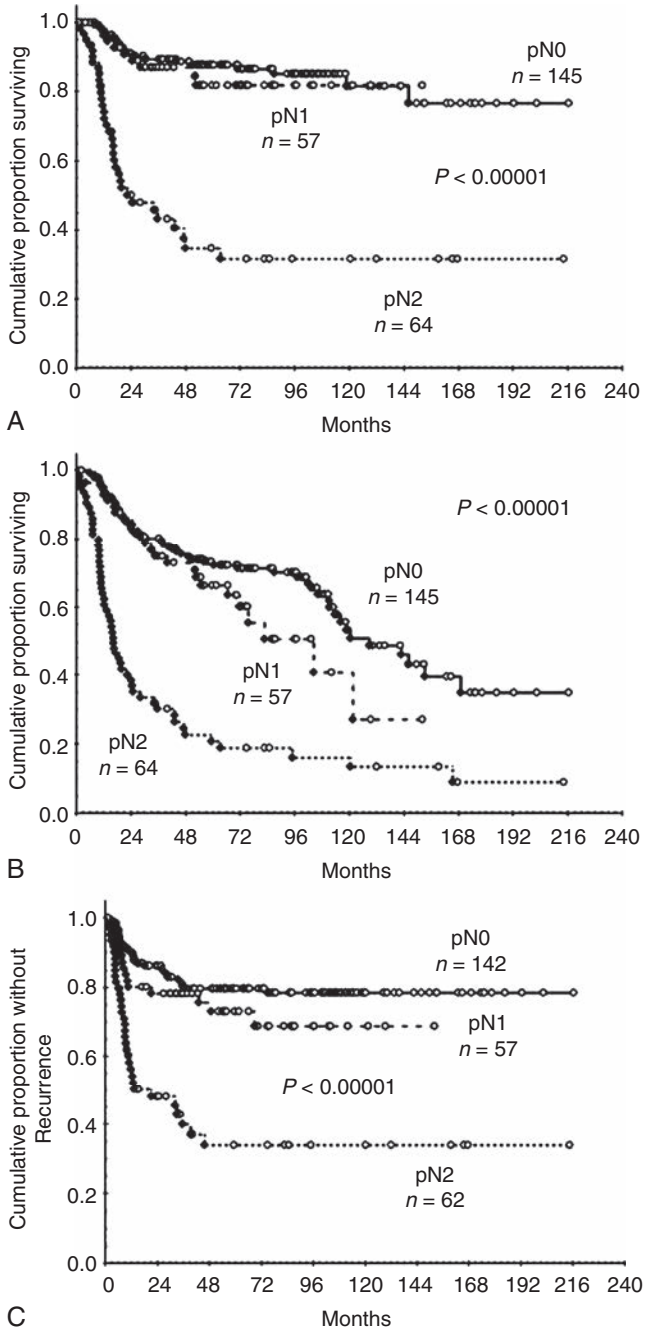

• **Figure 28-13** Impact of pathologic lymph node stage on **(A)** disease-specific survival, **(B)** overall survival, and **(C)** disease-free interval for patients with squamous cell carcinoma of the oral tongue who received neck dissection. Closed symbols died of disease **(A-B)** and recurrent disease **(C).** Open symbols censored. (Courtesy Greenberg JS, El Naggar AK, Mo V, et al: Disparity in pathologic and clinical lymph node staging in oral tongue carcinoma. Implication for therapeutic decision making, *Cancer* 98[3]:508-515, 2003.)

were universal. Not surprising given the uniformity of results, risk-assessed variations in follow-up were not present.[131]

Ultrasonographic examinations have been added to the armamentarium of imaging devices used for identification of cervical node metastasis for follow-up of patients with head and neck cancer who did not receive neck dissection. In a study published by Hiroshi Yusa and colleagues,[132] 52 patients were examined by ultrasound after the initial primary resection. They accurately diagnosed 24 nodes in 10 patients, while 21 of the nodes were not palpable. Ultrasound examination appears to be useful for follow-up of cervical node metastasis in patients with oral and maxillofacial cancer.

Summary

Squamous cell carcinoma of the oral and maxillofacial region continues to present a challenge in regard to diagnosis, treatment, and patient survival. A number of risk factors have been identified, with others under debate. As our understanding of the genetic changes involved evolves, so may our treatment options. At present, once a patient is diagnosed, a thorough workup must ensue and treatment must be rendered in an expeditious fashion. In the oral cavity, surgery remains the primary modality, with adjuvant therapy (radiation or chemoradiation) as indicated. Close follow-up of patients is required long term in order to identify recurrence or second primary disease and should be tailored based on patient risk factors from the initial cancer as well as the presence of persistent high-risk behaviors.

References

1. American Cancer Society: *Cancer facts and figures*, 2006. http://www.cancer.org/index.
2. Johnson N: Tobacco use and oral cancer: a global perspective, *J Dent Educ* 65:328–339, 2001.
3. McFarlane GJ, Zheng T, Marshall JR, et al.: Alcohol, tobacco, diet and the risk of oral cancer: a pooled analysis of three case-control studies, *Eur J Cancer B: Oral Oncol* 31B:181–187, 1995.
4. EU-Working Group on Tobacco and Oral Health: Tobacco and oral diseases-report of EU Working Group, 1999, *J Ir Dent Assoc* 46:12–19, 2000.
5. Moreno-Lopez LA, Esparaza-Gomez GC, Gonzalez-Navarro A, et al.: Risk of oral cancer associated with tobacco smoking, alcohol consumption, and oral hygiene: a case control study in Madrid, Spain, *Oral Oncol* 36:170–174, 2000.
6. Muscat JE, Richie JP, Thompson S, et al.: Gender differences in smoking and risk for oral cancer, *Cancer Res* 56:5192–5197, 1996.
7. International Agency for Research on Cancer: Tobacco smoking, *IARC Monogr Eval Carcinog Risk Chem Hum* 38:35–394,1986.
8. Winn DM, Blot WJ, Shy CM, et al.: Snuff dipping and oral cancer among women in the southern United States, *N Engl J Med* 305:745–749, 1986.
9. Bouquot JE, Meckstroth RL: Oral cancer in a tobacco-chewing US population—no apparent increased incidence or mortality, *Oral Surg Oral Med Oral Pathol Oral Radiol Endod* 86: 697–706, 1998.
10. Accortt NA, Waterbor JW, Beall C, et al.: Cancer incidence among a cohort of smokeless tobacco users (United States), *Cancer Causes Control* 16:1107–1115, 2005.
11. Accortt NA, Waterbor JW, Beall C, et al.: Need to educate primary caregivers about the risk factor profile of smokeless tobacco users, *J Cancer Educ* 20:222–228, 2005.
12. Ko YC, Huang YL, Lee CH, et al.: Betel quid chewing, cigarette smoking and alcohol consumption related to oral cancer in Taiwan, *J Oral Pathol Med* 24:450–453, 1995.
13. Rothman KJ, Keller AZ: The effect of joint exposure to alcohol and tobacco on the risk of cancer of the mouth and pharynx, *J Chron Dis* 25:711–716, 1972.
14. Lewin F, Norell S, Johansson H, et al.: Smoking tobacco, oral snuff, and alcohol in the etiology of squamous cell carcinoma of the head and neck—a population-based case-referent study in Sweden, *J Cancer* 82:1367–1373, 2000.
15. Brugere J, Guenel P, Leclerc A, et al.: Differential effects of tobacco and alcohol in cancer of the larynx, pharynx and mouth, *Cancer* 57:391–395, 1986.
16. Shillitoe EJ, Greenspan D, Greenspan JS, et al.: Neutralising antibody to herpes simplex virus type 1 in patients with oral cancer, *Cancer* 49:2315–2320, 1982.
17. Hirsch JM, Johansson SL, Vahlne A: Effect of snuff and herpes simplex virus-1 on rat oral mucosa: possible association with development of squamous cell carcinoma, *J Oral Pathol* 13:52–62, 1984.
18. Miller CS, Johnstone BM: Human papillomavirus as a risk factor for oral squamous cell carcinoma: a meta-analysis, 1982-1997, *Oral Surg Oral Med Oral Pathol Oral Radiol Endod* 91:622–635, 2001.
19. Miller CS, White DK: Human papillomavirus expression in oral mucosa, premalignant conditions, and squamous cell carcinoma: a retrospective review of the literature, *Oral Surg Oral Med Oral Pathol Oral Radiol Endod* 82:57–68, 1996.
20. Sugiyama M, Bhawal UK, Kawamura M, et al.: Human papillomavirus-16 in oral squamous cell carcinoma: clinical correlates and 5-year survival, *Br J Oral Maxillofac Surg* 45:116–122, 2007.
21. Boy S, Van Rensburg EJ, Engelbrecht S, et al.: HPV detection in primary intra-oral squamous cell carcinomas—commensal, aetiological agent or contamination? *J Oral Pathol Med* 35(2):86–90, 2006.
22. Kansky AA, Seme K, Maver PJ, et al.: Human papillomaviruses (HPV) in tissue specimens of oral squamous cell papillomas and normal oral mucosa, *Anticancer Res* 26(4B):3197–3201, 2006.
23. Negri E, Francheschi S, Boscetti C, et al.: Selected micronutrients and oral and pharyngeal cancer, *Int J Cancer* 86:122–127, 2000.
24. Levi F, Pasche C, Lavecchia C, et al.: Food groups and risk of oral and pharyngeal cancer, *Int J Cancer* 77:705–709, 1998.
25. Day GL, Shore RE, Blot WJ, et al.: Dietary factors and second primary cancers: a follow-up of oral and pharyngeal cancer patients, *Nutr Cancer* 21:223–232, 1994.
26. Talamini R, Vaccarella S, Barbone F, et al.: Oral hygiene, dentition, sexual habits and risk of oral cancer, *Br J Cancer* 83:1238–1242, 2000.
27. Osella P, Carlson A, Wyandt H, et al.: Cytogenetic studies of eight squamous cell carcinomas of the head and neck, *Cancer Genet Cytogenet* 59:73–78, 1992.
28. Pinkel D, Straume T, Gray JW: Cytogenetic analysis using quantitative, high sensitivity fluorescence hybridization, *Proc Natl Acad Sci USA* 83:2934–2938, 1986.
29. Rosen MP, Cheng X, Poh C, et al.: Use of allelic loss to predict malignant risk for low-grade oral epithelial dysplasia, *Clin Cancer Res* 6:357–362, 2000.
30. Mao L, El-Naggar AK, Papadimitrakopoulou V, et al.: Phenotype and genotype of advanced premalignant head and neck lesions after chemopreventive therapy, *J Natl Cancer Inst* 90:1545–1551, 1998.
31. Mao L, Lee D, Tockman M, et al.: Microsatellite alterations as clonal markers for the detection of human cancer, *Proc Natl Acad Sci USA* 91:9871–9875, 1994.

32. Ha PK, Pilkington TA, Westra WH, et al.: Progression of microsatellite instability from premalignant lesions to tumors of the head and neck, *Int J Cancer* 102:615–617, 2002.
33. Temam S, Casiraghi O, Lahaye JB, et al.: Tetranucleotide microsatellite instability in surgical margins for prediction of local recurrence of head and neck squamous cell carcinoma, *Clin Cancer Res* 10:4022–4028, 2004.
34. Yin Y, Tainsky MA, Bischoff FZ, et al.: Wild-type p53 restores cell cycle control and inhibits gene amplification in cells with mutant p53 alleles, *Cell* 70:937–948, 1992.
35. Sionov RV, Haupt Y: The cellular response to p53. The decision between life and death, *Oncogene* 18:6145–6157, 1999.
36. Somers KD, Merrick MA, Lopez ME, et al.: Frequent p53 mutations increases with progression of head and neck cancer, *Cancer Res* 53:4477–4480, 1993.
37. Alsner J, Sorensen SB, Overgaard J: TP53 mutation is related to poor prognosis after radiotherapy, but not surgery, in squamous cell carcinoma of the head and neck, *Radiother Oncol* 59:179–185, 2001.
38. Carlos de Vicente J, Gutierrez LMJ, Zapatera AH, et al.: Prognostic significance of p53 expression in oral squamous cell carcinoma without neck noted metastases, *Head Neck* 26:22–30, 2004.
39. Grandis JR, Tweardy DJ: Elevated level of transforming growth factor alpha and epidermal growth factor receptor messenger RNA are early markers of carcinogenesis in head and neck cancer, *Cancer Res* 53:3579–3584, 1993.
40. Dassonville O, Formento JL, Francoual M, et al.: Expression of epidermal growth factor receptor survival in upper aerodigestive tract cancer, *J Clin Oncol* 11:1873–1878, 1993.
41. Grandis JR, Melhem MF, Gooding WE, et al.: Levels of TGF-alpha and EGFR protein in head and neck squamous cell carcinoma and patient survival, *J Natl Cancer Inst* 90:824–832, 1998.
42. Takes RP, Baatenburd de Jong RJ, Schuuring E, et al.: Differences in expression of oncogenes and tumor suppressor genes in different sites of head and neck squamous cell, *Anticancer Res* 18:4793–4800, 1998.
43. O-Charoenrat P, Modjtahedi H, Rhys-Evans P, et al.: Epidermal growth factor-like ligands differentially up-regulate matrix metalloproteinase 9 in head and neck squamous carcinoma cells, *Cancer Res* 60:1121–1128, 2000.
44. Bonner JA, Harari PM, Giralt J, et al.: Radiotherapy plus cetuximab for squamous-cell carcinoma of the head and neck, *N Engl J Med* 354:567–578, 2006.
45. Ghosh S, Karin M: Missing pieces in the NF-κB puzzle, *Cell* 109(suppl):81–96, 2002.
46. Garg A, Aggarwal BB: Nuclear transcription factor-κB as a target for cancer drug development, *Leukemia* 16A:1053–1068, 2002.
47. Nakayama H, Ikebe T, Beppu M, et al.: High expression levels of nuclear factor kappaB, IkappaB kinase alpha, and Akt kinase in squamous cell carcinoma of the oral cavity, *Cancer* 95:3037–3044, 2001.
48. Yamamoto Y, Gaynor RB: Therapeutic potential of inhibition of the NF-kappaB pathway in the treatment of inflammation and cancer, *J Clin Invest* 107:135–142, 2001.
49. Fracchiolla NS, Pignataro L, Capaccio P, et al.: Multiple genetic lesions in laryngeal squamous cell carcinomas, *Cancer* 75:1292–1301, 1995.
50. Bartkova J, Lukas J, Muller H, et al.: Abnormal patterns of D-type cyclin expression and G1 regulation in human head and neck cancer, *Cancer Res* 55:949–956, 1995.
51. Akervall JA, Michalides RJ, Mineta H, et al.: Amplification of cyclin D1 in squamous cell carcinoma of the head and neck and the prognostic value of chromosomal abnormalities and cyclin D1 overexpression, *Cancer* 79:380–389, 1997.
52. Bova RJ, Quinn DI, Naankervis JS, et al.: Cyclin D1 and p16INK4A expression predict reduced survival in carcinoma of the anterior tongue, *Clin Cancer Res* 5:2810–2819, 1999.
53. Ries LA, Miller Hankey FB, et al.: *SEER cancer statistics review, 1973-1991: tables and graphs (Pub No. 94-2789)*, Bethesda, MD, 1994, U.S. Department of Health and Human Services, U.S. Public Health Service, National Institutes of Health, National Cancer Institute.
54. Mashberg A, Samit AM: Early diagnosis of asymptomatic oral and oropharyngeal squamous cancers, *CA Cancer J Clin* 45:328, 1995.
55. Warnakulasuriya KAAS, Ekanayake ANI, Sivayoham S, et al.: Utilisation of primary care workers for early detection of oral cancer and precancer cases in Sri Lanka, *Bull World Health Organ* 62:243–250, 1984.
56. Wamakulasuriya K, Harris C, et al.: An alarming lack of public awareness towards oral cancer, *Br Dent J* 187(6):319–322, 1999.
57. Stahl S, Meskin L, Brown J: The American Dental Association's oral cancer campaign: the impact on consumers and dentists, *J Am Dent Assoc* 135:1261–1267, 2004.
58. Holmes J, Dierks E, Homer L, et al.: Is detection of oral and oropharyngeal squamous cancer by a dental health care provider associated with a lower stage at diagnosis? *J Oral Maxillofac Surg* 61:285–291, 2003.
59. National Health Care Disparities Report: *Agency for Healthcare Research and Quality*, U.S. Department of Health and Human Services, 2003.
60. Warnakulasuriya KA, Johnson NW: Sensitivity and specificity of Ora Scan toluidine blue mouthrinse in the detection of oral cancer and precancer, *J Oral Pathol Med* 25:97–103, 1996.
61. Mashberg A: Tolonium: (toluidine blue) rinse—a screening method for recognition of squamous carcinoma. Continuing study of oral cancer IV, *JAMA* 23:2408–2410, 1981.
62. Sankaranarayanan R, Ramadas K, Thomas G, et al.: Effect of screening on oral cancer mortality in Kerala, India: a cluster-randomised controlled trial, *Lancet* 365:1927–1933, 2005.
63. Kujan OGlenny AM, Oliver RJ, Thakker N, et al.: Screening programmes for the early detection and prevention of oral cancer, *Cochrane Database Syst Rev* 1, 2007.
64. Mashberg A: Final evaluation of tolonium chloride rinse for screening of high-risk patients with asymptomatic squamous carcinomas, *J Am Dent Assoc* 106:314–315, 1983.

64a. Onofre MA, Sposto MR, Navarro CM: Reliability of toluidine blue application in the detection of oral epithelial dysplasia and invasive squamous cell carcinomas, *Oral Surg Oral Med Oral Pathol Oral Radio Endod* 91:535–540, 2001.

65. Scuibba JJ, U.S. Collaborative OralCDx Study Group: improving detection of precancerous and cancerous oral lesions: computer-assisted analysis of the oral brush biopsy: *J Am Dent Assoc* 130: 1445–1457, 1999.
66. Potter T, Summerlin D, Campbell J: Oral malignancies associated with negative transepithelial brush biopsy, *J Oral Maxillofac Surg* 61:674–677, 2003.
67. Hong WK, Endicott J, Itri LM, et al.: 13-*cis*-Retinoic acid in the treatment of oral leukoplakia, *N Engl J Med* 315:1501, 1986.
68. Poate TW, Buchanan JA, Hodgson TA, et al.: An audit of the efficacy of the oral brush biopsy technique in a specialist Oral Medicine unit, *Oral Oncol* 40:829–834, 2004.

69. Scheifele C, Schmidt-Westhausen AM, Dietrich T, et al.: The sensitivity and specificity of the OralCDx technique evaluation of 103 cases, *Oral Oncol* 40:824–828, 2004.
70. Greenwald P, Nixon DW, Malone WF, et al.: Concepts in cancer chemoprevention research, *Cancer Res* 65(7):1483–1490, 1990.
71. Greenwald P: Section 3. Micronutrients and chemoprevention. In DeVita VT, Hellman S, Rosenberg SA, editors: *Principles and practice of oncology*, ed 4, Philadelphia, 1993, JB Lippincott, p 460.
72. Lippman SM, Batsakis JG, Toth BB, et al.: Comparison of low-dose isotretinoin with beta carotene to prevent oral carcinogenesis, *N Engl J Med* 328:15, 1993.
73. Hong WK, Lippman SM, Wolf GT: Recent advances in head and neck cancer—larynx preservation and cancer chemoprevention, *Cancer Res* 53:5113, 1994.
74. Reith A, Sudbo J: Impact of genomic instability in risk assessment and chemoprevention of oral premalignancies, *Int J Cancer* 101(3):205–209, 2002.
75. Pass H: Photodynamic therapy in oncology: mechanisms and clinical use, *J Natl Cancer Inst* 85:442–456, 1993.
76. Haeffner AC, Zepter K, Elmets CA, et al.: Analysis of tumor-infiltrating lymphocytes in cutaneous squamous cell carcinoma, *Arch Dermatol* 133:585–590, 1997.
77. Biel M: Advances in photodynamic therapy for the treatment of head and neck cancers, *Lasers Surg Med* 38:349–355, 2006.
78. Fan K, Hopper C, Speight P, et al.: Photodynamic therapy using mTHPC for malignant disease in the oral cavity, *Int J Cancer* 73:25–32, 1997.
79. Copper M, Tan I, Oppelaar H, et al.: *meta*-Tetra(hydroxyphenyl) chlorine photodynamic therapy in early-stage squamous cell carcinoma of the head and neck, *Arch Otolaryngol Head Neck Surg* 129:709–711, 2003.
80. Sahin U, Tureci O, Schmitt H, et al.: Human neoplasms elicit multiple specific immune responses in the autologous host, *Proc Natl Acad Sci USA* 92:11810–11813, 1995.
81. Timar J, Ladanyi A, Forster-Horvath C, et al.: Neoadjuvant immunotherapy of oral squamous cell carcinoma modulates intratumoral CD4/CD8 ratio and tumor microenvironment: a multicenter phase II clinical trial, *J Clin Oncol* 23:3421–3432, 2005.
82. Cavazzana-Calvo M, Hacein-Bey S, de Saint Basile G, et al.: Gene therapy of human severe combined immunodeficiency (SCID)-X1 disease, *Science* 288:669–672, 2000.
83. Xi S, Grandis JR: Gene therapy for the treatment of oral squamous cell carcinoma, *J Dent Res* 82(1):11–16, 2003.
84. Rayter Z: History of breast cancer therapy. In Rayter Z, Mansi J, editors: *Medical therapy of breast cancer*, London, 2007, Cambridge University Press.
85. Sanders-Goebel P: Crisis and controversy: historical patterns in breast cancer surgery, *Can Bull Med Hist* 8:77–90, 1991.
86. Brandwein-Gensler M, Teixeira MS, Lewis CM, et al.: Oral squamous cell carcinoma: histologic risk assessment, but not margin status, is strongly predictive of local disease-free and overall survival, *Am J Surg Pathol* 29(2):167–178, 2005.
87. Clark JR, Franklin JH, Naranjo N, et al.: Sublingual gland resection in squamous cell carcinoma of the floor of mouth: is it necessary? *Laryngoscope* 116(3):382–386, 2006.
88. Ord RA, Lee VE: Submandibular duct repositioning after excision of floor of mouth cancer, *J Oral Maxillofac Surg* 54(9):1075–1078, 1996 (discussion 1078-1079).
89. Spiro RH, Huvos AG, Wong GY, et al.: Predictive value of tumor thickness in squamous carcinoma confined to the tongue and floor of mouth, *Am J Surg* 152(4):345–350, 1986.
90. Lin CS, Jen YM, Cheng MF, et al.: Squamous cell carcinoma of the buccal mucosa: an aggressive cancer requiring multimodality treatment, *Head Neck* 28(2):150–157, 2006.
91. Diaz Jr EM, Holsinger FC, Zuniga ER, et al.: Squamous cell carcinoma of the buccal mucosa: one institution's experience with 119 previously untreated patients, *Head Neck* 25(4):267–273, 2003.
92. Strome SE, To W, Strawderman M, et al.: Squamous cell carcinoma of the buccal mucosa, *Otolaryngol Head Neck Surg* 120:375–379, 1999.
93. Nair MK, Sankaranarayanan R, Padmanabhan K: Evaluation of the role of radiotherapy in the management of carcinoma of the buccal mucosa, *Cancer* 61:1326–1331, 1988.
94. Canto MT, Devesa SS: Oral cavity and pharynx cancer incidence rates in the United States, 1975-1998, *Oral Oncol* 36:610–617, 2002.
95. Shiboski CH, Schmidt BL, Jordan RC: Tongue and tonsil carcinoma: increasing trends in the U.S. population ages 20-44 years, *Cancer* 103:1843, 2005.
96. Friedlander PL, Schantz SP, Shaha AR, et al.: Squamous cell carcinoma of the tongue in young patients: a matched-pair analysis, *Head Neck* 20(5):363–368, 1998.
97. Bell RB, Kademani D, Homer L, et al.: Tongue cancer: is there a difference in survival compared with other subsites in the oral cavity? *J Oral Maxillofac Surg* 65(2):229–236, 2007.
98. Sparano A, Weinstein G, Chalian A, et al.: Multivariate predictors of occult neck metastasis in early oral tongue cancer, *Otolaryngol Head Neck Surg* 131(4):472–476, 2004.
99. Greenberg JS, El Naggar AK, Mo V, et al.: Disparity in pathologic and clinical lymph node staging in oral tongue carcinoma. Implication for therapeutic decision making, *Cancer* 98(3):508–515, 2003.
99a. Helman SN, Schwedhelm T, Kadakia S, et al.: Transoral robotic surgery in oropharyngeal carcinoma, *Arch Pathol Lab Med* 139:1389–1397, 2015.
100. Lane AP, Buckmire RA, Mukherji SK, et al.: Use of computed tomography in the assessment of mandibular invasion in carcinoma of the retromolar trigone, *Otolaryngol Head Neck Surg* 122(5):673–677, 2000.
101. Tsuchimochi M, Katagiri M, Maeda K, et al.: Autoradiographic evaluation of ^{99m}Tc-methylene diphosphonate accumulation in oral cancer invading the mandible, *J Oral Maxillofac Surg* 57(3):245–254, 1999.
102. Crecco M, Vidiri A, Angelone ML, et al.: Retromolar trigone tumors: evaluation by magnetic resonance imaging and correlation with pathological data, *Eur J Radiol* 32(3):182–188, 1999.
103. Brown JS, Griffith JF, Phelps PD, et al.: A comparison of different imaging modalities and direct inspection after periosteal stripping in predicting the invasion of the mandible by oral squamous cell carcinoma, *Br J Oral Maxillofac Surg* 32:347–359, 1994.
104. Genden EM, Ferlito A, Shaha AR, et al.: Management of cancer of the retromolar trigone, *Oral Oncol* 39:633–637, 2003.
105. Werning JW, Byers RM, Novas MA, et al.: Preoperative assessment for and outcomes of mandibular conservation surgery, *Head Neck* 23(12):1024–1030, 2001.
106. McGregor IA, McDonald DG: Spread of squamous cell carcinoma to the nonirradiated edentulous mandible—a preliminary report, *Head Neck* 9:157–161, 1987.
107. McGregor AD, MacDonald DG: Routes of entry of squamous cell carcinoma to the mandible, *Head Neck Surg* 10:294–301, 1988.

108. Boyle JO, Strong EW: Oral cavity cancer. In Shah JP, editor: *American Cancer Society atlas of clinical oncology, cancer of the head and neck*, pp 100–126, Hamilton, ON, 2001, BC Decker.
109. Truitt TO, Gleich LL, Gordon PH, et al.: Surgical management of hard palate malignancies, *Otolaryngol Head Neck Surg* 121(5):548–552, 1999.
110. Truitt TO, Gleich LL, Gordon PH, et al.: Surgical management of hard palate malignancies, *Otolaryngol Head Neck Surg* 121(5):548–552, 1999.
111. Chung CK, Rahman SM, Constable WC: Malignant salivary gland tumors of the palate, *Arch Otolaryngol* 104:501–504, 1978.
112. Soo KC, Spiro RH, King W, et al.: Squamous cell carcinoma of the upper gums, *Am J Surg* 156:281–285, 1988.
113. Overholt SM, Eicher SA, Wolf P, et al.: Prognostic factors affecting outcome in lower gingival carcinoma, *Laryngoscope* 106:1335–1339, 1996.
114. Simental Jr AA, Johnson JT, Myers EN: Cervical metastasis from squamous cell carcinoma of the maxillary alveolus and hard palate, *Laryngoscope* 116:1682–1684, 2006.
115. Zwetyenga N, Miquel L, Garuet A, et al.: Treatment of squamous cell carcinoma of the upper gum and the hard palate, *Rev Stomatol Chir Maxillo-Fac* 107(2):80–85, 2006.
115a. Eskander A, Givi B, Gullane PJ, et al.: Outcome predictors in squamous cell carcinoma of the maxillary alveolus and hard, *Laryngoscope* 123(10):2453–2458, 2013.
115b. Montes DM, Schmidt BL: Oral maxillary squamous cell carcinoma: management of the clinically negative neck, *J Oral Maxillofac Surg* 66(4):762–766, 2007.
116. Jawdynski FI: Przypadek raka pierwotnego syzi. T.z. raka skrzelowego volkmann'a. Wyciecie nowotworu wraz z rezekkcyja tetnicy szjowej wspolnej i zyly szyjowej wewnetrznej, *Wyzdrowieneie Gaz Lek* 28:530–535, 1888.
117. Crile G: Excision of cancer of the head and neck, with special reference to the plan of dissection based on 132 patients, *JAMA* 47:1780–1784, 1906.
118. Martin H, Del Valle B, Ehrlich H, et al.: Neck dissection, *Cancer* 4:441–499, 1951.
119. Suarez O: El problema de las metastasis linfaticas y alejadas del cancer de laringe e hipofaringe, *Rev Otorrinolaringol* 23:83–99, 1963.
120. Bocca E, P'Oignataro O: A conservation technique in radical neck dissection, *Ann Otol Rhino Laryngol* 76: 975–987, 1967.
121. Lindberg R: Distribution of cervical lymph node metastasis from squamous cell carcinoma of the upper respiratory and digestive tracts, *Cancer* 29:1446–1449, 1972.
122. Shah J: Patterns of cervical lymph node metastasis from squamous cell carcinomas of the upper aerodigestive tract, *Am J Surg* 160:405–409, 1990.
123. Byers RM, Wolf PF, Ballantyne AJ: Rationale for elective modified neck dissection, *Head Neck Surg* 10:160–167, 1988.
124. Ferlito A, Rinaldo A, Silver CE, et al.: Neck dissection: then and now, *Auris Nasus Larynx* 33:365–367, 2006.
125. Subramanian S, Chiesa F, Lyubaev V, et al.: The evolution of surgery in the management of neck metastasis, *Acta Otorhinolaryngol Ital* 26:309–316, 2006.
126. Robbins KT, Clayman G, Levine PA, et al.: Neck dissection classification update, *Arch Otolaryngol Head Neck Surg* 128:751–758, 2002.
127. Jose J, Coatesworth AP, Johnston C, et al.: Cervical node metastasis in squamous cell carcinoma of the upper aerodigestive tract: the significance of extracapsular spread and soft tissue deposits, *Head Neck* 25:451–456, 2003.
128. Johnson TM, Bradford CR, Gruber SB, et al.: Staging workup, sentinel node biopsy and follow-up tests for melanoma: update of current concepts, *Arch Dermatol* 140:107–113, 2004.
129. Newman LA: Lymphatic mapping and sentinel lymph node biopsy in breast cancer patients: a comprehensive review of variations in performance and technique, *J Am College Surg* 199:804–816, 2004.
130. Devaney KO, Rinaldo A, Rodrigo JP, et al.: Sentinel node biopsy and head and neck tumors—where do we stand today? *Head Neck* 28:1122–1131, 2006.
131. Erawala CJ, Newlands C, Coombes D: Follow-up treatment of squamous cell carcinoma of the oral cavity: current maxillofacial practice in the United Kingdom, *Br J Oral Maxillofac Surg* 45(5):361–363, 2007.
132. Yusa H, Yoshida H, Ueno E, et al.: Follow up ultrasonography for late neck metastasis of head and neck cancer, *Ultrasound Med Biol* 28(6):725–730, 2002.

29 Melanoma

RABIE M. SHANTI, DONGSOO DAVID KIM, GHALI E. GHALI

Epidemiology

Skin cancer is the most common malignant neoplastic entity affecting humans. These neoplasms can be divided into non-melanoma skin cancers (NMSCs) and malignant melanoma, a malignancy of melanocytes. NMSCs account for 95% of all skin neoplasms and melanomas for the remaining 5%. The American Cancer Society (ACS) estimated that 76,100 cases of melanoma would be diagnosed in the United States in 2014.[1] Approximately 55,000 cases of malignant melanoma were diagnosed in 2004, and 62,190 cases were diagnosed in 2006, indicating a steady increase in incidence. Furthermore from 2006 to 2010, the incidence of melanoma among whites increased by 2.7% per year.[1]

Even though melanoma makes up a small fraction of all skin cancers, it is responsible for the majority (75%) of all skin cancer–related deaths. Malignant melanoma was responsible for approximately 5020 deaths in the United States in 2006, and the ACS estimated 9710 deaths in 2014.[1] Malignant melanoma accounts for approximately 4% of all cancer-related deaths in the United States (Box 29-1). Such staggering statistics make melanoma a significant public health problem in the United States and globally.

The mortality rate and incidence of melanoma have been on the rise since the 1960s; however, in patients whose disease is detected early, 5-year survival appears to be improved.[1] Since the primary mode of therapy (i.e., surgery) has not changed, one can attribute an improvement in disease prognosis to increased public awareness and early detection of these lesions. Unfortunately, this improvement is limited to disease detected at an early stage, for the overall mortality rate secondary to melanoma is still on the rise. This chapter discusses the etiology, risk factors, clinical and histologic characteristics, diagnosis, staging, and management of this potentially fatal skin neoplasm.

Incidence and Etiology

Melanoma is one of a few malignancies in the United States with an increasing incidence. In 1935, the incidence of melanoma was 1:1500; however, by 2008-2010 the incidence had increased to 1:34 in men and 1:53 in women.[1] In considering the epidemiology of melanoma, one must recognize that age is an important risk factor for its development. While the incidence and mortality of melanoma have been increasing steadily, those older than 65 have experienced a significantly higher rise in incidence and mortality rates in comparison to younger age groups.[2] The previously mentioned 1:34 men and 1:53 women incidence of melanoma is from birth to death; however, the incidence from birth until the age of 49 is 1:284 men and 1:206 women.[1] The incidence will increase with age reaching an incidence of 1:48 men and 1:113 women for those 70 years of age and older.[1] At present, 25% of individuals affected by this disease are under the age of 40. It is the most common malignancy in women ages 25 to 29 and is second only to breast cancer in women ages 30 to 34.[3] Children make up 1% to 4% of the melanoma patient population, and as has been observed in all patient populations, the incidence of melanoma in children has also increased significantly.[4] Strouse and colleagues reported a 46% increase in the incidence of melanoma in pediatric patients from 1973 to 2001.[5]

Approximately 20% of all melanomas are found in the head and neck region. Fewer than 1% of lesions are found in the oral cavity.[6] These oral lesions, although rare, are associated with a high mortality rate. In general, the torso, back, and head and neck are the most common anatomic sites in men, whereas the extremities are the most common anatomic sites in women.[3] This topographic difference between the two genders has been used to explained the higher incidence of mortality among men in comparison to women; the sites involved in men are considered to have a worse prognosis.[7]

Excessive ultraviolet (UV) light exposure was thought to be the primary etiologic factor in the development of malignant melanomas. The link between Caucasian race and living nearer the equator, such as in Australia or the southeastern United States, is undeniable. However, this link does not provide a biologic explanation for many cases, such as subungual or mucosal melanomas. There is now compelling evidence that, as in all malignant neoplasms,

genetic aberrations play a crucial role in the development of all melanomas. Evidence also links periods of high-intensity UV light exposure, rather than chronic exposure, with the development of melanomas.[8] An exception is the lentigo maligna melanoma. This form of melanoma, as with the NMSCs (i.e., basal cell and squamous cell carcinomas), tends to be associated with more prolonged UV light exposures.

Caucasians are the typical patients who develop malignant melanomas. African-American, Hispanic, and Asian individuals rarely develop the disease. Darker-skinned races tend to have higher mortality rates with melanoma because of the predilection toward developing the acral lentiginous subtype and typically presenting with advanced-stage disease at diagnosis. Women tend to be slightly more affected than men worldwide and have slightly better overall survival than males. The countries with the highest rates of melanoma are Australia and New Zealand, with 37.7 cases per 100,000 men and 29.4 cases per 100,000 women. In comparison, the United States has approximately 6.4 cases per 100,000 men and 11.7 cases per 100,000 women. California, Florida, Texas, New York, and Pennsylvania have the highest estimated rates of new melanoma cases.[1]

Many risk factors for the development of melanoma have been identified (Box 29-2). Generally accepted risk factors are Fitzpatrick skin type 1 or 2 (Table 29-1), red or blonde hair, family history, actinic keratosis, pronounced freckling of the upper back, three or more blistered sunburns before adulthood, and an outdoor job (e.g., lifeguard) for more than 3 years before the age of 20. Individuals with two of these risk factors have an estimated threefold to fourfold increase in incidence of developing a melanoma; those with three or more have an increase incidence of approximately 20-fold.

• Box 29-1 Melanoma Statistics

4% of all cancer deaths
5% of all skin cancers
75% of all skin cancer–related deaths
20% occur in head and neck region
1:34 men, 1:53 women incidence rate in 2008-2010

• Box 29-2 Melanoma Risk Factors

Family history
Fitzpatrick skin type 1 or 2
Three or more blistering sunburns before age 20
Three or more years before age 20 with an outdoor job (e.g., lifeguard)
Actinic keratosis lesions
Pronounced freckling of upper back
Red or blonde hair
Immunosuppression
Older age
Dysplastic nevus syndrome
Congenital nevi >20 mm

These risk factors do not adequately address melanomas in areas not exposed to UV light. These lesions are thought to arise de novo and not as a result of environmental exposure. A family history of melanoma increases the risk by two to eight times. Immunosuppression has also been associated with an increased risk of melanoma development. Older age is also a well-recognized risk factor.[4]

An association between benign melanocytic proliferations (e.g., nevus) and malignant melanoma has clearly been established by Skender-Kalnenas and co-workers.[9] They evaluated 289 cases of thin, malignant melanomas and the association with benign melanocytic proliferations. A nevus was found to be associated with more 50% of lesions, and of these nevi, 56% were dysplastic, 41% were common acquired, and 3% were congenital. The association with melanocytic proliferation was greater with increasing age of the patient.

The majority of melanomas arising in the head and neck region, approximately 70%, have been found to arise in pigmented lesions. This includes pigmented lesions of the oral cavity (Figures 29-1 and 29-2). A change in the character of pigmented lesions, particularly in patients with

TABLE 29-1 Fitzpatrick Skin Type Classification

Type	Characteristics
1	Always burns easily, no immediate pigment darkening, never tans
2	Always burns easily, trace immediate pigment darkening, tans with difficulty and minimally
3	Burns minimally, immediate pigment darkening, tans gradually and uniformly (light brown)
4	Burns minimally, immediate pigment darkening, tans well (moderate brown)
5	Rarely burns, immediate pigment darkening, tans very well (dark brown)
6	Rarely burns, immediate pigment darkening, tans profusely (black)



• Figure 29-1 Oral melanoma.

any other risk factors, should raise the level of suspicion for a malignant transformation. All pigmented lesions (Figure 29-3) without an obvious etiology (e.g., amalgam tattoo) in the oral cavity should be biopsied and followed periodically, because the mortality of intraoral melanomas approaches 100%. Congenital nevi larger than 20 mm have a malignant transformation rate of approximately 20%, and lesions associated with dysplastic nevus syndromes have a 100% rate of malignant transformation over an individual's lifetime; removal of these lesions is recommended.[9]



• **Figure 29-2** Oral melanoma.

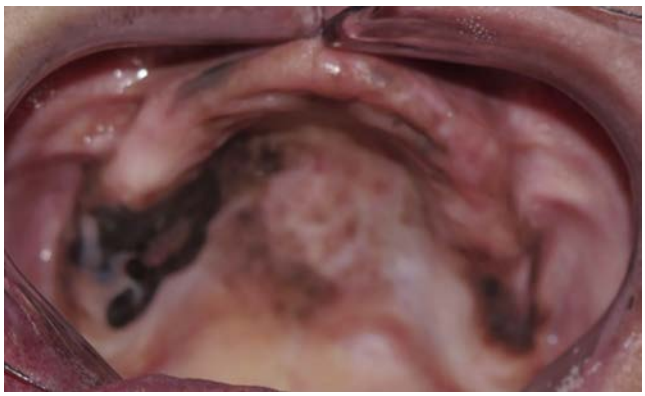

• **Figure 29-3** Mucosal melanoma involving the hard palate, and bilateral maxillary gingiva.

As a result of the high mortality associated with late melanomas, the index of suspicion with pigmented lesions of the head, neck, and oral cavity should be high. The authors recommend using, and instructing patients to use, the ABCDE and P method of evaluation:

Asymmetry: Irregular "lopsided" lesions
Border: Notched, angled, nonlinear borders
Color: Multiple colors within a lesion or loss of color (amelanotic)
Diameter: Greater than 6 mm lesion or changes in size of existing lesion
Elevation: Changes in height or new-onset nodularity of lesion
Persistence: Lesion that demonstrates persistent erythema, scaling, itching, or ABCDE changes.

Melanomas have been clinically and histologically subdivided into five types (Table 29-2): superficial spreading (Figure 29-4), nodular (Figure 29-5), lentigo maligna (Figure 29-6), acral lentiginous (Figure 29-7), and desmoplastic. Of all of these melanoma histologic variants, the superficial spreading form is the most common, and lentigo maligna is the least common. Nodular melanoma is considered the most aggressive type of malignant melanoma.

Diagnosis

Accurate diagnostic and prognostic information yielded by the pathologic specimen is critical in deciding the patient's treatment options. The "gold standard" for the diagnosis of melanoma remains conventional hematoxylin and eosin (H&E) stained tissue sections (Figure 29-8). The first step in diagnosis of melanoma begins with a biopsy. The ideal biopsy, if the size of lesion permits, is an incisional biopsy with 1- to 3-mm margins and with enough depth to ensure that the lesion is not transected.[10]

TABLE 29-2 Subtypes of Malignant Melanoma

	Prevalence	Age	Clinical Features	Common Sites
Superficial spreading	70% of all; common in light-skinned people	4th-5th decade	Classic ABCDE features; pigmented macule	Head, neck, trunk, back, extremities
Nodular	15% of all	4th-5th decade	Rapid growth; usually from normal skin; poorer prognosis; 5% amelanotic	Head, neck, trunk
Acral lentiginous	10% of all	6th-7th decade	Tan, flat irregular macule; not associated with sun-exposed areas	Plantar, hands, subungal surfaces common
Desmoplastic	Rare; commonly associated with lentigo maligna lesions	6th-7th decade	Sun-exposed areas; pigmented or flesh colored	Head and neck
Lentigo maligna	5%-10% of all; associated with chronic sun exposure	7th-8th decade	Irregular, tan-brown macule	Head and neck; neck and cheeks commonly

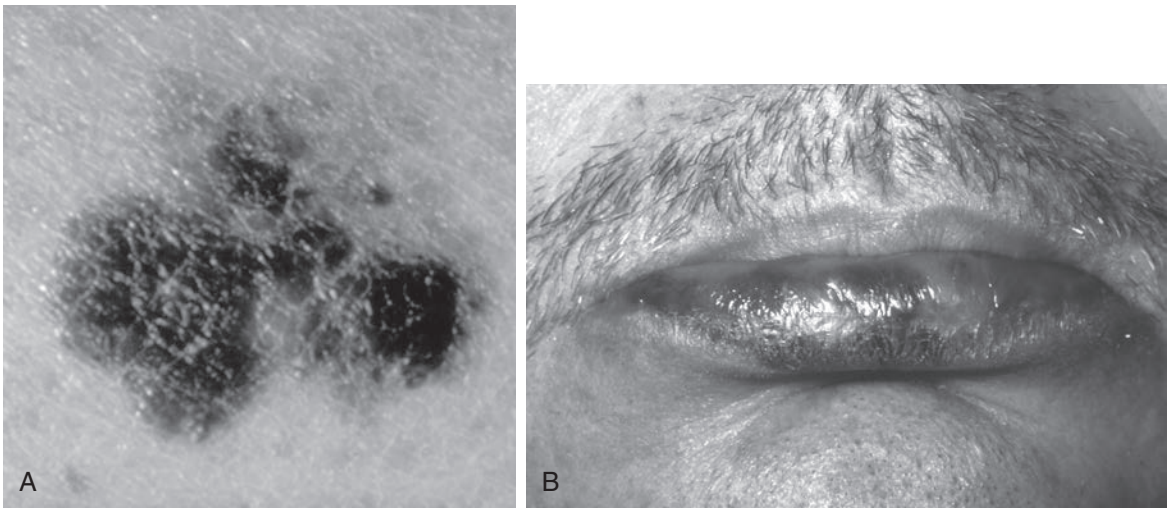

• **Figure 29-4** **A,** Superficial spreading melanoma of face. **B,** Superficial spreading melanoma of lips.

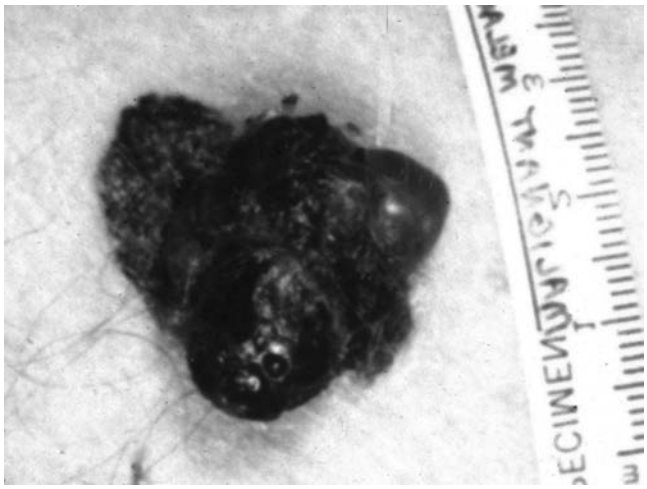

• **Figure 29-5** Nodular melanoma.

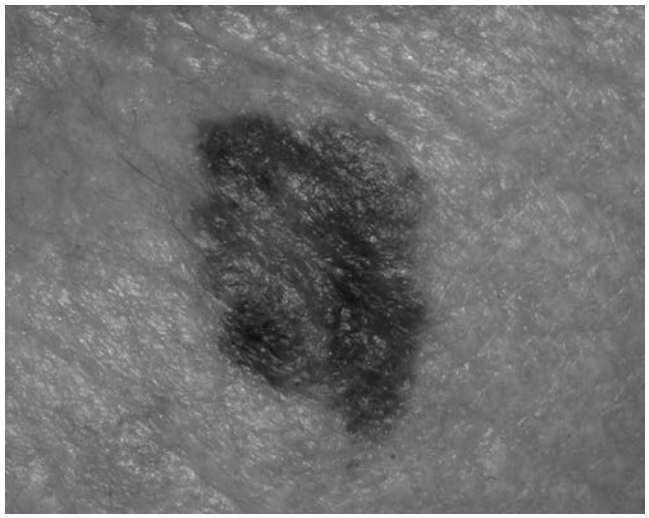

• **Figure 29-6** Lentigo maligna melanoma of cheek.

Typically, the biopsy is performed either by a punch biopsy or scalpel elliptical excision. Performing an excisional rather than incisional biopsy allows for more accurate microscopic staging of the lesion. However, in critical areas of the face or in the presence of large lesions, an incisional biopsy is acceptable.

Variation in histologic morphology and similarity to benign melanocytic lesions make the histopathologic diagnosis quite difficult. Shoo and colleagues reported a 14.3% discordance rate in the histopathologic diagnosis of thin melanoma and benign nevi between referring centers and their institution.[11] In comparison to other cutaneous and mucosal neoplasms, numerous histologic criteria are used to establish a diagnosis of melanoma, but none alone are adequate enough to establish this diagnosis.[9] The pathologist must include in the pathology report the following information: the melanoma subtype, thickness, anatomic level, presence or absence of microscopic ulceration, positive or negative margins, perineural involvement, perivascular involvement, presence of mitoses, and presence of vertical growth phase (Figure 29-9). Although the staging of cutaneous and mucosal melanoma is discussed later in this chapter, it is worth noting that the previous American Joint Committee on Cancer (AJCC) melanoma TNM staging included only tumor thickness and presence of tumor ulceration in the T category strata, except for T1 lesions, which included Clark's level. However, the revised melanoma staging system released by the AJCC in 2009 included primary tumor mitotic rate, which has replaced Clark's level in the T category strata because of its significance as an adverse predictor of survival (see Table 29-6).[12] The mitotic rate of melanoma has been traditionally evaluated by counting mitotic figures on H&E-stained tissue sections, and averaging the number of mitotic figures per square millimeter (mitoses/mm^2).[13] Today, an area of ongoing scientific research is the incorporation of computer-assisted analysis for calculation of immunolabeled mitoses in order to simplify and standardize this process.[13]

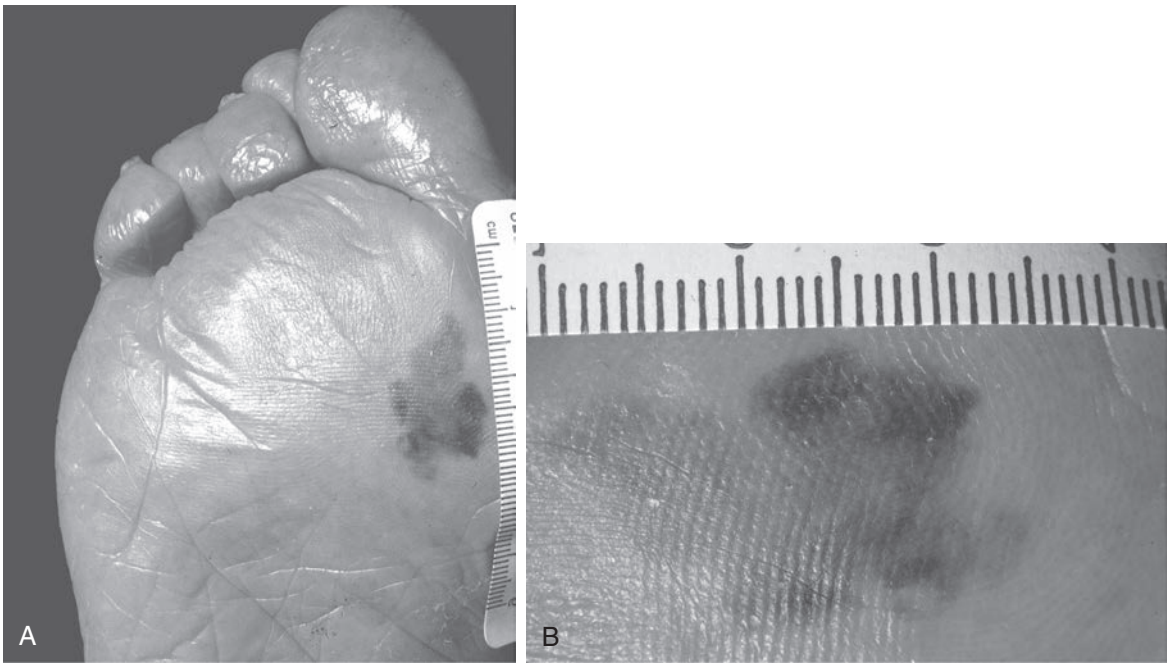

• **Figure 29-7** **A,** Acral lentiginous melanoma of right foot. **B,** Close-up view of **A**.

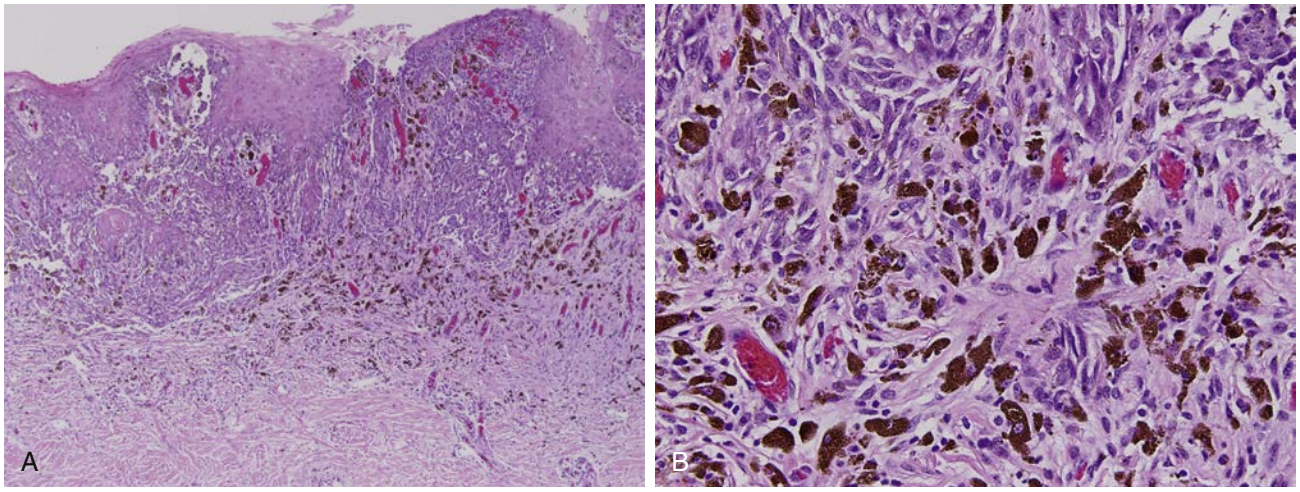

• **Figure 29-8** **A,** Medium-power hematoxylin and eosin photomicrograph of a mucosal melanoma. **B,** Close-up view of **A**.

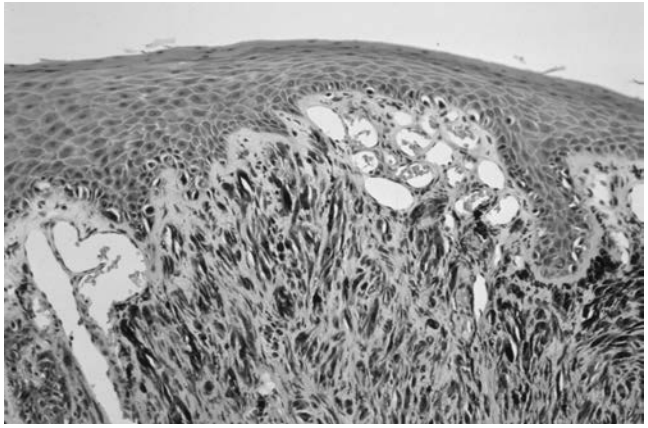

• **Figure 29-9** Medium-power hematoxylin and eosin photomicrograph of a melanoma with vertical growth phase.

Histologically, the features of melanomas are somewhat dependent on the subtype and phase of growth. All melanomas show melanocyte cellular atypia and an altered cellular maturation. Fine intracellular granules, abnormal mitoses, hyperchromatic nuclei, prominent nucleoli, multinucleated giant melanocytes, and abnormal collections of cells ("nests") may all be seen. Various immunohistochemical markers have become useful in the pathologic diagnosis of melanoma (Table 29-3). Of these, S-100 and HMB-45 are the most frequently used melanocytic markers.[14] Anti-HMB-45 is a monoclonal antibody that recognizes the melanosomal glycoprotein gp100; thus positive staining is related to active early melanosome formation.[15] A more sensitive test for the diagnosis of melanoma is the monoclonal antibody to S-100 protein. The sensitivity of

TABLE 29-3 Common Immunohistochemical Markers for Melanoma

	S-100	HMB-45	MART-1/Melan-A and Tyrosinase
Antigen	Calcium channel binding protein	Cytoplasmic glycoprotein (part of gp 100 premelanosome complex)	Transmembrane protein (melanocyte differentiation antigen)
Cell type	Melanoma cells, nevus components, histiocytes, schwannomas, neurofibromas, nerve sheath tumor cells	Melanoma cells, fetal and neonatal melanocytes, nevus components	Melanocytic cells, perivascular smooth muscle cells, adrenocortical tumors, ovarian tumors
Drawbacks	Not specific for melanoma; cannot differentiate benign and malignant cells	Not specific for melanoma; spindle cell variants do not stain with HMB-45; cannot differentiate benign and malignant cells	Not specific for melanoma; cannot differentiate benign and malignant cells

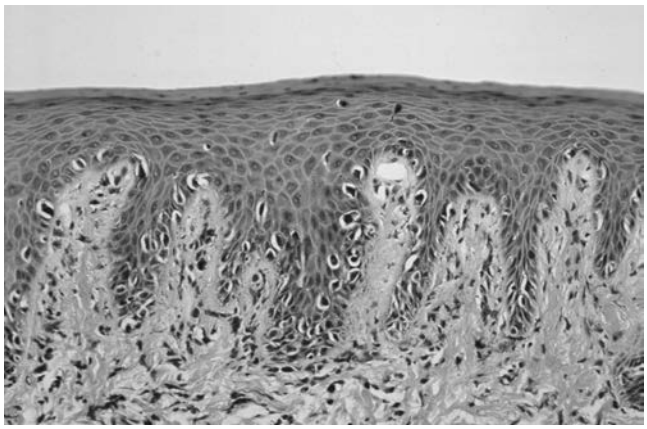

• **Figure 29-10** Medium-power hematoxylin and eosin photomicrograph of a melanoma with radial growth phase.

S-100 antibody as a melanocytic marker is near 100%. However, the S-100 protein antibody does retain immunoreactivity to tumors that originate from adipocytes, chondrocytes, Schwann cells, and myoepithelial cells.[14] Therefore, the monoclonal antibody against the HMB-45 antigen is more specific for melanocytic neoplasms, with the exception of the spindle cell and desmoplastic melanoma variants.[14]

Microinvasive melanoma and melanoma in situ represent the radial growth phase of these lesions (Figure 29-10). Melanoma in situ is a proliferation of malignant melanocytes restricted to the epidermis. Pagetoid spread (single, atypical cells spread through the epidermis) and atypical, dendritic melanocytes arrayed along the dermoepithelial junction are classic histologic findings seen with melanoma in situ. Melanoma in situ is seen in all major subtypes except the nodular form. Microinvasive melanoma is characterized by epidermal involvement with *microscopic* extension into the papillary dermis. Microinvasiveness can be defined as follows: the largest dermal nest of cells is smaller than the largest epidermal nest of cells; and no dermal mitoses are present. Frequently a lymphocytic infiltrate is also present as well.[16]

When a melanoma breaches the basement membrane and involves the underlying dermis, it is said to be in a vertical growth phase (see Figure 29-9). In this phase the lesion has metastatic potential and thus a poorer prognosis. The vertical phase is characterized by at least one dermal mitosis or one or more dermal cell nests larger than the largest epidermal cell nest. Table 29-4 describes the basic histologic features of the various subtypes of malignant melanoma.

The growth characteristics of melanomas typically manifest with a long horizontal radial growth phase. These early lesions tend to spread within the epithelium without violating the basement membrane and penetrating into the underlying tissues. Late lesions tend to penetrate the basement membranes, grow vertically, and invade deeper tissues. This vertical growth phase was noted by early investigators to have profound significance in predicting overall survival and in directing treatment of the disease. In 1969 and 1970, Clark and Breslow, respectively, developed histologic classifications based on the depth of the lesion alone[17,18] (Table 29-5). Clark's anatomically based system has been replaced in the current staging protocols in favor of Breslow's millimetric depth system. Breslow's classification, which measures from the granular cell layer to the depth of the tumor, has been shown to have better predictive value and less variability between observers. Melanoma depth has also been shown to have a strong relationship with regional lymph node metastasis and distant metastatic disease. These prognostic implications of lesion depth make it one of the major prognostic indicators of melanoma, and thus it is currently a major part of the AJCC staging system for melanoma.[12]

Several lesions can be mistaken for melanoma. These include pigmented basal cell carcinomas, seborrheic keratosis, nevi, lentigines, and dermatofibromas. Clinicians should have a high index of suspicion for melanoma, and excisional biopsies should be performed. Improved rates of survival were demonstrated in patients who had excisional (8.9%) versus incisional (25%) biopsies.[19] Delay in definitive treatment, altered local host factors, and an increased time for lesion dissemination have been postulated as reasons for the

TABLE 29-4 Histologic Features of Melanoma

	Superficial Spreading	Lentigo Maligna	Acral Lentiginous	Nodular	Desmoplastic
Radial growth pattern	Pagetoid	Lentiginous	Lentiginous	Not present	Not present
Characteristic radial phase cell type	Epithelioid	Spindle cell, epithelioid	Spindle cell, epithelioid, dendritic	N/A	N/A
Epidermal characteristics in radial phase	Normal or hyperplastic	Atrophic	Hyperplastic	N/A	N/A
Characteristic vertical phase cell type	Epithelioid	Spindle cell, epithelioid	Spindle cell, epithelioid	Epithelioid	Fibroblastic, spindle cell

TABLE 29-5 Depth Classifications and Associated Survival Rates

Clark's Level	Clark's Classification	Breslow's Depth (mm)	Clark's 10-yr Survival	Breslow's 10-yr Survival
Within epithelium	Level I	N/A	96%	N/A
Penetrates papillary dermis	Level II	0.0-0.75 mm	96%	98%
Fills papillary dermis	Level III	0.76-1.69 mm	90%	89%
Penetrates reticular dermis	Level IV	1.70-3.59 mm	67%	67%
Invades subcutaneous tissue	Level V	>3.6 mm	26%	43%

decreased survival rate. Shave biopsies should not be performed, because they do not indicate the depth of lesion involvement. As previously stated, biopsies with 2- to 3-mm margins of surrounding tissue extending down to the underlying fascia are preferred. Incisional or punch biopsies should only be considered with very large lesions.

Definitive excision of the lesion and the extent is a source of debate. There have been five multicenter prospective randomized clinical trials which have evaluated the relationship between excision margin status and risk of local recurrence, as well as the impact of margin status on survival in patients with cutaneous melanoma.[20] These trials include the World Health Organization (WHO) Melanoma Program Trial No. 10,[21] United Kingdom Melanoma Study Group,[22] French Cooperative Group Trial,[23] Swedish Melanoma Trial Group,[24] and Intergroup Melanoma Surgical Trial.[25] The WHO Melanoma Program Trial No. 10 investigated a randomized cohort of 612 melanoma patients. In this trial, patients were stratified into either a Breslow depth < 1 mm or a Breslow depth 1 to 2 mm. The investigators compared 1-cm versus 3 to 5 cm excision margins. With a greater than 15-year follow-up, the investigators did not identify a statistically significant difference in distant recurrence rates and survival rates based on these margins of excision. Of note, patients managed with a 1-cm margin of excision had a greater local recurrence rate, but this was not of statistical significance. The United Kingdom Melanoma Study Group investigated the margin of excision necessary for cutaneous melanoma that are 2 mm or greater in thickness. The investigators in this study identified that for tumors that were 2 mm or greater in thickness a 1-cm margin was associated with a statistically significant increase in locoregional recurrence in comparison to 3 cm margins.

The French Cooperative Group Trial consisted of 337 patients with melanoma of the trunk, limbs, and head and neck with tumors ≤2 mm Breslow thickness; 2-cm versus 5-cm excision margins were compared. This multicenter trial could not identify a statistically significant advantage for 5-cm margins in the management of tumors ≤2 mm Breslow thickness. Likewise, the Swedish Melanoma Group Trial also could not identify a statistical difference in recurrence rates when comparing 2-cm versus 5-cm margins of excision. Furthermore, the Intergroup Melanoma Surgical Trial stratified patients into two groups: Group A were proximal extremity and trunk melanoma patients, and Group B were head and neck melanoma and distal extremity patients. Group A patients were randomly subdivided into either 2-cm or 4-cm margin of excision subgroups, whereas all Group B patients had a 2-cm margin of excision. Of note, all patients in this study were additionally stratified by tumor thickness and presence/absence of ulceration. The investigators reported that the 10-year survival was not statistically different when comparing 2-cm versus 4-cm margin of excision in Group A patients. Furthermore, locoregional control was the same when comparing 2-cm versus 4-cm margin of excision in Group A patients.

In summary, as Cruse and colleagues[26] have proposed, local recurrence is not affected by excision margins, but is by lesion thickness. The WHO proposes that 1-cm margins should be used for lesions less than 1 mm in thickness, and

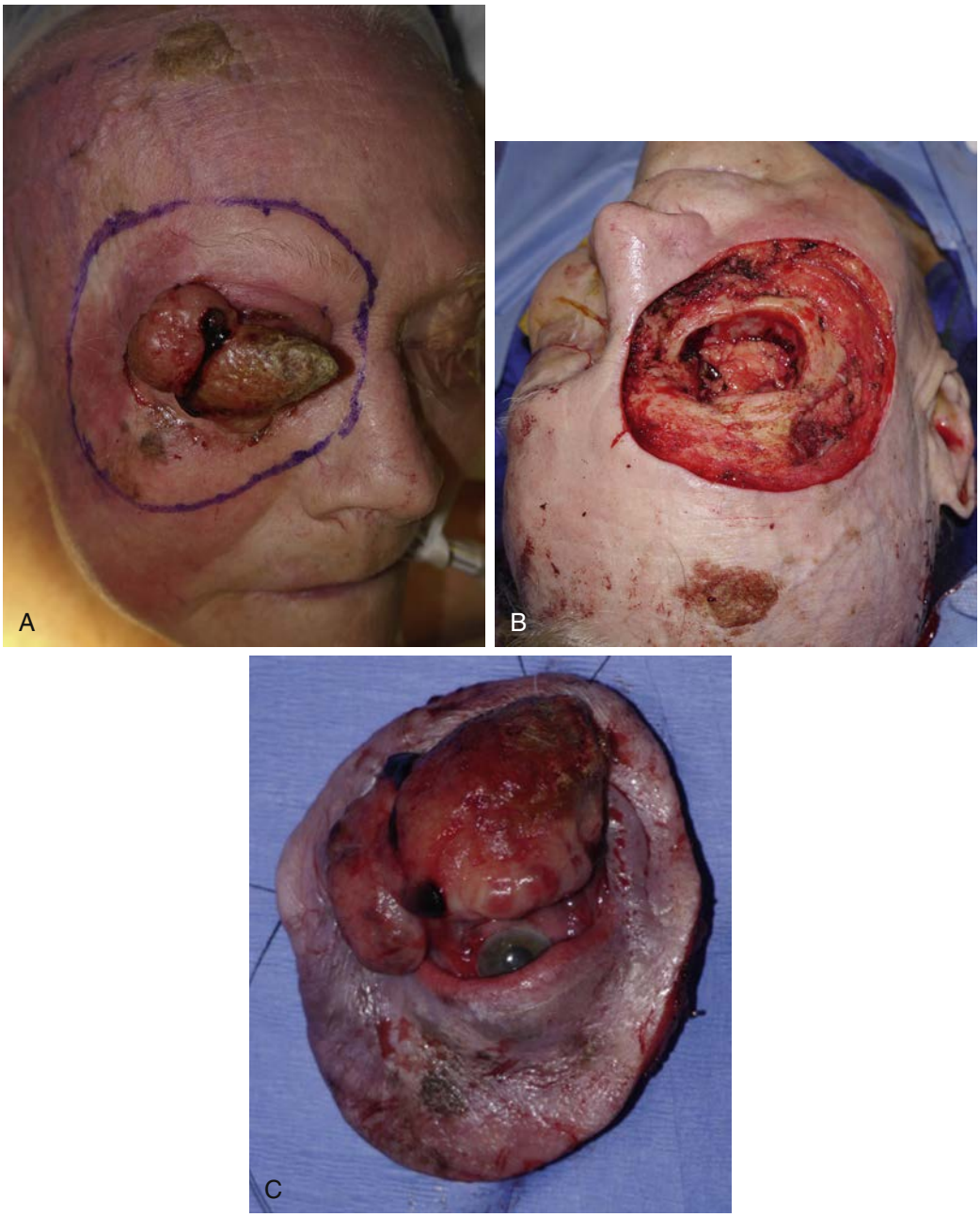

• **Figure 29-11** **A,** Patient with upper eyelid cutaneous melanoma with a tumor thickness of 8 mm underwent resection with a 3-cm margin of excision including exenteration. **B,** Final defect. **C,** Clinical photo of specimen. (Photos courtesy Dr. Melvyn Yeoh, Shreveport, LA.)

3-cm margins should be used for lesions greater than 1 mm (Figure 29-11).[21] The authors feel that 1- to 2-cm margins, with appreciation of facial aesthetic subunits and adjacent vital structures, are adequate in all except scalp lesions. Scalp lesions have been shown to have higher rates of in-transit metastasis, and it is recommended to take wider margins (3-4 cm) with these resections.

Management of Regional Disease

The treatment of choice for melanoma is surgical excision. In most cases wide local excision adequately controls local disease. Melanoma is believed to initially metastasize via spread to regional lymphatics. At the time of initial diagnosis, 82% of patients have localized disease and 11% of patients are found to have spread to regional sites.[27,28] Accurate assessment of the regional node status is a major prognostic factor for overall survival and locoregional control; it also plays an important role in directing therapy. The management of regional lymphatics is a topic of considerable debate in the literature—in particular, management of patients with a clinically negative neck.

In patients with clinically positive lymph nodes, or a positive sentinel lymph node biopsy (SLNB), the suggested

therapy is a therapeutic lymphadenectomy (removal of *all* nodes in the involved drainage basin). This approach may be curative or at least decrease the morbidity associated with a regional recurrence. The morbidity of the dissection and the ability of the patient to tolerate the procedure must be taken into account before a therapeutic neck dissection. In the case of head and neck cutaneous melanoma, a positive SLNB will allow for appropriate escalation of treatment, such as regional lymph node dissection, addition of adjuvant therapies, and/or enrollment in a clinical trial. Performing an SLNB is not indicated for patients presenting with a lymph node with clinical features highly suggestive for regional disease. In these cases, a fine-needle aspirate is typically performed, and also for patients with disseminated disease.[29]

Elective lymph node dissection (ELND) is based on the same physiologic and anatomic rationale as the therapeutic neck dissection. However, prospective randomized trials have shown no improvement in overall survival associated with ELNDs,[30-33] one of these being the Intergroup Melanoma Surgical Trial. The low risk for thin melanomas to involve regional lymphatics, the potential morbidity of neck dissections, and the success of sentinel lymph node biopsies have effectively limited the usefulness of elective neck dissections.

SLNB has been used successfully in the treatment of melanoma and is currently the standard of care for evaluating the regional lymphatics in thin lesions and with clinically negative necks.[34,35] Most centers use the following indications for SLNB: Breslow thickness 1.0 mm, Clark level IV, ulceration or regression, subungual location, and no clinical or radiographic evidence of lymph node metastasis. The concept of SLNB is based on studies showing that lymphatic drainage is predictable and the initial nodes involved fall within a specific nodal basin. In theory, if the sentinel node(s) have not been involved with metastatic disease, the other remaining "downstream" nodes in that basin will not harbor disease. A therapeutic lymphadenectomy is completed if a patient is found to have a positive sentinel node.

Sentinel node mapping requires a coordinated effort by the surgeon, pathologist, and nuclear medicine physician. Currently, the most predictable way to identify sentinel nodes is by using a combined vital blue dye (sulfan blue) and technetium-99m sulfur colloid mapping technique. The periphery of the lesion is injected with the vital dye, lymphoscintigraphy is performed, and the markers are given time to distribute into the regional nodes. A conservative incision is made to access the nodal basin identified by the prior lymphoscintigraphy. The incision is placed so the surgeon is able to access the neck or parotid region for a therapeutic lymphadenectomy, if the sentinel node biopsy is positive. Intraoperatively, dye staining of the lymphatics and verification with a gamma probe are used to identify the sentinel node(s). The pathologist then performs serial sections on the collected lymph nodes. The protocol used to evaluate sentinel nodes varies according to the institution. However, some combination of serial sectioning, hematoxylin and eosin staining, and immunohistochemical stains is generally used. Serial sectioning is work-intensive for the pathologist and, although better than standard node evaluation techniques, still examines only less than 1% of the submitted node. Recently, molecular analysis techniques have been investigated and have been found to increase the accuracy of SLNB techniques while decreasing the workload involved with serial sectioning. These techniques will likely play a more important role in the future of SLNB analysis, but they should not be used currently in management decisions and escalation of treatment.

Positivity with SLNB has been reported to occur in 17% to 19% of cases of trunk or extremity melanoma, and 10% of head and neck cases. It is important to mention that in cases of head and neck melanoma, SLNB allows for identification of microscopic nodal disease and subsequent escalation of treatment.[36] The identification of microscopic nodal disease via SLNB has been shown to improve regional disease control. However, a Surveillance Epidemiology and End Results (SEER) database cohort analysis of 7266 patients published in 2014 was unable to demonstrate a significant association between SLNB and improved disease-specific survival for patients with head and neck melanoma.[28]

Staging of Melanoma

It is important that all providers use the same criteria and definitions in the literature and in a patient's management. The nomenclature and criteria for discussing melanomas have been provided by the AJCC.[12] Staging is important in the stratification of disease, in the prognostication of mortality, and in directing therapy. It was recognized that improvements in the staging of melanoma could be made by applying evidence-based methods to create and then validate a staging system for melanoma. Buzaid and associates[37] published a paper pointing out the inadequacies of the preexisting AJCC staging system for melanoma. The Melanoma Staging Committee of the AJCC was formed in 1998.[37] It was made up of experts from all relevant medical specialties and included leaders from most of the major melanoma treatment centers. An additional modification of the existing staging system was included in the 7th edition of the AJCC Cancer Staging Manual in their paper published in 2009.[12] The previous staging system in the 6th edition of the AJCC Cancer Staging Manual emphasized that thickness and ulceration are the predominant predictors of survival and that depth of invasion matters only in thin (≤1 mm) lesions. In the 7th edition of the AJCC Cancer Staging Manual, primary tumor mitotic rate has replaced Clark's level of invasion as the main criterion differentiation subcategory T1a from T1b. Thickness proved meaningful in whole numbers groups (≤1 mm, 1.01-2 mm, 2.01-4 mm, >4 mm). Ulceration was a negative predictor of survival throughout all groups. The number of metastatic lymph nodes was also found to be a prognostic factor. Site of distant metastasis and the presence of elevated lactate dehydrogenase (LDH) levels were also found to be prognostic and

TABLE 29-6 T Classification of Melanoma

Tumor Thickness	Tumor Ulceration Status/ Mitoses
T1 ≤1.0 mm	a: Without ulceration and mitosis <1/mm^2
	b: With ulceration or mitoses ≥1/mm^2
T2 1.01-2.0 mm	a: Without ulceration
	b: With ulceration
T3 2.01-4.0 mm	a: Without ulceration
	b: With ulceration
T4 >4.0 mm	a: Without ulceration
	b: With ulceration

TABLE 29-7 N Classification of Melanoma

Nodal Metastases	Nodal Mass
	a, micrometastasis*; b, macrometastasis†; c, in-transit/satellite(s) with (–) nodes
N0	
0 nodes	n/a
N1	
1 node	a, b
N2	
2-3 nodes	a, b
N3	
≥4 nodes, matted nodes, in-transit or satellite(s) with (+) nodes	a, b, c

*Micrometastasis diagnosed after sentinel node biopsy or elective lymphadenectomy.
†Macrometastasis with clinically detectable nodes, confirmed with therapeutic lymphadenectomy or with gross extracapsular spread.

TABLE 29-8 M Classification of Melanoma

Metastasis Site	Serum LDH
M0	
0 sites	N/A
M1a	
Distant skin, subcutaneous tissue or node metastasis	Normal
M1b	
Lung metastases	Normal
M1c	
Any other visceral metastases	Normal
Any distant metastasis	Elevated

TABLE 29-9 Clinical Staging Groups for Melanoma*

Clinical Stage	T Classification	N Classification	M Classification
0	T in situ	N0	M0
IA	T1a	N0	M0
IB	T1b	N0	M0
	T2a	N0	M0
IIA	T2b	N0	M0
	T3a	N0	M0
IIB	T3b	N0	M0
	T4a	N0	M0
IIC	T4b	N0	M0
III	Any T	Any N	M0
IV	Any T	Any N	Any M

*Includes microstaging of primary melanoma and metastasis evaluation; *after* completed primary excision and clinical evaluation for metastasis.

were included in the staging system.[10,38,39] Patients with an elevated LDH are all categorized as M1c irrespective of all other M-category strata. Tables 29-6 through 29-10 describe the current AJCC (TNM) staging system for cutaneous malignant melanoma.

Today, the role of positron emission tomography (PET), and other advanced imaging modalities such as computed tomography (CT) or magnetic resonance imaging (MRI), for staging of malignant melanoma has yet to be defined. Wasif and colleagues evaluated use of staging studies in 25,643 patients with cutaneous melanoma using the SEER database.[36] Based on their analysis, in the year 2000, 4.2% of patients with early-stage cutaneous melanoma had a cross-sectional imaging study performed, and in 2007 this had increased to 12.2%. The 2012 National Comprehensive Cancer Network (NCCN) guidelines for staging of cutaneous melanoma do not recommend any cross-sectional imaging studies for stage I through IIC disease. They do, however, state that a chest x-ray is optional for patients with stage IIB or IIC disease.[37] Based on their recommendation, cross-sectional imaging studies (e.g., PET, MRI, CT) are optional for patients with stage III or stage IV disease. Similarly, the American Academy of Dermatology does not recommend any imaging study for patients with a primary melanoma with a thickness less than 4 mm.[10,36] PET has been found to have a lower sensitivity for the detection of occult nodal disease when compared to SLNB.[10,36] In summary, cross-sectional imaging studies should be reserved for patients with advanced-stage disease (stage III/IV).

TABLE 29-10 Pathologic Staging of Melanoma

Pathologic Stage	T Classification	N Classification	M Classification
0	T in situ	N0	M0
IA	T1a	N0	M0
IB	T1b	N0	M0
	T2a		
IIA	T2b	N0	M0
	T3a		
IIB	T3b	N0	M0
	T4a		
IIC	T4b	N0	M0
IIIA	T1→4a	N1a	M0
	T1→4a	N2a	M0
IIIB	T1→4b	N1a	M0
	T1→4b	N2a	M0
	T1→4a	N1b	M0
	T1→4a	N2b	M0
	T1→4a	N2c	M0
	T1→4b	N2c	M0
IIIC	T1→4b	N1b	M0
	T1→4b	N2b	M0
	Any T	N3	M0
IV	Any T	Any N	Any M

Includes microstaging of primary melanoma and nodes after lymphadenectomy; Stage 0 and IA do not require pathologic evaluation of nodes.

In summary, appropriate therapy is based on accurate staging and, in the case of malignant melanoma, consists of assessment of histologic features of the primary tumor and measurement of serum LDH level. As with any neoplastic disease process, assessment of the patient's performance status will aid in risk stratification of patients for surgery and other adjuvant therapies.

Treatment

As mentioned previously, surgery is the mainstay of current melanoma treatment. Wide local excision of small, thin lesions is curative in many cases. SLNB with therapeutic lymphadenectomy, when indicated, is the current standard of care for the surgical management of melanoma in the head and neck. There is some question as to the efficacy of this approach in extremity melanomas, related to the morbidity of groin or axillary lymphadenectomy, without a benefit in overall survival. The current literature also debates the therapeutic value of many current treatments, including sentinel node biopsy (as a staging intervention), radiation therapy, chemotherapy, molecular targeted therapy, and interferon alfa therapy.

SLNB is not used as a therapeutic modality in itself. It is currently used to direct therapy (surgical vs. adjuvant). Gutzmer and colleagues[40] described three theories as to how SLNB itself may affect prognosis. The first, which improves prognosis, is that micrometastatic disease is removed from the regional nodal basin. This implies that early metastatic disease is primarily within the lymphatics, and the disease then spreads to distant sites after some time. The second, which does not change overall prognosis, is that lymphatic and hematogenous metastasis occur simultaneously and that lymphatic micrometastasis found in SLNB indicates aggressiveness of the tumor (aka the marker hypothesis). The last theory, which worsens prognosis, is that malignant cells are removed from an immunologically active environment, therefore impairing the body's response to the malignant cells. The results of their paper showed an improvement in locoregional control, but no advantage in death from distant metastasis. Their conclusions favored the marker hypothesis.

The Multicenter Selective Lymphadenectomy Trial (MSLT-I) raised the question of whether SLNB was beneficial.[41] In the MSLT-I study, patients were randomized into two groups; 60% of patients underwent SLNB, and those with positive sentinel nodes underwent a therapeutic lymphadenectomy. The remaining patients had a wide local excision and observation. Regional recurrences were then treated with therapeutic lymphadenectomy. The findings of the MSLT-I study showed no significant differences in overall survival between the two groups. However, there was a significantly higher 5-year survival rate in the SLNB-positive group (who underwent therapeutic lymphadenectomy) and higher 5-year distant disease-free survival in the SLNB group. The MSLT-I study suggested that SLNB was more a tool of prognosis and for identifying patients who may benefit from adjuvant therapy.[41] Regardless of any positive or negative therapeutic effects, SLNB has been shown to be invaluable in prognosis and is the standard of care in the evaluation of nodal disease in melanoma.

Melanomas have been traditionally thought to be a radioresistant tumor. The facts dispute this assumption. Although not recommended as a primary treatment modality, the use of adjuvant radiation therapy for regional disease is well supported in the literature. The use of radiation does improve local control of disease. However, there have been no compelling data showing an increase in overall survival.[42,43] The ideal radiation dose schedule has yet to be defined. Ballo and co-workers[43] have used a hypofractionated schedule in their practice consisting of 30 Gy in five 6-Gy fractions twice per week for 2.5 weeks. The authors explain that patients who present with extracapsular extension, disease in more than 3 nodes, nodes ≥3 cm, recurrent disease, and cervical location are more appropriate candidates for adjuvant radiotherapy.

Systemic therapy in the management of malignant melanoma is essentially in an adjuvant or palliative role. The role of conventional chemotherapy has yet to be defined, and also has yet to show any significant survival benefits. Dacarbazine and temozolomide are the chemotherapeutic agents of choice. Dacarbazine (DTIC, Bayer Pharmaceuticals, West Haven, CT) is an intravenous DNA alkylating agent, whereas temozolomide (Temodar, Merck & Co., White House Station, NJ) is an oral DNA alkylating agent. Both of these agents have shown poor response rates when used for single-agent therapy. A phase III clinical trial reported by Middleton and colleagues demonstrated equal efficacy of dacarbazine and temozolomide from a survival perspective; however, because temozolomide is an oral alternative that has been shown to have a better overall response, one can argue for selective temozolomide over dacarbazine.[44] Nevertheless, one must not forget that for cases of advanced-stage disease or metastatic melanoma, immunotherapy (see later discussion) offers better outcomes than do conventional chemotherapeutic agents.

Today, immunotherapy and cytotoxic chemotherapy are the pharmacologic agents of choice for patients with advanced disease (stage III/IV) or those with disseminated disease.[45] Interferon alfa-2b is the primary systemic agent in use today for adjuvant therapy in patients with advanced disease. There is debate as to the effectiveness of this agent; however, the results of the Eastern Cooperative Oncology Group trials, documented by Kirkwood and co-workers, showed a significant 5-year disease-free survival and an improvement in overall survival in the high-dose interferon (HDI) groups.[46,47] Furthermore, Wheatley and associates[48] performed a meta-analysis of 12 interferon alfa-2b trials and concluded there was a benefit in disease-free survival, but that there was no change in overall survival. Because of data such as these and the toxicities (e.g., fatigue, cognitive dysfunction, depression, suicide risk) associated with HDI, some practitioners may not recommend interferon therapy. In the United States, although debated, interferon alfa-2b is currently recommended for use in high-risk melanoma as an adjuvant therapy. The rationale for the use of HDI following disease resection is based on histologic and animal model evidence that interferon alfa-2b induces tumor regression via an indirect immunomodulatory mechanism.[49,50] These studies and others have shown that the effect of alfa-2b interferon is based on modulation of the host immune system, rather than via a direct antitumor mechanism.[51] IL-2, a cytokine-based agent, is used to stimulate the proliferation and activity of T cells in hopes of inducing tumor regression.[52,53] Today, recombinant IL-2 is recommended as a first-line agent for unresectable stage IV melanoma with a good performance status and no evidence of or treated central nervous system (CNS) disease, irrespective of BRAF mutation status.[52] This intravenous agent is marketed under the trade name Proleukin (aldesleukin, Prometheus Laboratories, San Diego).

Because of the rise in the incidence of melanoma, current statistics such as a 20% 5-year survival for patients with advanced melanoma and unresectable tumors, and the resistance of melanoma to radiation therapy and conventional chemotherapy, there has been significant scientific effort to identify pharmacologic agents that can directly induce or substitute the host's antitumor immune mechanism.[51] In the previous edition of this chapter, the treatment of melanoma with systemic therapy was limited to interferon alfa-2b for adjuvant therapy, and interleukin-2 (IL-2) and the aforementioned DNA alkylating agents (i.e., dacarbazine and temozolomide) for metastatic disease.[43]

However, today there are three new systemic agents that are approved for the treatment of melanoma: ipilimumab, an anti-CTLA4 monoclonal antibody, pegylated-interferon-alpha 2b for adjuvant therapy; BRAF inhibitor for patients with metastatic melanoma harboring $BRAF^{V600}$ mutation; and trametinib, a specific inhibitor of mitogen-activated protein kinase (MEK).

In the previous edition of this text, we described an ongoing phase III clinical trial involving the aforementioned anti-CTLA4 monoclonal antibody, ipilimumab, which was administered with or without a glycoprotein 100 (gp100) peptide vaccine for patients with unresectable stage II or IV melanoma. In 2010, Hodi and colleagues reported in the *New England Journal of Medicine* the results of this phase III trial.[54] Of the 676 patients enlisted in the trial, the median overall survival was 10 months among patients receiving ipilimumab plus gp100, as compared to 6.4 months for patients receiving gp100 alone. In 2011 the FDA approved ipilimumab (Yervoy, Bristol-Myers Squibb, New York) for treatment of metastatic melanoma.[55] Today, ipilimumab is recommended as a first-line agent in the treatment of unresectable BRAF mutation–negative tumors in patients with a poor performance status and untreated CNS disease.[51] For the case of BRAF mutation–negative tumors in a patient with a good performance status with absent/treated CNS disease, ipilimumab is considered a second-line agent, second to IL-2.[51]

Pegylated interferon alpha-2b (pIFN alfa-2b) is interferon alfa-2b that is conjugated to polyethylene glycol in order to reduce its rate of absorption and rate of clearance, while also increasing its immunogenicity.[52] In 2011 the FDA approved subcutaneous pegylated interferon alfa-2b (Sylatron, Merck & Co., Whitehouse Station, NJ) as a treatment for melanoma with microscopic nodal involvement after surgical resection. The Society for Immunotherapy of Cancer consensus statement on tumor immunotherapy, released in 2013, recommends standard interferon alpha-2b for patients with macroscopic nodal disease.[52] In summary, pegylated interferon alfa-2b could be considered in patients with microscopic nodal disease after surgical resection, whereas standard interferon alfa-2b should be used in patients with macroscopic nodal disease (N1b and N2-N3 disease).[45,51]

About half of melanomas harbor a mutation in BRAF; the most common genotypes are $BRAF^{V600E}$ and $BRAF^{V600K}$.[56,57] Detection of $BRAF^{V600}$ mutations has become routine in the evaluation of patients with advanced

disease or metastatic melanoma. Historically the presence of metastatic CNS disease is associated with lack of benefit from systemic therapies; however, today mainly BRAF inhibitors have shown evidence of benefit from systemic therapy if the tumor is BRAF mutation positive.[51] Today, two compounds are available within the selective BRAF inhibitor class: vemurafenib (Zelboraf, Genentech, South San Francisco, CA) and dabrafenib (Tafinlar, GlaxoSmithKline, London). The aforementioned mutations are point mutations causing $BRAF^{V600E}$ and $BRAF^{V600K}$ kinases to be constitutively active, resulting in sustained MAPK signaling and perpetual cell growth.[57] The BREAK-1 (phase I),[58] BREAK-2 (phase II),[59] BREAK-3 (phase III),[60] and BREAK-MB (phase II)[61] clinical trials have proven the safety of dabrafenib in patients with metastatic melanoma. Furthermore, a benefit of dabrafenib was identified for patients with unresectable stage III/IV BRAF mutation positive tumors in improving progression-free and overall patient survival. For instance, in the BREAK-3 trial an objective response rate with dabrafenib was determined to occur in 53% of patients, whereas with dacarbazine only 19% of patients had an objective response to treatment. Furthermore, these trials identified a higher response rate in the $BRAF^{V600E}$ positive tumors. Similarly, trametinib (GSK1120212, GlaxoSmithKline Pharmaceuticals, Philadelphia, PA), an oral MEK inhibitor, has also been found to improve overall survival in patients with metastatic melanoma with a BRAF mutation as a single agent when compared with conventional chemotherapy, dacarbazine.[62] In summary, today oncologists have at their disposal several pharmaceutical agents to combat disseminated melanoma. One must also not overlook the necessity and value of recommending a clinical trial for patients with unresectable disease.

Oral Mucosal Malignant Melanoma

As previously discussed, melanoma is a cancer of melanocytes. Within the skin, melanocytes are located within the stratum basale of the epidermis, and their function is to produce melanin, a vital pigment that serves to protect the skin from damage from ultraviolet rays. However, melanocytes have been identified in extracutaneous tissues, including the nasal cavity, paranasal sinuses, oral cavity, larynx, tracheobronchial tree, uvea, esophagus, gallbladder, rectum, anal canal, vagina, and cervix.[63] Given that these anatomic sites are sun-shielded, the true function of melanocytes within these tissues is not well understood. Some studies have described non-pigment functions of melanocytes that include phagocytosis, antigen presentation, and cytokine production.[63-65] Therefore, the current thought is that melanocytes could play a role in the innate immune system within mucosal surfaces, as well as the skin. Similar to skin melanocytes, these extracutaneous melanocytes have the potential to become cancerous. However, mucosal malignant melanomas are still considered rare neoplasms, representing 1.4% of all melanomas.[63] The head and neck is the most common location of mucosal melanomas, accounting for 25% to 50% of cases, with the nasal cavity being the most common head and neck subsite.[66] Although these lesions are rare, they are unfortunately associated with a high mortality rate (5-year survival is around 25% irrespective of tumor stage), which is indicative of their highly aggressive biologic behavior.

TABLE 29-11 AJCC-TNM Classification and Clinical Staging of Mucosal Melanoma

Primary Tumor			
T3	Mucosal disease		
T4a	Moderately advanced disease. Tumor involving bone, deep soft tissue, cartilage, or overlying skin		
T4b	Very advanced disease. Tumor involving brain, dura, skull base, lower cranial nerves (IX, X, XI, XII), masticator space, carotid artery, prevertebral space, or mediastinal structures		
Regional Lymph Nodes			
Nx	Regional lymph nodes cannot be assessed		
N0	No regional lymph node metastases		
N1	Regional lymph node metastases present		
Distant Metastasis			
M0	No distant metastasis		
M1	Distant metastasis present		
Clinical Stage			
Stage III	T3	N0	M0
Stage IVA	T4a	N0	M0
	T3-T4a	N1	M0
Stage IVB	T4b	Any N	M0
Stage IVC	Any T	Any N	M1

Oral mucosal malignant melanoma is typically detected on routine oral evaluation. It is worth noting that whereas fewer than 2% of cutaneous melanomas are amelanotic, within the oral cavity 25% to 75% of cases are amelanotic.[66,67] With regard to the distribution of oral and sinonasal mucosal melanoma, 48% of lesions will occur in the oral cavity and 52% in the sinonasal region.[68,69] With sinonasal mucosal melanoma, 84% of cases will involve the nasal cavity. Within the oral cavity, Hicks and colleagues reviewed 703 cases of oral mucosal melanoma and reported that 32% of cases involved the palate, making the palate the most commonly involved subsite followed by maxillary gingiva.[69] The diagnosis of mucosal melanoma of the head and neck, unlike its cutaneous counterpart, should include an incisional biopsy. The reason we recommend an incisional biopsy is that the depth of invasion and microscopic features of a mucosal melanoma are not part of the staging process (Table 29-11). Therefore, preserving the periphery of the lesion could aid in determining surgical margins at the time of tumor extirpation. Furthermore, histologic diagnosis is

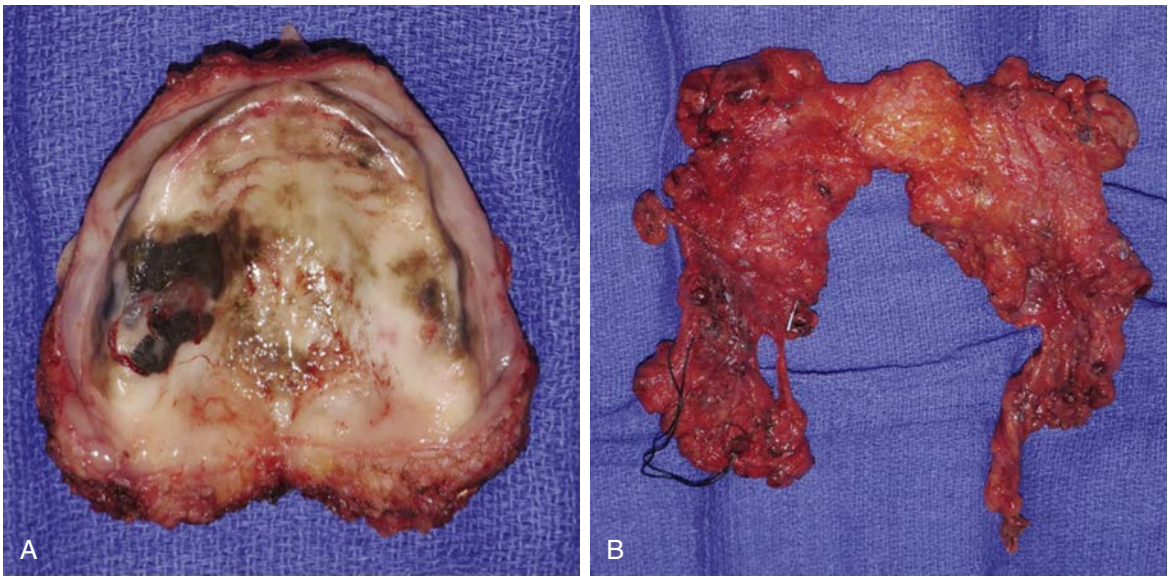

• **Figure 29-12** **A,** Specimen following bilateral subtotal maxillectomy for T3 mucosal melanoma (no bony invasion) with 3-cm surgical margin. **B,** Specimen following bilateral selective neck dissection (level I-IV).

complicated by the fact that only 50% to 70% of oral cavity melanomas stain positive for melanin.[70] Therefore, immunohistochemistry staining for S-100, MART-1, and HBM-45 is frequently performed to aid in histologic diagnosis.

Unfortunately, because of the rarity of this malignancy, there are no set guidelines or randomized clinical trials to aid in the management of these patients. Furthermore, from a public health perspective, unlike cutaneous melanoma, there is no known risk factor for mucosal melanomas to aid in disease prevention.

Because of the aggressive biologic behavior of this neoplasm and its poor overall survival, treatment consists of surgery, adjuvant radiation, and adjuvant chemotherapy/immunotherapy. Patients should be treated with multimodality therapy unless the extent of disease renders tumor unresectable, or the patient's performance status contraindicates surgery or adjuvant therapies. Nonetheless, as with all other forms of malignant melanoma, surgery typically offers the best outcome for the patient. However, because of the complexity of the local anatomy of the maxillo-mandibular complex, especially the maxilla, tumors that are diagnosed at a later stage could be deemed unresectable. Unlike cutaneous melanoma, surgeons treating oral mucosal melanoma do not have any randomized clinical trials to guide their decision making in choosing the size of surgical margin, and indication for SLNB versus ELND. The authors feel that a wide surgical margin (≥3 cm) should be safe enough (Figure 29-12). A liberal margin is imperative because frozen-section analysis is unreliable when dealing with mucosal melanoma, a result of the necessity for immunohistochemistry in histologic analysis. Furthermore, there is evidence to suggest that a negative margin offers survival benefit to these patients. Similarly, the role of lymph node dissection is not known. The incidence of nodal disease at first presentation for oral mucosal melanoma ranges from 25% to 48%.[71] Therefore, in the authors' practice, patients with oral mucosal melanoma will undergo an ELND, with the goal of appropriate staging and directing adjuvant radiation therapy. If the patient is able to tolerate adjuvant radiation therapy to the cervical lymph nodes, one could consider this option in patients with extracapsular extension and/or presence of two or more involved lymph nodes. Six percent to 14% of patients will present with distant metastasis.[71] Furthermore, there have been documented cases of distant metastasis of mucosal melanoma without lymph node involvement in other anatomic sites (i.e., anorectal); therefore, consideration should be given to obtaining an initial PET scan to assess for regional and distant disease.

Wushou and colleagues performed one of the more comprehensive and up-to-date reviews on oral mucosal malignant melanoma and identified a 4.69-fold increase in mortality in patients 60 years of age or younger.[68] These investigators also reported a 1.52-fold increase in mortality in patients managed with surgery alone, and a 12.84-fold increase in mortality in patients treated with nonsurgical modalities. These data highlight the importance of surgery in the management of oral mucosal malignant melanoma, and the need for adjuvant therapy. Even though both cutaneous and mucosal melanomas are considered radioresistant, it is common practice to recommend adjuvant radiation to the primary tumor site because of subclinical disease.[72]

As previously mentioned, 50% of malignant melanomas will be positive for BRAF mutation; however, in the case of all mucosal melanomas, only 9% will harbor this mutation.[73] Yet roughly 25% of all mucosal melanomas will harbor mutations in c-Kit.[73] In patients with c-Kit gene mutation, imatinib (Gleevec, Novartis Pharmaceuticals, Basel) could be beneficial. As in the case of cutaneous melanoma, vemurafenib and dabrafenib could be considered in patients with BRAF gene mutation. Del Vecchio

and colleagues evaluated the role of ipilimumab in 855 patients with unresectable cutaneous, ocular, and mucosal melanoma who had failed all other therapeutic options.[74] Within their cohort, 71 patients had metastatic mucosal melanoma, and with a medial follow-up of 21.8 months, they reported a response rate of 12% with immune-related disease control rate of 36%, and an overall survival of 6.4 months. The role of systemic therapies is less defined with mucosal melanomas. Adjuvant chemotherapeutics such as dacarbazine, platinum analogues, nitrosoureas, and IL-2 have shown a poor response rate.[72] Therefore, the role of chemotherapeutics in mucosal melanoma is primarily adjuvant or palliative. In conclusion, oral mucosal melanoma is a disease with a very poor prognosis; therefore, these patients should be managed with tumor extirpation with wide surgical margins with consideration for ELND, adjuvant radiation therapy, and conventional or novel systemic melanoma therapies.

Summary

Malignant melanoma is an increasingly common, potentially deadly entity that the oral and maxillofacial surgeon must be able to recognize. This disease is on the rise in pediatric and adult patient populations and has become a global health burden. Just within the United States, new cases of invasive melanoma will cost close to $2 billion annually.[53] It is imperative to fully understand the treatment and prognostic factors associated with this disease. Proper management requires a high index of suspicion and use of proper biopsy and excision techniques, as well as understanding the role of surgery in identifying and controlling locoregional and distant disease. Current issues in the management of malignant melanomas include an emphasis on sentinel node biopsy, as well as a treatment stratification based on the new AJCC staging system. Ongoing clinical trials will hopefully allow for better diagnostic and prognostic information, which will improve the management of this formidable disease.

References

1. American Cancer Society: *Cancer facts and figures 2014*, Atlanta, 2014, American Cancer Society.
2. Lasithiotakis KG, Petrakis IE, Garbe C: Cutaneous melanoma in the elderly: epidemiology, prognosis, and treatment, *Melanoma Res* 20:163–170, 2010.
3. Friedman RJ, Rigel DS, Silverman M, Kopf AW: The continued importance of early detection of malignant melanoma, *Cancer J Clin* 41:201–226, 1991.
4. Azoury SC, Lange JR: Epidemiology, risk factors, prevention, and early detection of melanoma, *Surg Clin N Am* 94:945–962, 2014.
5. Strouse JJ, Fears TR, Tucker MA, et al.: Pediatric melanoma: risk factors and survival analysis of the Surveillance, Epidemiology and End Results database, *J Clin Oncol* 23:4735–4741, 2005.
6. Rigel DS: Epidemiology and prognostic factor in malignant melanoma, *Ann Plast Surg* 28:7–8, 1992.
7. Harris JP, Weisman MH: *Head and neck manifestations of systemic disease*, New York, 2007, Informa Healthcare USA.
8. Osterlind A, Tucker MA, Stone BJ, Jensen DM: The Danish case-control study of cutaneous malignant melanoma. II. Importance of UV-light exposure, *Int J Cancer* 42:319–324, 1988.
9. Skender-Kalnenas TM, English DR, Heenan PJ: Benign melanocytic lesions: risk markers or precursors of cutaneous melanoma? *J Am Acad Dermatol* 33:1000–1007, 1995.
10. Bichakjian CK, Halpern AC, Johnson TM, et al.: Guidelines of care for the management of primary cutaneous melanoma. American Academy of Dermatology, *J Am Acad Dermatol* 65:1032–1047, 2011.
11. Shoo BA, Sagebiel RW, Kashani-Sabet M: Discordance in the histopathologic diagnosis of melanoma at a melanoma referral center, *J Am Acad Dermatol* 62:751–756, 2010.
12. Balch CM, Gershenwald JE, Soong SJ, et al.: Final version of 2009 AJCC melanoma staging and classification, *J Clin Oncol* 27:6199–6206, 2009.
13. Hale CS, Qian M, Ma MW, et al.: Mitotic rate in melanoma: prognostic value of immunostaining and computer-assisted image analysis, *Am J Surg Pathol* 37:882–889, 2013.
14. Sheffield MV, Yeeh H, Dorvault CC, et al.: Comparison of five antibodies as markers in the diagnosis of melanoma in cytologic preparations, *Am J Clin Pathol* 118:930–936, 2002.
15. Yu CH, Chen HH, Liu CM, et al.: HMB-45 may be a more sensitive marker than S-100 or Melan-A for immunohistochemistry diagnosis of primary oral and nasal mucosal melanoma, *J Oral Pathol Med* 34:540–545, 2005.
16. Elder DE, Guerry D, Epstein MN, et al.: Invasive malignant melanoma lacking competence for metastasis, *Am J Dermatopathol* 1:55–61, 1984.
17. Clark W, From L, Bernardino EA, Mihm MC: The histogenesis and biologic behavior of primary human malignant melanomas of the skin, *Cancer Res* 29:705–727, 1969.
18. Breslow A: Thickness, cross sectional areas, and depth of invasion in the prognosis of cutaneous melanoma, *Arch Surg* 172:902–908, 1970.
19. Austin JR, Byers RM, Brown WD, Wolf P: Influence of biopsy on the prognosis of cutaneous melanoma of the head and neck, *Head Neck* 18:107–117, 1996.
20. Rigel DS, Robinson JK, Ross MI, et al.: *Cancer of the skin*, ed 2, Philadelphia, 2011, Elsevier Saunders.
21. Veronesi U, Cascinelli N, Adamus J, et al.: Thin stage I primary cutaneous malignant melanoma. Comparison of excision with margins of 1 or 3 cm, *N Engl J Med* 318:1159–1162, 1988.
22. Thomas JM, Newton-Bishop J, A'Hern R, et al.: Excision margins in high-risk malignant melanoma, *N Engl J Med* 350:757–766, 2004.
23. Khayat D, Rixe O, Martin G, et al.: Surgical margins in cutaneous melanoma (2 cm versus 5 cm for lesions measuring less than 2.1 mm thick), *Cancer* 97:1941–1946, 2003.
24. Cohn-Cedermark G, Rutqvist Le, Andersson R, et al.: Long term results of a randomized study by the Swedish Melanoma Study Group on 2 cm versus 5 cm resection margins of patients with cutaneous melanoma with a tumor thickness of 0.8-2.0 mm, *Cancer* 89:1495–1501, 2000.

25. Balch CM, Soong SJ, Smith T, et al.: Long-term results of a prospective surgical trial comparing 2 cm vs. 4 cm excision margins for 740 patients with 1-4 mm melanomas, *Ann Surg Oncol* 8:101–108, 2001.
26. Cruse CW, Wells KE, Schroer KR, Reintgen DS: Etiology and prognosis of local recurrence in malignant melanoma of the skin, *Ann Plast Surg* 21:26–28, 1992.
27. Pollack LA, Li J, Berkowitz Z, et al.: Melanoma survival in the United States, 1992 to 2005, *J Am Acad Dermatol* 65:S78–S86, 2011.
28. Sperry SM, Charlton ME, Pagedar NA: Association of sentinel lymph node biopsy with survival for head and neck melanoma survival analysis using the SEER database, *JAMA Otolaryngol Head Neck Surg* 140:1101–1109, 2014.
29. Fadaki N, Li R, Parrett B, et al.: Is head and neck melanoma different from trunk and extremity melanomas with respect to sentinel lymph node status and clinical outcome? *Ann Surg Oncol* 20:3089–3097, 2013.
30. Veronesi U, Adamus J, Bandiera DC, et al.: Delayed regional lymph node dissection in stage I melanoma of the skin of the lower extremities, *Cancer* 49:2420–2430, 1982.
31. Balch CM: Randomized surgical trials involving elective node dissection for melanoma, *Adv Surg* 32:255–270, 1999.
32. Sim FH, Taylor WF, Pritchard DJ, Soule EH: Lymphadenectomy in the management of stage I malignant melanoma: a prospective randomized study, *Mayo Clin Proc* 61:697–705, 1986.
33. Balch CM, Soong SJ, Ross MI, Urist MM: Long term results of a multi-institutional randomized trial comparing prognostic factors and surgical results for intermediate thickness melanomas (1.0 to 4.0 mm). Intergroup Melanoma Surgical trial, *Ann Surg Oncol* 7:87–97, 2000.
34. Rousseau DL, Ross MI, Johnson MM, et al.: Revised American Joint Committee on Cancer staging criteria accurately predict sentinel lymph node positivity in clinical node-negative melanoma patients, *Ann Surg Oncol* 10:569–574, 2003.
35. Balch CM, Buzaid AC, Soong SJ, et al.: Final version of the American Joint Committee on Cancer Staging System for Cutaneous Melanoma, *J Clin Oncol* 19:3636–3648, 2001.
36. Wasif N, Etzioni D, Haddad D, et al.: Staging studies for cutaneous melanoma in the United States: a population-based analysis, *Ann Surg Oncol* 22(4):1366–1370, 2015.
37. Buzaid AC, Ross MI, Balch CM, et al.: Critical analysis of the current American Joint Committee on Cancer staging for cutaneous melanoma and proposal of a new staging system, *J Clin Oncol* 15:1039–1051, 1997.
38. Balch CM, Soong SJ, Atkins MB, et al.: An evidence based staging system for cutaneous melanoma, *CA Cancer J Clin* 54:131–149, 2004.
39. Harris CM, Bailey J, Blanchaert RH: Surgical management of cutaneous melanoma of the head and neck, *Oral Maxillofacial Surg Clin North Am* 17:191–204, 2005.
40. Gutzmer R, Al-Ghazal M, Geerlings H, Kapp A: Sentinel node biopsy in melanoma delays recurrence but does not change melanoma related survival: a retrospective analysis of 673 patients, *Br J Dermatol* 153:1137–1141, 2005.
41. Morton DL, Thompson J, Essner R, et al.: Validation of the accuracy of intraoperative lymphatic mapping and sentinel lymphadenectomy for early stage melanoma: a multicenter trial—Multicenter Selective Lymphadenectomy Trial Group, *Ann Surg* 230:453–463, 1999.
42. Bonnen MD, Ballo MT, Myers JN, et al.: Elective radiotherapy provides regional control for patients with cutaneous melanoma of the head and neck, *Cancer* 100:383–389, 2004.
43. Ballo MT, Bonnen MD, Garden AS, et al.: Adjuvant irradiation for cervical lymph node metastases from melanoma, *Cancer* 97:1789–1796, 2003.
44. Middleton MR, Grob JJ, Aaronson N, et al.: Randomized phase III study of temozolomide versus dacarbazine in the treatment of patients with advanced metastatic malignant melanoma, *J Clin Oncol* 18:158–166, 2000.
45. Coit DG, Andtbacka R, Bichakjian CK, et al.: Melanoma, *J Natl Compr Canc Netw* 7:250–275, 2009.
46. Kirkwood JM, Strawderman MH, Ernstoff MS, et al.: Interferon alfa-2b adjuvant therapy of high risk resected cutaneous melanoma: the Eastern Cooperative Oncology Group trial EST 1684, *J Clin Oncol* 14:7–17, 1996.
47. Kirkwood JM, Manola J, Ibrahim J, et al.: A pooled analysis of Eastern Cooperative Oncology Group and Intergroup trials of adjuvant high dose interferon for melanoma, *Clin Cancer Res* 10:1670–1677, 2004.
48. Wheatley K, Ives N, Hancock B, et al.: Does adjuvant interferon-alpha for high risk melanoma provide a worthwhile benefit? A meta-analysis of randomized trials, *Cancer Treat Rev* 29:241–252, 2003.
49. Moschos SJ, Edington HD, Land SR, et al.: Neoadjuvant treatment of regional stage IIIB melanoma with high-dose interferon alfa-2b induces objective tumor regression in association with modulation of tumor infiltrating host cellular immune responses, *J Clin Oncol* 24:3164–3171, 2006.
50. Lesinski GB, Anghelina M, Zimmerer J, et al.: The antitumor effects of IFN-alpha are abrogated in a STAT1-deficient mouse, *J Clin Invest* 112:170–180, 2003.
51. Kaufman HL, Kirkwood JM, Hodi FS, et al.: The Society of Immunotherapy of Cancer consensus statement on tumor immunotherapy for the treatment of cutaneous melanoma, *Nat Rev Clin Oncol* 10:588–598, 2013.
52. Rotte A, Bhandaru M, Zhou Y, et al.: Immunotherapy of melanoma: present options and future promises, *Cancer Metastasis Rev* 34(1):115–128, 2015.
53. Rosenberg SA: IL-2: the first effective immunotherapy for human cancer, *J Immunol* 192:5451–5458, 2014.
54. Hodi FS, O'Day SJ, McDermott DF, et al.: Improved survival with ipilimumab in patients with metastatic melanoma, *N Engl J Med* 363:711–723, 2010.
55. FDA approves new treatment for a type of late-stage skin cancer. Available at: www.fda.gov/newsevents/newsroom/pressannouncements/ucm1193237.htm.
56. Spagnolo F, Ghiorzo P, Orgiano L, et al.: BRAF-mutant melanoma: treatment options, resistance mechanisms, and diagnostic strategies, *Onco Targets Ther* 8:157–168, 2015.
57. Trinh VA, Davis JE, Anderson JE, et al.: Dabrafenib therapy for advanced melanoma, *Ann Pharmacother* 48:519–529, 2014.
58. Falchook GS, Long GV, Kurzrock R, et al.: Dabrafenib in patients with melanoma, untreated brain metastases, and other solid tumors: a phase 1 dose-escalation trial, *Lancet* 379:1893–1901, 2012.
59. Ascierto PA, Minor D, Ribas A, et al.: Phase II trial (BREAK-2) of the BRAF inhibitor dabrafenib (GSK2118436) in patients with metastatic melanoma, *J Clin Oncol* 31:3205–3211, 2013.
60. Hauschild A, Grob JJ, Demidov LV, et al.: Dabrafenib in BRAF-mutated metastatic melanoma: a multicenter, open-label, phase 3 randomised controlled trial, *Lancet* 380:358–365, 2012.
61. Long GV, Trefzer U, Davies MA, et al.: Dabrafenib in patients with Val600Glu or Val600Lys BRAF-mutant melanoma metastatic to the brain (BREAK-MB); a multicenter, open-label-phase 2 trial, *Lancet Oncol* 13:1087–1095, 2012.

62. Flaherty KT, Robert C, Herrsey P, et al.: Improved survival with MEK inhibition in BRAF-mutated melanoma, *N Engl J Med* 367:107–114, 2012.
63. Mihajlovic M, Vlajkovic S, Jovanovic P, et al.: Primary mucosal melanoma: a comprehensive review, *Int J Clin Exp Pathol* 5:739–753, 2012.
64. Mackintosh JA: The antimicrobial properties of melanocytes, melanosomes and melanin and the evolution of black skin, *J Theor Biol* 211:101–113, 2001.
65. Plonka PM, Passeron T, Brenner M, et al.: What are melanocytes really doing all day long… ? *Exp Dermatol* 18:799–819, 2009.
66. Seetharamu N, Ott PA, Pavlick AC: Mucosal melanomas: a case-based review of the literature, *Oncologist* 15:772–781, 2010.
67. Adisa AO, Olawole WO, Sigbeku OF: Oral amelanotic melanoma, *Ann Ib Postgrad Med* 10:6–8, 2012.
68. Wushou A, Zhao YJ: The management of site-specific prognostic factors of primary oral mucosal malignant melanoma, *J Craniofac Surg* 26(2):430–434, 2015.
69. Hicks MJ, Flaitz CM: Oral mucosal melanoma: epidemiology and pathobiology, *Oral Oncol* 36:152–169, 2000.
70. Manolidis S, Donald PJ: Malignant mucosal melanoma of the head and neck: a review of the literature and report of 14 patients, *Cancer* 8:1373–1386, 1997.
71. Werning JW: *Oral cancer diagnosis, management, and rehabilitation*, New York, 2007, Thieme Medical.
72. Warszawik-Hendzel O, Slowinska M, Olszewska M, et al.: Melanoma of the oral cavity: pathogenesis, dermascopy, clinical features, staging and management, *J Dermatol Case Rep* 60–66, 2014. 2014.
73. Khalil DN, Carvajal RD: Treatments for noncutaneous melanoma, *Hematol Oncol Clin North Am* 28:507–521, 2014.
74. Del Vecchio M, Di Guardo L, Ascierto PA, et al.: Efficacy and safety of ipilimumab 3mg/kg in patients with pretreated, metastatic, mucosal melanoma, *Eur J Cancer* 50:121–127, 2014.

30 Lymphoma

KETAN PATEL, AVANTI MEHROTRA, DEEPAK KADEMANI

Introduction

Lymphoma is a general term for a complex group of heterogeneous lymphoreticular malignancies. Lymphoma is the sixth most common malignancy and the second most common neoplasm of the head and neck after squamous cell carcinoma and accounts for 50% to 59% of head and neck neoplasms in children.[1,2] They constitute approximately 3% to 5% of all known malignancies and are generally divided into two morphologically distinct types: Hodgkin lymphoma (HL) and non-Hodgkin lymphoma (NHL).[3-6] These malignancies typically arise within the lymphatic tissues and can progress to extranodal disease as in NHL. Cervical lymph node involvement can be present in any type of lymphoma. HL extends by means of contiguous nodal spread, whereas NHL tends to disseminate hematogenously and is typically a systemic diagnosis. Within the head and neck, Waldeyer ring is the most common site of involvement,[7-9] accounting for more than half of all extranodal head and neck lymphomas. Oral involvement by lymphoma may represent a localized disease process but is more often part of a systemic process that secondarily involves the cervical lymph nodes.

Lymphoma arising within the oral cavity accounts for less than 5% of all oral malignancies, and approximately 85% of these lesions involve the pharyngeal tonsil and the palate (Figure 30-1). Extralymphatic sites include the salivary glands, paranasal sinuses, oral cavity, and larynx.

Lymphomas are currently classified based on morphologic, immunophenotypic, genetic, and clinical features. Several classification systems have been used to classify lymphomas, including the World Health Organization (WHO) classification, which is based on the principles defined in the Revised European-American Classification of Lymphoid Neoplasm (REAL). Both the WHO and REAL classifications divide lymphomas based on cell of origin into two large categories: Hodgkin Lymphoma and Non Hodgkin Lymphoma (NHL).

HL is subdivided into Classical Hodgkin and Nodular Lymphocyte Predominant HL (NLPHL).

NHL is a group of heterogenous diseases that vary widely in pathology, behavior, and therapy. This is broadly divided into B-cell NHL and T-NK (natural killer)-cell lymphoma, which are then further subdivided[3,4,10-12] (Box 30-1).

Diagnosis

Patients often present with a neck mass to oral and maxillofacial surgeons (Figure 30-2). Therefore, it is critical when assessing neck masses to have a well-developed algorithm for their evaluation (Figure 30-3). This will enable earlier-stage diagnosis and expeditious treatment.

Nodal presentation of a lymphoma typically presents with a neck mass of small to medium-sized lymph nodes with a rubbery consistency that progressively become larger. Lymph nodes larger than 1 cm that persist for more than 4 to 6 weeks in the absence of infection should be evaluated histologically.[13] There are several specific criteria for biopsy of suspected lymphoma. It is preferable that the largest accessible lymph node be removed for histologic diagnosis. Excisional biopsy provides the highest yield diagnostically. The excised lymph node should preferably be intact and undistorted. Fine-needle aspiration (FNA) may on occasion be diagnostic when augmented with immunophenotyping studies and is a useful diagnostic modality for intra-abdominal, thoracic, or retroperitoneal lymph nodes. FNA is often used to obtain tissue for surveillance in the post-treatment setting.[9,13]

The diagnosis of lymphoma is based on the histopathologic examination of enlarged cervical lymph nodes or from extralymphatic tissue. Immunophenotyping of lymphomas, by either immunohistochemistry or flow cytometry, is critical for accurate classification of a lymphoma. The majority of B-cell lymphomas express the pan-B cell antigen CD20, whereas T-cell lymphomas express the T-cell antigen CD3. Both sets are positive for the leukocyte common antigen CD45. Hodgkin lymphoma lacks the B-cell and T-cell antigens. The classical Hodgkin pathognomic cell is the Reed-Sternberg cell that typically expresses CD15 and CD30.

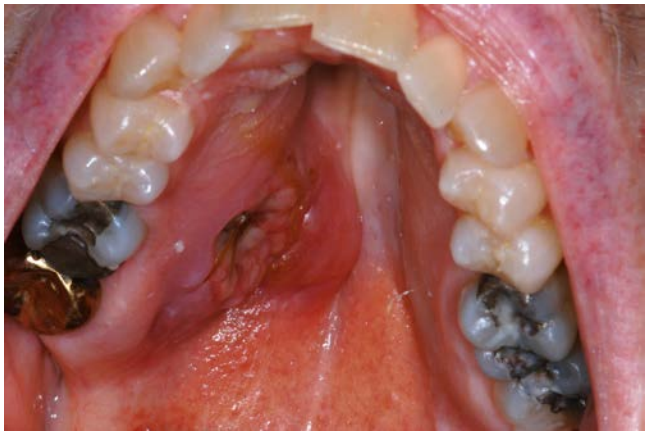

• **Figure 30-1** Non-Hodgkin lymphoma (follicular type) presenting as an intraoral palatal mass with mucosal ulceration.

• BOX 30-1 Classifications of Lymphomas

Hodgkin Lymphoma

- Classical Hodgkin lymphoma
- Nodular sclerosis
- Mixed cellularity
- Lymphocyte-rich
- Lymphocyte-depleted
- Nodular lymphocyte predominant Hodgkin lymphoma

Non-Hodgkin Lymphoma

- Precursor B-cell neoplasms
- Mature B-cell neoplasms
- Small cell lymphoma/chronic lymphocytic leukemia
- Extranodal marginal zone B-cell lymphoma of mucosa associated lymphoid tissue (MALT-lymphoma)
- Follicular
- Mantle cell
- Diffuse large cell
- Burkitt (African and endemic)
- Others
- Precursor T-cell
- Mature NK/T-cell
- Extranodal NK/T-cell lymphoma, nasal type
- Anaplastic large cell
- Mycosis fungoides
- Others

The clinical staging of NHL and HL is based on a combination of clinical, radiologic, and surgical findings. In order to appropriately stage lymphoma, a complete medical history, physical examination, urinalysis, blood chemistries, complete blood count with differential, and bone marrow biopsy are required. Imaging modalities are also required, and this centers on obtaining a computed tomography (CT) scan with intravenous contrast, which should include the head and neck, mediastinum, abdomen, and pelvis. Positron emission tomography (PET)-CT scan is now used whenever possible for initial staging. A bone marrow biopsy is typically performed from the iliac crest, because approximately 18% of non-HLs involve the bone marrow.[13-16] If central nervous system (CNS) involvement is suspected, a lumbar puncture is indicated. Lumbar puncture with cerebrospinal fluid flow cytometry is performed in high-risk cases of DLBCL involving the head and neck area, paranasal sinuses, or bone marrow and in testicular and extranodal disease. For patients with head and neck lesions, a nasopharyngoscopy should also be performed. The immunohistochemical analysis of the tumor is essential for diagnosis and for targeting novel therapies.



• **Figure 30-2** Elderly female patient with palpable cervical and parotid tail enlargement. Diagnosed as diffuse large cell non-Hodgkin lymphoma.

The Ann Arbor staging system (see Figure 30-3) is applicable to both HL and NHL and provides the basis for staging.[9,12,13,15,17] The Ann Arbor system depends on the number of lymph node regions involved, the presence of extranodal disease, the presence of disease above and below the diaphragm, and the existence of concomitant constitutional symptoms (*category A* for those patients without systemic symptoms; *category B* for patients with defined systemic symptoms including fever, chills, night sweats, and greater than 10% weight loss). These symptoms are more commonly associated with HL and are prognostically significant if present for both NHL and HL. In addition to routine histologic examination, the presence of genetic and chromosomal abnormalities is common in lymphoma. Aneuploidy occurs in HL; translocations such as *c-myc* gene may be seen in Burkitt lymphoma, and *bcl-2* may often be found in follicular lymphomas. Infection such as Epstein-Barr virus, HIV-1, *Helicobacter pylori,* hepatitis B and C, and human herpesvirus 8 may all be implicated in the pathogenesis of lymphoma.[3,12,15,18-21] The presence of chronic inflammation also increases the risk of developing

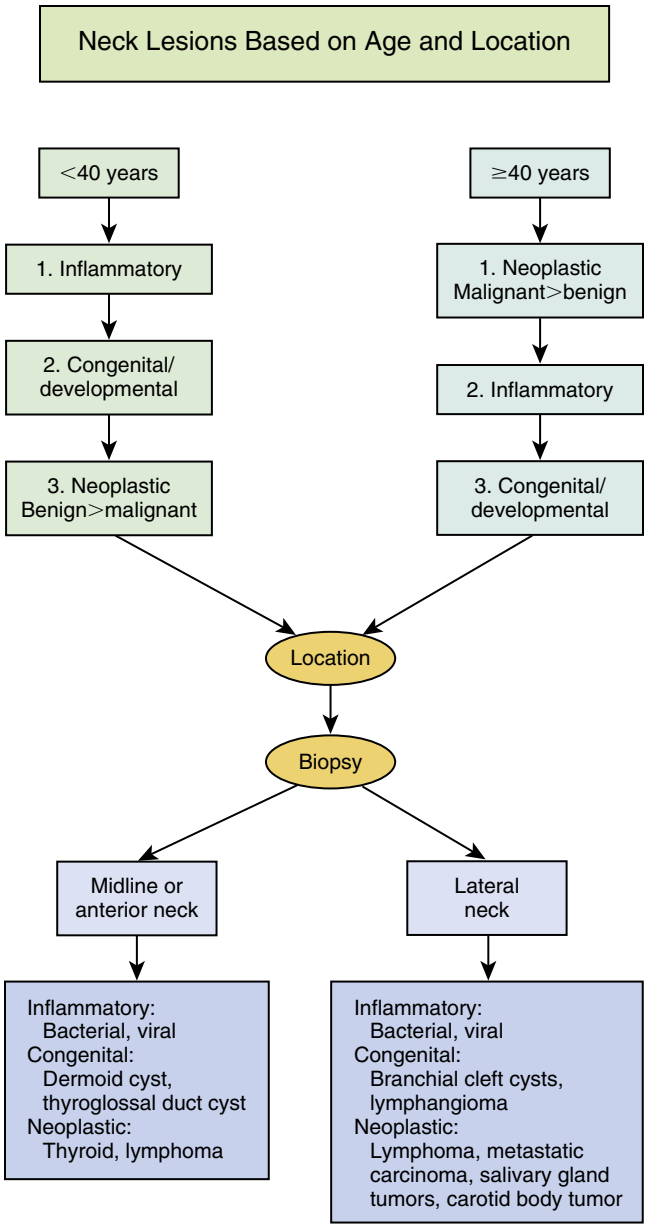

• **Figure 30-3** Evaluation of a neck mass. (Adapted from Bagheri S: *Clinical review of oral and maxillofacial surgery*, St Louis, 2008, Mosby.)

lymphoma as is seen with mucosa-associated lymphoid tissue (MALT) lymphoma in patients with Sjögren syndrome and rheumatoid arthritis.[16,21-27]

Hodgkin Lymphoma

HL is a disorder that is localized to the lymph nodes in more than 90% of cases. HL can be divided into two forms: classical HL (CHL) and nodular lymphocyte predominant HL (NLPHL). CHL is further subtyped into nodular sclerosis, mixed cellularity, lymphocyte-rich, and lymphocyte-depleted forms. Distinguishing CHL from NLPHL is the most important breakpoint because of their differing clinical presentation, behavior, and immunohistologic features. The majority of cases (95%) are of the classical form, with

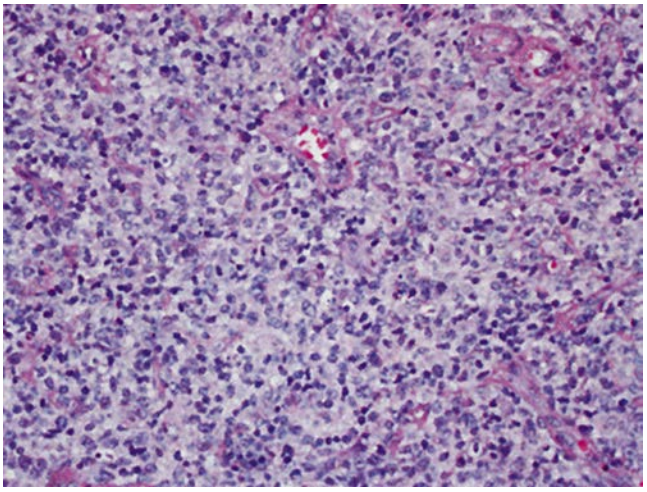

• **Figure 30-4** Large collection of Hodgkin cells. Multinucleated Reed-Sternberg cells are also present.

the nodular sclerosis subtype accounting for 70% of these cases.[13,28] This type of classic lymphoma has a bimodal age distribution, with a peak incidence between 20 and 25 years and a second peak in the eighth decade. In the majority of cases (98%), the malignant cells of CHL arise from a mature B-cell.[28] The uninucleated forms are referred to as Hodgkin cells or Reed-Sternberg cell variants, whereas the multinucleated, diagnostic cells are referred to Reed-Sternberg cells (Figure 30-4). All Hodgkin cells in CHL have a similar immunophenotype: *CD15 +ve, CD30 +ve, and CD20 –ve.* Approximately 5% of HL cases are of the NLPHL type, which may occur at any age with a peak between 30 and 50 years old.[28] Like CHL, NLPHL also arises from a mature B cell. However, the neoplastic cells in this type are characterized as large cells with convoluted nuclei. Hence, they are referred to as popcorn or L&H cells (lymphocytic and/or histiocytic Reed-Sternberg cell variants). In contrast to classic RS cells, L&H cells are typically *CD30 –ve, CD45 +ve, and CD20 +ve.*[12] HL is very uncommon in children less than 5 years of age.[12]

HL accounts for approximately 14% of all lymphomas, making it significantly less common than NHL.[3,6,10,15] HL presents rarely as extranodal disease (1% to 4%), whereas NHL occurs in extranodal sites in up to a third of cases.[13,29] Classically, HL occurs in a single lymph node that then progressively involves contiguous lymph node structures. This pattern is in contrast to NHL, where noncontiguous spread to lymphatic structures or extranodal sites is more commonly seen. Clinically, HL causes generalized symptoms or laboratory abnormalities in 41% of patients, as compared with 27% of patients with NHL.[9] The distinction between HL and NHL can only be made histopathologically, because clinical and radiographic presentation often fail to distinguish between these two groups of lymphomas. The distribution of lymph node involvement between HL and NHL varies, with 24% of patients with HL versus 33% of patients with NHL presenting with cervical lymphadenopathy.

Non-Hodgkin Lymphoma (NHL)

NHL represents a diverse group of lymphoreticular neoplasms, which may be divided broadly into B-cell and T-cell forms. Mature B-cell lymphomas constitute more than 85% of NHL worldwide.[28] Some forms include follicular lymphoma, B-cell chronic lymphocytic leukemia/small lymphocytic lymphoma, diffuse large B-cell lymphoma, lymphoplasmacytic lymphoma, splenic marginal zone lymphoma, extranodal marginal zone B-cell lymphoma of MALT lymphoma, mantle-cell lymphoma, and Burkitt lymphoma. All of these lymphomas share expression of the pan-B-cell marker CD20. In addition, many of them also have other specific immunophenotypic profiles that allow for definitive classification. Plasma cell proliferations, such as myeloma or plasmacytoma, also fall under the category of mature B-cell neoplasms, but these are typically CD20(–).

The gastrointestinal system is the most frequently involved extranodal site, which occurs in over 50% of patients.[16,20,30-33] This is followed by the head and neck, which is affected in 11% to 33% of patients.[33] NHL of the head and neck arises in lymph nodes in 65% of cases and in extranodal sites in 25% to 30%.[16] NHL of the head and neck occurs predominantly in patients between the ages of 50 and 60. NHL may spread to regional and distant lymphatic sites as well as parenchymal organs including liver, spleen, lung and bone marrow.

Follicular lymphoma (FL) occurs in an older population, has a relatively indolent course, and constitutes approximately 40% of NHL in adults. It typically manifests as painless lymphadenopathy, splenomegaly, and bone marrow involvement. This lymphoma has a follicular center cell origin and histologically has nodular effacement of the lymph node. The lymphoma cells are CD20, CD10, BCL6, and BCL2(+). BCL2 is an anti-apoptosis gene, which is expressed in FL and allows for distinction from reactive follicular hyperplasia, which is BCL2(–).[28]

Extranodal marginal zone B-cell lymphoma of MALT lymphoma also displays an indolent clinical evolution. This type of lymphoma is commonly seen within the head and neck and in particular extralymphatic sites such as the thyroid and salivary glands and is commonly associated with other autoimmune diseases such as Hashimoto thyroiditis and Sjögren syndrome.[24,25,30,34-38] This lymphoma forms characteristic lymphoepithelial lesions in which the neoplastic lymphocytes infiltrate and injure ducts and glands of the involved organ (Figure 30-5).

Diffuse large B-cell lymphoma (DLBCL) is the most common type of NHL in the head and neck, constituting over 50% of cases. This form of lymphoma has a median age of occurrence of 60 and most often presents as a rapidly enlarging single or extranodal mass.[2,39] Waldeyer ring is the most commonly involved site in the head and neck for DLBCL, which can also affect the paranasal sinuses and oral cavity but is relatively rare in the orbital adnexa. Histologically, the lymphoma cells are CD20(+) B-cells whose nuclei are larger than the nuclei of a macrophage or endothelial cells. This lymphoma typically causes a diffuse effacement of the lymph node architecture (Figure 30-6). Some cases of DLBCL represent transformation of a more indolent lymphoma, such as FL or B-cell CLL/SLL. Gene expression profiling and identifying genetic subtype of DLBCL by molecular tying is rather important. DLBCL that have c-myc translocation portend poorer prognosis and have lesser response to therapy.[40] An even more aggressive form of DLBCL is when there is coexpression of c-myc and bcl-2 protein by IHC.[41] The term "double-hit" lymphoma is now used for DLBCL that have translocations of both c-myc gene at (8q24) and bcl 2 gene at (18q21).[39,42]

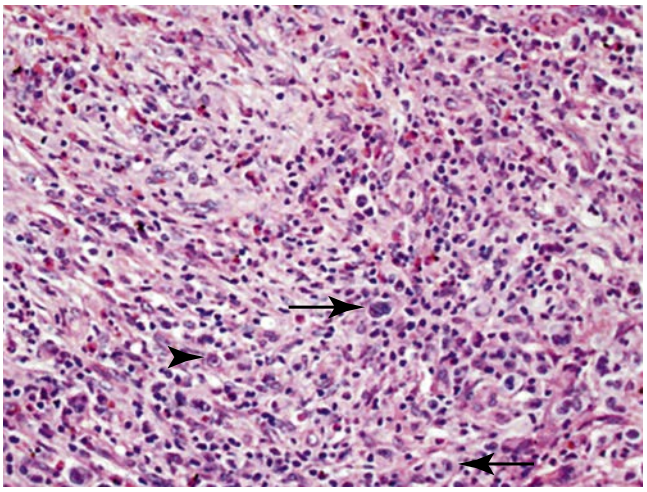

• **Figure 30-5** Diffuse large B-cell lymphoma. Medium-high power view showing sheet of large, atypical cells with moderate amounts of amphophilic cytoplasm. Small, reactive lymphocytes are interspersed. Scattered Reed-Sternberg cells *(arrows)* and uninucleated Hodgkin cells *(arrowhead)* present in the typical inflammatory background of classical Hodgkin lymphoma. Numerous eosinophils and plasma cells are a common finding.

Burkitt lymphoma, an aggressive form of B-cell lymphoma, has three notable forms: endemic (African), sporadic, and immunodeficiency associated.[32] Endemic BL involves the maxillofacial region in 50% of cases. Sporadic BL more often tends to involve the intra-abdominal contents. Immunodeficiency-associated BL often involves lymph nodes and bone marrow.

Angiocentric Lymphoma

Some lymphomas that involve the sinonasal tract show a peculiar angiocentric/angiodestructive growth pattern. These processes have historically gone by various confusing terms, including polymorphic reticulosis, lethal midline granuloma, lymphomatoid granulomatosis, and malignant midline reticulosis.[28] Histologically there is ulceration and a mixed inflammatory infiltrate, not the typical monotonous proliferation seen in other lymphomas. In addition to T-cell lymphoma, which would be CD3(+), and EBV-associated B-cell lymphoma (CD20+), extranodal NK/T-cell lymphoma, nasal type, can cause this pattern.

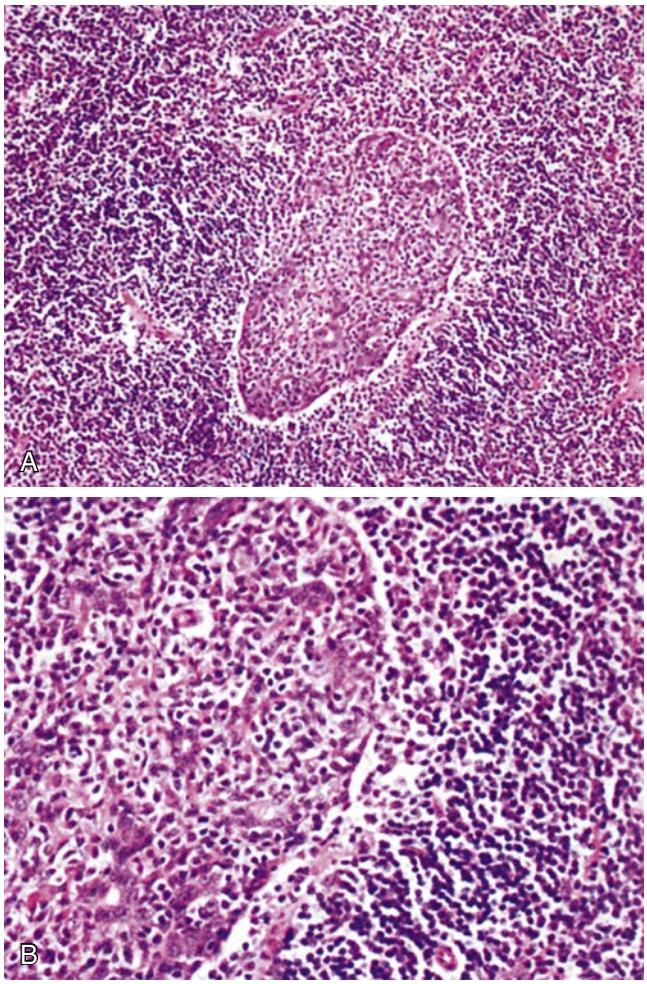

• **Figure 30-6** Extranodal marginal zone B-cell lymphoma of mucosa-associated lymphoid tissue (MALT lymphoma). **A,** Aggregates of small to medium-sized lymphocytes with moderate amounts of cytoplasm. The lymphoma cells characteristically infiltrate the epithelial glands and ducts, forming lymphoepithelial lesions. **B,** Higher-power view of a lymphoepithelial lesion *(left half of field)*.

Nasal-type NK/T-cell lymphoma is almost always associated with EBV and typically is surface CD3(–) (as opposed to most T-cell lymphomas) and CD56(+). This lymphoma is thought to arise from activated NK cells or cytotoxic T-cells. Nasal-type NK/T-cell lymphoma has a variable prognosis, but often behaves in an aggressive manner.[28]

Post-transplant Lymphoproliferative Disorder

Patients who have undergone a solid organ transplant or allogeneic stem-cell transplant for hematologic malignancies are placed on immunosuppressive medications such as cyclosporine and mycophenolate to prevent transplant rejection or to reduce graft-versus-host disease. These patients are at an increased risk of development of lymphomas. This can frequently occur in the buccal mucosa or any lymphoid aggregate in the head and neck region. The disorder can range from a mild lymphoproliferative disorder, to low-grade lymphoma, to aggressive high-grade lymphoma. These are mostly EBV associated as well. Treatment involves reduction of immunosuppression, which places them at risk of transplant rejection. However, this is quite effective in the treatment of the lymphoma.

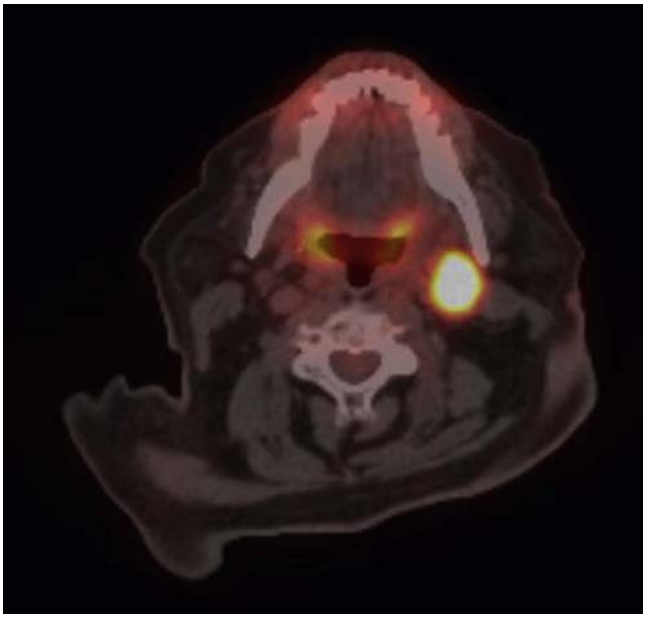

• **Figure 30-7** Positron emission tomography/computed tomography (PET/CT) scan of a diffuse large cell lymphoma with fluorodeoxyglucose-avid node in left neck.

Radiographic Evaluation

CT scan with intravenous contrast is the primary modality for radiologic assessment of enlarged lymph nodes associated with head and neck lymphoma. Enlarged cervical lymph nodes are typically isodense with muscle and usually appear as a homogeneous conglomerate mass. More recently, PET/CT has become the modality for the initial staging for lymphomas (Figure 30-7). Necrosis is not a prominent primary feature of lymphoma. Aggressive lymphoid lesions may have extracapsular lymph node extension with invasion of adjacent soft tissue structures. It is not uncommon for cervical lymph nodes to form a large matted mass, mimicking an extranodal primary malignancy.[43-45]

An extranodal lymphoma typically manifests as a firm submucosal mass, often lobulated; however, it classically presents with an intact overlying mucosa, unlike squamous cell carcinomas of the head and neck. Osteolytic bone lesions can be displayed by aggressive high-grade lesions similar to other malignant processes. Low-grade lymphomas such as MALT lymphoma are rarely associated with bone destruction. Magnetic resonance imaging (MRI) typically manifests low signal intensity on T1-weighted images, with intermediate signal intensity on T2-weighted images. However, the mainstay of diagnosis continues to be CT scan

with intravenous contrast with formal immunophenotypic analysis of lymphoid tissue and bone marrow biopsy.[45-47]

There are several specific sites within the head and neck that may develop lymphomatous disease and deserve special discussion. Waldeyer ring comprises a network of lymphoid tissue within the nasopharynx, which includes the nasopharynx, base of tongue, and pharyngeal tonsils. It is the most common site of extranodal lymphoma within the head and neck and accounts for more than 60% of extranodal lymphoma. The majority of Waldeyer ring–associated lymphoma is seen in patients in the sixth to seventh decade of life and has a 10% association with concomitant gastrointestinal tract lymphoma.[8,24,37] DLBCL is the most frequently seen morphologic variety of lymphoma in 50% to 60% of cases, and most patients present with early stage I or stage II disease.[13] HL has rarely been reported in the Waldeyer ring or nasopharynx. Radiographic examination typically demonstrates a large bulky mass involving one or all three lymphoid sites within Waldeyer ring. The most commonly affected site within Waldeyer ring is the pharyngeal tonsil, seen in 37% to 52% of cases, followed by the nasopharynx and least commonly the base of the tongue.[48,49] On radiographic examination, these lesions typically present as an isolated isodense mass to muscle with submucosal extension with relatively normal overlying mucosal tissue. Mucosal ulceration as seen in squamous cell carcinoma is not a typical feature.

Lymphomas of the oral cavity constitute 2% of extranodal lymphomas.[26] The majority of site involvement includes the palate, maxilla, and gingival tissues. Oral cavity lymphoma is more frequently seen in patients with immunosuppressive diseases and in particular those who have HIV infection.[50,51] More than 50% of lymphomas within the oral cavity are of the DLBCL variety, with follicular lymphoma and MALT lymphoma being the next most common, respectively.[52] The tumor may originate within the soft tissue structures as a localized exophytic bulky mass or may have osteolytic lesions as is typically seen with Burkitt lymphoma.[26,53]

Lymphoma is the second most common malignancy of the paranasal sinuses after squamous cell carcinoma.[35,54] In extranodal NHL of the head and neck, approximately 6% to 13% occur in the paranasal sinuses.[35,54] The most common variant is DLBCL. T-cell lymphoma invariably involves the nasal cavity, which is the primary site for this form of malignancy. Paranasal sinus lymphomas are considered moderately aggressive and commonly will extend into the orbital vaults. They are clinically and radiographically indistinguishable from the more commonly seen epidermoid tumors of the head and neck. Direct involvement of the nasal vault from paranasal sinus tumors is not unusual. However, a small percentage of lymphomas arise primarily in the nasal cavity. These are typically extranodal NK/T-cell lymphomas. The median age of presentation is 50, with a typical male predominance.[55] Lymphoma localized to the nasal vault will typically cause osteolytic bone destruction with concomitant extension into the paranasal sinuses, alveolar bone, or hard palate with soft tissue extension into the masticator, buccinator, pharyngotemporal, and infratemporal fossa, nasopharynx orbit, or intracranial vault. NK/T-cell lymphoma typically exhibits an aggressive clinical course with early multi-organ involvement and poor patient survival. Extranodal nasal NK/T-cell lymphoma is much more prevalent in Asia than in Latin America or Europe and has a high association with Epstein-Barr virus.[55-57]

Salivary gland lymphomas comprise 2% to 5% of all salivary gland neoplasms, with the parotid gland involved in more than 70% of cases.[58-60] Histopathologically, these are typically B-cell lymphomas, with the MALT-type occurring in one third of cases, follicular lymphoma in one third, and DLBCL in the remaining one third. MALT-type lymphomas are typically seen in the parotid parenchyma, whereas follicular lymphomas are more commonly seen within intraparotid lymph nodes.[58-60] Twenty percent of patients have an association with other immunotypical diseases such as Sjögren syndrome, as is seen with MALT lymphoma.[29] An important diagnostic and prognostic finding is the presence of extra salivary gland involvement to adjacent cervical lymph nodes, which is seen in 20% to 45% of cases.[29]

NHL may involve the mandible or maxilla. The peak incidence is between 25 and 40 years of age, with clinical manifestation representing persistent facial swelling, loose teeth, and gingival bleeding. The majority of maxillofacial lymphomas are DLBCL.[43,46] HL as a primary lesion is infrequently seen in the maxillofacial structures. However, 20% of cases with systemic involvement are associated with bony involvement, which may include the maxillofacial structures secondarily. Bone lesions are typically osteolytic in 70% of cases, sclerotic in 4.3%, and mixed in 16%.[26,61] Periosteal reaction can be seen with a variable soft tissue mass. Burkitt lymphoma will often present with primary disease being localized to the maxillofacial structures. Jaw lesions are seen in up to 50% of patients, most often occurring at the angle of the mandible. Typical radiographic features include loss of lamina dura with an associated osteolytic lesion with concomitant periosteal reaction.[62]

PET scan is now an important part of initial staging of lymphomas. Lymphoma masses are usually associated with increased hypermetabolic uptake. PET scan is used to monitor response as well. Resolution of hypermetabolic uptake on PET scan (negative PET scan even though mass may still be present) midway through chemotherapy is an extremely important prognostic factor and portends good prognosis. In Hodgkin lymphoma, PET scans are obtained after the initial two cycles of chemotherapy for prognostic information.

After the treatment is completed, disease may be followed by surveillance. Maximum recurrences occur within the first year, and most of the remaining recurrences happen within the second year after completion of treatment. Thus, having normal scan results at 1 year and 2 years after treatment is considered an important landmark in the course of treatment of lymphomas.

Treatment

Lymphomas are typically treated with medical management with chemotherapy or radiotherapy or else a combination of these, rather than primary surgical management. In most instances, for early stage I/II disease, treatment involves a reduced schedule of chemotherapy followed by radiation. However, for advanced-stage disease, treatment is chemotherapy. In advanced-stage disease, radiation therapy is added only for bulky disease. Radioimmunotherapy is yet another modality used for relapsed disease. It is a combination of monoclonal antibody labeled with a radioisotope such as yttrium-90 or iodine-131.

Several chemotherapeutic options are available for systemic management of lymphoreticular diseases. This is mostly a combination of targeted therapy (usually a monoclonal antibody) along with conventional cytotoxic chemotherapy. Some important regimens for NHL are:

- R-CHOP: rituximab-cyclophosphamide, hydroxyadriamycin, vincristine, and prednisone
- BR: bendamustine-rituximab
- RICE: rituximab-ifosfamide, carboplatin, etoposide
- R-DHAP: rituximab-dexamethasone, cytarabine, cisplatin
- R-CVP: rituximab-cyclophosphamide, vincristine, prednisone
- R-Hyper-CVAD: rituximab-cyclophosphamide, vincristine, doxorubicin, dexamethasone, methotrexate, cytarabine
- R-CODOX-M/ IVAC: rituximab-cyclophosphamide, doxorubicin, vincristine, methotrexate/ifosfamide, etoposide, cytarabine
- R-EPOCH: rituximab-etoposide, vincristine, infusional doxorubicin, cyclophosphamide, prednisone

Chemotherapy for NHL is very successful and produces excellent local, regional, and systemic control of the disease. The International Prognostic Index (IPI) helps predict prognosis and outcomes. The IPI scoring system incorporates age, clinical factors (ECOG performance status and serum lactate dehydrogenase concentration), and stage of the disease. This is therefore, used as a guide to establish a treatment plan as well. Depending on the IPI score, relapse and cure rates for different disease states are determined.

When patients relapse after first-line treatment, they are treated with salvage high-dose chemotherapy followed by autologous stem-cell transplantation. Certain types of NHL deserve some additional discussion. Indolent B-cell NHL (for example, follicular lymphoma, marginal zone lymphoma, low-grade mantle-cell lymphoma, or splenic marginal zone lymphomas) may be managed with observation for a certain period of time. They are followed along and treatment is undertaken only when progressive disease is identified or if the patient develops considerable constitutional symptoms. Sometimes, this happens years after initial diagnosis. For these asymptomatic, low-grade, indolent NHLs, cure is not possible. Thus, delaying therapy until symptom development or disease progression is no significant detriment to overall survival outcome.[63]

Mantle cell lymphoma can have different courses. Some are very aggressive and need aggressive chemotherapy. Intensive chemotherapy regimens such as hyper-CVAD regimen (fractionated cyclophosphamide, vincristine, doxorubicin, dexamethasone) seem to improve initial response rate and remission.[64] However, this regimen is highly toxic, which can be associated with significant morbidity and mortality. Patients with mantle-cell lymphoma will often undergo autologous stem-cell transplantation during the first remission because of poor outcomes with less intensive treatment regimens. However, there is another subset of patients with mantle-cell lymphoma who have a more indolent course and have outcomes similar to those of patients with follicular lymphomas.

Burkitt lymphoma is a highly aggressive B-cell lymphoma associated with EBV and is traditionally associated with a dismal prognosis, with the majority of patients dying within 1 year of diagnosis. However, the use of intensive chemotherapy regimens has significantly improved patient survival. The use of the R-CODOX-M regimen (cyclophosphamide, vincristine, doxorubicin, high-dose methotrexate), as described by Magrath and colleagues,[65] has shown the potential to cure the majority of adults with Burkitt lymphoma. The use of stem-cell transplantation in the initial management of patients with Burkitt lymphoma has not been shown to increase patient survival. Patients with relapse are rarely salvaged with any treatment approach.

MALT lymphomas are low-grade lymphomas. The majority of MALT lymphomas occur within the gastrointestinal tract and are associated with *H. pylori* infection. Frequently in patients with early-stage disease, eradication of *H. pylori* leads to tumor regression. Patients who do not respond to initial eradication of *H. pylori* or do not have documented *H. pylori* infection with gastric MALT lymphoma may be treated with combined chemo-radiotherapy. Patients with localized MALT lymphoma to the head and neck again are managed primarily with chemo-radiotherapy with localized field radiotherapy, with surgical dissection limited to local regional recurrence.[66,67]

T-cell non-Hodgkin lymphomas are also treated with the same regimens. However, these do not express the target CD20 on the surface. Thus, targeted therapy with rituximab is not used for T-cell NHL. Response to chemotherapy in T-cell NHL is not as robust. Regimens used include:

- CHOP: cyclophosphamide, hydroxyadriamycin, vincristine (Oncovin), prednisone
- Pralatrexate
- Anti-CD30 antibody: brentuximab vedotin

Hodgkin lymphoma is treated with different chemotherapy regimens. The early stage is treated with fewer cycles of chemotherapy in combination with radiation to follow. Advanced-stage disease is treated with chemotherapy alone.

Radiation therapy is employed for early-stage disease and for bulky disease. Commonly used chemotherapy regimens are:

- ABVD: adriamycin, bleomycin, vinblastine, dacarbazine
- BEACOPP: bleomycin, etoposide, doxorubicin, cyclophosphamide, vincristine, procarbazine, prednisone
- Stanford V: mechlorethamine, doxorubicin, vinblastine, vincristine, bleomycin, etoposide, prednisone

Cure rates are high even in advanced-stage disease in younger patients, being more than 85%.[68]

For relapse disease, high-dose chemotherapy followed by autologous stem-cell transplant is a very effective salvage therapy. Anti-CD30 targeted therapy with brentuximab has shown excellent control for relapsing disease. Thus, long-term consequences of therapy need to be kept in mind when choosing treatment for these patients. Radiation therapy typically involves field radiation and is effective for local control. It does increase the risk of second malignancies in these patients. The risk for solid tumors increases from 2% at 10 years to 13% at 19 years. Potential long-term side effects of chemotherapy include myelodysplasia, cardiomyopathy, and pulmonary toxicity.

Post-transplant lymphoproliferative disease is a varied group of diseases. It can respond to reduction of immunosuppression. However, sometimes therapy with targeted agents such as rituximab is added. For aggressive, advanced disease or disease not responding to reduction of immunosuppression, chemotherapy with CHOP or R-CHOP can be used with an excellent success rate.

• BOX 30-2 Ann Arbor Staging System for Lymphoma

Stage I

Involvement of a single lymph node or localized involvement of a single extralymphatic organ or site.

Stage II

Involvement of two or more lymph node regions on the ipsilateral side of the diaphragm.

Localized involvement of the extralymphatic organ or site and one or more lymph node regions on the same side of the diaphragm (IIE).

Stage III

Involvement of lymph node regions on bilateral sides of the diaphragm, which may be accompanied by localized involvement of an associated extralymphatic organ or site.

Stage IV

Diffuse or disseminated involvement of one or more extralymphatic organs or tissues with or without associated lymph node involvement.

Letter Designations

A—Asymptomatic
B—Constitutional symptoms: Fever >38° C, drenching night sweats, >10% weight loss within 6 months
E—Extranodal
X—Bulky disease; tumor diameter is greater than >10 cm

Discussion

Lymphomas are a heterogeneous group of lymphoreticular neoplasms. Patients with lymphomas generally have a better prognosis than patients with squamous cell carcinoma of the head and neck. The 5-year survival rate for HL is 73% and 65% for extranodal NHL head and neck lymphoma. HL accounts for approximately 30% of all malignant lymphomas. The typical presenting feature of lymphoma for both HL and NHL is the development of a mass within the head and neck or pain. There are several classification systems for lymphomatous disease, including the WHO and REAL classification systems. The Ann Arbor staging classification system is widely used in North America and is based on the anatomic extent of tumor involvement (Box 30-2). Patients presenting with stage I or stage II disease have a more favorable prognosis compared with patients presenting with advanced stage III or stage IV disease. The natural history and prognosis of HL are based on the histologic type, stage, and the presence or absence of systemic symptoms. The 5-year survival for all tumor types managed with chemo-radiotherapy is greater than 80%.

NHL is a neoplastic proliferation of lymphoid cells that is often disseminated and can be prognostically differentiated into several immunophenotypes as well as into low-, intermediate-, and high-grade lesions. Disease that is low- or intermediate-grade has a more favorable prognosis and, when localized, may well respond to localized field radiotherapy alone. Localized stage I and stage II low-grade NHLs are primarily treated with radiotherapy. Surgery is primarily used as a diagnostic modality. In deeply invasive disease or with documented evidence of systemic involvement, the addition of chemotherapy has improved patient survival.

The overall prognosis of patients with lymphoma is associated with histologic type and stage of disease at presentation. The IPI scoring system is rather helpful in predicting prognosis. Low-grade lesions have a 5-year survival of over 80% compared with 52% for those with high-grade histologic types. Stage is also an important prognostic feature, with 83% of patients with stage I disease surviving more than 5 years compared with only 49% of patients with stage II and higher.[15,65] Although post-treatment remission often occurs in treatment of low-grade lymphomas, the disease can often have an indolent course with a significant risk of transformation to a more aggressive lesion.

Oropharyngeal and oral cavity lymphomas are the second most common malignant disease in the oral cavity. It is critical for health care providers, and in particular maxillofacial surgeons, to be able to identify a well-defined algorithm for the management of neck masses and to recognize and initiate appropriate early management of lymphoreticular disease in order to improve overall survival.

References

1. Cunningham MJ, Myers EN, Bluestone CD: Malignant tumors of the head and neck in children: a twenty-year review, *Int J Pediatr Otorhinolaryngol* 13(3):279–292, 1987.
2. Kaplinsky C, Zaizov R: Childhood B-cell non-Hodgkin's lymphoma in Israel, *Leuk Lymphoma* 14(1-2):49–53, 1994.
3. Harris NL, et al.: A revised European-American classification of lymphoid neoplasms: a proposal from the International Lymphoma Study Group, *Blood* 84(5):1361–1392, 1994.
4. Kennedy BJ, Fremgen AM, Menck HR: The National Cancer Data Base report on Hodgkin's disease for 1985-1989 and 1990-1994, *Cancer* 83(5):1041–1047, 1998.
5. Yamada T, et al.: Enlargement of mandibular canal without hypesthesia caused by extranodal non-Hodgkin's lymphoma: a case report, *Oral Surg Oral Med Oral Pathol Oral Radiol Endod* 89(3):388–392, 2000.
6. Boring CC, Squires TS, Tong T: Cancer statistics, 1993, *CA Cancer J Clin* 43(1):7–26, 1993.
7. Rowley H, et al.: Lymphoma presenting to a head and neck clinic, *Clin Otolaryngol Allied Sci* 20(2):139–144, 1995.
8. Saul SH, Kapadia SB: Primary lymphoma of Waldeyer's ring. Clinicopathologic study of 68 cases, *Cancer* 56(1):157–166, 1985.
9. Urquhart A, Hutchins LG, Berg RL: Preoperative computed tomography scans for parotid tumor evaluation, *Laryngoscope* 111(11 Pt 1):1984–1988, 2001.
10. Carbone PP, et al.: Report of the Committee on Hodgkin's Disease Staging Classification, *Cancer Res* 31(11):1860–1861, 1971.
11. Devesa SS, et al.: Cancer incidence and mortality trends among whites in the United States, 1947-84, *J Natl Cancer Inst* 79(4):701–770, 1987.
12. Jaffe ES, et al.: World Health Organization classification of neoplastic diseases of the hematopoietic and lymphoid tissues. A progress report, *Am J Clin Pathol* 111(1 Suppl 1):S8–S12, 1999.
13. Weber AL, Rahemtullah JA, Ferry A: Hodgkin and non-Hodgkin lymphoma of the head and neck: clinical, pathologic, and imaging evaluation, *Neuroimaging Clin N Am* 13(3):371–392, 2003.
14. Aisenberg AC: Coherent view of non-Hodgkin's lymphoma, *J Clin Oncol* 13(10):2656–2675, 1995.
15. Armitage JO, et al.: Lymphoma 2006: classification and treatment, *Oncology (Williston Park)* 20(3):231–239, 2006. discussion 242, 244, 249.
16. Hanna E, et al.: Extranodal lymphomas of the head and neck. A 20-year experience, *Arch Otolaryngol Head Neck Surg* 123(12):1318–1323, 1997.
17. Epstein JB, et al.: Characteristics of oral and paraoral malignant lymphoma: a population-based review of 361 cases, *Oral Surg Oral Med Oral Pathol Oral Radiol Endod* 92(5):519–525, 2001.
18. Conley SF, et al.: Non-Hodgkin's lymphoma of the head and neck: the University of Iowa experience, *Laryngoscope* 97(3 Pt 1): 291–300, 1987.
19. DePena CA, Van Tassel P, Lee YY: Lymphoma of the head and neck, *Radiol Clin North Am* 28(4):723–743, 1990.
20. Ruijs CD, et al.: Treatment of localized non-Hodgkin's lymphomas of the head and neck, *Cancer* 74(2):703–707, 1994.
21. Ansell SM, Grant CS, Habermann TM: Primary thyroid lymphoma, *Semin Oncol* 26(3):316–323, 1999.
22. Cheng CJ, et al.: Primary malignant lymphoma of mucosa-associated lymphoid tissue of larynx, *Otolaryngol Head Neck Surg* 121(5):661–662, 1999.
23. Coltrera MD: Primary T-cell lymphoma of the thyroid, *Head Neck* 21(2):160–163, 1999.
24. Zinzani PL, et al.: Nongastrointestinal low-grade mucosa-associated lymphoid tissue lymphoma: analysis of 75 patients, *J Clin Oncol* 17(4):1254, 1999.
25. Derringer GA, et al.: Malignant lymphoma of the thyroid gland: a clinicopathologic study of 108 cases, *Am J Surg Pathol* 24(5):623–639, 2000.
26. Maxymiw WG, Goldstein M, Wood RE: Extranodal non-Hodgkin's lymphoma of the maxillofacial region: analysis of 88 consecutive cases, *SADJ* 56(11):524–527, 2001.
27. Moghe GM, et al.: Hodgkin's disease involving Waldeyer's ring: a study of four cases, *Leuk Lymphoma* 41(1-2):151–156, 2001.
28. Jaffe ES: *World Health Organization: Pathology and genetics of tumours of haematopoietic and lymphoid tissues. World Health Organization classification of tumours*, Oxford, 2001, IARC Press.
29. Wolvius EB, et al.: Primary non-Hodgkin's lymphoma of the salivary glands. An analysis of 22 cases, *J Oral Pathol Med* 25(4):177–181, 1996.
30. Freeman C, Berg JW, Cutler SJ: Occurrence and prognosis of extranodal lymphomas, *Cancer* 29(1):252–260, 1972.
31. Shindoh M, et al.: Comparison between submucosal (extranodal) and nodal non-Hodgkin's lymphoma (NHL) in the oral and maxillofacial region, *J Oral Pathol Med* 26(6):283–289, 1997.
32. Shrivastava SK, et al.: Head and neck extranodal non-Hodgkin's lymphomas in Indian patients, *Radiother Oncol* 12(2):113–120, 1988.
33. Wulfrank D, et al.: Extranodal non-Hodgkin's lymphoma of the head and neck, *Radiother Oncol* 8(3):199–207, 1987.
34. Baldini L, et al.: Treatment and prognosis in a series of primary extranodal lymphomas of the ocular adnexa, *Ann Oncol* 9(7):779–781, 1998.
35. Cobleigh MA, Kennedy JL: Non-Hodgkin's lymphomas of the upper aerodigestive tract and salivary glands, *Otolaryngol Clin North Am* 19(4):685–710, 1986.
36. Fukuda Y, et al.: Malignant lymphoma of the oral cavity: clinicopathologic analysis of 20 cases, *J Oral Pathol* 16(1):8–12, 1987.
37. Pecorari P, Melato M: Non-Hodgkin's lymphoma (NHL) of the oral cavity, *Anticancer Res* 18(2B):1299–1302, 1998.
38. Takahashi H, et al.: Primary malignant lymphoma of the salivary gland: a tumor of mucosa-associated lymphoid tissue, *J Oral Pathol Med* 21(7):318–325, 1992.
39. Green TM, et al.: Immunohistochemical double-hit score is a strong predictor of outcome in patients with diffuse large B-cell lymphoma treated with rituximab plus cyclophosphamide, doxorubicin, vincristine, and prednisone, *J Clin Oncol* 30(28):3460–3467, 2012.
40. Barrans S, et al.: Rearrangement of MYC is associated with poor prognosis in patients with diffuse large B-cell lymphoma treated in the era of rituximab, *J Clin Oncol* 28(20):3360–3365, 2010.
41. Johnson NA, et al.: Concurrent expression of MYC and BCL2 in diffuse large B-cell lymphoma treated with rituximab plus cyclophosphamide, doxorubicin, vincristine, and prednisone, *J Clin Oncol* 30(28):3452–3459, 2012.
42. Kawasaki C, et al.: Rearrangements of bcl-1, bcl-2, bcl-6, and c-myc in diffuse large B-cell lymphomas, *Leuk Lymphoma* 42(5):1099–1106, 2001.
43. Bragg DG: Radiology of the lymphomas, *Curr Probl Diagn Radiol* 16(4):177–206, 1987.
44. Braunstein EM: Hodgkin disease of bone: radiographic correlation with the histological classification, *Radiology* 137(3):643–646, 1980.
45. Eustace S, et al.: Skeletal muscle lymphoma: observations at MR imaging, *Skeletal Radiol* 25(5):425–430, 1996.

46. Ohnishi T, et al.: MR imaging in patients with primary thyroid lymphoma, *AJNR Am J NeuroRadiol* 13(4):1196–1198, 1992.
47. Takayama F, et al.: MR imaging of primary malignant lymphoma in the larynx, *Eur Radiol* 11(6):1079–1082, 2001.
48. Barton JH, et al.: Non-Hodgkin's lymphoma of the tonsil. A clinicopathologic study of 65 cases, *Cancer* 53(1):86–95, 1984.
49. Tewfik TL, et al.: Burkitt's lymphoma of the tonsil in children, *J Otolaryngol* 25(3):205–208, 1996.
50. Levine AM: Acquired immunodeficiency syndrome-related lymphoma, *Blood* 80(1):8–20, 1992.
51. Epstein JB, Scully C: Neoplastic disease in the head and neck of patients with AIDS, *Int J Oral Maxillofac Surg* 21(4):219–226, 1992.
52. Delecluse HJ, et al.: Plasmablastic lymphomas of the oral cavity: a new entity associated with the human immunodeficiency virus infection, *Blood* 89(4):1413–1420, 1997.
53. Sarda AK, et al.: Isolated involvement of the mandible by non-Hodgkin's lymphoma, *J Postgrad Med* 41(3):90–92, 1995.
54. Harbo G, et al.: Cancer of the nasal cavity and paranasal sinuses. A clinico-pathological study of 277 patients, *Acta Oncol* 36(1):45–50, 1997.
55. Weiss LM, Arber DA, Strickler JG: Nasal T-cell lymphoma, *Ann Oncol* 5(Suppl 1):39–42, 1994.
56. Eavey RD, Goodman ML: Hodgkin's disease of the nasopharynx, *Am J Otolaryngol* 3(6):417–421, 1982.
57. Cuadra-Garcia I, et al.: Sinonasal lymphoma: a clinicopathologic analysis of 58 cases from the Massachusetts General Hospital, *Am J Surg Pathol* 23(11):1356–1369, 1999.
58. Gleeson MJ, Bennett MH, Cawson RA: Lymphomas of salivary glands, *Cancer* 58(3):699–704, 1986.
59. Gorsky M, Epstein JB: Head and neck and intra-oral soft tissue sarcomas, *Oral Oncol* 34(4):292–296, 1998.
60. Mehle ME, et al.: Lymphoma of the parotid gland, *Laryngoscope* 103(1 Pt 1):17–21, 1993.
61. Ngan H, Preston BJ: Non-Hodgkin's lymphoma presenting with osseous lesions, *Clin Radiol* 26(3):351–356, 1975.
62. McGurk M, Goepel JR, Hancock BW: Extranodal lymphoma of the head and neck: a review of 49 consecutive cases, *Clin Radiol* 36(5):455–458, 1985.
63. Portlock CS, Rosenberg SA: No initial therapy for stage III and IV non-Hodgkin's lymphomas of favorable histologic types, *Ann Intern Med* 90(1):10–13, 1979.
64. Romaguera JE, et al.: High rate of durable remissions after treatment of newly diagnosed aggressive mantle-cell lymphoma with rituximab plus hyper-CVAD alternating with rituximab plus high-dose methotrexate and cytarabine, *J Clin Oncol* 23(28):7013–7023, 2005.
65. Magrath I, et al.: Adults and children with small non-cleaved-cell lymphoma have a similar excellent outcome when treated with the same chemotherapy regimen, *J Clin Oncol* 14(3):925–934, 1996.
66. Wotherspoon AC, et al.: Regression of primary low-grade B-cell gastric lymphoma of mucosa-associated lymphoid tissue type after eradication of Helicobacter pylori, *Lancet* 342(8871):575–577, 1993.
67. Thiede C, et al.: Long-term persistence of monoclonal B cells after cure of Helicobacter pylori infection and complete histologic remission in gastric mucosa-associated lymphoid tissue B-cell lymphoma, *J Clin Oncol* 19(6):1600–1609, 2001.
68. Moccia AA, et al.: International Prognostic Score in advanced-stage Hodgkin's lymphoma: altered utility in the modern era, *J Clin Oncol* 30(27):3383–3388, 2012.

31

Non-melanoma Skin Cancer of the Head and Neck

FAYETTE C. WILLIAMS, JON D. HOLMES

Introduction

Non-melanoma skin cancer (NMSC) is the most common malignancy in the United States, with more than 2 million patients treated each year.[1] More than $426 million is spent yearly on skin cancer treatment, with the majority of care provided in an office setting.[2] When defined as impaired ability to work and lost future earning potential due to premature death, an estimated $10.2 billion in yearly lost productivity has been calculated to result from skin cancers, excluding melanoma.[3] Available research on cost reveals a broad range of expenditures depending on the care setting and the treatment modality. Office settings offer the lowest average cost per episode of care ($492),[4] whereas inpatient treatment can result in more than a 10-fold increase in cost.[5] Although the true economic impact of NMSC treatment is likely underestimated, Medicare data show NMSC to be one of the five most costly cancers to treat. Further analysis suggests this high cost is due to the high frequency of diagnosis rather than the actual cost of each cancer treatment.[6] Given its increasing incidence, NMSC expenditures will only increase, and along with prevention, effective and efficient management is paramount. Although this chapter focuses on the diagnosis and treatment of the most common non-melanoma cutaneous malignancies—basal cell carcinoma (BCC) and squamous cell carcinoma (SCC)—other select skin cancers are included for completeness. In general, oncologic principles for the management of these cancers can be applied to other malignancies affecting the skin.

Epidemiology and Etiology

The increasing incidence of NMSC is multifactorial and may be attributed to increased photodamage from sun exposure, ozone depletion, increased longevity, and improved detection.[7] White populations show increased risk, especially with lighter skin type, blue eyes, freckles, and red/blonde hair. NMSC is uncommon in Black, Asian, and Hispanic populations. Blacks do not appear to be as affected by increased sun exposure, as their skin cancers tend to be in areas not exposed to sunlight. Indoor tanning among adolescents is common in the Unites States (21% of high school females engaged in indoor tanning in 2011) and increases the risk of basal cell carcinoma by 40% and squamous cell carcinoma by 102%.[8]

The role of ionizing radiation is further highlighted by the significant geographic variability in the incidence of NMSC. Certain areas of Australia show NMSC development in over 2% of the population, which is a 10-fold increase over European and United States cohorts of similar ancestry. Younger people are affected more frequently in Australia and the southwestern United States. Proximity to the equator influences rates of NMSC for White populations, with the incidence of squamous cell carcinoma doubling for every 10 degrees in latitude closer to the equator.[9]

In addition to ionizing radiation, several other risk factors deserve mention. Secondary NMSC can result from previous radiation treatment. The Childhood Cancer Survivor Study found a 6.3-fold increase in risk of developing NMSC within the radiation field, with 42% of these cases occurring in the head and neck. The median age at diagnosis of their first NMSC was 31, and almost half of patients had multiple recurrences.[10] Long-term immunosuppression increases the risk of skin cancer. A 2015 review noted kidney transplant recipients have a 65- to 250-fold greater risk than the general population of developing NMSC.[11,12] Similar increases in risk have been noted for heart, lung, liver, and pancreas transplant patients.[12-15] Skin cancer risk associated with transplantation is increased for sun-exposed skin even for patients living in regions of relatively low sun exposure, with lip cancer among the most common.[12] Interestingly, immunosuppression caused by HIV carries a 2-fold higher risk for skin SCC, but not BCCn.[16]

One of the most important risk factors for the development of a skin cancer is a history of prior skin cancer. The

5-year cumulative risk for development of a NMSC in a patient with a prior NMSC is 40%. Risk further increases over time as additional skin cancers are diagnosed in the same person. For a patient with a prior NMSC who develops a second skin cancer, there is an 82% risk that yet another NMSC will develop over the next 5 years.[17] In patients with a history of BCC, the risk for developing an SCC is 6%. Regardless of primary treatment modality, patients with skin cancer require structured follow-up, given their high risk for development of second primaries.

Pathology and Epidemiology

Epithelial Cancers

Basal Cell Carcinoma

The most common NMSC is basal cell carcinoma (BCC), which makes up approximately 80% of NMSCs.[18] Basal cell carcinomas arise from the basal cells of the epidermis and skin appendages. Although rarely associated with metastasis, they are capable of extensive local tissue destruction and, uncommonly, may invade deeper structures, including cartilage, bone, and muscle. Basal cell cancers are most commonly located in the head and neck, with the skin of the periorbital, perioral, and auricular areas being especially at risk (Figure 31-1). Rarely, large, neglected lesions can be fatal through local invasion of vital structures or distant metastasis.

Basal cell carcinomas are the most common skin cancer found in Whites, Asians, and Hispanics. In Black populations, BCC is the second most common skin cancer after SCC.[19] Although exposure to ultraviolet radiation is the major cause of BCC, other risk factors for BCC include age, skin type, radiation exposure, immunosuppression, and exposure to certain chemicals. Men have a 2-fold higher incidence than females, which may be related to their increased involvement in outdoor occupations and leisure activities and consequent increased exposure to solar radiation.[18] In addition to the association of basal cell carcinoma with basal cell nevus syndrome (Gorlin syndrome), other syndromes, including albinism and xeroderma pigmentosum, are also associated with BCC.[20,21] Although once considered infrequent before the age of 40, basal cell cancers are appearing in younger patients, likely secondary to increased sun exposure and tanning.[8]

Presentation

Basal cell carcinomas can be subdivided into four types, listed here in decreasing order of incidence: nodular (or nodulo-ulcerative), sclerosing (or morphea), basosquamous, and multicentric (superficial) type. Friedrich and colleagues reviewed 216 patients with BCCs that primarily affected the middle third of the face. Of the 216 patients, 124 were treated with surgery. Friedrich found that 83% of the BCCs were solid (or nodular), 10% were sclerosing, 4% were metatypical (basosquamous), and 3% were multicentric.[22] The nodular type usually appears as a firm, translucent (pearly) papule with telangiectatic blood vessels. Pigmentation can be present and can lead to a concern for melanoma, which should be taken into consideration when planning a biopsy (see biopsy techniques in Figure 31-5). Late stages are accompanied by crusting and a central ulcerated depression as the central portion becomes necrotic from lack of blood supply. This results in the classic "rodent ulcer" recognized by most clinicians as a BCC. Histologically, the lesions contain nests and strands extending perpendicular to the basement membrane. Squamous differentiation can occur within the lesion, leading to the basosquamous variety (Figure 31-2), which behaves in a more aggressive fashion that is more analogous to a squamous cell cancer with an increased incidence of recurrence and metastases.[23] The sclerosing variant may appear as a scar or fibrotic skin and lack elevation. It is made up of nests and cords of tumor cells within a dense fibrosis. Its borders are often indistinct, and microscopic extension into the surrounding dermis can lead to positive margins and an increased chance of recurrence following excision. As these lesions enlarge, the sclerosing type can develop central depressions, giving them the appearance of a scar. Finally, the superficial or multicentric form typically presents as a red, scaling



• **Figure 31-1** Basal cell carcinoma of the upper lip.



• **Figure 31-2** Basosquamous cell carcinoma of the ear.

lesion, and although it occurs on the skin of the head and neck, it is more common on the trunk and extremities. As these lesions enlarge, they can assume the appearance of a nonspecific dermatitis.[18]

Metastatic basal cell carcinoma is extremely uncommon, with fewer than 400 cases reported, and an estimated incidence of 0.0028% to 0.55% of cases. Metastasis can occur by both lymphatic and hematogenous spread. Metastasis to lymphatic basins seems to be associated with longer survival than hematologic spread to distant organs, which include bone, liver, and lung.[24] Given its rarity, management of metastatic BCC is not standardized. The most promising research currently focuses on inhibition of the Hedgehog signaling pathway. Vismodegib was approved in 2012 by the FDA as the first Hedgehog signaling pathway inhibitor to treat metastatic or recurrent locally advanced basal cell carcinoma in adults who cannot be treated with surgery or radiation.[25]

Squamous Cell Carcinoma

Squamous cell carcinoma (SCC) is the second most common cutaneous malignancy and accounts for approximately 20% of skin cancers. Approximately 200,000 to 300,000 cases are diagnosed yearly, and 2000 people die each year from this disease.[26] SCC arises from the common precursor cell, the keratinocyte. Compared to most BCCs, SCCs are typically more aggressive and are more commonly associated with metastases and locoregional recurrence following treatment. Like BCC, cutaneous squamous cell cancer is strongly associated with exposure to UV radiation, and there is a direct correlation between cumulative solar exposure and risk for development of cutaneous SCC. A history of childhood sunburn and long-term exposure to solar radiation is common.[9]

Similarly, chronic immunosuppression in solid organ transplant patients is also associated with an increased incidence of squamous cell cancers. These cancers typically arise in sun-exposed areas, suggesting that UV radiation and immunosuppression combine to increase overall risk.[12] Additional etiologic factors include human papillomavirus (HPV-5, -16, and -18), exposure to certain chemicals (organic hydrocarbons and arsenic-containing compounds), and long-standing inflammatory conditions, such as fistulas and ulcers (e.g., Marjolin ulcer).[26]

Presentation

Squamous cell cancers are the most common skin cancer in Blacks and Asian Indians and the second most common cutaneous malignancy in Caucasians.[27] SCC is predominantly a cancer of the older patient (average age at diagnosis 70), and males predominate, again likely related to increased outdoor activities. The vast majority occur in the head and neck, with the skin of the upper face being especially susceptible. Squamous cell cancers typically arise in an area of actinic keratosis (AK) that appears as hyperkeratotic plaques. Approximately 10% of actinic keratoses will ultimately transform to squamous cell cancer.[28] Ulceration, possibly accompanied by bleeding, may develop with thickening of the plaque.

There are several varieties of squamous cell cancer worth noting. The vast majority are typical SCCs, which can be subdivided into well, moderate, and poorly differentiated based on the amount of keratin production (keratin pearls), and on how closely the tumor mimics normal skin histologically. A well-differentiated SCC typically contains an abundance of keratin pearl formation surrounded by well-formed keratinocytes lacking nuclei. Conversely, poorly differentiated tumors lack keratin formation, and the nucleated keratinocytes are haphazardly arranged and have a high mitotic index. Histologic evaluation may also take note of a dense inflammatory infiltrate, which is often associated with improved local control rates.

Keratoacanthoma (KA) is a controversial lesion that some consider a very well-differentiated squamous cell cancer. Keratoacanthomas are common lesions that, like BCC and SCC, usually occur on sun-exposed areas. They typically present as red, raised lesions with hyperkeratotic centers and are often difficult to distinguish from an SCC clinically. Characteristic rapid growth is usually followed by spontaneous involution in the majority of cases. Pronounced scarring can occur in some cases. Although a clinical history of rapid growth coupled with the clinical appearance can provide clues to the diagnosis, these lesions should be excised and examined histologically for confirmation of diagnosis and margin assessment. Rarely, keratoacanthomas can be associated with more aggressive behavior, including recurrence and metastasis, although the latter is controversial. Most clinicians recommend that KAs be treated as well-differentiated SCCs with surgical excision and margin analysis.[29-31]

Carcinomas of Skin Appendages

Microcystic Adnexal Carcinoma

Microcystic adnexal carcinoma arises from the sweat ducts and most commonly affects the skin of the head and neck, with more than half of cases occurring on the upper or lower lip. It usually presents in middle-aged and elderly Caucasians, and there does not seem to be a male or female predilection. Lack of symptoms and slow growth often result in late diagnosis. Perineural invasion, however, is common (as high as 80%), and patients who are symptomatic often present with complaints of numbness or pain.[32] As many as 60% of patients will experience metastatic spread. Deep infiltration with extension well beyond the clinical margin can be present and lead to a high recurrence rate (up to 70%) following traditional surgical excision.[33] For this reason, consideration should be given to Mohs micrographic excision (see discussion later) if available. Frozen section analysis during traditional surgical excision can also be of assistance. Radiation therapy plays little role in primary management, as these tumors are considered somewhat radiation resistant. It is usually reserved for palliation.[32] Benign tumors from adnexal structures can occur but can be clinically indistinguishable from malignant tumors (Figure 31-3).



• **Figure 31-3** Syringocystadenoma of the scalp.

Sebaceous Gland Carcinoma

Sebaceous gland carcinoma (SGC) is the most common eyelid malignancy in Asians and is most commonly associated with the meibomian glands of the upper eyelid.[34] Lower lid involvement and origin from the glands of Zeis is less common. Although extraocular SGC can occur in the head and neck, cases are rare. Its clinical presentation can lead it to be mistaken for a chalazion or other benign inflammatory condition affecting the eyelid.

Surgical excision is the treatment of choice, but recurrences are common. Deep orbital involvement makes complete excision difficult, and orbital exenteration should be considered. Mohs micrographic excision has been used with some success. Regional and distant metastases are not unusual and are usually associated with large size and recurrent tumors.[35] Although radiation treatment is typically reserved for a palliative role in most cases, some authors have suggested its use as an adjunct to surgical excision in an attempt to decrease local recurrence.[36]

Nonepithelial Cancers

Merkel Cell Carcinoma

First described by Toker in 1972, Merkel cell carcinoma (cutaneous neuroendocrine carcinoma) is a rare neuroendocrine malignancy known for its rapid growth, high recurrence rate, and propensity to metastasize to regional lymph nodes.[37,38] Merkel cell carcinomas are usually associated with male and female Caucasians of advanced age, and 50% are located in the head and neck.[39] Although suspected, sun exposure has not been established as a definite etiologic factor in their development. Clinically, Merkel cell carcinoma typically presents as an indiscreet red or violaceous papule or plaque that grows rapidly. Originally thought to be of indolent behavior, it is now recognized that Merkel cell cancers are aggressive tumors with a high incidence of local recurrence, as well as metastases. Regional and distant metastasis rates as high as 75% have been reported.[29]

The rarity of Merkel cell cancer (MCC) precludes large trials to develop and compare treatment regimens, and therefore, treatment recommendations based on clinical experience are the norm. Most authors recommend aggressive treatment, including elective management of the at-risk lymph node basins. More recently, interest in sentinel lymph node biopsy has developed, and authors have reported on its utility in the management of MCC.[30,31,39] The behavior of MCC is often compared to that of melanoma, and some authors advocate wide excision margins (2 to 3 cm) to include the subcutaneous tissue and underlying fascia.[31] Others have suggested Mohs micrographic excision (see discussion later) as an acceptable alternative to wide excisions with arbitrary margins. Despite the aforementioned recommendations of most clinicians, there remains considerable controversy regarding the need for elective dissection of the nodal basins at risk. Recommendations vary, but some authors have suggested node dissection in cases of size greater than 1.5 cm or clinically apparent nodes. Multimodality therapy combining surgery and irradiation is indicated in most cases of this potentially lethal cutaneous cancer. MCC is radiosensitive, and in most cases, adjunctive radiation therapy should be considered to the primary site, as well as to the at-risk nodal basins to improve local and regional control.[40,41] Interestingly, Merkel cell carcinoma is one of the few cutaneous malignancies in which chemotherapy can play a significant role. MCC is chemosensitive, and chemotherapy has been used with some success in palliating patients deemed non-operative. Although chemotherapy has been shown to lead to significant remission rates (up to 70%), an improved overall survival rate has not been demonstrated.[31]

Dermatofibrosarcoma Protuberans

Dermatofibrosarcoma protuberans (DFP) is a malignant tumor known for its indolent growth but propensity to recur following excision. It is rare, accounting for less than 0.1% of all malignancies. It primarily affects middle-aged patients (age 20 to 50 years), but it may present at any age and has a slight male predominance. Some authors report an increased incidence in African Americans.[42]

The majority of DFP occurs on the trunk, with only 10% to 15% occurring on the head and neck.[43] They usually present as a skin-toned or brown plaque that produces multiple protuberant nodules, although a solitary nodule can occur. DFP has an indolent growth phase initially, which is then followed by a more rapid growth in which the multiple nodules are usually noticed by the patient and medical care is sought. Invasion into the subcutaneous tissue is common, and long-standing lesions can invade fascia, muscle, and even bone.[42] Diagnosis is made following a biopsy, which is best obtained from a nodular area and extending into the subcutaneous tissue. Treatment of DFP is adequate surgical excision and annual follow-up. The hallmark of DFP is its propensity to recur following surgical excision. The tumor produces multiple, irregular extensions into the surrounding tissue, leading to extension well beyond the clinical margin. Early recommendations for conservative margins led to a disappointingly high recurrence rate. Currently, recommendations include peripheral margins of 3 to 4 cm that include the deep fascia,

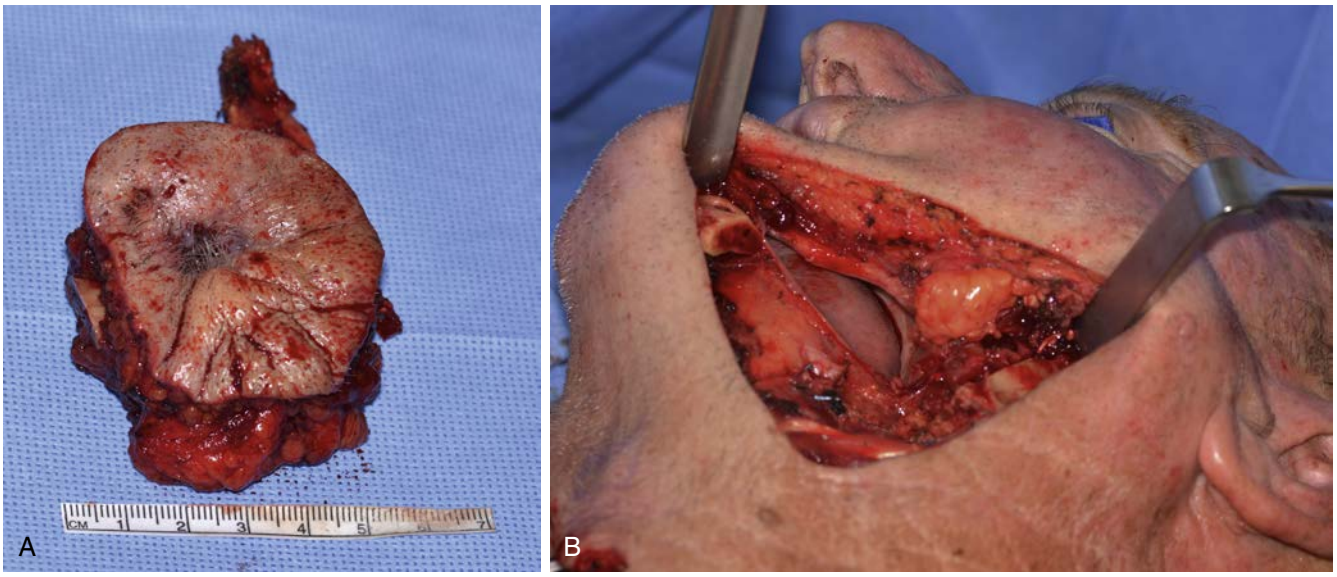

• **Figure 31-4** **A,** Specimen of basal cell carcinoma of the cheek invading into the mandible resulting in a pathologic fracture. **B,** A segmental mandibulectomy was performed, which created a defect communicating with the oral cavity.

which results in recurrence rates from 20% to 60%.[35,43] Unfortunately, these margins are often difficult in the head and neck. Alternatively, Mohs micrographic excision (see discussion later) has been suggested to offer a more complete evaluation of the surgical margin and preserve uninvolved tissue. Mohs' technique has been recommended for primary excision in critical areas and in cases of recurrent tumor.[35,42] Recurrences, which usually occur in the first 3 years, are more common in lesions excised from the head and neck compared to other sites.[42] Death can occur and is usually the result of uncontrolled growth following multiple attempts at excision followed by direct extension into critical anatomic structures. Radiation therapy has been used in some cases as an adjunct to surgical excision and also in cases that are not amenable to surgical excision. The role of chemotherapy is only in cases of distant metastatic disease.[44]

Aggressive Skin Cancer of the Head and Neck

The vast majority of skin cancers affecting the skin of the head and neck are basal and squamous cell cancers, and most patients present with localized disease in which appropriate surgical excision will effect a cure. There is a significant subset of patients, however, who will present with a skin cancer that displays aggressive behavior and fails to respond to standard therapy, with multiple recurrences leading to substantial morbidity and, rarely, death. The challenge to the surgeon is to predict which tumors warrant more workup, such as imaging with computed tomography (CT) or magnetic resonance imaging (MRI) (see discussion later), or more aggressive therapy, such as lymph node sampling or consideration of adjunctive radiation therapy. Ideally, the ability to predict which cancers will behave more aggressively would spare the vast majority of patients additional unwarranted costs and the morbidity associated with a more aggressive approach. Although far from exact, there are several predictors of biologic aggressiveness that can be used to judge behavior in some cases of basal and squamous cell cancers, including location, diameter, depth, differentiation, perineural invasion, and patient characteristics.

Topographically, certain locations are associated with a more aggressive clinical course. This is described as the so-called "H-zone," which includes the eyelids, canthi, nose, nasolabial folds, upper lip, periauricular skin (including the preauricular skin of the cheek), and frontozygomatic region of the forehead.[45] For reasons incompletely understood, tumors arising in these locations tend to have a more vertical, as opposed to horizontal, growth pattern and therefore tend to invade more deeply. Additional factors suggested as contributing to the more aggressive behavior seen with tumors arising in these areas include embryonic fusion planes, density of nerve endings, and proximity to muscles of facial expression, cartilage, and bone. Cancers arising near the medial canthus can invade the orbit with involvement of the lacrimal apparatus and periorbital fat, making eradication without orbital exenteration difficult. Periauricular cancers can spread deeply along the cartilage of the helix, making a clear, deep margin difficult without temporal bone excision.[46]

The surface dimension of skin cancers has a well-accepted influence on prognosis, and for that reason it is included in the staging of these cancers. Both BCCs and SCCs larger than 2 cm have a much higher potential for recurrence following excision.[47,48] Depth of invasion may be equally or even more important than surface dimension in predicting behavior, with deeper invasion (greater than 4 mm) associated with an increased risk of local recurrence, as well as regional and distant metastases.[47-49] Neglected skin cancers can eventually invade facial bones (Figure 31-4).

Tumor histology has a direct bearing on behavior. Poorly differentiated SCCs and sclerosing BCCs have a distinctly more aggressive behavior. Other histologic variables appear to correlate with more aggressive behavior, with the most important being perineural invasion (PNI) or neurotropism, which is defined as invasion in, around, and through peripheral nerves. The loose connective tissue of the perineural space offers a well-known conduit for the conduction of cancerous cells. Although early investigators believed tumor cells traveled within lymphatics surrounding the nerve, currently it is known that tumor cells simply follow a path of least resistance in the natural cleavage plane that exists beneath the perineurium and endoneurium. Perineural invasion can either be noted clinically with a nerve deficit or be noted on biopsy or specimen examination.[50] SCCs more commonly demonstrate perineural invasion compared to BCCs, but involvement by either is an ominous finding. Sensory nerves are more commonly affected compared to motor, and most often the second and third divisions of the trigeminal nerve are affected in cutaneous malignancies affecting the face. Most patients with perineural invasion are asymptomatic, but patients may present with pain, burning sensation, anesthesia, or facial paralysis.[51] Clinically evident perineural invasion is associated with decreased 5-year local control rates compared to microscopic perineural invasion.[52] Cranial nerve deficits rarely improve following therapy. Histologic perineural invasion is associated with a 45% incidence of local recurrence, a 10% to 35% incidence of regional metastasis, and a 65% 5-year survival.[50,53] At 2 years, 46% of patients with PNI were dead of disease or alive with recurrence, in contrast to 9.1% of patients without PNI who were dead of disease or alive with recurrence.[54]

Perineural invasion is also associated with an increased risk of nodal metastases. The concept of "skip lesions" along the nerve is controversial and may be due to difficulty with histologic interpretation or a processing error. In examining nerve margins for tumor clearance, however, it is suggested that clearance of signs of perineural inflammation be used as an end-point rather than clearance of tumor cells. Patients with perineural invasion, especially those with clinically evident deficits, should be considered for more aggressive therapy, including sampling of at-risk nodal basins and consideration of adjunct radiation therapy if a major (named) nerve is involved.[49,50]

Certain patient characteristics may also serve as a guide to the potential for more aggressive tumor behavior. The effect of immunocompromise on the incidence and outcomes of cutaneous malignancy is well recognized. Transplant recipients are regarded as high risk for the development of NMSC, and their outcome following standard treatment is worse. Southwell and colleagues, along with others, have demonstrated a significantly higher incidence of recurrence and decreased survival in patients with immunocompromise.[55]

Most importantly, a recurrence following standard therapy is an indication of biologic aggressiveness and portends a worse outcome. Recurrent tumors are indicated for more aggressive therapy, and recurrence is often an indication for Mohs micrographic excision (see discussion later), which results in a significantly lower recurrence in these patients compared to traditional surgical excision or radiation.[56,57] It is hoped that the future will bring improved genetic markers for biologic aggressiveness to aid in therapy selection and prognosis.

Screening and Clinical Exam

Most skin cancers are not symptomatic. Given the relative low mortality associated with NMSC involving the head and neck, the primary benefit from early detection is the potential for less morbidity and disfigurement with excision. Although screening for malignancies has come under increasing scrutiny,[58] the American Cancer Society still recommends a cancer-related checkup every 3 years for asymptomatic men and women 20 to 39 years of age, and yearly for men and women age 40 and older. This includes examination of the skin. Clinical history, including environmental exposures that place patients at increased risk, may warrant more frequent checkups.[59] Although screening for skin cancers would seem relatively easy, considering the ability to visualize the area of concern, studies have failed to demonstrate the effectiveness of routine screening. In a review of the literature, Helfand and associates[60] found that although skin examination was accurate (sensitivity of 94% and specificity of 98% in one of the largest prospective studies evaluated), there was little support for formal, routine screening. They did find some support for screening of high-risk populations and suggested that strategies be developed to identify and screen those at highest risk. Because their review was not limited to NMSC of the head and neck, it would be difficult to know if screening and early detection do help minimize disfigurement in treatment of this subset.[60] Surgeons often deal with neglected cancers that reach large sizes, and it is difficult to know if these patients would avail themselves of screening opportunities even if they were available.

Physical Exam

Anatomy

The skin is made up of three layers: an outer epidermis, middle dermis, and subcutaneous layer. The outer layer consists of an outer keratinized layer with an underlying stratified squamous epithelium and innermost layer of germinative cells and melanocytes. The dermis is made up of connective tissue fibers embedded in an amorphous matrix of mucoproteins and mucopolysaccharides. The subcutis consists of adipose tissue with an underlying fascial layer. Supporting adnexal structures, including hair follicles, sebaceous glands, and sweat glands, reside in the deep dermis and subcutis. The many cell types that collectively make up the components of the skin give rise to the variety of malignant tumors classified as "skin cancer."

Skin Types

Exposure to ultraviolet radiation plays an important role in the development of most skin cancers. Likewise, a

TABLE 31-1 Fitzpatrick's Sun Reactive Skin Types

Skin Type	Skin Color	Tanning Response
I	Caucasian	Always burns, never tans
II	Caucasian	Usually burns, tans with difficulty
III	Caucasian	Sometimes mild burn, average tan
IV	Brown	Rarely burns, tans easily
V	Dark brown	Very rarely burns, tans very easily
VI	Black	No burn, tans very easily

patient's skin type predisposes to damage from exposure to solar radiation. Fitzpatrick[61] described a scale (Table 31-1) based on skin reactivity to 30 minutes of sun exposure in the Northern Hemisphere. Although the Fitzpatrick scale is commonly used in the assessment of a patient's suitability for certain aesthetic skin resurfacing procedures, it is also useful for evaluating a patient's risk for the development of cutaneous malignancies that arise secondary to UV exposure.[61] Glogau's photoaging scale (Box 31-1) is also useful to quantify an individual's cumulative damage from solar exposure.[62]

• BOX 31-1 Glogau's Photoaging Groups

Group I: Mild (typically ages 28-35)
- Little wrinkling or scarring
- No keratoses
- Requires little or no makeup

Group II: Moderate (typically ages 35-50)
- Early wrinkling, mild scarring
- Sallow color with early actinic keratoses
- Little makeup

Group III: Advanced (typically ages 50-65)
- Persistent wrinkling or moderate acne scarring
- Discoloration with telangiectasias and actinic keratoses
- Always wears makeup

Group IV: Severe (typically ages 60-75)
- Wrinkling: photoaging, gravitational and dynamic
- Actinic keratoses with or without skin cancers or severe acne scarring
- Makeup with poor coverage

Nodes

Skin cancers typically spread by local extension; as noted previously, metastasis to regional lymph nodes is rare and represents an ominous finding. Lymph node involvement is usually associated with large, deeply invasive, or recurrent tumors. Distant metastasis is more rare, with the most common visceral site involved being the lung, especially for squamous cell cancers. The exact rate of lymph node metastasis from NMSC of the head and neck is unknown. O'Brien and his colleagues[63] reported on patterns of lymph node spread from cutaneous squamous cell cancer of the head and neck among 209 patients with known regional metastases. Among 209 patients, 171 (82%) had clinical parotid involvement, and of these, 28 had clinical neck disease. Whereas 143 patients had parotid disease alone, 38 (18%) had neck disease only. Level II was most commonly involved in the neck. Common sites of origin for metastases were usually lateral and included the cheek, pinna, and temple. Lesions from the anterior inferior face tend to metastasize to levels I, II, and III, whereas metastases from the nose tend to involve level I.[64] Involvement of parotid nodes can lead to facial nerve paralysis. At-risk patients presenting with a parotid mass, with or without facial nerve paralysis, should be carefully screened for potential skin cancer primary sites.

Biopsy

The goal of a biopsy is to remove a representative piece of tissue to allow histologic diagnosis. There are a variety of techniques available for obtaining tissue for histologic diagnosis, but all generally fall into two categories: incisional biopsy, including shave and punch biopsy techniques; and excisional biopsy (Figure 31-5).[65] The decision to perform an incisional or excisional biopsy should take into account the size and location of the lesion, as well as the surgeon's clinical impression of the lesion's behavior (benign or malignant). Incisional biopsies remove a portion of the lesion for histopathologic analysis before definitive treatment. A portion of adjacent tissue can be removed to allow the pathologist an opportunity to examine the transition between normal and abnormal tissue. Removal of tissue from this transition zone is more important in some vesiculobullous and pustular entities. It should be avoided in cases of suspected malignancy where there is a concern for seeding adjacent tissue, requiring a larger excision in the future. Obviously necrotic areas should be avoided for biopsy. Incisional biopsies are typically indicated in larger lesions, where complete removal is not appropriate without knowledge of the histologic diagnosis. Incisional biopsies are also indicated in areas where maximal preservation of tissue is important (e.g., eyelids) and histologic confirmation of diagnosis is necessary before planning definitive treatment. Incisional biopsies can take the form of shave or punch biopsy. Shave biopsy is best suited for raised lesions of suspected epidermal origin, such as basal cell carcinoma, early squamous cell carcinomas, and actinic keratosis. Although it can be used to remove benign nevi, it should not be used in cases of suspected melanoma in which the depth of the lesion guides therapeutic choices. It can also be a good technique for sampling bullous lesions because it allows the blister roof to remain attached. The technique is best performed with a straight razor blade slightly bowed between the thumb and index finger. The tissue to be sampled can be elevated by pinching the surrounding tissue, or placing the surrounding tissue under slight tension. The tissue can also be elevated with infiltration of local anesthetic directly deep, but not directly into, to the lesion. Excessive traction on

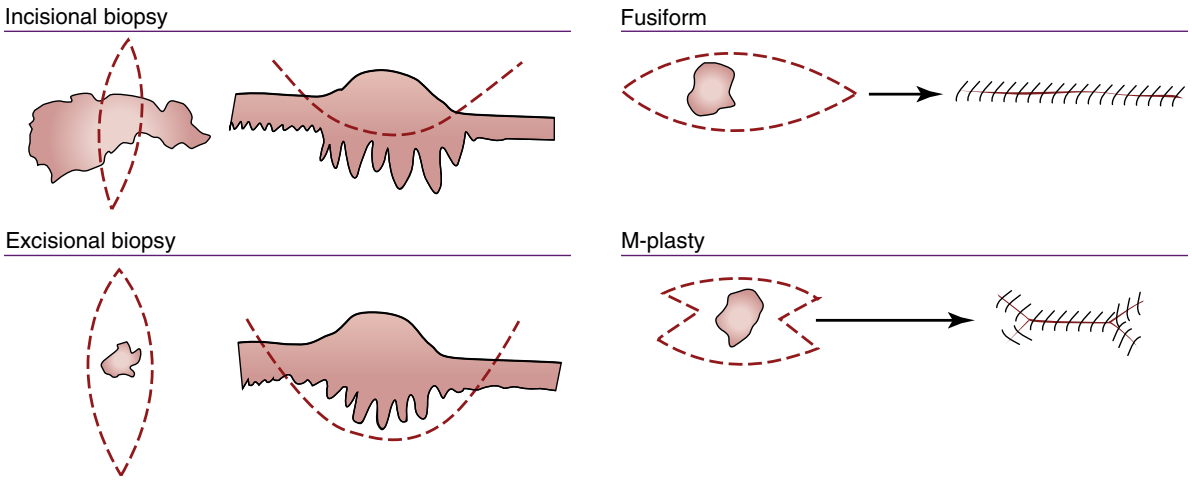

• **Figure 31-5** Biopsy techniques.

the surrounding tissue should be avoided because this can lead to a depressed scar. Bleeding is controlled with pressure, electrocautery, or application of a hemostatic agent, such as silver nitrate. Advantages of shave biopsy include less trauma and scarring at the biopsy site. The most important disadvantage is the potential that there will be inadequate tissue for diagnosis. Attempts to perform shave biopsies in larger squamous cell or verrucoid cancers, for example, can lead to sampling only superficial keratinaceous or necrotic debris. Sellheyer and colleagues[66] sought to compare the practice of shave versus excisional biopsy among plastic surgeons and dermatologists and found that dermatologists were more likely to perform shave biopsies of actinic keratosis (AK) and plastic surgeons were more likely to perform excisional biopsies. They suggested that shave biopsies were more appropriate in cases of diagnostically uncertain cutaneous lesions. They argued that this was especially true in cases of actinic keratosis, where shave biopsies provided a more cosmetic outcome and allowed treatment of confirmed AKs with cryosurgery or other topical therapy, sparing the morbidity of excision. Many surgeons would argue, however, that biopsy techniques that provide deeper tissue samples are preferred in cases of suspected malignancy. In addition to melanoma, the thickness of certain other cutaneous malignancies, including squamous cell and basal cell cancers, carries prognostic information (as discussed earlier) that is not available from shave biopsies. For this reason, in the authors' opinion, shave biopsy should be reserved for suspected benign or smaller malignant lesions. Full-thickness biopsies that extend into the subcutis are preferred for all other lesions.

An alternative biopsy technique is the punch biopsy, which can be either incisional or excisional, depending on the size of the lesion. Its utility lies in its ability to provide a full-thickness sample of the lesion for histologic examination. Available punch sizes range from 2 to 8 mm, with 3 to 4 mm being the most commonly employed. The technique is accomplished with the patient receiving a local anesthetic, and multiple samples can be obtained quickly. The punch

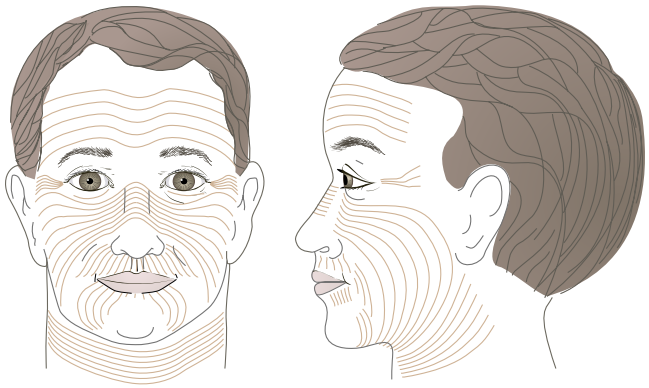

• **Figure 31-6** Relaxed skin tension lines (RSTLs) of the head and neck region.

should be held perpendicular to the skin surface, and tension can be placed on the surrounding tissue perpendicular to the resting skin tension lines (RSTLs) (Figure 31-6), which allows the final wound to take an oval shape parallel to the RSTLs, and more aesthetic healing. Once adequate depth is reached, the resulting core of tissue is amputated with a scalpel blade or scissors, taking care not to crush the specimen. The biopsy wound can be closed or left to heal by secondary intention.[65] Incisional biopsies can also be performed with a scalpel blade. Typically, fusiform incisions are designed to allow closure parallel to RSTLs. Incisional scalpel biopsies may be indicated when a larger piece of tissue is needed, or if the lesion in question lies deeper in the subcutaneous tissue. They are also helpful when tissue adjacent to the lesion is needed, as noted previously. If melanoma is suspected, the biopsy should be taken from the thickest portion, because depth and thickness serve as important prognostic indicators and guide selection of further therapy.

Excisional biopsies are typically reserved for smaller lesions, typically less than 2 cm. Fusiform type excisions with a length to width ratio of 3:1 are outlined parallel to the RSTLs. A margin of healthy-appearing tissue 2 to 3 mm wide at its closest point should be taken. A scalpel blade is

then used to excise the tissue, taking care not to crush or distort the specimen. Undermining of the adjacent tissue may be required for tension-free closure, but should be avoided if there is a question of incomplete removal so as to avoid seeding and distortion of adjacent tissue. If questionable, wounds may be dressed, and definitive closure delayed until final margins are available. The specimen should be oriented with a suture or ink. Advantages of excisional biopsy include providing the pathologist with the complete specimen for review and the possible convenience of a single surgery. The main disadvantage is that the pathology and margin status are unknown at the time of excision, and patients should be advised that final pathology may dictate further therapy.

In addition to choosing the appropriate technique for sampling the lesion, the surgeon must also decide on the most appropriate media in which to send the material to the pathologist. Although the vast majority of specimens are submitted for routine pathology in formalin, special circumstances may dictate that all or a portion of the specimen be submitted fresh or in alternative media. This decision is often made in concert with the histologist and is based on the need for special stains or studies, such as flow cytometry.

Imaging

Although advances in imaging have arguably had the greatest impact on the surgical care of head and neck cancer patients in general, imaging is rarely part of the workup of the routine patient with cutaneous malignancy of the face and neck. Clinical exam alone provides enough information in the majority of cases. Surgeons may consider imaging, however, in cases of deeply infiltrating, recurrent, or multiple lesions. Involvement of critical areas (eyelid or conchal bowl, for example) or higher potential for lymph node involvement (see discussions under management of lymph nodes and predictors of biologic aggressiveness) can also be indicators for cross-sectional imaging. In the past, surgeons dealing with larger skin malignancies were confronted with operating on tumors with only a clinical examination of the surface characteristics. Currently, excellent three-dimensional representations are available with which to plan surgery and allow more conformal radiation treatment.

In the 1980s computed tomography (CT) scan became a part of the evaluation of this subset of patients with more advanced cutaneous malignancies in an attempt to examine the extent of the primary involvement of adjacent anatomic structures and to search for evidence of regional nodal metastases. CT scans with 3-mm cuts and soft tissue windows are effective for evaluating depth of invasion and potential lymph node metastasis. Specific criteria, such as size, loss of fatty hilum, central necrosis and spherical shape, are available for defining nodes as suspicious for metastatic involvement.[67] Additional indications for CT imaging include long-standing scalp lesions or other lesions suspicious for bone involvement, which should be imaged with finer (1 mm) cuts with bone windows through the area of concern.

In the 1990s, magnetic resonance imaging (MRI) began to challenge the CT scan. Its exquisite anatomic detail and lack of radiation, however, are associated with higher cost and a lengthy, uncomfortable exam. At this point, MRI is reserved for evaluation of tumors with extensive soft tissue involvement and is especially helpful in evaluating potential perineural extension.[67] Also, newer techniques that modulate the magnetic field in an attempt to examine changes in the bone marrow hold promise for evaluating bone involvement that may offer better sensitivity than CT with fine cuts. Tumor invasion into the marrow space is accompanied by a lower intermediate signal and is best seen on T1-weighted sequences.[68]

The role of positron emission tomography/computed tomography (PET/CT) has yet to be fully defined in NMSC. Although this whole-body imaging modality has become a standard procedure in detecting malignancy in many areas of clinical oncology, data to support PET in routine staging of NMSC are still emerging. Isolated case reports document the use of PET in basal cell carcinoma[69,70] and squamous cell carcinoma[71,72] but few large studies exist to make useful conclusions. Cho et al[73] retrospectively reviewed 12 cases of cutaneous squamous cell carcinoma and noted that PET/CT detected the primary lesion in nine cases, lymph node involvement in three cases, and distant organ involvement in one case. All these areas were confirmed positive by histology, although PET-negative areas were not confirmed to be negative by histology. The authors noted that all patients with regional or distant metastatic disease had high-risk primaries as determined by size, location, poorly differentiated histology, and immune status of the patient. Fosko et al[74] published a series of six patients with head and neck basal cell carcinomas larger than 1 cm and noted that three of the primary lesions were not detected by PET/CT, including an aggressive 3.1-cm recurrent BCC with extensive perineural spread. Although the majority of cutaneous malignancies are SCC and BCC, PET imaging has been advocated in uncommon forms of skin cancer such as Merkel cell carcinoma,[75] apocrine sweat gland carcinoma,[76] primary cutaneous lymphoma,[77] and melanoma.[78-80]

Staging of Skin Cancer

Accuracy in staging of cancer is critical for comparison of treatment modalities and for following outcomes. The staging of non-melanoma skin cancers follows the tumor, node, and metastases (TNM) system proposed by the American Joint Committee on Cancer (AJCC) and the International Union Against Cancer (IUAC).[81] The staging system undergoes constant review and updating, and the rules for staging of skin cancer are specific. Most cutaneous basal cell carcinomas are not staged, leading to the primary application of the non-melanoma staging to squamous cell carcinomas. Clinicians should be familiar with changes in the staging system and strive for consistency in staging. Technological advances lead to stage migration; for example, improved ability to detect earlier metastatic disease with CT scans leads to more patients being diagnosed with late-stage disease. Clinical staging of skin cancer is based on all clinical data available

before initiation of treatment, which at a minimum includes data from the physical exam. If available, imaging data are included. It does not include information gained during the surgical procedure. If surgery is performed, a pathologic staging is possible based on examination of the surgical specimen. This is designated by inserting the letter *p* in front of the TNM stage. Standard staging of non-melanoma skin cancer of the face excludes the eyelid, which has its own staging criteria based on different prognostic variables.

A summary of the current staging follows:

Primary Tumor

- TX: Primary tumor cannot be assessed
- T0: No evidence of primary tumor
- Tis: Carcinoma in situ
- T1: Tumor less than 2 cm in greatest dimension with less than 2 high-risk features
- T2: Tumor more than 2 cm or Tumor any size with 2 or more high-risk features
- T3: Tumor with invasion of maxilla, mandible, orbit, or temporal bone
- T4: Tumor with invasion of skeleton (axial or appendicular) or perineural invasion of skull base

If there are multiple synchronous tumors, the lesion with the highest T stage is used and the number of separate tumors is indicated in parentheses. For example, if the largest lesion is 3 cm and there are 3 other lesions, all of which are smaller, the clinical T stage would be T2(3).

Regional Lymph Nodes

- NX: Regional lymph nodes cannot be assessed
- N0: No regional lymph node metastasis
- N1: Metastasis in a single ipsilateral lymph node, ≤3 cm in greatest dimension
- N2a: Metastasis in a single ipsilateral lymph node, >3 cm but ≤6 cm in greatest dimension; or in multiple ipsilateral lymph nodes, ≤6 cm in greatest dimension; or in bilateral or contralateral lymph nodes, ≤6 cm in greatest dimension
- N2b: Metastases in multiple ipsilateral lymph nodes, ≤6 cm in greatest dimension
- N2c: Metastases in bilateral or contralateral lymph nodes, ≤6 cm in greatest dimension
- N3: Metastasis in a lymph node, >6 cm in greatest dimension

Distant Metastases

- MX: Distant metastasis cannot be assessed
- M0: No distant metastasis
- M1: Distant metastasis

Stage Grouping

- Stage 0: TisN0M0
- Stage I: T1N0M0
- Stage II: T2N0M0
  - T3N0M0
- Stage III: T4N0M0
  - Any TN1M0
- Stage IV: Any TN2M0
  - Any T
  - Any NM1

Also, additional descriptors are available to better define the system: an *m* suffix (T(m)NM) designates multiple primary sites, a *y* prefix (yTNM) indicates that staging was performed during or following multimodality treatment, an *r* prefix (rTNM) indicates a recurrent tumor staged after a disease-free interval, and an *a* prefix (aTNM) designates a stage determined at autopsy.

The current staging system offers clinicians a consistent system to classify tumors for comparison of treatment strategies and evaluating prognosis. Certain factors known to affect prognosis are taken into account. There are, however, shortcomings. The current system does not take into account several known factors that influence skin cancer behavior and survival. The most important factor neglected in the current system is the tumor-host relationship and factors that influence it, such as nutrition, immunologic factors, and performance status. Head and neck skin cancer patients typically are older and suffer from multiple other medical conditions. Certainly the TNM staging system will continue to undergo revisions to enhance its utility. Unfortunately, with these revisions, the simplicity of the system will be difficult to maintain. O'Brien[63,82] has suggested that the staging system should be altered to include the location of nodal disease (e.g., neck vs. parotid). The authors found that involvement of neck nodes was worse than involvement of parotid nodes. They also noted that involvement of neck nodes was a predictor of survival and that involvement of multiple nodes was associated with a worse outcome.

The seventh edition of the *AJCC Staging Manual*[81] introduces new parameters previously not incorporated into staging criteria for cutaneous squamous cell carcinoma. The T stage now accounts for high-risk features that are outlined in Table 31-2. The presence of two or more of these high-risk features elevates a T1 tumor to a T2. This highlights potentially more aggressive tumors regardless of size. Although this is a helpful addition, some clinicians have been critical of the omission of additional high-risk features such as basosquamous morphology, lymphovascular invasion, or inflammatory response.[83] Nodal involvement has been expanded to note size of nodes, number of nodes, and laterality. These updates should improve data

TABLE 31-2 High-Risk Features for Primary Tumor (T) Staging for Cutaneous Squamous Cell Carcinoma

Depth/invasion	>2 mm thickness (Breslow thickness)
	Clark level ≥IV
	Perineural invasion
Anatomic location	Primary site ear
	Primary site hair-bearing lip
Differentiation	Poorly differentiated or undifferentiated

collection and guide prognosis, but some authors believe additional characteristics should be included in the staging criteria. Organ transplant patients are well recognized as higher-risk groups because of their immune suppression, and many believe their tumors behave more aggressively.[84,85] Extracapsular extension in nodal basins is not included in the N-staging, although this is a known poor prognostic factor.[83]

Treatment

Surgery

Once the diagnosis is made and the indicated workup completed, the clinician must decide on treatment. Surgery is the mainstay of therapy for the vast majority of cutaneous head and neck malignancies. Because basal cell and squamous cell cancers make up the vast majority of skin cancers, our discussion focuses on the surgical principles involved in their treatment.

Cryotherapy

Although not specifically a surgical therapy, cryotherapy creates a wound more akin to traditional surgery than other medical therapies and is therefore considered here. Indeed cryotherapy (or cryosurgery) can be used in lieu of surgical excision in cases of actinic keratosis and some early BCC and SCC. The most common technique includes the application of liquid nitrogen with a spray device that cools the skin to −50° C and to a depth of 1 to 3.5 mm.[86] Multiple applications may be used, but most commonly two applications are performed. An area of surrounding skin should be frozen as well to ensure clearance of cancerous cells. The diameter of the surrounding "halo" that is visualized around the application area correlates roughly with the depth of the freeze. Use of local anesthetic is optional in most cases, as the cooling has an anesthetic effect. A local anesthetic can be infiltrated, however, if the thaw phase causes undue discomfort. Cryotherapy does not provide a specimen for histologic examination and is generally reserved for actinic keratosis and very early BCC and SCC with well-defined borders. An additional disadvantage is the potential for unfavorable scarring, including hypopigmentation. Cure rates in actinic keratosis are around 99%, and in smaller BCC and SCC (<2 cm) cure rates are also satisfactory (94% to 99%).[86-88]

Curettage/Electrodesiccation

Curettage of skin lesions followed by electrocautery or chemical cautery is used with success on many smaller skin lesions of the trunk and extremities, but it is rarely indicated on the skin of the face, where the potential for unfavorable scarring precludes its use in most cases. The technique involves removal of the lesion using sequentially smaller curettes and relies on the tactile sensation of the surgeon to identify when normal tissue has been reached and the tumor has been removed. It is used by many dermatologists as a first-line treatment of smaller BCCs.[89] Some authors have recommended curettage alone without the electrodesiccation in an attempt to avoid some of the hypertrophic scarring associated with the use of electrodesiccation. Alterations in pigmentation can still result in an unacceptable scar. If it is performed on the face, its use should be restricted to those areas known to heal well by secondary intention—the so-called NEET areas: concave surfaces of the nose, ear, eye, and temple. In contrast, it should be avoided on the NOCH surfaces: convex surfaces of the nose, lips, cheeks, and chin (Figure 31-7).[90] Curettage is best suited for the treatment of thick actinic keratosis and smaller, exophytic squamous and basal cell cancers (typically less than 1 to 2 cm). Cure rates are high (>90%) with selection of appropriate lesions. As with cryotherapy, no specimen is generated for histopathologic exam.[86,91]

Laser Excision, Ablation, and Resurfacing

A variety of lasers are available for use by surgeons to ablate and excise lesions; lasers also can act as an energy source for activating photosensitizers, which are administered to patients and selectively taken up by tumor cells. The biologic effect of a laser is dependent on its absorption by the target tissue, and the wavelength determines the ultimate effect. A variety of laser media are available, including CO_2, argon, ruby, and Nd:YAG, to alter the absorption characteristics of the beam. In addition, altering the size of the beam as well as the delivery mode—continuous, pulsed, or

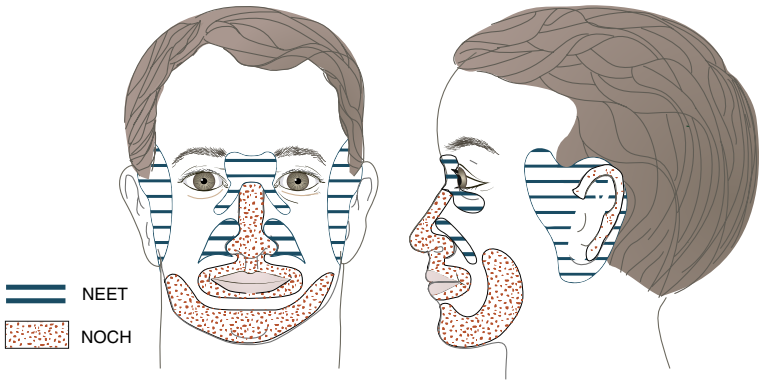

• **Figure 31-7** Areas of the face that can heal by secondary intention.

Q switched—changes the effect on the tissue as well. Lasers can be used in a continuous, focused mode for excisions with minimal thermal injury to surrounding tissue and excellent hemostasis. Larger beam sizes in a variety of energy modes can be used to ablate larger areas with minimal thermal injury to the underlying tissue, allowing for more rapid and complete healing by secondary epithelialization. Laser ablation is often indicated for resurfacing large areas of skin with actinic photodamage as an alternative to chemical peeling or other medical therapies. Hantash and colleagues[92] compared carbon dioxide laser resurfacing, topical 5% fluorouracil, and 30% trichloroacetic acid (TCA) peel for the prevention of squamous and basal cell carcinomas in patients with actinic keratosis and a history of non-melanoma skin cancer associated with severe photoaging. All demonstrated a statistically similar reduction in the number of actinic keratoses (range 83% to 92%), a lower incidence of NMSC, and decrease in the development of second primary skin cancers compared to the control group.

Mohs Micrographic Surgery

The current technique of Mohs micrographic surgery evolved from Dr. Frederic E. Mohs' chemosurgery technique, which he developed while working with Professor M. F. Guyer in the Department of Zoology at the University of Wisconsin.[93] Dr. Mohs was evaluating the effects of zinc chloride on cancerous tissue when he discovered that in addition to tissue necrosis, zinc chloride resulted in fixation of the tissue, which provided an excellent specimen for histologic examination. A paste was ultimately developed, which contained a binder *(Sanguinaria canadensis)*, a matrix (Stibnite; Hummel Chemical Co., South Plainfield, NJ), and zinc chloride 45% by weight. In 1941, Mohs presented his technique of chemosurgery. This technique involved application of the fixative for a prescribed time (maximum tissue penetration occurs at 18 hours following application), followed by removal and microscopic examination of the fixed tissue. Depth of penetration was controlled by altering the thickness and surface area on which the paste was applied. Successive layers were removed until tumor clearance was accomplished.[93,94] An important part of the procedure was the specific way in which Dr. Mohs oriented his specimen, which in theory allowed examination of 100% of the margin. Others argue that the most important component of the technique is that the surgeon performing the excision is also evaluating the margins. This decreases the potential for communication error, especially regarding specimen orientation, that may occur between surgeon and pathologist, because in this case they are one and the same.[95] At the time of his original work, frozen section analysis of margins was not available, and although labor intensive, the fixed tissue technique allowed for significantly improved cure rates compared to traditional surgical excision. Several modifications of the technique occurred, including elimination of the fixative in most cases, and in 1953 Dr. Mohs presented his technique modified for use with fresh tissue and frozen analysis of margins. Careful orientation of the specimen was the same, and the entire margin was still evaluated, which offered advantages over traditional surgical excision and margin analysis.

Although it is beyond the scope of this chapter to discuss the nuances of processing tissue for histologic examination, some discussion of margins is necessary to understand the advantage of Mohs surgery. A clinical margin refers to the edge of the lesion as appreciated clinically. A surgical margin is defined as the tissue edge of the specimen. Margins can be assessed as clear, close, or involved. Close margins are often defined differently by various pathologists, and surgeons should discuss the meaning of a "close" margin with the pathologist in order to decide whether or not further treatment, most commonly re-excision, is warranted. Tumor shrinkage of up to 40% can occur when a specimen is removed and processed, leading to a close margin when the excision seemed adequate clinically.[96] When a specimen is removed and oriented for the pathologist, there are several techniques for processing it for analysis. Traditionally, specimens are bisected or cross-sectioned in a vertical plane for examination. Alternatively, the specimen may be "bread-loafed" and cross-sectioned for greater visualization of the tumor and margins. The most comprehensive processing technique involves peripheral sectioning of all four sides of the tumor with or without a deep layer. Despite these variations, often less than 0.1% to 1% of the tumor margin is analyzed in the vertical sectioning techniques of traditional pathologic processing. It is impossible to examine the entire margin in a vertical technique because complete serial sectioning of a 1-cm tumor would require 2000 5-µm sections. By necessity, skip sectioning is performed. Asymmetric tumor growth can lead to tumor extensions between areas examined in a vertical technique.[95] By contrast, Mohs' micrographic excision technique is a horizontal and oblique sectioning technique, which theoretically allows examination of 100% of the deep and lateral tumor margins.

Mohs micrographic surgery is typically accomplished with the patient receiving a local anesthetic. The tumor is initially debulked using scalpel excision or curettes. This is followed by a lateral, beveled excision (45 degrees) joining a more horizontal excision of the deeper portion of the tumor bed. The specimen is carefully oriented with an accurate specimen map (Figure 31-8). Larger specimens may be divided by cross-sectioning, which is reflected on the specimen map. Inking edges with different colored inks can also aid in orientation. The specimen is inverted and mounted on the cryostat. Frozen margins are processed and examined from the undersurface of the specimen. These frozen sections are then evaluated and residual tumor is documented on the specimen map. Further layers are taken from the areas that were positive for tumor. The process is continued until a clear layer is reached. Typically this takes two or three layers.[97] Mohs' micrographic technique is best suited for tumors that grow in a contiguous fashion. Discontinuous tumor extension (emboli, for example) limits its utility because a clear margin may not ensure complete tumor removal—"skip" tumors may remain.

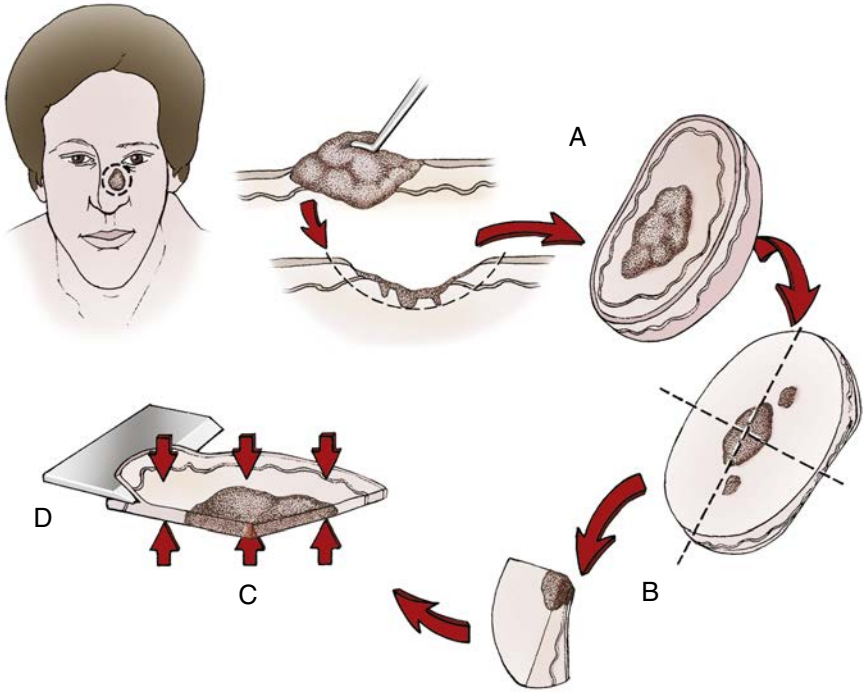

• **Figure 31-8** Mohs micrographic surgery. **A,** Tumor may be debulked with a curette and the remaining defect is excised. **B,** The specimen is oriented and frozen sections are obtained. **C,D,** The specimen is inverted on a cryostat to obtain full view of the deep margins by slicing with a microtome.

Reported indications for Mohs' micrographic technique include aggressive tumors (poor histologic characteristics), recurrent tumors, high-risk anatomic locations (H-zone of the face; see discussion earlier), and areas in which preservation of uninvolved tissue is of paramount importance for aesthetics or function (eyelids, for example) (Box 31-2).[98]

• BOX 31-2 Selected Indications for Mohs' Micrographic Surgery

Recurrent tumor
Tumor larger than 2 cm in diameter
Aggressive pathology or histologic features (perineural invasion, poorly differentiated squamous cell carcinoma, morphea-form basal cell carcinoma)
Tumors in certain anatomic locations where maximal preservation of tissue is desired (eyelid, canthus, ear, lip, nose)
Ill-defined borders
Tumors located in areas associated with aggressive behavior (H-zone)

Traditional Surgical Excision

Traditional surgical excision (TSE) involves removal of an arbitrary margin of healthy tissue in an attempt to encompass the tumor. This is followed by analysis of the margins with either intraoperative frozen sections or postsurgical permanent sections. The initial margin outlined around the lesion should take into account the size and histology of the lesion. Although there is no "gold standard" for initial margins, the literature does offer recommendations based on recurrence rates and positive margins following excision using various margins. For example, an initial peripheral margin of 4 mm will clear 98% of nodular basal cell cancers, whereas a 2-mm margin will clear only 75%. More generous margins, 8 to 10 mm, have been suggested for more aggressive BCC, such as the morphea-form subtype. For smaller BCCs (5 mm or less), initial margins of 3 mm may be acceptable.[99-102] Initial margins of 4 to 6 mm, which will clear the tumor in 95% of cases, are suggested for small to medium SCCs. More advanced lesions require margins of 10 to 20 mm. The depth of excision should include the subcutaneous tissue immediately subjacent to the tumor in most cases of squamous and basal cell cancers. Underlying fascia or periosteum is included in tumors with deep extension or fixation, and routinely in other histologies, such as DFP and Merkel cell carcinoma.[103]

Surgeons can use intraoperative examination of margins similar to Mohs' technique. Strong and his colleagues[104] describe their use of intraoperative peripheral in-continuity tissue examination in which 4-mm margins are taken for basal cell cancers and 6-mm margins are taken for squamous cell cancers. This is followed by orientation of the specimen and processing that allows frozen section examination of the margins similar to Mohs micrographic surgery. It requires excellent communication with the interpreting pathologist. The accuracy of intraoperative frozen section analysis for cutaneous malignancies of the head and neck is high (85% to 98.3%), but must be weighed against the resources necessary to carry out these procedures, and the low incidence of positive frozen margins requiring further excision.[105,106]

Treatment following positive margins on the final pathology report must be tailored to the individual patient. Most surgeons would recommend re-excision of squamous cell cancers with positive margins.[107] Treatment of positive margins in basal cell cancer excision is more controversial. Although some authors have suggested a watch and wait approach, most surgeons would opt for further excision if possible, with strong consideration given to Mohs' technique.[57,107,108] In some cases, however, re-excision may not be possible. Patients may refuse further surgery, or extensive flap coverage accomplished before final margin status may make accurate re-excision impossible. For this latter reason, surgeons may opt for delayed repair of the defect with careful analysis of permanent sections before committing to complex repair techniques. Positive margins can be an indication of biologic aggressiveness. In cases of initial positive margins, consideration should be given to postoperative radiation therapy even if re-excision has been performed. In addition, the need for a structured follow-up regimen should be stressed to the patient.

Traditional Surgical Excision versus Mohs Micrographic Surgery

There is ongoing debate regarding the choice of surgical technique for cutaneous malignancies of the head and neck. Kropp and colleagues noted that the 5-year overall survival in patients with head and neck skin cancer treated with Mohs excision was 86%, as compared to traditional surgical excision resulting in a 76% 5-year survival.[109] Despite the advantages of Mohs surgery discussed previously, there are well-known disadvantages, including the labor and time intensiveness of the technique, which can drive up costs of excision. Cost comparisons between Mohs micrographic surgery and traditional surgical excision (TSE) have been difficult, and results contradictory.[110,111] Bialy and colleagues[112] performed an interesting study comparing TSE and Mohs excision, and found that the costs were comparable when the Mohs technique was compared to TSE with frozen section control of margins or when compared to cases that included further treatment for inadequate margins. They cautioned, however, that choice of repair technique often influenced costs more than the method of excision. Dermatologic surgeons experienced in the Mohs technique often allow certain wounds to heal by secondary intention instead of performing coverage by local flap or grafting. Also, their excisions take place in an outpatient clinic. Patients undergoing surgery using local anesthesia may not tolerate excision of larger tumors, which often require multiple layers and lengthy procedures. This can build in a case selection bias when investigators attempt to compare the two techniques as larger, more complex tumors are more likely to undergo traditional surgical excision. Mohs surgery can be performed using a general anesthetic, but costs are increased significantly.[112] Given the sheer number of cutaneous malignancies, some have argued that Mohs surgery should be reserved for specific indications (see Box 31-2), and that traditional surgical excision is faster and allows for an acceptable cure rate. Finally, the decision to perform Mohs' excision technique versus traditional surgical excision may be determined by availability. Patients in many areas simply do not have access to a surgeon or dermatologist with training and competence in Mohs' surgical technique. Properly performed traditional surgical excision, with or without frozen section control, remains an option for most lesions in the head and neck.

Lymph Node Involvement in Cutaneous Malignancy

Regional lymph node metastases from cutaneous malignancies of the head and neck, although rare, must be considered. Lymph node metastases are an ominous finding and are usually associated with a poor outcome. Although clinically apparent nodal involvement is a clear indication for therapy, surgeons continue to search for predictors that would indicate the need for elective evaluation, including sampling of nodal basins at risk, in cutaneous malignancy, and without known regional metastasis. There are currently no accepted guidelines, and surgeons must rely on data gathered mostly from retrospective analysis and their own experience. Factors associated with regional metastases include recurrent lesions, thickness greater than 4 mm, and size greater than 2 cm. In addition, clinical perineural invasion is associated with a higher risk of nodal disease, and according to some authors, therapy should include treatment of first-echelon nodes (see earlier discussion on indicators of aggressive behavior in skin cancer).[54,113]

The lymph nodes in the parotid area deserve special attention because they serve as first-echelon nodes for many facial cutaneous malignancies.[114] As many as 20% of malignant parotid masses represent spread from cutaneous malignancy.[115] In Australia, metastatic cutaneous cancer is the most common parotid malignancy, with SCC occurring most frequently.[64] Metastatic parotid involvement by cutaneous SCC indicates the need to address the ipsilateral neck. In 73 patients with metastatic SCC involving the parotid, O'Brien found a high incidence of clinical and occult neck disease, 26% and 35%, respectively.[82] Based on a follow-up study, reported by Vauterin,[63] they recommended elective treatment of the neck with a supraomohyoid neck dissection, including the external jugular nodes, in patients with parotid involvement and a clinically negative neck. In cases of posterior lesions, level V should be included as well. In patients with clinical neck involvement, they recommended a comprehensive neck dissection.[103] One of the challenges facing surgeons is predicting which nodal basin would harbor occult disease if it is present. Lymphatic drainage of the face is not always predictable, and lymphoscintigraphy and sentinel node biopsy (SNB) techniques used in melanoma have demonstrated that drainage patterns can vary from predicted routes, and extended dissections may be needed to address occult disease.[116]

The sentinel node technique, previously validated in melanoma and breast cancer, has been investigated for use

in head and neck cancer, including non-melanoma skin cancer.[117-119] Theoretically, it allows the identification and removal of the lymph node that would first receive metastases from a given site. The technique involves injecting the area surrounding the primary site with a radioactive labeled tracer, usually ^{99m}Tc-sulfur colloid. Various molecular weights can be chosen depending on the transit time desired. At this point a radiograph can be taken to localize the sentinel node, which is the first node that receives lymph flow from the area of the tumor. The patient is then taken to the operating room, where the surgeon may inject a blue dye around the tumor. Again, this will drain to the first-echelon node, staining it blue, and assist the surgeon in identification during surgery. Also, the surgeon can use a gamma detection counter probe to identify the node with the highest concentration of radioactive colloid. This node is then removed. If it is positive, further treatment, such as radiation or more extended nodal dissection, may be indicated. Although its utility in cutaneous melanoma has been demonstrated, with accuracy of 82% to 100% and very few false negatives, the technique has shown only modest utility in non-melanoma skin cancers.[117,118] Basal cell cancers have a very low propensity for metastases, and therefore sentinel node biopsy does not seem to be warranted. Cutaneous squamous cell cancer, however, carries a higher risk for regional metastasis. Some studies have reported rates as high as 16% in cutaneous head and neck sites.[119] Sentinel node sampling may play a role in evaluation of patients whose cutaneous squamous cell cancer demonstrates poor histologic variables or those who present with large, deep lesions.[117,120] The sentinel-node technique can help overcome some of the inherent difficulties in nodal dissection for cutaneous malignancies, such as identifying which nodal basin is most likely draining the involved site, and therefore allow a more focused removal of the at-risk nodes. It may be especially indicated in Merkel cell cancers, which are known for their propensity to metastasize to regional nodes.[117,121] Devaney offered an excellent review of the current role of sentinel node biopsy for head and neck tumors, including cutaneous malignancies, and concludes that we will likely see further refinements and applications of the technique to a variety of head and neck cancers.[122] At this time, elective treatment of the neck with traditional or sentinel-node technique is not warranted without clinical evidence of involvement of regional lymph nodes, parotid, or neck.

Repair

The ability to repair or refer for repair a variety of wounds is an integral part of the management of skin cancers. The majority of wounds can be managed using healing by secondary intention, primary repair, or local flaps. Regional and even distant flaps may be necessary in a minority of cases. With experience, most surgeons develop their own preferences and "go-to" repair techniques. Here we review some of the general principles involved in repair of facial defects following excision of skin lesions. Before surgery, surgeons should have a reconstructive plan, which will be altered as necessary following excision, at which time the most appropriate method of repair is selected based on patient and defect characteristics. Consideration of the repair options preoperatively will help orient the excision in the appropriate manner, whether for primary closure or flap repair. An attempt should be made to orient the excision in such a way as to allow its closure along resting skin tension lines (see Figure 31-6). Likewise, if a local flap is required, proper planning can allow closure of the defect created by flap development along RSTLs as well. Although primary repair is convenient and possible in many cases, patients with large tumors or those with indications of biologic aggressive behavior (see earlier) may be best served with delayed repair. Delayed repair offers several advantages, including time for assessment of margins with permanent technique and an opportunity to assess the defect and choose the best technique for repair. Friedrich[22] examined 124 patients who underwent surgical treatment for 216 basal cell carcinomas, the majority of which were located in the middle third of the face. Further resections were indicated in 71% after histologic examination of the margins. Because of the complexity of techniques involved, surgeons should consider delayed reconstruction in cases of questionable margin status, aggressive histologic variables (such as perineural invasion or bone involvement), or if postoperative radiation is planned. Importantly, delayed repair can allow the patient an opportunity to see the defect and participate in the decision-making process. Wound contracture during the delay can result in a more favorable defect. In addition, granulation tissue that develops in the bed during the delay often results in better acceptance of skin grafts. Properly maintained, cutaneous wounds can be maintained with a moist dressing for weeks without an increased risk of infection. Escobar and Zide[123] reviewed 280 patients managed with delayed repair techniques following excision of skin lesions. Some patient repairs were delayed up to 35 days with minimal complications. Delayed repair may also be indicated to take advantage of the ability of skin to expand when placed under tension (skin creep). Skin creep occurs by two mechanisms: mechanical, which is a more acute phenomenon, and biologic, which is a more long-term response of skin to load. For example, skin expanders can be used intraoperatively to expand flaps, taking advantage of mechanical creep. They can also be buried and activated over weeks to allow expansion through growth of new tissue (biologic creep).[124] Some patients, however, will not accept delayed repair, and others may not be candidates for delayed repair for a variety of reasons; in these cases, repair at the time of excision may be warranted.

Surgical repair of all wounds is not always necessary, and healing by secondary intention is a viable alternative in some cases. Certain areas of the face are more amenable to healing by secondary intention and may not require repair (see Figure 31-7). Concave surfaces of the nose, ears, eyes, and temple are associated with more acceptable scarring following healing by secondary intention, whereas convex

surfaces of these same areas typically heal poorly by secondary intention (see previous discussion under biopsy). Wounds located at the junction of facial aesthetic subunits typically are well hidden.[125] Patient characteristics, such as age, should be taken into account. Although aged skin tends to heal with less scarring, these individuals may be unable to care for the wound without assistance.

In recent years, negative pressure applied to wounds by use of a vacuum-assisted closure (VAC) device has gained popularity. This device accelerates and improves wound contracture. Vacuum-assisted closure increases blood flow and granulation tissue formation and aids in the removal of fluid and surface contaminants.[126] Aside from aiding in the management of open wounds, it serves as an excellent bolster for skin grafting, leading to increased survival.[127] It may also be used in preparation for delayed skin grafting, as it typically results in an excellent granulation bed. It is not recommended in cases in which there is concern for residual tumor in the wound bed.

Full- or split-thickness skin grafting allows repair of large wounds that are not amenable to healing by secondary intention and in which flap repair is not indicated or necessary. Unlike flaps, grafts are dependent on nutrition from the recipient bed (plasmatic circulation or imbibition) for 48 to 72 hours until capillary ingrowth and inosculation occurs. During the early wound healing phase, absolute stability of the graft provides the best opportunity to prevent shearing and graft loss. Full-thickness grafts include the epidermis and dermis and usually provide a more aesthetic result with less late wound contracture if there is satisfactory acceptance of the graft. The supraclavicular and postauricular areas provide good-quality skin for full-thickness grafting with good color match for most facial sites. Skin harvested from the upper eyelids provides an excellent thin full-thickness graft. Disadvantages of full-thickness grafting include need for closure of the donor site and increased risk for either partial or complete graft failure. Split-thickness grafts include epidermis and a portion of the dermis. Healing of the donor site depends on epithelial migration from skin appendages and lateral edges. Split-thickness grafts are less aesthetic in most cases and are susceptible to more contracture. Advantages include the ability to cover larger areas and greater success with graft take.

Composite grafts contain skin and additional tissue, such as cartilage. Although sometimes used for reconstruction of small alar defects, healing of composite skin/cartilage grafts from the helix is unpredictable.

Flaps

Wounds that are not amenable to grafting require flap coverage. Flaps import their own blood supply, which may be random or axial. Most facial skin defects resulting from cancer extirpation can be managed with random, local flaps, including advancement, rotation, and transposition flaps. Use of flaps creates a second wound, which must be repaired, and the design of the flap should keep this in mind. Advancement and rotation flaps usually create excess tissue at one or both ends of the incision. Although they can occasionally be removed with Burow excision or some modification, this "dog ear" or "standing cone" frequently should be left in place, as it will resolve with time and allow maximal preservation of tissue. Axial pattern flaps are based on larger caliber vessels and can be designed with a narrow base carrying a large territory of tissue. They may be regional or distant in the form of free tissue transfer. Regional flaps commonly employed for larger facial wounds include cervicofacial and cervicopectoral flaps.[128] Free tissue transfer is indicated when local and regional tissues are not adequate and are usually required when composite defects have been created.

Regardless of technique, secondary procedures, such as dermabrasion or scar revision, are frequently necessary for an acceptable result. Patient education plays a critical role in managing expectations, because some patients have unrealistic goals, and surgeons can be drawn into an endless series of efforts to create an "invisible" wound with diminishing returns.

Medical Management

Systemic and Topical Medications

Basic sun protection is the starting point for all skin cancer prevention protocols. Targeted approaches to higher-risk patients are used on an as-needed basis. Chemoprevention involves administering a drug in the hopes of reversing or preventing malignant transformation. It has been applied successfully, using tamoxifen, to patients at increased risk for breast cancer. Chemoprevention is an appealing approach to patients who are at high risk for development of cancers. Field cancerization, as presented by Slaughter in 1953,[129] is a concept that is well known to oral cancer surgeons who have dealt with multiple recurrences following seemingly margin-free resections. Slaughter described histologic abnormalities in tissue not contiguous with the primary tumor, and proposed that this may result in multiple recurrences following treatment. Later work demonstrated that seemingly clear histologic margins harbored precancerous genetic abnormalities.[130] Similarly, some patients with NMSC suffer from multiple recurrences, leading to multiple surgical interventions, and certain populations are known to be at higher risk. These include patients with xeroderma pigmentosum, a rare, autosomal recessive disorder characterized by an impaired ability to repair UV radiation induced damage to DNA, with a resultant increase in skin cancer. These patients develop skin cancers early in life (as early as 2 years old) and with a frequency 1000 times that of the general population.[131] Also, patients with basal cell nevus syndrome—a rare autosomal dominant disorder characterized by multiple odontogenic keratocysts, multiple basal cell carcinomas, hypertelorism, frontal bossing, palmar or plantar pitting, calcified falx cerebri, bifid ribs, and medulloblastomas—are at risk and have been shown to benefit from chemoprevention with retinoids in some cases.[132] As discussed previously, non-melanoma skin cancers have been a vexing problem for transplant surgeons ever since chronic

immunosuppression, which leads to a marked increase in susceptibility to NMSC, made solid organ transplants feasible. For this reason, these high-risk patients have served as a popular test group for chemopreventive agents. Systemic retinoids were investigated early in an attempt to decrease this risk.

Retinoids are vitamin A derivatives and have been widely studied as chemopreventive agents in skin, oral, breast, and cervical cancers. The relationship between hypovitaminosis A and development of certain cancers led to the study of retinoids for chemoprevention when they were synthesized in the 1970s. By binding to two families, retinoid acid receptors and retinoid X receptors, retinoids affect keratinocytes by modifying their maturation, growth, cell surface, and immune modulation. Retinoids, both systemic and topical, have been the most widely studied medication for chemoprevention. Currently, two retinoids are available: isotretinoin and acitretin, which has a longer half-life. De Graaf and colleagues reviewed topical and systemic retinoids in transplant patients and found that acitretin was particularly effective for prevention of NMSC development in these patients, but the effect was present only while the patient was receiving therapy. Topical retinoids had some effect on actinic keratosis only. Unfortunately, side effects, such as elevation of triglyceride and cholesterol levels and negative liver function tests, limit their long-term use in many patients.[133] Campbell[134] also reviewed the use of the systemic retinoids isotretinoin, etretinate, and acitretin for skin cancer chemoprevention in high-risk patients, such as patients with basal cell nevus syndrome, transplant patients receiving immunosuppression therapy, and patients with multiple recurrent skin cancers. He also recommended starting with low doses and employing appropriate laboratory and radiographic screening to determine toxicity and side effects. Although systemic retinoids do not inhibit healing of surgical wounds, they can predispose to excessive granulation tissue. In addition, the dryness associated with retinoids can increase bacterial colonization, leading to increased risk of infection following surgery. Additionally, side effects of systemic retinoids, including dryness of nasal mucosa, cheilitis, xerosis, blepharitis, and conjunctivitis, often decrease patient compliance. Early treatment of these mucocutaneous effects with appropriate emollients and wetting agents can improve patient acceptance. Laboratory monitoring is required for hyperlipidemia and increased liver enzymes. Despite known risks of birth defects, there are still pregnancies in patients undergoing therapy with systemic retinoids. This has prompted a program, iPledge, which requires physicians, pharmacists, and patients to register through a central office and verify pregnancy-free status before filling prescriptions.[134] In an attempt to overcome the side effects of systemic medication, there has been a continuous search for effective topical medication for chemoprevention of cutaneous malignancies.

Topical Medications

Because patients at risk for development of skin cancers typically have large areas of photodamaged skin, investigators have sought methods to deal with this field effect in an attempt to prevent the development of skin cancers (chemoprevention) and improve the health and appearance of damaged skin while avoiding the side effects of systemic therapy. Common topical treatments for the prevention of NMSC include topical retinoids, topical 5-fluorouracil, diclofenac sodium, and topical imiquimod cream. Although some clinicians use some of these agents for the treatment of superficial cancers, the high relapse rate once therapy is stopped limits their utility in this regard, and most do not recommend their use for invasive cancer. Patients receiving topical therapy must be followed closely for side effects and compliance, and a structured follow-up regimen is recommended to monitor for the development of invasive lesions requiring surgical intervention. Here an overview of topical treatments is presented; more detailed reviews are available.[135,136]

Topical retinoids attempt to avoid the systemic side effects that limit the use of systemic formulations (see earlier discussion). Similar to the systemic formulations, topical retinoids, such as tretinoin, function to inhibit the growth of abnormal cell lines and induce normal maturation into dysregulated growth. Topical therapy with retinoids consists of application of topical tretinoin cream to affected areas. Although it has been used in the treatment of BCC, high relapse rates limit its use to noninvasive skin conditions. Side effects, including irritation and burning sensation, can limit patient compliance, and a variety of formulations and application schedules have been developed in an attempt to counter these side effects.[135]

Antimetabolites, such as 5-fluorouracil (5-FU), block development of certain metabolites critical for cell metabolism. 5-Fluorouracil is a fluoridated pyrimidine analogue that inhibits thymidylate synthetase, blocking the generation of thymidine, which is necessary for DNA synthesis. 5-Fluorouracil is available as a topical formulation, Efudex 5% (Valient Pharmaceuticals, Costa Mesa, CA). It is approved for the treatment of actinic keratosis, and clearance rates of 83% have been published. It has also been used for superficial BCC and SCC in situ. It is not indicated for invasive SCC. Application is associated with a brisk inflammatory response, which can limit patient compliance. Unfortunately, patients with the most intense inflammatory response often have the best result once healing has occurred. A more recent formulation of 0.5% fluorouracil has shown decreased side effects, and may be more tolerable, but is only indicated for the treatment of AK. Treatment with 5-FU is contraindicated in patients with dehydropyrimidine dehydrogenase deficiency (DPD).[135]

The use of nonsteroidal anti-inflammatory drugs has been investigated as a potential chemopreventive agent in a variety of neoplastic conditions, including squamous cell cancers and colon polyps. Cyclooxygenase (COX), specifically COX-2, has been demonstrated to be upregulated in areas of tumor growth. COX-2 inhibitors have been shown to alter the development of neoplasms, although the exact mechanism by which they produce antineoplastic effects is

unknown. Topical diclofenac sodium gel (Solaraze gel 3%, Bioglan Pharmaceuticals, Malvern, PA) is FDA approved for the treatment of actinic keratosis and is better tolerated than topical 5-fluorouracil treatment. Minor skin irritation can still be a concern, and contact allergic dermatitis develops in some patients. Treatment times are longer (up to 3 months), limiting patient compliance, and response rates of 47% on facial lesions are lower than that of topical 5-FU. It is an alternative, however, in patients who will not tolerate the side effects of Efudex.[135]

Imiquimod (Aldara, 3M Pharmaceuticals, St. Paul, MN), is an immunomodulator applied topically. The exact mechanism by which it exerts its effects on actinic keratosis is unknown, but it stimulates T-cell response, leading to upregulation of antitumor effects, such as production of tumor necrosis factor, and this effect can be long-term through the establishment of immunologic memory. Although initially approved for the treatment of genital warts, dermatologists began to use it "off label" in their clinical practices for a variety of neoplastic and non-neoplastic skin conditions, and it was recently approved by the Food and Drug Administration for the treatment of actinic keratosis.[137]

Imiquimod has been shown to be a well-tolerated and effective treatment for actinic keratosis.[83,138] When administered over a 12-week course, 92% of patients demonstrated some response, with 84% showing complete resolution and only 10% showing recurrence 1 year after treatment. Early work has demonstrated some effect on superficial BCC and SCC in situ, but at this time it is approved for treatment of AK only. As with Efudex, a brisk inflammatory response can limit its use in some patients.

Photodynamic Therapy

Given the high rates of multiple lesions in patients with NMSC and their propensity to recur, photodynamic therapy (PDT) is gaining popularity as a potential method for dealing with multiple, diffuse lesions. Photodynamic therapy relies on a complex interaction of a photosensitizing agent that is preferentially concentrated in abnormal tissue with light of various wavelengths, depending on the photosensitizer, to create necrosis through a non-thermal reaction. Tissue necrosis is mediated through the creation of singlet oxygen, a highly reactive species that induces cellular damage through several mechanisms. Advantages of PDT include minimal damage to surrounding tissues and no cumulative damage, which theoretically allows unlimited treatments. Given the propensity for many cutaneous malignancy patients to develop multiple lesions, this is an important advantage over excision or ablation using traditional methods. Minor discomfort, erythema, and itching are common side effects of treatment. Areas treated undergo healing through secondary intention with minimal or no scarring. Disadvantages include marked photosensitivity with systemic PDT, especially with regard to sun exposure, for variable lengths of time after the administration of the agent. Although a complete review of PDT is beyond the scope of this chapter, excellent reviews are available.[135,139]

Photodynamic therapy has been used with success in the treatment of actinic keratosis using systemic 5-aminolevulinic acid PDT, but photosensitivity not relieved with sunscreen can last up to 3 months. In response, investigators began using topical PDT with 5-aminolevulinic acid (ALA), a protoporphyrin precursor. It is absorbed by keratinocytes and converted into an endogenous photosensitizing agent. Effective management of actinic keratosis is possible while minimizing systemic side effects. Clearance rates for actinic keratosis are excellent and range from 70% to 90% at 3 years. Early response of superficial SCC and BCC led some investigators to recommend PDT, but disappointing results at longer term follow-up led most to not recommend PDT for invasive lesions.[140,141]

Radiation

Because of its efficiency and effectiveness, surgery is the treatment of choice for the vast majority of skin cancers. Radiation therapy, however, is indicated for some patients who are not surgical candidates (e.g., large lesions in anatomic locations not amenable to surgical excision without undue morbidity) and in a salvage role for multiply recurrent or multicentric lesions. It can also serve as an adjunct to surgery in lesions with poor prognostic factors, such as perineural extension, positive margins, or nodal involvement.[54] Older orthovoltage radiation machines were ideal for treatment of skin cancers because of the superficial absorption of these lower-energy beams. Indeed, skin damage from radiation treatment was one of the impetuses leading to the introduction of newer high-energy megavoltage linear accelerators. These higher energy machines can also be used to generate low-energy electrons that are better suited for treating skin cancers. Higher energy beams can be used for more deeply seated tumors. Although typically administered over multiple fractions, some investigators have demonstrated good control rates with single-fraction treatment.[142-144]

When used as a single modality, control rates for BCC and SCC are high (95% to 97% and 90%, respectively), but lesions that recur following radiation treatment tend to behave aggressively.[144] Whether this is an effect of the radiation or shows that failure to respond completely to radiation is an indicator of biologic aggressiveness is unknown, but the latter is probably more likely. In addition to its role as primary treatment, radiation therapy can play an important role in recurrent lesions as an adjunct to surgery.[144] With special shielding techniques, radiation can also be an effective tool for management of eyelid and canthal lesions, avoiding the morbidity associated with large resections of this complex area.[144] Radiation therapy generally leads to good cosmetic results following healing, but studies directly comparing radiation to surgery or other treatment modalities are lacking. In addition to its role at the primary site, radiation therapy is recommended as adjuvant therapy in cases of known nodal disease. It has been shown to improve locoregional control and survival.[115]

In contrast to other NMSCs, adjuvant radiation therapy has become standard in the treatment of Merkel cell

carcinoma. Veness et al[129] found that adjuvant locoregional radiation following surgery results in a longer median disease-free interval in Merkel cell carcinoma (23 versus 6 months) and decreased nodal relapse. This is in agreement with other studies that have demonstrated that adjuvant radiation should be considered standard therapy.[129]

Regardless of primary treatment modality, patients with skin cancer require structured follow-up for evaluation of recurrence, as well as new primary lesions.

Special Considerations

Lip Cancer

Although classified as an oral cancer, squamous cell carcinomas of the lip typically follow a different clinical course than that of typical oral squamous mucosal cancers. The behavior of lip cancers typically lies somewhere between that of oral squamous cancers and cutaneous squamous cancers. For staging purposes, the lips are defined anteriorly by the skin-vermilion junction and include the mucosal portion that comes in contact with the opposing lip. Upper and lower lips join at the commissures. The lip consists of an inner mucosal lining (more properly known as buccal mucosa), vermilion (that which touches the opposing lip), and the skin on the outer surface. Cancers involving the lip may arise from any of these areas, and determining the epicenter or point of origin is often difficult.

Most commonly the lower lip vermilion is the origin, and squamous cell cancers account for the majority of malignancies affecting the lip. Most lesions arise in an area of actinic keratosis (Figure 31-9), which can be treated with a vermilionectomy. Often it is difficult to discern the epicenter of the tumor and stage it accurately. Some cancers are so large that it is difficult to decide if they arose from the skin of the lip, the vermilion, or the buccal mucosa.

A summary of the current staging follows:

Primary Tumor

- TX: Primary tumor cannot be assessed
- T0: No evidence of primary tumor
- Tis: Carcinoma in situ
- T1: Tumor less than 2 cm in greatest dimension
- T2: Tumor more than 2 cm but less than 4 cm in greatest dimension
- T3: Tumor more than 4 cm in greatest dimension
- T4a: Tumor invades through cortical bone, inferior alveolar nerve, floor of mouth, or skin of face, that is, chin or nose
- T4b: Tumor invades masticator space, pterygoid plates, or skull base and/or encases internal carotid artery

Regional Lymph Nodes

- NX: Regional lymph nodes cannot be assessed
- N0: No regional lymph node metastases
- N1: Metastases in a single ipsilateral lymph node, 3 cm or less in greatest dimension
- N2: Metastases in a single, ipsilateral lymph node, more than 3 cm but less than 6 cm in greatest dimension; or in multiple ipsilateral lymph nodes, none more than 6 cm in greatest dimension; or in bilateral or contralateral nodes, none greater than 6 cm
- N2a: Metastases in a single, ipsilateral lymph node more than 3 cm but less than 6 cm
- N2b: Metastases in multiple, ipsilateral lymph nodes, none more than 6 cm in greatest dimension
- N2c: Metastases in bilateral or contralateral lymph nodes, none more than 6 cm in greatest dimension
- N3: Metastases in a lymph node more than 6 cm in greatest dimension

Distant Metastases

- MX: Distant metastases cannot be assessed
- M0: No distant metastases
- M1: Distant metastases

Stage Grouping

- Stage 0: TisN0M0
- Stage I: T1N0M0
- Stage II: T2N0M0
- Stage III: T3N0M0
  - T1N1M0
  - T2N1M0
  - T3N1M0

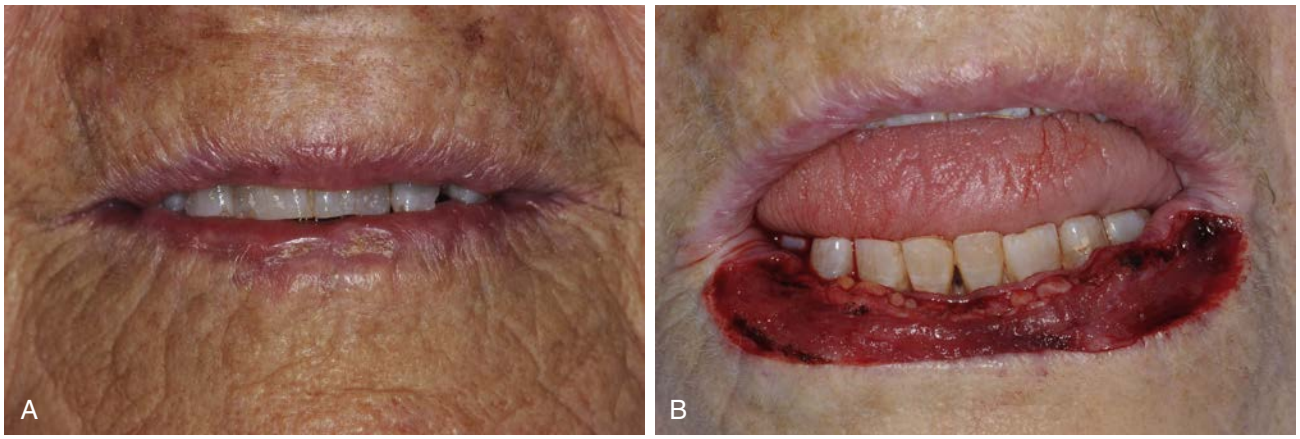

• **Figure 31-9** **A,** Actinic keratosis. **B,** Vermilionectomy defect, which is easily closed by mucosal advancement.

- Stage IVa: T4aN0M0
  - T4aN1M0
  - T1N2M0
  - T2N2M0
  - T3N2M0
  - T4aN2M0
- Stage IVb: AnyTN3M0
  - T4bAnyNM0
- Stage IVc: AnyTAnyNM1

The primary etiologic agent for lip cancer (sun exposure) is different than for oral cancers, and the highly visible location of lip carcinomas usually leads to earlier discovery. The behavior of squamous cell cancers of the vermilion border is usually intermediate between that of SCC of the skin and that of the mucosa. The vast majority arise on the lower lip, where sun exposure plays an important etiologic role. Most lip cancers are treated surgically with resection using 0.5- to 1.0-cm margins confirmed with frozen section. Excisions typically take the form of wedge excisions, which may be combined with a lip shave procedure removing vermilion that has suffered extensive actinic damage or contains carcinoma in situ. Mohs micrographic surgery is an alternative to traditional surgical excision. There is potential for perineural invasion and/or mandibular involvement with larger lesions, which can require extensive resections and reconstructive efforts (Figure 31-10).

Certain factors are associated with more aggressive behavior in lip cancer with increased recurrence and metastatic rates. Size greater than 2 cm is associated with local recurrence and metastases more frequently than those less than 2 cm.[145] Histologic grade also influences local recurrence and metastatic rates. Well-differentiated tumors are associated with lower local recurrence rates and metastases compared to poorly differentiated tumors.[83] Perineural involvement is also associated with higher local recurrence and distant metastases, with up to 34% of patients developing distant spread.[84] Finally, age less than 40 years has been associated with increased risk of local recurrence and distant metastases.[145]

As with the cutaneous sites, there is a significant amount of controversy surrounding the need for elective neck dissection of at-risk nodal basins in lip cancer. Early investigators believed that the risk of metastasis was low, at around 0.5%,



• **Figure 31-10** **A,** 3-cm lip carcinoma with perineural invasion, extensive induration and subcutaneous spread, and palpable lymph nodes. **B,** Defect after excision. **C,** Specimen with at least 1-cm margin around palpable tumor. **D,** Reconstruction with radial forearm free flap.

but more recent investigators reported significantly higher rates of metastasis (up to 16%) with longer follow-up.[84]

Although some authors recommend elective neck dissection only in cases of clinical evidence of lymph node involvement by exam or imaging, others recommend consideration of elective treatment of at-risk nodal basins in cases with poor prognostic indicators. For clinical N0 necks, factors that should prompt consideration of elective neck dissection include T3 or T4 tumors, commissure involvement, recurrence, and perineural spread.[146] Although these guidelines exist, at this time elective treatment of the N0 neck in lip cancers is controversial.[71,73] Investigators continue to search for biologic markers and improved predictors of aggressive behavior that will better select patients requiring more intensive therapy.[72,74] Elective nodal dissection for lower lip cancers should include level I bilaterally at a minimum, although some recommend bilateral supraomohyoid dissection. Supraomohyoid (levels I to III) or modified neck dissection of levels I to V is indicated in cases of therapeutic neck dissection.[147] It should be noted that upper lip cancers account for only 10% of lip cancers and have unique characteristics. The upper lip and the commissure may metastasize to the periparotid lymph nodes, and superficial parotidectomy may be required if there are clinically enlarged nodes.[148]

Again, sentinel-node biopsy may play a role in the elective management of lip cancers when there is a question of metastatic potential.

In an effort to preserve cosmesis and function, radiation therapy, both external and brachytherapy, may be used as primary treatment in larger lesions.[149] Radiation therapy may also be indicated as an adjunct to surgery in cases of positive margins or nodal disease.

Summary

Although it makes up only 10% of the surface area of the body, the skin of the head and neck is the site for development of the majority of cutaneous malignancies because of its exposure to harmful ultraviolet radiation. Its increasing incidence associated with the significant costs of treatment will require practitioners to be well-versed in the effective and efficient management of these malignancies to limit their morbidity and costs. Oral and maxillofacial surgeons may be called upon to treat skin cancers primarily, or to reconstruct complex defects following tumor extirpation by other surgeons.

References

1. Rogers HW, et al.: Incidence estimate of nonmelanoma skin cancer in the United States, 2006, *Arch Dermatol* 146(3):283–287, 2010.
2. Chen JG, et al.: Cost of nonmelanoma skin cancer treatment in the United States, *Dermatol Surg* 27(12):1035–1038, 2001.
3. Bickers DR, et al.: The burden of skin diseases: 2004 a joint project of the American Academy of Dermatology Association and the Society for Investigative Dermatology, *J Am Acad Dermatol* 55(3):490–500, 2006.
4. Mudigonda T, et al.: The economic impact of non-melanoma skin cancer: a review, *J Natl Compr Canc Netw* 8(8):888–896, 2010.
5. John Chen G, et al.: Treatment patterns and cost of nonmelanoma skin cancer management, *Dermatol Surg* 32(10):1266–1271, 2006.
6. Housman TS, et al.: Skin cancer is among the most costly of all cancers to treat for the Medicare population, *J Am Acad Dermatol* 48(3):425–429, 2003.
7. Christenson LJ, et al.: Incidence of basal cell and squamous cell carcinomas in a population younger than 40 years, *JAMA* 294(6):681–690, 2005.
8. Guy Jr GP, et al.: State indoor tanning laws and adolescent indoor tanning, *Am J Public Health* 104(4):e69–e74, 2014.
9. Diepgen TL, Mahler V: The epidemiology of skin cancer, *Br J Dermatol* 146(Suppl 61):1–6, 2002.
10. Perkins JL, et al.: Nonmelanoma skin cancer in survivors of childhood and adolescent cancer: a report from the childhood cancer survivor study, *J Clin Oncol* 23(16):3733–3741, 2005.
11. Burke MT, et al.: Genetics and nonmelanoma skin cancer in kidney transplant recipients, *Pharmacogenomics* 16(2):161–172, 2015.
12. Lindelof B, et al.: Incidence of skin cancer in 5356 patients following organ transplantation, *Br J Dermatol* 143(3):513–519, 2000.
13. Jensen P, et al.: Skin cancer in kidney and heart transplant recipients and different long-term immunosuppressive therapy regimens, *J Am Acad Dermatol* 40(2 Pt 1):177–186, 1999.
14. Euvrard S, et al.: Skin cancers following pediatric organ transplantation, *Dermatol Surg* 30(4 Pt 2):616–621, 2004.
15. Rashtak S, et al.: Incidence and risk factors for skin cancer following lung transplantation, *J Am Acad Dermatol* 72(1):92–98, 2015.
16. Silverberg MJ, et al.: HIV infection status, immunodeficiency, and the incidence of non-melanoma skin cancer, *J Natl Cancer Inst* 105(5):350–360, 2013.
17. Wehner MR, et al.: Timing of subsequent new tumors in patients who present with basal cell carcinoma or cutaneous squamous cell Carcinoma, *JAMA Dermatol* 151(4):382–388, 2015.
18. Rubin AI, Chen EH, Ratner D: Basal-cell carcinoma, *N Engl J Med* 353(21):2262–2269, 2005.
19. Agbai ON, et al.: Skin cancer and photoprotection in people of color: a review and recommendations for physicians and the public, *J Am Acad Dermatol* 70(4):748–762, 2014.
20. Kiprono SK, Chaula BM, Beltraminelli H: Histological review of skin cancers in African Albinos: a 10-year retrospective review, *BMC Cancer* 14:157, 2014.
21. Yang LC, et al.: Xeroderma Pigmentosum Complementation Group C Protein (XPC) expression in basal cell carcinoma, *In Vivo* 29(1):35–38, 2015.
22. Friedrich RE, et al.: Diagnosis, treatment and follow-up control in 124 patients with basal cell carcinoma of the maxillofacial region treated from 1992 to 1997, *Anticancer Res* 25(3A):1693–1697, 2005.
23. Betti R, et al.: Basosquamous cell carcinoma: a survey of 76 patients and a comparative analysis of basal cell carcinomas and squamous cell carcinomas, *Eur J Dermatol* 23(1):83–86, 2013.
24. McCusker M, et al.: Metastatic basal cell carcinoma: prognosis dependent on anatomic site and spread of disease, *Eur J Cancer* 50(4):774–783, 2014.
25. Proctor AE, Thompson LA, O'Bryant CL: Vismodegib: an inhibitor of the Hedgehog signaling pathway in the treatment of basal cell carcinoma, *Ann Pharmacother* 48(1):99–106, 2014.

26. Gurudutt VV, Genden EM: Cutaneous squamous cell carcinoma of the head and neck, *J Skin Cancer* 2011:502723, 2011.
27. Gloster Jr HM, Neal K: Skin cancer in skin of color, *J Am Acad Dermatol* 55(5):741–760, 2006. quiz 761–764.
28. Glogau RG: The risk of progression to invasive disease, *J Am Acad Dermatol* 42(1 Pt 2):23–24, 2000.
29. Acikalin A, et al.: A unique case of Merkel cell carcinoma with ovarian metastasis, *Balkan Med J* 31(4):356–359, 2014.
30. Raju S, et al.: Treatment of Merkel cell carcinoma of the head and neck: a systematic review, *Dermatol Surg* 40(12):1273–1283, 2014.
31. Tseng J, et al.: Merkel cell carcinoma: what makes a difference? *Am J Surg* 209(2):342–346, 2015.
32. Zhang L, Ge S, Fan X: A brief review of different types of sweat-gland carcinomas in the eyelid and orbit, *Onco Targets Ther* 6:331–340, 2013.
33. Avraham JB, et al.: Survival after resection of cutaneous adnexal carcinomas with eccrine differentiation: risk factors and trends in outcomes, *J Surg Oncol* 108(1):57–62, 2013.
34. Wang LS, et al.: Surgery and adjuvant radiation for high-risk skin adnexal carcinoma of the head and neck, *Am J Clin Oncol*, 2015 Jan 16. [Epub ahead of print].
35. Kallini JR, Khachemoune A: Dermatofibrosarcoma protuberans: is Mohs surgery truly superior? And the success of tyrosine kinase inhibitors, *J Drugs Dermatol* 13(12):1474–1477, 2014.
36. Kyllo RL, Brady KL, Hurst EA: Sebaceous carcinoma: review of the literature, *Dermatol Surg* 41(1):1–15, 2015.
37. Jackson PC, et al.: Merkel cell carcinoma in East Yorkshire: A case series and literature review of current management, *J Plast Reconstr Aesthet Surg* 68(5):667–672, 2015.
38. Yin VT, et al.: Eyelid and ocular surface carcinoma: Diagnosis and management, *Clin Dermatol* 33(2):159–169, 2015.
39. Bishop AJ, et al.: Merkel cell carcinoma of the head and neck: favorable outcomes with radiotherapy, *Head Neck*, 2015 Feb 2 http://dx.doi.org/10.1002/hed.24017. [Epub ahead of print].
40. Agelli M, Clegg LX: Epidemiology of primary Merkel cell carcinoma in the United States, *J Am Acad Dermatol* 49(5):832–841, 2003.
41. Medina-Franco H, et al.: Multimodality treatment of Merkel cell carcinoma: case series and literature review of 1024 cases, *Ann Surg Oncol* 8(3):204–208, 2001.
42. Erickson BP, Henry C, Alabiad CR: Recurrent dermatofibrosarcoma protuberans masquerading as a lacrimal sac neoplasm: a case report and review, *Ophthal Plast Reconstr Surg* 31(5):e135–e138, 2015.
43. Liansheng L, et al.: Report of two cases of recurrent scalp dermatofibrosarcoma protuberans and literature review, *Indian J Dermatol* 59(6):602–605, 2014.
44. Ugurel S, et al.: Neoadjuvant imatinib in advanced primary or locally recurrent dermatofibrosarcoma protuberans: a multicenter phase II DeCOG trial with long-term follow-up, *Clin Cancer Res* 20(2):499–510, 2014.
45. Wetzig T, et al.: No clinical benefit of preoperative fluorescence diagnosis of basal cell carcinoma localized in the H-zone of the face, *Br J Dermatol* 162(6):1370–1376, 2010.
46. Farley RL, Manolidis S, Ratner D: Aggressive basal cell carcinoma with invasion of the parotid gland, facial nerve, and temporal bone, *Dermatol Surg* 32(2):307–315, 2006, discussion 315.
47. Vasconcelos L, et al.: Invasive head and neck cutaneous squamous cell carcinoma: clinical and histopathological characteristics, frequency of local recurrence and metastasis, *An Bras Dermatol* 89(4):562–568, 2014.
48. Szewczyk MP, et al.: Analysis of selected recurrence risk factors after treatment of head and neck basal cell carcinoma, *Postepy Dermatol Alergol* 31(3):146–151, 2014.
49. Szewczyk M, et al.: Analysis of selected risk factors for nodal metastases in head and neck cutaneous squamous cell carcinoma, *Eur Arch Otorhinolaryngol* 272(10):3007–3012, 2015.
50. Warren TA, et al.: Outcomes following surgery and post-operative radiotherapy for perineural spread of head and neck cutaneous squamous cell carcinoma, *Head Neck* 38(6):824-831, 2014.
51. Yosipovitch G, et al.: Association of pain and itch with depth of invasion and inflammatory cell constitution in skin cancer: results of a large clinicopathologic study, *JAMA Dermatol* 150(11):1160–1166, 2014.
52. Gupta A, et al.: Management of squamous cell and basal cell carcinomas of the head and neck with perineural invasion, *Australas J Dermatol* 57(1):3–13, 2016.
53. Adams CC, Thomas B, Bingham JL: Cutaneous squamous cell carcinoma with perineural invasion: a case report and review of the literature, *Cutis* 93(3):141–144, 2014.
54. Garcia-Serra A, et al.: Carcinoma of the skin with perineural invasion, *Head Neck* 25(12):1027–1033, 2003.
55. Southwell KE, et al.: Effect of immunocompromise on metastatic cutaneous squamous cell carcinoma in the parotid and neck, *Head Neck* 28(3):244–248, 2006.
56. Snow SN, Madjar Jr DD: Mohs surgery in the management of cutaneous malignancies, *Clin Dermatol* 19(3):339–347, 2001.
57. Palmer VM, Wilson PR: Incompletely excised basal cell carcinoma: residual tumor rates at Mohs re-excision, *Dermatol Surg* 39(5):706–718, 2013.
58. Carroll AE: How useful are screening tests? *JAMA* 313(13):1304, 2015.
59. Zoorob R, et al.: Cancer screening guidelines, *Am Fam Physician* 63(6):1101–1112, 2001.
60. Helfand M, et al.: Screening for skin cancer, *Am J Prev Med* 20(3 Suppl):47–58, 2001.
61. Fitzpatrick TB: The validity and practicality of sun-reactive skin types I through VI, *Arch Dermatol* 124(6):869–871, 1988.
62. Glogau RG, Matarasso SL: Chemical peels. Trichloroacetic acid and phenol, *Dermatol Clin* 13(2):263–276, 1995.
63. O'Brien CJ, et al.: Significance of clinical stage, extent of surgery, and pathologic findings in metastatic cutaneous squamous carcinoma of the parotid gland, *Head Neck* 24(5):417–422, 2002.
64. Vauterin TJ, et al.: Patterns of lymph node spread of cutaneous squamous cell carcinoma of the head and neck, *Head Neck* 28(9):785–791, 2006.
65. Neitzel CD: Biopsy techniques for skin disease and skin cancer, *Oral Maxillofac Surg Clin North Am* 17(2):143–146, 2005.
66. Sellheyer K, Bergfeld WF: Differences in biopsy techniques of actinic keratoses by plastic surgeons and dermatologists: a histologically controlled pilot study, *Arch Dermatol* 142(4):455–459, 2006.
67. Saindane AM: Pitfalls in the staging of cervical lymph node metastasis, *Neuroimaging Clin N Am* 23(1):147–166, 2013.
68. Arya S, Rane P, Deshmukh A: Oral cavity squamous cell carcinoma: role of pretreatment imaging and its influence on management, *Clin Radiol* 69(9):916–930, 2014.
69. Beer K, Waibel J: Recurrent basal cell carcinoma discovered using positron emission tomography (PET) scanning, *J Drugs Dermatol* 7(9):879–881, 2008.
70. Ducic Y, Marra DE: Metastatic basal cell carcinoma, *Am J Otolaryngol* 32(6):455–458, 2011.

71. Ko Y, et al.: Role of 18F-FDG PET/CT in the diagnosis of clinically suspected Marjolin ulcer, *AJR Am J Roentgenol* 199(6):1375–1379, 2012.
72. Joshi P, et al.: Detection by (18)F-FDG PET of unsuspected extensive bone marrow metastases in a case of basosquamous carcinoma of the cheek, *Hell J Nucl Med* 14(3):307–308, 2011.
73. Cho SB, et al.: Fluorodeoxyglucose positron emission tomography in cutaneous squamous cell carcinoma: retrospective analysis of 12 patients, *Dermatol Surg* 31(4):442–446, 2005, discussion 446–447.
74. Fosko SW, et al.: Positron emission tomography for basal cell carcinoma of the head and neck, *Arch Dermatol* 139(9):1141–1146, 2003.
75. Yao M, et al.: Merkel cell carcinoma: two case reports focusing on the role of fluorodeoxyglucose positron emission tomography imaging in staging and surveillance, *Am J Clin Oncol* 28(2):205–210, 2005.
76. Singh H, et al.: Apocrine sweat gland carcinoma: initial evaluation, staging, and response monitoring using ^{18}F-FDG PET/CT, *Clin Nucl Med* 38(5):e223–e225, 2013.
77. Kumar R, et al.: ^{18}F-fluorodeoxyglucose-positron emission tomography in evaluation of primary cutaneous lymphoma, *Br J Dermatol* 155(2):357–363, 2006.
78. Keu KV, Iagaru AH: The clinical use of PET/CT in the evaluation of melanoma, *Methods Mol Biol* 1102:553–580, 2014.
79. Danielsen M, et al.: Positron emission tomography in the follow-up of cutaneous malignant melanoma patients: a systematic review, *Am J Nucl Med Mol Imaging* 4(1):17–28, 2013.
80. Roh JL, et al.: Use of ^{18}F-fluorodeoxyglucose positron emission tomography in patients with rare head and neck cancers, *Clin Exp Otorhinolaryngol* 1(2):103–109, 2008.
81. Edge SB: *American Joint Committee on Cancer: AJCC cancer staging manual*, ed 7, New York, 2010, Springer.
82. O'Brien CJ, et al.: Incidence of cervical node involvement in metastatic cutaneous malignancy involving the parotid gland, *Head Neck* 23(9):744–748, 2001.
83. Buethe D, et al.: Focus issue on squamous cell carcinoma: practical concerns regarding the 7th Edition AJCC Staging Guidelines, *J Skin Cancer* 2011:156391, 2011.
84. Lardaro T, et al.: Improvements in the staging of cutaneous squamous-cell carcinoma in the 7th edition of the AJCC Cancer Staging Manual, *Ann Surg Oncol* 17(8):1979–1980, 2010.
85. Farasat S, et al.: A new American Joint Committee on Cancer staging system for cutaneous squamous cell carcinoma: creation and rationale for inclusion of tumor (T) characteristics, *J Am Acad Dermatol* 64(6):1051–1059, 2011.
86. Ermertcan AT, Hellings PW, Cingi C: Nonmelanoma skin cancer of the head and neck: nonsurgical treatment, *Facial Plast Surg Clin North Am* 20(4):445–454, 2012.
87. Bahner JD, Bordeaux JS: Non-melanoma skin cancers: photodynamic therapy, cryotherapy, 5-fluorouracil, imiquimod, diclofenac, or what? Facts and controversies, *Clin Dermatol* 31(6):792–798, 2013.
88. Lansbury L, et al.: Interventions for non-metastatic squamous cell carcinoma of the skin: systematic review and pooled analysis of observational studies, *BMJ* 347:f6153, 2013.
89. White GM, Zhou HC, Burchette RJ: Biopsy followed by immediate curettage and electrodesiccation of suspected basal cell carcinomas at the first visit, *JAMA Dermatol* 149(8):980–981, 2013.
90. Donaldson MR, Coldiron BM: Scars after second intention healing, *Facial Plast Surg* 28(5):497–503, 2012.
91. Alexiades-Armenakas M, Ramsay D, Kopf AW: The appropriateness of curettage and electrodesiccation for the treatment of basal cell carcinomas, *Arch Dermatol* 136(6):800, 2000.
92. Hantash BM, et al.: Facial resurfacing for nonmelanoma skin cancer prophylaxis, *Arch Dermatol* 142(8):976–982, 2006.
93. Mohs FE: Mohs micrographic surgery. A historical perspective, *Dermatol Clin* 7(4):609–611, 1989.
94. Mohs FE: Chemosurgery: microscopically controlled surgery for skin cancer—past, present and future, *J Dermatol Surg Oncol* 4(1):41–54, 1978.
95. Lane JE, Kent DE: Surgical margins in the treatment of nonmelanoma skin cancer and Mohs micrographic surgery, *Curr Surg* 62(5):518–526, 2005.
96. Gardner ES, Sumner WT, Cook JL: Predictable tissue shrinkage during frozen section histopathologic processing for Mohs micrographic surgery, *Dermatol Surg* 27(9):813–818, 2001.
97. Fahrner 3rd LJ: Mohs micrographic surgery for mucocutaneous malignancies, *Oral Maxillofac Surg Clin North Am* 17(2):161–171, 2005.
98. Nouri K, Rivas MP: A primer of Mohs micrographic surgery: common indications, *Skinmed* 3(4):191–196, 2004.
99. Thomas DJ, King AR, Peat BG: Excision margins for nonmelanotic skin cancer, *Plast Reconstr Surg* 112(1):57–63, 2003.
100. Gulleth Y, et al.: What is the best surgical margin for a basal cell carcinoma: a meta-analysis of the literature, *Plast Reconstr Surg* 126(4):1222–1231, 2010.
101. Bisson MA, et al.: Do plastic surgeons resect basal cell carcinomas too widely? A prospective study comparing surgical and histological margins, *Br J Plast Surg* 55(4):293–297, 2002.
102. Griffiths RW, Suvarna SK, Stone J: Basal cell carcinoma histological clearance margins: an analysis of 1539 conventionally excised tumours. Wider still and deeper? *J Plast Reconstr Aesthet Surg* 60(1):41–47, 2007.
103. Huang CC, Boyce SM: Surgical margins of excision for basal cell carcinoma and squamous cell carcinoma, *Semin Cutan Med Surg* 23(3):167–173, 2004.
104. Strong JW, Worsham GF, Hagerty RC: Peripheral in-continuity tissue examination: a modification of Mohs' micrographic surgery, *Clin Plast Surg* 31(1):1–4, 2004.
105. Manstein ME, Manstein CH, Smith R: How accurate is frozen section for skin cancers? *Ann Plast Surg* 50(6):607–609, 2003.
106. DiNardo LJ, et al.: Accuracy, utility, and cost of frozen section margins in head and neck cancer surgery, *Laryngoscope* 110(10 Pt 1):1773–1776, 2000.
107. Hallock GG, Lutz DA: A prospective study of the accuracy of the surgeon's diagnosis and significance of positive margins in nonmelanoma skin cancers, *Plast Reconstr Surg* 107(4):942–947, 2001.
108. Wilson AW, et al.: Surgical management of incompletely excised basal cell carcinomas of the head and neck, *Br J Oral Maxillofac Surg* 42(4):311–314, 2004.
109. Kropp L, et al.: Mohs resection and postoperative radiotherapy for head and neck cancers with incidental perineural invasion, *Am J Otolaryngol* 34(5):373–377, 2013.
110. Ravitskiy L, Brodland DG, Zitelli JA: Cost analysis: Mohs micrographic surgery, *Dermatol Surg* 38(4):585–594, 2012.
111. Rogers HW, Coldiron BM: A relative value unit-based cost comparison of treatment modalities for nonmelanoma skin cancer: effect of the loss of the Mohs multiple surgery reduction exemption, *J Am Acad Dermatol* 61(1):96–103, 2009.
112. Bialy TL, et al.: Mohs micrographic surgery vs traditional surgical excision: a cost comparison analysis, *Arch Dermatol* 140(6):736–742, 2004.

113. Wermker K, et al.: Prediction score for lymph node metastasis from cutaneous squamous cell carcinoma of the external ear, *Eur J Surg Oncol* 41(1):128–135, 2015.
114. Wiener M, Uren RF, Thompson JF: Lymphatic drainage patterns from primary cutaneous tumours of the forehead: refining the recommendations for selective neck dissection, *J Plast Reconstr Aesthet Surg* 67(8):1038–1044, 2014.
115. Hong TS, et al.: Parotid area lymph node metastases from cutaneous squamous cell carcinoma: implications for diagnosis, treatment, and prognosis, *Head Neck* 27(10):851–856, 2005.
116. Lin D, et al.: Lymphatic drainage patterns of head and neck cutaneous melanoma observed on lymphoscintigraphy and sentinel lymph node biopsy, *Head Neck* 28(3):249–255, 2006.
117. Wagner JD, et al.: Sentinel node biopsy for high-risk nonmelanoma cutaneous malignancy, *Arch Dermatol* 140(1):75–79, 2004.
118. Sahn RE, Lang PG: Sentinel lymph node biopsy for high-risk nonmelanoma skin cancers, *Dermatol Surg* 33(7):786–792, 2007, discussion 792–793.
119. Allen JE, Stolle LB: Utility of sentinel node biopsy in patients with high-risk cutaneous squamous cell carcinoma, *Eur J Surg Oncol* 41(2):197–200, 2015.
120. Weisberg NK, Bertagnolli MM, Becker DS: Combined sentinel lymphadenectomy and Mohs micrographic surgery for high-risk cutaneous squamous cell carcinoma, *J Am Acad Dermatol* 43(3):483–488, 2000.
121. Michl C, et al.: Sentinel lymphonodectomy in nonmelanoma skin malignancies, *Br J Dermatol* 149(4):763–769, 2003.
122. Devaney KO, et al.: Sentinel node biopsy and head and neck tumors—where do we stand today? *Head Neck* 28(12):1122–1131, 2006.
123. Hwang S, et al.: Prognostic impact of tumor growth type on 7th AJCC Staging System for Intrahepatic Cholangiocarcinoma: a single-center experience of 659 cases, *J Gastrointest Surg* 19(7):1291–1304, 2015.
124. Shi G, et al.: Evaluation of the value of 7th editions of UICC-AJCC esophageal and gastric cancer TNM staging systems for prognostic prediction of adenocarcinoma of esophagogastric junction (Siewert type II), *Zhonghua Zhong Liu Za Zhi* 36(12):916–921, 2014.
125. Tang X, et al.: The 7th AJCC/UICC TNM staging system may be not suitable in predicting prognosis of synchronous multiple gastric carcinoma patients with D2 gastrectomy, *Tumour Biol* 36(5):3653–3659, 2015.
126. Zong J, et al.: Impact of intensity-modulated radiotherapy on nasopharyngeal carcinoma: Validation of the 7th edition AJCC staging system, *Oral Oncol* 51(3):254–259, 2015.
127. Deutsch GB, et al.: Incorporating surgical quality into the AJCC 7th edition improves staging accuracy in gastric cancer, *Ann Surg Oncol* 22(1):11–16, 2015.
128. Vrachimis A, et al.: No significant difference in the prognostic value of the 5th and 7th editions of AJCC staging for differentiated thyroid cancer, *Clin Endocrinol (Oxf)* 80(6):911–917, 2014.
129. Chu VH, et al.: Impact of the 2009 (7th edition) AJCC melanoma staging system in the classification of thin cutaneous melanomas, *Biomed Res Int* 2013:898719, 2013.
130. Zhang J, et al.: Comparison of metastatic lymph node ratio staging system with the 7th AJCC system for colorectal cancer, *J Cancer Res Clin Oncol* 139(11):1947–1953, 2013.
131. Kreppel M, et al.: Comparison of TNM-based stage grouping versus UICC/AJCC stage grouping (7th edition) in malignant parotid gland tumors, *Oral Oncol* 49(9):903–910, 2013.
132. Pan J, et al.: A comparison between the Chinese 2008 and the 7th edition AJCC staging systems for nasopharyngeal carcinoma, *Am J Clin Oncol* 38(2):189–196, 2015.
133. Crawford C, et al.: Application of the AJCC 7th edition carcinoma of the eyelid staging system: a medical center pathology based, 15-year review, *Clin Ophthalmol* 5:1645–1648, 2011.
134. Lee HL: Usefulness of 7th UICC/AJCC classification for stomach cancer in Korean patients, *Korean J Gastroenterol* 58(5):233–234, 2011.
135. Kim SH, Ha TK, Kwon SJ: Evaluation of the 7th AJCC TNM Staging System in point of lymph node classification, *J Gastric Cancer* 11(2):94–100, 2011.
136. McGhan LJ, et al.: Validation of the updated 7th edition AJCC TNM staging criteria for gastric adenocarcinoma, *J Gastrointest Surg* 16(1):53–61, 2012, discussion 61.
137. Santiago JM, Sasako M, Osorio J: TNM-7th edition 2009 (UICC/AJCC) and Japanese Classification 2010 in Gastric Cancer. Towards simplicity and standardisation in the management of gastric cancer, *Cir Esp* 89(5):275–281, 2011.
138. Qiu MZ, et al.: Comparison of 6th and 7th AJCC TNM staging classification for carcinoma of the stomach in China, *Ann Surg Oncol* 18(7):1869–1876, 2011.
139. Droll L, Seigler D, Esmaeli B: Prospective collection of data using the 7th edition of the AJCC Cancer Staging Manual for cancers of the eyelid, orbit, and conjunctiva, *Ophthal Plast Reconstr Surg* 27(2):142, 2011.
140. Rice TW, Blackstone EH, Rusch VW: 7th edition of the AJCC Cancer Staging Manual: esophagus and esophagogastric junction, *Ann Surg Oncol* 17(7):1721–1724, 2010.
141. Brandwein-Gensler M, Smith RV: Prognostic indicators in head and neck oncology including the new 7th edition of the AJCC staging system, *Head Neck Pathol* 4(1):53–61, 2010.
142. Edge SB, Compton CC: The American Joint Committee on Cancer: the 7th edition of the AJCC cancer staging manual and the future of TNM, *Ann Surg Oncol* 17(6):1471–1474, 2010.
143. Rootman J, White VA: Changes in the 7th edition of the AJCC TNM classification and recommendations for pathologic analysis of lacrimal gland tumors, *Arch Pathol Lab Med* 133(8):1268–1271, 2009.
144. Finger PT: 7th Edition, AJCC-UICC Ophthalmic Oncology Task Force: The 7th edition AJCC staging system for eye cancer: an international language for ophthalmic oncology, *Arch Pathol Lab Med* 133(8):1197–1198, 2009.
145. Metchnikoff C, et al.: The 7th edition AJCC staging system for cutaneous squamous cell carcinoma accurately predicts risk of recurrence for heart and lung transplant recipients, *J Am Acad Dermatol* 67(5):829–835, 2012.
146. Meani RE, et al.: Emergence of chemoresistance in a metastatic basal cell carcinoma patient after complete response to hedgehog pathway inhibitor vismodegib (GDC-0449), *Australas J Dermatol* 55(3):218–221, 2014.
147. Carvalho CT, et al.: Metastatic basal cell carcinoma: a frequent disease with rare clinical evolution, *BMJ Case Rep* 2015, 2015 Apr 24.
148. Nongrum HB, et al.: Metastatic basal cell carcinoma to the lungs: case report and review of literature, *Indian Dermatol Online J* 5(Suppl 1):S26–S29, 2014.
149. Bilir Y, et al.: Metastatic basal cell carcinoma accompanying Gorlin syndrome, *Case Rep Oncol Med* 2014:362b32, 2014.

32

The Use of Radiation Therapy in Treatment of Head and Neck Cancer

WILLIAM L. BARRETT, MICHELLE L. MIERZWA

Almost since Wilhelm Roentgen discovered the x-ray in 1896, there has been interest in the use of radiation as treatment for malignant disease, including cancers of the head and neck. The ability of radiotherapy to reduce and sometimes eradicate cancer was appreciated in the early years of experimentation with the new modality. The use of radiation therapy for treatment of cancer of the head and neck was of particular interest because of the frequent morbidity of surgical resection of head and neck cancer with the frequent deleterious effects on speech and swallowing function as well as cosmesis associated with surgical resection. After many years of improving radiotherapy delivery methods and dose schedules, the approach remains attractive today and is frequently preferred, allowing for preservation of speech and swallowing function with eradication of disease in many cases. The modality has evolved through the years with the development of high-energy radiation machines capable of sparing superficial normal tissues; the development of effective radioisotopes for interstitial and intracavitary applications; the appreciation of biologic differences between normal tissues and tumors relative to response to radiation, allowing more optimal radiation dose schedules; the integration of systemic therapies with radiation; and the complex delivery of radiotherapy from multiple orientations and dose modifications to enhance tumor response with protection of normal tissue. The past 100 years have been extremely exciting in the evolution of radiotherapy as definitive treatment and as adjuvant therapy for patients with carcinomas of the head and neck, and the field is currently improving rapidly with continued improvements in technology.

Overview

Histologies

Squamous cell carcinoma is the most common cancer—over 90%—of the head and neck. It has been associated with chronic tobacco and/or alcohol exposure. Prognosis varies with the extent of disease present at the time of treatment, subsites involved, and technical aspects of the treatment delivery. Biologic aspects of the tumor, largely undefined to date, also affect the natural history of the disease and prognosis.

Other cancers include Hodgkin lymphoma (HL) and non-Hodgkin lymphoma (NHL), sarcomas of soft tissue and bone, thyroid cancers, salivary gland malignancies, and skin cancers. Mucosal melanomas are uncommon, as are carcinoids and small cell carcinomas.

Lymphomas are considered sensitive to both radiation and chemotherapy, and these modalities are used in treatment strategies for either HL or NHL. Surgery is generally not a part of the therapy regimen for these diseases. Hodgkin disease is most often managed by radiation therapy, chemotherapy, or a combination of those treatments, depending on the extent of the disease and the patient's age, gender, and comorbidities. Radiotherapy is typically delivered as once-per-day treatment with five treatments per week, with total doses typically totaling between 3000 and 4000 cGy, which is associated with high efficacy for disease eradication.[1] NHLs of the head and neck can be managed by observation, chemotherapy, and/or radiation therapy, depending on the histologic grade, extent of disease, patient age, and patient comorbidities. Most NHLs are sensitive to radiation, with doses between 3000 and 4500 cGy most often used.

Sarcomas of the head and neck are most often managed by a combination of surgical resection and radiation therapy given preoperatively or postoperatively. Typical preoperative radiation doses include 4500 cGy in 25 treatments at 180 cGy per day, and postoperative doses are typically on the order of 5940 cGy in 33 treatments with 180 cGy per day. Interstitial radiation when used alone typically entails approximately 4500 cGy delivered over 4 to 5 days, commonly with continuous iridium. When interstitial radiation

is used as a boost following preoperative radiation or before planned postoperative external radiation, the interstitial boost is typically approximately 2000 cGy over 2 days, most often with iridium.[2]

Thyroid cancers can be grossly divided into differentiated carcinomas that concentrate iodine (papillary and follicular) and poorly differentiated carcinomas that typically do not concentrate iodine, including medullary and anaplastic histologies. Papillary or follicular carcinomas of the thyroid are most often managed with surgical resection and frequently adjuvant iodine-131 (^{131}I) treatment. Indications for external radiation therapy include extracapsular extension of disease at the primary site, persistent known or suspected residual disease following ^{131}I therapy on the basis of grossly apparent disease clinically and/or radiographically, or a persistently elevated thyroglobulin level. When adjuvant radiation therapy is delivered, the radiotherapy is typically 5000 to 6000 cGy, typically 180 to 200 cGy per day with five treatments per.[3-5] Similar doses are frequently delivered postoperatively after resection of medullary carcinoma of the thyroid.[6] Anaplastic carcinoma of the thyroid has an extremely poor prognosis and is managed sometimes with surgical resection with adjuvant radiation therapy, sometimes radiation alone, and sometimes radiation with systemic therapy. Radiation doses are typically in the 6000 to 7000 cGy range at 200 cGy per day.

Mucosal melanomas are uncommon. When treated with radiation therapy definitively or as adjuvant therapy, larger fractions of typically 250 cGy or more daily are used to a total dose of 5000 cGy.[7] Cutaneous and mucosal melanomas are thought to require higher doses per treatment than squamous cell carcinomas of the head and neck because of an inherent biologic radioresistance.

Head and Neck Sites of Disease

Oral Cavity

Squamous cell carcinomas of the oral cavity most frequently involve the oral tongue and/or floor of mouth, but other potential primary sites include the lips, buccal mucosa, hard palate, gingiva, and retromolar trigone. Surgical resection is generally the first consideration if the disease is thought amenable to resection with preservation of speech and swallowing function. In the situation of technically unresectable disease or the anticipation that resection would be particularly deleterious to speech and/or swallowing function, radiotherapy as definitive treatment, with or without systemic therapy, is frequently a consideration. Adjuvant radiation delivered preoperatively or postoperatively is frequently considered in the setting of locoregionally advanced disease.

Definitive radiotherapy frequently entails external radiation directed to the primary sites and regional lymph nodes in the neck to a dose on the order of 5000 cGy in 25 treatments with subsequent localized boost radiation to the primary site and any gross adenopathy. Palpable lymph nodes typically receive an additional 2000 cGy in 10 treatments, whereas the primary disease in the oral cavity can be further treated with an electron cone on the order of 2400 cGy in eight treatments or with an interstitial implant, often with iridium delivering 2500 cGy to the tumor over 2 to 3 days. Local tumor control rates by stage of disease are listed in Table 32-1. In the absence of obvious nodal disease, the neck is generally prophylactically treated for the possibility of occult nodal disease. If the decision is made to observe the neck, the primary site can be treated with an interstitial implant alone on the order of 6000 cGy over 6 days with iridium. An oral tongue interstitial implant is pictured clinically and radiographically in Figure 32-1.

Oropharynx

Subsites of the oropharynx include the base of tongue, palatine tonsils, soft palate, and pharyngeal wall. Radiotherapy is frequently used as part or all of the treatment for patients with squamous cell carcinomas in these sites. If disease is considered technically unresectable or if resection is thought to be associated with significant morbidity, radiation therapy alone or with systemic therapy is frequently used. For advanced resectable disease, radiation is frequently delivered preoperatively or postoperatively as an adjuvant treatment. Definitive radiation therapy for tonsil, soft palate, and pharyngeal wall squamous cell carcinomas is typically external radiation throughout. Figure 32-2 demonstrates a patient treated with definitive radiotherapy for a tonsillar cancer. Base-of-tongue cancers are sometimes treated with a combination of external radiation therapy and interstitial implant with doses similar to those used for oral cavity squamous cell carcinomas. Treatment results are listed in Table 32-2.

Larynx

The larynx is typically divided into the glottis, including the true vocal cords and anterior commissure; the subglottis, just below the glottis; and the supraglottic larynx, including the epiglottis, arytenoids, aryepiglottic folds, false vocal cords, and ventricles. Squamous cell carcinomas of the larynx are frequently treated with definitive radiation therapy with or without systemic therapy in an attempt to preserve speech function. Cancers clinically confined to the glottis are thought to have low metastatic lymph node potential and are typically treated with relatively small external radiation therapy fields, as depicted in Figure 32-3. More advanced glottic cancers and supraglottic cancers are considered at risk of lymph node metastases, and lymph nodes are typically treated. A typical 3D conformal field used to

TABLE 32-1 Local Control Rates of Oral Cavity Tumors Treated with Radiation Alone by Stage of Disease

Disease Stage	5-Year Local Control Rate[59,60]
T1	88-100
T2	85-93
T3	50-70
T4	30-60

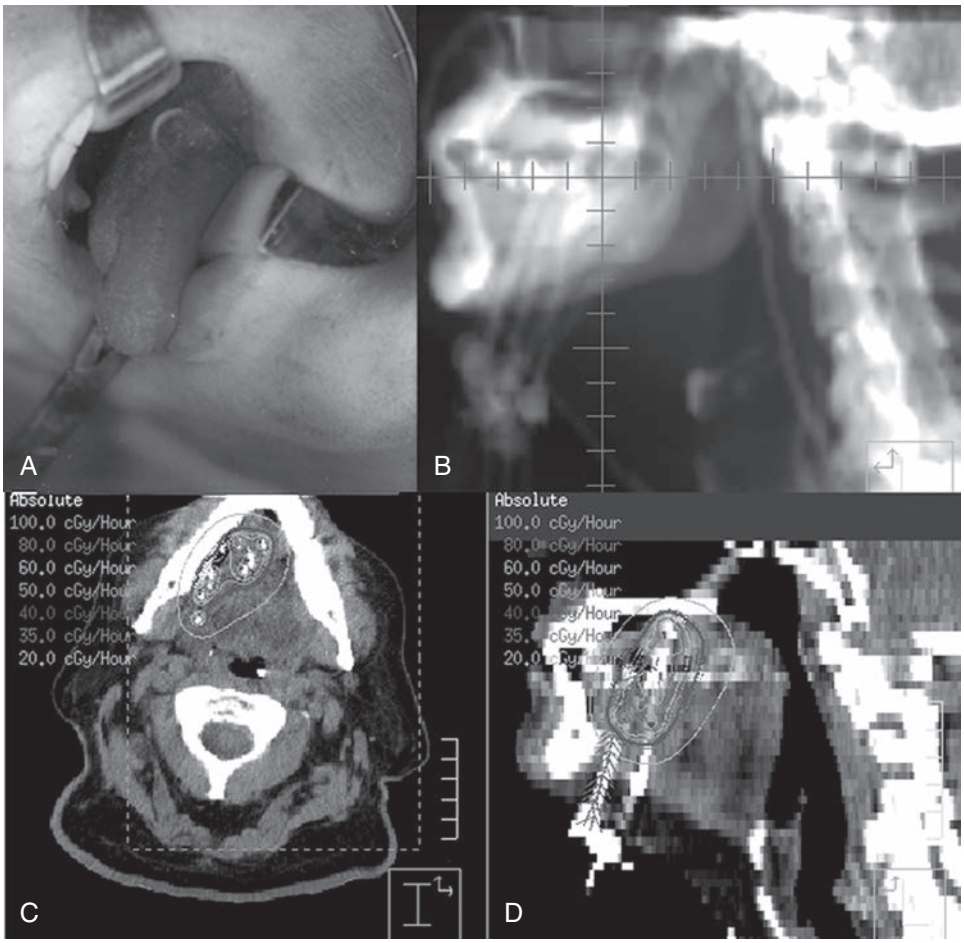

• **Figure 32-1** **A,** Oral tongue interstitial brachytherapy implant with catheters placed through the tongue. **B,** Digitally reconstructed radiograph of interstitial catheters placed in the tongue. **C,** Dosimetric calculations for iridium-192 tongue implant in transverse and, **D,** sagittal computed tomographic reconstructions. Note the sharp dose falloff with distance from the iridium sources.

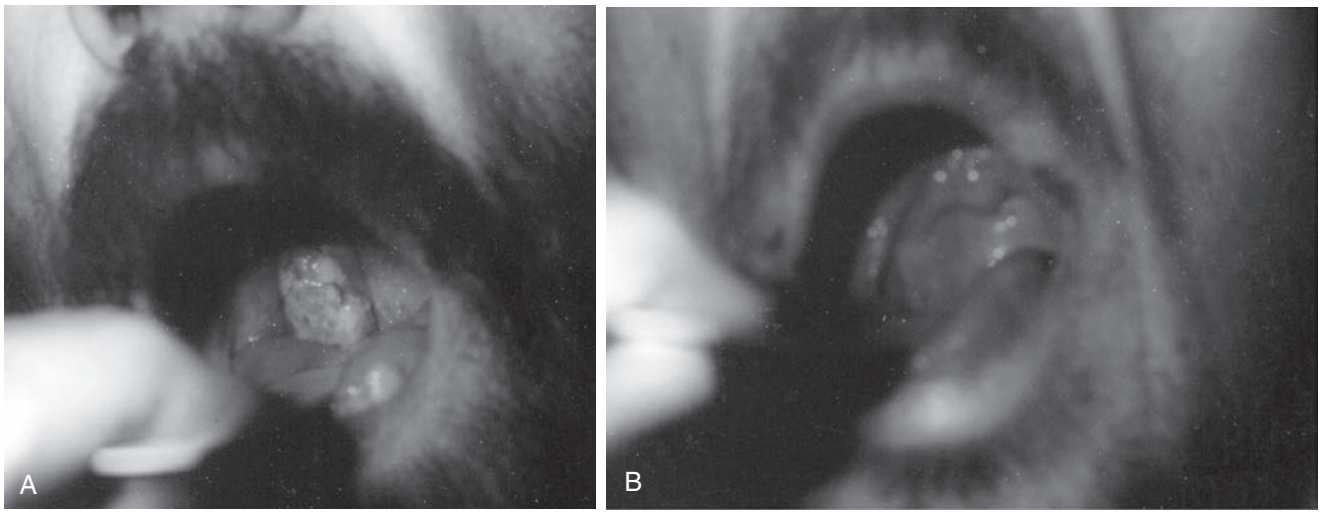

• **Figure 32-2** Clinical appearance of a squamous cell carcinoma of the tonsillar fossa **(A)** before and **(B)** after treatment with definitive radiotherapy.

treat an advanced laryngeal cancer is shown in Figure 32-4. Patients who present with hoarseness frequently experience improvement in voice function in the first 2 to 3 weeks of the radiation course with subsequent decline in voice function as a result of mucositis and laryngeal edema, which are typically transient with typical improvement in voice function by several weeks after radiation therapy. Treatment results are shown in Table 32-3. Neoadjuvant chemotherapy prior to radiation therapy has been shown to be no worse than up-front laryngectomy and postoperative radiation therapy for locally advanced laryngeal cancer in a randomized trial,[8] but neoadjuvant chemotherapy followed by radiation therapy has been shown to be no more effective than radiation therapy alone in another randomized trial.[9] That trial did show an advantage to the addition of concurrent cisplatin with radiation for locally advanced laryngeal cancer.

TABLE 32-2 Local Control Rates at 5 years of Oropharyngeal Carcinoma by Site and Stage of Disease Treated with External Beam with or without Interstitial Radiation Therapy

Disease Site	T1	T2	T3	T4
Base of tongue[18-21]	87%-96%	74%-93%	59%-82%	28%-52%
Tonsil[22-25]	83%-95%	79%-88%	58%-74%	40%-60%
Soft palate[26-28]	90%-100%	65%-95%	50%-77%	24%-37%
Pharyngeal wall[29-31]	91%	73%-93%	82%-61%	37%

Hypopharynx

Subsites of the hypopharynx include the pyriform sinuses, post-cricoid region, and posterior pharyngeal wall. Squamous cell carcinomas of the hypopharynx are managed sometimes with surgical resection, often with preoperative or postoperative external radiation therapy, sometimes with definitive radiation therapy, and sometimes with radiation therapy with concurrent systemic therapy. Surgical resection is typically morbid relative to speech and swallowing function where larger tumors require laryngopharyngoesophagectomies. Radiation doses are similar to those discussed for cancers of the oral cavity and oropharynx. Results for treatment of cancers of the hypopharynx are shown in Table 32-4.

Nasopharynx

Cancers of the nasopharynx typically come in two general varieties. Squamous cell carcinomas of the nasopharynx behave in similar fashion to squamous cell carcinomas of other head and neck sites, typically with sequential growth at the primary site and subsequent development of lymph node metastasis and possible later hematologic metastases. The other form of nasopharyngeal cancer, sometimes referred to as lymphoepithelioma or undifferentiated carcinoma of the nasopharynx, (1) is associated with Epstein-Barr virus, (2) is much more common in the Far East than

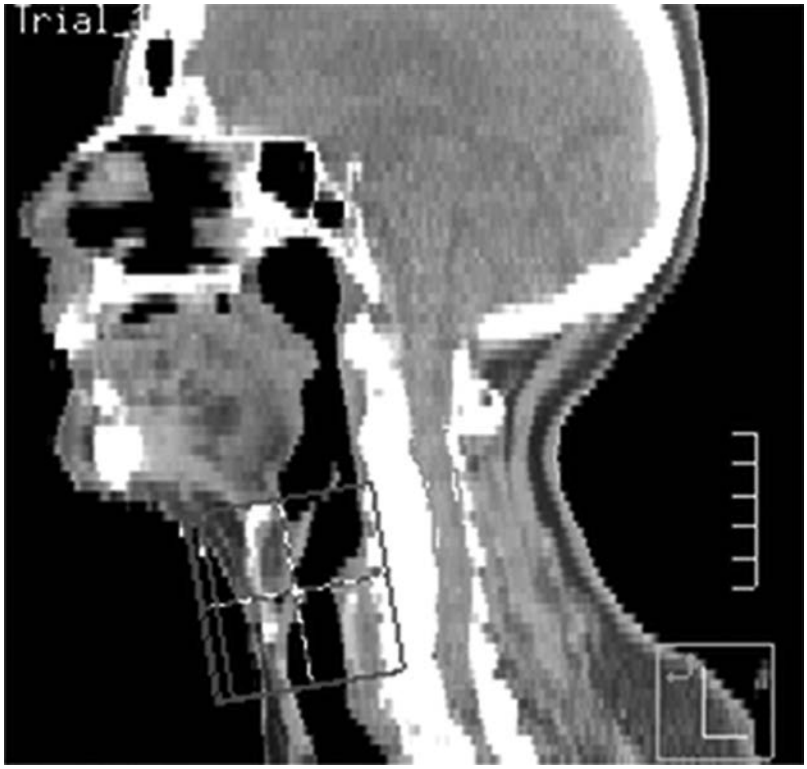

• **Figure 32-3** Typical small-field radiation treatment portal for an early-stage laryngeal cancer confined to the glottis.

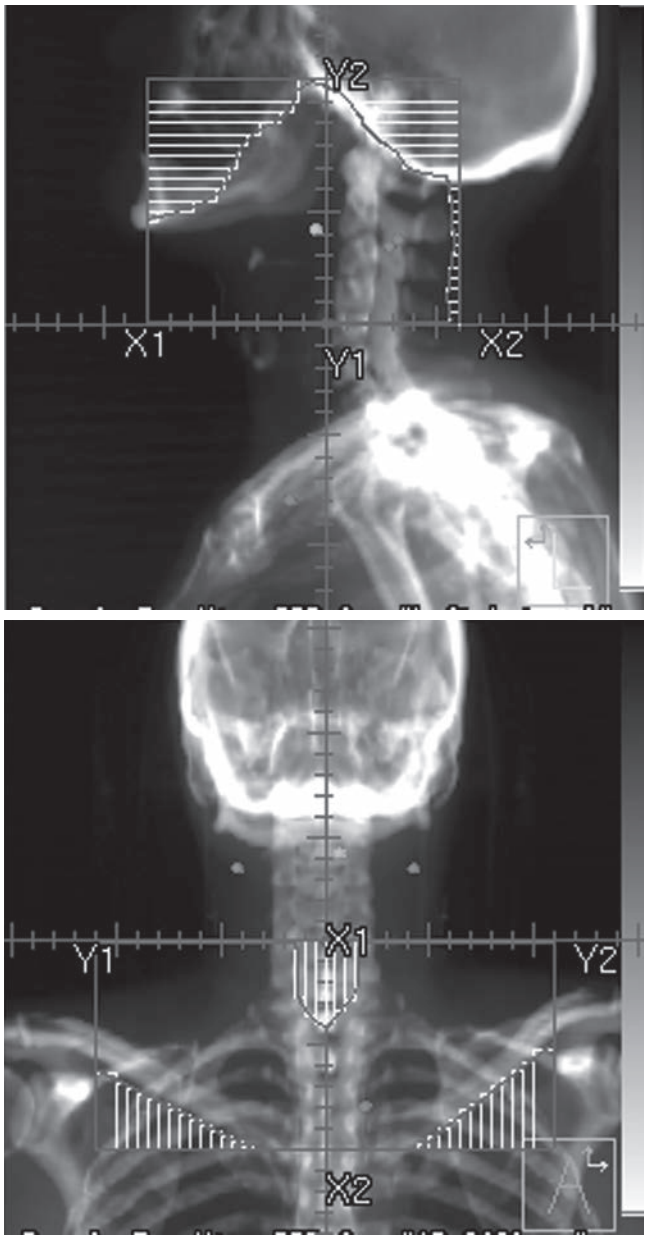

• **Figure 32-4** Typical 3D conformal radiation treatment portals used in the treatment of advanced head and neck cancers. Cervical lymph node levels 1 through 5 are typically treated.

TABLE 32-3 Local Control Results for Laryngeal Cancer Treated with Radiation at 5 Years (by T Stage)

Disease Site	T1	T2	T3	T4
Glottis[32-40]	84%-100%	61%-90%	40%-75%	38%-49%*
Supraglottis[41-45]	80%-93%*	66%-77%*	50%-65%	36%-67%

*Ultimate control rates after surgical salvage 65%-95%.

in the Western world, (3) typically presents with large adenopathy, (4) is particularly sensitive to radiotherapy, and (5) has a high propensity for distant metastases. Radiation therapy with concurrent cisplatin and adjuvant post-radiotherapy, 5-fluorouracil (5-FU), and cisplatin has been shown to be superior to radiotherapy alone for advanced cancers of the nasopharynx.[10] Radiotherapy is typically external radiation therapy alone on the order of 7000 cGy to the primary site and gross adenopathy with 5000 cGy delivered to areas thought to be at risk for microscopic lymph node disease. Results of treatment are shown in Table 32-5.

Unknown Primary

Squamous cell carcinoma involving lymph nodes in the neck without an apparent primary lesion is an uncommon but not rare presentation. The most common management includes a careful clinical and radiographic assessment to rule out an apparent primary tumor, which typically includes a thorough examination of the skin, oral cavity, oropharynx, nasopharyngoscopy, laryngoscopy, esophagoscopy, and bronchoscopy, as well as imaging including computed tomography (CT) scan of the neck, chest x-ray, and frequently CT of the chest and positron emission tomography (PET) scan. If no primary tumor is apparent, the most common management includes neck dissection followed by radiation therapy to both necks and the most likely sites of an occult primary, including the nasopharynx, palatine tonsils, base of tongue, and pyriform sinuses. Results of treatment are shown in Table 32-6.

Treatment

Definitive Radiotherapy

Many cancers of the head and neck are amenable to definitive radiotherapy as the primary mode of treatment as a curative attempt, frequently with the preservation of function and cosmesis. Adjuvant surgery is sometimes used in a setting of advanced neck disease where neck dissection is performed before or more commonly after definitive radiation. Systemic therapy is sometimes used with definitive radiation therapy in an attempt to sensitize tumor cells to radiation and eradicate tumor cells that may not have been otherwise killed by the radiation. Definitive radiotherapy can be with external radiation therapy alone, sometimes interstitial radiation alone, or sometimes the combination of external and interstitial radiation. Definitive radiotherapy is typically used in the setting of technically unresectable disease or disease in which resection would be anticipated to cause significant morbidity, particularly relative to the patient's speech and/or swallowing function.

Preoperative and Postoperative Radiotherapy

Adjuvant or neoadjuvant preoperative radiation therapy is frequently a consideration for locoregionally advanced cancers of the head and neck. Preoperative radiation may increase

TABLE 32-4 Local Control Rates at 5 years for Hypopharyngeal Carcinomas by Site and Stage of Disease

Pyriform Sinus Cancer[30,46-50]

	T1	T2	T3	T4
Radiotherapy (RT)	74%-90%	59%-94%	33%-49%	33%-49%
Resection and postoperative RT	68%-89%	68%-89%	51%-89%	51%-89%

Pharyngeal Wall Cancer (Including Pyriform Sinus)[30,51-53]

	T1	T2	T3	T4
Radiotherapy	74%-90%	59%-94%	31%-61%	31%-44%
Resection and postoperative RT	66%-100%	66%-100%	51%-89%	51%-89%

TABLE 32-5 Local Control and Disease-Free Survival at 5 Years for Nasopharyngeal Carcinoma Treated with Radiation Therapy with or without Concurrent Chemotherapy

Trial	Stage	Treatment	LC	DFS
Intergroup 0099[10]	III-IV	Radiation alone	59%	24%
		Concurrent chemoradiation	86%	69%
AOCOA[54]	III-IV	Radiation alone	69%	46%
		Concurrent chemoradiation	75%	58%
INSG[55]	IV	Radiation alone	77%	31%
		Concurrent chemoradiation	85%	47%

TABLE 32-6 Treatment Results for Head and Neck Nodal Carcinomas of Unknown Primary

	Treatment	Failure Rate in the Head and Neck Mucosa	Neck Control Rate	5-yr CSS	5-yr OS
Erkal et al[56]	RT alone	13%	78%	67%	47%
Colletier et al[57]	ND + RT	6%			60%
Reddy et al[58]	ND alone	44%			47%
	ND + RT	8%			53%

CSS, Cancer-specific survival; *ND,* neck dissection; *OS,* overall survival; *RT,* radiotherapy.

resectability of disease, and tumor cells are thought more sensitive to radiation in the preoperative setting compared with the postoperative setting because oxygenation is better before the potential surgical disruption of vascular supply. Typically, lower doses are used in the preoperative setting (i.e., 5000 cGy at 200 cGy/day) compared with the postoperative setting (i.e., 6000 cGy at 200 cGy/day) because of this difference in oxygenation and associated tumor radiosensitivity. The potential disadvantages of preoperative radiation are the possibilities of increased wound complications, delay of the definitive surgical resection during which time the tumor could potentially grow or metastasize, and the lack of detailed pathologic information regarding the extent of the disease, which is available postoperatively. In a randomized study, the Radiation Therapy Oncology Group (RTOG) found postoperative radiation to be advantageous for locoregionally advanced squamous cell carcinoma of the head and neck compared with preoperative treatment.[11]

Altered Fractionation

The most commonly used fractionation scheme for squamous cell carcinoma of the head and neck as definitive treatment has been 7000 cGy in 35 treatments over 7 weeks with typically 200-cGy fractions delivered Monday through Friday. Altered radiation fractionation schemes have been studied in

TABLE 32-7 Randomized Phase III Trials of Radiation Therapy versus Concurrent Chemoradiation

Study	Subsites Included	Treatment	3 yr LC	3 yr OS
Bonner et al[14]	Stage III/IV OP, HP, L	RT alone (70 Gy)	34%	45%
		RT (70 Gy) + concurrent cetuximab	47%	55%
Intergroup 0123[13]	Stage III/IV OP, HP, L, OC	RT alone (70 Gy)	NR	23%
		RT (70 Gy) + concurrent cisplatin	NR	37%
		Split course RT (60-70 Gy) + concurrent cisplatin/5-FU	NR	27%
RTOG 91-11[9]	Stage III/IV L only	RT alone (70 Gy)	56%*	56%†
		RT (70 Gy) + concurrent cisplatin	71%*	54%†
		Induction cisplatin/5-FU, then RT (70 Gy)	68%*	55%†

5-FU, 5-Fluorouracil; *HP*, hypopharynx, *L*, larynx; *NR*, not recorded; *OC*, oral cavity; *OP*, oropharynx; *OS,* overall survival; *RT*, radiation therapy.
*2-year locoregional control.
†5-year overall survival.

an attempt to manipulate biologic differences between tumor and normal tissue to improve prognosis without increasing morbidity. The RTOG studied four fractionation schemes for locoregionally advanced squamous cell carcinoma of the head and neck: standard 7000 cGy in 7 weeks with five daily treatments per week; 120 cGy twice a day, 5 days per week to 7500 cGy (hyperfractionation); 3.5 weeks of once-a-day treatment followed by 2.5 weeks of twice-per-day treatment (concomitant boost); and 160 cGy twice a day for 3.5 weeks with a 2-week break, followed by an additional 2 weeks of the same treatment (hyperfractionated split course radiation). The altered fractionation schemes showed increased acute toxicity with a small improvement in efficacy compared with conventional fractionation.[12]

Radiation with Systemic Therapy

Efforts have been made for many years to optimize treatment of head and neck cancer with a combination of radiation and chemotherapy. For locoregionally advanced squamous cell carcinoma of the head and neck, several studies have suggested benefit to radiation and concurrent chemotherapy, most often cisplatin.[13] 5-FU alone and with cisplatin has been used concurrently with radiation as well, but because severe mucositis is typical with the combination of 5-FU and radiation, this is not often used. Results of randomized trials comparing radiation therapy alone to concurrent chemoradiation are noted in Table 32-7.

Cetuximab is a newer systemic therapy that is not chemotherapy per se and avoids many of the systemic side effects of chemotherapy. It is a monoclonal antibody to the extracellular domain of the epidermal growth factor receptor (EGFR) of cancer cells. Blocking of this receptor causes impaired cell growth. A prospective randomized trial has shown cetuximab delivered concurrently with radiation to be superior to radiation alone for locally advanced squamous cell carcinoma of the head and neck.[14] Neoadjuvant chemotherapy before definitive radiation therapy is frequently associated with dramatic tumor responses, but generally not with improved outcome in prospective randomized trials relative to radiation alone.[9,15]

Radiotherapy Techniques

Radiotherapy for head and neck cancers can be via teletherapy (external radiation) or brachytherapy (interstitial or intracavitary use of radioactive seeds). Teletherapy is the predominant form of therapeutic radiation and most commonly entails the production of high-energy photons or electrons by a linear accelerator. The radiation is typically aimed at the tumor, often from multiple orientations and with the shaping of radiation fields from each orientation to limit the volume of tissue receiving the full radiation dose. Photons have their maximal effect at a tissue depth depending on their energy, which can be varied depending on the desired depth of treatment. Whereas photons continue to pass through tissue and deposit decreasing amounts of radiation with further penetration, electrons stop more abruptly and are used to treat more superficial tumors with avoidance of more deeply seated normal tissues. Two-dimensional radiation treatment planning refers typically to radiation being directed from anterior, posterior, right lateral, or left lateral orientations where bony structures can be well recognized on x-rays taken from those orientations and the target tissue can be correlated relative to those bony structures. Three-dimensional conformal radiation refers to the use of CT scans and computers to better target tumors relative to normal tissues (see Figure 32-4). The technique involves obtaining a CT scan and putting the CT information into the computer to allow for contouring on the computer work station the target tissue to be treated and the normal tissues to be

avoided. With the help of the computer, orientations and shapes of radiation fields can be devised to better accomplish this. Intensity-modulated radiation therapy (IMRT) adds the ability to vary the amount of radiation coming through each part of each field of radiation to further conform the radiation dose to the target tissues relative to the normal tissues to be spared. Isodose patterns for the treatment of an advanced base-of-tongue cancer with IMRT are shown in Figure 32-5.

Brachytherapy can entail the permanent or temporary placement of radiation seeds directly into (interstitial) tumor-containing tissue or within an orifice adjacent to tumor (intracavitary radiation). Temporary brachytherapy is more commonly used in the treatment of head and neck cancers. Brachytherapy may have the advantage of exposing tumor cells to substantially higher doses of radiation compared with normal tissues distant from the radiation sources, thereby decreasing side effects. Temporary brachytherapy applications can be low-dose-rate radiation in which radioactive sources are typically placed for a matter of a few days, or high-dose-rate radiation in which higher-activity (strength) sources are placed for a matter of minutes. Both forms of brachytherapy are physically advantageous in placing the radiation dose at the location of the disease. The biologic differences in tumor response and normal tissue effects between continuous

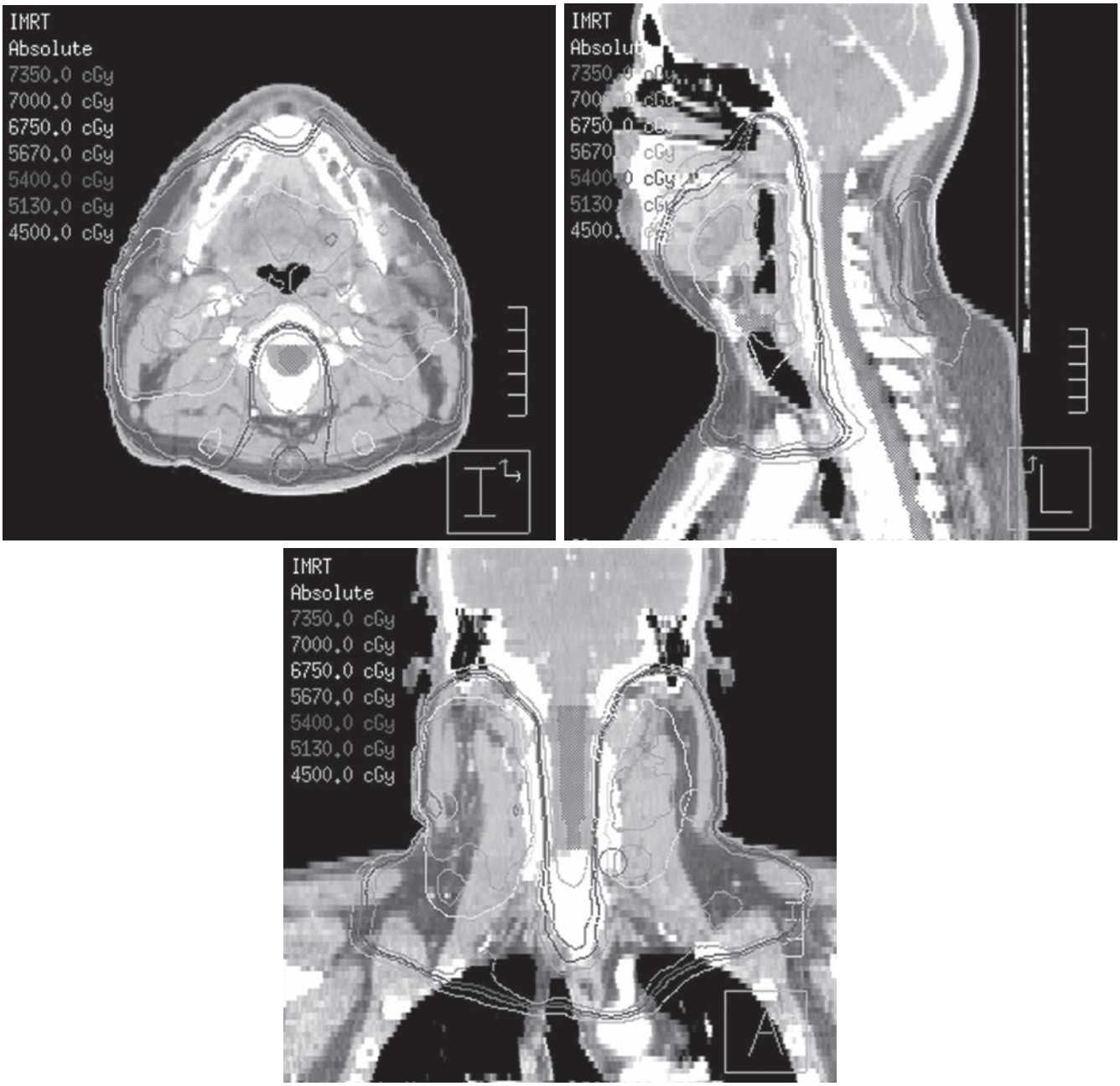

• **Figure 32-5** Isodose distributions for an intensity-modulated radiation therapy (IMRT) plan used to treat an advanced base-of-tongue cancer.

low-dose-rate radiation and fractionated high-dose-rate radiation continue to be studied.

Complications of Treatment

Effects of radiation on normal tissues include acute and late effects. Acute effects occur during and immediately after a course of radiotherapy, are typically progressive in nature, and generally resolve 3 to 4 weeks after therapy. These include mucositis, hair loss, skin irritation, loss of taste, dry mouth, bone marrow suppression, and hoarseness from effects of radiation on rapidly proliferating normal tissues. In a 7-week course of daily Monday-through-Friday radiation therapy for cancers of the head and neck, acute side effects are typically noticeable beginning in the second or third week of treatment. Progression of those effects is variable and is typically counterbalanced to some extent by accelerated repopulation of normal cells in response to radiation damage. The acute side effects sometimes increase through the course of treatment as the cumulative radiation dose increases and at times plateaus because of the accelerated repopulation of normal cells. Mucositis and skin changes are typically largely resolved by 3 weeks following completion of radiation therapy. Taste typically takes a matter of months to recover, and xerostomia is frequently long lasting. The addition of concurrent chemotherapy to radiation typically augments all of the normal tissue effects and delays recovery.

Amifostine is an organic thiophosphate drug found to have normal tissue cytoprotective effects on multiple organ systems during chemotherapy or radiation therapy. It has been shown in a randomized trial to reduce acute and chronic xerostomia in patients receiving head and neck radiation therapy and to objectively increase salivary flow over placebo.[16] Unfortunately, this increase in objective salivary flow has not translated into subjective xerostomia improvements in other trials. Furthermore, amifostine is typically given as a subcutaneous injection daily during radiation therapy, and its use has been limited by toxicities including hypotension, nausea, vomiting, and allergic reaction.

Late effects of radiation on normal tissues are ischemic, in which the blood supply to normal tissues is compromised by endothelial fibrosis of small blood vessels induced by radiation. These side effects typically manifest between 6 and 24 months after radiation. Late side effects of head and neck radiation include soft tissue fibrosis of the head and neck, trismus, osteoradionecrosis of the jaw, xerostomia, and esophageal strictures. Chronic laryngeal edema and laryngeal chondronecrosis can occur as well. Osteoradionecrosis of the mandible is a potentially serious late complication of radiation therapy; however, radionecrosis of bones other than the mandible is uncommon. The complication is uncommon but is related to the volume of mandible radiated, the radiation dose delivered, radiation treatment fraction size, and dentition. Edentulous patients rarely develop osteonecrosis, and patients with poor dentition are at higher risk. It has been generally recommended that patients with poor dentition have tooth extractions before, rather than after, radiation to decrease the likelihood of developing osteoradionecrosis. With the frequent urgency to commence radiation, there may be a window for safe extractions between approximately 2 and 4 months after radiation. When teeth are extracted following radiation therapy, prophylactic hyperbaric oxygen treatment is frequently recommended, with 20 treatments before tooth extractions and 10 treatments afterward. Whether this practice is in fact necessary on a routine basis has been questioned.[17]

Second malignancies occur rarely after radiation therapy, with an average latency of 10 years. The risk increases with time after completion of radiotherapy. Criteria for second malignancy include a solid tumor within the previously treated radiation portal, tumor of a different histology than previously treated, and tumor occurring in the correct latency period.

References

1. Duhmke E, Diehl V, Loeffler M, et al.: Randomized trial with early stage Hodgkin's disease testing 30 Gy vs 40 Gy extended field radiotherapy alone, *Int J Radiat Oncol Biol Phys* 36(2):305–310, 1996.
2. Pisters PW, Harrison LB, Leung DH, et al.: Long-term adjuvant results of a prospective randomized trial of adjuvant brachytherapy in soft tissue sarcoma, *J Clin Oncol* 14(3):859–868, 1996.
3. Tubiana M, Haddad E, Schlumberger M, et al.: External radiotherapy in thyroid cancers, *Cancer* 55:2061–2072, 1985.
4. Farahati J, Reiners C, Stuschke M, et al.: Differentiated thyroid cancer, *Cancer* 77:172–180, 1996.
5. O'Connell ME, A'Hern RP, Harmer CL: Results of external beam radiotherapy in a differentiated thyroid carcinoma: a retrospective study from the Royal Marsden Hospital, *Eur J Cancer* 30(6):733–739, 1994.
6. Birerley JD, Tsang RW, Gospodarowicz MK, et al.: Medullary thyroid cancer-analyses of survival and prognostic factors and the role of radiation therapy in local control, *Thyroid* 6:305, 1996.
7. Sause WT, Cooper JS, Rush S, et al.: Fraction size in external beam radiation therapy in the treatment of melanoma, *Int J Radiat Oncol Biol Phys* 20:429–432, 1991.
8. Wolf GT, Hong WK, Urba S, et al.: Induction chemotherapy plus radiation compared with surgery plus radiation in patients with advanced laryngeal cancer, *N Engl J Med* 324:1685–1690, 1991.
9. Forastiere AA, Gephfort H, Maor M, et al.: Concurrent radiation therapy and chemotherapy for organ preservation in advanced laryngeal cancer, *N Engl J Med* 349(22):2091–2098, 2003.
10. Al-Sarraf M, LeBlanc M, Giri PJ, et al.: Chemoradiotherapy versus radiotherapy in patients with advanced nasopharyngeal cancer: phase III randomized intergroup study 0099, *J Clin Oncol* 16(4):1310–1317, 1998.
11. Kramer S, Gelber RD, Snow JB, et al.: Combined radiation therapy and surgery in the management of advanced head and neck cancer: final report of 73-03 of the Radiation Therapy Oncology Group, *Head Neck Surg* 10(1):19–30, 1987.

12. Fu KK, Pajak TF, Trotti A, et al.: A Radiation Therapy Oncology Group (RTOG) phase III randomized study to compare hyperfractionation and two variants of accelerated fractionation to standard fractionation radiotherapy for head and neck squamous cell carcinomas: first report of RTOG 9003, *Int J Radiat Oncol Biol Phys* 48(1):7–16, 2000.
13. Adelstein DJ, Li Y, Adams GL, et al.: An Intergroup Phase III comparison of standard radiation therapy and two schedules of concurrent chemoradiotherapy in patients with unresectable squamous cell head and neck cancer, *J Clin Oncol* 21(1):92–98, 2003.
14. Bonner JA, Giralt J, Harari PM, et al.: Radiotherapy plus cetuximab for squamous cell carcinoma of the head and neck, *N Engl J Med* 354(6):567–578, 2006.
15. Pignon JP, Bourhis J, Domenge C, et al.: Chemotherapy added to locoregional treatment for head and neck squamous-cell carcinoma: three meta-analyses of updated individual data. MACH-NC Collaborative Group. Meta-Analysis of Chemotherapy on Head and Neck Cancer, *Lancet* 355(9208):949–955, 2000.
16. Wahl MJ: Osteoradionecrosis prevention myths, *Int J Radiat Oncol Biol Phys* 64(3):661–669, 2006.
17. Bennett MH, Feldmeier J, Hampson N, et al.: Hyperbaric oxygen therapy for late radiation tissue injury, *Cochrane Database Syst Rev* 20(3):CD005005, 2005.
18. Foote RL, Parsons JT, Mendenhall WM, et al.: Is interstitial implantation essential for the successful radiotherapeutic treatment of case of tongue carcinoma? *Int J Radiat Oncol Biol Phys* 18:1293–1298, 1990.
19. Harrison LB, Lee HJ, Pfister DG, et al.: Long-term results of primary radiotherapy with/without neck dissection for squamous cell carcinoma of base of tongue, *Head Neck* 20:668–673, 1998.
20. Puthawala A, Syed AM, Eads DL, et al.: Limited external beam and interstitial iridium-192 irradiation in the treatment of the base of tongue: a ten year experience, *Int J Radiat Oncol Biol Phys* 14:839–848, 1988.
21. Mak AC, Morrison WM, Garden AS, et al.: Base-of-tongue carcinoma: treatment results using concomitant boost radiotherapy, *Int J Radiat Oncol Biol Phys* 33:289–296, 1995.
22. Wong CS, Ang KK, Fletcher GH, et al.: Definitive radiotherapy for squamous cell carcinoma of the tonsillar fossa, *Int J Radiat Oncol Biol Phys* 16:657–662, 1989.
23. Mendenhall WM, Amdur RJ, Stringer SP, et al.: Radiation therapy for squamous cell carcinoma of the tonsillar region: a preferred alternative to surgery? *J Clin Oncol* 18:2219–2225, 2000.
24. Mazeron JJ, Luschini A, Marinello G, et al.: Interstitial radiation therapy for squamous cell carcinoma of the tonsillar region: the Creitel experience, *Int J Radiat Oncol Biol Phys* 12:895–900, 1986.
25. Bataini JP, Asselain B, Jaulerry C, et al.: A multivariant primary tumor control analysis in 465 patients treated by radical radiotherapy for cancer of the tonsillar region: clinical and treatment parameters as prognostic factors, *Radiother Oncol* 14:265–277, 1989.
26. Wang CC: *Radiation therapy for head and neck neoplasms*, ed 3, New York, 1997, Wiley-Liss, pp 187–203.
27. Fein DA, Lee WR, Amos WR, et al.: In *Oropharyngeal carcinoma treated with radiotherapy: a 30 year experience*, 34. 1996, pp 289–296.
28. Lindberg RD, Fletcher GH: The role of irradiation in the management of head and neck cancer: analysis of results and causes of failure, *Tumor* 64:313–325, 1978.
29. Selek U, Garden AS, Morrison WH, et al.: Radiation therapy for early carcinoma of the oropharynx, *Int J Radiat Oncol Biol Phys* 59:743–751, 2004.
30. Meoz-Mendez RT, Fletcher GH, Guillamondegui OM, et al.: Analysis of the results of irradiation in the treatment of squamous cell carcinoma of the pharyngeal walls, *Int J Radiat Oncol Biol Phys* 4:579–584, 1978.
31. Peters LJ: Accelerated fractionation using concomitant boost: a contribution of radiobiology to radiotherapy, *Br J Radiol* 24:200–203, 1992.
32. Wang CC: *Radiation therapy for head and neck neoplasms*, ed 3, New York, 1997, Wiley-Liss, pp 187–203.
33. Le QX, Fu KK, Kroll S, et al.: Influence of fraction size, total dose, and overall time on local control of T1-T2 glottic carcinoma, *Int J Radiat Oncol Biol Phys* 39:115–126, 1997.
34. Yu E, Shenouda G, Beaudet MP, et al.: Impact of radiation therapy fraction size on local control of early glottic carcinoma, *Int J Radiat Oncol Biol Phys* 37:587–591, 1997.
35. Klintenberg C, Lundgren J, Adell G, et al.: Primary radiotherapy of T1 and T2 glottic carcinoma-analysis of treatment results and prognostic factors in 223 patients, *Acta Oncol* 35:81–86, 1996.
36. Pellitteri PK, Kennedy TL, Vrabec DP, et al.: Radiotherapy—the mainstay in the treatment of early glottic carcinoma, *Arch Otolaryngol Head Neck Surg* 117:297–301, 1991.
37. Burke LS, Greven KM, McGuirt WT, et al.: Definitive radiotherapy for early glottic carcinoma: prognostic factors and implications for treatment, *Int J Radiat Oncol Biol Phys* 38:37–42, 1997.
38. Schwaab G, Mamelle G, Lartigau E, et al.: Surgical salvage treatment of T1/T2 glottic carcinoma after failure of radiotherapy, *Am J Surg* 168:474–475, 1994.
39. Olszewski SJ, Vaeth JM, Green JP, et al.: The influence of field size, treatment modality, commissure involvement, and histology in the treatment of early vocal cord cancer with irradiation, *Int J Radiat Oncol Biol Phys* 11:1333–1337, 1985.
40. Mendenhall WM, Parsons JT, Mancuso AA, et al.: Definitive radiotherapy for T3 squamous cell carcinoma of the glottic larynx, *J Clin Oncol* 15:2394–2402, 1997.
41. Mendenhall WM, Parsons JT, Mancuso AA, et al.: Radiotherapy for squamous cell carcinoma of the supraglottic larynx: an alternative to surgery, *Head Neck* 18:24–35, 1996.
42. Wendt CW, Peters LJ, Ang KK, et al.: Hyperfractionated radiotherapy in the treatment of squamous cell carcinoma of the supraglottic larynx, *Int J Radiat Oncol Biol Phys* 17:1057–1062, 1989.
43. Bataini JP, Ennuyer A, Poncet P, et al.: Treatment of supraglottic cancer by radical high dose radiotherapy, *Cancer* 33:1253–1262, 1997.
44. Wang CC: *Radiation therapy for head and neck neoplasms*, ed 3, New York, 1997, Wiley-Liss, pp 187–203.
45. Weems DH, Mendenhall WM, Parsons JT, et al.: Squamous cell carcinoma of the supraglottic larynx treated with surgery and/or radiation therapy, *Int J Radiat Oncol Biol Phys* 13:148, 1987.
46. Mendenhall WM, Parsons JT, Cassisi NJ, et al.: Squamous cell carcinoma of the pyriform sinus treated with surgery and/or radiotherapy, *Head Neck* 10:88–92, 1987.
47. Mendenhall WM, Parsons JT, Stringer SP, et al.: Radiotherapy alone or combined with neck dissection for T1-T2 carcinoma of the pyriform sinus: an alternative to conservation surgery, *Int J Radiat Oncol Biol Phys* 27:1017–1027, 1993.
48. Vandenbrouck C, Eschwege F, DeLa Rochefordiere A: Squamous cell carcinoma of the pyriform sinus: retrospective study of 351 cases treated at the Institute Gustave-Roussy, *Head Neck Surg* 10:4, 1987.
49. Dubois JB, Guerrier B, DiRuggeriero JM, et al.: Cancer of the pyriform sinus: treatment by radiation therapy alone and after surgery, *Radiology* 160:831, 1986.

50. Million RR, Cassisi NJ, Mancuso AA, et al.: Hypopharynx: pharyngeal walls, pyriform sinus, post-cricoid pharynx. In *Management of head and neck cancer: a multi-disciplinary approach*, ed 2, Philadelphia, 1994, JB Lippincott, pp 505–532.
51. Pene F, Avedean V, Eschwege F, et al.: A retrospective study of 136 cases of carcinoma of the posterior pharyngeal wall, *Cancer* 42:2490, 1978.
52. Emami B, Marks JE, Senunus L, et al.: *Carcinoma of the pharyngeal wall. In Proceedings of the Second World Congress on Laryngeal Cancer*, 1994. Amsterdam, Netherlands.
53. Wang CC: *Carcinoma of the hypopharynx. In Radiation therapy for head and neck neoplasms: indications, technique and results*, ed 2, Chicago, 1990, Year Book.
54. Chua D, Sham J, Choy D, et al.: Preliminary report of Asian-Oceanian clinical oncology association randomized trial comparing cisplatin and epirubicin followed by radiotherapy versus radiotherapy alone in the treatment of patients with locoregionally advanced nasopharyngeal carcinoma, *Cancer* 78:202–210, 1998.
55. International Nasopharynx Cancer Study Group: Preliminary results of a randomized trial comparing neoadjuvant chemotherapy plus radiotherapy alone in stage IV undifferentiated nasopharyngeal carcinoma: a positive effect on progression-free survival, *Int J Radiat Oncol Biol Phys* 35:463–469, 1996.
56. Erkal HS, Mendenhall WM, Amdur RJ, et al.: Squamous cell carcinoma metastatic to cervical lymph nodes from an unknown head-and-neck mucosal site treated with radiation therapy alone or in combination with neck dissection, *Int J Radiat Oncol Biol Phys* 50:55–63, 2001.
57. Colletier PJ, Foote RL, Olsen KD, et al.: Postoperative radiation for squamous cell carcinoma metastatic to cervical lymph nodes from an unknown primary site: Outcomes and patterns of failure, *Head Neck* 20:674–681, 1998.
58. Reddy SP, Marks JE: Metastatic carcinoma of the cervical lymph nodes from an unknown primary site: results of bilateral neck plus mucosal irradiation vs. ipsilateral neck dissection, *Int J Radiat Oncol Biol Phys* 37:797–802, 1997.
59. Marcial V, Amato D, Pajak T, et al.: Patterns of failure after treatment for cancer of the upper respiratory and digestive tracts: a Radiation Therapy Oncology Group report, *Cancer Treat Symp* 2:33–40, 1983.
60. Wallner PE, Hanks GE, Kramer S, et al.: Patterns of care study: analysis of outcome survey data—anterior two-thirds of tongue and floor of mouth, *Am J Clin Oncol* 9:50–57, 1986.

33

Principles of Medical Oncology in the Management of Head and Neck Cancer

JANAKIRAMAN SUBRAMANIAN, WAHID T. HANNA

Introduction

Medical oncology is an important aspect of treatment in head and neck malignancies. Specific medical therapy in head and neck malignancy is tailored to specific cell types. More than 95% of primary head and neck tumors are squamous cell carcinomas, with adenocarcinoma representing less than 5%. This chapter focuses on squamous cell carcinoma of the head and neck (SCCHN) and on salivary gland adenocarcinomas.

Epidemiology

According to the American Cancer Society's *Cancer Facts & Figures,* approximately 45,780 new cases of cancer of the oral cavity and pharynx would be diagnosed in the United States in 2014. The incidence of head and neck cancer in men is more than twice the incidence in women. Men older than 50 years are at increased risk of developing head and neck cancer. The American Cancer Society estimated that 8,650 people would die of cancer of the oral cavity and pharynx in 2015.[1]

The trend in 5-year survival rates is improving, but a disparity still exists between Caucasian and African American individuals. Five-year survival for Caucasians was 69% in the years 2004 to 2010 compared with 57% in 1987 to 2089; 5-year survival for African Americans was 62% in 2004 to 2010, although this represented an improvement from 43% in 1987 to 1989. Survival rates for head and neck cancer also differ widely depending on the extent of disease, as would be expected. Five-year survival for localized disease is 83%, compared with 51.3% for regional involvement, and only 27.6% for distant metastases.[1] This underlines the importance of early detection, particularly in the population at high risk for development of head and neck malignancy. Screening should be performed by an individual's dentist or primary care provider during regular checkups.[1]

Risk factors for the development of squamous cell carcinoma of the head and neck are known to include tobacco use via smoking (cigarette, pipe, and cigar) and the use of smokeless (chewing) tobacco. This risk is further compounded by excessive alcohol consumption.[1]

Data suggest that passive smoking also increases the risk of development of squamous cell carcinoma of the head and neck.[2] Human papillomavirus (HPV) infection has now been identified as a risk factor for the development of oropharyngeal squamous cell carcinoma, particularly in never smokers.[3]

Background

The process of carcinogenesis requires multiple genetic alterations that occur over time, producing a cumulative effect on cell division and differentiation.[4] Proto-oncogenes are responsible for cell growth. When mutated, proto-oncogenes become oncogenes, which are perpetually activated to promote uncontrolled growth of the cell (Figure 33-1).

Historically, the main treatment regimen for head and neck cancer had been surgery. But with recent advances, radiation is an option in both the definitive and adjuvant treatment setting. Traditionally chemotherapy was restricted to treatment of patients with advanced-stage disease. Results from randomized trials have shown that chemotherapy in combination with radiation is effective in the definitive treatment of locally advanced SCCHN and also as adjuvant therapy after surgical resection in selected patients. Also, some randomized trials have examined the role of adding induction chemotherapy prior to chemo-radiotherapy as a treatment option for patients with locally advanced SCCHN. Recent advances in our understanding of novel molecular alterations in cancer have opened new avenues of treatment with targeted agents.

Treatment of Locally Advanced Squamous Cell Carcinoma of the Head and Neck

Patients with TNM stage III and IV SCCHN without distant metastasis are categorized as having locally advanced disease. It is associated with a high rate of disease recurrence,

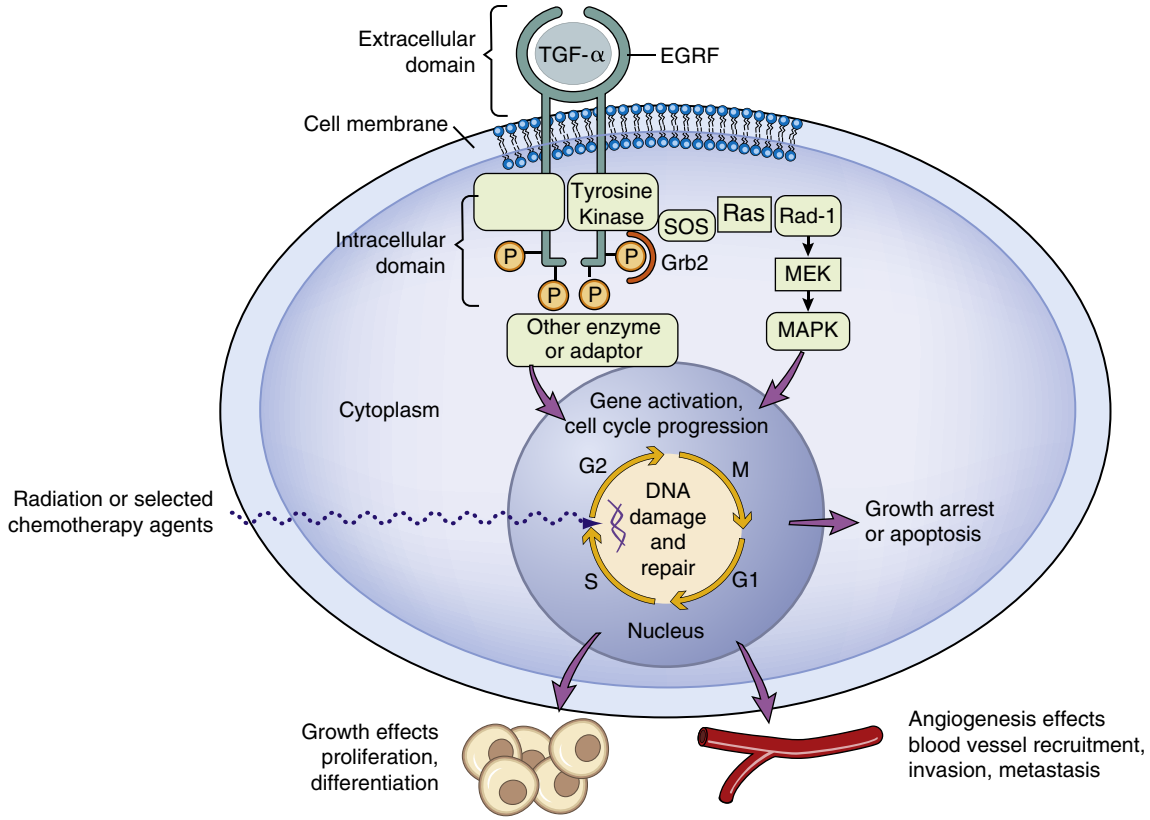

• **Figure 33-1** Oncogenes implicated in head and neck cancer include cyclin D1, or the epidermal growth factor receptor (EGFR) family.

requiring a multidisciplinary treatment approach, with the site of primary tumor playing a key role in choosing treatment options. Treatment could involve surgical resection followed by adjuvant radiotherapy or chemo-radiotherapy; organ-sparing approaches with chemo-radiotherapy (CRT) alone may be an option as well. Choosing among these different treatment options will depend on various factors such as treatment availability, skill and experience of the treating physician, and the site of primary tumor.

Adjuvant Chemo-radiotherapy

Historically, surgery has been the mainstay of treatment for SCCHN. Even now for most locally advanced oral SCC, surgical resection is the preferred option. After surgical resection, patients should be evaluated for the need for adjuvant therapy. With surgery alone, locoregional control rates and 5-year survival rates have ranged between 10% and 40%.[5] Therefore efforts have been ongoing to improve local control and overall survival after surgical resection. Since the 1970s, adjuvant chemotherapy has been tested both sequentially and concomitantly with radiation treatment. The rationale for inclusion of chemotherapy in the therapeutic management of locally advanced tumors is based on three primary observations:

1. Even though 70% to 75% of patients remain free of disease at 2 years, the long-term prognosis remains poor. Five-year survival rates rarely exceed 30% to 35%.
2. Although a fairly large number of deaths are linked to intercurrent disease, metastasis can occur at a rate from 15% to 20%.
3. A variety of cytotoxic agents have demonstrated efficacy against epithelial cell cancers.[6]

The use of chemotherapy alone has proved disappointing. However, compliance has not been optimal, especially after surgery and radiation treatment. Evidence of a biologic effect was seen, in that the pattern of failure was associated with a decrease in distant metastases in selected studies; no convincing improvement in overall survival was apparent.[7,8]

To improve the prognosis for patients with stage III to IV disease, investigators began to combine chemotherapy with radiation. In an intergroup study (0034; Lawrence GE 1992), radiation treatment was administered with or without three cycles of cisplatin/5-fluorouracil (5-FU) to patients with completely resected SCCHN. This study reported no difference in overall survival (OS), disease-free survival, or locoregional failure between the two groups. A significant decrease in distant metastases was seen in the chemotherapy/radiation therapy (CRT) arm versus the radiation therapy (RT) alone arm (15% vs. 23%, respectively; P = .03). Subgroup analysis showed that patients with high-risk pathologic features (at least two positive neck lymph nodes, extracapsular extension, and/or positive surgical margins) improved more with the addition of chemotherapy than did those in the low-risk group in terms of both tumor control and survival.[8]

Starting in the early 1990s, analyses of clinical trials undertaken to compare CRT versus RT showed that CRT significantly increased locoregional control and survival rates.[9-11]

Platinum compounds and 5-FU have been used most often in prospective clinical trials.[12-15] Various studies have tested the effects of CRT and reported associated benefits.[16-18] However, considerable variability in schedule, dose, and chemotherapeutic agents used was seen in these studies. Because of this, two randomized trials conducted by the European Organization for Research and Treatment of Cancer (EORTC) and the Radiation Therapy Oncology Group (RTOG) were designed to compare the use of high-dose cisplatin (100 mg/m^2) on days 1, 22, and 43, given concurrently with radiation, versus radiation alone in patients with resected, poor-risk SCCHN of the upper aerodigestive tract (high-risk patients were more broadly defined).[19,20]

The EORTC study demonstrated a significant (P = 0.04) difference in progression-free survival (PFS). The primary end-point of overall survival favored the CRT group. Estimated median PFS was 23 months in those given RT and 55 months in the CRT group. Five-year Kaplan-Meier PFS estimates were 36% and 47%, respectively (P = 0.04). OS (P = 0.02) and locoregional control (P = 0.07) also significantly improved.[20] The RTOG study showed significant benefit for disease control with CRT over RT.

Disease-free survival and locoregional control rates at 2 years favored the CRT arm (P = 0.04 and P = 0.01, respectively). Also, a trend toward higher OS rates was seen with CRT (P = 0.19). No impact on distant control was noted. Both studies yielded positive results with regard to favorable impact of CRT on disease control. The magnitude of impact of chemotherapy on outcomes was greater in the EORTC than in the RTOG trial, but this may reflect variations in patient selection.

Data from a combined analysis of the EORTC and RTOG data indicated that CRT's benefit was primarily seen in tumors with extracapsular nodal spread (ECS) and/or microscopically involved surgical margins.[21] A trend favorable toward CRT was seen in patients with stage III to IV disease, perineural infiltrates, vascular embolism, and/or clinically enlarged lymph nodes at level IV or V associated with tumors in the oral cavity or the oral pharynx. Patients with two or more histologically involved lymph nodes who did not exhibit ECS or positive margins as additional risk factors did not appear to benefit from the addition of chemotherapy in this analysis.

Functional Organ-Preservation Approaches

In many patients with locoregional disease, even though surgical resection maybe feasible, a nonsurgical approach with concurrent CRT can be considered for functional organ preservation. In general concurrent CRT is the preferred option in this setting.

Oropharyngeal Squamous Cell Carcinoma

Several trials have examined the benefit of CRT over RT in the treatment of locally advanced oropharyngeal SCC. The most definitive evidence is provided by the Meta-analysis of Chemotherapy on Head and Neck Cancer (MACH-NC) study.[22] This analysis included studies on CRT and RT alone as well as induction chemotherapy. With 5872 patients with oropharyngeal SCC, the study concluded that regimens with chemotherapy and RT were superior to RT alone (hazard ratio [HR] 0.88; 95% confidence interval [CI] 0.82-0.93).[23] The study also reported that CRT was associated with an improvement in overall survival (HR 0.81, 95% CI 0.78-0.86) but not with induction chemotherapy followed by RT (HR 0.96; 95% CI 0.90-1.02), though it did not include the more modern trials evaluating induction with docetaxel, cisplatin, and 5-FU (TPF) followed by RT. The study also compared different chemotherapy regimens and concluded that platinum-based regimens were superior to non-platinum regimens.

Laryngeal Squamous Cell Carcinoma

Functional organ preservation for laryngeal SCC was first studied in the Veterans Affairs (VA) Laryngeal Cancer Study Group Trial.[24] In this study 332 patients with stage III or IV laryngeal SCC were randomized to surgery followed by adjuvant RT or induction chemotherapy with three cycles of cisplatin and 5-FU followed by RT. Patients who failed induction chemotherapy underwent surgery followed by RT. The 3-year survival was similar for both treatment arms (56% vs. 53%), and the larynx was successfully preserved in 64% of patients on the induction arm.

Results from the 2011 MACH-NC analysis showed that adding chemotherapy to RT versus RT alone for the treatment of laryngeal SCC (n = 3216) improved overall survival (HR 0.87; 95% CI 0.80-0.96).[23] This improvement in survival was restricted to CRT and not seen with induction or adjuvant chemotherapy. Like the MACH-NC analysis published in 2009, this study did not include the induction studies with the TPF regimen. The addition of chemotherapy to radiation was seen to improve survival in patients with hypopharyngeal SCC as well (HR 0.88; 95% CI 0.80-0.96), though the timing of chemotherapy administration, whether concurrent, induction, or adjuvant, did not appear to affect survival. Based on these data for patients with laryngeal and hypopharyngeal SCC, our experience has been to administer cisplatin 100 mg/m^2 on days 1, 22, and 43 concurrent with radiotherapy.

Induction Chemotherapy in Squamous Cell Carcinoma of the Head and Neck

The role for induction chemotherapy prior to locoregional therapy for locally advanced SCCHN has generated a lot

of discussion and controversy. The potential benefits from the induction approach are to decrease the risk of developing distant metastasis, reduce disease volume, and improve organ function, thereby allowing a more tolerable and effective locoregional therapy. Induction chemotherapy can also increase the risk of toxicity.

In locally advanced oral SCC, induction chemotherapy has been evaluated in the preoperative setting. Induction with three cycles of cisplatin and 5-FU followed by surgery versus immediate surgery was evaluated in a randomized trial.[25] Induction chemotherapy did not improve survival, but it did reduce the rate of mandibulectomy (31% vs. 52%). Also, the rate of postoperative radiation was lower in patients receiving induction chemotherapy (33% vs. 46%). More recent long-term follow-up from this trial confirmed absence of difference in overall survival between the two arms, and there was no difference in locoregional control and rates of distant metastasis. In a subsequent trial, induction with TPF prior to surgery and postoperative RT did not improve overall survival (HR 0.98; 95% CI 0.63-1.51) or disease-free survival (HR 0.97; 95% CI 0.65-1.45) when compared to surgery and RT.[26] Induction chemotherapy prior to surgery does not improve survival for locally advanced oral SCC.

The MACH-NC meta-analysis 2009 update included 31 trials with 5311 patients comparing induction chemotherapy to RT alone or surgery with or without RT and did not identify any significant difference in overall survival between these different treatment modalities (HR 0.96; 95% CI 0.90-1.02).[22] Induction chemotherapy and CRT were compared in six trials, and they showed no significant difference in overall survival between these two treatment modalities (HR 0.90; $P = 0.15$).

More recently there has been an effort to combine induction chemotherapy with CRT to maximize benefits. In the TAX 324 trial, 531 patients were randomized to receive TPF or PF (platinum and 5 FU) followed by CRT with weekly carboplatin.[27] The addition of docetaxel to platinum and 5FU was associated with an improvement in 5-year survival (52% vs. 42%; HR 0.74; 95% CI 0.58-0.94). The addition of docetaxel was also associated with increased incidence of both hematologic and nonhematologic toxicities. Subsequent trials have compared induction TPF followed by CRT to CRT alone. In the Spanish Head and Neck Cancer Cooperative phase III trial, 439 patients were randomized to receive CRT with cisplatin on days 1, 22, and 43, or two different induction regimens with TPF or PF followed by CRT with cisplatin.[28] There was no significant difference in overall survival, progression-free survival, or time to progression between the three treatment arms. Sub-analysis identified improved progression-free survival for patients receiving TPF induction who were also able to receive at least one cycle of CRT when compared to CRT alone: 20.4 months versus 13.3 months (HR 0.72, $P = 0.03$). PARADIGM and DeCIDE were randomized phase III trials that examined TPF induction followed by CRT to CRT alone.[29,30] Both studies were limited by poor accrual, and they did not show any significant survival benefit to adding TPF induction to CRT. Both studies also showed an increased incidence of adverse effects in the induction arms. The DeCIDE trial did identify a trend toward improved overall survival for patients with N2c and N3 disease, but the study was not powered to detect meaningful differences in this subgroup. Therefore we do not routinely recommend induction chemotherapy prior to CRT in patients with locally advanced SCCHN. There may still be a role for induction chemotherapy with locally advanced laryngeal cancer with tumor stage less than T4a for functional organ preservation purposes.

Chemotherapy of Patients with Recurrent or Metastatic Head and Neck Carcinoma

More than 50% of patients given a new diagnosis of SCCHN will experience a recurrence after receiving primary treatment. Patients with SCCHN have a poor prognosis once primary treatment has been unsuccessful and recurrent disease has occurred. Outcomes are poor and have not changed significantly over the past 30 years.[31,32] Several treatment options are available for patients with recurrent disease. Palliative chemotherapy has shown survival benefit over best supportive care alone in one study.[33] Multivariate analysis of data from palliative chemotherapy clinical trials has shown that time to progression and overall survival are greatly influenced by factors other than the chemotherapy agents that are used; poor performance status, prior treatments, and advanced stage of disease all are associated with poor outcomes despite chemotherapy.[34,35] Because treatment is palliative and may be associated with significant adverse effects, clinicians must be careful in selecting patients for chemotherapy treatment. The benefits must be weighed against the side effects and complications of treatment before a patient can be committed to palliative chemotherapy. Salvage surgical intervention for local recurrence has resulted in 15% to 30% long-term disease control. However, if the recurrent disease is inoperable, or if it is metastatic in nature, systemic chemotherapy and/or local radiotherapy should be considered for palliative purposes.

In the 1980s, several clinical trials compared different chemotherapeutic combinations. The outcomes of these trials are presented in Table 33-1.

Multiagent chemotherapy in general was associated with a higher response rate but also had a higher degree of toxicity. Platinum-based combination chemotherapy yielded the highest response rates, approaching 50%.[36-39] The combination of cisplatin (CDDP) plus 5-FU emerged as the most effective treatment for SCCHN in the 1980s and 1990s. In a three-arm study conducted by Clavel and colleagues, 5-FU and CDDP combinations were compared with carboplatin, methotrexate, bleomycin, and vincristine and with CDDP alone. Results with the CDDP plus 5-FU and carboplatin arms were superior to

TABLE 33-1 Clinical Trial Comparisons

Trial	No. of Patients	Response Rate% (CR %)	Median Survival(months)	Year of Publication	High-Grade Toxicity*
CDDP ± cetuximab	117†	26 *v* 10	9.2 *v* 8.0	2005	173 *v* 93
CDDP + FU *v* CDDP + Tax	218†	27 *v* 26	8.7 *v* 8.1; OS at 1 year, 41% *v* 32%	2005	334 *v* 198
MTX *v* docetaxel (weekly)	57	15 (5) *v* 27 (3)	3.7 *v* 3.9	2004	6 *v* 21
CDDP + high-dose Tax *v* CDDP + conventional Tax	210†	35 *v* 36	7.6 *v* 6.8	2001	321 *v* 320
Raltitrexed + CDDP + FU/LV *v* MTX + CDDP + FU/LV	72	81 (28) *v* 42 (8)		2002	67 *v* 32
Edatrexate *v* MTX	264†	21 *v* 16	6 for both groups	1995	90 *v* 45
CABO *v* CDDP + FU *v* CDP	382†	34 (9.5) *v* 31 (1.7) *v* 15 (2.5)	7.3 (TTP, 4.8 *v* 4.3 *v* 3)	1994	34 *v* 35 *v* 20
MTX ± lonidamine	89	26 (10.5) *v* 18 (0)		1994	78 *v* 41
CDDP 100 mg/m^2 + FU 4 g/m^2 q21d *v* CBDCA 300 mg/m^2 + FU 4 g/m^2 q21d *v* MTX 40 mg/m^2 wkly	277†	32 *v* 21 *v* 10	6.6 *v* 5.0 *v* 5.6	1992	66 *v* 47 *v* 35
CDDP 100 mg/m^2 + FU 4 g/m^2 *v* CDDP 100 mg/m^2 *v* FU 4 g/m^2; all q21d	249†	32 *v* 17 *v* 13	5.7 for all groups	1992	77 *v* 34 *v* 32
CBDCA + MTX *v* MTX	40†	25 *v* 25	3 *v* 2	1989	
CABO *v* CDDP	209†	30 *v* 15	9 (TTP, 4.5)	1988	57 *v* 11
CABO *v* vincristine + MTX + bleomycin	185†	50 (16) *v* 28 (5)	9 (TTP, 4.5 *v* 3.5)	1987	35 *v* 41
CDDP + bleomycin + vincristine *v* MTX	191	24 *v* 16	7.2 *v* 7.8	1986	43 *v* 57
Control *v* bleomycin *v* CDDP + bleomycin *v* CDDP	117	NA *v* 14 *v* 24 (5) *v* 13 (3)	NS except CDDP arms *v* others 4.3 *v* 1.8	1985	NA *v* 4 *v* 25 *v* 24
MTX + bleomycin + CDDP *v* MTX	163†	48 (16) *v* 35 (8)	5.6 for both groups (TTP, 3.5)	1985	
CDDP *v* MTX	100†	8 *v* 16	4.5 *v* 5	1985	260 *v* 174
High-dose (1.5 g/m^2) MTX + LV *v* conventional (40 mg/m^2) MTX	47†	32 *v* 22	4.2 for both groups	1984	30 *v* 10

CABO, CDDP + MTX + bleomycin + vincristine; *CBDCA*, carboplatin; *CDDP*, cisplatin; *CR*, complete response; *FU*, fluorouracil; *LV*, leucovorin; *MTX*, methotrexate; *OS*, overall survival; *NA*, not assessable; *NS*, not significant; *q21d*, every 21 days; *Tax*, paclitaxel; *TTP*, time to progression.
*Wherever toxicity was quantified by grade, relative number or percentage of grade 3 to 5 toxicities are reported. This is a sum of the worst event per patient for each toxicity type based on either absolute values or percentages reported in the publication.
†Majority of patients on this trial had prior therapy (excluding chemotherapy).

those with CDDP alone, with a median survival of 73 months. However, greater toxicity was encountered in all CDDP arms.[41]

Numerous single agents have been found to be effective against SCCHN (Table 33-2).[25] When taxanes became available in the 1990s, clinical trials were undertaken to evaluate these drugs. A single taxane agent, either paclitaxel or docetaxel, produced a response rate of 30% to 40%.[41-43] Because of the high rate of single-agent activity and the non-overlapping side effects seen with other agents, taxanes were used in clinical trials in combination with CDDP or carboplatin (Table 33-3).[44-49] These studies showed a response rate of 27% to 53%, with median survival of 5 to 12 months. When double-chemotherapy regimens were found to be successful, triple-chemotherapy combinations were given in an attempt to enhance response rates. Indeed, an increased response rate up to 60% and a complete response rate of 15% were attained with the combination of ifosfamide, paclitaxel, and CDDP or carboplatin.[50,51] The improvement in response rate has been consistent across other three- or four-drug combinations; unfortunately these treatment regimens resulted in significant toxicity and did not improve survival when compared to single or doublet regimens.

TABLE 33-2 Single Agents

Agent	No. of Patients Assessable	Response Rate (%)	Median Survival (months)	Year of Publication
Methotrexate		8-77 (average 31)		1984
Bleomycin		6-45 (average 21)		1977-1984
Cisplatin		14-41 (average 28)		1983-1994
Carboplatin		25		1986
Oxaliplatin		10		1996
Cyclophosphamide		36		1980
Doxorubicin		24		1980
Hydroxyurea	18	39		1980
Vinblastine		29		1980
Vinorelbine		6		1994
Fluorouracil		15		1984
Gemcitabine	61	13		1994
Capecitabine	14	8		2003
Orzel	42	21		2001
Irinotecan		0-14		2005
Paclitaxel 24-hour infusion	34	40 (4 CRs)	9.2	1998
Paclitaxel 96-hour infusion	Chemotherapy naïve/paclitaxel naïve/paclitaxel exposed	13/0/0	5.5	2004
Docetaxel		21-42		1994-2005
Pemetrexed	35	26	6.4	2001
Ifosfamide		26		2003
Cetuximab	103	13		2005
Erlotinib	115	4		2004
Gefitinib	47	11	8.1	2003
Sorafenib (BAY 43-9006)	10	6 SD (60%); 4 SCCHN + 2NPC; range, 3-6 cycles		2005

CR, Complete response; *NPC,* nasopharyngeal carcinoma; *SCCHN,* squamous cell carcinoma of the head and neck; *SD,* Stable disease.

Epidermal Growth Factor Receptor Inhibitors in the Treatment of Squamous Cell Carcinoma of the Head and Neck

The epidermal growth factor receptor (EGFR) is highly expressed in SCCHN; both gefitinib and erlotinib have shown activity against EGFR.[52] Gefitinib has been shown to inhibit other proteins in malignant cells, and this fact could have affected study outcomes.[53,54] However, with SCCHN, it seems that these agents mainly inhibit EGFR and downstream effectors; this appears to be the primary mechanism of action.

Multiple EGFR blockade agents have been used in various clinical trials (Table 33-4).[55] Gefitinib has been studied as a single-agent treatment in SCCHN that yielded an overall response rate of 10.6%, including one patient who exhibited complete response with 1-year survival.[56] Gefitinib seems to be more active when used as first-line treatment than when administered to previously treated patients. However, this difference is not statistically significant.[57]

Erlotinib has been investigated in SCCHN.[58] A 4% partial response was reported, with 1-year survival of 20%. EGFR expression did not correlate with response to or severity of skin rash. The combination of gefitinib and erlotinib with systemic chemotherapy was investigated.

TABLE 33-3 Clinical Trials in Metastatic and Recurrent SCCHN

Agent	No. of Patients Assessable	Response Rate (%)	Survival (months)	Year of Publication
Cisplatin + fluorouracil				
Locally recurrent post-XRT	19	89	8	1984
Metastatic	11	36	6	
Overall	30	70 (27% CR)		
Cisplatin + fluorouracil				
No prior treatment	31	84 (23% CR)		1985
Recurrent post-XRT	30	50 (1% CR)	9	
Docetaxel + fluorouracil	17	24		2000
Prior chemotherapy	20	25		2004
No prior chemotherapy	43	19		
Paclitaxel + cisplatin				
3-hour IV	36	41 (6 CR)	11	2004
No prior chemotherapy; 3-hour IV	50	32 (10% CR)	10	2002
Paclitaxel + carboplatin				
Paclitaxel 3-hour IV	37	27 (3% CR)	4.9	2001
Paclitaxel 1-hour IV weekly	31	52 (3 CR)	12.8	2003
Docetaxel + cisplatin	40	53 (18% CR)	11	2002
No prior chemotherapy	34	53 (17% CR)		2002
Cisplatin + vinorelbine	42	33 (10% CR)	6	2002
TIP				
Paclitaxel 3-hour IV	53	58 (17% CR)	8.8	1998
TIC				
Paclitaxel 3-hour IV	56	59 (17% CR)	9.1	2001
TPF				
Chemotherapy naïve	19	44 (12.5% CR)	11	2000
Docetaxel + irinotecan				
Chemotherapy naïve	17	18	9.8	2005
Prior chemotherapy	34	3	4.9	
Cetuximab + cisplatin				
Prior PD to cisplatin	96	10	6.5	2005
Gefitinib, docetaxel, and cisplatin	24	50 (30% CR)		2005
Cetuximab + cisplatin or carboplatin				
No response to prior platinum	132	13	6.5	2005
Erlotinib + bevacizumab	48	15	6.8	2005
Gefitinib + celecoxib				
Prior chemotherapy	19	22		2005

CR, Complete response; *PD,* Progressive disease; *TIC,* paclitaxel, ifosfamide, carboplatin; *TIP,* paclitaxel, ifosfamide, cisplatin; *TPF,* docetaxel, cisplatin, FFU; *XRT,* radiation therapy.

TABLE 33-4 EGFR Agents

Agent	Dose/Schedule	Prior Therapy	No. of Patients	RR (%)	PFS (months)	OS (months)
Gefitinib[17]	250 mg daily	No limit	70	1	1.8	5.5
Gefitinib[13]	500 mg daily	≤1 prior	47	11	3.4	8.1
Gefitinib[14]	500 mg daily	Cohort A, none	20	15	3	6
Gefitinib[14]	500 mg daily	Cohort B, ≤1 prior	12	0	NA	NA
Erlotinib[18]	150 mg daily	≤1 prior	115	4	3.8	NA
Cetuximab[35]	400 mg/m^2 loading, 250 mg/m^2 weekly	1 prior platinum-containing regimen	103	13	2.3	5.9
Cetuximab*[36]	400 mg/m^2 loading, 250 mg/m^2 weekly	1 prior platinum-containing doublet	96	10	2.2	5.2
Cetuximab*[37]	400 mg/m^2 loading, 250 mg/m^2 weekly	1 prior platinum-containing doublet	766	10	2.8	6.1

Note: Prior therapy represents the eligibility restrictions on patients enrolled on the trials.
EGFR, Epidermal growth factor receptor; *NA*, not available; *OS*, median overall survival; *PFS*, median progression-free survival; *RR*, overall response rate.
*After failure of a platinum-containing regimen, patients on these studies received cetuximab in combination with a platinum.

Docetaxel, cisplatin, and gefitinib showed a 50% overall response rate, with seven patients achieving complete remission.[59] Another study that studied the use of erlotinib with docetaxel and cisplatin showed an overall response of 78%, with complete response reported in 27 patients.[60]

A phase I/II study investigated the combination of erlotinib and bevacizumab-monoclonal antibodies against vascular endothelial growth factor (VEGF) in patients with recurrent and metastatic SCCHN. An overall response rate of 15% and a median survival of 6.8 months were reported.[61] The combination was well tolerated, but skin toxicity with skin rash occurred. For those patients who had not received prior treatment, objective response rate, median PFS, and median OS were 17%, 4.8 months, and 7.5 months, respectively.

Cetuximab is a human murine chimeric immunoglobulin G (IgG) monoclonal antibody that competitively binds to the extracellular domain of EGFR. This drug has been approved by the U.S. Food and Drug Administration (FDA) for the treatment of patients with advanced SCCHN, on the basis of recent study findings.[62]

In the phase III EXTREME trial, treatment-naïve patients with advanced SCCHN were randomized to receive platinum plus 5-FU with or without cetuximab.[63] The addition of cetuximab was associated with an improvement in overall survival (median overall survival 10.1 months vs. 7.4 months; HR 0.80; 95% CI 0.64-0.99. Treatment with cetuximab was associated with increased risk for grade 3 or 4 skin rash, hypomagnesemia, sepsis, and infusion-related reactions. Other grade 3 and 4 adverse effects were similar between the two treatment groups.

As in other studies, a correlation was seen between skin rash and favorable outcomes. Cetuximab is also active in the second-line setting for platinum-refractory patients.[64] On progression during treatment with cetuximab, a platinum agent was added to the treatment and an overall response rate of 13% was reported, with five patients achieving complete response and median survival of 5.9 months. In all, 103 patients who received cetuximab progressed while receiving a platinum-based regimen.

In summary, the combination of a platinum agent plus 5-FU or platinum plus taxane are appropriate first line options for patients with advanced stage SCCHN who are chemotherapy naïve or have a prolonged period of disease control after definitive CRT and have good performance status. Adding cetuximab to this combination is an option as well. For patients who cannot tolerate combination chemotherapy or have rapid progression after definitive CRT, single-agent chemotherapy maybe a better option.

Salivary Gland Cancers

Salivary gland cancers (SGCs) make up a broader class of head and neck cancers that are relatively rare. By all accounts, less than 5% of tumors are classified as SGC.[65] Typically, these tumors arise from ductile components that are intercalated or secretory. Further classification has been distinguished by the frequency of disease site location, that is, major (parotid, submandibular) or minor (mucosal) gland. Most cases of SGC are benign and occur in the major gland. Malignancies such as adenoid cystic carcinoma (ACC), mucoepidermoid carcinoma (MEC), and salivary duct carcinoma (SDC) arise in the minor gland. Regardless of type, the therapeutic approach continues to consist of surgical intervention and radiotherapy, followed by chemotherapy in the palliative metastatic setting. Recent discoveries of targeted therapies have been advanced by the recognition of molecular abnormalities. In comparisons of healthy and abnormal samples, analysis of estrogen receptors has further opened investigation into targeted

therapies.[65] A decade of research has unveiled further histologic evidence by which these tumors can be classified into subsets, as initiated by the World Health Organization (WHO). The three predominant subtypes (ACC, MEC, and SDC) are discussed here.

Adenoid Cystic Carcinoma

Adenoid cystic carcinoma (ACC) is a relatively rare, slow-growing, malignant epithelial tumor of the salivary glands. Age of onset generally ranges from 40 to 60 years.[66,67] By all accounts, ACC occurs in less than 3% of malignancies. The recommended treatment regimen includes surgical intervention and postoperative radiotherapy. However, despite these modalities, ACC has a high rate of local recurrence, with an unfortunate outcome of 10-year survival of 29% to 40%, with demise often within 2 years.[65,68] Distant metastatic (DM) events, histologically speaking, occur in solid tumor more often than tubular and cribriform subtypes. Unfortunately, metastases of this nature are due to its hematogenous disposition, which primarily involves the lungs. Chemotherapy is reserved for patients with local recurrence and for systemic disease.

Some authors have suggested that trial agents used independently, such as mitoxantrone, vinorelbine, and epirubicin, may be promising, although paclitaxel has produced no response.[65] A series of trials have investigated agents in combination, such as cisplatin-doxorubicin-cyclophosphamide (CAP) with or without the addition of fluorouracil; these have shown inconsistent outcomes. Despite immunotherapy, a combination of surgery and radiotherapy offers these patients the best chance for disease control. Analysis via immunohistochemistry (IHC) has revealed an overexpression of the proteins ErbB2[69], epidermal growth factor (EGF), and vascular endothelial growth factor receptor 2 (VEGFR-2) in the salivary glands involved by ACC. As is the case with ErbB2, trastuzumab (Herceptin) has shown widely varying results, in the range of 0% to 100%. Regimens of AEE788, a multiple-receptor tyrosine kinase inhibitor (inhibition of phosphorylation of tyrosine kinase of EGFR, VEGF2, and ERbB2), induce tumor apoptosis.

Mucoepidermoid Carcinoma

Mucoepidermoid carcinoma (MEC), similar to ACC, has high rates of metastasis and locoregional tumor growth. It is the most common of the salivary gland carcinomas and, unfortunately, it exhibits a low response to therapy. In contrast to ACC, however, MEC has shown response to paclitaxel.[65] Overexpression of Her-2 displayed by IHC, EGFR, and gene amplification equates to a poor prognosis for this tumor. A phase II trial of trastuzumab objectively reported a partial response lasting 2 years. Additional studies are needed to examine tumor regression and the roles of paclitaxel, vinorelbine, and CAP in treatment.

Salivary Duct Carcinoma

Salivary duct carcinoma (SDC), the most invasive of the three malignancies, arises from the parotid gland. Its direct path of metastasis involves lymph nodes. Few data are available on the responsiveness of this tumor to chemotherapy, but in select patients, it is reasonable to use the same agents that are used for other salivary adenocarcinomas, such as CAP with or without 5-FU. Treatment regimens, as studied in phase II trials, consist mainly of palliative chemotherapy in the form of gefitinib or trastuzumab; these have resulted in stabilization of the disease for 26 to 46 weeks.[65] Other studies are ongoing with the goal of developing response of this unfortunate malignancy to multiple agents.

Histologically, salivary gland carcinomas must be clinically staged for identification of appropriate treatment regimens. Therapeutically, salivary gland carcinomas have a dismal prognosis; however, surgical resection and aggressive radiotherapy may provide benefit. Yet, palliative chemotherapy resides as the standard of care.

Phases of Oral Mucositis

Adoption of characterizing traits has been used to further classify mucositis into four distinct pathophysiologic phases. During the initial phase, called the inflammatory or vascular phase, tissue injury induces release of free radicals, inflammatory cytokines such as interleukin (IL)-2, prostaglandins, and tumor necrosis factor-alpha (TNF-α) via the epithelial, endothelial, and connective tissue of the oral canal. Induction of these components causes increased vascular permeability and accumulation of cytotoxic drugs.[70] The epithelial phase occurs 5 days to 1 week after treatment is initiated, or when cytotoxicity affects the dividing cells. Epithelial tissue erosion leads to fibrous exudates and forms a pseudomembrane or ulcerative tissue.[71,72] During this phase, denaturing of the epithelial mucosal lining results in the first symptoms of pain, which results from factors such as inflammation and infection attributed to microbial invasion. Epithelial destruction leads to the ulcerative phase, which can occur within 1 week after treatment is begun. The start of the pseudomembrane is seen during the epithelial phase. It becomes more prominent, leading to further destruction of the lining and ulceration. Further microbial colonization may be exacerbated by concomitant neutropenia.[73] Last, the healing phase commences on days 12 to 16. Tissue proliferation and differentiation and migration of epithelial cells restore the integrity of the mucosa (Figure 33-2).

Treatment

Investigational approaches have been used to attempt to treat or prevent mucositis.[74] It has been suggested that alpha-tocopherol, a component of vitamin E (VE), may act as an antioxidant. In clinical trials, VE has been shown to be potentially advantageous for mucosal preservation. A

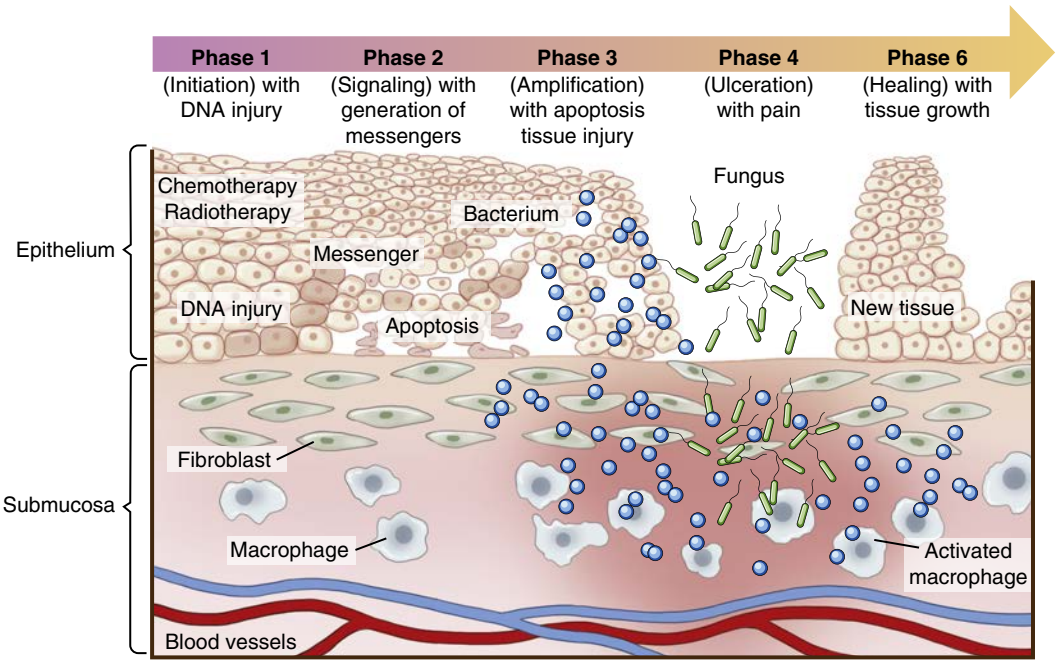

• **Figure 33-2** Phases of mucositis.

double-blind randomized trial examined 54 patients with cancer of the oral cavity and oropharynx. Patients rinsed the oral cavity with an oil solution that included VE or a placebo before radiotherapy (RT) and again 8 to 12 hours later. Results indicated that VE reduced the risk of oral mucositis by 36%.[72]

Amifostine is an antioxidant cytoprotective agent that is used in cancer chemotherapy involving DNA-binding chemotherapeutic agents; it acts as a tissue-protective agent. Amifostine serves as a free radical scavenger and radioprotectant. Studies have shown that the benefit of amifostine for episodic events of mucositis is seen in patients with head and neck cancer who are undergoing usual treatment protocols. Additional studies evaluating amifostine during radiotherapy have reported a reduction in the incidence and severity of oral mucositis, but findings have been inconsistent, especially considering the tolerability of the drug and side effects such as nausea, vomiting, and hypertension. Antimicrobial agents are frequently an important adjunctive treatment for mucositis. Because the mucosa usually is colonized by a variety of microorganisms, secondary infection occurs whenever the integrity of the mucosa has been disturbed, particularly because these patients exhibit changes in the saliva and neutropenia, which cause an immunocompromised state.

Antifungal agents constitute important adjunctive treatment. Although fungal infection is not primarily involved in the development of mucositis, these agents are the most frequent causes of infection of the damaged mucosa in the immune compromised host. Prophylactic and therapeutic uses of antifungal agents, either topical (e.g., nystatin) or systemic (e.g., fluconazole), are very important in the treatment of patients with mucositis.

Second only to fungi, viruses, particularly herpes simplex virus (HSV) and varicella zoster virus (VZV), represent the most aggravating mucositis in the immunocompromised host, because of the pain and lack of response to general supportive care that they cause; these viruses respond well to antiviral agents such as acyclovir (Zovirax) or famciclovir (Famvir). Because of the severe pain that is involved, oral solutions with local anesthetics such as diphenhydramine, viscous xylocaine, lidocaine, or dicyclomine hydrochloride frequently serve as the palliative and supportive treatment required for the management of painful and damaged mucosa.

Evaluating therapeutic interventions remains difficult because of the variability of treatment regimens, the heterogeneity of patient populations, and the small number of double-blind and placebo-controlled clinical trials that have been completed.[73]

References

1. American Cancer Society: *Cancer facts & figures, 2015*, Atlanta, 2015, American Cancer Society, p 4.
2. Zhang Z, Margenstern H, Spitz MR, et al.: Environmental tobacco smoking, mutagen sensitivity, and head and neck squamous cell carcinoma, *Cancer Epidemiol Biomarkers Prev* 9(10):1043–1049, 2000.
3. Kingsley K, Johnson D, O'Malley S: Transfection of oral squamous cell carcinoma with human papillomavirus-16 induces proliferative and morphological changes independent of cellular adhesion in vitro, *Cancer Cell Int* 6:14, 2006.
4. Harari P, Huang S: Modulation of molecular targets to enhance radiation, *Clin Cancer Res* 6:323–325, 2000.
5. Vokes EE, Kies MS, Haraf DJ, et al.: Concomitant chemoradiotherapy as primary therapy for locoregionally advanced head and neck cancer, *J Clin Oncol* 18:1652–1661, 2000.

6. Bernier J, Bentzen SM: Postoperative treatment of locally advanced head and neck cancers. In Adelstein DJ, editor: *Current clinical oncology: squamous cell head and neck cancer*, Totowa, NJ, 2005, Humana Press, pp 197–210.
7. Adjuvant chemotherapy for advanced head and neck squamous carcinoma: final report of the Head and Neck Contracts Program, *Cancer* 60:301–311, 1987.
8. Laramore GE, Scoot CB, Al-Sarraf M, et al.: Adjuvant chemotherapy for resectable squamous cell carcinoma of the head and neck: report on Intergroup study 0034, *Int J Radiat Oncol Biol Phys* 23:705–713, 1992.
9. Browman G, Hodson DI, Mackenzie RJ, et al.: Choosing a concomitant chemotherapy and radiotherapy regimen for squamous cell head and neck cancer: a systematic review of the published literature with subgroup analysis, *Head Neck* 23:579–589, 2001.
10. Stell PM, Rawson NS: Adjuvant chemotherapy in head and neck cancer, *Br J Cancer* 61:779–787, 1990.
11. Pignon JP, Bourhis J, Domenge C, et al.: Chemotherapy added to locoregional treatment for head and neck squamous-cell carcinoma: three meta-analyses of updated individual data—MACH-NC Collaborative Group: meta-analysis of chemotherapy on head and neck cancer, *Lancet* 355:949–955, 2000.
12. Jacobs JR, Pajak TF, Al Sarraf M, et al.: Chemotherapy following surgery in head and neck cancer, *Am J Clin Oncol* 12:185–189, 1989.
13. Haselow RE, Warshaw MG, Okin MM, et al.: Radiation alone versus radiation with weekly low-dose cis-platinum in unresectable cancer of the head and neck. In Fee WE, Goepfert H, Johns ME, et al.: *Head and neck cancer*, ed 1, Toronto, ON, 1990, Marcel Dekker, pp 279–281.
14. Vokes EE, Awan AM, Weichselbaum RR: Radiotherapy with concomitant chemotherapy for head and neck cancer, *Hematol Oncol Clin North Am* 5:753–767, 1991.
15. Al-Sarraf M, Hussein M: Head and neck cancer: present status and future prospects of adjuvant chemotherapy, *Cancer Invest* 13:41–53, 1995.
16. Weissberg J, Son Y, Papac R: Randomized clinical trial of mitomycin C as an adjunct to radiotherapy in head and neck cancer, *Int J Radiat Oncol Biol Phys* 17:3–9, 1989.
17. Bachaud JM, David JM, Boussin G, et al.: Combined postoperative radiotherapy and weekly cisplatin infusion for locally advanced squamous cell carcinoma of the head and neck: preliminary report of a randomized trial, *Int J Radiat Oncol Biol Phys* 20:243–246, 1991.
18. Haffty B, Son Y, Sasaki C, et al.: Mitomycin C as an adjunct to postoperative radiation therapy in squamous cell carcinoma of the head and neck: results from two randomized clinical trials, *Int J Radiat Oncol Biol Phys* 27:241–250, 1993.
19. Bernier J, Domenge C, Ozsahin M, et al.: Postoperative irradiation with or without concomitant chemotherapy for locally advanced head and neck cancer, *N Engl J Med* 350:1945–1952, 2004.
20. Cooper JS, Pajak TF, Forastiere AA, et al.: Postoperative concurrent radiotherapy and chemotherapy in high-risk squamous cell carcinoma of the head and neck, *N Engl J Med* 350:1937–1944, 2004.
21. Bernier J, Cooper JS, Pajak TF, et al.: Defining risk levels in locally advanced head and neck cancers: a comparative analysis of concurrent postoperative radiation plus chemotherapy trials of the EORTC (#22931) and RTOG (#9501), *Head Neck* 27:843–850, 2005.
22. Pignon JP, le Maitre A, Maillard E, et al.: Meta-analysis of chemotherapy in head and neck caner (MACH-NC): an update on 93 randomized trials and 17,346 patients, *Radiother Oncol* 92:4, 2009.
23. Blanchard P, Baujat B, Holostenco V, et al.: Meta-analysis of chemotherapy in head and neck caner (MACH-NC): a comprehensive analysis by tumour site, *Radiother Oncol* 100:33, 2011.
24. U.S. Department of Veterans Affairs Laryngeal Cancer Study Group: Induction chemotherapy plus radiation compared with surgery plus radiation in patients with advanced laryngeal cancer, *N Engl J Med* 324:1685–1690, 1991.
25. Licitra L, Grandi C, Guzzo M, et al.: Primary chemotherapy in resectable oral cavity squamous cell cancer: a randomized trial, *J Clin Oncol* 21:327, 2003.
26. Zhong L, Zhong C, Ren G, et al.: Randomized phase III trial of induction chemotherapy with docetaxel, cisplatin and fluorouracil followed by surgery versus up-front surgery in locally advanced resectable oral squamous cell carcinoma, *J Clin Oncol* 31:744–751, 2013.
27. Posner MR, Hershock DM, Blajman CR, et al.: Cisplatin and fluorouracil alone or with docetaxel in head and neck cancer, *N Engl J Med* 357:1705–1715, 2007.
28. Hitt R, Grau JJ, Lopez-Pousa A, et al.: A randomized phase III trial comparing induction chemotherapy followed by chemoradiotherapy versus chemoradiotherapy alone as treatment of unresectable head and neck cancer, *Ann Oncol* 25:216, 2014.
29. Haddad R, O'Neill A, Rabinowits G, et al.: Induction chemotherapy followed by concurrent chemoradiotherapy (sequential chemoradiotherapy) versus chemoradiotherapy alone in locally advanced head and neck cancer (PARADIGM). A randomized phase 3 trial, *Lancet Oncol* 14:257–264, 2013.
30. Cohen EW, Karrison TG, Kocherginsky M, et al.: Phase III randomized trial of induction chemotherapy in patients with N2 or N3 locally advanced head and neck cancer, *J Clin Oncol* 32:2735–2743, 2014.
31. Forastiere A, Koch W, Trotti A, Sidransky D: Head and neck cancer, *N Engl J Med* 345:1890–1900, 2001.
32. Khuri FR, Shin DM, Glissen BS, et al.: Treatment of patients with recurrent or metastatic squamous cell carcinoma of head and neck: current status and future direction, *Semin Oncol* 27:25–33, 2000.
33. Mortar RP, Rugman F, Dorman EB, et al.: Cisplatinum and bleomycin for advanced or recurrent squamous cell cancer of head and neck: a randomized factorial phase III controlled cancer chemotherapy, *Pharmacology* 15:283–289, 1985.
34. Paccagnella A, Orlando A, Marchiori C, et al.: Phase III trial of initial chemotherapy in stage III or IV head and neck cancers: a study by the Gruppo di Studio sui Tumori della Testa e del Collo, *J Natl Cancer Inst* 86:265–272, 1994.
35. Amer MH, Al-Sarraf M, Vaitkevicius VK: Factors that affect response to chemotherapy and survival of patients with advanced head and neck cancer, *Cancer* 43:2202–2206, 1979.
36. Glick JH, John H, Zehngebot MD, et al.: Chemotherapy for squamous cell carcinoma of the head and neck: a progress report, *Am J Otolaryngol* 1:306–321, 1980.
37. Chauvergne J, Cappelaere P, Fargeot P, et al.: A randomized study comparing cisplatin alone or combined in the palliative treatment of carcinoma of the head and neck: analysis of a series of 205 patients, *Bull Cancer* 75:9–22, 1988.
38. Clavel M, Cognetti F, Dodion P, et al.: Combination chemotherapy with methotrexate, bleomycin, and vincristine with or without cisplatin in advanced squamous cell carcinoma of the head and neck, *Cancer* 60:1173–1177, 1987.
39. Vogl SE, Schoenfeld DA, Kaplan BH, et al.: A randomized prospective comparison of methotrexate with a combination of methotrexate, bleomycin, and cisplatin in head and neck cancer, *Cancer* 56:432–442, 1985.

40. Williams SD, Velez-Garcia E, Essessee I, et al.: Chemotherapy for head and neck cancer: comparison of cisplatin + vinblastine + bleomycin vs methotrexate, *Cancer* 57:18–23, 1986.
41. Clavel M, Vermorken JB, Cognetti F, et al.: Randomized comparison of cisplatin, methotrexate, bleomycin and vincristine (CARBO) versus cisplatin and 5-fluorouracil (CF) versus cisplatin (C) in recurrent or metastatic squamous cell carcinoma of the head and neck: a phase III study of the EORTC Head and Neck Cancer Cooperative Group, *Ann Oncol* 5:521–526, 1994.
42. Catimel G, Verweij J, Mattijssen V, et al.: Docetaxel (Taxotere): an active drug for the treatment of patients with advanced squamous cell carcinoma of the head and neck—EORTC Early Clinical Trials Group, *Ann Oncol* 5:533–537, 1994.
43. Smith RE, Thornton DE, Allen J: A phase II trial of paclitaxel in squamous cell carcinoma of the head and neck with correlative laboratory studies, *Semin Oncol* 22:41–46, 1995.
44. Forastiere AA, Shank D, Neuberg D, et al.: Final report of a phase II evaluation of paclitaxel in patients with advanced squamous cell carcinoma of the head and neck: an Eastern Cooperative Oncology Group trial (PA390), *Cancer* 82:2270–2274, 1998.
45. Adamo V, Ferraro G, Pergolizzi S, et al.: Paclitaxel and cisplatin in patients with recurrent and metastatic head and neck squamous cell carcinoma, *Oral Oncol* 40:525–531, 2004.
46. Moosmann P, Egli F, Stahel RA, Jost L: Weekly paclitaxel and carboplatin combination chemotherapy in patients with advanced squamous cell carcinoma of the head and neck, *Onkologie* 26:568–572, 2003.
47. Gedlicka C, Formanek M, Selzer E, et al.: Phase II study with docetaxel and cisplatin in the treatment of recurrent and/or metastatic squamous cell carcinoma of the head and neck, *Oncology* 63:145–150, 2002.
48. Clark JI, Hofmeister C, Choudhury A, et al.: Phase II evaluation of paclitaxel in combination with carboplatin in advanced head and neck carcinoma, *Cancer* 92:2334–2340, 2001.
49. Baur M, Kienzer HR, Schweiger J, et al.: Docetaxel/cisplatin as first-line chemotherapy in patients with head and neck carcinoma: a phase II trial, *Cancer* 94:2953–2958, 2002.
50. Basaran M, Bavbek SE, Gullu I, et al.: A phase II study of paclitaxel and cisplatin combination chemotherapy in recurrent or metastatic head and neck cancer, *J Chemother* 14:207–213, 2002.
51. Shin DM, Glisson BS, Khuri FR, et al.: Phase II trial of paclitaxel, ifosfamide, and cisplatin in patients with recurrent head and neck squamous cell carcinoma, *J Clin Oncol* 16:1325–1330, 1998.
52. Shin DM, Khuri FR, Glisson BS, et al.: Phase II study of paclitaxel, ifosfamide, and carboplatin in patients with recurrent or metastatic head and neck squamous cell carcinoma, *Cancer* 91:1316–1323, 2001.
53. Ciardiello F, Tortora G: A novel approach in the treatment of cancer: targeting the epidermal growth factor receptor, *Clin Cancer Res* 7:2958–2970, 2001.
54. Brehmer D, Greff Z, Godl K, et al.: Cellular targets of gefitinib, *Cancer Res* 65:379–382, 2005.
55. Nakamura Y, Oka M, Soda H, et al.: Gefitinib ("Iressa," ZD 1939), an epidermal growth factor receptor tyrosine kinase inhibitor, reverses breast cancer resistance protein/ABCG2-mediated drug resistance, *Cancer Res* 65:1541–1546, 2005.
56. Cohen EEW: Role of epidermal growth factor receptor pathway-targeted therapy in patients with recurrent and/or metastatic squamous cell carcinoma of the head and neck, *J Clin Oncol* 24:2659–2665, 2006.
57. Cohen EE, Rosen F, Stadler WM, et al.: Phase II trial of ZD1839 in recurrent or metastatic squamous cell carcinoma of the head and neck, *J Clin Oncol* 21:1980–1987, 2003.
58. Wheeler RH, Jones D, Sharma P, et al.: Clinical and molecular phase II study of gefitinib in patients (pts) with recurrent squamous cell cancer of the head and neck (H&N Ca), *J Clin Oncol* 23:507S, 2005 (Suppl abstr 5531).
59. Soulieres D, Senzer NN, Vokes EE, et al.: Multicenter phase II study of erlotinib, an oral epidermal growth factor receptor tyrosine kinase inhibitor, in patients with recurrent or metastatic squamous cell cancer of the head and neck, *J Clin Oncol* 22:77–85, 2004.
60. Belon J, Irigoyen A, Rodriguez I, et al.: Preliminary results of a phase II study to evaluate gefitinib combined with docetaxel and cisplatin in patients with recurrent and/or metastatic squamous-cell carcinoma of the head and neck, *J Clin Oncol* 23:515S, 2005 (Suppl abstr 5563).
61. Kim ES, Kies M, Sabichi A, et al.: Phase II study of combination cisplatin, docetaxel and erlotinib in patients with metastatic/recurrent head and neck squamous cell carcinoma (HNSCC), *J Clin Oncol* 23:511S, 2005 (Suppl abstr 5546).
62. Vokes EE, Cohen EEW, Mauer AM, et al.: A phase I study of erlotinib and bevacizumab for recurrent or metastatic squamous cell carcinoma of the head and neck (HNC), *J Clin Oncol* 23:501S, 2005 (Suppl abstr 5504).
63. Bonner JA, Harari PM, Giralt J, et al.: Radiotherapy plus cetuximab for squamous-cell carcinoma of the head and neck, *N Engl J Med* 354:567–578, 2006.
64. Vermorken JB, Mesia R, Rivera F, et al.: Platinum based chemotherapy plus cetuximab in head and neck cancer, *N Engl J Med* 359:1116–1127, 2008.
65. Trigo J, Hitt R, Koralewski P, et al.: Cetuximab monotherapy is active in patients (pts) with platinum-refractory recurrent/metastatic squamous cell carcinoma of the head and neck (SCCHN): results of a phase II study, *J Clin Oncol* 22:488S, 2004 (Suppl abstr 5502).
66. Laurie SA, Licitra L: Systemic therapy in the palliative management of advanced salivary gland cancers, *J Clin Oncol* 24:2673, 2006.
67. Lufkin R, Borges A, Villablanca P: *Teaching atlas of head and neck imaging*, New York, 2000, Thieme.
68. Mukherji SK, Chong V: *Atlas of head and neck imaging: the extracranial head and neck*, New York, 2004, Thieme.
69. Dori S, Vered M, David R, Buchner A: HER2/neu expression in adenoid cystic carcinoma of salivary gland origin: an immunohistochemical study, *J Oral Pathol Med* 31:463–497, 2002.
70. Davies A, Finlay I: *Oral care in advanced disease*, New York, 2005, Oxford University Press, p 17.
71. Osaki T, Ueta E, Yoneda K, et al.: Prophylaxis of oral mucositis associated with chemoradiotherapy for oral carcinoma by Azelastine hydrochloride (Azelastine) with other antioxidants, *Head Neck* 16:331–339, 1994.
72. Teicher BA: *Tumor models in cancer research*, Totowa, NJ, 2002, Humana Press, p 324.
73. Ferreira PR, Fleck JF, Diehl A, et al.: Protective effect of alpha-tocopherol in head and neck cancer radiation-induced mucositis: a double-blind randomized trial, *Head Neck* 26:313–321, 2004.
74. Köstler WJ, Hejna M, Wenzel C, Zielinski CC: Oral mucositis complicating chemotherapy and/or radiotherapy: options for prevention and treatment, *CA Cancer J Clin* 51:290–315, 2001.

34 History of Temporomandibular Surgery

GREGORY M. NESS

Despite a vast body of supportive scientific literature reaching back into the 19th century, surgical treatment of patients with temporomandibular joint disease remains controversial in the early 21st century, perhaps in part because relatively few surgeons (or patient advocates) have examined the rich history of these operations. Certainly, reading about the history of temporomandibular joint surgery enhances our understanding of the principles behind contemporary surgical therapy. Yet, as we read the unfamiliar and dated language of individuals whose names may sometimes be known but whose faces have faded from human memory, the mists of time lift slightly and we catch glimpses of what it meant to be a surgeon 50, 80, or 100 years ago. Although this chapter can only briefly summarize the accomplishments (and failures) whose legacy is our contemporary knowledge and practice, it will fulfill its purpose if the reader is inspired to visit some of the pioneering articles themselves, seeing them in their original context among papers describing advances in general, orthopedic, or plastic surgery, and (in more recent decades) encased by advertisements for the latest and best materials, pharmaceuticals, and instruments, most of which are now long forgotten.

In fact, it is often difficult for the contemporary reader to examine outdated techniques and concepts without an anachronistic and even arrogant sense of omniscience. To understand the significance of our surgical forefathers' accomplishments, we must abandon our comparatively vast understanding of human physiology, inflammation, pain, and healing, not to mention our sophisticated technology, instrumentation, imaging capabilities, and pharmaceutical armamentarium. Imagine instead devising an approach to a temporomandibular joint that you have not imaged and whose normal structure and function are largely matters of speculation. Then, perform your operation on a patient anesthetized with an open cloth soaked in ether or chloroform. The latest textbooks discuss the comparative risks and benefits of these two anesthetic gases; both are known to have major safety and efficacy risks to patient and surgical team alike. Finally, hope that any infection afterward does not prove to be fatal, and that the operation leaves the patient better off, not worse.

Pioneers

Numerous advances notwithstanding, most fundamental surgical procedures employed in the treatment of temporomandibular joint (TMJ) disease have been known, practiced, and described in the surgical literature for a century or longer.

Thomas Annandale[1] generally is credited with the first published description of temporomandibular joint disc repair in 1887 (Figure 34-1). He describes successfully treating two patients with locking or painfully clicking TMJs using surgical disc repositioning, having correctly hypothesized that the problems lie with the "inter-articular" cartilage of the TMJ displaced "either from a sudden tearing of their connections or from a gradual stretching of them." The contemporary wisdom of the time was represented by a textbook that he quoted, which describes the disorder as "an affection occurring principally in delicate women . . . thought to depend upon relaxation of the ligaments of the joint permitting too free a movement . . . and possibly a slipping of the inter-articular cartilage."[2] This opinion may sound eerily familiar to the contemporary reader, but other 19th-century concepts are now unthinkable: Annandale's second patient was kept in hospital 10 days before her surgery and 13 days after.

Treating the temporomandibular joint was by no means a standard operation in the 19th and early 20th centuries. Annandale used a small incision comparable with a modern conservative preauricular approach. In contrast, the 1895 edition of Stimson's *Manual of Operative Surgery* describes excision of the mandibular condyle through a T-shaped incision with its horizontal arm along the inferior aspect of the zygoma about 1¼ inches in length and the vertical arm, through skin only, about 1 inch long. The "parotid, nerves and vessels" were retracted inferiorly to prevent injury.[3] In 1914, John Murphy of Chicago produced a detailed report

ON

DISPLACEMENT OF THE INTER-ARTICULAR CARTILAGE OF THE LOWER JAW, AND ITS TREATMENT BY OPERATION.

BY THOMAS ANNANDALE, F.R.S.E.,
REGIUS PROFESSOR OF CLINICAL SURGERY, UNIVERSITY OF EDINBURGH

THAT the proper movements of the temporo-maxillary joint may be interfered with by conditions inside the articulation is a fact recognised by all surgical authorities. That a displacement of the inter-articular cartilage—the "subluxation" of Sir Astley Cooper—may be one of these conditions is also recognised. But most modern works on surgery describe this affection as being generally due either to relaxation of the ligaments of the joint allowing a too free movement, or to inflammatory changes of a simple, gouty, or rheumatic nature. Heath[1] writes upon the subject thus: "It is an affection occurring principally in delicate women, and has been thought to depend upon relaxation of the ligaments of the joint permitting a too free movement of the bone, and possibly (though this is conjecture) a slipping of the inter-articular cartilage." Believing with Mr. Heath and other authors that inflammatory results may cause interference with the movements of this joint, I feel further convinced that, as in the case of the semilunar cartilages of the knee, the inter-articular cartilages of the temporo-maxillary joint may become displaced either from a sudden tearing of their connexions or from a gradual stretching of them.

But the chief object of this short paper is to advocate a new method of treating by operation cases of this condition which resist counter-irritation and the other means usually advised, and in which there are symptoms of a too free movement of one or both of these cartilages. The operation is upon the same principle as that which I have described and successfully carried out in connexion with the displacement of the semilunar cartilages of the knee-joint. The method is as follows:—An incision slightly curved, about three-quarters of an inch in length, is made over the posterior margin of the external lateral ligament of this joint, and is carried down to its capsule. Any small bleeding vessels having been secured, the capsule is divided, and the inter-articular cartilage is seized, drawn into position, and secured to the periosteum and other tissues at the outer margin of the articulation by a catgut suture. The following two cases illustrate the condition, and also the good result obtained by the operation suggested.

CASE 1.—Mary M'C——, aged thirty-eight, was admitted into my wards on March 2nd, 1886. Nine years before her admission she injured her temporo-maxillary joints during an attack of vomiting. The joints remained "locked" for a few minutes, but after a little manipulation she herself put the condition right. Ever since this time she has suffered great discomfort in the joint upon the left side, for whenever any extra movement of the jaws was made this joint became fixed, and remained so until she had practised some manipulations, when movement returned. Frequently also, when she tried to open her mouth, she found that she could only do so to a limited extent, but by using the manipulations the proper separation of the jaws was completed. On March 12th an incision was made over the left temporo-maxillary joint, and, its capsule having been divided, the inter-articular cartilage was found to be loosened from its attachments, and much more movable than usual. The cartilage, having been seized with artery forceps, was drawn into position, and a catgut suture passed through it and the periosteum and other tissues at the outer margin of the joint. The wound healed rapidly, and she left the infirmary on March 25th. At this time the movements of the joint were natural, and she could close and separate the jaws perfectly, without any locking or catch.

CASE 2.—Ann M——, aged eighteen, admitted on Jan. 20th, 1885. Two years before admission, the patient when yawning found her jaws fixed. After a little manipulation she was able to close the jaws, but with a "click" on the right side. Since then she has suffered from pain and stiffness upon the left side, and the movements of the joint were constantly interfered with by something "slipping" in it. She had been treated by blistering and other remedies without obtaining any relief. On July 23rd the usual operation was performed, and the left inter-articular cartilage, being found loosened, was stitched in position with a catgut suture, as in the former case. The wound was healed at the end of a week, and she left the infirmary on July 31st, with perfect and proper movement of the jaws.

[1] Injuries and Diseases of the Jaws, third edition, p. 415.

PHOSPHATIC DIABETES.[1]

BY CHARLES HENRY RALFE, M.D. CANTAB., F.R.C.P.L.,
ASSISTANT-PHYSICIAN, LONDON HOSPITAL.

AMONG the numerous investigations that have engaged the attention of physiologists during the last fifteen years, few yield in interest and importance to the study of the part played by the inorganic constituents of the body in histogenesis, and their influence in producing the daily and hourly variations which occur in the chemical composition of the secretions. Although this branch of animal physiology is only partially developed, yet our knowledge in this direction is steadily and constantly advancing, and the advance will be more rapid when it becomes clearly perceived how greatly minute variations of the inorganic constituents conveyed by the blood plasma to the cells influence for good or evil the processes of nutrition going on in the tissues. I can here only glance at some of the more important facts that have been established in this direction, and touch only on those points which are most closely related to the subject matter of the present paper.

Twenty years ago it was stated in most text-books that inorganic substances passed unaltered through the body, and that the same weight of saline constituents was recoverable from the urine and fæces as was introduced during the same period with the food and drink. The first advance on this simple view was made when it was discovered that chloride of sodium was retained in the body, and consequently disappeared from the urine, in certain diseases attended with increased cell-formation; and that even under normal conditions only four-fifths of the common salt ingested left the body as such, the remaining fifth being decomposed and altered in constitution within the system. Further researches led to the important discovery that whilst inorganic salts pass with immense and usually uniform rapidity into the circulation, and thence to the tissues, their discharge is by no means so regular, and they are detained for very unequal periods, which apparently depends on the need of the tissue to which they are supplied. Thus both Hoffmann and Lascar have shown that, however great the tendency of the alkaline bases is to combine with acids and acid salts, these cannot be withdrawn from the alkaline blood, but are powerfully withheld to maintain its alkalinity. And this fact is illustrated by what occurs in scurvy, for, as I pointed out in 1877,[2] and it has since been corroborated by Zuelzer,[3] as soon as the alkaline carbonates cease to be supplied by means of vegetables, the alkaline phosphates begin at once to disappear from the urine, evidently to maintain the alkalescence of the blood diminished by the withdrawal of the alkaline carbonates. In connexion with this it is interesting to notice that Dr. Gee[4] has likewise called attention to the remarkable fact that in ague, on the days of the paroxysms, the phosphates almost entirely disappear from the urine; and although Dr. Gee has not attempted an explanation of the phenomenon, still it is not unlikely that this is again an instance of a salt being withheld to supply a special requirement, whilst another is being discharged in excess; for it is important to notice in connexion with this withdrawal of phosphoric acid during the ague fit that the chlorides are at that time eliminated in considerable excess. It would be easy to multiply examples, but enough has been said to emphasise the importance of the *rôle* played by the inorganic substances in the economy.

Of all inorganic constituents phosphorus has always been regarded as holding the prominent position. When first separated from the urine by Brandt (1669) it was at once hailed by the physiologists of the day as the "blood of

[1] Read before the Medical Society of London, Jan. 10th, 1887.
[2] General Pathology of Scurvy (Lewis. London, 1877).
[3] Untersuchungen über die Semiologie des Harns; Berlin, 1884.
[4] St. Bartholomew's Hospital Reports, vol. viii.

• **Figure 34-1** Thomas Annandale's landmark article in *The Lancet* is just over a single column in length, has no illustrations, and includes only a single formal reference citation. (From Annandale T: Displacement of the inter-articular cartilage of the lower jaw, and its treatment by operation, *Lancet* 8:411, 1887.)

on nine cases of TMJ ankylosis treated by arthroplasty with rotation of an interpositional flap of temporal fat and temporalis fascia.[4] His incision was L-shaped, with its base along the superior aspect of the zygomatic arch and a vertical arm at the posterior end, extending upward 1½ inches. Murphy claimed that keeping the horizontal incision above the zygomatic arch avoided branches of the facial nerve.

Behan published a detailed and well-illustrated description of TMJ arthrotomy in 1918, returning to the vertical preauricular approach.[5] In the same year, John Blake in Boston noted the difficulties of approaching the TMJ: "It is hard to reach for the purpose of careful detailed attack, as it lies deep below the surface, and is surrounded by good-sized arteries and nerves; a clear dry field is hard to obtain, and accurate work on the joint is consequently far from easy."[6] Even so, others pressed on: In Philadelphia, Ashhurst called Blake's concerns "undue emphasis" and reached the joint through an inverted L-shaped incision, following the zygomatic arch horizontally for 2 cm, then turning inferiorly from the posterior end for 3 cm.[7]

These early TMJ surgeons and several others in the United States, Great Britain, and Europe were pioneers in devising approaches to the TMJ and procedures to restore the joint to better function. According to contemporary standards, their incision designs range from unsophisticated to dangerous and disfiguring, but these men were hardly unsophisticated themselves. All were exceptional anatomists and broadly trained surgeons who critically reassessed the little TMJ pathophysiology known to them, brought fresh thinking to their patients' problems, and applied principles gained from experience in other operations and diseases to the TMJ in novel and perceptive ways. They were certainly aware of one another's work: Most cited one another, and nearly all referenced Annandale's article from a quarter-century before, as well as still earlier compilations of jaw dysfunction cases[8] that offered insight into the TMJ symptoms they faced, although they were of little use regarding surgical therapy.

Early Arthroplasty

The Snapping Jaw

By the 1920s, a reasonable body of literature and clinical experience had accumulated regarding TMJ anatomy and function, and several distinct joint pathologies now possessed documented surgical remedies. Annandale had treated painful locking and clicking joints with disc repositioning 30 years earlier, but for many years, little more was published on surgery for this particular condition. In 1918, Behan[5] described finding either anterior or posterior disc attachments torn and he repaired them to reposition the disc. That same year, Pringle[9] hypothesized that the lateral pterygoid muscle could displace the articular disc anteriorly and medially, and treated the condition with what he believed to be the first excision of the disc. Ashhurst duplicated this operation successfully in 1921 on a 16-year-old female patient.[7] Unknown to both of them, the Swiss surgeon Otto Lanz (Figure 34-2), professor of surgery in Amsterdam, had published two cases of TMJ discectomy on an 18-year-old and a 24-year-old woman that he had performed in 1906 and 1908.[10] Lanz, who also invented the mesh skin graft during this time,[11] had reported his surgeries a decade earlier in the German-language journal *Zentralblatt für Chirurgie*.

It was Ashhurst, however, who resurrected a term first used nearly a century earlier by Cooper and christened the internally deranged TMJ the "snapping jaw," a term applied for the next several decades to a rather vaguely defined painful popping or snapping jaw that might intermittently become stuck open, closed, or something in between.

In fact, confusion reigned regarding the actual location and movement of the articular disc in normal function, not to mention its role in the intermittently locking, subluxing, dislocating, and/or snapping joint. Early on, Cooper had compared the subluxing TMJ to injured knees and hypothesized that capsular ligamentous laxity allowed subluxation, although he also believed that the disc could become displaced behind the mandibular condyle and thus prevent full mandibular closure.[8] The debate on whether capsular laxity or disc displacement was responsible for the



• **Figure 34-2** Otto Lanz, the surgeon who first treated painful locking temporomandibular joints in 1906 by removing the intra-articular disc. (Reproduced in Haeseker B: Historical notes on 50 years of plastic surgery in the Netherlands, *Eur J Plast Surg* 23:164, 2000.)

observed symptoms continued for a century and longer. Despite multiple reports of encountering the disc displaced anteriorly at surgery and repositioning it posteriorly, some authors persisted in blaming a posteriorly displaced disc or a loose lateral capsule for the pain and snapping noises in the TMJ. Some confusion may stem from inconsistent use of terminology: Many case reports were unclear on precisely what jaw mobility dysfunction was present, and the term *subluxation* seems to have been applied sometimes to the disc and sometimes to the mandible (without specifying whether the disc was thought to be malpositioned anteriorly or posteriorly). Contemporary understanding of anterior disc displacement and reduction is relatively recent, and perhaps the early confusion is understandable. If one considers the broadly diverse treatments available today for chronic subluxation/dislocation, it can be seen that we may have not progressed all that far in our understanding of this condition.

Although Lanz, Ashhurst, and Pringle directed surgery at the disc, others attempted to control "subluxation" through extracapsular procedures. Blake[6] successfully prevented recurrent dislocation in an adult male patient by wiring the coronoid process to the zygomatic arch to restrict mandibular opening. And in Germany, Nieden[12] improved on safe access to the TMJ and devised a new procedure to restrict condylar movement. He elevated an inferiorly based flap of temporalis fascia, rotated it inferiorly, and secured the free end to the lateral joint capsule to tighten it and restrict condylar movement. Several years later, this surgery was declared to be "based upon the soundest surgical principles" for treating hypermobility,[13] and the loose lateral capsule was believed to be the main point of origin for several more decades.

The story of Professor Doctor Nieden illustrates another aspect of reviewing history: Our admiration of an important figure's achievement should not automatically extend to his character. Nieden's story would not be complete without taking note of a darker side. A highly decorated military surgeon during World War I, Nieden chose a less than noble course during the National Socialist years. He joined the Nazi party early, worked with the Gestapo before and during World War II, and served in the SS. Published accounts name him as a surgeon who performed compulsory sterilization on mixed-race children in the 1930s.[14,15]

Ankylosis

Painful snapping was not the only TMJ pathology treated by operation, nor the most common. Ankylosis was perhaps the earliest TMJ condition treated surgically, although most 19th-century surgeons in Europe attempted to solve the problem with osteotomies away from the TMJ itself. In the United States, Murphy reported on nine patients with TMJ ankylosis whom he treated during the years leading up to 1914.[4] His paper is a grim reminder of the fearsome complications caused by infection in the pre-antibiotic era. Table 34-1 lists the ages of onset and causes of ankylosis for his case series.

TABLE 34-1 Age at Onset and Cause of Ankylosis in Murphy's Case Series, 1914

Case #	Onset Age	Cause
1	6 mo	Otitis media, mastoiditis
2	6 yr	Kicked in jaw by horse, angle fracture with infection
3	Birth?	Difficult delivery, facial deformity noted early in life
4	9 yr	Fall from third story, chin impact, immediate trismus
5	Birth	Unknown
6	2½ yr	Severe mastoiditis, otitis, recurrent abscesses for over 6 months
7	14	Fall from horse without direct facial injury; progressive hip, spine, and jaw immobility
8	2½ yr	Throat infection, subsequent generalized abscesses
9	17	Sepsis, osteomyelitis

Data from Murphy JB: Arthroplasty for intra-articular bony and fibrous ankylosis of temporomandibular articulation, *JAMA* 62:1783-1794, 1914.

Although some cases appear to represent congenital deformities or sequelae of direct trauma, a significant number of his ankyloses appear to be late effects of local (especially mastoiditis) or widely disseminated infection, leading to septic arthritis of the TMJ, a condition very rarely seen today. His treatment consisted of freeing the ankylosis by removing the bone in the area of the condyle and rotating a fascia and a fat flap from the temple into the gap, then propping the patient's mouth open for 2 weeks with a wedge-shaped wooden block. His purpose for this was to "prevent possible compression necrosis of the interposing flap." He reported good mandibular movement at follow-up periods of 4 to 11 months, with one recurrent ankylosis.

The Role of Dental Occlusion

During the early 20th century, intrinsic pathology of the TMJ was addressed with little apparent consideration for the state of the patient's dental occlusion. Orthopedic principles derived from greater experience in other joints were applied to the TMJ, with results reportedly satisfactory to patient and surgeon alike. By 1930, John Morris was able to present a thorough and insightful review of the state of the art in treating the snapping jaw.[13] He perpetuated the assertion that capsular laxity with consequent excessive condylar movement was responsible for the observed snapping, pain, and hypomobility. However, he recognized that posterior disc displacement was anatomically unlikely and therefore an unacceptable cause. Building on the work of Pringle,[9] he postulated that anterior displacement ultimately led to secondary joint laxity, which, in turn, produced symptoms.

• BOX 34-1 Treatment Options for "Subluxation of the Inferior Maxilla"

I. Nonoperative methods
  A. Dental technical procedures
    1. Outside mouth
      (a) Apparatus, fastened around chin and held in position by cap on head; limits chewing motion and depression of point of jaw
    2. Inside mouth
      (a) Splint, fastened to upper and lower jaw with intervening catch hinge, is adjustable to limit motion of lower jaw (Schroeder)
      (b) Hard rubber plate, fixed to upper jaw and provided with process pointing of edge of masseter muscle or coronoid process, limits excursion of latter (Fritzsche)
  B. Injection of corrosive fluids into joint (to produce shrinkage of capsule and promote adhesions)
    1. Tincture of iodine (0.75 mL tincture of iodine injected into joint posteriorly secured permanent cure in case of girl, aged 20 years, as reported by Perthes)
    2. Alcohol
II. Operative method
  A. Treatment of capsule
    1. Excision of portion of capsule is followed by suture to overcome redundancy (Perthes)
    2. Simple plication of capsule after exploration of joint takes up redundancy and tightens joint
  B. Use of fascial strip (turned down from temporal region to check excursion of head, as described by Nieden)
  C. Treatment of meniscus
    1. Fixation of disc by suture to periosteum of mandibular fossa (Haeber)
    2. Fixation of disc in vertical position in front of condylar process (Konjetzny)
    3. Removal of the articular disc (Ashhurst)

From Morris JH: Chronic recurring temporomaxillary subluxation: surgical consideration of "snapping jaw" with report of a successful operative result, *Surg Gynecol Obstet* 50:483-491, 1930.

More significantly, he summarized the contemporary treatments available for the snapping jaw (Box 34-1) and argued convincingly that joint surgery offered the best solution.

Morris's writings reflect progress made since the time of Annandale nearly half a century earlier, not only with respect to the TMJ but for all of orthopedic surgery. He decries that "standard surgical texts limit operative indications to such conditions as ankylosis, arthritis, irreducible dislocations, and a few unusual fractures. Subluxation of the joint as a surgical consideration is either dismissed as of no importance, or its existence is completely ignored." He responds by asserting that "operative indications, which were formerly limited to the more grave pathological conditions, have been gradually extended to include a variety of derangements the minor character of which did not justify the hazards imposed by the older methods. The acceptance of the minor joint lesions for radical surgical treatment indicates the highest degree of confidence in the safety and efficiency of the methods employed and offers as well the most convincing evidence of the advances made in this field."

However, within a few years, the philosophy undergirding temporomandibular joint care would turn in the opposite direction. Washington University otolaryngologist James Costen studied a large cohort of patients with varying combinations of headache, ear pain, neuralgia, glossodynia, and other less common complaints associated with abnormal jaw movement and malocclusion. He theorized that loss of posterior occlusal support (a common phenomenon of the time) led to excessive pressure on the TMJ with subsequent destruction, dysfunction, and nerve compression. His theory was ultimately published in the *Journal of the American Medical Association*[16] and gained widespread acceptance for nearly two decades; the "snapping jaw" became "Costen's syndrome."

Treatment of patients with this new syndrome, whose symptoms were correctly observed to be much more common than was previously recognized, was dental. The posterior occlusion was gradually opened; this was believed to decompress the nerves and other tissues within the TMJ and to allow healing. Most patients improved; those who did not were sometimes assumed by their treating physicians to have received poor care from their dentists.[16] In fact, Costen even advocated against removing the molar teeth in any patient with a head and neck neuralgia.

Although surgery for TMJ internal derangements did continue to be practiced, Costen's syndrome validated and energized an entire school of thought that attributed joint pathology to occlusal disharmonies. In fact, therapy following Costen's principles and the many subsequent dental refinements was reasonably effective, although probably not for the reasons cited. However, as early as 1940, some authors questioned the anatomic basis of Costen's neurologic symptoms. Dingman[17] concludes a thorough review of TMJ therapy by warning, "We must not lose sight of the fact that many of the statements made regarding this subject [Costen's syndrome] are still within the realm of speculation and need further scientific investigation for substantiation. . . . By assuming a critical attitude and proceeding in a cautious manner, the dental profession may avert severe criticism that might arise as a result of misguided therapy." His advice remains wise today.

Finally, in 1948, Harry Sicher, the legendary teacher and anatomist at Loyola School of Dentistry, published a definitive anatomic study that refuted the neural compression mechanism underlying Costen's syndrome.[18] His article concludes with a balancing perspective. He notes that "destruction of the disk and degenerative and proliferative changes on the condyle and tubercle" meet "the well-defined picture of deforming arthritis. . . . The symptoms of pain, local and irradiating (referred), cracking of the joint and the restriction of movements of the joint are simply the symptoms of arthritis." Yet he does attribute TMJ arthritis to mandibular overclosure or displacement and concludes by stating, "The beneficial influence of reconstructive dentistry has to be fully recognized." Thus, the two schools of TMJ treatment, surgical and occlusal, remained established and in some tension with one

another, although perhaps forming the beginnings of a stronger scientific foundation.

The Mid-20th Century and the Science of TMJ Therapy

Professor Cecil Wakely of King's College, London, published a new review on surgery of the temporomandibular joint in 1939.[19] In a series of 38 patients (30 male and 8 female) with mandibular dislocation, he found only two whose condition was recurrent and did not operate even on those. He advocated arthroplasty with a gap for treating ankylosis and was the first to use a pedicled temporalis flap, tunneled beneath the zygomatic arch, as an interpositional tissue graft (Figure 34-3). Regarding allografts, he noted presciently, "The human body does not tolerate foreign tissue kindly."

The largest part of Wakely's paper is devoted to the displaced articular disc, a topic that he had explored a decade earlier.[20] He describes this condition as "an uncommon accident, but a much more difficult condition to treat than dislocation of the joint." He believed that synovitis resulting from displacement was in part responsible for the pain, which is perhaps the first recognition of a noninfectious, intracapsular inflammatory process as a contributing cause of the disorder. He also bluntly associated gender-related emotional issues with chronic disc displacement: "The psychologic effect of a snapping joint may be very marked, especially in females. They become introspective and nervous and are afraid to have meals in public."[19] In cases that failed "every other form of treatment" (which he does not describe), he performed discectomy and claimed good outcomes with follow-up of up to 15 years, comparing the procedure to the well-established successful operation of excising torn medial menisci from the knee.

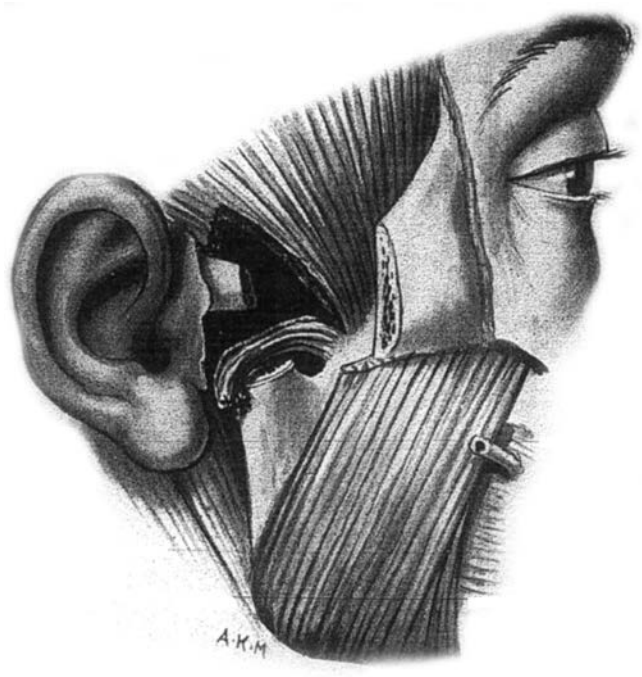

• **Figure 34-3** Professor Wakely's temporalis flap, 1939. (From Wakely CPG: The surgery of the temporomandibular joint, *Surgery* 5:697-706, 1939.)

The following year, Reed Dingman of Washington, DC, also published a broad review of diagnosis and treatment of TMJ disorders.[17] Many of the conditions he identified are curiosities to the modern reader. Suppurative lesions of the TMJ were becoming less frequent but might still result from middle ear infection, gonorrheal ophthalmitis or urethritis (he cites a large series that found TMJ infection in 3% of gonorrheal urethritis cases), measles, scarlet fever, diphtheria, pertussis, typhoid, pneumonia, or influenza. He attributed the reduction in cases to the introduction of vaccination for many of these diseases, the use of sulfanilamide to treat infection, and the instillation of silver nitrate eyedrops to prevent gonorrhea neonatorum. He notes that without incision and drainage, a suppurative TMJ can be expected to drain preferentially into the middle ear or the external auditory canal and much less commonly to the pretragal area. Yet even with proper care, many of these cases ended in ankylosis, which remained a relatively common indication for TMJ surgery. In such cases, Dingman advocated arthroplasty with a pedicled interpositional temporalis flap, although he abandoned Murphy's mouth wedge.

Dingman also wrote at length on arthritis of the TMJ—both atrophic (rheumatoid) and hypertrophic (osteoarthritis). In either case, unless the patient developed an ankylosis or severely symptomatic disc displacement, he advocated nonsurgical care consistent with that given for other afflicted joints. He noted that TMJ arthritis previously had been thought to be rare, but its actual, more common incidence had become widely recognized. With respect to subluxation and dislocation, Dingman, like many before him, appears to have considered cases of disc displacement and condylar subluxation/dislocation as a single broad entity. He describes nonoperative treatment with intermaxillary fixation or sclerosing injections, the latter as "generally ineffectual," although he gives details of the method used by Schultz[21] with good effect. Of published surgeries for internal derangements, he concludes (although without providing evidence) that discectomy "seems to be the best and most logical procedure."[17]

Dingman and Wakely were by no means the only surgeons performing TMJ operations in the 1930s and 1940s. Caroll Silver, an orthopedic surgeon who trained in New York in the late 1930s, participated in several cases as an intern wherein mandibular hypermobility was treated by grafting a block of bone to the articular eminence. Patients were kept in a plaster head cast for 6 weeks and were fed through a straw; they reportedly did not suffer from subluxation or dislocation after healing.[22] Later in his career, Silver performed hundreds of discectomies and contributed some of the largest series of long-term outcomes in the literature.[23] In Stockholm, Karl Bowman published his doctoral dissertation entitled "Temporomandibular Joint Arthrosis

and Its Treatment by Extirpation of the Disk: A Clinical Study."[24] This landmark scientific treatise was arguably its time's most complete, well-documented compilation of knowledge regarding the TMJ and its anatomy, pathophysiology, normal and impaired function, and response to discectomy (including measured outcomes). He summarizes, saying in part the following[24]:

> Examination of a healthy material including 1350 individuals of all ages showed that symptoms of arthrosis, such as snappings, crepitations and disturbances in motion are very common and more frequent in women than in men. At least ⅓ of all grown-up persons have or have had such symptoms. They can occur already at the age of 6-8, but are more common in later ages.
>
> Contrary to information in the literature, there have been no incongruities as regards the frequency of symptoms in individuals with normal bites, straight bites and deep bites, whether the molar-premolar supports have been good or bad. In individuals with incomplete bites, down to total loss of teeth, temporomandibular joint symptoms have not occurred more frequently than in individuals without noteworthy loss of teeth. In persons without teeth, temporomandibular joint symptoms are less frequent than in denture cases. The symptoms of arthrosis are, as a rule, associated with very slight trouble. They can disappear spontaneously without leaving any clinically demonstrable traces. In exceptional cases, however, they can be associated with more severe symptoms which require treatment. . . . There is nothing to indicate a detrimental effect of the extirpation of the disk on the unoperated joint. There is no reason always to perform a bilateral extirpation of the disk, as has been recommended. In cases with bilateral symptoms, the most severely affected joint should be operated. Even the other joint is often improved thereby. There are no disadvantages of a subsequent operation on the other joint, if necessary. . . . The treatment of the temporomandibular joint arthrosis should, first and foremost, be conservative. . . . In cases with severe symptoms (constrictions, luxations, pains, disturbing snappings) which cannot be improved by conservative therapy, an extirpation of the disk is indicated. The operation offers immediate and permanent relief from these symptoms.

Nearly 70 years later, Bowman's assertions remain valid. His conclusions can hardly be better stated today.

These men and the many other surgeons they represented continued the search for better ways to treat TMJ dysfunction, applying the dramatic new medical knowledge and surgical techniques that were revolutionizing all of surgery. Their work provided the foundation for the creative treatment concepts about to emerge.

The Era of Innovation

At the end of World War II, medical and surgical innovation accelerated dramatically, and TMJ surgery received its share of attention from creative, and sometimes bold, surgeons. As Costen's influence faded and that of Wakely, Dingman, Bowman, and others grew, care of the TMJ drew renewed interest. With clearer distinction between diagnostic entities, it became easier for clinicians to choose appropriate therapies for their patients and, in turn, to assess their outcomes. The influence of basic science was felt in the world of patient care as well, not only through an exponential increase in knowledge and the resultant drugs and technologies, but also via application of scientific criteria to clinical research. It would no longer do to perform an operation a few times, declare the patient qualitatively better, describe his or her satisfaction, and publish the operation as an appropriate and successful treatment.

Nonsurgical Therapy

Not all innovations in therapy were surgical. Although occlusal equilibration continued to find acceptance, other nonoperative treatments were devised for specific conditions. Although others had attempted TMJ sclerosis using a variety of agents, Louis Schultz of Chicago had reported an improved method of reducing TMJ hypermobility with sclerosing injections in 1937, and in 1947, he published a report on 10 years' experience.[21] His method was innovative, appealing when compared with other contemporary alternatives (he mentions either surgery or mandibular fixation by head bandage for 1 to 1½ years—to be repeated if necessary), and apparently successful, although he follows the older tradition of providing no outcome data. In 1954, while treating the opposite end of the TMJ disease spectrum, Laszlo Schwartz applied the newly described concepts of myofascial pain, myalgia, and trigger areas to stiff, sore muscles in the masticatory muscle system.[25] Along with these concepts, he introduced the new therapies of local anesthetic injection and vapocoolant "spray and stretch" treatment to the TMJ literature. Of equal significance, he presented tabular data showing outcomes for a series of cases, including patients treated and those observed only. Although not blinded, randomized, placebo controlled, quantitative, or authorized by an institutional review board, his presentation of evidence was nevertheless a great leap forward from the preceding body of literature, perhaps excepting Bowman's scientifically rigorous publication.

Early Implants

Operative treatment remained the only viable alternative for severe fibrous or bony joint ankylosis, and attention was turned toward reducing the common complication of recurrence. Most surgeons used a flap of fascia, fat, or muscle in the hope of preventing bony regrowth, but with unpredictable results. In 1946, Eggers[26] reported the use of an alloplastic material, tantalum foil, to line bony surfaces at the ankylosis resection site in a 4-year-old girl. At 13 months, she had good mandibular opening, but long-term follow-up was not available. His description of the material and its use may make a contemporary surgeon who is familiar with the catastrophic failures of later alloplasts cringe: "It is a bit brittle and cracks, but satisfactory coverage can be secured

and even small pieces can be packed in areas where intervening material is desired."

Gordon,[27] when treating patients with subluxation (clicking joints), reported having 3 years' good experience placing polyethylene caps in the joint space after removing discs. His purpose was to prevent long-term malocclusion from an assumed reduction in vertical dimension at the condyle, although he admitted that in the short term, this was rarely a problem. Again, long-term follow-up was not available on this cohort of patients.

In July 1960, Sir Terence Ward lectured the Royal College of Surgeons on surgery of the mandibular joint.[28] He distilled surgical treatment of the TMJ into three operations: (1) condylectomy for pathology, (2) arthroplasty for ankylosis, and (3) condylotomy for internal derangements. His description of arthroplasty was remarkable for several innovations. He casually mentioned two advances in anesthesiology used in his cases: endotracheal intubation and controlled hypotension. These techniques were relatively new, although it is now difficult for the modern surgeon to imagine operating without them. He also illustrated the use of a rounded chrome-cobalt cap, which was inserted at surgery on a curved osteotomy into the mandibular ramus above the mandibular foramen. In this way, a new rotational joint was created below the mass of the ankylosis, and the bony surfaces separated and presumably were prevented from fusing by the chrome-cobalt cover. Ward reported "good" function following bilateral implants, without noting the duration of observation.

At the forefront of autogenous grafting, Georgiade at Duke University and colleagues reported a new application of transplanting autogenous dermis into the TMJ in 1957.[29] Tested first on dogs, the procedure was then performed on eight patients with ankylosis, and only one partial re-ankylosis was formed, although at relatively short follow-up. This landmark work gave TMJ surgeons a new biocompatible graft option that offered success at least as good as historical experience with fascia, fat, or muscle flaps.

From our vantage point a half-century later, it would be easy to fault these innovators for risking great complications or spectacular failure. However, at the time, the risks of alloplast failure could hardly seem worse than an all-too-predictable re-ankylosis, which was not only a failure but a terrible challenge to re-treat, or a malocclusion that would condemn the patient to heroic dental reconstruction or orthognathic operations that were in their infancy as well. These surgeons' contributions represented pioneering efforts to improve outcomes, and although we must surmise that these treatments failed, because they were generally abandoned, implanted materials with documented long-term success were only a few years away.

Joint Reconstruction

TMJ implants took a substantial leap forward in 1964, with Christensen's publication of a new arthroplasty technique in which a cast Vitallium glenoid fossa prosthesis was used.[30] He created a set of 20 cast prostheses based on impressions on skulls with varying anatomy, then selected the best-fitting implant for insertion into the patient.

Implants were secured with screws into the zygomatic arch, away from the occlusal surface. They were intended to provide a stable surface against which the mandibular condyle might function, preventing re-ankylosis by serving as a permanent mechanical barrier. In time, some surgeons advocated extending the indications for placement of the Christensen fossa to discectomy patients, to prevent the hypothetical but dreaded "bone-on-bone" contact and its presumed negative consequences.

The Christensen fossa implant soon was joined by a matching condylar prosthesis with a polymethylmethacrylate condylar head, thus forming the first total alloplastic temporomandibular joint prosthesis. Although other total joint replacement systems with advanced materials and engineering principles have been developed more recently, the Christensen implant remains on the market today as the first and longest used TMJ replacement system available.

Nonsurgical Treatment Revisited

Technical advances notwithstanding, surgery on the TMJ remained an imperfect and unpredictable science, facing criticism from those whose philosophy (and case study outcomes) supported nonsurgical treatment of all but tumor and ankylosis cases. During the 1960s, interest grew in the work of Schwartz and others, who believed that TMJ dysfunction was less a result of mechanical failure (either capsular or intracapsular) and more an outcome of masticatory muscle dysfunction. This in turn was attributed in large part to emotional stress and anxiety in patients, most of whom were young and female. In 1969, Daniel Laskin published an articulate paper in the *Journal of the American Dental Association* that proposed a shift of emphasis from joint to muscle pathology.[31] He provided a cogent argument for a strong psychological origin behind the physiologic muscle disorder in many patients and suggested the term *myofascial pain-dysfunction* to describe the condition.

In contrast to Costen's work, which was based to a significant extent on speculation, Laskin provided sound evidence for his theory. The paper became a lightning rod for renewed and sometimes contentious debate over the relative importance of psychological, emotional, occlusal, muscular, and intracapsular factors in patients with pain, popping and clicking joints, and stiff jaws. Unfortunately, despite its reasoned and scientific principles, the writing also reinforced the preconceptions of many clinicians who had always quietly believed TMJ disease to be a weak woman's affliction that was more "supratentorial" than organic in origin.

For a time, TMJ surgery was unpopular. Even so, amid the controversy and renewed interest in occlusal and muscle therapy, a new generation of surgical pioneers prepared the next round of advances.

The Return of the Operation

Open Joint Surgery

In the 1970s and 1980s, Wilkes brought new understanding to TMJ surgery, advancing interpretation of imaging, creating a clinical and radiographic staging system for characterizing TMJ internal derangements, and even developing new instrumentation for open TMJ surgery.[32,33] McCarty and Farrar,[34,35] Dolwick and colleagues,[36] and many others promoted a more complete understanding of the normal and abnormal function of the articular disc, leading to a resurgence of interest in disc surgery. Although discectomy continued to be performed, new techniques for disc preservation surgery were widely promoted by these and other authors (Figure 34-4).

The preauricular approach became standard, with modifications in skin incision placement behind the tragus by Kiehn[37] and widely cited improvements based on research by Al-Kayat and Bramley.[38] Indresano and Mobati have written an excellent summary of advances in TMJ surgery, particularly during the late 20th century.[39]

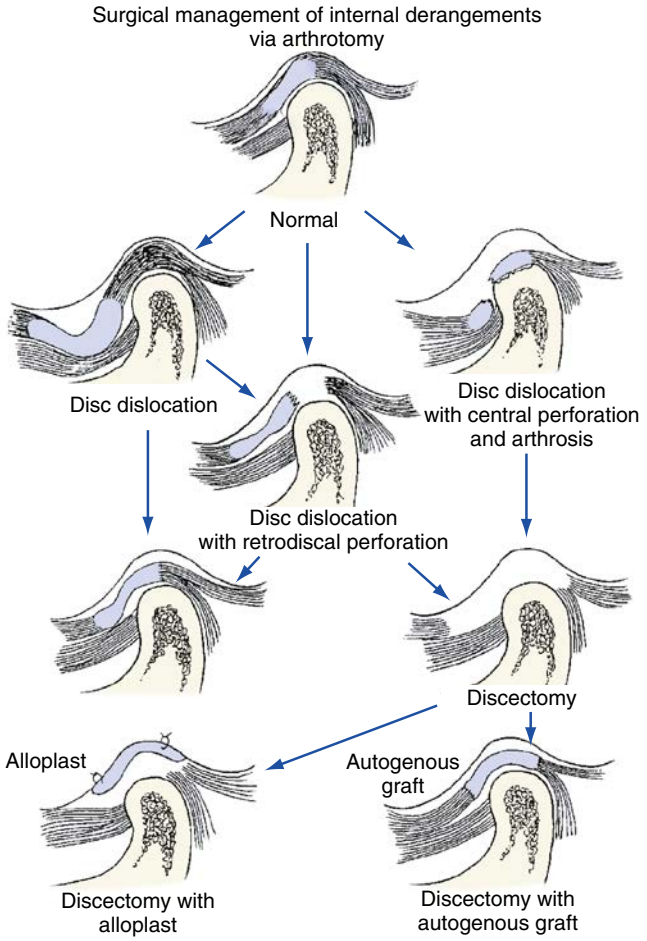

• **Figure 34-4** A schematic of options for temporomandibular joint disc surgery, 1989. (From Braun T, Kent J: Temporomandibular joint surgery, part II: partial and total joint reconstruction and osseous procedures, *Selected Readings Oral Maxillofac Surg* 1:1-24, 1989.)

The wide resurgence of interest in TMJ surgery contributed to a tragic chapter in its history. With disc surgical procedures being performed in great numbers, attention was directed to finding a suitable disc replacement. Autogenous grafts, including Georgiade's dermal graft, were widely used, although evidence for their improving outcomes was minimal. However, many surgeons turned to alloplastic materials for implantation. By the mid 1980s, two commonly used implants—silicone sheeting and a Teflon-Proplast implant specifically developed as an articular disc replacement—proved to be poor choices. The Teflon-Proplast implant in particular was prone to fragmentation and evoked an intense and locally destructive foreign-body giant cell reaction, resulting in catastrophic local destruction and, in many cases, consigning the patient to a lifetime of intractable pain. The manufacturing company withdrew it from the market (Figure 34-5), was subject to extensive litigation, and ultimately went bankrupt. Silicone sheeting was also subject to degeneration and foreign body reaction, but with less intense local destruction.

The TMJ implant debacle brought repercussions well beyond those felt by the unfortunate patients who received them. Critics of surgical therapy for TMJ internal derangement renewed their attacks. Insurance companies, alarmed by disastrous and expensive outcomes in their affected clients, simply wrote blanket exclusions for any TMJ-related care into most of their policies. Furthermore, a large cohort of patients with iatrogenically created chronic pain now joined the TMJ surgeons' caseloads, bringing complex long-term medical management issues into practices that were more comfortable providing acute surgical care to a relatively straightforward patient population. As a result of these forces, many surgeons stopped providing TMJ care in their practices, thereby reducing patient access to interested and qualified TMJ surgeons—a situation that persists to the present day.

Total Joint Replacement

The 1980s were a time of new developments in alloplastic total joint reconstruction. Although relatively few patients required total joint replacement, a small number with severe rheumatoid arthritis, traumatic joint destruction, failed reconstruction with autogenous grafts (most commonly costochondral grafts), or ankylosis had few other reasonable alternatives. The Christensen implant system remained the state-of-the-art total joint replacement technique throughout the 1970s, but then advances in materials, biomechanical engineering, and understanding of joint pathophysiology dramatically altered joint reconstruction in general orthopedics. Joint replacement for knees, hips, and other joints had become frequent and predictably successful surgery, and oral and maxillofacial surgeons began working to bring the same contemporary technologies to the TMJ. Kent and others[40,41] developed a joint reconstruction system with a polymeric fossa prosthesis and a metallic condylar head—the opposite of Christensen's design,

VITEK, Inc.
Technology for Life

March 23, 1990

VOLUNTARY SAFETY ALERT

PRODUCT: VITEK TEMPOROMANDIBULAR JOINT (TMJ) INTERPOSITIONAL IMPLANT (IPI) - ALL LOTS

Dear Doctor:

The purpose of this letter is to inform you of the following reported concerns which affect the Vitek TMJ IPI. The corresponding product catalogue numbers are 912.71, 912.72, 912.74, 912.76, 912.77 and 912.78. Vitek's IPI's may fragment, delaminate or otherwise be damaged or punctured. Debris in the joint from alloplastic implants can contribute to progressive bone degenerative changes and to giant cell reaction. All patients, including asymptomatic patients, should be monitored closely to assure proper patient maintenance. This monitoring should include clinical and radiographic examination. The radiographic examination may include transcranial or tomographic x-rays, CAT scans or bone scans.

As you know, the 1984 AAOMS criteria for meniscus surgery recommends continuing postsurgical follow-up. Because it is often difficult to distinguish between normal bone remodeling changes that can occur and long term extensive bone resorption in presently asymptomatic patients who have received alloplastic implants such as the TMJ IPI, it is strongly recommended that these patients be followed indefinitely. Please inform all your patients who have received a Vitek IPI of the importance of follow-up.

The prophylactic removal of Vitek's IPI is not recommended.

Additionally, do not implant any more of these devices if you have any of them in your possession. These implants should be returned for credit. Return these implants to the address below in their original boxes with, if available, a copy of the corresponding shipping memorandum.

For our records, we would appreciate your completion and return of the enclosed postage paid, self-addressed postcard.

If you have any questions, concerning this notification, please call Sue Tellkamp at the telephone numbers given below.

Thank you for your assistance and cooperation.

Enclosure

3143 Yellowstone Blvd. / Houston, Texas 77054
713-747-9296 / In USA and Canada 800-366-8485
Telex: 293166 VITEK UR / Fax: (713) 747-5958

• **Figure 34-5** The letter distributed to oral and maxillofacial surgeons announcing the recall of the Vitek Teflon-Proplast implant. By the time of its distribution, many surgeons were already well aware of the implant's risks for patient safety.

but consistent with contemporary biomechanical research. This system was used successfully in many cases, but it was manufactured by the ill-fated Vitek Corporation and disappeared from the market with that company's collapse. Several other investigators and large manufacturers developed TMJ implant designs, but in the aftermath of the Teflon-Proplast debacle, a combination of relatively few potential patients (compared with the market for large orthopedic joints) and a particularly—and understandably—harsh regulatory climate brought nearly all to a halt before production or while still in early clinical trials. Ironically, many of the patients most in need of total alloplastic reconstruction were those with severe iatrogenic joint destruction from failed fossa implants.

Ultimately, one TMJ reconstruction system completed rigorous trials and was approved by the FDA for use in limited indications in the mid-1990s. This system uses a computer-aided design/computer-aided manufacturing (CAD-CAM) design with custom-fitted fossa and condylar implant that differed from prior systems, which allowed selection from a set of stock sizes and configurations. Computed tomography (CT)-derived data are used to construct a full-size model of the patient's jaw and skull base, which in turn is used to design and manufacture the implants (Figure 34-6).

Their custom-fitted nature eliminated the need to shim or backfill the implants, particularly the fossa component, with polymethylmethacrylate or other materials, and resulted in a stable prosthesis without micro-movement, even in patients with severely mutilated joints. This system remains on the market today, with numerous reports of good function and stability generated over a decade or longer.[42-44] A second total TMJ replacement system, designed using similar principles and materials, offers standard-sized, as opposed to custom, components. Nevertheless, a well-documented and significant drawback to these and all TMJ reconstruction technologies available to date is their inability to predictably reduce or eliminate pain, even when movement and function are improved.

Minimally Invasive Treatment

In 1975, Ohnishi published the first description of arthroscopy of the temporomandibular joint in the Japanese literature.[45] Until that time, arthroscopes were too large for the TMJ, but Watanabe developed a suitably thin instrument for small joints. Ohnishi and Murakami developed a protocol for TMJ arthroscopic lysis and lavage, which they successfully used in the treatment of internal derangements. A large series of results was published in the English literature in 1986,[46] and TMJ arthroscopy rapidly became popular in North America as an alternative to open surgery, with lower costs and less morbidity. Early adaptors included Sanders and McCain, both of whom published extensively on the technique,[47-51] including the development of elegant and sophisticated advanced operative techniques.[52] A large multicenter retrospective study was published in 1992 by several leading authorities to document high success rates for the procedure.[53]

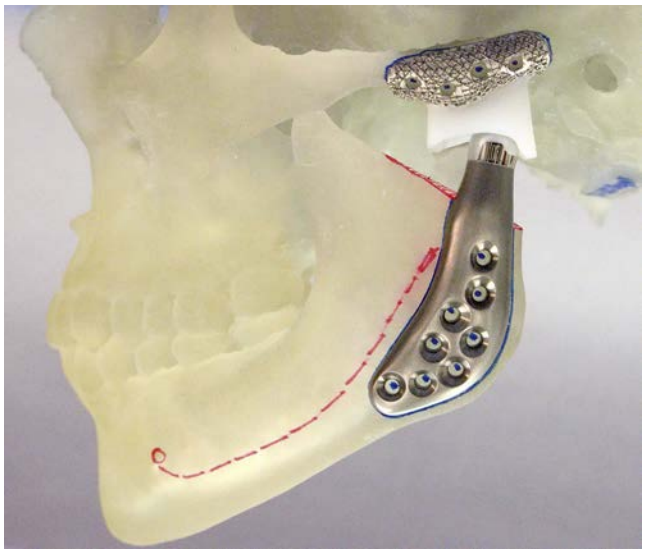

• **Figure 34-6** The TMJ Concepts Patient-Fitted Implant. The components are shown here on the laser stereolithographic model derived from computed tomography data and used in their fabrication. (Courtesy of TMJ Concepts Inc., Ventura, CA.)

Arthroscopy itself represented a major advance in TMJ surgery, allowing minimally invasive treatment for patients who would otherwise be candidates for open surgical procedures. However, critical evaluation of the success and outcomes of arthroscopic lysis and lavage led to new theories about the mechanical basis of TMJ disease. In 1990, Nitzan, Dolwick, and Heft published an article in which they questioned the direct primary role of disc displacement in TMJ symptoms, based on strong evidence that arthroscopic surgery was highly successful clinically but failed to reduce discs to the "normal" position in all but a few cases.[54] In 1991 Nitzan, Dolwick, and Martinez described a novel technique for treating patients with acute closed lock of the TMJ, which they called *arthrocentesis*.[55] Moreover, they postulated that anterior disc displacement in the TMJ might better represent an anatomic variant than a true pathology. They offered alternative hypothetical explanations for mandibular hypomobility not dependent on mechanical obstruction of the condyle by an anterior disc.[56] These theories remain somewhat controversial to the present day, but they represent a further evolution in our understanding of the pathophysiologic mechanisms underlying TMJ symptoms.

TMJ arthroscopy and arthrocentesis have given researchers the tools with which they can sample healthy and diseased joints and gather clues on the molecular basis of TMJ disease. Scientist clinicians, as represented by Milam[57,58] at the University of Texas in San Antonio, are essential allies of the current generation of surgeons. Today they bring the tools of molecular biology to bear on the diseases Cooper struggled to describe 165 years ago.

Summary

Diseases of the temporomandibular joint have been recognized in the Western medical literature for 200 years or more, and they have been treated with surgery since the latter part of the 19th century. The earliest operations were pioneering efforts by early general surgeons, whose solutions for the most seriously debilitating problems were, in many cases, not dissimilar to contemporary operations. Advances in the early 20th century paralleled those in other arenas of medicine and surgery, including the introduction of minimally invasive surgery near the end of the century.

Surgical management of TMJ disease, particularly internal derangement, has been provided with varying degrees of tension with nonsurgical therapy almost since the beginning. Over the 20th century, expert opinion and clinical practice swung between the two poles, and some confusion and dogma persist on both sides to the present day. As scientific study has improved our knowledge about the origin and natural course of internal derangements and has clarified the outcomes a clinician might expect from a given treatment, both types of therapy have found their place in the contemporary surgeon's armamentarium.

Perhaps the most critical lesson to be learned by reviewing the history of treatment for temporomandibular joint disease is that we can still learn from the errors of our predecessors. It is remarkable how little is truly new in TMJ arthroplasty, for example, and the surgeon who is considering a clever "innovation" probably should examine the literature from longer ago than he or she might have thought necessary before declaring the idea new. Perhaps the direction most likely to yield truly new knowledge and therapies will be molecular medicine. Even with this, future scientists likely will wish to read the works of contemporary arthroscopists and surgeon-scientists, or they will risk re-invention rather than true innovation.

References

1. Annandale T: Displacement of the inter-articular cartilage of the lower jaw and its treatment by operation, *Lancet* 8:411, 1887.
2. Heath C: *Injuries and diseases of the jaws*, ed 3, London, 1884, Churchill, p 415.
3. Stimson LA: *Manual of operative surgery*, ed 3, Philadelphia, 1895, Lea Bros & Co.
4. Murphy JB: Arthroplasty for intra-articular bony and fibrous ankylosis of temporomandibular articulation, *JAMA* 62:1783–1794, 1914.
5. Behan RJ: Loose cartilage in the temporomandibular joint: subluxation of the inferior maxilla, *Ann Surg* 67:536–537, 1918.
6. Blake JB: Recurrent dislocation of the lower jaw, *Ann Surg* 68:141–145, 1918.
7. Ashhurst APC: Recurrent unilateral subluxation of the mandible: excision of the interarticular cartilage in cases of snapping jaw, *Ann Surg* 73:712–715, 1921.
8. Cooper AP: *A treatise on dislocations and fractures of the joints*, London, 1842, Bangor House, pp 341–347.
9. Pringle JH: Displacement of the mandibular meniscus and its treatment, *Br J Surg* 6:385–389, 1918.
10. Lanz A: Discitis mandibularis, *Zentralbl Chir* 36:289–291, 1909.
11. Haeseker B: Historical notes on 50 years of plastic surgery in the Netherlands, *Eur J Plast Surg* 23:163–167, 2000.
12. Nieden H: Über operative Behandlung habitueller Kieferluxationen, *Dtsch Zeitschr Chirurg* 183:358–363, 1923.
13. Morris JH: Chronic recurring temporomaxillary subluxation: surgical consideration of "snapping jaw" with report of a successful operative result, *Surg Gynecol Obstet* 50:483–491, 1930.
14. Behrendt KP: *Die Kriegschirurgie von 1939-1945 aus der Sicht der beratenden Chirurgen des deutschen Heeres im zweiten Weltkrieg*, Freiburg, Germany, 2003, Institut für Geschichte der Medizin der Albert-Ludwigs-Universität Freiburg, p 232.
15. Pommerin R: The fate of mixed blood children in Germany, *German Studies Rev* 5:315–323, 1982.
16. Costen JB: Neuralgias and ear symptoms associated with disturbed function of the temporomandibular joint, *JAMA* 107:252–258, 1936, discussion 258.
17. Dingman RO: Diagnosis and treatment of lesions of the temporomandibular joint, *Am J Orthod Oral Surg* 26:374–390, 1940.
18. Sicher H: Temporomandibular articulation in mandibular overclosure, *J Am Dent Assoc* 36:131–139, 1948.
19. Wakely CPG: The surgery of the temporomandibular joint, *Surgery* 5:697–706, 1939.
20. Wakely CPG: The causation and treatment of displaced mandibular cartilage, *Lancet* 2:543, 1929.
21. Schultz LW: Report of ten years' experience on treating hypermobility of the temporomandibular joints, *J Oral Surg* 5:202–207, 1947.
22. Silver CM: *Disk removal for internal derangements. Presented at the American Society of Temporomandibular Joint Surgeons Annual Scientific Meeting*, March 27, 1993. Nashville, TN.
23. Silver CM: Long-term results of meniscectomy of the temporomandibular joint, *Cranio* 3:46–57, 1984.
24. Bowman K: Temporomandibular joint arthrosis and its treatment by extirpation of the disk: a clinical study, *Acta Chir Scand Suppl* 118, 1947.
25. Schwartz LL: Ethyl chloride treatment of limited, painful mandibular movement, *J Am Dent Assoc* 48:497–507, 1954.
26. Eggers GWN: Arthroplasty of the temporomandibular joint in children with interposition of tantalum foil: a preliminary report, *J Bone Joint Surg* 28:603–606, 1946.
27. Gordon SD: Surgery of the temporomandibular joint, *Am J Surg* 95:263–266, 1958.
28. Ward TG: Surgery of the mandibular joint, *Ann Royal Coll Surg Engl* 20:139–152, 1961.
29. Georgiade N, Altany F, Pickrell K: An experimental and clinical evaluation of autogenous dermal grafts used in the treatment of temporomandibular joint ankylosis, *Plast Reconstr Surg* 19:321–336, 1957.
30. Christensen RW: Mandibular joint arthrosis corrected by the insertion of a cast-Vitallium glenoid fossa prosthesis: a new technique: report of a case, *Oral Surg Oral Med Oral Pathol* 17:712–722, 1964.
31. Laskin DM: Etiology of the pain-dysfunction syndrome, *J Am Dent Assoc* 79:147–153, 1969.
32. Wilkes CH: Arthrography of the temporomandibular joint in patients with the TMJ pain-dysfunction syndrome, *Minn Med* 61:645–652, 1978.

33. Wilkes CH: Structural and functional alterations of the temporomandibular joint, *Northwest Dent* 57:287–294, 1978.
34. Farrar WB, McCarty Jr WL: Arthrography of the TMJ, *J Am Dent Assoc* 100:655–656, 658, 1980.
35. McCarty WL, Farrar WB: Surgery for internal derangements of the temporomandibular joint, *J Prosthet Dent* 42:191–196, 1979.
36. Dolwick MF, Reid R, Sanders B, et al.: *1984 criteria for TMJ meniscus surgery*, Chicago, 1984, American Association of Oral and Maxillofacial Surgeons, p 30.
37. Kiehn CL: Meniscectomy for internal derangement of temporomandibular joint, *Am J Surg* 83:364–367, 1952.
38. Al-Kayat A, Bramley P: A modified pre-auricular approach to the temporomandibular joint and malar arch, *Br J Oral Surg* 17:91–103, 1979.
39. Indresano AT, Mobati DA: History of temporomandibular joint surgery, *Oral Maxillofac Surg Clin North Am* 18:283–290, 2006.
40. Kent JN, Misiek DJ, Akin RK, et al.: Temporomandibular joint condylar prosthesis: a ten-year report, *J Oral Maxillofac Surg* 41:245, 1983.
41. Kent JN, Block MS, Honsy DA, et al.: Experience with a polymer glenoid fossa prosthesis for partial or total temporomandibular joint reconstruction, *J Oral Maxillofac Surg* 44:520–533, 1986.
42. Wolford LM, Cottrell DA, Henry CH: Temporomandibular joint reconstruction of the complex patient with the Techmedica custom-made total joint prosthesis, *J Oral Maxillofac Surg* 52:2–10, 1994.
43. Mercuri LG: Subjective and objective outcomes in patients reconstructed with a custom-fitted alloplastic temporomandibular joint prosthesis, *J Oral Maxillofac Surg* 57:1427–1430, 1999.
44. Mercuri LG, Wolford LM, Sanders B, et al.: Long-term follow-up of the CAD/CAM patient fitted total temporomandibular joint reconstruction system, *J Oral Maxillofac Surg* 60:1440–1448, 2002.
45. Ohnishi M: Arthroscopy of the temporomandibular joint, *Kokubyo Gakkai Zasshi* 42:207–213, 1975.
46. Murakami K, Iizuka T, Matsuki M, et al.: Diagnostic arthroscopy of the TMJ: differential diagnoses in patients with limited jaw opening, *Cranio* 4:117–126, 1986.
47. Sanders B: Arthroscopic surgery of the temporomandibular joint: treatment of internal derangement with persistent closed lock, *Oral Surg Oral Med Oral Pathol* 62:361–372, 1986.
48. Sanders B, Buoncristiani R: Diagnostic and surgical arthroscopy of the temporomandibular joint: clinical experience with 137 procedures over a 2-year period, *J Craniomandib Disord* 1:202–213, 1987.
49. McCain JP: Arthroscopy of the human temporomandibular joint, *J Oral Maxillofac Surg* 46:648–655, 1988.
50. McCain JP, de la Rua H, Le Blanc WG: Correlation of clinical, radiographic, and arthroscopic findings in internal derangements of the TMJ, *J Oral Maxillofac Surg* 47:913–921, 1989.
51. McCain JP: TMJ arthroscopy, *J Am Dent Assoc* 121:10, 1990.
52. McCain JP, Podrasky AE, Zabiegalski NA: Arthroscopic disc repositioning and suturing: a preliminary report, *J Oral Maxillofac Surg* 50:568–579, 1992.
53. McCain JP, Sanders B, Koslin MG, et al.: Temporomandibular joint arthroscopy: a 6-year multicenter retrospective study of 4,831 joints, *J Oral Maxillofac Surg* 50:926–930, 1992.
54. Nitzan DW, Dolwick MF, Heft MW: Arthroscopic lavage and lysis of the temporomandibular joint: a change in perspective, *J Oral Maxillofac Surg* 48:798–801, 1990, discussion 802.
55. Nitzan DW, Dolwick MF, Martinez GA: Temporomandibular joint arthrocentesis: a simplified treatment for severe, limited mouth opening, *J Oral Maxillofac Surg* 49:1163–1167, 1991, discussion 1168–1170.
56. Nitzan DW, Dolwick MF: An alternative explanation for the genesis of closed-lock symptoms in the internal derangement process, *J Oral Maxillofac Surg* 49:810–815, 1991, discussion 815–816.
57. Milam SB, Zardeneta G, Schmitz JP: Oxidative stress and degenerative temporomandibular joint disease: a proposed hypothesis, *J Oral Maxillofac Surg* 56:214–223, 1998.
58. Milam SB: Pathogenesis of degenerative temporomandibular joint arthritides, *Odontology* 93:7–15, 2005.

35

Structure and Function of the Temporomandibular Joint

ROBERT GASSNER

Providing motion is the central function of the craniomandibular or temporomandibular articulation, where mandible and cranium are connected as the temporomandibular joint (TMJ). As part of the stomatognathic system, the TMJ allows simple and complex movements such as free movement during phonation, gesticulation, swallowing, and breathing, as well as different types of load-bearing movements during incision and chewing. Although all other bony segments of the head are fused via synostoses, only the three ossicles within the middle ear also show articulations. Therefore, the description of the phylogenetic development of the TMJ is helpful for an understanding of its structure and function.[1-8]

Developmental Perspective of the Craniomandibular Articulation

In mammals, the articulating bony parts of the TMJ are derived from membrane bone. These are formed directly from intramembranous centers of ossification. These developing bones, the squamous portion of the temporal bone, and the condyles of the mandible become completely surrounded by periosteum, including areas that eventually form the articular surfaces of the TMJ and build the "secondary" TMJ there.[9,10] In contradistinction to that is the development of the "primary" TMJ of nonmammalians, deriving from cartilage. In bony fish, reptiles, and birds, the proximal parts of the mandible constitute the TMJ, which is actually the primary TMJ. In mammals, the primary or primitive TMJ is subjected to complex changes, also ultimately forming the joints for three ossicles within the middle ear. The secondary TMJ in humans starts to develop by the 10th week of gestation from mesenchymal condensations of two separate blastemas for the mandibular condyle and the temporal bone.[5,10-12] The condylar and temporal mesenchymal cells differentiate into osteoblasts, which lay down membrane bone. The periosteum that lines these articular surfaces gradually is transformed during its early development into the dense fibrous articular tissues of the TMJ.[6] In the center of the condyle, cartilage develops and becomes the growth center, with subchondral bone formation by an enchondral mechanism.[13] Superior to the condylar blastema, a band of mesenchymal cells develops that differentiates into the disc, which is considered as deriving from an extension of lateral pterygoid muscle.[5,9,14,15] The configuration and shape of the TMJ are also related to the development of dentition. During infancy, the articular fossa is a flat furrow with almost no eminence. Eruption of the primary dentition increases the groove, forming a fossa. The final adult formation of the TMJ is associated with eruption of the permanent dentition. Articular forces acting through the TMJ play an important role in this gradual transformation.[6,16] Depending on the preservation of the dentition, the TMJ may maintain a stable form throughout life. Edentulism of the jaws again causes secondary changes within the TMJ, with flattening of the articular fossa and eminence. The configuration and shape of the TMJ depend on skeletal and dental relationships of the maxilla and mandible. For example, a deep bite is correlated with a steep eminence.[4,9]

Most synovial joints have hyaline cartilage that lines their articulating surfaces, because bones of typical synovial joints are endochondrally formed bones that are initially preformed in hyaline cartilage. In contrast, articulating surfaces of the TMJ are lined by dense, avascular, fibrous connective tissue. Most of this cartilage eventually is calcified and then is replaced by bone, although the cartilage that lines the articular surfaces persists in a modified form. Thus, the lack of hyaline cartilage on the articular surfaces of the TMJ reflects its unique ontogenetic and phylogenetic development; although it is not a hyaline cartridge-covered joint, it is capable of bearing loads. Although a secondary cartilage is present in the condyle of the growing mandible, this



• **Figure 35-1** Lateral view of human cranium and mandible.



• **Figure 35-2** Basal view of human cranium.

cartilage does not form part of the articular surface because the periosteum-derived articular tissues cover it.[17,18]

Surgical Anatomy and Histology

The mandible and cranium make up the craniomandibular articulation, which frequently is referred to as the *temporomandibular articulation.* This articulation of the mandible consists of two synovial joints: left- and right-sided TMJs. The bony components include the mandibular condyles below and the squamous temporal bones above (Figure 35-1). The articular space of each TMJ is divided into upper and lower compartments because of the interposition of the fibrous articular disc between the temporal bone and the mandible. Gliding or translatory movements occur primarily in the upper compartment, while the lower compartment functions primarily as a hinge or rotary joint.[1,4,6,18-23]

Glenoid Fossa—Articular Eminence

The *glenoid* or *mandibular fossa,* is the concavity within the temporal bone that houses the mandibular condyle. Its anterior wall is built by the articular eminence of the squamous temporal bone and its posterior wall by the tympanic plate of the temporal bone, which also forms the anterior wall of the external acoustic meatus. The bony roof of the glenoid fossa is thin and often appears translucent when transilluminated (Figure 35-2).

It is important to note that the term *articular fossa* refers to the particular portion of the glenoid fossa that is covered by articular tissues. It is built entirely by the squamous portion of the temporal bone (see Figure 35-1). The posterior part of the articular fossa is elevated to a ridge called the *posterior articular lip.* In most individuals, the posterior articular lip is higher and thicker at its lateral end and thus is visible from the side as a cone-shaped process between the articular fossa and the tympanic plate. This structure is the postglenoid process. The lateral border of the articular fossa sometimes is marked by a narrow, low ridge or crest.

In the posterior and lateral parts of the *glenoid fossa,* a fissure separates the articular and nonarticular portions of the glenoid fossa. This fissure, called the *tympanosquamosal fissure,* also separates the tympanic portion from the squamous portion of the temporal bone. Medial to this fissure, a bony plate of the petrous portion of the temporal bone, the tegmen tympani, protrudes between the tympanic and squamous portions. Therefore, instead of a tympanosquamosal fissure along the medial aspect of the glenoid fossa, an anterior petrosquamosal fissure and a posterior petrotympanic fissure occur. The petrotympanic fissure is slightly widened laterally to permit passage of the chorda tympani nerve and the anterior tympanic blood vessels. These neurovascular structures are located within the glenoid fossa, but not within the articular fossa (see Figure 35-2).

The *articular eminence* is the transverse bar of dense bone that forms the posterior root of the zygomatic arch and the anterior wall of the articular fossa. It has a large articular surface. It is strongly convex on a side view and moderately concave when viewed from the front or back. The degree of this convexity and concavity is highly variable. Fine bony ridges often outline the medial and lateral borders of the articular eminence. Although a thin layer of fibrous tissue covers the roof of the articular fossa, the fibrous tissue that covers the articular eminence is thick and quite firm. Moreover, different from the roof, the articular eminence is made up of a fairly thick layer of dense bone. Lateral to the articular eminence, a small bony projection, the *articular tubercle,* is located. The articular tubercle is not an articular surface. Instead, it serves as the attachment area for portions of the temporomandibular ligament (TML).[24-26]

Articular Disc—Disc Ligaments

The *articular disc* is a firm, oval, fibrous plate that is positioned between the mandibular condyle and the articular fossa and eminence (Figure 35-3). Its central part, the

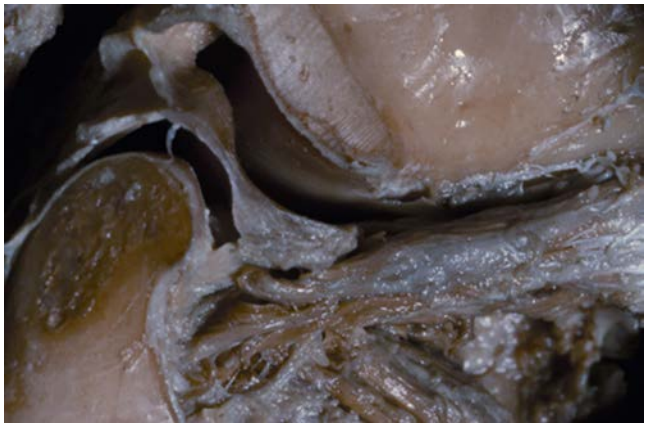

• **Figure 35-3** Parasagittal section of temporomandibular joint disc area and lateral pterygoid muscle.



• **Figure 35-4** Parasagittal section of temporomandibular joint disc area.

intermediate zone, is considerably thinner than its periphery—the anterior and posterior bands. Anteriorly, the disc continues as the anterior attachment and is fused to the capsule of the TMJ. Posteriorly, the disc continues as the posterior attachment or bilaminar zone—a thick double layer of vascularized connective tissue. The bilaminar zone splits into two parts: (1) an upper fibroelastic layer that attaches to the postglenoid process, posterior articular lip, and tympanosquamosal fissure; and (2) a lower fibrous layer that attaches to the posterior portion of the condylar neck immediately below the articular tissues. Posteriorly, these two layers are separated by the intermediate layer, which contains loose connective tissue that attaches to the posterior wall of the joint capsule. The posterior attachment has a profuse supply of nerves and blood vessels.[11,12,27-30]

Unlike its anterior and posterior attachments, the disc is not attached to the capsule laterally or medially. Instead, it is tightly bound directly to the medial and lateral poles of the mandibular condyle. The position of the disc relative to the condyle also is influenced by the pull of the superior head of the lateral pterygoid muscle because a small portion of this muscle often attaches to the disc (Figure 35-4). Because the superior head of the lateral pterygoid also attaches to the mandibular condyle, and the disc is tightly bound to the medial and lateral poles of the condyle, this muscle arguably may have no special influence on movements of the articular disc relative to the condyle.[31,32]

Ontogenetically, the articular disc derives from a mesenchymal block of tissue that also gives rise to the capsule of the TMJ and the lateral pterygoid muscle.[33] This tissue mass is located between the developing squamous temporal bone and mandibular condyle. In adults, the uppermost part (or superior head) of the lateral pterygoid muscle often retains its original connection to the capsule and articular disc of the TMJ.

Blood vessels and nerves are absent in the intermediate zone, that is, the firm central region of the articular disc, as well as in the avascular fibrous layers that cover the mandibular and temporal articular surfaces of the joint. A lack of these neurovascular structures is compatible with the hypothesis that a considerable reaction force occurs along this portion of the joint. It has been suggested that one main function of the articular disc is to reduce stress concentrations between the articular surfaces of the mandibular condyle and the squamous temporal bone—that is, the compliant nature of the disc helps to distribute reaction force more evenly along these joint surfaces.[7,20,34-36]

Condyle

The articular surface of the mandible is the upper and anterior surface of the condyle (Figure 35-5). The adult human condyle is about 15 to 20 mm from side to side and 8 to 10 mm from front to back. Its long axis lies at right angles to the plane of the mandibular ramus. Because of the flare of the ramus, however, the long axes of the left and right condyles cross approximately at the anterior margin of the foramen magnum, forming an obtuse angle varying from 145 to 170 degrees.[37]

The articular surface of the condyle is strongly convex when viewed from the side and less so when viewed from the front. The articular surface faces upward and forward, so that in side view, the condylar neck is bent forward. As seen from the front, the articular convexity often resembles a tentlike configuration that is divided into medial and lateral slopes by a variably prominent crest. The lateral pole of the condyle extends slightly beyond the outer surface of the ramus and is roughened for the attachment of the articular disc and the TML.[19] The medial pole of the condyle protrudes considerably beyond the inner surface of the ramus and also is slightly roughened for the attachment of the articular disc. Variations in the shape of the condyle are frequent. Irregularities of the bony articular surfaces are obscured and smoothed by the thick covering of fibrous tissue that is derived from and directly continuous with the periosteum of the mandible.



• **Figure 35-5** Mandibles with different condylar head shapes and angles.

Synovial Membrane

The synovial membrane, a highly vascularized layer of connective tissue, lines all structures of the articulation that do not experience compressive forces. The largest area of synovial lining covers the upper and lower surfaces of the posterior attachment, including the loose connective tissue that binds the posterior border of the disc to the capsule. Synovial tissue also lines the inner aspect of the fibrous capsule. When the condyle is positioned in the glenoid fossa, the synovial membrane forms rather heavy folds posteriorly (see Figure 35-4). When the condyle is protruded toward the summit of the articular eminence, the folds disappear as the synovial tissues are stretched.[38]



• **Figure 35-6** Lateral view of temporomandibular joint capsule and position of maxillary artery.

Capsule—Extracapsular Ligaments

The articular capsule is quite thin anteromedially, medially, and posteriorly, but it is thick anterolaterally and laterally, where it attaches to the articular tubercle.[39] This reinforced lateral portion of the capsule is the temporomandibular ligament. The capsule attaches to the squamous portion of the temporal bone along the outer limits of the articular surface of the articular eminence, fossa, and preglenoid plane. Posteriorly, the capsule arises from the postglenoid process, the posterior articular lip, and the tympanosquamosal fissure (Figure 35-6).

The anatomy of the capsule and that of the TML show considerable variability.[16,40-43] The TML can be split into two layers: a wide, fan-shaped superficial portion, and a narrow deep portion. The broad origin of the superficial portion along the articular tubercle and its narrower insertion along the condylar neck account for its somewhat fan-shaped morphology. Its anterior fibers run from the articular tubercle obliquely down and back; the posterior fibers have a more vertical orientation. Fibers of the deep portion are oriented horizontally (anteroposteriorly), attaching along the lateral pole of the mandibular condyle and extending to a crest situated along the articular tubercle. This deep horizontal band sometimes is named the *lateral polar ligament.*[19,39]

The fibrous capsule of the TMJ and the TML allows and limits jaw movements. The vertical fibers control distraction movements of the condyle from the articular eminence and fossa, the horizontal fibers (polar ligaments) prevent excessive retrusive movements of the condyle, and the posterior portion of the capsule limits protrusive movements. The anterior part of the capsule and the anterolateral part of the TML may limit condylar rotation during jaw opening, although most of this limitation is imposed by the stretched jaw-closing muscles.[19,39]

Accessory Ligaments

The sphenomandibular and the stylomandibular ligaments are considered accessory ligaments of the temporomandibular articulation (Figure 35-7).



• **Figure 35-7** Posterior view of temporomandibular joint capsule and ligaments.



• **Figure 35-8** Masseter muscle: superficial and deep parts.

Sphenomandibular Ligament

The sphenomandibular ligament arises from the spine of the sphenoid bone and is directed downward and outward, inserting on the mandible at the mandibular lingula, which is located along the upper border of the mandibular foramen. It is derived from Meckel cartilage. In most individuals, the sphenomandibular ligament is a thin layer of connective tissue with indistinct anterior and posterior borders that protects the blood vessels and nerves passing through the mandibular foramen from additional tensile stress during jaw opening and closing.[44] It normally has no influence on mandibular movement.

Stylomandibular Ligament

The stylomandibular ligament is a reinforced sheet of cervical fascia that extends from the styloid process and the stylohyoid ligament to the region of the mandibular angle. Many of its fibers are attached to the back edge of the lower part of the mandibular ramus; others continue onto the deep fascia along the medial surface of the medial pterygoid muscle. The upper border of the stylomandibular ligament normally is a thickened cordlike structure.

This ligament is relatively loose when the jaws are closed and when they are wide open; it is tensed only when the mandible is maximally protruded. Thus, apparently this ligament can limit excessive protrusive movements.

Muscles

Various muscle groups of the face, tongue, palate, and hyoid are involved in TMJ motion. In addition to the four powerful masticatory muscles (masseter, temporalis, medial pterygoid, and lateral pterygoid), the morphology and function of other important muscles that play a role in mandibular movements are described here.[45,46]

Masseter Muscle

The masseter muscle reaches as a rectangular plate from the zygomatic arch to the lateral surface of the mandibular ramus (Figure 35-8). It is divided into a superficial and a smaller deep portion. The superficial masseter arises from the lower border of the zygomatic arch as strong tendinous fibers. The most anterior fibers may arise from the outer corner of the zygomatic process of the maxilla. Posteriorly, the origin of the superficial portion ends along the zygomaticotemporal suture. The superficial masseter is covered on its outer surface by a strong tendinous layer that extends down from the zygomatic arch over the upper third or half of the muscle.

In a frontal view, these fibers are directed downward and medially. In a side view, the muscle fibers of the superficial masseter are directed downward and backward to insert along the angle of the mandible. The mandibular attachment of the superficial masseter extends along the lower one third of the posterior border of the ramus and along the lower border of the mandible anterior to the third molar; it covers, more or less, the lower half of the lateral surface of the ramus. The field of insertion has ridges into which the tendons insert, as well as grooves between the ridges into which the fleshy fibers insert.

Posteriorly, the fibers of the superficial masseter wrap around the posterior and inferior aspects of the angle of the mandible, joining fibers of the medial pterygoid muscle in a tendinous raphe. This muscular arrangement is called the *pterygomasseteric sling.* The deep and superficial portions of

the masseter fuse anteriorly, but posteriorly, the two can be separated. Fibers of the deep masseter arise from the entire length of the zygomatic arch up to the anterior slope of the articular eminence. Some of its fibers also may arise from the lateral wall of the TMJ capsule.[31,47]

The deep masseter inserts above the superficial masseter along the mandibular ramus as a triangular insertion field. The base of this triangle faces posteriorly, and the apex faces anteriorly. In the side view, the fibers of the deep masseter, which have a near vertical alignment, pass downward at an angle of about 30 to 40 degrees to the fibers of the more obliquely aligned superficial masseter.

The masseter muscle is a powerful elevator of the mandible. A lateral view reveals that the deep masseter exerts primarily a vertical force on the mandible. In contrast, the superficial masseter exerts a vertical and slightly anteriorly directed force on the mandible that is approximately perpendicular to the occlusal plane of the molars. The entire masseter also exerts a lateral component of force on the mandible.[48]

Temporalis Muscle

The temporalis muscle has a fan-shaped origin along the lateral surface of the skull and the dense fascia overlying this muscle (Figure 35-9). The bony attachment field, the temporal fossa, is encircled above by the inferior temporal line. This attachment field includes a narrow strip of the parietal bone, the greater part of the temporal squama, the temporal surface of the frontal bone, and the temporal surface of the greater wing of the sphenoid bone. Muscle fibers and tendons also arise from the postorbital septum, which is the bony partition that separates the temporal fossa from the orbit. Both the zygomatic and frontal bones and the greater wing of the sphenoid contribute to the formation of the postorbital septum. The bony field of origin of the temporalis muscle reaches downward to include the infratemporal crest of the sphenoid.

Many of the temporalis muscle fibers originate from the medial surface of the temporalis fascia. The temporalis fascia attaches to the superior temporal line and the upper border of the zygomatic arch. Passing downward from the superior temporal line, the temporalis fascia thickens considerably and then splits into two layers; the superficial layer continues into the periosteum of the zygomatic arch along its lateral surface, and the deep layer extends into the periosteum of the zygomatic arch along its medial surface.

The bundles of the temporalis muscle converge toward the opening located between the zygomatic arch and the lateral surface of the skull (temporal foramen). The tip of the coronoid process projects into this opening. The anterior fibers of the temporalis muscle, which form the major bulk of the muscle, are largely vertical; the fibers in the middle part of the muscle are increasingly oblique. The most posterior fibers run forward almost horizontally, bend around the posterior root of the zygomatic arch in front of the articular eminence, and pass downward vertically to the mandible.

The middle and posterior portions of the temporalis muscle, respectively, are attached along the apex of the coronoid process and along its posterior slope to the deepest point of the mandibular notch. The more superficial fibers of the anterior temporalis muscle insert along the apex of the coronoid process, the anterior surface of the coronoid process, and the mandibular ramus. The deeper fibers of the anterior temporalis attach along the medial anterior surface of the mandibular ramus.



• **Figure 35-9** Temporalis muscle.

Similar to the masseter muscle, the temporalis muscle mainly elevates the mandible. Its fan-shaped morphology indicates that its direction of pull varies considerably, depending on which portions are mechanically active. Superficially, it appears that its most posterior fibers retract the mandible because of their horizontal orientation along the side of the skull; however, as previously noted, when the condyle is situated in the mandibular fossa, the fibers of the posterior temporalis are bent around the posterior root of the zygomatic arch at a sharp angle and thus are oriented vertically. Therefore, this portion of the temporalis muscle exerts primarily an upward force on the mandible during normal

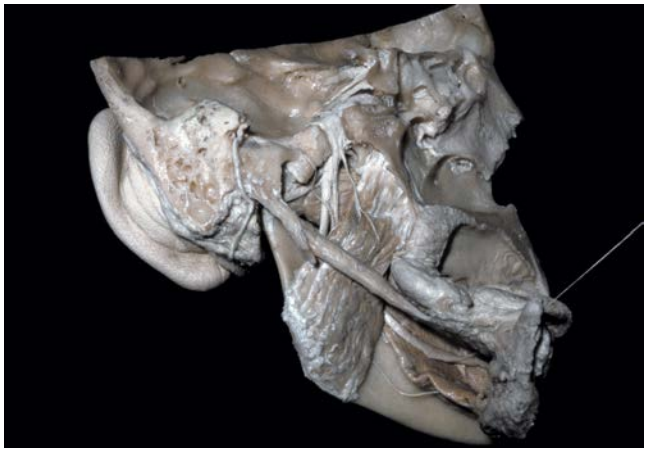

• **Figure 35-10** Medial view of medial pterygoid muscle.



• **Figure 35-11** Medial view of medial and lateral pterygoid muscle.



• **Figure 35-12** Oblique view of lateral pterygoid muscle.

closure. When the condyle is translated anteriorly into a more protruded position, these posterior fibers likely cause the mandible to retrude because, in this instance, the posterior temporalis is aligned more horizontally. Because its most posterior fibers pass very close to the condyle, the posterior temporalis probably also functions as a stabilizer of the TMJ.

The middle and obliquely aligned portion of the temporalis muscle is capable of exerting a vertical and retracting force on the mandible. Most of the anterior portion is capable of a vertical pull on the mandible. That portion of the anterior temporalis that originates from the postorbital septum, however, likely pulls the mandible upward and forward. Finally, the deep fibers of the anterior temporalis that originate along and just above the infratemporal crest pull the mandible upward and somewhat medially. Thus, the morphology of the entire temporalis muscle indicates that its fibers are capable of considerable variability in their direction of pull.

Medial Pterygoid Muscle

The medial pterygoid muscle is situated on the medial side of the mandibular ramus as a powerful rectangular muscle (Figure 35-10). Its main origin is the pterygoid fossa, a depression that is located between the back edges of the medial and lateral pterygoid plates of the sphenoid bone. The deepest fibers arise from strong tendons; others arise directly from the medial surface of the lateral pterygoid plate. A flat tendon covers the medial surface of the muscle at its origin, and it is as wide as the tensor veli palatini, with which it is in contact.

The most anterior fibers of the medial pterygoid arise from the outer and inferior surface of the pyramidal process of the palatine bone and from adjacent parts of the maxillary tuberosity. These fibers, which are referred to as the superficial head of the medial pterygoid, are positioned lateral to the lateral pterygoid muscle. The remaining and largest portion of this muscle, the deep head, is positioned medial or deep to the lateral pterygoid muscle.

The fibers of the medial pterygoid muscle run downward, backward, and laterally and are inserted along the medial surface of the angle of the mandible. The field of insertion is approximately triangular and is located between the mandibular angle and the mylohyoid groove. As noted earlier, the fibers of the medial pterygoid muscle often meet fibers of the masseter in a tendinous raphe behind and below the mandibular angle (the pterygomasseteric sling). Because of the overall fiber orientation of the medial pterygoid muscle, it is primarily an elevator of the mandible (Figure 35-11).

Lateral Pterygoid Muscle

The lateral pterygoid muscle arises from two heads (Figure 35-12). The inferior head is about three times larger than the superior head.[49,50] The superior head (sometimes called the *superior pterygoid*)[51] originates from the infratemporal surface of the greater wing of the sphenoid medial to the infratemporal crest. From its origin, the fibers of the superior head run almost horizontally backward and laterally in close relation to the external surface of the cranial base. The inferior head originates from the outer surface of the lateral pterygoid plate. Although the fibers of the inferior head also run backward and laterally, they pass upward at an angle of about 45 degrees relative to the superior head.

The two heads of the lateral pterygoid muscle are separated at their origins by a wide gap but fuse in front of the TMJ. The fibers of the superior head are attached



• **Figure 35-13** Digastric muscle and mylohyoid muscle.

primarily to a roughened fossa on the anteromedial surface of the condylar neck. This fossa is called the *pterygoid fovea.* In addition, a small portion of the superior head frequently is attached directly to the anteromedial part of the TMJ capsule and extends into the anteromedial part of the articular disc. All fibers of the inferior head insert into or along the periphery of the pterygoid fovea. This description of the lateral pterygoid is based on the work of numerous authors.[16,27,31,32,39,47,49,52-54]

The lateral pterygoid muscle also consists of two functionally distinct parts. The superior head contracts during jaw closing, and the inferior head contracts during protraction, opening, and shifting of the jaw to one side.[55-58] The superior head of the lateral pterygoid stabilizes the mandibular condyle against the articular eminence during biting and mastication.[16,59] Bilateral contraction of the lower head of the lateral pterygoid muscle creates a protruding mandibular movement. Unilateral action of the inferior head shifts the midline of the mandible to the opposite side (lateral excursion). Finally, if either or both heads of the lateral pterygoid muscle are actively recruited during mandibular closure, this muscle must experience an eccentric or lengthening contraction.[14,39] Under these conditions, the lateral pterygoid muscle exhibits considerable stiffness; this also facilitates joint stability by controlling or limiting condylar movements.[6,32,60]

Digastric Muscle

As the name implies, the digastric (two-bellied) muscle consists of an anterior belly and a posterior belly (Figure 35-13). The posterior belly arises from the mastoid notch medial to the mastoid process; the intermediate tendon is held to the body of the hyoid bone by a fascial loop. The anterior belly attaches to the digastric fossa of the mandible. This fossa is located at the lower lingual border of the mandible slightly lateral to the midline. In the side view, the two bellies of the muscle form an obtuse angle. The posterior belly is much longer than the anterior belly and is only slightly flattened in the mediolateral direction.

If the hyoid is fixed by the action of the infrahyoid muscles, contraction of the digastric muscles pulls the front of the mandible back and down and thus facilitates retrusive and opening movements of the mandible.[61,62] If the teeth are held firmly in occlusion (by the jaw-closing muscles), then contraction of the entire digastric elevates the hyoid as long as the infrahyoid muscles are relatively relaxed.

Mylohyoid Muscle

The mylohyoid muscle builds a muscular diaphragm or floor for most of the oral cavity (see Figure 35-13). It is a flat, continuous, pentagonal sheet of muscle located deep to the anterior belly of the digastric. The base of this pentagon attaches to the body of the hyoid bone, and the two adjacent sides of the base have a free edge. The remaining two sides attach to the medial or lingual aspect of the left and right mandible corpora along the mylohyoid line. The apex of this pentagon attaches to the midline lingual surface of the mandible. It also attaches to a midline mylohyoid raphe that connects the body of the hyoid with the lingual midline surface of the mandible. This raphe divides the mylohyoid into left and right sides.

The mylohyoid slightly raises the hyoid (and tongue) and floor of the mouth. Moreover, if the mandible is stabilized, it can also pull the hyoid forward. In the event that the hyoid is stabilized or is being pulled down and/or backward, this muscle also can depress the mandible.

Geniohyoid Muscle

The geniohyoid muscle is a strap-shaped muscle that runs from the ventral surface of the body of the hyoid to the lingual aspect of the mandible immediately lateral to the midline (Figure 35-14). It is located superficial to the mylohyoid. The muscle is made up of nearly parallel muscle fibers that run straight from origin to insertion. The anatomy of the geniohyoid indicates that if the mandible is stabilized in occlusion, these muscles can slightly raise the hyoid (and tongue) during contraction, and it can pull these structures forward. Conversely, in the event that the hyoid is pulled downward and/or backward, the geniohyoids can depress the mandible. The geniohyoid muscles are not branchial arch derivatives. These muscles are the serial homologs of the musculi rectus abdominis; this is why they are often described as belonging to the "rectus cervicis" group—the straight muscles of the neck.[63]

Innervation and Blood Supply

The sensory nerves of the *capsule* for proprioception and pain are branches of the auriculotemporal, deep temporal,



• **Figure 35-14** Geniohyoid muscle.



• **Figure 35-15** Lateral view of trigeminal nerve when condyle is removed.

and masseteric nerves. The blood supply to the capsule and disc is provided mainly by branches from a maxillary artery. Nerves (Figure 35-15) and blood vessels are numerous in the posterior portions of the articular disc and fibrous capsule.[4,6]

The *masseter muscle* is derived from the first branchial arch and therefore is innervated by the trigeminal nerve (cranial nerve V). More specifically, the masseteric nerve, a small branch of the mandibular or third division of the trigeminal nerve (V_3), innervates the masseter muscle. This nerve passes above the lateral pterygoid muscle and then, after passing through the mandibular notch behind the tendon of the temporalis muscle, enters the medial surface of the deep masseter muscle. The masseteric nerve supplies the deep masseter, perforates it, and then enters the superficial masseter.

The *temporalis* muscle is innervated by the deep temporal branches of the anterior trunk of V_3. Of the three deep temporal nerves ordinarily present, the posterior and middle branches arise as separate filaments from the anterior trunk immediately after the trigeminal nerve emerges through the foramen ovale. The anterior branch initially is united with the buccal nerve; this common trunk, which lies in a sulcus adjacent to the foramen ovale, runs anteriorly and laterally, close to the base of the skull. It is held in place by a ligament that bridges the sulcus. If this ligament ossifies, it contributes to the formation of the temporobuccal foramen.

The anterior temporal nerve usually separates from the buccal nerve after the latter has passed between the two heads of the lateral pterygoid muscle. Its most anterior portion, however, is not positioned nearly as far forward as the anterior portion of the superficial masseter.

The nerve to the *medial pterygoid* arises from V_3 immediately before it divides into its anterior and posterior trunks. The medial pterygoid nerve, which also innervates the tensor tympani and tensor veli palatini muscles, reaches the medial pterygoid muscle at its upper posterior border.

The nerve to the *lateral pterygoid muscle* is usually a branch of the buccal nerve, which is a branch of the anterior trunk of V_3.

The bellies of the *digastric muscle* are derived from the first and second branchial arches and are innervated by the mandibular division of the trigeminal (V_3) and facial nerves (cranial nerve VII), respectively. The mylohyoid nerve, which is a branch of the inferior alveolar nerve, innervates the anterior belly, a first-arch derivative. A branch of the facial nerve supplies the posterior belly, a second-arch derivative.

V_3 innervates the *mylohyoid muscle* via the mylohyoid nerve. Occasionally, the anterior belly of the digastric is fused to the ventral surface of the mylohyoid. This fusion reflects the embryologic origin of these two muscles from a common muscle mass derived from the first branchial arch.

The *geniohyoids* are innervated by ventral rami of the first and second cervical nerves. These nerve fibers connect to the left and right hypoglossal nerves (cranial nerve XII) to reach the floor of the mouth.

TMJ Function

Comprehending TMJ function requires consideration of the relationship of fossa, disc, and condyle during motion. If a finger is placed just in front of the tragus of the ear, the forward and downward sliding of the mandibular condyle can be felt. Soft tissues behind the moving condyle

• BOX 35-1 Main Actions of Muscles in Groups

Elevating Muscles

Temporalis
Masseter
Medial pterygoid

Depressing Muscles

Digastric
Mylohyoid
Geniohyoid

Protracting Muscles

Lateral pterygoid

Retracting Muscles

Digastric

sink in slightly, and a shallow groove often becomes visible during jaw opening. If a finger is introduced into the external acoustic meatus, it is easy to feel the prominence of the lateral pole of the mandibular condyle on the cartilaginous anterior wall of the meatus and the widening of this passage when the mouth is opened. Differences due to active and passive motion-free (or empty) movements of the mandible, which are those that occur without food in the oral cavity, are distinguished from incision and mastication movements, which are associated with biting and chewing of food (Box 35-1).[1-6,64-76]

The muscles of the TMJ combine in various patterns to execute movements of the mandible. A muscle may act synergistically with different muscles at different times. Moreover, antagonistic muscles may act simultaneously to control jaw movements. Muscles that affect the movements of the mandible are divided into groups. These include elevators—the temporalis, masseter, and medial pterygoid muscles; depressors—the digastric, mylohyoid, and geniohyoid muscles; and protractors—the lateral pterygoid muscles (see Box 35-1). Retractors of the mandible do not constitute an independent group; they are the digastric muscles and the obliquely aligned fibers of the temporalis muscles. When the stylohyoid and infrahyoid muscles fix the hyoid, the mylohyoid and geniohyoid also may help to retract the protruded mandible. The fibers of the deep portion of the masseter also help in this. Thus, both elevators and depressors can function as retractors of the mandible. The infrahyoid muscles function to control hyoid movements; therefore, their action is important during both jaw opening and jaw closing.

Free Movements of the Mandible

Two basic movements of the mandible can occur: (1) the rotary or hinge movement, which consists of rotation of the mandible around a transverse axis that passes through the centers of the mandibular condyles, and (2) the translatory or sliding movement, which involves bodily movement of the mandible in the anteroposterior and/or mediolateral direction. Whereas rotating movement occurs mainly between the disc and the condyle in the lower joint compartment, anteroposterior and mediolateral translatory movements occur mainly between the articular eminence and the disc (and mandible) in the upper compartment of the temporomandibular articulation. Sometimes, the translation movements are not symmetric between the left and right joints. Generally, translation occurs simultaneously with rotation, so during normal rotary movements, the center of rotation is not located within the mandible or the condyle.[66]

Free movements of the mandible, which combine rotation and translation, include opening and closing, protrusion and retrusion (symmetric forward and backward movements), and lateral shifts of the mandible. The extreme or outer limits of the various combinations of these movements make up what have been called the border movements of the mandible.[67,68]

Opening

Although highly variable, on average, a nearly equal or linear combination of translation and rotation is observable in the opening and closing movements of the mandible.[66] Translation brings the disc and the condyle forward and downward along the posterior slope of the articular eminence. The condyle and disc may even move anterior to the greatest height of the articular eminence onto the preglenoid plane. The opening movement is so extensive that normally the opening between the maxillary and mandibular incisors easily accommodates three fingers (40 to 60 mm).

The opening movement is caused by gravity, relaxation of the elevator muscles, and a combined action of the lateral pterygoid, geniohyoid, mylohyoid, and digastric muscles. If the opening movement occurs without resistance, the depressors act without any great force. If the amount of opening is only slight, relaxation of the elevators and the force of gravity can accomplish this movement. When wide opening occurs, the protracting force of the inferior head of the lateral pterygoid muscles, which act on the condyles and discs, combines with the depressing and retracting forces of the geniohyoid, digastric, and mylohyoid muscles, which act on the chin and body of the mandible.

Closing

The elevators of the mandible execute the closing movement. If the mouth is opened to its maximal extent, timing of the activation and relaxation of different parts of these muscles may be important for proper closure. During maximum opening, each disc and condyle glides anterior to the summit of the articular eminence onto the preglenoid plane. At the beginning of mouth closure, the discs and condyles are moved back from this anterior position. The elevators execute this phase of the closing movement. This action returns the jaw to the rest or occlusal position.

Protrusion

During protrusion, the mandible is pulled forward, with the mandibular teeth slightly separated from or in light contact with the maxillary teeth. The mandibular condyles are pulled forward together with the articular discs at this time. Therefore, movement occurs primarily in the upper compartment of the TMJ, and it is symmetric.[19] Protrusion of the mandible is primarily the result of contraction of the inferior heads of the lateral pterygoid muscles, although slight activity of the masseter and medial pterygoid muscles also is noted at this time. The temporalis muscle usually is not active during this movement, and the depressors are only slightly active. The lateral pterygoid muscles pull the mandibular condyles (and discs) forward and downward along the articular eminences, while the elevators and depressors apparently stabilize the position of the mandible relative to the maxilla. Contraction of the elevators and the depressors in an unresisted forward thrust often is not noticeable on palpation. However, if the mandible is moved to the extreme forward position, contraction of the superficial masseters can be felt. The forward and backward movements of the mandible are mainly, but not exclusively, translatory.

Retrusion

The reversal of the forward movement, retrusion, is also mainly translatory. These forward condylar movements, which can be confirmed easily by palpation, are limited by the posterior portion of the joint capsule.[43] Most people with a relatively normal masticatory apparatus can retrude the mandible 1 to 2 mm from the full occlusal position or centric occlusion. The capsular and polar ligaments of the TMJ limit retrusion from this position. This retruded position beyond centric occlusion (referred to as centric relation) is not reached during normal jaw movements in humans, although by definition, it falls along the border movements of the mandible. When the condyles are situated in the mandibular fossa, the obliquely aligned middle fibers of the temporalis muscle combine forces with the depressors so as to retrude the mandible, while the remaining elevators exhibit varying amounts of activity. From the maximum protruded position, the posterior temporalis assists the middle temporalis during mandibular retrusion.

Lateral Shift

A lateral shift of the mandible (e.g., a shift to the right) results if the condyle and disc on the opposite or left side are pulled forward, downward, and medially along the articular eminence. In this instance, the left side is often called the *balancing side (b-s) condyle,* whereas the right side is called the *working-side (w-s) condyle.* The w-s condyle, sometimes called the *resting condyle,* executes very limited movement at this time. This movement consists primarily of a rotation of the mandible around a nearly vertical axis located within or immediately behind the w-s condyle. This movement also results in a slightly transverse translation of the two condyles toward the working side.

Lateral shift of the mandible results from an asymmetric variation of protrusion, that is, the b-s lateral pterygoid muscle combines forces with the slightly active elevators. The middle portion of the w-s temporalis muscle must assist in this movement by holding the w-s condyle and preventing it from deviating anteriorly to any great extent. Continued rotation of the w-s condyle is prevented as the lateral polar ligament is pulled straight. Under guidance of this ligament, the center of the w-s condyle is forced to move slightly forward and laterally. The lateral component of this movement often is called the *Bennett movement.* As noted, the different movements of the w-s and b-s condyles can be palpated easily.

Masticatory Movements of the Mandible

The two basic mandibular movements, namely, rotation and translation, combine during masticatory jaw movement. Two general types exist: a cutting movement, as occurs when a piece of food is bitten off, and a crushing and grinding movement, which is used to comminute a piece of food. The cutting of food into bite-sized pieces, often referred to as *incision,* is carried out mainly by the incisors. The rhythmic and repetitive crushing and grinding of food, termed *mastication,* is carried out almost exclusively along the premolars and molars. When mechanically resistant foods are eaten, chewing usually occurs unilaterally, that is, chewing takes place on only one side of the dental arch.[75-89]

Incision

Incision consists of three parts, namely, (1) opening, (2) closing, and (3) power strokes.[69,70] (1) Starting from the rest or occlusal position, depression of the mandible opens the mouth, and the extent of opening is primarily dependent on the size of the food object. (2) The mandible is elevated or closed. An upward and forward movement of the mandibular incisors occurs along with an upward and backward movement of the mandibular condyles during jaw closure, and this part of the incision continues until the maxillary and mandibular incisors contact the food object. (3) Following food contact, the jaw continues to close with the simultaneous application of force on the food object. In many instances, the closing stroke does not occur simply, because when the food object is large (e.g., a whole apple), the amount of jaw opening is just enough to accommodate this object between the maxillary and mandibular incisors.[6]

Mastication

Similar to incision, mastication or chewing consists of three basic parts: opening, closing, and power strokes,[71] which combine to make up a single chewing cycle. All chewing cycles associated with the mastication of a single piece of food are referred to as a *chewing sequence.* A chewing cycle begins with opening of the mouth. During the opening stroke, the amount of opening varies from one chewing cycle to the next, and this depends in part on the size and

consistency of the food object. The closing stroke starts from the position of maximum opening. The mandibular incisors then are moved upward, forward, and away from the midline toward the working side. Completion of the closing stroke leads to the power stroke, which is the forceful contact of the food between the occlusal surfaces of the molar and premolar teeth. The w-s teeth posterior to the canine are moved back toward the midline during the power stroke. With the exception of those movements associated with contact between the maxillary and mandibular teeth, mandibular incisor movements during mastication are well within the border movements.

When tough, mechanically resistant foods are chewed, the power stroke of mastication often ends before the maxillary and mandibular teeth make contact. This type of power stroke is called *puncture crushing.* However, a power stroke often does involve direct contact between the maxillary and mandibular teeth; this type of power stroke is called *tooth-tooth contact.*[77-83] When a large food object suddenly breaks during incision, the holding force and stiffness of each lateral pterygoid muscle prevent uncontrolled posterior and upward displacement of the mandibular condyles, as the condyles and discs are situated precariously near the summit or along the posterior slope of the articular eminence.

Summary

Clinicians constantly are challenged to deal more effectively with their patients' TMJ problems when they do arise. Moreover, the very narrow definitions of ideal intraindividual and interindividual TMJ morphology and mandibular function may divert clinicians to regard otherwise normal variability in asymptomatic populations as a pathologic condition that requires treatment. This chapter has provided insights into the structure and function of the craniomandibular articulation. In keeping with the evolutionary history of this articulation, which is reflected in its early ontogeny, unique aspects of the TMJs were highlighted. The articulating surfaces are covered by fibroelastic tissue distinct from hyaline cartilage in other synovial joints. The TMJs as load-bearing joints always must function bilaterally and are influenced by dental occlusion. The articular discs are interposed between articular fossae and condyles, allowing complex rotational and translatory movements, especially during incision and mastication. In conclusion, the craniomandibular articulation within the stomatognathic system has an enormous capacity to function in a wide variety of patterns and displays great ability to adapt to different functional demands.

Acknowledgment

The author is grateful to Professor Helga Fritsch, MD, PhD (Rector of the Medical University of Innsbruck and previous Head of the Institute of Anatomy at the University Hospital of Innsbruck, Innsbruck, Austria) and in particular to Axel Pomaroli, MD, DMD, PhD, retired Professor of Anatomy, and Stefano Longato, MD, Anatomist, for their excellent support in providing the figures for this chapter.

References

1. Agarwal S, Long P, Gassner R, et al.: Cyclic tensile strain suppresses catabolic effects of IL-1β in fibrochondrocytes from temporomandibular joint, *Arthritis Rheum* 44:608–617, 2001.
2. Gassner R, Agarwal S: Biological basis for the effectiveness of continuous passive motion-mediated repair in TMJ diseases, *Cranio* 20:152–153, 2002.
3. Gassner R, Buckley M, Studer R, et al.: Interaction of strain and interleukin-1 in articular cartilage: effects on proteoglycan synthesis in chondrocytes, *Int J Oral Maxillofac Surg* 29:389–394, 2000.
4. Lang J: *Lanz Wachsmuth Praktische Anatomie*, Kopf, Berlin, 2004, Springer, pp 122–126.
5. Sharawy M: Developmental and clinical anatomy and physiology of the temporomandibular joint. In Fonseca R, editor: *Oral and maxillofacial surgery*, Philadelphia, 2000, Saunders, pp 3–19.
6. Hylander W: Functional anatomy and biomechanics of the masticatory apparatus. In Laskin D, Greene C, Hylander W, editors: *TMDs: an evidence based approach to diagnosis and treatment*, Chicago, 2006, Quintessence, pp 3–34.
7. Nickel JC, Iwasaki LR, McLachlan KR: Effect of the physical environment on growth of the temporomandibular joint. In McNeill C, editor: *Science and practice of occlusion*, Chicago, 1997, Quintessence, pp 115–124.
8. Beek M, Koolstra JH, van Ruijven LJ, van Eijden TMGJ: Three-dimensional finite element analysis of the human temporomandibular joint disc, *J Biomech* 33:307–316, 2000.
9. Tillman B, Töndury G: Kauapparat. In Tillman B, Töndury G, editors: *Bewegungsapparat*, vol. 1. Stuttgart, 1998, Thieme, pp 730–738.
10. Siebert JR, Swindler DR: Evolutionary changes in the midface and mandible: establishing the primate form. In Mooney MP, Siegel MI, editors: *Understanding craniofacial anomalies: the etiopathogenesis of craniosynostoses and facial clefting*, New York, 2002, Wiley-Liss, pp 345–378.
11. Perry HT, Xu Y, Forbes DP: The embryology of the temporomandibular joint, *J Craniomandib Pract* 3:125–132, 1985.
12. Sato I, Ishikawa H, Shimada K, et al.: Morphology and analysis of the development of the human temporomandibular joint and masticatory muscle, *Acta Anat* 149:55–62, 1994.
13. Carlsson GE, Oberg T: Remodelling of the temporomandibular joints, *Oral Sci Rev* 6:53, 1974.
14. Ogutcen-Toller M, Juniper RP: The development of the human lateral pterygoid muscle and the temporomandibular joint and related structures: a three-dimensional approach, *Early Hum Dev* 39:57–68, 1994.
15. Vazquez R, Velasco M, Collado J: Relationships between the temporomandibular joint and the middle ear in human fetuses, *J Dent Res* 72:62–66, 1993.
16. Hylander WL: Functional anatomy of the temporomandibular joint. In Sarnat BG, Laskin DM, editors: *The temporomandibular joint: a biological basis for clinical practice*, ed 4, Philadelphia, 1992, Saunders, pp 60–92.
17. Duterloo HS, Jansen HW: Chondrogenesis and osteogenesis in the mandibular condylar blastema, *Rep Congr Eur Orthod Soc* 109–118, 1969.

18. Dechow PC, Carlson DS: Development of mandibular form: phylogeny, ontogeny, and function. In McNeill C, editor: *Science and practice of occlusion*, Chicago, 1997, Quintessence, pp 3–22.
19. Scapino RP: Morphology and mechanism of the jaw joint. In McNeill C, editor: *Science and practice of occlusion*, Chicago, 1997, Quintessence, pp 23–40.
20. Emshoff R, Rudisch A, Bösch R, Gassner R: Effect of arthrocentesis and hydraulic distension on the temporomandibular joint disk position, *Oral Surg Oral Med Oral Pathol Oral Radiol Endodon* 89:271–277, 2000.
21. Rasse M: Recent developments in therapy of condylar fractures of the mandible, *Mund Kiefer Gesichtschir* 4:69–87, 2000.
22. Neff A, Mühlberger G, Karoglan A, et al.: Stability of osteosyntheses for condylar head fractures in the clinic and biomechanical simulation, *Mund Kiefer Gesichtschir* 8:63–74, 2004.
23. Undt G, Murakami K, Rasse M, Ewers R: Open versus arthroscopic surgery for internal derangement of the temporomandibular joint: a retrospective study comparing two centres' results using the Jaw Pain and Function Questionnaire, *J Craniomaxillofac Surg* 34:234–241, 2006.
24. Meyer H: Das Kiefergelenk, *Arch Anat Physiol Wis Med* 719–731, 1865.
25. Fick R: *Handbuch der Anatomie und Mechanik der Gelenke: Anatomie der Gelenke*, Jena, Germany, 1904, Fischer.
26. Tandler J: *Lehrbuch der systematischen Anatomie*, vol. 1. Leipzig, 1919, Vogel.
27. Griffin CJ, Sharpe CJ: The structure of the adult human temporomandibular meniscus, *Aust Dent J* 5:190–195, 1960.
28. Rees L: The structure and function of the mandibular joint, *Br Dent J* 96:125–133, 1954.
29. Minarelli AM, De Santo JM, Liberti EA: The structure of the human temporomandibular joint disc: a scanning electron microscopy study, *J Orofac Pain* 11:95–100, 1997.
30. Chen YJ, Gallo LM, Palla S: The mediolateral temporomandibular joint disc position: an in vivo quantitative study, *J Orofac Pain* 16:29–38, 2002.
31. Meyenberg K, Kubik S, Palla S: Relationships of the muscles of mastication to the articular disc of the temporomandibular joint, *Schweiz Monatsschr Zahnmed* 96:815–834, 1986.
32. Wilkinson TM: The relationship between the disk and the lateral pterygoid muscle in the human temporomandibular joint, *J Prosthet Dent* 60:715–724, 1988.
33. Van der Linden EJ, Burdi AR, de Jongh HJ: Critical periods in the prenatal morphogenesis of the human lateral pterygoid muscle, the mandibular condyle, the articular disk, and medial articular capsule, *Am J Orthod Dentofac Orthop* 91:22–28, 1987.
34. Emshoff R, Bertram S, Rudisch A, Gassner R: The diagnostic value of ultrasonography to determine the temporomandibular disc position, *Oral Surg Oral Med Oral Pathol Oral Radiol Endodon* 84:688–696, 1997.
35. Schmolke C, Hugger A: The human temporomandibular joint region in different positions of the mandible, *Ann Anat* 181:61–64, 1999.
36. Schmolke C: The relationship between the temporomandibular joint capsule, articular disc and jaw muscles, *J Anat* 184:335–345, 1994.
37. Krenkel C, Grunert I: The mandibular condyles in the submentovertex projection—their morphology and topographical relationship to the foramina spinosa, *J Oral Rehabil* 16:417–424, 1989.
38. Sambajon V, Cillo J, Gassner R, Buckley M: The effects of mechanical strain on synovial fibroblasts, *J Oral Maxillofac Surg* 61:707–712, 2003.
39. DuBrul EL: *Oral anatomy*, St Louis, 1988, Ishiyaku-EuroAmerica.
40. Savalle WP: Some aspects of the morphology of the human temporomandibular joint capsule, *Acta Anat* 131:292–296, 1988.
41. Nell A, Niebauer G, Sperr W, Firbas W: Special variations of the lateral ligament of the human TMJ, *Clin Anat* 7:267–270, 1994.
42. Koolstra JH, Naeije M, van Eijden TMGJ: The three dimensional active envelope of jaw border movements and its determinants, *J Dent Res* 80:1908–1912, 2001.
43. Moss M: Functional anatomy of the temporomandibular joint. In Schwartz L, editor: *Disorders of the temporomandibular joint: diagnosis, management, relation to occlusion of teeth*, Philadelphia, 1959, Saunders.
44. Paturet G: Muscles masticateurs. In Masson C, editor: *Traité d'anatomie humaine: tome I, ostéologie, arthrologie, myologie*, Paris, 1951, Libraires de l'académie de médicine, pp 659–676.
45. Herring SW: Muscles of mastication: architecture and functional organization. In Davidovitch Z, editor: *Biological mechanisms of tooth movement and craniofacial adaptation*, Columbus, 1992, Ohio State University, College of Dentistry, pp 541–548.
46. Paturet G: Muscles masticateurs. In Masson C, editor: *Traité d'anatomie humaine: tome I, ostéologie, arthrologie, myologie*, Paris, France, 1951, Libraires de l'académie de médicine, pp 659–676.
47. Widmalm SE, Lillie JH, Ash Jr MM: Anatomical and electromyographic studies of the lateral pterygoid muscle, *J Oral Rehabil* 14:429–446, 1987.
48. Hylander WL, Johnson KR, Crompton AW: Muscle force recruitment and biomechanical modeling: an analysis of masseter muscle function in Macaca fascicularis, *Am J Phys Anthropol* 88:365–387, 1992.
49. Honée GL: The anatomy of the lateral pterygoid muscle, *Acta Morphol Neerl Scand* 10:331–340, 1972.
50. Schumacher GH: *Funktionelle Morphologie der Kaumuskulatur*, Jena, Germany, 1961, Fischer.
51. Stern Jr JT: *Essentials of gross anatomy*, Philadelphia, 1988, Davis.
52. Moritz T, Ewers R: Der Ansatz des Musculus pterygoideus lateralis am Kiefergelenk des Menschen, *Dtsch Zahnarztl Z* 42:680–685, 1987.
53. Sicher H: Functional anatomy of the temporomandibular joint. In Sarnat BG, editor: *The temporomandibular joint*, ed 2, Springfield, IL, 1964, Thomas, pp 28–57.
54. Wilkinson TM, Maryniuk GA: Sequential sagittal dissections of the temporomandibular joint, *J Dent Res* 62:655, 1983.
55. Gibbs CH, Mahan PE, Wilkinson TM, Mauderli A: EMG activity of the superior belly of the lateral pterygoid muscle in relation to other jaw muscles, *J Prosthet Dent* 51:691–702, 1984.
56. Lipke DP, Gay T, Gross BD, Yaeger JA: An electromyographic study of the human lateral pterygoid muscle, *J Dent Res* 56B:230, 1977.
57. McNamara Jr JA: The independent functions of the two heads of the lateral pterygoid muscle, *Am J Anat* 138:197–205, 1973.
58. Wood WW, Takada K, Hannam AG: The electromyographic activity of the inferior part of the human lateral pterygoid muscle during clenching and chewing, *Arch Oral Biol* 31:245–253, 1986.
59. Hylander WL: An experimental analysis of temporomandibular joint reaction force in macaques, *Am J Phys Anthropol* 51:433–456, 1979.
60. Hylander WL, Johnson KR, Crompton AW: Loading patterns and jaw movements during mastication in Macaca fascicularis: a bone-strain, electromyographic, and cineradiographic analysis, *Am J Phys Anthropol* 72:287–314, 1987.
61. Crompton AW, Cook P, Hüemae K, Thexton AJ: Movement of the hyoid apparatus during chewing, *Nature* 258:69–70, 1975.

62. Palmer JB, Rudin NJ, Lara G, Crompton AW: Coordination of mastication and swallowing, *Dysphagia* 7:187–200, 1992.
63. Cartmill M, Hylander WL, Shafland J: *Human structure*, Cambridge, MA, 1990, Harvard University Press.
64. Gassner R, Buckley M, Studer R, et al.: Cyclic tensile stress exerts antiinflammatory properties by inhibiting iNOS induction in chondrocytes, *J Immunol* 163:2187–2192, 1999.
65. Ferretti M, Gassner R, Wang Z, et al.: Biomechanical signals suppress proinflammatory responses in cartilage: early events in experimental antigen-induced arthritis, *J Immunol* 177:8757–8766, 2006.
66. Merlini L, Palla S: The relationship between condylar rotation and anterior translation in healthy and clicking temporomandibular joints, *Schweiz Monatsschr Zahnmed* 98:1191–1199, 1988.
67. Posseit U: *Physiology of occlusion and rehabilitation*, Oxford, 1968, Blackwell Scientific.
68. Ramfjord SP, Ash Jr MM: *Occlusion*, Philadelphia, 1971, Saunders.
69. Jankelson B, Hoffman GM, Hendron JA: Physiology of the stomatognathic system, *J Am Dent Assoc* 46:375–386, 1953.
70. Sheppard IM: Incisive and related movements of the mandible, *J Prosthet Dent* 14:898–906, 1964.
71. Hüemae KM: Mammalian mastication: a review of the activity of the jaw muscles and movements they produce in chewing. In Butler PM, Joysey KA, editors: *Development, function and evolution of teeth*, New York, 1978, Academic Press, pp 359–398.
72. Gallo LM, Airoldi GB, Airoldi RL, Palla S: Description of mandibular finite helical axis pathways in asymptomatic subjects, *J Dent Res* 76:704–713, 1997.
73. Latif A: An electromyographic study of the temporalis muscle in normal persons during selected positions and movements of the mandible, *Am J Orthod* 43:577–591, 1957.
74. Pruzansky S: The application of electromyography to dental research, *J Am Dent Assoc* 44:49–68, 1952.
75. Huddleston Slater JJ, Visscher CM, Lobbezoo F: Naeije M: The intra-articular distance within the TMJ during free and loaded closing movements, *J Dent Res* 78:1815–1820, 1999.
76. Phanachet I, Whittle T, Wanigaratne K, et al.: Functional heterogeneity in the superior head of the human lateral pterygoid, *J Dent Res* 82:106–111, 2003.
77. Palla S, Gallo LM, Gossi D: Dynamic stereometry of the temporomandibular joint, *Orthod Craniofac Res* 6(suppl 1):37–47, 2003.
78. Gossi DB, Gallo LM, Bahr E, Palla S: Dynamic intra-articular space variation in clicking TMJs, *J Dent Res* 83:480–484, 2004.
79. Fushima K, Gallo LM, Krebs M, Palla S: Analysis of the TMJ intraarticular space variation: a non-invasive insight during mastication, *Med Engl Phys* 25:181–190, 2003.
80. Phanachet I, Wanigaratne K, Whittle T, et al.: A method for standardizing jaw displacements in the horizontal plane while recording single motor unit activity in the human lateral pterygoid muscle, *J Neurosci Meth* 105:201–210, 2001.
81. Phanachet I, Whittle T, Wanigaratne K, Murray GM: Functional properties of single motor units in inferior head of human lateral pterygoid muscle: task relations and thresholds, *J Neurophysiol* 86:2204–2218, 2001.
82. Móller E: Action of the muscles of mastication. In Kawamura Y, editor: *Frontiers of oral physiology*, Basel, 1974, Karger, pp 121–158.
83. Greenfield BE, Wyke BD: Electromyographic studies of some of the muscles of mastication, *Br Dent J* 100:129–143, 1956.
84. Hylander WL, Johnson KR: Temporalis and masseter muscle function during incision in macaques and humans, *Int J Primatol* 6:289–322, 1985.
85. Naeije M, Hofman N: Biomechanics of the human temporomandibular joint during chewing, *J Dent Res* 82:528–531, 2003.
86. Wall CE, Vinyard CJ, Johnson KR, et al.: Phase II jaw movements and masseter muscle activity during chewing in Papio anubis, *Am J Phys Anthropol* 129:215–224, 2006.
87. Hylander WL: Mandibular function and temporomandibular joint loading. In Carlson DS, McNamara JA, Ribbens KA, editors: *Developmental aspects of temporomandibular joint disorder*, Ann Arbor, 1985, University of Michigan, pp 19–35.
88. Detamore M, Hegde J, Wagle R, et al.: Cell type and distribution in the porcine temporomandibular joint disc, *J Oral Maxillofac Surg* 64:243–248, 2006.
89. Obrez A, Gallo L: Anatomy and function of the TMJ. In Laskin D, Greene C, Hylander W, editors: *TMDs: an evidence based approach to diagnosis and treatment*, Chicago, 2006, Quintessence, pp 35–52.

36

Assessing Temporomandibular Disorders

GARY M. HEIR

This chapter discusses the assessment of pathology and abnormal function of the temporomandibular joint (TMJ). In order to comprehend pathologic processes resulting in pain and dysfunction of the temporomandibular joints, a clear understanding of normal anatomy and biomechanics is essential. Assessment of the temporomandibular joint, typically performed on a symptomatic patient, requires an understanding of the various clinical conditions that encompass temporomandibular disorders.

Research in the field of temporomandibular disorders is limited in its utility because of a lack of consistency in the standardized nomenclature, in definitions of the various disorders that might affect the masticatory system, and in the quality of research.[1] In an attempt to better define temporomandibular disorders, the International RDC/TMD Consortium Network and Orofacial Pain Special Interest Group has recently published validated diagnostic criteria of the assessment of the temporomandibular joint.[2] A persistent problem appearing in the literature, addressed by the Diagnostic Criteria for Temporomandibular Disorders (DC/TMD), is use of "Temporomandibular Disorders (TMD)" as a comprehensive term incorporating all aspects of masticatory pain, regardless of etiology or severity. The DC/TMD addresses this by separating out two categories of painful TMD: myogenous, or muscle-generated pain, and arthrogenous, or joint-generated pain. The DC/TMD further subdivides myogenous and arthrogenous TMDs into subgroups of local pain with and without referral, disc displacement disorders, degenerative joint disease, and subluxation[3] (Table 36-1). Non–TMJ-related topics are beyond the scope of this chapter, but familiarity with these diagnostic entities and techniques is encouraged.

Temporomandibular Disorders

Temporomandibular disorders are defined as clinical problems involving the masticatory musculature, the temporomandibular joints and associated structures, or both. Articular disorders of the TMJ often coexist with masticatory muscle pain, and a clear differential diagnosis is necessary, especially when surgery is a possibility. Articular disorders include disc displacement disorders, arthritic or degenerative changes, and neoplasm.[4] Other conditions that may affect the temporomandibular joints include congenital disorders, inflammatory conditions, and systemic disease.

TMDs are considered the most common cause of musculoskeletal orofacial pain. Common features of a TMD include: (1) pain with mandibular function, (2) limitation of mandibular movement, and (3) joint sounds. One, two, or all three conditions, when present, may represent signs of chronic adaptation of the anatomy of the joint that require no treatment interventions, or may reveal symptoms of dysfunction that may affect the activities of daily life due to dysfunction and/or pain.

Although pain in the masticatory system can arise from the muscles of mastication or can be referred to the orofacial region from remote musculoskeletal structures, a discussion of muscle pain is not within the scope of this chapter. However, it is important to consider that myogenous pain occurs more frequently than pain arising from articular disorders.[4]

A differential diagnosis of myogenous pain and dysfunction, as opposed to a true internal derangement or temporomandibular *joint* dysfunction, is essential to successful treatment.[5] For the purpose of classification, temporomandibular disorders will be considered as pain or dysfunction of the musculoskeletal system involving the temporomandibular joints and the masticatory muscles.

With myogenous pain, the patient typically provides a history of regional pain, a sense of muscle weakness, easy fatigability of the masticatory muscles, and a limited passive mandibular range of motion. A palpatory examination of the masticatory muscles often reveals myofascial trigger points and muscle tenderness, which also can produce referral patterns to the region of the temporomandibular joints.

TABLE 36-1 Detailed and Validated Diagnostic Approach to Temporomandibular Disorders as Proposed by the DC/TMD

Disc Displacement with Reduction (ICD-10 M 26.63)

Description	An intracapsular biomechanical disorder involving the condyle-disc complex. In the closed mouth position, the disc is in an anterior position relative to the condylar head and the disc reduces upon opening of the mouth. Medial and lateral displacement of the disc may also be present. Clicking, popping, or snapping noises may occur with disc reduction. A history of prior locking in the closed position coupled with interference in mastication precludes this diagnosis.
History	Positive for at least one of the following: 1. In the last 30 days,* any TMJ noise(s) present with jaw movement or function; OR 2. Patient report of any noise present during the exam.
Exam	Positive for at least one of the following: 1. Clicking, popping, and/or snapping noise during both opening and closing movements, detected with palpation during at least one of three repetitions of jaw opening and closing movements; OR 2a. Clicking, popping, and/or snapping noise detected with palpation during at least one of three repetitions of opening or closing movement(s); AND 2b. Clicking, popping, and/or snapping noise detected with palpation during at least one of three repetitions of right or left lateral, or protrusive movement(s).
Validity	Without imaging: sensitivity 0.34; specificity 0.92. Imaging is the reference standard for this diagnosis.
Imaging	When this diagnosis needs to be confirmed, TMJ MRI criteria are positive for both of the following: 1. In the maximum intercuspal position, the posterior band of the disc is located anterior to the 11:30 position and the intermediate zone of the disc is anterior to the condylar head; AND 2. On full opening, the intermediate zone of the disc is located between the condylar head and the articular eminence.

Disc Displacement with Reduction with Intermittent Locking (ICD 10 M 26.63)

Description	An intracapsular biomechanical disorder involving the condyle-disc complex. In the closed mouth position, the disc is in an anterior position relative to the condylar head, and the disc intermittently reduces with opening of the mouth. When the disc does not reduce with opening of the mouth, intermittent limited mandibular opening occurs. When limited opening occurs, a maneuver may be needed to unlock the TMJ. Medial and lateral displacement of the disc may also be present. Clicking, popping, or snapping noises may occur with disc reduction.
History	Positive for both of the following: 1a. In the last 30 days,* any TMJ noise(s) present with jaw movement or function; OR 1b. Patient report of any noise present during the exam; AND 2. In the last 30 days,* jaw locks with limited mouth opening, even for a moment, and then unlocks.
Exam	Positive for both of the following: 1. Clicking, popping, and/or snapping noise detected during both opening and closing movements, detected with palpation during at least one of three repetitions of jaw opening and closing movements; OR 2a. Clicking, popping, and/or snapping noise detected with palpation during at one of three repetitions of opening or closing movement(s); AND 2b. Clicking, popping, and/or snapping noise detected with palpation during at least one of three repetitions of right or left lateral, or protrusive movement(s).
Validity	Without imaging: sensitivity 0.38; specificity 0.98. Imaging is the reference standard for this diagnosis.
Imaging	When this diagnosis needs to be confirmed, the imaging criteria are the same as for disc displacement with reduction if intermittent locking is not present at the time of imaging. If locking occurs during imaging, an imaging-based diagnosis of disc displacement without reduction will be rendered and clinical confirmation of reversion to intermittent locking is needed.
Note	Although not required, when this disorder is present clinically, examination is positive for inability to open to a normal amount, even momentarily, without the clinician or patient performing a maneuver to reduce the lock.

Disc Displacement without Reduction with Limited Opening (ICD 10 M 26.63)

Description	An intracapsular biomechanical disorder involving the condyle-disc complex. In the closed mouth position, the disc is in an anterior position relative to the condylar head, and the disc does not reduce with opening of the mouth. Medial and lateral displacement of the disc may also be present. This disorder is associated with persistent limited mandibular opening that does not reduce with the clinician or patient performing a manipulative maneuver. This is also referred to as “closed lock.” This disorder is associated with limited mandibular opening.
History	Positive for both of the following: 1. Jaw locked so that the mouth would not open all the way; AND 2. Limitation in jaw opening severe enough to limit jaw opening and interfere with ability to eat.

TABLE 36-1 Detailed and Validated Diagnostic Approach to Temporomandibular Disorders as Proposed by the DC/TMD—cont'd

Exam	Positive for the following: 1. Maximum assisted opening (passive stretch) movement including vertical incisal overlap <40.
Validity	Without imaging: sensitivity 0.80; specificity 0.97. Imaging is the reference standard for this diagnosis.
Imaging	Maximum assisted opening of <40 mm is determined clinically.
Note	Presence of TMJ noise (e.g., click during opening) does not exclude this diagnosis.

Disc Displacement without Reduction without Limited Opening (ICD 10 M 26.63)

Description	An intracapsular biomechanical disorder involving the condyle-disc complex. In the closed mouth position, the disc is in an anterior position relative the condylar head and the disc does not reduce with opening of the mouth. Medial and lateral displacement of the disc may also be present. This disorder is NOT associated with current limited opening.
History	Positive for both of the following in the past: 1. Jaw locked so that the mouth would not open all the way; AND 2. Limitation in jaw opening severe enough to limit jaw opening and interfere with ability to eat.
Exam	Positive for the following: 1. Maximum assisted opening (passive stretch) movement including vertical incisal overlap ≥40 mm.
Validity	Without imaging: sensitivity 0.54; specificity 0.79. Imaging is the reference standard for this diagnosis.
Imaging	When this diagnosis needs to be confirmed, TMJ MRI criteria are the same as for disc displacement without reduction with limited opening. Note: Maximum assisted opening of ≥40 mm is determined clinically.
Note	Presence of TMJ noise (e.g., click during opening) does not exclude this diagnosis.

Degenerative Joint Disease (ICD 10 M 26.69)

Description	A degenerative disorder involving the joint characterized by deterioration of articular tissue with concomitant osseous changes in the condyle and/or articular eminence.
History	Positive for at least one of the following: 1. In the last 30 days,* any TMJ noise(s) present with jaw movement or function; OR 2. Patient report of any noise present during the exam.
Exam	Positive for the following: 1. Crepitus detected with palpation during at least one of the following: opening, closing, right or left lateral, or protrusive movement(s).
Validity	Without imaging: sensitivity 0.55; specificity 0.61. Imaging is the reference standard for this diagnosis.
Imaging	When this diagnosis needs to be confirmed, then TMJ CT criteria are positive for at least one of the following: Subchondral cyst(s), erosion(s), generalized sclerosis, or osteophyte(s). Note: Flattening and/or cortical sclerosis are considered indeterminate findings for degenerative joint disease (DJD) and may represent normal variation, aging, remodeling, or a precursor to frank DJD.

Subluxation (ICD 10 M 26.69)

Description	A hypermobility disorder involving the disc-condyle complex and the articular eminence: In the open mouth position, the disc-condyle complex is positioned anterior to the articular eminence and is unable to return to a normal closed mouth position without a manipulative maneuver. The duration of dislocation may be momentary or prolonged. When the patient can reduce the dislocation himself/herself, this is referred to as subluxation. When the patient needs the assistance of the clinician to reduce the dislocation and normalize jaw movement, this is referred to as luxation. This disorder is also referred to as "open lock." The sensitivity and specificity have been established for only subluxation.
History	Positive for both of the following: 1. In last 30 days,* jaw locking or catching in a wide open mouth position, even for a moment, so could not close from the wide-open position; AND 2. Inability to close the mouth from a wide-open position without a self-maneuver.
Exam	Although no exam findings are required, when this disorder is present clinically, examination is positive for inability to return to a normal closed mouth position without the patient performing a manipulative maneuver.
Validity	Without imaging and based only on history: sensitivity 0.98; specificity 1.00.
Imaging	When this diagnosis needs to be confirmed, imaging criteria are positive for the condyle positioned beyond the height of the articular eminence with the patient unable to close his/her mouth.

*Validity for assessing selected biomechanical intra-articular disorders is in "the last 30 days"' since the stated sensitivity and specificity of these criteria were established using this time frame.

CT, Computed tomography; *DJD,* degenerative joint disease; *ICD-10,* International Classification of Diseases 10th Revision; *MRI,* magnetic resonance imaging; *TMJ,* temporomandibular joint.

Adapted from Schiffman E, Ohrbach R, Truelove E et al: Diagnostic Criteria for Temporomandibular Disorders (DC/TMD) for clinical and research applications: recommendations of the International RDC/TMD Consortium Network and Orofacial Pain Special Interest Group, *J Oral Facial Pain Headache* 28:6-27, 2014

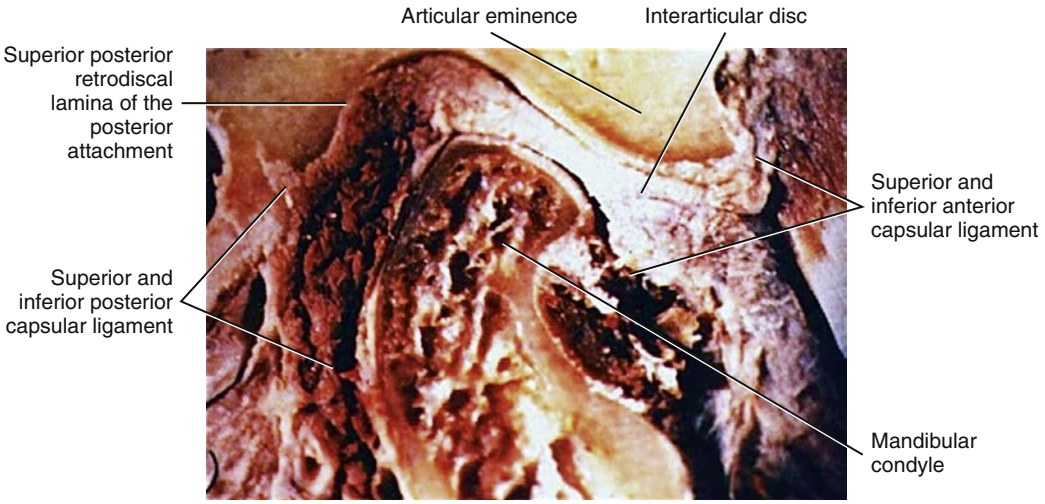

• **Figure 36-1** Cross-sectional anatomy of the temporomandibular joint. (Courtesy Dr. Peter Neff.)

Included in the myogenous pain group are conditions such as myositis or muscle inflammation, which often result from local trauma or infection. Upon palpation, muscles with myositis may also be tender and feel swollen and warm.

Myospasm is an often-overused diagnostic term that describes an involuntary muscle contraction. The patient with myospasm may present with a restricted mandibular range of motion that must be differentiated from an internal derangement of the joint, because this condition also can restrict mandibular movement. Spastic muscles may be tender to palpation. True myospasm may be secondary to a neuromuscular disorder and can be diagnosed by needle electrode electromyography.

With time, masticatory muscles exhibiting chronic contraction or other local myopathies may develop myofibrotic contracture. This may not be a painful condition, but will also limit the mandibular range of motion. For this reason, a differential diagnosis requires a detailed history and thorough evaluation. Myofibrotic contracture may be characterized by local tenderness and may be differentiated from other forms of muscle disorders via needle electrode electromyography.

Anatomy

The temporomandibular articulation is among the most complex in the body. It is a synovial joint that has two joint compartments and four articular surfaces, contains vascularized tissue within the joint capsule, and has articular surfaces of fibrous rather than chondrocartilage.

The temporomandibular joint functions within the glenoid or temporomandibular fossa of the skull. The fossa is located in the temporal bone bilaterally, just anterior to the external auditory meatus. The TMJ fossa is not so much a precise socket as a depression in the base of the skull, within which the mandibular condyle functions.

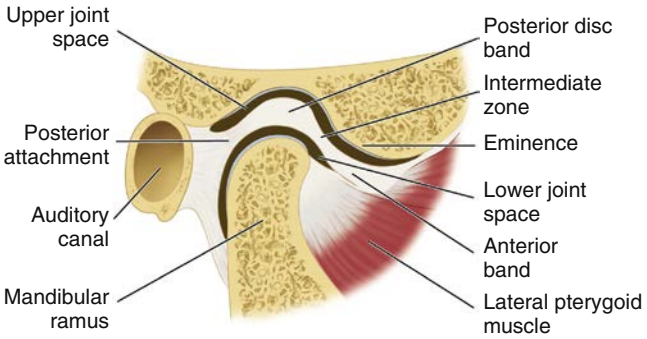

• **Figure 36-2** Articular disc and associated structures. (From Nelson SJ: *Wheeler's dental anatomy, physiology and occlusion*, ed 10, St Louis, 2015, Elsevier.)

The mandibular condyle is a spheroidal structure that is capable of a wide range of anterior, posterior, and lateral movements. The fibrocartilaginous articular surfaces of the condyle and fossa function against the fibrous interarticular disc that is interposed between these two bony structures (Figure 36-1). The disc is attached to the mandibular condyle by lateral and medial collateral ligaments and blends into the capsule anteriorly. Posteriorly, the disc attaches to the complex retrodiscal tissues. Although the disc is avascular and is not innervated, the retrodiscal tissue is highly vascularized and richly innervated (Figure 36-2). Therefore, intracapsular pain may be due to injury or inflammation of the retrodiscal tissue (retrodiscitis).

Like any synovial joint, the temporomandibular joint is encapsulated and stress bearing. The disc and its circumferential attachments separate the joint into upper and lower joint spaces. The disc-condyle complex and the mandibular fossa are enclosed within the capsular ligament, which is lined by synovial tissue with collateral ligaments that blend into the capsule. The TMJ lateral ligament complex arises from the articular eminence and attaches to the posterior aspect of the neck of the condyle (Figure 36-3). The lateral ligament complex functions to limit lateral movement.

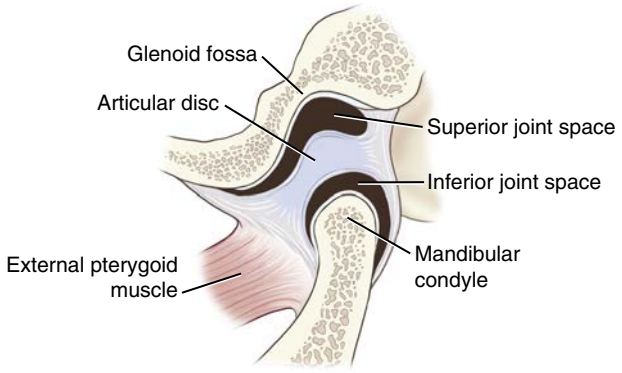

• **Figure 36-3** Components of the temporomandibular joint.

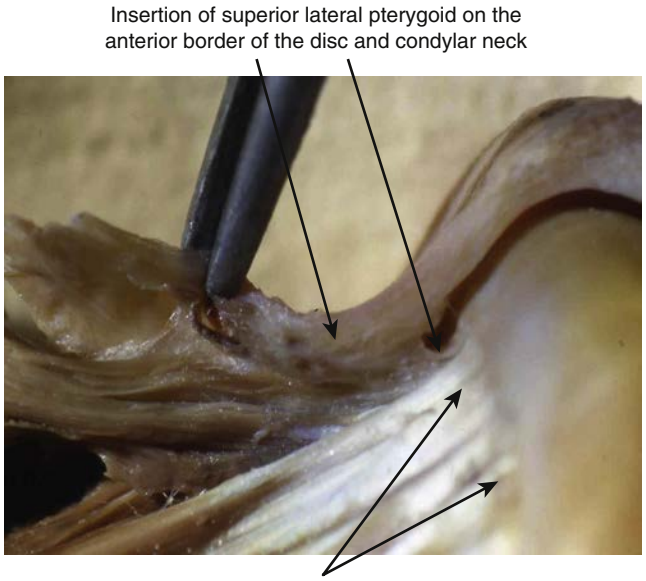

• **Figure 36-4** The superior and inferior lateral pterygoid muscles insert on the condylar neck. The inferior lateral pterygoid protrudes the mandible, whereas the superior lateral pterygoid contracts during mandibular closure. Some fibers of this muscle attach to the anterior border of the disc and contract eccentrically to stabilize the disc against the posterior slope of the articular eminence during closure. (Courtesy Thomas M. Wilkinson, BDS, MSO.)

Normal Biomechanics

The TMJ is a ginglymoarthrodial joint that is capable of both rotational movements in the inferior compartment and translational movements in the superior compartment (Figure 36-4). During function, the lateral and medial discal collateral ligaments allow for rotational movement of the condyle on the inferior surface of the disc, and the superior surface of the disc translates or slides along the posterior aspect of the articular eminence. Biomechanically, the TMJ exhibits significant mobility. The mandibular condyle freely rotates on the inferior surface of the interarticular disc, and the disc-condyle complex moves within the fossa and translates unimpeded along the posterior slope of the articular eminence. In addition, limited lateral movements are possible. During all of these movements of a normal temporomandibular joint, the interarticular disc is always positioned between the fossa/eminence and the condyle by the action of the superior lateral pterygoid muscle and the uppermost elastic properties of the posterior attachment known as the posterior, superior retrodiscal lamina of the retrodiscal tissue. Translation of the condyle occurs as a result of the action of the inferior lateral pterygoid muscle, which protrudes the mandible, acting in concert with other mandibular depressors of the infrahyoid and suprahyoid musculature. Movement of the disc is also controlled by a second structure. The superior, posterior retrodiscal lamina acts passively to pull the disc posteriorly during opening as the condyle translates anteriorly. The superior lateral pterygoid muscle contracts eccentrically during closure to stabilize the disc against the distal slope of the articular eminence (Figure 36-5). Normal disc/condyle/fossa relationships are demonstrated in Figure 36-6.

Abnormal Biomechanics

Smooth and coordinated opening and closing, in the absence of pain or joint sounds, characterize normal function of all synovial joints, including the TMJ. Signs of a TMD therefore include limited or irregular jaw movements, discomfort, and/or sounds emanating from the joint during function.

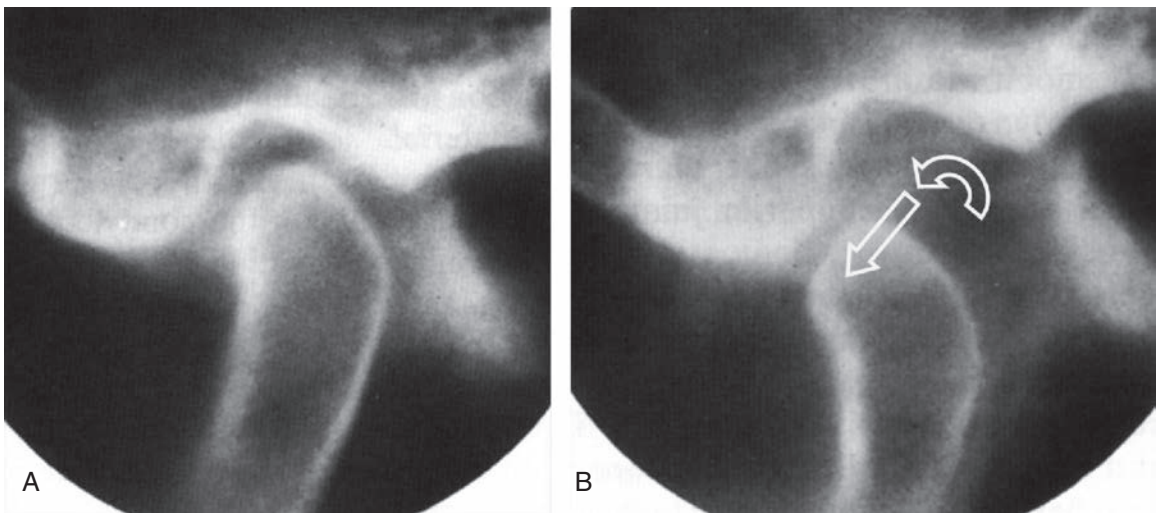

• **Figure 36-5** Tomographic imaging of normal translation of the temporomandibular joint. **A,** Closed mouth position. **B,** Open mouth position after rotational and translatory movements.

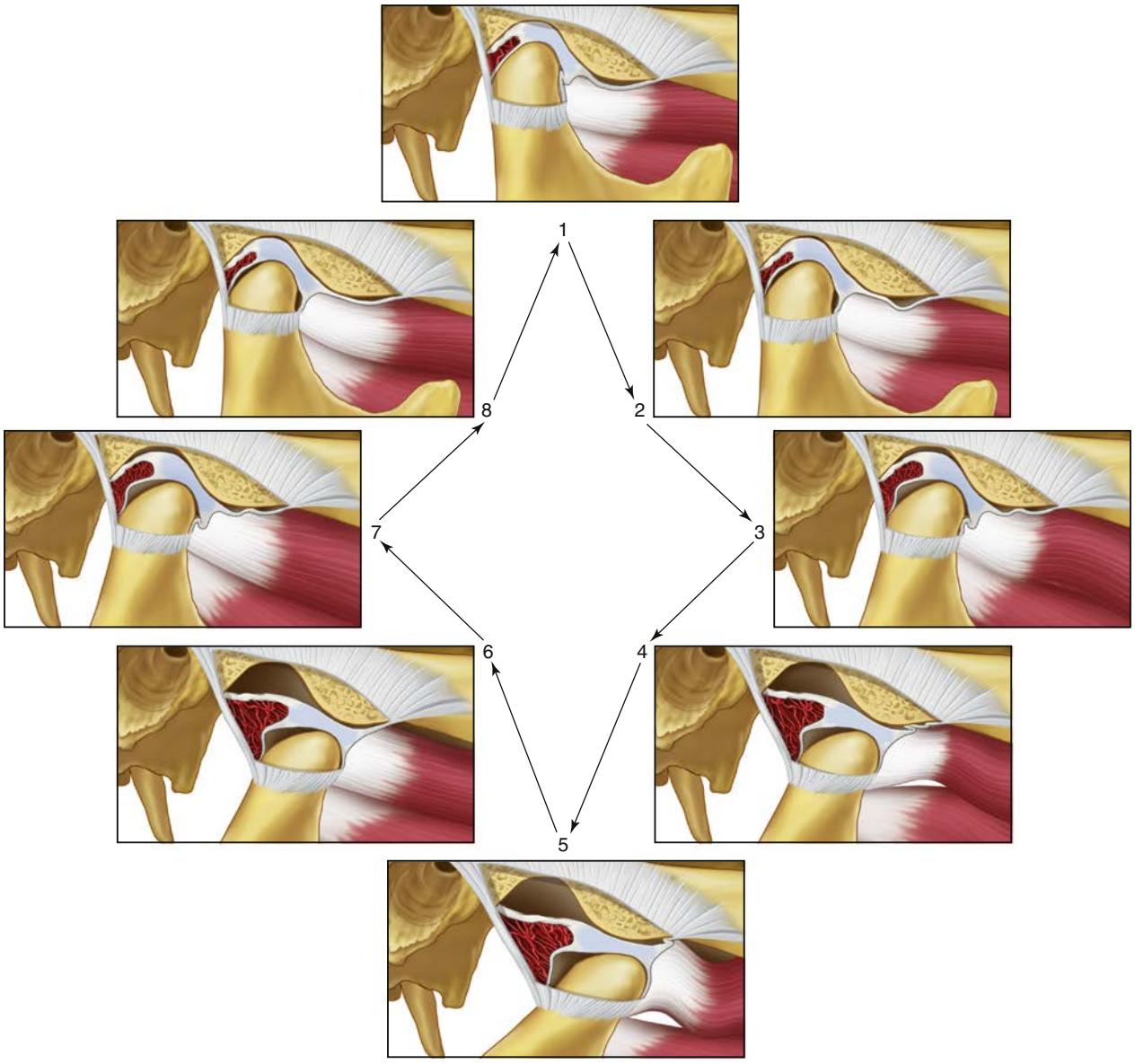

• **Figure 36-6** Normal functional movement of the condyle and disc during the full range of opening and closing. Note that the disc is rotated posteriorly on the condyle as the condyle is translated out of the fossa. The closing movement is the exact opposite of opening. (From Okeson JP: *Management of temporomandibular disorders and occlusion*, ed 7, St Louis, 2013, Elsevier.)

Impediments to normal joint movement can be extracapsular or intracapsular. A temporomandibular joint assessment must differentiate between the two.

As was previously discussed, extracapsular conditions that affect joint movement typically are caused by muscle dysfunction, although osseous anomalies also may interfere with mandibular movement. These include coronoid hypertrophy, calcified styloid processes, osteochondromatosis, or other bony abnormalities (Figures 36-7 through 36-9).

Synovial chondromatosis is an uncommon arthropathy, but it is one that should be considered in the differential diagnosis of TMJ-pain dysfunction syndrome[6] (Figure 36-10). Limitation of mandibular function caused by calcified bodies found within the TMJ capsule may displace the mandibular condyle, impede mandibular function, and mimic disc displacement or disc interference disorders.

Myofascial pain, myositis, myalgia, and muscle contracture not only can limit mandibular depression but also can result in pain during movement.[7] Myofascial trigger points of the masticatory musculature can refer pain to the TMJ.[8] Care must be taken during the history and physical examination to clearly define the source of the problem. If mandibular dysfunction is not due to extracapsular or myogenous causes, attention should be directed at possible intracapsular disorders.

Intracapsular Pathofunctional Disorders

Intracapsular pathofunctional disorders include anterior disc displacement with and without reduction.



• **Figure 36-7** Hypertrophic hamulus preventing normal mandibular opening.

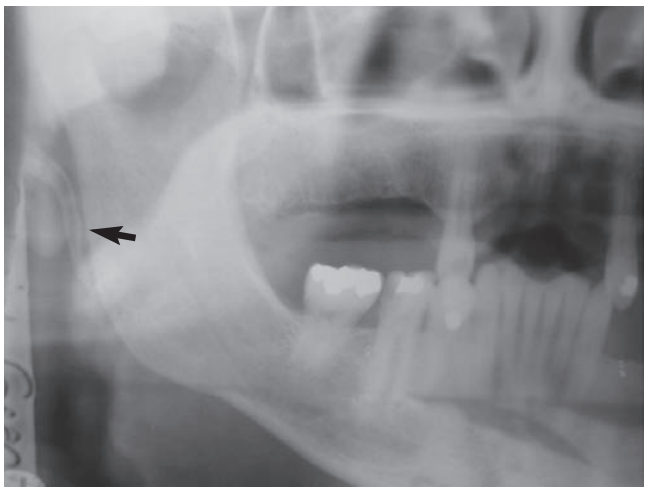

• **Figure 36-8** Calcified styloid process growing along the posterior border of the ramus, preventing normal mandibular depression.

Anterior disc displacement is a partial anterior or anteromedially displaced disc, characterized by joint sounds during function that occur at variable points during mandibular movement (Figure 36-11). Chronic anterior disc displacement may occur for a variety of reasons and may be an adaptive change that occurs within the joint as a result of functional demands (Figure 36-12). Adaptation should not be presumed to be pathologic. Some research indicates that a large segment of the general population, perhaps 90%, exhibits mild disc displacements similar to those of patients seeking treatment. Nearly one third were asymptomatic—that is, without pain or dysfunction—and had documented discal displacement. Therefore, the occurrence of disc displacement is common in the general population, and caution is necessary in differential diagnosis and in determining the need to initiate treatment for asymptomatic individuals based merely on an asymptomatic adaptive disc displacement.[9]

Differential diagnosis involves a physical examination in which the mandibular range of motion is measured, the gait of movement is observed, and the joint is auscultated. Assessing the mandibular range of motion is an important factor in the evaluation for TMDs. A limited mandibular range of motion may be a sign of a biomechanical dysfunction, muscular restriction of movement, extracapsular mechanical factors interfering with movement, or a variety of systemic conditions.

When assessing the mandibular range of motion there is an assumption that normal opening is 40 to 55 mm; however, there are no supporting validated studies. A review of published literature finds that maximal opening varies greatly and is described by several authors as, for example, 39 to 69 mm[10] or 46.9 to 60 mm.[11-13] These data are observational reports only, not taking into account the variations in individual anatomy that might be predictors of an individual's maximum opening. Methods for measuring the mandibular range of motion are also inconsistent; for example, maximum mandibular opening is often measured as the interincisal distance while opening as wide as possible, but inclusion of overbite in the measurement is not consistent.[10] Other literature suggests measurement should begin at the alveolar crest.[14] The lack of standardization in measuring the mandibular range of motion may account for these range discrepancies.

Even accepting a normal range of motion of 40 to 55 mm, as multiple authors have done,[4,15,16] does not eliminate confusion. The normal range of motion is reported anecdotally as less in women, and decreasing with increasing age.[15] Furthermore, range of motion may depend on the height of the patient. A young male of small stature might have a mandibular range of motion of less than 40 mm, while a tall and older female might approach 60 mm. A more accurate measure of normal opening might involve assessment of condylar translation to the crest of the articular eminence. This may be demonstrated radiographically, but the use of x-ray or magnetic resonance imaging (MRI) for this purpose is not suggested; it would be considered overuse of diagnostic imaging.

In anterior disc displacement, soft tissue imaging such as MRI can reveal a displaced disc with improved position during jaw opening. Hard tissue imaging may show an absence of degenerative changes, even though adaptive remodeling of the articular surfaces may occur. Disc displacement with reduction also may be accompanied by pain with joint movement and deviation of the mandible during

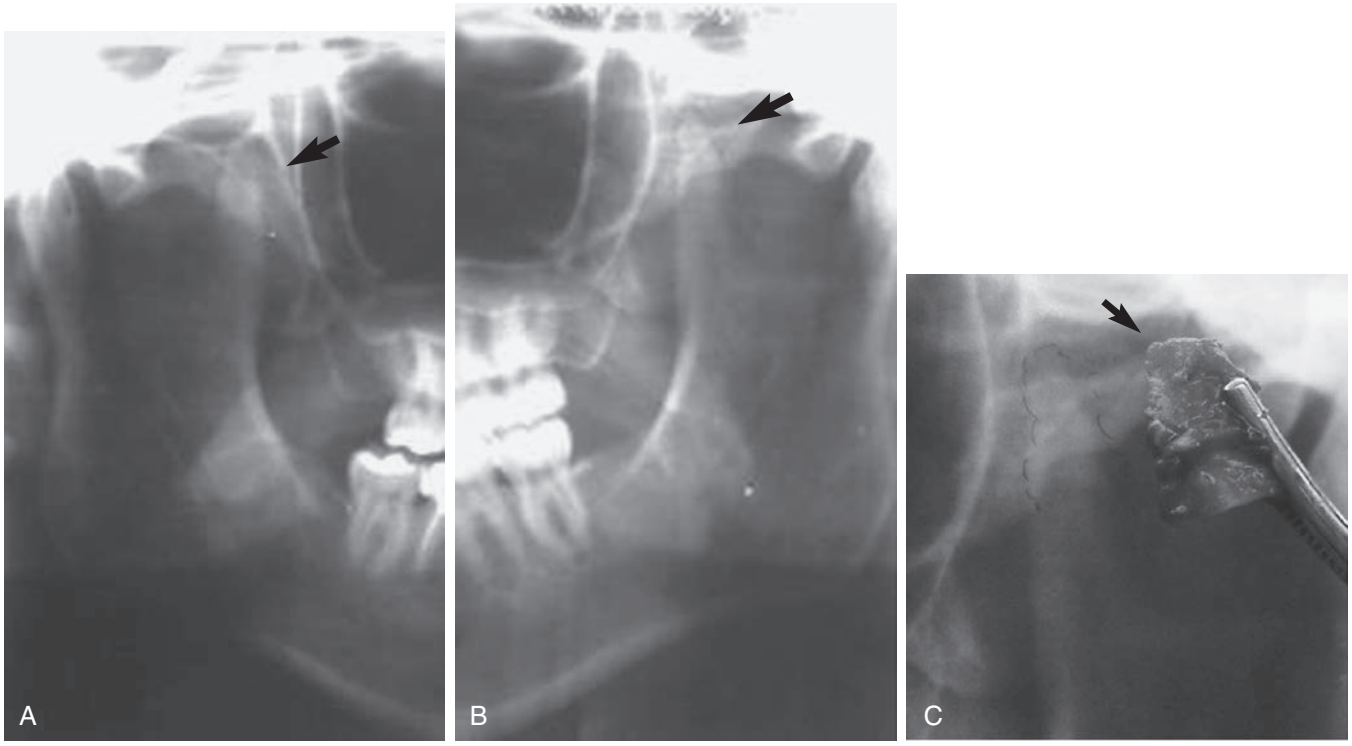

• **Figure 36-9** **A-B,** Hypertrophic coronoid processes are visualized radiographically. The surgical specimen has been removed and is shown next to the radiograph **(C).** (Courtesy Dr. Cibele Nasri.)



• **Figure 36-10** Synovial chondromatosis. Radiopaque, loose bodies, as seen here, anterior to the left temporomandibular joint within the synovial joint space. (Courtesy John F. Johnson, II, DDS, MS.)

opening, possibly coinciding with a click as the displaced disc returns to normal. No restriction is placed on mandibular movement despite the possibility of an episodic and momentary catch during jaw movement. An abnormal disc/condyle relationship is characteristic of disc displacement with reduction.[4]

Anterior disc displacement without reduction is the state in which the anteriorly displaced disc is maintained in this position throughout translation. This is often referred to as a closed lock. Essentially, the disc no longer allows the condyle to translate along the articular eminence. Thickening of the disc or damage to the posterior attachment may contribute to the disc getting caught or interfering with condylar movement.[4] Disc displacement without reduction is typically chronic, but initially presents as an acute problem. Some patients with anterior disc displacement with reduction evolve to nonreducing disc displacement. However, it is impossible to determine which patients will evolve to more advanced dysfunction.

Although a patient with disc displacement without reduction frequently reports a history of clicking during mandibular movement, a nonreducing disc displacement typically

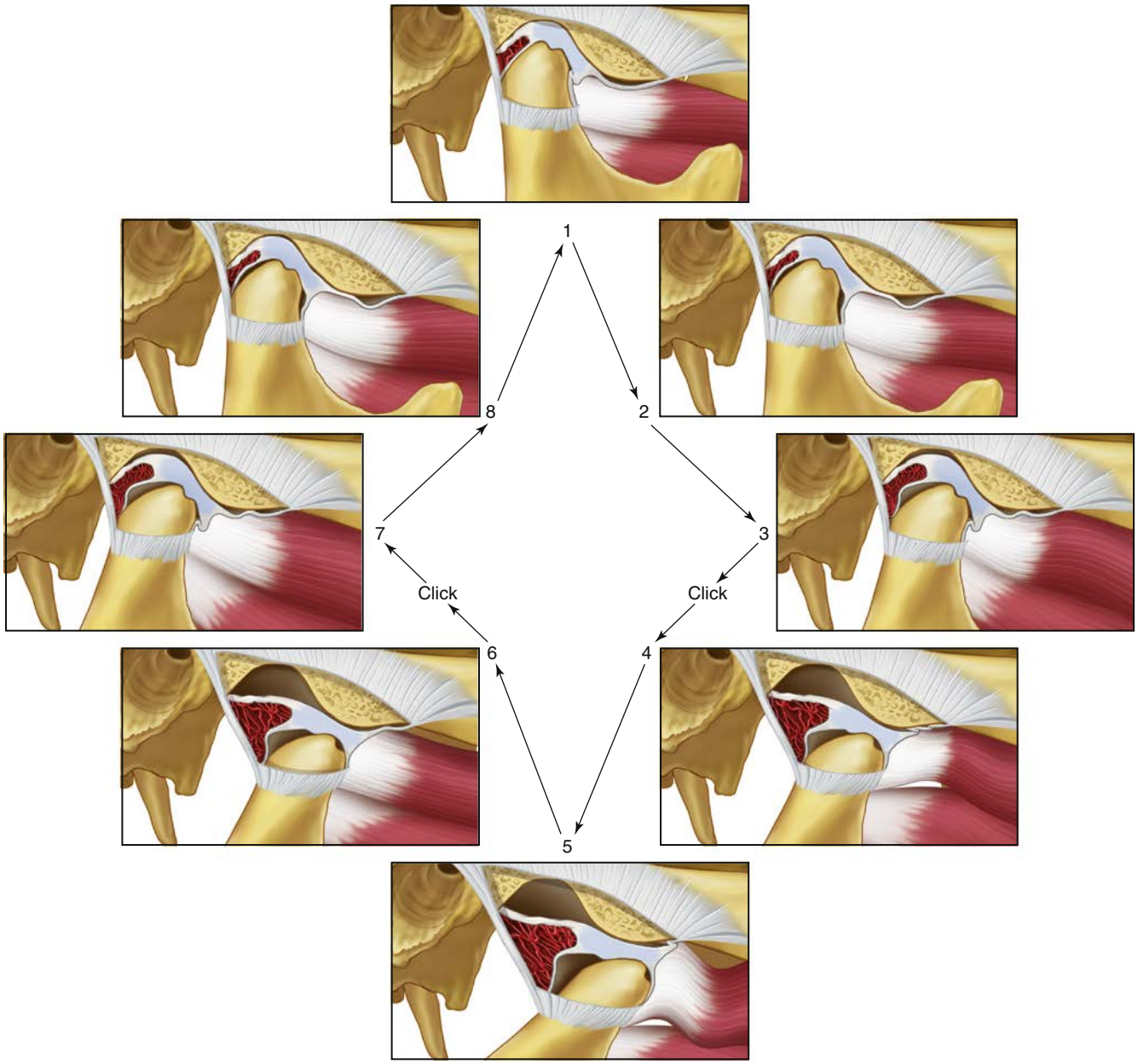

• **Figure 36-11** In position 1, the structural defect (alteration in form) in the condyle and disc. Between positions 3 and 4 the condyle moves out of the defect, creating a click. The condyle returns to this defect between positions 6 and 7. The opening and closing click occurs at the same degree of opening. (From Okeson JP: *Management of temporomandibular disorders and occlusion*, ed 7, St Louis, 2013, Elsevier.)

occurs in the absence of joint sounds. Therefore, the presence or absence of joint sounds may not be diagnostic. In fact, patients with chronic anterior disc displacement may have a normal mandibular range of motion with no joint sounds. Soft tissue imaging reveals a displaced disc that does not improve its position during jaw opening. Hard tissue imaging may show degenerative changes. An acute closed lock or nonreducing anterior disc displacement has a sudden onset with nearly immediate limited mouth opening of less than 25 mm. The mandible deflects to the affected side, and lateral movement to the opposite side is limited. Soft tissue imaging reveals the displaced disc, although hard tissue imaging may be normal.[4]

Chronic anterior disc displacement without reduction or chronic closed lock typically includes a history of sudden onset of limited mouth opening with continued limitation of opening for longer than 4 months. Soft tissue imaging shows the displaced disc without reduction. Typically, arthritic or degenerative changes are not extensive[4] (Figure 36-13).

Another post-traumatic condition that may affect mandibular and TMJ function involves intracapsular adhesions. As was previously described, the TMJ functions within a capsular ligament. This ligament exhibits varying degrees of toughness, with the strongest portion at the medial aspect of the superior joint space. The superior/anterior TMJ capsular

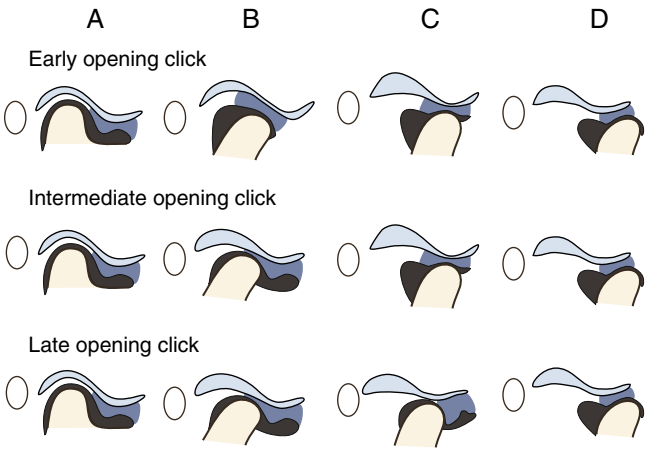

• **Figure 36-12** Diagrammatic representation of anterior disc displacement with reduction during early, intermediate, and late condylar translation. **A,** Closed. **B,** Partial translation. **C** and **D,** Full opening. (Adapted from Farrar W, McCarty WL Jr: *A clinical outline of temporomandibular joint diagnosis and treatment*, Montgomery, AL, 1982, Normandie Press.)

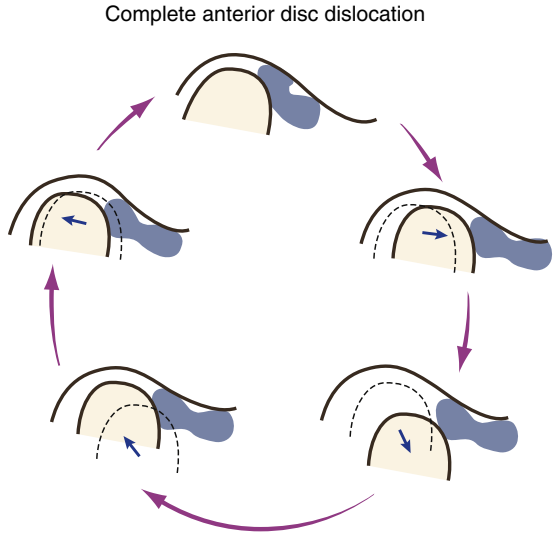

• **Figure 36-13** Disc displacement without reduction of the temporomandibular joint. (Adapted from Farrar W, McCarty WL Jr: *A clinical outline of temporomandibular joint diagnosis and treatment*, Montgomery, AL, 1982, Normandie Press.)

ligament is comparatively fragile. A sudden hypertranslation or condylar subluxation could allow the condyle to traumatically encroach on this structure. If injured, bleeding may occur into the superior joint space, resulting in the organization of fibrous bands known as adhesions. These intracapsular adhesions can prevent normal translation of the disc and, while giving the appearance and history of chronic disc displacement without reduction, can actually fixate the disc to the roof of the fossa. MRI or computed tomography (CT) may demonstrate the disc in a normal, closed position.

Another explanation for what appears to be a clinical closed lock in the presence of a normal discal position has been described. A sudden and persistent severely limited mouth opening associated with a total lack of disc translation along the articular eminence may be due to adhesion of



• **Figure 36-14** End-range, bilateral subluxation resulting in a deviation first to the left as the right condyle subluxates, then to the right as the left condyle does the same. After bilateral subluxation, the mandible returns to the midline position. Subluxation may be accompanied by a joint sound that should not be confused with a disc interference disorder.

the disc to the articular eminence secondary to joint overloading. In view of the fact that it is promptly released by lavage (arthrocentesis) of the upper joint space, inefficient lubrication of the joint is hypothesized. It has been postulated that overloading may reduce lubrication and may be responsible for this adhesion of the disc to the fossa and/or eminence. This also may explain the immediate release of the disc following arthrocentesis.[17]

In contrast to hypomobility caused by disc interference or muscle contraction is the chronic subluxation or hypermobility that is seen when, because of laxity of the supporting ligaments, the mandibular condyle translates beyond the articular eminence. Subluxation of the condyle will result in a soft or hard click as the condyle passes beyond the articular eminence at maximum opening. This is accompanied by unilateral or bilateral deflective movements at the end of the opening range. The joint sound associated with a subluxation should not be confused with that of a disc interference disorder (Figure 36-14).

Aside from mechanical dysfunction of the TMJ, inflammation that may accompany abnormal joint mechanics may contribute to the patient's discomfort. Intracapsular swelling from inflammation also may impede joint movement. Inflammation of the joint capsule (capsulitis) or inflammation of the joint lining (synovitis) can result in pain with jaw movement. Intracapsular edema my result in disocclusion of posterior teeth and referred otalgia.

Trauma to the highly innervated and richly vascularized retrodiscal tissue, as might occur with a blow to the jaw that drives the condyle upward and backward, can impart a



• **Figure 36-15** Panoramic view shows mild degenerative changes in the mandibular condylar articulation.

direct trauma to this tissue, resulting in swelling and pain. Pain within the joint may result in secondary muscle splinting or protective guarding of the joints that may cause a more limited mandibular range of motion and pain. Inflammatory mediators within the injured joint may perpetuate pain and dysfunction. Central pain mechanisms may be initiated, resulting in pain referral patterns extending beyond the temporomandibular joints.[18] Synovial fluid may be diminished in quality and/or quantity; this compromises nutrition of the articular surfaces and diminishes protection and lubrication of the joints. Although the quality of synovial fluid within an inflamed joint may be poor, a tendency for excessive synovial fluid formation may result in increased intracapsular pressure, which may lead to further dysfunction and pain.

Evaluation

Regardless of the cause, pain, dysfunctional movements, and sounds during function characterize a TMD. Although trauma may have been the precipitating event leading to the onset of the patient's complaints, other contributing factors may result in lengthier and less productive treatment, if they are not recognized and eliminated. Therefore, the first goal in implementing a well-defined management program is to identify contributing factors. This involves addressing physical, emotional, and psychological factors.

History

A comprehensive evaluation must include a detailed history that reviews the following:

- Chief complaint
- History of the present illness
- Chronology of onset
- Description of any trauma
- Patient's medical and dental histories
- Prior history of joint dysfunction
- Has this individual ever been treated for a similar problem?
- What were the results of that treatment?
- Are any comorbid systemic disorders present?
- Findings of the clinical examination include the following:
  - Evaluation of the muscles of mastication and the supporting muscles of the neck and shoulders
  - Conditions found within the oral cavity that might be contributing to the patient's pain complaints (i.e., an evaluation of the soft tissues, periodontium, and teeth)
  - Myofunctional and/or parafunctional habits
  - Mandibular range of motion measurements
  - Auscultation of the temporomandibular joints during movement
  - Radiologic findings

Diagnostic Imaging

Temporomandibular disorders often involve displacement or dislocation of the interarticular disc and arthritic changes in the bony components of the joint. These alterations from normal anatomy and function may result from various causes, including trauma, degenerative joint processes, developmental anomalies, and neoplasm. It is acceptable to include some form of diagnostic imaging in a temporomandibular joint evaluation to facilitate diagnosis. Various methods of radiologic imaging are available.

Hard Tissue Imaging

The most readily available diagnostic radiograph used in the dental office is the panoramic radiograph. This type of study often is all that is necessary to identify fractures, gross arthritic changes, or hard tissue abnormalities, such as tumors, bone cysts, or malformations (Figures 36-15 and 36-16).

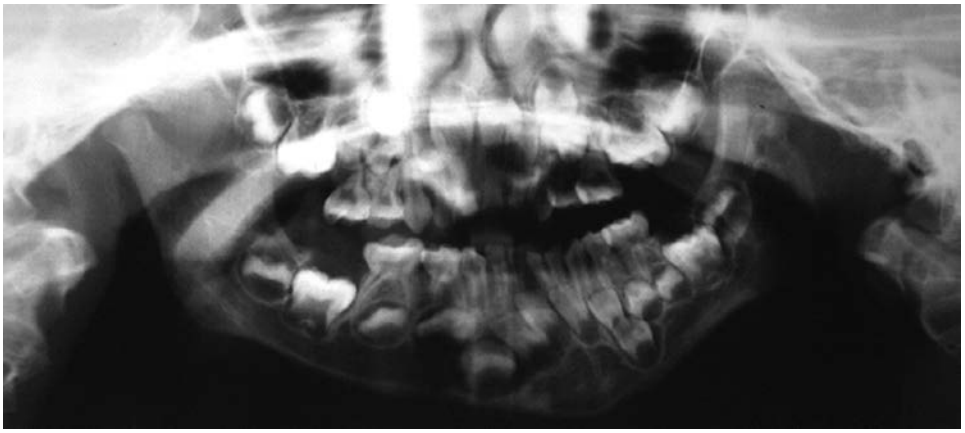

• **Figure 36-16** Condylar aplasia in a 9-year-old child seen on panoramic radiograph.

An alternative radiographic study, which is also easily performed in a dental office, is the transcranial view. This study, which uses standard dental x-ray equipment, normally includes views of each condyle in the open, closed, and rest positions. Transcranial radiographs provide information concerning the contours of bony elements. Transcranial radiographs often are inappropriately used to determine condylar position in the fossa—a determination that is not possible with this type of study. As with the panoramic radiograph, transcranial radiographs may be useful in ruling out gross arthritic changes, as well as fractures. Although greater detail is offered on transcranial radiographs, the information provided is similar to that seen on the panoramic radiograph (Figure 36-17).

Tomography offers an evaluation of the osseous structures (Figure 36-18). It is a more accurate study in that it can focus on planes ("cuts") that are only several millimeters thick. This ability enables a tomographic study to evaluate a temporomandibular joint similarly to a loaf of bread, that is, to evaluate one slice at a time. Greater detail of the articular surfaces is rendered. More accurate information regarding condylar displacement and arthritic changes also may be attained.

Cone-beam computed tomography (CBCT) provides superior reliability and greater accuracy than standard tomography and TMJ panoramic projections in the detection of condylar cortical erosion.[19] Although earlier studies reported that CBCT had not been shown to offer significant differences in diagnostic accuracy from that available with conventional tomograms,[20] enhanced osseous detail is obtained with the use of three-dimensional CT (Figure 36-19). In a study comparing imaging from patients diagnosed with osteoarthritis or closed lock of the TMJ to records of non-TMD patients, there were significant correlations between CBCT findings and a clinical diagnosis of TMD.[21]

Soft Tissue Imaging

Although transcranial, tomographic, and cone-beam studies are acceptable for evaluating hard tissues of the temporomandibular joints, they do not demonstrate the

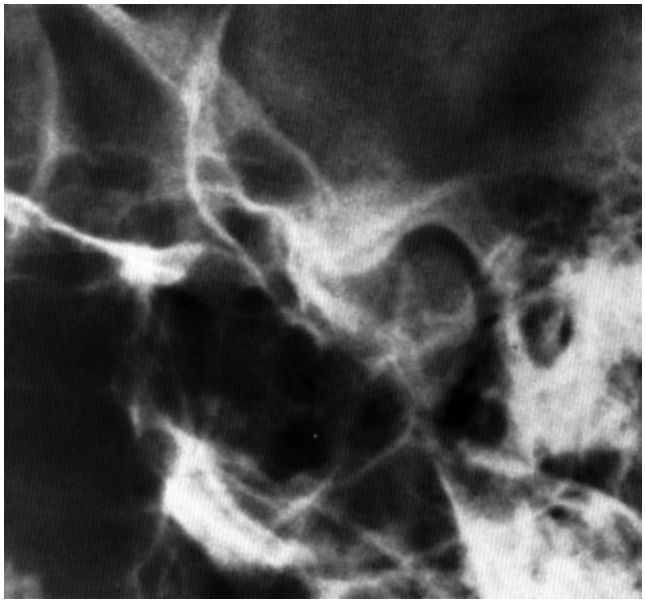

• **Figure 36-17** Transcranial view of the temporomandibular joint, demonstrating normal bony configuration.

interarticular disc. Various imaging techniques may be used to determine the position of the disc. Arthrography is an excellent method of imaging disc position. This test has been replaced by MRI and is now rarely used, but is of historic value. It is performed by injecting a small amount of radiopaque material into the inferior and/or superior joint compartment. The radiopaque solution outlines the disc (Figure 36-20). This procedure, which may be combined with video fluoroscopy, provides a great deal of information. Difficulties associated with this type of radiographic study include the following: (1) It is often painful for the patient, (2) it requires a great degree of expertise on the part of the radiologist, and (3) it exposes the patient to a significant amount of radiation.

Noninvasive imaging studies include CT scan and MRI. Computed axial tomography has the capacity to image not only the hard, bony tissues but soft tissues as well. Through computer analysis of the x-ray signal, soft tissues

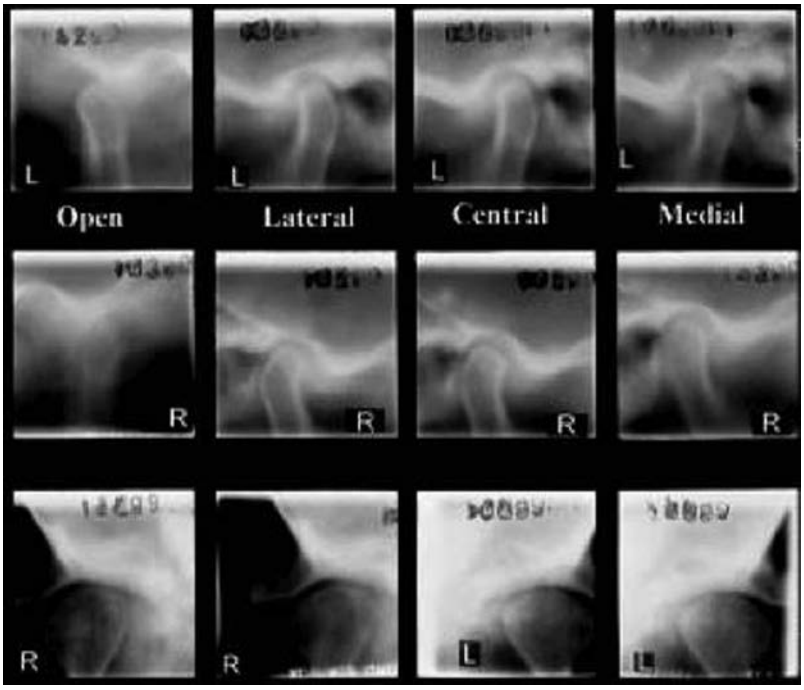

• **Figure 36-18** Tomographic study of a normal temporomandibular joint. Assessment of bony architecture and condyle/fossa relationship is possible on tomographic cuts. Lateral, central, and medial refer to the depth of the cut in each example.

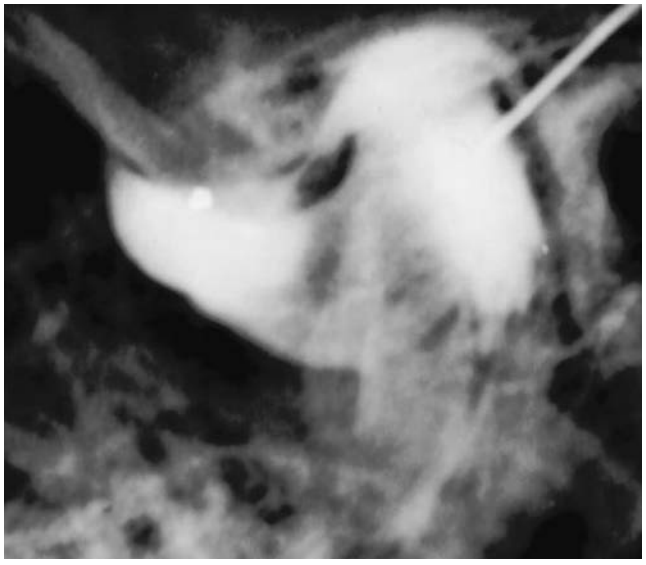

• **Figure 36-19** Radiopaque material injected into the inferior joint space permeates into the superior joint space during an arthrography demonstrating discal perforation.

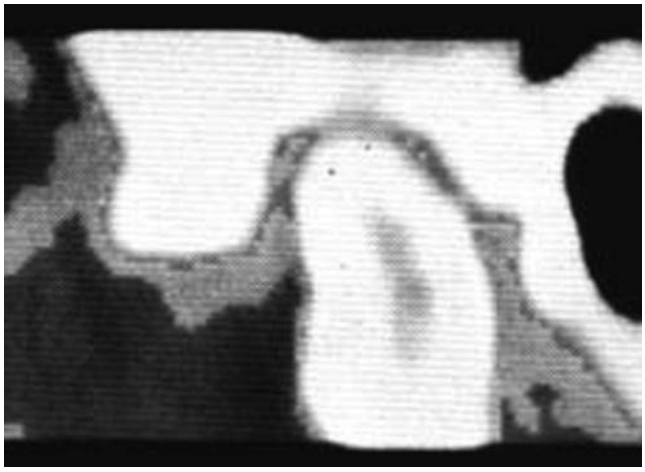

• **Figure 36-20** Computed axial tomography shows anterior disc displacement.

such as the temporomandibular joint disc can be visualized (Figure 36-21). This procedure has proved fairly accurate in its depiction of discal position, although the image often lacks detail. On the negative side is the fact that with this test, as with arthrography, the patient is exposed to substantial radiation.

MRI represents the current gold standard for soft tissue diagnostic imaging technology. It does not use radiation; the image is produced through computer analysis of signals emitted by the oscillation of molecules of water contained within bodily tissues. These signals are produced by placing the patient into a strong magnetic field. MRI is quite effective. The detail of soft tissues revealed by an MRI study is often quite remarkable. Not only can MRI allow visualization of the TMJ interarticular disc, often in more detail than former studies, it also can reveal scar tissue and inflammation (Figure 36-22). In addition, the muscles of mastication can be imaged. No side effects or radiation are associated with MRI. The study is noninvasive and provides a maximum amount of information with the smallest risk.[22-24] The patient experiences no discomfort. A drawback is the cost of this study. Also,

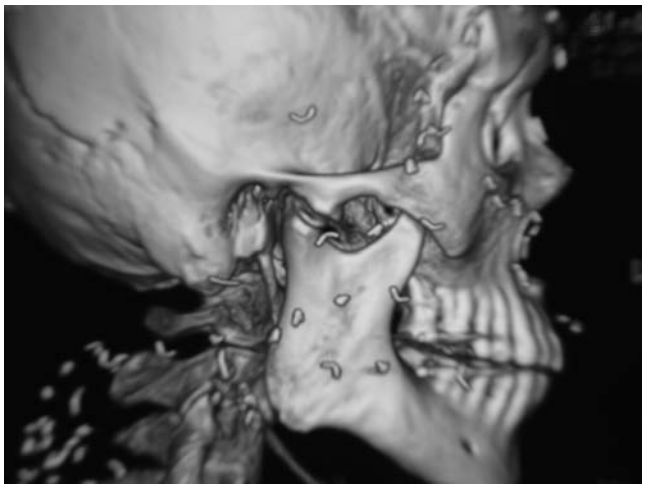

• **Figure 36-21** Three-dimensional computed axial tomography shows degenerative changes in the right condyle and fossa.

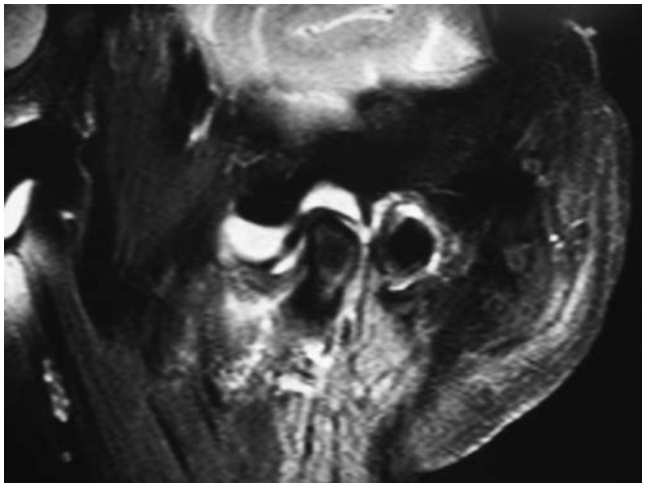

• **Figure 36-22** Nonreducing anterior disc displacement seen on T2-weighted magnetic resonance imaging during condylar translation. Note effusion in upper and lower joint spaces.

patients with claustrophobia may have difficulty with the MRI technique, but this has been overcome by the innovation of open MRI.

In cases in which it is necessary to determine the position of a suspected displaced disc, or when confirmation of intracapsular adhesions is necessary, CT or MRI studies may be considered appropriate. Conversely, these imaging studies should not be done routinely for every patient or as initial diagnostic tests. Although panoramic radiographs, transcranial studies, or tomographic images may be considered acceptable initial diagnostic tests, the use of more sophisticated imaging studies should be restricted to those cases for which they are indicated.

Adjunctive Diagnostic Testing

Numerous diagnostic aids may be employed in the evaluation of a TMD. These include movement and sound recording devices, as well as those that monitor muscle activity. Because the diagnosis of a TMD is best made via a meticulous history and clinical evaluation, the use of adjunctive testing devices is not discussed here. Suffice it to say that any adjunctive testing should be secondary to a well-taken history and thorough clinical examination. Adjunctive tests should be used judiciously, and the type of adjunctive diagnostic testing employed should be individualized for the specific patient's need. Consideration of their use depends on the potential for adding significant information to determine a diagnosis or formulate a treatment plan, as well as the cost effectiveness of the test.

• Box 36-1 A Screening Questionnaire for Temporomandibular Disorders

Do you have difficulty, pain, or both when opening your mouth, for instance, when yawning?	Yes ☐ No ☐
Does your jaw "get stuck," "lock," or "go out"?	Yes ☐ No ☐
Do you have difficulty, pain, or both when chewing, talking, or using your jaws?	Yes ☐ No ☐
Are you aware of noises in the jaw joints?	Yes ☐ No ☐
Do your jaws regularly feel stiff, tight, or tired?	Yes ☐ No ☐
Do you have pain in or about the ears, temples, or cheeks?	Yes ☐ No ☐
Do you have frequent headaches, neck aches, or toothaches?	Yes ☐ No ☐
Have you had a recent injury to your head, neck, or jaw?	Yes ☐ No ☐
Have you been aware of any recent changes in your bite?	Yes ☐ No ☐
Have you been previously treated for unexplained facial pain or a jaw joint problem?	Yes ☐ No ☐

From de Leeuw JR, Klasser G, editors: *Orofacial pain: guidelines for assessment, diagnosis and management*, Chicago, 2013, Quintessence.

Assessment of Orofacial Pain Disorders

Because musculoskeletal disorders are the most common sources of orofacial pain, all patients should be screened for TMD and other orofacial pain disorders during a general dental examination. A brief review of the history and use of a screening questionnaire and examination may lead to the diagnosis of a variety of musculoskeletal disorders. The need for a comprehensive history and clinical examination will depend on positive findings and their clinical significance. One option for a screening questionnaire is shown in Box 36-1, and a second option for screening is shown in Box 36-2. Any single positive finding may be enough to prompt a comprehensive examination.

• Box 36-2 TMD—Pain Screener

1. In the last 30 days, how long did any pain last in your jaw or temple area on either side?
   a. No pain
   b. Pain comes and goes
   c. Pain is always present
2. In the last 30 days, have you had pain or stiffness in your jaw on awakening?
   a. No
   b. Yes
3. In the last 30 days, did the following activities change any pain (that is, make it better or make it worse) in your jaw or temple area on either side?
   A. Chewing hard or tough food
      a. No
      b. Yes
   B. Opening your mouth or moving your jaw forward or to the side
      a. No
      b. Yes
   C. Jaw habits such as holding teeth together, clenching, grinding, or chewing gum
      a. No
      b. Yes
   D. Other jaw activities such as talking, kissing, or yawning
      a. No
      b. Yes

Copyright Gonzalez YM. Available online at http://www.rdc-tmdinternational.org/LinkClick.aspx?fileticket=GhbRF6tczN4%3d&tabid=1210&portalid=18&mid=2911

• Box 36-3 Recommended Screening Examination Procedures for Temporomandibular Disorder

- Measure range of motion of the mandible on opening, right, and left lateral movement. (Note any uncoordinated movements.)
- Palpate for preauricular temporomandibular joint (TMJ) tenderness.
- Auscultate and/or palpate for TMJ sounds (i.e., clicking or crepitus).
- Palpate for tenderness in the masseter and temporalis muscles.
- Note excessive occlusal wear, excessive tooth mobility, buccal mucosal ridging, or lateral tongue scalloping.
- Inspect symmetry and alignment of the face, jaws, and dental arches.

From de Leeuw JR, Klasser G, editors: *Orofacial pain: guidelines for assessment, diagnosis and management*, Chicago, 2013, Quintessence, p 26.

The screening examination should include the information in Box 36-3.

TMJ Evaluation

Minimal requirements for the examination of the TMJ include the following:

- Measurement of mandibular range of motion
- Evaluation of mandibular gait
- Auscultation
- Palpation

A description of these examination techniques follows; however, there is a tendency to focus on symptoms and chief complaints, passing over often important steps in the examination and diagnostic process. This can only be avoided by following an examination outline in order to ensure that all etiologic possibilities are assessed. Inconsistent data reporting has been mentioned as problematic when attempting to review the literature. The same may hold true for the examination; inconsistent evaluation of patients may be problematic for attempting to arrive at a diagnosis. Carefully following examination instruments such as the DC/TMD may play an important role in a systematic documentation of symptoms and clinical findings as well as a means by which to monitor a patient's progress.

Clinical observation and the use of a millimeter ruler is the most common method for assessing the mandibular range of motion and gait. Stethoscopic auscultation is the most common technique for detecting joint sounds, although more sophisticated "listening" devices are available.

Range of Motion

As previously noted, the normal mandibular range of motion is generally accepted as 40 to 55 mm,[25-27] but this varies extensively with stature, gender, craniofacial form, and other factors.[28,29] A limited mandibular range of motion, or hypomobility, can result from intracapsular or extracapsular disorders. Intracapsular disorders may include internal derangements (e.g., disc displacement with and without reduction, calcified bodies within the joint space), fibrosis, fracture, ankylosis, and tumor. Extracapsular disorders that limit range of motion include muscle dysfunction, especially dysfunction of muscles involved in mandibular elevation, hypertrophy of the coronoid processes, fractures, and capsular scarring.

Hypermobility with translation of the mandibular condyle beyond the articular eminence may or may not represent a clinical disturbance. Radiographic correlation for clinically evident hypermobility or hypomobility is helpful and is assessed by the relationship of the translated condyle to the crest of the articular eminence.

Mandibular range of motion is the measurement of vertical and sagittal opening and lateral movements of the mandible. Three vertical opening measurements are suggested: (1) maximum comfortable opening, (2) full, unassisted opening, and (3) assisted opening.[30] Several techniques and aids for assessing mandibular range of motion are available, ranging from a millimeter ruler to elaborate electrodiagnostic measuring systems.

Maximum comfortable opening is assessed by asking the patient to open the mouth within a comfortable range. The distance between the maxillary and mandibular incisors, that is, the interincisal distance, is measured.[22] Adding overlap to the measurement is suggested. In the edentulous patient, measurement from the crest

of the alveolar ridge is suggested, noting the absence of dentition.

A full, unassisted range of motion is attained by asking the patient to open the mouth as widely as possible regardless of pain. This is called the active range of motion (AROM).

Assisted opening is assessed by asking the patient to open as widely as possible. The clinician then applies gentle, steady force to determine whether further opening is possible. This measurement, also referred to as passive range of motion (PROM), demonstrates the joint "end feel." To test end feel, light force is applied in an attempt to depress the mandible. If additional opening is possible, the joint end feel is classified as "soft." If, however, the sensation perceived by the clinician is firm and no further mandibular depression is possible, the joint "end feel" is classified as "hard." Although the joint end-feel might be noted, this test has poor reliability and is difficult to interpret.[23,24]

The location of pain provoked when AROM and PROM are tested should be noted. Although this is a reliable sign,[25] the patient's perception of reduced movement, or change in movement, may be more useful than actual measurements.[26]

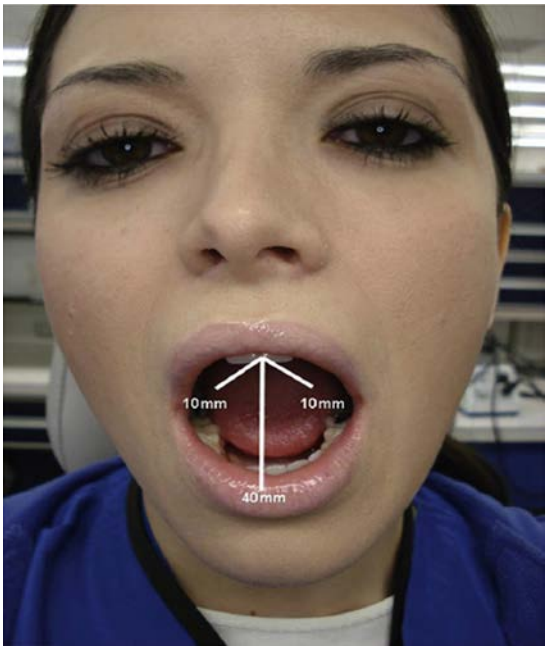

• **Figure 36-23** The normal opening-to-lateral movement ratio is typically 4:1. Opening should be smooth, pain free, and coordinated, and with an absence of joint sounds.

Gait

Gait is the pattern, direction, and quality of mandibular movements. Abnormal mandibular gait arises from intracapsular and extracapsular disorders. The presence and time of occurrence (early, middle, or late opening and/or closing) of clicking, crepitus, or interference with jaw movement should be documented.[27] Normal opening should be smooth, coordinated, sound and pain free (Figure 36-23). Abnormal or uncoordinated movements are easily observed clinically (Figure 36-24).

Assessment of the opening gait can aid in determining the status of temporomandibular joint biomechanics. The following section is adapted from *A Clinical Outline of Temporomandibular Joint Diagnosis and Treatment,* by William Farrar, DDS, and William L. McCarty Jr., DMD, of the Normandie Study Group for TMJ Dysfunction (Normandie Press, 1982). Although somewhat dated, the observations of Drs. Farrar and McCarty are still relevant.

When the opening-to-lateral movement ratio is observed, 4:1 is considered within normal limits. This would indicate

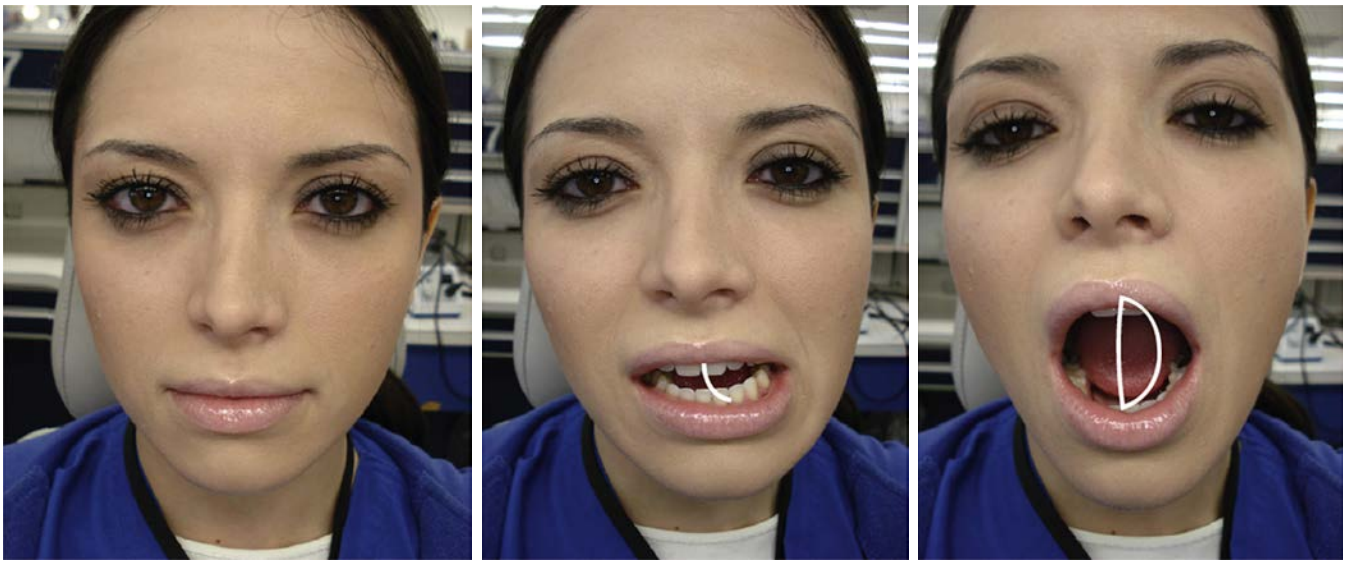

• **Figure 36-24** Example of deflection of mandibular movement during opening. The mandible deflects to the left, consistent with a left disc interference disorder, preventing normal condylar translation. After reduction of the disc, the condyle is free to translate, and the mandible returns to the midline.

that an opening of 40 mm should be accompanied by lateral movements of 10 mm (Figure 36-25).

Disc interference disorders often result in a deflection to the affected side during movement with a return to the midline if the disc reduces to a normal or noninterfering position during translation (Figure 36-26). After reduction (the opening click), lateral movements are normal, that is, the 4:1 ratio. The diagram represents disc displacement with reduction of the right TMJ and normal opening that follows a click or disc reduction at approximately 10 mm of opening.

Disc dislocation without reduction that impairs normal translation will result in a lack of lateral movement away from the affected side and a deviation toward the locked joint. Figure 36-27 represents an anterior disc displacement of the left joint that prevents normal translation of that side. Lateral movement away from the locked joint is not possible, and during opening, the mandible deviates toward the locked joint. Note that the sagittal opening is limited to approximately half of the normal opening range, consistent with rotational (hinge) movement only.

As a disc dislocation becomes more chronic, the opening-to-lateral movement ratio may increase. The opening range may even approach normal, but a deviated opening may still be observed (Figure 36-28).

As a chronic lock enters later stages, the mandibular range of motion may once again approach normal, reassuming the 4:1 opening-to-lateral movement ratio. At this point, the joint or joints may have gone through various adaptive changes, which may be demonstrated on soft tissue imaging.

A subluxation occurs when the mandibular condyle translates beyond the crest of the articular eminence. This is considered a hypermobility disorder and may be associated with joint sounds similar to those of a disc interference disorder. As shown in Figures 36-29 and 36-30, this is characterized by unilateral or bilateral deflection of mandibular movement at the end of the opening range.

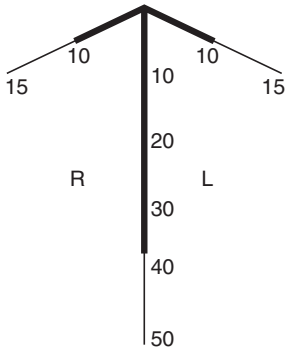

• **Figure 36-25** Normal opening-to-lateral excursion ratio. In this illustration, 40 mm of opening and bilateral movement of 10 mm, or a 4:1 ratio, is considered normal. The opening range and lateral movements may vary with the patient's stature, but the 4:1 ratio should remain.

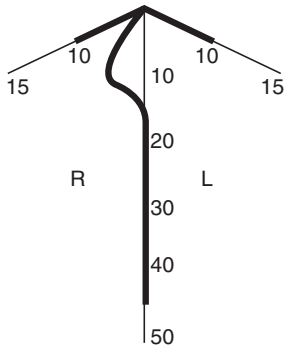

• **Figure 36-26** Early disc interference. The opening gait in this case demonstrates a sharp, early deflection to the right, followed by a return to midline. Opening beyond that point is seen along the midline. The opening-to-lateral movement ratio is normal, but the deflection with return to midline at the same moment as a click of the right temporomandibular joint is consistent with anterior disc displacement with reduction.

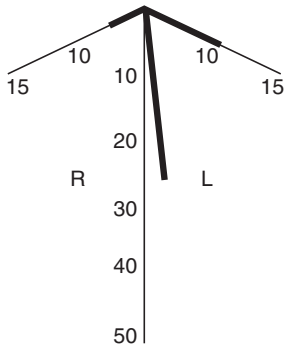

• **Figure 36-27** Nonreducing disc displacement. This illustration maps jaw movement that is limited in opening to approximately 25 mm. The mandible deflects to the left at maximum opening. Lateral movement to the left is normal at 10 mm but is limited to 3 to 5 mm to the right. This is consistent with a nonreducing disc displacement of the left temporomandibular joint. The opening is limited by the nonreducing disc, which causes the mandible to deflect to the affected side. Lateral movement is possible to the side of disc displacement but is limited to the opposite right side because of limited left condylar translation, which prevents movement away from the disc displacement.

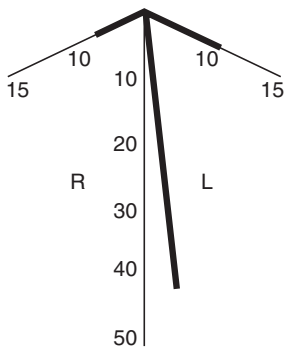

• **Figure 36-28** Chronic anterior disc displacement. If the condition of acute, nonreducing anterior disc displacement seen in Figure 36-27 persists, it may enter a phase of chronic anterior disc displacement without reduction. As the retrodiscal tissues and capsular and collateral ligaments become permanently stretched and the interarticular disc becomes deformed, mandibular range of motion may return to a normal opening-to-lateral excursion ratio. Disc interferences, deviations, and deflections of movement and joint sounds consistent with possible degenerative joint changes may be evident.

A patient with limited opening and normal lateral movements likely will have an extracapsular source of limited mandibular opening such as muscle dysfunction. In Figure 36-31, the mandibular range of motion demonstrates normal lateral movements and a limited opening with deflection to the left, possibly consistent with left masticatory muscle dysfunction.

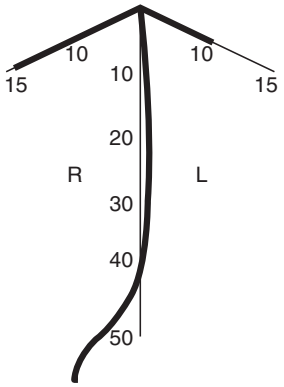

• **Figure 36-29** Unilateral subluxation of the left condyle.

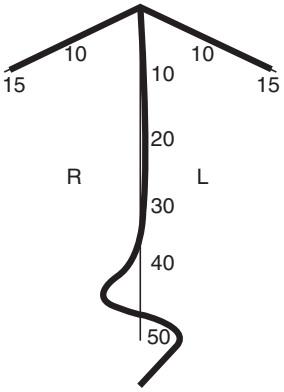

• **Figure 36-30** Bilateral subluxation, first left, then right.

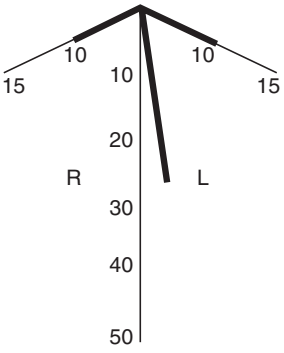

• **Figure 36-31** Muscular restriction of mandibular movement. Another cause of limited mandibular opening is illustrated in this diagram. Lateral movements are normal, but mandibular opening is limited. This opening-to-lateral excursion ratio is 2.5:1, consistent with contracture of jaw elevator muscles. Normal bilateral translation is possible and disc displacement therefore is not likely. Sagittal opening is restricted by mandibular elevator muscle dysfunction.

Auscultation

Intra-articular joint sounds may result from mandibular movement. Joint sounds may be signs of intracapsular pathology such as internal derangement, degenerative processes, or architectural defects of articulating surfaces.



• **Figure 36-32** In the closed mouth position, the condyle is illustrated within the central portion of the temporomandibular joint fossa, behind the posterior slope of the articular eminence. Space for the interarticular disc and retrodiscal tissues is adequate.

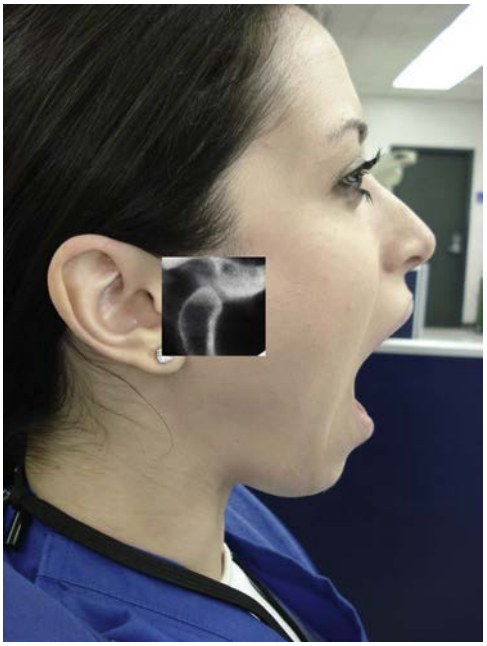

• **Figure 36-33** During normal mandibular depression or jaw opening, the condyle rotates on the inferior surface of the interarticular disc. The disc-condyle complex translates forward along the articular eminence. This movement takes place between the posterior slope of the articular eminence and the superior surface of the disc. This illustration shows normal opening with the crest of the condyle approaching the lowest point of the articular eminence.

Sounds may correlate with pain or pathologic function or may be due to functional adaptations not associated with pain or dysfunction. Joint sounds are common among the general population and must be evaluated within the context of other presenting signs and symptoms.[31] Nonpainful joint sounds not associated with impairment of mandibular function do not require treatment.

Auscultation of the temporomandibular joints should discern the presence and timing of early, middle, or late opening and/or closing, clicking, and crepitus, as well as their correlation with interference with jaw movement. Joints sounds, that is, clicking, crunching, grinding, or grating noises classified as crepitus, have not been validated as consistent with clinical findings.[2]

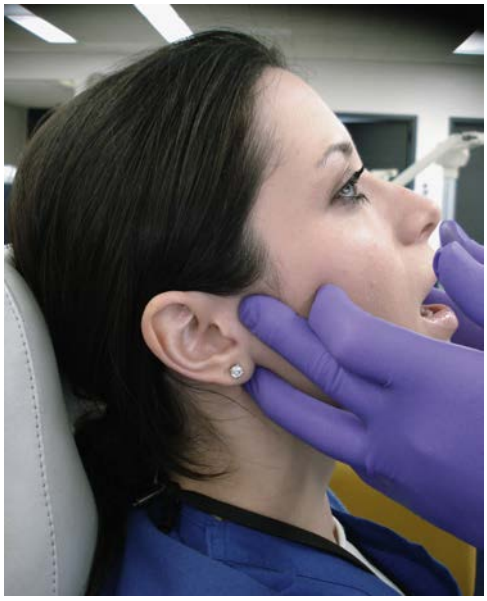

• **Figure 36-34** With the mouth partially open (early translation), palpate the lateral pole to assess capsular tenderness.

Palpation

The temporomandibular joints are palpated bilaterally so that patterns of condylar movement, tenderness, pain, and swelling can be perceived. Temporomandibular joints may be palpated for assessment of tenderness consistent with inflammation of the joint capsule and retrodiscal tissue. Although the predictive value of joint palpation is low in asymptomatic populations,[32,33] positive findings may have clinical significance in symptomatic patients.[34]

During a palpatory examination, movement patterns, tenderness, pain, and swelling are evaluated. The temporomandibular joints should be assessed by direct, gentle palpation of the lateral pole of the condyle (preauricular), as well as the posterior aspect of the condyle in the region of the posterior attachment or retrodiscal tissue (Figures 36-32 through 36-34). Intrameatal palpation achieved by placing the fingers in the external auditory canals and pressing forward during mandibular function may produce artifactual jaw movement and discomfort. The recommended technique has the patient with the mandible in a mild protrusive position and the tip of the index finger gently positioned in the depression formed posterior to the translated condyle. Mild pressure in a forward direction will allow palpation of the posterior-lateral aspect of the condyle and the lateral portion of the retrodiscal tissue (Figure 36-35).

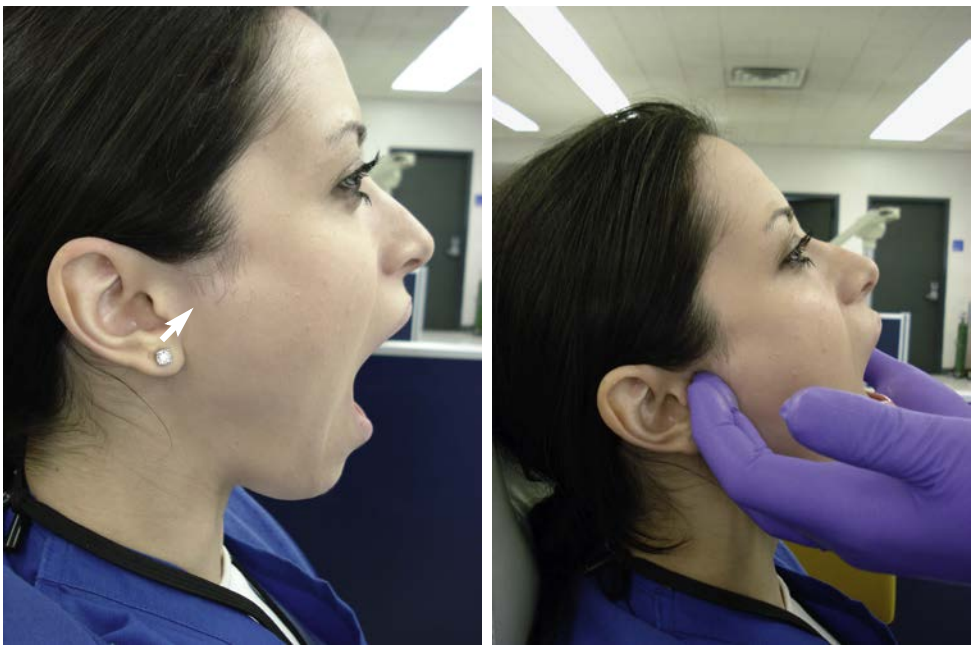

• **Figure 36-35** Full opening (maximum condylar translation) results in the formation of a depression posterior to the translating condyle *(arrow)*. Digital pressure in an anterior direction can be used to assess for posterior capsular pain.

Muscle Evaluation

Local myalgia, myositis, myospasm, muscle contracture, and myofascial pain are conditions that affect all muscles in the body, including the masticatory muscles. These structures must be evaluated for sources of mandibular pain and dysfunction.

The muscles of mastication are palpated bilaterally so that equality of size and firmness can be determined; however, tenderness to palpation is the most important information derived from palpation. The temporalis, deep and superficial masseter, medial pterygoid, and suprahyoid muscles should be examined. Palpation of the lateral pterygoid muscle is difficult in that this muscle is difficult to approach intraorally.[35,36] Evaluation of the lateral pterygoid may be accomplished by functional manipulation and by challenging the muscle to contract against resistance.[37] Myalgia may be exacerbated during this maneuver.

Pressure algometry has been shown to provide reliable measures of muscle and TMJ tenderness[37-39] but is not often used in a clinical setting. Calibration training for finger pressure and site location also can produce reliable data. Palpation pressure for women should be less than that for men[38] and should be adjusted for stature.

Needle electrode electromyography detects abnormal muscle unit firing as in neuromuscular diseases, and it is used to assess innervation of a muscle or groups of muscles.[39,40]

An organized approach to a clinical evaluation is recommended. A suggested data collection form for orofacial pain and temporomandibular disorder evaluation is provided in Box 36-4.

Table 36-2 summarizes this text and offers a guide to the most common temporomandibular disorders.

A summary of various stages of disc interference disorders is presented in Figure 36-36.

• Box 36-4 Orofacial Pain and Temporomandibular Disorder Evaluation Form

Patient's Name _____ Date of Examination _____
Review of chief complaints:
1. _____
_____
2. _____
_____
3. _____
_____
Date of onset of symptoms: _____
Chronology of pain onset: _____
Pain location: _____
Pain duration: _____
Pain frequency: _____
Pain quality: _____
Exacerbating factors: _____
Ameliorating factors: _____
Comments:

Facial symmetry: Yes _____ No _____
Comments:

Facial type [by appearance of soft tissues only]:
Class I _____ II _____ III _____
Normal _____ Short _____ Long _____
Ramus height: Equal _____ Unequal _____ (by gross observation)
Note discrepancy in mm: _____
Deviant swallow: Yes _____ No _____
Tongue position and appearance: _____
Parafunctional habits:

_____ Bruxism	_____ Tongue position	Other_____
_____ Clenching	_____ Nail biting	_____
_____ Lip biting	_____ Telephone	_____
_____ Tongue thrust	_____ VDT	_____

Presenting occlusion:
Static occlusion: Normal ___ Malocclusion ___
Mutilated ___ Functional ____
Anterior attrition: None _____ Slight _____ Moderate _____
Severe _____
Posterior facets: None _____ Slight _____ Moderate _____
Severe _____
Freeway space: Within normal limits _____ Minimal _____
Anterior _____ mm; Posterior _____ mm
Loss of vertical dimension: Yes _____ No _____
Anterior _____ Posterior _____
Excessive incisal guidance: Yes _____ No _____
Anterior horizontal overlap: _____%
Anterior vertical overjet: _____ mm
Anterior open bite: Yes _____ No _____
Posterior open bite: Yes _____ No _____ Left _____ Right _____
Anterior cross-bite: Yes _____ No _____
Posterior cross-bite: Yes _____ No _____ Left _____ Right _____
Curve of Spee: Norm ____ Flat _____ Steep _____ Inverted _____
Palatal form: Flat _____ Moderate _____ High _____
Dental midline discrepancy in habitual centric occlusion:
____ Right ____ Left ____ mm
Orthodontic classification:

	R	L
Class I:	_____	_____
Class II—Div 1:	_____	_____
Class II—Div 2:	_____	_____
Class III:	_____	_____

Missing, mobile, or broken down teeth (source of odontogenic pain):
BD = broken down; 1, 2, 3 = mobility; X = missing; N = not replaced; T = tilted; E = extruded; P = possible pain source.

1	2	3	4	4	6	7	8	9	10	11	12	13	14	15	16
32	31	30	29	28	27	26	25	24	23	22	21	20	19	18	17

Periodontal status: Excellent _____ Good _____ Fair _____ Poor _____
Hygiene: Excellent _____ Good _____ Fair _____ Poor _____
Temporomandibular joint examination:
Pain upon palpation extrameatally
Lateral pole: _____ Right _____ Left
Posterior capsular area: _____ Right _____ Left
Swelling: _____ Right _____ Left
Auscultation:

Right opening	Right closing	Left opening	Left closing

• Box 36-4 Orofacial Pain and Temporomandibular Disorder Evaluation Form—cont'd

Rubbing	_____	_____	_____	_____
Clicking	_____ mm	_____ mm	_____ mm	_____ mm
Grating	_____	_____	_____	_____

Functional Analysis

Pattern of mandibular movement:

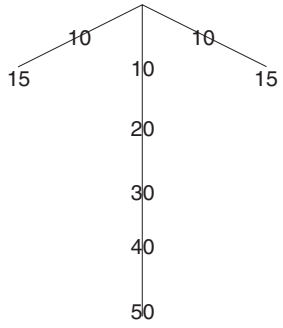

Widest interincisal opening, including overbite, _____ mm

Deflection at maximum opening:
Left _____ Right _____ _____ mm

Protrusive: _____ mm
Protrusive deviation: Right _____ Left _____ _____ mm

Note pain during mandibular movements with P opening and closing at the point at which it occurs, gait in mm _____

Muscle Evaluation of Head, Neck, and Upper Quarter

0 = no response; 1 = report of discomfort; 2 = facial movement such as palpebral reflex along with a report of pain; 3 = retreat of head in anticipation of palpation along with a report of considerable pain on contact. Note referral patterns under remarks. Note trigger points as "TP" under remarks.

TENDERNESS TO PALPATION										REMARKS
Temporalis										
Anterior	Right	0	1	2	3	Left	0	1	2	3
Middle	Right	0	1	2	3	Left	0	1	2	3
Posterior	Right	0	1	2	3	Left	0	1	2	3
Masseter										
Superficial	Right	0	1	2	3	Left	0	1	2	3
Deep	Right	0	1	2	3	Left	0	1	2	3
Coronoid process	Right	0	1	2	3	Left	0	1	2	3
Lateral pterygoid	Right	0	1	2	3	Left	0	1	2	3
Medial pterygoid	Right	0	1	2	3	Left	0	1	2	3
Digastric anterior belly	Right	0	1	2	3	Left	0	1	2	3
Suprahyoids	Right	0	1	2	3	Left	0	1	2	3
Infrahyoids	Right	0	1	2	3	Left	0	1	2	3
Sternocleidomastoid										
Superior	Right	0	1	2	3	Left	0	1	2	3
Body	Right	0	1	2	3	Left	0	1	2	3
Sternal head	Right	0	1	2	3	Left	0	1	2	3
Clavicular head	Right	0	1	2	3	Left	0	1	2	3
Mastoid process	Right	0	1	2	3	Left	0	1	2	3
Scalene										
Anterior	Right	0	1	2	3	Left	0	1	2	3
Middle	Right	0	1	2	3	Left	0	1	2	3
Trapezius										
Neck	Right	0	1	2	3	Left	0	1	2	3
Shoulders	Right	0	1	2	3	Left	0	1	2	3
Splenius/ Rectus capitis	Right	0	1	2	3	Left	0	1	2	3
Levator scapulae	Right	0	1	2	3	Left	0	1	2	3

Diagnostic Tests

- Stretch and spray
- Manipulation
- Diagnostic analgesic block
- Reposition (wax bite)
- Muscle provocation
  - Opening resistance
  - Closing resistance
  - Protruding against resistance
  - Clenching on teeth
  - Clenching on tongue blade
  - Loading of joint via manipulation
  - Cervical manipulation, compression, or traction

Radiographic Findings

Type of film reviewed:
panoramic radiograph _____ transcranial _____ tomography _____ MRI _____ other _____
Within normal limits: _____
Loss of joint space: _____ Right _____ Left
How determined: _____
Condylar displacement:
Right: _____ Superior _____ Posterior _____ Anterior
Left: _____ Superior _____ Posterior _____ Anterior
How determined: _____
Degenerative changes:
Other:

Recommendation for Additional Studies:

Diagnosis:

Treatment Plan:

Referral to Other Medical Specialties:

TABLE 36-2 A Simplified Summary for a Diagnostic Approach to Temporomandibular Disorders

Differential Diagnosis	Diagnostic Tests
Congenital or Developmental Disorders	
• Aplasia • Hypoplasia • Hyperplasia • Acquired disorders • Neoplasia	Imaging • Panoramic radiograph • Transcranial • Tomographic
Disc Derangement Disorders	
• Disc displacement with reduction • Disc displacement without reduction • F0B7 Temporomandibular joint dislocation	Physical examination • Range-of-motion studies • Gait of movement • Auscultation • Imaging • Magnetic resonance imaging (MRI)—T1
Inflammatory Disorders	
• Capsulitis/Synovitis • Polyarthritides	History • Trauma • Systemic illness • Physical examination • Joint palpation • Gait of movement • Alteration of occlusion due to retrodiscal swelling • Imaging • MRI—T1 and T2 • Serology • Erythrocyte sedimentation rate (ESR) • C-reactive protein
Polyarthritides	History • Systemic illness • Physical examination • Joint palpation • Gait of movement • Alteration of occlusion due to retrodiscal swelling • Imaging • MRI—T1/T2 • Serology • ESR • C-reactive protein • Rheumatoid panel
Osteoarthritis (Noninflammatory Disorders)	
• Osteoarthritis: primary • Osteoarthritis: secondary • Ankylosis • Fracture (condylar process)	History • Trauma • Systemic illness • Physical examination • Joint palpation • Gait of movement • Alteration of occlusion due to retrodiscal swelling • Imaging • Panoramic radiograph • Transcranial • Tomographic
Masticatory Muscle Disorders	

Myofascial pain	History
	• Regional pain
	• Muscle weakness
	• Fatigue of muscles
	• Limited active range of motion
	• Physical examination
	• Palpation
	  • Myofascial trigger points
	  • Referral patterns
	  • Positive for diagnostic anesthetic block

Myositis	History
	• Local pain
	• Trauma
	• Infection
	• Physical examination
	• Palpation
	  • Local tenderness
	  • Swelling

Myospasm	History • Muscle contraction from which the patient cannot voluntarily relax • Physical examination • Restricted range of motion • May be painful to palpation • Needle electrode electromyography (EMG)
Local myalgia—unclassified	History • Local pain • Physical examination • Palpation • Local tenderness
Myofibrotic contracture	History • Muscle contraction from which the patient cannot voluntarily relax • Physical examination • Restricted range of motion • May be painful to palpation • Needle electrode EMG
Neoplasia	Imaging • Panoramic radiograph • Transcranial • Tomographic • Computed tomography • MRI

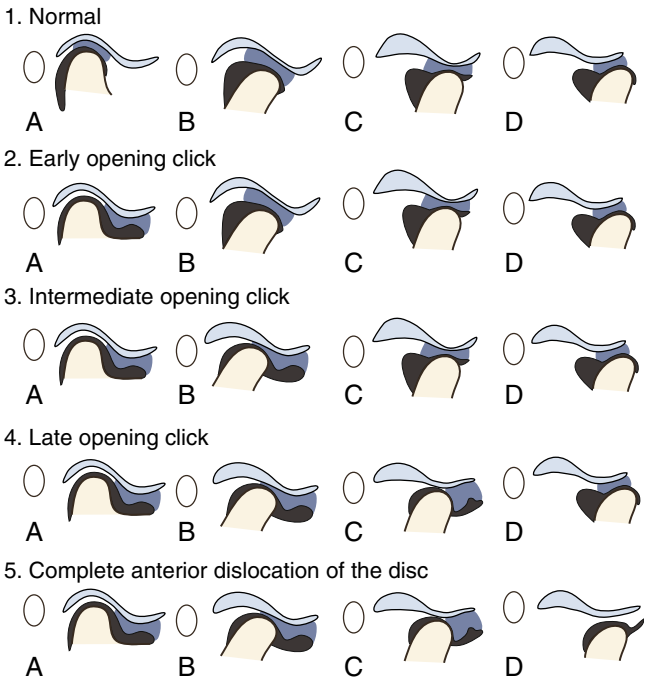

• **Figure 36-36** Diagrammatic representation of the various stages and phases of internal derangements of the temporomandibular disc and condyle. These derangements cause the common symptoms of reciprocal clicking and locking. **A,** Closed. **B,** Partial translation. **C** and **D,** Full opening. (Adapted from Farrar W, McCarty WL Jr: *A clinical outline of temporomandibular joint diagnosis and treatment*, Montgomery, AL, 1982, Normandie Press.)

Summary

Dysfunction of the temporomandibular joints and associated structures can be a source of acute and chronic orofacial pain and masticatory dysfunction. Successful treatment depends on an accurate assessment of these disorders. Therefore, the treatment plan must be based on a comprehensive evaluation and accurate diagnosis.

Disorders that may affect the TMJ are similar to those involving other synovial joints; therefore, treatment of patients with TMD should be consistent with that provided to patients with any other musculoskeletal disorder. A clear understanding of the anatomy, biomechanics, and pathologic processes that may afflict the TMJ is necessary if an acceptable course of treatment is to be determined.

An organized approach to the assessment of orofacial pain and of patients with TMD, as well as an accurate diagnosis, is essential. This chapter is intended to provide some basic tools that can be used in assessment of the patient with TMD.

Acknowledgment

Appreciation to Dr. Cibele Nasri-Heir for her invaluable assistance in the preparation of this manuscript and to Dr. Adi Ram Adini her assistance assessing the mandibular range of motion literature.

References

1. Gewandter JS, Smith SM, McKeown A, et al.: Temporomandibular disorders: details of efficacy estimates and randomized clinical trials of pain in temporomandibular disorders: analgesic, anesthetic, and addiction clinical trial translations, innovations, opportunities, and networks systematic review, *J Am Dent Assoc* 146(4):246–254, 2015.
2. Schiffman E, Ohrbach R, Truelove E, et al.: Diagnostic Criteria for Temporomandibular Disorders (DC/TMD) for clinical and research applications: recommendations of the International RDC/TMD Consortium Network and Orofacial Pain Special Interest Group, *J Oral Facial Pain Headache* 28:6–27, 2014. http://www.rdc-tmdinternational.org/Portals/18/protocol_DC-TMD/DC-TMD%20Axis%20I%20&%20Axis%20II%20Protocol%20-%202013_06_08.pdf.
3. Schiffman E, Ohrbach R, Truelove E, et al.: Diagnostic Criteria for Temporomandibular Disorders (DC/TMD) for clinical and research applications: recommendations of the International RDC/TMD Consortium Network and Orofacial Pain Special Interest Group, *J Oral Facial Pain Headache* 28:6–27, 2014.
4. de Leeuw JR, Klasser G, editors: *Orofacial pain: guidelines for assessment, diagnosis and management*, Chicago, 2013, Quintessence.
5. Lobbezoo F, Drangsholt M, Peck C, et al.: Topical review: new insights into the pathology and diagnosis of disorders of the temporomandibular joint, *J Orofac Pain* 18:181–191, 2004.
6. Manc LG, DeLuke DM: CT diagnosis of synovial chondromatosis of the temporomandibular joint, *AJR Am J Roentgenol* 148:574–576, 1987.
7. Greene CS, Laskin DM: Long-term status of TMJ clicking in patients with myofascial pain and dysfunction, *J Am Dent Assoc* 117:461–465, 1988.

8. Simons DG, Travel JG, Simons LS: *Travel & Simons' myofascial pain and dysfunction: the trigger point manual*, ed 2, Baltimore, 1999, Williams & Wilkins.
9. Salé H, Bryndahl F, Isberg A: Temporomandibular joints in asymptomatic and symptomatic nonpatient volunteers: a prospective 15-year follow-up clinical and MR imaging study, *Radiology* 267(1):183–194, 2013.
10. Obwegeser HL, et al.: Findings of mandibular movement and the position of the mandibular condyles during maximal opening, *Oral Surg Oral Med Oral Pathol Oral Radiol Endod* 63(5):517–525, 1987.
11. Sheppard IM, Sheppard SM: Range of condylar movement during mandibular opening, *J Prosthet Dent* 15(2):263, 1965.
12. Agerberg G: Maximal mandibular movements in young men and women, *Sven Tandlak Tidskr* 67(2):81–100, 1974.
13. Agerberg G, Osterberg T: maximal mandibular movements and symptoms of mandibular dysfunction in 70 year old men and women, *Sven Tandlak Tidskr* 67(3):147–163, 1974.
14. Landtwing K: Evaluation of normal range of vertical mandibular opening in children and adolescents with special reference to age and stature, *J Maxillofac Surg* 6(3):157–162, 1978.
15. Szentpétry A: Clinical utility of mandibular movement ranges, *J Orofac Pain* 7:163–168, 1993.
16. Celić R, Jerolimov V, Knezović Zlatarić D, Klaić B: Measurement of mandibular movements in patients with temporomandibular disorders and in asymptomatic subjects, *Coll Antropol* 27(Suppl 2):43–49, 2003.
17. Nitzan DW, Etsion I: Adhesive force: the underlying cause of the disc anchorage to the fossa and/or eminence in the temporomandibular joint—a new concept, *Int J Oral Maxillofac Surg* 31:94–99, 2002.
18. Lam DK, Sessle BJ, Cairns BE, Hu JW: Neural mechanisms of temporomandibular joint and masticatory muscle pain: a possible role for peripheral glutamate receptor mechanisms, *Pain Res Manag* 10:145–152, 2005.
19. Honey OB, Scarfe WC, Hilgers MJ, et al.: Accuracy of cone-beam computed tomography imaging of the temporomandibular joint: comparisons with panoramic radiology and linear tomography, *Am J Orthodont Dentofac Orthoped* 132(4):429–438, 2007.
20. Hintze H, Wiese M, Wenzel A: Cone-beam CT and conventional tomography for the detection of morphological temporomandibular joint changes, *Dentomaxillofac Rad* 36(4):192–197, 2007.
21. Talaat W, Al Bayatti S, Al Kawas S: CBCT analysis of bony changes associated with temporomandibular disorders, *Cranio* 34(2):88–94, 2016.
22. Bates B, Bickley LS, Hoekelman RA: *Physical examination and history taking*, ed 6, Philadelphia, 1995, Lippincott, pp 505–510.
23. Lobbezii-Scholte AM, De Wijer A, Steenks MHJ, et al.: Interexaminer reliability of six orthopedic tests in diagnostic subgroups for craniomandibular disorders, *J Oral Rehabil* 21:273–285, 1994.
24. McCarroll RS, Hesse JR, Naeije M, et al.: Mandibular border positions and their relationships with peripheral joint mobility, *J Oral Rehabil* 14:125–131, 1987.
25. Stegenga B, DeBont L, DeLeeuw R, et al.: Assessment of mandibular function impairment associated with temporomandibular joint osteoarthrosis and internal derangement, *J Orofac Pain* 71:195, 1993.
26. Szentpétry A: Clinical utility of mandibular movement ranges, *J Orofac Pain* 7:163–168, 1993.
27. Curl DD: The visual range of motion scale: analysis of mandibular gait in a chiropractic setting, *J Manipulative Physiol Ther* 15:115–122, 1992.
28. Tallgren A, Mizutani H, Tryde G: A two-year kinesiographic study of mandibular movement patterns in denture wearers, *J Prosthet Dent* 62:594–600, 1989.
29. Ingervall B: Variation of the range of movement of the mandible in relation to facial morphology in young adults, *Scand J Dent Res* 79:133–140, 1971.
30. John MT, Zwijnenburg AJ: Interobserver variability in assessment of signs of TMD, *Int J Prosthodont* 14:265–270, 2001.
31. Tallents R, Hatala M, Katzberg R, et al.: Temporomandibular joint sounds in asymptomatic volunteers, *J Prosthet Dent* 69:298–304, 1993.
32. Kirveskari P: Prediction of demand for treatment of temporomandibular disorders, *J Oral Rehabil* 28:572–575, 2001.
33. Brown FF, Robinson ME, Riley 3rd JL, et al.: Better palpation of pain: reliability and validity of a new pressure pain protocol in TMD, *Cranio* 18:58–65, 2000.
34. Glaros AG, Glass EG, Williams KB: Clinical examination findings of temporomandibular disorder patients: a factor analytic study, *J Orofac Pain* 12:193–202, 1998.
35. Johnstone DR, McCormick J: The feasibility of palpating the lateral pterygoid muscle, *J Prosthet Dent* 44:318, 1980.
36. Stratmann U, Mokrys K, Meyer U, et al.: Clinical anatomy and palpability of the inferior lateral pterygoid muscle, *J Prosthet Dent* 83:548–554, 2000.
37. Okeson JP: *Management of temporomandibular disorders and occlusion*, ed 3, St Louis, 1993, Mosby-Year Book, pp 245–247.
38. Chung S-C, Kim J-H, Kim H-S: Reliability and validity of the pressure pain threshold (PPT) in the TMJ capsules by electronic algometer, *J Craniomandib Pract* 11:171–177, 1993.
39. Preston DC, Shapiro BE: Needle electromyography: fundamentals, normal and abnormal patterns, *Neurol Clin* 20:361–396, 2002.
40. Mayer RF: The motor unit and electromyography—the legacy of Derek Denny-Brown, *J Neurol Sci* 189:7–11, 2001.

37

Imaging of the Temporomandibular Joint

ANITHA POTLURI, ADITYA TADINADA

The temporomandibular joint (TMJ) has a complex joint architecture comprising the mandibular condyle, temporal bone, and an articular disc. This hard and soft tissue combination has a unique joint orchestra that makes it very difficult to image. Clinical examination alone cannot provide a complete picture of the multitude of challenges associated with the joint. Imaging plays a critical role in the diagnosis, treatment planning, and outcomes assessment associated with the joint. Conventional imaging of the joint with two-dimensional (2D) imaging offers limited information regarding the joint. Advancements in image capture technology and evolution of postprocessing image algorithms are changing the way the TMJ is being imaged and evaluated. Significant developments in imaging technology and evolution of faster acquisition techniques that reduce motion artifacts have paved the way to a more holistic imaging approach. The radiation dose associated with ionizing radiation is a perennial challenge, but good clinical practice strikes a balance between dose and diagnostic-quality images. Various techniques have been described in the literature with specific indications and contraindications.[1] The evolution of lower-dose, three-dimensional (3D) imaging modalities such as cone-beam computed tomography (CBCT) and the ability to modify the acquisition protocols have brought a paradigm shift in the radiographic analyses of the osseous components of the joint.[2,3]

The scope of TMJ disorders includes myofascial pain that involves discomfort or pain in the muscles that control jaw function, internal derangement of the joint, or arthritis, which refers to a group of degenerative/inflammatory joint disorders.[4]

The logical diagnostic approach to this complex group of conditions includes clinical and radiologic correlation. A comprehensive history and clinical exam and a 2D screening exam such as a panoramic radiograph will allow for task-specific evaluation and guide the clinician in choosing the appropriate advanced imaging modality, when indicated, to further evaluate the joint complex.

This chapter provides an overview of existing imaging modalities and their indications and contraindications.

Conventional Imaging

Conventional radiography is the most common 2D imaging modality used to examine the TMJ. It serves as a cost-effective, low-dose diagnostic tool that provides an overview of the joint and is easily accessible to the practitioner. Various projections are used to view specific areas of the TMJ. The objective is to obtain nondistorted, possibly superimposition-free diagnostic radiographs with clear visibility of anatomic detail. With the ubiquitous availability of 3D imaging, the use of 2D imaging is declining, but it is important to appreciate the value of these projections and their use. Routine projections include transcranial, transmaxillary, panoramic, pseudo-tomographic, lateral oblique, submentovertex (basal), and reverse Towne views. A combination of these projections is typically used to evaluate the joint based on clinical symptoms. In addition, conventional linear or multidirectional tomography may be used for sectional imaging of the TMJ.

Film-based imaging continues to be routinely employed in clinical practice. However, the benefits of digital imaging have resulted in an exponential increase in the use of this technology. Many imaging options are available now; their use is facilitated by faster and more efficient digital sensors with higher quantum efficiency, which enables direct or indirect capture of images.[5] The most commonly used technological devices include solid-state sensors such as charge-coupled device (CCD)-based units, complementary metal oxide semiconductor (CMOS)-based units, and others such as photostimulable phosphor (PSP)-based sensors that are widely used in high-volume settings such as a hospitals and trauma centers. Advantages of using digital imaging include reduced doses in



• **Figure 37-1** Transcranial view: Note the superimposition of overlying anatomy on the temporomandibular joint. Only one joint can be imaged at a time. The series shows the position of the condyle during mouth opening. The *arrows* are pointing to the condyle position in relation to the eminence in closed, open, and widely open views.

comparison with earlier-generation film-screen systems; the ability to process images to tease out the signal of interest (postprocessing) without having to re-expose the patient for possible retakes; the ability to transmit, archive, and retrieve images efficiently and in a timely manner with no change in image quality; and the ability to synthesize or reformat images in other planes with the use of image processing algorithms. Such processing and synthesis of 3D volumes are not possible with film-based images unless they are digitized. All advanced imaging modalities use direct-capture electronic sensors.

Conventional imaging modalities are less expensive and more easily accessible than advanced modalities, and they entail lower radiation doses when compared with modalities such as computed tomography (CT). However, image acquisition in two dimensions does not provide a spatial perception of depth. Regional anatomy superimposed on the regions of interest precludes complete evaluation of the TMJ. In addition, image distortion, nonuniform magnification, and the generation of artifacts and other processing errors are potential challenges. Multiple radiographs generally are acquired using differing projection geometry in order to visualize the entire joint and to localize pathology. A single radiograph is seldom diagnostic because the information that is captured is limited to two planes as dictated by the specific projection geometry. The cumulative addition of radiation dose often equals or surpasses the more modern low-dose advanced imaging options such as CBCT.[6]

Transcranial

This method was very popular before the advent of advanced imaging modalities that use low radiation doses, such as CBCT. A transcranial image serves to provide a better view of the lateral aspect of the TMJ than the medial or central portion by virtue of projection geometry. However, most osseous lesions are known to start in this region. Significant superimposition of the mediolateral poles of the condyle occurs in this 2D projection, in addition to other overlying anatomy in the path of the beam as it traverses the skull. Adequate contrast and density are critical for obtaining a diagnostically acceptable image. The lateral portion of the condyle is nearer to the plane of the film and hence appears with relatively greater clarity (Figure 37-1).



• **Figure 37-2** Transmaxillary or transorbital view: Coronal view of the temporomandibular joints. (Courtesy James C. Pettigrew Jr, University of Florida.)

Transmaxillary or Transorbital

In order to better view the medial and central portions of the condyles, it is recommended that an additional coronal view of the TMJ be acquired. This can be achieved with the use of transmaxillary or transorbital projections. Anteroposterior projection geometry places the TMJ closer to the plane of the receptor (Figure 37-2).

Reverse Towne Projection

Another projection that is commonly used to evaluate the condyle is reverse Towne projection, which is a posteroanterior

(PA) projection.[7-9] A PA view is preferred because of the relative proximity of the condyles to the plane of the receptor (film or digital sensor), which results in an image with relatively greater detail. The patient opens the mouth, allowing translation and rotation of the condyle out of the glenoid fossa. This motion may be limited in trauma. However, if obtained accurately, the view facilitates acceptable evaluation of the medial and lateral poles of the condyle without a corrected axis view, but with a good overview of the subcondylar and upper ramal regions to help rule out fractures. Localization of fractures is facilitated because any displacement along the mediolateral axis can be evaluated (Figure 37-3).

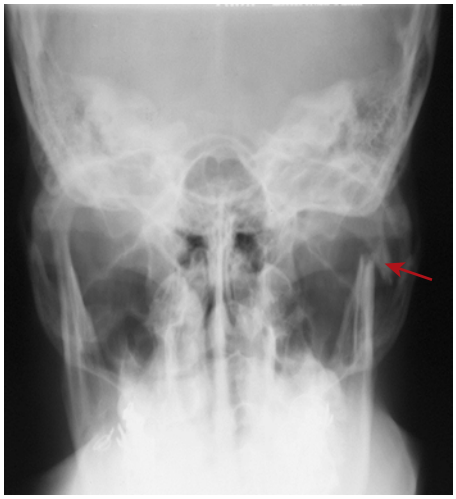

• **Figure 37-3** Reverse Towne projection: Open-mouth view enables visualization of the condyles as they translate and rotate out of the glenoid fossa. This view enables bilateral comparison of the two condyles. Note the *arrow* pointing to the left condylar neck fracture.

Submentovertex (SMV) Projection

The angulation of the condylar axis with respect to the midsagittal plane can be determined with use of the basal projection, also known as the SMV.[10] The base of the skull is imaged, and the condyles are captured on this projection. However, significant superimposition of the floor of the middle cranial fossa onto the TMJ does not permit a meaningful evaluation. This projection has limited TMJ applications and is most commonly used to acquire corrected-axis tomograms of the TMJ. The mediolateral axes of the condyles are plotted in conventional tomography software to assist with generation of slices parallel to the long axes (Figure 37-4).

Lateral Oblique Views

The lateral oblique view of each condyle/ramus, a commonly used projection before the introduction of panoramic radiography, can capture relatively good images of the TMJs, one at a time. In the absence of a panoramic imaging unit, this view provides an excellent option for viewing the condyles and the ramus. The glenoid fossa usually is superimposed by overlying anatomy. The central beam is directed at the midpoint of the ramus (Figure 37-5).

Panoramic Radiography

Panoramic radiographs are used as screening images to evaluate the TMJ. The inherent distortion, magnification, presence of superimposing ghost artifacts, double shadows, and so on prevent a thorough and quantitative examination of the osseous components of the TMJ.[11,12] However, this view allows bilateral visualization of both TMJs, enabling a reasonable comparative evaluation. The patient's position in the focal trough of the panoramic unit, as well as

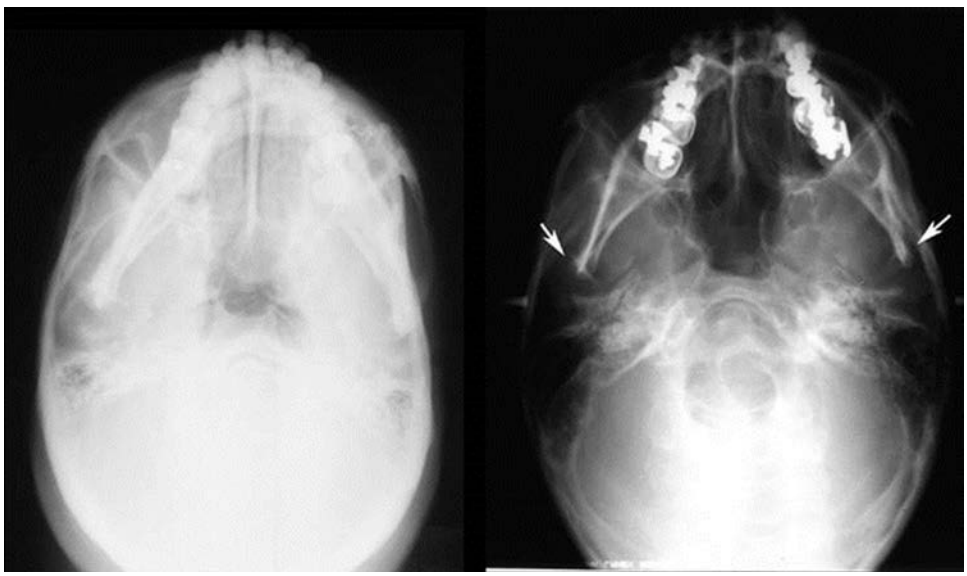

• **Figure 37-4** Submentovertex view: Also known as the basal view or jug handle view. Enables visualization of the condyles along their mediolateral axis, so the angle with the midsagittal plane can be determined for generation of corrected axis tomograms. *Left* image is showing the right zygomatic arch fracture. The *arrows* are pointing to the zygomatic arches bilaterally.

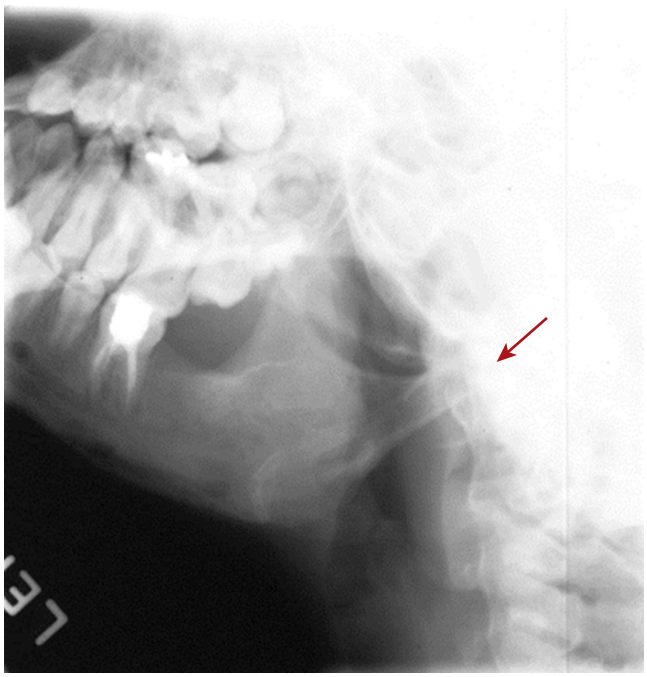

• **Figure 37-5** Lateral oblique view: Provides an overview of one temporomandibular joint at a time. Superimposition of overlying and transcranial anatomy is a problem. The *arrow* points to the condyle which is superimposed by the transcranial anatomy.

the choice of imaging parameters such as the configuration of the focal trough itself, are of paramount significance in this context to reduce uneven magnification of the areas of interest. Alterations in imaging geometry have been implemented in some panoramic units to limit exposure to the TMJ. Variable magnification of the images in all three axes has been documented to severely impair the ability to make measurements for diagnosis or for treatment planning purposes. Soft tissue components of the TMJ are not captured adequately, and direct visualization of these structures is not possible, as on any other conventional 2D radiographs. Because panoramic radiographs are "Mercator" projections of the area of interest, it is challenging to accurately assess the anatomic area being imaged, but because pantomography has been around for a long time and the focal trough and technique have evolved over time, the depiction of joint anatomy is now well understood.[12]

Modifications of the focal trough, as well as changes in the configuration of motion of panoramic imaging units, have been introduced to generate local views of TMJs, as well as pseudo-tomograms. Pseudo-tomograms are full-thickness images that appear very similar to tomograms. Many modern panoramic units offer various TMJ imaging options, including true linear tomographic capabilities with corrected axis acquisition capabilities. However, these usually are time-consuming procedures that require limited stabilization and positioning devices; in addition, they generate artifacts that may be seen on linear tomography (Figure 37-6).

When the clinical examination suggests some form of pathology, panoramic imaging is recommended for initial TMJ screening by the American Academy of Pediatric Dentistry, the American Academy of Orofacial Pain, and the American Academy of Oral and Maxillofacial Radiology.[12] Although panoramic imaging is extensively used in routine clinical practice and is valuable as a screening exam, the coming of multiple field of view (FOV) CBCT machines is changing the imaging approach to TMJ evaluation.

Panoramic imaging is a very good screening imaging modality. With the advent of newer machines with TMJ specific protocols, pseudo-tomogram–like images can be obtained. Significantly less radiation exposure occurs compared to advanced imaging modalities. Major disadvantages of this imaging are altered image geometry and variable magnification in all three axes. Because of the 2D aspect of the imaging, anatomic relationship cannot be evaluated with accuracy. Only osseous components with limited and incomplete depiction of the joint can be evaluated. No soft tissue evaluation can be done.

Conventional Linear and Multidirectional Tomography

Conventional tomography was extensively used before the advent of CBCT, but the coming of newer 3D imaging modalities has made these methods redundant. Conventional tomography[9-11] is a process by which slices of regions of interest are generated, one at a time, through different types of simultaneous motion of the x-ray source and the receptor (film or digital). Synchronous movement of these two elements about a center of rotation effectively captures a slice of the region of interest placed at this point. Slice thickness varies inversely with the angle circumscribed by the x-ray source during translational or rotational motion. The more complex the motion, the more effective will be the blurring of superimposing anatomy, thus improving visualization detail. However, it should be borne in mind that a decrease in slice thickness beyond a certain value (2-3 mm) will adversely affect contrast as the thickness of imaged tissue lessens. Artifacts are known to degrade image quality in simple motion configurations such as the linear mode. Many panoramic units offer this basic capability for generating linear tomograms. The procedure is very technique sensitive and time consuming, as only one slice is generated at a time. However, it does provide an accurate evaluation of the osseous components of the TMJ. Most panoramic units with true tomographic imaging capabilities offer special positioning devices and programs to correct for the mediolateral angulation of the condylar axis, in order to help generate a true orthogonal view of the anatomy. The condylar angle is assessed with respect to the midsagittal plane with the use of an SMV view that is acquired first.

Multidirectional tomography units use complex motions such as tri-spiral, hypocycloidal, and figure of eight to generate tomographic slices with minimal artifacts and smaller slice thicknesses (Figure 37-7). Computer-driven platforms are used for this purpose. Laser positioning lights and the

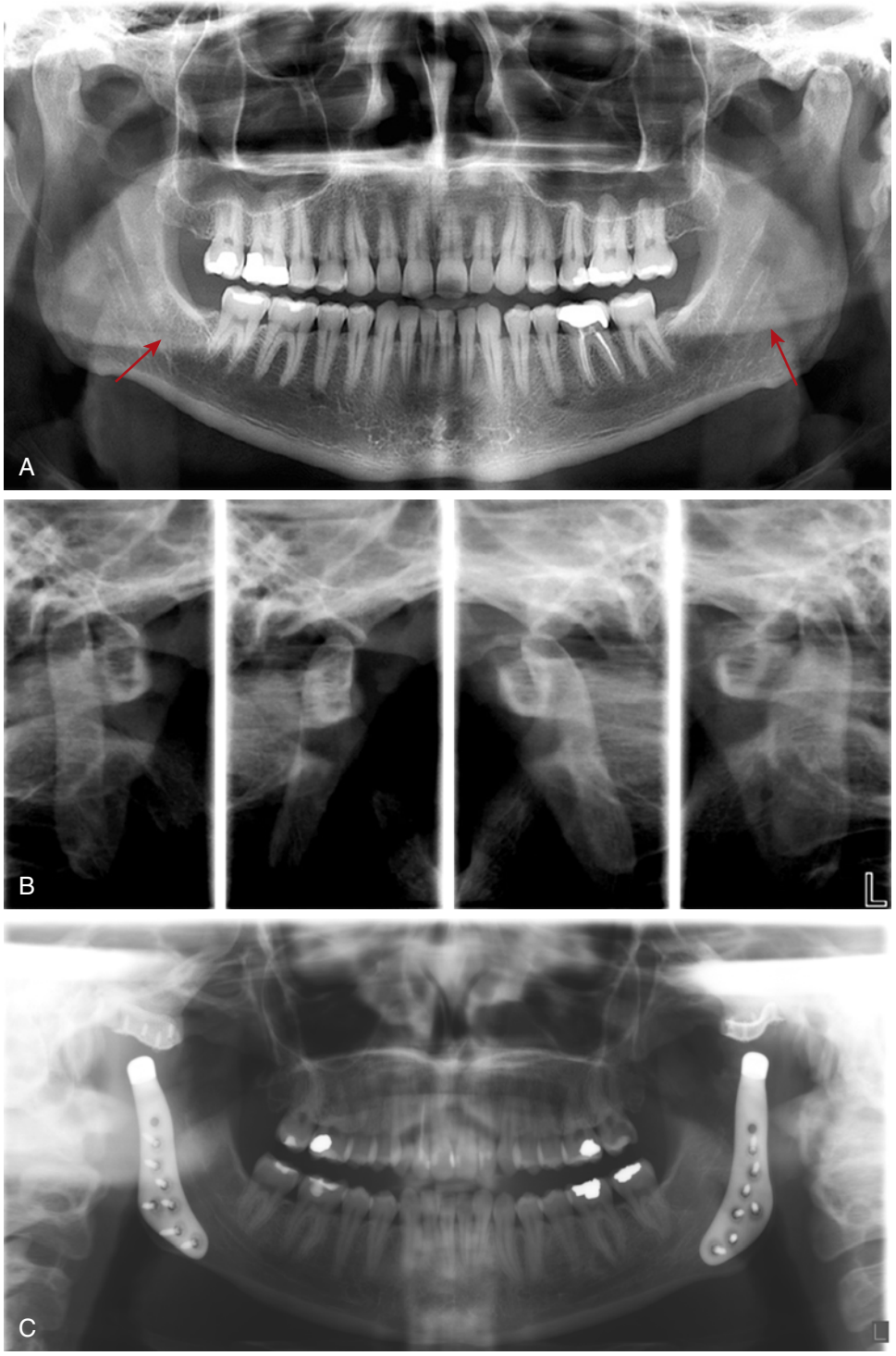

• **Figure 37-6** **A,** Panoramic radiograph (sometimes referred to as a Panorex). Note the ghost shadows of the contralateral angle of the mandible on both sides *(arrows)*. Also note the superimposition of overlying anatomy on the temporomandibular joints (TMJs). **B,** Pseudo-tomograms generated from a panoramic unit utilizing a modified acquisition method. **C,** Note the ghost artifacts from bilateral TMJ prostheses. This is a significant problem in patients who have had such surgery. Also C-spine overlap on the anterior portion.

registration of appropriate coordinates in the *x, y,* and *z* axes are possible with such units. This is advantageous for long-term follow-up studies, for which some reproduction of imaging geometry may be required. An SMV may be generated and imported into the software with a flatbed scanner to compute the correction needed to generate orthogonal tomograms. Conventional tomography permits accurate measurement of the regions of interest because magnification is known a priori and stays constant over the entire image.

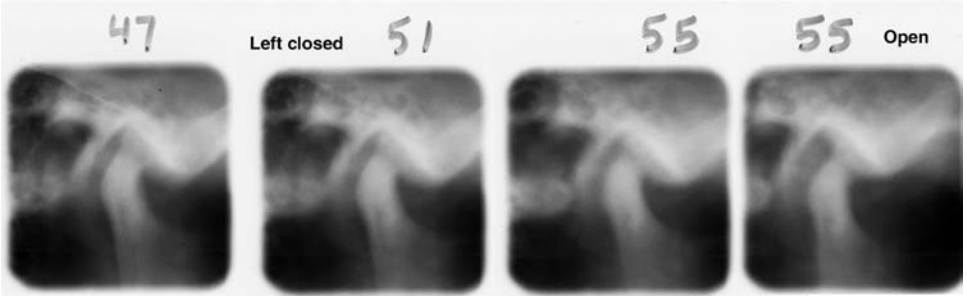

• **Figure 37-7** Conventional tomograms: Sagittal slices through the temporomandibular joint. Note the condyles in open- and closed-mouth positions.

Advanced Imaging Modalities

Three-dimensional imaging finds numerous applications in diagnostic TMJ imaging, owing to its capability of demonstrating depth-specific information in an interactive manner. Most such imaging is done to evaluate internal derangement, a common problem in about 50% of the population.[13,14] Anterior disc displacement is more common and is followed by anterolateral positioning. Disc displacement patterns vary to a large extent, which is very well depicted with magnetic resonance imaging (MRI). Other pathologic entities such as degenerative joint disease, ankylosis, tumors, and developmental anomalies often necessitate 3D imaging. In addition, soft tissue components can be adequately visualized with MRI and the use of appropriate techniques in CT. Advanced imaging modalities provide diagnostic information that also can be quantified to characterize pathology and thus determine the optimal mode of intervention.

CT is also used as a basis for therapeutic options such as patient-fitted total joint replacement. The evolution of better materials and more refined radiographic imaging for preoperative planning has changed the landscape of this procedure. The DICOM data from the scan is used to create an accurate 3D plastic model of the TMJ and associated jaw structures. Stereolithography, CAD-CAM fabrication, or more recently 3D printing technology is used to make a functional 3D model, to best restore the patient to normal joint function. The new joint is created based on this model.[15]

Computed Tomography

Computed tomography (CT) uses an image-forming algorithm to reconstruct a 3D image data set from multiple 2D images of the TMJ. The patient is positioned on the gantry; the x-ray sources and the electronic detector array rotate around the patient and undergo translation as images are continuously acquired. Direct acquisition in most units occurs in an axial plane, but coronal acquisition can also be achieved.[1] The patient will have to be placed in an uncomfortable position for direct coronal capture to occur. However, images can be synthesized or reformatted in any plane such as sagittal or coronal.[1] This process is referred to as multiplanar reconstruction (MPR). An entire region of interest thus can be examined in a single acquisition. MPR reduces the resolution of images slightly, but contemporary techniques yield adequate imagery for diagnosis. Earlier generations of CT units used less efficient modes of image collection, resulting in longer study times and the potential for motion artifact. Later generations of imaging units are capable of much quicker image generation, such as spiral CT, in which the gantry continues to translate as the x-ray sources and detector array rotate around the patient, thus generating a spiral motion and significantly reducing image acquisition times. Newer units have superior detector technologies and are capable of relatively high spatial resolution. The contrast resolution offered by CT is the highest that can be achieved. Examination of osseous structures with CT, therefore, is considered optimal. However, spatial resolution is still lower than that of digital radiography (DR) in that pixel sizes of the sensors in a CT unit are larger.

CT data can be visualized interactively, in static or dynamic modes, with the use of different display settings. MPR facilitates the generation of images in the coronal and sagittal planes. Scout images are generated first to ensure that the patient has been positioned appropriately in the gantry, and appropriate slices are selected for image generation. The images are displayed as shades of gray that are based on attenuation of the x-ray beam as it passes through the tissues of interest. This value, which is expressed as the attenuation coefficient of the tissue, is compared with the attenuation coefficient of water and is expressed as a logarithmic ratio, resulting in a value commonly referred to as a Hounsfield unit (HU). HU values of different tissues have been identified, thus yielding a range of values that are best for viewing different types of tissue. Further image processing through windowing and leveling of data results in display of desired shades of gray on the image based on the specific diagnostic task. Osseous tissues thus can be best visualized in a bone window setting. Likewise, soft tissue window settings are ideal for viewing such components of the TMJ and adjacent anatomy. The disc usually is difficult to visualize with the use of CT, especially if it is thin and small.[1] Larger discs and posterior attachments may present as areas of differential attenuation, permitting some visualization. Anterior displacement of the disc also may permit visualization. Indirect localization of the disc may occur through observation of displacement of the fat pad adjacent

to the lateral pterygoid muscle attachment to the condylar head. Windowing and leveling can be interactively carried out at the workstation.

For TMJ imaging, closed- and open-mouth views are generated, allowing examination of translation and rotation of the condyles and the dynamic range of motion. The patient must be immobilized during image acquisition by biting down on an object in the open position. CT also allows examination of the glenoid fossa, morphologic alterations or erosions of the condyles, and the articular eminentia and trauma. Perforation of the glenoid fossa into the middle cranial fossa also can be visualized well. If the disc is visualized, sagittal views render the disc much more visible in open and closed positions than do coronal and axial views. However, medial or lateral displacement of the disc may be noted in the coronal view.

CT imaging provides multiple advantages, because 3D information is captured and displayed interactively as a stack of 2D slices in any desired plane through MPR. In addition, 3D volumes can be displayed as surface rendering and volumetric rendering. Surface rendering, as the term implies, generates a surface-only 3D image; volumetric rendering generates the entire volume by making the superficial pixels transparent on the basis of their attenuation properties. In addition, CT is an excellent imaging modality for visualizing osseous components of the TMJ. CT also permits visualization of soft tissue components of the TMJ to some extent, although soft tissue examination is best performed by MRI. CT of the TMJ exposes the patient to higher radiation doses than do conventional techniques. The artifacts in CT may require that the study be repeated or that another modality be chosen. The most commonly seen artifacts include: (1) those induced by metallic fixtures or prostheses in or near the TMJ, (2) restorations such as amalgam and stainless steel crowns that produce a starburst pattern, and (3) motion artifacts induced by patient movement, especially in pediatric patients or those with involuntary movements. Adequate modes of stabilization or a sedation protocol should be used in these instances (Figures 37-8 through 37-10).

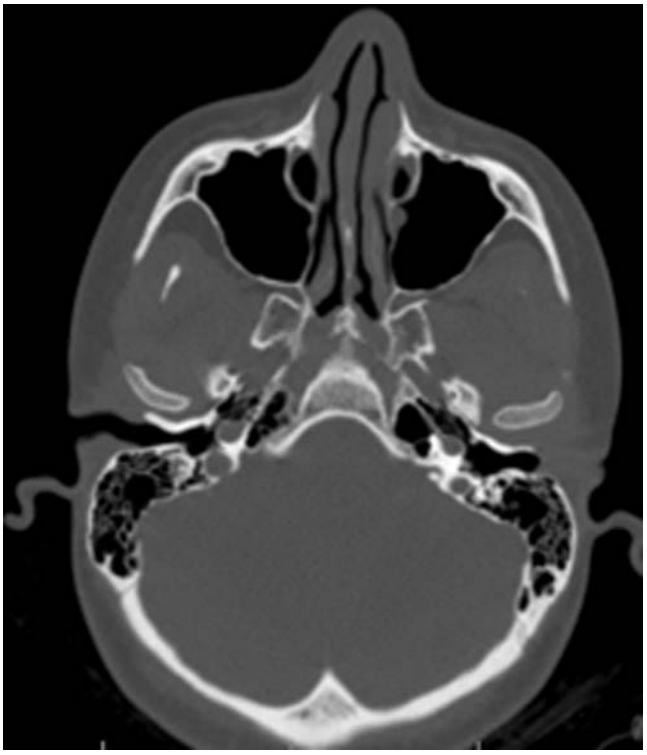

• **Figure 37-8** Computed tomography (CT): Bone window of an axial slice through the temporomandibular joint. Note the condyles.



• **Figure 37-9** Computed tomography (CT): Soft tissue window. Muscle attachments, including the lateral pterygoid muscles, are visible *(arrows)*.

Magnetic Resonance Imaging

MRI is being used increasingly for TMJ imaging and has largely replaced invasive arthrography, because it offers three major advantages: (1) It does not entail the use of ionizing radiation, (2) it provides excellent images of soft tissue components of the TMJ and permits direct visualization of inflammatory changes and the presence of effusion, and (3) it can be acquired in any desired plane. However, bone is not directly visualized on MRI. Detection of joint effusion and osseous changes of varying degrees is well documented,[16] and long-term prospective imaging studies have been advocated to track changes over time.[17] Such studies are useful for evaluating morphologic alterations and remodeling following surgical intervention, or in cases where only nonsurgical therapy is adopted. MRI has also been shown to be the optimal imaging modality in cases where no evidence of effusion, osteoarthritic changes, or internal derangement can be found.[17] Furthermore, changes in bone marrow signals can be detected with accuracy on MRI.[16] Studies have also shown that MRI and CT can detect occult fractures of the articular eminentia and the glenoid fossa.[18] These

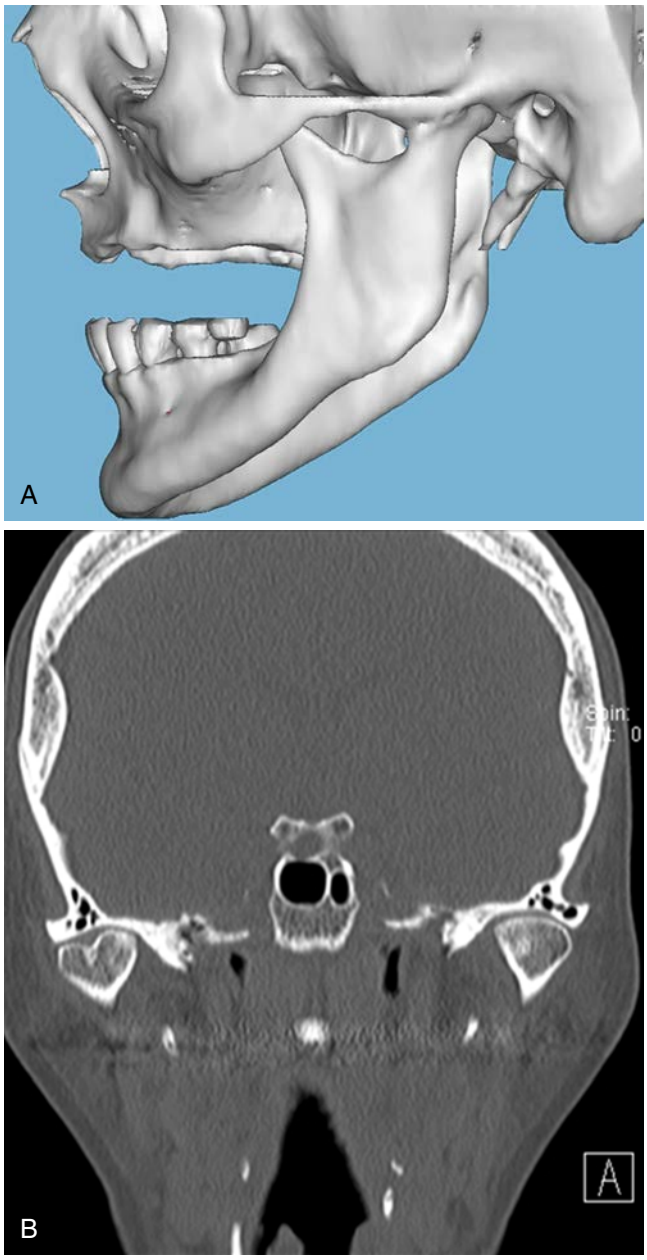

• **Figure 37-10** **A,** Three-dimensional volumetric reconstruction from a computed tomography study showing traumatic ankylosis of the left joint. **B,** Bone window of a coronal slice through temporomandibular joints. Note the right condyle showing bifid appearance.

distinct advantages for several applications make MRI an indispensable tool for diagnosis and treatment planning.

Magnetic resonance images are generated via the magnetic properties of hydrogen atoms in water molecules under the influence of powerful external magnetic fields. Radiofrequency (RF) pulses are delivered at a certain frequency and time interval to the region of interest that helps flip the protons within hydrogen atoms by a certain degree from their original axis of spin. Relaxation of hydrogen atoms upon termination of the RF pulse results in emission of the signal, which then is interpreted by the algorithm and displayed as the signal. Various protocols for MR imaging are based on pulse sequences that are determined by the diagnostic task. Image property varies according to method of acquisition. Differential response of different tissue types in normal and unhealthy states enables the generation of signals that facilitate interpretation of MR images. Image weighting is achieved by alteration of the time of repetition (TR) of the RF pulse and the time of echo (TE) of the signal from tissues of interest. Commonly used weighting includes T1, T2, and proton density. T1 images provide anatomic details, with fat enhancing as a bright signal. Bone appears dark on MRI as hydrogen atoms are tightly bound, failing to generate a signal. T2-weighted images, on the other hand, are appropriate for visualizing inflammatory changes in the capsule, as well as the presence of effusion. Proton density–weighted images provide excellent anatomic detail in that the position of the disc is more clearly outlined in relation to surrounding osseous and soft tissue structures.[1]

Open- and closed-mouth views are generated in MRI studies. The relative positions of the disc and its attachments can be studied at different positions of translocation[17,18,19] of the mandible, thus documenting TMJ dynamics.[17,19] Assessment of disc recapture can be made in suspected cases of internal derangement.[20] Images in any plane can be acquired directly without the need to reformat images from axial projections, as is done in CT. Patients do not have to be positioned differently. Scout images are acquired initially for slice location planning purposes.

MRI of the TMJ yields information that is not captured by any other modality, directly and in a noninvasive pattern.[21-30] MRI imaging of the TMJ provides hard tissue and soft tissue details along with functional information without using ionizing radiation. Extraction of signals of interest within a reconstructed volume using specific exposure and image processing parameters results in the collection of unique data that then can be viewed interactively. MRI thus continues to be routinely used in instances where (1) clinical signs and symptoms warrant such examination for effective definitive diagnoses,[24] particularly in relation to delineation and evaluation of soft tissue components, and (2) other imaging modalities including arthrography[28] are not considered appropriate. Arthrography has been shown to be relatively insensitive for the detection of medial and lateral displacements.[25] Disc degeneration has been shown on MRI to start in the retrodiscal attachment complex.[26]

TMJ imaging by MRI continues to evolve with improving technology. For TMJ imaging, special circular polarized transmission and receiver coils (surface coils) are used to emit and receive signals to enhance resultant image quality.[26,28] One or two coils may be used to capture the signals. Slice thickness of 3 mm or less is used with interslice spacing of 0.3 to 1.5 mm. MRI must be used to determine disc recapture in patients with internal derangement during splint therapy. Preoperative and postoperative images permit evaluation of the functional efficiency of the splint. Studies have shown that the use of high-quality, superconducting receiver coils significantly enhances image quality on low-field and other open scanners[28] (Figures 37-11 and 37-12).

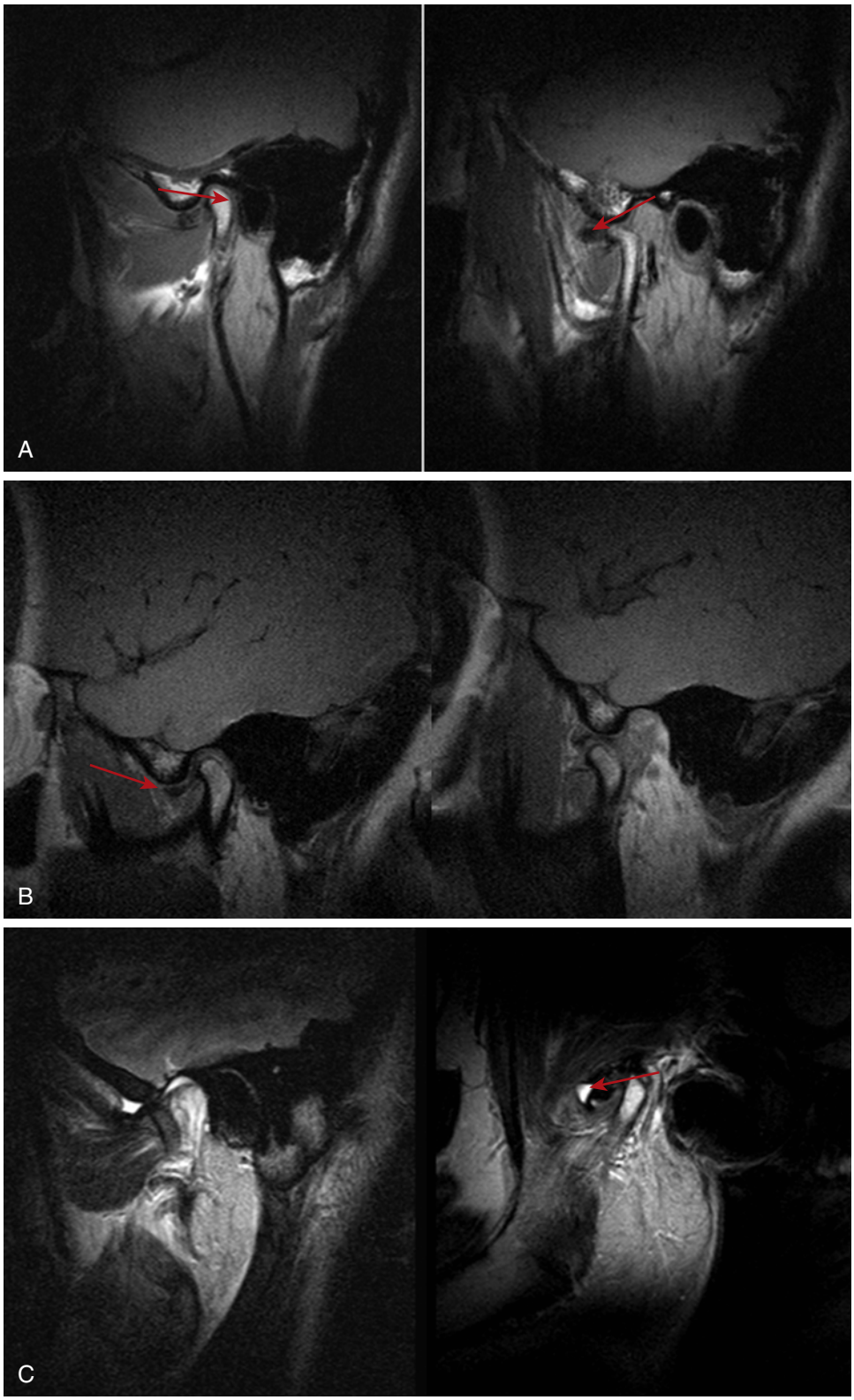

• **Figure 37-11** Magnetic resonance imaging (MRI): Imaging of soft tissue detail, as well as effusion and inflammatory processes, is possible. **A,** T1-weighted parasagittal slices through the temporomandibular joint (TMJ) showing disc displacement without reduction: optimal for visualization of anatomy, condylar and disc position. Condyles are visible with a dark cortical outline and bright fatty marrow *(arrow on the right side).* Disc is visible as graying dark shape anterior to the condyle in the left image *(arrow on the left side)*. **B,** T1-weighted parasagittal slices through the TMJ showing disc displacement with reduction. Disc is pointed on the right image *(arrow on the left side).* **C,** T2-weighted parasagittal slices through the TMJ showing disc displacement with reduction. Note the bright white signal *(arrow on the right side)* representing the joint space effusion.

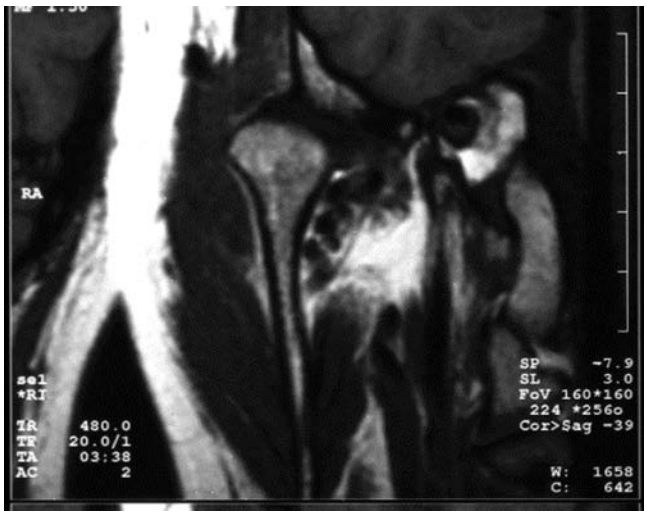

• **Figure 37-12** Magnetic resonance imaging (MRI): T1-weighted paracoronal slice through the TMJ.

There are multiple advantages that are unique to MRI. MRI imaging yields information that is not captured by any other imaging modality, noninvasively and with no radiation to the patient.[29] Functional and physical evaluation of the joint and joint space components is facilitated by more accurate images.[30] Evaluation of pathologic conditions with inflammation can be done at high resolution.[31] Various imaging protocols are available that can be used to enhance desired tissue with unique interactive data.[32] Disadvantages include potential for artifact generation from field distortions caused by ferromagnetic metallic objects, prostheses, and implants in the maxillofacial region[33] and an inability to image patients with implanted cardiac pacemakers[34] or aneurysm clips in the brain,[35] as well as patients with claustrophobia.[36] However, open units are available for patients with claustrophobia. Such units generally use magnets with lower field strengths, resulting in lower signal-to-noise ratios.

Tuned-Aperture Computed Tomography

Tuned-aperture computed tomography (TACT) is an imaging modality that was developed from the basic principles of tomosynthesis. However, none of the limitations of tomosynthesis apply to TACT. Multiple conventional images of the volume of interest are acquired from different loci in space, resulting in 2D radiographs. Software is used to reconstruct 3D volume with these data. 2D slices then can be generated, or the entire volume can be examined interactively at the workstation in static or dynamic modes. The stack of slices lends itself to image processing like CT (see Figure 37-11). Before the advent and wide availability of cone-beam volumetric imaging, TACT was a promising new modality to get 3D images in less time than conventional tomography and with fewer artifacts compared to CT. TACT was evaluated for TMJ arthroplasty, as it provided images with fewer metal and streak artifacts to evaluate the joint after arthroplasty. Disadvantages include the time required to acquire and reconstruct the images. TACT continues to be evaluated for a variety of diagnostic tasks and is used in medical applications such as mammography.[37,38]

Cone Beam Computed Tomography (CBCT)

CBCT is a relatively new 3D diagnostic imaging modality in dentistry that is finding numerous applications in maxillofacial imaging.[38-43] It uses an x-ray source that delivers a cone-shaped beam, resulting in exposure of the entire volume of interest at the same time and not just one or more slices of the tissue at a time. The result is a faster image acquisition process with significantly lower radiation doses. The linear accuracy of measurements from CBCT scans is very reliable, as the image acquisition is done using isotropic voxels. Because CBCT has poor contrast resolution, scatter artifacts from metallic structures are significantly fewer. First-generation CBCT units were designed to acquire the scan in a supine position, but most current CBCT units are designed to image the patient in a seated or standing position. Most standing and chairless units accommodate patients in wheelchairs. Numerous units are in use, most of which use sensors with high spatial resolution capabilities. Reconstruction times vary according to the unit, but some vendor software can achieve real-time secondary multiplanar reconstructions. Panoramic and other dental modes of view are available in the reconstruction schemes. Field of view and voxel size play a key role in the detection of subtle osseous changes and can help in early diagnosis of arthritic changes; research in this area is emerging and is helpful in developing imaging protocols for evaluation of the TMJ.[44] A new area of emerging research is the ability of CBCT scanners to acquire 3D information using fewer basis projections by modifying the acquisition protocol to do a 180-degree rotation as compared to the conventional 360-degree rotation. This modified acquisition technique is showing promising results in the detection of small and large arthritic lesions associated with the TMJ.[45] This is largely due to the evolution of postprocessing algorithms and small voxel sizes that deliver high-resolution images and better sensors. Newer sensors have resulted in 14-bit capture of data in the recent past and provide an opportunity to postprocess images to glean more valuable diagnostic information. Efforts to achieve 16-bit capture are ongoing. The definitive advantage of increased bit depth in the absence of soft tissue visualization remains to be proved. Cone-beam acquisition does not permit diagnostic imaging of most soft tissue such as muscle attachments and fascial planes, as is seen in conventional CT. Contrast imaging and soft tissue imaging using CT are still best achieved through conventional CT. CBCT does, however, facilitate evaluation of some soft tissue structures such as airway spaces outlined by regional soft tissue, a profile of the patient's face for orthognathic or other reconstructive operative needs, and imaging of subtle calcifications within soft tissue entities. Also available are units that could generate images of selected regions

of the patient's anatomy with the use of smaller detectors and tightly collimated beams, resulting in significantly higher spatial resolution levels. However, these are limited area views, and only a small portion of the anatomy can be captured.

Surface and volumetric reconstructions can be done with CT data for treatment planning purposes. Surface reconstruction yields an image with surface pixels processed to show the exterior of the region of interest; volumetric reconstruction facilitates visualization of internal anatomic details. This is especially useful for reconstructive surgical treatment planning, simulation procedures, and establishment of visual treatment objectives[46] (Figures 37-13 through 37-17).

A major advantage of CBCT imaging is that it is a low-dose 3D imaging modality with high spatial resolution for imaging the hard tissues in the maxillofacial region. It has a significantly lower radiation dose, lower cost, and smaller footprint compared to multi-slice CTs. A major disadvantage of CBCT in comparison with multi-slice CTs is its poorer contrast resolution, which depicts soft issue details poorly. Other disadvantages such as patient motion artifact and metal artifacts are similar between both imaging modalities.

Functional Imaging

All of the image generation techniques discussed previously fall under the category of morphologic imaging modalities. Functional imaging modalities capture images that provide information on the functional integrity of the region of interest.[47-57] Applications in TMJ imaging are very limited. Examples include evaluation of functional changes following orthopedic treatment,[47] pre-splint and post-splint therapy imaging,[48] condylar hyperplasia,[49] necrosis of the condyle, chronic craniofacial pain refractory to treatment,[50,51] craniofacial osteomyelitis,[52] solid tumor invasion, and so forth. Thus, in instances where such information is needed to evaluate the presence of primary or secondary lesions in the TMJ, functional imaging is used in conjunction with morphologic imaging. These methods include scintigraphy, positron emission tomography (PET), and single photon emission computed tomography (SPECT), among others. Radioactive isotope-labeled tracer agents with short half-lives are administered intravenously, followed by image capture with the use of specialized cameras. Anatomic entities are not well outlined on the resultant images; however, those areas within the volume of interest that take up more of the tracer agent as a result of increased metabolic activity present as bright signals and vice versa. Although the sensitivity of this technique has increased with the use of SPECT, specificity is rather low, leading to false-positive results. Therefore, functional studies should be interpreted with caution. Increased physical activity just prior to imaging is known to generate signals in regions of hyperactivity that may not necessarily result from pathologic activity. In addition, internal radiation doses are delivered when this procedure is followed. Therefore, this imaging modality is not selected without prior acquisition of morphologic imaging through CT or MRI; it should be advocated only in those instances where an undisputed indication for such functional assessment exists.

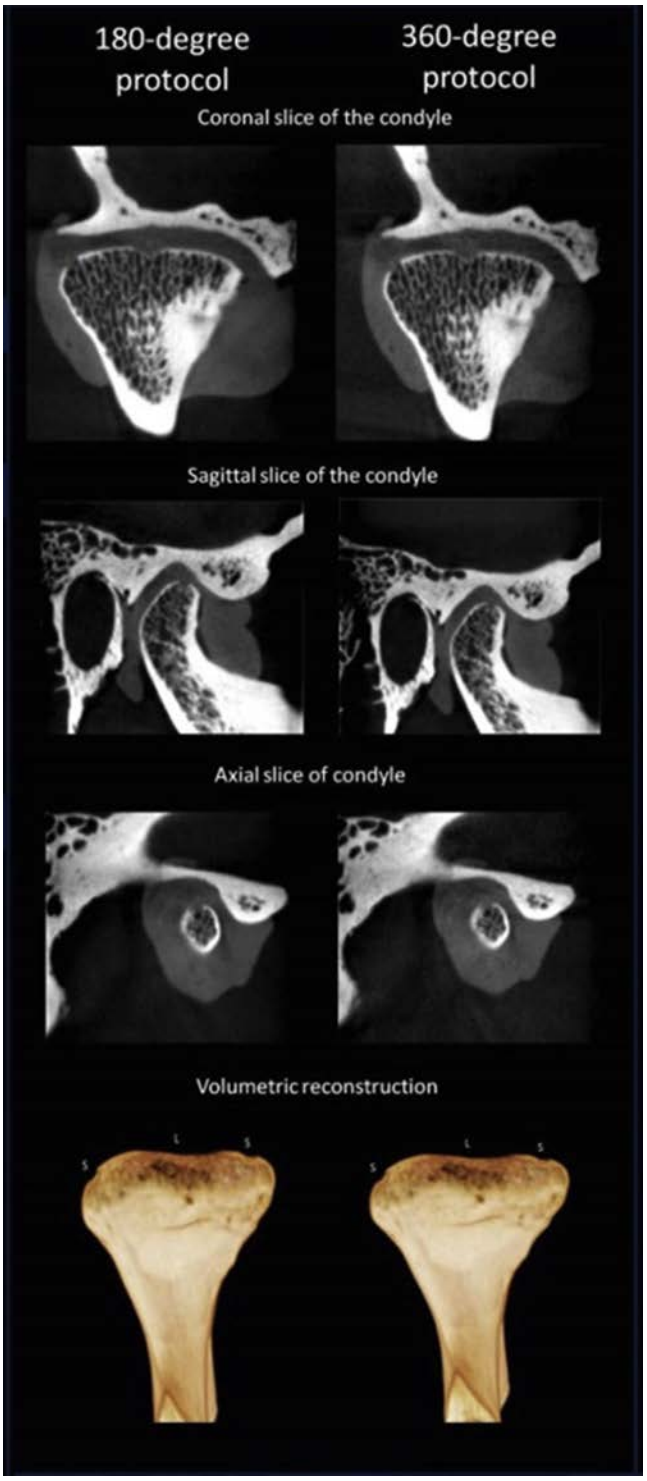

• **Figure 37-13** Cone-beam computed tomography (CBCT): Modified and conventional small-volume, low-dose scans: sagittal, coronal slices and volumetric rendering through condyles. Note the condylar surface erosion and defects in both coronal slices and volumetric rendering images through condyles consistent with degenerative changes.



• **Figure 37-14** Cone-beam computed tomography (CBCT): Lateral reconstruction with maximum intensity projection (MIP).



• **Figure 37-15** Cone-beam computed tomography (CBCT): Postero-anterior open-mouth reconstruction with maximum intensity projection (MIP).

Fusion Imaging

The concept of fusion imaging arose from the need to correlate findings on morphologic and functional imaging studies in a meaningful manner in 3D space. PET/SPECT-CT thus was introduced as a fusion imaging modality.[53-57] Images acquired with the use of the unit would contain both CT and PET/SPECT components, resulting in visualization of data that have been spatially correlated within the volume. It is thus easier to localize areas of increased or decreased metabolic activity to slice planes without compromising visualization of regional anatomy. Post-acquisition fusion of images from two different modalities can be done but is often not as accurate as when images are acquired together. Functional imaging is thus an invasive procedure that has the potential for false-positive results; it must be used only in conjunction with morphologic imaging modalities.[50]

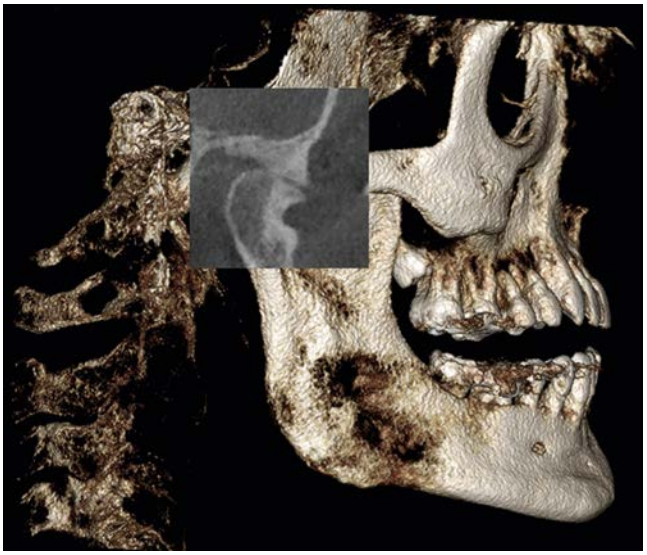

• **Figure 37-16** Cone-beam computed tomography (CBCT): Lateral volumetric reconstruction in a bone window with x-ray window overlapping the right condyle. Note joint space reduction and osteophyte formation on right condyle.

Ultrasonography

Ultrasonography (US) is a noninvasive, inexpensive morphologic imaging procedure that can provide valuable information about TMJ components.[58-61] It may be used as a screening tool to evaluate the osseous contours of joints and may be used to evaluate joint spaces. Good diagnostic accuracy and reliability depend on appropriate use of this technique. The procedure can be completed in a short time. TMJ components present as hyperechoic areas of differing signal intensity, making them distinguishable from each other. Correlation of US findings with results of other imaging modalities such as MRI has shown that morphologic changes can be detected with some accuracy, including measurement of joint spaces as an indication of the presence of effusion as seen on MRI. Effusions present as hypoechoic or anechoic areas on US. Other applications include detection of disc position and dynamic evaluation of TMJ components in motion. More powerful transducers, positioning and size of the transducer for image acquisition, and the expertise of the operator have a direct bearing on image quality. However, it should be noted that evaluation of the medial aspect of the joint continues to be a problem. Some challenges to the routine use of US in diagnostic imaging of the TMJ have arisen, but the future seems to be bright as the technology continues to evolve.

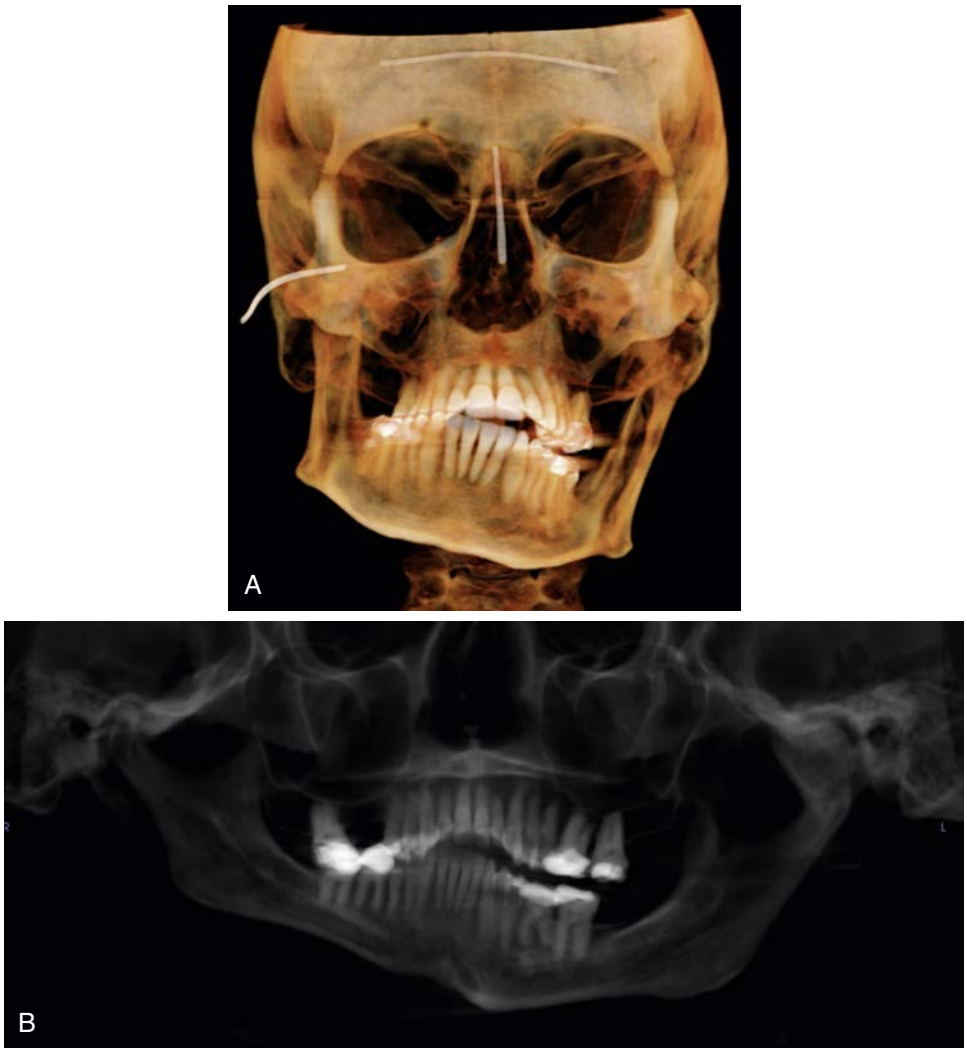

• **Figure 37-17** Cone-beam computed tomography (CBCT): **A**, 3D volumetric rendering showing left condylar hyperplasia. **B,** Panoramic reconstruction from CBCT showing left condylar hyperplasia, joint space reduction, and ankylosis.

Summary

With recent advances in imaging technology and the introduction of newer imaging modalities, noninvasive evaluation of the TMJ has become a more efficient process. Static and dynamic observation of TMJ components is being done with significant reduction of radiation dose and, when necessary, by fusing or co-registering two imaging modalities together. The ideal imaging modality for a specific diagnostic task must be determined on the basis of clinical signs and symptoms, in consultation with a radiologist, because imaging protocols and acquisition schemes constantly change with technological upgrades.

References

1. Westesson PL, Yamamoto M, Sano T, Okano T: Temporomandibular joint. In Som PM, Curtin HD, editors: *Head and neck imaging*, ed 4, Philadelphia, 2002, Mosby.
2. Honey OB, Scarfe WC, Hilgers MJ, et al.: Accuracy of cone-beam computed tomography imaging of the temporomandibular joint: comparisons with panoramic radiology and linear tomography, *Am J Orthod Dentofacial Orthop* 132:429–438, 2007.
3. Farman TT, Farman AG: Temporomandibular joint pantomography using charge-coupled device, photostimulable phosphor, and film receptors: a comparison, *J Digit Imaging* 12:9–13, 1999.
4. U.S. Department of Health and Human Services: *TMJ Disorders*, NIH Publication No.13-3487, Bethesda, MD. http://www.nidcr.nih.gov/oralhealth/Topics/TMJ/Documents/TMJDisorders_100113_508C.pdf, August, 2013.
5. Larheim TA, Abrahamsson AK, Kristensen M, Arvidsson LZ: Temporomandibular joint diagnostics using CBCT, *Dentomaxillofac Radiol* 44:20140235, 2015.
6. Pauwels R, Beinsberger J, Collaert B, et al.: Effective dose range for dental cone beam computed tomography scanners. SEDENTEXCT Project Consortium, *Eur J Radiol* 81:267–271, 2012.

7. Hlawitschka M, Loukota R, Eckelt U: Functional and radiological results of open and closed treatment of intracapsular (diacapitular) condylar fractures of the mandible, *Int J Oral Maxillofac Surg* 34:597–604, 2005.
8. Nair MK, Nair UP: Imaging of mandibular trauma: ROC analysis, *Acad Emerg Med* 8:689–695, 2001.
9. Silvennoinen U, Raustia AM, Lindqvist C, Oikarinen K: Occlusal and temporomandibular joint disorders in patients with unilateral condylar fracture: a prospective one-year study, *Int J Oral Maxillofac Surg* 27:280–285, 1998.
10. Maxwell MF, Farman AG, Haskell BS, Yancey JM: Submentovertex radiology: cephalometric considerations in temporomandibular dysfunction, *Cranio* 13:15–21, 1995.
11. Schmitter M, Gabbert O, Ohlmann B, et al.: Assessment of the reliability and validity of panoramic imaging for assessment of mandibular condyle morphology using both MRI and clinical examination as the gold standard, *Oral Surg Oral Med Oral Pathol Oral Radiol Endod* 102:220–224, 2006.
12. Fallon SD, Fritz GW, Laskin DM: Panoramic imaging of the temporomandibular joint: an experimental study using cadaveric skulls, *J Oral Maxillofac Surg* 64:223–229, 2006.
13. White SC, Pharoah MJ: Temporomandibular joint abnormalities. In White SC, Pharoah MJ, editors: *Oral radiology: principles and interpretation*, ed 7, St Louis, 2014, Elsevier, pp 492–523.
14. De Farias JF, Melo SL, Bento PM, et al.: Correlation between temporomandibular joint morphology and disc displacement by MRI, *Dentomaxillofac Radiol* 44:20150023, 2015.
15. Wolford LM, Mehra P: Custom-made total joint prostheses for temporomandibular joint reconstruction, *Proc (Bayl Univ Med Cent)* 13:135–138, 2000.
16. Kersey ML, Nebbe B, Major PW: Temporomandibular joint morphology changes with mandibular advancement surgery and rigid internal fixation: a systematic literature review, *Angle Orthod* 73:79–85, 2003.
17. Larheim TA: Role of magnetic resonance imaging in the clinical diagnosis of the temporomandibular joint, *Cells Tissues Organs* 180:6–21, 2005.
18. Miyauchi K, Sano K, Nagai M, et al.: Occult fractures of articular eminence and glenoid fossa presenting as temporomandibular disorder: a case report, *Oral Surg Oral Med Oral Pathol Oral Radiol Endod* 101:e101–e105, 2006.
19. Matsumoto K, Honda K, Sawada K, et al.: The thickness of the roof of the glenoid fossa in the temporomandibular joint: relationship to the MRI findings, *Dentomaxillofac Radiol* 35:357–364, 2006.
20. Simmons 3rd HC, Gibbs SJ: Recapture of temporomandibular joint disks using anterior repositioning appliances: an MRI study, *Cranio* 13:227–237, 1995.
21. Emshoff R, Brandlmaier I, Schmid C, et al.: Bone marrow edema of the mandibular condyle related to internal derangement, osteoarthrosis, and joint effusion, *J Oral Maxillofac Surg* 61:35–40, 2003.
22. Foucart JM, Carpentier P, Pajoni D, et al.: MR of 732 TMJs: anterior, rotational, partial and sideways disc displacements, *Eur J Radiol* 28:86–94, 1998.
23. Ogutcen-Toller M, Taskaya-Yilmaz N, Yilmaz F: The evaluation of temporomandibular joint disc position in TMJ disorders using MRI, *Int J Oral Maxillofac Surg* 31:603–607, 2002.
24. Magnusson T, Karlsson C: Clinical impact of radiological examinations of patients with suspected temporomandibular disorders, *Swed Dent J* 26:67–74, 2002.
25. Westesson PL: Reliability and validity of imaging diagnosis of temporomandibular joint disorder, *Adv Dent Res* 7:137–151, 1993.
26. Orhan K, Nishiyama H, Tadashi S, et al.: Comparison of altered signal intensity, position, and morphology of the TMJ disc in MR images corrected for variations in surface coil sensitivity, *Oral Surg Oral Med Oral Pathol Oral Radiol Endod* 101:515–522, 2006.
27. Tomas X, Pomes J, Berenguer J, et al.: MR imaging of temporomandibular joint dysfunction: a pictorial review, *Radiographics* 26:765–781, 2006.
28. Ma QY, Chan KC, Kacher DF, et al.: Superconducting RF coils for clinical MR imaging at low field, *Acad Radiol* 10:978–987, 2003.
29. Katsumata A, Nojiri M, Fujishita M, et al.: Condylar head remodeling following mandibular setback osteotomy for prognathism: a comparative study of different imaging modalities, *Oral Surg Oral Med Oral Pathol Oral Radiol Endod* 101:505–514, 2006.
30. Pullinger AG, White SC: Efficacy of TMJ radiographs in terms of expected versus actual findings, *Oral Surg Oral Med Oral Pathol Oral Radiol Endod* 79:367–374, 1995.
31. Whyte AM, McNamara D, Rosenberg I, Whyte AW: Magnetic resonance imaging in the evaluation of temporomandibular joint disc displacement-a review of 144 cases, *Int J Oral Maxillofac Surg* 35:696–703, 2006.
32. Chen YJ, Gallo LM, Meier D, Palla S: Dynamic magnetic resonance imaging technique for the study of the temporomandibular joint, *J Orofac Pain* 14:65–73, 2000.
33. Harris CA, White LM: Metal artifact reduction in musculoskeletal magnetic resonance imaging, *Orthop Clin North Am* 37:349–359, 2006.
34. Faris OP, Shein M: Food and Drug Administration perspective: magnetic resonance imaging of pacemaker and implantable cardioverter-defibrillator patients, *Circulation* 114:1232–1233, 2006.
35. Olsrud J, Latt J, Brockstedt S, et al.: Magnetic resonance imaging artifacts caused by aneurysm clips and shunt valves: dependence on field strength (1.5 and 3 T) and imaging parameters, *J Magn Reson Imaging* 22:433–437, 2005.
36. Spouse E, Gedroyc WM: MRI of the claustrophobic patient: interventionally configured magnets, *Br J Radiol* 73:146–151, 2000.
37. Nair MK: Diagnostic accuracy of tuned aperture computed tomography (TACT), *Swed Dent J Suppl* 159:1–93, 2003.
38. Suryanarayanan S, Karellas A, Vedantham S, et al.: Evaluation of linear and nonlinear tomosynthetic reconstruction methods in digital mammography, *Acad Radiol* 8:219–224, 2001.
39. Honda K, Larheim TA, Maruhashi K, et al.: Osseous abnormalities of the mandibular condyle: diagnostic reliability of cone beam computed tomography compared with helical computed tomography based on an autopsy material, *Dentomaxillofac Radiol* 35:152–157, 2006.
40. Honda K, Bjornland T: Image-guided puncture technique for the superior temporomandibular joint space: value of cone beam computed tomography (CBCT), *Oral Surg Oral Med Oral Pathol Oral Radiol Endod* 102:281–286, 2006.
41. Tsiklakis K, Syriopoulos K, Stamatakis HC: Image-guided puncture technique for the superior temporomandibular joint space: value of cone beam computed tomography (CBCT), *Oral Surg Oral Med Oral Pathol Oral Radiol Endod* 102:281–286, 2006.
42. Hilgers ML, Scarfe WC, Scheetz JP, Farman AG: Accuracy of linear temporomandibular joint measurements with cone beam computed tomography and digital cephalometric radiography, *Am J Orthod Dentofac Orthop* 128:803–811, 2005.

43. Honda K, Matumoto K, Kashima M, et al.: Single air contrast arthrography for temporomandibular joint disorder using limited cone beam computed tomography for dental use, *Dentomaxillofac Radiol* 33:271–273, 2004.
44. Librizzi ZT, Tadinada AS, Valiyaparambil JV, et al.: Cone-beam computed tomography to detect erosions of the temporomandibular joint: effect of field of view and voxel size on diagnostic efficacy and effective dose, *Am J Orthod Dentofacial Orthop* 140:e25–e30, 2011.
45. Yadav S, Palo L, Mahdian M, et al.: Diagnostic accuracy of 2 cone-beam computed tomography protocols for detecting arthritic changes in temporomandibular joints, *Am J Orthod Dentofacial Orthop* 147:339–344, 2015.
46. Kaga K, Takegoshi H, Yamasoba T, et al.: Aplasia of zygomatic arch and dislocation of temporomandibular joint capsule in Treacher-Collins syndrome: three-dimensional reconstruction of computed tomographic scans, *Int J Pediatr Otorhinolaryngol* 67:1189–1194, 2003.
47. Guner DD, Ozturk Y, Sayman HB: Evaluation of the effects of functional orthopaedic treatment on temporomandibular joints with single-photon emission computerized tomography, *Eur J Orthod* 25:9–12, 2003.
48. Hersek N, Canay S, Caner B, Ulutuncel N: Bone SPECT imaging of patients with internal derangement of temporomandibular joint before and after splint therapy, *Oral Surg Oral Med Oral Pathol Oral Radiol Endod* 94:576–580, 2002.
49. Dimonte M, Inchingolo F, Minonne A, et al.: Bone SPECT in management of mandibular condyle hyperplasia: report of a case and review of literature, *Minerva Stomatol* 53:281–285, 2004.
50. Nuebler-Moritz M, Marienhagen J, Held P, et al.: High-resolution SPECT of the temporomandibular joint in chronic craniofacial pain disorders: a pilot study, *Acta Stomatol Belg* 92:125–128, 1995.
51. DeNucci DJ, Chen CC, Sobiski C, Meehan S: The use of SPECT bone scans to evaluate patients with idiopathic jaw pain, *Oral Surg Oral Med Oral Pathol Oral Radiol Endod* 90:750–757, 2000.
52. Seabold JE, Simonson TM, Weber PC, et al.: Cranial osteomyelitis: diagnosis and follow-up with In-111 white blood cell and Tc-99m methylene diphosphonate bone SPECT, CT, and MR imaging, *Radiology* 196:779–788, 1995.
53. Coutinho A, Fenyo-Pereira M, Dib LL, Lima EN: The role of SPECT/CT with 99mTc-MDP image fusion to diagnose temporomandibular dysfunction, *Oral Surg Oral Med Oral Pathol Oral Radiol Endod* 101:224–230, 2006.
54. Horger M, Eschmann SM, Pfannenberg C, et al.: The value of SPECT/CT in chronic osteomyelitis, *Eur J Nucl Med Mol Imaging* 30:1665–1673, 2003.
55. Strumas N, Antonyshyn O, Caldwell CB, Mainprize J: Multimodality imaging for precise localization of craniofacial osteomyelitis, *J Craniofac Surg* 14:215–219, 2003.
56. Schimming R, Juengling FD, Lauer G, et al.: Computer-aided 3-D 99mTc-DPD-SPECT reconstruction to assess mandibular invasion by intraoral squamous cell carcinoma: diagnostic improvement or not? *J Craniomaxillofac Surg* 28:325–330, 2000.
57. Curran AJ, Toner M, Quinn A, et al.: Mandibular invasion diagnosed by SPECT, *Clin Otolaryngol Allied Sci* 21:542–545, 1996.
58. Landes CA, Goral WA, Sader R, Mack MG: 3-D sonography for diagnosis of disk dislocation of the temporomandibular joint compared with MRI, *Ultrasound Med Biol* 32:633–639, 2006.
59. Rudisch A, Emshoff R, Maurer H, et al.: Pathologic-sonographic correlation in temporomandibular joint pathology, *Eur Radiol* 16:1750–1756, 2006.
60. Manfredini D, Tognini F, Melchiorre D, et al.: Ultrasonography of the temporomandibular joint: comparison of findings in patients with rheumatic diseases and temporomandibular disorders: a preliminary report, *Oral Surg Oral Med Oral Pathol Oral Radiol Endod* 100:481–485, 2005.
61. Tognini F, Manfredini D, Melchiorre D, Bosco M: Comparison of ultrasonography and magnetic resonance imaging in the evaluation of temporomandibular joint disc displacement, *J Oral Rehabil* 32:248–253, 2005.

38

Pathology of the Temporomandibular Joint

ROBERT GASSNER

This chapter on the pathology of the temporomandibular joint (TMJ) consists of three parts. The first part deals with joint physiology and pathophysiology. The second part assesses the plethora of TMJ arthritides. Finally, the last part provides insight into the occurrence of benign and malignant tumors of the TMJ.

Joint Physiology and Pathophysiology

Motion is a fundamental event throughout biology.[1] It is an especially powerful modulator of cellular events, altering and interfering with effects of cytokines and growth factors in the musculoskeletal system.[2] Until recently, mechanical effects on joint tissue, especially the activation of cells such as chondrocytes, synovial fibroblasts, and osteoblasts, were considered beneficial only in disease-free tissue and were regarded as detrimental in the presence of inflammatory disease. When assessing the literature on the TMJ, usually in place of *motion*, the term *mechanical stress* is used in association with breakdown of joint function.[3,4]

This provides a small glimpse of results and work of the past 10 years regarding the interaction of motion and inflammation in articular tissue in vitro and in vivo.[5-12] It reveals how motion provides anti-inflammatory effects even in inflamed articular tissue through intracellular mechanisms. It further outlines how motion-based therapies such as continuous passive motion exert beneficial effects in various states of inflamed joint tissues. The in vitro model compares chondrocyte behavior when chondrocytes are subjected to four different conditions: (1) inflammation (interleukin-1 [IL-1]), (2) motion (cyclic tensile strain[CTS]), (3) inflammation and motion, and (4) experimental control. The in vivo model compares inflamed cartilage behavior when cartilage is subjected to two different conditions: (1) immobilization (IMM), and (2) motion (continuous passive motion [CPM]).

Understanding this can help in the clinical decision-making progress regarding therapeutic regimens of medical, surgical, and/or physical therapy interventions used in the treatment of temporomandibular disorders (TMDs). It can also help in understanding the molecular basis of joint diseases.

Interplay of Cytokines, Growth Factors, and Mechanical Signals

Articular cartilage maintains normal TMJ function through a specialized, hydrated extracellular matrix.[13] The major constituents of fibro-cartilage include type-II collagen fibrils providing tensile strength, and aggregating proteoglycans (aggrecans), nonaggregating proteoglycans, and water providing compressive resilience.[14] Less abundant components, types IX and XI collagen[15] and small proteoglycans,[16] also influence matrix organization.

Glycosaminoglycans are the polysaccharide side chains attached to the core proteins of proteoglycans. The distribution of proteoglycans close to the inferior and superior surfaces[14,17] in a given articular tissue is not uniform.[13,17] Chondroitin sulfate is evenly distributed in cartilage; dermatan sulfate is largely concentrated in the periphery and keratan sulfate in the middle of TMJ discs.[13,17] This may reflect different loading patterns in various regions of the TMJ disc.

Chondrocytes embedded in the articular cartilage express distinct functional properties in development and aging, while maintaining homeostasis in the mature organism and during cartilage remodeling after traumatic or inflammatory injury.[18] Physiologically, these responses lead to the formation or restitution of cartilage extracellular matrix (ECM). Dysregulation of these responses can lead to qualitatively or quantitatively abnormal formation or degradation of ECM, resulting in impaired joint function.[14]

Additionally, mechanical stimuli affect articular chondrocyte metabolism. During normal daily activity, a variety of mechanical forces including stresses, strains, and pressures is distributed within the joint; the long-term stability of the cartilage matrix depends mainly on the response

of chondrocytes to mechanical stimuli [6,19] and their limited capability to balance between anabolic and catabolic processes.[20-22]

Chondrocyte activation and the induction of anabolic or catabolic responses are thought to be primarily the function of cytokines and growth factors. The catabolic cascade is induced by proinflammatory stimuli such as interleukin-1 (IL-1) and tumor necrosis factor alpha (TNF-α) and is characterized by the secretion of proteases, suppression of matrix synthesis, and inhibition of chondrocyte proliferation. The anabolic process is associated with the secretion of antagonistic cytokines, synthesis of protease inhibitors, production of extracellular matrix, and cell replication.[18]

During inflammation in degenerative TMJ diseases, proinflammatory cytokines such as IL-1 and TNF-α decrease synthesis and increase degradation of proteoglycans and collagens.[19,20,22] Growth factors such as transforming growth factor beta (TGF-β) are unable to stimulate chondrocyte synthesis of collagens and proteoglycans and ultimately reduce the activity of IL-l–stimulated proteinases.[23-25]

It is most important to note that mechanical signals generated by tensile strain of low magnitude (TENS-L) are anti-inflammatory, whereas tensile strain of high magnitude (TENS-H) is proinflammatory and catabolic.[5-8] Both low and high magnitudes of mechanical strain exploit nuclear factor NF-κB as a common pathway for transcriptional inhibition/activation of proinflammatory genes and catabolic processes as described for the intracellular mechanism of action of applied tensile forces in osteoblast-like cells.[26] TENS-L is a potent inhibitor of IL-1β-induced I-κBβ degradation and prevents dissociation of NF-κB from cytoplasmic complexes and thus its nuclear translocation. This leads to sustained suppression of IL-1β-induced NF-κB transcriptional regulation of proinflammatory genes. In contrast, TENS-H is a proinflammatory signal that induces I-κBβ degradation, nuclear translocation of NF-κB, and transcriptional activation of proinflammatory genes (Figure 38-1).

Articular chondrocytes synthesize copious amounts of the free radical nitrous oxide (NO) following activation by IL-l.[21] NO is generated by the NO synthase (NOS) group of enzymes, which synthesize NO by combining molecular oxygen with the terminal guanidino nitrogen of the amino acid L-arginine, yielding L-citrulline as a coproduct.[27] Under aerobic conditions, NO spontaneously oxidizes to its stable metabolites, nitrate (NO_3) and nitrite (NO_2). Because the half-life of NO is on the order of seconds, NO production is assessed indirectly by measuring the conversion of ^{14}C-labeled L-arginine to L-citrulline in tissue homogenates or by measuring the accumulation of the stable NO metabolites NO_3 and NO_2 in biological fluids such as the synovial fluid.[6,20-22,28] To date three distinct isoforms of NOS have been identified: a neuronal form (nNOS) initially isolated from brain, an endothelial form (ecNOS) initially isolated from the endothelium, and an inducible form (iNOS) initially isolated from macrophages.[20,22]

The iNOS pathway is principally regulated at the transcriptional level. Proinflammatory cytokines and endotoxin are potent inducers of iNOS in a wide variety of cell types, whereas glucocorticoids and the anti-inflammatory cytokines IL-4, IL-10, and the growth factor TGF-β suppress NO production. NO, acting as a endogenous mediator of catabolic actions, inhibits proteoglycan synthesis directly,[20-22] whereas TGF-β suppresses that NO production, reversing the NO-mediated inhibition of proteoglycan synthesis.[22]

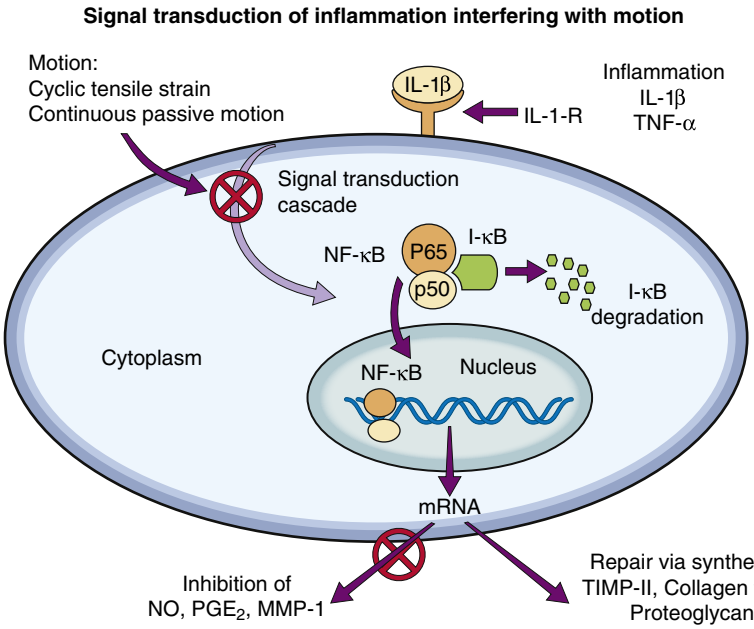

• **Figure 38-1** Scheme: Interaction of inflammatory cytokine interleukin-1 (IL-1) and motion (cyclic tensile strain/CTS; continuous passive motion/CPM). *NO,* Nitrous oxide; *PGE_2,* prostaglandin E_2; *TNF-α,* tumor necrosis factor alpha.

The synovial fluid of arthritic TMJs also contains inflammatory mediators such as IL-1β, TNF, NO, leukotriene B_4, and prostaglandin E_2. Elevated levels of IL-1 and NO in the pathogenesis of arthritic conditions signal downstream events including the induction of matrix metalloproteinases (MMPs), eventually leading to the destruction of stromal tissue.[10]

Matrix metalloproteinases represent a family of structurally and functionally related enzymes responsible for the proteolytic degradation of extracellular matrix. They have been traditionally subdivided into three classes based on their substrate specificity: collagenases, gelatinases, and stromelysins. Their substrates include fibrillar collagen, collagen type IV or denatured collagen (gelatin), and other extracellular matrices (proteoglycan, laminin, fibronectin, casein), respectively. MMPs have been detected in TMJ synovial fluid aspirates and lavage collections, confirming that MMPs are involved in the degenerative component of TMJ disorders.[10,12]

To treat acutely and chronically inflamed joints, both immobilization and mobilization are used as therapeutic measures, with variable success.[29-31] This is partly due to the fact that mechanisms by which these two differing treatments exert their effects remain unclear. Recent in vitro studies demonstrate that biomechanical signals are potent anti-inflammatory signals that attenuate proinflammatory gene induction in chondrocytes. These signals act on chondrocytes in a magnitude-dependent manner. At low magnitudes, biomechanical signals inhibit IL-1β- or TNF-α-induced transcriptional activation of COX-2, MMPs, IL-1β, and other proinflammatory molecules.[32-35] These mediators are involved in cartilage destruction, and by blocking their gene expression, biomechanical signals can potentially attenuate cartilage destruction. Additionally, biomechanical signals upregulate expression of proteins associated with cartilage repair, such as aggrecans, collagen type II, and sulfated glycosaminoglycans. Not surprisingly, mechanical signals intercept the IL-Iβ-signaling pathway and inhibit nuclear translocation of NF-κB and subsequent transcriptional activation of genes under its control.[34,36] Because NF-κB transactivation occurs within a few minutes following activation of chondrocytes with IL-1β or TNF-α, the actions of biomechanical signals are rapid and can be observed within a few hours. Moreover, biomechanical signals act on cells in a sustained manner and can be observed in the presence of an inflammatory stimulus.[34,36] Additionally, mechanistic analysis of the actions of biomechanical signals in vivo is indicated to understand the biological basis of motion-based therapies that may contribute significantly to the healing of inflamed joints.

The Arthritic Condition and Cyclic Tensile Strain in Vitro

CTS vs. CTS+IL-1 vs. Experimental Control Group vs. IL-1 Alone

Mimicking the arthritic condition in in vitro chondrocyte function has to be assessed under at least four different conditions: (1) motion (CTS), (2) motion and inflammation (IL-1), (3) inflammation (IL-1) alone, (4) and experimental control (Figure 38-2). Exposure of chondrocytes to the proinflammatory cytokine IL-1 leads to upregulation of presence of iNOS mRNA and iNOS protein and NO itself via activation of IL-1 receptor on the cell surface and following dissociation of NF-κB from cytoplasmic complexes and thus its nuclear translocation (lane 4). In particular, Figure 38-2 shows that CTS itself does not induce the inflammatory cascade for NO (lane 1), while CTS is clearly downregulating the inflammatory pathway of NO (lane 2). Resting chondrocytes in the control group do not show activation of the proinflammatory NO signaling cascade (lane 3).[5,36]

Chondrocytes in the tangential layers of cartilage are most responsive to IL-1β and synthesize high levels of iNOS as compared with chondrocytes in the deeper layers.[20,21] As shown in Figure 38-3, immunochemical staining for iNOS shows the distinct presence of inflammatory response in chondrocytes following exposure to inflammatory signals alone in comparison to simultaneous exposure to mechanical and inflammatory signals. Absence of the iNOS-protein occurs in control groups and during CTS alone (see Figure 38-3, *A* and *B*). About 35% of all chondrocytes are iNOS-positive cells representing the cells derived from the tangential layer of articular cartilage (see Figure 38-3, *C*). This population of chondrocytes is most likely the one that is also responsive to CTS, showing a 62% decrease of iNOS protein immunostaining (see Figure 38-3, *D*).

These in vitro findings provide evidence that mechanical signals play an important and critical role as modulators of inflammatory joint diseases. CTS functions as a potent effector mechanism for suppressing pathologic effects of IL-1β in vitro through inhibition of inducible

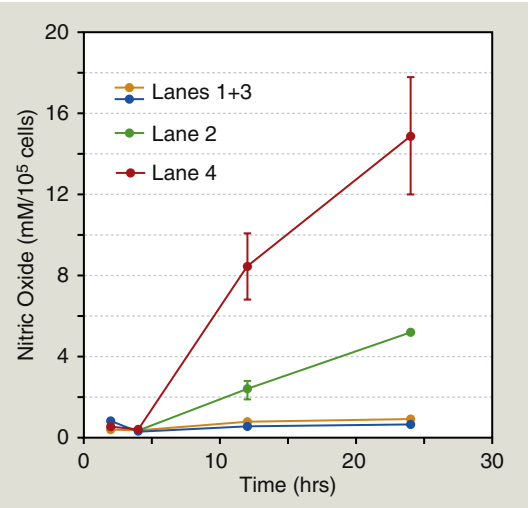

• **Figure 38-2** Nitric oxide (NO): A marker of inflammatory cell response during (*lane 1*) motion (cyclic strain), (*lane 2*) motion and inflammation (interleukin-1 [IL-1]), (*lane 3*) experimental control, and (*lane 4*) inflammation (IL-1) alone. (From Gassner R, Buckley M, Studer R, et al: Cyclic tensile stress exerts antiinflammatory properties by inhibiting iNOS induction in chondrocytes, *J Immunol* 163:2187-2192, 1999.)

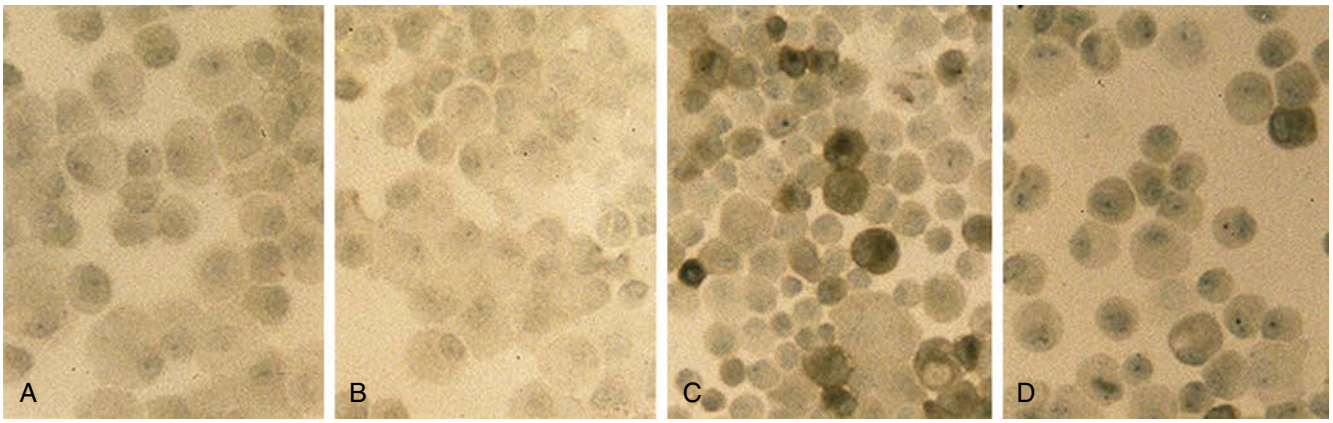

• **Figure 38-3** Immunochemically stained protein inducible nitric oxide synthase (iNOS) (brown color) during **(A)** control – no motion, **(B)** motion alone, **(C)** inflammation alone (interleukin-1 [IL-1]) alone, and **(D)** motion and inflammation (IL-1 IL-1β. Motion inhibits inflammation.). (From Gassner R, Buckley M, Studer R, et al: Cyclic tensile stress exerts antiinflammatory properties by inhibiting iNOS induction in chondrocytes, *J Immunol* 163:2187-2192, 1999.)

NO production.[5] It is likely that in vivo mechanical signals may exert their effects on arthritic joints in a similar manner by inhibiting the inflammatory effects induced by IL-1β via interruption of iNOS expression. In turn, this would limit the production of NO and its catabolic effects on cartilage. Furthermore, mechanical signals do not only inhibit NO production, but also upregulate proteoglycan synthesis at concentrations of IL-Iβ frequently observed in inflamed arthritic joints, suggesting that the actions of mechanical signals are clinically relevant in suppressing the sustained effects of pathological levels of IL-1β in vivo. Maintaining anabolic capabilities of chondrocytes within inflamed joint tissue is an additional anti-inflammatory asset for the treatment of arthritic conditions.

The Arthritic Condition and Continuous Passive Motion in Vivo

Immobilization versus Continuous Passive Motion

Destruction of cartilage integrity is a hallmark of arthritic conditions as evidenced in a rabbit model of antigen-induced arthritis (AIA).[12] The histopathogenesis of AIA has been well characterized, and the model demonstrates many features of human rheumatoid arthritis (RA), including joint inflammation and damage to articular cartilage via both increased breakdown and decreased synthesis of cartilaginous matrix.[32-34] To evaluate the molecular basis of interaction between motion and inflammation, the in vivo model compares inflamed cartilage behavior where cartilage is subjected to either of two different conditions: (1) IMM or (2) motion (CPM). Given that maintenance of cartilage integrity is due to chondrocyte function, regulation and control of proinflammatory molecules in inflamed cartilage depends on the presence of biomechanical signals. Mobilization clearly prevents cartilage degradation. CPM protects matrix integrity in AIA-afflicted articular cartilage. Inflammation is mainly driven by monocytic cells in immobilized knees as compared with CPM knees. CPM downregulates the proinflammatory cytokine IL-1β mRNA expression and synthesis in inflamed chondrocytes (Figure 38-4). CPM suppresses COX-2 synthesis in inflamed cartilage (data not shown). Finally, CPM suppresses MMP-1 synthesis in inflamed chondrocytes (Figure 38-5). CPM upregulates IL-10 synthesis in inflamed cartilage (Figure 38-6).

Joint mobilization is suggested to disseminate the inflammatory exudates, whereas IMM is suggested to create a stagnant environment in the synovium, leading to increased inflammation and cartilage damage. Although these effects of mobilization and IMM cannot be excluded, the fact that mechanical signals directly interfere with the proinflammatory gene induction in chondrocytes suggests that mechanical signals regulate inflammation at the intracellular level. The in vitro and ex vivo data demonstrate that chondrocytes are mechanosensitive cells and respond to mechanical signals in a magnitude-dependent manner.[33-38] For example, cyclic tensile or compressive forces, in the presence of inflammatory signals, induce matrix synthesis in chondrocytes and fibrochondrocytes.[35-38] The in vivo findings confirm the in vitro and ex vivo data and demonstrate that mechanical signals act directly on chondrocytes to prevent cartilage destruction due to inflammation. Appropriate mechanical signals play a profound role in attenuating localized joint inflammation in vivo. These signals act on inflamed chondrocytes by two equally important mechanisms. First, these signals are potent inhibitors of proinflammatory gene induction and inhibit expression of catabolic mediators, such as IL-1β, COX-2, and MMP-l. Second, these signals induce expression of the anti-inflammatory cytokine IL-10. Together, the results demonstrate that biomechanical signals have profound effects in minimizing cartilage destruction in a severe

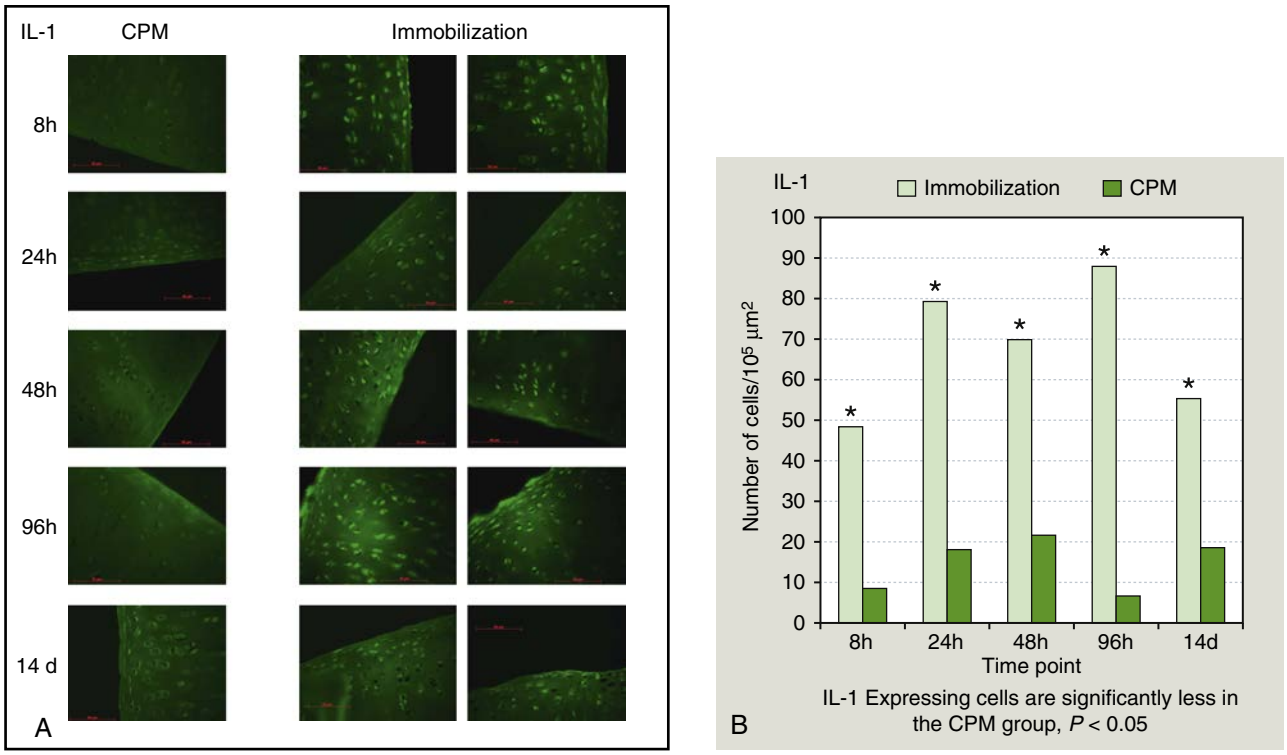

• **Figure 38-4 A,** Rabbit knee with antigen-induced arthritis (AIA)/in vivo conditions: green staining illustrates expression of Interleukin-1 (IL-1ß). **B,** Graphic illustration of Part **A**. (A From Ferretti M, Gassner R, Wang Z, et al: Biomechanical signals suppress proinflammatory responses in cartilage: early events in experimental antigen-induced arthritis, *J Immunol* 177:8757-8766, 2006.).

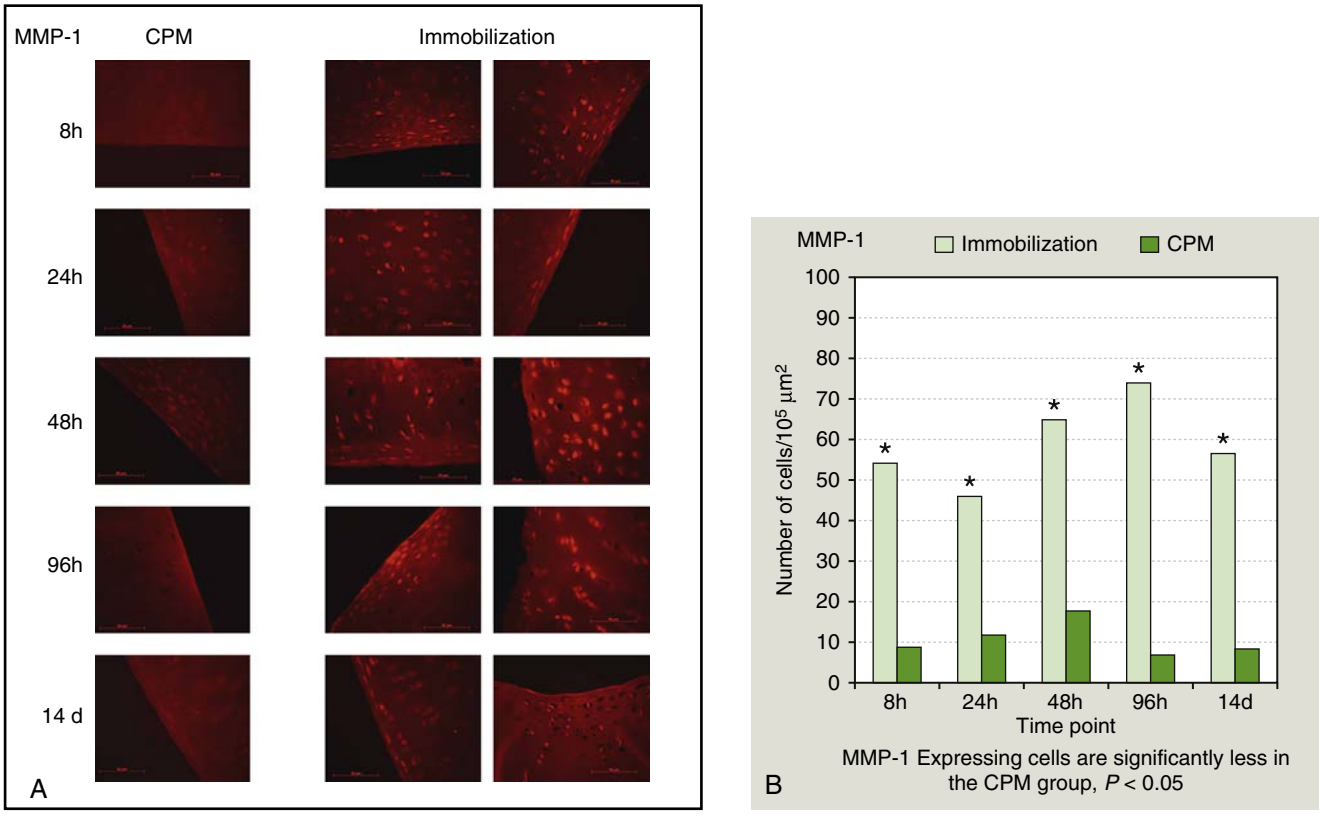

• **Figure 38-5 A,** Rabbit knee with antigen-induced arthritis (AIA)/in vivo conditions: red staining illustrates expression of Matrix Metallo Proteinase -1 (MMP-1) **B,** Graphic illustration of **A.** (A From Ferretti M, Gassner R, Wang Z, et al: Biomechanical signals suppress proinflammatory responses in cartilage: early events in experimental antigen-induced arthritis, *J Immunol* 177:8757-8766, 2006.)

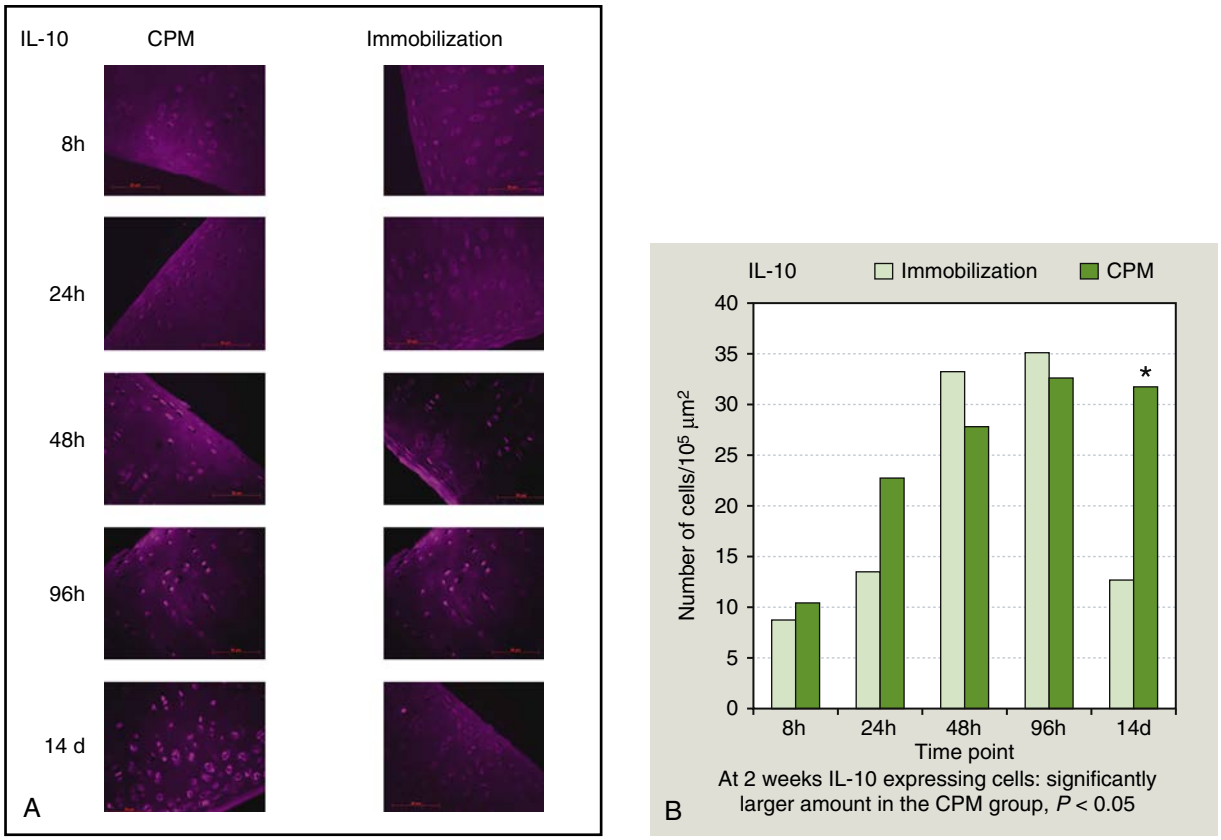

• **Figure 38-6** **A,** Continuous passive motion (CPM) versus immobilization: CPM upregulates IL-10 synthesis in inflamed cartilage. **B,** Graphic illustration of **A**. (**A** From Ferretti M, Gassner R, Wang Z, et al: Biomechanical signals suppress proinflammatory responses in cartilage: early events in experimental antigen-induced arthritis, *J Immunol* 177:8757-8766, 2006.)

proinflammatory environment and provide continuing evidence that motion-based therapies are more efficacious than perceived earlier.[12]

Arthritides of the Temporomandibular Joint

More than 10% of the population suffers from arthritic diseases leading to pain, loss of function, disabilities, and joint replacement and economically measured as major loss of human productivity and especially early retirement.[5,6,12] In the United States alone, more than 40 million people suffer from some form of arthritis; among these, 12 million have osteoarthritis (OA) and 8 million have RA. Arthritis is also the most common disease affecting the TMJ. All of the arthritic forms that involve other joints in the body occur in this joint, too. Therefore, these conditions are to be considered in the differential diagnosis whenever a patient presents with chronic TMJ pain and dysfunction.[39-45]

Arthritic diseases of the TMJ are inflammation-derived alterations of the synovium, cartilage, and surrounding structures such as the capsule, bursa, tendons, and bone. Similarities of signs and symptoms of the many variants of arthritis necessitate the establishment of a working differential diagnosis based on the patient's history, physical examination, and radiographic evaluation distinguishing these conditions from other causes of TMJ symptoms.

Patient evaluation includes questions regarding swelling, redness, pain at rest, duration of symptoms, rate of onset, location of involved joints, pattern of joint involvement, preceding events such as trauma, and time of day when symptoms are worse. Discussion of medications influencing symptoms and a thorough review of organ systems follows.[39-41,46] Physical examination extends beyond the involved joints, as the skin, heart, lungs, and mucous membranes are often affected by the same disease process. Involved joints are observed for deformity, symmetry, and proximity. Palpation of these areas assesses pain, temperature, and range of motion.

Diagnostic studies also include radiologic studies (magnetic resonance imaging [MRI], computerized tomography [CT] scan, and bone scans), laboratory tests, and synovial fluid analysis.[39-41,43,46] Normal synovial fluid is clear or straw colored and viscous from hyaluronic acid. Viscosity is reduced in inflammatory arthritides, and the synovial fluid flows like water—unlike the stringing produced by normal synovial fluid. Evaluation of cell counts, clot formation, and differences between serum and synovial glucose levels can aid in the diagnosis and differentiate arthritic conditions.

The presence of crystals and evaluation of their size, shape, and compensation under polarized light can be useful in the diagnosis of metabolic arthritides.[39-41]

Classification of Arthritis

Symptoms and signs of the different arthritic diseases are similar. Yet, clinically individual conditions can be distinguished.

1. Traumatic arthritis
2. Degenerative (osteo)arthritis
3. Inflammatory arthritis:
   a. Rheumatoid arthritis
   b. Juvenile rheumatoid arthritis
   c. Psoriatic arthritis
   d. Ankylosing spondylitis
   e. Reiter syndrome
4. Infectious arthritis:
   a. Gonococcal arthritis
   b. Syphilitic arthritis
   c. Tuberculous arthritis
   d. Lyme disease–associated arthritis
5. Metabolic arthritis:
   a. Gout
   b. Pseudogout
6. Arthritides associated with connective tissue diseases: systemic lupus erythematosus, scleroderma, chronic inflammatory bowel disease, reflex sympathetic dystrophy, and sarcoidosis.

Traumatic Arthritis

The immediate intra-articular response of the joint tissues to single or repetitive episodes of acute trauma is release of proinflammatory cytokines starting a cascade of inflammatory events.[46] This response, traumatic arthritis, is manifested in the form of pathologic and clinical states, the nature of which is generally determined by the magnitude of the trauma sustained by the joint tissues.[39,40] *Minor trauma* to the joint tissue may result in compression, or shearing of the retrodiscal tissue and capsule or dislocation of the disc.

Moderate trauma may cause damage to the synovial lining, resulting in subsequent edema and mild serohemorrhagic effusion that can cause hemarthrosis and an inflammatory response in the synovial membrane. This inflammation may eventually result in a hypertrophic synovial response and fibrosis, causing cicatricial contractions and adhesions between the joint components and even fibrous ankylosis. In children, traumatic arthritis can cause growth abnormalities, malocclusion, and facial asymmetry. *Severe trauma*, short of producing a condylar fracture, can cause damage to the articular surfaces, subchondral bone, or both, eventually predisposing to or causing degenerative joint disease.

Clinical Findings

Acute traumatic arthritis presents with severe jaw pain both at rest and with movement. The joint is tender to palpation, is occasionally swollen, and has a decreased range of motion. Effusion in the joint space and edema or hemorrhage in the retrodiscal tissue can cause an increased distance between the articulating components on the traumatized side that results in a posterior open bite. The acute symptoms usually subside within a few days or weeks.[47] In cases of severe trauma, however, the condition may eventually progress to persistent limitation of motion, ganglion formation, intra-articular disc derangement, or degenerative joint disease.

Imaging Findings

As a result of edema and swelling, the intracapsular and capsular structures can increase in thickness. This can be reflected radiographically as an increased distance between the roof of the glenoid fossa and the condylar surface in the closed-mouth position. Late severe traumatic changes in the joint may be manifested as degenerative joint disease or as bony ankylosis.

Diagnosis

A thorough history must be taken and a careful physical examination of the TMJ must be performed after injury to exclude presence of condylar or other mandibular fractures. The diagnosis of traumatic arthritis of the TMJ is based on a history of trauma and on the absence of the characteristic features of the other forms of arthritis. Trauma to the TMJ can aggravate the inflammatory status of other preexisting forms of arthritis. The use of arthroscopy to evaluate the intra-articular disc and for lavage of the joint after condylar trauma has been reported, but the long-term benefit of such a procedure is still uncertain.[48,49]

Degenerative (Osteo)arthritis

Osteoarthritis is the most common form of arthritis affecting the human skeleton and is related to increased mechanical loading, physical stress, and traumatic injury of the joint. Consequently, the joints most often affected are the weight-bearing joints such as the hips, spine, and knees. Hand joints are also commonly affected, especially in women. Systemic, genetic, endocrinologic, metabolic, and/or vascular factors, in combination with local mechanical factors, influence the development and progression of the disease.[39-41]

OA is also the most common disease affecting the TMJ. Radiographic evidence of OA of the TMJ occurs in 14% to 44% of symptom-free individuals, and histologic evidence of the disease occurs in 40% to 60% of studied populations.[50] However, clinical evidence of the disease occurs in only 8% to 16% of the population. OA of the TMJ has a strong predilection for women and affects patients at any age, but is more prevalent beyond the age of 40 years. Generally OA is unilateral, although bilateral involvement does occur; in these cases, one side usually shows greater severity.[39-42]

OA characteristically affects the articular cartilage of synovial joints and is associated with simultaneous remodeling of the underlying subchondral bone and secondary

involvement of the synovium. Synonymous terms such as osteoarthrosis, arthrosis, and arthritis deformans are commonly used in Europe, whereas osteoarthritis, degenerative joint disease, and degenerative arthritis are the most commonly used terms in North America.

Clinical Findings

The large weight-bearing joints are predominantly affected by OA. A gradual onset is followed by a chronic course. When the TMJ is affected, the patient usually complains of pain and tenderness in the joint and masticatory muscles. The patient may also complain of jaw muscle fatigue, stiffness and tiredness, difficulty opening the mouth, reduced range of motion, and crepitation during mandibular movements.[51] Osteoarthritis is usually characterized by a lack of morning jaw stiffness; if present, this stiffness lasts no more than 30 minutes.[39,40] The TMJ symptoms may be present in the absence of similar symptoms in other joints of the body. Because of the bony thickening and marginal osteophyte formation in the mandibular condyle, a palpable swelling may occur over the joint.

Although radiographic changes in the TMJ may be observed bilaterally, symptoms may be unilateral. Other associated symptoms include referred head and neck pain and earache. OA may affect the TMJ primarily (primary OA) as a result of the normal wear and tear of the joint components that occur with aging. This form of OA usually begins in the fifth decade of life, with slow onset, and runs a course of mild symptoms. The other form of OA of the TMJ is secondary and is usually associated with macrotrauma or chronic microtrauma. This form affects patients 20 to 40 years old and produces more symptoms than the primary form. In these patients, the symptoms may be associated with chronic myofascial pain and dysfunction (MPD) or intra-articular disc derangement.[39-42,52]

Articular cartilage receives its nutrition from the synovial fluid, not the subchondral bone. After maturity of the epiphyseal plate, perforating vessels can no longer supply the cartilage with nutrients or remove waste products. Changes in the synovial fluid therefore influence the metabolism of the cartilage.[53,54]

Many hypotheses regarding the initial event triggering OA have been postulated, including mechanical, inflammatory, and chemical insults that release collagenases and proteolytic enzymes, causing degradation of the cartilage. Abnormal and repetitive mechanical stresses may exceed the functional capacity of normal articular tissues. The result is a decreased collagen stiffness, leading to increased hydration of the proteoglycan-water gel.[53] Other hypotheses suggest that cartilage breakdown is the result of weakness of the subchondral bone secondary to microfractures from excessive loading. Inflammatory mediators and waste products are also likely causes of degeneration. Alterations of synovial fluid or reduced quantities, causing improper lubrication and nutrition of the cartilage, may also play a role. These phenomena lead to friction of the cartilage and collagen destruction.[55]

Early in OA and chondromalacia, which are indistinguishable, the water content of the cartilage matrix is increased from swelling and breakdown of the collagen fibrils.[41,51,56] Proteoglycans are depleted, and chondrocytes cluster while proliferating in an attempt to repair. These histologic findings are manifested mostly in the deeper layers of cartilage, sparing the superficial layer until advanced disease develops, which may take years.[57] As the disease progresses, chondrocytes degenerate and synovial cells destruct, releasing proteolytic and collagenolytic enzymes; this results in more degradation. As the process advances, tissues lose integrity, and the cartilage splits and fibrillation occurs. This leads to adhesions as the cartilage thins. The marrow contained within the subchondral bone then fibroses. Macroscopic changes identifiable on radiographs include osteophyte formation, sclerosis, surface erosions, subchondral cysts, and deformations. Extra-articular responses such as muscle pain and atrophy may be evident as the mandible length is altered and the occlusion changes.[58]

Although OA may develop without disc displacement, internal derangements are highly correlated with TMJ OA.[39-41,59,60] Cartilage degradation, altering the sliding properties of the joint surfaces, and alterations of the synovial fluid, giving rise to increased friction and adhesive wear, impair disc movement.[45] Degradative products from the OA cartilage are then released into the synovial fluid. When it is produced in large quantities, it cannot be reabsorbed by the synovial membrane or cleared. Mediators of inflammation are also released in response, causing synovitis. The osteoarthrosis and synovitis is termed osteoarthritis. The synovial membrane is not innervated, but the mediators of inflammation produced by the synovium stimulate capsular nociceptors.[61] This leads to joint tightness and continued stretching and elongation of the attachments, causing anterior displacement. Limitation of the mandibular opening can then ensue from the malpositioned disc. The peridiscal tissues, such as ligaments and muscles, are also subject to alteration from the changes in the articular surface. As the posterior attachment elongates, the nociceptors within the tissue are stimulated, causing pain. As the ligaments are subjected to tensile forces from the altered frictional capacity and elongation, they extend beyond their span of elasticity and deform. As they elongate, the collagenous component of the ligament is disrupted and the tissue may rupture or lacerate. It is these ligamentous attachments of the disc that keep it anchored to the condylar head and resist displacement. As the functional limits of the ligament are exceeded, nociceptors are stimulated, causing sprains and pain.[58] Anteriorly displaced discs are also subject to compressive loads placed on their posterior attachment. Maladaption, inflammation, and perforation are then possible as the inflammatory process continues. However, these are not the only adaptive changes that occur. There can be decreased vascularity and elastin content as collagen increases and fibrosis occurs. This can act as a pseudodisc and withstand compressive loads. Autopsy studies revealed that 50% of elderly patients had joint degeneration, although no disc

problems were reported in life. Eighty percent of patients with displaced discs had similar findings. This may suggest that displaced discs are a sign of OA, not a cause of OA.[62]

Classification and findings of TMJ OA should include the stage of cartilage destruction and the grade of synovitis rather than the degree of internal derangement. As reported by Dijkgraaf and others,[63] TMJ cartilage degeneration can be separated into four stages. In the *first stage* of OA, the initial repair stage, an imbalance of synthesis and degradation of extracellular matrix by chondrocytes is encountered. Growth factors, including insulin-like growth factor I, become evident in this stage.[63] Electron microscopy reveals increased metabolic activity, with increased DNA synthesis evident in chondrocytes and increased synthesis of the extracellular matrix. In the *second stage* of OA, the early stage, extracellular matrix synthesis increases but is exceeded by degradation from the increased activity of proteases. Cartilage swelling ensues, resulting in an irregular surface and a net loss of articular cartilage.[40,58] Characteristic clusters of chondrocytes with increased metabolic activity in the swollen areas are also seen. Chondrocyte and cartilage necrosis follow in all cell layers, leaving attempts at repair disorganized.[59] Synovial fluid analysis during this early stage reveals metabolic products of arachidonic acid, IL-1, IL-6, TNF-α, and other proteases. Arthroscopic examination reveals swelling, softening, and fibrillations. Common clinical complaints during this phase include pain and limited range of motion. In the *third stage* of OA, the intermediate stage, articular cartilage is lost as synthesis is exceeded by degradation. Histologic evaluation reveals thinning, vertical splitting, and fibrillations of the cartilage as clusters of chondrocytes continue to necrose. Staining of proteoglycan continues to be reduced, and the collagen network becomes more haphazard. Biochemical markers such as cytokines and fibronectin continue to fill the joint space. Arthroscopically, cartilage continues to thin, and a displaced disc may be evident. Pain with limited range of motion continues and can now be accompanied by joint clicking. In the *fourth stage* of OA, the late stage, increased degradation exceeds synthesis or reduced degradation equals decreased synthesis. Histologically, fibrillations are extensive, bone becomes denuded, and proteoglycan staining is nearly lost. Extracellular matrix synthesis is reduced, whereas protease activity can be reduced or increased if residual OA is occurring. Arthroscopic evaluation is remarkable for severe fibrillations, exposed bone, disc displacement, and possibly angiogenesis.[39-41]

Imaging Findings

Radiographic studies of OA of the TMJ reveal an incidence of 40% in patients older than 40 years and 100% in patients older than 80 years. Approximately 50% of the population has radiographic changes, but only 30% of these patients are symptomatic.[39,40] Because OA affects the articular cartilage first, the early changes may escape radiographic detection, or the radiograph may only show a reduced joint space, indicating loss of the articular cartilage and/or perforation of the disc. The most common early radiographic change in the condyle is subchondral bone sclerosis because of thickening of the subchondral bony plate. As the disease progresses, there may be flattening and marginal lipping of the condyle and flattening of the articular eminence. In the late stages of the disease, the changes are in the form of erosion of the cortical plate, osteophyte formation, or both. Occasionally, in the late stages of the disease, subchondral bone breakdown may also occur, causing the formation of a bone "cyst" within the condyle.[39,40]

MRI of the TMJ with OA may reveal perforation, damage, or displacement of the articular disc, whereas osseous changes are best delineated by computed or linear tomography.[28,89] High-resolution ultrasonography may also be a valuable diagnostic aid for the detection of abnormal condylar morphology in OA.[64]

Laboratory Findings

A combination of arthroscopy and synovial fluid analysis is useful as an important diagnostic modality for the early detection of OA. Recent studies using synovial fluid analysis have shown a correlation of pain and disease progression with TNF-α, interleukin 1β, stromelysin, and bradykinin.[65-68] Keratan sulfate levels in the synovial fluid are higher in joints that had arthroscopic evidence of early OA than in normal joints.[65]

The synovial fluid aspirate may show a slight elevation of white blood cells (often less than 2000/μL) and fewer than 30% polymorphonuclear cells, and rheumatoid factor is usually absent.[40] The ESD is usually normal or only slightly elevated, and high values may only be present when the disease has an acute inflammatory component.

Diagnosis

The diagnosis of OA is based mostly on clinical findings and radiographic studies and is usually easy to make when the typical features of the disease are present. The most difficulty is encountered in differentiating OA from early MPD and from RA. Therefore, the differential diagnosis of OA of the TMJ should include RA and its variants, MPD, and various forms of intra-articular disc derangement. Features distinguishing OA from MPD include the more localized nature of the pain, the frequent presence of joint tenderness, and the presence of joint crepitation in the former. When both conditions are present concurrently, as is often the case, the history may help determine which is the primary condition.[40,42]

Inflammatory Arthritis

Rheumatoid Arthritis

Rheumatoid arthritis is a chronic inflammatory disease that primarily affects the periarticular structures such as the synovial membrane, capsule, tendons, tendon sheaths, and ligaments. It secondarily involves the articular cartilage and subchondral bone. The prevalence of RA among the general population is about 2% to 2.5%, with a female-to-male predilection ratio of 2.5 to 3.0:1 and a peak onset of the

• BOX 38-1 Classification Criteria for Rheumatoid Arthritis

Morning stiffness (>1 hour)
Swelling (soft tissue) of three or more joints
Swelling (soft tissue) of hand joints (PIP, MCP, or wrist)
Symmetric swelling (soft tissue)
Subcutaneous nodules
Serum rheumatoid factor
Erosion and/or periarticular osteopenia, in hand or wrist joints, seen on x-ray

The first four of the listed criteria must be continuous for 6 weeks and observed by a physician. Diagnosis requires at least four criteria.

Approximately 50% to 75% of patients with rheumatoid arthritis have involvement of the temporomandibular joint during the course of the disease.[40,57,70-72]

disease between the patient ages of 40 and 60 years.[69,70] To guarantee uniformity in investigational and epidemiologic studies, the American College of Rheumatology has developed classification criteria (Box 38-1).

Clinical Findings

The disease often has an insidious onset and runs a slow, chronic course with progressive destruction of the articular soft tissues and eventual destruction of the cartilage and bone. It has asymmetric, polyarticular involvement, and the small peripheral joints are affected first (wrists, elbows, and ankles). It then progresses symmetrically toward the central skeleton, involving the knee, shoulders, and cervical spine. In the advanced stages, when the inflammatory tissue infiltrates the articular cartilage and bone, erosion and destruction of the articular disc, cartilage, and subchondral bone result.[73]

Such total destruction causes joint deformity and loss of joint function. Joint deformity may also result, in part, from involvement of the tendons, muscles, and ligaments.[39-41,46] RA also has characteristic extra-articular and systemic features that include ocular involvement such as episcleritis, iritis, and keratoconjunctivitis; pulmonary features such as pleurisy, pleural effusion, and fibrosis; cardiac features such as pericarditis and cardiac arrhythmias; vasculitis causing skin ulcerations and osteoporosis; and the presence of subcutaneous nodules in pressure and friction areas in 20% to 25% of patients. Systemic signs and symptoms of RA include fatigue, weight loss, fever, and anemia.[40] When RA is present in combination with anemia, neutropenia, thrombocytopenia, and hypersplenism, the condition is called *Felty syndrome*.[40,74]

A close relationship exists between involvement of the TMJ and the severity of the systemic disease. When the TMJ is involved, it is bilateral in 34% to 75% of those patients.[72] Signs and symptoms of TMJ involvement include deep, dull, aching pain in the preauricular area, especially during function; muscle tenderness with decreased bite force; limited range of motion; crepitation or clicking; and morning joint stiffness.[55,75-77] The pain is occasionally referred to the temporal region and angle of the mandible. As the disease progresses, the condylar bone is resorbed and scar tissue is formed between the joint surfaces and within the joint capsule. This causes further limitation of movement of the jaw.[39,40]

Mandibular movement may be severely limited in the late stages of the disease. This is usually caused by fibrous ankylosis and rarely by bony ankylosis.[78] Perhaps the most striking feature of advanced RA affecting the TMJ is development of a progressive class II malocclusion and anterior open bite deformity with impairment of chewing and phonation. This deformity is caused by loss of normal ramus height secondary to destruction of the mandibular condyles.

Imaging Findings

Because RA is primarily a soft tissue disease, the early stages are characterized by the absence of radiographic changes. Even when these changes are present, they lack specificity and are difficult to interpret. However, with the use of MRI, changes such as disc destruction and/or displacement, condylar cortical bone erosion, joint effusion, and cartilage irregularity and thinning can be seen.[79,80] Once bone is involved in the later stages of the disease, radiographic changes in the TMJ occur in 19% to 84% of patients[55,71]; the incidence and severity of these changes are related to the duration of the disease.

The radiographic features of RA of the TMJ include loss of joint space, condylar destruction, and flattening and anterior positioning of the condyle. This may be accompanied by flattening and anterior positioning of the condyle as well as flattening of the articular eminence and erosion of the glenoid fossa.[81-83] In advanced stages of the disease, the radiographic changes may include a sharp, pointed condyle, osteophyte formation, lipping, shortened posterior ramus length causing premature posterior occlusion, an anterior open bite, and deepening of the antegonial notch.[39,40]

Laboratory Findings

RA has an autoimmune component, with 80% of RA patients testing positive for an immunoglobulin (Ig) directed at the Fc region of IgG known as rheumatoid factor (RF). High titers of RF have been correlated with severe joint destruction and subcutaneous nodules. Testing for RF by latex agglutination or sensitized sheep cell agglutination detects IgM antibodies, although IgG, IgA, IgE, and IgD antibodies have been described. IgM antibodies have the ability of complexing with five IgG molecules and are believed to be the cause of synovial inflammation. Smaller molecules, such as IgG antibodies, are believed to participate in the systemic manifestations and vasculitis common to this disease. Despite the strong association of RF with RA, it is not found only in this disease state. Chronic antigen presentation, as seen in diseases such as bacterial endocarditis, tuberculosis, viral infections, and advanced age, has also resulted in the formation of RF. None of these states is associated

with HLA-DR4, suggesting that the etiology may result from a combination of RF with the genetic antigen.[41,60] Other test results that are less specific for RA include a decreased serum albumin level and the presence of antinuclear antibody (ANA) in 15% of RA patients. HLA-Dw5 and HLA-DRw antigens are also both positive in 50% of RA patients.[39-42,46]

The preliminary diagnosis of RA is frequently based on clinical and radiographic findings, and laboratory tests are used to confirm the diagnosis. The most commonly used test is for RF, which is positive in 70% to 80% of patients with RA. Although the test is not totally diagnostic, it has a good diagnostic and prognostic value when the factor is present in high titers (above 1:1280). In these patients, the disease has a more severe and progressive course. However, the test is also occasionally positive in patients with one of the rheumatoid variants and in approximately 5% of healthy subjects.[84]

The Westergren erythrocyte sedimentation rate (ESR), although not a highly specific test for RA, is elevated in approximately 90% of patients during active stages of the disease, and the test often is used to follow the course of the disease.[77] The complete and differential blood cell counts frequently show a normal white blood cell count, although leukocytosis or leukocytopenia can occur in patients with RA. An elevated platelet count may accompany the stages of high activity of the disease, while mild anemia is reported in approximately 25% of patients. Most of the latter patients have a normochromic or slightly hypochromic, normocytic anemia. Synovial fluid aspirated from a joint with RA is usually cloudy; the viscosity is reduced and the white cell count is high (greater than 20,000/μL).

Diagnosis

The criteria for diagnosis of generalized RA are based on the presence of several clinical, radiographic, and laboratory findings for at least 6 weeks.[39,40,46] The diagnosis of RA of the TMJ is frequently less difficult because involvement of the TMJ often occurs in the advanced stages of the disease and, at that point, the diagnosis of RA has already been established. In these instances, the signs and symptoms, along with the positive radiographic findings, form the basis for diagnosing involvement of the TMJ by the disease.[84] However, in the absence of an already established diagnosis, the differential diagnosis of TMJ involvement should include psoriatic arthritis (PA), ankylosing spondylitis (AS), gout, and OA.

Differentiation of RA from the rheumatoid variants is based on factors such as age of the patient, pattern of involvement (symmetry), number and type of joints involved (polyarticular and peripheral joints), presence of rheumatoid nodules, and, to a lesser degree, laboratory findings (positive RF). Differentiation of RA from OA is less difficult and also is based on the clinical and radiographic findings and, to a greater extent, on some of the laboratory tests.[85]

Juvenile Idiopathic Arthritis

Juvenile idiopathic arthritis (JIA; also juvenile rheumatoid arthritis, JRA) is a chronic inflammatory involvement of the joint lining that has an onset before the age of 16 years. The overall prevalence of JIA is uncertain, but estimates of the number of children affected in the United States range from 30,000 to 250,000.[86] The disease occurs predominantly in girls, with a female-male ratio of 2:1 to 3:1, and it has two peaks of onset, one between the ages of 1 and 3 years and the other between the ages of 8 and 12 years.[39-41]

The reported TMJ involvement in patients with JIA varies considerably, mostly because of the difference in the methods of examination in different studies. Nonetheless, up to 41% of children with JIA have TMJ involvement, with significant adverse effects on occlusion, oral health, and facial growth.[87-89]

Clinical Findings

Based on the manifestations of the disease during the first 6 months and a number of other factors, JIA is classified into three major subtypes: systemic, polyarticular, and pauciarticular. The latter two are often further subdivided into two subtypes.[46]

Systemic JIA, called *Still disease,* occurs mostly in boys 5 years of age or younger, can affect any joint, and is usually accompanied by several systemic signs, including high fever, a rheumatoid rash, cardiopulmonary involvement, lymphadenopathy, and hepatosplenomegaly. The major complication of this disease is cardiac failure, but the majority of patients go into remission with minimal or no residual articular complications. Generally, patients in this subtype are seronegative for both RF and ANA.

Polyarticular JIA involves more than four joints and has fewer systemic signs. This subtype can be seropositive for RF and ANA in 50% of patients. The major complication of this subtype is the long-term possibility of deformity and disability from the polyarthritis.[74]

Pauciarticular JIA affects girls more often than boys, involves four or fewer joints, and has fewer systemic signs. This subtype usually affects large joints such as the knee, hip, and sacroiliac, but patients rarely experience severe arthritis. Patients in this group are generally seronegative for RF, but the ANA test is positive in 60% to 80% of patients.[40,90] The major hazards of this subtype are iridocyclitis and blindness. The prognosis for articular disability is greater than with the other two forms of JIA.

Although the TMJ can be involved in any of these subtypes, it is mostly affected by the polyarticular subtype. The clinical features of JIA of the TMJ include pain, joint tenderness, crepitation, stiffness, and decreased range of motion.[87-89] Some patients may even develop fibrous or bony ankylosis.

A characteristic feature associated with advanced JIA of the TMJ is a combination of micrognathia and a Class II skeletal deformity[91,92] and is frequently referred to as bird-face deformity. This deformity is a result of the impaired growth of the mandible caused by destruction of the

condylar growth site. Alterations in the soft tissues adjacent to the TMJ, such as scarring of the capsule and ligaments and changes in muscle strength, also can interfere with the normal growth processes of the mandible. The prevalence and severity of such deformity in patients with JIA of the TMJ are influenced by the age of onset and the duration of the disease. The prevalence of this deformity ranges from 0% to 38%.[78,92]

Imaging Findings

The early radiographic changes of JIA of the TMJ may not be visible on a conventional radiograph. However, these changes can be detected on MRI and include cortical bone erosion, disc thinning and perforation, reduction of the joint space, and pannus and effusion in the joint.[92-94] The radiographic changes usually appear late, and the severity of these changes is generally related to the duration of the disease. The radiographic findings in JIA of the TMJ in general resemble those of the adult disease and include erosion of the superior surface of the condyle (leaving a flat, horizontal, or inclined articular surface). The eminence may be eroded and flattened to the same degree as the condyle.

In advanced stages of the disease, these changes may significantly affect growth of the mandible and face. The mandible appears micrognathic, with a downward and backward rotation of the chin and an anterior open bite. This deformity is associated with radiographic evidence of deepening of the antegonial notch.[47,95,96]

Laboratory Findings

Laboratory findings in patients with JIA are not consistent and, when present, the abnormality varies with the mode of onset. RF is positive in 5% to 20% of patients with JIA, mostly with the pauciarticular and polyarticular subtypes, while the ANA test is positive mostly in patients with the pauciarticular subtypes (60% to 80% of these patients). Other laboratory findings, including low-grade anemia, leukocytes, thrombocytopenia, and elevated ESR, may also vary according to the subtype of JIA.

Diagnosis

A diagnosis of JIA of the TMJ is often not difficult to make because involvement of the TMJ usually occurs in the later stages. Because of the presence of fever and generalized arthralgia with the onset of systemic JIA, the differential diagnosis should include bacterial infection, viral polyarthritis, traumatic arthritis, infectious arthritis, and joint involvement with rheumatic fever.

Psoriatic Arthritis

Psoriasis is a dermatologic disease that affects approximately 1% to 2% of the general population. It is characterized by a rash of silvery scales affecting the elbow, scalp, and back. Approximately 5% to 7% of patients with psoriasis develop psoriatic arthritis.[97-99] In 75% of these patients, skin lesions appear before the joint symptoms, whereas arthritis appears first in 10% to 15% of patients; in another 10% to 15% of patients, the symptoms appear simultaneously.[100] PA is an inflammatory, mostly asymmetric, oligoarticular, seronegative arthritis that affects a limited number of joints including those of the hand, knee, and foot.

Reports on the disease incidence relative to sex differ from a predilection for males to equal predilection for males and females.[49,50] The onset of the disease is usually between the ages of 35 and 45 years. PA affecting the TMJ was first described by Franks.[101]

The cause is probably multifactorial, but histocompatibility studies support a propensity for the condition to be associated with several other systemic conditions such as Crohn disease; Reiter, Behçet, and Sjögren syndrome; and aortic incompetence.[46] Heredity and a history of trauma are significant factors in the development of PA.[40,100,102]

Despite the prevalence of PA in other joints, fewer than 35 cases of PA of the TMJ have been reported in the English literature.[103-105] However, some authors suggest that involvement of the TMJ with PA is more common and could be as great as 20%.[106] When PA affects the TMJ, the onset of symptoms occurs by the fourth decade of life and is usually associated with a history of trauma.[107,108]

Clinical Findings

The arthritic changes of PA are mostly limited to the distal interphalangeal and metacarpophalangeal joints, but occasionally may extend to the proximal interphalangeal joints, producing characteristic sausage-shaped digits. Systemic symptoms of PA include fever, fatigue, myalgia, weight loss, and malaise. Joint symptoms include morning stiffness and pain, swelling, and limitation of motion. Other associated symptoms may include nail dystrophy in the form of pitting and oncolysis in 80% of patients, and eye symptoms including conjunctivitis, iritis, and uveitis.[98]

Based on the presence of different clinical features, four distinct patterns of PA are currently recognized: (1) arthritis affecting mostly the distal interphalangeal joints; (2) severe arthritis affecting single or multiple joints, with widespread bone destruction and ankylosis; (3) seronegative polyarthritis that may be difficult to distinguish from seronegative RA; and (4) arthritis that is characterized by the presence of sacroiliitis, spondylitis, and peripheral joint involvement, as well as the presence of HLA-B27 antigen.[40,46]

PA of the TMJ often is unilateral, has a sudden onset, is episodic in nature, and may have a spontaneous remission. Symptoms include pain and tenderness of the joint area and the muscles of mastication, morning stiffness, tiredness in the jaws, joint crepitation, occasional painful swelling of the TMJ capsule, and painful mandibular movements associated with a progressive decrease in the interincisal opening.[103] In severe cases, ankylosis of the TMJ may occur.[104]

Imaging Findings

Radiographic changes associated with PA may be seen in as many as 82% of patients with affected TMJs and include erosion, flattening, osteoporosis, loss of joint mobility, and extreme joint space narrowing. Subchondral bone cysts,

subluxation, and ankylosis are also observed occasionally.[79,106,108,109] The radiographic changes are nonspecific and cannot be easily distinguished from those of other types of arthritis, particularly RA and AS.

Diagnosis

Because the symptoms of TMJ involvement are generally nonspecific, the diagnosis of PA of the TMJ is difficult and is made mainly on the basis of the systemic presentation of the disease. In general, the diagnosis is based on a triad of (1) psoriasis, (2) radiographic evidence of erosive polyarthritis, and (3) a negative serologic test for RF. However, even in the presence of a skin rash, the diagnosis of PA cannot be absolutely confirmed. The differential diagnosis of PA should always include entities such as RA, Reiter syndrome, AS, and gout.

Ankylosing Spondylitis

Ankylosing spondylitis is a disease known by many other terms, but two of the most commonly used are *Marie-Strümpell disease* and *seronegative spondylitis*. It is a chronic and usually progressive inflammatory disease that primarily affects the axial skeleton, most commonly the sacroiliac joint and the vertebral column. When the disease spreads to the peripheral joints, the most commonly affected are the hips, shoulders, knees, wrists, hands, and TMJ. The disease has a prevalence of 0.4% to 1.6% among whites, with a strong familial tendency.[45] It affects both sexes, with a predilection for men up to 10 times greater that for women, and has an onset between the ages of 20 and 30 years.[40,46,110]

When affected, the TMJ is usually involved several years after the onset of the systemic disease and frequently during the late stages of spinal and peripheral joint involvement. Although only sporadic case reports of AS of the TMJ have been published, involvement with AS is reported to occur in 4% to 50% of such patients.[111-113]

Clinical Findings

The clinical signs and symptoms of AS generally arise from chronic inflammation of the synovial tissues and joint capsule and sites of insertion of ligaments and tendons. The inflammation later progresses to ossification and eventually causes limitation of joint motion. In the spine, this results in low back pain and stiffness that are usually worse in the morning but that can be alleviated by mobility and exercise. In the late stages, fusion of the adjacent vertebrae and fixation of the back in extreme flexion causes decreased spinal mobility, lumbar lordosis, and increased thoracic and lumbar kyphosis with limitation of chest movement. The back pain may be referred to the buttocks and the posterior aspect of the leg. Extra-articular manifestations of AS include iritis or anterior uveitis and cardiac symptoms such as aortic insufficiency and conduction defects.[46]

When the TMJ is affected, pain, stiffness, limitation of jaw movements, and, in advanced cases, ankylosis of the joint may occur.[114-116] Often the severity of the TMJ involvement correlates with the severity of the spinal and peripheral involvement, although TMJ symptoms have been reported in patients with only a slightly affected spine.

Imaging Findings

The radiographic features of the disease usually include ossification of ligaments and tendons and sclerotic fusion between the vertebrae. In the late stages of the disease, calcification of the annulus under the paraspinal ligaments gives rise to the characteristic "bamboo spine" appearance. The pelvic radiographs usually show fusion of the sacroiliac joint and sclerotic widening of the margins of the pubic symphysis.[114]

The radiographic features of AS in the TMJ are nonspecific and are observed in 30% of patients. These features usually involve erosive changes in the condyle and fossa, subchondral sclerosis, and osteophyte formation. In the later stages of the disease, narrowing of the joint space and radiographic evidence of restricted anterior translation of the condyle may be detected.[114,115,117]

Laboratory Findings

AS characteristically has a hereditary component; the incidence of occurrence of HLA-B27 antigen is higher in patients with AS than in patients with any other disease of the inflammatory arthritis group. An elevated ESR is reported in as many as 70% of patients with AS, although the test is generally nonspecific and serves only as a rough gauge of the disease. Tests for RF are generally negative.[40,41,46]

Diagnosis

Because of the similarities among RA, PS, and AS, the differential diagnosis should include these entities. However, some features exist that may be helpful in distinguishing AS from the other two conditions. These include involvement of the sacroiliac joint, which, although possible with any of the other types, is only common in AS and is rare in RA. Furthermore, whereas AS may involve peripheral joints, it usually spares the small joints of the hands and feet. Although radiographically apparent erosive changes and narrowing of joint space and osteophyte formation are common in all three diseases, localized or extensive sclerosis is more common in AS, whereas cortical erosion and subcortical bone cyst formation are more common in RA.[39,40,45]

Reiter Syndrome

Classically, Reiter syndrome (RS) is a triad of arthritis, conjunctivitis, and urethritis occurring mostly in men between the ages of 20 and 30 years. More recently, additional frequent features of the disease have been recognized, including mucocutaneous lesions and cardiac and central or peripheral nervous system involvement. The exact cause of the disease is unknown, but the frequent presence of HLA-B27 alloantigen in the patient population has been established. The disease occurs mostly in young men after venereal infection and in both men and women after dysenteric infection.[70] Hans Reiter first described RS in 1916, when a lieutenant in the Prussian army developed the three typical features.[118]

The arthritis in Reiter syndrome often involves multiple joints (resembling RA), but affects mainly the lower extremities. Involvement of the TMJ is rare, but some authors believe its incidence may be grossly underreported because of the lack of specific clinical or histologic features of the disease.[119,120]

Clinical Findings

The manifestations of the disease include development of urethritis, conjunctivitis, and finally arthritis either sequentially or simultaneously. Fever, fatigue, weight loss, and lymphadenopathy often accompany the arthritis. Both the urethritis and the conjunctivitis can develop and resolve without sequelae, or they can cause long-lasting urologic and ocular complications. Skin lesions, known as keratoderma blennorrhagica, may occur on the palms, soles, and glans penis. As many as 80% of patients with Reiter syndrome may show oral lesions in the form of 1- to 10-mm papules on the lips, gingivae, buccal mucosa, and tongue.[107]

When the TMJ is affected, the symptoms are generally acute and asymmetric and include tenderness, erythema, and warmness of the joint.[119]

Imaging and Laboratory Findings

Radiographically, bony changes in the joints affected by Reiter syndrome are only observed in the late stages and consist of erosion of the condyle and loss of the joint space.[119,120] The laboratory findings are mostly nonspecific and may include an elevated ESR, leukocytosis, mild anemia, and negative tests for RF and ANA. Serologic evidence of recent infection and an HLA-B27 marker may be present.[70]

Diagnosis

The diagnosis of Reiter syndrome is clinical and is based on the triad of symptoms that are present in 70% of patients in the first 10 days. However, only the presence of seronegative, oligoarticular, asymmetric arthritis and urethritis is adequate for diagnosis of the syndrome. The differential diagnosis should include PA and other forms of reactive arthritis, such as those associated with ulcerative colitis and regional enteritis and that occurring after intestinal bypass surgery.

Infectious Arthritis

General

Although infectious or septic arthritis of the TMJ is frequently considered a possible complication of such systemic diseases as tuberculosis, syphilis, and gonorrhea, only 22 cases have been reported.[40,121] Some authors attribute the small number of reported cases to misdiagnosis or underreporting and suggest that misdiagnosed septic arthritis in children may account for a significant percentage of cases of mandibular ankylosis.[122,123]

Infectious arthritis can involve the TMJ by direct extension of local odontogenic infections via the pterygomandibular space, from osteomyelitis of the mandible (Figure 38-7), or from parotid, ear, or throat infections.[124] Direct infection can also occur as a result of inoculation of organisms into the joint space during traumatic injury or joint surgery.[125]

The other major route of infection of the TMJ is from a systemic disease such as gonorrhea, syphilis, tuberculosis, or actinomycosis.[40] Risk factors for TMJ infection include the presence of RA, diabetes mellitus, intravenous drug abuse,[126] burn wounds,[127] sexually transmitted diseases,[128] preexisting joint disease,[129] trauma, and steroid therapy.[40,46]

Despite the decreased incidence of some of the systemic infectious diseases known to predispose to septic arthritis, an increase in the frequency of septic arthritis can be expected in the future because of the large number of immunocompromised patients with acquired immunodeficiency syndrome (AIDS) and the wider use of immunosuppressive agents. This form of septic arthritis may be either bacterial (including chlamydia) or fungal in origin.[78,130] Another form of infectious arthritis that can have serious consequences involves infection of a joint prosthesis. Such infection can occur immediately after implant placement or later from hematogenous dissemination of bacteria.[46] However, despite several reports of such infections in the orthopedic literature, only two cases involving the TMJ have been reported.[126]

Clinical Findings

When the cause of the infectious arthritis is systemic, the joint symptoms may be preceded by a prodromal period of symptoms of the primary disease. The acute presentation of septic arthritis includes signs of malaise, fever, chills, sweating, and regional lymphadenopathy. The affected joint (usually one side) is painful, tender, swollen, warm, and erythematous. Movement of the mandible is usually limited and typically elicits severe pain. Occasionally, malocclusion, deviation of the mandible to the contralateral side, and a posterior open bite will occur secondary to the increased amount of joint fluid.

Fluctuation may be present in the region of the joint if the fluid collection is not drained. If septic arthritis is left untreated, it may progress to complete destruction of the condylar cartilage and bone, causing ankylosis, which in children may cause underdevelopment of the mandible and facial asymmetry later in life.

Imaging Findings

Because no bony involvement occurs in the first 7 to 10 days of infectious arthritis, radiographic changes are not demonstrable.[78] However, because of accumulation of intra-articular fluid or pus, a separation of the articular surfaces, in which the mandibular condyle is in a more anteroinferior position, can be seen on either a panoramic radiograph or CT scan of the joint. Later, if the infection is left untreated, bony changes range from destruction of the articular cartilage to total destruction of the joint.

MRI can be used to detect intra-articular pus or accumulation of exudate,[39,40] although it is not helpful in

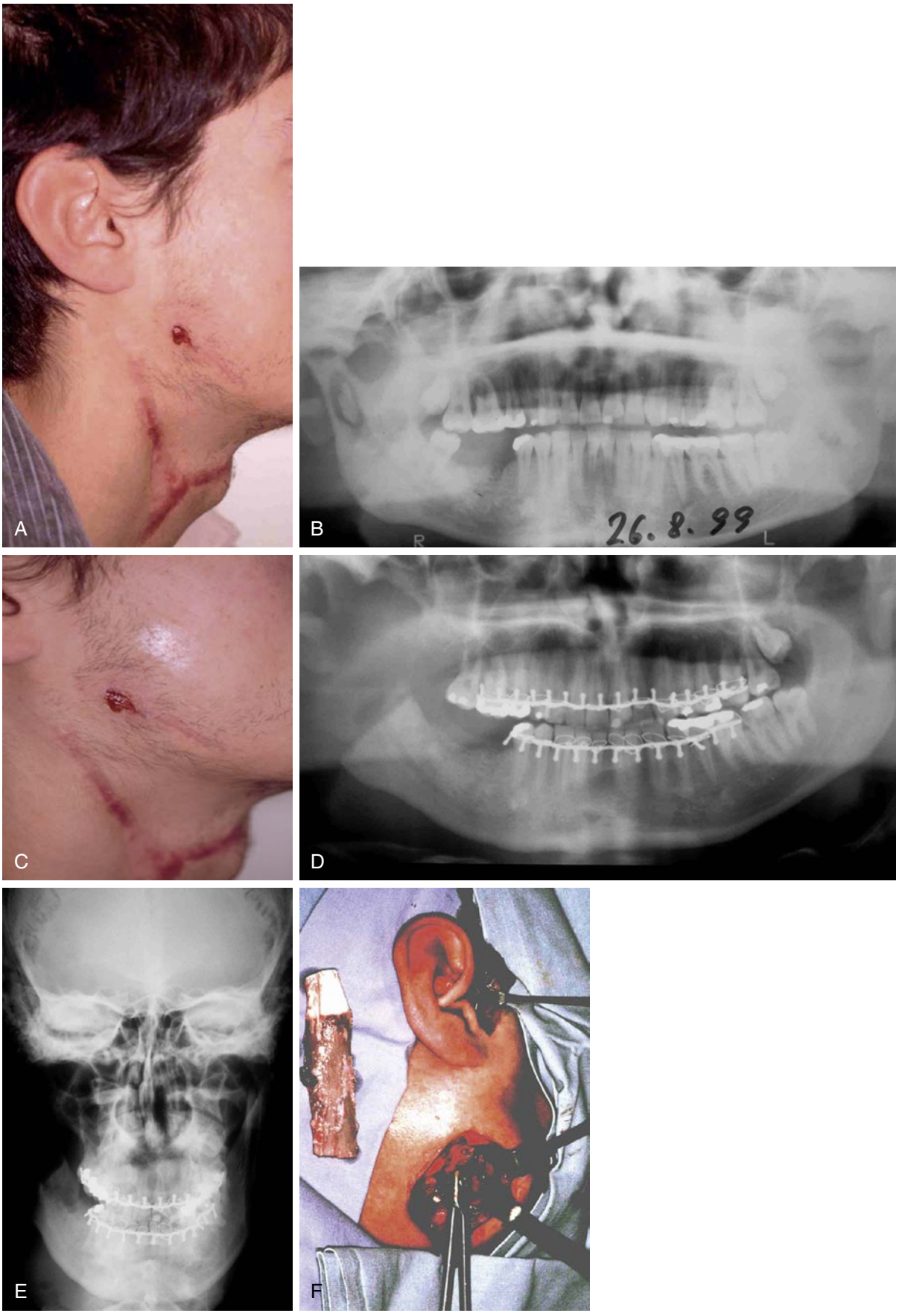

• **Figure 38-7** Clinical case of infectious arthritis deriving from molar dental infection followed by live threatening mediastinitis and proceeding into condyle osteomyelitis. **A,** Side view of patient with incision scars at the right submandibular neck and pus drainage at the mandibular angle. **B,** Preoperative panoramic radiograph with affected right condyle and TMJ. **C,** Close-up side view. **D,** Panoramic radiograph after resection of right condyle. **E,** Anteroposterior radiograph after resection of right condyle. **F,** Osteochondral rib graft, preauricular and submandibular access.

distinguishing infection from inflammatory, traumatic, or degenerative processes in the joint.[40] A bone scan usually shows an increased uptake in the joint capsule in the presence of septic arthritis, and it can detect bone changes sooner than other imaging studies.[121]

Laboratory Findings

Laboratory tests for septic arthritis in the presence of systemic signs should include a complete blood cell count, a differential cell count, ESR, C-reactive protein determination, and blood culture. Joint fluid should be aspirated for analysis and culture whenever feasible. The aspirated fluid should be examined with a Gram stain, culture, and antibiotic sensitivity testing, a complete blood cell count, and a differential cell count. Glucose and hyaluronic acid levels also should be analyzed. These levels are usually decreased. Typically, the aspirated fluid from an infected joint contains cloudy exudate and sometimes pus. The number of leukocytes is elevated, and the cells are predominantly of the polymorphonuclear type.

Although bacterial growth is obtained in only 62% of cases,[121] when positive it confirms the diagnosis of septic arthritis. The most commonly isolated organism from patients with septic arthritis of the TMJ is *Staphylococcus aureus*,[131,132] although isolation and growth of other organisms, such as gonococci[128] and viruses,[133] have also been reported.

Diagnosis

The diagnosis of septic arthritis should be considered in all cases of monoarthritis associated with high-grade fever, acute severe pain, and tenderness of the TMJ. The diagnosis is confirmed by identification of the organism in the joint aspirate. In the absence of such a laboratory finding, the clinical presentation, radiographic features, other positive laboratory values, and response to antibiotic therapy should provide a basis for the diagnosis.[40,41,134] The differential diagnosis should include RA with acute exacerbation, JIA, PA, traumatic arthritis, viral polyarthritis, disseminated malignancy, and gout.

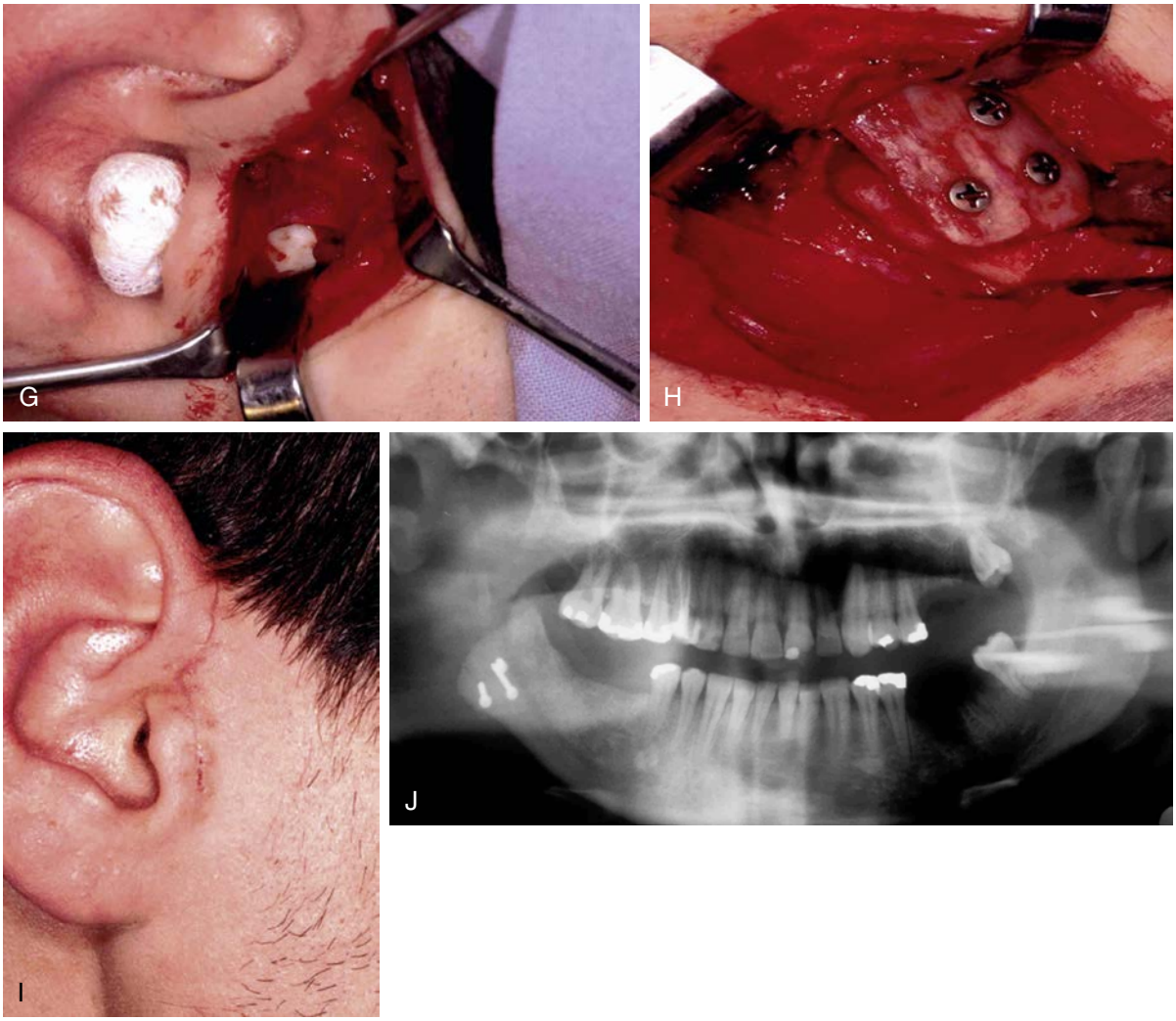

Figure 38-7, cont'd **G,** Preauricular view of inserted graft. **H,** Submandibular view of inserted graft. **I,** Preauricular scar after 2 weeks. **J,** Panoramic radiograph after reconstruction with osteochondral rib graft.

Continued

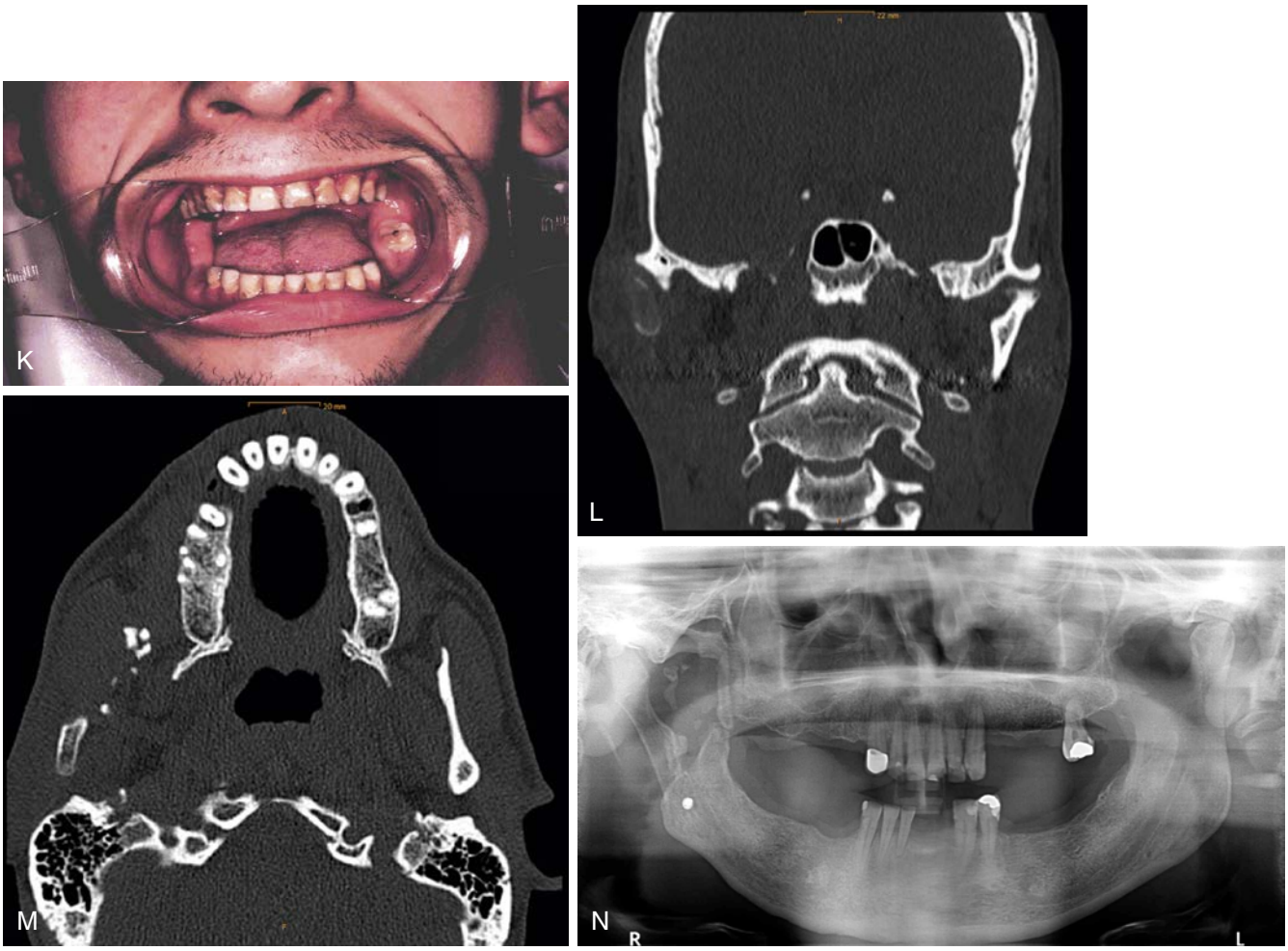

Figure 38-7, cont'd **K,** Mouth opening without mandibular deviation. **L,** Coronal view on patient's computed tomography (CT) scan—10 years after surgery. **M,** Axial view on patient's CT scan—10 years after surgery. **N,** Panoramic radiograph—15 years after surgery.

Lyme Disease–Associated Arthritis

Lyme disease (named after the town of Lyme, CT) is a multisystem disorder that involves the skin, joints, nervous system, and heart. It is caused by the spirochete *Borrelia burgdorferi* and is mostly transmitted by the tick *Ixodes dammini*.[135] Although the disease usually affects only one or two large joints, often the knee, the TMJ can also be involved.[136,137]

Clinical Findings

The initial presentation of the disease is marked by the appearance of a characteristic skin lesion called erythema chronicum migrans (ECM), a clinical marker for Lyme disease. ECM begins as a red macule or papule at the site of a tick or insect bite. Days to a month later, the lesion expands to an average diameter of 10 cm (range, 8 to 68 cm), with partial clearing of the center of the lesion. The outer borders become red and generally flat, while the center is indurated, vesicular, or necrotic. The lesions are usually warm but not painful. They are frequently associated with constitutional symptoms such as fever, malaise, headaches, and regional lymphadenopathy.[138] Generalized lymphadenopathy and splenomegaly are less common findings.

Within a few days to months of the onset of ECM, secondary lesions develop. These lesions are similar in appearance to the ECM but are usually smaller, migrate less, lack the indurated centers, and are not associated with tick bite sites. In some patients, the secondary lesions are associated with a malar rash, conjunctivitis, or, rarely, with a diffuse urticaria.[46] Other systemic signs include neurologic involvement, which appears at the same time as the ECM or weeks to months later. They also include meningoencephalitis, vertigo, short-term memory loss, numbness or tingling of the extremities, atypical facial pain, and bilateral facial nerve paralysis. Cardiac abnormalities are less common, can last from a few days to several weeks, and may be recurrent. They include atrioventricular block, myopericarditis, and cardiomegaly.[138]

Musculoskeletal involvement by Lyme disease occurs in approximately 60% of patients and appears from a few weeks to 7 years after the onset of the disease. The arthritis is usually manifested as a migratory polyarthritis or myalgia

associated with joint swelling. Months to years later, frank arthritis occurs, characterized by intermittent attacks of painful swelling of one or two large peripheral joints such as the knee. The pain is often episodic and of short duration, followed by periods of complete remission and then recurrence. The affected joints are usually swollen and may be warm but are rarely erythematous. Occasionally, joint involvement is polyarticular and symmetric, including the small joints of the hands and feet.

In approximately 10% of patients with arthritic signs of Lyme disease, the condition evolves into chronic arthritis, causing deformity and disability.[46]

Diagnosis

Because many of the signs and symptoms of Lyme disease are nonspecific and may mimic TMJ involvement from other causes, the diagnosis can be difficult, especially in the early stages. Therefore, these conditions should be included in the differential diagnosis. The diagnosis of Lyme disease can be facilitated by a history of tick bite and skin rash. In the absence of such a history, the diagnosis is more difficult, but the presence of an immunoglobulin M antibody to spirochetes may be a helpful diagnostic test.

B. burgdorferi has also been cultured from the skin lesions of ECM and from several body fluids, including the synovial fluid of affected joints.[138,139] Lyme arthritis that persists after antibiotic treatment is correlated with persistence of the spirochete in the synovial fluid.[138,139] Other laboratory findings useful in the diagnosis include an elevated white blood cell count in the synovial fluid (approximately 25,000/μL) that consists mostly of neutrophils, and an elevated serum aspartate aminotransferase.[40,46]

Metabolic Arthritis

Gout and Pseudogout

Gout (uric acid arthritis) and pseudogout (pyrophosphate arthropathy, chondrocalcinosis articularis, and calcium pyrophosphate dihydrate arthropathy) are the two main types of metabolic arthritis affecting the TMJ.[78,140] They are characterized by inflammation of the joint tissues caused by deposition of microcrystals in the synovium. In gout these crystals are sodium urate, and in pseudogout they are calcium pyrophosphate dihydrate.

Gout is characterized by an increase in the serum level of uric acid, generally arising from an inherited anomaly that causes an increase in purine (and uric acid) production and/or a decrease in the excretion of uric acid in the urine. However, it may also be caused by an increase in uric acid production resulting from blood dyscrasias (where cells rich in purine are broken down) or by use of certain medications, such as diuretics.

Pseudogout is regarded by some as an independent disease that often occurs in association with other metabolic diseases, such as hyperparathyroidism and diabetes mellitus.[78] Gout is uncommon in men and women younger than 40 years. It mostly affects men older than 40 years. A suggestion of genetic inheritance exists, with a family prevalence that varies from 40% to 60%. The disease is often associated with tophi (urate deposits) in and around the ear and joints of the extremities, renal disease, uric acid nephrolithiasis, and some degree of renal failure. Although the prevalence of gout is 5% among men 65 years and older and 2% among women of the same age,[140] only a few cases of TMJ involvement have been reported.[140,141] The exact prevalence of pseudogout in the TMJ is uncertain, but it frequently affects persons after the age of 40 to 50 years and has an equal sex predilection.[141,142]

Clinical Findings

The clinical presentation of a metabolic arthropathy is quite characteristic. The onset is usually sudden and is most often monoarticular, affecting the proximal interphalanx of the great toe, the ankle, and the wrists and causing pain and swelling in about 50% to 70% of patients. The affected joint is usually erythematous, warm, and extremely tender. In the acute presentation of the disease, the patient may feel ill and feverish.

When the TMJ is involved, the patient's ability to open the mouth wide and masticate is significantly decreased.[140,142-144] Occasionally, the onset and presentation may be less dramatic in the TMJ than in other joints, and the signs and symptoms are less severe. The latter include mild pain, limited mouth opening, and noise in the joint.

Imaging Findings

Radiographic changes do not become apparent in the joint until several years after the onset of gout. Although no specific radiographic features exist for gout, the changes in the advanced form of the disease have been described as bony erosion, "punched-out" cystic lesions of the bone, bone spurs, and exostoses.

In the case of pseudogout, osseous tophi within the joint and calcification of the disc may be demonstrable in the radiographs. The crystal deposits may have a punctate or linear appearance.[78,142]

Laboratory Findings

Typically, the serum uric acid level is elevated in gout. Aspiration of joint fluid reveals an opalescent fluid. Monosodium urate crystals are present when the fluid is examined under the polarizing microscope. Acute attacks are generally associated with leukocytosis and an elevated ESR. In pseudogout, the serum uric acid is increased in only 30% of patients.[78]

Diagnosis

The diagnosis of gout can be readily made if the disease presents in its acute form. If the symptoms are mild, determination of the serum uric acid level may be helpful. Because the serum uric acid level may also be increased in numerous other conditions, the diagnosis can only be confirmed by identification of uric acid crystals in the synovial fluid or in the surgical specimen. The monosodium urate crystals are needle shaped and have a strongly negative birefringence

when examined by compensated polarized light microscopy. In the absence of such findings, a past history of acute synovitis (especially in the great toe), a history of renal colic, and a family history of gout make the diagnosis more likely. The differential diagnosis of gout should include septic arthritis, pseudogout, acute RA, PA, OA, and local trauma.

Arthritides Associated with Connective Tissue Diseases

Systemic lupus erythematosus (SLE) is a chronic autoimmune multisystem disease arising from a combination of genetic and environmental factors that interact to cause a state of immune hyperactivity. Systems that SLE commonly may affect include the brain and peripheral nervous system, skin, joints, kidneys, lungs, serous membranes, and components of the blood, but other organs of the body also may be affected. The characteristic immune response is caused by certain self-antigens and involves both T- and B-cell activity. One of the most common symptoms of SLE is symmetric polyarthritis, most frequently occurring in the fingers, knees, and wrists. TMJ involvement has been found in a few studies.[45,145,146] In a controlled study of SLE patients, one third had subjective TMJ symptoms, 22% had clinical signs, and 11% had radiographic changes.[45,146]

Scleroderma

Progressive systemic sclerosis is a generalized disorder of connective tissue recognized clinically by thickening and fibrosis of the skin (scleroderma) and specific forms of involvement of organs including the heart, lungs, kidneys, and gastrointestinal tract. Scleroderma occurs in all racial groups and in all geographic regions, showing the highest onset between the ages of 30 and 50 years. The disease is three to four times more frequent in women. Because better diagnostic techniques are now available, the prevalence may be higher than previously recognized. The precise incidence remains undefined, but most studies suggest between 4 and 12 subjects per million per year.[147] Characteristic oral manifestations that may complicate dental treatment include limited mouth opening, TMJ dysfunction, mucogingival problems, xerostomia, telangiectasia, increased periodontal ligament width, and osseous resorption of the mandible.[148,149]

Mixed Connective Tissue Disease

Mixed connective tissue disease (MCTD) is a disorder showing overlapping features with a number of different connective tissue diseases. Because of the various overlapping features that have been reported, the existence of MCTD as a distinct disease entity has previously been considered controversial. Today, however, it is regarded as a distinct rheumatoid disease, although the exact prevalence is not known.[150] Clinical manifestations of MCTD often include concurrent development of features of SLE, scleroderma, polymyositis, dermatomyositis, and RA, but the overlapping features usually occur sequentially. Because of these overlapping features, it often takes several years to verify the most appropriate diagnosis. Early symptoms include fatigue, myalgia, arthralgia, and Raynaud phenomenon. Nearly all patients have joint pain and stiffness.[150] In a series of 10 patients with MCTD analyzed for signs and symptoms in the masticatory system, all 10 patients showed symptoms or signs of temporomandibular disorders, and 7 had radiographic changes in the TMJ.[151] In five patients with normal-appearing mucosa, histologic examination revealed chronic inflammation.

Sjögren Syndrome

Sjögren syndrome (SS) is a systemic autoimmune disease of unknown etiology and pathogenesis leading to xerostomia and dry eyes.[152] These "sicca" ("dry") symptoms result from an autoimmune process that often may affect other organs, such as neural systems, skin, mucosa, lungs, and kidneys. SS also can develop as a secondary phenomenon, in which the sicca symptoms are associated with RA, SLE, or scleroderma. The prevalence of primary SS, judging from blood donor subjects, has been estimated to be 0.08%. SS is sometimes associated with polyarthritis, and thus the TMJ may also be affected.[45]

Summary

More than 100 heterogenous acute and chronic conditions, some with multisystem involvement, can affect the musculoskeletal system. Clinically, the most important of these conditions that affect the temporomandibular joint (TMJ) complex are the systemic diseases of the musculoskeletal system and the systemic connective tissue disorders. The more common systemic diseases affecting the TMJ are seropositive rheumatoid arthritis and juvenile rheumatoid arthritis. Far less common diseases and disorders are ankylosing spondylitis; psoriatic arthritis; Reiter syndrome, also known as reactive arthritis; gout and calcium pyrophosphate deposition disease; systemic lupus erythematosus; scleroderma; mixed connective tissue disease; and Sjögren syndrome, chronic inflammatory bowel disease, reflex sympathetic dystrophy, and sarcoidosis.

Tumors

Tumors of the TMJ are rare. They may develop from the disc, the synovial membrane, and the articular capsule but also the articulating bones, that is, the glenoid fossa and especially the mandibular condyle. As in most other sites benign proliferations are more common than malignancies. As in other bones, the most frequently occurring malignancy is metastatic carcinoma (Figure 38-8). Despite metastatic lesions, consideration should be given to locally invasive proliferations of lymphocytic, parotid, or middle ear origin.[153-155]

Space-occupying lesions of the TMJ may present with preauricular swelling, pain, trismus, deviation of mandibular motion, and malocclusion. All these symptoms also correlate with far more common entities within the plethora of

temporomandibular disorders. Therefore immediate correct diagnosis of neoplasms in the TMJ is demanding and can be delayed. Radiographic examination and interpretation is necessary, and CT and MRI techniques are often helpful. When clinical and radiographic examinations suggest the presence of a tumor, arthroscopy or open arthrotomy is warranted to obtain tissue for histologic evaluation and diagnosis.[153-158]

Although early symptoms are consistent with findings attributable to internal derangement such as limited mouth opening, jaw deviation, and clicking or popping joint sounds, the following signs are indicative of advanced disease. The tumor mass may extend into the middle cranial fossa through the roof of the glenoid fossa. It may also invade through the glenoid fossa posteriorly and present as a lesion of the external auditory canal or middle ear. Growing laterally, it may mimic a parotid neoplasm, creating a preauricular swelling. Anteromedially it can extend into the infratemporal and pterygopalatine fossae and produce symptoms of cranial nerve involvement. Pathologic fracture with sudden onset of pain may also occur.[153-155]

When formulating a differential diagnosis for any jaw lesion, it is helpful to organize the pathologic entities into several categories and then compare the characteristics of the presenting lesions with those of lesions in each category. In the field of oral and maxillofacial surgery, jaw lesions are suggested to be organized into the following six categories[155-159]:

1. Developmental cysts
2. Odontogenic cysts

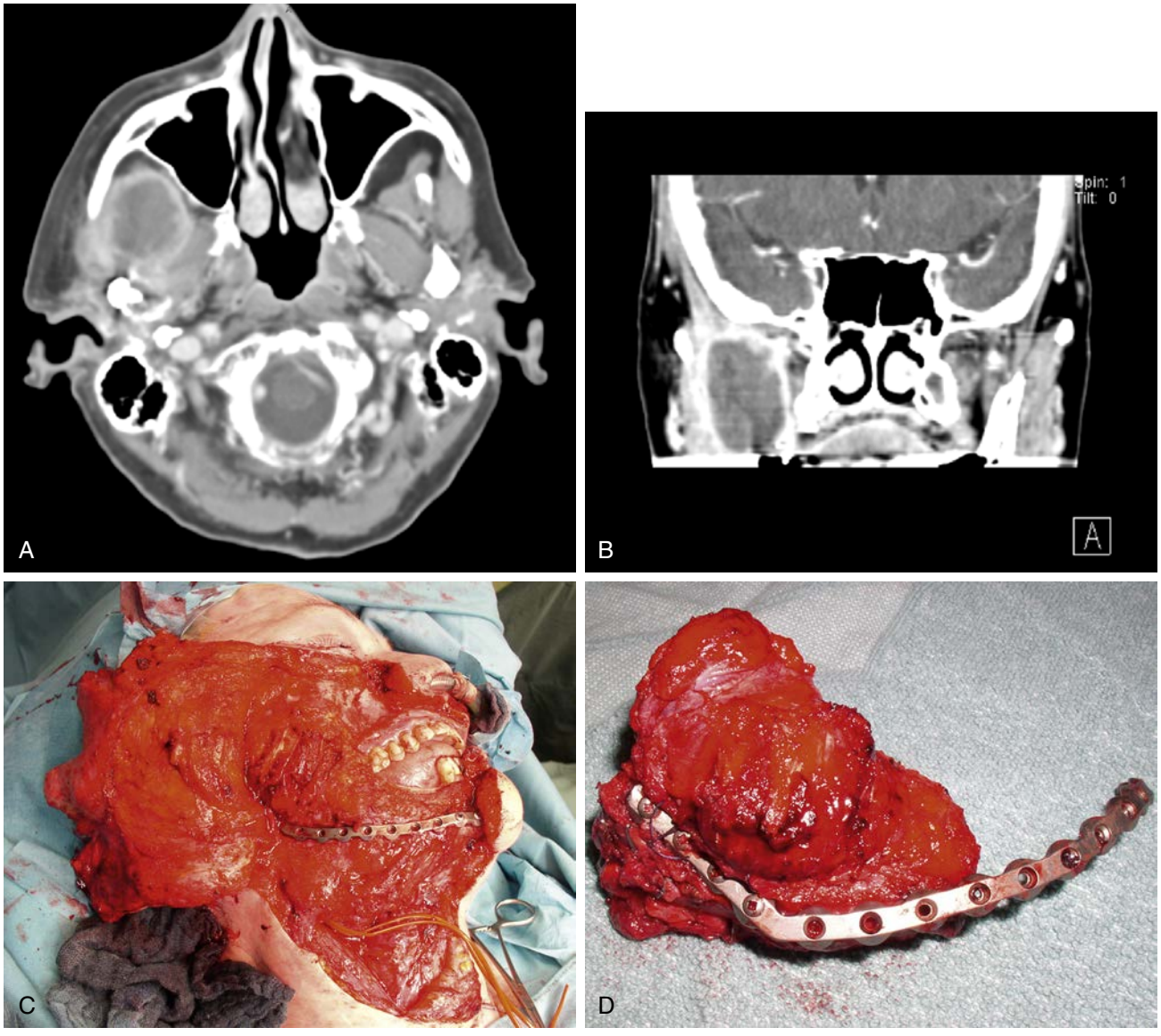

• **Figure 38-8** Clinical case of tumor of the temporomandibular joint (TMJ): recurrence of an oral squamous cell carcinoma in the infratemporal region involving the right TMJ. **A,** Axial view on patient's CT scan—recurrence, right infratemporal region. **B,** Coronal view on patient's CT scan—recurrence, right infratemporal region. **C,** Access via soft tissue degloving and temporary zygoma resection. **D,** Resected tumor specimen including TMJ and attached mandibular reconstruction plate from previous surgery.

Continued

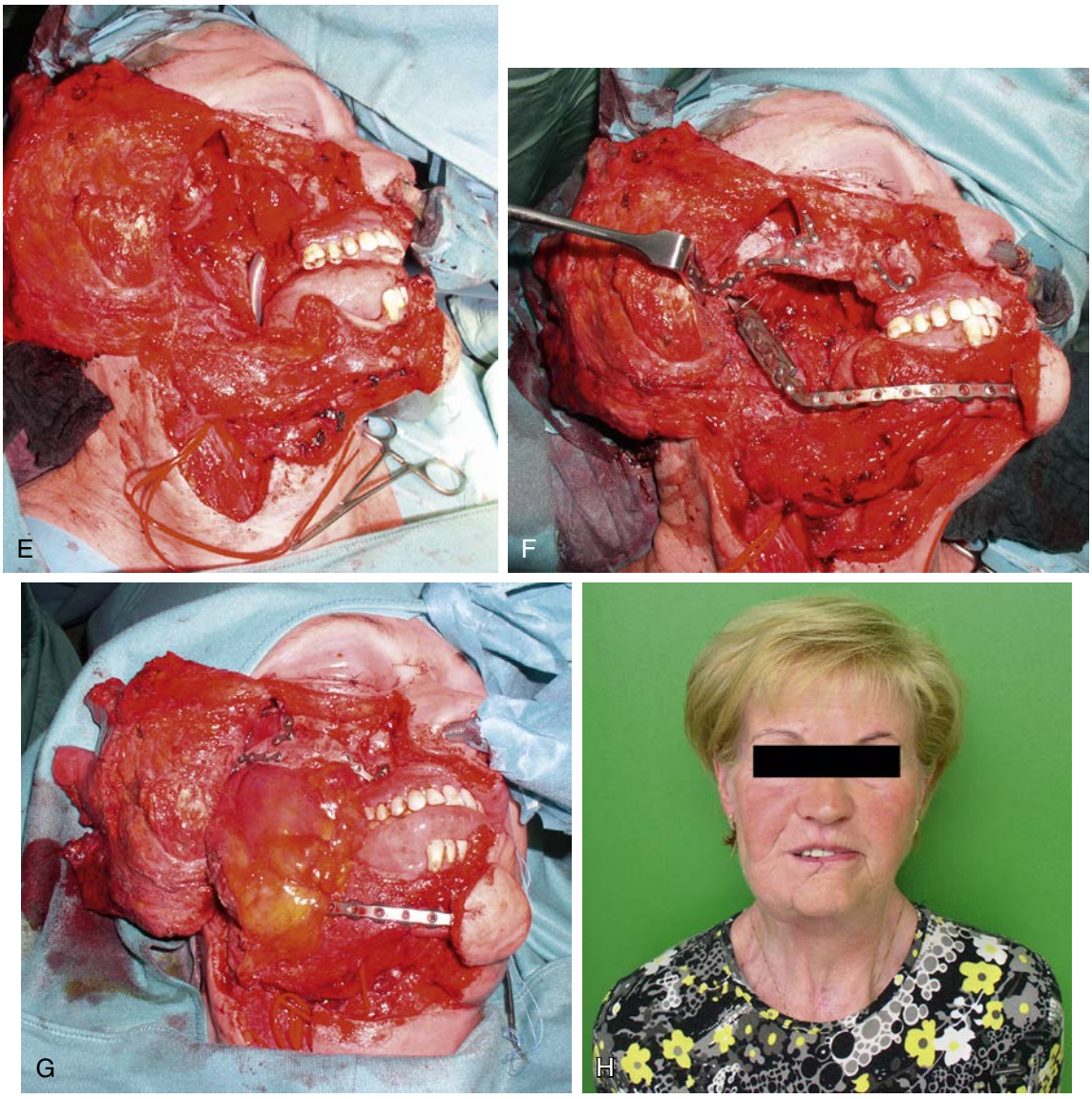

Figure 38-8, cont'd **E,** Empty infratemporal region. **F,** Immediate reconstruction with placement of mandibular reconstruction plate including prosthetic condyle. **G,** Immediate reconstruction with insertion of microanastomosed myocutaneous latissimus dorsi flap. **H,** Postoperative image of patient.

3. Benign odontogenic tumors and lesions
4. Benign non-odontogenic tumors and lesions
5. Inflammatory, metabolic, and genetic disorders
6. Malignant and locally invasive lesions

The presence of developmental cysts, odontogenic cysts, and benign odontogenic tumors in the condyle or TMJ is rare and generally represents an extension of a process that initiated in the tooth-bearing segments of the mandible. Diagnosis and management of those lesions are covered elsewhere and are not discussed here. The benign conditions that are considered here do not all represent neoplasms. Some are cystic lesions but are important in differential diagnosis. Others may be reactive or hyperplastic proliferations, in which the distinction from a benign neoplasm is often unclear.

Benign Tumors, Cysts, and Cystlike Lesions

Condylar Hyperplasia

The articular surface of a normal condyle is composed of fibrocartilage that exhibits appositional growth in contrast to endochondral ossification. Histologic sections of hyperplastic condyles demonstrate the abnormal presence of hyaline cartilage that undergoes ossification and results in abnormal growth. Therefore condylar hyperplasia can have presenting symptoms similar to those of space-occupying benign or malignant lesions, which can displace the condyle from the fossa and cause asymmetry with malocclusion. The etiology of this disorder is not well understood.

Condylar hyperplasia is categorized into two types. The type I deformity, or *hemimandibular elongation*, is the most



Figure 38-8, cont'd **I,** Intraoral soft neopalate of patient 3 years after surgery. **J,** Image of patient 3 years after surgery.

common variant. The mandible is asymmetric, with deviation of the chin to the contralateral side and a concomitant dental crossbite. In patients with the type II deformity, or *hemimandibular hypertrophy*, deviation of the chin is not a prominent feature, but a marked vertical open bite is present on the ipsilateral side of the hyperplasia.[160,161]

Condylar hyperplasia is not a truly neoplastic process but actually a self-limited disorder. Radionuclide bone scans with technetium-99m can be useful in differentiating between active and inactive disorders. Some surgeons favor the use of a high condylar shave to remove the zone of abnormal tissue if the disorder is diagnosed early in its active stage. Removal of only 5 or 6 mm of the most superior condylar surface is usually adequate, and condylectomy is unnecessarily aggressive.[162,163]

Recontouring of the inferior border and angle of the mandible is sometimes necessary to correct the inferior component of the asymmetry. When a bone scan indicates that the process is inactive, orthognathic procedures, such as a vertical subsigmoid osteotomy, can be useful in correcting an open bite while maintaining a functional joint articulation.[162,163]

Chondroblastoma

These tumors develop in the medullary cavity of a bone and are thought to arise from the cartilage of the growth plates. Thus, most cases occur prior to skeletal maturity; the vast majority occur in patients aged 10 to 20 years.

Chondroblastomas usually involve the epiphysis of the distal femur and proximal tibia. These sites are followed in frequency by the proximal humerus and proximal femur. When the tumors develop in more unusual locations, the patients are usually older. Thus, the mean age of patients with tumors of a long bone is 16 years, whereas the mean age in patients with flat and short tubular bone involvement is 28 years.[164] In the mandibular condyle the reported age range has been from 27 to 41 years,[165] and there is a 2:1 male predilection.

Pain is the dominant symptom in the extremities, but swelling or limited motion is prevalent with condylar tumors. Radiographically, they produce a well-defined radiolucency with a sclerotic margin. Flocculent radiopacities may be seen within the lesion.

Chondroblastomas of the skull and facial bones are very uncommon, but it is interesting to note that among the 30 cases reported in a single series, three arose in the mandibular condyle. Twenty-one patients had tumors in the temporal bone, and two of these also extended into the TMJ.[166]

The chondroblastoma is a benign tumor of immature cartilage cells with foci of cartilage matrix formation. The proliferating cell is believed to be a chondroblast. The cells are round to oval, with central or eccentric round to oval nuclei that may have a longitudinal cleft. These cells may be densely packed, and scattered multinucleated giant cells are usually prominent. Interspersed areas show cartilage differentiation and an immature cartilaginous matrix, which appears as an amorphous pinkish tissue. The proportion of these two types of tissue is quite variable. Calcifications tend to form a fine, "chicken wire" pattern around

the chondroblastic cells, although a coarser pattern may be present. Aneurysmal bone cysts develop in about 20% of cases.

Aneurysmal Bone Cyst

Several cases of aneurysmal bone cyst have been reported in the TMJ.[167] These lesions are not actually cysts but rather tumors in which there are widely dilated, blood-filled spaces that are not lined by endothelium. Frequently these tumors occur as a secondary phenomenon within a preexisting pathologic process, most often a giant cell tumor, but also with other conditions such as osteoblastoma, chondroblastoma, and nonossifying fibroma. There is a near-equal distribution between the sexes, and the majority arise in individuals younger than 20 years. In 32 cases in the mandible reported by Trent and Byl,[168] only 2% occurred in the condyle.

The histories concerning the cases in the condyle have varied from rapidly expanding, destructive lesions to incidental findings. The majority of patients had experienced previous trauma.

Pseudocysts

Pseudocysts of the mandibular condyle are asymptomatic radiolucencies with corticated margins. They are seen in the anterior aspect of the condyle and are the result of cupping of the pterygoid fovea; the margins are formed by the dense medial and lateral condylar ridges.

The image is the result of a radiographic distortion when the central x-ray beam does not pass through the condyle at right angles but rather passes obliquely in the horizontal plane and superiorly in the vertical plane. Consequently, the medial ridge is projected posteriorly and superiorly, and the lateral ridge is projected anteriorly and inferiorly. These "lesions" are thus not pathologic processes.

In a Veterans Affairs population of 507 patients aged 22 to 96 years, 9 (1.8%) such cases were found.[169] In a population of 1193 patients aged 18 years and younger, 18 (1.5%) such cases were found.[170]

Idiopathic Bone Cavity (Traumatic Bone Cyst, Hemorrhagic Bone Cyst, Simple Bone Cyst)

Idiopathic bone cavities in the jaw usually are located in the body or symphysis. Approximately 10 cases have been reported in the TMJ.[171] These are essentially asymptomatic lesions. When associated symptoms have occurred, they have usually been caused by a pathologic fracture.

The diagnostic criteria for an idiopathic bone cavity include the presence of a single lesion, the absence of an epithelial lining, and the absence of infection. The lumen should be empty save for some fluid or air. The wall is bony, although a scant amount of fibrous tissue may be present. Many of these cavities appear to undergo spontaneous regression. Similar lesions may be observed in association with other entities, such as florid osseous dysplasia and other fibro-osseous processes.

Central Giant Cell Granuloma

Central giant cell granulomas represent fewer than 7% of all benign jaw tumors; of these, 70% occur in the mandible. The body of the mandible is the area of predilection. There is a female preponderance, and the majority of patients are younger than 30 years. The condyle is an unusual location, although several eases have been reported.[172]

In the condyle, both unilocular and multilocular lesions have been described. Some have been asymptomatic, without functional impairment, even in the presence of preauricular swelling. Histologically, these tumors consist of randomly scattered multinucleated giant cells within a cellular fibrous stroma that also contains extravasated blood. The giant cells are osteoclastic cells, so these lesions represent an osteoclastoma.

A more aggressive giant cell lesion, referred to as a *giant cell tumor,* has been described in the jaws and facial bones but not in the mandibular condyle.[153]

Ganglion and Synovial Cysts

The literature does not always clearly distinguish these two lesions. Whereas the synovial cyst is a true cyst with an epithelial lining, the ganglion cyst is not. *Ganglion cysts* arise in a joint capsule as a consequence of myxoid degeneration of the connective tissue, possibly secondary to a deficiency in the vascular supply. They are not connected to the joint cavity. There is a female predilection with an age range of 30 to 50 years. These lesions are very rare in the TMJ area; only about 10 cases have been reported.[173]

They present as a preauricular swelling, and there may also be joint dysfunction, pain, and tenderness. Bone scans will reveal an increased uptake of technetium-99m. Histologically, these lesions are lined by fibrous tissue and contain a gelatinous material.

Synovial cysts are also uncommon in the TMJ. Five cases have been reported, two of which were associated with a history of trauma.[174] These lesions also present as a preauricular swelling. They are lined by flat or cuboidal cells, which are of synovial origin, and the lumen contains a gelatinous material. These cysts may be the consequence of herniation of the synovium or possibly the result of displacement of tissue during embryogenesis. Following trauma, increased intracapsular pressure may cause degeneration of the adjacent connective tissue.

Hemangioma

Intraosseous Hemangioma

Only five cases of intraosseous hemangioma in the TMJ have been reported.[175] Hemangiomas of bone are found most frequently in the vertebrae and are uncommon in the jaws, where their usual location is in the body of the mandible. These lesions have a 2:1 female-to-male ratio, and there is an age predilection for the second decade.

Among the patients with a lesion involving the TMJ, one was asymptomatic. The others presented with joint pain,

aggravated by movement of the mandible, as well as tenderness over the joint and restricted mouth opening.

Synovial Hemangioma

Synovial hemangiomas are rare lesions, occurring predominantly in the knee joint. They are most unusual in other sites. There is a predilection for female children and young adults.

The findings are typically recurrent, long-standing pain, decreased range of motion, and a spongy, compressible mass over the joint. They may be localized and well circumscribed or diffuse and infiltrative. These hemangiomas are of the cavernous type, with large, dilated, blood-filled vessels that are separated by an edematous, myxoid, or focally hyalinized matrix. Inflammatory cells may also be present. The synovium may develop villous projections, with hemosiderin deposition in the synovial cells.

These lesions may be juxta-articular, intra-articular, or mixed. The intra-articular type is the most frequent, and the tumor is lined by a synovial membrane. The mixed type originates from the synovium and lies both juxta-articularly and intra-articularly, whereas the juxta-articular type is located adjacent to the joint without actual involvement of the synovial membrane.

Radiographs usually reveal nonspecific radiolucencies or opacities. However, the presence of phleboliths is a helpful diagnostic feature.

TMJ involvement has been reported.[176] The case was that of a 43-year-old woman who had been treated for 3 years for masticatory myalgia associated with localized intermittent preauricular pain, restricted motion, and deviation on opening. However, there was no muscle tenderness and no preauricular mass, although there was a painful preauricular depression. Aspiration was not productive. A CT scan showed a soft tissue mass in the posterior portion of the joint. Grossly it was confluent with the synovial membrane.

Arteriovenous Malformation

Facial vascular anomalies are not uncommon findings in maxillofacial surgical patients. Many of these vascular anomalies, such as port wine stains, have a benign course. However, the subset of anomalies classified as arteriovenous malformations (AVMs) has significant morbidity and mortality. Intraosseous AVMs are particularly difficult to diagnose, may not present until adolescence or early adulthood, and often present with symptoms that mimic periodontal disease. Mandibular AVMs account for approximately 1% of all facial AVMs. A small percentage of these present in the TMJ. Death secondary to intractable hemorrhage is reported to occur in approximately 8% of patients.[155]

Treatment of these malformations continues to provide a clinical challenge. Because of the poor prognosis of untreated AVMs, radical cure is mandatory. Treatment modalities used in the past have included radiation therapy, sclerosing therapy, cryosurgery, selective embolization, and surgical resection. Resection of the malformation and the surrounding bone is considered the optimal treatment to prevent recurrence. However, profound surgical hemorrhage and significant postoperative deformity have prompted clinicians to pursue alternative treatments that may have a lower morbidity and mortality. A major advance in the treatment of these malformations has been the development of selective embolization. Selective embolization can serve as the only treatment but is often used as a surgical adjunct to provide preoperative devascularization. Reznik and colleagues[160] and Flandroy and Pruvo[161] described a technique for the treatment of mandibular AVMs in which embolization is performed through direct transosseous puncture. This technique has been further modified to perform the embolization with transosseous microcatheters.

Histologically, AVMs consist of numerous medium- to large-caliber arteries and veins that are directly connected without intervening capillary-size vessels. These vessels are supported by a variable collagenous stroma.

Fibrous Dysplasia

Fibrous dysplasia most commonly presents as an asymptomatic, slow enlargement of the involved bone. Monostotic fibrous dysplasia accounts for up to 80% of reported cases. Jaw involvement is common in this form of the disease. The entire ramus-condyle complex can be involved and present as facial asymmetry.[155] Often the clinical presentation is difficult to distinguish from that of condylar hyperplasia. The radiographic presentation is sometimes similar to that of Garre osteomyelitis.

Following a variable period of growth, fibrous dysplasia frequently stabilizes. Growth typically slows significantly after the onset of puberty. Once pathologic diagnosis is confirmed by biopsy, the only treatment required may be periodic follow-up. However, if significant cosmetic or functional deformity has occurred, surgical intervention with osseous recontouring may be undertaken.[155]

The histologic findings in fibrous dysplasia consist of a cellular, fibrous connective tissue proliferation that contains foci of irregularly shaped trabeculae of immature bone. A relatively constant ratio of fibrous tissue to bone throughout a given lesion has been described as characteristic. The collagen fibers may completely lack orientation or, alternatively, may be arranged in a storiform pattern of interlacing collagen bundles. The fibroblasts exhibit uniform spindle- to star-shaped nuclei. The bony trabeculae assume bizarre, irregular shapes, likened to Chinese characters. These trabeculae do not display any apparent functional orientation. The bone is predominantly woven bone that appears to arise directly from the collagenous stroma without prominent osteoblastic activity. In a mature fibrous dysplasia lesion, lamellar bone may be found. Aneurysmal bone cysts have been reported in association with fibrous dysplasia. It should be noted that fibrous dysplasia shares many microscopic features with the ossifying fibroma.

Nonossifying Fibroma (Fibrous Cortical Defect)

This is a common benign lesion that is generally noted as an incidental radiographic finding in the metaphyses of long bones in skeletally immature patients. It appears to be a self-limiting process that is related to incomplete ossification. It is found almost exclusively in children and adolescents. The lesion frequently resolves spontaneously. The lower extremity is the site of predilection; the distal femoral metaphysis is the most frequent site, followed by the proximal tibial metaphysis.

Occasionally these lesions are multifocal and symmetric. Multiple lesions have been associated with neurofibromatosis and are also found in Jaffe-Campanacci syndrome.

Nonossifying fibromas are typically asymptomatic, but when large, they may cause some expansion and even a pathologic fracture. When found in its typical location, the radiographic appearance is pathognomonic. It appears as an eccentric cortical-based radiolucency with scalloped sclerotic margins. The overlying cortex may be considerably thinned and slightly expanded.

Involvement of the TMJ is extremely rare. Several cases have been reported in the neck of the condylar process.[177-179] These lesions have not caused joint dysfunction and are typically asymptomatic. The jaw lesions appear to be more common in females, whereas in the long bones more males are affected.

Histologically, the lesion consists of a cellular fibroblastic stroma with a storiform pattern. Some multinucleated giant cells and foci of foamy histiocytes are present, and hemosiderin is visible in the stromal cells. Some mononuclear inflammatory cells are usually present.

Cystic change, hemorrhage, and necrosis may occur, and secondary aneurysmal bone cysts have developed. The nonossifying fibroma tends to stabilize at puberty and heals by peripheral sclerosis or solid opacification.

Osteochondroma (Osteocartilaginous Exostosis)

The osteochondroma constitutes about 35% of all benign bone tumors. It is a hamartomatous proliferation that arises from endochondral bone and is thus usually found in the long bones, most frequently the distal metaphysis of the femur and proximal metaphysis of the tibia. Patients are usually younger than 20 years, and there is a 2:1 male predilection. Tumors of the mandibular condyle occur over a much wider age range and have a 2:1 female predilection.

Seventy-five percent are solitary lesions, and 25% are multiple lesions. Multiple osteochondromatosis is an autosomal-dominant hereditary disorder. In these cases, about 11% undergo sarcomatous change, in contrast to 1% of solitary lesions. However, no cases of sarcomatous change have been reported in the mandibular condyle.

Osteochondromas occur infrequently in the mandibular condyle. They form an exophytic mass emanating from the cortex that may cause limited mouth opening, jaw deviation, and unilateral open bite. The radiographic appearance of an osteochondroma of the condyle is pathognomonic. A tapering radiopaque mass extends from the anteromedial aspect of the condyle along the tendon of the lateral pterygoid.

Histologically, the bony mass is covered by a cap of fibrocartilage and hyaline cartilage of varying thickness and cellularity, which is surrounded by the fibrous tissue of the perichondrium. In the deepest aspect of the cartilage, where it interfaces with bone, endochondral ossification occurs.

Spontaneous regression of an osteochondroma has occurred in rare instances.[180] This is most likely due to cessation of growth of the cartilage cap and subsequent resorption and incorporation of the lesion into the cortex through appositional growth. Cessation of growth may also be the consequence of a pathologic fracture. It is also possible that involution of the cartilage cap may result in the lesion resembling an osteoma.

Osteoma

Osteomas occur in several clinicopathologic guises, and frequent sites of involvement include the cranium, mandible, facial bones, orbit, and paranasal sinuses. In the condyle, osteomas usually appear as spherical or lobular enlargements. They may even have a pedicle. They generally consist of dense lamellar cortical bone that is well circumscribed, but a cancellous form also has been described. Although usually occurring as single, isolated lesions, osteomas may also arise in the condyle as part of Gardner syndrome.[153]

Osteoid Osteoma

These tumors are very uncommon in the jaws. One case has been reported in which the inferolateral aspect of the mandibular condyle was involved.[181] The patient was a 21-year-old woman who experienced trismus and spontaneous pain that, in the classic presentation of this tumor, occurred essentially at night. The radiographic appearance was also classic, in that it appeared as a subcortical nodule, 0.8 cm in diameter, with a sclerotic border.

Osteoid osteomas consist of active osteoblasts that deposit abundant osteoid to form a small nidus within normal bone. The lesion generally does not exceed 1.0 cm in diameter.

In general, osteoid osteomas are found in the 10- to 25-year age group, and there is a 3:1 male predilection. About half the cases involve the lower extremity. They have a limited growth potential and may undergo spontaneous regression.

Benign Osteoblastoma

Osteoblastomas do not occur frequently in the jaws. In this region, the most common site is the body of the mandible, but several cases involving the TMJ have been reported.[182]

Most osteoblastomas arise in the vertebrae and long bones, with a 2:1 male-to-female ratio. The average age of patients is 17 years, and the age range is from the first through eighth decades. The sex and age distributions of TMJ lesions are similar to those in other locations.

They are typically well-circumscribed, solitary lesions that expand within the medullary cavity and exceed 1 cm in diameter. They often produce a tender swelling. When osteoblastomas occur in the TMJ, there is often a history of trauma and, as in other locations, a tender swelling is the frequent presentation. In some cases, there is not only an expanding deformity of the condyle but also a secondary deformity of the glenoid fossa.

These neoplasms, as in the osteoid osteoma, consist of active osteoblasts that lay down abundant osteoid. The osteoblasts are concentrated along the osteoid seams. The fibrous stroma is very vascular with numerous dilated capillaries. Because of the vascularity of the lesion, angiography and scintigraphy are diagnostically useful.

Pigmented Villonodular Synovitis

This term is applied to a group of fibrohistiocytic lesions that involve joints, tendon sheaths, bursae, and adjacent fascial and ligamentous tissues. They are believed to represent a reactive inflammatory process. However, the fact that there may be bone destruction and a significant rate of recurrence suggests a locally aggressive neoplastic process.[183]

Essentially, these are destructive lesions that produce villous and nodular protrusions of the articular and extra-articular synovial membranes. They have been divided into intra-articular (diffuse and localized) and extra-articular (diffuse and nodular) forms. However, the nomenclature and classification involving these lesions have not been consistent.

They are relatively rare lesions, constituting fewer than 5% of all primary soft tissue tumors, and occur over a wide age range, with a peak in the third and fourth decades. Most are located intra-articularly. Eighty percent of cases involve the knee (including both diffuse and local types). The nodular extra-articular form (also called *pigmented villonodular tenosynovitis* or *giant cell tumor of tendon sheath*) is seen predominantly in the finger, carpal, and metacarpal joints.

These lesions are very rare in the TMJ. The majority are extra-articular, although this cannot always be confirmed. Although only about 22 cases have been reported in the literature, approximately a third of them have extended into the temporal bone and middle cranial fossa.[184]

Among the presenting symptoms, preauricular swelling is the most frequent. Hearing loss and tinnitus arising from compression of the auditory canal, as well as pain, trismus, and clicking, may also be present. Some cases have occurred in conjunction with synovial chondromatosis.

Histologically, the lesions consist of fibroblasts, mononuclear histiocytic cells, and irregularly interspersed multinucleated giant cells. Scattered and clustered foamy histiocytes are present, giving the lesion its yellow color, and there is abundant hemosiderin, responsible for the brown color. The hemosiderin may be found in the synovial cells and macrophages or lying free in the proliferative connective tissue, associated with multinucleated giant cells. The irregular villi are covered by thickened synovium or may be denuded. The histiocytes and giant cells are of monocyte-macrophage origin.

The histologic components of the different fibrohistiocytic lesions under this rubric are similar; the distinction is in the clinical presentation and behavior. Localized lesions are well circumscribed and may be partially encapsulated, whereas the diffuse lesions exhibit infiltrative and destructive growth. Thus the overall prognosis is more favorable for localized disease. This issue has not been addressed directly in the reported TMJ cases, but it is clear that many of these cases did behave in an aggressive fashion.

Synovial Chondromatosis

This uncommon entity has generally been considered to represent a non-neoplastic, metaplastic process. However, certain characteristics suggest the possibility that it may be neoplastic. The evidence of monoclonal chromosomal changes has given this theory strong support.[185] In addition, not only may synovial chondromatosis (SC) recur, but also the cartilaginous component may exhibit atypia. Synovial chondrosarcoma has also developed within preexisting SC.[186] In some cases, SC reaches considerable size and behaves in a destructive fashion.[187] SC may develop as a primary lesion or may arise secondary to trauma or another disease process such as osteoarthritis. The aggressive neoplastic features appear to be associated with the primary disease. Thus, it is possible that the primary type is neoplastic and the secondary form is metaplastic.[188]

SC usually affects the joints of the knee, hip, elbow, and ankle; approximately 70% of cases occur in the knee. It is rare in the TMJ; slightly fewer than 100 cases have been reported in the literature. In at least one reported case, the lesion developed from the disc. In the TMJ, SC occurs more frequently in females than in males and usually in the fourth through sixth decades. At other sites, there is a male preponderance and presentation generally occurs two decades earlier.

Pain is the most frequently cited symptom, followed by swelling, clicking, mandibular deviation, and limited mouth opening. CT scans and MRI can be very helpful diagnostically, although the presence of loose bodies in the joint space is not pathognomonic, because they may also be seen with intracapsular fractures and the osteoarthroses.

Initially, the lesion develops within the synovium as a proliferation of undifferentiated cells. Then fibroblast-like cells form a chondroid matrix from which cartilaginous nodules develop. This early phase has been called *stage 1.* Subsequently the nodules begin to lose their attachment and extrude into the joint cavity. The synovial fluid helps to maintain their nutrition and growth. *Stage 2* is the transitional phase, in which there is synovial involvement and detached nodules are found in the joint space. The cartilaginous foci within the synovium and joint space may calcify or even ossify, at which time the term *osteochondromatosis* is appropriate. This process commences at the periphery of the nodule and progresses inward. Eventually the nodules may coalesce to form an

irregular mass. *Stage 3* is advanced disease in which there is no longer synovial involvement and all the nodules have detached. Although the nodules or masses are typically confined to the joint space, in some cases they may erode the underlying bone or joint capsule and invade the periarticular tissues.

Cellular atypia is not unusual in SC, where large cells and binucleated cells may be observed. However, this does not indicate aggressive behavior. The most important consideration in the differential diagnosis is chondrosarcoma.[153]

Malignant Neoplasms

Chondrosarcoma

The majority of reported sarcomas arising in the TMJ have been chondrosarcomas. However, because this amounts to some 14 cases, this is still a very rare occurrence.[189] The age and sex of the patients were not known in three cases. Among the others, the age ranged from 17 to 75 years; four cases arose in the patient's fifth decade. Six patients were female and three were male.

Swelling was a consistent finding and, in most instances, pain or discomfort was also noted. Limited mouth opening and diminished hearing have also been described. Overall, chondrosarcomas constitute about 25% of primary bone sarcomas, with only 1% to 3% arising in the facial bones and jaws.

These tumors develop from mesenchymal stem cells, which show partial chondroblastic differentiation. They are typically slow-growing tumors, and the majority are low grade. They tend to show a lobular growth pattern with hypercellularity. The cells are often pleomorphic and may be binucleated. Malignant cartilage is formed but, in distinction to the osteosarcoma, no osteoid is formed directly from the malignant stroma.

High-grade tumors may metastasize to regional lymph nodes. Low-grade tumors have an excellent prognosis, but recurrences can develop, often after many years.

Synovial Chondrosarcoma

These tumors may arise as a primary malignancy of the synovium or secondarily in a preexisting synovial chondromatosis. They are rare occurrences, and only 21 cases have been reported in the literature. The knee, hip, and ankle are the sites of predilection. The age range of the patients is 30 to 70 years, and two thirds occur in the fifth to seventh decades. There is a female preponderance. The tumors form a soft tissue mass associated with pain and joint dysfunction.

Only six cases occurring in the TMJ have been reported.[190-195] Because there are very close similarities in the clinical, radiologic, and histologic aspects between synovial chondromatosis and synovial chondrosarcoma, the diagnosis may be difficult. Local recurrence and invasion of bone and surrounding soft tissue are clinical features that are also shared by these two entities. Radiographically, in addition to the presence of a soft tissue mass, clumps of ca1cification may be seen within the lesion, and there may be marginal erosion of the articular bone. As in synovial chondromatosis, nodules may be seen grossly, lying free within the joint space and/or the soft tissues.

The histology may also be ambiguous because cytologic atypia is common in synovial chondromatosis. The following histologic criteria are suggested to recognize malignancy:

1. Qualitative differences in the cartilage in different parts of the tumor, in which a clustering pattern is juxtaposed with abundant matrix and tumor cells arranged in sheets
2. Myxoid changes in the matrix
3. Hypercellularity, with crowding and spindling of the nuclei at the periphery
4. Necrosis
5. Permeation of trabecular bone, with "filling up" of marrow spaces rather than a pushing margin[2]

In the series reported by Bertoni and colleagues,[186] the nine patients available for follow-up, in whom the tumors occurred in the lower extremity (knee, hip, and ankle), all developed recurrences following local excision with "lesional margins." In spite of aggressive follow-up surgery, five patients developed metastases.

Synovial Sarcoma

These tumors represent about 5% to 10% of all soft tissue sarcomas. They are the fourth most frequently occurring soft tissue sarcoma, following malignant fibrous histiocytoma, liposarcoma, and rhabdomyosarcoma. They arise near tendons and tendon sheaths and next to joint capsules. They do not arise from mature synovial cells but rather from pluripotential mesenchyme.

Joint involvement per se is very uncommon, occurring in less than 5% of cases. Usually they occur in periarticular areas of the extremities, particularly around the knee, but approximately 9% occur in the head and neck, where the perivertebral structures give rise to most of the tumors, which then present in the pharynx, larynx, or esophagus. The tumors are generally rather slow growing. Up to 50% show calcifications radiographically, a helpful finding diagnostically.

Most cases occur in patients in the 15- to 40-year age range. The four patients with lesions in the TMJ ranged in age from 22 to 57 years.[174] At this site they have tended to present with a preauricular mass, which was painless in some instances.

Histologically, two types of synovial sarcoma may occur: biphasic and monophasic. Both types have occurred in the TMJ. The biphasic tumor consists of plump, uniform spindle cells that resemble a fibrosarcoma but lack a herringbone pattern, and cuboidal to columnar epithelial-like cells that line spaces or clefts and form nests. There also may be a pseudoglandular pattern. Both the spindle and epithelial-type cells stain positively for cytokeratin and epithelial membrane antigen. Mitoses are infrequent, and calcifications may be present.

The monophasic form is usually of the fibrous type, and most of the spindle cells exhibit the same immunohistochemistry as the biphasic form. A monophasic epithelial

form also exists but is very rare. Synovial sarcomas are associated with the chromosomal translocation t (X:18) (p11.2;q11.2).

About half of cases of synovial sarcoma will have local recurrences, even after wide surgical excision and a neck dissection. Most recur within the first 2 years, but recurrence may also take place many years later. Although the lung is the most frequent metastatic site, synovial sarcoma is one sarcoma that may metastasize to the lymph nodes (20% of cases).

Osteosarcoma

Osteosarcomas represent about 30% of all primary bone malignancies, and 6% to 13% involve the craniofacial bones. The maxilla and mandible are involved with almost equal frequency. It is unusual for these tumors to originate in the TMJ.[196] The age of patients with such tumors has ranged from 17 to 69 years.

Patients generally complain of pain, often mild; limited mouth opening; and altered occlusion. Radiographically, the lesions show extensive destruction.

These tumors arise from pluripotential mesenchymal stem cells and may thus show considerable histologic diversity. This includes chondroid and fibrous differentiation. The diagnosis rests on the identification of osteoid formed directly from a malignant stroma.

Lung metastases may occur early in the course of the disease.

Multiple Myeloma

Multiple myeloma represents about 43% of malignant tumors of bone. Most cases arise in individuals older than 60 years, and there is a slight male preponderance.

There appear to be seven cases of multiple myeloma reported in the literature in which there was a mandibular condyle lesion.[197] These patients ranged from 41 to 70 years in age, which is typical for this disease. Two patients had pathologic fractures. The most frequent finding was pain, usually associated with trismus. One patient had a tender preauricular swelling. In some patients, additional bone lesions were found at time of presentation, but in others no additional bone lesions were identified.

Multiple myeloma is a plasma cell dyscrasia in which sheets of proliferating plasma cells form bone tumors. Radiographically, the lesions are typically well-defined radiolucencies that lack a sclerotic rim.

Langerhans Cell Histiocytosis

Approximately 13 cases of Langerhans cell histiocytosis have been reported in the mandibular condyle.[198] The majority were solitary lesions. One patient was found to have additional bone lesions at presentation, and another developed an additional lesion in the bone within 6 months. Four patients were female and nine were male. Three cases occurred in the patients' first decade, three in the third, four in the fourth, and three in the fifth.

All patients had pain in the area of the TMJ. Most had preauricular swelling, and limited mouth opening was also frequently reported. At least four patients developed pathologic fractures. In all cases, a lytic lesion could be identified radiographically within the condyle.

Histologically these tumors consist of sheets of histiocytes with focal collections of eosinophils. Some plasma cells and lymphocytes may also be present. The proliferating histiocytic cells can be identified as Langerhans cells by staining for S100 protein and more definitively by immunostaining for CD1a antigen, as well as by ultrastructural examination and identification of cytoplasmic Birbeck granules.

Although there is still some controversy concerning the nature of these lesions, the finding that these are clonal proliferations suggests that they are indeed neoplasms.

Metastatic Carcinoma

Metastatic carcinoma is the most frequently occurring malignancy of bone. However, the jaws are an uncommon site for metastases, and the condyle is an even less frequent location. In a review of 390 cases of metastatic tumors to the jaws, Hirshberg and colleagues[199] reported that 81% occurred in the mandible but only 11 cases (3.5%) involved the condyle. They also noted that overall there was a female preponderance, probably accounting for the fact that the breast was the most prevalent primary tumor site. Other reported primary sites with metastases to the condyle have included lung, prostate, liver, pancreas, uterus, rectum, and skin of the toe. One particularly unusual report involved a testicular teratoma with metastases to both condyles.[200]

The most prevalent presentation of metastases to the condyle was TMJ dysfunction, but a pathologic fracture may also be found. Although in most cases the patient has a known primary lesion, in some series condylar metastasis was the first sign of a neoplasm in as many as half of the patients. Unfortunately, patients with these metastases have a very poor prognosis, and treatment is generally palliative.

Hypotheses regarding the paucity of metastases to the condyle include the scant amount of red marrow; the separate blood supply from the circular penetrating branches of the maxillary and superficial temporal arteries; the slow circulation; and the limiting osseous plate that shuts off the condylar marrow cavity from the spongiosa of the rest of the mandible.

Other Tumors

Many other tumors have been described as occurring within the condyle. Most of these have been single cases. They have included nodular fasciitis,[201] neurofibroma,[202] malignant schwannoma,[203] leiomyosarcoma,[204] malignant fibrous histiocytoma,[205] fibrosarcoma,[206] and Ewing sarcoma.[207]

Inflammatory, Metabolic, and Genetic Disorders

The inflammatory-metabolic-genetic category accounts for a small percentage of TMJ pathology and includes acromegaly, Garre osteomyelitis, hemifacial hypertrophy, hemifacial microsomia, heterotopic bone formation, phantom bone disease, and septic arthritis. The characteristics of hemifacial microsomia, hemifacial hypertrophy, and acromegaly are well outlined elsewhere in this text and are not discussed in this chapter.

Garre Osteomyelitis

Garre osteomyelitis can be considered a variant of chronic osteomyelitis with a concomitant prominent periosteal inflammatory reaction. This type of osteomyelitis is uncommon. It has been described in the tibia and in the maxillofacial region. In the mandible, it most commonly results from a periapical abscess associated with a molar. It has also been associated with pericoronal infections and infections following tooth extraction.[155] Rarely, this process may involve bone in the area of the TMJ. Patients typically present with a bony hard swelling of the posterior mandible. The overlying skin and mucosa characteristically appear normal. Occasionally the swelling may be tender.

The radiographic appearance is that of a centrally mottled radiolucency similar to chronic osteomyelitis. The peripheral periosteal reaction provides a distinctive radiographic appearance. The mandibular cortex is expanded, with concentric opaque layers (onion skin) noted on occlusal radiographs or CT scans. The clinician must differentiate Garre osteomyelitis from benign mandibular neoplasms. Radiographs are helpful to rule out certain neoplasms, but the radiographic presentation of fibrous dysplasia is often similar. Biopsy for histopathologic examination and bone culture is useful.

Removal of the etiologic agent is of paramount importance in the treatment of Garre osteomyelitis. Some surgeons advocate additional treatment with antibiotic therapy. Others advocate wide exposure of the affected area with perforation of the mandibular cortex to allow for capillary ingrowth.

Heterotopic Bone Formation

Heterotopic ossification is a condition in which mature lamellar bone is formed in tissues that do not normally ossify. Heterotopic ossification is considered to occur in three basic forms: traumatic, neurogenic, and myositis ossificans progressiva. It has also been described, although rarely, following tetanus, burns, poliomyelitis, and some forms of carcinoma. It is a well-recognized entity following injuries such as total hip arthroplasty and internal fixation of acetabular fractures.[155] It rarely occurs in the TMJ.

The onset of heterotopic bone formation usually occurs approximately 2 weeks after injury, although symptoms may not present until 8 to 10 weeks later. A diminished range of motion of the joint is a hallmark characteristic and is often the earliest sign. Patients may also complain of pain, swelling, and local tenderness. Management includes arthroplasty and physiotherapy. Radiotherapy and pharmacologic therapy with agents such as bisphosphonates and nonsteroidal anti-inflammatory drugs have been advocated as prophylaxis to prevent heterotopic bone formation.

Phantom Bone Disease

Phantom bone disease, also known as vanishing bone disease or massive osteolysis, is a rare clinical entity, with approximately 70 cases reported since its initial description in 1838. Only 15 cases have been reported in the maxillofacial region. The clinical course is characterized by a slowly progressive localized destruction of bone. Although the disease is progressive, its course can vary. With time, the bone destruction may spontaneously abate, or the bone may gradually disappear. No effective treatment is known for phantom bone disease.[155] Recently, controversy has developed as to whether this process represents a distinct entity or is a misinterpretation of other pathologic processes. Practitioners are encouraged to consider other pathologic entities when presented with a condition diagnosed as "phantom bone disease."

Conclusion

In the study of temporomandibular disorders, much emphasis has been placed on the commonly occurring conditions such as masticatory myalgia and internal derangements. Practitioners must approach such patients with an open mind, because many other conditions can produce similar signs and symptoms. These include arthritides and neoplasms. Although most neoplasms of the TMJ are benign, features that may suggest the possibility of malignancy include swelling, paresthesia, paresis, trismus, and occlusal changes. In addition, there may be auditory changes, including tinnitus and vertigo secondary to eighth nerve involvement and decreased auditory acuity secondary to eustachian tube involvement. When occlusal changes are of sudden onset, the immediate cause may be a pathologic fracture. The development of symptoms of myofascial pain and jaw dysfunction later in life (i.e., beyond the typical 20- to 40-year age range for patients with masticatory myalgia), or failure of the initial treatment for this condition, should make clinicians suspicious of more serious problems.[153-158,208]

The use of good radiographs and other imaging studies is of paramount importance in developing a correct diagnosis. Although the diagnosis is frequently suggested by the clinical and imaging information, in most cases the final diagnosis will only be made by microscopic tissue examination. However, histologic analysis alone is not sufficient. Only by assessing the clinical, radiographic, and histologic information together can the clinician achieve an accurate diagnosis.

Acknowledgments

The in vitro work was supported by National Institutes of Health Grants ROI AR42025 and R15 DE12976 and the Oral and Maxillofacial Surgery Foundation.

The in vivo work was supported by National Institutes of Health Grants HD40939 (National Institute of Child Health and Human Development), AR48781 (National Institute of Arthritis and Musculoskeletal and Skin Diseases), and AT0006646 (National Center for Complementary and Alternative Medicine).

References

1. Einhorn TA: One of nature's best kept secrets, *J Bone Miner Res* 13:10–12, 1998.
2. Banes A, Tsuzaki M, Yamainato J, et al.: Mechanoreception at the cellular level: the detection, interpretation, and diversity of responses to mechanical signals, *Biochem Cell Biol* 73:349–365, 1995.
3. Abubaker AO: TMJ arthritis. In Laskin D, Greene C, Hylander W, editors: *TMDs: an evidence based approach to diagnosis and treatment*, Chicago, 2006, Quintessence, pp 229–248.
4. Milam SB: Pathophysiology of articular disc displacements of the temporomandibular joint. In Fonseca R, editor: *Oral and maxillofacial surgery*, Philadelphia, 2000, Saunders, pp 46–72.
5. Gassner R, Buckley M, Studer R, et al.: Cyclic tensile stress exerts antiinflammatory properties by inhibiting iNOS induction in chondrocytes, *J Immunol* 163:2187–2192, 1999.
6. Gassner R, Buckley M, Studer R, et al.: Interaction of strain and interleukin-1 in articular cartilage: effects on proteoglycan synthesis in chondrocytes, *Int J Oral Maxillofac Surg* 29:389–394, 2000.
7. Agarwal S, Long P, Gassner R, et al.: Cyclic tensile strain suppresses catabolic effects of IL-1β in fibrochondrocytes from temporomandibular joint, *Arthritis Rheum* 44:608–617, 2001.
8. Long P, Gassner R, Agarwal S: Tumor necrosis factor-alpha-dependent proinflammatory gene induction is inhibited by cyclic tensile strain, *Arthritis Rheum* 44:2311–2319, 2001.
9. Gassner R, Agarwal S: Biological basis for the effectiveness of continuous passive motion-mediated repair in TMJ diseases, *Cranio* 20:152–153, 2002.
10. Sambajon V, Cillo J, Gassner R, Buckley M: The effects of mechanical strain on synovial fibroblasts, *J Oral Maxillofac Surg* 61:707–712, 2003.
11. Ferretti M, Srinivasan A, Deschner J, et al.: Anti-inflammatory effects of continuous passive motion on meniscal fibrocartilage, *J Orthop Res* 23:1165–1171, 2005.
12. Ferretti M, Gassner R, Wang Z, et al.: Biomechanical signals suppress proinflammatory responses in cartilage: early events in experimental antigen-induced arthritis, *J Immunol* 177:8757–8766, 2006.
13. Mow VC, Zhu W, Ratcliffe A: Structure and function of articu1ar cartilage and meniscus. In Mow VC, Hayes WC, editors: *Basic orthopaedic biomechanics*, New York, 1991, Raven Press, p 143.
14. Mao JJ, Rahemtulla F, Scott PG: Proteoglycan expression in the rat temporomandibular joint in response to unilateral bite raise, *J Dent Res* 77:1520–1528, 1998.
15. Eyre DR: The collagens of articular cartilage, *Semin Arthritis Rheum* 21:2–11, 1991.
16. Rosenberg L: Structure and function of dermatan sulfate proteoglycans in articular cartilage. In Kuettner K, Schleyerbach R, Peyron JG, Hascall VC, editors: *Articular cartilage and osteoarthritis*, New York, 1992, Raven Press, pp 45–62.
17. Nakano T, Scott PG: A quantitative chemical study of glucosaminoglycans in the articular disc of bovine temporomandibular joint, *Arch Oral Biol* 34:749–757, 1989.
18. Lotz M, Blanco FJ, von Kempis J, et al.: Cytokine regulation of chondrocyte functions, *J Rheumatol* 22:104–108, 1995.
19. Das P, Schurman DJ, Smith RL: Nitric oxide and G proteins mediate response of bovine articular chondrocytes to fluid-induced shear, *J Bone Joint Surg* 15:87–93, 1997.
20. Häuselmann HJ, Stefanovic-Racic M, Michel BA, Evans CH: Differences in nitric oxide production by superficial and deep human articular chondrocytes: implications for proteoglycan turnover in inflammatory joint diseases, *J Immunol* 160:1444–1448, 1998.
21. Stadler J, Stefanovic-Racic M, Billiar TR, et al.: Articular chondrocytes synthesize nitric oxide in response to cytokines and lipopolysaccharide, *J Immunol* 147:3915–3920, 1991.
22. Studer RK, Georgescu ID, Miller LA, Evans CH: Inhibition of transforming growth factor beta production by nitric oxide-treated chondrocytes: implications for matrix synthesis, *Arthritis Rheum* 42:248–257, 1999.
23. Blanco FJ, Geng Y, Lotz M: Differentiation-dependent effects of IL-1 and TGF-β on human articular chondrocyte proliferation are related to inducible nitric oxide synthase expression, *J Immunol* 154:4018–4026, 1995.
24. Lum ZP, Hakala BE, Mort JS, Recklies AD: Modulation of the catabolic effects of interleukin 1β on human articular chondrocytes by transforming growth factor β, *J Cell Physiol* 166:351–359, 1996.
25. Van Beuningen IM, van der Kraan PM, Arntz OJ, van den Berg WB: Protection from interleukin-l induced destruction of articular cartilage by transforming growth factor β: studies in anatomically intact cartilage in vitro and in vivo, *Ann Rheum Dis* 52:185–191, 1993.
26. Agarwal S, Long P, Seyedain SA, et al.: A central role for the nuclear factor-kappaB pathway in anti-inflammatory and proinflammatory actions of mechanical strain, *FASEB J* 17:899–901, 2003.
27. Furchgott RF: The 1996 Albert Lasker Medica1 Research Awards. The discovery of endothelium-derived relaxing factor and its importance in the identification of nitric oxide, *JAMA* 276:1186–1188, 1996.
28. Takahashi T, Kondoh T, Kamei K, et al.: Elevated levels of nitric oxide in synovial fluid from patients with temporomandibular disorders, *Oral Surg Oral Med Oral Pathol Oral Radiol Endod* 82:505–509, 1996.
29. Aufderheide AC, Athanasiou KA: A direct compression stimulator for articular cartilage and meniscal explants, *Ann Biomed Eng* 34:1463–1474, 2006.
30. Huang MH, Yang RC, Lee CL, et al.: Preliminary results of integrated therapy for patients with knee osteoarthritis, *Arthritis Rheum* 53:812–820, 2005.
31. Feinglass J, Thompson JA, He XZ, et al.: Effect of physical activity on functional status among older middle-age adults with arthritis, *Arthritis Rheum* 53:879–885, 2005.
32. Deschner J, Rath-Deschner B, Agarwal S: Regulation of matrix metalloproteinase expression by dynamic tensile strain in rat fibrochondrocytes, *Osteoarthritis Cartilage* 14:264–272, 2006.

33. Ferretti M, Srinivasan A, Deschner J, et al.: Anti-inflammatory effects of continuous passive motion on meniscal fibrocartilage, *J Orthop Res* 23:1165–1171, 2005.
34. Agarwal S, Deschner J, Long P, et al.: Role of NF-kappaB transcription factors in antiinflammatory and proinflammatory actions of mechanical signals, *Arthritis Rheum* 50:3541–3548, 2004.
35. Chowdhury TT, Bader DL, Lee DA: Anti-inflammatory effects of IL-4 and dynamic compression in IL-1beta stimulated chondrocytes, *Biochem Biophys Res Commun* 339:241–247, 2006.
36. Xu Z, Buckley M, Evans C, Agarwal S: Cyclic tensile strain acts as an antagonist of IL-1β action in chondrocytes, *J Immunol* 165:453–460, 2000.
37. Buschmann MD, Kim YJ, Wong M, et al.: Stimulation of aggrecan synthesis in cartilage explants by cyclic loading is localized to regions of high interstitial fluid flow, *Arch Biochem Biophys* 366:1–7, 1999.
38. Wong M, Carter DR: Articular cartilage functional histomorphology and mechanobiology: a research perspective, *Bone* 33:1–13, 2003.
39. Marchiori E, Matos F, Sato F, Moreira R: Imaginologia da ATM. In Moreira R, editor: *Atlas colorido de cirurgia da articulacao temporomandibular: revinter*, 2015, pp 27–55.
40. Abubaker AO: TMJ arthritis. In Laskin D, Greene C, Hylander W, editors: *TMDs: an evidence based approach to diagnosis and treatment*, Chicago, 2006, Quintessence, pp 229–248.
41. Silverstein K: Arthritis of the temporomandibular joint. In Fonseca R, editor: *Oral and maxillofacial surgery*, Philadelphia, 2000, Saunders, pp 73–92.
42. Milam SB: TMJ osteoarthritis. In Laskin D, Greene C, Hylander W, editors: *TMDs: an evidence based approach to diagnosis and treatment*, Chicago, 2006, Quintessence, pp 105–123.
43. Landesberg R, Huang LL: Analysis of TMJ synovial fluid. In Laskin D, Greene C, Hylander W, editors: *TMDs: an evidence based approach to diagnosis and treatment*, Chicago, 2006, Quintessence, pp 181–192.
44. Milam SB: Pathophysiology of articular disc displacements of the temporomandibular joint. In Fonseca R, editor: *Oral and maxillofacial surgery*, Philadelphia, 2000, Saunders, pp 46–72.
45. Könönen M, Wenneberg B: Systemic conditions affecting the TMJ. In Laskin D, Greene C, Hylander W, editors: *TMDs: an evidence based approach to diagnosis and treatment*, Chicago, 2006, Quintessence, pp 137–146.
46. McCarthy DJ: Differential diagnosis of arthritis; analysis of signs and symptoms. In McCarthy DJ, editor: *Arthritis and allied conditions: a textbook of rheumatology*, ed 9, Philadelphia, 1979, Lea & Febiger, pp 37–50.
47. Worth HM: Radiology of the temporomandibular joint. In Zarb GA, Carlson GE, editors: *Temporomandibular joint: function and dysfunction*, St Louis, 1979, Mosby, pp 321–372.
48. Undt G, Murakami K, Rasse M, Ewers R: Open versus arthroscopic surgery for internal derangement of the temporomandibular joint: a retrospective study comparing two centres' results using the Jaw Pain and Function Questionnaire, *J Craniomaxillofac Surg* 34:234–241, 2006.
49. Goss AN, Bosanquet AG: The arthroscopic appearance of acute temporomandibular joint trauma, *J Oral Maxillofac Surg* 48:780–783, 1990, discussion 784.
50. Dijkgraaf LC, Liem RS, de Bont LG: Synovial membrane involvement in osteoarthritic temporomandibular joints: a light microscopic study, *Oral Surg Oral Med Oral Pathol Oral Radiol Endod* 83:373–386, 1997.
51. Rohlin M, Westesson PL, Eriksson L: The correlation of TMJ sounds with joint morphology in fifty-five autopsy specimens, *J Oral Maxillofac Surg* 43:194–200, 1985.
52. Emshoff R, Rudisch A, Bösch R, Gassner R: Effect of arthrocentesis and hydraulic distension on the temporomandibular joint disk position, *Oral Surg Oral Med Oral Pathol Oral Radiol Endod* 89:271–277, 2000.
53. DeBont LGM, Stegenga B: Pathology of the temporomandibular joint: internal derangement and osteoarthrosis, *Int J Oral Maxillofac Surg* 22:71–74, 1993.
54. Stegenga B: Osteoarthritis of the temporomandibular joint organ and its relationship to disc displacement, *J Orofac Pain* 15:193–205, 2001.
55. Zarb GA, Carlsson GE: Osteoarthrosis, osteoarthritis. In Zarb GA, Carlsson GE, Sessle BJ, Mohl ND, editors: *Temporomandibular joint and masticatory muscle disorders*, ed 2, Copenhagen, 1995, Mosby, p 298.
56. Stegenga B, DeBont LGM, Boering G: Osteoarthritis as the cause of craniomandibular pain and dysfunction: a unifying concept, *J Oral Maxillofac Surg* 47:249, 1989.
57. DeBont LGM, Boering G, Liem RSB: Osteoarthrosis and internal derangement of the temporomandibular joint. A light microscopy study, *J Oral Maxillofac Surg* 44:634, 1986.
58. Stegenga B, DeBont LGM, Boering G, Van Willigen JD: Tissue responses to degenerative changes in the temporomandibular joint: a review, *J Oral Maxillofac Surg* 49:1079–1088, 1991.
59. Katz WA: *Diagnosis and management of rheumatic diseases*, ed 2, Philadelphia, 1988, JB Lippincott.
60. Dieppe PA, Harkness JAL, Riggs ER: Osteoarthritis. In Wall PA, Melzack R, editors: *Textbook of pain*, ed 2, Edinburgh, 1989, Churchill Livingstone, p 306.
61. Howell DS: Etiopathogenesis of osteoarthritis. In Moskowitz RW, Howel DS, Golberg VM, et al., editors: *Osteoarthritis, diagnosis and management*, Philadelphia, 1984, WB Saunders, p 129.
62. Emshoff R, Bertram S, Rudisch A, Gassner R: The diagnostic value of ultrasonography to determine the temporomandibular disc position, *Oral Surg Oral Med Oral Pathol Oral Radiol Endod* 84:688–696, 1997.
63. Dijkgraaf LC, De Bont LGM, Boering G, Liem RSB: The structure, biochemistry and metabolism of osteoarthritic cartilage: a review of the literature, *J Oral Maxillofac Surg* 53:1182, 1995.
64. Brandlmaier I, Bertram S, Rudisch A, et al.: Temporomandibular joint osteoarthrosis diagnosed with high resolution ultrasonography versus magnetic resonance imaging: how reliable is high resolution ultrasonography? *J Oral Rehabil* 30:812–817, 2003.
65. Israel HA, Saed-Nejad F, Ratcliffe A: Early diagnosis of osteoarthrosis of the temporomandibular joint: correlation between arthroscopic diagnosis and keratan sulfate levels in the synovial fluid, *J Oral Maxillofac Surg* 49:708–711, 1991, discussion 712.
66. Nishimura M, Segami N, Kaneyama K, et al.: Relationships between pain-related mediators and both synovitis and joint pain in patients with internal derangements and osteoarthritis of the temporomandibular joint, *Oral Surg Oral Med Oral Pathol Oral Radiol Endod* 94:328–332, 2002.
67. Emshoff R, Puffer P, Rudisch A, Gassner R: Temporomandibular joint pain: relationship to internal derangement type, osteoarthrosis, and synovial fluid mediator level of tumor necrosis factor-alpha, *Oral Surg Oral Med Oral Pathol Oral Radiol Endod* 90:442–449, 2000.

68. Kubota E, Imamura H, Kubota T, et al.: Interleukin 1 beta and stromelysin (MMP3) activity of synovial fluid as possible markers of osteoarthritis in the temporomandibular joint, *J Oral Maxillofac Surg* 55:20–27, 1997, discussion 27–28.
69. Velin E: Arthritis: the cumulative impact of a common condition, *Arthritis Rheum* 35:489–497, 1992.
70. Wilson JD, Braunwald E, Isselbacher KJ, et al., editors: *Harrison's principles of internal medicine*, ed 12, New York, 1991, McGraw-Hill.
71. Akerman S, Kopp S, Nilner M, et al.: Relationship between clinical and radiologic findings of the temporomandibular joint in rheumatoid arthritis, *Oral Surg Oral Med Oral Pathol* 66:639–643, 1988.
72. Tabeling HG, Dolwick MF: Rheumatoid arthritis: diagnosis and treatment, *Fla Dent J* 56:16–18, 1985.
73. Koh ET, Yap AU, Koh CK, et al.: Temporomandibular disorders in rheumatoid arthritis, *J Rheumatol* 26:1918–1922, 1999.
74. Ruderman M, Miller LM, Pinals RS: Clinical and serologic observations on 27 patients with Felty's syndrome, *Arthritis Rheum* 11:377–384, 1968.
75. Larheim TA, Floystrand F: Temporomandibular joint abnormalities and bite force in a group of adults with rheumatoid arthritis, *J Oral Rehabil* 12:477–482, 1985.
76. Tegelberg A, Kopp S: Clinical findings in the stomatognathic system of individuals with rheumatoid arthritis and osteoarthrosis, *Acta Odontol Scand* 45:65–75, 1987.
77. Yoshida A, Higuchi Y, Kondo M, et al.: Range of motion of the temporomandibular joint in rheumatoid arthritis: relationship to the severity of disease, *Cranio* 16:162–167, 1998.
78. Carlsson GE, Kopp S, Oberg T: Arthritis and allied diseases of the TMJ. In Zarb GA, Carlson GE, editors: *Temporomandibular joint: function and dysfunction*, St Louis, 1979, Mosby, pp 269–320.
79. Melchiorre D, Calderazzi A, Maddali Bongi S, et al.: A comparison of ultrasonography and magnetic resonance imaging in the evaluation of temporomandibular joint involvement in rheumatoid arthritis and psoriatic arthritis, *Rheumatology (Oxford)* 42:673–676, 2003.
80. Larheim TA, Haanaes HR: Micrognathia, temporomandibular joint changes and dental occlusion in juvenile rheumatoid arthritis of adolescents and adults, *Scand J Dent Res* 89:329–338, 1981.
81. Voog U, Alstergren P, Eliasson S, et al.: Progression of radiographic changes in the temporomandibular joints of patients with rheumatoid arthritis in relation to inflammatory markers and mediators in the blood, *Acta Odontol Scand* 62:7–13, 2004.
82. Narvaez JA, Narvaez J, Roea Y, Aguilera C: MR imaging assessment of clinical problems in rheumatoid arthritis, *Eur Radiol* 12:1819–1828, 2002.
83. Gynther GW, Tronje G, Holmlund AB: Radiographic changes in the temporomandibular joint in patients with generalized osteoarthritis and rheumatoid arthritis, *Oral Surg Oral Med Oral Pathol Oral Radiol Endod* 81:613–618, 1996.
84. Celiker R, Gokce-Kutsal Y, Eryilmaz M: Temporomandibular joint involvement in rheumatoid arthritis. Relationship with disease activity, *Scand J Rheumatol* 24:22–25, 1995.
85. Zide MF, Carlton DM, Kent JN: Rheumatoid disease and related arthropathies. 1. Systemic findings, medical therapy, and peripheral joint surgery, *Oral Surg Oral Med Oral Pathol* 61:119–125, 1986.
86. Gewanter HL, Roghmann KJ, Baum J: The prevalence of juvenile arthritis, *Arthritis Rheum* 26:599–603, 1983.
87. Svensson B, Adell R, Kopp S: Temporomandibular disorders in juvenile chronic arthritis patients. A clinical study, *Swed Dent J* 24:83–92, 2000.
88. Harper RP, Brown CM, Triplett MM, et al.: Masticatory function in patients with juvenile rheumatoid arthritis, *Pediatr Dent* 22:200–206, 2000.
89. Ronchezel MV, Hilario MO, Goldenberg J, et al.: Temporomandibular joint and mandibular growth alterations in patients with juvenile rheumatoid arthritis, *J Rheumatol* 22:1956–1961, 1995.
90. Mericle PM, Wilson VK, Moore TL, et al.: Effects of polyarticular and pauciarticular onset juvenile rheumatoid arthritis on facial and mandibular growth, *J Rheumatol* 23:159–165, 1996.
91. Kjellberg H: Craniofacial growth in juvenile chronic arthritis, *Acta Odontol Scand* 56:360–365, 1998.
92. Fries JF: Approach to the patient with musculoskeletal disease. In Wyngaarden JB, Smith Jr LH, Bennett JC, editors: *Textbook of medicine*, ed 19, Philadelphia, 1988, WB Saunders, p 1488.
93. Taylor B, Babyn P, Blaser S, et al.: MR evaluation of the temporomandibular joint in juvenile rheumatoid arthritis, *J Comput Assist Tomogr* 17:449–454, 1993.
94. Kuseler A, Pedersen TK, Herlin T, Gelineck J: Contrast enhanced magnetic resonance imaging as a method to diagnose early inflammatory changes in the temporomandibular joint in children with juvenile chronic arthritis, *J Rheumatol* 25:1406–1412, 1998.
95. Pearson MH, Ronning O: Lesions of the mandibular condyle in juvenile chronic arthritis, *Br J Orthod* 23:49–56, 1996.
96. Hanna VE, Rider SF, Moore TL, et al.: Effects of systemic onset juvenile rheumatoid arthritis on facial morphology and temporomandibular joint form and function, *J Rheumatol* 23:155–158, 1996.
97. Hellgren L: Association between rheumatoid arthritis and psoriasis in total populations, *Acta Rheumatol Scand* 15:316–326, 1969.
98. van Romunde LK, Valkenburg HA, Swart-Bruinsma W, et al.: Psoriasis and arthritis. 1. A population study, *Rheumatol Int* 4:55–60, 1984.
99. Espinoza LR, Cuellar ML, Silveira LH: Psoriatic arthritis, *Curr Opin Rheumatol* 4:470–478, 1992.
100. Laurent R: Psoriatic arthritis, *Clin Rheum Dis* 11:61–85, 1985.
101. Franks AST: Temporomandibular joint arthrosis associated with psoriasis, *Oral Surg* 19:301–303, 1965.
102. Moll J, Wright V: Psoriatic arthritis, *Semin Arthritis Rheum* 3:55–78, 1973.
103. Koorbusch GE, Zeitler DL, Fotos PG, Doss JB: Psoriatic arthritis of the temporomandibular joint with ankylosis, *Oral Surg Oral Med Oral Pathol* 17:267–274, 1991.
104. Miles DA, Kaugars GA: Psoriatic involvement of the temporomandibular joint: literature review and report of two cases, *Oral Surg Oral Med Oral Pathol* 71:770–774, 1991. [Erratum 1991;72:363.)
105. Wilson A, Brown JS, Ord RA: Psoriatic arthropathy of the temporomandibular joint, *Oral Surg Oral Med Oral Pathol* 70:555–558, 1990.
106. Könönen M: Craniomandibular disorders in psoriasis, *Community Dent Oral Epidemiol* 15:108–112, 1987.
107. Blair G: Psoriatic arthritis and the temporomandibular joint, *J Dent* 4:123–128, 1976.
108. Wood N, Stankler L: Psoriatic arthritis of the temporomandibular joint, *Br Dent J* 154:17–18, 1983.

109. Könönen M, Kilpinen E: Comparison of three radiographic methods in screening of temporomandibular joint involvement in patients with psoriatic arthritis, *Acta Odontol Scand* 48:271–277, 1990.
110. Carter ET, McKenna CH, Brian DD, Kurland LT: Epidemiology of ankylosing spondylitis in Rochester, Minnesota, 1935-1973, *Arthritis Rheum* 22:365–370, 1979.
111. Crum RJ, Loiselle RJ: Temporomandibular joint symptoms and ankylosing spondylitis, *J Am Dent Assoc* 83:630–633, 1971.
112. Resnick D: Temporomandibular joint involvement in ankylosing spondylitis: comparison with rheumatoid arthritis and psoriasis, *Radiology* 112:587–591, 1974.
113. Wenneberg B: Inflammatory involvement of the temporomandibular joint. Diagnostic and therapeutic aspects and a study of individuals with ankylosing spondylitis, *Swed Dent J Suppl* 20:1–54, 1983.
114. Heir GM, Berrett A, Worth DA: Diagnosis and management of TMJ involvement in ankylosing spondylitis, *J Craniomandib Pract* 1:75–81, 1983.
115. Wenneberg B, Hollender L, Kopp S: Radiographic changes in the temporomandibular joint in ankylosing spondylitis, *Dentomaxillofac Radiol* 12:25–30, 1983.
116. Ramos-Remus C, Major P, Gomez-Vargas A, et al.: Temporomandibular joint osseous morphology in a consecutive sample of ankylosing spondylitis patients, *Ann Rheum Dis* 56:103–107, 1997.
117. Ramos-Remus C, Perez-Rocha O, Ludwig RN, et al.: Magnetic resonance changes in the temporomandibular joint in ankylosing spondylitis, *J Rheumatol* 24:123–127, 1997.
118. Calin A: Reiter's syndrome. In Kelley WN, Harris Jr ED, Ruddy S, Sledge CB, editors: *Textbook of rheumatology*, ed 3, Philadelphia, 1989, Saunders, pp 1033–1046.
119. Bomalaski JS, Jiminez SA: Erosive arthritis of the temporomandibular joint of Reiter's syndrome, *J Rheumatol* 11:400–402, 1984.
120. Könönen M, Kovero O, Wenneberg B, Konttinen YT: Radiographic signs in the temporomandibular joint in Reiter's disease, *J Orofac Pain* 16:143–147, 2002.
121. Leighty SM, Spach DM, Myall RW, et al.: Septic arthritis of the temporomandibular joint: review of literature and report of two cases in children, *Int J Oral Maxillofac Surg* 22:292–297, 1993.
122. Irby WB: Etiologic factors in TMJ pain, muscle dysfunction, and mandibular hypomobility. In Irby WB, editor: *Current advances in oral surgery*, vol. 3. St Louis, 1980, Mosby, pp 227–252.
123. Topazian RG: Etiology of ankylosis of temporomandibular joint: analysis of 44 cases, *J Oral Anesth Surg Hosp Dent Serv* 22:227–233, 1964.
124. Thomson HG: Septic arthritis of the temporomandibular joint complicating otitis externa, *J Laryngol Otol* 103:319–321, 1989.
125. McCain JP, Zabiegalski NA, Levine RL: Joint infection as a complication of temporomandibular joint arthroscopy: a case report, *J Oral Maxillofac Surg* 51:1389–1392, 1993.
126. Haug R, Picard U, Matejczyk MB, Indresano AT: The infected prosthetic total temporomandibular joint replacement: report of two cases, *J Oral Maxillofac Surg* 47:1210–1214, 1989.
127. Hilbert L, Peters WJ, Tepperman PS: Temporomandibular joint destruction after a burn, *Burns Incl Therm Injury* 10:214–216, 1984.
128. Chue PWY: Gonococcal arthritis of the temporomandibular joint, *Oral Surg Oral Med Oral Pathol* 39:572–577, 1975.
129. Bounds GA, Hopkins R, Sugar A: Septic arthritis of the tempоro-mandibular joint: a problematic diagnosis, *Br J Oral Maxillofac Surg* 25:61–67, 1987.
130. Henry CH, Hudson AP, Gerard HC, et al.: Identification of Chlamydia trachomatis in the human temporomandibular joint, *J Oral Maxillofac Surg* 57:683–688, 1999, discussion 689.
131. Regev E, Koplewitz BZ, Nitzan DW, Bar-Ziv J: Ankylosis of the temporomandibular joint as a sequela of septic arthritis and neonatal sepsis, *Pediatr Infect Dis J* 22:99–101, 2003.
132. Wang CL, Wang SM, Yang YJ, et al.: Septic arthritis in children: relationship of causative pathogens, complications, and outcome, *J Microbiol Immunol Infect* 36:41–46, 2003.
133. Gue TB, Bonner Jr WM: Articular manifestations of infectious hepatitis, *J S C Med Assoc* 63:279–281, 1967.
134. Goldenberg DL, Reed JI: Bacterial arthritis, *N Engl J Med* 312:764–771, 1985.
135. Steere AC, Malawista SE, Syndman DR, et al.: Lyme arthritis: an epidemic of oligoarticular arthritis in children and adults in three Connecticut communities, *Arthritis Rheum* 20:7–17, 1977.
136. Harris RJ: Lyme disease involving the temporomandibular joint, *J Oral Maxillofac Surg* 46:78–79, 1988.
137. Lader E: Lyme disease misdiagnosed as a temporomandibular joint disorder, *J Prosthet Dent* 63:82–85, 1990.
138. Berger BW, Kaplan MH, Rothenberg IR, Barbour AG: Isolation and characterization of the Lyme disease spirochete from the skin of patients with erythema chronicum migrans, *J Am Acad Dermatol* 13:444–449, 1985.
139. Nocton JJ, Dressler F, Rutledge BJ, et al.: Detection of Borrelia burgdorferi DNA by polymerase chain reaction in synovial fluid from patients with Lyme disease arthritis, *N Engl J Med* 330:229–234, 1994.
140. Gross BD, Williams RB, DiCosimo CJ, Williams SV: Gout and pseudogout of the temporomandibular joint, *Oral Med Oral Surg Oral Pathol* 63:551–554, 1987.
141. DeVos RAI, Brants J, Kusen GJ, Becker AE: Calcium pyrophosphate dihydrate arthropathy of the temporomandibular joint, *Oral Surg Oral Med Oral Pathol* 51:497–502, 1981.
142. Good AE, Upton LG: Acute temporomandibular arthritis in a patient with bruxism and calcium pyrophosphate deposition disease, *Arthritis Rheum* 25:353–355, 1982.
143. Hutton CW, Doherty M, Dieppe PA: Acute pseudogout of the temporomandibular joint: a report of three cases and review of the literature, *Br J Rheumatol* 26:51–52, 1987.
144. Chuong R, Piper MA: Bilateral pseudogout of the temporomandibular joint: report of case and review of the literature, *J Oral Maxillofac Surg* 53:691, 1995.
145. Liebling MR, Gold RH: Erosions of the temporomandibular joint in systemic lupus erythematosus, *Arthritis Rheum* 24:948–950, 1981.
146. Jonsson R, Lindvall AM, Nyberg G: Temporomandibular involvement in systemic lupus erythematosus, *Arthritis Rheum* 26:1506–1510, 1983.
147. Seibold JR: Connective tissue diseases characterized by fibrosis. In Kelley WN, Harris Jr ED, Ruddy S, Sledge CB, editors: T*extbook of rheumatology*, ed 5, vol. 2. Philadelphia, 1997, Saunders, pp 1133–1162.
148. Robbins JW, Craig Jr RM, Correll RW: Symmetrical widening of the periodontal ligament space in a patient with multiple systemic problems, *J Am Dent Assoc* 113:307–308, 1986.

149. Tai CC, Lee P, Wood RE: Progressive systemic sclerosis in a child: case report, *Pediatr Dent* 15:275–279, 1993.
150. Bennett RM: Mixed connective tissue disease and other overlap syndromes. In Kelley WN, Harris Jr ED, Ruddy S, Sledge CB, editors: *Textbook of rheumatology*, ed 5, vol. 2. Philadelphia, 1997, Saunders, pp 1065–1078.
151. Konttinen YT, Tuominen TS, Piirainen HI, et al.: Signs and symptoms in the masticatory system in ten patients with mixed connective tissue disease, *Scand J Rheumatol* 19:363–373, 1990.
152. Lahita RG: Clinical presentation of systemic lupus erythematosus. In Kelley WN, Harris Jr ED, Ruddy S, Sledge CB, editors: *Textbook of rheumatology*, ed 5, vol. 2. Philadelphia, 1997, Saunders, pp 1028–1039.
153. Stern D: Benign and malignant tumors. In Laskin D, Greene C, Hylander W, editors: *TMDs: an evidence based approach to diagnosis and treatment*, Chicago, 2006, Quintessence, pp 319–333.
154. Clayman L: Surgical management of benign and malignant tumors. In Laskin D, Greene C, Hylander W, editors: *TMDs: an evidence based approach to diagnosis and treatment*, Chicago, 2006, Quintessence, pp 509–532.
155. Stanton DC, Stewart JCB: Tumors of the temporomandibular joint. In Fonseca R, editor: *Oral and maxillofacial surgery*, Philadelphia, 2000, Saunders, pp 363–386.
156. Franklin CD: Mini-symposium: head and neck pathology. Pathology of the temporomandibular joint, *Curr Diagn Pathol* 12:31–39, 2006.
157. Jones AV, Franklin CD: An analysis of oral and maxillofacial pathology found in adults over a 30-year period, *J Oral Pathol Med* 35:392–401, 2006.
158. Jones AV, Franklin CD: An analysis of oral and maxillofacial pathology found in children over a 30-year period, *Int J Paediatr Dent* 16:19–30, 2006.
159. Regezi JA, Sciubba JJ: *Oral pathology: clinical pathologic correlations*, ed 3, Philadelphia, 1998, WB Saunders.
160. Reznik SA, Russell EJ, Hanson DH, Pecaro BC: Embolization of a life-threatening mandibular vascular malformation by direct percutaneous puncture, *Head Neck* 14:372–379, 1992.
161. Flandroy P, Pruvo J: Treatment of mandibular arteriovenous malformations by direct transosseous puncture: report of two cases, *Cardiovasc Intervent Radiol* 17:222–225, 1994.
162. Carlson E: Pathologic facial asymmetries, *Atlas Oral Maxillofac Surg Clin* 4:28–35, 1996.
163. Obwegeser HL, Makek MS: Hemimandibular hyperplasia, hemimandibular elongation, *J Maxillofac Surg* 14:183–208, 1986.
164. Bloem JL, Mulder JD: Chondroblastoma: a clinical and radiologic study of 104 cases, *Skeletal Radiol* 14:1–9, 1985.
165. Kondoh T, Hamada Y, Kamei K, Seto K: Chondroblastoma of the mandibular condyle: report of a case, *J Oral Maxillofac Surg* 60:198–203, 2002.
166. Bertoni F, Unni KK, Beabout JW, et al.: Chondroblastoma of the skull and facial bones, *Am J Clin Pathol* 88:1–9, 1987.
167. Motamedi MHK: Destructive aneurysmal bone cyst of the mandibular condyle: report of a case and review of the literature, *J Oral Maxillofac Surg* 60:1357–1361, 2002.
168. Trent C, Byl FM: Aneurysmal bone cyst of the mandible, *Ann Otol Rhinol Laryngol* 102:917–924, 1993.
169. Friedlander AH, Monson ML, Friedlander MD, Esquerra AC: Pseudocysts of the mandibular condyle, *J Oral Maxillofac Surg* 50:821–824, 1992.
170. Collins TE, Laskin DM, Farrington FH, et al.: Pseudocysts of the mandibular condyle in children, *J Am Dent Assoc* 128:747–750, 1997.
171. Tanaka H, Westesson PL, Emmings FG, Marashi AH: Simple bone cyst of the mandibular condyle: report of a case, *J Oral Maxillofac Surg* 54:1454–1458, 1996.
172. Abu-El-Naaj I, Ardekian L, Liberman R, Peled M: Central giant cell granuloma of the mandibular condyle: a rare presentation, *J Oral Maxillofac Surg* 60:939–941, 2002.
173. Chang YM, Chan CP, Kung Wu SF, et al.: Ganglion cyst and synovial cyst of the temporomandibular joint; two case reports, *Int J Oral Maxillofac Surg* 26:179–181, 1997.
174. Wamer BF, Luna MA, Newland JR: Temporomandibular joint neoplasms and pseudotumors, *Adv Anat Pathol* 7:365–368, 2000.
175. Whear NM: Condylar haemangioma—a case report and review of the literature, *Br J Oral Maxillofac Surg* 29:44–47, 1991.
176. Atkinson TJ, Wolf S, Anavi Y, Wesley R: Synovial hemangioma of the temporomandibular joint; report of a case and review of the literature, *J Oral Maxillofac Surg* 46:804–808, 1988.
177. Makek M: Non-ossifying fibroma of the mandible. A common lesion with unusual location, *Arch Orthop Trauma Surg* 96:225–227, 1980.
178. Aldred MJ, Breckon JJW, Holland CS: Non-osteogenic fibroma of the mandibular condyle, *Br J Oral Maxillofac Surg* 27:412–416, 1989.
179. Hudson JW, Livesay KW, McCoy JM: Condylar lesion, *J Oral Maxillofac Surg* 61:824–826, 2003.
180. Copeland RL, Meehan PL, Morrissy RT: Spontaneous regression of osteochondroma. Two case reports, *J Bone Joint Surg* 67:971–973, 1985.
181. Tochihara S, Sato T, Yamamoto H, et al.: Osteoid osteoma in mandibular condyle, *Int J Oral Maxillofac Surg* 30:455–457, 2001.
182. Weinberg S, Katsikeris N, Pharaoh M: Osteoblastoma of the mandibular condyle: review of the literature and report of a case, *J Oral Maxillofac Surg* 45:350–355, 1987.
183. Vogrincic GS, O'Connell JX, Gilks CB: Giant cell tumor of tendon sheath is a polyclonal cellular proliferation, *Hum Pathol* 28:815–819, 1997.
184. Chow LTC, Kumta SM, King WWK: Extra-articular pigmented villonodular synovitis of the temporomandibular joint, *J Laryngol Otol* 112:182–185, 1998.
185. Sciot R, Dal Cin P, Bellemans J, Samson I: Synovial chondromatosis: clonal chromosome changes provide further evidence for a neoplastic disorder, *Virchows Arch* 433:189–191, 1998.
186. Bertoni F, Unni K, Beabout JW, Sim FR: Chondrosarcoma of the synovium, *Cancer* 67:155–162, 1991.
187. Kadis V, Gliekman RS, Zaslow M: Synovial chondromatosis of the temporomandibular joint with intracranial extension, *Oral Surg Oral Med Oral Pathol Oral Radiol Endod* 86:664–666, 1998.
188. Marx RE, Stern D: Synovial chondromatosis. In Marx RE, Stern D, editors: *Oral and maxillofacial pathology. A rationale for diagnosis and treatment*, Chicago, 2003, Quintessence, pp 796–798.
189. Sesenna E, Tullio A, Ferrari S: Chondrosarcoma of the temporomandibular joint: a case report and review of the literature, *J Oral Maxillofac Surg* 55:1348–1352, 1997.
190. Merrill RG, Yih WY, Shamloo J: Synovial chondrosarcoma of the temporomandibular joint: a case report, *J Oral Maxillofac Surg* 55:1312–1316, 1997.
191. Ichikawa T, Miyauchi M, Nikai H, Yoshiga K: Synovial chondrosarcoma arising in the temporomandibular joint, *J Oral Maxillofac Surg* 56:890–894, 1998.

192. Allias-Montmayeur F, Durroux R, Dodart L, Combelles R: Tumours and pseudotumorous lesions of the temporomandibular joint: a diagnostic challenge, *J Laryngol Otol* 111:776–781, 1997.
193. Stadelmann WK, Cruse CW, Messina J: Synovial cell sarcoma of the temporomandibular joint, *Ann Plast Surg* 35:664–668, 1995.
194. Delbalso M, Pyatt RS, Busch RF, et al.: Synovial cell sarcoma of the temporomandibular joint. Computed tomographic findings, *Arch Otolaryngol* 108:520–522, 1982.
195. Marx RE, Stern D: Synovial sarcoma. In Marx RE, Stern D, editors: *Oral and maxillofacial pathology. A rationale for diagnosis and treatment*, Chicago, 2003, Quintessence, pp 495–496.
196. Zorzan G, Tullio A, Bertolini F, Sesenna E: Osteosarcoma of the mandibular condyle: case report, *J Oral Maxillofac Surg* 59:574–577, 2001.
197. Gonzalez J, Elizondo J, Trull JM, De Torres I: Plasma-cell tumours of the condyle, *Br J Oral Maxillofac Surg* 29:274–276, 1991.
198. Wong GB, Pharaoh MJ, Weinberg S, Brown DH: Eosinophilic granuloma of the mandibular condyle: report of three cases and review of the literature, *J Oral Maxillofac Surg* 55:870–878, 1997.
199. Hirshberg A, Leibovich P, Buchner A: Metastatic tumors to the jawbones: analysis of 390 cases, *J Oral Pathol Med* 23:337–341, 1994.
200. Porter SR, Chaudhry Z, Griffiths MJ, et al.: Bilateral metastatic spread of testicular teratoma to mandibular condyles, *Eur J Cancer B Oral Oncol* 32B:359–361, 1996.
201. Van Royen C, Wackens G, Goossens A: Nodular fasciitis in a temporomandibular joint, *Int J Oral Maxillofac Surg* 22:168–170, 1993.
202. Pasturel A, Bellavoir A, Cantaloube D, et al.: Temporomandibular joint dysfunction and neurofibromatosis: apropos of a case [in French], *Rev Stomatol Chir Maxillofac* 90:17–19, 1989.
203. Bavitz JB, Chewning LC: Malignant disease as temporomandibular joint dysfunction: review of the literature and report of a case, *J Am Dent Assoc* 120:163–166, 1990.
204. Farole A, Manalo AE, Iranpour B: Lesion of the temporomandibular joint, *J Oral Maxillofac Surg* 50:510–514, 1992.
205. Yoshimura Y, Kawano T, Takada K, et al.: Malignant fibrous histiocytoma of the temporomandibular joint: report of a case, *Int J Oral Surg* 7:573–579, 1978.
206. Gobetti JP, Turp JC: Fibrosarcoma misdiagnosed as a temporomandibular disorder: a cautionary tale, *Oral Surg Oral Med Oral Pathol Oral Radiol Endod* 85:404–409, 1998.
207. Talesh KT, Motamedi MHK, Jeihounian M: Ewing's sarcoma of the mandibular condyle: report of a case, *J Oral Maxillofac Surg* 61:1216–1219, 2003.
208. Schmelzle R: Tumoren des Unterkiefers. In Naumann HH, Kastenbauer ER, Tardy Jr ME, editors: *Kopf- und Halschirurgie,* Band 1*, Gesicht, Nase und Gesichtsschädel,* Teil II, Stuttgart, 1995, Thieme, pp 663–670.

39

Nonsurgical Management of Temporomandibular Joint Disorders

A. THOMAS INDRESANO, CHAN M. PARK

Introduction

Temporomandibular joint (TMJ) disorders are a diverse collection of problems involving the joint itself and/or the surrounding masticatory system. This masticatory system includes the muscles of mastication, their nerve supply, the surrounding afferent neural tracts, central oromotor control, and the maxillary and mandibular dentoskeletal relationship. Given this diversity and the complex cause of the disorders, management is equally diverse. Treatment regimens can be divided into two broad categories: surgical and nonsurgical management. Surgical modalities will be discussed elsewhere in this text.

Accurate diagnosis of the particular TMJ disorder is paramount in determining a treatment regimen. For example, intracapsular joint disorders will be treated differently than musculoskeletal disorders. With virtually all TMJ disorders, however, numerous nonsurgical therapies are part of a treatment regimen (Box 39-1, Figure 39-1).

Philosophies of Treatment

The treatment of TMJ disorders involves philosophical differences among patients and practitioners. These differences often involve what one individual believes is the most appropriate course of treatment. Several treatment philosophies are universally accepted, including the use of a multidisciplinary approach, the use of reversible therapies first, and management of pain by alteration of the disease process.

Multidisciplinary Approach

TMJ disorders, as discussed earlier, involve a variety of diagnoses. The disorders also influence multiple aspects of patients' lives. For example, depression has been positively associated with TMJ complaints, especially painful symptoms.[1-4] Because of this, a sole-practitioner approach to treating TMJ disorders is often inappropriate. A "team" approach is often necessary, using multiple specialties. Professionals from diverse disciplines, such as general dentistry, oral and maxillofacial surgery, orthodontics, physical therapy, occupational therapy, psychiatry, and neurology, are often needed for thorough treatment.

Reversible Versus Nonreversible Treatment

A widely held philosophy is that the most appropriate disease therapy is the least invasive therapy that provides a positive outcome. A large reason for this is that the least invasive therapies are often reversible. Once the therapy is completed, the patient's physiology is not significantly altered. Nonsurgical TMJ therapies often, but not always, fall into this category of reversible treatment.[198] For example, long-term splint therapy can alter disc position and condylar morphology.[5-8] After reversible therapies have been attempted and it has been determined that a disease process has not been adequately interrupted, nonreversible modalities should be initiated.

Pain Management Versus Disease Therapy

Most patient's complaints of TMJ disorders involve pain.[9] Clear delineation must be made within the therapy of TMJ disorders between palliative pain management and a therapy used to *treat* a disease process. Pain can be managed in multiple ways, but the most effective is with removal of the offending stimulus or disease process. During this process, however, medicinal pain management may be necessary. Patients must be educated in the nature of the disease process and what impact each treatment modality will have on that process.

Splint Therapy

The use of occlusal splint therapy for the treatment of TMJ disorders dates back to Kingsley in 1877.[10] Occlusal splints

have, over the years, been advocated for the use of a variety of purposes. It follows that the design of the splints has been modified for each purpose. For example, Sved, Block, and Christensen used occlusal appliances to restore the vertical dimension of occlusion.[11-13] In the 1940s, Thompson advocated mandibular repositioning using intraoral appliances.[14] This form of treatment was postulated to "unload" the condyle. In the 1960s, Ramfjord popularized the use of splint therapy for patients with muscular dysfunction by using electromyographic studies.[15] Further attempts were made to "unload" the condyle in the 1970s and 1980s with anterior repositioning appliances.[10]

Splint therapy remains a popular method of treating TMJ disorders.[16,17] Several studies have concluded that splint therapy is often an effective therapy, but the type of splint used seems to have little consequence.[18-22] This is likely because the exact mechanism of action of splint therapy is not well understood. This section will highlight the different splints used and their specific uses (Box 39-2).

• BOX 39-1 Nonsurgical Options for Treating TMJ Disorders

Splint therapy
Pharmacotherapy
Occlusal management
Physical therapy
Adjunctive therapies (acupuncture, acupressure, botulinum toxin A, etc.)

Types

- Stabilization splints: Stabilization splints are the most commonly used splints to treat myofascial pain[23] (Figure 39-2). They consist of acrylic full coverage of the maxillary or mandibular occlusal shelf. Most commonly, there is interdigitation with one arch, but little to no interdigitation with the other arch. Balanced, bilateral occlusal contacts are a must. If any interdigitation

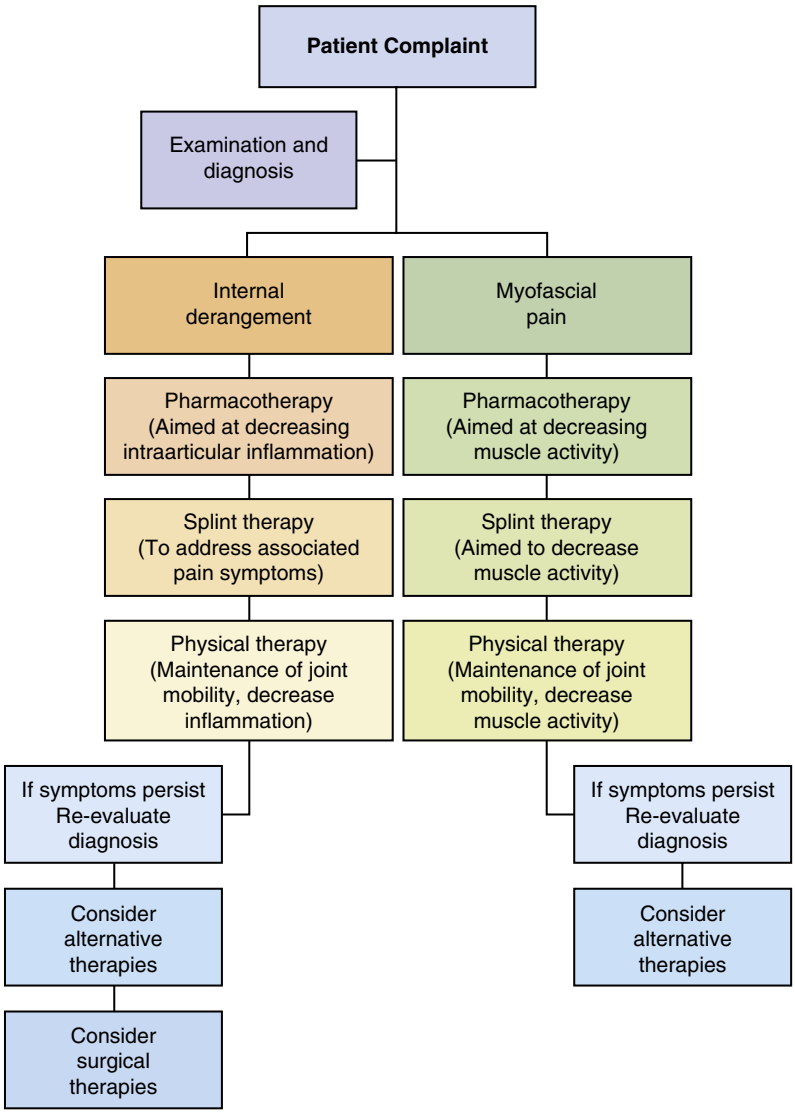

• Figure 39-1 Nonsurgical treatment algorithm of TMJ disorders.

• BOX 39-2 Types of Occlusal Splints Used in TMJ Disorders

Stabilization splints
Repositioning splints
Pivot splints
Soft splints
Bite plane splints

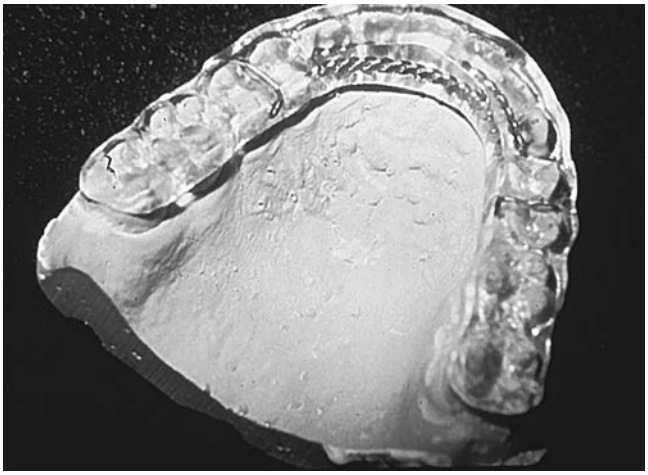

• Figure 39-2 Stabilization splint.

exists, anterior disclusion and canine guidance or group function is established. Stabilization splints are usually constructed in a centric relation. They have been shown to be moderately successful in reducing pain in longitudinal studies.[24] Studies of full-coverage stabilization splints have been shown to have favorable results in symptoms related to joint, muscular, and motion pain, but demonstrate poor results at decreasing joint noise.[25,26] Schmitter et al recently determined that patients treated with stabilization splints were treated more effectively than those with distraction splints.[27] A recent Cochrane Database review of studies using stabilization splints concluded that there was insufficient evidence to support or discourage their use.[28,29] This highlights the need for further well-controlled studies examining their efficacy.

- Repositioning splints: Repositioning splints are primarily used to alter the condylar position at occlusal contact and to recapture a displaced disc (Figure 39-3). They are constructed out of hard acrylic for the maxillary or mandibular arch with cuspal interdigitation or inclines to guide the mandible to a predetermined position. Repositioning splints became popular in the early 1980s with promising results shown to decrease pain and joint noise in patients with anteriorly displaced discs with reduction.[30-32] This initial enthusiasm, however, dwindled with controlled long-term studies showing a high rate of joint noise returning and progressive pain.[33,34] Other studies have shown a significant improvement in pain, but marginal success in "recapturing" discs.[35]

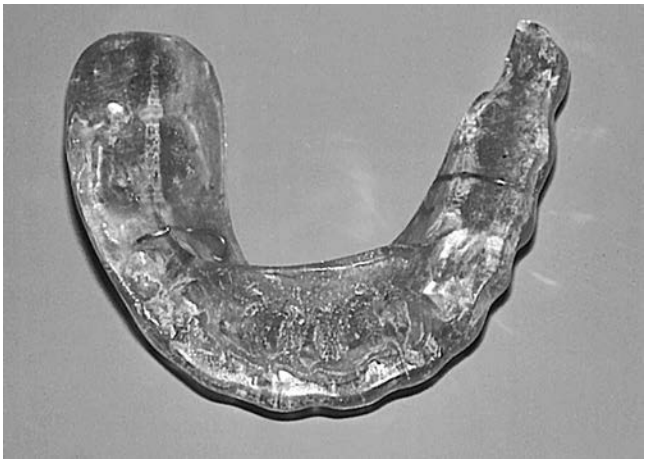

• Figure 39-3 Maxillary anterior repositioning appliance worn unsupervised for 2 years.



• Figure 39-4 A pivot splint. Note that posterior acrylic blocks are thought to gently distract the condylar head when patient is in centric occlusion.

- Pivot splints: First described by Goodwillie in 1881, these splints are designed to "unload" the TMJ and to mildly stretch the joint[10] (Figure 39-4). They can be made for the mandibular or maxillary arch and made unilateral or bilateral depending on the involved joint(s). They were theorized to be useful in patients with intracapsular inflammation. Unfortunately, the elevator muscles of the mandible lie on or posterior to the most distal portion of the dentition. Without the use of a chin cup or other orthopedic device, unloading of the joint is difficult to achieve.[36]
- Soft splints: Soft, or resilient, splints are made from a pliable material and are often effective for immediate results in patients with myofascial pain[37,38] (Figure 39-5). They have an advantage of low cost and ease of fabrication. It is believed, however, that hard splints are superior to their soft counterparts, especially in cases of bruxism.[39,40]
- Bite plane splints: Bite plane splints are used to disrupt mandibular proprioception, thereby decreasing muscle activity[41] (Figure 39-6). They are constructed by indexing only the anterior teeth with no posterior contact.

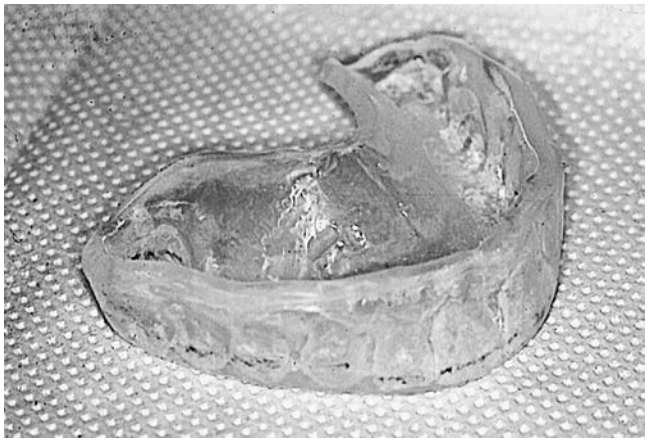

• **Figure 39-5** Soft splint.

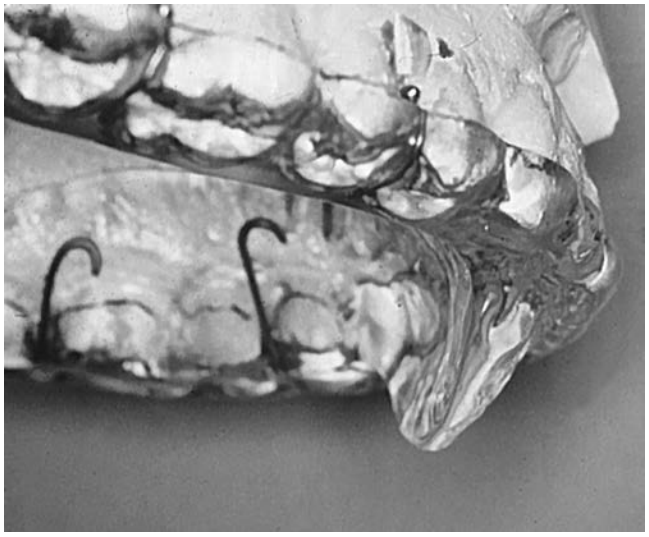

• **Figure 39-6** Lateral view of maxillary anterior repositioning appliance. Note that resting of lower incisors is anterior to this flange.

Prolonged use can cause occlusal discrepancies (Figure 39-7), and stabilization splints are more effective in bruxism cases.

Uses

Myofascial Pain

Numerous studies have shown that splint therapy is effective for myofascial pain. Stabilization splints are the most common splints used.[23] Other forms of splints have been advocated for myofascial pain with similar value; these are effective in 70% to 90% of cases.[10] The exact reason why splint therapy is effective in myofascial pain is not yet determined. Numerous electromyography (EMG) studies have shown a short-term decrease in muscle activity, especially the temporalis and masseter muscles.[42-44] Long-term EMG studies, however, have shown ambiguous results.[45-47] This may be due to a traditionally cyclic nature of symptoms related to myofascial disorders.[48]

A study by deLeeuw et al determined that patients with myofascial pain had a decrease in symptoms with splint usage compared with a control group. These patients were also shown to have a decrease in depression and an increase in the use of planned actions and rational thinking.[49] It is not clear, however, if the reduction in symptoms caused a decrease in depression or if a decrease in depression caused a reduction in symptoms.



• **Figure 39-7** Patient's occlusion after 2 years of unsupervised wear. Note open posterior malocclusion.

The effectiveness of splint therapy for myofascial pain has been brought into question by a study by Dao et al. In a parallel randomized controlled blinded study, patients were divided into three groups: brief splint usage only at recall appointments, palatal splint usage 24 hours a day (no occlusal coverage), and stabilization splint usage 24 hours a day. All three groups demonstrated a decrease in symptoms, with no statistically significant difference between the groups.[50] The findings of this study support the theory of other authors who suggest that cognitive awareness and positive patient expectations may have an as large or larger role in treatment of TMJ disorders than the biomechanical impact of occlusal appliances.[18,51-53]

The exact reason why splint therapy is effective for myofascial pain is yet to be determined. Further controlled studies are needed to validate any number of theories. The most effective type of splint used is also yet to be definitively determined. It is important, however, to use conservative and reversible appliances because some splints can have adverse effects on a patient's occlusion.[54]

Bruxism

Bruxism can cause several deleterious effects. First, bruxism can cause irreversible wear on the dentition.[55,56] Second, bruxism can also cause moderate hypertrophy of the masticatory muscles, most notably the masseter.[57] Third, bruxism can result in alteration of the TMJ anatomy over time.[58] Lastly, the link between bruxism and myofascial pain is strong and quite possibly causative in many cases.[59,60] Therefore if a patient with bruxism has a myofascial pain component, the same rationale for splint therapy applies.

EMG studies have shown a significant decrease in masseter and temporalis muscle activity with splint use in patients exhibiting nocturnal bruxism.[39,61-63] These studies also

show that the effect of splint therapy is not maintained once splint usage is halted.[61,62] Muscle activity often returned to the pretreatment levels within several weeks after cessation of treatment. Further, a recent study by Raphael et al found pain to improve in patients with bruxism, but the splint therapy had little effect on the severity of the bruxism.[64] This raises questions of the exact mechanism of splint therapy and if there is an exact causative nature of bruxism and myofascial pain.

Internal Derangement

Splint therapy has been used extensively for various intracapsular TMJ disorders with little definitive evidence indicating their therapeutic value. In attempting to treat anterior displaced discs with or without reduction, splints have been hypothesized to "recapture" a displaced disc into its natural position over the condylar head, especially during function. Cohen and MacAfee submitted that a proper meniscal-condylar position is essential to prevent future degenerative joint disease.[65] This theory, however, has not been supported by further studies. Studies show that recapturing the disc with the use of splints is marginally effective in the short and long term.[66-69] Furthermore, the use of repositioning splints can permanently alter the patient's occlusion. The most effective use is in relation to pain symptoms, where likely the joint is "unloaded" leading to a decrease in inflammation. A decrease in inflammation may result in an increase in the range of motion.[67,70,71]

In the case of anterior displaced discs *with* reduction, the theory is that a "joint unloading" will allow the disc to resume its natural position over the condylar head. Consistent repositioning of the disc has not been proven, but splint therapy has been shown to result in a decrease in joint loading. Nitzan studied the intraarticular pressure within the TMJ with and without an intraocclusal appliance. During clenching there was a decrease in intraarticular pressure of 81.2% with the occlusal appliance in place versus without it.[71] Pivot splints have also been used for joint unloading and have shown that a fulcrum at the second molar area results in 1 to 3 mm of condylar lowering.[70]

Similarly, splints have been used to treat anterior displaced discs *without* reduction. Their effectiveness, however, has been brought into question. A similar "joint unloading" phenomenon has been reported with a decrease in pain.[72,73] It is theorized that over time the retrodiscal tissue becomes more fibrotic, with a decrease in vascularity and innervation.[74-76] A study by Lundh et al, however, found no statistical benefit in pain or range of motion with the use of splints in patients with anterior disc displacement without reduction.[77] Conversely a study by Ohnuki et al observed that pain symptoms improved with splint therapy with patients with anterior disc displacement without reduction. Post-treatment magnetic resonance imaging (MRI) studies, however, revealed that splint therapy had minimal effect on the disc's position.[78]

It is therefore reasonable to conclude that a definitive role of splint therapy in patients with internal derangement is yet to be determined. Splints do have a role in decreasing joint load, which may lead to an improvement in pain symptoms. Given the lack of a conclusive role, splint therapy, if chosen, should remain conservative and not cause irreversible changes to the occlusion or TMJ anatomy.

Degenerative Joint Disease

Degenerative joint disease includes osteoarthritis and rheumatoid arthritis. Splint therapy has been shown to have a favorable therapeutic index to treat symptoms related to muscle activity and inflammation in the joint as a result of overload. If a patient is exhibiting pain in association with degenerative changes, splint therapy may be effective at treating the symptoms. Splint therapy, however, has not been shown to alter the course of degenerative joint disease.[79,80]

Pharmacotherapy

The treatment of TMJ disorders is often not effective with one modality alone. A complete treatment regimen involves multiple types of treatment reflective of the multifactorial nature of the disease process. Pharmacologic therapy quite often plays a central or adjunctive role in the treatment of TMJ disorders.

Pharmacologic therapy can be divided into two main categories: medications used to treat a certain disorder and medications used to palliate symptoms associated with the disorder. Several types of medication are used for both purposes. Imperative is a detailed discussion with the patient regarding the reason(s) why a certain medication is being prescribed and what is the desired end point. Continuing a medication, especially an analgesic, for an extended period of time is not a desirable method of treating TMJ disorders. Dependency, tolerance, or adverse side effects may occur. Furthermore, giving medications on an "as needed" basis should be avoided as much as possible. Instructions to take a medication "as needed" require the symptom to be present.[72,81,82] This leads to an oscillating or cyclical process to the patient's symptoms. More appropriate is to give medications on a schedule to prevent these variations in symptoms. The goal is to develop an individualized regimen that relieves the symptoms for a period of time, hopefully breaking the disease process and causing permanent improvement.

The categories of various pharmacologic treatment modalities are listed in Box 39-3. The choice of one type of medication over another depends on the TMJ diagnosis

• BOX 39-3 Categories of Medications Used to Treat TMJ Disorders

NSAIDs
Corticosteroids
Analgesics
Muscle relaxants
Antidepressants
Anxiolytics

and the severity of the patient's symptoms. It is not uncommon to use medications from several categories to treat an individual's disease process.

Nonsteroidal Anti-inflammatory Drugs (NSAIDs)

NSAIDs are used to treat TMJ disorders by two mechanisms: their analgesic effects and anti-inflammatory properties. NSAIDs have been used in myofascial pain syndrome, synovitis, osteoarthritis, and symptomatic disc displacement.[83] NSAIDs' mechanism of action is to inhibit cyclooxygenase from converting arachidonic acid into prostaglandins and thromboxane. Arachidonic acid is released from cell membrane phospholipids in response to noxious stimuli. Prostaglandins promote multiple physiologic effects, including both inflammation and pain (Figure 39-8).

NSAIDs act by temporarily preventing the binding of arachidonic acid to the cyclooxygenase enzyme. The exception to this is aspirin, where the cyclooxygenase enzyme is acetylated. Aspirin's effects take longer to wear off because production of new cyclooxygenase molecules is needed to restore baseline function.[84]

Two different cyclooxygenase enzymes (Cox-1 and Cox-2) produce prostaglandins. Cox-1 is a constitutive enzyme that is stimulated by normal physiologic processes and is always present. It affects platelet aggregation and renal blood flow, protects stomach mucosa, and regulates vasomotor tone.[84,85] The Cox-2 enzyme is increased dramatically with the action of macrophages. This results in the formation of multiple prostaglandins that result in pain, increased swelling, and increased temperature.[86,87]

All NSAIDs are active against Cox-1 and Cox-2, but the degree of effect that a particular NSAID has on either enzyme varies greatly. For example, aspirin is highly selective for Cox-1, whereas naproxen has a relatively equal effect on both enzymes.[86] In general, the greater the effect that a particular NSAID has on Cox-1, the greater side effect profile it has. Most notably, this manifests as gastrointestinal irritation. It follows that NSAIDs should be chosen to maximize their Cox-2 effects and decrease their impact on Cox-1. This idea, though still believed, has been brought into question by reports of selective Cox-2 inhibitors causing various cardiovascular problems.[88,199] Commonly prescribed NSAIDs are shown in Table 39-1. Currently, ibuprofen and naproxen are the most prevalent, after usage of the selective Cox-2 inhibitors has decreased.

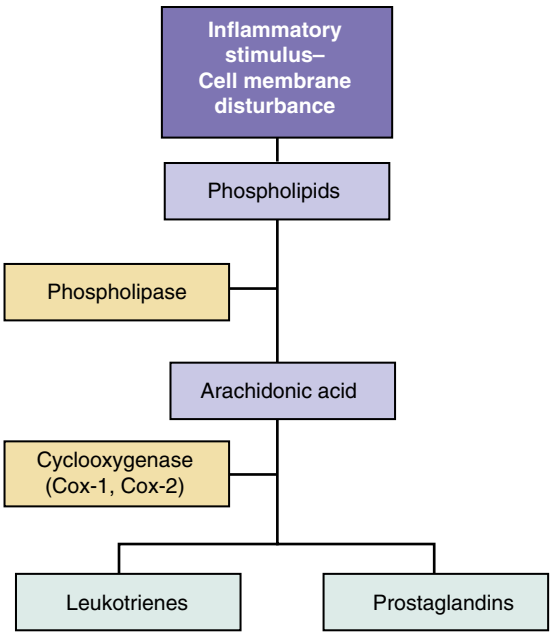

• **Figure 39-8** The cyclooxygenase pathway.

Corticosteroids

Various corticosteroids used in TMJ disorders are shown in Table 39-2. Corticosteroids interrupt the inflammatory cascade by completely blocking the formation of arachidonic acid by blocking phospholipase (see Figure 39-8). This results in a greater effect on the formation of prostaglandins than that found with NSAIDs. Their effect on acute TMJ pain and hypomobility is therefore greater than that found with NSAIDs. Long-term use of corticosteroids for the treatment of TMJ disorders, however, is contraindicated. It has been shown that usage of prednisone more than 10 to 20 mg a day for 2 weeks can cause suppression of the hypothalamic-pituitary-adrenal axis.[89] This can result in a Cushing's-like disease process, acute adrenal crisis, hypotension, electrolyte abnormalities, and diabetes. Chronic steroid administration can also result in the formation of osteoporosis including the TMJ. This is because the mandibular condyle has a reduced ability to withstand stress and may go through destructive changes.[90-92]

The use of intracapsular corticosteroid injections is discussed elsewhere in this text. The use of oral corticosteroids should be reserved for significant acute TMJ discomfort or for diagnostic purposes. The course of drug administration should be short and repeated as infrequently as possible. A typical regimen is a tapering dose lasting 5 to 7 days.

Analgesics

Practitioners have a wide array of opinions regarding the role of analgesics in TMJ disorders. Prescribed duration and dosage vary significantly. Patients' attitudes toward analgesics are also variable. Patients must be aware that the use of analgesic medications likely will not "cure" their TMJ disorder. It is permissible for patients to use analgesics for symptomatic relief, but they must be aware that by taking the medication the disease process is not halted.

The use of analgesics in TMJ disorders can be divided into two main categories: narcotic and nonnarcotic analgesics. The primary nonnarcotic medications used are the NSAIDs, which were discussed previously. Acetaminophen is another commonly used nonnarcotic analgesic. Acetaminophen does have some anti-inflammatory properties, but is mainly used for pain relief. High dose or long-term

TABLE 39-1 Nonsteroidal Anti-inflammatory Drugs Used in TMJ Disorders

Category	Generic Name	Brand Name	Usual Dosage	Relative Specificity Ratio of Cox-1 to Cox-2
Salicylates	Aspirin (acetylsalicylic acid) Diflunisal	Bayer Dolobid	650 mg qid (EC) 250 mg bid	166
Acetic acids	Indomethacin Sulindac Diclofenac	Indocin Clinoril Voltaren	25 mg tid 150 mg bid 50 mg tid	60 100 –1.4
Propionic acids	Ibuprofen Naproxen Ketoprofen Flurbiprofen	Motrin, Advil Naprosyn Orudis Ansaid	600 mg tid 375 mg bid 50 mg tid 100 mg bid	15 –1.7 1.2
Fenamic acids	Meclofenamate Mefenamic acid	Medomen Ponstel	50 mg qid 250 mg qid	7
Oxicams	Piroxicam Meloxicam	Feldene Mobicox	20 mg qod 7.5 mg qod	250 –3.0
Pyranocarboxylic acids	Etodolac	Ultradol	300 mg bid	0.1
Naphthylalkanones	Naburnetone	Relafen	1 g qod	
Cox-2 inhibitors	Celecoxib Profecoxib Valdecoxib	Celebrex Vioxx Bextra	200 mg qod 25 mg qod 20 mg qod	0.003 0.026

TABLE 39-2 Oral Corticosteroids Used in TMJ Disorders

Drug	Alternative Name	Relative Potency	Usual Dose
Hydrocortisone	Hydrocortone	1	20-240 mg/day
Prednisone	Deltasone, Orasone	4	5-60 mg/day
Prednisolone	Delta-Cortef	4	5-60 mg/day
Dexamethasone	Decadron	25	0.75-9.0 mg/day
Betamethasone	Celestone	25	0.6-7.2 mg/day

usage of acetaminophen can cause liver dysfunction. It is contraindicated in patients with liver disease or moderate alcohol consumption.

Opioid analgesics are a class of phenanthrene alkaloids with a first known use in sixteenth century Egypt.[93] Multiple opioid receptors have been discovered over the years, but the *mu* receptor has been found to be the principle receptor involved in analgesia.[94] Opioid analgesics act at sites in the brainstem for descending pain inhibition, elsewhere in the brain raising the threshold to a painful stimulus, or peripherally in peripheral nociceptors.[95-99] Opioid analgesics have adverse effects, including decreased gastrointestinal motility, respiratory depression, urine retention, sedation, and nausea and vomiting.

A large drawback to the use of opioids is a potential tolerance to the medication with chronic usage. Physical and psychological dependence on opioids is possible with repeated administration. Commonly used opioid analgesics are shown in Table 39-3 with their relative risk of causing dependence. The tolerance and dependence are both reversible, but the psychological dependence is the most difficult to completely resolve.

If prescribing opioid analgesics for patients with TMJ disorders, it is important to educate the patient on the proper use of the medications and potential risks. Further, a patient's medication intake should be monitored as closely as possible to decrease the abuse potential. Opioids should be prescribed for short durations during times of acute discomfort.

Muscle Relaxants

Muscle relaxants have been used for many years in treating symptoms associated with TMJ disorders. Proper diagnosis is paramount to determine if muscle relaxants are indicated.

TABLE 39-3 Commonly Used Opioid Analgesics in TMJ Disorders

Drug	Alternative Name	Therapeutic Dose	Abuse Potential
Codeine		30-60 mg	Low
Pentazocine	Talwin	50 mg	Low
Propoxyphene	Darvon	32-65	Low
Tramadol	Ultram	50-100 mg	Low
Hydrocodone	Dicodid, in Vicodin	5-10 mg	Moderate
Meperidine	Demerol	50-100 mg	Moderate
Methadone	Dolophine	5-15 mg	Moderate
Morphine	MS Contin	20-60 mg	Moderate
Hydromorphone	Dilaudid	2-4 mg	High
Levorphanol	Levo-Dromoran	2-3 mg	High
Oxycodone	In Percodan	5-10 mg	High

Symptoms associated with myofascial pain, bruxism, and hyperactivity of the masticatory musculature can benefit from muscle relaxants.[100,101] It follows that muscle relaxants will have minimal effects on meniscal disorders. Muscle relaxants are divided into two categories: centrally acting or peripherally acting.

Most commonly, centrally acting muscle relaxants are used to treat TMJ disorders. Antianxiety medications do have centrally acting muscle relaxation properties, but will be discussed elsewhere in this section. Centrally acting muscle relaxants act by diminishing nerve output to voluntary muscles. They involve several areas of the CNS, including the brainstem, thalamus, and basal ganglia. The most commonly used centrally acting muscle relaxants are cyclobenzaprine (Flexeril), carisoprodol (Rela, Soma), and methocarbamol (Robaxin) (Table 39-4).

The most common peripherally acting muscle relaxant is baclofen (Lioresal). Baclofen is an analogue to γ-aminobutyric acid (GABA), which binds to GABA receptors and reduces the release of excitatory amino acids, thus reducing motor tone.[102] Baclofen has been used in traumatic spinal cord injuries, multiple sclerosis, and trigeminal neuralgia in addition to TMJ disorders. Baclofen is reserved for use in patients who are experiencing marked muscle spasms or pain stemming from a neurogenic origin.

An additional method of muscle relaxation is the use of botulinum toxin A (Botox).[103-105] Botulinum toxin A functions by inhibiting the release of acetylcholine from cholinergic neurons, which decreases the transmission of the neural stimulus to the muscle. Botulinum toxin A has been used extensively to treat various dystonic syndromes.[106] Administration of botulinum toxin A requires direct injection into the affected muscle. Most precise administration is accomplished with the use of EMG-guided needles. Repeat dosing of botulinum toxin A is delayed for approximately 6 months, giving time for the botulinum toxin A to defuse from the acetylcholine receptors. Repetitive dosing can result in a tolerance in the recipient muscle.[106] Often botulinum toxin A administration will decrease muscle activity enough that the patient's disease cycle is broken, resulting in an improvement of symptoms for a period of time after the medication has worn off. Some have used botulinum toxin A for treatment of TMJ clicking with success.[200-202]

TABLE 39-4 Commonly Used Muscle Relaxants in TMJ Disorders

Generic Name	Brand Name	Usual Dosage
Centrally Acting		
Cyclobenzaprine	Flexeril	5-30 mg/day
Methocarbamol	Robaxin	1500-4500 mg/day
Carisoprodol	Rela, Soma	1000-1400 mg/day
Chlorzoxazone	Paraflex	750-3000 mg/day
Peripherally Acting		
Baclofen	Lioresal	15-80 mg/day
Botulinum toxin A	Botox	20-100 units/ 6 months

Antidepressants

Several classes of antidepressant medications exist, including tricyclic antidepressants, monoamine oxidase (MAO) inhibitors, and selective serotonin reuptake inhibitors. In general, antidepressants are used to treat a variety of disorders, including depression, eating disorders, chronic pain syndromes, obsessive-compulsive disorders, and sleeping disorders. It is well known that there is a complicated link between chronic pain and depression, and treatment of both entities is often necessary.[107] Magni reported that nearly all patients (97%)

with a chronic pain syndrome without an organic lesion causing the pain were found to have a psychiatric condition compared with 39% of patients with chronic pain resulting from an obvious cause.[108] The majority of patients with TMJ disorders have demonstrated evidence of depression on presentation or through the course of the disorder.[109,110]

For TMJ disorders, tricyclic antidepressants (TCAs) are the most commonly used class of antidepressant medications. TCAs have not only antidepressant properties but have been shown to possess analgesic potential.[111] Amitriptyline, the most commonly used TCA for TMJ disorders, has analgesic properties at low doses, much lower than the therapeutic levels to achieve significant antidepressant effects. Numerous studies have demonstrated their effectiveness in treating chronic pain from TMJ disorders.[112-114] Common side effects include xerostomia, sedation, constipation, and orthostasis[115] (Table 39-5).

Anxiolytics

Anxiolytic medications are occasionally used to treat patients with TMJ disorders. They decrease the anxiety related to the disease process, which often accompanies the depression characteristics. Anxiolytic medications also serve to decrease insomnia and decrease muscle activity, which is often associated with nocturnal bruxism. Anxiolytic medications are often not the only line of treatment for TMJ disorders, but function well as periodic adjunctive therapy.

The most commonly used anxiolytic medications are benzodiazepines (Table 39-6). Their popularity stems from a high selectivity for treatment of anxiety and a larger margin of safety than other medications (e.g., barbiturates). The benzodiazepine receptors in the CNS are coupled with the inhibitory neurotransmitter GABA receptors, leading to an increase in chloride influx. This leads to membrane hyperpolarization and neural inhibition.[116] Benzodiazepines, especially diazepam, have muscle relaxant properties, which can be very effective at treating symptoms associated with nocturnal bruxism. Adverse effects of benzodiazepines include somnolence, muscle weakness, confusion, apathy, and dependency. It is recommended to not use benzodiazepines to treat TMJ disorders for long periods of time. Syrop recommended usage for a maximum of 3 continuous weeks for the treatment of nocturnal bruxism.[83]

Buspirone (BuSpar) is an azaspirodecanedione medication used for anxiolysis. It is not related to benzodiazepines, but has the same anxiolytic properties, without the sedative, anticonvulsant, and muscle relaxant characteristics. It also does not result in physical dependence, as is the case with benzodiazepines. The major disadvantage to using buspirone is a delayed onset to clinical effect of 1 to 3 weeks.

Several other medications are occasionally used for anxiolysis. For example, meprobamate was commonly used before the advent of benzodiazepines, but its popularity has decreased substantially. Antihistamines are used for both their anxiolytic and sedative properties. They have a relatively low toxicity and minimal abuse potential.

Occlusal Management

For many years, dentistry has maintained the position that the cause of TMJ disorders is multifactorial, which usually implies that the profession is unsure about the specific cause. Dental and skeletal occlusion is at the center of a complete maxillofacial examination. This likely has lead to the historical thought that occlusion is the most important etiologic factor in the development of TMJ disorders. Presently, there are no studies that suggest that orthodontics, restorative dentistry, or oral and maxillofacial surgery prevents an individual from developing symptoms or promotes the development of symptoms. The rationale for the treatment of TMJ disorders in association with skeletal malocclusions using orthognathic surgery will be discussed elsewhere in this text.

Anterior Overjet, Overbite, and Open Bites

Numerous sources have suggested that an increase in both the anterior overbite and overjet can predispose individuals

TABLE 39-5 Commonly Used Antidepressant Medication for TMJ Disorders

Class	Generic Name	Brand Name	Usual Dose
TCA	Amitriptyline	Elavil	10-100 mg/day
	Nortriptyline	Pamelor, Aventyl	2.5-75 mg/day
	Doxepin	Sinequan	50-150 mg/day
	Imipramine	Tofranil	10-40 mg/day
	Desipramine	Norpramin	50-150 mg/day
Serotonin modulator	Trazodone	Desyrel	25-50 mg/day
SSRI	Fluoxetine	Prozac	1-20 mg/day
	Paroxetine hydrochloride	Paxil	5-20 mg/day
	Sertraline	Zoloft	50-200 mg/day

TABLE 39-6 Commonly Used Anxiolytic Medications in TMJ Disorders

Class	Generic Name	Brand Name	Usual Dosage
Azaspirodecanedione	Buspirone	BuSpar	15-30 mg/day
Antihistamine	Hydroxyzine	Vistaril	75-300 mg/day
	Promethazine	Phenergan	25-50 mg/day
Carbamate	Meprobamate	Miltown	1.2-1.6 mg/day
Benzodiazepine	Alprazolam	Xanax	0.75-4 mg/day
	Lorazepam	Ativan	2-6 mg/day
	Oxazepam	Serax	30-90 mg/day
	Temazepam	Restoril	15-30 mg/day
	Triazolam	Halcion	0.125-0.5 mg/day
	Chlordiazepoxide	Librium	15-100 mg/day
	Diazepam	Valium	8-40 mg/day
	Flurazepam	Dalmane	15-30 mg/day
	Prazepam	Verstran, Centrax	30-60 mg/day

to mandibular dysfunction.[117-120] There are not, however, suitable studies to support this claim definitively. Many of the currently available studies do not have sufficient numbers, controls, or longitudinal data.

Pullinger et al demonstrated a small but significant correlation between increased horizontal overjet and TMJ disorders.[121] A recent longitudinal study by Pahkala and Qvarnstrom supported this conclusion. Excessive overjet was the only variable that correlated with an increased risk of TMJ disorders.[122]

Definitive data regarding anterior open bites are not available. Numerous studies suggest that there is a higher percentage of open bites in patients with TMJ disorders.[121,123,124] No longitudinal studies, however, have determined that the open bite is the *cause* of the TMJ disorder. More likely, the open bite is a result of the TMJ disorder, possibly because of an alteration in the disc position or condylar resorption.

Therefore minimal conclusions can be made in regard to overjet, overbite, and open bites. There is likely a slight increase in TMJ disorders in patients with an increase in horizontal overjet. Therefore a treatment recommendation *may* be made to correct excessive horizontal overjet. Further longitudinal studies are necessary to completely describe the role, if any, overjet, overbite, and open bites play in TMJ disorders.

Angle's Classification and Anterior Contact

As discussed in the previous section, an increase in horizontal overjet may correlate with a small increase in TMJ disorders. It follows that this increase in horizontal overjet is often associated with an Angle's class II, division 1 occlusion. Studies have found that there is a small increase in TMJ disorders in Angle's class II patients compared with the overall population.[125-128]

The question of the superiority of one type of anterior contact (canine versus group function) over another has been debated in the literature. There is no scientific evidence regarding the impact of these occlusal schemes on either the success or failure of restorative dentistry treatment outcomes or on the prevention of TMJ disorders.

A study by Okano et al demonstrated a decrease in electromyographic activity in the masseter muscles with a canine-guided occlusion compared with group function and balanced occlusions. This study, however, used overlay-constructed occlusal patterns, not patients' natural occlusions.[129] Conversely, Belser and Hannam found there to be no significant change in muscle activity between group function and canine-protected occlusions.[130] Further, numerous studies have shown that occlusal splints have had minimal change on bruxism long term when splint usage is discontinued.[62,131] Therefore an alteration in occlusal scheme (i.e., usage of an occlusal splint) does not significantly decrease muscle activity long term. These results suggest that altering the occlusal scheme probably has little effect on oral habits or the development of intraarticular TMJ disorders.

Missing Posterior Teeth

Historically, it was believed that missing posterior teeth lead to TMJ disorders and the associated pain and dysfunction. Restoring the posterior occlusion would treat these symptoms.[132-134] Many studies have investigated whether missing posterior teeth increased the risk of intraarticular TMJ

disorders or increased the risk of symptoms and if restoring posterior occlusion would treat TMJ disorders.

Loss of posterior teeth has been positively correlated with osteoarthritic changes.[135-138] Tallents et al also found an association between missing mandibular molar teeth and the presence of disc displacement.[139] This has not, however, correlated with the development of symptoms.[140,141]

Several studies have shown that restoring missing posterior teeth does not decrease the prevalence of TMJ disorders.[121,142,143] A longitudinal study by Witter et al demonstrated that loss of posterior teeth did not increase the risk of TMJ disorders.[144] They also suggested that removable partial dentures do not prevent TMJ disorders and do not improve oral function. Lederman and Clayton found dysfunction in 68% of patients with fixed partial dentures in all posterior quadrants.[145] These observations pose two concerns: restorative dentistry to restore posterior occlusion is not justified as a solution to prevent TMJ disorders, and even if a symptomatic patient is restored, he or she may continue to have pain. There are other possible causes for facial pain in a patient with missing posterior teeth.

Centric Relation Versus Maximal Intercuspation

A widely debated question is whether a discrepancy between initial occlusal contact and maximal intercuspation increases the risk of developing TMJ disorders. Numerous epidemiologic studies have been done investigating the degree of TMJ disorders in relation to centric relation and/or maximal intercuspation slides.[125,127,146] The current literature does not strongly support the role of dental occlusion as an etiologic factor in TMJ disorders from the standpoint of centric relation and/or maximal intercuspation slides.[147] Several studies, however, have been done showing that alteration of the vertical dimension or introducing occlusal interferences (i.e., with "high" restoration) can incite pain and synovial changes.[148-150]

It follows that occlusal adjustments should not be used to treat TMJ disorders.[151,152] Most telling was a Cochrane Database publication concluding that there is an absence of evidence that occlusal adjustment treats or prevents TMJ disorders and cannot be recommended for the management or prevention of TMJ disorders.[153] Therefore occlusal adjustments are only recommended when TMJ pain symptoms have been introduced by recent restorative dentistry or occlusal changes. The traditional recommendation to eliminate centric relation and/or maximal intercuspation slides for the treatment of TMJ disorders has little merit.

Physical Therapy

Throughout the history of treating TMJ disorders, physical therapy modalities have been widely used. Virtually all treatment regimens for TMJ disorders involve physical therapy. The primary focus is to treat neuromuscular conditions relating to the TMJ. Physical therapy incorporates many different treatment modalities. They include stretch and/or range of motion exercises, massage, thermal treatments, ultrasonography, and electrical stimulation.

These therapies can be delivered in several manners. Trained dental professionals can carry out the therapy themselves or teach the patient the proper technique, interval, and duration of the treatment. However, physical therapists trained in caring for TMJ disorders are often necessary and highly beneficial. The physical therapists' primary goal is to treat impairments and functional limitations that are related to the patients' disability, which may or may not have a correlation to the medical diagnosis. This does not limit the necessity for an accurate diagnosis so that a proper and complete treatment regimen can be established. Table 39-7 illustrates the functional limitation and the treatment modality that can be used to improve the impairment.

Exercise Therapy

It is well established throughout the orthopedic literature that synovial joints need movement to maintain function. Early mobilization, even during the inflammatory phase after an injury, is widely accepted in the rehabilitation of other joints.[154] These same principles apply to the TMJ.[155] To maintain proper function and joint integrity, full joint motion is necessary. Furthermore, hypomobile TMJs require range of motion exercises. Exercise therapy is best used when hypomobility exists in one or both TMJs or as a result of surrounding soft tissues.[156] Conflicting opinions exist concerning the degree of hypomobility that warrants exercise therapy, but a maximum incisal opening of less than 30 mm is often used as a cutoff. Hypomobility resulting from periarticular tissue tightness and a disc displacement without reduction responds the best to exercise therapy.

The technique of joint mobilization can be done in either an active or passive manner. The active jaw motion technique involves the activation of the mandibular depressor muscles. Passive joint mobilization is a more popular technique where the musculature is relaxed and the jaw is opened manually (finger pressure, tongue blades, mandibular opening devices). Often some degree of distraction technique is necessary for proper passive mobilization. This can include medicinal therapy in extreme cases.

TABLE 39-7 Physical Therapy Treatment Concerns and Treatment Modalities to Consider

Treatment Concerns	Physical Therapy Treatment Modality
Inflammation	Heat, cold, ultrasound, TENS, iontophoresis
Hypermobility	Awareness, yawning, tongue control
Hypomobility	Heat, exercise therapy
Masticatory muscle hyperactivity	Massage, exercise therapy, ultrasound, iontophoresis

Two passive joint mobilization techniques are often used. First is to have the mandible stretched open and the position held for a short period of time (5 to 15 seconds). This is repeated 5 to 10 times in a session and can be repeated several times throughout the day. The second technique uses a low-load prolonged stretch. This technique has been demonstrated effective in laboratory studies to stretch tendinous soft tissues.[157,158] Heat therapy is often coupled with this technique because it produces greater elongation of the treated tissues. Continuous passive motion is often used after surgical procedures to maintain a proper range of motion.[159] The jaw is stretched open for approximately 10 minutes one to three times per day. It is important to not forget lateral excursive and protrusive movements during passive joint mobilization.

Exercise therapy is also often recommended for symptoms associated with masticatory muscle hyperactivity (resulting in myofascial pain). These therapies are often isometric where there is minimal movement of the mandible. The theory is that contracting one muscle group will cause the antagonist muscle(s) to relax. Therefore contraction of the mandibular depressor muscles will cause the elevator muscles (muscles of mastication) to relax.[160] Care must be taken, however, because excessive exercise and stretching of the masticatory muscles may worsen the myofascial pain.

Exercise therapy used to recapture displaced discs has been found to be minimally effective. Kurita et al found that only 9% of permanently anteriorly displaced discs can be reduced by mandibular manipulation.[161] It is important to remember that exercise therapy is not used to treat the disease process, but to minimize the sequelae. A recent study by Maloney et al concluded that exercise therapy is effective in both joint (intracapsular) and muscle (extracapsular) disorders to relieve pain and increase the range of motion.[162] Exercise therapy may therefore be used to alleviate painful symptoms and maintain functional integrity.

Massage

Minimal research has been done on the effectiveness of massage therapy on symptoms related to TMJ disorders. Massage therapy is only effective in cases involving a muscular component. Techniques, duration, and intervals of massage of the muscles of mastication vary depending on the clinician. Patients can also be instructed at self-massage if they think that it is effective for them. It has been speculated that acupressure techniques are effective at relaxing trigger points within the musculature.[163,164]

Thermal Therapy

Thermal agents are often used in the symptomatic management of TMJ disorders. Patients often express an improvement in symptoms when exercise therapy is incorporated with thermal agents. The use of heat and cold therapy is best used when an inflammatory component is present or with hypomobile TMJs. If marked inflammation is present, heat therapy may be contraindicated.

Superficial heating of the TMJ or surrounding musculature results in an elevation of the pain threshold, increases nerve conduction velocity, and decreases muscle tension.[165-167] No benefit has been cited between moist and dry heat. Heat therapy in the form of a moist washcloth or heating pad is typically applied for approximately 20 minutes to the effected area(s). Application of heat often allows for a greater range of motion with a decrease in pain.

Cold therapy, or cryotherapy, is helpful at decreasing inflammation by causing vasoconstriction and a decrease in tissue metabolism. Furthermore, a *decrease* in nerve conduction velocity has been shown to cause and increase the pain threshold.[168] The "spray and stretch" method has been described to decrease pain while attempting to increase maximal incisal opening.[169] Travell and Simons theorized that stimulation of afferent delta fibers (detecting temperature) produced a decrease in C fiber stimulation (detecting pain).[170] Many clinicians believe that the pain originates from "trigger points" in myofascial pain and the "spray and stretch" technique is effective at decreasing their sensitivity.[171-173]

Ultrasound

Ultrasound has been used widely in various fields of medicine as an additional method of delivering heat to tissues. Unlike superficial heating, however, the tissue interaction is 1 to 5 cm below the skin surface. The deep heat functions similar to superficial heating, intended to decrease pain, increase tissue perfusion, and allow for greater mobility.[174]

In addition to heating the tissues, ultrasound decreases inflammation by increasing cell membrane and vascular wall permeability.[175] Success has been reported in the orthopedic literature when exercise therapy is applied in conjunction with ultrasound.[176] In addition to causing a temperature rise and increased tissue permeability, ultrasound causes an increase in the viscoelastic properties of collagen and hyaluronic acid.[177] This results in greater joint and soft tissue laxity in case of TMJ hypomobility. Care must be taken to perform ultrasound with a proper acoustic conductive gel and use continuous motion so as not to overheat the tissues. Furthermore, ultrasound should not be used over areas of active bone growth; it may cause further aberrant growth.[178]

Electrical Stimulation

The most commonly used method of electrical stimulation is transcutaneous electrical nerve stimulation (TENS). The TENS unit is a small, portable low-voltage electrical device used in an outpatient setting or as a home therapy. The frequency, pulse width, and amplitude of the alternating current can be adjusted. The electrodes are placed over symptomatic areas, areas of inflammation, muscle hyperactivity, or trigger points.[179,180] TENS is most effective

in myofascial pain, resulting in pain relief and muscle relaxation.[181]

The exact mechanism of action of TENS is not known, but it likely involves a counterstimulation of the afferent nerves and controls pain based on the gate control theory.[182] The gate control theory postulates that the pain perception is blocked because the larger proprioceptive afferent fibers are selectively stimulated, inhibiting the smaller nociceptive fibers.[183] TENS has also been shown to produce vasodilation, which increases circulation and lymphatic drainage.[184] Contraindications to TENS treatment include epilepsy, demand-type pacemakers, a history of transient ischemic attacks, or a history of cerebrovascular accidents.[185]

Another method of using electrical stimulation is iontophoresis. Iontophoresis shifts water-soluble ions through the skin to the underlying soft tissue.[186-188] Commonly used ionizing drugs are dexamethasone, methylprednisolone, lidocaine, and salicylates. Medications administered by iontophoresis have been shown to have higher tissue levels than medications taken enterally, but lower tissue levels than achieved by injection.[189] Further research is required on the medication levels achievable in the TMJ. Several studies have shown minimal improvement of pain with the use of iontophoresis, but have shown an improvement in mandibular function.[190,191]

Summary

TMJ disorders are a complex combination of bone disorders, articular problems, inflammatory reactions, connective tissue breakdowns, myalgias, and neural ailments. This can seem quite daunting and has created a stigma against treating TMJ disorders for some clinicians. This has lead to the unfortunate circumstance of specialization of a few clinicians, and the alienation of many others, treating these disorders. As illustrated throughout this chapter, TMJ disorders are quite often multifactorial and require several forms of treatment. This treatment is often best carried out by several members of a team, rather than one individual. Ideally, after an accurate and complete diagnosis has been made, there would be one clinician who is a "team leader" who refers to appropriate specialists (such as orthodontists, oral and maxillofacial surgeons, physical therapists, psychologists, etc.).[192,193]

One method of treatment of TMJ disorders is often ineffective. Common reasons why the treatment of TMJ disorders fails include an inaccurate initial diagnosis and treatment plan, poor patient compliance with treatment, coexisting morbidities, or significant psychosocial problems.[194] It is commonly believed, however, that the treatment should begin with nonsurgical management in the majority of cases. If the initial course of treatment proves to be insufficiently effective, consideration should be made to add additional treatments, surgical or nonsurgical, and to reevaluate the original diagnosis. Nonsurgical management of TMJ disorders, however, has been shown to be quite effective. Okeson reviewed the long-term studies using conservative therapy and found that there was a reported 70% to 95% success rate.[72] The majority of cases have no surgical intervention. Longitudinal studies have shown that patient symptoms fluctuate over time, but the majority improves with a reported remission rate of 31%.[195-197]

References

1. Celic R, Panduric J, Dulcic N: Psychological status in patients with temporomandibular disorders, *Int J Prosthodont* 19(1): 28–29, 2006.
2. Yap AU, et al.: Relationships between depression/somatization and self-reports of pain and disability, *J Orofac Pain* 18(3): 220–225, 2004.
3. Yap AU, et al.: Depression and somatization in patients with temporomandibular disorders, *J Prosthet Dent* 88(5):479–484, 2002.
4. Sipila K, et al.: Association between symptoms of temporomandibular disorders and depression: an epidemiological study of the Northern Finland 1966 Birth Cohort, *J Craniomandibular Pract* 19(3):183–187, 2001.
5. Kai S, et al.: Long-term outcomes of nonsurgical treatment in nonreducing anteriorly displaced disk of the temporomandibular joint, *Oral Surg Oral Med Oral Pathol Oral Radiol Endod* 85(3):258–267, 1998.
6. Davies SJ, Gray RJ: The pattern of splint usage in the management of two common temporomandibular disorders. Part III: long-term follow-up in an assessment of splint therapy in the management of disc displacement with reduction and pain dysfunction syndrome, *Br Dent J* 183(8):279–283, 1997.
7. Fayed MM, et al.: Occlusal splint therapy and magnetic resonance imaging, *World J Orthod* 5(2):133–140, 2004.
8. Sindelar BJ, Edwards S, Herring SW: Morphologic changes in the TMJ following splint wear, *Anat Rec* 266(3):167–176, 2002.
9. Nassif NJ, Talik YF: Classic symptoms in temporomandibular disorder patients: a comparative study, *J Craniomandibular Pract* 19(1):33–41, 2001.
10. McNeill C: History and evolution of TMD concepts, *Oral Surg Oral Med Oral Pathol Oral Radiol Endod* 83(1):51–60, 1997.
11. Sved A: Changing the occlusal level and a new method of retention, *Am J Orthod* 30:527–535, 1944.
12. Block IS: Diagnosis and treatment of disturbances of the temporomandibular joint, especially in relation to vertical dimension, *J Am Dent Assoc* 34:253–260, 1947.
13. Christensen J: Effect of occlusion-raising procedures on the chewing system, *Dent Pract* 20:233–238, 1970.
14. Thompson JR: The rest position of the mandible and its significance to dental science, *J Am Dent Assoc* 33:151–180, 1946.
15. Ramfjord SP, Ash MM: *Occlusion*, ed 3, Philadelphia, 1983, WB Saunders.
16. Glass EG, Glaros AG, McGlynn FD: Myofascial pain dysfunction: treatments used by ADA members, *J Craniomandibular Pract* 11(1):25–29, 1993.

17. Pierce CJ, et al.: Dental splint prescription patterns: a survey, *J Am Dent Assoc* 126(2):248–254, 1995.
18. Clark GP: A critical evaluation of orthopedic interocclusal appliance therapy: design, theory, and overall effectiveness, *J Am Dent Assoc* 108(3):359–364, 1984.
19. Davies SJ, Gray RJ: The pattern of splint usage in the management of two common temporomandibular disorders. Part I: the anterior repositioning splint in the treatment of disc displacement with reduction, *Br Dent J* 183(6):199–203, 1997.
20. Jokstad A, Mo A, Krogstad BS: Clinical comparison between two different splint designs for temporomandibular disorder therapy, *Acta Odontol Scand* 63(4):218–226, 2005.
21. Stiesch-Scholz M, et al.: Comparative prospective study on splint therapy of anterior disc displacement without reduction, *J Oral Rehabil* 32(7):474–479, 2005.
22. Carlson N, et al.: Comparison of muscle activity between conventional and neuromuscular splints, *J Prosthet Dent* 70(1): 39–43, 1993.
23. Yoda T, et al.: Response of temporomandibular joint intermittent closed lock to different treatment modalities: a multicenter survey, *J Craniomanibular Pract* 24(2):130–136, 2006.
24. Ekberg E, Nilner M: A 6- and 12-month follow-up of appliance therapy in TMD patients: a follow-up of a controlled trial, *Int J Prosthodont* 15(6):564–570, 2002.
25. Carraro JJ, Caffesse RG: Effect of occlusal splints on TMJ symptomatology, *J Prosthet Dent* 40(5):563–566, 1978.
26. Okeson JP, Kemper JT, Moody PM: A study of the use of occlusion splints in the treatment of acute and chronic patients with craniomandibular disorders, *J Prosthet Dent* 48(6):708–712, 1982.
27. Schmitter M, et al.: Conservative therapy in patients with anterior disc displacement without reduction using 2 common splints: a randomized clinical trial, *J Oral Maxillofac Surg* 63(9):1295–1303, 2005.
28. Al-Ani MZ, et al.: Stabilisation splint therapy for temporomandibular pain dysfunction syndrome, *Cochrane Database Syst Rev*(1)CD002778, 2004.
29. Al-Ani MZ, et al.: Stabilization splint therapy for the treatment of temporomandibular myofascial pain: a systematic review, *J Dent Educ* 69(11):1242–1250, 2005.
30. Clark GT: Treatment of jaw clicking with temporomandibular repositioning: analysis of 25 cases, *J Craniomandibular Pract* 2:246, 1984.
31. Anderson GC, Schulte JK, Goodkind RJ: Comparative study of two treatment methods for internal derangement of the temporomandibular joint, *J Prosthet Dent* 53(3):392–397, 1985.
32. Lundh H, et al.: Disk-repositioning onlays in the treatment of temporomandibular joint disk displacement: comparison with a flat occlusal splint and with no treatment, *Oral Surg Oral Med Oral Pathol* 66(2):155–162, 1988.
33. Moloney F, Howard JA: Internal derangement of the temporomandibular joint. III. Anterior repositioning splint therapy, *Aust Dent J* 31(1):30–39, 1986.
34. Lundh H, Westesson PL: Long-term follow-up after occlusal treatment to correct abnormal temporomandibular joint disk position, *Oral Surg Oral Med Oral Pathol* 67(1):2–10, 1989.
35. Simmons III HC, Gibbs SJ: Anterior repositioning appliance therapy for TMJ disorders: specific symptoms relieved and relationship to disk status on MRI, *J Craniomandibular Pract*(2):89–99, 2005.
36. Lous I: Treatment of TMJ syndrome by pivots, *J Prosthet Dent* 40(2):179–182, 1978.
37. Pettengill CA, et al.: A pilot study comparing the efficacy of hard and soft stabilizing appliances in treating patients with temporomandibular disorders, *J Prosthet Dent* 79(2):165–168, 1998.
38. Wright E, Anderson G, Schulte J: A randomized clinical trial of intraoral soft splints and palliative treatment for masticatory muscle pain, *J Orofac Pain* 9(2):192–199, 1995.
39. Okeson JP: The effects of hard and soft occlusal splints on nocturnal bruxism, *J Am Dent Assoc* 114(6):788–791, 1987.
40. Al-Quran FA, Lyons MF: The immediate effect of hard and soft splints on the EMG activity of the masseter and temporalis muscles, *J Oral Rehabil* 26(7):559–563, 1999.
41. Boero RP: The physiology of splint therapy: a literature review, *Angle Orthod* 59(3):165–180, 1989.
42. Williamson EH, Navarro EZ, Zwemer JD: A comparison of electromyographic activity between anterior repositioning splint therapy and a centric relation splint, *J Craniomandibular Pract* 11(3):178–183, 1993.
43. Carr AB, et al.: Postural contractile activities of human muscles following use of an occlusal splint, *J Oral Rehabil* 18(2):185–191, 1991.
44. Erlandson Jr PM, Poppen R: Electromyographic biofeedback and rest position training of masticatory muscles in myofascial pain-dysfunction patients, *J Prosthet Dent* 62(3):335–338, 1989.
45. Harada T, et al.: The effect of oral splint devices on sleep bruxism: a 6-week observation with an ambulatory electromyographic recording device, *J Oral Rehabil* 33(7):482–488, 2006.
46. Canay S, et al.: Effect of muscle relaxation splint therapy on the electromyographic activities of masseter and anterior temporalis muscles, *Oral Surg Oral Med Oral Pathol Oral Radiol Endod* 85(6):674–679, 1998.
47. Holmgren K, et al.: The effects of an occlusal splint on the electromyographic activites of the temporal and masseter muscles during maximal clenching in patients with a habit of nocturnal bruxism and signs and symptoms of craniomandibular disorders, *J Oral Rehabil* 17(5):447–459, 1990.
48. Truelove E, Blasberg B: Orofacial pain review of the literature. In Millard HB, Mason DK, editors: *Perspectives on the second world workshop on oral medicine*, Ann Arbor, MI, 1995, University of Michigan Continuing Dental Education, School of Dentistry.
49. de Leeuw JR, et al.: Assessment of treatment outcomes in patients with craniomandibular dysfunction, *J Oral Rehabil* 21(6):655–666, 1994.
50. Dao TT, et al.: The efficacy of oral splints in the treatment of myofascial pain of the jaw muscles: a controlled clinical trial, *Pain* 56(1):85–94, 1994.
51. Greene CS, Laskin DM: Splint therapy for the myofascial pain-dysfunction (MPD) syndrome: a comparative study, *J Am Dent Assoc* 84(3):624–628, 1972.
52. Rugh JB: Home care and behavioral therapy. In McNeill C, editor: *Current controversies in temporomandibular disorders*, Chicago, 1992, Quintessence.
53. Stohler CS: Occlusal therapy in treatment of temporomandibular disorders, *Oral Maxillofac Surg Clin North Am* 7(1):129–139, 1995.
54. NIH Technology Assessment Conference: Management of temporomandibular disorders, *J Am Dent Assoc* 127:1595–1606, 1996.
55. Abrahamsen TC: The worn dentition-pathognomonic patterns of abrasion and erosion, *Int Dent J* 55(4 Suppl 1): 268–276, 2005 .

56. Xhonga FA: Bruxism and its effect on the teeth, *J Oral Rehabil* 4(1):65–76, 1977.
57. Balatsouras D, et al.: Two case reports, *Acta Otorhinolaryngol Ital* 24(3):165–170, 2004.
58. Guler N, et al.: Temporomandibular internal derangement: correlation of MRI findings with clinical syndromes of pain and joint sounds in patients with bruxing behaviour, *Dentomaxillofac Radiol* 32(5):304–310, 2003.
59. Glaros AB, Burton E: Parafunctional clenching, pain, and effort in temporomandibular disorders, *J Behav Med* 27(1):91–100, 2004.
60. Glaros AG, Tabacchi KN, Glass EG: Effect of parafunctional clenching on TMD pain, *J Orofac Pain* 12(2):145–152, 1998.
61. Sheikholeslam A, Holmgren K, Riise C: A clinical and electromyographic study of the long-term effects of an occlusal splint on the temporal and masseter muscles in patients with functional disorders and nocturnal bruxism, *J Oral Rehabil* 13(2):137–145, 1986.
62. Kydd WL, Daly C: Duration of nocturnal tooth contacts during bruxing, *J Prosthet Dent* 53(5):717–721, 1985.
63. Hamada T, et al.: Effect of occlusal splints on the EMG activity of masseter and temporal muscles in bruxism with clinical symptoms, *J Oral Rehabil* 9(2):119–123, 1982.
64. Raphael KG, et al.: Is bruxism severity a predictor of oral splint efficacy in patients with myofascial face pain? *J Oral Rehabil* 30(1):17–29, 2003.
65. Cohen SG, MacAfee II KA: The use of magnetic resonance imaging to determine splint position in the management of internal derangement of the temporomandibular joint, *J Craniomandibular Pract* 12(3):167–171, 1994.
66. Zamburlini I, Austin D: Long-term results of appliance therapies in anterior disk displacement with reduction: a review of the literature, *J Craniomandibular Pract* 9(4):361–368, 1991.
67. Kirk Jr WS: Magnetic resonance imaging and tomographic evaluation of occlusal appliance treatment for advanced internal derangement of the temporomandibular joint, *J Oral Maxillofac Surg* 49(1):9–12, 1991.
68. Eberhard D, Bantleon HP, Steger W: The efficacy of anterior repositioning splint therapy studied by magnetic resonance imaging, *Eur J Orthod* 24(4):343–352, 2002.
69. Chen CW, Boulton JL, Gage JP: Effects of splint therapy in TMJ dysfunction: a study using magnetic resonance imaging, *Aust Dent J* 40(2):71–78, 1995.
70. Moncayo S: Biomechanics of pivoting appliances, *J Orofac Pain* 8(2):190–196, 1994.
71. Nitzan DW: Intraarticular pressure in the functioning human temporomandibular joint and its alteration by uniform elevation of the occlusal plane, *J Oral Maxillofac Surg* 52(7):671–679, 1994.
72. Okeson J: *Management of temporomandibular joint disorders and occlusion*, ed 4, St Louis, 1998, CV Mosby.
73. Stiesch-Scholz M, et al.: Comparative prospective study on splint therapy of anterior disc displacement without reduction, *J Oral Rehabil* 32(7):474–479, 2005.
74. Okeson JP: Non-surgical treatments of internal derangement, *Oral Maxillofac Surg Clin North Am* 7(1):63–71, 1995.
75. Chung SC, Kim HS: The effective stabilization splint on TMJ close lock, *J Craniomandibular Pract* 11(2):95–101, 1993.
76. Sato S, Kawamura H, Motegi K: Management of nonreducing temporomandibular joint disk displacement. Evaluation of three treatments, *Oral Surg Oral Med Oral Pathol Oral Radiol Endod* 80(4):384–348, 1995.
77. Lundh H, et al.: Temporomandibular joint disk displacement without reduction. Treatment with flat occlusal splint versus no treatment, *Oral Surg Oral Med Oral Pathol* 73(6):655–658, 1992.
78. Ohnuki T, et al.: Evaluation of the position, mobility, and morphology of the disc by MRI before and after four different treatments for temporomandibular joint disorders, *Dentomaxillofac Radiol* 35(2):103–109, 2006.
79. Emshoff R: Clinical factors affecting the outcome of occlusal splint therapy of temporomandibular joint disorders, *J Oral Rehabil* 33(6):393–401, 2006.
80. Clark GT: A critical evaluation of orthopedic interocclusal appliance therapy: effectiveness for specific symptoms, *J Am Dent Assoc* 108(3):364–368, 1984.
81. Black RG: The chronic pain syndrome, *Surg Clin North Am* 55(4):999–1011, 1975.
82. Fordyce WE: *Behavior methods for chronic pain and illness*, St Louis, 1976, Mosby.
83. Syrop S: Pharmacologic management of myofascial pain and dysfunction, *Oral Maxillofac Surg Clin North Am* 7:87–97, 1995.
84. Vane JR: Introduction: mechanism of action of NSAIDs, *Br J Rheumatol* 35(suppl 1):1–3, 1996.
85. Williams CS, DuBois RN: Prostaglandin endoperoxide synthase: why two isoforms?, *Am J Physiol* 270(3) (pt 1):G393–G400, 1996 .
86. Tannenbaum H, et al.: An evidence-based approach to prescribing NSAIDs in musculoskeletal disease: a Canadian consensus. Canadian NSAID consensus participants, *CMAJ* 155(1):77–88, 1996.
87. Polisson R: Nonsteroidal anti-inflammatory drugs: practical and theoretical considerations in their selection, *Am J Med* 100(2A):31S–36S, 1996.
88. Mukherjee D, Nissen SE, Topol EJ: Risk of cardiovascular events associated with selective COX-2 inhibitors, *JAMA* 286(8): 954–959, 2001.
89. Halpern LR, Chase DC: Perioperative management of patients with endocrine dysfunction: physiology, presurgical, and postsurgical treatment protocols, *Oral Maxillofac Surg Clin North Am* 10:491, 1998.
90. Streeten DH: Corticosteroid therapy. II. Complications and therapeutic indications, *JAMA* 232(10):1046–1059, 1975.
91. Wolfe CS, Hughes GR: The optimum management of arthropathies, *Drugs* 36(3):370–381, 1988.
92. Schreiber AM, Brooks P: Immunosuppressive drugs and corticosteroids in the treatment of rheumatoid arthropathies, *Drugs* 36(3):340–363, 1988.
93. Sapira JD: Speculations concerning opium abuse and world history, *Perspect Biol Med* 18(3):379–398, 1975.
94. Gebhart GF: Opioid analgesics and antagonists. In Yagiela JA, Neidle EA, Dowd FJ, editors: *Pharmacology and therapeutics for dentistry*, St Louis, 1998, Mosby.
95. Cousins MJ, Mather LE: Intrathecal and epidural administration of opioids, *Anesthesiology* 61:276–310, 1984.
96. Gebhart GF, Randich A: Brainstem modulation of nociception. In Klemm WR, Vertes RP, editors: *Brainstem mechanisms of behavior*, New York, 1990, John Wiley & Sons.
97. Price DD: *Psychological and neural mechanisms of pain*, New York, 1988, Raven Press.
98. Sandkuhler J, et al.: Differential effects of spinalization on discharge patterns and discharge rates of simultaneously recorded nociceptive and non-nociceptive spinal dorsal horn neurons, *Pain* 60(1):55–65, 1995.

99. Yaksh TL: The spinal action of opioids. In Hertz A, editor: *Opioids II. Handbook of experimental pharmacology*, vol. 104. Berlin, 1993, Springer-Verlag.
100. Manfredini D, et al.: Muscle relaxants in the treatment of myofascial face pain. A literature review, *Minerva Stomatol* 53(6):305–313, 2004.
101. Glass EG, McGlynn FD, Glaros AG: A survey of treatments for myofascial pain dysfunction, *J Craniomandibular Pract* 9(2):165–168, 1991.
102. Davidoff RA: Antispasticity drugs: mechanisms of action, *Ann Neurol* 17(2):107–116, 1985.
103. Karakalar A, et al.: Botulinum toxin for the treatment of temporomandibular joint disk disfigurement: clinical experience, *J Craniofac Surg* 16(3):476–481, 2005.
104. von Lindern JJ, et al.: Type A botulinum toxin in the treatment of chronic facial pain associated with masticatory hyperactivity, *J Oral Maxillofac Surg* 61(7):774–778, 2003.
105. Schwartz M, Freund B: Treatment of temporomandibular disorders with botulinum toxin, *Clin J Pain* 18(suppl 6):S198–S203, 2002.
106. Jankovic J, Hallett M: *Therapy with botulinum toxin*, New York, 1994, Marcel Dekker.
107. Auerbach SM, et al.: Depression, pain, exposure to stressful life events, and long-term outcomes in temporomandibular disorder patients, *J Oral Maxillofac Surg* 59(6):628–633, 2001.
108. Magni G, Merskey H: A simple examination for the relationship between pain, organic lesions and psychiatric illness, *Pain* 29(3):295–300, 1987.
109. Kinney RK, et al.: Major psychological disorders in chronic TMD patients: implications for successful management, *J Am Dent Assoc* 123(10):49–54, 1992.
110. Turner JA, Dworkin SF: Screening for psychosocial risk factors in patients with chronic orofacial pain: recent advances, *J Am Dent Assoc* 135(8):1119–1125, 2004.
111. Brown RS, Bottomley WK: Utilization and mechanism of action of tricyclic antidepressants in the treatment of chronic facial pain: a review of the literature, *Anesth Prog* 37(5):223–229, 1990.
112. Sharav Y, et al.: The analgesic effect of amitriptyline on chronic facial pain, *Pain* 31(2):199–209, 1987.
113. Plesh O, et al.: Amitriptyline treatment of chronic pain in patients with temporomandibular disorders, *J Oral Rehabil* 27(10):834–841, 2000.
114. Rizzatti-Barbosa CM, et al.: Clinical evaluation of amitriptyline for the control of chronic pain caused by temporomandibular joint disorders, *J Craniomandibular Pract* 21(3):221–225, 2003.
115. Pettengill CA, Reisner-Keller L: The use of tricyclic antidepressants for the control of chronic orofacial pain, *J Craniomandibular Pract* 15(1):52–56, 1997.
116. Felpel LP: Antianxiety drugs and centrally acting muscle relaxants. In Yagiela JA, Neidle EA, Dowd FJ, editors: *Pharmacology and therapeutics for dentistry*, St Louis, 1998, Mosby.
117. Stack BC, Funt LA: Temporomandibular dysfunction in children, *J Pedod* 1(3):240–247, 1977.
118. Owen AH: Orthodontic/orthopedic treatment of craniomandibular pain dysfunction. Part 2. Posterior condylar displacement, *J Craniomandibular Pract* 2(4):333–349, 1984.
119. Gilarakou IK, et al.: Comparison of skeletal and dental morphology in asymptomatic volunteers and symptomatic patients with bilateral disk displacement without reduction, *Angle Orthod* 74(5):684–690, 2004.
120. Gilarakou IK, et al.: Comparison of skeletal and dental morphology in asymptomatic volunteers and symptomatic patients with bilateral disk displacement with reduction, *Angle Orthod* 74(2):212–219, 2004.
121. Pullinger AG, Seligman DA, Gornbein JA: A multiple logistic regression analysis of the risk and relative odds of temporomandibular disorders as a function of common occlusal features, *J Dent Res* 72(6):968–979, 1993.
122. Pahkala R, Qvarnstrom M: Can temporomandibular dysfunction signs be predicted by early morphological or functional variables? *Eur J Orthod* 26(4):367–373, 2004.
123. Riolo ML, Brandt D, TenHave TR: Associations between occlusal characteristics and signs and symptoms of TMJ dysfunction in children and young adults, *Am J Orthod Dentofacial Orthop* 92(6):467–477, 1987.
124. Byun ES, Ahn SJ, Kim TW: Relationship between internal derangement of the temporomandibular joint and dentofacial morphology in women with anterior open bite, *Am J Orthod Dentofacial Orthop* 128(1):87–95, 2005.
125. Pullinger AG, Selingman DA, Solberg WK: Temporomandibular disorders. Part I: functional status, dentomorphologic features, and sex differences in a nonpatient population, *J Prosthet Dent* 59(2):228–235, 1988.
126. Pullinger AG, Selingman DA, Solberg WK: Temporomandibular disorders. Part II: occlusal factors associated with temporomandibular joint tenderness and dysfunction, *J Prosthet Dent* 59(3):363–367, 1988.
127. de Laat A, van Steenberghe D: Occlusal relationships and temporomandibular joint dysfunction. Part I: epidemiologic findings, *J Prosthet Dent* 54(6):835–842, 1985.
128. Kahn J, et al.: Prevalence of dental occlusal variables and intraarticular temporomandibular disorders: molar relationship, lateral guidance, and nonworking side contacts, *J Prosthet Dent* 82(4):410–415, 1999.
129. Okano N, et al.: The influence of altered occlusal guidance on condylar displacement, *J Oral Rehabil* 29(11):1091–1098, 2002.
130. Belser UC, Hannam AG: The influence of altered working-side occlusal guidance on masticatory muscles and related jaw movement, *J Prosthet Dent* 53(3):406–413, 1985.
131. Holmgren K, Sheikholeslam A, Riise C: Effect of a full-arch maxillary occlusal splint on parafunctional activity during sleep in patients with nocturnal bruxism and signs and symptoms of craniomandibular disorders, *J Prosthet Dent* 69(3):293–297, 1993.
132. Hannam AG: Optimum occlusal relationships are essential for craniomandibular harmony. Position paper. In Klineberg I, Sessle B, editors: *Oro-facial pain and neuromuscular dysfunction: mechanisms and clinical correlates. Advances in biosciences*, Oxford, England, 1984, Pergamon Press.
133. Hylander WL: Mandibular function and temporomandibular joint loading. In Carlson DS, McNamara JA, Ribbens KA, editors: *Development aspects of temporomandibular joint disorders. Craniofacial growth series*, no 16, Ann Arbor, Mich, 1985, University of Michigan.
134. Faulkner MG, Hatcher DC, Hay A: A three-dimensional investigation of temporomandibular joint loading, *J Biomech* 4: 35–42, 1987.
135. Akerman S, et al.: Relationship between clinical and radiologic findings of the temporomandibular joint in rheumatoid arthritis, *Oral Surg Oral Med Oral Pathol* 66(6):639–643, 1988.

136. Tegelberg A, et al.: Relationship between disorder in the stomatognathic system and general joint involvement in individuals with rheumatoid arthritis, *Acta Odontol Scand* 45(6):391–398, 1987.
137. Martinez M, Aguilar N, Barghi N: Prevalence of TMJ clicking in subjects with missing posterior teeth, *J Dent Res* 63–345, 1984.
138. Barghi N, et al.: Prevalence of types of temporomandibular joint clickings in subjects with missing posterior teeth, *J Prosthet Dent* 57(5):617–620, 1987.
139. Tallents RH, et al.: Prevalence of missing posterior teeth and intraarticular temporomandibular disorders, *J Prosthet Dent* 87(1):45–50, 2002.
140. Kirveskari P, Alanen P: Association between tooth loss and TMJ dysfunction, *J Oral Rehabil* 12(3):189–194, 1985.
141. Wilding RJ, Owen CP: The prevalence of temporomandibular joint dysfunction in edentulous non-denture wearing individuals, *J Oral Rehabil* 4(2):175–182, 1987.
142. De Boever JA, Adriaens PA: Occlusal relationship in patients with pain-dysfunction symptoms in the temporomandibular joints, *J Oral Rehabil* 10(1):1–7, 1983.
143. Witter DJ, et al.: A 6-year follow-up study of oral function in shortened dental arches. Part II: craniomandibular dysfunction and oral comfort, *J Oral Rehabil* 21(4):353–366, 1994.
144. Witter DJ, et al.: A 6-year follow-up study of oral function in shortened dental arches. Part I: occlusal stability, *J Oral Rehabil* 21(2):113–125, 1994.
145. Lederman KH, Clayton JA: Restored occlusions. Part II: the relationship of clinical and subjective symptoms to varying degrees of TMJ dysfunction, *J Prosthet Dent* 47(3):303–309, 1982.
146. Solberg WK, Woo MW, Houston JB: Prevalence of mandibular dysfunction in young adults, *J Am Dent Assoc* 98(1):25–34, 1979.
147. Seligman DA, Pullinger AG: Association of occlusal variables among refined TM patient diagnostic groups, *J Craniomandibular Disord* 3(4):227–236, 1989.
148. Kubo Y: The uptake of horseradish peroxidase in monkey temporomandibular joint synovium after occlusal alteration, *J Dent Res* 66(5):1049–1054, 1987.
149. Rugh JD, Barghi, Drago CJ: Experimental occlusal discrepancies and nocturnal bruxism, *J Prosthet Dent* 51(4):548–553, 1984.
150. Riise C, Sheikholeslam A: The influence of experimental interfering occlusal contacts on the postural activity of the anterior temporal and masseter muscles in young adults, *J Oral Rehabil* 9(5):419–425, 1982.
151. Tsukiyama Y, Baba K, Clark GT: An evidence-based assessment of occlusal adjustment as a treatment for temporomandibular disorders, *J Prosthet Dent* 86(1):57–66, 2001.
152. Koh H, Robinson PG: Occlusal adjustment for treating and preventing temporomandibular joint disorders, *J Oral Rehabil* 31(4):287–292, 2004.
153. Koh H, Robinson PG: Occlusal adjustment for treating and preventing temporomandibular joint disorders, *Cochrane Database Syst Rev* (1)CD003812, 2003.
154. Salter RB: The biologic concept of continuous passive motion of synovial joints. The first 18 years of basic research and its clinical application, *Clin Orthop Relat Res* (242):12–25, 1989.
155. Israel HA, Syrop SB: The important role of motion in the rehabilitation of patients with mandibular hypomobility: a review of the literature, *J Craniomandibular Pract* 15(1):74–83, 1997.
156. Karlis V, et al.: Effectiveness of supervised calibrated exercise therapy on jaw mobility and temporomandibular dysfunction, *J Oral Maxillofac Surg* 52(8 Suppl 2):147, 1994.
157. Lehmann JF, et al.: Effect of therapeutic temperatures on tendon extensibility, *Arch Phys Med Rehabil* 51(8):481–487, 1970.
158. Warren CG, Lehmann JF, Koblanski JN: Heat and stretch procedures: an evaluation using rat tail tendon, *Arch Phys Med Rehabil* 57(3):122–126, 1976.
159. Sebastian MH, Moffet BC: The effect of continuous passive motion on the temporomandibular joint after surgery, *Oral Surg Oral Med Oral Pathol* 67:644–653, 1989.
160. Smith AM: The coactivation of antagonist muscles, *Can J Physiol Pharmacol* 59:733, 1981.
161. Kurita H, Kurashina K, Ohtsuka A: Efficacy of a mandibular manipulation technique in reducing the permanently displaced temporomandibular joint disc, *J Oral Maxillofac Surg* 57:784–787, 1999.
162. Maloney GE, et al.: Effect of a passive jaw motion device on pain and range of motion in TMD patients not responding to flat plane intraoral appliances, *J Craniomandibular Pract* 20(1):55–66, 2002.
163. Matsumura WM: Use of acupressure techniques and concepts for nonsurgical management of TMJ disorders, *J Gen Orthod* 4(1):5–16, 1993.
164. Gerald MJ: Physical medicine modalities and trigger point injections in the management of temporomandibular disorders and assessing treatment outcome, *Oral Surg Oral Med Oral Pathol Oral Radiol Endod* 83(1):118–122, 1997.
165. Deleo JA: Basic science of pain, *J Bone Joint Surg Am* 88(suppl 2): 58–62, 2006.
166. Melzack R, Wall P: Pain mechanisms: a new theory, *Science* 150:971–979, 1965.
167. Nelson SJ, Ash Jr MM: An evaluation of a moist heating pad for the treatment of TMJ/muscle pain dysfunction, *J Craniomandibular Pract* 6(4):355–359, 1988.
168. Michlovitz S: Cryotherapy: the use of cold as a therapeutic agent. In Michlovitz S, editor: *Thermal agents in rehabilitation: contemporary perspectives in rehabilitation*, Philadelphia, 1990, FA Davis.
169. Nielsen AJ: Spray and stretch for myofascial pain, *Phys Ther* 58(5):567–569, 1978.
170. Travell J, Simons D: *Myofascial pain and dysfunction: the trigger point manual*, New York, 1983, Williams & Wilkins.
171. Hou CR, et al.: Immediate effects of various physical therapeutic modalities on cervical myofascial pain and trigger-point sensitivity, *Arch Phys Med Rehabil* 83(10):1406–1414, 2002.
172. Alvarez DJ, Rockwell PG: Trigger points: diagnosis and management, *Am Fam Physician* 65(4):653–660, 2002.
173. Han SC, Harrison P: Myofascial pain syndrome and trigger-point management, *Reg Anesth* 22(1):89–101, 1997.
174. van der Windt DA, et al.: Ultrasound therapy for musculoskeletal disorders: a systematic review, *Pain* 81(3):257–271, 1999.
175. Mannheimer H: Postoperative physical therapy protocols. In Kraus SL, editor: *Clinics in physical therapy: temporomandibular disorders*, ed 2, New York, 1994, Churchill Livingstone.
176. Munting E: Ultrasonic therapy for painful shoulders, *Physiotherapy* 64(6):180–181, 1978.
177. Ziskin MC, McDiarmid T, Michlovitz SL: Therapeutic ultrasound. In Michlovitz S, editor: *Thermal agents in rehabilitation: contemporary perspectives in rehabilitation*, Philadelphia, 1990, FA Davis.

178. Adler RC, Adachi NY: Physical medicine in the management of myofascial pain and dysfunction: medical management of temporomandibular disorders, *Oral Maxillofac Clin North Am* 7(1):99–106, 1995.
179. Clark GT, Adachi NY, Dornan MR: Physical medicine procedures affect temporomandibular disorders: a review, *J Am Dent Assoc* 121(1):151–162, 1990.
180. Mohl ND, et al.: Devices for the diagnosis and treatment of temporomandibular disorders. Part III: thermography, ultrasound, electrical stimulation, and electromyographic biofeedback, *J Prosthet Dent* 63(4):472–477, 1990.
181. Gold N, Greene CS, Laskin DM: Transcutaneous electrical nerve stimulation therapy for treatment of myofascial pain dysfunction syndrome, *J Dent Res* 62:244, 1983.
182. Wolf SL: Neurophysiologic mechanisms in pain modulation: relevance to TENS. In Manheimer JS, Lampe GN, editors: *Clinical transcutaneous electrical nerve stimulation*, Philadelphia, 1984, FA Davis.
183. Melzack R, Wall PD: Pain mechanisms: a new theory, *Science* 150(699):971–979, 1965.
184. Manheimer JS, Lampe GN: *Clinical transcutaneous electrical nerve stimulation*, Philadelphia, 1984, FA Davis.
185. Ersek RA: Transcutaneous electrical neurostimulation: a new therapeutic modality for controlling pain, *Clin Orthop Relat Res* 128:314–324, 1977.
186. Gangarosa Sr LP, Mahan PE, Ciarlone AE: Pharmacologic management of temporomandibular joint disorders and chronic head and neck pain, *J Craniomandibular Pract* 9(4):328–338, 1991.
187. Lark MR, Gangarosa Sr LP: Iontophoresis: an effective modality for the treatment of inflammatory disorders of the temporomandibular joint and myofascial pain, *J Craniomandibular Pract* 8(2):108–119, 1990.
188. DuPont Jr JS: Clinical use of iontophoresis to treat facial pain, *J Craniomandibular Pract* 22(4):297–303, 2004.
189. Glass J, Stephen R, Jacobson C: The quality and distribution of radiolabeled dexamethasone delivered to tissue by iontophoresis, *Int J Dermatol* 19:519, 1980.
190. Reid LI, et al.: Evaluation of iontophoretically applied dexamethasone for painful pathologic temporomandibular joints, *Oral Surg Oral Med Oral Pathol* 77(6):605–609, 1994.
191. Schiffman EL, Braun BL, Lindgren BR: Temporomandibular joint iontophoresis: a double-blind randomized clinical trial, *J Orofac Pain* 10(2):157–165, 1996.
192. Israel HA, Scrivani SJ: The interdisciplinary approach to oral, facial and head pain, *J Am Dent Assoc* 131(7):919–926, 2000.
193. Gil IA, et al.: Multidisciplinary approach to chronic pain from myofascial pain dysfunction syndrome: a four-year experience at a Brazilian center, *J Craniomandibular Pract* 16(1):17–25, 1998.
194. Abdel-Fattah RA: Considerations before surgical intervention in management of temporomandibular joint disorders, *J Craniomandibular Pract* 15(1):94–95, 1997.
195. Egermark I, Carlsson GE, Magnusson T: A 20-year longitudinal study of subjective symptoms of temporomandibular disorders from childhood to adulthood, *Acta Odontol Scand* 59(1):40–48, 2001.
196. Magnusson T, Egermark I, Carlsson GE: A longitudinal epidemiologic study of signs and symptoms of temporomandibular disorders from 15 to 35 years of age, *J Orofac Pain* 14(4): 310–319, 2000.
197. Rammelsberg P, et al.: Longitudinal outcome of temporomandibular disorders: a 5-year epidemiologic study of muscle disorders defined by research diagnostic criteria for temporomandibular disorders, *J Orofac Pain* 17(1):9–20, 2003.
198. Wieckiewicz M, et al.: Reported concepts for the treatment modalities and pain management of temporomandibular disorders, *J Headache Pain* 16:106, 2015.
199. Nussmeier NA, Whelton AA, Brown MT, et al.: Complications of the COX-2 inhibitors parecoxib and valdecoxib after cardiac surgery, *N Engl J Med* 352:1081–1091, 2005.
200. Emara AS, Faramawey MI, et al.: Botulinum toxin injection for management of temporomandibular joint clicking, *Int J Oral Maxillofac Surg* 42(6):759–764, 2013.
201. Bakke M, Moller E, et al.: Treatment of severe tempromandibular joint clicking with botulinum toxin in the lateral pterygoid muscle in two cases of anterior disc displacement, *Oral Surg Oral Med Oral Pathol Oral Radiol Endod* 100(6):693–700, 2005.
202. Karacalar A, Yilmaz N, et al.: Botulinum toxin for the treatment of temporomandibular joint disk disfigurement: clinical experience, *J Craniofac Surg* 16(3):476–481, 2005.

40

Arthrocentesis of the Temporomandibular Joint

VINCENT B. ZICCARDI, SAMI A. NIZAM II

Introduction

Arthrocentesis is a safe and rapid procedure used to treat a multitude of disorders affecting the temporomandibular joint (TMJ). The popularity of this procedure followed the success of arthroscopic surgical procedures with the initial application for treatment of disc displacement without reduction. Since that time, arthrocentesis has been described for other clinical indications; however, it is not indicated for all temporomandibular joint disorders. This procedure does not change the shape or position of the disc or the anatomic structure of the mandibular condyle and glenoid fossa. Pathology involving bony degeneration, osteophytes and bone spicules, disc perforation or fibro-osseous ankylosis are not amendable to arthrocentesis. Treatment with arthrocentesis is generally indicated when other nonsurgical and pharmacologic methods have failed to alleviate TMJ pain and dysfunction.[1]

The etiology of pain associated with the TMJ is multifaceted. Possible sources of pain include impingement, compression and inflammatory changes in the retrodiscal tissues, inflammatory changes in the synovial membrane with joint effusion, and capsulitis. Biochemical investigations of TMJ synovial fluid obtained through arthroscopic lavage and arthrocentesis have yielded information regarding the pathophysiology of pain in the TMJ. Lysis and lavage of the joint space allows for removal and dilution of inflammatory mediators which may contribute to reduction of pain. Elevated protein levels in synovial fluid parallel the degree of inflammation due to increased permeability of the synovial membrane to plasma proteins. Joint effusion as detected on T2 weighted magnetic resonance images reflects hypertrophic synovial lining and exudation from inflamed tissues. Joint effusion is also observed in joints at a more advanced degree of internal derangement.[2]

Prior to performing arthrocentesis, patients must undergo appropriate diagnosis and treatment planning. This is based on medical history, visual analogue pain scales if indicated, and clinical and radiographic findings. Clinical examination should include interincisal opening, lateral excursions, deviation on opening, and documentation of any occlusal discrepancies. Auscultation of the joint may be performed to ascertain any clicks or crepitus which may indicate disc displacement or degenerative joint disease, respectively. Radiographic imaging should minimally include a panoramic screening film followed by other imaging modalities including tomography, computed tomography, magnetic resonance imaging or nuclear medicine studies, as indicated based upon the clinical and physical findings for the specific patient.

Nonoperative management for TMJ disorders may include physical therapy, avoidance of traumatic behaviors such as clenching or gum chewing, dietary changes, nonsteroidal anti-inflammatory drugs, muscle relaxants, and occlusal appliances. Patients who fail conservative measures may be considered as candidates for arthrocentesis. Nonsurgical management for internal derangement without reduction improves symptoms comparably to surgical intervention; however, improvement takes a longer period of time. Patients with TMJ internal derangements without reduction who do not respond to nonsurgical management benefit from arthrocentesis or arthroscopic lysis and lavage.[3]

TMJ internal derangements have been described to progress through clinical stages that initially present as clicking with normal interincisal opening to limited opening lacking translational movement where clicking ceases due to a nonreducible disc. Excessive loading on the joint with a nonreducible, anteriorly displaced disc that restricts the ability of the condyle to translate on the articular surfaces can be treated effectively with arthrocentesis of the superior joint space. When originally described by Nitzan, arthrocentesis was limited to patients with closed locked TMJs. Today, due to its ease and low morbidity, arthrocentesis has found an expanded list of clinical indications including:

1. Acute closed lock due to anteriorly displaced disc
2. Acute open lock due to condyle entrapped anterior to the disc after the more common pathology involving anterior translation past the eminence has been ruled out[4]
3. Palliation of acute episodes of degenerative or inflammatory osteoarthropathies
4. Evacuation of hemarthrosis after traumatic injury[5]
5. Fluid sampling and lavage of septic joints[6]

Contraindications to TMJ arthrocentesis would include those patients who have not undergone appropriate nonsurgical and pharmacologic treatment, demonstrate bony or fibrous ankyloses, or exhibit extracapsular sources of pain such as myofascial or neuropathic pain.[7] Interestingly, some literature has called into question the need for initial conservative therapy, and found better initial pain control and mobility when arthrocentesis was used in place of nonsurgical management, although both study groups ultimately had similar outcomes at 26 weeks.[8]

Pathophysiology of TMJ Dysfunction

There are several sources regarding the development of pain and dysfunction within the TMJ including the musculature, bony structures, synovium, and discal tissues. Past interest has been directed at the changes observed in the shape and position of the articular disc. More recent research has focused on the biomechanical and biochemical processes involved in TMJ dysfunction. Anchored disc phenomenon as described by Nitzan is a sudden onset of limited mouth opening with deviation of the mandible toward the affected side. Forced opening of the mouth may provoke pain. The disc will appear to be stuck to the fossa with the condyle sliding underneath the disc on MRI studies. This is in distinction to disc displacement without reduction where the patient tends to evolve through stages with intermittent popping and clicking leading to internal derangement with reduction and eventual development of limitation of opening with internal derangement without reduction.[9]

The suction cup effect is one of the forces possibly responsible for maintaining the articular disc adherent to the fossa in anchored disc phenomenon. In an earlier study, greater negative pressures were measured in the upper joint space of patients with anchored disc phenomenon compared to normal joints. The negative pressure was thought to be strong enough to keep the disc from sliding in a normal manner. Insertion of a needle into the superior joint space would reduce the negative pressure; however, other factors may contribute to this condition.[10] Joint overloading may cause collapse of the lubrication system through increased intra-articular pressure and hypoxia that is compensated by re-oxygenation on termination of overloading. The hypoxia-reperfusion cycle can lead to the release and production of reactive oxygen species, which can result in the degradation of hyaluronic acid (HA) and a marked reduction in synovial fluid viscosity.[11] Within the TMJ, surface-active phospholipids function as boundary lubricants and protectors of the articular surfaces. Lysis of these surface-active phospholipids by phospholipase A_2 can result in a significant increase in friction and adhesion between articular surfaces. HA plays a role in joint lubrication through its protection of the surface-active phospholipids from lysis by phospholipase A_2. Injection of hyaluronic acid after arthrocentesis/arthroscopy has been postulated to contribute to a boundary layer of lubrication after surgery so that patients may immediately begin with their postoperative physical therapy.[12]

Temporomandibular joints with internal derangements may be painful as well as demonstrate restricted mobility. Proinflammatory cytokines, which are induced by inflammatory stimuli, may be involved in the pathogenesis of internal derangements. Interleukin-1-beta (IL-1-β) and tumor necrosis factor-alpha (TNF-α) are responsible for destruction of cartilage through degradation of proteoglycans. IL-6 may act to protect cartilage through promotion of the production of tissue inhibitors. It has been suggested that IL-1-β and IL-6 in synovial fluid may be associated with the development of osteoarthritis and the presence of IL-6 may be an index of synovitis. Patients with internal derangements treated with arthrocentesis underwent analysis of synovial fluid aspirates for the assessment of proinflammatory cytokines. It was determined that the detection of IL-6 and IL-1-β in synovial fluid may be an indicator for possible unsuccessful treatment after arthrocentesis for internal derangement of the TMJ.[13] Therefore, techniques aimed at increasing joint function, palliation of pain, and halting the progression of disease should be used. What follows is a summary of current TMJ arthrocentesis techniques described in the literature, indications, contraindications, and adjunctive therapies used to address the pathophysiology and better tailor treatments to each patient using an evidence-based approach.

Technique of Temporomandibular Joint Arthrocentesis

As with any surgical procedure, new techniques and modifications are proposed in the literature, which can cause confusion if there is no universally accepted classification system. Senturk and Cambazoglu created a simple classification system in 2015, taking into account the published techniques for TMJ arthrocentesis. They divided the procedure into two groups: group 1, single puncture arthrocentesis, in which a single needle is inserted into the joint space; and group 2, double puncture techniques in which two needles are placed into the joint at two separate sites. Group 1 is further subdivided into type i, in which inflow and outflow is through the same cannula and lumen, and type ii, in which inflow and outflow are through the same cannula but different lumens and ports.[14] Figure 40-1 presents a simplified diagram of this categorization scheme and can be referenced when comparing and contrasting techniques in the following text.

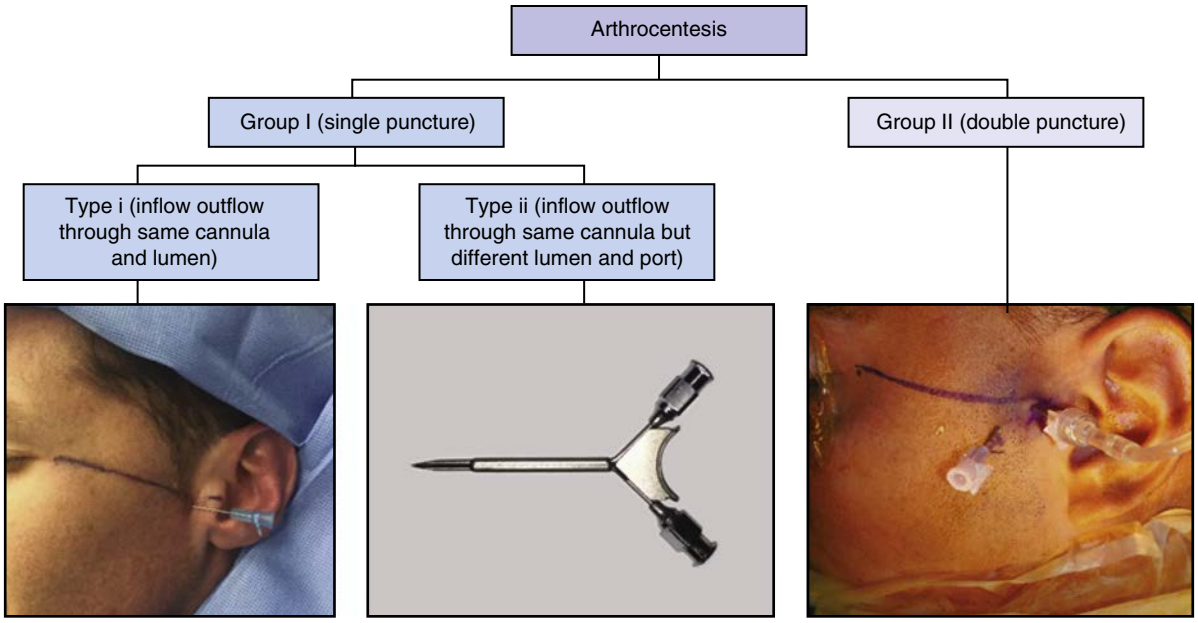

• **Figure 40-1** Classification scheme of arthrocentesis as devised by Senturk and Cambazoglu. (Senturk MF, Cambazoglu M: A new classification for temporomandibular joint arthrocentesis techniques, *Int J Oral Maxillofac Surg* 44(3):417–418, 2015.)

Double Puncture Technique (Group 2)

Arthrocentesis of the TMJ may be performed under local anesthesia, sedation, or general anesthesia, depending on the surgeon and patient preferences. It is most conveniently performed with the patient in the office suite in a semi-reclined position. The hair is pulled from the surgical field and retracted using a combination of sterile surgical towels and antibiotic ointment. The external auditory canal should be protected from fluid and blood accumulation using an antibiotic-impregnated cotton pledget. A canthal-tragal line is drawn from the midpoint of the tragus to the lateral canthus of the ipsilateral eye. A point is made 10 mm forward from the tragus and 2 mm inferior to the line. This 10-2 point approximates the posterior extent of the articular fossa. This should be confirmed by palpation with the patient opening and closing the mouth. A second point corresponding to the height of the articular eminence can be marked at 20 mm anterior to the midtragal point and 10 mm below the tragal-canthal plane. This can function as a landmark for the placement of the second portal for the outflow of irrigant (Figure 40-2).

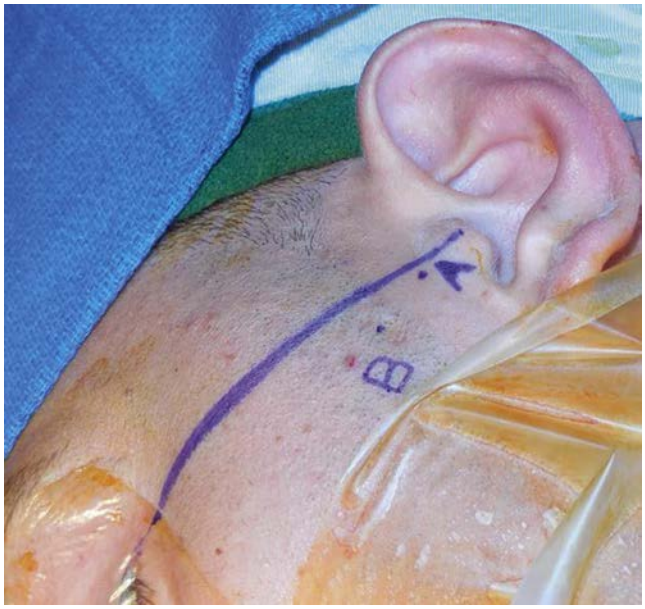

• **Figure 40-2** Canthal-tragal line with entry points marked at 10-2 and 20-10.

An auriculotemporal block and infiltration to the preauricular area for joint penetration are completed with local anesthesia. The superior joint is then entered with an 18-gauge needle directed in an anterior-medial-inferior direction at the 10-2 entry point, aiming for the posterior aspect of the articular eminence or anterior recess. Alternatively, some surgeons prefer to gently touch the zygomatic arch and gently walk the needle into the superior joint space. Once the joint space is entered, it may be insufflated with saline or lactated Ringer's solution. Several milliliters of solution can be injected rather passively into the joint space to the end point where there is rebound of the syringe pressure with jaw movement. With the needle in place, the syringe is removed and either a larger syringe can be attached for irrigation or connection to an intravenous fluid bag may be performed (Figure 40-3). A second needle must be inserted for the outflow portal at either the 20-10 point or slightly anterior to the initial needle placement. The joint is then lavaged, maintaining good outflow to confirm maintenance of the needles in the intra-articular space (Figure 40-4). After the procedure is completed, the joint can be manipulated by the assistant who is not part of the sterile field and has a gloved hand in the patient's mouth, going



• **Figure 40-3** System of IV tubing with syringe attached to provide high flow pressure irrigation.



• **Figure 40-4** Same system in use showing maintenance of outflow to confirm intra-articular positioning of the needle.

through opening, protrusive, and excursive movements. A goal of 30 to 40 mm interincisal opening should be achieved at the completion of the arthrocentesis procedure.

This technique can be used for all indications of arthrocentesis because it allows copious volumes of fluid to be flushed in an expedient manner. In particular, it is helpful for palliation of exacerbations of the inflammatory arthropathies, irrigation of a septic joint, or washing out hematoma after trauma.

Single Puncture Technique (Group 1 Type i)

As noted previously, arthrocentesis can be carried out with the use of one needle. The landmarks and procedure remain the same as in the two needle technique, however only the 10-2 posterior point of entry is used. The patient is asked to open his or her mouth and the needle is introduced. The patient then closes the mouth and small aliquots of irrigant are introduced with removal of the irrigating device to allow passive efflux of fluid. This increased hydrostatic pressure is postulated to expand the joint space and break up adhesions. The procedure is repeated several times until more passive movement of the jaw is observed.[15,16]

Insertion of only one needle posteriorly reduces the potential complication of penetrating the frontal branch of the facial nerve. In joints with advanced degenerative changes, the single puncture technique avoids the difficulty often seen with insertion of a second needle. This remains a good option if multiple attempts at second needle insertion have failed and avoids the trauma of multiple punctures to not only the joint capsule but also the glenoid fossa. If a steroid or hyaluronic acid solution is being injected postoperatively, the single needle technique theoretically allows more to stay within the joint space because there is no second perforation of the capsule allowing these substances to leak out. These considerations make the single puncture technique a good option for joints with significant hypomobility from adhesions, especially those with advanced degenerative changes. Of interest, a recently conducted randomized clinical trial demonstrated no statistically significant difference between single and double needle techniques when looking at range of motion (ROM), patient perceived improvement in pain, and surgical procedure tolerability.[17]

Single Puncture (Group 1 Type ii)

This group of techniques makes use of either commercially available needles such as the Shepard Cannula (Normed, Germany) or custom fabricated needles inserted through one puncture site, which combines the advantages of group 1 and 2. Needle entry is again obtained at the 10-2 point as in the previously described techniques. The disadvantages are related to problems with the device itself such as dulling, rusting after sterilization, and a potentially more difficult access due to the larger gauge of the device. Additionally, some have theorized that these devices may not allow adequate pressure for joint distentsion and lysis of adhesions.[5] However, this could be obviated simply by periodically blocking the outflow port.

Irrigant Volume

Because one of the goals of arthrocentesis is to wash out inflammatory mediators responsible for inflammation within the joint, it would be necessary to provide adequate volume to irrigate the joint space and meet that purpose. Repeatedly injecting solution into the joint will increase pressure to release adhesions, but not necessarily eliminate the inflammatory mediators. It was observed that 200 mL of perfusate was sufficient to achieve a statistically significant reduction in protein, bradykinin, and IL-6 concentrations. An ideal lavage volume between 300 to 400 mL perfusate resulted in no detectable level of protein and bradykinin.[18] Previous recommendations were for 100 mL of perfusate to effectively decrease the concentration of protein in synovial fluid and provide therapeutic lavage. Recommendations should probably be for a minimum of 100 mL of total

arthrocentesis volume to achieve therapeutic lavage of the superior joint space of the human TMJ and, if feasible, up to 300 to 400 mL solution.[19]

In 2009 Alkan and Kilic described use of the irrigation pump on self-irrigating surgical motors to provide higher pressures and reduce treatment time, allowing more infusion. They described the two needle technique, confirming outflow before they attached the pump and then irrigating the joint space in 2 minutes with 300 mL of effluent. They cautioned that if outflow stops or rapid swelling occurs, the procedure should cease immediately and an outflow obstruction should be suspected. No mention of actual pressures achieved in the joint were described.[20]

Irrigant Pressure

Arthrocentesis of the TMJ under low pressure with an elevated infusion bag or syringe has been reported to be effective in treating patients with acute closed lock of the TMJ.[21] Irrigation and lavage under sufficiently high hydraulic pressure has also been postulated to widen the joint space and potentially remove adhesions to improve mandibular mobility. This can be an effective procedure for treating patients with chronic closed lock and adhesions in the superior joint space. High-pressure infusion using the infusion with a maximum pressure of 40 KPa, may offer wider application of arthrocentesis for patients other than those patients with acute closed lock.[22]

Number of Treatment Sessions

In 2012 Manfredini et al. reported an overall positive trend with no statistical significance in clinical outcomes using a protocol of 5 weekly sessions utilizing the two needle technique with HA injection.[23] This was tested in 2015 in a randomized clinical trial evaluating three treatment protocols: two group 1 type i single needle procedures (one group with medium molecular weight HA and the other with high molecular weight HA), each utilizing one session, and one group 2 traditional two needle technique utilizing five sessions with HA at each session. This trial did show a significant improvement on visual analog scale at 6 months, however, other variables such as patient perceived effectiveness and maximal incisal opening remained unchanged.[24] The issues when evaluating these studies are the confounding variable of HA addition and use of different arthrocentesis techniques (group 1 vs. group 2). The authors also commented that further research utilizing a three-session protocol should be attempted to maximize cost/benefit ratio. At this time it does seem that a multitreatment session protocol may be more effective when combined with HA, although the specific number of sessions remains in question.

Adjunctive Substances

Steroids have been the most commonly injected adjunctive agent administered after arthrocentesis. Most protocols make use of betamethasone, dexamethasone, or methylprednisolone. They have been shown either alone or in conjunction with arthrocentesis to decrease pain and provide increased MIO for up to a year, although other studies have found no difference.[25] Steroids remain a good adjunctive treatment, due to their availability and marginal cost.

Hyaluronic acid has been one of the recent focuses of literature because it contributes to joint function by maintaining lubrication, minimizing mechanical wear, and playing a role in the nutritional support of the avascular portion of the disc and condylar cartilage.[26] Most injections consist of 0.5- to 2-mL injections. A Cochrane systematic review of the literature through 2010 found that although HA was effective for treating internal joint derangements when compared to placebo, it was no better than intra-articular steroid injection or oral appliances.[27] Unfortunately, most studies looked at use of HA after arthrocentesis, introducing confounding variables. To further investigate, Triantaffillidou and Venetis performed a randomized clinical trial comparing saline placebo with five sessions of HA alone. They found no statistically significant changes at 1 month, but at 6 months and 1 year, all parameters studied were significantly better, including MIO.[28] Another randomized trial performed in 2014 demonstrated single HA injection performance was statistically significantly superior at 1 and 6 weeks when compared to tenoxicam and betamethasone.[29] No difference has been found in using low molecular weight (600 kDa) and medium molecular weight (1200 kDa) formulations.[30] It seems that hyaluronic acid does have proven superiority to other supplemental joint injections, especially when viewed over longer periods of time, and should be contemplated despite its cost when an adjunctive medication is considered.

Intra-articular injection of opioids holds promise as adjunctive therapy and has been studied in two randomized clinical trials. One study compared use of 5 and 10 mg of morphine versus saline and Marcaine and assessed pain relief at 1 week. Although the levels of pain relief drastically fell off after 48 hours for saline placebo and Marcaine 5 mg, 10 mg of morphine had lasting pain relief at 1 week.[31] Another trial comparing lactated Ringer's placebo, 50 mg tramadol, and 1 mg morphine injected intra-articularly after standard arthrocentesis, found a statistically significant improvement in pain up to 6 months postoperatively with morphine. This pain relief was attributed to more potent agonist at the μ opioid receptor.[32] Of note, neither of these studies demonstrated statistically significant increases in oral opening.

The relationship between muscle activity and TMJ dysfunction is not always precisely defined. Many cases of TMJ dysfunction have a component of muscle hyperactivity which can lead to joint overloading and promotion of inflammation and the potential for development of internal derangements. It has been suggested that injection of Botox-A into the muscles of mastication as an adjunct to TMJ arthrocentesis may be more effective at prolonging the improvement of symptoms compared to arthrocentesis

alone by addressing both the joint and the musculature simultaneously. The positive effect may be attributed to the result of mechanical unloading of the joint or possible anti-inflammatory properties of the Botox-A.[33]

Regenerative medicine using growth factors and stem cell therapy is an area of interest. Many studies have found beneficial properties to the use of growth factors throughout the human body. Hanci et al. conducted a trial comparing the injection of platelet rich plasma (PRP) to arthrocentesis and found that PRP had statistically significant increases in maximum opening, decreased joint sounds, and decreased pain when compared to a control group consisting of arthrocentesis alone.[34] As growth factors and stem cell processing units become more popular, these treatments will undoubtedly see increased application.

The literature has clearly shown benefit to all of the described adjunctive treatments in addition to arthrocentesis. Questions remain as to specific formulations, treatment protocols, and superiority of one modality versus another. Selection should be based on the evidence-based findings and combined with known pathophysiology of different internal derangements of the TMJ. For instance, if the patient's chief complaint is limitation in opening, steroids may be selected and combined with a high pressure arthrocentesis to lyse adhesions and provide long-lasting gains in function. If pain is the chief complaint in an end stage joint, intra-articular opioids can be given to provide long-lasting relief and combined with group 1 single needle procedures for ease of insertion.

Outcome Assessment of Arthrocentesis of the Temporomandibular Joint

Nitzan et al. reported that arthrocentesis is a valuable modification of arthroscopic lavage. They demonstrated that arthrocentesis was very effective in the treatment of closed lock with regard to lack of recurrence of symptoms and significant improvement in pain and jaw function within a year of treatment. Furthermore, the authors recommended that arthrocentesis should be performed without delay in those patients in whom attempts at releasing the closed lock by nonsurgical means have failed. Additionally, it was noted that approximately 30% of the joints presented with no history of clicking, implying that the disc became anchored without the presence of an internal derangement, providing clinical evidence that disc displacement without reduction does not always follow disc displacement with reduction.[35]

Carvajal and Laskin[36] reported an overall success rate of 88% in their retrospective review of 26 patients (39 joints) with mean follow-up of 48.7 months after undergoing arthrocentesis. The authors stated that arthrocentesis can reduce pain and dysfunction in patients with anterior disc displacement both long- and short-term. Patients with disc displacement with both reduction and nonreducing discs have interrelated symptoms including pain, which leads to decreased opening, which in turn causes increased dysfunction. Increasing joint mobility may be more important for restoring physiologic function rather than repositioning a disc. Arthrocentesis has been found to be particularly effective in treating patients with disc displacement without reduction, possibly through release of adhesions reducing the obstruction of the displaced disc and by elimination of inflammatory mediators within the joint. For patients with anterior disc displacement with reduction in whom adhesions play a lesser role, the benefits may be derived from the reduction of inflammation and inflammatory mediators.

Kunjur et al.[37] performed a retrospective audit of 298 patients over a 10-year period that had undergone arthrocentesis for refractory TMJ pain. The pain was assessed at 1, 6, and 12 months after the procedure. A significant reduction in their pain score was found and 90% of the patients stated the procedure was beneficial. All patients in this study had failed to respond to conservative therapy including soft diet, physiotherapy, and oral appliances. The joints in these procedures were lavaged with 50 mL of normal saline followed by infusion of 10 mg of morphine and gentle manipulation. These results were reported by the investigators to demonstrate significant improvement in TMJ pain and were recommended as a first-line intervention with patients with TMJ pain refractory to conservative treatment.

Alpaslan[38] reported a 5-year retrospective evaluation of TMJ arthrocentesis patients with a mean follow-up of 22 months. Included patients completed questionnaires as part of the analysis. At long-term follow-up, 26% of the patients were pain free and 88% of patients had decreased pain. There was a significant increase in the maximal mouth opening postoperatively that persisted long-term. Pain and dysfunction levels at follow-up were significantly lower than preoperative levels. A greater reduction in dysfunction with improvement in maximal mouth opening was noted in nonbruxers. Duration of symptoms before undergoing arthrocentesis did not affect outcomes in this study. The authors concluded that arthrocentesis would continue to be a valuable treatment modality for TMJ internal derangements based on its reliable and predictable outcomes with minimal invasiveness.

In a meta-analysis of surgical treatments for patients with TMJ disorders, Reston et al.[39] reported that in patients refractory to nonsurgical management, surgical arthrocentesis and arthroscopy were most reliably effective for patients with disc displacement without reduction. This study reviewed 1,600 journals and included 22 articles that met their criteria of including at least 10 patients, diagnosis of disc displacement with or without reduction, report on the use of a surgical procedure, as well as other factors. In a reappraisal of the study, Ng et al.[40] performed a systematic review of the data using additional inclusion criteria of follow-up duration of 12 months or longer and improvement based on increased maximal mouth opening. The authors discussed the lack of published prospective randomized studies with long-term results to assist the surgeon in selecting a particular surgical option. Their results

indicated that arthrocentesis provided the greatest degree of improvement after intervention compared to the historical controls of discectomy and disc repair. The number of patients enrolled in studies was greater for arthroscopy compared to arthrocentesis, however, it was concluded that arthrocentesis and arthroscopy are effective for patients with disc displacement without reduction.

Prognostic and Predictive Factors for the Effectiveness of Arthrocentesis

Prognostic factors for successful arthrocentesis have been analyzed. Nishimura[41] reviewed 103 TMJ arthrocentesis procedures performed on 100 patients and evaluated the effectiveness of treatment in terms of maximal mouth opening and degree of pain on a visual analogue scale. Other prognostic factors also were evaluated, including age, gender, duration of symptoms, presence of clicks, and radiographic imaging. There were statistically significant differences noted between successful and unsuccessful cases immediately and 1 week after the procedure in maximal mouth opening and visual analogue pain scales. There were no statistically significant differences noted in age, gender, range of preoperative opening, duration of painful locking, and report of preoperative clicking before locking. The degree of condylar deformity on magnetic resonance imaging was statistically lower in successfully treated cases. Pain on the visual analogue scale was significantly lower in the successful cases, which may be related to increased inflammation reducing the effectiveness of the arthrocentesis procedure. In summary, severe preoperative pain, relapse of maximal mouth opening within 1 week after treatment, and the preoperative presence of condylar deformation may be indicators of potentially unsuccessful outcome following TMJ arthrocentesis.

Clinical pain and TMJ dysfunction have been linked to magnetic resonance imaging of internal derangements and osteoarthritis. There was a high rate of MRI confirmed changes in patients with symptomatic internal derangements, which may support the concept that internal derangements of the TMJ may be significantly involved in the production of TMJ pain and dysfunction and, in fact, osteoarthritis and internal derangements of the TMJ may be closely related entities. Internal derangements may be associated with radiographically evident degenerative changes including condylar flattening, sclerosis, and exophyte formation. Comparison of pretreatment versus 2-month post-treatment magnetic resonance images demonstrated no change for those patients with internal derangements, and slight increase in those patients with osteoarthritis. At 2-month follow-up, clinical examination confirmed a significant reduction in pain during function, significant reduction in the clinical diagnosis of internal derangement without reduction, and a significant increase in mandibular range of motion. It was concluded that although clinical pain may be related to TMJ magnetic resonance imaging findings of internal derangements and osteoarthritis, these disorders were not linked to the therapeutic outcomes from TMJ arthrocentesis and hydraulic distention as related to pain and mandibular range of motion.[42]

Patients with successful outcomes from arthrocentesis were more likely to be associated with a magnetic resonance image finding of osteoarthritis compared to those patients with unsuccessful outcomes. Patients with a clinical diagnosis of internal derangement without reduction and concomitant magnetic resonance imaging finding of disc displacement without reduction had a higher rate of osteoarthritis. The presence of osteoarthritis on magnetic resonance imaging is related to clinical finding of pain and osteoarthritis may be an important prognostic determinant of successful arthrocentesis. Osteoarthritis is significantly involved in the production of TMJ pain and dysfunction, although it is not always associated with TMJ pain and dysfunction. This observation emphasizes the fact that prediction of treatment outcomes is not a matter of simple linearity involving only one risk factor. Treatment plans should be based on identified risk factors to optimize outcomes with successful surgical treatment.[43]

TMJ internal derangements and osteoarthritis are frequently cited as causes of TMJ pain and dysfunction. Osteoarthritis is a noninflammatory joint disease characterized by deterioration of the articular surface with subsequent bony remodeling. Internal derangements and osteoarthritis have been recognized as closely related clinical entities with internal derangements described as associated with degenerative changes including surface irregularities, flattening, sclerosis, and osteophyte formation. Arthrocentesis has been demonstrated to be less successful in patients with chronic pain of duration greater than 6 months in regards to outcome of pain reduction. Patients with osteoarthritis were reported to receive greater benefit from arthrocentesis with respect to the elimination of internal derangements compared to non-osteoarthritic patients. TMJ patients with pain associated with internal derangements without reduction were associated with a higher rate of osteoarthritis. This further supports the concept that prediction of outcomes is not based on individual factors, but rather a complex interaction among different variables. As duration of pain increases, the condition becomes more refractory to traditional medical treatments.[44]

Successful intervention based on risk factors may have important implications with regards to the management of TMJ disorders. It has been demonstrated through logistic regression analysis that a significant increase in the benefit of successful outcomes occurred with age less than 25 years, visual analogue pain scale of greater than 75 mm, and range of motion of less than 25 mm preoperatively. The ages of patients in the unsuccessful group were significantly higher than those patients with a successful outcome. Patients with a successful outcome had a higher visual analogue scale pain level and more restricted range of motion compared to those with an unsuccessful outcome. It was hypothesized that these cases may have a more severe inflammatory process

associated with altered constituents in the synovial fluid which was effectively treated with the lavage of arthrocentesis. Predictive modeling may help identify patients who may benefit from arthrocentesis to initiate specific treatments earlier.[45]

Conclusions

Arthrocentesis of the TMJ has been shown to be an effective initial surgical treatment modality for the management of a variety of TMJ disorders in patients who do not respond to conservative nonsurgical management. It has great utility in the treatment of internal derangements without reduction, but also has applicability to other acute and chronic disorders affecting the TMJ. The physical action of lysis and lavage is thought to break down adhesions and remove inflammatory mediators, including cytokines and interleukins, which may lead to chronic pain. It allows a port for deposition of therapeutic medicaments, which are backed by a growing body of literature. These attributes lead to relief of pain, resulting in increased opening and decreased dysfunction. Arthrocentesis can be performed effectively as an outpatient procedure with minimal potential morbidity and should be considered as a first-line intervention and when other noninvasive modalities have not been successful. Outcomes have been reported to be very successful for those cases that are appropriate for this surgical intervention and should be considered prior to open arthrotomy surgical procedures except in those cases where open surgery is the only option.[46]

References

1. Nitzan DW, Price A: The use of arthrocentesis for the treatment of osteoarthritic temporomandibular joints, *J Oral Maxillofac Surg* 59(10):1154–1159, 2001, discussion 1160.
2. Guler N, et al.: Temporomandibular joint internal derangement: relationship between joint pain and MR grading of effusion and total protein concentration in the joint fluid, *Dentomaxillofac Radiol* 34(3):175–181, 2005.
3. Iwase H, et al.: Characterization of patients with disc displacement without reduction unresponsive to nonsurgical treatment: a preliminary study, *J Oral Maxillofac Surg* 63(8):1115–1122, 2005.
4. Nitzan DW: Temporomandibular joint "open lock" versus condylar dislocation: signs and symptoms, imaging, treatment, and pathogenesis, *J Oral Maxillofac Surg* 60(5):506–511, 2002, discussion 512-513.
5. Tozoglu S, Al-Belasy FA, Dolwick MF: A review of techniques of lysis and lavage of the TMJ, *Br J Oral Maxillofac Surg* 49(4):302–309, 2011.
6. Gayle EA, et al.: Septic arthritis of the temporomandibular joint: case reports and review of the literature, *J Emerg Med* 45(5):674–678, 2013.
7. Haddle KR: Arthrocentesis of the TMJ, *Oral Maxillofac Surgery Knowledge Update* 3:41–51, 2001.
8. Vos LM, Huddleston Slater JJ, Stegenga B: Arthrocentesis as initial treatment for temporomandibular joint arthropathy: a randomized controlled trial, *J Craniomaxillofac Surg* 42(5):e134–139, 2014.
9. Nitzan DW, Etsion I: Adhesive force: the underlying cause of the disc anchorage to the fossa and/or eminence in the temporomandibular joint—a new concept, *Int J Oral Maxillofac Surg* 31(1):94–99, 2002.
10. Nitzan DW, Mahler Y, Simkin A: Intra-articular pressure measurements in patients with suddenly developing, severely limited mouth opening, *J Oral Maxillofac Surg* 50(10):1038–1042, 1992, discussion 1043.
11. Nitzan DW: "Friction and adhesive forces"—possible underlying causes for temporomandibular joint internal derangement, *Cells Tissues Organs* 174(1-2):6–16, 2003.
12. Sanroman JF: Closed lock (MRI fixed disc): a comparison of arthrocentesis and arthroscopy, *Int J Oral Maxillofac Surg* 33(4):344–348, 2004.
13. Nishimura M, et al.: Comparison of cytokine level in synovial fluid between successful and unsuccessful cases in arthrocentesis of the temporomandibular joint, *J Oral Maxillofac Surg* 62(3):284–287, 2004, discussion 287-288.
14. Senturk MF, Cambazoglu M: A new classification for temporomandibular joint arthrocentesis techniques, *Int J Oral Maxillofac Surg* 44(3):417–418, 2015.
15. Shinohara EH, et al.: Single puncture for TMJ arthrocentesis: an effective technique for hydraulic distention of the superior joint space, *Natl J Maxillofac Surg* 3(1):96–97, 2012.
16. Guarda-Nardini L, Manfredini D, Ferronato G: Arthrocentesis of the temporomandibular joint: a proposal for a single-needle technique, *Oral Surg Oral Med Oral Pathol Oral Radiol Endod* 106(4):483–486, 2008.
17. Guarda-Nardini L, Ferronato G, Manfredini D: Two-needle vs. single-needle technique for TMJ arthrocentesis plus hyaluronic acid injections: a comparative trial over a six-month follow up, *Int J Oral Maxillofac Surg* 41(4):506–513, 2012.
18. Kaneyama K, et al.: The ideal lavage volume for removing bradykinin, interleukin-6, and protein from the temporomandibular joint by arthrocentesis, *J Oral Maxillofac Surg* 62(6):657–661, 2004.
19. Zardeneta G, Milam SB, Schmitz JP: Elution of proteins by continuous temporomandibular joint arthrocentesis, *J Oral Maxillofac Surg* 55(7):709–716, 1997, discussion 716-717.
20. Alkan A, Kilic E: A new approach to arthrocentesis of the temporomandibular joint, *Int J Oral Maxillofac Surg* 38(1):85–86, 2009.
21. Nitzan DW, Dolwick MF, Martinez GA: Temporomandibular joint arthrocentesis: a simplified treatment for severe, limited mouth opening, *J Oral Maxillofac Surg* 49(11):1163–1167, 1991, discussion 1168-1170.
22. Yura S, Totsuka Y: Relationship between effectiveness of arthrocentesis under sufficient pressure and conditions of the temporomandibular joint, *J Oral Maxillofac Surg* 63(2):225–228, 2005.
23. Manfredini D, et al.: Arthrocentesis with or without additional drugs in temporomandibular joint inflammatory-degenerative disease: comparison of six treatment protocols, *J Oral Rehabil* 39(4):245–251, 2012.
24. Guarda-Nardini L, Rossi A, Arboretti R, et al.: Single- or multiple-session viscosupplementation protocols for temporomandibular joint degenerative disorders: a randomized clinical trial, *J Oral Rehabil* 42(7):521–528, 2015.
25. Machado E, Bonotto D, Cunali PA: Intra-articular injections with corticosteroids and sodium hyaluronate for treating temporomandibular joint disorders: a systematic review, *Dental Press J Orthod* 18(5):128–133, 2013.

26. Alpaslan GH, Alpaslan C: Efficacy of temporomandibular joint arthrocentesis with and without injection of sodium hyaluronate in treatment of internal derangements, *J Oral Maxillofac Surg* 59(6):613–618, 2001, discussion 618-619.
27. Manfredini D, Piccotti F, Guarda-Nardini L: Hyaluronic acid in the treatment of TMJ disorders: a systematic review of the literature, *Cranio* 28(3):166–176, 2010.
28. Triantaffilidou K, Venetis G, Bika O: Efficacy of hyaluronic acid injections in patients with osteoarthritis of the temporomandibular joint. A comparative study, *J Craniofac Surg* 24(6):2006–2009, 2013.
29. Gencer ZK, et al.: A comparative study on the impact of intra-articular injections of hyaluronic acid, tenoxicam and beta-metazon on the relief of temporomandibular joint disorder complaints, *J Craniomaxillofac Surg* 42(7):1117–1121, 2014.
30. Guarda-Nardini L, et al.: Comparison of 2 hyaluronic acid drugs for the treatment of temporomandibular joint osteoarthritis, *J Oral Maxillofac Surg* 70(11):2522–2530, 2012.
31. Ziegler CM, Wiechnik J, Muhling J: Analgesic effects of intra-articular morphine in patients with temporomandibular joint disorders: a prospective, double-blind, placebo-controlled clinical trial, *J Oral Maxillofac Surg* 68(3):622–627, 2010.
32. Sipahi A, Satilmis T, Basa S: Comparative study in patients with symptomatic internal derangements of the temporomandibular joint: analgesic outcomes of arthrocentesis with or without intra-articular morphine and tramadol, *Br J Oral Maxillofac Surg* 53(4):316–320, 2015.
33. Freund BJ, Schwartz M: Intramuscular injection of botulinum toxin as an adjunct to arthrocentesis of the temporomandibular joint: preliminary observations, *Br J Oral Maxillofac Surg* 41(5):351–352, 2003.
34. Hanci M, et al.: Intra-articular platelet-rich plasma injection for the treatment of temporomandibular disorders and a comparison with arthrocentesis, *J Craniomaxillofac Surg* 43(1):162–166, 2015.
35. Nitzan DW, Samson B, Better H: Long-term outcome of arthrocentesis for sudden-onset, persistent, severe closed lock of the temporomandibular joint, *J Oral Maxillofac Surg* 55(2):151–157, 1997, discussion 157-158.
36. Carvajal WA, Laskin DM: Long-term evaluation of arthrocentesis for the treatment of internal derangements of the temporomandibular joint, *J Oral Maxillofac Surg* 58(8):852–855, 2000, discussion 856-857.
37. Kunjur J, et al.: An audit of 405 temporomandibular joint arthrocentesis with intra-articular morphine infusion, *Br J Oral Maxillofac Surg* 41(1):29–31, 2003.
38. Alpaslan C, Dolwick MF, Heft MW: Five-year retrospective evaluation of temporomandibular joint arthrocentesis, *Int J Oral Maxillofac Surg* 32(3):263–267, 2003.
39. Reston JT, Turkelson CM: Meta-analysis of surgical treatments for temporomandibular articular disorders, *J Oral Maxillofac Surg* 61(1):3–10, 2003, discussion 10-12.
40. Ng CH, et al.: Temporomandibular articular disorders can be alleviated with surgery, *Evid Based Dent* 6(2):48–50, 2005.
41. Nishimura M, et al.: Prognostic factors in arthrocentesis of the temporomandibular joint: evaluation of 100 patients with internal derangement, *J Oral Maxillofac Surg* 59(8):874–877, 2001, discussion 878.
42. Emshoff R, Rudisch A: Are internal derangement and osteoarthrosis linked to changes in clinical outcome measures of arthrocentesis of the temporomandibular joint?, *J Oral Maxillofac Surg* 61(10):1162–1167, 2003, discussion 1167-1170.
43. Emshoff R, et al.: Prognostic indicators of the outcome of arthrocentesis: a short-term follow-up study, *Oral Surg Oral Med Oral Pathol Oral Radiol Endod* 96(1):12–18, 2003.
44. Emshoff R, Rudisch A: Determining predictor variables for treatment outcomes of arthrocentesis and hydraulic distention of the temporomandibular joint, *J Oral Maxillofac Surg* 62(7):816–823, 2004.
45. Emshoff R: Clinical factors affecting the outcome of arthrocentesis and hydraulic distension of the temporomandibular joint, *Oral Surg Oral Med Oral Pathol Oral Radiol Endod* 100(4):409–414, 2005.
46. Brennan PA, Ilankovan V: Arthrocentesis for temporomandibular joint pain dysfunction syndrome, *J Oral Maxillofac Surg* 64(6):949–951, 2006.

41

Arthroscopy of the Temporomandibular Joint

A. THOMAS INDRESANO, CHAN M. PARK

History

Tagaki performed the first arthroscopic examination in 1918. He used a cystoscope to look at a cadaver knee.[1] Several further attempts to look into the knee joint were made, but the equipment was problematic. Watanabe then developed several working arthroscopes and described their use in various joints in 1957.[2] Fiberoptic lighting was incorporated in the 1970s, which allowed for reproducible examination. In 1975, Ohnishi used a Watanabe small-joint arthroscope to enter the temporomandibular joint (TMJ).[3]

Sanders brought the Japanese techniques to the United States, and others, like Holmlund in Sweden, developed diagnostic uses for the arthroscope.[4,5] Murakami published descriptions of the arthroscopic anatomy and pathology in 1982.[6] The main operative usage of arthroscopy in the United States became the lysis and lavage procedure popularized by Sanders and others.[7,8] Operative arthroscopy in the TMJ was first limited by the size of the joint and the lack of miniaturization of instruments that had been developed for the knee.[9] The use of fiberoptic laser delivery in the 1980s by Indresano and Braderick and by Koslin advanced operative capabilities.[10,11] McCain developed suturing techniques that allowed operative arthroscopy to rival open arthroplasty for disc stabilization.[12] Later Dolwick and Nitzan showed that a simple procedure known as arthrocentesis, and performing a lysis and lavage without putting the arthroscope into the joint, gave similar results.[13] Today, therefore, arthroscopic lysis and lavage has been all but replaced by arthrocentesis.[14] Operative arthroscopic arthroplasty is used for more advanced maneuvers by those able to perform them. A modern surgical algorithm for internal derangement will generally include arthrocentesis and may use operative arthroscopic surgery or open surgery as the next step. This has decreased the volume of arthroscopic procedures that were performed in the 1980s and early 1990s.[15]

Anatomic Considerations

The general anatomy of the TMJ is described in Chapter 35. There are several special anatomic concerns that must be mentioned pertaining specifically to arthroscopy. Anatomic landmarks, first enumerated by Murakami, added new terms to those anatomic structures established from dissection.[6]

The volume of fluid in the upper and lower compartments is important to understand. The volume of the normal upper joint space is about 2 mL, but it can increase to as much as 6 mL with pathology. The lower space volume is about 1 mL and can increase to 2 mL. Knowing this is essential to prevent a capsular tear when the initial joint puncture and joint insufflation is attempted.

The joint functions with a complex rotation and sliding motion. The upper compartment is involved in the sliding motion, and most mechanical hindrances and pathologic entities occur here. This is the reason that most arthroscopic surgery is performed in the superior joint space. Since inferior joint space arthroscopy is much more technically difficult to perform, it is quite fortunate that the upper space is where arthroscopy can achieve desired results.

In either the upper or the lower compartment, one must verify that sufficient joint space exists to establish and maintain fluid flow and to accept arthroscopic portals. The ligamentous and capsular structures are thin in the normal joints and can easily be violated by too many puncture attempts, or from too much fluid distention. Attempts to pass an arthroscope in severely fibrosed or bony ankylosed joints are subject to major complications. With pathologic changes, these structures are much more substantial and can be difficult to traverse.

It is imperative that the anatomy of the region specific to arthroplasty be understood before attempting arthroscopic surgery. The bony roof can be interrupted by a sharp trocar in the deep superior portion of a thin mandibular fossa. The proximity of the external auditory canal must be considered. In a large patient, the mandibular fossa position may be topographically difficult to differentiate from portions

of the external and even the middle ear. The temporal vessels and the facial nerve are also of great concern during the puncture maneuver. Injuries to these structures will be described under the section, *Complications*.

Finally, arthroscopy should not be attempted by anyone not capable of performing open joint surgery. If bleeding occurs or instruments break, it may be necessary to surgically explore the joint. One should always be prepared and have informed consent for that eventuality.

Normal Arthroscopic Anatomy

Superior (Upper) Compartment

Puncture places the arthroscope in the superior space, showing the medial capsule. The synovium is glistening white with a shiny consistency. Posteriorly the synovium folds over the posterior attachment, which is richly vascular, but the vessels are crisp and discrete. When inflammation is present, however, the vascular region is diffuse and blurred. In the normal joint, the posterior band of the disc is raised and glistening but not vascular. The normal disc is white and smooth with no visible vascularity. A folded posterior attachment has been labeled the oblique protuberance and signifies a ligamentous band. The anterior wall is reflected over the pterygoid muscle and is very thin and translucent. Posteriorly and medially the medial capsule is seen. The consistency changes from thin to thick as one moves more posteriorly. The lateral capsule is not easily seen from the inferolateral approach.[17] Figure 41-1 shows a typical posterior recess as viewed arthroscopically, with the corresponding normal MRI appearance.

Inferior (Lower) Compartment

Generally, vascularity is not seen in the lower compartment. The surfaces are glistening and smooth, as is the condylar cartilage cap. Because of the small volume and narrow recesses, generally not much is seen and one must be suspect that the scope itself may cause seemingly pathologic changes.

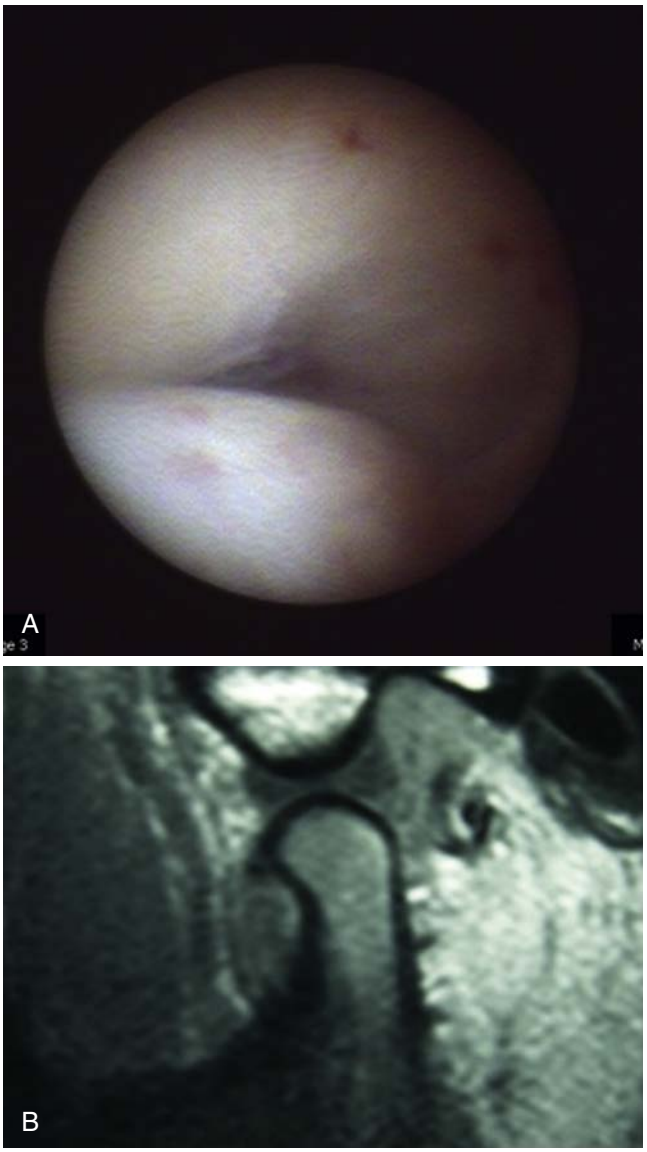

• **Figure 41-1** Normal joint. **A,** Normal view of upper joint space with arthroscopy. **B,** Corresponding normal MRI.

Diagnostic Uses

When temporomandibular joint arthroscopic examination was first performed, its diagnostic usefulness was felt to be the primary benefit. After more than 20 years used as a common tool, direct visualization of the joint is not routinely needed for diagnosis. Although many forms of joint pathology can occur in the TMJ, there may be no correlation with changes in the synovial or cartilage surfaces. Therefore diagnostic arthroscopy must be used in conjunction with history, clinical signs, and imaging to formulate a diagnosis in the TMJ patient.

The main abnormality seen in the temporomandibular joint is the internal derangement/osteoarthritis continuum categorized by the Wilkes classification.[18] Arthroscopy can be most useful in staging this disease and determining treatment options.

Other arthritides are seen, with rheumatoid arthritis being the most common, but arthroscopy is rarely, if ever, the deciding factor in diagnosis. Diagnosis and treatment of traumatic conditions may be helped by arthroscopic evaluation. Biopsy is essential if dealing with the very rare tumor that may occur.

Pathology

Internal Derangement

Although the most common condition to be treated with arthroscopy, internal derangement shows various levels of nonspecific changes that are mostly attributed to inflammation. Increased vascularity in the posterior

attachment, vessels encroaching onto the avascular disc, and blurring of vascular markings may all be seen. Signs of cartilage degeneration in later stages may also be seen. This information may direct the operative therapy when performing arthroscopic surgery, such as the use of laser, anti-inflammatory medications, or lubrication therapy. It might also indicate the need for an open procedure if an undiagnosed perforation of the disc is seen. Figure 41-2 depicts various pathologic conditions as encountered by arthroscopy.

Fluid Analysis

Analysis of joint fluid has brought a greater understanding of the degradation process in internal derangement as well as theories for the causation of pain emanating from the joint. Substances such as interleukin-6 (IL-6) and IL-10 have been shown to be markers predicting outcome in lysis and lavage for chronic closed lock.[19] Fluid analysis will be discussed elsewhere.

Equipment

There is much written about arthroscopic equipment, especially at the advent of its use.[20,21] Figure 41-3 shows a typical equipment set-up. Telescopes run from 0.7 to 2.7 mm in diameter. The angle of view can range from zero to 35 degrees. Generally an angled arthroscope is better for visualization of all areas, and a zero-degree arthroscope is better for operative techniques that include triangulation. Various light and camera systems are available. A complex three-chip camera will give the best video reproduction. There has not been much research and development in TMJ arthroscopic equipment recently. Manufacturers have concluded that there is not a large market for this equipment in the United States. With most joint lavage now being accomplished through arthrocentesis, only a few changes in arthroscope design have occurred. These have been accomplished in Japan, and much of the newer equipment is not exported to the United States.

Arthroscopic Puncture—The Inferolateral Technique

Arthroscopy is very technique-sensitive. There is a large learning curve to master before feeling comfortable performing this procedure effortlessly. Partly, this is due to the process of learning to operate while watching a monitor and making very minor hand movements to achieve objectives, and partly from complications that can occur if not performed skillfully.

Arthroscopy can be undertaken with the patient receiving a local anesthetic, but this is usually a single-puncture observation of the joint, possibly with biopsy. Most often it is performed with the patient receiving a general anesthetic in an operating room, especially if multiple punctures are used and operative equipment such as lasers are required.

Peri-operative antibiotics directed to prevent skin contamination and glucocorticoids for edema management are often used. The patient is placed in the supine position on the operating table and receives nasal endotracheal intubation. Preparation of the skin with povidone iodine or comparable antibacterial solution is performed. After the surgical field is isolated, circular holed aperture (eye) drapes are affixed anteriorly over the ear to provide an isolated field in front of the ear. Neurosurgical drapes may be helpful in keeping the copious irrigating fluid off the floor and shoes.

Lidocaine with epinephrine may be injected subcutaneously for hemostasis at the puncture site. It is controversial as to whether epinephrine should be injected directly into the joint space because it may affect visualization of synovial vascularity. The pattern and character of synovial vessels may indicate the level of inflammation present. After the initial evaluation, vasoconstrictor may also be added for hemostasis.

Several different size syringes are needed on the field. Ringer's lactate solution is the preferred irrigant, but normal saline may also be used. It is injected into the superior joint capsule using a 3-mL syringe, so that back-pressure can be felt when the joint space is entered. After a successful circuit is achieved, a large syringe (30 to 60 mL) should be used for irrigation. Some operators suspend a bag of fluid under pressure for this purpose. The drawback to this method may be fluid extravasation.

Puncture using the sharp trocar of a 1.9- to 2.3-mm arthroscope should be along the tragocanthal line approximately 1 cm anterior of the midtragus. As the operator becomes more experienced, the topographic measurement will often give way to palpation to establish the entrance point. The inferolateral approach described by Murakami is standard[8] (Figure 41-4). Moses described an endaural approach that can be used for visualizing the lateral capsule, but it is rarely used.[22] Once the capsule is entered the blunt trocar is used to establish the position inside the joint space. An 18-gauge needle is used as an outflow port temporarily while the arthroscope is inserted and a methodic examination around the superior space is performed. Most diagnoses can be established in this first sweep. Once done, the arthroscope is positioned in the anterior recess, so that a second puncture is performed to provide fluid outflow and triangulation. By measuring the length of the first trocar, the second puncture point can be established. If the lights are dimmed the arthroscope light will transilluminate the position in a thin patient. The second puncture is performed at 90 degrees to the first. The operator should be able to see the entrance of the second trocar in the field in the anterior recess. Now, the operator is prepared to perform any surgical maneuver necessary. Operators who do not instrument the joint, but only observe and lavage the joint, may be able to use only an outflow needle, which simplifies the procedure greatly.

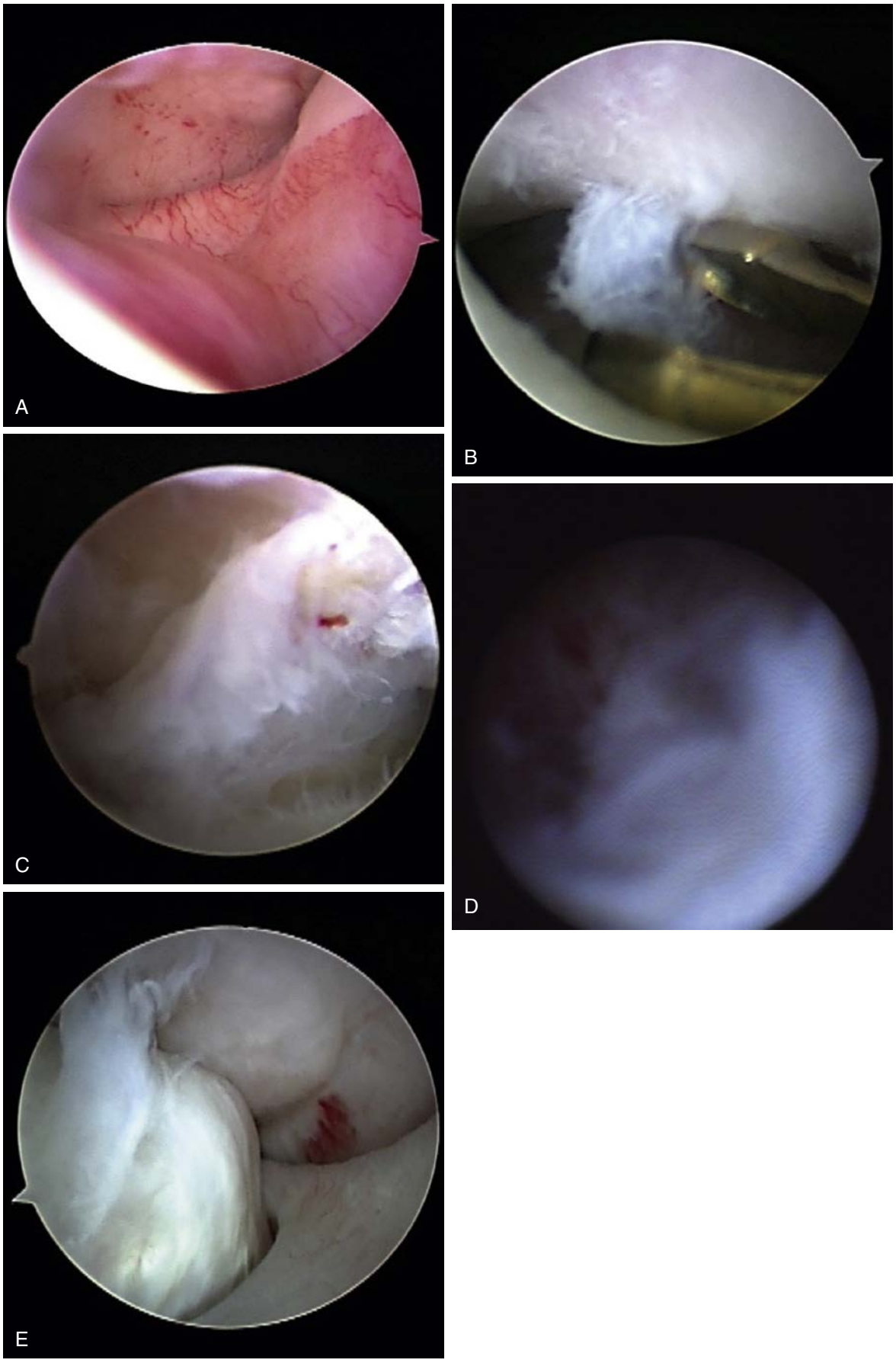

• **Figure 41-2** Upper compartment of the left joint showing various pathologic conditions. **A,** Loss of well-defined boundary between the posterior band of the disc and the posterior disc attachment. The area shows capillary hyperemia. **B,** Biopsy of fibrillation of the fibrocartilage on the posterior slope of the eminence. The disc, below, is unaffected. **C,** Pronounced fibrillation of the central part of the disc. **D,** Close view of the fibrocartilage in the glenoid fossa, showing arthritic lesions and remodeling. **E,** Joint perforation.





• **Figure 41-3** **A,** Sharp and blunt trocars and arthroscopic cannula. **B,** Standard arthroscopic equipment tower with monitor, camera, light source, CO_2 insufflator (not used for TMJ arthroscopy), and printer.

Operative Arthroscopy

The goals of arthroscopic surgery vary with the diagnosis, but generally follow several paths.

Various arthritides may require diagnostic observation and biopsy. Anti-inflammatory medications can be directly applied by lavage, or by direct needle placement for injection into the pathologic tissues. Laser energy can be used to remove pathologic tissue or to contract redundant or hypermobile tissues.

However, internal derangement is the disorder most often encountered. The goals of therapy depend on the diagnostic stage. Usually the surgery is directed to increasing motion and function. These goals can be obtained by stretching the capsular tissues with probes, cutting the restrictive capsular elements with knives or laser, removing scarred or hyperplastic tissues with shavers or laser, removing adhesions, or placing anti-inflammatory agents with direct needle injection.

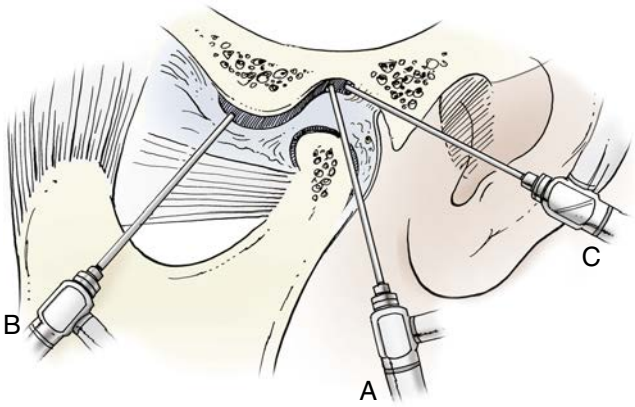

• **Figure 41-4** Puncture direction for the upper compartment of the temporomandibular joint. **A,** Inferolateral approach. **B,** Anterolateral approach. **C,** Endaural approach.



• **Figure 41-5** A zero-degree telescope suitable for arthroscopic surgery. Small-diameter scissors and forceps must be of high quality.

More severe degenerative joint disease may require the ablation and resurfacing of the joint surfaces. This can be attained with mechanical shavers or laser, and application of medications (Figure 41-5).

Arthroscopic Lysis and Lavage

Joints with surface breakdown caused by mechanical injury or arthritides may benefit from lavage with a suitable fluid.[4-9] Lavage is a normal part of all arthroscopic procedures. The fluid can be used as a mechanical dilator in the joint space, releasing some adhesions through distention or breaking the "suction cup" effect described by Nitzan.[25] Fluid is also used to wash out cytokines, interleukins, and other pain mediators and breakdown products of cartilage damage and arthritic destruction. Milam has also determined that the greater volume of lavage fluid removes the larger molecules more effectively.[28]

Lysis of adhesions may be performed with the arthroscopic "sweep" described by Sanders,[4] with surgical instruments or



• **Figure 41-6** Lysis of fibrotic bands using the blunt trocar in sweeping movements from anterior to posterior.

with laser[10] (Figure 41-6). This technique is usually part of all arthroscopic surgery, and is used to free the superior joint space to gain increased motion. Lysis and lavage was the first arthroscopic procedure described and was the predominant procedure for internal derangement in the late 1980s. The success rate of this procedure is reported to range between 70% and 90%.[15,27] Since the procedure included several components, it was difficult to ascribe success to any specific part of the procedure. The evolution of arthrocentesis, with lavage and manipulation alone, brought into question whether arthroscopy with visualization was necessary as a routine procedure.[23-26]

Arthroscopic Arthroplasty

The addition of miniaturized hand instruments, mechanical shavers, and lasers to the armamentarium created arthroscopic arthroplasty of the TMJ. Procedures performed previously only in open arthroplasty could now be performed arthroscopically. These techniques increased the difficulty of the procedure, requiring increased technical ability. Consequently, the pool of surgeons performing arthroscopic arthroplasty decreased, with the majority performing arthrocentesis.

Arthroscopic Removal of Adhesions

Superior joint space adhesions can be released with the sweep of a surgical probe. More definite and thick bands require sharp or laser dissection. Multiple severe adhesive bands may require a mechanical shaver, but can also be lysed using a holmium laser fiber.

Capsular Releases

Generally, joint restriction resulting from internal derangement may be improved by anterior or lateral capsular release.

Anterior Capsular Release

The arthroscope is placed into the anterior recess and the anterior wall may be stretched using a probe or released using sharp dissection or laser (Figure 41-7). Immediate widening of the anterior wall is achieved. This may have a profound effect on joint translation.

Lateral Release

Lateral capsular release, described by Moses,[29] increases translation and lateral excursion. The release is performed by stretching with probes or sharp laser dissection. The Moses elevator was designed for this procedure.

Disc Repositioning

The efficacy of open disc repositioning in internal derangement has been questioned,[30,32] but it was once the mainstay of surgical treatment with success rates of about 85%.[31] Arthroscopic repositioning can be achieved by performing anterior release and contracting the posterior attachment by either using laser, injecting sclerosing agent, or performing a suturing maneuver as described by McCain[33] (Figures 41-8 through 41-11). There does not seem to be any difference when compared with open arthroplasty with suturing. Successful disc repositioning that has been maintained over time has not been reported. When using laser, there is no pretense of repositioning the disc to normal position, but this combination technique has been shown to be successful in a prospective study.[15] It should be recalled that success is based on return to normal function with minimal pain, not based on the preconceived notion of restoring normal anatomic position. Arthroscopic suturing is technically difficult and requires a high level of expertise. It is, therefore, employed by very few surgeons.[34]

The holmium:YAG laser is most often used, although any laser with fiberoptic delivery can be potentially used. Holmium has the advantage of being precise and safe. With a small amount of energy, the laser can perform pinpoint cutting or the beam can be defocused to contract tissues and ablate blood vessels (Figures 41-12 through 41-14). The laser is of little use on bony surfaces, where it is inefficient at cutting and may char the surface. Electric cautery can be used for contraction of tissues, but it has been replaced by the laser for ease of use and safety.[35]

Both Ohnishi and Merrill studied the use of chemical sclerosants as a means of limiting motion in a hypermobile joint.[36,37] Several agents (Sotradeccol, sodium morrhuate) have been injected into the posterior attachment under direct vision. The technique is underutilized, but is successful at stabilizing loose joint tissues.

Complications

The complication rate for arthroscopic temporomandibular joint surgery is small,[38,45] but the arthroscopist must be able to perform all open procedures in order to assure safety. Extravasations of fluid are possible with extensive procedure time, multiple failed punctures, or excessive pressures. The swelling can usually be controlled with pressure dressings, but possible airway compromise must be considered when large volumes of fluid extravasate.

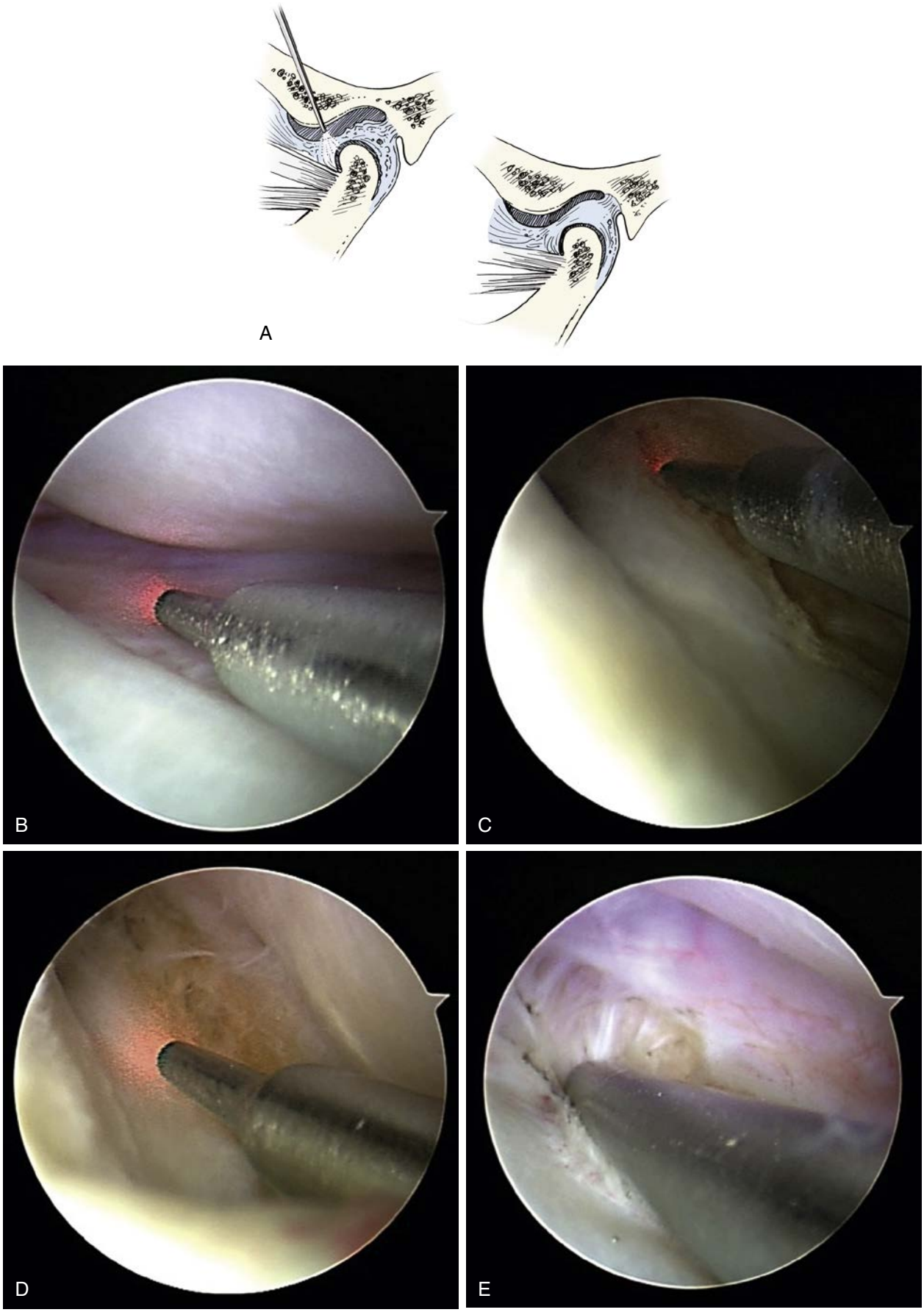

• **Figure 41-7** Anterior release and repositioning of the disc using laser technique. **A,** Diagram demonstrating effect of anterior capsule release. **B,** Anterior recess with laser probe. **C,** HoYAG laser incision. **D,** After incision, pterygoid muscle is visualized. **E,** Followed by blunt probe to expand incision.

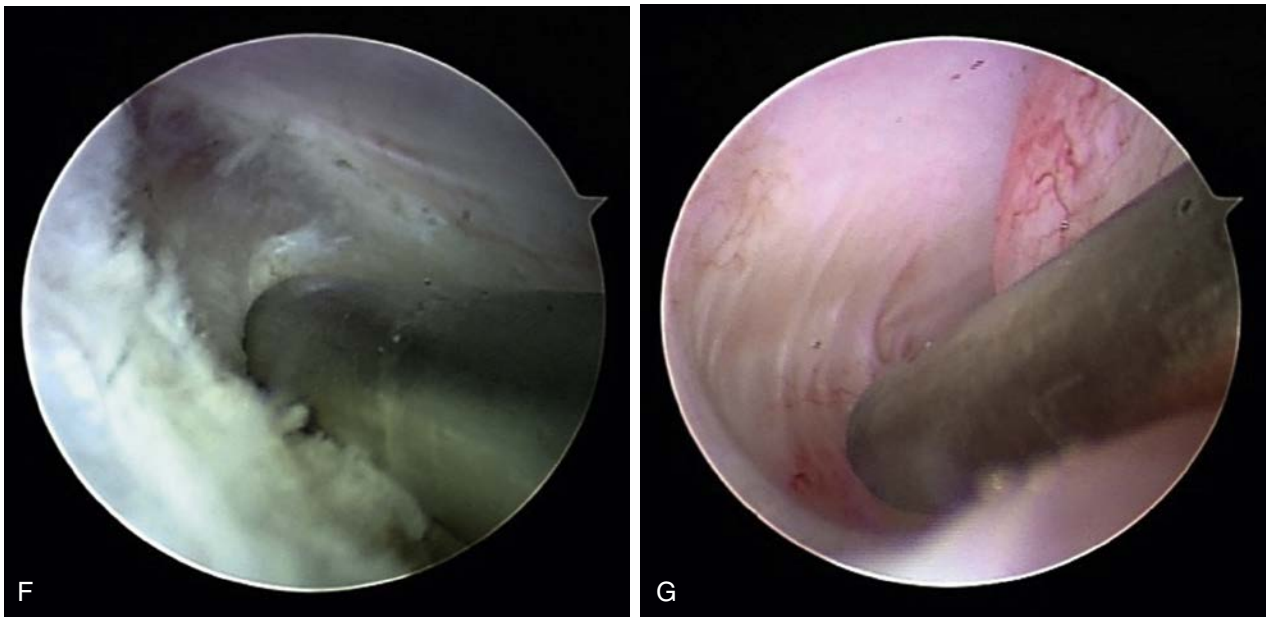

• **Figure 41-7, cont'd** **F,** Anterior disc attachment is freed. **G,** Lastly, probe distracts disc posteriorly.

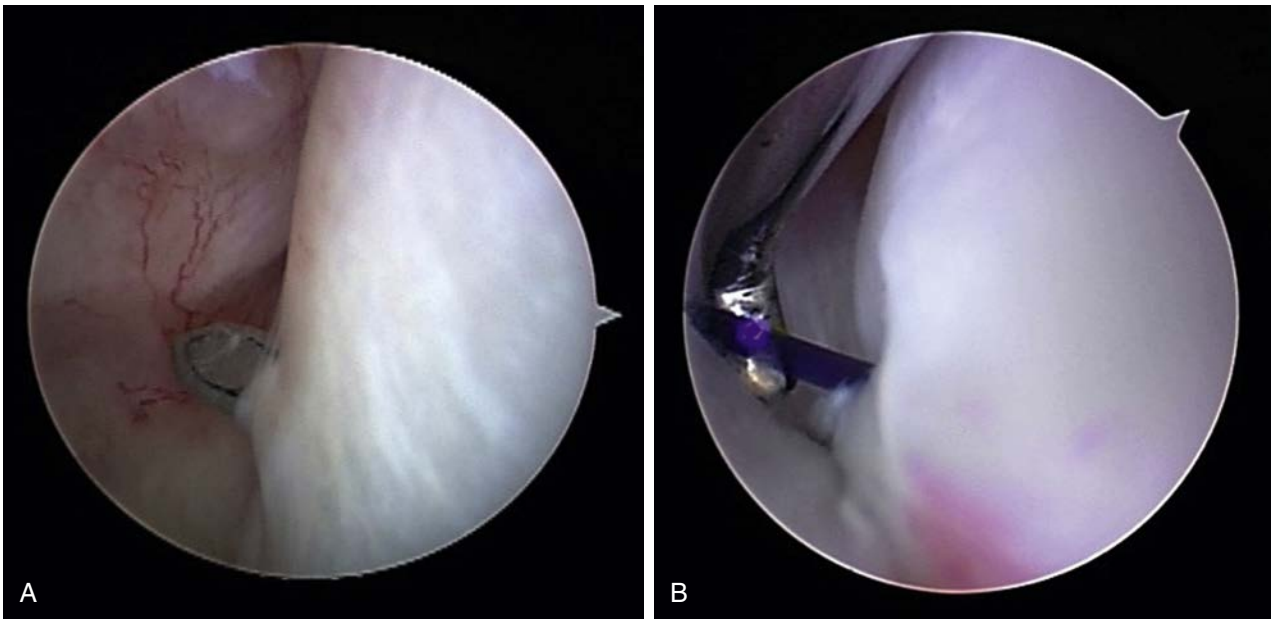

• **Figure 41-8** **A,** Spinal needle through posterior aspect of the disc. **B,** Hook probe used to manipulate suture.



• **Figure 41-9** Alligator forceps used for suture retrieval.



• **Figure 41-11** Laser energy directed at oblique protuberance.

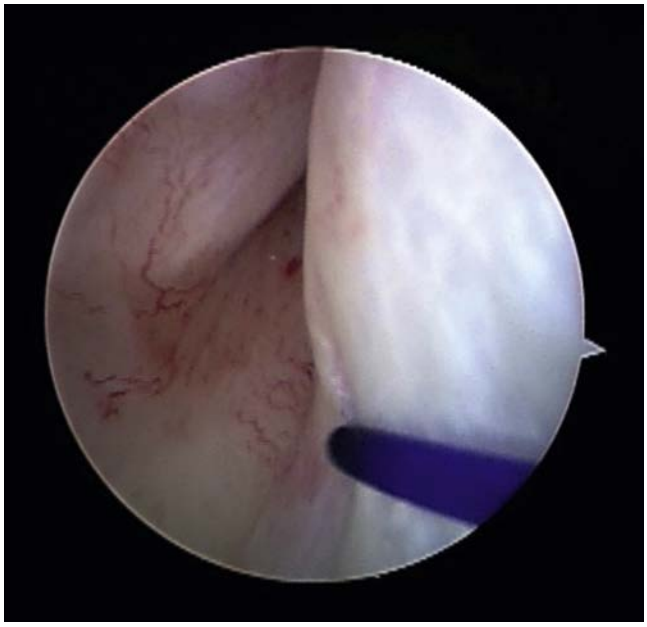

• **Figure 41-10** Suture has been passed to the outside of joint for disc stabilization.

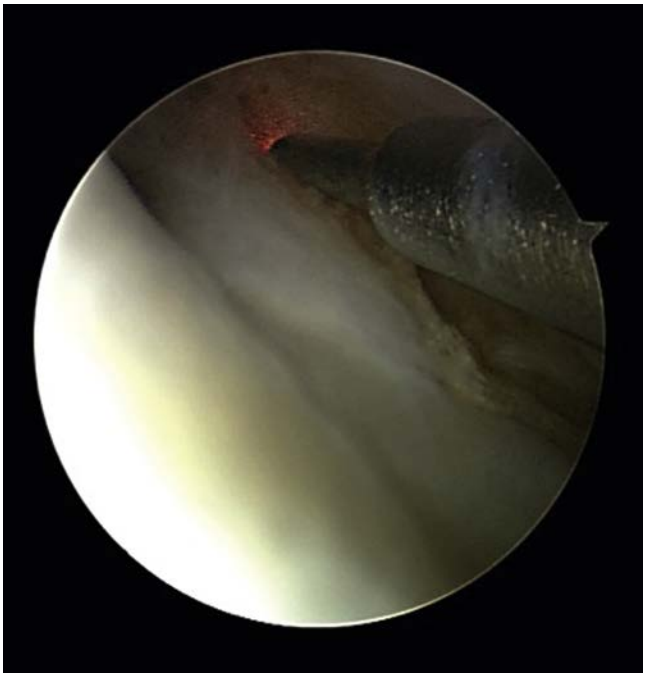

• **Figure 41-12** Anterior release through disc to the underlying pterygoid muscle.

Vascular damage was seen in about 2% of patients in a study by Carter.[16] Hemorrhage can be controlled in the superficial vessels with pressure or with ligation. Intraoperatively, deep hemorrhage from within the posterior attachment can usually be treated by retruding the condyle to put direct pressure on the posterior attachment for at least 5 minutes. In the rare instance that bleeding cannot be controlled, arthrotomy must be performed. Rarely, an arteriovenous fistula may occur, in which case the patient will be bothered by a whooshing sound that occurs several days post surgery. Arthrotomy with direct ligation of the vessel or endovascular treatment may then be required. [44]

Broken instruments are rare and can often be removed with a magnetic probe or with a biopsy forceps.[39] It is imperative that visualization of the instrument be maintained from the time it is broken. If it cannot be removed, then fluoroscopically guided open surgery may be necessary.

Otic injuries are the result of instrument positioning errors and can result in external, middle ear complications or intracranial injuries, all of which are quite rare. Infection occurs in less than 0.5% of cases.[12]



• **Figure 41-13** Posterior tissue after laser treatment.



• **Figure 41-14** Posterior synovial hyperplasia with pain.

Postoperative Care

Immediate postoperative care is directed to controlling swelling and pain. A pressure dressing is usually applied short term, and may be removed in the recovery room before discharge. Peri-operative antibiotics may be given during surgery with a second dose before discharge. Dexamethasone is also administered at the beginning of the case and before discharge. Other medication schedules exist, but there is generally no rationale for long-term antibiotics or steroids. Moderate pain medication is prescribed for home use.

Postoperative Physical Therapy

Postoperative physical therapy is often the most important part of the overall treatment plan, especially if joint restriction is present. A regimen of 1 hour 3 times a week with a therapist is necessary until goals are met, which usually occurs in 2 to 4 weeks. Specific goals of maximum incisal opening, protrusion, and excursions are established by the surgeon as they apply to each patient. A decrease in pain to a level that the patient can tolerate with nonnarcotic pain medicine and a return to a normal diet are also therapeutic goals.

Evidence

Published arthroscopic results have been mostly retrospective case series, with varying techniques and populations. They are difficult to compare and many have no controls. Retrospective studies that report results as "excellent" or "successful" provide the preponderance of these results. [46] Success is usually defined as increased mobility and function and decreased pain and disability. Authors often mix the use of lysis and lavage with other operative techniques, and apply medicines described in one generic term of "arthroscopy," which makes comparisons difficult. However, the volume of case series from around the world accentuates the results. When most reports agree that "success" rates are 80% to 90%, one has to conclude that the technique is achieving the results indicated. It is difficult to design prospective, controlled studies with surgical options that might have to be withheld to satisfy the design.

In 1993 Sanders and Buonchristiani reported 86% excellent results and 9% good results for 306 patients who had undergone lysis and lavage and were followed for 5 years.[39] McCain and colleagues reported a multicenter study in 1992, the largest study to date; this study had a 6-year follow-up on 1114 patients, with an overall success rate of 91% using multiple techniques.[12] The study by White[40] in 2001 reported on 100 patients who had received lysis and lavage and were followed for 13 years; 94% of these patients were greatly or moderately improved.[41] Indresano reported on 400 patients using lysis and lavage and later laser operative arthroscopy, with 80% success results over 5 to 8 years, making comparisons between the two techniques.[41]

Generally, the reported procedure may be divided into two groups: lysis and lavage or arthroscopic arthroplasty, which may include either mechanical or laser manipulations. Arthroscopic placement of medications is more difficult to track since many surgeons use medicinal adjuncts to arthroscopic surgery. It may be impossible do distinguish the effects of these agents without specific studies such as that published by Kopp.[42]

More research must be done in the area of therapy directed to joint lubricaton.[43] The advent of high molecular weight hyaluronate compounds has only added to the need for research into the loss of lubrication and how replacement may contribute to joint health. Arthroscopic lysis and lavage has been shown to provide most of the benefits of more complex operative arthroscopic surgery in many TMJ patients. However, arthrocentesis may often achieve these same goals with less risk, and it has significantly reduced performance of arthroscopy. The more complicated procedures, such as operative arthroscopy, are increasingly limited to few surgeons.

References

1. Tagaki K: Practical experience using Takagi's arthroscope, *J Jpn Orthop Assoc* 14:359, 1939.
2. Watanabe M, Takeda S, Ikeuguchi H: *Atlas of Arthroscopy*, Tokyo, 1969, Igaku, Shoin.
3. Ohnishi M: Arthroscopy of the temporomandibular joint, *J Jpn Stomatol* 42:207, 1975.
4. Sanders B: Arthroscopic surgery of the temporomandibular joint: treatment of internal derangement with persistent closed lock, *Oral Surg Oral Med Oral Pathol* 62:361, 1986.
5. Holmlund A, Hellsing G: Arthroscopy of the temporomandibular joint: an autopsy study, *Int J Oral Surg* 14:169, 1985.
6. Murakami K, Hoshino K: Regional anatomic nomenclature and arthroscopic terminology in human temporomandibular joints, *Okajimas Folia Anat Jpn* 58:745, 1982.
7. Sanders B, Buonchristiani R: Diagnostic and surgical arthroscopy of the temporomandibular joint: clinical experience with 136 procedures over a two-year period, *J Craniomandib Dis* 1:202, 1987.
8. Murakami K, Ono T: Temporomandibular joint arthroscopy by inferolateral approach, *J Oral Maxillofac Surg* 15:410, 1986.
9. McCain JP: Arthroscopy of the temporomandibular joint, *J Oral Maxillofac Surg* 46:648, 1988.
10. Indresano AT, Braderick JP: Laser assisted arthroscopy of the temporomandibular joint. In Bronstein RD, editor: *Principles and practices in arthroscopy*, ed 22, Philadelphia, 1991, WB Saunders, p 327.
11. Koslin M: Electrosurgery and laser technology. In McCain JP, editor: *Principles and Practice of Temporomandibular Joint Arthroscopy*, ed 12, St Louis, 1996, Mosby.
12. McCain JP, et al.: Temporomandibular joint arthroscopy: a six-year multicenter retrospective study of 4831 joints, *J Oral Maxillofac Surg* 50:962, 1992.
13. Nitzan DW, Dolwick MF, Martinez A: Temporomandibular joint arthrocentesis: a simplified treatment for severe, limited mouth opening, *J Oral Maxillofac Surg* 49:1163, 1991.
14. Nitzan DW: Arthrocentesis—incentives for using this minimally invasive technique for TMJ disorders, *Oral Maxillofac Surg Clin N Am* 18:311, 2006.
15. Hall HD, Indresano AT, Kirk, et al.: Prospective multicenter comparison of four TMJ operations, *J Oral Maxillofac Surg* 63:1174, 2005.
16. Carter JB, Testa L: Complications of TMJ arthroscopy: a review of 2225 cases: review of the 1988 annual scientific session abstracts, *J Oral Maxillofac Surg* 46:M14, 1988.
17. Holmlund A: Arthroscopy. In Fonseca RJ, editor: *Oral and maxillofacial surgery*, ed 4, Philadelphia, 2000, WB Saunders, p 255.
18. Wilkes CH: Structural and functional alterations of the temporomandibular joint, *Northwest Dent* 57:287, 1978.
19. Hamada Y, Condo T, et al.: Inflammatory cytokines correlated with clinical outcome of temporomandibular joint irrigation in patients with chronic closed lock, *Oral Surg Oral Med Oral Path Oral Radiol Endod* 102:556, 2006.
20. Holmlund A: Temporomandibular joint arthroscopy. In Parisien JS, editor: *Current techniques in arthroscopy*, Philadelphia, 1994, Thieme, p 33.
21. Bonell L, Buonchristiani RD, Koslin M, et al.: In McCain JP, editor: *Principles and practice of TMJ arthroscopy*, St Louis, 1996, Mosby, p 11.
22. Moses JJ, Poker ID: Temporomandibular joint arthroscopy: the endaural approach, *J Oral Maxillofac Surg* 18:347, 1989.
23. Dimitrious G, Dolwick MF, Martinez A: Temporomandibular joint arthroscentesis and lavage for the treatment of closed lock: a follow up study, *Br J Oral Maxillofac Surg* 33:23, 1995.
24. Hosaka H, Murakami K, Goto K, et al.: Outcome of arthroscentesis for temporomandibular joint closed lock at 3 years follow-up, *Oral Surg Oral Med Oral Path Oral Radiol Endod* 82:501, 1996.
25. Nitzan DW, Samson B, Better H: Long-term outcome of arthrocentesis for sudden-onset, persistent, closed lock of the temporomandibular joint, *J Oral Maxillofac Surg* 55:151, 1997.
26. Murakami KI, Iizuka T, et al.: Recapturing the persistent anteriorly displaced disk by mandibular manipulation after pumping with hydraulic pressure to the upper joint cavity of the temporomandibular joint, *Cranio* 5:17, 1987.
27. Murakami K, Segami N, et al.: Outcome of arthroscopic surgery for internal derangement of the temporomandibular joint: long term results covering ten years, *J Craniomaxillofac Surg* 28:264, 2000.
28. Zardenatta G, Milam SB, Schmitz JP: Elution of proteins by continuous temporomandibular joint arthrocentesis, *J Oral Maxillofac Surg* 55:709, 1997.
29. Moses J: Lateral impingement syndrome and endaural surgical technique, *Oral Maxillofac Surg Clin N Am* 1:175, 1989.
30. Zeitler DL, Porter BT: A retrospective study comparing arthroscopic surgery with arthrotomy and disk repositioning. In Clark GT, Sanders B, Bertolami CN, et al.: *Advances in diagnostic and surgical arthroscopy of the temporomandibular joint*, Philadelphia, 1993, Saunders, p 61.
31. Dolwick MF, Dimitroulis G: A re-evaluation of the importance of disc position in temporomandibular disorders, *Aust Dent J* 41:184, 1996.
32. Undt G, Murakami K, Rasse M, et al.: Open versus arthroscopic surgery for internal derangement of the temporomandibular joint: a retrospective study comparing two centers' results using the jaw pain and function questionnaire, *J Craniomaxillofac Surg* 34:234, 2006.
33. McCain JP, Podransky AE: Arthroscopic disc repositioning and suturing: a preliminary report, *J Oral Maxillofac Surg* 50:568, 1992.
34. Tarro AW: A fully visualized arthroscopic suturing technique, *J Oral Maxillofac Surg* 52:362, 1994.
35. Kaneyama K, Segami N, et al.: Outcomes of 152 temporomandibular joints following arthroscopic anterolateral capsular release by Holmium : YAG laser or electrocautery, *Oral Surg Oral Med Oral Path Oral Radiol Endod* 98:628, 2004.
36. Ohnishi M: Arthroscopic surgery for hypermobile and recurrent temporomandibular dislocations, *Oral Maxillofac Surg Clin N Am* 1:153, 1989.
37. Merrill RG: Arthroscopic temporomandibular joint lysis, lavage, and manipulation for painful hypermobility and recurrent mandibular dislocation. In Clark GT, Sanders B, Bertolami CN, et al, editors: *Advances in diagnostic and surgical arthroscopy of the temporomandibular joint*, Philadelphia, 1993, Saunders, p 75.
38. Gonzales-Garcia R, Rodriguez-Campo FJ, et al.: Complications of temporomandibular joint arthroscopy: a retrospective analytic study of 670 arthroscopic procedures, *J Oral Maxillofac Surg* 64:1587, 2006.
39. Sanders B, Buonchristiani RD: A 5-year experience with arthroscopic lysis and lavage for the treatment of painful temporomandibular joint hypomobility. In Clark GT, Sanders B, Bertolami CN, et al, editors: *Advances in diagnostic and surgical arthroscopy of the temporomandibular joint*, Philadelphia, 1993, Saunders, p 51.
40. White RD: Arthroscopic lysis and lavage as the preferred treatment for internal derangement of the temporomandibular joint, *J Oral Maxillofac Surg* 59:313, 2001.

41. Indresano AT: Surgical arthroscopy as the preferred treatment for internal derangement of the temporomandibular joint, *J Oral Maxillofac Surg* 59:308, 2001.
42. Kopp S, Wenneberg B, et al.: The short-term effect of intra-articular injections of sodium hyaluronate and corticosteroid on human temporomandibular joint pain and dysfunction, *J Oral Maxillofac Surg* 43:429, 1985.
43. Nitzan DW, Kreiner B, Zeltser R: TMJ lubrication system: its effect on the joint function, dysfunction, and treatment approach, *Compend Contin Educ Dent* 25:437, 2004.
44. Sacho RH, Kryshtalskyi B, Krings T: Arteriovenous fistula of the middle meningeal artery—a rare complication after arthroscopic temporomandibular joint surgery readily amenable to endovascular treatment, *J Oral Maxillofac Surg* 72(7):1258–1265, 2014.
45. Zhang S1, Yang C, et al.: Prevention and treatment for the rare complications of arthroscopic surgery in the temporomandibular joint, *J Oral Maxillofac Surg* 69(11):e347–353, 2011.
46. Al-Moraissi EA: Arthroscopy versus arthrocentesis in the management of internal derangement of the temporomandibular joint: a systematic review and meta-analysis, *Int J Oral Maxillofac Surg* 44(1):104–112, 2015.

42

Surgery for Internal Derangement of the Temporomandibular Joint

WILLIAM CHUNG, ALEJANDRO J. ALMARZA

The term temporomandibular joint disorder (TMD) describes a condition that involves temporomandibular joint (TMJ) pain and dysfunction. TMD may arise from a muscular disorder or may involve the joint itself or any of its associated structures. Effective management of TMD becomes more critical, and potentially complex, when a patient presents with both myofascial pain and articular disease. DeBont et al created a detailed classification system for the articular disorders of the TMJ[1] (Box 42-1).

The earliest recognized and reported dysfunction of the TMJ involved joint ankylosis or dislocation. Another articular condition, internal derangement (ID), was first described by Hey and Davies in 1814.[2] ID involves an abnormality of the disc-fossa relationship resulting in a mechanical disorder that creates irregular joint noises and prohibits normal, smooth condylar movements. A staging system for ID was created by Wilkes, which describes the clinical and radiographic characteristics of this disorder (Box 42-2).[3] Stage I is clinically consistent with painless clicking but no limitation of jaw opening. In Stage II the patient experiences occasional painful clicking and intermittent joint locking. As the patient progresses to Stage III, more significant joint pain on function occurs along with restricted jaw opening. In Stage V, the patient's exam is positive for crepitus, episodic and variable joint pain, and restriction of opening.

The presence of parafunctional oral habits, concomitant medical and/or psychological conditions, and other past and present treatment need to be carefully identified and considered prior to pursuing surgery. Proper patient selection is also a fundamental and essential aspect of TMJ surgery. Although nonsurgical, conservative therapies should be undertaken, and often exhausted, before pursuing surgery, certain pathologic disorders of an articular origin are best treated by surgery, specifically TMJ dislocation, ankylosis, certain condylar fractures, neoplasms, and degenerative joint disease.

The evolution of surgery for ID is well documented in the literature. In 1887 Annandale reported the first intracapsular procedure for ID,[4] while in 1909 Lanz reported the first use of a discectomy for painful joint dysfunction.[5] An array of procedures ranging from minimally invasive techniques to arthrotomy have been used to treat ID, and the benefits of each have been clearly documented.[6-14] The use of TMJ arthrography was instrumental in establishing disc pathology as a factor in TMD,[15,16] and studies by Dolwick elaborated on the role of various disc surgeries, such as repositioning and repair, in the treatment of ID.[17-19] Yet the exact role of surgery for the management of ID remains controversial. Detractors of surgery for ID are quick to point out that amidst progressive anatomic degenerative changes, TMJ pain and dysfunction can still decrease in the absence of any treatment.[20,21]

This chapter discusses key elements in a patient's history and physical exam that assist the surgeon in selecting the proper surgical candidate. The chapter also lists the goals of surgery for ID and the role of diagnostic imaging in treatment planning. Only open arthrotomy techniques are reviewed, as other minimally invasive procedures used to treat ID and TMD are covered elsewhere in this text. Lastly, complications of surgery and the importance of postoperative physical therapy will be discussed.

History and Physical Examination

The diagnosis of ID is achieved through a thorough history and detailed clinical examination, and an accurate diagnosis is paramount in determining either the most appropriate surgical technique or the need for surgery altogether. However, establishing the patient's diagnosis can be an obstacle for the surgeon because each patient's symptoms are highly individualized. Additionally, the patient may not always accurately report or describe his or her symptoms. Focused questionnaires regarding TMJ pain

• BOX 42-1 Classification of Temporomandibular Joint Disorders

Articular Disorders

Non-inflammatory arthropathies
Osteoarthrosis

Primary
Chondromalacia

Secondary
Internal derangements
Condyle-eminence mobility disturbances
Trauma
Avascular necrosis

Bone and Cartilage Disorders with Articular Manifestations

Inflammatory arthropathies

Primary
Rheumatoid arthritis
Juvenile rheumatoid arthritis
Psoriatic arthritis
Ankylosing spondylitis
Seronegative polyarthritis

Secondary
Synovitis
Traumatic arthritis
Osteoarthritis
Crystal-induced arthropathy

Growth Disorders

Neoplasms
Developmental or acquired
Diffuse connective tissue disorders
Miscellaneous articular disorders

Adapted from deBont L, Dijkgraaf L, Stegenga B: Epidemiology and natural progression of articular temporomandibular disorders, *Oral Surg Oral Med Oral Path Oral Rad Endo* 83:72-76, 1997.

• BOX 42-2 Wilkes Classification of Internal Derangement of TMJ

Stage I Early

Clinical—Painless clicking
No limitation of opening
Radiographic—Mild disc displacement with early reduction
Normal disc morphology

Stage II Early/Intermediate

Clinical—Occasional painful clicking
Intermittent locking
Radiographic—Mild to moderate disc displacement with late reduction
Mild disc deformity

Stage III Intermediate

Clinical—Joint tenderness
Limited opening
Frequent pain
Radiographic—Displaced, *nonreducing* disc
Disc deformity

Stage IV Intermediate/Late

Clinical—Chronic pain
Limited opening
Radiographic—Severe displacement, without reduction
Deformity of disc
Degenerative osseous changes

Stage V Late

Clinical—Variable joint pain
Joint crepitus
Radiographic—Nonreduction of disc with perforation of disc attachment or disc
Degenerative osseous changes

and dysfunction can be completed by the patient to help the surgeon rule out certain subtypes of TMDs that may not be amenable to surgery. If the patient reports a history of painful joint noises and pain on mandibular function, a diagnosis of ID is likely and surgery may be indicated. One scenario that should cause concern for the surgeon is a recent resolution of a patient's history of painful joint noises in lieu of continued joint pain. This clinical picture may indicate acute disc perforation. Physical exam findings consistent with ID include:

1. Pain on palpation directly over the TMJ, particularly during joint loading
2. Limitation in joint range of motion
3. Deviation on opening, if unilateral
4. Joint noises consistently associated with pain
5. Joint crepitus

If concomitant myofascial pain or dysfunction exists, it must be specifically addressed in the comprehensive treatment of the patient. Myofascial pain may develop secondarily in patients with ID, and ID may develop secondarily in patients with myofascial pain. In cases of disc dislocation with reduction, a patient may experience significant pain while trying to move past the obstructing portion of the disc. When a patient has a unilaterally dislocated disc, the mandible will deviate to the affected side during rotation and then correct its path toward the midline once the condyle has moved past the obstruction and has reduced itself into the disc. In bilateral disc dislocation with reduction, the mandible will deviate to one side and then click. The mandible may deviate to the contralateral side and then click again.

Pathogenesis

Recent studies have related the molecular biology of the joint to the pathogenesis of ID. An imbalance favoring catabolic over anabolic processes has been implicated in the development of degenerative disease. Milam proposed that mechanical stresses in the joint make the TMJ susceptible to formation of free radicals that are thought to contribute to the production of other metabolites and enzymes that promote degenerative changes.[22] One specific free radical, nitric oxide, has been formed in increased levels in

arthritic joints. Nitric oxide also promotes the formation of enzymes and prostaglandins that lead to inflammation and tissue breakdown within the joint.[23] Nitzan hypothesized that free radical formation leads to oxidative stress, which subsequently may impair the lubrication system of the joint.[24] The ultimate disruption of joint lubrication leads to increased friction within the joint space. Nitzan and Etsion suggested that this increased friction due to a lack of disc lubrication is what causes disc dislocation as the disc is repetitively pressed against the articular surfaces.[25]

Synovial fluid analysis of the TMJ has shed light on the role of cytokines, proteinases, and other substances in the development of ID. Interleukins are specific cytokines that mediate inflammation and have been detected in both ID and osteoarthritis (OA) of the TMJ.[26] Cytokines appear to contribute to tissue damage by inducing the release of proteinases and collagenases. Gruber et al[27] reported on the possible role of one such marker, matrix metalloproteins (MMPs) produced by synoviocytes and articular chondrocytes, as mediators of cartilage degradation. Kubota et al[28] compared the TMJ synovial fluid between asymptomatic patients and those with established ID or OA for differences in interleukin-1 (IL-1β) and IL-6 levels to determine whether the IL levels would reflect the pathogenesis of ID. Results indicated higher levels of IL-1β in the synovial fluid of joints with ID or OA compared to the normal, asymptomatic group. IL-1β and IL-6 levels were also significantly higher in the OA group than in the ID group. This study concluded that elevated levels of cytokines can be potential markers for cartilage degradation in the TMJ. The findings from the above-mentioned studies lend support to the role of arthrocentesis or arthroscopy as the initial surgical intervention for ID such as closed lock, as lavage of inflammatory mediators and lysis of adhesions can be accomplished by either technique. Other past and more recent studies continue in their attempts to establish the role of molecular biology of the TMJ with ID.[29-33]

Goals and Criteria for Surgery

Surgery is reserved for patients whose TMJ pain and dysfunction are refractory to conservative nonsurgical modalities and when symptoms result in significant impairment.[34,35] The goal of surgery is to preserve the articular tissues while returning the patient to a more regular diet and reestablishing a normal range of motion to the jaw. Individualized goals of surgery are discussed with each patient before undertaking any form of surgery. The American Association of Oral & Maxillofacial Surgeons (AAOMS) published the first guidelines for disc surgery in 1984 based on a literature review and the general consensus of surgeons.[36] This document was succeeded by another in 1990 stating the standards and criteria for TMJ surgery.[37] TMJ arthrotomy is performed for TMJ ankylosis, trauma, previous surgery, severe degenerative disease, growth disturbances, and neoplasms.[38-44] As recently as 2005, a study by Hall et al compared the outcomes of four commonly used techniques in treating ID.[6]

Two reports by Holmlund and The Second International Consensus Meeting in 1992 have stated criteria for successful TMJ disc surgery.[45,46] These criteria include:

1. Mild, brief, or infrequent pain of no concern to the patient
2. A vertical range of motion greater than 35 mm and lateral range of motion greater than 6 mm
3. Ability of patient to eat a regular diet, at worst avoiding tough or hard foods
4. Stabilization of possible degenerative imaging changes
5. Absence of symptoms for at least 2 years
6. Absence of significant complications

A common form of ID is closed lock. This condition is associated with either an acute or chronic anterior disc dislocation without reduction. When TMJ arthroscopy is undertaken for this condition, adhesions are often noted in the superior joint space. These adhesions can subsequently be removed by arthroscopic techniques. Adhesions can be noted in the superior joint space particularly during diagnostic arthroscopy and then subsequently removed by arthroscopic surgery.[47-51] Arthrotomy is performed for closed lock if arthroscopic techniques fail to correct the mechanical disturbance.

Diagnostic Imaging

Hard tissue abnormalities of the TMJ are most readily identifiable by plain films and computed tomography (CT) scans.[52-54] Panoramic radiographs best serve as a screening tool to identify any gross bony abnormalities, while CT scans are superior to plain tomography in evaluating hard tissues. CT scans provide only limited evaluation of the soft tissues surrounding the TMJ, particularly the disc. Soft tissue disorders of the joint can be determined by arthrography.[54,55] However, an MRI is the study of choice to evaluate ID. MRI studies differentiate the variable proton density within a given tissue volume and then use variable pulse sequences to configure images. The TMJ disc has a low signal pattern and appears black due to its low proton density. Tissues that are higher in either water or proteins appear white on an MRI, which may be indicative of tissue edema. No direct correlation has been definitively reported linking higher signal intensities of TMJ discs with perforations or other surface damage.

Studies of disc displacement or degenerative changes of the condyle have been clearly demonstrated in asymptomatic patients.[56-58] Thus, one must avoid over-emphasizing radiographic findings so as to prevent unnecessary or overly aggressive treatment. Figure 42-1, *A* and *B* show an MRI that displays anterior disc displacement without reduction. This patient was involved in a motor vehicle accident and sustained a whiplash-type injury and developed a unilateral TMD. Figures 42-1, *C* and *D* illustrate how the same patient can manifest the identical anatomic abnormality on the contralateral side. However, this patient reported no symptoms from the contralateral side.

When ordering an MRI for ID, the surgeon should request both sagittal and coronal views to accurately depict

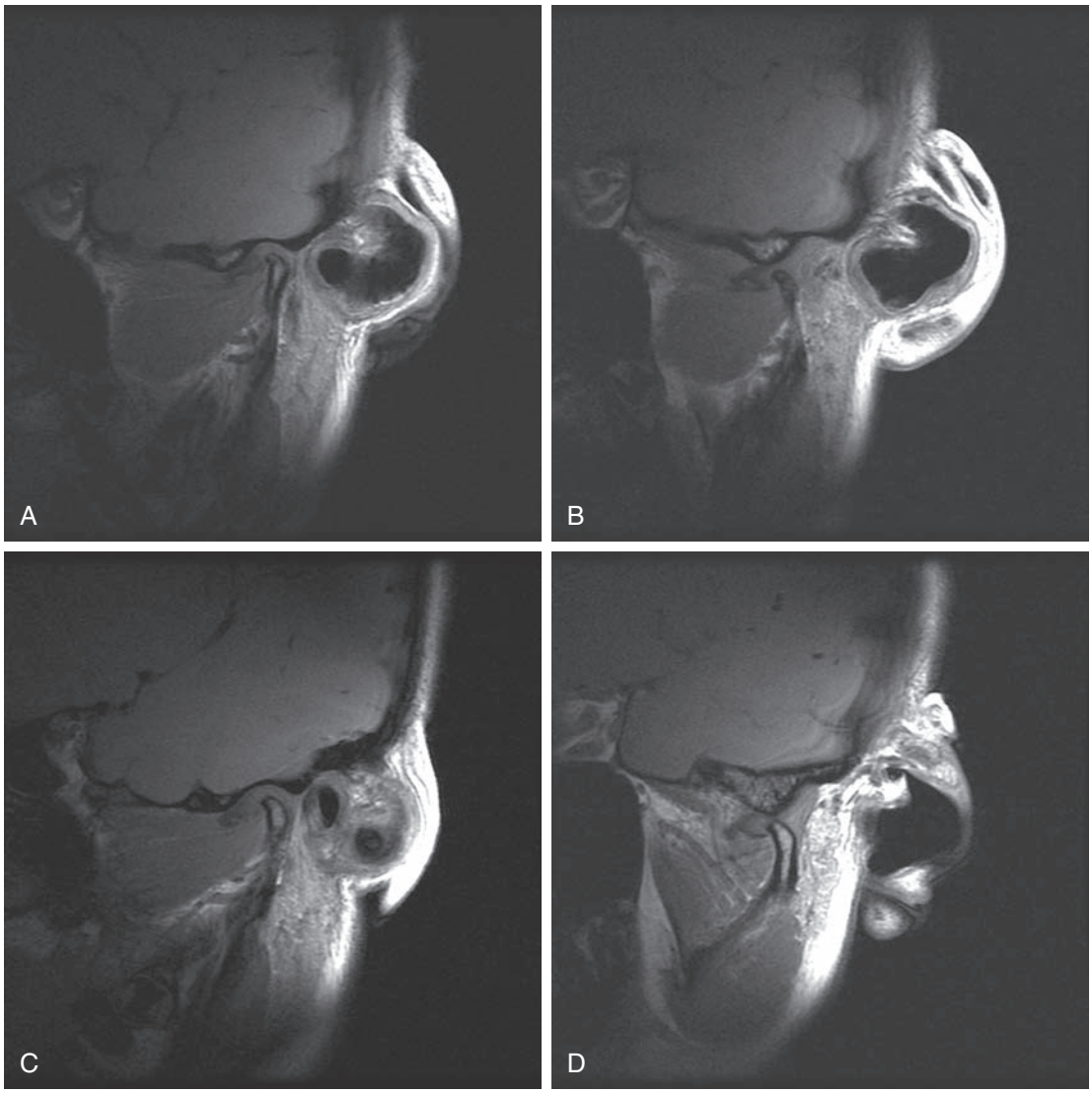

• **Figure 42-1** **A,** Direct sagittal magnetic resonance image (MRI) of an anteriorly dislocated disc in the closed mouth position. The disc is located anterior to its normal position relative to the condyle and articular eminence. **B,** Direct sagittal MRI of patient in part **A** in the open mouth position. The nonreducing dislocated disc is situated at the bottom of the articular eminence with the condyle articulating against the posterior attachment of the disc. **C,** Direct sagittal MRI of contralateral disc in the closed mouth position in the same patient. The disc is anteriorly dislocated. **D,** Direct sagittal MRI of the same disc in the open mouth position. The disc is severely dislocated without reduction.

the three-dimensional aspect of ID. Sagittal views alone may not depict medial or lateral disc displacement. Liedberg and Katzberg have reported the diagnostic value of coronal MRI views in verifying disc displacement.[59,60] An MRI should also be ordered in both T1- and T2-weighted images. T1-weighted images best depict the anatomy of the TMJ, while T2-weighted images allow for visualization of joint effusions. No studies have been able to consistently or accurately determine disc perforations.

Preoperative Therapies

Nonsurgical, conservative therapies used in the treatment of TMD are covered in greater detail in other chapters of this text. Non-steroidal anti-inflammatory drugs, a soft diet, physical therapy, splint therapy, and behavioral therapy when indicated are among the various nonsurgical, conservative therapies that are typically implemented, and sometimes exhausted, before surgery is considered in the treatment of ID. When myofascial pain exists concurrently with ID, splint therapy may relieve one pain but aggravate another. If an anterior repositioning splint is implemented because of the presence of the ID, the patient's myofascial pain may be aggravated. If the more common maxillary stabilization splint is fabricated, the myofascial pain may be improved, but joint pain may still exist, especially if the patient is functioning on the posterior attachment of the disc.

Surgical Approaches

A variety of open surgical techniques exist for the treatment of ID. These include the following:

1. Disc repositioning
2. Disc repair
3. Discectomy alone
4. Discectomy with autologous graft replacement
5. Condylotomy

The above-mentioned procedures are all performed through either a preauricular, endaural, or postauricular skin incision. Regarding grafting procedures, this chapter will discuss only those techniques that use autologous tissue sources, as numerous studies have concluded that the use of alloplastic graft materials in TMJ surgery is unsupported.[61-66] The specific arthrotomy technique chosen is usually dependent on the surgeon's skills and experiences. The procedure should also result in the fewest complications, such as facial nerve injury, permanent occlusal changes, and relapse of joint pain and dysfunction. Another consideration is if a second surgical site is required for procurement of an autologous graft.

Preauricular Incision

The preauricular incision is commonly used and a modification of an incision designed by Blair.[67] The incision provides maximal lateral and anterior access to the joint space. The preauricular incision is approximately 3 cm long and has a superior and inferior component, which meet at a point level with the superior aspect of the tragus. The incision is placed within a preauricular skin crease that lies posterior to the superficial temporal vessels and the auriculotemporal nerve. The vessels can be avoided by following the preauricular cartilage during the dissection. Sufficient surgical access in the inferior portion of the incision can be easily achieved by carrying the incision to a point just below the tragus, but the incision can be extended inferiorly to the level of the lobule.

The skin and subcuticular tissues are sharply incised with a No. 15 blade. The superior portion of the incision is progressively dissected with mosquito hemostats down to the intensely white temporalis fascia. The inferior portion of the incision is dissected down to the lateral TMJ ligament. Since the external auditory canal is angled nearly 45 degrees anteromedially to the skin surface, the inferior portion of the dissection follows the pretragal pocket to avoid perforating into the external auditory canal. Small retractors are placed into the superior and inferior pockets. A sharp, curved Metzenbaum scissors is placed on top of the temporalis fascia and used to connect the superior and inferior pockets, and the overlying tissues are sharply incised. A flap is reflected anteriorly and superiorly, clearly exposing the temporalis fascia. This flap is then retracted anteriorly away from the tragus. A No. 15 blade is used to make a vertical incision through the temporalis fascia, then the dissection proceeds down to the root of the zygomatic arch. A full-thickness flap is then elevated anteriorly off of the arch until the articular eminence is visualized.

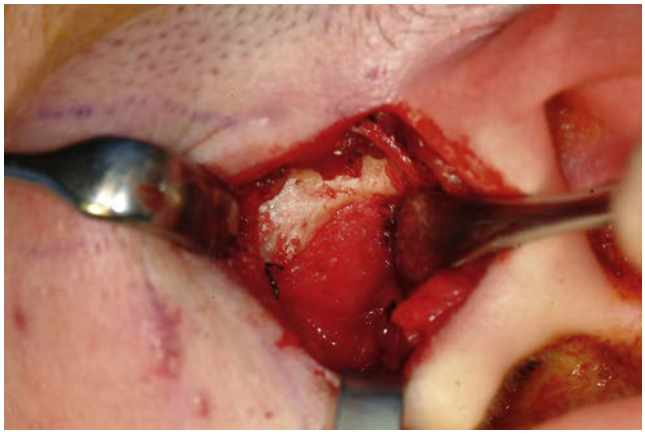

• **Figure 42-2** Preauricular incision with exposure of the articular eminence and TMJ capsule.

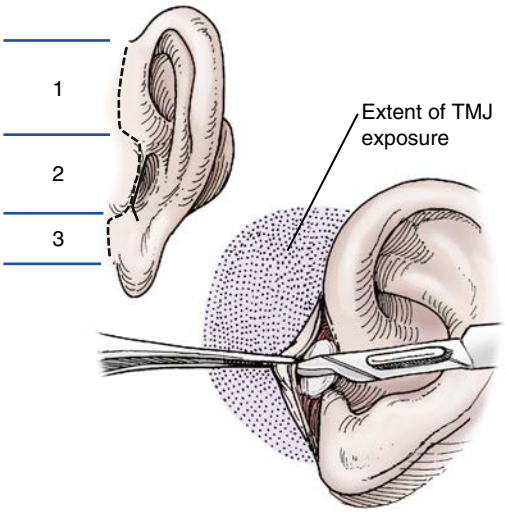

• **Figure 42-3** Endaural incision. Although the skin incisions are made in creases to hide them, the deeper dissection hugs the cartilage of the pinna or external auditory canal cartilage. The shaded area is that which is eventually exposed.

The mandible can be manipulated through a sterile drape, allowing the surgeon to become oriented and possibly identify the lateral pole of the condyle. The overlying tissues are bluntly dissected with Metzenbaum scissors until the lateral capsule is identified (Figure 42-2). Small Obwegeser right angle retractors can be used inferiorly and anteriorly to expose the articular eminence and the lateral capsule. A superior extension of the preauricular incision allows access to the temporalis muscle if a temporalis muscle flap must be harvested for reconstructive purposes. The primary disadvantage of the preauricular incision is the risk of injury to the superficial temporal vessels.

Endaural Incision

The endaural incision described by Rongetti is a modification of an endaural approach first reported by Lempert for treatment of otosclerosis.[68] The endaural incision is more esthetic because the incision is made in the external auditory

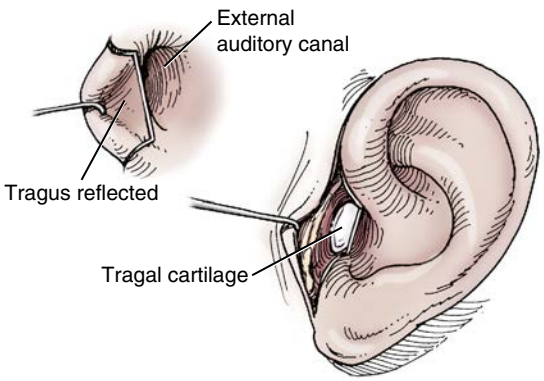

• **Figure 42-4** The skin incision inside the tragus connects the superior and inferior portions of the endaural incision at right angles to facilitate reapproximation and closure. A supraperichondrial dissection is continued on the anterior aspect of the tragal cartilage deep into the wound following the contour of the cartilage.

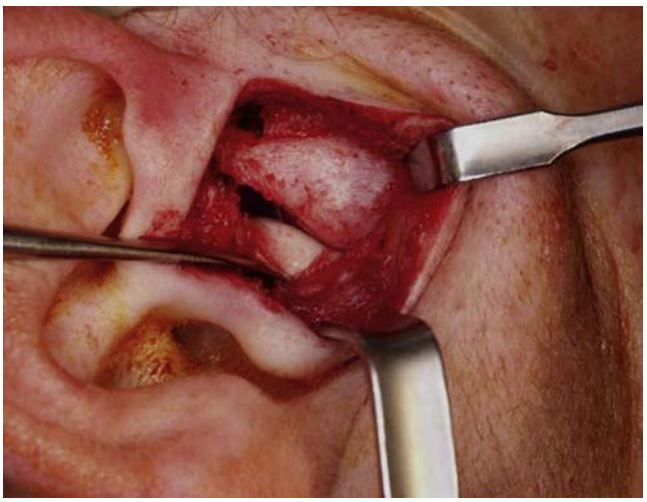

• **Figure 42-5** Lateral capsule incised and an intact, shiny, white, and firm disc is visualized.

canal (Figure 42-3). However, this incision does carry the disadvantage of possible perichondritis. The superior portion of this incision begins at the junction of the face and pinna and extends to the top of the tragus. The incision is made at a 90-degree angle to the skin surface just anterior to the pinna, following the cartilage of the pinna. The inferior portion of the incision begins at the base of the tragus and extends to the junction of the lobe and the face. The tragus is retracted anteriorly and an incision is made 2 to 3 mm inside the crest of the tragus, connecting the superior and inferior incisions (Figure 42-4). The skin is dissected off of the tragal cartilage without creating a perforation of the skin while it is being reflected over the cartilage.

Metzenbaum scissors are used at the superior extent of the incision to bluntly dissect down to the temporalis fascia. The superficial temporal vessels can be avoided by closely following the cartilage of the pinna. The dissection anterior to the tragus follows a supraperichondrial plane, over the cartilage that forms the anterior wall of the external auditory canal. An important landmark during this dissection is the bony postglenoid tubercle, which is located anterior to the cartilage of the external auditory canal. The dissection along the anterior portion of the cartilaginous canal must stop at the postglenoid tubercle because the tympanic membrane is attached to the cartilaginous canal near the junction of the cartilaginous and bony canal. If the bony canal is perforated, the tympanic membrane can be injured. The plane of dissection follows that of the cartilage of the canal rather than the skin surface, or the parotid gland may be violated. Inferiorly, the dissection proceeds down to the skin just beneath the lobe. Sutures can be placed through the tragal cartilage and the superior flap to assist in retraction.

Other Skin Incisions

Alexander wrote on the postauricular approach for TMJ surgery.[69] More recently, Politi described a deep subfascial approach to the TMJ or zygomatic arch.[70] The incision is a modification of the preauricular incision that follows a deep subfascial dissection, passing deep to both layers of the temporalis fascia. No injuries to the facial nerve were reported with this incision and it was not necessary to ligate any superficial temporal vessels except an occasional posterior branch of the superficial temporal artery. The deep subfascial approach was recommended in second procedures of the TMJ or in delayed surgery. The specific incision used is ultimately determined by the surgeon's experience, as no studies have indicated that the incision affects the intended goals of the surgery.

Capsular Incisions

Once the lateral capsule is identified, the mandible can be distracted through a sterile drape, enabling the lateral pole of the condyle to be palpated through the capsule. The capsule can be incised through any number of different incision designs to gain access to the superior joint space. The most commonly used incisions involve making an incision either over the lateral rim or just below the lateral rim of the glenoid fossa (Figure 42-5). The superior joint space is insufflated with 2% lidocaine with 1:100,000 of epinephrine-impregnated local anesthesia through the lateral capsule. The local anesthesia will rapidly escape once the capsule is either dissected off of the rim with a periosteal elevator or incised with a No. 15 blade. In the case of the latter design, the incision is extended anteriorly and posteriorly with a pair of sharp scissors. The surgeon should excise any adhesions within the superior joint space, but should not be overly aggressive with removing tissue from the undersurface of the fossa, as the synovial lining may be inadvertently removed.

Care must be taken not to damage the posterior attachment of the disc while dissecting the capsule. If the surgeon must access the inferior joint space, the capsule can be incised off of the disc and the periosteal elevator can reflect a flap to expose the condyle. Vertical reduction of the articular eminence can be performed to maximize the surgeon's view of the superior joint space. Reduction typically involves removal of 4 to 5 mm of bone on the most lateral aspect of the eminence along the lateral tubercle. If necessary, an



• **Figure 42-6** The endaural incision is closed in layers. The skin immediately anterior to the tragal cartilage is sutured before skin closure to prevent tenting of the skin over the tragus, obliterating the natural depression in the face anterior to the tragus. The skin is closed with interrupted sutures at the corners of the endaural incision with 5-0 monofilament sutures. The inferior portion is closed with interrupted sutures, while the superior portion is closed with a continuous subcuticular 5-0 monofilament "pullout" suture.

additional 1 to 3 mm of bone can be removed from the medial aspect of the eminence to optimize movement of the condyle within the fossa during the arthroplasty.

Wound Closure

Regardless of the specific incision design used, the wound is closed in layers. If the capsule is incised below the lateral aspect of the zygomatic arch, the capsule can be reapproximated and closed with interrupted 4.0 vicryl sutures. The deeper tissues that lie over the capsule and the subcuticular layer are also closed with interrupted 4.0 vicryl sutures. In a preauricular incision, the skin is closed with a running 5.0 monofilament suture. Closure of an endaural incision begins by suturing the corners of the tragal portion of the incision with interrupted sutures (Figure 42-6). Then interrupted sutures are placed to close the inferior portion of the incision by the lobe. The superior portion of the incision is closed with a continuous subcuticular suture.

Arthrotomy Procedures

Disc Repositioning

In 1979 McCarty and Farrar first reported surgery to reposition the disc into its normal anatomic relationship relative to the condyle and fossa.[71] Disc integrity, or deformity, must be carefully assessed if repositioning is to be contemplated. The chances of successful repositioning increase if the disc has maintained its normal appearance (white, shiny, firm) and length, and is minimally displaced. The posterior aspect of the disc is positioned over the superior portion of the condyle in a normal, healthy joint. If the disc is severely displaced and does not reduce, loading by the condyle increases on the retrodiscal tissues, making them hypovascular. Both the condyle and articular eminence can undergo remodeling, and a "pseudodisc" may eventually form. However, an MRI may not be able to distinguish the pseudodisc from remnants of the true disc.

One must closely inspect the disc before proceeding with its repositioning. The disc should not be distorted or placed under tension during posterior repositioning. Dense adhesions that result from longstanding disc displacement often require releasing incisions in the anterior and/or medial regions of the disc. If a releasing incision must be performed on the medial aspect of the disc, it must be made with caution because of the risk of significant hemorrhage. Violation of the medial capsule, lateral pterygoid muscle, or internal maxillary artery can contribute to hemorrhage in this region. Intraoperatively, if the disc is amenable to repositioning, it is plicated posteriorly or posterolaterally to return the anteromedially displaced disc to its more normal anatomic location.

Hall described a partial-thickness plication of the disc if the disc can be repositioned without entering the lower joint space.[72] If a situation exists where the inferior joint space must be entered, such as osseous recontouring of the condyle, then a full-thickness plication should be performed as described by Dolwick and Sanders.[73] Numerous studies have reported disc repositioning success rates based on the reduction of TMJ pain and an increased range of motion, of 80% or more[19,71,74-76] (Figure 42-7). Weinberg and others have reported how an eminectomy or condyloplasty may also facilitate improved disc repositioning.[77-79]

After disc repositioning is completed, the patient should be educated on the possibility of recurrent joint noises. The patient should not worry about either continued joint dysfunction or progression of the ID as long as the joint noises are not accompanied by pain. Further surgery is not recommended for the treatment of unremitting postoperative pain.[46]

Disc Repair

When indicated, perforations of the disc can be managed by reparative techniques.[17,80] For smaller perforations, the disc can be undermined from the surrounding soft tissue for a tension-free primary closure with a non-resorbable suture. Osteophytes and bony overgrowths are commonly found under disc perforations. Any necessary arthroplasty of the condyle can be conveniently performed during disc repair procedures through the perforation. Larger perforations of a dislocated disc require a more extensive repair, because the disc is unlikely to reduce after the margins of the perforation are excised due to more dense adhesion formation and scarring. If the disc cannot be adequately repaired, then the surgeon must make the decision to replace the disc with either an autologous or homologous graft, or perform a discectomy.

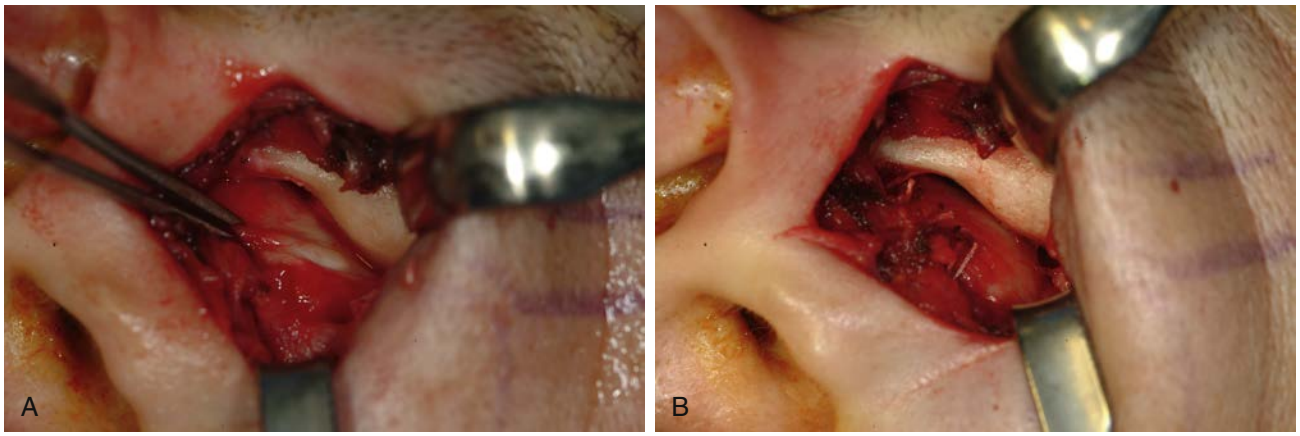

• **Figure 42-7** **A,** Disc repositioning through a preauricular incision. Adhesions have been removed from the undersurface of the fossa. The disc is without perforations and is white, shiny, and firm. The disc is being repositioned with Adson tissue forceps. **B,** Disc from part **A** has been plicated posteriorly.

Discectomy

Intraoperatively, if a surgeon believes that a deformed disc is not beyond repair, a discoplasty can be performed. However, if a deformed disc is determined to be unsalvageable, a discectomy is considered. Additionally, if the disc is anatomically amenable to repositioning and/or repair but prohibits the fluid, smooth movement of the condyle, the disc should be excised. First described by Lanz in 1909,[5] discectomy is indicated in several instances: irreparable disc perforation; complete loss of elasticity of the disc; or persistent pain and dysfunction even after disc repositioning. Excising the irreparable disc allows the jaw to move without an impediment. Both partial and total discectomies have been described.[81,82] Kondoh described a procedure referred to as disc reshaping, which is a modification of a partial discectomy.[80] Only that portion of the disc and posterior attachment deemed unsalvageable is excised to eliminate diseased tissue and remove any obstacle for smooth condylar movement.

During a discectomy, all remnants of the disc do not need to be removed to avoid unnecessary, significant hemorrhage, particularly in the highly vascular retrodiscal or medial regions of the joint space. After the disc and posterior attachment are excised and a smooth motion of the condyle can be consistently repeated intraoperatively, the condyle can be conservatively recontoured to remove any irregularities or osteophytes (Figure 42-8). Intact articular cartilage should not be removed from either the condylar head or the fossa. Excessive removal of articular cartilage may predispose the joint to heterotopic bone formation and subsequent ankylosis.

Both short-term[83,84] and long-term[85,86] favorable results from discectomy have been documented. Most patients from these studies were pain-free and had little in the way of dietary restrictions. Takaku and Toyoda's study followed 39 discectomy patients over an average of 20 years after surgery.[87] All but two of their patients had no pain and none experienced masticatory disorders. Mouth opening of 35 mm was attained by 38 of the patients. Eriksson and Westesson's long-term evaluation of 15 discectomy patients with a mean follow-up of 29 years also revealed successful results.[85] All patients were free of pain and none had reported mandibular dysfunction. Only one of the patients could not open beyond 39 mm.



• **Figure 42-8** Large perforation through the disc. The top of the condylar head can be seen through the perforation.

Of interest is the significant bony remodeling as evident by the flattening of the fossa and condyle that has been reported with discectomy.[88,89] These changes were noted to stabilize after just 2 years and were not viewed as degenerative due to a lack of symptomatology.[90-92] Post-discectomy physical therapy is essential because the therapy helps the patient reestablish an adequate range of motion. Additionally, in unilateral cases, it assists the patient in compensating for the expected deviation of the mandible to the operated side. When bilateral discectomies are performed, an anterior open bite may occur because of posterior displacement of the condyles. Use of "light" elastics for a period of 6 weeks may prevent this.

Discectomy with Replacement

Intuitively, a surgeon may feel compelled to replace a disc to avoid a scenario where a patient's TMJ is allowed to

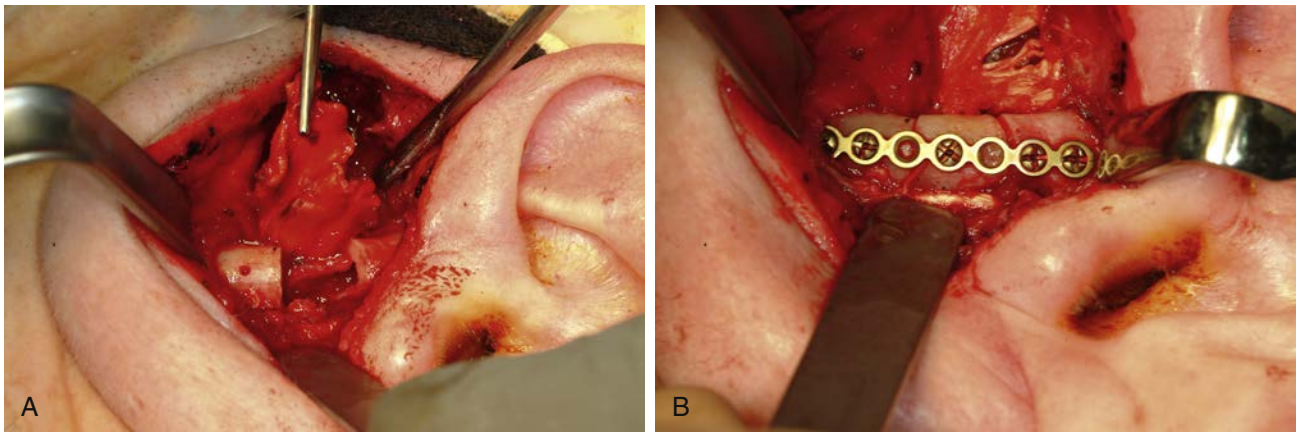

• **Figure 42-9** **A,** Partial-thickness temporalis muscle flap. The patient's zygomatic arch was preplated with a 1.2-mm miniplate. The miniplate and screws were removed and the osteotomies completed. The zygomatic arch was removed to gain access to the temporalis muscle. **B,** Temporalis muscle flap inset into the fossa and secured with sutures. The arch is placed back with the miniplate and screws.

function against the bony fossa without any intermediary tissue. The rationale behind disc replacement with a graft was to protect the articular surfaces from further degenerative changes and to deter joint adhesion formation. The graft material was to create a scaffold for synovial tissue in-growth, and some studies have reported this process to partially occur.[93,94] Yet clinical uncertainty still surrounds performing a discectomy without replacement versus disc replacement.

Animal studies have suggested that autogenous graft placement after discectomy is beneficial.[93] Thyne et al investigated the changes that occur to the joint tissues following the use of temporalis muscle as an interpositional graft following discectomy in sheep.[95] The results revealed that although the temporalis muscle in sheep underwent avascular necrosis and subsequent displacement, the condyle and fossa could still remodel. A study by Tucker et al evaluated the histologic changes in primate TMJs after autogenous auricular cartilage grafts were placed following discectomy.[93] Viable auricular cartilage was found in each of the sacrificed monkeys. A variable amount of fibrous connective tissue was found in all grafts, and one graft was fused to the glenoid fossa, while a second graft was fused to the condyle. Regardless of the positive results reported by these and other animal studies, Takaku et al[89] and McKenna[96] have reported long-term evaluations in humans with discectomy alone that surpass those short-term results of discectomy with grafts.

Reports by Wagner, Westesson, Ryan, Heffez, Dolwick, and others have clearly documented the poor clinical outcomes of alloplastic materials such as silastic, silicone, and Proplast-Teflon for disc replacement.[61-66] Autogenous tissues have been used as both disc replacement material following discectomy and as an interpositional material in the treatment of joint ankylosis. Autogenous sources such as temporalis muscle flaps, auricular cartilage, and dermal grafts have proven far better options for disc replacement than their alloplastic counterparts.[97-100]

Temporalis Myofascial Flaps

The primary uses for a temporalis myofascial flap are as an interpositional graft in the TMJ to avoid ankylosis and to reconstruct a joint with significant degenerative remodeling. Temporalis myofascial flaps can also be used as a replacement material after discectomy. In choosing the type of autogenous tissue material, remote or adjacent donor site morbidity is a consideration. Avoiding a separate, remote donor site is one advantage of the temporalis flap. It also has the distinct advantage over other autogenous sources of being a vascularized flap, maintaining a viable blood supply. Umeda et al reported that the muscle tissue in the flap maintained its viability with only some fibrosis for 15 months.[101]

The temporalis myofascial flap owes its versatility to its ability to be harvested in variable thicknesses to allow for reconstruction of defects of variable sizes. A flap 3 to 4 cm wide is usually sufficient to adequately cover the fossa. The zygomatic arch can be preplated prior to it being osteotomized if the surgeon desires to place the myofascial flap under the arch and over the eminence (Figure 42-9). The procedure has also been described by placement of the flap over the arch.[102] In unilateral cases of ID where the disc is determined intraoperatively to be unrepairable, a temporalis flap can minimize or avoid a posterior open bite that can occur on the non-operated side. Disadvantages of this flap include possible flap necrosis and fibrosis or adhesion formation within the joint space. The temporalis muscle flap is similar to other arthrotomy techniques in its risk of postoperative decreased interincisal opening.

Auricular Cartilage Grafts

The auricular cartilage graft is procured with the intent to use it as an interpositional material after discectomy and occasionally in the treatment of ankylosis. It is most commonly harvested through a posterior approach to the ear (Figure 42-10). A vertical incision is made on the posterior side of the conchal bowl. A supraperichondrial dissection is performed on the convex side of the cartilage. The cartilage

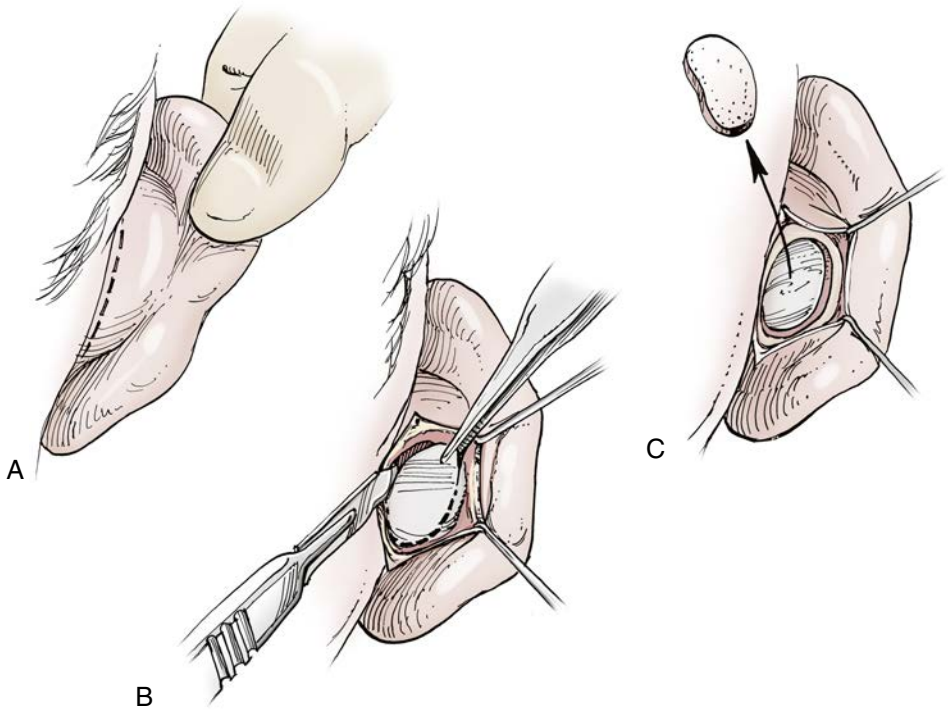

• **Figure 42-10** **A,** Auricular cartilage is harvested via a vertical incision on the posterior aspect of the concha. **B,** The cartilage is exposed, and the desired size of the graft is outlined. The perichondrium is left on the convex surface of the cartilage. **C,** The outlined portion is excised so the perichondrium is not removed with the graft. The graft should only have perichondrium on the convex side and none on the concave side.

is incised parallel to the helix. A subperichondrial dissection is created on the concave side of the cartilage. Sufficient cartilage must remain to support the ear. The skin is then closed primarily. The graft is sutured with several horizontal mattress sutures to the surrounding tissues (Figure 42-11).

Although not commonly used at the present time, the auricular cartilage graft was previously used to replace a failed alloplastic graft when alloplasts were still widely used. It is important to recall that if an auricular cartilage graft is being considered, the perichondrium is left intact on the convex side of the graft, which opposes the glenoid fossa. Auricular cartilage grafts do not induce a foreign-body reaction and appear to resist most occlusal loading forces. However, histologic analysis in both animal and human studies has shown that dense adhesions or a fibrous fusion occurs between the graft and either the fossa or condyle.[94,95,104] A disadvantage of the auricular cartilage graft is that it requires a second donor site, although it is in close proximity to the primary surgical field. Reported complications related to auricular cartilage grafts include the graft becoming prematurely displaced and infections of the graft.

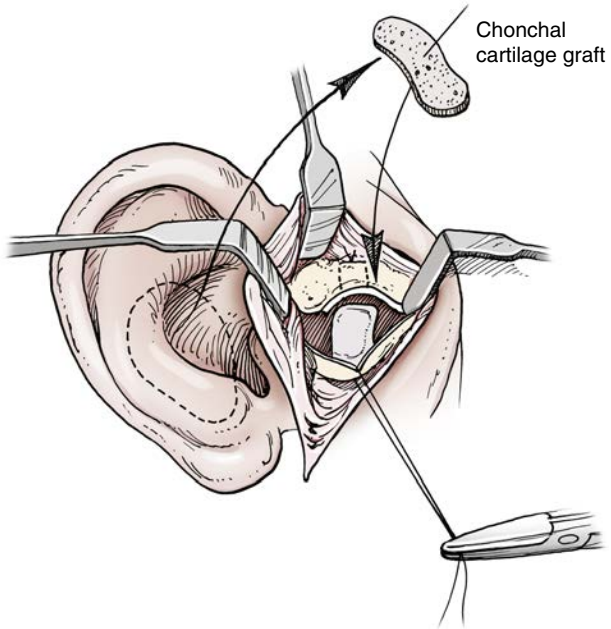

• **Figure 42-11** The graft is sutured to the fossa and the posterior slope of the eminence with either wires or heavy sutures.

Dermal Grafts

Dermal grafts have been used for disc replacement but are more commonly used for repair of disc perforations and as an interpositional material in cases of TMJ ankylosis. The most common sites from which to harvest dermal grafts for TMJ surgery include the upper lateral thigh, buttock, and groin. Dermal grafts are harvested as either partial-thickness or full-thickness grafts. A dermatome is used to obtain a partial-thickness graft. Complete removal of the epidermis from the graft is preferable to avoid leaving epithelial remnants on the graft, which may lead to epithelial cyst formation on the condyle from the undersurface of the graft. A

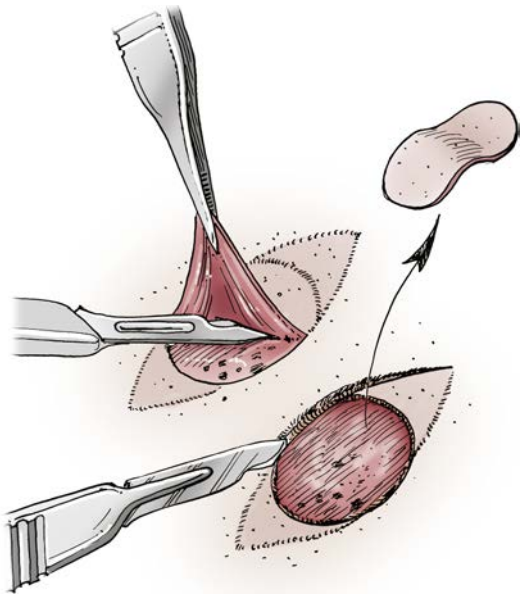

• **Figure 42-12** Dermal harvest includes removal of epidermis over an ovoid area of skin. The epidermis is discarded.

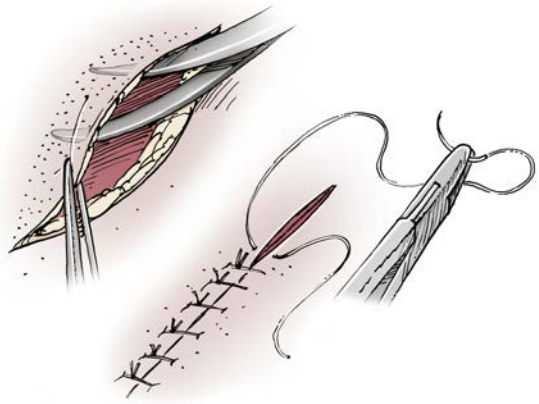

• **Figure 42-13** The oval is converted to a full-thickness fusiform shape, three times longer than wide. The split-thickness oval, along with the remainder of the fusiform, is excised down to the subcutaneous fat. The full-thickness ends are excised. The wound is then undermined and closed primarily.

thin film of antibiotic ointment is coated over the donor site, and a transparent, occlusive wound dressing is placed over the area.

Full-thickness grafts begin by drawing a fusiform outline of the desired graft on the skin (Figure 42-12). A circular area of epidermis is removed from the center of the fusiform outline. Next, the entire outlined area is excised down to the subcutaneous fat. The graft site is undermined and closed primarily (Figure 42-13). The dermis alone is excised from the central portion of the fusiform-shaped graft, and then defatted by hand with either a No. 15 blade or scissors (Figure 42-14). Removal of fat from the dermal graft assists in revascularization of the graft by capillary in-growth from the tissues in the recipient bed. An animal study by Tucker et al indicated that vascular perfusion of dermal grafts placed



• **Figure 42-14** The dermal graft being defatted by hand.

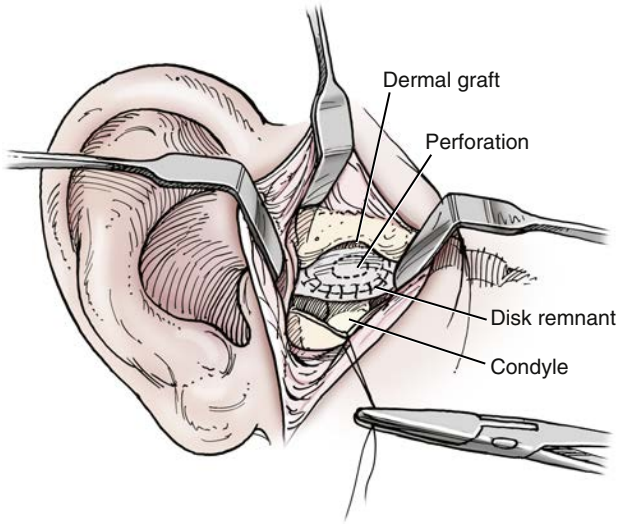

• **Figure 42-15** The dermal graft sutured in place.

in the TMJ occurred soon after its placement.[105] The graft appears to remain viable as a free graft.

When dermal grafts are harvested for disc repair, the margins of the perforation should be freshened. The harvested graft should be approximately twice the diameter of the measured defect to allow for anticipated contraction of the graft (Figure 42-15). The dermal graft should also extend well beyond the extent of the perforation to avoid exposure of the condylar head if the dermal graft were to migrate. Postoperative physical therapy will help to prevent possible fibrous adhesion formation within the joint space. One disadvantage of the dermal graft is that it requires a remote donor site. Additionally, dermal grafts, much like auricular cartilage grafts, can result in fibrous tissue formation with subsequent fibrous ankylosis.

Regenerative Medicine Alternatives for Future Treatment of Disc Perforation

Epidemiologic surveys report that 20% to 25% of the population has TMD symptoms,[106] while patient studies show that 3% to 4% of the population seeks treatment.[107] The TMJ disc is relatively avascular and does not spontaneously regenerate or repair itself in vivo.[108] It has been shown that almost 70% of patients with TMDs suffer from disc displacement,[109] a finding that identifies the TMJ disc as a key structure in the cascade of events that lead to progressive

pathology and morbidity. A novel, effective treatment for disc regeneration may signal a paradigm shift in the treatment of perforated TMJ discs and prevent the inevitable consequence of degenerative articular surface damage with subsequent total joint replacement.

Tissue Engineering Strategies

From 2004 through 2008, Almarza et al[110,111] published 13 articles describing the use of porcine TMJ disc cells for creating a tissue-engineered TMJ disc in vitro. These studies optimized monolayer culture conditions, scaffold selection, seeding density and technique, growth factor regimens, and biomechanical stimulation regimens, but the ability to create a TMJ disc with properties that matched the native disc was limited. More recently, a series of studies has been published in which costal cartilage was evaluated as an autologous cell source for a tissue-engineered disc.[112-114] This autologous tissue would be appealing as many craniofacial surgeons also have experience replacing the mandibular condyle with a rib graft. However, this procedure has variable results and significant questions remain regarding cell source, scaffold choice, and stimulation regimen.

The latest work with extracellular matrix (ECM) scaffolds by the collaborative group of Chung, Badylak, Brown, and Almarza[115,116] represents a novel regenerative medicine approach for TMJ disc replacement and a departure from purely in vitro strategies. The approach involves recruitment of progenitor cells with local modulation of the host innate immune response by promoting an M2 versus M1 macrophage phenotype. These processes are centered on the use of a biologic scaffold material composed of xenogeneic ECM.

Macrophage Phenotype as a Predictor of Constructive Remodeling

Badylak and co-workers have shown that the phenotype of macrophages that participate in the remodeling of ECM scaffolds plays a critical role in determining whether the events follow a pro-inflammatory course leading to fibrosis and scarring, or a constructive remodeling course resulting in deposition and organization of site appropriate tissue.[117-119] Macrophages have been classified as having either an M1 or an M2 phenotype, based on their biologic function.[120] The causes and effects of this macrophage dichotomy toward a given phenotype have been studied in the context of tissue engineering. It was shown that M1 and M2 macrophages have distinct effects on the recruitment of progenitor stem cells, a cell population believed to play a critical role in repopulating the ECM scaffold material.[121] M2 macrophages promote the chemotaxis/recruitment of these cells, while M1 cells inhibit the chemotaxis of these stem cells.

Canine Unilateral Discectomy Model

A prototype ECM derived from porcine urinary bladder mucosa (UBM) was first evaluated as a scaffold for TMJ disc reconstruction in a canine model.[115] Five dogs were subjected to unilateral resection of the native disc and subsequent replacement with the UBM-ECM (Figure 42-16). Analyses were performed at 3, 4, 8, 12, and 24 weeks in this pilot study. Macroscopically, the scaffold remodeled rapidly, and it was indistinguishable from newly deposited host tissue at all time points, including the 3-week time point. Microscopically, remodeling was characterized by intense vascularization during the first 2 months, and a dense infiltration of predominantly CD68+ mononuclear cells (i.e., macrophages) and smooth muscle actin (SMA)+ large, round cells at early time points. The cell population changed over time to a sparse population of SMA spindle-shaped cells resembling those of the native TMJ disc (i.e., fibrochondrocytes) (Figure 42-17). Furthermore, the remodeling process showed deposition of predominantly collagen type I (as determined by Herovici staining),[122] the density and organization of which resembled that of the native disc by the 6-month time point. In-growth of skeletal muscle tissue was observed at the interface of the remodeled UBM with the host periarticular musculature. No adverse changes in the articulating surfaces of the condyle or fossa were observed, thus confirming the protective function of the remodeled scaffold. Results of this pilot study suggest that the xenogeneic ECM scaffolds have the potential to provide an effective interpositional material while serving as a template for host-driven reconstruction of the TMJ disc. The number of samples at each time point was only one and therefore prompted the following study.

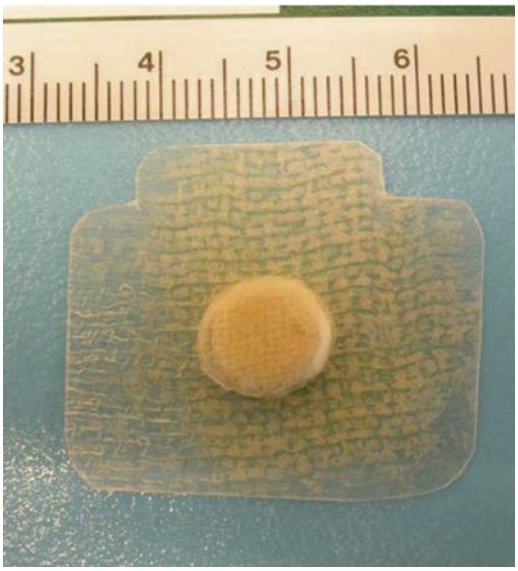

• **Figure 42-16** Macroscopic image of the pre-implantation UBM-ECM device. The central "pillow" consists of a fine particulate form of the same ECM that encases the deformable pillow. The encasing sheets serve as the brim for attachment to the joint capsule.

Canine Bilateral Discectomy Model

In light of the promising findings in the pilot study described above, a more definitive study was conducted in which 10 dogs were allowed to survive for 6 months following UBM implantation.[116] It was decided that confirmation of the long-term (6 month) remodeling events was needed.

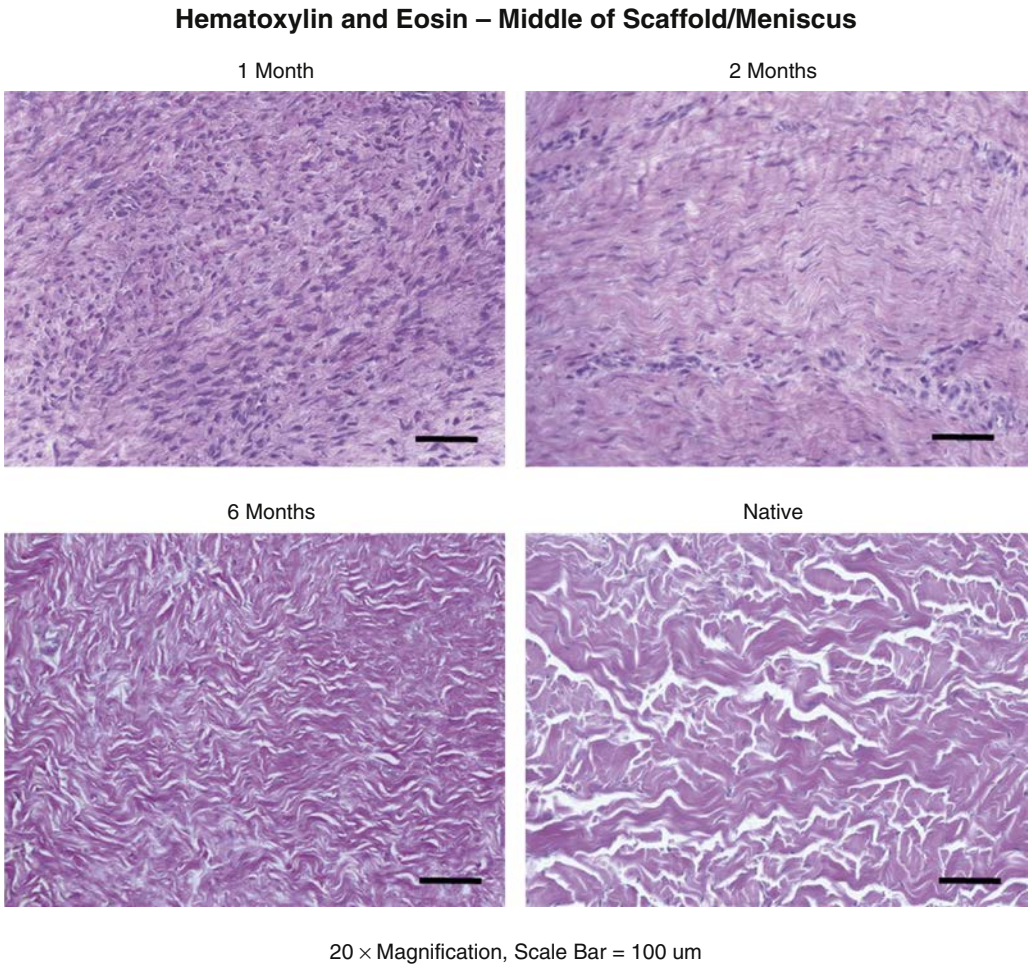

• **Figure 42-17** Histologic appearance of the remodeling process at 1, 2, and 6 months. The dense cell infiltrate at 1 month transforms into a fibrocartilaginous tissue very similar to the native TMJ disc *(lower right)*. Recall that the original implant is totally acellular.

The goal of this study was to examine the 6-month gross morphologic and histologic outcome in a more comprehensive manner than the initial pilot study and to evaluate the biomechanical properties and biochemical content of the remodeled tissues at 6 months post-implantation.

Unlike the pilot study, a bilateral discectomy was performed in this trial with one side being treated with the xenogeneic UBM and the opposite side serving as a control and left empty. The results in 9 out of the 10 dogs showed excellent remodeling of the scaffold with articular surface protection while the contralateral, untreated control side clearly displayed pitted articular surface irregularities within 6 months and no regrowth of the TMJ disc tissue.

Gross morphologic findings showed little to no change in the articulating surfaces of the temporal fossa or the mandibular condyle following placement with the UBM device, again confirming the protective effect of the ECM device even during the remodeling process. Consistent with the pilot study results, the UBM in the second study was replaced with a dense collagen fiber structure that resembled the native TMJ disc by the 6-month post-surgery time point in 9 of 10 animals. The one animal in which the ECM scaffold did not remodel in a constructive manner showed degeneration and scar tissue deposition at the site of UBM, the cause of which is unknown.

Immunolabeling for CD31 showed that the number and size of blood vessels within the remodeled device at 6 months were similar to those of the native disc. Immunolabeling for CD68 was negative, indicating that the macrophages present at early time points were replaced with a population of cells that resembled those of the native disc.

Biomechanical testing showed that the pre-implantation ECM device had a higher maximum stress, equilibrium stress, and tangent modulus than did the native TMJ disc tissue and a lower percentage of relaxation. By 6 months post-implantation, however, the mechanical properties values of the remodeled UBM and the native disc were indistinguishable (Figure 42-18). Biochemical testing showed that both the pre-implantation UBM device and the remodeled UBM had collagen and water contents that were similar to those of the native disc tissue (see Figure 42-18, *B*). The remodeled UBM had higher glycosamino glycans (GAG) content than both the pre-implantation device and the native tissue (see Figure 42-18, *C*).

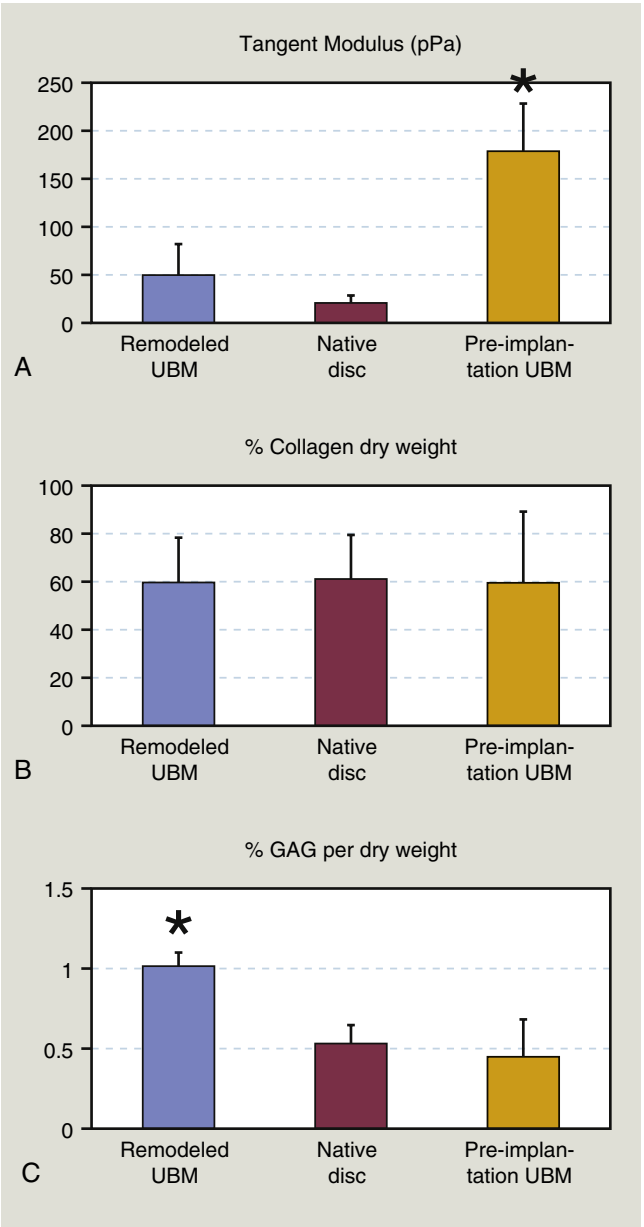

• **Figure 42-18** Biomechanical and biochemical results of the second study. The first group (*blue*) is the remodeled ECM scaffold after 6 months of implantation (N=5). The second group (*red*) is native canine TMJ disc (N=6). The third group (*orange*) is the pre-implantation ECM scaffold (N=6). **A,** Tangent modulus in kPa from stress-strain behavior, with pre-implantation ECM scaffold significantly higher than the other two groups. **B,** Collagen content per dry weight basis, with no differences found. **C,** GAG content per dry weight basis, with remodeled ECM scaffold showing higher values than the other two groups.

In summary, the tissue into which the UBM scaffold material had remodeled showed remarkable morphologic, biochemical, and mechanical similarity to the native TMJ disc tissue.

Porcine Bilateral Discectomy Model

Current efforts are being shifted to adapt the bilateral meniscectomy procedure to a porcine model (Figure 42-19), a species in which the structure and function of the TMJ disc is more like human than other species.[123-125]

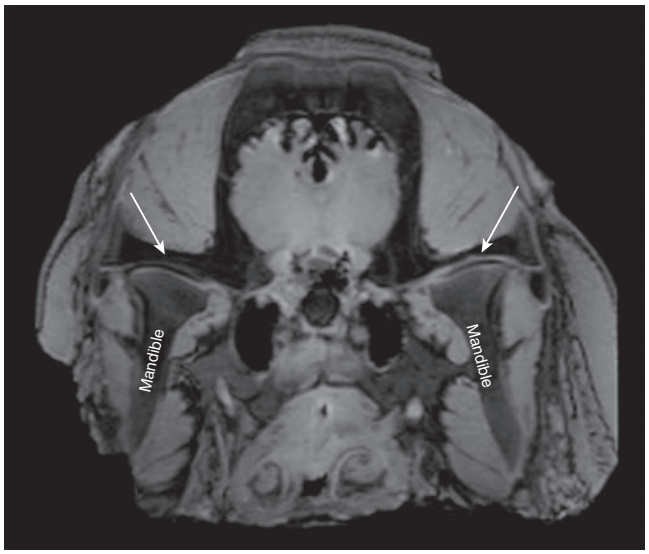

• **Figure 42-19** MRI of adult porcine skull from a recent study showing bilateral TMJ discs *(arrows)*.

The pig is thought to be the most suitable non-primate model of human TMJ anatomy and function.[123-125] Berg[123] examined pigs, sheep, calves and dogs, and noted that the pig was best suited for experiments in replacing the TMJ disc. Bermejo et al[124] also concluded that the pig was the only suitable experimental animal model after comparison to dogs, cats, rabbits, rats, cows, sheep, and goats. Similarities of the pig to human include the size of the articular structures, shape of the disc, and the omnivorous diet. Ström et al[125] recommended the domestic pig as a useful model in the investigation of masticatory system function. Thus, it has been established that pig and human TMJs have similar gross morphology, size, and structure of each TMJ component, including the disc, which will prompt further studies in this model.

Data from these two novel studies show a dramatic and rapid change from an acellular ECM scaffold to a fibrocartilaginous tissue in the dog discectomy model. Additional work shows that ECM remodeling includes a process of cellular infiltration that involves M2 macrophages, multipotential stem cells, and transient vascularization. Chemical crosslinking of ECM scaffolds shifts the macrophage response to a proinflammatory M1 phenotype in soft tissue applications[126] and markedly inhibits degradation and release of bioactive peptides.[118] The temporospatial pattern of remodeling is largely unexplored and the relative contribution and importance of factors such as scaffold degradability, the innate immune response, and the mechanical loading are unknown, especially in an intra-articular environment. Therefore, in the future these different aspects of ECM remodeling will be studied in the porcine model.

Condylotomy

The principal indication for condylotomy is reduction of pain in disc displacement with reduction, but it can be

used for any Wilkes stages I-III. Studies have reported favorable outcomes with a condylotomy for painful ID but no restricted range of motion.[127,128] The condylar sag that results from the condylotomy creates increased joint space and decreased articular pressure. This procedure has also been used for treatment of recurrent TMJ dislocation. Campbell described the first condylotomy, a closed procedure, which was performed with a Gigli saw.[129] Nickerson modified the procedure in 1983 by changing the osteotomy to one that resembles an intraoral vertical osteotomy.[130]

Several technical aspects of importance exist when performing the condylotomy for ID. The first important technical aspect is the location of the osteotomy. The vertical ramal osteotomy must be performed just posterior to the antelingular prominence to avoid the mandibular canal and unnecessary injury to the inferior alveolar nerve and vessels. The surgeon also needs to avoid placement of the inferior portion of the vertical osteotomy through the posterior border. The osteotomy should be carried through the inferior border of the mandible to allow for the desired condylar sag and better control of the condylar (proximal) segment.[132,133] Additionally, if the inferior portion of the osteotomy is made too far posteriorly along the ramus, the tip of the proximal segment may be either palpable or visible after resolution of the surgical edema. This result can be avoided by removing the tip of the proximal segment at the time of surgery with a rongeur.[134]

The amount of condylar sag is estimated by the distance created between the tip of the proximal segment and the inferior border. Factors such as the amount of medial pterygoid muscle attachment on the proximal segment and joint laxity determine the amount of condylar sag and proximal segment mobility. Proximal segment mobility can be appreciated by pushing up on the inferior portion of the proximal segment with a gauze director. A 3- to 4-mm step at the inferior border implies adequate condylar sag.

A second technical aspect of importance is the amount of bone removed along the osteotomy site. Nickerson and Veaco first described the modified condylotomy with a forward position of the proximal segment.[130] The proximal segment is placed slightly anterior and lateral to the distal segment by creating a step in the medial edge of the proximal segment. Hall later stated that forward positioning of the proximal segment was not necessary.[132] He advocated creation of a butt joint between the proximal and distal segments and encouraged creation of a medial step on the proximal segment only if a greater anterior positioning of the proximal segment was necessary.

The primary proposed advantage of the condylotomy over other arthrotomy procedures is less intra-articular scarring because the condylotomy is an extra-articular procedure. Less scarring in the joint space results in an increased range of motion, and the disc and posterior attachment remain unaltered. Maxillo-mandibular fixation (MMF) via Erich arch bars is used for 1 week in a unilateral condylotomy and for 2 weeks for bilateral condylotomy followed by application of light training elastics for an additional 4 to 5 weeks in either case to avoid an anterior open bite.[132] Active range of motion exercises are initiated 4 weeks after surgery to restore a normal range of motion. A regular diet can be reinstituted in 6 to 8 weeks.

The most significant complication associated with condylotomy is malocclusion as a result of condylar sag and changes in ramal segment position. Hemorrhage; injury to the inferior alveolar, lingual, or long buccal nerves; infection; and condylar dislocation are among the other complications.[131]

Controversy still surrounds the use of the condylotomy in the treatment of ID, and the procedure has both its strong advocates as well as opponents.[131,132,134] Proponents of the condylotomy are quick to point out how the normal disc-condyle relationship is restored and pain relief is achieved to a greater degree and more quickly than with other arthrotomy procedures. Various studies by Nickerson and Veaco,[130] Upton,[134] and McKenna[135] all showed significant decreases in pain after modified condylotomies for ID.

Complications

The common complications associated with all arthrotomy procedures include hemorrhage, auriculotemporal nerve and facial nerve injury (particularly of the temporal branch), fibrous adhesion formation, persistent pain, and occlusal changes.[136] The inferior alveolar, lingual, and long buccal nerves can also be at risk for injury from surgical retraction or manipulation of the condyle. Complications more likely with a discectomy involve heterotopic bone formation and joint ankylosis. Infection rarely occurs with TMJ arthrotomy.

Postoperative Therapies

The 1990 AAOMS standards and criteria of surgical procedures (for TMJ surgery) list a number of factors that impact a patient's postoperative course.[37] Several of these factors are issues remote from the intrinsic joint pathology, such as concomitant facial pain from other sources, poorly controlled parafunctional habits, psychological disorders, and systemic disease affecting the muscles, ligaments or bone. Myofascial pain and dysfunction can also exist concurrently with ID. If these issues are not addressed both preoperatively and postoperatively, a patient will not attain the goals of the surgery.

Postoperative therapy involves a combination of physical therapy, pharmacologic management, and occasionally splint therapy, each playing an integral role in enabling the patient to achieve an acceptable postoperative pain level and condylar range of motion. Patients who have undergone discectomy are encouraged to begin conservative range of motion exercises shortly after surgery. Disc repositioning or repair patients are typically instructed to begin conservative stretching exercises within a week after surgery. Many who undergo an arthrotomy procedure regain a normal, or close to normal, range of motion in 2 to 3 months with a

regimented course of postoperative physical therapy. A Therabyte (ACTOS Medical) appliance is routinely prescribed as a part of the patient's physical therapy. Patients who do not exhibit a decreased range of motion preoperatively should regain a normal range of motion postoperatively without much difficulty. However, patients who had a poor range of motion preoperatively will have a more difficult time attaining a normal, or even near normal, range of motion postoperatively. Thus, strict adherence to a regimented physical therapy program becomes critical.

The role of physiotherapy on the recovery of patients undergoing surgery for ID has been reported by Oh.[137] The study compared a treatment group of 22 patients who received postoperative physiotherapy versus a surgery-only group of an identical size. The groups were evaluated for two characteristics: pain intensity and temporomandibular joint function. Both groups were evaluated at three intervals: before surgery, 6 weeks after surgery, and 7 months after surgery. The group receiving physiotherapy reported less pain and dysfunction after each postoperative interval than the surgery-alone group.

Splint therapy can be beneficial in maintaining a stable postoperative occlusion. More importantly, a splint is necessary if the patient resumes any documented preoperative parafunctional habits that may cause delayed pain reduction in the postoperative phase. The splint may require adjustment as postoperative changes in the soft and hard tissues of the joint occur. Postoperative joint noises that are asymptomatic should not create any concern for either the patient or surgeon.

Summary

The literature has clearly documented the benefits of surgery for ID.[6-14] Numerous studies have documented the success of minimally invasive techniques such as arthroscopy and arthrocentesis in the treatment of ID.[22-33,138-140] Although arthrotomy is not indicated for all cases of ID, nonsurgical treatment or other less invasive techniques may not always be indicated or even be considered better alternatives in some situations. Determining an accurate diagnosis is a critical first step, and obtaining the diagnosis is often marred by the challenge of the patient's lack of understanding of his/her own symptoms. Strict adherence to surgical treatment algorithms for ID is not always beneficial or possible because each patient's underlying disorder and symptoms are unique and must be treated as such. The surgeon must avoid overemphasizing radiographic findings when determining if arthrotomy will effectively treat the ID and not cause any unnecessary morbidity. Regardless, careful patient selection is a fundamental and essential factor prior to pursuing surgery, particularly arthrotomy.

References

1. deBont L, Dijkgraaf L, Stegenga B: Epidemiology and natural progression of articular temporomandibular disorders, *Oral Surg Oral Med Oral Path Oral Rad Endo* 83:72–76, 1997.
2. Hey W, Davies C, editors: *Practical observations in surgery*, ed 3, London, 1814, T. Cadell and W. Davies.
3. Wilkes CH: Internal derangement of the temporomandibular joint pathologic variations, *Arch Otolaryngol Head Neck Surg* 115:469–477, 1989.
4. Annandale T: On displacement of the interarticular cartilage of the lower jaw and its treatment by operation, *Lancet* 1:411, 1887.
5. Lanz AB: Discitis mandibularis, *Zentralbl Chir* 36:289–291, 1909.
6. Hall HD, Indresano AT, Kirk WS, et al.: Prospective multicenter comparison of 4 temporomandibular joint operations, *J Oral Maxillofac Surg* 63:1174–1179, 2005.
7. Nyberg J, Adell R, Svensson B: Temporomandibular joint discectomy for treatment of unilateral internal derangement—a 5 year follow-up evaluation, *Int J Oral Maxillofac Surg* 33:8–12, 2004.
8. Krug J, Jirousek Z, Suchmova H, et al.: Influence of discoplasty and discectomy of the temporomandibular joint on elimination of pain and restricted mouth opening, *Acta Medica (Hradec Kralove)* 47:47–53, 2004.
9. Vazquez-Delgado E, Valmaseda-Castellon E, Vazquez-Rodriguez E, et al.: Long-term results of functional open surgery for the treatment of internal derangement of the temporomandibular joint, *Brit J Oral Maxillofac Surg* 42:142–148, 2004.
10. McCain JP, Sanders B, Koslin MG, et al.: Temporomandibular joint arthroscopy—a 6 year multicenter retrospective study of 4831 patients, *J Oral Maxillofac Surg* 50:926–930, 1992.
11. Kaneyama K, Segami N, Sato J, et al.: Outcomes of 152 temporomandibular joints following arthroscopic anterolateral release by holmium:YAG laser or electrocautery, *Oral Surg Oral Med Oral Path Oral Rad & Endo* 97:546–551, 2004, discussion 552.
12. Nitzan DW, Samson B, Better H: Long-term outcome of arthrocentesis for sudden-onset, persistent, severe closed lock of the temporomandibular joint, *J Oral Maxillofac Surg* 55:151–157, 1997.
13. Krug J, Jirousek Z, Suchmova H, et al.: Influence of discoplasty and discectomy of the temporomandibular joint on elimination of pain and restricted mouth opening, *Acta Medica (Hradec Kralove)* 47:47–53, 2004.
14. Reston JT, Turkelson CM: Meta-analysis of surgical treatment for temporomandibular articular disorders, *J Oral Maxillofac Surg* 61:3–10, 2003, discussion 10-12.
15. Eriksson L, Westesson P-L: Clinical and radiological study of patients with anterior disc displacement of the temporomandibular joint, *Swed Dent J* 7:55–64, 1983.
16. Isberg AM, Westesson P-L: Movement of the disc and condyle in temporomandibular joints with clicking. An arthrographic and cineradiographic study on autopsy specimens, *Acta Odontol Scand* 40:151–164, 1982.
17. Dolwick MF: Disc preservation surgery for the treatment of internal derangements of the temporomandibular joints, *J Oral Maxillofac Surg* 59:1047–1050, 2001.
18. Dolwick MF, Nitzan DW: The role of disc repositioning surgery for internal derangements of the temporomandibular joint, *Oral Maxillofac Surg Clin North Am* 6:271, 1994.
19. Dolwick MF, Nitzan DW: TMJ disk surgery: 8 year follow-up evaluation, *Fortschr Kiefer Gesichtschir* 35:162–167, 1990.

20. Rasmussen DC: Description of population and progress of symptoms in a longitudinal study of temporomandibular arthropathy, *Scand J Dent Res* 89:196–203, 1981.
21. Toller PA: Osteoarthrosis of the mandibular condyle, *Br Dent J* 134:223–231, 1973.
22. Milam SB, Zardeneta G, Schmitz JP: Oxidative stress and degenerative temporomandibular joint disease: a proposed hypothesis, *J Oral Maxillofac Surg* 56:214–223, 1998.
23. Takahashi T, Kondoh T, Ohtani M, et al.: Association between arthroscopic diagnosis of osteoarthritis and synovial fluid nitric oxide levels, *Oral Surg Oral Med Oral Path Oral Rad & Endo* 88:129–136, 1999.
24. Nitzan DW: The process of lubrication impairment and its involvement in temporomandibular joint disc displacement: a theoretical concept, *J Oral Maxillofac Surg* 59:36–45, 2001.
25. Nitzan DW, Etsion I: Adhesive force: the underlying cause of disk anchorage to the fossa and/or eminence in the temporomandibular joint—a new concept, *Int J Oral Maxillofac Surg* 31:94–99, 2002.
26. Kubota E, Imamura H, Kubota T, et al.: Interleukin 1β and stromelysin (MMP3) activity of synovial fluid as possible markers of osteoarthritis in the temporomandibular joint, *J Oral Maxillofac Surg* 55:20–27, 1997.
27. Gruber BL, Sorbi D, French DL, et al.: Markedly elevated serum MMP-9 (gelatinase B) levels in rheumatoid arthritis: a potentially useful laboratory marker, *Clin Immunol Immunopathol* 78:161, 1996.
28. Kubota E, Kubota T, Matsumoto J, et al.: Synovial fluid cytokines and proteinases as markers of temporomandibular joint disease, *J Oral Maxillofac Surg* 56:192–198, 1998.
29. Murakami KI, Shibata T, Kubota E, et al.: Intra-articular levels of prostaglandin E2, hyaluronic acid, and chondroitin-4 and -6 sulfates in the temporomandibular joint synovial fluid of patients with internal derangement, *J Oral Maxillofac Surg* 56(2):199–203, 1998.
30. Lai WF, Tsai YH, Su SJ, et al.: Histological analysis of regeneration of temporomandibular joint discs in rabbits by using a reconstituted collagen template, *Int J Oral Maxillofac Surg* 34(3):311–320, 2005.
31. Kelly MA, Moskowitz RW, Lieberman JR: Hyaluron therapy: looking toward the future, *Am J Orthopedics* 33(Suppl 2):23–28, 2004.
32. Almarza AJ, Athanasiou KA: Seeding techniques and scaffolding choice for tissue engineering of the temporomandibular joint disk, *Tissue Engineering* 10(11-12):1787–1795, 2004.
33. Gu Z, Shibata T, Cao Z, et al.: Chondrocyte apoptosis in temporomandibular joints with disc displacement, *J Oral Maxillofac Surg* 60(9):1026–1031, 2002, discussion 1031.
34. Dimitroulis G, Dolwick MF, Gremillion HA: Temporomandibular disorders. 3. Surgical treatment, *Aust Dent J* 41:16–20, 1996.
35. Dolwick MF, Dimitroulis G: Is there a role for temporomandibular joint surgery? *Br J Oral Maxillofac Surg* 32:307–313, 1994.
36. American Association of Oral & Maxillofacial Surgeons: *1984 criteria for TMJ meniscus surgery*, Chicago, 1984, AAOMS.
37. American Association of Oral & Maxillofacial Surgeons: *1990 standards and criteria of surgical procedures*, Chicago, 1990, AAOMS.
38. Long X, Li X, Chen Y, et al.: Preservation of the disc for treatment of traumatic temporomandibular joint ankylosis, *J Oral Maxillofac Surg* 63(7):897–902, 2005.
39. Kaban LB, Perrott DH, Fisher K: A protocol for management of temporomandibular ankylosis, *J Oral Maxillofac Surg* 48:1145, 1990.
40. Chossegros C, Guyot L, Cheynet F, et al.: Comparison of different materials for interpositional arthroplasty in the treatment of temporomandibular joint ankylosis; long-term follow-up in 25 cases, *Br J Oral Maxillofac Surg* 35:157–160, 1997.
41. Matteson SR, Proffit WR, Terry BC, et al.: Bone scanning with technetium phosphate to assess condylar hyperplasia, *Oral Surg Oral Med Oral Path* 60:356, 1985.
42. Forsell H, Happonen RP, Forsell K, et al.: Osteochondroma of the mandibular condyle. Report of a case and review of the literature, *Br J Oral Maxillofac Surg* 23:183–189, 1985.
43. Hecker KJ, Freeman NS, Quick CA: Adenocarcinoma metastatic to the temporomandibular joint, *J Oral Maxillofac Surg* 43:629, 1985.
44. Hartman GL, Robertson GR, Sugg WE, et al.: Metastatic carcinoma of the mandibular condyle, *J Oral Surg* 31:716–719, 1973.
45. Holmlund AB: Surgery for TMJ internal derangement. Evaluation of treatment and criteria for success, *Int J Oral Maxillofac Surg* 22:75–77, 1993.
46. Goss AN: Toward an international consensus on temporomandibular joint surgery. Report of the Second International Consensus Meeting, April 1992, Buenos Aires, Argentina, *Int J Oral Maxillofac Surg* 22:78–81, 1993.
47. Dimitroulis G: A review of 56 cases of chronic closed lock treated with temporomandibular joint arthroscopy, *J Oral Maxillofac Surg* 60:519–524, 2002.
48. Nitzan DW, Samson B, Better H: Long-term outcome of arthrocentesis for sudden-onset, persistent, severe closed lock of the temporomandibular joint, *J Oral & Maxillofac Surg* 55:151–157, 1997.
49. Dimitroulis G, Dolwick MF, Martinez A: Temporomandibular joint arthrocentesis and lavage for the treatment of closed lock: a follow-up study, *Br J Oral Maxillofac Surg* 33:23–27, 1995.
50. Clark GT, Moody DG, Sanders B: Arthroscopic treatment of temporomandibular joint locking resulting from disc derangement, *J Oral Maxillofac Surg* 49:157, 1991.
51. Nitzan DW, Dolwick MF, Heft MW: Arthroscopic lavage and lysis of the temporomandibular joint: a change in perspective, *J Oral Maxillofac Surg* 48:798–801, 1990.
52. Manzione JV, Katzberg RW, Brodsky GL, et al.: Internal derangements of the temporomandibular joint: diagnosis by direct sagittal computed tomography, *Radiology* 150:111–115, 1984.
53. Westesson P-L, Katzberg RW, Tallents RH, et al.: CT and MR of the temporomandibular joint: comparison with autopsy specimens, *Am J Roentgenol* 148:1165–1171, 1987.
54. Schellhas KP: Imaging of the temporomandibular joint, *Oral Maxillofac Surg Clinics North Am* 1:13–26, 1989.
55. Kozeniauskas JJ, Ralph WJ: Bilateral arthrographic evaluation of unilateral temporomandibular joint and dysfunction, *J Prosth Dent* 60:98–105, 1988.
56. Kircos LT, Ortendahl DA, Mark AS, et al.: Magnetic resonance imaging of the TMJ disc in asymptomatic volunteers, *J Oral Maxillofac Surg* 45:397–401, 1987.
57. Hatala MP, Westesson P-L, Tollents RH, Katzbert RW: TMJ disc displacement in asymptomatic volunteers detected by MR imaging, *J Dent Res* 70:278, 1991.
58. Nitzan DW, Dolwick MF: An alternative explanation for the genesis of closed-lock symptoms in the internal derangement process, *J Oral Maxillofac Surg* 49:810–815, 1991.

59. Liedberg J, Westesson P-L: Sideways position of the temporomandibular joint disk: coronal cryosectioning of fresh autopsy specimens, *Oral Surg Oral Med Oral Path* 66:644–649, 1988.
60. Katzberg RW, Westesson P-L, Tallents RH, et al.: Temporomandibular joint: MR assessment of rotational and sideways disk displacements, *Radiology* 169:741–748, 1988.
61. Wagner JD, Mosby EL: Assessment of Proplast-Teflon disc replacements, *J Oral Maxillofac Surg* 48:1140–1144, 1990.
62. Westesson P-L, Eriksson L, Lindstrom C: Destructive lesions of the mandibular condyle following diskectomy with temporary silicone implant, *J Oral Maxillofac Surg* 47:1290–1293, 1989.
63. Ryan DE: Alloplastic implants in the temporomandibular joint, *Oral Maxillofac Surg Clin N Am* 1:427–441, 1989.
64. Westesson P-L, Eriksson L, Lindstrom C: Destructive lesions of the mandibular condyle following discectomy with temporary silastic implant, *Oral Surg Oral Med Oral Path* 63:143–150, 1987.
65. Heffez L, Mafee MF, Rosenberg H, et al.: CT evaluation of temporomandibular disc replacement with a Proplast-Teflon laminate, *J Oral Maxillofac Surg* 45:657–660, 1987.
66. Dolwick MF, Aufdemorte TB: Silicone-induced foreign body reaction and lymphadenopathy after temporomandibular joint arthroplasty, *Oral Surg Oral Med Oral Path* 59:449–452, 1985.
67. Blair VP: Operative treatment of ankylosis of the mandible, *South Surg Gynecol* 26:436, 1913.
68. Rongetti JR: Meniscectomy—a new approach to the temporomandibular joint, *Arch Otolaryngol* 60:566–572, 1954.
69. Alexander RW, James RB: Postauricular approach for surgery of the temporomandibular articulation, *J Oral Surg* 33:346–350, 1985.
70. Politi M, Toro C, Cian R, et al.: The deep subfascial approach to the temporomandibular joint, *J Oral Maxillofac Surg* 62(9):1097–1102, 2004.
71. McCarty WL, Farrar WB: Surgery for internal derangement of the temporomandibular joint, *J Prosthet Dent* 42:191–196, 1979.
72. Hall MB: Meniscectomy of the displaced temporomandibular meniscus without violating the inferior joint space, *J Oral Maxillofac Surg* 42:788–792, 1984.
73. Dolwick MF, Sanders B: TMJ internal derangement and arthrosis. In *Surgical atlas*, St. Louis, 1985, Mosby.
74. Dolwick MF: Disc preservation surgery for the treatment of internal derangement of the temporomandibular joints, *J Oral Maxillofac Surg* 59:1047–1050, 2001.
75. Zeitler DL, Porter BT: A retrospective study comparing arthroscopic surgery with arthrotomy and disc repositioning. In Clark GT, Sanders B, Bertolami CN, editors: *Advances in diagnostic and surgical arthroscopy*, Philadelphia, 1993, Sanders.
76. Kerstens HCJ, Tuinzing DB, Van Der Kwast WAM: Eminectomy and discoplasty for correction of the displaced temporomandibular joint disc, *J Oral Maxillofac Surg* 47:150–152, 1989.
77. Weinberg S, Cousens C: Meniscocondylar plication: a modified operation for surgical repositioning of the ectopic temporomandibular joint meniscus, *J Oral Surg* 63:393–402, 1987.
78. Mercuri LG, Campbell HL, Shanaskin RC: Intraarticular meniscus dysfunction surgery—a preliminary report, *Oral Surg Oral Med Oral Path* 54:613–621, 1982.
79. Baldwin AJ, Cooper JC: Eminectomy and plication of posterior disc attachment following arthroscopy for temporomandibular joint internal derangement, *J Cranio-Maxillofac Surg* 32(6):354–359, 2004.
80. Kondoh T, Hamada Y, Kamei K, et al.: Simple disc reshaping surgery for internal derangement of the temporomandibular joint: 5 year follow-up results, *J Oral Maxillofac Surg* 61(1):41–48, 2003, discussion 48.
81. Eriksson L, Westesson P-L: Diskectomy in the treatment of anterior disk displacement of the temporomandibular joint. A clinical and radiological one-year follow-up study, *J Prosthet Dent* 55:106–116, 1986.
82. Hall HD: Meniscectomy for damaged discs of the temporomandibular joint, *South Med J* 78:569–572, 1985.
83. Eriksson L, Westesson P-L: Temporomandibular joint discectomy, *Oral Surg Oral Med Oral Path* 74:259–272, 1992.
84. Hall HD, Link J: Diskectomy alone and with ear cartilage in joint reconstruction, *Oral Maxillofac Surg Clin N Am* 1:329–340, 1989.
85. Eriksson L, Westesson P-L: Long-term evaluation of meniscectomy of the temporomandibular joint, *J Oral Maxillofac Surg* 43:263–266, 1985.
86. Silver CML: Long-term results of meniscectomy of the temporomandibular joint, *J Craniomandib Pract* 3:46–49, 1984.
87. Takaku S, Toyoda T: Long-term evaluation of discectomy of the temporomandibular joint, *J Oral Maxillofac Surg* 52:722–726, 1994.
88. Widmark G, Grondahl H, Kahnberg K, Haraldson T: Radiographic morphology in the temporomandibular joint after discectomy, *Cranio* 14:37–41, 1996.
89. Takaku S, Sano T, Yoshida M: Long-term magnetic resonance imaging after temporomandibular joint discectomy without replacement, *J Oral Maxillofac Surg* 58:739–745, 2000.
90. Agerberg C, Lundberg M: Changes in the temporomandibular joint after surgical treatment. A radiologic follow-up study, *Oral Surg Oral Med Oral Path* 32:865–875, 1971.
91. Hall HD: The role of discectomy for treating internal derangements of the temporomandibular joint, *Oral Maxillofac Surg Clin North Am* 6:287–294, 1994.
92. Hansson LG, Hansson T, Peterson A: A comparison between clinical and radiological findings in 259 temporomandibular joint patients, *J Prosthet Dent* 50:89–94, 1983.
93. Tucker MR, Kennedy MC, Jacoway JR: Autogenous auricular cartilage implantation following diskectomy in the primate temporomandibular joint, *J Oral Maxillofac Surg* 48:38–44, 1990.
94. Yih W, Zysset M, Merrill RG: Histologic study of the fate of autogenous auricular cartilage grafts in the human temporomandibular joint, *J Oral Maxillofac Surg* 50:964–967, 1992, discussion 968.
95. Thyne GM, Yoon JH, Luyk NH, Goss AN: Temporalis muscle as a disc replacement in the temporomandibular joint of sheep, *J Oral Maxillofac Surg* 50:979–982, 1992.
96. McKenna SJ: Discectomy for the treatment of internal derangement of the temporomandibular joint, *J Oral Maxillofac Surg* 59:1051–1056, 2001.
97. Pogrel MA, Kaban LB: The role of a temporalis fascia and muscle flap in temporomandibular joint surgery, *J Oral Maxillofac Surg* 48:14–19, 1990.
98. Waite PD, Matukas VJ: Use of auricular cartilage as a disc replacement, *Oral Maxillofac Surg Clin N Am* 6:349–354, 1994.
99. Meyer RA: The autogenous dermal graft in temporomandibular joint disc surgery, *J Oral Maxillofac Surg* 46:948–954, 1988.
100. Dimitroulis G: The use of dermis grafts after discectomy for internal derangement of the temporomandibular joint, *J Oral Maxillofac Surg* 63(2):173–178, 2005.

101. Umeda H, Kaban L, Pogrel M, Stern M: Long-term viability of the temporalis muscle/fascia flap used for temporomandibular joint reconstruction, *J Oral Maxillofac Surg* 51:530–533, 1993.
102. Albert T, Merrill R: Temporalis myofascial flap, *Oral Maxillofac Surg Clin N Am* 1(2):341–349, 1989.
103. Reference deleted in page proofs.
104. Matukas VJ, Lachner J: The use of autogenous auricular cartilage for temporomandibular joint disk replacement: a preliminary report, *J Oral Maxillofac Surg* 48:348–353, 1990.
105. Tucker M, Jacoway R, White R: Autogenous dermal grafts for repair of temporomandibular joint disc perforations, *J Oral Maxillofac Surg* 44:781–789, 1986.
106. Solberg WK, Woo MW, Houston JB: Prevalence of mandibular dysfunction in young adults, *J Am Dent Assoc* 98(1):25–34, 1979.
107. Gray RJM, Davies SJ, Quayle AA: *Temporomandibular disorders: a clinical approach*, London, 1995, British Dental Association.
108. Lai WF, Bowley J, Burch JG: Evaluation of shear stress of the human temporomandibular joint disc, *J Orofac Pain* 12(2):153–159, 1998.
109. Farrar WB, McCarty Jr WL: The TMJ dilemma, *J Ala Dent Assoc* 63(1):19–26, 1979.
110. Almarza AJ, Athanasiou KA: Effects of initial cell seeding density for the tissue engineering of the temporomandibular joint disc, *Ann Biomed Eng* 33(7):943–950, 2005.
111. Almarza AJ, Athanasiou KA: Evaluation of three growth factors in combinations of two for TMJ disc tissue engineering, *Arch Oral Biol* 51(3):215–221, 2005.
112. Johns DE, Athanasiou KA: Improving culture conditions for temporomandibular joint disc tissue engineering, *Cells Tissues Organs* 185(4):246–257, 2007.
113. Johns DE, Athanasiou KA: Growth factor effects on costal chondrocytes for tissue engineering fibrocartilage, *Cell Tissue Res* 333(3):439–447, 2008.
114. Johns DE, Wong ME, Athanasiou KA: Clinically relevant cell sources for TMJ disc engineering, *J Dent Res* 87(6):548–552, 2008.
115. Brown BN, et al.: Extracellular matrix as an inductive template for temporomandibular joint meniscus reconstruction: a pilot study, *J Oral Maxillofac Surg* 69(12):e488–e505, 2011.
116. Brown BN, et al.: Inductive, scaffold-based, regenerative medicine approach to reconstruction of the temporomandibular joint disk, *J Oral Maxillofac Surg* 70(11):2656–2668, 2012.
117. Brown BN, et al.: Macrophage phenotype and remodeling outcomes in response to biologic scaffolds with and without a cellular component, *Biomaterials* 30(8):1482–1491, 2009.
118. Valentin JE, et al.: Macrophage participation in the degradation and remodeling of extracellular matrix scaffolds, *Tissue Eng Part A* 15(7):1687–1694, 2009.
119. Badylak SF, et al.: Macrophage phenotype as a determinant of biologic scaffold remodeling, *Tissue Eng Part A* 14(11):1835–1842, 2008.
120. Mantovani A, et al.: The chemokine system in diverse forms of macrophage activation and polarization, *Trends Immunol* 25(12):677–686, 2004.
121. Crisan M, et al.: A perivascular origin for mesenchymal stem cells in multiple human organs, *Cell Stem Cell* 3(3):301–313, 2008.
122. Turner NJ, et al.: Quantitative multispectral imaging of Herovici's polychrome for the assessment of collagen content and tissue remodelling, *J Tissue Eng Regen Med* 7(2):139–148, 2013.
123. Berg R: Contribution to the applied and topographical anatomy of the temporomandibular joint of some domestic mammals with particular reference to the partial resp. total resection of the articular disc, *Folia Morphol (Praha)* 21(2):202–204, 1973.
124. Bermejo A, Gonzalez O, Gonzalez JM: The pig as an animal model for experimentation on the temporomandibular articular complex, *Oral Surg Oral Med Oral Pathol* 75(1):18–23, 1993.
125. Ström D, et al.: Gross anatomy of the mandibular joint and masticatory muscles in the domestic pig *(Sus scrofa)*, *Arch Oral Biol* 31(11):763–768, 1986.
126. Badylak SF, et al.: Macrophage phenotype as a determinant of biologic scaffold remodeling, *Tissue Eng Part A* 14(11):1835–1842, 2008, http://dx.doi.org/10.1089/ten.tea.2007.0264.
127. Banks P, MacKenzie I: Condylotomy. A clinical and experimental appraisal of a surgical technique, *J Maxillofac Surg* 3:170–181, 1975.
128. Hall HD, Nickerson JW, McKenna SJ: Modified condylotomy for treatment of the painful temporomandibular joint with a reducing disc, *J Oral Maxillofac Surg* 51:133–142, 1993.
129. Campbell W: Clinical radiological investigations of the mandibular joints, *Br J Radiol* 38:401–421, 1965.
130. Nickerson Jr JW, Veaco NS: Condylotomy in surgery of the temporomandibular joint, *Oral Maxillofac Surg Clin N Am* 1:303–327, 1989.
131. Hall HD, Nickerson JW, McKenna SJ: Modified condylotomy for treatment of the painful temporomandibular joint with a reducing disc, *J Oral Maxillofac Surg* 51:133–142, 1993.
132. Hall HD: Modification of the modified condylotomy, *J Oral Maxillofac Surg* 54:548–551, 1996.
133. McKenna S: Modified mandibular condylotomy, *Oral Maxillofac Surg Clin N Am* 18(3):369–381, 2006.
134. Upton LG: The case for mandibular condylotomy in the treatment of the painful, deranged temporomandibular joint, *J Oral Maxillofac Surg* 55:64–69, 1997.
135. McKenna S, Cornella F, Gibbs S: Long-term follow-up of modified condylotomy for internal derangement of the temporomandibular joint, *Oral Surg Oral Med Oral Path Oral Rad Endo* 81(5):509–515, 1996.
136. Vallerand WP, Dolwick MF: Complications of temporomandibular joint surgery, *Oral Maxillofac Clin N Am* 2:481–488, 1990.
137. Oh DW, Kim KS, Lee GW: The effects of physiotherapy on post-temporomandibular joint surgery patients, *J Oral Rehab* 29(5):441–446, 2002.
138. Dolwick MF, Dimitroulis G: A re-evaluation of the importance of disc position in temporomandibular disorder, *Aust Dent J* 41:184–187, 1996.
139. Dolwick MF: Intra-articular disc displacement. Part 1. Its questionable role in temporomandibular joint pathology, *J Oral Maxillofac Surg* 53:1069, 1995.
140. Dolwick MF: Disc preservation surgery for the treatment of internal derangement of the temporomandibular joint, *J Oral Maxillofac Surg* 59:1047–1050, 2001.

43

Temporomandibular Joint Replacement

LOUIS G. MERCURI

Introduction

Temporomandibular joint (TMJ) total joint replacement (TJR) presents unique problems because of the integral and complex role the TMJ plays in establishing and maintaining proper form and function within the stomatognathic system. The TMJ not only acts as a secondary growth center for the mandible in prepuberty, but its integrity is vital to the functions of mastication, speech, airway support, and deglutition in both children and adults.

Prior to the mid-1980s, the primary indications for TMJ TJR were the management of developmental maxillofacial deformities, ankylosis, severe inflammatory joint disease, or TMJ replacement after ablative tumor surgery or trauma.

Thereafter, along with these form and function challenges, there arose a group of patients requiring TMJ TJR who had previously undergone multiple failed TMJ surgical procedures. Many of these patients' joints were anatomically distorted and functionless secondary to the failure of interpositional materials such as Proplast-Teflon (Vitek, Houston, TX) and/or Silastic (Dow-Corning-Wright, Arlington, TX) (Figure 43-1).

Considering not only function and form, but also a patient's neurologic and psychological issues, surgeons developed physiologically reasonable, biologically rational, technically achievable outcome objectives based on decades of orthopedic joint replacement experience.

The following TMJ replacement goals were developed:[1]

1. Improvement of mandibular function and form
2. Reduction of further suffering and disability
3. Containment of excessive treatment and cost
4. Prevention of further morbidity

End-stage disease and/or pathology with accompanying anatomic form and physiologic function distortions dictate the need for TMJ TJR. Due to the complex nature of its anatomic and masticatory muscle functional relationships, it is unreasonable to expect that a TMJ TJR will return a patient to their premorbid mandibular functional status. Therefore, as with orthopedic joint replacements, there will always be some functional disability after TMJ replacement.

Further, in multiply operated, anatomically distorted patients, chronic neuropathic and centrally mediated pain often play a major role in their disability. Therefore it is important that both the surgeon and the patient understand that the primary goal of TMJ replacement is the restoration of mandibular function and form, and that any subjective pain relief achieved must only be considered as a secondary benefit.[2]

Historic Perspective of TMJ Replacement

Autogenous TMJ Replacement

Bone—Vascularized and Non-vascularized

Earliest TMJ replacement involved the use of autogenous tissues. In 1909 Bardenheuer[3] performed a mandibular condyle replacement with the fourth metatarsal. This technique was also reported in 1920 by Gillies.[4] The use of an autogenous metatarsal head to reconstruct the mandibular condyle was also reported by Dingman[5] in 1964, Glahn[6] in 1967, and Spiessl[7] in 1972. Use of a non-vascularized metatarsophalangeal joint to correct a facial deformity was reported by Entin[8] in 1958 (Figure 43-2). Datillo[9] in 1986, and Dierks[10] in 2000 reported the use of a vascularized metatarsophalangeal joint to replace the TMJ.

TMJ replacement has also been performed using vascularized rib[11,12] and iliac crest.[13] Other autogenous tissues such as fibula[14,15] and iliac bone free grafts,[16-20] clavicle, and sternoclavicular joint have been used.[21-23] However, none of these reports provided long-term follow-up.

The non-vascularized costochondral free graft has been the most frequently recommended autogenous bone for TMJ replacement because of its conjectured ease of adaptation to the recipient site, its ostensibly gross anatomic similarity to the mandibular condyle, its low morbidity at the donor site, and its theoretic growth potential in juveniles[24-29] (Figure 43-3).



• **Figure 43-1** Anatomically distorted and functionless left TMJ attributable to Proplast-Teflon foreign body giant cell reaction. Note the osteolysis of the temporal zygomatic arch, articular eminence, glenoid fossa, and mandibular condyle.

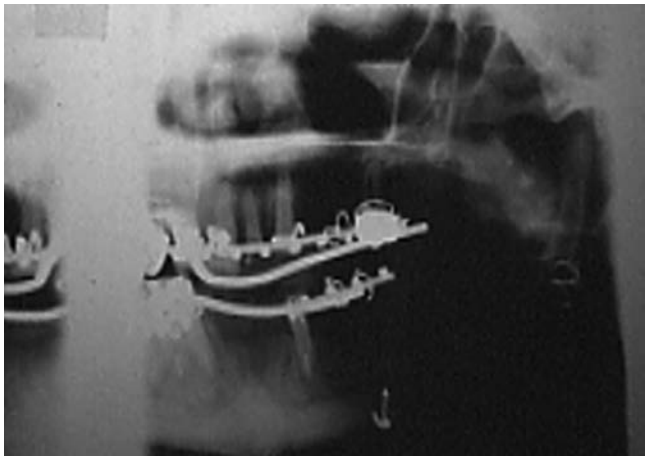

• **Figure 43-2** Non-vascularized fifth metatarsal graft reconstruction of the left TMJ.

Tissue—Vascularized and Non-vascularized

A number of different autogenous tissues—temporalis fascia,[30-34] masseter, temporalis muscle flaps,[35-54] dermal grafts,[55-59] and fascia lata[60,61]—have been advocated as a replacement for the TMJ articular disc. However, the vascularized local temporalis muscle flap remains the most popular.

Vascularized Temporalis Muscle Flap

The advantages of the temporalis muscle flap are its proximity to the TMJ and its reliable blood supply.[51,52,54] Feinberg and Larsen[47] stated that one of the most important roles of the temporalis muscle flap is the maintenance of TMJ functional movements. These authors state that since the flap is attached to the coronoid process, when the mandible translates, the movement of the mandible pulls the muscle flap in an anterior direction, simulating the natural functional movements of the articular disc (Figure 43-4). Investigators reported that follow-up studies on patients with temporalis muscle replacement discovered the presence of viable muscle tissue within the joint.[51-53]

Tong and Tideman[62] reported the re-formation of a disc-like interpositional structure, after 18 months, with use of the pedicled temporalis muscle flap after TMJ discectomy in four Rhesus monkeys with osteoarthritis. They also reported a milder degree of osteoarthritis was observed histologically in three of the four monkey joints where the muscle flaps survived.

Henry and Wolford[63] offered the following contraindications for the use of the temporalis muscle/fascia graft: failed Proplast-Teflon (Vitek, Houston, TX) or Silastic (Dow-Corning-Wright, Arlington, TX) with continuing foreign body giant cell reaction;[64-66] rheumatoid arthritis or other high-inflammatory connective tissue diseases;[67] progressive osteoarthritis;[67] and two or more prior surgeries.[67,68]

Auricular Cartilage

Ioannides and Maltha[69] reported use of autogenous auricular cartilage as a TMJ disc replacement in 1988. However, Takatsuka et al.[70] studied the use of auricular cartilage after discectomy in the rabbit TMJ. On histologic examination, these authors found fibrous adhesion of the grafted auricular cartilage to the condyle and the presence of a fibrous layer containing fragmented cartilage at the articular surface. They concluded that auricular cartilage did not appear to be an ideal material for disc replacement. Other investigators reported similar findings.[71,72]

In the past, autogenous tissue has been called the "gold standard" for management of primary, uncompromised TMJ replacement. However, because of the potential morbidity associated with harvest of autogenous tissues, the inability of these tissues to survive either the transplantation process or the functional demands of the forces applied to them, and for the reasons discussed below, there arose the need for the development and use of alloplastic materials to replace the anatomically and functionally impaired TMJ. This is a similar course followed by orthopedic surgery in replacement of other end-stage diseased body joints.

Alloplastic TMJ Replacement

John Murray Carnochan,[73] a New York surgeon, was credited with the idea of interposing alloplastic material between the surfaces of diseased, excised joints in an attempt to prevent ankylosis and promote function. In 1840 he reported an attempt to mobilize a patient's ankylosed TMJ by placing a small block of wood between the raw bony surfaces of the residual mandible after gap arthroplasty.[73]

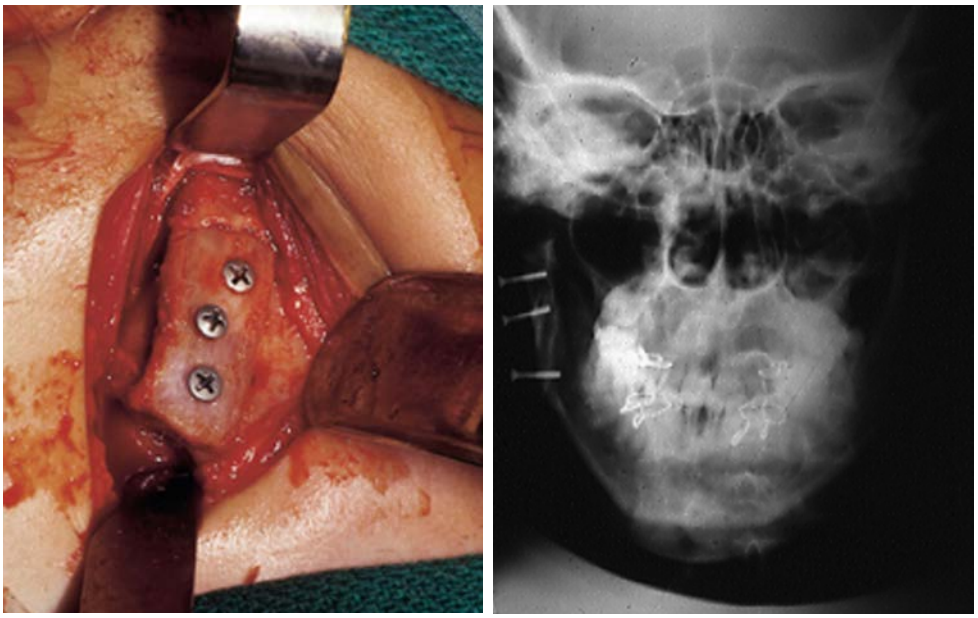

• **Figure 43-3** Non-vascularized costochondral graft reconstruction of the right TMJ.

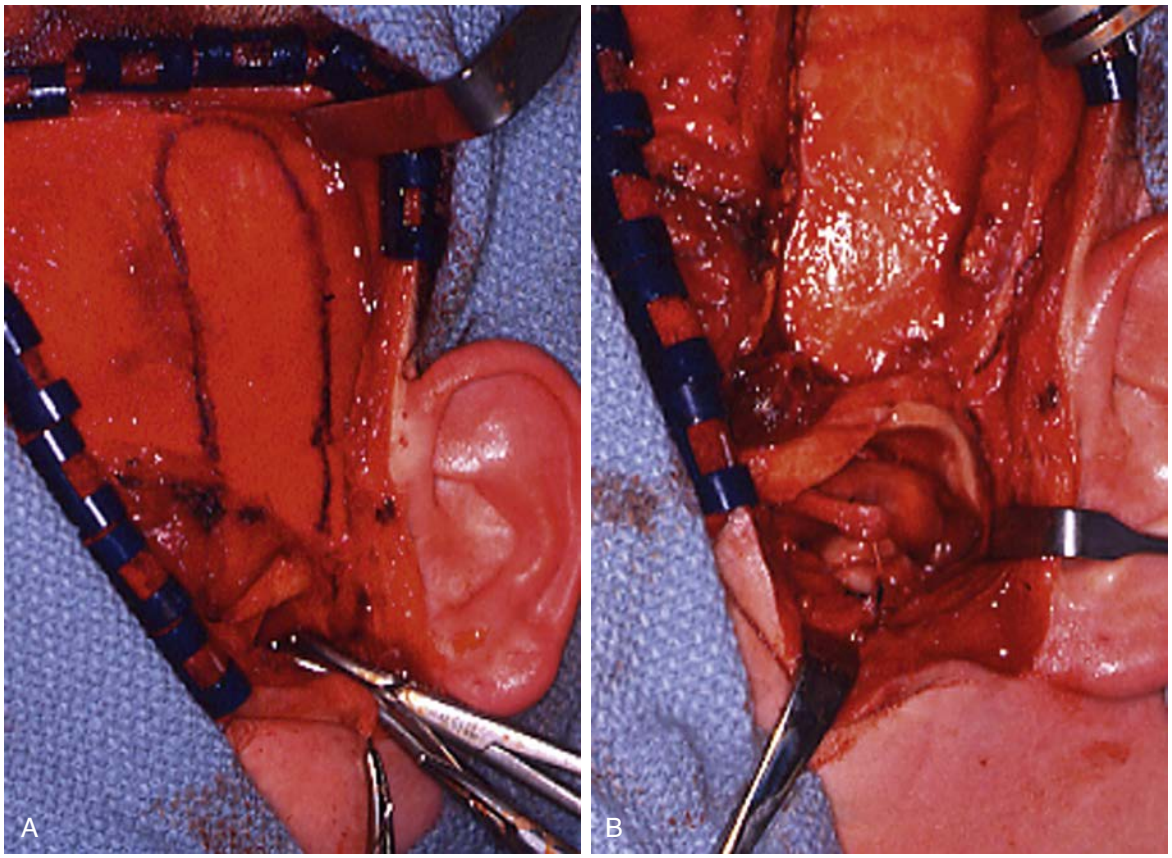

• **Figure 43-4** Temporalis muscle flap. **A,** Outline of flap. **B,** Flap fed under temporal process of zygoma and into the glenoid fossa.

Tracing the use of alloplastic materials for the management of severe anatomic end-stage TMJ disease and associated mandibular dysfunction, ankylosis was the primary problem that led patients to surgery. Every new material developed was used in an attempt to manage any joint ankylosis, including the TMJ.[74-133]

In 1960 Sir John Charnley reported the development of a total alloplastic prosthetic hip replacement system composed of a metal-backed polyethylene acetabular cup articulating with a metal femoral head, attached to a metal femoral shaft which was cemented into place with polymethylmethacrylate.[134] Modifications of Charnley's device have become

the "gold standard" for hip, knee, and shoulder total joint replacement devices in orthopedic surgery.[135]

In 1963, 1964, and 1970, Christensen[84-86] reported the use of a thin cast vitallium fossa-eminence prosthesis for management of TMJ ankylosis (Figure 43-5). He later added a cast vitallium ramus-condyle with a polymethylmethacrylate head to create a total joint device (Figure 43-6).

Between 1974 and 1985, a number of reports were published involving the use of partial and total alloplastic TMJ replacement devices. These were typically case reports with small numbers of patients for whom the diagnosis was ankylosis or reconstruction after ablative malignant neoplasia surgery.[95-99,106-123] Of these, the two most significant reports were those by Kiehn[111,112] and Kummoona.[117]

In 1985[119] and again in 1990[120] S. Sonnenburg and M. Sonnenburg reported the use of a TMJ TJR device consisting of a cast chromium-cobalt-molybdenum ramus-condyle component articulating against an ultra–high-molecular-weight polyethylene fossa, mimicking the materials and geometry used in the design of alloplastic joint devices by orthopedic surgeons.

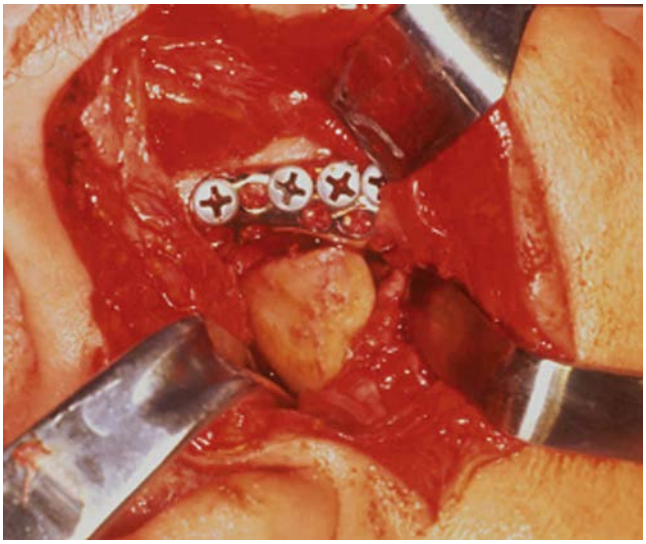

• **Figure 43-5** Alloplastic thin cast vitallium fossa-eminence device (TMJ Inc., Golden, CO), right TMJ.

Hinds, Homsy, and Kent[107] in 1974 reported the use of a Proplast-Teflon-coated vitallium ramus-condyle component for hemi-articulation reconstruction of the TMJ. Kent, in 1983, reported the use of a Dacron/Proplast-Teflon (VK-I) and later a Dacron/Proplast-Teflon/ultra–high-molecular-weight polyethylene (VK-II) fossa.[108,109] The ramus-condyle and fossa components were then used as TMJ TJR devices (Vitek, Houston, TX). In 1993 Kent et al.[110] reported a long-term follow-up study using these devices (Figure 43-7).

From 1990 to 1995, reports surfaced regarding the development and use of alloplastic partial and total TMJ replacement devices. The indications for use ranged from ankylosis to reconstruction after ablative surgery and trauma to the unsuccessfully managed, multiply operated patient.[124-130]

In 1993 Henry and Wolford[66] reported prospective results with the use of the Techmedica (Camarillo, CA; now TMJ Concepts, Ventura, CA) computer assisted designed/computer aided manufactured (CAD/CAM) TMJ TJR device used to manage end-stage TMJ disease in 26 patients followed a mean of 46 months with anatomically divergent, functionless TMJs after Proplast-Teflon exposure and failure. Wolford, Cottrell, and Henry[23] then reported in 1994 the use of the same device in 56 multiply operated TMJ patients followed for a mean of 30 months. Mercuri et al.[130] in 1995 reported the preliminary results in a prospective multicenter clinical study with the Techmedica device in 215 patients followed for a mean of 4 years. In 2004 Mercuri et al.[131] published a 10-year follow-up study; and in 2006 Edibam et al.[132] reported a 14-year follow-up study of these

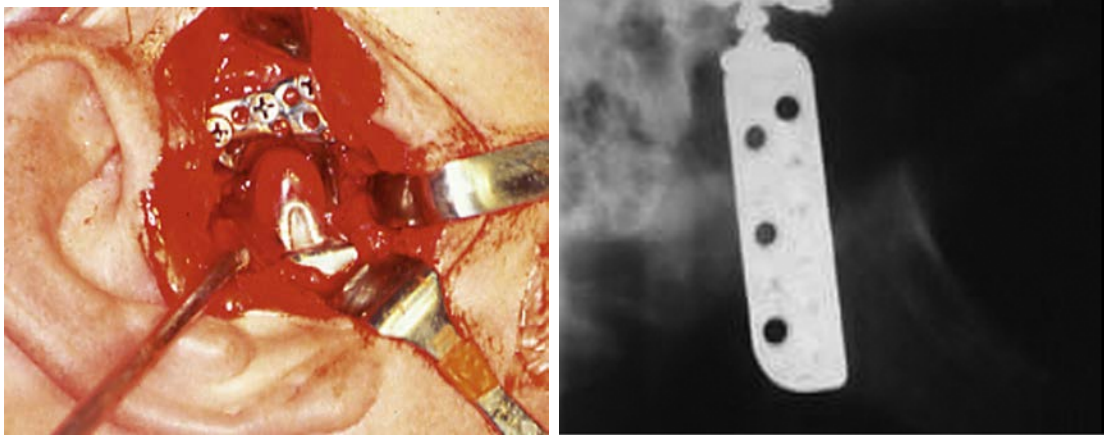

• **Figure 43-6** Cast vitallium ramus-condyle and fossa-eminence components of a total TMJ alloplastic device with polymethylmethacrylate condylar head (TMJ Inc., Golden, CO).

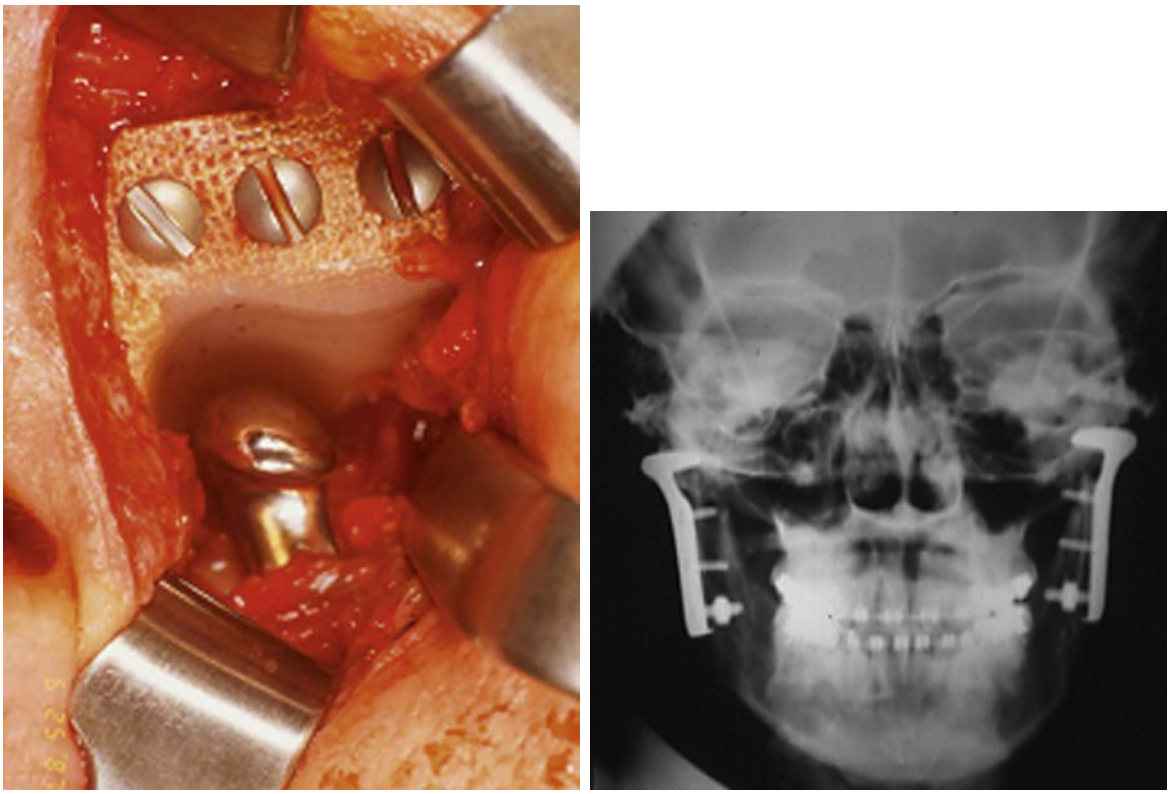

• **Figure 43-7** Cast vitallium Proplast-Teflon coated ramus-condyle and Dacron/Proplast-Teflon/ultra–high-molecular-weight polyethylene components of a total TMJ alloplastic device (Vitek, Houston, TX), right TMJ.

patients (Figure 43-8). In 2015, Wolford et al. reported a 20-year follow-up of 99 Techmedica/TMJ Concepts TMJ TJR devices. The results indicated that these devices continue to function well and patients showed sustained improvement in TMJ pain, jaw function, ability to eat solid food, and quality of life.[133,134]

In 1995 Chase et al.[87] reported retrospective results with the use of the Christensen (TMJ Inc., Golden, CO) TMJ TJR device in 21 patients followed for a mean of 2.4 years. Garrett et al.[88] reported the use of a custom modification of the standard Christensen total TMJ device employed in 20 multiply operated patients followed for a mean of 7.5 months. In 2000 Gerard and Hudson[135] reported on the use of the modified metal-on-metal Christensen TMJ device implanted in 23 patients followed for a mean of 26 months (Figure 43-9).

Wolford et al.[136] presented the first comparison of pre- and postoperative subjective and objective domains from similar groups of patients implanted with two different TMJ TJR systems: Techmedica (Camarillo, CA; now TMJ Concepts, Ventura, CA) and TMJ, Inc. TMJ TJR device (Golden, CO; now Nexus CMF, Salt Lake City, UT). These authors found statistically significant better outcomes in both domains in patients implanted with the Techmedica TMJ TJR device than the TMJ, Inc.

All implanted alloplastic devices (dental implants, orthopedic, and TMJ TJR) depend on the principle of osseointegration of their fixation components for their ultimate stability and longevity. Osseointegration implies the direct incorporation of the implant fixation into the bone without the preliminary phase of fibrous tissue in-growth. The requirements for osseointegration are

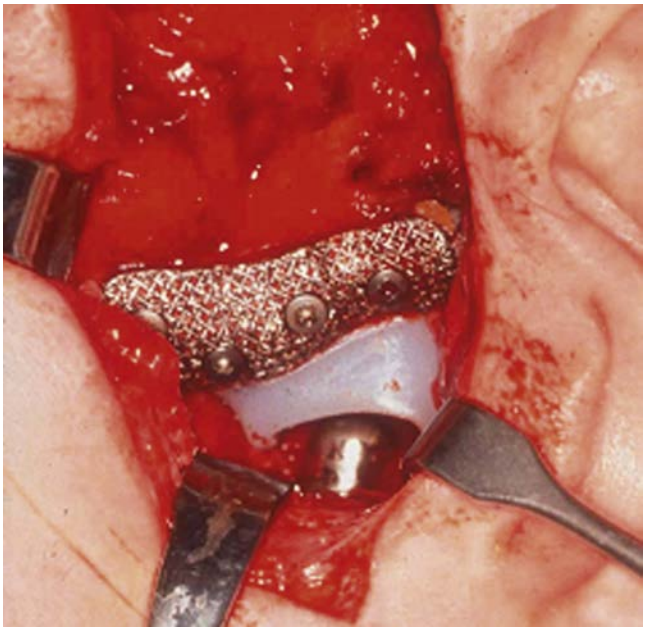

• **Figure 43-8** Wrought alloyed titanium ramus, cobalt-chrome-molybdenum condyle, and commercially pure titanium and ultra–high-molecular-weight polyethylene fossa components of a patient-fitted alloplastic total TMJ device (Techmedica, Camarillo, CA).

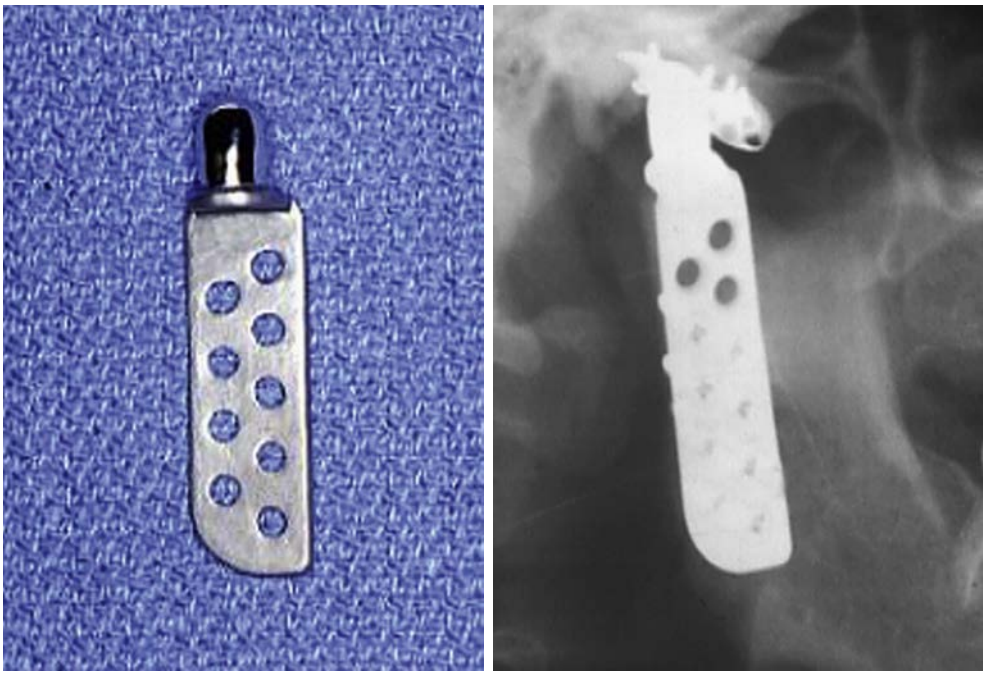

• **Figure 43-9** Cast vitallium ramus-condyle and fossa-eminence components of a total TMJ alloplastic device with vitallium condyle (TMJ Inc., Golden, CO).

essentially the same as for primary fracture healing: the transmission of forces from the implant to the bone and vice versa must occur without relative motion or without intermittent loading.[137] Therefore, just as with a dental implant, the most important principle in TMJ TJR is primary stability of the device fixation and components from the moment they are implanted.

In orthopedic surgery, TJR devices can be initially stabilized by press-fitting or, now less frequently, cementation of the components into the host bone. In the case of the TMJ, the anatomy of both the mandible and the temporal glenoid fossa does not provide for such a fixation option. Therefore screw fixation of both TMJ TJR fossa and the ramus/condyle components must be utilized to provide initial fixation and stabilization.

Compounding the normal TMJ stability issues are patients who have distorted anatomy following prior surgical and/or material failures, or the result of local or systemic pathology. This makes it extremely difficult to replace the TMJ with an "off-the-shelf" or so-called "stock" device and obtain primary component stability.

Using TMJ TJR stock devices, the surgeon may be tempted to bend, shim with bone or alloplastic cement, or remove precious host bone to make them fit. Any of these maneuvers can lead to component material fatigue or overload, promoting micromotion or breakage.

Micromotion or movement under functional loading leads to the formation of a fibrous connective tissue interface between any mobile TMJ TJR component and the host bone. This can result in early loosening of that component and potential early catastrophic or later premature device failure (Figure 43-10).

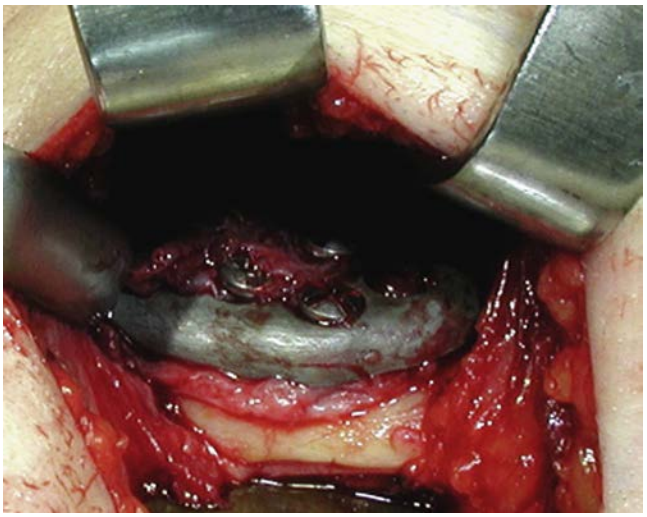

• **Figure 43-10** Failed "stock" alloplastic total TMJ device. Note loose screws and fibrous connective tissue interface between the ramus component and the host mandibular bone caused by micromotion under function, right TMJ.

Therefore a patient-fitted or custom-made TMJ TJR device appears to be the most appropriate solution for such complex cases.[130-134] Patient-fitted or custom TMJ TJR devices, designed and manufactured for each specific anatomic situation, conform to any unique anatomic condition. They require no alteration or supplementation to achieve initial implantation stability. The screw fixation of TMJ TJR custom devices secures the components with accuracy to the host bone, mitigating any chance for micromotion while maximizing the opportunity for osseointegration of the fixation screws (Figure 43-11).



• **Figure 43-11** Wrought alloyed titanium ramus, cobalt-chrome-molybdenum condyle, and commercially pure titanium and ultra–high-molecular-weight polyethylene fossa components of a patient-fitted alloplastic total TMJ device (TMJ Concepts, Ventura, CA) on a CT-generated stereolithographic model.

When calculating procedural costs, it is important not only that the price of the TMJ TJR device is considered, but also that all factors associated with its implantation should be evaluated. The major advantage of alloplastic TMJ TJR over autogenous TMJ replacement is that alloplastic TMJ TJR does not require a second surgical site. Therefore, the potential morbidity of the second surgical donor site, associated intraoperative time, and postoperative hospital expenses are all greatly decreased. Despite the fact that TMJ TJR devices can be expensive, the relative costs involved with their use overall is either equal to or ultimately less than costs for autogenous TMJ replacement procedures.

Indications For TMJ Replacement

TMJ TJR is indicated to manage any of the following conditions,[1] each of which is described in detail in the following sections:

1. Inflammatory arthritis involving the TMJ not responsive to other modalities of treatment
2. Recurrent fibrosis and/or bony ankylosis not responsive to other modalities of treatment
3. Failed tissue grafts (bone and soft tissue)
4. Failed alloplastic joint reconstruction
5. Loss of vertical mandibular height and/or occlusal relationship attributable to bony resorption, trauma, developmental abnormalities, or pathologic lesions

Inflammatory Arthritis Involving the TMJ

In 1988 Lindqvist[138] presented a clinical 10-year mean follow-up study of 16 of the 60 patients he previously reported. Of the 16, all were unilateral and 4 had the preoperative diagnosis of "severe TMJ arthritis." There was no indication whether the 4 "severe TMJ arthritis" patients suffered from low-inflammatory or high-inflammatory arthritis. However, based on the symptoms described, one might surmise that these patients had low-inflammatory TMJ arthritic disease (osteoarthritis), which demographically is more common unilaterally than is high-inflammatory TMJ arthritis. The authors concluded that their long-term clinical results utilizing autogenous costochondral TMJ grafting in adult patients were "fairly good."

Obeid,[139] in a mean 5-year (range 2 to 11 years) retrospective follow-up study, reported results with autogenous costochondral TMJ grafting in 22 patients (14 unilateral). He concluded that autogenous costochondral grafting was a successful method for replacement of the TMJ, despite a 10% infection rate and an unpredictable growth rate in the younger patients, all of whom required later corrective osteotomies.

In 1994 Perrott[140] presented a retrospective study of TMJ autogenous costochondral grafting in 26 patients, 7 growing and 19 nongrowing, with a mean follow-up of approximately 4 years. One of the non-growing patients had a diagnosis of "autoimmune arthritis" (high-inflammatory arthritis) and two others "DJD" (degenerative joint disease, that is, osteoarthritis). When reviewing the follow-up data, the "autoimmune arthritis" patient demonstrated on radiographic measurement significant bilateral loss of posterior mandibular vertical dimension, and the only incidence of a decrease in maximum interincisal opening (MIO). However, follow-up data for the two "DJD" patients revealed that their radiographic measurements and MIO corresponded with the other nonarthritic pre-reconstruction diagnoses. These authors concluded that their results indicated that costochondral grafting may be used to successfully replace the TMJ.

MacIntosh[141-143] discussed a rationale and provided clinical examples for the use of autogenous costochondral grafting in the management of the functional and esthetic consequences of TMJ osteoarthritis, rheumatoid arthritis, and juvenile arthritis, but provided no clinical data upon which to evaluate his clinical results. He advocated disc preservation in early-stage high-inflammatory arthritic disease and two-stage autogenous temporalis flap and autogenous costochondral grafting in late-stage high-inflammatory TMJ arthritic disease.[142] MacIntosh[142] stated, "Absolute guidelines for determining the appropriate time to operate on the rheumatoid arthritis patient do not exist. The author has found a quiescent period of 2 years, during which the number of affected body articulations remain stable (although not normal), and imaging of the temporomandibular joint and status of jaw position-occlusion remain unchanged, to offer reasonable expectations for postsurgical stability." However, again, no data were provided to support this observation or his management recommendations.

Frietas et al.[144] reported 12 arthritic, adult patients (24 joints) requiring TMJ TJR. Six were managed utilizing autogenous sternoclavicular or costochondral grafts, and six with TMJ TJR devices. These groups were followed for a

mean of 48.8 months and 58.5 months respectively. The authors reported that based on the study criteria, the TMJ TJR device patients demonstrated statistically significantly better subjective and objective domain outcomes than did those replaced with autogenous bone. In light of these results, the authors concluded that TMJ TJR devices were more appropriate for the management of patients with end-stage low- or high-inflammatory arthritic disease. TMJ TJR avoided the need for another operative site and its potential morbidity, decreased the operating room time, and allowed for simultaneous mandibular advancement, all with predictable long-term results and stability.[145]

Troulis et al.[146] studied 10 patients (17 joints) followed a mean of 17 months (range 8 to 38 months) who underwent endoscopic condylectomy and autogenous costochondral grafting. They reported satisfactory clinical results with low morbidity over the short period of this initial study and stated they would be pursuing long-term follow-up studies. To date neither longer follow-up nor any further studies have been reported.

Saeed and Kent[147] retrospectively reviewed 76 TMJ costochondral grafts (57 patients) with a mean follow-up of 53 months (range 24 to 161 months). Nine patients (three with ankylosis and six without ankylosis) had a preoperative diagnosis of arthritis. They never stated whether it was a low-inflammatory or a high-inflammatory arthritic condition. They concluded that in patients with no previous TMJ surgery, arthritic disease, or congenital deformity, the costochondral graft performed well. However, a preoperative diagnosis of ankylosis was associated with a high complication rate, suggesting caution when using the autogenous costochondral grafts in ankylosis patients.

Neither orthopedic textbooks nor journal articles published recently discuss the use of autogenous bone in the replacement of any joint in the adult patient affected by either end-stage low- or high-inflammatory arthritic disease. Alloplastic total joint replacement is the recommended management modality when orthopedic joint replacement is required in such cases[148,149] (Figure 43-12).

Other high-inflammatory arthritic conditions affect both the upper and the lower compartment of the TMJ. This may account for the poor performance of costochondral grafting resulting in ankylosis often experienced in these cases.

The role of TMJ TJR in the management of juvenile idiopathic arthritis (JIA) has not been studied.[150] Despite the many clinically successful applications of the costochondral graft, its use in children has been associated with excessive cartilaginous growth, resulting in malocclusion and facial deformity.[155-158]

Peltomäki,[159] in the marmoset, and Ellis,[160] in the monkey, studied the growth of the mandible after costochondral grafting with emphasis on the amount of cartilage included in the graft. Peltomäki found that depending on the amount of cartilage in the unilateral costochondral graft, the mandible shifted toward the nonoperated side. This occurred during the entire period of growth, which the authors concluded indicated a strong hormonal influence.

Ellis compared the use of sternoclavicular grafts to costochondral grafts and concluded that both behaved similarly with regard to growth/over-growth in the monkey. Ellis suggested that in growing patients, maintenance of biomechanical architecture and reasonably normal function may be more important than the nature of the autogenous graft used for condylar replacement. Further, Ellis recommended

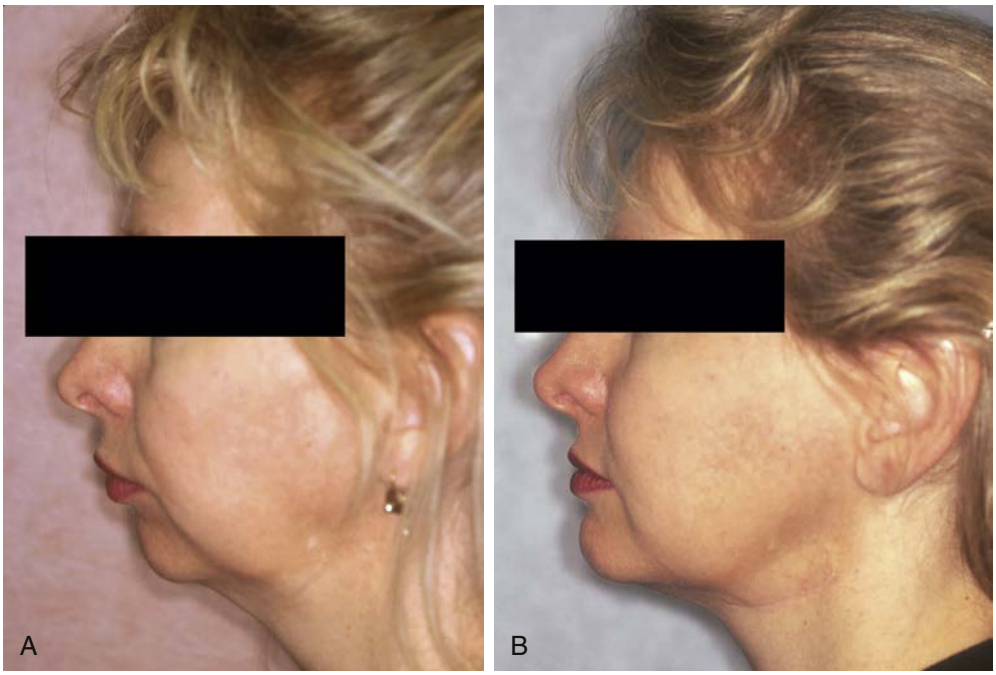

• **Figure 43-12** Rheumatoid arthritis. Bilateral patient-fitted alloplastic TMJ reconstruction. **A,** Preoperative. **B,** Postoperative.

retaining as little cartilage as possible to prevent over-growth when replacing the mandibular condyle with a costochondral graft in growing individuals.

In light of the data supporting the reports by Frietas,[144] Mehra,[145] Saeed et al.,[161,162] and the orthopedic experience in other synovial joints,[148,149] it appears that autogenous costochondral grafting should be re-evaluated for use in adult patients afflicted with low- and high-inflammatory TMJ arthritis requiring TMJ replacement.

Recurrent Fibrosis and/or Bony Ankylosis

The traditional management of complete bony TMJ ankylosis has been gap arthroplasty with autogenous tissue graft replacement or alloplastic hemiarthroplasty. While the autogenous grafting techniques can lead to improved mandibular function and form, function is delayed due to the healing process required. Since graft micromotion during healing will jeopardize its incorporation into the host environment by compromising neovascularization, early mandibular mobility often leads to graft/host interface failure. Matsuura[163] reported a high incidence of failure and ankylosis of autogenous TMJ costochondral grafts in sheep after condylectomy if the jaws were only partially immobilized.

Saeed and Kent[164] reported a high incidence of re-ankylosis in patients with ankylosis who underwent TMJ autogenous costochondral replacement. They advised caution when employing this technique for ankylosis cases. For the patient with re-ankylosis, placing autogenous bone into an area where reactive or heterotopic ossification has occurred intuitively makes no sense. In similar situations in other joints, orthopedic surgeons will opt for total alloplastic joint replacement.[148,149]

In light of the biologic facts and the orthopedic experience, TMJ TJR should be considered in the management of recurrent fibrosis and bony ankylosis of the TMJ (Figure 43-13, Table 43-1).

Failed Tissue Grafts

The success of any autogenous tissue graft requires a rich vascular bed at the recipient site. Scar tissue that inevitably develops around the TMJ in the multiply operated patient does not provide an environment conducive to the predictable success of an autogenous tissue graft. Marx reports that capillaries can penetrate a maximum thickness of 180 to 220 μm of tissue, whereas scar tissue surrounding previously operated bone averages 440 μm in thickness.[165] This fact may account for the clinical observation that free, non-vascularized autogenous tissue grafts, such as cartilage, costochondral, and sternoclavicular grafts, often fail in the case of the multiply operated patient or those patients with severe anatomic architectural discrepancies resulting from pathology (e.g., failed autogenous materials).

Reitzik[166] reported, in an analogous situation to autogenous costochondral grafting, cortex-to-cortex healing after vertical ramus osteotomy in monkeys required 20 weeks and probably 25 weeks in humans. Typically in patients reconstructed with costochondral grafts, maxillo-mandibular fixation is maintained for only 4 to 6 weeks to prevent ankylosis. Despite screw/plate fixation, micromotion of these non-vascularized free grafts will invariably occur after this short period of immobilization based on Reitzik's work. Early mandibular function results in shear movements of the graft that lead to poor neovascularization, nonunion, and/or failure.[167] This, along with the compromise in vascularity discussed previously undoubtedly accounts for autogenous costochondral graft failures. Therefore, in light of the fundamental biologic and mechanical issues discussed, TMJ cases involving multiply operated patients—especially those exposed to failed autogenous tissue grafts and/or those with anatomically distorted and severe intra-articular end-stage pathology—should be managed with TMJ TJR devices to achieve optimal functional and esthetic outcomes (Figure 43-14).

Failed Alloplastic Materials

As a result of the osteolysis around failed TMJ replacement alloplasts and the resultant host bone architectural discrepancies, it is difficult to adapt and fixate replacement TMJ TJR devices stably to the bony remnants of either the fossa or the ramus. As discussed above, the foreign body giant cell reactions associated with failed or failing devices provide a poor vascular environment into which to introduce an autogenous graft.[66]

Mercuri and Giobbe-Hurder[131] discussed this issue at length in a report where they evaluated long-term outcomes with TMJ TJR in patients with prior exposure to failed Proplast-Teflon and/or silicone rubber. They found that the TMJ TJR devices remained functional long-term (60.2 months mean), but that patients exposed to failed materials had lower subjective domain improvement scores (pain, jaw function, diet consistency) when matched to a TMJ TJR group of patients never exposed to failed TMJ alloplasts. Therefore, based on the available literature, it appears appropriate to replace TMJs affected by prior failed alloplasts with TMJ TJR devices rather than autogenous tissues (Figure 43-15).

Orthopedists and biomedical engineers have been studying the effect of failed and failing devices on the long-term outcomes of future implanted alloplastic devices. There is now evidence that failure of a prior implanted device in some patients results in a cell-mediated immune response that bodes poorly for the outcomes of any future implanted alloplast.[168-171]

Loss of Vertical Mandibular Height and/or Occlusal Relationship

Loss of TMJ bone stock leading to decreased posterior mandibular vertical dimension is caused by developmental abnormalities, pathology, or traumatic injury. This condition results in maxillomandibular form and function discrepancies. These situations should be managed

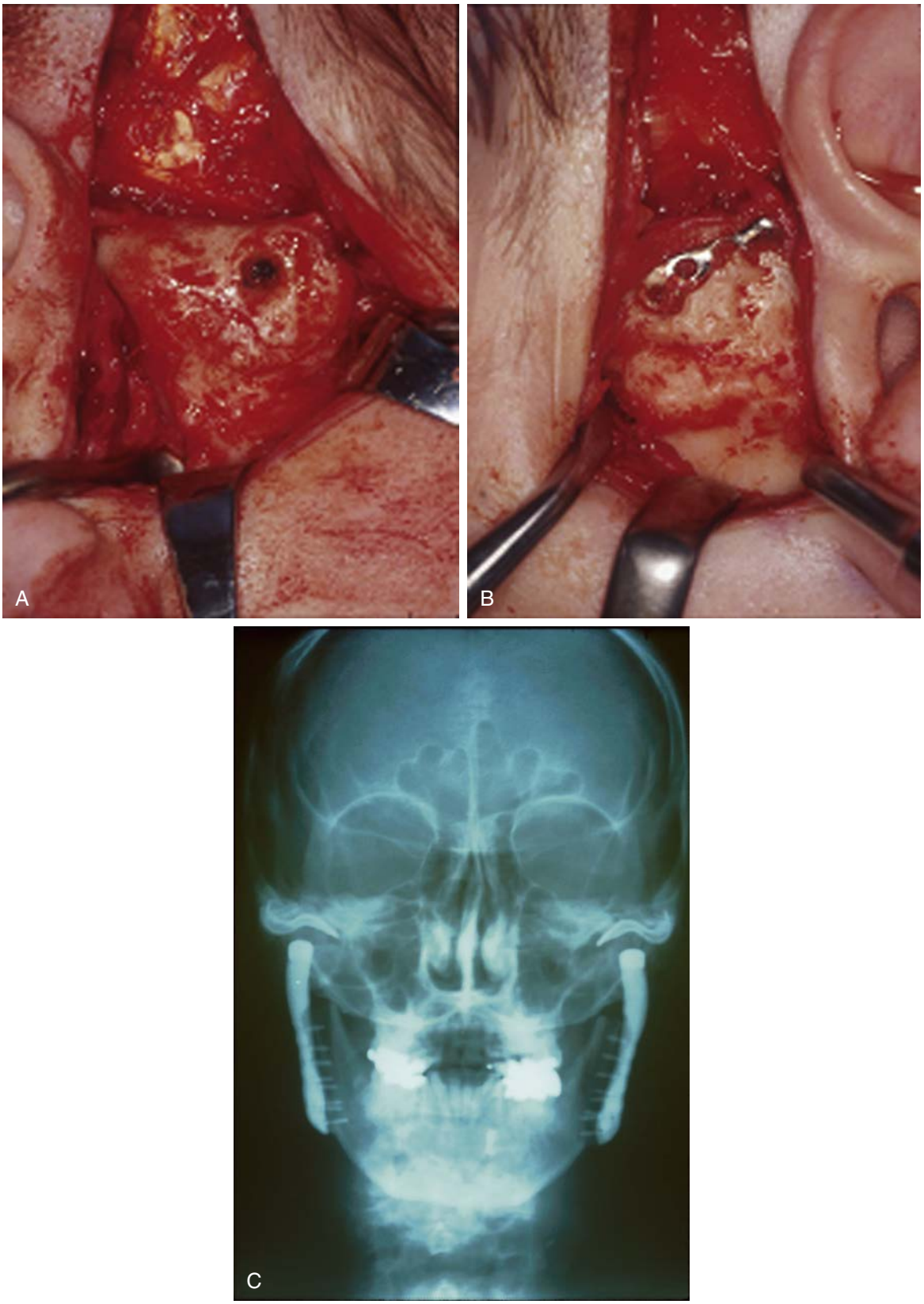

• **Figure 43-13** Bilateral TMJ ankylosis. **A,** Preoperative right TMJ. **B,** Preoperative left TMJ with embedded fossa-eminence device. **C,** Postoperative bilateral patient-fitted alloplastic TMJ reconstruction.

TABLE 43-1 Indications for the Use of Various Modalities for TMJ Replacement

	Autogenous	Alloplast	Distraction*	Bio-engineered*
Inflammatory arthritis		+++		
Ankylosis		+++	+	++
Failed autogenous graft		+++		++
Failed alloplast		+++		
Loss of vertical height	+†	+++	+†	++*

*Future potential after further in vitro and in vivo studies.
†Growing children.

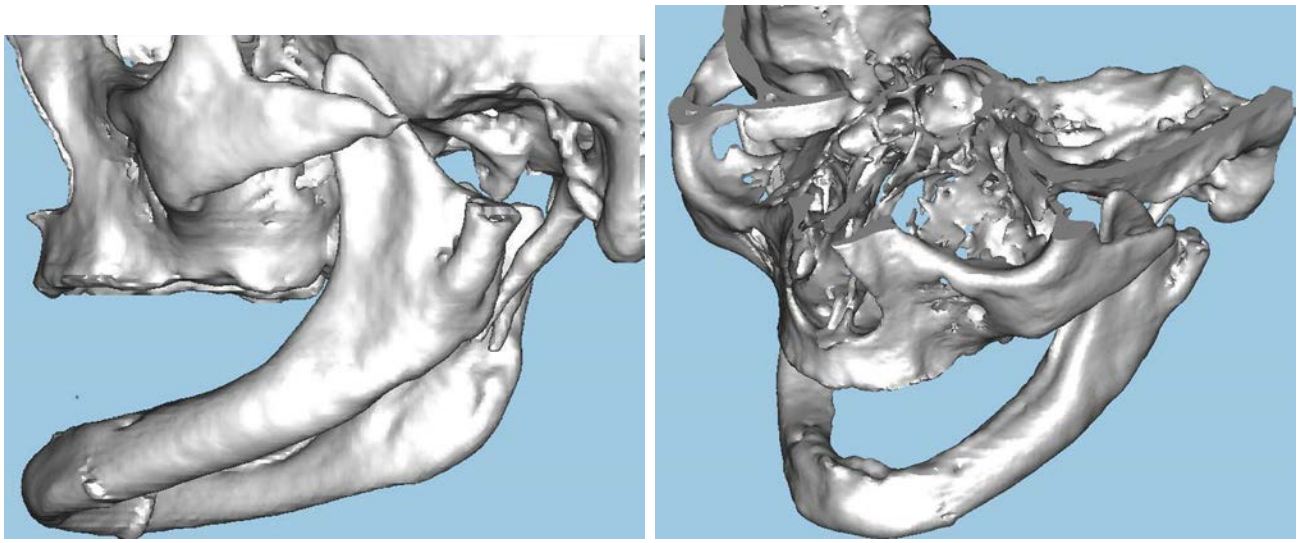

• **Figure 43-14** Preoperative CT images of a failed costochondral graft, left TMJ, in an edentulous patient who had been exposed to failed Proplast-Teflon. Note the destruction of the left temporal process of the zygoma and glenoid fossa.

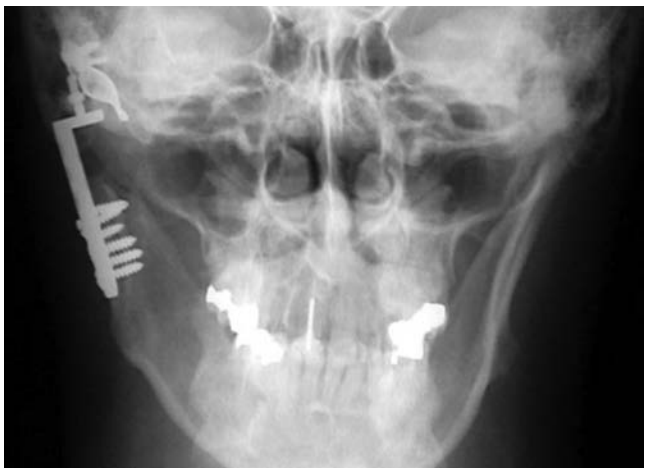

• **Figure 43-15** Failed alloplastic TMJ reconstruction caused by the inability of a stock device to accommodate the lateral flare of the mandibular ramus. Note the resultant fracture/displacement of the vitallium fossa and lateral displacement of the polyethylene condylar component.

by identifying the etiology of the problem and correcting it at the site directly affected by the pathology. In the case of a primary TMJ etiology (i.e., high-inflammatory arthritis, benign neoplasia), TMJ TJR rather than osteotomy should be considered. The surgeon must understand the nature of the pathology leading to the loss of vertical mandibular height, the patient's prior local surgical history, and the state of the host bone architecture before deciding on the type of TMJ replacement best suited to the situation (Figure 43-16).

Further, there is always a component of counterclockwise mandibular rotation in the surgical management of loss or posterior mandibular vertical height. Expecting a free, non-vascularized autogenous costochondral graft, or end-stage disease affected compromised condyloid process remnant to withstand functional loading forces generated after orthognathic surgery or distraction is fraught with the relapse potential.[172] The long-term stability using patient-fitted TMJ TJR in such cases is well documented.[173-176]

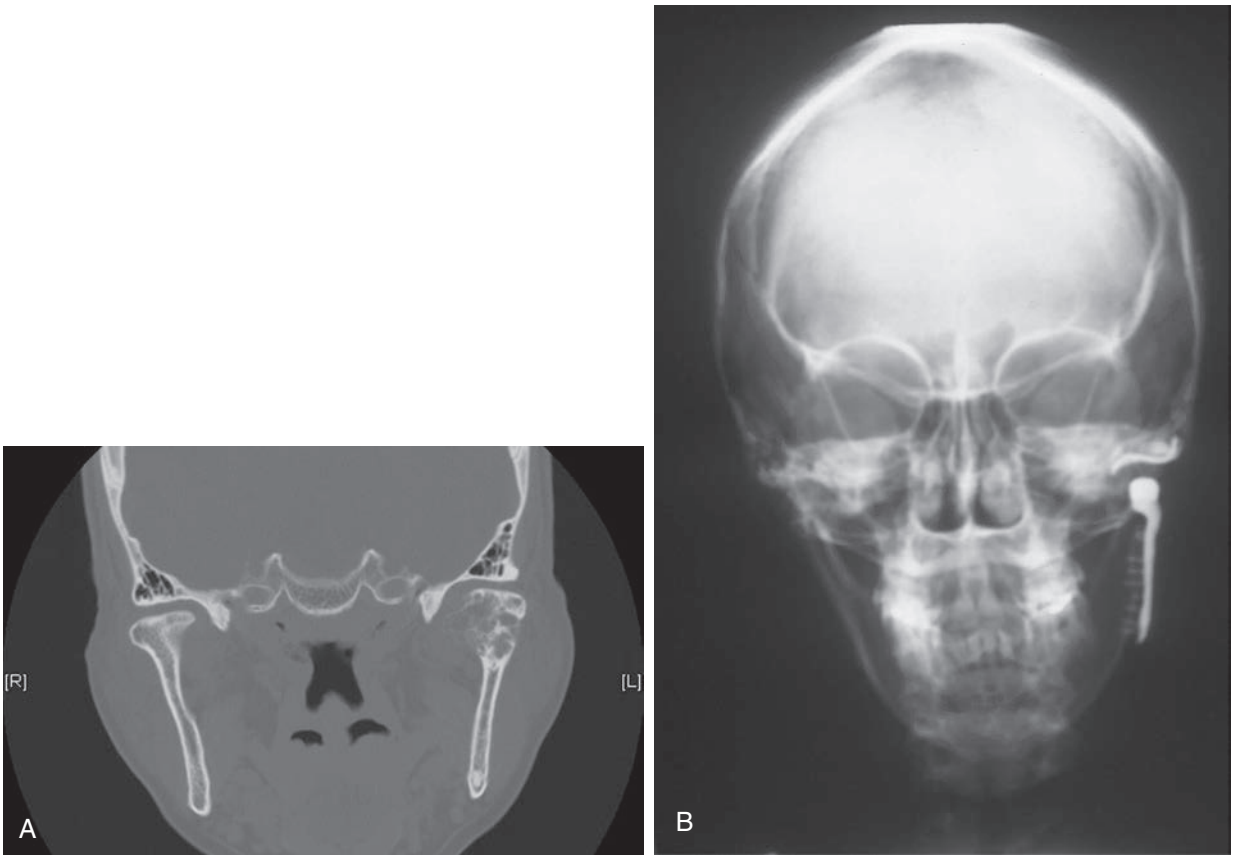

• **Figure 43-16** **A,** Low-grade fibrosarcoma of the left TMJ, preoperative. **B,** Patient-fitted alloplastic reconstruction of the left TMJ, postoperative.

The Skeletally Immature Patient

Theoretically, in growing patients, autogenous costochondral grafts will "grow with the patient." However, the growth potential of costochondral grafts used to replace the TMJ in growing patients has been reported to be unpredictable or result in ankylosis. Either or both can occur as the consequence of graft and/or fixation failure or the uncooperative nature of the young patient with regard to the rigorous physical therapy required after surgery.[139,177-180] Some studies have even questioned the necessity for using a cartilaginous graft to restore and maintain mandibular growth.[15,160]

Long-term reports of mandibular growth in children who underwent autogenous costochondral TMJ TJR reveal that excessive growth on the treated side occurred in 54% of the 72 cases examined and growth equal to that on the opposite side occurred in only 38% of the cases.[140,181-185] Furthermore, Peltomäki et al., in an investigation of mandibular growth after CCG, supported previous experiments with regard to the inability of the graft to adapt to the growth velocity of the new environment.[159, 186-187]

Reported unreliability of autogenous costochondral TMJ TJR in children includes graft failure, unpredictable growth, ankylosis, and potential for donor-site morbidity. On the basis of the orthopedic experience and success reported with alloplastic TJR in improving the quality of life of growing patients with severe anatomic and functional joint disorders,[188] it seems reasonable to consider alloplastic TMJ TJR for the following conditions in children:

1. High-inflammatory TMJ arthritis unresponsive to other modalities of treatment
2. Recurrent fibrosis and/or bony ankylosis unresponsive to other modalities of treatment
3. Failed tissue grafts (bone and soft tissue)
4. Loss of vertical mandibular height and/or occlusal relationship because of bony resorption, trauma, developmental abnormalities, or pathologic lesions

To continue to re-operate children with failed, overgrown, or ankylosed costochondral grafts employing the same autogenous tissues that failed when there may be an appropriate solution available seems myopic. These patients would be better managed with TMJ TJR devices understanding that, depending on growth, revision and/or replacement surgery may be required in the future. This would appear to be a sounder option rather than incurring continued autogenous tissue failures that will also very likely require future surgical intervention.[188]

Future Considerations

Distraction Osteogenesis

Distraction osteogenesis, which induces new bone formation along the vector of pull without the use of a bone

graft, has been employed as a reconstruction method for mandibular defects.[189-191] Stucki-McCormick et al.[192,193] reported the application of transfer osteogenesis to reconstruct the mandibular condyle in two patients. Cavaliere et al.[194] reported using similar methods to manage hemifacial microsomia patients with 1- and 2-year follow-up. The long-term growth potential for the use of this modality in the reconstruction of prepubescent cases also has yet to be determined.

Despite the short-term promising clinical results, the histomorphologic changes in the associated joint structures (i.e., cartilage, disc, and masticatory musculature) have not been elucidated completely. Experimental studies with rabbits and monkeys addressing this issue are appearing in the literature.[195,196]

Based on their animal experiments, Hu et al.[196] list several potential advantages of mandibular condyle reconstruction using transport distraction over conventional autogenous bone grafting:

1. Donor site morbidity is avoided.
2. The rigid distraction device allows for immediate postoperative physical therapy, which allows for the formation of a pseudo-arthrosis and prevents ankylosis.
3. The risk of bone graft necrosis and resorption is greatly reduced compared to non-vascularized free bone grafts (e.g., costochondral) because the transported bone in this technique retains its internal muscle and periosteal blood supply.

However, these experimental studies were carried out in animals with normal temporomandibular joints, and extrapolation of these data to patients with compromised temporomandibular joint anatomy caused by prior surgery or pathology remains a question and concern when using this technique.

Tissue Engineering

Mandibular condyle tissue engineering has been proposed to address limitations of both autogenous and alloplastic reconstructions.[197] A tissue-engineering strategy would incorporate a biodegradable scaffold delivering biologics such as cells, genes, and/or proteins to regenerate the bone/cartilage tissues of the mandibular condyle. Tissue engineering could be applied to regenerate localized defects or, theoretically, the entire articulating condylar surface. Implementation could take one of three approaches: (1) ex vivo growth of tissue on the scaffold/biologic composite in a bioreactor before implantation on the mandible, (2) implantation of the scaffold/biologic composite at a secondary surgical site before implantation on the mandible, and (3) direct implantation at the mandible site.[198]

While this modality holds the potential to revolutionize TMJ reconstruction in the future, there are many biologic, physiologic, mechanical, regulatory, and ethical issues that must be tested and addressed before it becomes a reality.

Summary

At the present time, based on the available published clinical data, TMJ TJR appears to provide the most predictable functional and esthetic outcomes for patients with end-stage low- and high-inflammatory TMJ arthritis, re-ankylosis, failed alloplastic TMJ replacements, and loss of posterior mandibular vertical dimension.[199-200]

Soft tissue (temporalis muscle) appears to have limited use in TMJ replacement surgery as an interpositional material in the initial management of ankylosis.

Osteodistraction may supplant autogenous bone grafting in the future as more long-term studies are reported. Tissue-engineered TMJ replacement, while still in its infancy, may ultimately provide an answer for TMJ cases in the future. However, both osteodistraction and tissue engineered TMJ replacements suffer from the same local and systemic biologic and pathologic issues as autogenous tissue grafting discussed above.

References

1. Mercuri LG: Alloplastic temporomandibular joint reconstruction, *Oral Surg* 85:631–637, 1998.
2. Mercuri LG: Considering total alloplastic temporomandibular joint replacement, *Cranio* 17:44–48, 1999.
3. Lexer E: Joint transplantations and arthroplasty, *Surg Gynecol Obstet* 40:782–809, 1925.
4. Gillies HD: *Plastic surgery of the face*, London, 1920, Oxford University Press.
5. Dingman RO, Grabb WC: Reconstruction of both mandibular condyles with metatarsal bone grafts, *Plast Reconstr Surg* 34:441–445, 1964.
6. Glahn MT, Winther JE: Metatarsal transplants for the lost mandibular condyle (3 years follow-up), *Scand J Plast Reconstr Surg* 1:97–100, 1967.
7. Spiessl B, Morscher E, et al.: Transplantation of the proximal phalanx of the second toe as a substitute for the temporomandibular joint in cases of ankylosis, *Proceedings of the First International Symposium on Aesthetic Surgery*, vol. 1. New York, 1972, Grune & Straton, pp 217.
8. Entin MA: Reconstruction in congenital deformity of the temporomandibular joint component, *Plast Reconstr Surg* 21: 461–469, 1958.
9. Datillo DJ, Granick MS, Sotereanos GS: Free vascularized whole joint transplant for reconstruction of the temporomandibular joint: a preliminary case report, *J Oral Maxillofac Surg* 44:227–229, 1986.
10. Dierks EJ, Buehler MJ: Complete replacement of the temporomandibular joint with a microvascular transfer of the second metatarsal-phalangeal joint. In Donlon WC, editor: Total temporomandibular joint reconstruction, *Oral Maxillofac Surg Clin N Am* 12:133–137, 2000.

11. Fukuta K, Jackson IT, Topf JS: Facial lawn mower injury treated by a vascularized costochondral graft, *J Oral Maxillofac Surg* 50:194–198, 1992.
12. Guelnick PJ, Sinsel NK: The "Eve" procedure: the transfer of vascularized seventh rib, fascia, cartilage and serratus muscle to reconstruct different defects, *Plast Reconstr Surg* 97:527–535, 1996.
13. Taylor GI: Reconstruction of the mandible with free composite iliac crest bone graft, *Ann Plast Surg* 9:361–376, 1982.
14. Wax MK, Winslow CP, et al.: A retrospective analysis of temporomandibular joint reconstruction with free fibula microvascular flap, *Laryngoscope* 110:977–981, 2000.
15. Guyot L, Richard O, et al.: Long-term radiological findings following reconstruction of the condyle with fibular free flaps, *J Craniomaxillofac Surg* 32:98–102, 2004.
16. Smith AE, Robinson M: A new surgical procedure in bilateral reconstruction of the condyles utilizing iliac bone grafts and creation of new joints by means of non-electrolytic metal: a preliminary report, *Plast Reconstr Surg* 9:393–409, 1952.
17. Bromberg BE, Walder RH, Rubin LR: Mandibular bone grafts: a technique for fixation, *Plast Reconstr Surg* 32:376–388, 1963.
18. Osborne R: The treatment of the underdeveloped ascending ramus, *Br J Plast Surg* 17:376–388, 1964.
19. Matukas VR, Szymela VF, Schmidt JF: Surgical treatment of bony ankylosis in a child using a composite cartilage-bone iliac graft, *J Oral Surg* 38:903–905, 1980.
20. Kummoona R: Chondro-osseous iliac crest graft for one stage reconstruction of the ankylosed TMJ in children, *J Maxillofac Surg* 14:215–220, 1986.
21. Snyder CC, Benson AK, Slater PV: Construction of the temporomandibular joint by transplanting autogenous sternoclavicular joint, *South Med J* 64:807–814, 1971.
22. Siemssen SO: Temporomandibular arthroplasty by transfer of the sternoclavicular joint on a muscle pedicle, *Br J Plast Surg* 35:225–238, 1982.
23. Wolford LM, Cottrell DA, Henry C: Sternoclavicular grafts for temporomandibular joint reconstruction, *J Oral Maxillofac Surg* 52:119–128, 1994.
24. Ware WH, Taylor RC: Cartilaginous growth centers transplanted to replace mandibular condyles in monkeys, *J Oral Surg* 24:33–43, 1966.
25. Poswillo DE: Experimental reconstruction of the mandibular joint, *Int J Oral Surg* 3:400–411, 1974.
26. Poswillo DE: Biological reconstruction of the mandibular condyle, *Br J Oral Maxillofac Surg* 25:100–104, 1987.
27. Ware WH, Brown SL: Growth center transplantation to replace mandibular condyles, *J Maxillofac Surg* 9:50–58, 1981.
28. MacIntosh RB: Current spectrum of costochondral grafting. In Bell WH, editor: *Surgical correction of dentofacial deformities: new concepts*, vol. III. Philadelphia, 1985, Saunders, pp 355–410.
29. MacIntosh RB: The use of autogenous tissue in temporomandibular joint reconstruction, *J Oral Maxillofac Surg* 58:63–69, 2000.
30. Murphy JB: Bony ankylosis of the jaw, with interposition of flaps from temporal fascia, *Surg Clin N Am* 2:659, 1913.
31. Blair VP: Operative treatment of ankylosis of the mandible with a history of operation and an analysis of 212 cases, *Surg Gynecol Obstet* 19:436, 1914.
32. Morris JH: Chronic recurring temporomandibular joint subluxation, *Surg Gynecol Obstet* 1:483–491, 1930.
33. Wakeley CPG: The mandibular joint, *Ann Roy Coll Surg* 2:111, 1948.
34. Straith CL, Lewis JR: Ankylosis of the temporomandibular joint, *Plast Reconstr Surg* 3:464, 1948.
35. Verneuil A: De la creation d'une fausse articulation par section ou resection partielle de le maxillarie inferieure, comme moyen de remedier a l'ankylose vraie ou fausse de la machoire inferieure, *Arch Generale de Med V Serie* 15:174, 1860.
36. Helferich J: Ein neues operationsverfahren zur heilung der knochernen keifergelenksankylose, *Arch F Klin Chir* 48:864, 1894.
37. Bellinger DH: Temporomandibular joint ankylosis and its surgical correction, *JADA* 27:1563, 1940.
38. Dingman RO: Ankylosis of the temporomandibular joint, *Am J Orthod Oral Surg* 32:120, 1946.
39. Pickrell KL, Wilde NJ, Edwards BF, et al.: The correction of ankylosis of the jaw and associated deformities of the face, *Ann Surg* 134:55, 1951.
40. Converse JM: *Surgical treatment of facial injuries*, ed 3, Baltimore, 1974, Williams & Wilkins, pp 1224.
41. Bradley P, Brockbank J: The temporalis flap in oral reconstruction, *Br J Oral Maxillofac Surg* 9:139, 1981.
42. Bradley P, Brockbank J: The temporalis muscle flap in oral reconstruction—a cadaveric, animal and clinical study, *J Maxillofac Surg* 9:139–145, 1981.
43. Rowe NL: Ankylosis of the temporomandibular joint, *J Roy Coll Surg Edinb* 27:67–79, 1982.
44. Habel G, Hensher R: The versatility of the temporalis muscle flap in reconstructive surgery, *Br J Oral Maxillofac Surg* 24:96, 1986.
45. Bowerman J: Reconstruction of the temporomandibular joint for acquired deformity and congenital malformation, *Br J Oral Maxillofac Surg* 25:149, 1987.
46. Tideman H, Doddridge M: Temporomandibular joint ankylosis, *Austral Dent J* 32:171, 1987.
47. Feinberg SE, Larsen PE: The use of a pedicled temporalis muscle-pericranial flap for replacement of the TMJ disc: preliminary report, *J Oral Maxillofac Surg* 47:142, 1989.
48. Herbosa EG, Rotskoff KS: Composite temporalis pedicle flap as an interpositional graft in temporomandibular joint arthroplasty: preliminary report, *J Oral Maxillofac Surg* 48:1049, 1990.
49. Pogrel MA, Kaban LB: The role of a temporalis fascia and muscle flap in temporomandibular joint surgery, *J Oral Maxillofac Surg* 48:14, 1990.
50. Brusati R, Raffaini M, Sesenna E, et al.: The temporalis muscle flap in temporomandibular joint surgery, *J Craniomaxillofac Surg* 18:352, 1990.
51. Rotskoff KS: Long-term viability of the temporalis muscle/fascia flap for temporomandibular joint reconstruction, *J Oral Maxillofac Surg* 51:534, 1993.
52. Thyne GM, Yoon JH, et al.: Temporalis muscle as a disc replacement in the temporomandibular joint of sheep, *J Oral Maxillofac Surg* 50:979–987, 1992.
53. Umeda H, Kaban LB, et al.: Long-term viability of the temporalis muscle-fascia flap used for temporomandibular joint reconstruction, *J Oral Maxillofac Surg* 51:530–533, 1993.
54. Cheung LK: The vascular anatomy of the human temporalis muscle: implications for surgical splitting techniques, *Int J Oral Maxillofac Surg* 25:414–421, 1996.
55. Georgiade N, Altany F, Pickrell K: Experimental clinical evaluation of autogenous dermal grafts used for the treatment of temporomandibular joint ankylosis, *Plast Reconstr Surg* 19: 321–335, 1957.

56. Georgiade NG: The surgical correction of temporomandibular joint dysfunction by means of autogenous dermal grafts, *Plast Reconstr Surg* 30:68, 1962.
57. Zetz M, Irby W: Repair of the adult temporomandibular joint meniscus with an autogenous dermal graft, *J Oral Maxillofac Surg* 42:167, 1984.
58. DeChamplain R, Stewart H, Hann J, et al.: Histologic fate of dermal grafts following implantation for temporomandibular joint meniscus perforation: a preliminary study, *Oral Surg* 62:481, 1986.
59. Meyer RA: The autogenous dermal graft in temporomandibular joint disc surgery, *J Oral Maxillofac Surg* 46:948, 1988.
60. Kazanjian VH, Converse JM: *The surgical treatment of facial injuries*, Baltimore, 1949, Williams & Wilkins, pp 481–485.
61. Narang R, Dixon RA: Temporomandibular joint arthroplasty with fascia lata, *Oral Surg* 39:45–50, 1975.
62. Tong CA, Tideman H: A comparative study on meniscectomy and autogenous graft replacement of the Rhesus monkey temporomandibular joint articular disc—part II, *Int J Oral Maxillofac Surg* 29:146–154, 2000.
63. Henry CH, Wolford LM: Reconstruction of the temporomandibular joint using a temporalis graft with or without simultaneous orthognathic surgery, *J Oral Maxillofac Surg* 53:1250–1256, 1995.
64. Yih WY, Merrill RG: Pathology of alloplastic interpositional implants in the temporomandibular joint, *Oral Maxillofac Surg Clin N Am* 1:415, 1989.
65. Ryan DE: Alloplastic implants in the temporomandibular joint, *Oral Maxillofac Surg Clin N Am* 1:427, 1989.
66. Henry CH, Wolford LM: Treatment outcomes for temporomandibular joint reconstruction after Proplast-Teflon implant failure, *J Oral Maxillofac Surg* 51:352, 1993.
67. Bradrick JP, Indresano AT: Failure of repetitive temporomandibular joint surgical procedures, *J Oral Maxillofac Surg* 50(Suppl 3):145, 1992.
68. Mercuri LG: Subjective and objective outcomes in patients with a custom-fitted alloplastic temporomandibular joint prosthesis, *J Oral Maxillofac Surg* 57:1427–1430, 1999.
69. Ioannidis C, Maltha JC: Replacement of the intraarticular disc of the craniomandibular joint with fresh autogenous sternal or auricular cartilage, *J Craniomaxillofac Surg* 16:343, 1988.
70. Takatsuka S, Narinobou M, Nakagawa K, et al.: Histologic evaluation of articular cartilage grafts after discectomy in the rabbit craniomandibular joint, *J Oral Maxillofac Surg* 54:1216, 1996.
71. Tucker MR, Kennedy MC: Autogenous auricular cartilage implantation following discectomy in the primate temporomandibular joint, *J Oral Maxillofac Surg* 48:38, 1990.
72. Yih WY, Zysset M, Merrill RG: Histologic study of the fate of autogenous auricular cartilage grafts in the human temporomandibular joint, *J Oral Maxillofac Surg* 50:964, 1992.
73. Carnochan JM: Mobilizing a patient's ankylosed jaw by placing a block of wood between the raw bony surfaces after resection, *Arch de Med* 284, 1860.
74. Gluck T: Referat uber die durch das moderne chirurgische experiment gewonnenen positiven resultate, betreffenddie naht und den ersatz von defecten hoerer gewebe, sowie uber die verwerthung resorbirbarer und bebendiger tampons in der chirgurie, *Arch Klin Chir* 4:186, 1891.
75. Risdon F: Ankylosis of the temporomandibular joint, *JADA* 21:1933–1937, 1933.
76. Eggers GWN: Arthroplasty of the temporomandibular joint in children with interpositional tantalum foil, *J Bone Joint Surg* 28:603–606, 1946.
77. Goodsell JO: Tantalum in temporomandibular joint arthroplasty: report of case, *J Oral Surg* 5:41–45, 1947.
78. Castigliano SG, Gross PP: Immediate prosthesis following radical resection in advanced primary malignant neoplasm of the mandible, *J Oral Surg* 9:31–38, 1951.
79. Kleitch WP: Vitallium reconstruction of a hemimandible and temporomandibular joint, *Plast Reconstr Surg* 7:244–253, 1951.
80. Smith AE, Robinson M: A new surgical procedure in bilateral reconstruction of condyles utilizing iliac crest bone grafts and creating new joints by means of non-electric metal: a preliminary report, *Plast Reconstr Surg* 9:393–410, 1952.
81. Ueno T, Miura I, Kohno H: The use of zirconium metal plate in arthroplasty of temporomandibular joint ankylosis, *Bull Tokyo Med Dent Soc* 2:137–139, 1955.
82. Henry TC: *Prosthetic restoration of the left temporomandibular joint in a case of partial ankylosis, Transactions of the Second Congress of the International Society of Plastic Surgeons*, London, 1960, Livingstone, pp 59.
83. Robinson M: Temporomandibular joint ankylosis corrected by creating a false stainless steel fossa, *J So Calif* 6:186–190, 1960.
84. Christensen RW: The correction of mandibular ankylosis by arthroplasty and insertion of a cast vitallium glenoid fossa, *Am J Orthop* 48:16–24, 1963.
85. Christensen RW: Mandibular joint arthrosis corrected by insertion of cast vitallium glenoid fossa prosthesis, *Oral Surg* 17:712–722, 1964.
86. Christensen WR: *Arthroplastic implantation of the TMJ, oral implantology*, Springfield, 1970, Charles C. Thomas, pp 284–298.
87. Chase DC, Hudson JW, Gerard DA, et al.: The Christensen prosthesis, *Oral Surg* 80:273–278, 1995.
88. Garrett WR, Abbey PA, Christensen RW: Temporomandibular joint reconstruction with a custom total temporomandibular joint prosthesis: use in the multiply operated patient. In Szbo Z, et al.: *Surgical technology international VI*, San Francisco, 1997, University Medical Press, pp 347–354.
89. Small IA, Brown S, Kobernick SD: Teflon and silastic for mandibular replacement: experimental studies and reports of cases, *J Oral Surg* 22:37–41, 1964.
90. Robinson M: Temporomandibular joint ankylosis corrected by creating a false silastic sponge fossa, *J So Calif Dent Assoc* 36: 14–16, 1968.
91. Hansen WC, Deshazo BW: Silastic reconstruction of temporomandibular joint meniscus, *Plast Reconstr Surg* 43:388–391, 1969.
92. Rast WC, Waldrep AC, Irley WC: Bilateral temporomandibular joint arthroplasty, *J Oral Surg* 27:871–874, 1969.
93. Wukelich S, Marshall J, Walden R, et al.: Use of a silastic testicular implant in reconstruction of the temporomandibular joint of a 5-year-old child, *Oral Surg* 32:4–9, 1971.
94. Cook HP: Teflon implantation in temporomandibular arthroplasty, *Oral Surg* 33:706–716, 1972.
95. Hartwell SW, Hall MD: Mandibular condylectomy with silastic rubber replacement, *Plast Reconst Surg* 53:440–444, 1974.
96. Howe DJ: Preformed silastic temporomandibular joint implant, *J Oral Surg* 37:59, 1979.
97. Cope MR, Moos KF, Hammersley N: The compressible silicone rubber prosthesis in temporomandibular joint disease, *Br J Oral Maxillofac Surg* 31:376–384, 1993.
98. Hellinger MJ: Bony ankylosis of the temporomandibular joint, *Oral Surg* 18:293–302, 1964.

99. Hahn GW, Corgill DA: Surgical implant replacement of the fractured displaced mandibular condyle: report of three cases, *J Oral Surg* 28:898–901, 1970.
100. Morgan DH: Dysfunction, pain, tinnitus, vertigo corrected by mandibular joint surgery, *J So Calif Dent Assn* 39:505, 1971.
101. Morgan DH: Surgical correction of temporomandibular joint arthritis, *J Oral Surg* 33:766–773, 1975.
102. Morgan DH, Hall WP, Vamvas SJ: *Diseases of the temporomandibular apparatus. A multidisciplinary approach*, St Louis, 1977, CV Mosby, pp 318–324.
103. House LR, Morgan DH, Hall WP, et al.: Temporomandibular joint surgery. Report of a 14 year joint implant study, *Laryngoscope* 94:537–538, 1984.
104. Morgan DH: Development of alloplastic materials for temporomandibular joint prosthesis: a historical perspective with clinical illustrations, *J Craniomand Pract* 10:192–204, 1992.
105. Tauras SP, Jordan JE, Keen RR: Temporomandibular joint ankylosis corrected with a gold prosthesis, *J Oral Surg* 30: 767–773, 1972.
106. Hinds EC, Homsy CA, Kent JN: Use of biocompatible interface for compatible interface for combining tissues and prostheses in oral surgery. In Kay LW, editor: *Transactions of the IVth International Conference on Oral Surgery*, Copenhagen, 1972, Munksgaard, pp 210–216.
107. Hinds EC, Homsy CA, Kent JN: Use of a biocompatible interface for binding tissues and prosthesis in temporomandibular joint surgery, *Oral Surg* 38:512–519, 1974.
108. Kent JN, Misiek DJ, Akin RK, et al.: Temporomandibular joint condylar prosthesis: a ten year report, *J Oral Maxillofac Surg* 41:245–254, 1983.
109. Kent JN, Block MS, Homsy CA, et al.: Experience with a polymer glenoid fossa prosthesis for partial or total temporomandibular joint reconstruction, *J Oral Maxillofac Surg* 44:520–533, 1986.
110. Kent JN, Block MS, Halpern J, et al.: Long-term results on VK partial and total temporomandibular joint systems, *J Long-Term Effects Med Imp* 3:29–40, 1993.
111. Kiehn CL, DesPrez JD, Converse CF: A new procedure for total temporomandibular joint replacement: case report, *Plast Reconstr Surg* 53:221–226, 1974.
112. Kiehn CL, DesPrez JD, Converse CF: Total prosthetic replacement of the temporomandibular joint, *Ann Plast Surg* 2:5–15, 1979.
113. Kameros J, Himmelfarb R: Treatment of TMJ ankylosis with methyl methacrylate interpositional arthroplasty, *J Oral Surg* 33:282–291, 1975.
114. Spiessl B, Schmoker R, Mathys R: Treatment of ankylosis of the mandible. In Spiessl B, editor: *New concepts in maxillofacial bone surgery*, New York, 1976, Springer.
115. Silver CM, Motamed M, Carlotti E: Arthroplasty of the temporomandibular joint with the use of a vitallium condyle prosthesis: report of three cases, *J Oral Surg* 35:909–914, 1977.
116. Seymour RL, Bray TE, Irby WB: Replacement of condylar process, *J Oral Surg* 35:405–408, 1977.
117. Kummoona R: Functional rehabilitation of ankylosed temporomandibular joints, *Oral Surg* 46:495–505, 1978.
118. Kiersch TA: 9 years of success with Teflon-Proplast disc replacement interpositional implant, *AAOMS Clinical Congress*, 1984.
119. Sonnenburg S, Sonnenburg M: Total condylar prosthesis for alloplastic jaw articulation replacement, *J Craniomaxillofac Surg* 13:131–135, 1985.
120. Sonnenburg M, Sonnenburg I: Development and clinical application of the total temporomandibular joint (TMJ) endoprosthesis, *Rev Stomatol Chir Maxillofac* 91:165–169, 1990.
121. Raveh J, Sutter F, Hellum S: Surgical procedures for reconstruction of the lower jaw using the titanium-coated hollow-screw reconstruction plate system: bridging defects, *Otolaryngol Clin N Am* 20:535–558, 1987.
122. Boyne PJ, Matthews FR, Stringer DE: TMJ bone remodeling after polyoxymethylene condylar replacement, *Int J Oral Maxillofac Implant* 2:29, 1987.
123. Hellum S, Olofsson J: Titanium-coated hollow screw and reconstruction plate system (THORP) in mandibular reconstruction, *J Craniomaxillofac Surg* 16:173–183, 1988.
124. Szabo G, Barabas J, Matrai J: Application of compact aluminum oxide ceramic implants in maxillofacial surgery, *J Oral Maxillofac Surg* 48:354–361, 1990.
125. Westermark AH, Sindet-Pedersen S, Boyne PJ: Bony ankylosis of the temporomandibular joint: case report of a child treated with Delrin condylar implants, *J Oral Maxillofac Surg* 48: 861–865, 1990.
126. Chassagne JF, Flot F, Stricker M, et al.: Prosthese totale intermediaire d'articulation temporo-mandibulaire, *Rev Stomatol Chir Maxillofac* 91:423–429, 1990.
127. McAfee KA, Quinn PD: Total temporomandibular joint reconstruction with Delrin titanium implant, *J Craniofac Surg* 3:160, 1992.
128. McBride KL: *Total temporomandibular joint reconstruction. Controversies in oral and maxillofacial surgery*, Philadelphia, 1994, Saunders, pp 381–396. Chapter 30.
129. vanLoon JP, DeBont LGM, Boering G: Evaluation of temporomandibular joint prostheses: review of the literature from 1946-1994 and implications for future designs, *J Oral Maxillofac Surg* 53:984–996, 1995.
130. Mercuri LG, Wolford LM, Sanders B, et al.: Custom CAD/CAM total temporomandibular joint reconstruction system: preliminary multicenter report, *J Oral Maxillofac Surg* 53:106–115, 1995.
131. Mercuri LG, Giobbe-Hurder A: Long-term outcomes after total alloplastic temporomandibular joint reconstruction following exposure to failed materials, *J Oral Maxillofac Surg* 62:1088–1096, 2004.
132. Edibam NR, Mercuri LG, Giobbie-Hurder A: 14-Year follow-up of a patient fitted total temporomandibular joint reconstruction system, *J Oral Maxillofac Surg* 64(Suppl 1):55, 2006.
133. Wolford LM, Mercuri LG, Schneiderman ED, Movahed R, Allen W: Twenty-year follow-up study on a patient-fitted temporomandibular joint prosthesis: the Techmedica/TMJ Concepts device, *J Oral Maxillofac Surg* 73:952–960, 2015.
134. Mercuri LG: Alloplastic TMJ replacement. Rationale for custom devices, *Int J Oral Maxillofac Surg* 41:1033–1040, 2012.
135. Gerard DA, Hudson JW: The Christensen temporomandibular joint system. In Donlon WC, editor: Total temporomandibular joint reconstruction, *Oral Maxillofac Surg Clin N Am* 12:61–72, 2000.
136. Wolford LM, Dingworth DJ, Talwar RM, et al.: Comparison of 2 temporomandibular joint prosthesis systems, *J Oral Maxillofac Surg* 61:685–690, 2003.
137. Branemark PI, Hansson HA, Adell R: Osseointegrated implants in the treatment of the edentulous jaw: experience from a ten year period, *Scand Plast Reconstr Surg* 16:1–132, 1977.

138. Lindqvist C, Jokinen J, et al.: Adaption of autogenous costochondral grafts used for temporomandibular joint reconstruction: a long-term clinical and radiologic follow-up, *J Oral Maxillofac Surg* 46:465–470, 1988.
139. Obeid G, Guttenberg SA, Canole PW: Costochondral grafting on condylar replacement and mandibular reconstruction, *J Oral Maxillofac Surg* 48:177–182, 1988.
140. Perrott DH, Umeda H, Kaban LB: Costochondral graft construction/reconstruction of the ramus/condyle unit: long-term follow-up, *Int J Oral Maxillofac Surg* 23:321–328, 1994.
141. MacIntosh RB: The use of autogenous tissue in temporomandibular joint reconstruction, *J Oral Maxillofac Surg* 58:63–69, 2000.
142. MacIntosh RB: Current spectrum of costochondral and dermal grafting. In Bell WH, editor: *Modern practice in orthognathic and reconstructive surgery*, vol. 2. Philadelphia, 1992, Saunders, pp 904–949.
143. MacIntosh RB: The case for autogenous reconstruction of the adult temporomandibular joint. In Worthington P, Evans JR, editors: *Controversies in oral and maxillofacial surgery*, Philadelphia, 1994, Saunders, pp 356–380.
144. Frietas RZ, Mehra P, Wolford LM: Autogenous versus alloplastic TMJ reconstruction in rheumatoid-induced TMJ disease, *J Oral Maxillofac Surg* 58(Suppl 1):43, 2002.
145. Mehra P, Wolford LM: Custom-made TMJ reconstruction and simultaneous mandibular advancement in autoimmune/connective tissue diseases, *J Oral Maxillofac Surg* 58(Suppl 1):95, 2000.
146. Troulis MJ, Williams WB, Kaban LB: Endoscopic mandibular condylectomy and reconstruction: early clinical results, *J Oral Maxillofac Surg* 62:460–465, 2004.
147. Saeed NR, Kent JN: A retrospective study of the costochondral graft in TMJ reconstruction, *Int J Oral Maxillofac Surg* 32: 606–609, 2003.
148. Skinner HB: *Current diagnosis and treatment in orthopedics*, ed 2, New York, 2000, Lang Medical Books, McGraw-Hill.
149. Chapman MW: *Chapman's orthopaedic surgery*, ed 3, Philadelphia, 2001, Lippincott Williams & Wilkins.
150. Ringold S, Cron RQ: The temporomandibular joint in juvenile idiopathic arthritis: frequently used and frequently arthritic, *Pediatr Rheumatol Online J* 7:11, 2009.
151. Reference deleted in pages.
152. Reference deleted in pages.
153. Reference deleted in pages.
154. Reference deleted in pages.
155. Kaban LB, Perrott DH: Unpredictable growth pattern of costochondral graft. Discussion, *Plast Reconstr Surg* 90:887–889, 1992.
156. MacIntosh RB, Henny FA: A spectrum of application of autogenous costochondral grafts, *J Maxillofac Surg* 5:257–267, 1977.
157. Politis C, Foission E, Bossuyt M: The use of costochondral grafts in arthroplasty of the temporomandibular joint, *J Craniomaxillofac Surg* 15:345–354, 1987.
158. Link JO, Hoffman DC, Laskin DM: Hyperplasia of a costochondral graft in an adult, *J Oral Maxillofac Surg* 51:1392–1394, 1993.
159. Peltomäki T, Vähätalo K, Rönning O: The effect of a unilateral costochondral graft on the growth of the marmoset mandible, *J Oral Maxillofac Surg* 60:1307–1314, 2002.
160. Ellis E, Schneiderman ED, Carlson DS: Growth of the mandible after replacement of the mandibular condyle: an experimental investigation in Macaca mulatta, *J Oral Maxillofac Surg* 60:1461–1479, 2002.
161. Saeed NR, McLeod NMH, Hensher R: Temporomandibular joint replacement in rheumatoid-induced disease, *Br J Oral Maxillofac Surg* 39:71–75, 2001.
162. Saeed N, Hensher R, McLeod R, et al.: Reconstruction of the temporomandibular joint: autogenous compared with alloplastic, *Br J Oral Maxillofac Surg* 40:296–299, 2002.
163. Matsuura H, Miyamoto H, Ishimura J, et al.: Effect of partial immobilization on reconstruction of ankylosis of the temporomandibular joint with autogenous costochondral graft, *Br J Oral Maxillofac Surg* 39:196–203, 2001.
164. Saeed NR, Kent JN: A retrospective study of the costochondral graft in TMJ reconstruction, *Int J Oral Maxillofac Surg* 32: 606–609, 2003.
165. Mercuri LG: Total joint reconstruction—autologous or alloplastic, *Oral Maxillofac Surg Clin N Am* 18:399–410, 2006.
166. Reitzik M: Cortex-to-cortex healing after mandibular osteotomy, *J Oral Maxillofac Surg* 41:658–663, 1983.
167. Lienau J, Schell H, Duda G: Initial vascularization and tissue differentiation are influenced by fixation stability, *J Orthopaed Res* 23:639–645, 2005.
168. Black J: Systemic effects of biomaterials, *Biomaterials* 5:11–18, 1984.
169. Hallab JH, Mickecz K, Vermes C: Differential lymphocytic reactivity to serum derived metal-protein complexes produced from cobalt-chrome and titanium based implant alloy degradation, *J Biomed Mater Res* 56:427–436, 2001.
170. Willert HG, Buchhorn GH, Ing D, et al.: Metal-on-metal bearings and hypersensitivity in patients with artificial hip joints. A clinical and histomorphological study, *J Bone Joint Surg (Am)* 87:28–36, 2005.
171. Hallab N: Material hypersensitivity. In Mercuri LG, editor: *Total temporomandibular joint replacement. a comprehensive reference for surgeons, researchers, and materials scientists*, New York, 2015, Springer.
172. Burr DB: Muscle strength, bone mass, and age related bone loss, *J Bone Miner Res* 12:1547–1551, 1997.
173. Dela Coleta KE, Wolford LM, Gonçalves JR, et al.: Maxillomandibular counter-clockwise rotation and mandibular advancement with TMJ Concepts total joint prostheses: part I—skeletal and dental stability, *Int J Oral Maxillofac Surg* 38: 126–138, 2009.
174. Coleta KE, Wolford LM, Gonçalves JR, et al.: Maxillo-mandibular counter-clockwise rotation and mandibular advancement with TMJ Concepts total joint prostheses: part II—airway changes and stability, *Int J Oral Maxillofac Surg* 38:228–235, 2009.
175. Coleta KE, Wolford LM, Gonçalves JR, et al.: Maxillomandibular counter-clockwise rotation and mandibular advancement with TMJ Concepts total joint prostheses: part IV—soft tissue response, *Int J Oral Maxillofac Surg* 38:637–646, 2009.
176. Pinto LP, Wolford LM, Buschang PH, et al.: Maxillo-mandibular counter-clockwise rotation and mandibular advancement with TMJ Concepts total joint prostheses: part III—pain and dysfunction outcomes, *Int J Oral Maxillofac Surg* 38:326–331, 2009.
177. Ware WH, Taylor RC: Cartilaginous growth centers transplanted to replace mandibular condyles in monkeys, *J Oral Surg* 24:33, 1966.
178. Ware WH, Brown SL: Growth center transplantation to replace mandibular condyles, *J Maxillofac Surg* 9:50, 1981.

179. Samman N, Cheung LK, Tideman H: Overgrowth of a costochondral graft in an adult male, *Int J Oral Maxillofac Surg* 24:333, 1995.
180. MacIntosh RB, Henny FA: A spectrum of application of autogenous costochondral grafts, *J Oral Maxillofac Surg* 5:257, 1977.
181. Guyuron B, Lasa CI: Unpredictable growth pattern of costochondral graft, *Plast Reconstr Surg* 90:880, 1992.
182. Marx RE: The science and art of reconstructing the jaws and temporomandibular joints. In Bell WH, editor: *Modern practice in orthognathic and reconstructive surgery*, vol. 2. Philadelphia, 1992, Saunders, pp 1448.
183. Svensson A, Adell R: Costochondral grafts to replace mandibular condyles in juvenile chronic arthritis patients: Long-term effects on facial growth, *J Craniomaxillofac Surg* 26:275, 1998.
184. Ross RB: Costochondral grafts replacing the mandibular condyle, *Cleft Palate Craniofac J* 36:334, 1999.
185. Wen-Ching K, Huang C-S, Chen Y-R: Temporomandibular joint reconstruction in children using costochondral grafts, *J Oral Maxillofac Surg* 57:789, 1999.
186. Peltomäki T, Rönning O: Interrelationship between size and tissue-separating potential of costochondral transplants, *Eur J Orthod* 13:459, 1991.
187. Peltomäki T: Growth of a costochondral graft in the rat temporomandibular joint, *J Oral Maxillofac Surg* 50:851, 1992.
188. Mercuri LG, Swift JQ: Considerations for the use of alloplastic temporomandibular joint replacement in the growing patient, *J Oral Maxillofac Surg* 67:1979–1990, 2009.
189. McCarthy JG, Schreiber JS, Karp N, et al.: Lengthening of the human mandible by gradual distraction, *Plast Reconstr Surg* 89:1, 1992.
190. Molina F, Monasterio FO: Mandibular elongation and remodeling by distraction: a farewell to major osteotomies, *Plast Reconstr Surg* 96:825, 1995.
191. Perrott DH, Berger R, Vargervik K, et al.: Use of a skeletal distraction device to widen the mandible: a case report, *J Oral Maxillofac Surg* 51:435, 1993.
192. Stucki-McCormick SU: Reconstruction of the mandibular condyle using transport distraction osteogenesis, *J Craniofac Surg* 8:48, 1997.
193. Stucki-McCormick SU, Fox RM, Mizrahi RD: Reconstruction of a neocondyle using transport distraction osteogenesis, *Semin Orthod* 5:59, 1999.
194. Cavaliere CM, Buchman SR: Mandibular distraction in the absence of an ascending ramus and condyle, *J Craniofac Surg* 13:527, 2002.
195. Hikiji H, Takato T, Matsumoto S, et al.: Experimental study of reconstruction of the temporomandibular joint using bone transport technique, *J Oral Maxillofac Surg* 58:1270, 2000.
196. Hu J, Zhu S, Li J, et al.: Reconstruction of mandibular condyle by transport distraction osteogenesis: experimental study in Rhesus monkey, *J Oral Maxillofac Surg* 64(10):1487–1492, 2006.
197. Abukawa H, Terai H, Hannouche D, et al.: Formation of a mandibular condyle in vitro by tissue engineering, *J Oral Maxillofac Surg* 61:94–100, 2003.
198. Zouhary KJ, Feinberg SE: Regeneration of the mandibular condyle in minipigs, *J Oral Maxillofac Surg* 64(3):565, 2006.
199. Sidebottom AJ: Alloplastic or autogenous reconstruction of the TMJ, *J Oral Biol Craniofac Res* 3:135–139, 2013.
200. Mercuri LG, editor: *Total temporomandibular joint replacement. a comprehensive reference for surgeons, researchers, and materials scientists*, New York, 2015, Springer.

44

Chronic Facial Pain: Evaluation, Differential Diagnosis, and Management Strategies

JAMES Q. SWIFT, MARYANN (MA'ANN) C. SABINO, HADAS LEHMAN-NAAMAN

Introduction

According to the National Health Interview Survey (NHIS) conducted by the Centers for Disease Control and Prevention (CDC) in 2005, approximately 7% of Americans suffer from facial pain each year.[1] The term facial pain may be used to describe any unpleasant, annoying, or descriptive sensation in the facial region, including those emanating from the oral cavity, dentition, maxilla, mandible, sinus, orbital, cranial, and nasal regions of the head and neck. While it is clear that facial pain is mediated primarily by nerve fibers of trigeminal nerve origin, other sensory nerves and nerve fibers may also play a role in facial pain transmission. In order to understand facial pain, one must first understand the neurophysiology of pain: from the release of pain-producing neurotransmitters and the interaction with receptors on peripheral nerve fibers innervating head and neck structures to the complex cortical reorganization and processing that occurs in chronic pain. This chapter will highlight the key neurophysiologic mechanisms that underlie both acute and chronic facial pain entities.

Chronic facial pain is one of the most challenging entities for a clinician to diagnose and treat. It is usually of greater than 6 months' duration, unrelenting, and recalcitrant to conventional modes of pharmacotherapy and/or surgical intervention.[2] The chronic pain patient who relies on chronic opioid therapy poses a particular challenge to the oral and maxillofacial surgeon from an intraoperative and postoperative pain management standpoint. This chapter will discuss differential diagnoses of chronic facial pain, treatment recommendations, and barriers that currently exist for the management of the chronic facial pain patient. Identifying the barriers and eliminating them through discussions with the patient and health care providers will allow for effective pain management and abolition of biases that currently affect many chronic pain sufferers.

Facial pain, like other types of pain, can be complex and multidimensional and therefore clinical evaluation becomes an important aspect in the diagnosis of the facial pain patient. Many clinical specialties play a role in the diagnosis and management of facial pain. These include anesthesiologists, dentists, endodontists, oral and maxillofacial surgeons, facial pain experts, otolaryngologists, neurologists, neurosurgeons, physical therapists, psychiatrists, psychologists, and chemical dependency physicians. In complex cases of facial pain, a team approach is usually taken, resulting in improved therapeutic outcomes.[3] With an understanding of the complex neurophysiology that exists in the facial pain patient, an idea of how to delineate the correct facial pain diagnosis, and an understanding of the alternative treatment modalities that currently exist, the clinician will be enabled to manage one of the most complex and challenging pathologic entities—a patient with chronic facial pain.

Neurophysiology of Pain

Trigeminal Anatomy

A thorough understanding of neuroanatomy and neurophysiology is imperative to fully appreciate the complex nature of facial pain. While it is clear that other sensory fibers are important in the transmission of painful information from the head and neck (e.g., cervical spinal nerves, sympathetic fibers), the majority of pain in the head and neck is transmitted via branches of the fifth cranial nerve—the trigeminal nerve. The trigeminal nerve is considered the largest of the cranial nerves. The primary sensory neurons (also known as first-order neurons) of the trigeminal nerve are located within the largest ganglia in the human body—the trigeminal ganglia. The trigeminal ganglia are housed within the petrous portion of the temporal bone in the middle cranial fossa in close proximity to the internal

carotid artery and cavernous sinus. It is considered a bipolar neuron in that its primary afferent (peripheral nerve) fibers terminate within the head and neck while its central fibers terminate within the medullary dorsal horn and cervical spinal cord. Its extensive distribution highlights the amount of sensory input the head and neck receives.

The trigeminal sensory fibers synapse with second-order neurons located within the spinal trigeminal nuclear complex. The trigeminal brainstem nuclear complex is subdivided into the (1) chief main sensory nucleus, (2) spinal trigeminal nucleus oralis, (3) spinal trigeminal nucleus interpolaris, and (4) spinal trigeminal nucleus caudalis. The spinal trigeminal nucleus caudalis has been implicated as the main nucleus that receives painful or nociceptive input from peripheral targets. There is a significant convergence of non–trigeminal nerve fibers arising from the cervical spine and vagus and glossopharyngeal nerve terminals onto trigeminal nuclei. The large convergence of cranial and spinal nerves explains the presence of referred pain to non–head and neck structures in the facial pain patient.

Neurons within the spinal trigeminal sensory nuclear complex project to higher brain centers such as the *thalamus* and *reticular formation.* The pathways are known as the trigeminothalamic and trigeminoreticular tracts, respectively, and they project to higher-order neurons located within the somatosensory cortex and anterior cingulated cortex. The processing of both discriminative (quality, severity, and location) and affective (emotional) components of pain occurs at these cortical levels[4] (Figure 44-1).

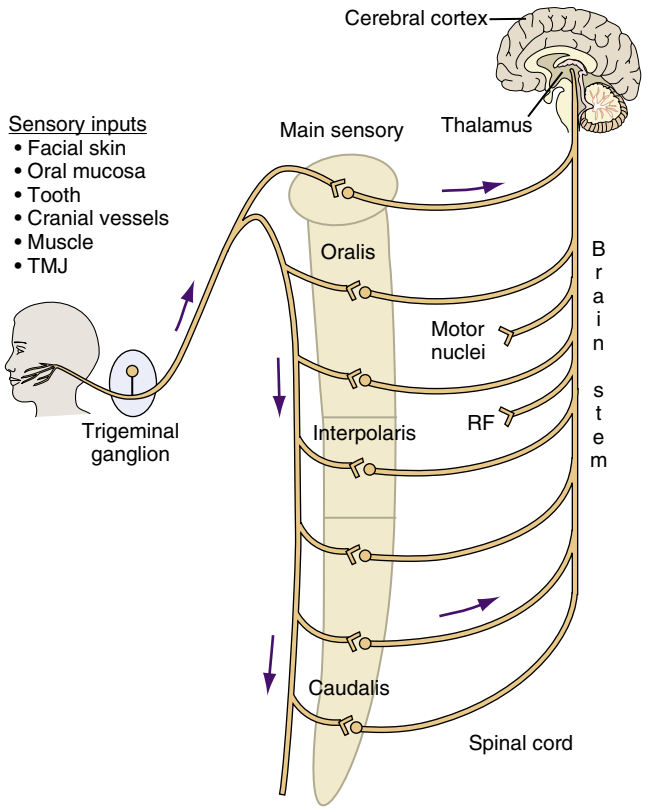

• **Figure 44-1** Trigeminal nerve pain pathway. Pain information within the head and neck is transmitted via the branches of the trigeminal nerve (cranial nerve V), whose sensory neurons are located in the trigeminal ganglion. Information is further processed as it courses through second-order neurons in the spinal trigeminal nuclear complex within the brainstem, thalamus, and cerebral cortex. (From Sessle BJ: Acute and chronic craniofacial pain: brainstem mechanisms of nociceptive transmission and neuroplasticity, and their clinical correlates, *Crit Rev Oral Biol Med* 11(1):57-92, 2000.)

Peripheral Mechanisms of Pain

Considerable advances have been made in the past 2 decades in identifying cellular and molecular mechanisms involved in facial pain transmission. Injury to peripheral tissues certainly occurs during oral and maxillofacial surgical procedures. Pain generally occurs during tissue damage and is a result of release of neurotransmitters, cytokines, and factors from damaged cells, adjacent blood vessels, and nerve terminals. Prostaglandins, substance P, calcitonin gene–related peptide (CGRP), bradykinins, histamine, interleukin-1 and interleukin-6, and serotonin are examples of proinflammatory mediators that are involved in the generation of the inflammatory state that accompanies tissue destruction.[5-7]

Pain transduction occurs when these proinflammatory mediators interact with channels and receptors expressed on the peripheral nerve membrane. These are specialized structures that detect a diversity of chemical and thermal stimuli (Figure 44-2). During minor tissue damage, proinflammatory mediators are released and bind to their respective receptor or channel, and pain transduction occurs and resolves over time. Peripheral sensitization occurs when the peripheral nerve becomes sensitized because of constant stimulation and activation. This may be in the form of decreased excitation thresholds, upregulation of receptors and/or channels in both nerve terminals and sensory neurons, or recruitment of previously silent pain receptors or nociceptors.[8-9]

Neurophysiology of Peripheral Nerve Fibers

Peripheral nerve fibers, also known as primary afferent nerve fibers, are generally classified according to degree of myelination and conduction velocities. The A beta (Aβ) fibers are myelinated and have fast conduction velocities (35-120 m/sec). These fibers transmit mechanosensory information and have specialized terminals called Meissner's, Pacinian, Merkel's, and Ruffini's corpuscles located within skin.[10] Although this fiber type does not transmit painful information, current studies have now demonstrated their role in chronic pain states. Nerve fibers that transmit pain and thermal information are known as A delta and C fibers and are lightly myelinated and unmyelinated, respectively. The A delta (Aδ) fibers have relatively fast conduction velocities (5-30 m/sec) when compared to C fibers (0.5-2 m/sec). Both Aδ and C fibers terminate in skin, bone, muscle, and joints as free nerve endings.

Peripheral nerve fibers that innervate the head and neck arise from the ophthalmic (V1), maxillary (V2), and mandibular (V3) divisions of the trigeminal nerve (cranial nerve V [CN V]) as well as cutaneous inputs from cervical spinal nerves as far caudal as spinal C7.[4,11] The extensive rostrocaudal input of painful information from the head

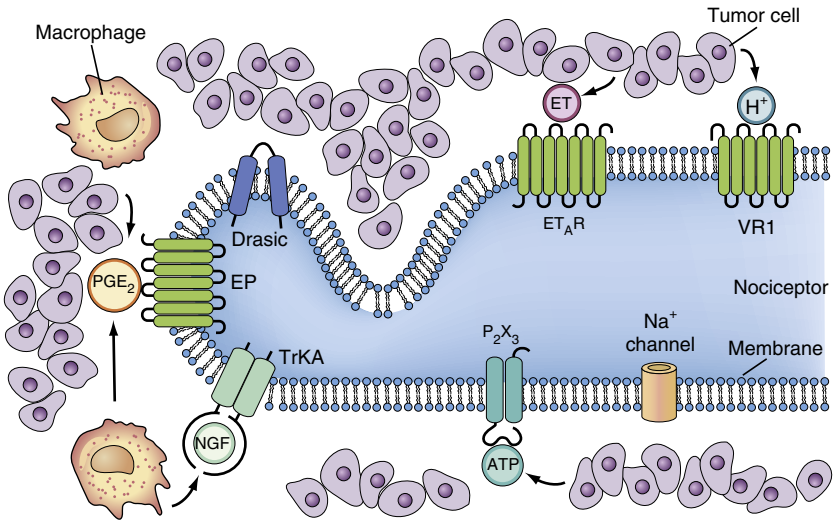

• **Figure 44-2** Interaction between inflammatory mediators and receptors. Schematic diagram of a peripheral pain fiber expressing receptors and ion channels. Interaction between neurotransmitters and inflammatory mediators and their cognate receptor results in pain transduction and signaling. (From Mantyh PW, Clohisy DR, Koltzenburg M, et al: Molecular mechanisms of cancer pain, *Nature Rev Cancer* 2(3):201-209, 2002.)

and neck as well as significant convergence of input from other cranial and spinal nerves (e.g., CN X, CN XII, cervical spinal nerves) may in part explain the referral patterns in the chronic pain patient.[12]

Central Mechanisms of Pain

Centrally mediated pain is defined as pain initiated or caused by a primary lesion or dysfunction in the central nervous system. While it is rare in practice to see patients with primary CNS lesions, it is not uncommon for chronic facial pain patients to be first evaluated by an oral and maxillofacial surgeon. The primary mechanism for chronic pain lies in neuroplastic changes that occur within the central nervous system in response to chronic painful stimuli.[13] Much of the research in central pain mechanisms is related to other chronic pain conditions such as traumatic neuropathy and diabetic neuropathy in both animal and human models.[14] Certainly animal models of chronic facial pain exist that have increased our understanding of the pathophysiology of centrally mediated chronic facial pain.[4]

Central Sensitization

Central sensitization refers to the heightened reactivity of central nervous system neurons in the face of sustained peripheral neural input. While this may occur within the thalamus and cortex, research has been primarily focused on the dorsal horn of the spinal cord. Electrophysiologic and anatomic studies have demonstrated a change in the activity and responsiveness of dorsal horn neurons in response to persistent painful stimulation.

Persistent stimulation of unmyelinated C fibers results in the increased activity and responsiveness of spinal neurons that receive input from the stimulated unmyelinated C fiber. This increased responsiveness is of short (10 sec) duration and is known as *wind up*. Sensitization can also occur when persistent stimulation results in phenotypic changes in neurons that do not receive persistent painful stimulation, but are adjacent to neurons that do receive painful input. Typically these neurons receive input from Aβ fibers that normally do not transmit painful stimuli. However, once sensitized, these neurons are capable of transmitting both nonpainful and painful information. Central sensitization is mediated in part by glutamate, substance P, prostaglandins, and growth factors. These receptors/ion channels are known as *N*-methyl-D-aspartate (NMDA), neurokinin-1 (NK-1), EP, and tyrosine kinase B (trkB), respectively. Upregulation of transient receptor potential (TRPV1) and sodium channels has also been reported in central sensitization. Pain evoked from a stimulus that normally does not evoke pain (allodynia) may result from central sensitization.[4,13]

Descending Inhibitory Control

A protective mechanism exists in which adrenergic and serotoninergic fibers arising from the hypothalamus and periaqueductal gray matter descend and terminate in the medulla and superficial dorsal horn. This descending pathway controls or dampens painful sensory input from primary afferent fibers arising from the periphery. Chemical denervation of the inhibitory pathway results in an increased response to a stimulus that is normally painful (hyperalgesia). Inhibitory receptors have also been shown to be reduced in animal models of chronic pain. Thus disruption of inhibitory pathways that are normally tonically active may also result in chronic pain.[15]

The constant barrage of neurochemicals that are implicated in pain transmission results in changes in the activity and phenotype of nerve fibers and neurons within the

peripheral and central nervous system. These changes result in a chronic and debilitating condition that is recalcitrant to many conventional modes of acute pain therapy. The chronic pain patient has a "pain portrait" that is distinct from the acute pain patient and its management reflects this difference. However, not all chronic facial pain entities are alike. Diagnosis of the facial pain patient requires meticulous investigation and educated elimination of other pain entities.

Evaluation of the Facial Pain Patient

The chronic facial pain patient poses one of the most challenging cases to the oral and maxillofacial surgeon. One major reason is because pain is primarily subjective in nature. It is difficult to measure pain objectively because it cannot be seen nor is it palpable on clinical exam. The clinician is required to gather clinical and historical information, formulate a list of differential diagnoses, and systematically eliminate least likely entities until a final diagnosis is achieved. To formulate a list of differential diagnoses assumes that the most common and simplest forms of pain have been eliminated. A thorough assessment of the patient's history of present illness can be obtained by asking pointed questions that may identify the etiology or etiologies of the patient's facial pain. Questions regarding incidence, character, and duration as well as treatment modalities—particularly those that have already been employed to treat the pain—may also assist in the diagnosis of facial pain. The key to successful diagnosis of the chronic facial pain patient lies in comprehensive and accurate inquiry aimed to identify and answer key questions to develop a list of differential diagnoses.

Chief Complaint

The patient's chief complaint should always be documented in his/her own words with the use of parentheses. The severity of the patient's pain at time of examination must be documented. The two most frequently used methods to assess pain intensity are the visual analogue scale (VAS) and the numeric pain rating scale (NPRS). In the VAS the patient marks a line to indicate pain severity which will be measured in centimeters from 0 (no pain) to the patient marked rating on a horizontal or vertical 10-cm line.[16] The NPRS is different in that the patient verbalizes a number corresponding to the extent of his/her pain: 0 is no pain and 10 is the worst pain imaginable.

History of Present Illness

Pain onset and duration are important to determine whether the onset was acute in nature or developed gradually over time. This is a particularly challenging task with most facial pain patients. In general, there is an association made with an event, procedure, or circumstance that may not have a role in the generation of the symptoms. If the facial pain is acute, one must further question the events surrounding its onset. If the facial pain is chronic, one must further question acceleration and remission periods. A history of previous surgical and nonsurgical therapies to treat facial pain must also be elucidated to establish a diagnosis, assess prognosis, and define a surgical plan if indicated.

The location, quality, character, and radiation of pain should be assessed in the facial pain patient. Diffuse or localized pain will identify whether the pain is isolated to a single anatomic entity or whether multiple structures are involved. The patient must be asked to indicate, by one finger pointing to the area, where the pain is most severe. Descriptions of pain character such as "dull and throbbing" or "sharp and stabbing" will help to identify what dominant peripheral nerve fiber type is involved, which will assist in determining type of facial pain entity. Facial pain may radiate or be referred to adjacent muscular structures and the forehead, sometimes suggesting generalized myofascial pain disorder.

The pain impact on the patient's sleeping, function, and quality of life is very significant for numerous reasons. Sleep disturbance may imply an acute dental condition such as irreversible pulpitis or acute dentoalveolar abscess.[17] Sleep disturbance may result in generalized muscle pain, reduced pain thresholds, and reduced coping ability. Sleeping and daily function can influence treatment protocols and prognosis.[17]

The patient should be asked about analgesics used in attempts to alleviate facial pain and whether these analgesics are efficacious. The chronic use of opioids, spasmolytics, and antidepressants to manage facial pain is typically seen in patients with a preexisting diagnosis of chronic facial pain. Questions should be directed towards identifying therapies or medications that relieve pain. For example, if nonsteroidal anti-inflammatory drugs and heat packs relieve pain, the patient likely suffers from mild inflammation of the muscle and/or joint. Habits should also be assessed to determine if the etiology of facial pain arises from parafunctional habits such as repetitive jaw motion or extreme jaw forces from gum chewing or clenching, respectively.

Past Medical History Related to the Facial Pain Patient

The review of a patient's medical history is always important; however, it is clear that certain systemic conditions are commonly observed in the chronic facial pain patient. It is important to determine whether anxiety, depression, and/or other psychogenic disorders are present and appropriately managed. Clearly, facial pain patients with concomitant depression derive benefit from antidepressant medication. Fibromyalgia is another chronic pain entity that affects 4% of Americans. It is generally associated with diffuse generalized pain and fatigue and occurs in approximately 15% to 20% of facial pain patients.[12] Other systemic disorders that are commonly observed in the chronic facial pain patient include autoimmune diseases such as osteoarthritis, rheumatoid arthritis, and

migraine symptoms and headaches.[18] The concomitant comorbidities of systemic disease and chronic facial pain add to the complexity of the diagnosis and management of this challenging condition.

Clinical Examination

A thorough dental examination must be performed to rule out odontogenic sources of pain and avoid unnecessary dental treatments (Figure 44-3). In most clinical practice, the referring general dentist or clinician will have diagnosed the most common entities that cause pain: dental caries and infection. Facial pain may be referred from teeth and/or supportive structures and therefore pathology associated with such structures must be ruled out.

The most common and frequently seen pathology that results in facial pain includes the following:

- Tooth fractures
- Caries
- Temporomandibular disorders (TMDs)
- Salivary gland disease
- Ulcers
- Infection
- Neoplasms

Although the clinical examination and radiologic findings associated with these pathologies are beyond the scope of this chapter, it is important to exclude these entities to obtain the diagnosis of chronic facial pain. In addition, patients with no observable etiology of facial pain cannot be dismissed as hypochondriacs. Some insidious neoplasms, both benign and malignant, develop slowly. Pain may be the first sign that a neoplasm is present before progressing to a size that is detectable by either clinical evaluation or imaging.

The clinical examination of the chronic facial pain patient is very challenging because there is no visible entity that can easily be seen or felt. Instead, the clinical examination should focus on the following aspects to derive a list of differential diagnoses:

- Location
  - Identify etiology of pain by location (sensory nerve innervation).
  - Does the pain arise from dental, gingival, dentoalveolar or other structures?
  - Does the pain arise from stimulation of a specific sensory nerve distribution?
  - Is the pain limited to a specific sensory distribution?
  - Does the pain radiate to other structures within or beyond the head and neck?
  - Do the involved structures demonstrate abnormalities in color, temperature, turgor, or sensation?
- Duration
  - Identify whether the pain is intermittent or constant.
  - If evoked, identify the type of stimuli that causes the pain.
  - Is the pain sharp and stabbing when stimulated?
  - Is the pain reproducible and consistent?
  - Does the pain spontaneously resolve?
- Character
  - Identify the general pain sensation.
  - Is the pain sharp, dull, or lancinating?
  - Is the pain a burning sensation?
  - Are there any sensations other than pain that coexist (for example, tingling, numbness, formication)?
- Presence of sensory or motor deficits
  - Quantitative clinical neurosensory testing must be performed for all patients with documented sensory deficits.[19]



• **Figure 44-3** Panoramic radiograph of a facial pain patient who underwent multiple root canal therapies to treat her facial pain. Following referral to an appropriate facial pain specialist, the patient was properly diagnosed and medically managed. (Courtesy Donald Nixdorf, University of Minnesota.)

- Level A testing assesses spatiotemporal sensory discrimination using two methods: brush stroke directional testing and two-point discrimination. Both methods assess the discriminatory competency of myelinated Aβ fibers.
- Level B testing assesses static sensory discrimination using Semmes-Weinstein nylon monofilaments of graded thicknesses. Electronic versions are available.
- Level C testing assesses sharp-dull discrimination and pain thresholds. Specialized equipment such as calibrated thermodes or pain algometers is available although a sharp instrument (e.g., needle) may be used. This level of testing assesses the competency of unmyelinated C fibers and lightly myelinated Aδ fibers.
- Responses to interventions
- Are there any modalities, activities or action that reduces or eliminates the pain?
- Is the pain diminished, changed or resolved by pharmacologic agents, including over the counter interventions, opioids, or other analgesics?

Pain Descriptors

A sensory map should be developed based on the clinical neurosensory examination. In unilateral cases, both sides of the head and neck should be evaluated; the contralateral side may serve as an internal control. Based on the clinical findings and patient interview, the facial pain entity may now be described using conventional pain terminology (Table 44-1). Following the patient interview and clinical examination, the clinician is now able to describe the facial pain entity. Utilization of appropriate terminology will improve communication between health care professionals, assist in formulating a list of differential diagnoses, and assess the progress of both the pain condition and the treatment rendered.

Imaging Modalities

Appropriate imaging studies may be necessary to allow the clinician to derive a list of differential diagnoses and exclude certain conditions. Depending on the source, character, and complexity of pain, multiple imaging modalities may be considered. While it is appropriate to consider imaging studies, chronic facial pain is difficult to diagnose with imaging studies as there is a lack of definitive abnormalities that are characteristic or pathognomonic for facial pain.[20]

- Orthopantomogram: The orthopantomogram is the most common screening film used in the oral and maxillofacial surgery practice. It is both economical and practical in its use and provides minimum radiation exposure to the patient. Additionally, patients often have panoramic radiographs that predate the consultation visit or date of onset of pain that can be used as a reference or baseline image. While panoramic imaging may not establish the clinical diagnosis, it has its utility as a screening tool before requesting more advanced imaging.[21]

TABLE 44-1 Pain Definitions

Type of Pain	Definition
Allodynia	Pain evoked with stimulus that normally does not provoke pain
Analgesia	Absence of pain in response to stimulation that would normally be painful
Causalgia	A syndrome of sustained burning pain, allodynia, and hyperpathia after a traumatic nerve lesion, often combined with vasomotor and sudomotor dysfunction and later trophic changes
Dysesthesia	An unpleasant abnormal sensation, whether spontaneous or evoked
Hyperesthesia	Increased sensitivity to stimulation
Hypoesthesia	Diminished sensitivity to stimulation
Hyperalgesia	Increased pain from a stimulus that normally provokes pain
Hypoalgesia	Diminished pain in response to a normally painful stimulus
Hyperpathia	A painful syndrome characterized by an abnormally painful reaction to a stimulus, especially a repetitive stimulus, as well as an increased threshold
Neuralgia	Pain in distribution of nerve or nerves
Neuropathic pain	Pain caused by a lesion or disease of the somatosensory nervous system
Neuropathy	A disturbance of function or pathologic change in a nerve: in one nerve, mononeuropathy; in several nerves, mononeuropathy multiplex; if diffuse and bilateral, polyneuropathy
Paresthesia	An abnormal sensation, whether spontaneous or evoked

From Merskey H, Bogduk N, editors: IASP Task Force on Taxonomy. In *Classification of chronic pain,* ed 2, Seattle, 1994, IASP Press, pp 209-214.

- Computed tomographic (CT) imaging including cone beam CT scans (CBCT): Although CT imaging is not a standard modality for chronic pain, newer techniques that use CT technology are being used for facial pain patients. CT imaging is useful mostly to evaluate the bony elements of the TMJ. 3D CT and a stereolithography model fabrication are crucial in the processing of planning complex reconstructive surgeries.
- The role of single photon emission computed tomography with technetium 99m methylene diphosphonate (SPECT with 99mTc-MDP) and computed tomography (CT) to diagnose facial pain has been reported.[22] This technology uses radiolabeled technetium to identify areas of increased bone metabolism and uses diphosphonates, which display strong affinity to hydroxylapatite crystals within bone. Using SPECT technology, data are acquired in all three planes (axial, coronal, and sagittal planes) to allow for three-dimensional mapping. When used in conjunction with conventional CT data, functional anatomic mapping is obtained, which allows for 3D rendering. Advantages include (1) low radiation requirements (0.00675 Gy per 70-kg adult) and (2) high sensitivity. Disadvantages include (1) the need for specialized equipment and staff, (2) cost, and (3) poor specificity. SPECT in conjunction with CT is currently being used in oncology as a surveillance tool.
- Magnetic resonance imaging (MRI): Clinical evaluation of the TMJ can be nonspecific due to overlap of symptoms between internal derangement and myofascial pain and dysfunction. MRI should be part of the standard evaluation when an internal structural joint abnormality is suspected. The MRI imaging allows for a detailed evaluation of the anatomy as well as biomechanics of the joint through open and closed mouth imaging.[23] It is also used as a tool to eliminate any intracranial lesion that can mimic craniofacial pain symptoms.
- Functional magnetic resonance imaging (fMRI) is an indirect method used to assess neural activity within the central nervous system. It utilizes the BOLD effect, or changes in blood oxygenation, by quantifying the relative concentrations of oxyhemoglobin and deoxyhemoglobin. An increase in blood flow and, hence, neural activity results in a decrease in deoxyhemoglobin level. These changes are then mapped onto previously obtained anatomic maps of the patient's brain. Functional MRI has been used in studies of headache, acute dental pain, trigeminal neuropathy, and atypical facial pain to examine areas within the cortex that are involved in pain processing.[20,24] Both discriminative and affective components of pain have been mapped to the somatosensory cortex and anterior cingulate cortex, respectively, based on fMRI studies. While its utility in examining treatment success has been reported, its diagnostic capabilities remain limited because of a relative paucity of neuroimaging studies on trigeminal pain pathways.[24]

Differential Diagnosis

After establishing the character, duration, quantity, and quality of the facial pain entity, the clinician must eliminate more common facial pain causation or etiology. Then, augmenting information gleaned from the patient interview and exam with appropriate imaging modalities, the clinician is able to derive a list of differential diagnoses of chronic facial pain entities. While the differential diagnoses are only a partial listing of all chronic facial pain states, these are the most commonly encountered and the most challenging to diagnose.

Complex Regional Pain Syndrome (CRPS)

Complex regional pain syndrome (CRPS) is a pathology that has been described as occurring almost always in an appendage. However, there are patients in whom the face, head, and neck are affected. Very few patients were found to meet the International Association for the Study of Pain criteria for this disease. The clinical characteristics were similar to those of CRPS elsewhere in the body, with the main features being burning pain, hyperalgesia, and hyperesthesia starting after a trauma to the craniofacial region.[25] The diagnosis of CRPS is based almost exclusively on clinical examination. Two types of CRPS exist: type I or reflex sympathetic dystrophy (RSD) and type II or causalgia. Based on the 2005 consensus meeting of the International Association for the Study of Pain (IASP), the diagnosis of CRPS can be made if the following criteria are fulfilled:

- The presence of a noxious initiating event without nerve damage (type I: reflex sympathetic dystrophy) or with nerve damage (type II: causalgia)
- Spontaneous pain or hyperalgesia that is disproportionate to the inciting event and that extends beyond a single nerve territory
- Autonomic dysfunction: edema, cutaneous blood flow changes (increased or decreased), motor changes, and/or trophic changes
- All other diagnoses are excluded.

Nearly 75% of patients with CRPS type I or RSD will demonstrate pain that is described as aching, burning, or pricking in nature. Sometimes the pain can be "shooting" in character. All will describe some type of hyperalgesia to innocuous mechanical stimuli that may extend beyond the site of injury. This finding highlights the central sensitization that occurs in RSD. Muscle weakness or tremors may be observed in as high as 75% of RSD patients. Autonomic disturbances, such as edema and thermal cutaneous dysregulation, and trophic changes, such as disruptions in hair growth and skin atrophy, are seen in more severe cases of RSD.[14]

CRPS II or causalgia is distinguished from RSD if nerve damage is present. Similar to other neuropathic pain conditions, pain resulting from causalgia is described as electrical or shooting pain. Some patients may also exhibit areas of simultaneous hypoesthesia and extreme allodynia. Autonomic and motor disturbances similar to those seen in RSD are present.[26]

Management of CRPS should be aimed at reducing pain and enabling function. Pharmacologic treatment with tricyclic antidepressants, selective serotonin reuptake inhibitors (SSRIs), anticonvulsants, gabapentin, steroids, and opioids has been described.[27] In the head and neck region a treatment including a series of stellate ganglion anesthetic blocks was reported to have a good outcome.[25]

Neuralgia-Inducing Cavitational Osteonecrosis (NICO)

Since first described, the concept of NICO has been questioned by some clinicians.[28-30] NICO has been defined as a syndrome of chronic neuralgia-like facial pain associated with intraosseous cavity formation and long-standing cancellous bone necrosis of the jaws with minimal regenerative capabilities.[31] The pathophysiology of NICO is not clear. Multiple etiologies have been suggested including infection, bone marrow ischemia, coagulation related factors, and autoimmune concept based on antibodies to peripheral nerve myelin.[30,31] From an epidemiologic standpoint the prevalence of this condition is unknown. Patients with NICO complain of continuous or paroxysmal pain that is sharp, stabbing, burning, and lancinating in character. The location of pain is primarily at the site over the alveolar bone of a previously extracted tooth site. Symptoms have been reported to be unilateral or bilateral and involve both the maxillary and mandibular tooth-bearing areas. The symptoms may be referred to a larger area, often crossing midline structures.

Diagnosis requires a multifaceted approach that includes palpation, diagnostic anesthesia testing, radiographs, computed tomography scan, MRI (looking for chronic bone marrow ischemia), and Tc-99 scan. According to Bouquot, between 75% and 79% of patients with atypical facial neuralgia pain will demonstrated hot spots with technetium-99 scan.[28,30]

A definitive diagnosis of NICO is clinically difficult to establish and recommended treatment is moderately invasive. Treatment of NICO lesions has been primarily debridement of cavitary lesions with removal of cortical bone and exploration of medullary bone until "bone cavities" are identified. Long-term management includes either gauze-impregnated packing or injectable antibiotics for up to 9 weeks' duration. Approximately 70% of patients report decreases in pain after surgery; however, recurrence in pain symptoms is often seen. Management of NICO with warfarin and stanozolol has been reported; however, pain relief and side effect profiles limit their utility.

Persistent Idiopathic Facial Pain (Atypical Facial Pain)

Atypical facial pain (AFP) or persistent idiopathic facial pain (PIFP) is primarily a diagnosis of exclusion that is based primarily on history and clinical examination. Like many chronic facial pain entities, atypical facial pain cannot be diagnosed based on laboratory and/or radiologic findings as these are typically normal. AFP has an incidence of 1 in 100,000, affects mainly adults, and is equally distributed between men and women. The etiology of PIFP remains unknown. This syndrome consists of mostly unilateral long-lasting facial pain that lasts most of the day, and is described as a severe ache, burning, or crushing sensation. The level of the pain is mild to severe, and no autonomic abnormalities are noted.[32] According to the International Headache Society's 2004 classification, PIFP is "Persistent facial pain that does not have the characteristics of the cranial neuralgias and is not attributed to another disorder."[33]

There are four criteria to be met for the diagnosis:

1. There is pain in the face present for most of the day or all day and occurring daily.
2. Initially, the pain may be confined to a portion of the face, but is poorly localized and deep.
3. It is not associated with other physical signs or loss of sensation.
4. Workup in terms of imaging is unrevealing of an obvious anatomic or structural cause.

It may follow an operation or trauma to the face, teeth, or gums, but persists without a known local factor.

The treatment modalities can include pharmacologic treatment such as tricyclic antidepressants or anticonvulsant drugs. Topical anesthetic agents, Botulinum toxin A, and cannabis have been suggested as a treatment as well.

Atypical Odontalgia

Atypical odontalgia (AO) is one of the most challenging conditions an oral and maxillofacial surgeon will face. To fulfill the diagnostic criteria for atypical odontalgia, the following conditions must be met:

- Pain is located in the mouth or face.
- Pain is described as a constant, deep, and dull ache.
- Onset of pain is associated with a dental procedure (e.g., extraction, endodontic therapy) and develops within 1 month of the procedure and persists for more than 4 months.
- Sleep is undisturbed.
- The area of hyperalgesia associated with trauma is surrounded by an area of less hyperalgesia.
- Local anesthetic injections are equivocal.
- Radiographic and laboratory tests are negative.

Atypical odontalgia can occur in as many as 6% of patients who have undergone endodontic therapy and has a reported incidence rate of 25% within the chronic facial pain community.[34] It has a female predilection and occurs in the fourth decade of life. Psychogenic, neurovascular, and

neuropathic etiologies have been hypothesized. An association between atypical odontalgia and concomitant depression and/or personality disorder was shown in as many as 66% of sufferers. However, a deafferentation injury to trigeminal nerves appears to be the most accredited theory. Trauma to dentoalveolar structures has been hypothesized to result in both peripheral and central sensitization, resulting in allodynia and hyperalgesia commonly found in AO. Management of AO is primarily pharmacologic as dental intervention only worsens the condition.[35] The patient's psychogenic background should always be considered in the treatment and/or management of AO.[9]

Stomatodynia (Burning Mouth Syndrome)

Stomatodynia or burning mouth syndrome (BMS) is characterized by a burning mucosal pain with no evidence of mucosal pathology, often accompanied by dysgeusia and xerostomia. It commonly affects women more than men (7:1) in the age range of 38 to 78 years. The incidence of BMS worldwide ranges from 0.7% to 14.8% depending on diagnostic criteria used.

Inclusion criteria include the following:[16]

- Oral pain or dysesthesia of a burning quality
- Present daily and persisting most of the day
- Oral mucosa is of normal appearance
- Unremitting pain for at least 3 months
- Pain does not interfere with sleep

The pain associated with stomatodynia is described as a prolonged burning, tingling, and numbing pain, onset of which does not generally coincide with an inciting event. However, previous dental procedures have been implicated in some cases of stomatodynia. The pain never worsens from, but may be relieved by, eating or drinking. The duration of pain is typically greater than 3 months and may persist beyond 12 years. Spontaneous pain remission is rare. The pain is often accompanied by dysgeusia and/or xerostomia; more than half of stomatodynia patients complain of persistent taste alterations that are characterized as bitter and/or metallic. Xerostomia and salivary dysfunction are also a common finding in the stomatodynia patient.[13] BMS can be associated with mood changes or disruptions in personality traits.

The etiology of stomatodynia is poorly understood and remains elusive to many facial pain experts. It may be due to psychogenic, nutritional, and neuronal disturbances. The current neuronal disturbance etiology supports two main theories: a sensory neuropathy either peripheral and/or central or disturbance in the balance between the gustatory and sensory system. Systemic nutritional factors should be identified and corrected. Patients with stomatodynia and concomitant psychologic disturbances should be referred for appropriate management. Medical management of stomatodynia with systemic[36] and topical[11] capsaicin are described. Systemic and topical benzodiazepines (most frequently Clonazepam) were used with variable success.[37-41]

Medical management of stomatodynia with topical capsaicin, anticonvulsants, and tricyclic antidepressants has been proposed; however, these treatment options remain unsatisfactory. No definitive cure exists.

Nerve Injury From Dental Procedures

Chemical or traumatic nerve injury may occur following endodontic therapy, placement of endosseous implants, mandibular third molar extractions, and administration of local anesthetics. These types of nerve injuries may also occur in association with facial trauma and their subsequent treatment as well as during orthognathic surgery, particularly sagittal split ramus osteotomy. Nerve injury associated with trauma and orthognathic surgery is less likely to result in complaints of chronic facial pain compared to dentoalveolar procedures. Sensory disturbances may vary from partial anesthesia or paresthesia, to complete anesthesia, to dysesthesia with or without anesthesia. Multiple hypotheses regarding the pathophysiology of nerve injury exist and are dependent on the mode of injury.

- Direct surgical trauma/nerve manipulation (induced nerve injury): It is clear from review of the literature that the most likely common surgical procedure that results in temporary or permanent nerve injury is surgical removal of mandibular third molars. The incidence rates are as follows although some have opined that these rates of injury are a likely underestimation of true incidence: [42]
  - Inferior alveolar nerve (IAN) permanent injury: 4 per 1000 cases
  - Lingual nerve permanent injury: 1:1000 cases
  - 80% of IAN injuries have a known cause.
  - 57% of lingual nerve injuries have an unknown etiology.

Endosseous implant placement is a potential source of surgically induced nerve injury. Similar to third molar extraction, the inferior alveolar nerve canal and lingual nerve are adjacent to the surgical sites during mandibular implant osteotomy and placement. This proximity increases the likelihood of damaging the adjacent peripheral nerves. The prevalence of temporary sensory disturbances ranges from no damage to 43% while permanent damage may be as high as 13% of patients undergoing implant placement.[43,44] Prompt management is recommended if nerve damage is directly visualized.

When known, the likely etiology for both extraction-induced and implant placement–induced nerve injury is direct trauma to the neurovascular bundle (IAN) or nerve (lingual). The reader is directed to the dentoalveolar chapter for further information regarding surgical management of nerve injury.

- Endodontic therapy–induced nerve injury: The inferior alveolar nerve is more commonly damaged during endodontic therapy than the lingual nerve. Nerve injury is likely due to chemical injury from extrusion of root canal–filling materials beyond the apex of the root.[45,46] Materials such as paraformaldehyde-containing Sargenti

paste[47] (Figure 44-4) and inert gutta-percha[45] have been reported to cause painful dysesthesias following root canal treatment. Neurologic disturbances such as hyperesthesia and dysesthesias in the distribution of the IAN are commonly observed. Hyperesthesia is rarely seen. Surgical management in the form of careful debridement and decompression of the nerve with conservation of teeth has been reported.[46]

- Mandibular nerve block–induced nerve injury: Recent attention has focused on nerve injuries following administration of local anesthetics via the mandibular nerve block. The prevalence of temporary sensory deficits following block anesthesia ranges from 0.15% to 0.54% whereas permanent damage occurs with a much larger range: from as low as <0.01%[48] to as high as 3%.[49]

Many hypotheses exist regarding the etiology of nerve injury from mandibular block anesthesia. Direct fascicular damage to the nerve sheath has been proposed. This may be due to either direct needle penetration within the nerve or tearing of the epineurial sheath with a barbed needle. It has been well documented that the lingual nerve is more commonly injured during mandibular blocks. This may be due to the lingual nerve being ensheathed within the interpterygoid fascia, therefore being unable to deflect during needle contact. An electrical shock during initial needle placement has been reported in over 50% of patients with nerve injury[49] and further supports the direct injury theory.

Alternatively, the type and concentration of local anesthetic delivered have been examined.[5,48,50] In these studies, the most common local anesthetics associated with permanent sensory deficits were 4% articaine and 3% prilocaine with vasoconstrictors. Such high concentrations have been shown to cause microstructural damage to neural architecture in an experimental model; however, no gross structural abnormalities were observed clinically.[49] The volume of local anesthetic did not appear to influence onset or severity of nerve injury. Of the patients with sensory nerve deficits from mandibular block anesthesia, 85% to 94% will have symptoms that resolve spontaneously, and this occurs over an 8-week period. Of those who do not spontaneously resolve, more than two thirds will have permanent sensory impairment. Surgical intervention does not appear to resolve symptoms and may in fact worsen the clinical course.

It is difficult to determine or predict which patients with direct nerve injury will suffer from chronic pain. The patient who exhibits symptoms of paresthesia or anesthesia in conjunction with chronic facial pain symptoms may be a daunting diagnostic and treatment challenge. Treatment must be focused on goals of restoring sensation while at the same time controlling or eliminating pain. Many patients with facial pain will choose sensory deficit over facial pain if given a choice or ultimatum.

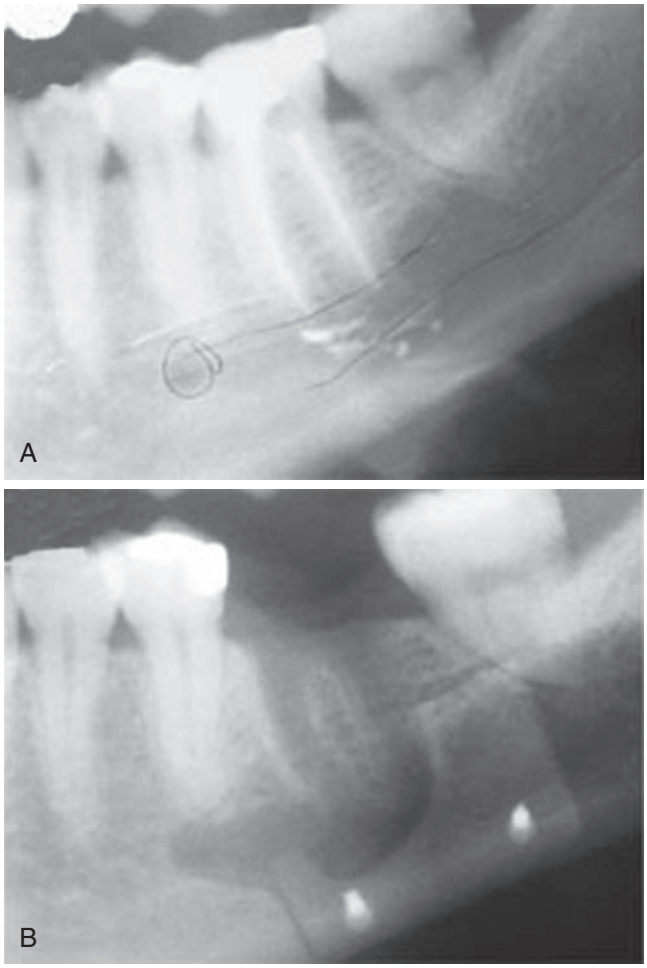

• **Figure 44-4** **A,** Panoramic radiographs of a patient who underwent endodontic therapy with Sargenti paste to tooth #19. Note the opaque material within the area of the inferior alveolar nerve canal. The patient complained of significant burning and shooting pain. She subsequently underwent multiple surgical procedures including lateral corticotomy, debridement, nerve decompression, and translocation, **B,** without resolution of her symptoms.

Facial Pain of Cardiac Origin

Case reports describing facial pain of cardiac origin have been documented[51-53] and may occur in as many as 18% of cardiac patients who complain of jaw and tooth pain.[53] This pain is primarily due to pain as a result of cardiac ischemia. The neurophysiologic basis for this occurrence is due to significant convergence of vagal nerve fibers arising from cardiac smooth muscle within the same spinal segments (medullary dorsal horn and cervical spinal cord) as trigeminal sensory neurons. Orofacial pain of cardiac origin most often will be described as burning and oppressive toothache that occurs spontaneously, usually in relation to exercise, and can be bilateral; the pain decreases with nitroglycerin tablets and is usually associated with chest pain, anterior neck pain, and/or shoulder pain, although it can also manifest as an isolated case. Toothache of cardiac origin may occur as a single clinical manifestation in the oral cavity, affecting adults as well as the elderly and children. There are also other craniofacial regions where this "heterotopic pain" (a pain in this region even though the source may be located elsewhere in the body) of cardiac origin can manifest in isolation as the paranasal sinuses, head, mandibular area, and

the temporomandibular joint region, though mainly it will be located in the mandible and throat. It can radiate to other craniofacial structures.[54] Clinicians should consider cardiac ischemia as a potential etiology of chronic constant or recurring facial pain without obvious dental or orofacial etiology. Prompt referral for cardiac evaluation is recommended.

Eagle's Syndrome

Eagle's syndrome is characterized by an elongated styloid process or calcified stylohyoid ligament and facial pain; this syndrome affects women more than men. The pain is variable and can be complex. Pain can be constant within the throat, ear, or temporal region or it can be elicited with changes in head position or palpation of the styloid process. Eagle divided his syndrome into two subgroups: classic type and carotid type. The most common symptoms of classic type are as follows: [55]

- Vague pain in neck
- Foreign body sensation
- Throat pain
- Pain on swallowing
- Pain on changing head position

In the carotid type, compression over the internal carotid artery can cause pain in the parietal region of the skull or in the superior periorbital region. Dizziness, transient visual loss, syncope, stroke, Horner's syndrome, headache during exercise and straining, and even sudden death have also all been described as a consequence of internal carotid artery compression.

Eagle's syndrome is diagnosed based on the following criteria:

- Patient symptoms
- Palpation of the elongated styloid process overlying the tonsillar pillar
- Temporary relief of symptoms following administration of local anesthetic
- Radiographic evidence of an elongated styloid process or calcified stylohyoid ligament

The syndrome was seen most frequently in women in their fourth and fifth decades. Occasionally, Eagle's patients described prior styloid chain trauma (including tonsillectomy).[56]

The average length of the styloid process is approximately 20 to 30 mm and approximately 4% to 20% of the general population will demonstrate radiologic evidence of an elongated styloid process or mineralized stylohyoid ligament. Of those who present with an enlarged styloid process, less than 0.5% will report painful symptoms, suggesting a poor correlation between patient symptoms and radiologic findings.[57] Panoramic radiographs remain the most common radiologic modality to identify an elongated styloid process. However, lateral skull films, Towne's view radiographs, lateral oblique mandibular radiographs, and CT have all been utilized[58] (Figure 44-5). Because of the character of pain, it is important that the oral and maxillofacial surgeon rule out temporomandibular disorders because TMDs have been found in patients with Eagle's syndrome.[57]

The pathophysiology of Eagle's syndrome is likely caused by (1) impingement of the glossopharyngeal nerve, vagus nerve, or branches of the trigeminal nerve, (2) impingement of the carotid vessels, or (3) inflammation of the tendinous portion of the stylohyoid ligament. Management is by surgical excision of the elongated styloid process via a transoral or transcutaneous approach. Advantages of a transoral approach include that this approach has minimal scar formation, is safe, and is less time-consuming; also, a cutaneous scar is avoided. Disadvantages include poor visibility, risk for possible deep neck infection, and proximity to major vessels. The advantages of a transcutaneous approach include excellent visibility; however, risk for facial nerve injury and a neck scar are possible. While surgical excision remains the standard for managing patients with Eagle's syndrome, facial pain recurs in as many as 20% of

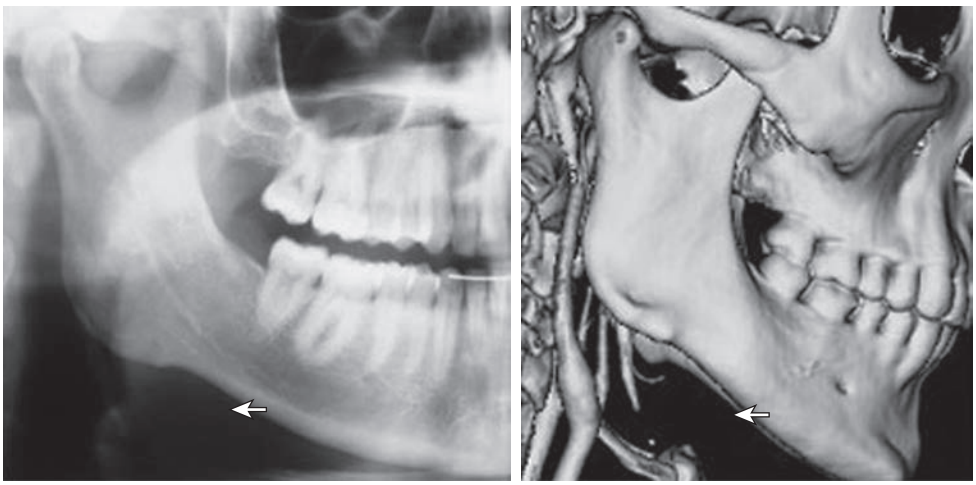

• **Figure 44-5** Reformatted 3D CT and panoramic radiograph of patient with Eagle's syndrome. Note the calcified stylohyoid ligament *(arrow).* Patient complained of vague neck and shoulder pain and dizziness with rotation of his head.

patients who have undergone surgery. Noninvasive management has been described to result in temporary relief of symptoms.

Facial Pain From Osteonecrosis

Radiation exceeding 6000 cGy and chronic intravenous antiresorptive therapy including bisphosphonates have been associated with the development of osteonecrosis of the maxilla and mandible. While the pathophysiology and surgical management of these entities can be found in other chapters within this text, it is important to understand the management of the chronic pain associated with these conditions. Radiation therapy and surgery is the most common treatment regimen used to treat oral cancers. However, it has a clear impact on the cancer survivor's quality of life from a functional, esthetic, and pain perspective. Patients may undergo dental and surgical reconstruction to reestablish masticatory, speech, and facial harmony; however, chronic pain may remain poorly treated.[59] Current pharmacologic strategies using nonsteroidal anti-inflammatory drugs (NSAIDs) and opioid analgesics have only little to moderate benefit. Physical therapy is suggested to be a useful adjunct to manage chronic pain as some patients have shown modest improvement.[59]

Medication-Related Osteonecrosis of the Jaw

Medication-related osteonecrosis of the jaw (MRONJ) is a relatively newly diagnosed clinical entity that has had the medical and dental community concerned.[60,61] MRONJ refers to osteonecrosis cases associated with either bisphosphonates or other antiresorptive and antiangiogenic therapies. It is clear that these therapies improve survival and quality of life in this patient population. However, because of the prolonged life span and, subsequently, prolonged duration of treatment, clinicians must also consider how to manage the sequelae of the chemotherapeutic agent. Diagnostic criteria were established for MRONJ, and patients are considered to have MRONJ if all of the following characteristics are present:[62]

- Current or previous treatment with antiresorptive or antiangiogenic agents
- Exposed bone or bone that can be probed through an intraoral or extraoral fistula in the maxillofacial region that has persisted for longer than 8 weeks
- No history of radiation therapy to the jaws or obvious metastatic disease to the jaws

Similar to other chronic pain conditions, the management of pain associated with MRONJ revolves around the use of NSAIDs and opioid analgesics. Depending on the presence of peripheral neuropathy, adjuvant medication can be considered. While the use of hyperbaric treatment to manage MRONJ remains under scrutiny, several reports have demonstrated its analgesic efficacy and it should be considered.[63-66]

Barriers to the Management of the Chronic Facial Pain Patient

The management of the chronic pain patient has been under scrutiny in recent years resulting in the development of chronic opioid therapy guidelines by the Centers for Disease Control in 2016. The guideline is intended to ensure that clinicians consider the safest and most effective drug therapies, while minimizing the development of adverse effects and/or side effects related to chronic opioid therapy.[67]

Multiple barriers exist between oral and maxillofacial surgeons and the adequate management of the chronic pain patient. Certainly concerns over addiction, tolerance, and side effect profiles of medication all play an important role in pain management strategies. Addiction is defined as a primary chronic disease with psychosocial and environmental factors that influence its development. Addictive behaviors include inability to control drug use, inability to discontinue use despite harmful sequelae, compulsive use of the drug, and craving of the drug. This is not to be mistaken for dependence, an adaptive state whereby discontinuation of drug results in specific withdrawal symptoms related to specific drug cessation or disruption. Finally, tolerance is an expected outcome during chronic drug therapy whereby chronic exposure to drug results in diminished drug effects, potentially necessitating increasing dosages for adequate pain relief. This may also relate to the side effect profile.[68]

In the management of the chronic pain patient, one must expect that dependence and tolerance will occur because of the chronicity of the pain disorder. It should be noted that in most cases, increasing analgesic requirements reflect more about the progression of disease rather than development of tolerance. Tolerance to the respiratory and CNS depressant effects and nausea from chronic opioid use has been observed. However, tolerance to other side effects such as constipation does not occur. Certainly, side effect profiles should not prevent surgeons from adequately treating pain. Such side effects should and can be managed with appropriate pharmacotherapy including antiemetics, promotility agents, and stool softeners.

It is critically important that surgeons discuss the postoperative pain management strategy with the chronic pain patient before surgery. This not only provides the patient with some satisfaction that his/her pain needs have been thoroughly considered, but also provides the platform for establishing an opioid contract.[69] For chronic pain patients who are managed by their primary care physician (PCP), a trilateral opioid contract may be made involving the patient, surgeon, and PCP.[70] The opioid contract should include the following:

- Address issues related to improper use of opioid (including overdosing, seeking medicines elsewhere, selling medicine, or abruptly stopping medicine)
- Terms for disciplinary action (including abuse, missing appointments, violating contract, inappropriate behavior)
- Establish limitations for replacing medications or changing prescriptions

- Inform surgeon of relevant information (e.g., side effects, changes in medical history)

Pain Management Considerations in the Substance Abuser

The substance abuser requires special consideration from a controlled substance pain management standpoint. Opioid and illicit drug abuse is seen in as high as one third of chronic pain patients receiving treatment for chronic pain.[68] The most common illicit drugs abused are marijuana, cocaine, and methamphetamines, occurring in 11%, 5%, and 2% of chronic pain patients, respectively. Approximately 50% of patients who are current illicit drug abusers have had a history of illicit drug abuse and 16% of them also abuse opioids. A history of illicit drug abuse, however, is not correlated with opioid abuse. The concern for substance abuse is a major barrier in the management of the chronic pain patient; however, it should not deter the surgeon from appropriately managing the pain.

Diversion of controlled substances can occur through illegal Internet pharmacies, drug theft, prescription medication forgeries, or through doctor shopping. Doctor shopping remains the most common way physicians believe their patients obtain controlled substances. The following key measures can be taken to help prevent diversion and abuse of controlled substances:

- Ensure that a single physician/surgeon/pain specialist manages all controlled substances.
- Establish an opioid contract.
- Obtain a thorough history including medication use and illicit drug use. Include type, duration, and chronicity of use.
- Obtain medication prescription history before long-term pain management. Discussions with previous physicians and pharmacists should be considered.

Treatment Modalities for Chronic Facial Pain

Currently 70 million Americans suffer from chronic pain and chronic pain results in $100 billion in lost productivity annually. The importance of pain assessment and management is highlighted in The Joint Commission's (TJC) statement mandating that pain be the "fifth" vital sign. Many states now require health care providers to provide appropriate pain management and have even reprimanded health care providers who fail to treat pain.[71] In the new era of chronic pain management, emphasis is placed on graded polypharmacy and utilization of nonpharmaceuticals to augment treatment strategies.

Physical Therapy

The benefits of physical therapy as an integral part of the multidisciplinary management of the facial pain patient are clear. Physical therapy modalities include cautious isometric and repetitive muscle stretching and relaxation exercises, joint mobilization, iontophoresis of specific muscle groups with corticosteroids, continuous or pulsed ultrasound, hot and cold therapy including vapocoolant spray to release taut bands, and transcutaneous electrical neural stimulation (TENS). The main goals for physical therapy include decreasing or eliminating pain, increasing range of motion in patients whose myofascial pain limits mandibular opening, and returning masticatory function. Benefits include cost-effectiveness, reversibility, and noninvasiveness. Indeed, the success of physical therapy relies on the compliance of the patient. Thus patient education becomes critically important. Patients must understand that physical therapy is reversible and therefore they will require both short-term professional therapy and long-term home therapy.[72,73]

Opioid Therapy

For acute breakthrough pain, opioid analgesics may be used. Opioids remain the gold standard drug for the management of moderate to severe pain. They exert their analgesic effects by interacting primarily with mu (μ) receptors, but there are also kappa (κ) opioid receptors located in spinal sites. Expression of μ receptors in peripheral nerve fibers suggests peripheral actions of opioids as well.[74] Side effects of opioid analgesics are related to dosing and patient sensitivity and include nausea and vomiting, sedation, respiratory depression, constipation, and physical dependence. Unfortunately, the concern for abuse and physical dependence has unnecessarily limited clinicians in their willingness to prescribe opioids. Opioids commonly used for acute pain management include codeine, hydrocodone, and oxycodone.

For the chronic pain patient, it is clear that management strategies must be altered compared to managing acute pain. First, a stepwise approach must be initiated where scheduled (or "round the clock") medications are given for the constant pain while rescue medications are given for breakthrough pain. Dose escalation can then be performed by the practitioner until pain is appropriately controlled (Table 44-2). Long-acting opioids should always be used instead of short-acting opioids for round the clock dosing. Morphine sulfate is the most common orally available opioid used for the management of chronic pain.

Fentanyl is an opioid derivative that is 80 times more potent than morphine. It is available in injectable, transdermal, and transmucosal forms, the latter two being more commonly used for chronic pain management.[75] Fentanyl should NOT be used in opioid-naïve patients. Opioid-tolerant individuals are defined as those who require at least (1) 60 mg of oral morphine daily, (2) 30 mg of oral oxycodone daily, or (3) 8 mg of oral hydromorphone daily (Duragesic prescribing information pack, Janssen Pharmaceutica Products, Titusville, NJ). Calculations for transdermal fentanyl (Duragesic) dose conversion are based on the following:

1. Calculate the previous 24-hour analgesic requirements (mg/day).

TABLE 44-2 Management of Chronic Pain With Orally Available Morphine Sulfate

Steps	Morphine Sulfate Immediate Release: Scheduled	Morphine Sulfate Immediate Release: Rescue	Morphine Sulfate Controlled Release: Scheduled	Morphine Sulfate Controlled Release: Rescue
I	10 mg q4h	5 mg q1h	30 mg q4h	7.5 mg q1h
II	15 mg q4h	7.5 mg q1h	60 mg q4h	15 mg q1h
III	30 mg q4h	15 mg q1h	90 mg q4h	15 mg q1h
IV	45 mg q4h	22.5 mg q1h	100 mg q4h	30 mg q1h

Adapted from Lee KF, Ray JB, Dunn GP: Chronic pain management and the surgeon: barriers and opportunities, *J Am Coll Surg* 193(6):689-701, 2001.

TABLE 44-3 Conversion Table for Common Oral Opioids to Transdermal Fentanyl Patch

Current Analgesic	Daily Dosage (mg/d)			
Oral morphine	60-134	135-224	225-314	315-404
IM/IV morphine	10-22	23-37	38-52	53-67
Oral oxycodone	30-67	67.5-112	112.5-157	157.5-202
Oral codeine	150-447	448-747	748-1047	1048-1347
Oral hydromorphone	8-17	17.1-28	28.1-39	39.1-51
IV hydromorphone	1.5-3.4	3.5-5.6	5.7-7.9	8-10
IM meperidine	75-165	166-278	279-390	391-503
Oral methadone	20-44	45-74	75-104	105-134
	⇓	⇓	⇓	⇓
Recommend DURAGESIC dose	25 mcg/h	50 mcg/h	75 mcg/h	100 mcg/h

Table 44-3 should not be used to convert from DURAGESIC to other therapies because this conversion to DURAGESIC is conservative. Use of Table 44-3 for conversion to other analgesic therapies can overestimate the dose of the new agent. Overdosage of the new analgesic agent is possible. DURAGESIC (fentanyl transdermal system), CII Prescribing Information. Janssen Pharmaceuticals, Inc. April, 2014.

2. Convert amount to equianalgesic oral morphine dose (mg/day).
3. Use manufacturer-recommended conversion table (Table 44-3).

The transdermal fentanyl patch has an elimination half-life of 20 to 27 hours and therefore may take as many as 6 days to achieve steady-state concentrations. During the first 16 hours of transdermal therapy, analgesics must be prescribed for chronic breakthrough pain and to prevent withdrawals. The transdermal patch is replaced every 72 hours and should never be cut as this will result in a rapid release and absorption of a potentially fatal dose of fentanyl. Fentanyl patches are commercially available in 12, 25, 50, 75, and 100 mcg/hr systems. These patches are not indicated for the management of acute pain associated with surgical procedures.

Gaining a clear appreciation of the extent of the patient's pain and an understanding of pain management including "round the clock" and "breakthrough" rescue dosing with opioids, using adjunctive pharmacologic and behavioral therapies, and, most importantly, ensuring management of all medications by a single clinician will ensure the most appropriate treatment for the chronic pain patient.[68-70]

Nonsteroidal Anti-Inflammatory Drugs

Nonsteroidal anti-inflammatory drugs (NSAIDs) are generally used to treat the inflammatory component of facial pain. NSAIDs exert their actions by inhibiting prostaglandin biosynthesis in the arachidonic acid cascade. There are two main types of NSAIDs, nonselective and selective. The terms nonselective and selective refer to different NSAIDs' ability to inhibit specific types of cyclooxygenase (COX) enzymes. Nonselective NSAIDs inhibit both COX-1 and COX-2 enzymes. Examples of nonselective NSAIDs commonly used are ibuprofen (Advil, Motrin, Nuprin), and naproxen (Aleve). Selective NSAIDs inhibit COX-2. The

TABLE 44-4 Pharmacotherapy for the Management of Acute and Chronic Facial Pain

Drug (Proprietary Name)	Initial Dose (Maximum Daily Dose)	Maintenance Dose Range (Maximum Daily Dose)
NSAID and Opioid Analgesics for Acute Pain		
Ibuprofen (Advil, Motrin)	200-400 mg q6-8h	400-800 mg q6-8h (2400 mg)
Naproxen (Naprosyn, Aleve)	250-375 mg bid	500 mg bid
Celecoxib (Celebrex)	100 mg bid or 200 mg once a day	up to 400 mg daily
Hydrocodone/acetaminophen 5/500 mg (Vicodin)	1-2 tablets q4-6h prn breakthrough pain (4 g acetaminophen)	Not to be used as maintenance drug
Oxycodone/acetaminophen 5/325 mg (Percocet)	1-2 tablets q4-6h prn breakthrough pain	Not to be used as maintenance drug
Antidepressants		
Amitriptyline (Elavil)	10-25 mg nightly	75-100 mg nightly
Venlafaxine (Effexor XR)	37.5 mg /day	75-225 mg/day
Duloxetine	20-40 mg/day	60-120 mg/day
Anticonvulsants		
Gabapentin (Neurontin)	100-300 mg nightly or tid	1200-2400 mg per day
Pregabalin (Lyrica)	50 mg tid or 75 mg bid	50-100 mg tid or 75-150 mg bid up to 300mg/day
Muscle Relaxants		
Clonazepam (Klonopin)	0.25 mg nightly or bid	0.5-1.0 mg qid max
Cyclobenzaprine (Flexeril)	10 mg nightly or tid	10-20 mg nightly or tid max
Diazepam (Valium)	5 mg nightly	5 mg tid max
Tizanidine (Zanaflex)	2-4 mg nightly to qid	36 mg/day max
Corticosteroids		
Betamethasone (Celestone)	6 mg IM	9 mg/day max
Methylprednisolone (Depo-Medrol)	10-80 mg IM	Dose interval 1-5 weeks
Dexamethasone (Decadron)	4-16 mg IM	Dose interval 1-3 weeks
Topical Medication		
Capsaicin cream (Zostrix)	0.075% qid topical	Dose interval up to 8 weeks

role of COX-2 in peripheral inflammation and in development of central hyperalgesia had been demonstrated,[76] and these NSAIDs are less likely to cause gastrointestinal injury. Celecoxib (Celebrex) is a selective NSAID that is available in the United States. Other selective NSAIDs that can be found elsewhere in the world include etoricoxib (Arcoxia) and lumiracoxib (Prexige). Selective COX-2 inhibitors were initially promoted for chronic use in patients with osteoarthritis, rheumatoid arthritis, dysmenorrhea, and dental pain. However, an increased risk for significant adverse effects on cardiovascular and renal systems was noted when compared to NSAIDs and controls.[77] Because of these recent findings, Merck withdrew rofecoxib (Vioxx) from the market in September 2004 and Pfizer has placed a "black box warning" on celecoxib (Celebrex) and suspended sales of valdecoxib (Bextra) in both the United States and European Union as of April 2006.

Chronic use of NSAIDs is discouraged because of the risk for developing upper gastrointestinal complications, major vascular events, renal toxicity and/or failure, and abdominal pain and cramping. Therefore, for chronic use, if necessary, close monitoring is recommended. Suggested dosing regimens are listed in Table 44-4.

Antidepressants

Tricyclic antidepressants (TCAs) and selective serotonin reuptake inhibitors (SSRIs) have been shown to be useful in many chronic pain states including fibromyalgia and those related to clinical depression. It is particularly useful in myofascial pain patients with sleep disturbances and in those with a neuropathic pain component. Although the mechanism of action of TCAs is poorly understood, it is believed to be the inhibition of reuptake of norepinephrine,

dopamine, and serotonin. In contrast, the SSRIs selectively block the reuptake of serotonin only. The analgesic efficacy of TCAs and SSRIs in facial pain appears to be independent of its antidepressant properties and is supported by reduced dose requirements to alleviate facial pain.[78] TCAs provide effective pain relief for a period of 2 to 8 weeks whereas SSRIs provide effective pain relief for a period of 3 to 6 months.[79] If used clinically as an antidepressant, clinicians trained in the diagnosis and treatment of depression should be responsible for its prescription. Adverse effects include sedation, xerostomia, constipation, dizziness, and confusion.

Venlafaxine was initially developed as an antidepressant, although it is now used as a neuropathic agent. It is considered a bicyclic antidepressant as it prevents the reuptake of serotonin, dopamine, and norepinephrine. Although used primarily to treat anxiety and depression, it has been used off-label to treat migraines and diabetic neuropathy. It is only modestly efficacious in the treatment of facial pain.[80] Side effects include headache, nausea, sedation, xerostomia, dizziness, insomnia, and sexual dysfunction.

Anticonvulsant drugs, including gabapentin (Neurontin), pregabalin (Lyrica), topiramax (Topamax), and carbamazepine (Tegretol), are often tried in chronic neuropathic pain and are thought to be indicated especially when the pain is lancinating or burning. Their molecular mechanisms are varied, but typically involve action at the level of cell membrane ion channels. They have narrow therapeutic indices and are therefore best applied by knowledgeable practitioners.[32]

Anticonvulsant Agents

Gabapentin (Neurontin) and pregabalin (Lyrica) have been used as adjuvants to manage both neuropathic and myofascial pain disorders. The exact mechanism of action of gabapentin is unknown. The molecular structure of gabapentin resembles the inhibitory neurotransmitter gamma-aminobutyric acid (gaba), although it does not bind to the gaba receptor; rather, it is believed that gabapentin interacts with the $\alpha_2\delta$ subunit of the voltage-gated calcium channel[81] within the central nervous system to disrupt calcium ion conduction, resulting in inhibition. Gabapentin is not considered a controlled substance and has little to no abuse potential. The $\alpha_2\delta$ calcium-channel antagonists provide effective neuropathic pain relief for assessment periods ranging from 5 to 12 weeks and are recommended for patients with neuropathic pain. Common side effects include dizziness, sedation, ataxia, and peripheral edema.[79]

Muscle Relaxants

Muscle relaxants are used to reduce muscle hyperactivity and tone and are commonly prescribed to manage TMDs. Their mode of action is primarily disruption of spinal reflexes within the brainstem and spinal cord to inhibit firing of motor neurons. Some relaxants such as cyclobenzaprine have been found to be particularly efficacious when prescribed with an NSAID and physical therapy.[82] In contrast, diazepam is efficacious when used alone.[83] Although no randomized controlled studies have been performed, tizanidine (Zanaflex), an α_2-adrenergic agonist, appears to be effective in treating muscle spasms. Because of their activity within the central nervous system, muscle relaxants have CNS side effects including sedation, somnolence, and cognitive dysfunction. Chronic use should be avoided.

Therapeutic Injections

Injections of aqueous solutions of local anesthetics, corticosteroids, and/or physiologic normal saline into target muscle groups have been performed with some success. The basis for local injections is to disrupt the afferent and efferent neural pathways within the contracted muscles to allow for muscle elongation. Combination local anesthetic with corticosteroid injections can be used; however, combination injection is not clinically superior to local anesthetic or steroid injection alone.[84] Injection of normal saline (0.9%) appears to be as efficacious as local anesthetics in reducing myofascial pain.[85]

Local anesthetics commonly used are 0.5% to 2% lidocaine without vasoconstrictor or 0.25% to 0.5% bupivacaine without vasoconstrictor. Local anesthetics exert their actions via blockade of sodium conductance through sodium channels located on peripheral nerve fibers. Disruption of sodium conductance results in blockade of action potentials and thus sensory and motor activity. Side effects include CNS depression, seizures, tinnitus, and dysrhythmias and are related to exceeding maximum single daily dose. In addition, risks associated with injection technique have been discussed, including soft tissue infection, necrosis, and, less commonly, accidental intrathecal injection resulting in respiratory depression and hemiplegia requiring endotracheal intubation.[86] Careful aspiration before injection is recommended. Local anesthetic injections may also be used as a diagnostic tool to rule out neuropathic central pain syndromes including trigeminal and glossopharyngeal neuralgias.

Implantable pump systems such as the On-Q Pain Management System, the Pain Buster Pain Management System, the Don Joy Pain Pump, and the Stryker Pain Pumps are commercially available that allow for controlled amounts of local anesthetics to be administered in a specific anatomic area for postoperative pain management. Medication is delivered directly to the surgical wound site or in close proximity to the nerves associated with the surgical area. These systems are used for the management of acute postoperative pain and remain implanted for 3 to 7 days depending on the system used. Although a paucity of data exist in the oral and maxillofacial surgery literature, such systems have been found to be efficacious in the plastic and reconstructive, gastrointestinal, and orthopedic literature. Common side effects include wound infection, toxicity of drug, and accidental premature removal.

Corticosteroid injections either alone or in combination with local anesthetics have been advocated. Steroids exert their analgesic effect by inhibition of phospholipase A_2 production within the arachidonic acid cascade. This blocks the formation of the proinflammatory mediators prostaglandin and leukotriene within damaged or traumatized tissues. Commonly used corticosteroids include methylprednisolone (Depo-Medrol), dexamethasone (Decadron), and betamethasone (Celestone), and each differs based on solubility. Betamethasone is the most soluble injectable corticosteroid and therefore has the least risk for development of muscle wasting, fat atrophy, hypopigmentation, and tendon rupture. The more insoluble methylprednisolone has greater duration of action than either dexamethasone or betamethasone. Adverse reactions include facial flushing, insomnia, dizziness, and nervousness. Use steroids with caution in patients with poorly controlled diabetes, active infections, ulcerative colitis, severe gastroesophageal reflux disease, renal disease, and congestive heart failure. Chronic steroid injections are not recommended because of related systemic side effects. Repeat dosing intervals of 1 to 5 weeks are generally recommended to decrease risk of side effects.

Botulinum Toxin Injections

Botulinum toxin is produced by the bacterium *Clostridium botulinum,* and eight distinct types exist (types A, B, C1, C2, D, E, F, and G). Two types—botulinum toxin A (BTA, Botox, and Botox Cosmetic, Allergan Inc., Irvine, CA) and botulinum toxin B (BTB, Myobloc, Elan Pharmaceuticals Inc., New York, NY)—are commercially available in the United States. Primary indications for BTA are treatment of blepharospasms, strabismus, tension headaches, hyperhidrosis, spasmodic dysphonia, oromandibular dystonia, torticollis, cosmetic treatment of facial rhytides, myofascial pain that is resistant to physical therapy and oral pharmacotherapy, and muscle spasticity related to cerebral palsy, cerebrovascular accidents, and multiple sclerosis.[87] The mechanism of action is disruption of acetylcholine release from the neuromuscular junction. This prevents the repetitive and consecutive muscular contraction and development of local tissue ischemia.

Botox is supplied in 100 mouse unit vials and must be reconstituted with unpreserved saline before use. One unit is equal to the amount that would be lethal in 50% of mice. The human lethal dose for Botox is 3,000 units or 40 to 50 units/kg. Flaccid paralysis occurs after 3 days and lasts for 3 to 5 months. Typically, 1 mL of unpreserved saline is carefully injected into the vial and gently mixed so as not to incorporate bubbles. A 1-mL tuberculin syringe with a 30-gauge 1-inch needle is then used to draw up the solution with a final concentration of 10 units per 0.1 mL. Other authors have advocated using 6 mL of unpreserved saline and placing the solution into six 1-mL tuberculin syringes with a final concentration of 1.7 units/0.1 mL.[88] The manufacturer recommends using Botox within 4 hours of reconstitution although it may be stored refrigerated for up to 1 week. A dose of 10 mouse units per muscle group is recommended but may be higher in larger muscle compartments.[89] The maximum dose in a single muscle is 25 units with a maximum 30-day cumulative dose of 200 units.

The most common side effects associated with Botox injection are postinjection ecchymosis, bruising, and unwanted temporary paralysis of the facial muscles of expression. If possible, patients should refrain from platelet inhibitors such as aspirin and NSAIDs 7 to 14 days before injections. Contraindications for Botox injections include pregnancy (category C) and breastfeeding, prior allergic reaction, and injections into sites of infection or inflammation. Use with caution in patients with neuromuscular diseases such as myasthenia gravis, amyotrophic lateral sclerosis, and Lambert-Eaton syndrome. Approximately 6% of patients will develop neutralizing antibodies against botox A and become nonresponsive to treatment. In this population, botox B (Myobloc) may be used.[90] Myobloc is supplied in 2500-unit to 10,000-unit vials and is not equivalent to Botox. One unit of Botox is equivalent to 50 units of Myobloc. Injection doses exceeding 4500 units of Myobloc have been associated with an increased incidence of side effects including ptosis, burning on injection, visual disturbances, xerostomia, xerophthalmia, headache, and facial muscle weakness. Paralysis lasts for 7 weeks and increases to 8 weeks with higher doses.

Botulinum toxin may be used to treat myofascial pain and for neuropathic pain with presumed local pain generation as third-line therapy mainly because of insufficient evidence of therapeutic benefit.[79]

Topical Capsaicin

Topical capsaicin is used for a variety of chronic pain conditions including causalgia, herpetic neuralgia, diabetic neuropathy, osteoarthritis, and rheumatoid arthritis.[91] The compound capsaicin, alkylamine with the chemical formula C18H27NO3 found in various chili peppers, has long been known to produce a hot, burning, stinging sensation, whether on ingestion of spicy food or when applied to the skin. As somewhat of a paradox, capsaicin has also been known to provide superficial pain relief despite, again, an initial unpleasant sensation. Although this has been known for a century, the molecular target and mechanism for capsaicin's effects have only relatively recently been investigated and brought to light. Modern scientific technique has allowed for a more complete characterization of not only capsaicin and its action but also of its target—the TRPV1 receptor—itself and the class of receptors to which it belongs.[92]

High-concentration topical capsaicin (8%) can be used to treat postherpetic neuralgia and HIV neuropathy.[93] Topical capsaicin has been available for some time in a low dose (i.e., less than 1%). Many studies have been published in an attempt to evaluate its efficacy and safety. Again, it is important to note that "low-dose capsaicin" here actually refers to two different concentrations: 0.025% and 0.075%.

According to meta-analysis of randomized controlled trials to determine the efficacy of topical (0.075%) capsaicin in the treatment of chronic pain from neuropathic and musculoskeletal disorders, it is efficacious in at least 50% pain reduction in 60% of patients with painful neuropathies when used for an 8-week period and in 57% of patients when used for a 4-week period; of note, the placebo effect was estimated as 42% in both groups. In musculoskeletal conditions the efficacy was slightly lower but the capsaicin concentration was lower as well. With manipulation of those data for neuropathic conditions, in patients using topical capsaicin 0.075%, for approximately every six patients, one would achieve at least a 50% reduction in pain in patients who would not have experienced pain reduction if given placebo.[94]

Winocur et al. in a double-blind 4-week study on 30 TMD patients found that capsaicin cream (0.025%) produced no statistically significant influence on measured variables when compared to placebo.[95]

The Cochrane review by Derry et al.[93] based on the existing data available, concluded that there are insufficient data to draw any conclusions about the efficacy of low-concentration capsaicin cream in the treatment of neuropathic pain. The data do suggest that low-concentration topical capsaicin is without meaningful effect beyond that found in placebo creams. Local skin irritation, which was often mild and transient but may lead to withdrawal, was common. Systemic adverse effects were rare.

Thus, although the majority of available data do seem to suggest that low-dose capsaicin for neuropathic or musculoskeletal pain is not an effective treatment option, there are some data to suggest that in some patients low-dose capsaicin may be a reasonable therapeutic option when others have failed to provide sufficiently complete pain relief and quality of life improvement.

Surgical Intervention

Chemical denervation with potent preservatives such as alcohol or glycerol has been reported as a treatment regimen for chronic facial pain, especially trigeminal neuralgia. Performed as a transcutaneous gasserian block, each compound is delivered via a spinal needle at a volume of 0.2 to 0.5 mL. Although many patients report symptomatic relief hours after injection, recurrence may occur within 1 year following injection. Injections are performed in an operating room or clinical setting (depending on surgeon experience) with immediate video fluoroscopy for confirmation of needle placement. Side effects include permanent or temporary cutaneous hyperesthesia, dysesthesia or anesthesia, anesthesia dolorosa, cutaneous necrosis, risk for corneal abrasion (for permanent V1 anesthesia), pain recurrence, and failure to achieve relief.[7,96]

Surgery may be considered in the facial pain patient who remains refractory to conventional nonsurgical modalities and is often viewed as the "last resort." Surgical techniques such as nerve transection, microvascular decompression, thermorhizotomy, and stereotactic gamma knife radiosurgery have all been described in the literature for treating chronic facial pain.[97] The latter three surgical techniques are commonly used for managing trigeminal neuralgia and are beyond the scope of this chapter. However, nerve transection may be performed for intractable pain developing from branches arising from the trigeminal nerve. While success rates are minimal, many chronic facial pain patients are willing to give up somatic sensation if pain is even slightly diminished. As to be expected, complete anesthesia in the distribution of the transected nerve is expected with no recovery of sensation. Diagnostic tests in the form of local anesthetic blockade are necessary before proceeding with surgical denervation to ensure that central sensitization has not occurred. Surgical or chemical denervation will not successfully resolve chronic pain disorders that have a central pain component.

Clinically Based Comprehensive Pain Management Programs

Many clinical specialties play a role in the diagnosis and management of facial pain. For more complex cases, a team approach is usually considered.[3] In all chronic pain conditions, the more severe cases involve some degree of psychologic disturbance.[98] It is unclear whether, for example, the depression that accompanies many chronic pain states is a result of or contributes to the underlying disease process. Because it is clear that pain has both a discriminatory and an affective component, focusing treatment on one aspect will have less successful results. The multidisciplinary approach to chronic pain management ensures all aspects of the pain disorder are treated. The pain clinic team may be comprised of psychologists, psychiatrists, physical therapists, anesthesiologists, TMD specialists, oral and maxillofacial surgeons, neurologists, neurosurgeons, and integrative medicine specialists. There is evidence demonstrating the psychologic ramifications that chronic facial pain has on diagnosis and treatment outcomes[99,100] and the need for the multidisciplinary approach.

Future Directions in Pain Management

Pain research has significantly improved our understanding of acute and chronic pain mechanisms. By highlighting key molecular mechanisms involved in pain transmission, new drugs are currently being investigated as potential novel and selective therapies. Currently available medications such as opioids are certainly fraught with side effect profiles that may limit their clinical utility. Research is now focused on specific receptor or channel targets within the nervous system that limit systemic complications. It appears from the available data that while low-dose capsaicin is generally ineffective as an analgesic in either musculoskeletal or multiple forms of chronic neuropathic pain in adults, high-dose capsaicin has shown efficacy in certain forms of chronic neuropathic pain. A logical evolution in research into investigation of TRPV1 agonism, then, most likely ought to

focus on either 8% topical capsaicin in musculoskeletal pain or forms of chronic neuropathic pain not yet investigated, be it diabetic peripheral neuropathy, or distal painful polyneuropathy. Further investigation into TRPV1 antagonists may continue to yield fruitful results

Growth factors are important in the differentiation, maturation, and plasticity of cells within the nervous system. Key growth factors that have been implicated in pain include nerve growth factor (NGF), glial-derived growth factor (GDNF), and brain-derived growth factor (BDNF).[101] Receptors for such growth factors are expressed on C fibers and Aδ fibers that terminate within the spinal cord. In animal models of chronic pain, NGF levels are elevated in damaged peripheral tissues. Neutralizing antibodies against NGF are effective, at least in animal models, in reducing and, in some cases, preventing chronic pain. Interestingly, administration of NGF has also been shown to reduce neuropathic pain. Phase III clinical trials are currently underway assessing the efficacy of recombinant NGF to treat diabetic neuropathy. BDNF has been implicated in the modulation of central sensitization as its expression is increased in nociceptive neurons in models of peripheral neuropathy. BDNF sensitizes C fiber activity, resulting in hyperalgesia and allodynia. Inhibition of BDNF and its cognate receptor trkB results in decreased C fiber firing and a reduction in pain behaviors. Finally, GDNF is important in the survival of sensory neurons and supporting cells. Neuropathic pain behaviors commonly observed in animal models of chronic pain are prevented or reversed following GDNF administration. The timing of administration determined whether treatment was protective or therapeutic in nature.

Other directions for further investigation could include randomized controlled trials of the effectiveness of botulinum toxin injections. Further trials measuring the safety and the efficacy of autologous administration of stem cells for neuropathic trigeminal pain reduction may offer a viable treatment option.[102] Evaluation of neuromodulation with electrical stimulus to treat atypical neuropathic pain refractory to other treatments also may prove to be of value. Development of novel compounds to improve safety and tolerability of NSAIDs may also be beneficial in the treatment of chronic facial pain.

References

1. Lipton JA, Ship JA, Larach-Robinson D: Estimated prevalence and distribution of reported orofacial pain in the United States, *J Am Dent Assoc* 124(10):115–121, 1993.
2. Sarlani E, Balciunas BA, Grace EG: Orofacial Pain—Part II: Assessment and management of vascular, neurovascular, idiopathic, secondary, and psychogenic causes, *AACN Clin Issues* 16(3):347–358, 2005.
3. Israel HA, Ward JD, Horrell B, Scrivani SJ: Oral and maxillofacial surgery in patients with chronic orofacial pain, *J Oral Maxillofac Surg* 61(6):662–667, 2003.
4. Sessle BJ: Acute and chronic craniofacial pain: brainstem mechanisms of nociceptive transmission and neuroplasticity, and their clinical correlates, *Crit Rev Oral Biol Med* 11(1):57–91, 2000.
5. Haas DA, Lennon D: A 21 year retrospective study of reports of paresthesia following local anesthetic administration, *J Can Dent Assoc* 61(4):319–326, 1995.
6. Sessle BJ: Peripheral and central mechanisms of orofacial pain and their clinical correlates, *Minerva Anesthesiol* 71(4):117–136, 2005.
7. Hargreaves KM, Bowles WR, Garry MG: An in vitro method to evaluate regulation of neuropeptide release from dental pulp, *J Endod* 18(12):597–600, 1992.
8. Hunt SP, Mantyh PW: The molecular dynamics of pain control, *Nat Rev Neurosci* 2(2):83–91, 2001.
9. Lavigne G, Woda A, Truelove E, Ship JA, Dao T, Goulet JP: Mechanisms associated with unusual orofacial pain, *J Orofac Pain* 19(1):9–21, 2005.
10. Pritchard T, Alloway K: *Medical neuroscience*, ed 1, Madison, CT, 2015, Fence Creek.
11. Marino R, Torretta S, Capaccio P, Pignataro L, Spadari F: Different therapeutic strategies for burning mouth syndrome: preliminary data, *J Oral Pathol Med* 39(8):611–616, 2010.
12. Browne PA, Clark GT, Kuboki T, Adachi NY: Concurrent cervical and craniofacial pain. A review of empiric and basic science evidence, *Oral Surg Oral Med Oral Pathol Oral Radiol Endod* 86(6):633–640, 1998.
13. Woolf CJ, Salter MW: Neuronal plasticity: increasing the gain in pain, *Science* 288(5472):1765–1769, 2000.
14. Birklein F: Complex regional pain syndrome, *J Neurol* 252(2): 131–138, 2005.
15. Campbell JN, Meyer RA: Mechanisms of neuropathic pain, *Neuron* 52(1):77–92, 2006.
16. Sharav Y, Benoliel R, editors: *Orofacial pain and headache*, ed 1, Philadelphia, 2008, Mosby.
17. Sharav Y, Leviner E, Tzukert A, McGrath PA: The spatial distribution, intensity and unpleasantness of acute dental pain, *Pain* 20(4):363–370, 1984.
18. Bender SD: Orofacial pain and headache: a review and look at the commonalities, *Curr Pain Headache Rep* 18(3):400, 2014.
19. Zuniga JR, Meyer RA, Gregg JM, Miloro M, Davis LF: The accuracy of clinical neurosensory testing for nerve injury diagnosis, *J Oral Maxillofac Surg* 56(1):2–8, 1998.
20. Borsook D, Burstein R, Becerra L: Functional imaging of the human trigeminal system: opportunities for new insights into pain processing in health and disease, *J Neurobiol* 61(1):107–125, 2004.
21. Epstein JB, Caldwell J, Black G: The utility of panoramic imaging of the temporomandibular joint in patients with temporomandibular disorders, *Oral Surg Oral Med Oral Pathol Oral Radiol Endod* 92(2):236–239, 2001.
22. Coutinho A, Fenyo-Pereira M, Dib LL, Lima EN: The role of SPECT/CT with 99mTc-MDP image fusion to diagnose temporomandibular dysfunction, *Oral Surg Oral Med Oral Pathol Oral Radiol Endod* 101(2):224–230, 2006.
23. Bag AK, Gaddikeri S, Singhal A, Hardin S, Tran BD, Medina JA, et al.: Imaging of the temporomandibular joint: An update, *World J Radiol* 6(8):567–582, 2014.
24. de Leeuw R, Albuquerque R, Okeson J, Carlson C: The contribution of neuroimaging techniques to the understanding of supraspinal pain circuits: implications for orofacial pain, *Oral Surg Oral Med Oral Pathol Oral Radiol Endod* 100(3):308–314, 2005.
25. Melis M, Zawawi K, Al Badawi E, Lobo LS, Mehta N: Complex regional pain syndrome in the head and neck: a review of the literature, *J Orofac Pain* 16(2):93–104, 2002.

26. Harden RN, Bruehl SP: Diagnosis of complex regional pain syndrome: signs, symptoms, and new empirically derived diagnostic criteria, *Clin J Pain* 22(5):415–419, 2006.
27. Rowbotham MC: Pharmacologic management of complex regional pain syndrome, *Clin J Pain* 22(5):425–429, 2006.
28. Bouquot JE, McMahon RE: Neuropathic pain in maxillofacial osteonecrosis, *J Oral Maxillofac Surg* 58(9):1003–1020, 2000.
29. Zuniga JR: Challenging the neuralgia-inducing cavitational osteonecrosis concept, *J Oral Maxillofac Surg* 58(9):1021–1028, 2000.
30. Sciubba JJ: Neuralgia-inducing cavitational osteonecrosis: a status report, *Oral Dis* 15(5):309–312, 2009.
31. Gruppo R, Glueck CJ, McMahon RE, Bouquot J, Rabinovich BA, Becker A, et al.: The pathophysiology of alveolar osteonecrosis of the jaw: anticardiolipin antibodies, thrombophilia, and hypofibrinolysis, *J Lab Clin Med* 127(5):481–488, 1996.
32. Nguyen CT, Wang MB: Complementary and integrative treatments: atypical facial pain, *Otolaryngol Clin North Am* 46(3):367–382, 2013.
33. Olesen J, Steiner TJ: The International classification of headache disorders, 2nd edn (ICDH-II), *J Neurol Neurosurg Psychiatry* 75(6):808–811, 2004.
34. Vickers ER, Cousins MJ, Walker S, Chisholm K: Analysis of 50 patients with atypical odontalgia. A preliminary report on pharmacological procedures for diagnosis and treatment, *Oral Surg Oral Med Oral Pathol Oral Radiol Endod* 85(1):24–32, 1998.
35. Melis M, Lobo SL, Ceneviz C, Zawawi K, Al Badawi E, Maloney G, et al.: Atypical odontalgia: a review of the literature, *Headache* 43(10):1060–1074, 2003.
36. Petruzzi M, Lauritano D, De Benedittis M, Baldoni M, Serpico R: Systemic capsaicin for burning mouth syndrome: short-term results of a pilot study, *J Oral Pathol Med* 33(2):111–114, 2004.
37. Gremeau-Richard C, Woda A, Navez ML, Attal N, Bouhassira D, Gagnieu MC, et al.: Topical clonazepam in stomatodynia: a randomised placebo-controlled study, *Pain* 108(1-2):51–57, 2004.
38. Rodriguez de Rivera CE, Lopez-Lopez J, Chimenos-Kustner E: Response to topical clonazepam in patients with burning mouth syndrome: a clinical study, *Bull Group Int Rech Sci Stomatol Odontol* 49(1):19–29, 2010.
39. Amos K, Yeoh SC, Farah CS: Combined topical and systemic clonazepam therapy for the management of burning mouth syndrome: a retrospective pilot study, *J Orofac Pain* 25(2):125–130, 2011.
40. Heckmann SM, Kirchner E, Grushka M, Wichmann MG, Hummel T: A double-blind study on clonazepam in patients with burning mouth syndrome, *Laryngoscope* 122(4):813–816, 2012.
41. Ko JY, Kim MJ, Lee SG, Kho HS: Outcome predictors affecting the efficacy of clonazepam therapy for the management of burning mouth syndrome (BMS), *Arch Gerontol Geriatr* 55(3): 755–761, 2012.
42. Robert RC, Bacchetti P, Pogrel MA: Frequency of trigeminal nerve injuries following third molar removal, *J Oral Maxillofac Surg* 63(6):732–735, 2005.
43. Chaushu G, Taicher S, Halamish-Shani T, Givol N: Medicolegal aspects of altered sensation following implant placement in the mandible, *Int J Oral Maxillofac Implants* 17(3):413–415, 2002.
44. Kraut RA, Chahal O: Management of patients with trigeminal nerve injuries after mandibular implant placement, *J Am Dent Assoc* 133(10):1351–1354, 2002.
45. Blanas N, Kienle F, Sandor GK: Inferior alveolar nerve injury caused by thermoplastic gutta-percha overextension, *J Can Dent Assoc* 70(6):384–387, 2004.
46. Grotz KA, Al Nawas B, de Aguiar EG, Schulz A, Wagner W: Treatment of injuries to the inferior alveolar nerve after endodontic procedures, *Clin Oral Investig* 2(2):73–76, 1998.
47. Kleier DJ, Averbach RE: Painful dysesthesia of the inferior alveolar nerve following use of a paraformaldehyde-containing root canal sealer, *Endod Dent Traumatol* 4(1):46–48, 1988.
48. Hillerup S, Jensen R: Nerve injury caused by mandibular block analgesia, *Int J Oral Maxillofac Surg* 35(5):437–443, 2006.
49. Pogrel MA, Thamby S: Permanent nerve involvement resulting from inferior alveolar nerve blocks, *J Am Dent Assoc* 131(7): 901–907, 2000.
50. Malamed SF: Nerve injury caused by mandibular block analgesia, *Int J Oral Maxillofac Surg* 35(9):876–877, 2006.
51. Kreiner M, Okeson JP: Toothache of cardiac origin, *J Orofac Pain* 13(3):201–207, 1999.
52. Durso BC, Israel MS, Janini ME, Cardoso AS: Orofacial pain of cardiac origin: a case report, *Cranio* 21(2):152–153, 2003.
53. Oliveira Franco AC, de Siqueira JT, Mansur AJ: Bilateral facial pain from cardiac origin. A case report, *Br Dent J* 198(11): 679–680, 2005.
54. Lopez-Lopez J, Garcia-Vicente L, Jane-Salas E, Estrugo-Devesa A, Chimenos-Kustner E, Roca-Elias J: Orofacial pain of cardiac origin: review literature and clinical cases, *Med Oral Pathol Oral Cir Bucal* 17(4):e538–e544, 2012.
55. Prasad KC, Kamath MP, Reddy KJ, Raju K, Agarwal S: Elongated styloid process (Eagle's syndrome): a clinical study, *J Oral Maxillofac Surg* 60(2):171–175, 2002.
56. Fusco DJ, Asteraki S, Spetzler RF: Eagle's syndrome: embryology, anatomy, and clinical management, *Acta Neurochir (Wien)* 154(7):1119–1126, 2012.
57. Zaki HS, Greco CM, Rudy TE, Kubinski JA: Elongated styloid process in a temporomandibular disorder sample: prevalence and treatment outcome, *J Prosthet Dent* 75(4):399–405, 1996.
58. Savranlar A, Uzun L, Ugur MB, Ozer T: Three-dimensional CT of Eagle's syndrome, *Diagn Interv Radiol* 11(4):206–209, 2005.
59. Gellrich NC, Schramm A, Bockmann R, Kugler J: Follow-up in patients with oral cancer, *J Oral Maxillofac Surg* 60(4):380–386, 2002.
60. Ruggiero SL, Mehrotra B, Rosenberg TJ, Engroff SL: Osteonecrosis of the jaws associated with the use of bisphosphonates: a review of 63 cases, *J Oral Maxillofac Surg* 62(5):527–534, 2004.
61. Marx RE: Pamidronate (Aredia) and zoledronate (Zometa) induced avascular necrosis of the jaws: a growing epidemic, *J Oral Maxillofac Surg* 61(9):1115–1117, 2003.
62. Ruggiero SL, Dodson TB, Fantasia J, Goodday R, Aghaloo T, Mehrotra B, et al.: American Association of Oral and Maxillofacial Surgeons position paper on medication-related osteonecrosis of the jaw—2014 update, *J Oral Maxillofac Surg* 72(10):1938–1956, 2014.
63. Shimura K, Shimazaki C, Taniguchi K, Akamatsu S, Okamoto M, Uchida R, et al.: Hyperbaric oxygen in addition to antibiotic therapy is effective for bisphosphonate-induced osteonecrosis of the jaw in a patient with multiple myeloma, *Int J Hematol* 84(4):343–345, 2006.
64. Lugassy G, Shaham R, Nemets A, Ben Dor D, Nahlieli O: Severe osteomyelitis of the jaw in long-term survivors of multiple myeloma: a new clinical entity, *Am J Med* 117(6):440–441, 2004.
65. Mignogna MD, Fedele S, Lo RL, Ciccarelli R, Lo ML: Case 2. Osteonecrosis of the jaws associated with bisphosphonate therapy, *J Clin Oncol* 24(9):1475–1477, 2006.

66. Freiberger JJ, Padilla-Burgos R, McGraw T, Suliman HB, Kraft KH, Stolp BW, et al.: What is the role of hyperbaric oxygen in the management of bisphosphonate-related osteonecrosis of the jaw: a randomized controlled trial of hyperbaric oxygen as an adjunct to surgery and antibiotics, *J Oral Maxillofac Surg* 70(7):1573–1583, 2012.
67. Dowell D, Haegerich TM, Chou R: CDC Guideline for Prescribing Opioids for Chronic Pain—United States, 2016, *MMWR Recomm Rep* 65:1–49, 2016.
68. Lee KF, Ray JB, Dunn GP: Chronic pain management and the surgeon: barriers and opportunities, *J Am Coll Surg* 193(6):689–701, 2001.
69. Swift JQ, Roszkowski MT: The use of opioid drugs in management of chronic orofacial pain, *J Oral Maxillofac Surg* 56(9):1081–1085, 1998.
70. Fishman SM, Mahajan G, Jung SW, Wilsey BL: The trilateral opioid contract. Bridging the pain clinic and the primary care physician through the opioid contract, *J Pain Symptom Manage* 24(3):335–344, 2002.
71. Manchikanti L, Cash KA, Damron KS, Manchukonda R, Pampati V, McManus CD: Controlled substance abuse and illicit drug use in chronic pain patients: an evaluation of multiple variables, *Pain Physician* 9(3):215–225, 2006.
72. Michelotti A, Steenks MH, Farella M, Parisini F, Cimino R, Martina R: The additional value of a home physical therapy regimen versus patient education only for the treatment of myofascial pain of the jaw muscles: short-term results of a randomized clinical trial, *J Orofac Pain* 18(2):114–125, 2004.
73. Decker K, Bromaghim C, Fricton J: Physical therapy for temporomandibular disorder and orofacial pain. In Fricton JR, Dubner R, editors: *Orofacial pain and temporomandibular disorders*, New York, 1995, Raven.
74. Skaer TL: Transdermal opioids for cancer pain, *Health Qual Life Outcomes* 4:24, 2006.
75. Swift JQ: Nonsteroidal anti-inflammatory drugs and opioids: safety and usage concerns in the differential treatment of postoperative orofacial pain, *J Oral Maxillofac Surg* 58(10 Suppl 2):8–11, 2000.
76. Brune K, Patrignani P: New insights into the use of currently available non-steroidal anti-inflammatory drugs, *J Pain Res* 8: 105–118, 2015.
77. Joris JL, Dubner R, Hargreaves KM: Opioid analgesia at peripheral sites: a target for opioids released during stress and inflammation? *Anesth Analg* 66(12):1277–1281, 1987.
78. Bombardier C, Laine L, Reicin A, Shapiro D, Burgos-Vargas R, Davis B, et al.: Comparison of upper gastrointestinal toxicity of rofecoxib and naproxen in patients with rheumatoid arthritis. VIGOR Study Group, *N Engl J Med* 343(21):1520–1528, 2000. 2.
79. Practice guidelines for chronic pain management: an updated report by the American Society of Anesthesiologists Task Force on Chronic Pain Management and the American Society of Regional Anesthesia and Pain Medicine, *Anesthesiology* 112(4):810–833, 2010.
80. Gee NS, Brown JP, Dissanayake VU, Offord J, Thurlow R, Woodruff GN: The novel anticonvulsant drug, gabapentin (Neurontin), binds to the alpha2delta subunit of a calcium channel, *J Biol Chem* 271(10):5768–5776, 1996.
81. Sharav Y, Singer E, Schmidt E, Dionne RA, Dubner R: The analgesic effect of amitriptyline on chronic facial pain, *Pain* 31(2):199–209, 1987.
82. Forssell H, Tasmuth T, Tenovuo O, Hampf G, Kalso E: Venlafaxine in the treatment of atypical facial pain: a randomized controlled trial, *J Orofac Pain* 18(2):131–137, 2004.
83. Herman CR, Schiffman EL, Look JO, Rindal DB: The effectiveness of adding pharmacologic treatment with clonazepam or cyclobenzaprine to patient education and self-care for the treatment of jaw pain upon awakening: a randomized clinical trial, *J Orofac Pain* 16(1):64–70, 2002.
84. Singer E, Dionne R: A controlled evaluation of ibuprofen and diazepam for chronic orofacial muscle pain, *J Orofac Pain* 11(2):139–146, 1997.
85. Wheeler AH: Myofascial pain disorders: theory to therapy, *Drugs* 64(1):45–62, 2004.
86. Tschopp KP, Gysin C: Local injection therapy in 107 patients with myofascial pain syndrome of the head and neck, *ORL J Otorhinolaryngol Relat Spec* 58(6):306–310, 1996.
87. Nelson LS, Hoffman RS: Intrathecal injection: unusual complication of trigger-point injection therapy, *Ann Emerg Med* 32(4):506–508, 1998.
88. von Lindern JJ, Niederhagen B, Berge S, Appel T: Type A botulinum toxin in the treatment of chronic facial pain associated with masticatory hyperactivity, *J Oral Maxillofac Surg* 61(7):774–778, 2003.
89. Niamtu III J: Botulinum toxin A: a review of 1,085 oral and maxillofacial patient treatments, *J Oral Maxillofac Surg* 61(3): 317–324, 2003.
90. Reilich P, Fheodoroff K, Kern U, Mense S, Seddigh S, Wissel J, et al.: Consensus statement: botulinum toxin in myofascial [corrected] pain, *J Neurol* 25(Suppl1):I36–I38, 2004.
91. Mason L, Moore RA, Derry S, Edwards JE, McQuay HJ: Systematic review of topical capsaicin for the treatment of chronic pain, *BMJ* 328(7446):991, 2004.
92. Smith H, Brooks JR: Capsaicin-based therapies for pain control, *Prog Drug Res* 68:129–146, 2014.
93. Derry S, Sven-Rice A, Cole P, Tan T, Moore RA: Topical capsaicin (high concentration) for chronic neuropathic pain in adults, *Cochrane Database Syst Rev* 2:CD007393, 2013.
94. Mason L, Moore RA, Derry S, Edwards JE, McQuay HJ: Systematic review of topical capsaicin for the treatment of chronic pain, *BMJ* 328(7446):991, 2004.
95. Winocur E, Gavish A, Halachmi M, Eli I, Gazit E: Topical application of capsaicin for the treatment of localized pain in the temporomandibular joint area, *J Orofac Pain* 14(1):31–36, 2000.
96. Waltz TA, Dalessio DJ, Ott KH, Copeland B, Abbott G: Trigeminal cistern glycerol injections for facial pain, *Headache* 25(7):354–357, 1985.
97. Broggi G, Ferroli P, Franzini A, Galosi L: The role of surgery in the treatment of typical and atypical facial pain, *Neurol Sc* 26(Suppl 2):s95–100, 2005.
98. Workman EA, Hubbard JR, Felker BL: Comorbid psychiatric disorders and predictors of pain management program success in patients with chronic pain, *Prim Care Companion J Clin Psychiatry* 4(4):137–140, 2002.
99. Turner JA, Dworkin SF: Screening for psychosocial risk factors in patients with chronic orofacial pain: recent advances, *J Am Dent Assoc* 135(8):1119–1125, 2004.
100. Macfarlane TV, Kincey J, Worthington HV: The association between psychological factors and oro-facial pain: a community-based study, *Eur J Pain* 6(6):427–434, 2002.
101. Sah DW, Ossipo MH, Porreca F: Neurotrophic factors as novel therapeutics for neuropathic pain, *Nat Rev Drug Discov* 2(6):460–472, 2003.
102. Vickers ER, Karsten E, Flood J, Lilischkis R: A preliminary report on stem cell therapy for neuropathic pain in humans, *J Pain Res* 7:255–263, 2014.

45

Temporomandibular Muscle Disorders: Diagnostic and Management Considerations

JAMES FRICTON, GREGORY M. NESS

Intrinsic pain of the masticatory muscles is sometimes perceived by oral and maxillofacial surgeons as a vaguely defined syndrome managed by somewhat mysterious—but definitely nonsurgical—treatment. In fact, myogenous temporomandibular disorders (TMDs), or masticatory myalgias, are characterized by pain and dysfunction arising from a number of well-defined, distinct pathologic and functional processes in the masticatory muscles. These include myofascial pain (MFP), myositis, muscle spasm, and muscle contracture.[1] The surgeon who would operate on the temporomandibular joint (TMJ) must also be familiar with the diagnosis and nonsurgical management of these muscular problems. This chapter defines these disorders and suggests effective and evidence-based therapies for each.

MFP is the most common muscle pain disorder.[2] It is an acute to chronic condition that includes the presence of regional pain associated with tender areas called *trigger points* (TrPs), which are expressed in taut bands of skeletal muscles, tendons, or ligaments. Although the pain most often occurs in the region over the TrP, pain can be referred to areas distant from the TrP (e.g., the temporalis referring to the frontal area and the masseter referring into the ear and/or the posterior teeth). Reproducible duplication of pain complaints with specific palpation of the tender area is often diagnostic.

Myositis is an acute condition with localized or generalized inflammation of the muscle and connective tissue and is associated with pain and swelling overlying the muscle. Most areas in the muscle are tender, with pain in active range of motion. The inflammation is usually due to local causes such as overuse, excessive stretch, drugs (e.g., ecstasy), local infection from pericoronitis, trauma, or cellulitis. Myositis is also termed *delayed onset muscle soreness* in cases of acute overuse.

Muscle spasm is also an acute disorder characterized by a brief involuntary tonic contraction of a muscle. It can occur as a result of overstretching of a previously weakened muscle, from protective splinting of an injury, as a centrally mediated phenomenon such as prochlorperazine (Compazine)-induced spasm of the lateral pterygoid muscle, or through overuse of the muscle. A muscle in spasm is acutely shortened and painful, causing limited range of motion in the affected joint. Lateral pterygoid spasm on one side can also cause a shift of the occlusion to the contralateral side.

Muscle contracture is a chronic condition characterized by continuous gross shortening of the muscle with significant limited range of motion. It can begin as a result of factors such as trauma, infection, or prolonged hypomobility. If the muscle is maintained in a shortened state, muscular fibrosis and contracture may develop over several months. Pain is often minimal in the process from protection of the muscle.

Etiology and Epidemiology

Prevalence

Muscle pain disorders are the most common cause of persistent pain in the head and neck, affecting about 50% of a chronic head and neck pain population.[3] They are also a common cause of pain in the general population, with 20% to 50% of people having muscle pain disorders and about 6% having symptoms severe enough to warrant treatment.[4,5]

Etiologic Factors

Onset factors for myogenous TMDs include both direct or indirect macrotrauma to the muscle and repetitive strain activities.[6] Macrotrauma includes a direct blow to the jaw and opening the mouth too wide or for too long a period during activities such as undergoing dental work, eating, yawning, or engaging in sexual activity. Indirect trauma due to a whiplash-type injury may initiate muscle pain in some cases. Local infection and trauma may cause myositis and lead to muscle contracture if not resolved. Occupational and repetitive strain injury may result in MFP and, if acute, muscle spasm. Sleep disturbance and nocturnal habits can contribute to MFP. Psychosocial stressors such as relationship conflicts, monetary problems, feelings of hurriedness, overscheduling, and poor pacing skills can also play an indirect role.

Postural strain caused by a forward head posture, increased cervical or lumbar lordosis, some occlusal abnormalities, and poor positioning of the head or tongue have also been implicated in MFP; so have static postural problems such as unilateral short leg, small hemipelvis, occlusal discrepancies, and scoliosis or functional postural habits such as forward head, jaw thrust, shoulder phone bracing, and lumbar lifting. In a study of postural problems in 164 head and neck muscle pain patients, poor sitting and standing posture in 96%, forward head in 84.7%, rounded shoulders in 82.3%, lower tongue position in 67.7%, abnormal lordosis in 46.3%, scoliosis in 15.9%, and leg length discrepancy in 14.0% were found to contribute to muscle pain.[2]

Oral parafunctional muscle tension produces habits such as teeth clenching, jaw thrust, gum chewing, and jaw tensing. Nocturnal bruxism is often cited as a common cause of MFP but probably is better thought of as a perpetuating cofactor.

Pathophysiology and Mechanisms

Because there are no specific anatomic changes in the myogenous pain, there are no conclusive mechanisms identified in nontrauma cases. Therefore there are several processes that may explain the development and persistence of masticatory myogenous pain.[6]

Repetitive Strain Hypothesis

Repetitive strain from oral parafunctional habits contributes to localized progressive increases in oxidative metabolism and depleted energy supply (decrease in the levels of adenosine triphosphate [ATP], adenosine diphosphate [ADP], and phosphoryl creatine and abnormal tissue oxygenation). The result is changes in the muscle nociception, particularly with type I muscle fiber types associated with static muscle tone and posture. Tenderness and pain in the muscle are mediated by type III and IV muscle nociceptors, which may be activated by locally released noxious substances such as potassium, histamine, kinins, or prostaglandins, causing tenderness.

Neurophysiologic Hypothesis

Tonic muscular hyperactivity may be a normal protective adaptation to pain instead of its cause. Phasic modulation of excitatory and inhibitory interneurons supplied by high-threshold sensory afferents may be involved.

Central Hypothesis

Convergence of multiple afferent inputs from the muscle and other visceral and somatic structures in the lamina I or V of the dorsal horn on the way to the cortex can result in perception of local and referred pain.[7]

Central Biasing Mechanism

Multiple peripheral and central factors may inhibit or facilitate central input through modulatory influence of the brainstem. This may explain the diverse factors that can either exacerbate or alleviate the pain, such as stress, repetitive strain, poor posture, relaxation, medications, temperature change, massage, local anesthetic injections, and electrical stimulation.

Clinical Presentation

The major characteristics of masticatory myalgia include pain, muscle tenderness, limited range of motion, and other symptoms such as fatigability, stiffness, and subjective weakness. Comorbid conditions and complicating factors are also common and discussed. Each will be discussed for the different subtypes.

Pain

The common sites of pain in the masticatory system include jaw pain; facial pain; temporal, frontal, or occipital headaches; preauricular pain; earache; and neck pain. The pain is often a constant steady dull ache that fluctuates in intensity and can be acute to chronic. The duration may vary from hours to days.

Muscle Tenderness

In MFP the tenderness is in a deep, localized (2 to 5 mm), taut band of skeletal muscle, a TrP, which is associated with consistent patterns of pain referral. In contrast, muscle tenderness in myositis and muscle spasm can be generalized over the whole muscle. Myofascial TrPs are very common and may be active or latent. Active TrPs are hypersensitive and display continuous pain in the zone of reference that can be altered with specific palpation. Latent TrPs display only hypersensitivity with no continuous pain. This localized tenderness has been found to be a reliable indicator of the presence and severity of MFP with both manual palpation and pressure algometers.[8-10] However, the presence of taut bands appears to be a characteristic of skeletal muscles

in all subjects regardless of the presence of MFP. Palpating the active TrP with sustained deep single finger pressure on the taut band will elicit an alteration of the pain (intensification or reduction) in the zone of reference (area of pain complaint) or cause radiation of the pain toward the zone of reference. This can occur immediately or be delayed a few seconds. The pattern of referral is both reproducible and consistent with patterns of other patients with similar TrPs (Figure 45-1). This enables a clinician to use the zone of reference as a guide to locate the TrP for purposes of treatment.

Limited Range of Motion

Diminished mandibular opening may result from structural disorders of the TMJ system such as ankylosis, internal derangements, coronoid hypertrophy, or gross osteoarthritis, all of which must be ruled out by clinical examination and joint imaging. In MFP, limitation in range of motion may be slight (10% to 20%) and unrelated to joint restriction, whereas in muscle spasm, myositis, and contracture it may be gross (50% or more). A study of jaw range of motion in patients with MFP and no joint abnormalities demonstrated a slightly diminished range of motion of 35 to 45 mm (approximately 10% compared with unaffected individuals) and pain in the full range of motion. This is considerably less limitation than was found with joint locking due to a TMJ internal derangement (20 to 35 mm).[11] This restriction may perpetuate the TrP and develop other TrPs in the same muscle and in other agonist muscles. This can cause multiple TrPs with overlapping areas of pain referral, with subsequent changes in pain patterns over time as TrPs are inactivated.

Other Symptoms

Other associated signs and symptoms that may occur include increased fatigability, stiffness, subjective weakness, pain in movement, otologic symptoms including dizziness, tinnitus, and plugged ears, paresthesias including numb feelings, decreased sensation and tingling, and dermatographia including increased redness of the skin on palpation or rolling. The affected muscles may also display an increased fatigability, stiffness, subjective weakness, pain in movement, and slight restricted range of motion that is unrelated to joint restriction.[1,4-7] The muscles are painful when stretched, causing the patient to protect the muscle through poor posture and sustained contraction.[12] There are no neurologic deficits associated with muscle pain disorders unless a nerve entrapment syndrome with weakness and diminished sensation coincides with the muscle tightness. Although routine clinical electromyography (EMG) shows no significant abnormalities associated with TrPs, some specialized EMG studies reveal differences.[13-16] The consistency of soft tissues over the TrPs has been found to be denser than over adjacent muscle.[17,18] Skin overlying the TrPs in the masseter muscle appears to be warmer as measured by infrared emission.[19,20] Routine clinical utility of these measurements remains controversial, however.

Comorbid Conditions and Complicating Factors

There are many comorbid conditions with myogenous TMD pain that reflect both common causative factors and mechanisms of pain. In most recent classifications, the regional pain found with MFP is distinguished from the widespread muscular pain associated with fibromyalgia (FM). These two disorders have many similar characteristics and may represent two ends of a continuous spectrum. For example, as Simons[21] points out, 16 of the 18 tender point sites in FM lie at well-known TrP sites. Many of the clinical characteristics of FM such as fatigue, morning stiffness, and sleep disorders can also accompany MFP. Bennett[22] compares these two disorders and concludes that they are two distinct disorders but may have similar underlying pathophysiology. The clinical significance of distinguishing between them lies in the more common centrally generated contributing factors in FM (sleep disorders, depression, and stress) versus the more common regional contributing factors in MFP (trauma, posture, and muscle tension habits) as well as the better prognosis in treatment of MFP as compared with FM.

Other comorbid conditions that have often been cited to accompany myogenous disorders include joint disc displacement and osteoarthritis, malocclusion and functional occlusal dysfunction, connective tissue diseases, neuropathic pain disorders, migraine and tension type headaches, gastrointestinal disorders, and hypothyroidism. It is not clear what mechanism underlies the coexistence of these conditions. Common central and peripheral pain mechanisms and causes may play a role.

Furthermore, many associated behavioral and psychosocial factors can accompany the chronic pain associated with myogenous disorders, including behavioral factors such as muscle tension, oral parafunctional, and maladaptive postural habits; psychologic factors such as frustration, anxiety, and depression; secondary gain from pain behaviors such as pain verbalization and avoidance of activities; medication dependencies; and sleep disturbance.

Diagnostic Tests

Diagnoses of masticatory myalgia are typically determined through the clinical diagnostic criteria that are listed in Box 45-1. However, some diagnostic strategies can be helpful. In MFP, injections of local anesthetic into the active TrP will reduce or eliminate the referred pain and the tenderness. Imaging studies often used to evaluate for dental or TMJ disease, including radiographs and magnetic resonance imaging, are generally normal. Routine clinical EMG studies are abnormal in muscle spasm only. Some specialized EMG studies (twitch response) reveal differences in cases of MFP but have limited applicability in routine clinical

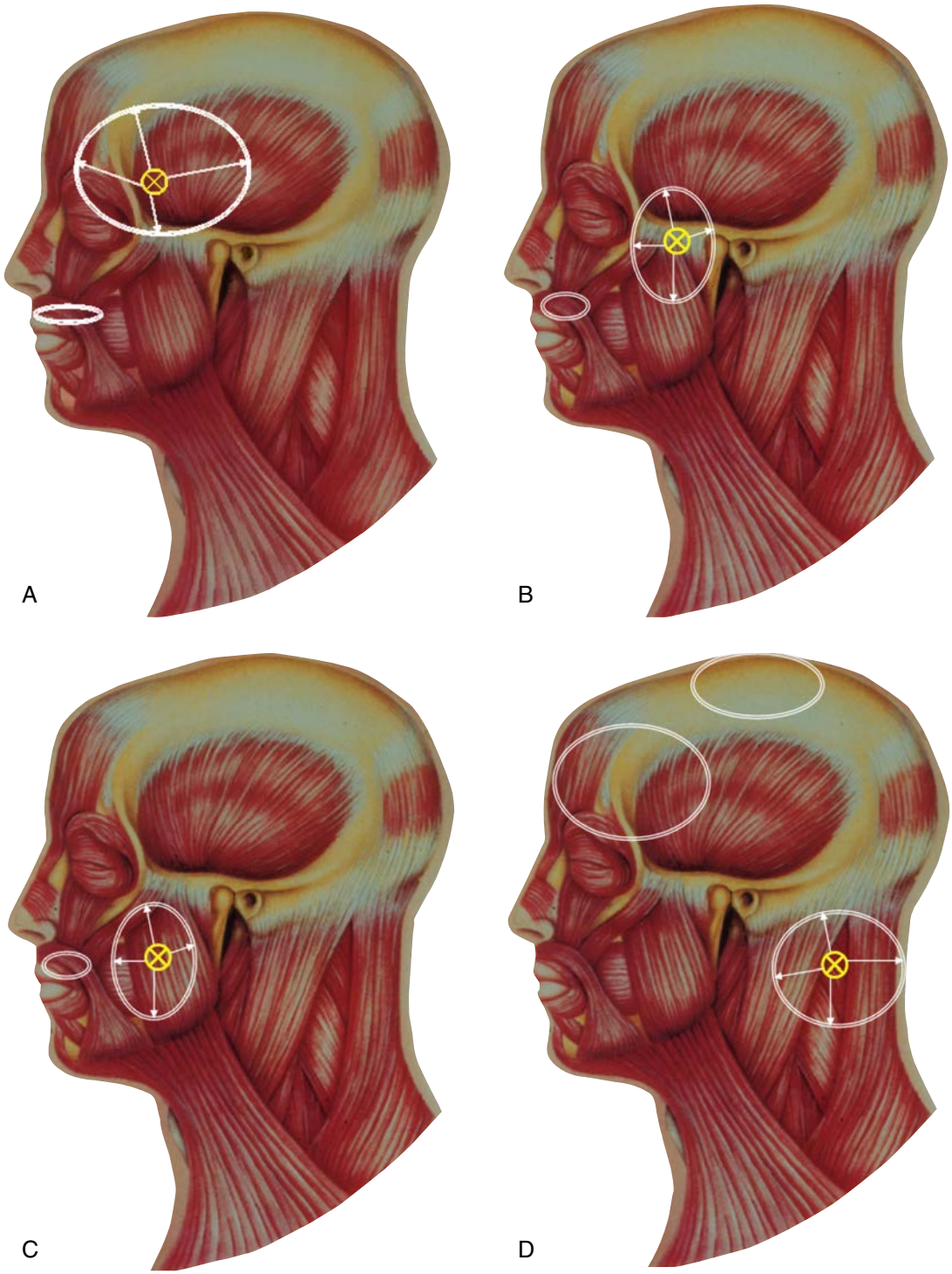

• **Figure 45-1** Trigger points in myofascial pain with associated patterns of referral in the jaw, head, and neck. **A,** The pain source is the anterior temporalis trigger point. Pain occurs as temple, frontal, and retro-orbital headaches and pain in the maxillary anterior teeth. These muscles are activated by clenching, bruxism, and other oral parafunctional habits. **B,** The pain source is the deep masseter trigger point. Pain occurs as preauricular pain, earaches, and pain in the maxillary posterior teeth. These muscles are also activated by clenching, bruxism, and other oral parafunctional habits. **C,** The pain source is the middle masseter trigger point. Pain occurs as temple, frontal, and retro-orbital headaches and as pain in the maxillary anterior teeth. These muscles are also activated by clenching, bruxism, and other oral parafunctional habits. **D,** The pain source is the splenius capitus trigger point in the posterior cervical area. Pain occurs as posterior cervical pain, vertex headache, and frontal headache. These muscles are also activated by clenching and forward head pressure.

• BOX 45-1 Diagnostic Criteria for Masticatory Myalgia Disorders

Myofascial Pain—Repetitive Strain

- Dull aching pain in the jaw, face, ear, temples, or forehead
- Localized tenderness (trigger points) in specific taut muscle bands with tenderness on the same side as the pain; see Figure 45-1 for sites and referral patterns
- Duplication of the pain with palpation of the tender trigger points

Muscle Spasm—Acute Overuse

- Acute onset of pain in the jaw, face, ear, or temples at rest and in function
- Moderate to severe acute limited range of motion due to continuous muscle contraction; in lateral pterygoid spasm, the jaw has a shift to one side with subsequent acute malocclusion that is reversible
- Generalized tenderness of the muscle

Myositis—Injury or Infection

- Pain, usually continuous, in a localized muscle area after injury or infection; pain is increased with mandibular movement
- Diffuse tenderness over the entire muscle area involved
- Moderate to severe limited range of motion
- Swelling over muscle area involved

Muscle Contracture—Muscle Fibrosis

- Gross limited range of mandibular motion
- Unyielding firmness on passive stretch (hard end feel)
- Little or no pain unless the involved muscle is forced to lengthen
- Remote history of trauma, infection, or long period of disuse and limited range of motion

practice. Blood and urine studies are generally normal unless caused by a concomitant disorder. Pain questionnaires such as the Chronic Pain Battery and TMJ Scale may identify contributing factors including emotional issues, somatization, secondary gain, and disability.

Treatment

Simple to Complex

Treatment of myogenous pain can range from simple cases with transient single muscle syndromes to complex cases involving multiple muscles and many interrelating contributing factors. Many authors have found success in treatment of myogenous pain using a wide variety of techniques such as exercise, TrP injections, vapocoolant spray and stretch, transcutaneous electrical nerve stimulation (TENS), biofeedback, posture correction, tricyclic antidepressants, muscle relaxants and other medications, and addressing of perpetuating factors.[13,23-25] However, the management challenge lies in the critical need to match the level of complexity of the management program with the complexity of the patient. Failure to address the entire problem, including all involved muscles, concomitant diagnoses, and contributing factors, may lead to failure to resolve the pain or, worse, perpetuation of the pain.

• BOX 45-2 Criteria for Complex Cases

Fulfilling any one of these criteria suggests that this patient's case is complex and may require the use of team treatment to address the contributing factors and improve the prognosis.

- Persistent pain (daily or regular) longer than 6 months in duration
- Significant lifestyle disturbances such as loss of work, social activities, or home activities
- High use of past health care including medications for problem or related problems
- Emotional difficulties related to problem including depression, anxiety, or anger
- Daily oral habits such as clenching or grinding of the teeth
- Significant stressful life events such as pacing problems, divorce, or recent death in family

Although there are no prospective studies examining progression of chronic pain syndromes, results from clinical studies reveal that many patients with muscle pain have seen many clinicians and received numerous medications and multiple other singular treatments for years without receiving more than temporary improvement. In one study of 164 muscle pain patients, the mean duration of pain was 5.8 years for males and 6.9 years for females, with a mean of 4.5 past clinicians seen for the study.[2] In another study of 102 consecutive TMJ and craniofacial pain patients including 59.8% muscle pain patients, the mean duration of pain was 6.0 years, with 28.8 previous treatment sessions, 5.1 previous doctors, and 6.4 previous medications.[26] These and other studies of chronic pain suggest that regardless of the pathogenesis of muscular pain, a major characteristic of many of these cases is the failure of traditional approaches to resolve the problem. Therefore each clinician confronted with a patient with muscle pain needs to recognize and address the whole problem to maximize the potential for a successful outcome.

Treating only those patients whose complexity matches the treatment strategy available to the clinician can improve success. Simple cases with minimal behavioral and psychosocial involvement can typically be managed by a single clinician. Complex cases (Box 45-2) should be managed within an interdisciplinary pain clinic setting that uses a team of clinicians to address different aspects of the problem in a concerted fashion. Box 45-3 presents a hierarchy of treatment strategies depending on whether the condition is acute, simple, or complex.

Treatment Goals

The short-term goal is to restore the muscle to normal length and posture and allow full joint range of motion through exercises and TrP therapy. This is followed long term with a regular muscle stretching, postural, and strengthening exercise program, as well as control of contributing factors.

• BOX 45-3 Protocol Checklist for Managing Masticatory and Cervical Myalgia Pain

I. Evaluation
  A. Identify masticatory and cervical muscles involved
  B. Identify each area of pain
    - Frequency
    - Duration
    - Intensity
  C. Identify contributing factors
    - Direct macrotrauma (e.g., blow to jaw)
    - Indirect macrotrauma (e.g., whiplash injuries)
    - Repetitive postural strain (e.g., phone bracing)
    - Oral parafunctional habits (e.g., clenching and grinding of teeth)
    - Dietary factors (e.g., caffeine)
    - Sleep disturbance
    - Psychosocial stressors
    - Anxiety and depression
  D. Determine simple versus complex
    - Simple: single clinician evaluation and treatment
    - Complex: team evaluation including dentist, physical therapist or chiropractor, psychologist

II. Management
  A. Acute
    - Palliative self-care
  B. Simple case management with single clinician
    - Self-care
    - Splint
    - Jaw exercises
    - Vapocoolant spray or other modality with stretching
    - Oral habit instruction
  C. Complex case management
    - Self-care
    - Splint
    - Trigger point or muscle injections
    - Medications (muscle relaxants and anti-inflammatories as needed)
    - Exercises with physical therapist
    - Cognitive-behavioral therapy
    - Counseling as needed

Long-term control of pain depends on patient education, self-responsibility, and development of long-term doctor-patient relationships. This often requires shifting the paradigms implicit in patient care as listed in Table 45-1. The difficulty in long-term management often lies not in treating the TrPs, but rather in the complex task of changing the identified contributing factors because they can be integrally related to the patient's attitudes, lifestyles, and social and physical environment. Interdisciplinary teams integrate various health professionals in a supportive environment to accomplish both long-term treatment of illness and modification of these contributing factors. Many approaches, such as habit reversal techniques, biofeedback, and stress management, have been used to achieve this result within a team approach.

Management follows goals including self-care, muscle exercises, muscle therapy, and reducing all contributing factors and is directed at rehabilitating the muscle to improving tenderness and range of motion, reducing tenderness, and reducing or eliminating contributing factors. Muscle rehabilitation is focused on exercise to improve range of motion, relaxation, and strength of the muscle. Reduction of contributing factors includes reducing biomechanical strain to the muscles from oral parafunctional habits such as clenching, gum chewing, and other repetitive strain activities. In addition, improved posture of the head, neck, and tongue will reduce sustained muscle activity and encourages healing. Reducing tenderness can be accomplished by inhibiting peripheral neural input through various treatment modalities such as cold, heat, analgesic medications, massage, muscle injections, and TENS. Reducing central modulating factors requires the patient to manage contributing factors such as improving stress, sleep, anxiety, and depression.

TABLE 45-1 Shifting Paradigms in Patient Care

Shifting the doctor-patient paradigms involves each member of the team following the same concepts by conveying the same messages implicit in the dialogue with the patient.

Concept	Statement
Self-responsibility	You have more influence on your problem than we do.
Self-care	You will need to make daily changes in order to improve your condition.
Education	We can teach you how to make the changes.
Long-term change	It will take at least 6 months for the changes to have an effect.
Doctor-patient relationship	We will support you as you make the changes.
Patient motivation	Do you want to make the changes?

Control of Contributing Factors

One of the common causes of failure in managing masticatory myalgia is failure to recognize and subsequently control contributing factors that may perpetuate muscle restriction and tension. As noted earlier, postural contributing factors, whether behavioral or biologic, perpetuate muscle pain if not corrected. In general, a muscle is more predisposed to developing problems if it is held in sustained contraction in the normal position and especially if it is in an abnormally shortened position. Such a situation exists with structural problems such as loss of posterior teeth, an excessive lordosis of the cervical spine, a unilateral short leg, or a small hemipelvis.[11] An occlusal imbalance can be corrected with an occlusal stabilization splint, also termed a *flat plane* or *full-coverage splint*. Other postural factors that can be corrected include a foot lift for a unilateral leg length discrepancy, a pelvic lift for a small hemipelvis, and proper height of arm rests in chairs for short upper arms.

• BOX 45-4 Palliative Self-Care Program for Acute Episodes of Masticatory Myalgia

- Eat a soft diet and avoid caffeine.
- Keep your tongue up and gently resting on the palate. Keep teeth apart as the rest position of the jaw.
- Chew on both sides at the same time or alternate sides to minimize strain to muscles.
- Avoid oral parafunctional habits such as clenching and grinding the teeth, jaw tensing, or gum chewing.
- Avoid excessive or prolonged opening of mouth.
- Avoid sleeping on your stomach to minimize strain to the jaw during sleep.
- Use over-the-counter analgesics or nonsteroidal anti-inflammatories as directed for pain.
- Use heat or ice over the tender muscles.

Behavioral factors causing sustained muscle tension can also occur with habits such as a receptionist cradling a phone between the head and shoulder for hours each day, a laborer lifting with lumbar strain, a student studying with the head forward for hours at a time, or bruxism, clenching, gum chewing, or other oral parafunctional habits. Correcting poor habits through education and long-term reinforcement is essential to preventing a reduced TrP from returning. Biofeedback, meditation, hypnosis, stress-management counseling, psychotherapy, antianxiety medications, antidepressants, and even placebos have been reported to be effective in treating masticatory myalgia.[26-30] Many of these treatments are directed toward reducing muscle tension that produces habits such as bruxism or bracing of muscles. Teaching control of habits is a difficult process because of the relationship that muscle tension may have to psychosocial factors. Simply telling a patient to stop the habits may be helpful with some, but with others it may result in noncompliance, failure, and frustration. An integrated approach involving education, increased awareness, and other treatments, such as behavior modification, biofeedback, hypnosis, or drug therapy, may prove to be more successful.

Simple Management

Self-Care

Most acute recent symptoms are self-limited and resolve with minimal intervention. Initial treatment should be a self-care program (Box 45-4) to reduce repetitive strain of the masticatory system and encourage relaxation and healing of the muscles.

This strategy includes jaw range of motion exercises, oral habit change, and protective gentle use of the jaw. Most patients respond well to self-care in 4 to 6 weeks; if not, further assessment and treatment are indicated.

Orthopedic Intraoral Splints

Orthopedic intraoral splints can encourage relaxation of the muscles, alter muscular recruitment patterns, and reduce oral habits. Stabilization splints allow passive protection of the jaw and reduction of oral habits owing to the flat passive occlusal surface on mandibular or maxillary teeth. Mandibular splints can be smaller and result in higher patient satisfaction in some cases. Splints should be adjusted to achieve mutually protected occlusion with bilateral balanced contact on all posterior teeth with the condyles in their most seated positions, with anterior guidance (lateral and protrusive) provided by the canines and/or incisors.

Anterior repositioning splints can be efficacious for concomitant joint problems with intermittent jaw locking with limited range of motion, especially on awakening, and are recommended for short-term, part-time use, primarily during sleep. Long-term or continuous use must be avoided because they can cause occlusal changes.

Partial coverage splints may cause occlusal changes in some patients. Splints should cover all of the mandibular or maxillary teeth to prevent movement of uncovered teeth resulting in iatrogenic malocclusion.

Cognitive-Behavioral Therapy

Cognitive-behavioral therapy (CBT) approaches can help change maladaptive habits and behaviors that contribute to myalgia such as jaw tensing, teeth clenching, and teeth grinding. Although many simple habits are easily abandoned when the patient becomes aware of them, changing persistent habits requires a structured program that is facilitated by a clinician trained in behavioral strategies. Habits do not change themselves, and patients are responsible for initiating and maintaining behavior changes.

Habit reversal can be accomplished by becoming more aware of the habit, knowing how to correct it (e.g., what to do with the teeth and tongue), and knowing why to correct it. Correcting a habit during the day will also help reduce it at night. These educational points from the clinician must be combined with the patient's commitment to conscientious self-monitoring and focus on the goal.

Muscle Exercises

The most useful exercise techniques for muscle rehabilitation include muscle stretching, posture, and strengthening exercises.[13,24,25,31] In patients with muscle pain, a home program of active and passive muscle stretching exercises will reduce the activity of muscle pain, and postural exercises will reduce susceptibility to reactivation of pain by physical strain (Figure 45-2). Strengthening and cardiovascular fitness exercises will improve circulation, strength, and durability of the muscles.

Pharmacotherapy

Pharmacotherapy is a useful adjunct to initial treatment of muscle pain. The most commonly used medications for pain are classified as nonnarcotic analgesics (nonsteroidal anti-inflammatory agents [NSAIDs]), narcotic analgesics, muscle relaxants, tranquilizers (ataractics), sedatives, and antidepressants. Analgesics are used to allay pain; muscle



• **Figure 45-2** Jaw exercises. These jaw stretching exercises can be used for initial postural correction and range of motion restoration for masticatory myofascial pain. They can restore normal joint function and mobility and result in a more comfortable and normal jaw position. They are performed gradually and gently six times daily for about 1 minute each. The jaw should be progressively stretched slightly beyond the point of tightness and pain. Caution should be taken to avoid overstretching with acutely strained jaws or capsulitis of the temporomandibular joint. Place one finger between the teeth for 1 minute. Rest and repeat. Then place two fingers between the teeth for 1 minute. Rest and repeat. In some cases without significant joint restriction, using three fingers to stretch may be needed.

relaxants and tranquilizers for anxiety, fear, and muscle tension; sedatives for enhancing sleep; and antidepressants for pain, depression, and enhancing sleep.[23]

Randomized clinical trials on NSAIDs such as ibuprofen and piroxicam suggest that for myalgia, short-term use of these medications for analgesic and/or anti-inflammatory effects certainly can be considered as a supplement to overall management. Chronic, long-term use is undertaken with caution owing to the long-term systemic and gastrointestinal effects. If some therapeutic result is not apparent after 7 to 10 days or if the patient develops any side effects, especially gastrointestinal symptoms, the medication should be discontinued.

For muscle pain, especially with stress and sleep disturbance, benzodiazepines, including diazepam and clonazepam, have been shown to be effective. Experience suggests that these are best used before bedtime to minimize sedation while awake. Cyclobenzaprine (Flexeril) has also been shown in clinical trials of myalgia to be efficacious in reducing pain and improving sleep[32,33] and can be considered when a benzodiazepine is too sedating. These medications, with or without NSAIDs, can also be considered for a 2- to 4-week trial with minimal habituation potential. However, long-term use has not been adequately tested.

Advanced Management

Cognitive-Behavioral Therapy

When necessary, basic habit reversal may be supplemented with additional behavioral strategies such as biofeedback, meditation, stress management, or relaxation techniques. It may also be important to address poor pacing or hurrying related to a day overloaded with commitments, depression, anxiety, sleep disorders, or emotional problems. This may require behavioral and psychologic therapy and/or medications and is best managed by a competent psychologist or psychiatrist.

Muscle Exercises

Passive and active stretching of the muscles will increase the opening to the normal range as well as decrease the pain. Passive stretching of the masticatory muscles during counter stimulation of the tender muscle can be accomplished through placing a properly trimmed and sterile cork, tongue blades, or other object between the incisors while the spray and stretch technique is accomplished. It must be emphasized to avoid rapid, jerky stretching or overstretching of the muscle to reduce potential injury to the muscle.

Postural exercises are designed to teach the patient mental reminders to hold the body in a balanced relax position and use the body with positions that afford the best mechanical advantage. In improving posture, specific skeletal conditions such as structural asymmetry or weakness of certain muscles need to be considered. For the masticatory system the patient should be instructed to place the tongue gently on the roof of the mouth and keep the teeth slightly apart. For the cervical spine, a forward or lateral head posture must be corrected by guiding the chin in and the head vertex up. The shoulders will naturally fall back if the thorax is positioned up and back with proper lumbar support. Patients need to be instructed in proper posture for each position—sitting, standing, and lying down—as well as in movements that are done repetitively throughout the day such as lifting or turning the head to the side. Sleeping posture on the side or back is particularly important for patients who wake up with soreness.

Improved posture is also facilitated by regular physical conditioning. Patients need to be placed on a conditioning program to facilitate increased aerobic capacity and strength. Aerobic programs, such as becoming involved in an exercise class, regular running, walking, biking, or swimming, will improve comfort, endurance, and functional status of patients with muscle pain.[11]

Muscle Therapy

There are many methods suggested for providing repetitive stimulation to tender muscles. Massage, acupressure, and ultrasound provide noninvasive mechanical disruption to

reduce tenderness. Moist heat applications, ice packs, fluoromethane, and diathermy provide skin and muscle temperature change as a form of counter stimulation. TENS, electroacupuncture, and direct current stimulation provide electric currents to stimulate the muscles and TrPs. Acupuncture and TrP injections of local anesthetic, corticosteroids, or saline cause direct mechanical or chemical alteration of TrPs. However, the two most common techniques for treating muscle pain include spray and stretch technique and TrP injections.

With the spray and stretch technique, an application of a vapocoolant spray such as fluoromethane over the muscle with simultaneous passive stretching can provide immediate reduction of pain, although lasting relief requires a full management program.[8] The technique involves directing a fine stream of fluoromethane spray from the finely calibrated nozzle toward the skin directly overlying the muscle with the TrP. A few sweeps of the spray are first passed over the TrP and zone of reference before the addition of sufficient manual stretch to the muscle to elicit pain and discomfort. The muscle is put on a progressively increasing passive stretch while the jet stream of spray is directed at an acute angle from 30 to 50 cm (1 to 1½ feet) away. It is applied in one direction from the TrP toward its reference zone in slow even sweeps over adjacent parallel areas at a rate of about 10 cm/sec. This sequence can be repeated up to four times if the clinician warms the muscle with his or her hand or uses warm moist packs to prevent overcooling after each sequence. Frosting the skin and excessive sweeps should be avoided because they may lower the underlying skeletal muscle temperature, which tends to aggravate TrPs. The range of passive and active motion can be tested before and after spraying as an indication of responsiveness to therapy. Failure to reduce TrPs with spray and stretch may be due to inability to secure full muscle length because of bone or joint abnormalities, muscle contracture, or the patient avoiding voluntary relaxation; incorrect spray technique; or failure to reduce perpetuating factors. If spray and stretch fails with repeated trials, direct needling with TrP injections may be effective.

TrP muscle injections have also been shown to reduce pain, increase range of motion, increase exercise tolerance, and increase circulation of muscles.[9,10,14] The pain relief may last from the duration of the anesthetic to many months, depending on the chronicity and severity of TrPs and the degree of reduction in perpetuating factors. Because the critical factor in relief appears to be the mechanical disruption of the TrP by the needle, precision in needling of the exact TrP and the intensity of pain during needling appear to be the major factors in TrP inactivation.[15] TrP injections with local anesthetic are generally more effective and comfortable than dry needling or injecting other substances, such as saline, although acupuncture may be helpful for patients with chronic TrPs in multiple muscles. The effect of needling can be complemented with the use of local anesthetics in concentrations less than those required for a nerve conduction block. This can markedly lengthen the relative refractory period of peripheral nerves and limit the maximum frequency of impulse conduction. Local anesthetics can be chosen for their duration, safety, and versatility. Three percent chloroprocaine (short acting) and 5% procaine (medium acting) without vasoconstrictors are suggested.

Pharmacotherapy

Research on medications for FM, especially with sleep disturbances, indicates that tricyclic antidepressants such as amitriptyline (Elavil) have a significant impact on sleep disturbances, anxiety, and pain in FM patients. Therefore these medications can be used in appropriate cases long term.[34] However, the side effects with amitriptyline can be significant, and nortriptyline (Pamelor) can be considered an analogous medication with fewer side effects. Typically the dose for either of these medications in patients without depression is in the 25- to 75-mg range, taken at bedtime. The use of selective serotonin reuptake inhibitors (SSRIs) has been suggested for depression and pain but may also have the common side effect of increasing muscle tension and aggravating the pain.

For chronic pain conditions that are resistant to interventions, use of opioids can be considered. Tramadol has been shown to be effective in FM. However, there are no randomized clinical trials evaluating the appropriateness of opioids in the long-term treatment of chronic pain. At this time, chronic opioid use is mainly indicated for patients with chronic intractable severe pain conditions that are refractory to all other reasonable treatments because of their side effects, including constipation, sedation, potential for dose escalation, and unknown effects with long-term use.

Despite the advantages of medications for pain disorders, there exists an opportunity for problems to occur owing to their misuse. The problems that can occur from use of medications include chemical dependency, behavioral reinforcement of continuing pain, inhibition of endogenous pain relief mechanisms, side effects, and adverse effects from the use of polypharmaceuticals. For this reason the use of medication should proceed with caution.

Pain Clinic Team Management

Although each clinician may have limited success in managing the "whole" patient alone, the assumption behind a team approach is that it is vital to address different aspects of the problem with different specialists in order to enhance the overall potential for success.[17-19] Although these programs provide a broader framework for treating the complex patient, they have added another dimension to the skills needed by the clinician: working as part of a coordinated team. Failure to adequately integrate care may result in poor communication, fragmented care, distrustful relationships, and eventually confusion and failure in management.

However, team coordination can be facilitated by a well-defined evaluation and management system that clearly integrates team members.

A prerequisite to a team approach is an inclusive medical model and conceptual framework that places the physical, behavioral, and psychosocial aspects of illness on an equal and integrated basis.[20,35] With an inclusive theory of human systems and their relationship to illness, a patient can be assessed as a whole person by different clinicians from diverse backgrounds. Although each clinician understands a different part of the patient's problem, she or he can integrate understanding with other clinicians' perspectives and see how each part is interrelated in the whole patient. For example, a physician or dentist will evaluate the physical diagnosis, a physical therapist will evaluate poor postural habits, and a psychologist will evaluate behavioral problems or social stressors. Each factor will become part of the problem list to be addressed in the treatment plan. In the process, the synergism of each factor in the cause of the disorder can become apparent to clinicians. For example, social stressors can lead to anxiety, anxiety can lead to poor posture and muscle tension, the poor posture and muscle tension can lead to MFP syndrome, the pain contributes to more anxiety, and a cycle continues. Likewise, a reduction of each factor will work synergistically to improve the whole problem. Treatment of only one factor may improve the problem, but relief may be partial or temporary. Treatment of all factors simultaneously can have a cumulative effect that is greater than the effects of treating each factor individually.

The problem list for a patient with a specific chronic illness includes both a physical diagnosis and a list of contributing factors. In establishing the problem list the clinician needs to determine if the patient's case is complex and requires a team approach. Recommended criteria for determining complexity include any one of the following: multiple diagnoses, persistent pain longer than 6 months in duration, significant emotional problems (depression, anxiety), frequent use of health care services or medication, daily oral parafunctional habits, and significant lifestyle disturbances. The use of a screening instrument such as IMPATH, the McGill Pain Questionnaire, or the Multidimensional Inventory can readily elicit the degree of complexity of a case at initial evaluation.[1,36-38] The more complex the case is, the greater the need for a team approach. The decision to use a team must be made at the time of evaluation and not partway through a failing singular treatment plan. If a team is needed, the broad understanding of the patient is then used to design a long-term management program that both treats the physical diagnosis and helps reduce these contributing factors.

The primary goals of the program include reducing the symptoms and their negative effects and helping the patient return to normal function without need for future health care. The patient first participates in an educational session with each clinician to learn about the diagnoses and contributing factors, why it is necessary to change these factors, and how to do it. The dentist or physician is responsible for establishing the physical diagnosis, providing short-term medical or dental care, and monitoring medication and patient progress. The health psychologist is responsible for providing instruction about contributing factors; diagnosing, managing, or referring for primary psychologic disturbances; and establishing a program to support the patient and family in making changes. The physical therapist is responsible for providing support, instruction, and a management program for specifically assigned and common contributing factors, such as an exercise and posture program. Depending on the therapist's background and the patient's needs, this person may also provide special care such as physical therapy modalities or occupational therapy. Each clinician is also responsible for establishing a trusting, supportive relationship with the patient while reaffirming the self-care philosophy of the program, reinforcing change, and ensuring compliance. The patient is viewed as responsible for making the changes. The team meets weekly to review current patient progress and discuss new patients.

Summary

Goals of treatment of masticatory myalgia include reducing or eliminating pain, restoring normal jaw function, reducing the need for future health care, and restoring normal lifestyle functioning. The short-term strategy is to restore the muscle to normal length, posture, and full joint range of motion with exercises. The long-term strategy includes reducing the symptoms through muscle rehabilitation while helping the patient reduce contributing factors and return to normal function without the need for future health care.

Recent onset cases can often be managed with palliative self-care strategies designed to protect the muscles and encourage healing. Simple cases with minimal behavioral and psychosocial involvement can be managed by a single clinician (monodisciplinary fashion) with self-care, exercises, and a stabilization splint. Complex cases can be most effectively managed within an interdisciplinary pain clinic setting that uses a team of clinicians to address different aspects of the problem in a concerted fashion. Behavioral and psychosocial evaluation should be conducted on all patients with persistent pain to determine complexity and contributing factors. To improve outcomes, it is important to match the level of complexity of the management program with the complexity of the cases and use a pain clinic team approach to facilitate success in complex cases. Employing clinical paradigms of self-care, education, and self-responsibility in care will enhance long-term outcomes and maintain positive relationships between the patient and clinician.

References

1. Okeson JP: *Bell's orofacial pain*, ed 5, Chicago, 1995, Quintessence.
2. Fricton J, Kroening R, Haley D, Siegert R: Myofascial pain syndrome of the head and neck: a review of clinical characteristics of 164 patients, *Oral Surg Oral Med Oral Pathol* 60:615, 1985.
3. Fricton JR: Myofascial pain syndrome: characteristics and epidemiology. In Fricton JR, Awad EA, editors: *Myofascial pain and fibromyalgia*, New York, 1990, Raven Press.
4. Skootsky S, Jaeger B, Oye RK: Prevalence of myofascial pain in general internal medicine practice, *West J Med* 151:157, 1989.
5. Fricton JR: Recent advances in temporomandibular disorders and orofacial pain, *J Am Dent Assoc* 122:24, 1991 (see comments; review).
6. Okeson JP, editor: *Orofacial pain: guidelines for assessment, diagnosis, and management*, Chicago, 1996, Quintessence.
7. Lund JP, Donga R, Widmer CG, Stohler CS: The pain-adaptation model: a discussion of the relationship between chronic musculoskeletal pain and motor activity, *Can J Physiol Pharmacol* 69:683, 1991 (review).
8. Travell J: Myofascial trigger points: clinical view. In Bonica JJ, Albe-Fessard DG, et al.: editors: *Advances in pain research and therapy*, New York, 1976, Raven Press.
9. Cifala J: Myofascial (trigger point pain) injection: theory and treatment, *Osteopath Med*, April:31, 1979.
10. Cooper AL: Trigger point injection: its place in physical therapy, *Arch Phys Med* 42:704, 1961.
11. Travell J, Simons DG: *Myofascial pain and dysfunction: the trigger point manual*, Baltimore, 1998, Williams & Wilkins.
12. Fricton JR: Myofascial pain. In Masi AT, editor: *Fibromyalgia and myofascial pain syndromes*, London, 1994, Baillière Tindall.
13. Dall Arancio D, Fricton J: Randomized controlled study of exercises for masticatory myofascial pain, *J Orofac Pain* 7:117, 1993.
14. Jaeger B, Skootsky SA: Double blind, controlled study of different myofascial trigger point injection techniques, *Pain* 4(Supp): S292, 1987.
15. Lewit K: The needle effect in the relief of myofascial pain, *Pain* 6:83, 1979.
16. Fields HL, Liebeskind JC, editors: *Pharmacological approaches to the treatment of chronic pain: new concepts and critical issues*, Seattle, 1994, IASP Press.
17. Ng LK, editor: *New approaches to treatment of chronic pain: a review of multidisciplinary pain clinics and pain centers*, Washington DC, 1981, U.S. Government Printing Office.
18. Fricton J, Dall AD: Interdisciplinary management of myofascial pain of the masticatory muscles. In Fricton JR, Dubner R, editors: *Orofacial pain and temporomandibular disorders*, New York, 1995, Raven Press.
19. Aronoff GM, Evans WO, Enders PL: A review of follow-up studies of multidisciplinary pain units, *Pain* 16:1, 1983.
20. Rodin J: Biopsychosocial aspects of self management. In Karoly P, Kanfer FH, editors: *Self management and behavioral change: from theory to practice*, New York, 1974, Pergamon Press.
21. Simons D: Muscular pain syndromes. In Fricton J, Awad EA, editors: *Myofascial pain and fibromyalgia*, New York, 1990, Raven Press.
22. Bennett R: Myofascial pain syndromes and the fibromyalgia syndrome: a comparative analysis. In Fricton J, Awad EA, editors: *Myofascial pain and fibromyalgia*, New York, 1990, Raven Press.
23. Fricton JR, Kroening R: Practical differential diagnosis of chronic craniofacial pain, *Oral Surg Oral Med Oral Pathol* 54:628, 1982.
24. Shata R, Mehta NR, Forgione AG: Active resistance exercise for TMD related tension pain, *J Dent Res* 79(special issue):351, 2000 (abstract 3541).
25. Au AR, Klineberg IJ: Isokinetic exercise management of temporomandibular joint clicking in young adults, *J Prosthet Dent* 70:33, 1993.
26. Fricton JR, Hathaway KM, Bromaghim C: Interdisciplinary management of patients with TMJ and craniofacial pain: characteristics and outcome, *J Craniomandib Disord* 1:115, 1987.
27. Clarke NG, Kardachi BJ: The treatment of myofascial pain-dysfunction syndrome using the biofeedback principle, *J Periodontol* 48:643, 1977.
28. Fricton J: *Psychosocial characteristics of patients with low back pain compared to patients with head and neck pain, American Congress of Rehabilitation Medicine Annual Meeting*, Orlando, 1987, Florida.
29. Fricton JR: Myofascial pain. In Masi AT, editor: *Fibromyalgia and myofascial pain syndromes*, London, 1994, Baillière Tindall.
30. Graff-Radford SB, Reeves JL, Jaeger B: Management of chronic head and neck pain: effectiveness of altering factors perpetuating myofascial pain, *Headache* 27:186, 1987.
31. Magnusson T, Syren M: Therapeutic jaw exercises and interocclusal appliance therapy. A comparison between two common treatments of temporomandibular disorders, *Swed Dent J* 23:27, 1999.
32. Dionne RA: Pharmacologic treatments for temporomandibular disorders, *Oral Surg Oral Med Oral Pathol Oral Radiol Endod* 83:134, 1997.
33. Singer E, Dionne R: A controlled evaluation of ibuprofen and diazepam for chronic orofacial muscle pain, *J Orofac Pain* 11:139, 1997.
34. Wedel A, Carlsson GE: Sick-leave in patients with functional disturbances of the masticatory system, *Swed Dent J* 11:53, 1987.
35. Schneider F, Kraly P: Conceptions of pain experience: the emergence of multidimensional models and their implications for contemporary clinical practice, *Clin Psychol Rev* 3:61, 1983.
36. Fricton JR, Nelson A, Monsein M: IMPATH: microcomputer assessment of behavioral and psychosocial factors in craniomandibular disorders, *Cranio* 5:372, 1987.
37. Kerns RD, Turk DC, Rudy TE: The West Haven–Yale Multidimensional Pain Inventory (WHYMPI), *Pain* 23:345, 1985.
38. Turk DC, Rudy TE, Salovey P: The McGill Pain Questionnaire reconsidered: confirming the factor structure and examining appropriate uses, *Pain* 21:385, 1985.

Index

A
A-delta nerve fiber, I-225
AAAASF. *See* American Association for Accreditation of Ambulatory Surgery Facilities (AAAASF)
AAAHC. *See* Accreditation Association for Ambulatory Health Care (AAAHC)
AAOMS. *See* American Association of Oral and Maxillofacial Surgeons (AAOMS)
Abbe flap, II-286, II-297–298, II-291f
Ablation, laser for, I-330, I-338f, III-352–355
ABMS. *See* American Board of Medical Specialties (ABMS)
Abrasion, exodontia and, I-301
Abutment
  anterior, decision tree for, I-637f
  cement-retained implant on, I-625f
  cementable, I-626f
  custom, I-630
  direct, I-626f
  gold, I-636
  Locator, I-657–658
  material choices, I-636–639
  posterior, decision tree, I-632f
  projection, in three-dimensional imaging, I-693–696, I-696f
  Snappy, I-626f
  stock, I-630, I-630f, I-634f
  temporary, immediate implant and, I-416–418
  titanium, I-636
  zirconia, I-625f, I-628, I-630f, I-636
Acantholysis, II-564
Acanthosis nigricans, III-668
Accelerated osteogenic orthodontics (AOO), III-247–248
  alternative options, III-261
  case study, III-251b–257b, III-259b–260b
  contraindications, III-250–261
  indications, III-250–261
  mandible, case study, III-251b–252b
  maxilla, case study, III-253b–257b
  orthodontic technique following, III-250
  orthognathic surgery with, III-259–261
  surgical technique, III-248–250
Accountant, for oral and maxillofacial surgical practice, I-63
Accreditation
  benefits, I-99–100
  definition, I-98–99
  outpatient surgery facility, I-96–101
Accreditation Association for Ambulatory Health Care (AAAHC), I-98, I-98t, I-100t
Accudent System, I-656f
ACE Distractor, I-539–540
Acellular dermal matrix, I-558, I-561f, III-611–612
Acetaminophen, I-232
  dosage, I-232t
  for temporomandibular joint disorders, II-870–871
Acetazolamide, II-207
ACGME. *See* American Council for Graduate Medical Education (ACGME)
Acinic cell carcinoma, II-498
Acinus, II-481
Acitretin, II-733
Acne, laser treatment, III-357–358
Acquired immunodeficiency syndrome (AIDS)
  lymphoepithelial cyst associated with, II-485
  osteoradionecrosis associated with, II-591f–594f
  parotid gland affected by, II-488
Acral lentiginous melanoma, II-692t, II-694f
Acrylic resin
  restoration with, I-597–599
  try-in, I-602f
  wraparound prosthesis, I-599f
Actinic keratitis, III-354
Actinic keratosis, II-719, II-723–724
  medical management, II-733–734
  photodynamic therapy for, II-734
  treatment, II-727
Actinobacillus actinomycetemcomitans, I-350
Actinomycin D, II-455
Active range of motion, II-806
Actonel. *See* Risedronate (Actonel)
Acute kidney injury
  preoperative evaluation of, I-158–159
  Rifle criteria for, I-153t
Acute suppurative parotitis, II-485–487
Acute suppurative sialadenitis, II-487
Acyclovir, II-553–556
Ad modum Brånemark technique, I-572–573, I-577, I-578f
ADA. *See* American Dental Association (ADA)
Addiction
  definition, II-952
  ethics and, I-12
  facial pain management and, II-952
  medical professional affected by, I-144
  opioid drug use and, I-228
  sexual, I-145
  treatment, I-145
Adenocarcinoma, polymorphous, II-503f
Adenoid cystic carcinoma, II-493t, II-498, II-500–501, II-759–760
Adenoidectomy, codeine warning, I-254
Adenoma
  monomorphic, II-493t
  pleomorphic, II-492–494, II-493t
Adenomatoid odontogenic tumor (AOT), II-368, II-394–397, III-744–745
Adipocyte, III-434, III-435f
Adipose tissue, III-429, III-434
Adolescent
  craniosynostosis care algorithm, III-677–678
  dentoalveolar injury, II-114
  heart rate, II-249–250
  neurologic abnormalities, III-284
  trauma outcomes, II-245
Adolescent internal condylar resorption, III-224–225
Adrenal insufficiency
  craniomaxillofacial trauma management and, II-3t
  preoperative evaluation of, I-158–159
Adrenergic system, local anesthesia and, I-179
Adrenocorticoid deficiency, I-159t
Adriamycin. *See* Doxorubicin (Adriamycin)
Advanced Beneficiary Notice (ABN), I-91
Advanced Trauma Life Support (ATLS), II-1, II-2b
  for dentoalveolar injury, II-115–116
  for gunshot patient, II-307, II-310–311
  for injured child, II-246
  for mandibular fracture, II-152
  midface fracture diagnosis and, II-212
  pediatric facial trauma evaluation with, II-232
Advil. *See* Ibuprofen (Advil, Motrin)
Aerodigestive tract, III-670–671
Afferent nerve fiber
  neurophysiology, II-942–943
  pain transmission, I-225
Affordable Care Act, I-95
Ageusia, definition, I-355t
Aging
  bone graft healing affected by, I-432
  forehead and brow ptosis in, III-395
  impairment caused by, I-146
  retirement and, I-140–141
Agonist-antagonist drugs, I-226
Agonist drugs, I-226
AHI. *See* Apnea-hypopnea index (AHI)
Airway
  adult, pediatric compared to, I-239–240, I-240f, II-249f
  assessment, II-9–10, I-213–214
  breathing
    circulation, disabilities, exposure (ABCDE), child trauma assessment with, II-246
    circulation (ABC), II-9
  in craniosynostosis care algorithm, III-671–672
  emergency equipment, I-245–247
  injuries affecting, II-11–12, II-11, II-11
  monitoring, I-167
  in nasal fracture, II-187
  obstruction, II-10
  patency, I-213–214
  pediatric, I-239–241, I-248–249, II-249f, II-258–260
  physical examination, II-10–11
  preanesthetic assessment, I-242
  preoperative evaluation, III-282–283
  upper, pediatric, I-239–240
Airway management
  advanced techniques, II-13–14
  in avulsive facial injury, II-282
  in craniomaxillofacial trauma, II-1–2, II-2f
  in craniosynostosis care algorithm, III-671–672
  for maxillofacial gunshot wound patient, II-308–309

This index contains all entries from Volume I, II, and III. Each entry lists the volume number first followed by the page number.
Page numbers followed by b, indicate boxes; f, figures; and t, tables.

Airway management *(Continued)*
in oculoauriculovertebral spectrum, III-692
pediatric, I-238, I-258–260
in pediatric trauma, II-248–249
surgical, II-14
for trauma patient, II-9–15
in Treacher Collins syndrome, III-705
Alar cinch, III-167–168
Alar-columellar relationship, III-370f
Alar width, III-368
Albumin, local anesthetics and, I-178
Alcohol use, oral cancer associated with, II-671
Aldrete scoring system, I-172–173, I-173t
Alendronate sodium (Fosamax), II-508t
Aleve. *See* Naproxen (Naprosyn, Aleve)
Alfentanil, I-197–198, I-199f
Algae, alloplastic implant with, I-440–441
Allele, II-603, II-606–607
Allergy
to dental cement, I-716
to local anesthesia, I-182–183
Allis clamp, III-77f
Allodynia
definition, I-355t, II-946t
neurosensory testing of, I-359
Allogenic, definition, I-437
Allogenic bone, I-439–440
demineralized, I-439
mineralized, I-439–440
Allograft, I-428–429
for burn injury, II-67
demineralized, I-439f
in esthetic contour graft, I-490
mineralized, I-440f
particulate, I-485f–487f, I-494f, I-500b
ridge augmentation and, I-483
stem cells combined with, I-439f
Alloplast
bone graft with, I-430–432
interpositional bone graft, I-527–528
Alloplast entubulation, I-372
Alloplastic, definition, I-437
Alloplastic bone graft, I-430–432, I-483–484
Aloe vera, II-67
Alopecia
in forehead and brow lift, III-425
in rhytidectomy, III-334
Alpha1-acid glycoprotein (AAG), I-178
Alpha-hydroxy acid, for chemical peel, III-443–444
Alprazolam (Xanax)
half-life, I-195t
protein binding, I-195t
for temporomandibular joint disorders, II-874t
Alveolar bone
classification, I-537
deficiency, I-526, I-538, I-538b
examination, in dentoalveolar injury, II-117
fracture, II-123t, II-133–137
healing, after trauma, II-138
injury treatment, II-133–137
Alveolar cleft, III-588, III-624f
Alveolar cleft lip, I-665, I-679–683
Alveolar distraction osteogenesis. *See* Distraction osteogenesis (DO), alveolar
Alveolar nerve, II-147
injury, I-368–369, I-377
bilateral sagittal split osteotomy and, I-378–379
coronectomy and, I-381–382
during exodontia, I-302
outcomes and conclusions, I-382–383
in sagittal split osteotomy, III-301–305
from third molar extraction, I-382–390
Alveolar nerve *(Continued)*
neurofibroma and, II-472
neuroma, I-317f
pediatric, I-259f
Alveolar osteitis, I-283
exodontia and, I-303
third molar extraction and, I-293–294
treatment, I-294
Alveolar process fracture, II-133–135
Alveolar repositioning osteotomy, I-529
Alveolar ridge
anatomy, II-670
augmentation, I-484, I-534
case study, I-500b–501b, I-503b
guidelines, I-538t, I-538b
horizontal, I-538–539
indications, I-537–538
vertical, I-538–539
capillary malformation in, II-538
defect, I-485f–490f, I-491–493, I-539
distraction, I-545f–546f
smile line and, I-588–589
squamous cell carcinoma, II-681–683
Alveolar socket, comminution, II-123t, II-133
Alveolar soft part sarcoma, II-644t, II-645–646, II-663–664
Alveolar split graft, I-528–529
Alveolar width, distraction osteogenesis and, I-529–532
Alveolus
augmentation, III-587
cleft, III-497, III-583
lack of, zygomatic implant for, I-570
reconstruction, III-589–592
three-dimensional image, I-691f
unrepaired, III-609–610
Alzheimer's disease, I-146
AMA. *See* American Medical Association (AMA)
Ameloblastic fibro-odontoma, II-451–453, III-745
Ameloblastic fibrodentinoma (AFD), II-453–454
Ameloblastic fibroma, II-449–451, III-745
Ameloblastic fibrosarcoma, II-454–455
Ameloblastic sarcoma, II-454–455
Ameloblastoma, II-401–424, III-744
anaplastic, II-421f
basal cell carcinoma compared to, II-401
clear cell, II-425, II-429
clinical forms, II-404–422
clinicopathologic considerations, II-402
cytologic malignant, II-420–422
dentigerous cyst and, II-345–347
extraosseous, surgical management, II-423–424
growth mechanism, II-404–422
intraosseous unicystic, II-423
magnetic resonance image of, III-742f
malignant, II-401, II-420–422
multicystic, II-404, II-407–409, II-410f–414f
pediatric, III-770f
peripheral, II-409–420, II-417f–418f, II-423–424
solid, II-404, II-407–409, II-415f–416f
surgical management, II-422–424
two-stage treatment, II-361
types of, II-402
unicystic, II-361, II-363f, II-404–407, II-408f–409f, III-744
American Academy of Pediatric Dentistry (AAPD), I-258
American Academy of Pediatrics (AAP), I-258
American Association for Accreditation of Ambulatory Surgery Facilities (AAAASF), I-98, I-98t, I-100t
American Association of Oral and Maxillofacial Surgeons (AAOMS), I-10
American Board of Medical Specialties (ABMS), I-1
American Cleft Palate-Craniofacial Association, III-491–492
American Council for Graduate Medical Education (ACGME), I-4–5
American Dental Association (ADA)
Code of Ethics, I-10
Principles of Ethics, I-9
recommendations on pediatric visits from, I-258
American Heart Association, I-181–182
American Joint Committee on Cancer (AJCC), II-693, II-698–699, II-702t, II-725–726
American Medical Association (AMA), I-9
American Society of Anesthesiologists (ASA), I-181–182, I-243
Amides, local anesthetics and, I-176–177
Amifostine, II-749, II-761
Amine, terminal, local anesthetics and, I-177
Aminoglycoside drugs, I-149t
Amitriptyline (Elavil)
for facial pain, II-955t
for fibromyalgia, II-970
for neuropathic pain, I-364
for temporomandibular joint disorders, II-873t
Amnesia, benzodiazepines and, I-192, I-194
Amoxicillin
for autogenous bone graft prophylaxis, I-451
for bite wound, II-62–63
AMPLE history (allergies, medications, pregnancy/past illnesses, last meal, events), II-10
Analgesia
cannabinoid, I-233
definition, I-211, II-946t
inpatient, I-234–235
ketamine for, I-206
nitrous oxide for, I-207
non-opioid, I-228–232, I-232t
nonsteroidal antiinflammatory drugs, I-228–230
patient-controlled, I-234–235
Analgesic drugs
compounded, I-363–364
for nerve injury, I-363–364
opioid, I-198–199, I-226–228
systemic, I-364–365
for temporomandibular joint disorders, II-870–871
Anaphylaxis
drugs associated with, I-252t
pediatric anesthesia and, I-252
Anatomic abutment, I-627f, I-634
Anchor
history of implants as, I-311
implant, complications, I-323
implant types as, I-313–316
miniplate, I-313–314
Anchor unit, I-312, I-312
Anchorage
direct, I-319, I-312, I-312
implant for, I-213
indirect, I-319, I-319, I-312
miniplate, I-314
miniscrew implant, I-314
orthodontic, I-312
Andreasen classification of dentoalveolar injury, II-120
Andrew's analysis, III-25
Anemia
evaluation, I-160f
preoperative evaluation, I-159
wound healing affected by, II-259

Anesthesia, II-9–15
ambulatory, I-191–210
of auricle, III-450f
BIS monitoring, I-171–172
choice of agents, I-218–219
combined infusions, I-219–220
complications, I-222–223
concepts, I-211–224
definition, I-355t
delivery techniques, I-218–219
depth of, I-171–172, I-217–218
drug pharmacology, I-191–210
electrocardiogram during, I-167
electronic dental, I-187–188
equipment, in oral and maxillofacial surgery, I-49
fluid administration, I-216–217
for forehead and brow lift, III-408
general, I-46–54, I-164–165
for nasal fracture reduction, II-179–180
for trauma patient, II-12–13
intraosseous, I-187
for Le Fort I osteotomy, III-161–162
levels, I-165t
for liposuction, III-431
local, I-176–190, I-232–233
chemistry of, I-176
complications of, I-182–184
drug-drug interaction in, I-181
duration of action of, I-178
duration of blockade of, I-178
efficacy, I-178
future of, I-187–188
history, I-176
for nasal fracture reduction, II-179–181
nerve injury caused by, I-376–377
pregnancy and, I-186
for rhinoplasty, III-377
systemic complications from, I-184–185
management, II-9–15
mandibular nerve block, II-950
monitoring, I-164, I-217–218
nerve block, I-178
outpatient, I-96
pediatric, I-238–256, I-258
alarms, I-245
complications, I-251–253
equipment, I-245–248
monitoring, I-244–245
preanesthetic assessment, I-242–244
recovery and discharge, I-253–254
room preparation, I-245–248
techniques, I-251
worksheet, I-246f
perioperative complications, I-251–253
pharmacology of drugs for, I-191–210
preoperative assessment for, I-212
pulse oximeter used during, I-168
recovery, I-221–222
for rhinoplasty, III-377
for rhytidectomy, III-329
risk management and, I-78, I-81–82
strategies, II-12–15
techniques, I-211–224
for trauma patient, II-9–15
tumescent, III-430
Anesthesia dolorosa, I-361
Anesthesia information system, I-172
Anesthesia nurse
position, I-50
role, I-53–54
Anesthesia record, I-172
Anesthetic drugs, local, I-176–190, I-232–233
allergy to, I-182–183
amide-linked, I-186
chemistry, I-176
Anesthetic drugs, local *(Continued)*
complications, I-182–184
drug-drug interaction, I-181
duration of action, I-178
duration of blockade, I-178
efficacy, I-178
ester-linked, I-185–186
extended release formulations for, I-187
for facial pain, II-956
future, I-187–188
history, I-176
injectable, I-179t
lipid solubility of, I-177t
long-acting, I-178
nerve injury associated with, I-183t, I-376–377
nerve injury caused by, II-81
onset time, I-178t
pediatric, I-258
pregnancy and, I-186
prolonged sensory alteration and, I-183–184
speed of onset, I-177
structure and properties, I-176–177
systemic complications, I-184–185
Anesthetic equipment, I-212–213
Aneurysmal bone cyst, II-467–468, II-751, III-752f–753f, III-852
Angiofibroma, juvenile nasopharyngeal, III-751, III-754f
Angiogenesis
bone healing and, I-427
in cancer progression, II-600
tumor progression, II-617–618
tumor-stroma interaction, II-618f
Angiography, of craniomaxillofacial pathologies, III-739
Angiosarcoma, II-644t, II-658–659
Angle, Edward H., III-44, III-1, III-4–5
Angle's classification, II-874
Anhydrase inhibitor drugs, II-207
Animal bite, II-61–67
Ankyloglossia, prominent lingual frenum as cause of, I-271
Ankylosing spondylitis, II-842
Ankylosis
bony, joint replacement for, II-931
condylar fracture associated with, II-270
Murphy's case series, II-767t
in pediatric patient, II-130–131
temporomandibular joint, II-137f–141f, III-209f–210f, III-932f
treatment history, II-767
Ann Arbor staging system, for lymphoma, II-708–709, II-714b
Annandale, Thomas, II-764
Anorganic bovine bone (ABB), bone graft with, I-429
Antagonist drugs, I-226
Anterior nasal spine, facial symmetry and, III-96
Anterolateral thigh flap, II-294, II-295f
Antiangiogenic drugs, II-509t
bone remodeling and, II-510
for cancer, II-514–515
drug holiday from, II-515
jaw osteonecrosis associated with, II-510
medication-related osteonecrosis of jaw associated with, II-514
for osteoporosis, II-514–515
Antibiotic drugs
anaphylaxis associated with, I-252t
for autogenous bone graft prophylaxis, I-451
Anticoagulant drugs
management, I-161f
preoperative management, I-161
Anticonvulsant drugs
for facial pain, II-956
for nerve injury, I-364
Antidepressant drugs
drug interaction with, I-181
for facial pain, II-955–956
for neuropathic pain, I-318–319
for temporomandibular joint disorders, II-872–873
Antifungal drugs, II-761
Antihistamine drugs, for temporomandibular joint disorders, II-874t
Antilingular eminence, III-88–89, III-89f
Antiresorptive associated osteonecrosis of the jaw (ARONJ), II-507
Antiresorptive drugs, II-507–508, II-508t
for cancer, II-514–515
medication-related osteonecrosis of jaw associated with, II-514
for osteoporosis, II-514–515
Antiviral drugs, II-556, II-761
Antrum of Highmore, I-509
Anxiety
management, I-234
pediatric, premedication for, I-248
Anxiolysis, benzodiazepines and, I-192–194
Anxiolytic drugs, for temporomandibular joint disorders, II-873
Apert syndrome, III-16, III-639–642, III-668–669, III-672, III-778
Apertognathia, III-172–173
Apexification procedure, II-130
Aphthous stomatitis, II-559–560
Aphthous ulcer, II-559
Apicocoronal anatomy, implant restoration and, I-391–392, I-395
Apicocoronal placement, I-396–397
Apicoectomy, laser, III-350
Apnea-hypopnea index (AHI), III-265–266
Apoptosis
evasion, cancer cell and, II-614–616
process, II-614–615
suppression, II-627–628
Aprotinin, anaphylaxis associated with, I-252t
Arachidonic acid, II-870
Arch bar, II-147, II-155
Arch form, I-173, III-595f
Arch provisional prosthesis, I-605–623
Arcus marginalis, III-397
Army Medical Department (AMEDD), I-24–26
Aromatic ring, I-176
ARONJ. *See* Antiresorptive associated osteonecrosis of the jaw (ARONJ)
Arteriovenous malformation, II-544–547, II-853
Artery(ies)
carotid, III-399
ear, III-448
facial, III-328, III-399
forehead, III-399
frontal sinus, II-230–231
maxillary, I-162f, III-510
nasal, II-176, III-365f
palatine, III-165
superficial temporal, III-399
Arthralgia, definition, II-946t
Arthritis
classification, II-836
connective tissue disease associated with, II-848
histopathogenesis, II-833
infectious, II-843–847
inflammatory, II-838–843
juvenile idiopathic, II-131, III-840–841
Lyme disease, II-846–847
metabolic, II-847–848
psoriatic, II-841–842
reactive, II-225, III-561–562
septic, II-843–847
temporomandibular joint, II-832–833, II-835–848

Arthritis *(Continued)*
temporomandibular joint replacement, II-929–931
traumatic, II-836
Arthrocentesis, temporomandibular joint, II-774, II-883–891
contraindications, II-884
double puncture, II-885–886
outcomes, II-888–889
single puncture, II-886
technique, II-884–888
Arthroplasty
arthroscopic, II-897
history, II-766–767
laser, III-358–359
Arthroscopy
arthroplasty, II-897
capsular release, II-897
complications, II-897–900
disc repositioning, II-897
equipment, II-894
inferolateral puncture technique, II-894
laser, III-358–359
lysis and lavage, II-896–897
operative, II-896–901
postoperative care, II-901
temporomandibular joint, II-774, II-892–903
anatomic considerations, II-892–893
complications, II-897–900
diagnostic uses, II-893
postoperative care, II-901
Arthrotomy
complications, II-918
in temporomandibular joint internal derangement surgery, II-910–918
Articaine (Septocaine), I-186
chemical neurotoxicity associated with, I-376
concentration, I-177t
duration of, I-179t
local anesthesia with, I-232–233
nerve injury associated with, I-183t
onset time, I-178t
Articular disc, II-778–779
displacement, II-769, II-792t–793t, II-797–798
illustration of, II-794f
osteoarthritis, II-837–838
in temporomandibular joint, II-815
in temporomandibular joint dysfunction, II-884
in temporomandibular joint internal derangement, II-910
Articular eminence, II-778
Articular fossa, II-778
Articulation
craniomandibular, II-777–778
in model surgery, III-49
temporomandibular joint, II-778, II-794
Articulator, in model surgery, III-50
Asenio, Dr. Oscar, III-516
Asenio technique for rotation and advancement flap, III-517–518, III-519f
Ashhurst, A.P.C, II-766
Aspiration
biopsy, II-331
for odontogenic tumor biopsy, II-393
in pediatric patient, I-253
prevention, in trauma patient, II-12
pulmonary, I-243t
Aspirin, I-232
dosage, I-232t
management, I-149t
preoperative management, I-161
rhytidectomy complications associated with, III-332
for temporomandibular joint disorders, II-870, II-871t
Assistant's stool, I-48
Associateship, I-41, I-44
Association of Medical Colleges (AAMC), I-4
Asthma
classification, I-153t
orthognathic surgery and, III-282
pediatric anesthesia and, I-244
preoperative evaluation and, I-152
severity classification, III-282t
vasoconstrictor drugs and, I-182b
Ativan. *See* Lorazepam (Ativan)
ATLS. *See* Advanced Trauma Life Support (ATLS)
Atracurium, anaphylaxis associated with, I-252t
Attachment
ball, I-654
Locator, I-654
Attenuation coefficient, in computed tomography, II-820–821
Attorney, for oral and maxillofacial surgical practice, I-63
Atypical facial pain, II-948
Atypical odontalgia, II-948–949
Auditory canal, II-96
Auricle
anesthesia, III-450f
cartilage, III-447–448
embryology, III-446–447
Auricular cartilage, III-447–448
Auriculocephalic angle, III-447f
Auscultation
chest, II-9
temporomandibular joint, II-808–809
in trauma patient, II-9
Autogenous graft
free, I-556
for temporomandibular joint surgery, II-772
Autograft, particulate bone for, I-452f
Autograft entubulation, I-371–372
Autoimmune disease, temporomandibular joint disorders and, III-225–226
Autologous, definition, I-437
Autologous bone, I-438
in sinus graft, I-465
Autologous fat transfer, in forehead and brow lift, III-419
Autonomy, principle of, I-9
Avance nerve graft, I-371
Avastin. *See* Bevacizumab (Avastin)
Aventyl. *See* Nortriptyline (Pamelor, Aventyl)
Avulsion
calcium hydroxide root canal fill, II-131
in dentoalveolar injury, II-124f, II-128–131
Axon, in nerve anatomy, II-77
Axonotmesis
causes of, II-70–71
description of, III-316
exodontia associated with, I-303
Azacitidine, II-625
Azaspirodecanedione, II-874t
Azathioprine, II-562

B

Baclofen (Lioresal), II-872t
Bacteremia, following exodontia, I-303
Bacteria
bone graft infected by, I-434
membrane contaminated with, I-482
parotitis from, II-485–486
peri-implantitis and, I-724
Bag-mask-valve device, I-13, II-245–247
Bag-mask ventilation, II-13, II-249
Ballistic missile
components, II-303
physics, II-305–307
soft tissue injury from, II-306
Ballistics, wound, II-304–305
Band of Büngner, II-77
Banker, for oral and maxillofacial surgical practice, I-63
Bar
attachments for, I-654
CAD-CAM, I-652–653, I-652f, I-658, I-661f
four-implant, I-650f
implants connected with, I-645–647, I-647f
milled, I-648–649, I-652–653
placement of, for overdenture, I-644f
Barbiturate drugs, I-200–203
action, I-201
clinical effects, I-202–203
discovery and development, I-200–201
metabolism, I-203
pharmacokinetics, I-203
side effects, I-203f
structure, I-201
Bardach, Janusz, III-535
Bardach palatoplasty, III-505, III-537, III-538f, III-611
Bariatric surgery, III-268
Barrier membrane, I-462–463
history, I-475
selection, I-480–483
in sinus augmentation, I-513
tent-pole technique, I-488f
Basal cell carcinoma, II-350, II-352–354, II-718–719, II-721f
ameloblastoma compared to, II-401
in basal cell nevus syndrome, II-367f
laser surgery for, I-343
radiation therapy for, II-734
treatment, II-727
types, II-718–719
Basal cell nevus syndrome, II-361–364, II-364t, II-366f–367f, II-718, II-732–733
Basic Life Support (BLS)
for gunshot patient, II-307
for pediatric patient, I-260
Basicranium, III-738
Battle sign, midface fracture associated with, II-216
Bauer retractor, III-88f
Beauty, definition of, III-13
Behavior, disruptive, I-143–146
Behavior guidance, I-272
Behavior therapy, for velopharyngeal dysfunction, III-579–580
Behavioral pain management, I-365
Behçet syndrome, II-560–561
classification, II-561
clinical features, II-560–561
treatment, II-561
Bell, William, III-5
Bell's palsy, II-100–101
Beneficence, principle of, I-9–10
Bennett movement, II-787
Benzocaine, I-185
Benzodiazepine drugs, I-191–197
clinical effects, I-192–195
development, I-191
discovery, I-191
half-life, I-195t
intravenous sedation with, I-220
for masticatory myalgia, II-969
metabolism, I-195–197
muscle relaxant effect, I-194
pharmacokinetics, I-195–197
side effect profile, I-193f
structure and activity, I-191–192
for temporomandibular joint disorders, II-873, II-874t
Benzodiazepine-gamma-aminobutyric acid - chloride ionophore complex, I-192f

Beta (ß) blocker drugs, drug interaction with, I-181
Beta (ß) tricalcium phosphate (ß-TCP), I-440–441
Betamethasone (Celestone), III-287t
  for facial pain, II-955t, II-957
  in orthognathic surgery, III-289
  in temporomandibular joint arthrocentesis, II-887
  for temporomandibular joint disorders, II-871t
Bevacizumab (Avastin), II-509t, II-511
Bicuspid
  supernumerary, I-268f
  transplantation, I-268
Bicycle, pediatric injury and death associated with, II-245
Bifid uvula, III-618–619
Bilateral cleft deformity, III-565
Bilateral coronal suture craniosynostosis, II-660
Bilateral sagittal split osteotomy (BSSO), I-354, III-367
  complications, III-79–80, III-144–145
  history, III-113–114, III-183
  for mandibular asymmetry, III-72b
  nerve injury from, I-378
  relapse after, III-116b, III-777–778
  unfavorable bony split, III-81–82
Billroth, Christian, III-534
Bioactive glass, I-440–441
Biologic, definition of, I-437
Biologic materials, implant with, I-441
Biological width
  immediate implant and, I-412–413
  for multiple implants, I-420–422
Biology, molecular, of cancer, II-599–642
Biomarker, in cancer diagnosis, II-622–624
Biomaterial, definition, I-437
Biomechanics, orthodontic, I-312, I-311–312
Biopsy
  aspiration, II-331
  definition, II-330
  excisional, II-724f
  frozen section, II-330–331
  fusiform, II-724f
  incisional, II-724f
  laser for, III-347
  for lymphoma diagnosis, II-707
  M-plasty, II-724f
  for melanoma diagnosis, II-692–693
  odontogenic myxoma, II-444
  odontogenic tumor, II-393
  punch, II-724
  for sarcoma diagnosis, II-646
  sentinel lymph node, II-697–698, II-730
  shave, II-723–724
  for skin cancer, II-723–725
  techniques, II-330, II-724f
Biphasic calcium phosphate (BCP), I-430–431
Birbeck granule, II-524–525
Bird-face deformity, III-113
BIS. *See* Bispectral index (BIS)
Bispectral analysis, for pediatric anesthesia monitoring, I-245
Bispectral index (BIS), I-217–218
  monitoring, I-171–172
  for pediatric anesthesia monitoring, I-245
Bisphosphonate drugs, II-507
  chemical structure, II-508f
  drug holiday from, II-514–515
  osteonecrosis associated with, I-304, II-507, II-509–511, II-514–515
  for osteoporosis, II-514
Bisphosphonate-related osteonecrosis (BRON), I-304, I-305t
Bite
  animal or human, wound from, II-61–67
  microbiology, II-62b
Bite-jig, III-31–35
Bite plane splint, temporomandibular joint, II-867–868
Bite registration, for model surgery, III-46
Bite wound, II-61–67
  antibiotic therapy, II-62b
  pediatric, II-278–279
Blair, Major Vilray P., I-24, III-113, III-492, III-1, III-4–5
Bleeding
  in forehead and brow lift, III-425
  impacted tooth removal and, I-292
  in orthognathic surgery, III-289
  postsurgical, I-281
  in rhinoplasty, III-383
Bleeding disorders, orthognathic surgery and, III-285
Bleomycin, II-714, II-756t–757t
Blepharoplasty, III-388–394
  brow lift compared to, III-407f, III-413f
  complications, III-393
  definition, III-388
  eyelid and orbital anatomy, III-388–389
  history, III-388
  laser, I-346, III-356
  postoperative care, III-393
  preoperative evaluation, III-389–391
  surgical technique, III-391–393
Blindness, herpetic infection as cause of, II-552
Blog, marketing and, I-104–105
Blood pressure
  errors in monitoring, I-165–166
  monitoring, I-165–166
  pediatric, I-239, II-249–250
Blood supply
  ear, III-448, III-449f
  to eyelid, III-391f
  to maxilla, III-161, III-162f
  to midface, II-214
  nasal, II-176–177, III-364, III-366f
  nasal septum, III-366f
Blood vessel(s)
  anomalies, II-534–549
  forehead, III-399–402
  rhytidectomy evaluation and, III-327–328
Blood volume, in pediatric trauma, II-250
BLS. *See* Basic Life Support (BLS)
Body composition, aging effects on, I-242
Body dysmorphic disorder (BDD), III-326, III-368, III-458
Body temperature, monitoring of, I-170
Bohr, Neils, III-336
Bolton discrepancy, III-196–197
Bone-anchored hearing aid, III-733
Bone density, immediate implant loading and, I-607
Bone flap. *See* Osteoperiosteal flap
Bone graft
  allogenic, I-437, I-439–440, I-440f
  allograft, I-427–429, I-490, I-500b
    ridge augmentation and, I-483
  alloplastic, I-427, I-430–432, I-440–441, I-483–484
  alveolar split, I-528–529
  augmentation procedures for, I-441–443, I-447–448
  autogenous, I-427–428, I-446–474
    advantages, I-446
    antibiotic prophylaxis, I-451
    block, I-461–462
    disadvantages, I-446
    donor sites, I-451–460
    guide bone regeneration and, I-483
Bone graft *(Continued)*
    for midface deficiency, III-602–605
    particulate bone for, I-452f
    patient preparation, I-451
    postoperative care, I-461
    sites for, I-428
  autologous, I-438
  for avulsive facial injury, II-287f
  barrier membrane for, I-462
  biological models, I-696–699
  block, I-428f, I-461–462, I-463f
  bone shaving for, I-448f
  cancellous, I-446–447, I-447f, I-462
  categories of, I-427
  circular block, I-451f, I-454f
  classification materials for, I-437–438
  for cleft lip and palate, I-619, III-679
  for cleft maxilla reconstruction, III-590–591, III-619
  cortical, I-446–447, I-447f, I-462
  corticocancellous, I-458
  in corticotomy surgery, III-248
  digital workflow protocols, I-688–710
  donor sites, I-451–460, I-704–706
  for ectodermal dysplasia, I-674–675
  esthetic contour, I-487–491
  in facial trauma reconstruction, II-284–285
  failure, I-441
  fixation screws, I-461–462
  flap closure, I-450f
  flap coverage, I-461
  for gunshot wound, I-667f
  histology, I-437–445
  iliac block, I-569–570
  iliac crest, I-673–674, II-297
  ilium as donor site, I-458–460
  implant placement, I-468
  implant restoration and, I-394
  interpositional, I-527–528
  in inverted L osteotomy, III-128f–130f
  in Le Fort I osteotomy, III-167
  local, I-451–452
  mandibular ramus as donor site, I-455–457
  mandibular symphysis, I-453–455
  materials for, I-426–436
  for maxilla cleft, III-584
  maxillary tuberosity as site, I-452–453
  for maxillomandibular defect, I-671–672
  for midface cleft reconstruction, III-602–605
  for midface fracture, II-220
  mobility of, I-434
  nerve injury associated with, II-84
  non-vascularized, I-671–672
  for orbital floor repair, II-231f
  for osteomyelitis, II-590
  in pediatric reconstruction, III-769
  peri-implantitis and, I-727
  placement, in biomedical model, I-701f
  preoperative evaluation, I-432, I-448–451
  recipient site, I-460–461
  rectangular block, I-454f
  remodeling, I-466–467
  resorption, I-466–467
  secondary, III-584
  simulation, I-700f
  sinus, I-464–465
  sinus-lift subantral, I-509–525
  space maintenance, I-483–484
  statistics on, I-426
  stereolithography for, I-696–699
  storage, I-447
  suboptimal healing of, I-432–434
  techniques and materials for, I-426–436
  techniques for, I-426–436

Bone graft *(Continued)*
three-dimensional imaging for, I-688–710
case study, I-688–696
simulation from, I-700f
tibia as donor site, I-457–458
titanium mesh technique, I-465
tuberosity block, I-452f
vascular compromise of, I-434
xenogeneic, I-437, I-441f, I-483
xenograft, I-429–430
Bone loss
bisphosphonate drugs for, II-507
grafting and, I-415–416
implant and, I-398–401
maxillary implant and, I-647–648
multiple implants and, I-401
smoking and, I-514
Bone marrow, stem cells from, I-438–439
Bone morphogenetic protein (BMP), I-427, II-586f–589f, III-591
in autogenous bone graft, I-446–447
bone growth and, I-441
as growth factor, I-431–432
space maintenance and, I-526–527
Bone remodeling
bisphosphonate drugs and, II-509–510
fixation screw and, II-164f
implant platform switching and, I-400
Bone spreader, in alveolar width osteotomy, I-529–531
Bone to implant contact (BIC), I-571
Bone transport
bifocal, III-217
dental implant in, III-218
in distraction osteogenesis, III-214–218
maxillary, III-218
multifocal, III-217
Bone tunnel, in forehead and brow lift, III-409f, III-415
Bone(s)
allogenic, I-428, I-439–440
alloplastic, I-440–441
aneurysmal cyst, III-751, III-752f–753f
augmentation
guided bone regeneration for, I-464
titanium mesh for, I-465–466
using guided bone regeneration, I-464
augmentation failure and, I-441, I-447–448
augmentation materials, I-437–438
augmentation procedures, I-441–443
augmentation techniques, I-438–441
autogenous, I-427
advantages, I-446
for cleft maxilla reconstruction, III-590
disadvantages, I-446
in sinus graft, I-465
autologous, I-438, I-465
biology, I-426–427, I-446–448
bundle, I-413–414
calcified, staining for visualization of, I-443f
cancellous, I-444f, I-446–447
bone graft with, I-427
ilium as donor site, I-458
from tibia, I-457–458
cortical, I-427, I-446–447
corticocancellous, ilium as donor site, I-458
craniofacial, III-628–629
crestal height, I-398–399
disease, II-508–509
facial
grafting of, I-415–416
in restored implant, I-411
forehead, III-396–397
fracture. *See* Fracture
Bone(s) *(Continued)*
frontal
fracture of, II-20–22
injury, II-230–243
surgical anatomy, II-230–231
growth
augmentation failure for, I-441
enhancing materials for, I-438
example of, I-442f
stem cells and, I-438–439
xenogeneic graft and, I-440
healing, I-257–258, II-426–427
heterotopic formation, II-858
injury, in dentoalveolar injury, II-123t
long-term changes, genioplasty and, III-104–105
midface, II-211
miniscrew implant and, I-315
nasal, II-175–176, III-367
necrosis, in osteomyelitis, II-575
orbital, II-18, II-19f
osteosarcoma, II-647–649
palatal, implant and, I-412
quality
immediate implant loading and, I-607
in maxilla, I-594
removal
for impacted molar extraction, I-287
in surgical extraction, I-280–281
resorption, I-643f
after graft, I-466–467
dentures and, I-642
spicule, I-305
squamous cell carcinoma, II-682
substitute materials for, I-437–438
temporal, II-815
for temporomandibular joint replacement, II-923
vascularized, II-286
xenogeneic, I-440
zygomatic, I-189, I-570–571
quad, I-570f
Boniva. *See* Ibandronate (Boniva)
Bony split, sagittal split osteotomy and, III-308–310
Bony wall, defect evaluation and, I-476
Book flap, I-528–529
Borrelia burgdorferi, II-846–847
Botox. *See* Botulinum neurotoxin (Botox)
Botryoid odontogenic cyst, II-365
Botulinum neurotoxin (Botox), I-319, III-365–377
adverse effects, III-442
contraindications, II-442, III-957
dilution table, III-440t
for facial pain, II-957
history, III-439–440
pharmacology, III-439–440
preparations, III-440
for temporomandibular joint disorders, II-872t
treatment technique, III-441–442
Botulism, III-439
Boundary violation, I-143–147
Bowman, Karl, II-769–770
Bowstring test, II-232–233
Boyne, Phillip, III-492, III-584
Brachycephaly, III-660, III-673
Brachytherapy, II-747–749
Bradycardia, pediatric, I-239, I-239t
BRAF inhibitor, II-701–702
Brain injury, II-254
Branchial arch syndrome, III-778f
Branchial cleft cyst, II-383–385
Brånemark, P. I., I-723
Brånemark fixture, for zygomatic implant, I-576f
Brånemark protocol, I-605
Breast cancer, malignant bone disease and, II-508
Breath sounds, in trauma patient, II-9
Breathing
assessment, in pediatric trauma, II-249
obstructed, facial cleft and, III-605–606
Brentuximab, II-714
Breslow melanoma classification, II-696t
BRON. *See* Bisphosphonate-related osteonecrosis (BRON)
Bronchospasm, in pediatric patient, I-252–253
Brophy, Truman, III-492
Broselow Emergency Pediatric Tape, I-245
Brow. *See* Eyebrow
Brown tumor, II-464–465
Brush biopsy, II-332, II-674–675
Bruxism, splint therapy for, II-868–869
BSSO. *See* Bilateral sagittal split osteotomy (BSSO)
Buccal bifurcation cyst, II-343, II-344f
Buccal nerve, II-75–76
Buccal plate
immediate implant and, I-410–411
remodeling, after immediate implant, I-413–414
thickness of, implant success and, I-413–414
Bucco-palatal dimension, I-413
Budgeting, for oral and maxillofacial surgical practice, I-67–68
Bullet
classification of, II-303
components, II-303
injury from, factors influencing degree of, II-307
movement, II-305, II-305f
soft tissue injury, II-306
types of, II-304
Bullous pemphigoid, II-563–564
Bundle bone, I-413–414
Bupivacaine, I-186
anaphylaxis associated with, I-252t
concentration, I-177t
duration of, I-179t
local anesthesia with, I-232–233
onset time, I-178t
potency of, I-176
systemic complications associated with, I-184
Bupivacaine liposome injectable suspension (Exparel), I-187
Buprenorphine (Buprenex), I-229t–230t
Burkitt lymphoma, II-710, II-713
Burn injury, II-67–68
Burn scar, laser surgery for, III-357–358
Burning mouth syndrome, II-949
Burnout, medical education and, I-6
Burn(s)
exodontia and, I-301
facial, II-67–68
management, II-67–68
Business management, of oral and maxillofacial surgical practice, I-58–72
Business model, for surgical practice, I-16–17
Buspirone (BuSpar), II-873, II-874t
Butorphanol (Stadol), I-229t–230t
Buy-sell agreement, I-60–61
BZD. *See* Benzodiazepine drugs

C

C corporation, I-58–59, I-59t
C nerve fiber, I-225
Cal bar stabilizing implant, I-573f
Calcified marine algae, alloplastic implant with, I-440–441
Calcifying epithelial odontogenic tumor (CEOT), II-398–401, II-424–425

Calcifying odontogenic cyst, II-368–371
Calcitonin, giant cell lesion treated with, II-462–463
Calcium hydroxide
  injury associated with, I-378
  root canal fill, II-131
Calcium phosphate
  alloplastic implant with, I-440–441
  for bone graft, I-483–484
Calcium sulfate, for bone graft, I-483–484
Caldwell-Luc procedure, I-295
Calhoun and Gibson method, chin position analysis with, III-460t–461t
Cancer. *See also* Carcinoma
  antiresorptive therapy for, II-514–515
  apoptosis and, II-615f
  biologically based treatment, II-626f
  chromosomal abnormalities, II-672
  diagnosis, II-622–624
  epithelial, II-600f, II-718–720
  genetic influence, II-602
  genomic sequencing, II-623
  head and neck, II-752–763
    epidemiology, II-752
    treatment, II-745–747
  histology, II-599–602
  incidence, II-599
  laryngeal, II-745t
  lip, II-735–737
  metastasis, II-619–621, II-620f
  molecular biology, II-599–642
  molecular diagnostics, II-622–624
  molecular therapeutics, II-624–629
  nasopharyngeal, II-744–745
  neovascularization, II-617–619
  nonepithelial, II-720
  nucleic acid dysregulation, II-606–609
  oncology principles, II-752–763
  oral
    deaths from, II-670
    diagnosis and evaluation, II-675
    epidemiology, II-671–675
    follow-up, II-684–685
    genetic factors, II-672–673
    nonsurgical management, II-677–679
    screening, II-673–674
    staging, II-675–677
    surgical management, II-679–683
  protein dysregulation, II-609–622
  radiation therapy, II-741–751
  salivary gland, II-759–760
  signal pathway altered by, II-602–622
  skin. *See* Skin cancer
  telomerase and, II-617f
  thyroid, radiation therapy for, II-742
  treatment, II-622–629, II-626f
Cancer cell
  apoptosis evasion, II-614–616
  biology, II-601–602
  chromosomal abnormalities, II-606–607
  differentiation, II-614
  DNA alterations in, II-606
  epigenetic alteration, II-609
  example, II-601f
  growth inhibitory signal and, II-612–614
  immortalization, II-616–617
  molecular changes, II-602f, II-621–622
  neovascularization, II-617–618
  nucleic acid alterations, II-609
  nucleotide sequence abnormalities, II-607–609
  release from growth signal requirement, II-617f
Cancer stem cell (CSC), II-599–600
Canine
  impacted, I-261–262, I-289–291
    excisional exposure of, I-263
    preoperative planning, I-289
    surgical technique, I-289–291
    treatment, I-262–269
  mandibular, impacted, I-291, I-291f
  maxillary
    extraction, I-277, I-278f
    impacted, I-289–291
    implant replacement, I-403
  transverse discrepancy, III-299
Cannabinoid drugs, I-363–364, I-364–365
Cannabis, I-233–234
Cant, occlusal, III-23
Canthopexy, transnasal, II-224
Canthotomy, lateral, II-194, II-196
Cantilever
  failure of, I-601f
  implant and, I-599–600, I-600f
Capecitabine, II-757t
Capillary malformation, II-538–539
Capnography, I-168–169
  circulatory system monitoring and, I-165
  normal morphology, I-170f
  for trauma patient assessment, II-9–10
Capnometry, for pediatric anesthesia monitoring, I-245
Capsaicin (Zostrix)
  for facial pain, II-955t
  for nerve injury, I-363
  topical, II-957–958
Capsule, temporomandibular joint, II-780
Carbamate, II-874t
Carbamazepine (Tegretol), I-364, II-956
Carbon dioxide (CO_2) laser. *See* Laser, carbon dioxide (CO_2)
Carbonic anhydrase inhibitor drugs, II-207
Carboplatin, II-755, II-757t
Carboxyhemoglobin, I-168
Carcinoembryonic antigen (CEA), II-623–624
Carcinogen, environmental, II-602
Carcinoma. *See also* Cancer.
  acinic cell, II-493t, II-498
  adenoid cystic, II-493t, II-498, II-500–501, II-759–760
  ameloblastic, II-401
  basal cell, II-718–719
  clear cell odontogenic, II-424–431
    clinicopathologic considerations, II-427–429
    differential diagnosis, II-427
  cutaneous, lymph node involvement, II-730
  epidermoid, II-493t
  head and neck
    chemotherapy for, II-755–756
    treatment, II-745–747
  hypopharyngeal, II-746t
  intraosseous odontogenic, II-431–435
  intraosseous odontogenic squamous cell, II-431f
  laser surgery for, I-343, III-354
  lip, II-735–737
  Merkel cell, II-720
  microcystic adnexal, II-719
  mucoepidermoid, II-492–493, II-493t, II-498, II-500–501, II-504t, II-759–760
  oropharyngeal, II-744t
  salivary duct, II-759–760
  sebaceous gland, II-720
  of skin appendages, II-719–720
  squamous cell. *See* Squamous cell carcinoma
  temporomandibular joint, II-848, II-857
  thyroglossal duct cyst associated with, II-383
  thyroid, radiation therapy for, II-742
Carcinoma in situ, II-599–600, II-600f
Cardiac arrest, in child, II-249
Cardiac assessment, preoperative, I-150f
Cardiac ischemia, II-950–951
Cardiac output
  definition, I-239
  pediatric, I-239, I-242
Cardiac risk index, I-150t
Cardiovascular complications
  endocarditis and, I-151t
  risk of, I-148–151
Cardiovascular disease, craniomaxillofacial trauma management and, II-3t
Cardiovascular system
  evaluation, for orthognathic surgery, III-280–282
  monitoring, during anesthesia, I-222
  pediatric, I-238–239
  preoperative evaluation of, I-138, III-148–151
  rhytidectomy evaluation and, III-327–328
Care
  access to, I-3
  continuous improvement of, I-3
Care plan, for craniomaxillofacial trauma, II-5–6
Caries
  exodontia for, I-275
  third molar removal and, I-284
Carisoprodol (Rela, Soma), II-872t
Carnegie stages, III-477f, III-478, III-479f–480f
Carney triad, II-644
Carnochan, John Murray, II-924
Carroll-Girard screw, II-193–194
Cartilage
  auricular, III-447–448
  for ear reconstruction, III-732
  graft, in cleft-nasal reconstruction, III-620
  Meckel, I-526
  nasal, II-175–178
  for temporomandibular joint replacement, II-924
Caspase cascade, II-615
CASS. *See* Computer-aided surgical simulation (CASS)
Cat, bite wound from, II-63
Catheter, intraosseous, I-247
Cauliflower ear deformity, II-57–58
Causalgia, II-946t, II-947
CDT. *See* Current Dental Terminology (CDT)
Cehpalosporin, for autogenous bone graft prophylaxis, I-451
Celebrex. *See* Celecoxib (Celebrex)
Celecoxib (Celebrex), I-232
  dosage, I-232t
  for facial pain, II-955t
  for temporomandibular joint disorders, II-871t
Celestone. *See* Betamethasone (Celestone)
Cell cycle clock, II-613f
Cell(s)
  apoptosis, II-614–616
  bone, I-446–447
  cancer, II-601–602, II-601f
  cycle control, II-613f
  dendritic, II-600–601
  division of, II-613f
  endothelial, II-257
  gene regulation of, II-603–606
  growth signal requirements, II-611f
  Hodgkin, II-709f
  natural killer, II-600–601
  normal division, II-612–613
  replication, II-616
  T, II-600–601
Cellulitis
  frontal sinus fracture associated with, II-243f
  lymphatic malformation associated with, II-539

Cement
acrylic urethane, I-715–716
allergic reaction to, I-716
clinical protocols for, I-717–720
complications, I-639
controlling flow of, I-713–714
corrosion from, I-716–717
effect of, on soft tissue, I-632
excess
avoidance of, I-639
issues associated with, I-711–712
implant, characteristics of, I-714
interactions, I-716
microbial growth and, I-715–716
orthozinc phosphate, I-715–716
peri-implant disease and, I-711
resin-based, I-715–716
selection, I-714–715
zinc oxide/eugenol, I-715–716
Cementable abutment, I-624–626, I-633–634
Cemento-osseous dysplasia, II-470–471
Cemento-ossifying fibroma, II-468–469
Cementoblastoma, II-438–439
Center for Medicare and Medicaid Services (CMS), I-87
Central deafferentation syndrome, I-361
Central giant cell granuloma, II-462–464, II-750–751, III-852
classification, II-463t
example, II-463f
Central nervous system (CNS), I-226
Centrax. *See* Prazepam (Verstran, Centrax)
Centric relation
inconsistent, of mandible, III-187–188
orthognathic surgery planning and, III-15
in temporomandibular joint disorders, II-875
Cephalometric analysis
for temporomandibular joint disorders, III-226
for velopharyngeal function, III-574–575
Cephalosporin, parotitis treated with, II-486–487
Cerebrospinal fluid (CSF), leakage, II-221, II-223
following midface fracture, II-226–227
frontal sinus fracture associated with, II-239–240, II-232, II-243
in pediatric facial trauma, II-241
in self-inflicted gunshot wound, II-323
Cerebrospinal fluid halo test, II-233f
Cerebrospinal fluid rhinorrhea, II-187, II-216, II-226–227
Cerebrovascular accident (CVA)
craniomaxillofacial trauma management and, II-3t
preoperative evaluation of, I-161
Certification. *See also* Accreditation
history of, I-96–97
Cervical injury
craniomaxillofacial fracture associated with, II-38
orthognathic surgery evaluation and, III-16–17
Cervical spine injury, II-11
Cervicofacial flap, II-290, II-293f
Cetuximab (Erbitux), II-673, II-747, II-756t–757t, II-759, II-759t
Champy, Maxime, II-63, III-162, III-6
Charnley, Sir John, II-298
Cheek, reconstruction, II-274–275
Chemical burn, endodontic materials associated with, I-378
Chemical injury
endodontic materials associated with, I-378
nerve injury associated with, II-87
Chemical peel, III-439–445
agents, III-443–444
complications, III-444
contraindications, III-443
history, III-442–443
procedure, III-444
Chemo-radiotherapy, for head and neck squamous cell carcinoma, II-753–754
Chemoprevention
for oral cancer, II-677
for skin cancer, II-732–733
Chemotherapy
for ameloblastic fibrosarcoma, II-455
concurrent radiation therapy with, II-747t
induction, for squamous cell carcinoma, II-754–756
for lymphoma, II-713
for melanoma, II-701
for metastatic head and neck cancer, II-755–756
for osteosarcoma, II-648–649
for rhabdomyosarcoma, III-760–762
for squamous cell carcinoma, II-753
Chemotherapy/radiation therapy (CRT)
induction chemotherapy combined with, II-755
for squamous cell carcinoma, II-753–754
Cherubism, II-466–467
Chest auscultation, in trauma patient, II-9
Chest wall, pediatric, I-240
Chewing sequence, II-787–788
Child. *See also* Infant
ablative defect reconstruction, III-763–769
airway management, I-238, II-241
ameloblastic fibro-odontoma in, II-452
ameloblastic fibroma in, II-449
anaphylaxis, I-252
anatomy and physiology, I-238–242, II-248t
anesthesia, I-238–256
complications, I-251–253
techniques, I-251
anesthesia worksheet, I-246f
anesthetic monitoring, I-244–245
assessment and management of injury, II-245–263
asthma, I-244
avulsive injury, II-274–275
axonal injury, II-251–252
bite wound, II-278–279
blood circulation, II-249–250
body composition, I-242
bradycardia in, I-239t
canine extraction for, I-262
cardiovascular conditions, III-280–281
cardiovascular system, I-238–239
codeine warning for, I-253–254
concussion, II-252
condylar fracture, II-270
craniofacial skeleton development, II-241–243
craniomaxillofacial pathology management, III-738–773
craniomaxillofacial surgery, III-627–644
craniomaxillofacial trauma, II-264–280
assessment, II-231–232
epidemiology, II-230–231
imaging, II-233–240
management, II-243
physical evaluation, II-232–233
craniosynostosis, III-646, III-671–677
demographics, I-257–258
dental development, I-258
dental extraction, I-260
dentoalveolar injury, II-270–271, II-114
dentoalveolar surgery, I-257–274
distraction osteogenesis, III-775
Child *(Continued)*
drug dosage for, I-250t
ear development in, III-446–447
endotracheal tube for, I-247
evaluation, for orthognathic surgery, III-280–281
Ewing sarcoma, II-662
facial fracture, II-35–38, II-38f
fear and anxiety in, premedication for, I-248
fracture management, II-243
glandular and ductal injury, II-272
growth and development, II-240
herpes simplex infection, II-555–556
impacted canine, I-261–262
impacted incisor, I-265
impacted molar, I-265–266
impacted premolar, I-265
impacted tooth, I-260–261
implant, I-269–270
infection, I-260
inhalation anesthesia, I-250–251
inhalation induction, I-220
injured, II-245–263
injury evaluation, II-246
injury patterns, II-260–261
injury prognosis, II-138–139
intracranial hemorrhage, II-252–254
intracranial pressure, III-645–646
intraoperative fluids for, I-248
intravenous access, I-247–248
kidney, I-241
local anesthesia complications, I-184
malignant hyperthermia, I-253
malignant tumor, III-757–763
mandibular fracture, II-270, II-167
mandibular hyperplasia, III-638
mechanism of injury, II-245
melanoma in, II-690
methemoglobinemia, I-185
midface fracture, II-270
nasal fracture in, II-269–270, II-186–187
nerve injury, II-272
neurologic status, II-247–248
obesity, II-259–260
operating room preparation, I-245–248
oral anatomy, I-258–260
orbital fracture, II-267–268
parotid gland abscess in, II-486–487
pharmacology, I-238–242
pharmacosedation, I-248–251
physiology, I-260
preanesthetic assessment, I-238, I-242–244
preoperative fasting, I-243
primary herpetic gingivostomatitis, II-552
primary tooth injury, II-131–133
protruding ear correction in, III-450
recovery and discharge, I-253–254
respiratory rate, II-249
respiratory system, I-239–241
rhabdomyosarcoma, II-654
sedation, I-212, I-238–256
seizure, post-traumatic, II-255–256
sinus development, II-241
skeletal fracture patterns, II-261
skull fracture, II-253
soft tissue injury, II-271–273
soft tissue physiology, II-256–257
soft tissue procedures, I-270–272
superficial wound, II-272
supernumerary teeth, I-266–268
temporomandibular joint replacement in, II-934
tension pneumothorax in, II-250f
thermoregulation, I-241–242
tissue recruitment, II-274–275
tooth avulsion, II-128

Child *(Continued)*
tooth transplantation, I-268–269
trauma, II-245–263
trauma outcomes, II-245
traumatic brain injury in, II-246–247, II-250–252
Treacher Collins syndrome, III-705–706
treatment challenges, I-272
upper respiratory infection, I-243–244
vital signs, I-239t
volume resuscitation for, II-250
wound healing, II-256–261
Child abuse
dentoalveolar injury associated with, II-114
facial injury from, II-231–232
trauma from, II-245, II-250–251
Child-Pugh Scoring System, I-156t
Chin
advancement, III-110f
augmentation
allograft, III-464b
alloplastic, III-463b
extraoral, III-464b
botulinum neurotoxin for, III-441
definciency, III-203f
deformity correction, with computer-aided surgical simulation, III-39
facial symmetry and, III-96
genioplasty, III-96–112
hyperplasia, III-306f
hypoplasia, III-309f
implant, III-104, III-321
in orthognathic surgery, III-28
position
analysis for, III-460t–461t
orthodontic treatment and, III-303t
small, cosmetic surgery, III-459b–463b
Chin wing osteotomy, III-319
Chlordiazepoxide (Librium)
discovery, I-191
structure, I-191f
for temporomandibular joint disorders, II-874t
Chlorhexidine
for autogenous bone graft prophylaxis, I-451
in mouthwash, II-551
Chlorhexidine gluconate, II-595
Chlorzoxazone (Paraflex), II-872t
Chondroblastoma, II-851–852
Chondrocramium, III-629–630
Chondrocyte
in cartilage, II-832
inflammation, II-833–835
joint function and, II-830
in osteoarthritis, II-838
synthesis by, II-831
Chondroma, II-475–476
Chondromalacia, II-837
Chondromatosis, synovial, II-796, II-798f, II-855–856
Chondrosarcoma, II-644t, II-649–651, II-856
classification, II-649–650
synovial, II-856
treatment, II-650–651
Christensen fossa implant, II-771
Christensen implant system, II-772–774
Chromatin
chromosome composed of, II-605f
gene activity and, II-603
Chromatolysis, II-72
Chromophore, I-328–329, III-339
carbon dioxide laser, I-331
diode laser, I-332
Chromosome
abnormalities
in cancer cells, II-606–607
oral cancer and, II-672
Chromosome *(Continued)*
alterations, II-607f, II-609f
composition, II-603, II-605f
deletion, II-607
Philadelphia, II-622–623
rearrangement, II-607
translocation, II-607, II-608f
Chronic bullous dermatosis of childhood, II-565
Chronic facial pain, II-941–961
cardiac origin, II-950–951
clinical examination, II-945–946
differential diagnosis, II-947–952
evaluation, II-944–947
pharmacotherapy, II-955t
surgical intervention, II-958
therapeutic injection, II-956–957
treatment, II-953–958
Chronic kidney disease, I-154t
preoperative evaluation of, I-152–155
stages, III-283t
Chronic obstructive pulmonary disease (COPD)
craniomaxillofacial trauma management and, II-3t
oral surgery and, I-151
orthognathic surgery and, III-282
preoperative evaluation of, I-151–152
Chronic obstructive sialoadenitis, II-490–492
Chymopapain, anaphylaxis associated with, I-252t
Cigarette smoking
airway patency and, I-215
autogenous bone graft failure, I-451
bone graft healing affected by, I-433
implant failure and, I-412
as mandibular surgery risk factor, III-297–298
oral cancer associated with, II-671
orthognathic surgery risk associated with, III-282–283
peri-implant disease associated with, I-723–724
preoperative evaluation and, I-152
rhytidectomy complications associated with, III-332
sinus augmentation and, I-514
Cinnamic aldehyde, II-550
Circulation
monitoring, I-169, I-244–245
pediatric, II-249–250
in pediatric trauma, II-250
Circulatory system, monitoring, I-165–167
Cisplatin, II-747, II-755, II-756t–757t
Claims professional, I-83
Clark melanoma classification, II-696t
Clark's rule, I-260–261
Clear cell
in ameloblastoma, II-402, II-425
in calcifying epithelial odontogenic tumor, II-399–400, II-424–425
in periodontal cyst, II-425f
Clear cell odontogenic carcinoma (CCOC), II-424–431, II-426f–427f
clinicopathologic considerations, II-427–429
differential diagnosis, II-427
with metastases, II-428f–430f
surgical management, II-429–431
Clear cell odontogenic tumor, II-425–427
Cleft deformity
bilateral, III-565
child feeding, III-494–496
classification, III-496f
complex, III-506–508
dentition abnormalities in, III-584–586
embryogenesis, III-493
genetics and etiology, III-493–494
management, III-491–512
obstructed breathing, III-605–606
Cleft deformity *(Continued)*
in oculoauriculovertebral spectrum, III-692
orofacial embryogenesis and, III-476–490
orthognathic surgery, III-596–608
prenatal counseling, III-494
reconstruction stages, III-610t
revision surgery, III-609–626
sites, III-486–489
treatment planning, III-496–497
unilateral, III-563–565
Cleft lip, I-679–683
bilateral, III-211f–212f, III-500–502, III-600b, III-605f–606f, III-621f–622f
bone grafting for, I-679
child feeding, III-494–496
configurations, III-495f
dentition abnormalities, III-584–586
etiology, III-513, III-561
genetics and etiology, III-493–494
genioplasty for, III-98
history of repair, III-491–493
implant and, I-680–683
incidence, I-561, III-665
infant orthopedic treatment, III-561–567
management, III-491–512
in oculoauriculovertebral spectrum, III-692
prenatal counseling, III-494
revision surgery, III-609–626
surgical techniques, III-514–515
timing of surgery, I-679
treatment planning, III-496–497
unilateral, III-499–500, III-600b, III-623f
repair, III-513–533
surgical techniques, III-514–515
Cleft lip repair, III-497–508, III-513–533
functional, III-525–526
midface growth, III-542–543
revision surgery, III-609–626
scar repair, III-620–622
secondary surgery, for scar revision, III-620–622
stages, III-610t
surgical techniques, III-514–515
timing, I-513–514, III-679
treatment planning, III-496–497
Cleft maxilla
bilateral, III-589–592
bone graft reconstruction, III-619
management, III-583–595
reconstruction, III-589–592
stabilization, III-606–607
surgical options, III-583–584
timing of grafting procedure, III-586–587
unilateral, III-589
Cleft palate, I-679–683
anatomy, III-535–536
bilateral, III-211f–212f, III-600b, III-621f–622f
bone grafting for, I-679
dentition abnormalities, III-584–586
etiology, III-561
fistula closure, III-611–612
genetics and etiology, III-493–494
genioplasty for, III-98
history of repair, III-491–493
implant and, I-680–683
incidence, III-561
infant orthopedic treatment, III-561–567
management, III-491–512
in oculoauriculovertebral spectrum, III-692
prenatal counseling, III-494
revision surgery, III-609–626
speech affected by, III-540–542, III-568–582
speech disorders, etiology, III-568–570
submucous, III-618–619
timing of surgery, I-679

Cleft palate *(Continued)*
treatment planning, III-496–497
unilateral, III-506f, III-600b
vocal dysfunction, III-572
Cleft palate repair, III-497–508, III-534–560
bone graft reconstruction, III-619
dental rehabilitation after, III-622–623
fistula, III-539–540
fistula closure, III-609–612
goals, III-610
history, III-534–535
midface growth, III-542–543
otologic and audiologic issues, III-540
revision surgery, III-609–626
secondary surgery, III-612–616
speech disorders and, III-568–582
stages, III-610t
surgical technique, III-536–539
timing of surgery, I-679
treatment planning, III-496–497
two-stage, III-548–549, III-551–552
Clindamycin
for autogenous bone graft prophylaxis, I-451
medication-related osteonecrosis treated with, II-516
parotitis treated with, II-486–487
postoperative infection treated with, I-303
Clinical examination
for implant overdentures, I-656–658
risk management and, I-76
Clinical margin, II-728
Clonazepam (Klonopin)
after nerve surgery, I-373
for facial pain, II-955t
for masticatory myalgia, II-969
for nerve injury, I-363
Clonidine, management, I-149t
Clopidogrel, I-161
Clostridium botulinum, III-439
Cloverleaf skull, III-669
CMS. *See* Center for Medicare and Medicaid Services (CMS)
CMS 1500 form, I-88
CNS. *See* Central nervous system (CNS)
Coagulation, laser for, I-330, I-335
Coagulation disorders
preoperative evaluation of, I-161
wound healing affected by, II-259
Coagulopathy, craniomaxillofacial trauma management and, II-3t
Cobalt chromium, framework with, I-599
Cocaine, I-176, I-185
Cocamidopropyl betaine, II-550–551
CODA. *See* Commission on Dental Accreditation (CODA)
Code of Ethics, American Dental Association (ADA), I-10
Code of Professional Conduct, AAOMS, I-9–10
Code set, for oral and maxillofacial surgery, I-89–90
Codeine, I-228
dose and potency, I-229t–230t
equianalgesic dosage, I-231t
for facial pain, II-953
FDA warning, I-253–254
for temporomandibular joint disorders, II-872t
Coding
evaluation and management, I-92–95
insurance, I-87–95
modifiers in, I-93–94
for pathology, I-92
radiology, I-94
for systemic diseases, I-94–95
for trauma, I-91–92
Cognitive-behavioral therapy, for temporomandibular joint disorders, II-968–969
Collagen
nerve anatomy and, II-77–78
in wound healing, II-257
Collagen matrix, I-558, I-560–561
Collagen membrane, I-462–463, I-485f–487f
natural, I-482
peri-implantitis treated with, I-727f
resorbable, I-482
Cologne Classification for Alveolar Ridge Defects, I-447–448
Columella
lengthening, III-500–501, III-505f
in rhinoplasty evaluation, III-369–370
Combitube, II-13–14
Commission on Dental Accreditation (CODA), I-5
accreditation of residency programs, I-8
Commission on Professional Conduct (CPC), I-9–10
Communication
empathy and, I-102
intraoffice, I-80–81
marketing through, I-134–136
in patient evaluation, I-120
with pediatric patient, I-257–258
personal, I-20
with postoperative patient, I-132
principles of, I-134–136
risk management and, I-80–81
in surgical practice, I-18
Community-based surgeon, I-12–13
Community service, I-132, I-126
Compensation, in oral and maxillofacial surgical practice, I-70–71, I-71t
Complex regional pain syndrome (CRPS), I-361b, I-362f, II-947–948
Composite model
in computer-aided surgical simulation, III-31–33
creation of, III-33f
frame of reference, III-33
orientation, III-36f
Comprehensive Accreditation Manual for Hospitals (CAMH), I-231b
Computed tomography (CT). *See also* Imaging
for bone graft preoperative evaluation, I-448–449, I-449f
computer-aided surgical simulation and, III-31
cone-beam, I-448–449, II-824–825
computer-aided surgical simulation and, III-31
for dentoalveolar injury, II-120
facial bone evaluated with, I-411
history, III-6–7
of impacted third molar, II-80f
of impacted tooth, I-261
for implant overdenture planning, I-656–657
for nerve imaging, II-79–80
palatofacial dimension measured with, I-413f
of temporomandibular joint, II-826f
for temporomandibular joint disorder, II-802
for temporomandibular joint reconstruction, III-223–226
three-dimensional imaging and, I-688
conventional linear, for temporomandibular joint, II-818–819
of craniomaxillofacial pathologies, III-738–739
of dentoalveolar injury, II-120
Computed tomography (CT) *(Continued)*
for facial nerve imaging, II-99–100
for facial pain, II-947
of frontal sinus fracture, II-241, II-232
image interpretation, II-17–20
of Le Fort fracture, II-217f
of lymphoma, II-711
of mandibular fracture, II-153
maxillofacial, II-20
of medication-related osteonecrosis of jaw, II-513f
for melanoma diagnosis, II-699
micro, I-443
of midface fracture, II-213, II-214f
multi-dectector, II-17
multidirectional, for temporomandibular joint, II-818–819
nasal fracture diagnosis with, II-178
of naso-orbito-ethmoid fracture, II-223
for nerve imaging, II-78–80
odontogenic tumor, II-392
for oral cancer evaluation, II-675
of osteomyelitis, II-586f–589f
of parotid gland tumor, II-493–494
for pediatric brain injury, II-251
pediatric trauma assessment with, II-247
salivary gland, II-481–483
of sarcoma, II-645
of skin cancer, II-725
of skull fracture, II-255f
temporomandibular joint, II-820–821
for temporomandibular joint disorder, II-802, II-820–821
of temporomandibular joint internal derangement, II-906
three-dimensional, I-207–208, II-688
computer-aided surgical simulation and, III-31–33, III-35
of frontal sinus fracture, II-234f
genioplasty planning with, III-101
for Le Fort I osteotomy, III-153–161, III-158f–160f
in Le Fort I segmental surgery, III-174, III-175f
for midface fracture, II-213, II-214f, II-227
of odontogenic tumor, II-392
trauma patient assessment with, II-5
of Treacher Collins syndrome, III-708f–709f, III-711f–712f
tuned-aperture, II-824
of zygomatic fracture, II-191, II-192f
for zygomatic implant, I-570–571
Computer, in oral and maxillofacial surgery, I-49
Computer-aided surgical simulation (CASS), III-31–34
accuracy, III-40–42
algorithm, III-32f
clinical implementation, III-34–40
cost-effectiveness, III-42
data processing, III-35–38
final symmetry in, III-39
for inverted L osteotomy, III-120
for mandibular deformity, III-39
for maxillary deformity, III-38–39
in orthognathic surgery, III-190
outcomes, III-40–42
preoperative records, III-34–35
surgical execution, III-39–40
surgical planning, III-38–39
for temporomandibular joint total replacement, III-229–232
Computer-controlled injection, I-187
Concomitant TMJ total joint replacement and orthognathic surgery (C-TJR-OS), III-222–245
case studies, III-235b, III-239b–240b

Concomitant TMJ total joint replacement and orthognathic surgery (C-TJR-OS) *(Continued)*
outcomes, III-238–242
surgical planning, III-229–232
surgical procedure, III-233–242
surgical sequence, III-232
traditional, III-228–229
Concussion
in dentoalveolar injury, II-127
pediatric, II-252
Condylar hyperplasia, II-145–147, III-850–851
Condylar resorption, adolescent internal, III-224–225
Condylar/subcondylar region, fracture of, II-28, II-31–34, II-36f
Condyle, II-779
aplasia, II-802f
arthritic, III-225f
computed tomography of, II-821
description of, II-794
displacement, in sagittal split ramus osteotomy, III-81
endoscopic approach, II-161–162
fracture, II-31–34, II-36f, II-149, II-165–166
head shapes, II-780f
imaging, II-816
internal derangement, II-813f
movement, II-795, II-796f
pediatric fracture, II-270
postoperative displacement, III-317
pseudocyst, II-852
replacement, II-923
resorption, III-145–146, III-148f–150f
in sagittal split ramus osteotomy, III-81
surgical access, III-740
in temporomandibular joint, II-815
in Treacher Collins syndrome, III-712–713
Condyle-disc complex, II-792t–793t, II-799f
Condylectomy, III-145–147
Condylotomy, II-917–918
Conflict of interest, management, I-3
Conflict resolution, in surgical practice, I-18–19
Congenital epulis, III-756–757
Congenital hemangioma, II-536–538
Congestive heart failure, oral surgery and, I-139
Connective tissue
ameloblastic fibroma, II-449–450
cementoblastoma, II-438–439
grafting of, I-415–416
myxoma, II-439
connective tissue disorders
arthritides associated with, II-848
temporomandibular joint disorders and, III-225–226
wound healing affected by, II-259
Consultant, use of, I-125–126, I-110–111
Consultation visit, for pediatric patient, I-257
Continuous passive motion, in temporomandibular joint, II-833–835
Continuous positive airway pressure (CPAP)
for obstructive sleep apnea, III-267
for pneumonitis, I-253
for velopharyngeal dysfunction, III-580
Converse, J. M., III-3–5
Convex profile, correction of, III-184
Copy abutment technique, I-718
Coral, alloplastic implant with, I-440–441
Cornelia de Lange syndrome, III-635f
Coronal suture craniosynostosis, III-654–657, III-658f–659f
Coronectomy, alveolar nerve injury and, I-381–382
Coronoid hyperplasia, III-150f–151f
Coronoid process
coronoidectomy, III-147
fracture, II-34, II-149
Coronoidectomy, III-147
Correct Coding Initiative (CCI), I-88
Corticosteroid drugs, I-233
for congenital hemangioma, II-537
for facial pain, II-957
giant cell lesion treated with, II-462–463
for lichen planus, II-559
for nerve injury, I-363
in orthognathic surgery, III-289
for pemphigoid, II-564
for temporomandibular joint disorders, II-870, II-871t
Corticotomy surgery
history, III-246–248
technique, III-248–250
Cortisone, equivalent dosage, III-287t
Cosmetic surgery. *See also* Rhytidectomy
case study, III-459b–463b
endoscopic facial, III-359
facial implant, III-458–475
forehead and brow lift, III-395–428
laser-assisted, I-343–347, III-355–358
marketing, I-130–132
problem patient, III-458
Costen, James, II-768
Costen's syndrome, II-768
Cottle test, III-371
COX. *See* Cyclooxygenase (COX)
Coxsackie virus, II-556–557
CPT. *See* Current Procedural Terminology (CPT)
Cranial vault, III-645
in craniosynostosis, III-673
distraction osteogenesis, III-780–781
dysmorphology, III-648–649, III-663f
sutures, III-646f
Cranio-orbito-zygomatic region, in Treacher Collins syndrome, III-706
Craniocerebral disproportion, III-673
Craniofacial disjunction, II-28
Craniofacial dysostosis, III-667
Craniofacial fibrous dysplasia, III-751–753, III-761f–762f
Craniofacial growth and development, III-738
Craniofacial management, in syndromic craniosynostosis, III-670–671
Craniofacial skeleton. *See* Skeleton, craniofacial
Craniofacial surgery
laser used in, I-351
in oculoauriculovertebral spectrum, III-696
Craniomandibular articulation, II-777–778
Craniomaxillofacial surgery
access, III-739–741
history, III-738
incisions, III-739–741
pediatric, III-627–644, III-738–773
Craniomaxillofacial tumor, III-739
endoscopic approaches, III-741
pathology, III-741–769
Cranioplasty, in craniosynostosis treatment, III-678
Craniosynostosis, III-630, III-631f, III-636, III-645–686
bilateral coronal suture, III-660
care algorithm, III-671–678
coronal suture, III-654–657, III-658f–659f
definition, III-645
diagnosis, III-647–648
distraction osteogenesis for, III-780–781
functional consequences, III-645–647
hydrocephalus in, III-646
lambdoid suture, III-659–660, III-664f
Craniosynostosis *(Continued)*
metopic suture, III-653–654, III-661f–662f
multiple-suture, III-646
neurodevelopmental effects, III-647
nonsyndromic, III-645–666
complications, III-650–651
diagnosis, III-647–648
forms of, III-653–660
treatment, III-648–660
ophthalmologic effects, III-647
sagittal suture, III-653–654
syndromes, III-667–686
care algorithm, III-671–678
craniofacial management, III-670–671
genetics, III-667–669
timing of surgery, III-670
timing of surgery, III-649–650
treatment complications, III-650–651
Craniotomy
craniosynostosis treatment and, III-648
frontal, II-241f
Cranium
growth, III-628–630, III-738
growth rate, III-629t
sutures, III-645
Cribriform plate, II-221, II-226–227
Cricothyroidotomy, II-15f, II-282
Cricothyrotomy, emergency, II-14–15
Crossing the Quality Chasm: A New Health System for the 21st Century, I-97
Crouzon syndrome, III-16, III-213f–214f, III-633f, III-639–642, III-668, III-672, III-778
Crown
cement-retained implant, I-625f, I-630f, I-632
cemented-screw-retained, I-720
copy abutment technique, I-718
damage to, during exodontia, I-298–299
discoloration, after injury, II-138–139
fracture, in dentoalveolar injury, II-123–125, II-124f
infraction, II-122–123
provisional, immediate implant and, I-416–418
swallowing of, during exodontia, I-302
zirconia, I-628
Crow's feet, botulinum neurotoxin for, III-441
CRPS. *See* Complex regional pain syndrome (CRPS)
Cryotherapy
for odontogenic keratocyst, II-356–357
for skin cancer, II-727–730
Curettage, for skin cancer, II-727
Current Dental Terminology (CDT), I-88–89
coding, I-87
Current Procedural Terminology (CPT), I-87–89
Curve of Spee
leveling, III-300
open bite treatment and, I-317
Cuspid, impacted, I-265f
CVA. *See* Cerebrovascular accident (CVA)
Cyanoacrylate, for superficial wound, II-272
Cyanosis, anesthesia associated with, I-168
Cyclin, cell division and, II-612–613
Cyclin D1, II-673
Cyclin-dependent kinase (CDK), II-627
Cyclobenzaprine (Flexeril)
for facial pain, II-955t
for masticatory myalgia, II-969
for temporomandibular joint disorders, II-872t
Cyclooxygenase (COX)
nonsteroidal antiinflammatory drugs and, I-228–230
for skin cancer, II-733–734
temporomandibular joint disorders and, II-870

Cyclooxygenase pathway, II-870f
Cyclophosphamide (Cytoxan), II-455, II-713, II-757t
Cyclopropane, I-207
Cyclovir, II-554
Cyst, II-338–390
  aneurysmal bone, II-467–468, II-751, III-752f–753f, III-852
  botryoid odontogenic, II-365
  branchial cleft, II-383–385
  buccal, II-343, II-344f
  calcifying odontogenic, II-368–371
  definition, II-338
  dentigerous, II-339–340, II-343–348, II-345f, II-355f
  dermoid, II-377, II-380f
  developmental, II-339t, II-343–371
  epidermoid, II-377
  ganglion, II-852
  gingival, II-365, II-424
  globulomaxillary, II-375–376
  inflammatory, II-339t
  of jaw, II-340b
  lateral periodontal, II-365, II-424
  lymphoepithelial, II-485
  maxillary, II-346f
  median mandibular, II-375
  median palatal, II-375
  mouth floor, II-380f
  mucous retention, laser for removal, III-349
  nasolabial, II-371–372, II-374f
  nasopalatine duct, II-372–375, II-376f–378f
  non-odontogenic, II-371–385
  odontogenic, II-338–343, II-347f, II-365–371
    intraosseous carcinoma from, II-433
    site of, II-340f
  palatine, II-375
  paradental, II-343
  parakeratotic, II-360f–361f
  parotid gland, II-485
  radicular, II-340–341, II-342f–343f
  residual, II-341–342
  salivary gland, II-483–485, II-493t
  surgical management, II-338
  synovial, II-852
  temporomandibular joint, II-850–856
  third molar removal and, I-284
  thyroglossal duct, II-378–383
  traumatic bone, II-852
  World Health Organization classification, II-339t
Cystic hygroma, II-539
Cytokine, joint function and, II-830–832
Cytologic malignant ameloblastoma, II-420–422, II-424
Cytology, exfoliative, II-331–332
Cytomegalovirus, parotid gland affected by, II-488
Cytoxan. *See* Cyclophosphamide (Cytoxan)

D

Dabrafenib, II-701–704
Dacarbazine, II-701, II-714
Dal Pont, Giorgio, III-62
Dalmane. *See* Flurazepam (Dalmane)
Dautrey, Jaque, III-6
Davis method, for otoplastic surgery, III-451–453, III-452f
Deafferentation pain syndrome, I-361
Debridement
  for gunshot wound, II-283, II-290
  for peri-implantitis, I-725–727
Decadron. *See* Dexamethasone (Decadron)
Decision making, in surgical practice, I-18
Decitabine, II-625
Decompression, for odontogenic keratocyst, II-357–361
Dedo classification of facial profiles, III-327t
Deep circumflex iliac artery flap, II-296
Defect
  acquired, I-665–679
    implant in, I-665–687
    pathology, I-666
    reconstruction, I-665–666
  alveolar ridge, I-485f–490f, I-491–493, I-501b
  concave, I-484
    bone graft and, I-477f
  configuration, guided bone regeneration and, I-476
  congenital, I-665–687
  dehiscence, I-499b
  fenestration, I-491, I-492f
  grafting options for, I-666
  maxillary, from failed implant, I-450f
  multiple tooth, I-476f
  peri-implant, I-493
  ridge, I-476
  single tooth, I-476f, I-478f
  site preparation, I-479
  socket, I-476
Deformation, definition, III-628t
Degenerative (osteo)arthritis, II-836–838
Degenerative joint disease, II-792t–793t, II-869
Dehydration, herpetic infection as cause of, II-555
Delaire craniofacial analysis, III-100f
Delaire philosophy, cleft lip repair and, III-514–515
Deltasone, for temporomandibular joint disorders, II-871t
Dementia, I-146, II-3t
Demineralized freeze-dried bone allograft (DFDBA), I-428–429
Demoral. *See* Meperidine (Demerol)
Dendritic cell, II-600–601
Denosumab (Xgeva, Prolia), II-463–464, II-508–510, II-508t
Dental arch form, I-595–596
Dental cement. *See* Cement
Dental education
  behavior in, I-6–9
  history, I-2
  oral and maxillofacial surgeon in, I-33–35
  professionalism in, I-4
  statistics, I-34
  teaching professionalism in, I-7–8
Dental history, for implant overdentures, I-656–658
Dental maintenance service organization (DMSO), I-40–41
Dental support organization, I-37
Dentigerous cyst, II-343–348, II-345f, II-355f
Dentition
  abnormality, in cleft lip and palate, III-584–586
  after cleft palate repair, III-622–623
  after orthognathic surgery, III-290–291
  eruption sequence of, I-259t
  permanent, injury prognosis, II-139–141
Dentoalveolar injury, II-114–145
  classification, II-121t
  crown-root fracture, II-125
  evaluation, II-115–117
  gingival, II-137
  incidence, II-114
  mucosal, II-137
  pediatric, II-270–271, II-114
  periodontal tissue injury, II-122t, II-127–131
  physical examination, II-117–119
  prevention, II-141
Dentoalveolar injury *(Continued)*
  prognosis, II-137–141
  radiographic examination, II-119–120
  root fracture, II-125–127
  splint therapy, II-135–137
  supporting bone injury in, II-123t
  treatment, II-120–122
Dentoalveolar surgery
  complications, I-298–310
  goals, I-257–258
  pediatric, I-257–274
Dentofacial deformity
  asymmetry and, III-279
  cervical spine abnormality associated with, III-16–17
  clinical evaluation, III-14–29
  combined maxillary and mandibular osteotomy for, III-184
  genioplasty, III-96
  Le Fort I osteotomy for, III-153
  orthognathic surgery for, III-278
  transverse discrepancy, III-173
Dentures
  base reinforcement, I-655
  bone resorption associated with, I-642
  CAD-CAM fabricated, I-619f, I-621f
  complete, I-594f
    example, I-606f
    implant-fixed, I-642–643
    implant overdentures compared to, I-641–642
    mandibular, I-608–614, I-641–642
    screw-retained, I-614
  fitting of, I-658
  overpartial, I-642f
  screw-retained, I-614
Deoxycholic acid, III-432
Deoxyribonucleic acid (DNA)
  alterations, in cancer cells, II-606
  cancer diagnosis and, II-622–623
  cancer treatment and, II-625
  damage to, cancer and, II-602
  function, II-603
  whole genomic sequencing, II-623
Dependence, facial pain management and, II-952
Depo-Medrol. *See* Methylprednisolone (Depo-Medrol)
Depression, facial pain and, II-944–945
Deproteinized bovine bone mineral (DBBM), I-429–430, I-490–491
Dermal filler, III-465b–467b, III-472b–473b
Dermatofibrosarcoma protuberans, II-644t, II-653–654, II-720–721
Dermoid cyst, II-377, II-380f
Desflurane (Suprane), I-207–208
Desipramine (Norpramin), II-873t
Desmethyldiazepam, I-196f
Desmoplastic fibroma, II-476–478
Desmoplastic melanoma, II-692t
Desyrel. *See* Trazodone (Desyrel)
Dexamethasone (Decadron), III-287t
  after nerve surgery, I-373
  for autogenous bone graft prophylaxis, I-451
  for facial pain, II-955t, II-957
  for lymphoma, II-713
  for nausea and vomiting, I-253
  in orthognathic surgery, III-289
  in temporomandibular joint arthrocentesis, II-887
  for temporomandibular joint disorders, II-871t
Dexmedetomidine, I-13, II-221
Dextran, I-252t

Diabetes mellitus
bone graft healing affected by, I-433
complications associated with, I-141
craniomaxillofacial trauma management and, II-3t
orthognathic surgery and, III-286–287
peri-implant disease associated with, I-723–724
preoperative evaluation of, I-157
wound healing affected by, II-258–259
Diagnostic techniques, II-329–337
Diagnostic wax-up, I-449f
Diatrizoate meglumine, II-483
Diazepam (Valium), I-195
anxiety management with, I-234
clinical effects, I-194
for facial pain, II-955t, II-956
half-life, I-195t
for masticatory myalgia, II-969
pharmacokinetics, I-204t
protein binding, I-195t
structure, I-196f
for temporomandibular joint disorders, II-873, II-874t
Diclofenac, I-232
dosage, I-232t
for temporomandibular joint disorders, II-871t
DICOM. *See* Digital Imaging and Communications in Medicine dataset (DICOM)
Didrone. *See* Etidronate (Didrone)
Didusch, J. F., III-476–477
Dieffenback, Johann, III-534
Diet, after orthognathic surgery, III-291
Differential diagnosis, risk management and, I-76
Diffuse axonal injury, II-251
Diffuse large B-cell lymphoma, II-708b, II-710
Diflunisal
dosage, I-232t
for temporomandibular joint disorders, II-871t
Digastric muscle, II-784–785
DiGeorge syndrome, III-493–494
Digital Imaging and Communications in Medicine dataset (DICOM), I-692–696
Dilaudid. *See* Hydromorphone (Dilaudid)
Dingman, Reed, II-769
Dingman mouth gag, III-543–544
Diphenhydramine, II-551, II-556
Diplopia, zygomatic fracture as cause of, II-203–204
Diprivan. *See* Propofol (Diprivan)
Direct Abutment, I-624–626, I-633–634
Disc displacement, temporomandibular joint reconstruction, III-224
Discectomy
auricular cartilage graft after, II-912–913
autogenous graft after, II-912
dermal graft after, II-913–914
temporalis myofascial flap, II-912
for temporomandibular joint internal derangement, II-911
Discharge notes, risk management and, I-78
Disciplinary action, I-6–9
Displacement, craniofacial, III-628–629
Disruption, definition, III-628t
Disseminated intravascular coagulation, infantile hemangioma associated with, II-534
Distraction histogenesis, III-775
Distraction osteogenesis (DO), I-196–221, III-526–554, III-774–785
advantages, III-775
alveolar, I-535
consolidation period, I-536–537
devices for, I-539
Distraction osteogenesis (DO) *(Continued)*
distraction period, I-536
example, I-539f–546f
fan-shaped, I-545–547, I-548f
guidelines, I-538b
horizontal, I-538–539, I-543
indications, I-537–539
latency period, I-536
mesiodistal, I-547–549, I-548f–551f
oblique, I-543–545
prerequisities, I-537f
protocol, I-535–537
three-dimensional, I-539–549
vertical, I-538–543
alveolar vertical, I-532
alveolar width, I-529–532
bifocal, III-217
biologic basis, III-775–776
bone transport, III-214–218
for cleft deformity, III-492–493
consolidation period, I-536–537
cranial vault, III-780–781
in craniosynostosis treatment, III-676–677
devices for, I-197, III-539
disadvantages, III-776
distraction rate, I-536
distraction rhythm, I-536
history, I-534–535, III-774–775, III-7–8
interdental, I-547
mandibular, III-147, III-637, III-776–778
for mandibular lengthening, III-202–208
for mandibular widening, III-196–202
maxillary, III-208–214, III-778
miniplate for, I-313
multifocal, III-217
nerve injury associated with, II-84
in oculoauriculovertebral spectrum, III-695–696
pediatric, III-637, III-768
postoperative care, III-202, III-206
protocol, I-535–537
relapse, III-777–778
for segmental defect, I-668
temporomandibular joint replacement and, II-934–935
three-dimensional alveolar, I-534–551
transport, I-547–549
in Treacher Collins syndrome, III-730
vertical, I-532
Diversity, in surgical practice, I-15–16
Divinyl ether, I-207
DMSO. *See* Dental maintenance service organization (DMSO)
DO. *See* Distraction osteogenesis (DO)
Docetaxel, II-755, II-756t–757t
Docking site, in distraction osteogenesis, III-214
Docking site surgery, III-217–218
Doconasol, II-553–554
Doctor's stool, I-47–48, I-48f
Documentation
claim form and, I-87–88
electronic health record, I-79
informed consent, I-77
of noncompliance, I-79–80
principles, I-87–88
risk management and, I-75–80
Dog, bite wounds from, II-61–62, II-62b
Dolder bar, I-648–649
Donor site
location, I-705f
for nerve graft, II-95
protocol for, I-704–706
Dose and potency, I-229t–230t
Double-opposing Z-plasty, III-536, III-542–543, III-610
limitations and complications, III-548
Double-opposing Z-plasty *(Continued)*
speech and, III-546–547
technique, III-543–546
Down syndrome
airway assessment in, I-243
orthognathic surgery and, III-286
Doxepin (Sinequan), II-873t
Doxorubicin (Adriamycin), II-455, II-713–714, II-757t
Doxycycline
for avulsed tooth, II-130
medication-related osteonecrosis treated with, II-516
peri-implantitis treated with, I-725–726
Drill, rotary, thermal trauma from, I-607
Droperidol, III-288
Drug-induced sleep endoscopy (DISE), III-265–266
Drugs. *See* Medication
Dry socket, I-283
exodontia and, I-303
third molar extraction and, I-293–294
treatment, I-294
DSO. *See* Dental support organization
Ductal stenosis, II-483
Duloxetine (Cymbalta)
for facial pain, II-955t
for neuropathic pain, I-364
Dynamic Abutment, I-638–639
Dysesthesia
definition, I-355t, II-946t
patient-reported, I-358
Dysmorphic disorder, I-106
Dysmorphology
cranio-orbital, III-636–637
definition, III-628t
Dysplasia
in cancer histology, II-599, II-600f
cemento-osseous, II-470–471
craniofacial fibrous, III-751–753, III-761f–762f
fibrous, II-470
florid cemento-osseous, II-471
focal cemento-osseous, II-471
periapical cemental, II-470–471
Dysplasia ablation, laser for, I-338f

E

E-plane, chin position analysis with, III-462f
Eagle's syndrome, II-951–952
Ear
blood supply, III-448, III-449f
deformities, III-448–450
in oculoauriculovertebral spectrum, III-695
in rhytidectomy, III-334–335
innervation, III-448, III-449f
laceration repair, II-276, II-235f
protruding, III-446–457
reconstruction
in oculoauriculovertebral spectrum, III-695–696
in Treacher Collins syndrome, III-732–733
surgical anatomy, III-447–448
surgical correction, III-450–453
in Treacher Collins syndrome, III-707
wound closure, II-57–58
Earlobe, protruding, surgical correction, III-453–455
Early implant loading (EIL), I-605–608
Eating disorders, craniomaxillofacial trauma management and, II-3t
Ecchymosis
frontal sinus fracture as cause of, II-231–232
midface fracture and, II-216
periorbital, skull fracture indicated by, II-254
postoperative, I-306f

ECG. *See* Electrocardiogram (ECG)
Ectasia, laser treatment, I-347
Ectodermal dysplasia, I-683–684
Ectropion, eyelid, II-203
Edatrexate, II-756t
Edema
  in mandibular surgery, III-314
  in orthognathic surgery, III-289–290
  in sagittal split ramus osteotomy, III-79
EEG. *See* Electroencephalogram (EEG)
Effexor XR. *See* Venlafaxine (Effexor XR)
Ehlers-Danlos syndrome, II-259
Einstein, Albert, III-336
Elavil. *See* Amitriptyline (Elavil)
Elderly patient
  benzodiazepine effects on, I-194
  bone graft healing in, I-432
Elective lymph node dissection, II-698
Electrocardiogram (ECG), I-166–167
Electrocautery, for skin cancer, II-727
Electrodesiccation, for skin cancer, II-727
Electroencephalogram (EEG)
  for pediatric anesthesia monitoring, I-245
  sedation monitoring and, I-171
Electromagnetic spectrum, III-337f
Electromyogram, for masticatory myalgia, II-964–966
Electromyography, II-103–104
Electron microscopy, II-335
Electroneurography, II-103–104
Electronic dental anesthesia (EDA), I-187–188
Electronic health record
  documentation with, I-79
  in VA system, I-32
Elevation
  of impacted third molar, I-288
  in simple extraction, I-276
Elevator, in simple extraction, I-276
Embolism, prevention, II-6
Embryo, Carnegie stages, III-477f, III-479f–480f
Embryogenesis
  cleft deformity and, III-493
  orofacial, III-476–490
Emergency care
  risk management in, I-77–78, I-81–82
  simulation of, I-212–213
Emergency equipment, for pediatric anesthesia, I-245
Emergency protocol, in oral and maxillofacial surgery, I-55
Emotional intelligence, I-144
Empathy, communication and, I-144
Emphysema, I-301
Employee
  family as, I-112
  hiring and firing, I-116–117, I-112–114, I-110
  interview, I-113
  as marketing asset, I-133–134
  salary and benefits, I-112
  superior, characteristics of, I-115–116, I-114, I-114
Employee relations, I-111–117, I-113
Enamel fracture, in dentoalveolar injury, II-123–124, II-124f
Enanthema, II-557
Encephalitis, herpetic, II-555
End-tidal CO_2, I-169
Endocannabinoid drugs, I-233
Endocarditis, III-281b
  cardiac conditions associated with, I-151t
  prophylaxis, I-151t
Endocrine system, preoperative evaluation of, I-142, III-286–287
Endodontics
  chemical burn from, I-378
  nerve injury associated with, I-87, II-377–378
  nerve trauma from, I-377
Endoneurium, in nerve anatomy, II-77–78
Endoscope
  example of, III-146f
  in forehead and brow lift, III-408–416
Endoscopy
  craniomaxillofacial tumor, III-741
  in forehead and brow lift, III-408–416
  for frontal sinus fracture, II-240
  in mandibular osteotomy, III-144–152
  for midface fracture repair, II-227
Endosseous cylinder, as anchor, I-313
Endothelial cell, wound healing and, II-257
Endotracheal intubation
  in laser surgery, III-343
  pediatric, I-239, II-248
Endotracheal tube, sizing, I-247
Enflurane (Ethrane), I-207
Enophthalmos, II-205–206, II-226
Enterovirus disease, II-556–557
Entropion, eyelid, II-203
Entubulation, for neural regeneration, II-96f
Environmental factors, in sarcoma etiology, II-644
Eosinophilic granuloma, II-523
Epidermal growth factor receptor (EGFR), II-607f, II-612, II-627
  in head and neck cancer, II-753f
  inhibitors, II-757–759, II-759t
  squamous cell carcinoma and, II-672–673
Epidermoid cyst, II-377
Epidermolysis bullosa, II-566–568
  clinical features, II-567
  treatment, II-567–568
Epignathus, III-756–757
Epilepsy, I-161
Epinephrine
  local anesthetics and, I-178–179
  maximum dosage, I-182t
  selectivity and potency, I-180t
  side effects, I-180–181
Epineurium
  internal neurolysis and, II-94
  in nerve anatomy, II-77–78
Epiphora, in midface fracture, II-226
Epistaxis
  midface fracture associated with, II-216
  nasal fracture as cause of, II-187
Epithelial cancer, II-718–720
Epithelial-mesenchymal transition, II-619–620
Epithelial odontogenic tumor, II-444–455
Epker, Bruce, III-5
Epstein-Barr virus, II-622–623
Epulis, congenital, III-756–757
Epulis fissuratum, III-349
Epworth Sleepiness Scale, III-265
Equal-appearing interval scale, III-574
Equipment
  anesthetic, I-212–213
  in oral and maxillofacial surgery, I-49
  for sitting position, I-46–50
Erbitux. *See* Cetuximab (Erbitux)
Erbium-doped yttrium-aluminum-garnet laser, peri-implantitis treated with, I-726–727
Erich arch bar, II-148f, II-153, II-155
Erickson Model Table, III-52, III-53f, III-54
Erlotinib, II-757, II-757t, II-759t
Ernst, Franz, III-535
Erythema chronicum migrans, II-846
Erythema multiforme, II-552–553, II-568
Erythrocyte sedimentation rate (ESR), II-840
Erythromycin, medication-related osteonecrosis treated with, II-516
Erythroplakia, laser treatment, I-336–338
Escherichia coli, peri-implantitis and, I-728
Esters, local anesthetics and, I-176–177
Esthetic Abutment, I-634
Esthetic contour graft, I-487–491, I-492f
Esthetic zone, implant planning and, I-449–450
Esthetics
  edentulous maxilla treatment planning and, I-592
  facial, III-13–14, III-16
Estrogen receptor, II-623–624
Ethics
  definition, I-9
  dilemmas, I-11–12
  professionalism and, I-1–13
Ethnicity, supernumerary teeth and, I-266–267
Etidocaine
  local anesthesia with, I-232–233
  onset time, I-178t
  systemic complications associated with, I-184
Etidronate (Didrone), II-508t
Etodolac
  dosage, I-232t
  for temporomandibular joint disorders, II-871t
Etomidate, II-13, II-192
Etoposide, II-714
Etretinate, II-733
Euclid, III-13
Eustachian tube
  cleft palate and, III-548
  dysfunction, III-568
Evaluation and management codes, I-92–95
Ewing sarcoma, II-644t, II-645–646, II-662–663, III-762–763
Exanthema, II-557
Exarticulation, in dentoalveolar injury, II-128–131
Exercise, aging and, I-140–141
Exercise therapy, for temporomandibular joint disorders, II-875–876
Exfoliative cytology, II-331–332
Exodontia
  basic and complex, I-275–297
  bone fracture and, I-307–308
  burns and abrasion during, I-301
  complications, I-298–308
  damage to adjacent structure during, I-298–299
  diagnosis, I-276
  flap design, I-280
  fracture and, I-307f
  hemorrhage, I-306–307
  indications, I-275–276
  infection following, I-303
  nerve injury during, I-302–303
  pain and swelling after, I-304
  patient positioning, I-276
  removal of wrong tooth, I-298
  soft tissue injury during, I-301
  treatment planning, I-276
  trismus after, I-304
Expander, maxillary, III-587
Exparel. *See* Bupivacaine liposome injectable suspension (Exparel)
Expert witness, surgeon as, I-10
External auditory canal, II-96
External neurolysis, II-93–94
Extra-oral vertical ramus osteotomy (EVRO), III-113
Extracellular matrix
  joint function and, II-830
  in temporomandibular joint disc repair, II-915

Extraction
flapless, implant success and, I-415–416
immediate implant after, I-410
of impacted canine, I-262
patient positioning, I-276
of pediatric canine, I-262
in pediatric patient, I-260
for primary tooth injury, II-132
simple, I-276–279
surgical, I-279–281
bone removal, I-280–281
complications, I-281–283
flap design, I-280
of impacted tooth, I-283–295
indications, I-280b
multi-rooted teeth, I-281
technique, I-286–288
third molar, I-283–286
Extranodal marginal zone B-cell lymphoma of mucosa associated lymphoid tissue, II-708b, II-710, II-711f
Eye
examination, in trauma patient, II-4, II-4f
herpetic infection involvement, II-552
muscles, II-204t
Eye injury, gunshot wound as cause of, II-311
Eyebrow
asymmetry, III-408
blood vessels, III-399–402
malposition, III-424
muscles, III-397f
muscles in, III-397–399
position, III-389–391
ptosis, III-395
Eyebrow lift, III-395–428
blepharoplasty compared to, III-407f, III-413f
complications, III-423–425
direct, III-418–419
eyebrow malposition following, III-424
mid-forehead, III-419
neurotoxin-assisted, III-421
postoperative care, III-422–423
preoperative assessment, III-405–408
techniques, III-408–419
transpalpebral/transblepharoplasty, III-419
tricophytic, III-419f
Eyelid
anatomy, III-388, III-390f
blood supply, III-391f
facial esthetics and, III-16
malposition, III-393
reconstruction, II-52
sebaceous gland carcinoma of, II-720
trauma repair, II-276–277
wound closure, II-51–52, II-54f
zygomatic fracture and, II-203
Eyewear, protective, for laser surgery, III-342, III-343f

F

Face. *See also* Midface
anteroposterior deficiency, III-98
asymmetric, case study, III-84b
avulsive injury, II-282
airway management, II-282
assessment, II-282
complications, II-300
management, II-282–283
pediatric, II-274–275
reconstruction, II-287f, II-296–297, II-283–300
rehabilitation, II-300
surgical management, II-265–266
balance, osteotomy and, III-184–185
bipartition osteotomy, III-677f
Face *(Continued)*
botulinum neurotoxin for enhancement, III-439–445
burn injury, II-67–68
buttresses of, II-212b
chemical peel, III-439–445
cleft
classification of, III-496f
complex, III-506–508
Dedo classification, III-327t
deformity, III-596–600
esthetic units, II-16, III-51f
esthetics, III-13–14
examination, in trauma patient, II-4
fracture, from gunshot wound, II-316
fracture patterns, II-20
growth abnormality, III-627–628
growth and development, III-738
imaging, II-18
implant, in cosmetic surgery, III-458–475
innervation, I-227f
lower, reconstruction, II-296–297
measurements, III-127t–128t
morphogenesis, III-476–486
osteotomy and facial proportions, III-184–185
paralysis, II-101t
pediatric fracture, II-35–38
pediatric trauma, II-264–280
plastic surgery, III-359
projection, osteotomy and, III-184–185
proportions, III-119f
racial variation in, III-25
reconstruction, in Treacher Collins syndrome, III-731–732
rhytidectomy evaluation, III-326–327
soft tissue injury, II-41–69
evaluation, II-41–42
postoperative care, II-60–61
subunits, II-51f
sunken, III-465b–467b
symmetry and proportion of, III-13–14, III-96, III-184–185
transplantation, gunshot wound treatment with, II-326
transverse asymmetry, III-98
upper, evaluation, III-16
upper third, rejuvenation, III-395
vertical deficiency, III-98
vertical excess, III-97–98
vertical support, II-211
Face height
long
case study, III-70b–71b
mandibular deficiency with, III-70b–71b
mandibular deficiency case study, III-65b
normal, mandibular deficiency and, III-65b
osteotomy and, III-184
short, mandibular deficiency with, III-68b–69b
short posterior
causes, III-118b
mandibular deficiency with, III-113–143
treatment planning, III-119–120
in Treacher Collins syndrome, III-706–707, III-724
Face-lift. *See* Rhytidectomy
Facebook, marketing and, I-139
Facebow record, for model surgery, III-46–47
Faceguard, dentoalveolar injury prevention with, II-141
Facial artery, rhytidectomy evaluation and, III-328
Facial artery musculomucosal flap, II-286–290, II-292f
Facial bone
grafting of, I-415–416
in restored implant, I-411
Facial cleft. *See* Cleft deformity
Facial nerve, III-400, III-402f
anatomy, II-96–99
Bell's palsy and, II-100–101
branching pattern, II-98f
description, II-70
extratemporal segment, II-98–99
identification of, II-161f
imaging, II-99–100
injury
classification, II-100, II-100t
clinical evaluation of, II-103–104
diagnosis and management, II-70–113
extratemporal, II-104–106
iatrogenic, II-102–103
infection as cause of, II-102
in mandibular fracture, II-168
outcomes, II-106
pediatric, II-272
in rhytidectomy, III-333–334
sagittal split osteotomy associated with, III-305–308
in sagittal split ramus osteotomy, III-80
from trauma, II-101–102
treatment, II-102, II-104–106
injury mechanism, II-100–103
intracranial segment, II-96–97
intratemporal segment, II-97–98
laceration, II-60
mastoid segment, II-97–98
microanatomy, II-77–78, II-99
paralysis of, from local anesthesia, I-184
parotidectomy and, II-495–496
rhytidectomy evaluation and, III-328
traumatic injury, II-101–102
tympanic segment, II-97
Facial profile, implant planning and, I-585–587
Facial resurfacing, III-355–356
Facial support, for implant, I-584–588
Facial surgery, laser-assisted, I-343–347
Facial wound, reconstruction following, I-665–666
Faciolingual anatomy, implant restoration and, I-392, I-395
Faciolingual placement, implant, I-397–398, I-398f
Failure to diagnose, I-82
Famciclovir, II-554, II-556
Farrior technique, for otoplastic surgery, III-453, III-455f
Fascia
in forehead, III-397–399
upper face, III-401f
FAST, pediatric trauma assessed with, II-246
Fasting
pediatric patient, I-243
preoperative, I-215–216
pulmonary aspiration and, I-243t
Fat, procurement, in fat transfer, III-436
Fat graft, III-433–437
in forehead and brow lift, III-419
in temporomandibular joint total reconstruction, III-238
Fat transfer
autologous, III-434, III-467b
complications, III-437
fat procurement, III-436
in forehead and brow lift, III-419
preoperative evaluation, III-434
techniques, III-429–438
Faulk-Effleston, Col. Jan, I-24
Fear, pediatric, premedication for, I-248
Feeding, infant, in craniosynostosis care algorithm, III-672
Felty syndrome, II-839

Fentanyl, I-200
dose and potency, I-229t–230t
equianalgesic dosage, I-231t
for facial pain, II-953
midazolam combined with, I-218
pediatric dosage, I-250t
for pediatric patient, I-249, I-251
structure, I-199f
synthesis, I-197–198
transdermal, II-954
Fibrin sealant, for frontal sinus fracture, II-238–240
Fibro-osseous lesion, II-468–471
Fibroblast
cancer-associated, II-600
tumor invasion and, II-620–621
wound healing and, II-257
Fibroma
ameloblastic, II-449–451, III-745
juvenile ossifying, III-751, III-755f–756f
nonossifying, II-854
odontogenic, II-435–438
differential diagnosis, II-437
management, II-438
ossifying, III-743f
Fibromatosis
juvenile aggressive, III-745–748
paragnathic, III-748f
Fibromyalgia
facial pain and, II-944–945
pharmacotherapy, II-955–956, II-970
Fibrosarcoma, II-644t, II-652–653, II-652f
ameloblastic, II-454–455
temporomandibular joint, II-934f
Fibrosis, temporomandibular joint replacement for, II-931
Fibrous dysplasia, II-470, II-853
Fibula free flap, II-294, II-296
Fiducial facebow, III-31–33, III-35
Field-of-view (FOV) device, I-692
Financial management, for oral and maxillofacial surgical practice, I-67–71
Fine needle aspiration biopsy, II-331, II-338
for lymphoma diagnosis, II-707
for parotid gland tumor, II-494
salivary gland, II-481–483
for sarcoma, II-646
Fire, laser surgery as cause of, III-342
Firearms
classification, II-303
deaths associated with, II-303
injuries from, I-307, II-665
pediatric injury and death from, II-245
types of, II-303–304
Fistula
in cleft palate repair, III-539–540
closure, III-609–612
in double-opposing Z-plasty, III-548
indications for repair, III-610–611
rate, after palatoplasty, III-610
timing of surgery, III-610–611
Fitzpatrick skin classification system, I-344, II-691, II-691t, II-723t
5-fluorouracil, II-733–734, II-747, II-754–755, II-756t–757t
Fixation
of alveolar fracture, II-134
for atrophic mandibular fracture, II-166–167
bioresorbable material, III-63–64
Champy's technique, II-162
for cleft maxilla stabilization, III-606
ear, III-452–453
endoscopic approach, II-161–162
external, II-155, II-156f
in forehead and brow lift, III-409, III-415
for genioplasty, III-104–105
Fixation *(Continued)*
intermaxillary, III-188
in Le Fort I osteotomy, III-166–167
for sagittal split ramus osteotomy, III-62–63
internal, II-162
intraoral/transbuccal approach, II-155–158
inverted L osteotomy and, III-119t
ivy loop, II-233f
lag screw, II-164
mandibular, history, II-146
materials for, II-162–164
maxillary, in Le Fort I osteotomy, III-167
maxillomandibular, II-153, II-155, II-270, II-280
for condylectomy, III-147
example of, II-148f
history, II-146
for mandibular osteotomy, III-145
open reduction and internal, II-147
osteosynthesis, in sagittal split ramus osteotomy, III-76–77
position screw technique, III-78f
resorbable materials in, III-79b
resorbable plate, II-162
resorbable screw, in sagittal split ramus osteotomy, III-77–79
rigid, II-162
for sagittal split ramus osteotomy, III-62–63
screw, III-7
semirigid, II-162
transcervical-retromandibular approach, II-160–161
transcervical-submandibular approach, II-158–160
transosseous wire, II-162
Fixation device
example of, II-318f
external, for gunshot wound, II-316–318
maxillomandibular, II-316
Fixation screw, I-461–462
case study, I-693
designs, II-164f
lag, II-164f
maxillomandibular, II-316
for mesh graft, I-465–466
passive bone, II-164f
placement, in biomedical model, I-701f
removal, I-468
Fixed restoration
arch form, I-595–596
case presentation, I-601–602
classification for, I-590
cost, I-596–597
denture conversion to, I-608–614
for edentulous maxilla, I-584–604
extraoral examination for, I-591–602
extraoral parameters for, I-586f
force placed on, I-594–595
implant distribution and placement, I-596
material selection, I-597–602
ridge form, I-595–596
screw-retained, I-614
treatment planning, I-592–597
Flap
Abbe, II-286, II-291f, II-297–298
anterolateral thigh free, II-294, II-295f
cervicofacial, II-290, II-293f
complications, II-300
deep circumflex iliac artery, II-296
design
bone augmentation and, I-460
for guided bone regeneration, I-476
for impacted tooth removal, I-286–287
in surgical extraction, I-280
Flap *(Continued)*
envelope, I-280, I-286
for eyelid laceration, II-51–52
facial artery musculomucosal, II-286–290, II-292f
fibula free, II-294
free, II-294–296
laceration, during exodontia, I-301
local, for avulsive facial injury, II-297–298, II-286–294
microvascular free, II-294–296
open-book, I-492f, I-494f
osteoperiosteal, I-526–554
paramedian forehead, II-290, II-292f
in pediatric ablative defect reconstruction, III-768
pericranial, II-241
radial forearm, II-294, II-295f
reconstructive, II-296b
reflection, in guided bone regeneration, I-480f
regional, for avulsive facial injury, II-286–294
for skin cancer repair, II-731–732
submental island, II-290–294
temporalis muscle, II-924, II-925f
temporalis myofascial, II-912
temporoparietal fascia, II-290, II-294f
trapezoidal, I-280
triangle, I-280
vascularized free, I-668–671
Flexeril. *See* Cyclobenzaprine (Flexeril)
Flickr, marketing and, I-105
Florid cemento-osseous dysplasia, II-471
Flow cytometry, II-335–336
Fluid
administration, I-216–217
intraoperative, for pediatric patient, I-248
perioperative, I-217
Fluid management, for pediatric patient, I-248
Flumazenil, I-197
discovery, I-191
half-life, I-195t
protein binding, I-195t
structure, I-196f
Fluoromethane, II-970
Fluorouracil, II-757t
Fluoxetine (Prozac), II-873t
Flurazepam (Dalmane), II-874t
Flurbiprofen, II-871t
Focal cemento-osseous dysplasia, II-471
Focused assessment by sonography for trauma (FAST), II-246
Follicular lymphoma, II-710
Follicular sac, II-437, II-437f, II-441–444
Food and Drug Administration (FDA), codeine warning from, I-253–254
Forced duction test, II-196, II-203, II-205f
Forceps
Ash, I-278f
cowhorn, I-279f
English, I-278f
extraction, I-277, I-278f
Hayton-Williams, II-217f
luxation, in simple extraction, I-277–278
No. 23, I-279f
No. 53, I-279f
No. 150, I-277, I-278f–279f
No. 151, I-277, I-278f–279f
No. 210, I-279f
No. 88 L/R, I-279f
rotation, I-278f
Rowe maxilla disimpaction, II-217f
Forehead
blood vessels, III-399–402
bone anatomy, III-396–397
lift, III-395–428
morphogenesis, III-476

Forehead *(Continued)*
muscles in, III-397–399, III-397f
nerves in, III-397f, III-399–402
ptosis, III-395
wound closure, II-50
Forehead and brow lift, III-395–428
adjunctive procedures, III-419–422
anatomic considerations, III-395–405
complications, III-423–425
coronal, III-416
endoscopic anatomy, III-402–405
endoscopic technique, III-408–416
esthetic considerations, III-395–405
mid-forehead, III-419
muscle and fascial anatomy, III-397–399
postoperative care, III-422–423
preoperative assessment, III-405–408
techniques, III-408–419
treatment approach, III-408–419
treatment goals, III-405–408
trichophytic and trichophylic, III-416–418
Forehead line, botulinum neurotoxin for, III-441
Foreign body
pediatric wound healing and, II-260
swallowing of, during exodontia, I-302
Fosamax. *See* Alendronate sodium (Fosamax)
Fospropofol, I-201, I-202f
Fox Plane, III-24
Fractional photothermolysis, III-339
Fracture
alveolar, II-120–121, II-133–137
alveolar process, II-133–135
angle, II-166, II-169f
blow-in, II-22
blowout, II-22
bone healing after, II-257–258
buccal plate, in sagittal split ramus osteotomy, III-82
buckle-type, II-261
complete, II-261
condylar, II-270, II-31–34, II-165–166
craniomaxillofacial, spine injury and, II-38
crown, II-123–125
crown-root, II-125
dentoalveolar, II-123t, II-149, II-233f
classification, II-120
pediatric, II-233f
treatment, II-120–122
exodontia and, I-307–308
facial, II-20
from gunshot wound, II-316
pediatric, II-230
following third molar extraction, I-307f
frontal bone, II-266–267, II-20–22
frontal sinus, II-230, II-21f, II-22t
classification, II-232–233
clinical evaluation, II-231–232
complications, II-241–243
endoscopic repair, II-240
images, II-234f
management, II-236
management algorithm, II-237
postoperative care, II-241
radiologic evaluation, II-232
surgical management, II-233–240
greenstick, II-261
Knight and North classification, II-27t
mandibular. *See* Mandibular fracture
Markowitz, II-221–223
maxillary, II-27–28, II-32f–33f, II-320f
maxillofacial, I-17, II-374–376
midface. *See* Midface fracture
nasal. *See* Nasal fracture
naso-orbito-ethmoid, II-213, II-220–225
classification, II-221–222
diagnosis, II-222–223
Fracture *(Continued)*
exposure, II-223–224
treatment, II-223
orbital, II-22
palatal, II-28, II-220
pediatric
blowout, II-268
facial, II-35–38
management, II-243
orbital, II-267–268
patterns of, II-261
sinus, II-266–267
skull, II-253
primary teeth, II-131–132
root, in dentoalveolar injury, II-125–127
septal, II-178–179
sinus, II-20f
skull
images, II-233f, II-232f
pediatric, II-253
socket wall, II-133
symphyseal, pediatric, II-270
temporal bone, facial nerve injury from, II-101–103
trapdoor, II-268
zygomatic. *See* Zygomatic fracture
Framework
case presentation, I-601–602
cobalt chromium, I-599
material selection for, I-597–602
zirconia, I-599–601, I-601f
zirconia titanium, I-601
Free autogenous graft, I-326, II-556
Free flap
non-vascularized, I-675
for osteoradionecrosis, II-596
vascularized, I-668–671, I-675
Free gingival graft, I-556, I-557f, I-560–561, I-562f
Freeze-dried bone allograft (FDBA), I-428–429
Frenectomy, I-270–271
for ankyloglossia release, I-271
laser, I-336f, III-348–349
lingual, I-271f
Frenotomy, I-270–271
Frenum
labial, surgery for, I-270–271
pediatric, procedures for, I-270
Fresh-frozen bone allograft (FFBA), I-428
Friedman Palate Position, III-266f
Friedman Staging System, III-267t
Frontal bone injury, II-266–267, II-230–243
Frontal sinus, II-20–22, II-22t
axial view, II-230
classification, II-232–233
clinical evaluation, II-231–232
comminution of, II-239f
coronal view, II-230f
fracture, II-20f
anterior wall, II-242
classification, II-232–233
complications, II-241
endoscopic repair, II-240
management algorithm, II-237
management of, II-236
pediatric, II-266–267
posterior wall, II-238–240
postoperative care, II-241
radiologic evaluation, II-232
surgical management, II-233–240
injury, II-230
management of, II-236
obliteration, II-236–238
radiologic evaluation, II-232
sagittal view, II-230
surgical anatomy, II-230–231
surgical management, II-233–240
Frost, Harold, III-247
Frozen section, II-330–331, II-393
Functional capacity, preoperative evaluation and, I-139
Functional cleft lip repair, III-525–526
principles, III-527–530
studies, III-530–531
surgical technique, III-527–528
Functional endoscopic sinus surgery, I-580, I-582f
Functional magnetic resonance imaging (fMRI), II-947
Functional matrix repair, III-525–531
Functional Outcomes of Sleep Questionnaire, III-265
Functional residual capacity (FRC)
age values, I-241t
pediatric, I-241, I-241t
Furlow double-opposing Z-plasty, III-505, III-546–547, III-610
example, III-507f
limitations and complications, III-548

G

Gabapentin (Neurotin)
for facial pain, II-955t, II-956
for nerve injury, I-364
Gabapentinoid drugs, I-233, I-364
Gait, in mandibular movement, II-806–808
Galetti articulator, III-49
Gamma (g)-aminobutyric acid (GABA)
action, I-191–192
discovery, I-191
Gamma (g)-aminobutyric acid - benzodiazepine receptor complex, I-192, I-194f
Ganglion cyst, temporomandibular joint affected by, II-852
Ganz-Rinaldi surgical protocol, I-705f–706f, I-706
Ganzer, Hugo, III-535
Gardner syndrome, II-464, II-475, II-476f, II-644
Garre osteomyelitis, II-858
Gas exchange, pediatric, II-249
Gastric emptying, anesthesia and, I-216
Gastroesophageal reflux disease (GERD), I-141, III-286
Gastrointestinal disease, preoperative management and, I-141–142
Gastrointestinal system
non-Hodgkin lymphoma, II-710
preoperative management and, I-141–142
GBR. *See* Guided bone regeneration (GBR)
Gefitinib, II-757, II-757t, II-759t
Gelatin, anaphylaxis associated with, I-252t
Gemcitabine, II-757t
Gender, pediatric trauma and, II-245
Gene
amplification, II-607, II-607f
cancer treatment based on, II-622, II-625
cell regulation, II-603–606
classification, II-603
epigenetic alteration, II-609
epigenetic control, II-605f
molecular paradigm, II-604f
Ras family, II-612
regions, II-603
sequencing, II-623
tumor suppressor, II-602–603, II-609, II-614, II-616
Gene expression
alterations, II-607, II-609
cancer diagnosis and, II-623
epigenetic alteration, II-609
epigenetic control, II-605f
molecular paradigm, II-603, II-604f
prevention, II-603

Gene therapy, for oral cancer, II-678–679
General partnership, I-58–59, I-59t
Genetics
  cancer development and, II-602
  cancer treatment based on, II-622, II-625
  cell regulation and, II-603–606
  in cleft deformity, III-493–494
  craniosynostosis syndromes, III-667–669
  melanoma and, II-690–691
  oral cancer and, II-672–673
  sequencing, II-623
  in Treacher Collins syndrome, III-703–705
Geniculate ganglion, II-97
Genioglossal advancement, III-268
Geniohyoid muscle, II-784
Genioplasty, III-96–112, III-319–321
  alloplastic, III-103–104
  bony changes, III-104–105
  chin position and, III-303t
  chin repositioning, III-108f
  complications, III-319–321
  in computer-aided surgical simulation, III-35–36
  facial orientation and, III-28
  fixation devices, III-104–105
  functional, III-96–97, III-101
  history, III-2
  indications, III-97–98
  mandibular widening with, III-201
  Michelet, III-101
  model surgery and, III-60
  neurosensory disturbance, III-320
  sagittal split, III-103, III-104f–105f
  sliding, III-101–103
  for small chin, III-463b
  surgery, III-101–104
  tissue analysis, III-98
  treatment planning, III-98–101
  vertical reduction, III-111f
  wound healing failure, III-320
Gerdy's tubercle, I-457–458
Ghost cell, II-370, II-372f–373f
Giant cell granuloma, II-462–464, II-750–751, III-852
  classification, II-463t
  example, II-463f
Giant cell tumor, II-464
Gingiva
  avulsive wound, II-137
  in dentoalveolar injury evaluation, II-117, II-123t
  in fixed restoration, I-589, I-590f
  hypertrophic, III-352
  injury treatment, II-137
  minimal display, treatment for, I-585f
  miniscrew implant and, I-316
Gingival cyst, II-365, II-424
Gingival graft, I-450–451, I-450f
Gingivectomy, laser, III-348–349
Gingivoperiosteoplasty, III-498, III-562, III-584
Gingivoplasty, laser, III-352
Glabella, III-395–396
  botulinum neurotoxin for, III-440
  horizontal line correction, III-411
  innervation, III-400
  muscles, III-404–405
Glandular odontogenic cyst, II-365–368, II-369f
Glasgow Coma Scale (GCS), II-9, II-247
Glenoid fossa, II-778, II-821
Globulomaxillary cyst, II-375–376
Glogau skin classification, I-343, II-723b
Glucocorticoid deficiency, I-159t
Glutamate, I-205
Glycolic acid, for chemical peel, III-443
Glycolysis, in cancer cell metabolism, II-601–602
Glycopyrrolate
  for autogenous bone graft prophylaxis, I-451
  for pediatric patient, I-251
Glycosaminoglycans, joint function and, II-830
Gold alloy
  for abutment, I-636
  for single anterior implant, I-630–631
Gold Humanism Foundation, I-4
Golden ratio, III-13, III-14f–15f
Goldenhar syndrome, III-687, III-689f, III-694f
Goldman tip, III-376
Goode's method, chin position analysis with, III-460t–461t
Goode's method of nasal projection, III-369
Gorlin-Goltz syndrome, II-361–364, II-364b
Gorlin syndrome, II-718
Gout, II-847–848
Graft
  auricular cartilage, II-912–913
  autogenous
    after discectomy, II-912
    for temporomandibular joint surgery, II-772
  bone. *See* Bone graft
  connective tissue, I-415–416
  costochondral, II-326
  dermal, II-913–914
  for ear laceration, II-58
  failed, temporomandibular joint replacement after, II-931
  free fibula, II-326
  free gingival, I-557f
  pediculated, I-556, I-560f
  peri-implant, I-415–416
  rib, in pediatric ablative defect reconstruction, III-766–767
  for skin cancer lesion repair, II-731–732
  soft tissue. *See* Soft tissue graft
  spreader, in rhinoplasty, III-371f
  techniques and materials for, I-426–436
  tip onlay, III-374
  umbrella, III-374
  vascularized interpositional, I-558
Granuloma
  central giant cell, II-750–751, III-852
  laser excision, III-349
Grayson nasoalveolar molding appliance, III-498
Greenstick fracture, II-261
Growth, definition, III-628t
Growth factor
  bone graft and, I-431–432
  cancer cell growth and, II-612
  cell division and, II-611f
  joint function and, II-830–832
  pain management and, II-959
  in temporomandibular joint arthrocentesis, II-888
Growth inhibitory signal, cancer cell growth and, II-612–614
Growth signal
  cell division and, II-611f
  release from, II-617f
GSW. *See* Gunshot wound (GSW)
GTR. *See* Guided tissue regeneration (GTR)
Guerrero, Caesar, III-5, III-7–8
Guided bone regeneration (GBR), I-462–464
  in alveolar distraction, I-538–539
  applications, I-484–493
  case study, I-499b–500b
  complications, I-464
  defect configuration and, I-476
  history, I-475
  horizontal augmentation, case study, I-502b
  horizontal bone augmentation, I-464
  implant placement, case study, I-495b, I-497b–498b
Guided bone regeneration (GBR) *(Continued)*
  implant simultaneous with, I-487–491
  incision design, I-476–479
  membrane selection, I-480–483
  multiple tooth, I-478f
  patient selection, I-476
  for peri-implant defect, I-493
  postoperative considerations, I-493–504
  principles, I-476–480
  single tooth, I-478f
  socket preservation, I-493
  soft tissue closure, I-479–480
  space maintenance, I-483–484, I-526–527
  titanium mesh in, I-484
  vertical augmentation, case study, I-501b–503b
  vertical bone augmentation, I-464
Guided tissue regeneration (GTR), I-475–508
Gunshot wound (GSW), II-282, II-284
  algorithm for treatment plan, II-312f
  assessment, II-308–309
  avulsive injury, I-665
  ballistics, II-304–305
  categories, II-305
  classification, II-304–305
  classification system, II-304–305
  complications associated with, II-300
  deaths associated with, II-303
  debridement, II-313–314
  facial injury from, II-282, II-294–296
  factors influencing degree of, II-307
  hemorrhage control, II-309
  high-energy, II-318–320
  low-velocity, II-316
  management diagram, II-312f
  mandibular fracture from, II-315–316
  maxillofacial, II-303–328
    assessment, II-308–309
    external fixator for, II-316–318
    reconstructive phase of treatment, II-324–326
    self-inflicted, II-320–323
    treatment, II-307–313, II-323–324
  neurologic evaluation, II-311
  ophthalmologic assessment, II-311
  reconstruction, I-667f
  self-inflicted, II-320–323
  soft tissue injury from, II-306
  surgical management, II-265–266
  trajectory patterns, II-283f
  treatment
    high-energy, II-318–320
    intermediate phase, II-323–324
    reconstructive phase, II-324–326
  treatment algorithm, II-312f
  treatment guidelines, II-313–314
Gutta percha, injury associated with, I-378

H

Hader bar, I-644f, I-646f, I-648f
Hair
  laser removal, I-349, III-358
  laser transplant, III-358
Halcion. *See* Triazolam (Halcion)
Hall, Richard John, I-176
Halothane (Fluothane), I-207
Halsted, William Stewart, I-176
Hand, foot, and mouth disease, II-556–557
Hand-Schuller-Christian disease, II-523
Handgun
  types of, II-303
  wound from, II-305–306
Hanks balanced salt solution, II-129–130
Hard palate
  anatomy, II-612–615, III-671
  repair, III-503, III-534

Hard palate *(Continued)*
squamous cell carcinoma, II-681–683
submucous cleft, III-618–619
surgical technique, III-537–539
two-stage repair, III-548–549, III-551–552
Hard tissue, peri-implant grafting and, I-415–416
Hargis, Harold, III-6
Harvest guide, I-705f
Hashimoto-Pritzker syndrome, II-523
Hashimoto thyroiditis, I-158, II-710
Hayes-Martin maneuver, II-158–160
Hayflick limit, II-616
Hayton-Williams forceps, II-217f
HBO. *See* Hyperbaric oxygen therapy (HBO)
HCPCS. *See* Healthcare Common Procedure Coding System (HCPCS)
Head and neck
abnormal shape, III-647–648
angiosarcoma, II-658
cancer
chemotherapy for, II-755–756
epidemiology, II-752
metastatic, II-755–756
oncology principles in, II-752–763
radiation therapy for, II-741–751
sites, II-742–745
treatment, II-745–747
chondrosarcoma, II-649
dissection, II-683
embryogenesis, III-478–480, III-481f–482f
fibrosarcoma, II-652
liposuction, III-429–438
lymphoma, II-707
malignant fibrous histiocytoma, II-651
melanoma, II-690
neurofibroma, III-755
non-Hodgkin lymphoma, II-710
non-melanoma skin cancer, II-717–740
in oculoauriculovertebral spectrum, III-690b
osteosarcoma, II-647
radiation therapy for, II-741–751
sarcoma, II-643, II-644t
skin cancer, II-721–725
soft tissue injury, II-41–42, II-41–69
squamous cell carcinoma, II-670–689, II-719, II-752
chemotherapy for, II-754–756
clinical trials, II-758t
risk factors, II-752
treatment, II-752–754
Headache
chronic, frontal sinus fracture as cause of, II-243
facial pain and, II-944–945
Healing cap, I-626f, I-634f
Health
behavioral, I-140–141
cognitive, I-141
Health care
access to, I-3
continuous improvement of, I-3
safety, I-96
Health history
preoperative evaluation and, I-138
risk management and, I-75–76
Health Insurance Portability and Accountability Act (HIPAA), I-85
Healthcare Common Procedure Coding System (HCPCS), I-87–89
Hearing, in craniosynostosis care algorithm, III-672
Hearing aid, bone-anchored, III-733
Hearing loss
in oculoauriculovertebral spectrum, III-696
in Treacher Collins syndrome, III-705, III-707, III-732–733
Heart disease, vasoconstrictor drugs and, I-182b
Heart failure
classes of, III-281t
oral surgery following, I-139
Heart murmur, pediatric, I-242
Heart rate, infant, II-249–250
Helicobacter pylori
lymphoma associated with, II-713
peptic ulcer disease associated with, I-140
Hemangioma
congenital, II-536–538
definition, II-534
infantile. *See* Infantile hemangioma (IH)
intraosseous, II-852–853
laser treatment, I-338, I-347
local anesthetics, III-356
management, II-537–538
resection, II-537–538
synovial, II-853
temporomandibular joint, II-852–853
as vascular anomaly, II-534
Hemangiopericytoma, II-644t, II-659–660
Hematologic disorders
orthognathic surgery and, III-284–285
wound healing affected by, II-259
Hematologic system, preoperative evaluation of, I-159–161
Hematoma
in blepharoplasty, III-393
epidural, II-252
local anesthetics and, I-184
in oculoauriculovertebral spectrum, III-688–690
otoplastic surgery and, III-455–456
postoperative, II-7f
in rhinoplasty, III-383
in rhytidectomy, III-332
septal, II-187
subdural, II-253–254
Hematoxylin and eosin (H&E) stain, II-331–332, II-692–693
Hemifacial microsomia, III-15–16, III-158f–160f
Hemimandibular elongation, III-17f–22f
Hemochromatosis, II-644
Hemoglobin, absorption spectrum, I-329f
Hemophilia, preoperative evaluation of, I-161
Hemorrhage
in gunshot wound patient, II-309
intracranial, II-252–254
intraoperative, I-306–307
in Le Fort I osteotomy, III-169
postoperative, I-306–307
in sagittal split osteotomy, III-82, III-310–313
subarachnoid, II-253
in vertical ramus osteotomy, III-314
Hemorrhagic bone cyst, II-852
Hemostasis
laser for, I-330
in orthognathic surgery, III-289
Hemostatic sponge, I-512–513
Henderson-Hasselbalch equation, I-177
Hendrickson classification of palatal fractures, II-216f
Heparin, preoperative management, I-161
Hepatic disease
preoperative evaluation of, I-141–142
preoperative management and, I-141–142
Hepatitis C, allograft material and, I-429
Heroin, synthesis, I-197–198
Herpangina, II-556–558
clinical findings, II-557
treatment, II-557–558
Herpes labialis, II-554–556
Herpes simplex virus infection, II-551–556
clinical features, II-552–553
diagnosis, II-553
diseases associated with, II-551–552
erythema multiforme associated with, II-568
pediatric, II-555–556
recurrent, II-554–555
secondary, II-553
systemic agents for, II-554
treatment, II-553–554
Herpes zoster, osteomyelitis and, II-582f–585f
Herpes zoster oticus, II-102
Herpetic encephalitis, II-555
Herpetic meningitis, II-555
Herpetiform aphthae, II-559
Heterotopic bone formation, II-858
High-reliability organization (HRO), I-97–98
Hinge articulator, III-49
Hip, bone harvested from, I-458–460
HIPAA. *See* Health Insurance Portability and Accountability Act (HIPAA)
Histamine release, opioid drugs associated with, I-199–200, I-201b
Histiocyte, definition, II-524–525
Histiocytosis, Langerhans cell, II-857
Histiocytosis X, II-523, II-525b
Histomorphometric analysis, I-443
History and physical examination (H&P), I-75–76
Hodgkin cell, II-709, II-709f
Hodgkin lymphoma, II-707, II-709
clinical staging, II-708b
radiation therapy for, II-741
survival rate, II-714
treatment, II-713–714
Holdaway method, chin position analysis with, III-460t–461t
Holoprosencephaly, III-487
Homeostasis, genetic regulation, II-603–604
Honesty, professionalism and, I-5
Horizontal alveolar transport osteogenesis, I-547–549
Hounsfield unit, II-820–821
House-Brackmann facial nerve grading scale, II-100, II-100t, II-103
H&P. *See* History and physical examination (H&P)
HRO. *See* High-reliability organization (HRO)
Hullihen, Simon, III-62, III-113, III-492, III-1
Human immunodeficiency virus (HIV)
allograft material and, I-429
lymphoepithelial cyst associated with, II-485
parotid gland affected by, II-488
Human papillomavirus (HPV), oral cancer associated with, II-672
Human resources
alternatives, I-67
in oral and maxillofacial surgical practice, I-65–67
Hunsuck, Ervin E., I-24
Hutchinson sign, II-552
Hyaluronic acid (HA), II-884, II-887
Hydrocephalus, III-646, III-672
Hydrocodone (Vicodin)
equianalgesic dosage, I-231t
for facial pain, II-953, II-955t
prescription, I-228
for temporomandibular joint disorders, II-872t
Hydrocortisone
equivalent dosage, III-287t
for temporomandibular joint disorders, II-871t
Hydrocortone, II-871t

Hydromorphone (Dilaudid)
dose and potency, I-229t–230t
pharmacokinetics, I-230t
synthesis, I-197–198
for temporomandibular joint disorders, II-872t
Hydroquinone, I-345
Hydroxyadriamycin, II-713
Hydroxyapatite
alloplastic implant with, I-440–441
for bone graft, I-483–484
bone graft with, I-430
Hydroxyurea, II-757t
Hydroxyzine (Vistaril), II-874t
Hyperalgesia, definition, I-355t, I-360, II-946t
Hyperbaric oxygen therapy (HBO), I-590, II-595, II-678
Hyperesthesia, definition, I-355t, II-946t
Hyperglycemia, complications associated with, I-141
Hyperkeratosis, laser treatment, I-336–338
Hypernasality, III-570
Hyperparathyroidism, II-464–466, II-465f
Hyperpathia, definition, I-355t, I-360
Hyperplasia
definition, III-628t
mandibular, III-638
Hypertension, intracranial, III-674–675
Hyperthyroidism, I-141, I-158, I-158t
Hypertrophy, definition, III-628t
Hypodontia, in cleft lip and palate, III-585
Hypoesthesia, definition, I-355t, II-946t
Hypoglossal nerve stimulation, III-269
Hypoglycemia, postoperative, I-216–217
Hypohidrotic ectodermal dysplasia, I-683
Hyponasality, III-570–571
Hypopharynx
carcinoma of, II-746t
radiation therapy for carcinoma of, II-744
Hypopigmentation, skin resurfacing and, I-345–346
Hypoplasia
mandibular, III-637–638
maxillary, III-638–642, III-639f, III-778
midface, III-630–632
Hypotension, rapid-onset, I-165
Hypothermia
perioperative, I-170
therapeutic, II-256
Hypothyroidism, I-141, I-158, I-158t
Hypoventilation, pediatric cardiac arrest and, II-249
Hypoxemia, anesthesia associated with, I-168

I

IAJ. *See* Implant-abutment junction (IAJ)
IAN. *See* Inferior alveolar nerve
Ibandronate (Boniva), II-508t
Ibuprofen (Advil, Motrin)
dosage, I-232t
for facial pain, II-954–955, II-955t
for masticatory myalgia, II-969
for nerve injury, I-363
preoperative, I-231
for temporomandibular joint disorders, II-871t
ICD-10 CM code set, I-89–92, I-90t
ICP. *See* Intracranial pressure (ICP)
Idiopathic bone cavity, II-852
Ifosfamide, II-757t
IH. *See* Infantile hemangioma (IH)
Iliac block graft, I-569–570
Iliac crest bone graft, I-437, I-458–459
for cleft maxilla reconstruction, III-590
complications, III-592
Ilium, as bone graft donor site, I-458–460
Ilizarov, Gavriel, III-247, III-774
Illness
progressive, I-146
short-term, I-145–146
Imaging. *See also* Computed tomography (CT); Magnetic resonance imaging (MRI)
avulsive facial injury, II-283
charge-coupled device, II-815–816
complementary metal oxide semi-conductor device, II-815–816
craniomaxillofacial pathology, III-738–739
dentoalveolar injury, II-119–120
digital, for temporomandibular joint, II-815–816
facial nerve, II-99–100
for facial pain, II-946–947
frontal sinus fracture, II-232
functional, II-825
fusion, II-826
head and neck skin cancer, II-721, II-725
interpretation, II-17–20
mandibular fracture, II-31, II-153
maxillofacial trauma, II-17–40
for melanoma diagnosis, II-699
midface fracture, II-213
naso-orbito-ethmoid fracture, II-223
odontogenic tumor, II-392–393
osteomyelitis, II-576
pediatric craniomaxillofacial trauma, II-233–240
pediatric facial fracture, II-38
pediatric trauma, II-246–247
photo-stimulable phosphor device, II-815–816
reverse Towne projection, II-816–817
salivary glands, II-481–483
sarcoma, II-645
submentovertex projection, II-817
temporomandibular joint, II-815–829
temporomandibular joint disorder, II-801–804
temporomandibular joint internal derangement, II-906–907
temporomandibular joint prosthetic reconstruction, III-223–226
three-dimensional, I-207–208, II-688–710
for anterior maxillary deficiency, I-688–696
history, III-7
midface fracture, II-213
sinus augmentation, I-705–706
temporomandibular joint, II-815, II-820, II-824–825
trigeminal nerve, II-78–81
zygomatic fracture, II-191–193
Imatinib, II-703–704
Imbrication, III-330
Imipramine (Tofranil), II-873t
Imiquimod, II-734
Immediate implant loading (IIL), I-605–623
advantages, I-606
case study, I-608–610
clinical findings for, I-606
digitally planned and converted technique, I-613–614
extraoral conversion technique, I-613
implant angulation, I-608
intraoral conversion technique, I-610–613
literature review, I-605–608
prosthetic principles, I-607
surgical and prosthetic principles, I-607–608
Immediate implant with immediate provisionalization (IIIP), I-410
advantages of, I-416
esthetic complications of, I-410–412
flapless procedure, I-412f
flapless procedure for, I-413–414
molar, I-418–420
surgical principles for, I-412–418
Immediate provisional restoration, I-416–418
Immune system
description, II-600–601
tumor invasion and, II-620–621
Immunoconjugate therapy, for cancer, II-625–626
Immunodeficiency
craniomaxillofacial trauma management and, II-3t
wound healing affected by, II-259
Immunofluorescence study, II-332
Immunoglobulin, in rheumatoid arthritis, II-839–840
Immunoglobulin A, in linear IgA disease, II-565
Immunohistochemistry, II-333–334
cancer diagnosis and, II-623–624
for melanoma diagnosis, II-694–695, II-695t
Immunostain, II-333f–335f
Immunotherapy, for oral cancer, II-678
Impairment
aging and, I-146
medical professional, I-106
physical and mental, I-143–147
Implant
in acquired and congenital defects, I-665–687
adjacent, I-420–422
adjacent teeth root position and, I-393
alignment, in implant overdentures, I-650–653
allogenic bone graft for, I-428–429
allograft, for chin augmentation, III-464b
alloplastic, I-440–441
for chin augmentation, III-463b
in oculoauriculovertebral spectrum, III-696
in rhinoplasty, III-380
for temporomandibular joint surgery, II-772
alveolar distraction and, I-539f–542f
apicocoronal, I-396–397
autogenous bone graft for, I-427–428, I-446–474
biological models, I-696–699
bone loss around, I-398–401
in bone transport, III-218
Cal bar stabilizing, I-573f
cantilever in, I-599–600, I-600f
case presentations, I-316–320
cement
clinical protocols, I-717–720
issues associated with, I-711–712
properties of, I-714
cement-retained single anterior, I-630–631
chin, III-96, III-104, III-321
in cleft palate repair, III-623
in cleft patient, I-680–683
clinical application, I-316–320
complications, I-323–324
connected, I-647–649
decision making process for, I-632–635
depth, cement margin site and, I-712–720
diameter, I-400
digital workflow protocols, I-688–710
for ectodermal dysplasia, I-675
esthetic
diagnosis, I-391–409
multiple implants and, I-401–405
treatment plan, I-391–409
extraoral, for chin augmentation, III-464b
facial, in cosmetic surgery, III-458–475
facial and lip support, I-584–588
failure, guided bone regeneration for, I-493, I-494f
failure rate of, smoking and, I-412
height, I-653
history, I-311
hyperbaric oxygen therapy, I-678

Implant *(Continued)*
immediate, I-410–425
angulation principles, I-608
buccal plate remodeling after, I-413–414
case study, I-608–610
denture conversion to, I-608–614
digitally planned and converted technique, I-613–614
esthetic complications of, I-410–412
extraoral conversion technique, I-613
intraoral conversion technique, I-610–613
mandibular, I-605–623
molar, I-418–420
multiple, I-420–422
positioning of, I-414–415
surgical and restorative principles for, I-412–418
individual *versus* connected, I-647–649
laser used in, I-340–341, III-349–350
lip, III-474b
location of, for overdentures, I-649–650
malar, III-468b–469b, III-470t
mandibular, I-605–623
maxillary anterior
esthetic zone evaluation, I-449–450
position of, I-414
microthreads at coronal aspect, I-399–400
miniplate, I-313–314
miniscrew, I-311
molar, I-418–420
multiple, I-401–405
neck design, I-399
nerve injury associated with, I-379–380, II-379–380
causes, I-379–380
repair, I-379–380
treatment, I-380
number of
for fixed prosthesis, I-594
illustration, I-647f
one-piece, I-400
osseointegration, I-678
patient condition, I-672–674
pediatric, I-269–270
placement, I-397f
in bone graft site, I-468
case study, I-498b
faciolingual, I-397–398, I-398f
mesiodistal, I-397
platform switching, I-400–401
pontic site development, I-404
position, I-396, I-397f, I-414–415
posterior, decision tree, I-632f
premaxillary, I-575
radiotherapy and, I-677–678
restorative aspects, I-711–722
screw-retained single anterior, I-631
screw *versus* cement, I-631–632, I-711
simultaneous with guided bone regeneration, I-487–491
case study, I-499b
single anterior, I-629–631, I-635
decision tree for, I-635, I-636f
single posterior, I-624–629, I-632–635
cement-retained, I-624–627
decision tree, I-632–635, I-632f
single tooth, I-478f, I-624–640
cement-retained, I-624–627
screw channel in, I-637–639
sinus augmentation simultaneous with, I-517f, I-519–520
sinus lift simultaneous with, I-519f
site development
case study, I-496b–497b
in guided bone regeneration, I-484–487
skeletally based, I-311–324
Implant *(Continued)*
smile line and, I-391–393
soft tissue attachment, I-712, I-713f
soft tissue interface, I-555, I-556f
splinted, I-647–649
surface characteristics, I-400
survival rates, I-672
temporal, in forehead and brow lift, III-421–422
temporomandibular joint, II-771
for temporomandibular joint disorders, II-770–771
tent-pole technique, I-485f–487f
three-dimensional alveolar distraction osteogenesis, I-534–551
three-dimensional imaging for, I-688–710
timing of, I-674–675
tooth position and, I-391–392
types, I-313–316, I-646
virtual planning of, I-611f
zygomatic. *See* Zygomatic implant
Implant-abutment junction (IAJ), I-400–401
Implant overdentures, I-641–664
base adaptation, I-654
base reinforcement, I-655
clinical procedures, I-656–658
complications, I-643–645
contact with ridge, I-654
controversy associated with, I-643–644
design principles, I-645–655
disadvantages, I-643
four-implant, I-656–658
implant alignment, I-650–653
implant-fixed dentures compared to, I-642–643
implant location, I-649–650
implant types for, I-646
loosening of retentive mechanism, I-644–645
mandibular, I-643–646
maxillary, I-646
natural tooth overdentures compared to, I-641–643
number of implants in, I-647f
occlusion, I-655
retentive mechanisms, I-654
three-implant, I-656–658
two-implant, I-645, I-656–658
Implant site, bony anatomy of, I-394–396
Improvised explosive device (IED), II-318, II-319f
Incisal edge, I-591–592
Incision
in alveolar distraction osteogenesis, I-535–536
for bone graft recipient site, I-460
capsular, II-909–910
coronal, for craniomaxillofacial surgery, III-739
craniomaxillofacial surgery, III-739–741
craniosynostosis surgery, III-670
double-opposing Z-plasty, III-544f
endaural, II-908–909
forehead and brow lift, III-408f
guided bone regeneration, I-476–479
impacted maxillary canine, I-290f
intracartilaginous, III-372, III-373f
Killian, III-372, III-373f
laser for, I-330
Le Fort I osteotomy, III-163
Lynch, II-184–185
mandibular movement for, II-787
open-book, I-478f
preauricular, II-908
rhinoplasty, III-371–372, III-377–381
sulcular, I-281f
temporomandibular joint internal derangement surgery, II-908–909
transfixion, III-373f
Incisor
fracture, II-126f
impacted, I-265
implant replacement, I-403
inclination, III-300, III-302f
maxillary
extraction, I-277
fracture, II-132f
implant for, I-420–422
primary, loss of, II-132
Indian Health Service, I-31
Indomethacin
dosage, I-232t
for temporomandibular joint disorders, II-871t
Infant
abnormal head shape, III-647–648
airway, I-239
body composition, I-242
chest wall, I-240
cleft lip and palate
management, III-491–512
presurgical orthopedic treatment, III-561–567
repair, III-503, III-513–533
treatment planning, III-496–497
cleft palate repair goals, III-610
cranial vault sutures, III-646f
craniosynostosis, care algorithm, III-671–675
endothelial tumor, II-534
gingival cyst of, II-365
heart rate, II-249–250
herpes simplex infection, II-555
lymphatic malformation in, II-539
rib cage, I-240f
thermoregulation, I-241–242
Treacher Collins syndrome, III-705–706
Infantile hemangioma (IH), II-534–536
anomalies associated with, II-536
incidence, II-535
management, II-537–538
PHACE association, II-536
phases, II-535
resection, II-537–538
steroid therapy for, II-537
Infection
after otoplastic surgery, III-456
allograft material and, I-429
bone graft healing affected by, I-433–434
facial nerve injury caused by, II-102
frontal sinus fracture associated with, II-241
herpes simplex virus, II-551–556
impacted molar removal and, I-292–293
lymphoma associated with, II-708–709
mandibular fracture and, II-168
in orthognathic surgery, III-290, III-315–316
pediatric, I-260
postsurgical, I-283, I-303
in rhinoplasty, III-383
in rhytidectomy, III-333–335
in sagittal split ramus osteotomy, III-82
salivary gland, II-485–488
sinus, I-579–581, I-581f
wound healing affected by, II-260
Infectious arthritis, II-843–847
Infective endocarditis, III-281b
Inferior alveolar nerve, II-74–75
in distraction osteogenesis, III-776–777
furcation, II-75t
imaging, II-78
injury, II-81
implant surgery as cause of, II-82
in intraoral vertical ramus osteotomy, III-91
in mandibular surgery, III-318
neurosensory testing for, II-88–90
in sagittal split ramus osteotomy, III-80, III-80b
third molar removal as cause of, II-82

Inferior alveolar nerve *(Continued)*
in mandibular fracture, II-168
in sagittal split osteotomy, III-301–305
surgical access, II-91–92, II-93f
Inferior alveolar nerve block (IANB), for pediatric patient, I-258
Inflammation
bone healing and, I-426–427
implant anchor and, I-323
salivary gland, II-485–488
Informed consent, I-62
documentation of, I-77
preoperative, for orthognathic surgery, III-280
professionalism and, I-2
risk management and, I-76–78
Infraction, crown, II-122–123
Infraorbital artery, I-510
Infraorbital nerve, II-76
injury, I-202, II-367–368
surgical access, II-91–92
Infraorbital paresthesia, II-202–203
Infraorbital rim, surgical approaches, II-196–199
Infratemporal fossa, displacement into, I-299–300
Infusion pump, I-218–219
Inhalation anesthesia, pediatric, I-250–251
Inhalation anesthetic drugs, I-206–208
action, I-207
clinical effects, I-207–208
induction, I-220
nitrous oxide, I-220
physical and chemical characteristics, I-207t
structure, I-207
Injection, local, nerve injury associated with, II-81
Injection device
computer-controlled, I-187
needleless, I-187
Injury
avulsive facial, II-282–302
complications, II-300–302
reconstruction, II-283–300, II-287–290f, II-296–297
rehabilitation, II-300
surgical management, II-283
axonal, II-251–252
blunt, pediatric, II-245
burn, II-67–68
cervical, craniomaxillofacial fracture and, II-38
dentoalveolar. *See* Dentoalveolar injury
facial
evaluation, II-41–42
pediatric, II-264–280
firearm-related, II-303, II-307
inhalation, airway affected by, II-11–12
intracranial, craniomaxillofacial fracture and, II-38
lacrimal, II-272–273
maxillofacial gunshot, II-303–328
assessment, II-308–309
treatment, II-307–314
mechanism
in craniomaxillofacial trauma, II-2
trauma patient assessment and, II-10
neurologic, pediatric, II-250–252
ocular, in midface trauma, II-213
pediatric, II-245–263
assessment, II-231–232
epidemiology, II-230–231
evaluation, II-246
patterns of, II-260–261
wound repair after, II-256–261
pediatric craniomaxillofacial, imaging, II-233–240
pediatric facial, physical evaluation, II-232–233
Injury *(Continued)*
shotgun, II-320
soft tissue, pediatric, II-271–273
thermal, airway affected by, II-11–12
zygomatic
complications associated with, II-202–207
treatment, II-193
Instagram, marketing and, I-105–106
Institute of Medicine (IOM), I-73, I-97
Instrumentation, for surgical removal of impacted tooth, I-286, I-286b
Insulin, oral surgery and, I-157t
Insulin growth factor (IGF), II-257–258, II-258t
Insurance, I-82, I-87–95
Insurance claim
incident *versus*, I-83
against oral and maxillofacial surgeon, I-82–83
Insurance contract, I-89
Integrin, II-619–620, II-629
Intensity-modulated radiation therapy, II-590, II-747–748
Interdental distraction osteogenesis (IDO), I-547
Interferon alfa-2b, II-701
Interleukin-1 (IL-1), II-831f, II-832–833, II-884
Interleukins
in temporomandibular joint dysfunction, II-884
in temporomandibular joint internal derangement, II-906
Intermaxillary fixation screw, II-147, II-148f
Internal auditory canal, II-96
Internal derangement (TMJ), II-813f, II-889, II-893–894
arthrotomy procedures, II-910–918
condylotomy for, II-917–918
diagnostic imaging, II-906–907
discectomy, II-911
pathogenesis, II-905–906
patient history, II-904–905
physical examination, II-904–905
postoperative therapies, II-918–919
preoperative therapies, II-907
stages, II-904, II-905b
surgery, II-904–922
surgical approaches, II-908–910
Wilkes classification, II-905b
wound closure, II-910
Internal neurolysis, II-94
International Association for Dental Traumatology (IADT), II-120
Internet
medical information on, I-80
oral and maxillofacial surgery marketing, I-102
Interpersonal relationships, surgical practice and, I-17–22
Interpositional bone graft, I-527–528
Interview
employee, I-113
key points, I-114b
Intracranial hypertension, III-674–675
Intracranial pressure (ICP)
in brachycephaly, III-660
in craniosynostosis, III-645–646, III-675
monitoring, in pediatric brain injury, II-254
in pediatric brain injury, II-252
Intraocular pressure, retrobulbar hemorrhage and, II-207
Intraoral vertical ramus osteotomy (IVRO), III-62–95
case study, III-84b, III-86b
complications, III-90–92
history, III-64
indications, III-83
limitations, III-83
surgical sequence, III-83–90
Intraosseous catheter, I-247
Intraosseous defect, in anterior maxilla, I-448f
Intraosseous hemangioma, II-852–853
Intraosseous odontogenic carcinoma (IOC), II-431–435, II-431f
clinicopathologic considerations, II-435
from epithelial odontogenic tumor, II-435
from odontogenic cyst, II-433
from odontogenic residue, II-433
outcomes, II-435
Intravelar veloplasty, III-535–536, III-538, III-539f, III-612–615
Intravenous access, pediatric, I-247–248
Intravenous agents, pharmacokinetics, I-204t
Intravenous line, in oral and maxillofacial surgery, I-50
Intubation
for airway patency, I-213–214
for pediatric trauma, II-248
Invasion-metastasis cascade, II-619
ION. *See* Infraorbital nerve
Ipilimumab, II-701, II-703–704
Irinotecan, II-757t
Irradiated cancellous allograft (ICA), I-429–430
Isocarboxazid, I-149t
Isoflurane (Forane), I-207–208
Isotretinoin, II-733
Isotretinoin (Accutane), III-355
Itinerant surgery, I-10, I-12
IVRO. *See* Intraoral vertical ramus osteotomy (IVRO)
Ivy, Robert H., I-24, II-146, III-492
Ivy loop fixation, II-146

J

Jaffe-Lichtenstein syndrome, II-470
Jaw
benign non-odontogenic lesion, II-462–480
cysts of, II-340b
exercises for, II-969f
Langerhans cell histiocytosis, II-524
lesions, II-462–480
medication-related osteonecrosis, II-507–522
clinical presentation, II-511–512
pathophysiology, II-509–510
research, II-517
risk factors, II-510–511
staging, II-512–513
treatment, II-514–517, II-516t
non-odontogenic developmental cyst, II-371–375
odontogenic myxoma, II-439–444
osteonecrosis, II-952
osteosarcoma, II-647
sarcoma, II-643–669
snapping, II-766–767
Jaw fracture, third molar removal and, I-285
Jaw recorder, I-657f
Jaws, examination, in dentoalveolar injury, II-117
JCAH. *See* Joint Commission on Accreditation of Hospitals (JCAH)
Jessner's solution, III-443
Joe Hall Morris external fixator, II-317, II-318f
The Joint Commission, I-96–98, I-98t–100t
Joint Commission on Accreditation of Hospitals (JCAH), I-96–97
Joint Commission on the Accreditation of Healthcare Organizations (JCAHO), I-228
Joint mobilization, for temporomandibular joint disorders, II-875
Joint sounds, temporomandibular joint, II-808–809
Justice, principle of, I-10
Juvenile aggressive fibromatosis, III-745–748

Juvenile idiopathic arthritis (JIA), II-131, III-840–841
example, III-137f–141f
temporomandibular joint total replacement, III-239b–240b, III-242
Juvenile nasopharyngeal angiofibroma, III-751, III-754f
Juvenile ossifying fibroma, II-469–470, III-751, III-755f–756f

K

K-wire, mandibular fixation with, II-316, II-317f
Kasabach-Merritt coagulopathy, II-534
Kazanjian, V. H., III-1–2, III-5
KCOT. *See* Keratocystic odontogenic tumor (KCOT)
Keloid, formation of, after otoplastic surgery, III-456
Keratinocyte, II-719
Keratoacanthoma, II-719
Keratoconjunctival herpes, II-555
Keratocyst, odontogenic, II-346–361
Keratocystic odontogenic tumor (KCOT), II-348–361
clinical features, II-350–352
in nevoid basal cell carcinoma syndrome, II-364–365
pathology, II-352–354
surgical management, II-356–361
ultrastructure, II-354
Keratosis, laser surgery for, I-343
Ketamine, I-203–206
action, I-205–206
adverse effects, I-206
BIS monitoring and, I-172
clinical effects, I-206
contraindications, I-206
general anesthesia with, II-13
intravenous sedation with, I-220
metabolism, I-206
for nerve injury, I-318
for neuropathic pain, I-323
for pediatric patient, I-249–251, I-250t
pharmacokinetics, I-204t, I-206
propofol combined with, I-219t
side effects, I-206
structure, I-205–206
topical, I-320–321
Ketoprofen
dosage, I-232t
for temporomandibular joint disorders, II-871t
Ketorolac
dosage, I-232t
preoperative, I-231
Kidney, pediatric, I-241
Kidney disease
preoperative evaluation of, I-140
stages, III-283t
Kiesselbach's plexus, III-366, III-366f
Kinetic energy, gunshot wound and, II-303–305
King-Denborough syndrome, I-253
Kleeblattschädel anomaly, III-669
Klonopin. *See* Clonazepam (Klonopin)
Knight and North fracture classification, II-27t
Koebner phenomenon, I-345–346, II-558
Köle, Heinrich, III-246
Kostecka, F., III-1
Kreins, Otto, III-535
Kybella. *See* Deoxycholic acid

L

L-lysine, II-555
Lacrimal apparatus, II-221
Lambdoid suture craniosynostosis, III-659–660, III-664f
Langerhans cell, II-524–530
Langerhans cell disease, II-464
Langerhans cell histiocytosis (LCH), II-523–533, II-857
classification, II-524t, II-525–526, II-526t, II-526b
clinical varieties, II-523–524
clonality, II-526–527
diagnosis, II-527–530
example, II-525f
histopathology, II-527
prognosis, II-527–530
treatment, II-527–530
Lanz, Otto, II-766, II-769f
Laryngeal mask airway (LMA), I-213–214, I-245–247
description and use, I-214–215
in maxillofacial trauma, II-14, II-14, II-14
sizes, I-247f
Laryngoscope, II-14
Laryngospasm
airway obstruction caused by, I-215
in pediatric patient, I-251–252
treatment, I-252
Larynx
chemotherapy/radiation therapy for carcinoma of, II-754
radiation therapy for carcinoma of, II-742–744, II-745t
Laser
ablation techniques, III-347, III-352–355
absorption, I-327, I-329f, III-340f
alexandrite, III-346
for aphthous ulcer, II-560
argon, III-344
in arthroscopy, II-897
benefits, I-333
blepharoplasty, I-346, III-356
carbon dioxide (CO_2), III-336, III-344
action, I-328–329
for blepharoplasty, III-356
disadvantages, I-333–334
for gingivectomy, III-348
for gingivoplasty, III-352
hard tissue surgery, I-329–330
implant surgery, I-340
incisional and excisional techniques, III-346–347
peri-implantitis treated with, I-727
for skin resurfacing, I-344
wavelength, I-331
components, I-327–328, I-328f, III-337
contact, III-347–348
copper vapor, III-345
cosmetic surgery with, I-343–347, III-355–358
in craniofacial surgery, I-351
diode, I-328–329
crown lengthening with, I-349
for implant surgery, I-341
for scaling and root planing, I-350
wavelength, I-331–332
disadvantages, I-333–334
emission, I-327, I-328f
endodontic treatment with, I-350
endoscopic surgery, III-358–359
erbium, I-333
erbium:chromium:YSGG, I-328–329
erbium:yttrium-aluminum-garnet (Er:YAG), I-328–330, I-333, I-345, III-355
implant surgery, I-340
skin resurfacing, I-344–345
excimer, III-345–346
exposure time, III-340
facial resurfacing with, III-355–356
facial surgery with, I-343–347
Laser *(Continued)*
flashlamp-pumped pulsed dye (FLPPD), III-345
in general dentistry, I-349–350
gingival tissue removal, I-349
hair removal, I-349
hair transplant and removal, III-358
history, III-336
holmium:yttrium-aluminum-garnet, I-341–342, III-359
holmium:yttrium-aluminum-garnet (Hol:YAG), III-345
human tissue affected by, I-328–329
implant care, III-349–350
implant surgery, I-340–341
incisional and excisional techniques, III-346–347
intraoral procedures, III-348–352
KTP, III-345
lesions treated with, I-347–349, III-352–354
light generation, I-327–331
low-level therapy, I-338–340, III-359–360
for lymphatic malformation, II-540
in maxillofacial surgery, III-336–363
mechanical design, III-339–341
microscopic surgery, III-358–359
neodymium:yttrium-aluminum-garnet (Nd:YAG), III-336, III-344–345
description and use, I-332–333
pigmented lesion, I-348, III-357
vascular lesion, I-347–348
nominal hazard zone, III-343
in oral surgery, I-327–353
peri-implantitis treated with, I-350, III-727
photocoagulation techniques, III-346
physics, I-327–331, III-336–337
pigmented lesion treated with, III-357
power, III-337
power density, I-330
Q-switched ruby, I-345, III-348–349
risk associated with, III-341
safety, I-334–335, III-341–344
scar revision, I-346, III-357–358
skin cancer treated with, I-343, II-727–728
skin resurfacing, I-343–344, I-344f
complications, I-345–346
contraindications, I-345
soft tissue, I-335–338
spot size, III-338
surgical technique, I-330, III-337–339, III-346
systems, III-344–346
tattoo treated with, I-348–349
temporomandibular joint surgery, I-341–343
tissue interaction, I-329f, III-339
types, III-339
uvulopalatoplasty, III-351–352
vaporization techniques, III-347
vascular lesion treated with, I-347–348
wavelength, I-331–333
wound healing, I-340, III-348
Laser-assisted uvulopalatoplasty (LAUPP), III-268, III-351–352
Laskin, Daniel, II-771
Lateral crural steal, III-374
Lateral periodontal cyst, II-365, II-424
Lateral pterygoid muscle, II-783–785
Lateral still cephalometry, III-574–575
Latex gloves, anaphylaxis associated with, I-252t
Latex sensitivity, III-284
Latham appliance, III-498, III-516, III-561–562
Law of Primacy, I-46
Lawsuit
frequency of, I-85
resolution, I-84
risk management and, I-83–84

LCH. *See* Langerhans cell histiocytosis (LCH)
Le Fort fracture, II-28, II-213–220
  anatomy, II-214
  diagnosis, II-215–217
  illustration, II-31f
  malunion, II-226
  for midface fractures, II-211–212, II-212f
  radiography of, II-217
  treatment, II-217–220
  type I, II-28, II-32f, II-212f
    description, II-212, II-215
    illustration, II-215f
    treatment, II-217–218
  type II, II-28, II-33f, II-212f
    description, II-212, II-215
    illustration, II-215f
    treatment, II-218
  type III, II-28, II-212f
    description of, II-212, II-215
    illustration, II-216f
    treatment, II-218–220
Le Fort I osteotomy, I-54–55, I-153–171, III-458, III-569–570, III-3
  anesthesia, III-161–162
  for cleft deformity, III-492–493
  complications, III-169–170
  in computer-aided surgical simulation, III-35–36, III-37f
  diagnosis, III-153–161
  history, III-153
  indications, III-153
  lip-to-tooth relationship in, III-24
  for lymphatic malformation, II-540–542
  maxillary hypoplasia and, III-638–639
  maxillary segmentation, III-165–166
  in maxillomandibular advancement, III-271f
  multi-piece, III-54–55
  in oculoauriculovertebral spectrum, III-696
  operative technique, III-161–168
  patient positioning, III-161–162
  planning, III-153–161
  segmental, III-172–182
  single-piece, III-54
  three-piece, III-176f
  in Treacher Collins syndrome, III-731
  two-segment, III-28–29
  for vertical maxillary excess, III-156f–157f
Le Fort I segmental surgery, III-172–182
  complications, III-178
  indications, III-172–173
  postoperative care, III-177–178
  presurgical preparation, III-173–174
  surgical technique, III-175–177
Le Fort III fracture, II-18
Le Fort III osteotomy, III-678f, III-4
  mandibular
    complications, III-144–145
    endoscopically assisted, III-144–152
    history, III-113–114, III-144, III-1–2
    with maxillary, III-183–195
    surgical technique, III-144–147
  mandibular ramus, III-62–95
  mandibular subapical, III-2
  maxillary, III-163–164
    history, III-2–3
    with mandibular, III-183–195
    in multiple segments, III-3
    three-piece, III-176f
  maxillary distraction and, III-208–212
  midface, III-4
  for midface cleft reconstruction, III-601
  nasal, III-164–165, III-378–380
  in oculoauriculovertebral spectrum, III-696
  relapse after sagittal split, III-116b
  sagittal split, II-86, III-113–114, III-144, III-204, III-2, III-4
Le Fort III osteotomy *(Continued)*
    complications, III-298–319
    nerve injury associated with, III-301–308
  sagittal split ramus, III-62–95
  septal, III-164–165
  sinus augmentation, I-514
  sliding genioplasty, III-102
  subcranial, III-678f
  symphysis widening, III-200
  vertical ramus, III-62–95, III-144–145
  vertical subcondylar ramus, III-313–314
  vomerine, III-164–165
  zygomatic fracture malunion, II-204–205
  zygomatic implant, I-574, I-576
LEAD system, I-539–540
Leadership, in oral and maxillofacial surgical practice, I-108
Lease agreement, I-61
Legacy, I-139
Legal documents, I-59–61
Legal entity
  comparison of, I-59t
  oral and maxillofacial surgical practice as, I-58–59
Legan's angle, chin position analysis with, III-460t–461t
Leiomyosarcoma, II-644t, II-645–646, II-656–658
Lentigo maligna melanoma, II-692t, II-693f
Lesion, II-338–390. *See also* Cyst
  aneurysmal bone cyst, II-467–468
  benign non-odontogenic, II-462–480
  central giant cell granuloma, II-462–464
  cherubism, II-466
  desmoplastic fibroma, II-476–478
  fibro-osseous, II-468–471
  giant cell
    classification, II-463t
    hyperparathyroidism and, II-464–465
  giant cell granuloma, II-462–464
  granular cell, III-756–757
  intraoral vascular, III-354–355
  jaw, II-849
  juvenile ossifying fibroma, II-469–470
  Langerhans cell histiocytosis, II-523
  laser for ablation, III-347
  laser for excision, I-336f, I-338, I-339f
  laser treatment, I-336–338, I-348–349, III-352–354
  malignant, III-354
  margin, II-728
  mouth floor, II-379f
  mucosal, laser for, I-336
  multinucleated giant cell, II-462–468
  neurofibroma, II-472
  odontogenic, II-391–392
  oral and maxillofacial region, II-338–390
  osteoblastoma, II-473–474
  osteochondroma, II-476
  parotid gland, II-485
  pigmented, laser treatment, I-348–349, III-357
  salivary gland, II-482
  skin, herpetic infection and, II-552
  vascular, laser treatment, I-347–348, III-356–357
Letterer-Siwe disease, II-523
Leukoplakia, laser treatment, I-336–338, III-352–353
Levonordefrin
  local anesthetics and, I-178–179
  maximum dosage of, I-182t
  selectivity and potency of, I-180t
Levorphanol (Levo-Dromoran)
  dose and potency, I-229t–230t
  for temporomandibular joint disorders, II-872t
Li-Fraumeni syndrome, II-644
Liability insurance, I-82
Librium. *See* Chlordiazepoxide (Librium)
Lichen planus, I-336–338, II-352, III-558–559
Lidocaine, I-186
  chemistry of, I-177f
  concentration, I-177t
  contraindications, II-555–556
  duration, I-179t
  local anesthesia with, I-232–233
  for nerve injury, I-316
  nerve injury associated with, I-183t
  onset time, I-178t
  potency, I-176
  side effects, I-180–181
Ligament(s)
  articular disc, II-778–779
  capsular, II-799–800
  extracapsular, in temporomandibular joint, II-780
  orbital, III-402, III-404f
  periodontal. *See* Periodontal ligament
  sphenomandibular, II-780–781
  stylomandibular, II-780–781
  temporomandibular joint, II-780–781, II-799–800
Light
  absorption of, III-336–337
  exposure, melanoma associated with, II-690–691
  laser emission of, III-337, III-338f
Lighting, for oral and maxillofacial surgery, I-48
Limited liability company, I-58–59, I-59t
Limited partnership, I-58
Linear IgA disease, II-565–566
Linezolid, parotitis treated with, II-486–487
Lingual frenum
  prominent, I-271f
  surgery, I-271–272
Lingual nerve, II-75, II-147
  furcation, II-75t
  injury, I-81–87, I-317f, II-367
    bilateral sagittal split osteotomy and, I-379
    during exodontia, I-302
    local anesthetic associated with, I-377
    outcomes and conclusions, I-382–383
    sagittal split osteotomy associated with, III-305
    in sagittal split ramus osteotomy, III-80
    from third molar extraction, I-380–382
  neuroma, II-94f
  relationship of, to mandible, II-76t
  retraction, I-381
  surgical access, II-92f
Lioresal. *See* Baclofen (Lioresal)
Lip
  botulinum neurotoxin for, III-441
  cancer, II-735–737
  competency, III-97f
  deformity, genioplasty for, III-98
  in dentoalveolar injury evaluation, II-117
  filler, III-472b–473b
  implant, III-474b
  maxillary incisor relationship, III-24
  reconstruction, II-297–298
  trauma repair, II-276
  wound closure, II-54–57
Lip adhesion, in cleft repair, III-498–499
Lip length, smile line and, I-588–591
Lip-lift technique, I-699–701, I-702f
Lip support
  classification, I-585
  derivation, I-587
  for implant, I-584–588
  maxilla positioning and, I-592
Lip-to-tooth relationship, III-24

Lipid solubility, local anesthetic drugs and, I-177t, I-178
Lipoadenoma, II-500–503
Lipophilic aromatic ring, I-176
Liposarcoma, II-644t, II-645–646, II-661
Liposuction, III-429–438
  complications, III-433
  postoperative care, III-433
  preoperative evaluation, III-430–431
  technique, III-431–432
Lithium, management, I-149t
Lithotripsy, laser, III-359
Little's area, III-366
Liver
  benzodiazepine metabolism in, I-195
  metabolic reactions of drugs, I-196t
  pediatric, I-241
Liver failure, craniomaxillofacial trauma management and, II-3t
LLLT. *See* Low-level laser therapy
LMA. *See* Laryngeal mask airway (LMA)
Loading, immediate implant, I-605–623
  denture conversion to, I-608–614
  success, I-606–607
  surgical and prosthetic principles, I-607–608
Local anesthetics. *See* Anesthetic drugs, local
Locator attachment, I-652f, I-654, I-656–658
Lonidamine, II-756t
Lorazepam (Ativan), I-197
  half-life, I-195t
  protein binding, I-195t
  structure, I-196f
  for temporomandibular joint disorders, II-874t
Lorenz, Walter, III-6
Loss of consciousness, pediatric trauma assessment and, II-246–247
Low-level laser therapy (LLLT), I-338–340, III-359–360
Luhr, Hans, III-63, III-183
Luminal. *See* Phenobarbital (Luminal)
Lung, pediatric, I-240–241
Luxation
  in dentoalveolar injury, II-124f, II-127
  extrusive, II-127
  intrusive, II-127–128
  lateral, II-127
Lyme disease, II-846–847
Lymph node
  biopsy, for melanoma diagnosis, II-697–698
  divisions, II-670
  groups, II-676t
  lymphoma, II-707
  oral cancer staging and, II-676t
  oral cancer survival rates, II-685f
  radiation therapy, II-742
  skin cancer involvement in, II-723, II-726, II-730–732
Lymphadenopathy, Langerhans cell histiocytosis and, II-527
Lymphangioma, II-539
Lymphatic malformation, II-539–542
Lymphoepithelial cyst, II-485
Lymphoepithelioma, II-744–745
Lymphoma, II-707–716
  angiocentric, II-710–711
  Ann Arbor staging system, II-708–709, II-714b
  B-cell, II-707, II-710
  diagnosis, II-707–709
  parotid gland, II-500
  post-transplant, II-711
  radiation therapy, II-741
  radiographic evaluation, II-711–712
  staging, II-708, II-714b
  survival rate, II-714
  T-cell, II-707, II-710
  treatment, II-713–714
Lymphonodular pharyngitis, II-556–557
Lynch incision, II-184–185
Lyrica. *See* Pregabalin (Lyrica)

M

Macrophage, wound healing and, II-257
Mafenide acetate, II-67
Magnetic resonance imaging (MRI). *See also* Imaging
  cervical spine injury assessment with, II-11
  craniomaxillofacial pathologies, III-738–739
  facial nerve imaging, II-99–100
  facial pain, II-947
  nerve imaging, II-80–81
  odontogenic tumor, II-392
  oral cancer evaluation, II-675
  parotid gland tumor, II-493–494
  pediatric brain injury, II-251f
  process, II-822
  salivary gland, II-481–483
  sarcoma, II-645
  skin cancer, II-725
  temporomandibular joint, II-821–824, II-823f
  temporomandibular joint disorder, II-802–804, II-820–824
  temporomandibular joint internal derangement, II-906
  temporomandibular joint reconstruction, III-223–224
Malformation, definition, III-628t
Malignancy
  in cancer progression, II-600f
  laser treatment, III-354
  maxillofacial region, II-590
  pediatric, III-757–763
Malignant ameloblastoma, II-401, II-420–422
Malignant fibrous histiocytoma, II-644t, II-645–646, II-651–652
Malignant hyperthermia (MH)
  in pediatric patient, I-253
  treatment, I-253
Malignant mixed tumor, II-493t
Mallampati classification, I-213t, I-242–243, III-283, III-283t
Mallampati test, I-213
Malocclusion
  class II, I-319, I-322, III-637
  class III, III-596
    correction of, I-320, III-184
    in maxillary hypoplasia, III-638–639
  in mandibular fracture treatment, II-168
  midface fracture as cause of, II-216
  severe, miniplate for, I-313
  in Treacher Collins syndrome, III-703, III-706, III-724
Malpractice insurance, I-82
MALT lymphoma, II-708b, II-710, II-711f, II-713
Managed care
  contracting, I-62
  marketing and, I-132–133, I-107
Management
  principles, I-134
  surgical practice, I-18
Mandible
  advancement, III-110f, III-147
  ameloblastoma in, II-402, II-412f–414f
  anatomic regions, II-149f
  anatomy, II-147–152
  aneurysmal bone cyst, II-467
  arteriovenous malformation, II-88f, II-547f
  asymmetric, III-72b
  atrophy, II-166
  blood supply, II-147
  bone graft, I-666–668
Mandible *(Continued)*
  bone harvested from, I-453–455
  cherubism, II-466–467
  condylar head shapes, II-780f
  condyle, II-794
  counterclockwise rotation, III-116–119
  cysts in, II-340f
  deformity correction, with computer-aided surgical simulation, III-39
  distraction osteogenesis, III-147, III-776–778
  examination, in trauma patient, II-4–5
  extraoral surgery, III-189
  fracture. *See* Mandibular fracture
  free movement, II-786–787
  growth rate, III-629t, III-632–635
  high-energy gunshot wound, II-318–320
  hyperplasia, III-638
  hypoplasia, III-637–638
  impacted molar, I-265–266
  inconsistent centric relation, III-187–188
  innervation, II-147
  keratocystic odontogenic tumor, II-350
  Langerhans cell histiocytosis, II-524
  lateral shift, II-787
  lengthening, III-202–208
    clinical indications, III-202–204
    in oculoauriculovertebral spectrum, III-695
  lingual nerve relationship to, II-76t
  malformation, in Treacher Collins syndrome, III-707–731
  masticatory movement, II-787–788
  mobilization, III-3–4
  morphogenesis, III-476–477
  movement, II-786–787, II-807
  myeloma, II-89f
  non-Hodgkin lymphoma, II-712
  odontogenic fibroma, II-436f
  odontogenic myxoma, II-440f–443f
  osteoblastoma, II-473–474
  osteomyelitis, II-89f
  osteosarcoma, II-647
  overdentures, I-643–644
  pediatric ablative defect reconstruction, III-766
  posterior, as bone graft donor site, I-455–457
  prognathic, III-83, III-84b, III-86b
  protrusion, II-787
  range of motion, II-16, III-805–806
  reconstruction, II-296–297, II-298f
    rib graft for, III-766–767
    in Treacher Collins syndrome, III-724–730
  relapse of advancement, III-637
  resection guide, I-675f–677f
  retrognathia, III-115f
  retrognathic, case study, III-86b
  retrusion, II-787
  segmental resection, I-666, I-668
  surgical access, III-740
  three-dimensional image, I-690–692
  transverse deficiency, III-196, III-200f
  in Treacher Collins syndrome, III-706–731
  vertical defect, I-539f–544f
  widening, III-196–202
    genioplasty with, III-201
    postoperative care, III-202
    surgical planning, III-197–199
Mandibular deficiency, III-300, III-301t, III-637–638
  case study, III-65b, III-68b–71b
  chin hyperplasia, III-306f
  chin hypoplasia, III-309f
  inverted L osteotomy, III-113–143
  with long face, case study, III-70b–71b
  treatment planning, III-119–120
Mandibular fossa, II-778

Mandibular fracture, II-28–35, II-37f, II-146–173
  angle fracture, II-166, II-169f
  atrophic, II-166–167
  biomechanics, II-149–151
  bone healing, II-151
  classification, II-148–151
  comminuted, II-319f
  complications, II-168
  condyle fracture, II-165–166
  controversy, II-165–167
  in dentoalveolar injury, II-123t
  displacement, II-151
  exodontia associated with, I-307
  favorable, II-149, II-150f
  following third molar removal, I-295
  gunshot wound, II-315–316
  hardware materials, II-162–164
  history of treatment, II-146–147
  imaging, II-153
  infection associated with, II-168
  multiple, II-35f
  muscular forces on, II-149
  nerve injury associated with, II-84–85, II-168
  open reduction, II-135f
  pathogenesis, II-147
  pathologic, II-34–35, II-37f
  patient assessment, II-152–153
  pattern and incidence, II-34f, II-151
  pediatric, II-270, II-35–38, II-38f, II-167
  stabilization, II-1–2
  tooth removal associated with, II-165
  treatment, II-153–164
    closed technique, II-153
    endoscopic approach, II-161–162
    intraoral/transbuccal approach, II-155–158
    open techniques, II-155
    transcervical-retromandibular approach, II-160–161
    transcervical-submandibular approach, II-158–160
  unfavorable, II-149, II-150f
Mandibular nerve block, nerve injury associated with, II-950
Mandibular osteotomy, III-62–95, III-144–152
  complications, III-144–145
  history, III-113–114, III-1–2
  mandibular osteotomy combined with, III-183–195
  subapical, III-2
  surgical technique, III-144–147
Mandibular ramus, as bone graft donor site, I-455–457
Mandibular region, bones of, II-18–20
Mandibular retrognathia, III-115f, III-776
Mandibular ridge
  bilateral atrophic, I-527f
  deficient, I-669f–670f
  triangular, three-implant prosthesis for, I-648f
Mandibular space, airway assessment and, I-243
Mandibular surgery, III-297–324
  complications, III-297, III-316–319
  hemorrhage in, III-310–313
  infection, III-315–316
  nerve injury in, III-300–301
  relapse following, III-317–318
  risk factors, III-297–298
  temporomandibular joint dysfunction associated with, III-317
Mandibular symphysis, as bone graft donor site, I-453–455
Mandibulofacial dysostosis, III-703
Mannitol, intraocular pressure treated with, II-207
Mantle cell lymphoma, II-710, II-713
Marfan syndrome, II-259
Margin
  in surgical excision, II-729–730
  tumor, II-728
Marginal bone loss, smoking and, I-514
Marie-Strümpell disease, II-842
Marine algae, alloplastic implant with, I-440–441
Marketing, I-102–136
  academic, I-107
  blog, I-104–105
  communication, I-134–136
  consultation, I-125–126
  cosmetic surgery, I-130–132
  definition, I-107
  employee hiring and firing, I-110
  Facebook, I-105
  Flickr, I-105
  four P's of, I-107
  image, I-118
  internal, I-126–127, I-131
  logo, I-118
  managed care, I-132–133
  materials, I-122–123
  to media outlet, I-128–129
  newsletter, I-127–128
  oral and maxillofacial surgical practice, I-64
  out-of-town patients, I-106
  patient waiting time and, I-120–121
  payment plans, I-129–130
  plan, I-117–136
  procedure-specific, I-126
  professional consultation, I-110–111
  Realself, I-106
  social media for, I-103–106
  synergy, I-123
  target market, I-122
  website for, I-103
  YouTube, I-105
Marketing plan, I-117–136
Markowitz classification, II-30f, II-222f
Markowitz fracture, II-221–223
Marsupialization, for odontogenic keratocyst, II-357–361
Massad impression tray, I-656f
Massad jaw disposable recorder, I-657f
Massage, for temporomandibular joint disorders, II-876
Masseter muscle, II-781–782, II-785
Mast cell, in neurofibroma, II-472
Mastication, mandibular movement for, II-787–788
Masticatory muscle
  evaluation, II-810
  pain, II-962
Maxilla
  advancement, III-106f–107f, III-596–598, III-600
  ameloblastoma, II-402, II-415f–416f
  anatomy, III-161
  aneurysmal bone cyst, II-467
  anterior deficiency, three-dimensional imaging for, I-688–696
  anterior teeth, positioning of, I-592
  aseptic necrosis, III-178
  atrophic subtotal, I-545f–546f
  bone-borne template, I-699–704, I-704f
  bone quality, I-594
  capillary malformation, II-538
  cherubism, II-466–467
  chondrosarcoma, II-649
  cleft, III-497
    bilateral, III-589–592
    history, III-583–584
    management, III-583–595
    reconstruction, III-589–592
    stabilization, III-606–607
Maxilla *(Continued)*
    surgical options, III-583–584
    timing of grafting procedure, III-586–587
    unilateral, III-589
  cyst, II-340f, II-346f
  deformity correction, with computer-aided surgical simulation, III-38–39
  dentigerous cyst, II-355f
  distraction osteogenesis, III-208–214, III-778
  double jaw surgery repositioning, III-53–55
  down-fracture, III-165, III-175–177, III-176f
  edentulous
    arch form in, I-595–596
    case presentation, I-601–602
    cost of restoration, I-596–597
    fixed restoration, I-584–604
    historic perspective, I-569–570
    prosthetic conversion technique, I-577–578
    ridge form in, I-595–596
    surgical options, I-573
    treatment planning, I-592–597
    zygomatic implant for, I-569–583
  examination, in trauma patient, II-4–5, II-6f
  fracture, II-15, II-32f–33f
    comminuted, II-320f
    in dentoalveolar injury, II-123t
    exodontia associated with, I-307
    pediatric, II-35–38, II-243
  growth rate, III-629t, III-630–632
  high-energy gunshot wound, II-318–320
  horizontal position, III-24–27
  hypoplasia, III-638–642, III-639f, III-778
  impacted canine, I-261–262
  implant in, example of, I-463f
  intraosseous defect, I-448f
  Langerhans cell histiocytosis, II-524
  midface fracture effect on, II-216
  mobilization, III-3–4
  morphogenesis, III-476–477
  non-Hodgkin lymphoma, II-712
  osteosarcoma, II-647
  reconstruction, I-299f, II-283–300, III-724–730
  repositioning, III-17f–22f
  resection guide, I-675f–677f
  roll orientation, III-23–24
  segmental bone defect, I-549f–551f
  segmental surgery, III-172
    complications, III-178
    postoperative care, III-177–178
    preparation, III-173–174
    technique, III-175–177
  segmentation, III-172
    in Le Fort I osteotomy, III-165–166
    in orthognathic surgery, III-28–29
  subluxation, II-768b
  three-dimensional image, I-690–692
  transverse deficiency, III-199f
  Treacher Collins syndrome, III-706, III-724–730
  v-shaped, III-197f
  vascular supply, III-161, III-162f
  vertical defect, I-547f, III-642
  vertical distraction osteogenesis, I-532
  yaw orientation, III-23
  zones, I-570f
Maxillary arch
  reconstruction, II-285–286
  thermoregulation, I-691f
  three-dimensional image, I-690–692
Maxillary artery, I-510
Maxillary cant, correction, III-137f–141f
Maxillary crest, load bearing function, I-571
Maxillary hypoplasia, Le Fort I osteotomy for, III-153
Maxillary obturator appliance, III-550–551, III-553–554

Maxillary osteotomy, III-163–164, III-183–195
Maxillary region, bones of, II-18
Maxillary sinus, I-509–510
  ameloblastoma, II-415f–416f
  augmentation
    graft materials, I-510–513
    preoperative evaluation, I-513–514
    pretreatment, I-510–513
  blood supply, I-510, I-510f
  cone-beam computed tomography evaluation, I-514
  displacement into, I-299
  drainage, I-581f
  infection, I-579–581
  injury, during exodontia, I-301–302
  pseudocyst, I-510
  radiographic evaluation, I-514
  vascular supply, I-510
Maxillary tuberosity, as bone graft donor site, I-452–453
Maxillofacial region
  cancer, II-742
  cysts, II-338–390
  herpes simplex infection, II-551–552
  lymphoma, II-707, II-712
  malignancy, II-590
  pathology, nerve injury associated with, II-87
  trauma, pediatric, II-264–280
  in Treacher Collins syndrome, III-706
  vascular anomalies, II-534–549
Maxillomandibular advancement (MMA)
  for obstructive sleep apnea, III-269–274
  outcomes, III-272–274
  postoperative care, III-272
  risks and complications, III-272
Maxillomandibular complex, counterclockwise rotation, III-116, III-121f–123f
Maxillomandibular fixation (MMF), II-316
  for condylectomy, III-147
  in Le Fort I osteotomy, III-166–167
  for Le Fort I segmental surgery, III-177–178
  for mandibular osteotomy, III-145
  in maxillomandibular advancement, III-271
  for pediatric condylar fracture, II-270
  for pediatric patient, II-280, II-270
  Risdon wire, II-270
Maxillomandibular region, in Treacher Collins syndrome, III-706
Maxillomandibular relationship, assessment, I-688–689
Maximal stimulation test, II-103–104
Mayo stand, I-49
McCune-Albright syndrome, II-470, III-751, III-753, III-757f–760f
McGill Pain Inventory, I-90, II-313
McKinney's point, III-328–329
Mechanical stress, joint function and, II-830
Mechanism of injury
  craniomaxillofacial trauma, II-2
  facial nerve, II-100–103
  pediatric, II-245
  trauma patient assessment, II-10
  trigeminal nerve injury, II-81–87
Mechlorethamine, II-714
Meckel's cartilage, I-526
Meclofenamate, II-871t
Media, marketing to, I-128–129, II-869–873
Medial pterygoid muscle, II-783, II-785
Median mandibular cyst, II-375
Median palatal cyst, II-375
Medical conditions, trauma management and, II-3t
Medical education
  behavior in, I-6–9
  history, I-2
  professionalism in, I-4
  teaching professionalism in, I-7–8
Medical Group Management Association (MGMA), I-125
Medical history
  craniomaxillofacial trauma assessment and, II-2–4
  for facial pain evaluation, II-944–945
Medical leave of absence, I-145
Medicare, I-89–91
Medication
  adjunct, I-233–234
  for cancer treatment, II-626–627
  for dental procedure, I-152t
  non-opioid analgesic, I-232
  osteonecrosis of jaw and, II-507–522
  pediatric dosage, I-250t
  pediatric response, I-242
  pharmacology, I-191–210
  preoperative evaluation, I-139
  selection, for sedation, I-212
  temporomandibular joint disorder, II-869–873
  topical, for skin cancer, II-733–734
Medication-related osteonecrosis of the jaw (MRONJ), II-507–522, II-952
  clinical presentation, II-511–512
  established, therapy for, II-515–517
  pathophysiology, II-509–510
  research, II-517
  risk factors, II-510–511
  risk minimization, II-514
  staging, II-512–513
  treatment, II-514–517, II-516t
Mefenamic acid, for temporomandibular joint disorders, II-871t
Megakaryocyte proliferation, I-160t
Melanin, absorption spectrum, I-329f
Melanocyte, II-357, III-702
Melanoma, II-690–706
  classification, II-696t
  clinical staging groups, II-699t
  diagnosis, II-692–697
  epidemiology, II-690
  etiology, II-690–692
  histologic features, II-696t
  incidence, II-690–692
  laser surgery for, I-343
  M classification, II-699t–700t
  management, II-697–698
  microinvasive, II-695
  mucosal malignant, II-702–704
  N classification, II-699t–700t
  nodular, II-693f
  oral, II-691f–692f, II-702–704
  pathologic staging, II-700t
  pediatric, II-690
  risk factors, II-691, II-691b
  in situ, II-695
  staging system, II-693, II-698–700
  statistics, II-691b
  subtypes, II-692t
  T classification, II-699t–700t
  treatment, II-700–702
Melanosome, III-357
Melanotic neuroectodermal tumor of infancy, III-757
Meloxicam, II-871t
Membrane
  bacterial contamination, I-482
  barrier, I-462–463, I-475
    selection, I-480–483
    in sinus augmentation, I-513
    tent-pole technique, I-488f
  collagen, I-462–463, I-482, I-485f–487f
  non-resorbable, I-481–482
  placement, I-479
  polytetrafluoroethylene, I-462–464, I-464f, I-480–482
Membrane *(Continued)*
  requirements, I-480
  resorbable, I-462–463, I-479, I-482–483
  selection, I-480–483
  socket preservation and, I-493
  space maintenance and, I-479
  synthetic, I-482
Meningitis
  frontal sinus fracture associated with, II-243
  herpetic, II-555
Mental health, patient, preoperative evaluation, III-286
Mental nerve
  in genioplasty, III-101, III-102f
  injury, during exodontia, I-302
  surgical access, II-91–92
Mentocervical angle, III-99
Menton point
  facial symmetry and, III-96
  ideal, III-100f
Meperidine (Demerol), I-199–200
  anaphylaxis associated with, I-252t
  dose and potency, I-229t–230t
  equianalgesic dosage, I-231t
  neurotoxicity, I-228
  pharmacokinetics, I-230t
  structure, I-199f
  synthesis, I-197–198
  for temporomandibular joint disorders, II-872t
Mepivacaine, I-186
  concentration, I-177t
  duration, I-179t
  local anesthesia with, I-232–233
  nerve injury associated with, I-183t
  onset time, I-178t
Meprobamate (Miltown), II-874t
Merkel cell carcinoma, II-720, II-734–735
Merrifield Z-angle, chin position analysis with, III-460t–461t
Mesenchymal odontogenic tumor, II-435–455
Mesiodistal placement, implant, I-397
Mesoneurium, in nerve anatomy, II-77–78
Messenger ribonucleic acid (mRNA), II-603, II-604f, II-623
Metabolic arthritis, II-847–848
Metabolic equivalent (MET)
  of activities, III-281t
  preoperative evaluation and, I-139, I-151t
Metabolism, monitoring, I-169
Metastasis
  cancer progression, II-600f
  cancer therapy and, II-629
  description, II-619–621
  diagram, II-620f
  perineural invasion and, II-722
  skin cancer, II-726
Methadone (Dolophine)
  dose and potency, I-229t–230t
  pharmacokinetics, I-230t
  for temporomandibular joint disorders, II-872t
Methemoglobin, I-168
Methemoglobinemia, I-185
Methocarbamol (Robaxin), II-872t
Methohexital, I-201–203
  distribution, I-205f
  pharmacokinetics, I-204t
Methotrexate, II-562, II-713, II-756t–757t
Methoxazepam, I-196f
Methylnaltrexone, I-198f
Methylparaben, I-176–177, I-182
Methylprednisolone (Depo-Medrol), III-287t
  after nerve surgery, I-373
  for facial pain, II-955t, II-957
  in orthognathic surgery, III-289
  in temporomandibular joint arthrocentesis, II-887

Metopic suture craniosynostosis, III-657–659, III-661f–662f
Metronidazole
  medication-related osteonecrosis treated with, II-516
  peri-implantitis treated with, I-725–726
  postoperative infection treated with, I-303
MH. *See* Malignant hyperthermia (MH)
Michelet genioplasty, III-101
Michel's solution, II-332
Micro-computed tomography, I-443
Microcystic adnexal carcinoma, II-719
Microneurosurgery
  contraindications, II-92t
  indications, II-90–91, II-92t
  outcomes, II-96
  for trigeminal nerve injury, II-91–96
Microsatellite instability (MSI), II-608–609
Microsomia
  craniofacial, III-636f
  hemifacial, III-158f–160f, III-638f
Microvascular free flap, II-294–296
Midazolam, I-195–196
  clinical effects, I-194
  fentanyl combined with, I-218
  half-life, I-195t
  pediatric dosage, I-250t, I-251
  pediatric premedication with, I-248–249
  pharmacokinetics, I-204t
  protein binding, I-195t
  structure, I-196f
Middorsum palatal stop, III-572
Midface
  anatomy, II-211
  blood supply, II-214
  bones, II-18
  in craniosynostosis, III-676
  description, II-211
  distraction osteogenesis for advancement, III-778
  growth, in cleft palate repair, III-542–543
  high-energy gunshot wound, II-318–320
  hypoplasia, III-630–632
  innervation, II-214
  pediatric injury patterns, II-260
  reconstruction, II-297–300
  surgical access, III-740
  in two-stage palatal repair, III-548–549
Midface deficiency, III-596
  bone graft, III-602–605
  orthognathic surgery, III-619
  presurgical evaluation, III-596–597
  psychosocial considerations, III-597
  surgical reconstruction, III-597–600
  timing of surgery, III-597
Midface fracture, II-211–229
  classification, II-211–213, II-215
  complications, II-225–227
  diagnosis, II-212–213, II-215–217
  endoscopic repair, II-227
  imaging, II-213
  Le Fort classification, II-213–220
  malunion, II-225–226
  pediatric, II-270
  treatment, II-217–220
Midline, facial, in orthognathic surgery, III-23
Migraine headache, facial pain and, II-944–945
Milk, avulsed tooth stored in, II-130
Millard, Ralph, III-492
Millard technique
  anatomical landmarks, III-516f
  cleft lip repair with, III-513–516
  markings and measurements, III-517f
  surgical procedures, III-516–519
  Tennison technique compared to, III-521–523, III-525
Miltown. *See* Meprobamate (Miltown)
Miniplate, I-313–314
  as anchor, I-313, I-311
  case presentation, I-318, I-319f
  clinical applications, I-316–318
  complications, I-323
  materials, I-320–323
  maxillary, placement of, I-322f
  open bite treated with, I-316–318, I-313
  placement, I-320–321
  screw fixation, I-313
  surgical placement, I-318
  surgical technique, I-320–323
Miniscrew implant (MSI), I-314–316, I-311
  adjunctive care, I-322
  as anchor, I-313
  bone considerations, I-315–316
  case presentations, I-318–319
  for class II malocclusion, I-322f
  complications, I-323
  design, I-315
  drill *versus* self-drill, I-316
  example of, I-315f
  for impacted second molar, I- 321f
  orthodontic loading, I-316
  placement angle, I-316, I-323
  placement technique, I-321–322
  self-drilling, I-321
  success rate, I-314
  torque, I-315
Minocycline HCL
  peri-implant disease treated with, I-725f
  peri-implantitis treated with, I-725–726
Mirror image routine, III-39, III-39f
Mitochondria, cancer diagnosis and, II-622–623
Mixed connective tissue disease, II-848
Mixed odontogenic tumor, II-444–455
Model, presurgical, III-44
Model for End Stage Liver Disease (MELD), I-141, I-156f
Modifiers, in coding, I-93–94
Mohs micrographic surgery, II-719–720, II-728–729, II-729b
  surgical excision *versus*, II-730
  surgical margin in, II-730
Molar
  displacement of, into submandibular space, I-300–301
  immediate implant for, I-418–420
  impacted, I-265–266, I-267f
  mandibular
    extraction, I-277–278
    sectioning and removal, I-281, I-282f
  maxillary
    extraction, I-277, I-279f
    sectioning and removal, I-281, I-283f
  second, impacted, I-319, I-321
  third
    caries, I-284
    cyst, II-343, II-345f
    displacement into infratemporal fossa, I-299–300
    dry socket after removal of, I-303
    eruption potential, I-286
    extraction complications, I-77
    impacted, I-80f, II-286–288
    incision for, I-287
    indications for removal, I-283–284
    infection following extraction, I-293
    injury from removal of, II-82
    nerve damage following extraction, I-294, I-380–382
    nerve damage treatment, I-382
    in orthognathic surgery, III-279
    pain following extraction, I-225
    postsurgical periodontal healing, I-295
Molar *(Continued)*
    sectioning for removal, I-287–288
    surgical extraction complications, I-293–295
    surgical technique for removal, I-286–288
    trigeminal nerve injury and, I-354
  transplantation, I-268
Molecular biology, II-336
  of cancer, II-599–642
  cancer treatment and, II-622–629
Monitored anesthesia care (MAC), I-213
Monitoring
  anesthesia, I-164
  blood pressure, I-165–166
  body temperature, I-170
  circulation, I-169
  history and evolution, I-165–173
  metabolism, I-169
  neuromuscular, I-170–171
  patient, I-164–175
  recovery, I-172–173
  respiration, I-169–170
  respiratory system, I-167–169
  sedation depth, I-171–172
Monoamine oxidase inhibitor drugs
  management, I-149t
  for temporomandibular joint disorders, II-872–873
Monroe-Kellie doctrine, II-252
Moose, Sanford, III-64, III-2
Morphine
  anaphylaxis associated with, I-252t
  discovery, I-197
  dose and potency, I-229t–230t
  equianalgesic dosage, I-231t
  for facial pain, II-953, II-954t
  pharmacokinetics, I-230t
  structure, I-198f
  for temporomandibular joint disorders, II-872t
Morris, Joe Hall, I-24
Morris, John, II-767–768
Motion, passive, in temporomandibular joint, II-833–835
Motor vehicle accident (MVA), II-10
  dentoalveolar injury from, II-114
  injury from, II-41–42
  pediatric injury and death from, II-245
Motrin. *See* Ibuprofen (Advil, Motrin)
Mouth floor
  anatomy, II-671
  cancer, II-679–680
  cyst, II-380f
  in dentoalveolar injury evaluation, II-117
  lesion, II-379f
Mouth rinse, steroid, II-551
Mouthguard, II-271
  dentoalveolar injury prevention, II-141
  types, II-141
Mouthwash
  oral hygiene and, II-551
  steroid, II-551
MRONJ. *See* Medication-related osteonecrosis of the jaw (MRONJ)
MSI. *See* Miniscrew implant (MSI)
Mucocele
  frontal sinus fracture as cause of, II-243
  laser for removal, I-337f, III-349
  salivary gland, II-483
Mucoepidermoid carcinoma, II-492–493, II-493t, II-498, II-500–501, II-504t, II-759–760
Mucoperiosteal flap
  for impacted maxillary canine, I-290f
  for impacted third molar, I-287f
  in surgical extraction, I-280

Mucosa
augmentation, I-558f
example, I-559f
keratinized, I-562f
with vestibular incision tunnel access, I-563
buccal, II-670
cancer, II-680–681
in dentoalveolar injury evaluation, II-117, II-123t
herpetic infection involvement, II-552–553
injury treatment, II-137
keratinized, I-555–557, I-559f
peri-implant, I-555–556
urinary bladder, for disc repair, II-915
Mucositis
oral, II-760–761
peri-implant, I-723
phases, II-761f
prevention, I-724–725
treatment, II-760–761
Mucous membrane pemphigoid, II-562–564
Mucous plug, in parotid gland, II-490
Mudd, Harvey, III-1
Muenke syndrome, III-668
Multiple myeloma, II-857
Mumps, II-487–488
Murphy, John, II-764–766, II-767t
Muscle relaxant drugs, I-234
for facial pain, II-956
for temporomandibular joint disorders, II-871–872, II-872t
Muscle(s)
digastric, II-784–785
exercises, for temporomandibular joint disorders, II-969
eye, II-204t
forehead, III-397f
geniohyoid, II-784
labiomental, III-97f
lateral pterygoid, II-783–785
mandibular, II-147, II-149
masseter, II-781–782, II-785
masticatory, II-794
evaluation, II-810
pain, II-962
medial pterygoid, II-783, II-785
mylohyoid, II-784–785
nasal, II-174–175, III-364, III-365f
ocular, midface fracture and, II-226
orbicularis, III-388–389, III-390f, III-398
pterygoid, II-783–784, II-795f, II-810
in secondary palate, III-612–615
soft palate, III-535–536
spasm, II-962, II-966b
temporalis, II-399, II-782–783, III-785
temporomandibular joint, II-781–784
actions, II-786b
disorders, II-962–972
evaluation, II-810
tenderness, II-963–964
velopharyngeal, III-614t
zygomatic, II-189
Musculoskeletal system, preoperative evaluation, III-285–286
Mustardé method, for otoplastic surgery, III-453, III-454f
Myalgia
central, II-967b
masticatory, II-962–963
clinical presentation, II-963–964
diagnosis, II-964–966
management, II-967b
pharmacotherapy, II-968–969
self-care program, II-968b
treatment, II-966–971
Mycoplasma pneumoniae, erythema multiforme associated with, II-568
Myelin, in nerve anatomy, II-77
Myeloma, multiple, II-857
Mylohyoid muscle, II-784–785
Myocardial infarction (MI), oral surgery following, I-139
Myofascial pain, II-962
clinical presentation, II-963–964
diagnostic tests, II-964–966
etiology, II-963
pathophysiology, II-963
pharmacotherapy, II-955–956, II-968–969
splint therapy for, II-868
treatment, II-966–971
trigger points, II-965f
Myofibroblast, II-600, II-620–621
Myositis, II-962, II-966b
Myospasm, II-794
Myxoma
odontogenic, II-439–444, III-745
differential diagnosis, II-441–444
management, II-444
soap bubble, III-746f

N

Naburnetone, II-871t
Nager syndrome, III-690, III-705, III-776
Nalbuphine (Nubain), I-229t–230t
Naloxone, I-198f, I-200
Naltrexone, I-198f
Nanomedicine, peri-implantitis treated with, I-728
Naprosyn. *See* Naproxen (Naprosyn, Aleve)
Naproxen (Naprosyn, Aleve)
dosage, I-232t
for facial pain, II-954–955, II-955t
for temporomandibular joint disorders, II-871t
Nasal air emission, III-571
Nasal complex
anatomy, II-174–177
blood supply, II-176–177
bony framework, II-175
fracture, II-174
hard tissue, II-175–176
innervation, II-177
lymphoma, II-712
pathogenesis, II-174–177
pediatric, II-186
Nasal deformity, revision surgery, III-620–622
Nasal dorsum, II-225
Nasal emission test, III-573
Nasal fracture, II-24–27, II-27f, II-174–188
algorithm for, II-181f
causes, II-174
classification of, II-178, II-179t
classification system, II-28t
closed reduction, II-180–182
complications, II-187
diagnosis and evaluation, II-177–178
dislocation with, II-176f
management, II-179–186
Markowitz classification, II-30f
nasal hump associated with, II-176f
open reduction, II-182–186
pediatric, II-269–270, II-35–38, II-186–187
treatment, II-178–186
Nasal region
bones of, II-18
fracture, II-24–27, II-27f
Nasal resonance, III-570
Nasal septum, II-175–176
blood supply, II-176, III-366f
composition, II-175
description, III-367
Nasal septum *(Continued)*
deviation, II-177–178
hematoma, II-187
open reduction, II-182–183
reduction of, in naso-orbito-ethmoid fracture, II-224–225
Nasal tip
control, in rhinoplasty, III-372–373
projection, III-373–375
rotation, III-375–376
shape, III-376–377
Nasal trumpet, I-54–55, I-56f
Nasal valve, II-175, III-370–371, III-371f
Nasalance, III-578
Nasendoscopy, for velopharyngeal function assessment, III-575–576
Naso-orbito-ethmoid (NOE) complex
anatomy, II-221
fracture, II-24–27, II-27f, II-29f–30f, II-30t, II-213, II-220–225
classification, II-221–222
diagnosis, II-222–223
exposure, II-223–224
in Le Fort type III fracture, II-218–219
pediatric, II-35–38
treatment, II-223
gunshot wound injury, II-323
injury to, II-5f
Markowitz classification of fracture, II-30f, II-222f, II-223
nasal fracture and, II-177–178
Nasoalveolar molding (NAM), III-562–565
Nasofacial angle, III-99
Nasofrontal duct (NFD), II-233, II-230–231
endoscopy of, II-240
in frontal sinus fracture, II-236–238, II-236
image of injury to, II-235f
Nasofrontal suture line, III-397
Nasolabial cyst, II-371–372, II-374f
Nasolabial fold, botulinum neurotoxin for, III-441
Nasolacrimal apparatus, II-221
Nasolacrimal duct, III-161f
Nasomaxillary buttress, II-211
Nasomental angle, III-99
Nasometry, III-541, III-578
Nasopalatine duct cyst, II-372–375, II-376f–378f
Nasopharyngoscopy, III-615
Nasopharynx
radiation therapy for carcinoma of, II-744–745, II-746t
surgical access, III-741
Natural head position (NHP), III-15
Nausea
anesthetic recovery and, I-222
in orthognathic surgery, III-288–289
in pediatric patient, I-253
postoperative, III-314
Neck. *See also* Head and neck
botulinum neurotoxin for, III-441
dissection, II-683
examination, for gunshot wound patient, II-311
lymphoma, II-709f
non-odontogenic developmental cyst, II-376–385
penetrating injury, II-60
range of motion, orthognathic surgery evaluation and, III-16–17
sarcoma, II-643, II-644t
zones of, II-310, II-310f
Needle breakage, local anesthetic injection and, I-184
Needleless injection, I-187
Needle(s), for wound closure, II-50t

Neoplasm
malignant, temporomandibular joint affected by, II-856–857
salivary gland, II-482, II-492, II-493t
Neovascularization, tumor, II-617–619, II-628
Nepotism, I-112
Nerve block
chemical, I-365
mandibular, nerve injury associated with, II-950
trigeminal, I-361–362
Nerve conduction, I-176
Nerve excitability test (NET), II-103–104
Nerve fiber
peripheral, neurophysiology, II-942–943
types of, local anesthesia and, I-179t
Nerve injury
acute, repair, I-375–376, I-379
agents for, I-363
axonal and cellular response, II-72–73
chronic, I-363–365
classification, I-355–356, II-72t, II-311
clinical measurement, I-357–362
clinical terms, I-355t
complex regional pain syndrome, I-361
computed tomography for, II-78–80
decompression, I-368–369
from dental procedure, II-949–950
diagnosis, I-357–362
endodontic, I-377–378
entubulation, I-371–372
during exodontia, I-302–303
facial, diagnosis and management, II-70–113
graft for, I-95, I-369–371
impacted tooth extraction and, I-294
implant, I-379–380
implant surgery as cause of, II-82–84, II-83f
internal neurolysis, I-372–373
in intraoral vertical ramus osteotomy, III-91
in inverted L osteotomy, III-124
local anesthetics associated with, I-183t, I-376–377
magnetic resonance imaging of, II-81
maxillofacial pathology as cause of, II-87
maxillofacial trauma, I-374–376
nerve redirection, I-373–374
neurectomy, I-373
neurosensory testing for, I-358f, I-358–360
nonsurgical treatment, I-362–365
orthognathic, I-86, II-378–379
in orthognathic surgery, III-316
outcomes and conclusions, I-382–383
pediatric, II-272
persistent postsurgical pain, I-374
post-traumatic, I-375
postsurgical management, I-373–374
recovery, I-360t, I-382–383
response to, I-356–357
in rhytidectomy, III-333–334
in sagittal split ramus osteotomy, III-79–80
secondary repair, I-376, I-379
Seddon-Sunderland classification, I-355–356, I-356t
surgical management, I-365–374, I-367, I-373–374
surgical repair cascade, I-368f, I-368
testing, II-87–90
third molar extraction, I-380–382
trigeminal. *See* Trigeminal nerve injury
vertical ramus osteotomy, III-314
wrapping for, I-371
Nerve Injury Recovery Scale (NIRS), I-360t
Nerve(s)
allogenic graft, I-371
alveolar, I-368–369
injury to, I-294
Nerve(s) *(Continued)*
neuroma, I-371f
pediatric, I-259f
auricular, III-400–402, III-448
blood supply, II-78
buccal, II-75–76
computed tomography of, II-78–80
cranial
magnetic resonance imaging of, II-80–81
pain transmission and, I-226
ear, III-448, III-449f
facial, III-400, III-401f–402f
anatomy, II-96–99
clinical evaluation, II-103–104
extratemporal injury, II-104–106
extratemporal segment, II-98–99
iatrogenic injury, II-102–103
imaging, II-99–100
infection, II-102
injury mechanism, II-100–103
injury treatment, II-104–106
intracranial segment, II-96–97
laceration, II-13–14
local anesthesia and paralysis, I-184
mandibular fracture, II-168
microanatomy, II-77–78, II-99
parotidectomy, II-495–496
rhytidectomy evaluation, III-328
surgical intervention outcomes, II-106
traumatic injury, II-101–102
fibrosis, I-369
forehead, III-397f, III-399–402
graft, I-95, II-369–371
allogenic, II-95–96
for facial nerve injury, II-104–105
hypoglossal, III-269
inferior alveolar, II-74–75
injury, II-300, III-81
in mandibular fracture, II-168
surgical access, II-91–92
infraorbital, I-76, II-367–368
lingual, I-367, II-76t, II-367
injury, II-81
surgical access, II-91–92
magnetic resonance imaging of, II-80–81
mandibular, II-147
mental, II-74–75
in genioplasty, III-101, III-102f
surgical access, II-91–92
microanatomy, II-77–78
nasal, II-177, III-367, III-368f
pain transmission, I-225
schematic representation, II-77f
spinal, pain transmission and, I-226
supraorbital, III-399–400
supratrochlear, III-400
trigeminal. *See* Trigeminal nerve
ultrasonography, II-81
vascular supply, II-78f
wrapping, I-371
Nervous system
opioid drugs effect, I-200f
pediatric, I-239
preoperative evaluation of, I-161, III-284
Neuralgia
definition, II-946t
hyperesthetic, I-361
hypoesthetic, I-361
Neuralgia-inducing cavitational osteonecrosis (NICO), II-948
Neurectomy, I-373
Neurilemmoma, II-472
Neuroanatomy, pain and, I-225–226
Neurocranium, III-629–630
Neurofibroma, II-472, II-474f, III-755
Neurofibromatosis, II-472, II-474f, III-753–756
Neurofibromatosis type I, II-644, II-660–661
Neurogenic sarcoma, II-660–661
Neurologic injury, pediatric, II-250–252
Neurolysis
external, II-93–94
internal, I-94, II-372–373
Neuroma
alveolar nerve, I-371f
example, II-73f
excision and restoration, II-94–95
lateral exophytic, II-73f
lingual nerve, II-94f
removal, II-94f
resection, I-369
trigeminal, I-370f
types of, II-73
Neuromuscular blockade, I-170–171
Neuromuscular system, monitoring, I-170–171
Neuron
trigeminal nerve, II-941–942
types of, local anesthesia and, I-179t
Neuropathic pain, definition, II-946t
Neuropathy
definition, II-946t
orthognathic, I-378–379
post-traumatic, I-375
Neuropraxia
cause of, II-70–71
description of, III-316
exodontia associated with, I-303
Neurorrhaphy
direct, II-94f
for facial nerve injury, II-104–105
for orthognathic trigeminal nerve injury, I-379
for trigeminal nerve, I-369
Neurosensory disturbance (NSD), III-316
Neurosensory testing, I-358–360, I-358f, II-315
algorithm for, II-92f
levels of, II-90
recording of, I-360
Neurotin. *See* Gabapentin (Neurotin)
Neurotmesis
description of, II-71–72, III-316
exodontia associated with, I-303
Neurotoxicity, chemical, I-376
Neurotoxin, in forehead and brow lift, III-421
Neurovascular bundle
injury, implant surgery as cause of, II-82
local anesthetics and injury to, I-183–184
Neutral head posture (NHP), III-33–34
Nevoid basal cell carcinoma syndrome, II-361–365, II-644
clinical features, II-350, II-364–365
pathologic features, II-352–354
Nevus flammeus neonatorum, II-538
Newborn
craniosynostosis algorithm of care, III-671–675
Treacher Collins syndrome, III-730
Newsletter, marketing with, I-127–128
Nexavar. *See* Sorafenib (Nexavar)
NFD. *See* Nasofrontal duct (NFD)
NHP. *See* Natural head position (NHP); Neutral head posture (NHP)
Nicotine
bone metabolism affected by, I-433
effects, I-215
as mandibular surgery risk factor, III-297–298
wound healing affected by, I-451
Nicotinic stomatitis, laser treatment, III-352
Nikolsky sign, II-563, II-565
Nitrate (NO_3), II-831
Nitric oxide (NO), II-832f, II-905–906
Nitric oxide synthase (NOS), II-831, II-833f
Nitrite (NO_2), II-831

Nitrous oxide (NO)
adverse effects, I-208
chondrocyte synthesis of, II-831
clinical effects, I-207–208
discovery, I-206–207
as inhalation agent, I-220
inhalation induction of, I-220
for pediatric patient, I-250
Node of Ranvier, II-77
Nodular melanoma, II-692t
Nominal hazard zone, III-343
Non-Hodgkin lymphoma, II-707, II-710
B-cell, II-710
clinical staging, II-708b
radiation therapy for, II-741
survival rate, II-714
T-cell, II-710
treatment, II-713–714
Non-malfeasance, principle of, I-9
Non-melanoma skin cancer (NMSC), II-717–740
clinical examination, II-722–725
epidemiology, II-718–721
epidemiology and etiology, II-717–718
imaging, II-725
incidence, II-717
lymph node involvement, II-730–732
medical management, II-732–735
metastasis, II-723
pathology, II-718–721
photodynamic therapy, II-734
recurrence, II-732–733
repair of wound, II-731–732
risk factors, II-717
screening, II-722–725
staging, II-725–727
surgical excision for, II-729–730
treatment, II-727–730
Non-odontogenic cyst, II-371–385
Noncompliance, risk management and, I-79–80
Noninvoluting congenital hemangioma (NICH), II-536–538, II-537f
Nonlipid reticuloendotheliosis, II-523
Nonossifying fibroma, II-854
Nonsteroidal antiinflammatory drugs (NSAID)
analgesia with, I-228–230
contraindications, I-230–231, I-233b
for facial pain, II-954–955, II-955t
peptic ulcer disease associated with, I-140
for reactive arthritis, II-562
rhytidectomy complications associated with, III-332
for skin cancer, II-733–734
for temporomandibular joint disorders, II-870, II-871t, II-968–969
Norepinephrine
local anesthetics and, I-178–179
selectivity and potency of, I-180t
Norpramin. *See* Desipramine (Norpramin)
Nortriptyline (Pamelor, Aventyl)
for fibromyalgia, II-970
for temporomandibular joint disorders, II-873t
Nose
anatomy, II-174–177, III-364–367
blood supply, II-176–177, III-364, III-366f
cartilage, II-175
cosmetic surgery, III-364
dissection, in functional cleft lip repair, III-529
examination, in trauma patient, II-4
facial esthetics and, III-16
floor, in orthognathic surgery, III-28
fracture of. *See* Nasal fracture
function, III-370–371
herpes simplex infection and, II-552
Nose *(Continued)*
innervation, II-177
morphogenesis, III-476
muscles, III-364, III-365f
nerve supply, III-367, III-368f
pathogenesis, II-174–177
pediatric, II-186
reconstruction, II-292f, II-297, II-299f, III-286
reshaping, in cleft lip repair, III-518–519
skin thickness, III-370
superficial musculoaponeurotic system, II-174–175
surface landmarks, III-384b
tip. *See* Nasal tip
trauma repair, pediatric, II-277–278
in Treacher Collins syndrome, III-731–733
wound closure, II-52–54, II-55f–56f
Nostril pinch test, III-573
Novocaine. *See* Procaine (Novocaine)
NST. *See* Neurosensory testing
Nubain. *See* Nalbuphine (Nubain)
Nuclear factor-kappa B, II-673
Nucleic acid
alterations, II-609
dysregulation, II-606–609
Nucleosome, II-605f
Nucleotide, mutations, II-610f
Nucleotide sequence abnormality, II-607–609, II-610f
Nurse, anesthesia. *See* Anesthesia nurse

O

OAVS. *See* Oculoauriculovertebral spectrum (OAVS)
Obesity
airway patency and, I-214
obstructive sleep apnea associated with, III-286
orthognathic surgery and, III-286
pediatric, II-259–260
wound healing affected by, II-259–260
Objectives Based Practice Transitions (OBT), I-42
Observer's Assessment of Alertness and Sedation Scale, I-217–218
Obstructive sleep apnea (OSA), I-185, III-214
accelerated osteogenic orthodontic procedure for, III-259b–260b
after pharyngeal flap procedure, III-618
in craniosynostosis, III-675
laser-assisted uvulopalatoplasty, III-351
nonsurgical treatment, III-267–268
orthognathic surgery, III-264–278
pathophysiology, III-264
patient evaluation, III-264–266, III-281
prevalence, III-264
surgical treatment, III-268
in Treacher Collins syndrome, III-730
treatment, III-266–274
Obturator appliance, III-550–551, III-553–554, III-579
Obwegeser, Hugo L., III-62, III-113, III-153, III-183, III-2–4
Occlusal plane
alteration, III-226–227
surgical decrease, III-227
Occlusal splint, II-865–869, II-867b
Occlusion
after orthognathic surgery, III-290–291
in computer-aided surgical simulation, III-35–36
final, for model surgery, III-49–50
implant overdentures, I-655
temporomandibular joint disorder management and, II-873–875
Occlusion *(Continued)*
in temporomandibular joint disorders, II-767–769
temporomandibular joint prosthetic reconstruction, III-226–227
temporomandibular joint replacement and, II-931–933
Ocular injury, zygomatic fracture associated with, II-191
Oculoauriculovertebral spectrum (OAVS), III-687–702
airway management, III-692
classification, III-690–691
cleft lip and palate, III-692
distraction osteogenesis, III-695
dysmorphology, III-687–690
ear reconstruction, III-695–696
mandibular lengthening, III-695
orthognathic surgery, III-696
pathogenesis, III-687–690
staged reconstruction, III-691–692
velopharyngeal insufficiency, III-692
Odontoameloblastoma, II-446–449
Odontogenesis
pediatric, I-258
process, II-338–339
Odontogenic cyst, II-338–343, II-347f, II-365–371
intraosseous carcinoma from, II-433
site of, II-340f
Odontogenic fibroma, II-435–438
differential diagnosis, II-437
management, II-438
Odontogenic keratocyst, II-345–361
pathology, II-356–361
surgical management, II-356–361
Odontogenic myxoma, II-439–444, III-745
differential diagnosis, II-441–444
management, II-444
Odontogenic residue, intraosseous carcinoma from, II-433
Odontogenic tumor, II-391–461, III-741–745
adenomatoid, II-394–397
biopsy, II-393
calcifying epithelial, II-398–401
classification, II-391–392
clinical considerations, II-392
definition, II-391
epithelial, II-394–435
imaging, II-392–393
mixed, II-444–455
squamous, II-397–398
surgical management, II-393–394
Odontoma, II-444–446, II-447f–448f, III-745
compound, I-269f
pediatric, I-268
Older patient. *See* Elderly patient
Oliver, Col. Robert T., I-24
OMENS classification system for oculoauriculovertebral spectrum, III-691b
OMS. *See* Oral and maxillofacial surgeon (OMS); Oral and maxillofacial surgery (OMS)
Oncocytoma, II-493t
Oncogene, II-602, II-612
apoptosis suppression and, II-627–628
in head and neck cancer, II-753f
Oncology
molecular biology, II-622–629
molecular diagnostics, II-622–624
molecular therapeutics, II-624–629
principles, in head and neck cancer management, II-752–763

Ondansetron, I-253, III-288
Open bite
anterior, III-172–173
case presentation, I-318, I-319f
intraoral vertical ramus osteotomy for, III-86b
miniplate anchor for, I-316–318, I-313
skeletal anterior, miniplate anchor for, I-316–318
in temporomandibular joint disorder, II-873–874
Open-book incision, I-478f
Open reduction and internal fixation (ORIF), II-147, II-166
Open reduction and semi-rigid fixation, II-166
Operating chair, I-46–47
Operative notes, risk management and, I-78
Operculectomy, laser, III-348–349
Ophthalmologic assessment, for gunshot wound, II-311
Opioid drugs, I-197–200
action, I-198, I-200f
addiction associated with, I-228
adverse effects, I-228b
analgesia, I-226–228
anaphylaxis associated with, I-252t
clinical effects, I-198–200
commonly prescribed, I-227–228, I-229t–230t
discovery, I-197–198
effects, I-226
equianalgesic dosage, I-231t
for facial pain, II-953–954, II-954t
for neuropathic pain, I-364
receptors, I-198
side effects, I-201b, I-226, I-228b
structure, I-198
for temporomandibular joint disorders, II-871, II-872t
Oral and maxillofacial surgeon (OMS)
academic career, I-33–35
addiction and, I-144
in associateship, I-41, I-64–65
boundary violations, I-143–147
compensation plan, I-70–71, I-71t
in Department of Veterans Affairs, I-31–33
in DMSO, I-41
as educator, I-15
employment agreement for, I-60b
exit planning, I-43–45
as expert witness, I-10
impairment of, I-143–147, I-145–147
insurance claims against, I-82–83
as leader, I-109, I-108
as managing partner, I-64
orthodontic concepts for, I-311–312
in partnership, I-16, I-40
pathologist interaction with, II-329–330
patient relationship, I-20–21
peer relationships, I-21
practice entrance planning, I-39–42
practice transition, I-39–45
role, I-51–52
in solo practice, I-16, I-40
substance abuse by, I-144–145
surgeon-scientist, I-35–37
in U. S. Air Force, I-29–30
in U. S. Army, I-24–26
in U. S. Navy, I-26–29
in U. S. Public Health Service, I-30–31
Oral and maxillofacial surgery (OMS)
academic careers, I-33–35
for accelerated orthodontic movement, III-246–263
for ameloblastoma, II-422
boundaries, I-143
code sets, I-89–90
Oral and maxillofacial surgery (OMS) *(Continued)*
complications, I-298–310
cosmetic, facial implant in, III-458–475
craniofacial, III-670–671
craniomaxillofacial, III-627–644
cyst, II-338–390
dentoalveolar, complications, I-298–310
double jaw, III-50–53, III-226–227
emergency procedure, I-55
ethics in, I-1–13
facial wound, I-665
Ganz-Rinaldi protocol, I-706f
high-energy gunshot wound trauma, II-318–320
history, I-96, III-1
infection following, I-303
interactions, II-329–337
for keratocystic odontogenic tumor, II-356–361
for labial frenum, I-270–271
lasers in, I-327–363
Le Fort I segmental, III-172–182
lighting for, I-48
maxillary, III-55
maxillomandibular advancement, III-269–274
melanoma, II-697, II-700
model, III-44–61
nasal fracture, II-179–186
nerve injury, I-365–374
neurological, II-90–91
odontogenic tumor, II-391–461
orthognathic. *See* Orthognathic surgery
otoplastic, III-446–457
pathology, II-329–337
patient positioning, I-221
pediatric, I-257–274
postsurgical pain, I-374
practice transition, I-39–45
professionalism in, I-1–13
reconstruction, I-283, II-283–284
risk management, I-73–86
segmental maxillary, III-172
sitting position, I-46–57
anesthesia administration, I-46–54
equipment, I-46–50
skin cancer, II-727–730
squamous cell carcinoma, II-670–689
support organizations, I-37
team member locations, I-50
techniques, II-329–337
temporomandibular joint internal derangement, II-904–922
third molar, complications, II-82
training, I-1
training programs, I-34
trigeminal nerve injury, II-96
two-jaw, III-23
zygomatic arch fracture, II-201–202
zygomatic fracture, II-190–194
Oral and maxillofacial surgical practice
academic *versus* private, I-34, I-35b
accounting, I-68
advisor for, I-62–64
alternatives to private practice, I-23–38
articles of incorporation, I-59
associateship, I-41, I-44
benchmarking, I-64
boundaries, I-143
budgeting, I-67–68
business management, I-58–72
business model, I-16–17
buy-in, I-44, I-61
buy-out, I-41, I-44
buy-sell agreement, I-60–61
collection protocol, I-71
Oral and maxillofacial surgical practice *(Continued)*
collection ratios, I-69–70
communication in, I-18
compensation plan, I-70–71
compliance with regulations, I-67
conflict resolution, I-18–19
consultant for, I-125–126, I-110–111
decision making, I-18
deferred or incremental sale, I-41–42
in Department of Veterans Affairs, I-31–33
disruptive behavior, I-143–146
diversity, I-15–16
employee assessment, I-65
employee relations, I-111–117
employee retention, I-66–67
employees, I-19–20
employment agreement, I-60
entrepreneurial model, I-16, I-19
exit planning, I-43–45
financial management, I-67–71
financial trend analysis, I-69–70
goals, I-14–16
group practice, I-64
hiring practices, I-65–66
human resources, I-65–67
insurance broker, I-63
interpersonal relationships in, I-17–22
leadership, I-109, I-108
lease agreement, I-61
legal documents, I-59–61
legal entities, I-58–59
management, I-18
marketing, I-102–136, I-64
medical errors in, I-97–98
operating agreement, I-59
options for entering, I-41–42
organizational structure, I-64–67
outpatient surgery facility, accreditation of, I-96–101
overhead ratio, I-70
partnership, I-16
partnership model, I-16–18
philosophical basis, I-14–22
policy manual, I-116
practice administrator, I-63–64
profits, I-117, I-15
quality assurance, I-62
regulation, I-96
revenue cycle, I-68–69
risk management, I-61–62, I-73–86
sale, I-44
solo practice, I-64
solo practice model, I-16–17
succession planning, I-19
transition, I-39–45
in U. S. Air Force, I-29–30
in U. S. Army, I-24–26
in U. S. Navy, I-26–29
in U. S. Public Health Service, I-30–31
valuation, I-42
vision in, I-109
Oral appliance, for obstructive sleep apnea, III-267
Oral cavity
anatomy, II-670–671
cancers, II-742
diagnosis and evaluation, II-675
follow-up, II-684–685
nonsurgical management, II-677–679
screening, II-673–674
squamous cell, II-670–689
staging, II-675–677
surgical management, II-679–683
lymphoma, II-707, II-712
radiation therapy for, II-742t

Oral cavity *(Continued)*
subsites, II-670
tumor, III-740–741
Oral hygiene, salivary pellicle and, II-551
Oral mucosa
in dentoalveolar injury evaluation, II-117, II-123t
laser surgery on, I-335
lesion, I-336
Oral mucosal malignant melanoma, II-702–704
Oral teratoma, III-757
Orasone, II-871t
OraVerse. *See* Phentolamine (OraVerse)
Orbicularis muscle, III-388–389, III-390f, III-398
Orbit
fracture, pediatric, I-106
growth rate, III-629t, III-630
reconstruction
in oculoauriculovertebral spectrum, III-695
in Treacher Collins syndrome, III-713–715
retrobulbar hemorrhage and, II-206–207
Orbital cleft, III-507
Orbital compartment syndrome, II-206–207
Orbital floor
fracture, pediatric, II-268
surgical approaches to, II-196–199
Orbital ligament, III-402, III-404f
Orbital region
anatomy, II-190f
fracture, II-22
imaging, II-18
structure, II-19f
surgical approaches, II-196–199
Orbital rim, III-397
fixation, II-219f
in naso-orbito-ethmoid fracture, II-224
Orbital septum, III-388–389
Orbital wall, reconstruction, II-224
Orofacial embryogenesis, III-476–490
Orofacial region
innervation, I-227f
pain assessment, II-804–810, II-810b–811b
Oropharyngeal sphincter, III-535–536
Oropharynx, carcinoma
chemotherapy/radiation therapy for, II-754
radiation therapy, II-742, II-744t
Orthodontia, exodontia for, I-275
Orthodontic needs, third molar removal and, I-284
Orthodontic treatment
for impacted molar, I-266f
for pediatric impacted tooth, I-262, I-264
Orthodontics
accelerated osteogenic, III-247–248
after mandibular lengthening, III-206–208
anchorage, I-312, I-312
corticotomy-facilitated, III-246
following accelerated osteogenic procedure, III-250
goals, I-312
implant assisted, I-311–324
laser used in, I-350
miniplate, I-313–314
orthognathic surgery and, III-279–280
preoperative, III-299
skeletally based implant assisted, I-311–324
surgical, III-246
Orthognathic measurement
in double jaw surgery, III-52–53
for model surgery, III-46, III-48f
Orthognathic surgery
for accelerated orthodontic movement, III-246–263
accelerated osteogenic orthodontic procedure with, III-259–261
Orthognathic surgery *(Continued)*
airway evaluation, III-282–283
cleft, III-596–608
bone grafting in, III-602–605
presurgical evaluation, III-596–597
psychosocial considerations, III-597
timing of surgery, III-597
complications, III-297–298, III-316–319
computer-aided, III-31–34, III-190
dental rehabilitation needs in, III-20
dentofacial considerations, III-278–280
double-jaw, III-38, III-50–55
facial skeleton evaluation, III-16–20
hematologic evaluation, III-284–285
for hemimandibular elongation, III-17f–22f
history, III-1–2
infection, III-290, III-315–316
injury associated with, I-378–379
juvenile idiopathic arthritis and, III-131
laboratory testing, III-287–288
mandible-first, III-58–59
maxillary
multi-piece, III-56–58, III-58f
single-piece, III-55
maxillomandibular
planning for, III-21–29
stability, III-116–119
for midface deficiency, III-619
model, III-44–61
for asymmetric genioplasty, III-60f
genioplasty and, III-60
special considerations, III-60
musculoskeletal system evaluation, III-285–286
nerve injury associated with, II-86
nervous system evaluation in, III-284
oculoauriculovertebral spectrum, III-691, III-696
orthodontic considerations, III-279–280
patient evaluation, III-280–287
perioperative patient management, III-278–296
pitch orientation, III-27–28
postoperative management, III-288–292
relapse following, III-185, III-317–318
single-jaw, III-38
for sleep apnea, III-264–277
splint fabrication, III-50, III-55–59
stability after, III-185
temporomandibular joint replacement with, III-136
temporomandibular joint total reconstruction, III-222–245
in Treacher Collins syndrome, III-717f–722f
treatment planning, III-13–30
virtual, III-31–43
two-jaw, III-23, III-32f
venous thromboembolism in, III-298t
virtual treatment planning, III-31–43
Orthokeratin, II-354
Orthopantomogram, II-946
Orzel, II-757t
Os zygomaticum, I-571–573
OSA. *See* Obstructive sleep apnea (OSA)
Osseointegration, temporomandibular joint replacement and, II-927–928
Osseous crest, I-395
Ossifying fibroma, II-468–469, III-743f
juvenile, II-469–470
treatment, II-469
Osteoarthritis, II-835–838
facial pain and, II-944–945
splint therapy, II-869
temporomandibular joint, II-889
Osteoblast
in cancellous bone, I-427–428
staining for visualization of, I-442f
Osteoblastoma, II-472–474, II-475f
benign, II-854–855
cementoblastoma compared to, II-438
Osteochondroma, II-476, II-854
Osteochondromatosis, II-855–856
Osteoconduction
alloplastic implant and, I-440–441
bone growth and, I-439–440
definition, I-426, I-438
xenogeneic bone graft and, I-440
Osteogenesis
autologous stem cells and, I-438–439
bone growth and, I-438
definition, I-426, I-438
horizontal alveolar transport, I-547–549
Osteogenic, definition, I-438
Osteogenic distraction, for gunshot wound repair, II-326
Osteoid
bone healing and, I-426–427
staining for visualization of, I-443f
Osteoid osteoma, II-472–473, II-854
Osteoinduction
biologics and, I-441
definition, I-426, I-438
Osteoma, II-475, II-476f, II-854
Osteomyelitis, II-575–598
classification, II-575
clinical case, II-577f–585f
diagnosis, II-575
following exodontia, I-303
Garre, II-858
imaging, II-576
laboratory studies, II-575–576
management, II-576–590
mandibular, II-89f
temporomandibular joint affected by, II-858
Osteonecrosis
facial pain associated with, II-952
medication-related, II-507–522
clinical presentation, II-511–512
established, II-515–517
pathophysiology, II-509–510
research, II-517
risk factors, II-510–511
risk minimization, II-514
staging, II-512–513
treatment, II-514–517, II-516t
Osteoperiosteal flap, I-526–554
alveolar bone deficiency corrected with, I-526
free vascularized, I-668–671
space maintenance with, I-526–534
Osteoporosis, II-509
antiresorptive therapy for, II-514–515
osteonecrosis risk and, II-514
Osteoradionecrosis (ORN), I-304, II-575–598, II-749
clinical case, II-591f–594f
incidence, II-590
mandibular, II-34–35, II-37f
treatment, II-590–595
Osteosarcoma, II-644t, II-647–649, II-857
computed tomography of, II-646f
diagnosis, II-645–646
mandibular, II-645f
risk factors, II-647
treatment, II-647–648
Osteosynthesis
lines of, II-147f
in sagittal split ramus osteotomy, III-76–77
Osteotome, for sinus lift, I-520f
Osteotomy
alveolar, I-526–534
in alveolar distraction osteogenesis, I-536
alveolar repositioning, I-529
bilateral sagittal split, III-113–114

Osteotomy *(Continued)*
chin wing, III-319
combined maxillary and mandibular, III-183–195
case reports, III-191b
indications, III-184–186
mandible-first, III-187–189
maxilla-first, III-186–187
in computer-aided surgical simulation, III-35–36
craniosynostosis, III-650f, III-670
distraction osteogenesis following, III-775
extra-oral vertical ramus, III-113
facial bipartition, III-677f
horizontal ramus, III-204
implant transposition, I-529, I-530f
intraoral vertical ramus, III-62–95
history, III-64
indications, III-83
surgical sequence, III-83–90
inverted L, III-113–143
in combined maxillary and mandibular osteotomy, III-189
complications, III-124
indications, III-115–116
juvenile idiopathic arthritis and, III-131, III-137f–141f
modified, III-116f
nerve injury in, III-124
special considerations, III-131
stability, III-116–119, III-119t
surgical technique, III-120–124
virtual surgical plan, III-120, III-128f–130f
lateral nasal, III-164–165
Le Fort I, I-54–55, I-153–171, III-458, III-569–570, III-3
anesthesia, III-161–162
for cleft deformity, III-492–493
complications, III-169–170
in computer-aided surgical simulation, III-35–36, III-37f
diagnosis, III-153–161
history, III-153
indications, III-153
lip-to-tooth relationship in, III-24
for lymphatic malformation, II-540–542
maxillary hypoplasia and, III-638–639
maxillary segmentation, III-165–166
in maxillomandibular advancement, III-271f
multi-piece, III-54–55
in oculoauriculovertebral spectrum, III-696
operative technique, III-161–168
patient positioning, III-161–162
planning, III-153–161
segmental, III-172–182
single-piece, III-54
three-piece, III-176f
in Treacher Collins syndrome, III-731
two-segment, III-28–29
for vertical maxillary excess, III-156f–157f
Le Fort III, III-678f
mandibular
complications, III-144–145
endoscopically assisted, III-144–152
history, III-113–114, III-144, III-1–2
with maxillary, III-183–195
surgical technique, III-144–147
mandibular ramus, III-62–95
mandibular subapical, III-2
maxillary, III-163–164
history, III-2–3
with mandibular, III-183–195
in multiple segments, III-3
three-piece, III-176f

Osteotomy *(Continued)*
midface, III-4
for midface cleft reconstruction, III-601
nasal, III-164–165, III-378–380
in oculoauriculovertebral spectrum, III-696
relapse after sagittal split, III-116b
sagittal split, II-86, III-113–114, III-144, III-204, III-2, III-4
complications, III-298–319
nerve injury associated with, III-301–308
sagittal split ramus, III-62–95
septal, III-164–165
sinus augmentation, I-514
sliding genioplasty, III-102
symphysis widening, III-200
vertical ramus, III-62–95, III-144–145
vertical subcondylar ramus, III-313–314
vomerine, III-164–165
zygomatic fracture malunion, II-204–205
zygomatic implant, I-574, I-576
Otitis media, III-540, III-568–569
Otoplastic surgery, III-446–457
complications, III-455–456
Davis method, III-451–453, III-452f
Farrior technique, III-453, III-455f
Mustardé method, III-453, III-454f
protruding ear, III-450–453
protruding earlobe, III-453–455
techniques, III-450–453
Outpatient surgery facility, accreditation, I-96–101
Outpatient visit, coding for, I-92
Overbite, in temporomandibular joint disorder, II-873–874
Overdentures
controversy associated with, I-643–644
implant, I-641–664
maxillary long-bar, I-646f
natural tooth, I-641–643
two-implant, I-645
Overjet, in temporomandibular joint disorder, II-873–874
Oxaliplatin, II-757t
Oxazepam (Serax), I-196f, II-874t
Oxcarbazepine, I-369
Oxycodone (Percocet)
dose and potency, I-229t–230t
equianalgesic dosage, I-231t
for facial pain, II-953, II-955t
pharmacokinetics, I-230t
prescription, I-228
for temporomandibular joint disorders, II-872t
Oxygen
anesthetic recovery and, I-222
supplemental, for trauma patient, II-9–10
Oxygenation, monitoring, for pediatric patient, I-244
Oxyhemoglobin, I-168
Oxymorphone (Numorphan), I-229t–230t

P

Paclitaxel, II-757t
Pain
acute, management, I-234–235
behavioral pain management, I-365
central, definition, II-946t
central mechanisms, II-943–944
chronic facial, II-941–961
clinical examination, II-945–946
differential diagnosis, II-947–952
evaluation, II-944–947
management barriers, II-952–953
definition, I-225, II-946t
descriptors, II-946
facial, II-941–961

Pain *(Continued)*
cardiac origin, II-950–951
clinical examination, II-945–946
differential diagnosis, II-947–952
evaluation, II-944–947
management barriers, II-952–953
pharmacotherapy, II-955t
surgical intervention, II-958
therapeutic injection, II-956–957
treatment, II-953–958
as Fifth Vital Sign, I-234
following simple extraction, I-281
following surgical extraction, I-281
imaging, II-946–947
local anesthetic injection as cause of, I-184
management, I-225–237
myofascial, II-962
clinical presentation, II-963–964
diagnostic tests, II-964–966
splint therapy for, II-868
treatment, II-966–971
myogenous, II-791
nerve injury as cause of, II-90
neuropathic, I-233, I-360–362, II-946t
neurophysiology, II-941–943
orofacial
assessment, II-804–810, II-810b–811b
cardiac origin, II-950–951
temporomandibular joint disorder and, II-791
pathophysiology, I-225–226
patient assessment, I-234
patient perception, I-225
perioperative management, I-235f
peripheral mechanisms, II-942
postoperative, I-304
craniomaxillofacial trauma and, II-7
lasers and, I-340
management, I-225–237
postoperative management, I-235f
postsurgical, I-374
preoperative management, I-235f
sensory reeducation, I-365, I-366f
sympathetic mediated, I-361
temporomandibular joint, II-883
temporomandibular joint disorder, screening questionnaire for, II-804b–805b
third molar extraction and, I-293
Pain management
for chronic facial pain, II-941–961
future directions, II-958–959
in orthognathic surgery, III-288
for substance abuser patient, II-953
in temporomandibular joint disorder treatment, II-865
for temporomandibular joint disorders, II-970–971
Palatal bone, implant success and, I-412
Palatal fracture, II-28, II-220
Palate. *See also* Hard palate; Soft palate
free autogenous graft from, I-556
primary, III-502
secondary, III-502
soft tissue graft, I-556
squamous cell carcinoma, II-681–683
Palatine artery, III-165
Palatoplasty, III-505
Bardach, III-537, III-538f, III-611
fistula after, III-540
Furlow, III-546–548
speech and, III-540–542
two-flap, III-534, III-542, III-610
two-stage, III-548–549, III-551–552
Veau-Wardill-Kilner, III-538f, III-542
von Langenbeck, III-537f, III-542, III-611

Palpation, of temporomandibular joint, II-809
PALS. *See* Pediatric Advanced Life Support (PALS)
Pamelor. *See* Nortriptyline (Pamelor, Aventyl)
Pamidronate (Aredia), II-508, II-508t
Panoramic curve, I-688–689, I-689f
Panorex radiograph, I-570
Papanicolaou stain, II-331
Papaver somniferum, I-197
Papilla, interdental, implant and, I-401, I-402f
Papillary hyperplasia, laser treatment for, III-354
Papillomatosis, laser treatment for, III-354
Para-aminobenzoic acid (PABA), local anesthesia
  allergic reaction and, I-176–177, I-182, I-185
Paradental cyst, II-343
Paraflex. *See* Chlorzoxazone (Paraflex)
Parakeratin, II-352–354
Parakeratotic cyst, II-360f–361f
Paramedian forehead flap, II-290, II-292f
Paranasal sinus, lymphoma, II-712
Paraneoplastic pemphigus, II-564
Parasymphysis
  mandible, II-148
  widening, III-199–200
Parathyroid hormone (PTH)
  elevated, II-465–466
  hyperparathyroidism and, II-464
  osteonecrosis treated with, II-515–516
Parathyroid hormone-related protein (PTHrP), II-409, II-420
Parent
  of pediatric patient, I-257–258
  pediatric patient fear and anxiety and, I-248
Paresthesia
  after orthognathic surgery, III-291
  definition, I-355t, II-946t
  infraorbital, II-202–203
  local anesthetics and, I-183–184
  in osteomyelitis, II-575–576
Pargyline, I-149t
Parotid duct, laceration, II-58–60
Parotid gland
  benign tumor, II-494–496
  chronic obstructive sialoadenitis, II-491–492
  infection, II-485–486
  lesion, II-485
  malignant fibrous histiocytoma in, II-651
  nonsalivary tumor, II-500–503
  stone, II-490
  swelling, II-486f
  tumor, II-493–494, II-493t
  viral infection, II-487–488
Parotid sialocele, III-335
Parotidectomy, II-102–103, II-494–496
Parotitis, acute suppurative, II-485–487
Paroxetine hydrochloride (Paxil), II-873t
Paroxysmal positional vertigo (PPV), I-522
Partial pressure arterial oxygen (PaO_2), I-12
Partial pressure of CO_2, I-168–169
Partial pressure of oxygen (PaO_2), pediatric, I-241
Passive range of motion, II-806
Pathology. *See also* Surgical pathology
  coding for, I-92
  of dentigerous cyst, II-346–347
  of keratocystic odontogenic tumor, II-352–354
  oral and maxillofacial, II-329–337
  radicular cyst, II-341
  surgical interaction with, II-329–330
Patient
  agitated, I-55
  attitude, prosthesis choice and, I-643
  diabetic, anesthetic recovery, I-222
  informed consent, I-62
Patient *(Continued)*
  for orthognathic surgery, III-280
  risk management and, I-76–78
  lumbar support, I-54, I-56f
  monitoring, I-164–175
  noncompliance, I-79–80
  pain management, I-225–237
  pain perceived by, I-225
  payment history, I-129–130
  postoperative, communication with, I-132
  preoperative evaluation, I-148–163
  problematic, in cosmetic surgery, III-458
  rehydration, I-217
  sedation goals for, I-211–212
  selection
    for guided bone regeneration, I-476
    implant restoration and, I-391–393
    for zygomatic implant, I-570
  surgeon relationship with, I-20–21
  survey of, I-123–124
Patient confidentiality
  autonomy and, I-9
  professionalism and, I-3
Patient-controlled analgesia (PCA), I-234–235
Patient education, for peri-implant disease, I-725
Patient evaluation, I-119–120. *See also* Preoperative evaluation
  airway assessment and, I-213
  for blepharoplasty, III-389–391
  for craniofacial surgery, III-670
  for forehead and brow lift, III-405–408
  for liposuction, III-430–431
  for obstructive sleep apnea, III-264–266, III-281
  for orthognathic surgery, III-280–287
  for pain, I-234
  for rhinoplasty, III-367–368
  for rhytidectomy, III-325–327
  for soft tissue injury, II-41–42
  for temporomandibular joint prosthetic reconstruction, III-222–223
Patient health record, risk management and, I-75–80
Patient history
  airway assessment and, I-213
  for chronic facial pain evaluation, II-944
  craniomaxillofacial trauma assessment and, II-2–4
  for dentoalveolar injury evaluation, II-115–116
  for mandibular fracture evaluation, II-152–153
  preoperative evaluation and, I-138
  risk management and, I-75–76
  for temporomandibular joint disorder, II-801, II-904–905
  for temporomandibular joint internal derangement, II-904–905
  trauma management and, II-3t
  in trauma patient assessment, II-10
  zygomatic fracture assessment, II-190–191
Patient positioning, I-54
  anesthesia, I-221
  for exodontia, I-276
  for Le Fort I osteotomy, III-161–162
Patient preparation, for autogenous bone graft, I-451
Patient referral, I-122–123, I-122, I-81
Patient survey, I-123–124
Patient's rights, I-9
Paxil. *See* Paroxetine hydrochloride (Paxil)
Payment plan
  marketing and, I-129–130
  types of, I-129–130
Peck and Peck method, chin position analysis with, III-460t–461t
Peck graft, III-374
Pediatric Advanced Life Support (PALS), I-244, I-260
Pediatric Glasgow Coma Scale (PGCS), II-247, II-247t–248t
Pemphigoid, II-562–564
  clinical features, II-563
  treatment, II-564
Pemphigus, II-564–565
  clinical features, II-564–565
  treatment, II-565
Penciclovir, II-553–554
Penicillin
  anaphylaxis associated with, I-252t
  medication-related osteonecrosis treated with, II-516
  postoperative infection treated with, I-303
Pentazocine (Talwin)
  dose and potency, I-229t–230t
  for temporomandibular joint disorders, II-872t
Pentoxifylline, II-595–596
Peptic ulcer disease, I-141
Percocet. *See* Oxycodone (Percocet)
Peri-implant disease, I-711–730
  cement excess and, I-632, I-711
  laser treatment, III-350
  prevention, I-724–725
  risk factors, I-723–724
  scope, I-723
  treatment, I-725–727
Peri-implant inflammation, I-653f
Peri-implant mucositis, I-723
  prevention, I-724–725
  treatment, I-725–727
Peri-implantitis, I-723
  cement excess and, I-711
  definition, I-412–413
  example, I-712f
  laser treatment, I-340–341, III-350
  prevention, I-724–725
  risk factors, I-723–724
  scope, I-723
  treatment, I-725–727
Periadenitis mucosa necrotica recurrens, II-559
Periapical cemental dysplasia, II-470–471
Periapical root surgery, nerve injury caused by, II-87
Perichondritis, III-456
Pericoronitis
  third molar removal and, I-284
  treatment, I-284
Perineural invasion, tumor cell migration and, II-722
Perineurium, in nerve anatomy, II-77–78
Periodontal disease
  exodontia for, I-275
  third molar removal and, I-284
Periodontal ligament (PDL)
  bundle bone blood supply from, I-413–414
  healing, after trauma, II-137–138
  injury, II-122t
  luxation, II-127
  miniscrew implant and, I-315
  in simple extraction, I-276
Periodontal tissue, injury, II-127–131
Periodontally accelerated osteogenic orthodontics, III-247
Periodontitis
  exodontia for, I-275
  peri-implant disease associated with, I-723–724
Periodontium, biotype, I-393–405
Periorbital region, II-19f
Persistent idiopathic facial pain, II-948

Persistent postsurgical pain (PPSP), I-374
acute, I-374
chronic, I-374–375
management, I-375t
transition, I-374
Pfeiffer syndrome, III-669, III-672, III-778
PHACE vascular anomaly, II-536
Phantom bone disease, II-858
Pharmacologic prophylaxis, III-298
Pharmacosedation
general anesthesia and, I-248–251
pediatric, I-238–256
Pharyngeal cleft, II-383, II-383f
Pharyngeal flap procedure, III-616–618, III-616f
Pharyngeal structure, airway assessment and, I-243f
Pharyngeal wall, radiation therapy for carcinoma of, II-742
Pharyngoplasty, sphincter, III-579, III-617–618, III-617f
Pharynx, pediatric, I-240
Phencyclidine, I-203–204
Phenelzine, management, I-149t
Phenergan. *See* Promethazine (Phenergan)
Phenobarbital (Luminal), I-200–201, II-255–256
Phenol, for chemical peel, III-443–444
Phentolamine (OraVerse), I-188
Phenylephrine, selectivity and potency of, I-180t
Phenylpiperidine, structure, I-199f
Philadelphia chromosome, II-622–623
Photodynamic therapy, III-353
for oral cancer, II-677–678
for skin cancer, II-734
Photography, for model surgery, III-44–46
Physical examination
airway assessment with, II-10–11
for dentoalveolar injury evaluation, II-115–119
for mandibular fracture evaluation, II-152–153
for midface fracture diagnosis, II-212–213
for obstructive sleep apnea, III-265–266
oral cancer evaluation and, II-675
preoperative evaluation and, I-138
for rhytidectomy evaluation, III-326
risk management and, I-75–76
for skin cancer, II-722–725
for temporomandibular joint internal derangement, II-904–905
Physical therapy
after arthroscopy, II-901
after internal derangement surgery, II-918–919
for chronic facial pain, II-953
for temporomandibular joint disorders, II-875–877
Physicians' Charter, I-2, I-4
Pichler, Hans, III-113
Pierre Robin syndrome, III-547, III-776
Pigmented villonodular synovitis, II-855
Pindborg tumor, II-398
Pinterest, marketing and, I-105–106
Piroxicam
for masticatory myalgia, II-969
for temporomandibular joint disorders, II-871t
Pitch orientation
in computer-aided surgical simulation, III-38–39, III-120
model surgery and, III-44f
in orthognathic surgery, III-27–28
Pittsburgh Fistula Classification System, III-539–540, III-540f
Pivot splint, temporomandibular joint, II-867
Plagiocephaly, III-647
anterior, III-654–657
posterior, III-659–660
Plaque, control, II-551
Plasma, platelet-rich, I-460
Plasmatic inhibition, I-426–427
Plaster of Paris, alloplastic implant with, I-440–441
Plastic surgery, facial, laser used in, III-359
Plate
titanium, II-164
types of, II-164f
Platelet-derived growth factor (PDGF), I-257–258, I-258t, I-431–432, II-441
interpositional bone graft, I-527–528
Platelet-rich plasma, I-460, I-510–512
Platform switching, I-413
Pleomorphic adenoma, II-492–494, II-493t, II-500
Plication, III-330
Pneumonitis, continuous positive airway pressure for, I-253
Pocket mask, I-245–247
Pogonion position, III-28
Policy manual, I-116
Polyetheretherketone (PEEK), I-416–418
Polylactic acid/polyglycolic acid copolymer membrane, I-482–483
Polymethylmethacrylate (PMMA), I-416–418
Polymorphous low-grade adenocarcinoma, II-500–501, II-503f
Polysomnography, III-265
Polytetrafluoroethylene membrane, I-462–464, I-464f, I-480–482
Pontic site, development, I-404
Porcelain-fused metal (PFM), I-416–418, I-417f
Port-wine stain, II-538
Positioning. *See* Patient positioning
Positron emission tomography (PET)
cancer diagnosis, II-624
craniomaxillofacial pathologies, III-738–739
lymphoma, II-711–712
melanoma diagnosis, II-699
odontogenic tumor, II-392
oral cancer evaluation, II-675
temporomandibular joint, II-825
Post-transplant lymphoproliferative disorder, II-711
Post-traumatic seizure, II-255–256
Postanesthesia Discharge Scoring System, I-172–173
Posterior plagiocephaly, III-659–660
Posterior superior alveolar artery, I-510
Postoperative nausea and vomiting (PONV), III-288
Postoperative recovery, from anesthesia, I-221–222
Posttraumatic concussion syndrome, frontal sinus fracture associated with, II-243
Potassium ion, nerve conduction and, I-176
Powell and Humphreys method, chin position analysis with, III-460t–461t
Prazepam (Verstran, Centrax), II-874t
Prednisolone
equivalent dosage, III-287t
for temporomandibular joint disorders, II-871t
Prednisone
Bell's palsy treated with, II-101
for lymphoma, II-713
for pemphigus, II-565
for temporomandibular joint disorders, II-871t
Pregabalin (Lyrica), I-364, II-955t, II-956
Pregnancy
craniomaxillofacial trauma management and, II-3t
local anesthesia and, I-186
Premedication, for pediatric patient, I-248
Premolar
cyst at, II-343
impacted, I-265
mandibular
extraction, I-278f
impacted, I-291
maxillary
extraction, I-277
impacted, I-291, I-292f
roots, I-278f
Preoperative evaluation, I-148–163
airway assessment, I-213–214
anesthesia, I-212
asthma, I-139
cardiac assessment, I-150f
cardiac risk index, I-150t
cardiovascular, I-138
cerebrovascular accident, I-161
chronic obstructive pulmonary disease, I-139
coagulation disorders, I-161
components, I-138–139
endocrine system, I-142
exodontia, I-276
gastrointestinal disease, I-141–142
hematologic, I-159–161
nervous system, I-161
pulmonary system, I-139
renal disease, I-140–141
smoking, I-139
Preoperative fasting, I-215–216, I-243
Pressure-flow method, III-576–578
Pressure indicating paste (PIP), I-658
Presurgical infant orthopedics, III-561–562
Presurgical orthopedic appliance, III-498
Prilocaine, I-186
concentration, I-177t
duration of, I-179t
nerve injury associated with, I-183t
onset time, I-178t
Primary bone grafting, III-584
Primary herpes stomatitis, II-556
Primary herpetic gingivostomatitis, II-552, II-554
Primary intraosseous odontogenic carcinoma, II-431–432
Principles of Ethics, I-9
Procaine (Novocaine), I-185
chemistry, I-177f
history, I-176
onset time, I-178t
Procarbazine, II-714
Profecoxib, II-871t
Professional employment organization (PEO), I-67
Professional liability insurance, I-82
Professionalism
behaviors associated with, I-4
commitment to, I-3
definition, I-1–4
ethics and, I-1–13
framework for, I-5f
history of, in dentistry, I-2–4
Physicians' Charter description of, I-2
student evaluation and adherence to, I-4–6
teaching, I-4–5, I-7–8
unprofessional behavior, I-4
Proffit, William, III-5
Progress notes, risk management and, I-78–79
Proliferation phase, of bone healing, I-426–427
Prolonged sensory alteration, I-183–184
Promethazine (Phenergan), II-288, III-874t

Propacetamol, I-252t
Propofol (Diprivan), I-192, I-202–203
  anaphylaxis associated with, I-252t
  development, I-201
  general anesthesia with, II-13
  ketamine combined with, I-219t
  pediatric dosage, I-250t
  for pediatric patient, I-250–251
  pharmacokinetics, I-204t, I-218–219
  remifentanil combined with, I-219t
  side effects, I-204f
  structure, I-202f
Propofol infusion syndrome, I-203
Proportion
  facial, osteotomy and, III-184–185
  in facial esthetics, III-13–14
Propoxycaine, onset time, I-178t
Propranolol, for congenital hemangioma, II-537
Prostate-specific antigen (PSA), II-623–624
Prosthesis
  angle of emergence, I-587–588
  arch provisional, I-605–623
  decision making process for, I-632–635
  fixed
    angle of emergence, I-587–588
    case presentation, I-601–602
    cost, I-596–597
    denture conversion to, I-608–614
    diagnosis for, I-584–591
    edentulous maxilla, I-584–604
    esthetics, I-592
    extraoral examination, I-591–602
    extraoral parameters, I-586f
    force placed on, I-594–595
    implant distribution and placement, I-596
    implant-supported, I-608–614
    material selection, I-597–602
    number of implants, I-594
    restorative classification, I-590
    treatment planning, I-592–597
  four-implant, I-649f
  in immediate implant loading, I-607
  overdenture, I-641
  removable, I-461, I-592
  retrievability, I-631–632
  screw retention *versus* cement retention, I-631
  six-implant, I-641f
  for temporomandibular joint total reconstruction, III-228, III-229f, III-230–232, III-234f, III-242
  three-implant, I-648f
  two-implant, I-642f, I-654f
  in zygomatic implant, I-581–582
Protamine, I-252t
Protein
  cancer-associated, II-623–624
  as cancer therapy target, II-625–626
  cell structure and, II-605–606
  dysregulation, II-609–622
  gene expression and, II-604f
Protein binding, local anesthetic drugs and, I-178
Proteomic analysis, II-624
Proto-oncogene, II-602, II-612
Prozac. *See* Fluoxetine (Prozac)
Pseudo-tomogram, II-818, II-819f
Pseudocyst
  definition, II-338
  sinus, I-510
  temporomandibular joint affected by, II-852
Pseudogout, II-847–848
Psoriatic arthritis, II-841–842
Pterygoid muscle, II-783–785, II-795f, II-810
Pterygomaxillary buttress, II-211
Pterygomaxillary disjunction, III-164
Ptosis, in craniosynostosis treatment, III-678
Public relations, for oral and maxillofacial surgical practice, I-64
Pulmonary complications
  adolescent, III-282
  prevalence of, I-139
Pulmonary system, preoperative evaluation of, I-139, III-282–283
Pulp
  exposure, II-124
  healing, after trauma, II-138
  injury
    in dentoalveolar injury, II-124
    prognosis, II-138–139
    treatment of, II-122–127
  necrosis, after injury, II-140
Pulp testing, in dentoalveolar injury, II-118–119
Pulpitis, II-138–139
Pulse oximeter, II-12, II-168
Pulse oximetry
  error rate, I-168
  for pediatric anesthesia monitoring, I-245
Puncture wound, I-301
Pyriform rim, III-28
Pyrophosphate, II-550

Q

Quality assurance, I-62
Quantitative Sensory Test Recording and Neuropathic Mapping Form, I-359f
Quinolone, II-516

R

R-point, cell cycle and, II-612–613
Rabies, II-62b
Raccoon eye sign, II-216, II-254
Race, facial variation and, III-25
Radial forearm flap, II-294, II-295f
Radiation
  emission, laser and, III-336–337
  ionizing, non-melanoma skin cancer associated with, II-717
  tissues damaged by, I-675–677
  ultraviolet, skin cancer associated with, II-722–723
Radiation therapy, II-590, II-741–751
  complications, II-749
  concurrent chemoradiation *versus*, II-747t
  definitive, II-745
  dosage, II-741–742
  fractionation, II-746–747
  head and neck cancer, I-675–678
  histologies, II-741–742
  history, II-741
  intensity-modulated, II-590, II-747–748
  Langerhans cell histiocytosis, II-530
  laryngeal, II-742–744
  lymphoma, II-713
  melanoma, II-700
  nasopharyngeal, II-744–745, II-746t
  oropharyngeal, II-742, II-744t
  osteoradionecrosis prevention and, II-590
  osteosarcoma, II-649
  overview, II-741–745
  postoperative, II-745–746
  preoperative, II-745–746
  rhabdomyosarcoma, III-760–762
  side effects, II-749
  skin cancer, II-734–735
  systemic therapy with, II-747
  techniques, II-747–749
  third molar removal and, I-285
  tissues damaged by, I-675–677
Radicular cyst, II-340–341, II-342f–343f
Radiofrequency ablation, II-540
Radiography
  dentoalveolar injury, II-119–120
  digital, III-6–7
  impacted tooth, I-260–261, I-261f
  insurance codes for, I-94
  lymphoma, II-711–712
  mandibular fracture, II-154f
  midface fracture, II-217
  model surgery, III-47–49
  odontogenic tumor, II-392
  osteomyelitis, II-586f–589f
  panoramic, II-79f
    for nerve imaging, II-78
    for temporomandibular joint, II-817–818
  Panorex, I-570
  temporomandibular joint, II-815
  temporomandibular joint disorder, II-801
  three-dimensional, for temporomandibular joint, II-815
  trauma patient assessment with, II-5
  zygomatic fracture, II-191–193
Radiotherapy. *See* Radiation therapy
Ramsay Hunt syndrome, II-102
Ramus
  fracture, II-34, II-149
  osteotomy, in sagittal split ramus procedure, III-75f
  reconstruction, in oculoauriculovertebral spectrum, III-692–695
Ramus/condylar unit (RCU), III-144
Range of motion
  mandibular, II-805–806
  temporomandibular joint, II-964
RANKL. *See* Receptor activator of nuclear factor-KB ligand (RANKL)
Ranula
  laser for removal of, III-350
  sublingual gland, II-483
Rapamune. *See* Sirolimus (Rapamune)
Rapidly involuting congenital hemangioma (RICH), II-536–538
Rathke's pouch, I-258
Rating site, marketing and, I-103–104
Reactive arthritis, II-225, III-561–562
  clinical features, II-562
  treatment, II-562
RealSelf, marketing and, I-106
Receptionist, as marketing asset, I-133
Receptor activator of nuclear factor-KB ligand (RANKL), II-507
Recombinant human bone morphogenetic protein-2 (rhBMP-2), I-458, I-510–512
Reconstruction
  complications, II-276
  flap options, II-296b
  Ganz-Rinaldi surgical protocol, I-706f
  implant placement timing, I-674–675
  lip, II-297–298
  mandibular, II-296–297, II-298f
  maxillary, I-299f, II-283–300
  nasal, II-297, II-299f
  protocol for, I-704–706
  scalp, II-298–300, II-301f
  site-specific, II-296–297
Reconstruction plate, in inverted L osteotomy, III-128f–130f
Recovery
  monitoring during, I-172–173
  stages, I-172
Recurrent intracranial hypertension, III-674–675
Reed-Sternberg cell, II-707, II-709
Reflex sympathetic dystrophy, II-947
Refusal of treatment, I-77–78
Regenerative medicine, for temporomandibular joint disc repair, II-914–917

Regional acceleratory phenomenon, III-247
Registration, in computer-aided surgical simulation, III-31–33
Regulation, awareness of, I-85
Reiter syndrome, II-561–562, II-842–843
Rela. *See* Carisoprodol (Rela, Soma)
Relative value unit (RVU), I-88
Remifentanil, I-200
  advantages, I-220–221
  clearance, I-201f
  infusion duration, I-201f
  propofol combined with, I-219t
  structure, I-199f
  synthesis, I-197–198
Remodeling
  craniofacial, III-628–629
  definition, III-628t
Remodeling phase, of bone healing, I-426–427
Renal disease
  orthognathic surgery and, III-283–284
  pediatric, III-283
  physiologic disorders of, I-154t–155t
  preoperative evaluation of, I-140
Renal failure, I-154t–155t
  craniomaxillofacial trauma management and, II-3t
  preoperative management, I-155t
Renal system
  pediatric, I-241
  preoperative evaluation, III-283–284
Repositioning splint, temporomandibular joint, II-867
Rescue, from sedation, I-212–213
Residual cyst, II-341–342
Residual ridge form, I-595–596
Resonance, speech, in cleft palate, III-570–571
Resource-Based Relative Value Scale (RBRVS), I-88
Respiration
  age values, I-241t
  monitoring, I-169–170, I-222
  opioid drugs effect, I-199
  pediatric, I-241t
Respiratory failure, cervical spine injury associated with, II-11
Respiratory system
  cigarette smoking effects, I-215
  monitoring, I-167–169
  pediatric, I-239–241
Rest of Malassez, II-338–340
Rest of Serres, II-338–339
Resting skin tension lines (RSTL), II-724
Restoration
  cement-retained single anterior, I-630–631
  decision making process for, I-632–635
  fixed. *See* Fixed restoration
  retrievable, I-600, I-637
  screw-retained single, I-627–629
  screw-retained single anterior, I-631
  screw retention *versus* cement retention, I-631–632
  zirconia, I-628
Restoril. *See* Temazepam (Restoril)
Reticular formation, trigeminal nerve pathway and, II-942
Retinoblastoma, II-599, III-762–763
Retinoblastoma pathway, II-613
Retinoid medication, II-733
Retirement, I-138–142
  aging process, I-140–141
  balance in, I-138–139
  family and friends, I-139
  legacy, I-139
  recreation in, I-139
  spirituality, I-139
  work in, I-138
Retractor, Bauer, III-88f
Retrobulbar hemorrhage, II-206–207
Retromolar trigone, II-671, II-681–683
Reverse Towne projection, II-816–817
Reviews, marketing and, I-103–104
Rhabdomyosarcoma, II-644t, II-654–656, III-760–762, III-765f
  classification, II-655
  prognosis, II-655t
  spindle cell, II-657f
  treatment, II-655–656
  tumor-node-metastasis staging, II-655t
Rheumatoid arthritis, II-833, II-835, II-838–840
  facial pain and, II-944–945
  splint therapy for, II-869
  temporomandibular joint replacement for, II-930f
Rheumatoid factor, II-839–840
Rhinoplasty, III-364–387
  anesthesia, III-377
  case reports, III-384b–385b
  clinical evaluation, III-368–371
  closed, III-377–383
  complications, III-383–386
  consultation, III-367–368
  in craniosynostosis treatment, III-678
  incisions, III-371–372, III-377–381
  nasal function evaluation, III-370–371
  nasal tip control, III-372–373
  nasal tip rotation, III-375–376
  nasal tip shape, III-376–377
  open, II-186f, III-377–383
  patient evaluation, III-367–368
  postoperative care, III-383
  surgical technique, III-377–383
  in Treacher Collins syndrome, III-731
Rhytidectomy, III-325–335
  anatomic considerations, III-327–328
  anesthesia, III-329
  complications, III-332–333
  facial evaluation, III-326–327
  generations, III-326t
  infection following, III-333–335
  nerve injury, III-333–334
  patient evaluation, III-325–327
  patient marking, III-328–329
  postoperative care, III-331–332
  skin necrosis, III-333
  surgical technique, III-328–332
Rib
  adult *versus* infant, I-240f
  bone graft from, III-591
Rib graft, in pediatric ablative defect reconstruction, III-766–767
Ribonucleic acid (mRNA), messenger, cancer diagnosis and, II-623
Ribonucleic acid (RNA)
  function, II-603
  messenger, II-603, II-604f
Ribonucleic acid interference (RNAi), II-625
Rickett's divider, III-15f
Ridge, edentulous, III-60
Ridge augmentation, I-483
  in alveolar distraction, I-538–539
  example, I-488f
  three-dimensional, I-539
Ridge crest, prosthesis at, I-586f–587f
Ridge form, I-595f–596f
Rifle, injury from, II-303–304
Risedronate (Actonel), II-508t
Rish technique, chin position analysis with, III-460t–461t
Risk management, I-61–62
  anesthesia, I-78, I-81–82
  case studies, I-74–75
Risk management *(Continued)*
  communication with patient and, I-80–81
  definition, I-73–74
  documentation, I-75–80
  emergency preparedness, I-81–82
  failure to diagnose, I-82
  informed consent, I-76–78
  lawsuit, I-83–84
  mandibular surgery, III-297–298
  oral and maxillofacial surgery, I-73–86
  patient noncompliance, I-79–80
  patient referral, I-81
  patient refusal of treatment, I-77–78
  prevention and mitigation, I-74–82
  treatment plan, I-76
Risk manager, I-83
Rituximab, II-713
Robaxin. *See* Methocarbamol (Robaxin)
Rocker deformity, III-379–380
Rocuronium
  anaphylaxis associated with, I-252t
  general anesthesia with, II-13
  for laryngospasm, I-252
Roll orientation
  in computer-aided surgical simulation, III-38, III-120
  model surgery and, III-44f
  in orthognathic surgery, III-23–24
Root
  contact, miniscrew anchor failure and, I-323
  fracture, in dentoalveolar injury, II-124f, II-125–127
  miniscrew implant and, I-315
  position, implant restoration and, I-393
  reabsorption, third molar removal and, I-284–285
  residual, exodontia and, I-299
Root canal
  healing, after trauma, II-138
  nerve injury associated with, I-377, II-949–950
Root canal fill, calcium hydroxide for, II-131
Root membrane technique, I-420–422
Root submergence technique, I-420–422
Root tip
  displacement, I-299–301
  swallowing of, during exodontia, I-302
Rotary drill, thermal trauma from, I-607
Rotation and advancement flap technique, III-514–516
  Asenio technique, III-517–518
  nasal reshaping, III-518–519
  postoperative care, III-519
  surgical procedures, III-516–519
Roux, Philibert, III-534
Rowe maxilla disimpaction forceps, II-217f
Rule of tens, cleft lip repair and, III-513–514

S

S corporation, I-58–59, I-59t
Saddle nose, II-225
Saethre-Chotzen syndrome, III-631f, III-669
Safety, for pediatric anesthesia, I-238
Sagittal split genioplasty, III-103, III-104f–105f
Sagittal split osteotomy (SSO), III-62–95
  bilateral, III-64b
    indications for, III-64
    for mandibular asymmetry, III-72b
  chin position and, III-303t
  complications, III-79–80, III-298–319
  hemorrhage in, III-82, III-310–313
  history, III-144, III-183, III-4
  infection, III-82
  limitations, III-64–74
  nerve injury associated with, II-86, III-300–301, III-305–308, III-316–317

Sagittal split osteotomy (SSO) *(Continued)*
Obwegeser technique, III-63f
ramus, III-204
relapse after, III-82–83, III-116b, III-777–778
surgical sequence, III-74–79
in Treacher Collins syndrome, III-731
treatment planning, III-299
unfavorable bony split, III-81–82
Sagittal split ramus osteotomy (SSRO). *See* Sagittal split osteotomy (SSO)
Sagittal suture craniosynostosis, III-653–654
Salary and benefits, employee, I-112
Saliva
composition, II-481
formation, II-481
viscosity, II-482t
Salivary duct
carcinoma, II-759–760
obstruction, II-483
Salivary gland
cancer, II-759–760
cystic conditions, II-483–485
disease. *See* Salivary gland disease
imaging, II-481–483
infection, II-485–488
inflammatory conditions, II-485–488
lymphoepithelial cyst, II-485
lymphoma, II-712
neoplasms, II-493t
nonsalivary tumor, II-500–503
obstructive disease, II-488–492
pediatric injury, II-272
physiology, II-481
sialolithiasis, II-488–490
stones, III-359
tumor, II-492–503, II-493t, III-763
tumor stages, II-494t
types, II-482t
viral infection, II-487–488
Salivary gland disease, II-481–506
Salivary pellicle, II-550
Sarcoidosis, II-503
Sarcoma
alveolar soft part, II-663–664
ameloblastic, II-454–455
classification, II-643–644
definition, II-643
diagnosis, II-644–647
environmental factors, II-644
etiology, II-644
Ewing, II-662–663
head and neck, II-643, II-644t
incidence, II-643
jaw, II-643–669
neurogenic, II-644t, II-660–661
pediatric, II-654, III-760–763
radiation therapy, II-741–742
risk factors, II-644
synovial, II-661–662, II-856–857
temporomandibular joint, II-856
Saunders, William, I-24
Save-A-Tooth, II-130f
Scaling and root planing (SRP), I-350
Scalp
layers of, II-189–190
reconstruction, II-298–300, II-301f
wound closure, II-11
Scaphocephaly, III-653–654
Scar revision, laser surgery for, I-346, III-357–358
Scatter artifact, I-692–693
Schirmer test, II-103, III-392f
Schneiderian membrane, I-509–510
perforation, I-515–518
in zygomatic implant, I-574
Schultz, Louis, II-770
Schwann cell, II-472
nerve injury and, II-72
proliferation, II-73
trigeminal nerve anatomy and, II-77
Schwannoma, II-472, II-473f, II-660
Scientific knowledge, commitment of, I-3
Scleroderma, II-848
Sclerotherapy
for lymphatic malformation, II-539
for venous malformation, II-543
Screw channel, single implant and, I-637–639
Screw fixation, III-7
osteosynthesis, in sagittal split ramus osteotomy, III-76–77
position technique, III-78f
resorbable screws in, III-77–79, III-79b
Screw tent-pole technique, I-484
Scroll, nasal, III-367
Sebaceous gland carcinoma, II-720
Secondary intention healing
after biopsy, II-724
after Mohns procedure, II-730
after surgical excision, II-731
facial areas for, II-727, II-727f
for wounds, II-731–732
Secretory duct, II-481
Sedation
benzodiazepines and, I-192
BIS monitoring, I-171–172
bispectral index, I-217t
complications, I-222–223
deep, I-164, I-165t, I-211
depth, I-171–172
general, I-165t, I-211
goals, I-211–212
levels, I-165t, I-211
minimal, I-164, I-165t, I-211
moderate, I-164, I-165t, I-211
patient-controlled, I-219–220
pediatric, I-238–256
pediatric techniques, I-251
rescue, I-212–213
Sedative-hypnotic drugs, I-200–203
Seddon classification of nerve injury, II-70–73, II-71f
Seddon-Sunderland classification of nerve injury, I-311, I-355, I-356t
Seizure
epileptic, I-161
orthognathic surgery and, III-284
post-traumatic, II-255–256
Seizure disorder, craniomaxillofacial trauma management and, II-3t
Selective photothermolysis, III-339
Selective serotonin reuptake inhibitors (SSRI)
for facial pain, II-955–956
for fibromyalgia, II-970
for temporomandibular joint disorders, II-872–873
Selective transparency, in three-dimensional imaging, I-694f–695f
Self-inflicted gunshot wound (SIGSW), II-320–323
Sensation, altered, testing for, I-358f
Sensitization
chronic facial pain and, II-943
definition, I-355t
Sensory reeducation, I-365, I-366f
Sentinel lymph node biopsy, II-697–698, II-700, II-730
Sentinel vein, III-399
Septa
in maxillary sinus, I-509–510
orientation, I-511f–512f
Septocaine. *See* Articaine (Septocaine)
Septoplasty, III-380, III-382
Septorhinoplasty, II-180
Serax. *See* Oxazepam (Serax)
Seronegative spondylitis, II-842
Sertraline (Zoloft), II-873t
Sevoflurane (Ultane), I-207–208
inhalation induction of, I-220
mask induction with, I-251
for pediatric patient, I-251
Sexual addiction, I-145
Sexual harassment, I-113, I-111
Shaken baby syndrome, II-250–251
Shira, Maj. Gen. Robert B, I-24, III-4
Shock, in child, II-249–250
Shotgun
injury from, II-304, II-320
wound classification system, II-304
wound from, II-305–306
Sialadenitis
acute suppurative, II-487
chronic obstructive, II-490–492
Sialodochoplasty, II-679–680
Sialography
for chronic obstructive sialoadenitis, II-491–492
salivary gland, II-481–483
Sialolith
laser for excision of, I-336, III-350
location, II-488
parotid gland, II-490–492
submandibular gland, II-490
surgery, II-488
Sialolithiasis, II-488–490
Sicher, Harry, II-768–769
Sickle cell disease, I-159, III-285
Signal pathway, cancer and, II-602–622
Silver, Caroll, II-769–770
Silver sulfadiazine, II-67
Simon's method of nasal projection, III-369
Simulator, anesthetic, I-213
Sinequan. *See* Doxepin (Sinequan)
Single photon emission computed tomography (SPECT)
cancer diagnosis, II-624
facial pain, II-947
temporomandibular joint, II-825
Sinonasal tract
chondrosarcoma in, II-649
lymphoma, II-710
malignant fibrous histiocytoma in, II-651
Sinus
ameloblastoma, II-415f–416f
biology and anatomy, I-509–510
bone graft, I-464–465
floor, comminution of, II-239f
fracture, pediatric, II-266–267
frontal. *See* Frontal sinus
infection
management, I-579–581
sinus fracture as cause of, II-243
zygomatic implant associated with, I-581f
lateral approach, I-514–518
maxillary, I-509, I-510f
morphology, I-509–510
obliteration, II-236–238
paranasal, lymphoma, II-712
pediatric, II-241
pneumatization, I-509
pseudocyst, I-510
size, I-509
subantral surgery and graft, I-509–525
Sinus augmentation, I-464–465
complications, I-520–522
crestal approach, I-521f
Ganz-Rinaldi surgical protocol, I-705f–706f
graft materials, I-510–513
implant placement with, I-517f, I-519–520

Sinus augmentation *(Continued)*
indirect (transcrestal) approach, I-518–522, I-518f, I-521f
lateral approach, I-514–518, I-516f
perforation, I-515–518, I-518f, I-520–522
postoperative stage, I-522
preoperative evaluation, I-513–514
pretreatment, I-510–513
protocol, I-514–515
techniques, I-514–522
three-dimensional imaging for, I-705–706
transcrestal approach, I-518–522
Sinus graft, I-704–706
Sinus graft guide, I-705–706
Sinus lift
complications, I-520–522
implant simultaneous with, I-519f
indirect, I-519f
perforation, I-520–522
postoperative stage, I-522
for resorbed maxilla, I-569–570
techniques, I-514–522
Sinusitis, I-513–514
Sirolimus (Rapamune), II-509t
Sitting position
anesthesia administration, I-46–54
equipment, I-46–50
oral surgery from, I-46–57
Sjögren syndrome, II-483, II-503–504
lymphoma and, II-710, II-712
temporomandibular joint affected by, II-848
Skeleton
craniofacial, III-627–628, III-674f
concepts, III-628–629
dysmorphology, III-636
evaluation of growth, III-635
growth and development, III-629–635
growth discrepancy, III-627–628
injury, II-18
pediatric, II-241–243
craniomaxillofacial, distraction osteogenesis, III-774–785
facial
access, III-739
evaluation of, III-16–20
facial bipartition osteotomy, III-677f
growth and development, III-628–629
Skin
anatomy, II-722
nasal, II-174–177
nasal thickness, III-370
necrosis, III-333
types, II-722–723
wound closure, II-9–10
Skin cancer
biopsy, II-723–725
clinical examination, II-722–725
epithelial, II-718–720
head and neck, II-717–740
incidence, II-690
laser surgery for, I-343
lymph node involvement, II-730–732
medical management, II-732–735
metastasis, II-723
non-melanoma, II-717–740
nonepithelial, II-720
photodynamic therapy, II-734
radiation therapy, II-734–735
recurrence, II-732–733
repair of wound, II-731–732
risk factors, II-717
screening, II-722–725
staging, II-725–727
surgical excision, II-729–730
treatment, II-727–730
Skin creep, II-731
Skin lesion, hepatic infection and, II-552
Skin resurfacing
complications, I-345–346
contraindications, I-345
laser, I-343–344, I-344f
wound healing, I-345
Skull
basal view of, II-778f
cloverleaf, III-669
Kleeblattschädel, III-669
lateral view of, II-778f
surgical access, III-741
Skull fracture
images of, II-233f, II-232f
pediatric, II-253
Sleep apnea. *See* Obstructive sleep apnea (OSA)
Sleep study, III-265
Sliding genioplasty, III-101–103
SMARTlock Hybrid maxillomandibular fixation system, II-155
SMAS. *See* Superficial musculoaponeurotic system (SMAS)
Smile, favorable, orthognathic surgery and, III-26–27
Smile line, III-26–27
implant and, I-391–393, I-392f
lip length and, I-588–591
transition line and, I-570f
Smokeless tobacco, oral cancer risk and, II-671
Smoking. *See* Cigarette smoking
Snapping jaw, II-766–767
Snappy abutment, I-624–626, I-633–634
Snoring, treatment, III-351
SOAP. *See* Subjective objective assessment plan (SOAP)
Social media, oral and maxillofacial surgical practice marketing, I-103–106
Socket
after third molar removal, I-288
defect, I-476
immediate implant into, I-410
preservation
case study, I-495b, I-500b
in guided bone regeneration, I-493
in simple extraction, I-278–279
Socket shielding technique, I-420–422
Socket wall fracture, II-133
Sodium hypochlorite, injury associated with, I-378
Sodium ion channel
local anesthesia and, I-177
nerve conduction and, I-176
Sodium lauryl sulfate, II-550
Soft palate
anatomy, III-535, III-612–615
musculature, III-536f, III-612–615
radiation therapy for carcinoma of, II-742
repair, III-503, III-534
speech and, III-541
two-stage, III-548–549
surgical technique, III-536–537
Soft splint, temporomandibular joint, II-867
Soft tissue
attachment, to implant, I-712, I-713f
bone graft preoperative evaluation, I-450–451
cement retention effect, I-632
closure, in guided bone regeneration, I-479–480
dentoalveolar injury evaluation, II-117
emphysema, I-301
evaluation, in orthognathic surgery, III-16
examination, in trauma patient, II-4
facial wound and, I-666
fibrosarcoma, II-652
gunshot wound, II-306
Soft tissue *(Continued)*
implant interface, I-555
injury, II-256–257
burn, II-67–68
during exodontia, I-301
in osteotomy, III-312f
pediatric, II-271–273
postoperative care, II-14–15
treatment, II-137
in vertical ramus osteotomy, III-314
injury management, pediatric, II-271–273
laser interaction, III-339, III-341t
leiomyosarcoma, II-656
liposarcoma, II-661
matrix expansion technique, I-484
measurements, for genioplasty, III-99, III-99f
midface fracture effect, II-216
nasal, II-174–177
non-odontogenic developmental cyst, II-371–375
pediatric
injury patterns, II-260–261
procedures, I-270–272
wound healing, II-256–257
physiology, II-256–257
readaptation, in naso-orbito-ethmoid fracture, II-225
rhabdomyosarcoma, II-654
separation, in simple extraction, I-276
in Treacher Collins syndrome, III-706–707, III-731–732
wound closure, II-42–45
wound healing, II-256–257
zygomatic fracture complications and, II-203
Soft tissue augmentation, I-555–568
graft substitutes for, I-558–561
indications for, I-563
peri-implant, I-555–568, I-564f
peri-implant grafting and, I-415–416
periodontal, I-565f–566f
vestibular incision tunnel access for, I-561–563, I-565f–566f
Soft tissue graft
autogenous, I-556
pediculated, I-556–558
substitutes, I-558–561
vascularized interpositional, I-558, I-560f
Soft voice syndrome, III-572
Solar cheilitis, laser treatment, III-354
Sole proprietorship, I-58
Solvent-dehydrated allograft (SDA), I-429–430
Soma. *See* Carisoprodol (Rela, Soma)
Sorafenib (Nexavar), II-509t
Space maintenance
in guided bone regeneration, I-479, I-483–484
in metal and acrylic restoration, I-599f
in osteoperiosteal flap, I-526
osteoperiosteal flap for, I-526–534
strategy, I-526–532
Speech
articulation, III-571–572
characteristics, with cleft palate, III-570–572
cleft palate repair and, III-503, III-540–542
double-opposing Z-plasty and, III-546–547
evaluation, III-572–574
horizontal transition line and, I-591–592
intelligibility, III-571–572
normal development of, III-568–569
Speech disorders
in cleft palate, III-568–582
etiology, III-568–570
evaluation, III-572–574
Speech therapy, III-579–580
Speed of onset, of local anesthetics, I-177
Sphenomandibular ligament, II-780–781

Sphincter pharyngoplasty, III-617–618, III-617f
Spine injury
  cervical, II-11
  craniomaxillofacial fracture associated with, II-38
  orthognathic surgery evaluation, III-16–17
Splint
  acid-etch resin arch wire, II-135, II-136f
  bracket arch wire, II-136–137
  fabrication, III-51f
  intermediate
    fabrication of, III-55–59
    for mandible-first surgery, III-59f
  lingual, II-155
  in model surgery, III-50
  occlusal, III-177–178, III-187f
  in orthognathic surgery, III-290
  titanium trauma, II-136–137, II-137f
Splint therapy
  after internal derangement surgery, II-919
  alveolar fracture, II-134
  avulsed tooth, II-128–129
  dentoalveolar injury, II-135–137
  masticatory myalgia, II-967
  orthopedic intraoral, II-968
  primary tooth displacement, II-132
  techniques, II-135–137
  temporomandibular joint disorder, II-865–869, II-967–968
Spontaneous emission of radiation, III-336–337
Sports, dentoalveolar injury associated with, II-141
Spray and stretch technique, II-970
Squamous cell carcinoma, II-431f, II-498, II-499f, II-599, II-670–689, II-719
  buccal mucosa, II-680–681
  chemotherapy for, II-754–756
  diagnosis and evaluation, II-675
  epidemiology, II-671–675
  epidermal growth factor receptor inhibitors for, II-757–759
  follow-up, II-684–685
  genetic abnormalities associated with, II-672–673
  head and neck
    chemo-radiotherapy, II-753–754
    clinical trials, II-758t
    epidemiology, II-752
    treatment, II-752–754
  keratocystic odontogenic tumor, II-352–354
  laryngeal, chemotherapy/radiation therapy, II-754
  laser surgery, I-343
  lip, II-735–737
  lymph node involvement, II-730
  mouth floor, II-679–680
  nasopharyngeal, II-744–745
  nonsurgical management, II-677–679
  oncology principles in management of, II-752–763
  oropharygneal, chemotherapy/radiation therapy, II-754
  radiation fractionation scheme, II-746–747
  radiation therapy, II-734, II-741
  risk factors, II-671–672, II-752
  screening, II-673–674
  sites, II-742
  staging, II-675–677, II-726t
  surgical management, II-679–683
  tongue, II-681
  tonsillar fossa, II-743f
  treatment, II-727, II-752–754
Squamous odontogenic tumor (SOT), II-397–398
SRP. *See* Scaling and root planing (SRP)
SSRO. *See* Sagittal split osteotomy (SSO)
Stabilization splint, temporomandibular joint, II-866–867
Stadol. *See* Butorphanol (Stadol)
Staining
  histochemical, II-332
  immunoperoxidase, II-333
Stambaugh method, chin position analysis with, III-460t–461t
Staphylococcus aureus
  methicillin-resistant, II-486–487
  parotitis and, II-485–486
  peri-implantitis and, I-727–728
Stem cell
  autologous adult, I-438–439
  cancer, II-599–600
  in temporomandibular joint arthrocentesis, II-888
  transplantation, for lymphoma, II-713
Stem cell entubulation, I-372–373
Stereolithography, I-696–699
Stereotactic navigation system, II-227
Steroid drugs, I-233
  Bell's palsy treated with, II-101
  for congenital hemangioma, II-537
  equivalent dosages, III-287t
  in orthognathic surgery, III-287, III-289
  in temporomandibular joint arthrocentesis, II-887
Stethoscope, precordial/pretracheal, I-167–168
Stickler syndrome, III-493–494
Still disease, II-840
Stimulated emission of radiation, III-336–337
Stomatodynia, II-949
STOP BANG questionnaire, I-214t
Strain, repetitive, temporomandibular joint pain associated with, II-963, II-966b
Streeter, G. L., III-476–477
Streptococcus pyogenes, peri-implantitis and, I-727–728
Stroke. *See* Cerebrovascular accident (CVA)
Student, evaluation of, I-4–6
Sturge-Weber syndrome, II-538, II-538f
Stylomandibular ligament, II-780–781
Subarachnoid hemorrhage (SAH), II-253
Subjective objective assessment plan (SOAP), I-78–79
Sublingual gland
  cystic conditions, II-483–485
  nonsalivary tumor, II-500
  sialolithiasis, II-488
  tumor, II-493t
Subluxation, in dentoalveolar injury, II-127
Submandibular gland
  chronic obstructive sialadenitis, II-490
  excision, II-491f
  infection, II-487
  nonsalivary tumor, II-500
  sialolithiasis, II-488–490
  stone, II-490
  tumor, II-493t
Submandibular space, tooth displacement into, I-300–301
Submental island flap, II-290–294
Submucous cleft palate, III-618–619, III-692
Substance abuse, I-144–145
  craniomaxillofacial trauma management and, II-3t
  ethics and, I-12
  facial pain management and, II-953
Success, definition, I-14–17
Succinylcholine
  anaphylaxis associated with, I-252t
  general anesthesia with, II-13
  for laryngospasm, I-252
Sufentanil
  structure, I-199f
  synthesis, I-197–198
Sulindac, II-871t
Sunderland classification of nerve injury, I-71–72, II-71f, II-356t
Sunitinib (Sutent), II-509t, II-511
Superficial musculoaponeurotic system (SMAS), II-174–175, III-325, III-330, III-331f
Superficial spreading melanoma, II-692t
Supernumerary teeth, I-266–268
Suprane. *See* Desflurane (Suprane)
Surgeon. *See* Oral and maxillofacial surgeon (OMS)
Surgeon-scientist, oral and maxillofacial surgeon as, I-35–37
Surgery
  bariatric, III-268
  mandibular. *See* Mandibular surgery
  nasal, for obstructive sleep apnea, III-269
  oral. *See* Oral and maxillofacial surgery (OMS)
  orthognathic. *See* Orthognathic surgery
Surgical assistant, I-111
  position, I-50
  role, I-52–53
Surgical excision, II-729–730
  Mohs micrographic surgery *versus*, II-730
  repair after, II-731–732
  for skin cancer, II-729–730
Surgical guide
  custom tray from, I-615f
  in digital workflow protocol, I-688
  example, I-612f
  fabrication, I-699–704
  immediate implant loading and, I-607–608, I-611f
  resin pattern, I-704f
  three-dimensional imaging of, I-699–704
Surgical margin, II-728
Surgical pathology, II-329–337
  electron microscopy, II-335
  flow cytometry, II-335–336
  histochemical staining in, II-332
  immunofluorescence studies in, II-332
  immunohistochemistry in, II-333–334
  molecular biology in, II-336
Surgical practice. *See* Oral and maxillofacial surgical practice
Surgical repair cascade, nerve injury and, I-368, I-368f
Surgical resection
  arteriovenous malformation, II-547
  lymphatic malformation, II-539
  squamous cell carcinoma, II-753
  venous malformation, II-544
Surgically assisted rapid maxillary expansion (SARME), III-172
Surgically assisted rapid palatal expansion (SARPE), III-172–174, III-197
Sutent. *See* Sunitinib (Sutent)
Sutton disease, II-559
Suture
  absorbable, II-48t
  alar cinch, III-167–168
  ear laceration, II-57–60
  eyelid laceration, II-51–52
  lip laceration, II-54–57
  materials, II-42–44, II-46t
  nonabsorbable, II-49t
  selection, II-46t
  soft tissue injury, II-42–44
Swelling
  lasers and, I-340
  postsurgical, I-282, I-304
  third molar extraction and, I-293

Symmetry
esthetic implant restoration and, I-393f
facial, osteotomy and, III-184–185
in facial esthetics, III-13–14
final, in computer-aided surgical simulation, III-39
Sympathetic mediated pain, I-361
Sympathetic nervous system, pediatric, I-239
Symphysis
mandible, II-148
widening, III-199–200
Syndactyly, in Apert syndrome, III-669f
Synergy, in marketing, I-123
Synovial chondromatosis, II-796, II-798f, II-855–856
Synovial chondrosarcoma, II-856
Synovial fluid
arthritis effect on, II-835–836
in osteoarthritis, II-838
in temporomandibular joint dysfunction, II-884
temporomandibular joint inflammation and, II-832
temporomandibular joint internal derangement and, II-906
Synovial hemangioma, II-853
Synovial membrane, II-780
Synovial sarcoma, II-644t, II-661–662, II-856–857
Synovitis, II-837–838, II-855
Systemic disease, insurance codes for, I-94–95
Systemic lupus erythematosus (SLE), II-848

T

T cell, II-600–601
TAD. *See* Temporary anchorage device (TAD)
Talwin. *See* Pentazocine (Talwin)
Tattoo, laser treatment, I-348–349, III-357
TCS. *See* Treacher Collins syndrome (TCS)
Teeth. *See* Tooth
Teflon-Proplast implant, II-772
Tegretol. *See* Carbamazepine (Tegretol)
Telangiectasia
laser treatment, I-338
local anesthetics, I-347
Telecanthus, in naso-orbito-ethmoid fracture, II-221–222, II-224, II-226
Telephone ear deformity, III-456
Teletherapy, II-747–748
Telogen effluvium, III-418f, III-425
Telomerase, II-616–617, II-617f, II-628
Temazepam (Restoril)
structure, I-196f
for temporomandibular joint disorders, II-874t
Temozolomide, II-701
Temperature, monitoring, I-170
Temporal bone, in temporomandibular joint, II-815
Temporalis muscle, II-399, II-782–783, III-785
Temporalis muscle flap, II-924, II-925f
Temporary anchorage device (TAD), I-314–316, I-311
Temporomandibular joint (TMJ)
abnormal biomechanics, II-795–796
anatomy, II-766, II-794, II-892–893
ankylosing spondylitis effect on, II-842
ankylosis, II-209f–210f, II-767, II-769, III-932f
joint replacement for, II-931
arthritis, II-769, II-832–848, II-929–931
arthrocentesis, II-883–891
contraindications, II-884
double puncture, II-885–886
outcomes, II-888–889
single puncture, II-886
technique, II-884–888
Temporomandibular joint (TMJ) *(Continued)*
arthropathy, III-81, III-317
arthroscopy, II-892–903
complications, II-897–900
disc repositioning, II-897
lysis and lavage, II-896–897
postoperative care, II-901
articulation, II-794
auscultation, II-808–809
biomechanics, II-795
blood supply, II-784–785
capsule, II-780
computed tomography, II-818–821
cone beam computed tomography, II-824–825, II-826f
continuous passive motion, II-833–835
cross-sectional anatomy, II-402f, III-794f
cyst, II-850–856
development, II-777–778
disc derangement, II-813f, II-883
osteoarthritis associated with, II-837–838
repair, II-910
disc displacement, II-792t–793t, II-797–798, II-800f, II-807
disc perforation, I-342–343, II-910, II-914–917
dysfunction, in sagittal split ramus osteotomy, III-81
evaluation, II-805–809
function, II-777–790
functional imaging, II-825
fusion imaging, II-826
gait of movement, II-806–808
hemangioma, II-852–853
histology, II-778–785
hypermobility, I-342
imaging, II-815–829
immobilization, II-833–835
infectious arthritis effect on, II-843–847
inferior (lower) compartment, II-893
inflammation, II-832, II-858
inflammatory arthritis, II-929–931
innervation, II-784–785
internal derangement. *See* Internal derangement (TMJ)
joint adhesions, I-342
juvenile idiopathic arthritis effect on, II-131, III-840–841
laser-assisted surgery, I-341–343, III-358–359
lateral oblique view, II-817
ligaments, II-780–781
magnetic resonance imaging, II-821–824, II-823f
malignant neoplasms, II-856–857
metabolic arthritis effect on, II-847–848
metastatic carcinoma, II-857
movement, II-795
muscle disorders, II-962–972
clinical presentation, II-963–964
diagnostic tests, II-964–966
etiology and epidemiology, II-962–963
mechanisms, II-963
pathophysiology, II-963
pharmacotherapy, II-968–969
self-care for, II-968
treatment, II-966–971
muscles, II-781–784
actions, II-786b
combinations, II-786
evaluation of, II-810
in oculoauriculovertebral spectrum, III-690
osteoarthritis, II-836–838
osteochondroma, II-854
palpation, II-809
panoramic radiography, II-817–818, II-819f
parasagittal section, II-779f
Temporomandibular joint (TMJ) *(Continued)*
pathology, II-830–864, II-893–894
pathophysiology, II-830–835, II-884
pediatric, II-934
physiology, II-830–835
range of motion, II-797, II-805–806, II-964
reconstruction
in oculoauriculovertebral spectrum, III-692–695
orthognathic surgery and, III-222–245
replacement, II-923–940
alloplastic, II-924–929
autogenous, II-923–924
custom-made device for, II-928
distraction osteogenesis and, II-934–935
history, II-923–929
indications, II-929–933, II-933t
for loss of mandibular height, II-931–933
with orthognathic surgery, III-136
pediatric, II-934
reverse Towne projection, II-816–817
rheumatoid arthritis effect on, II-838–840
in sagittal split osteotomy, III-204
structure, II-777–790
subluxation, II-792t–793t, II-800f, II-807
submentovertex projection, II-817
superior (upper) compartment, II-893, II-895f
surgical anatomy, II-778–785
surgical trauma to, I-305–306
total prosthetic reconstruction
case studies, III-235b, III-239b–240b
imaging, III-223–226
magnetic resonance imaging, III-224
occlusal plane alteration, III-226–227
orthognathic surgery and, III-222–245
outcomes, III-238–242
patient evaluation, III-222–223
surgical procedure, III-233–242
virtual surgical planning, III-229–232
transcranial view, II-816, II-816f
transmaxillary view, II-816
traumatic arthritis, II-836
in Treacher Collins syndrome, III-707–731
tumors, II-848–858
ultrasonography, II-826
Temporomandibular joint disorder (TMD), II-764
abnormal biomechanics, II-795–796
algorithm for nonsurgical management, II-866f
arthritis, II-833–848, II-929–931
arthrocentesis for, II-883–891
double puncture, II-885–886
outcomes, II-888–889
single puncture, II-886
technique, II-884–888
arthroscopy for, II-892–903
assessment, II-791–814
background, II-791–796
cephalometric analysis, III-226
classification, II-905b
common features, II-791
computed tomography for, II-820–821
condylectomy, III-145–146
definition, II-791–796
diagnostic approach, II-792t–793t, II-812t
disc displacement, II-792t–793t, II-797–798, II-800f, II-807
imaging of, II-820
nonsurgical management, II-883
splint for, II-869
evaluation, II-801–804
evaluation form, II-810b–811b
exodontia and, I-306
genetic, II-858

Temporomandibular joint disorder (TMD) *(Continued)*
imaging, II-801–804
implant for, II-770–771
inflammatory, II-858
internal derangement. *See* Internal derangement (TMJ)
intracapsular adhesion, II-799–800
intracapsular pathofunctional, II-796–801
joint replacement, II-923–940
laser surgery, I-343
magnetic resonance imaging, II-821–824
metabolic, II-858
muscle disorders, II-962–972
clinical presentation, II-963–964
diagnostic tests, II-964–966
etiology and epidemiology, II-962–963
mechanisms, II-963
pathophysiology, II-963
pharmacotherapy, II-968–969
self-care for, II-968
treatment, II-966–971
nonsurgical management, II-865–883
nonsurgical therapy, II-770–771
occlusal management, II-873–875
occlusion role in, II-767–769
in oculoauriculovertebral spectrum, III-690
orofacial pain associated with, II-804–810
orthognathic surgery evaluation and, III-16
osteoarthritis, II-929–931
pathology, II-830–864
pathophysiology, II-884
pharmacotherapy, II-869–873
physical therapy, II-875–877
posterior teeth missing, II-874–875
risk management and, I-76
screening questionnaire, II-804b–805b
splint therapy, II-865–869
subluxation, II-792t–793t, II-800f, II-807
total prosthetic reconstruction, III-222–245
in Treacher Collins syndrome, III-707–731
treatment philosophies, II-865
Temporomandibular joint surgery
disc derangement, II-904–922
history, II-764–776
implants used in, II-770–771
laser-assisted, I-341–343
minimally invasive, II-774
open joint, II-772
total joint replacement, II-772–774
Temporomandibular ligament, II-780
Temporoparietal fascia flap, II-290, II-294f
Tendon, medial canthal, II-221–224
Tennison technique
cleft lip repair with, III-513–514, III-520–521
Millard technique compared to, III-521–523, III-525
outcomes, III-527f
surgical planning and markings, III-522–523
surgical technique, III-523–524
Tensile strength, II-831–833
Tension pneumothorax, pediatric trauma and, II-249, II-250f
Tent-pole technique, I-484, I-485f–487f
Tenting screw, I-484, I-488f, I-500b
bone graft support with, I-696f
case study, I-693
Teratoma, oral, III-757
Terminal amine, local anesthetics and, I-177
Termination, employee, I-116–117
Tessier, Paul, III-667, III-668f, III-4, III-6
Tessier cleft line, III-486, III-496f
Tetanus
prophylaxis, II-61t
wounds prone to, II-61t
Tetracaine, I-185–186
Tetracycline, nerve injury associated with, I-377
Thalamus, trigeminal nerve pathway and, II-942
Thalidomide, III-688, III-690
Thermal therapy, for temporomandibular joint disorders, II-876
Thermistor, I-170
Thermocouple, I-170
Thermoregulation, pediatric, I-241–242
Thiopental, I-200–201, I-252t
Third molar, extraction
complications, I-77
in orthognathic surgery, III-279
Third-party payer, I-87–95
Three-dimensional computerized scan, II-207–208
Three-dimensional printing, I-696–697, I-699f
Thrombocytopenia, I-160–161
Thromboembolism, III-298, III-299t
Thrombosis, II-6
Thyroglossal duct cyst, II-378–383
Thyroid cancer, radiation therapy for, II-742
Thyroid disease
orthognathic surgery and, III-287
preoperative evaluation of, I-152
vasoconstrictor drugs and, I-182b
Thyroid gland, thyroglossal duct cyst and, II-378
Thyroid storm, I-141
Thyromental distance, airway assessment and, I-213, I-243
Tibia, as bone graft donor site, I-457–458
Tidal volume
age values, I-241t
pediatric, I-241t
TiDesign abutment, I-627f, I-634
Tiludronate (Skelid), II-508t
Time-out, risk management and, I-78
Tissue
adipose, III-429, III-434
autogenous, for temporomandibular joint replacement, II-924
emphysema, I-301
expansion, in child, II-274–275
hard, pediatric surgery for, I-260–262
injury
classification of, II-121t
of face, head, and trunk, II-41–69
suture technique, II-42–44
laser interaction, I-329f, III-339, III-341t
laser light effects, I-328–329
laser surgery, I-335–338
mesenchymal, II-643
metastasis and, II-619–621
nasal, II-174–177
peri-implant grafting and, I-415–416
periodontal, injury to, II-122t, II-127–131
soft, laser surgery, I-335–338, I-349
Tissue engineering
for temporomandibular joint disc perforation, II-915
temporomandibular joint replacement and, II-935
Titanium
for abutment, I-636
dental cement interaction with, I-717
for fixation hardware, III-63
restoration with, I-597–599
for screw-retained restoration, I-627–628
for single anterior implant, I-630–631
Titanium bar
example, I-602f
fixation with, II-147
Titanium mesh, I-465–466, I-484
with bone graft, I-669f–670f
space maintenance and, I-526–527
Tizanidine (Zanaflex), II-955t, II-956
TMD. *See* Temporomandibular joint disorder (TMD)
TNM staging, for oral cancer, II-675–677
To Err is Human: Building a Safer Health System, I-73, I-97
Tobacco smoking. *See* Cigarette smoking
Tobacco use
as mandibular surgery risk factor, III-297–298
oral cancer associated with, II-671
squamous cell carcinoma and, II-752
Tocopherol, II-595–596
Tofranil. *See* Imipramine (Tofranil)
Tolerance, facial pain management and, II-952
Toluidine blue, cancer screening with, II-674
Tomography. *See* Computed tomography (CT)
Tongue
airway assessment and, I-242–243, I-243f
anatomy, II-671
avulsed, in gunshot wound, II-314f
cancer, II-681, II-682f
in dentoalveolar injury evaluation, II-117
interstitial brachytherapy implant, II-743f
lymphatic malformation of, II-540f–541f
reduction, III-269
squamous cell carcinoma, II-742
tumor, III-740–741
Tonsil
radiation therapy for carcinoma of, II-742
size, III-266f
Tonsillectomy
codeine warning, I-254
for sleep apnea, III-268
Tooth
aspiration, II-118f
avulsed
in dentoalveolar injury, II-120–121, II-128–131
storage, II-130
concussed, II-127
congenitally missing, I-679
damage to, during exodontia, I-298–299
deciduous, I-258
delivery, in simple extraction, I-278–279
development, I-258
dislodged, retrieval of, I-300
displacement
during exodontia, I-299–301
into submandibular space, I-300–301
erupted
removal, I-275–283
surgical complications, I-281–283
examination, in dentoalveolar injury, II-117
extraction, in pediatric patient, I-260
fracture
in dentoalveolar injury, II-123–124
during extraction, I-282f
third molar extraction and, I-293
impacted, I-283–295
angulation classification, I-286f
complications following extraction, I-293–295
contraindications for extraction, I-285–286
decision tree for, I-265f
distoangular, I-288f
flap design, I-286–287
horizontal, I-288f
mesioangular, I-288f
nerve damage following extraction, I-294
in older patient, I-285
in pediatric patient, I-260–261
removal, I-283–285
sectioning, I-287–288
socket care after removal, I-288
surgical extraction complications, I-293–295
surgical management, I-275–297

Tooth *(Continued)*
surgical technique, I-286–288
treatment, I-262–269
injury types, in dentoalveolar trauma, II-119f
luxation, II-127
maxillary, positioning of, I-592
mobility, in dentoalveolar injury, II-118
multi-rooted, removal, I-281
permanent
eruption sequence, I-259t
formation, I-258
injury prognosis, II-139–141
position, implant esthetics and, I-391–392
primary
dentoalveolar injury, II-124f
displacement, II-132–133
eruption sequence, I-259t
formation of, I-258
fracture, II-131–132
injury prognosis, II-138–139
injury treatment, II-131–133
removal of wrong, I-298
replanted, II-130–131, II-140–141
shape of, implant restoration and, I-393–405
soft tissue interface, I-556f
subluxation, II-127
supernumerary, I-266–268, III-585
swallowing of, during exodontia, I-302
transplantation
complications, I-269
pediatric, I-268–269
Tooth bud, I-258
Toothbrush
manual, II-551
sonic, II-551
Toothpaste, salivary pellicle affected by, II-550
Topiramax (Topamax), II-956
Total metabolic equivalent (MET), preoperative evaluation and, I-151t
"Town and gown" politics, I-12–13
Towne projection, II-816–817
Trachea, pediatric, I-240
Tracheostomy, III-268
TRACK PLUS system, I-539–540
Tramadol
action, I-228
equianalgesic dosage, I-231t
for fibromyalgia, II-970
for neuropathic pain, I-364
for temporomandibular joint disorders, II-872t
Trametinib, II-701
Transcription factor
cancer cell growth and, II-612
cell differentiation, II-614
Transcutaneous capnometry, for pediatric anesthesia monitoring, I-245
Transcutaneous electrical nerve stimulation (TENS)
electronic dental anesthesia and, I-187–188
for temporomandibular joint disorders, II-876–877
Transforming growth factor beta (TGF-ß), II-256–258, II-258t
Transition line
movement of, I-591
smile line and, I-570f
Transmission electron microscopy (TEM), II-335
Transnasal canthopexy, II-224
Transoral vertical ramus osteotomy (TOVRO), III-90f–91f
Transpalatal appliance (TPA), open bite treatment and, I-317
Transplantation
facial, II-326
lymphoma following, II-711
stem-cell, for lymphoma, II-713
tooth
complications, I-269
pediatric, I-268–269
Transtracheal jet ventilation, I-245–247
Transverse mandibular deficiency, III-196, III-199f–200f
surgical risk and, III-299
treatment, III-301t
Transverse maxillary deficiency, III-199f, III-299
Tranylcypromine, management, I-149t
Trauma
airway assessment, II-9–10
airway management, II-9–15
anesthesia management, II-12–15, II-9–15
arthritis caused by, II-836
avulsive facial, II-282–302
complications, II-300
reconstruction, II-283–300, II-287f, II-296–297
rehabilitation, II-300
blunt
head and neck, II-2
pediatric, II-245
coding and billing for, I-91–92
craniomaxillofacial, II-1–8
airway management, II-9–12, II-1–2
cervical spine injury associated with, II-11
clinical examination, II-4–5
imaging in, II-17–40
mechanism of injury, II-2
medical conditions affecting management of, II-3t
patient medical history and, II-2–4
postoperative management, II-7
preoperative care, II-6
treatment, II-5–6
defect caused by, I-665–679
dentoalveolar, II-114–145
necrosis associated with, II-515
osteonecrosis associated with, II-515
prevention, II-141
prognosis, II-137–141
radiographic examination, II-119–120
facial
evaluation, II-9–12
nerve injury associated with, II-949
statistics, II-1
facial nerve, II-101–102
from improvised explosive device, II-319f
initial and postoperative management, II-1–8
jaw osteonecrosis associated with, II-510–511
maxillofacial
assessment, II-1–2
imaging, II-17–40
nerve injury associated with, I-374–376, II-374–376
trigeminal nerve injury from, I-354–355
maxillofacial gunshot, II-303–328
assessment, II-308–309
treatment, II-307–314
nasal, algorithm for, II-181f
orbital, II-213
pediatric, II-264–280, II-245–263
assessment, II-231–232
costs, II-246
epidemiology, II-230–231, II-245–256
evaluation, II-246
imaging, II-233–240
neurologic status assessment for, II-247–248
outcomes, II-245
patterns, II-260–261
Trauma *(Continued)*
physical evaluation, II-232–233
wound repair after, II-256–261
pediatric craniomaxillofacial, II-264–280
risk factors, II-4
temporomandibular joint disorder from, II-800–801, II-963
Traumatic bone cyst, II-852
Traumatic brain injury (TBI)
intracranial pressure monitoring in, II-254
management, II-254–255
pediatric, II-246–247, II-250–252
hematoma in, II-252f
secondary brain damage, II-254
Traumatic optic neuropathy, II-204
Trazodone (Desyrel), II-873t
Treacher Collins syndrome (TCS), III-15–16, III-690, III-703–737, III-776
description, III-703
dysmorphology, III-706–707
ear reconstruction, III-732–733
facial growth, III-707
genetic markers, III-703–705
inheritance, III-703–705
maxillomandibular reconstruction, III-724–730
nasal reconstruction, III-731–733
newborn mandibular reconstruction, III-730
reconstruction, III-713–715
skeletal reconstruction, III-713
soft tissue reconstruction, III-731–732
testing, III-703–705
Treatment plan
cleft lip repair, III-496–497
cleft palate repair, III-496–497
concomitant temporomandibular joint replacement and orthognathic surgery, III-227–228
gunshot wound, II-318–320
implant overdentures, I-656–658
mandibular deficiency, III-119–120
mandibular distraction osteogenesis, III-776
orthognathic surgery, III-13–30
pediatric ablative defect reconstruction, III-765
risk management and, I-76–78
software, I-688
Trial, lawsuit settled by, I-84–85
Triamcinolone
equivalent dosage, III-287t
giant cell lesion treated with, II-462–463
Triangular flap technique, III-514, III-520–521
Triazolam (Halcion), I-196–197
half-life, I-195t
protein binding, I-195t
structure, I-196f
for temporomandibular joint disorders, II-874t
Tricalcium phosphate, I-430, I-483–484
Trichloroacetic acid, III-443
Tricyclic antidepressant drugs
for facial pain, II-955–956
for temporomandibular joint disorders, II-872–873
Trigeminal nerve, II-74f, II-941–942
anatomy, II-74–78
description, II-70
fibrosis, I-369
graft for, II-95
illustration, II-74f
imaging, II-78–81
lateral view, II-785f
magnetic resonance imaging, II-81
microanatomy, II-77–78
midface innervation by, II-214
nerve block of, I-318
neuroma, I-370f
orofacial innervation by, I-227f

Trigeminal nerve *(Continued)*
pain neurophysiology and, II-941–942
surgical principles and techniques, I-367
surgical repair, I-365–374
vascular supply, II-78f
Trigeminal nerve injury, I-354, II-354–390
behavior pain management for, I-365
bone graft as cause of, II-84
causes, I-354–357
chronic, I-363–365
classification, I-355–356
clinical terms, I-355t
diagnosis, I-354–357
diagnosis and management, II-70–113
endodontic, I-377–378
entubulation, I-371–372
graft for, I-369–371
implant, I-379–380
from local anesthetic, I-376
maxillofacial trauma associated with, I-374–376
microneurosurgery for, II-91–96
nerve block, I-361–362
neurorrhaphy, I-369
neurosensory testing for, I-358–360, I-358f, II-315
nonsurgical treatment, I-362–365
orthognathic, I-378–379
outcomes, II-96
outcomes and conclusions, I-382–383
patient-reported impaired functions, I-313–314
persistent postsurgical pain, I-357–358
postsurgical management, I-373–374
recovery, I-382–383
recovery scale, I-360t
response to, I-356–357
Seddon-Sunderland classification, I-355–356
surgical management, I-365–374, II-321–322
contraindications, I-366–367
indications, I-365–366
timing, I-366–367
surgical repair cascade, I-368f, I-368
third molar extraction, I-82, II-380–382
wrapping for, I-371
Trigeminal neuralgia, definition, I-355t
Trigger point
injection, II-970
myofascial pain and, II-962, II-965f
Trigonocephaly, III-657–659, III-661f–662f
Tripartite process, I-83–84
Trismus
local anesthetics and, I-184
postoperative, I-304
Trunk, soft tissue injury, II-41, II-41–42
Tube-shift technique, I-261f
Tuberculosis, parotitis associated with, II-486–487
Tuberosity
as donor site, I-563
free autogenous graft from, I-556
laser reduction, III-348–349
Tumescent anesthesia, III-430
Tumor
adenomatoid odontogenic, III-744–745
benign, temporomandibular joint, II-850–856
brown, II-464–465
calcifying odontogenic, II-368–371
chondroma, II-475–476
classification, II-599
craniofacial, III-738–739
craniomaxillofacial, pathology, III-741–769
desmoplastic fibroma, II-476–478
epithelial odontogenic, II-435
giant cell, II-464
growth, II-600
Tumor *(Continued)*
head and neck, II-721
hemangioma, II-534
hyperparathyroidism and, II-464
immunohistochemistry for diagnosis, II-333–334
of infancy, II-535
infantile endothelial, II-535
infantile hemangioma, II-534–536
keratocystic odontogenic, II-348–361
malignant, pediatric, III-757–763
malignant mixed, II-493t
mandibular, I-675f–677f
margin, II-728
maxillary, I-675f–677f
melanotic neuroectodermal, III-757
mesenchymal odontogenic, II-435–444
neovascularization, II-617–619, II-628
neurogenic, II-472
nonodontogenic, III-745–757
nonsalivary, II-500–503
odontogenic, II-391–461, III-741–745
odontogenic mixed, II-444–455
oral cavity, II-740–741, III-742t
osteoblastoma, II-473–474
osteochondroma, II-476
osteoma, II-475
parameningeal, III-760–762
parotid gland, II-494–496
pediatric, reconstruction, III-763–769
primary, in squamous cell carcinoma, II-679, II-726t
salivary gland, II-482, II-492–503, III-763
stroma, II-600
surgical pathology and management, II-391–461
targeted therapy based on, II-627–629
temporomandibular joint, II-848–858
third molar removal and, I-284
tongue, III-740–741
Warthin, II-482, II-493t, II-495
Tumor-associated macrophage (TAM), II-620–621
Tumor dormancy therapy, II-628
Tumor necrosis factor-alpha receptor (TNFR), II-614–615
Tumor-node-metastasis (TMN) staging
for rhabdomyosarcoma, II-655t
for skin cancer, II-725–726
Tumor suppressor gene, II-602–603, II-609, II-614
apoptosis suppression and, II-627–628
p16, II-616
p53, II-614, II-616, II-625
reduction of function, II-614
Tumorigenesis, II-599–601
apoptosis resistance, II-614
genetic events leading to, II-603
progression of, II-602
Tuned-aperture computed tomography (TACT), II-824
Turbinate, modification of, III-381
Twitter, marketing and, I-105–106
Two-flap palatoplasty, III-534, III-542

U

Ulcer
aphthous, III-354
herpetic, III-354
Ultane. *See* Sevoflurane (Ultane)
Ultrasonography
facial nerve imaging, II-100
nerve assessment, II-81
osteoradionecrosis, II-595–596
salivary gland, II-481–483
temporomandibular joint, II-826
Ultrasound
for osteoradionecrosis, II-595–596
for temporomandibular joint disorders, II-876
Ultraviolet light
exposure, melanoma associated with, II-690–691
skin cancer associated with, II-722–723
Ultraviolet radiation, skin cancer associated with, II-722–723
Umbrella graft, III-374
Underwood septa, I-509–510
Unilateral cleft deformity, III-563–565
United States Air Force, I-29–30
United States Army, I-24–26
United States Army Dental Corps, I-24–25
United States Navy, I-26–29
United States Public Health Service, I-30–31
Unprofessional behavior, I-4
causes, I-6
types of, I-7
Upper airway resistance syndrome, III-351
Upper respiratory infection (URI), pediatric anesthesia and, I-243–244
Uranoplasty, III-551
Urinary bladder mucosa, for temporomandibular joint disc repair, II-915
U.S. Food and Drug Administration (FDA), codeine warning from, I-253–254
Uvula, bifid, III-618–619
Uvulopalatopharyngoplasty (UPPP), III-268, III-351–352

V

VA. *See* Veterans Affairs (VA)
Vacuum-assisted closure device, II-732
Valacyclovir, II-554, II-556
Valdecoxib, II-871t
Van der Woude syndrome, III-493–494
Van Langenback, B. V., III-2
Vancomycin, parotitis treated with, II-486–487
Vaporization, laser for, I-330
Varicella zoster virus (VZV), II-102
Vascular anomaly
classification, II-535b
etiology, II-534
oral and maxillofacial, II-534–549
of oral and maxillofacial region, II-534–549
PHACE, II-536
Vascular endothelial growth factor (VEGF), II-257–258, II-618–619
Vascular malformation, II-534, II-538–547
definition, II-534
fast-flow, II-544–547
lymphatic malformation, II-539–542
slow-flow, II-538–544
venous malformation, II-543–544
Vascular system, rhytidectomy evaluation and, III-327–328
Vascularized interpositional graft, I-558, I-560f
Vasoconstrictor drugs, I-178–182
benefits, I-180
complications, I-182b
concentration, I-180
drug interactions, I-181
maximum dosage, I-181–182
selectivity and potency, I-180t
side effects, I-180–181
Vasodilation, opioids associated with, I-226
Vasopressor drugs, I-178–182
Veau, Victor, III-535
Veau-Wardill-Kilner palatoplasty, III-538f, III-541–542
Vein(s)
forehead, III-399
frontal sinus, II-230–231
jugular, rhytidectomy evaluation and, III-328

Vein(s) *(Continued)*
nasal, II-177
sentinel, III-399
Velopharyngeal dysfunction, III-540–541, III-568–569
alveolar anomaly, III-569
behavioral approaches, III-579–580
causes, III-569–570
consonants affected by, III-569t
dental anomaly, III-569
diagnosis, III-541
evaluation, III-572–578
management, III-578–580
secondary surgery, III-579, III-612–616
speech appliances, III-579
Velopharyngeal incompetence, III-540–541
Velopharyngeal insufficiency, III-497, III-540–541
after cleft palate repair, III-612–615
in oculoauriculovertebral spectrum, III-692
secondary surgery, III-615–616, III-618
surgical management, III-547, III-616–618
Velopharyngeal mechanism, III-612–615, III-614t
Velopharyngeal sphincter, III-607
Velopharynx
anatomy, III-535–536, III-536f
in cleft maxilla, III-607
Veloplasty, intravelar, III-535–536, III-538, III-539f, III-612–615
Velum, III-535, III-612–615
reconstruction, III-537
in two-stage palatal repair, III-549–550
Vemurafenib, II-701–704
Venlafaxine (Effexor XR), II-955t, II-956
Venous malformation, II-543–544
Venous thromboembolism (VTE), III-298, III-299t
Ventilation
age values, I-241t
bag-mask, II-13
monitoring, for pediatric patient, I-244
pediatric, I-241t
in trauma patient, II-9
Ventriculoperitoneal shunt, III-676
Veracity, principle of, I-10–11
Verrill sign, I-192–194
Verstran. *See* Prazepam (Verstran, Centrax)
Vertical distraction osteogenesis, I-532
Vertical maxillary excess (VME), III-153, III-156f–157f, III-642
Vesiculobullous disease, II-550–574
Vestibular incision subperiosteal tunnel access (VISTA), I-561–563, I-564f–566f
Vestibuloplasty, laser, III-350–351
Veterans Affairs (VA), oral and maxillofacial surgical practice in, I-31–33
Vicodin. *See* Hydrocodone (Vicodin)
Video nasendoscopy, III-575–576
Videofluoroscopy, III-575
Videolaryngoscope, II-14
Vinblastine, II-714, II-757t
Vincristine, II-455, II-713, II-756t
Vinorelbine, II-757t
Virtual surgical planning (VSP), III-114, III-173–174, III-174f
for inverted L osteotomy, III-120, III-128f–130f
in orthognathic surgery, III-190
protocol, III-120f
for temporomandibular joint total replacement, III-229–232
Virus, oral cancer associated with, II-672
Vision
in craniosynostosis care algorithm, III-672
craniosynostosis effects, III-647
Vision *(Continued)*
loss of, after head injury, II-204
in oral and maxillofacial surgical practice, I-109
in Treacher Collins syndrome, III-706
zygomatic injury repair and, II-193
Vistaril. *See* Hydroxyzine (Vistaril)
Vital capacity
age values, I-241t
pediatric, I-241t
Vital signs
by age, I-239t
anesthetic recovery and, I-222
pediatric, I-239t
in trauma patient assessment, II-10
Vitamin E, for mucositis, II-760–761
Vitek Teflon-Proplast implant, II-772
Vitiligo, skin resurfacing and, I-345–346
Voice, disorders, III-572
Vomiting
anesthetic recovery and, I-222
in pediatric patient, I-253
postoperative, III-314
Von Graefe, Carle, III-534
Von Langenbeck, Bernhard, III-534
Von Langenbeck palatoplasty, III-537f, III-542, III-611
Von Recklinghausen disease, III-753–755
Von Willebrand disease, I-161

W

Wakely, Cecil, II-769
Waldeyer ring, II-707, II-710, II-712
Walker, Robert V., III-5
Wallerian degeneration, II-72
Warburg effect, II-601–602
Ward, Sir Terence, II-771
Warfarin
management, I-149t
preoperative management, I-161
Warren, John, III-534
Warthin tumor, II-482, II-493t, II-495
Wassmund, Martin, III-113
Water, absorption spectrum, I-329f
Website
importance of, I-102
marketing, I-103
Webster's triangle, III-379–380
Werner syndrome, II-644
Westergren erythrocyte sedimentation rate, II-840
Wharton's duct, II-483–485
example, II-484f
sialolithiasis, II-488, II-490f
Whole genomic sequencing (WGS), II-623
Wickam striae, II-558
Wilcko, Thomas and William, III-246–247
Wilkes classification, of temporomandibular joint internal derangement, II-905b
Wolff's law, II-151–152
Wolford, Larry, III-5
Work-life balance, I-138–139
World Health Organization (WHO)
cyst classification from, II-339t
odontogenic tumor classification from, II-392
Wound
avulsive facial, II-282
management, II-286b
reconstruction, II-283–300
bite, II-278–279
closure, II-42–44
in internal derangement surgery, II-910
principles, II-10
in craniomaxillofacial trauma, II-2
deep, II-272
Wound *(Continued)*
dog bite, II-62b
ear, pediatric, II-276
facial, I-9, I-665–666, II-41
gunshot. *See* Gunshot wound (GSW)
nasal, pediatric, II-277–278
pediatric, II-272, II-272
puncture, I-301
superficial, pediatric, II-272
tetanus-prone, II-61t
Wound ballistics, II-304–305
Wound care
after orthognathic surgery, III-291–292
scar prevention and, II-234f
Wound closure
ear, II-57
eyelid, II-51–52, II-54f
facial nerve, II-60
forehead, II-50
in Le Fort I osteotomy, III-167–168
lip, II-12–14
nose, II-52–54, II-56f
parotid duct, II-12–13
postoperative care, II-60–61
scalp, II-50
suture materials, II-46t
suture selection, II-46t
Wound healing
barriers, II-258–260
cigarette smoking and, I-433, I-451
diabetes and, I-433
facial resurfacing, III-355–356
failure, in orthognathic surgery, III-320
growth factors in, I-431–432
infection and, I-260, II-433–434
inflammatory response, II-256–257
laser and, I-340
laser surgery, III-348
pediatric injury, II-256–261
principles, II-44–45
proliferative phase, II-257
remodeling phase, II-257
skin cancer, II-731–732
skin resurfacing, I-345
systemic factors and, II-259t
Wright-Giemsa stain, II-331

X

Xanax. *See* Alprazolam (Xanax)
Xenogenic, definition, I-437
Xenogenic collagen matrix (XCM), I-558, I-560–561, I-562f
Xenograft, I-429–430, I-437
bovine-derived, I-441f
materials, I-483
peri-implantitis treated with, I-727f
Xeroderma pigmentosum, II-732–733
Xerostomia
postradiation, II-483
radiation therapy associated with, II-749
in salivary gland disease, II-504
salivary pellicle affected by, II-551
in stomatodynia, II-949

Y

YAG laser. *See* Laser, erbium: yttrium-aluminum-garnet (Er:YAG)
Yaw orientation
in computer-aided surgical simulation, III-38–39, III-120
model surgery and, III-44f
in orthognathic surgery, III-23
YouTube, marketing and, I-105
Yttria-stabilized tetragonal zirconia polycrystal (Y-TZP), I-636

Z
Z-plasty
cleft repair with, III-505, III-507f
double-opposing, III-536, III-543
limitations and complications, III-548
speech and, III-546–547
technique, III-543–546
for labial frenum, I-270
in lingual frenectomy, I-271f
ZAGA classification, I-579f
Zanaflex. *See* Tizanidine (Zanaflex)
Zero-meridian of Gonzales-Ulloa, chin position analysis with, III-460t–461t
Zhao-Brånemark biomechanical analysis, for zygomatic implant, I-576f
Zide Quick Analysis of the Chin, III-460t–461t
Zinc chloride, II-551
Zirconia
for abutment, I-636
disadvantages, I-600
framework with, I-599–601, I-600f–601f
for screw-retained restoration, I-627–628
for single anterior implant, I-630–631
Zoledronic acid (Zometa), II-508t, II-510
Zoloft. *See* Sertraline (Zoloft)
Zone of adherence, III-397–398, III-402–404
Zostrix. *See* Capsaicin (Zostrix)
Zygoma
anatomy, II-189–190, II-190f
growth rate, III-629t, III-630
malunion, II-204–205
Zygoma *(Continued)*
processes of, II-189
reconstruction
in oculoauriculovertebral spectrum, III-695
in Treacher Collins syndrome, III-713–715
zygomatic arch and, II-200
Zygoma complex, II-27t
anatomy, II-189–190
fracture, II-27t
Zygomatic arch, II-189
cross section, III-402f
fracture, II-200–207
surgical approaches, II-199–202
Zygomatic complex, surgery, II-193–194
Zygomatic fracture, II-22–24, II-25f, II-27t, II-189–210
Carroll-Girard screw, II-193–194
complications, II-202–207
diplopia caused by, II-203–204
enophthalmos caused by, II-205–206
fixation, II-200
malunion, II-204–205, II-226
management, II-189–210
patient history, II-190–191
pediatric, II-243
physical examination for, II-190–191
radiography for, II-191–193
retrobulbar hemorrhage caused by, II-206–207
soft tissue complications, II-203
surgery, II-191–194
coronal approach, II-199–200
eyebrow approach, II-195–196
Zygomatic fracture *(Continued)*
lower eyelid approach, II-196
subciliary approach, II-197–198
subtarsal approach, II-198–199
transconjunctival approach, II-196–197
upper eyelid approach, II-194–195, II-195f
vestibular approach, II-194
treatment, II-193
Zygomatic implant, I-569–583, I-678–679
axis, I-573f
deformation under function, I-571–573
design, I-573
historical perspective, I-569–570
occlusal loading, I-572f
patient selection, I-570
postoperative care, I-578
preoperative considerations, I-573
prosthesis fabrication, I-581–582
prosthetic conversion technique, I-577–578
radiographic evaluation, I-570–571
sinus infection associated with, I-579–581
stress under load, I-572, I-572f
surgical complications, I-579–581
surgical options, I-573
surgical protocol, I-574–577
trajectory, I-572–573, I-576–577
Zygomatico-orbital reconstruction, in Treacher Collins syndrome, III-725f–729f
Zygomaticofrontal region, surgical approaches, II-194–196
Zygomaticomaxillary buttress, II-211
Zygomaticomaxillary complex, II-192f

This page intentionally left blank

ORAL AND MAXILLOFACIAL SURGERY

third edition

VOLUME 3

Orthognathic Surgery
Esthetic Surgery
Cleft and Craniofacial Surgery

This page intentionally left blank

ORAL AND MAXILLOFACIAL SURGERY

third edition

VOLUME 3

Orthognathic Surgery
Esthetic Surgery
Cleft and Craniofacial Surgery

VOLUME EDITOR

Raymond J. Fonseca, DMD
Private Practice
Oral and Maxillofacial Surgery
Asheville, North Carolina;
Clinical Professor, Department of Oral and Maxillofacial Surgery
University of North Carolina
Chapel Hill, North Carolina

SECTION EDITORS

Timothy A. Turvey, DDS, FACS
Bernard J. Costello, DMD, MD, FACS
Ramon L. Ruiz, DMD, MD

ELSEVIER

ELSEVIER

3251 Riverport Lane
St. Louis, Missouri 63043

ORAL AND MAXILLOFACIAL SURGERY, VOLUME 3, THIRD EDITION Set ISBN: 978-0-323-41499-9
Volume 1 ISBN: 978-0-323-41497-5
Volume 2 ISBN: 978-0-323-41496-8
Volume 3 ISBN: 978-0-323-41495-1

Copyright © 2018 by Elsevier, Inc. All rights reserved.
Cover image from Posnick JC: *Orthognathic surgery: principles and practice,* St Louis, 2014, Elsevier.

No part of this publication may be reproduced or transmitted in any form or by any means, electronic or mechanical, including photocopying, recording, or any information storage and retrieval system, without permission in writing from the publisher. Details on how to seek permission, further information about the Publisher's permissions policies and our arrangements with organizations such as the Copyright Clearance Center and the Copyright Licensing Agency, can be found at our website: www.elsevier.com/permissions.

This book and the individual contributions contained in it are protected under copyright by the Publisher (other than as may be noted herein).

Notices

Knowledge and best practice in this field are constantly changing. As new research and experience broaden our understanding, changes in research methods, professional practices, or medical treatment may become necessary.

Practitioners and researchers must always rely on their own experience and knowledge in evaluating and using any information, methods, compounds, or experiments described herein. In using such information or methods they should be mindful of their own safety and the safety of others, including parties for whom they have a professional responsibility.

With respect to any drug or pharmaceutical products identified, readers are advised to check the most current information provided (i) on procedures featured or (ii) by the manufacturer of each product to be administered, to verify the recommended dose or formula, the method and duration of administration, and contraindications. It is the responsibility of practitioners, relying on their own experience and knowledge of their patients, to make diagnoses, to determine dosages and the best treatment for each individual patient, and to take all appropriate safety precautions.

To the fullest extent of the law, neither the Publisher nor the authors, contributors, or editors, assume any liability for any injury and/or damage to persons or property as a matter of products liability, negligence or otherwise, or from any use or operation of any methods, products, instructions, or ideas contained in the material herein.

Previous editions copyrighted 2009 and 2000.

Library of Congress Cataloging-in-Publication Data

Names: Fonseca, Raymond J., editor.
Title: Oral and maxillofacial surgery.
Other titles: Oral and maxillofacial surgery (Fonseca)
Description: Third edition. | St. Louis, Missouri : Elsevier, [2018] |
Includes bibliographical references and indexes.
Identifiers: LCCN 2017002982| ISBN 9780323414999 (set : hardcover : alk. paper) | ISBN 9780323414975 (v. 1 : hardcover : alk. paper) | ISBN 9780323414968 (v. 2 : hardcover : alk. paper) | ISBN 9780323414951 (v. 3 : hardcover : alk. paper)
Subjects: | MESH: Oral Surgical Procedures | Face--surgery | Facial Bones--surgery | Maxilla--surgery
Classification: LCC RD523 | NLM WU 600 | DDC 617.5/2059--dc23 LC record available at https://lccn.loc.gov/2017002982

Senior Content Strategist: Jennifer Flynn-Briggs
Professional Content Development Manager: Jolynn Gower
Publishing Services Manager: Jeffrey Patterson
Senior Project Manager: Mary Pohlman
Design Direction: Ashley Miner

Printed in China.

Last digit is the print number: 9 8 7 6 5 4 3 2 1

ELSEVIER Book Aid International Working together to grow libraries in developing countries
www.elsevier.com • www.bookaid.org

To Chester, Lady, Cheerio, Moxie, Domino, Sasha, Tuxedo, Chairman Meow, Zoey, Apollo, Ayla, Annabelle, and Atticus for enriching our lives.

Raymond J. Fonseca

To my wife, Martha, and my children, Samantha, Amanda, Blake, and Mackenzie, for their patience and understanding.

Timothy A. Turvey

To my family, Jackie, Mia, and Michael, who inspire me every day. To my parents, for giving me every opportunity. To my mentors, including Drs. Thomas W. Braun, Jeffrey Posnick, Raymond Fonseca, and Peter Quinn, for the opportunity to experience their uncommon knowledge, skill, and compassion. To my colleagues and students, for the ever-present scholarly challenge.

Bernard J. Costello

To Drs. Peter D. Waite, Timothy A. Turvey, Jeffrey C. Posnick, and the late Victor J. Matukas, for teaching me by example. To my parents, Ramon R. and Aurora M. Ruiz, for teaching me about the beauty of intellectual pursuit. To my beautiful daughters, Julia, Maia, and Josephine, for their love and joy. To my wife, Laura, whose unconditional love, beauty, sweet intellect, and strength constantly inspire me.

Ramon L. Ruiz

In Memoriam

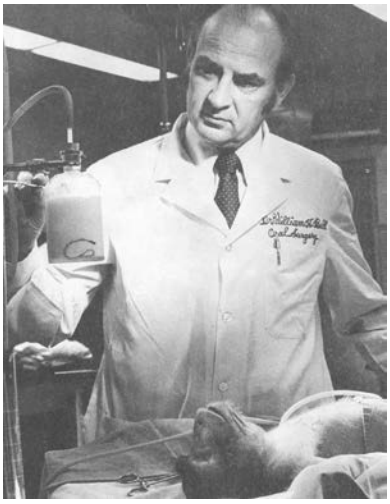

William H. Bell, DDS

We respectfully dedicate this edition of *Oral and Maxillofacial Surgery* to the memory of Dr. William "Bill" Harrison Bell. Matchless among his peers, Dr. Bell was an inimitable leader in surgery and medicine throughout his career.

In the early 1970s, Dr. Bell revolutionized oral and maxillofacial surgery through his landmark research on the biologic basis and clinical rationale for the Le Fort I osteotomy. In subsequent decades, he guided the hands of generations of surgeons, whether in academic medical centers across the world or through his meticulously detailed textbooks. It is a testament to Dr. Bell's always-passionate and always-persistent pursuit of excellence that his textbooks still remain contemporary decades after their publication.

While Dr. Bell was a revolutionary in our field, it is not simply in this spirit that we dedicate this book. Dr. Bell also served as an inspiration and mentor to us throughout our careers and lives, showing us always a readiness to inspire and a passion to change lives however he could. We are, quite simply, not alone in this feeling. It was this passion that compelled him to devote his life to improving patient care. It was this passion that affected so many others in our field. And it was this passion that also characterized so many areas of his vibrant and rich life—a life very well-lived.

It was an honor to learn from and know Bill. He was unwavering and uncompromising, and his love was unconditional. We know that the passion that burned in him to help others will continue to ignite the spirits of generations of surgeons to come. It will guide our hands and our actions as well.

Section Editors

Bernard J. Costello, DMD, MD, FACS
Associate Dean for Faculty Affairs
Professor and Fellowship Program Director
Department of Oral and Maxillofacial Surgery
University of Pittsburgh School of Dental Medicine
Pittsburgh, Pennsylvania

Ramon L. Ruiz, DMD, MD
Director
Pediatric Craniomaxillofacial Surgery
Arnold Palmer Hospital for Children
Associate Professor
Department of Surgery
University of Central Florida College of Medicine
Orlando, Florida

Timothy A. Turvey, DDS, FACS
Professor and Chairman
Oral and Maxillofacial Surgery
University of North Carolina
Chapel Hill, North Carolina

Contributors

David M. Alfi, DDS, MD
Oral and Maxillofacial Surgery
Houston Methodist Hospital
Houston, Texas
Chapter 3: Virtual Treatment Planning for Orthognathic Surgery

Manik Bedi, MD, DDS
Resident
Oral and Maxillofacial Surgery
University of Florida
Gainesville, Florida
Chapter 22: Forehead and Brow Lift

R. Bryan Bell, MD, DDS, FACS
Medical Director
Providence Oral, Head and Neck Cancer Program and Clinic
Providence Cancer Center
Investigator
Robert W. Franz Cancer Research Center
Earle A. Chiles Research Institute
Affiliate Professor
Oral and Maxillofacial Surgery
Oregon Health & Science University
Partner
Head and Neck Surgical Institute
Portland, Oregon
Chapter 7: Inverted L Osteotomy for Management of Severe Mandibular Deficiency with Short Posterior Face Height

[†]William H. Bell, DDS, FACD
Oral and Maxillofacial Surgeon
University of Texas Southwestern Medical Center
Department of Oral and Maxillofacial Surgery
Dallas, Texas
Chapter 12: Intraoral Distraction Osteogenesis

Scott B. Boyd, DDS, PhD
Research Professor
Department of Oral and Maxillofacial Surgery
Department of Neurology, Sleep Disorders Division
Vanderbilt University School of Medicine
Nashville, Tennessee
Chapter 15: Orthognathic Surgery for Obstructive Sleep Apnea

Carolyn Dicus Brookes, DMD, MD
Assistant Professor
Division of Oral and Maxillofacial Surgery
Department of Otolaryngology and Communication Sciences
Medical College of Wisconsin
Milwaukee, Wisconsin
Chapter 15: Orthognathic Surgery for Obstructive Sleep Apnea
Chapter 38: Syndromes with Craniosynostosis: Evaluation and Reconstruction

John F. Caccamese, Jr., MD, DMD, FACS
Associate Professor and Vice Chairman
Oral and Maxillofacial Surgery
University of Maryland Dental School
Clinical Associate Professor, Pediatrics
Clinical Associate Professor, Otorhinolaryngology
University of Maryland School of Medicine
Co-director, Kernan Hospital and Greater Baltimore Cleft Teams
Baltimore, Maryland
Chapter 10: Le Fort I Segmental
Chapter 39: Oculoauriculovertebral Spectrum: Staged Reconstruction
Chapter 41: The Management of Pediatric Craniomaxillofacial Pathology

Bernard J. Costello, DMD, MD, FACS
Associate Dean for Faculty Affairs
Professor and Fellowship Program Director
Department of Oral and Maxillofacial Surgery
University of Pittsburgh School of Dental Medicine
Pittsburgh, Pennsylvania
Chapter 19: The Use of Lasers in Oral and Maxillofacial Surgery
Chapter 23: Liposuction and Fat Transfer Techniques
Chapter 28: Comprehensive Management of Facial Clefts
Chapter 29: Repair of the Unilateral Cleft Lip: A Comparison of Surgical Techniques
Chapter 33: Management of the Cleft Maxilla
Chapter 34: Cleft Orthognathic Surgery
Chapter 35: Revision Surgery for Cleft Malformations
Chapter 36: Craniomaxillofacial Surgery in the Pediatric Patient: Growth and Development Considerations
Chapter 37: Nonsyndromic Craniosynostosis: Diagnosis and Contemporary Surgical Management
Chapter 39: Oculoauriculovertebral Spectrum: Staged Reconstruction

[†] Deceased.

William Curtis, DMD, MD
Oral and Maxillofacial Surgery
New Hanover Regional Medical Center
Wilmington, North Carolina
Chapter 30: Cleft Palate Repair

Angelo Cuzalina, MD, DDS
Cosmetic Surgery, Private Practice
Tulsa Surgical Arts
Chairman, AACS Fellowship Training Program
Adjunctive Faculty, OSU Medical School
Tulsa, Oklahoma
Chairman, AACS Cosmetic Surgery Fellowship Program
2016 President, Cosmetic Surgery Foundation
2013 President, American Board of Cosmetic Surgery
2011 President, American Academy of Cosmetic Surgery
Chapter 22: Forehead and Brow Lift

Enif Dominguez, DDS
Associate Professor
Oral and Maxillofacial Surgery
University of Kentucky
Lexington, Kentucky
Chapter 12: Intraoral Distraction Osteogenesis

Katherine E. Duncan, MD
Clinical Fellow
Orbital, Oculoplastic and Aesthetic Surgery Service
Department of Ophthalmology
University of Pittsburgh Medical Center
Pittsburgh, Pennsylvania
Chapter 21: Blepharoplasty

Elda L. Fisher, DMD, MD
Department of Oral and Maxillofacial Surgery
Adjunct Assistant Professor
University of North Carolina
Chapel Hill, North Carolina;
Attending Staff Surgeon
Veterans Affairs Medical Center
Durham, North Carolina
Chapter 18: Rhytidectomy

Natasha Fürchtgott, DDS, MS
Private Practice
Oral and Maxillofacial Surgery
Puyallup, Washington;
Affiliate Professor, Department of Oral and Maxillofacial Surgery
University of Washington
Seattle, Washington
Chapter 19: The Use of Lasers in Oral and Maxillofacial Surgery
Chapter 35: Revision Surgery for Cleft Malformations

Pamela M. Gallagher, MD
Medical Director
Hagedorn Cleft Palate and Craniofacial Center
North Shore University Hospital
Manhasset, New York
Chapter 30: Cleft Palate Repair

Jaime Gateno, DDS, MD
Chairman
Oral and Maxillofacial Surgery Department
Houston Methodist Hospital
Houston, Texas;
Professor of Clinical Surgery
Oral and Maxillofacial Surgery
Weill Cornell Medical College
New York, New York
Chapter 3: Virtual Treatment Planning for Orthognathic Surgery

Brent Golden, DDS, MD
Assistant Professor
Oral and Maxillofacial Surgery
University of North Carolina
Chapel Hill, North Carolina
Chapter 11: Combined Maxillary and Mandibular Osteotomies
Chapter 38: Syndromes with Craniosynostosis: Evaluation and Reconstruction

Batya R. Goldwaser, DMD, MD
Former Fellow and Resident
Oral and Maxillofacial Surgery
Massachusetts General Hospital
Boston, Massachusetts
Chapter 8: Endoscopically Assisted Mandibular Osteotomies

Marianela Gonzalez, DDS, MS, MD
Clinical Assistant Professor and Director
Undergraduate Education
Texas A&M College of Dentistry
Oral and Maxillofacial Surgery
Baylor University Medical Center
Dallas, Texas
Chapter 12: Intraoral Distraction Osteogenesis

Cesar A. Guerrero, DDS
Assistant Professor
Division of Oral and Maxillofacial Surgery
University of Texas, Medical Branch
Galveston, Texas
Chapter 12: Intraoral Distraction Osteogenesis

Rishi Jay Gupta, DDS, MD, MBA
Staff Surgeon
Surgery (Oral and Maxillofacial Surgery)
Stanford University
Stanford, California;
Staff Surgeon/Assistant Professor
Oral and Maxillofacial Surgery
San Francisco Veterans Affairs Medical Center
University of California
San Francisco, California
Chapter 6: Genioplasty

Charles D. Hasse, DDS, MD
Director
Center for Oral Facial Reconstruction
Hoag Memorial Hospital
Irvine, California
Chapter 14: Surgery for Accelerated Orthodontic Movement

Michael Jaskolka, DDS, MD
Cleft and Craniomaxillofacial Surgery
New Hanover Regional Medical Center
Wilmington, North Carolina;
Adjunct Assistant Professor
Oral and Maxillofacial Surgery
University of North Carolina Hospitals
Chapel Hill, North Carolina
Chapter 11: Combined Maxillary and Mandibular Osteotomies
Chapter 16: Perioperative Management of the Orthognathic Patient
Chapter 30: Cleft Palate Repair
Chapter 37: Nonsyndromic Craniosynostosis: Diagnosis and Contemporary Surgical Management

Lewis C. Jones, DMD, MD
Assistant Professor
Oral and Maxillofacial Surgery
University of Louisville
Louisville, Kentucky
Chapter 16: Perioperative Management of the Orthognathic Patient

Paul Kloostra, DDS, MD
Faculty and Co-Director FACES
Oral and Maxillofacial Surgery
Charleston Area Medical Center
Charleston, West Virginia
Chapter 30: Cleft Palate Repair

James Koehler, MD, DDS
Private Practice
Cosmetic Surgery
Eastern Shore Cosmetic Surgery
Fairhope, Alabama
Chapter 20: Basic Rhinoplasty

Caitlin B.L. Magraw, DDS, MD
Resident Surgeon
Department of Oral and Maxillofacial Surgery
The University of North Carolina at Chapel Hill
Chapel Hill, North Carolina
Chapter 11: Combined Maxillary and Mandibular Osteotomies

Andrei Marechek, DDS
Oral and Maxillofacial Surgery
Case Western Reserve University
Cleveland, Ohio
Chapter 24: Botulinum Toxin and Facial Chemical Peels for Skin Enhancement

Nicholas A. Medel, DDS, MD
Oral Surgeon
Private Practice
Athens Oral and Facial Surgery
Athens, Texas
Chapter 5: Common Mandibular Ramus Osteotomies: Sagittal Split Ramus Osteotomy and Intraoral Vertical Ramus Osteotomy

Gabriele A. Millesi, MD, DMD
Vice President Elect of the IAOMS
Assistant Professor
Medical University of Vienna
Vienna, Austria
Chapter 43: Complications: Maxilla

Mark P. Mooney, PhD
Professor and Chair
Department of Oral Biology
Professor, Departments of Anthropology, Plastic Surgery, Orthodontics, and Communication Science and Disorders
School of Dental Medicine
University of Pittsburgh
Pittsburgh, Pennsylvania
Chapter 36: Craniomaxillofacial Surgery in the Pediatric Patient: Growth and Development Considerations

Elena Victoria Mujica, DDS
Resident
Department of Oral and Maxillofacial Surgery
Central University of Venezuela
Caracas, Venezuela
Chapter 12: Intraoral Distraction Osteogenesis

Sumit K. Nijhawan, DDS, MD
Chief Resident
Department of Oral and Maxillofacial Surgery
Case Western Reserve University, University Hospitals
Cleveland, Ohio
Chapter 26: Facial Implants in Cosmetic Surgery

Esther S. Oh, DDS, MD
Clinical Assistant Professor
Oral and Maxillofacial Surgery
University of Florida
Gainesville, Florida
Chapter 4: Orthognathic Model Surgery

Neil Oishi, DDS, MD
Oral and Maxillofacial Surgery
University of Florida College of Dentistry
Gainesville, Florida
Chapter 4: Orthognathic Model Surgery

Robert A. Ord, MD, DDs, MS
Professor and Chairman
Oral and Maxillofacial Surgery
University of Maryland
Baltimore, Maryland
Chapter 41: The Management of Pediatric Craniomaxillofacial Pathology

Todd G. Owsley, DDS, MD
Private Practice
Oral, Maxillofacial, Facial Cosmetic and Reconstructive Surgery
Greensboro, North Carolina
Chapter 25: Otoplastic Surgery for the Protruding Ear

Bonnie L. Padwa, DMD, MD
Boston Children's Hospital
Department of Plastic and Oral Surgery
Boston, Massachusetts
Chapter 9: Le Fort I

Neeraj H. Panchal, DDS, MD, MA
Faculty
Section Chief, Penn Presbyterian Department of Oral and Maxillofacial Surgery
Section Chief, Philadelphia Veterans Affairs Medical Center
University of Pennsylvania School of Dental Medicine
Philadelphia, Pennsylvania
Chapter 34: Cleft Orthognathic Surgery
Chapter 40: Treacher Collins Syndrome: Evaluation and Treatment

Brian C. Paterson, DMD, MD
Private Practice
Oral and Maxillofacial Surgery
Matawan, New Jersey;
Assistant Attending, Department of Dentistry
Jersey Shore University Medical Center
Neptune, New Jersey
Chapter 19: The Use of Lasers in Oral and Maxillofacial Surgery

Jeffrey C. Posnick, DMD, MD, FRCS(C), FACS
Director
Posnick Center for Facial Plastic Surgery
Chevy Chase, Maryland;
Clinical Professor of Surgery and Pediatrics
Georgetown University
Adjunct Professor of Oral and Maxillofacial Surgery
Howard University College of Dentistry
Washington, DC;
Adjunct Professor of Orthodontics
University of Maryland
Baltimore College of Dental Surgery
Baltimore, Maryland
Chapter 2: Treatment Planning in Orthognathic Surgery
Chapter 40: Treacher Collins Syndrome: Evaluation and Treatment

David S. Precious, DM, DDS, MSc, FRCDC, FRCS, Dhc
Dean Emeritus and Professor
Oral and Maxillofacial Surgery
Dalhousie University
Halifax, Nova Scotia
Chapter 6: Genioplasty

Faisal A. Quereshy, MD, DDS, FACS
Associate Professor/Residency Program Director
Oral and Maxillofacial Surgery
Case Western Reserve University
Cleveland, Ohio
Chapter 24: Botulinum Toxin and Facial Chemical Peels for Skin Enhancement
Chapter 26: Facial Implants in Cosmetic Surgery

Cory M. Resnick, DMD, MD
Oral and Maxillofacial Surgeon
Plastic and Oral Surgery
Boston Children's Hospital and Harvard School of Dental Medicine
Boston, Massachusetts
Chapter 9: Le Fort I

Ann M. Ritter, MD
Clinical Associate Professor
Pediatric Neurosurgery
Richmond, Virginia
Chapter 37: Nonsyndromic Craniosynostosis: Diagnosis and Contemporary Surgical Management

Gerardo P. Romeo, DDs, MD
Associate Residency Program Director of Oral and Maxillofacial Surgery
Division of Oral and Maxillofacial Surgery
North Shore—Long Island Jewish Medical Center
New Hyde Park, New York;
Assistant Professor
Department of Dental Medicine
Hofstra North Shore—LIJ School of Medicine
Hempstead, New York
Chapter 30: Cleft Palate Repair
Chapter 33: Management of the Cleft Maxilla

Ramon L. Ruiz, DMD, MD
Director
Pediatric Craniomaxillofacial Surgery
Arnold Palmer Hospital for Children
Associate Professor
Department of Surgery
University of Central Florida College of Medicine
Orlando, Florida
Chapter 28: Comprehensive Management of Facial Clefts
Chapter 29: Repair of the Unilateral Cleft Lip: A Comparison of Surgical Techniques
Chapter 34: Cleft Orthognathic Surgery
Chapter 35: Revision Surgery for Cleft Malformations
Chapter 37: Nonsyndromic Craniosynostosis: Diagnosis and Contemporary Surgical Management
Chapter 39: Oculoauriculovertebral Spectrum: Staged Reconstruction

Andrew R. Salama, DDS, MD
Assistant Professor
Oral and Maxillofacial Surgery
Boston University, Goldman School of Dental Medicine
Boston, Massachusetts
Chapter 41: The Management of Pediatric Craniomaxillofacial Pathology

Pedro E. Santiago, DMD
Director of Orthodontics, Consulting Associate Professor of Surgery (Craniofacial Orthodontics)
Department of Surgery
Duke University
Durham, North Carolina
Chapter 31: Presurgical Infant Orthopedic Treatment for Patients with Cleft Lip and Palate

Stephen A. Schendel, MD, DDS
Professor Emeritus, Surgery
Adjunct Clinical Professor, Neurosurgery
Stanford University Medical Center
Stanford, California
Chapter 6: Genioplasty

Lindsay A. Schuster, DMD, MS
Director, Cleft-Craniofacial Orthodontics
Pediatric Plastic Surgery
Children's Hospital of Pittsburgh of UMPC
Clinical Assistant Professor of Plastic Surgery
Department of Plastic Surgery
University of Pittsburgh, School of Medicine
Pittsburgh, Pennsylvania
Chapter 31: Presurgical Infant Orthopedic Treatment for Patients with Cleft Lip and Palate

Jocelyn M. Shand, MBBS, MDSc, BDS, FRACDS, FDSRCS
Deputy Head, Oral and Maxillofacial Surgery Unit
Melbourne Craniofacial Unit, Department of Plastic and Maxillofacial Surgery
The Royal Children's Hospital of Melbourne
Melbourne, Victoria, Australia
Chapter 36: Craniomaxillofacial Surgery in the Pediatric Patient: Growth and Development Considerations

Douglas P. Sinn, DDS
Clinical Professor
Oral and Maxillofacial Surgery
University of Texas Southwestern
Dallas, Texas
Chapter 5: Common Mandibular Ramus Osteotomies: Sagittal Split Ramus Osteotomy and Intraoral Vertical Ramus Osteotomy

Kevin S. Smith, DDS, FACS
Professor and Residency/Fellowship Program Director
Oral and Maxillofacial Surgery
University of Oklahoma Health Sciences Center
Co-director, JW Keys Cleft and Craniofacial Clinic
University of Oklahoma
Oklahoma City, Oklahoma;
Co-director, MK Chapman Cleft and Craniofacial Clinic
University of Tulsa
Tulsa, Oklahoma
Chapter 42: Distraction Osteogenesis of the Craniomaxillofacial Skeleton

Andrew M. Sohn, DMD, MD, FACS
Private Practice
North Texas Center OMS
Trophy Club, Texas
Chapter 23: Liposuction and Fat Transfer Techniques

Kathleen K. Sulik, PhD
Professor
Cell and Developmental Biology and Bowles Center for Alcohol Studies
University of North Carolina, Chapel Hill
Chapel Hill, North Carolina
Chapter 27: Orofacial Embryogenesis: A Framework for Understanding Clefting Sites

John F. Teichgraeber, MD
Professor and Chief
Department of Pediatric Surgery
Division of Pediatric Plastic Surgery
The University of Texas Health Science Center at Houston
Houston, Texas
Chapter 3: Virtual Treatment Planning for Orthognathic Surgery

Tinerfe J. Tejera, DMD, MD
Southwest Florida Oral and Facial Surgery
Fort Myers, Florida;
Adjunct Professor
Oral and Maxillofacial Surgery
Nova Southeastern
Davie, Florida
Chapter 25: Otoplastic Surgery for the Protruding Ear

Paul S. Tiwana, DDS, MD, MS, FACS
Sinn Chair and Professor of Oral & Maxillofacial Surgery and Neurological Surgery
Residency Program Director
Division Director Pediatric Oral & Maxillofacial Surgery
University of Texas Southwestern Medical School
Dallas, Texas
Chapter 34: Cleft Orthognathic Surgery

Maria J. Troulis, DDS, MSc
Chief
Oral and Maxillofacial Surgery
Massachusetts General Hospital
Walter C. Guralnick Professor and Chair
Oral and Maxillofacial Surgery
Harvard School of Dental Medicine
Boston, Massachusetts
Chapter 8: Endoscopically Assisted Mandibular Osteotomies

Timothy A. Turvey, DDS, FACS
Professor and Chairman
Oral and Maxillofacial Surgery
University of North Carolina
Chapel Hill, North Carolina
Chapter 1: The History of Orthognathic Surgery
Chapter 34: Cleft Orthognathic Surgery
Chapter 37: Nonsyndromic Craniosynostosis: Diagnosis and Contemporary Surgical Management
Chapter 38: Syndromes with Craniosynostosis: Evaluation and Reconstruction

Harshiv J. Vyas, BDS
Fellow
Department of Oral and Maxillofacial Surgery
University of Pittsburgh Medical Center
Pittsburgh, Pennsylvania
Chapter 23: Liposuction and Fat Transfer Techniques

Ingeborg M. Watzke, DDS, MD
Professor, Head
Competence Center of Oral and Maxillofacial Surgery and Children's Dentistry
SMZ Ost Donauspital Wien
Vienna, Austria
Chapter 17: Mandibular Surgery: Prevention and Management of Complications

Andrew Weeks, DDS, MD
Fellow, Cleft and Craniofacial Surgery
Department of Oral and Maxillofacial Surgery
University of Oklahoma Health Science Center
Oklahoma City, Oklahoma
Chapter 7: Inverted L Osteotomy for Management of Severe Mandibular Deficiency with Short Posterior Face Height

Jenny Yu Will, MD, FACS
Vice Chair, Clinical Operations, Assistant Professor
Ophthalmology
Assistant Professor, Otolaryngology
University of Pittsburgh Medical Center
Pittsburgh, Pennsylvania
Chapter 21: Blepharoplasty

Larry M. Wolford, DMD
Clinical Professor
Department of Oral and Maxillofacial Surgery
Clinical Professor
Department of Orthodontics
Texas A&M University Health Science Center, Baylor College of Dentistry
Dallas, Texas
Chapter 13: Concomitant TMJ Total Joint Prosthetic Reconstruction and Orthognathic Surgery

James J. Xia, MD, PhD, MS
Professor, Oral and Maxillofacial Surgery
Institute for Academic Medicine
Houston Methodist Hospital
Director of Surgical Planning
Oral and Maxillofacial Surgery
Houston Methodist Research Institute
Houston, Texas;
Professor
Surgery—Oral and Maxillofacial Surgery
Weill Medical College at Cornell University
New York, New York
Chapter 3: Virtual Treatment Planning for Orthognathic Surgery

Robin Yang, DDS, MD
Chief Resident
Department of Oral and Maxillofacial Surgery
University of Maryland/Shock Trauma Center
Baltimore, Maryland
Chapter 10: Le Fort I Segmental

Peng Yuan, MS
Chief Software Engineer
Surgical Planning Laboratory
Senior Research Assistant
Department of Oral and Maxillofacial Surgery
Houston Methodist Research Institute
Houston, Texas
Chapter 3: Virtual Treatment Planning for Orthognathic Surgery

David J. Zajac, PhD, CCC-SLP, ASHA Fellow
Professor, Department of Dental Ecology
Director, Speech-Language Pathology, Craniofacial Center
Adjunct Associate Professor, Division of Speech and Hearing Sciences
University of North Carolina
Chapel Hill, North Carolina
Chapter 32: Evaluation and Management of Speech Disorders for the Patient with Cleft Palate

Preface

We are excited to present the third edition of *Oral and Maxillofacial Surgery*. This three-volume text is the result of the collaboration of multiple contributors. The first edition, published in 2000, and the second edition, published in 2009, were very well-received. However, with all the advances in our profession, we felt it was time for a new edition. The section editors have done an excellent job recruiting the most knowledgeable individuals in their specific areas of expertise. The authors have submitted chapters that reflect the state of the art in their areas of responsibility.

This text is a comprehensive resource on oral and maxillofacial surgery. Every area in our specialty has been addressed. It defines the scope of the specialty. Every surgical procedure performed by an oral surgeon is covered in this text. This multi-volume text provides coverage of a wide range of issues related to surgical care, such as anesthesia, diagnostic imaging treatment planning, rehabilitation, physical therapy, and psychological considerations.

After an analysis of the changing field of oral and maxillofacial surgery, we strove to present a comprehensive, current book that covers the complete scope of our specialty. We hope that the reader appreciates and agrees with our efforts. We stated in the preface of the first edition that we hoped that our future attempts will present an even broader scope of oral and maxillofacial surgery. The fact that this edition has succeeded in that regard is a testament to the individuals who are constantly expanding the envelope.

Acknowledgments

The third edition of *Oral and Maxillofacial Surgery* is a team approach. The section editors—Timothy A. Turvey, Bernard J. Costello, and Ramon L. Ruiz—were invaluable contributors to the success of this effort. They diligently pestered authors so that deadlines were almost met. This edition, like the last two, attempts to define the scope of oral and maxillofacial surgery and could not have come to fruition without these contributors.

Residents are the lifeblood of our specialty. Many have helped to contribute portions of chapters in this book. They have also provided us with friendship, dedication, intellectual stimulation and humility, without which this book would not have been written.

Last, I would like to thank all the staff who helped to prepare these manuscripts and the editorial staff at Elsevier, who were so patient with our procrastination, and meticulous in their development and editing of this book. Additionally, I would like to thank my staff—Laynee Adams, Sally Brown, Heather Early, Patty Martin, Sarah Merrill, Josie Ray, and Ashley Wood—who collectively and individually make my life so enjoyable.

Raymond J. Fonseca, DMD

Contents

VOLUME 3 CONTENTS

Orthognathic Surgery, Esthetic Surgery, Cleft and Craniofacial Surgery

Volume Editor: Raymond J. Fonseca

Section 1: Orthognathic Surgery

1 **The History of Orthognathic Surgery 1**
Timothy A. Turvey

2 **Treatment Planning in Orthognathic Surgery 13**
Jeffrey C. Posnick

3 **Virtual Treatment Planning for Orthognathic Surgery 31**
James J. Xia, Jaime Gateno, John F. Teichgraeber, David M. Alfi, Peng Yuan

4 **Orthognathic Model Surgery 44**
Esther S. Oh, Neil Oishi

5 **Common Mandibular Ramus Osteotomies: Sagittal Split Ramus Osteotomy and Intraoral Vertical Ramus Osteotomy 62**
Nicholas A. Medel, Douglas P. Sinn

6 **Genioplasty 96**
Rishi Jay Gupta, David S. Precious, Stephen A. Schendel

7 **Inverted L Osteotomy for Management of Severe Mandibular Deficiency with Short Posterior Face Height 113**
R. Bryan Bell, Andrew Weeks

8 **Endoscopically Assisted Mandibular Osteotomies 144**
Batya R. Goldwaser, Maria J. Troulis

9 **Le Fort I 153**
Cory M. Resnick, Bonnie L. Padwa

10 **Le Fort I Segmental 172**
John F. Caccamese Jr, Robin Yang

11 **Combined Maxillary and Mandibular Osteotomies 183**
Brent Golden, Caitlin B. L. Magraw, Michael Jaskolka

12 **Intraoral Distraction Osteogenesis 196**
Cesar A. Guerrero, William H. Bell, Elena Victoria Mujica, Marianela Gonzalez, Enif Dominguez

13 **Concomitant TMJ Total Joint Prosthetic Reconstruction and Orthognathic Surgery 222**
Larry M. Wolford

14 **Surgery for Accelerated Orthodontic Movement 246**
Charles D. Hasse

15 **Orthognathic Surgery for Obstructive Sleep Apnea 264**
Carolyn Dicus Brookes, Scott B. Boyd

16 **Perioperative Management of the Orthognathic Patient 278**
Lewis C. Jones, Michael Jaskolka

17 **Mandibular Surgery: Prevention and Management of Complications 297**
Ingeborg M. Watzke

Section 2: Esthetic Surgery

18 **Rhytidectomy 325**
Elda L. Fisher

19 **The Use of Lasers in Maxillofacial Surgery 336**
Natasha Fürchtgott, Brian C. Paterson, Bernard J. Costello

20 **Basic Rhinoplasty 364**
James Koehler

21 **Blepharoplasty 388**
Katherine E. Duncan, Jenny Y. Yu

22 **Forehead and Brow Lift 395**
Angelo Cuzalina, Manik Bedi

23 **Liposuction and Fat Transfer Techniques 429**
Harshiv J. Vyas, Andrew M. Sohn, Bernard J. Costello

24 **Botulinum Toxin and Facial Chemical Peels for Skin Enhancement 439**
Faisal A. Quereshy, Andrei Marechek

25 **Otoplastic Surgery for the Protruding Ear 446**
Todd G. Owsley, Tinerfe J. Tejera

26 **Facial Implants in Cosmetic Surgery 458**
Faisal A. Quereshy, Sumit K. Nijhawan

Section 3: Cleft and Craniofacial Surgery

27 **Orofacial Embryogenesis: A Framework for Understanding Clefting Sites 476**
Kathleen K. Sulik

28 **Comprehensive Management of Facial Clefts 491**
Bernard J. Costello, Ramon L. Ruiz

29 **Repair of the Unilateral Cleft Lip: A Comparison of Surgical Techniques 513**
Ramon L. Ruiz, Bernard J. Costello

30 **Cleft Palate Repair 534**
Michael Jaskolka, William Curtis, Paul Kloostra, Gerardo P. Romeo, Pamela M. Gallagher

31 **Presurgical Infant Orthopedic Treatment for Patients with Cleft Lip and Palate 561**
Lindsay A. Schuster, Pedro E. Santiago

32 **Evaluation and Management of Speech Disorders for the Patient with Cleft Palate 568**
David J. Zajac

33 **Management of the Cleft Maxilla 583**
Gerardo P. Romeo, Bernard J. Costello

34 **Cleft Orthognathic Surgery 596**
Paul S. Tiwana, Timothy A. Turvey, Ramon L. Ruiz, Bernard J. Costello, Neeraj H. Panchal

35 **Revision Surgery for Cleft Malformations 609**
Natasha Fürchtgott, Ramon L. Ruiz, Bernard J. Costello

36 **Craniomaxillofacial Surgery in the Pediatric Patient: Growth and Development Considerations 627**
Bernard J. Costello, Mark P. Mooney, Jocelyn M. Shand

37 **Nonsyndromic Craniosynostosis: Diagnosis and Contemporary Surgical Management 645**
Ramon L. Ruiz, Michael Jaskolka, Ann M. Ritter, Timothy A. Turvey, Bernard J. Costello

38 **Syndromes with Craniosynostosis: Evaluation and Reconstruction 667**
Brent Golden, Carolyn Dicus Brookes, Timothy A. Turvey

39 **Oculoauriculovertebral Spectrum: Staged Reconstruction 687**
Bernard J. Costello, Ramon L. Ruiz, John F. Caccamese, Jr.

40 **Treacher Collins Syndrome: Evaluation and Treatment 703**
Jeffrey C. Posnick, Paul S. Tiwana, Neeraj H. Panchal

41 **The Management of Pediatric Craniomaxillofacial Pathology 738**
John F. Caccamese Jr., Robert A. Ord, Andrew R. Salama

42 **Distraction Osteogenesis of the Craniomaxillofacial Skeleton 774**
Kevin S. Smith

1

The History of Orthognathic Surgery

TIMOTHY A. TURVEY

Introduction

This historical account is authored by a North American whose principal language is English. Although there are many foreign references and some written in English that I have not included or have overlooked, my apologies in advance. There is no slight intended.

The author proposes to touch on the major events that shaped the development of orthognathic surgery over 170 years. I would appreciate hearing of any corrections, deletions, and additions from readers. It is only with your comments that an accurate account of orthognathic surgery will pass on to other generations.

The Pioneering Era

Little did Simon Hullihen realize that his 1849 publication would serve as the ignition switch for the development of the subspecialty of orthognathic surgery. His publication is the first known record of an operation performed to address jaw deformity and malocclusion.[1] The significance of this publication is the undertaking of a novel operation to reposition the dentoalveolus of the mandible. Also of significance is that the operation occurred prior to the development of antibiotics or general anesthetics. Another monumental milestone recorded in this manuscript is the recognition that soft tissue scarring which contributed to the patient's skeletal deformity had to be released to improve success. This bold maneuver was not accomplished in a major teaching center with observation theaters; it took place in the rural mining community of Wheeling, West Virginia. Hullihen is the first surgeon in the United States known to limit his practice to the face and neck and is considered the father of oral and maxillofacial surgery in this country.

Mandibular Osteotomies

Not much occurred in the development of mandibular osteotomies until near the end of the 19th century when several French surgeons, Jaboulay, Berard and Berger, published on subcondylar osteotomies for correction of prognathism.[2,3] In the United States, Whipple and Angle, both orthodontists, reported cases of prognathism correction in 1898.[4,5] The surgeons involved were Harvey Mudd and Vilray Blair. Blair was a general surgeon by training but his interest in mandibular corrective surgery led to the publication of several textbooks on this topic. Blair recognized the importance of orthodontic involvement in jaw surgery and relied on the expertise of Angle—who is considered the father of orthodontics—and others in the dental profession for guidance and advice. Blair and Angle seemed to have mutual respect and collaborated but never published together. Both were prolific writers and documented their experiences well.[6-9] Angle published seven editions of a textbook, *Treatment of Malocclusion of the Teeth and Fractures of the Mandible,*[10] and documented several orthognathic surgical cases. Blair's book on *Surgery of the Mouth and Jaws* (Mosby) was also published in several editions and he also documented multiple osteotomy case. It appears that they were the first surgeon/orthodontist team whose work paved the way for the future. They recognized the importance of surgical and orthodontic collaboration and discussed pre- and postsurgical orthodontic treatment, timing and sequencing of surgery, and growth considerations. Most of Blair's early surgical experience was in the body of the mandible, which he approached through neck incisions. By 1915 he altered his approach to the vertical ramus of the mandible.

Kostecka, a Czech surgeon, led the mandibular surgery pioneering efforts in Eastern Europe and performed ramus osteotomies with a closed, Gigli saw approach while the French continued to favor subcondular osteotomies.[11] Although Kostecka's procedure could be done as an open or closed technique, there were many complications with both approaches including nonunion, relapse, nerve injury, scarring, and parotid fistulas.

By 1932 American surgeon Kazanjian reported a 2-stage mandibular body osteotomy technique, which was conducted through premolar extraction sites. He experienced infection when he attempted a single-stage (intraoral and

neck approaches) operation and reported better results when staging the procedure.[12,13] Dingman, another American, published on mandibular body osteotomies as well. He advocated preservation of the inferior alveolar nerve.[14,15]

In 1945 Sanford Moose, a U.S. surgeon, introduced an intraoral approach to the ramus of the mandible for correction of prognathism. Another American, Sloan, described a similar approach in 1951, and Moose published refinements of the technique in 1964.[16-18] By 1956 Robinson published on correction of prognathism via an extraoral vertical ramus osteotomy.[19,20] Thoma published on a similar procedure shortly after.[21] In 1954 Caldwell and Letterman proposed a vertical ramus osteotomy done through a neck incision and they reported good results.[22] They advocated decortication of the bone segments to promote wound healing. This maneuver was studied extensively by Boyne using tetracycline staining in a monkey model. Boyne's findings suggested that the maneuver was unnecessary for bone healing.[23] Caldwell, Haywood, and Lister published on the inverted L osteotomy primarily for mandibular advancement in 1968.[24]

Genioplasty

A German surgeon, Hofer, first described a genioplasty conducted on a cadaver in 1942.[25] It wasn't until 1957 that Trauner and Obwegesser published the intraoral horizontal osteotomy of the inferior border leaving the free segment pedicled to the lingual musculature.[26,27] Stability and outcome of this procedure was far superior to the free grafts suggested by Converse in 1950, who placed the bone grafts intraorally to help project the chin further forward.[28] Since then many modifications have been described to enhance the results of this procedure but the basic principle of a pedicled bone graft remains. Those who have published on this include Schendel, Triacca, Precious, and others.[29-31]

Segmental Maxillary and Mandibular Osteotomies

In 1959 an Austrian surgeon, Köle, published in the American literature on maxillary and mandibular subapical osteotomies.[32] These procedures were performed more commonly in Europe at the time while they were relatively unheard of in the United States. Cohn-Stock from Berlin initiated enthusiasm for segmental maxillary osteotomies, which he published in 1921.[33] Some consider him to be the father of maxillary osteotomy techniques.[34] Later reports by Wassmund, Axhausen, Immenkamp, Wunderer, Cupar, and others documented extensive experience with these and other osteotomies of both jaws by the Germans and Austrians.[33-40] A textbook co-authored by Reichenbach and Köle and published in 1964 served as the resource for many surgeons wanting to learn these techniques.[41] Although multiple authors described different soft tissue incisions, they all stressed the need for maintaining well-perfused vascular pedicles to the mobilized dento-osseous segments. There were concerns expressed about bone healing, soft tissue healing, and tooth survival but little non-human experimentation was evident at this time.

Sagittal Osteotomy

In 1953 Obwegeser performed the first sagittal osteotomy of the mandible and he reported this in 1955.[42] This operation was inspired by Schlossman, described by Perthes and Schuchardt, but completely described, performed, and published by Trauner and Obwegeser.[43-46] By 1959 Obwegesser had moved from Graz to Zurich and had accumulated considerable experience with the procedure. Although modifications of the procedure have been published by Obwegeser himself, multiple other surgeons have modified the procedure to fit their own needs, including Dalpont, Hunsuck, Epker, Bell, and others.[47-50] The major advantages of this operation were the lack of scar, because it was conducted transorally, and the wide surface area of cancellous bone, which helped promote healing and obviate the need for bone grafting.[51] The advantages of a transorally conducted ramus osteotomy were recognized by Obwegeser and the earlier pioneer Moose.[16]

Total Mandibular Subapical Osteotomies

Macintosh, an American who spent 2 years at Obwegeser's clinic in Zurich in the late 1960s, described a unique operation that mobilized and repositioned the entire mandibular dentoalveolar. This was published in 1973 and again in 1975 with Carlotti to demonstrate the procedure's efficacy for treating anterior open bite.[52,53] As with all operations, modifications were made by multiple other surgeons, including Booth and Buckley.[54,55]

Maxillary Osteotomies

The introduction of maxillary osteotomies lagged behind mandibular osteotomies. Von Langenback, a German surgeon of remarkable talents, originally published a technique for infracturing the maxilla unilaterally for tumor access in 1849.[56] Billroth was another early pioneer of maxillary mobilization for surgery access. He was a very popular Viennese surgeon whose image appeared on Austrian coins and stamps in honor of his surgical talents. There remains a beautifully restored meeting hall in Vienna bearing his name as a tribute to his surgical legacy. Cheever, an American, published what appears to be a down fracture of the entire maxilla in 1867.[57-59] This procedure too was done for tumor access. Other surgeons who published on maxillary osteotomies early on commented about the blood loss and difficulty with the operation.

In 1927 Wassmund from Berlin (a student of Cohnstock) published on complete maxillary osteotomy to correct post-traumatic malocclusion. During the operation he never released the posterior attachments of the maxilla to the pterygoid plates and relied on postsurgical traction to achieve the desired movement.[35,36]

Auxhausen, another Berlin surgeon, described osteotomy of the maxilla in 1934.[37] This is the first recording of complete osteotomy of the maxilla with the release of the pterygoid plates and repositioning. Most surgeons around the world would not undertake this type of surgery for fear of blood loss, necrosis, and difficulty performing the procedure. The early pioneers who performed this surgery used multiple vertical incisions on the buccal, or transfacial incisions to maintain blood supply. Some used palatal incisions as well and others staged the procedure.[56-64]

When the great wars occurred, there was tremendous need for facial reconstruction of the wounded and the disfigured survivors. Ganzer, Pichler, Gilles, Rowe, Killey, Kazanjian, Schuchardt, Schmidt, and many other surgeons on both sides of the Atlantic developed extensive experience caring for the facially disfigured as a result of these catastrophic events. The major beneficiaries of these horrific events were not the war injured but the patients with dentofacial and craniofacial anomalies who eventually benefited from the learning experiences created by the victims of war injuries. These war-related experiences further encouraged the development of facial osteotomies and orthognathic surgery for congenital and developmental problems.

It is not surprising that the decades from 1950 through 1970 were very productive times for many surgeons worldwide who recognized the functional and esthetic benefits of jaw repositioning surgery not just for the war injured or post-trauma patients but also for those with birth or developmental defects. This seemed to have occurred more in Europe than in the United States.

By 1959 Obwegeser recognized the importance of separating the pterygoid plates and completely mobilizing the maxilla for success with maxillary surgery. He encouraged the use of bone grafts in the defects to help with healing.[43] By 1969 he had gained enough experience with complete mobilization and repositioning of the maxilla as well as utilizing a circumvestibular incision, that he published the technique in English.[65] It is notable that several of the cases required segmentation of the maxilla in 2 pieces. Converse and Shapiro and Dingman and Harding described performing LeFort I osteotomies in 1951 and 1952.[15,60] Gilles and Rowe also published on total maxillary segmental osteotomy in 1954 but they relied on postsurgical elastic forces to reposition the maxilla.[61] Karl Hogeman from Malmo was another early pioneer of LeFort I osteotomy, and most of his early experience was with cleft lip and palate patients.[66] He accumulated enough experience by 1973 that he and Willmar published a report on more than 100 patients undergoing the procedure.[67] Most others shied away from maxillary osteotomies in the United States. The diagrams of Converse's operation leave doubts about the survivability of the maxilla with both palatal and buccal flaps being elevated as extensively as is illustrated. Converse mentions in his article incomplete bone coverage at the completion of surgery and problems with bone sequestration following surgery; however, he did not indicate loss of teeth or substantial amounts of bone following this operation. He did not publish the postoperative photographs but provided only a short description of the postoperative course.[60] Dingman's approach to LeFort I osteotomy was confined to a vestibular incision, bone cuts and then impression trays, cement, and brute force as well as external traction to complete the repositioning effort. Dingman offered postoperative photographs with external traction in place approximately 3 weeks following surgery.[15] These two pioneering efforts set the stage for Obwegeser's later visit to the United States.

Posterior Maxillary Osteotomies

Schuchardt, a student of Wassmund's who relocated to Hamburg, introduced a two-stage posterior maxillary osteotomy technique for closure of anterior open bite in 1955.[62] Schuchardt was obviously aware of the esthetic issues of trying to close open bite with anterior maxillary osteotomies only and proposed that moving the posterior maxilla superiorly would facilitate closure of the bite while maintaining good upper lip to incisor relationships. During the first stage of Schuchardt's posterior maxillary osteotomy a palatal flap and bone cuts were made. The palate was sutured and three weeks later the buccal osteotomies were performed as well as pterygoid maxillary separation. A mallet and soft wooden wedge were then used to drive the posterior maxilla superiorly into the sinus. When the procedure was done with local anesthesia, the patient was asked to bite forcefully to help with the mobilization. By 1960, Josef Kufner from Prague published a single-stage posterior maxillary osteotomy for open bite closure. This was written in his native Czech language and not many people were aware of the contribution until he published and presented it in English in 1968 at the 3rd International Congress on Oral Surgery.[68,69] The approach was all buccal with transantral access to the palate. The virtues of a transantral approach to maxillary osteotomies was later described in detail by Perko.[70] The usefulness and stability of this procedure was further elaborated by West and Epker and Stoker and Epker.[71,72]

Complete Maxillary Osteotomy in Multiple Segments

Mobilization of the entire maxilla at LeFort I level and then segmenting it had been described by multiple pioneer surgeons including Auxhausen, Gilles, Rowe, and Obwegeser as well as many others. Most of the early reports involved cleft palate or trauma victims. During the evolution of orthognathic surgery, advancement, widening, leveling, and space closure in the maxillary arch were recognized issues that were addressed and the details of the procedure were later described and illustrated thoroughly by Epker, Wolford, Bell, and others.[73-75]

Simultaneous Mobilization of the Entire Maxilla and Mandible

Hogeman and Obwegeser were early pioneers of simultaneous mobilization of the entire maxilla and mandible.[66,76]

Obwegeser indicates that his first experience took place in 1965.[76] Köle was a champion of simultaneous maxillary and mandibular osteotomies but his experience did not involve complete mobilization of both jaws.[32] Mohnac, an American surgeon, published his experience with simultaneous mobilization of the maxilla and mandible in 1965. Like Köle, his cases did not involve complete mobilization of the entire maxilla and mandible conducted simultaneously.[77]

In 1975 two Americans, Gross and James, reported their experiences with simultaneous mobilization of the entire maxilla and mandible.[78] Lindorf and Steinhauser from Ehrlagen reported their experiences in 1978.[79] By the early 1980s the timing and sequencing of simultaneous complete mobilization of the maxilla and mandible had been described in detail and many Americans adopted the procedures, recognizing the benefits.[80-83]

Higher Level Mid-face Osteotomy

The development of higher level mid-facial osteotomies was much slower in comparison to the lower level procedures. Gilles and Harrison are credited with publishing the first attempt of a LeFort III osteotomy accomplished in 1950.[84] Although Gilles performed several of these procedures on post-trauma and congenital malformation patients, he indicated that the complexity and difficulty of the procedure should carefully be considered before it is attempted.[61,84] There were several others who pioneered high level mid-facial osteotomies, including Burien who was assisted by Kufner. They attempted LeFort III osteotomy in 1958 in Prague.[85] In 1967, Paul Tessier stunned the world when he presented very impressive results of LeFort III osteotomy for patients with Crouzon and Apert syndrome as well as malunited mid-facial fractures. At the same time he also introduced the transcranial approach to orbital hypertelorism correction.[86-88] The enthusiasm created by his and Obwegesser's accomplishments inaugurated the development of craniofacial surgery.

In the decade between 1970 and 1980 multiple surgeons described a variety of high level mid-facial osteotomies, including Murray, Converse, Edgerton, Epker, Wolford, Psilakis, Henderson, and Jackson.[89-97] Sailer from Zurich described combining LeFort I with LeFort III mid-facial osteotomies to address anterior open bite simultaneously with mid-face advancement.[98]

The Discovery Phase

The pioneering phase of orthognathic surgery demonstrated that surgery for repositioning the facial skeleton was possible. During the discovery phase, surgeons learned the indications and contraindications of these interventions, the biologic and physiologic basis of these procedures were delineated, and instrumentation was developed, manufactured, and sold to facilitate the performance of surgery. Treatment outcomes were studied extensively and safe anesthetic techniques were also developed. Refinements of the basic techniques described by the pioneers were numerous.

Nothing was more seminal to the development of orthognathic surgery worldwide than Obwegeser's visit to the Walter Reed Army Hospital in Washington, D.C. This occurred in June of 1966 when Robert Shira invited Obwegeser to lecture about the techniques of orthognathic surgery and other maxillofacial surgical procedures that he pioneered. Shira was then a U.S. Army General and oral and maxillofacial surgeon who was impressed with Obwegeser's work. He invited more than 500 U.S. oral surgeons to the lectures and the event breathed new life into a fledging specialty in the United States. At that time oral and maxillofacial surgery was under siege by a group of postwar influential and disgruntled competitors who tried desperately to discredit the specialty and bar its practioners from hospitals through their influence with hospitals and with hospital accreditation groups. The stimulation of Obwegeser's presentations empowered the specialty with new meaning and relevance to health care. With levelheaded leadership and perseverance by people like Fred Henny, R.V. Walker, Scott McCallum, Elmer Bear, and Daniel Laskin this specialty resurrected itself in health care and gained increased relevance within hospital communities.

During Obwegeser's visit he demonstrated his famous sagittal split osteotomy for both advancement and setback of the mandible. He also demonstrated segmental maxillary and mandibular surgery as well as LeFort I level maxillary osteotomy. These lectures also included many cleft and preprosthetic surgical applications.

After Obwegeser's presentation in 1966, it didn't take Americans long to accumulate experience with the procedures demonstrated. Walker, Bell, Costich, White, Hinds, and many others quickly adopted Obwegeser's techniques in their practices. Just as important, they began to publish their experiences.

Within two years of Obwegeser's lecture, White published on his experience with sagittal osteotomy in 17 patients followed for more than a year and Bell published on anterior maxillary osteotomy in a similar time frame.[99,100] Kent and Hinds also published on anterior maxillary and mandibular osteotomies.[101] Friehofer and others began to examine the results of patients treated in Zurich.[102,103]

After Obwegeser's visit, an American tradition had a breakthrough. Although Vilray Blair and Edward Angle both published in the early 20th century and indicated the importance of interdisciplinary collaboration, they never published together. Prior to Obwegeser's visit, Converse and Shapiro and later Converse and Horowitz published together.[60,91] After Obwegeser's visit, a cascade of teams of surgeons and orthodontists began publishing in the United States. These included R.V. Walker and Phelps Murphy, William Bell and Tom Creekmore, William Ware and Don Poultan, Bruce Epker and Chuck Fish, Raymond White and William Proffit, Larry Wolford and Frank Hilliard, Roger West and Bill McNeil. By publishing in tandem, these discoverers were able to establish the credibility of orthognathic surgery to both the surgical and orthodontic communities. From these early reports, techniques were modified, safety

of treatment improved, problems were identified, instruments were developed, anesthetic protocols were defined, and studies ensued to determine and improve outcomes.

The benefits of orthognathic surgery were recognized and extended to the preprosthetic populations early on. Kazanjian published on the correction of mandibular prognathism to assist denture construction in 1932.[12] West and Burk published on using maxillary osteotomy techniques and applying it to the preprosthetic population.[104] This was followed later by publications involving the posterior maxilla.[105] Eventually, Sailer and others published on using orthognathic surgery in conjunction with bone grafting and implant rehabilitation simultaneously to improve the outcomes of preprosthetic patients.[106]

Pivotal to the worldwide acceptance of orthognathic surgery as a legitimate treatment option for dentofacial and craniofacial abnormalities were the works of William Bell, whose revascularization studies provided a biologic basis for many of the commonly performed surgical procedures. Mohnac's communication to Bell in the late 1960s about the vascularity of the maxilla stimulated Bell to pursue investigations of flap design applicable to LeFort I osteotomy. Using the microangiography techniques of Rhinlander, Bell and many of his students and colleagues studied wound healing following facial osteotomies.[107-111] Without Bell's works and investigations, skeptics' doubts and questions about the soundness of orthognathic surgery would still be looming.

Orthodontist William Proffit studied and published extensively on the physiologic adaptations that occur with orthognathic surgery and the stability of the changes. Bite force changes, lip and tongue pressure changes, airway and breathing pattern changes, neurosensory changes, speech and velopharyngeal function changes, and psychosocial changes were studied extensively.[112] In addition to Proffit, there were multiple other investigators who pursued these same studies. Proffit was awarded an NIH grant to study the long-term stability of orthognathic surgery in 1979 and this grant remained funded for more than 35 years. Throughout the lifetime of this grant, there were more than 300 manuscripts and a similar number of abstracts published on the subject. Proffit teamed with biostatistician and clinical researcher Ceib Phillips, as well as a cadre of others, and learned and shared more about the stability of orthognathic surgery than is even known about conventional orthodontics.[113,114] The data bank built as a result of this effort includes the records of more than 8,000 patients at the University of North Carolina.

Another monumental step toward the acceptance of orthognathic surgery was the publication of major textbooks dedicated to the subject. Liberally and beautifully illustrated, these classic texts made it easier for other surgeons to follow the steps of orthognathic surgery and avoid the pitfalls of the early pioneers. The three-volume text by Bell, Proffit, and White and the textbook by Epker and Wolford are highly relevant to the development of orthognathic surgery.[73,74] Prior to 1980 there were two textbooks published on orthognathic surgery. Steinhauser cites the textbook of Reichenbach, Köle, and Schuchart as the authoritative reference for European maxillofacial surgeons.[41,115] In 1972 Hines and Kent from Houston published the first textbook on orthognathic surgery that was written in English.[116] Bridging the gap from 1980 until recently were four additional texts by Proffit and White and by Epker and Fish that documented advances in treatment and research.[117-120] Today there are multiple texts published in a variety of languages on orthognathic surgery, including a recent comprehensive treatise by Posnick.[121]

Throughout the 1970s and 1980s, there were multiple modifications to surgeries described, surgical and orthodontic protocols were developed, and instruments were designed and manufactured. Although the Europeans pioneered the development of orthognathic surgery, Americans and Europeans took it to the next level primarily by promoting surgical and orthodontic interaction and in developing reliable and well-designed instruments and power equipment to conduct these operations.[122,123]

Another seminal step in the acceptance of orthognathic surgery was the continuing education efforts via seminars, lectures, and mini residencies conducted by Bruce Epker, Larry Wolford, William Bell, Raymond White, Raymond Fonseca, and these surgeons included their orthodontic collaborators Charles Fish, Frank Hilliard, William Proffit, Harry Legin, David Hall, John Casko, and Robert Vanarsdale in the education of surgeons and orthodontists. In no other area of interest in oral and maxillofacial surgery has there ever been as much continuing education offered.

Bruce Epker is a prolific writer and speaker whose works helped to demystify orthognathic surgery. He confronted the issues of importance with surgical techniques, instrumentation, stability, and adaptation with the methodical approach of a scientist as well as a clinician. Analysis of results with data and statistical review were critical parts of his works.

Larry Wolford, a very talented surgeon with gifted dexterity, often combined TMJ surgery with orthognathic surgery and introduced total alloplastic joint replacement with orthognathic surgery.

The charismatic Robert V. Walker was responsible for recruiting William Bell and Bruce Epker to the faculty at the University of Texas Southwestern Health Science Center in Dallas, and to the oral and maxillofacial surgery faculty of Parkland Memorial Hospital and John Peter Smith Hospital. He provided a pathway and atmosphere for these very talented orthognathic surgeons to grow and develop professionally. His efforts as well as those of Bell and Epker, lead to the training of an entire generation of orthognathic surgical leaders including Roger West, Raymond Fonseca, Douglas Sinn, Timothy Turvey, Ghali Ghali, Stephen Schendell, Richard Finn, Caesar Guerrero, Scott Boyd, and many others.

The material to be published about orthognathic surgery during the decades between 1980 and 2000 was so voluminous that traditional scientific journals could not absorb it all. Orthodontist Robert Vanarsdale and surgeon Raymond White initiated a special journal, published by

Quintessence, *Adult Orthodontics and Orthognathic Surgery,* which encouraged publication and dissemination of the most current findings of orthognathic surgery.

Americans were hungry to learn orthognathic surgical techniques and many flocked to Europe to observe surgery performed by Obwegeser. However, there were multiple sites other than Zurich that were open and receptive to having visitors come to learn, including the unit in Nymejgen headed by Paul Stöelinga and Henk Tiedeman. For many years they hosted visitors from around the world to observe and participate in orthognathic surgery. Jaque Dautrey, a Frenchman from Straussburg, was a gracious host to many visitors. He was a clever innovator who not only was a gifted surgeon but also was highly instrumental in promoting orthognathic surgery in France and Europe. His colleague Maxine Champy was another maxillofacial surgeon/innovator who developed small plating systems for the facial bones and promoted their use in orthognathic surgery. Jean Delaire from Nante possessed a keen intellect and developed many facial analysis methods. He was a very talented cleft surgeon and also developed treatment algorithms for patients with facial bone abnormalities.[124,125] He commonly hosted visitors as well. Rudy Fries from Lientz, Frans Harlë from Kiel, Wilifred Schilli from Freiberg, Derek Henderson and Kersheed Moose from Cannesburn, Norman Rowe from Roehampton, and Rolf Ewers from Vienna were also frequent hosts for surgeons wanting to learn orthognathic surgery and other maxillofacial surgical techniques. Paul Tessier from Paris, the father of craniofacial surgery, was also a gracious host to many visiting surgeons wishing to learn his techniques including craniofacial and orthognathic surgery.

The origin of the term "orthognathic surgery" can be traced to Harold Hargis. Hargis was a U.S. Army oral and maxillofacial surgeon who was fortunate to be assigned to duty in Obwegeser's clinic in Zurich in the late 1960s. While there, Hargis shared many activities with Emile Steinhauser, Obwegeser's first trainee, and Bruce MacIntosh, another American who was sent to Obwegeser's unit by Fred Heney, the chairman of oral and maxillofacial surgery at Henry Ford Hospital in Detroit. After participating in many of the exciting jaw surgeries conducted in Zurich, Hargis coined the term "orthognathic surgery" (ortho-straight, gnathic-jaw). Although he frequently used the term (as did many clinicians), it never appeared in the literature until the late 1970s. Hargis returned from Zurich, completed his army career, and became the chairman of oral and maxillofacial surgery at the University of California-Los Angeles.

Walter Lorenz was a German-born American citizen who began a surgical instrument company in New York City. Initially he traveled from office to office, selling and servicing his products. His outstanding support for the oral and maxillofacial surgical community allowed him to parlay his entrepreneurial skills into becoming one of the leading oral and maxillofacial surgery instrument distributors in the world. From his modest early setup he developed a multinational corporation which prided itself in manufacturing high quality instruments with ergonomic designs that permitted orthognathic and craniofacial surgery to be conducted. He employed instrument designers who worked with surgeons to improve the conduct of orthognathic and craniofacial surgery. Obwegeser's original instruments were sold exclusively by the Walter Lorenz company in the United States. Now the only true Obwegeser equipment sold in the United States is by the KLS Corporation of Jacksonville, FL, which specializes exclusively in craniomaxillofacial surgical instruments.

Although there were early references to soft tissue surgery being a useful adjunct to orthognathic surgery, its popularity became apparent in the late 1980s and 1990s.[126,127] This was an era when many U.S. oral and maxillofacial surgeons were introduced to the benefits of esthetic soft tissue procedures and rhinoplasty. Although there was stimulation to learn and develop soft tissue surgery from within the OMFS community, external stimulation came from the American Academy of Cosmetic Surgery and the American Academy of Facial Plastic Surgery. Both groups sponsored educational opportunities that allowed oral and maxillofacial surgeons to learn the techniques and adapt them to their patients. Many surgeons popularized simultaneous orthognathic surgery and soft tissue surgery efforts. Among them were Bruce Epker, Peter Waite, Joe Niamtu, John Griffin, Kevin McBride, Douglas Sinn, Ghali Ghali, and orthodontist David Sarver. [126-133] These surgeons explored the benefits and pitfalls of simultaneous rhinoplasty and other soft tissue procedures performed with orthognathic surgery. Blepharoplasty, lip surgery, face-lift, forehead lift, and submental lipectomy with platysma tightening were all cited as procedures that could be done concomitantly with orthognathic surgery without wound healing issues and with major benefit of reducing the time of recovery.

Approaching the turn of the 21st century, most surgeons recognized the importance of esthetics and function in the diagnosis and treatment planning for orthognathic surgery. Johan Reyneke, from Johannesburg, and now Cape Town, published a book dedicated to the basics of diagnosis and treatment planning, emphasizing the importance of the most esthetically pleasing placement of the maxillary incisors relative to the lip. The book is beautifully illustrated by the author, emphasizing the importance of soft and hard tissue relationships and the benefits of occlusal plane rotation.[134]

Computers and technology have impacted every facet of life and orthognathic surgery is no exception. Beginning with Geoffrey Walker's introduction to the benefits of digitizing cephalometric radiographs, cephalometry's use in orthognathic surgery planning and analysis of results has advanced substantially.[135] Conventional radiographs have given way to digital radiographs, and now cone beam CT imaging is improving diagnostic capabilities. Blending three-dimensional radiographic images and magnetic resonance scans with three-dimensional photography is a quickly evolving field of interest that will have an impact on orthognathic surgery in the future. By 1980, Eisenfeld and Mishelevich were demonstrating the use of computers for

data analysis with orthognathic surgery patients.[136,137] Corporate America has contributed to the commercialization of computer software products to facilitate cephalometric data organization and planning of treatment. Dolphin Imaging, SAS Institute, and Quintiles are examples of U.S. companies that have contributed to the advancement of orthognathic surgery treatment planning, data storage, and analysis of results.

Gatano and Xia from Houston and Swennan from Belgium independently developed systems utilizing three-dimensional imaging to assist virtual planning for orthognathic surgery. [138-140] Andy Christiansen, who founded Medical Modeling Corporation in Golden, CO, quickly embraced the technology and made virtual treatment planning available to all U.S. surgeons. Using 3D CT scans of the face and teeth and 3D photographic images, the latest technology permits planning without plaster study modes or hand-fabricated acrylic splints. Cutting guides and customized plates and screws are other examples of how this technology is revolutionizing orthognathic surgery.[141] Christiansen also made available the production of accurate stereolithic skull models from 3D CT scans. This technology employs 3D printers, computer technicians, and simulations that allow surgeons to plan treatment in all dimensions. Although it is time-saving and is less messy than conventional treatment planning, the expense and need for technological support is substantial. The accuracy has been tested in a limited capacity and it seems favorable for the conduct of accurately planned orthognathic and craniofacial surgery.

Intraoperative navigation is another technologic advance that is impacting surgery with the hopes of improving accuracy. Its efficacy has been realized in tumor surgery and trauma and is being tested in orthognathic surgery.[142-144] Endoscopically assisted surgery is an additional technology impacting the conduct of orthognathic surgery.[145]

Orthodontist Lucia Cevidanes must be cited for her ingenious work of calculating size, shape, and volumetric changes as well as positional and remodeling changes of soft and hard tissues following orthognathic surgery. Utilizing 3D cone beam CT scans, she has developed methods of analysis that will provide invaluable understanding to adaptive changes associated with orthognathic surgery.[146] Nooreyazdan and Trotman, who are also orthodontists, are using 3D photography to further delineate soft tissue esthetic changes associated with orthognathic surgery.[147] These are more examples of how technology is improving the predictability of orthognathic surgery.

As with every other aspect of craniomaxillofacial surgery, bone plates and screw technology has had a significant impact on the conduct of orthognathic surgery and patient care. Without the need for intermaxillary fixation, orthognathic surgery has become a more attractive treatment option for patients and families. Prior to Luhr's introduction of compression bone plates and screws, primitive bone plates and screws existed (Collison, Robinson, Sampson) for maxillofacial surgery but were seldom used for anything other than trauma. As Luhr's work progressed, compression plates and screws were developed for facial use.[148-150] Michelet, Lodde, and Champy are credited with the development of miniature stainless steel bone plates and screws for maxillofacial fracture use.[151,152] In 1974 Spiessel published on use of screw fixation for stabilizing sagittal ostetomies.[153] Spiessel's technique included transfacial placement of the screws, but later others described transoral placement with good results.[154] In 1982 Steinhauser discussed the use of bone plates and screws for orthognathic surgery and by 1986 he had developed an all-titanium system for orthognathic surgery use.[155,156] Many surgeons are credited for their efforts in developing the rationale, instrumentation, and usage of this exciting breakthrough, including Van Sickles, Jeters, Härle, Terry, and Tucker.[157-160]

In some countries it is customary to remove all metallic devices at the completion of wound healing. The Finns developed biodegradable bone plating and screw systems to permit orthognathic surgery to be accomplished without the need for a secondary operation to remove the hardware. Surronen and Linquvist are credited for their works with the development of polylactate bone plates and screws for application during orthognathic surgery.[161,162] The efficacy of using bioresorbable materials for stabilizing facial osteotomies has been studied by many and found to be equally successful when compared to titanium.[163-166] Cost, difficulty with insertion, and instrumentation are issues impeding the advancement of this technology.

The facial application of distraction osteogenesis, which was resurrected by Illizaroth as a viable orthopedic method of limb lengthening, was initially introduced by Snyder in 1973.[167-170] Almost two decades later, McCarthy, Bell and Guerrero, and many others began promoting this concept as an alternative to orthognathic surgery.[171,172] Tairov from Tajikistan was an early pioneer of midfacial distraction osteogenesis who dates his introduction to 1977.[173] The promoted benefits of these techniques were: less invasive surgery, no need for bone grafting, and less morbidity. McCarthy and Guerrero and Bell published textbooks documenting the biologic and physiologic basis of this approach and demonstrated many successfully treated cases.[171,172] The level of sophistication of results demonstrated by Guerrero in his text are unsurpassed, and clearly he has mastered the technique better than most. Careful planning, intensive postoperative monitoring, and attention to the details of esthetics and occlusal function are the requirements for success with these techniques. Numerous contributions by many talented surgeons including Walker, Smith, Cohen, Polly, Rachmiel, Wangerin, Hoffmeister, MacCormick, Chin, and many others are testimony to the popularity and efficacy of the technique.[174-182] Its exact place in routine orthognathic surgical applications remains under investigation. When initially introduced, the distraction devices were bulky and awkward and were transfacially placed, leaving obvious scarring. Today, most devices are sleek (in comparison) and are transorally placed or placed in the hair-bearing area of the scalp. Molina's claim that the technique signals

a farewell to major facial skeletal surgery is yet to be realized.[183] Most agree that the cleft- and syndrome-involved populations are the major beneficiaries of distraction osteogenesis techniques.

The application of orthognathic surgery to improve disease processes is yet another recent recognition of the versatility of orthognathic surgery. Powell and Riley, both otolaryngologists who were disciples of William Ware and Roger West, were early advocates of orthognathic surgical techniques to improve the symptoms of obstructive sleep apnea. They published that these techniques could be applied to patients with airway issues, with favorable changes.[184] Waite reported similar findings.[185] The obstructive sleep apnea population can be substantially improved with orthognathic surgery. More recently, Boyd and Bundell have assembled convincing data that demonstrates that bimaxillary advancement has the best cure rate for obstructive sleep apnea over other treatment modalities.[186,187]

The psychosocial aspect of orthognathic surgery is a fascinating subject that has been studied by many, including Kiyak, Broder, and Phillips.[188-194] Most agree that if patients perceive the changes of treatment to be positive, self-concept and self-image changes are also positive. Orthognathic surgery seems to have a positive impact on quality of life and helps people attain their potential.

Conclusion

Orthognathic surgery is a vibrant part of the health care system offering patients an opportunity to improve their situation. As the functional, esthetic, and psychosocial benefits of surgery have been realized, its popularity has increased. The length of time in treatment is substantial and the expense is considerable. Moving forward, surgeons must develop protocols for reducing treatment time, improving accuracy and predictability, and keeping expense under control. Constant reinforcement to government officials and commercial health insurance carriers is critical to keep this treatment available to those in need.

References

1. Hullihen SP: Case elongation of the underjaw and distortion of the face and neck, caused by a burn, successfully treated, *Am J Dent Sci* 9:157, 1849.
2. Jaboulay M, Benard L: *Traitements chirurgical du prognathisme inferieur*, Paris, 1898, Press Med.
3. Berger P: *Du traitment chirurgical du prognathisme*, Lyon, France, 1897, Med. Trese.
4. Angle EH: Double resection of the lower maxilla, *Dent Cosmos* 40:635, 1898.
5. Whipple JW: Double resection of the inferior maxilla for protruding lower jaw, *Dent Cosmos* 40:552, 1898.
6. Blair VP: Report of a case of double resection for the correction of protrusion of the mandible, *Dent Cosmos* 48:817, 1906.
7. Blair VP: Operations on the jaw-bone and face, *Surg Gynecol Obstet* 4:67, 1907.
8. Blair VP: *Surgery and diseases of the mouth and jaws*, St Louis, 1912, Mosby.
9. Angle EH: Double resection for the treatment of mandibular protrusion, *Dent Cosmos* 45:268, 1903.
10. Angle EH: *Treatment of malocclusion of the teeth and fractures of the mandible, angles system*, Philadelphia, 1915, White Dental Manufacturing.
11. Kostecka F: Die chirurgische Therapie der Progenie, *Zahnarztl Rundschau* 40:669, 1931.
12. Kazanjian VH: Surgical correction of mandibular prognathism, *Int J Orthod* 18:1224, 1932.
13. Kazanjian VH: Jaw reconstruction, *Am J Surg* 3:249, 1939.
14. Dingman RO: Surgical correction of mandibular prognathism, an improved method, *Am J Orthodont* 30:683, 1944.
15. Dingman RO, Harding RL: The treatment of malunited fractures of the facial bones, *Plast Reconstruct Surg* 7:505–519, 1951.
16. Moose SM: Correction of abnormal mandibular protrusion by intraoral operation, *J Oral Surg* 3:304, 1945.
17. Sloan AC: Intraoral osteotomy of the ascending rami for correction of prognathism, *Texas Dent J* 69:375, 1951.
18. Moose S: Intraoral subcondylar osteotomy for the correction of mandibular prognathism, *J Oral Surg Anesth Hosp Dent Serv* 22:197, 1964.
19. Robinson M: Prognathism corrected by open vertical condylotomy, *J Southern California State Dental Assn* 24:22, 1956.
20. Robinson M: Prognathism corrected by the vertical subcondylectomy, *J Oral Surg* 16:215, 1958.
21. Thoma KH: *Oral surgery*, vol. 2. St Louis, 1958, Mosby.
22. Caldwell JB, Letterman GS: Vertical osteotomy in the mandibular rami for correction of prognathism, *J Oral Surg* 12:185, 1954.
23. Boyne PJ: Osseous healing after oblique osteotomy of the mandibular ramus, *J Oral Surg* 24:125, 1966.
24. Caldwell JB, Haywood JR, Lister RL: Correction of mandibular retrognathia by vertical L osteotomy: a new technique, *J Oral Surg* 26:259, 1968.
25. Hofer O: Die vertikale Osteotomie des einseitig verkurzten aufsteigenden Unterkieferastes, *Z Stomat* 34:826, 1936.
26. Trauner R, Obwegeser H: Surgical correction of mandibular prognathism and retrognathia with consideration of genioplasty. Part I, Operating methods for microgenia and distocclusion, *Oral Med Oral Path* 10:677, 1957.
27. Trauner R, Obwegeser H: Surgical correction of mandibular prognathism and retrognathia with consideration of genioplasty. Part II, Operating methods for microgenia and distocclusion, *Oral Med Oral Path* 10:899, 1957.
28. Converse JM: Restoration of facial contour by bone grafts introduced through the oral cavity, *Plast Reconstr Surg* 6:295–300, 1950.
29. Schendel SA: Sagittal split genioplasty: a new technique, *J Oral Maxillofac Surg* 68:931–943, 2010.
30. Triacca A, Minorelli R, Sculacic N: Mandibular wing osteotomy for correction of the mandibular plane: a case report, *Brit J Oral Maxillofac Surg* 48:182–184, 2010.
31. Precious DS, Delaire J: Correction of anterior mandibular vertical excess: the functional genioplasty, *Oral Surg Oral Med Oral Path* 59:229–235, 1985.
32. Köle H: Surgical operations on the alveolar ridge to correct occlusal abnormalities, *Oral Surg Med Oral Path* 12:277, 1959.
33. Cohn-Stock G: Die chirurgische Immediatregulierung der Kiefer, speziell die chirurgische Behandlung der Prognathie, *Vjschr Zahnheilk* 37:320, 1921.
34. Wolfe SA: Gunther Cohn-Stock, MS, DDS, father of maxillary orthognathic surgery, *J Craniomaxillofac Surg* 17:331–334, 1989.

35. Wassmund M: *Frakturen und Luxationen des Gesichtsschädels*, Leipzig, 1927, Muesser.
36. Wassmund M: *Lehrbuch der praktischen Chirurgie des Mundes und der Kiefer*, Bd. I, Leipzig, 1935, Meusser.
37. Axhausen G: Zur Behandlung veralteter disloziert geheilter Oberkieferbruche, *Dtsch Zahn-Mund-Kieferheilk* 6:582, 1934.
38. Immenkamp A: Beitraege zur maxilla-facielen chirugie unter besonderer berueckssuechtigung der korrehtur reon fihlbiddungen des mittelgieschtun, *Dtsch Zahnaergtl Z* 15:1073, 1960.
39. Wunderer S: De prognathic operation mittels frontal gestieltem maxillofragment, *Osterr Z Stomato* 59:98–102, 1962.
40. Cupar I: Die chirurgische Behandberg der Form-und Stellungsverardeungen des oberkiefer, *Osterr Z Stomat* 51:565, 1954.
41. Reichenbach EH, Köle H: *Brückl: Chirurgische Kieferorthopädie*, Leipzig, 1964, JA Barth.
42. Obwegeser HL: In Trauner R, Obwegeser HL, editors: *Zur operationstechnik bei der Progenie und anderen, unterkieferanomalien, Dtsch Zahn-Mund-u Kiefeheilk*, 23:1–26, 1955.
43. Obwegeser HL: Orthognathic surgery and a tale of how three procedures came to be. A letter to the next generation of surgeons, *Clin Plastic Surg* 34:331–355, 2007.
44. Perthes G: Operative Korrektur der Progenie, *Zentralbl Chir* 49:1540, 1922.
45. Perthes G: *Ueber fracturen und luxations-fracturen des kieferkopfchens und ihre operative behundlung*, Berlin, 1924, Springer, pp 418–433.
46. Schuchardt K: Ein beitraq zur chirurgischen kieferorthopadie unter beruchsichtigung ihrer bedentienq fur bihandlung angeloener und erworbener kieferdeform itaten ber soldaten, *Dtsch Zahn Mund Kieferhlkd* 9:73, 1942.
47. Dal Pont G: L'osteotomia retromolare per la correzione della progenia, *Minerva Chir* 18:1138–1141, 1958.
48. Hunsuck EE: A modified intraoral sagittal splitting technique for correction of mandibular prognathism, *J Oral Surg* 26:249, 1968.
49. Epker BN: Modifications in the sagittal osteotomy of the mandible, *J Oral Surg* 35:157–159, 1977.
50. Bell WH, Schendel S: Biological basis for the modification of sagittal split ramus osteotomy, *J Oral Surg* 35:362, 1977.
51. Obwegeser HL: *Mandibular growth anomalies*, Berlin, 2001, Springer.
52. MacIntosh RB: Total mandibular alveolar osteotomy: encouraging experiences with an infrequently indicated procedure, *J Maxillofac Surg* 2:210, 1973.
53. MacIntosh RB, Carlotti AE: Total mandibular alveolar osteotomy in the management of skeletal (infantile) apertognathia, *J Oral Surg* 33:921, 1975.
54. Booth DF, Dietz V, Gianeldy AA: Correction of class II malocclusions by combined sagittal ramus and subapical body osteotomy, *J Oral Surg* 34:630, 1976.
55. Buckley MJ, Turvey TA: Total mandibular subapical osteotomy; A report on long term stability and surgical techniques, *Int J Adult Orthodont Orthog Surg* 2(3):121–130, 1987.
56. von Langenback BV: Bietriage zur osteoplastic die osteoplastische resection de oberkeafers. In Goschen A, editor: *Deutche klinck*, Berlin, 1859, Reimer.
57. Cheever DW: Displacement of the upper jaw, *Med Surg Rep Boston City Hosp* 1:156, 1870.
58. Maloney F, Worthington P: The origin of the LeFort I osteotomy: Cheevers operation, *J Oral Surg* 39:731, 1981.
59. Halvorson EG, Mulliken JB: Cheever's double operation: the first LeFort I osteotomy, *Plast Reconstr Surg* 121:1375–1381, 2008.
60. Converse JM, Shapiro HH: Treatment of developmental malformations of the jaws, *Plast Reconstr Surg* 10:473, 1952.
61. Gillies H, Rowe NL: L'osteotomies des maxillaire superieur envisage essentiellement dans le cas de bec-de-lievre total, *Reb Stomatol Chir Maxillofac* 55:545, 1954.
62. Schurchardt K: Formen des offenen Bisses und ihre operative Behandlungsmöglichkeiten. In *Fortschritte der Kiefer Gesichtschirurgie, Bd I*, Stuttgart, 1955, Thieme.
63. Drommer RB: The history of LeFort I osteotomy, *J Maxillofac Surg* 14:119, 1986.
64. Schuchardt K: *Treatment of patients with clefts of lip, alveolus and palate. 2nd Hamburg International Symposium 1964, Index*, Stuttgart, 1966, George Thieme Verlag.
65. Obwegeser H: Surgical correction of small or retrodisplaced maxillae, *J Plast Reconstr Surg* 43:351, 1969.
66. Hogeman KE, Wilmar K: *Die Vorverlagerung des Oberkiefers zur Korrektur von GebiBanomalien*. *Fortschritte der Kiefer Gesichtschirurgie, Bd 12*, Stuttgart, 1967, Thieme.
67. Willmar K: On LeFort I osteotomy. A follow up study of 106 operated patients with maxillofacial deformity, *Scand J Plast Reconstr Surg* 12(suppl):1–68, 1974.
68. Kufner J: Nove otedy chirugickeho leceni otevrensho skusu, *Cslk Stomat* 60:5, 1960.
69. Kufner J: Experience with a modified procedure for correction of open bite. In Walker RV, editor: *Transactions of the Third International Conference of Oral Surgery*, London, 1970, Livingstone.
70. Perko M: Maxillary sinus and surgical movement of the maxilla, *Int J Oral Surg* 1:177, 1972.
71. West RA, Epker BN: Posterior maxillary surgery: its place in the treatment of dentofacial deformities, *J Oral Surg* 30:562–563, 1972.
72. Stoker N, Epker BN: The posterior maxillary osteotomy: a retrospective study of treatment results, *Int J Oral Surg* 3:153, 1974.
73. Epker BN, Wolford LM: *Dentofacial deformities surgical-orthodontic correction*, St Louis, 1980, Mosby.
74. Bell WH, Proffit WR, White RP: *Surgical correction of dentofacial deformities*, Philadelphia, 1980, Saunders.
75. Turvey TA: Surgical expansion of the maxilla, *J Maxillofac Surg* 13:51–59, 1985.
76. Obwegeser H: Die einzeitige Vorbewegung des Oberkiefers und R flick bewegung des Unterkiefers zur Korrektur der extremen 'Progenie,', *Schweiz Mschr Zahnheilk* 80:305, 1970.
77. Mohnac AM: Surgical correction of maxillomandibular deformities, *J Oral Surg* 23:205–407, 1965.
78. Gross BD, James RB: The surgical sequence of combined total maxillary and mandibular osteotomies, *J Oral Surg* 36:513–522, 1978.
79. Lindorf H, Steinhauser EW: Correction of jaw deformities involving simultaneous osteotomy of the mandible and maxilla, *J Maxillofac Surg* 6:239–244, 1978.
80. Turvey TA: Simultaneous mobilization of the maxilla and mandible: surgical techniques and results, *J Oral Maxillofac Surg* 40:96–99, 1982.
81. Epker BN, Turvey TA, Fish LC: Indications for simultaneous mobilization of the maxilla for the correction of dentofacial deformities, *Oral Surg Oral Path Oral Med* 54:369–381, 1982.
82. LaBanc JP, Turvey TA, Epker BN: Results following simultaneous mobilization of the maxilla and mandible for correction of dentofacial deformities: analysis of 100 consecutive patients, *Oral Surg Oral Path Oral Med* 54:607–612, 1982.

83. Bell WH, Sinn DP, Finn RA: Cephalometric treatment planning for superior repositioning of the maxilla and concomitant mandibular advancement, *J Oral Maxillofac Surg* 10:42, 1982.
84. Gillies H, Harrison SA: Operative correction by osteotomy of recessed malar maxillary compound in a case oxycephaly, *Br J Plast Surgery* 2:23–127, 1950.
85. Kufner J: Four year experience with major maxillary osteotomy for retrusion, *J Oral Surg* 29:549–553, 1971.
86. Tessier R, Guist G, Rougerie J, et al.: Cranio-naso-orbito-facial osteotomies (hypertellorism), *Ann Chir Plast* 12:103–118, 1967.
87. Tessier P: The definitive plastic surgical treatment of severe facial deformities of craniofacial synostosis: Crouzon and Apert disease, *Plast Reconstr Surg* 48:419, 1971.
88. Tessier P: Total osteotomy of the middle third of the face for faceostenosis or for sequelae of LeFort III fracture, *Plast Reconstr Surg* 48:533, 1971.
89. Murray J, Swanson LT: Midface osteotomy and advancement for craniosynostosis, *Plast Reconstr Surg* 41:299–307, 1968.
90. Converse JM, Wood Smith D: An atlas and classification of midfacial and craniofacial osteotomies. In *Transactions of the 5th Int Congress of Plastic Surgery*, Melbourne, 1971, Butterworth, p 937.
91. Converse JM, Horowitz SL, Valouri AJ, Montandon D: The treatment of nasomaxillary hyperplasia. A new pyramidal naso-orbital maxillary osteotomy, *Plast Reconstr Surg* 45:527, 1970.
92. Converse JM, Telsey D: The tripartite osteotomy of the midface for orbital expansion and correction of the deformity in craniosynostosis, *Brit J Plast Surg* 24:365–374, 1971.
93. Epker BN, Wolford LM: Middle third facial advancement: treatment considerations in atypical cases, *J Oral Surg* 37:31–41, 1979.
94. Epker BN, Wolford LM: Middle third facial osteotomies. Their use in the correction of acquired and developmental dentofacial and craniofacial deformities, *J Oral Surg* 33:491, 1975.
95. Psillakis JM, Lapa F, Spina V: Surgical correction of mid-facial retrusion (nasomaxillary hypoplasia) in the presence of normal dental occlusion, *Plast Reconstr Surg* 51:67, 1963.
96. Jabaley ME, Edgerton MT: Surgical correction of congenital midface retrusion in the presence of mandibular prognathism, *Plast Reconstr Surg* 44:1, 1969.
97. Henderson D, Jackson IT: Naso-maxillary hypoplasia: the LeFort III osteotomy, *Brit J Oral Surg* 2:77–93, 1973.
98. Sailer HF: *LeFort III osteotomy versus LeFort III and simultaneous LeFort I osteotomy in patients with clefts and craniofacial deformities*. *Transactions of the 8th International Congress on Cleft Palate and Related Craniofacial Anomalies*, September 1997. Singapore.
99. White RP, Peters PB, Costich ER, Page HL: Evaluation of sagittal split ramus osteotomy in 17 patients, *J Oral Surg* 27:851, 1969.
100. Bell WH: Surgical correction of anterior maxillary retrusion: report of a case, *J Oral Surg* 26:57, 1968.
101. Kent JN, Hinds EC: Management of dental facial deformities by anterior alveolar surgery, *J Oral Surg* 29:13–21, 1971.
102. Freihofer HP, Petrovic EV: Late results after advancing the mandible by sagittal splitting of the ramus. Second Congress EAMFS, Zurich, September, 1974, *J Maxillofac Surg* 3(4):250–257, 1975.
103. Freihofer HPM: Results after midface osteotomies, *J Maxillofac Surg* 1:30–36, 1973.
104. West RA, Burk JL: Maxillary osteotomies for pre-prosthetic surgery, *J Oral Surg* 32:13, 1974.
105. McArthur R, Turvey TA: Maxillary segmental osteotomies for mandibular removal partial denture patients, *J Prosthetic Dent* 4:381–387, 1979.
106. Sailer HF: A new method of inserting endosseous implants in totally atrophic maxilla, *J Cranio Max Fac Surg* 17:299–305, 1989.
107. Rhinelander FW, et al.: Microangioplasty in bone healing. Displaced closed fracture, *J Bone Joint Surg* 50:643, 1968.
108. Bell WH: Revascularization of bone healing after anterior maxillary osteotomy: a study using adult rhesus monkeys, *J Oral Surg* 27(4):249–255, 1969.
109. Bell WH, Levy BM: Revascularization and bone healing following total maxillary osteotomy, *J Oral Surg* 28:196, 1970.
110. Bell WH: Biological basis for maxillary osteotomies, *Am J Phys Anthropol* 38:279–290, 1973.
111. Bell WH, Fonseca RJ, et al.: Bone healing and revascularization after total maxillary osteotomy, *J Oral Surg* 33:253, 1975.
112. Proffit WR, White RP, Sarver DM: *Contemporary treatment of dentofacial deformities*, St Louis, 2003, Mosby.
113. Proffit W, Turvey TA, Phillips C: Orthognathic surgery: a hierarchy of stability, *Int J Orthod Orthognath Surg* 11:191–204, 1996.
114. Proffit WR, Turvey TA, Phillips C: The hierarchy of stability and predictability in orthognathic surgery with rigid fixation; an update and extension, *Head Face Med* 3:21, 2007.
115. Steinhauser EW: Historical development of orthognathic surgery, *J Craniomaxillofac Surg* 24(4):195–204, 1996.
116. Hinds E, Kent J: *Surgical treatment of developmental jaw deformities*, St Louis, 1972, Mosby.
117. Proffit WR, White RP: *Surgical-orthodontic treatment*, St Louis, 1991, Mosby.
118. Proffit WR, White RP, Sarver DM: *Contemporary treatment of dentofacial deformities*, Philadelphia, 2003, Elsevier.
119. Epker BN, Fish LC: *Dentofacial deformities/integrated orthodontic and surgical correction*, St Louis, 1986, Mosby.
120. Epker BN, Stella JP, Fish LC: *Dentofacial deformities/integrated orthodontic and surgical correction*, ed 2, St Louis, 1999, Mosby.
121. Posnick JC: *Orthognathic surgery principles and practice*, Philadelphia, 2014, Elsevier.
122. West RA, McNeill RW: Diagnosis and treatment planning: a coordinated effort between oral and maxillofacial surgery and orthodontics, *J Oral Surg* 39:809–816, 1977.
123. Lines PA, Steinhauser EW: Diagnosis and treatment planning in surgical orthodontic therapy, *Am J Orthod* 66:378–397, 1974.
124. Delaire J: L'analyse architecturale et strudurale craniofasiale (de profil): principes theoriques: quelque exemples d'emploir en chirurgre maxillofacile, *Rev Stomatal* 79:1–33, 1978.
125. Delaire J, Schendel S, Tulasne JR: An architectural and structural craniofacial analysis: a new later cephalometric analysis, *Oral Surg* 52:226–238, 1981.
126. Turvey TA, Epker BN: Soft tissue procedures adjunctive to orthognathic surgery for improvement of facial balance, *J Oral Surg* 32:572–577, 1974.
127. Epker BN, Wolford LM: Reduction cheiloplasty: its place in the correction of dentofacial deformities, *J Maxillofac Surg* 5:134–141, 1977.
128. Epker BN: *Esthetic maxillofacial surgery*, Mahaven PA, 1994, Lea and Febeger.
129. Waite PD, Matukas VJ: Indications for simultaneous orthognathic and septo-rhinoplastic surgery, *J Oral Maxillofac Surg* 49:133, 1991.

130. Niamtu J: *Cosmetic facial surgery*, St Louis, 2011, Elsevier Mosby, pp 1–11.
131. Griffin JE, Kim K: *Cosmetic surgery for the oral and maxillofacial surgeon*, Chicago, 2010, Quintessence.
132. Sinn DP, Ghali GE, editors: *Combined orthognathic and esthetic surgery*, Philadelphia, 1996, Saunders.
133. Sarver DM: *Esthetic orthodontics and orthognathic surgery*, St Louis, 1997, Mosby.
134. Reyneke JP: *Essentials of orthognathic surgery*, Chicago, 2003, Quintessence.
135. Walker GF: A new approach to the analysis of craniofacial morphology and growth, *Am J Orthod* 61:221–230, 1972.
136. Eisenfeld J, Barker DR, Mishelevich DJ: Iconic representation of the human face with computer graphics, *Comp Graphics* 8:9–11, 1974.
137. Eisenfeld J, Mishelevich DJ: Computer based research studies on the correction of dentofacial deformities. In Bell WH, Proffit WR, White RP, editors: *Surgical correction of dentofacial deformities*, Philadelphia, 1980, Saunders. (Chapter 25.
138. Swennen GRJ, Barth EL, Eulger C, Schutyser F: The use of a new 3-D splint and double CT scan procedure to obtain an accurate anatomical virtual augmented model of the skull, *Int J Oral and Maxillofac Surg* 36:146–152, 2007.
139. Xia JHH, Samman N, Wang D, et al.: Computer assisted three dimensional surgical planning and imulation: 3-D virtual osteotomy, *Int J Oral and Maxillofac Surg* 29:11–17, 2000.
140. Gatano J, Xia JJ, Teichgraber JF: Clinical feasibility of computer aided surgical simulation (CASS) in the treatment of complex craniofacial deformities, *J Oral Maxillofac Surg* 65:728, 2007.
141. Mazzoni S, Bianchi A: Computer-aided design and computer-aided manufacturing cutting guides and customized titanium plates are useful in upper maxillary waferless repositioning, *J Oral Maxillofac Surg* 73:701–707, 2015.
142. Hassfeld S, Muhling J: Computer assisted oral and maxillofacial surgery—a review and an assessment of technology, *Int J Oral Maxillofac Surg* 30:2, 2001.
143. Schmelzeisen R, Gellrich NC, Schoen R, et al.: Navigation aided reconstruction of medial orbital wall and floor contour in craniomaxillofacial reconstruction, *Injury* 35:955, 2004.
144. Markowicz MR, Dierks FJ, Bell RB: Does intraoperative navigation restore orbital dimensions in traumatic and post ablative defects? *J Craniomaxillofac Surg* 40:142, 2012.
145. Troulis M: Endoscopically assisted mandibular osteotomies. In Fonseca RJ, Walker RB, Betts NJ, editors: *Oral and maxillofacial surgery*, ed 3, vol. 3. Philadelphia, 2005, Saunders.
146. Cevidanes LH, Bailey LJ, Tucker SF, et al.: Three dimensional cone beam computed tomography for assessment of mandibular changes after orthognathic surgery, *Am J Orthod Dentofac Orthoped* 131:44–50, 2007.
147. Nooreyazdan M, Trotman CA, Faroway JJ: Modeling facial movement: I A dynamic analysis of differences caused by orthognathic surgery, *J Oral Maxiollfac Surg* 62:1380–1386, 2004.
148. Luhr HG: Zur stabilen osteosynthese bei unterkiefer-frakturen, *Dtsch Zahnarztl Z* 23:754, 1968.
149. Luhr HG: The compression osteosynthesis of mandibular fracture in dogs. A histological contribution to "primary bone healing," *Eur Surg Res* 1:3, 1967.
150. Luhr HG: The compression osteosynthesis of mandibular fracture in dogs. A histological contribution to "primary bone healing," *Eur Surg Res* 1:3, 1967.
151. Champy M, Lodde J, Jaeger JH, Wilk A: Osteosynthesis mandibulares selon la techniques de Michelet. I Bases biomechaniques II Presentation d'un nouveau material, *Resultats Rev Stomatol* 77:569–576, 1976. 577–582.
152. Champy M, Lodde JP, Wilk A, Grasset D: Plattenosteosynthesen bei mittelgisecht sfrakturen und osteotomien, *Dtch Z Mund Kiefer Geischts Chir* 2:26–36, 1978.
153. Spiessel B: *Osteosynthese bei sagittaler Osteotomie nach Obwegeser-Dal Pont. Fortschr Kiefer Gesichtschir, Bd 18*, Stuttgart, 1974, Thieme.
154. Turvey TA, Hall DJ: Intraoral self-threading screw fixation for sagittal osteotomies: early experiences, *Int J Adult Orthod Orthog Surg* 1:243–249, 1986.
155. Steinhauser EW: Bone plates and screws in orthognathic surgery, *Int J Oral Surg* 11:209, 1982.
156. Steinhauser EW: Historical development of orthognathic surgery, *J Craniomaxillofac Surg* 24:195–204, 1996.
157. Jeter PS, Van Sickels JS, Dolwick FM: Modified techniques for internal fixation of sagittal ramus osteotomies, *J Oral and Maxillofac Surg* 42:270–272, 1984.
158. Van Sickels JS, Jeter TS, Aragon SB: Management of unfavorable fracture in sagittal split osteotomies, *J Oral Maxillofac Surg* 43:808–809, 1985.
159. Van Sickels JS, Jeter TS, Thereot BA: Rigid fixation of maxillary osteotomies: A technique article, Oral Surg Oral Med Oral Path 60:262–265.
160. Härle F, Champy M, Terry BC: *Atlas of craniomaxillofacial osteosynthesis*, Stuttgart, 1999, Thieme, p 2009.
161. Suuronen R: *Biodegradable self-reinforced polylactide plates and screws in fixation of osteotomies*, Ph D Thesis, 1992, University of Helsinki.
162. Suuronen R, Laine P, Pohjonen T, et al.: Sagittal ramus osteotomies fixed with biodegradable screws. A preliminary report, *J Oral Maxillofac Surg* 52:715, 1994.
163. Landes CA, Ballon A: Skeletal stability in bimaxillary orthognathic surgery: P(L/DL)LA-resorbable vs. titanium osteofixation, *Plast Reconstr Surg* 118:703, 2006.
164. Turvey TA, Bell RB, Phillips C, et al.: Self reinforced biodegradable screw fixation compared to titanium screw fixation in mandibular advancement, *J Oral Maxillofac Surg* 64:40, 2006.
165. Blakey GH, Rossouw E, Turvey TA, et al.: Are bioresorbable polylactate devices comparable to titanium devices for stabilizing LeFort I advancement? *Int J Oral Maxillofac Surg* 43:437, 2014.
166. Suuronen R, Haers PE, Lindquist C, Sailer HF: Update on bioresorbable plates in maxillofacial surgery, *Facial Plast Surg* 15:61–72, 1999.
167. Ilizarov G: The tension-stress effect on the genesis and growth of tissues. Part I. The influence of stability of fixation and soft-tissue preservation, *Clin Orthop Relat Res* 238:249–281, 1989.
168. Ilizarov G: The tension-stress effect on the genesis and growth of tissues. Part II. The influence of stability of fixation and soft-tissue preservation, *Clin Orthop Relat Res* 238:215–248, 1989.
169. Ilizarov G: *Transosseous osteosynthesis. Theoretical and clinical aspects of the regeneration and growth of tissue*, Berlin, 1992, Springer-Verlag.
170. Snyder CC, Levin GA, Swason HM, Browne EZJ: Mandibular lengthening by gradual distraction, *Plast Reconstr Surg* 51:506–508, 1973.
171. Bell WH, Guerrero C: *Distraction osteogenesis of the facial skeleton*, Hamilton, ON, Canada, 2007, Decker.

172. McCarthy JG: *Distraction of the craniofacial skeleton*, New York, 1999, Springer.
173. Tairov U: *Personal communication*, 2015.
174. Walker D: Vector planning and treatment visualization in distraction osteogenesis, *J Craniomaxillofac Surg* 20(suppl 1):61, 2002.
175. Chin M, Toth BA: LeFort III advancement with gradual distraction using internal devices, *Plast Reconstr Surg* 100:819–830, 1997.
176. Polly JW, Figeroa AA: Management of severe maxillary deficiency in childhood and adolescence through distraction osteogenesis with an external, adjustable rigid distraction device, *J Craniofac Surg 8*1997, 1811.
177. Smith KS: Internal distraction in neonates, treatment of obstructive apnea. In Arnaud E, Dines P, editors: *Third Int Congress on Cranio and Facial Bone Distraction Osteogenesis. Paris, France*, Bologna, Italy, 2001, Monduzzi Editore, pp 237–242.
178. Rachmiel A, Levy M, Laufer D: Lengthening of the mandible by distraction osteogenesis report of cases, *J Oral Maxillofac Surg* 53:838–846, 1995.
179. Cohen SR, Rutrich RE, Burstein FD: Distraction osteogenesis of the human craniofacial skeleton; initial experience with new distraction system, *J Craniomaxillofac Surg* 23:368–374, 1995.
180. Wangerin K: Our concept of intraoral distraction, *Stomatologie* 102:59–66, 2005.
181. MacCormick S, McCarthy J, Grayson B, et al.: The effect of mandibular distraction on the temporomandibular joint, part I a canine study, *J Craniofac Surg* 6:358–363, 1995.
182. Hoffmeister B, Marcks CH, Wolff KP: The floating bone concept in intraoral mandibular distraction, *J Craniomaxillofac Surg* 26(suppl 1):76, 1998.
183. Molina F, Ortez-Monasterio F: Mandibular elongation and remodeling by distraction: a farewell to major osteotomies, *Plast Reconstr Surg* 96:825–840, 1995.
184. Riley RW, Powell NB, Li KK, et al.: Surgery and obstructive sleep apnea. Long term clinical outcomes, *Otolaryng Head Neck Surg* 122:415–421, 2000.
185. Waite P, Wooten V, Lachner J, et al.: Maxillomandibular advancement surgery in 23 patients with obstructive sleep apnea syndrome, *J Oral Maxillofac Surg* 47:1256–1261, 1989.
186. Boyd SB, Walters AS, Song Y, et al.: Comparative effectiveness of maxillomandibular advancement and uvulopalatopharyngoplasty for treatment of moderate to severe obstructive sleep apnea, *J Oral Maxillofac Surg* 71:743, 2013.
187. Bundell JR: Primary and secondary tegnathic maxillomandibular advancement with or without adjunctive procedures for obstructive sleep apnea in adults. A literature review and treatment recommendations, *J Oral Maxillofac Surg* 70:1659–1677, 2012.
188. Kiyak HA, Hohl T, Sherrick RA, et al.: Sex differences in motives for and outcomes of orthognathic surgery, *J Oral Surg* 39:757–764, 1981.
189. Kiyak HA, Hohl T, West RA, et al.: Psychological changes in orthognathic surgery patients: a 24-month follow up, *J Oral Maxillofac Surg* 42:506–512, 1984.
190. Jacobson A: Psychological aspects of dentofacial esthetics and orthognathic surgery, *Angle Orthod* 54:18–35, 1984.
191. Phillips C, Bennett ME: Psychological ramifications of orthognathic surgery. In Fonseca RJ, editor: *Oral and maxillofacial surgery*, Philadelphia, 2000, Saunders.
192. Phillips C, Broder HL, Bennett ME: Dentofacial disharmony: motivations for seeking treatment, *Int J Adult Orthod Orthognath Surg* 12:7–15, 1997.
193. Phillips C, Bennett ME, Broder HL: Dentofacial disharmony: psychological status seeking treatment consultation, *Angle Orthod* 68:547–556, 1998.
194. Kiyak HA, McNeill RW, West RA: The emotional impact of orthognathic surgery and conventional orthodontics, *Am J Orthod* 88:224–234, 1985.

2

Treatment Planning in Orthognathic Surgery

JEFFREY C. POSNICK

Importance of Proportions and Symmetry to Establish Ideal Facial Esthetics

Fundamental Concepts

We use the word *proportion* to describe the comparative relationship between parts of things in an attempt to describe harmonious and disharmonious relationships between different parts of a whole.[1] The first clear, and still unsurpassed, definition of what has become known as the *Golden Ratio* was given by Euclid of Alexandria around 300 BC.[2] Euclid is best known as the founder of geometry, a branch of mathematics that uses deductive reasoning.[1] Euclid defined a harmonious proportion derived from the simple division (sectioning) of a line into what he called its "extreme and mean ratio." In Euclid's own words: "A straight line is said to have been cut in extreme and mean ratio when, as the whole line is to the greater segment, so is the greater to the lesser." [2] Stated in another way, if the ratio of the length of a line (AC) to that of the greater segment of the line (CB) is the same as the ratio of the segments AB to CB, then the line "has been cut or sectioned" into "extreme and mean ratio" (Figure 2-1), which Euclid named the golden ratio. Interestingly, this ratio represents a never-ending (irrational) number 1.6180339887… . The common symbol for the golden ratio is the Greek letter thau (τ) the meaning of which is "the cut" or "the section." It was later renamed phi (ψ) after the Greek sculptor Phidias who was said to have employed it.[3]

Webster's Unabridged Dictionary defines beauty as "the quality which makes an object seem pleasing or satisfying in a certain way." The golden ratio is said to be an important feature found in many of the classically beautiful works of art, architecture, objects designed for human use, the music of the great composers, and most of what is found in nature (Figures 2-2 and 2-3).[4] Objects of "classic" beauty and "attractive" forms found in nature consistently reveal the golden ratio.[5,6] An important question, however, is: Does form and function really follow? Richard Buckminster Fuller, a great American architect and writer (1895-1983), once stated, "When I am working on a problem, I never think about beauty. I think only of how to solve the problem. But when I finish, if the solution is not beautiful, I know it is wrong."[5]

In their simplest form, attractive facial images, whether in drawings, photographs, or in reality seem to incorporate a consistent symmetry of proportion. It has been stated that most people have a common appreciation of what is attractive when they visualize it even if they cannot quite explain why. This has been demonstrated across cultures and throughout the ages, and has been relatively consistent in art.[7] A strict mathematic formula may not be required to define classic attractiveness, but the question remains: Can the golden ratio (a mathematic formula) be found in these commonly agreed upon beautiful images (Figure 2-4)?

Current Philosophy

From Pythagoras, Polykleitos, Plato, Aristotle, Euclid, Vitruvian, Galen, Fibonacci, Piero, da Vinci, and Pacioli, to the more recent Le Corbusier and all of their disciples for over two millennia, we have learned that the proportions of the parts to the whole affect the observers' impression of beauty and attractiveness.[8,9] From the premier artists, architects, and designers throughout the centuries, we know that mirror image symmetry and the harmony of proportions matter when judging facial esthetics. Studies in each of these fields have also shown that the precise (to the millimeter) achievement of an exacting mathematic ratio is not sufficient or even preferred for the creation of the most important end products, but an approximation of the golden ratio is.

In the realm of facial esthetic and reconstructive surgery, clinicians from all involved fields have from time to time attempted to match facial esthetics to a strict mathematic model (ex normative cephalometric measurements) without always considering individual biologic variations

and esthetic nuances (Figure 2-5).[7,10-15] When doing so, they have often fallen short of the objective. In 1984 Ricketts reported on a significant number of golden proportions when analyzing the facial skeleton and overlying soft tissues.[16-18] He was a strong advocate of the use of these "divine proportions" as a guide for planning the correction of dentofacial deformities (orthognathic surgery) (Figure 2-6). The validity of Ricketts' approach to facial analysis for the correction of jaw deformities has been questioned by some while supported by most.[16-18] For the clinician who is asked to correct a congenital or developmental craniofacial or maxillofacial deformity, attention is directed to both form and function. As Buckminster Fuller stated, "rarely are the two objectives divergent." In the achievement of a harmonious face, attention is directed toward the practical objectives of improving the upper airway and occlusion, which will effect speech, swallowing, chewing, and breathing. Facial esthetic perfection is not a specific millimeter distance or degree of angulation but a visual impression at conversational distance in three-dimensional life.[19-24] At the same time, neither "divine proportions" nor biologic realities or the patient's personal preferences can be ignored in the process. Rediscovery of the importance of achieving an approximation of Euclidean proportions and mirror image symmetry as a treatment objective in the correction of dentofacial deformities remains an essential step in the education of all students of the human face.[25-32]

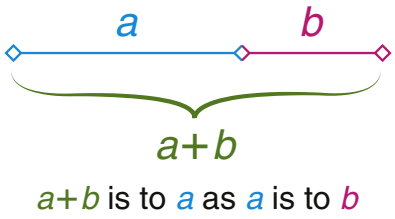

• **Figure 2-1** Golden ratio (section) of a straight line. (From Posnick JC: *Orthognathic surgery treatment planning. Orthognathic surgery: Principles and practice*, St Louis, 2014, Elsevier, pp. 338, Fig. 12-1).

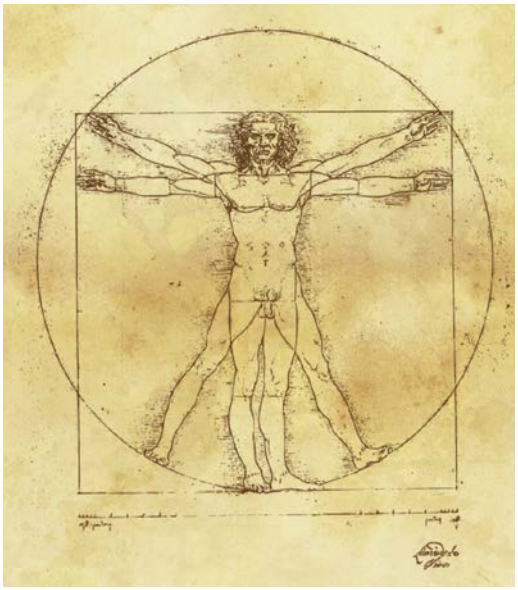

• **Figure 2-2** Vitruvius man described by Marcus Vitruvius Polio and drawn by Leonardo da Vinci. (From Posnick JC: *Orthognathic surgery treatment planning. Orthognathic surgery: Principles and practice*, St Louis, 2014, Elsevier.)

Clinical Evaluation of the Dentofacial Deformity Patient

Background

For the correction of a dentofacial deformity, the clinician's esthetic sense and knowledge of patient-specific biologic and psychosocial factors must be condensed into precise millimeter measurements and angular changes that are then accomplished on the surgically sectioned (osteotomized) maxilla, mandible, and chin with a goal of establishing Euclidean facial proportions and improved functions.[25, 33-40] Although there is no singular normative table of numbers or a formula that can be relied on to direct the surgeon to the golden ratio, a methodical approach is nevertheless required. The clinician's vision is based on: fundamental

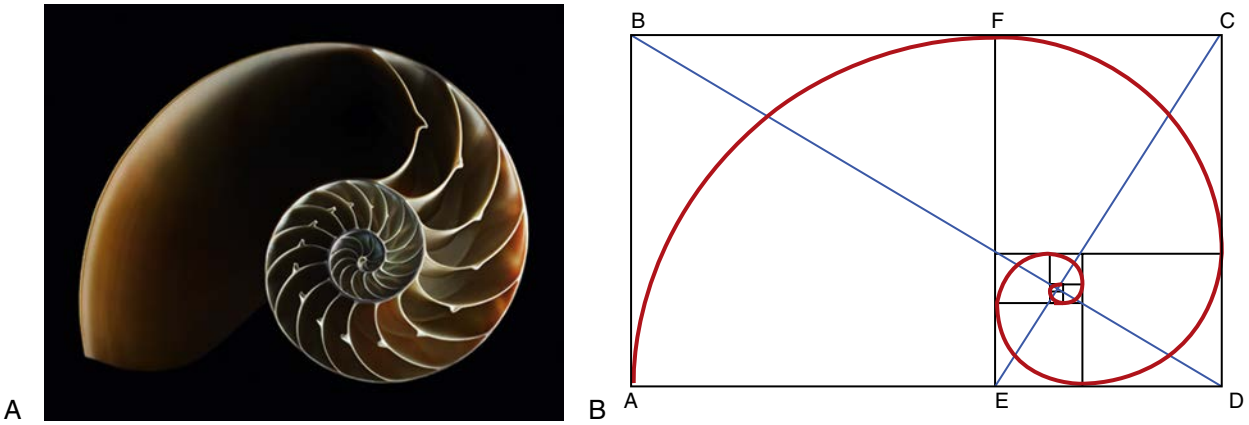

• **Figure 2-3** **A,** Photograph of the chambered nautilus, demonstrating structural anatomy. **B,** The golden ratio as found in nautilus spiral structural anatomy. (Reprinted from Posnick JC: *Orthognathic surgery treatment planning. Orthognathic surgery: Principles and practice*, St Louis, 2014, Elsevier.)

esthetic principles; biologic realities of the tissues; patient specific dysfunctions (i.e., chewing, swallowing, speech articulation, breathing, lip closure/posture); and treatment preferences (i.e., timing, techniques, and extent of intervention).[25] It is expected that a degree of uneasiness about the end result will be felt by both the operating surgeon and patient/family in this process. With clinician experience, this creative tension for the surgeon and patient/family uncertainty is reduced but can never be fully alleviated prior to surgery.

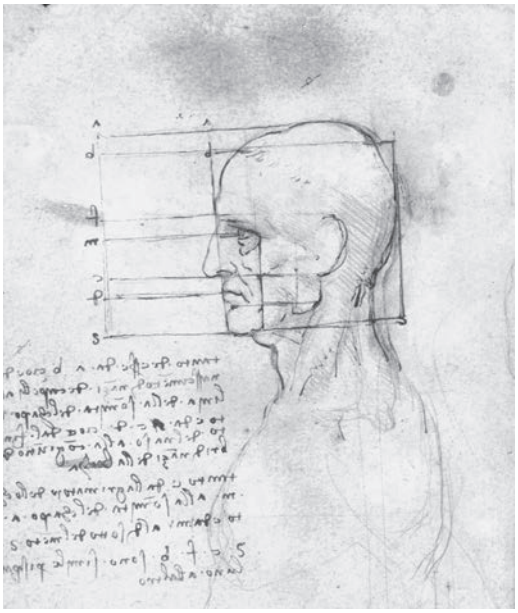

• **Figure 2-4** *Head of an Old Man* by Leonardo da Vinci, confirming the golden ratio. (From Royal Library, Windsor Castle, Windsor, Great Britain. Photo Credit: Alinari/Art Resource, NY. In Posnick JC: *Orthognathic surgery treatment planning. Orthognathic surgery: Principles and practice*, St Louis, 2014, Elsevier.)

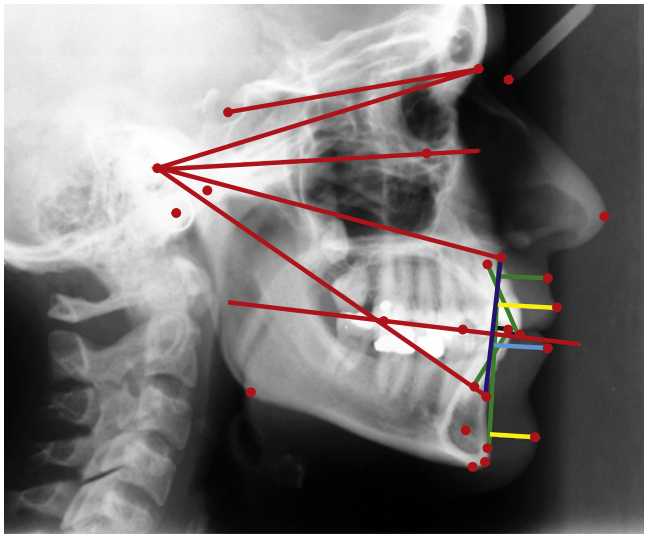

• **Figure 2-5** Skeletal proportions according to cephalometric analysis. (Reprinted from Posnick JC: *Orthognathic surgery treatment planning. Orthognathic surgery: Principles and practice*, St Louis, 2014, Elsevier.)

By the time of the preoperative direct face-to-face planning patient examination by the operating surgeon, several evaluations will have already been carried out. Review of relevant medical data, combined with facial photographic, radiographic, and dental analysis should be fresh in mind. The patient's facial structures are examined while he/she is upright and sitting in the natural head position (NHP). This is considered the most rational, physiologic, and anatomic orientation of the head and neck for evaluating the face, jaws, and teeth.[33,41-44] This is generally not the head and neck position that the patient with a dentofacial deformity naturally relaxes into; the surgeon must place the patient in the NHP. The teeth are also placed in centric relation (CR) or with a normal freeway space and the lips are relaxed (not pursed together). The surgeon then observes the patient three-dimensionally at different angles in both repose and with dynamic facial expression. It is from this position (NHP) that the surgeon makes crucial decisions of what facial features are abnormal and will require surgical reorientation.

Global head and neck assessment includes evaluation of the following aspects:

1. **Quality of the overlying soft tissue envelope** of the head and neck. The surgeon must recognize distortions of the soft tissue envelope that will self correct once the skeleton is reconstructed versus intrinsic soft tissue malformations/deformities that will not (i.e., hypoplasia, hyperplasia, effects of trauma and aging).
2. **Symmetry and harmony of the upper facial skeleton** (i.e., cranial vault, orbits, nasofrontal process, and zygomatic arches). Although most individuals with a dentofacial deformity have a relatively normal upper facial skeleton, some do not (i.e., hemifacial microsomia, Treacher Collin syndrome).
3. **Morphology of unique esthetic units of the face** (i.e., external nose, external ears, periorbital soft tissues)
4. **History of temporomandibular joint disorder** (TMD) symptoms and signs and documentation of any current limitations in mandibular range of motion

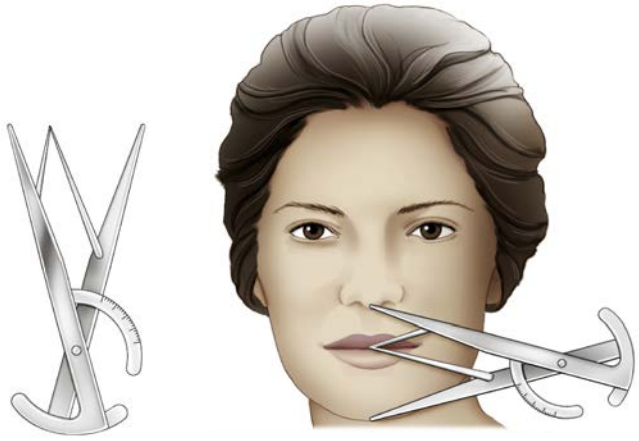

• **Figure 2-6** Human face with use of the Rickett's divider confirming the golden ratio. (Reprinted from Posnick JC: *Orthognathic surgery treatment planning. Orthognathic surgery: Principles and practice*, St Louis, 2014, Elsevier.)

5. **History of cervical spine symptoms and signs** and documentation of current safe neck range of motion
6. **Symmetry and harmony of the lower facial skeleton** (i.e., maxilla, mandible, chin region). The dentofacial deformity patient will have significant variations from normal in this region of the craniofacial skeleton
7. **Dental rehabilitative needs** (i.e., restorative and periodontal) as well as orthodontic aspects

Evaluation of the Overlying Soft Tissue Envelope

An individual with a routine developmental jaw disproportion will generally have a normal overlying soft tissue envelope, which is simply distorted by the underlying skeletal disharmony. On the other hand, normal variations in thickness and quality of the skin, density of sweat glands, fat distribution, and degree of pigmentation are to be expected. An example of soft tissue distortion (not deformity) is seen in maxillomandibular deficiency (i.e., short face growth pattern). The impression of "chubby cheeks" and excess fat in the neck is typical. With maxillomandibular (skeletal) advancement and vertical lengthening the normal facial contours/curvatures will be restored. There are exceptions where the soft tissue envelope is directly affected due to a malformation (e.g., Treacher Collins syndrome, hemifacial microsomia, cleft lip, hemifacial hypertrophy), previous trauma (burns, lacerations), or scarring after infection. When a jaw deformity is associated with a syndrome, clefting, or a soft tissue traumatic deformity, facial esthetics and head and neck functions are further negatively impacted and the soft tissue envelope may require special consideration.

Evaluation of the Upper Facial Skeleton

In most individuals presenting with a dentofacial deformity, the upper facial skeleton (i.e., cranial vault, orbits, and zygomas) will be reasonably symmetric and proportionate. There are exceptions due to congenital anomalies (craniofacial microsomia, Treacher Collins syndrome, Apert syndrome, Crouzon syndrome), traumatic events (molding in infancy, torticollis, previous facial bone fractures with malunion), and/or tumors (fibrous dysplasia, neurofibromatosis). In routine dentofacial deformities, minor upper face skeletal variations from normal are expected and may include differences in convexity of the forehead (anterior cranial vault) and/or prominence of the supraorbital ridge (anterior frontal sinus wall bulging). Minor mirror image asymmetries in the upper face are also common (external ear position, eyebrow height, CN VII dysfunction). When present, facial variations and asymmetries should be documented through medical quality photographs and then discussed with the patient/family from the outset.

In the presence of a dentofacial deformity the cheeks/cheekbones may appear "bigger or smaller" than they actually are. Correction of the jaw deformity toward Euclidian proportions is likely to change the observer's impression. This phenomenon is typically seen in a maxillary deficiency (i.e., relative mandibular excess) jaw growth pattern (Figure 2-7). Once the maxilla is advanced and rotated clockwise in conjunction with mandibular ramus osteotomies (clockwise rotation), the apparent flat cheekbones, deficient infra-orbital rims, and enlarged nose typically disappear.

Evaluation of Unique (Discrete) Facial Esthetic Units

There are discrete esthetic units of the face that stand out and should be independently considered, including the periorbital (eyelid) regions, external ears, and the nose. The periorbital (adnexal) tissues may be of special concern as a result of congenital hypoplasia (Treacher Collins syndrome, hemifacial microsomia, upper eyelid ptosis), previous trauma (medial or lateral canthal injury, nasolacrimal apparatus injury, upper or lower eyelid injury), or the normal aging process (descent, deflation, ptosis). The individual's eyelid appearance may either add a sparkle to or be a distracting focal point of the face. The external ears display considerable variation in size, shape, extent of protuberance, and asymmetry. The external nose will display a wide range of esthetic variation due to unique bony, cartilaginous, and soft tissue anatomy. In the presence of a dentofacial deformity, the middle third of the face (nose) may appear "bigger" or "smaller" than its actual size (see Figure 2-7). Correction of the presenting jaw discrepancy toward Euclidean proportions will improve harmony between the upper, middle, and lower thirds of the face. Once this is accomplished, a more accurate assessment of the actual nasal esthetic unit can be made. Disproportion of the nose as a stand-alone esthetic unit may nevertheless exist and benefit from alteration. Dysfunction of the nose characterized by chronic obstructive nasal breathing and inadequate sinus drainage should also be recognized and dealt with at the appropriate time. Clarification of these issues with the patient/family at the first consultation visit, and rediscussion at the time of orthognathic planning and again after surgical healing is essential to achieve patient satisfaction.

Assessment for TMD and Current Mandibular Range of Motion

An accurate history of any past and current TMD symptoms and signs should be documented, including any previous therapy, subjective complaints, joint noise, mandibular range of motion, any centric relation to centric occlusion discrepancy, masticatory muscle tenderness to palpation, and current radiographic findings. Active TMD will require treatment to diminish symptoms and achieve adequate range of motion before orthodontic treatment is initiated.

Assessment of the Cervical Spine and Current Neck Range of Motion

An accurate history of past and current cervical spine symptoms and signs should be documented. Individuals with a dentofacial deformity are at higher than average risk for cervical spine anomalies. If suspicion of cervical spine dysfunction exists, consultation with an appropriate specialist (i.e., neurologist, orthopedic surgeon, neurosurgeon) and

focused imaging studies (i.e., MRI, CT scan, plain cervical spine radiographs) should be carried out. Confirming the safe range of motion of the neck (while awake) in the office setting and understanding any limitations is important for safe orthognathic surgery and recovery.

Evaluation of the Lower Facial Skeleton

Confirmation that the upper facial skeleton and the overlying soft tissue envelope of the face do not require surgical alteration and that the neck and mandible can be put through an adequate range of motion without significant limitations

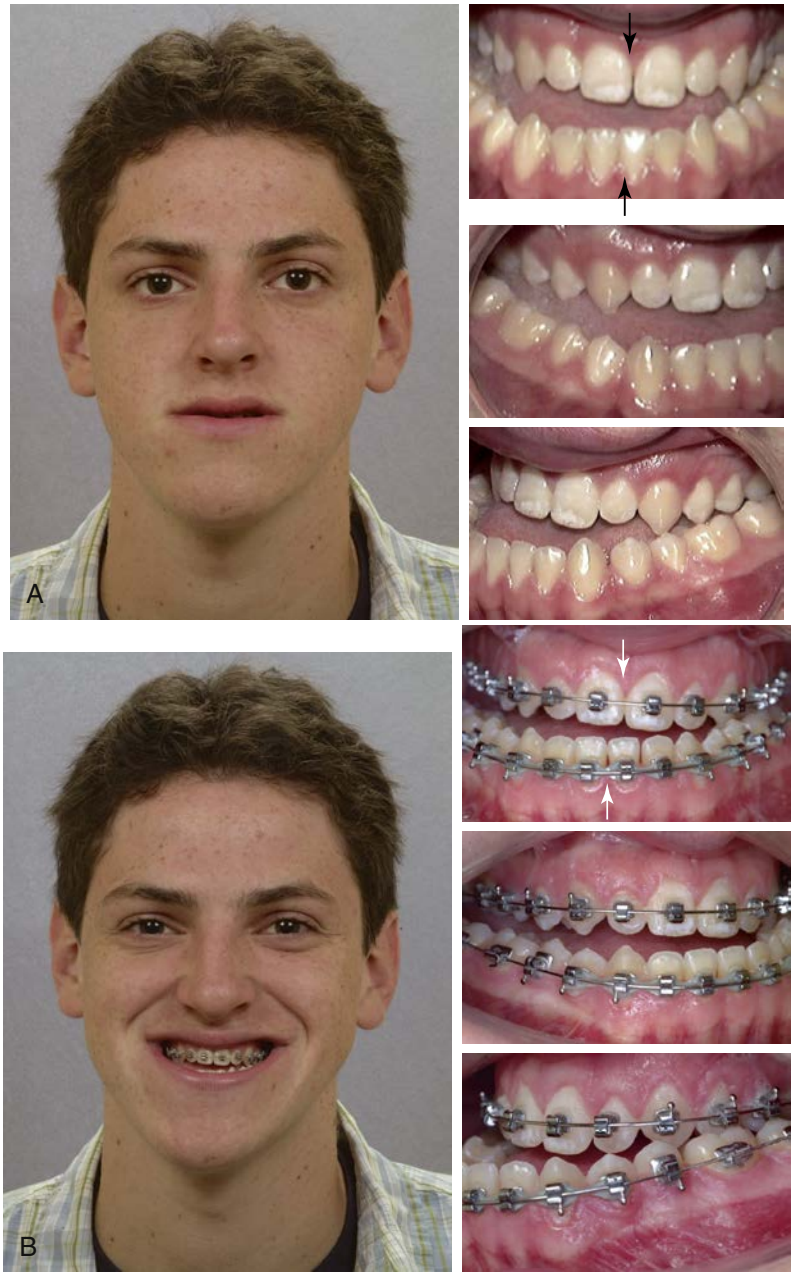

• **Figure 2-7** A 17-year-old with the diagnosis of left hemimandibular elongation (HE). The dentofacial deformity affects chewing, swallowing, speech articulation, lip closure/position, and breathing. He has normal cervical spine function and neck range of motion. He is without TMD and has a full range of mandibular motion. The upper facial skeleton (i.e., cranial vault, orbits, zygomas) is symmetric and with normal proportions. The facial soft tissue envelope is distorted by the maxillomandibular deformity but without malformation. In the early teenage years, he underwent an initial phase of orthodontics without success. He was referred for surgical evaluation and then underwent a combined orthodontic and surgical approach. With relief of dental compensation, surgery included: maxillary Le Fort I osteotomy (horizontal advancement, cant correction, vertical change, arch expansion, clockwise rotation); bilateral sagittal split ramus osteotomies (cant correction, mandibular straightening); osseous genioplasty (straightening and minimal advancement) and septoplasty/inferior turbinate reduction. **A,** Frontal facial view in repose prior to treatment. Occlusal views prior to orthodontic retreatment are also shown. **B,** Frontal view with smile prior to surgery. Occlusal views with orthodontic (dental) decompensation in progress.

Continued



Maxillary Surgical Plan		
Frontal View:		
Maxillary midline	No change	
Cant correction	4 mm	−2 mm (L) +2 mm (R)
Anterior vertical	+2 mm	





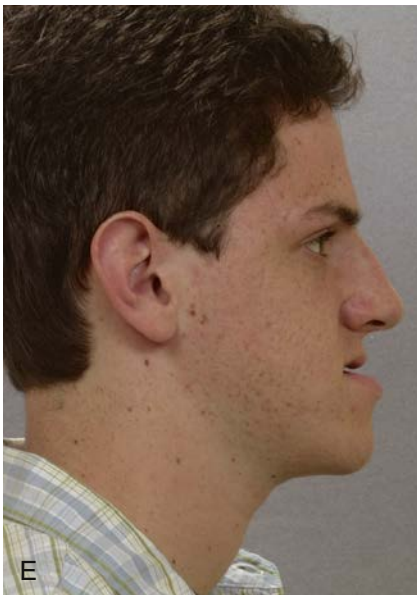

Maxillary Surgical Plan	
Profile View:	
Anterior vertical	+2 mm (lengthen)
Posterior vertical	0 mm
Horizontal	+8 mm (advance)

• **Figure 2-7, cont'd** **C,** The planned surgical repositioning of the maxilla is clarified at the preoperative direct visual examination. Frontal view changes will include: no maxillary dental midline change; 4-mm cant correction (up 2 mm at the left first molar and down 2 mm at the right first molar); and a 2-mm vertical lengthening at the incisors. **D,** Profile facial view prior to retreatment. Lateral cephalometric radiograph prior to retreatment. **E,** The planned maxillary repositioning is clarified at the pre-operative direct visual examination. Profile view changes will include: vertical lengthening of the incisors (2 mm); horizontal advancement at the incisors (8 mm); and maxillary clockwise rotation (2 mm).

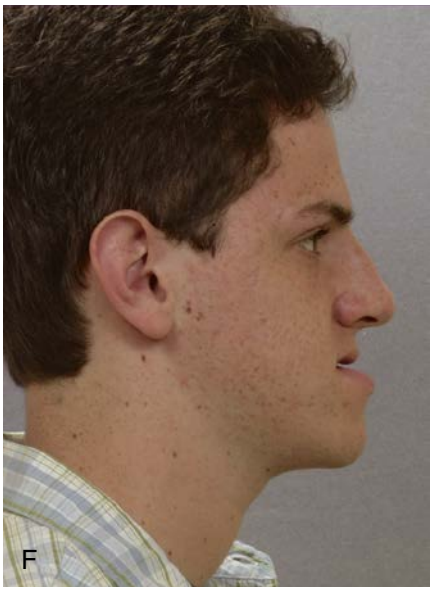

Maxillary Surgical Change	
Horizontal change at incisors	+8
Vertical change at incisors	+2
Midline change at incisors	0
Cant correction -*TOTAL*	4
↓ +2 on right ↑ −2 on left	
Maxillary plane change -*TOTAL* (Clockwise) Counterclockwise	2
Vertical change at T#3 (right) molar (Base + Cant + Plane)	+2 +2 −2 = +2
Vertical change at T#14 (left) molar (Base + Cant + Plane)	+2 −2 −2 = −2



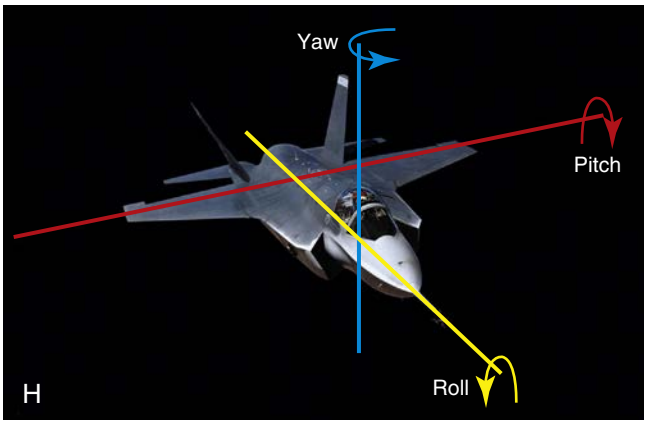

• **Figure 2-7, cont'd** **F,** The surgical plan for repositioning of the maxilla is indicated on the standard orthognathic surgery model planning data sheet. The data is then relied on to reorient the maxilla on the articulator with use of the Erickson Model Table. This is accomplished prior to splint construction. **G,** Articulated dental casts indicate model planning **H,** Illustration of roll, yaw, and pitch orientation. Consideration for reorienting the maxilla according to these parameters is an essential part of planning.

Continued



• **Figure 2-7, cont'd** **I,** Frontal views in repose before and after reconstruction. **J,** Frontal views with smile before and after reconstruction.

is essential prior to focusing on detailed maxillomandibular surgical planning. Qualitative decisions concerning which components of the maxillomandibular skeleton are asymmetric and/or disproportionate and require surgical repositioning will have already been discussed with the patient/family and other treating clinicians prior to initiating treatment. These details should be reconfirmed by the surgeon at the immediate preoperative planning visit.

Assuming that both the maxilla and mandible are part of the dentofacial deformity that requires reconstruction, quantitative (to the millimeter) decisions of the preferred esthetic and best functional repositioning of the upper jaw (at the time of Le Fort I osteotomy) must first be made.[25,27,36,37] When thinking through the details of maxillary (surgical) repositioning, it is understood that the "new" upper jaw position (in two-jaw surgery) will serve as the platform on which the mandible is to be placed. Where the lower jaw "ends up" is equally important and will be entirely dependent on the "new" (surgical) position of the maxilla and the orthodontic alignment of the teeth.[45]

Evaluation of Overall Dental Rehabilitation Needs

Recognizing when a patient seeking orthognathic surgery has additional dental needs beyond standard orthodontics is essential to achieving a favorable outcome. The need for a periodontal evaluation and treatment as well as the need for complex dental restorative work should be considered in every patient prior to initiating a coordinated orthodontic and jaw surgical approach. This is especially true for the adult who has suffered dental and periodontal sequelae from a long-standing uncorrected dentofacial deformity and who may have undergone camouflage treatment in attempts to neutralize the malocclusion (e.g., orthodontics, occlusal equilibration, restorative dentistry).

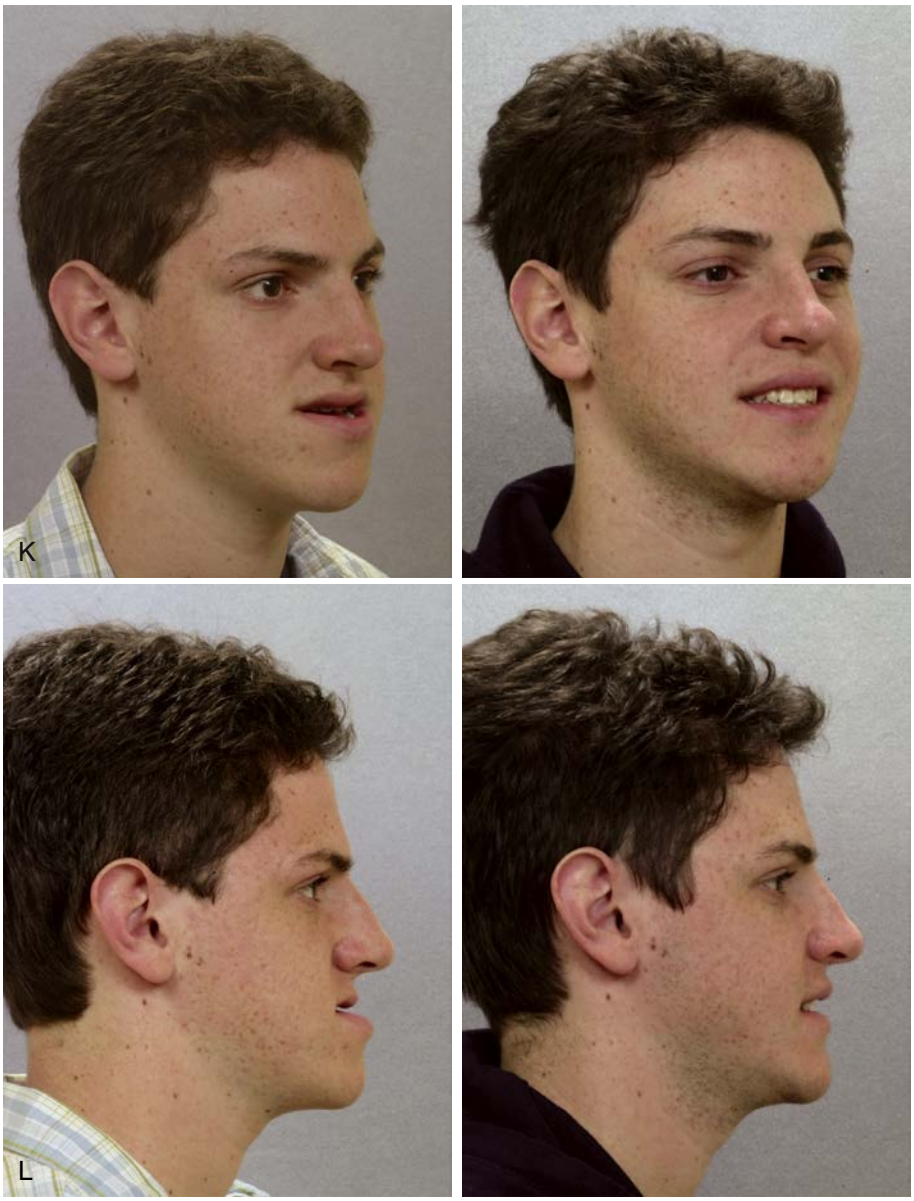

• **Figure 2-7, cont'd** **K,** Oblique facial views before and after reconstruction. **L,** Profile views before and after reconstruction.

Continued

Detailed Maxillomandibular Surgical Planning: Eight Critical Quantitative-to-the-Millimeter Decisions

1. Assess current and preferred position of the maxillary dental midline with reference to the upper face (yaw orientation). Anticipate any potential yaw effect of the new (surgical) maxillary orientation on the mandible and mid-face (cheeks) (see Figure 2-7).
2. Assess for presence of any maxillary cant (role orientation) with reference to the upper face. Decide the preferred upper jaw repositioning for cant correction (see Figure 2-7).
3. Assess current and preferred vertical position of the maxillary incisor crown with reference to the upper face. Consideration is given to the upper lip to incisor relationship in both repose and smile (see Figure 2-7).
4. Assess current and preferred horizontal position of the maxillary incisor crown with reference to the upper face (see Figure 2-7).
5. Assess current and preferred A-point to B-point relationship of the jaws (pitch orientation) when the face is viewed in profile (NHP). Consider the need to differentially alter the vertical maxillary height at the first molars and/or at the incisors (maxillary plane change) to achieve objectives (see Figure 2-7).
6. Assess the baseline pyriform rim/floor of nose/anterior nasal spine morphology. Anticipate the location of each after maxillary reorientation including any planned maxillary plane change. Consider advantages of skeletal recontouring of the pyriform rims/floor of nose/ANS to achieve airway and esthetic objectives (see Figure 2-7).



Prior to retreatment



Presurgery



4 years after treatment

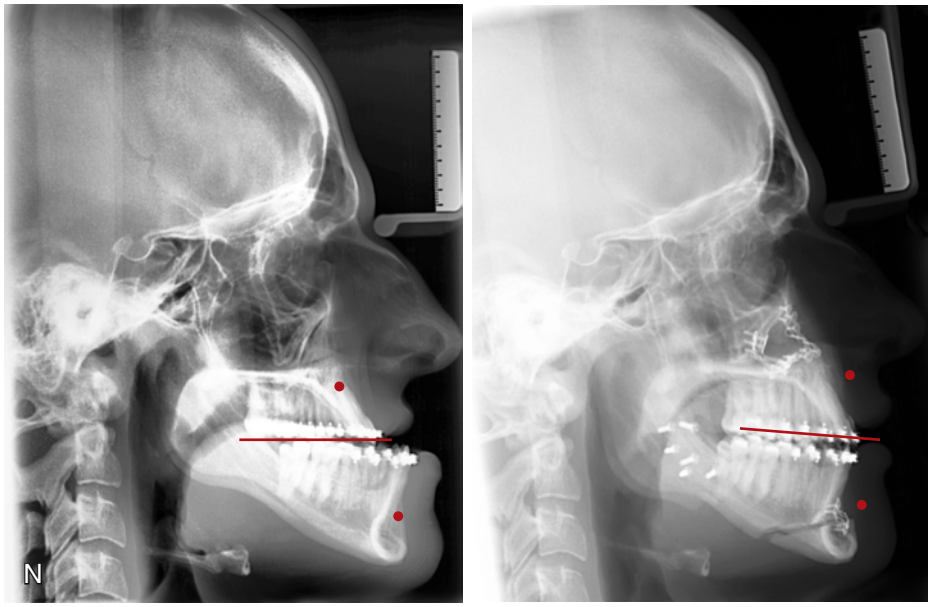

• **Figure 2-7, cont'd** **M,** Occlusal views prior to retreatment, with orthodontic decompensation in progress, and 4 years after treatment. **N,** Lateral cephalometric radiographs before and after surgery. (From Posnick JC: *Orthognathic surgery treatment planning. Orthognathic surgery: Principles and practice*, St Louis, 2014, Elsevier.)

7. Assess the baseline chin morphology. Anticipate location of pogonion after jaw reorientation that may also include mandibular plane change. Consider advantages of chin reshaping (osseous genioplasty) to achieve preferred horizontal and vertical esthetics and shape of the chin (see Figure 2-7).
8. Reconfirm advantage of (need for) segmentation of the maxilla to achieve preferred arch form and occlusion with the mandible (see Figure 2-7).

Assess Position of the Maxillary Dental Midline with Reference to the Upper Face (Yaw Orientation)

Once the decision has been made to surgically reposition the maxilla and mandible (two-jaw surgery), no additional risk is encountered in making a change in the maxillary dental midline position. In fact, the surgeon must make a conscious decision to either leave the midline as it is or to adjust it. At the immediate preoperative direct (face-to-face) examination, the operating surgeon should consider the preferred location of the maxillary dental midline. This is a clinical observation when viewing the patient at conversational distance and closer up. It is measured in millimeters of variation of the maxillary dental midline (point between the incisors at the incisal edge) in comparison to the baseline upper facial midline. Ideally, the midline of the maxillary central incisor should coincide within 2 mm with the facial midline. When the upper face has satisfactory basic symmetry the decision of where to position the maxillary dental midline is generally straightforward (see Figure 2-7). In the presence of upper face asymmetry, especially when combined with canting of the maxilla, and asymmetry/disproportion of the mandible, the decision of where to reposition the maxillary midline becomes more complex.

When the surgeon decides on the new preferred location of the maxillary (incisor) midline (at the time of surgery) the "yaw effect" (of the midline change) must also be taken into account (see Figure 2-7). For example, the maxilla may be either bodily moved to one side (to correct the incisor midline) or the maxillary dental midline may be corrected while leaving the buttress regions (side to side) essentially unchanged. This would require a rotation (twisting) of the maxilla (rather than a bodily movement) so that the posterior maxilla moves slightly anterior on one side while the other side moves slightly posterior. This is a similar movement to the twisting open of a lid on a jar. As stated, a twisting movement of the maxilla around the vertical axis of rotation (yaw orientation) will result from a simultaneous anterior incisor midline shift and a posterior shift at the molars. When "twisting" the maxilla, the resulting posterior shift will cause a relative ipsilateral class III and a contralateral class II molar relationship change. On the other hand, a lateral (side to side) shift of the maxilla would cause a different yaw orientation change (see Figure 2-7).

Establishing the correct maxillary dental midline position and yaw orientation is especially of concern in cases that present with moderate to severe 3D facial asymmetry of multiple bones (i.e., hemifacial microsomia). A 3D CT scan (top of the skull through bottom of the chin) can be helpful to appreciate where specific mirror image dysmorphology exists and how best to manage it. At surgery, the introduction of unwanted yaw effects are often visualized as asymmetries in:

- The maxillary incisor midline compared to the facial midline
- The cheek region (side to side) with fullness on one side and deficiency on the other
- The angle of mandible region (side to side) with fullness on one side and deficiency on the other

Assess for any Maxillary Cant with Reference to the Upper Face (Roll Orientation)

Once the decision has been made to surgically reposition both the maxilla and mandible (two-jaw surgery), no additional risk is encountered when making a change (correction) of any observed cant (roll orientation) of the maxilla. The operating surgeon is forced to make a conscious decision to either leave the roll orientation (cant) as is or to alter it and, if so, by how much. Studies confirm that a three-degree occlusal cant is perceived as a noticeable asymmetry by 50% of both professionals and lay people while a four-degree cant is noticeable by 90% of professionals and lay people.[46] At the preoperative direct planning examination, the clinician should make an observation when viewing the patient face to face that the maxilla is vertically "even" (side to side) or, if not, how much of a deviation (cant) is present. What is generally called a maxillary cant (vertical height discrepancies of the maxilla side to side) may also be viewed from the perspective of the esthetic line of the dentition or at the functional line of the occlusion (see Figure 2-7). Maxillary cant considerations are in comparison to the upper face (structures above the maxilla). When the upper face is basically symmetric, the interpupillary line may be used as an accurate baseline reference (see Figure 2-7).

The presurgical planning visit is a good opportunity for the surgeon to clarify and discuss directly with the patient/family both major and minor presenting facial asymmetries. This can be done by viewing a medical quality frontal facial photograph or while the patient is looking into a handheld mirror. Typical minor asymmetries include differences in height (position) and shape between the external ears, eyebrows, lateral canthi, as well as asymmetries in cheek/lip (soft tissue) elevation during smiling. Quantifying any presenting maxillary cant and the extent of correction planned (to the mm) may be complicated by upper facial skeletal asymmetries, other directional abnormalities of the maxilla (transverse, horizontal, or dental midline to facial midline), and any asymmetry/disproportion of the mandible. When present, these compounding factors make it difficult to correctly predict the most esthetically pleasing outcome.

Thought is simultaneously given to the yaw orientation (rotation around the Y-axis) of the presenting maxillary deformity and the yaw effect at the level of the mandibular angles and the mid-face (cheek) regions anticipated from the (planned) maxillary change (see Figure 2-7). In complex facial asymmetry cases, the clinician's ability to simultaneously analyze the presenting yaw and roll orientations and the subsequent esthetic changes of the planned correction can be augmented with use of craniofacial 3D CT scan imaging.

The clinicians' assessment of the extent of maxillary cant and the desired correction may be facilitated by:

1. **Use of a Fox Plane during the direct visual examination:** Placement of a Fox Plane directly over the occlusal surfaces of the maxillary dentition is helpful to judge the presence and extent of maxillary cant compared to the upper face (interpupillary reference line). Soft wax can be added to the deficient side (wax placed between the Fox Plane and occlusal surfaces of teeth) until the cant is corrected (in comparison to upper face). The mm amount of wax built up (for example at the first molar, mesiobuccal cusp) is a measure of the cant. When using a Fox Plane, the clinician must consider the patient's maxillary arch form. Often, two separate dento-alveolar planes (steep curve of Spee) have been accentuated by the orthodontic mechanics and will be managed with segmental osteotomies. How the Fox Plane is seated to the patient maxillary occlusal plane is important when assessing for a cant.
2. **Comparison measurements from posterior-anterior (PA) cephalometric radiograph (left to right sides):**
   - Incisal edge to nasofrontal suture (mm distance left and right sides)
   - Canine edge to nasofrontal suture (mm distance left and right sides)
   - First molar edge to fronto-zygomatic suture (mm distance left and right sides)
3. **Comparison measurements from a 3D craniofacial CT scan (left to right sides)**
   - Incisal edge to nasofrontal suture (mm distance left and right sides)
   - Canine edge to nasofrontal suture (mm distance left and right sides)
   - First molar edge to fronto-zygomatic suture (mm distance left and right sides)
4. **Comparison measurements taken directly from the anthropometric (facial) surface (left to right sides)**
   - Incisal edge to medial canthus (mm distance left and right sides)
   - Canine edge to medial canthus (mm distance left and right sides)
   - First molar edge to lateral canthus (mm distance left and right sides)

Assess Preferred Vertical Position of the Maxillary Incisor Crown with Reference to the Upper Face

The upper lip to maxillary incisor relationship represents a key facial esthetic landmark.[47] Ideally, with the upper lip at rest, several millimeters (1-3 mm) of the lower aspect to the maxillary incisor crowns should be seen in frontal view. With a broad smile, the upper lip elevates and, ideally, the entire maxillary incisor crown and a few millimeters (1-2 mm) of the gingiva will be seen. This will vary when evaluating a posed (as for a photograph) versus a dynamic (as seen when laughing) smile. The so-called *esthetic line of the dentition* follows the surfaces of the maxillary anterior and posterior teeth. The *functional line of occlusion* takes into account arch form, arch width, and symmetry. In the presence of malocclusion due to distortions in arch width, curve of Spee, and overall arch form, the functional line of occlusion may not be even (on a single plane) (see Figure 2-7). In many of the typical developmental jaw deformities the lip-to-tooth relationship (i.e., esthetic line and functional line) will find variation from ideal. Effected individuals will benefit from differential surgical repositioning of the anterior and posterior maxilla (i.e., intrusion or lengthening) as part of the surgical correction not only to positively influence the occlusion itself but also the esthetic line of the dentition and the functional line of occlusion.

Through a Le Fort I osteotomy with vertical intrusion, less gingiva with smile and incisor crown height in repose will be seen. With surgical (vertical) lengthening of the upper jaw (at Le Fort I osteotomy), more dental show and gingival exposure is to be expected (see Figure 2-7). Unfortunately, even with a pure vertical vector change of the maxilla, the upper lip soft tissue response is generally less than a one-to-one relationship and not entirely predictable. Soft tissue predictions become even less accurate with: combined upper jaw vector changes (vertical, horizontal, and transverse); in the presence of maxillary asymmetries (cant and dental midline shifts); when other procedures are simultaneously carried out (mandible and chin osteotomies and pyriform rim/nasal floor/anterior nasal spine recontouring); and in the presence of a hypotonic upper lip (long-standing skeletal class III) or an immobile scarred upper lip (fibrosis after cleft lip repair). Nevertheless, with thoughtful planning, a favorable esthetic outcome of the incisor vertical position to upper lip relationship should be achieved for the vast majority of orthognathic patients (see Figure 2-7). As a general rule, it is best to prevent too little maxillary incisor and gingival show in relationship to the upper lip (i.e., edentulous/aged/sad look). Also, remember that with age the upper lip lengthens (i.e., loss of muscle tone). As long as excess lip separation at rest and mentalis strain with closure is avoided, erring on the side of more rather than less incisor show is generally a preferred esthetic objective.

Note: I prefer to make final decisions concerning the exact esthetic vertical position of the maxillary incisors at operation once the maxilla is secured to the mandible through the intermediate splint. At this point, with the condyles seated in the terminal hinge position, all other vector changes for the maxilla are predetermined. The maxillomandibular complex is rotated, the vertical height is measured (i.e., medial canthus to incisor height), and the final incisor (vertical) position is decided.

Assess Preferred Horizontal Position of the Maxillary Incisor Crown with Reference to the Upper Face

The "ideal" esthetic horizontal position of the maxilla is not a specific millimeter or angular number but represents a limited range of what will be considered proportionate within the overall face. For each specific developmental jaw growth pattern (i.e., long face, short face, maxillary deficiency with relative mandibular excess, cleft maxilla), the needed directional horizontal surgical change of the maxilla should be

clear at the initial consultation. This will be reconfirmed at the preoperative planning examination by the operating surgeon. An exact preferred horizontal (millimeter) change at the maxillary incisors can be gauged through a combination of analysis including:

1. **Cephalometric Analysis. Evaluation of the Lateral Cephalogram:** Taken in the adjusted natural head position, lips relaxed, centric relation.
2. **Andrew's Profile Analysis. Evaluation of the Lateral Facial Photograph:** Taken in the adjusted natural head position, in centric relation, with broad smile (exposing the maxillary incisors) and with exposure of forehead skin (i.e., hair pulled back).
3. **Anthropometric Surface Analysis. Visual Examination of the Face:** When viewing the patient on direct examination in the adjusted natural head position from varied perspectives in both repose and with smile.

Comment: Normative cephalometric measurements such as the SNA angle generally underestimate but may also overestimate the preferred horizontal esthetic projection of the maxilla and therefore cannot be relied on. On the other hand, Andrew's Profile analysis of how much to advance the maxilla in the horizontal plane can be useful to the clinician when evaluating a patient with a dentofacial deformity. Spending time with an experienced orthognathic surgeon is a valuable way for a clinician in training to gain the knowledge required to make consistent favorable esthetic judgments of the preferred 3D reorientation of the maxilla at operation.

Andrew's Profile analysis can be an extremely useful tool to assess the preferred horizontal projection of the maxilla in the dentofacial deformity patient.[33] This author's application of Andrew's "Element II of Orofacial Harmony" is described in Figure 2-8. A step-by-step outline of how to do so follows:

- Photograph the face (head and neck) in profile. This is with the patient in the natural head position (NHP) and with a broad smile (i.e., so that the labial surfaces of the maxillary incisors are fully visualized). The forehead skin up to the hairline must also be exposed (i.e., hair pulled back). The dentition should be in centric relation or with a normal freeway space. There should be a calibration scale confirming 1:1 life-size measurements included on the facial photograph.
- Identify *trichion* (junction of forehead skin and anterior hairline and is the most superior aspect of the forehead when the forehead is relatively flat).
- Identify *superion* (i.e., the most superior aspect of the forehead, when the forehead is either rounded or angular in contour).
- Identify *glabella* (most anterior projection of the lower forehead).
- Draw a line connecting superion and glabella.
- Identify the midpoint between trichion and glabella (i.e., for foreheads with rounded or angular contour). This is called the *forehead anterior (FA) point.*
- Locate and drop a vertical line through the FA point. The line should be perpendicular to the floor with the patient in the NHP. This is called the *forehead anterior limit line* (FALL).
- Measure the angle at the superior forehead between these two lines. This angle is a measure of the forehead inclination.
- Locate and drop a second vertical line parallel to the FALL. The location of this line is measured in millimeters anterior to the FALL according to the formula (forehead inclination angle – 7) × 0.6. This is called the *goal anterior limit line* (GALL). Note: The GALL is parallel and anterior to the FALL.
- Locate and drop a third vertical line that is parallel to both the FALL and GALL. This line runs through the anterior surface of maxillary central incisors. This is assuming that element I is correct (i.e., the maxillary incisor inclination is correct). This is called the *dental anterior limit line* (DALL). The difference between GALL and DALL is the "recommending" distance in millimeters that the maxilla should be horizontally (sagittally) advanced to improve mid-face esthetics in the maxillary deficient mid-face.

Suggested adjustments to Andrew's Profile standard analysis are as follows:

- I have found that a strict interpretation of Andrew's analysis for the preferred horizontal position of the maxillary incisors is best suited for the Caucasian rather than Asian or African morphology. Facial variation according to race has much to do with forehead, nasal, and mid-face morphology.
- I have found that variations in thickness of the facial soft tissue envelope have an effect on preferred esthetic horizontal position of the maxilla. This is an additional factor that should be taken into account when reorienting the maxilla in conjunction with Le Fort I osteotomy. For example, the individual with a "thick" soft tissue envelope (i.e., obstructive sleep apnea patient with elevated body mass index) will typically estetically require (handle) greater horizontal advancement than Andrew's analysis indicates. The opposite may be true for the individual with a "thin" skin facial soft tissue envelope.
- Andrew's points out that mid-face esthetics in profile is highly dependent on the proper positioning of the maxillary teeth within the arch (element I). For example, in the maxillary deficient/relative mandibular excess growth pattern, if the decision is to avoid maxillary bicuspid extractions to fully retract the incisors toward a normal inclination, then mid-face esthetics may be negatively impacted. In this case, the maxillary incisal edge may be positioned correctly in the horizontal plane, but due to procumbency of the anterior teeth the basal bone of the maxilla remains retrusive. As a consequence of incisor procumbency, the nasolabial angle in repose and with elevation of the upper lip during smile may be esthetically compromised.

Achieving a favorable smile is influenced by several factors, including but not limited to: (1) the quality of the perioral soft tissues; (2) the vertical position of the maxilla; (3) the horizontal position of the maxilla; (4) the maxillary arch width; and (5) the inclination of the anterior teeth within the arch (see Figure 2-7). The *smile arc* is analyzed in frontal view by evaluating parallel lines representing the lower lip and upper dentition. The ideal smile arc or *consonant smile line* is characterized by the curvature of the lower lip line paralleling the curvature of the maxillary incisal edges. A consonant smile line is felt to project a happy and youthful appearance. The *buccal corridor* is the space created between the buccal surfaces of the posterior teeth and the inner aspect of the oral commissure when the individual is smiling. Those with excessive buccal corridors *(negative space)* are generally rated as less attractive than those with smaller buccal corridors. When a maxilla is narrow and horizontally retrusive, the visual appearance of *dark buccal corridors* reduces smile attractiveness. Smile esthetics are also enhanced when the *display zone* is filled with the maxillary teeth. This concept is best appreciated when viewing the before-and-after orthognathic surgery smile in an individual with maxillary deficiency (relative mandibular excess) who presents with a class III negative overjet malocclusion (see Figure 2-7). Improvement of smile esthetics in the maxillary deficient patient is often accomplished through

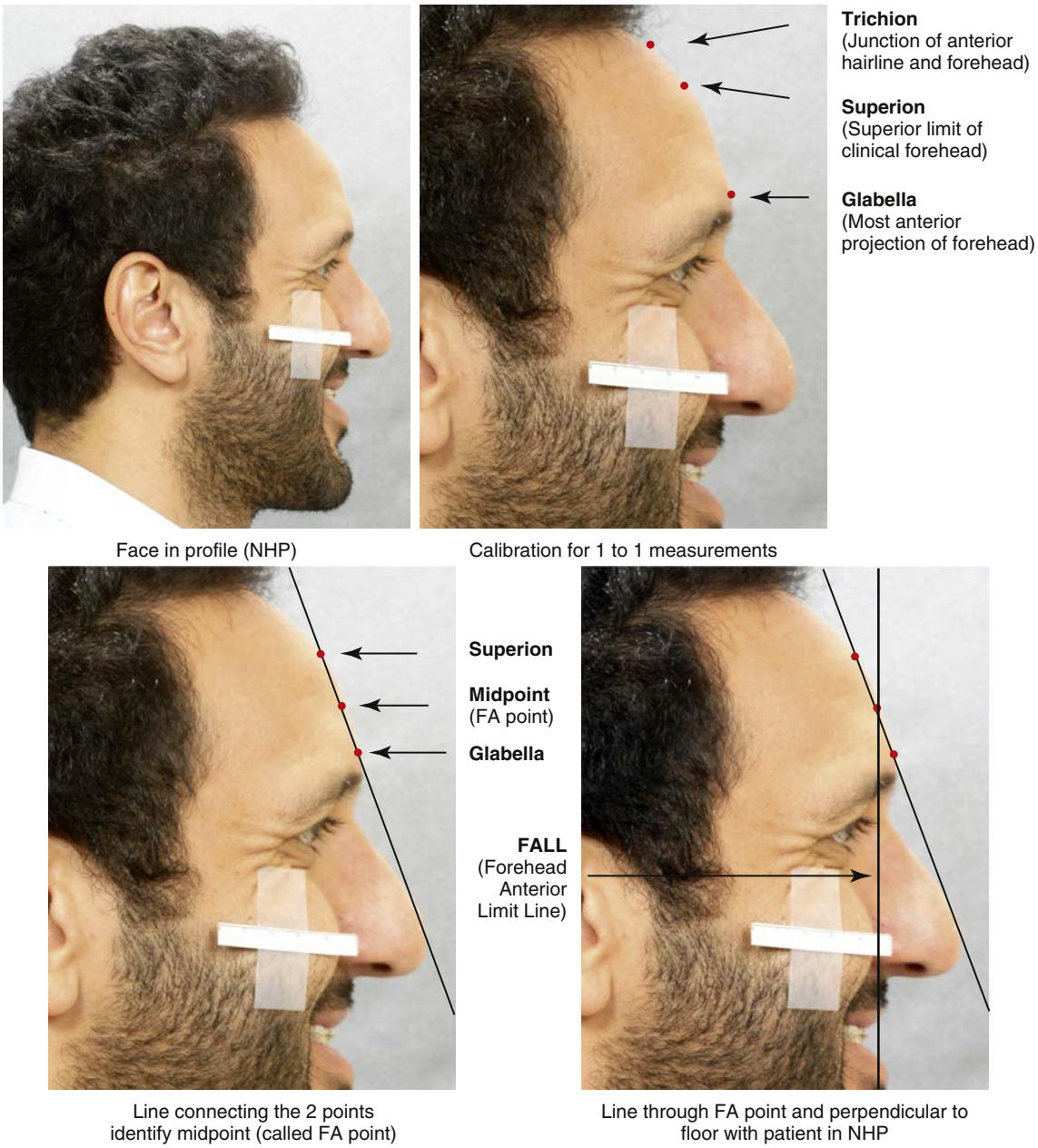

• **Figure 2-8** Patient viewed in profile in the natural head position (NHP). He is shown as a case example to demonstrate application of Andrew's "Element II of Orofacial Harmony" (see text). (Reprinted from Posnick JC: *Orthognathic surgery treatment planning. Orthognathic surgery: Principles and practice*, St Louis, 2014, Elsevier.)

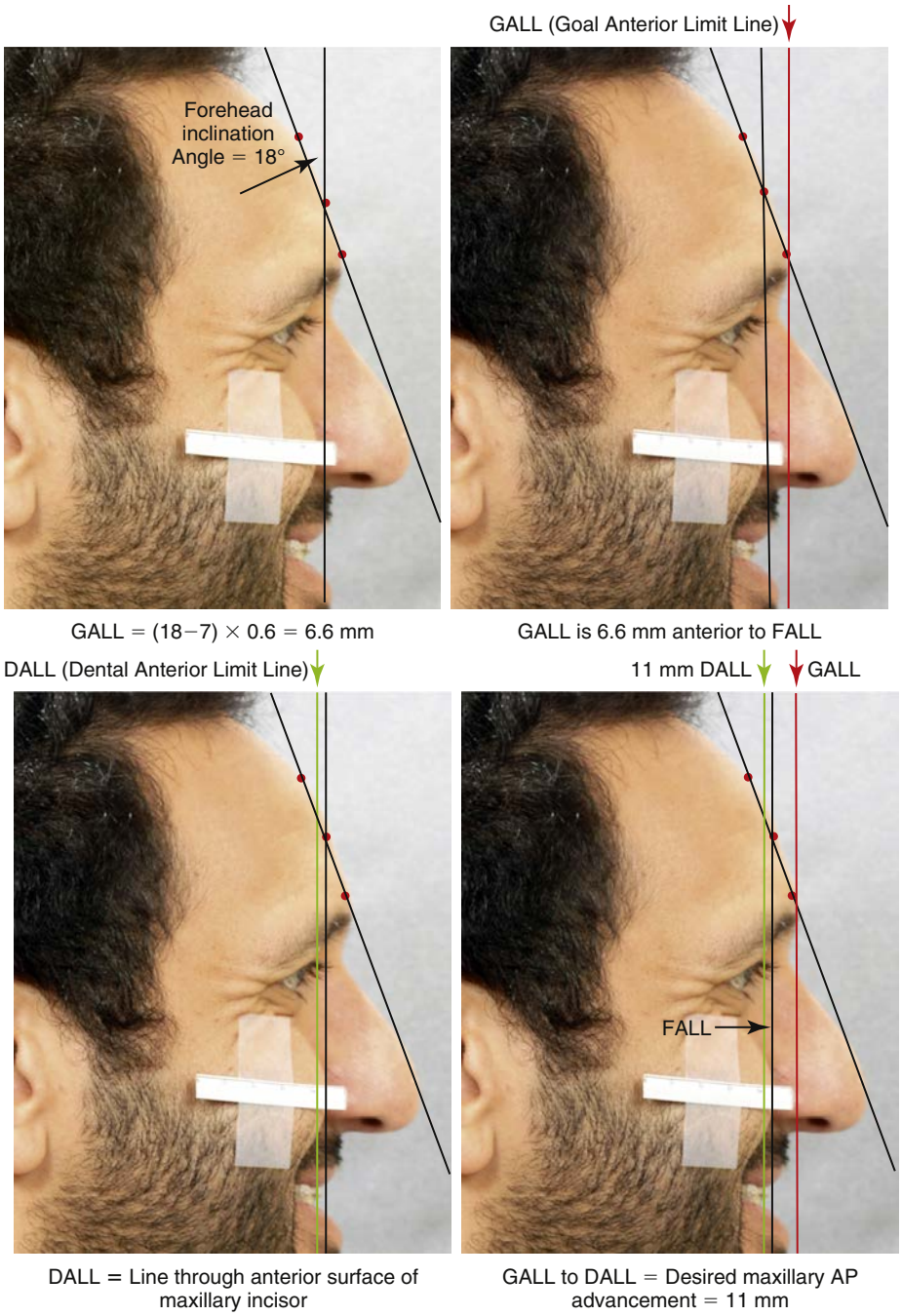

• **Figure 2-8, cont'd**

a combination of maxillary arch expansion, horizontal advancement, and adjustment of the vertical height. Decisions concerning where to position the maxillary incisors (vertical and horizontal) at the time of Le Fort I osteotomy will greatly affect smile esthetics.

Assess Preferred A-Point to B-Point Relationship of the Jaws When Viewed in Profile (Pitch Orientation)

The facial esthetic advantage of achieving an ideal A-point, B-point relationship has been discussed by contemporary orthodontists and orthognathic surgeons.[25,26,34-36,48-50] This may require clockwise or counterclockwise rotation of the maxillary and/or mandibular planes, but rarely requires a true lengthening or shortening of the posterior facial height. When using sagittal split ramus osteotomies, the unchanged proximal segment of the mandible establishes the posterior facial height, while any plane change carried out occurs in the distal segment. The height of the proximal segment (i.e., posterior facial height) does not change with either clockwise or counterclockwise rotation of the distal segment in conjunction with a sagittally split ramus osteotomy. When establishing the preferred A-point to B-point relationship and achieving full mid-face projection and vertical height through orthognathic technique, the upper airway will also improve.

Assessment of profile esthetics should be in the adjusted NHP, with the teeth in centric relation and then relaxed to allow the normal freeway space, but without anterior mandibular posturing through a "dual" bite. The lips are first relaxed (i.e., not pursed together) and then also assessed with full smile (see Figure 2-8). Individuals who present with a jaw discrepancy frequently have an altered mode of respiration and tend to rest their head in a position that an experienced evaluator will consider either neck extended or flexed or with a head tilt. Adjustment of the individual's head position (by the clinician) to the NHP is required to accurately assess the profile. Often, the patient's lateral facial photograph and/or lateral cephalometric radiograph are also not taken in the NHP. If the profile photograph, 3D CT, and/or lateral cephalometric radiograph are to be used in facial esthetic analysis, then the image should first be rotated to establish natural head position. A perpendicular (vertical) line can then be dropped from which to consider the patient's current A-point to B-point relationship and what surgical corrections will be helpful to achieve the desired facial esthetic and upper airway results (see Figure 2-8).

Achieving the preferred A-point and B-point relationship will influence the relative position of the skeletal structures above (i.e., anterior wall of the maxilla, pyriform rims, anterior nasal spine) and below (i.e., pogonion) as well as the dentoalveolar components of each jaw (i.e., incisor inclination) (see Figure 2-7). The position of these superior and inferior skeletal structures will then be reflected through the overlying facial soft tissue envelope. This includes the soft tissues of the lower eyelids (i.e., improvement in tear trough/negative vector), cheeks (i.e., improvement in nasolabial folds), nose (i.e., improvement in depressed nasal sills/plunging tip), lips (i.e., improvement in turned down oral commissures/marionette lines), chin (i.e., prevention of ptosis), and neck (i.e., improvement in obtuse neck angle/double chin).

Surgical repositioning of the jaws to improve the A-point and B-point relationship is also carried out with consideration of its effects on the relative inclination of the maxillary and mandibular incisors (see Figure 2-7). Rotation of the maxillary plane can improve the relationship of the maxillary smile arc, making it consonant with the lower lip. With respect to incisor inclination, when the maxillary plane is surgically rotated clockwise, the relative incisor inclination decreases. When the maxillary plane is surgically rotated counterclockwise, the incisors become more procumbent. When the mandibular plane is rotated clockwise, the incisors become more proclined. When the mandibular plane is rotated counterclockwise, the incisors become more retroclined. These effects must be considered during the presurgical orthodontic phase and again at the time of detailed preoperative planning.

Assess the Baseline Pyriform Rim/Floor of Nose/Anterior Nasal Spine Morphology: Anticipate the Location of Each After Maxillary Repositioning

Surgical positioning of the A-point and B-point to a corrected pattern will generally result in more pleasing esthetics at the pyriform aperture (paranasal) regions (see Figure 2-7).[25,34-36,48-51] However, at the time of Le Fort I osteotomy recontouring of the pyriform rims, the anterior floor of the nose, and the anterior nasal spine region to correct baseline skeletal deformities may also be beneficial. The advantage of these recontouring procedures to the upper lip/tooth relationship and base of the nose esthetics should always be considered in the preoperative planning.

Riola's textbook of cephalometric measurements confirms that the normal mean vertical height of the anterior nasal spine down to the maxillary incisal edge is 30 mm (±3 mm) for females, and 33 mm (±3 mm) for males.[52] At the time of Le Fort I osteotomy, the patient's specific measurement can be confirmed with a caliper. This is useful information to guide nasal recontouring. For example, in the long face growth pattern, a patient undergoing Le Fort I osteotomy with vertical intrusion to reduce a "gummy" smile will frequently have an average height of between 40 to 45 mm. After down-fracture, recontouring and lowering the floor of the nose and anterior nasal spine toward 30 mm is useful to normalize anatomy. In so doing, the nasal airway and nasal esthetic unit will be favorably enhanced.

Assess the Baseline Chin Morphology: Anticipate the Position of Pogonion After Jaw Repositioning and the Potential Benefits of an Osseous Genioplasty

An individual's lateral cephalometric radiograph is useful to assess the anterior facial heights, any baseline bony chin dysmorphology, maxillary and mandibular incisor inclination, and A-point to B-point relationships (see Figure 2-7). Riola's table of normative mandibular cephalometric values confirms that the mean vertical height of a chin (mandibular incisal edge to menton) is approximately 42 mm (±2.7 mm) for females and 49.4 mm (±2.9 mm) for males. These measurements can be a useful benchmark from which to judge preferred vertical height of the chin.

Effective alteration of the A-point to B-point relationship at the time of orthognathic surgery will generally have a positive effect on pogonion position.[25,34-36,48-51] Additional direct surgical alteration of the chin (i.e., osseous genioplasty) is also frequently beneficial to achieve enhanced facial esthetics (i.e., vertical lengthening or shortening, midline shifts, horizontal advancement or recontouring of the chin surface anatomy). This should be considered at the immediate preoperative (face-to-face) examination and discussed with the patient/family. A plan for chin region management is agreed to and then executed at the time of orthognathic surgery with a goal to further improve esthetics, lip function, and possibly breathing (i.e., genioglossal advancement in the individual with OSA).

Reconfirm Advantage of (Need for) Segmentation of the Maxilla

The advantage of segmentation of the maxilla will have been considered prior to initiating orthodontic treatment. Maxillary segmentation is often a necessary procedure to achieve favorable long-term occlusal stability and periodontal



• **Figure 2-9** *Mona Lisa* by Leonardo da Vinci. (From Posnick JC: *Orthognathic surgery treatment planning. Orthognathic surgery: Principles and practice*, St Louis, 2014, Elsevier.)

health. It may be required to achieve an ideal curve of Spee, arch width, and incisor inclination, and successful closure of dental gaps. Segmentation is generally performed as either a two-segment LeFort I with osteotomies between the incisors and then parasagittally through the hard palate, or as a three-segment Le Fort I with osteotomies between the lateral incisor and canine (on each side) and then down the parasagittal midline on one or both sides. Segmentation of the upper jaw is not an excuse for poor orthodontic preparation. It does provide an opportunity to correct skeletal anomalies through the basal bone rather than through orthodontic (dental) compensation that would otherwise position the teeth outside (or on the edge of) the alveolar process. An orthodontic compensation (i.e., dental camouflage) approach would be unstable for the occlusion and periodontium in the long run. Plans for maxillary segmentation should be agreed on prior to commencing orthodontic treatment, reconfirmed at the time of immediate presurgical planning, demonstrated on the articulated dental models, registered on the prefabricated acrylic splints, and then executed during surgery (see Figure 2-7).

Conclusions

From a patient/family perspective, facial esthetic aspects are of significant importance in the correction of a dentofacial deformity. The most attractive faces will always incorporate a consistent symmetry of proportions in which the golden ratio can be found. An in-depth visual facial analysis, use of radiographic and photographic imaging, meticulous model planning, and experienced surgical execution remain the important components to achieving success in orthognathic surgery. There is much to be said for both the scientific and artistic aspects and a methodical approach to accomplish facial esthetic objectives, restoration of dental health and improved head and neck function (i.e., breathing, swallowing, chewing, speech) in the reconstruction of a dentofacial deformity. Accomplishing Euclidian facial proportions through orthognathic surgery by attempting to reach the *Kanon of Beauty,* as described by Polyclitus and visualized in the nautilus found in nature, is the ultimate objective.

In current clinical practice, we can take some solace in knowing that even Leonardo da Vinci was not entirely able to articulate the link between theory and practice in the establishment of ideal facial esthetics. When analyzing the Mona Lisa, academicians still disagree about Leonardo's intent and the meaning of his work vis-à-vis the golden ratio (Figure 2-9). Nevertheless, with a working knowledge of the golden ratio and its fascinating impact on the arts, architecture, and nature, the clinician's esthetic sense of harmony and symmetry is enhanced for the benefit of patients.

References

1. Heath TL: Euclid and the traditions about him. In Heath TL, editor: *Euclid elements, 1*, at Perseus Digital Library, 1908, pp 1–6.
2. Heath TL: *The thirteen books of Euclid's elements*, ed 2, 3 vols. New York, 1956, Dover Publications.
3. Livio M: *The golden ratio: The story of phi, the world's most astonishing number*, New York, 2002, Broadway Books.
4. Pacioli L: *De divina proportione*, Venice, 1509, Paganinus de Paganinis.
5. Hogarth W: Analysis of beauty. In Paulson R, editor: *Analysis of beauty*, New Haven, CT, 1997, Yale University Press, pp 5, 94.
6. Kingsley P: *Ancient philosophy, mystery and magic: Empedocles and the Pythagorean tradition*, Oxford, 1995, Oxford University Press.
7. Enlow D, Kuroda T, Lewis A: The morphological and morphogenic basis for craniofacial form and pattern, *Angle Orthod* 41:161–188, 1971.
8. Baker BW, Woods MG: The role of the divine proportion in the aesthetic improvement of patients undergoing combined orthodontic/orthognathic surgical treatment, *Int J Adult Orthodon Orthognath Surg* 16(2):108–120, 2001.
9. Corbusier Le: *The modulor*, London, 1951, Faber and Faber Ltd.
10. Broadbent Sr BH, Broadbent Jr GH, Golden WH: *Bolton standards of dentofacial developmental growth*, St Louis, 1975, Mosby.
11. Downs WB: The role of cephalometrics in orthodontic case analysis and diagnosis, *Am J Orthod* 38:162–182, 1952.
12. Downs WB: Analysis of the dentofacial profile, *Am J Orthodont Oral Surg* 26:192–212, 1956.
13. Holdaway RA: A soft tissue cephalometric analysis and its use in orthodontic treatment planning: Part 1, *Am J Orthod* 84(1):1–28, 1983.
14. Holdaway RA: A soft-tissue cephalometric analysis and its use in orthodontic treatment planning: Part II, *Am J Orthod* 85: 279–293, 1984.
15. Peck S, Peck L: Selected aspects of the art and science of facial esthetics, *Semin Orthod* 1:105–126, 1995.
16. Ricketts RM: Cephalometric synthesis, *Am J Orthodont* 46: 647–673, 1960.
17. Ricketts RM: Divine proportion in facial aesthetics, *Clin Plast Surg* 9(4):401–422, 1982.
18. Ricketts RM: The biologic significance of the divine proportion and Fibonacci series, *Am J Orthod* 81(5):351–370, 1982.
19. Farkas LG, Posnick JC: Growth and development of regional units in the head and face based on anthropometric measurements, *Cleft Palate-Craniofacial J* 29(4):301–302, 1992.

20. Farkas LG, Posnick JC, Hreczko T: Anthropometric growth study of the head, *Cleft Palate-Craniofacial J* 29(4):303–308, 1992.
21. Farkas LG, Posnick JC, Hreczko T: Growth patterns of the face: A morphometric study, *Cleft Palate-Craniofacial J* 29(4): 308–315, 1992.
22. Farkas LG, Posnick JC, Hreczko T, Pron G: Growth patterns in the orbital region: A morphometric study, *Cleft Palate-Craniofacial J* 29(4):315–318, 1992.
23. Farkas LG, Posnick JC, Hreczko T, Pron G: Growth patterns of the nasolabial region: A morphometric study, *Cleft Palate-Craniofacial J* 29(4):318–324, 1992.
24. Posnick JC: Quantitative computer tomographic scan analysis: Normal values and growth patterns. In Posnick JC, editor: *Craniofacial and maxillofacial surgery in children and young adults*, Philadelphia, 2000, WB Saunders, pp 3, 36-54.
25. Posnick JC: *Orthognathic surgery treatment planning. Orthognathic surgery: principles and practice*, St Louis, 2014, Elsevier, pp 337–373.
26. Proffit WR, Fields HW, Sarver DM: *Contemporary orthodontics*, ed 4, St Louis, 2007, CV Mosby.
27. Proffit WR, White Jr RP, Sarver DM: *Contemporary treatment of dentofacial deformities*, St Louis, 2002, Mosby.
28. Rosen H: Aesthetics in facial skeletal surgery, *Perspect Plast Surg* 6:1, 1993.
29. Rosen HM: *Aesthetic perspectives in jaw surgery*, New York, 1999, Springer.
30. Sarver DM: Diagnosis and treatment planning of hypodivergent skeletal pattern with clockwise occlusal plane rotation, *Int J Adult Orthodon Orthognath Surg* 8:113–121, 1993.
31. Sarver DM: *Aesthetic orthodontics and orthognathic surgery*, St Louis, 1997, Mosby.
32. Sarver DM, Ackerman MB: Dynamic smile visualization and quantification. Part 2: Smile analysis and design, *Am J Orthod Dentofacial Orthop* 124:116–127, 2003.
33. Andrews W, Andrews L: Six elements of orofacial harmony, *Andrews J Orthodont Orofacial Harmony* 1:1, 2000.
34. Arnett GW, Bergman RT: Facial keys to orthodontic diagnosis and treatment planning: Part I, *Am J Orthod Dentofacial Orthop* 103:299–312, 1993.
35. Arnett GW, Bergman RT: Facial keys to orthodontic diagnosis and treatment planning: Part II, *Am J Orthod Dentofacial Orthop* 103:395–411, 1993.
36. Arnett GW: *RP McLaughlin: Facial and dental planning for orthodontists and oral surgeons*, London, 2004, Mosby/Elsevier.
37. Epker BN, Stella JP, Fish LC: Essentials of treatment planning. In *Dentofacial deformities: Integrated orthodontic and surgical correction*, ed 2, St Louis, 1995, Mosby-Year Book.
38. Farkas LG, Cheung G: Facial asymmetry in healthy North American Caucasians: An anthropometrical study, *Angle Orthod* 51:70–77, 1981.
39. Reyneke JP: *Essentials of orthognathic surgery*, Chicago, 2003, Quintessence.
40. Steiner CC: The use of cephalometrics as an aid to planning and assessing orthodontic treatment, *Am J Orthod Dentofacial Orthop* 46:721, 1960.
41. Bjork A: The face in profile: An anthropological x-ray investigation on Swedish children and conscripts, *Svensk Tandl Tidskr* 40(5B, Suppl), 1947.
42. Bjork A: Cranial base development, *Am J Orthodont* 41:198–225, 1955.
43. Moorrees CF, Kean MR, Coenroad FA: Natural head position: A basic consideration for the analysis of cephalometric radiographs, *Am J Physical Anthropol* 16:213–234, 1958.
44. Moorrees CF: Natural head position: A revival, *Am J Orthodont Dentofacial Orthoped* 105:512–513, 1994.
45. Turvey TA, et al.: Surgical-orthodontic treatment planning for simultaneous mobilization of the maxilla and mandible in the correction of dentofacial deformities, *Oral Surg* 54:491, 1982.
46. Padwa BL, Kaiser MO, Kaban LB, et al.: Occlusal cant in the frontal plane as a reflection of facial asymmetry, *J Oral Maxillofac Surg* 55:811, 1997.
47. O'Ryan F, Lassetter J: Optimizing facial esthetic in the orthognathic surgery patient, *J Oral Maxillofac Surg* 69:702–715, 2011.
48. Ackerman JL, Proffit WR, Sarver DM, Ackerman MB, Kean MR: Pitch, roll, and yaw: Describing the spatial orientation of dentofacial traits, *Am J Orthod Dentofacial Orthop* 131:305–310, 2007.
49. Posnick JC: Discussion: Occlusal plane rotation: Aesthetic enhancement in mandibular micrognathia, *Plastic Reconstr Surg* 91:1241–1244, 1993.
50. Posnick JC, Fantuzzo J, Orchin J: Deliberate operative rotation of the maxillo-mandibular complex to alter the A-point to B-point relationship for enhanced facial esthetics, *J Oral Maxillofac Surg* 64:1687–1695, 2006.
51. Posnick JC, Sami A: Individuals with a long face growth pattern and excess inferior scleral exposure: is there improvement after maxillary (Le Fort I) advancement and vertical shortening, *J Oral Maxillofac Surg* 73(9):1809–1815, 2015.
52. Riola ML, Moyers RE, McNamara JA, Hunter WS: *An atlas of craniofacial growth: Cephalometric standards from the University School Growth Study. Monograph 2, Craniofacial growth series*, Ann Arbor, MI, 1974, Center for Human Growth and Development, University of Michigan.

3

Virtual Treatment Planning for Orthognathic Surgery

JAMES J. XIA, JAIME GATENO, JOHN F. TEICHGRAEBER, DAVID M. ALFI, PENG YUAN

Introduction

The success of orthognathic (CMF) surgery depends not only on surgical techniques, but also on an accurate surgical plan. The adoption of computer-aided surgical simulation (CASS) is creating a paradigm shift in surgical planning for patients with CMF deformities, including maxillofacial surgery,[1-5] craniofacial surgery,[6] and trauma and distraction osteogenesis.[6-8] Our Surgical Planning Laboratory has developed a CASS protocol that is specifically designed for orthognathic surgery.[5] In this protocol, a three-dimensional (3D) composite skull model of a patient is generated to accurately represent the CMF skeleton, the dentition, and the facial soft tissue.[9-12] In addition, an anatomic reference frame is created for the 3D composite skull model.[13-15] Virtual osteotomies are then performed and orthognathic surgery is simulated.[1,5,10,16,17] Finally, surgical splints and templates are designed in the computer, fabricated by a rapid prototyping machine, and used during surgery to accurately position the bony segments.[18,19] The protocol has been proven to be more accurate and efficient than the traditional planning methods.[5,9,15,18,20-23]

Planning an orthognathic surgery using CASS differs fundamentally from planning the same surgery using traditional methods.[24,25] Over the years, we have developed and significantly improved a new planning protocol using CASS to plan orthognathic surgeries (Figure 3-1). The purpose of this chapter is to present this streamlined CASS protocol.

The Streamlined CASS Protocol

Before employing the CASS protocol, a clinician must confirm that the patient is ready for surgery. The desired occlusion should be achievable and the patient's growth and medical condition should be optimal for the surgery. To assess the occlusion, progress dental models may be hand-articulated into Class I occlusion, confirming that the patient is ready for surgery. Because our CASS protocol is mainly designed for a traditional orthodontics-first approach, this step is required because a computed tomography (CT) or cone-beam CT (CBCT) scan is needed for CASS, and patients should not be exposed to ionizing radiation if they are not going to have the surgery. However, this protocol can also be adapted to a surgery-first approach with minor alterations. In this chapter we use the term *CT* to refer to both CT and CBCT, unless otherwise specified.

Our CASS protocol accomplishes the tasks of modeling, planning, and preparing for plan execution. The task of the modeling is to construct a virtual model of the head (cranium and face). This model should have three distinct characteristics: (1) it renders the patient's bones, teeth, and soft tissues with accuracy; (2) its mandible is in centric relation, an important reference position in orthognathic surgery; (3) it has an anatomic reference frame.

CT scans can be used to create 3D models of the facial skeleton, teeth, and soft tissues. However, the teeth of these 3D CT models are not sufficiently accurate for surgical planning. Our CASS protocol solves this problem by replacing the inaccurate teeth of the CT with accurate digital dental models that are created by scanning stone dental models.[9] This facial model created by aligning and merging digital dental models into a maxillofacial CT is called a *composite model*. This aligning and merging process is called *registration*. The registration is done by aligning corresponding features (fiducial markers) that are presented in both images. The fiducial markers can be part of the anatomic structures being imaged, or easy to identify parts that are added in, on, or around the objects (or subjects)

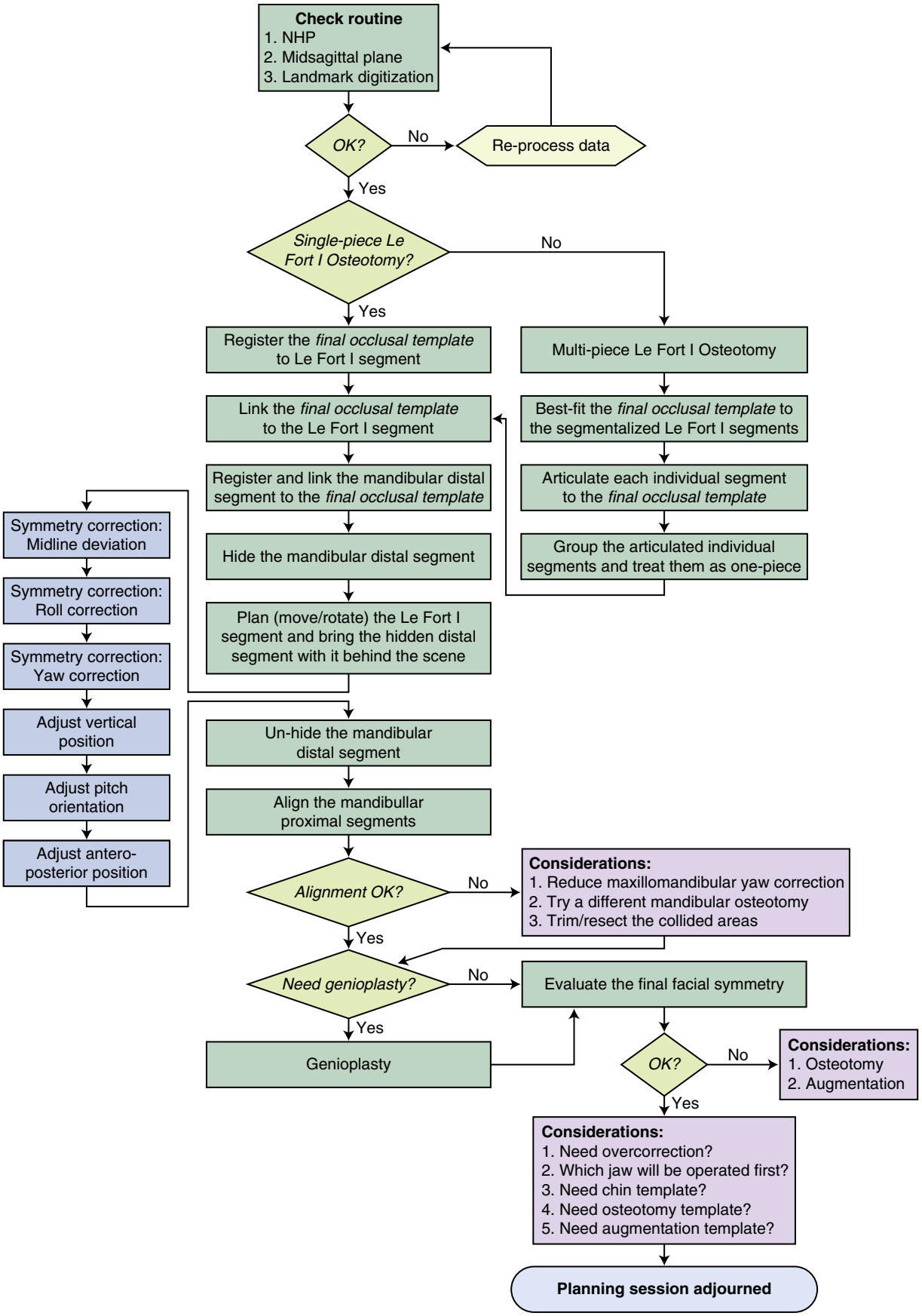

• **Figure 3-1** Algorithm for planning a double-jaw orthognathic surgery using the CASS protocol.

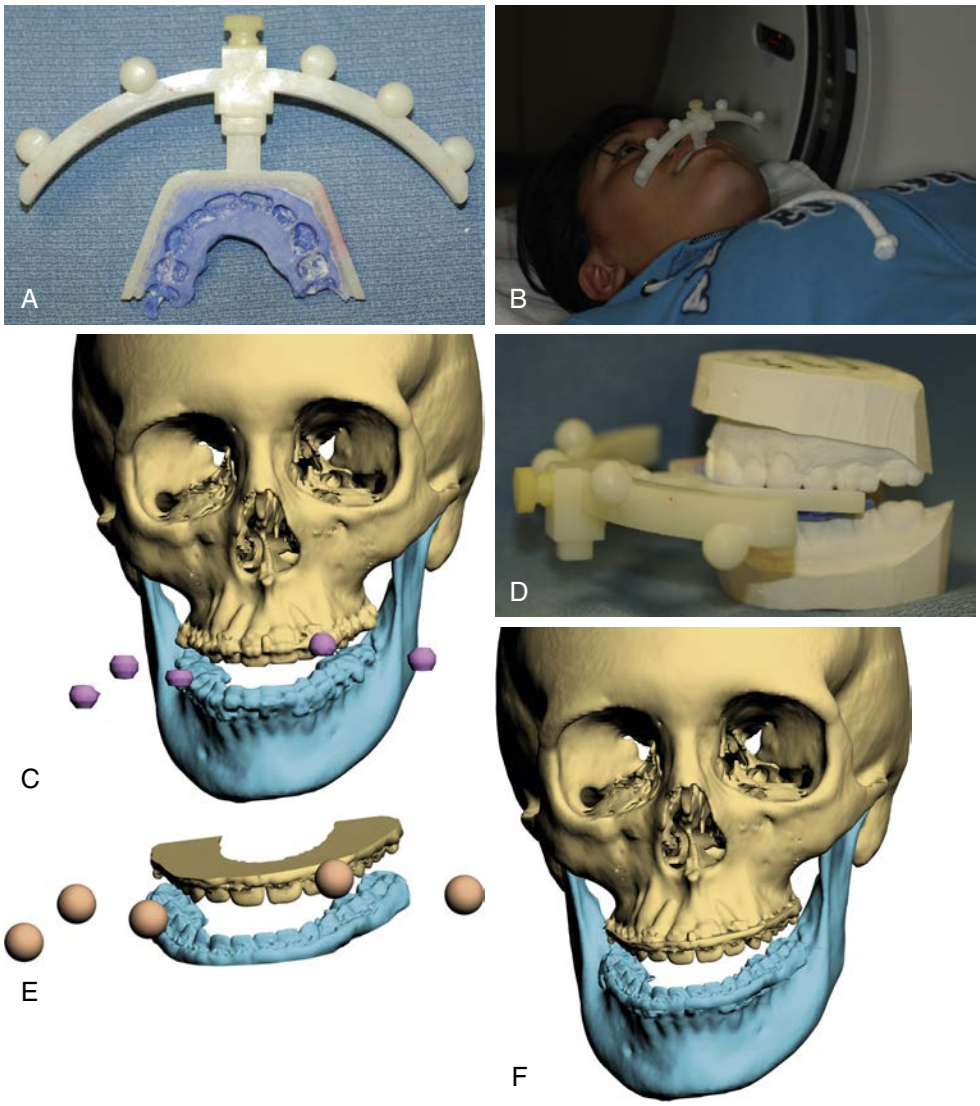

• **Figure 3-2** Creation of the composite model. **A,** A facebow with fiducial markers is attached to the bite-jig. **B,** The patient bites on the bite-jig and facebow during the CT scan. **C,** Four separate but correlated computer models are reconstructed: a mid-face model, a mandibular model, a fiducial marker model, and a soft tissue model (not shown). **D,** The bite-jig and facebow is placed between the upper and lower plaster dental models during the scanning process. **E,** Three separate but correlated digital dental models are also reconstructed: a maxillary dental model, a mandibular dental model, and a fiducial marker model. **F,** By aligning the fiducial markers, the digital dental models are incorporated into the 3D-CT skull model. The computerized composite skull model is thus created. It simultaneously displays an accurate rendition of both the bony structures and the teeth.

before the image acquisition. Our method utilizes a two-component device that consists of a bite-jig and a fiducial facebow (Figure 3-2, *A*). The bite-jig serves two purposes: it anchors the fiducial facebow to the patient for accurate registration, and keeps the mandible in unique centric relation during the CT acquisition and the stone dental model scanning.[9,21,22]

The composite model used for planning must have an accurate anatomic frame of reference. This is a *Cartesian* frame that includes a mid-sagittal plane, an axial plane, and a coronal plane. The reference reframe is the basis for most diagnostic and treatment decisions. Incorrectly defining the reference frame may cause postoperative deformity. The reference frame for a composite model is usually established using the neutral head posture (NHP) method, because traditional anatomic landmark method is problematic.[26]

The principle behind using NHP is that a reference frame for the head can be derived from the patient's head posture. When a patient stands upright looking straight forward, the cardinal directions of the face are orthogonal to gravity. The axial plane is perpendicular to the gravitational pull and the mid-sagittal and coronal planes are aligned with it. Thus, when the head is in the NHP, it is simple to construct a reference frame for the face. The axial plane is the horizontal plane that passes through both porions. The mid-sagittal

plane is a vertical plane that best divides the face into right and left halves. The coronal plane is the vertical plane that is perpendicular to the other planes and is aligned with the coronal suture.

The remaining tasks in the CASS protocol are surgical planning and preparing for plan execution. Surgical planning uses a Visualized Treatment Objective (VTO) approach, simulating the operation until the desired outcome is attained and visualized. Preparing for plan execution is getting ready for surgery. To complete this task, a clinician collects clinical measurements and fabricates physical appliances such as occlusal splints, templates, and drill guides. These appliances are designed in the computer and fabricated using a rapid prototyping machine.

Clinical Implementation of CASS Protocol

CASS is implemented clinically in four major steps: preoperative record collection, data processing, surgical planning and simulation, and preparation for plan execution. The first and the third steps are completed by a clinician, whereas the other two can be outsourced, either to a planning specialist within one's clinic or institution or to an independent service provider.

Collection of Preoperative Records

In this step, preoperative data is gathered in an hour-long appointment. This appointment is scheduled 2 to 4 weeks prior to the surgery. The surgeon and an assistant accrue the records. They include: dental impressions and their stone models, a bite-jig, clinical measurements, photographs, an NHP recording, a CT scan, and a bite registration of the final occlusion. This appointment has eight steps: (1) taking and pouring dental impressions; (2) fabricating a bite-jig; (3) taking clinical measurements; (4) clinical photographing of the patient; (5) recording the patient's NHP; 6) testing the fit of the bite-jig on the stone dental models; (7) acquiring a CT scan; and (8) establishing final occlusion.

The *preoperative record appointment* begins by taking and pouring upper and lower dental impressions. We recommend utilizing wax to block and eliminate the undercuts caused by orthodontic braces and wires. This is to prevent impression distortion or separation between the dental impression material (e.g., alginate) and impression tray. Once the impressions are taken, they should be immediately poured by an assistant. The impressions should be taken and poured at the beginning of the appointment to shorten its length, because the fitting of the stone dental models on the bite-jig must be confirmed before the patient is CT scanned and this check cannot be done until the stone models are set. Since it takes about 45 minutes for the stone to set, postponing the models will delay the CT. Thus pouring the impressions early allows the models to be ready on time. In addition, the number of impressions needed for planning depends on the type of surgery. Obviously, a clinician needs to take at least one upper and one lower impression. But, when one is planning to segmentalize a dental arch into two or more pieces, the clinician should take two impressions of the arch needing segmentalization.

In the second step of the preoperative appointment, a patient-specific bite-jig is constructed by customizing a stock jig frame (see Figure 3-2, *A*). The surgeon customizes the frame by adding a self-curing, dimensional-stable and rigid bite-registration material (e.g., LuxaBite, DMG America, Englewood, NJ) to the frame. The jig is then placed between the patient's teeth until the material is cured. This bite registration should be taken in centric relation.

In the third step of the preoperative appointment, key clinical measurements needed for planning are recorded. They include: (1) incisal show at rest and smile dentogingival show to determine the vertical position of the maxilla; and (2) dental midpoint (midline) deviations to determine transverse jaw position.

In the fourth step, the clinical photographs are taken of the patient. The photographs should image both the face and the teeth. The facial photographs should be taken with the patient in the NHP. In addition, a plumb line should be shown on the background, so the correct orientation of the face can be determined later. These photographs will be used to verify that the *virtual head model* is correctly oriented for planning.

In the fifth step of the preoperative appointment the NHP is recorded. This measurement is needed to create an anatomic reference frame (mid-sagittal, axial, and coronal planes) for the virtual facial model. To record the NHP, the authors use an electronic orientation sensor (3DM, MicroStrain Inc, Williston, VA).[13-15] The sensor is first attached to the previously fabricated bite-jig (see Figure 3-2, *A* and *B*), and then the jig is placed between the patient's teeth. The patient is asked to stand upright with her head in NHP. Finally, in this posture, the pitch, roll, and yaw of the sensor are recorded. The NHP can be attained by asking patients to self-balance into this stance, or by manipulating their heads into this posture. The authors begin with a self-balance position but feel free to manipulate it if the patient posture is incorrect.

In the sixth step, a clinician or an assistant tests the fit of the stone dental models on the bite-jig. This test is done to confirm that the models and the bite-jig are correct. If the models do not fit the bite registration, one can assume that either the dental models or the bite-jig are distorted. Common reasons for the lack of fit are air bubbles on the occlusal surfaces of the dental impressions, deep indentations in the bite registration, and slight separation between the dental impression material (e.g., alginate) and impression tray. Air bubbles in an impression are filled with stone during pouring, resulting in spherical bumps that arise from the surfaces of teeth. They prevent the model from seating into the bite registration. However, they can be easily spotted and removed with a sharp instrument to improve the fitting. Deep indentations in the bite registration, especially those that extend above the height of contour of the teeth, also prevent the models from fully seating on the bite

registration. This lack of seating occurs because the material used for bite registration is rigid. This problem can be solved by grinding the bite registration to reduce the indentations.

If the dental models and bite-jig still don't fit after the above maneuvers, the bite-jig should be retested on the patient's teeth. If the bite-jig fits the patient well, it must be assumed that the stone models are distorted. The dental impressions should be repeated. If the bite-jig does not fit well, the jig should be relined, and the NHP recording should be repeated, because relining of the bite-jig can affect the alignment of the orientation sensor.

In the seventh step of the preoperative appointment, a CT scan is obtained. Before scanning, the fiducial registration facebow is attached to the bite-jig, and the jig is affixed to the patient (see Figure 3-2, *B*). The patient is instructed to keep his/her facial soft tissues relaxed during scanning. The scan can be completed using either a spiral multislice CT scanner (using the standard scanning algorithm, matrix of 512 × 512 at 0.625- to 1.25-mm slice thickness, 25 cm or lesser field-of-view, and 0° gantry tilt) or a CBCT scanner (with 0.4-mm isotropic voxel).

In the last step (eighth) of the preoperative appointment, a clinician establishes the final occlusion. This is usually done after the patient leaves the clinic. Currently, we establish the final occlusion on stone dental models because there is no reliable method to establish final occlusion in the computer, especially when one of the jaws is segmentalized. When dental arch segmentalization is not required, the maxillary and the mandibular stone dental models are mounted on a Galetti articulator and articulated into final occlusion. Final occlusion is then captured with a bite-registration taken with a stable material like silicone or polyvinyl siloxane. When arch segmentalization is required (e.g., a three-piece Le Fort I osteotomy), a clinician cuts the extra stone dental model into the require number of segments. The clinician then hand articulates each segment into final occlusion and makes a new plaster base for the segmentalized model. Finally, he articulates the upper and lower models into final occlusion (in a Galetti articulator), capturing the occlusion with a bite registration. Currently our Surgical Planning Laboratory is working on digital establishment of final occlusion for both one- and three-piece Le Fort I osteotomies.[27-30] We expect that in the future, the need of the stone dental models will be eliminated and this step will be done within our software.[a]

Data Processing

The second major step of CASS is data processing. This takes place after all the preoperative records have been gathered. It can be done by the surgeon, or it can be outsourced to an independent service provider, or to a person familiar with CASS planning within the surgeon's clinic or institution. Data processing entails the creation of a composite head model, the creation of an anatomic reference frame for the head model, the digitization of cephalometric landmarks, the creation of the virtual osteotomies, and the establishment of final occlusion.

The first step in data processing is to create a virtual model that displays an accurate rendition of the skeleton, the soft tissues and the teeth. Four separate but correlated 3D CT models are generated: a mid-face model, a mandibular model, a soft tissue model, and a fiducial marker model (see Figure 3-2, *C*). This task is completed using specialized planning software. Digital dental models (see Figure 3-2, *E*) are then generated by scanning the stone dental models with the fiducial registration frame in place (see Figure 3-2, *D*), either with a high-resolution laser scanner, or with a CBCT scanner (at a high resolution setting of 0.125-mm to 0.2-mm isotropic voxel). Next, the digital dental models are incorporated into the 3D CT models by registering the fiducial markers of the digital dental models to the markers of the 3D CT (see Figure 3-2, *F*).

The second step in data processing is to establish an anatomic reference frame for the head model. An accurate anatomic reference frame is critical for planning. The recorded NHP (the pitch, roll, and yaw of the head) is used to orient the computer head model to the NHP. Using the fiducial facebow as reference, the NHP of the computer model is established by applying the recorded pitch, roll, and yaw to the facebow frame (Figure 3-3, *C* and *E*).[15] Once the virtual head model is in the NHP, the construction of a reference frame is straightforward. The mid-sagittal plane is the vertical plane that best divides the head into right and left halves. The axial plane is the horizontal plane that is perpendicular to the mid-sagittal plane, passing closest to the right and left porion. The coronal plane is the vertical plane that is perpendicular to the other planes, aligned with the coronal suture.

The third data processing step is to digitize all the cephalometric landmarks and to perform a cephalometric analysis. The surgeon may request any cephalometric analysis but he/she should take into consideration that 3D cephalometry is significantly more complex than its 2D counterpart. Simply adapting 2D cephalometric measurements to 3D space may cause diagnostic errors.[31-33] If necessary, landmark digitization can be altered later in the planning phase.

The fourth data processing step is to perform virtual osteotomies (e.g., a Le Fort I osteotomy, mandibular ramus osteotomies, and a genioplasty) (Figure 3-4, *A*). If necessary,

[a] Any commercial computer graphic software that is capable of handling and manipulating 3D models may be used for CASS planning (e.g., SimplantOMS [Materialise Dental Inc, Glen Burnie, MD], ProPlan CMF [Materialise NV, Leuven, Belgium], 3D Studio Max [Autodesk Inc, San Rafael, CA], or Dolphin 3D [Dolphin Imaging & Management Solution, Chatsworth, CA]). In addition, the authors are developing a CASS planning software package, *AnatomicAligner*. It is designed specifically for orthognathic surgery. The software will be available freely to broader clinical and research communities in the future (www.AnatomicAligner.com). This project is partially sponsored by National Institutes of Health/National Institute of Dental and Craniofacial Research (NIH/NIDCR).

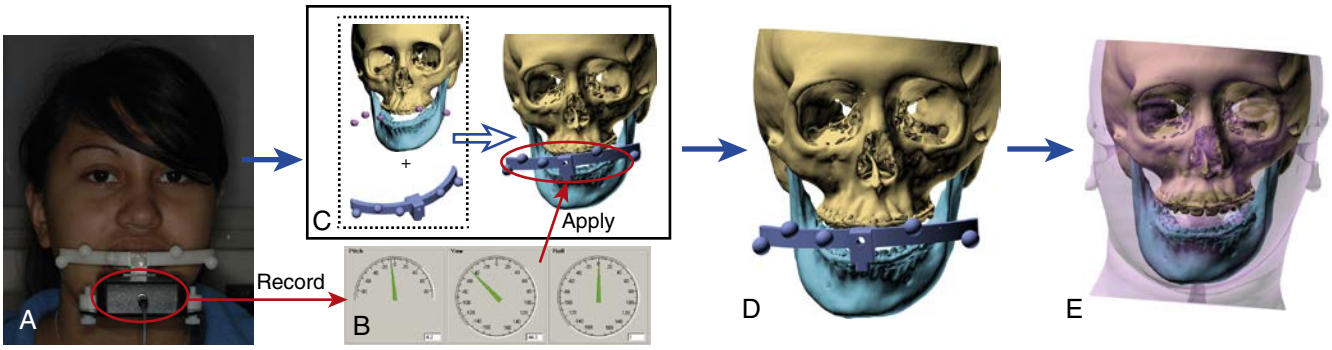

• **Figure 3-3** Orientation of the composite skull model to the neutral head posture (NHP) using the digital orientation sensor method. **A,** A digital orientation sensor is attached to the bite-jig and facebow. **B,** The pitch, roll, and yaw of the sensor are recorded. **C,** In the computer, a digital replica (CAD model) of the fiducial facebow is registered and attached to the composite skull model via the fiducial markers. **D,** The recorded pitch, roll, and yaw are applied to the facebow frame, reorienting the composite skull model to the NHP. **E,** After the composite skull is orientated to the NHP, the CAD model of the fiducial facebow is marked hidden.

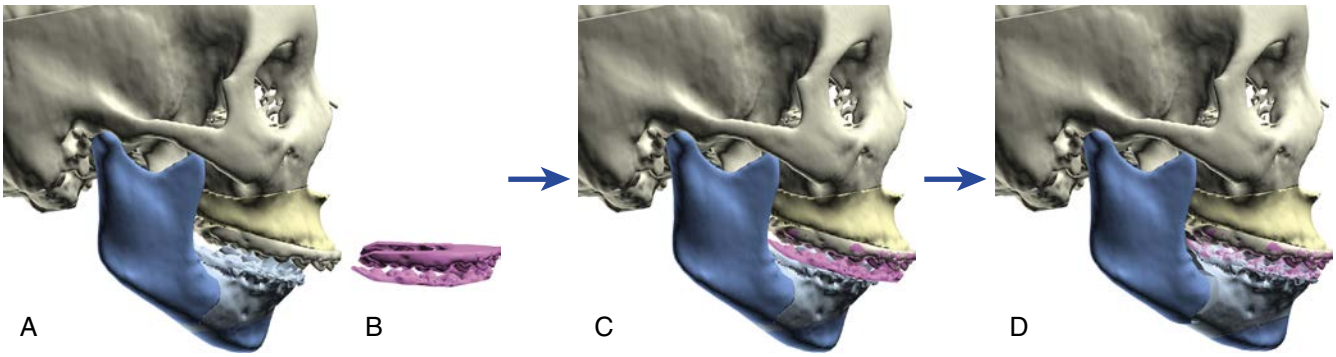

• **Figure 3-4** Incorporating the final occlusal template and placement of the mandibular distal segment into final occlusion in a single-piece Le Fort I osteotomy. **A,** In this example, virtual osteotomies, including a single-piece Le Fort I osteotomy and bilateral sagittal split osteotomy, are completed. Each bony segment is located in its original location. **B,** The digital final occlusal template is generated by scanning the hand-articulated stone models using a high-resolution scanner. **C,** The upper part (maxillary teeth) of the final occlusal template is first registered to the maxillary teeth in the composite model. **D,** The mandible is set into the final occlusion by registering the distal mandibular teeth to the lower part (mandibular teeth) of the template.

these osteotomies can be revised or redone during the planning phase. At this stage, all the osteotomized segments remain in their original position. Their movements are completed later in the planning phase.

The last step of data processing step is to establish virtual final occlusion (see Figure 3-4). This is done by copying the final occlusion which was established by the surgeon on the stone dental models. First, the upper and lower stone models are articulated into final occlusion using the bite registration provided by the surgeon. Next, the models are scanned together, using a high-resolution optical surface scanner, or a CBCT scanner. Finally, the scan is segmented to create a 3D image of the upper and lower teeth in final occlusion (see Figure 3-4, *B*). This image, the *final occlusal template*, is imported into the planning software and is used as a guide to articulate the jaws in final occlusion.

The virtual final occlusion is established in the following manner: First, the upper teeth of the final occlusion template are aligned to the upper teeth of the Le Fort I segment (see Figure 3-4, *C*). Then, the distal mandibular segment is moved until its lower teeth are aligned to the lower teeth of the template (see Figure 3-4, *D*). Because the upper and lower teeth of the template are in final occlusion, aligning the template to one jaw and then aligning the other jaw to the template, automatically places both jaws into final occlusion.

After the distal mandible is set in final occlusion, it is linked to the Le Fort I segment. As a result, future movements of the Le Fort segment will be automatically transferred to the mandibular segment. This guarantees that the final occlusion is maintained during the planning process. Maintaining the final occlusal relationship during the maxillary movements simplifies mandibular planning,

In a double-jaw surgery with a single-piece Le Fort I osteotomy, it is simple to align the upper teeth of the final occlusion template to the upper teeth of the Le Fort I segment, since they are identical (Figure 3-5). This is not true in a multi-piece Le Fort I. In this case, the shapes of the upper dental arches of the virtual head model and the final occlusal

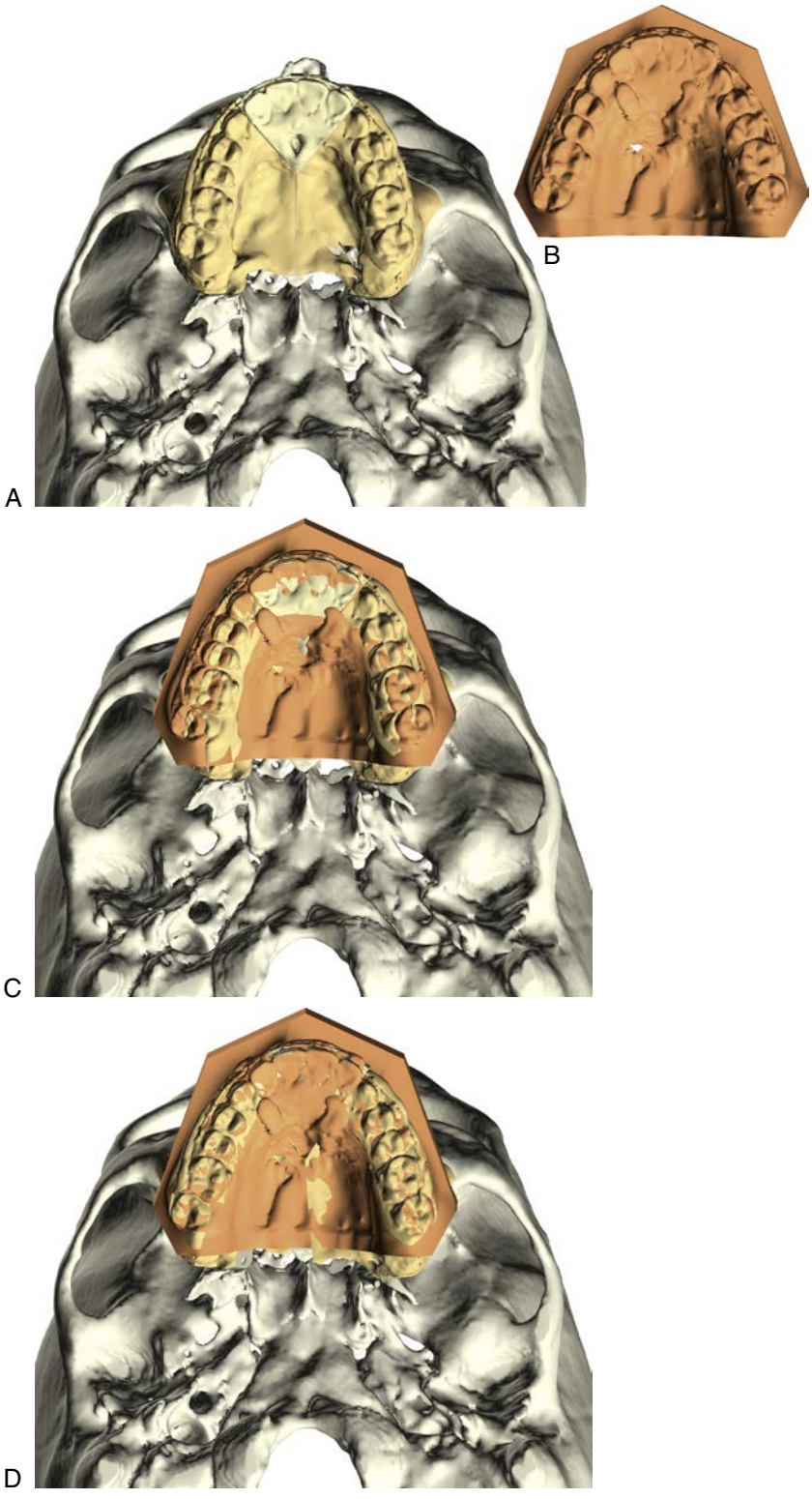

• **Figure 3-5** Incorporating the final occlusal template in a multiple-piece Le Fort I osteotomy. **A,** In this example, a three-piece Le Fort I osteotomy is completed. All bony segments *(yellow)* are located in their original locations. **B,** The upper part (maxillary teeth) of the digital final occlusal template. The template is also generated by scanning the hand-articulated stone models, in which the upper stone model is first cut into three pieces, then hand-articulated to the final occlusion without using an articulator. Note that the posterior Le Fort I segments in the composite model are medial. **C,** The upper part of the final occlusal template is registered to the maxillary teeth at the central dental midline, best fitting the posterior parts of the teeth. **D,** All Le Fort I segments are then perfectly registered to the corresponding segment in the final occlusal template, resulting in a new intra-arch relationship among the Le Fort I segments.

template are different. This is because the template depicts the upper jaw segments in their final alignment, while virtual head model depicts the upper teeth in their original condition (see Figure 3-5). In this situation the alignment is completed in two steps.

First, the final occlusal template is best fit to the maxillary arch of the composite models, and then each Le Fort I segment is individually moved until their teeth are aligned with the template. This creates a new intra-arch relationship for the Le Fort I segments (see Figure 3-5, *D*). Afterwards, the individual Le Fort segments are grouped together forming one piece. From then on, the Le Fort I unit is treated as one piece, as in a one-piece Le Fort I osteotomy.

Surgical Planning

The third major step of the CASS protocol is surgical planning. It is done in the computer using CASS software. It is important to note that planning an orthognathic surgery using CASS is conceptually different from planning the same operation using traditional planning methods (e.g., stone dental models). In stone dental model surgery, one intuitively executes all transformations, including rotations, as linear translations of particular points. It is different in CASS. It has six degrees of freedom, enabling the measurements of inclinations (pitch, roll, and yaw) in degrees and positions (anteroposterior, vertical, and transverse) in millimeters, independently of each other. Another difference between the CASS and the traditional planning methods is the sequence of the planning process. In traditional double-jaw stone dental model surgery, the position of the upper jaw is established first and the lower jaw is then placed in the final occlusion for the final alignment. In CASS, the final occlusion is established first and then both jaws are moved together into the final alignment while they are occluded in final occlusion.

The CASS planning process may be completed by a surgeon working alone, or by a surgeon working together with a planning specialist who is familiar with the software. In the case where an outside service center is utilized, the planning specialist from the service center communicates with the surgeon, and any other parties (e.g., orthodontist) via web meeting. In this meeting, all parties view the same images, even if the people involved are located in different countries. Guided by clinical measurements and real-time 3D cephalometric measurements, a surgeon plans orthognathic surgery by simulating surgical procedures and visualizing their outcomes. This VTO process is iterated until the desired results are obtained.

The planning process begins with a checklist to ensure that the data processing is correct. The checklist includes the following items: (1) Is the anatomic reference frame correctly defined? (2) Are all the cephalometric landmarks correctly digitized? (3) Are all virtual osteotomies correct? and, (4) Is the final occlusion accurate?

Orthognathic surgery may involve one jaw or both jaws. Planning a single-jaw surgery is simpler than planning a double-jaw operation. In order to best describe how to plan an orthognathic surgery using CASS, we will use a double-jaw surgery as an example (see Figure 3-1). Once the planning algorithm for a double-jaw surgery is understood, it is easy to adopt it to a single-jaw procedure.

CASS planning for any double-jaw surgery should always begin with the maxilla (see Figure 3-1) even when mandibular surgery is desired to be performed first. The reason is that the surgeon is more certain of where the maxilla should go than the mandible. The maxilla should not be canted (zero roll) and should have zero yaw. The upper dental midline (incisal midpoint) should be on the mid-sagittal plane. And, vertically, the incisor show should be normal at rest and smiling.

Correction of Maxillary Deformities

Planning begins by hiding the mandible and moving the maxilla into the ideal alignment. A series of transformations (translations and rotations) are needed to reach this alignment. Rotational transformations are best done on a single point, following a specific sequence. Empirically, we have determined that the best point at which all transformations should be performed is the incisal midpoint, the point at the intersection of the dental midline and the arc defined by the incisal edges. This point represents the middle of the dental arch. Selecting it avoids iterations. For the same purpose, we have also established the following planning sequence:

1. Symmetric alignment
   a. Normalization of transverse position
   b. Normalization of roll
   c. Normalization of yaw
2. Normalization of vertical position
3. Normalization of pitch
4. Normalization of anteroposterior position

In the first step, the maxilla is symmetrically aligned to the mid-sagittal plane. Symmetric alignment involves three transformations: transverse translation, roll rotation, and yaw rotation. Transverse translation places the maxillary incisal midpoint on the mid-sagittal plane. Roll rotation pivots the maxilla around the incisal midpoint until the right and left teeth are vertically leveled. Finally, yaw rotation pivots the maxilla around the incisal midpoint. This makes sure that the posterior teeth are as equidistant as possible to the mid-sagittal and coronal planes.

In the second step, the vertical position of the maxilla is normalized. The planner translates the maxilla up or down, placing its incisal midpoint in an ideal position in relation to the upper lip stomion.

In the third step, one normalizes the maxillary pitch. The planner pivots the maxilla around the incisal midpoint until its pitch is optimized. Maxillary pitch rotation affects the inclination of the maxillary central incisors, the inclination of the maxillary occlusal plane, the airway size, the projection of the anterior nasal spine, and chin projection. It is necessary to consider all these items when deciding on the ideal maxillary pitch for a given patient. The first three items

relate to function, the last two to esthetics. Frequently, the planner needs to make compromises among the items based on the priorities of an individual case.

The final adjustment aligns the maxilla in an anteroposterior position. This adjustment is left for the last because previous transformations can alter one's decision as to how much to advance the maxilla. For example, decreasing the maxillary pitch or changing its yaw can produce a collision between the maxillary tuberosities and the pterygoid plates. These collisions can be easily avoided by advancing the upper jaw.

Correction of Mandibular Deformities

After the maxilla is set into an ideal alignment, the mandible is rendered. The distal segment of the mandible will automatically be in the final alignment because it had been previously linked to the maxilla into final occlusion. Each of the transformations applied to the maxilla was transferred to the distal mandible.

In the next step, the proximal segments of the mandible are aligned. Each proximal segment is rotated around the center of its condyle until the segment is well aligned with the distal mandible. Ideally, there should be no overlap between the proximal and distal segments, because overlap corresponds to areas of bony collision. When present, segment overlap can be avoided by readjusting the yaw of the maxilla and distal mandible, by planning the resection (ostectomy) of the areas of overlap, or by planning a different ramus osteotomy.

Readjustment of the yaw of the maxilla and distal mandible by one or two degrees may avoid proximal segment collision without altering esthetics. Adjustments larger than two degrees should be avoided because they can produce buccal corridor asymmetry—the right to left difference in the amount of posterior teeth displayed while smiling. To prevent displacement of the previous corrections, all yaw readjustment must be made around the upper incisal midpoint. Small areas of bone overlap are amenable to ostectomy. However, large areas of collision that remain after maxillary yaw adjustment can be avoided only by selecting a different operation (e.g., by selecting an inverted L osteotomy over a sagittal split).

Correction of Chin Deformities

In the next step, the planner reexamines the chin. This assessment is necessary because the movement of the mandibular distal segment alters chin position. If the chin is normal, the planner proceeds to the final step. If it is abnormal, the planner should simulate a genioplasty, moving the chin segment until satisfied with the outcome.

Examination of the Residual Final Symmetry

In the last step, the planner assesses final symmetry. When the mandible is abnormal but symmetric, placing the distal mandible in final occlusion maintains symmetry. But when the patient has intrinsic mandibular asymmetry, placing the distal mandible into final occlusion may not correct the asymmetry. Because mild to moderate degrees of intrinsic asymmetry may be imperceptible to the eye, it is important to complete a final symmetry assessment on all patients.

The final assessment of symmetry is done using a mirror image routine (Figure 3-6). In this routine, the composite model is cut in half across the median plane. One side is then copied and reflected (flipped) across the median plane, superimposing it over the contralateral half. The right-left differences are calculated using a Boolean subtraction—a mathematic operation that shows differences between objects. If the symmetry is good, the plan is complete. However, if there is residual asymmetry, the surgeon should consider an osteoplasty, which may entail augmentation or reduction.

Preparing for Plan Execution

A computerized plan is of no clinical value if it cannot be executed at the time of surgery. The final step of the CASS protocol is to prepare the tools necessary for transferring the computerized surgical plan to the patient at the time of the surgery. This is usually outsourced to an independent service provider.

The tables and images that display the planned movements, including mapped areas collision, are generated

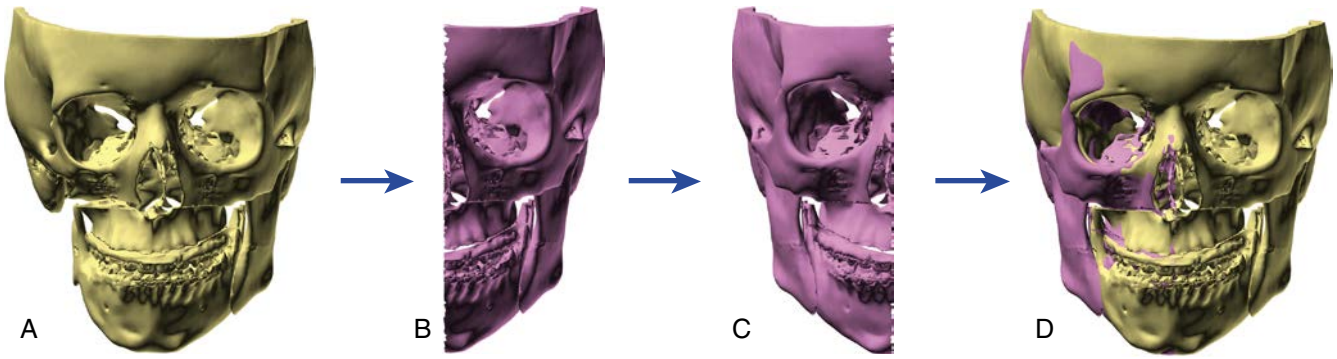

• **Figure 3-6** Mirror image routine. **A,** The planned outcome after all bony segments are moved to their desired positions. **B,** One side of the face is first copied. **C,** The copy is flipped horizontally. **D,** The flipped copy is superimposed on the contralateral side; finally, side-to-side differences are calculated.

and displayed at surgery to guide the operation. Moreover, surgical splints are designed in the computer and fabricated using a rapid prototyping machine.[5,10,16,18,21] Genioplasty and other bone templates (e.g., graft or ostectomy) and cutting and drilling guides can also be fabricated as needed.[5,10,16,21] Surgical plates can be either prebent on a physical model[10,16,34] or custom-fabricated.[35] If necessary, a roadmap can also be created for the navigational surgery to guide the surgeon performing osteotomies and drilling screw holes.[10,34,36]

Outcome Evaluations

An old engineering adage holds that a new technology should provide at least one of the following advantages to be considered a significant advance in a routine practice: better outcome, better accuracy, or better cost-effectiveness. The same is true of our CASS protocol, and the authors have evaluated outcomes of our protocol in those three aspects.

Surgical Outcome Evaluation

The authors have completed a study to evaluate whether the surgical outcomes achieved with CASS are better than those achieved with traditional methods.[20] In this study, a total of 12 consecutive patients with CMF deformities were enrolled. Following the CASS clinical protocol,[5] a 3D computer composite skull model for each patient was generated and reoriented to the NHP. These models underwent two virtual surgeries: one was based on CASS (experimental group) and the other was based on traditional methods (control group). Once both virtual surgeries were completed, two experienced CMF surgeons at two different settings evaluated both surgical outcomes. They were blinded to the planning method used on the virtual models and to each other's evaluation results. The primary outcome was overall CMF skeletal harmony. The secondary outcomes were individual maxillary, mandibular, and chin harmonies.

Finally, statistical analyses were performed. The results showed that the overall CMF skeletal harmony achieved with CASS was statistically better than that achieved with traditional methods. In addition, the maxillary and mandibular surgical outcomes achieved with the CASS method were also statistically better. Furthermore, although not included in the statistical model, the chin symmetry achieved by CASS tended to be better. Finally, the study discovered that the most critical step in achieving better overall CMF skeletal harmony was to restore mandibular symmetry.[20]

Accuracy Evaluation

The authors evaluated the accuracy of CASS in the treatment of patients who had dentofacial deformities requiring double-jaw orthognathic surgery.[21] In this study, the accuracy of the CASS protocol was assessed by comparing the planned and postoperative outcomes of 65 consecutive patients. Computer-generated occlusal splints were used for all patients. For the genioplasty, one center utilized computer-generated chin templates to reposition the chin segment of patients with asymmetry. For the remaining patients, standard intraoperative measurements were utilized. The primary outcome measurements were positional and orientation differences for the maxilla, mandible, and chin; planned and postoperative models were registered at the cranium. Secondary outcome measurements were: maxillary dental midline difference between the planned and postoperative positions; and positional and orientational differences of the chin segment between the groups with and without the use of the template. The latter was measured when the planned and postoperative models were registered at the mandibular body. Statistical analyses were performed, and the accuracy was reported using root mean square deviation (RMSD) and Bland and Altman's method for assessing measurement agreement.[37]

In the primary outcome measurements there was no statistically significant difference amongst the three centers for the maxilla and mandible. The largest RMSD was 1.0 mm and 1.5 degrees for the maxilla, and 1.1 mm and 1.8 degrees for the mandible. For the chin, there was a statistically significant difference between the groups with and without the use of the chin template. The chin template group showed excellent accuracy with the largest positional RMSD of 1.0 mm and the largest orientational RSMD of 2.2 degrees. However, larger variances were observed in the group not using the chin template (3.5 mm in positional difference and 5.8 degrees for orientation). Positional differences were significant in the anteroposterior and superoinferior directions. Orientation differences were significant in pitch and yaw. The results of Bland and Altman's method for assessing measurement agreement are presented in Table 3-1.

In the secondary outcome measurements, the RMSD of maxillary dental midline position was 0.9 mm, with a Bland and Altman's limit of –1.3 mm and 1.1 mm. When registered at the body of the mandible, the positional and orientational differences of the chin segment between the groups with and without the use of the chin template were consistent with the results found in the primary outcome measurements (1.1 mm versus 2.0 mm in positional difference, and 1.6 degrees versus 5.0 degrees in orientational difference, respectively). The results of Bland and Altman's method for assessing measurement agreement are presented in Table 3-2.

Finally, a recent published systematic review of 9 studies (out of 375) also evaluated the accuracy and benefit of virtual planning for orthognathic surgery.[38] The accuracy of translation was <1.2 mm in the maxilla (vertical) and <1.1 mm in the mandible (sagittal), and for rotation was <1.5 degrees in the maxilla (pitch) and <1.8 degrees in the mandible (pitch). The results indicated that computer-aided planning was considered accurate. The authors also concluded that high quality randomized clinical trials are

TABLE 3-1 Accuracy (Bland and Altman Upper and Lower Limits) of Positional and Orientational Differences Between Planned and Postoperative Outcomes (Models Registered at the Cranium)

			Positional Difference (95% CI)			Orientational Difference (95% CI)	
			Lower Limit	Upper Limit		Lower Limit	Upper Limit
Maxilla		Mediolateral	–1.7 mm (–2.0 to –1.4)	1.4 mm (1.0 to 1.7)	Pitch	–2.3° (–2.9 to –1.7)	3.4° (2.8 to 4.0)
		Anteroposterior	–0.7 mm (–0.9 to –0.4)	1.6 mm (1.4 to 1.9)	Roll	–1.8° (–3.2 to –1.4)	1.8° (1.4 to 2.1)
		Superoinferior	–0.8 mm (–1.0 to –0.6)	0.9 mm (0.7 to 1.0)	Yaw	–2.7° (–3.2 to –2.1)	2.3° (1.7 to 2.8)
Mandible		Mediolateral	–1.4 mm (–1.5 to –1.0)	1.0 mm (0.8 to 1.3)	Pitch	–3.7° (–4.5 to –2.9)	3.6° (2.8 to 4.3)
		Anteroposterior	–0.9 mm (–1.1 to –0.6)	1.5 mm (1.3 to 1.8)	Roll	–2.0° (–2.4 to –1.6)	1.8° (1.4 to 2.2)
		Superoinferior	–0.8 mm (–1.0 to –0.6)	0.7 mm (0.6 to 0.9)	Yaw	–3.3° (–4.0 to –2.6)	3.3° (2.6 to 4.0)
Chin	Intraoperative linear Measurements	Mediolateral	–2.9 mm (–4.9 to –0.1)	3.9 mm (2.0 to 5.8)	Pitch	–9.4° (–15.6 to –3.2)	12.9° (6.6 to 19.1)
		Anteroposterior	–6.2 mm (–10.1 to –2.2)	7.8 mm (3.8 to 11.7)	Roll	–5.8° (–9.3 to –2.4)	6.3° (2.9 to 9.7)
		Superoinferior	–5.3 mm (–8.2 to –2.5)	4.6 mm (1.8 to 7.4)	Yaw	–7.1° (–11.5 to –2.8)	8.4° (4.1 to 12.8)
	Template	Mediolateral	–1.7 mm (–2.6 to –0.7)	1.8 mm (0.8 to 2.8)	Pitch	–4.1° (–6.5 to –1.7)	4.9° (2.5 to 7.3)
		Anteroposterior	–2.1 mm (–3.3 to –1.0)	2.0 mm (0.8 to 3.2)	Roll	–4.0° (–6.1 to –2.0)	3.7° (1.6 to 5.7)
		Superoinferior	–1.4 mm (–2.1 to –0.8)	1.0 mm (0.3 to 1.6)	Yaw	–4.0° (–6.2 to –1.9)	4.1° (1.9 to 6.2)

TABLE 3-2 Accuracy (Bland and Altman Upper and Lower Limits) of Chin Position and Orientation for Genioplasties Done with Intraoperative Measurements versus Those Done with Chin Templates (Models Registered at Body of Mandible)

			Positional Difference (95% CI)			Orientational Difference (95% CI)	
			Lower Limit	Upper Limit		Lower Limit	Upper Limit
Chin	Intraoperative Measurements	Mediolateral	–2.9 mm (–4.5 to –1.2)	2.9 mm (1.3 to 4.6)	Pitch	–9.7° (–12.8 to –4.9)	10.4° (1.2 to 9.1)
		Anteroposterior	–4.1 mm (–6.4 to –1.8)	4.0 mm (1.7 to 6.2)	Roll	–5.5° (–7.2 to –3.1)	5.0° (0.2 to 4.3)
		Superoinferior	–3.4 mm (–5.1 to –1.7)	2.7 mm (1.0 to 4.4)	Yaw	–4.3° (–4.9 to –0.9)	6.6° (2.2 to 6.2)
	Template	Mediolateral	–1.2 mm (–2.0 to –0.5)	1.4 mm (0.7 to 2.1)	Pitch	–1.7° (–2.9 to –0.6)	2.6° (1.4 to 3.7)
		Anteroposterior	–2.1 mm (–3.4 to –0.8)	2.4 mm (1.1 to 3.7)	Roll	–3.5° (–5.3 to –1.7)	3.3° (1.5 to 5.2)
		Superoinferior	–1.1 mm (–1.7 to –0.6)	0.9 mm (0.4 to 1.5)	Yaw	–3.5° (–5.2 to –1.7)	3.1° (1.3 to 4.8)

needed to definitively compare the accuracies of computer-aided and conventional planning methods.

Cost-Effectiveness Evaluation

Recent reports also demonstrated the cost-effectiveness of using CASS planning compared with the conventional planning method for routine orthognathic surgery.[5,23] The initial CASS records appointment (dental impressions, bite-jig fabrication, clinical examination, anthropometric measurements, recording neutral head posture) takes about 60 minutes.[5,23] It takes another 5 to 10 minutes to set the final occlusions on the stone dental models. After the patient's CT scan is completed, the preparation of the computer data, including dental model scanning, segmentation of CT images, 3D model reconstruction, composite skull model creation, landmark digitization and virtual osteotomies, is completed by a planning specialist or an outsourced service provider. Once the computer data is prepared, it is electronically transmitted to the clinician. The clinician only spends time on examining the cephalometric analysis results, formulating a surgical plan, and testing the plan with the virtual surgical movements. Although there is a learning curve in this process, after the process is mastered it usually takes 10 to 20 minutes to plan a routine case and up to an hour for a complex one. After the plan is finalized, based on the clinician's request (which jaw is operated first), the service facility designs the surgical splints and templates and fabricates them using a rapid prototyping machine. CASS may further save clinicians time during the surgery. This is because the 3D nature of computer planning allows the clinician to anticipate potential complications and pitfalls, which may not be readily apparent during conventional stone model surgery. Currently, at the service center, the entire process takes around 4 hours and costs up to $1000.[39] This is slightly above the amount that is now reimbursed by insurance companies for the fabrication of an oral surgical splint (CPT code 21085). Ultimately, in this entire CASS planning process, the total surgeon's time is reduced to 70 to 100 minutes per case in comparison to 9.75 hours[40] in the conventional planning process.

Acknowledgement

This work was partially supported by NIH/NIDCR research grants R42DE016171, R01DE022676, and R01DE021863.

References

1. Xia J, Ip HH, Samman N, Wang D, et al.: Computer-assisted three-dimensional surgical planning and simulation: 3D virtual osteotomy, *Int J Oral Maxillofac Surg* 29:11–17, 2000.
2. Xia J, Samman N, Yeung RW, et al.: Three-dimensional virtual reality surgical planning and simulation workbench for orthognathic surgery, *Int J Adult Orthodon Orthognath Surg* 15:265–282, 2000.
3. Xia J, Samman N, Yeung RW, et al.: Computer-assisted three-dimensional surgical planing and simulation. 3D soft tissue planning and prediction, *Int J Oral Maxillofac Surg* 29:250–258, 2000.
4. Xia J, Ip HH, Samman N, Wong HT, et al.: Three-dimensional virtual-reality surgical planning and soft-tissue prediction for orthognathic surgery, *IEEE Trans Inf Technol Biomed* 5:97–107, 2001.
5. Xia JJ, Gateno J, Teichgraeber JF: New clinical protocol to evaluate craniomaxillofacial deformity and plan surgical correction, *J Oral Maxillofac Surg* 67:2093–2106, 2009.
6. Gateno J, Teichgraeber JF, Xia JJ: Three-dimensional surgical planning for maxillary and midface distraction osteogenesis, *J Craniofac Surg* 14:833–839, 2003.
7. Gateno J, Teichgraeber JF, Aguilar E: Computer planning for distraction osteogenesis, *Plast Reconstr Surg* 105:873–882, 2000.
8. Gateno J, Allen ME, Teichgraeber JF, Messersmith ML: An in vitro study of the accuracy of a new protocol for planning distraction osteogenesis of the mandible, *J Oral Maxillofac Surg* 58:985–990, 2000, discussion 990–991.
9. Gateno J, Xia J, Teichgraeber JF, Rosen A: A new technique for the creation of a computerized composite skull model, *J Oral Maxillofac Surg* 61:222–227, 2003.
10. Xia JJ, Gateno J, Teichgraeber JF: Three-dimensional computer-aided surgical simulation for maxillofacial surgery, *Atlas Oral Maxillofac Surg Clin North Am* 13:25–39, 2005.
11. Swennen GR, Mommaerts MY, Abeloos J, et al.: The use of a wax bite wafer and a double computed tomography scan procedure to obtain a three-dimensional augmented virtual skull model, *J Craniofac Surg* 18:533–539, 2007.
12. Swennen GR, Mollemans W, Schutyser F: Three-dimensional treatment planning of orthognathic surgery in the era of virtual imaging, *J Oral Maxillofac Surg* 67:2080–2092, 2009.
13. Schatz EC: A new technique for recording natural head position in three dimensions (MS thesis). In *Orthodontics*, Houston, 2006, University of Texas Health Science Center at Houston (Advisors: Xia JJ, English JD, Garrett FA, et al).
14. Schatz EC, Xia JJ, Gateno J, et al.: Development of a technique for recording and transferring natural head position in 3 dimension, *J Craniofac Surg* 21:1452–1455, 2010.
15. Xia JJ, McGrory JK, Gateno J, et al.: A new method to orient 3-dimensional computed tomography models to the natural head position: a clinical feasibility study, *J Oral Maxillofac Surg* 69:584–591, 2011.
16. Gateno J, Xia JJ, Teichgraeber JF, et al.: Clinical feasibility of computer-aided surgical simulation (CASS) in the treatment of complex cranio-maxillofacial deformities, *J Oral Maxillofac Surg* 65:728–734, 2007.
17. Bell RB: Computer planning and intraoperative navigation in orthognathic surgery, *J Oral Maxillofac Surg* 69:592–605, 2011.
18. Gateno J, Xia J, Teichgraeber JF, et al.: The precision of computer-generated surgical splints, *J Oral Maxillofac Surg* 61: 814–817, 2003.
19. Swennen GR, Barth EL, Eulzer C, Schutyser F: The use of a new 3D splint and double CT scan procedure to obtain an accurate anatomic virtual augmented model of the skull, *Int J Oral Maxillofac Surg* 36:146–152, 2007.
20. Xia JJ, Shevchenko L, Gateno J, et al.: Outcome study of computer-aided surgical simulation in the treatment of patients with craniomaxillofacial deformities, *J Oral Maxillofac Surg* 69: 2014–2024, 2011.
21. Hsu SS, Gateno J, Bell RB, et al.: Accuracy of a computer-aided surgical simulation protocol for orthognathic surgery: a prospective multicenter study, *J Oral Maxillofac Surg* 71:128–142, 2013.

22. Xia JJ, Gateno J, Teichgraeber JF, et al.: Accuracy of the computer-aided surgical simulation (CASS) system in the treatment of patients with complex craniomaxillofacial deformity: a pilot study, *J Oral Maxillofac Surg* 65:248–254, 2007.
23. McCormick SU, Drew SJ: Virtual model surgery for efficient planning and surgical performance, *J Oral Maxillofac Surg* 69: 638–644, 2011.
24. Bell WH, editor: *Surgical correction of dentofacial deformities*, Philadelphia, 1980, WB Saunders.
25. Bell WH, editor: *Modern practice in orthognathic and reconstructive surgery*, Philadelphia, 1992, WB Saunders.
26. Xia JJ, Gateno J, Teichgraeber JF, et al.: Algorithm for planning a double-jaw orthognathic surgery using computer-aided surgical simulation (CASS) protocol: 1. Planning sequence, *Int J Oral Maxillofac Surg* 44(12):1431–1440, 2015.
27. Chang YB, Xia JJ, Gateno J, et al.: In vitro evaluation of new approach to digital dental model articulation, *J Oral Maxillofac Surg* 70:952–962, 2012.
28. Chang YB, Xia JJ, Gateno J, et al.: An automatic and robust algorithm of reestablishment of digital dental occlusion, *IEEE Trans Med Imaging* 29:1652–1663, 2010.
29. Xia JJ, Chang YB, Gateno J, et al.: Automated digital dental articulation, *Med Image Comput Comput Assist Interv* 13:278–286, 2010.
30. Li J, Ferraz F, Shen S, Lo Y-F, et al.: Automated three-piece digital dental articulation, *Med Image Comput Comput Assist Interv*, 2015. In press.
31. Gateno J, Xia JJ, Teichgraeber JF: Effect of facial asymmetry on 2-dimensional and 3-dimensional cephalometric measurements, *J Oral Maxillofac Surg* 69:655–662, 2011.
32. Gateno J, Xia JJ, Teichgraeber JF: New 3-dimensional cephalometric analysis for orthognathic surgery, *J Oral Maxillofac Surg* 69:606–622, 2011.
33. Xia JJ, Gateno J, Teichgraeber JF, et al.: Algorithm for planning a double-jaw orthognathic surgery using computer-aided surgical simulation (CASS) protocol: 2. Three-dimensional cephalometry, *Int J Oral Maxillofac Surg* 44(12):1441–1450, 2015.
34. Xia JJ, Gateno J, Teichgraeber JF: A new paradigm for complex midface reconstruction: a reversed approach, *J Oral Maxillofac Surg* 67:693–703, 2009.
35. Ciocca L, Mazzoni S, Fantini M, et al.: A CAD/CAM-prototyped anatomical condylar prosthesis connected to a custom-made bone plate to support a fibula free flap, *Med Biol Eng Comput* 50: 743–749, 2012.
36. Malis DD, Xia JJ, Gateno J, et al.: New protocol for 1-stage treatment of temporomandibular joint ankylosis using surgical navigation, *J Oral Maxillofac Surg* 65:1843–1848, 2007.
37. Bland JM, Altman DG: Statistical methods for assessing agreement between two methods of clinical measurement, *Lancet* 1:307–310, 1986.
38. Haas Jr OL, Becker OE, de Oliveira RB: Computer-aided planning in orthognathic surgery-systematic review, *Int J Oral Maxillofac Surg* 2014 Nov 25. pii: S0901–5027(14)00430-5. http://dx.doi.org/10.1016/j.ijom.2014.10.025. [Epub ahead of print].
39. Christensen AM: *Cost and time spent on the computer data preparation and splint fabrication for computer-aided surgical simulation for orthognathic surgery,* Personal Communication with JJ Xia and JF Teichgraeber on March 25, 2009: Golden, CO (AMC) and Houston, TX (JJX and JFT).
40. Xia JJ, Phillips CV, Gateno J, et al.: Cost-effectiveness analysis for computer-aided surgical simulation in complex craniomaxillofacial surgery, *J Oral Maxillofac Surg* 64:1780–1784, 2006.

4

Orthognathic Model Surgery

ESTHER S. OH, NEIL OISHI

Introduction

Orthognathic surgery involves complex three-dimensional movements of the maxilla and mandible. A plan of precise surgical moves is formulated to achieve a desired functional and esthetic outcome based on many factors, including: facial symmetry and balance, occlusion, incisor tooth show at rest and full smile, soft tissue drape, and co-morbidities such as obstructive sleep apnea. These surgical moves can be described as translations or rotations (roll, pitch, and yaw) along the anterior-posterior, transverse, and vertical axes, respectively (Figure 4-1).

Presurgical model surgery allows the surgeon to carry out the planned osteotomies and movements ex vivo. This exercise enables the surgeon to plan and preview the exact surgical movements and outcome prior to entering the operating room. Additionally, model surgery allows for fabrication of rigid interdental splints to replicate the planned surgical movements intraoperatively. These splints relate the teeth and corresponding skeletal segments in their planned positions during application of rigid internal fixation.

Prior to the advent of model surgery, the earliest form of orthognathic surgery was described in 1849 when Hullihen published an article describing a case of "elongation of the underjaw," where a prognathic patient from burn contractures was successfully treated.[1] In 1898, Edward Angle, Jr. published an article in *The Dental Cosmos* suggesting the use of presurgical model surgery for "double resection of the lower maxilla."[2] In his article, he recommended the use of plaster models to replicate the intended osteotomies, and then fabrication of a vulcanite or metal splint to be used during surgery to achieve more accurate results. Since that time, the use of model surgery and surgical splints for orthognathic surgery have become the gold standard. Model surgery has increased the precision of surgery, decreased intraoperative time, and resulted in predicable and repeatable surgical results. There are various ways and styles to perform model surgery, but we present one of these ways with our usual and customary technique.

Data Collection

Model surgery begins with data collection at a workup appointment. Immediate presurgical records are obtained for model surgery which may include the following items.

Intraoral and Extraoral Photographs

High quality standardized photos should be taken for documentation, treatment planning, and medico-legal purposes. These photos can assist in verifying accuracy of mounting the casts as well. Obtaining photographs prior to impressions is recommended because residual alginate may get lodged between orthodontic brackets and wires, which can lead to suboptimal pictures (Figure 4-2). Suggested intraoral and extraoral photograph views are listed in the following paragraphs.

Full Head/Extraoral Views

These include frontal views at rest and at full smile, left and right lateral views, and left and right ¾ views. All

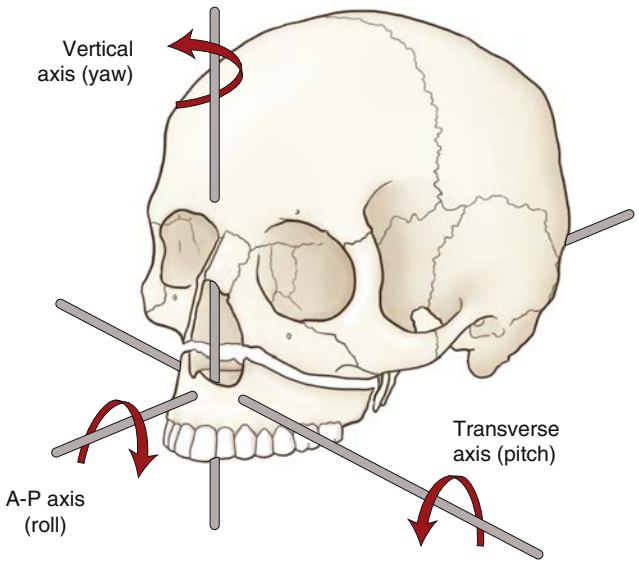

• **Figure 4-1** Roll, pitch, and yaw.



• **Figure 4-2** Poor quality photos.

photos should be taken straight on with the Frankfort horizontal plane parallel to the floor for consistency. With the exception of the full smile view, patients should have their lips relaxed in all the views to document any lip incompetency and to increase accuracy for the lateral cephalometric tracing and soft tissue predictions. Additional views such as bird's eye or worm's eye views may be indicated in select patients such as a person with a cleft lip and palate to document his or her alar collapse (Figure 4-3).



• **Figure 4-3** Clinical extraoral photos. (Courtesy Timothy Turvey.)

Continued

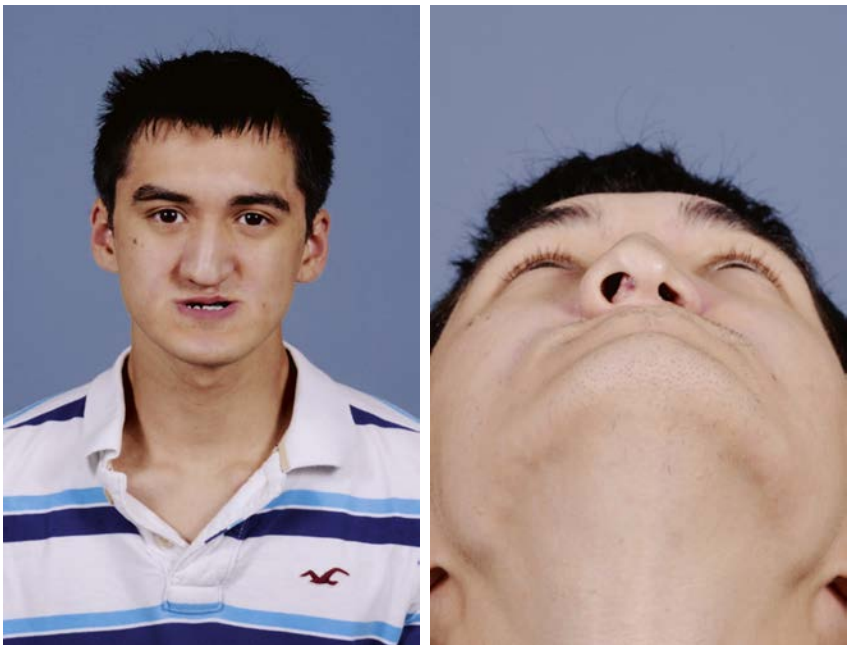

• **Figure 4-3, cont'd.**

Intraoral Views

These include maxillary and mandibular occlusal arch views, global and close-up frontal views, and left and right posterior lateral views to demonstrate canine and molar Angle's classification. Additional left and right anterior lateral views may be taken to demonstrate overbite and overjet (Figure 4-4).

Clinical Measurements

A worksheet is useful during the workup appointment to ensure that all key landmarks and measurements are recorded (Figure 4-5).

Impressions and Models

If single jaw surgery is planned, only one set of impressions for the maxilla and mandible is necessary. If a double jaw surgery is planned, two sets of impressions are necessary: one set for the final occlusion and one set for the model surgery. If a multi-piece Le Fort is planned, one extra impression of the maxilla is required. With the required number of impressions in mind, one extra set of impressions is suggested as a "spare" set. Once the models are poured, the most accurate (i.e., without air bubbles on the occlusal surface, chips, etc.) set of impressions should be used for the final occlusion, and the second best set should be used to perform the model surgery to set the intermediate occlusion. The remaining "spare" set can be set aside and used only if there is a chip or break in the other casts. Duplicating the casts instead of taking multiple impressions on the patient is another option, but is not ideal because duplication can decrease the accuracy and detail of the casts (Figure 4-6).

Bite Registration Record

The bite registration should be recorded in centric relation (CR), with the condyles in the most posterior superior position in the glenoid fossa, to create a repeatable position in the operating room. Leaning the patient back in the chair may help to relax the patient's jaw with gravity. Multiple materials can be used for this record, including wax, compound, or polyvinylsiloxane (PVS) products (i.e., BluMousse). Practicing with the patient prior to taking the actual record will allow the patient to feel his or her jaw relaxed and then guided into centric relation. At least two bite registration records should be taken and compared to ensure that the patient's jaw position is repeatable and accurately captured.

Facebow Record

The facebow that corresponds to the surgeon's particular semiadjustable articulator should be used in the usual fashion. Accurate capture of the maxillary relationship to the skull base is critical for mounting the maxillary cast with precision. From the frontal view, the facebow is adjusted to be parallel with the pupils at the level of the infraorbital rims. In many cases, mounting the maxilla while using the facebow can facilitate identification of midline, cant, or yaw discrepancies, and further highlight asymmetric faces, ears, or pupils.

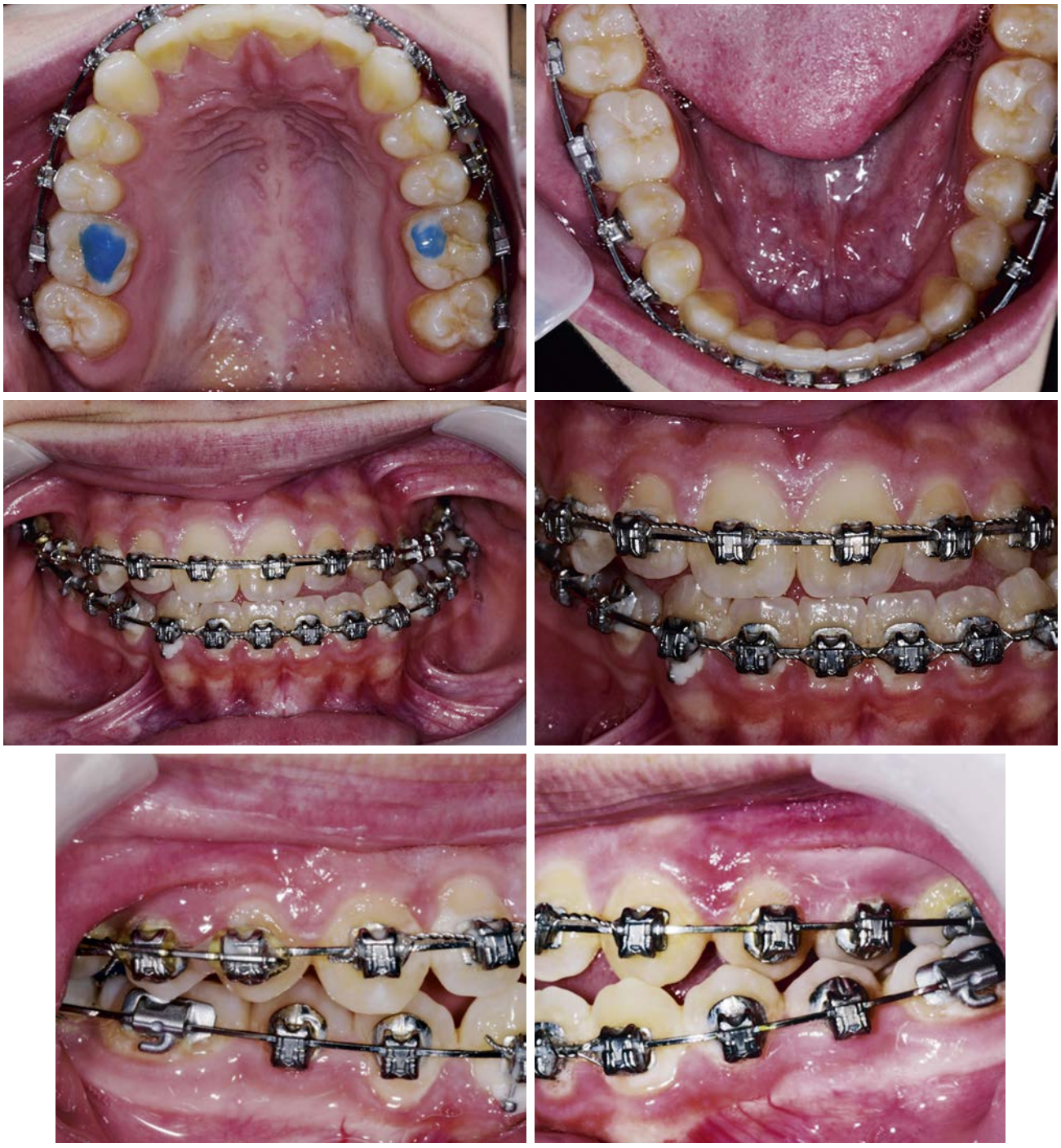

• **Figure 4-4** Clinical intraoral photos. (Courtesy Timothy Turvey.)

Continued

Patients with a grossly asymmetric face may pose a particular challenge. Key points for these asymmetric patients include the following:

- If the patient's orbits are asymmetric (i.e., hemifacial microsomia), Posnick suggests using a plane parallel to the floor in the natural head position as the reference plane instead of the interpupillary line.[3]
- If the ear canals are asymmetric, the ear prong on the side of the malpositioned ear should be placed at the appropriate position to approximate the contralateral "normally positioned" ear.

Once the facebow is recorded, it is used to mount the maxillary cast on the semiadjustable articulator. The mandibular cast is then related to the maxillary cast via the bite registration and then mounted on the articulator with the vertical pin set at zero.

Radiographs

Each patient requires either a cone beam CT (CBCT) reconstruction or three plain films: panorex, PA cephalometric (PA ceph), and lateral cephalometric (lateral ceph) radiographs.



• **Figure 4-4, cont'd.**

Orthognathic Measurements

Name: Jane Dough DOB: 1/1/97 Sex: F

Chart #: 1234-1234 Date: 1/1/15

Examiner: EO

Occlusal plane: 2mm cant R / L canine 2 mm below R / (L) canine

Upper CI exposed at rest: 6 mm CI length: 10

Upper CI exposed at full smile: 10 mm + 1 mm of gingiva

Maxillary dental midline 0 mm to R / (L) of facial skeletal midline

Mandibular dental midline 6 mm to R / (L) of maxillary dental midline

Mandibular dental midline 6 mm to R / L of mandibular skeletal midline

Overjet: 0 mm (end-to-end) Overbite/openbite: 0 mm

Lip incompetence: 8-10 mm

MIO: 55 mm Protrusive: 6 mm R lat: 7 mm L lat: 7 mm

Facial symmetry: (L) orbital dystopia (~ 1-2 mm inferior)

Facial width: 130 mm (137 mm) Facial height: 110 mm (114 mm)

Facial height/width ratio: 83 %

Naso-labial angle: 95 deg Mand incisor to chin length: 40 mm

Other comments:

PLAN: 1) Ext teeth # 1, 16, 17, 32
2) Cranial BG harvest → maxilla
3) LFI (keep maxillary midline, move R maxilla ↑)
4) BSSO, mandible BG harvest → maxilla
5) Genteplasty

• **Figure 4-5** Worksheet of clinical facial measurements. (Courtesy University of North Carolina Oral Maxillofacial Surgery residency program.)



• **Figure 4-6** Poor quality casts due to air bubbles on the occlusal surface. (Courtesy Carrie Baldwin.)

The panorex will give a general overview of the patient's dentition and anatomy, and will reveal any pathology or impacted teeth. The PA ceph will reveal any skeletal asymmetries, and the lateral ceph will show a general view of the posterior airway space and will be necessary for the cephalometric tracing.

The patient should be instructed to keep his or her teeth together and lips relaxed during the radiographs for a repeatable position. If the patient has trouble relaxing their lips, have the patient lick his or her lips and/or hold the lips still after saying "Mississippi" prior to taking the radiograph. This small but key detail is especially important during the lateral ceph for the best accuracy during both the hard and soft tissue cephalometric tracings.

If the patient is overclosed, two lateral ceph radiographs are recommended: one in relaxed mandibular position and one in maximal intercuspation. The difference in distance can be measured to assess how much the mandible is overclosed. The cephalometric tracing and surgical planning should strive to not exceed the vertical limit of the relaxed mandible (Figure 4-7).

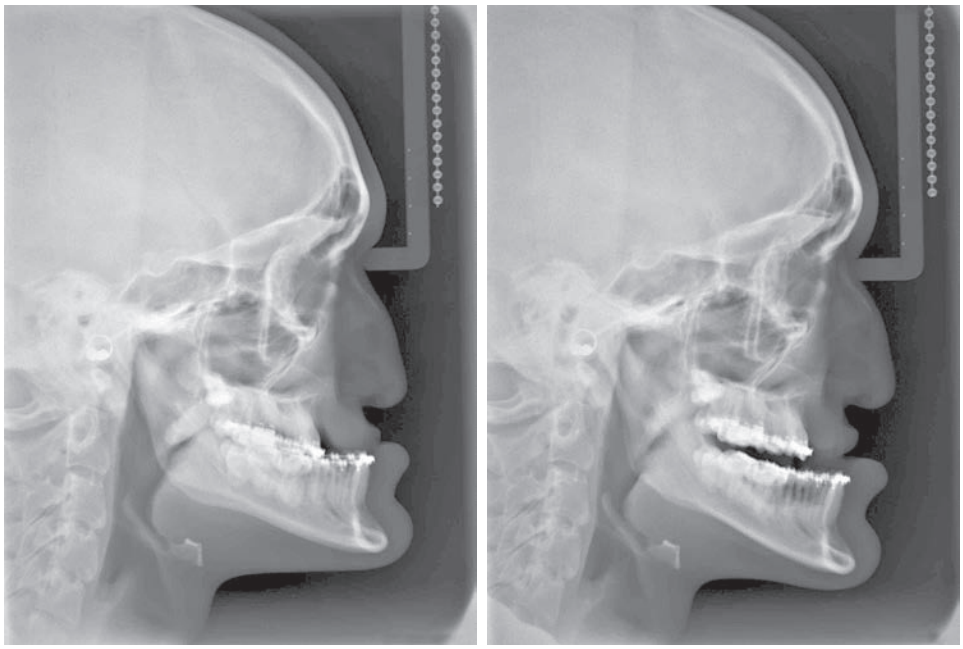

• **Figure 4-7** Lateral ceph (over-closed and relaxed). (Courtesy Timothy Turvey.)

If a multi-piece Le Fort is planned, periapical radiographs should be taken at the planned interdental osteotomy sites to assess for adequate bony space and root flaring. We recommend a minimum of 3 mm of space between roots to decrease the risk of dental trauma during the osteotomies.

Setting the Final Occlusion

Prior to setting the occlusion, casts may be treated with die hardener to prevent abrasion of stone or chipping of teeth, but care should be taken not to use an excess amount, which can create interferences. The dental casts are mounted in a simple hinge or Galetti articulator in their proposed final occlusal relationship for fabrication of the final splint. If using the hinge articulator, wooden sticks from a cotton tip applicator may be spanned and fixated between the maxillary and mandibular cast bases with hot glue or sticky wax. These sticks act as struts prior to mounting the casts on the upper and lower segments of the simple hinge articulator with dental plaster or stone (Figure 4-8).

When possible, the final occlusion should be determined with the orthodontist's preferences and the following criteria in mind:

1. Achieve ideal overbite and overjet (1-3 mm each).
2. Place the canines and first molars in Angle's class I occlusion. A class II molar relationship may be acceptable to the orthodontist, but a class III molar relationship is less desirable because mandibular first molars will function against the maxillary second premolars.[4]
3. Correct transverse discrepancies.
4. Align maxillary and mandibular dental midlines. Although coincidental midlines of the face, maxilla, and mandible are ideal, a study by Profitt and colleagues found that patients may be able to tolerate up to 3 mm of



• **Figure 4-8** Simple hinge and Galetti articulators with the casts in final occlusion.

midline discrepancy before becoming noticeable by the general public and significantly affecting facial esthetics.[5]

5. Close open bites. Although the occlusion should come as close as possible to the final position intended for the orthodontist, extrusion of posterior molars is one of the most straightforward movements for the orthodontist to perform post-operatively.

With ideal presurgical orthodontic preparation, all of the aforementioned criteria may be met. However, presurgical orthodontic results often are less than ideal due to patient or orthodontic factors. In such cases, the compromises and surgical objectives should be discussed with the orthodontist.

Fabricating the Final Splint

For single jaw surgery (maxilla only or mandible only), the final occlusal relationship is the only cast mount needed, which can be mounted on a hinge or Galetti articulator. A final splint is fabricated from the mounted final occlusion. The maxillary and mandibular casts are coated with a thin layer of petroleum jelly to prevent the acrylic from sticking to the cast. For the log roll technique the acrylic resin powder and polymer liquid are mixed to a workable doughy consistency and flattened to a log roll or a sheet approximately 5 mm thick (thicker if there is a larger open bite in the final occlusion). The acrylic is flattened between two tongue blades that have been lubricated with petroleum jelly and the excess is trimmed with Dean scissors. This trimmed strip is placed between the maxillary and mandibular occlusal teeth surfaces and the articulator is closed. Dean scissors are used to trim the gross excess acrylic around the entire buccal and palatal surfaces. Removal of excess acrylic at this stage will significantly reduce the time it takes to trim the splint in later stages.

The articulator is continuously opened and closed until the acrylic hardens to prevent the acrylic from locking into under-cuts around the teeth. After the acrylic starts to feel hot, the articulator is closed and a rubber band may be tied around the articulator to prevent separation of the teeth during the minor expansion that occurs during the self-curing process. A pressure pot may be utilized to increase the strength of the splint. After the splint cools and hardens, easy opening and closing of the articulator should be ensured, and the posterior molar area may be ramped to remove any interferences or excess acrylic with an acrylic bur. The splint should be made as thin as possible to minimize interferences and error, as well as maximize patient comfort. Afterwards, the splint should be polished with coarse and fine pumice for a smooth, glass-like finish for patient comfort and cleanliness.

If the surgeon plans to leave the final splint in place after surgery, the splint is replaced between the maxillary and mandibular casts. Using a pencil or thin permanent marker, marks are made in the buccal embrasures where the surgeon would like holes for circumdental wires to secure the splint intraoperatively. Some surgeons prefer to place a hole in every embrasure to increase options intraoperatively, whereas others may prefer to place select holes in the midline and one or two bilaterally. Minimizing the number of holes helps to maximize the strength of the splint, and drilling these holes after the polishing process helps minimize the risk of breaking the splint. A 701 burr is used to drill these wiring holes, ensuring that the flutes of the bur are cleared after every 1-2 holes. If the flutes are not cleared, acrylic sticks to the burr and progressively increases the diameter of each subsequent hole drilled. Afterwards, each hole should be cleared with a burr or wire to ensure that residual acrylic does not occlude the hole and prevent passing of the wire intraoperatively (Figure 4-9).

Double Jaw Surgery

Mounting the Casts

For double jaw surgery or other complex cases, mounting the casts on a semiadjustable articulator is indicated. The articulator needs to replicate the relationship of the maxilla and mandible to the condylar hinge axis as accurately as possible using a facebow transfer for the maxilla and a bite registration record in CR for the mandible. The accuracy of these reference points is critical because the uncut jaw serves as a reference point for the cut jaw during the intermediate move.

Reference Lines and Marking the Casts

There are various methods for marking casts to simulate the planned surgical moves. We prefer to create horizontal markings that are parallel to the baseplate, and therefore, the Frankfort horizontal plane. A ruler may be used to measure and mark three parallel lines: one indicating the proposed osteotomy line, and two lines about 5 mm on either side of the osteotomy line to be used as reference lines.

A pencil or thin permanent marker can be used to dot several key points on the maxillary dentition: the middle of the incisive edge of the bilateral central incisors, cusp tips of the bilateral canines, and the mesiobuccal cusp tips of the bilateral first molars. These markings serve as measuring reference points to confirm predicted movements during model surgery. Therefore, these dots should be as small as possible to ensure precision of measurements. These dots may be coated with a thin layer of die hardener to prevent abrasion or accidental erasing or these points.

Vertical reference lines are then placed perpendicular to the baseplate from each of these marked dots to the base plate. Another vertical line drawn at the maxillary midline (or mandibular midline if it aligns better with the facial midline) is helpful in visualizing midline shifts. In addition, a vertical line is marked on the posterior side of the cast behind the bilateral maxillary tuberosities to monitor against unintentional yaw shifts during the proposed movements. These horizontal and vertical reference lines are used for evaluation of movements and midline changes of the model surgery (Figure 4-10).



• **Figure 4-9** Fabricating the final splint. (**A-E,** courtesy Carolyn Dicus.)



• **Figure 4-10** Marking reference lines.

Measurements

Now that the patient's maxillofacial and occlusal relationships are accurately replicated on the semi-adjustable articulator, the previously marked occlusal surfaces on the maxillary teeth are recorded on a worksheet as starting reference points in the AP, vertical, and transverse dimensions. Additional reference points such as the anterior nasal spine (ANS), point A, or posterior maxilla also may be recorded as adjuncts. If a multi-piece Le Fort surgery is planned, measurements between both the first molar to first molar at the mesiolingual cusps and the canine to canine should be recorded before and after the model surgery to help assess the amount of planned transverse expansion (Figure 4-11).

The Erickson Model Table (Great Lakes Orthodontics, Tonawanda, NY) is a measuring instrument with a flat granite base and an electronic caliper positioned at 90 degrees which provides a simple, repeatable method for accurately recording these measurements on the dental casts. The caliper is capable of metric measurements to an accuracy of 0.01 mm. The device comes with a model block that secures the mounted maxillary cast via a mounting screw that attaches to the baseplate. The model block is rectangular with precise 90 degree angles and acts as a fixed plane of reference for orientation and measurements in the AP, vertical, and transverse dimensions (Figure 4-12).

These presurgical measurements can be correlated to the clinical facial assessments and photos to check accuracy. For example, if the patient's maxillary midline is coincident with the midsagittal plane clinically, the maxillary midline should line up with the middle of the Erickson mounting block along the transverse axis. Likewise, if the patient clinically has a cant about 2 mm down on the right at the canines, one would expect the vertical Erickson table measurements to be about 2 mm greater for the right canine as compared to the left canine. These simple checks are useful in verifying accuracy of the initial mounting (Figure 4-13).

Orthognathic Surgery Measurements

	Pre-op	+/-	Post-op	Actual
Vertical				
Right central incisor	____	____	____	____
Right canine	____	____	____	____
Right first molar	____	____	____	____
Left central incisor	____	____	____	____
Left canine	____	____	____	____
Left first molar	____	____	____	____
Anterior-Posterior				
Right central incisor	____	____	____	____
Right canine	____	____	____	____
Right first molar	____	____	____	____
Left central incisor	____	____	____	____
Left canine	____	____	____	____
Left first molar	____	____	____	____
Transverse				
Right side down				
Left central incisor	____	____	____	____
Left canine	____	____	____	____
Left first molar	____	____	____	____
Left side down				
Right central incisor	____	____	____	____
Right canine	____	____	____	____
Right first molar	____	____	____	____
Articulator anterior-posterior backup measurements				
RCI to guide pin	____	____	____	____
LCI to guide pin	____	____	____	____
Mounting base plate vertical backup measurements				
Right central incisor	____	____	____	____
Right canine	____	____	____	____
Right first molar	____	____	____	____
Left central incisor	____	____	____	____
Left canine	____	____	____	____
Left first molar	____	____	____	____
Expansion (segmental Le Fort) measurements				
Inter-incisor width	____	____	____	____
Inter-canine width	____	____	____	____
Inter-1st molar width	____	____	____	____

• **Figure 4-11** Model surgery worksheet. (Courtesy University of North Carolina Oral Maxillofacial Surgery residency program.)

Once these values are obtained and recorded, the planned surgical movements should be added or subtracted from



• **Figure 4-12** Erickson Model Table.

these values as indicated to obtain the desired final measurements. For example, if planning a 4 mm maxillary advancement, 4 mm should be added to each AP value to determine the planned final value. These planned final values are also recorded on the worksheet.

Repositioning the Maxilla

Double jaw surgery may be performed by starting with either the maxilla or the mandible. Regardless of the sequence of osteotomies, the primary role for model surgery is to replicate correct maxillary repositioning as determined during the initial clinical and cephalometric evaluation. The position of the mandible is dictated by the maxillary position and previously determined final occlusion. Now that the



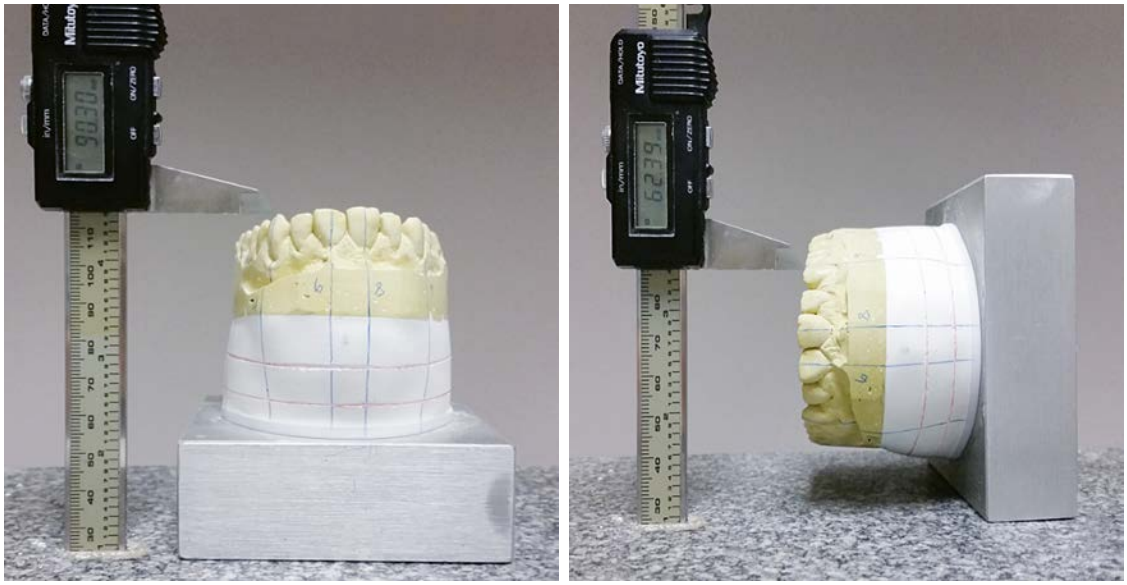

• **Figure 4-13** Initial measurements with the Erickson Model Table.



• **Figure 4-14** Measuring the cut cast with the Erickson Model Table after repositioning with modeling clay.

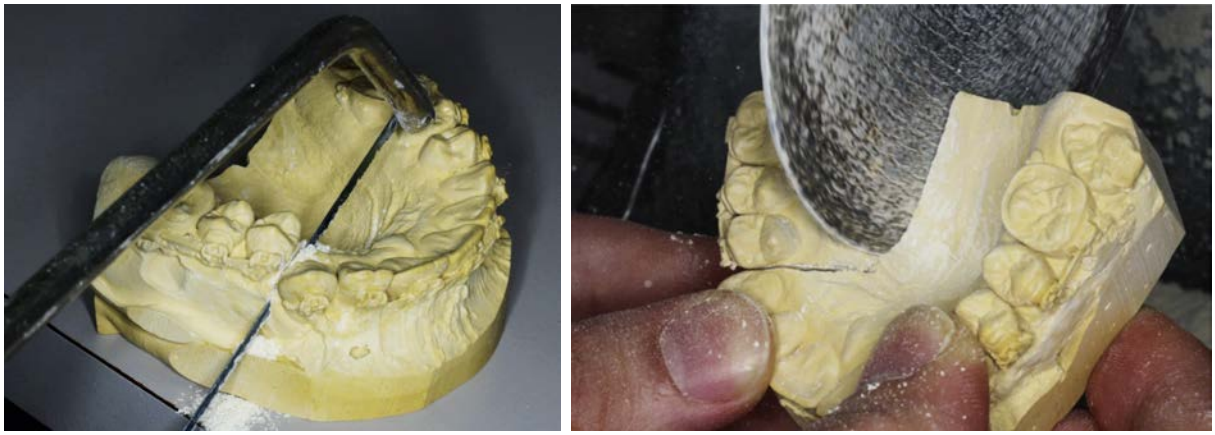

• **Figure 4-15** Sectioning the cast for a multi-piece Le Fort.

casts are mounted, marked, and measured, model surgery usually is performed on the maxillary cast first.

Single-Piece Le Fort I Osteotomy

The mounting plaster of the maxillary cast is cut with a lathe along the previously drawn middle horizontal line to separate the maxillary cast from the baseplate. This cut roughly should simulate the height of the maxillary osteotomy. At this point, the cast and baseplate segments should be trimmed to allow room to freely position the maxillary cast in the proposed final position without interference. In impaction cases, larger amounts of mounting plaster should be removed to allow adequate space for manipulation of the cast.

The baseplate segment is placed on the mounting block of the Erickson Model Table, and a thin layer of modeling clay such as Play-Doh is placed on the baseplate segment. The maxillary cast segment is then seated on the modeling clay to approximate the final position. The maxillary cast is then manipulated on the modeling clay until the calculated final AP, transverse, and vertical measurements are achieved to within 0.02 mm. Once the desired position of the maxilla is achieved, the cast segment is secured in position to the baseplate segment with a hot glue gun or sticky wax. The final measurements of the maxillary occlusal reference points are recorded in the AP, vertical, and transverse dimensions on the worksheet to verify the accuracy of the movement (Figure 4-14).

Multi-piece Le Fort I Osteotomy

In cases planned for a multi-piece Le Fort I osteotomy, the maxilla is sectioned with either a die saw, lathe, and/or a 701 fissure burr along the bony cut, and then a chisel and mallet may be used to guide the break through the contact point between the teeth at the proposed osteotomy sites. If abrasion of the interproximal areas of the adjacent teeth during the interdental osteotomies is unavoidable, one must keep that detail in mind during the actual surgery. One alternative to this scenario to prevent intraoperative interproximal reductions that are not reproducible is to set a gap the width of the saw blade between the maxillary segments. This gap can be closed easily post-operatively with orthodontics.[6] Every effort should be made to avoid or at least minimize step defects in the bony portion of the models because this setup will create periodontal issues for the patient post-operatively (Figure 4-15).



• **Figure 4-16** Multi-piece segments secured and rebased.

The sectioned maxillary pieces are then related to the mandibular cast in accordance with the aforementioned criteria for the final occlusion, and then the maxillary pieces are stabilized to each other with modeling clay and a hot glue gun or sticky wax. The maxillary model then may be rebased with stone to further stabilize the glued maxillary cast. Some surgeons prefer duplicating the reconstituted cast and utilizing this duplicated maxillary model for intermediate and final splints. But the first method of rebasing the cast in stone mimics the steps followed intraoperatively, and therefore, more likely provides greater accuracy than does using duplicate casts. After the reconstituted maxillary cast and the mandibular cast are secured into the final occlusal relationship in the simple hinge or Galetti articulator, a final splint is fabricated.

For the intermediate move, the baseplate segment is mounted on the mounting block of the Erickson Model Table, and modeling clay is placed on the baseplate segment. The reconstituted maxillary cast is then placed on the modeling clay by using the final splint as a guide, and then manipulated to achieve the desired final AP, transverse, and vertical measurements as described for the single-piece Le Fort I osteotomy. Once the desired position of the maxilla is achieved, the reconstituted cast segment is secured in position to the baseplate segment with a hot glue gun or sticky wax. The final measurements of the AP, vertical, and transverse dimensions of the maxillary occlusal reference points are recorded on the worksheet (Figure 4-16).

Fabricating the Intermediate Splint

The intermediate splint is imperative for intraoperative use during double jaw surgery. After the osteotomy of the first jaw (whether maxilla or mandible), this splint helps position the cut jaw in relation to the uncut jaw. Once this position is established intraoperatively, the cut jaw is secured with internal fixation.

Maxilla-first Surgery

After the maxillary segment is oriented and secured on the baseplate in its final position, it is mounted back on the semi-adjustable articulator. The intermediate setup is achieved by mounting the unmoved mandibular cast against the repositioned maxillary cast, mimicking the setup that will be achieved during surgery after the first osteotomy. The fabrication of the intermediate splint is dependent on whether the surgery is for a single-piece or multi-piece maxillary surgery.



• **Figure 4-17** Intermediate splint. (Courtesy Michael Huang.)

Single-piece Maxillary Surgery

In single-piece maxillary surgery, the splint is made directly between the repositioned maxillary cast and unmoved mandibular cast on the semi-adjustable articulator. The articulator pin should be set at zero to minimize inaccuracies, and then the splint is fabricated in a similar fashion to the final splint. Some authors recommend using colored monomer powder to help differentiate between the intermediate and final splints during the operation. We recommend the log roll technique rather than the sheet technique to fabricate the intermediate splint, because large inter-occlusal gaps in the intermediate occlusion usually require a larger amount of acrylic compared to the final splint.

The intermediate splint also should be trimmed as thin as possible with an acrylic burr to minimize interferences and error. Because the intermediate splint is not retained following surgery, wiring holes are not necessary. Particular attention should be directed towards eliminating occlusal bracket interferences and achieving a low buccal profile to minimize interferences intraoperatively when wiring the patient into maxillomandibular fixation. The splint is then polished with coarse and fine pumice for a smooth finish (Figure 4-17).



• **Figure 4-18** Foil technique.

Multi-piece Maxillary Surgery

In multi-piece maxillary surgery a "splint-within-a-splint" technique is recommended. The final splint is wired to the maxillary segments intraoperatively to orient the segments in their proposed final relationship. Because this final splint usually is retained postoperatively to stabilize the segments for healing, the intermediate splint is fabricated around the final splint.

To fabricate the "splint-within-a-splint," the final splint is luted onto the moved maxilla with a hot glue gun or sticky wax. The unmoved mandible is mounted in the semi-adjustable articulator, and the articulator pin is set to zero. The final splint and the mandibular cast occlusal surfaces are coated with a generous but thin layer of petroleum jelly. One alternative to ensure that the intermediate and final splints do not lock together is to adapt aluminum foil around the mandibular teeth using a pencil eraser. The outer surface of the foil and the mandibular casts then are coated with petroleum jelly (Figure 4-18).

The intermediate splint is fabricated between the maxillary final splint and mandibular cast with the log roll technique as described previously, paying special attention to adapt the acrylic along the full extent of the buccal and lingual aspects of the final splint. Encasing the final splint along the buccal and lingual aspects of the intermediate splint prevents rotation and inaccurate seating of the intermediate splint intraoperatively. Once the intermediate splint polymerizes and hardens, the inner surface of the intermediate splint should be flat, and the outer surface should outline the final splint's perimeter.



• **Figure 4-19** Fabrication of a "splint-within-a-splint." (**A-C,** courtesy Carrie Baldwin. **D-E,** courtesy Carolyn Dicus Brookes, MD, DMD.)

Once again, the intermediate splint is trimmed as thin as possible with an acrylic burr to minimize interferences and error. This intermediate splint should have a low buccal profile to match the height of the final splint for easy verification of complete seating of the splint intraoperatively. Although wiring holes are not necessary, the "splint-within-a-splint" naturally will have more buccal prominence and, therefore, some surgeons prefer placing buccal grooves in the intermediate splint where the wires will be passed buccally. The splint is then polished with coarse and fine pumice in the usual fashion (Figure 4-19).

Other adjuncts to increase stability of the multi-piece maxillary segments include incorporation of a palatal strap, either as a continuation of the acrylic used for the final splint, or adding a 0.036 mm orthodontic wire onto the final splint. One must pay close attention to the palatal area by adding wax to the palate of the cast to ensure that the palatal strap is not impinging on the palatal tissues intraoperatively. Another option is to have the orthodontist fabricate a buccal strap by adapting a 0.036 mm wire across the buccal surfaces of the maxillary teeth on the cast in final occlusion. For this option, the orthodontist will need to place maxillary molar headgear tubes preoperatively so that this buccal wire can be secured into these headgear tubes intraoperatively (Figure 4-20). In addition, the headgear tubes can be utilized intraoperatively to widen the maxilla by placing a temporary 22-gauge wire as a "handle". After placing the wire in each headgear tube on either both the right and left molars, one can pull them independently and

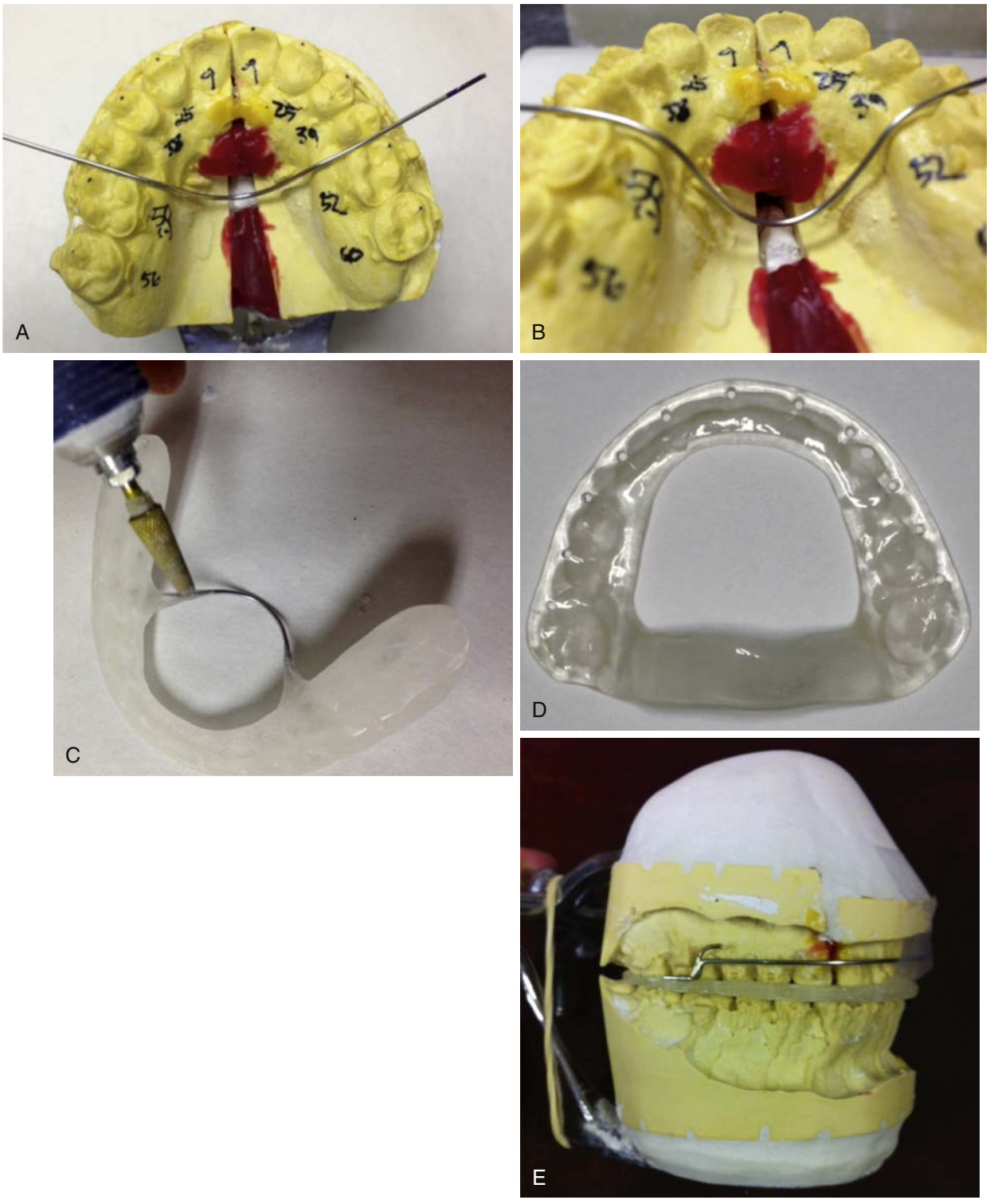

• **Figure 4-20** Adjuncts for multi-piece maxillary surgery. (**A-C,** courtesy Carolyn Dicus Brookes, MD, DMD. **D-E,** courtesy Carrie Baldwin.)

away from each other to place them into the final splint with more control in all three dimensions.

Mandible-first Surgery

Cottrell and Wolford published an article in 1994 suggesting that mandible-first orthognathic surgery may improve surgical accuracy.[7] They argued that when repositioning the maxilla first, the thin bony walls of the maxilla and/or large mandibular advancements may cause maxillary shifting when maxillo-mandibular fixation is applied. Such shifting may decrease surgical accuracy and cause compromised surgical results. Although most surgeons typically do maxilla-first surgery, occasionally mandible-first surgery may be indicated for the following: large mandibular advancements for the reasons mentioned by Cottrell and Wolford, major interferences and



• **Figure 4-21** Indication for mandible-first surgery.

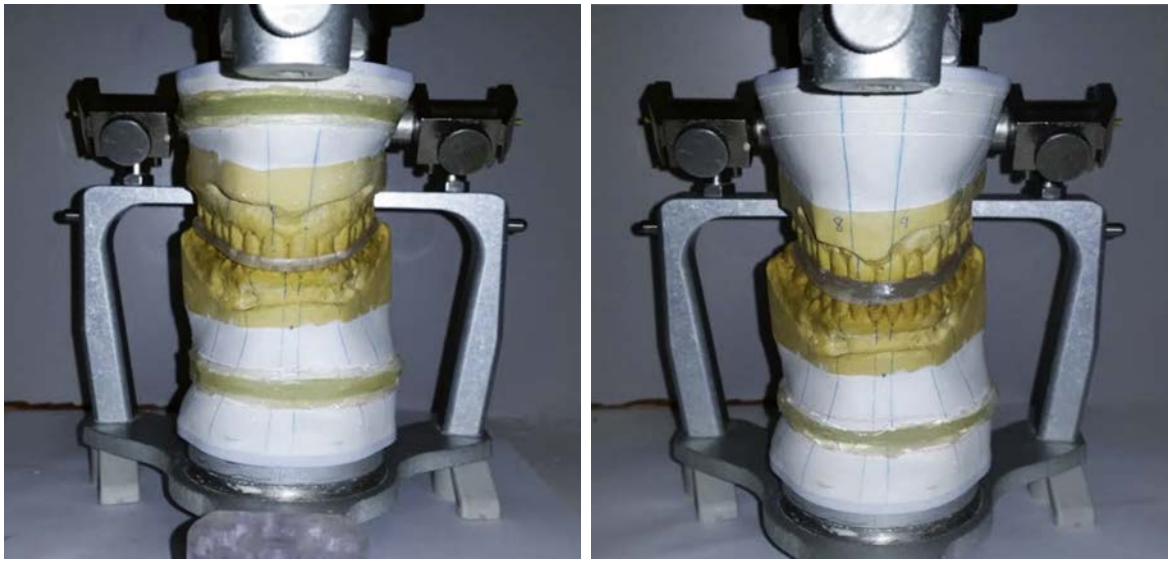

• **Figure 4-22** Intermediate splint for mandible-first surgery.

subsequent inaccuracies with a bulky intermediate splint, and potential instability of maxillo-mandibular fixation with the intermediate splint (Figure 4-21).

In the case of mandible-first surgery, two maxillary casts and one mandibular cast need to be mounted on a semi-adjustable articulator. Both maxillary casts should be marked and measured in the aforementioned fashion and then the measurements compared to assess the precision of the mountings. Even though mandible-first surgery is planned, model surgery is still carried out on the maxillary cast, and the final splint is secured against the repositioned maxillary cast with either a hot glue gun or sticky wax.

The mandibular cast is separated from the baseplate as previously described, and the mounting plaster is trimmed to allow free movement of the mandibular cast without interference. The mandibular cast is seated into the final splint opposing the moved maxilla and secured with a hot glue gun or sticky wax. The mandibular cast is remounted onto a baseplate in its final position with the semi-adjustable articular pin set to zero. The glue or sticky wax is then removed from the final splint, leaving the maxillary and mandibular casts in their proposed final position. Finally, the repositioned maxillary cast is replaced by the second unmoved maxillary cast to achieve the intermediate setup. The pin is set to zero and an intermediate splint is fabricated in this position. Unlike maxilla-first surgery, a "splint-within-a splint" technique is not required for mandible-first surgery for a planned multi-piece maxilla, because the intermediate splint will relate the mandible to an uncut maxilla intraoperatively (Figure 4-22).



• **Figure 4-23** Model surgery for an asymmetric genioplasty. (Courtesy Nicholas Politano.)

Special Considerations

Edentulous Ridges

When a patient is partially or fully edentulous, maxillo-mandibular fixation can be a particular challenge, and the role of the assistant surgeon intraoperatively is especially critical. For fully edentulous patients, one solution is to fabricate Gunning splints with an Erich archbar incorporated into the buccal surface of the acrylic. The splints can be fixated to the jaws using skeletal wiring or screws. But intraoperative error can be introduced by over-compression of the soft tissues during application of the maxillo-mandibular fixation. These small errors can result in unintentional asymmetries, over-, or under-rotation of the occlusal plane, and inaccurate AP movements. Therefore, internal skeletal reference marks, "eye-balling" the final jaw position, and the surgeon's background knowledge of where the edentulous ridge should be in relation to the remaining skeleton, all can help the surgeon get "in the ballpark." Ultimately, dentures and possibly dental implants likely will dictate the patient's final occlusion and vertical dimension.[6]

Splints for partially edentulous patients also deserve careful consideration, especially when only the patient's anterior teeth are present. The acrylic of the splint should fully engage the lingual and occlusal/incisal aspects of the remaining teeth in the arch, where lingual holes can be utilized to secure the splint with circumdental wires. Erich archbars should be incorporated into the buccal portion of the edentulous areas of the acrylic splint to allow for adequate maxillo-mandibular fixation. The circumdental wires will help prevent movement of the splints and jaws during the application of the rigid fixation. Although an acceptable occlusion may be achieved, inattention to these critical details may result in inaccurate positioning with a poor skeletal relationship.[6]

Genioplasty

When a genioplasty move is not straightforward (i.e., asymmetric jaw), model surgery can be used to assess the effects of the maxillary and mandibular movements on the chin point. The distance between the patient's lower incisal edge (L1) to soft tissue menton should be measured clinically at the time of data collection. A repositioned maxillary cast is mounted against an unmoved mandibular cast on a semi-adjustable articulator. A vertical reference line through the maxillary dental midline should then be marked on the maxillary and mandibular casts. An approximated soft tissue menton point is then marked on the mandibular cast along this vertical line using the previously measured L1 to soft tissue menton distance. A horizontal line is then drawn on the cast at the level of the approximated soft tissue menton point, and the base is cut along this mark. The mandibular cast is then placed into final occlusion using the final splint. With the vertical pin of the articulator set to zero, the mandibular cast is then resecured to the baseplate with a hot glue gun or sticky wax. The vertical reference line from the baseplate is then continued onto the mandibular cast. The distance between the original vertical reference line to the new vertical reference line estimates the effects of the maxillary and mandibular movements on the soft tissue menton. This distance can assist in planning the genioplasty move (Figure 4-23).



• **Figure 4-24** Virtual model surgery. The maxilla has more detail due to the iTero scanning of the teeth directly, whereas the mandible shows less detail from scanning the casts of the teeth. (2017 © Materialise, All Rights Reserved.)

Summary

Presurgical model surgery allows for precise surgical planning of complex three-dimensional movements of the maxilla and mandible for orthognathic surgery. Since Edward Angle II suggested the use of plaster models and fabrication of vulcanite or metal splints in 1898, model surgery has gradually evolved with advances in technology and dental materials. The advent of the semi-adjustable articulator, facebow, Erickson Model Table, acrylic, PVS, and various dental stones, all have led to improvements in accuracy and precision of model surgery.

Perhaps the greatest advancement in recent years has been the introduction of virtual surgical planning. Both popularization of CBCT and improvements in computer technology and 3D printing have made the role of virtual surgical planning increasingly apparent. Anatomic data from a CBCT in combination with digital dental impressions or data from scanned dental casts can be used to create virtual 3D models. This digital process minimizes possible error that may be introduced with traditional facebow transfer and mounting, which especially may be instrumental in asymmetric patients. With the assistance of a computer engineer, model surgery can be performed virtually and surgical guides can be computer manufactured. Visualization of the movements on the screen allows the surgeon to better anticipate and prevent adverse sequelae, such as revealing the need for infracturing the proximal segment when over-torquing the condyle. Virtual surgical planning may increase the efficiency and accuracy of the presurgical workup, and eventually may replace traditional model surgery as we know it (Figure 4-24).

References

1. Hullihen SP: Case of elongation of the under jaw and distortion of the face and neck, caused by a burn, successfully treated, *Am J Dent Sci* 9:157–165, 1849.
2. Angle EH: Double resection for treatment of mandibular protrusion, *Dental Cosmos* 45:268–274, 1903.
3. Posnick J: *Principles & practice of orthognathic surgery*, ed 1, St Louis, 2013, Elsevier Saunders.
4. Wolford L, Stevao E, Alexander CM, Goncalves JR: *Peterson's principles of oral and maxillofacial surgery*, ed 3, Shelton, CT, 2011, People's Medical Publishing House.
5. Proffit WR, Fields HW, Sarver DM: *Contemporary orthodontics*, ed 5, St Louis, 2013, Elsevier Mosby.
6. Ruvo A, Scully R, Vandersea B: Model surgery. Oral and maxillofacial surgery, ed 2, vol. 3. St Louis, 2009, Elsevier Saunders.
7. Cottrell D, Wolford L: Altered orthognathic surgical sequencing and a modified approach to model surgery, *JOMS* 52(10):1010–1020, 1994.

5

Common Mandibular Ramus Osteotomies: Sagittal Split Ramus Osteotomy and Intraoral Vertical Ramus Osteotomy

NICHOLAS A. MEDEL, DOUGLAS P. SINN

Historical Background

The earliest performed mandibular ramus osteotomies[1,2] at the turn of the last century seemed to be modifications of Simon Hullihen's original reports of mandibular setback with various body osteotomies.[3] Although landmark in nature, these operations had their shortcomings; they were approached extraorally, and addressed mandibular prognathism only via setting the mandible back. Nearly 50 years later in Austria, Hugo Obwegeser pioneered the first mandibular ramus osteotomy that was not only approached intraorally, but also could shorten and lengthen the mandible.[4]

Obwegeser had observed sagittal traumatic fractures of the mandible, and then performed sagittal splitting of the mandibular ramus on cadavers. While training with Professor Richard Trauner, at the department of surgery, at the Medical University of Graz, Austria in 1953, Obwegeser executed the first sagittal split ramus osteotomy. Obwegeser did so on one side of a patient whose contralateral mandibular ramus was cut by Dr. Trauner via a combined intra-orally and extra-orally approached L-shaped osteotomy. The sagittal split ramus osteotomy was subsequently published internationally by Obwegeser in 1957 (Figure 5-1, *A*).[5] Today, the bilateral sagittal split ramus osteotomy (SSRO) is one of the most frequently utilized osteotomies to correct mandibular prognathism, retrognathia, and asymmetries.

Two modifications to the sagittal split ramus osteotomy were eventually implemented. Giorgio Dal Pont, while visiting Obwegeser in Zurich, experimentally designed a modification in an effort to create more osseous contacting surface area of the split segments to enhance bony union and allow for increased advancement of the distal segment (see Figure 5-1, *B*). He altered the horizontal orientation of the lateral corticotomy of the ascending ramus to a vertically oriented lateral corticotomy of the mandibular body.[6] Obwegeser found this modification possible and indeed likely beneficial after performing it on a patient. Dal Pont returned to his home in Italy in 1958 to independently publish his results on jaw models and cadavers, omitting a description of the clinical execution of the modification by Dr. Obwegeser.[7-9]

A second modification of Obwegeser's osteotomy later evolved.[10,11] Hunsuck and Epker found that an incomplete lingual osteotomy extending just beyond the neurovascular bundle simplified splitting of the medial ramus compared with the original full-length lingual osteotomy carried to the posterior border, which was at times difficult and could propagate unfavorable splits. The Hunsuck modification employs an incomplete extension of the lingual cut (see Figure 5-1, *C*), resulting in a favorable incomplete fracture along the medial ramus. Splitting the ramus in this fashion left more muscular attachment on the proximal segment, freeing up the distal segment for positioning. Despite less bony contact with an incomplete fracture of the medial ramus, the sagittal split ramus osteotomy (SSRO) in combination with the compensating Dal Pont modification remains the workhorse ramus osteotomy of today.

For the next couple of decades after the birth of the SSRO, fixation was achieved with a combination of

intermaxillary fixation (IMF) for a considerable amount of time and wire stabilization of bony segments. Although wire osteosynthesis of segments was occurring, surgeons sought greater stability, improved bony union, and avoidance of long periods of IMF. Stable compression osteosynthesis with steel bone screws for the SSRO, introduced in 1974 by B. Spiessl from Switzerland,[12] brought about a major breakthrough and began to replace osteosynthesis by wire fixation and/or intermaxillary fixation. Immediate postoperative stability improved, and for many, obviated the need for IMF. Spiessl's steel screws utilized a lag screw technique, and many surgeons realized the technique's inherent technical challenge to prevent condylar dislocation and resultant malocclusion from torsion occurring at SSRO lag sites.

Soon thereafter, some surgeons began utilizing a "bicortical" (non-lag screw) fixation technique to eliminate torqueing of the proximal segment of the SSRO. Lindorf and Niederdellmann and colleagues described this technique, now known as "positional screws."[13,14]

Around the same time, other major developments were taking place. Hans Luhr, often credited as the first to apply maxillofacial compression osteosynthesis in humans with his Vitallium fixation set,[15] set forth miniplate applications in maxillofacial trauma,[16] Le Fort I osteotomies and the SSRO. Maxime Champy was utilizing steel miniplates for mandible fractures and Le Fort I osteotomies.[17,18] Francois Michelet's report in 1971 out of France documents using miniplate fixation of Obwegeser's sagittal split osteotomy.[19]

Throughout the 1980s, fixation hardware continued to improve and took hold throughout the world. Titanium replaced other metal alloys and steel with its far superior biologic compatibility. Plates and screw size profiles decreased, enabling easier anatomic contouring. Although still widely used today in orthognathic surgery, titanium fixation components and their permanent nature can at times illustrate some inherent material imperfections. The risk of infection or rejection of titanium is low, but sometimes requires retrieval from the human body. There are other proposed drawbacks to titanium such as growth restriction, palpability, scatter formation with future imaging, and interference in radiation therapy.

The quest for an ideal fixation material has expanded into the realm of bioresorbable materials. Poly-alpha-hydroxy acids (copolymers of polylactide and polyglycolide), first proposed for the repair of bone fractures in the late 1960s,[20] are now available in the form of small plates and screws and manufacturers claim sufficient stability until hydrolytic resorption at 12 weeks. Researchers began reporting use of bioresorbables in orthognathic surgery around the turn of the twentieth century.[21-23] Turvey and colleagues subsequently published their findings in 2006 with bioresorbable screw fixation: similar stability

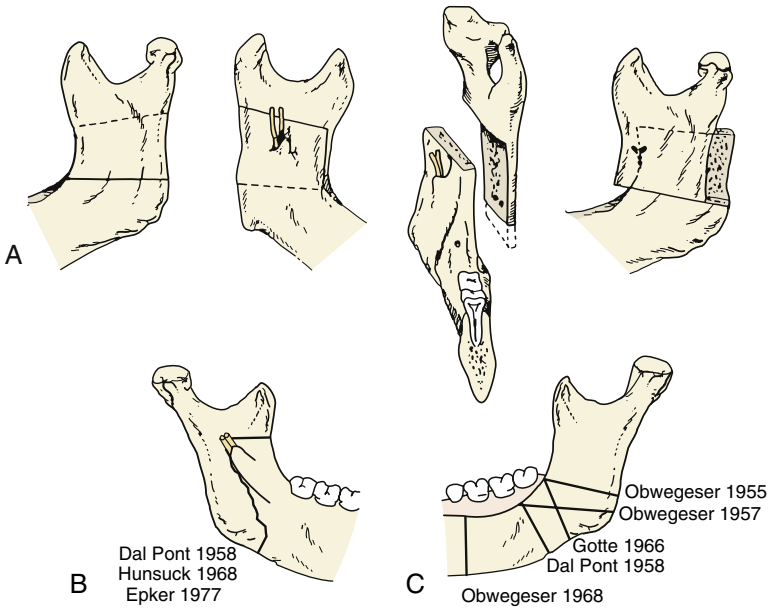

• **Figure 5-1** **A,** Obwegeser's technique of intraoral sagittal split osteotomy. The cut at the outer cortex ends at the gonial angle, which allows rotation, but not large advancements. **B,** The Dal Pont technique sets the cut at the horizontal ramus farther forward, which allows advancements up to 15 mm. **C,** Hunsuck showed a technique whereby the cut at the inner cortex of the ascending ramus ends immediately behind the entrance to the neurovascular bundle. Muscles of mastication stay attached to the proximal segment. Positioning of the condyle into the fossa during fixation is easier. (**A,** From Obwegeser HL: *Mandibular growth anomalies,* Berlin, 2001, Springer, Fig 80c, p 360; **B,** from Obwegeser HL: *Mandibular growth anomalies*, Berlin, 2001, Springer, Fig 85d, p 372; **C,** from Obwegeser HL: *Mandibular growth anomalies*, Berlin, 2001, Springer, Fig 85b, p 372.)

at one year compared to traditional titanium screw fixation for mandibular advancement via bilateral sagittal split ramus osteotomies.[24] Currently, titanium hardware remains the most widely used fixation method in orthognathic surgery.

Another intraoral mandibular ramus osteotomy, later to be known as the intraoral vertical ramus osteotomy or IVRO, was described by Moose in 1964.[25] This particular ramus osteotomy seemed to originate from Limberg's original extraoral subcondylar osteotomy,[26] and was used to set the mandible back in cases of mandibular prognathism. Moose's technique differed from the subcondylar osteotomy in using an intraoral approach from the medial side of the mandible and incorporated a vertical rather than a more horizontal/oblique ramus cut. The osteotomy coursed from the sigmoid notch, just behind the mandibular foramen, to the inferior border of the mandible. Winstanley modified the IVRO with his lateral approach in 1968,[27] and in 1970 Herbert and colleagues introduced the currently employed method of cutting the mandible from the lateral side with an oscillating saw. In comparison with the SSRO, surgeons predictably achieved osteosynthesis after the IVRO with the use of IMF. Initially, efforts were made to fixate both segments of the IVRO with wires or screws, and researchers advocated favorable bony union with rigid fixation.[28-30] Surgeons, however, began to notice successful bony union occurring through cortical overlapping of the segments, without intersegment fixation, but with early allowance of mandibular movement after a 2-week period of IMF,[31,32] and a replicated study on adult dogs found the same.[33]

Description and Indications for Bilateral Sagittal Split Ramus Osteotomy

Since its introduction in 1956, the bilateral sagittal split ramus osteotomy has become the most widely used ramus osteotomy for correction of mandibular growth discrepancies. It has been modified in many ways to optimize its numerous benefits and advantages (Box 5-1), which have been well demonstrated over the last 50 years. Obwegeser's original osteotomy design in combination with the various modifications now commonly incorporated make the sagittal split ramus osteotomy especially effective for surgical correction of nearly all mandibular deformities.

The versatility of the procedure stems from its wide application in either mandibular advancement, setback, and asymmetry correction. Compared to dental movements achieved through orthodontic treatment alone, it tremendously increases the range of possible movements as demonstrated by Proffit's envelope of discrepancy.[34] Furthermore, the broad surface area of bony overlap created along the sagittal osteotomy allows not only advancement or setback of the distal tooth-baring mandible, but also rotations. Large anterior and posterior movements still result in excellent healing secondary to the broad bony interfaces. The pterygomandibular sling stays attached to the proximal segment at the gonial angle. With rigid fixation from an intraoral approach, little detachment of the musculature is necessary. This technique results in very little muscle traction, offering protection against long-term relapse. Because these muscles of mastication stay attached to bone, it is easier to position the condyle during fixation of the segments. Correct positioning of the condyle is required to prevent postoperative arthropathy and possible malocclusion as the condyle returns to a more centric position in the fossa. Over the years, its repeated application has made the surgical procedure itself quite standardized, helping to minimize the risk of complications and shorten operating time (Case Study 5-1 to 5-4).

• BOX 5-1 Characteristics and Advantages of BSSO

Great three-dimensional flexibility in repositioning the distal fragments
which allows accurate intraoperative positioning of the fragments
Broad bony overlap of osteotomized segments
which results in excellent healing
Minimal alteration of the natural position of muscles of mastication
which prevents relapse from muscular traction
Minimal alteration of the original position of the temporomandibular joint
which minimizes the risk of postoperative athropathy
Short operating time and low complication rate

Limitations of the Sagittal Split Ramus Osteotomy

Without question, the SSRO is the most commonly selected ramus osteotomy for a vast list of mandibular growth discrepancies, mainly because there are very few limitations to the surgical procedure itself. Large mandibular setbacks of the mandible can produce amounts of bony interference removal found to be cumbersome by some surgeons, especially in cases where the mandibular rami are significantly laterally flared, producing a triangular or "V-shaped" mandible. With the aid of virtual surgical planning, one can know preoperatively the exact dimensions and location of the bony interference to be removed, decreasing intraoperative time spent doing so. A concern with large setbacks approaching a centimeter is the risk of iatrogenically induced obstructive sleep apnea in certain patients such as overweight males. In some cases of severe mandibular hypoplasia (i.e., when the ramus is rendered so thin that little marrow space is left for sagittal splitting) surgeons have opted for other ramus osteotomies. The extremes of mandibular advancement, especially with concurrent counterclockwise rotation, can significantly

CASE STUDY 5-1

Mandibular Deficiency With Normal Face Height

R.J. was referred for orthodontic treatment at age 12. She presented with class II malocclusion and severe crowding in the lower arch. She wanted her teeth fixed and hadn't liked her teeth for as long as she could remember (Figures 5-2, 5-3, 5-4).

Oral health was good, and some bone loss was evident at the right medial lower incisor. R.J. had some clicking in the right joint and occasional pain.

On clinical examination of her face, AP mandibular deficiency was noted. Combined orthodontic-surgical treatment was suggested. Her parents believed she was too young for surgery at this point. Because of the joint pain, splint therapy was suggested. Orthodontic treatment was started when R.J. was 15 years old. Cephalometric analysis confirmed AP mandibular deficiency. At that time, bone loss at both of the medial lower incisors had worsened.

The treatment plan was as follows: To align the crowded lower arch, the left lower medial incisor had to be extracted; because some bone loss was apparent and all other teeth were in good health without caries, bilateral sagittal split osteotomy (BSSO) to advance the mandible was recommended.



• **Figure 5-2** The patient at age 12. Facial view shows her lower lip everted. At rest, she shows 4-mm lip incompetence. The lower dental arch is severely crowded.

Continued

Mandibular Deficiency With Normal Face Height



• **Figure 5-3** **A-C,** The patient at age 16 after orthodontic stabilization of the dental arches. Facial view shows the lower lip everted with a deep sublabial fold. The profile is convex. **D** and **E,** The teeth are well aligned, overjet is 9 mm and overbite 4 mm. The patient shows 3 mm of upper incisor at rest. The lower arch has only three incisors after extraction of the left medial incisor and the remaining right incisor with some bone loss. **F,** Lateral cephalometric radiograph confirms the anterior-posterior (AP) mandibular deficiency.

Mandibular Deficiency With Normal Face Height



• **Figure 5-4** At 3-year recall, the patient presents with good balance of the facial thirds and relaxed lips. She is very satisfied with the outcome. She thinks that her quality of life has improved; she likes her teeth and her profile and has no difficulty eating all kinds of food. Both the temporomandibular joint (TMJ) clicking and the pain that she experienced prior to treatment have disappeared.

CASE STUDY 5-2

Mandibular Deficiency With Short Face

This 25-year-old patient was seeking orthodontic treatment because of a deep bite that caused inflammation lingual to the maxillary teeth (Figures 5-5 and 5-6). He had some facial esthetic concern because of the strong chin button, but this was not his main reason for seeking orthodontic treatment.

The patient had difficulty with chewing and pain because of the inflammation, which had increased in intensity and duration over previous months.

On clinical examination, the periodontal condition was good except for severe inflammation lingual to the maxillary incisors.





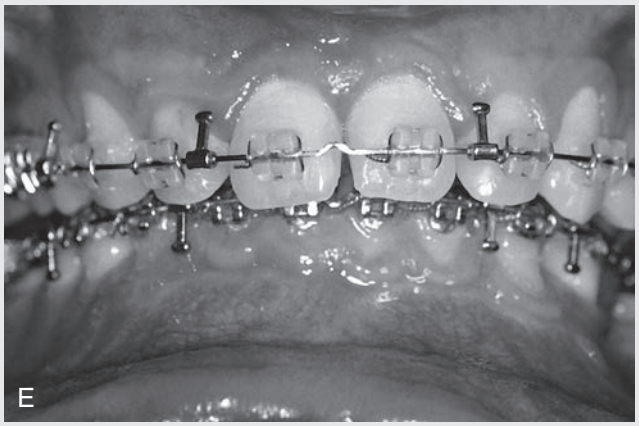

• **Figure 5-5** **A-C,** Facial examination shows reduced lower face height and anterior-posterior (AP) mandibular deficiency with a prominent chin button and a deep labiomental fold. **D,** Cephalometric radiograph confirms the AP deficiency of the mandible and the skeletal deep bite. The mandibular forward and upward rotation is obvious; the chin button seems higher than the gonial angle. **E,** The severe overbite "hides" the lower incisors.

CASE STUDY 5-2—cont'd

Mandibular Deficiency With Short Face

He had 10 mm overjet and 7 mm overbite. He had lost his left lower first molar because of caries, but oral health was good. Lower face height was short with a strong chin button, a retrusive lower lip, and an exaggerated labiomental fold. Cephalometric analysis showed AP mandibular deficiency and skeletal deep bite with the mandible rotated upward and forward.

The treatment plan was as follows: BSSO should be performed to advance the mandible and rotate the distal segment to increase the mandibular plane angle and correct the deep bite, followed by inferior border osteotomy to further increase lower face height.

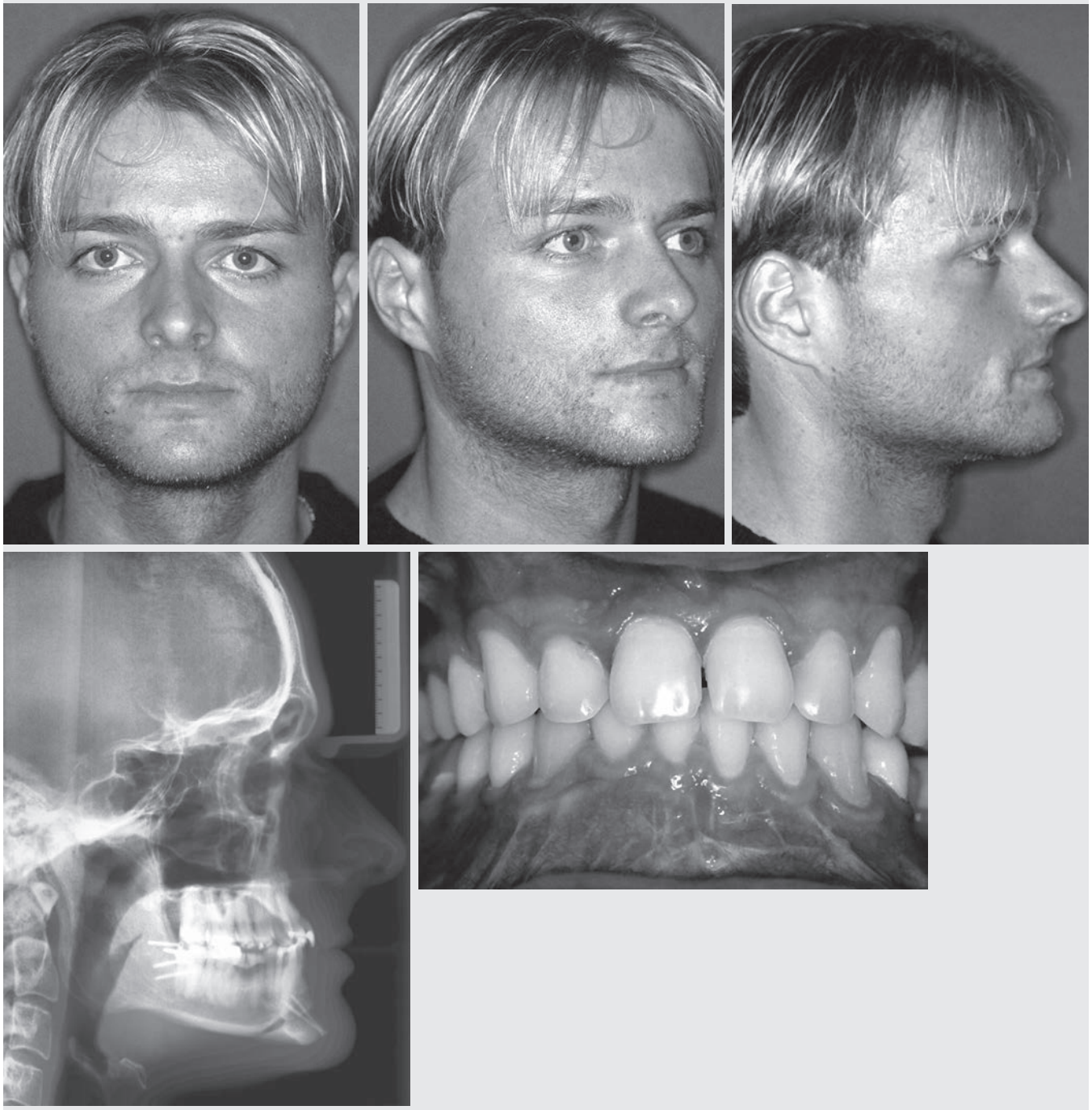

• **Figure 5-6** On 2-year recall, facial proportions and occlusal relationship had been maintained. Overbite and overjet remained ideal. The patient was very pleased with the outcome of the surgical treatment. Because facial esthetics was not an important aspect, advancement and downward rotation of the maxilla were not suggested.

CASE STUDY 5-3

Mandibular Deficiency With Long Face

This 24-year-old student was referred for combined surgical-orthodontic treatment. The patient's chief concerns were his deep bite and the fact that his teeth did not fit together properly. He found that his chin was a little deficient and that he had a "protrusive maxilla." He underwent orthodontic treatment when he was a child for about 3 years. He felt very uncomfortable with his profile, and chewing was difficult. Clinical examination showed a good nasolabial angle. The long face deformity was due to excessive length of the chin. Clicking was noted in both joints as was 9 mm overjet and 8 mm overbite; the dental midline was slightly off to the right side (Figures 5-7 and 5-8).

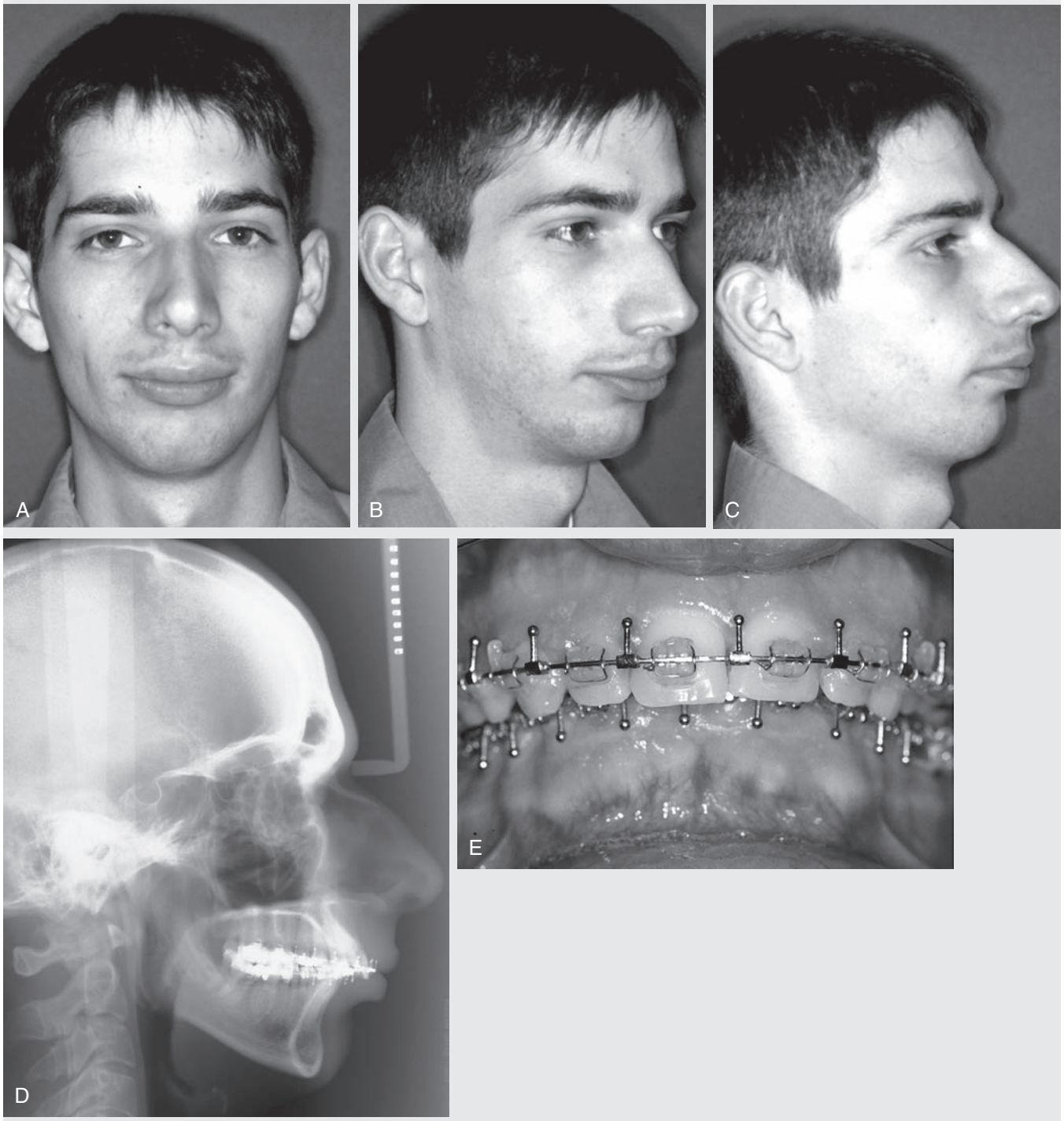

• **Figure 5-7** **A-C,** On frontal view, the lower face height appears long despite the deep bite. The lower lip is curled and fuller compared with the upper lip. On profile, the anterior-posterior (AP) mandibular deficiency is obvious. The nasolabial angle is good, and no maxillary protrusion is evident. The profile is convex, and the tip of the nose, lips, chin, and Adam's apple are on a straight line. Chin projection is markedly deficient. **D,** Cephalometric radiograph shows an exaggerated curve of Spee, a skeletal deep bite, retrogenia, and mandibular deficiency. **E,** Severely deep bite; teeth are well aligned after orthodontic treatment.

CASE STUDY 5-3—cont'd

Mandibular Deficiency With Long Face

The treatment plan for this patient included BSSO to correct the mandibular deficiency and rotation at the gonial angle to correct the deep bite. For correction of the retrogenia and reduction of increased anterior face height, an inferior border osteotomy was planned.

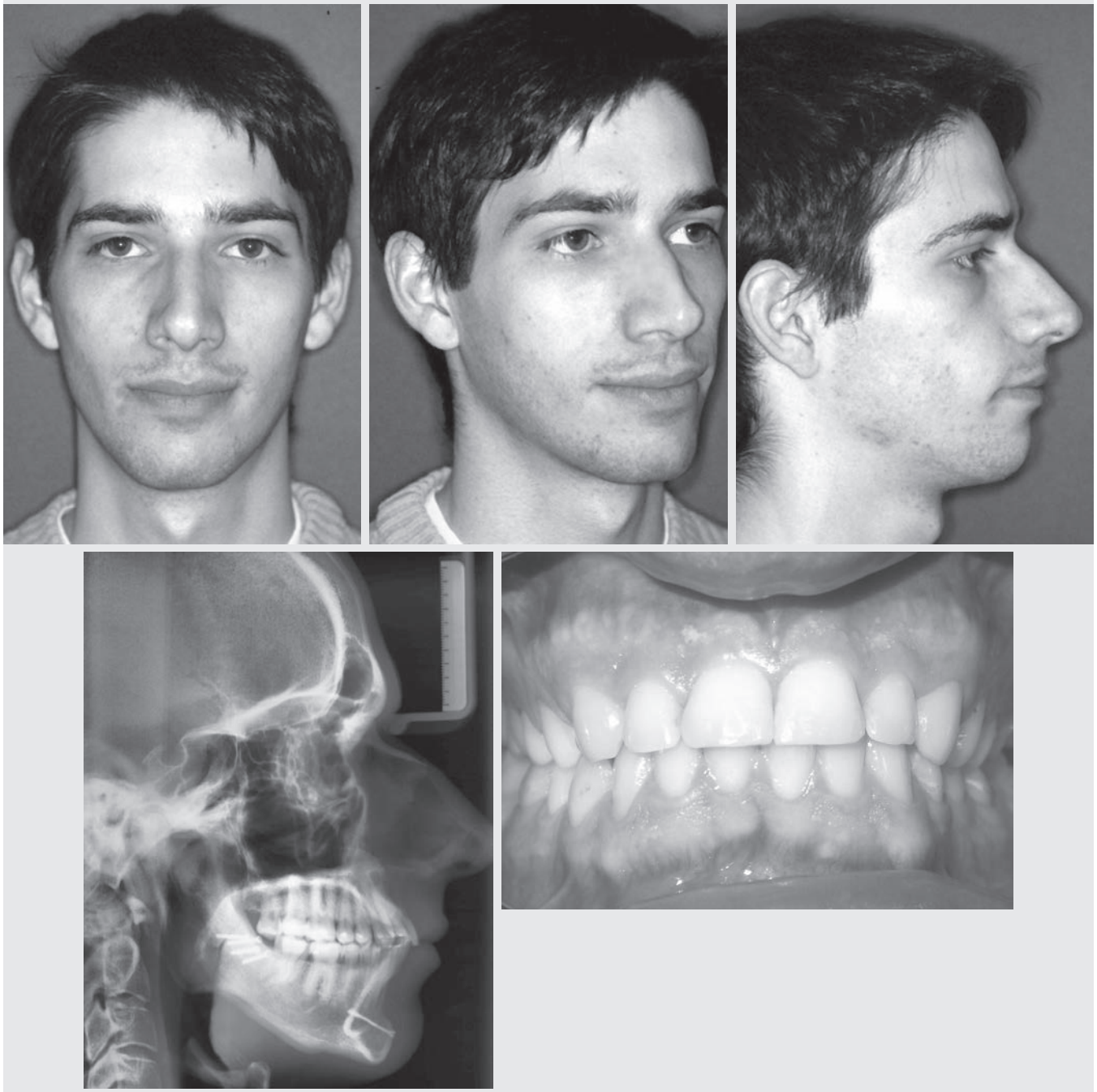

• **Figure 5-8** Two-year follow-up shows well-balanced facial proportions. Upper and lower lips are relaxed and have equal width. On profile, the anterior-posterior (AP) relationship has remained stable. The patient has a nice throat-chin relationship. His temporomandibular joints (TMJs) still click occasionally on maximum mouth opening, and he has slight deviation on maximum mouth opening to the right side. He is very pleased with esthetics and function.

CASE STUDY 5-4

Mandibular Asymmetry

G.G., age 27, was seeking surgical orthodontic treatment because of facial asymmetry. Clinical examination revealed deviation of the lower jaw to the left side (Figures 5-9 and 5-10). The chin was deviated 12 mm to the left, nonaffected side. The dental midline was deviated one and a half incisors to the left side. The patient said that this had started 2 years ago and had become worse since that time. He was very uncomfortable, and chewing was difficult; clicking of both TMJs had become worse. A control 99Tc scan performed prior to surgery showed no activity.

Treatment plan for this patient included BSSO to shift the mandible to the right side and a lower border osteotomy to reposition the chin.

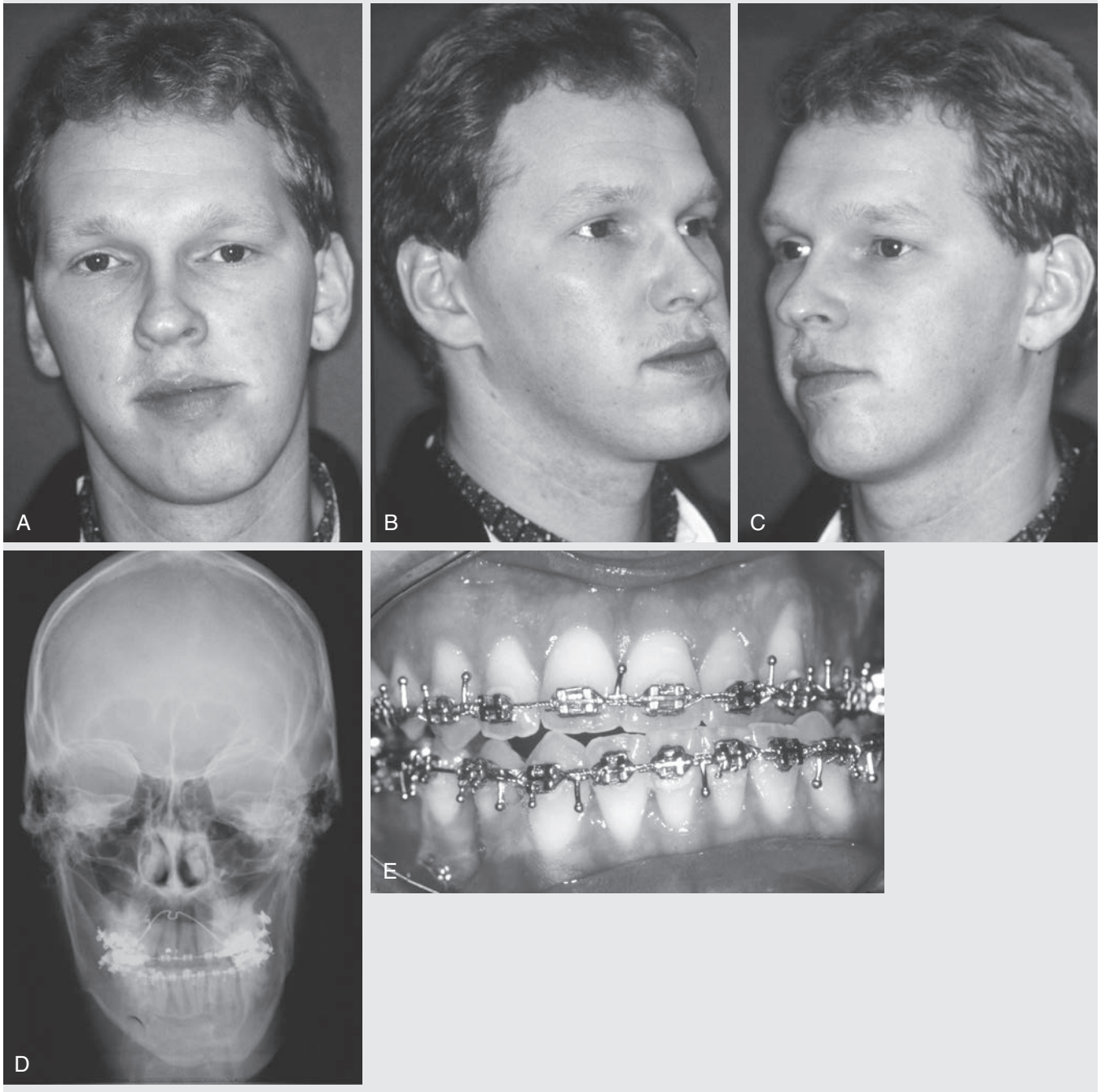

• **Figure 5-9** Hemimandibular elongation of the right mandible. **A-C,** Facial view shows severe deviation of the mandible to the left side. The chin is 12 mm to the left side. Half-profiles look completely different. **D,** Posterior-anterior (PA) cephalometric radiographs show severe asymmetry. **E,** Dental midline is shifted to the left side. The lower right canine is in contact with the upper right medial incisor.

CASE STUDY 5-4—cont'd

Mandibular Asymmetry



• **Figure 5-10** The patient 5 years following surgery. Facial proportions are well balanced. The right side of the face seems slightly more prominent, but the patient is very pleased with the functional and esthetic result. Occlusion remains stable, and dental midline is on.

reduce the amount of bone to bone contact for healing. In terms of postoperative incidence of neurosensory disturbance to the inferior alveolar nerve, the SSRO is thought to cause more than the IVRO,[35-40] although many surgeons find the impact on quality of life over the long term to be negligible.

Sagittal Split Ramus Osteotomy: Surgical Sequence

Soft Tissue Access

The soft tissue of the cheek is retracted with two Langenbeck hooks or Obwegeser toe-ins and a broad Austin retractor. At the level of the occlusal plane and 1 cm lateral, the incision begins at the anterior aspect of the ramus (Figure 5-11). The incision should be 2 cm long and course down the lateral crest of the external oblique ridge, ending in the buccal vestibule at approximately the first molar region. An incision extending too far superiorly, or failing to keep the soft tissues retracted laterally will expose buccal fat. After sharp dissection through mucosa, the buccinator muscle is positioned over the medial aspect of the ramus before incising through, to keep as much soft tissue as possible laterally. The incision is then completed through the periosteum down to bone.

Periosteal reflection is initiated laterally over the body of the mandible, extending to the inferior border just below the second molar, creating space for a channel retractor. It continues posteriorly over the anterior aspect of the ramus and then superiorly. Remaining in the subperiosteal plane with limited freeing of the temporalis muscle attachment over the ramus prevents bleeding and protects critical blood supply to the ramus. Dissection is carried up the ramus to a point where the temporalis fibers are visualized attaching into the coronoid process. At this level, the curved Kocher retractor is inserted deep enough to engage the coronoid process with the tips in the sigmoid notch. The lingula and mandibular foramen are then identified, usually at the same level with the greatest concavity of the anterior border of the ascending ramus. Next, when elevating the periosteum lingually it is essential to stay beneath the periosteum but above the mandibular foramen and the neurovascular bundle. Doing so will prevent bleeding and minimize damage to the neurovascular bundle. Once the periosteum has been reflected just beyond the lingual, the created tunnel should provide space for instrumentation to perform the medial cut without tension on the neurovascular bundle. The subperiosteal envelope created prior to initiating the osteotomy should allow sufficient visualization, but overzealous exposure of the mandible compromises blood supply and increases postoperative edema. A Hannihan retractor is placed medially to stretch the soft tissues to allow visualization of the lingula and the inferior alveolar nerve as it enters the mandible. In the event that you cannot visualize the lingula and the nerve, an abruptly curved freer elevator may assist in visualizing the nerve. The tip of a suction apparatus retracts soft tissue cranially. This allows protection of soft tissue during osteotomy while providing access and visualization (Figure 5-10).

Osteotomy

A horizontal bone cut through the medial cortex of the ascending ramus starts the osteotomy. The level of this cut should be at a point about 2 to 3 mm superior to the lingula. The cut extends from the anterior border of the ascending ramus to a point just posterosuperior to the lingula, staying parallel to the occlusal plane. In other words, the cut extends about 4 to 5 mm posterior to the lingula or two thirds of the anterior posterior dimension of the medial ramus. The depth of this cut at the anterior border of the ramus penetrates the medial cortex or about half way

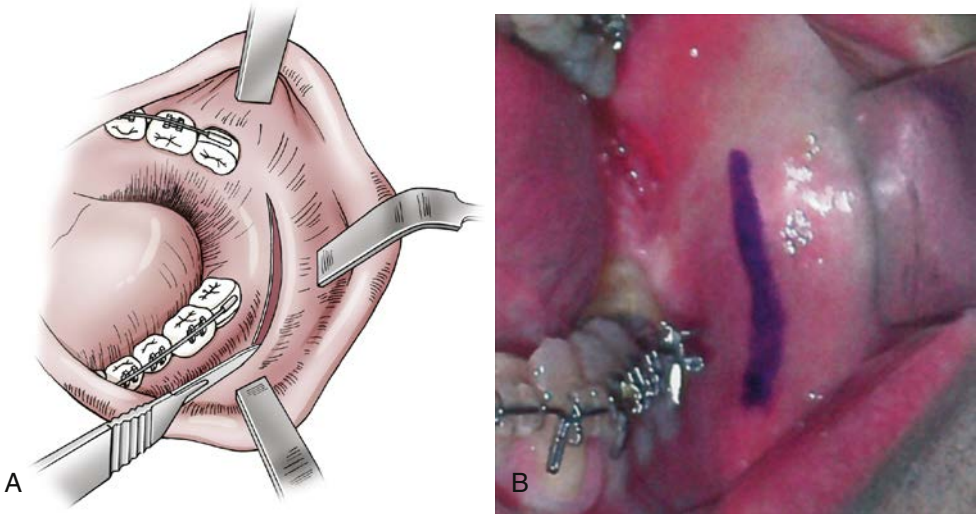

• **Figure 5-11** **A,** Soft tissue dissection for sagittal split osteotomy. **B,** Surgical status. (From Proffit WR, White RP Jr, Sarver DM: *Contemporary treatment of dentofacial deformity*, St Louis, 2003, Mosby.)

through the ramus if no cancellous space can be identified, which sometimes occurs. The depth is tapered shallower posteriorly as the saw blade or burr enters the concavity above and behind the lingula.

The anterior border of the ascending ramus may sometimes display a prominent bony shelf medially. This sometimes necessitates bone reduction with the use of a rotary instrument on the medial anterior ramus and the temporal crest to gain access to the medial ascending ramus before the cut is made, remaining only slightly into medullary bone (Figure 5-12, *A*). A longer rotating burr (Lindemann burr) or a 703 burr can suffice for this step. Many surgeons then prefer switching to a reciprocating saw to deepen the cut at the inner cortex of the ascending ramus to confirm slight penetration into the medullary bone and begin transition to the sagittal portion of the osteotomy (see Figure 5-12, *B* and *C*).

The sagittal portion of the osteotomy then proceeds down the ascending ramus, staying just inside the external oblique ridge, once again maintaining a depth of a single cortex to avoid trauma to the neurovasculature. This cut is carried inferiorly to the mesial area of the second molar where the vertical cut will be initiated. There is usually a prominence of cortical bone, sometimes referred to as a lateral bulge, adjacent to the second molars, offering protection from the underlying inferior alveolar nerve.

A channel retractor is placed at the inferior border and the vertical cut is extended superiorly from the inferior border through the buccal cortex connecting the aforementioned cuts. The inferior alveolar nerve is especially vulnerable at this point, requiring strict adherence to monocortical depth. This vertical cut should run perpendicular from the inferior border. The reciprocating saw can be held at a 45- to 60- degree angle (rather than at a right angle) to the surface of the bone to further minimize risk of damage to the inferior alveolar nerve and providing a channel for upcoming osteotome placement.

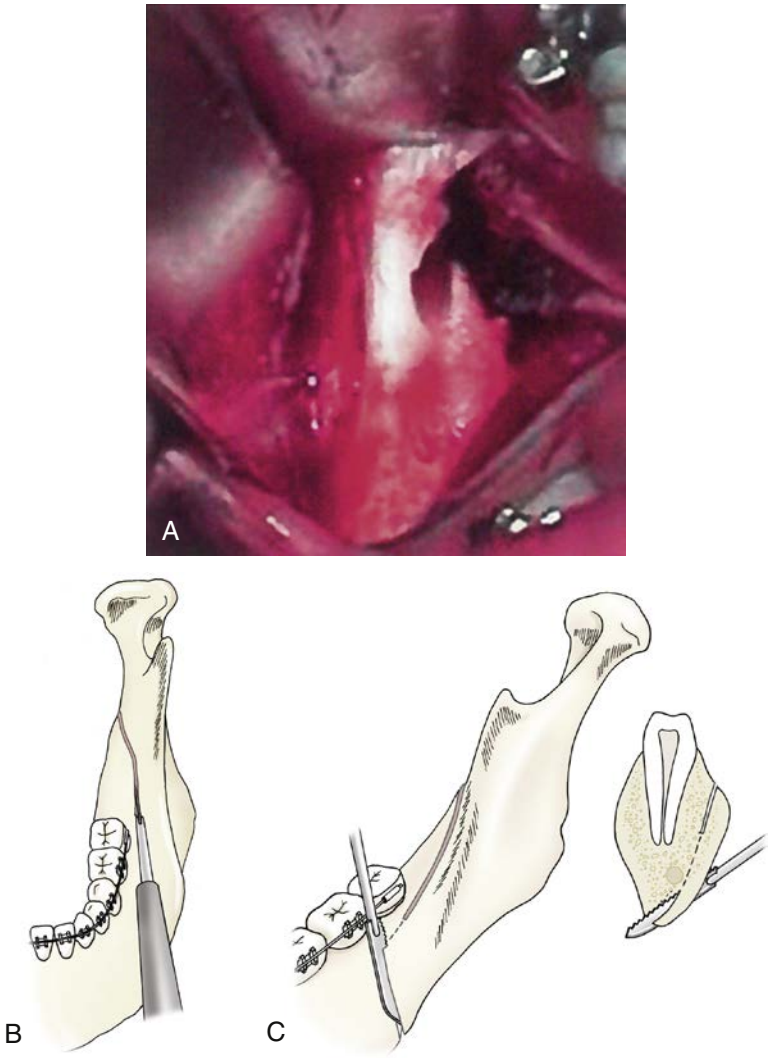

• **Figure 5-12** Osteotomy at the inner cortex of the ascending ramus. **A,** Soft tissue is protected by suction tip and freer elevator. Surgical status. **B,** The cut with a long rotating burr through the medial cortical bone of the ramus. **C,** The osteotomy is extended into medullary bone with a reciprocating saw. (From Proffit WR, White RP Jr, Sarver DM: *Contemporary treatment of dentofacial deformity*, St Louis, 2003, Mosby.)



• **Figure 5-13** Large handle osteotome seen propagating the sagittal split along the inferior border while the Smith spreader is used for superior access.

To further define the osteotomy, a fine 6-mm spatula or Epker osteotome is used starting at the medial cut of the inner cortex of the ascending ramus to begin the splitting of the buccal from the lingual cortex. The osteotome is then worked down the anterior border of the ramus and follows the osteotomy cut along the body of the ramus to the inferior border of the mandible. The osteotome should penetrate just beneath the cortical plate in a meticulous fashion to avoid damage to the inferior alveolar nerve. Next, some surgeons prefer to further define the osteotomy with an Epker osteotome prior to finalizing the split. A large-handled, flat cutting osteotome is then used to propagate the inferior split along the inferior border of the mandible. This can easily be done while holding a Smith sagittal spreader at the superior access of the split (Figure 5-13). Next, opening pressure is applied to stabilize the superior aspect while advancing the osteotome through the inferior border.

As the mandible splits, an eye is kept on the inferior alveolar nerve and along the ramus looking for any splintering buccal or lingual plate fractures. Ideally, the inferior alveolar neurovascular bundle should separate from the proximal segment and be allowed to fall medially. A freer elevator can be used to assist in gently teasing the bundle from the proximal segment. Occasionally, the bony nerve canal remains within the proximal segment. In this case, a small 4 mm straight or curved chisel can be used to separate it from the proximal segment. Once the neurovascular bundle has been freed from the proximal segment, the osteotome can be used in a more vigorous manner to guide the separation posterosuperiorly along the ramus on the desired course of the osteotomy. To ensure split completion, a Kocher is placed on the distal segment just anterior to the vertical cut and mobilized while holding the proximal segment seated in the fossa with a wire director. At this point it is helpful to mobilize the proximal segment posteriorly to stretch the muscular sling. This is especially important in large advancements. The medial pterygoid muscle is then stripped from the inferior border of the distal segment to reduce the relapse and allow the mandible to passively move forward. In large posterior movements the medial pterygoid should also be stripped from the proximal segment to prevent movement posteriorly.

Any sharp projections along the course of the inferior alveolar nerve are smoothed prior to fixation. For a planned setback or asymmetry case, bone along the anterior aspect of the vertical cut of the proximal segment is reduced to allow passive segment approximation during fixation (Box 5-2).

• BOX 5-2 Osteotomy Precautions

Vertical cut between first and second molars, curving to the inferior border
Exact cuts through cortical bone only
Identification of course of neurovascular bundle prior to separation with fiber handle osetotome
Removal of all bony interferences before osteosynthesis

Osteosynthesis

Upon completion of splitting the mandible bilaterally, IMF is secured using a prefabricated interocclusal acrylic wafer splint. Good condylar position is established by gently positioning the proximal segment into the fossa with the use of a ramus pusher, a wire director, or a periosteal elevator. Once this is done, the proximal and distal segments should align passively and with little to no step at the inferior border. At this point, a modified Allis clamp can be applied to the ramus engaging both segments of bone to hold them while applying rigid fixation (Figure 5-14). If bony interferences exist along the osteotomy (usually along the vertical portion), a burr of choice can be used to recontour the proximal segment.

Historically, osteosynthesis was achieved with either upper border wire, lower border wire, or circum-ramus body wire. This is currently hard to justify for use on a routine basis owing to its requirement for MMF for weeks following surgery. Bicortical position, lag screws, plates with monocortical screws, as well as resorbable screws are used to fixate the two segments.

Osteosynthesis With Screws

Screw fixation with either a lag or position screw technique can be accomplished either intraorally or very simply from an extraoral approach with a trocar. Stabilization usually is achieved with three bicortical screws. The screw pattern is usually either three screws at the superior border or two screws at the superior border and one at the inferior border (inverted L pattern). Screws may be placed as position (bicortical) or lag screws. Lag screws may be indicated only



• **Figure 5-14** Modified Allis clamp which can be used to stabilize both the proximal and distal segments during fixation.

when passive bone contact without any tension exists as they have been known to torque the condyle laterally upon tightening.

For placement of a commonly used 2.0-mm screw, a 1.5-mm drill hole is passed through the proximal and distal segments. This is often done using a standard trocar technique. The two segments must remain aligned and are held together as the first hole is drilled with a 1.5-mm wire-passing burr. Good retraction of the lingual tissues is necessary at this point to visualize the proximal and distal segments lined up as you pass the burr through them. Next, a 2-mm self-tapping screw engages both segments of cortical bone. It is essential that the pilot screw is placed at a point of overlapping bone contact between segments, avoiding the inferior alveolar nerve and roots of the second molar, and keeping the condyle in a passively seated position within the fossa. Figure 5-15 illustrates this positioning between the distal and proximal segments. Stability can be confirmed by gently attempting to pry apart the two bony segments with a periosteal elevator.

Proponents of the lag-screw technique like the excellent bone-to-bone contact it provides. Placing screws in a lag fashion, such that screw threads engage the lingual cortex only while the screw head alone compresses the buccal cortex, can easily precipitate lateral displacement of the condyle if the bony fragments are not in absolute passive contact. Lag screws are available in different sizes (2 mm, 2.3 mm, 2.4 mm). To place a 2-mm diameter lag screw, a 2-mm wire-passing burr is used to make an initial hole into the proximal condylar segment, followed by passing a 1.5-mm wire-passing burr through the distal segment. A depth gauge is then used to measure the length drilled and the hole with a smaller diameter has to be tapped with a special tapping device. The lag screw can then be placed. It is possible to use a combination of lag and positional screws in certain scenarios.

Osteosynthesis with Miniplates

Fixation may be achieved by bridging the osteotomy gap with a bone plate. A 4-hole bone plate with two screws on each side of the cut is sufficient for stable fixation and is often employed. Nonlocking monocortical screws provide adequate stability. An added benefit of plate fixation is its ability to be secured without extraoral trocar access. We prefer a single 2.0-mm semi-rigid 4-hole plate at the mid-body region as shown in Figure 5-16 and have found it to provide adequate stability. A single low-profile malleable plate with 1.8-mm diameter does not bear enough load for function. Therefore, when using nonrigid plates for fixation, we recommend a second plate or position screws to provide additional stability.

Osteosynthesis With Resorbable Fixation Screws

The use of biologically inert resorbable screws eliminates the possible need for a second operation to remove fixation material. Although the incidence of infection of titanium implants overall is very low, there are still times when titanium hardware must be removed due to infection, biofilm formation, hardware loosening, and, rarely, palpability.

To accomplish stabilization with resorbable screws, proponents of the technique have recommended using four screws per osteotomy site. If bony contact on the superior border is sufficient for placement of three screws, the fourth screw is inserted at the inferior border. The two screws at the inferior border of the mandible then are placed through a transoral technique, as described earlier. Typically, an appropriate trocar that can accommodate a long-shank drill is placed through an extraoral approach. The length of the required screw is measured with a depth gauge; a screw tap and a screwdriver are used to set the screw through the trocar.

Resorbable materials such as polyglycolic acid, polylactic acid, and polyester polyparadioxanon are organic macromolecular compounds that are degraded and absorbed by the body. These compounds do possess enough rigidity, tensile strength, and flex strength for use as internal fixation devices in orthognathic surgery. Manufacturers claim that about 70% of the material in resorbable implants remains in situ for about 3 months prior to degradation, affording the aforementioned properties to provide stability.

The rate of degradation appears to be dependent on several factors: molecular weight, crystallinity, and the thermal history and geometry of the resorbable implant. This

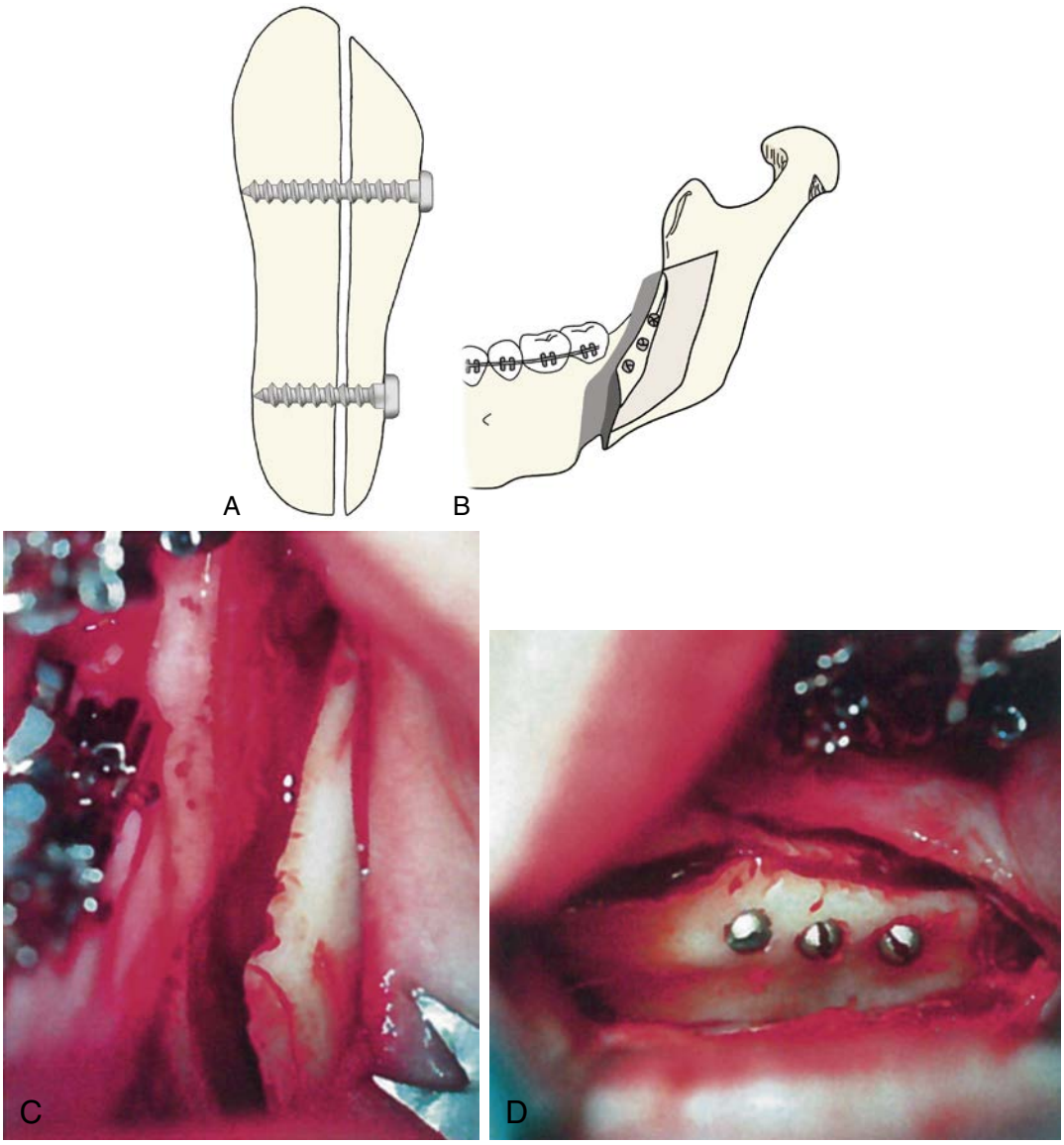

• **Figure 5-15** **A,** Position screw technique allows proper position of the proximal segment, without torque of the condyle; interbony gap is maintained. **B,** Osteosynthesis with screws. **C,** The cut is completed. **D,** Three position screws in place. (**A,** From Proffit WR, White RP Jr, Sarver DM: *Contemporary treatment of dentofacial deformity*, St Louis, 2003, Mosby.)

means that the bulk of a resorbable screw donates prolonged degradation in contrast to a thin porous sheet that dissolves much more rapidly. Degradation occurs mainly as a result of hydrolytic activity and, to a lesser extent, via nonspecific enzymatic reactions. It has been shown that these polymers are completely absorbable within bony tissue, and that new bone is deposited on and within the implants as degradation proceeds.[41] The principal route of elimination after degradation is respiration, in the form of CO_2 and H_20. Excretion through the urine and feces plays a minor role.

Inflammatory foreign body reactions have been cited as one of the few major potential problems with resorbable screws. Recurring episodes of soft tissue swelling around implantation sites and, in rare cases, draining fistulas have been observed.[42] Clinical reports speculate that these problems may secondary to the delayed resorption rate of the polymer.[43]

Commercially available materials include pure polyglycolic acid (PGA) in the form of screws and pins, pure poly-L-lactic acid (PLLA), and a co-polymer of PLLA and PGA. The latter has been found to be most appropriate for stabilization in orthognathic surgery, as it represents a combination of the best physical and chemical properties of PLLA and PGA. It is likely that these co-polymers maintain most of their strength for 8 weeks, and that they will be completely resorbed within 12-15 months. Few complications have been reported so far when these co-polymers were used.

Prior to closure of the osteotomy site, the surgeon must confirm desired occlusion. Although some surgeons prefer to keep the patient in MMF for a 2-3 week period in cases incorporating large movements and/or

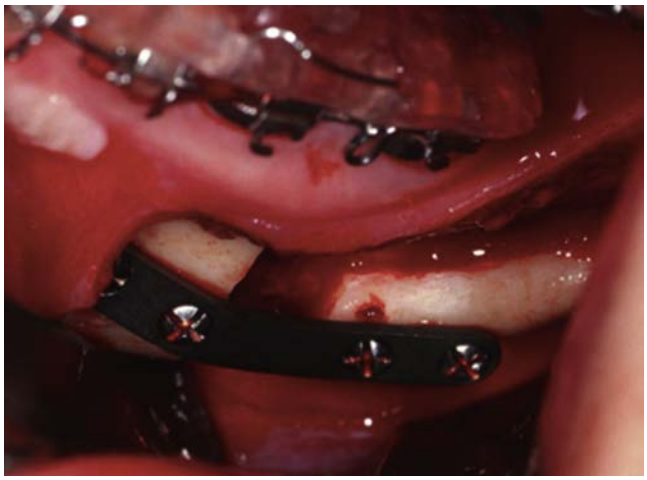

• **Figure 5-16** The author's preference for fixation of the sagittal split ramus osteotomy as seen here; 2.0-mm semi-rigid 4-hole plate at the mid-body region.

highly unstable movements, MMF is routinely released and the occlusion is examined. Mouth opening, left and right excursive movements, and protrusive movements are then evaluated. Doing so also helps confirm appropriate condyle position within the fossa. Any resistance to full range of motion, clicks, or occlusal discrepancies require removal of the fixation, repositioning, and revision of fixation.

The wounds are then irrigated copiously with saline, and hemostasis is confirmed. For wound closure, we recommend closing mucosa primarily with a 3-0 resorbable chromic gut suture in a running locking horizontal mattress suture technique. The mucosa and submucosal tissue are closed to reapproximate and evert some of the deeper tissue to reduce the possibility of wound dehiscence (Box 5-3).

SSRO Complications

Despite the routine nature of the SSRO for most oral and maxillofacial surgeons, a wide range of complications exists. Their overall frequency and severity are rather low, with death being very rare and inferior alveolar neurosensory disturbance being the most common.[44-46] Most complications, such as unanticipated bony splits, can be corrected sufficiently intraoperatively. Others, such as neurosensory disturbances, may be immediately repaired or may necessitate postoperative therapeutic interventions. Maintaining an engaging attitude at the preoperative consultation to educate patients thoroughly regarding the perioperative risks thus becomes imperative.

Edema

Although postoperative edema is expected, it can rarely become life threatening and thus complicating. Unlike maxillary surgery where intraoperative hemorrhage is the most common severe complication, the most common severe complication (although still rare) as a result of SSRO is life-threatening airway compromise secondary to edema.[44] Postoperative compressive dressings are contraindicated because they may cause increased medial edema compromising the airway.

No matter the length of surgery, edema can be expected to occur in a moderate to severe amount. In most cases, it is only discomforting for the patient and not hazardous, but corticosteroids, ice packs, and nonsteroidal anti-inflammatory agents help reduce edema.

• BOX 5-3 Advantages and Features of Resorbable Implants

Tensile and flex strengths are comparable with titanium plating systems
Wide selection of implant sizes and shapes available
Convenient hex-drive breakaway delivery system simplifies screw placement
Resorbs completely, which may eliminate the need for second operation
Does not induce late-stage inflammatory reaction

Nerve Injury

Neurosensory impairment after SSRO most often involves the inferior alveolar nerve, but can involve the lingual nerve, and, very rarely, the facial nerve. Facial nerve impairment, if encountered, will likely be transient and is thought to arise from compression during retraction. Numbness of the lower lip and chin is the most commonly reported complication after SSRO. Patients may experience varying degrees of inferior alveolar nerve sensory deficit for 6 months or longer. The prevalence of immediate postoperative trigeminal impairment ranges from 12% to 100%. Long-term follow-up has shown nerve dysfunction to persist 40% of the time 1 to 2 years after bilateral SSRO,[47] although many surgeons feel the incidence of permanent paresthesia after bilateral SSRO performed by experienced hands to be closer to 10% to 20%. Increasing age and the use of concurrent genioplasty are two main risk factors.[48,49] An inherent flaw to any study reporting neurosensory outcomes after SSRO is the wide variance of methods used to test the neurosensory disturbance seen throughout the literature. Fortunately, patients seem to adapt to mild sensory deficits and report sensory function as normal despite slightly altered sensation objectively. The majority of patients experience a return to baseline sensation a year after SSRO. Over the last decade, there has been more attention dedicated to performing SSRO with piezoelectric surgery to decrease neurosensory deficits. Reports have been contradictory on whether piezoelectric surgery positively affects the incidence of neurosensory deficit after SSRO.[50,51]

Nerve injuries may be caused by direct trauma in the form of compression, tear, or cut with a rotary instrument.

• BOX 5-4 Mechanisms of Injury to the Inferior Alveolar Nerve (IAN)

Application of local anesthesia
Stretching of the nerve from the medial protecting retractors
Deep osteotomy with reciprocating saw or chisel during splitting
Abnormal anatomic position of the IAN canal
Presence of an impacted third molar

They may also develop by indirect trauma such as compression from postoperative edema. Patient's should receive counseling regarding the possibility of significant sensory deficits such as numbness, pain, burning, tingling, or hyposensitivity that can affect the lips or chin in the event of an injury to the inferior alveolar nerve (IAN). Sequelae of such an injury such as lip biting during mastication and difficulty with eating, tooth brushing, speaking, shaving, or kissing are distressing experiences for the patient.

Facial nerve injury is a rare but devastating possible complication of SSRO. The incidence of facial nerve impairment has been reported as less than 1% in bilateral SSRO, and has only been reported in setback procedures. Prognosis was found to be good with mild impairment of function but poor with complete loss of function.[52]

Injury to the Inferior Alveolar Nerve (IAN)

Postoperative neurosensory deficits are generally considered to be caused by direct damage to the IAN. Any laceration, compression, or significant stretching of the sensory fibers of the IAN results in a postoperative neurosensory disturbance of the lower lip and chin. Even in cases in which the IAN is not visibly traumatized during surgery, postoperative neurosensory deficit can occur. This can be referred to as a closed injury and may result from edema, hematoma, protruding bone fragments within the osteotomy, or from penetrating screws during fixation.

A prolonged neurosensory disturbance is strongly related to age and the degree of manipulation of the IAN during surgery. At all times during the SSRO instrumentation is in close proximity to the IAN and many factors can lead to damage of the nerve (Box 5-4). Maneuvers to free the IAN when stuck within the proximal segment after splitting and overcutting the inferior border osteotomy both place the nerve at higher risk, for example.

The long-term incidence of paresthesia from IAN injury ranges from 0% to 20%,[39,53] and has been found to be greater when performed concurrently with inferior border osteotomy.[54]

Unintentional, witnessed transection of the IAN may occur while performing the SSRO. Immediate primary repair with 8 or 9-0 prolene suturing of the epineurium under loupe or microscope vision provides the optimum chance for recovery. If circumstances prevent such repair, establishing care with a microsurgeon early in the postoperative course is important.

• BOX 5-5 Keys to Prevent Injury to the IAN During BSSRO

Remaining subperiosteal along the medial side of the ascending ramus
Judicious use of the medial protecting retractors
Osteotomes and saws should penetrate just to a single cortical depth
Suction tip should be placed at the superior border of the split for safe visualization while splitting
Removal of impacted third molars at least 6-12 months before surgery

Furthermore, anatomic variation of the course of the nerve within the mandible predisposes to injury. One study found the distance between the mandibular canal and the buccal cortex was less than 1.2 mm in 91% of sides associated with a severe grade of neurosensory disturbance persisting 3 months after bilateral SSRO.[55] Severely prognathic mandibles are known to be associated with a more cephalad entrance of the IAN into the mandible. Occasionally, the course of the IAN runs very close to the inferior border of the mandible near the molar region. Close examination of the panoramic radiograph affords the surgeon valuable insight to such nuances (Box 5-5).

Injury to the Lingual Nerve

Although less frequent than IAN injury, a temporary disturbance of the lingual nerve can occur. The incidence varies from 1% to 19%,[56] and is usually transient. Long-lasting anesthesia of the lingual nerve seems to be exceedingly rare after SSRO, but has been reported.[57] Disturbances in lingual nerve function likely occur from one of two causes: bicortical screw placement with over-extended or prepared superior positioning screws, or through pressure neuropathy secondary to development of a lingual hematoma. Bicortical superior positioning screws in the region of the third molar should not extend beyond the medial cortex of the mandible because they may damage the lingual nerve in this region. Painful sensations when moving the tongue postoperatively may be reported if such an error occurs. This can require revision of fixation. Typically, it is safe to use screws up to 15 mm long. In cases where longer screws are required, measurement of the depth of the drilled hole is important.

Hematoma ensuing after hemorrhage along the medial side of the mandible exerts pressure on the lingual nerve. This can lead to temporary paresthesia of the tongue that is characterized by loss of sensation and taste on the affected side. If screw placement is acceptable and the hematoma mild, acute interventions are usually not necessary and spontaneous recovery can be expected. Extensive hematoma formation should be drained to allow quick recovery (Box 5-6).

• BOX 5-6 Keys to Prevent Lingual Nerve Injury During BSSO

Subperiosteal dissection
Use of a depth gauge to ensure proper screw length for superior positioning screws
Recognition and drainage of hematomas to allow quick recovery from pressure on lingual nerve

Arthropathy of the Temporomandibular Joint

Dysfunction of the Temporomandibular Joint

TMJ dysfunction, most commonly exhibited by joint noises (clicking, popping) or pain, is a relatively common occurrence in the "normal" population. The prevalence of TMJ dysfunction in patients with dentofacial deformities seems to be the same and is estimated to range from 20% to 25%, although reports have shown an incidence of TMJ dysfunction prior to surgery of up to 41%.[58]

The exact position of the condyle is almost always changed during mandibular surgery. After IVRO, the condylar sag that occurs postoperatively leads to an equilibrated condyle-disc relationship improving TMJ noises and pain. With the SSRO, it is likely that some rotation around and across the condylar axis occurs. Despite knowing this, no conclusive evidence exists suggesting that the osteotomy and associated condylar changes influence the development of post-surgical TMJ problems. All patients experience some degree of limited mouth opening after surgery as a result of muscle stripping and soft tissue edema. In addition, there is likely a short period of condylar remodeling post-surgically that also contributes to functional impairment. After resolution of swelling, muscle reattachment and rehabilitation, and condylar remodeling, patients usually regain their presurgical level of function several months after surgery is performed.

Displacement of the Condyle and Condylar Resorption

Displacement of the condyle can occur in an anterior-posterior or vertical plane of rotation as a result of surgery. Resultant condylar torque may induce a clinically apparent midline shift and sometimes pain.[59] Severe hypomobility can be another sign of condylar malposition, particularly of lateral or medial condylar displacement.

During the SSRO, efforts should be directed to keeping the condyle in a passive position near centric relation during fixation. Malpositioning of the condyle can cause early occlusal changes postoperatively from immediate skeletal relapse. Such failure to seat the proximal segments properly into the fossa during surgery and resultant condylar displacement is thought to be the main reason for TMJ symptoms after bilateral SSRO in those who were without symptoms prior to surgery. Resorption of the condyle has been described as a consequence of this malpositioning.[59-61] This phenomenon reportedly occurs in between 1% to 31% of patients.[62] Other predisposing factors include high mandibular plane angle, condyle with posterior inclination, and a low posterior-to-anterior face/height ratio.[63] Contributing surgical factors include counterclockwise rotation of the proximal segment, preoperative TMJ disorder, and possible avascular necrosis of the condyle secondary to overstripping of the proximal segment.[64]

Preoperative management of existing TMJ disorder remains controversial. Some authors have suggested that TMJ derangements should be corrected prior to orthognathic surgery because symptoms may deteriorate or even lead to condylar resorption.[65] Others have found that orthognathic surgery alone establishes skeletal and occlusal harmony and leads to resolution of TMJ symptoms without the need for isolated TMJ surgery.[66,67] We tend to agree that the majority of patients with preoperative popping or clicking and pain experience improvement or resolution after surgical correction of dentofacial deformities and associated malocclusions. It seems prudent, however, to control any acute exacerbations of TMD with at minimum conservative management prior to performing orthognathic surgery. Patients with documented disc displacement (confirmed by MRI) and limited opening should receive intervention with disc repositioning either prior to or simultaneously with orthognathic surgery.

Unfavorable Bony Split

A particularly complicating but not very common problem associated with the SSRO is an unfavorable bony split. Its occurrence ranges from 2% to 20% throughout the literature.[59] An unfavorable split may occur on the distal tooth-bearing segment or along the proximal segment.

A poor split of the distal segment most often affects the lingual cortical bone posterior to the third molar region. Left unstabilized, this may result in sequestration of the fragment, delayed union, malunion of the osteotomy site, or even infection. Stabilization of the unfavorable fracture can be quite challenging but helps prevent post-surgical instability and healing issues. A positional screw placed from the proximal segment into and through the fractured lingual segment will serve to stabilize this segment, reducing the incidence of these problems.

Unanticipated splits of the proximal segment may occur before or after splitting of the mandible and are best prevented by recognizing its development before the fracture is complete. Often, bone is used as a fulcrum against an incomplete osteotomy where bridges of cortical bone are left intact. Some believe that the most common reason for an unfavorable split is incomplete cortical bone removal along the inferior border. Prior to splitting, careful inspection to ensure the osteotomy is completely through the outer cortex and inferior border

• BOX 5-7 Keys to Prevent Unfavorable Split During BSSRO

Careful technique with complete cortical cuts
Careful inspection of the inferior border and ascending ramus during separation
Removal of third molars at least 6-12 months prior to BSSRO

is paramount. It is important to initiate the inferior border separation with an osteotome directed from the vertical cut posteriorly splitting the inferior border from the distal segment.

There are known predisposing factors that increase the risk of an unfavorable split. These include difficult anatomic variants, poor osteotomy design, and the presence of impacted third molars.

Wide anatomic variations from the norm in terms of width and thickness of the ascending ramus and the relationship between canal location exist.[68] Lack of cancellous bone between the two cortices makes the split more difficult, as does a high mandibular foramen (Box 5-7).

Complete cuts through cortical bone with the use of a reciprocating saw or a burr are essential for avoiding a bad split. This is especially true for the medial ramus cut and the inferior border prior to application of the chisel to the osteotomy.[69]

The presence of impacted third molars has been associated with an increased risk of unanticipated fracture during bilateral SSRO.[70] They have been postulated to compromise the anatomic structure of the mandible, causing adverse proximal and distal segment splits. Most authors recommend removal of impacted lower third molars at least 6 to 12 months prior to orthognathic surgery; others found no reduction in fracture incidence when impacted third molars were removed at the time of surgery. Fracture of the lingual or buccal plate can occur when non-erupted third molars are present during SSRO. The buccal cortex of the mandible is thinner posterior to the second molar. The presence of a lower third molar can further complicate splitting of the mandible as medullary bone between the cortices is lacking where the third molar is. Fractures often start at the lingual cortex during removal of the tooth or at the outer cortex during splitting. Horizontal fracture of the ramus and even subcondylar fractures make reduction and fixation of remaining segments difficult.[71] Stabilization is more challenging than in non-fractured splits, often requiring more hardware material. Plates, bicortical screws, or a combination of these can be used to stabilize fractured bony segments. If circumstances call for concurrent third molar removal during orthognathic surgery, we recommend extending the buccal cortical osteotomy no differently other than extending the cut deeper along the third molar itself to section it. When appropriately managed, unanticipated bony splits shouldn't influence stability or the long-term success of the sagittal split.

• BOX 5-8 Preventive Measures

Allow sufficient time for vasoconstriction after local anesthesia
Subperiosteal dissection
Good soft tissue retraction and visualization when using rotary instruments and chisels
Placement of the suction tip into the bottom of the split

• BOX 5-9 Preventive Measures

Duration of operation
High dosage and short perioperative course of antibiotics
Good oral hygiene and wound cleanliness

Hemorrhage

Uncontrolled hemorrhage is exceedingly rare in mandibular surgery. When encountered, it likely results as a consequence of clumsy or inexperienced use of rotating instruments or chisels. The retromandibular vein, inferior alveolar vessels, and, rarely, facial vessels can be traumatized inadvertently. Mandibular hemorrhage, of life-threatening severity, is very rare and found to be usually an intraoperative problem, unlike delayed bleeds that can occur after maxillary orthognathic surgery.[72] Transfusion of blood products occurs only on rare occasions in BSSRO.[59] Most bleeding episodes are minor and can be controlled by administering local anesthetics and gauze packs. Bleeding from laceration of the facial artery requires suture or clip ligation. Even minor oozing can impede visualization and effective surgical execution, thus making its avoidance important (Box 5-8).

Infection

Wound dehiscence and/or infection is a rare complication[73] and most often thought to be related to poor oral hygiene. Tobacco smoking seems to be an additional risk factor. Contributing factors include lengthy duration of the operation, the patient's age, the presence of foreign bodies, sequestrum formation after bone fracture, and hematoma. Although not common, sometimes loose hardware and associated infections require wound re-exploration. Care to preserve vascularity of segments will aid in prevention of infection. The use of a single preoperative dose of antibiotics and two days of postoperative antibiotics has been found to substantially reduce the risk of postoperative infection[2] (Box 5-9).

Relapse

Stability and predictability of orthognathic surgical procedures have improved as a result of constantly evolving surgical techniques and instrumentation. Relapse rates range throughout the literature and seem to be highly dependent on the presurgical diagnosis. Relapse is a multifactorial problem that is hard to attribute to a single etiology. Proper

• BOX 5-10 Preventive Measures to Minimize Relapse

Proximal segment control including proper condyle positioning, and avoidance of condyle rotation
Caution with counterclockwise rotation of the distal segment with high mandibular angle cases
Careful evaluation of TMJ prior to surgery
Care by orthodontist to avoid building in dental compensations of skeletal discrepancies

diagnosis, adequate treatment planning, and well-executed surgical technique are essential contributions of the surgeon. The soft tissue envelope, muscle tension, and orofacial habits may influence postoperative stability. Other factors that have an effect on relapse include fixation choices, magnitude and vector of mandibular movement,[74,75] position of the proximal segment, and disc displacement. Long-term relapse in mandibular deficiency appears greatest with large mandibular advancement (>6 mm) in non-growing patients.[76] Some authors have noted a correlation between relapse and counterclockwise rotation[77] (Box 5-10).

Although some have reported similar stability after orthognathic surgery with wire fixation in comparison to more rigid plates and/or screws,[78] we recommend the use of plates and/or position screw fixation. Modern hardware is user friendly and places less reliance on IMF. Reports have shown improved stability with the use of more rigid internal fixation.[74,79,80] Resorbable screws have been shown to provide equal stability to titanium hardware.[24,22]

Immediate relapse, hours to days after surgery, may occur with mandibular advancement in patients with TMJ functional problems caused by internal derangements not correctly repositioned prior to surgery. When this is the case, it becomes difficult to place the condyle correctly into the fossa intra-operatively. Shortly after surgery, the anteriorly displaced disk can slip back into the fossa as the result of complete relaxation of the muscles and the absence of chewing. Condylar displacement from being positioned too far posteriorly in the fossa during surgery is another cause of immediate relapse. Postoperatively, the condyle settles back into a passive position within the glenoid fossa, which may result in unsatisfactory occlusal changes.[59] Confirming complete and passive mobilization of the distal segment and removal of all obstructive bone fragments are crucial for proper positioning of the condyle after SSRO.

Description and Indications for Intraoral Vertical Ramus Osteotomy

The IVRO is a simple and quick surgical procedure to set back the prognathic mandible. It can also be used to address mandibular asymmetry to rotate one side of the mandible. The IVRO finds its main application in cases of mandibular excess with concomitant widely flared rami, often referred to as "V-shaped" mandibles. Sometimes, executing the SSRO on such cases of mandibular anatomy can result in lateral flaring of the condyle/proximal segment when a significant amount of bony interference is encountered with large setbacks or asymmetry corrections. Unfavorable condylar displacement that can occur during fixation of the SSRO has been repeatedly documented,[81-84] and many surgeons attribute this problem to bony interferences on large setbacks or asymmetry corrections that are no doubt magnified in cases with "V-shaped" mandibles.

The condylar head undergoes immediate anterior sagging, but ultimately returns upright after the IVRO is performed.[85,86] For this reason, intersegmental fixation is not mandatorily used with the IVRO because it can precipitate postoperative open bites as the condylar head repositions. The passively positioned condyle after IVRO renders the procedure helpful often in cases of concomitant temporomandibular disorder. IMF is required to facilitate intersegmental union, and most surgeons prefer a 2-week period with early return to physiotherapy. Despite absence of fixation, long-term results on maintenance of the mandibular position and occlusion show excellent postoperative stability after the IVRO procedure[87] (Case Study 5-5 and 5-6).

Limitations of the Inraoral Vertical Ramus Osteotomy

The principal limitation of the IVRO is the need for IMF[88,89] and the required patient cooperation with physiotherapy. After release of IMF, close follow-up is required to guide return to normal function.

The morphology of the mandibular ramus, specifically the thickness, or in cases of large setbacks, can impede passive overlapping of the two segments requiring reduction of the medial volume of the proximal segment. Such limitations can be easily overcome by reducing the medial volume of the proximal segment. The segmental overlapping can alter bigonial width which can be problematic, although in some cases has seen to result in favorable esthetic changes.[90,91]

Another limitation is the mechanical interference between the coronoid process and the skull base, or with the TMJ capsule when significant posterior impaction of the maxilla or significant setback of the mandible occurs simultaneously. In these cases, coronoidectomy can relieve the interference, however, removal of the coronoid process can further impose difficulties in physiotherapy.

Introral Vertical Ramus Osteotomy: Surgical Sequence

Soft Tissue Access

For convenience of sequencing, many prefer to secure the surgical splint to the maxillary dentition prior to incision. The incision design and location for the IVRO is modified slightly compared to the SSRO. It is extended approximately one centimeter longer to allow for instrumentation of both the superior and inferior portion of the lateral ramus.

CASE STUDY 5-5

Mandibular Prognathism and Maxillary Retrognathism With Severe Facial Asymmetry

A 21-year-old young man visited our clinic with a chief complaint of facial asymmetry, prognathic mandible, and chewing difficulties (Figure 5-17, *A* through *C*, *J*, *K*). On the basis of initial dentofacial deformity (DFD) analysis, mandibular prognathism and maxillary retrognathism with severe asymmetry and mild open bite were diagnosed. For treatment, preoperative orthodontic treatment for dental decompensation was planned first. Then, according to surgical treatment objectives (STO), as illustrated in Figures 5-17, *P* and *Q*, we planned orthognathic surgery for advancement (2.0 mm), posterior impaction (3.0 mm), and canting correction of the maxilla and TOVRO setback of the mandible, thereby establishing a proper upper and lower dental midline that coincided with the facial midline. In keeping with the treatment plan, the patient first received preoperative orthodontic treatment for about 1.5 years (see Figure 5-17, *J* and *K*); then he received two-jaw orthognathic surgery according to the STO plan. Postoperative physiotherapy was enforced for 2 weeks after our routine protocol without interference. After routine 2-year follow-up, we were fortunate to evaluate his status 45 months after the surgery. He had an excellent symmetric face (see Figure 5-17, *G* and *H*), a normal profile (see Figure 5-17, *I*), and excellent occlusion without an open-bite tendency (see Figure 5-17, *N* and *O*).

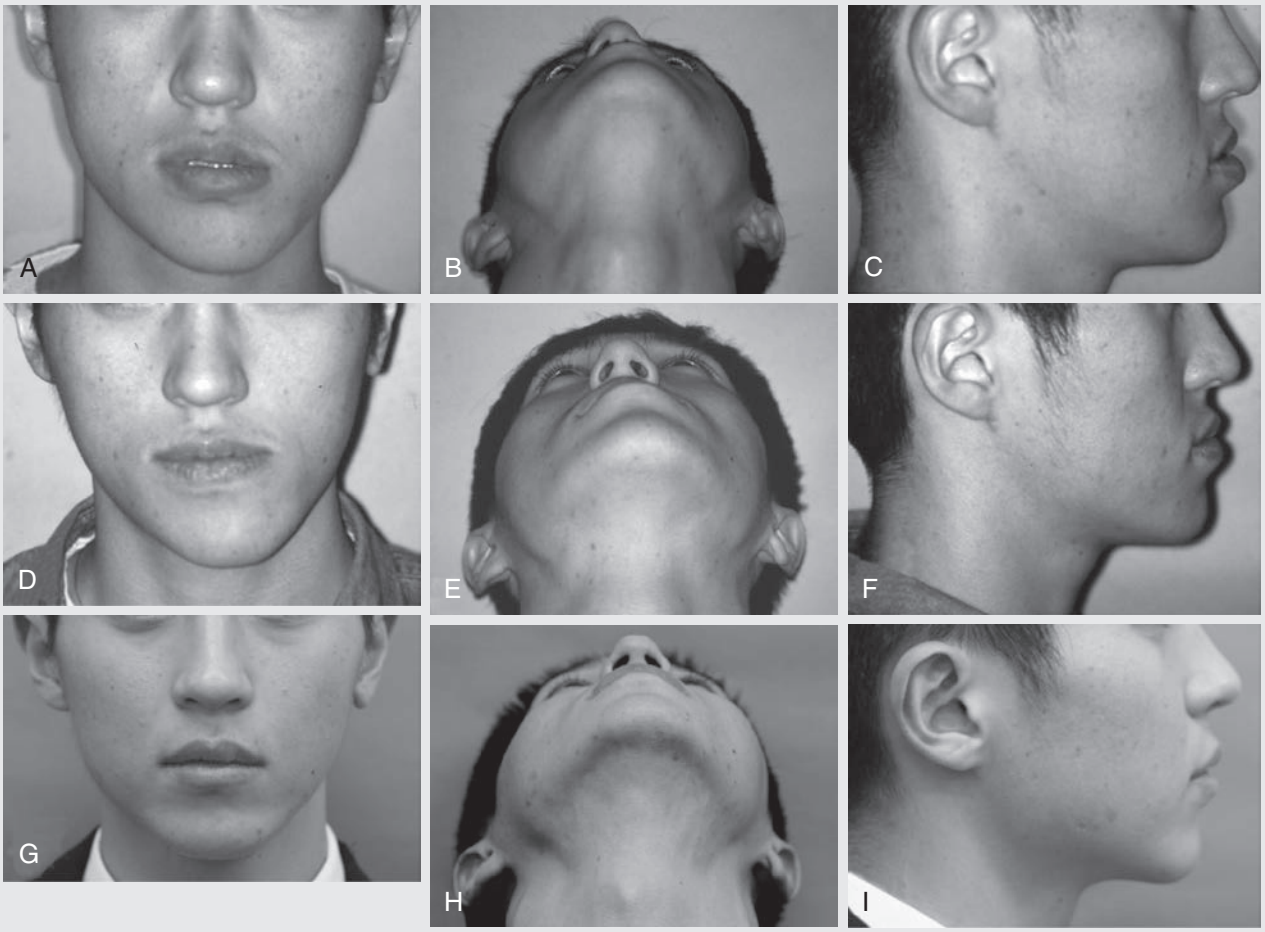

• **Figure 5-17** Facial appearance of a 21-year-old man with mandibular prognathism, maxillary retrognathism, and severe asymmetry. **A-C,** Facial appearance at first examination. **D-F,** Facial appearance before orthognathic surgery since completion of preoperative orthodontic treatment shows no remarkable change. **G-I**, Facial appearance at 45 months after two-jaw surgery, including transoral vertical ramus osteotomy (TOVRO), shows an excellent symmetric face and normal profile.

CASE STUDY 5-5—cont'd

Mandibular Prognathism and Maxillary Retrognathism With Severe Facial Asymmetry

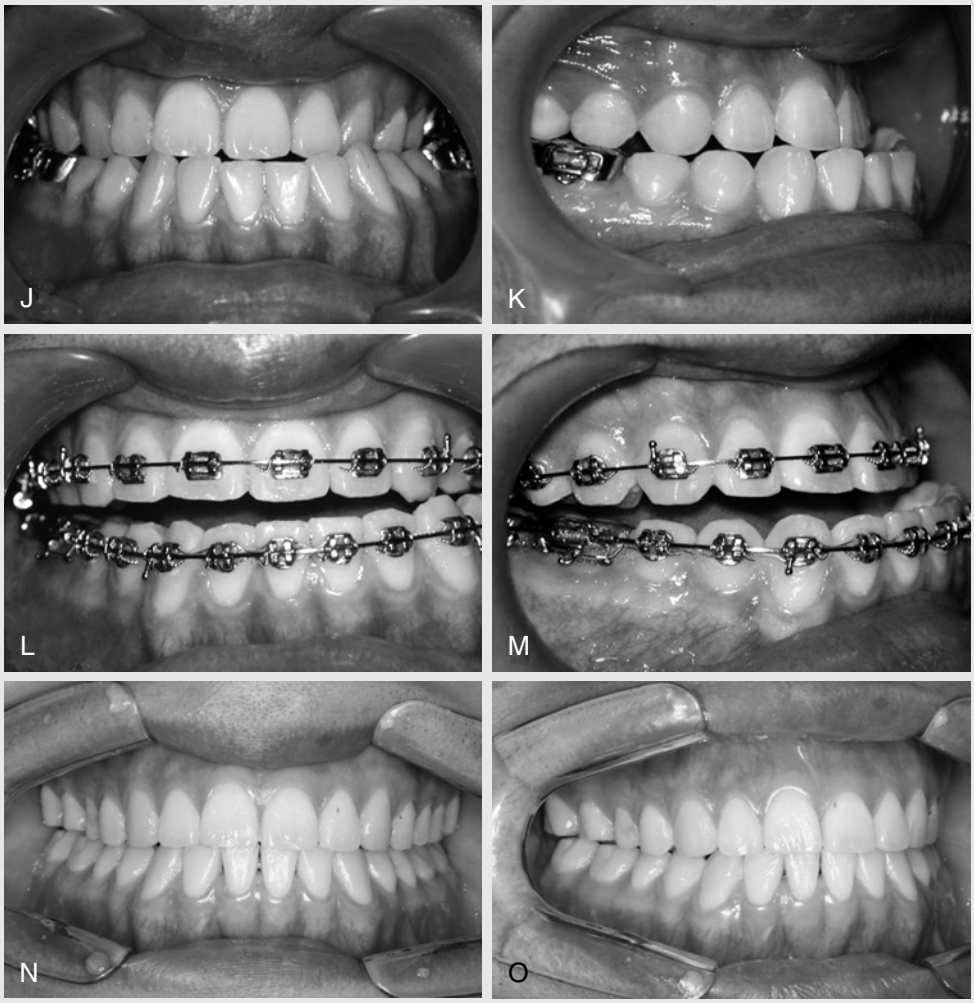

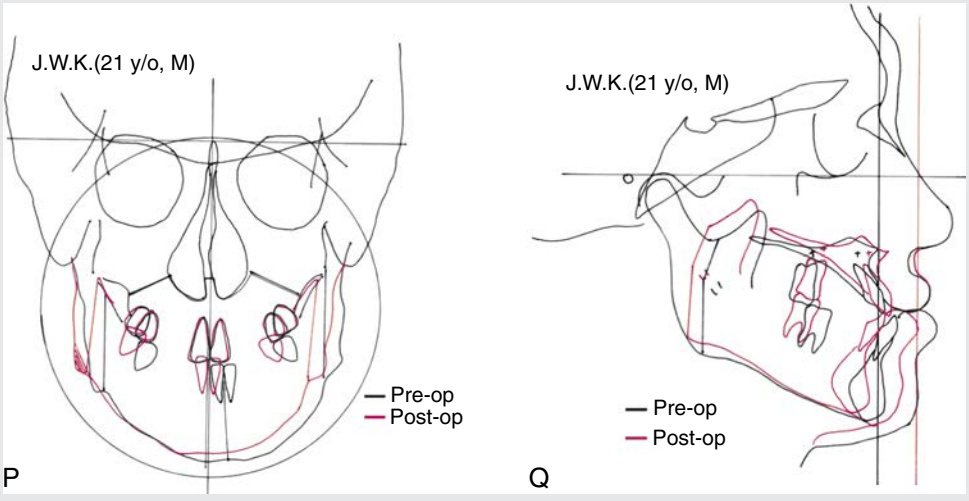

•**Figure 5-17, cont'd** **J** and **K,** Occlusion at initial examination shows remarkable difference between maxillary and mandibular dental midlines. **L** and **M,** Dental decompensation and arch alignment were finished before surgery. Mandibular dental midline was moved far from the maxillary dental midline, and the anterior open bite was increased compared with initial examination. **N** and **O,** Occlusion at 45 months after surgery shows excellent occlusion and stable maintenance. Dentofacial deformity (DFD) prediction and surgical treatment objectives (STO) for surgery on posteroanterior cephalogram **(P)** and lateral cephalogram **(Q).**

CASE STUDY 5-6

Mandibular Prognathism, Maxillary Retrognathism, and Severe Open Bite

A 22-year-old man was given the diagnosis of mandibular prognathism and maxillary retrognathism, accompanied by severe open bite and mild asymmetry (Figure 5-18, *A* through *C*, *J*, *K*). After DFD analysis, it was decided that the upper right and left first bicuspid should be extracted, and preoperative orthodontic treatment proceeded for 2 years (see Figure 5-18, *L*, *M*). Once preoperative orthodontic treatment had been completed, two-jaw orthognathic surgery was performed; it included Le Fort I osteotomy for maxillary advancement (3.0 mm) with posterior impaction (4.0 mm) and TOVRO setback of the mandible, which were performed according to the preoperative STO (see Figure 5-18, *S* and *T*). Routine physiotherapy was enforced for 2 weeks. Once stable occlusion had been confirmed, the patient was sent to the orthodontist for detailed dental alignment. At 36-month follow-up, the patient showed excellent facial esthetics (see Figure 5-18, *G* through *I*), excellent bony remodeling on radiography (see Figure 5-18, *P* through *R*), and proper occlusion that was maintained as stable without an open-bite tendency (see Figure 5-18, *N* and *O*).

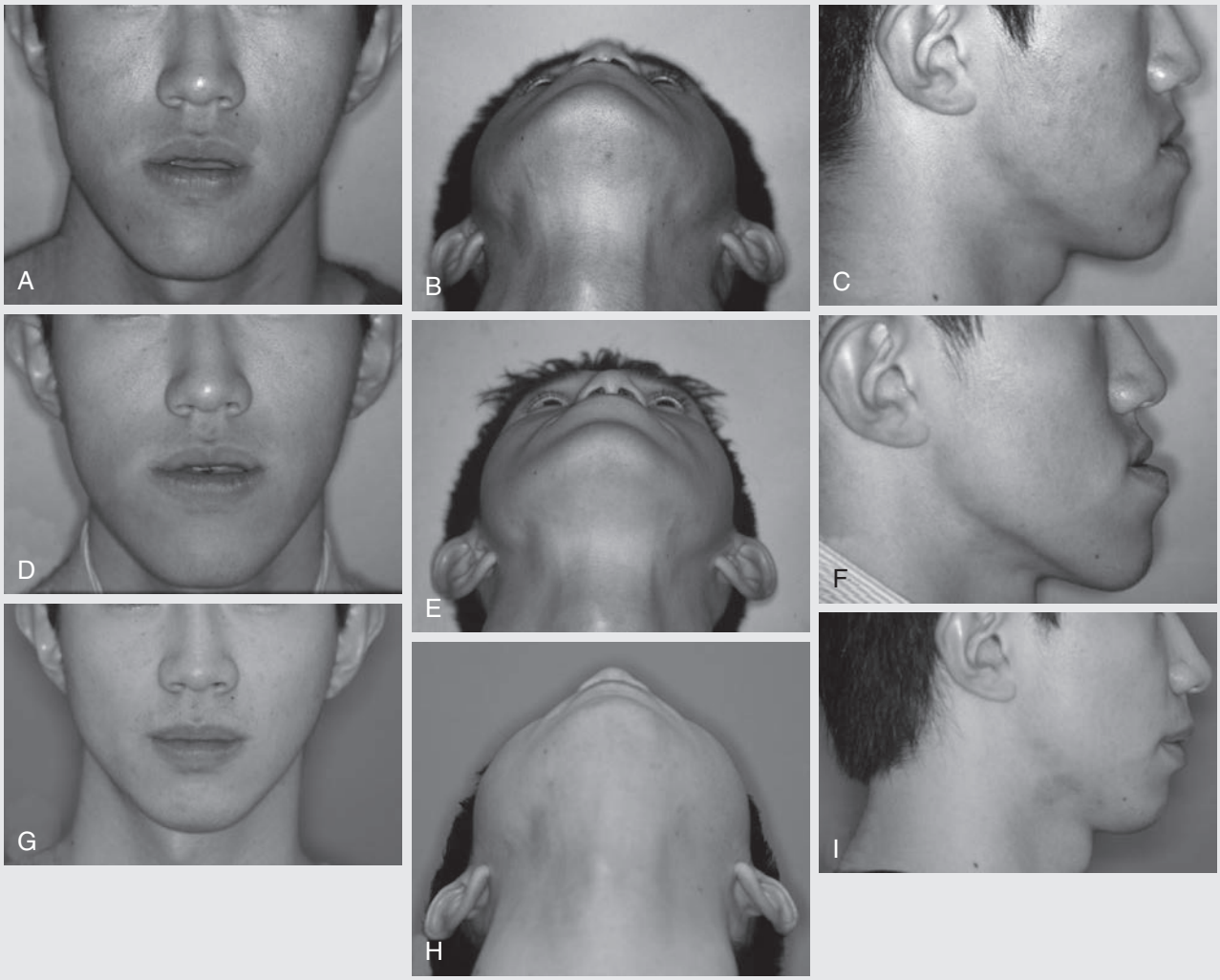

• **Figure 5-18** Facial appearance of a 22-year-old man with mandibular prognathism, maxillary retrognathism, and severe anterior open bite. **A-C,** Facial appearance at first examination. **D-F,** Facial appearance before orthognathic surgery at completion of preoperative orthodontic treatment. **G-I**, Facial appearance at 36 months after two-jaw surgery, including transoral vertical ramus osteotomy (TOVRO), shows an excellent symmetric face and normal profile.

CASE STUDY 5-6—cont'd

Mandibular Prognathism, Maxillary Retrognathism, and Severe Open Bite

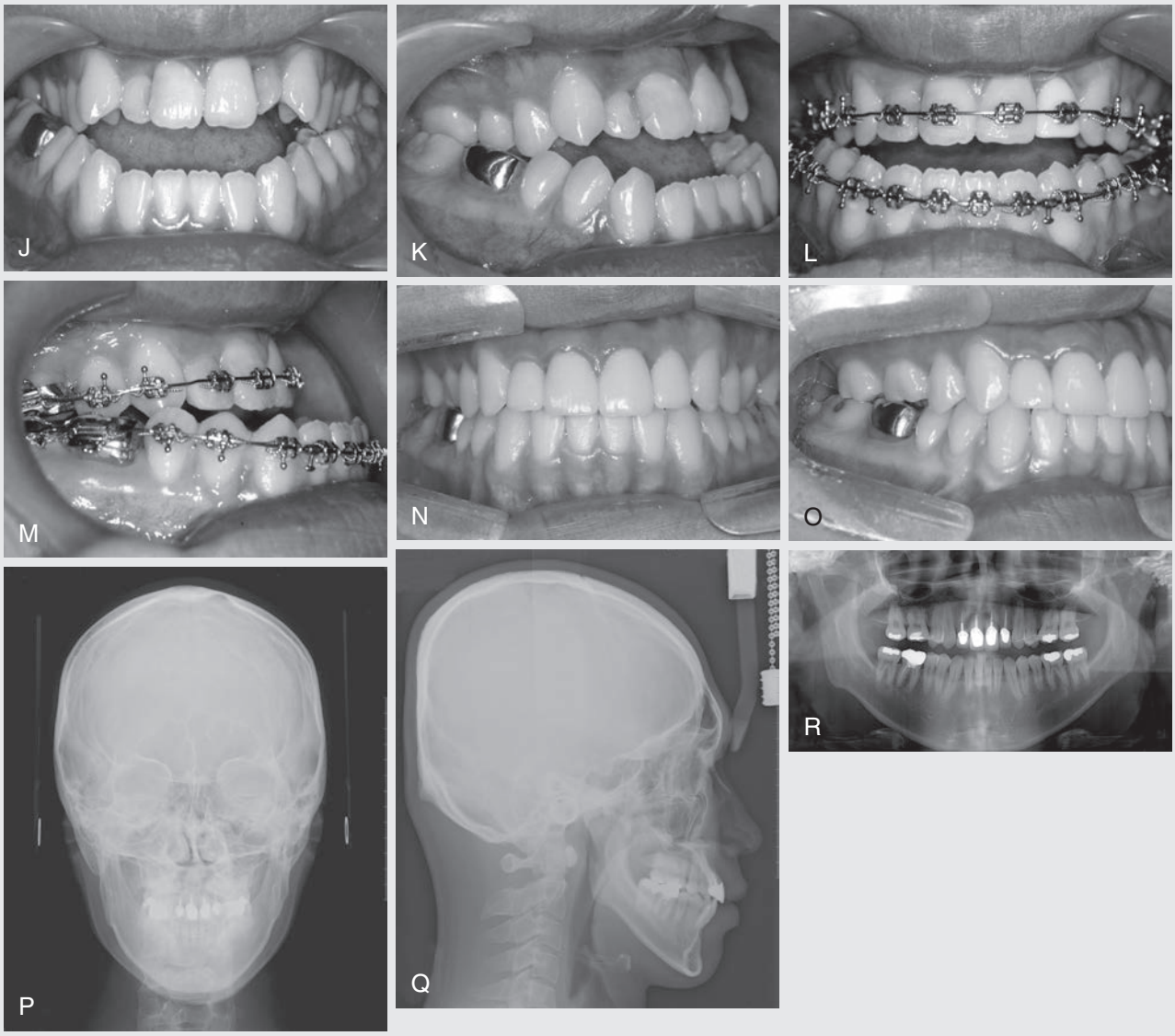

• **Figure 5-18, cont'd** **J** and **K,** Occlusion at initial examination shows remarkable anterior open bite and mild difference between maxillary and mandibular dental midlines. **L** and **M,** Arch alignment and leveling state prior to surgery show absence of right and left first bicuspids with space consolidation, continued open bite, and difference between maxillary and mandibular dental midlines. **N** and **O,** Occlusion at 36 months after surgery shows excellent interocclusion and stable maintenance. **P** and **R,** X-rays at 36 months after surgery. Posteroanterior cephalograph **(P)** and Panex **(R)** show excellent remodeling of the mandibular rami after TOVRO. Lateral cephalograph **(Q)** shows excellent maintenance of the stable occlusion without open bite.

Continued

CASE STUDY 5-6—cont'd

Mandibular Prognathism, Maxillary Retrognathism, and Severe Open Bite

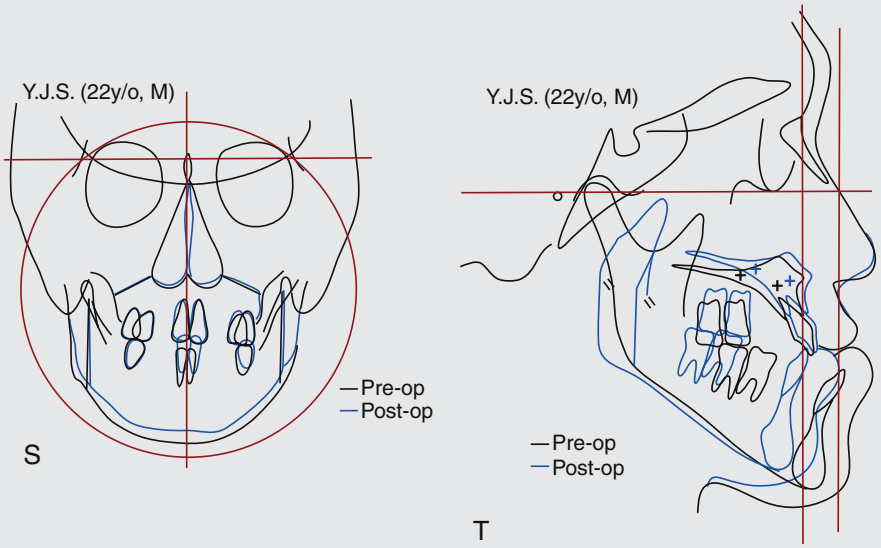

• **Figure 5-18, cont'd** Dentofacial deformity (DFD) prediction and surgical treatment objectives (STO) on posteroanterior cephalogram **(S)** and lateral cephalogram **(T).**

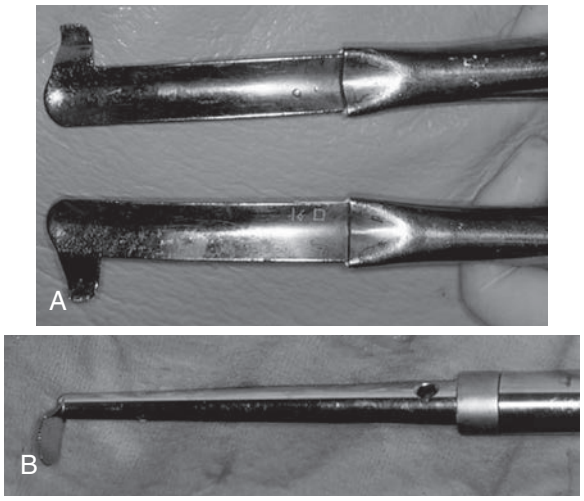

• **Figure 5-19 A,** Bauer retractor. **B,** A round oscillating saw blade (Stryker's).

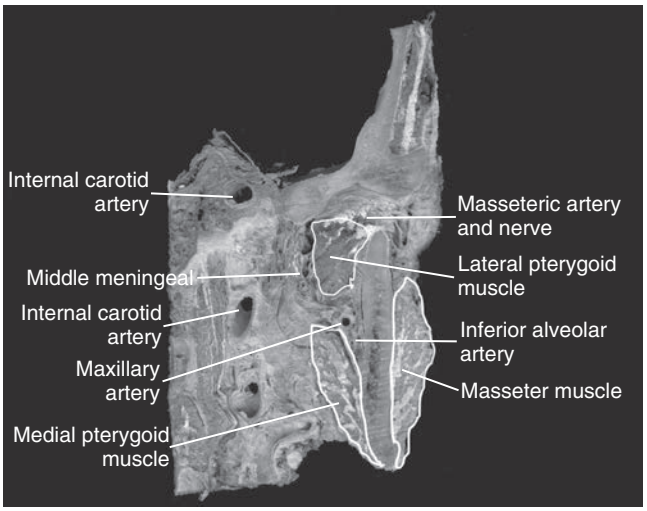

• **Figure 5-20** Vertical sectional view of important anatomic structures around the osteotomy line of a transoral vertical ramus osteotomy (TOVRO) in human cadaver.

Following incision down through the submucosal layer, the periosteum is incised along the anterior border of the ramus with a fine tipped bovie. A full thickness mucoperiosteal flap including muscle attachments along the lateral surface of the ramus is reflected broadly from the sigmoid notch to the antegonial notch, although some of the pterygomandibular sling attachments should be left attached at the posterior border of the mandible and angle. Clean and subperiosteal stripping of the soft tissue attachment around the sigmoid notch is important for safe insertion of a wing of a Bauer retractor (Figure 5-19), to avoid damage to the masseteric branch of the maxillary artery located near the notch during osteotomy (Figure 5-20). Each wing of two Bauer retractors is inserted into the sigmoid notch and the antegonial notch simultaneously (Figure 5-21), and the lateral surface of the ramus is wiped with a gauze sponge and important landmarks on the bone surface can be marked with a sterile #2 pencil if desired. We recommend using the antilingular eminence, located on the lateral surface of the ramus as is shown in Figure 5-22, *A* as a general guideline only for the lateral correspondence of the mandibular foramen. The antilingular prominence is a small protuberance

located at the posterior one third from the posterior border in the horizontal aspect of the ramus and about 10 mm above the occlusal plane of the lower molars in the vertical aspect. Hall[92] recommended that the cut should begin 6 to 7 mm from the posterior border of the ramus and, like Hogan and Ellis,[93] described that it is less reliable to use the antilingula eminence as a landmark for the mandibular foramen. A recent cadaveric study found that at a measurement of 5 mm posterior to the antilingula (at the level of the antilingula), there was no risk of damaging the neurovascular bundle.[94] We advise marking the osteotomy location about 7 mm anterior to the posterior border near the level of the mandibular foramen to avoid injury to its contents.

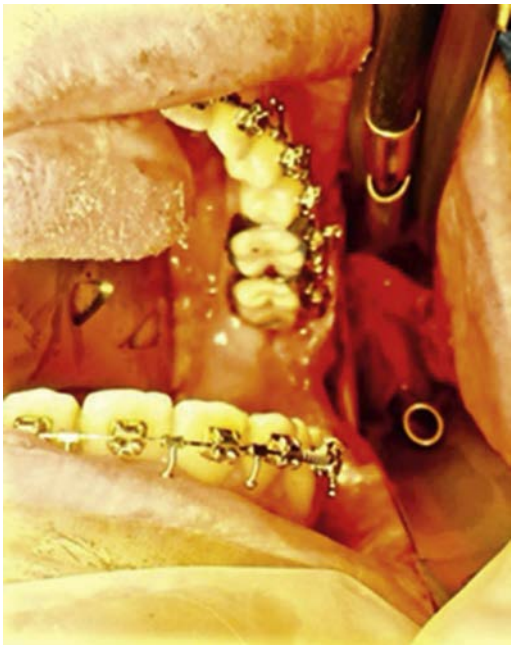

• **Figure 5-21** Presentation of the ramus with two Bauer retractors inserted just prior to performing the intraoral vertical ramus osteotomy.

Osteotomy

Figure 5-23 illustrates a vertical guide line for osteotomy that should be drawn from the sigmoid notch to the inferior border staying 7 mm anterior to the posterior border and keeping parallel to the posterior border of the ramus. This line can be confirmed with the use of a mouth mirror as is shown in Figure 5-22, *B* or with insertion of a curved freer elevator with markings at 7 mm. The osteotomy is started to completion through both the medial and lateral cortices with an oscillating saw under copious irrigation. Once the saw blade is confirmed to have passed through the medial cortex, a downward cutting movement of the saw is carried out to the antegonial notch without resultant injury to the inferior alveolar neurovascular bundle inside of the ramus; which runs anterior to the guide line (Figure 5-24). If positioned correctly, this osteotomy carries little risk to any major vessels.

After completion of the inferiorly directed osteotomy, the saw blade is directed cephalad to the anterior half of the sigmoid notch (see Figure 5-23, *A*). Notice that the osteotomy courses in an oblique direction from the posterior border of the ramus and that the mandible becomes thinner, requiring careful adaptation of the depth of the saw blade.

Figure 5-25 demonstrates the increased risk of damage to branches of the maxillary artery that are located medially near the mandibular foramen. The oscillating saw blade should not be inserted deeply when the level of the mandibular foramen is passed during the cephalad portion of the osteotomy. Furthermore, this anatomy highlights the importance of securing the wing of a Bauer retractor at the sigmoid notch to the end for protecting the masseteric branches of the maxillary artery.

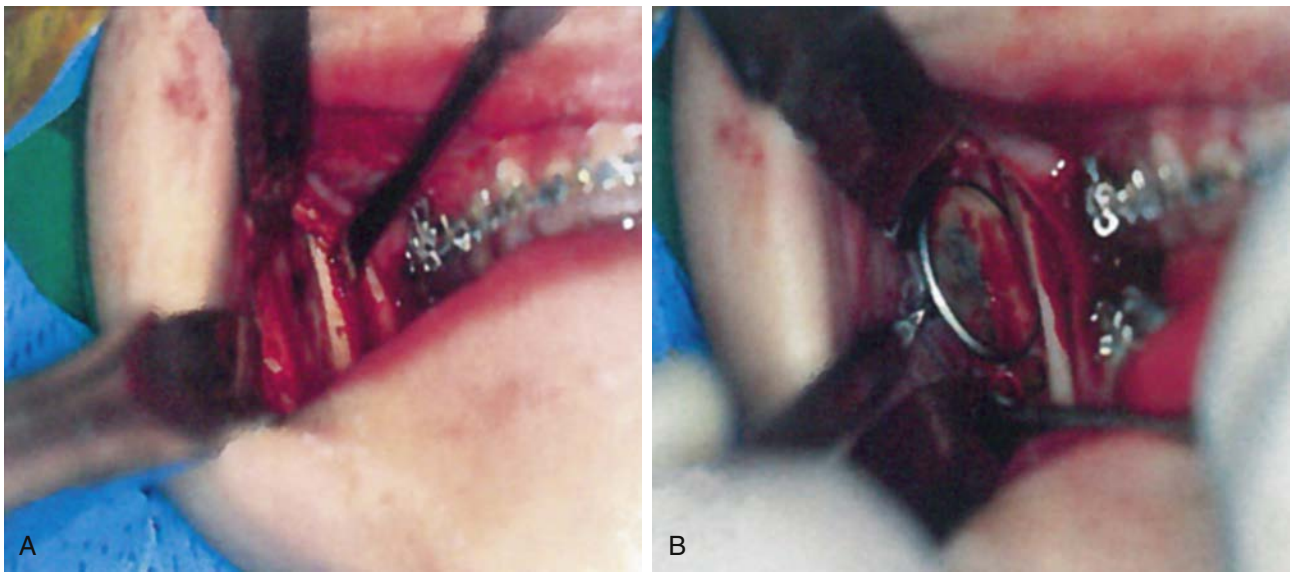

• **Figure 5-22** Marking of the antilingular eminence **(A)** and drawing with a black pencil of a lower guide line for osteotomy on the lateral surface of the mandible. An inferior osteotomy line made by an oscillating saw blade run along it **(B).** Note up and down securing of Bauer retractors **(B).**

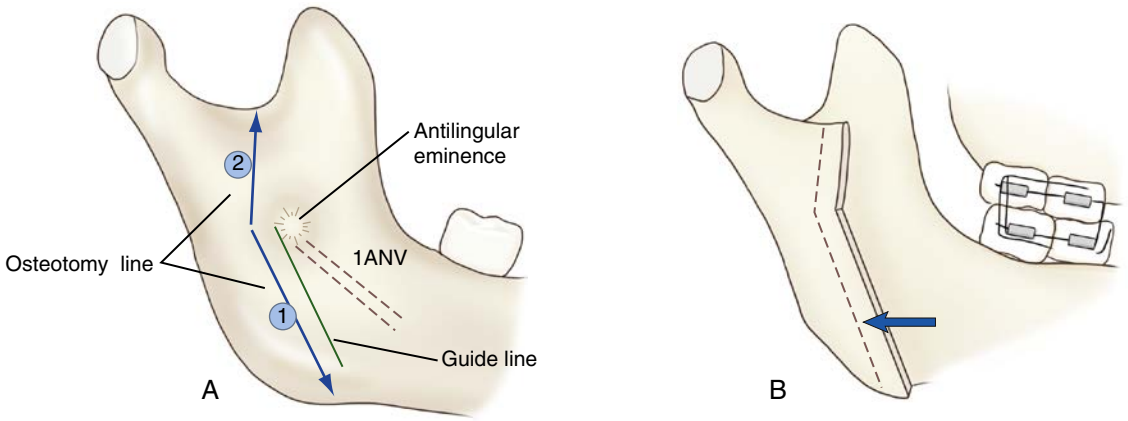

• **Figure 5-23** **A,** Schematic illustration of safe guide line for transoral vertical ramus osteotomy (TOVRO) to avoid inflicting injury on the inferior alveolar neurovascular bundle (IANV). **B,** Schematic illustration shows setback of the distal segment after osteotomy in TOVRO and overlapping between the proximal and distal segments.



• **Figure 5-24** Photograph shows lateral overlapping of the proximal and distal segments after successful completion of transoral vertical ramus osteotomy (TOVRO).

When the IVRO is performed to completion, the proximal segment usually becomes mobile and its lateromedial cut surface can be seen partially. A periosteal elevator can then be introduced to aid in lateral mobilization and overlap of the proximal segment. The same procedure is performed on the opposite side.

After copious irrigation of the wounds with normal saline, an orogastric tube is passed to suction gastric contents reducing postoperative nausea and vomiting. The final planned occlusion is obtained with or without the use of a surgical splint, and MMF is achieved with loop wires. At this point, careful inspection is given to confirm passive overlapping of the lateral proximal segments and a periosteal elevator can be used between the proximal and distal segments to facilitate. If any interference is visualized during setback of the distal segment, or if large divergence of the proximal segment is noted, the medial portion of the proximal segment should be reduced. This can be achieved with rotary instrumentation. Finally, the level of the inferior border of the proximal segment should be evaluated. If it is at any portion overextended over the inferior border of the distal segment, it should also be reduced to prevent abnormal irritation of soft tissue and an excessively prominent gonial angle. The incisions are closed primarily with a running chromic gut suture. After 14 to 21 days, MMF is removed and active physiotherapy is begun (Box 5-11).

During this phase, the use of elastics enables adjustments in postoperative occlusion, thereby promising prolonged stability, and offering a curable effect on preoperative TMD as muscle activation realigns the sagging condyle. As patients begin active physiotherapy while in elastics, any developing anterior open bite must be closely supervised by the surgeon. Self-exercise to maximize hinge opening, protrusion, and lateral excursion should be guided as illustrated in Figure 5-26. If the occlusion remains stable after three to four weeks, guiding elastics can be transitioned to night-time only during sleep and the surgical splint can be removed. By the sixth week, if the occlusion is stable and full range of mandibular motion established, the patient is referred to the orthodontist for retentive and maintenance orthodontics. Until the sixth week, patients are kept on a non-chew diet.

Any open-bite tendency should be evaluated carefully every day or on alternate days during the first week of physiotherapy after removal of MMF. If an open bite greater than 2 mm of interincisal distance develops within the first week of the physiotherapy period, MMF should be again instituted for 3-5 days. The same protocol of physiotherapy should be then repeated.

IVRO Complications

Stability

Controversy remains on the stability of the IVRO. This could be related to movements that create changes that are beyond the limits of this procedure. Using the IVRO for

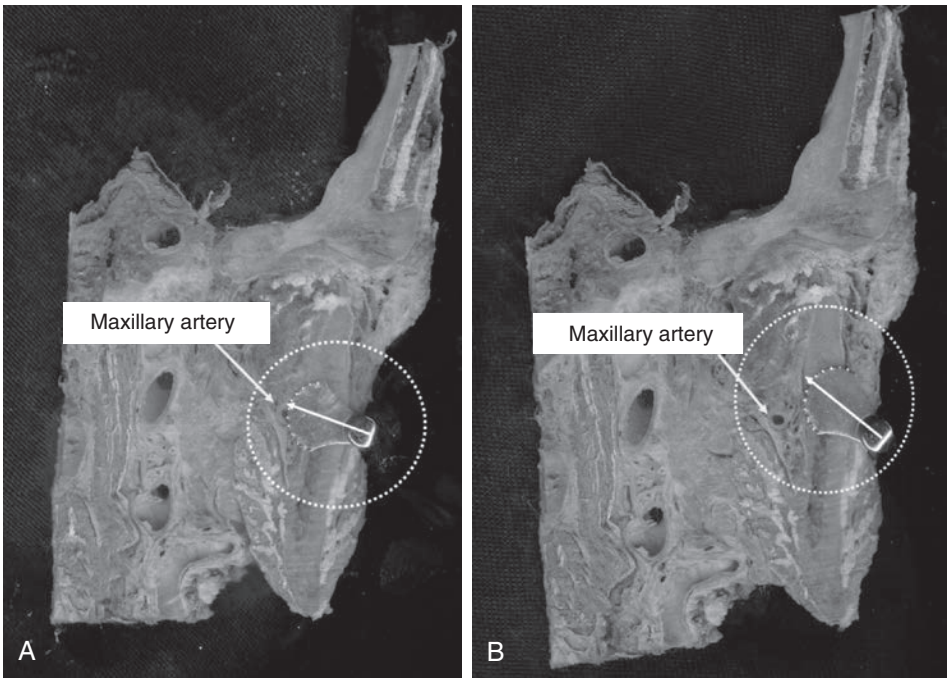

• **Figure 5-25** Important anatomic location of the maxillary artery in association with penetrating direction and depth of a round oscillating saw blade along transoral vertical ramus osteotomy (TOVRO). High risk of injury to the maxillary artery in perpendicular direction of the saw blade **(A)** and safe modification of its direction **(B).**

• BOX 5-11 Postoperative Physiotherapy Requirements

Active physiotherapy initiated by patient after 14-21 days/wire MMF released
Frequent office visits to monitor open bite development
Re-application of wire MMF or heavy elastics for 3-5 days if open bite develops
Aim to achieve normal mandibular range of movement by 6 weeks

large movements, closure of open bites, or in cases with high mandibular plane angles is contraindicated. Literature does not support horizontal overcorrection as a method to prevent skeletal or dental relapse.

Nerve Damage

Given the lesser degree of complexity of the IVRO as compared to the SSRO, the incidence of permanent IAN paresthesia is much less. Recent studies have shown faster recovery of IAN sensation after IVRO compared to SSRO.[95,96] The IAN is not subject to stretching injury with the IVRO and the saw blade usually remains in less proximity to the nerve canal. Studies comparing long-term sensory disturbance after SSRO versus IVRO support this finding.[97,98] Many surgeons believe the incidence of permanent IAN paresthesia after IVRO is close to zero. The nature of subjectivity complicating neurosensory testing is likely the reason studies reporting the incidence of long-term sensory deficit after IVRO range from 0% to 30%.

Other Complications

In regards to infection and edema, there exists little difference in incidence or management of these complications when comparing the IVRO and SSRO. There are, however, certain more infrequently occurring complications specific to the IVRO. Inadvertent bone cuts may decrease the amount of bony contact between poorly overlapping segments and predispose to segment malpositioning. Medial displacement of the proximal segment or dorsal positioning may lead to unplanned changes in the appearance of the angle region and possibly lead to chronic pain. This arrangement may lead to impingement of the IAN with associated neurosensory deficit, but does not seem to impede eventual bony union.[99] Although one should strive for healthy intersegmental overlap, malunions and fibrous unions are exceedingly rare after the IVRO. Complete stripping of all soft tissue at the angle of the mandible has generated concern for the possibility of avascular necrosis of the proximal segment and should be avoided. In some cases where the tip of the proximal segment curves laterally or in cases where there is a large distance between the vascularity from the condyle area, the lower 5-7 mm of the proximal segment is removed to allow passive overlap of the segments.

There exists a significant potential for bleeding while performing the cephalad extension of the osteotomy.

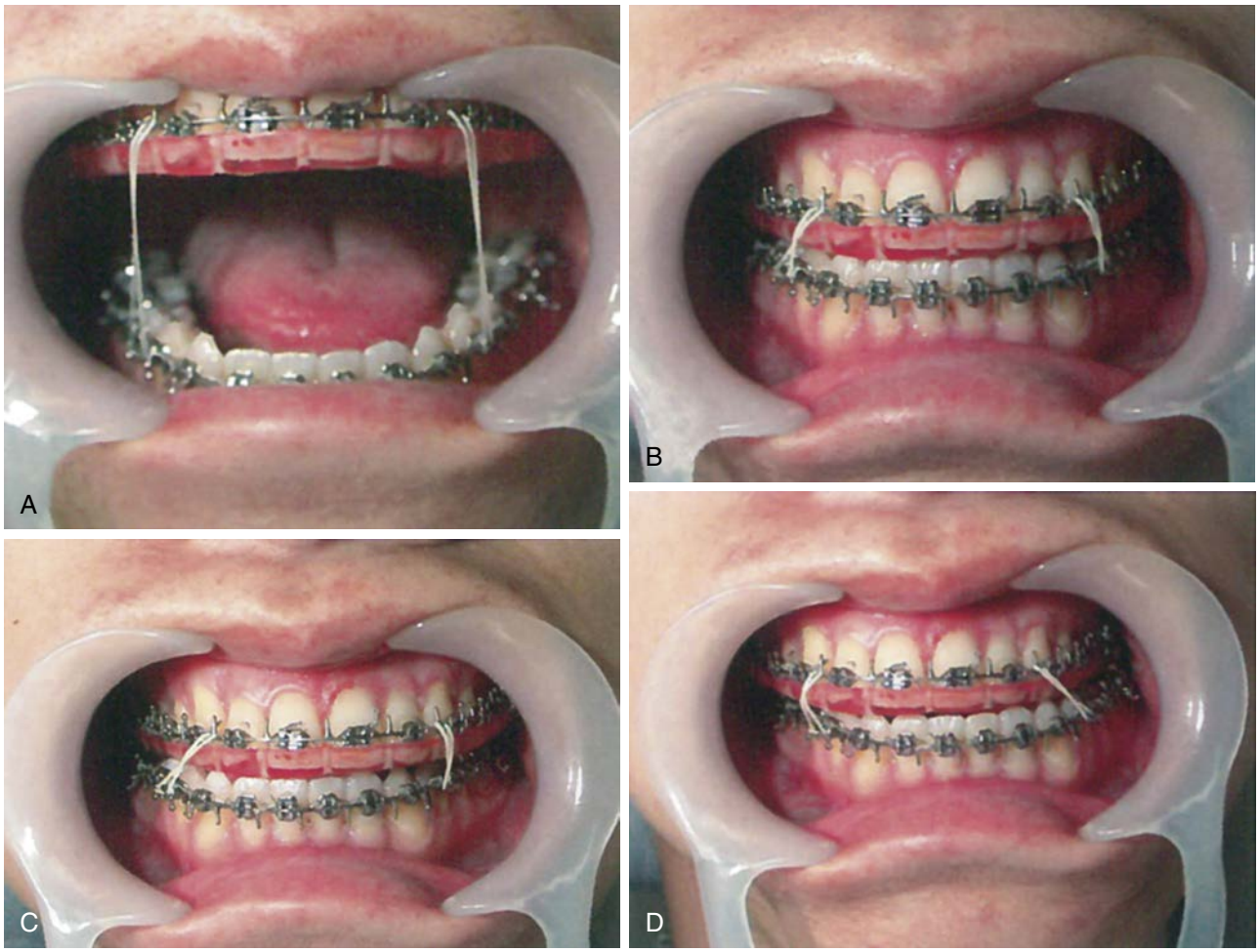

• **Figure 5-26** Basic movements of the mandible required for postoperative active physiotherapy. **A,** Hinge opening movement. **B,** Protrusive excursion movement. **C** and **D,** Lateral excursion movement of the mandible.

Overpenetration through the medial cortex with the oscillating saw could potentially lacerate the internal maxillary artery as it courses medial to the ascending ramus. Another pitfall for hemorrhage during the IVRO exists where the masseteric artery passes through the sigmoid notch, making soft tissue retraction with a well-placed Bauer retractor critical for adjusting the depth of the saw cut as one moves superiorly.

Acknowledgments

The authors wish to acknowledge the previous edition's authors, Dr. Ingeborg M. Watzke and Dr. Hyung-Sik Park, for their previous contributions to this chapter.

References

1. Babcock WW: Surgical treatment of certain deformities of the jaw associated with malocclusion of the teeth, *JAMA* 53:833, 1909.
2. Blair VP: Report of a case of double resection for the correction of protrusion of the mandible, *Dent Cosmos* 48:817–820, 1906.
3. Aziz SR, Simon P: Hullihen & the origin of orthognathic surgery, *Oral Maxillofac Surg* 62:1303–1307, 2004.
4. Trauner R, Obwegeser H: Zur Operationstechnik bei der Chirurgie, *Deutsche Zahn-Mund-und Kieferheilkunde* 23, 1955.
5. Trauner R, Obwegeser H: The surgical correction of mandibular prognathism and retrognathia with consideration of genioplasty. Part I. Surgical procedures to correct mandibular prognathism and reshaping of the chin, *Oral Surg Oral Med Oral Pathol* 10(7):677–689, 1957.
6. Obwegeser HL: Orthognathic surgery and a tale of how three procedures came to be: a letter to the next generation of surgeons, *Clin Plast Surg* 34:331–355, 2007.
7. Dal Pont G: L'osteotomia retromolare per la correzione della progenia, *Minerva Chir* 14:1138–1141, 1959.
8. Dal Pont G: Retro-molar osteotomy for correction of prognathism, *J Oral Surg* 19:42–49, 1961.
9. Steinhäuser E: Rückblick auf die Entwicklung der Dysgnathiechirurgie und Ausblick, *Mund-Kiefe-r und Gesichtschirurgie* 7/6;371–379, 2003.
10. Hunsuck EE: A modified intraoral sagittal splitting technic for correction of mandibular prognathism, *J Oral Surg* 26(4):250–253, 1968.
11. Epker BN: Modifications in the sagittal osteotomy of the mandible, *J Oral Surg* 35(2):157–159, 1977.

12. Spiessl B: Osteosynthesis in sagittal osteotomy using the Obwegeser-Dal Pont method, *Fortschr Kiefer Gesichtschir* 18:145–148, 1974.
13. Lindorf HH: Sagittal ramus osteotomy with tandem screw fixation: technique and results, *J Maxillofac Surg* 14:311, 1998.
14. Niederdellmann H, Schilli W, Ewers R, et al.: Photoelastic behavior of osteosynthesis plates with different arrangements of screw holes for mandible fractures, *Int J Oral Surg* 4:27, 1975.
15. Luhr HG: A micro-system for craniomaxillofacial surgery, *J Craniomaxillofac Surg* 16:312, 1988.
16. Luhr HG: Zur stabilen osteosynthese bei unterkiefer-frakturen, *Dtsch Zahmarztl Z* 23:754, 1968.
17. Champy M, Lodde JP, Wilk A, Grasset D: Plattenosteosynthesen bei mittelgesichtsfrakturen und osteomien, *Dtsch Z Mund-Kiefer-u Gesichts-Chir* 2:26–36, 1978.
18. Champy M: Surgical treatment of midface deformities, *Head Neck Surg* 2:451–465, 1980.
19. Michelet FX, Deymes J, Dessus B: osteosynthesis with minituarized screws and plates in maxillofacial surgery, *J Maxillofac Surg* 1:79, 1973.
20. Bostman OM: Absorbable implants for the fixation of fractures, *J Bone Joint Surg Am* 73(1):148–153, 1991.
21. Suuronen R, Haers PE, Lindqvist C, Sailer HF: Update on bioresorbable plates in maxillofacial surgery, *Facial Plast Surg* 15:61–72, 1999.
22. Champy M, Lodde J, Wilke A, Grasser D: Platenosteotsynthesen, bei mittelgesichlsfrakturten und osteotomien, *Dtsch Z Mund-Kiefer-u Gesichts-Chir* 2:26–36, 1978.
23. Turvey TA, Bell RB, Tejera TJ, Proffit WR: The use of self-reinforced biodegradable bone plates and screws in orthognathic surgery, *J Oral Maxillofac Surg* 60:59–65, 2002.
24. Turvey TA, Bell RB, Phillips C, Proffit WR: Self-reinforced biodegradable screw fixation compared with titanium screw fixation in mandibular advancement, *J Oral Maxillofac Surg* 64(1):40–46, 2006.
25. Moose SM: Surgical correction of mandibular prognathism by intraoral subcondylar osteotomy, *J Oral Surg* 22:197, 1964.
26. Limberg A: Treatment of open-bite by means of plastic oblique osteotomy of the ascending rami of the mandible, *Dent Cosmos* 67:1191, 1925.
27. Winstanley RP: Subcondylar osteotomy of the mandible and the intraoral approach, *Br J Oral Surg* 6:134, 1968.
28. Boyne PJ: Osseous healing after oblique osteotomy of the mandibular ramus, *J Oral Surg* 24:125–133, 1966.
29. Reitzik M: Cortex-to-cortex healing after mandibular osteotomy, *J Oral Maxillofac Surg* 41:658–663, 1983.
30. Hall HD: Intraoral vertical ramus osteotomy. In Bell WH, editor: *Modern practice in orthognathic and reconstructive surgery: mandibular prognathism*, Philadelphia, 1992, WB Saunders.
31. Frost DE: The vertical sigmoid osteotomy. In Booth PW, Schendel SA, Hausamen J-E, editors: *Maxillofacial surgery: orthognathic surgical techniques*, Edinburgh, Scotland, 1999, Churchill Livingstone.
32. Park HS: A clinical study on prognosis of intraoral vertical ramus osteotomy for mandibular setback in the mandibular prognathism, *J Korean Assoc Oral Maxillofac Surg* 23:561–580, 1997.
33. Lee SH, Park HS: Bone healing process in early mobilization after vertical ramus osteotomy of the mandible in adult dogs, *J Korean Assoc Oral Maxillofac Surg* 23:434–457, 1997.
34. Proffit WR: *Contemporary orthodontics*, ed 3, St Louis, 2000, Mosby.
35. Hall HD: Intraoral vertical ramus osteotomy. In Bell WH, editor: *Modern practice in orthognathic and reconstructive surgery: mandibular prognathism*, Philadelphia, 1992, Saunders.
36. Al-Bishri A, Barghash Z, Rosenquist J, et al.: Neurosensory disturbance after sagittal split and intraoral vertical ramus osteotomy as reported in questionnaires and patients' records, *Int J Oral Maxillofac Surg* 34:247–251, 2005.
37. Fontura RA, Vasconcellos HA, Campos AEC: Morphologic basis for the intraoral vertical ramus osteotomy: anatomic and radiographic localization of the mandibular foramen, *J Oral Maxillofac Surg* 60:660–665, 2002.
38. Gahli GE, Sikes Jr JW: Intraoral vertical ramus osteotomy as the preferred treatment for mandibular prognathism, *J Oral Maxillofac Surg* 58:313, 2000.
39. Karas ND, Boyd SB, Sinn DP: Recovery of neurosensory function following orthognathic surgery, *J Oral Maxillofac Surg* 48:124–134, 1990.
40. Manor Y, Blinder D, Taicher S: Sequence of treatment in mandibular prognathism patients, *J Craniomandib Pract* 24:95–97, 2006.
41. Böstman OM: Osteolytic changes accompanying degradation of absorbable fracture fixation implants, *J Bone Joint Surg Br* 73(4):679–682, 1991.
42. Böstman O, Hirvensalo E, Mäkinen J, Rokkanen P: Foreign body reactions to fracture fixation implants of biodegradable synthetic polymers, *J Bone Joint Surg Br* 72:592, 1990.
43. Brady JM, Cutright DE, Miller RA, Battistone GC: Resorption rate, route of elimination and ultra structure of implant site of polylactic acid in the abdominal wall of the rat, *J Biomed Mater Res* 7:155–166, 1973.
44. Van de Perre JPA, Stoelinga PJW, Blijdorp PA, et al.: Perioperative morbidity in maxillofacial orthopedic surgery: a retrospective study, *J Cranio-Maxillofac Surg* 24:263–270, 1996.
45. Panula K, Finne K, Oikarinen K: Incidence of complications and problems related to orthognathic surgery: a review of 655 patients, *J Oral Maxillofac Surg* 59:1128–1137, 2001.
46. Kim SG, Park SS: Incidence of complications and problems related to orthognathic surgery, *J Oral Maxillofac Surg* 65:2438–2444, 2007.
47. Westermark A, Bystedt H, von Konow L: Patients' evaluation of the final result of sagittal split osteotomy: is it influenced by impaired sensitivity of the lower lip and chin? *Int J Adult Orthodon Orthognath Surg* 14(2):135–139, 1999.
48. Gianni AB, D'Orto O, Biglioli F, et al.: Neurosensory alterations of the inferior alveolar and mental nerve after genioplasty alone or associated with sagittal osteotomy of the mandibular ramus, *J Craniomaxillofac Surg* 30(5):295–303, 2002.
49. Van Sickels JE, Hatch JP, Dolce C, et al.: Effects of age, amount of advancement and genioplasty on neurosensory disturbance following a BSSO, *J Oral Maxillofac Surg* 60:1012–1017, 2002.
50. Shirota T, et al.: Effectiveness of piezoelectric surgery in reducing surgical complications after bilateral sagittal split osteotomy, *Br J Oral Maxillofac Surg* 52(3):219–222, 2014.
51. Landes CA, Stubinger S, et al.: Piezoosteotomy in orthognathic surgery versus conventional saw and chisel osteotomy, *Oral Maxillofac Surg* 12(3):139–147, 2008.
52. Jones JK, Van Sickels JE: Facial nerve injuries associated with orthognathic surgery: a review of incidence and management, *J Oral Maxillofac Surg* 49:740–744, 1991.
53. Nishioka GJ, Zysset MK, Van Sickels JE: Neurosensory disturbance with rigid fixation of the bilateral sagittal split osteotomy, *J Oral Maxillofac Surg* 45:20–26, 1987.

54. Posnick JC, Al-Qattan MM, Stepner NM: Alteration in facial sensibility in adolescents following sagittal split and chin osteotomies of the mandible, *Plast Reconstr Surg* 97:920–927, 1996.
55. Yoshida T, Nagamine T, Kobayashi T, et al.: Impairment of the inferior alveolar nerve after sagittal split osteotomy, *J Craniomaxillofac Surg* 17:271–278, 1989.
56. Jacks SC, Zuniga JR, Turvey TA, Schalit C: A retrospective analysis of lingual nerve sensory changes after mandibular bilateral sagittal split osteotomy, *J Oral Maxillofac Surg* 56:700–704, 1998.
57. Pepersack WJ, Chausse JM: Long term follow-up of the sagittal splitting technique for correction of mandibular prognathism, *J Maxillofac Surg* 6:117–140, 1978.
58. Karabouta I, Martis C: The TMJ dysfunction syndrome before and after sagittal split osteotomy of the rami, *J Maxillofac Surg* 13:185–188, 1985.
59. Panula K, Finne K, Oikarinnen K: Incidence of complications and problems related to orthognathic surgery: a review of 655 patients, *J Oral Maxillofac Surg* 59:1128–1136, 2001.
60. Arnett GW, Milam SB, Gottesman L: Progressive mandibular retrusion—idiopathic condylar resorption, Part I, *Am J Orthod Dentofac Orthop* 110:8–15, 1996.
61. Arnett GW, Milam SB, Gottesman L: Progressive mandibular retrusion—idiopathic condylar resorption, Part II, *Am J Orthod Dentofac Orthop* 110:117–127, 1996.
62. DeClercq CA, Neyt LF, Mommaerts MY, et al.: Condylar resorption in orthognathic surgery: a retrospective study, *Int J Adult Orthodon Orthognath Surg* 9:233–240, 1994.
63. Hwang S-J, Haers PE, Sailer HF: The role of posteriorly inclined condylar neck in condylar resorption after orthognathic surgery, *J Craniomaxillofac Surg* 28:85–90, 2000.
64. Cutbirth M, Van Sickels JE, Thrash WJ: Condylar resorption after bicortical screw fixation of mandibular advancement, *J Oral Maxillofac Surg* 56:178–182, 1998.
65. Wolford LM, Karras S, Mehra P: Concomitant temporomandibular joint and orthognathic surgery: a preliminary report, *J Oral Maxillofac Surg* 60:356–362, 2002.
66. Goldstein BH: Temporomandibular disorders: a review of current understanding, *Oral Surg Oral Med Oral Pathol Oral Radiol Endod* 88:379, 1999.
67. Onizawa K, Schmelzeisen R, Vogt S: Alteration of temporomandibular joint symptoms after orthognathic surgery: comparison with healthy volunteers, *J Oral Maxillofac Surg* 53:117, 1995.
68. Tamas F: Position of the mandibular canal, *Int J Oral Maxillofac Surg* 16(1):65–69, 1987.
69. Lupori JP, Kewitt GF, Van Sickels JE: Bilateral sagittal split osteotomy advancement and setback. In Fonseca RJ, editor: *Oral and maxillofacial surgery*, Philadelphia, 2000, Saunders, pp 297–310.
70. Schwartz HC: The timing of third molar removal in patients undergoing a bilateral sagittal split osteotomy, *J Oral Maxillofac Surg* 60(1):132–133, 2002.
71. Epker BN, Le Banc JP: Orthognathic surgery: management of postoperative complications, *Oral Maxillofac Surg Clinics North Am* 2:901, 1990.
72. Lanigan DT, Hey HJ, West RA: Hemorrhage following mandibular osteotomies: a report of 21 cases, *J Oral Maxillofac Surg* 49:713, 1991.
73. Chow LK, Singh B, Chie WK: Prevalence of postoperative complications after orthognathic surgery: a 15-year review, *J Oral Maxillofac Surg* 65(5):984–992, 2007.
74. Proffit WR, Turvey TAT, Phillips C: Orthognathic surgery: a hierarchy of stability, *Int J Adult Orthodon Orthognath Surg* 11(3):191–204, 1996.
75. Lee JH, Kim SO, Jeon JH: The assessment of the stability in mandibular setback surgery related to spatial factors under rotational control of the proximal segment, *Oral Surg Med Oral Pathol Oral Radiol* 117:560–566, 2014.
76. Borstlap WA, Stoelinga PJ, Hoppenreijs TJ, van't Hof MA: Stabilisation of sagittal split advancement osteotomies with miniplates: a prospective, multicentre study with two-year follow-up, Part III, Condylar remodelling and resorption, *Int J Oral Maxillofac Surg* 33(7):649–655, 2004.
77. Proffit WR, Phillips C, Turvey TA: Stability after surgical-orthodontic corrective of skeletal Class III malocclusion: mandibular set back, *Int J Adult Orthodon Orthognath Surg* 6(1):7–18, 1991.
78. Watzke IM, Turvey TA, Phillips C, Proffit WR: Stability of mandibular advancement after sagittal osteotomy with screw or wire fixation: a comparative study, *J Oral Maxillofac Surg* 48(2):108–123, 1989.
79. Van Sickels JE, Richardson DA: Stability of orthognathic surgery: a review of rigid fixation, *Br J Oral Maxillofac Surg* 34:279–285, 1996.
80. Dolce C, Hatch JP, Van Sickels JE, Rugh JD: Rigid versus wire fixation for mandibular advancement: skeletal and dental changes after 5 years, *Am J Orthod Dentofacial Orthop* 121:610–619, 2002.
81. Kundert M, Hadjianhelou O: Condylar displacement after sagittal splitting of the mandibular rami, *J Maxillofac Surg* 8:278, 1980.
82. Spitzer WJ, Steinhauser EW: Condylar position following ramus osteotomy and functional osteosynthesis, *Int J Oral Maxillofac Surg* 16:257–261, 1987.
83. Timmis DP, Chilcoat CC, Skoczylas LJ, et al.: *Correlating TMJ symptoms with condylar position following rigid fixation of sagittal splits*, New Orleans, La, September 24-28, 1986, Abstract presented at 68th Annual American Association of Oral and Maxillofacial Surgeons (AAOMS) Scientific Session.
84. Turvey TA, Hall DJ: Intraoral self-threading screw fixation for sagittal osteotomies: early experiences, *Int J Adult Orthodon Orthognath Surg* 1:243–250, 1986.
85. Bell WH, Yamaguchi Y: Condyle position and mobility before and after intraoral vertical ramus osteotomies and neuromuscular rehabilitation, *Int J Adult Orthodon Orthognath Surg* 6:97–104, 1991.
86. Ueki K, Marukawa K, Nakagawa K, et al.: Condylar and temporomandibular joint disc positions after mandibular osteotomy for prognathism, *J Maxillofac Surg* 60:1424–1432, 2002.
87. Park HS: A clinical study on prognosis of intraoral vertical ramus osteotomy for mandibular setback in the mandibular prognathism, *J orean Assoc Oral Maxillofac Surg* 23:561–580, 1997.
88. Fontura RA, Vasconcellos HA, Campos AEC: Morphologic basis for the intraoral vertical ramus osteotomy: anatomic and radiographic localization of the mandibular foramen, *J Oral Maxillofac Surg* 60:660–665, 2002.
89. Gahli GE, Sikes Jr JW: Intraoral vertical ramus osteotomy as the preferred treatment for mandibular prognathism, *J Oral Maxillofac Surg* 58:313, 2000.
90. Boyd SB, Karas ND, Sinn DP: Recovery of mandibular mobility following orthognathic surgery, *J Oral Maxillofac Surg* 49:924–931, 1991.
91. Park HS, Huh JY, Lee WJ: Evaluation of gonial angle asymmetry after IVRO in facial asymmetry with mandibular prognathism, *J Korean Assoc Oral Maxillofac Surg* 23:78–88, 1997.
92. Hall HD: Intraoral vertical ramus osteotomy. In Bell WH, editor: *Modern practice in orthognathic and reconstructive surgery: mandibular prognathism*, Philadelphia, 1992, WB Saunders.

93. Hogan G, Ellis E: The "antilingula"—fact or fiction? *J Oral Maxillofac Surg* 64:1248–1254, 2006.
94. Aziz SR, Dorfman BJ, Ziccardi VB: Accuracy of using the antilingula as a sole determinant of vertical ramus osteotomy position, *J Oral Maxillofac Surg* 65:859–862, 2007.
95. Hasegawa T, Tateishi M, Asai Y: Retrospective study of changes in the sensitivity of the oral mucosa:sagittal split ramus osteotomy (SSRO) versus intraoral vertical ramus osteotomy (IVRO), *Int J Oral Maxillofac Surg* 44:349–355, 2015.
96. Hasegawa T, Tateishi M, Asano N: Changes in the sensitivity of cutaneous points and the oral mucosa after intraoral vertical ramus osteotomy, *Int J Oral Maxillofac Surg* 42:1454–1461, 2013.
97. Al-Bishri A, Barghash Z, Rosenquist J, et al.: Neurosensory disturbance after sagittal split and intraoral vertical ramus osteotomy as reported in questionnaires and patients' records, *Int J Oral Maxillofac Surg* 34:247–251, 2005.
98. Westermark A, Bystedt H, Von Konow L: Inferior alveolar nerve function after mandibular osteotomies, *Br J Oral Maxillofac Surg* 36(6):425–428, 1988.
99. Tuinzing DB, Greebe RB: Complications related to the intraoral vertical ramus osteotomy, *Int J Oral Surg* 14(4):319–324, 1985.

6

Genioplasty

RISHI JAY GUPTA, DAVID S. PRECIOUS, STEPHEN A. SCHENDEL

Introduction

Surgical alteration of the chin is an important aspect of achieving or restoring global facial balance in the management of dentofacial deformities. Genioplasty is performed to restore muscle function and osseous anatomy of the anterior mandible. Cephalometric and three-dimensional (3D) analysis enables the clinician to assess the various components of the dentofacial complex, including the chin. In current practice, the two common genioplasty techniques include augmentation with an alloplastic implant or osteotomy and/or ostectomy.

Each technique has its benefits and limitations. Chin alloplastic implants have limitations when addressing vertical bony excess and improving muscle function and strain. However, chin alloplastic implants can facilitate lateral contour augmentation, which can be a problem when chin osteotomy is performed alone. Various genioplasty techniques by osteotomy-ostectomy have been described in the literature, which include sliding genioplasty, functional genioplasty with creation of a tenon and mortise, and sagittal split genioplasty. Osseous genioplasty is an osteotomy-ostectomy of the anterior mandible that helps maintain the lower anterior facial height to 55% of total anterior facial height. This procedure is indicated particularly when the long-face syndrome is caused by bony excess of the anterior mandible. Superior repositioning and advancement of the chin and myocutaneous structures produce both functional and esthetic benefits for the patient. Osseous genioplasty not only corrects cosmetic deformities and vertical height of the chin, but it also ameliorates hyperactivity of the mentalis muscle complex and improves obstructive sleep apnea syndrome through the advancement of the genioglossus muscle and genial tubercle complex. Anatomic placement of fixation devices used in genioplasty is an important long-term consideration.

Functional Genioplasty

The term *functional genioplasty* seems to represent something of a paradox because, in the past, surgery on the chin has been thought of primarily in the context of cosmetics. In humans, changes in form produce attendant changes in function; the functional genioplasty is an example of an operation that can bring about a beneficial change in function by altering the position and form of the chin and its associated myocutaneous structures.

The maxillary component of vertical excess of the anterior face has been described in detail with respect to both diagnosis[1,2] and treatment.[3,4] However, less attention has been directed to the anterior mandible as a component of the excessive vertical dimension. Muller[5] has stressed the importance of the state of balance that exists in the normal face between the hard structures of the lower face (namely, the maxilla, the mandible, and the teeth) and the soft tissue elements (namely, the tongue, the labiomental musculature, and the overlying skin). During growth, if the hard tissues and the soft tissues of the lower face are in balance, the lower face will register itself harmoniously in the rest of the face. Artists, among others, have interpreted this harmony as equality in height of the upper face and the lower face.

Subjective clinical impression of facial harmony and symmetry is imprecise. Fields and associates[6] have shown that experienced clinicians poorly categorize underlying skeletal deformities solely on the basis of evaluation of the soft tissue profiles. Wylie[7] demonstrated radiographically that the upper anterior face, measured from nasion (Na) to anterior nasal spine (ANS), constitutes 45% of the total anterior facial height and that the lower anterior facial height, measured from ANS to menton (Me), constitutes 55%. Delaire[8] has confirmed via architectural and structural craniofacial analysis that these percentages represent constants of ideal vertical facial height.

When an anomaly of form and function of the hard or soft tissue elements of the lower face is present during growth, it affects the neighboring structures, which together can produce a progressive regional disequilibrium until maturity is reached. This is demonstrated in cases with excessive ANS-Me distance in the presence or absence of vertical maxillary excess. The lips become incompetent in repose and no longer oppose the thrust of the tongue, which now can interpose itself between the teeth. To occlude the lips, active contraction of the labiomental musculature is

necessary; this, in turn, ultimately causes flattening of the soft tissue contour of the chin and can be associated with dental changes with associated gingival recession (Figure 6-1). On the other hand, deficient ANS-Me distance due to retrogenia or deep bite cause the patient to appear aged due to deep labiomental sulcus and redundant submental tissue. These anatomical discrepancies lead to functional habits that produce clinical problems, which represent the indications for surgical intervention.

Indications

Indications for genioplasty are as follows.

Vertical Excess

Vertical excess of the lower anterior facial height resulting from the anterior mandible requires a reduction genioplasty by removal of a precise amount of bone. A wedge resection and rotation of the inferior chin segment superiorly is the most predictable approach. Anterior advancement is sometimes required because most chins that are vertically long are also retrusive. If the soft tissue remains attached to the inferior border, then the soft tissue change is approximately 90% of the vertical osseous change. The following clinical signs and radiographic findings are present in patients with vertical excess of the lower anterior facial height (Figure 6-2).

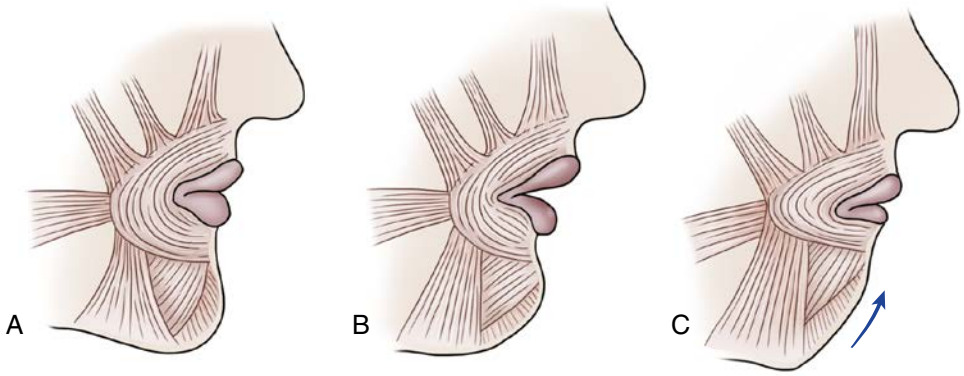

• **Figure 6-1** **A,** Normal harmonious labiomental balance with lip competency. **B,** Open mouth posture associated with lip incompetency when labiomental muscles are at rest. **C,** Typical flattening of the anterior surface of the chin due to contraction of the labiomental muscles in an attempt to achieve bilabial contact.



• **Figure 6-2** **A,** Labiomental muscles at rest showing lip incompetency. **B,** Bilabial contact results in flattening of the contour of the chin. **C,** Muscle dysfunction evidenced by "mentalis strain."

Clinical Signs

1. Lip incompetence when the lips are in repose and a normal relationship exists between the maxillary incisor to the upper lip
2. Open mouth posture with interposition of the tongue between the teeth
3. Elevation of the mental soft tissues to obtain lip closure resulting in a strained appearance of the overlying skin on the chin with flattening of the profile and loss of labiomental sulcus
4. Thinning of the alveolar bone overlying the facial surfaces of the roots of the anterior mandibular teeth

Radiographic Findings

1. ANS-Me distance, which constitutes more than 55% of the total anterior facial height, in the absence of vertical maxillary excess
2. ANS-Me distance, which persists in constituting more than 55% of the total anterior facial height after predicted or actual appropriate correction of vertical maxillary excess, open bite, or anteroposterior dentofacial deformities

Vertical Deficiency

The vertical deficiency of the lower anterior facial height constitutes less than 55% of the total anterior facial height. A deep labiomental sulcus and redundant submental tissue may be present. Horizontal osteotomy and inferior repositioning of the chin segment or placement of alloplastic implant are used to vertically augment the symphysis region. The osseous change results in 100% of soft tissue change.

Anteroposterior Excess

Anteroposterior excess can be appreciated with deep labiomental sulcus and lip incompetence. Treatment includes a sliding genioplasty with posterior placement or shaving of the anterior mandible. This discrepancy is the most technically challenging to address. A posterior sliding genioplasty causes the inferior bony component to appear in the facial view, which can be unesthetic. The amount of bony shaving is limited due to concerns of stripping too much soft tissue and muscle from the chin leading to ptosis. Reducing the chin by more than 7 mm indicates significant skeletal disharmony, which may require bimaxillary surgery and shortening of the posterior facial height. This will lead to rotation of the pogonion posteriorly. Generally, soft tissue changes approximately 90% of the amount of bony change with a sliding genioplasty. If the soft tissue is stripped off the anterior mandible, care must be taken to resuspend the mentalis muscle to prevent ptosis of the chin.

Anteroposterior Deficiency

The anteroposterior deficiency of the symphysis region requires augmentation with an advancement osseous genioplasty or alloplastic implant. If the chin is narrow in the transverse dimension, then the face will appear more tapered after an advancement osseous genioplasty. An alloplastic genioplasty can be used for 4- to 5-mm advancements. A sliding genioplasty is used when the goal is to augment both the anterior and vertical dimensions. The soft tissue changes approximately 80% to 85% of the amount of bony augmentation. Furthermore, the anterior bony resorption can occur over time, resulting in 80% of the original bony advancement.

Associated Deformities of the Upper Lip or Cleft Lip/Cleft Palate

Residual and associated deformities of the upper lip or cleft lip/cleft palate, particularly in the case of insufficient cheiloplasty in which the upper lip is too short, can be further improved with a genioplasty. Superior repositioning of the mental osseous and the myocutaneous tissues can aid in achievement of lip competence and development of the upper lip.

Transverse Facial Asymmetries

Genioplasty can be utilized as a complementary procedure to adjust lower anterior facial height and horizontal asymmetry when maxillary and mandibular osteotomies are performed for correction of anteroposterior and transverse maxillofacial deformities. The sliding genioplasty will place the chin midpoint on with the midline of the face and correct asymmetries in the inferior border of the mandible.

Post-Orthodontic Treatment

Genioplasty can aid in stabilization of orthodontic treatment results by normalization of the osseous and myocutaneous elements of the lower face.

Genioglossus Advancement

The anterior mandible and attached genioglossus muscle are advanced to protract the tongue base, which increases the oropharyngeal space and alleviates obstructive sleep apnea symptoms.

Treatment Planning

A complete architectural and structural craniofacial analysis is carried out to determine the degree to which the individual patient varies from his or her "ideal." This analysis demonstrates all of the maxillofacial deformities and imbalances that require correction. The ideal analysis should also coincide with the clinician's clinical judgment.

Soft tissue esthetics are analyzed using a lateral facial photograph or a lateral skull film. The technique utilizes angles and their relative proportions to compare the major

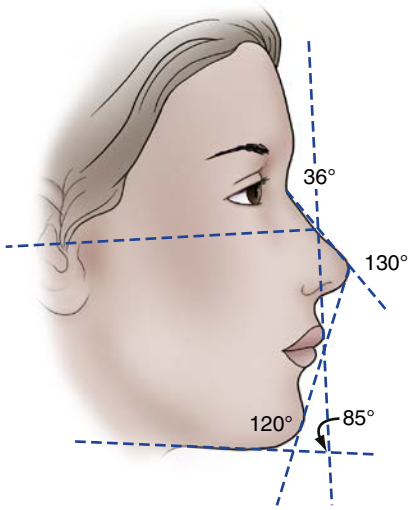

• **Figure 6-3** Esthetic Soft Tissue Analysis. The following angles are used to analyze the facial profile: nasofacial angle, 30 to 40 degrees; nasomental angle, 120 to 132 degrees; mentocervical angle, 80 to 95 degrees to vertical and 110 to 120 degrees to nasomental line.

soft tissue units of the face[8] (Figure 6-3). The following are the major angles of the normal adult face:

1. Nasofacial angle, 30 to 40 degrees
2. Nasomental angle, 120 to 132 degrees
3. Mentocervical angle, 80 to 95 degrees to the vertical and 110 to 120 degrees to the nasomental line

The angles are formed from five lines. The horizontal line is drawn along the Frankfort horizontal or the true horizontal line from a plumb line on a cephalometric radiograph taken in the natural head position. The vertical line is perpendicular to the horizontal line and is drawn through the glabella or the subnasale. The subnasale point is the preferred location for the vertical line. The third line is drawn tangent to the nasal dorsum and will intersect the vertical line, forming the nasofacial angle. The fourth line is drawn from the nasal tip to the pogonion, called the nasomental line. The nasal dorsal line and the nasomental line form the nasomental angle. The upper lip is 1 to 2 mm behind the nasomental line, and the lower lip is 2 to 4 mm behind the nasomental line. The fifth line is drawn tangent to the menton passing through the innermost curve at the junction of the neck and submental areas. This line will form an angle with the nasomental line and the vertical line.

Some key soft tissue measurements must be evaluated when assessing the lower face. The labiomental angle is formed between the lower lip and chin, and the average value is 110 to 130 degrees. Excessively proclined lower incisor teeth, a prominent chin, and a reduced lower anterior facial height may lead to an acute labiomental angle (deep labiomental sulcus). The normal upper lip length is 21 mm plus or minus 2 mm for men and 19 mm plus or minus 2 mm for women. There should be a ratio of 1:2 when comparing the distance between the subnasale-stomion and stomion-menton. The pogonion is typically 1 to 4 mm behind the vertical line through the subnasale. Hyperfunction of the facial muscles should also be examined to assess for abnormal tissue contours and changes in lip position.

Although the principles and details of the skeletal analysis have been presented in previous articles,[9,10] a brief review is presented here of those points and lines that are relevant to determination of the amount of osseous resection and chin advancement that will be required for a vertically excessive lower facial height at surgery (Figure 6-4).

Line C3

The superior line of the cranial base is traced from point M, the junction of the nasomaxillary and nasofrontal sutures, to point Clp, the apex of the posterior clinoid process; it is extended until it intersects the external surface of the occipital bone at point Op, the most posterior extremity of the occipital bulbosity.

Line CF1

The anterior line of craniofacial balance is traced through point FM, the frontomaxillary articulation, perpendicular to line C3 in adult males but at an angle of 85 degrees in women and children.

Line CF4

The craniopalatal line is traced parallel to line C3 through point ANS, to a point just below the lowest point of convexity of the squamous occipital bone.

Line CF5

The line of theoretical facial height is traced, by convention, perpendicular to line CF4 through point ANS. It is extended superiorly to point Ná, the projection of point Na, then inferiorly to point mé, the location of which is determined by the following formula:

$$\text{Ideal total anterior facial height} = \text{Ná} - \text{mé}$$
$$\text{Ná} - \text{mé} = (\text{Ná} - \text{ANS}) + (\text{ANS} - \text{mé})$$
$$= 2(\text{Ná} - \text{ANS}) + (2(\text{Ná} - \text{ANS}))/10 \text{ mm}$$

This formula is derived from the fact that the upper anterior facial height, Ná – ANS, constitutes 45% of the total anterior facial height.

Once the Ná – mé distance has been calculated, the arc of a circle (center Na with radius equal to the distance from Ná – mé) is traced via architectural and structural analysis. When this arc intersects line CF1, this is the "ideal" position of menton (point me). Both the amount of bone to be resected for the vertical correction and the distance by which the chin should be advanced can now be determined by comparing the ideal position of menton (me) with that of the patient's real menton (Me) (Figure 6-5).

This tracing maneuver is not valid when vertical maxillary excess, a significant open bite, or important anteroposterior deformities are present. In these cases, it is best to carry out the prediction tracing for correction of the major deformity, after which it is possible to apply the method described above to determine the amount of discrete osseous reduction and advancement of the chin.

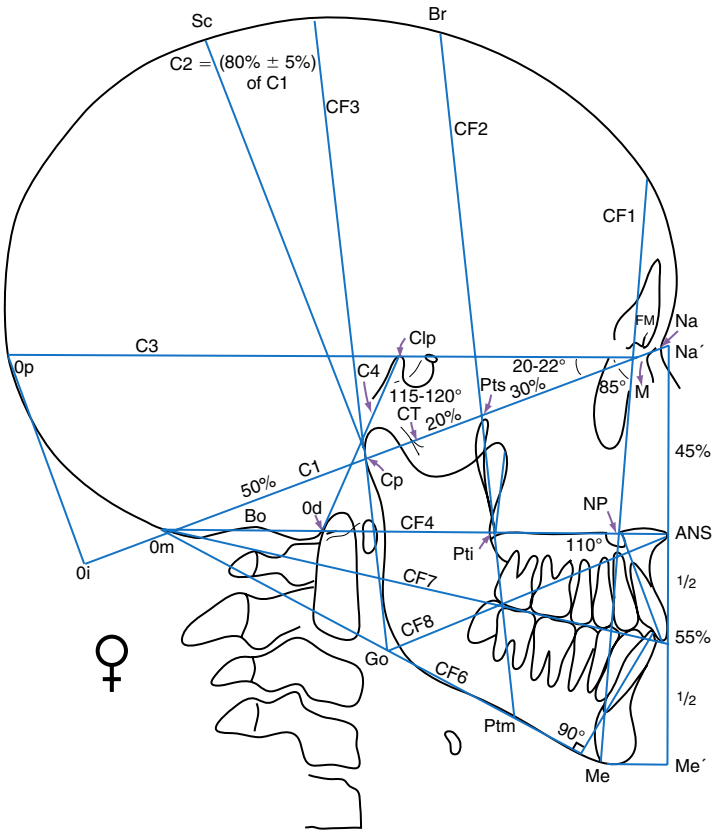

• **Figure 6-4** Architectural and structural craniofacial analysis of Delaire.

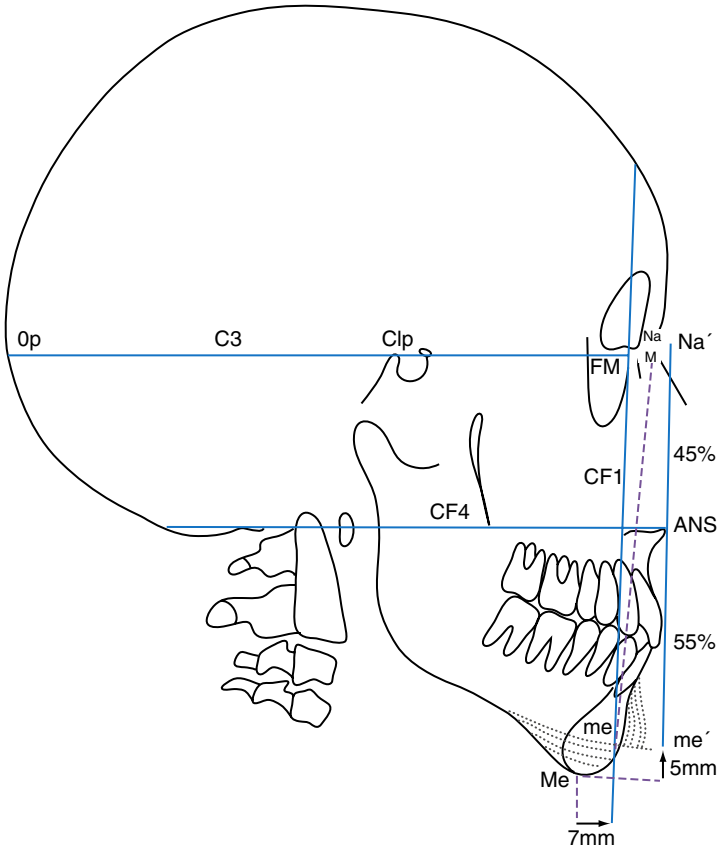

• **Figure 6-5** Determination of "ideal" position of menton point (*me′*). Broken line represents the radius *(Na/me)* of the circle centered at *Na*. Coarse stippling represents vertical excess of the anterior mandible. Fine stippling indicates predicted contour of the chin, based on 5 mm of superior movement and 7 mm of anterior movement, of existing menton point *(Me)* to position of ideal menton point *(me′)*.

In the particular case of open bite, it is possible to gain an appreciation of the amount of bone that ultimately will have to be resected by tracing the arcs of two circles—one with the center point I (the incisal tip of the mandibular incisor tooth), the other with the center Me (real menton), both with radius (ANS – mé)/2 F002B 3 mm. Three millimeters must be added to the distance (ANS – mé)/2 to account for the depth of overbite that will be present after the open bite itself has been corrected.[11]

The treatment planning discussed thus far entails analysis of two-dimensional images and soft tissue. Advances in spiral 3D computed tomography (CT) scans and computer hardware and software have made virtual 3D craniofacial surgery possible. Various companies have developed protocols to obtain current patient data, which includes CT scan of the face, bite registration, and recent upper and lower dental casts, to provide computer-based virtual planning of the orthognathic cases. This can be used for surgical simulation, planning with morphologic studies, and growth analysis. Based on the final simulated movements, the surgical splints for orthognathic surgery can then be printed. Similarly, genioplasty cutting and plating guides can also be fabricated based on the simulated movements. 3D planning and data analysis will standardize the qualitative and quantitative longitudinal follow-up of patients in different centers and improve treatment outcome.

Surgery

Michelet Genioplasty

The genioplasty surgical procedure described by Michelet and colleagues[12] consists of a horizontal osteotomy of the anterior mandible, with construction by segmental ostectomy of a superior tenon and an inferior, lingual mortise. The resected fragments are wedge shaped by design and thus are perfectly suited for placement as bone grafts in other surgical sites (for example, in the bony defects created by multi-segment Le Fort osteotomy of the maxilla[13]).

This is often called a functional genioplasty and can be carried out as soon as the mandibular permanent cuspid and premolars teeth have erupted, after the age of 12. This procedure is performed, with the patient under general anesthesia, through a mandibular labial vestibular incision, which is extended from one premolar area to the other, after infiltration of local anesthesia with 1:100,000 solution of epinephrine. The anterior aspect of the mandible is exposed via subperiosteal dissection, which stops before the inferior border, thereby preserving the insertions of the labiomental muscles (see Figure 6-5, *A*). Specifically, these muscles include the mentalis, depressor anguli oris, and depressor labii inferioris, and part of the orbicularis oris.

The osteotomy cuts are outlined with a small burr (see Figure 6-5, *B*). The height of the vertical arms of the tenon corresponds to the magnitude of the predetermined bony resection. The inferior horizontal osteotomy then is completed with a reciprocating saw, after which the bicortical tenon is constructed through resection of lateral wedge-shaped pieces of bone (see Figure 6-5, *C*). A mortise now is cut in the mid-superior portion of the lingual aspect of the inferior bony fragment. The depth of the mortise is the difference between the amount of predetermined chin advancement and the thickness of the inferior bony fragment (see Figure 6-5, *D*). The inferior fragment then is advanced and is repositioned superiorly by fitting the mortise on the tenon.

Fixation is accomplished by transosseous wires or single midline screws which are placed to create a directional pull where the anterior inferior mortise is brought into good apposition with the superior and now posterior tenon (see Figure 6-5, *E*). Watertight closure of the vestibular incision is accomplished with 4-0 polyglycolic acid sutures, after which a pressure dressing is placed for 5 days on the skin overlying the mental tissues (Figure 6-6). It is important to stress the simplicity of this technique. Morbidity is minimal, and a very low incidence of alteration in mental nerve function is associated with this procedure.[14]

Sliding Genioplasty

The sliding genioplasty is used for reduction and advancement of the chin (Figure 6-7). Periosteal elevation and muscle detachment are minimized to allow precise and predictable soft tissue repositioning. Long-term radiographic evaluation shows a stable advancement, with minimal bone resorption occurring at the superior edge of the distal segment. Bone deposition occurs near the B point of the alveolus.

This procedure can be done as an outpatient procedure under general anesthesia or with intravenous sedation. The anterior mandibular vestibule is infiltrated with local anesthetic and epinephrine from first bicuspid to first bicuspid. An incision is made from canine to canine on the inner surface of the lip 2 to 3 mm past the sulcus in order to leave an adequate sewing cuff. The initial cut is perpendicular to mucosa. Then, as muscle is transected, the angle of the cut is altered perpendicular to the bone and continued through the periosteum. A subperiosteal dissection is performed just inferior of the planned horizontal osteotomy. At least 5 mm of attached periosteum and muscle are left between the inferior border of the symphysis and the subperiosteal dissection. Detachment of all soft tissue from the distal segment results in chin sagging, retraction of the lower lip, and unpredictable soft tissue changes. Suture closure is assisted by slightly elevating mucosa superior to the incision.

The mental nerves are identified by placing the periosteal elevator at the corner of the incision and the inferior border of the mandible. The periosteum is elevated posteriorly and tented laterally, which exposes the neurovascular bundle without causing damage.

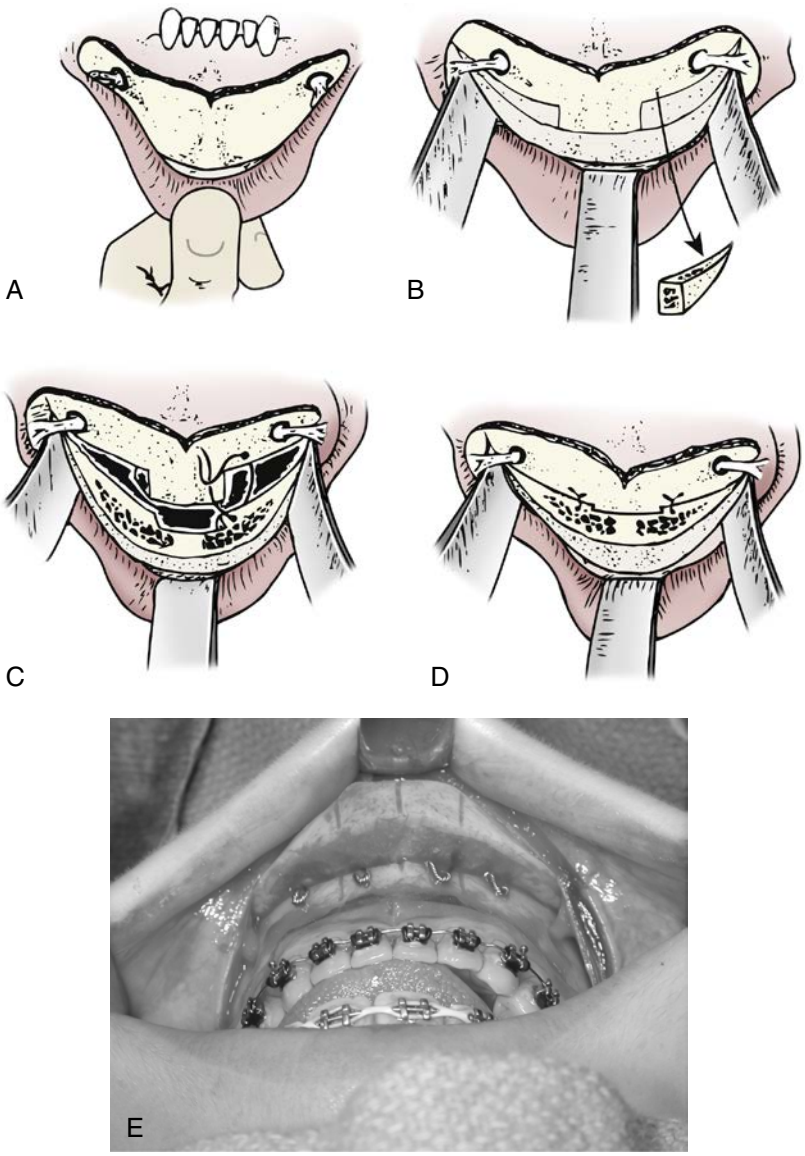

• **Figure 6-6** **A,** Subperiosteal exposure of the anterior surface of the chin and exposure of mental nerves. **B,** Outline of osteotomy-ostectomy design. **C,** Lateral bony wedges removed and creation of mortise and tenon. **D,** Superiorly repositioned and advanced inferior bony segment with attendant labiomental muscles. **E,** Clinical view showing excellent apposition of bony segments with fixation wires in an area of future bony apposition.

The mental nerve is superior to this position at the level of the canine apices. Once the mental nerves and foramina are visualized, the subperiosteal dissection is carried posterior and superior to them. If it is necessary to complete the osteotomy without tension on the mental nerves, the incision can be extended posteriorly above the nerves with scissors. A subperiosteal dissection is performed beneath the inferior border of the mandible adjacent to the nerves, which permits protective retraction for the bone cutting.

The osteotomy must be at least 4 mm below the incisor root apices to ensure tooth viability. The incisor length can be measured on the preoperative radiographs and is usually 24 mm from incisal edge to root apex. Calipers are used to mark the incisal midline 27 to 28 mm from the incisal edge. Burr holes (1-1.5 mm) are made 1 mm above and below the osteotomy line to keep the distal segment appropriately aligned at the time of fixation.

The osteotomy is made with a reciprocating saw from lateral to medial, with care taken to protect the nerve. Both the buccal and lingual cortices are cut simultaneously. In addition, the osteotomy should be 4 mm below the mental foramen because, as it extends posterior to the foramen, it enters the area where the nerve may dip inferiorly before its exit from the foramen. If a wedge ostectomy is being done, then the inferior osteotomy should be made before the superior osteotomy. This will prevent premature mobilization of the chin, which makes the second (inferior) cut more difficult.



• **Figure 6-7** Pressure dressing with elastic bandage is placed on the skin overlying the mental tissues for 5 days.

A similar procedure is carried out on the opposite side, and mobilization is completed with an osteotome. The removal of the osteotomized bone or the advancement of the chin is performed next. The inferior segment is fixed with 26-gauge stainless steel wire, a cancellous screw, or plates and screws. If the advancement is minimal, fixation can be accomplished by two wires passed through the buccal cortex 1.5 to 2 mm from the midline on each side. If the advancement is more substantial, the wires must be passed through the lingual cortex of the distal segment as well; in these cases a midline wire or the screw is used. For large advancements that approach the total width of the inferior segment or where a strong pull by the omohyoid muscle rotates the distal segment inferiorly, a plate system is best used.

The surgical site is irrigated, and the incision is closed with a single layer of 4-0 absorbable suture that bites mucosa and muscle simultaneously. Chin dressing is placed for up to 5 days as described above. Patients are kept on a soft diet for 1 week and given perioperative antibiotics.

Sagittal Split Genioplasty

A common concern with the sliding osteotomy is the hourglass esthetic deformity seen in the frontal view due to the notching at the inferior border of the mandible. This

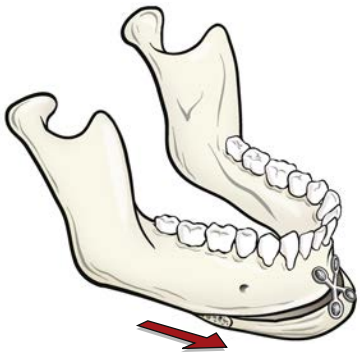

• **Figure 6-8** Sliding genioplasty. Osteotomy is made parallel to the occlusal surface. To increase vertical height, a bone graft is placed between the osteotomy site. To decrease the height, a wedge of bone can be removed.

deformity is accentuated with increasing the inferior segment advancement, which may require additional bone grafting. The sagittal split genioplasty technique described by Schendel avoids the notching complications and is indicated for the retrusive chin that is slightly vertically short or long.[15]

This procedure can also be performed as an outpatient.

The mucosal incision and subperiosteal is performed as described above. Once the periosteum is elevated inferiorly and posteriorly to the mental foramen, the midline of the chin is marked with three burr holes. The middle hole is around 24 mm from the lower incisors' incisal edges, and the other two holes are on either side of the first hole. The osteotomy is begun below and slightly posterior to the right or left mental foramen. The reciprocating saw blade is then oriented vertically and in the sagittal plane (Figure 6-8). The cut starts approximately 6 mm below the mental foramen and exits at the inferior border. The saw is carried forward in this plane until the area mesial to the cuspid tooth is reached. At this point the saw blade is rotated into a horizontal position as the remainder of the cut is completed in the usual manner as shown, this results in a sagittal split of the lateral one third to two thirds of the inferior chin segment. Advancement of the inferior chin segment then does not result in a gap at the inferior border of the mandible behind the advanced segment. The area behind the advanced chin segment still has the normal vertical mandibular height because of the sagittal splitting and no through-and-through gap is created. This is similar to what happens with the sagittal split ramus osteotomy when the mandibular body is advanced (Figure 6-9). The inferior chin segment is then secured in the anterior region by rigid fixation using a chin plate and screws. The oral incision is then closed in a similar fashion and a chin dressing is placed as described above.

Alloplastic Genioplasty

Many different synthetic materials to augment the chin have been reported and described in the literature. Alloplastic genioplasty may be performed after the mandibular anterior

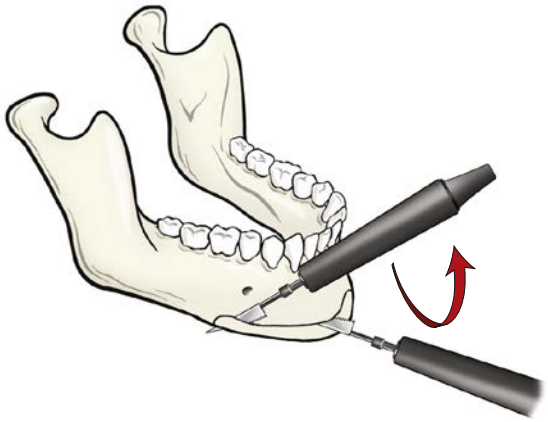

• **Figure 6-9** Sagittal split genioplasty. Orientation of the reciprocating saw for the sagittal sliding genioplasty. The saw is first oriented as vertical as possible with the blade in the sagittal sense lateral to the bicuspid teeth. The osteotomy is started at least 6 mm below the mental foramen and the blade exits at the inferior border in this region. The saw is then carried forward in the sagittal plane until the area mesial to the cuspid is reached. At this point the saw blade is curved into a horizontal position as its cuts and the remainder of the osteotomy is completed in the usual horizontal manner as shown. This results in a sagittal split of the lateral one third to two thirds of the inferior chin segment.

teeth have erupted. Rigid stabilization of the implant is important to ensure immobility and to prevent esthetic changes. Improver fixation and soft tissue coverage of the implant can lead to infections.

Alloplastic genioplasty is indicated for patients with retrogenia, minimal dentofacial deformity, and class 1 occlusion. Alloplastic genioplasty can be routinely combined with other esthetic procedures such as face-lift, rhinoplasty, and blepharoplasty. When compared to osseous genioplasty, this technique is simpler, has less postoperative pain, edema, and ecchymosis, and has a faster recovery. The surgical technique entails an intraoral approach as described above or an extraoral approach via an incision in the submental region. The dissection is carried down to the inferior border of the mandible. The alloplastic implant is placed subperiosteally and secured with screws.

Silastic chin implants do not allow bony in-growth into the implant and cause significant bone resorption with approximately 80% of soft tissue changes. This material is not commonly used today and not recommended. Porous block hydroxyapatite (Interpore 200) comes in a left and right segment that allows bony in-growth into the implant. The implant is stabilized with screws, and no bony resorption is clinically evident under the implant. This material is brittle and difficult to handle. Porous polyethylene implants contains interconnecting, omni-directional pore structure to allow for fibrovascular in-growth. This material comes in one or two segments and is also stabilized with a screw. No bony resorption is clinically evident under the polyethylene implant.

Complications

Osseous and alloplastic genioplasty can lead to various complications including infection, bone resorption, loss of osteotomized bone segment, displacement and esthetic concerns, paresthesia of lower lip and chin, mentalis dysfunction, and lip ptosis. Thorough irrigation and sterility of the implants is critical to prevention of infections. Bony resorption and displacement of the osseous or implant segments may require repeat surgeries to correct the issues. Lower lip and chin paresthesia can be avoided with careful dissection and avoidance of excessive traction on the nerve. If the nerve is transected, it should be repaired immediately. Lower lip ptosis may be caused by excessive detachment of the soft tissue from the inferior chin region or inadequate positioning and resuspension of the mentalis muscle.

Fixation Devices and Long-term Bony Changes

In the evaluation of postoperative radiographs after genioplasty, it has been reported that the inferior segment can be posteroinferiorly rotated in an appreciable number of cases.[16] This undesirable movement is compounded when significant advancement and wire osteosynthesis are placed on the lingual cortex of the inferior fragment with no other support. Use of rigid internal fixation (RIF) with metal plates and screws or screws alone appears to provide the solution for minimizing this displacement. Some authors[17-20] have also advocated the use of RIF in genioplasty to achieve both segmental stability and optimum bony union, especially in extensive anterior repositioning of the inferior bony segment.

The studies of McDonnell et al.[21] with human subjects and of Ellis[22] in experiments with primates have described osseous changes in the anterior mandibular profile after advancement genioplasty that resulted from resorption of bone at the anterosuperior aspect of the inferior fragment and from apposition of bone on the labial surface of the mandible, superior to the osteotomy (Figure 6-10). In posterior repositioning, the inverse pattern was observed as bone was lost from the labial surface of the mandible superior to the osteotomy and was deposited on the anterosuperior surface of the inferior segment[23] (Figure 6-10). Regardless of the direction of the bony reposition, the sharp angularity of the immediate post-osteotomy profile is refined over time to a curved, relatively smooth form. In all cases in which the metal was situated in a region of bone loss, the metal was externalized from the bone, and where the metal was placed in a region of bony apposition, it was buried by new bone. The specific pattern of bone apposition and resorption observed after genioplasty forms the basis for placement of fixation devices in areas of future bone apposition.

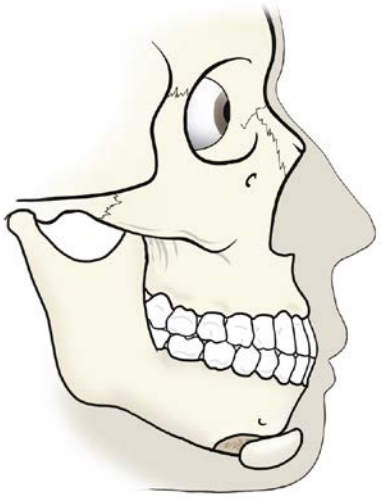

• **Figure 6-10** Lateral facial view demonstrating the change that occurs with advancement of the inferior chin segment in the sagittal split genioplasty. Similar to the sagittal split ramus osteotomy after advancement of the tooth bearing, no through and through gap is created.

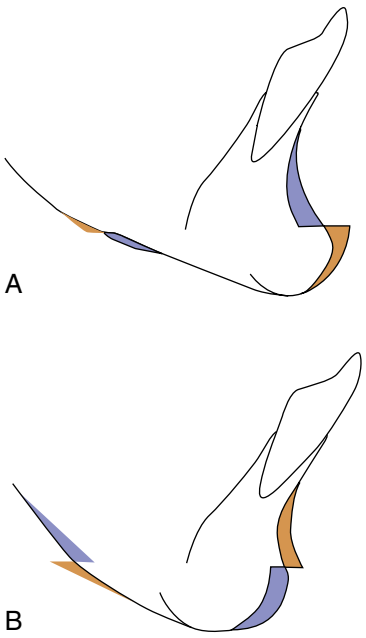

• **Figure 6-11** **A,** Stippled area indicates pattern of bone resorption, and solid area shows pattern of bone apposition following advancement genioplasty. **B,** Stippled area indicates pattern of bone resorption, and solid area shows pattern of bone apposition following "setback" genioplasty.

Overall, the sharp angles are softened, and a smooth, curvilinear profile is reestablished. The fact that the entire anterior mandible is placed into a new functional environment indicates that new demands or loads are applied throughout the region. Frost[24] states, "The architectural change produced by a change in bone loading usually improves the bone's ability to carry the new loads, so the architectural adaptations evoked by loads that threaten the structural competence reduce rather than accentuate that threat." Surgical intervention to restore facial balance creates new "physiologic" skeletal and soft tissue equilibrium. The pattern of osseous change observed reduces sharp edges and restores a smooth surface to the anterior mandible. This could represent a protective elimination of regions of stress concentration, as well as adaptation of the region to altered functional demands induced by concomitant orthognathic procedures and altered labiomental muscular function.

The magnitude of osseous change had been related to many factors. Tulasne[25] showed that at 6 months after genioplasty, adolescents underwent greater resorption than adults. Ellis et al.[22] demonstrated that greater tissue stripping favored increased resorption of bone after sliding genioplasty advancement in primates. Polido et al.[26] confirmed this finding with human subjects. Storum et al.[18] argue that minimal periosteal stripping and conservation of blood supply promote early revascularization of the inferior segment, and that this reduces net bone loss in the inferior segment. These latter authors also state that close bone approximation promotes early vascular bridging of the segments, osteogenesis, and enhanced stability of the segments. They conclude that maximum stability of the segments is required to achieve early osteogenesis. However, a distinction must be made between short-term bone healing and long-term adaptive modeling. In the short term, the use of rigid fixation as advocated by Wolford and Bates[20] may enhance bone healing. This is a basic tenet of the Association for the Study of Internal Fixation philosophy regarding the management of bone healing.[18] In the long term, metal placed in a region of bone modeling may become a liability, particularly if it is set in a region of resorption. On the basis of the observed pattern of bony change, it is recommended that fixation devices for genioplasty should be placed in areas of bony deposition. When this is not possible for clinical reasons, long-term monitoring of the relationships of the hardware, bone, and soft tissue may be prudent.

Conclusion

The genioplasty is a safe, predictable, and stable operation that can correct both functional and cosmetic aspects of dentofacial deformities. Osseous and alloplastic genioplasty permit improvement in form and normalization of functional habits through establishment or restoration of harmony among the osseous, dental, muscular, and cutaneous elements of the lower anterior face (Figures 6-11 through 6-16). Accordingly, it is a mandatory part of the orthognathic surgeon's skill set.



• **Figure 6-12** Facial photographs of patient who benefited from maxillary advancement and genioplasty for anterosuperior repositioning of the chin.

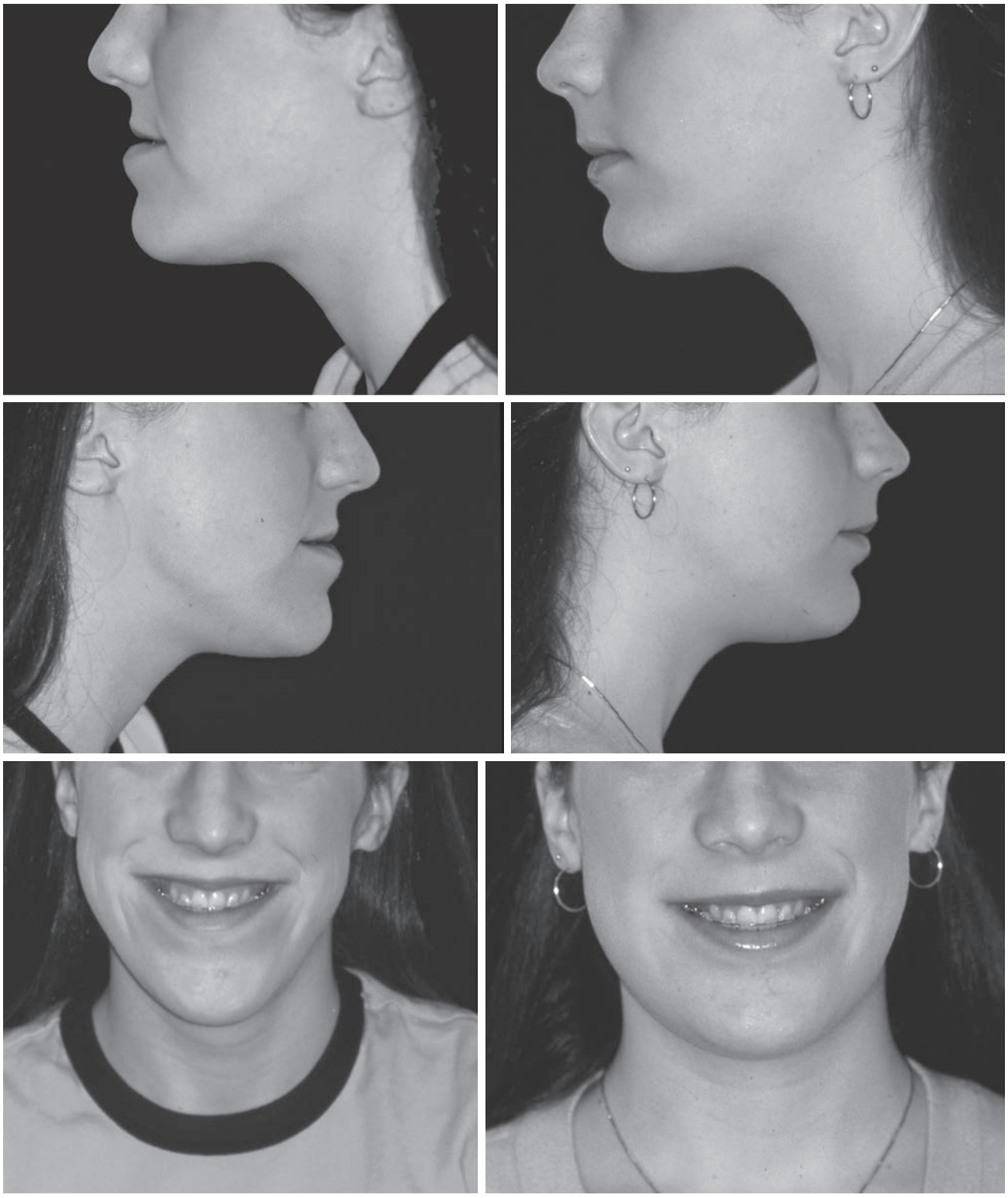

• **Figure 6-12, cont'd.**

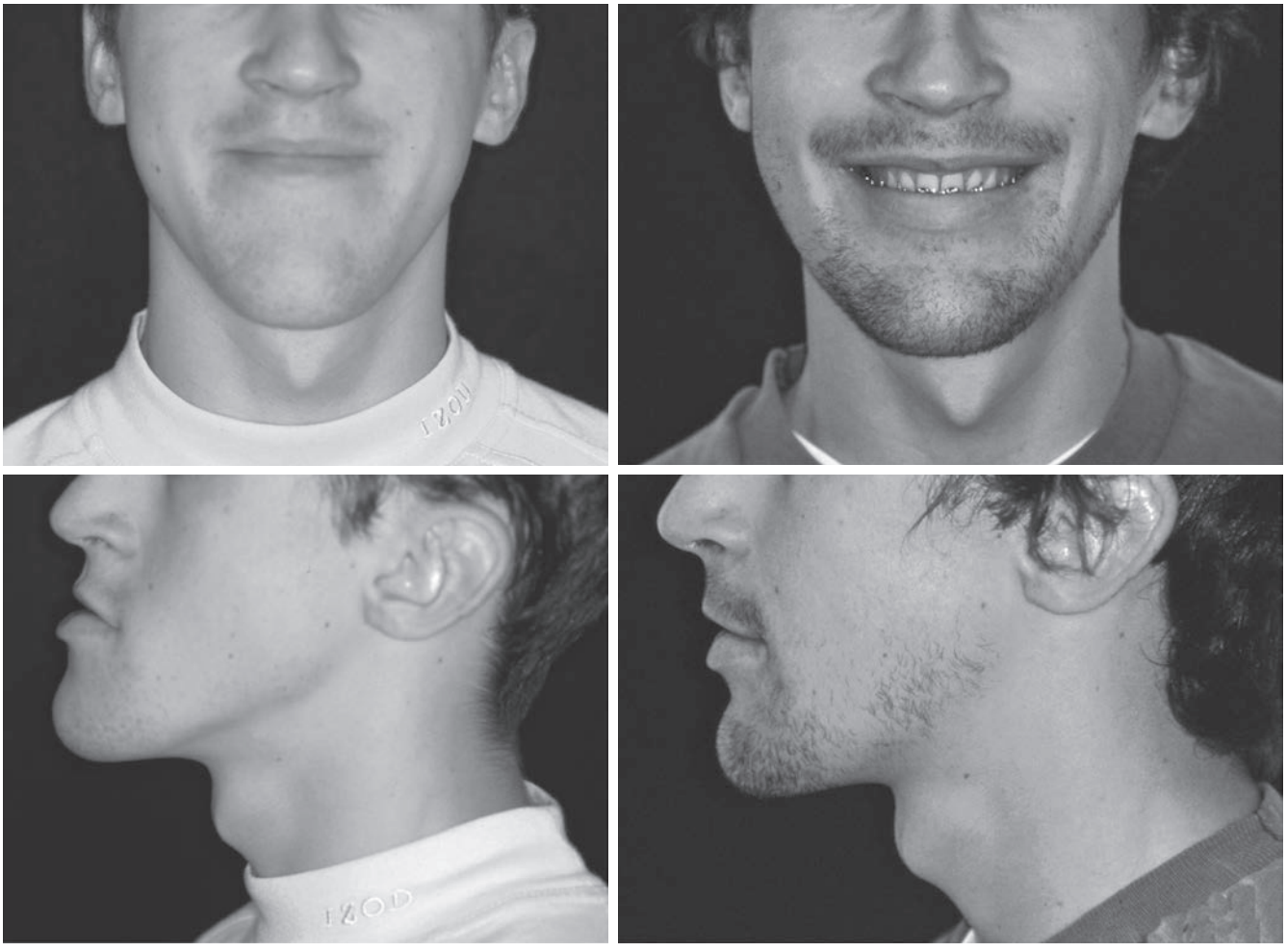

• **Figure 6-13** Comparison of before and after orthognathic surgery, which included genioplasty to superior repositioning of the chin.



• **Figure 6-14** Facial photographs showing improved facial balance after orthognathic surgery, which included genioplasty to anterosuperior repositioning of the chin.



• **Figure 6-15** Facial photographs of a young woman who benefited from mandibular advancement and chin advancement; facial balance was improved when lip competency was achieved.



• **Figure 6-16** Patient who underwent a 5-mm malar osseous augmentation and 8-mm vertical reduction osseous genioplasty. **A** to **C,** Preoperative. **D** to **F,** Postoperative at 6 months.

References

1. Nahoum HI: Vertical proportions and the palatal plan in anterior open bite, *Am J Orthod* 59:273, 1971.
2. Schendel SA, Eisenfeld J, Bell WH, Epker BN, Mishelevich DJ: The long face syndrome: vertical maxillary excess, *Am J Orthod* 70:398, 1976.
3. Bell WH: Le Fort I osteotomy for correction of maxillary deformities, *J Oral Surg* 33:412, 1975.
4. West RA, McNeil RW: Maxillary alveolar hyperplasia, diagnosis and treatment planning, *J Maxillofac Surg* 3:238, 1975.
5. Muller H: *Le synrome d'exces vertical anterieur de las face,* Thèse, Paris, 1970, Doctorat Chirurgie Dentaire.
6. Fields HW, Varm Jr WF, Vig KWL: Reliability of soft tissue profile analysis in children, *Angle Orthod* 52:159, 1982.
7. Wylie WL: Overbite and vertical facial dimensions in terms of muscle balance, *Angle Orthod* 14:13, 1944.
8. Powell N, Humphreys B: *Proportions of the aesthetic face*, New York, 1984, Thieme-Stratton.
9. Delaire J: L'analyse architectural et structural craniofaciale (de profil): principles theoriques quelques examples d'emploi en chirurgie maxillofaciale, *Rev Stomatol* 79:1, 1978.
10. Delaire J, Schendel SA, Tulasne JF: An architectural and structural craniofacial analysis: a new lateral cephalometric analysis, *Oral Surg Oral Med Oral Pathol* 52:22, 1981.
11. Delaire J, Tulasne JF: Les déséquilibres labio-mentonniers per excès vertical antérieur de l'étage inférieur de la face: apport de la géniectomie segmentaire horizontale, *Orthod Fr* 50:353, 1979.
12. Michelet FX, Goin JL, Pinsolle J, Dessus B: L'utilization de la symphyse mentionnière, *Ann Chir Plast* 19:69, 1974.
13. Precious DS: Alveolar bone grafting: cleft lip and palate—a physiological approach, *Oral Maxillofac Clin North Am* 12:501–513, 2000.
14. Plenier V, Delaire J: La genioplasty "fonctionelle," *Rev Stomatol Chir Maxillofac* 84:54–61, 1983.

15. Schendel S: Sagittal split genioplasty: a new technique, *J Maxillofac Surg* 68(4):931–934, 2010.
16. Epker BN, Fish LC: *Dentofacial deformities, vol. I: integrated orthodontic and surgical correction*, St Louis, 1986, Mosby, pp 103–127.
17. Trimble LD, West RA: Steinman pin stabilization after horizontal mandibular osteotomy, *J Oral Maxillofac Surg* 40:461–463, 1982.
18. Storum KA, Bell WH, Nagura H: Microangiographic and histologic evaluation of revascularization and healing after genioplasty by osteotomy of the inferior border of the mandible, *J Oral Maxillofac Surg* 48:210–216, 1988.
19. Labbe D, Slama M: Advancement genioplasty with miniaturized Paulus plates, *Ann Chir Plast Esthet* 34:263–268, 1989.
20. Wolford LM, Bates JD: Surgical modification for the correction of chin deformities, *Oral Surg Oral Med Oral Pathol* 66:279–286, 1988.
21. McDonnell JP, McNiell RW, West RA: Advancement genioplasty: a retrospective cephalometric analysis of osseous and soft tissue changes, *J Oral Surg* 35:640–647, 1977.
22. Ellis E, Dechow PC, McNamarra JA: Advancement genioplasty with and without soft tissue pedicle: an experimental investigation, *J Oral Maxillofac Surg* 42:637–645, 1984.
23. Bell WH, Brammer JA, McBride KL, Finn RA: Reduction genioplasty: surgical techniques and soft tissue changes, *Oral Surg Oral Med Oral Pathol* 51:471–477, 1981.
24. Frost HM: A determinant of bone architecture: the minimum effective strain, *Clin Orthop* 175:286–292, 1983.
25. Tulasne J-F: The overlapping bone flap genioplasty, *J Craniomaxillofac Surg* 15:214–217, 1987.
26. Polido WD, Declarifron Regis L, Bell WH: Bone resorption, stability and soft tissue changes following large chin advancements, *J Oral Maxillofac Surg* 49:251–256, 1991.

7

Inverted L Osteotomy for Management of Severe Mandibular Deficiency with Short Posterior Face Height

R. BRYAN BELL, ANDREW WEEKS

Introduction

Hugo Obwegeser popularized the term *vogelgesicht*, or bird-face deformity, to describe a facial skeletal abnormality that is characterized by severe mandibular retrognathism, short posterior facial height, steep mandibular plane angle, retrogenia, and skeletal class II malocclusion with or without anterior open bite[1] (Figure 7-1). The etiology of this facial dysmorphism is variable but is invariably caused by insufficient height of the mandibular condyle-ramus unit, as well as the resulting compensatory dentofacial changes.

Various orthognathic surgical techniques have been described to correct these disproportionate maxillomandibular relationships, generally involving bimaxillary advancement with counterclockwise rotation of the maxillomandibular complex. Obwegeser advocated elongation of the mandible by means of either a vertical osteotomy within the tooth-bearing area or sagittal split osteotomies of the mandibular ramus, combined with maxillary repositioning and osteoplastic genioplasty.[1] Although the mandibular body osteotomy that he advocated has not been widely used, primarily because of neurosensory disturbances and the need for interpositional bone grafting, use of the sagittal split osteotomy has been widely accepted. The problem with this technique, however, is that there are limits to the amount of mandibular advancement that can be achieved using sagittal split osteotomies, and significant lengthening of the ramus condyle unit is not possible (Figure 7-2). An alternative approach employs an older operation described in various manifestations in the early 20th century. The commonality between all of the so-called inverted L osteotomy (IVO) designs is that the ramus is horizontally sectioned above the mandibular foramen, joining a vertical cut anterior to the mandibular foramen and leaving the coronoid process attached to the proximal/condylar segment. This precludes any interference of the coronoid process with mandibular setback procedures and, more importantly, alleviates the temporalis muscular attachments to the coronoid process, theoretically minimizing muscular forces that contribute to relapse. This chapter reviews the use of a mandibular IVO as the preferred method for correction of bimaxillary deficiency with short posterior face height (Figure 7-3).

History of Mandibular Ramus Osteotomies

In 1846, Simon Hullihen described the first mandibular osteotomy for correction of a skeletal anterior open bite that resulted from scar contractures associated with a facial burn.[2] He performed a mandibular subapical osteotomy and repositioned the mandible backwards to correct the occlusion. Subsequent to that, V. P. Blair from St. Louis described a mandibular body osteotomy for correction of mandibular prognathism. The following year, Blair described a horizontal osteotomy of the mandibular ramus performed with a Gigli saw via a transcervical approach to facilitate mandibular advancement. In 1925, Limberg described a posterior oblique vertical ramus osteotomy, again via an external approach for correction of open bite malocclusions.

What we know today as the "inverted L osteotomy" (ILO) appears to have been independently described by Martin Wassmund and Hans Pichler in 1927.[3,4] This approach to advancing the mandible was performed via a transcervical incision and involved for the first time interpositional bone grafting (see Figure 7-3, *A*). Caldwell and Letterman modified the ILO technique in 1954, by taking the vertical cut through the sigmoid notch, subsequently termed the extraoral vertical ramus osteotomy (EVRO).[5]

The bilateral sagittal split osteotomy (BSSO) was described by Obwegeser in 1957 and quickly became the preferred



• **Figure 7-1** A 58-year-old woman with severe mandibular retrognathia and short posterior face height. **A**, Preoperative frontal repose. **B**, Preoperative profile. **C**, Preoperative lateral cephalometric radiograph demonstrating loss of posterior face height, downwards and backwards rotation of the maxillomandibular complex, and class II malocclusion.

technique for correction of mandibular deformities, primarily because of its versatility, predictability, and functional and esthetic results.[6] Because of this, the inverted L osteotomy never really gained popularity, likely due to the requirement for an extraoral incision and the related risk of marginal mandibular nerve injury, the additional time and morbidity associated with bone graft harvest, and fixation requirements.

In 1968, Caldwell modified the ILO by performing a "C" ramal osteotomy, again via an extraoral approach, allowing for greater bone contact and rotational advancements.[7] Then in 1970, Kent and Hinds described the intraoral vertical ramus osteotomy, although this was used primarily for treatment of prognathism.[8] In 1976, Levine and Topazian described an intraoral inverted L osteotomy,[9] to which additional modifications were made and rigid internal fixation was applied by Van Sickels and colleagues in 1990[10] (see Figure 7-3, *B*).

As virtual surgical planning (VSP) was introduced in the literature, Gateno,[11] Hirsch,[12] Bell,[13] and Farrell[14] and their co-workers have described innovative techniques that incorporate the use of interocclusal splints, guide stents, and cutting guides made using computer-aided design/computer-aided manufacturing (CAD/CAM) to optimize functional and esthetic outcomes.[11-15]

There is a paucity of literature regarding the inverted L osteotomy, and little is known about the long-term stability of results. However, because of improved instrumentation that has facilitated intraoral approaches, technologic advances in virtual surgical planning and cutting guides, as well as suboptimal results associated with sagittal split osteotomies in some cases of large advancement, there has recently been renewed interest in the inverted L technique.

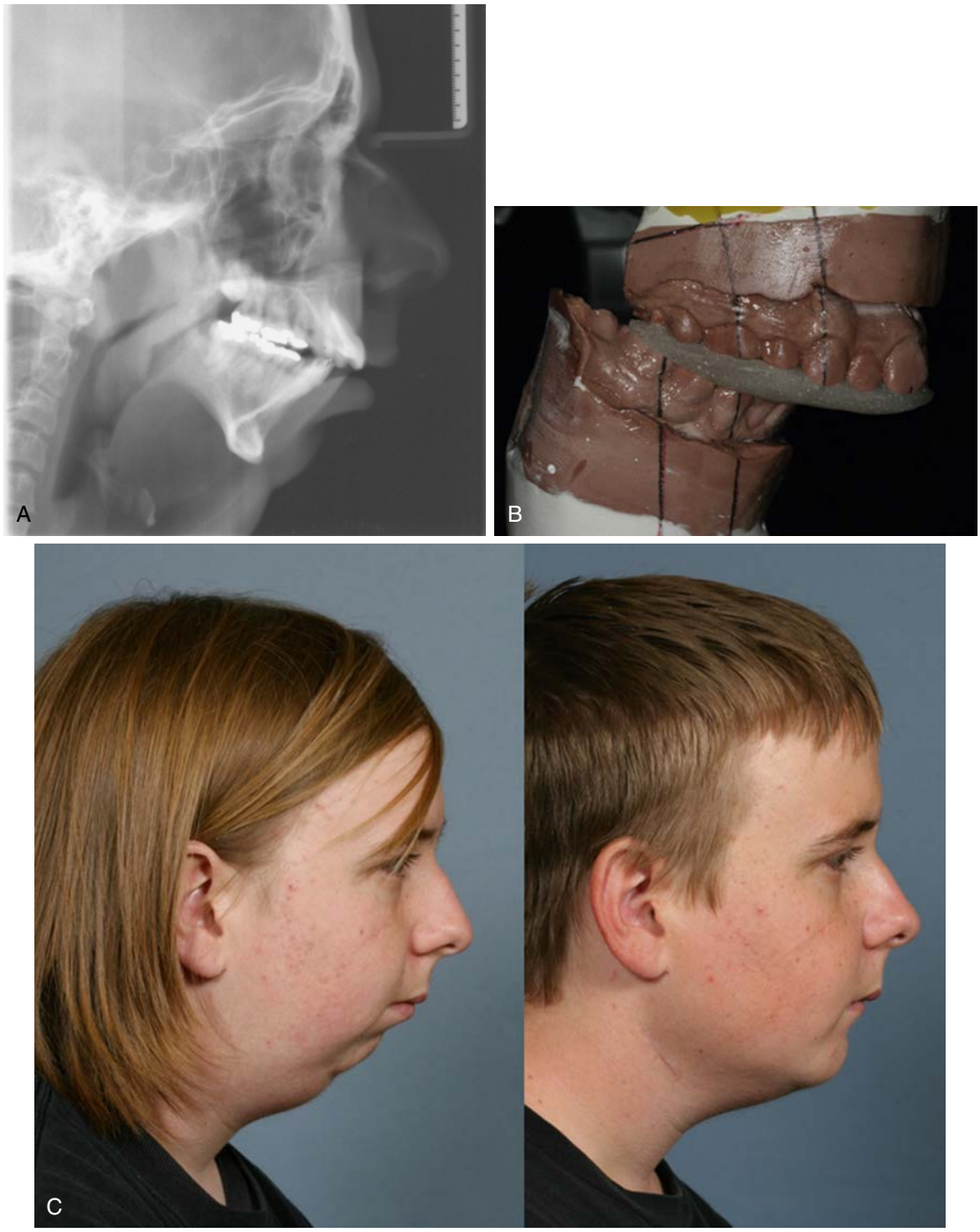

• **Figure 7-2** A 17-year-old boy with severe mandibular retrognathia. **A**, Preoperative lateral cephalometric radiograph demonstrating severely shortened ramus, steep mandibular plane angle as well as decreased posterior airway space. **B**, Preoperative models demonstrating a severe class II malocclusion. **C**, Pre- and postoperative profile views showing increased posterior facial height and improved mandibular projection.

Indications

The inverted L osteotomy has been advocated for the surgical management of short ramus height, skeletal anterior open bite, and mandibular retrognathism.[16] Although it has been used extensively by a number of authors in the treatment of mandibular prognathism,[9,17-19] this chapter focuses on its use in mandibular deficiency. Short ramus deformities often require large mandibular advancements (greater than 15-20 mm) combined with counterclockwise rotation of the maxillomandibular complex to lengthen the ramus-condyle unit and advance the dentate portion

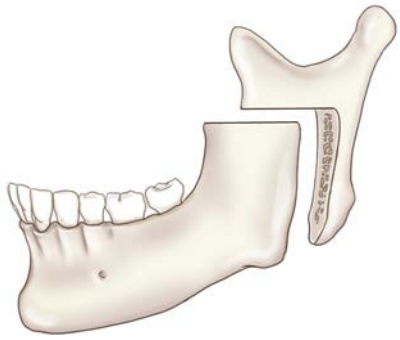

A Original inverted L osteotomy (ILO)

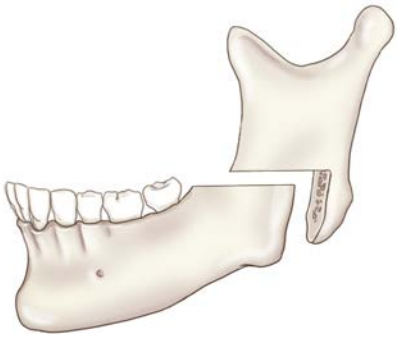

B Modified inverted L osteotomy (M-ILO)

• **Figure 7-3** **A**, Inverted L osteotomy and modification of inverted L osteotomy described by Aymach and colleagues. **B**, Inverted L osteotomy and counterclockwise rotation of the maxillomandibular complex. (From Aymach Z, Nei H, Kawamura H, Van Sickels J: Evaluation of skeletal stability after surgical-orthodontic correction of skeletal open bite with mandibular counterclockwise rotation using modified inverted L osteotomy. *J Oral Maxillofac Surg* 2011;69:853-860.)

• BOX 7-1 Factors Influencing Relapse after BSSO for Mandibular Advancement

1. Amount of advancement
2. Type and material of fixation
3. Low- and high-mandibular plane angle
4. Control of proximal segment
5. Soft tissue and muscles
6. Remaining growth and remodeling
7. Preoperative age
8. Skill of surgeon

From Joss CU, Vassalli IM: Stability after bilateral sagittal split osteotomy advancement surgery with rigid internal fixation: a systematic review, *J Oral Maxillofac Surg* 67(2):301-313, 2009.
BSSO, Bilateral sagittal split osteotomy.

of the mandible (see Figure 7-3). Conditions that may lead to short posterior facial height include condylar degeneration resulting from juvenile idiopathic arthritis or other arthritic conditions, craniofacial microsomia, craniofacial dysostosis, condylar trauma, and mandibular hypoplasia[1] (Box 7-1).

In addition, some altered ramus morphology is also better suited for inverted L osteotomies than for intraoral sagittal split osteotomies. For example, older patients may be at greater risk of unfavorable split with BSSO because of reduced medullary bone and brittle cortical plates.[19] Similarly, patients with masseteric hypertrophy may have less medullary bone, again increasing the possibility of a "bad split."[16] Furthermore, skeletal morphology may be altered due to previous surgery, necessitating alternative ramus osteotomy designs (Figure 7-4).

Although there are no absolute contraindications for the inverted L osteotomy, patients who are prone to hypertrophic scarring or keloids would not be ideal candidates because of the necessity of an extraoral neck incision. However, recent advancements in virtual surgical planning make intraoral inverted L osteotomies an acceptable alternative.

Stability

Postsurgical stability of counterclockwise maxillomandibular advancement surgery has long been controversial. Much of the controversy, however, is predicated on data generated in the pre–rigid fixation era, which suggested that counterclockwise mandibular advancement using sagittal split osteotomies invited relapse.[20] Other factors influencing relapse after mandibular advancement include the amount of advancement, type and material of fixation, mandibular plane angle, proximal segment control, soft tissue adaptation, remaining skeletal growth, preoperative age, and skill of the surgeon[21] (Box 7-2). More recently, however, Wolford and colleagues have shown that counterclockwise maxillomandibular advancement surgery is actually quite stable when rigid internal fixation is used.[22,23] Of note, however, in the Wolford papers is that although the occlusal plane and mandibular plane was flattened and pogonion advanced significantly, the pterygomaxillary sling and condyle ramus unit was not lengthened to a considerable degree. Therefore, an alternative approach is needed for patients with shortening of the posterior face caused by loss of ramus-condyle height.

Several studies have demonstrated improved skeletal stability using the inverted L osteotomy for counterclockwise rotation of the maxillomandibular complex (Table 7-1). Farrell and Kent were among the first to demonstrate the skeletal stability of the inverted L osteotomy as well as the C osteotomy. Their retrospective analysis of 20 cases showed a 5% relapse of posterior face height at 21 months of follow-up.[24] Dattilo and colleagues subsequently demonstrated an average relapse of 11.4% for inverted L osteotomies used to correct anterior open bites, whereas relapse rates for BSSOs used in similar clinical scenarios was 20% to 24%.[25] Significantly, both of these studies were performed in the pre–rigid fixation era.

More recently, Aymach and co-workers carried out a retrospective review of inverted L osteotomies used for counterclockwise rotation of the mandible and showed no statistically significant change in B-point, pogonion, or mandibular plane angle at 1 year postoperatively.[26] Furthermore, Hay and associates demonstrated stable

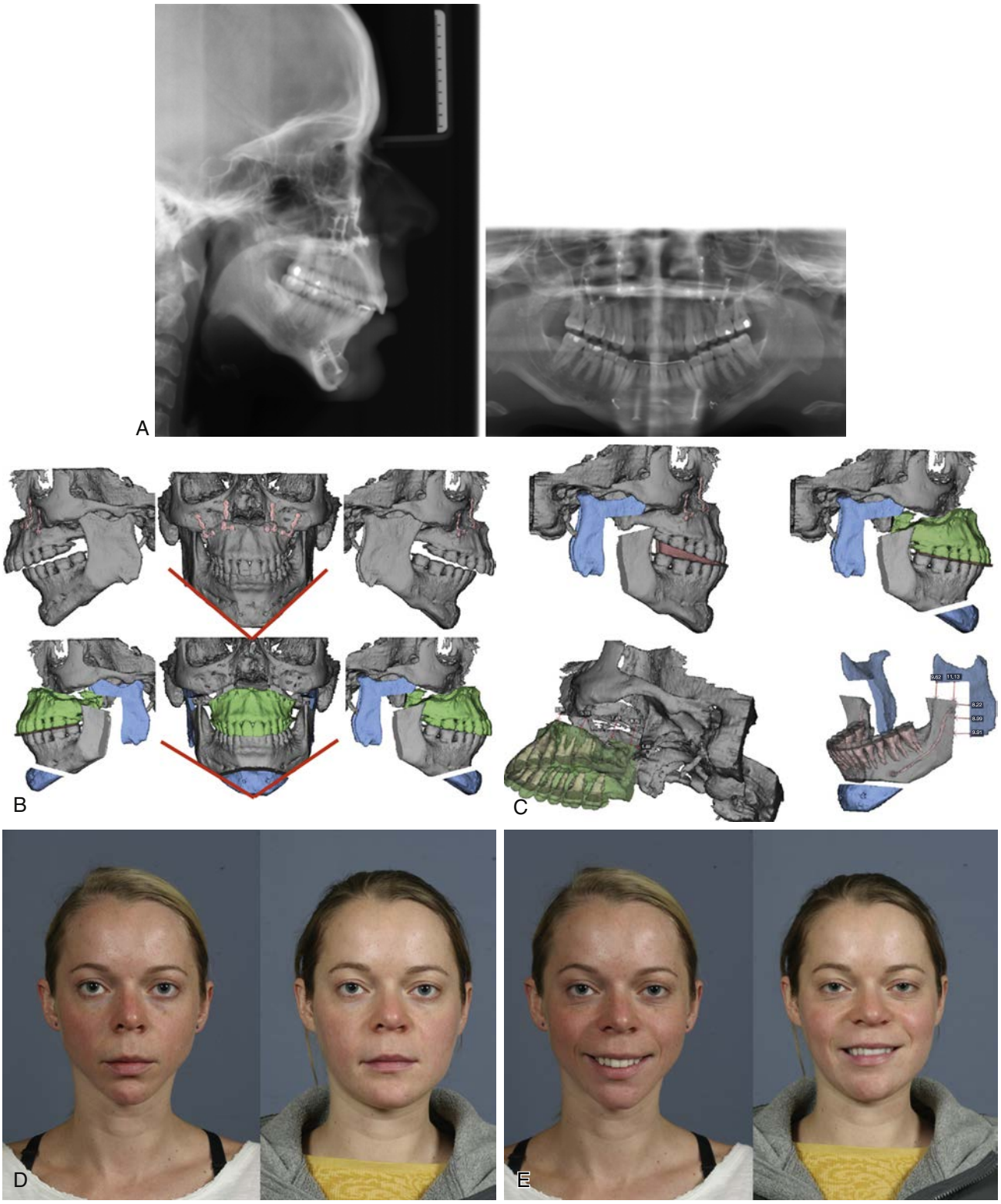

• **Figure 7-4** A 28-year-old woman with persistent short posterior facial height after orthognathic surgery to reposition the posterior maxilla and allow autorotation of the mandible with genioplasty for correction of an anterior open bite. Patient is unhappy with esthetic changes. **A**, Post-treatment/pre-reoperation lateral cephalometric and panoramic x-ray demonstrating shortened ramus and steep mandibular plane angle. **B**, Virtual surgical plan for counterclockwise rotation of the maxillomandibular complex, genioplasty with widening of bigonial width. **C**, Resultant bony gaps after counterclockwise rotation of the maxillomandibular complex. **D-H**, Pre- and postoperative pictures showing improved lower facial width and posterior facial height.

Continued



• **Figure 7-4, cont'd** I, Postoperative class I canine and molar occlusion.

• BOX 7-2 Conditions That Lead to Short Posterior Facial Height

- Condylar degeneration from juvenile idiopathic arthritis
- Craniofacial microsomia
- Craniofacial dysostosis
- Condylar trauma
- Mandibular hypoplasia

From Obwegeser HL, Hadjianghelou O: Two ways to correct bird-face deformity, *Oral Surg Oral Med Oral Pathol* 64(5):507-518, 1987.

results up to 2 years postoperatively when inverted L osteotomy was used to treat growing children with craniofacial microsomia.[27] Some relapse, however, was evident at 3 years after surgery. In a more recent case series, Zhu and colleagues showed minimal relapse in 11 patients who were treated with both intraoral and extraoral approaches in conjunction with semirigid fixation.[28] The reason behind the suggested increased skeletal stability of the inverted L osteotomy versus BSSO in counterclockwise rotations of the mandible is not entirely clear; however, studies have attributed the success of the

TABLE 7-1 Stability of the Inverted L Osteotomy: Pre-rigid versus Rigid Fixation

		Patients	Deformity	Points Measured	Relapse	Fixation	Mean Follow-up
Pre-rigid	Farrell and Kent[24]	20	Class II, III	Posterior face height	5%	MMF	15.7 mo (8-21)
	Dattilo et al.[25]	10	Class II open bite	Pogonion	11.4%	MMF	16.2 mo (6-36)
Rigid	Aymach et al.[26]	12	Class I, II, III open bite	Pogonion B point Menton	No significant difference	Miniplate	12 mo
	Zhu et al.[28]	11	Class II	Ramus height Ramus width	0.8% 5.0%	Miniplate × 2	9.7 mo (7-14)

inverted L osteotomy to the use of interpositional bone grafts and passive positioning of the temporomandibular joint (TMJ) during surgery.

Another benefit to the use of the inverted L osteotomy over the BSSO is the decreased incidence of neurosensory changes involving the inferior alveolar nerve. Kobayashi and colleagues showed that the long-term prognosis for resolution of postsurgical neurologic disturbances was better in the inverted L osteotomy patients than in bilateral sagittal split osteotomy patients.[29] Naples and coworkers demonstrated a significantly higher subjective incidence of lower lip and chin hypoesthesia, but sensory testing did not show any significant difference.[30] In Zhu's case series of 11 patients, only 1 had temporary hypoesthesia.[28] Numerous studies demonstrate decreased neurosensory disturbances in vertical ramus osteotomies versus the BSSO,[31] which may be applicable to the inverted L osteotomy.

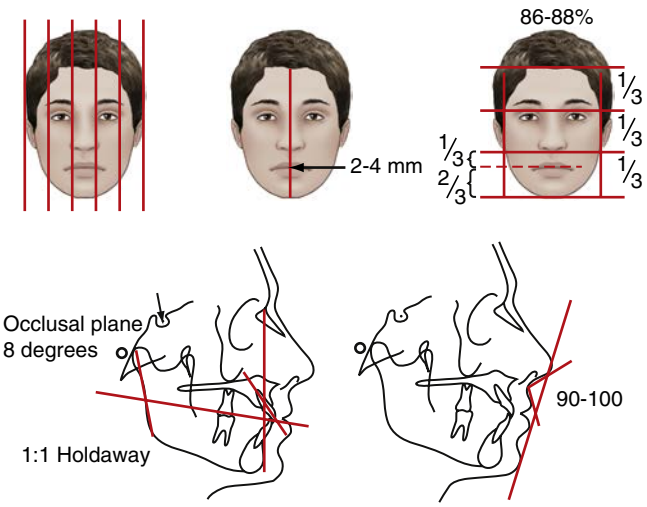

• **Figure 7-5** Ideal goals for facial proportions including equal facial fifths, 2 to 4 mm of incisor show at rest, bi-zygomatic width to lower facial height ratio of 86% to 88%, an occlusal plane angle of 8 degrees, a Holdaway ratio of approximately 1:1, and a nasolabial angle of 90 to 100 degrees.

Treatment Planning for Severe Mandibular Deficiency with Short Posterior Face Height

The senior author's (RBB) treatment approach to severe mandibular deficiency with short posterior face height involves a combination of clinical and radiographic evaluation. The goal in planning maxillomandibular repositioning is to achieve ideal facial proportions and a stable class I occlusal relationship (Figure 7-5). The horizontal fifths are analyzed for symmetry with respect to natural head position and taking into consideration asymmetry of the upper, middle, and lower facial thirds. Deformities of pitch, roll, and yaw must be identified and corrected. The anticipated vertical change in the maxilla is determined by what is needed to achieve a 2- to 4-mm lip-to-tooth ratio at repose. Additional vertical changes are planned based on the patient's anterior two-thirds face height relative to bizygomatic width, as well as linear vertical measurements of the lower facial third as described by Riolo and colleagues.[32] Osteoplastic genioplasty can be considered to increase or decrease the lower facial height as needed, so as to achieve a Holdaway ratio of 1:1 in men and slightly less in women. Occasionally, in tall patients with a relatively long face, malar augmentation can be performed to achieve increases in facial width rather than shortening the face. Next, the maxilla and mandible should be repositioned to achieve an ideal esthetic plane, with respect to nasolabial esthetics, which should result in a nasolabial angle of between 90 and 120 degrees (more for women, less for men).[33]

Particular importance is paid to alteration of the occlusal plane and ideal positioning of the anterior nasal spine to positively affect nasolabial esthetics. Furthermore, the position of the central incisors should be considered when rotating the maxilla in a counterclockwise fashion. Most of the time during treatment of short posterior face height, both the maxilla and mandible will be in a retruded position. This necessitates not only correction of the occlusal plane

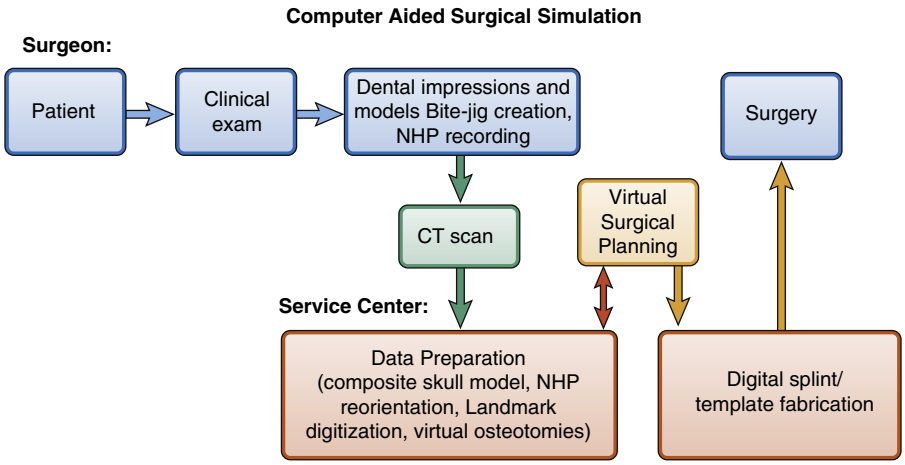

• **Figure 7-6** Virtual surgical planning protocol.

and mandibular plane, but substantial maxillary advancement to reposition the anterior nasal spine and the central incisor in a forward position to favorably affect nasolabial esthetics. It is this anterior maxillary repositioning that often necessitates mandibular advancements on the order of 25 to 35 mm. This type of mandibular advancement cannot be predictably achieved with BSSO.

Virtual Surgical Planning

Preoperative computer imaging software has recently been designed to facilitate three-dimensional analysis and transfer of a virtual surgical plan to the patient by use of CAD/CAM software that has substantially affected orthognathic surgical treatment planning. Maxillomandibular deformities of pitch, roll, and yaw can be more accurately identified and corrected than with traditional methods of two-dimensional cephalometry and analytical model surgery.

Xia and Gateno and their colleagues described a computer-aided surgical simulation (CASS) for use in treatment planning of complex craniomaxillofacial deformities[34] (Figure 7-6). The patient is examined in the usual fashion for an orthognathic surgical procedure, and anthropometric measurements are obtained and analyzed. A bite jig is created that registers centric relation, and natural head position is virtually defined utilizing a gyroscope to obtain numerical values for pitch, roll, and yaw. Plaster casts are then obtained, and a computed tomography (CT) scan of the patient is performed with a bite jig in place and the patient in centric relation. The upper and lower stone casts are surface scanned and integrated into the CT images to create a composite image. A three-dimensional cephalometric analysis is performed, and maxillary and mandibular osteotomies are segmented out of the CT image (Figure 7-7). Deformities of pitch, roll, and yaw are virtually corrected and accurately assessed using precise angular and linear digital measurements. Inaccuracies in the virtual plan can then be corrected using a virtual image analysis. Finally the virtual reconstruction is transferred to the patient by printing an intermediate and final splint. The technique can be further augmented by combining it with the use of a stereolithography to pre-bend reconstruction plates or construct custom guide stents to accurately design osteotomies and shape bone grafts. This technique is particularly useful for the inverted L mandibular ramus osteotomy in cases of severe mandibular deficiency or asymmetry.

Surgical Technique: Extraoral Inverted L Osteotomy

A 3-cm retromandibular or Risdon incision is made below the angle of the mandible. The platysma is sharply incised and a subplatysmal flap is raised to expose the superficial layer of the deep cervical fascia. The fascia is incised with care to ensure that the marginal mandibular branch of the facial nerve is not in the vicinity, and the pterygomasseteric sling is exposed beneath a right-angle retractor. The posterior facial vein may be ligated and retracted superiorly to protect the marginal mandibular branch of the facial nerve. Once exposed, the pterygomasseteric sling is sharply incised, and the lateral aspect of the mandibular ramus is exposed in a subperiosteal fashion. With retraction along the posterior border of the mandible as well as the ascending ramus, the antelingula can sometimes be identified and used as a guide to approximate the position of the mandibular foramen. Alternatively, custom cutting guides can be used to ensure proper design of the inverted L osteotomy, which is then completed with a reciprocating saw. Care is taken to minimize the medial extent of the tip of the saw blade and to protect the retromandibular vein posteriorly. The osteotomy can be completed with the aid of an osteotome if desired. It is important to completely dissect free the sphenomandibular ligament and pterygomasseteric sling to allow for passive lengthening of the ramus and advancement of the distal mandibular segment.

Mobilization of the mandible can be facilitated by the placement of 24-gauge wires at the inferior posterior aspect of the distal segment, which are used to help pull the

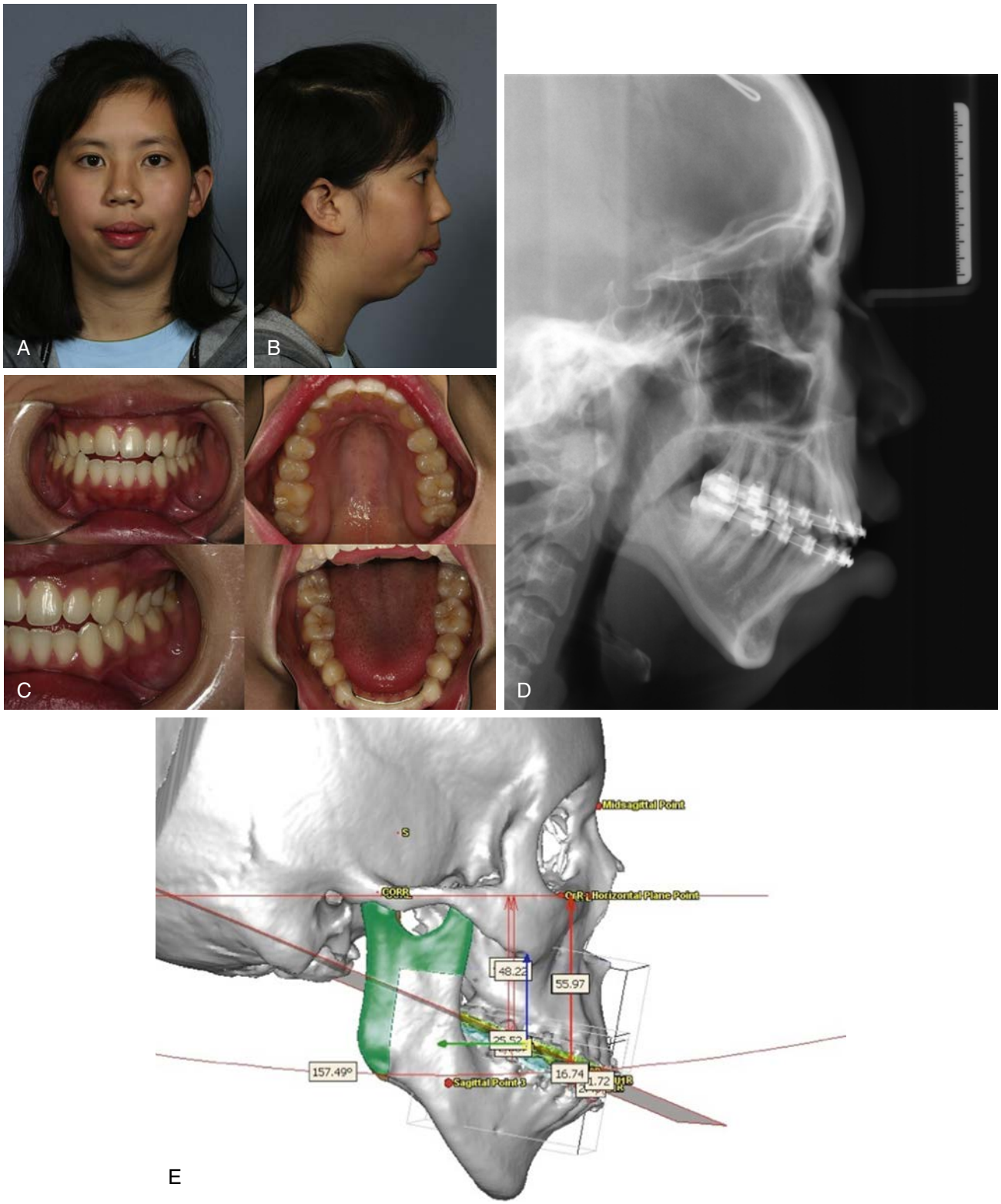

• **Figure 7-7** A 17-year-old girl with short posterior facial height, bird face deformity. **A**, Frontal repose demonstrating ovoid facial shape with narrow bigonial width. **B**, Profile view demonstrating convex shape and severe retrognathia. **C**, Anterior open bite deformity. **D**, Lateral cephalometric x-ray showing short ramus height and severe retrognathia. **E**, Virtual plan of inverted L osteotomies.

Continued

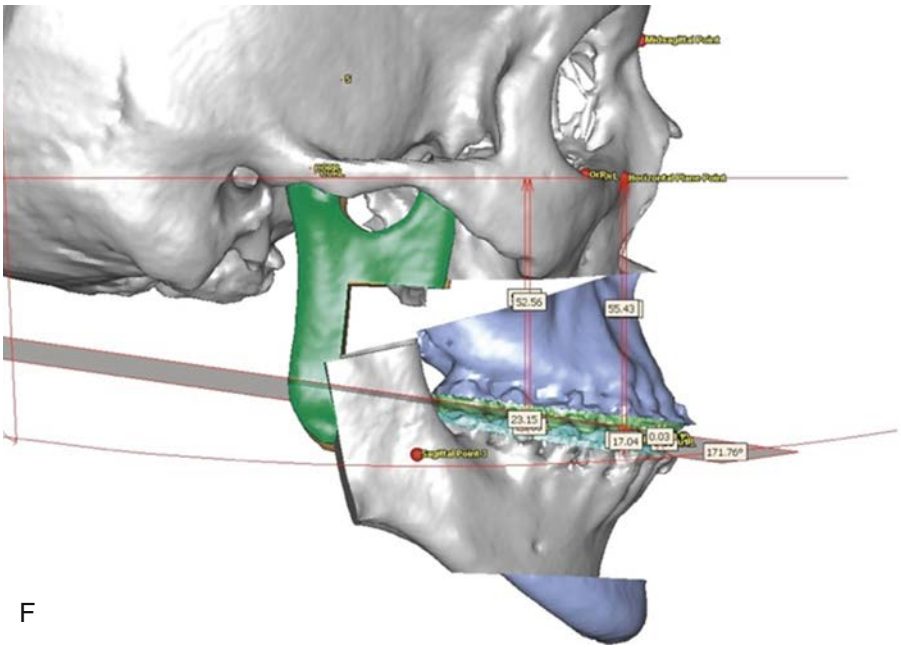

F

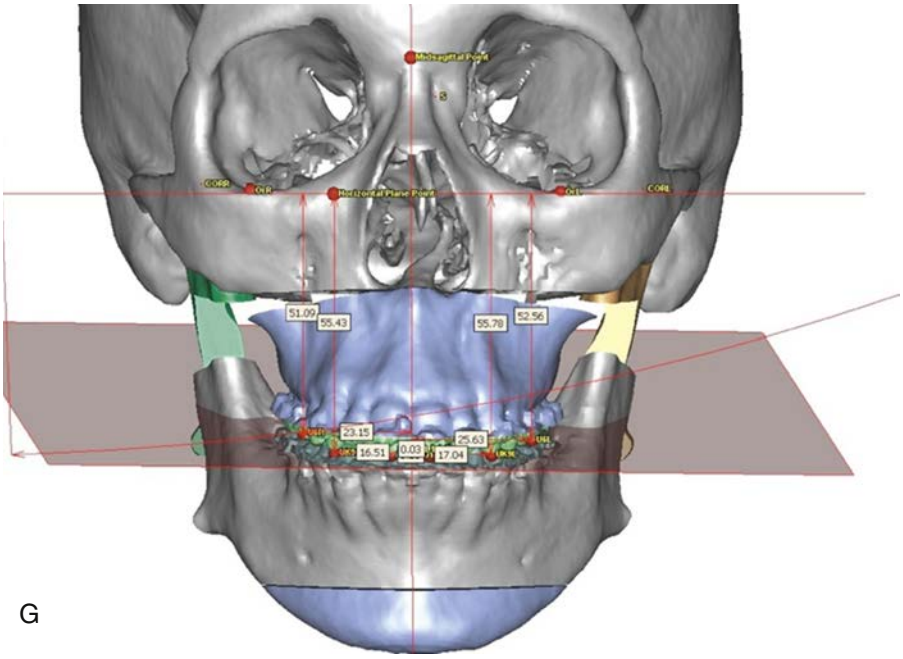

G



H



I

• **Figure 7-7, cont'd** **F**, Virtual plan of counterclockwise rotation of maxillomandibular complex. **G**, Occlusal cant correction. **H**, Stereolithographic models of planned movements allow for pre-bending of reconstruction plates. **I**, Placement of reconstruction plates via cervical approach.

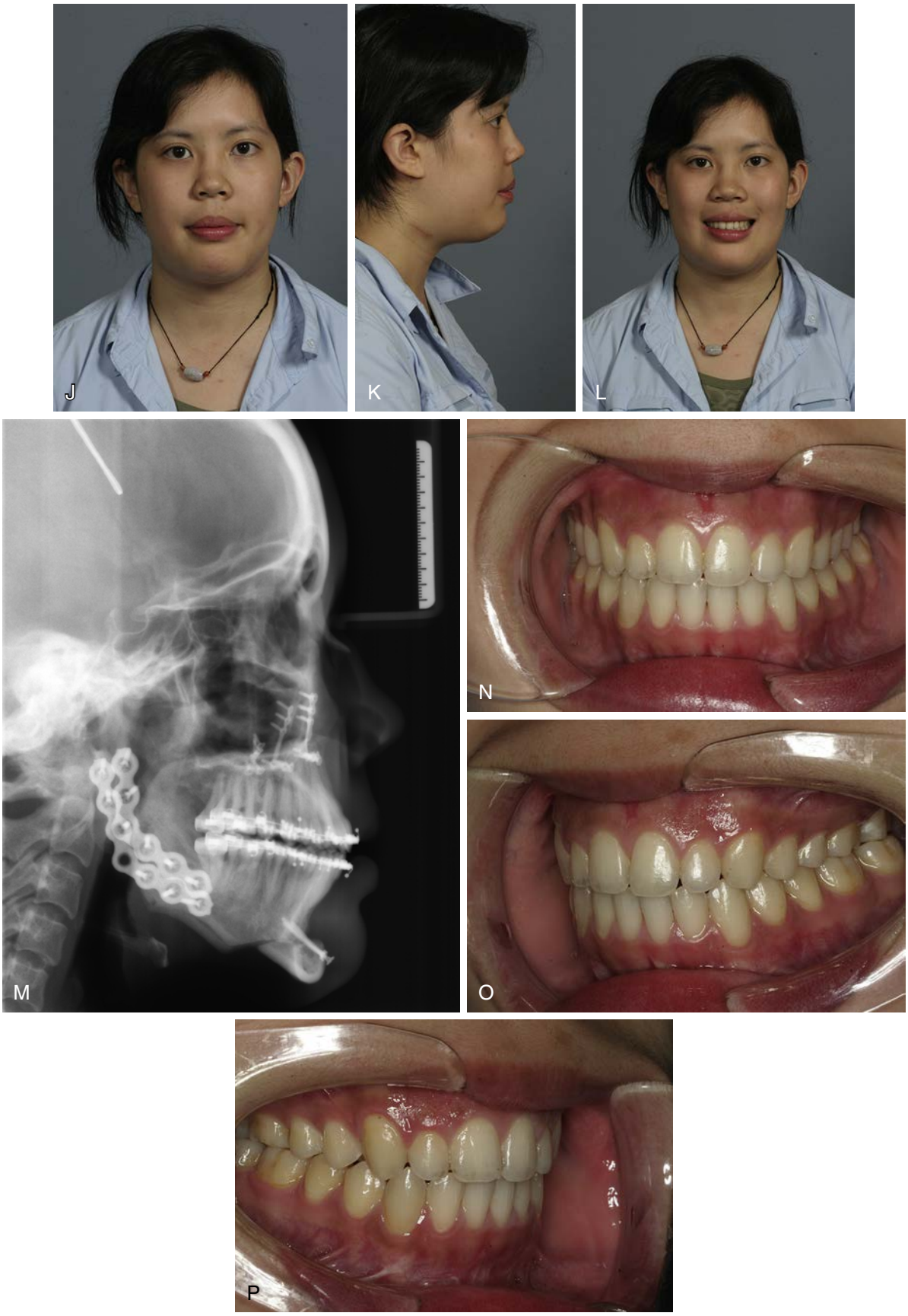

• **Figure 7-7, cont'd** **J**, Postoperative frontal repose. **K**, Postoperative profile. **L**, Postoperative smile. **M**, Postoperative lateral cephalometric x-ray demonstrating placement of reconstruction plates, improved posterior facial height, counterclockwise rotation of the maxillomandibular complex. **N**, Postoperative occlusion with closure of the anterior open bite. **O**-**P**, Postoperative class I canine and molar relationship.

mandible forward and relax the muscle attachments. The mandible is then repositioned into the prefabricated intermediate occlusal splint, and the patient is placed into intermaxillary fixation. Rigid internal fixation is then applied. The senior author prefers to use 2.0 locking reconstruction plates, which are pre-bent to a stereolithographic model. More recently, the senior author has employed custom plates and screws that provide an even more idealized fit and save operative time. It should be noted that before placement of rigid internal fixation, the proximal condylar segment must be positioned in the posterior superior portion of the glenoid fossa if possible. Autogenous iliac crest bone grafts can then be harvested and shaped according to templates provided by the virtual surgical plan, inset into the ramus defect as an interpositional graft, and secured with bicortical screws. Alternatively, a combination of coronoid bone grafts with or without allogeneic bone grafts and bone morphogenetic protein-II has been used by the senior author with excellent success. Once the procedure is repeated on both sides, the patient is released from intermaxillary fixation, and the occlusion is compared to that of the virtual surgical plan. Care is taken to ensure that the mandibular midline is in the desired position and that there is no unwanted asymmetry or cant to the occlusal plane. Following this, the Le Fort I osteotomy and genioplasty are performed in the usual fashion. The author prefers to use computer-generated guide stents to reposition the chin in these complex cases. The patient is placed into intermaxillary fixation for 2 weeks after the procedure, after which guiding elastics are used. A normal diet is resumed at approximately 6 weeks following surgery at which time the patient is returned to the orthodontist for finishing orthodontic treatment (Figure 7-8 and Table 7-2).

Surgical Technique: Intraoral Inverted L Osteotomy

The intraoral inverted L osteotomy, like its extraoral cousin, is performed before maxillary surgery. A 3- to 4-cm incision is made through the mucosa along the external oblique ridge similar to a standard BSSO incision. A subperiosteal dissection is carried out to expose the ascending ramus and coronoid process. A Kocher clamp may be used to aid in retraction. Dissection on the lateral aspect of the mandible is carried to the posterior border of the mandible. A J-stripper can be used to strip the periosteal attachments off of the posterior border (although this is not usually necessary), allowing placement of the Levasseur-Merrill retractor for visualization of the lateral aspect of the ramus. The medial aspect of the ramus is exposed in a limited fashion, and the lingula is identified if possible. Some authors advocate limiting this portion of the dissection, as the medial dissection has been shown to cause neurosensory disturbance.[18,35] A virtual guide stent is inserted and its accurate position is ensured by checking its adaptation to the inferior and posterior borders of the mandible (Figure 7-9 and Table 7-3). The osteotomy is then made on the lateral aspect of the mandible using an oscillating saw. Once separated, the guide stent is removed and the proximal and distal segments are mobilized. The patient is placed into intermaxillary fixation into the prefabricated intermediate splint. Guide stents are then applied for proper proximal and distal segment positioning, and prefabricated custom plates and screws are used to provide rigid internal fixation of the proximal and distal segments. An interpositional bone graft is placed as described previously, and the wound is closed with 3-0 chromic sutures. Following completion of the mandibular procedure, the maxillary osteotomy and genioplasty are performed as described earlier.

Complications

As with most orthognathic surgical procedures, complications from the inverted L osteotomy most commonly involve inferior alveolar nerve injury, bleeding, or unfavorable osteotomies. Inferior alveolar nerve injury is usually caused by inaccurate position of the vertical or horizontal segments of the osteotomy relative to the mandibular foramen. The prefabricated cutting guides are especially helpful to avoid this complication, given that there are no reliable landmarks of the mandibular foramen relative to the lateral aspect of the mandible.[36,37]

Bleeding encountered during the inverted L osteotomy is usually from injury to the inferior alveolar artery, masseteric artery, or retromandibular vein. Packing can readily control most bleeding.

Unfavorable osteotomies may occur if the horizontal cut is carried too far posteriorly, effectively performing a condylotomy. Should this occur, either the procedure can be aborted and the patient placed into intermaxillary fixation and treated as for a condyle fracture, or the vertical limb can be completed and rigid internal fixation applied to the condyle and remaining proximal segment of the ramus as one would do in a comminuted mandibular fracture repair.

Other possible complications include nerve injury to a branch of the facial nerve, most commonly the marginal mandibular branch, or rarely to the facial nerve trunk itself. Complete facial paralysis following this procedure warrants immediate exploration of the facial nerve and repair as appropriate. Ligation of the facial vein with retraction superiorly (known as the Hayes-Martin maneuver) may be employed to limit the possibility of facial nerve damage, although this is usually not necessary in the author's experience.

Finally, displacement of the condyle out of the glenoid fossa or fixation of the proximal and distal segments with the condyle inaccurately positioned can occur with both the intraoral and extraoral approaches. This unfortunate complication can result in midline discrepancies and facial asymmetry. It is best avoided by taking care to position the condyles in the posterior superior position within the condyle or using a proximal segment positioning plate as described by Van Sickels.[10]

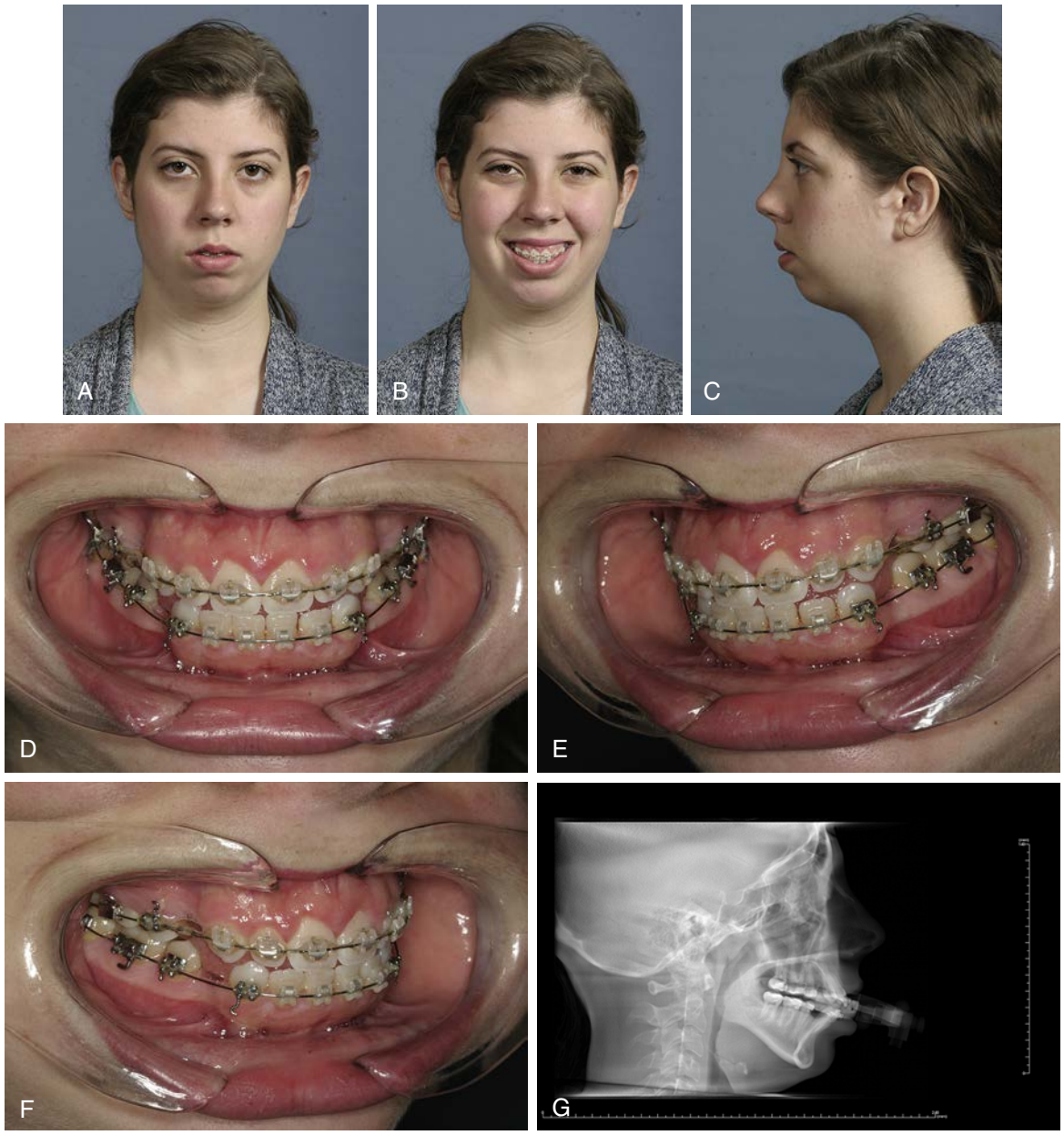

• **Figure 7-8** An 18-year-old woman with a history of juvenile idiopathic arthritis and severe retrognathia and short posterior facial height but normal temporomandibular joint function. **A**, Preoperative frontal repose. **B**, Preoperative smile. **C**, Preoperative profile. **D**-**F**, Preoperative occlusion with edge-to-edge occlusion premolar extractions and decompensation. **G**, Preoperative lateral cephalometric showing decreased posterior facial height.

Continued

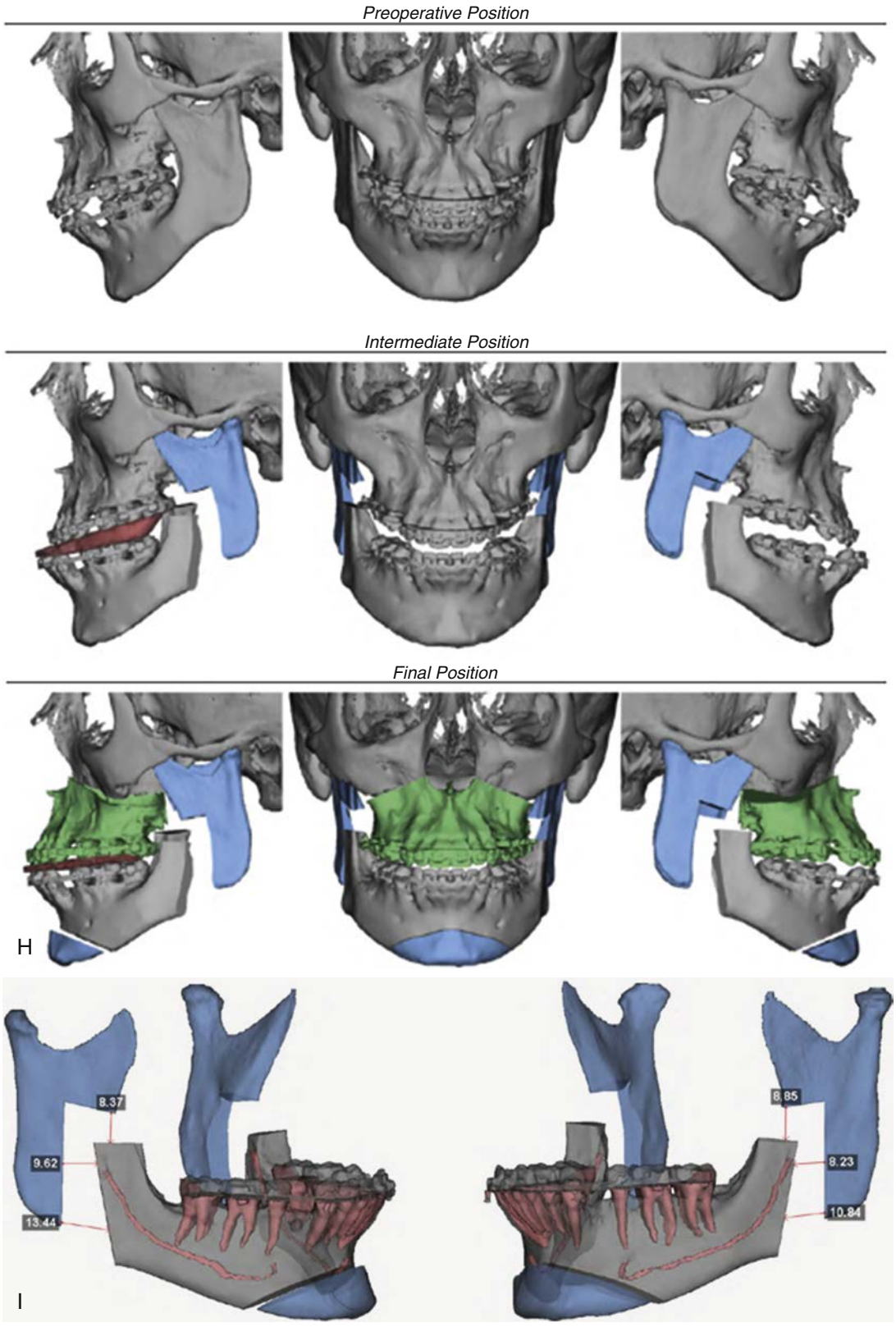

• **Figure 7-8, cont'd** **H**, Virtual surgical plan with Le Fort I and inverted L osteotomies and counterclockwise rotation of the maxillomandibular complex. **I**, Planned osteotomies demonstrating intersegmental gaps.

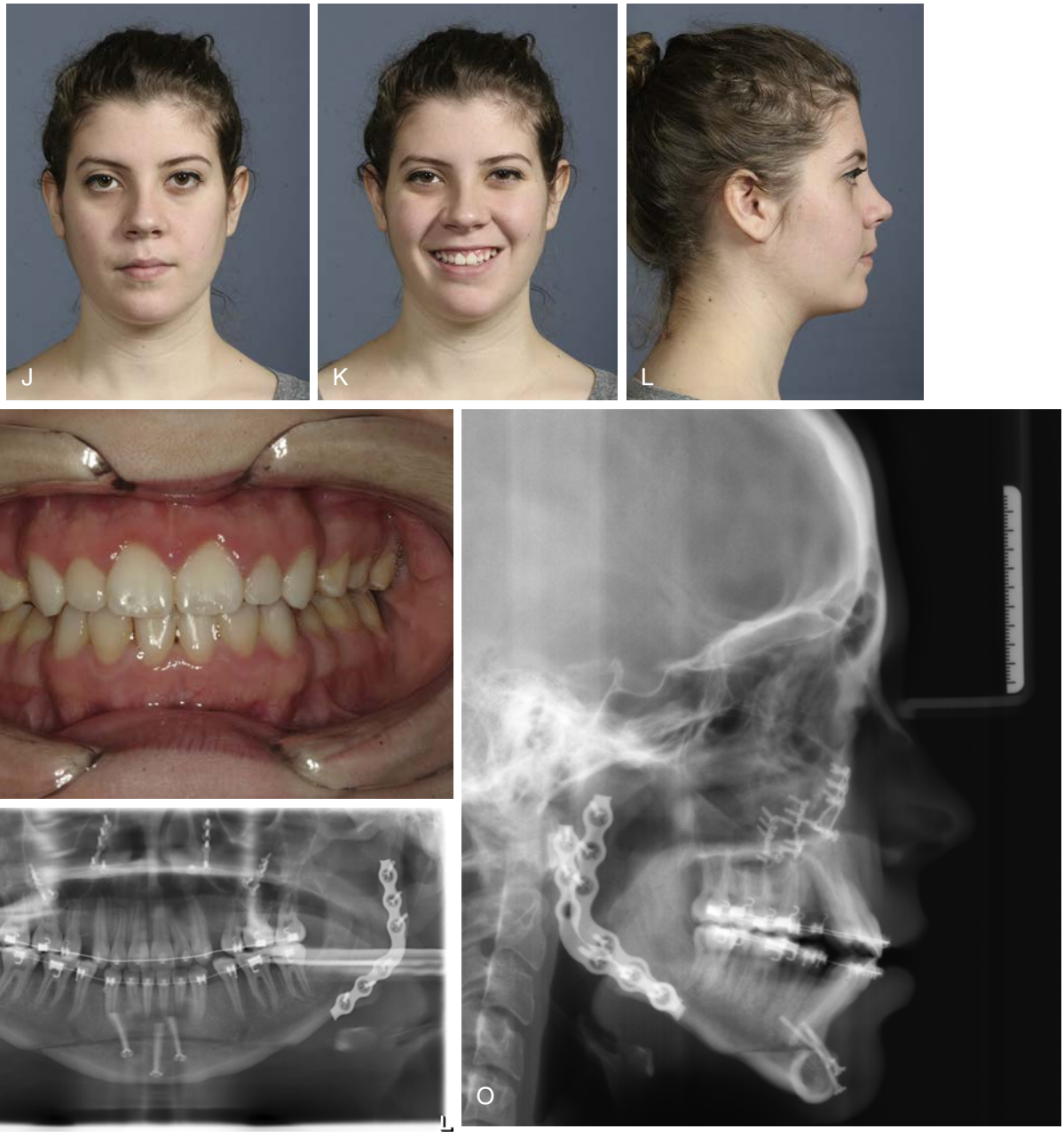

• **Figure 7-8, cont'd** **J**, Postoperative frontal repose demonstrating increased lower facial width. **K**, Postoperative smile. **L**, Postoperative profile with improved posterior facial height, chin projection. **M**, Postoperative class I canine and molar occlusion with 2 mm of overjet and overbite. **N**, Postoperative panoramic x-ray with placement of reconstruction plates and interpositional bone grafts. **O**, Postoperative lateral cephalometric x-ray demonstrating improved posterior facial height, facial profile.

TABLE 7-2 **Predicted Measurements of Virtual Surgical Plan with 24.5-mm Advancement at Pogonion**

Point	Name	Anterior/Posterior	Left/Right	Up/Down
ANS	Anterior nasal spine	3.34 mm anterior	0.00	3.51 mm up
A	A point	4.56 mm anterior	0.00	2.87 mm up
ISU1	Midline of upper incisor	10.00 mm anterior	0.00	4.00 mm up
U3L	Upper left canine	9.56 mm anterior	0.00	2.19 mm up
U6L	Upper left anterior molar (mesiobuccal cusp)	8.55 mm anterior	0.00	1.64 mm down
U3R	Upper right canine	9.63 mm anterior	0.00	2.23 mm up
U6R	Upper right anterior molar (mesiobuccal cusp)	8.60 mm anterior	0.00	1.68 mm down
ISL1	Midline of lower incisor	13.02 mm anterior	1.00 mm left	3.36 mm up

Continued

TABLE 7-2 **Predicted Measurements of Virtual Surgical Plan with 24.5-mm Advancement at Pogonion—cont'd**

Point	Name	Anterior/Posterior	Left/Right	Up/Down
L6L	Lower left anterior molar (mesiobuccal cusp)	11.46 mm anterior	0.71 mm left	2.37 mm down
L6R	Lower right anterior molar (mesiobuccal cusp)	11.94 mm anterior	0.71 mm left	2.64 mm down
B	B point	17.69 mm anterior	1.00 mm left	0.15 mm up
Pog	Pogonion	24.56 mm anterior	1.08 mm left	0.05 mm up



• **Figure 7-9** Correction of severe bimaxillary deficiency with short posterior face height, vertical maxillary excess in a 20-year-old female with a history of idiopathic condylar resorption, normal jaw function, and stable class II malocclusion. Virtual surgical planning for intraoral inverted L osteotomies to correct a short posterior face height, vertical maxillary excess, and severe maxillomandibular deficiency. **A,** Pretreatment, frontal; **B,** pretreatment, lateral; **C**, pretreatment, occlusal. **D,** Preoperative, frontal; **E,** preoperative, smiling; **F,** preoperative, oblique; **G,** preoperative, lateral; **H,** preoperative, occlusal.

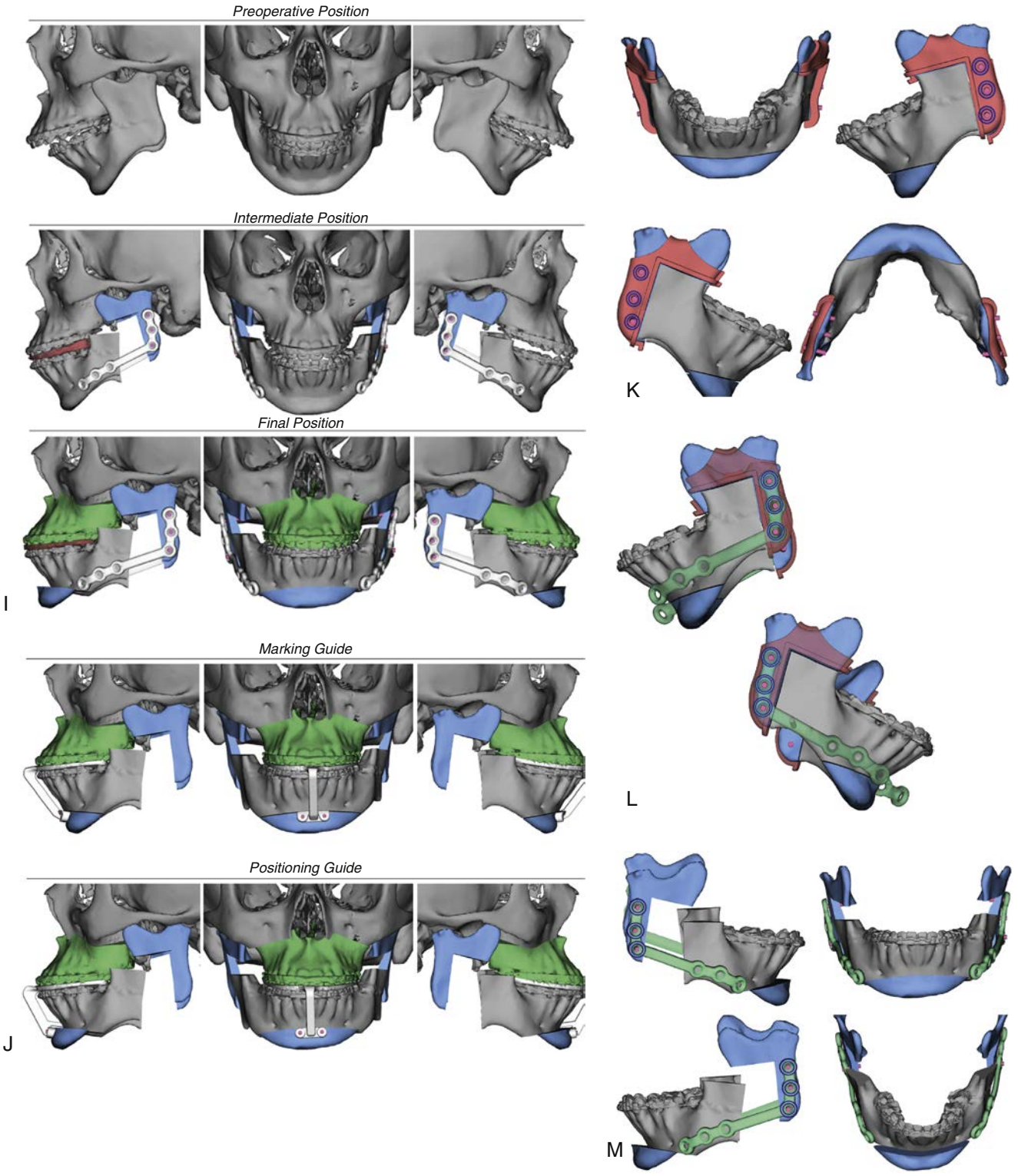

• **Figure 7-9, cont'd** **I,** Virtual surgical planning, preoperative position *(top);* intermediate position, mandible surgery first with intermediate splint *(middle);* postoperative position with final splint *(bottom).***J,** Genioplasty guides, marking guide *(top)*; positioning guide *(bottom)*. **K,** Virtual cutting guide, mandibular intraoral inverted L osteotomy; **L,** virtual cutting guide with predictive holes correlating with custom locking reconstruction plate holes; **M,** virtual custom locking reconstruction plates in final position.

Continued

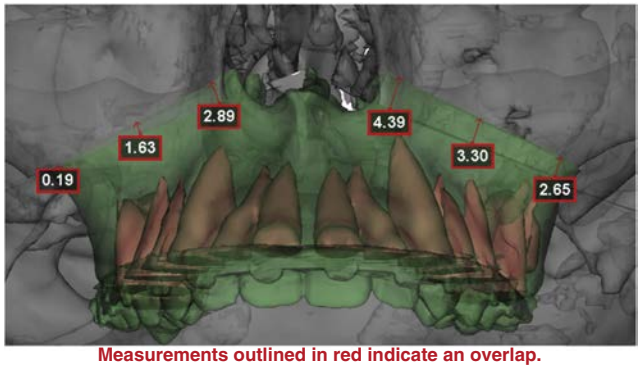

Measurements outlined in red indicate an overlap.

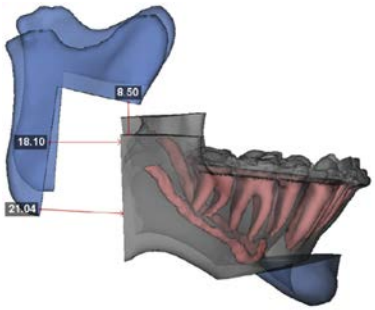

Measurements outlined in red indicate an overlap.

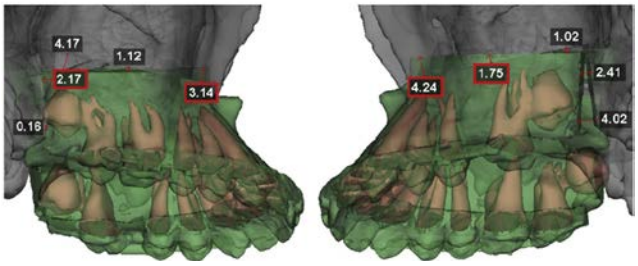

N

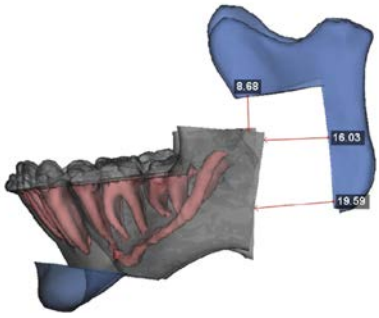

O

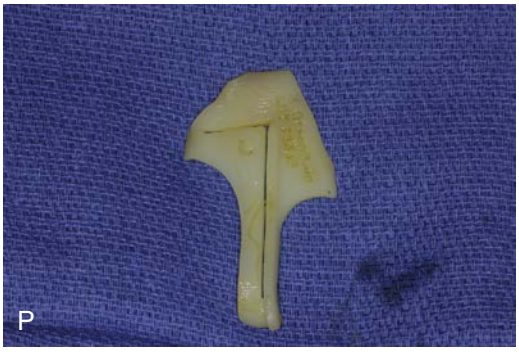



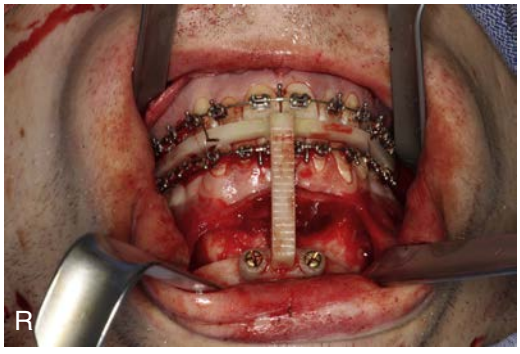







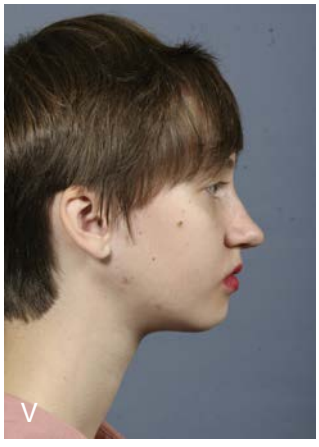



• **Figure 7-9, cont'd** **N,** Le Fort I overlap analysis; **O,** mandibular osteotomy gap analysis. **P,** Mandibular cutting guide; **Q,** intraoperative view of cutting guide in place; **R,** intraoperative view of final occlusal splint with final genioplasty positioning guide. **S,** Postoperative, frontal; **T,** postoperative, smiling; **U,** postoperative, oblique; **V,** postoperative, lateral; **W,** postoperative, occlusal.

TABLE 7-3 Predicted Measurements of Virtual Surgical Plan for Case in Figure 7-9

Point	Name	Anterior/Posterior	left/Right	Up/Down
ANS	Anterior Nasal Spine	0.60mm Posterior	0.61mm Left	6.85mm Up
A	A Point	1.19mm Anterior	0.68 mm Left	6.45mm Up
ISU1	Midline of Upper Incisor	6.00mm Anterior	0.00	8.00mm Up
U3L	Upper Left Canine	6.88mm Anterior	0.67 mm Left	5.89mm Up
U6L	Upper Left Anterior Molar (mesiobuccal cusp)	5.49 mm Anterior	2.36 mm Left	0.96mm Up
U3R	Upper Right Canine	4.58 mm Anterior	0.58 mm Left	6.39mm Up
U6R	Upper Right Anterior Molar (mesiobuccal cusp)	2.80mm Anterior	2.12mm Left	1.96mm Up
ISL1	Midline of Lower Incisor	15.25 mm Anterior	0.67 mm Left	7.69mm Up
L6L	Lower Left Anterior Molar (mesiobuccal cusp)	13.56mm Anterior	0.38 mm Left	1.00mm Up
L6R	Lower Right Anterior Molar (mesiobuccal cusp)	14.15mm Anterior	0.39 mm Left	0.68mm Up
B	B Point	21.79 mm Anterior	0.76 mm Left	3.19mm Up
Pog.	Pogonion	35.12mm Anterior	0.15 mm Right	3.02mm Up

Special Consideration: Juvenile Idiopathic Arthritis

Juvenile idiopathic arthritis (JIA) is a chronic childhood disease that can have profound effect on growth and development of the facial skeleton. Because the management of these patients is multidisciplinary and extends beyond the surgeon and orthodontist to rheumatologists and other physicians, the author's approach to this problem is included here as a special consideration.

The pathogenesis of JIA is derived from either inherited or environmental factors that produce an autoimmune reaction and result in the release of inflammatory mediators that cause joint effusion, resorption, limited range of motion, and ankylosis. Approximately 30% of patients with JIA have TMJ involvement.[38] Furthermore, there is a paucity of clinical symptoms, and approximately 50% to 70% of patients will be pain free. The most common sign is mandibular deviation upon mouth opening or limited mouth opening.

With regard to treatment of the TMJs, until the 1990s, the prevailing wisdom was that most children with JIA would "outgrow" the inflammatory component of their disease by adulthood. Data from multiple longitudinal studies published during the 1990s challenged this previous wisdom noting that remissions were, in fact, uncommon (between 31% and 63%) and joint erosion was significant, even in cases of "mild" disease.[39-41] The last decade has ushered in a new paradigm of combined aggressive medical and surgical therapy that involves the use of nonsteroidal anti-inflammatories, corticosteroids, methotrexate, and biologics such as tumor necrosis factor inhibitors and interleukin inhibitors.[42-44] Furthermore, rheumatologists and surgeons have advocated a more aggressive approach to local disease control using corticosteroid injections. The potential advantages of this approach are increased function, decreased symptoms, decreased joint damage, and decreased need for reconstructive or rehabilitative procedures.

Even when employing a proactive approach such as this, a minority of patients will have disease that is recalcitrant to local and systemic medications. Some patients will still require orthognathic surgery because of functional (limited mouth opening, malocclusion) or esthetic concerns, or both[45-47] (Figure 7-10).

When considering orthognathic surgery in a patient with a history of JIA, almost always the facial dysmorphology will be that described earlier: severe maxillomandibular deficiency, short posterior face height, steep mandibular plane angle, and class II malocclusion, with or without anterior open bite, limited mouth opening or TMJ ankylosis.

Orthognathic surgery can be considered in these patients taking into account the active disease process. As noted previously, most of these patients will have continued flare-ups and theoretically manifest persistent degenerative disease into adulthood. Given these constraints, strong consideration should be given to replacing the inflamed or destroyed TMJ in combination with maxillary and mandibular repositioning.[48] If a patient has a normal range of mouth opening and either nonexistent or diminutive condyles with no evidence of synovitis on magnetic resonance imaging, then that patient can be considered for bilateral inverted L osteotomies combined with Le Fort I osteotomy and osteoplastic genioplasty alone. However, if the patient has significant decrease in range of mouth opening or persistent synovitis within the TMJ, the senior author prefers to replace the joint with a custom alloplastic condyle and fossa prostheses (TMJ Concepts). Most of the time this will be a bilateral procedure; however, occasionally a unilateral joint replacement can be performed.

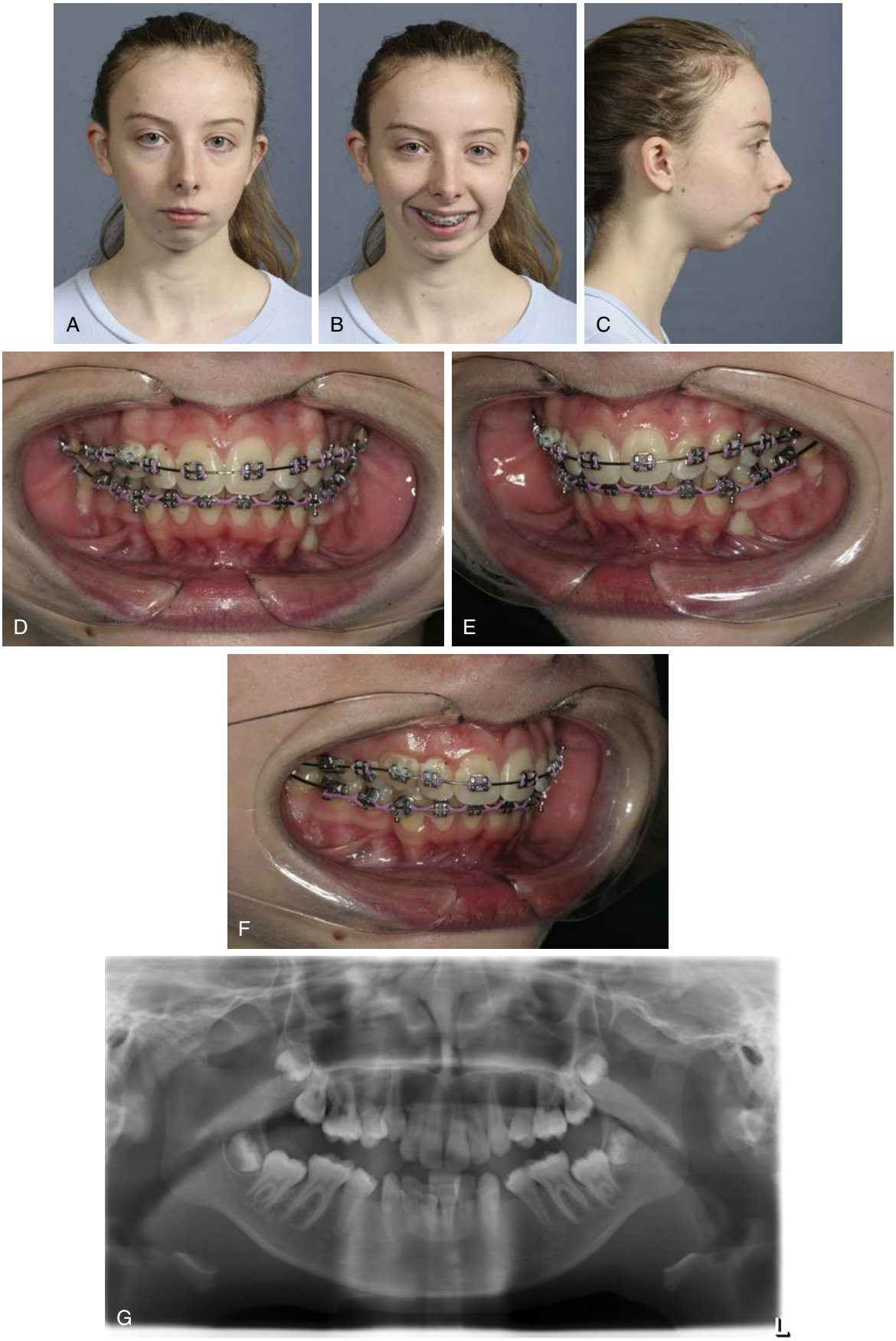

• **Figure 7-10** A 15-year-old girl with a history of juvenile idiopathic arthritis and right temporomandibular joint (TMJ) ankylosis. **A**, Preoperative frontal repose with narrow lower facial width. **B**, Preoperative smile. **C**, Preoperative facial profile with severe convexity. **D**-**F**, Preoperative occlusion with deep bite and class II malocclusion. **G**, Preoperative panoramic x-ray showing severe degeneration and flattening of the left condyle, calcifications and ankylosis of the right temporomandibular joint.

H



I

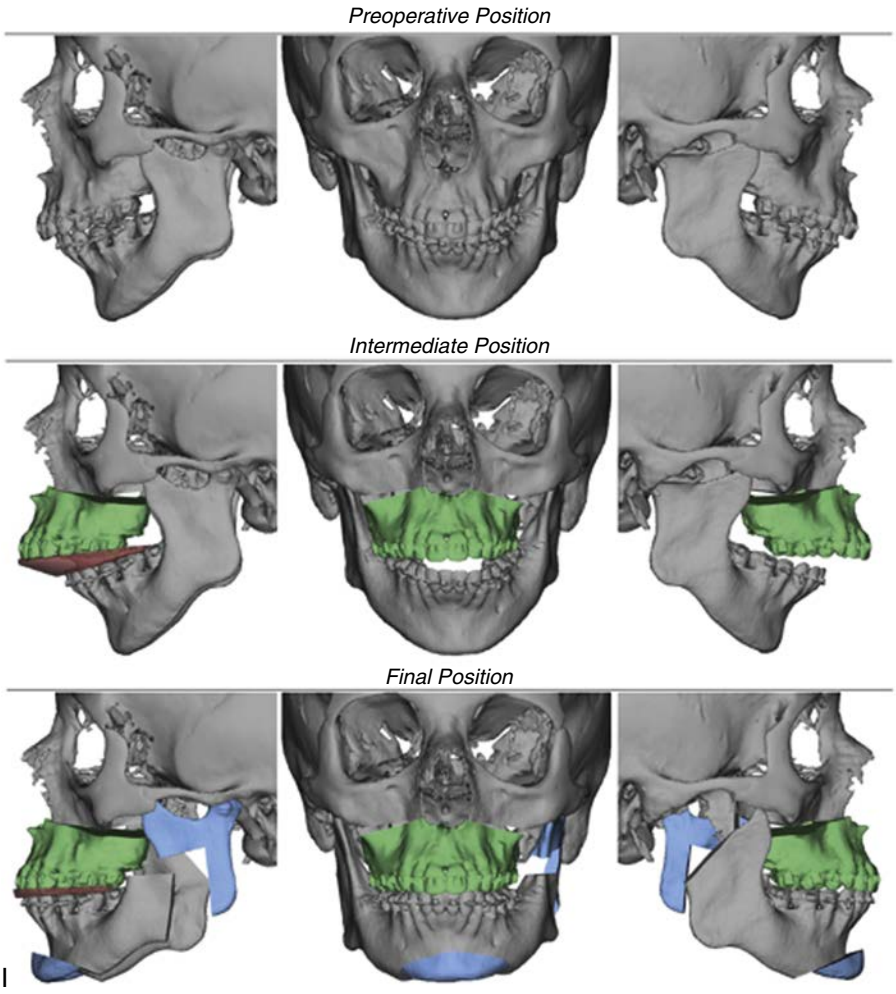

• **Figure 7-10, cont'd** **H**, Preoperative lateral cephalometric x-ray showing short posterior facial height, steep mandibular plane angle, and severe retrognathia. **I**, Virtual surgical plan with Le Fort I osteotomy, inverted L osteotomy on the left mandible, total joint replacement on the right mandible, genioplasty with cutting guide, counterclockwise rotation of the maxillomandibular complex.

Continued

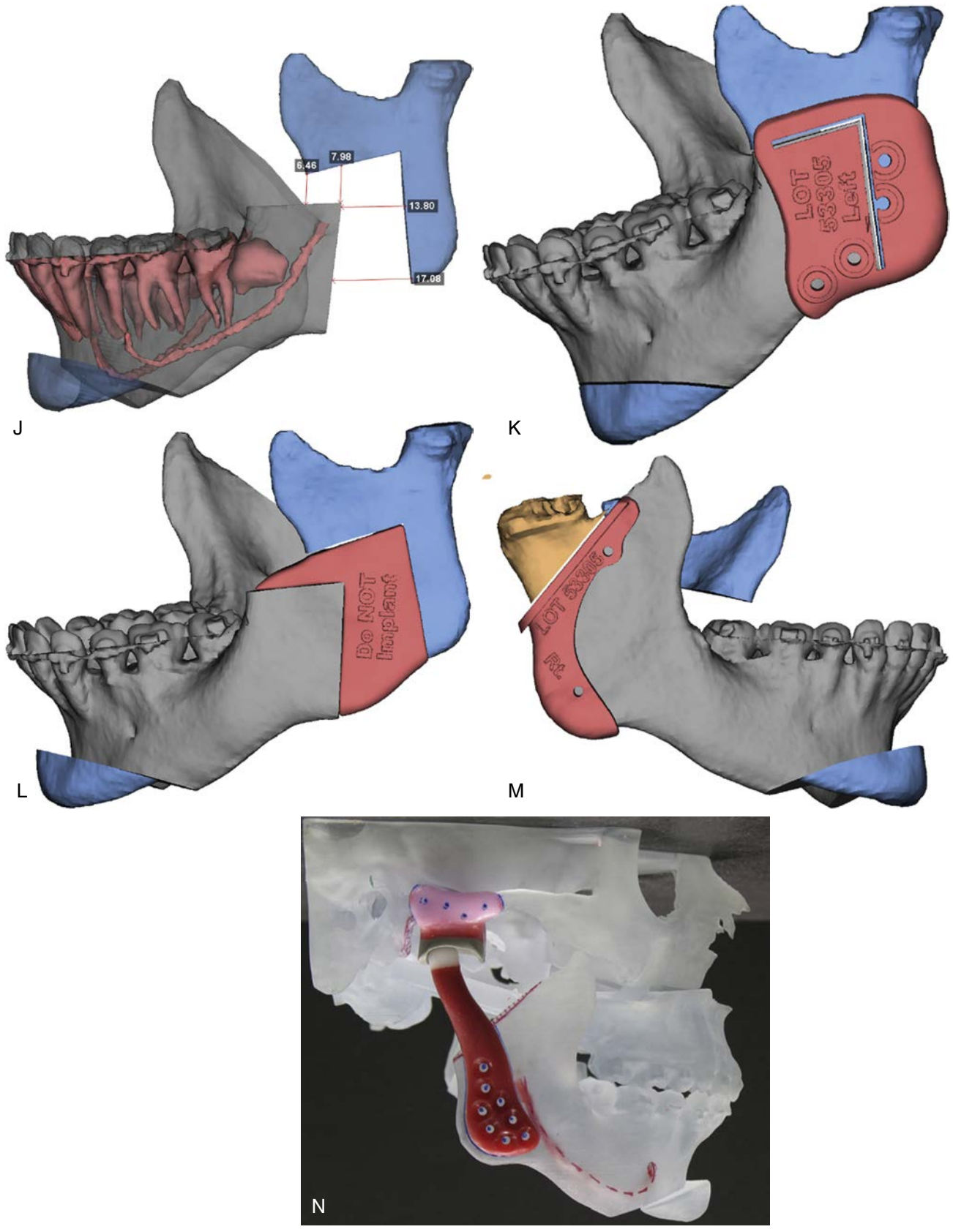

• **Figure 7-10, cont'd** **J**, Planned bony gaps after inverted L osteotomy. **K**, Cutting guide for inverted L osteotomy. **L**, Bone graft template. **M**, Condylectomy cutting guide. **N**, TMJ prosthesis on stereolithographic model.

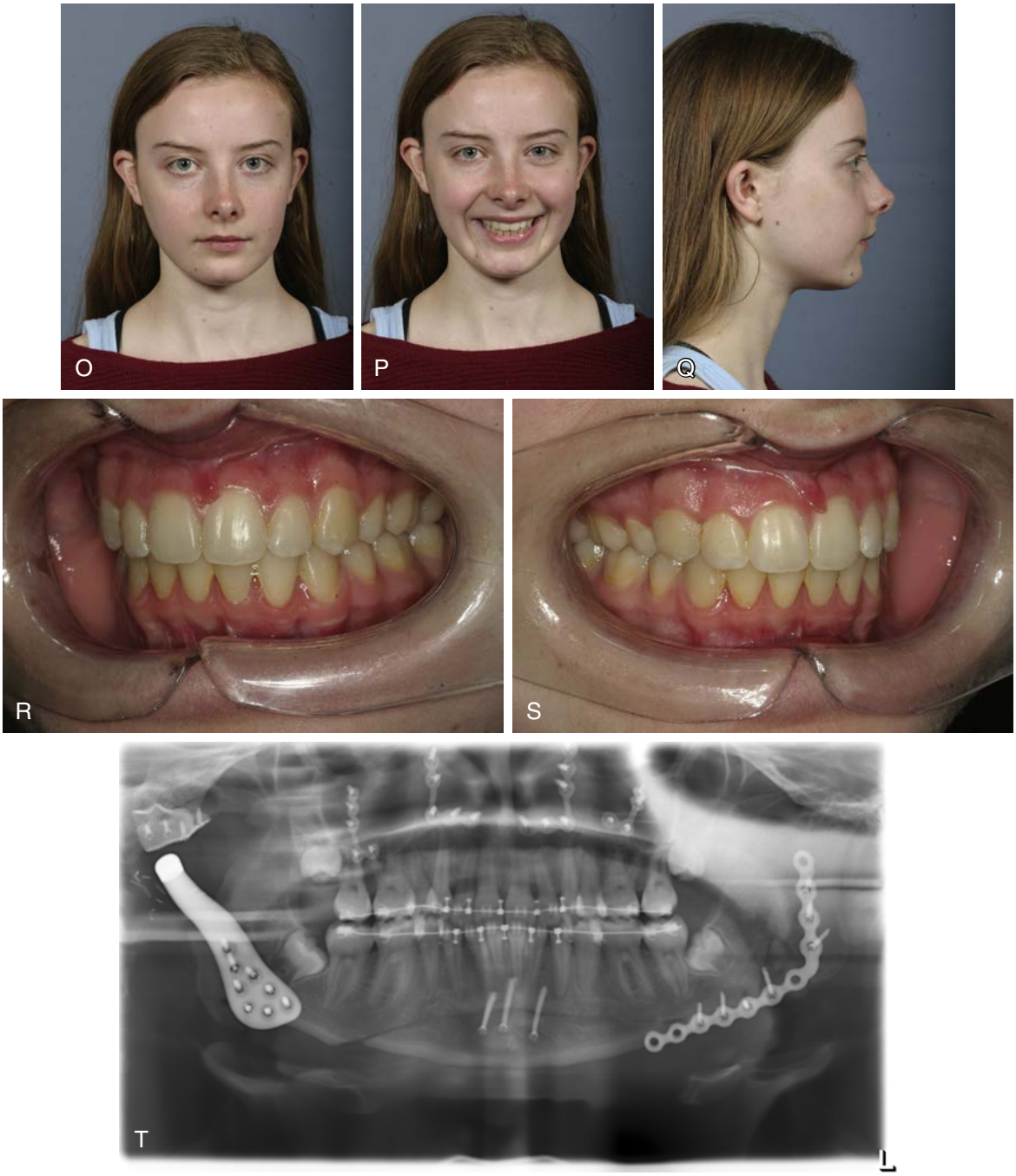

• **Figure 7-10, cont'd** O, Postoperative frontal repose with improved lower facial width. **P**, Postoperative smile. **Q**, Postoperative profile with improved posterior facial height and chin projection. **R**-**S**, Postoperative class I canine and molar occlusion. **T**, Postoperative panoramic x-ray with TMJ prosthesis, reconstruction plate, Le Fort and genioplasty hardware in place.

Continued





• **Figure 7-10, cont'd** **U**, Postoperative lateral cephalometric x-ray with improved mandibular projection. **V**, Postoperative posteroanterior cephalometric x-ray.

Special Consideration: ILOTMJ Replacement Combined with Orthognathic Surgery

Combined orthognathic surgery and TMJ replacement using VSP has been performed by the senior author since 2012[49] (Figure 7-11 and Table 7-4). The virtual surgical planning steps are as previously described in this chapter. Once completed, an osteotomy is designed to allow condylectomy in a fashion that facilitates joint replacement, with care taken to leave at least 3 cm of space for condyle and fossa replacement. Once this is accomplished, a stereolithographic model of the VSP is printed, and once it is approved, a custom condyle and fossa prosthesis is either designed, waxed, and casted, or designed virtually and printed. The mandibular osteotomies are performed first using custom guide stents. With the patient in intermaxillary fixation into the predesigned intermediate splint, the fossa and condyle prostheses are placed and stabilized with screws. Following this, the patient is released from intermaxillary fixation, and the mandibular midline and occlusal plane are evaluated for accuracy based on the preoperative virtual plan. The remainder of the operation is as detailed previously. The patient is placed into guiding elastics and returned to function rapidly.

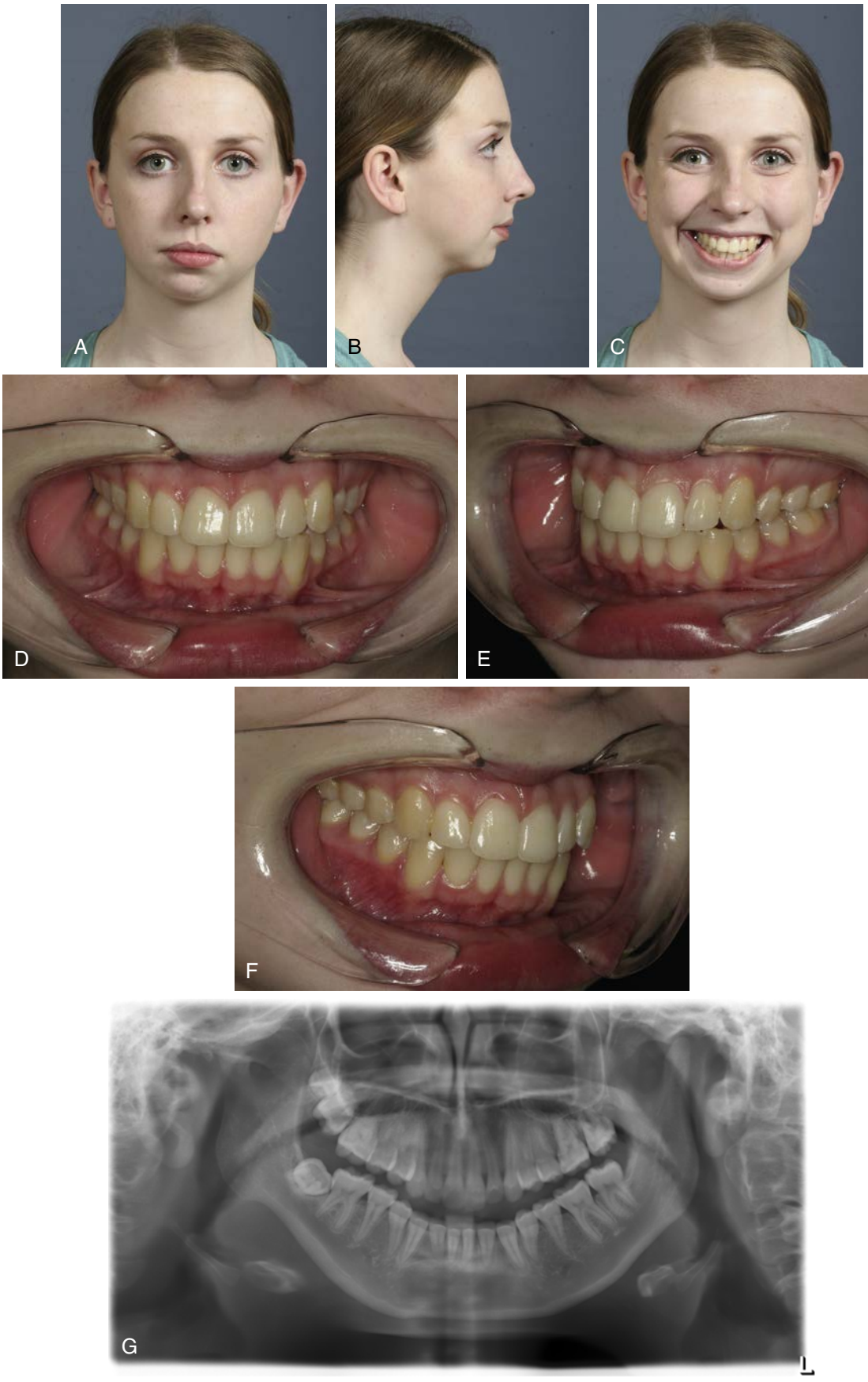

• **Figure 7-11** A 14-year-old girl with juvenile idiopathic arthritis and bilateral temporomandibular joint (TMJ) ankylosis. **A**, Pretreatment frontal view. **B**, Pretreatment lateral view. **C**, Preoperative smile. **D**-**F**, Preoperative intraoral view demonstrating class I canine and molar occlusion. **G**, Preoperative panoramic x-ray with flattening of the right condyle.

Continued



H

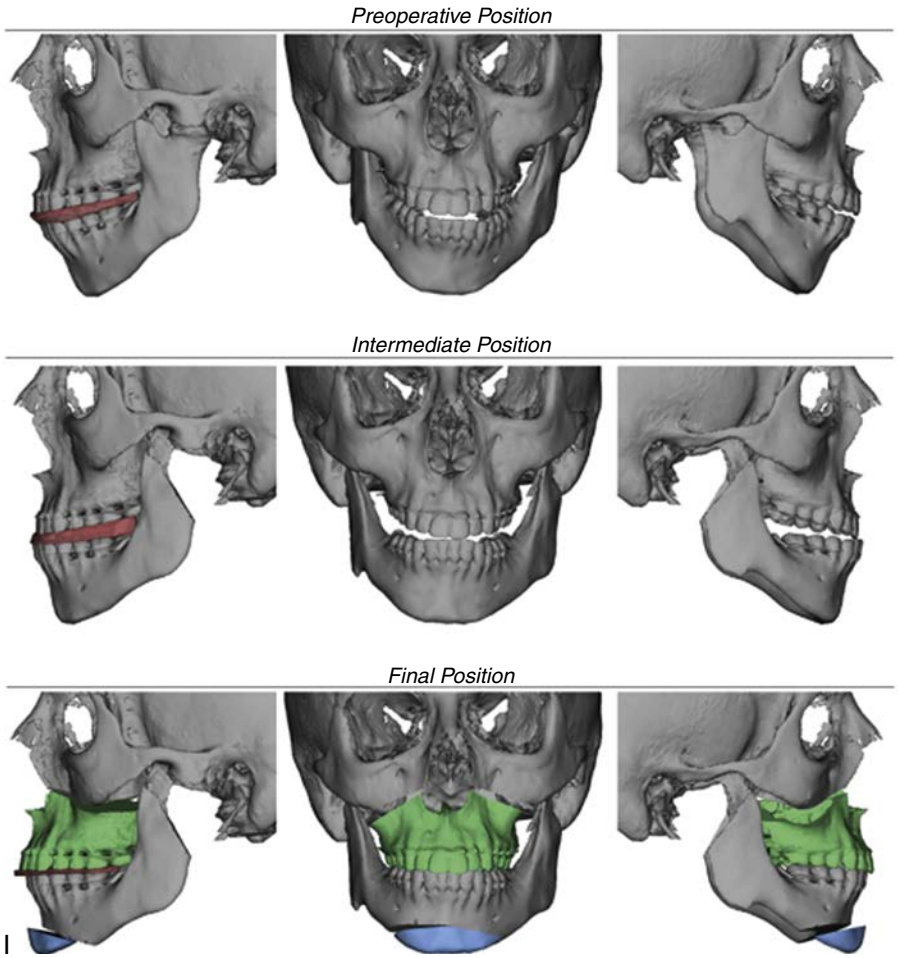

I

• **Figure 7-11, cont'd** **H**, Preoperative lateral cephalometric x-ray with short ramus height and pronounced retrognathia. **I**, Virtual surgical plan with bilateral condylectomy.

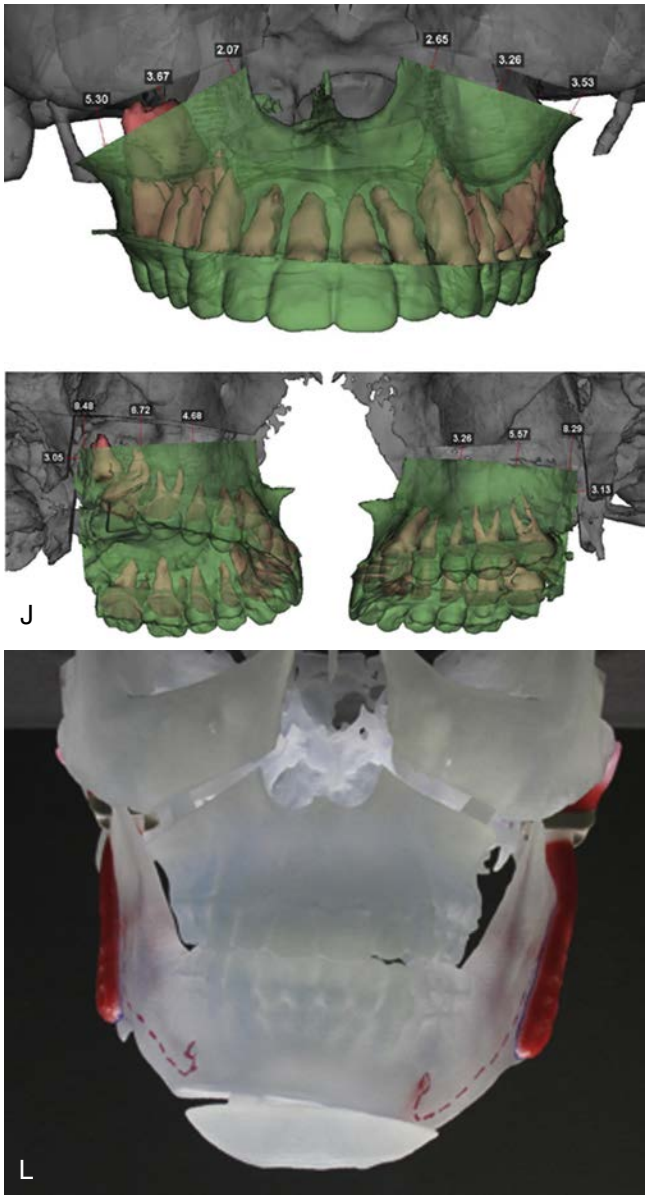

Per surgeon request, modified DICOM has been provided for intraoperative navigation.

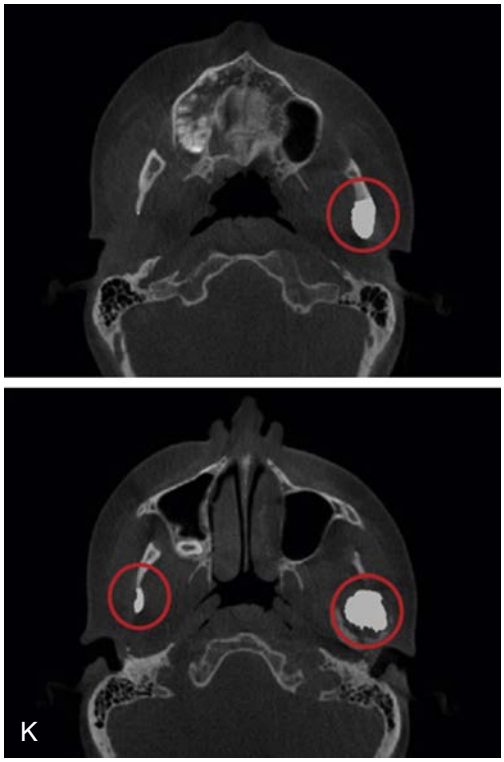

• **Figure 7-11, cont'd** **J**, Virtual plan for maxillary cant correction. **K**, Augmented computed tomography to facilitate intraoperative navigation. **L**, Stereolithographic model with TMJ concepts custom joint.

Continued



• **Figure 7-11, cont'd** **M**, Postoperative frontal repose with increased lower facial width and chin point coincident with midline. **N**, Postoperative smile. **O**, Postoperative profile with improved mandibular projection and posterior facial height. **P**-**R**, Postoperative occlusion with stable class I molar and canine relationships. **S**, Postoperative maximal incisal opening of 28 mm.

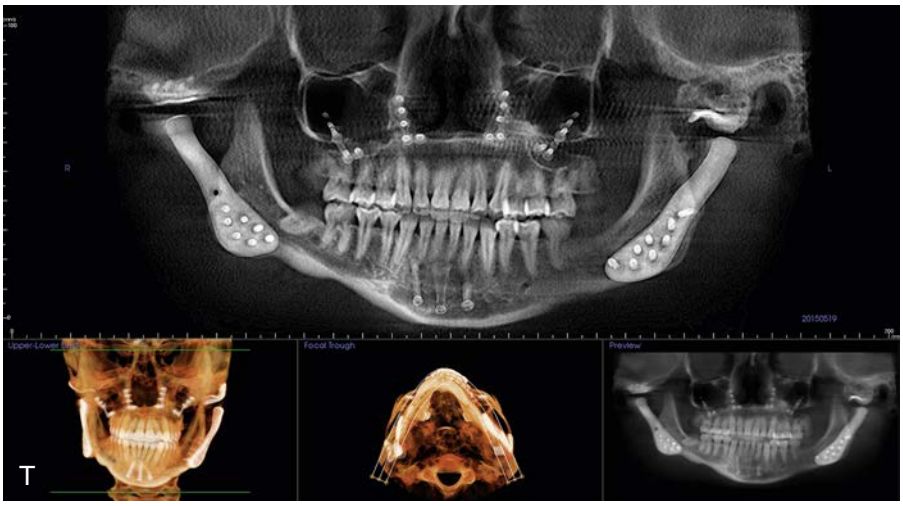



• **Figure 7-11, cont'd** **T-U**, Postoperative panoramic and cephalometric x-rays demonstrating placement of total joint prosthesis, Le Fort, and genioplasty hardware with improved mandibular projection after counterclockwise rotation and advancement.

TABLE 7-4 **Planned Movements Including 21.3-mm Advancement at Pogonion and 3-mm Cant Correction**

Point	Name	Anterior/Posterior	Left/Right	Up/Down
ANS	Anterior nasal spine	1.93 mm anterior	1.77 mm right	0.05 mm up
A	A point	3.40 mm anterior	1.28 mm right	0.59 mm down
ISU1	Midline of upper incisor	7.00 mm anterior	0.00	0.00
U3L	Upper left canine	6.62 mm anterior	0.14 mm right	0.20 mm down
U6L	Upper left anterior molar (mesiobuccal cusp)	6.15 mm anterior	0.41 mm right	3.83 mm down
U3R	Upper right canine	6.64 mm anterior	0.20 mm right	2.52 mm down
U6R	Upper right anterior molar (mesiobuccal cusp)	5.90 mm anterior	0.59 mm right	6.91 mm down
ISL1	Midline of lower incisor	6.27 mm anterior	1.80 mm right	4.39 mm up
L6L	Lower left anterior molar(mesiobuccal cusp)	6.14 mm anterior	1.31 mm right	1.46 mm down
L6R	Lower right anterior molar (mesiobuccal cusp)	4.38 mm anterior	1.53 mm right	3.81 mm down
B	B point	11.74 mm anterior	0.27 mm right	1.93 mm up
Pog	Pogonion	21.31 mm anterior	2.42 mm left	1.07 mm up

References

1. Obwegeser HL, Hadjianghelou O: Two ways to correct bird-face deformity, *Oral Surg Oral Med Oral Pathol* 64:507–518, 1987.
2. Aziz SR, Simon P: Hullihen and the origin of orthognathic surgery, *J Oral Maxillofac Surg* 62:1303–1307, 2004.
3. Wassmund M: *Frakturen und Luxationen des Gesichtsschädels unter Berücksichtigung der Komplikationen des Hirnschädels. Ihre Klinik und Therapie. Praktisches Lehrbuch*, Berlin, 1927, Hermann Meusser.
4. Pichler H, Trauner R: *Mund- und Kieferchirurgie für den Zahnarzt und Studenten*, Vienna, 1948, Urban & Schwarzenberg.
5. Caldwell JB, Letterman GS: Vertical osteotomy in the mandibular rami for correction of prognathism, *J Oral Surg (Chic)* 12:185–202, 1954.
6. Trauner R, Obwegeser H: The surgical correction of mandibular prognathism and retrognathia with consideration of genioplasty. I. Surgical procedures to correct mandibular prognathism and reshaping of the chin, *Oral Surg Oral Med Oral Pathol* 10:677–689, 1957.
7. Caldwell JB, Hayward JR, Lister RL: Correction of mandibular retrognathia by vertical L osteotomy: a new technic, *J Oral Surg* 26:259–264, 1968.
8. Hebert JM, Kent JN, Hinds EC: Correction of prognathism by an intraoral vertical subcondylar osteotomy, *J Oral Surg* 28:651–653, 1970.
9. Levine B, Topazian DS: The intraoral inverted-L double-oblique osteotomy of the mandibular ramus: a new technique for correction of mandibular prognathism, *J Oral Surg* 34:522–525, 1976.
10. Van Sickels JE, Tiner BD, Jeter TS: Rigid fixation of the intraoral inverted "L" osteotomy, *J Oral Maxillofac Surg* 48:894–898, 1990.
11. Gateno J, Xia JJ, Teichgraeber JF, et al.: Clinical feasibility of computer-aided surgical simulation (CASS) in the treatment of complex cranio-maxillofacial deformities, *J Oral Maxillofac Surg* 65:728–734, 2007.
12. Hirsch DL, Garfein ES, Christensen AM, et al.: Use of computer-aided design and computer-aided manufacturing to produce orthagnathically ideal surgical outcomes: a paradigm shift in head and neck reconstruction, *J Oral Maxillofac Surg* 67:2115–2122, 2009.
13. Bell RB: Computer planning and intraoperative navigation in cranio-maxillofacial surgery, *Oral Maxillofac Surg Clin North Am* 22:135–156, 2010.
14. Farrell BB, Franco PB, Tucker MR: Virtual surgical planning in orthognathic surgery, *Oral Maxillofac Surg Clin North Am* 26:459–473, 2014.
15. Bobek S, Farrell B, Choi C, et al.: Virtual surgical planning for orthognathic surgery using digital data transfer and an intraoral fiducial marker: the Charlotte method, *J Oral Maxillofac Surg* 73:1143–1158, 2015.
16. Medeiros PJ, Ritto F: Indications for the inverted-L osteotomy: report of 3 cases, *J Oral Maxillofac Surg* 67:435–444, 2009.
17. DiStefano JF, Spilka C: Inverted-L osteotomy for correction of mandibular prognathism after relapse, *J Oral Surg* 36:147–149, 1978.
18. Muto T, Akizuki K, Tsuchida N, Sato Y: Modified intraoral inverted "L" osteotomy: a technique for good visibility, greater bony overlap, and rigid fixation, *J Oral Maxillofac Surg* 66:1309–1315, 2008.
19. Rosenberg I, Lownie JF, Lurie R: The treatment of mandibular deformity using the intraoral inverted "L" osteotomy of the ascending ramus of the mandible, *J Dent Assoc S Afr* 35:223–231, 1980.
20. Epker BN, Fish L: Surgical-orthodontic correction of open-bite deformity, *Am J Orthod* 71:278–299, 1977.
21. Joss CU, Vassalli IM: Stability after bilateral sagittal split osteotomy advancement surgery with rigid internal fixation: a systematic review, *J Oral Maxillofac Surg* 67:301–313, 2009.
22. Gonçalves JR, Cassano DS, Wolford LM, et al.: Postsurgical stability of counterclockwise maxillomandibular advancement surgery: affect of articular disc repositioning, *J Oral Maxillofac Surg* 66:724–738, 2008.
23. Wolford LM, Chemello PD, Hilliard FW: Occlusal plane alteration in orthognathic surgery, *J Oral Maxillofac Surg* 51:730–740, 1993, discussion 740–741.
24. Farrell CD, Kent JN: Evaluation of the surgical stability of 20 cases of inverted-L and C osteotomies, *J Oral Surg* 35:239–245, 1977.
25. Dattilo DJ, Braun TW, Sotereanos GC: The inverted L osteotomy for treatment of skeletal open-bite deformities, *J Oral Maxillofac Surg* 43:440–443, 1985.
26. Aymach Z, Nei H, Kawamura H, Van Sickels J: Evaluation of skeletal stability after surgical-orthodontic correction of skeletal open bite with mandibular counterclockwise rotation using modified inverted L osteotomy, *J Oral Maxillofac Surg* 69:853–860, 2011.
27. Hay AD, Ayoub AF, Moos KF, Singh GD: Euclidean distance matrix analysis of surgical changes in prepubertal craniofacial microsomia patients treated with an inverted L osteotomy, *Cleft Palate Craniofac J* 37:497–502, 2000.
28. Zhu S-S, Feng G, Li J-H, et al.: Correction of mandibular deficiency by inverted-L osteotomy of ramus and iliac crest bone grafting, *Int J Oral Sci* 4:214–217, 2012.
29. Kobayashi A, Yoshimasu H, Kobayashi J, Amagasa T: Neurosensory alteration in the lower lip and chin area after orthognathic surgery: bilateral sagittal split osteotomy versus inverted L ramus osteotomy, *J Oral Maxillofac Surg* 64:778–784, 2006.
30. Naples RJ, Van Sickels JE, Jones DL: Long-term neurosensory deficits associated with bilateral sagittal split osteotomy versus inverted "L" osteotomy, *Oral Surg Oral Med Oral Pathol* 77:318–321, 1994.
31. Al-Moraissi EA, Ellis E: Is there a difference in stability or neurosensory function between bilateral sagittal split ramus osteotomy and intraoral vertical ramus osteotomy for mandibular setback? *J Oral Maxillofac Surg* 73:1360–1371, 2015.
32. Keeling SD, Riolo ML, Martin RE, Ten Have TR: A multivariate approach to analyzing the relation between occlusion and craniofacial morphology, *Am J Orthod Dentofacial Orthop* 95:297–305, 1989.
33. Bell WH, editor: *Modern practice in orthognathic and reconstructive surgery*, Philadelphia, 1992, Saunders.
34. Gateno J, Xia JJ, Teichgraeber JF, et al.: Clinical feasibility of computer-aided surgical simulation (CASS) in the treatment of complex cranio-maxillofacial deformities, *J Oral Maxillofac Surg* 65:728–734, 2007.
35. Teerijoki-Oksa T, Jääskeläinen SK, Forssell K, et al.: Risk factors of nerve injury during mandibular sagittal split osteotomy, *Int J Oral Maxillofac Surg* 31:33–39, 2002.
36. Pogrel MA, Schmidt BL, Ammar A: The presence of the antilingula and its relationship to the true lingula, *Br J Oral Maxillofac Surg* 33:235–238, 1995.
37. Monnazzi MS, Passeri LA, Gabrielli MFR, et al.: Anatomic study of the mandibular foramen, lingula and antilingula in dry mandibles, and its statistical relationship between the true lingula and the antilingula, *Int J Oral Maxillofac Surg* 41:74–78, 2012.
38. Ringold S, Torgerson TR, Egbert MA, Wallace CA: Intraarticular corticosteroid injections of the temporomandibular joint in juvenile idiopathic arthritis, *J Rheumatol* 35:1157–1164, 2008.
39. Sherry DD, Stein LD, Reed AM, et al.: Prevention of leg length discrepancy in young children with pauciarticular juvenile rheumatoid arthritis by treatment with intraarticular steroids, *Arthritis Rheum* 42:2330–2334, 1999.

40. Pedersen TK: Clinical aspects of orthodontic treatment for children with juvenile chronic arthritis, *Acta Odontol Scand* 56:366–368, 1998.
41. Wenneberg B, Kopp S, Gröndahl HG: Long-term effect of intra-articular injections of a glucocorticosteroid into the TMJ: a clinical and radiographic 8-year follow-up, *J Craniomandib Disord* 5:11–18, 1991.
42. Arabshahi B, Cron RQ: Temporomandibular joint arthritis in juvenile idiopathic arthritis: the forgotten joint, *Curr Opin Rheumatol* 18:490–495, 2006.
43. Weiss JE, Ilowite NT: Juvenile idiopathic arthritis, *Pediatr Clin North Am* 52:413–442, 2005.
44. Müller L, Kellenberger CJ, Cannizzaro E, et al.: Early diagnosis of temporomandibular joint involvement in juvenile idiopathic arthritis: a pilot study comparing clinical examination and ultrasound to magnetic resonance imaging, *Rheumatology (Oxford)* 48:680–685, 2009.
45. Leshem D, Tompson B, Britto JA, et al.: Orthognathic surgery in juvenile rheumatoid arthritis patients, *Plast Reconstr Surg* 117:1941–1946, 2006.
46. Proffit WR, White RP, Sanver D: *Contemporary treatment of dentofacial deformity*, Chapter 6. St. Louis, 2003, Mosby.
47. Kohjitani A, Miyawaki T, Kasuya K, et al.: Anesthetic management for advanced rheumatoid arthritis patients with acquired micrognathia undergoing temporomandibular joint replacement, *J Oral Maxillofac Surg* 60:559–566, 2002.
48. Dela Coleta KE, Wolford LM, Gonçalves JR, et al.: Maxillo-mandibular counter-clockwise rotation and mandibular advancement with TMJ Concepts total joint prostheses: part I—skeletal and dental stability, *Int J Oral Maxillofac Surg* 38:126–138, 2009.
49. Gelesko S, Markiewicz MR, Weimer K, Bell RB: Computer-aided orthognathic surgery, *Atlas Oral Maxillofac Surg Clin* 20:107–118, 2012.

8

Endoscopically Assisted Mandibular Osteotomies

BATYA R. GOLDWASER, MARIA J. TROULIS

Introduction

The first description of a mandibular osteotomy for the correction of prognathism and anterior open bite was by Simon Hullihen in 1849.[1] Since then, the major advance has been the sagittal split osteotomy, described in 1955 by Trauner and Obwegeser, which enabled surgeons to correct a variety of deformities with a single technique.[2] Other than minor technical modifications, the bilateral sagittal split osteotomy (BSSO) is still considered to be the workhorse for mandibular correction as it allows multidimensional movements. In the ensuing years, one of the main focuses in orthognathic surgery, and the field of surgery in general, has been reduction of patient morbidity. With the advent of rigid internal fixation, the need for routine postoperative maxillomandibular fixation has been eliminated.[3,4] In addition, controlled hypotensive anesthesia, patient positioning, and administration of perioperative steroids has decreased edema and postoperative pain and made the need for blood transfusion almost nonexistent.[5-7] Together this has resulted in an average hospital length of stay after mandibular osteotomy of only 1 to 2 days when standard techniques are used.[8,9]

The just-mentioned modifications in surgical technique and perioperative management have transformed mandibular corrective surgery into a safe and routine operation. However, available technology, widely used in general surgery, otorhinolaryngology, urology, and obstetrics and gynecology, has been underused in oral and maxillofacial surgery. With endoscopic assistance, the surgeon can visualize the entire ramus/condylar unit (RCU) using small, remotely placed incisions with minimal dissection, resulting in significantly decreased postoperative pain and swelling, minimal hospital stay, and rapid recovery with earlier return to normal activities.[10-13] A variety of mandibular osteotomies can be performed in this manner, including condylectomy, coronoidectomy, vertical ramus osteotomies with internal rigid fixation, and resection of pathologic lesions, as well as reduction and fixation of fractures and placement of mandibular distractors.[14-21]

Surgical Technique

A single approach to the RCU has been studied and implemented at the Massachusetts General Hospital. It includes marking out landmarks on the skin and then making a small, extraoral, submandibular incision (15 mm) to create a well-defined subperiosteal optical cavity. This approach results in less bleeding and swelling compared to intraoral approaches, and it allows the surgeon to view the mandible in a more natural "en face" orientation, making the learning curve less steep.[22] Another advantage of the extraoral approach is the ability to place the patient in maxillomandibular fixation without compromising access.

Anatomic landmarks are first marked on the skin and include the mandibular border and condyle and location of planned osteotomy (Figure 8-1). A 1.5-cm incision is made 1 finger-breadth below the angle of the mandible parallel to a neck skin crease. Dissection is then continued bluntly down to the pterygomasseteric sling which is incised in the avascular plane. Using an endoscopic elevator with a suction port, a subperiosteal dissection is continued up the lateral ramus establishing the optical cavity (Figure 8-2). Next, a 30-degree endoscope is placed in the wound and oriented parallel to the posterior border. This allows direct access to the entire RCU (Figure 8-3).[11-13] Anatomic landmarks are identified including the posterior border, the sigmoid notch, coronoid process, and anterior border of the mandible (Figure 8-4). A curved, long-handled retractor is placed in the sigmoid notch to maintain the visual field. Irrigation is performed through the endoscope irrigation port.[21]

Vertical Ramus Osteotomy

The most significant risk of mandibular ramus osteotomies for correction of prognathism is injury to the inferior alveolar nerve and subsequent postoperative neurosensory changes. This is true for both the BSSO which results in up to 100% chance of at least temporary paresthesia, as well as

the intraoral vertical ramus osteotomy (IVRO), which has a lower risk of injury, though more often permanent if it does occur.[23-26] In addition, the IVRO cannot be rigidly fixed and requires a course of maxillomandibular fixation. In contrast, the endoscopic vertical ramus osteotomy (EVRO) has minimal risk of nerve damage and the segments can be rigidly fixed under direct visualization.[23-26]

Once the endoscopic optical cavity has been developed, an osteotomy is made with a long-shaft reciprocating saw from the sigmoid notch to the mandibular angle. The medial pterygoid muscle is partially stripped to allow overlap of the proximal and distal segments. If more control of the proximal segment is needed, a clamp can be used. After placing the patient into maxillomandibular fixation (MMF) in the desired occlusion, the segments are fixated using three 12- to 14-mm length, 2.0-mm diameter screws or a rigid plate if there is minimal overlap of the segments (Figure 8-5). Screws can be placed either directly through the incision, or through a percutaneous trocar.[11-13] The same technique can be used for mandibular advancement, with placement of a bone graft in the gap if necessary.



• **Figure 8-1** Anatomic landmarks drawn on skin, including mandibular condyle, coronoid, angle, anterior and posterior border, zygomatic arch, planned incision, planned osteotomy, and path of endoscope.

In a 2004 retrospective analysis of 14 patients (23 sides) in whom this technique of EVRO was used, Troulis and Kaban reported a mean operative time of 37 minutes per side and successful rigid internal fixation in the preplanned occlusion through the 1.5-cm submandibular incision without the need for a trocar. Nine patients had mandibular prognathism with a mean setback of 4.7 mm (2 to 9 mm), and the remaining patients had mandibular asymmetry with asymmetric setback. Complications included temporary marginal mandibular nerve weakness, temporary inferior alveolar nerve paresthesia, and need for blood transfusion secondary to transection of the masseteric artery (n = 1). The majority of patients had less than 1 day hospital stay. Only one patient required prolonged MMF because of difficulty positioning the proximal fragment.[12] These findings were confirmed in a prospective study of 10 patients (17 sides) with mean operative time of 33 minutes per side. Follow up ranged from 3 to 5 years, with nine patients demonstrating skeletal stability and one patient with relapse secondary to late mandibular growth. There were no cases of facial nerve weakness. Four patients had temporary inferior alveolar nerve paresthesia. Average hospital length of stay was less than 2 days.[27]

Condylectomy

Indications for condylectomy include temporomandibular joint (TMJ) disorders that result in progressive change in shape or size of the condyle. These generally fall into

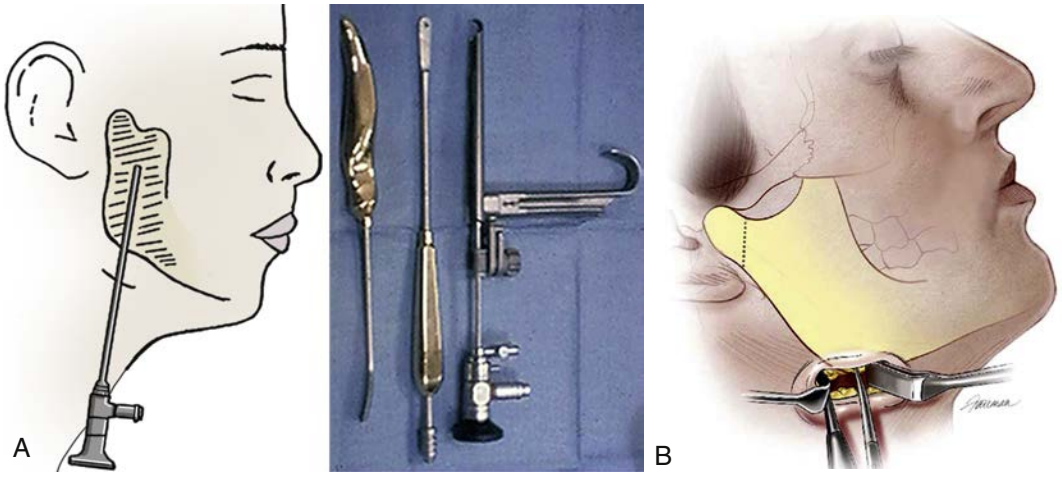

• **Figure 8-2** **A,** Diagram of vector of insertion (parallel to posterior border) and endoscopic instruments including suction/elevator, sigmoid notch retractor and camera. **B,** Incision and dissection. Schematic drawing of the dissection. Note the positioning of the Senn retractors, parallel to the marginal mandibular nerve.

two groups: condylar resorption or hyperplasia. Condylar resorption may be idiopathic, or due to trauma, arthritis, steroid use, neoplasm, or orthognathic surgery, and usually requires reconstruction with a bone graft or prosthesis at the time of condylectomy, and correction of secondary malocclusion.[28] Condylar hyperplasia, in contrast, results in overgrowth. If determined to be active, it either can be observed until the growth cycle is complete, or may be treated with a growth-arresting procedure, or high condylectomy, and subsequent ramus osteotomy to correct the malocclusion.[28,29] The diagnosis and management of these conditions is not the goal of this chapter, however. If low or high condylectomy, with or without reconstruction of the joint, is the treatment planned, the endoscopic approach can be used. This results in significantly decreased morbidity because the standard pre-auricular incision is avoided, thus eliminating risk to the frontal branch of the facial nerve in addition to decreasing the risk to the marginal mandibular branch.

The same 1.5-cm incision and dissection as described for the EVRO is used. To facilitate dissection of the condylar head and neck, the RCU is distracted inferiorly using a 26-gauge wire placed at the mandibular angle for traction.

In patients with condylar resorption being treated with condylectomy and costochondral graft reconstruction, the condylectomy is performed from the sigmoid notch to the posterior border and the condyle removed, exposing the undersurface of the disc. The patient is then placed into MMF, usually with a bite-opening splint on the involved side to account for the loss of vertical height that occurs with remodeling of the graft. The costochondral graft is then harvested using standard techniques and placed into

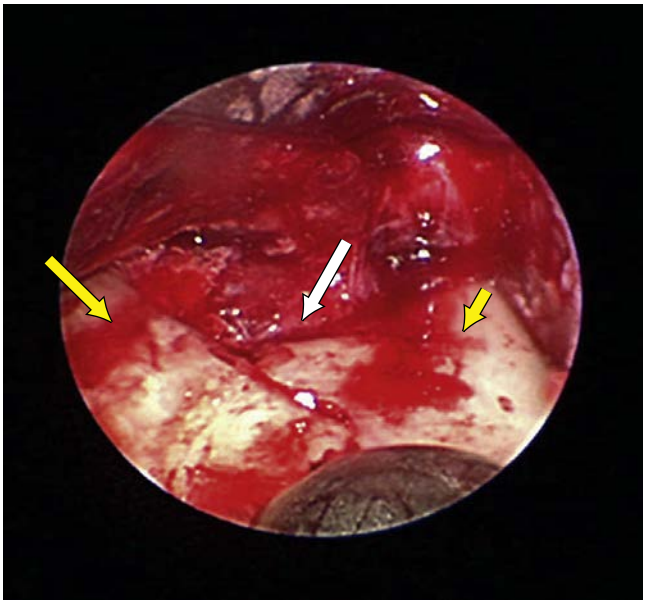

• **Figure 8-4** Case of subcondylar fracture. Optical cavity with view of fracture line from sigmoid notch *(white arrow),* coronoid *(long yellow arrow),* condyle *(long yellow arrow),* sigmoid notch, posterior border of mandible.

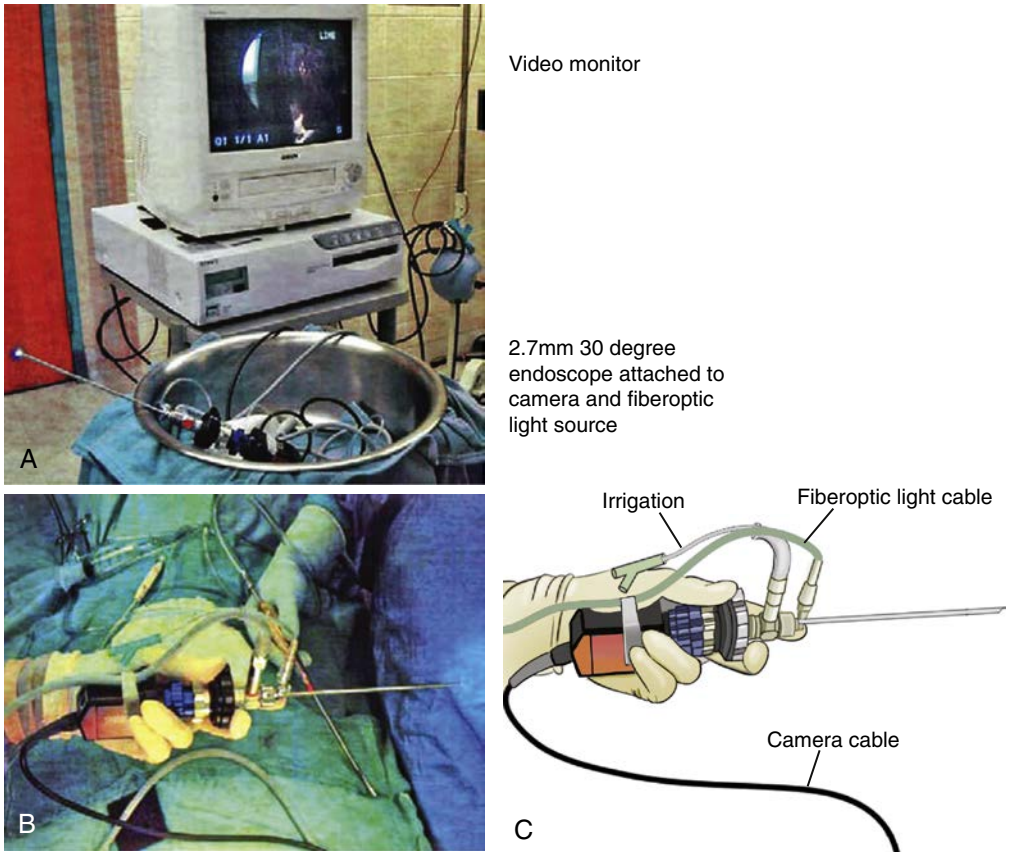

• **Figure 8-3** **A,** A tower and endoscope. **B,** Thescope. **C,** Schematic drawing of the endoscope coupled to camera.

the glenoid fossa under endoscopic visualization of the graft and the meniscus. The graft is fixed with plates and screws, usually requiring a trocar for access[13,28,30-32] (Figure 8-6).

A retrospective review of 10 patients (17 sides), with a mean age of 32 (range 19-46) undergoing endoscopic condylectomy and costochondral graft, showed mean operating time of 52 minutes per side (not including rib harvest). Average hospital length of stay was 2.5 days, and in all cases the entire operation was performed via the 1.5-cm submandibular incision. The planned occlusion was achieved in all patients, and rigid fixation was applied. Bleeding was minimal given subperiosteal dissection under direct visualization. All patients remained in MMF for 10 to 14 days postoperatively. There was one case of transient unilateral marginal mandibular nerve weakness that resolved by 2 weeks postoperatively. The patient cohort has since more than doubled, with none suffering any persistent neurosensory changes of the facial, inferior alveolar, or lingual nerve.[13]

For condylar hyperplasia, the standard approach includes a preauricular incision to access the TMJ in order to resect the hyperplastic condyle. This is followed by standard orthognathic surgery for correction of any malocclusion. In contrast, with endoscopic assistance, a single submandibular incision is used. The condyle is dissected, a vertical ramus osteotomy is performed, and the entire proximal segment is removed. The hyperplastic condyle is resected ex vivo on the back table, and then the proximal segment replaced and rigidly fixed in a more superior position, correcting the occlusion simultaneously.[11,12,28,32] Long-term follow-up of more than 3 years showed mean relapse of 0.3 mm, despite total stripping of the proximal segment and use as a free bone graft.[27]

Mandibular Distraction Osteogenesis

For patients requiring mandibular advancement, distraction osteogenesis is a minimally invasive technique that can be used instead of the standard BSSO. In addition to the lower risk of IAN damage during the osteotomy, the gradual separation of the proximal and distal segments allows the soft tissues and neurovascular structures to expand as well, making larger movements better tolerated.[23-26]

Mandibular distractors can be placed using intraoral or extraoral incisions. The intraoral approach is essentially a variant of the BSSO incision, exposing only the area of the planned osteotomy and fixating the device in place, with significantly less dissection required. Endoscopy has been used for making the mandibular osteotomy, as well for extraoral placement of mandibular distractors in human cadaver and live minipig studies, using a modified approach to the one previously mentioned.[33] In this case, two 1-cm submandibular incisions are made. The first is a working port located directly in line with the osteotomy where the endoscope is inserted. The second incision is used to insert the device after dissection and partial corticotomy are complete. Bicortical screws are used to fixate the device in position, using either port. The corticotomy is then completed with an osteotome, avoiding the neurovascular bundle.[33] Work is underway to further miniaturize distractor devices, and once this is accomplished, endoscopic placement will become clinically feasible.[34,35]

Coronoidectomy

Coronoidectomy is usually performed in patients with limited mouth opening and a coronoid process that extends above the zygomatic arch. If the patient can open at least 20 mm, an intraoral incision can be used for access. However, this is often not possible, and a bicoronal flap is required for access. In contrast, with endoscopic assistance, the coronoid process can be approached using the same small submandibular incision described earlier, avoiding the morbidity associated with the coronal incision and dissection (Figure 8-7). Using the same approach described in this chapter, endoscopic coronoidectomy was performed on 11 patients (17 sides), with bilateral (n = 7) or unilateral (n = 3) coronoid hyperplasia. This was completed via the 1.5-cm submandibular incision without any long-term neurologic deficit, and resultant improved maximal incisal opening (>35 mm).[21]

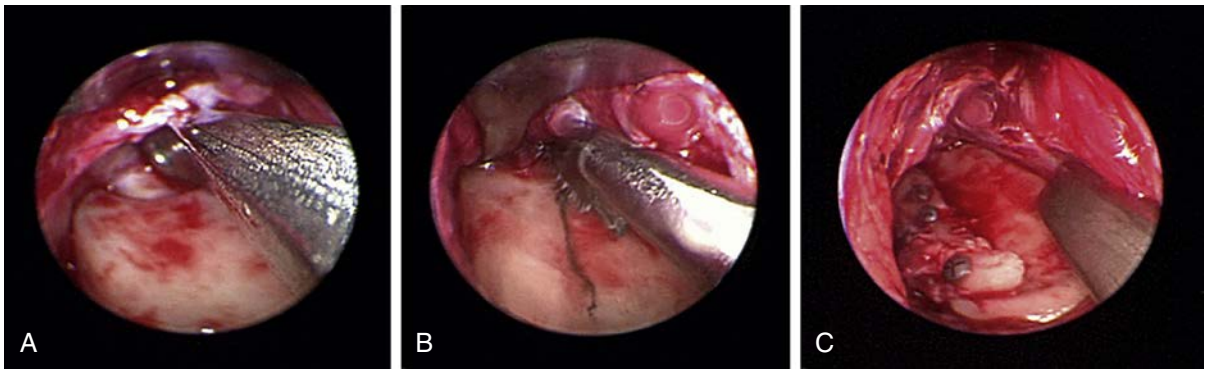

• **Figure 8-5** Endoscopic views of endoscopic vertical ramus osteotomy. **A,** Dissection and identification of sigmoid notch with suction/elevator. **B,** Vertical osteotomy with reciprocating saw from sigmoid notch to mandibular angle. **C,** Overlap of proximal and distal segments after mandibular setback and fixation with positional screws.

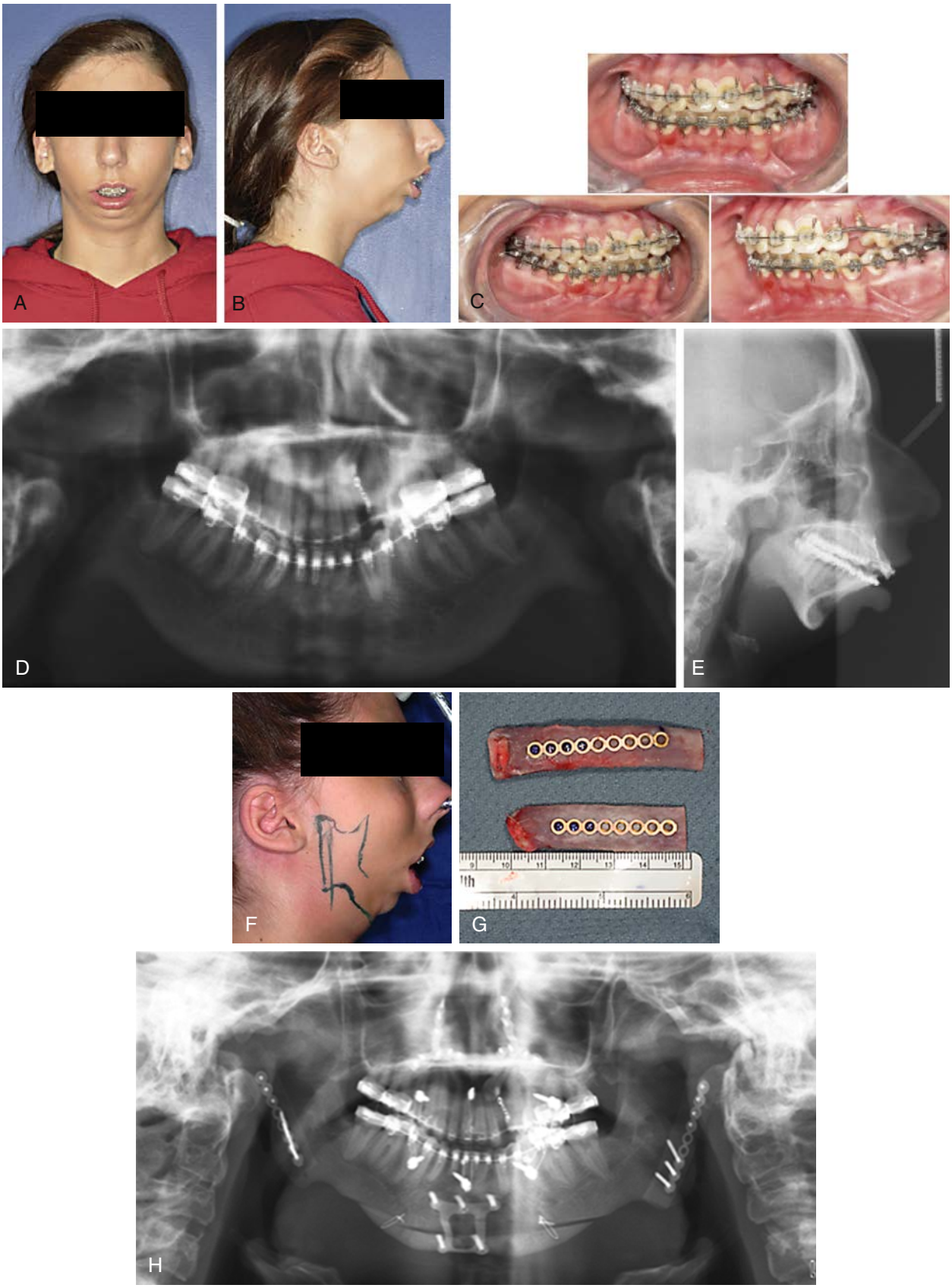

• **Figure 8-6** A 17-year-old girl with idiopathic condylar resorption with secondary clockwise rotation of the mandible, retrognathia, and a convex profile. **A,** Frontal rest, photograph. **B,** Lateral photograph. **C,** Preoperative occlusion. **D,** Preoperative panoramic x-ray. **E,** Preoperative lateral cephalogram. **F,** Anatomic landmarks. **G,** Costochondral rib grafts. **H,** Postoperative panoramic x-ray with ribs rigidly fixed in place.

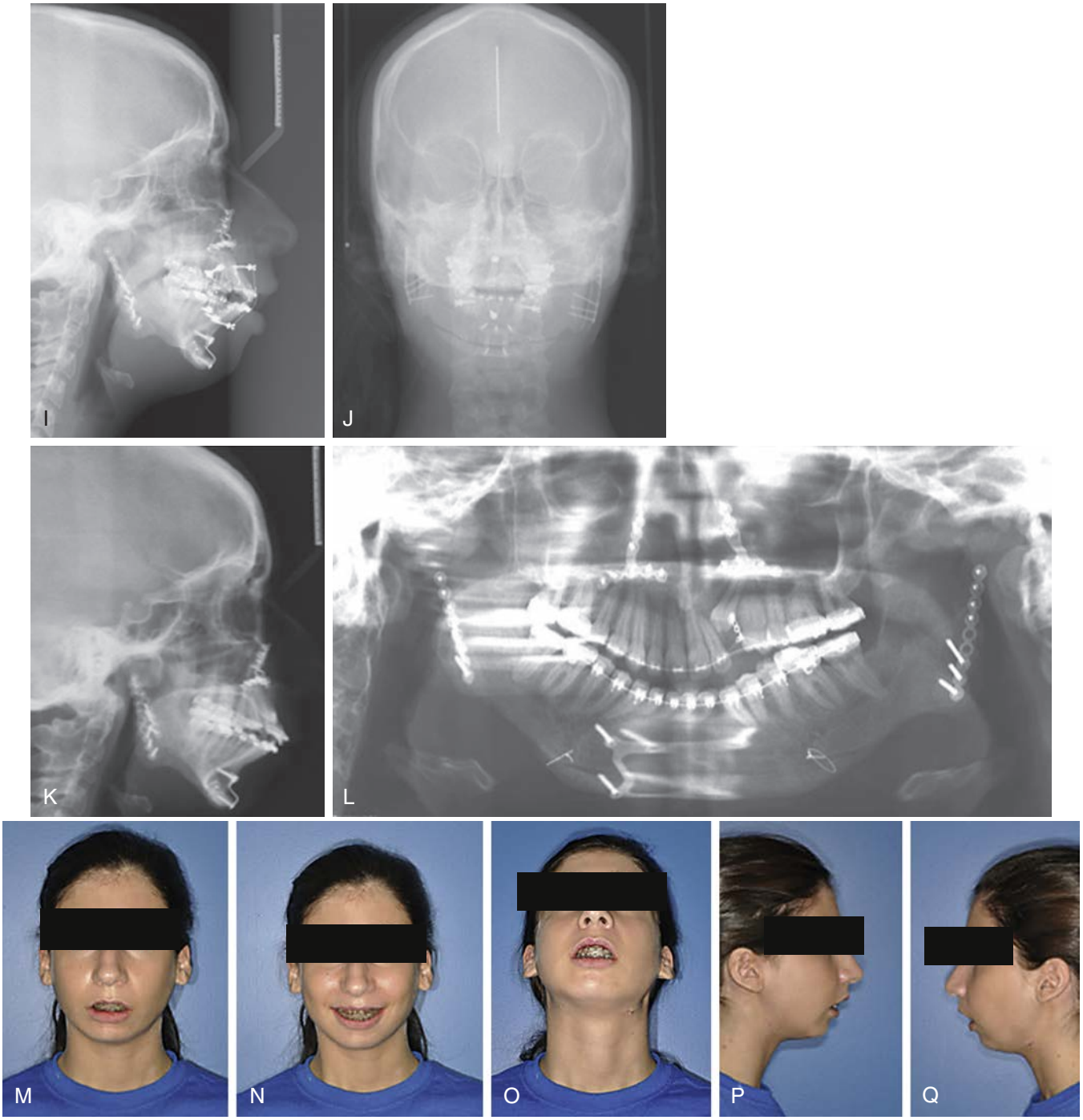

• **Figure 8-6, cont'd** **I-J,** Immediate postoperative lateral and anteroposterior cephalogram with patient in maxillomandibular fixation, and grafts in place. **K-L,** Lateral cephalogram and panoramic x-ray 5 months after surgery showing stability. **M-Q,** One month after surgery.

Continued



• **Figure 8-6, cont'd** R-W, Five months after surgery.

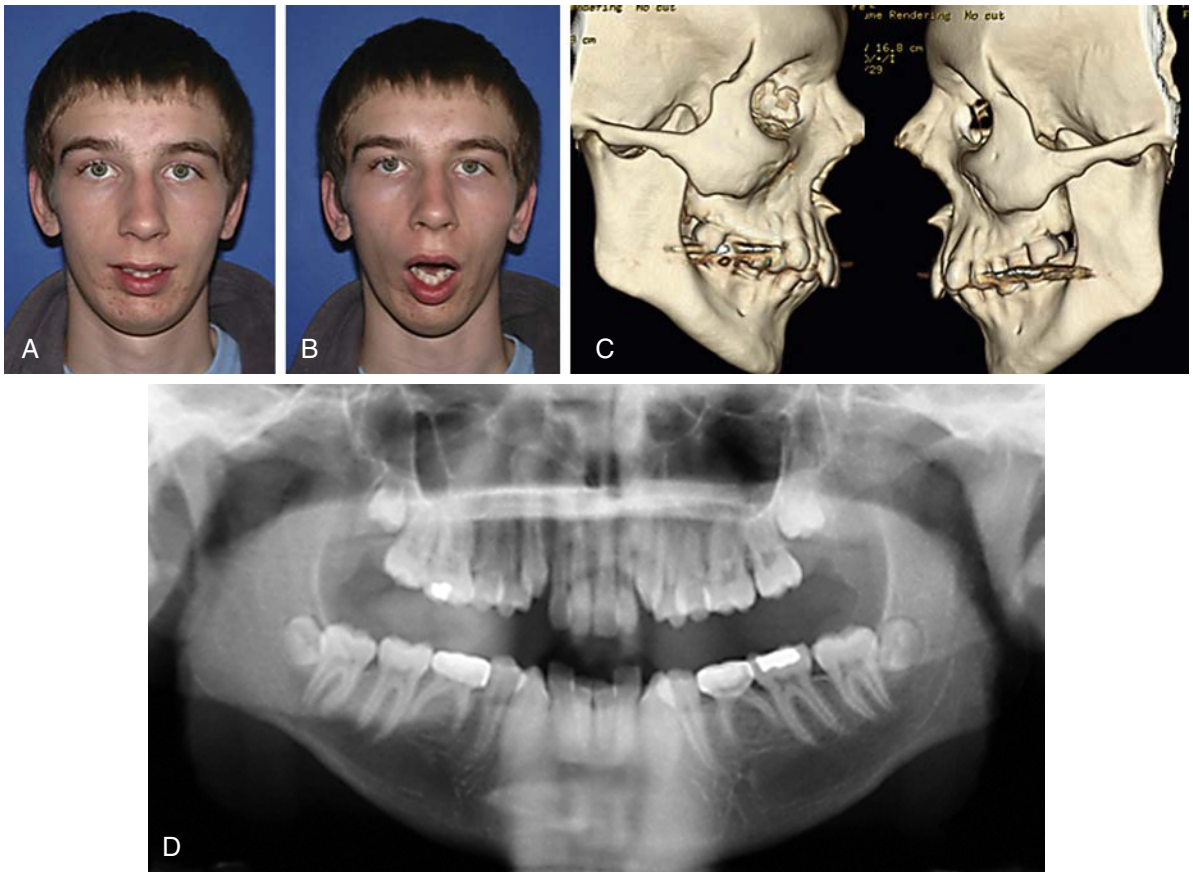

• **Figure 8-7** A 17-year-old boy with limited mouth opening of 20 mm secondary to bilateral coronoid hyperplasia. **A,** Frontal photograph. **B,** Maximal incisal opening. **C,** Preoperative three-dimensional computed tomography scan. **D,** Preoperative panoramic radiograph showing limited mouth opening.

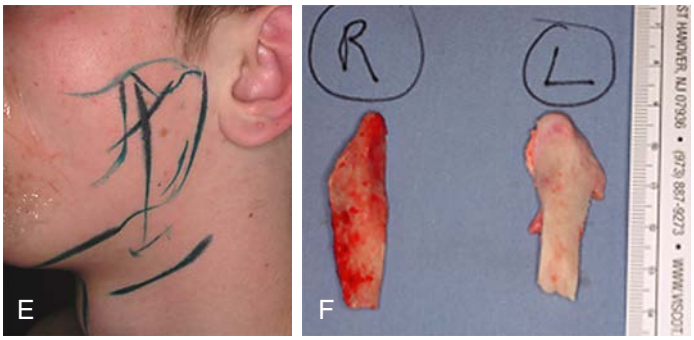



• **Figure 8-7, cont'd** **E,** Anatomic landmarks drawn. **F,** Surgical specimens of resected coronoids. **G,** Postoperative panoramic x-ray showing improved mouth opening.

Conclusion

Accessing the mandible with the aid of endoscopy via the minimally invasive surgical approach described here enables the surgeon to perform a variety of osteotomies using a single technique. Using a small, remotely placed incision, there is direct and magnified visualization of the operative field, requiring minimal dissection and tissue manipulation and resulting in reduced pain, swelling, and therefore overall recovery time. As the technology and skill become more widely available and refined, many of these operations, which traditionally necessitated prolonged hospitalization with high morbidity, may routinely be done in the outpatient setting.

References

1. Wolfe SA: Gunther Cohn Stock, MS, DDS, father of maxillary orthognathic surgery, *J Craniomaxillofac Surg* 17:331–334, 1989.
2. Trauner R, Obwegeser H: The surgical correction of mandibular prognathism and retrognathia with consideration of genioplasty, *Oral Surg* 10:899–909, 1957.
3. Hausamen JE: The scientific development of maxillofacial surgery in the 20th century and an outlook into the future, *J Craniomaxillofac Surg* 29:2–21, 2001.
4. Steinhauser EW: Historical development of orthognathic surgery, *J Craniomaxillofac Surg* 24:195–204, 1996.
5. Dolman RM, Bentley KC, Head TW, English M: The effect of hypotensive anesthesia on blood loss and operative time during Le Fort osteotomy, *J Oral Maxillofac Surg* 58:834–839, 2000.
6. Samman N, Cheung LK, Tong AC, Tideman H: Blood loss and transfusion requirements in orthognathic surgery, *J Oral Surg* 54:21–24, 1996.
7. Gersema L, Baker K: Use of corticosteroids in oral surgery, *J Oral Maxillofac Surg* 50:270–277, 1992.
8. Huáman ET, Juvet LM, Nastri A, et al.: Changing patterns of hospital length of stay after orthognathic surgery, *J Oral Maxillofac Surg* 66:492–497, 2008.
9. Troulis MJ, Ramirez JL, Kaban LB: Endoscopic approach for mandibular orthognathic surgery, *Fac Plast Surg Clin North Am* 14:45–50, 2006.
10. Williams WB, Abukawa H, Shuster V, et al.: A comparison of postoperative edema after intraoral vs. endoscopic mandibular ramus osteotomy, *J Oral Maxillofac Surg* 61(8S):61a–62, 2003.
11. Troulis MJ, Kaban LB: Endoscopic approach to the ramus/condyle unit: clinical applications, *J Oral Maxillofac Surg* 59:503–509, 2001.
12. Troulis MJ, Kaban LB: Endoscopic vertical ramus osteotomy: early clinical results, *J Oral Maxillofac Surg* 62:824–828, 2004.
13. Troulis MJ, Williams BW, Kaban LB: Endoscopic mandibular condylectomy and reconstruction: early clinical results, *J Oral Maxillofac Surg* 62:460–465, 2004.
14. Shumrick KA, Ryzenman JM: Endoscopic management of facial fractures, *Facial Plast Surg Clin North Am* 9:469–474, 2001.
15. Pham AM, Strong EB: Endoscopic management of facial fractures, *Curr Opin Otolaryngol Head Neck Surg* 14:234–241, 2006.
16. Chen CT, Lai JP, Tung TC, Chen YR: Endoscopically assisted mandibular subcondylar fracture repair, *Plast Reconstr Surg* 103:60–65, 1999.
17. Kellman RM: Endoscopically assisted repair of subcondylar fractures of the mandible: an evolving technique, *Arch Facial Plast Surg* 5:244–250, 2003.

18. Miloro M: Endoscopic-assisted repair of subcondylar fractures, *Oral Surg Oral Med Oral Pathol Oral Radiol Endod* 96:387–391, 2003.
19. Kellman RM: Endoscopic approach to subcondylar mandible fractures, *Facial Plast Surg* 20:239–247, 2004.
20. Schon R, Fakler O, Gellrich NC, Schmelzeisen R: Five-year experience with the transoral endoscopically assisted treatment of displaced condylar mandible fractures, *Plast Reconstr Surg* 116:44–50, 2005.
21. Troulis MJ, Kaban LB: Endoscopic reconstruction of ramus condyle unit. In Troulis MJ, Kaban LB, editors: *Minimally invasive maxillofacial surgery*, Shelton, CT, 2013, People's Medical Publishing, p 15.
22. Williams WB, Abukawa H, Shuster V, et al.: A comparison of postoperative edema after intraoral vs. endoscopic mandibular ramus osteotomy, *J Oral Maxillofac Surg*(61 Suppl)61a–62, 2003.
23. MacIntosh RB: Experience with the sagittal osteotomy of the mandibular ramus: a 13 year review, *J Maxillofac Surg* 9:151–165, 1981.
24. August M, Marchena J, Donady J, Kaban L: Neurosensory deficit and functional impairment after sagittal ramus osteotomy: a long term follow-up study, *J Oral Maxillofac Surg* 56:1231–1235, 1998.
25. Ylikontiola L, Kinnunen J, Oikarinen K: Factors affecting neurosensory disturbance after mandibular bilateral sagittal split osteotomy, *J Oral Maxillofac Surg* 58:1234–1239, 2000.
26. Al-Bishri A, Rosenquist J, Sunzel B: On neurosensory disturbance after sagittal split osteotomy, *J Oral Maxillofac Surg* 62:1472–1476, 2004.
27. Papadaki ME, Kaban LB, Troulis MJ: Endoscopic vertical ramus osteotomy: a long-term prospective study, *Int J Oral Maxillofac Surg* 43:305–310, 2014.
28. Kaban LB: Acquired abnormalities of the temporomandibular joint. In Kaban LB, Troulis MJ, editors: *Pediatric oral and maxillofacial surgery*, Philadelphia, 2004, Saunders, pp 340–376.
29. Wolford LM, Mehra P: Efficacy of high condylectomy for management of condylar hyperplasia, *Am J Orthod Dentofacial Orthop* 121:136–150, 2002.
30. Papadaki ME, Tayebaty F, Kaban LB, Troulis MJ: Condylar resorption, *Oral Maxillofac Surg Clin North Am* 19:223–234, 2007.
31. Perrott DH, Umeda H, Kaban LB: Costochondral graft construction/reconstruction of the ramus/condyle unit: long term follow-up, *Int J Oral Maxillofac Surg* 23:321–328, 1994.
32. Resnick CM, Kaban LB, Troulis MJ: Minimally invasive orthognathic surgery, *Facial Plast Surg* 25:49–62, 2009.
33. Troulis MJ, Perrott DH, Kaban LB: Endoscopic mandibular osteotomy and placement and activation of a semiburied distractor, *J Oral Maxillofacial Surg* 57:1110–1113, 1999.
34. Magill JC, Byl MF, Goldwaser B, et al.: Automating skeletal expansion: an implant for distraction osteogenesis of the mandible, *J Med Device* 3:14502, 2009.
35. Goldwaser BR, Magill J, Papadaki ME, et al.: Continuous mandibular distraction osteogenesis: novel device and preliminary results in minipigs, *J Oral Maxillofac Surg* 71:e168–e177, 2013.

9

Le Fort I

CORY M. RESNICK, BONNIE L. PADWA

Introduction

The Le Fort I osteotomy is the most common maxillary operation in orthognathic surgery. It is a versatile procedure that allows the maxilla to be repositioned in three planes of space. Alone or in conjunction with mandibular osteotomies, the Le Fort I osteotomy can be used to correct a wide range of dentofacial deformities.

History

The earliest description of a maxillary osteotomy for access to nasopharyngeal polyps was by von Langenbeck in Germany in 1859.[1] Cheever was the first surgeon in the United States to use maxillary mobilization with bone chisels to relieve nasal obstruction caused by recurrent epistaxis.[2] Le Fort's classic description of the natural planes of maxillary fracture was published in 1901.[3] Wassmund was the first to apply osteotomies at the Le Fort I level for correction of mid-facial deformities.[4] The technique was subsequently modified by several surgeons including Axhausen,[5] Schuchardt,[6] and Willmar.[7] In 1965, Obwegeser improved the precision of the Le Fort I osteotomy by suggesting complete mobilization of the maxilla so that repositioning was achieved without tension.[8,9] The operation was slow to gain popularity until Bell's 1973 description of the remarkably resilient maxillary blood supply.[10] Fueled by improvements in technique and the introduction of safe hypotensive anesthesia, the Le Fort I osteotomy has been increasingly utilized over the last four decades.

Indications

The Le Fort I osteotomy can be used to treat a wide range of dentofacial deformities. This operation can also be used for treatment for obstructive sleep apnea, preparation for prosthetic rehabilitation of atrophied maxillae, and access to nasopharyngeal and spinal cord tumors.[11]

The most common indication for a Le Fort I osteotomy is maxillary hypoplasia with a class III skeletal pattern (Figure 9-1). Maxillary hypoplasia can occur in multiple planes, and correction may require maxillary advancement, inferior positioning, and/or transverse widening. Often the maxillary hypoplasia extends to the infraorbital rims, and this can be addressed at the time of orthognathic surgery with a modified Le Fort I osteotomy or insertion of alloplastic malar implants.

Vertical maxillary excess (VME) is another common dentofacial deformity treated with a Le Fort I osteotomy (Figure 9-2). Patients with VME commonly complain about a "gummy smile" or impaired masticatory function due to an anterior open bite. Three main features characterize this deformity: increased mandibular plane angle, increased total anterior facial height, and decreased contribution of the upper facial height to the total facial height. The vertical position of the maxilla must be planned based primarily on assessment of the resting relationship of the upper lip to the anterior maxillary dentition; planning only to the smile will result in an undesirable esthetic outcome. Correction involves superior repositioning of the maxilla, often with correction of the occlusal plane; bimaxillary surgery may be required.

A Le Fort I osteotomy is often needed in conjunction with a mandibular osteotomy to correct dentofacial asymmetries, as in asymmetric mandibular growth, condylar hyperplasia, and hemifacial microsomia (Figure 9-3). In these cases, determination of the correct vertical position of the maxilla is necessary to identify the fulcrum for maxillary rotation.

Diagnosis and Planning

Meticulous diagnostic assessment and preoperative planning are necessary to obtain the desired functional and esthetic results; the principles of facial assessment and orthognathic surgical planning are covered elsewhere in this book. Clear communication between the surgeon and the orthodontist during the preoperative orthodontic treatment phase is also critical to a successful outcome.

The advent of three-dimensional (3D) virtual treatment planning has transformed the planning process and accuracy of the Le Fort I osteotomy (see Figure 9-3, *L-Q*).[12] The complex 3D anatomy of the maxilla and mid-face now can be evaluated in ways never before possible. Concepts

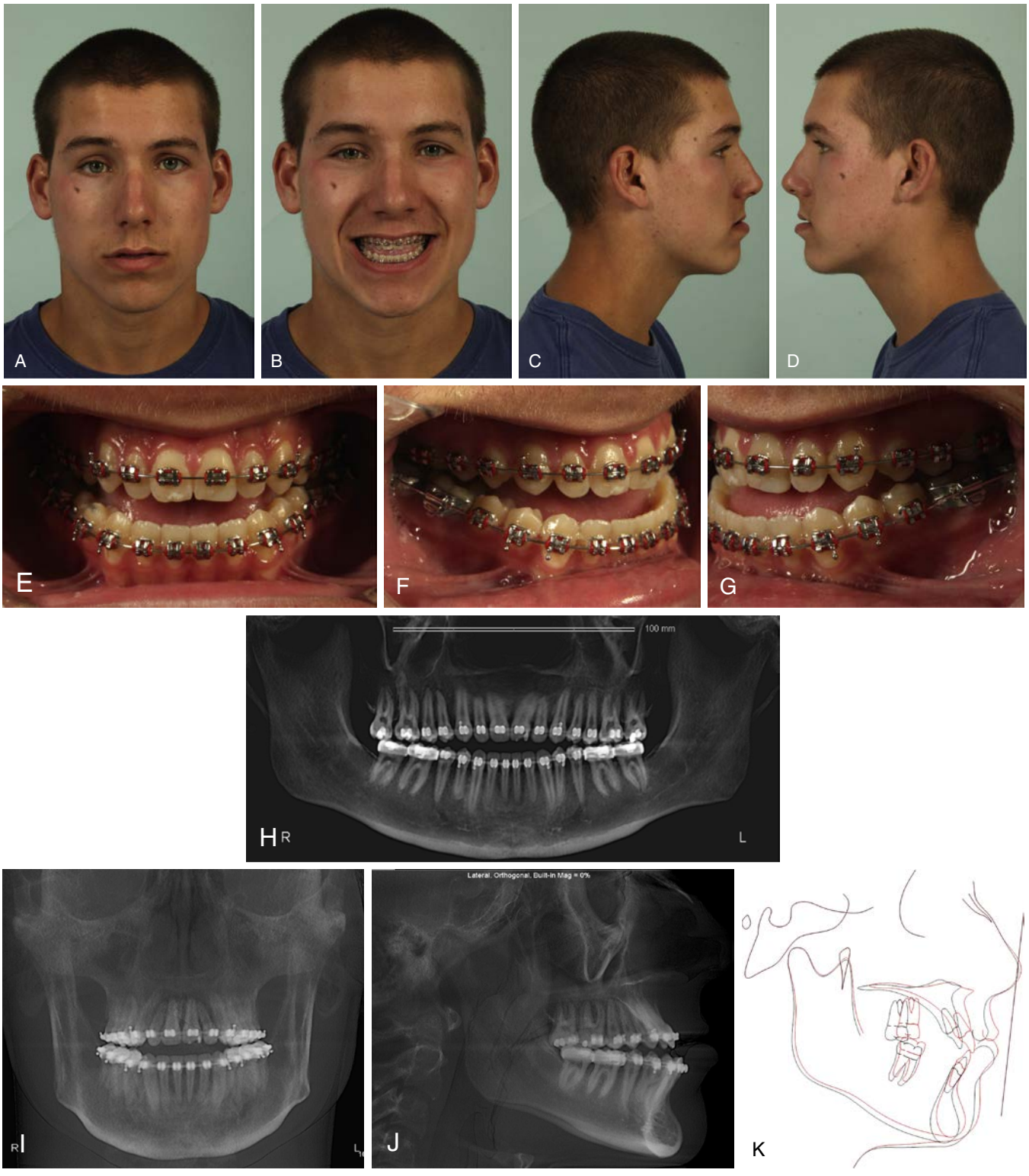

•**Figure 9-1** **A-J,** An 18-year-old with maxillary sagittal and vertical hypoplasia and an anterior open bite. **K,** Preoperative lateral cephalometric tracing in black, with planned movements overlayed in red. The operative plan included a Le Fort I osteotomy with posterior impaction of 3 mm, anterior lengthening of 1 mm, and advancement of 6 mm.

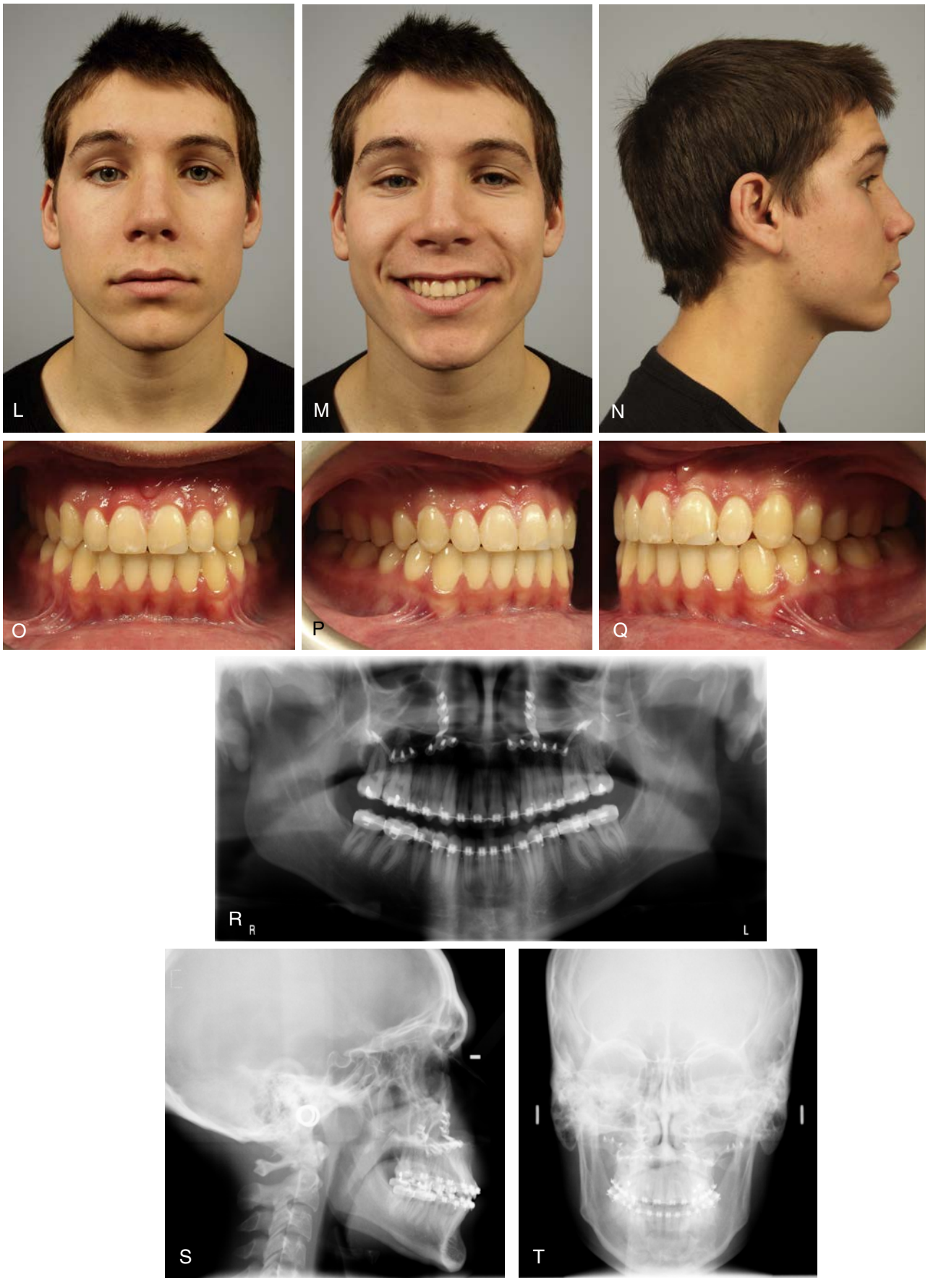

•**Figure 9-1, cont'd** **L-T,** Postoperative photographs and radiographs.

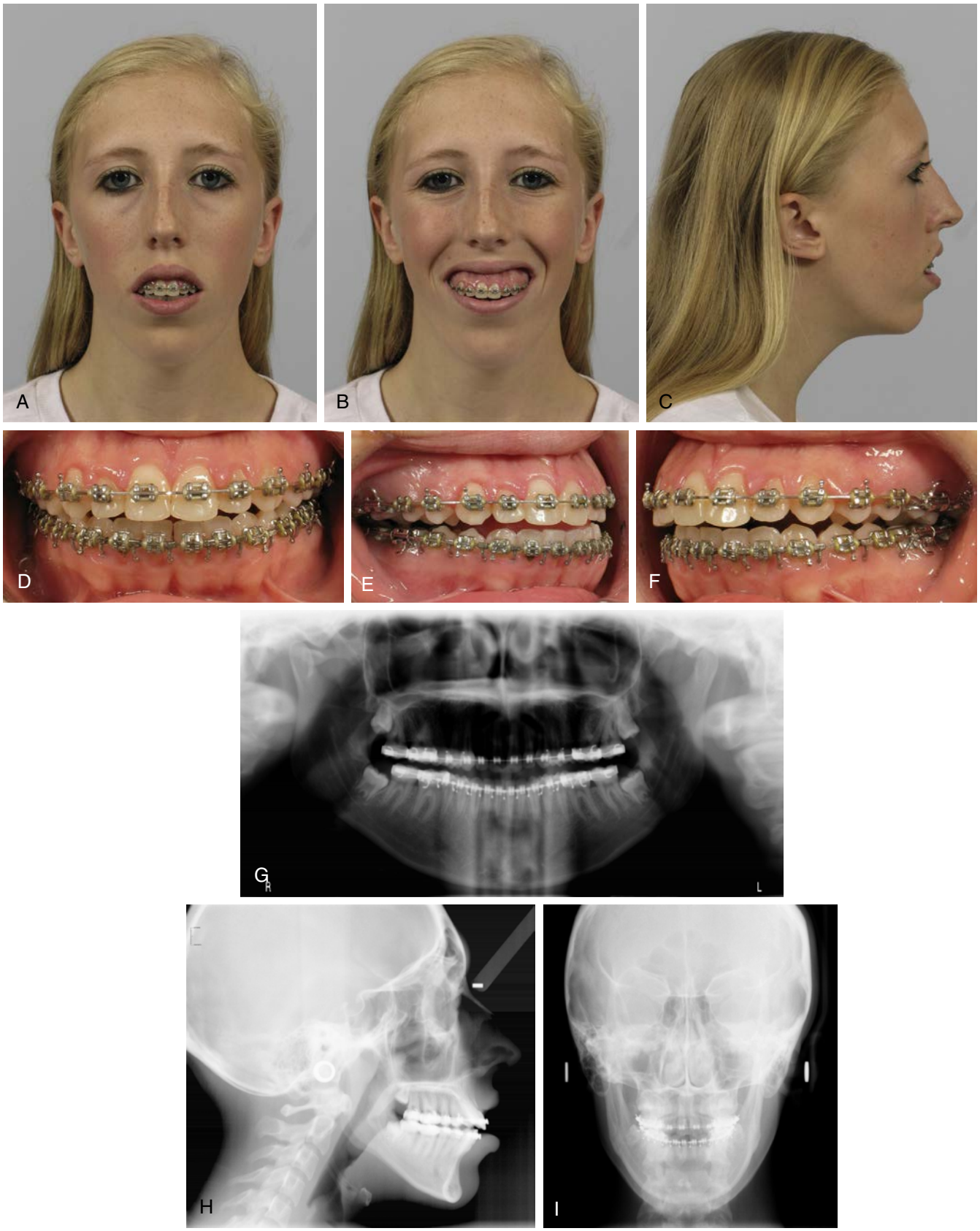

•**Figure 9-2** **A-I,** An 18-year-old with vertical maxillary excess.

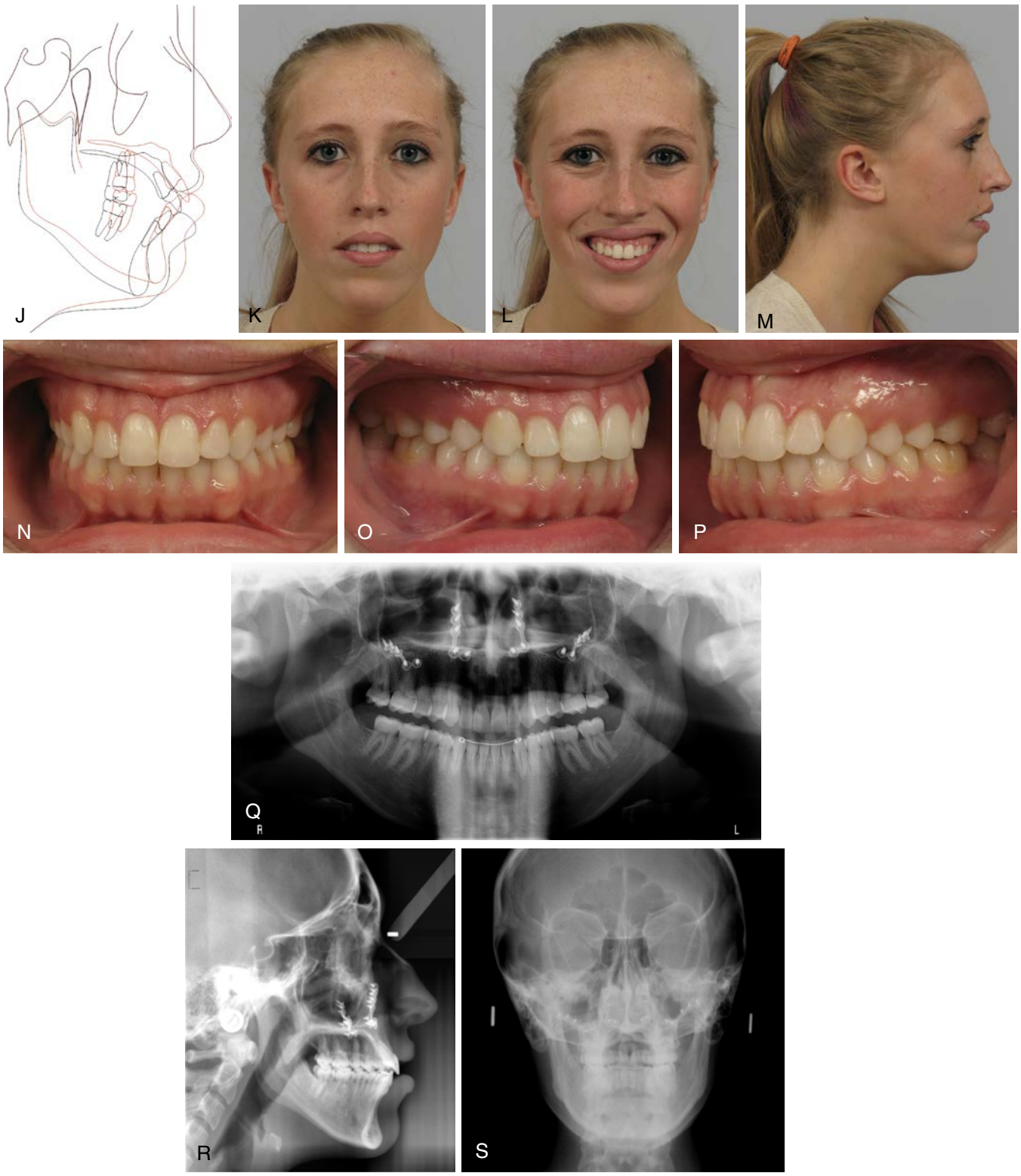

•**Figure 9-2, cont'd** **J,** Preoperative lateral cephalometric tracing in *black,* with planned movements overlayed in *red.* The operative plan included a Le Fort I osteotomy with complete impaction of 5 mm and advancement of 4 mm. **K-S,** Postoperative photographs and radiographs.

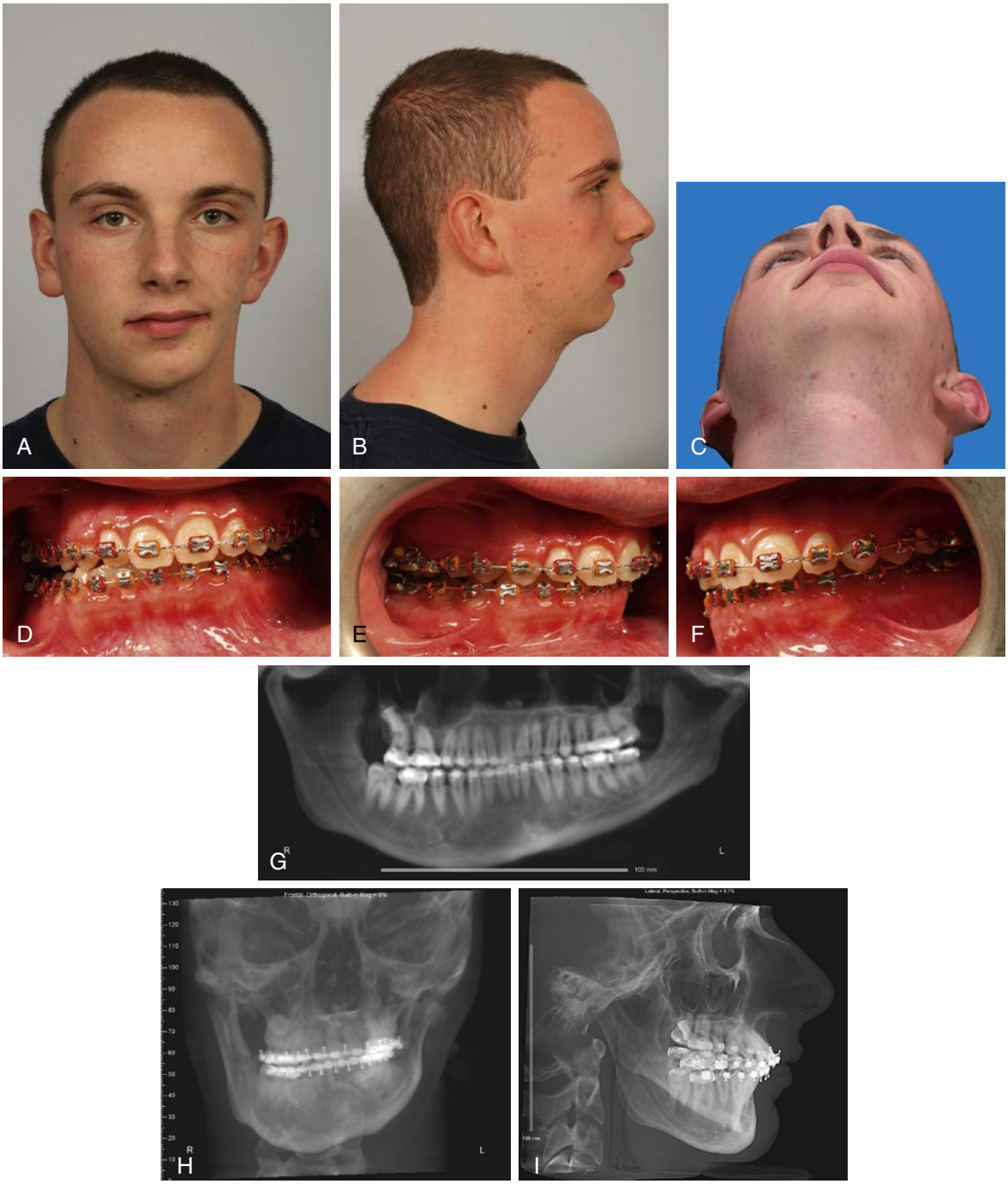

•**Figure 9-3** **A-I,** An 18-year-old with left-predominant hemifacial microsomia and associated facial asymmetry.

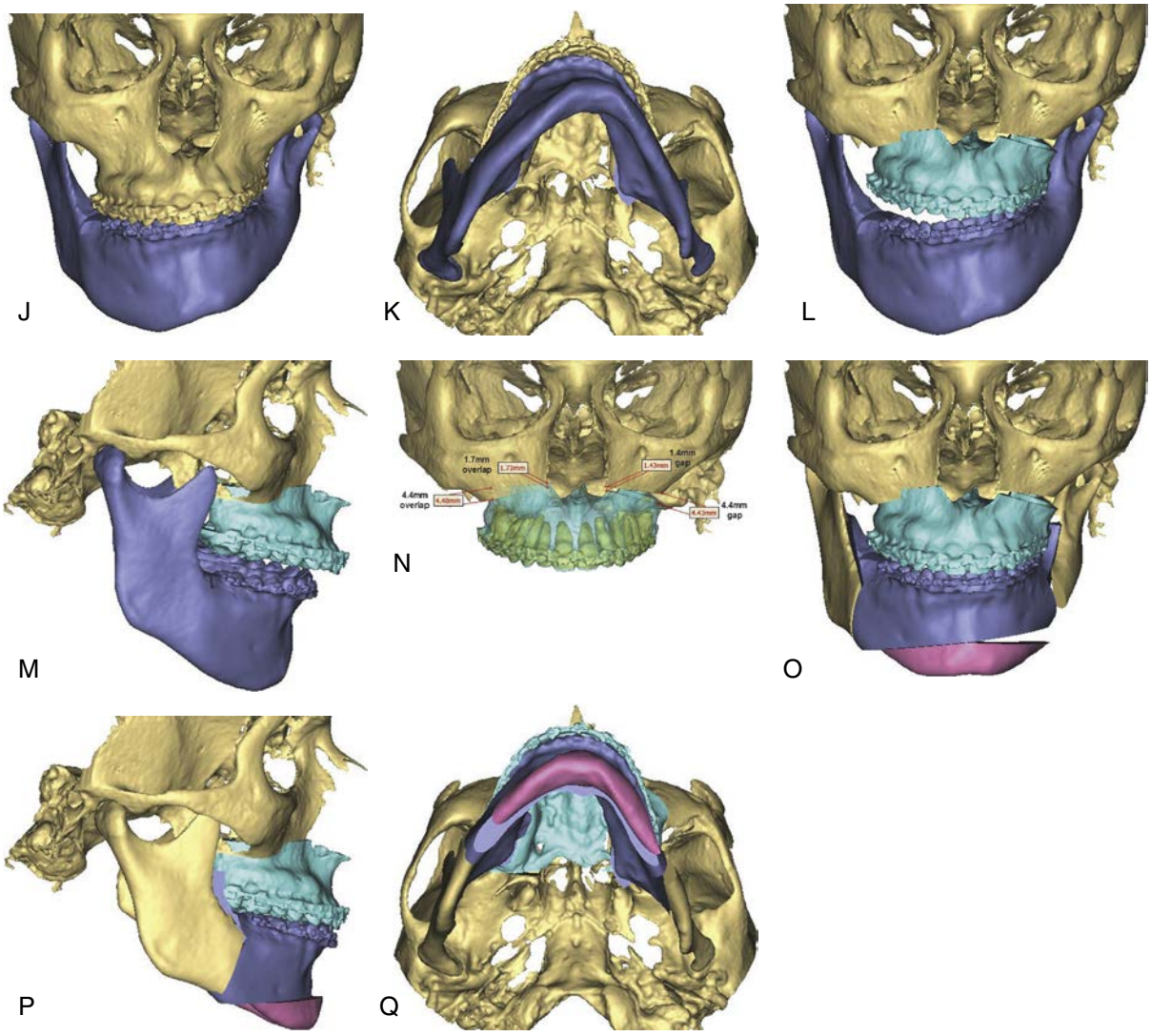

•**Figure 9-3, cont'd** **J-K,** Preoperative 3D CT, which was used for virtual surgical planning. **L-N,** Planned intermediate position, after Le Fort I osteotomy with leveling of the occlusal plane and advancement of 3 mm. **O-Q,** Planned final result after Le Fort I, bilateral sagittal split osteotomies with leveling and rotation of the mandible, and leveling genioplasty.

Continued

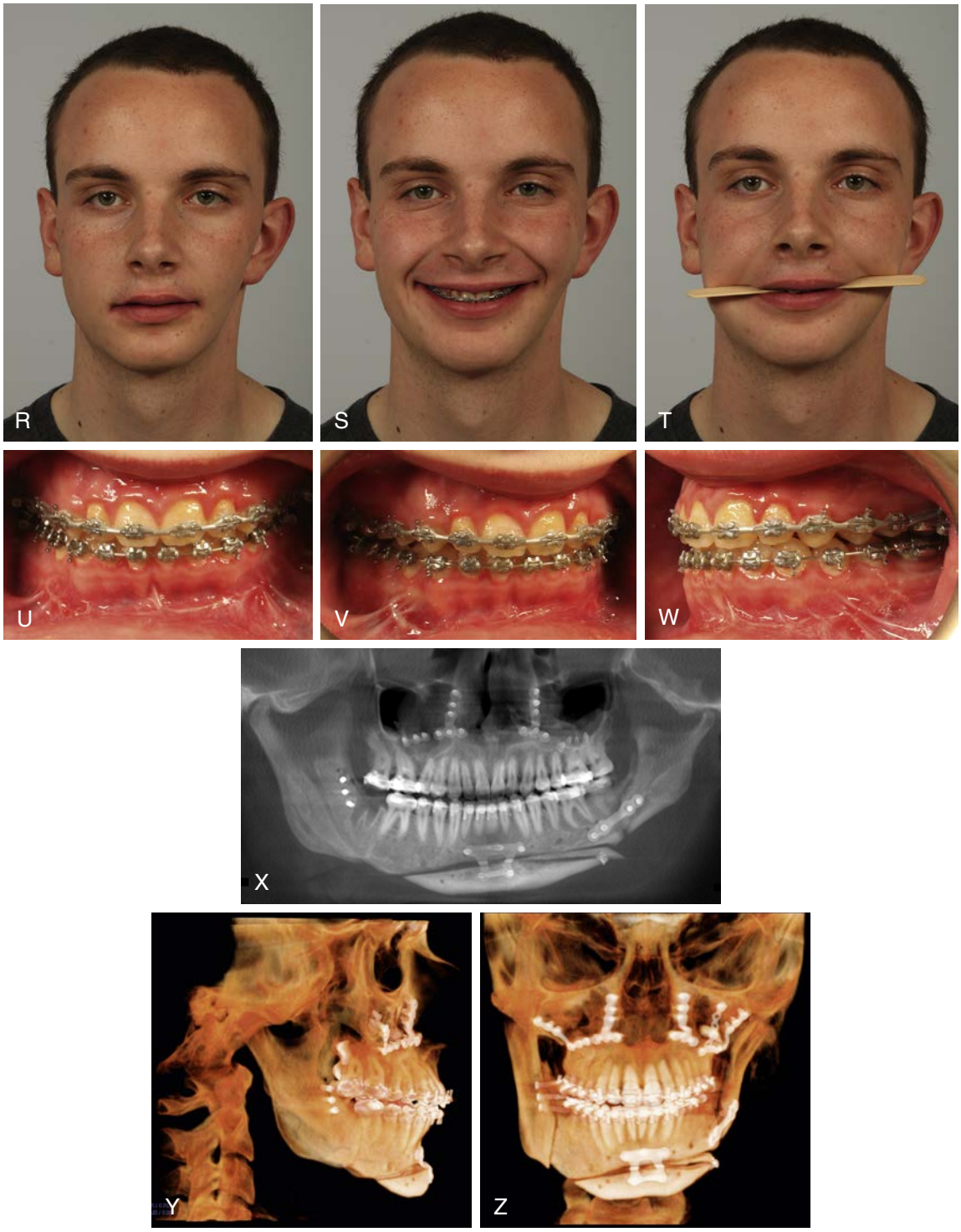

•**Figure 9-3, cont'd** **R-Z,** Postoperative photographs and radiographs.

borrowed from the aeronautic industry such as pitch, roll, and yaw have been added to the lexicon of the orthognathic surgeon.[13] Furthermore, virtual surgical plans can be transferred to the patient via 3D printing of surgical stents with greater accuracy.

During the planning process, it is important to consider the long-term stability of the operation. The hierarchy of stability for movements of the maxilla and mandible in orthognathic surgery has been defined for both nonrigid (wire)[14] and rigid fixation.[15] Superior repositioning of the maxilla is the most stable maxillary movement, regardless of the method of fixation. Maxillary advancement and maxillary rotation are also stable movements. Inferior positioning of the maxilla is much less stable, and widening of the maxilla is inherently unstable.

Surgical Anatomy

The paired maxillae are the central bones of the mid-face, and are each made up of a body and four projections: frontal, zygomatic, palatine, and the alveolar process. The maxilla forms the inferior and medial borders of the orbits. The infraorbital foramen is located a mean distance of 7.8 mm below the infraorbital rim in women and 8.5 mm in men.[16] The vascular and sensory supplies to the skin of the cheek, lateral aspect of the nose and upper lip exit the bone from this foramen. The anterior alveolar processes surround the piriform apertures and join to form the anterior nasal spine in the midline. The anterior nasal spine is the most anterior inferior attachment for the cartilaginous nasal septum, which extends posteriorly along the nasal crest and articulates with the vomer. The body of the maxilla contains the maxillary sinuses.

The hard palate is formed by the palatine processes of each maxilla anteriorly and the horizontal lamina of the palatine bones posteriorly. The greater palatine foramen is located on each side approximately 10 mm posteromedial to the second molar.

The nasolacrimal duct travels within the bony wall between the nasal cavity and the maxillary sinus before terminating below the inferior turbinate. The nasolacrimal duct can be injured during the Le Fort I osteotomy or during an inferior turbinectomy performed to allow superior repositioning of the maxilla (Figure 9-4).[17,18]

Posterolaterally, the maxilla articulates with the pyramidal processes of the palatine bones and the pterygoid plates of the sphenoid bone. This pterygomaxillary junction extends superiorly as a fissure, which ends at the pterygopalatine fossa. The terminal portion of the internal maxillary artery traverses the pterygopalatine fossa and gives off several branches that can be encountered during a Le Fort I osteotomy (Figure 9-5). The average distance from the inferior extent of the pterygomaxillary junction to the posterior superior alveolar artery is 15 mm, to the infraorbital artery is 32 mm, and to the descending palatine artery is 25 mm. The descending palatine arteries travel through the perpendicular plate of the palatine bones and are located approximately 34 mm posterior to the piriform rims and within 10 mm medial to the pterygomaxillary fissures.[19] Osteotomies of the lateral nasal walls and at the pterygomaxillary fissures must be completed carefully to avoid injuring these vessels. The internal maxillary artery is 23 to 25 mm superior to the base of the junction of the maxilla with the pterygoid plates, and its average diameter is 2.5 mm.

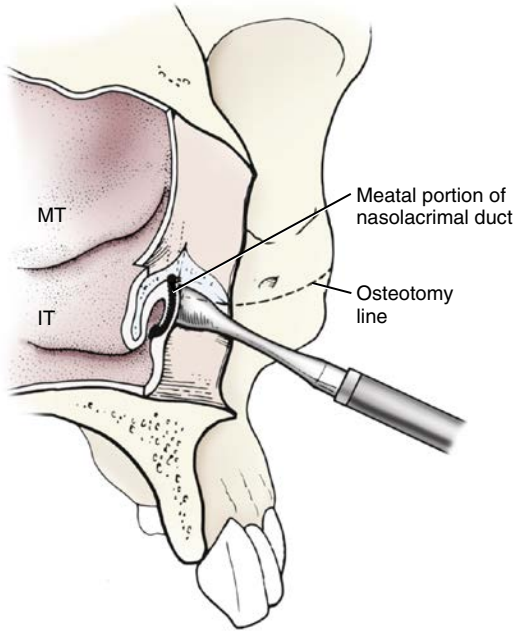

•**Figure 9-4** Relationship of the nasolacrimal duct to the Le Fort I osteotomy.

In addition to the direct vascular supply of the maxilla by the descending palatine arteries, there is a rich collateral vascular network from the soft palate supplied by the ascending pharyngeal arteries and the ascending palatine branches of the facial arteries (Figure 9-6). Bell's work revealed that ligation of the bilateral descending palatine arteries does not compromise the vascularity of the maxilla as long as the soft palate pedicle is preserved.[10,20,21]

The pterygoid plexus of veins is located between the temporalis and lateral pterygoid muscles and between the medial and lateral pterygoid muscles. It receives tributaries corresponding to the branches of the maxillary artery and drains into the maxillary vein. Venous bleeding from this plexus may be encountered during the posterolateral maxillary dissection and pterygomaxillary disjunction.

Operative Technique

There are many acceptable modifications to the Le Fort I osteotomy and the sequence of steps may vary from surgeon to surgeon. The following is a description of the authors' preferred approach.

Anesthetic and Positioning Considerations

Controlled hypotensive anesthesia has been shown to reduce bleeding from mucosal and bone edges that contain a rich

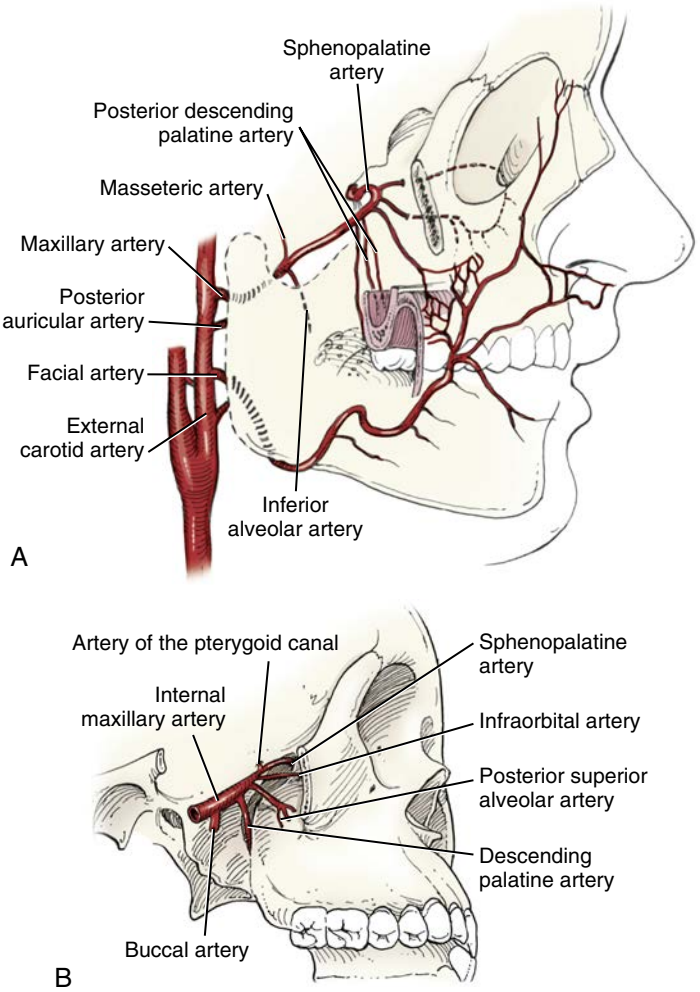

•**Figure 9-5** **A,** Branches of the external carotid artery in relation to the maxilla. **B,** Terminal branches of the internal maxillary artery as it traverses the pterygopalatine fossa.

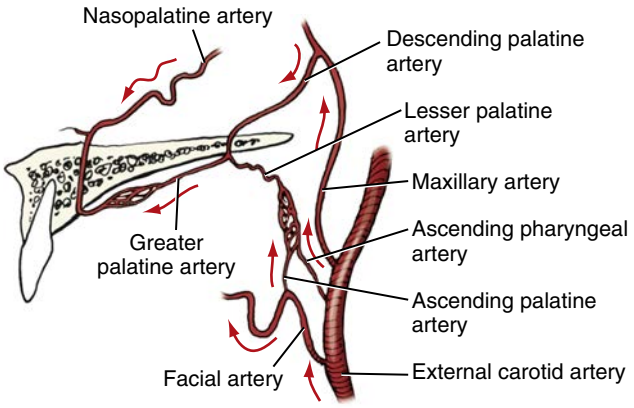

•**Figure 9-6** Arterial supply to the maxilla.

network of small vessels, which cannot easily be identified and controlled with surgical techniques. In healthy patients, a reduction in mean arterial pressure (MAP) of 30% below the patient's baseline with a minimum MAP of 50 mm Hg is safe.[22] In bimaxillary surgery, postoperative blood transfusions are necessary in 13% to 48% of patients who do not have controlled hypotension during the operation.[23,24] The need for transfusion has been nearly eliminated by using this technique. Placement of an indwelling bladder catheter for intraoperative monitoring of urine output as a marker of renal perfusion should be considered when using controlled hypotension.

After induction of general anesthesia, the patient is nasally intubated. A shoulder roll is inserted to extend the neck without creating hyperextension. A sterile preparation and draping is performed, leaving the orbits and nasion exposed. After the planned mucosal incision is marked, local anesthetic with vasoconstrictor (lidocaine with 1:100,000 epinephrine) is infiltrated in the labial sulcus. Palatal injection should be avoided so as not to induce vasoconstriction in the palatal pedicle.

External Reference Marker

An external reference marker is placed at the nasion to facilitate proper positioning of the maxilla in the vertical plane (Figure 9-7). Common techniques include insertion of a Kirschner wire or a bone fixation screw. Less invasive methods include marking with a skin scribe, a suture or tape, but

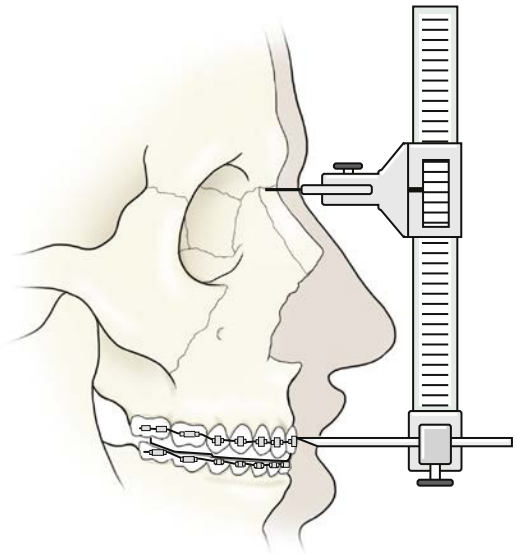

•**Figure 9-7** Measurement from an external reference marker at the nasion to an orthodontic bracket. (From Bell WH: *Modern practice in orthognathic and reconstructive surgery*, Philadelphia, 1992, WB Saunders.)

these may be less reproducible due to skin mobility at the site. External reference points have been shown to be superior to internal references (lines or burr holes placed on the maxilla above and below the osteotomy), which are prone to inaccuracy due to the complex three-dimensional movement of the maxilla.[25,26] Preoperative measurements are then obtained from the reference site to reproducible midline and lateral maxillary landmarks, typically the maxillary dental midline and the bilateral canine cusp tips or orthodontic brackets.

Incision and Subperiosteal Dissection

A vertical midline marking is made with a blade or electrocautery to aid in realignment of the incision during closure. A horizontal incision is created in the gingivobuccal sulcus about 5 to 10 mm superior to the mucogingival junction and from first molar to first molar (Figure 9-8). The Stensen duct papillae are identified and protected by retraction during the incision. The mucosal cut is made with the blade or electrocautery pen directed perpendicular to the mucosal surface. The blade is then redirected to be perpendicular to the underlying maxilla and continued through periosteum. The submucosal incision is brought inferiorly near the midline to avoid perforation of the nasal mucosa.

A periosteal elevator is then used with definitive sweeps to raise a subperiosteal flap. If the incision was made cleanly through periosteum, the subperiosteal flap will elevate easily. The dissection is continued along the anterior maxillary walls to the infraorbital foramina, medially to expose the piriform rims, and laterally to the zygomaticomaxillary suture. Dissection is then continued posterolaterally around the maxillary buttress to the pterygomaxillary fissure. Extra care must be taken during this portion of the dissection to remain subperiosteal at all times, because a small periosteal

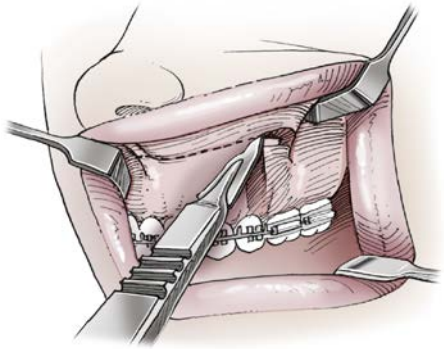

•**Figure 9-8** A horizontal incision is made in the buccal vestibule 5-10 mm superior to the mucogingival junction. (Adapted from Miloro M, et al: *Peterson's principles of oral and maxillofacial surgery*, Hamilton, Ontario, Canada, 2004, BC Decker.)

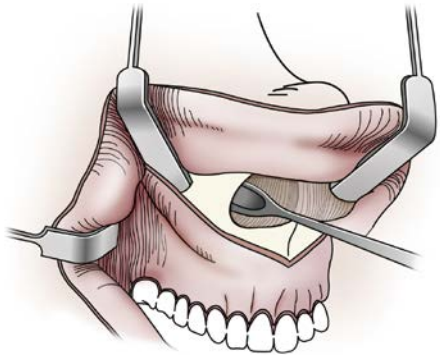

•**Figure 9-9** A freer or Cottle elevator is used to dissect the nasal mucosa from the piriform rim and maxillary crest, beginning superolaterally and sweeping inferiorly and medially. (Adapted from Miloro M, et al: *Peterson's principles of oral and maxillofacial surgery*, Hamilton, Ontario, Canada, 2004, BC Decker.)

perforation may lead to herniation of the buccal fat pad which will complicate visualization for the remainder of the operation. If the buccal fat pad is encountered, it should be contained as much as possible with a patty and retracted away from the visual pocket. At this point the posterolateral pocket can be distended with a sponge or patties, which may be soaked in epinephrine or pseudoephedrine for additional hemostasis.

A periosteal elevator is then used to release the periosteum around the anterior nasal spine and define the edges of the piriform rims. A freer or Cottle elevator is used to dissect the nasal mucosa from the piriform rim and maxillary crest, beginning superolaterally and sweeping inferiorly and medially (Figure 9-9). The nasal mucosa is carefully separated from the caudal septum, and the elevator is directed posteriorly to lift the mucosa from the remainder of the maxillary crest. The nasal mucosal dissection is then completed superolaterally to the inferior turbinates.

Maxillary Osteotomy

The canine and first molar root tips (the longest tooth roots) are identified on each side, and the osteotomy is planned

5 mm superior to these roots. A reciprocating saw or a piezoelectric saw is used to create a horizontal osteotomy beginning at the maxillary tuberosity and continuing through the maxillary buttress to the piriform rim on each side (Figure 9-10). A retractor is placed in the lateral piriform rim during this osteotomy to protect the nasal mucosa. The osteotomy is typically parallel to the occlusal plane, but can be angled as desired to facilitate the planned movements.

Pterygomaxillary Disjunction

A long curved osteotome is inserted into the pterygomaxillary fissure at a level at and inferior to the horizontal osteotomy (Figure 9-11). The osteotome is oriented in an anterior, medial, and inferior direction so that it will be driven into the fissure. A finger is placed intraorally on the pterygoid hamulus as an assistant taps the osteotome with a mallet. It is important that the operating surgeon holds the osteotome in one hand and palpates the hamulus with the other hand, as this bimanual tactile sensation is critical in determining when the disjunction has been achieved. The osteotome may be redirected as necessary to complete the disjunction to the level of the horizontal osteotomy. A small straight osteotome is then used to complete the osteotomy at the posterior maxillary wall to connect the horizontal osteotomy to the pterygoid fissure. The osteotome blade must remain in contact with the lateral maxillary wall at all times; if the osteotome strays medially, it may sever the descending palatine artery. These osteotomies are completed on the contralateral side.

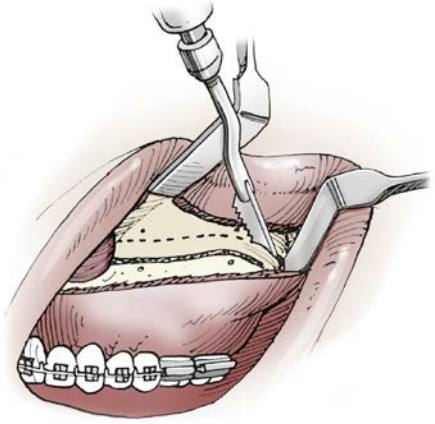

•**Figure 9-10** A horizontal osteotomy is made from the maxillary tuberosity to the piriform rim on each side.

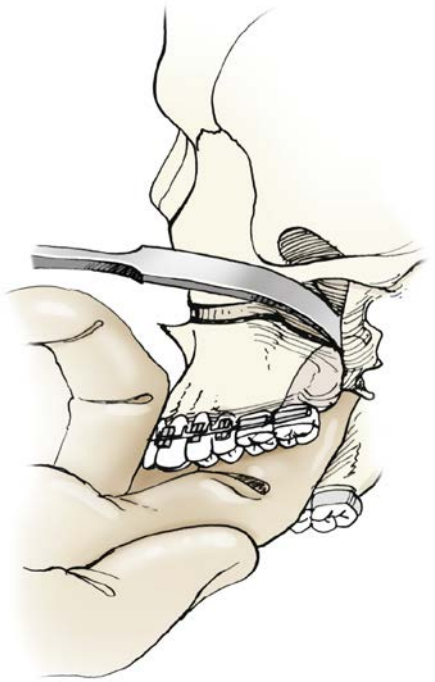

•**Figure 9-11** The maxilla is separated from the pterygoid plates with a long curved osteotome directed anteriorly and inferiorly while a finger is placed on the pterygoid hamulus.

Septal, Vomerine, and Lateral Nasal Osteotomies

A guarded nasal septal osteotome is inserted to engage the caudal nasal septum (Figure 9-12). A finger is inserted past the uvula to lie between the posterior nasal spine and the endotracheal tube. The osteotome is angled inferiorly toward the nasal floor and tapped with a mallet to osteotomize the septal cartilage and vomer. This is continued until the tip of the osteotome is palpated from the nasopharynx. This distance is typically 25 to 30 mm posterior to the anterior nasal spine.

A guarded lateral nasal osteotome is placed at the piriform rim with the guarded side abutting the nasal mucosa. The osteotome is directed slightly lateral to follow the anatomy of the nasal cavity, which is wider posteriorly than anteriorly. It is helpful to obtain direct visualization of this osteotomy as it progresses posteriorly, and this may be facilitated by applying slight inferior pressure on the maxilla just posterior to the anterior nasal spine with a bone hook. The operating room should be quieted during this osteotomy so that an audible change can be identified when the osteotome reaches the perpendicular plate of the palatine bone, which defines the posterior extent of the osteotomy. Continuing the osteotomy beyond this point will engage the

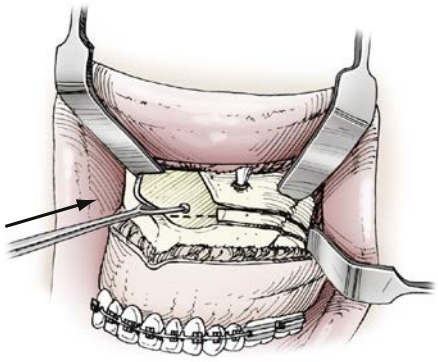

•**Figure 9-12** A guarded nasal septal osteotome is directed posteriorly and inferiorly, starting above the anterior nasal spine.

descending palatine vessels. This osteotomy is repeated on the contralateral side.

Down-fracture

When all of the maxillary osteotomies are completed, the maxilla must be down-fractured (Figure 19-13). Downward pressure using the thumbs on each side and a bone hook in the midline is typically all that is necessary to complete the down-fracture. Smith spreaders can also be used at the bilateral buttresses. The down-fracture should occur with minimal pressure. If significant resistance is encountered, the surgeon should stop and reevaluate all maxillary osteotomies, with special attention to the pterygoid disjunctions and the lateral nasal osteotomies, because they are the most difficult osteotomies to complete.

When the maxilla has partially down-fractured, the posterior osteotomies are evaluated. Specifically, the level of the osteotomies at the perpendicular plates of the palatine bones and the posterior walls of the maxilla are visualized, and should be redirected with osteotomes if necessary. The down-fracture is then completed.

Evaluation of the Descending Palatine Arteries

The descending palatine vessels are identified on each side. Bone should be carefully removed with a rongeur or small osteotome to clear the entrance of the vessels into the hard palate (Figure 9-14). The vessels should be evaluated for tears.

It is the authors' practice that ligation of these vessels is needed only if there are signs of damage and bleeding, or if posterior maxillary impaction requires their ligation to achieve the desired surgical movement. Sacrifice of one or both arteries, however, does not increase the risk for avascular necrosis.[21,27] There is a small risk of late postoperative nasal bleeding associated with pseudoaneurysm formation from unrecognized trauma to the vessel wall when the vessel is left intact.[28] For these reasons, some surgeons routinely ligate both vessels.

Mobilization of the Maxilla

Adequate mobilization of the maxilla such that it fits passively into the surgical splint in the planned position is imperative. If passive adaptation is not achieved, the mandibular condyles may be distracted from their centric relation positions when the maxilla is brought into the surgical splint and placed in intermaxillary fixation. This will result in a malocclusion after the release of intermaxillary fixation. Maxillary mobilization is achieved with Rowe disimpaction forceps and pterygoid lifts. Stretching of the soft tissue attachments may be achieved simply, or may be a prolonged process, especially in patients with large movements or a history of cleft palate.

Maxillary Segmentation

When the preoperative plan calls for maxillary segmentation and the orthodontic setup has been completed with this in mind (including divergence of the dental roots in the planned segmental osteotomy positions), this is completed after the maxillary down-fracture. Separation in two to four pieces is generally well tolerated.[29] The incidence of aseptic necrosis, however, is higher in multi-piece compared to single-segment osteotomies, and increases with increased subdivision.[30]

Common patterns of segmentation include "2-piece" and "3-piece" osteotomies. In the "2-piece," a median osteotomy may be made from the interdental space between the central incisors to the posterior nasal spine. This allows for transverse widening of the maxilla posteriorly. However, the hard palate is thickest and the palatal mucosa is thinnest in the midline, making the risk for palatal mucosal tear high with this osteotomy design. Because the palatal soft tissue pedicle is critical to preservation of the maxillary blood supply, the osteotomy is often modified to take advantage of the thinner maxillary bone and thicker palatal soft tissue that is found between the midline and the medial maxillary

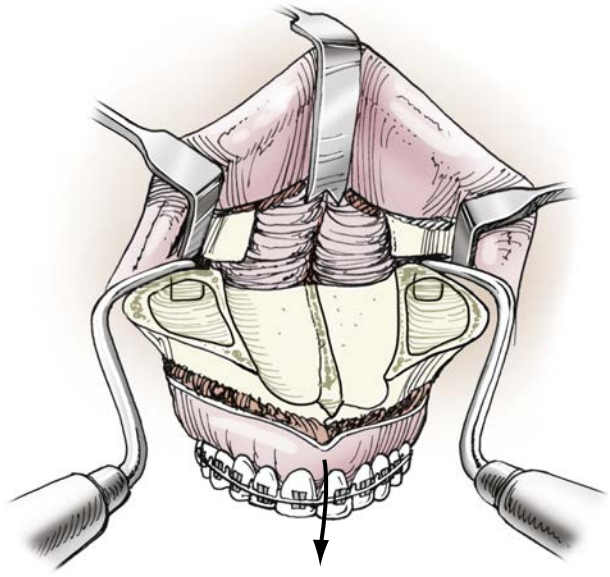

•**Figure 9-13** The maxilla is down-fractured. (From Fonseca RJ: *Oral and maxillofacial surgery*, Philadelphia, 2000, WB Saunders.)

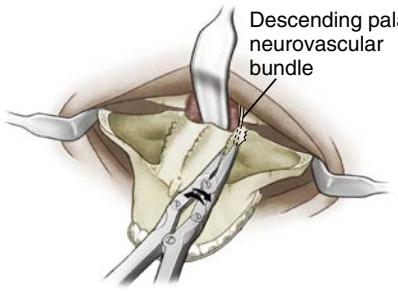

•**Figure 9-14** The perpendicular plate at the entrance of the descending palatine vessel is removed with a rongeur.

sinus walls. With this modification, a midline osteotomy is made between the central incisors and through the premaxilla to the incisive foramen. Curved paramedian osteotomies are then made, extending to the posterior extent of the hard palate on each side. This "2-piece" design really creates three maxillary segments, which are attached only by palatal mucosa.

A "3-piece" design will facilitate posterior widening as well as independent vertical repositioning and rotation of the maxillary central and lateral incisors, with or without the canines. For the reasons previously stated, paramedian osteotomies are preferred to a midline osteotomy, allowing four sections to be created. Bilateral osteotomies are made extending from the interdental spaces either between the canines and first premolars or between the lateral incisors and canines, and extending to the incisive foramen. Paramedian osteotomies are then made from the incisive foramen to the posterior extents of the hard palate on each side.

Intermaxillary Fixation, Repositioning, and Adjustment

The maxilla is then positioned into the prefabricated surgical splint and intermaxillary fixation is applied with wires. The maxillomandibular complex is then rotated superiorly while posterior and superior pressure is applied to the mandibular angles to fully seat the condyles (Figure 9-15). Bony interferences are identified and marked.

All interferences should be identified and reduced prior to final maxillary positioning. The preoperative planning will help determine expected areas of interference. The maxillary buttresses and piriform rims commonly require reduction unless the maxilla is being inferiorly positioned. The posterior maxillary walls and maxillary tuberosities are also common areas of interference, sometimes abutting the pterygoid plates. The relationship between the caudal nasal septum and the maxillary crest should be evaluated to ensure that the septum does not buckle, particularly with superior positioning of the maxilla. If there is interference with the septum, a trough can be created along the maxillary crest with a rongeur or burr (Figure 9-16). Additionally, the perichondrium can be dissected from the caudal septum and a fine scissor can be used to resect the caudal septal cartilage (Figure 9-17). When a large superior movement of the maxilla is planned, the inferior turbinates may interfere with repositioning. Soft tissue and osseous turbinectomies may be necessary (Figure 19-18).

After all interferences have been relieved, the maxillomandibular complex is rotated superiorly and the final vertical position is checked by evaluating the maxillary incisors relative to the upper lip. The dental midline is observed to confirm proper maxillary positioning in the frontal plane.

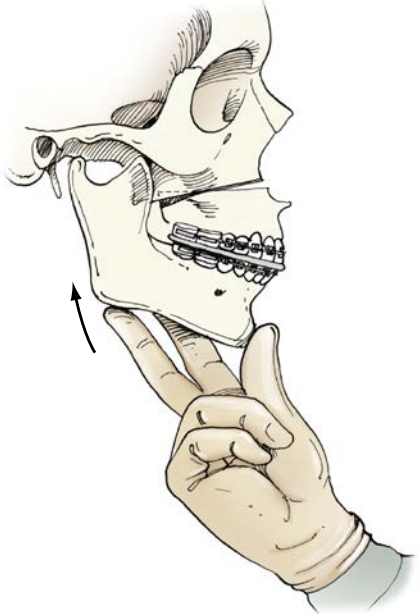

•**Figure 9-15** Posterior and superior pressure is applied to the mandibular angles to fully seat the condyles.

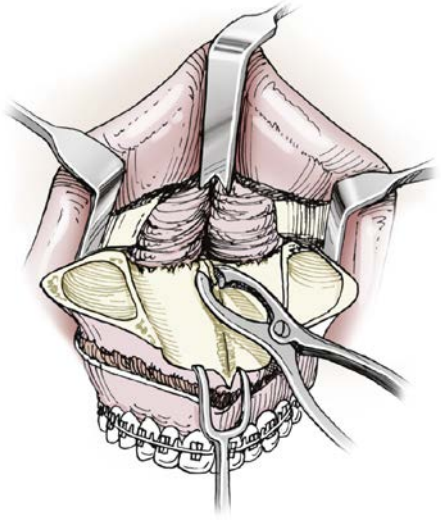

•**Figure 9-16** Bone is removed from the maxillary crest to allow the nasal septum to sit passively without buckling.

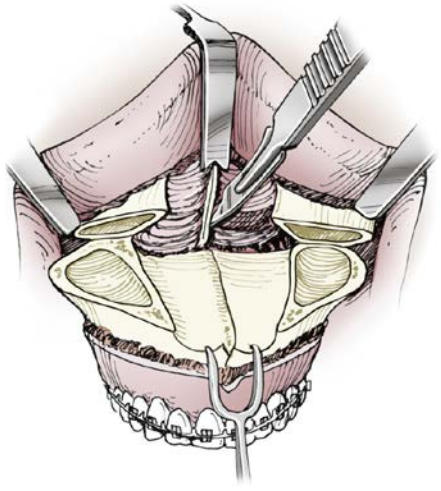

•**Figure 9-17** The cartilaginous nasal septum is exposed in order to perform a caudal septoplasty.

Measurements from the external reference point are repeated to confirm that the planned movements have been achieved and that no unintended cant has been created.

Maxillary Fixation

With the maxillomandibular complex rotated into its planned position and the condyles fully seated, fixation is applied. Rigid fixation has replaced wire fixation methods due to increased stability with rigid techniques.[31-33] Fixation is applied to the bilateral piriform rims and zygomaticomaxillary buttresses (Figure 9-19), according to the concept of the structural pillars of the facial skeleton.[34] The authors favor 0.7-mm thickness (rigid) titanium plates fixated with six 1.5-mm diameter and 6-mm long screws (three above and three below the osteotomy) at the piriform rims and 0.5 or 0.6 mm thickness (malleable) titanium plates fixated with six 1.5-mm diameter and 6-mm long screws at the zygomaticomaxillary buttresses. The plates must be adapted precisely to the maxillary walls prior to insertion to avoid inadvertent maxillary displacement during screw tightening. Each screw is inserted partially and then evenly tightened to distribute any remaining inaccuracies in plate adaptation. Resorbable bone plates may provide adequate fixation, particularly in smaller movements, and may be an alternative to titanium fixation systems.[35-40]

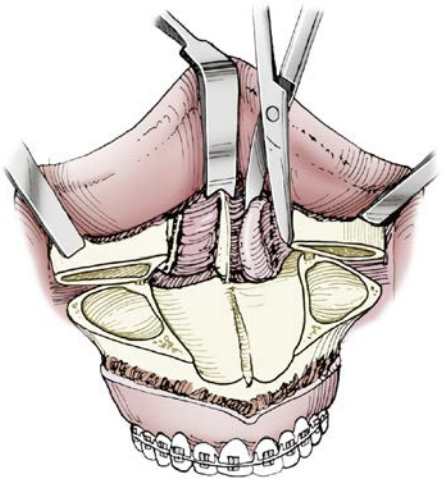

•**Figure 9-18** Inferior turbinectomy may be necessary when the turbinate interferes with superior maxillary repositioning.

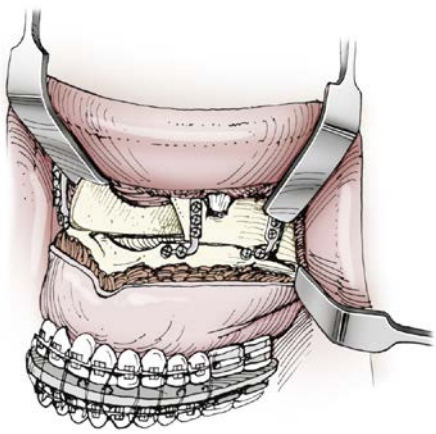

•**Figure 9-19** The maxilla is stabilized with bone plates at the piriform rims and zygomaticomaxillary buttresses.

Bone Grafting

Repositioning the maxilla inferiorly such that no bone contact is maintained across the osteotomy is an unstable movement.[14,41,42] When this is planned, block or particulate bone grafting should be used to increase stability.[43,44] When bimaxillary surgery is performed, bone that is removed from the mandibular osteotomies may be available for grafting. Common extraoral autologous graft harvest sites include iliac crest and calvarium, and banked allogeneic bone also may be used.[45]

Occlusal Evaluation

Wire intermaxillary fixation is removed and the mandible is rotated up and down while applying posterior pressure on the chin to ensure condylar seating. The occlusion is evaluated, first with the splint in place and then with the splint removed. If the planned occlusion has not been achieved, intermaxillary fixation must be reapplied either with or without the surgical splint and maxillary fixation must be removed and repeated. The final occlusion must be evaluated honestly as this is the best opportunity to correct a discrepancy.

Alar Cinch and Wound Closure

The alar bases tend to widen due to detachment of the paranasal muscles during the dissection.[46,47] This widening may be lessened by insertion of an alar base cinch suture (Figure 9-20).[48,49] Various techniques have been proposed. The "classic alar cinch suture" involves identifying the fibroareolar tissue under each alae by applying extraoral pressure at the nasofacial skin folds, passing a non-resorbable suture through this tissue on each side from an intraoral approach, and tying the sutures in the midline.[50-52] The "reinsertion method" is performed by passing a non-resorbable suture from the intraoral wound through the skin at the nasofacial skin fold at the most lateral point of the alae, passing the suture back from the skin side to the intraoral wound through the same skin puncture site, and tying the sutures from each side in the midline.[51,52] The sutures may also be tied through a hole that is drilled in the anterior nasal spine. The "transseptal alar cinch suture" is similar to the reinsertion method, with the addition of a pass of the suture needle through the caudal nasal septum when traversing from one side to the other.[50] While no alar cinch technique can completely eliminate this widening effect, the reinsertion and transseptal cinch methods perform better than the classic alar cinch suture.[48]

The wound is then thoroughly irrigated with saline or Bacitracin-impregnated solution. Irrigation with high

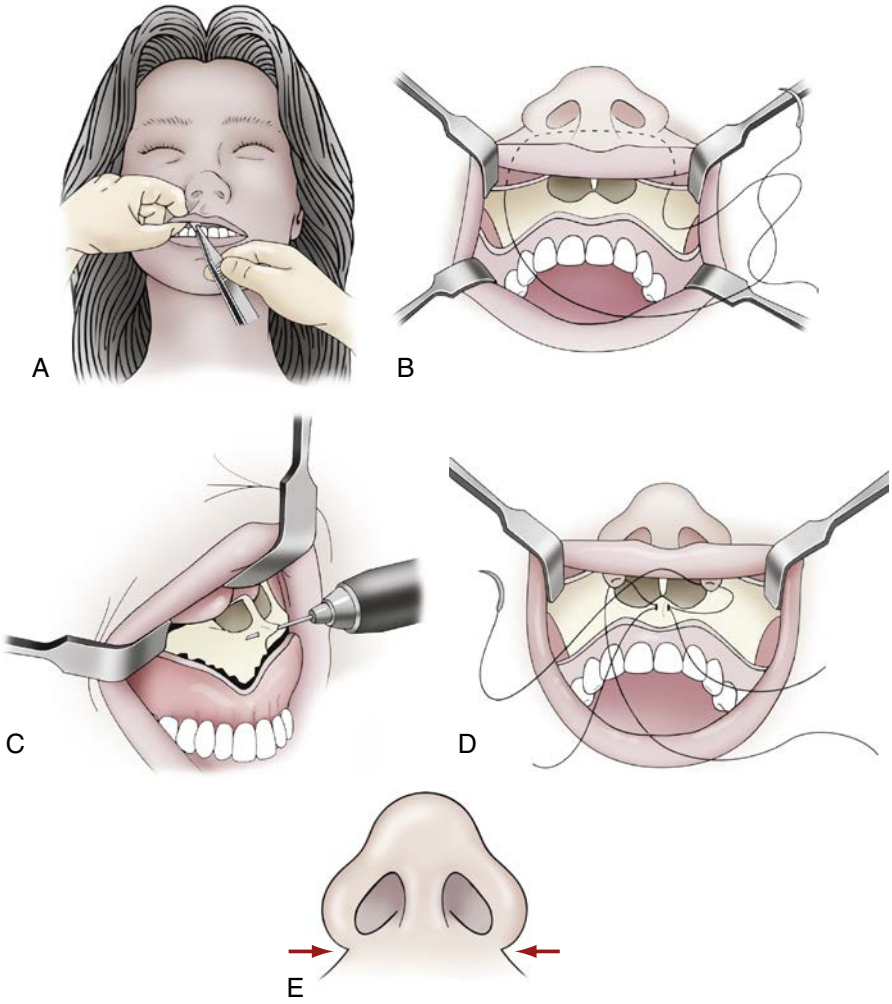

•**Figure 9-20** Alar base cinch suture. **A,** Nasalis muscles are grasped with heavy forceps. **B,** A suture is passed through both nasalis muscles for alar base cinch. **C,** A drill hole is made through the anterior nasal spine to support the alar base cinch suture. **D,** A suture is passed through the hole and is tied. **E,** Cinching at the nasal base is confirmed. (From Betts NJ: Techniques to preserve or modify lip form during orthognathic surgery, *Atlas Oral Maxillofac Surg Clin North Am* 8:71-79, 2000.)

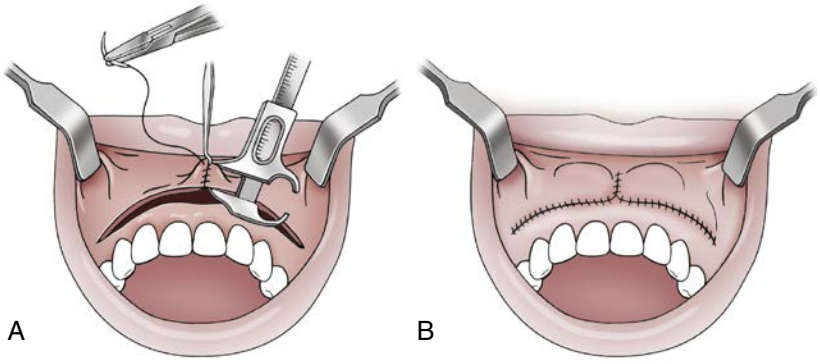

•**Figure 9-21** **A,** V-Y closure in the midline to lengthen the lip. **B,** Running suture for closure of the vestibular incisions. (From Betts NJ: Techniques to preserve or modify lip form during orthognathic surgery, *Atlas Oral Maxillofaci Surg Clin North Am* 8:71-79, 2000.)

pressure (70 psi) has been shown to decrease bacterial load more effectively than low-pressure lavage (1 to 2 psi).[53,54] The wound is then closed in either one or two layers (submucosa and mucosa or mucosa only). It is the authors' practice to perform a single-layer mucosal closure with 3-0 chromic gut suture in a running horizontal mattress fashion beginning posteriorly on each side. If lip lengthening is desired, a V-Y closure can be performed in the midline by elevating the mucosa with a single skin hook and suturing the two vertical limbs to one another (Figure 9-21).

Complications

Initial postoperative edema, bruising, and discomfort are expected. On average, 50% of swelling resolves by the third postoperative week, but some edema can remain for 6 to 12 months.[55] Transient neurosensory changes to the infraorbital and incisive nerve distributions (lower eyelids, upper lips, lateral nose, maxillary teeth, and gingiva) are typical. Most patients will experience temporary nasal and sinus congestion owing to edema and blood accumulation in the maxillary sinuses.

Complications can occur as early as the preoperative planning process. Inadequate assessment of the chief complaint and motivation to pursue surgery may lead to an unsatisfied patient even after a technically successful operation. Inaccurate facial assessment and diagnosis may contribute to an unesthetic result. Inappropriate planning, such as planning to the smile rather than the repose position in a patient with VME or failure to recognize a discrepancy between the centric relation and centric occlusion positions, may compromise the outcome. Incorrect orthodontic setup may limit the surgeon's ability to accomplish the desired correction. Insufficient patient preparation for the soft tissue changes that occur with a Le Fort I osteotomy, such as changes to the nasal alar base and tip, may also create an unhappy patient.

Intraoperative and postoperative complications occur relatively rarely. The risk for post-operative wound infection, abscess formation or maxillary sinusitis is only 1.1%,[56] and these typically respond to antibiotic treatment and sinus irrigation. The incidence of ischemic complications after Le Fort I osteotomy is estimated at 1%,[56] with loss of osseous and dental segments very rarely.[30] Deflection of the nasal septum off the maxillary crest can occur due to inadequate resection of the caudal septum and insufficient reduction of the maxillary crest, or due to trauma when the nasal endotracheal tube is removed.[56] The nasal septum should be evaluated immediately postoperatively because, if displacement has occurred, it is often correctible by gentle manipulation in the postoperative care unit. Sometimes a return trip to the operating room is necessary to reposition the septum.

Hemorrhage is the most concerning intraoperative and postoperative complication of the Le Fort I osteotomy.[57,58] The use of hypotensive anesthesia has significantly decreased intraoperative bleeding and the need for perioperative transfusion. In order of frequency, brisk intraoperative bleeding is most likely to occur from the posterior superior alveolar artery, the descending palatine artery, the pterygoid plexus of veins, the pterygoid muscles, or the terminal branches of the maxillary or internal carotid arteries.[59] The internal maxillary artery itself is less likely to be injured with proper osteotomy technique because the average location of this vessel is at least 10 mm superior to the superior aspect of the pterygoid osteotome during the pterygomaxillary disjunction.[59] If hemorrhage occurs intraoperatively and the source can be identified, the proximal and distal portions of the vessel should be ligated with hemoclips or sutures. Vessels such as the descending palatine artery tend to retract into the bony canal, which imparts a risk of delayed postoperative bleeding.[58] Additionally, a pseudoaneurysm that results from intraoperative trauma to the descending palatine artery may present with delayed postoperative nasal hemorrhage.[28,60] When the intraoperative source is venous or cannot be identified, controlled use of electrocautery, wound packing with vasoconstrictor-soaked sponges, microfibrillar collagen, and reverse-Trendelenburg positioning may improve hemorrhage control. Severe or uncontrollable hemorrhage can usually be managed with angiographic embolization in the interventional radiology suite.[60,61] Ligation of the external carotid artery has been shown to be minimally effective.[59]

If the osteotomies are inadequate, an unfavorable fracture may occur during maxillary down-fracture. Unfavorable fractures may extend into the orbit or skull base, or may fracture the horizontal process of the palatine bone or the pterygoid plates. These atypical fracture patterns can make mobilization and planned repositioning of the maxilla difficult or impossible. In rare cases, unfavorable fractures can lead to visual complications, damage to the cranial nerves within the pterygomaxillary fissure and the inferior or superior orbital fissures, or injury to the nasolacrimal ducts leading to postoperative epiphora. Unfavorable fractures can typically be avoided by meticulous osteotomy technique. The maxillary down-fracture should require minimal force. If significant force is necessary, this should alert the surgeon of the need to refine all osteotomies prior to proceeding with the down-fracture.

Moving the maxilla to its planned position can be difficult, particularly for large magnitude movements and in patients with a repaired cleft lip and palate. Inadequate mobilization and lack of passive repositioning into the surgical splint may lead to distraction of the mandibular condyles during maxillary fixation, resulting in a malocclusion when the intermaxillary fixation is released. This complication can typically be avoided by taking the time to adequately mobilize the maxilla intraoperatively, and with appropriate surgical planning. In very large movements and in some patients with cleft lip and palate, the use of distraction osteogenesis may be considered to allow the soft tissue envelope to slowly adapt to the change in maxillary position.

Pulpal tissues tend to tolerate the reduced vascularity that occurs after a Le Fort I osteotomy remarkably well. Vitality testing in the immediate postoperative period is not reliable, as 6% to 29% of teeth will test non-vital for up to 54 months after the operation.[62] However, pulpal necrosis does occasionally occur and may require endodontic treatment. Endodontic treatment should be delayed until at least 8 weeks postoperatively to confirm that spontaneous revascularization does not occur.[59]

Direct trauma to the teeth is possible with incorrect osteotomy design. Dental roots can be transected if the osteotomy is positioned too inferiorly.[63] The canine tooth is at greatest risk because it has the longest tooth root. If a segmental maxillary osteotomy is required, damage to the roots adjacent to the vertical osteotomies can occur. Additionally, lack of adequate remaining alveolar bone surrounding a tooth root after segmentation can lead to a periodontal defect.[64] Proper orthodontic preparation for segmental osteotomies with separation of the dental roots in the planned osteotomy sites is critical to avoid this complication.

Inadequate fixation, poor compliance with the prescribed period of a non-chewing diet, bruxism or traumatic dental occlusion may lead to fibrous non-union. This occurs in approximately 1% of Le Fort I osteotomies.[56] Unstable maxillary movements, particularly advancement with inferior repositioning with minimal or no bone contact may increase the risk for this complication.[65] Bone grafting of the defects created by inferior maxillary positioning may decrease this risk. Non-union requires re-operation with debridement of the fibrous tissue across the osteotomy gap, replacement or reinforcement of fixation, and bone grafting or use of bone morphogenetic protein.[66]

Summary

The Le Fort I osteotomy is one of the most common operations performed by orthognathic surgeons. Refinements in surgical and anesthetic techniques over the last century have made this a safe and predictable operation. Combined with methodical diagnostic and treatment planning approaches, the Le Fort I osteotomy can be used to correct a wide range of dentofacial deformities.

References

1. von Langenbeck B: *Beitrag zur Osteoplastik—die osteoplastische resektion des oberkiefers*, Berlin, 1859, Reimer.
2. Cheever D: Naso-pharyngeal polypus, attached to the basilar process of occipital and body of sphenoid bone successfully removed by a section, displacement, and subsequent replacement and reunion of the superior maxillary bone, *Boston Med Surg J* 8:162, 1867.
3. Le Fort R: Fractures de la machoire superieure, *Rev Chir* 4:360, 1901.
4. Wassmund M: *Frakturen und Lurationen des Gesichtsschadels*, 1927, Berlin.
5. Axhausen G: Zur Behandlung veralteter desloziert verheilter Oberkieferbrunche, *Dtsch Zahn Mund Kieferheilkd* 1:334, 1934.
6. Schuchardt D: Ein Beitrag zur chirurgeschen Kieferorthopadie unter Berucksichtigung ihrer Bedertung fur die Behandlung angeborener und erworbener Kieferdeformitaten bei Soldaten, *Dtsch Zahn Mund Kieferheilkd* 9:73, 1942.
7. Willmar K: On Le Fort I osteotomy: a follow-up study of 106 operated patients with maxillo-facial deformity, *Scand J Plast Reconstr Surg* 12(Suppl 12):11–68, 1974.
8. Obwegeser H: [Surgery of the maxilla for the correction of prognathism], *SSO Schweiz Monatsschr Zahnheilkd* 75:365–374, 1965.
9. Obwegeser HL: Surgical correction of small or retrodisplaced maxillae. The "dish-face" deformity, *Plast Reconstr Surg* 43:351–365, 1969.
10. Bell WH: Biologic basis for maxillary osteotomies, *Am J Phys Anthropol* 38:279–289, 1973.
11. Buchanan EP, Hyman CH: LeFort I osteotomy, *Semin Plast Surg* 27:149–154, 2013.
12. Stokbro K, Aagaard E, Torkov P, et al.: Virtual planning in orthognathic surgery, *Int J Oral Maxillofac Surg* 43:957–965, 2014.
13. Ackerman JL, Proffit WR, Sarver DM, et al.: Pitch, roll, and yaw: describing the spatial orientation of dentofacial traits, *Am J Orthod Dentofacial Orthop* 131:305–310, 2007.
14. Proffit WR, Turvey TA, Phillips C: Orthognathic surgery: a hierarchy of stability, *Int J Adult Orthodon Orthognath Surg* 11:191–204, 1996.
15. Proffit WR, Turvey TA, Phillips C: The hierarchy of stability and predictability in orthognathic surgery with rigid fixation: an update and extension, *Head Face Med* 3:21, 2007.
16. Aziz SR, Marchena JM, Puran A: Anatomic characteristics of the infraorbital foramen: a cadaver study, *J Oral Maxillofac Surg* 58:992–996, 2000.
17. Demas PN, Sotereanos GC: Incidence of nasolacrimal injury and turbinectomy—associated atrophic rhinitis with Le Fort I osteotomies, *J Craniomaxillofac Surg* 17:116–118, 1989.
18. You ZH, Bell WH, Finn RA: Location of the nasolacrimal canal in relation to the high Le Fort I osteotomy, *J Oral Maxillofac Surg* 50:1075–1080, 1992.
19. Cheung LK, Fung SC, Li T, et al.: Posterior maxillary anatomy: implications for Le Fort I osteotomy, *Int J Oral Maxillofac Surg* 27:346–351, 1998.
20. Bell WH: Revascularization and bone healing after anterior maxillary osteotomy: a study using adult rhesus monkeys, *J Oral Surg* 27:249–255, 1969.
21. Bell WH, Fonseca RJ, Kenneky JW, et al.: Bone healing and revascularization after total maxillary osteotomy, *J Oral Surg* 33:253–260, 1975.
22. Rodrigo C: Induced hypotension during anesthesia with special reference to orthognathic surgery, *Anesth Prog* 42:41–58, 1995.
23. Zellin G, Rasmusson L, Palsson J, et al.: Evaluation of hemorrhage depressors on blood loss during orthognathic surgery: a retrospective study, *J Oral Maxillofac Surg* 62:662–666, 2004.
24. Carlos E, Monnazzi MS, Castiglia YM, et al.: Orthognathic surgery with or without induced hypotension, *Int J Oral Maxillofac Surg* 43:577–580, 2014.
25. Van Sickels JE, Larsen AJ, Triplett RG: Predictability of maxillary surgery: a comparison of internal and external reference marks, *Oral Surg Oral Med Oral Pathol* 61:542–545, 1986.
26. Ferguson JW, Luyk NH: Control of vertical dimension during maxillary orthognathic surgery. A clinical trial comparing internal and external fixed reference points, *J Craniomaxillofac Surg* 20:333–336, 1992.
27. Dodson TB, Bays RA, Neuenschwander MC: Maxillary perfusion during Le Fort I osteotomy after ligation of the descending palatine artery, *J Oral Maxillofac Surg* 55:51–55, 1997.
28. Lanigan DT, Hey JH, West RA: Major vascular complications of orthognathic surgery: false aneurysms and arteriovenous fistulas following orthognathic surgery, *J Oral Maxillofac Surg* 49: 571–577, 1991.
29. Quejada JG, Kawamura H, Finn RA, et al.: Wound healing associated with segmental total maxillary osteotomy, *J Oral Maxillofac Surg* 44:366–377, 1986.
30. Lanigan DT, Hey JH, West RA: Aseptic necrosis following maxillary osteotomies: report of 36 cases, *J Oral Maxillofac Surg* 48:142–156, 1990.

31. Ayoub AF, Stirrups DR, Moos KF: A comparison of wire osteosynthesis and screw fixation in the stability of bimaxillary osteotomies, *Int J Adult Orthodon Orthognath Surg* 9:257–272, 1994.
32. Egbert M, Hepworth B, Myall R, et al.: Stability of Le Fort I osteotomy with maxillary advancement: a comparison of combined wire fixation and rigid fixation, *J Oral Maxillofac Surg* 53: 243–248, 1995, discussion 248-249.
33. Larsen AJ, Van Sickels JE, Thrash WJ: Postsurgical maxillary movement: a comparison study of bone plate and screw versus wire osseous fixation, *Am J Orthod Dentofacial Orthop* 95: 334–343, 1989.
34. Manson PN, Hoopes JE, Su CT: Structural pillars of the facial skeleton: an approach to the management of Le Fort fractures, *Plast Reconstr Surg* 66:54–62, 1980.
35. Araujo MM, Waite PD, Lemons JE: Strength analysis of Le Fort I osteotomy fixation: titanium versus resorbable plates, *J Oral Maxillofac Surg* 59:1034–1039, 2001, discussion 1039-1040.
36. Norholt SE, Pedersen TK, Jensen J: Le Fort I miniplate osteosynthesis: a randomized, prospective study comparing resorbable PLLA/PGA with titanium, *Int J Oral Maxillofac Surg* 33: 245–252, 2004.
37. Ueki K, Marukawa K, Shimada M, et al.: Maxillary stability following Le Fort I osteotomy in combination with sagittal split ramus osteotomy and intraoral vertical ramus osteotomy: a comparative study between titanium miniplate and poly-L-lactic acid plate, *J Oral Maxillofac Surg* 64:74–80, 2006.
38. Ueki K, Okabe K, Moroi A, et al.: Maxillary stability after Le Fort I osteotomy using three different plate systems, *Int J Oral Maxillofac Surg* 41:942–948, 2012.
39. van Bakelen NB, Buijs GJ, Jansma J, et al.: Comparison of biodegradable and titanium fixation systems in maxillofacial surgery: a two-year multi-center randomized controlled trial, *J Dent Res* 92:1100–1105, 2013.
40. Edwards RC, Kiely KD, Eppley BL: Fixation of bimaxillary osteotomies with resorbable plates and screws: experience in 20 consecutive cases, *J Oral Maxillofac Surg* 59:271–276, 2001.
41. Proffit WR, Phillips C, Prewitt JW, et al.: Stability after surgical-orthodontic correction of skeletal Class III malocclusion. 2. Maxillary advancement, *Int J Adult Orthodon Orthognath Surg* 6:71–80, 1991.
42. Quejada JG, Bell WH, Kawamura H, et al.: Skeletal stability after inferior maxillary repositioning, *Int J Adult Orthodon Orthognath Surg* 2:67–74, 1987.
43. Kerawala CJ, Stassen LF, Shaw IA: Influence of routine bone grafting on the stability of the non-cleft Le Fort 1 osteotomy, *Br J Oral Maxillofac Surg* 39:434–438, 2001.
44. Santos SE, Moreira RW, de Moraes M, et al.: Skeletal stability after inferior maxillary repositioning without interpositional graft, *Int J Oral Maxillofac Surg* 41:477–481, 2012.
45. Posnick JC, Sami A: Use of allogenic (iliac) corticocancellous graft for Le Fort I interpositional defects: technique and results, *J Oral Maxillofac Surg* 73:168, 2015.
46. Rauso R, Tartaro G, Tozzi U, et al.: Nasolabial changes after maxillary advancement, *J Craniofac Surg* 22:809–812, 2011.
47. Vasudavan S, Jayaratne YS, Padwa BL: Nasolabial soft tissue changes after Le Fort I advancement, *J Oral Maxillofac Surg* 70:e270–e277, 2012.
48. Liu X, Zhu S, Hu J: Modified versus classic alar base sutures after LeFort I osteotomy: a systematic review, *Oral Surg Oral Med Oral Pathol Oral Radiol* 117:37–44, 2014.
49. Howley C, Ali N, Lee R, et al.: Use of the alar base cinch suture in Le Fort I osteotomy: is it effective? *Br J Oral Maxillofac Surg* 49: 127–130, 2011.
50. Nirvikalpa N, Narayanan V, Wahab A, et al.: Comparison between the classical and a modified trans-septal technique of alar cinching for Le Fort I osteotomies: a prospective randomized controlled trial, *Int J Oral Maxillofac Surg* 42:49–54, 2013.
51. Rauso R, Gherardini G, Santillo V, et al.: Comparison of two techniques of cinch suturing to avoid widening of the base of the nose after Le Fort I osteotomy, *Br J Oral Maxillofac Surg* 48:356–359, 2010.
52. Ritto FG, Medeiros PJ, de Moraes M, et al.: Comparative analysis of two different alar base sutures after Le Fort I osteotomy: randomized double-blind controlled trial, *Oral Surg Oral Med Oral Pathol Oral Radiol Endod* 111:181–189, 2011.
53. Bhandari M, Thompson K, Adili A, et al.: High and low pressure irrigation in contaminated wounds with exposed bone, *Int J Surg Investig* 2:179–182, 2000.
54. Hughes MS, Moghadamian ES, Yin LY, et al.: Comparison of bulb syringe, pressurized pulsatile, and hydrosurgery debridement methods for removing bacteria from fracture implants, *Orthopedics* 35:e1046–e1050, 2012.
55. van der Vlis M, Dentino KM, Vervloet B, et al.: Postoperative swelling after orthognathic surgery: a prospective volumetric analysis, *J Oral Maxillofac Surg* 72:2241–2247, 2014.
56. Kramer FJ, Baethge C, Swennen G, et al.: Intra- and perioperative complications of the LeFort I osteotomy: a prospective evaluation of 1000 patients, *J Craniofac Surg* 15:971–977, 2004. discussion 978-979.
57. Lanigan DT, West RA: Management of postoperative hemorrhage following the Le Fort I maxillary osteotomy, *J Oral Maxillofac Surg* 42:367–375, 1984.
58. Tiner BD, Van Sickels JE, Schmitz JP: Life-threatening, delayed hemorrhage after Le Fort I osteotomy requiring surgical intervention: report of two cases, *J Oral Maxillofac Surg* 55:91–93, 1997, discussion 93-94.
59. Miloro MK, A. *Management of complications in oral and maxillofacial surgery*, West Sussex, UK, 2012, Wiley-Blackwell.
60. Khanna S, Dagum AB: A critical review of the literature and an evidence-based approach for life-threatening hemorrhage in maxillofacial surgery, *Ann Plast Surg* 69:474–478, 2012.
61. Manafi A, Ghenaati H, Dezham F, et al.: Massive repeated nose bleeding after bimaxillary osteotomy, *J Craniofac Surg* 18: 1491–1493, 2007.
62. Vedtofte P, Nattestad A: Pulp sensibility and pulp necrosis after Le Fort I osteotomy, *J Craniomaxillofac Surg* 17:167–171, 1989.
63. Kahnberg KE, Vannas-Lofqvist L, Zellin G: Complications associated with segmentation of the maxilla: a retrospective radiographic follow up of 82 patients, *Int J Oral Maxillofac Surg* 34:840–845, 2005.
64. Mordenfeld A, Andersson L: Periodontal and pulpal condition of the central incisors after midline osteotomy of the maxilla, *J Oral Maxillofac Surg* 57:523–529, 1999, discussion 529-530.
65. Imholz B, Richter M, Dojcinovic I, et al.: [Non-union of the maxilla: a rare complication after Le Fort I osteotomy], *Rev Stomatol Chir Maxillofac* 111:270–275, 2010.
66. Tressler MA, Richards JE, Sofianos D, et al.: Bone morphogenetic protein-2 compared to autologous iliac crest bone graft in the treatment of long bone nonunion, *Orthopedics* 34:e877–e884, 2011.

10

Le Fort I Segmental

JOHN F. CACCAMESE JR, ROBIN YANG

Segmental Maxillary Surgery

Transverse and sagittal maxillary plane discrepancies are commonly diagnosed problems with a prevalence of up to 15% in adolescents and up to 30% in adults.[1-3] Orthodontic compensation in some patients with minor discrepancies can be accomplished by buccal displacement of the maxillary teeth or lingual displacement of the mandibular dentition to establish a stable cusp-fossa relationship. Stable management of transverse maxillary deficiency with conventional orthodontics is limited by the capacity of the buccal bone and periodontium of the maxillary arch. The orthodontic management of sagittal occlusal plane problems such as anterior open bite with multiplanar maxillary occlusion is also fraught with relapse when excessive extrusion and uprighting is attempted. Orthodontic compensation, when applied inappropriately, can result in compromised dental health, function, and stability.

Surgical manipulation of the maxilla has historically been undertaken to treat certain isolated deformities of the maxilla using limited surgery of the anterior or posterior segments. As recently as the 1960s, the segmental Le Fort I osteotomy was popularized. While other options exist to treat transverse problems, including surgically assisted rapid palatal/maxillary expansion (SARPE or SARME), surgical mandibular narrowing, and rapid palatal expansion (prior to maxillary suture closure), most lack the ability to address sagittal and transverse plane issues at the same time. A complete diagnosis and problem list is important before undertaking treatment, as the segmental maxillary osteotomy is the most useful tool to control for transverse deficiency/excess, occlusal plane leveling, incisor angulation, and Bolton discrepancies—particularly at the incisor/canine interface. This chapter will review the use of the segmental Le Fort I osteotomy in the management of maxillary transverse and sagittal plane problems.

History

Initially, segmentation of the maxilla was difficult to achieve due to instability and access. Additionally, early operators were hesitant to completely mobilize the maxilla out of concern for vascular compromise.[4] Cohn-Stock was the first to introduce the anterior segmental osteotomy of the maxilla in 1921.[5,6] Wassmund subsequently modified the technique to one similar to what is utilized today.[7] Schuchardt developed a two-stage approach to the posterior maxillary segmental osteotomy whereby an initial palatal access was performed, followed by a delayed labial approach 4 weeks later to complete the lateral osteotomies.[8] West and Epker eventually described a procedure that involved the application of Schuchardt's two-stage technique and Kufner's single-stage posterior maxillary osteotomy for correction of posterior crossbites. This technique essentially separated the alveolus from the palate and was done in a single-stage fashion.[9,10] Heinz Köle then combined maxillary and mandibular subapical osteotomies to correct bimaxillary malocclusion.[11] Bell's landmark vascular studies of maxillary osteotomies eventually provided a scientific foundation for modern maxillary surgery.[12] Today, segmental maxillary surgery is most commonly performed via the standard Le Fort I osteotomy. Turvey further defined the importance and utility of segmental maxillary surgery in 1985. His series of 104 patients undergoing a combination of segmental maxillary osteotomies and grafting showed that a multi-segment maxilla was most appropriate to correct a hypoplastic maxilla in all three planes of space.[13]

Indications

Anterior Open Bite (Apertognathia)

The sagittal multi-planar maxilla, with vertical steps in the dental arch, is of particular concern when it is accompanied by an anterior open bite. Frequently, this pattern of growth also is accompanied by transverse maxillary hypoplasia and can contribute to the open bite. Nonsurgical orthodontic treatment is of questionable stability, especially if the treatment involves extrusion and uprighting of anterior teeth or buccal tipping of the posterior dentition. Initial reports for closure of anterior open bites with posterior dental intrusion using a variety of orthodontic anchorage appliances

have shown promise in select cases where the transverse relationship and Angle classification is appropriate.[14] Generally these techniques involve placement of bone-borne plates or screws in the posterior maxilla to generate skeletal rather than dental based force to intrude the posterior dentition and close the open bite. For some open bites—class I in particular—temporary orthopedic anchorage devices to intrude molar teeth have been used with some success. A study by Scheffler and Proffit found that moderate to severe anterior open bites were satisfactorily corrected with minimal tooth relapse.[15] If case selection is not appropriate, however, results can be well short of an optimal esthetic outcome for the patient.

While addressing sagittal occlusal plane problems in the orthodontic phase of preparation for segmental surgery, it is important not to attempt bite closure; in fact, many would advocate decompensation of the two planes of occlusion with separate or segmented archwires. Preoperative orthodontic open bite closure can lead to postoperative relapse, because the full magnitude of the deformity could be left unrecognized and subsequently undercorrected surgically. This is particularly problematic when the patient presents for consultation while in orthodontic appliances, with decompensation already underway or complete. Review of pre-treatment records can help to avoid these problems. If an open bite is recognized that has been orthodontically treated it is best to allow it to relapse prior to undertaking surgery.

If an anterior open bite is not due to a vertical step in the maxillary occlusion, segmental surgery can be avoided by altering the position of the occlusal plane until closure of the open bite is achieved, keeping in mind the esthetic needs of the patient. Some occlusions may be amenable to posterior maxillary impaction, whereas others with concomitant mandibular hypoplasia may benefit most from counterclockwise rotation of the occlusal plane. In this instance, care should be taken not to lengthen the ramus in the pterygomasseteric sling region because this can make the result more prone to mandibular relapse and recurrence of the open bite. When attempts to close an anterior open bite with clockwise rotation of the anterior maxilla and result in a posterior open bite, the gold standard of treatment is a segmental surgery.

Transverse Discrepancies

Minor transverse discrepancies are common dentofacial problems. These can be managed routinely with orthodontics alone. Many are realized in childhood and managed with orthopedic expansion and overcorrected slightly to allow for some relapse. In other instances, surgically improving the width of the maxilla is indicated to improve stability and arch form. Appropriate transverse arch relationships are important to optimize masticatory function as well as maintaining long-term mucosal health.[16] It is also important to understand that appropriate transverse relationships can enhance facial esthetics—especially the smile when buccal corrections are visible.

Transverse maxillary deficiencies often accompany vertical maxillary steps in the occlusion. When this occurs, maxillary segmental surgery and an appropriate retention plan are essential for the comprehensive treatment of the problem.

Presurgical Preparation

Presurgical planning for segmental maxillary surgery should be performed as per the surgeon's usual protocol. Usually, this begins by making the appropriate diagnosis at the pretreatment consultation so that an early discussion can be initiated with the orthodontist, and decompensation is carried out with a segmental osteotomy in mind. This includes preparation of the arch form in segments and the creation of space (if necessary) for the osteotomies. It is also important at this time to inform the patient that a segmental maxillary surgery is likely necessary. This will help the patient prepare for the longer course of splint therapy (6 weeks) that serves to provide transverse stability and immobilization of the maxillary segments at the occlusal level during the initial phases of healing and to prevent early recurrence of the crossbite or open bite.

Planning can be accomplished via a variety of methods including plain film analysis, model analysis, computed tomography (CT) scan evaluation, and of course, physical examination. The authors currently utilize virtual surgical planning (VSP) to facilitate preoperative planning and splint fabrication. This combines data from the physical exam, dental models, and three-dimensional (3D) CT derived anatomic information to best customize surgical outcomes for a given patient. While the preoperative and postoperative occlusion is still hand measured and articulated, this information is scanned and fused with the data from CT scan rather than performing model surgery on an articulator (Figure 10-1). Thorough evaluation of the magnitude of transverse discrepancy, anterior open bite, or both is undertaken with dental models that are properly articulated with a preoperative occlusal registration in centric relation. Interdental cuts are performed on the dental models and a best-fit occlusion is established and verified with the orthodontist to assure that the bite can be finished appropriately. In instances where an anterior Bolton discrepancy exists, plans for postoperative space to allow for restorations can be accommodated (especially in the lateral/canine area). The step or plane break in the maxillary occlusal plane is where the interdental osteotomy should be planned in open bite cases. This is usually observed between the lateral-canine region or the canine–first bicuspid region. When a transverse discrepancy exists, it is important to characterize the narrowing. If the intercanine and intermolar widths are both narrow, it may be beneficial to perform the osteotomies between the central incisors. For patients in whom there is a significant transverse discrepancy of this type (>7 mm), a V-shaped arch form, or teeth blocked out of the arch with the need for equal anterior and posterior expansion, a surgically assisted rapid palatal expansion (SARPE) can

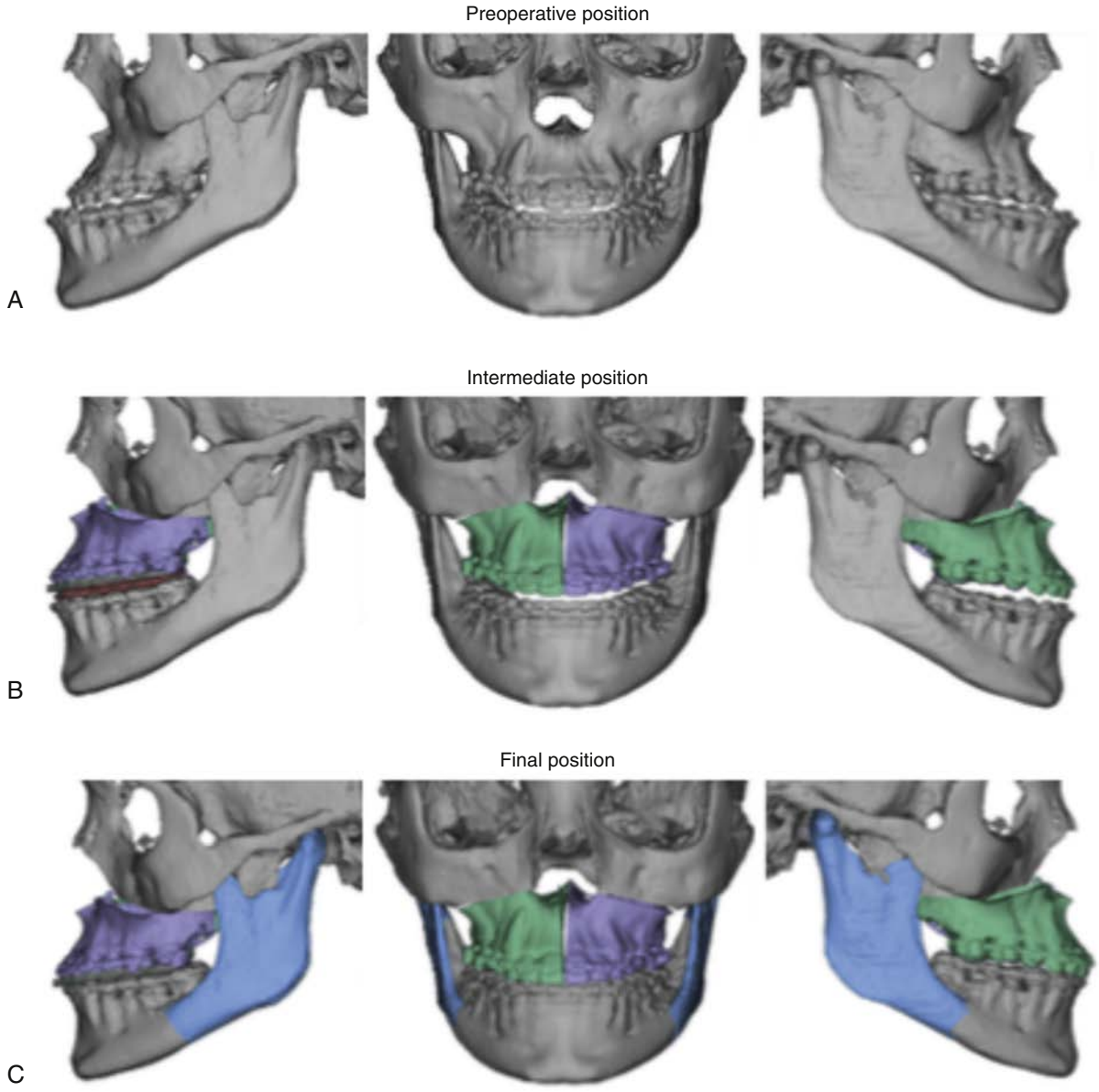

• **Figure 10-1** Virtual surgical planning. **A,** 3D CT of patient in natural head position and centric relation. **B,** Intermediate position of 2-piece segmental maxilla with mandible in centric relation. **C,** Final position of maxilla and mandible after BSSO (bilateral sagittal split osteotomy).

be considered as a first-stage operation. The indications and procedural details for this procedure are beyond the scope of this chapter and are discussed elsewhere. If the posterior region is narrow in isolation with adequate or near adequate intercanine width, an interdental osteotomy can be performed anterior or posterior to the canine.

Orthodontic preparation of the dentition prior to planned interdental osteotomies is helpful, though not always necessary. Ideally, 3 mm of space between the roots is established. This allows for the kerf of the saw blade (width of the osteotome), as well as the maintenance of healthy bone around the roots during healing. Parallel or divergent roots allow for ease of cutting and flexibility with the vector of the osteotomy. With the advent of 3D CT technology, the operative surgeon can now identify and visualize the osteotomy in three planes of view, which should help decrease the likelihood of damaging the dentition (Figure 10-2).

Once a final occlusion has been established with dental model planning, the models are scanned and sent for image fusion with the 3D CT images for virtual surgical planning and splint fabrication. The authors' preference is for the VSP engineers to fabricate the surgical splints. If the patient is scheduled for maxilla-first double-jaw surgery, a "sandwich" or "piggyback" splint (intermediate and final splint interdigitated as one unit) is typically utilized. This interdigitating splint decreases operative time by limiting the number of times the patient needs to have the maxilla wired into a surgical splint (Figure 10-3).

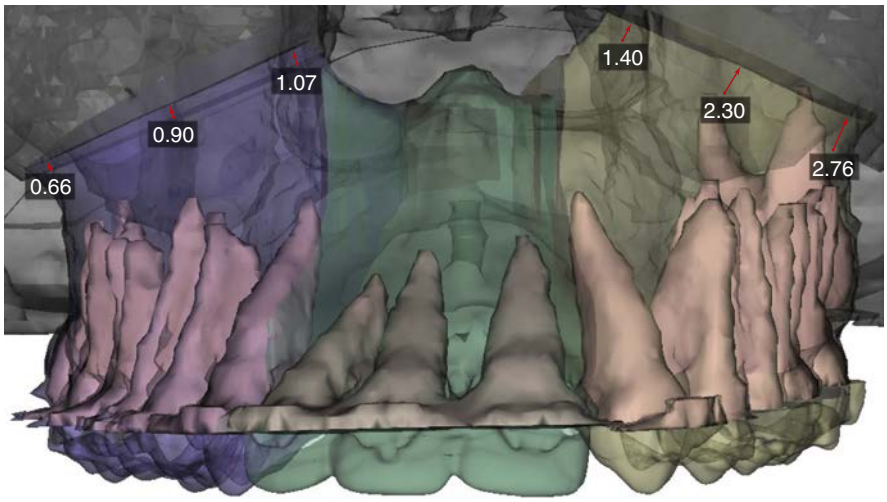

• **Figure 10-2** CT 3D view delineating canine anatomy to optimize cutting path during segmental osteotomy.

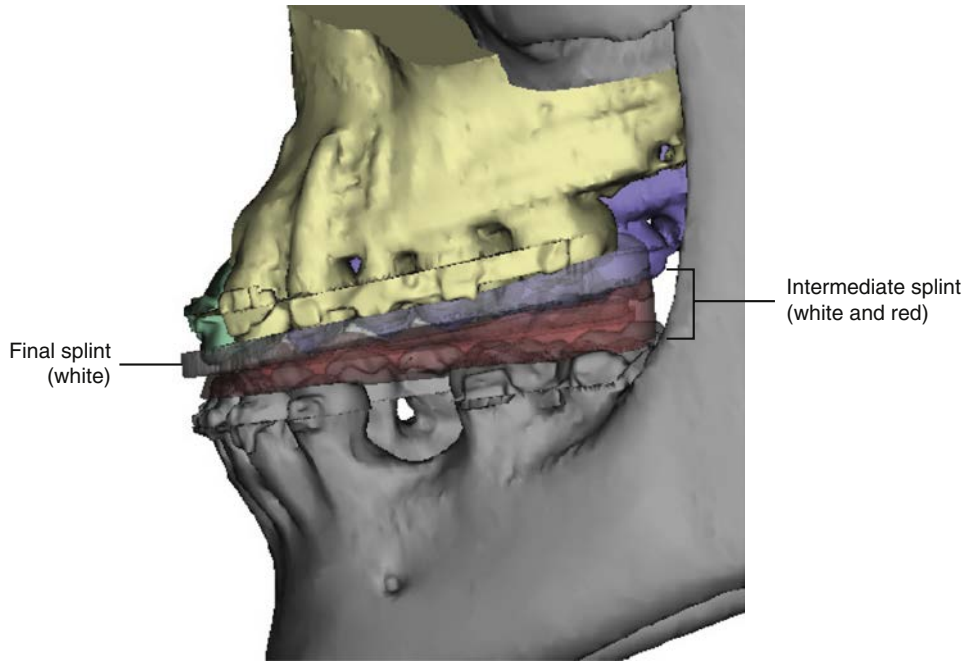

• **Figure 10-3** VSP fabricated surgical splints in "piggyback" form, collectively they represent the intermediate splint.

Surgical Technique

A standard vestibular incision is made in the maxilla with a broad mucosal pedicle left along the buccal surface and an adequate cuff of tissue for closure (5 to 7 mm). The incision should extend from the midline to the first molar on each side. Subperiosteal dissection should be performed to isolate the pyriform rim, lateral nasal walls, anterior nasal spine, and zygomaticomaxillary buttress.[4] Minimal mucosal/gingival dissection should be performed inferiorly towards the dentition with the exception of the location of the planned interdental osteotomy. The intention is to leave as much mucogingival tissue attached as possible to provide adequate blood supply for the alveolar structures. If the orthodontic surgical wire is a continuous one, it is sectioned in the vicinity of the segmental osteotomy to allow free manipulation of the segments and minimize intraoperative debonding or resistance to the planned surgical movements. This can be performed with wire cutters or with a diamond surgical burr. The authors prefer the use of a round diamond surgical burr because wire cutters can cause torqueing of the orthodontic wire and lead to inadvertent debonding. Once all of the soft tissue components of the nasal floor, wall, and septum are adequately released and the pterygomaxillary junction has been isolated, the traditional Le Fort I osteotomy should be performed in the usual fashion. Prior to down-fracture of the maxilla, the interdental segmental osteotomies can be performed as planned (Figures 10-4 and 10-5). In the authors'

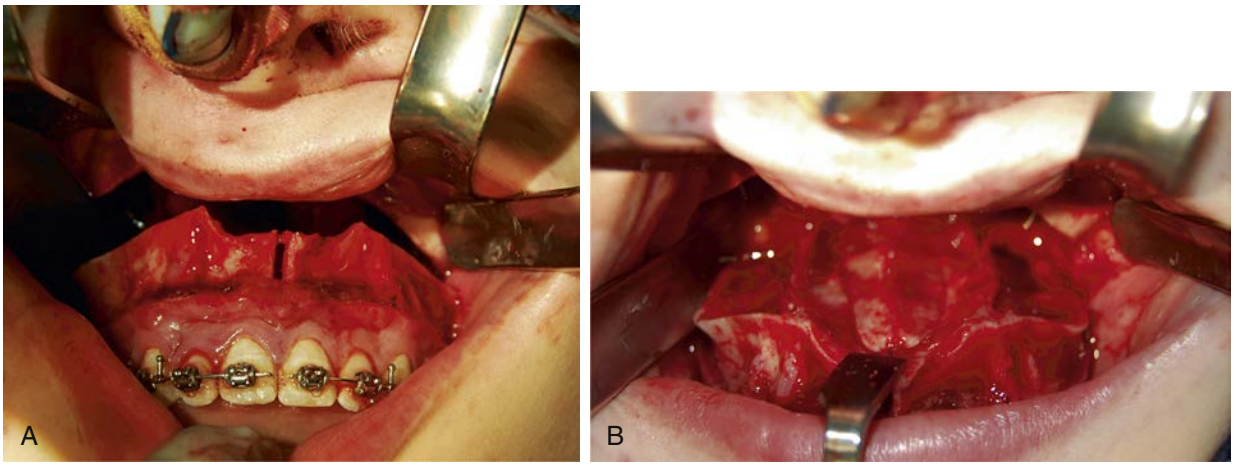

• **Figure 10-4** **A,** Intraoperative view of down-fractured segmented maxilla (2 piece) and divided arch wire. **B,** Intraoperative view of down-fractured segmented maxilla from above with bilateral paramidline palatal osteotomies to facilitate widening.

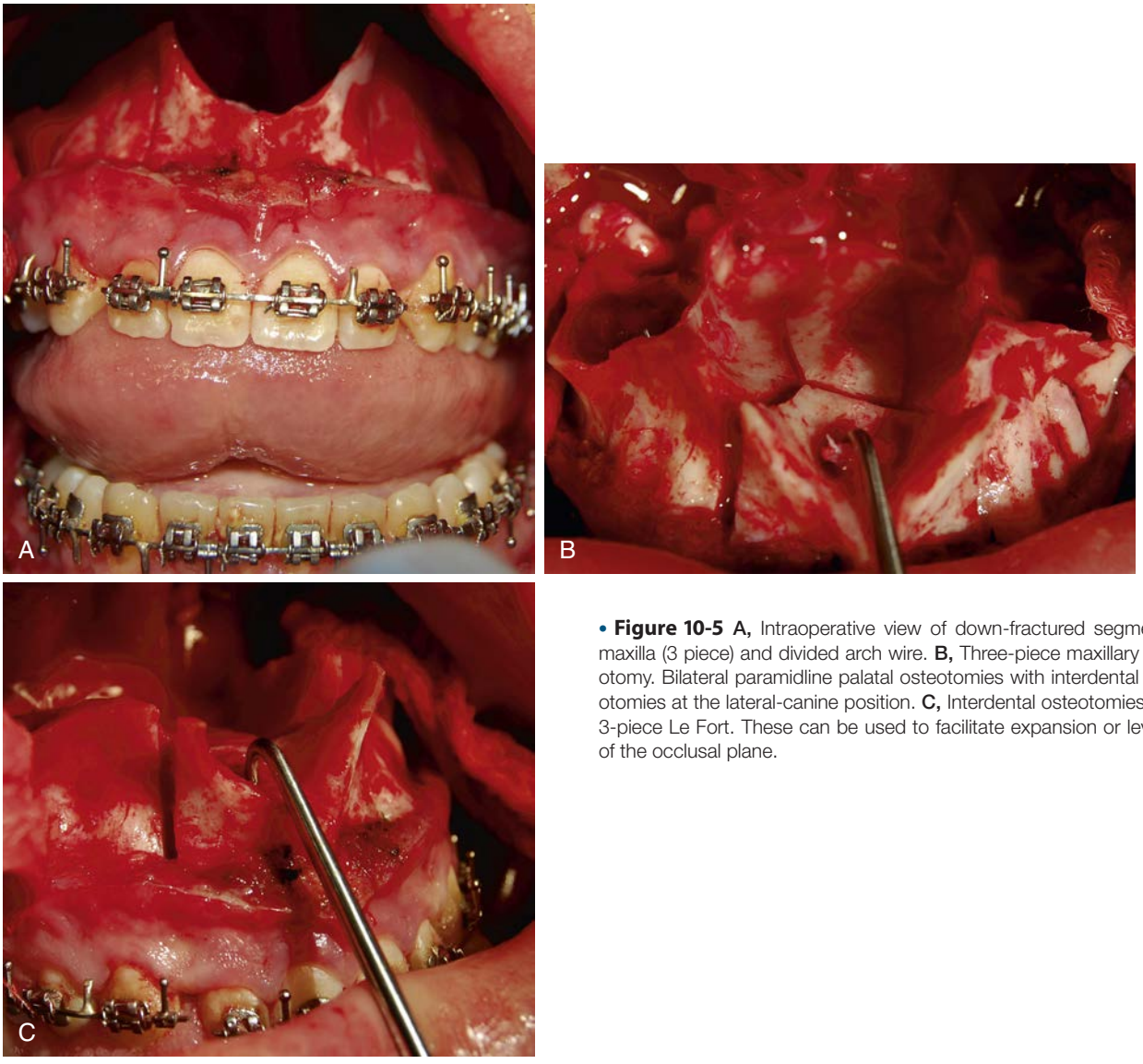

• **Figure 10-5** **A,** Intraoperative view of down-fractured segmented maxilla (3 piece) and divided arch wire. **B,** Three-piece maxillary osteotomy. Bilateral paramidline palatal osteotomies with interdental osteotomies at the lateral-canine position. **C,** Interdental osteotomies for a 3-piece Le Fort. These can be used to facilitate expansion or leveling of the occlusal plane.



• **Figure 10-6** Stryker sagittal safe blade. This blade enables the segmental cut with a minimal kerf, vertical and sagittal vectors, and minimal threat of trauma to the palatal mucosa.

experience, executing these osteotomies with precision is difficult to perform with a fully mobilized maxilla, so they are done before the down-fracture. Careful planning, visualization of root prominences, and tactile feedback from the saw can prevent most iatrogenic damage to the dental roots. A finger should also be placed on the palate to palpate for the vibrations of the saw and ensure that it is not damaging the palatal tissue. The authors' preferred instrument to complete the interdental osteotomies is a rounded sagittal saw or sagittal safe blade (Figure 10-6). When properly used with judicious force, damage to the soft tissues of the palate is unlikely. The remainder of the standard maneuvers is then undertaken for the down-fracture of the maxilla.

Once the maxilla is down-fractured, the nasal mucosa is inspected and any residual attachments are elevated. Full mobilization of the maxilla is indicated to give the operator access to the posterior maxilla. This is easier to accomplish prior to completing the segmentation. The palatal segmental osteotomies can then be performed and are made from posterior to anterior on the hard palate to connect with the anterior interdental osteotomies. These osteotomies are usually made para-midline where the bone is thinner and the palatal mucosa is thick (see Figures 10-4 and 10-5). The thicker palatal tissue in this location is a buffer to help prevent iatrogenic mucosal damage. The authors use a reciprocating saw for this purpose, but lateral osteotomies can also be performed with a small fissure burr, a round burr, or even a piezoelectric osteotome. When the lateral palatal osteotomies are connected to the interdental (alveolar) osteotomies it is important to note that the bone in the incisive foramen region of the hard palate is thicker and will require a deeper bony cut. An osteotome or periosteal elevator can be used to finalize the mobilization once the cuts are complete. Occasionally a Smith spreader is helpful to completely mobilize the palatal or alveolar bone. Care must be taken with the forces applied at this point because the hard palate and gingival mucosa are relatively thin and inelastic tissues, susceptible to tearing.

Once the maxillary segments have been mobilized, the occlusal splint is wired into place. If a large degree of maxillary widening is anticipated the palatal tissues can be undermined from the palatal bone of the lateral segments with the use of a Woodson or similar elevator. Maintaining as much soft tissue to the dento-osseous segment is key. This will cause the height of the palatal vault to drop

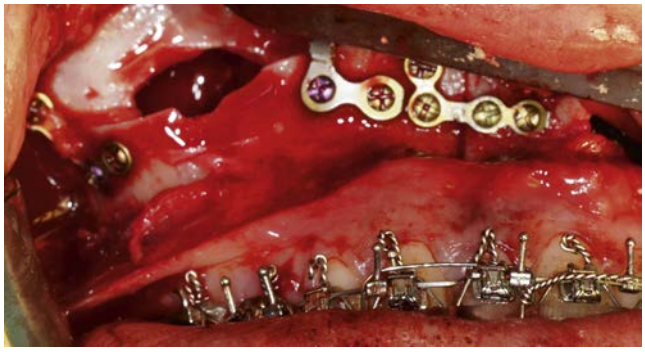

• **Figure 10-7** Placement of miniplates across segmental for additional stability.

a small amount but facilitate the maxillary expansion. It is important to not underestimate the strength and inherent noncompliance of the palatal mucosa. It may require multiple attempts at stretching, undermining, and manipulation in order for the maxilla to be passively seated into the final splint. One must assure the maxilla is freed completely so that the splint is not loaded with force and bending to the occlusion, only to rebound when the patient is released from maxillomandibular fixation. Wires can be placed through the anterior nasal spine or the buccal tubes of first molar bands to place gentle traction on the segments as needed to guide the segments into place. Once the maxilla is passively seated and the final splint is wired, the patient should be placed into maxillomandibular fixation. Necessary bone reductions are performed, and this bone can be used for interpositional bone grafts placed along the palatal gaps at the surgeon's preference. Likewise, grafts are placed in the interdental osteotomy gaps. This can help provide initial stability of the segments and help with healing. The maxilla is then positioned as it would be for any conventional Le Fort I osteotomy and the appropriate bone plates are placed for maxillary fixation. It is the authors' preference to place bone plates across the maxillary segments to help with additional early stability (Figure 10-7). When maxillomandibular fixation is released, the palatal tissue and the gingiva adjacent to the maxilla should be inspected for any signs of damage or ischemic compromise. Inadvertent tears in the palate or alveolar gingiva should be closed and then the Le Fort incision should be closed as to the operator's preference.

Postoperative Care

Management of patients after segmental maxillary surgery is similar to patient management after conventional single-piece Le Fort surgery with the exception of the need for postoperative splint use. Peri-operative antibiotics are given for 24 hours. Appropriate hygiene is also important to avoid early infection and optimize soft tissue healing. Patients are encouraged to start regular dental hygiene in the form of tooth brushing the day after surgery. Chlorhexidine mouth rinse is encouraged to assist with splint cleanliness. Each individual practitioner will determine his or her regime



• **Figure 10-8** Postoperative gingival recession and root exposure at the site of an interdental osteotomy for segmental surgery.

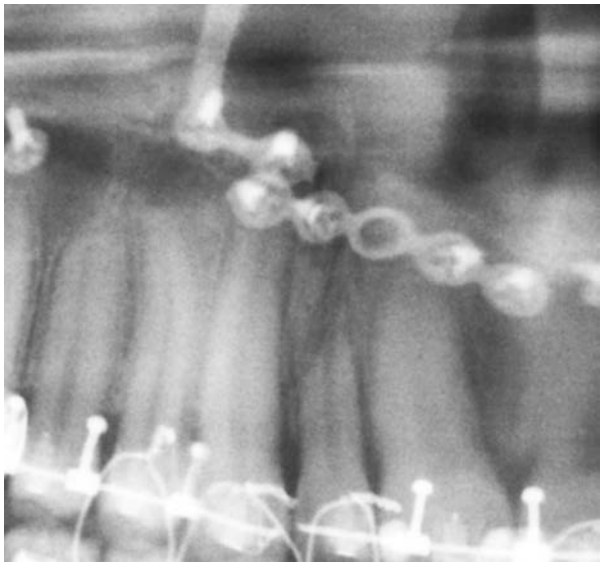

• **Figure 10-9** Fractured root at the site of an interdental osteotomy.

for occlusal splint therapy. The authors prefer to keep the patient in elastic maxillomandibular fixation for 1 week after surgery. The occlusal splint is left wired into place for a total of 6 weeks postoperative. Upon splint removal, the patient is encouraged to see the orthodontist the same or next day for insertion of a new stainless steel continuous archwire and a transpalatal appliance (TPA) that is used for transverse relapse prevention. The TPA is prefabricated based on the final surgical model width that was provided to the orthodontist. Typically the TPA is left in place for 3 months.

Complications

Loss of a dentoalveolar segment is a dreaded outcome after a segmental maxillary surgery, though exceedingly rare. Aseptic necrosis of the maxilla has been reported to occur in less than 1% of segmented cases.[17] The reported causes of aseptic necrosis range from patient factors such as smoking to iatrogenic surgical factors, which could result in compromised vascular flow to the maxilla.[18] There is no defined protocol for the treatment of aseptic necrosis of the maxilla, however, reported treatment options include surgical debridement of necrotic areas, expectant management with meticulous hygiene, hyperbaric oxygen therapy, antibiotics, and heparin.[18] Other local complications include damage to the dentition and gingiva, as well as localized periodontal defects associated with the interdental osteotomies (Figures 10-8 and 10-9). A small number of patients have been reported to develop pulpal necrosis requiring root canal treatment.[19] Lastly, relapse is always a concern given the inherent instability of maxillary expansion and open bite correction, however, this can largely be avoided with proper planning, intraoperative attention to detail, and a well devised postoperative retention strategy (Figure 10-10).



• **Figure 10-10 A,** A 22-year-old male with bimaxillary A-P deficiency, transverse maxillary deficiency, and a multiplanar occlusion with resultant apertognathia.

Continued

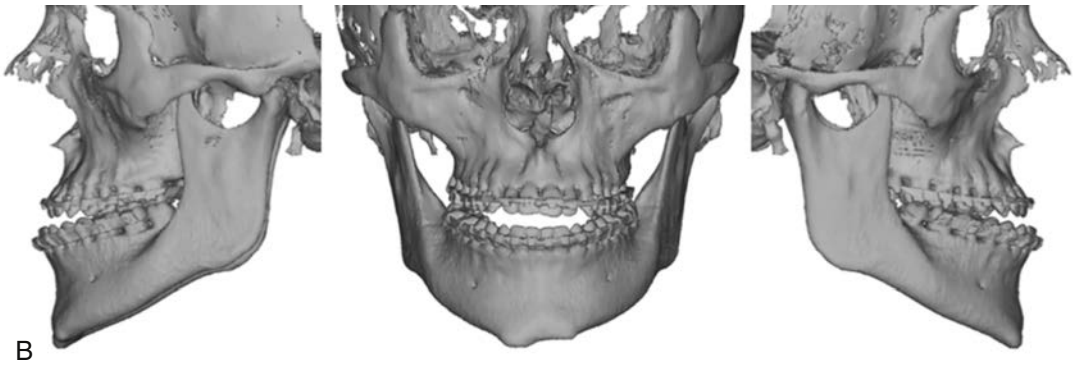

B

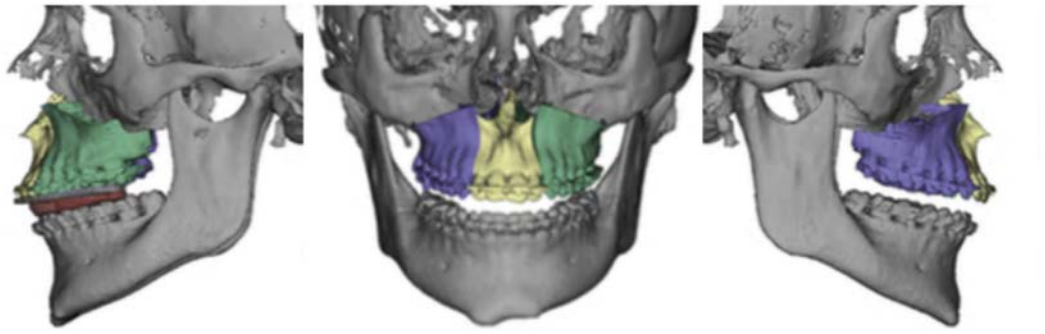

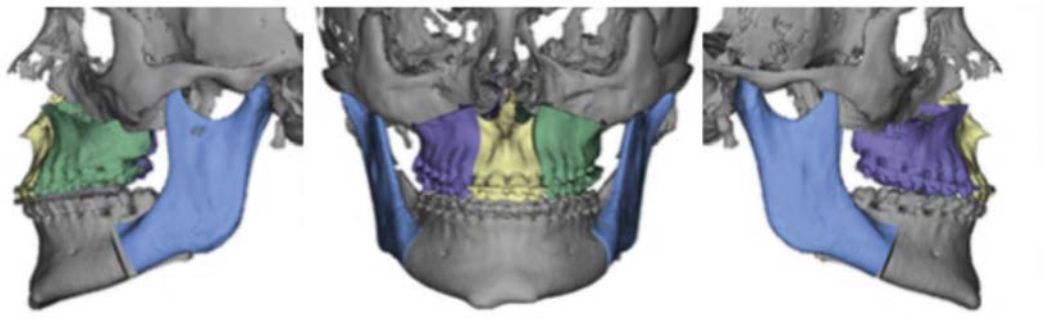

C

• **Figure 10-10, cont'd** **B,** Preoperative 3D CT scan taken in natural head position and the mandible in centric relation. **C,** Treatment includes a 3-piece segmental Le Fort I with leveling of the occlusal plane and transverse expansion, bilateral sagittal split osteotomies, and genial recontouring.

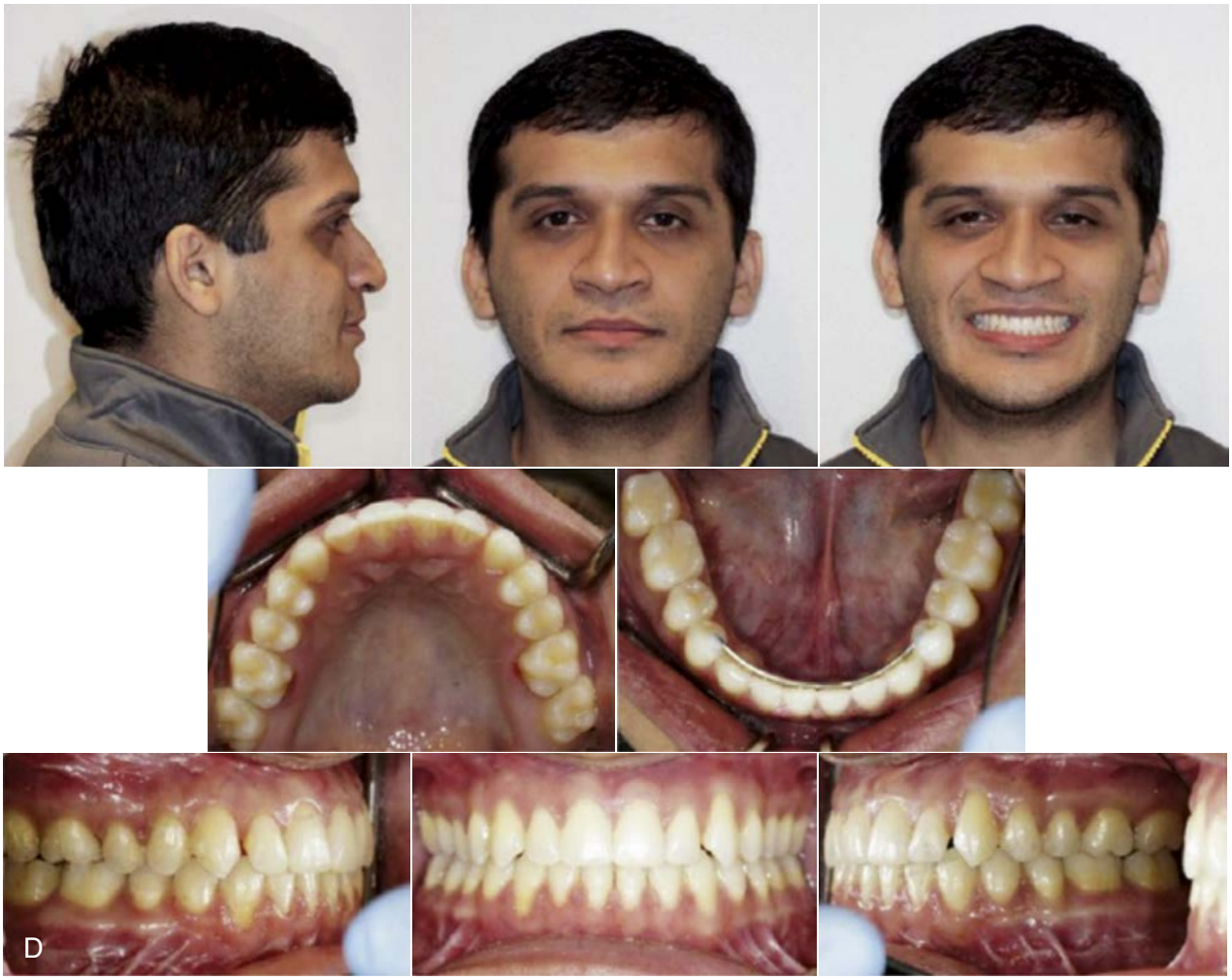

• **Figure 10-10,** cont'd **D,** Final postoperative results.

References

1. Kelly JE, Harvey CR: *An assessment of the occlusion of the teeth of youths 12-17 years*, U.S. Public Health Service Publication No 77:164, Government Printing Office, 1977.
2. McLain JB, Steedle JR, Vig PS: Face height and dental relationships in 1600 children: a survey, *J Dent Res* 62:308–313, 1983.
3. Bell WH: *Surgical correction of dentofacial deformities: new concepts*, Philadelphia, 1985, WB Saunders, pp 1–226.
4. Perciaccante VJ, Bays RA: *Principles of maxillary orthognathic surgery. In Peterson's principles of oral and maxillofacial surgery*, ed 3, Shelton, CT, 2011, Peoples Medical Publishing House, pp 1365–1392.
5. Cohn-Stock G: Die chirurgische Immediatregulierung der Kiefer, speziell die churgishce Behandlung der Prognathie, *Vjsch Zahnheilk* 37:320, 1921.
6. Wolfe SA: Gunther Cohn-Stock, M.S., D.D.S., father of maxillary orthognathic surgery, *J Craniomaxillofac Surg* 17:331–334, 1989.
7. Wassmund M: *Lehrbuch der praktischen Chirurgie des Mundes und der Kiefer*, Leipzig, 1935.
8. Schuchardt K: *Former des offenen Bisses und ihae operative. Behandlunganoglichen-keiten. Fortschr. Kefer Gesichtschir, Bd*, I Stuttgart, 1955, Thieme.
9. West RA, Epker BN: Posterior maxillary surgery: its place in the treatment of dentofacial deformities, *J Oral Surg* 30:562–563, 1972.
10. Kufner J: Experience with a modified procedure for correction of open bite. In Walker RV, editor: *Transactions of the Third International Conference of Oral Surgery*, London, 1970, Livingston, pp 18–23.
11. Köle H: Surgical operations on the alveolar ridge to correct occlusal abnormalities, *Oral Surg Oral Med Oral Pathol* 12:515–529, 1959.
12. Bell WH: Revascularization and bone healing after anterior maxillary osteotomy: a study using adult rhesus monkeys, *J Oral Surg* 27:249–225, 1969.
13. Turvey TA: Maxillary expansion: a surgical technique based on surgical-orthodontic treatment objectives and anatomical considerations, *J Maxillofac Surg* 13:51–58, 1985.
14. Sherwood K: Correction of skeletal open bite with implant anchored molar/bicuspid intrusion, *Oral Maxillofac Surg Clin North Am* 19(3):339–350, 2007.
15. Scheffler N, Proffit W, Phillips C: Outcomes and stability in patients with anterior open bite and long anterior face height treated with temporary anchorage devices and a maxillary intrusion splint, *Am J Orthodont Dentofacial Orthoped* 146:594–602, 2014.

16. Vanarsdall RL: Periodontal/orthodontic interrelationships. In Graber TM, Vanarsdall RL, editors: *Orthodontics: current principles and techniques*, ed 2, St Louis, 1994, Mosby, pp 712–749.
17. Lanigan DT: Ligation of the descending palatine artery: pro and con, *J Oral Maxillofac Surg* 55:1502, 1997.
18. Pedeira FL, Yaedu RYF, Sant'Ana AP, Sant'Ana E: Maxillary aseptic necrosis after Le Fort I osteotomy: a case report and literature review, *J Oral Maxillofac Surg* 68:1402, 2010.
19. Mesgarzadeh A, Motamedi MH, Akhavan H, et al.: Effects of Le Fort I osteotomy on maxillary anterior teeth: a 5-year follow-up of 42 cases, *Eplasty* 10:e10, 2010.

11

Combined Maxillary and Mandibular Osteotomies

BRENT GOLDEN, CAITLIN B.L. MAGRAW, MICHAEL JASKOLKA

History

Modern orthognathic surgery with combined maxillary and mandibular osteotomies has its origin in the second half of the 20th century. The initial burst of innovation came in the 1950s and 1960s as the various contemporary mandibular and maxillary osteotomy techniques were described and modified independently. These foundational procedures for correcting facial disproportion and malocclusion by maxillary and mandibular surgery were subsequently combined into a single stage of surgery where changes could be executed in the maxilla, mandible, and chin simultaneously. Amazingly, many of these advances can be attributed largely to the insights and vision of a single oral and maxillofacial surgeon, Hugo Obwegeser (Figure 11-1).

The bilateral sagittal split osteotomy (BSSO) was originally preformed by Obwegeser at the Medical University of Graz, Austria, in 1953,[1] although it was not published until 1955 in German[2] and English in 1957.[3] His technique was novel in its degree of control over mandibular length and healing, along with the advantage that it was completed intraorally. During this same period, he developed the intraoral sliding osseous genioplasty and included it in his English publication of 1957.[3] It should be noted that Hofer had published a similar sliding mandibular horizontal osteotomy in 1942; however, his approach was completed using an extraoral approach and was completed on a cadaver, not a patient.[1,4]

Although improvements in mandibular osteotomies allowed for greater interest and less morbidity in corrective jaw surgery, many patients still suffered from deformities involving the midface that were not adequately treated with mandibular surgery alone. Although there were historical precedents for maxillary osteotomies.[5-8] Obwegeser's description was the landmark that allowed the procedure to gain widespread use and utility. It was in 1964 that Obwegeser described a Le Fort I level osteotomy with a downfracture and mobilization technique through a horizontal circumvestibular incision that was both predictable and effective for treating jaw disproportion without substantial morbidity.[1] These advances culminated in the first bimaxillary surgery using a combination of BSSO and Le Fort osteotomy performed by Obwegeser in 1969, which he published the following year.[9]

Dr. Obwegeser famously presented in the United States on his innovations at Walter Reed Army Medical Center in 1966 and profoundly influenced the next generation of specialists treating these deformities. Major contributions from other surgeons and orthodontists have followed ever since.

Concomitant technological advancement in the field of fixation catalyzed further improvements as wire was replaced by bone plates and screws. Hans Luhr published his work on internal fixation in 1968,[10] allowing surgeons to incorporate this innovation in corrective orthognathic surgery with subsequent improvements in the predictability of osteotomy reconstruction, stability, and quality of life during recovery.

The 1970s and 1980s were a period of elucidating the biologic basis of these orthognathic procedures. Despite increased facility with the techniques as they gained popularity, orthognathic surgery needed scientific support for biologic plausibility[10-12] and the understanding of physiologic responses to treatment,[13-18] and attention was focused on defining the expectations with regard to skeletal and soft tissue responses following orthognathic surgery.

The details of surgical technique for each osteotomy in isolation are covered elsewhere in this text. This chapter's aim is to address the considerations involved in the combination of these techniques in a single stage including indications, stability, sequencing, and contemporary innovations.



• **Figure 11-1** Hugo Obwegeser. (From Posnick JC: *Orthognathic surgery: principles and practice*, St. Louis, 2014, Saunders, Copyright JC Posnick.)

Indications

Dentofacial deformity of a severity that would necessitate corrective jaw surgery occurs in between 2.5% and 5% of the U.S. population.[20,21] A thorough patient history, clinical evaluation, and relevant diagnostic records should generate accurate orthodontic and surgical diagnoses and a prioritized problem list from which all treatment objectives are set. Before undertaking corrective jaw surgery of any type, it is imperative to eliminate or control all acute systemic and oral disease as a precursor. Subsequently, the decision to operate with maxillary osteotomies, mandibular osteotomies, or a combination of the two is made based on the following:

1. Projection, proportion/balance, and symmetry of the facial hard and soft tissues
2. Functional status of the oral structures (including dental occlusion) and airway
3. Reported data on long-term stability of proposed interventions

Projection, Proportion, Balance, and Symmetry

Evaluation of projection, proportion, and symmetry is a fusion of clinical data collection compared against normative averages with personal esthetic clinical judgment. Here, the clinician uses accepted ideas about sagittal projection (e.g., balance of forehead, nose, lips and chin in profile), vertical proportion (e.g., facial index, facial thirds, incisor display), and transverse balance (e.g., orbitofacial symmetry, occlusal plane orientation, dental midlines) together with esthetic judgment to determine where the structural pathology exists. Although there are no clear boundaries between normal and abnormal, experienced clinicians generally agree on the presence or absence of disharmony in the three planes of space while allowing for some variance on degree. The majority of dentofacial deformity can be subcategorized into class III problems, long face problems, mandibular deficiency (short or normal face height), or asymmetry.

The pattern of patients seeking combined orthodontic-surgical treatment seems to have shifted in recent years, with patients who have a class III malocclusion (concave profile) becoming the majority.[22] The emphasis on projection of the jaws in the "class III" description should not distract the clinician from the concomitant vertical pathology that often exists with either backward rotation of the mandible when the face is long or overclosure when the face height is short. As surgical techniques have evolved to allow for treatment of midface deficiency in class III malocclusion, the overwhelming majority of patients are now treated with maxillary advancement, which is performed approximately half the time in isolation and half the time combined with mandibular setback.[23]

Patients with a convex profile can also comprise a significant portion of patients seeking treatment for dentofacial deformity. When face height is short or normal, then isolated mandibular advancement with or without genioplasty is often adequate. Conversely, patients with a convex profile and increased face height (long face deformity) frequently exhibit differences in both the maxilla (increased posterior vertical maxillary height) and the mandible (decreased projection, steep mandibular and occlusal plane).[24,25] Therefore, structural indications for bimaxillary surgery often exist for comprehensive treatment of the long face patient.

Asymmetry of a small degree is certainly a variant of normal and not detrimental. To begin to delineate pathologic asymmetry, it is useful to consider the transverse and the vertical dimensions separately, although most cases of asymmetry involve both. With appropriate orthodontic preparation and decompensation, the dental midlines as they relate to the facial and chin midline are quite reasonable surrogates for transverse skeletal asymmetry. Numerous studies have sought to identify how much the maxillary dental midline can deviate from the midsagittal plane before becoming socially detrimental, and most suggest that discrepancies of 2 mm or less are acceptable.[26,27] When the maxillary midline exceeds this amount, the diagnosis of transverse asymmetry is appropriate and consideration of surgery to correct the discrepancy is recommended.

Using the teeth at the occlusal plane also can provide information on vertical asymmetry, although it is important to note that many asymmetric conditions have bony disproportion distant from the dentoalveolus. Padwa and colleagues showed that a maxillary cant greater than 4 degrees was detected with 90% frequency by both professionals and laypersons, and Susarla later showed that the degrees of maxillary cant reasonably approximate the millimetric difference (i.e., 4 degrees ≅ 4 mm).[28,29] From this we can infer that occlusal canting greater than 4 degrees/4 mm is clearly pathologic, although lesser degrees of vertical asymmetry often benefit from correction as well. Of course, correction

of asymmetry overwhelmingly requires bimaxillary surgery because of compensatory changes between the jaws and the benefits of overcorrection in the asymmetric patient.

Functional and Esthetic Considerations

Functional considerations in determining the appropriateness of bimaxillary surgery include the need to create a balanced and stable occlusion, foster a patent airway with minimal obstruction, and support a healthy temporomandibular joint (TMJ). Achieving a balanced occlusion is a primary tenet of achieving an acceptable result and is dictated by orthodontic preparation, gross skeletal movement, and final orthodontic detailing. Additional coordination of the dental arches can require surgical segmentation when there is transverse incompatibility or a dual plane of occlusion. Notably, this surgical component of balancing the occlusion at the arch level may necessitate bimaxillary surgery even when projection, proportion, and symmetry are not markedly disturbed in both jaws.

Of great significance in surgical planning is consideration of airway patency and adaptability. It has been well documented that bimaxillary advancement has a role and a clear indication for treatment of documented severe obstructive sleep apnea (OSA) that has not responded to continuous positive airway pressure (CPAP).[30,31] It has also been shown that mandibular setback surgery has implications for the pharyngeal airway by decreasing cross-sectional area[32,33]; however, a causative association with increased OSA has not been shown to date with modest movements.[34,35] In light of this, bimaxillary advancement is the most comprehensive approach for opening the airway at multiple levels in patients with known obstructive symptoms, and mandibular setback in at-risk populations should be minimized or avoided.

The effects of malocclusion and bimaxillary surgery on TMJ health or disease remains obscured by questions regarding the classification of disease, overwhelmingly retrospective and small-size studies, and varying clinical experience. Much remains to be studied, and the role of bimaxillary surgery in treating known degenerative TMJ disease or exacerbating symptoms of TMJ disorder is unclear.[36,37] To date, there has been no conclusive evidence to linking the two. In the patient with significant degenerative pathology, simultaneous alloplastic reconstruction of the TMJ with Le Fort I osteotomy has become a reality in select centers with TMJ reconstruction expertise.[38,39]

In addition to functional considerations, all treatment decisions must take into account the significant psychosocial impact of inherent esthetic changes. Smile design and facial balance must be factored into the final treatment decisions.

Stability

Individuals undergoing treatment of their skeletal facial deformities with orthognathic surgery expect their functional and esthetic results to be maintained for many years.

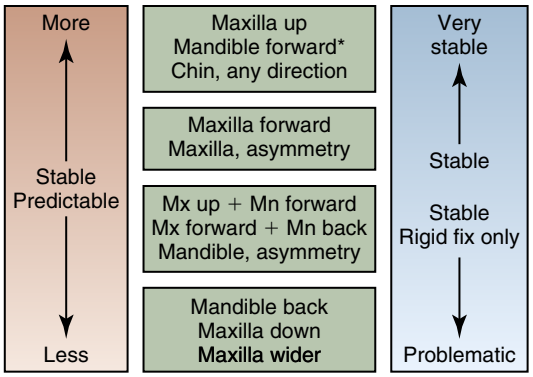

• **Figure 11-2** Hierarchy of stability. (From Proffit WR, Turvey TA, Phillips C: The hierarchy of stability and predictability in orthognathic surgery with rigid fixation: an update and extension, *Head Face Med* 30(3):21, 2007.)

Stability after orthognathic surgery is multifactorial, and it is important for surgeons to have an understanding of the principles that influence short- and long-term effects when planning treatment and counseling patients.

Relapse after orthognathic surgery is the result of either ongoing abnormal growth patterns or functional adaptations overpowering the anatomic form created by the surgeon. It is ideal to wait until the adolescent growth spurt is largely completed before treatment to minimize the negative effects of aberrant growth. Assuming minimal remaining growth, postsurgical changes seem to be related to the direction and magnitude of movement of each jaw, osteotomy techniques, fixation type used, and physiologic adaptation. In light of current knowledge about postsurgical stability, there do exist meaningful indications for bimaxillary surgery to improve the long-term outcomes in certain circumstances even when single-jaw surgery may be feasible.

When considering stability for orthognathic surgery, the most comprehensive information comes from the UNC data set as interpreted by Proffit and colleagues[40] (Figure 11-2). With class III correction, isolated mandibular setback registers as notably unstable, with up to 50% of patients experiencing clinically significant relapse of over 2 mm in the first year after surgery and 15% or more showing more than 4 mm of relapse (in the era prior to rigid fixation). Conversely, class III deformity can be treated with a stable outcome (defined as clinically significant relapse of less than 2 mm in at least 80% of patients and greater than 4 mm in almost none) if isolated maxillary advancement is used for movements of less than 6 to 8 mm and rigidly fixated bimaxillary surgery with maxillary advancement and mandibular setback is performed for larger movements.[21,40]

Posterior maxillary downgrafting is considered problematic with respect to stability, as 40% experience a postsurgical relapse of between 2 and 4 mm and another 20% have greater than 4 mm of change.[40] Because of this inherent instability, downgrafting of the posterior maxilla that lengthens the posterior face height is most often performed using an empirically derived combination of concurrent

mandibular surgery to decrease bite force in the early postoperative period, rigid fixation, and bone grafting of the maxillary defects.

Stability after bimaxillary surgery with mandibular advancement when the maxillomandibular complex (occlusal plane) is altered is dependent on the indication for treatment and direction of movement. When the mandible is advanced and only the anterior face height is increased to relieve vertical shortening, stability is well documented.[21] This is unlike mandibular advancement and superior repositioning by counterclockwise rotation in long-face patients, where stability is much more dubious. Introducing bimaxillary surgery to minimize counterclockwise movement with posterior maxillary impaction has historically been indicated. In contemporary practice, increasing the rigidity of fixation may allow for better stability of counterclockwise rotation, but further data will be helpful to support this change in practice.[21]

Technical Considerations for Performing Bimaxillary Surgery

Historical Norms and Orthodontic Collaboration

Soon after these techniques to treat dentofacial deformity became more widespread, orthodontists and surgeons began to appreciate that optimal outcomes were achieved only with coordinated care. Relatively early on, a three-phase protocol consisting of presurgical orthodontic preparation, surgical care with appliances in place, and a short phase of postsurgical orthodontic detailing became the standard of care.

Coordination of care between the orthodontist and surgeon ideally begins prior to starting definitive orthodontic care. This follows from the reality that orthodontic treatment markedly differs when decompensating dental changes for corrective jaw surgery versus camouflage treatment to fully compensate a malocclusion without surgery. Planning begins with the creation of a comprehensive patient database (chief complaint, clinical history and exam, anthropomorphic measurements, plain-film x-rays or three-dimensional [3D] radiographs, dental study casts, and bite in centric relation). Modern software tools allow for two-dimensional profile simulations that may aid in presenting a visual representation of possible treatment changes.[41] A prioritized problem list should be generated from all data to guide the development of definitive orthodontic and surgical treatment objectives.

Orthodontic treatment typically begins in advance of surgical care to allow for increased precision of surgical movements and to limit the amount of treatment following surgery. Although beyond the scope of this chapter, orthodontic objectives are generally to decompensate the incisor teeth vertically and anteroposteriorly, level and coordinate the dental arches, and provide stable appliances once surgery is imminent.

Once the patient is orthodontically prepared for surgery and a heavy arch wire is in place to stabilize the teeth for final surgical planning, comprehensive records (clinical history and exam, anthropomorphic measurements, plain-film x-rays or 3D radiographs, dental study casts, facebow transfer, and bite in centric relation) are updated. The final surgical plan is dictated by the prioritized problem list with the clinical exam preeminent. With increasing availability of advanced 3D imaging and virtual planning techniques, it is worth emphasizing that radiographs and 2D or 3D cephalometric references are adjunctive to the clinical exam but still do not fully capture hard and soft tissue relationships or the effects of animation and are not prescriptive of surgical movements in isolation.

The surgical plan is reliably translated to the operating room by using a custom fabricated interocclusal splint for each movement of the jaws (Figure 11-3). The process of creating a custom occlusal splint is fundamentally important to bimaxillary surgery and is known as model surgery. Model surgery in the late 20th century was entirely dependent on historical dental techniques using stone casts mounted on a semi-adjustable articulator. Because this process is so critical to achieving positive outcomes, the reader is directed to a full chapter dedicated to the specifics elsewhere in this text.

The greatest precision and best visualization of change with traditional stone model surgery occurs at the occlusal plane. In cases with significant asymmetry, virtual models and model surgery can greatly improve knowledge of changes at the bony landmarks more distant from the teeth and provide a substantive advantage. The expected relationships of the bone interfaces and landmarks are explicitly shown in the virtual environment with great advantage to the surgeon.

Maxilla-First Surgery

The traditional sequence of operative care begins with mandibular corticotomies without completing the sagittal osteotomy. The vertical position of the maxillary incisor teeth is referenced prior to the maxillary osteotomy by intraoperative measurements compared to soft tissue landmarks (i.e., medial canthus) or a K-wire pin placed in the nasal radix. The historical use of internal reference marks has largely been abandoned as external reference points have been shown to be more accurate.[42] The maxilla is then osteotomized and completely mobilized. If the maxilla needs to be segmentalized, this is accomplished after the downfracture, and the maxilla is placed into a final splint to stabilize the arch change. Placing the teeth into intermaxillary fixation using a custom intermediate occlusal splint creates the desired spatial relationship of the maxilla in every position except the vertical. The maxilla is then rotated into the correct vertical position, relying on the stable condylar centric relation position and the previously obtained external reference distances. Care must be taken to ensure that the teeth remain firmly in the occlusal splint and that the condyles do not rotate out of the fossa when assessing the maxillary final

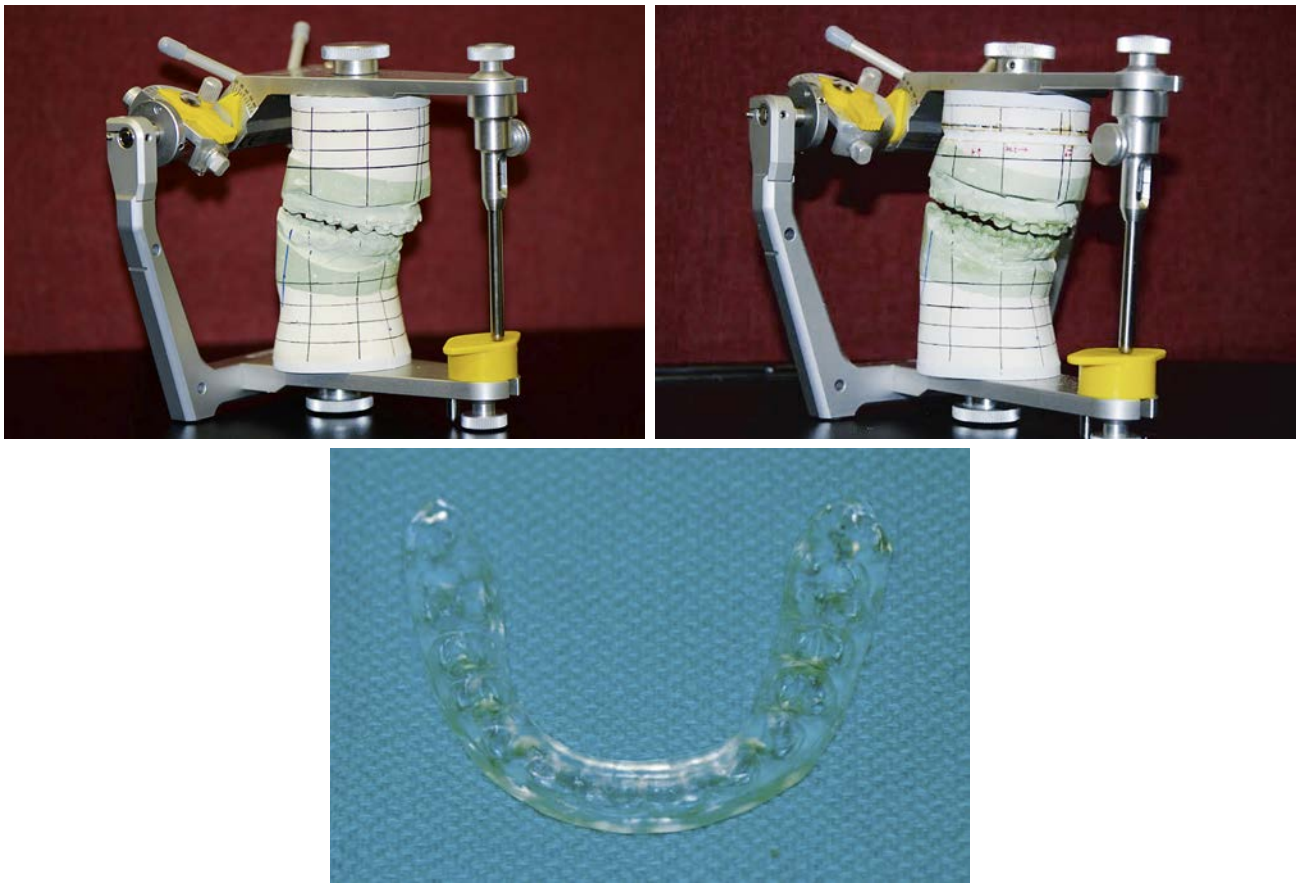

• **Figure 11-3** Occlusal splints.

position. The maxilla is then fixated in place using titanium miniplates and screws or, alternatively, resorbable plates and screws. After maxillary rigid fixation, the intermaxillary fixation is released and the relationship of the mandible to the maxilla is confirmed by occlusal relationships both into the intermediate splint and without the intermediate splint in place.

Next, completion of the mandibular osteotomies takes place, and the distal segment of the mandible is mobilized. Intermaxillary fixation is again used in conjunction with the final occlusal splint to create the desired occlusal relationship and distal mandibular position. The proximal segments of the mandible are positioned with the condyle in the posterior-superior aspect of the glenoid fossa while the distal end of the proximal segment is related to the distal segment based on the judgment of the surgeon and the anticipated relationship of the bone at the osteotomy site. Care must be taken not to lengthen the posterior face height. Once the segments have been passively related, the mandible is fixated with rigid fixation using position screws, bone plates, or some combination of the two. Genioplasty or other mandibular contouring is typically carried out last while the patient is in stable intermaxillary fixation. Finally, the patient is released from intermaxillary fixation, and the relationship of the jaws is verified by occlusal match into the splint and without the splint in place. The final occlusal splint can be secured to either arch for any length of time up to 6 weeks or discarded. The patient is maintained in elastic bands and not kept in maxillomandibular fixation. Postoperative care is consistent with single-jaw surgery and detailed elsewhere in this text.

This sequence of "maxilla-first" surgery is influenced heavily by the historic use of semirigid wire fixation that led to a fear of intraoperative instability from loss of fixation in the mandible. Many surgeons elect to continue the application of this sequence out of comfort and tradition. The development and application of rigid internal fixation, however, has allowed this topic to become one of surgical preference and practicality. Even so, it should be noted that clear indications for surgical repositioning of the mandible first do exist.[43,44]

Mandible-First Surgery

Inconsistent Centric Relation of the Mandible

Occasionally, patients present with an inability to consistently reproduce a stable position of the mandible. This may be caused by structural or functional abnormalities of the TMJ complex (e.g., hemifacial microsomia) and poses several challenges to orthognathic surgical treatment planning and execution. The first example of difficulty can occur during record taking and bite registration. If the captured mandibular position is incorrect in relation to the maxilla, error can propagate during mounting of stone casts as well as virtual model fabrication (i.e., registration of the

high-resolution dental models to the skeletal model). The second example of difficulty can occur if the mandible is used as the intraoperative reference for repositioning the maxilla (as is the case in traditional sequencing with an intermediate splint). In either of these circumstances, if the maxilla is moved first, its final position is likely to be inaccurate.

In the first example, "mandible-first" surgery will negate the inaccurate bite registration and mounting because of the use of the fixed maxilla as the reference with an intermediate splint. This can also be accomplished using the traditional sequence if a maxillary repositioning splint is used that is related to the fixed portion of the midface.[45]

Intraoperative Difficulty with Intermaxillary Fixation

A variety of intraoperative technical challenges can be related to surgical sequencing. When counter clockwise rotation of the maxillomandibular complex is planned and executed with "maxilla-first" surgery, inferior and posterior opening of the mandible occurs. This can present two problems with the accurate positioning of the maxilla. If the movement is large enough, the mandible may actually be forced to translate out of the glenoid fossa, making the intermediate splint erroneous. Secondly, challenges can present because of the size of the intermediate splint and difficulty with placement of secure intermaxillary fixation. These issues can again be accounted for by initial mandibular surgical repositioning with the use of an occlusal splint or the use of the skeletally based maxillary repositioning splint (Figure 11-4).

A similar situation can occur when a patient with a preoperative class II occlusion is planned for both maxillary and mandibular advancement. Maxillary advancement first can make fabrication of an intermediate occlusal splint and placement of intermaxillary fixation challenging.

Last, the opposite situation can present when planning for mandibular repositioning first if the patient is planned to undergo significant clockwise rotation of the occlusal plane. In this circumstance, there is a clear indication to perform maxillary surgery first to minimize the intraoperative difficulties noted earlier.

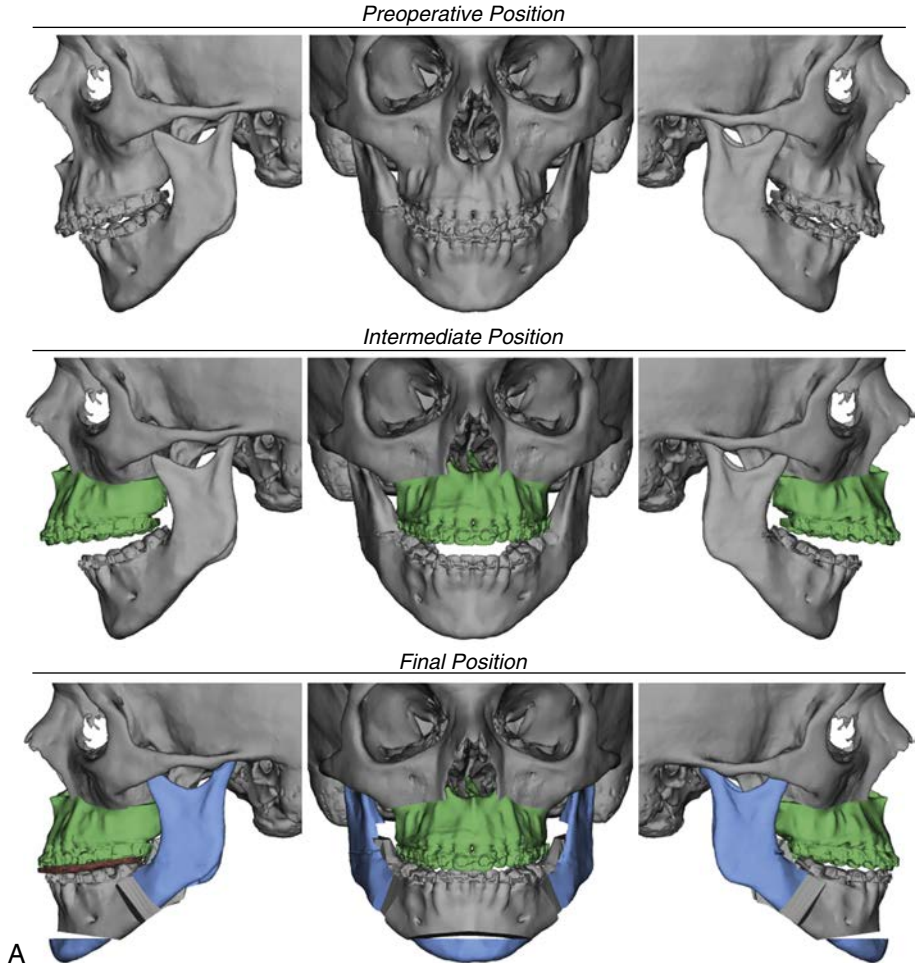

• **Figure 11-4** Alternative sequencing: **A,** Maxilla-first surgery and the challenges in splint fabrication as well as the challenges of maintaining condylar position.

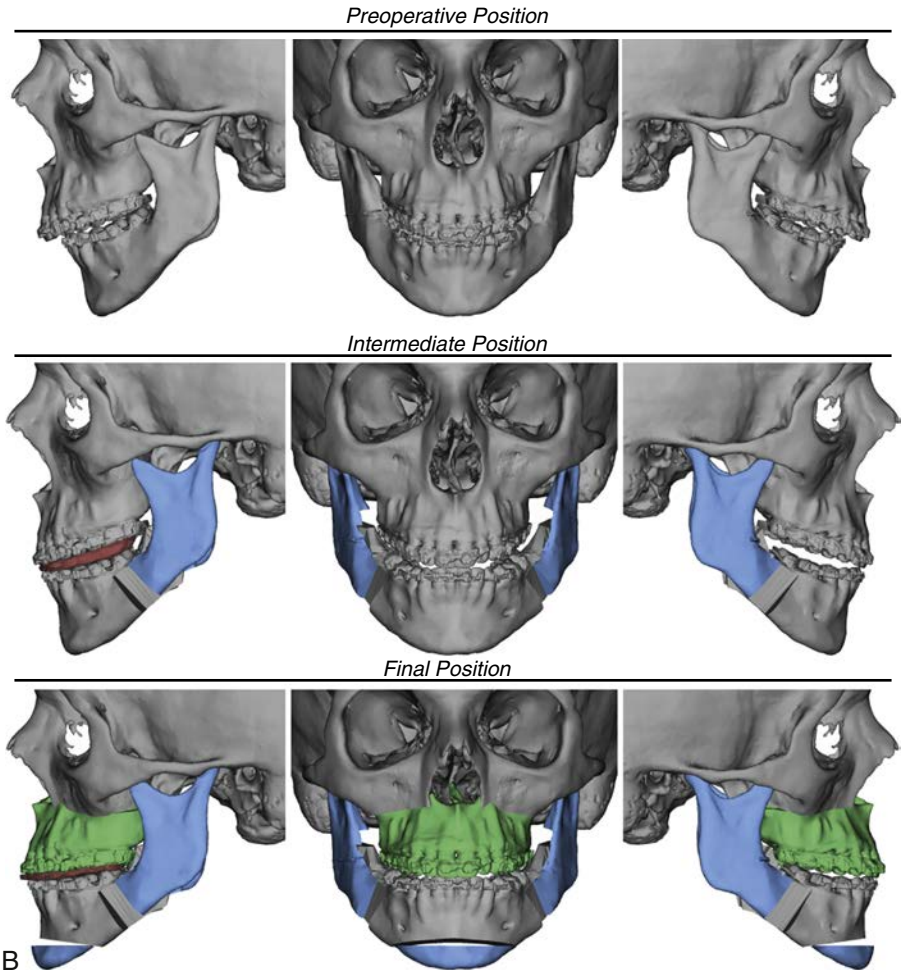

• **Figure 11-4, cont'd** **B,** The same case with improvements using mandible-first surgery.

Extraoral Surgery of the Mandible

Another consideration of surgical sequencing arises when either concomitant TMJ surgery or extraoral mandibular advancement (i.e., inverted L procedure) is planned. As discussed earlier, the predictable repositioning of the maxilla first using an intermediate occlusal splint is predicated on the reproducible positioning of the bilateral TMJ complex. In this circumstance, the maxilla may be repositioned first, followed by TMJ surgery and mandibular repositioning, but in this sequence, maintaining meticulous surgical sterility can be challenging. It is often more straightforward from an instrumentation perspective to perform the TMJ procedure first, followed by mandibular repositioning and finally maxillary repositioning.

Extraoral mandibular advancement is often planned in cases necessitating large mandibular advancements and bone grafting (i.e., Treacher Collins syndrome) or in those patients who require mandibular advancement with low tolerance for the potential of permanent inferior alveolar nerve paresthesia. Similar to those patients requiring TMJ surgery, it is often more practical from a sterility and instrumentation perspective to perform extraoral mandibular advancement first, followed by maxillary repositioning.

Contemporary Innovations

Early Surgery with Minimal Orthodontic Preparation

To accelerate the impact of positive changes from surgical intervention, "surgery first" sequencing was first reported by Brachvogel in 1991 with the goal of improvement of facial form first, followed by orthodontic correction.[46] A reduction in treatment time is attributed to more rapid postsurgical tooth movement associated with the regional acceleratory phenomenon.[47-53] To date, the literature consists largely of case reports[54,55] with a few larger case series.[56-58] Currently, application is most common in class III skeletal facial deformities with limited crowding and arch discrepancies; there continues to be wide variation in the details of the orthodontic and surgical treatment protocols in use.[59-62] The surgery-first paradigm presents exciting promise and patient benefit. Reports in the literature are beginning to delineate feasibility, indications, treatment protocols, outcomes, and stability,[58,63-65] but further study and high-quality evidence demonstrating equivalence or improvement over traditional sequencing is necessary before widespread adoption.

Computer-Aided Surgical Simulation (CASS) and Virtual Surgical Planning (VSP) in Orthognathic Surgery

Evolution

The application of computers to orthognathic surgical planning and simulation has been an incremental process, punctuated by several notable transformative events. The use of computed tomography (CT) and the ability to render axial data into 3D images[66] is the foundation of the transition from traditional 2D-based techniques. The ubiquity of cone-beam computed tomography (CBCT) now allows for the rapid acquisition of specific maxillofacial data with several advances over medical CT, including lower radiation exposure, upright patient positioning, improved convenience, and lower cost. The development of stereolithography, initially applied to the fabrication of physical 3D models,[67] has transformed into true rapid prototyping with an almost endless number of craniomaxillofacial surgery applications. Advances in hardware, as well as the development of specialized software applications such as 3D Surgery (Dolphin), ProPlan CMF (Materialise), and Maxilim (Medicim), have combined with the technologies discussed earlier to provide all of the tools necessary to create a virtual patient (including bone, dentition, and soft tissue), analyze the deformity, plan and simulate a surgical treatment, transfer the simulation to the operating room, and evaluate outcomes. In truth, neither the terms CASS nor VSP encompass the total paradigm shift that has occurred in state-of-the-art virtual orthognathic surgery—VOS.

Benefits

The application of new technology should be carefully considered before its adoption into clinical practice. Over the past 10 years, VOS has been refined and can be supported through the literature to show benefits in terms of improved patient outcomes[68,69] and reduced operative and overall surgeon time,[70] as well as a reduction in cost.[71] A beneficial impact on resident education and teaching is hypothesized and likely to be demonstrated in the literature in the future.

The Future

VOS is continuing to advance quickly both in terms of technology and implementation. It is predictable that in the near future, an exclusively digital-based workflow will evolve using current technology. This will be highlighted by the elimination of traditional impressions and the ability to rapidly and reproducibly establish final occlusion in single-piece and segmental cases. 3D printing technology is becoming less expensive, more accurate, and less time consuming and will also likely be found "in office" in the near future. The potential exists for haptic technology to upset the current workflow, but most likely this will first present as an educational tool in the application of true surgical simulation. Outcomes research using VOS technology will further define postoperative changes and stability and continue to refine algorithms for hard and soft tissue prediction as well as direct "ideal" treatment.

Conclusion

Dentofacial deformity causes a substantial quality-of-life burden for many people. Since the age of discovery in the middle of the last century, maxillofacial surgical techniques have been further developed and refined to produce predictable outcomes, especially when performed in a collaborative effort with an orthodontist. Combined surgery of the maxilla and mandible is a powerful tool that can address the overwhelming majority of facial skeletal malocclusion with data supporting the stability of results over time. The future holds the promise of further ongoing refinement with virtual orthognathic surgery.

CASE REPORT 11-1

Maxillary Hypoplasia, Transverse Deficiency, Mandibular Hyperplasia

A 16-year-old female patient presents with combined deformity of both jaws, including dental crowding, maxillary sagittal hypoplasia, maxillary transverse hypoplasia, and mandibular hyperplasia (Figure 11-5). Treatment is directed at the presenting problem list, so combined maxillary and mandibular surgery is planned. During the initial orthodontic phase of management, the dental crowding is relieved. In this case, the decision was made to coordinate the arches surgically in segments, so a transverse deficiency remains between the maxilla and mandible at the time of surgical planning. In preparation for surgery, dental models are obtained, as well as imaging that can be coordinated with the stone models. The maxillary cast is segmented into two pieces, and the arches are surgically coordinated. The final occlusion is set, and these records are then digitized for surgical planning. The final occlusal relationship is captured in a "final" splint for surgical execution. The maxillary move is completed first, and because the maxilla is stabilized, the final splint is secured to the maxillary arch only. A second "intermediate" acrylic splint generated from the surgical planning session relates the unstable maxilla to the stable mandible precisely in the sagittal and transverse dimension. The vertical position is set using an external vertical reference point. Following fixation, the mandible is osteotomized and secured into the final splint for completion of the surgical correction. In the final photos, the patient has been debanded and exhibits an accurate and stable correction.



• **Figure 11-5** **A,** Preoperative photos and occlusion.

Continued

CASE REPORT 11-1—cont'd

Maxillary Hypoplasia, Transverse Deficiency, Mandibular Hyperplasia

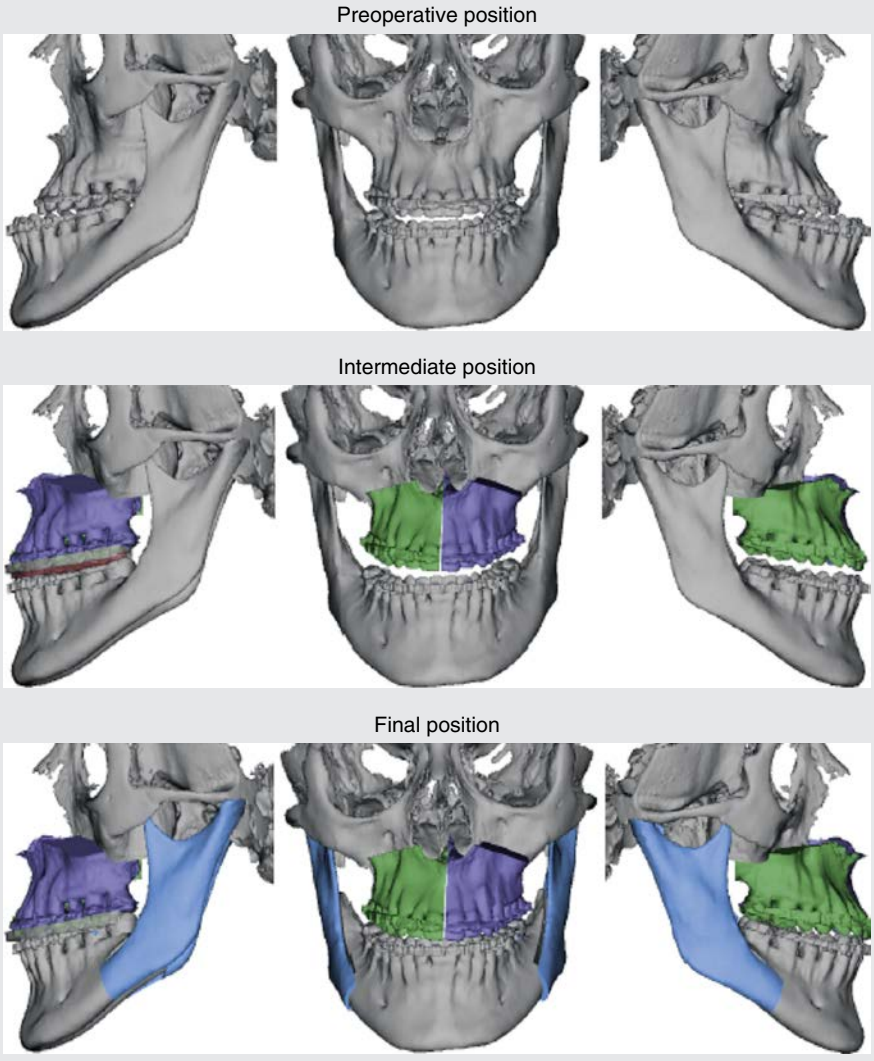

B

• **Figure 11-5, cont'd** B, Virtual surgical planning for maxilla-first bimaxillary surgery.

CASE REPORT 11-1—cont'd

Maxillary Hypoplasia, Transverse Deficiency, Mandibular Hyperplasia



• **Figure 11-5, cont'd** **C,** Post-treatment photos and occlusion.

References

1. Obwegeser HL: Orthognathic surgery and a tale of how three procedures came to be: a letter to the next generation of surgeons, *Clin Plast Surg* 34(3):331–355, 2007.
2. Trauner R, Obwegeser HL: Zur Operationstechnik bei der Progenia und anderen Unterkieferanomalien, *Dtsch Zahn Mund Kieferheilkd Zentralbl* 23:11–25, 1955.
3. Obwegeser HL: The surgical correction of mandibular prognathism and retrognathia with consideration of genioplasty, *Oral Surg Oral Med Oral Pathol* 10:677–689, 1957.
4. Hofer O: Operation del Prognathie und Microgenie, *Dtsch Zahn Mund Kieferheilkd Zentralbl* 9:121–132, 1942.
5. Cheever DW: *Surgical cases*, Private printing. Boston, 1869, David Clapp.
6. Halvorson EG, Mulliken JB: Cheever's double operation: the first Le Fort I osteotomy, *Plast Reconstr Surg* 121(4):1375–1381, 2008.
7. Wassmund M: *Lehrbuch der praktischen Chirurgie des Mundes und der Kiefer*, vol. 1. Leipzig, 1935, Meusser.
8. Axhausen G: Zur Behandlung veralteter disloziert geheilter Oberkieferbrache, *Dtsch Zahn-Mund Kieferheilkd Zentralbl* 6:582, 1934.
9. Obwegeser HL: The one time forward movement of the maxilla and backward movement of the mandible for the correction of extreme prognathism, *SSO Schweiz Monatsschr Zahnheilkd* 80(5):547–556, 1970.
10. Luhr HG: Zur stabilen Osteosynthese bei Unterkieferfrakturen, *Dtsch Zahnärztl Z* 223:754, 1968.
11. Bell WH, Levy BM: Revascularization and bone healing after posterior maxillary osteotomy, *J Oral Surg* 29:313–320, 1971.
12. Bell WH: Bone healing and revascularization after total maxillary osteotomy, *J Oral Surg* 33:253–260, 1975.
13. Bell WH: Revascularization and bone healing after anterior maxillary osteotomy: a study using rhesus monkeys, *J Oral Surg* 27:249–255, 1969.
14. Phillips C: The effect of orthognathic surgery on head posture, *Eur J Orthod* 13:397–403, 1991.
15. Frohlich K, Ingervall B, Schmoker R: Influence of surgical tongue reduction on pressure from the tongue on the teeth, *Angle Orthod* 63:191–198, 1993.
16. Turvey TA, Hall DJ, Warren DW: Alterations in nasal airway resistance following superior repositioing of the maxilla, *Am J Orthod* 85:109–114, 1984.
17. Spalding PM: The effects of maxillary surgery on nasal respiration, *Int J Adult Orthod Orthogn Surg* 6:191–199, 1989.
18. Proffit WR: The effect of orthognathic surgery on occlusal force, *J Oral Maxillofac Surg* 47:457–463, 1989.
19. Reference removed in page review.
20. Proffit WR, White Jr RP: Dentofacial problems: prevalence and treatment need. In Proffit W, White RP, Sarver DM, editors: *Contemporary treatment of facial deformity*, St. Louis, 2003, Mosby.
21. Proffit WR, White Jr RP: Combined surgical-orthodontic treatment: how did it evolve and what are the best practices now? *Am J Orthod Dentofacial Orthop* 147(Suppl 5):205–215, 2015.
22. Proffit WR, Jackson TH, Turvey TA: Changes in the pattern of patients receiving surgical-orthodontic treatment, *Am J Orthod Dentofacial Orthop* 143(6):793–798, 2013.
23. Bailey LJ, et al.: Class III Problems. In White, Sarver Proffit, editors: *Contemporary Treatment of Dentofacial Deformity*, St. Louis, 2003, Mosby.
24. Ellis 3rd E, McNamara Jr JA, Lawrence TM: Components of adult Class II open bite malocclusion, *J Oral Maxillofac Surg* 43:92, 1985.
25. Ellis 3rd E, McNamara Jr JA: Components of adult Class III adult open bite malocclusion, *Am J Orthod* 86:277, 1984.
26. Cardash HS, Ormanier Z, Laufer BZ: Observable deviations of the facial and anterior tooth midlines, *J Prosthet Dent* 89:282, 2003.
27. Beyer JW, Lindauer SJ: Evaluation of dental midline position, *Semin Orthod* 4:146, 1998.
28. Padwa BL, Kaiser MO, Kaban LB: Occlusal cant in the frontal plane as a reflection of facial asymmetry, *J Oral Maxillofac Surg* 55:811, 1997.
29. Susarla SM, Dodson TB, Kaban LB: Measurement and interpretation of a maxillary occlusal cant in the frontal plane, *J Oral Maxillofac Surg* 66(12):2498–2502, 2008.
30. Riley RW, Powell NB: Maxillofacial surgery and obstructive sleep apnea, *Otolaryngol Clin North Am* 23.4:809–826, 1990.
31. Camacho M, et al.: Large maxillomandibular advancements for obstructive sleep apnea: an operative technique evolved over 30 years, *J Craniomaxillofac Surg* 43.7:1113–1118, 2015.
32. Mattos CT, et al.: Effects of orthognathic surgery on oropharyngeal airway: a meta-analysis, *Int J Oral Maxillofac Surg* 40(12):1347–1356, 2011.
33. Saitoh K: Long-term changes in pharyngeal airway morphology after mandibular setback surgery, *Am J Orthod Dentofacial Orthop* 125(5):556–561, 2004.
34. Fernandez-Ferrer L, et al.: Effects of mandibular setback surgery on upper airway dimensions and their influence on obstructive sleep apnoea—a systematic review, *J Craniomaxillofac Surg* 43(2):248–253, 2015.
35. Hasebe D, et al.: Changes in oropharyngeal airway and respiratory function during sleep after orthognathic surgery in patients with mandibular prognathism, *Int J Oral Maxillofac Surg* 40(6):584–592, 2011.
36. Nadershah M, Mehra P: Orthognathic surgery in the presence of temporomandibular dysfunction: what happens next? *Oral Maxillofac Surg Clin North Am* 27(1):11–26, 2015.
37. von Bremen J, Ruf S: Orthodontic and dentofacial orthopedic management of juvenile idiopathic arthritis: a systematic review of the literature, *Orthod Craniofac Res* 14:107–115, 2011.
38. Mehra P, et al.: Single-stage comprehensive surgical treatment of the rheumatoid arthritis temporomandibular joint patient, *J Oral Maxillofac Surg* 67(9):1859–1872, 2009.
39. Wolford LM: Clinical indications for simultaneous TMJ and orthognathic surgery, *Cranio* 25(4):273–282, 2007.
40. Proffitt WR, Turvey TA, Phillips C: The hierarchy of stability and predictability in orthognathic surgery with rigid fixation: an update and extension, *Head Face* 3:21, 2007.
41. Phillips C, Hill BJ, Cannac C: The influence of video imaging on patients' perceptions and expectations, *Angle Orthod* 65(4):263–270, 1995.
42. Polido WD, Ellis 3rd E, Sinn DP: An assessment of the predictability of maxillary repositioning, *Int J Oral Maxillofac Surg* 20(6):349–352, 1991.
43. Turvey TA: Sequencing of two-jaw surgery: the case for operating the maxilla first, *J Oral Maxillofac Surg* 69(8):2225, 2011.
44. Perez D, Ellis 3rd E: Sequencing bimaxillary surgery: mandible first, *J Oral Maxillofac Surg* 69.8:2217–2224, 2011.
45. Polley JW, Figueroa AA: Orthognathic positioning system: intraoperative system to transfer virtual surgical plan to operating field during orthognathic surgery, *J Oral Maxillofac Surg* 71(5):911–920, 2013.

46. Brachvogel PI, Berten JL, Hausamen JE: [Surgery before orthodontic treatment: a concept for timing the combined therapy of skeletal dysgnathias], *Dtsch Zahn Mund Kieferheilkd Zentralbl* 79(7):557–563, 1991.
47. Frost HM: The biology of fracture healing. An overview for clinicians. Part I, *Clin Orthop Relat Res* 248:283–293, 1989.
48. Frost HM: The biology of fracture healing. An overview for clinicians. Part II, *Clin Orthop Relat Res* 248:294–309, 1989.
49. Shih MS, Norrdin RW: Regional acceleration of remodeling during healing of bone defects in beagles of various ages, *Bone* 6:377–379, 1985.
50. Strippoli J, Aknin JJ: [Accelerated tooth movement by alveolar corticotomy or piezocision], *Orthod Fr* 83:155–164, 2012.
51. Wilcko MT, Wilcko WM, Pulver JJ: Accelerated osteogenic orthodontics technique: a 1-stage surgically facilitated rapid orthodontic technique with alveolar augmentation, *J Oral Maxillofac Surg* 67:2149–2159, 2009.
52. Lee W, Karapetyan G, Moats R: Corticotomy-/osteotomy-assisted tooth movement microCTs differ, *J Dent Res* 87:861–867, 2008.
53. Yaffe A, Fine N, Binderman I: Regional accelerated phenomenon in the mandible following mucoperiosteal flap surgery, *J Periodontol* 65:79–83, 1994.
54. Villegas C, et al.: Expedited correction of significant dentofacial asymmetry using a surgery first approach, *J Clin Orthod* 44:97–103, 2010.
55. Hernández-Alfaro F, Guijarro-Martinez R, Molina-Coral A: "Surgery first" in bimaxillary orthognathic surgery, *J Oral Maxillofac Surg* 69:e201Ye207, 2011.
56. Liou EJ, et al.: Surgery-first accelerated orthognathic surgery: postoperative rapid orthodontic tooth movement, *J Oral Maxillofac Surg* 69:781–785, 2011.
57. Hernandez-Alfaro FI, Guijarro-Martinez R, Peiro-Guijarro MA: Surgery first in orthognathic surgery: what have we learned? A comprehensive workflow based on 45 consecutive cases, *J Oral Maxillofac Surg* 72(2):376–390, 2014.
58. Choi JW, et al.: The reliability of a surgery-first orthognathic approach without presurgical orthodontic treatment for skeletal class III dentofacial deformity, *Ann Plast Surg* 74(3):333–341, 2015.
59. Nagasaka H, et al.: Surgery first skeletal Class III correction using the Skeletal Anchorage System, *J Clin Orthod* 43:97–105, 2009.
60. Urube F, et al.: Three-dimensional cone-beam computed tomography-based virtual treatment planning and fabrication of a surgical splint for asymmetric patients: surgery first approach, *Am J Orthod Dentofacial Orthop* 144:748–758, 2013.
61. Huang CS, Hsu SS, Chen YR: Systematic review of the surgery-first approach in orthognathic surgery, *Biomed J* 37(4):184–190, 2014.
62. Sharma VK, Yadav K, Tandon P: An overview of surgery-first approach: recent advances in orthognathic surgery, *J Orthod Sci* 4.1:9–12, 2015.
63. Baek SH, et al.: Surgery-first approach in skeletal class III malocclusion treated with 2-jaw surgery: evaluation of surgical movement and postoperative orthodontic treatment, *J Craniofac Surg* 21.2:332–338, 2010.
64. Wang YC, et al.: Comparison of transverse dimensional changes in surgical skeletal class III patients with and without presurgical orthodontics, *J Oral Maxillofac Surg* 68:1807–1812, 2010.
65. Ko EW, et al.: Comparison of progressive cephalometric changes and postsurgical stability of skeletal class III correction with and without presurgical orthodontic treatment, *J Oral Maxillofac Surg* 69:1469–1477, 2011.
66. Marsh JL, Vannier MW: The "third" dimension in craniofacial surgery, *Plast Reconstr Surg* 71(6):759–767, 1983.
67. Stoker NG: Stereolithographic models for surgical planning: preliminary report, *J Oral Maxillofac Surg* 50(5):466–471, 1992.
68. Gateno J, et al.: Clinical feasibility of computer-aided surgical simulation (CASS) in the treatment of complex cranio-maxillofacial deformities, *J Oral Maxillofac Surg* 65(4):728–734, 2007.
69. Xia JJ, et al.: Outcome study of computer-aided surgical simulation in the treatment of patients with craniomaxillofacial deformities, *J Oral Maxillofac Surg* 69(7):2014–2024, 2011.
70. Schwartz HC: Does computer-aided surgical simulation improve efficiency in bimaxillary orthognathic surgery? *Int J Oral Maxillofac Surg* 43(5):572–576, 2014.
71. Xia JJ, et al.: Cost-effectiveness analysis for computer-aided surgical simulation in complex cranio-maxillofacial surgery, *J Oral Maxillofac Surg* 64(12):1780–1784, 2006.

12

Intraoral Distraction Osteogenesis

CESAR A. GUERRERO, WILLIAM H. BELL, ELENA VICTORIA MUJICA, MARIANELA GONZALEZ, ENIF DOMINGUEZ

Introduction

Many surgical centers have adopted intraoral distraction osteogenesis (DO) as another tool in the surgical-orthodontic armamentarium to help patients with dentofacial deformities who present with major growth deficiencies in three dimensions. Distraction osteogenesis also enables specific discontinuity defects (secondary to tumor resection, bone loss after trauma or infection) to be treated by utilizing bone transport. We will cover the new technologies, analyze morbidity, discuss costs, and critically review the indications with special attention to long-term outcomes and stability.

Virtual analysis, 3D models, and virtual prediction have made the surgical-orthodontic diagnosis, planning, and thinking process sequential, which makes the communication between the orthodontist, surgeon, patient, and family much easier.

Mandibular Widening

Distraction osteogenesis progressively stretches the bone and soft tissue envelope as the distraction appliances anchored to the bone.[1,2] After a complete osteotomy the surgical space are activated with collagen fibers that are then tightened and lengthened by controlled progressive pressure. These fibers and undifferentiated mesenchymal cells eventually mature into different tissue including: bone, muscles, mucosa, periosteum, and so on. This surgical philosophy treats the deformity creating new tissues through calibrated stimulation of the bone and soft tissues. The combination of orthodontics and surgery is the ideal modality to correct severe and untreatable deficiencies in the craniofacial region.[1,7]

Transverse Mandibular Deficiency

Severe dental crowding in a patient is usually part of a micrognathia, which will include a deficiency in growth in all of the three planes with skeletal and dental problems: anteroposterior (AP), transverse, and vertical. Today most patients are treated by orthodontics alone with limited results, such as teeth outside the alveolar bone, gingival recessions, premolar extractions, and poor facial esthetics and smile.[1-7]

Radiographs, photographs, dental models mounted in an articulator, clinical evaluation, and occlusogram should be analyzed to plan the ideal orthodontic and surgical treatment.

Clinical Indications for Mandibular Widening

- Narrow V-shaped mandibles
- Severe mandibular crowding to avoid dental extractions
- Scissors bite (Brodie's syndrome)
- Maxillomandibular transverse deficiency (tunnel smile, crocodile bite)
- Impacted anterior teeth to allow natural or forced eruption
- Retreatment after bicuspid extractions
- Congenital missing teeth

Dental Model Analysis

The amount of widening needed is calculated according to the following variables: Available space versus required space, inclination of the incisors (1 MPA = 90 degrees), deep bite or a marked curve of Spee, intermolar width, and size of the incisors

Soft and Hard Tissue Clinical Analysis

From the biologic standpoint, there should be a healthy periodontium around the teeth where the osteotomy is to be performed, with at least 1 mm of bone protecting the roots on either side of the osteotomy and to preserve vital bone capable of producing new bone under distraction. Lack of bone at the osteotomy can lead to delayed healing or periodontal defects. The osteotomy design and site are selected based on bone quantity between roots and inclination of the teeth. A Bolton discrepancy analysis is also performed to adequately calculate the amount of widening necessary

and to predict the final maxillomandibular anterior teeth overjet and overbite.

Surgical Planning

A variety of devices for mandibular widening have been developed since our first use in 1987. In our experience the tooth-borne lingual appliance or the UniArm device have been extensively utilized despite the hygiene concern, impingement of the tongue, inadequate access for activation, and the possibility of dislodging during surgery. It eases the surgical procedure and lessens expenses; the new uniarm device can be applied on either the buccal or the lingual side.

The bone-borne device to widen the mandible has very limited use today, because of costs and need for a secondary stage for removal. Equal surgical outcomes can be obtained with dental-borne, bone-borne or hybrid appliances.[2,7,8]

To avoid complications with the dental-borne appliance during or after surgery, several steps are fundamental to prevent distractor dislodgment. First, dental bands are selected one size larger than indicated, because in the welding process between the dental bands and the connector, the band metal contracts. Second, the orthodontist must position the distractor under the equator of the teeth, close to the gingival margin. Third, the appliance must be cemented to the teeth utilizing glass ionomer cement. Fourth, special attention must be given to the passiveness of the dental-borne appliance and parallelism to the occlusal plane. This is done to avoid inclination of mandibular segments that will result in asymmetric bone movements and consequent unilateral open bites and canted mandibular planes.[9-11]

Presurgical orthodontics includes complete maxillary arch alignment and leveling, the teeth are aligned, diastemas are closed, the molars are verticalized, and an ideal maxillary curve of Spee is obtained. Once the maxillary teeth are ideally positioned, a final diagnosis and reevaluation is made to change the mandibular arch to the new maxillary alignment. No appliances are placed in the mandible until the maxillary arch form is complete. The lower arch dental movements are restricted to obtain adequate interdental space to perform the osteotomy without damaging the dental roots, and to select the mandibular widening device. The orthodontist evaluates and selects the best appliance according to the circumstances already mentioned (checking the variables involved, and more important, calculating the amount of widening required, based on the occlusogram[2,5,7,11]).

When performing maxillary widening (surgical assisted rapid palatal expansion [SARPE]) the maxilla is expanded equally anteriorly and posteriorly, (Figure 12-1), since the hyrax appliance will expand the maxilla symmetrically if all osteotomies are completed.[12]

It is possible to widen the maxilla anteriorly or just posteriorly depending on the surgical technique and appliance positioning (Figure 12-2 and Figure 12-3); the maxilla can also be moved unilaterally, leaving one side uncut, which acts as an anchor for the distraction appliance. This permits unilateral expansion to occur.

A different scenario occurs when widening the mandible where the mandible is widened anteriorly and the distance decreases toward the back. As an example, from 7 mm widening in the incisors the intercondylar level only expands 0.9 mm; postoperatively there is always a transverse crossbite at the level of the canines and premolars that progresses to edge to edge at the first molars region and normal transverse bite at the second molar level. As the orthodontist closes the anterior gap the lateral crossbite is corrected. Planning must include all of these measurements that can be predicted in the models and occlusograms.[10]

Significant major mandibular crowding accompanying a Brodie bite requires mandibular widening accompanied with

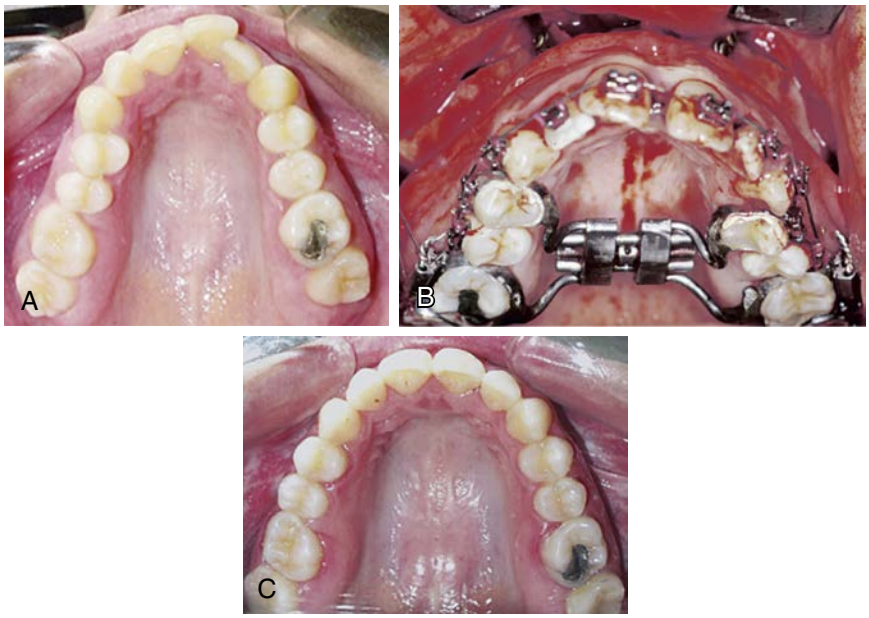

• **Figure 12-1** **A,** Moderate maxillary crowding in V-shaped maxilla. **B,** Intraoperative view. Simultaneous maxillary repositioning with midline distraction. **C,** Maxillary occlusal view in a 4-year follow-up.

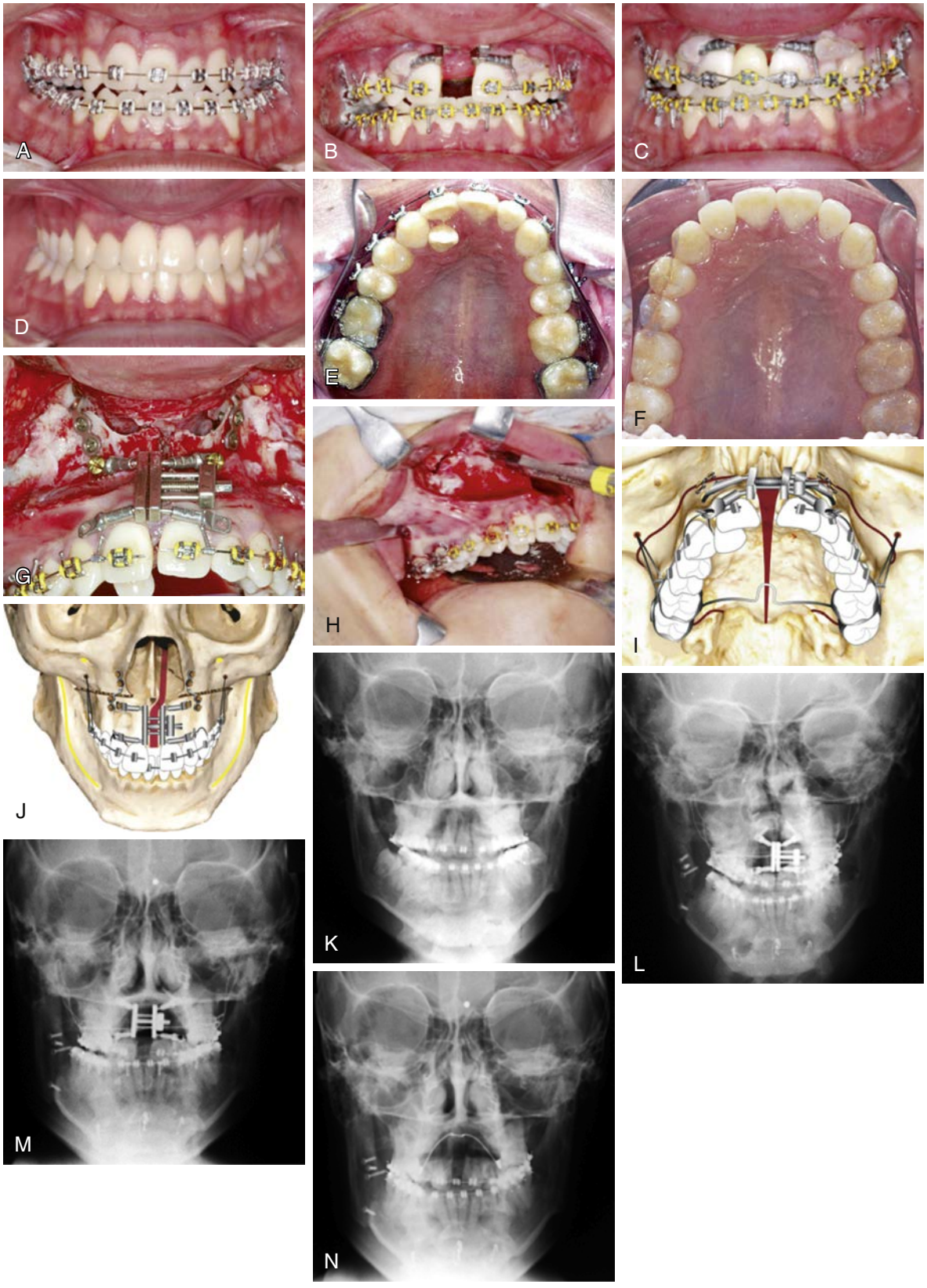

• **Figure 12-2** Seventeen-year-old patient with 3D maxillary deficiency and right lateral incisor without space in the arch. A selective anterior expansion was performed. **A-D,** Frontal view before; after distraction; once the desired interincisor space was created, a pontic was placed in the edentulous space and secured with an orthodontic bracket; and end of treatment. **E** and **F,** Preoperative occlusal view of anterior maxillary moderate crowding and occlusal view after treatment. **G** and **H,** Le Fort I osteotomy is performed with complete down-fracture. When simultaneous maxillary advancement is accomplished, prebent 2.0-mm bone plates are used with distraction amount calculated and fixed in piriform area. **I** and **J,** A bone-borne distractor was utilized in the anterior maxilla; the posterior maxillary intermolar distance was fixed utilizing transpalatal bar. After 7 days of latency period the distraction device was activated, at a rate of 1 mm per day, until adequate widening was obtained. This space will be progressively eliminated by mobilizing the adjacent teeth, 3 months after surgery. **K-N,** Preoperative radiograph, latency period, after distraction, and final radiograph at the end of treatment.

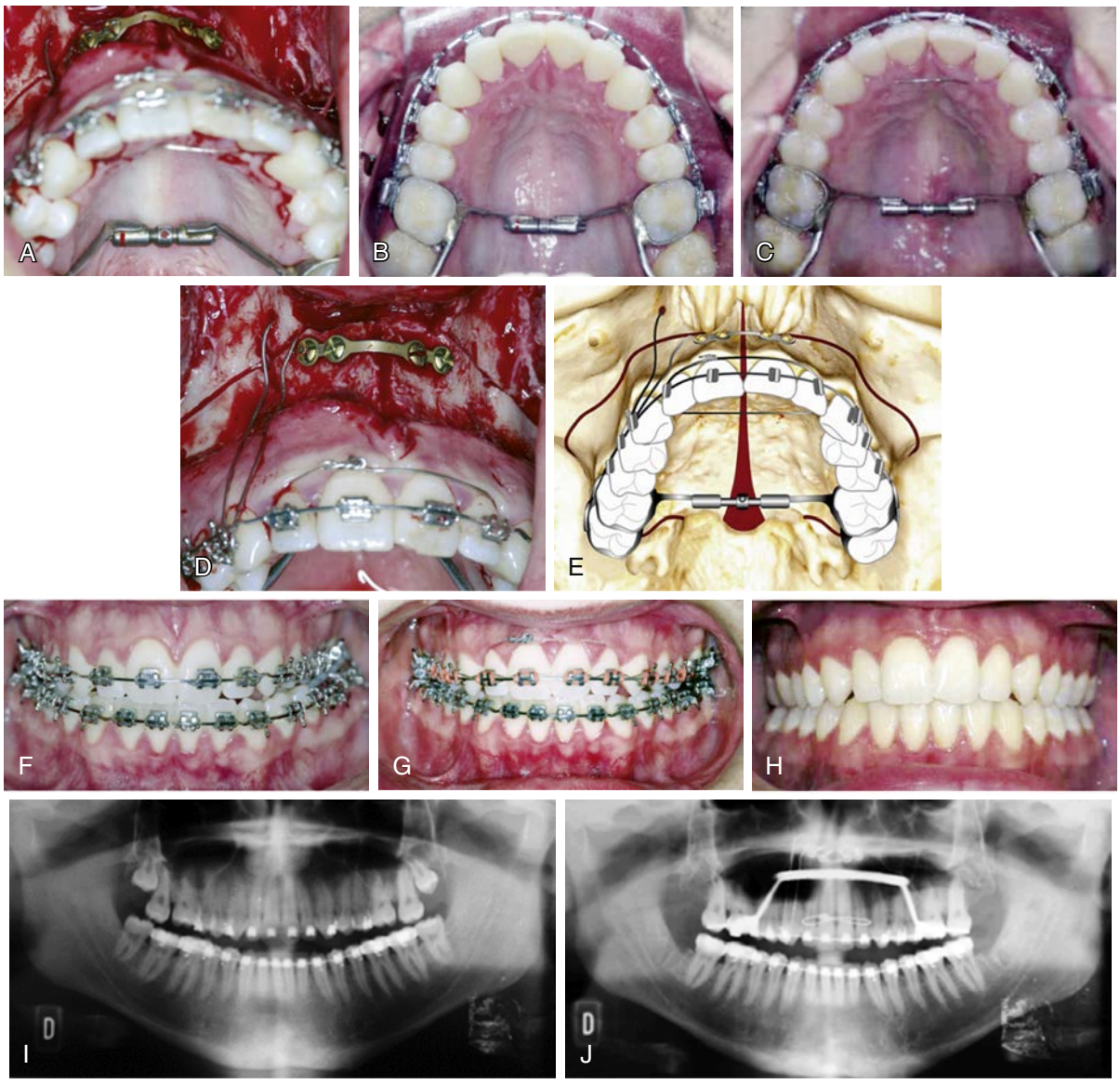

• **Figure 12-3** Eighteen-year-old patient with posterior transverse deficiency and posterior crossbite. **A-C,** The surgical technique includes a Le Fort I osteotomy, preoperative occlusal view of anterior maxillary moderate crowding, and occlusal view after treatment. **D** and **E,** Le Fort I osteotomy is made with complete down-fracturing, an off the midline osteotomy anteroposteriorly ending between the central incisors. When expanding posteriorly, a 4-hole rigid fixation plate was used inferior to the anterior nasal spine, the orthodontic arch was not sectioned, and a bridle wire was passed and tightened around the 4 incisors. The distraction device was an inter first molar screw that was activated 7 days after surgery, at a rate of 1 mm a day, until the posterior expansion was obtained. The distraction screw was secured with acrylic and removed at 3 months; a transpalatal bar was maintained for the remaining orthodontic treatment, to ensure stability. **F-H,** Frontal view before, **(G)** after distraction and end of treatment, and **(H)** five years long-term follow-up. The occlusion was stable, with adequate interdigitation, midline coincidence, molar and canine class I were observed. **I** and **J,** Preoperative and postoperative panoramic radiographs.

maxillary widening to obtain an adequate final transverse maxillomandibular relation that avoids premolar extractions and improves the smile width. This treatment eliminates the sinking lips look from the profile view, which occurs with orthodontics with premolar extractions. The nickel titanium (NiTi) arches that are widely used in orthodontics are thermically activated and progressively move the teeth outside the alveolar bone limits. These orthodontic mechanics may produce gingival recessions and root resorptions; all of these problems can be avoided with proper diagnosis and increasing bone volume by mandibular widening.[10]

Widening the Symphysis or Parasymphysis Region

Surgical Procedure

The incision is made 4 to 6 mm labial to the depth of the mandibular vestibule; the periosteum is reflected



• **Figure 12-4** **A,** Preoperative intraoral view demonstrating transverse mandibular deficiency. **B,** Vertical cut on the midline at the inferior border way up to 5 mm below the canine's apex, horizontal cut to the right side of the mandible and the final vertical osteotomy to reach the interdental space. **C,** A single-arm tooth-borne appliance in position. **D,** Preoperative occlusal view, (**E**) after distraction osteogenesis, (**F**) and finalizing orthodontics. **G,** Left inferior canine without space in the arch, (**H**) finalizing distraction protocol, **(I)** and postoperative lateral view during orthodontic final details. **J** and **K,** Preoperative and postoperative panoramic radiographs.

inferiorly to the inferior border of the mandible, where a small channel retractor is placed. The periosteum is carefully elevated and meticulously separated throughout the whole procedure, keeping in mind that much of the DO healing capacity originates from the periosteum. Next, the soft tissue between the mandibular central incisors is carefully reflected superiorly with a skin hook to the alveolar crest with minimal detachment of the neighboring tissues (Figure 12-4).[9-11]

Osteotomy

A vertical osteotomy is made through the symphyseal area with a reciprocating saw blade, starting at the inferior border of the mandible, sectioning both cortexes and continuing to the interdental space between the apices of the mandibular incisors. At this point the outer cortex only is cut with a straight handpiece and a 701 burr. No attempt is made to complete the cut to the lingual cortex between the roots of the teeth. It is important to select the site of distraction and to prepare the site by diverging the roots. The final sectioning is done with a mallet and a spatula osteotome. The forefinger should be used as a guide at all times to avoid tearing of the lingual soft tissues (see Figure 12-2). An alternative osteotomy site in severe crowding is between the lateral incisor and canine. The osteotomy should be completed interdentally and then continued toward the midline, since the lateral osteotomy would create an asymmetrical chin as the mandible widens (see Figure 12-4).[9-11]

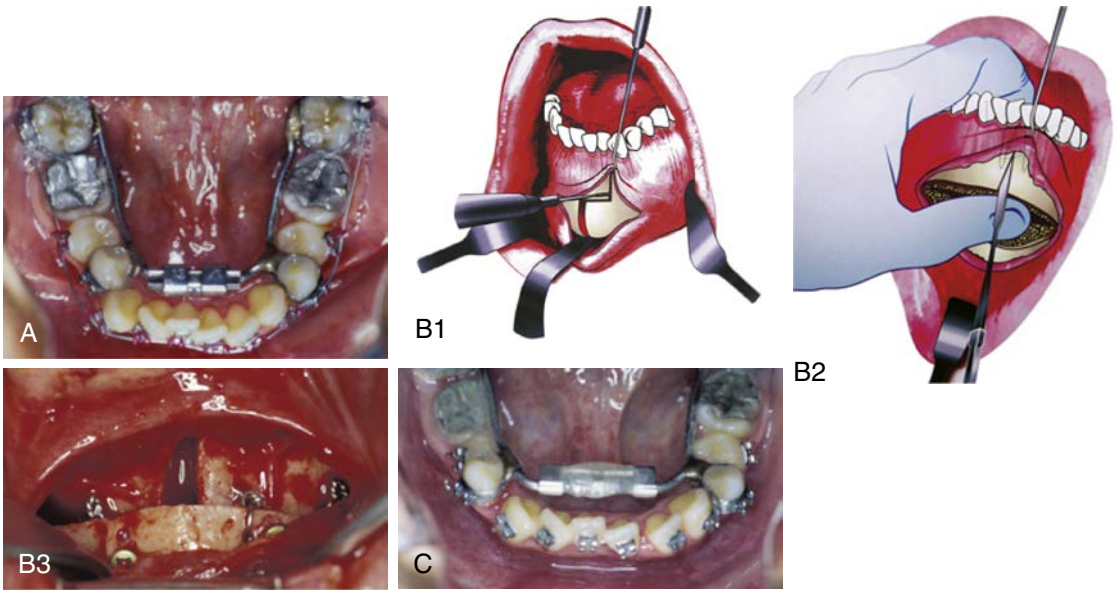

• **Figure 12-5** **A,** Single-arm tooth-borne appliance that can be placed on the buccal or lingual. **B,** Conventional osteotomy for the genioplasty is performed 5 mm below the canine's apices, then a vertical osteotomy in the midline is performed. The genioplasty is fixed while a periosteal elevator remains in place at the inferior border of the vertical osteotomy. Note the bicortical screws to fixate the genioplasty. **C,** End of distraction. Acrylic is placed over the distractor screw for patient's comfort and to advance to soft diet.

Combined Mandibular Widening and Genioplasty

Osteotomy

Once the soft tissues have been properly separated, a channel retractor is placed through a tunnel underneath the mental nerve to the level of the first molar. A dental caliper is used to measure the canine from the lateral cephalometric radiograph, and the distance plus 5 mm is transposed to the mandible, measuring from the incisal edge to an area underneath the apex of the canine on either side. Vertical lines are marked to serve as reference lines. A reciprocating saw is used to perform a bicortical osteotomy at the inferior border of the mandible starting at the first or second molar region, coming anteriorly toward the symphyseal midline, passing by the reference lines; care must be taken not to injure the alveolar nerve in those patients with downward curve of the neurovascular canal, which may be close to the inferior border of the mandible. The surgeon's forefinger is used externally to avoid damaging the soft tissue as the saw goes through the bone on the lingual side. The osteotomy must be completed with the reciprocating saw (Figure 12-5).[9-11]

At this point, the inferior segment remains attached to the soft tissues. It is important to maintain this pedicle at all times, limiting the periosteal elevation to the minimum. The rest of the mandibular symphysis is intact at this moment; then, the reciprocating saw is used to perform a vertical osteotomy at the preselected distraction site. The rest of the surgical procedure is done as previously described. The genioplasty fixation is done with wires, screws or plates; a periosteal elevator is used to open a gap at the distraction site base (inferior immediate distraction, creating a gap), between the two bone segments to be distracted, forcing them open while the wires are tightened or plates are fixated. The distraction chamber will have a triangular shape at the end of the surgery with an open base at the bottom. Once the distraction appliance is activated, the interdental space opens, and the triangular chamber transforms into a vertical rectangle at the end of the distraction period. The surgical wounds are closed in the routine fashion. A pressure bandage is used for 3 to 4 days to limit the edema and allow primary soft tissue wound healing. A liquid diet and pureed diet is recommended for 2 weeks, then acrylic is placed on the distractor to add stability, and a soft diet is indicated. Finally, at 6 weeks the patient may return to regular food intake, avoiding heavy chewing until the twelfth week (Figures 12-6 through Figure 12-9).[9-11]

Distraction Protocol[2-12]

1. Osteotomy: The bone is completely separated either with a reciprocating saw or small fissure burr, under abundant irrigation to avoid overheating. Sometimes the final separation is done with a small chisel, after fixating the distraction device, preventing fragment displacement.
2. Latency period: Seven days after the osteotomy is performed the distraction device is activated. There is no activation for 7 days.
3. Rate and rhythm: the distractor is activated one millimeter once a day, or half a millimeter twice a day, until the desired activation is completed. Usually, the family is instructed to activate the appliance for the patient.
4. Consolidation: The distractor remains in place 60 days for each centimeter of distraction. This time allows

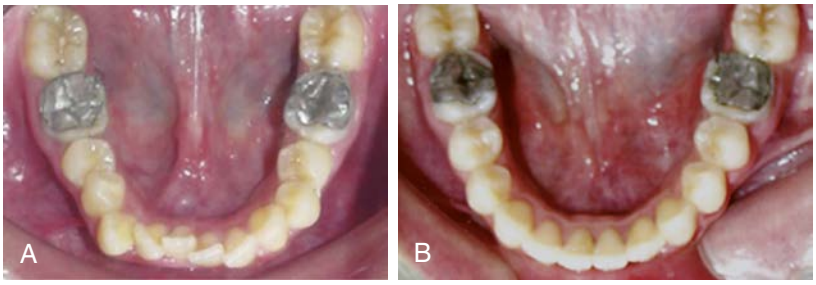

• **Figure 12-6** **A,** Same patient. Preoperative occlusal view of mandibular moderate crowding. **B,** Mandibular occlusal view 4 years after surgery.



• **Figure 12-7** Frontal view before, after distraction, and at the end of treatment.

mineralization deposits within the collagen fibers matrix. Removing the distractor before that time frame would produce distraction chamber contraction, deviation, or fracture.

5. Remodeling: This is the last distraction protocol phase. Function and orthodontics inter-maxillary elastics may mold the regenerate while muscles and other soft tissues settle into the last bone healing stage.
6. Variables: There are four important variables in distraction osteogenesis: age of the patient, amount of movement, quality of bone, and quantity of bone. These variables influence the distraction protocol; children may require a shorter latency period while an older patient would require an activation pattern of half a millimeter per day. Larger movements require much longer consolidation periods of up to a year.

Postoperative Care

At the end of the distraction, acrylic is placed over the distraction's rod and the wires around the teeth to provide more rigidity and advance the patient to a soft diet. At this time also the orthodontist adds a cosmetic acrylic tooth on the orthodontic arch to prevent the teeth from "walking" into the immature distraction area. After consolidation occurs, the appliance is removed and the clinician evaluates the radiographs for proper mineralization. The patient is referred to the orthodontist to continue the treatment. The interdental incisors distraction gap is filled with a plastic tooth, which is reduced 0.5 mm from each interproximal surface (1 mm) a month to progressively close the distraction gap and finish the orthodontic treatment. The orthodontic treatment is resumed 60 days after surgery for at least 6 months while the distraction chamber is still consolidating. The occlusion is carefully finished, and standard retention is indicated. The orthodontist must avoid moving the teeth into the newly formed distraction chamber. The trans-septal fibers will pull the adjacent teeth into the distraction chamber (in a matter of days) producing periodontal problems and loss of tooth vitality. It is advised to utilize wire ligatures to maintain the teeth in position during the consolidation period. Once good mineralization and distraction chamber radiopaque images are seen in the radiographs, the teeth are moved 1 mm per month, to slowly and progressively close the interdental space.

Mandibular Lengthening

Virtual analysis, 3D models, and virtual prediction have stepped strongly into the surgical-orthodontic scene to make the diagnosis, planning, and thinking process sequential and easier to communicate between the orthodontist, surgeon, patient, and family.

Intraoral distraction osteogenesis has been used since the late 1980s to achieve a mandible of normal size and anatomy. Complex 3D movements are possible and predictable. Since distraction osteogenesis follows a straight-line pattern, more than a single distractor device may be needed to successfully correct the myriad clinical presentations of mandibular deficiency. Precise preplanning considering the biomechanical effect of appliance orientation is fundamental for predictable widening and lengthening of the mandible[13-17] (Figure 12-10 and Figure 12-11).

Clinical Indications

- Major mandibular advancements
- TMJ degenerative joint disease as a precondition
- Sleep apnea (need to calibrate the advancement)
- Inadequate mandibular anatomy for conventional bilateral sagittal split osteotomy (BSSO)

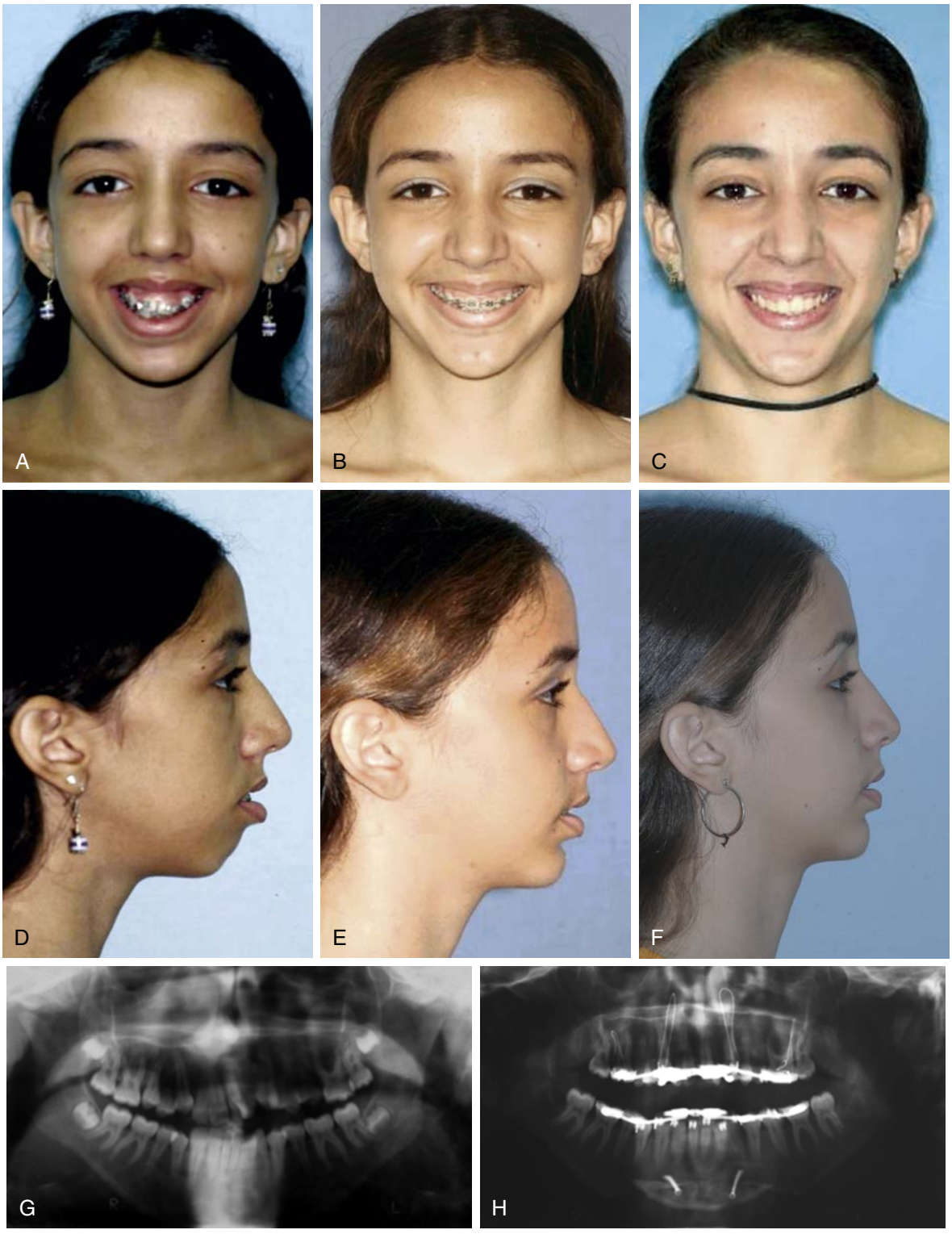

• **Figure 12-8** Fourteen-year-old female patient with bimaxillary crowding and chin deficiency. **A-C,** Preoperative full-face view; notice the maxillomandibular transverse deficiency and black tunnels in the smile photographs. **B** and **C,** 3-D maxillary distraction and mandibular widening with genioplasty, after distraction osteogenesis and orthodontic treatment and finals results after 10 years of follow-up. **D-F,** Preoperative profile view, after surgery (notice the chin and mentolabial sulcus projection), and profile view after 10 years of follow-up. **G** and **H,** Preoperative radiograph and postoperative panoramic radiograph during the consolidation period.

- Secondary mandibular advancements (relapse of mandibular advancements after conventional BSSO)
- Children with severe mandibular deformities

Surgical Procedures[18-23]

- Horizontal ramus osteotomy
- Sagittal split ramus osteotomy
- Body osteotomy (anterior to the mental nerve)

Horizontal Ramus Osteotomy

A 3-cm full thickness incision is made over the mandibular external oblique line; meticulous subperiosteal tunneling dissection is performed to expose the buccal cortex. The periosteum, muscles, and soft tissues are minimally detached to maintain the best blood supply possible. A Kelley clamp is placed in the anterior border of the ramus as high as possible, and an inferior border retractor is placed just above the inferior alveolar nerve at its entrance just superior to the lingula. The reciprocating saw is used to perform the horizontal osteotomy, protecting the soft tissues using abundant irrigation to avoid overheating. The osteotomy is extended from the posterior border of the mandible anteriorly, keeping the forefinger over the skin, feeling as the mandible is sectioned. It is an incomplete osteotomy, since the jaw must be in one piece to ease placing the transcutaneous screws that fixate the distraction device. The vertical distraction appliance is preselected and carefully positioned in the planned location, and then the transcutaneous trocar is utilized to insert the bicortical screws (a minimum of three in either side). Other distractors should be fixated before the fracture is finalized. Most sutures are also finalized before the final osteotomy completion. Leaving a small opening to introduce the small straight chisel and torqueing movement allows the osteotomy to be completed while the distraction appliance is already well fixated in place.

Ramus Sagittal Split Osteotomy

A standard sagittal split osteotomy is performed, maintaining the inferior alveolar nerve intact in the distal segment. An intermediate splint is used and intermaxillary fixation is applied to either the orthodontic hooks or bone screws. Proximal segment fixation with one or two bicortical screws is accomplished. If the vestibule is wide, secondary to the buccinator muscle being low, the wound is closed and the distraction appliance is transmucosally fixated. Once adequate device stability is obtained, the mandibular provisional bicortical screws fixation are removed. The advantage of having the appliance extramucosally is that the distraction chamber will be watertight with no saliva and food contamination. No collagen fibers contraction occurs, poor callus formation is prevented, and no postoperative infections occur. This also facilitates removal of the distraction device at the end of the consolidation period.

For those patients requiring bilateral advancement, the distractor must be placed parallel to the axis of distraction, as the mandible is wider posteriorly and narrower anteriorly. This requires some adjustment to the appliance by creating a step of 5 to 8 mm to compensate for this important variation in mandibular width. If this is not considered, different problems will appear such as lateral torque of the condyle, loosening of the screws, and bending of the appliance.

An important issue is the temporomandibular joint. Once the device has been activated there will be reciprocal forces against the mandibular fossa, causing flattening of the condylar cartilage layer, thinning and perforation of the disc, subchondral bone formation, and loss of suprameniscal and inframeniscal spaces. It is fundamental to unload the joints as the mandible is advanced. Rectangular surgical orthodontic archwires with welded vertical pins are used to apply class II elastics, 6 to 8 ounces per side. These unloading forces will be maintained for the activation period as well as for the consolidation phase. The elastics are kept in place at least 3 months.

An anterior open bite might develop during the activation of the appliance because of lack of parallelism between the occlusal plane and the distractor rod. Once the appliance is fully activated, the distractor arm is released, and the mandible is rotated until the open bite is closed and placed in the final acceptable new occlusal position. This is performed under intravenous sedation in the clinic. Lateral cephalic radiographs are essential to plan and evaluate the bony movements.

Body Osteotomy (Anterior to the Mental Nerve)

A 2.5-cm incision is made in the vestibule. The periosteal layer is elevated to the inferior border of the mandible while carefully looking for the mental nerve. A channel retractor is placed and a vertical osteotomy anterior to the mental nerve, between the canine and premolar or between the two premolars, is executed. The reciprocating saw is utilized to perform the osteotomy from the inferior of the mandible superiorly bicortically, with the forefinger on the lingual side to avoid mucosal perforation, up to the level of the dental roots. Then a 701 fissure burr is used to make a line of holes between the dental roots with the soft tissue elevated superiorly. Then the holes are united, just sectioning the buccal plate with abundant use of irrigation; finally, a spatula osteotome and a mallet are used to complete the osteotomy. Interdental bridle wires around the neck of the teeth, two on either side, are placed for temporary fixation. The wound is closed and the distraction device is fixed transmucosally with bicortical screws and interdental wires reinforced with acrylic on top for stabilization at the teeth level. This avoids dental root damage. The indication for this technique is major anteroposterior movements and the possibility to obtain a larger movement at the inferior border of the mandible and smaller movement between the teeth. The mandibular nerve is left intact with no possibility of post-surgery



• **Figure 12-9** **A** and **B,** Same patient as in Figure 12-8. Lateral preoperative radiograph and after treatment. **C-F,** Intraoperative view with the palatal and lingual hyrax appliances placed by the orthodontist 48 hours before surgery. Le Fort I osteotomy was performed to widen the segments and combined mandibular widening with genioplasty. **G-I,** Lateral preoperative view after distraction during orthodontics finalization, and after 10 years of follow-up. **J-M,** Severe maxillary and mandibular crowding and V-shaped, occlusal view before and after.

paresthesia. This technique also improves the mandibular shape, by changing the gonial angle. The new space created between teeth is closed with orthodontics, either by reciprocal movements or advancing the posterior teeth anteriorly using orthodontics mini-implants for elastics anchorage at the canine level.

Postoperative Considerations

The distractors should be removed after ossification has occurred. Different variables are involved, including age of the patient, amount of movement, and quality and quantity of bone. Other variables include infection, inadequate stability during consolidation, poor patient selection, and some systemic diseases. The only reliable method for determining healing is the radiographic evaluation.

Post-surgical Orthodontics

Use of class II elastics is indicated both during the distraction and consolidation periods to prevent forces on the temporomandibular joints.



• **Figure 12-10** A 10-year-old child seen long after a subcondylar fracture, with severe mandibular deficiency and mandibular hypomobility (5 mm). She was treated by unilateral mandibular ramus and body lengthening. Arch bars were used to control the occlusion and guide the physiotherapy. **A-D,** Before and after 3 years of treatment frontal. **E-H,** Intraoral frontal views. Orthodontics continued after arch bar was removal and microscrews were used to close the distraction chamber by advancing the right mandibular molars into an ideal class I.

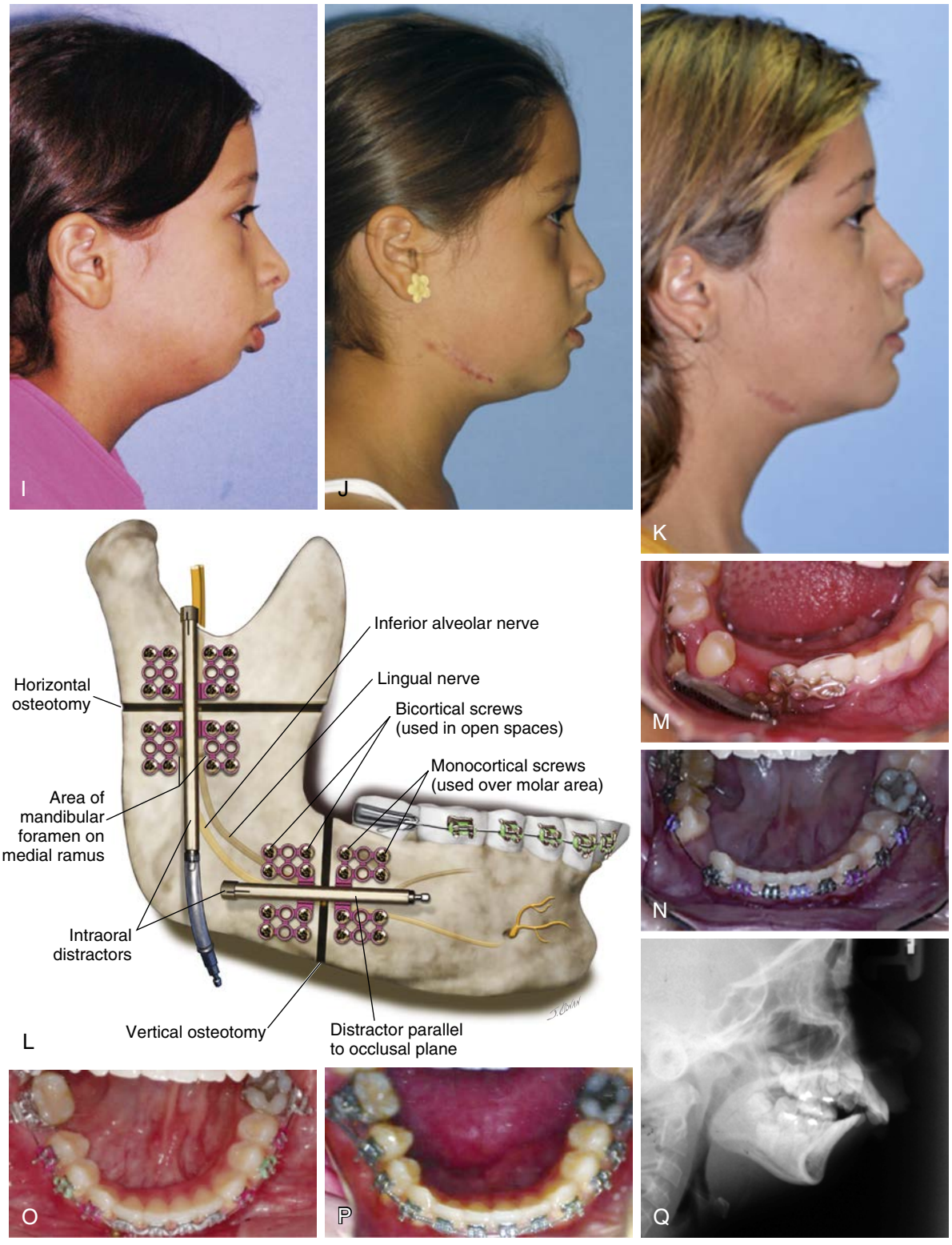

• **Figure 12-10, cont'd** **I-L,** Profile facial views. The distractors were removed and an arthroplasty was performed after the consolidation period. **M-P,** Occlusal view after distraction, during consolidation, and orthodontics closing the distraction chamber. **Q-S,** Cephalometric radiographs are shown and panoramic radiographs: preoperative

Continued

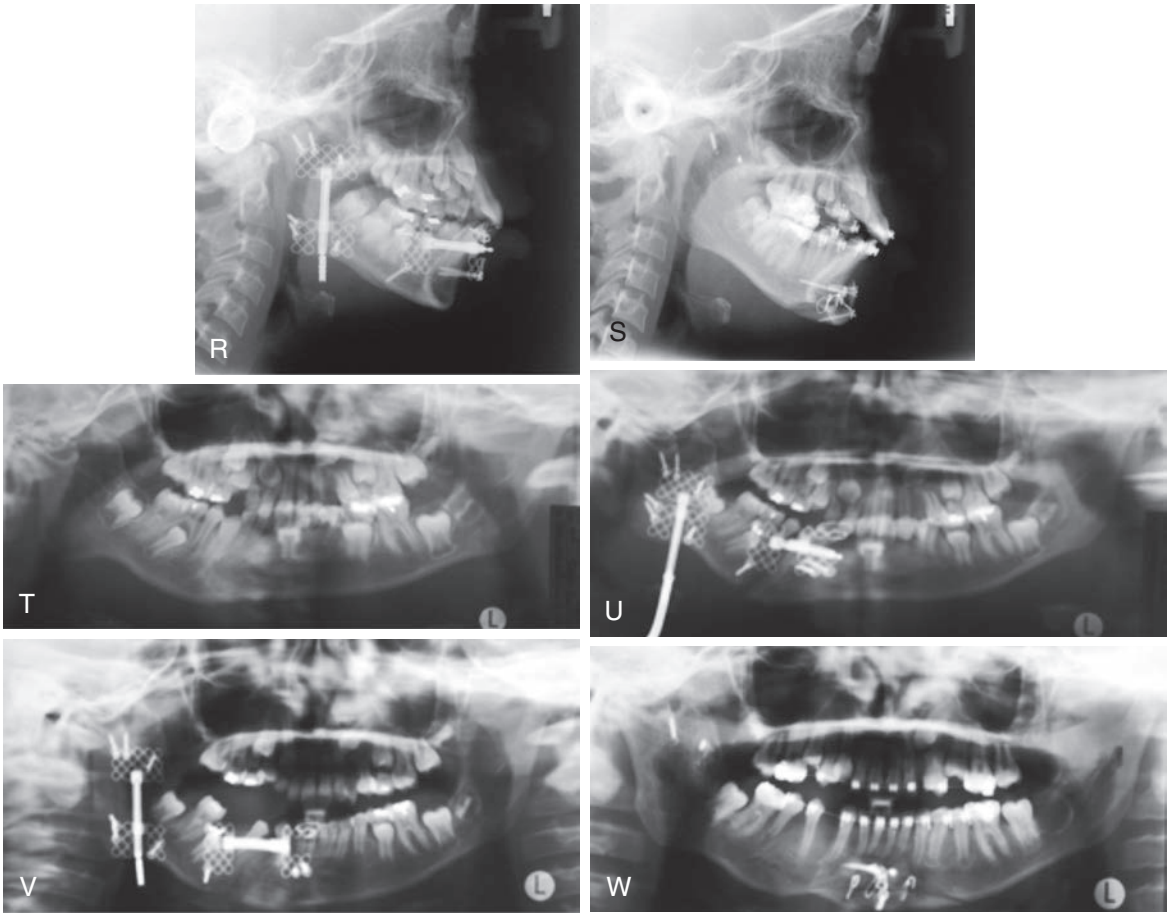

• **Figure 12-10, cont'd** **(T),** one week after surgery **(U),** after activation protocol (consolidation period) **(V),** and during remodeling period **(W).** (L From Kademani D, Tiwana PS: *Atlas of oral and maxillofacial surgery,* Saunders, St. Louis, 2016.)

Once the appliances are removed, the patient is referred to the orthodontist to complete the occlusion. It is recommended that the orthodontics appliances not be removed until 12 months after surgery to ensure adequate bone consolidation and stability; good communication within the team is encouraged.

Maxillary Distraction

Conventional craniomaxillofacial surgical techniques for advancements at different levels are less common today, secondary to major movement limitations. Other considerations include instability, bone grafting and extensive rigid fixation requirements that prolong the patient's recovery, and increased treatment costs. More important is the high infection rates, leading to meningitis and mortality. Distraction osteogenesis techniques allow for the development of frontal periosteal flaps to seal the anterior cranial fossa, the bony contact between the osteotomized bone flaps, and separation by distraction, without an open window for contamination. The distraction chamber wall separates the nasal and cranial cavities, allowing the craniofacial surgeons a safer, predictable, and low-morbidity surgical technique, with low mortality.[24-28]

Preoperative Planning and Surgical Technique

Patients with 2D or 3D maxillary deficiencies are treated by intraoral distraction osteogenesis to lengthen, widen, and/or augment vertically the maxillomalar complex at different osteotomy levels according to the individual clinical situation. Standard records including complete radiographs, CT scan, and photographs are obtained, and articulated dental and stereolithographic models are used to assist in planning. All patients undergo a combined surgical-orthodontic treatment to ideally correct the 3D problems[27-30] (Figure 12-12).

For a high Le Fort I, a conventional incision and osteotomy is accomplished, the maxilla is freely mobile, and two maxillary distractors are placed bilaterally, anchored to the base of the zygoma and fixed to the maxilla with the vectors determined by the 3D planning. Those patients requiring either a modified Le Fort III or classic Le Fort III osteotomy require an additional transconjunctival approach (Figure 12-13); the osteotomy divides the malar process, runs medially across the orbital, and continues underneath and obliquely anterior to avoid the nasolacrimal duct, reaching the piriform rim. The posterior maxilla is separated at the pterygomaxillary suture. Finally, two wide-curved osteotomes are placed behind



• **Figure 12-11**

Continued

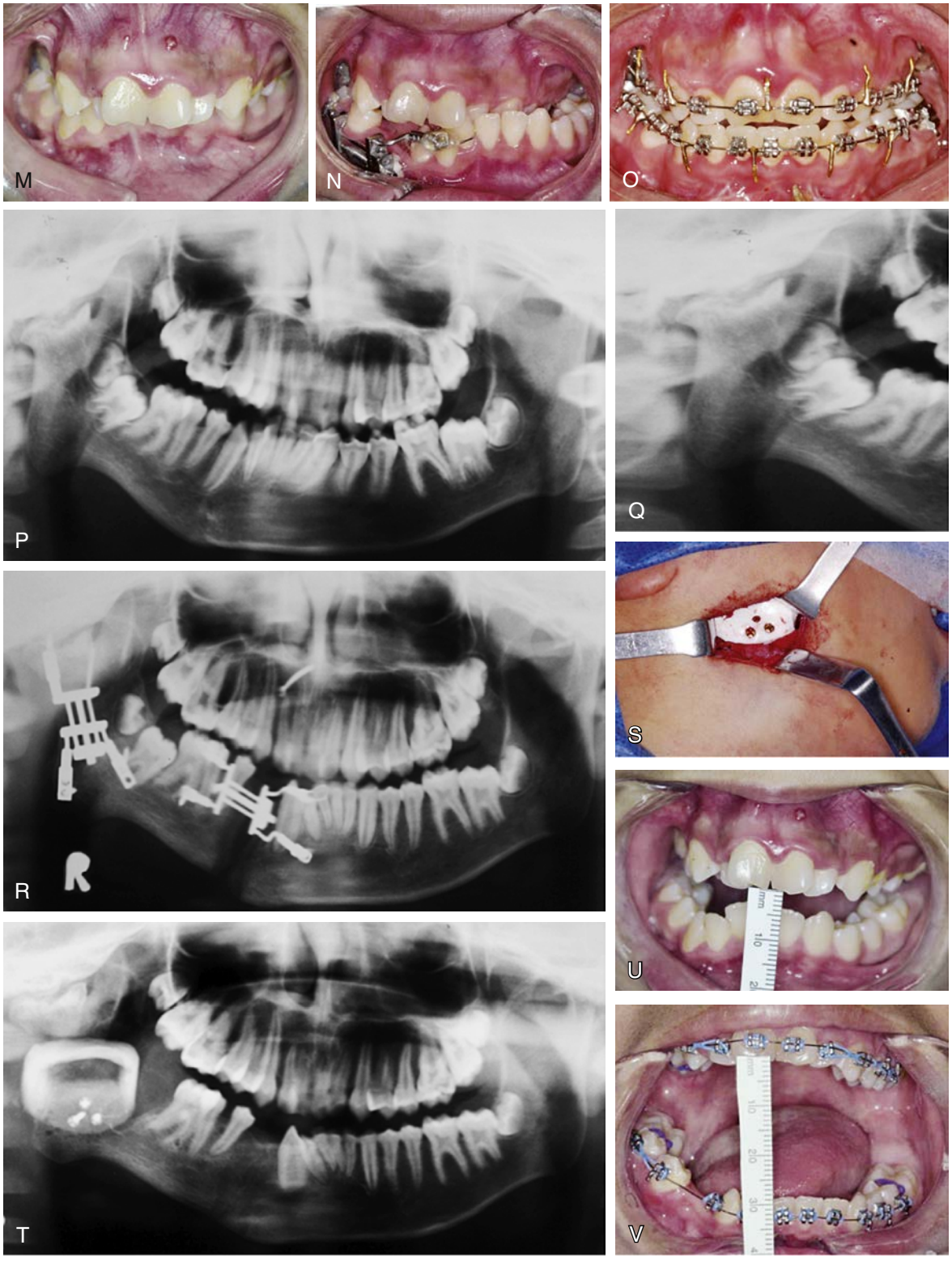

• **Figure 12-11, cont'd** **A,** TMJ ankylosis at 8 years of age, treated by unilateral mandibular ramus and body lengthening. **B,** Immediately postoperative. **C,** 6-year follow up. **D-F,** Profile view: preoperative, after distraction osteogenesis and TMJ arthroplasty, and final view after advancement genioplasty. **G-I,** Mandibular ramus approach and appliances in position. **J-L,** Intraoral approach for body osteotomy and the appliances fixed transmucosally. **M-O,** Intraoral views: preoperative, during distraction osteogenesis, and orthodontics treatment. **P-R,** Panoramic views: right TMJ ankylosis, ramus, and body appliances in position. **R** and **S,** Mandibular opening after right TMJ arthroplasty. **U** and **V,** Preoperative ankylosis open mouth and after treatment; 30-mm gain was obtained.



• **Figure 12-12**

Continued

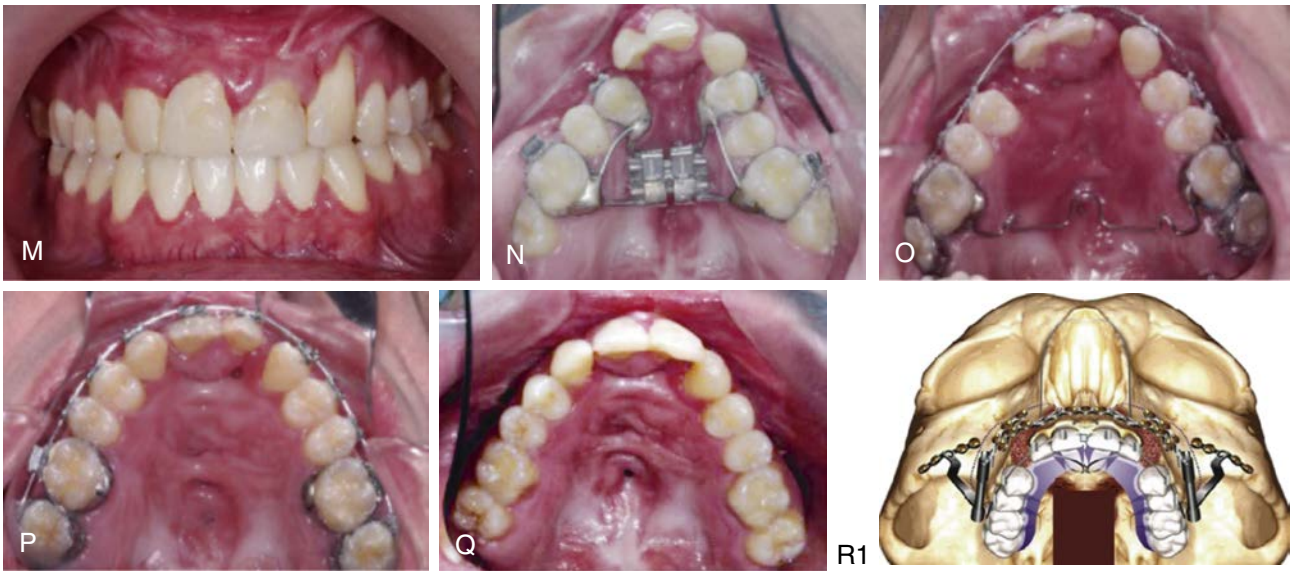

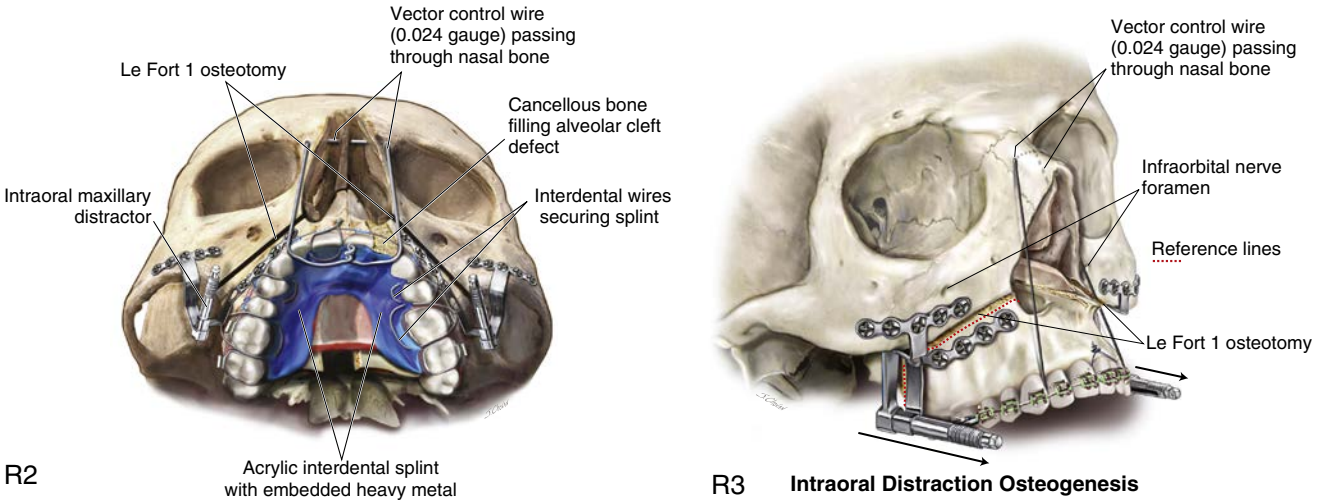

• **Figure 12-12, cont'd** **A-G,** A bilateral cleft lip and palate, treated by maxillary advancement via internal distraction osteogenesis and widening. **H-J,** Lateral cephalic radiographs preoperative, during latency period, and finalizing orthodontics. Note that the distractors are carefully fixated with the ideal vector. The rhinoplasty was performed when the internal distractors were removed. **K-R,** Intraoral view shows the followed protocols, including finishing orthodontics. (**R2,3** from Kademani D, Tiwana PS: *Atlas of oral and maxillofacial surgery,* Saunders, St. Louis, 2016.)

the maxillary tuberosities to free the malar-maxillary complex. Once it is completely free, the distractors are fixed with screws to the zygoma, the anterior-superior arm is fixed transmucosally to the maxilla above the teeth, and the anterior-inferior arm is either wired to the teeth or fixed transmucosally depending on the osteotomy level. A flexible connector is attached to the distractor activation head in those cases where the appliance was buried under the soft tissues.[24-30]

When maxillary widening is needed, a tooth-borne appliance is placed presurgically and a midline osteotomy is accomplished.[12] After all appliances are in place, a 2-mm activation is performed. The distraction protocol consists of a 7-day latency period with an adjustment rate of 1 mm per day until the desired movement is obtained. A 5- to 7-month consolidation period, corroborated by radiographs (depending on the quantity of activation), is required. The distractors are removed under intravenous sedation, with a small incision bilaterally at the distractor sites. The postero-superior plate is sectioned and left behind. There is no need to reopen the complete incision to remove the postero-superior parts of the distraction device.[25]

The age of treatment is based on three major considerations: the canine eruption level, the anatomic situation of the infraorbital nerve, and the nasolacrimal duct; underestimating any of these landmarks will permanently damage these structures, with untoward consequences. After an early consolidation period the patient is referred to the orthodontist to continue the occlusion finishing phase. The distractors are left in place until adequate consolidation is obtained; this period may vary between 3 and 12 months,



• **Figure 12-13** A 35-year-old with Crouzon syndrome underwent subcranial Le Fort III. During a second stage, the distractors were removed, and a rhinoplasty was performed. **A-D,** Frontal and profile views were obtained preoperatively and after treatment. **E-H,** Intraoral and transconjunctival approaches were used. The distraction rods emerged intraorally. **I-K,** Preoperative and postoperative lateral cephalometric radiographs.

Continued

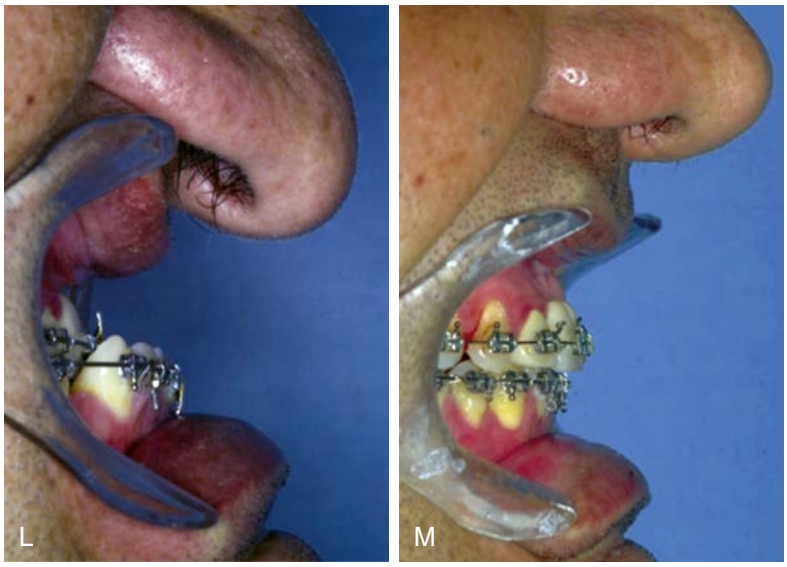

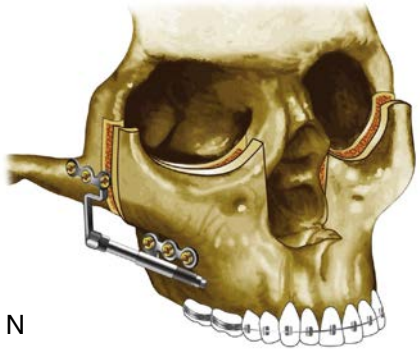

• **Figure 12-13, cont'd** **L** and **M,** Dental change 16290 s before and after **(N).**

according to age of the patient, amount of movement, and quality and quantity of bone. The devices are not particularly uncomfortable, and patients accept them well. Patients can return to school or work and conduct a normal life while the maxilla is properly healing.[25-30] This is an advantage over extraoral devices.

Distraction osteogenesis with intraoral devices allows maxillary 2D or 3D corrections without bone grafts, heavy rigid fixation, and facial scars. It requires meticulous surgical-orthodontics planning, adequate surgical timing and individual osteotomy design, vector control, and careful placement of the distractor according to the patient's needs. It is unacceptable to damage teeth, infraorbital nerves, and/or lachrymal ducts.[25-30]

Bone Transport

Bone transport is based on the concept of creating bone and soft tissues following the biologic principles of distraction osteogenesis. An osteotomy is performed, keeping adequate blood supply to the bone fragments. After collagen fiber matrix formation between the two segments (latency period), the bony fragments are separated progressively at a fixed rate and rhythm until the moving fragments collide. This is called the *docking site*. In order to unite the fragments, the tissue in between requires removal and either the segments are compressed or bone grafted, which is called *docking site surgery*. Depending on the number of segments traveling for the reconstruction, the surgery can be classified as bifocal, trifocal, tetrafocal, or pentafocal. Obviously, more segments traveling around the mandibular arch allows better positioning, less travel distance, and the possibility to create a true mandibular shape. This is particularly important when creating the parasymphyseal curvature and the mandibular angle. Distraction osteogenesis goes from point "A" to point "B" in a straight fashion; secondary fractures or several fragments are required to obtain curves and angles.[31-38]

The bone transport concept is based on blood supply and careful vector management (Figure 12-14 and Figure 12-15).[31,38-40]

Indications for Bone Transport

- Patients medically compromised where major bone grafts are not indicated
- As an alternative for reintervention after an unsuccessful bone graft reconstruction
- Following removal of benign tumors

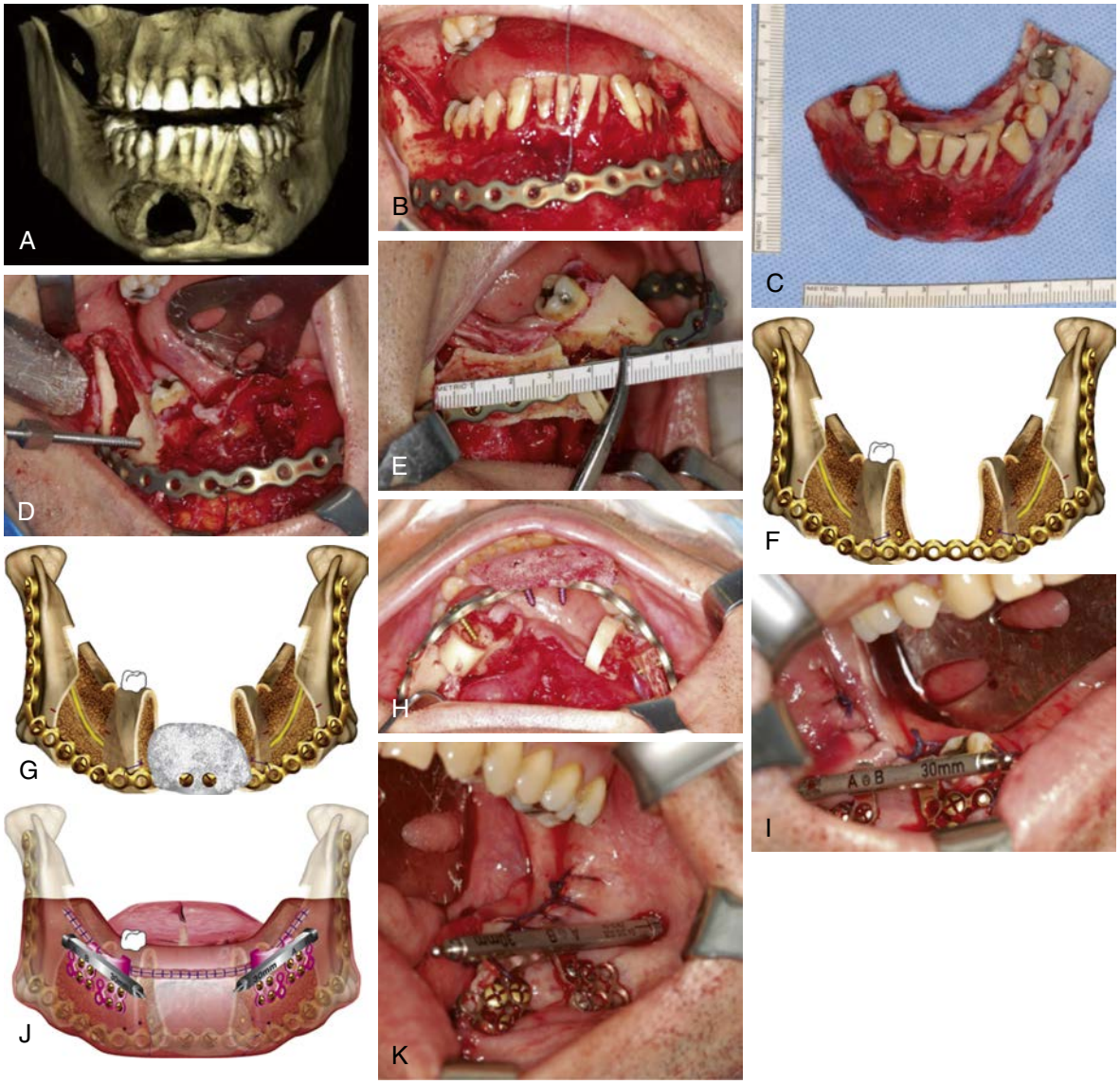

• **Figure 12-14** Ameloblastic carcinoma in 45-year-old male patient. **A-C,** Three-dimensional reconstruction tomography before resection is important to check reconstruction plate position and make posterior holes for screw. This allows easy plate insertion after resection. **D-F,** Plate is fixed on position. Pediculated osteotomized segments reconstruction was performed by bilateral sagittal splint, gaining 35 mm each part. Diagram shows the technique. Notice second molar position after sagittal splint advancement and fixation with reconstruction screws to the plate. The medial soft tissue attachment is maintained to allow vascularity. **G** and **H,** Porous polyethylene prosthesis fixed to the anterior plate segment to maintain chin soft tissue during distraction osteogenesis. **I-K,** Bilateral 30-mm appliances in trifocal bone transport to complete anterior mandibular defect.

- Reconstructing gunshot wound defects
- Managing osteomyelitis
- Treating malunions or nonunions.

Presurgical Preparation

Stereolithographic models, CT scans, and panoramic and cephalometric x-rays are used for surgical planning and prediction. The 3D model is very useful for planning large reconstructions with the exact measurements for prebending the reconstruction plate or devices, determining the distraction vector, and the location of the screws.

Principles

Ilizarov[1] studied the biology of distraction histogenesis and found periosteal and endosteal preservation to be the most important biologic variable. Abundant irrigation and small incisions are mandatory, cooling the bone while cutting; other critical variables are the quantity and quality of bone, degree of movement, soft tissue coverage, and protocol of distraction.[40-42]

- Because the distraction will occur in a linear plane, from point A to point B, the distraction chamber will form bone in a straight line. The stretched collagen elastic fibers will progressively mineralize in the



• **Figure 12-15** Same patient shown in Figure 12-14. **A** and **B,** Preoperative panoramic view, and during bone transport. **C-E,** After distraction period the appliance is maintained on position during mineralization to maintain segments stabilization, and is moved after this period. During consolidation, zygoma implants and conventional dental implants were inserted. **F-I,** Preoperative dental view, during bone transport, after distraction osteogenesis during consolidation (notice the second molar place in midline), and final prosthesis on dental implants. **J** and **K,** Preoperative facial frontal view and final results after 2 years follow-up. Notice excellent esthetics and functional results, avoiding facial scars and creating mandibular contour continuity.

months after surgery to finally convert into calcified bone.

- The size of the transport disc plays an important role in large reconstructions, especially when the symphysis is involved. The disc needs to be large enough for future sectioning in one or two segments as the bone travels along the defect to comply with the distance needed for the reconstruction and to create the mandibular curvature.
- The hourglass deformity effect will be formed if a single bone disc needs to travel a long distance, or if the original thickness is not enough to recreate good bone. The disc must be from 1.5 to 2.0 cm in thickness, height, and length.
- The soft tissues will also advance along and recreate soft tissues with the bone being transported. The significance of this becomes very important in major reconstructions because it includes all the musculature and other soft tissues.
- When bone transport is performed based on the symphyseal bone, special consideration for a genioplasty takes place in order to maintain the symmetry of the chin.

Bifocal Distraction[40-42]

Surgical Technique

A distraction disc is used to create new tissues for reconstructing the mucosa and bony defects. In bifocal bone transport, there are two healing areas: the osteotomy site where the distraction chamber is created and the junction where the traveling disc and the other end meet. This is based on two surgical stages:

- *First surgical stage:* Placement of the reconstruction plate, removal of the affected area, fixation of the distractor, and acute intraoperative activation of 2 mm. The disc travels as the osteotomy parts are distracted, until the disc meets with the host site. The rate is 1 mm a day after the latency period, and progresses until there is bony contact.
- *Second surgical stage:* Once the two bone segments are in contact, the cartilage-like tissue is removed and the distractor is activated. Local bone grafts are placed in between and two rigid fixation plates are placed utilizing bicortical screws. Radiographs are very useful to visualize bone formation and mineralization.

Multifocal Distraction

The concept is based on the use of as many bone discs as needed for the distraction to repair the defect and rigid fixation to maintain the segments in place.

The reconstruction plate is placed holding the bone segments in the correct position with at least three bicortical screws on each segment. For defects including the body and half or all of the symphyseal area, a complete side-to-side reconstruction plate is indicated. The appliance travels on top of the plate for vector control and it is placed supraperiosteally in order to prevent distraction chamber contamination with food and saliva, preventing infections and chamber contraction. Maintaining the biologic principle of DO of periosteal nutrition to the area is critical for success. Major angle-to-angle reconstructions are performed by stages.

- *First stage:* The tumor is resected after fixating the reconstruction plate, to avoid segment displacement, and distraction devices are fixated with transport disc design. Ideally, a 15-mm disc must be obtained and a 2-mm intraoperative activation is performed. This first disc is usually from the angle of the mandible or from the most posterior part of the body. This segment will travel up to the canine area. To avoid plate exposure in the symphyseal area (secondary to muscle traction), a chin silicon prosthesis is placed temporarily to the most anterior part of the plate. As the two lateral discs (distraction discs) come forward, they bring all the soft tissues. The chin prosthesis is removed once the segments are advanced to the parasymphysis area.
- *Second stage:* Reconstruction of the symphysis. Once the first disc reaches the canine area, the traveling disc is sectioned in half, forming a new disc. This is done using intravenous sedation. Rigid fixation of the posterior portion of the original disc to the reconstruction plate is accomplished and the distractor is removed. The anterior portion of this disc will continue traveling across the symphysis with a new distractor. It is very important to consider the rigid fixation of the already transported disc to the plate. This avoids the spring effect which occurs because of the contraction of the collagen fibers before the mineralization period. The consolidation period for major movements is prolonged for many months.
- *Third stage:* At the end of the distraction, docking site surgery is indicated to promote healing between the two docking segments. This is a short and simple procedure to be done under intravenous sedation.

Distraction Protocol

A 7-day latency period (no activation) is followed by a 1-mm or 0.5-mm activation once a day, until distraction is completed (the activation will be performed by the patient, family member, or office staff). The distractors remain in place for 2 months per each centimeter during the consolidation period as a fixation system, until they are exchanged for bicortical screws from the reconstruction plate to the bone.

Docking Site Surgery[36,41,42]

The docking site is the area where the two bone segments meet. At the end of treatment, the edges of these two bones are usually hypotrophic and sclerotic and covered by fibrous tissue. To close this gap at the end of the distraction, a docking site surgery is required. The two edges should be as closed

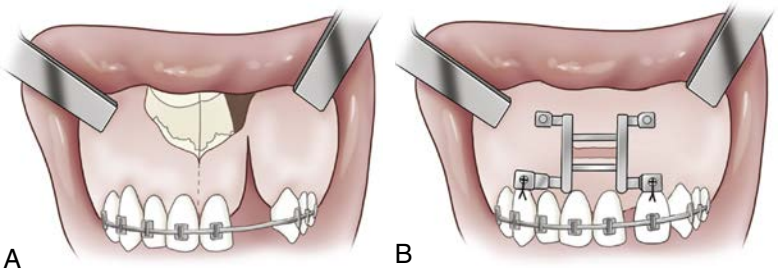

• **Figure 12-16** **A** and **B,** Diagrams show the alveolar defect and the treatment planning by intraoral bone transport.

as possible and the non-vital bone needs to be removed. A mucoperiosteal incision with minimal periosteal elevation is used to expose both ends; it is necessary to obtain a network of neoangiogenesis from the bone marrow and periosteum to enhance healing and promote better bone consolidation. The bone edges are prepared by making multiple perforations with a 701 burr into the cortical and medullary bone. The distractor is activated until the two segments closely meet, and then the bone graft obtained from the chin and tuberosity is placed over the joining bones. Additional osteoinductive material (e.g., rh-BMP2) can also be added. Rigid fixation is used to keep the two bone segments united either by the reconstruction plate or by two miniplates, depending on the bone stability and amount of reconstruction; the suture is protected with N-2-butylcyanocrylate to isolate the surgical site from the oral bacteria (see Figure 12-15).

Physiotherapy

The patient must be on a soft and liquid diet for a long period of time, and the masticatory function is diminished. This leads to mandibular hypomobility with the consequences of interincisal opening reduction at the end of the treatment. Functional and physiologic exercises are advised three times a day for 20 minutes to stimulate masticatory movement.

Dental Implants in Bone Transport

Today implant technology allows the use of inclined dental implants converted to parallel utilizing multi-unit abutments. Also the use of zygoma implants can be considered in areas where good quality and quantity of bone is available, but the implant base is placed where the prosthodontist can fabricate a fixed or hybrid dental rehabilitation. Most patients would have excellent bone in the symphysis area where zygoma implants could be inserted and the abutment base located at the level of canines or premolars (see Figure 12-15).

Maxillary Bone Transport

Indications:

- Tumor resection
- Trauma
- Palatal distraction
- Velopharyngeal incompetence
- Alveolar clefting in the adult

Horizontal Maxillary Bone Transport[43-49]

Surgical Technique

Alveolar clefts are treated with the orthodontic arch to guide the bony segment (Figure 12-16 and Figure 12-17). A small incision is made at the depth of the vestibule through the mucosa, muscles, and periosteum. The flap is elevated and small retractors are used to expose the bone adequately in a tunnel fashion. The transport disc is designed for each specific case, either bifocal or trifocal. The interdental osteotomy is performed with irrigation to avoid bone overheating. The osteotomy is completed with a spatula osteotome and the flap is carefully closed to enhance endosteal healing. The distractor is fixed over the reconstruction plate to the distraction disc and to the fixed maxilla with 2-mm positional screws and interdental wires. A latency period of 7 days is followed by activation of 0.5 mm every 12 hours (0.5 mm twice a day) until the two bony segments meet, or until the segment has arrived at the final distraction point.

Docking Site Surgery

Once the two segments dock with each other, a second procedure is required for uniting the two segments. The epithelial tissue between the two segments is removed, as well as the hypotrophic bone edges from each disc, adding some local bone graft and closing the wounds with the surrounding soft tissue excess as described for the bone transport for the mandible.

Future of Distraction Osteogenesis

Research studies have improved the biological knowledge, and there have been new developments in technology, especially in the area of miniaturizing and trans-oral distraction devices and the use of BMP-2 to improve and accelerate the healing process. There are enough data for long-term evaluation, making these procedures available to patients predictably and safely. Different research studies are trying to diminish the consolidation period using bone morphogenetic proteins, platelet enriched plasma, calcium, and other catalysts for the healing process. There are fewer indications for external devices. Education plays



• **Figure 12-17** **A-D,** Preoperative lateral intraoral view. A small incision is made deep in the sulcus to osteotomize the transport disc. The cut begins with a 701 burr in the cortical bone above and high between the dental roots under abundant irrigation. A spatula osteotome is used through the small incision to complete the osteotomy. Intraoral distractor placement is completed and wounds are closed. **E-I,** Occlusal and frontal intraoral views. **J-N,** Bone discontinuity on the left side and its alveolar reconstruction after bone transport. A plastic pontic is placed over the chamber awaiting the mineralization for implant position.

Continued

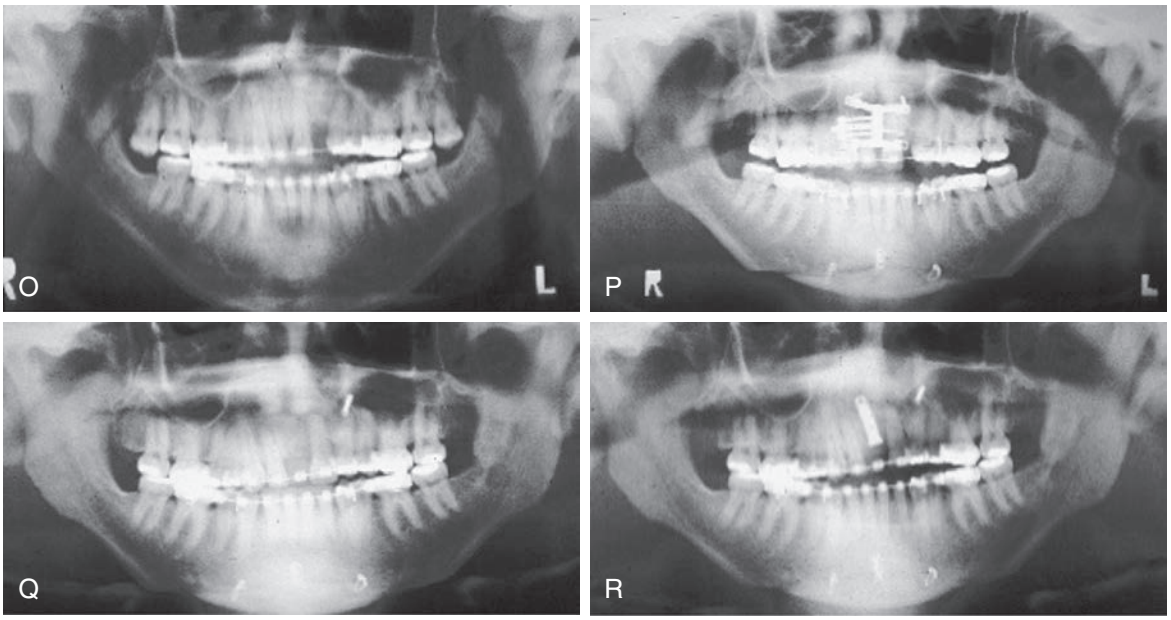

• **Figure 12-17, cont'd** **O-R**, Panoramic radiographs show the defect, appliance positioning, during mineralization period, and after dental implant placement.

a major role in selecting patients, applying the biologic principles and using the best technology available. As long-term studies are published more frequently and the variables are better identified, this new tool in oral and maxillofacial surgery will be the technique of choice in many major craniofacial deficiencies.

References

1. Ilizarov GA: The tension-stress effect on the genesis and growth of tissues: Part I. The influence of stability on fixation and soft tissue preservation, *Clin Orthop* 238:249, 1989.
2. Guerrero C: Rapid mandibular expansion, *Rev Venez Ortod* 48:1–2, 1990.
3. Little RM, Riedel RA, Artun J: An evaluation of changes in mandibular anterior alignment from 10 to 20 years post-retention, *Am J Orthod Dentofac Orthop* 93:423–428, 1988.
4. Karaharju-Suvanto T, Karaharju EO, Ranta R: Mandibular distraction: an experimental study in sheep, *J Cranio-Maxillofac Surg* 18:280–282, 1990.
5. Guerrero C, Bell WH, Flores A, et al.: Distracción osteogenica mandibular intraoral, *Odontol Dia* 11:116–132, 1995.
6. Bell WH, Harper RP, Gonzalez M, et al.: Distraction osteogenesis to widen the mandible, *Br J Oral Maxillofac Surg* 35:11–19, 1997.
7. Guerrero CA, Bell WH, Contasti GI, Rodriguez AM: Mandibular widening by intraoral distraction osteogenesis, *Br J Oral Maxillofac Surg* 35:383–392, 1997.
8. Bell WH, Gonzalez M, Guerrero CA, Samchukov ML: Intraoral widening of the mandible by distraction osteogenesis: histologic and radiographic assessment, *J Oral Maxillofac Surg* 55:97, 1997.
9. Bell WH, Gonzalez M, Samchukov ML, Guerrero CA: Intraoral widening and lengthening the mandible by distraction osteogenesis and histogenesis, *J Oral Maxillofac Surg* 57:548–562, 1999.
10. Guerrero CA, Bell WH, Contasti GI, Rodriguez AM: Intraoral mandibular distraction osteogenesis, *Semin Orthodont* 5:35–40, 1999.
11. Bell WH, Gonzalez M, Guerrero C, Samchukov M: Distraction histogenesis: effect of intraoral widening on gingival and periodontal ligament. In Arnaud E, Diner PA, editors: *3rd International Congress on facial distraction processes, Paris, France*, Bologna, 2001, Monduzzi editore, pp 173–178.
12. Bell WH, Epker BN: Surgical-orthodontic expansion of the maxilla, *Am J Orthod* 70(5):517–528, 1976.
13. McCarthy JG, Schreiber J, Karp N, et al.: Lengthening the human mandible by gradual distraction, *Plast Reconstr Surg* 89:1–8, 1992.
14. Chin M, Toth BA: Distraction osteogenesis in maxillofacial surgery using internal devices: review of five cases, *J Oral Maxillofac Surg* 54:45–53, 1996.
15. Harper RP, Bell WH, Hinton RJ, et al.: Reactive changes in the temporomandibular joint after midline osteodistraction, *Br J Oral Maxillofac Surg* 35:20–25, 1997.
16. DeDeyne PG, Paley D, Herzenberg JE: *Muscle and its connective tissue adaptation to distraction osteogenesis*, New Orleans, Louisiana, March 1998, Abstract #3 ASAMI North America, First International Meeting.
17. Guerrero CA, Bell WH, Meza LS: Intraoral distraction osteogenesis. Maxillary and mandibular lengthening, *Atlas Oral Maxillofac Surg Clin North Am (Distraction Osteogenesis)* 7(1):111–151, 1999.
18. Samchukov ML, Cope JB, Harper RP, Ross JD: Biomechanical considerations for mandibular lengthening and widening by gradual distraction, *Am J Oral Maxillofac Surg* 56:51–59, 1998.
19. Schendel SA, Wolford LM, Epker BN: Mandibular deficiency syndrome. III. Surgical advancement of the deficient mandible in growing children: treatment results in twelve patients, *Oral Surg Oral Med Oral Pathol* 45:364–377, 1978.
20. Gonzalez M, Bell WH, Guerrero CA, et al.: Positional changes and stability of bone segments during simultaneous bilateral mandibular lengthening and widening by distraction osteogenesis, *Br J Oral and Maxillofac Surg* 39:169, 2001.

21. Trauner R, Obwegeser H: The surgical correction of mandibular prognathism and retrognathia with consideration of genioplasty: Part I. Surgical procedures to correct mandibular prognathism and reshaping of the chin, *Oral Surg Oral Med Oral Pathol* 10:677–689, 1857.
22. Guerrero CA, Bell WH, Gonzalez M, Meza LS: Intraoral distraction osteogenesis. In Fonseca RJ, editor: *Oral and maxillofacial surgery*, Philadelphia, 2000, Saunders, pp 359–402.
23. Guerrero CA, Figueroa F, Bell WH, et al.: Surgical orthodontics in mandibular lengthening. In Bell-Guerrero WH, editor: *Distraction osteogenesis of the facial skeleton*, Hamilton, Ontario, 2007, BC Decker, pp 373–388.
24. Cohen SR, Holmes RE, Machado L: Midface distraction. In Samchukov ML, Cope JB, Cherkashin AM, editors: *Craniofacial distraction osteogenesis*, St. Louis, 2001, Mosby, p 520.
25. Guerrero CA, Bell WH: Intraoral distraction. In McCarthy, editor: *Distraction of the craniofacial skeleton*, New York, 1999, Springer-Verlag, pp 219–248.
26. Guerrero CA: Maxillary intraoral distraction osteogenesis. In Arnaud E, Diner PA, editors: *International Congress on Facial Distraction Processes, Paris, France*, Bologna, 2001, Monduzzi editore, p 381.
27. Guerrero CA, Bell WH, Gonzalez M, Rojas A: Maxillary advancement combined with posterior palate reposition via distraction osteogenesis: a case report. In Samchukov ML, Cope JB, Cherkashin AM, editors: *Craniofacial distraction osteogenesis*, St. Louis, 2001, Mosby, pp 531–534.
28. Guerrero CA: Maxillary intraoral distraction osteogenesis. In Arnaud E, Diner PA, editors: *3rd International Congress on Facial distraction processes, Paris, France*, Bologna, 2001, Monduzzi editore, pp 381–387.
29. Polley JW, Figueroa AA: Management of severe maxillary deficiency in childhood and adolescent through distraction osteogenesis with an external, adjustable, rigid distraction device, *J Craniofac Surg* 8:181, 1997.
30. Hugo L: Obwegeser: Surgical correction of small retro displaced maxillae: "The dish face deformity," *Plast Reconstr Surg* 43:351, 1969.
31. Guerrero CA, Bell WH, Gonzalez M, Figueroa F: Maxillomandibular reconstruction by intraoral bone transport. In Arnaud E, Diner PA, editors: *3rd International Congress on Facial Distraction Processes, Paris, France*, Bologna, 2001, Monduzzi 1:569–574.
32. Costantino PD, Shybut G, Friedman CD, et al.: Segmental mandibular regeneration by distraction osteogenesis: an experimental study, *Arch Otolaryngol Head Neck Surg* 116:535–545, 1990.
33. Fonseca RJ, Walker RV: *Oral and maxillofacial trauma*, Philadelphia, 1991, Saunders, p 275.
34. Guerrero CA, Bell WH, Gonzalez M, Rojas A: Intraoral mandibular bone transport: a case report. In Samchukov ML, Cope JB, Cherkashin AM, editors: *Craniofacial distraction osteogenesis*, St. Louis, 2001, Mosby, pp 372–375.
35. Gaggl AJ, Schultes GR, Karcher H: Alveolar ridge augmentation with the aid of distraction implants. In Samchucov ML, Cope JB, Cherkashin AM, editors: *Craniofacial distraction osteogenesis*, St. Louis, 2001, Mosby, pp 401–413.
36. Gonzalez M, Guerrero CA, Henriquez M, et al.: Docking site surgery in bone transport. In Arnaud E, Diner PA, editors: *5th International Congress of maxillofacial and craniofacial distraction, Paris, France*, Bologna, 2006, Monduzzi Editore, pp 99–104.
37. Guerrero CA, Bell HW, Gonzalez M: Mandibular remodeling: the fifth stage in distraction osteogenesis healing. In Arnaud E, Diner PA, editors: *3rd International Congress on cranial and facial bone distraction processes, Paris, France*, Bologna, 2001, Monduzzi Editore, pp 267–273.
38. Guerrero CA, Bell WH, Gonzalez M, Figueroa F: Maxillomandibular reconstruction by intraoral bone transport. In Arnaud E, Diner PA, editors: *3rd International Congress on facial distraction processes, Paris, France*, Bologna, 2001, Monduzzi Editore, pp 569–574.
39. Guerrero CA, Rojas A, Figueroa F, et al.: Radiographic evaluation of traditional versus rhBMP-2 inducted intraoral bone transport in mandibular reconstruction. In Arnaud E, Arnaud PA, editors: *4th International Congress of maxillofacial and craniofacial distraction, Paris, France*, Bologna, 2003, Monduzzi Editore, pp 391–396.
40. Guerrero CA, Figueroa F, Gonzalez M: 3-D alveolar distraction osteogenesis. In Diner PA, Arnaud E, editors: *Proceedings of the 4th International Congress of maxillofacial and craniofacial distraction; 2003 July 2-5; Paris, France*, Bologna, 2003, Monduzzi Editore, pp 37–42.
41. Guerrero CA, Gonzalez M, Dominguez E: Bone transport by distraction osteogenesis for maxillomandibular reconstruction. In Bell-Guerrero, editor: *Distraction osteogenesis of the facial skeleton*, Hamilton, Ontario, 2007, BC Decker, pp 501–519.
42. Makarov MR, Kochutina LN, Birch JG, et al.: Muscle histomorphology during distraction osteogenesis. In Stein H, Suk SI, Leung PC, et al.: *SIROT 99 International Research Society of Orthopaedic Surgery and Traumatology, Sydney, Australia, April 16-19, 1999*, Tel Aviv, 1999, Freund Publishing, pp 647–652.
43. Hidding J, Lazar F, Zoeller JE: Vertical distraction of the alveolar process: a new technique for reconstructing the alveolar ridge. In Samchucov ML, Cope JB, Cherkashin AM, editors: *Craniofacial distraction osteogenesis*, St Louis, 2001, Mosby, pp 393–400.
44. Jensen OT: Alveolar segmental "sandwich" osteotomies for posterior edentulous mandibular sites for dental implants, *J Oral Maxillofac Surg* 64:471–475, 2006.
45. Oda T, Sawaki Y, Ueda M: Experimental alveolar ridge augmentation by distraction osteogenesis using a simple device that permits secondary implant placement, *Int J Oral Maxillofac Implants* 15:95–102, 2000.
46. Guerrero CA, Laplana R, Figueredo N, Rojas A: Surgical implant repositioning: a clinical report, *Int J Oral Maxillofac Implants* 14:48–54, 1999.
47. Guerrero CA, Gonzalez M, Laplana R, Rojas A: Reconstrução do rebordo alveolar mediante distração ostogênica para implantes osseointegrados. In Dinato JC, Polido W, editors: *Implantes osseointegrados: Cirugia e Prótese*, Brazil, 2001, Artes Mèdicas, pp 423–439.
48. Razdolsky Y, Dessner S, El-Bialy: Correction of alveolar ridge deficiency using the ROD-5 distraction device: a case report. In Samchucov ML, Cope JB, Cherkashin AM, editors: *Craniofacial distraction osteogenesis*, St Louis, 2001, Mosby, pp 454–458.
49. Ueda M: Maxillofacial bone distraction processes using osseointegrated implants and an intraoral device. In Diner PA, Vasquez MP, editors: *Proceeding of the International Congress on cranial and facial bone distraction processes, 1997 June 19-21, Paris, France*, Bologna, Italy, 1997, Monduzzi Editore, pp 75–84.

13

Concomitant TMJ Total Joint Prosthetic Reconstruction and Orthognathic Surgery

LARRY M. WOLFORD

Introduction

Temporomandibular joint (TMJ) disorders/pathology and dentofacial deformities commonly co-exist. The TMJ pathology may be the causative factor of the jaw deformity, develop as a result of the jaw deformity, or the two entities may develop independent of each other. This chapter will focus on the most common TMJ pathologies that are indicated for TMJ total joint prostheses as well as orthognathic surgery. The health and stability of the TMJ is dependent on the structural integrity, position, and presence or absence of disease or injury affecting the articular disc, condyle, fossa, and associated soft tissues. The TMJ hard and soft tissue components may become degenerated, arthritic, and nonsalvageable with any of the following TMJ pathologies: articular disc dislocation (long duration), adolescent internal condylar resorption (AICR), reactive arthritis, ankylosis, congenital deformation or absence of the TMJ, trauma, connective tissue and autoimmune diseases, previously failed TMJ surgery, and other end-stage TMJ pathologies.[1-4] These TMJ conditions are often associated with dentofacial deformities, malocclusion, TMJ pain, headaches, myofascial pain, TMJ and jaw functional impairment, ear symptoms, and sleep apnea. Patients with these conditions may benefit from corrective surgical intervention including TMJ reconstruction with total joint prostheses, orthognathic surgery, and other adjunctive procedures. Many clinicians may have difficulty identifying the presence of a TMJ condition, diagnosing the specific TMJ pathology, and selecting the proper treatment for that condition. This chapter should improve the clinician's diagnostic and treatment planning skills, particularly in the end-stage TMJ pathologies requiring TMJ total joint prostheses.

Although most TMJ patients have associated symptoms, approximately 25% of patients with significant TMJ pathology/disorders may be asymptomatic. These patients are diagnostically challenging when undergoing orthognathic surgery because the TMJ pathology may not be recognized or treated appropriately, resulting in a poor treatment outcome with potential redevelopment of the skeletal and occlusal deformity by condylar resorption or overdevelopment as well as initiation of worsening pain, headaches, jaw and TMJ dysfunction, and other TMJ symptoms.[5] However, there are clinical and imaging factors that can indicate the presence of TMJ pathology in the asymptomatic patient.

Many clinicians choose to ignore the TMJ pathology and perform only orthognathic surgery for these types of cases, but this treatment philosophy can result in continuation or exacerbation of the presurgery TMJ pathology and reproduce the original deformity with worsening occlusion, jaw dysfunction, facial imbalance, and pain. Clinicians who address the dentofacial deformities and TMJ pathologies that require total joint prostheses can perform the surgery in one stage or two separate stages. The two-stage approach requires the patient to undergo two separate operations and anesthesia, significantly prolonging the overall treatment. However, performing concomitant TMJ and orthognathic surgery in these cases significantly decreases treatment time and provides better outcomes, but requires careful treatment planning and surgical proficiency in both surgical areas.

In the author's 26-year experience of using patient-fitted TMJ total joint prostheses, approximately two thirds of patients requiring total joint prostheses can benefit from concomitant orthognathic surgery for improvement in function and airway and breathing capabilities, better esthetic outcomes, and reduction or elimination of pain.

Patient Evaluation

It is important to know the patient's concerns, history, symptoms, and treatment expectations. We have previously published detailed information on patient evaluation for



• **Figure 13-1** Patients should be evaluated: **A,** In the frontal view with the pupillary and ear planes parallel to the floor, and **B,** in the clinical Frankfort horizontal plane (a line from the tragus of the ear through the bony inferior orbital rim) parallel to the floor.

orthognathic, TMJ, and sleep apnea surgery including clinical, radiographic, MRI, and dental model analyses,[1-4,6] so this information will not be included here.

However, it is important to realize that these patients are sometimes misleading in their clinical presentation because their "natural head position" may posture their head hyper-extended, lower jaw and chin tipped upward and forward to make the chin appear more prominent, but more specifically to open their oropharyngeal airway to improve their ability to breathe. If the patients are not evaluated with a proper corrected head position, the amount and degree of maxillary and mandibular retrusion and asymmetry may be missed: thus the importance of evaluating the patient with the pupillary plane and ear plane parallel to the floor in the frontal view (Figure 13-1, *A*), and clinical Frankfort horizontal plane (a line from the tragus of the ear through the bony infraorbital rim) parallel to the floor in the profile view (see Figure 13-1, *B*). Obviously there will be some variance in some individuals, but this is a basic guide.

Common factors in patients requiring TMJ total joint prostheses that are frequently overlooked by clinicians are: A-P and posterior vertical maxillary and mandibular hypoplasia, decreased oropharyngeal airway, nasal airway obstruction, and sleep apnea issues. Patients with TMJ pathologies, particularly those with condylar resorption, may experience progressively worsening breathing and sleep apnea issues. Patients with sleep apnea symptoms may be indicated for a sleep workup including polysomnography.

Many sleep apnea patients also have TMJ issues that need to be addressed at the same time or before orthognathic surgery is performed to provide a stable, predictable outcome and decrease preexisting pain. Advancing the maxillary and mandibular complex in a counterclockwise direction improves facial balance, and the oropharyngeal space opens significantly to improve the airway. Our studies[7-11] have shown that with double-jaw surgery with counterclockwise rotation of the maxillomandibular complex, with the first 10 mm of advancement measured at menton, the oropharyngeal airway opens up 65% to 70% of the amount of mandibular advancement. With 10 to 15 mm of advancement, the oropharyngeal airway continues to open, but at about 55% to 60% of the mandibular advancement. When the mandible is advanced 15 to 20 mm, the oropharyngeal airway continues to open, but only at about 40% to 45% of the amount of mandibular advancement.[1]

Imaging

Radiographic evaluation is helpful in the diagnostic process, and cone-beam computed tomography (CBCT) technology makes low-cost, low-radiation scans accessible. With CBCT imaging, the oropharyngeal and nasal airways can also be evaluated as well as the lateral and anteroposterior cephalometric images, TMJ tomograms, and panograph. The lateral cephalometric analysis can determine the severity of the jaw deformity, dental alignment, airway dimensions, and so forth.

One of the best diagnostic tools for TMJ disorders is magnetic resonance imaging (MRI) because it allows evaluation of TMJ disc position, morphology, mobility, extent of joint degenerative changes, inflammation, and the presence of connective tissue/autoimmune diseases. It can help in the diagnosis of TMJ disorders in the silent joint in which disc displacement and degenerative changes can be present, may not make noise or be particularly uncomfortable or painful, but may contribute to poor outcomes if only orthognathic surgery is performed. CT scans, bone scans, three-dimensional (3D) imaging may be helpful in

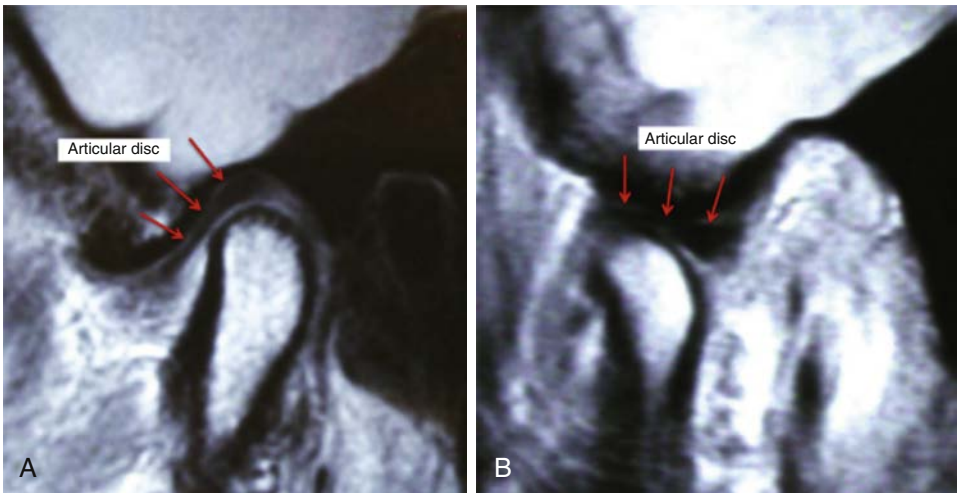

• **Figure 13-2** **A,** MRI of a normal TMJ in closed position with disc in position. **B,** Open view showing good translation forward of condyle and disc.

diagnosis and treatment planning. 3D stereolithic modeling is necessary for manufacture of patient-fitted TMJ total joint prostheses.

MRI Evaluation

Magnetic resonance imaging is one of the most important diagnostic tools that we have in evaluation, diagnoses, and treatment planning for TMJ pathology. In general, T-1 MRIs are helpful in identifying disc position, alteration in bone and soft tissue structures, and interrelationships of the bony and soft tissue anatomy. T-2 MRIs are more helpful in identifying inflammatory responses in the TMJ. The importance of disc position cannot be overemphasized. For MRI evaluation of the TMJs, a 1.5 Tesla or more powerful machine is recommended. "TMJ coils" are necessary to achieve diagnostic quality images of the TMJs. The basic views that are most helpful for TMJ diagnoses include: (1) sagittal views in centric relation and in maximum opening, (2) coronal views in centric relation, and (3) dynamic views, if available. The MRI imaging can be correlated to CBCT imaging of the TMJs for joint space and greater interpretation of bony pathology. Figure 13-2 shows a normal TMJ MRI with healthy structures and the disc in position.

Disc Displacement

When discs are anteriorly displaced for an extended time period they may become non-reducing, deformed with loss of the intermediate zone and thickening of the posterior and anterior bands (Figure 13-3). Also, there may be a degenerative process developing in the discs in which there is a breakdown of the cartilaginous substance with vascular invasion and degeneration. When discs are displaced and become non-reducing, the degenerative process progresses more rapidly as compared with displaced discs that reduce. When discs advance to a certain level of deformation and degeneration, they become nonsalvageable. In this situation

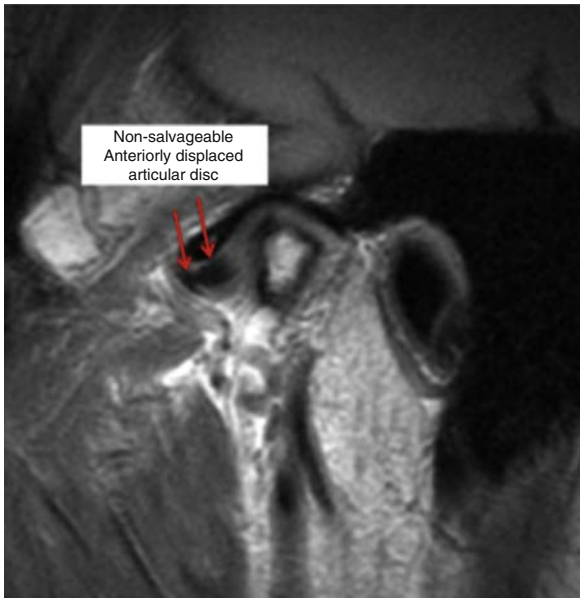

• **Figure 13-3** The articular disc is anteriorly displaced and significantly deformed, degenerated, and nonreducing, rendering it nonsalvageable. The condyle is arthritic.

when concomitant TMJ and orthognathic surgery are necessary, patient-fitted total joint prostheses are indicated to produce the most predictable and high quality outcome.

Adolescent Internal Condylar Resorption (AICR)

Adolescent internal condylar resorption (AICR) is a TMJ condition that develops during pubertal growth between the ages of 11 to 15 years, predominantly in females (ratio 8:1 females to males).[1-4,12,13] Clinically, the mandible will be noted to slowly retrude into a class II occlusal and skeletal relationship with a tendency towards anterior open bite. These patients all have high occlusal plane angle facial morphologic profiles. On the MRI, these cases present with a

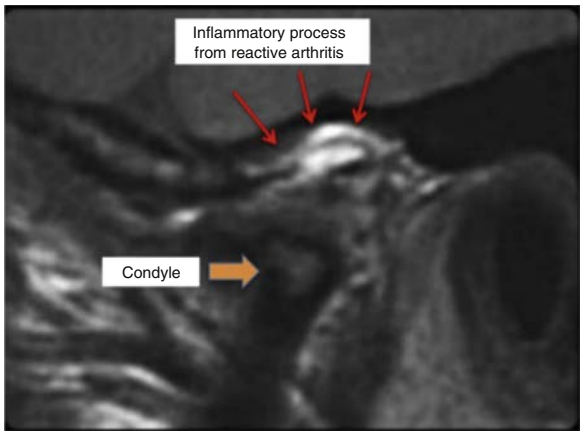

• **Figure 13-4** T2 MRI of right TMJ with reactive arthritis and significant condylar resorption. The inflammatory process is noted to occupy a significant volume between the fossa and arthritic condyle.

condyle that is slowly becoming smaller in size in all three planes of space and the disc is anteriorly displaced similar to Figure 13-3. In some cases, there is significant thinning of the cortical bone on top of the condyle contributing to the inward collapse of the condylar head in this pathologic process. The articular discs are anteriorly displaced and may or may not reduce on opening. Non-reducing discs will degenerate and deform at a more rapid rate as compared with discs that reduce. Our studies demonstrate that AICR is arrested if the articular discs are put back into position on top of the condyle and stabilized with the Mitek anchor technique. Results are best for AICR if the TMJ surgery for disc repositioning is performed within 4 years of the onset of the pathology. After 4 years the discs may become nonsalvageable and condyles significantly resorbed, at which point the indicated treatment becomes patient-fitted total joint prostheses to repair the TMJs and advance the mandible.

Reactive Arthritis

Reactive arthritis is commonly caused by bacterial or viral entities[1-4,14-19] and may show a localized area of inflammation with erosion of the condyle and/or fossa. It also can present as a more profuse inflammatory process through the bilaminar tissues and capsule (Figure 13-4). Surgical indication may include removal of the nidus of inflammation and repositioning the articular disc if salvageable. With extensive destruction of the TMJ, a total joint prosthesis is indicated.

Perforations

Perforations can occur in the TMJ area resulting in bone-on-bone contact. When perforations exist the discs are usually anteriorly and/or medially displaced. Almost always these perforations are posterior to the posterior band of the articular disc or lateral to the disc, and rarely do perforations occur through the disc itself (Figure 13-5). Clinically, crepitation will usually be present and, on the MRI, there will be evidence of bone-on-bone contact, arthritis of the condylar head and/or fossa, as well as an anteriorly displaced disc.

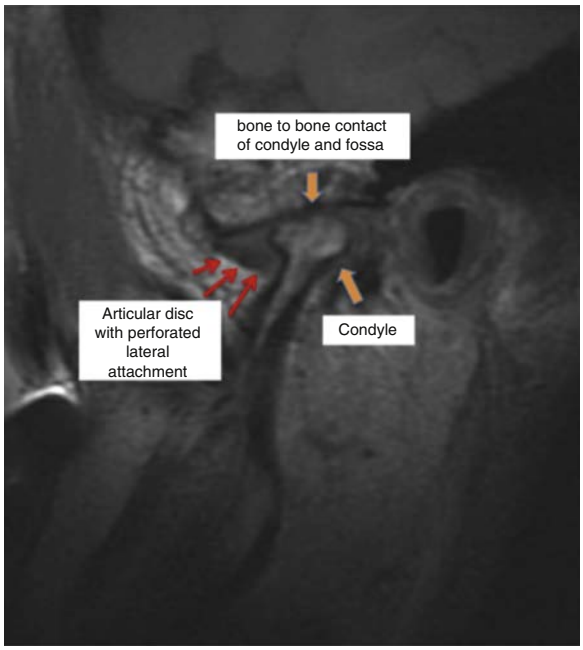

• **Figure 13-5** MRI of left arthritic condyle with perforation of the bilaminar tissue posterior to the anteriorly displaced disc. Bone-to-bone contact of condyle and fossa is observed with crepitation on jaw function.

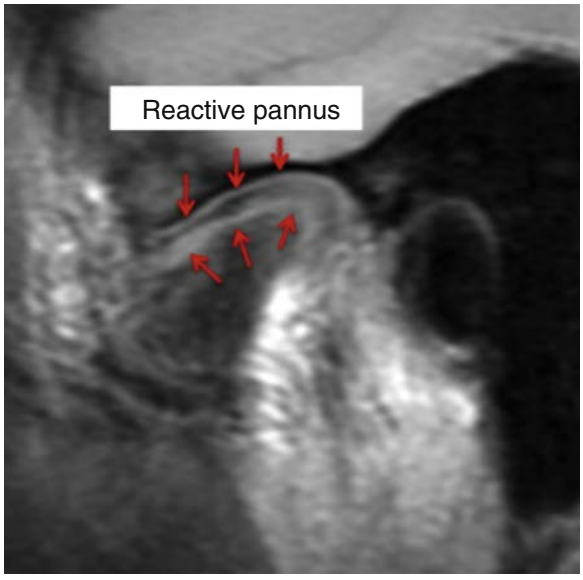

• **Figure 13-6** There are common TMJ changes in connective tissue/autoimmune disease. The disc may be in position but with a reactive pannus (gray tissue) surrounding the disc that destroys the disc, condyle, and articular eminence. The remaining condyle may have a "mushroom" appearance.

Connective Tissue/Autoimmune Diseases

The MRI presentation of connective tissue/autoimmune diseases is fairly pathognomonic. In these conditions, the articular disc often is in a relatively normal position, but there is progressive condylar resorption, "mushrooming" of the remaining condyle, and often resorption of the articular eminence, with slow but progressive destruction of the articular disc that is surrounded by a reactive pannus (Figure 13-6).[1-4,20-24] This presentation almost always

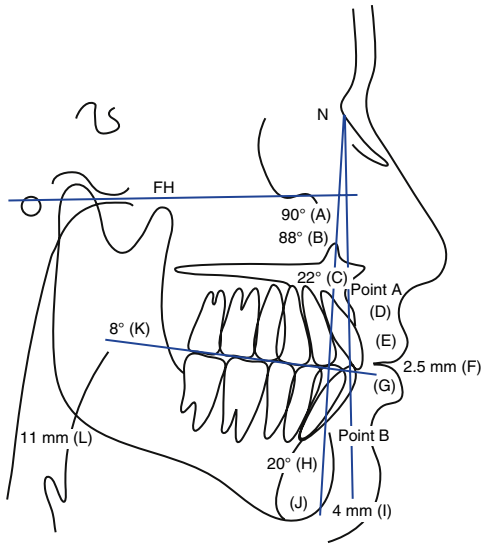

• **Figure 13-7** Cephalometric tracing landmarks and measurements to aid in diagnosis and treatment planning.

indicates the requirement of a total joint prostheses for jaw reconstruction to eliminate the pathologic process in the joint. Use of autogenous tissues in this scenario could result in the disease process attacking autogenous tissues placed into the joint, with subsequent failure.

Cephalometric Analysis

Cephalometric analysis is an important assessment for diagnosis and treatment planning for TMJ patients because the most dominant facial type with TMJ pathology is the high occlusal plane angle facial morphology with a retruded maxilla and mandible. Normal cephalometric relationships used by the author are demonstrated in Figure 13-7, and are described in detail in previously published papers.[3,6]

One of the primary factors contributing to sleep apnea is a decreased oropharyngeal airway which is commonly seen in TMJ patients, particularly with a history of TMJ condylar resorption. The normal cephalometric A-P dimension from the posterior pharyngeal wall to the soft palate and posterior pharyngeal wall to the base of the tongue is 11 mm, plus or minus 2 mm. In patients who have a retruded maxilla and mandible, this airway may be significantly decreased. Accompanying these deficiencies is usually a high occlusal plane angle. The normal cephalometric angle of the occlusal plane to the Frankfort horizontal plane is 8 degrees, plus or minus 4 degrees. With a retruded maxilla and mandible (particularly with condylar resorption), the occlusal plane commonly is significantly increased and is a factor to be addressed in the treatment planning.

There is a triad of factors that commonly go together in TMJ patients: (1) a high occlusal plane angle facial morphology associated with retruded maxilla and mandible, (2) nasal airway obstruction related to hypertrophied turbinates and/or nasal septal deviation or spurring, and (3) TMJ pathology. Our recent study[25] evaluated 1234 consecutive patients referred to the author for orthognathic surgery requiring at least maxillary osteotomies. There were 603 patients (49%) with hypertrophied turbinates requiring partial turbinectomies and 278 patients (23%) requiring nasal septoplasty. For patients requiring partial turbinectomies (n = 603), 84% had maxillary hypoplasia, 72% had mandibular hypoplasia, 69% had a high occlusal plane angle, and 49% of the patients required concomitant TMJ surgery. A female predominance was seen in the data reviewed. Approximately 67% of the turbinectomy cases and 73% of concomitant turbinectomy, orthognathic, and TMJ surgery cases involved female subjects. A strong correlation has been established between hypertrophied nasal inferior turbinates, hypoplastic maxilla and mandible, and a steep occlusal plane. Our findings correlate with other studies evaluating the morphology of mouth breathing and nasally obstructed patients.[26-29] Therefore, patients with the high occlusal plane angle facial morphology with a retruded maxilla and mandible should be assessed for nasal airway obstruction, decreased oropharyngeal airway, and sleep apnea, as well as TMJ pathology (even if asymptomatic).

Comprehensive Diagnostic List and Treatment Plan

Following completion of all necessary and required evaluations, a comprehensive diagnostic list can be compiled. A definitive treatment plan can then be established to address these issues and other treatment options that may be available to allow the patient to make an informed decision as to the preferred treatment.

Occlusal Plane Alteration

The correction of dentofacial deformities often requires double-jaw surgery to achieve a quality functional and esthetic result and address the airway issues. An often ignored but important cephalometric and clinical interrelationship in the diagnosis and treatment planning for the correction of dentofacial deformities is the *occlusal plane angulation.*[6,30-32] The occlusal plane angle is formed by the Frankfort horizontal plane and a line tangent to the cusp tips of the lower premolars and the buccal groove of the second molar. The normal value for adults is 8 degrees ± 4 degrees. An increased (high) occlusal plane angle usually is reflected in an increased mandibular plane angle (dolichocephaly), and a decreased (low) occlusal plane angle usually correlates with a decreased mandibular plane angle (brachycephaly).

High Occlusal Plane Facial Type

The common functional and esthetic characteristics of the high occlusal plane facial morphology generally include the following:

- Increased occlusal plane angulation (occlusal plane greater than 12 degrees)

- Increased mandibular plane angulation
- Anterior vertical maxillary hyperplasia and/or posterior vertical maxillary hypoplasia
- Increased vertical height of the anterior mandible and/or decreased vertical height of the posterior mandible
- Decreased projection of the chin (anteroposterior micrognenia)
- Anteroposterior and vertical posterior mandibular and maxillary hypoplasia
- Decreased angulation of maxillary incisors, although overangulation can occur
- Increased angulation of mandibular incisors
- Class II malocclusion is common, although class I and class III malocclusions also can occur
- An anterior open bite may be accompanied by an accentuated curve of Spee in the upper arch
- In more pronounced cases in which the occlusal plane approaches the slope of the articular eminence, the following may occur: loss of incisal guidance, loss of canine rise occlusion, and the presence of working and nonworking dental interferences in the molar areas
- The more severe cases may demonstrate moderate to severe sleep apnea symptoms as a result of posterior displacement of the tongue base and soft palate constricting the oropharyngeal airway (normal oropharyngeal airway space is 11 mm ± 2 mm)
- Nasal airway obstruction related to hypertrophied turbinates and/or septal deviation or spur
- TMJ pathology

Surgical Decrease of the Occlusal Plane

In the high occlusal plane facial type, the indicated surgical correction may include a counterclockwise rotation of the maxillomandibular complex to decrease the occlusal plane angle. In open bite cases the maxillary occlusal plane and the mandibular occlusal plane may be different and each should be evaluated independently. For illustrative purposes, a class I case is used with the maxillary incisor edge as the center of rotation (Figure 13-8). The anatomic changes that occur with the counterclockwise rotation include the following:

- Occlusal plane angle decreases
- Mandibular plane angle decreases
- Maxillary incisor angulation increases (the same amount that the maxillary occlusal plane decreases)
- Mandibular incisor angulation decreases (the same amount that the mandibular occlusal plane decreases)
- Projection of the chin increases relative to the lower incisor edges
- Posterior facial height may increase
- Prominence of the mandibular angles may increase
- Maxillary incisor edges move forward relative to the perinasal area
- Incisal guidance and canine rise occlusion improves, and posterior working and nonworking interferences are eliminated
- Oropharyngeal airway increases

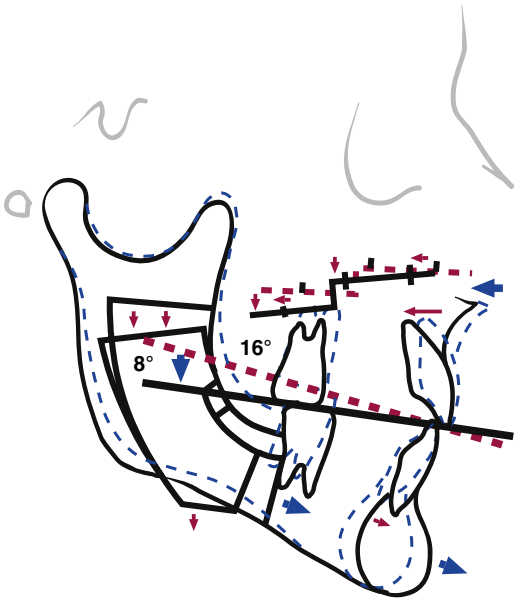

• **Figure 13-8** Surgical decrease of the occlusal plane from the dotted line to solid line (counterclockwise rotation) rotates the chin forward, decreased prominence of the perinasal areas, maxillary incisor angulation increases, mandibular incisor angulation decreases, and the oropharyngeal airway increases.

The center of rotation affects the aesthetic relationship of the jaws with the other facial structures. In the illustrative case shown in Figure 13-8, the center of rotation is at the maxillary incisor edge. Counterclockwise rotation of the maxillomandibular complex results in the perinasal area, subnasale area, and the nasal tip moving posteriorly but the mandible and chin moving forward. If rotation is around point A or higher, then the perinasal area and the nose are less affected, but the maxillary incisor edges come forward, increasing the anteroposterior support to the upper lip. The mandible and chin come further forward, demonstrating the significant esthetic difference that the alteration of the occlusal plane can make.[6,30-32] When decreasing the occlusal plane angle and advancing the mandible counterclockwise, the oropharyngeal airway increases approximately 50% to 70% of the advancement measured at the genial tubercles.[7-11]

Concomitant TMJ Total Joint Replacement and Orthognathic Surgery (C-TJR-OS)

Treatment planning for C-TJR-OS cases is based on cephalometric analysis, prediction tracing, clinical evaluation, MRI, and dental models, which provide the template for movements of the upper and lower jaws to establish optimal treatment outcome in relation to function, facial harmony, occlusion, and oropharyngeal airway dimensions. For patients who require total joint prostheses, a medical grade computed tomographic (CT) scan (of the maxillofacial region) with 1-mm overlapping cuts is recommended and includes the TMJs, maxilla, infraorbital rims, and mandible.

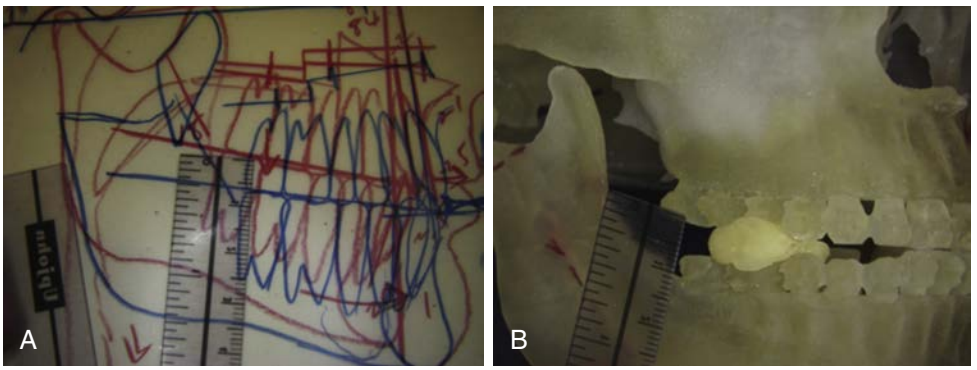

• **Figure 13-9** **A,** Measurement of the cephalometric tracing and prediction tracing for the amount of open bite produced at the second molar after counterclockwise rotation of the mandible into its final position. The original cephalometric tracing is in *red,* and the prediction tracing is in *blue.* **B,** Duplication of the measurement obtained from the prediction tracing to the final mandibular position on the stereolithic model (usually requiring creation of posterior open bites) and fixating the mandible to the maxilla with quick-cure acrylic.

The surgeon has two options for model preparation to aid in the construction of patient-fitted total joint prostheses using the TMJ Concepts System (Ventura, CA): traditional protocol versus virtual surgical planning (VSP).[33,34]

Traditional C-TJR-OS

Treatment planning for C-TJR-OS cases is based on prediction tracing, clinical evaluation, and dental models, which provide the template for movements of the upper and lower jaws to establish optimal treatment outcome in relation to function, facial harmony, occlusion, and oropharyngeal airway dimensions. For patients who require total joint prostheses, a CT scan is acquired of the maxillofacial region that includes the TMJs, maxilla, and mandible with 1-mm overlapping cuts. Using these CT scan data, a stereolithic model is fabricated, with the mandible as a separate piece. Using the original cephalometric tracing and prediction tracing (Figure 13-9, *A*), the mandible on the stereolithic model is placed into its future predetermined position using the planned measurements for correction of mandibular anteroposterior and vertical positions, occlusal plane alteration, pitch, yaw, and roll. The mandible is stabilized to the maxilla with quick-cure acrylic. Repositioning the mandible into its final position usually requires the development of posterior open bites on the model (see Figure 13-9, *B*). Because the mandibular position on the stereolithic models is established using hands-on measurements, the operator's manual dexterity and 3D perspective play a critical role in setting the mandible in its proper and final position. This step can predispose the planning process to a certain margin of error.

The next step requires condylectomies as well as preparation of the lateral aspect of the rami and fossae (Figure 13-10, *A* and *B*) for fabrication of the patient-fitted total joint prosthesis. The goal of this step is to recontour the lateral ramus to a relatively flat surface in the area where the mandibular component will be placed. The fossa requires recontouring only if heterotopic bone or unusual anatomy is present. The recontouring areas are marked in red for duplication of bone removal at surgery. Because most patients with TMJ problems requiring C-TJR-OS can benefit from counterclockwise rotation of the maxillomandibular complex, the stereolithic model will likely be set with posterior open bites, because the maxilla is maintained in its original position. To accommodate the prosthesis, 20 mm of space is required between the fossa and ramus.

Once the stereolithic model is finalized, the model is sent to TMJ Concepts (Ventura, CA) to perform the design, blueprint, and wax-up (see Figure 13-10, *C*) of the custom-fitted total joint prostheses for approval by the surgeon before manufacture of the prostheses. The period from CT acquisition to the manufacturer's completion of the patient-fitted prostheses is approximately 8 weeks. The final prostheses (see Figure 13-10, *D*) are sent to the hospital for subsequent implantation. The numbers on the printout indicate the length of screw necessary for bicortical engagement.

Prior to surgery, the surgical procedures are performed by the surgeon on articulator-mounted dental models. The mandible is repositioned on the articulator, duplicating the movements performed on the stereolithic model, and the intermediate splint is constructed. The maxillary model is repositioned, segmented if indicated, and placed into the maximal occlusal fit. Then, the palatal splint is constructed, or an occlusal splint if the surgeon prefers.

Protocol for Traditional C-TJR-OS

1. CT scan including the entire mandible, maxilla, and TMJs
2. Fabrication of stereolithic model with the mandible separated
3. Surgeon positions the mandible on the stereolithic model into its final position and fixates it
4. Remove condyles and recontour the lateral aspect of the rami and fossae if indicated

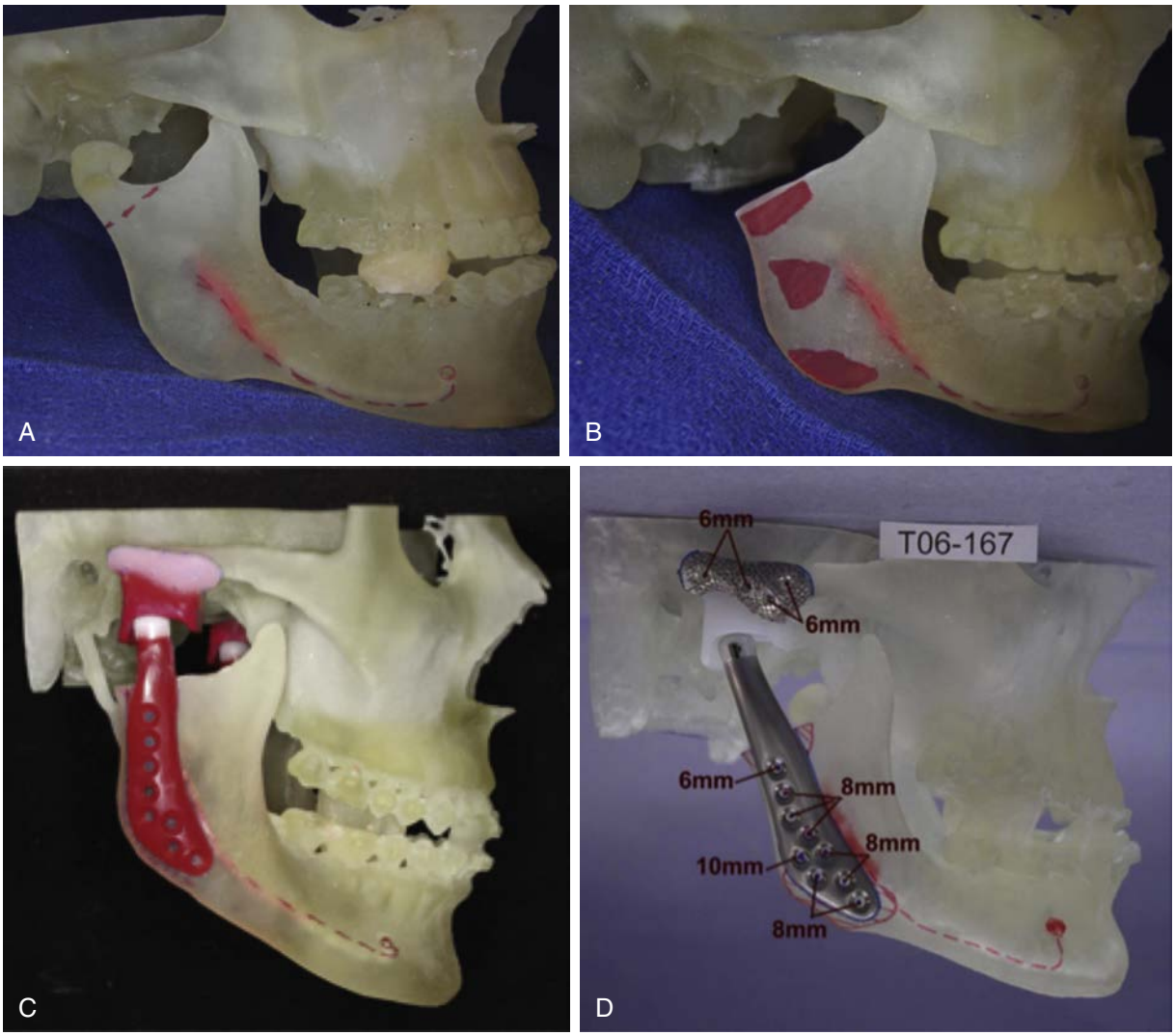

• **Figure 13-10** **A,** Model set for ramus and fossa preparation. The level for condylectomy is marked. **B,** The stereolithic model after condylectomy and recontouring of the fossae and rami (marked in *red*). Accommodation of the prosthesis requires 20 mm space between fossa and ramus. **C,** Stereolithic model with prosthesis wax-up for surgeon approval before manufacture. **D,** Prosthesis constructed. Numbers indicate recommended length of screws for bicortical stabilization of the joint components.

5. Model sent to TMJ Concepts for prostheses design, blueprint, and wax-up
6. Surgeon approves total joint prostheses blueprint and wax-up
7. Manufacture of custom-fitted total joint prostheses
8. Prostheses sent to hospital for surgical implantation
9. Dental model surgery for fabrication of splints
10. Surgery performed as planned

Steps in Traditional Orthognathic Surgery, Intermediate, and Palatal Splint Fabrication for C-TJR-OS

1. Acquisition of dental models
2. Mounting maxillary and mandibular dental models on an articulator
3. Reposition the mandibular dental model, duplicating the positional changes acquired on the stereolithic model
4. Fabrication of intermediate splint
5. Reposition maxillary dental model with segmentation if indicated
6. Construction of palatal splint (or occlusal splint if the surgeon prefers)
7. Ready for surgery

Virtual Surgical Planning

Virtual surgical planning (VSP) utilizes computer technology to simulate the planned surgical procedures. Over the past decade, computer-assisted surgical simulation (CASS) technology has been integrated to many maxillofacial surgical applications,[35,36] including dentofacial deformities, congenital deformities, defects after tumor ablation, post-traumatic defects, reconstruction of cranial defects,[37] and reconstruction of the TMJ.[33,34] CASS technology applied to orthognathic surgery can improve surgical accuracy,

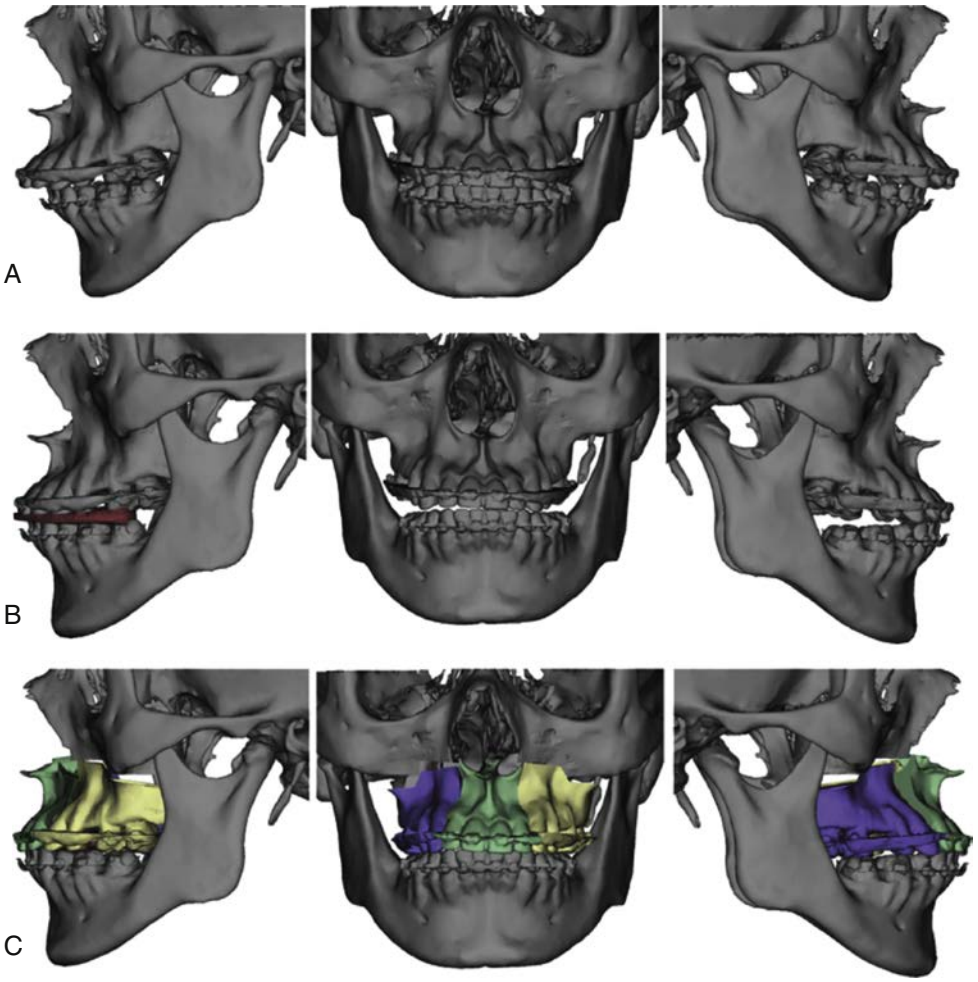

• **Figure 13-11** Staged computer-aided surgical simulation (CASS). **A,** Simulated preoperative position of the maxilla and mandible. **B,** The maxilla and mandible in the simulated intermediate position, with the maxilla in its original position, but mandible in its final position with the mandibular surgery performed first for fabrication of the intermediate splint. **C,** The final position of maxilla and mandible, after counterclockwise rotation-advancement of the mandible and segmented maxilla, for the production of a palatal splint or occlusal splint if the surgeon prefers.

provide intermediate and final surgical splints, and decrease the surgeon's time input for presurgical preparation compared with traditional methods of case preparation. Data for VSP in orthognathic surgery cases can be obtained from CBCT scans, but better quality simulation and accuracy can be acquired from medical grade CT scans of the jaws with 1-mm overlapping cuts.

Protocol for C-TJR-OS Using CASS

For C-TJR-OS cases, the orthognathic surgery can be planned using CASS technology and moving the maxilla and mandible into their final position in a computer-simulated environment (Figure 13-11, *A, C*). Using the computer simulation, the anteroposterior and vertical positions, occlusal plane alteration, pitch, yaw, and roll are accurately finalized for the maxilla and mandible based on clinical evaluation, dental models, prediction tracing, and computer-simulation analysis. Segmentation of the maxilla can be simulated. Figure 13-11, *B* simulates the mandible in its final position and the maxilla in its original position for fabrication of the intermediate splint since the mandible is usually repositioned first before the maxilla.

Using Digital Imaging and Communications in Medicine (DICOM) data, the stereolithic model is produced with the maxilla and mandible in the final position and provided to the surgeon for removal of the condyle and recontouring of the lateral rami and fossae if indicated. The stereolithic model is sent to TMJ Concepts for the design, blueprint, and wax-up of the prostheses. Via the Internet, the design, blueprint, and wax-up are approved by the surgeon. Then, the custom-fitted total joint prostheses are manufactured. It takes approximately 8 weeks to manufacture the total joint patient-fitted prostheses. Figure 13-12 demonstrates the basic design of the TMJ Concepts patient-fitted prosthesis. The black arrow points to the mesh framework on the underside of the custom-fitted titanium shell that secures the polyethylene articulating portion of the fossa component. The yellow arrow points to the mesh on the superior surface of the fossa component

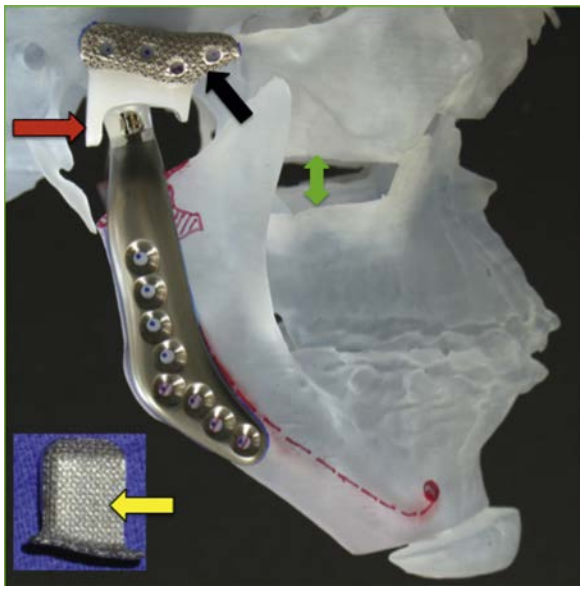

• **Figure 13-12** Stereolithic model fabricated after simulated maxillary and mandibular advancement to the final position. Condylectomy and recontouring of the lateral rami and fossae were performed and prostheses manufactured. The basic design of the TMJ Concepts patient-fitted prosthesis is observed. The *black arrow* points to the mesh framework on the underside of the custom-fitted titanium shell that secures the polyethylene articulating portion of the fossa component. The *yellow arrow* points to the mesh on the superior surface of the fossa component that allows osseo-integration with the fossa bone. The *red arrow* points to the posterior stop of the fossa, a necessary component for mandibular advancement and stability. The *green arrow* shows the bony defect created from the counterclockwise rotation of the posterior maxilla. These defects require bone or synthetic bone grafting and rigid fixation for stability of the maxilla.

that allows osseointegration with the fossa bone. The red arrow points to the posterior stop of the fossa, a necessary component for mandibular advancement and stability. The green arrow shows the bony defect created from the counterclockwise rotation of the posterior maxilla. These defects require bone or synthetic bone grafting and rigid fixation for stability of the maxilla.

Approximately 2 weeks before surgery, final dental models are acquired including two maxillary models if the maxilla is to be segmented or dental equilibration is required. One of the maxillary models is segmented if indicated, dental equilibration is performed, and the segments are placed in the best occlusion fit with the mandibular dentition and the maxillary segments are fixed to each other. The dental models do not require mounting on an articulator. The three or four models (two maxillary and one mandibular, or two mandibular models if equilibrations or dentoalveolar surgery are done on the mandible) are physically sent to the VSP company for scanning and simulation into the computer model. Alternatively, with an i-CAT machine, the models can be scanned and digitally sent to the VSP company, although the accuracy may not be quite as good as sending the actual models.

Because the author's surgical protocol routinely performs the TMJ reconstruction and mandibular advancement with the TMJ Concepts total joint prosthesis first, the unsegmented maxillary model is simulated into the original maxillary position and the mandibular model is simulated into the mandible in its final position. The intermediate splint is constructed (see Figures 13-11, *B*, 13-13, *A* and *B*). Then, the segmented maxillary model is simulated into the computer model in its final position, with the best occlusal fit with the mandibular occlusion, and the palatal splint is fabricated (see Figure 13-13, *C* and *D*) or an occlusal splint is made if the surgeon prefers. The dental models, splints, and images of the computer-simulated surgery are sent to the surgeon for implementation during surgery.

Steps in C-TJR-OS Using CASS

1. CT scan of entire mandible, maxilla, infraorbital rims, and TMJs (1-mm overlapping cuts recommended)
2. Processing of DICOM data to create a computer model in CASS environment
3. Correction of dentofacial deformity, including final positioning of the maxilla and mandible, with computer-simulated surgery
4. Stereolithic model constructed with jaws in final position and sent to surgeon for condylectomy as well as rami and fossae recontouring if indicated
5. Model sent to TMJ Concepts for prostheses design, blueprint, and wax-up
6. Surgeon approval of design, blueprint, and wax-up via the Internet
7. TMJ prostheses manufactured and sent to hospital for surgical implantation
8. Two weeks before surgery, acquisition of final dental models (two maxillary, one or two mandibular models if dental equilibrations are required); one maxillary model is segmented and models equilibrated if indicated to maximize the occlusal fit; models sent to the VSP company, or digitally sent
9. Models incorporated into computer-simulated surgery for construction of intermediate and final palatal splints
10. Models, splints, and printouts of computer-simulated surgery sent to surgeon

Using CASS technology for C-TJR-OS cases eliminates the "traditional" steps requiring the surgeon to manually set the mandible into its new final position on the stereolithic model, thus saving time and improving surgical accuracy. Although dental model surgery is necessary only if the maxilla requires segmentation or equilibration, the models do not require mounting on an articulator. This saves considerable time by eliminating the time required to mount the models, prepare the model bases for model surgery, reposition the mandible, construct the intermediate occlusal splint, and make the final palatal splint. With CASS technology, the splints are manufactured by the VSP company.



• **Figure 13-13** **A-B,** Intermediate splint is printed from the CASS model with the mandible in the final position and maxilla in the original position. **C,** Palatal splint printed and **(D)** inserted.

Surgical Sequencing for C-TJR-OS

1. Condylectomy
2. Coronoidotomy or coronoidectomy
3. Detach the masseter and media pterygoid muscles from ramus
4. Mobilize mandible
5. Maxillomandibular fixation with intermediate surgical splint
6. Placement of total joint prostheses
7. Bilateral TMJ fat grafts harvested from the abdomen or buttock
8. Maxillary osteotomies and mobilization
9. Turbinectomies, septoplasty, etc.
10. Maxillary segmentation and application of the palatal splint if indicated
11. Maxillary rigid fixation and bone grafting
12. Adjunctive procedures such as genioplasty, rhinoplasty, UPPP, facial augmentation, etc.

A potential risk to patients receiving TMJ total joint prosthesis is infection. The occurrence rate is less than 2% with greater risk for patients on immunosuppressant medications such as rheumatoid patients or others with connective tissue/autoimmune diseases. Bacterial or viral contamination of the prosthesis can occur during surgery or develop at a later time from bacterial seeding through a hematogenic route or localized bacterial sources. As a result, strict adherence to sterile technique for the procedures performed can prevent or reduce the chance of infection associated with the implantation of total joint prosthesis, and concomitant orthognathic surgery.

The TMJ Concepts prosthesis uses design principles and materials that are proven highly successful and are the gold standard in orthopedic joint reconstruction for hip and knee replacements. The prosthesis consists of a fossa component with a commercially pure titanium framework covered with a mesh and an ultra-high molecular weight polyethylene functional component fused to the mesh on the bottom side of the framework. The fossa component is attached to the lateral rim of the fossa with four 2-mm diameter screws. The mandibular component is composed of a titanium alloy shaft with a cobalt-chromium alloy head with the prosthesis secured to the mandibular ramus with seven to nine 2-mm diameter bicortical screws. The fossa and mandibular components osseointegrate with the fossa and ramus respectively.

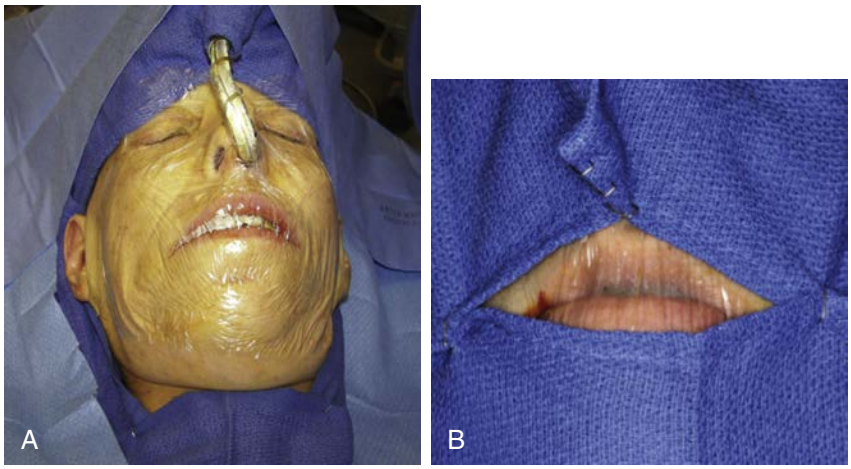

• **Figure 13-14** **A,** After preparation of the face, neck, ears, and oral cavity, a Tegaderm Film dressing, 6 × 8 in, is applied to seal off the oral cavity and nasal airway from the surgical field. **B,** Following mobilization of the mandible, sterile towels are draped around the face and mouth to prevent contamination of the extra-oral surgical sites. The Tegaderm dressing is cut to provide access to the oral cavity for placement of the intermediate splint and maxillomandibular fixation.

Surgical Procedure

1. After surgical prepping including the face, neck, mouth, ears, ear canals, nose, endotracheal tube, and abdomen, the abdomen, face, and neck are draped, the mouth and nose are isolated by application of a Tegaderm film dressing (6 × 8 inches), and the ear canal is gently packed with cotton (Figure 13-14, *A*).
2. The TMJs are approached through an endaural or pre-auricular incision to perform the condylectomy, joint debridement, and coronoidectomy (when the mandible is significantly advanced or vertically lengthened). The bone from the condylectomies and coronoidectomies is saved for use in grafting the bone defects that may be associated with the maxillary osteotomies.
3. Submandibular incisions are used to access the ramus to reflect the masseter and medial pterygoid muscles and to mobilize the mandible in a downward and forward direction. The lateral aspect of the ramus is prepared duplicating the alterations on the stereolithic model.
4. Following mandibular mobilization, the oral cavity is isolated by draping with sterile towels, exposing from commissure to commissure (see Figure 13-14, *B*). The Tegaderm is cut through and the oral cavity is entered. If the case includes bilateral total joint prostheses, then the intermediate splint is inserted and maxillomandibular fixation applied. If it is a unilateral total joint prosthesis case, then go to Step 5.
5. For unilateral total joint prosthesis, using separate instrumentation, a contralateral mandibular sagittal split osteotomy is performed and mandible mobilized on that side. The intermediate splint and maxillomandibular fixation are applied. Rigid fixation is placed to secure the mandibular segments and the incision is closed.
6. The temporary towels are removed, the surgeon changes gloves and gown, and the mouth is sealed off once again with a Tegaderm film dressing.
7. The total joint prostheses are inserted and fixed in position. A stab incision can be made about 1 centimeter below the earlobe and a trocar inserted to place screws in the holes at the top of the prosthesis that are difficult to access from the submandibular incision.
8. The surgical areas are thoroughly irrigated with saline with a final rinse using betadine solution. The masseter muscles are reattached to the mandible and submandibular incisions are closed.
9. Fat grafts are harvested from the abdomen or buttock with establishment of good hemostasis and closure of the incisions. A small drain can be inserted in the donor area if good hemostasis cannot be achieved.
10. The articulating area of the prostheses is thoroughly irrigated with saline through the endaural or pre-auricular incisions with a final rinse using betadine solution. The fat grafts are packed around the articulating area of the prostheses (Figure 13-15, *A-D*) and the incisions closed.
11. The oral cavity is then entered, maxillomandibular fixation released, and the intermediate splint removed.
12. Maxillary osteotomies are performed and maxilla mobilized. Intranasal procedures are done such as turbinectomies and septoplasty if indicated.
13. The maxilla is segmented, palatal splint inserted, and maxillomandibular fixation applied. The maxilla is rigidly fixated with four bone plates and bone grafting at the osteotomy sites as indicated.
14. The alar base cinch suture is placed and maxillary incision closed in a V-Y design.

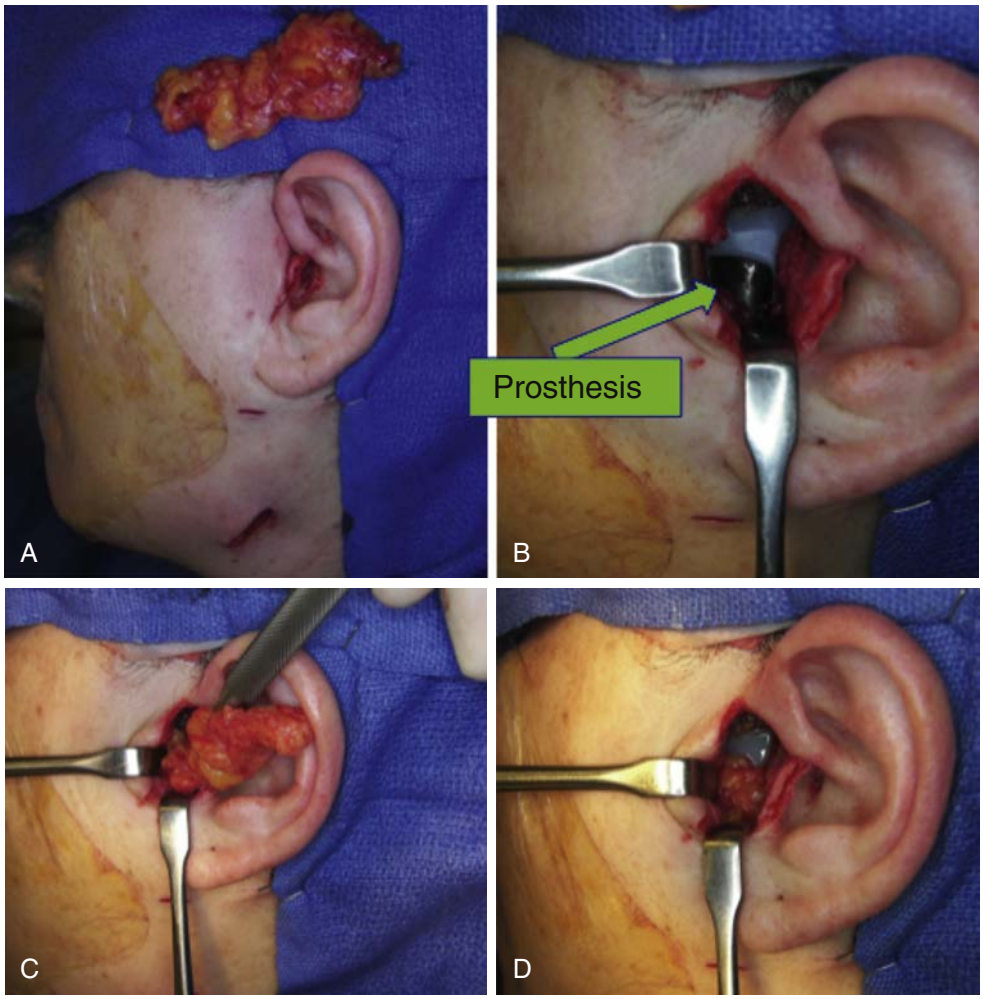

• **Figure 13-15** **A,** Fat harvested from abdomen for placement around the articulating area of the prosthesis. **B,** Patient-fitted prosthesis exposed via the endaural incision. **C,** Packing the fat into the joint area. **D,** Completion of fat packing and ready for incision closure.

15. Bone screws or temporary anchoring devices (TADs) can be placed in the alveolar bone area if the surgeon prefers, so that the required post-surgery interarch elastics to support the mandible and occlusion can be applied to these devices and not tooth borne, which could extrude or displace the teeth.
16. Any other adjunctive procedures can be performed such as genioplasty or rhinoplasty. Special care must be taken when performing a concomitant genioplasty procedure to use a conservative dissection along the symphysis/body region to prevent communication with the total joint prosthesis implantation site.

Appropriate IV antibiotics are used while in the hospital and then PO antibiotics for an additional 7 to 10 days. This patient management scheme should minimize the risk of infection.

Post-surgically, light force vertical elastics are necessary to support the mandible because the muscles of mastication are detached during surgery and may take a few weeks to reattach and provide adequate support to the mandible. Otherwise, post-surgical patient management is the same as routine double-jaw orthognathic surgery.[38,39]

CASE STUDY 13-1

This 19-year-old female had the onset of TMJ problems at the age of 15 secondary to bilateral TMJ reactive arthritis. She had previous orthodontics with four first bicuspid extractions from the age of 13 to 16 followed by splint therapy for 2 years, but the TMJ pathology and mandibular retrusion continued to worsen. She presented with a significant A-P hypoplasia of both maxilla and mandible and developed a class II anterior open bite occluding only on the second molars (Figures 13-16, *A-C;* 13-17, *A-C;* 13-18, *A*). She also had hypertrophied turbinates with nasal airway obstruction. Presurgery her TMJ pain was 8 (0 = no pain or no limitations; 10 = worst pain imaginable or total loss of function), headaches 7, jaw function 6, diet 7, and disability 6. Maximum incisal opening was 35 mm, but 27 mm without significant pain. CBCT (Figure 13-19, *A-D*) shows advanced arthritis with significant condylar resorption compatible with reactive arthritis. Presurgical MRI (Figure 13-20) shows the arthritic changes in the joints, low grade inflammatory response particularly on the left side, and the severely degenerated articular discs rendering them nonsalvageable, thus, the necessity for patient-fitted TMJ Concepts total joint prostheses to reconstruct the TMJs and advance the maxillomandibular complex in a counterclockwise direction. This case was prepared with the protocol of C-TJR-OS using CASS for virtual surgical planning as previously described.

The patient underwent the following surgical procedures: (1) bilateral TMJ reconstruction and counterclockwise rotation-advancement of the mandible (16 mm at pogonion) with TMJ Concepts total joint prostheses, (2) multiple maxillary osteotomies to counterclockwise rotate and advance the incisors 8 mm and upward positioning 5 mm (see Figure 13-18, *B*), (3) bilateral mandibular coronoidotomies, (4) bilateral TMJ fat grafts (harvested from the abdomen), and (5) bilateral partial nasal inferior turbinectomies.

At 2 years post-surgery she has a stable skeletal and occlusal relationship, improved facial balance, and good nasal and oropharyngeal airways (see Figures 13-16, *D-F*; 13-17, *D-F*). TMJ pain 0, headaches 0, jaw function 1, diet 2, disability 0, and incisal opening of 42 mm.



• **Figure 13-16** A 19-year-old female with bilateral TMJ reactive arthritis, with retruded mandible and maxilla. **A-C,** Presurgery clinical pictures. **D-F,** Clinical images at 2 years post-surgery for (1) bilateral TMJ total joint prostheses with counterclockwise rotation of the mandible, (2) maxillary osteotomies, (3) bilateral coronoidectomies, (4) bilateral TMJ fat grafts, and (5) bilateral partial turbinectomies.

Continued

CASE STUDY 13-1—cont'd



• **Figure 13-17** **A-C,** Presurgery occlusion with a Class II end-on open bite, previous extraction of four first bicuspids, and occlusal contact only on the second molars. **D-F,** At 2 years post-surgery, the occlusion is stable with a class I cuspid-molar relationship.

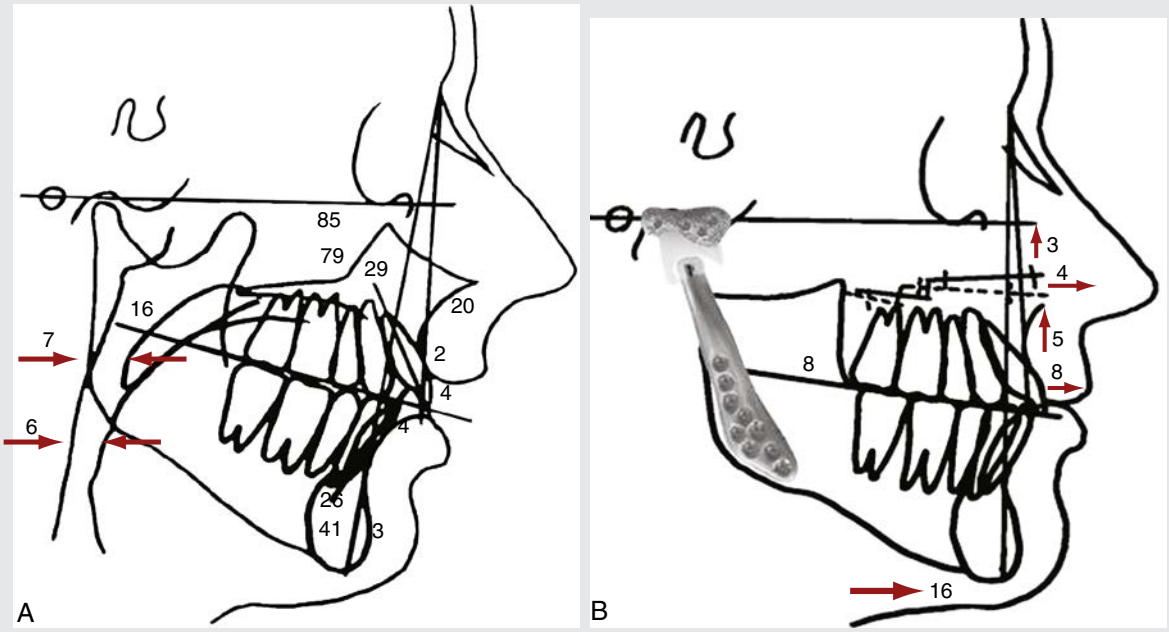

• **Figure 13-18** **A,** Presurgical cephalometric tracing shows the retruded maxilla and mandible as well as the high occlusal plane angle (16 degrees) and decreased oropharyngeal airway. **B,** The surgical treatment objective demonstrated the planned surgical changes with counterclockwise rotation-advancement with the maxillary incisal edges advancing 8 mm and moved upward 5 mm, with pogonion advancing 16 mm.

CASE STUDY 13-1—cont'd

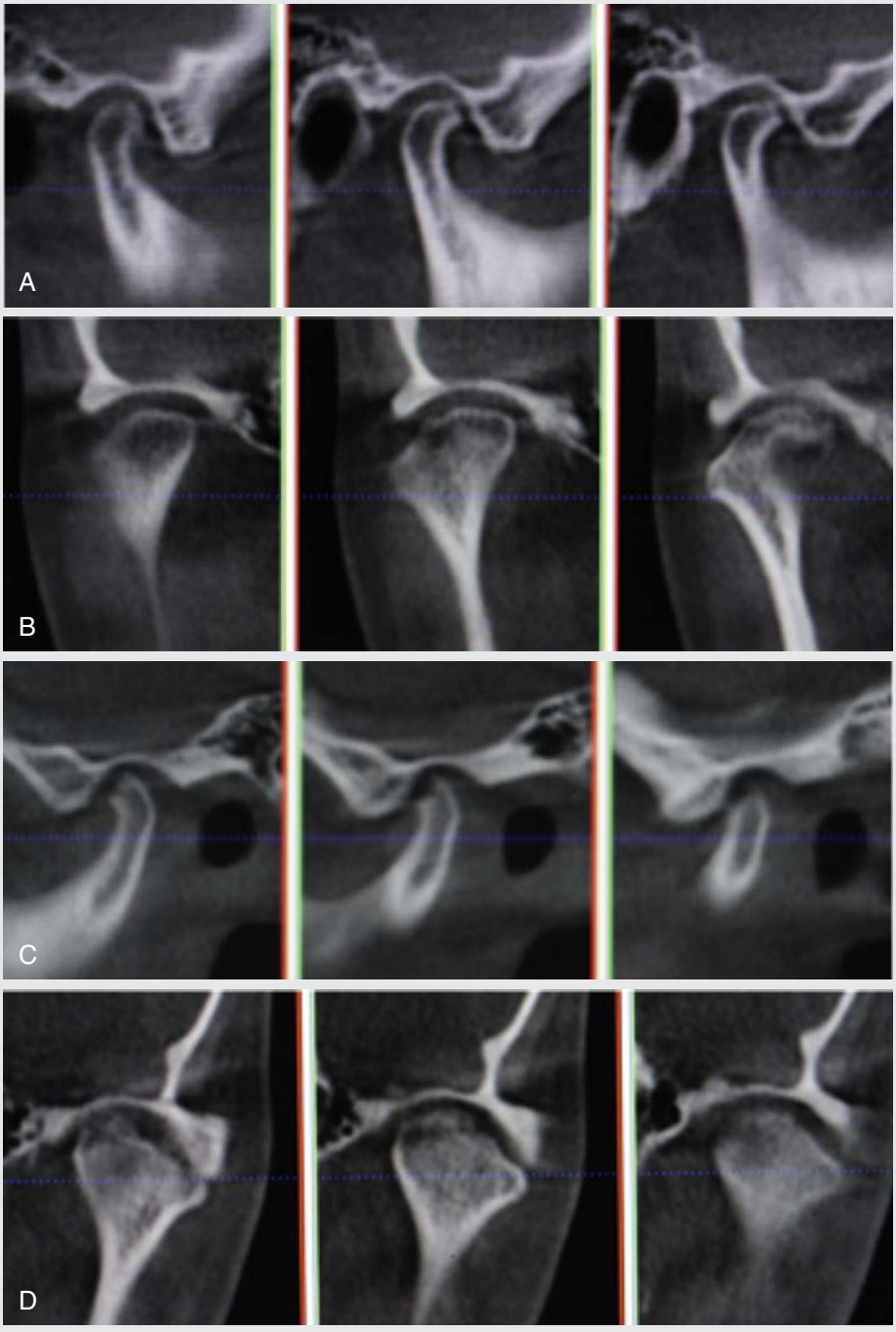

• **Figure 13-19** Presurgery sagittal and coronal images (CBCT) of bilateral TMJs demonstrating arthritic changes as a result of the reactive arthritis. **A,** Right TMJ sagittal view; **B,** right TMJ coronal view; **C,** left TMJ sagittal view; and **D,** left TMJ coronal view.

Continued

CASE STUDY 13-1—cont'd

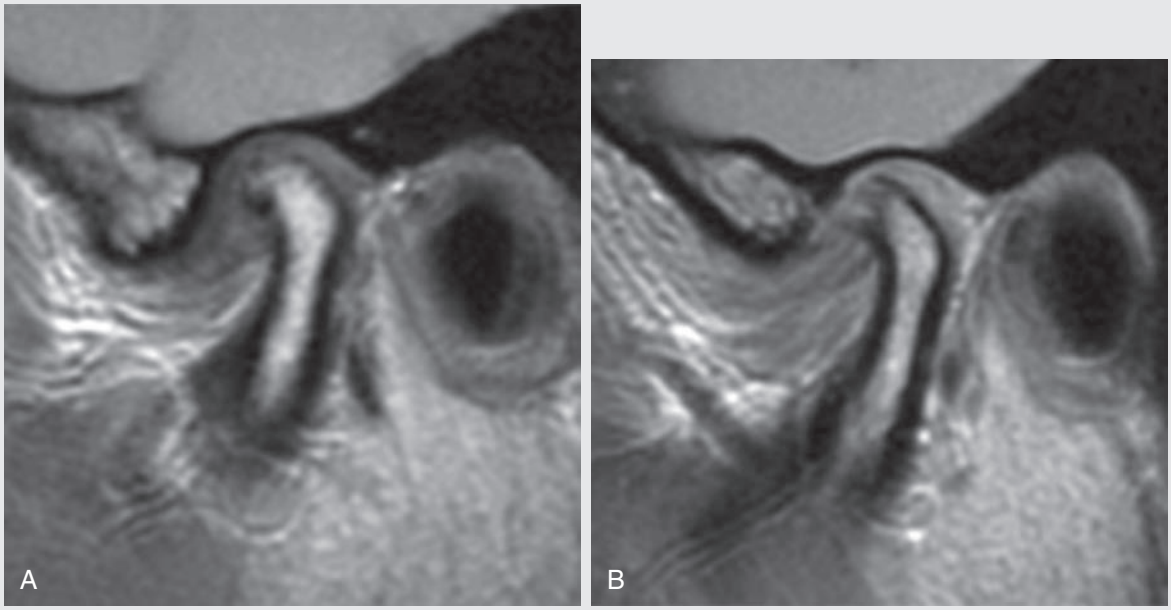

• **Figure 13-20** MRI presurgery sagittal T1 images of bilateral TMJs, showing anteriorly displaced, nonsalvageable discs with resorbed and arthritic condylar heads; **A,** right TMJ; **B,** left TMJ.

Fat Grafts

Early on in the use of total joint prostheses, a common problem encountered in approximately 35% of the patients was post-surgical fibrosis and heterotopic bone formation around the prostheses causing jaw dysfunction, decreased incisal opening, and pain.[40] In 1992, Wolford developed a technique to place fat grafts (harvested from the abdomen or buttock) around the articulating area of the total joint prosthesis to eliminate the dead space. This prevents blood clot formation in the space around the prosthesis that could provide a matrix for fibrous ingrowth and pluripotential cells migrating into the area that could develop heterotopic bone and dense fibrotic tissues. Also, in patients with previous failed alloplastic implants, the fat graft blocks out a large area in which the foreign body giant cell reaction (FBGCR) and reactive bone may otherwise redevelop. Wolford et al.[40-42] have demonstrated the improved outcomes for patients using fat grafts packed around the prostheses compared to patients that did not receive the fat grafts relative to function, pain, and elimination of additional surgical procedures for joint debridement. Mercuri et al.[43] reported the efficacy of the fat grafts packed around the prostheses in TMJ ankylosis cases.

Treatment Outcomes Using These Treatment Protocols

Dela Coleta et al.[44] evaluated 47 female patients for surgical stability following bilateral TMJ reconstruction using TMJ Concepts patient-fitted TMJ total joint prostheses, TMJ fat grafts, and counterclockwise rotation of the maxillomandibular complex with menton advancing an average of 18.4 mm and the occlusal plane decreasing an average of 14.9 degrees. Average follow-up was 40.6 months. Results demonstrated minor maxillary horizontal changes while the mandibular measurements remained very stable.

Pinto et al.[45] evaluated the same 47 female patients relative to pain and dysfunctional outcomes. Patients were divided into two groups based on the number of previous surgeries: group 1 had zero to one previous surgery while group 2 had two or more previous surgeries. Significant improvements (37% to 52%) were observed for TMJ pain, headaches, jaw function, diet, and disability. MIO increased 14%. Group 1 patients had better pain and jaw function results than group 2 patients. For patients who did not receive fat grafts around the prostheses and had previous failure of Proplast-Teflon (Vitek Inc., Houston, TX) or Silastic (Dow-Corning Inc., Midland, MI) TMJ implants, more than half required secondary surgery including TMJ debridement for removal of FBGCR, fibrosis, and/or heterotopic bone formation. These two studies demonstrated that end-stage TMJ patients could be treated in one operation with TMJ Concepts patient-fitted TMJ total joint prostheses, fat grafts, and maxillomandibular counterclockwise rotation for correction of an associated dentofacial deformity with good stability and improvement in pain and TMJ function.

Although the life expectancy of this device is unknown, Wolford et al.[46] recently published a 20-year follow-up

CASE STUDY 13-2

This 18-year-old patient (Figures 13-21, *A-C*; 13-22, *A-C*; 13-23, *A*) developed severe juvenile idiopathic arthritis (JIA), onset at age 7 years with milder effects in multiple other joints, had sleep apnea, nasal airway obstruction related to hypertrophied turbinates, and pain. TMJ pain was at 7, headaches at 7, myofascial pain at 7, jaw function at 7, diet at 6, and disability at 6. Incisal opening was 33 mm. MRI sagittal imaging of the left TMJ (Figure 13-24, *A*) and right TMJ (see Figure 13-24, *B*) demonstrates the classic appearance of JIA with: (1) loss of condylar height, (2) A-P mushrooming of the condylar stump, (3) articular disc in position between the remaining condyle and fossa, (4) resorption of the articular eminence, (5) Reactive pannus surrounding the disc, and (6) condyles positioned forward in the fossa. In the coronal view (see Figure 13-24, *C*) the condylar stumps are very narrow in a medial-lateral dimension with significant loss of vertical height. This patient was a candidate for patient-fitted TMJ Concepts total joint prostheses to reconstruct the TMJs and advance the maxillomandibular complex in a counterclockwise direction.

The treatment plan (see Figure 13-23, *B*) in a single-stage surgery included: (1) bilateral TMJ reconstruction and mandibular advancement (21 mm) in a counterclockwise direction with TMJ Concepts/Techmedica total joint prostheses, (2) bilateral coronoidectomies, (3) bilateral TMJ fat grafts, (4) multiple maxillary osteotomies with counterclockwise rotation to move the anterior aspect upward and posterior aspect downward, and advancing the incisors 4 mm,



• **Figure 13-21 A-C,** 18-year-old female with JIA and grossly resorbed mandibular condyles, severely retruded mandible and maxilla, and high occlusal plane angle facial morphology. **D-F,** The patient is seen at 3 years post-surgery demonstrating significantly improved facial balance and function.

Continued

CASE STUDY 13-2—cont'd

(5) 4-mm bony genioplasty with pogonion advancing a total of 25 mm, and (6) bilateral partial inferior turbinectomies.

The traditional C-TJR-OS protocol was used to prepare this case for surgery with the surgery performed on the stereolithic model by the surgeon for manufacture of the TMJ total joint prostheses, then duplicated on the articulator-mounted dental models for construction of the intermediate and final palatal splints.

With the counterclockwise rotation of the maxillomandibular complex and the genioplasty, the pogonion advanced 25 mm. The patient is seen at 3 years post-surgery (see Figures 13-21, *D-F*; 13-22, *D-F*) with good facial balance, skeletal and occlusal stability, significant reduction in pain, and an incisal opening of 39 mm.



• **Figure 13-22** **A-C,** A significant anterior open bite is present and class II occlusion. **D-F,** At 3 years post-surgery she demonstrates a stable class I occlusion.

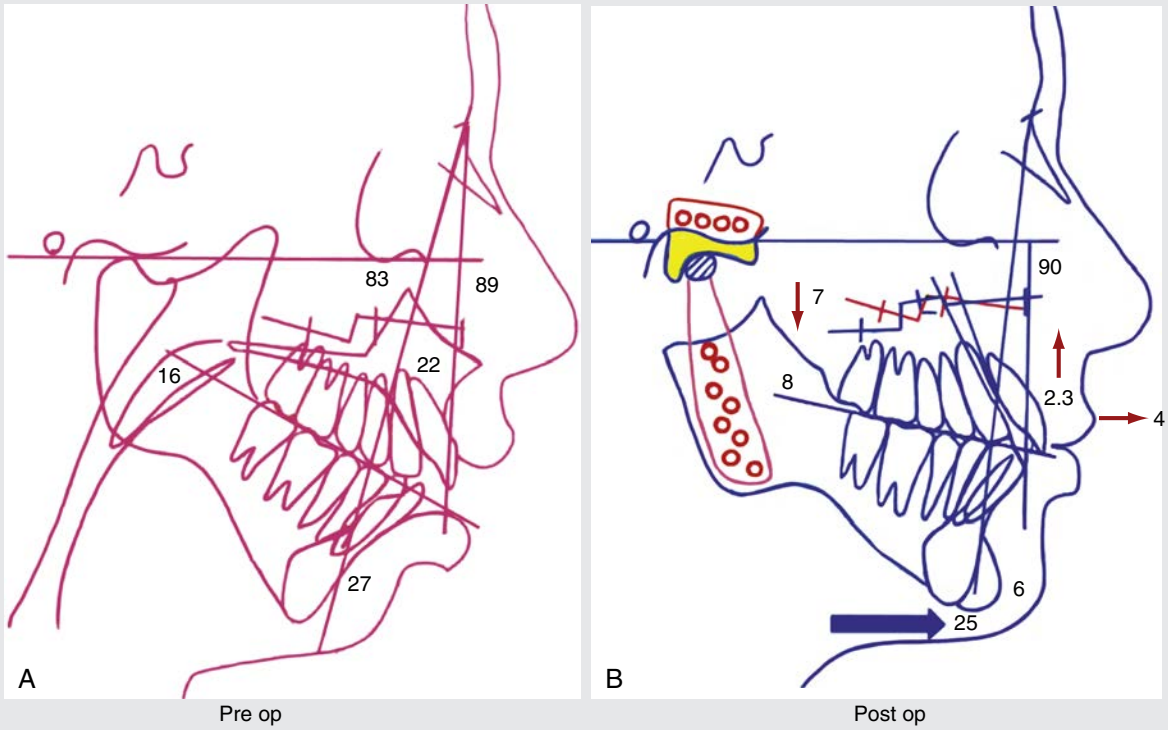

Pre op Post op

• **Figure 13-23** **A,** The cephalometric analysis shows the severe jaw deformity and high occlusal plane angulation. **B,** The prediction tracing demonstrates the counterclockwise rotation of the maxillomandibular complex. The chin is augmented 4 mm with pogonion advanced a total of 25 mm.

CASE STUDY 13-2—cont'd

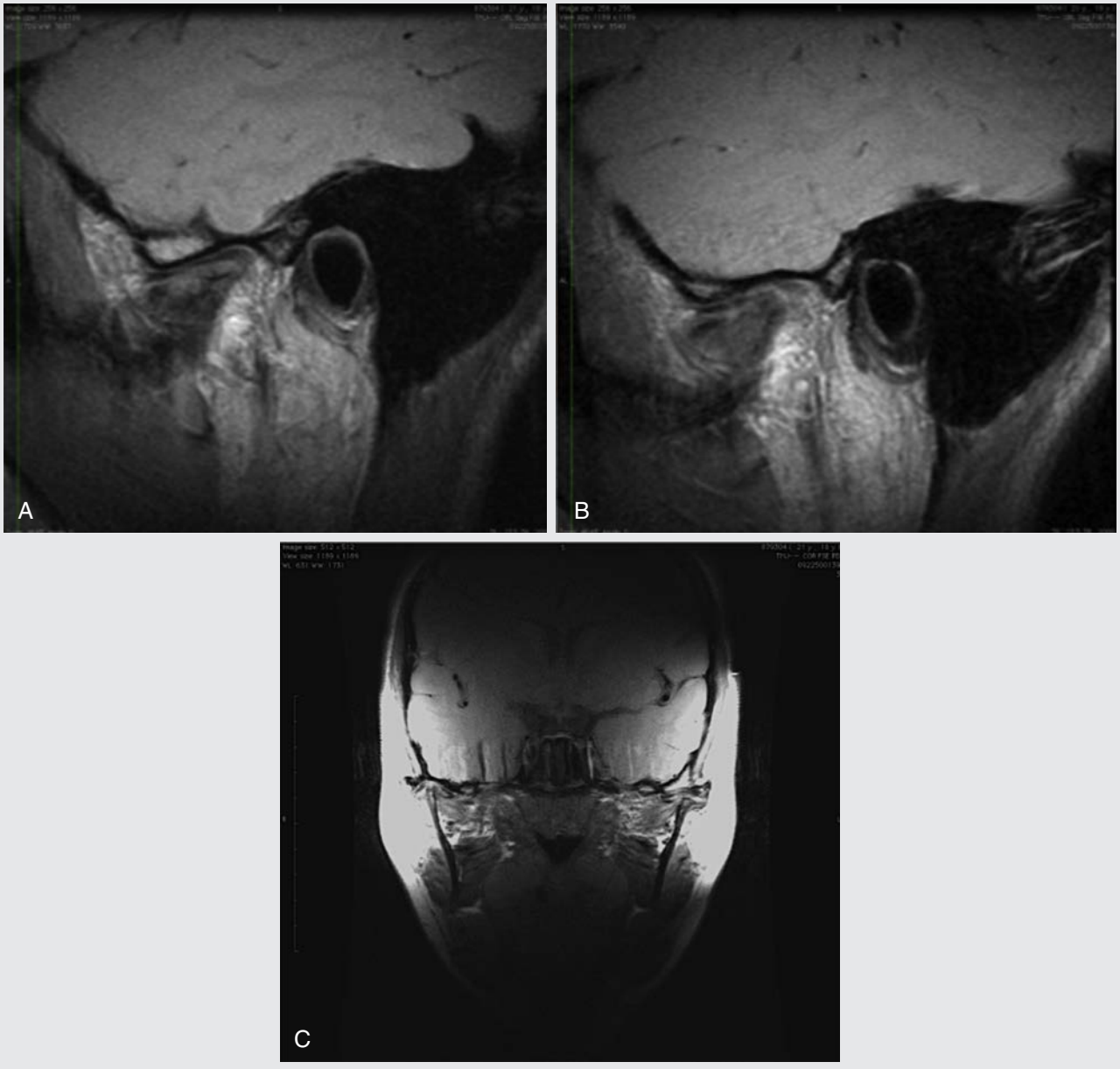

• **Figure 13-24** MRI of the TMJ T-1 sagittal views. **A,** Left TMJ. **B,** Right TMJ; show classic JIA imaging with (1) loss of condylar height, (2) A-P mushrooming of the condylar stump, (3) articular disc in position between the remaining condyle and fossa, (4) resorption of the articular eminence, (5) reactive pannus surrounding the disc, and (6) condyles positioned forward in the fossa. **C,** Coronal view shows the loss of condylar height and transverse narrowness of remaining condylar stump.

study of 56 patients who had received the Techmedica total joint prosthesis between 1989 and 1993. There were statistically significant improvements in all parameters including incisal opening, jaw function, TMJ pain, and diet, with 85.7% of the patients reporting significant improvement in their quality of life. The greater the number of previous TMJ surgeries, the lower degree of subjective improvement patients reported, but they did report increased objective mandibular function and improved quality of life. There were no reports of device removal due to material wear or failure.

Wolford et al.,[20-24,44-53] Mercuri et al.,[22,24,46,54-60] and others[61-64] have published numerous studies in reference to outcome data using TMJ total joint prostheses. A summary of these publications has produced the following facts in reference to the TMJ Concepts total joint prosthesis:

1. TMJ Concepts prostheses are superior to autogenous tissues for end-stage TMJ reconstruction relative to subjective and objective outcomes[23,47,57,58,60]
2. After two previous TMJ surgeries, autogenous tissues have a very high failure rate, whereas patient-fitted total joint prostheses have a high success rate[23,46,59,60]
3. No donor site morbidity
4. Increased number of previous TMJ surgeries produces a lower level of improvement related to pain and function outcomes compared to patients with no to one previous TMJ surgeries[21-24,45-47,52-60]
5. Failed TMJ alloplastic reconstruction (i.e., P/T, Silastic, metal-on-metal articulation, etc.) can create a foreign-body giant cell reaction and/or metallosis, best treated by joint debridement and reconstruction with patient-fitted total joint prostheses[21-24,45-47,50,53,56]
6. Fat grafts packed around the articulating area of the prostheses improves outcomes relative to decreased pain, improved jaw function, and decreased requirement for repeat surgery [40-43]
7. Osseointegration of the TMJ Concepts fossa and mandibular components occurs and is important for long-term stability[20,22-24,44,45-47,51-55]
8. Posterior stop on the fossa component is important to stabilize the joint, jaw position, and occlusion[20,23,21,44,45,51,52]
9. Concomitant orthognathic surgery can be performed at the same time as the TMJs are reconstructed[20,23,21,44,45,51,52]
10. A 20-year follow-up study[46] demonstrated improvements in pain, jaw function, diet, incisal opening, and quality of life

Age for Surgical Intervention

Although there are individual variations, females usually have the majority of their facial growth (98%) complete by the age of 15 years and males by the age of 17 to 18 years.[65] Predictability of results and limiting correction of the jaw and TMJ pathology related deformities to one major operation can best be achieved by waiting until growth is relatively complete if only the TMJ total joint prostheses are placed without maxillary surgery, particularly if only a unilateral prosthesis is required. However, there are definite indications for performing surgery during the growing years such as progressive TMJ deterioration, ankylosis, masticatory dysfunction, tumor removal, pain, and sleep apnea. Performing surgery during growth may result in the need for additional surgery at a later time to correct a resultant deformity and malocclusion that may develop during the completion of growth. Additional surgery is a greater probability with unilateral prosthesis and a normal contralateral TMJ if surgery is performed during the growing years. In addition, some orthognathic surgical procedures have a profound affect on subsequent facial growth and development, including maxillary Le Fort I osteotomies, where maxillary A-P growth is arrested, but the vertical alveolar growth of the maxilla and mandible continues contributing to a downward and backward rotation vector of facial development, but the occlusion should stay together. Therefore, bilateral TMJ patient-fitted total joint prostheses and maxillary osteotomies can be done at an earlier age with predictable results.

If repeat orthognathic surgery is required at a later time, the advancement of the mandible with the TMJ total joint prosthesis can be accomplished by one of four surgical options: (1) intraoral ramus sagittal split osteotomy; (2) extraoral sagittal split ramus osteotomy (ESSRO); (3) advance the mandible forward relative to the prosthesis by removing the screws from the mandibular component, separate it from the ramus, advance the mandible along the patient-fitted prosthesis and refixate the prosthesis with bone screws to the mandible in its new position; or (4) replace the mandibular component of the total joint prosthesis with a new longer mandibular component that would be reattached to the mandibular ramus after the mandible is moved into its new position.

We have previously published on maxillary and mandibular orthognathic surgery and the effects on growth, with guidelines for age considerations for surgical intervention[66-68] as well as TMJ surgery effects on facial growth.[69] We have successfully treated juvenile idiopathic arthritis (JIA) patients (ages 12–14 years and older) with the protocol described above in one stage with good functional and esthetic results without requiring secondary procedures.[20] These cases are predictable when performed at age 13 years or older in females and 15 years or older in males. However, the vector of facial growth will change in younger patients to a downward and backward direction.

Summary

Healthy and stable TMJs are necessary for quality treatment outcomes in orthognathic surgery. If the TMJs are not stable and healthy, orthognathic surgery results may be unsatisfactory relative to function, esthetics, skeletal and occlusal stability, and pain. The oral and maxillofacial surgeon should be suspicious of possible TMJ problems in the following types of patients:

1. High occlusal plane angle facial morphologies with retruded maxilla and mandible;
2. Class II high occlusal plane angle and retruded mandibular morphological type, particularly those with anterior open bites;
3. Progressively worsening class II occlusal and jaw relationship;
4. Facial asymmetry, particularly with progressive worsening; and
5. Patients reporting headaches, TMJ pain, myofascial pain, history of clicking and popping of the TMJs, and/or ear symptoms.

The surgeon should not ignore these symptoms. With one or more of these symptoms, patients should be evaluated for possible TMJ pathology. An MRI of the TMJs can aid in identification of the specific TMJ pathology and treatment options. Failure to recognize and treat these conditions for patients requiring orthognathic surgery can result in significant relapse, increased pain, and greater complexity of subsequent treatment.

During the past 25 years, major advancements have been made in TMJ diagnostics and the development of surgical procedures to treat and rehabilitate the pathologic, dysfunctional, and painful TMJ. Research has clearly demonstrated that TMJ and orthognathic surgery can be safely and predictably performed at the same operation, but it does require the correct diagnosis and treatment plan and a surgeon with expertise in both TMJ and orthognathic surgery. The surgical procedures can be separated into two or more surgical stages, but the TMJ surgery should be done first. With the correct diagnosis and treatment plan, combined TMJ and orthognathic surgical approaches provide complete and comprehensive management of patients with co-existing TMJ pathology and dentofacial deformities.

References

1. Wolford LM, Cassano DS, Goncalves JR: Common TMJ disorders: orthodontic and surgical management. In McNamara JA, Kapila SD, editors: *Temporomandibular disorders and orofacial pain: separating controversy from consensus*, vol. 46. Craniofacial Growth Series, Ann Arbor, MI, 2009, University of Michigan, pp 159–198.
2. Wolford LM, Movahed R: Concomitant TMJ and orthognathic surgery: diagnosis and treatment planning, Oral and Maxillofacial Surgery Knowledge Update, Available at: AAOMS online.
3. Wolford LM, Dhameja A: Planning for combined TMJ arthroplasty and orthognathic surgery. In Ness GM, editor: *Atlas of the oral and maxillofacial clinics of North America*, Philadelphia, 2011, Saunders, pp 243–270.
4. Wolford LM: Mandibular asymmetry: temporomandibular joint degeneration. In Bagheri SC, Bell RB, Khan HA, editors: *Current therapy in oral and maxillofacial surgery*, St Louis, 2012, Elsevier Saunders, pp 696–725.
5. Wolford LM, Reiche-Fischel O, Mehra P: Changes in temporomandibular joint dysfunction after orthognathic surgery, *J Oral and Maxillofacial Surg* 61(6):655–660, 2003; discussion 661.
6. Wolford LM: Surgical planning in orthognathic surgery (Chapter 60). In Booth PW, Schendel SA, Hausamen JE, editors: *Maxillofacial surgery*, vol. 2. St Louis, 2007, Churchill Livingstone, pp 1155–1210.
7. Goncalves JR, Gomes LCR, Vianna AP, et al.: Airway space changes after maxillomandibular counterclockwise rotation and mandibular advancement with TMJ Concepts total joint prostheses: three-dimensional assessment, *Int J Oral Maxillofac Surg* 42:1014–1022, 2013.
8. Wolford LM, Perez D, Stevao E, Perez E: Airway space changes after nasopharyngeal adenoidectomy in conjunction with Le Fort I osteotomy, *J Oral Maxillofac Surg* 70:665–671, 2012.
9. Coleta KE, Wolford LM, Gonçalves JR, et al.: Maxillomandibular counter-clockwise rotation and mandibular advancement with TMJ Concepts total joint prostheses: part II—airway changes and stability, *Int J Oral Maxillofac Surg* 38(3):228–235, 2009. Epub 2009 Jan 9.
10. Goncalves JR, Buschang PH, Goncalves DG, Wolford LM: Postsurgical stability of oropharyngeal airway changes following counter-clockwise maxillomandibular advancement surgery, *J Oral Maxillofac Surg* 64:755–762, 2006.
11. Mehra P, Downie M, Pitta MC, Wolford LM: Pharyngeal airway space changes after counterclockwise rotation of the maxillomandibular complex, *Am J Orthod Dentofac Orthop* 120:154–159, 2001.
12. Wolford LM, Cardenas L: Idiopathic condylar resorption: diagnosis, treatment protocol, and outcomes, *Am J Orthod Dentofac Orthop* 116:667–676, 1999.
13. Wolford LM: Idiopathic condylar resorption of the temporomandibular joint in teenage girls (cheerleaders syndrome), *Bayl Univ Med Cent Proc* 14:246–252, 2001.
14. Henry CH, Hudson AP, Gerard HC, et al.: Identification of *Chlamydia trachomatis* in the human temporomandibular joint, *J Oral Maxillofac Surg* 57:683–688, 1999.
15. Henry CH, Hughes CV, Gerard HC, et al.: Reactive arthritis: preliminary microbiologic analysis of the human temporomandibular joint, *J Oral Maxillofac Surg* 58:1137–1142, 2000.
16. Henry CH, Pitta MC, Wolford LM: Frequency of chlamydial antibodies in patients with internal derangement of the temporomandibular joint, *Oral Surg Oral Med Oral Pathol Oral Radiol Endod* 91(3):287–292, 2001.
17. Henry CH, Wolford LM: Substance P and mast cells: preliminary histologic analysis of the human temporomandibular joint, *Oral Surg Oral Med Oral Pathol Oral Radiol Endod* 92(4): 384–389, 2001.
18. Henry CH, Nikaein A, Wolford LM: Analysis of human leukocyte antigens in patients with internal derangement of the temporomandibular joint, *J Oral Maxillofac Surg* 60:778–783, 2002.

19. Henry CH, Whittum-Hudson JA, Tull GT, Wolford LM: Reactive arthritis and internal derangement of the temporomandibular joint, *Oral Surg Oral Med Oral Pathol Oral Radiol Endod* 104:e22–e26, 2007.
20. Mehra P, Wolford LM, Baran S, Cassano DS: Single-stage comprehensive surgical treatment of the rheumatoid arthritis temporomandibular joint patient, *J Oral Maxillofac Surg* 67:1859–1872, 2009.
21. Wolford LM, Pitta MC, Reiche-Fischel O, Franco PF: TMJ Concepts/Techmedica custom-made TMJ total joint prosthesis: 5-year follow-up study, *Int J Oral Maxillofac Surg* 32:268–274, 2003.
22. Mercuri LG, Wolford LM, Sanders B, et al.: Custom CAD/CAM total temporomandibular joint reconstruction system: preliminary multicenter report, *J Oral Maxillofac Surg* 53:106–115, 1995.
23. Wolford LM, Cottrell DA, Henry CH: Temporomandibular joint reconstruction of the complex patient with the Techmedica custom-made total joint prosthesis, *J Oral Maxillofac Surg* 52:2–10, 1994.
24. Mercuri LG, Wolford LM, Sanders B, et al.: Long-term follow-up of the CAD/CAM patient fitted total temporomandibular joint reconstruction system, *J Oral Maxillofac Surg* 60:1440–1448, 2002.
25. Movahed R, Morales-Ryan C, Allen WR, et al.: Outcome assessment of 603 cases of concomitant inferior turbinectomy and LeFort I osteotomy, *Bayl Univ Med Cent Proc* 26:376–381, 2013.
26. Linder-Aronson S: Adenoids. Their effect on mode of breathing and nasal airflow and their relationship to characteristics of the facial skeleton and the dentition. A biometric, rhino-manometric and cephalometro-radiographic study on children with and without adenoids, *Acta Otolaryngol Suppl* 265:1–132, 1970.
27. Harari D, Redlich M, Miri S, et al.: The effect of mouth breathing versus nasal breathing on dentofacial and craniofacial development in orthodontic patients, *Laryngoscope* 120(10):2089–2093, 2010.
28. Hultcrantz E, Larson M, Hellquist R, et al.: The influence of tonsillar obstruction and tonsillectomy on facial growth and dental arch morphology, *Int J Pediatr Otorhinolaryngol* 22(2):125–134, 1991.
29. Schendel SA, Eisenfeld J, Bell WH, et al.: The long face syndrome: vertical maxillary excess, *Am J Orthod* 70(4):398–408, 1976.
30. Chemello PD, Wolford LM, Buschang MS: Occlusal plane alteration in orthognathic surgery—part II: long-term stability of results, *Am J Orthod Dentofac Orthop* 106:434–440, 1994.
31. Wolford LM, Chemello PD, Hilliard F: Occlusal plane alteration in orthognathic surgery—part I: effects on function and esthetics, *Am J Orthod Dentofac Orthop* 106:304–316, 1994.
32. Wolford LM, Chemello PD, Hilliard FW: Occlusal plane alteration in orthognathic surgery, *J Oral Maxillofac Surg* 51:730–740, 1993.
33. Movahed R, Teschke M, Wolford LM: Protocol for concomitant temprormandibular joint custom-fitted total joint reconstruction and orthognathic surgery utilizing computer-assisted surgical simulation, *J Oral Maxillofac Surg* 71:2123–2129, 2013.
34. Movahed R, Wolford LM: Protocol for concomitant temporomandibular joint custom-fitted total joint reconstruction and orthognathic surgery using computer-assisted surgical simulation, *Oral Maxillofac Surg Clin N Am* 27(1):37–46, 2015.
35. Xia J, Ip HH, Samman N, et al.: Computer-assisted three-dimensional surgical planning and simulation: 3D virtual osteotomy, *Int J Oral Maxillofac Surg* 29:11, 2000.
36. Gateno J, Xia J, Teichgraeber J, et al.: Clinical feasibility of computer-aided surgical simulation (CASS) in the treatment of complex craniomaxillofacial deformities, *J Oral Maxillofac Surg* 65:728, 2007.
37. Rotaru H, Stan H, Florian I, et al.: Cranioplasty with custom-made implants: analyzing the cases of 10 patients, *J Oral Maxillofac Surg* 70:e169, 2012.
38. Wolford LM: Postsurgical patient management. In Fonseca RJ, Marciani RD, Turvey TA, editors: *Oral and maxillofacial surgery,* vol. III. ed 2, St Louis, 2008, Saunders, pp 396–418.
39. Wolford LM, Rodrigues DB, Limoeiro E: Orthognathic and TMJ surgery: postsurgical patient management, *J Oral Maxillofac Surg* 69:2893–2903, 2011.
40. Wolford LM, Karras SC: Autologous fat transplantation around temporomandibular joint total joint prostheses: preliminary treatment outcomes, *J Oral Maxillofac Surg* 55:245–251, 1997.
41. Wolford LM, Morales-Ryan CA, Garcia-Morales P, Cassano DS: Autologous fat grafts placed around temporomandibular joint (TMJ) total joint prostheses to prevent heterotopic bone, *Baylor Univ Med Center Proc* 21:248–254, 2008.
42. Wolford LM, Cassano DS: Autologous fat grafts around temporomandibular joint (TMJ) total joint prostheses to prevent heterotopic bone. In Shiffman MA, editor: *Autologous fat transfer*, Berlin Heidelberg, 2010, Springer-Verlag, pp 361–382.
43. Mercuri LG, Ali FA, Woolson R: Outcomes of total alloplastic replacement with periarticular autogenous fat grafting for management of reankylosis of the temporomandibular joint, *J Oral Maxillofac Surg* 66:1794–1803, 2008.
44. Coleta KED, Wolford LM, Goncalves JR, et al.: Maxillomandibular counter-clockwise rotation and mandibular advancement with TMJ Concepts 1 total joint prostheses: part I skeletal and dental stability, *Int J Oral Maxillofac Surg* 38:126–138, 2008.
45. Pinto LP, Wolford LM, Buschang PH, Bernardi FH, Goncalves JR, Cassano DS: Maxillomandibular counter-clockwise rotation and mandibular advancement with TMJ Concepts total joint prostheses: part III pain and dysfunction outcomes, *Int J Oral Maxillofac Surg* 38:326–331, 2009.
46. Wolford LW, Mercuri LG, Schneiderman ED, et al.: Twenty-year follow-up on a patient-fitted temporomandibular joint prosthesis: the Techmedica/TMJ Concepts device, *J Oral Maxillofac Surg* 73:952–960, 2015.
47. Henry CH, Wolford LM: Treatment outcomes for temporomandibular joint reconstruction after Proplast Teflon implant failure, *J Oral Maxillofac Surg* 51:352, 1993.
48. Wolford LM, Cottrell DA, Henry CH: Temporomandibular joint reconstruction of the complex patient with the Techmedica custom-made total joint prostheses, *J Oral Maxillofac Surg* 52:2, 1994.
49. Wolford LM, Pitta MC, Reiche-Fischel O, Franco PF: TMJ Concepts/Techmedica custom-made TMJ total joint prosthesis: 5-year follow-up study, *Int J Oral Maxillofac Surg* 32:268, 2003.
50. Franco PF, Talwar RM, Wolford LM: Unilateral TMJ Total joint reconstruction and the effects on the contralateral joint. AAOMS 79th Annual Meeting and Scientific Sessions, *J Oral Maxillofac Surg* 55:113, 1997.
51. Wolford LM, Bourland TC, Rodrigues D, et al.: Successful reconstruction of non-growing hemifacial microsomia patients with unilateral temporomandibular joint total joint prosthesis and orthognathic surgery, *J Oral Maxillofac Surg* 70:2835–2853, 2012.
52. Wolford LM, Pinto LP, Cardenas LE, Molina OR: Outcomes of treatment with custom-made temporomandibular joint total joint prostheses and maxillomandibular counter-clockwise rotation, *Bayl Univ Med Cent Proc* 21:18–24, 2008.

53. Wolford LM, Dingwerth DJ, Talwar RM, Pitta MC: Comparison of 2 temporomandibular joint total joint prosthesis systems, *J Oral Maxillofac Surg* 61:685–690, 2003.
54. Mercuri LG, Edibam NR, Giobbie-Hurder A: Fourteen-year follow-up of a patient-fitted total temporomandibular joint reconstruction system, *J Oral Maxillofac Surg* 65(6):1140–1148, 2007.
55. Mercuri LG, Giobbi-Hurder A: Long term outcomes after total alloplastic TMJ reconstruction following exposure to failed materials, *J Oral Maxillofac Surg* 62:1088–1096, 2004.
56. Mercuri LG: Subjective and objective outcomes for patients reconstructed with a patient-fitted total temporomandibular joint prosthesis, *J Oral Maxillofac Surg* 57:1427–1430, 1999.
57. Mercuri LG: The TMJ concepts patient fitted total temporomandibular joint reconstruction prosthesis, *Oral Maxillofac Surg Clin North Amer* 12:73, 2000.
58. Mercuri LG: The use of alloplastic prostheses for temporomandibular joint reconstruction, *J Oral Maxillofac Surg* 58:70, 2000.
59. Mercuri LG: Temporomandibular joint reconstruction. In Fonseca R, editor: *Oral and maxillofacial surgery*, Philadelphia, 2008, Elsevier, pp 945–960.
60. Mercuri LG: End-stage TMD and TMJ reconstruction. In Miloro M, Ghali G, Larsen P, Waite P, editors: *Peterson's principles of oral & maxillofacial surgery*, ed 3, Shelton, CT, 2012, People's Medical Publishing House-USA, pp 1173–1186.
61. Giannakopoulos HE, Sinn DP, Quinn PD: Biomet microfixation TMJ replacement system: a 3-year follow-up study of patients treated during 1995 to 2005, *J Oral Maxillofac Surg* 70:787–794, 2012.
62. Machon V, Hirjak D, Beno M, Foltan R: Total alloplastic TMJ replacement: the Czech-Slovak initial experience, *Int J Oral Maxillofac Surg* 41:514–517, 2012.
63. Sidebottom AJ, Gruber E: One-year prospective outcome analysis and complications following total replacement of the TMJ with the TMJ Concepts System, *Br J Oral Maxillofac Surg* 51:620–624, 2013.
64. Murdock B, Buchanan J, Cliff J: TMJ replacement: a New Zealand perspective, *Int J Oral Maxillofac Surg* 43:595–599, 2014.
65. Riolo ML, Moyers RE, McNamara JA, Hunter WS: *An atlas of craniofacial growth: cephalometric standards from the University School Growth Study, The University of Michigan*, Ann Arbor, MI, 1974, University of Michigan, pp 105–106.
66. Wolford LM, Karras SC, Mehra P: Considerations for orthognathic surgery during growth, part 1: mandibular deformities, *Am J Orthod Dentofac Orthop* 119:95–101, 2001.
67. Wolford LM, Karras SC, Mehra P: Considerations for orthognathic surgery during growth, part 2: maxillary deformities, *Am J Orthod Dentofac Orthop* 119:102–105, 2001.
68. Wolford LM, Rodrigues DB: Orthognathic considerations in the young patient and effects on facial growth. In Preedy VR, editor: *Handbook of growth and growth monitoring in health and disease*, New York, 2012, Springer, pp 1789–1808.
69. Wolford LM, Rodrigues DB: Temporomandibular joint (TMJ) pathologies in growing patients: effects on facial growth and development. In Preedy VR, editor: *Handbook of growth and growth monitoring in health and disease*, New York, 2012, Springer, pp 1809–1828.

14

Surgery for Accelerated Orthodontic Movement

CHARLES D. HASSE

Introduction

Since Professor Hugo Obwegeser's initial presentation to American oral and maxillofacial surgeons in 1966,[1] the science of orthognathic surgery has developed exponentially from life-threatening surgery to accurately planned computer-based surgery, performed meticulously and safely.[2] A myriad of clinical techniques have been introduced, and esthetic and radiographic parameters have developed over the past five decades to enable oral and maxillofacial surgeons and orthodontists to effectively manage dentofacial deformities.

Today, contemporary surgical orthodontics is a rapidly changing paradigm with the advent of new technology, new surgical techniques, and new products. In this regard, perhaps the most significant changes in conventional orthodontics have resulted from improvements in wire metallurgy, bracket design, and adhesive chemistry. Many of the preceding chapters have addressed surgical advances, particularly relative to hospital-based procedures. The purpose of this chapter is twofold: first, to present an effective surgical technique to facilitate accelerated orthodontic tooth movement in an office or outpatient surgery setting; and second, to illustrate how combining this technique with conventional orthognathic surgery can result in the correction of most facial deformities with their accompanying dental malocclusion in a time frame previously considered to be unattainable.[3] The introduction of adjunctive surgery to facilitate orthodontic tooth movement offers a significant benefit to our orthodontic colleagues in their ability to care for their patients, providing results that are stable, predictable, and reproducible with little morbidity.[4]

History of Corticotomy Surgery

Corticotomy-facilitated orthodontics is a technique that has gained little popularity in the modern era of orthognathic surgery. Nevertheless, a brief review of the history of corticotomy surgery is essential to understand and appreciate how the current technique of accelerated osteogenic orthodontics as developed by Thomas and William Wilcko[5] has evolved. Heinrich Köle[6] is generally credited with the introduction of corticotomy procedures, but his work was preceded by the efforts of others. Specifically, Talbot,[7] Skogsborg,[8] Bichlmayr,[9,10] Schönwald,[11] and Neumann[12] all introduced techniques to weaken bone through surgery. Spanier[13] developed a modification of Bichlmayr's technique and used it to augment orthodontics. Köle's technique, which he called "corticotomy surgery," necessitates cutting through both the buccal and lingual alveolar cortical bone surfaces but stopping short of the cancellous bone, thus preventing damage to the roots and preserving an adequate blood supply to the operated segments. According to Köle, the main resistance to tooth movement was encountered in the continuous cortical layer of bone. He theorized that this was likely attributable to the slower remodeling process in the cortical bone in comparison to medullary bone. He reasoned that by disrupting the continuity of the cortical layer, the speed of the tooth movement would be greatly increased. Accordingly, Köle performed cortical bone block surgery in which he moved blocks of bone that contained teeth. It was Köle's belief that leaving the medullary bone relatively intact would avoid periodontal injury and tooth devitalization. He theorized that because a block of bone was being moved rather than individual teeth, the root resorption previously attributed to rapid tooth movement of unaltered bone would not occur. Dr. Köle's combined corticotomy/osteotomy procedure was adopted almost without alteration by Horvath and Rehçk,[14] by Dal Pont,[15] and by Edland and Subrtova,[16] but it never gained wide acceptance or use by most oral and maxillofacial surgeons from 1970 to 2000.

Following Köle's work, in 1978, Epker and Paulus[17] reported their experience using corticotomy surgery to accompany orthodontic movement. Anholm and colleagues[18] reported correcting Class II cases using corticotomy facilitated surgery. Gantes[19] and coworkers reported their observations on the effects of the periodontium following corticotomy surgery. Finally, Suya[20] reported having successfully treated 395 Japanese patients combining corticotomy surgery with orthodontic tooth movement. All of these works had a common denominator of correcting malocclusions through what the Wilckos termed "bone block" surgery. That is, orthodontic correction was not a product of individual teeth orthodontically moving through bone, but rather, the movement of a surgerized block of bone that contained teeth.

The Wilckos proposed a different theory as to why corticotomy surgery was successful with their introduction of Wilckodontics at the 1998 Annual Scientific Session of the American Association of Orthodontists.[21] In Wilckodontics, or accelerated osteogenic orthodontics (AOO), or periodontally accelerated osteogenic orthodontics (PAOO), the Wilckos incorporated the principles of orthopedic surgeons Gavriel Ilizarov[22] and Harold Frost[23] into a successful technique for rapid movement of teeth through use of a bone healing process termed "regional acceleratory phenomenon."

Regional Acceleratory Phenomenon

Russian orthopedic surgeon Gavriel Ilizarov introduced the concept that stressing bone increases metabolic and cellular generation, resulting in new bone formation. Ilizarov was later called "the Magician from Kurgan" by his contemporaries, but most of his early theories regarding bone formation were disregarded as heresy and outside of conventional thinking.[22] It was not until Ilizarov successfully treated the Russian Olympic high jumper Valery Brumel, who had been seriously injured in a motorcycle accident, that his work was accepted. Today, many consider Ilizarov to be "the father of osseous distraction."

Harold Frost,[23] an orthopedic surgeon at Henry Ford Hospital in Detroit, Michigan, embraced Ilizarov's theorems and took them one step further. Not only did Frost recognize that stressing bone through injury induced a reciprocal metabolic response at the cellular level, but he saw that there was a direct correlation between the degree of bone injury and the intensity of the healing response. Frost coined the term "regional acceleratory phenomenon" or RAP to describe the stages of recovery and intensity of bone healing following injury. Bone healing normally proceeds in successive stages, termed the fracture, granulation, and modeling/remodeling stages. A separate regional acceleratory phenomenon speeds up each of the other stages. Frost theorized that osteoclast and osteoblast cells that make intercellular substances at each stage do not exist in sufficient numbers to heal the bone at the moment of injury. They are made by local multicellular mediator mechanisms that contain precursor and supporting cells, capillaries, lymph, and innervation, plus local autocrine and paracrine regulation. Under the influences of local and systemic agents, these mediator mechanisms determine whether new local osteoclasts and osteoblasts will appear, as well as when, where, how many, what kind, and for how long.

Beginning within a few days of the initial injury, RAP recruits osteoblasts and osteoclasts to accommodate healing of bone following surgery. RAP peaks at 1 to 3 months and is believed to take approximately 6 months to resolve itself. Frost described the process of RAP as a type of "SOS mechanism" that induces a dynamic remodeling process to potentiate local healing and tissue defense. After bone injury there is a temporary acceleration of localized soft and hard tissue remodeling. This proceeds to decalcification/recalcification of bone, which is completed within 6 months.

Using animal studies, Yaffe and associates[24] confirmed that RAP was observed and was indicated by a striking resorption of the cortical bone both on the surface and the bone proper following mucoperiosteal flap surgery in the jawbone of Wistar rats. This led to widening of the periodontal ligament space. Analyzing calcium retention data, Yaffe and colleagues concluded that an acceleration in mineral release occurred within the first weeks following injury, after which time the organic matrix was resorbed. The maximum alveolar resorption was seen approximately 3 weeks after surgery. The alveolar bone did recover, almost but not completely, to control levels 120 days following surgery. It was suggested that RAP may be responsible for increased mobility immediately following periodontal surgery and that bone dehiscence following full-thickness flap surgery may occur where bone is especially thin.

Accelerated Osteogenic Orthodontics

Using the principles of Frost and the results of the animal studies by Yaffe, Drs. Thomas and William Wilcko developed a coordinated approach to surgically facilitated orthodontic treatment. In 1995, the Wilckos patented their technique, initially known as "accelerated osteogenic orthodontics" (AOO) or "Wilckodontics"[25] but later termed "periodontally accelerated osteogenic orthodontics"[26] (PAOO). The Wilckos noted that following corticotomy surgery, there was a marked reduction in mineralization of the alveolar bone. They decided to incorporate the RAP phenomenon to facilitate tooth movement. They observed that it was possible to move teeth farther and faster with less resistance. They postulated that the collagenous matrix reorganizes during the process and that the periodontal ligament reorganizes while it is in a highly excitatory metabolic state resulting from the RAP phenomenon.

This reorganization results from the induced injury to bone caused by corticotomy surgery and decortication of the overlying alveolar surface. The periodontal ligament loses its memory because of high cellular turnover during the reorganization, and subsequently the teeth are more susceptible to movement through the application of directed orthodontic forces. To this mix, the Wilckos added a slowly resorbing cortical particulate allograft to maintain an open network for the proliferation of

bone-forming cells. During healing, the bone naturally goes through a phase known as osteopenia, where its mineral content is temporarily decreased. The tissues of the alveolar bone release rich deposits of calcium, and the new bone begins to mineralize in an estimated 3 to 8 weeks. While the bone is in this transient state, properly executed orthodontic technique can move teeth very quickly, because the bone is softer and there is less resistance to the orthodontic forces.

The Wilckos believed that somewhere between the time frame reported by Yaffe, of 120 days for bone to recover, and the 180 days reported by Frost, as to the completion of the decalcification/recalcification process, lay the window of opportunity for the orthodontist to move teeth at this highly accelerated rate. After this time frame, tooth movement was believed to return to its pretreatment state.

Two studies, one in humans[27] and the other in dogs,[24] provide additional insight as to the duration of the regional acceleratory phenomenon and its influence on the rate of tooth movement. Based on the results of these two studies, it seems that the length of the RAP influence is about 120 days. Although the authors acknowledge that it could be a bit longer, the regional acceleratory phenomenon does end, and with it, the impact on accelerating tooth movement. In our own experience in working with numerous orthodontists during the past 10 years, we conclude that the duration of the regional acceleratory phenomenon after corticotomy facilitated tooth movement is effective for a period of about 180 days in adults.[28]

Surgical Technique

The AOO technique as described by the Wilckos[5] is a combination of contemporary orthodontic therapy and surgical intervention. Fixed edgewise orthodontic appliances are placed during the week prior to surgery and non-extraction orthodontic treatment initiated. Full-thickness mucoperiosteal flaps are reflected both labially and lingually around all teeth to be moved orthodontically. In developing the flaps, we favor making a sulcular incision with a 12B scalpel blade, but a 15 scalpel blade, an Orban knife, or a "beaver blade" are viable alternatives depending on surgeon preference. Regardless of the approach, the most important aspect in developing the full-thickness mucoperiosteal flaps is maintaining the mucosal integrity of the papillae. Failure to do so can result in soft tissue dehiscence and periodontal problems. Some surgeons favor an alternative approach,[29] the use of a circumvestibular incision with tunneling. In our own experience, we reserve this approach principally for cases in which there is extreme crowding. This is because, when employing the conventional approach, we experienced some difficulties in repositioning and maintaining papillary height after reflection of the soft tissues.

Once adequate exposure to the bony alveolus is gained, corticotomy surgery is performed on both the labial and lingual aspects of the teeth to be moved. Ideally, the corticotomy cuts should be placed interproximally between the outline of the root surfaces, with the vertical cut terminating about 2 mm short of the crestal bone. Wilcko[30] initially performed the corticotomies using a high-speed dental drill with a no. 2 round burr and copious irrigation. We recommend using an ultrasonic micro-vibratory saw blade (Mectron, Piezosurgery Inc., Columbus, OH) instead, because we believe that it cuts more efficiently and with less potential chance for damaging teeth. When using the piezo-surgery unit, the OT7 surgical tip is ideal for making the interproximal corticotomy cuts. The horizontal connecting cuts below the apices can be effectively placed using the Piezo OT 8R or OT 8L angled saw blades. Once the interproximal saw cuts are completed, the surgeon then further decorticates the bone overlying the root surfaces using a small round burr. Care should be taken not to extend the "bleed holes" too deep, because it is indeed possible to injure the enamel surface of the underlying teeth. The Piezo OP 6 conical diamond burr can be used to create the bleed holes in situations in which the overlying bone is thin. The combination of the corticotomy cuts and stippling with bleed holes should be sufficient to induce the regional acceleratory phenomenon.

A composite bone graft combining freeze-dried demineralized bone and anorganic bone mixed in a 10% clindamycin (Cleocin) solution is wetted and spread in fairly equal proportions over the operated bone. In areas where there are root dehiscences or periodontal defects, it is advisable to use additional bone augmentation. Although some surgeons report that they do not feel that it is necessary to graft the palatal or lingual sides,[31] the Wilckos believed that the alveolar augmentation was critical to support and strengthen the periodontium, reasoning that the addition of bone to the alveolar housing of the teeth ensures root coverage as the dental arch form is modified and expanded. We agree with this argument and have found that the grafting of both labial and lingual sides, particularly when correcting transverse arch discrepancies, is essential to provide a long-term, stable result (Figure 14-1).

With rapid development and improvement in bone grafting materials and techniques, questions frequently center around the use of modern bioengineering technology to enhance the accelerated osteogenic orthodontic process. For instance, can the surgeon use Hemaseel (fibrin glue), PRP (platelet-rich plasma), membranes/barriers, rhBMP-2 (bone morphogenic protein), stem cells, or autogenous bone grafts to somehow improve the process? As of this writing, we do not have the answers, because there has not been sufficient research on modifying the technique as presented here. However, it should be noted that we have experienced outstanding results without significant variance from the technique as described by the Wilckos. Furthermore, it could be argued that by using PRP or rhBMP-2, for example, the time frame associated with RAP could be accelerated, resulting in less time for the orthodontist to effectively move teeth. Certainly research is needed to improve our understanding of the process and, ultimately, to determine how to obtain the best results for our patients. Once the bone grafting is complete, closure ensues with placement of an interproximal mattress stitch. We leave the sutures in place for 3 weeks, and favor using Gore-Tex suture both for its ease of placement between interproximal contacts and for its ability to remain intact for an extended period.

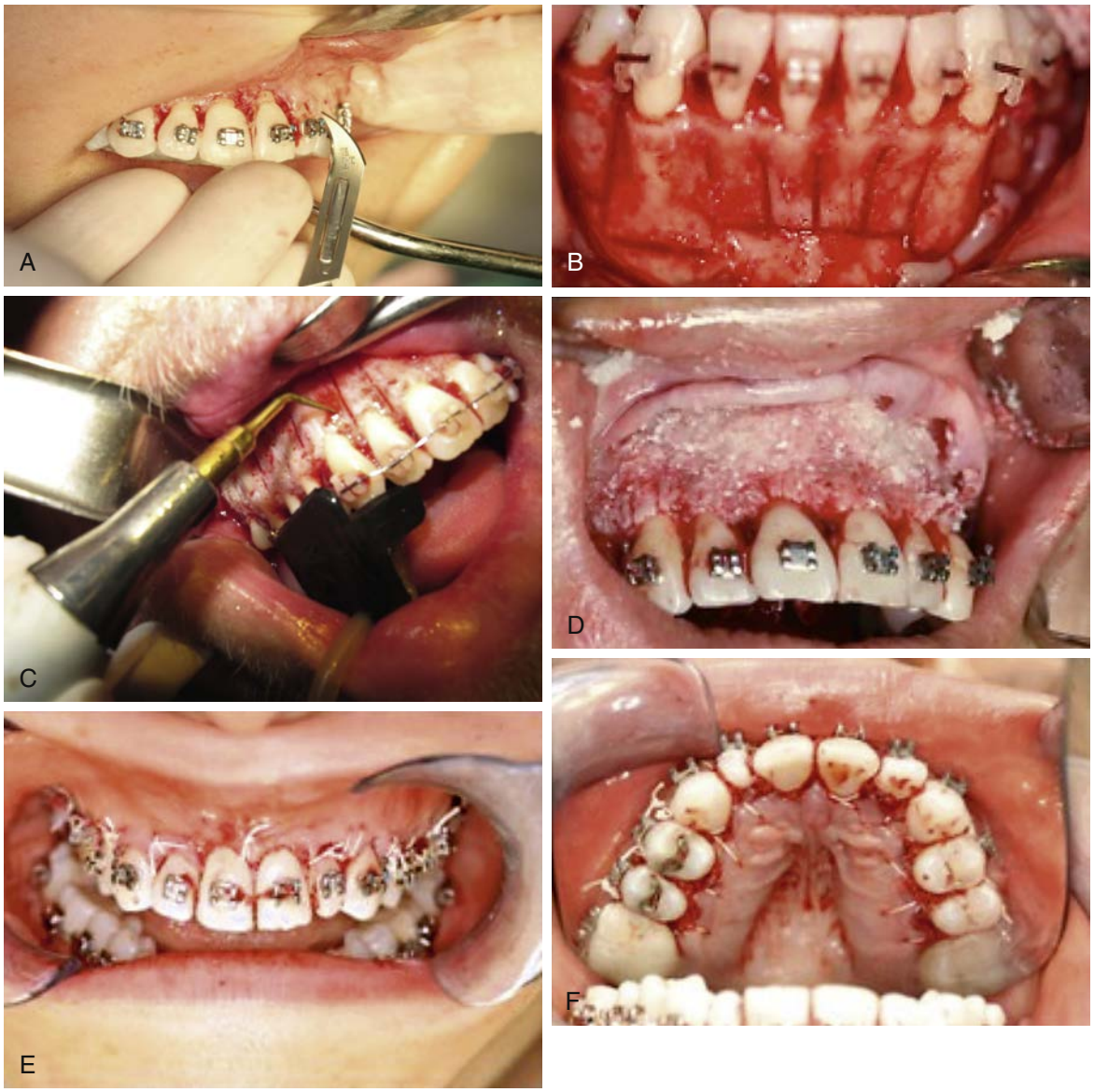

• **Figure 14-1** **A**, Sulcular incision with 12B scalpel blade. **B**, Corticotomy cuts 2 mm short of crest. **C**, Decortication with "bleed holes." **D**, Composite bone graft placed. **E**, Interproximal mattress sutures (labial view). **F**, Gore-Tex closure (palatal view).

The surgery can be performed under local, moderate sedation or general anesthesia. If the surgeon is treating an entire arch or both arches, we recommend the use of general anesthesia with the patient intubated nasoendotracheally and the airway protected. The reasons for this are twofold. First, the length of time necessary to complete a full arch case varies from patient to patient and most certainly depends on the skill of the surgeon, but 1 to 1½ hours per arch is not an uncommon timeframe. In our opinion, this is a lengthy period of time to maintain patient comfort if surgery is performed under local anesthesia only. Additionally, if a moderate sedation technique is employed, the cumulative effect of inducing a large volume of intravenous medication over long periods of time can be detrimental to the patient. Second, the piezo-surgery unit, by its very nature as an ultrasonic appliance, generates a lot of water, and the positioning of the patient's head during surgery, to allow access to the lingual and palatal areas to make the bone cuts, leaves an unguarded airway vulnerable to excessive fluids and difficulties with evacuation. Accordingly, in our approach, if we are performing AOO on more than eight teeth, we will usually intubate the patient.

Depending on the amount of surgery performed, it is not uncommon for the patient to abstain from normal activities for 2 or 3 days. We recommend a progressive diet starting with liquids and blenderized foods for the first few days, with advancement from soft chew to regular diet 2 weeks post-surgery. We avoid the use of steroids or nonsteroidal anti-inflammatory medications (NSAIDs) because they are prostaglandin inhibitors and can inhibit osteoclastic activity, which is crucial to the demineralization process essential to the regional acceleratory phenomenon. The

Gore-Tex sutures are usually removed in the third postoperative week.

Orthodontic Technique

The orthodontist may begin to move teeth within 2 to 3 weeks. The orthodontic techniques employed are standard to routine orthodontic treatment, but are significantly accelerated by the RAP induction. Because the teeth can move so rapidly, *it is highly recommended that orthodontic visits be maintained every 2 weeks*, to prevent untoward movements that could set the treatment back.

Orthodontic Technique

The following keys have been found helpful from an orthodontic treatment standpoint:

- Completely engage the brackets from the initiation of orthodontic treatment
- Use the largest Ni-Ti wires from the start
- Advance the wires as fast as orthodontic movement will allow
- If width expansion is desired, place a Hyrax expander 4 weeks after AOO surgery (Figure 14-2)
- Large tooth movements (particularly transverse width expansion) should be completed within the RAP time frame of 4 to 6 months
- TADS or other anchorage devices may be incorporated at any time to facilitate movement
- On occasion, if a tooth does not move as desired, give consideration to a repeat surgery

Indications, Contraindications, and Benefits of AOO

Indications, Contraindications, and Benefits of AOO

In our experience, accelerated osteogenic orthodontics has resulted in the successful correction of certain specific malocclusions with long-term stability:

- Dental crowding
- Impacted and transposed teeth
- Traverse maxillary width constriction
- Open bite malocclusions
- Maxillary hypoplasia with class III malocclusions of less than 4 mm underbite
- Class II dental malocclusions in children with less than 4 mm overbite
- Rapid setup of cases requiring orthognathic surgery to correct the skeletal malformation

Additionally, the AOO approach has been found to be extremely effective in orthodontic re-treatment cases due to relapse or in situations in which phase II orthodontics was completed early on and the patient experienced latent growth as an adolescent. Another clinical situation in which AOO has proven to be most beneficial is in the management of TMD patients who have a resultant disocclusion or malocclusion after the use of a repositioning orthotic appliance (splint), which often can result from a discrepancy between the centric occlusion and centric relation of the patient.



• **Figure 14-2** **A**, Transverse arch discrepancy with Hyrax in place (before accelerated osteogenic orthodontic [AOO] surgery); **B**, AOO + expansion with Hyrax can add 6 to 7 mm in cross-arch width.

There are relatively few contraindications to the accelerated osteogenic orthodontic approach. Preexisting oral infection and oral pathology should obviously be treated before beginning AOO treatment. Routine maintenance dentistry and dental prophylaxis should be accomplished prior to treatment from both an orthodontic and surgical standpoint. Advanced generalized periodontal bone loss of greater than 5 to 6 mm is a relative contraindication dependent on the clinical examination and stability of the teeth in bone. Patients with medical conditions that are being managed with long-term use of medications such as NSAIDs, corticosteroids, or immunosuppressives (e.g., patients with arthritis) are not good candidates for accelerated osteogenic orthodontics because of the osteoclastic inhibition inherent in the use of those drugs. Patients with osteoporosis may not be suitable candidates for treatment depending on their bone density values. Patients who are using bisphosphonates to treat this condition are *not* candidates for surgery unless the bisphosphonate treatment is aborted and a reasonable "drug holiday" has ensued. The use of CTX markers as advocated by Marx[32] and the judgment of the treating oral and maxillofacial surgeon are paramount in treating these patients to prevent osteonecrosis of the jaw.

The benefits of the accelerated osteogenic surgery approach are many. The most attractive advantage particularly from the patient standpoint is the accelerated timeframe. Most cases that are corrected by AOO solely can be completed within six to eight months. In general, this time

period represents 1/3 of the time compared with a conventional orthodontic approach. But there are other advantages to consider. As the Wilckos noted,[21] teeth can be moved farther using this approach. Additionally, the greater alveolar volume from grafting and the resultant better support to the periodontium provide greater stability and, accordingly, the potential for less relapse and fewer periodontal problems. The Wilckos[5] advocate this approach to achieve improved esthetics. A balanced occlusion supports lip function better and results in less perioral muscle strain, particularly in class II patients. AOO treatment has proven to be effective in rapid recovery of transposed and impacted teeth for delivery into the dental arch. The indirect benefits of AOO should not be overlooked. The need for fewer permanent extractions results in better support to the soft tissue matrix and an improved facial profile. The need for, and the cost of, conventional orthognathic surgery is eliminated in many instances. This is particularly helpful in borderline orthodontic/surgery cases in which surgical intervention is needed but does not take place because of expense, lack of insurance coverage, or the desire not to have a major "hospital-type" surgery. Similarly, in this author's experience, the need to perform a surgically assisted rapid palatal expansion (SARPE) has been replaced for the most part by the combined employment of AOO surgery and a Hyrax appliance activated as a rapid alveolar distractor. The indirect benefit of the psychological effect on patients cannot be ignored. Hasse[33] suggested that with long-term orthodontic treatment in teenage patients and young adults, depression and lack of a healthy self-image frequently becomes a byproduct that should not be ignored. Last, one cannot downplay the importance of returning the patient to the general dentist with a completed case in a timely fashion. The ability to reach the end point in a treatment continuum is important so that our patients are not lost in an abyss of endless years of orthodontic care (Figures 14-3 through 14-6).

CASE STUDY 14-1

AOO Treatment Mandible



• **Figure 14-3** **A**, Pre-treatment lateral and facial profile views in a 32-year-old woman. **B**, Pre-treatment open-bite malocclusion, lateral and frontal views.

Continued

CASE STUDY 14-1—cont'd

AOO Treatment Mandible



• **Figure 14-3, cont'd** **C**, Before accelerated osteogenic orthodontics (AOO): occlusion with bands placed. **D**, One month after AOO surgery in the mandible. **E**, Six weeks after AOO surgery. **F**, Three months after AOO surgery. **G**, Final occlusion following 17 weeks of orthodontia after AOO surgery. **H**, Comparative pre- and post-treatment frontal views. **I**, Note resolution of posterior dark corridors in final occlusion. (Orthodontist Gerald R. Eidenmuller, DDS.)

CASE STUDY 14-2

AOO Treatment Maxilla



• **Figure 14-4** **A**, Pre-treatment lateral and facial profile views in a 28-year-old male patient. **B**, Pre-treatment occlusion shows class III malocclusion, bilateral cross bites, midline discrepancy, super eruption of anterior teeth. **C**, Before accelerated osteogenic orthodontic (AOO) surgery with posterior buildup. **D**, Two weeks after AOO surgery on upper arch only.

Continued

CASE STUDY 14-2—cont'd

AOO Treatment Maxilla





• **Figure 14-4, cont'd** **E**, Six weeks after AOO surgery and initiation of orthodontic treatment. **F**, After 4 months of orthodontic treatment with class III elastics in place. **G**, Occlusion has rounded into place after 8 months of treatment. **H**, Final occlusion after 10 months of treatment. **I**, Before. **J**, Final. (Orthodontist Gerald R. Eidenmuller, DDS.)

CASE STUDY 14-3

AOO Treatment Maxilla

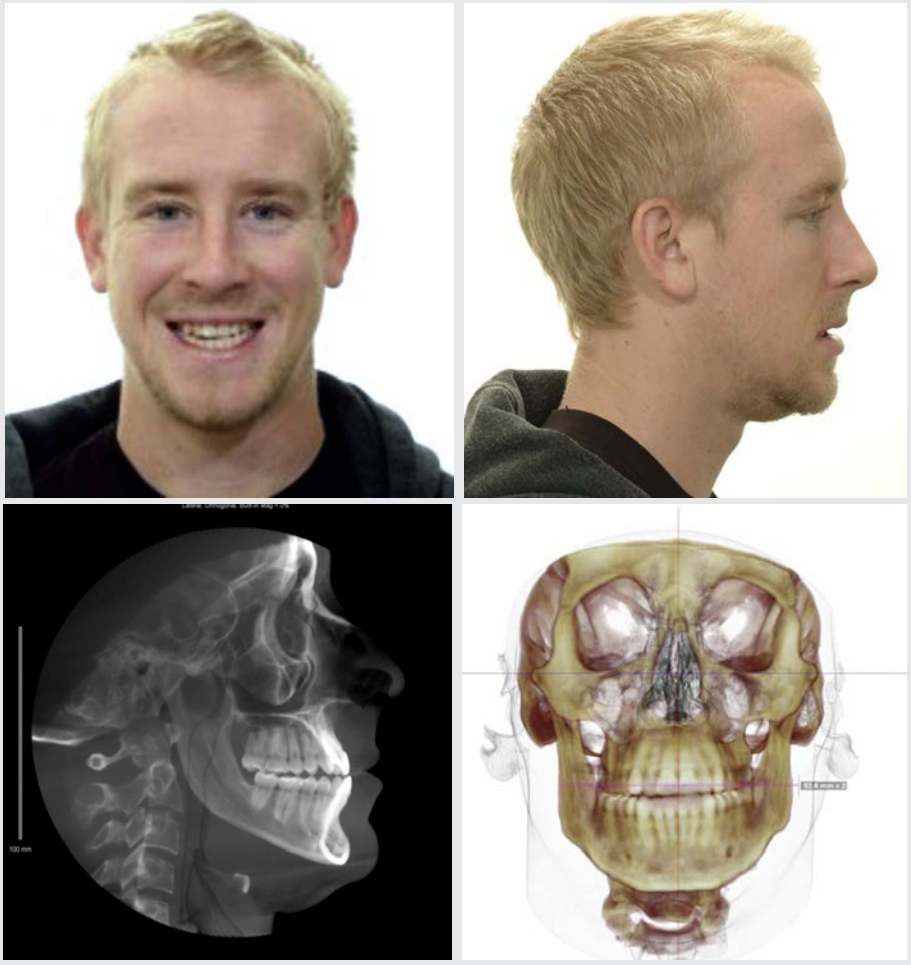

• **Figure 14-5** **A**, Frontal and lateral facial views of 32-year-old patient. **B**, Lateral cephalometric and frontal computed tomography views.

Continued

CASE STUDY 14-3—cont'd

AOO Treatment Maxilla

C







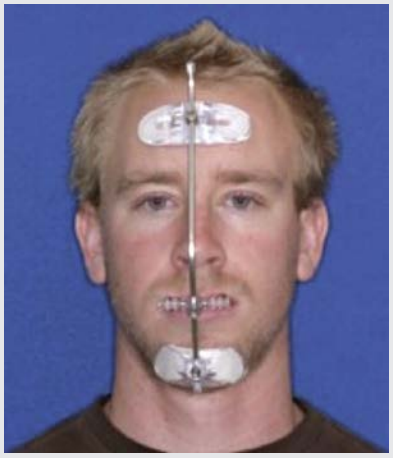

D

• **Figure 14-5, cont'd** **C**, Pre-treatment occlusion demonstrates an edge-to-edge bite, midline discrepancy, disocclusion, and transverse width inadequacy with bilateral cross bites. Patient did not want to have orthognathic surgery (surgically assisted rapid palatal expansion or segmental Le Fort advancement). **D**, Initiation of orthodontic treatment with aggressive class III elastic pull and head gear.

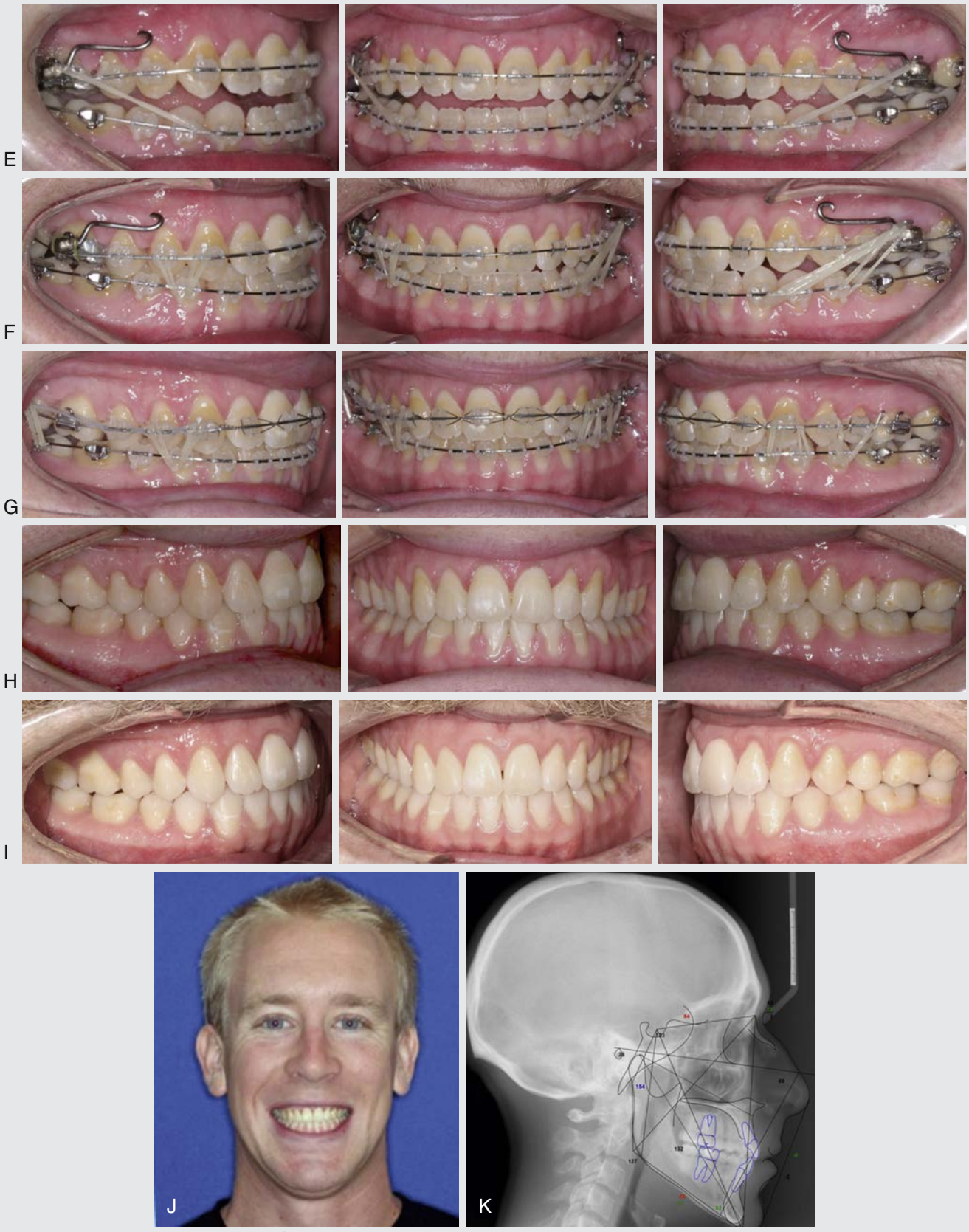

• **Figure 14-5, cont'd** **E**, Rapid tooth movement due to regional acceleratory phenomenon after only 6 weeks of orthodontia. **F**, After 3 months of orthodontia, disocclusion is almost corrected. **G**, Finishing elastics in place at 5 months. **H**, Case completed in 6 months of treatment time. **I**, Final occlusion remains stable after 2 years of follow-up. **J**, A healthy smile with adequate "show." **K**, Lateral ceph tracing shows a satisfactory result as an alternative to orthognathic surgery. (Orthodontist Shawn L. Miller, DMD, MMSc.)

CASE STUDY 14-4

Impacted and Transposed Teeth



• **Figure 14-6** **A**, Surgical exposure of transposed impacted cuspid. **B**, Bracket placed after accelerated osteogenic orthodontics (AOO) performed. **C**, Power chain placed to initiate movement. **D**, Closure with Gore-Tex suture. **E**, Six weeks after AOO. **F**, Three months after AOO. **G**, A most acceptable result in a compromised case. The patient was referred for periodontal grafting over the cuspid root to complete treatment. (Courtesy Shawn L. Miller, DMD, MMSc.)

CASE STUDY 14-5

AOO and Maxillomandibular Advancement to Treat Dentofacial Deformity and Obstructive Sleep Apnea



• **Figure 14-7** **A**, Lack of support in the midface is evident. Downturn of nose, lip inadequacy, retrognathism, mentalis muscle strain, and neck form need correction. Besides her dentofacial deformity, obstructive sleep apnea is another major problem for this patient. **B**, Preoperative occlusion with open bite before accelerated osteogenic orthodontic (AOO) surgery. **C**, Two weeks after AOO surgery. Gore-Tex sutures remain in place for 3 weeks. **D**, Three months after AOO surgery. Patient is now ready for orthognathic surgery.

Continued

AOO Combined with Orthognathic Surgery

We have shown a variety of clinical situations in which accelerated osteogenic orthodontics is invaluable as an adjunctive means to treat malocclusions. The potential for greater stability, improved periodontium, and a significantly shorter treatment time has made this approach a most valuable addition to our surgical armamentarium. However, in our opinion, one of the greatest advantages of using AOO is the ability to set up orthognathic surgery cases in rapid fashion. Patients who have true skeletal discrepancies pose significant challenges to the orthodontist in coordinating the arches in preparation for orthognathic surgery. The desired leveling and aligning of the arches that precedes surgery can be difficult to achieve, particularly in patients with prognathism, asymmetry, or excessive yaw, roll, or pitch. The orthodontist can reach the desired end point much more quickly by incorporating the AOO-facilitated technique. It

is also much easier to correct the dental compensation by taking advantage of the regional acceleratory phenomenon inherent to the AOO procedure.

In 2013, Hasse reported results of a retrospective study of 30 patients who were treated with combined skeletal/dental malocclusions using AOO and orthognathic surgery.[3] In the study, 13 patients underwent single-jaw surgery and 17 patients had both Le Fort osteotomies and lower jaw surgery (either sagittal split osteotomies or intraoral vertical oblique osteotomies). The average orthodontic setup time was about 17 weeks, and the mean total treatment time was 43 weeks. On completion of their treatment, the patients were placed into retention following conventional orthodontic protocol.

Following this recommended protocol, we feel confident that regardless of the complexity of the dentofacial deformity, treatment can be completed from beginning to end within 1 year while leaving the patient with a stable, reproducible occlusion and very little morbidity (Figure 14-7).

CASE STUDY 14-5—cont'd

AOO and Maxillomandibular Advancement to Treat Dentofacial Deformity and Obstructive Sleep Apnea

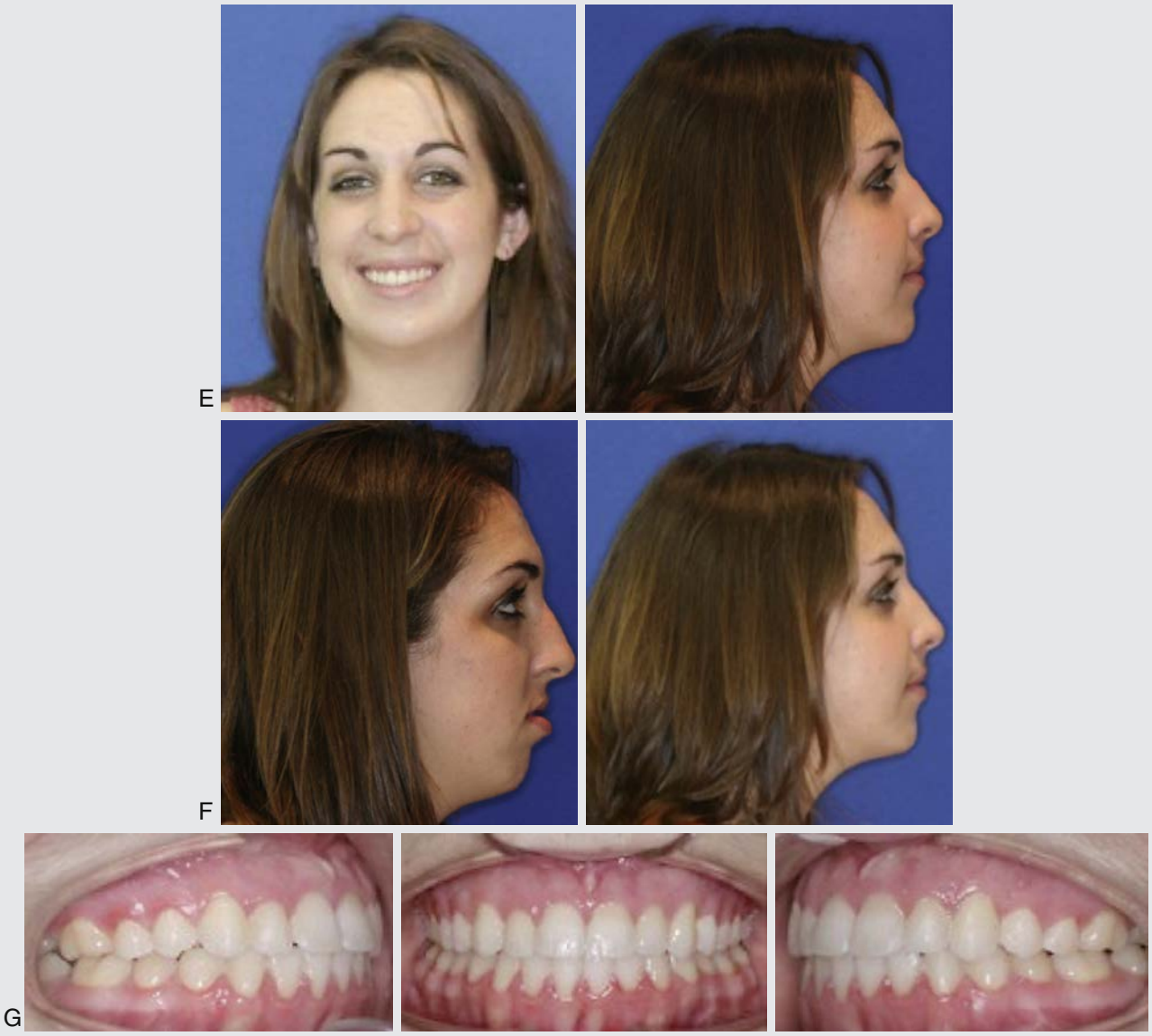

• **Figure 14-7, cont'd** **E**, AOO + two jaw surgeries and 7 months orthodontia + AOO. **F**, Comparison of preoperative and postoperative facial form. Note support to maxilla, nose, and lips and the improved neck line. **G**, Final occlusion with frontal and lateral views. (Orthodontist Shawn L. Miller, DMD, MMSc.)

Orthodontic Technique

Based on the results of the study, Hasse proposed the following treatment timetable when combining AOO and orthognathic surgery treatment:

- AOO surgery performed at week 1
- Orthodontics initiated at week 2 to 3
- Rapid alveolar distractor (Hyrax) placed at week 4 (if needed)
- Orthognathic surgery performed at weeks 17 to 20
- Orthodontics resumes 6 to 8 weeks after orthognathic surgery
- Debanding and completion of active treatment by weeks 36 to 50
- Orthodontic retention

Alternative Options for Clinical Acceleration

Alternative treatment options to the accelerated osteogenic orthodontics technique have recently been introduced as effective means to facilitate orthodontic movement. These methods bear mentioning for the sake of completeness, but in our opinion, they lack both the efficacy and versatility of the AOO approach. These modalities purport to use the regional acceleratory phenomenon to accomplish an accelerated rate of tooth movement.

In the piezo-incision technique, vertical interproximal incisions are made, below the interdental papilla, on the buccal aspect of the maxilla or mandible, 1 week after bonding brackets. These incisions are kept minimal, just to allow sufficient access for the piezo surgical saw. The piezo saw is used to create a cortical alveolar incision through the gingival opening to a depth of approximately 3 mm. Because of the rapid and temporary demineralization that occurs in response to the RAP effect, tooth movement is accelerated and treatment time is reported to be decreased as much as 60%. Because the interdental corticotomies are placed without the benefit of a full-thickness flap, grafting, if deemed necessary, must be performed through tunneling. In our opinion, there are several drawbacks to this technique when compared with AOO surgery. Specifically, access is limited because of the tunneling approach. It is difficult to graft much bone if needed because of the small incisions. Introduction of bleed holes in the AOO technique not only increases the RAP response but induces osteopenia, making it easier to move the teeth through less dense bone because it is softer and there is less resistance to orthodontic forces. Finally, it is not optimal to place an incision line directly over an osteotomy cut (Figure 14-8).

A second alternative treatment modality that has gained favor with some orthodontists is the use of a technique termed "alveolar micro-osteoperforation." In this instance, a device similar to a ratchet screwdriver is used to perforate the alveolus directly through both keratinized and mobile gingiva. The depth of the perforations or bleed holes is limited to 3, 5, or 7 mm and is controlled by setting the device through an adjustable depth dial. Proponents of this technique contend that the surgical injury to the periodontal tissue results in receptor activator of nuclear factor-kappa ligand (RANKL) gene expression on the surface of osteoblasts. This in turn increases osteoclast formation on the pressure side of the periodontal ligament during force application to an individual tooth. These factors are thought to activate the RAP, resulting in bone remodeling and ultimately accelerated tooth movement. This technique can probably best be used to complete simple space closure or in clinical situations where few teeth require repositioning. In our opinion the amount of the RAP that is induced through this approach is minimal. Also, it does not provide for bone augmentation, which is critical to expanding the alveolar housing as well as covering bony fenestrations and dehiscences.

Discussion

The preceding pages have presented an effective technique for using accelerated osteogenic orthodontics to facilitate orthodontic tooth movement. We have shown a multiplicity of clinical situations in which AOO can be successfully used to treat various dentofacial deformities and malocclusions. Specifically, we demonstrated that that the AOO procedure alone has been effective in treating mild class III malocclusions; moderate open-bite deformities; transverse width discrepancies up to about 6 to 7 mm in arch compromise; borderline orthodontic extraction cases; clinical situations requiring bite correction following mandibular orthotic appliance (splint) treatment; repositioning of impacted and transposed teeth; and orthodontic retreatment cases.

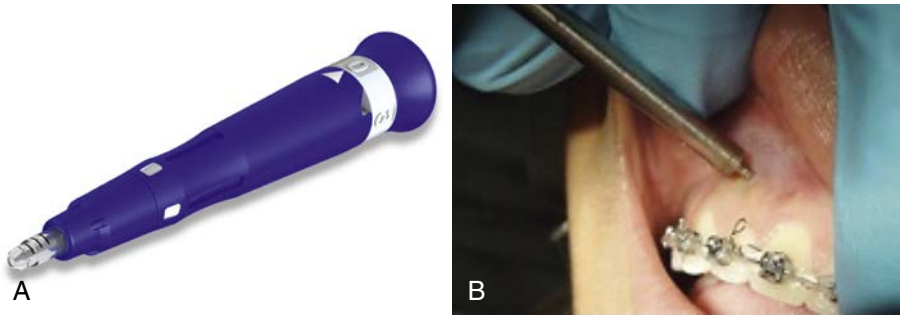

• **Figure 14-8** **A**, Alveolar microperforation device. **B**, Placement of perforations to facilitate orthodontic movement.

Additionally, we believe that one of the greatest benefits of the AOO technique is realized when using accelerated osteogenic orthodontics to set up an orthognathic surgery case. We concur with the Wilckos that the added bone during the RAP phase of metabolic reorganization leads to greater stability because of the increase in alveolar housing, coverage of exposed root surface and bony dehiscences, and healthier periodontium. A significantly shortened treatment time, combined with the potential for greater stability, improved periodontium, and the elimination of the need for major orthognathic surgery in many instances, makes the AOO technique a most valuable adjunct to our surgical armamentarium.

In a recent article, Kokich and Mathews[34] questioned the need for accelerated osteogenic orthodontics, stating a rationale for the case against corticotomy-induced orthodontics. Their major contention was that the efficacy of this technique as measured by how well treatment works in clinical trials or laboratory studies under ideal conditions has not been proven because there have not been sufficient studies to justify its use in clinical situations. We agree with their contention that, as of this writing, there has not been sufficient research with regard to the accelerated osteogenic orthodontic technique. We are hopeful that, with a greater acceptance of the technique in the future, this will be rectified as new ideas and clinical studies are developed. However, from our clinical experience, the effectiveness of AOO (that is, how well the technique works in daily practice) and the efficiency (evaluation of the value received relative to costs in terms of time, expense, and morbidity) is exceptional. In our opinion, a technique that can be performed rapidly with little morbidity, and can potentially save the cost of hospitalization generally associated with orthognathic surgery, warrants serious consideration for routine use. We feel that using this approach is a valuable addition in the service that surgeons can offer to our orthodontic colleagues, and, more importantly, to patient care.

Acknowledgment

The author wishes to acknowledge and thank the following individuals for their excellence in orthodontia and their contributions to the care of patients presented in the text: Gerald R. Eidenmuller, DDS and Shawn L. Miller, DMD, MMSc. Also, thank you to Lisa Holtgraver for her valuable assistance in the preparation of the manuscript.

References

1. Obwegeser HL: *Transactions of the Conference on Comprehensive Oral Surgery*, Washington, DC, June 20-22, 1966, Walter Reed Army Medical Center.
2. Reyneke JP: Orthognathic surgery is a science and an art: fact or fiction. Face to Face, *IAOMS Newsletter* 36:2, 2013.
3. Hasse CD: Rapid correction of dento-facial deformities combining accelerated osteogenic orthodontics (AOO) and orthognathic surgery, *Int J Oral Maxillofac Surg* 42(10):1329, 2013.
4. Hasse CD, Eidenmuller GR: *Using accelerated osteogenic orthodontics (AOO) to enhance orthognathic surgery treatment options*, Transactions of the 94th Annual Meeting of the American Association of Oral and Maxillofacial Surgeons, San Diego, September 15, 2012.
5. Wilcko MT, Wilcko WM, Pulver JJ, et al.: Accelerated osteogenic orthodontics: a 1-stage surgically facilitated rapid orthodontic technique with alveolar augmentation, *J Oral Maxillofac Surg* 67:2149–2159, 2009.
6. Köle H: Surgical operations of the alveolar ridge to correct occlusal abnormalities, *Oral Surg Oral Med Oral Pathol* 12:515, 1959.
7. Talbot ES: Teeth irregularities and their surgical correction, *Dental Cosmos* 38:907–911, 1896.
8. Skogsborg C: Die permanente Fixierung der Zähne nach orthodontischer Behandlung, *Vjschr Zahnheilkd* 4:278–293, 1926.
9. Bichlmayr A: Zur Spätbehandlung der Kiefer-anomalien, *Dtsch Zahnärztl Z* 45:15–23, 1942.
10. Bichlmayr A: Uber chirurgische Orthopädie bei Behandlung der Spätfälle, *Dtsch Zahnärztl Wschr* 45:613–614, 1942.
11. Schönwald R: Die chirurgische Kieferorthopädie Bichlmayr (Osteotomie), *Dtsch Zahnärztl Wschr* 37:407–409, 1934.
12. Neumann D: Die Bichlmayresche Keilresektion bei der kieferorthopädischen Spätbehandlung, *Fortschr Kiefer Gesichtschir* 1:205–210, 1955.
13. Spanier F: Prognathie-Operationen, *Z Zahnärztl Orthop* 24:76–85, 1932.
14. Horvath L, Rehçk R: Kieferchirurgische Massnahmen zur Unterstützung von Sprätregulierungen, *Dtsch Zahnärztl Z* 16:525–529, 1961.
15. Dal Pont G: Su una nuova technica di raddrizamento immediato dei denti a mezzo di trapianto alveolodentale pedunculato, *Mi nerva Stomat* 14:110–116, 1965.
16. Edland A, Subrtova J: *Corticotomy—cooperation of the oral surgeon and the orthodontist*. Proceedings of the Second International Conference on Oral Surgery, Copenhagen, 2:339–344, 1965.
17. Epker BN, Paulus PJ: Surgical orthodontic correction of adult malocclusions: single tooth dento-osseous osteotomies, *Am J Orthod* 74:551–563, 1978.
18. Anholm M, Crites D, Hoff R, Rathbun E: Corticotomy-facilitated orthodontics, *Calif Dent Assoc J* 7:8–11, 1986.
19. Gantes B, Rathbun E, Anholm M: Effects on the periodontium following corticotomy-facilitated orthodontics. Case reports, *J Periodontol* 61:234–238, 1990.
20. Suya H: Corticotomy in orthodontics. In Hösl E, Baldauf A, editors: *Mechanical and biological basics in orthodontic therapy*. Heidelberg, 1991, Hütlig Buch, pp 207–226.
21. Wilcko MT, Wilcko WM: *Accelerated orthodontic technique*, Transactions of the American Association of Orthodontists Annual Meeting, Dallas, 1998.
22. Ilizarov GA: *The treatment of open fractures*, Transactions of the 22nd Meeting of the European Association of Orthopedic Surgeons, Bellagio, Italy, June 12-14, 1981.
23. Frost HM: The biology of fracture healing: an overview for clinicians. Part I, *Clin Orthop Relat Res* 248:283–293, 1989. 1989.
24. Yaffe A, Fine N, Binderman I: Regional accelerated phenomenon in the mandible following mucoperiosteal flap surgery, *J Periodontol* 65:79–83, 1994.
25. Wilcko MT, Wilcko WM, Bouquot JE, Ferguson DJ: Rapid orthodontics with alveolar reshaping: two case reports of decrowding, *Int J Period Restor Dent* 21:9–19, 2001.

26. Wilcko MT, Wilcko WM, Bissada NF: An evidence based analysis of periodontally accelerated orthodontic and osteogenic techniques: a synthesis of scientific perspectives, *Semin Orthod* 14:305–316, 2008.
27. Baloul SS, Gerstenfeld LC, Morgan EF, et al.: Mechanism of action and morphological changes in the alveolar bone in response to selective alveolar decortication facilitated tooth movement, *Am J Orthod Dentofacial Orthop* 139(Supp):83–101, 2011.
28. Hasse CD, Eidenmuller G: *Accelerated osteogenic orthodontics*, Transactions of the 33rd Annual Scientific Conference and Exhibition of the American College of Oral and Maxillofacial Surgeons, Palm Beach, FL, April 29, 2012.
29. Mehra P, Caiazzo A: *Surgically-assisted accelerated orthodontics: an office-based alternative to orthognathic surgery*, Transactions of the 94th Annual Meeting of the American Association of Oral and Maxillofacial Surgeons, San Diego, September 14, 2012.
30. Wilcko MT, Wilcko WM: *Accelerated osteogenic orthodontics procedure*, Wilckodontics Certification Handbook, 2004.
31. Bell W: Personal communication.
32. Marx RE, Cillo Jr JE, Ulloa JJ: Oral bisphosphonate-induced osteonecrosis: risk factors, prediction of risk using serum CTX testing, prevention, and treatment, *J Oral Maxillofac Surg* 65:2397–2410, 2007 Dec. 2007.
33. Hasse CD: The case for accelerated osteogenic orthodontics [Letter to the editor], *Am J Orthod Dentofac Orthop*, October 2013.
34. Mathews DP, Kokich VG: Accelerated tooth movement: the case against corticotomy-induced orthodontics, *Am J Orthod Dentofac Orthop* 144(1):5–10, 2013.

15

Orthognathic Surgery for Obstructive Sleep Apnea

CAROLYN DICUS BROOKES, SCOTT B. BOYD

Introduction and Prevalence of Obstructive Sleep Apnea

Obstructive sleep apnea (OSA) is a prevalent chronic disease characterized by pharyngeal collapse during sleep. One large landmark study estimated that 24% of middle-aged men and 9% of middle aged women have OSA,[1] where OSA is defined as an apnea-hypopnea index (AHI) of more than 5 events per hour. More recent studies suggest a prevalence of OSA in middle-aged adults of just over 25%.[2,3] A recent review suggests that 1 in 5 adults has at least mild OSA (AHI 5 to 15) and 1 in 15 has moderate (AHI >15 to 30) to severe (AHI >30) OSA.[4]

The main objectives of this chapter are to:

1. summarize the pathophysiology and clinical features of OSA;
2. describe the essential components of patient evaluation including diagnostic criteria and outcome measures;
3. summarize treatment options for OSA;
4. describe maxillomandibular advancement (MMA) for management of adult OSA; and
5. discuss the clinical effectiveness and safety of MMA.

Pathophysiology of Obstructive Sleep Apnea

A detailed discussion of the pathophysiology of OSA is outside the scope of this chapter; however, a brief review of some of the major physiologic factors involved in OSA will help the surgeon understand various treatment modalities. Upper airway anatomy can predispose to collapse, through either decreased diameter or other factors, including traits of the surrounding soft tissue and decreased lung volumes. If anatomy predisposes to collapse, the decreased upper airway dilator activity (including that of the genioglossus muscle) observed during sleep may contribute to obstructive episodes.[5,6] Stability of ventilatory control and arousal threshold may also play a role in OSA.[5-8]

In OSA, sleep becomes fragmented, which diminishes time spent in deeper sleep stages and results in excessive daytime somnolence. Patients or bed partners may report snoring, observed apneas, or gasping on awakening. Oxygen desaturation, hypercarbia, and sympathetic activation occur.[5,8,9] Untreated OSA is associated with hypertension[2,4,10-13] and cardiovascular disease, including cardiac arrhythmias,[10,13] coronary artery disease,[13] congestive heart failure,[8,13] and increased risk of cardiovascular events. In men, untreated severe OSA significantly increases the risk of fatal and nonfatal cardiovascular events (odds ratio 2.87 and 3.17, respectively) as compared with non-snoring, age- and body mass index (BMI)-matched men without OSA.[15] OSA has been shown to increase the risk of stroke[16] and all-cause mortality; this risk seems to be higher with more severe OSA.[16] OSA is linked to insulin resistance and Type 2 diabetes.[14,17,18]

OSA has neurocognitive sequelae, as well. Vigilance, motor coordination, and executive functioning may be compromised by untreated OSA.[19] These factors may underlie the increased rate of motor vehicle collisions seen in patients with untreated OSA.[20,21] OSA is also associated with decreased quality of life[22-24] and depression.[25,26]

Major risk factors for OSA include obesity, male gender, and increasing age.[2,3,27,28] Craniofacial anomalies are also linked to OSA; this is discussed later in the chapter.

Patient Evaluation

Symptoms and History

Sleep quality is assessed by inquiring about snoring, excessive daytime sleepiness, witnessed apneic episodes, gasping/choking during sleep, non-refreshing sleep, morning headaches, decreased libido, and irritability.[9] Symptoms related to cognitive dysfunction such as decreased concentration and memory loss as well as impaired occupational performance should be noted.

Multiple validated instruments exist to assess sleepiness and quality of life. The Epworth Sleepiness Scale (ESS) is an easily administered questionnaire that is used to assess subjective sleepiness. The patient is asked to rate the likelihood of falling asleep during various activities from 0 to 3; the total score ranges from 0 to 24, with 10 or greater representing excessive or pathologic sleepiness.[29,30] The Functional Outcomes of Sleep Questionnaire (FOSQ) is a 30-question self-administered, disease-specific quality of life instrument that assesses multiple domains including activity level, vigilance, intimacy and sexual relations, general productivity, and social outcome. The total score ranges from 5 to 20, with normal defined as greater than or equal to 18.[31] The Sleep Apnea Quality of Life Index (SAQLI) is another sleep-specific quality of life instrument that assesses function in four domains: daily functioning, social interactions, emotional functioning, and symptoms. An optional fifth domain evaluates treatment-related symptoms.[32]

Sleep Studies

The gold standard for diagnosis of OSA is overnight, laboratory-based polysomnography (PSG), which defines the presence and severity of OSA. During PSG, electroencephalography, electrooculography, and chin electromyography are used to detect stages of sleep. Respiratory effort is measured by inductive plethysmography to assess rib and abdominal motion. Airflow at the nose and mouth is detected through thermal sensors or nasal pressure gauges. Oxygen saturation is also monitored by pulse oximetry. Leg electromyography and body position are measured. While multiple metrics are reported, the most commonly used index is the apnea-hypopnea index (AHI). The AHI is the number of apneas and hypopneas per hour of sleep. Apneas are defined as a drop in airflow of at least 90% lasting at least 10 seconds. An apnea is considered obstructive if respiratory effort is maintained or increased. There is some controversy regarding the definition of hypopnea, but the 2014 scoring manual of the *American Academy of Sleep Medicine* (AASM) defines a hypopnea as an event lasting more than 10 seconds with a greater than 30% reduction in airflow accompanied by either an arousal or greater than 3% oxygen desaturation from the pre-event baseline.[33] AHI determines disease severity (Figure 15-1). The respiratory disturbance index (RDI) is another commonly reported index and represents the number of apneas, hypopneas, and respiratory event related arousals (RERAs) per hour.

A streamlined home monitoring study that measures at least airflow, respiratory effort, and oxygenation is more convenient for patients and more cost-effective; this makes evaluation more accessible. Non-inferiority of portable home monitoring studies versus laboratory PSG has been demonstrated in select populations.[34] An AASM consensus statement recommends using portable monitoring in select patients with high pretest probability of moderate to severe OSA without certain comorbid conditions.[35] This is primarily because, when scoring portable monitoring studies, the number of respiratory-related events is scored over total recording time rather than total sleep time—this can result in underestimation of AHI/RDI and thus false-negative results. Portable monitoring studies may also play a role in monitoring response to therapies and in arriving at a diagnosis for those who cannot tolerate a laboratory-based PSG. Portable monitoring should be conducted and interpreted by accredited sleep centers or boarded sleep medicine specialists.[9,35]

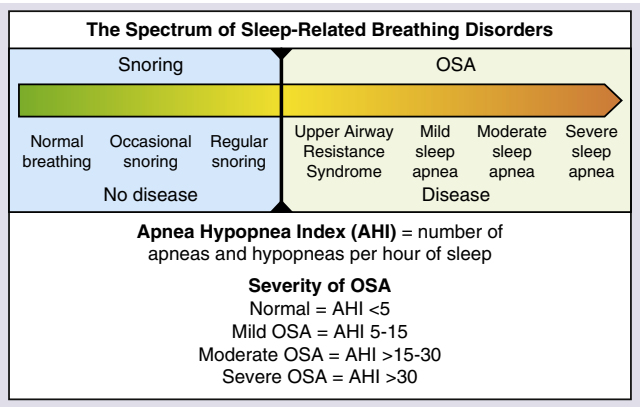

• **Figure 15-1** The spectrum of sleep-related breathing disorders.

Physical Examination

Physical examination involves recording of vital signs, body mass index (BMI), and neck circumference, as well as a description of the airway, from the nose to the visualized pharynx. Attention is paid to potential sites of nasal obstruction, tongue size and position, palatal length and thickness, and pharyngeal crowding. A simple clinical evaluation and staging system was introduced by Friedman to document palate position, tonsil size, and BMI (Figures 15-2 and 15-3 and Table 15-1).[36] It was initially proposed as a tool to predict responsiveness to uvulopalatopharyngoplasty (UPPP).

Additional upper airway assessment to determine the sites of obstruction is important as it allows for targeted intervention. Awake nasopharyngeal endoscopy with Muller's maneuver (forced inspiration with closed nasal and oral airways) is the classic method to assess level of obstruction. The site (retropalatal and/or retrolingual) and magnitude of the obstruction (0%, 25%, 50%, 75%, or 100%) are noted. Greater than 75% obstruction is typically considered severe, and surgical correction of the obstruction at the involved anatomic site(s) is indicated.

Drug-induced sleep endoscopy (DISE) was more recently introduced with the putative advantage of more closely mimicking the sleeping state. One comparative study suggests that, though the two are equally good at detecting retropalatal collapse, DISE identifies retrolingual collapse more often, particularly for those with low Friedman score.[37] A systematic review suggests that DISE in addition to awake endoscopy changed the surgical plan in just over 50% of cases, usually due to newly noted hypopharyngeal or laryngeal obstruction; however, there is conflicting evidence about whether DISE results in improved surgical

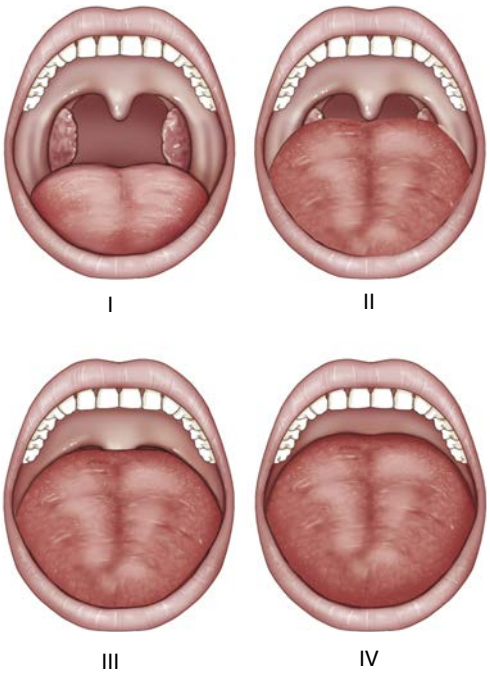

• **Figure 15-2** The Friedman Palate Position is based on visualization of structures in the mouth with the mouth open widely without protrusion of the tongue. Palate grade I allows the observer to visualize the entire uvula and tonsils. Grade II allows visualization of the uvula but not the tonsils. Grade III allows visualization of the soft palate but not the uvula. Grade IV allows visualization of the hard palate only. (From Friedman M, Ibrahim H, Joseph NJ: Staging of obstructive sleep apnea/hypopnea syndrome: a guide to appropriate treatment, *Laryngoscope* 114(3):454-459, 2004, with permission.)

outcomes, and concern has been raised that DISE may lead to unnecessary surgical interventions. Further, there is no consensus about the ideal anesthetic agent to be used for DISE.[38] Its role will likely continue to evolve.

Treatment of Obstructive Sleep Apnea

The goals of treatment are to eliminate OSA (AHI <5 events/hour) or to significantly reduce the severity of OSA (AHI ≤15 events/hour); to improve nadir oxygen saturation; to alleviate symptoms such as sleepiness; to address sequelae of OSA such as cardiovascular and neurocognitive issues; and to improve quality of life.

The AHI is the metric most commonly used to assess success of OSA treatment. Surgical cure is defined as a reduction in AHI to less than 5 events per hour. Surgical success has historically been defined as a 50% or greater reduction in AHI to less than 20 events per hour.[39] Although a greater than 50% reduction in the AHI is likely associated with better outcomes, the use of the just-described, generally accepted definition of surgical success facilitates comparison of outcomes.

Although the AHI is the primary reported measure of successful treatment, it does not take into account other important health-related and functional outcomes such as sleepiness, quality of life, or cardiovascular health. A recent publication by the AASM recommended the use of metrics that assess quality of life (e.g., FOSQ, SAQLI, and SF-36), sleepiness, and reduction in cardiovascular risk based on assessment of weight and blood pressure.[40] Resolution of

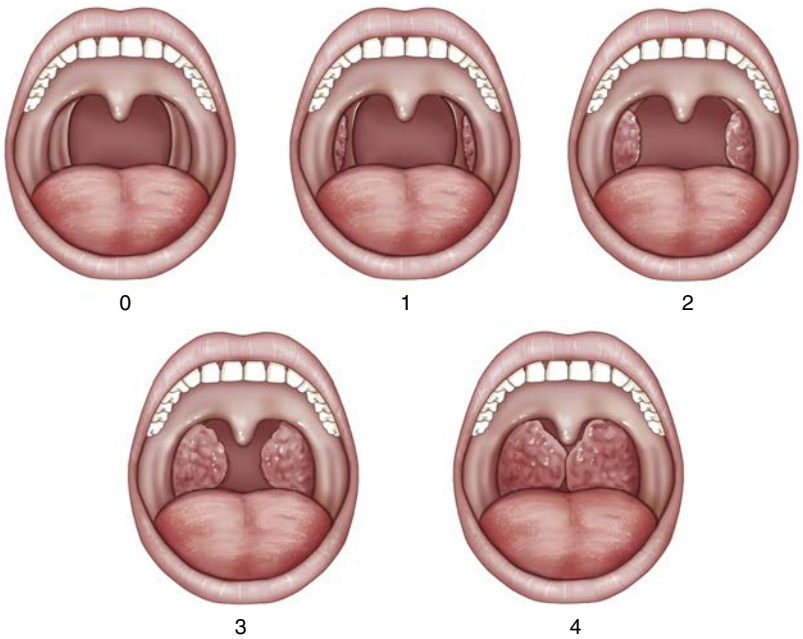

• **Figure 15-3** Tonsil size is graded from 0 to 4. Tonsil size 0 denotes surgically removed tonsils. Size 1 implies tonsils hidden within the pillars. Tonsil size 2 implies the tonsils extending to the pillars. Size 3 tonsils are beyond the pillars but not to the midline. Tonsil size 4 implies tonsils extend to the midline. (From Friedman M, Ibrahim H, Joseph NJ: Staging of obstructive sleep apnea/hypopnea syndrome: a guide to appropriate treatment, *Laryngoscope* 114(3):454-459, 2004, with permission.)

TABLE 15-1 Friedman Staging System

	Friedman Palate Position	Tonsil Size	Body Mass Index
Stage I	1	3, 4	<40
	2	3, 4	<40
Stage II	1, 2	1, 2	<40
	3, 4	3, 4	<40
Stage III	3	0, 1, 2	<40
	4	0, 1, 2	<40
Stage IV	1, 2, 3, 4	1, 2, 3, 4	<40

All patients with significant craniofacial or anatomic deformities.
Modified from Friedman M, Ibrahim H, Bass L: Clinical staging for sleep-disordered breathing, *Otolaryngol Head Neck Surg* 127(1):13-21, 2002; with permission.
From Lee NR: Evaluation of the obstructive sleep apnea patient and management of snoring, *Oral Maxillofac Surg Clin North Am* 21(4):377-387, 2009.

sleepiness should be documented using subjective scales (e.g., Epworth Sleepiness Scale) or objective measures (e.g., multiple sleep latency test).[9]

Importantly, any therapeutic intervention should have a long-term, durable treatment response, because OSA is a chronic, lifelong disease. Although there is no consensus about frequency of follow-up, all patients who undergo treatment for OSA require long-term monitoring to allow detection of recurrent disease.[41] It is worth noting that the benefits of surgical intervention do not require patient adherence and are thus enjoyed during every hour of sleep. This must be considered when comparing surgical and nonsurgical treatment outcomes. Finally, the ideal treatment should carry minimal risk of morbidity and mortality.

Nonsurgical Treatment

Continuous Positive Airway Pressure

Continuous positive airway pressure (CPAP) is the first-line treatment of choice for OSA and should be offered to all patients diagnosed with OSA. CPAP is highly efficacious and virtually eliminates OSA.[42] For most patients, lifelong use is required for disease control.

CPAP splints the upper airway, helping to maintain patency during sleep. Increased lung volumes due to PAP may further stabilize the upper airway.[43] CPAP improves sleepiness as well as functional outcomes including quality of life and both cognitive and driving performance.[9,43,44] However, these metrics do not improve for all patients even when CPAP is used consistently (>7 hr/night).[44] CPAP also decreases sympathetic activation and may improve functional residual capacity and control of hypertension.[43]

Acceptance, or patient willingness to attempt to use PAP, ranges from 72% to 91%.[43] Unfortunately, adherence to CPAP therapy is far from universal; one review cited a nonadherence rate of 46% to 83%, when adherence was defined as PAP use for at least 4 hours a night.[45] The duration of nightly use required for maximal benefit has not been established, though longer nightly use seems to yield more benefits,[46] including decreased 5-year mortality.[47] Barriers to adherence may include mask discomfort or skin breakdown; ocular, nasal, and pharyngeal dryness; nasal congestion or rhinorrhea; claustrophobia; and noise and bulk of the device.[9,43,46,48-50] CPAP is the most common positive airway delivery method, but other modalities such as bilevel and auto-titrating PAP may increase adherence for certain patients. Although highly effective, alternative treatments are required for those who refuse or cannot tolerate CPAP.

Oral Appliances

Oral appliances (OAs) used for treatment of OSA enlarge the upper airway by modifying the position of the tongue and associated structures of the upper airway. The recommended OA is a custom, titratable tooth-borne appliance designed to advance the mandible, thereby pulling the tongue forward.[51] OAs are less cumbersome than PAP devices and are generally well tolerated.[51] OAs reduce snoring, sleepiness, and blood pressure and improve quality of life[51] and have been shown to yield comparable results to CPAP in terms of the latter three parameters as well as improvement in cognitive function.[52] They have been shown to reduce AHI over a range of OSA severity, though CPAP tends to outperform OAs in terms of AHI reduction and improvement in nadir SpO_2.[51]

Adherence to OAs seems to be similar or slightly better than use of CPAP.[52] OAs are more effective in less obese patients and those with skeletofacial deformities.[53] Treatment effect seems to be proportional to the degree of mandibular advancement. Some patients (particularly those with mild to moderate OSA) may benefit from advancement to 50% of maximal protrusion, while others (e.g., those with severe OSA) may require advancement to 75% of maximal protrusion. Side effects increase beyond 50% of maximal protrusion, so it is recommended that the devices be titrated to effect.[53] Temporomandibular joint dysfunction, inadequate protrusion, and insufficient teeth to support the device are relative contraindications.[9] Discomfort and hyper-salivation or xerostomia may limit adherence. Long-term monitoring for adherence, worsening OSA, and dental and skeletal changes is required.[51,54]

Behavioral Treatment

Weight loss can improve AHI[55,56]; 10% weight loss predicts a 26% reduction in AHI. Minimizing weight gain is also important, as a 10% weight gain predicts a 32% increase in AHI.[56] Unfortunately, many individuals find it exceptionally difficult to maintain a 10% weight loss on a long-term basis.

Avoiding the supine positions during sleep may be helpful for some patients.[7,9] All those with OSA should be educated about good sleep hygiene practices, such as avoiding alcohol (which can also predispose to airway collapse), caffeine, and screen time before bed; regular exercise may also be beneficial.[9,54]

Medications

Intranasal steroids may be a helpful adjunct for patients with OSA and nasal obstruction.[9] Modafinil may be used to address daytime sleepiness that is not alleviated by PAP or other treatment modalities, provided other causes of daytime somnolence (e.g., depression, other sleep disorders, insufficient sleep, poor adherence to therapy) have been ruled out.[9]

Surgical Treatment

Preoperative Assessment

Candidates for surgical intervention are those with obstructive anatomy who are either intolerant of CPAP/OAs or have inadequate disease control with CPAP/OAs. Candidates must understand the risks, alternatives, and benefits of the proposed operation and must choose to proceed; they must be expected to tolerate the procedure medically. Several general principles apply to preoperative assessment before all surgical modalities to address OSA. The surgeon must confirm the diagnosis and establish the severity of OSA objectively through PSG. Attention should be paid to AHI, nadir oxygen saturation, and percentage of sleep time spent with an oxygen saturation of less than 90%. As with any surgical patient, medical history must be thoroughly reviewed, with a focus on potentially undiagnosed comorbid conditions. Engagement of the relevant physicians to optimize the patient's health preoperatively is critical.

Surgical Treatment Other Than Maxillomandibular Advancement

Bariatric Surgery

Bariatric surgery effectively achieves weight loss; it is indicated for patients with a BMI of 35 or greater with comorbidities or 40 or greater when diet and activity have proved ineffective. Bariatric surgery can be a helpful adjunctive treatment for OSA and generally results in more weight loss and more pronounced reduction in AHI than do nonsurgical weight loss interventions.[55] Unfortunately, OSA can return even in the absence of weight gain, so long-term follow-up is crucial.[57]

Tracheostomy

Tracheostomy bypasses the upper airway and has a nearly universal success rate with dramatic reduction in number of apneic episodes as well as sleepiness. Tracheostomy may also confer a mortality benefit over no treatment. However, significant morbidity limits its application in the OSA population, and it is generally considered only for patients who have failed, refused, or are not candidates for other interventions or those who require urgent correction of severe hypoxemia, particularly in the setting of severe cardiovascular disease.[58]

Tonsillectomy

Tonsillectomy is the treatment of choice for children with OSA in the absence of craniofacial anomalies.[59]

Palatal Procedures

Uvulopalatopharyngoplasty (UPPP) was originally described by Fujita and involves removal of the tonsils, uvula, and posterior velum with closure of the pillars.[60] Lateral pharyngoplasty may be added. AHI does not reliably normalize after UPPP for patients with moderate to severe OSA and is thus recommended only as an adjunctive treatment.[41] A meta-analysis reported a mean 33% reduction in AHI with a mean postoperative AHI of 29.8.[61] Complications may include bleeding, hypernasal speech, nasal regurgitation, and taste disturbances.[61]

Extended uvulopalatal flap or EUPF may be more effective than UPPP in select patients; one group reported success in 84% and cure in 40% of patients with a mean reduction in RDI from 44.5 to 13.4.[62]

Laser-assisted uvulopalatoplasty (LAUP) involves a series of laser ablations of the soft palate to shorten and stiffen the uvula and velum. Although some studies have reported large reductions in AHI, it is not generally recommended for OSA, as outcomes are not reliable enough to justify surgical risks.[41,61]

Radiofrequency treatment of the palate (or tongue) and palatal implants, both designed to stiffen the palate, may be effective in patients with mild to moderate OSA who do not tolerate PAP or OAs.[41] A meta-analysis of RFA treatments showed a reduction in AHI from 23.4 to 14.2.[61] The same analysis reported a mean 26% reduction in AHI after placement of palatal implants.[61]

Genioglossal Advancement with or without Hyoid Suspension

Genioglossal advancement (GA) refers to genial tubercle advancement; this may be accompanied by hyoid myotomy and suspension (GAHM). This procedure is rarely carried out in isolation but can be effective in conjunction with other therapies addressing retropalatal obstruction. A review of hypopharyngeal surgical options for OSA in subjects treated with palatal surgery reported surgical success of GA in over 50% of patients in some series; GAHM yielded variable results with a surgical success rate of 22% to 77% and was more likely to be successful in patients with a lower BMI and lower baseline AHI.[63] A series that coupled GAHM with palatal surgery reported 78.3% short-term surgical success and 65.2% long-term surgical success.[64]

Hypoglossal Nerve Stimulator (HNS)

Stimulation of the hypoglossal nerve activates airway dilators, including the genioglossus muscle. Implantable stimulators are a relatively recent addition to the surgical options for patients with OSA and received U.S. Food and Drug Administration (FDA) approval in 2014 for treatment of moderate or severe OSA in adults. In addition to a generator, the stimulator has leads that sense respiration and that stimulate the nerve during inspiration; the device is titrated postoperatively.

A multicenter, prospective cohort study known as the STAR (Stimulation Therapy for Apnea Reduction) Trial reported that, at 1 year after implantation of the device, the median AHI decreased 68% from 29.3 to 9.0 events per hour; quality of life also improved.[65] At 3 years after implantation, the same group reported that median AHI decreased from 28.2 to 6.2 events per hour; surgical success was achieved in 74% of the subjects followed for 3 years, though not all subjects used the device nightly.[66] Another study reported surgical success in 55% of subjects at 1 year post-implantation.[67] Symptoms and quality of life also seem to improve.[65-67] Hypoglossal nerve stimulation seems to be more successful in patients with a lower BMI, AHI less than 50, and an anteroposterior (vs. concentric) pattern of palatal collapse during DISE.[68,69] Complications include neurosensory deficit, tongue abrasion, and discomfort from the stimulator.[66,67]

Nasal Surgery

Nasal procedures, such as septoplasty or turbinectomy, are designed to improve nasal airflow. Though this may lead to resolution of OSA in certain patients with mild OSA, it is generally used as an adjunctive procedure only. A recent systematic review indicates that isolated nasal surgery in OSA patients may reduce therapeutic CPAP device pressures and may increase CPAP use in some patients.[70]

Tongue Reduction

Glossectomy and radiofrequency ablation of the tongue base are additional strategies to address hypopharyngeal obstruction. Both strategies have variable success rates, with reported surgical success from 20% to 83% based on AHI.[63] Transoral robotic surgery for OSA is less morbid than glossectomy and appears to be more effective for treating OSA. As part of a multilevel surgical approach, it may reduce the AHI and improve sleepiness.[71] However, cost and morbidity limit its role.

Maxillomandibular Advancement

Maxillomandibular advancement (MMA) addresses multiple levels of obstruction, decreasing airway collapsibility by advancing its skeletal framework.[72] MMA involves surgical facial advancement through concomitant maxillary and mandibular osteotomies (Figure 15-4). Candidates for MMA are those who meet criteria for surgical management of OSA and either have skeletofacial deficiency or can esthetically tolerate MMA. Those with severe OSA are likely to derive the most benefit from MMA. If the patient is a candidate for other forms of therapy that have not been tried or discussed, these should be reviewed with the patient, either by the surgeon or by a sleep specialist.

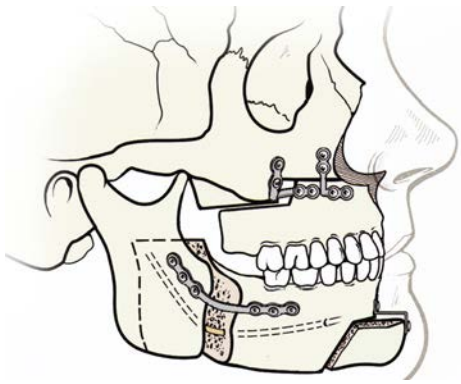

• **Figure 15-4** Schematic diagram of maxillomandibular advancement procedure consisting of Le Fort I maxillary osteotomy with step modification, bilateral sagittal split ramus osteotomies, and genial advancement. Shaded areas depicts sites of piriform rim recontouring and anterior nasal spine reduction. (From Boyd SB: Management of obstructive sleep apnea by maxillomandibular advancement, *Oral Maxillofac Surg Clin North Am* 21(4):447-457, 2009, with permission.)

MMA was initially advocated as phase II surgery for those who failed to improve after phase I surgery, which included UPPP and genioglossal advancement with hyoid myotomy.[73] However, a recent comparative study evaluated the effectiveness of MMA and UPPP. The study found that MMA alone is more effective than UPPP alone and that UPPP followed by MMA (phase I surgery followed by phase II surgery) is no more effective than MMA alone.[74] Offering MMA as a primary procedure confers additional benefits over staged surgery, including decreased total treatment time, fewer surgical and anesthetic risks to the patient, and an improved cost:benefit ratio.

Preoperative Assessment

In addition to the general presurgical history considerations outlined earlier, the initial consultation should focus on determining the patient's candidacy for MMA in particular. Prior therapy for OSA and its outcomes must be reviewed. The patient should be queried about prior facial trauma and orthodontics as well as any concerns with speech and masticatory or temporomandibular joint (TMJ) function. Esthetic goals should also be noted.

The physical examination must include vital signs and body mass index. The remainder of the examination is quite similar to that undertaken in a routine orthognathic consultation. Special attention is paid to sites of obstruction and need for presurgical orthodontics. Assessment should include a complete, multi-view facial analysis; mandibular range of motion and TMJ function; occlusal analysis; dental and periodontal status; anterior rhinoscopy; and cranial nerve function. The tongue, tonsils, velum, and posterior and lateral pharynx should be inspected at rest and with phonation to visualize potential sites of obstruction. If the

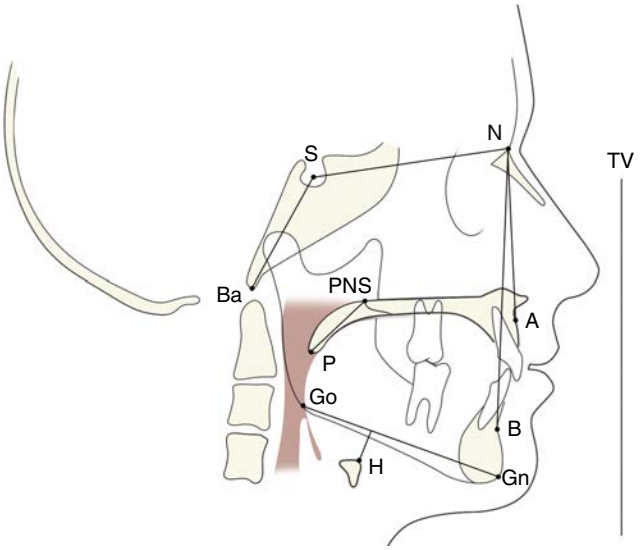

• **Figure 15-5** Cephalometric analysis for obstructive sleep apnea with depiction of skeletal and soft tissue anatomic landmarks and associated measurements (normal values): *A*, Subspinale; *B*, supramentale; *Ba*, basion; *Gn*, gnathion; *Go*, gonion; *H*, hyoid; *N*, nasion; *PNS*, posterior nasal spine; *S*, sella; *P*, palate.

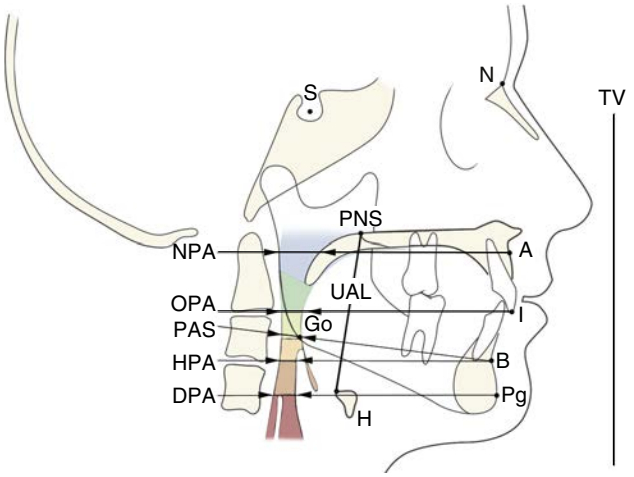

• **Figure 15-6** Airway analysis for obstructive sleep apnea. Linear measurements are depicted, but volumetric and cross-sectional measurements of each region can be made with preferred cone-beam computed tomography imaging. Each airway space is associated with a skeletal or dental landmark to facilitate measurement of the association between the magnitude of maxillary and mandibular movements and corresponding changes in the associated airway space. *A*, Subspinale; *B*, supramentale; *DPA*, deep pharyngeal airway; *Go*, gonion; *H*, hyoid; *HPA*, hypopharyngeal airway; *I*, incisal edge of maxillary central incisor; *N*, nasion; *NPA*, nasopharyngeal airway; *OPA*, oropharyngeal airway; *PAS*, posterior airway space; *Pg*, pogonion; *TV*, true vertical reference line with patient in natural head position; *UAL*, upper airway length.

surgeon is trained in endoscopy, an in-office endoscopic assessment of the pharynx can be very helpful. Alternatively, a colleague's endoscopic report can be reviewed or requested.

Records should include full facial and intraoral photographs and either plain panoramic radiograph and lateral cephalogram (with posteroanterior cephalogram if asymmetry is present) or a cone-beam CT scan (CBCT). Cephalometric analysis, although limited by the static representation of the airway, can be performed before and after treatment to assess baseline airway and skeletal characteristics and the corresponding changes resulting from surgery (Figures 15-5 and 15-6).

As with all orthognathic records, care must be taken to ensure that records are taken in centric relation. Natural head position and a relaxed lip posture are critical, as well. Patients with baseline obstruction may assume a head-up position to improve the airway; records taken in this position may be misleading. If consideration is being given to altering the current occlusion, impressions for study models should be taken.

Surgical and Anesthetic Planning

Mounted study models or virtual surgical planning are used to plan the patient's proposed maxillomandibular movements and to fabricate an intermediate and, if the surgeon prefers or if poor occlusion requires it, a final splint to translate the plan into the operating room. Though some advocate on-table advancement of the maxilla to the greatest extent possible, the authors believe that the maxillofacial surgeon's application of traditional orthognathic surgery planning principles yield maximal functional and esthetic benefit for the patient.

Few data are available about the degree of advancement required to achieve maximal benefit for the patient with OSA. An often-cited study suggests that mandibular advancement should be at least 10 mm.[75] However, a recent systematic review found no association between degree of mandibular advancement and surgical success on either study-level or patient-level analysis.[76] The review did report a higher surgical success rate with larger maxillary advancement (mean 9.9 vs. 8.4 mm) based on study-level analysis; the same held true with both uni- and multivariate patient-level analysis. In a multivariate analysis, the odds ratio for surgical success was 1.97 per 1 mm maxillary advancement.[76] A recent small-cohort study of 43 subjects who underwent smaller advancements (mean 5.2 mm in maxilla and 8.3 mm in mandible) reported 100% surgical success and 50% surgical cure in the subset of patients with AHI data (n = 12), suggesting that our understanding of the amount of advancement required to achieve surgical success is still evolving.[77]

Counterclockwise rotation of the maxillomandibular complex has been proposed to maximize mandibular advancement while minimizing the cosmetic impact of the surgery in the nasomaxillary region. This approach may benefit select patients. A recent meta-analysis found that there are insufficient data to determine whether MMA patients treated with counterclockwise rotation benefit more, but the study demonstrated that both strategies result in a significant reduction in AHI.[78]

Photographic predictions can be used to help the patient visualize the type of facial change that can be anticipated. A series examining hard to soft tissue change ratios in patients treated with MMA along with piriform

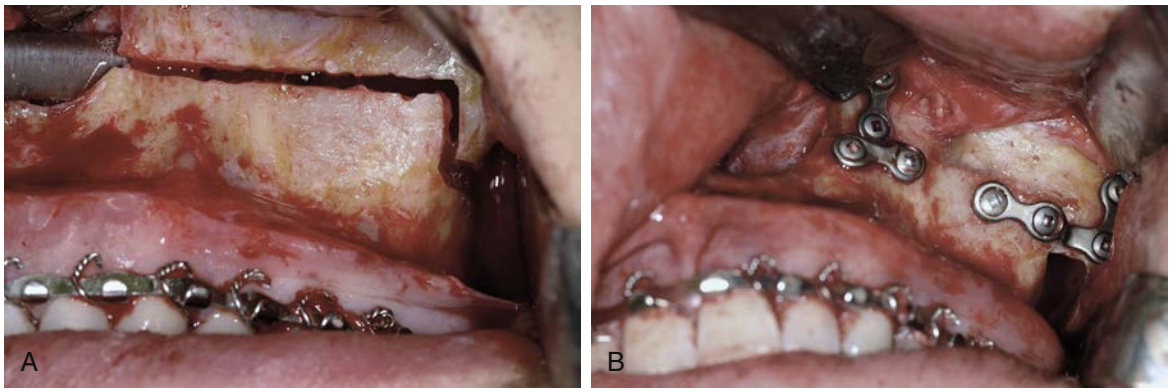

• **Figure 15-7** Total Le Fort I maxillary osteotomy with modified step design of lateral wall **(A),** reduction of anterior nasal spine and recontouring of piriform rims, followed by placement of maxillary bone plates at piriform rim and maxillary buttress **(B).** (From Boyd SB: Management of obstructive sleep apnea by maxillomandibular advancement, *Oral Maxillofac Surg Clin North Am* 21(4):447-457, 2009, with permission.)

and anterior nasal spine osteoplasty and alar cinch suturing reported a 0.9:1 ratio of soft to hard tissue throughout the upper and lower lip and chin; nasolabial angle became slightly more acute as forward rotation of the lip exceeded rotation of the nasal tip.[79] Each surgeon's technique will vary slightly, so critical analysis of one's own outcomes is imperative.

Anesthetic Management

A difficult airway should be anticipated, so appropriate review by the anesthesia care team is imperative. Most patients can be managed with fiberoptic nasal intubation, and the need for tracheostomy is rare. Careful attention should be paid to patient padding and positioning to minimize pressure sores and nerve injuries.

The degree of deliberate hypotension may be limited by baseline control of hypertension and comorbidities; if able, at least some degree of controlled hypotension should be used to minimize blood loss. Steroids may be administered to minimize postoperative edema.

Surgical Techniques

If expansion of the maxilla, mandible, or both is required, this is undertaken as a first-stage operation for surgical rapid maxillary expansion and/or mandibular midline osteotomy with distraction. Surgical rapid maxillary expansion has been shown to improve AHI (mean 56.2% reduction) and ESS (mean 12.5 to 7.2) as an isolated procedure.[80] In some cases maxillary expansion can be achieved through multi-piece maxillary osteotomies at the time of MMA.

Unless orthodontic appliances are in place, arch bars are applied at the beginning of the maxillomandibular advancement procedure. A Le Fort I osteotomy and bilateral sagittal split ramus osteotomies are completed; the merits of mandible first versus maxilla first surgery have been discussed elsewhere, and sequencing should be performed according to the surgeon's preference.

The authors generally complete the maxillary osteotomy first; a stepped osteotomy design may be used to maximize bone contact (Figure 15-7, *A*).[81,82] The maxilla is mobilized until it can be passively advanced to the desired final position. A judicious and progressive amount of pressure is used to mobilize the maxilla in order to minimize the risk of eliciting a trigeminocardiac reflex, which has been observed following maxillary osteotomies.[83] If encountered, consideration could be given to blocking the reflex with the use of a vagolytic drug. Following mobilization of the maxilla at the Le Fort I level, the intermediate occlusal splint is introduced and maxillomandibular fixation (MMF) is applied. The maxillomandibular complex is rotated closed, ensuring proper condylar seating. Interferences are carefully removed to achieve the desired vertical incisor position, which may be assessed based on either the lip position or an external reference point, such as a nasal Kirschner wire. The piriform aperture and the anterior nasal spine are recontoured as necessary to minimize unesthetic nasal changes. The maxilla is fixated into its desired position by placing plates at the nasomaxillary and zygomaticomaxillary buttresses (see Figure 15-7, *B*). Because of the large advancement, the surgeon may elect to use heavier plates and/or locking screws. With good bone contact, grafting is not generally required, though the surgeon may elect to place self-retentive grafts over the advancement gap to prevent soft tissue ingrowth during healing.

Bilateral sagittal split ramus osteotomies are then completed; the mandible is mobilized until it is readily advanced to its final position. MMF is again applied, using a final splint if indicated. With the condyles seated, the mandible is secured by the surgeon's preferred technique using either bicortical positional screws or plates and screws. MMF is again released, and occlusion is assessed.

If planned, a genial tubercle advancement or genioplasty is then performed through an anterior mandibular vestibular incision.

Once a satisfactory result has been obtained, the wounds are irrigated and closed. An alar cinch suture is placed prior to closing the maxillary vestibular wound in a V to Y fashion to minimize vermilion thinning.

Postoperative Care

Postoperative care is generally the same as that for patients undergoing routine orthognathic surgery and includes postoperative prophylactic antibiotics, additional steroids per surgeon preference, analgesics, and a non-chew diet.

Additional considerations for the MMA patient are directed toward airway management and comorbidities. Generally patients can be extubated in the operating room once they are sufficiently alert. Deep extubation is not recommended. Communication with the anesthesiologist is important as it is desirable to minimize agitation and the resultant increase in blood pressure, which can cause bleeding. Postoperative CPAP is rarely required; however, continuous oximetry and close observation for apneas are important for at least the first night. This may require admission to the intensive care unit. The patient is then transferred to the floor, provided there are no residual airway concerns. Opioid-sparing analgesia is employed to minimize narcotic use. Once patients are able to maintain good oxygen saturation on room air overnight, ambulate with minimal assistance, tolerate a non-chew diet, perform good oral hygiene, and achieve adequate pain control with oral analgesics, they may be discharged home. Patients are typically seen in the office every 1 to 2 weeks for the first 6 to 8 weeks after surgery. If in orthodontic appliances they return to the orthodontist at an agreed-upon interval, typically 4 to 6 weeks postoperatively.

A repeat PSG and review of sleep symptoms, both subjectively and using ESS and FOSQ, is important. Though an ideal interval for this has not been established, performing these assessments 3 to 6 months postoperatively allows recovery from the procedure and normalization of new patterns (Figure 15-8).

MMA Risks and Complications

Risks for MMA are similar to those associated with conventional orthognathic surgery and include pain, swelling, bleeding, infection, nonunion, relapse, malocclusion, altered facial sensation, unfavorable cosmetic outcomes, septal deviation, decreased mandibular range of motion, and need for hardware removal. Careful attention must be paid to postoperative airway management. Additional risks relate primarily to medical comorbidities.

In a systematic review, major complications (myocardial infarction, arrhythmia, and mandible fracture) were seen in 1% of subjects; minor complications excluding malocclusion and altered sensation were reported in 3.1%.[76]

A recent case series[84] evaluated 30 subjects; none required tracheostomy or reintubation, and none had serious cardiovascular, respiratory, or neurologic complications. Mandibular range of motion was maintained; TMJ function remained stable or improved. Of the 30 subjects, 2 experienced local wound infections controlled in the outpatient setting and 5 had subsequent hardware removal. Two subjects developed a malocclusion postoperatively. Only one subject required transfusion. Four patients (13.8%) reported worsening of facial appearance. Another series of 50 subjects reported no cardiovascular or respiratory events; 4% experienced bleeding and 2% phlebitis. Late hardware infection occurred in 16% and required hardware removal in 10%.[85]

The increased age of the average patient undergoing MMA presumably decreases the potential for neural recovery. Nonetheless, one series[85] reported that nearly 50% of subjects had full return of sensation an average of 18 months postoperatively. Another case series found that 40% of patients had a subjective decrease in lower lip/chin sensation, but the reported long-term change in sensation ranged from no problem to a moderate problem in terms of quality of life.[84]

Skeletal relapse may occur after any orthognathic surgery; however, reported relapse is generally minimal and deemed clinically insignificant after MMA.[77,86]

Regurgitation and hypernasality are theoretical complications, particularly if UPPP has been performed previously; however, these seem to be rare.[87] In a systematic review, velopharyngeal insufficiency was reported only in patients who had had prior phase I surgery.[76]

MMA Outcomes

A systematic review and meta-analysis of MMA outcomes showed significant improvement after MMA in terms of AHI (from mean 63.9 to 9.5), nadir oxygen saturation (from 71.9% to 87.7%), and sleepiness (ESS 13.2 to 5.1). Overall patient-level success rate was 84%. In a patient-level multivariate analysis, subjects with a lower preoperative BMI and those who underwent a larger maxillary advancement were more likely to experience surgical success.[76] Another systematic review and meta-analysis of outcomes after various surgical interventions to address OSA reported an 87% reduction in AHI after MMA with a mean postoperative AHI of 7.7 when MMA was performed as primary surgery.[61] The same review reported a 33% reduction in AHI after UPPP.

A more recent meta-analysis looked at 45 studies including 518 subjects; the authors reported a reduction in AHI from a mean of 57.2 to 9.5 with a mean 80% reduction in AHI.[88] Nadir oxygen saturation improved from mean 70.1% to 87%, and ESS score improved from mean 13.5 to 3.2. Surgical success rate was 85.5% with 38.5% cure in those subjects with AHI reported. Factors associated with surgical cure based on multivariate analysis were younger age, lower preoperative AHI, and higher preoperative nadir Spo_2. Subjects with a higher preoperative AHI tended to have lower baseline nadir Spo_2. Although less likely to achieve surgical success/cure, these subjects experienced a greater improvement in nadir Spo_2 and a greater reduction in events/hour than did those with lower baseline AHI. Genial tubercle advancement did not affect PSG outcomes.

In studies that compared preoperative AHI in patients treated with CPAP with post-MMA AHI, no difference was noted; MMA was as effective for these patients as CPAP.[76] A prospective randomized trial comparing outcomes using autotitrating positive airway pressure (APAP) versus MMA



• **Figure 15-8** Frontal facial **(A),** lateral facial **(B),** and lateral cephalometric **(C)** images of a 59-year-old man with severe obstructive sleep apnea (apnea-hypopnea index [AHI] = 45), decreased posterior airway space, and concomitant maxillofacial skeletal deformities (mandibular retrognathia, transverse maxillary hypoplasia, and transverse mandibular hypoplasia). Frontal facial **(D),** lateral facial **(E),** and lateral cephalometric radiograph **(F)** of the patient at long-term follow-up 5.5 years after maxillomandibular advancement (MMA). The patient had total resolution of obstructive sleep apnea (long-term post-MMA AHI = 0.8), increased posterior airway space, and correction of maxillofacial skeletal deformities and malocclusion. (Modified with permission from Conley RS, Legan HL: Correction of severe obstructive sleep apnea with bimaxillary transverse distraction osteogenesis and maxillomandibular advancement, *Am J Orthod Dentofacial Orthop* 129(2): 287, 2006.)

in subjects with severe OSA demonstrated similar reductions in AHI and sleepiness with these interventions.[89] Importantly, reduction in AHI after MMA has occurred despite stable or increased BMI.[61,84]

Systematic reviews suggest that blood pressure control improves after MMA.[61] A recent study reported long-term reduction in diastolic blood pressure following MMA.[84] A retrospective analysis demonstrated reduction of systolic (SBP) and diastolic (DBP) blood pressure after MMA by 3.8 mm Hg for SBP and 2.5 mm Hg for DBP, with larger reductions in the subset of patients with a diagnosis of hypertension.[90] This modest reduction in blood pressure is comparable to the reported impact of CPAP on blood pressure in a large systematic review and meta-analysis, which showed SBP reduction of 3.2 mm Hg and DBP reduction of 2.87 mm Hg.[91]

Subjective sleepiness (as assessed by ESS) and quality of life (as assessed by FOSQ) have been shown to improve after MMA.[76,84,88,92-95] A meta-analysis of CPAP therapy showed a mean reduction in ESS of 2.94 points, with a larger reduction of 4.75 in those with severe OSA and severe sleepiness.[96] Meta-analyses of MMA have shown larger reductions in ESS score from 13.2 to 5.1[76] and 13.5 to 3.2.[88]

An important question is whether MMA is a viable option for those with extremely high AHI values. Subjects intolerant of CPAP with an AHI greater than 100 who underwent MMA were evaluated retrospectively in a recent case series[94] where mean AHI values dropped from 117.9 to 16.1. Six of 13 subjects experienced surgical cure, and an additional 4 had a postoperative AHI less than 15. Mean ESS score dropped from 12.9 to 5. Interestingly, one subject's postoperative AHI was 95.5, though daytime somnolence improved and the subject would recommend the surgery to others. The authors were unable to identify any factors that explained this outlier response. Only one subject reported unfavorable facial changes, but family and friends saw the changes as positive.

Adjustment to a new facial appearance may be challenging for the MMA population; however, the majority of patients are satisfied with their facial appearance postoperatively. In a subject group treated to cephalometric norms, over 50% of patients were satisfied with their facial appearance, 13% were disappointed, and 5% were unsatisfied. Interestingly, these outcomes did not correlate with preoperative maxillomandibular retrusion, degree of advancement, or reduction in AHI. Of these patients, 94% said they would recommend the procedure to friends or family.[85] Other studies confirm high patient satisfaction after MMA.[76,89]

Linear and volumetric changes in the upper airway have been observed after MMA, as measured by CBCT. Specific changes include increases in airway volume, minimal cross-sectional area, and anterior-posterior dimension, along with decreases in airway length and airway resistance.[77,97-102] These changes likely result in decreased collapsibility of the upper airway and are associated with decreases in AHI.

Conclusion

MMA is an effective treatment for patients with moderate to severe OSA and has a favorable risk-to-benefit ratio. When performed alone, it is more effective than UPPP and offers similar benefit to CPAP, OAs, and upper airway stimulation. There is compelling evidence that MMA should be the treatment of choice for patients with moderate to severe OSA who are intolerant of CPAP or OAs.

References

1. Young T, Palta M, Dempsey J, et al.: The occurrence of sleep-disordered breathing among middle-aged adults, *N Engl J Med* 328(17):1230–1235, 1993.
2. Duran J, Esnaola S, Rubio R, Iztueta A: Obstructive sleep apnea-hypopnea and related clinical features in a population-based sample of subjects aged 30 to 70 yr, *Am J Respir Crit Care Med* 163(3 Pt 1):685–689, 2001.
3. Peppard PE, Young T, Barnet JH, et al.: Increased prevalence of sleep-disordered breathing in adults, *Am J Epidemiol* 177(9):1006–1014, 2013.
4. Young T, Peppard PE, Gottlieb DJ: Epidemiology of obstructive sleep apnea: a population health perspective, *Am J Respir Crit Care Med* 165(9):1217–1239, 2002.
5. Eckert DJ, Malhotra A: Pathophysiology of adult obstructive sleep apnea, *Proc Am Thorac Soc* 5(2):144–153, 2008.
6. Eckert DJ, White DP, Jordan AS, et al.: Defining phenotypic causes of obstructive sleep apnea: identification of novel therapeutic targets, *Am J Respir Crit Care Med* 188(8):996–1004, 2013.
7. Joosten SA, O'Driscoll DM, Berger PJ, Hamilton GS: Supine position related obstructive sleep apnea in adults: pathogenesis and treatment, *Sleep Med Rev* 18(1):7–17, 2014.
8. Somers VK, White DP, Amin R, et al.: Sleep apnea and cardiovascular disease: an American Heart Association/American College of Cardiology Foundation Scientific Statement from the American Heart Association Council for High Blood Pressure Research Professional Education Committee, Council on Clinical Cardiology, Stroke Council, and Council On Cardiovascular Nursing. In collaboration with the National Heart, Lung, and Blood Institute National Center on Sleep Disorders Research (National Institutes of Health), *Circulation* 118(10):1080–1111, 2008.
9. Epstein LJ, Kristo D, Strollo Jr PJ, et al.: Clinical guideline for the evaluation, management and long-term care of obstructive sleep apnea in adults, *J Clin Sleep Med* 5(3):263–276, 2009.
10. Golbin JM, Somers VK, Caples SM: Obstructive sleep apnea, cardiovascular disease, and pulmonary hypertension, *Proc Am Thorac Soc* 5(2):200–206, 2008.
11. Marin JM, Agusti A, Villar I, et al.: Association between treated and untreated obstructive sleep apnea and risk of hypertension, *JAMA* 307(20):2169–2176, 2012.
12. Peppard PE, Young T, Palta M, Skatrud J: Prospective study of the association between sleep-disordered breathing and hypertension, *N Engl J Med* 342(19):1378–1384, 2000.
13. Phillips B: Sleep-disordered breathing and cardiovascular disease, *Sleep Med Rev* 9(2):131–140, 2005.
14. Vgontzas AN, Bixler EO, Chrousos GP: Sleep apnea is a manifestation of the metabolic syndrome, *Sleep Med Rev* 9(3):211–224, 2005.
15. Marin JM, Carrizo SJ, Vicente E, Agusti AG: Long-term cardiovascular outcomes in men with obstructive sleep apnoea-hypopnoea with or without treatment with continuous positive airway pressure: an observational study, *Lancet* 365(9464):1046–1053, 2005.
16. Yaggi HK, Concato J, Kernan WN, et al.: Obstructive sleep apnea as a risk factor for stroke and death, *N Engl J Med* 353(19):2034–2041, 2005.
17. Tasali E, Ip MS: Obstructive sleep apnea and metabolic syndrome: alterations in glucose metabolism and inflammation, *Proc Am Thorac Soc* 5(2):207–217, 2008.
18. Wang X, Bi Y, Zhang Q, Pan F: Obstructive sleep apnoea and the risk of type 2 diabetes: a meta-analysis of prospective cohort studies, *Respirology* 18(1):140–146, 2013.
19. Beebe DW, Groesz L, Wells C, et al.: The neuropsychological effects of obstructive sleep apnea: a meta-analysis of norm-referenced and case-controlled data, *Sleep* 26(3):298–307, 2003.
20. Karimi M, Hedner J, Habel H, et al.: Sleep apnea-related risk of motor vehicle accidents is reduced by continuous positive airway pressure: swedish Traffic Accident Registry data, *Sleep* 38(3):341–349, 2015.
21. Tregear S, Reston J, Schoelles K, Phillips B: Obstructive sleep apnea and risk of motor vehicle crash: systematic review and meta-analysis, *J Clin Sleep Med* 5(6):573–581, 2009.
22. Moore P, Bardwell WA, Ancoli-Israel S, Dimsdale JE: Association between polysomnographic sleep measures and health-related quality of life in obstructive sleep apnea, *J Sleep Res* 10(4):303–308, 2001.

23. Moyer CA, Sonnad SS, Garetz SL, et al.: Quality of life in obstructive sleep apnea: a systematic review of the literature, *Sleep Med* 2(6):477–491, 2001.
24. Reimer MA, Flemons WW: Quality of life in sleep disorders, *Sleep Med Rev* 7(4):335–349, 2003.
25. BaHammam AS, Kendzerska T, Gupta R, et al.: Comorbid depression in obstructive sleep apnea: an under-recognized association, *Sleep Breath* 20(2):447–456, 2016.
26. Gupta MA, Simpson FC: Obstructive sleep apnea and psychiatric disorders: a systematic review, *J Clin Sleep Med* 11(2):165–175, 2015.
27. Punjabi NM: The epidemiology of adult obstructive sleep apnea, *Proc Am Thorac Soc* 5(2):136–143, 2008.
28. Schwartz AR, Patil SP, Laffan AM, et al.: Obesity and obstructive sleep apnea: pathogenic mechanisms and therapeutic approaches, *Proc Am Thorac Soc* 5(2):185–192, 2008.
29. Johns MW: A new method for measuring daytime sleepiness: the Epworth sleepiness scale, *Sleep* 14(6):540–545, 1991.
30. Johns MW: Reliability and factor analysis of the Epworth Sleepiness Scale, *Sleep* 15(4):376–381, 1992.
31. Weaver TE, Laizner AM, Evans LK, et al.: An instrument to measure functional status outcomes for disorders of excessive sleepiness, *Sleep* 20(10):835–843, 1997.
32. Flemons WW, Reimer MA: Development of a disease-specific health-related quality of life questionnaire for sleep apnea, *Am J Respir Crit Care Med* 158(2):494–503, 1998.
33. Berry RB, Gamaldo CE, Harding SM, et al.: AASM Scoring Manual Version 2.2 Updates: new chapters for scoring infant sleep staging and home sleep apnea testing, *J Clin Sleep Med* 11(11):1253–1254, 2015.
34. Rosen CL, Auckley D, Benca R, et al.: A multisite randomized trial of portable sleep studies and positive airway pressure autotitration versus laboratory-based polysomnography for the diagnosis and treatment of obstructive sleep apnea: the HomePAP study, *Sleep* 35(6):757–767, 2012.
35. Collop NA, Anderson WM, Boehlecke B, et al.: Clinical guidelines for the use of unattended portable monitors in the diagnosis of obstructive sleep apnea in adult patients. Portable Monitoring Task Force of the American Academy of Sleep Medicine, *J Clin Sleep Med* 3(7):737–747, 2007.
36. Friedman M, Ibrahim H, Bass L: Clinical staging for sleep-disordered breathing, *Otolaryngol Head Neck Surg* 127(1):13–21, 2002.
37. Soares D, Folbe AJ, Yoo G, et al.: Drug-induced sleep endoscopy vs awake Muller's maneuver in the diagnosis of severe upper airway obstruction, *Otolaryngol Head Neck Surg* 148(1):151–156, 2013.
38. Certal VF, Pratas R, Guimaraes L, et al.: Awake examination versus DISE for surgical decision making in patients with OSA: a systematic review, *Laryngoscope* 126(3):768–774, 2016.
39. Sher AE, Schechtman KB, Piccirillo JF: The efficacy of surgical modifications of the upper airway in adults with obstructive sleep apnea syndrome, *Sleep* 19(2):156–177, 1996.
40. Aurora RN, Collop NA, Jacobowitz O, et al.: Quality measures for the care of adult patients with obstructive sleep apnea, *J Clin Sleep Med* 11(3):357–383, 2015.
41. Aurora RN, Casey KR, Kristo D, et al.: Practice parameters for the surgical modifications of the upper airway for obstructive sleep apnea in adults, *Sleep* 33(10):1408–1413, 2010.
42. Giles TL, Lasserson TJ, Smith BH, et al.: Continuous positive airways pressure for obstructive sleep apnoea in adults, *Cochrane Database Syst Rev* 3:CD001106, 2006.
43. Gordon P, Sanders MH: Sleep.7: positive airway pressure therapy for obstructive sleep apnoea/hypopnoea syndrome, *Thorax* 60(1):68–75, 2005.
44. Antic NA, Catcheside P, Buchan C, et al.: The effect of CPAP in normalizing daytime sleepiness, quality of life, and neurocognitive function in patients with moderate to severe OSA, *Sleep* 34(1):111–119, 2011.
45. Weaver TE, Grunstein RR: Adherence to continuous positive airway pressure therapy: the challenge to effective treatment, *Proc Am Thorac Soc* 5(2):173–178, 2008.
46. Sawyer AM, Gooneratne NS, Marcus CL, et al.: A systematic review of CPAP adherence across age groups: clinical and empiric insights for developing CPAP adherence interventions, *Sleep Med Rev* 15(6):343–356, 2011.
47. Campos-Rodriguez F, Pena-Grinan N, Reyes-Nunez N, et al.: Mortality in obstructive sleep apnea-hypopnea patients treated with positive airway pressure, *Chest* 128(2):624–633, 2005.
48. Hsu AA, Lo C: Continuous positive airway pressure therapy in sleep apnoea, *Respirology* 8(4):447–454, 2003.
49. Malhotra A, Ayas NT, Epstein LJ: The art and science of continuous positive airway pressure therapy in obstructive sleep apnea, *Curr Opin Pulm Med* 6(6):490–495, 2000.
50. Sanders MH, Montserrat JM, Farre R, Givelber RJ: Positive pressure therapy: a perspective on evidence-based outcomes and methods of application, *Proc Am Thorac Soc* 5(2):161–172, 2008.
51. Ramar K, Dort LC, Katz SG, et al.: Clinical practice guideline for the treatment of obstructive sleep apnea and snoring with oral appliance therapy: an update for 2015, *J Clin Sleep Med* 11(7):773–827, 2015.
52. Li W, Xiao L, Hu J: The comparison of CPAP and oral appliances in treatment of patients with OSA: a systematic review and meta-analysis, *Resp Care* 58(7):1184–1195, 2013.
53. Sutherland K, Vanderveken OM, Tsuda H, et al.: Oral appliance treatment for obstructive sleep apnea: an update, *J Clin Sleep Med* 10(2):215–227, 2014.
54. Goldberg R: Treatment of obstructive sleep apnea, other than with continuous positive airway pressure, *Curr Opin Pulm Med* 6(6):496–500, 2000.
55. Ashrafian H, Toma T, Rowland SP, et al.: Bariatric surgery or non-surgical weight loss for obstructive sleep apnoea? A systematic review and comparison of meta-analyses, *Obes Surg* 25(7):1239–1250, 2015.
56. Peppard PE, Young T, Palta M, et al.: Longitudinal study of moderate weight change and sleep-disordered breathing, *JAMA* 284(23):3015–3021, 2000.
57. Pillar G, Peled R, Lavie P: Recurrence of sleep apnea without concomitant weight increase 7.5 years after weight reduction surgery, *Chest* 106(6):1702–1704, 1994.
58. Camacho M, Certal V, Brietzke SE, et al.: Tracheostomy as treatment for adult obstructive sleep apnea: a systematic review and meta-analysis, *Laryngoscope* 124(3):803–811, 2014.
59. Won CH, Li KK, Guilleminault C: Surgical treatment of obstructive sleep apnea: upper airway and maxillomandibular surgery, *Proc Am Thorac Soc* 5(2):193–199, 2008.
60. Fujita S, Conway W, Zorick F, Roth T: Surgical correction of anatomic abnormalities in obstructive sleep apnea syndrome: uvulopalatopharyngoplasty, *Otolaryngol Head Neck Surg* 89(6):923–934, 1981.
61. Caples SM, Rowley JA, Prinsell JR, et al.: Surgical modifications of the upper airway for obstructive sleep apnea in adults: a systematic review and meta-analysis, *Sleep* 33(10):1396–1407, 2010.

62. Li HY, Li KK, Chen NH, et al.: Three-dimensional computed tomography and polysomnography findings after extended uvulopalatal flap surgery for obstructive sleep apnea, *Am J Otolaryngol* 26(1):7–11, 2005.
63. Kezirian EJ, Goldberg AN: Hypopharyngeal surgery in obstructive sleep apnea: an evidence-based medicine review, *Arch Otolaryngol Head Neck Surg* 132(2):206–213, 2006.
64. Neruntarat C: Genioglossus advancement and hyoid myotomy: short-term and long-term results, *J Laryngol Otol* 117(6):482–486, 2003.
65. Strollo Jr PJ, Soose RJ, Maurer JT, et al.: Upper-airway stimulation for obstructive sleep apnea, *N Engl J Med* 370(2):139–149, 2014.
66. Woodson BT, Soose RJ, Gillespie MB, et al.: Three-year outcomes of cranial nerve stimulation for obstructive sleep apnea: the STAR Trial, *Otolaryngol Head Neck Surg* 154(1):181–188, 2016.
67. Kezirian EJ, Goding Jr GS, Malhotra A, et al.: Hypoglossal nerve stimulation improves obstructive sleep apnea: 12-month outcomes, *J Sleep Res* 23(1):77–83, 2014.
68. Van de Heyning PH, Badr MS, Baskin JZ, et al.: Implanted upper airway stimulation device for obstructive sleep apnea, *Laryngoscope* 122(7):1626–1633, 2012.
69. Vanderveken OM, Maurer JT, Hohenhorst W, et al.: Evaluation of drug-induced sleep endoscopy as a patient selection tool for implanted upper airway stimulation for obstructive sleep apnea, *J Clin Sleep Med* 9(5):433–438, 2013.
70. Camacho M, Riaz M, Capasso R, et al.: The effect of nasal surgery on continuous positive airway pressure device use and therapeutic treatment pressures: a systematic review and meta-analysis, *Sleep* 38(2):279–286, 2015.
71. Justin GA, Chang ET, Camacho M, Brietzke SE: Transoral robotic surgery for obstructive sleep apnea: a systematic review and meta-analysis, *Otolaryngol Head Neck Surg* 154(5):835–846, 2016.
72. Waite PD, Shettar SM: Maxillomandibular advancement surgery: a cure for sleep apnea syndrome, *Oral Maxillofac Surg Clin North Am* 7(2):327–336, 1995.
73. Riley RW, Powell NB, Guilleminault C: Obstructive sleep apnea syndrome: a review of 306 consecutively treated surgical patients, *Otolaryngol Head Neck Surg* 108(2):117–125, 1993.
74. Boyd SB, Walters AS, Song Y, Wang L: Comparative effectiveness of maxillomandibular advancement and uvulopalatopharyngoplasty for the treatment of moderate to severe obstructive sleep apnea, *J Oral Maxillofac Surg* 71(4):743–751, 2013.
75. Riley RW, Powell NB, Li KK, et al.: Surgery and obstructive sleep apnea: long-term clinical outcomes, *Otolaryngol Head Neck Surg* 122(3):415–421, 2000.
76. Holty JE, Guilleminault C: Maxillomandibular advancement for the treatment of obstructive sleep apnea: a systematic review and meta-analysis, *Sleep Med Rev* 14(5):287–297, 2010.
77. Ubaldo ED, Greenlee GM, Moore J, et al.: Cephalometric analysis and long-term outcomes of orthognathic surgical treatment for obstructive sleep apnoea, *Int J Oral Maxillofac Surg* 44(6):752–759, 2015.
78. Knudsen TB, Laulund AS, Ingerslev J, et al.: Improved apnea-hypopnea index and lowest oxygen saturation after maxillomandibular advancement with or without counterclockwise rotation in patients with obstructive sleep apnea: a meta-analysis, *J Oral Maxillofac Surg* 73(4):719–726, 2015.
79. Conley RS, Boyd SB: Facial soft tissue changes following maxillomandibular advancement for treatment of obstructive sleep apnea, *J Oral Maxillofac Surg* 65(7):1332–1340, 2007.
80. Vinha PP, Eckeli AL, Faria AC, et al.: Effects of surgically assisted rapid maxillary expansion on obstructive sleep apnea and daytime sleepiness, *Sleep Breath* 20(2):501–508, 2016.
81. Bennett MA, Wolford L: Maxillary surgery technical considerations. In Bell WH, editor: *Surgical correction of dentofacial deformities: new concepts*, Philadelphia, 1985, WB Saunders, pp 45–53.
82. Kaminishi RM, Davis WH, Hochwald DA, Nelson N: Improved maxillary stability with modified Lefort I technique, *J Oral Maxillofac Surg* 41(3):203–205, 1983.
83. Lang S, Lanigan DT, van der Wal M: Trigeminocardiac reflexes: maxillary and mandibular variants of the oculocardiac reflex, *Can J Anaesth* 38(6):757–760, 1991.
84. Boyd SB, Walters AS, Waite P, et al.: Long-term effectiveness and safety of maxillomandibular advancement for treatment of obstructive sleep apnea, *J Clin Sleep Med* 11(7):699–708, 2015.
85. Blumen MB, Buchet I, Meulien P, et al.: Complications/adverse effects of maxillomandibular advancement for the treatment of OSA in regard to outcome, *Otolaryngol Head Neck Surg* 141(5):591–597, 2009.
86. Lee SH, Kaban LB, Lahey ET: Skeletal stability of patients undergoing maxillomandibular advancement for treatment of obstructive sleep apnea, *J Oral Maxillofac Surg* 73(4):694–700, 2015.
87. Li KK, Troell RJ, Riley RW, et al.: Uvulopalatopharyngoplasty, maxillomandibular advancement, and the velopharynx, *Laryngoscope* 111(6):1075–1078, 2001.
88. Zaghi S, Holty JE, Certal V, et al.: Maxillomandibular advancement for treatment of obstructive sleep apnea: a meta-analysis, *JAMA Otolaryngol Head Neck Surg* 142(1):58–66, 2016.
89. Vicini C, Dallan I, Campanini A, et al.: Surgery vs ventilation in adult severe obstructive sleep apnea syndrome, *Am J Otolaryngol* 31(1):14–20, 2010.
90. Islam S, Taylor CJ, Ormiston IW: Effects of maxillomandibular advancement on systemic blood pressure in patients with obstructive sleep apnoea, *Br J Oral Maxillofac Surg* 53(1):34–38, 2015.
91. Schein AS, Kerkhoff AC, Coronel CC, et al.: Continuous positive airway pressure reduces blood pressure in patients with obstructive sleep apnea; a systematic review and meta-analysis with 1000 patients, *J Hypertens* 32(9):1762–1773, 2014.
92. Dattilo DJ, Drooger SA: Outcome assessment of patients undergoing maxillofacial procedures for the treatment of sleep apnea: comparison of subjective and objective results, *J Oral Maxillofac Surg* 62(2):164–168, 2004.
93. Goodday R, Bourque S: Subjective outcomes of maxillomandibular advancement surgery for treatment of obstructive sleep apnea syndrome, *J Oral Maxillofac Surg* 70(2):417–420, 2012.
94. Goodday RH, Bourque SE, Edwards PB: Objective and subjective outcomes following maxillomandibular advancement surgery for treatment of patients with extremely severe obstructive sleep apnea (apnea-hypopnea index >100), *J Oral Maxillofac Surg* 74(3):583–589, 2016.
95. Lye KW, Waite PD, Meara D, Wang D: Quality of life evaluation of maxillomandibular advancement surgery for treatment of obstructive sleep apnea, *J Oral Maxillofac Surg* 66(5):968–972, 2008.
96. Patel SR, White DP, Malhotra A, et al.: Continuous positive airway pressure therapy for treating sleepiness in a diverse population with obstructive sleep apnea: results of a meta-analysis, *Arch Intern Med* 163(5):565–571, 2003.

97. Abramson ZR, Susarla S, Tagoni JR, Kaban L: Three-dimensional computed tomographic analysis of airway anatomy, *J Oral Maxillofac Surg* 68(2):363–371, 2010.
98. Butterfield KJ, Marks PL, McLean L, Newton J: Linear and volumetric airway changes after maxillomandibular advancement for obstructive sleep apnea, *J Oral Maxillofac Surg* 73(6):1133–1142, 2015.
99. Hsieh YJ, Liao YF, Chen NH, Chen YR: Changes in the calibre of the upper airway and the surrounding structures after maxillomandibular advancement for obstructive sleep apnoea, *Br J Oral Maxillofac Surg* 52(5):445–451, 2014.
100. Rosário HD, Oliveira GM, Freires IA, et al.: Efficiency of bimaxillary advancement surgery in increasing the volume of the upper airways: a systematic review of observational studies and meta-analysis, *Eur Arch Otorhinolaryngol*, 2016. (Epub ahead of print.)
101. Susarla SM, Abramson ZR, Dodson TB, Kaban LB: Upper airway length decreases after maxillomandibular advancement in patients with obstructive sleep apnea, *J Oral Maxillofac Surg* 69(11):2872–2878, 2011.
102. Zinser MJ, Zachow S, Sailer HF: Bimaxillary "rotation advancement" procedures in patients with obstructive sleep apnea: a 3-dimensional airway analysis of morphological changes, *Int J Oral Maxillofac Surg* 42(5):569–578, 2013.

16

Perioperative Management of the Orthognathic Patient

LEWIS C. JONES, MICHAEL JASKOLKA

The perioperative management of patients seeking orthognathic surgery begins before the initiation of orthodontic therapy and continues indefinitely after their operation. The aim of this chapter is to review many of the preoperative factors that help determine the appropriateness of orthognathic surgery as a treatment modality for each individual patient. It also addresses the postoperative course, including management of early complications.

In general, there are two distinct patient populations that seek orthognathic surgery: the first are those with significant dentofacial deformity (DFD), and the second are those with obstructive sleep apnea (OSA). This chapter addresses the management of both populations.

In the DFD patient, the first surgical consultation ideally occurs before the initiation of orthodontic treatment. A preliminary treatment plan is developed after a discussion of the patient's chief complaint(s), physical exam, and review of other records (orthodontic models and radiographs). Treatment plan options may include orthodontic camouflage versus correction of the underlying skeletal deformity and should take additional patient-specific factors into account. It is at this point that the process of "informed consent" begins, as patients and their families should understand the nature of the surgical procedures that may be performed, as well as the inherent risks and benefits. In addition, any significant medical comorbidities that may lead to further testing, consultations, or alternative treatment recommendations should be identified.

For the OSA patient, the first surgical consultation is generally focused on the evaluation of the severity of their disease. This is likely to include a history (focused on symptoms and prior interventions), physical exam, review of polysomnographic testing, radiographic evaluation, and nasoendoscopy. Once the decision has been made to offer the patient jaw advancement, the majority of the preoperative planning relates to evaluation and optimization of existing medical comorbidities. Preoperative orthodontic preparation may or may not be part of the treatment plan depending on the patient's interest, medical condition, and occlusion—but the patient must understand that orthodontics may be indicated following surgical treatment.

Dentofacial Considerations

Growth and Timing

The patient's maturity at the time of surgery directly affects their propensity for relapse. When concern for continued growth exists, serial cephalometric images 6 to 12 months apart should demonstrate that the patient is not actively growing before proceeding with surgery.[1] Alternatively, analysis of hand-wrist films has been used as a predictor for facial growth for decades, and cervical spine imaging has also been described in estimating growth cessation[2-4] (Figures 16-1 and 16-2).

The timing of surgery also depends on the severity of the skeletal discrepancy, functional restrictions, and psychosocial considerations. Literature describing early correction of dentofacial deformities with orthognathic surgery is sparse, with relatively small studies showing a variety of results with regard to relapse in the growing, adolescent patient. One study of 22 patients undergoing bilateral sagittal split osteotomy (BSSO) for mandibular retrognathia demonstrated that relapse rates correlated with the amount of advancement—with those greater than or equal to 10 mm more likely to experience significant relapse due to condylar remodeling/resorption.[5] Several other studies have demonstrated stability, including Epker, Schendel, and Wolford's series of 12 patients in 1978, which demonstrated good stability following advancement of growing class II patients.[6] Studies such as these demonstrate the need for patient counseling regarding surgical timing. It is important to explain that early intervention, although more predictable in instances such as the advancement of a hypoplastic mandible/maxilla than that of a setback of a hyperplastic jaw, may require additional orthodontics and/or surgery if the corrections are outgrown.



• **Figure 16-1** Hand wrist film of skeletally immature patient. Note the open epiphyseal plates in the phalanges and lack of sesamoid bone at the thumb.



• **Figure 16-2** Hand wrist film of skeletally mature patient with closed epiphyseal plates and presence of sesamoid bone at thumb.

Asymmetry

Growth resulting in asymmetry requires the surgeon to investigate the cause of the growth pattern. Significant asymmetries can result from processes that are congenital (e.g., hemifacial microsomia), acquired (e.g., trauma, pathology), or idiopathic (e.g., hemimandibular hypertrophy, Parry-Romberg syndrome). Slowly developing asymmetries will allow for compensation in the opposing arch, thus initially masking the etiology of the asymmetry. Conversely, rapidly developing asymmetries are more apparent, as they do not allow for dental compensation. Depending on the differential diagnosis, additional studies may be required, such as a technetium-99m (^{99m}Tc) nuclear scan or single-photon emission computed tomography (SPECT) to evaluate for active uptake that indicates continued growth at the condyle.[7,8] In some cases, growth-arresting high condylectomy may be attempted to limit progressive deformity. In congenital conditions, arguments can be found in the literature both for and against early versus delayed intervention at the completion of skeletal maturity. The final category of conditions are those such as Parry-Romberg syndrome and idiopathic condylar resorption, which may necessitate a waiting period to ensure that the atrophy has ceased or "burned out" before corrective surgery is pursued. The condylar resorption patient should be made aware that even a quiescent condyle can undergo reactivation of the resorptive process following surgery, as several reports have demonstrated.[9-11]

Presence of Third Molars

The management of third molars in the context of orthognathic surgery has been debated, with many practitioners preferring to extract before surgery. At the very least, they are an inconvenience during the osteotomies of the mandible (and occasionally the maxilla). Cases have been made both for and against removal of third molars before surgery.[12,13] However, a prospective study has shown that their presence does not cause an increase in complications.[14] If they are to be removed prior to surgery, the recommended time frame is 6 to 9 months before the desired surgery date to allow for bony healing.[15]

Orthodontic Considerations/Preparation

Traditionally, orthodontic treatment comprising dental decompensation and independent arch coordination is completed before orthognathic surgery. Occasionally, in sleep apnea cases with a stable occlusion, orthodontic therapy may not be required at all. In some cases, surgery can be performed before orthodontics. In most of the "surgery-first" cases, no severe asymmetry exists, there is minimal orthodontic complexity and only mild jaw discrepancy, and the surgery is being performed for either airway or esthetic reasons.[16,17]

A patient who is orthodontically prepared for surgery should have final orthodontic models, photographs, and radiographs taken in preparation for final surgical planning. A passive stainless steel archwire placed 2 weeks before impressions ensures that no orthodontic movement of the teeth occurs between the time when final records are taken and the day of surgery. Surgical lugs should be placed between as many of the teeth as possible, usually only a few days before surgery to minimize discomfort. A case with inadequate surgical lugs can lead to intraoperative interarch instability and compromise the final result. Segmental surgery should have verification of root divergence

on radiographs in the regions of the planned osteotomies. The final plan and occlusion should be reviewed with both the patient and the orthodontist. Limitations of the surgical procedure should be noted (e.g., maxillary expansion with segmental maxillary surgery) so that the orthodontist can make appropriate plans for postoperative occlusal detailing. If an occlusal splint is to be used, it may be trialed for fit before the day of surgery. If orthodontic elastic traction is to be used postoperatively, patients may be provided supplies to practice with in advance of surgery. Intraoral manipulation of elastics can be frustrating in the setting of paresthesia, swelling, and pain (Figure 16-3).

Traditional sequencing of orthognathic surgery allows for orthodontic decompensation before surgery followed by orthodontic finishing. However, depending on the case and the orthodontist, surgery can be performed first. The concept of a regional acceleratory phenomenon in the 3 to 4 months following surgery is the theory behind the shortened treatment phase observed in these patients. This has been described by various surgeons, with the caveat that only mild to moderate crowding exists and that the arches are reasonably well coordinated.[18-20] This is a paradigm shift in the traditional method that will continue to be explored as its merits and limitations are further borne out in the literature.

Preoperative Informed Consent

The process of informed consent begins during the initial consultation and continues during the treatment planning appointments. The final appointment before surgery should include a detailed conversation with the patient regarding their expectations of the surgery, early postoperative period, and final goals/outcomes. This meeting allows the patient to ask additional questions and allows the surgeon to review the expected time frame for postoperative pain and swelling that will progress/increase for 48 to 72 hours following surgery. Risks discussed should include blood loss (and the remote possibility of need for transfusion), hardware placement, possible maxillomandibular fixation (planned or due to unfavorable fractures), and possible need for future procedures such as hardware removal. Temporary sensory nerve deficits in the trigeminal (V2/V3) distribution are expected in many cases, and in some cases the marginal mandibular motor nerves are also at risk of injury. Discussion of nerve injury should include the risk of permanent hypoesthesia, anesthesia, dysesthesia, or motor weakness within the context of the treatment plan. The patient must comprehend the importance of postoperative oral hygiene despite the difficulties imposed by edema, sutures, elastics, and an oral splint. Postoperative dietary restrictions and the need for supplementation should also be reinforced. Last, appropriate recovery time should be reviewed, as unrealistic expectations can discourage the patient if they feel they are not healing or progressing quickly enough.



• **Figure 16-3** Final occlusal splint on models. Ideally this should have enough buccal dimension to allow for holes for passing a wire to secure the splint to the maxillary archwire, but maintain a low profile to avoid undue patient discomfort.

Systems-Based Medical Evaluation

A systems-based patient evaluation should include review of cardiovascular, pulmonary, renal, neurologic, hematologic, musculoskeletal, mental health, and endocrine systems as they relate to both surgical and anesthetic risk. Absolute medical contraindications, where the risks associated with treatment are likely to outweigh the benefits, should be identified at the outset and may affect the overall treatment plan. Otherwise, the recognition of medical conditions that require optimization or specialized perioperative management is necessary. As the prevalence of orthognathic surgery as a treatment modality is expanded to include patients with congenital conditions, older age cohorts, and those with OSA, the population of patients seeking orthognathic surgery grows more medically complex.

Cardiovascular

Orthognathic surgery can stress the cardiovascular system. In addition to the possibility of significant blood loss, general anesthetics for maxillary surgery often incorporate a component of hypotensive anesthesia that requires cardiac compensation to maintain end-organ perfusion. Both the anesthesiologist and surgeon should be aware of the patient's cardiovascular risk factors in light of the planned surgery and anesthetic, including the timing and duration of the permissive hypotension. The preoperative history and physical will initiate the cardiovascular evaluation.

Pediatric cardiovascular conditions are highlighted by congenital malformation. The most common include valvular abnormalities (stenosis/regurgitation/bifid malformations) and aortic coarctation, as well as more complex conditions such as tetralogy of Fallot, transposition of the

great vessels, and truncus arteriosus. As pediatric cardiology and cardiothoracic reconstruction continues to advance, many patients with a history of congenital malformation are candidates for orthognathic surgery. Cardiac electrophysiologic abnormalities such as Wolff-Parkinson-White or long Q-T syndrome, paroxysmal supraventricular tachycardia, and sick sinus syndrome can also be present, more commonly in the adolescent patient.

Adult populations can present with a history of any of the above as well as acquired cardiovascular disease such as coronary artery disease, arterio/atherosclerosis, aneurysms, and/or hypertension. Arrhythmias such as atrial fibrillation are more common at advanced ages. Previous history of procedures and cardiovascular medications taken to mitigate these conditions should be elicited in the initial exam. As medical (and surgical) management of these conditions continues to expand, a thoughtful plan for perioperative management of these patients is required.

OSA patients seeking maxillomandibular advancement (MMA) surgery should be closely monitored for undiagnosed cardiovascular disease. OSA is a risk factor for hypertension, and evidence is mounting to suggest OSA as an independent risk factor for coronary artery disease. Untreated, severe OSA is also associated with increased cardiac mortality.[21-25]

The cardiovascular portion of the physical exam includes auscultation of the heart for normal S1/S2 sounds and a regular rate and rhythm. Any deviation from normal prompts further workup and referral to the patient's primary physician or cardiologist. The cardiovascular exam also includes assessment of the patient's extremities. This can illuminate peripheral vascular disease and congestive heart failure, as distal pulses are palpated and lower extremities inspected for edema. This swelling may be an indication of heart failure, which would also correlate with signs such as jugular venous distention and presence of a third heart sound. Finally, although most patients will receive antibiotics prior to incision, it is imperative that all patients requiring prophylaxis due to concerns for infective endocarditis receive preoperative antibiotics.[26] The most recent recommendations by the American Heart Association are listed in Box 16-1.

• BOX 16-1 2007 American Heart Association Guidelines for Infective Endocarditis Prophylaxis

1. Prosthetic heart valve or valve repair with prosthetic material
2. History of endocarditis
3. Heart transplant with abnormal heart valve function
4. Congenital heart defects that have not been fully repaired, those repaired with residual defects, and those repaired with prosthetic material (covered for 6 months postoperatively)

From Ball JW, Dains JE, Flynn JA, editors: *Seidel's guide to physical examination*, ed 8, St. Louis, 2015, Mosby.

Patients with cardiac conditions will most often require consultation with the patient's managing physician and review of existing laboratory work and studies. Most cardiac patients will have undergone multiple studies that may include 12-lead electrocardiography (ECG), echocardiogram, magnetic resonance imaging (MRI), and computed tomographic or conventional angiography. Patients should also be questioned regarding a history of angina, activity limitations, prosthetic implants, irregular heartbeat, and medication regimens that may affect their perioperative care. Discussions regarding exercise/activity tolerance will allow insight into the patient's overall cardiovascular status. The New York Heart Association's classification (first established in 1928 and subsequently amended) stratifies patients with heart failure according to tolerance of physical activities[27] (Table 16-1). Various activities have differing metabolic equivalents of task (METs); one MET is defined as the resting metabolic rate (or the amount of oxygen consumption at rest, sitting in a chair), which is equivalent to approximately 3.5 mL O_2/kg/min.[28] Therefore, an activity requiring 7.5 mL O_2/kg/min is a 2-MET activity (Table 16-2). A decreased ability to tolerate activities with minimal

TABLE 16-1 NYHA Classes of Heart Failure

Class	Functional Capacity
I	Cardiac disease present but does not limit physical activity. Physical activity does not cause inordinate fatigue, palpitation, dyspnea, or angina.
II	Cardiac disease that causes slight limitations in physical activity. Patient is comfortable at rest. Physical activity (ordinary) does result in fatigue, palpitation and/or angina.
III	Cardiac disease with marked limitation of physical activity. Patient is comfortable at rest. Less than ordinary activity induces fatigue, palpitation, and/or angina.
IV	Cardiac disease results in inability to have any physical activity without discomfort. Symptoms may even be present at rest.

TABLE 16-2 Metabolic Equivalents of Various Activities

Activity	METS
Driving a car	2
Yoga	3.2
Golf (riding cart/carrying clubs)	2-3/5.1
Bicycling	4.8
Swimming (2.5 km/hr)	6.8
Racquetball	8-12
Running a marathon	13.3

or moderate METs should raise concerns regarding the patient's ability to tolerate a general anesthetic for an elective procedure. Finally, many cardiovascular medications such as antiplatelet/anticoagulation therapies (aspirin, clopidogrel/prasugrel, Xa inhibitors, warfarin) and beta-blockers require the attention and coordination of the surgeon and cardiologist in their perioperative management.

Pulmonary/Airway

The patient's surgical tolerance is also closely tied to their pulmonary status. Some of the changes in the respiratory system that occur during a general anesthetic include decreased lung volume and vital capacity (due to supine positioning that changes the diaphragmatic action), decreased lung compliance, and decreased mucociliary clearance.[29] These changes affect all patients, but those with preexisting pulmonary dysfunction are more likely to have postoperative complications.

Pulmonary diseases encountered in the adolescent orthognathic population may include asthma, history of bronchopulmonary dysplasia, and inherited disease such as cystic fibrosis (CF). Adults with pulmonary disease can also have a history of the above as well as chronic obstructive pulmonary disease (COPD)/emphysema, pulmonary fibrosis, pneumoconiosis, and manifestations of systemic diseases such as sarcoidosis and lupus. Both adult and pediatric pulmonary diseases are most easily discussed when categorized into restrictive and obstructive disease processes, although there may be significant overlap in many conditions, such as CF.

The main types of restrictive lung disease include extraparenchymal processes (or chest wall disorders) such as obesity and kyphosis, and intraparenchymal processes such as pulmonary fibrosis, sarcoidosis, and pneumoconiosis. Restrictive lung diseases are characterized by a normal or increased ratio of forced expiratory volume 1 (FEV1) to forced vital capacity (FVC) (since both are decreased) and an overall decreased total lung capacity of less than 80% of expected.[30]

Obstructive lung diseases include diseases such as asthma and COPD. Obstructive pulmonary disease is demonstrated by a decrease in FEV1 with maintenance of a normal FVC, such that the FEV1/FVC ratio is decreased to less than 0.7. A review by the American College of Physicians of the existing literature with regard to preoperative pulmonary risk stratification for non-cardiothoracic surgery demonstrated that chronic obstructive pulmonary disease was the most frequently identified risk factor determining postoperative pulmonary complications.[31]

Asthmatics are at increased risk for perioperative complications such as bronchospasm.[32] Asthma encompasses a wide range of reactive airway disease and is classified according to severity and degree of control. The severity is divided into intermittent and persistent disease, with persistent disease being further categorized as mild, moderate, or severe (Table 16-3). All asthmatic patients should be questioned regarding their frequency of rescue inhaler use (beta agonist), their maintenance therapy, and their last emergency visit or hospital admission due to their disease. These questions will help to categorize the severity and degree of control of each asthmatic patient. The surgeon should ensure that each patient is optimized before surgery. Optimization of pulmonary diseases is demonstrated on pulmonary function tests and spirometry. If FEV1 results are less than 80% of baseline, then further optimization, often with inhaled corticosteroids, should be administered and pulmonary function restored before surgery.[33,34]

Systemic disease with pulmonary implications such as cystic fibrosis, sarcoidosis, and lupus can greatly affect the treatment plan in the patient seeking orthognathic surgery. These patients will require direct communication with the patient's pulmonologist for risk stratification. Some of these patients may not be candidates for an elective general anesthetic, and thus for elective surgical intervention. This determination must be made early in the treatment phase so that orthodontic camouflaging can be initiated instead of decompensation for surgical preparation. The decision to proceed with surgery should be based on the results of pulmonary testing to stratify risk for the risk/benefit analysis with both the pulmonologist and the patient.

Cigarette use is an independent risk factor affecting the likelihood of a postoperative pulmonary complication. A well-designed prospective cohort study demonstrated an odds ratio (OR) of 5.5 for postoperative pulmonary complications between smokers and nonsmokers, with 22% of smokers developing postoperative complications compared

TABLE 16-3 Asthma Severity Classification

Classification	Symptom Frequency and Need for Short Acting B-Agonist	FEV1	Required Oral Corticosteroids for Exacerbations	Interference with Normal Activity
Intermittent	≤2 days/week	>80% and normal between exacerbations	≤1× per year	None
Persistent-mild	>2 days/week, not daily	>80%	>2× per year	Minor limitations
Persistent-moderate	Daily	60%-80%	>2× per year	Some limitations
Persistent-severe	Multiple times per day	<60%	>2× per year	Extreme limitations

to only 4.9% of nonsmokers. This same study demonstrated that reduction in smoking just before surgery increased the OR to 6.7.[35] This increased risk in the smoking reduction group is likely linked to increased sputum production and continues for up to 2 months.[29] For this reason, smoking cessation should continue to be encouraged in all patient populations, and elective surgical procedures should be scheduled for a minimum of 2 months following cessation.

The pulmonary portion of the physical exam includes auscultation of all lung fields as well as an evaluation of the airway. Airway evaluation entails noting potential difficulties with management of both ventilation and intubation, both of which have been well described in the anesthesia literature. Mask ventilation problems correlate with increased body mass index (BMI), advanced age, macroglossia, facial hair, edentulism, low thyromental distance, increased modified Mallampati grade, and history of snoring (many of which correlate with the diagnosis of OSA).[36] Intubation difficulty is often noted in patients with decreased mouth opening, an increasing Mallampati classification (Table 16-4), short thyromental distance (<7 cm), inability to achieve a correct "sniffing" position due to cervical spine arthritides, and excessive cervical soft tissue.[37,38] As the airway is assessed, the surgeon should be mindful of the potential for postoperative swelling of the surrounding soft tissues that can lead to airway embarrassment, specifically in the OSA patient. Prolonged intubation or even a planned tracheostomy can help ensure a secure airway in the postoperative period in what may otherwise be a tenuous airway. A tracheostomy may seem aggressive as an adjunct procedure, but may be indicated by the pulmonary status of the patient if the need for a prolonged ventilator taper is expected.

Pulmonary testing to determine disease type/severity may include pulmonary function testing, which measures lung volumes and capacity as well as flows (peak expiratory flow/forced expiratory flow 25% and 75%). Exercise testing in a stress test format will demonstrate the effect of activity on pulmonary function. Gas diffusion tests can help determine how well gases are transferred from lungs to the circulating blood. These tests can help stratify pulmonary risk for the anesthetic/procedure.

Renal

Renal disease can affect surgery in regard to metabolism and clearance of drugs as well as electrolyte balance and fluid volume homeostasis. Renal disorders seen in the pediatric population can be structural (renal agenesis, hypoplasia, dysplasia, vesicouretural reflux), inherited (autosomal recessive polycystic kidney disease), or acquired (minimal change disease, polyarteritis nodosa, and nephritic processes).[39]

Adult renal processes of concern include any chronic kidney disease (Table 16-5)—which most frequently result from diabetes and/or hypertension.[40] Other diseases less commonly encountered that affect the kidneys are sarcoidosis, lupus, autosomal dominant polycystic kidney disease, and vasculitides. Finally, although the end-stage renal disease patient on dialysis is not likely to present for orthognathic or maxillomandibular advancement surgery, they may present for consultation after renal transplant and will require special perioperative considerations.

The physical examination of the patient should include an evaluation of fluid volume status through checking skin turgor, auscultation of heart and lungs, and an extremity exam for edema. The remainder of testing for renal function and/or structural abnormalities includes both laboratory work and imaging studies. Laboratory testing can include urinalysis to evaluate for hematuria, proteinuria, cast formation, presence of leukocyte esterase or nitrites, or abnormalities of specific gravity. A basic metabolic panel (or Chem 7) will evaluate electrolytes (K^+, Na^+, Cl^-, HCO_3^-) and renal function/hydration (through creatinine and blood urea nitrogen). Imaging studies ordered by the physician managing the renal disease may include renal ultrasound, cystourethrogram (CUG—usually a voiding CUG to check for reflux), or computed tomography. In some scenarios, a renal biopsy is required for definitive diagnosis.

Perioperative management of these patients includes pre-, intra-, and postoperative considerations. Depending on the underlying renal disease, metabolic panels assessing for electrolyte abnormalities should be checked at regular intervals beginning before induction. Electrolyte disturbances should be corrected before induction of anesthesia as they can lead to cardiac dysfunction/arrhythmias. Drugs administered to patients with impaired renal function may require dose adjustments depending on the medicine administered and the patient's glomerular filtration rate (GFR). Transplant patients will often remain on potent steroids and immune modulators as a component of their antirejection regimen and may require stress-dose steroids or other considerations

TABLE 16-4 Mallampati Classification

Score	Visible Structures
Class I	Soft palate, uvula, tonsillar fauces, tonsillar pillars
Class II	Soft palate, uvula, fauces
Class III	Soft palate, base of uvula
Class IV	Only hard palate

TABLE 16-5 Stages of Chronic Kidney Disease

Stage	GFR (mL/min/1.73 m^2)
1	>90
2	60-89
3	30-59
4	5-29
5	<15 or dialysis

during the perioperative period. The patient should be euvolemic before surgery and can remain euvolemic with proper management of medications and intraoperative fluid volumes. Placement of a Foley catheter (advised on all procedures longer than 3 hours) allows for monitoring of urine output and thus perfusion of the kidneys throughout surgery. Adequate urine output for a well-perfused kidney is 0.5 to 1 mL/kg/hr, and a mean arterial pressure of 60 mm Hg is required to maintain adequate end-organ perfusion including the kidneys. Anatomic genitourinary abnormalities such as hypospadias or urethral strictures may require the Foley catheter to be placed by a urologist.

Neurologic

Neurologic abnormalities cover a wide variety of diseases and conditions. In the adolescent population, these include attention deficit disorder (with or without hyperactivity), autism spectrum disorders, seizure disorders, movement disorders (Tourette syndrome, dystonias), neuromuscular disorders (muscular dystrophies and myopathies), cerebral palsy, congenital defects (spina bifida), and hereditary disorders such as neurofibromatosis. In addition to these, adult populations can have a history of neuromuscular junction disease (myasthenia gravis) or one of several types of headaches (tension, migraine, cluster, etc.). Occasionally patients are seeking orthognathic surgery and "fixing their bite" as a means to treat the headaches.[41]

A thorough preoperative neurologic assessment includes examination of extremities for function, strength, and sensation in addition to the routine cranial nerve examination. The cranial nerve exam should elaborate on any preoperative deficits. This also provides an opportunity to explain the expected distribution of postoperative hypoesthesia in the maxillary and mandibular distributions of cranial nerve V.

Perioperative medication management is paramount in this patient population. Patients with attention deficit disorders should continue their medications for the hyperactivity/attention deficit disorders, as missed doses of these medications can result in a less cooperative and adherent patient in the postoperative period. Seizure disorders require further insight regarding type of seizures (partial or generalized tonic-clonic), possible triggers, and frequency/degree of control of the disorder on their current medication regimen. Seizure disorders are a contraindication for maxillomandibular fixation; thus, procedures requiring postoperative MMF (such as vertical ramus osteotomies) should be avoided and caution should be exercised even with elastic MMF in the postoperative period. Antiseizure medications should be scheduled without interruption, but conversion to a different medication, route of administration, or dosage may be required in the postoperative period. Finally, patients with gingival overgrowth due to phenytoin may require gingival recontouring in conjunction with their orthognathic surgery for the most esthetic result.

Neuromuscular junction diseases such as myasthenia gravis require consultation with the patient's neurologist. Surgery should be planned during a stable phase of the patient's disease, which usually equates to a patient without current requirements for steroids, or only low-dose maintenance steroid treatment (depending on the patient's disease severity).[42] Intraoperatively, the inhalational anesthetics have a more profound effect in this patient population; for this reason, total intravenous anesthesia (TIVA) with propofol is used as an effective alternative to avoid profound, prolonged muscular relaxation.[43] These patients have an increased risk of postoperative respiratory insufficiency with any of the following criteria: disease duration greater than 6 years, pyridostigmine daily dosage greater than 750 mg, and vital capacity less than 2.9 L.[44] The surgeon should also be aware of any immunosuppressive therapy that will have deleterious effects on postoperative healing.

Muscular and myotonic dystrophies exhibit a high rate of malocclusions that may require orthognathic surgery for optimal treatment.[45-47] The surgeon should be aware that this patient population is known to have significant comorbidities, such as a high rate of cardiac involvement in Duchenne muscular dystrophy. Most surgeries in this population will require coordination with the patient's pulmonologist, because they will often require supplemental postoperative pulmonary therapy including measures such as noninvasive positive-pressure ventilation (NPPV).[44]

Patients with spina bifida and cerebral palsy have an especially high rate (40% to 48%) of latex sensitivity.[48-50] A latex-free environment is advisable for these patients, even if they have not previously been diagnosed with an allergy. Finally, all patients, regardless of preexisting conditions, require careful padding of pressure points before the initiation of surgery to help avoid any postoperative sequelae of compressed nerves that can result in hypoesthesia/numbness. Proper positioning may be especially challenging in certain instances (such as the cerebral palsy patient) because of contractures.

Hematologic

Surgery requires an appropriate response on a hematologic level for proper hemostasis and healing. Hematologic disorders that disrupt this process are concerning to the surgeon, including diseases that cause a bleeding diathesis, hypercoagulable states, or anemias.

In the pediatric population, the heritable diseases with bleeding tendencies include hemophilia A and B, von Willebrand factor disease, and platelet disorders such as Bernard-Soulier syndrome. Inherited hypercoagulable states include factor V Leiden, as well as protein C and S deficiencies. Sickle cell anemia also leads to clot formation as well as decreased hematocrit/hemoglobin (Hct/Hgb). Other types of anemia will present with decreased hemoglobin levels due to varying etiology (iron deficiency, B_{12} deficiency, hereditary spherocytosis, thalassemias). Some patients with severe hematologic disease will not be candidates for elective surgery.

Acquired bleeding tendencies that are more likely to surface in adult populations include medication induced anticoagulation/platelet dysfunction and thrombocytopenia due to various other medical conditions (liver disease, splenomegaly, etc.). Hypercoagulable states can be due to cancer, obesity, oral contraceptives or coexisting diseases such as lupus. Adult populations can also present with anemia due to dietary deficiencies, GI disorders (decreased absorption of B_{12}, folate, iron), or other coexisting disease such as chronic kidney disease.

The initial patient history should reveal bleeding tendencies, including anticoagulation and/or antiplatelet drugs that will require perioperative coordination with the patient's prescribing physician. Additionally, herbal supplements such as chamomile, motherwort, ginkgo, garlic, ginger, bilberry, ginseng, turmeric, and willow all affect platelet function and/or the coagulation cascade. In most cases, they should be discontinued several weeks before surgery.[51] All patients should be questioned regarding bleeding and bruising tendencies. A discussion with female patients can elicit history of menorrhagia, which is often the first manifestation of a bleeding diathesis. Bruising that is noticed during physical exam should prompt further questions to illuminate any tendency toward bleeding/bruising that may be related to a bleeding diathesis.

A history of previous thrombosis should prompt consultation regarding the patient's future risk of thrombosis and current management including anticoagulation. Depending on the severity of thrombosis and the patient's history, they may be on long-term anticoagulation. Coordination with the patient's managing physician should take place before surgery to determine timing for holding preoperative anticoagulation and resuming it postoperatively. In some circumstances, medications may need to be altered or transitioned to a different dose or form of administration.

Patients with sickle cell anemia should be optimized before surgery and managed with the goal of avoiding a sickle cell crisis. Optimization is accomplished by maintaining a hemoglobin of 10 g/dL (some patients require transfusion and/or hydroxyurea to accomplish this goal). Sickle cell crises can stem from dehydration, anxiety, pain, infection, hypoxia, hypotension, or acidosis. In order to avoid these, adequate hydration, pain control (with good local anesthesia during surgery and appropriate control postoperatively), supplemental oxygen, and avoidance of hypotension (even during downfracture) should be implemented. Antibiotics (both preoperative single dose and postoperative course) are recommended, as infection can precipitate a crisis, and autosplenectomy (which can occur due to sickle cell anemia) can increase the risk of various infections.

Patients with known or suspected hematologic disorders should be further characterized and investigated. This is accomplished through laboratory studies such as an international normalized ratio, prothrombin time, and activated partial thromboplastin time (INR, PT, and aPTT), bleeding time, and platelet function testing.

Before surgery, all patients (unless contraindicated) can be encouraged to take a multivitamin with iron, B_{12}, and folate. This can ensure that in the weeks leading up to surgery there are adequate stores for hemoglobin production. Daily requirements for menstruating women are approximately double those for men.[52]

Intraoperative blood loss (IOBL) can be prevented through a variety of measures. A recent meta-analysis of measures used in attempts to decrease IOBL during orthognathic surgery demonstrated varying degrees of success with use of the antifibrinolytics, including IV tranexamic acid (TEA), topical TEA, yunnin baiyao (an herbal supplement), and aprotinin.[53] Permissive hypotension during the maxillary portion of the procedure will also aid in decreasing IOBL.[54] Another factor within the control of the surgeon is the length of surgery, which will decrease blood loss with a corresponding decreased operative time.

All postoperative patients will have decreased ambulation and increased venous stasis (one of the requirements for the Virchow triad for thrombosis). Appropriate prophylaxis for deep venous thrombosis should include use of mechanical methods such as sequential compression devices (SCDs) and/or thromboembolism deterrent (TED) hose, because these carry minimal risk to the patient. Pharmacologic agents (heparin, enoxaparin, argatroban) help inhibit thrombosis formation and may be required in high-risk patients. Risk of thrombosis in the pediatric patient is less than that in adults. Published pediatric registries demonstrated an incidence of 0.07 to 5.3 per 10,000 admissions, most of which were associated with serious underlying disease or central venous lines.[55,56] Adult populations have an incidence of venous thromboembolic events of 1 to 2 per 1000 patients per year.[57] With this in mind, the MMA patient with multiple comorbidities may warrant pharmacologic therapy to help avoid thromboembolic complications during hospitalization in the postoperative period.

Musculoskeletal

Musculoskeletal (MSK) conditions should be identified and assessed during the physical exam because they affect the operation, the postoperative course, and relapse rates. Pediatric conditions affecting the MSK system with relevance to orthognathic surgery include juvenile idiopathic arthritis (JIA) and idiopathic condylar resorption, as well as Down syndrome, scoliosis, cerebral palsy, and muscular dystrophy. Adult conditions affecting the MSK system include autoimmune diseases such as scleroderma and rheumatoid arthritis as well as the degenerative process of osteoarthritis.

Patients with idiopathic arthritis and condylar resorption will require a detailed discussion regarding the potential for relapse or development of an anterior open bite in the years following surgery. Several studies have demonstrated stability of orthognathic surgery in patients with JIA.[1,58] However, patients with idiopathic condylar resorption do

have a higher potential for relapse.[59] Because of this, various treatment algorithms exist. Kaban has advocated waiting for orthognathic surgery until 2 years of documented inactivity of the resorption by ^{99m}Tc scan.[60] Posnick has advocated a minimum of 1 year of inactivity (also best evaluated by ^{99m}Tc bone scan) and demonstrated that an intact cartilaginous cap leads to improved long-term stability.[61] Wolford advocates for temporomandibular joint (TMJ) surgery in conjunction with orthognathic surgery for the removal of hyperplastic synovial tissue and disc repositioning/anchoring over the condyle.[62] Regardless of the method or algorithm chosen, the informed consent process must include the propensity for relapse in this population, where even the surgery to correct the occlusion may reactivate the resorption.

The MSK implications of Down syndrome require attention to positioning. Down syndrome is associated with atlanto-occipital instability, and one recent study in an adult population found radiographic incidence of 17.5% of atlanto-occipital instability and 11.2% with atlanto-axial instability.[63] Positioning is also important to optimize intubation and ventilation in patients with scoliosis, connective tissue conditions such as scleroderma, or rheumatologic conditions.

All patients, regardless of preexisting joint disease, should have a baseline TMJ evaluation for the presence or absence of popping, clicking, or crepitance; range of motion including maximal incisal opening and excursive movements; and identification of any abnormalities. TMJ symptoms should be addressed before orthognathic surgery. Various circumstances may arise in which an orthognathic procedure may be combined with a TMJ procedure. In each of these cases, careful planning and realistic expectations are paramount.[64] Expectations and results with regard to resolution of TMJ abnormalities following orthognathic surgery vary widely—the patient must acknowledge and understand this prior to operative intervention.[41,65,66]

Mental Health

The psychosocial implications of orthognathic surgery must not be overlooked. Some patients will present with psychological disorders, some of which may even affect their motivation for orthognathic surgery.[67] A study of 89 patients at Stanford demonstrated that 12% screened positive for body dysmorphic disorder and 38% had depressive symptoms.[68] Although many patients are excited to have their surgery performed and their underlying dentofacial deformity corrected, other patients will struggle with their new appearance after their procedure.[69] Therefore, any underlying mental illness should prompt the surgeon to initiate a discussion regarding the patient's motivation for surgery and the postoperative physical and emotional obstacles, including depression.[70] Known or suspected mental illness should also prompt a referral or consultation with a mental health professional for assessment and counseling.

Obesity

The rise in obesity in the pediatric populations is evident—obesity in adolescents aged 12 to 19 has increased from 5% in 1980 to 21% in 2012.[71-73] The epidemiology of obesity in adults shows that 35% of U.S. adults are obese.[74] These trends indicate that maxillofacial surgeons can expect to encounter obesity more often in patients presenting for orthognathic surgery. The obese patient has compromised lung function, an increased rate of complications, and an increased rate of comorbid diseases such as sleep apnea, reflux, cardiovascular disease, diabetes, arrhythmias, and poor wound healing.[75]

Obesity results in restrictive lung disease as evidenced by reduced functional residual capacity, vital capacity, and total lung capacity. It is important (from an anesthesia standpoint) to ensure preoxygenation with 100% oxygen before induction to maximize the patient's limited reserve to maintain saturations during induction.[76] Incentive spirometry and mobilization should also be part of the postoperative protocol in an effort to re-expand the alveoli.

Obese patients also have an increased risk of gastroesophageal reflux disease (GERD).[77] Patients with GERD (obese or nonobese) are at increased risk of aspiration; preoperative medications such as metoclopramide and proton pump inhibitors can be administered to decrease this risk.[75] Orogastric or nasogastric tubes can be placed to empty stomach contents before extubation and minimize risk of immediate post-extubation aspiration—especially in those who are in intermaxillary fixation (IMF).

Obesity (BMI >30 kg/m^2) is also one of the risk factors for developing OSA and as such is often observed in the patient presenting for MMA. Some of these patients will have undergone bariatric surgery and must be nutritionally optimized before and after surgery. This includes adequate protein (minimum of 1.5 g/kg ideal body weight per day) as well as supplemental vitamins and minerals that vary depending on the bariatric procedure that was performed.[78] Some of these patients may require special considerations with regard to postoperative medications, such as the lap band patient who cannot swallow pills.

Endocrine

The most likely endocrine disorders encountered in the orthognathic population are diabetes, thyroid disorders, and adrenal suppression secondary to chronic corticosteroid use. As the prevalence of obesity increases, the comorbid diseases such as diabetes will also become more prevalent. In 1980, 5.6 million people in the United States had a diagnosis of diabetes; 31 years later in 2011, that number had almost quadrupled to 20.9 million.[79] Patients with diabetes mellitus have an increased risk of adverse postoperative outcomes and are at risk for nephropathy, cardiovascular disease, cerebrovascular disease, dental disease (periodontitis), peripheral vascular disease, and neuropathies.[80] The American Heart Association places diabetics in the same

high-risk category as patients with known coronary artery disease.[81] Diabetics are more likely to have ischemic disease without the accompanying chest pain (silent ischemia).[82] As such, a patient with diabetes may require ECG or other cardiac workup before their anesthetic. Other preoperative evaluations could include a basic metabolic panel to evaluate abnormalities associated with glucose shifts, as well as baseline renal function, which can be compromised because of diabetic nephropathy. Optimization of preoperative glycemic control is also important and is evaluated by the Hgb A1c laboratory value. An A1c value less than or equal to 7 indicates average blood glucose of less than 154 over the 120-day life cycle of the average red blood cell. Patients with A1c values greater than 8.0 should be referred back to their endocrinologist and have elective surgery deferred until better glycemic control is attained.[83]

Perioperative and intraoperative glucose management should include cessation of pharmacotherapies that can increase the likelihood of undesirable side effects. Metformin, in the setting of dehydration, can lead to lactic acidosis, and although this is a rare complication, it carries a high mortality rate (50%).[84] Postoperative insulin can be required in patients who have previously taken only oral hypoglycemics. This allows for appropriate control of blood glucose in the setting of altered oral nutrition and/or difficulty with pill swallowing early in the postoperative period. Initially, a sliding scale with regular insulin may be implemented, but this insulin regimen should be transitioned to include longer-acting insulin. Specific recommendations can be found in articles specific to hyperglycemia management of the non-ICU patient.[85] Often, the patient's endocrinologist is consulted to help with glycemic control in the early postoperative period and to help with planning for future home glycemic control.

As insulin pumps are increasingly used for glycemic control, the surgeon and anesthesiologist will need to develop a plan for their management. It has been demonstrated that the intraoperative and postoperative continuation of insulin pumps is safe and effective for glucose control provided there is proper glucose monitoring to avoid hypoglycemic episodes.[86,87]

Thyroid disease often manifests when patients are in a hyperthyroid or hypothyroid state. Signs and symptoms of hypothyroidism include cold intolerance, dry skin, fatigue, and bradycardia. Conversely, hyperthyroidism may manifest as heat intolerance, unexplained weight loss, anxiety, muscle tremor, tachycardia, and the characteristic exophthalmos of Graves disease. Both hyper- and hypothyroid patients can have changes in the overall shape of the thyroid gland, which can have implications for intubation if the thyroid is enlarged and impinging on the trachea.[88] Changes in the patient's voice should raise concerns for this rare presentation. Hypothyroid and hyperthyroid states should be resolved under the direction of an endocrinologist, and the patient should be euthyroid as evidenced by laboratory testing of thyroid-stimulating hormone (TSH), thyroxine and triiodothyronine (T_4, T_3), and free T_4 before surgery.

Patients with a history of chronic steroid use can raise concerns for adrenal insufficiency. Traditionally, stress-dose steroids have been recommended for patients who have been taking daily doses for over 2 months that exceed 5 mg prednisone, 25 mg hydrocortisone, 4 mg triamcinolone, or 0.75 mg dexamethasone. The stress dose recommended is 50 mg hydrocortisone IV (single dose) for minor surgery, and 50 mg hydrocortisone IV every 8 hours for 40 to 72 hours for major surgery.[88-90] However, as recently as 2013 the necessity of stress dose steroids has been questioned because of the paucity of evidence that supports this practice.[91] The surgeon should, at a minimum, be familiar with the various steroids and their equivalent doses (Table 16-6).[92] Many surgeons incorporate perioperative steroids for the orthognathic patient, because they have been shown to aid with postoperative pain, swelling, trismus, and nausea/vomiting.[93,94] Dosing regimens range from a single intraoperative dose to multiple doses following the procedure.

Finally, the adult orthognathic patient who presents with progressive development of class III open bite should be questioned further regarding changes in finger/ring size, foot/shoe size, and/or vision suggestive of acromegaly. These patients will require further workup including serum levels of insulin-like growth factor 1 (IGF-1), growth hormone, and possible MRI depending on lab results to evaluate for a pituitary tumor.

"Routine" Preoperative Laboratory Testing

The population of patients seeking jaw surgery spans differing ages and medical conditions. The majority of young, healthy patients undergoing straight forward single jaw surgery are not likely to require from any preoperative testing. However, the appropriate preoperative testing depends on each individual patient's condition and risk for both the specific procedure(s) and anesthetic technique. Laboratory values including a complete blood count (CBC) to check hematocrit/hemoglobin as well as platelet count, coagulation studies (PT/PTT/INR). A bone morphogenetic protein (BMP) level with its accompanying electrolyte levels,

TABLE 16-6 Equivalent Steroid Dosages

Steroid	Equivalent Dose
Betamethasone	1.2 mg
Dexamethasone	1.5 mg
Methylprednisolone	8 mg
Triamcinolone	8 mg
Prednisone	10 mg
Prednisolone	10 mg
Hydrocortisone	40 mg
Cortisone	50 mg

glucose level, and renal function studies may also be appropriate. In addition to patient/procedure specific labs, ECG and chest radiographs can be considered in preoperative evaluation.

Postoperative Management

Postoperative management should include regimens to control pain, nausea, hemostasis, edema, infection, psychological adjustment, occlusion, nutrition, paresthesia, local wound care, and activity. This includes the identification and management of early postoperative complications.

Pain Control

Some surgeons advocate preoperative administration of analgesics. Tuzuner performed a prospective study of orthognathic patients who were randomized to receive preoperative tramadol, diclofenac, or saline. Less analgesic was required for postoperative pain control in the treatment group, without difference between the different medications, as compared to the placebo group.[95] Administration of corticosteroids has also been shown to aid in decreasing postoperative pain.[96] Prior to anesthetic emergence, additional long-acting local anesthesia can be injected at the surgical sites. Although the neuropraxia resulting from the surgery should theoretically leave the patient without pain, some patients will still complain of pain beginning immediately after surgery—and as all maxillofacial surgeons are aware, there is no substitute for adequate local anesthesia.

Early postoperative pain control is best accomplished with intravenous medications including a combination of nonsteroidal anti-inflammatory drugs (NSAIDs), acetaminophen, and opiates for breakthrough pain. As the patient increases oral intake, pain regimens should be transitioned to the oral route, with IV options remaining in place as needed. Changing to orally administered medications allows the team to develop a regimen for pain control that is easily transitioned to home care. Opiate medications for postoperative analgesia should be readily tapered to non-opioid regimens to avoid negative side effects such as nausea, constipation, and addiction.

Nausea

Postoperative nausea and vomiting (PONV) is quite common and occurs in approximately 41% of orthognathic patients in the first 24 hours after surgery.[97] A recent study of 252 consecutive orthognathic cases at University of North Carolina documented postoperative nausea in 67% of patients and 27% with episodes of emesis.[98] This is usually be attributed to one of the following triggers of PONV: intraoperative use of inhalational anesthetics (centrally mediated at the chemotactic trigger zone [CTZ]), oral bleeding that is swallowed during surgery or postoperatively (gastric irritation), or use of postoperative opioids (also at the CTZ).

It is important to note that some of the demonstrated factors that increase incidence of postoperative nausea include female gender, the use of nitrous oxide as an anesthetic component, the length of surgery, dehydration, and postoperative use of morphine for pain control.[79] There exist both pharmacologic and mechanical methods of treating PONV. On the preventative front, meticulous hemostasis with repair of any nasal mucosal lacerations and well-approximated mucosal wound closure will reduce the amount of blood that is swallowed postoperatively. In addition, an orogastric (or a carefully passed nasogastric) tube may be placed in order to empty the stomach and removed before emergence/extubation. Some surgeons elect to maintain a nasogastric (NG) tube overnight following surgery. This can be placed on intermittent-low wall suction and may prevent accumulation of blood in the stomach and avoid the gastric irritation that can result. It is the authors' opinion, however that the presence of the NG tube is irritating and may lead to agitation and nausea.

Pharmacologic treatment of nausea typically consists of ondansetron, droperidol, and/or promethazine. Adult doses of ondansetron (a 5HT-3 receptor antagonist) as an antiemetic will range from 4 to 8 mg and may cause constipation, especially in combination with the narcotics often used for pain control.[99] Therefore, when both are administered, a laxative or stool softener should also be considered. Another possible complication associated with the administration of ondansetron is the potential for QT interval prolongation that can lead to arrhythmia, particularly in patients at high risk for torsades de pointes.[100] Droperidol (a potent dopamine D_2 antagonist with some additional antagonist activity at histamine and serotonin receptors) is given in doses as low as 0.625 mg for its antinausea effects. Like ondansetron, it has a black box warning due to the potential for QT prolongation. Promethazine (a first-generation antihistamine) is given in doses ranging from 6.25 to 25 mg per dose. Because of the antihistamine effects, sedation is a side effect that may not be desired. Studies have shown that a dose of 6.25 mg is effective in quelling PONV and results in decreased sedation compared with higher doses.[101] Intravenous and rectal routes are available (in addition to oral) for the nauseated patient. IV promethazine should be diluted and delivered slowly due to the tissue injury that can otherwise result.[102]

While orthognathic surgery is associated with high rates of PONV, proper communication with the anesthesia care team can help mitigate this undesirable side effect. Other multimodal therapies have been used to decrease PONV, such as that by reported Anderson and colleagues. This study demonstrated that the use of TIVA with administration of ondansetron, droperidol, steroids, scopolamine, gastric decompression, postoperative avoidance of opioids, administration of prokinetic erythromycin, and maintenance of IV fluids at a minimum of 25 mg/kg decreased postoperative nausea from 70% in the control group to 24% and postoperative vomiting from 28% to 11%.[103]

Various combinations of this therapy can be tailored to the specific patient and procedure.

Hemostasis

When addressing postoperative bleeding, it is important to consider the site, severity, and thus possible source. Slow oozing from the incision sites is common and can usually be halted with gentle pressure. Hematomas are rare but can develop in the hours following surgery. The most concerning is a floor-of-mouth hematoma (following a genioplasty), which can cause airway distress/embarrassment.[85] Once identified, it may require evacuation; this should be accomplished in a controlled setting and includes an attempt to identify the source of bleeding before closing. If concern for airway compromise exists, the patient may require prolonged intubation.[104]

Postoperative nasal bleeding can be common, such as dark blood draining from the nose associated with tears in the nasal mucosa or residual blood from within the maxillary sinuses. However, bright red blood, brisk bleeding, or large volumes may indicate an active bleeding venous or arterial source (Table 16-7).[105] Delayed bleeding (presenting 1 to 2 weeks postoperatively) is often due to a descending palatine vessel wall injury that occurred at the time of surgery.[106] Fortunately, hemorrhagic complications are rare, occurring in less than 1% of patients for both Le Fort I and bilateral sagittal split osteotomies and 1.2% for intraoral vertical ramus osteotomies.[107-110] Depending on the clinical presentation, the patient may require hemostatic interventions including head of bed elevation, topical pharmacologic treatment (oxymetazoline, phenylephrine, topical thrombin), local mechanical measures (nasal packing anterior and/or posterior), return to the operating room for exploration and direct control, or interventional radiology (IR) for select embolization. The setting of treatment (bedside, OR, IR) should be determined by the stability of the patient, severity of bleeding, and access to appropriate equipment.

TABLE 16-7 Skeletal Structures and Associated Vasculature

Skeletal Structure	Arterial	Venous
Maxilla (Le Fort I)	Internal carotid Internal maxillary Descending palatine Sphenopalatine	Pterygoid plexus
Mandible (BSSO/IVRO)	Masseteric Facial Inferior alveolar	Retromandibular Facial Inferior alveolar
Mandible (genioplasty)	Sublingual	Deep lingual

BSSO, Bilateral sagittal split osteotomy; *IVRO,* intraoral vertical ramus osteotomy.

Edema

Postoperative edema following orthognathic surgery can be significant and alarming to patients and their families. Swelling often persists for many weeks, with approximately 50% resolving by 3 weeks.[111] Phillips and colleagues demonstrated in a prospective study of 170 patients that 75% of orthognathic patients experience minimal (if any) problem with swelling by day 22 after surgery. Of the remaining 25%, only 10% stated that the swelling was substantial, and by postoperative day 30 this number decreased to only 3%.[112] In order to minimize postoperative edema, care should be taken with intraoperative intravenous fluids to avoid volume overload.[113] Dissection should be limited to only the regions required, avoiding wide undermining of the soft tissues. Control of bleeding throughout surgery helps limit extravasation of blood into soft tissues that can contribute to postoperative ecchymosis and inflammation.

Administration of corticosteroids, when not contraindicated because of comorbidities such as diabetes, can help subdue some of the postoperative edema. The administration of steroids, in combination with hypotensive anesthesia and rigid fixation, has also been shown to correlate with decreased length of hospitalization following orthognathic surgery.[114] Steroids most often used include dexamethasone, methylprednisolone, and betamethasone; they are administered in various dosing regimens ranging from a single dose to three doses over 24 hours.[115,116] When selecting a glucocorticoid, the surgeon should be aware of the mineralocorticoid effect of the specific steroid used, as each has a different profile of activity in this regard (Table 16-8).[117] This mineralocorticoid effect will cause aldosterone-like effects on sodium (and therefore extracellular fluid) retention as well as a slight hypokalemia and alkalosis. The administration of steroids is not without controversy due to their potential (albeit rare) side effects, including avascular osteonecrosis, adrenal suppression, psychosis, decreased healing potential, and gastric ulceration (especially in light of concomitant stress and NSAID administration).

TABLE 16-8 Relative Glucocorticoid and Mineralocorticoid Activities

Steroid	Relative Glucocorticoid Activity	Relative Mineralocorticoid Activity
Cortisol	1.0	1.0
Cortisone	0.8	1.0
Prednisolone	4	0.8
Methylprednisolone	5	Almost 0
Dexamethasone	30	Almost 0

Cortisol is arbitrarily assigned a value of 1.0.

Cold temperature can help to soothe and cool the mid/lower face and decrease edema. Various types of cooling therapy can be applied, ranging from ice packs to coolant-infused polar packs that ensure cold therapy for a longer duration. Care should be used, however, to avoid any prolonged, extreme cooling of the skin that can lead to epithelial damage over areas with hypoesthesia due to surgery. Additional noninvasive measures such as facial support stockings and elevation of the head of bed can also aid in minimizing edema.

Infection

As with any surgery, early (first 24 hours) low-grade fevers are assumed to be due to atelectasis.[118] In the weeks that follow, signs of fever, swelling, or drainage from the incision sites are concerning for surgical site infection, including infected hardware or bone grafts. Fortunately, early infections are quite rare and are most often minor and managed with oral antibiotics, nasal decongestants, and local irrigation/wound care. Occasionally, more severe infections may require debridement and bone grafting.[105] Immunocompromised hosts (e.g., diabetics, chronic steroid users) and tobacco users are at higher risk for infection. One study by Thorén and colleagues indicated that smoking significantly increases the risk of infection following orthognathic surgery.[119] A 2015 Cochrane database review of antibiotics and orthognathic surgery showed some benefit in long-term (defined as greater than 24 hours after surgery) antibiotics for the prevention of infection in orthognathic surgery.[120] This same analysis failed to show a significant difference in prevention of postoperative infection between short-term (24-hour) regimens and a single presurgical dose of antibiotics. For these clean-contaminated procedures, a Peridex oral rinse before injections/incisions and a preoperative antibiotic administered within 1 hour before incision are recommended.

Psychological State

Most patients are excited regarding their postoperative appearance/changes; however, occasionally these changes in appearance—even if they help conform to cephalometric norms and appear esthetically pleasing to others—can be quite distressing to a patient. The patient should be forewarned that they are likely to experience an emotional low as the effects of the steroids wane in the days following surgery. Reassurance and positive reinforcement by the entire surgical team can help, but this may not be enough to combat postoperative despondency, or in some cases even depression. Prompt referral to appropriate resources such as a psychiatrist or psychologist is necessary in instances where there is any concern about the patient's psychological state following surgery. It is also the surgeon's responsibility to help the patient understand that their feelings are a part of the postoperative healing process and that the patient can be helped by mental health care professionals.

Dentition/Occlusion

Many surgeons use a splint for determining the final occlusion. Some surgeons elect to wire the splint into the maxilla or mandible for a number of weeks (2 to 6) following surgery, especially if the final position does not result in a balanced occlusion. Splints are generally left in place for 6 weeks following segmental surgery to help aid in what is a relatively unstable movement in the hierarchy of stability (maxillary expansion). Methods of stabilization may include a rigid splint that is thick or incorporates a transpalatal wire or strap, or the use of additional heavy wire ligated to molar headgear tubes (Figure 16-4).

Archwires that are cut during surgery for segmental surgery should be replaced postoperatively by the patient's orthodontist with a continuous archwire. Orthodontic tooth movement is often delayed for 6 weeks postoperatively, by which time osteotomy consolidation has occurred and the occlusal splint, if used, has been removed. However, as previously discussed with the "surgery-first" treatment, some orthodontists prefer early orthodontic movements after surgery based on the regional acceleratory phenomenon.

Elastics can be used to guide the operated mandible into the correct condylar position, can help with patient comfort by supporting closure of the mandible, and can begin to "settle" the occlusion if no splint is present. The configuration of elastics may vary over time depending on the desired changes to the occlusion. Nomenclature for placement of elastics is based on the malocclusion that would be addressed by the vector of pull. For instance, class II elastics will have a vector pulling the mandible forward with the elastic engaging a maxillary orthodontic lug anterior to the mandibular lug. However, elastics should be used with caution if the patient has an operated maxilla against an unoperated mandible. They are of limited use because the unoperated mandible has no need to undergo manipulation with elastics as the condyles have not been repositioned. Second, the



• **Figure 16-4** Patient with final splint in place. The patient had adequate surgical orthodontic lugs for elastics as needed and maintained good hygiene around a low-profile splint secured with six 24-gauge wires (central incisors, canines, and first molars).

force generated from an intact mandible in elastics against an operated maxilla may exceed that which is tolerated by the maxillary fixation.

Loss of fixation may be demonstrated by postoperative films, rotation of the proximal segment of the mandible, mandibular deviation to the fractured/failed side, or mobility of the maxilla. Treatment is by washout and replacement of fixation, heavier fixation, and/or IMF.

Diet

The patient should be prepared for their postoperative, non-chew diet before surgery. Generally, the diet for the first 6 weeks should consist of liquid or soft, non-chew foods (e.g., mashed potatoes, scrambled eggs) with a high caloric and protein content. The Internet is an excellent resource for "jaw surgery cookbooks."[121] After 6 weeks, the patient can progress over the next month to a regular diet. Any mobility or concern regarding fixation may require continuation of the soft diet (and possibly liquid diet with MMF) to prevent non-union or a fibrous union.

It is important to remind the patient that calories are easy to come by on a liquid or non-chew diet, but that the source of calories is very important. The amount of protein in a diet varies depending on many factors, but in general the post-surgical diet should include 1 to 1.8 g/kg/day for ideal body weight of protein. Proper nutrition consists of 10% to 35% proteins, 45% to 65% carbohydrates (avoiding simple sugars in place of complex carbohydrates), and limiting fat content to below 30% (with trans fatty acids <10%).[122,123] Recommendations to attain proper caloric intake include protein supplementation through a powder additive to shakes, or Ensure/Boost supplements. Vitamins and trace elements are also a crucial part of the healing process. For example, vitamin C is imperative for collagen production. Some weight loss is to be expected, but should be closely monitored as healing is an anabolic process and will require a surplus of calories. If the patient is losing weight, additional supplementation should be recommended, which can often be accomplished through smaller, more frequent meals.

The use of straws should be avoided for the first 2 weeks following surgery to prevent generation of intraoral negative pressure. Negative pressure can add to incision breakdown or dehiscence, and straws can be quite difficult for a patient to use because of the V2/V3 hypoesthesia. Instead, encourage the patient to use a regular spoon and drink from a regular glass or cup. Occasionally, a patient may require feeding syringes to help accommodate postoperative ingestion of fluids and soft foods. Some patients experience difficulty swallowing with a hypoesthetic velum following a Le Fort osteotomy and/or and insensate tongue after retraction of the lingual nerve during mandibular surgery. The best treatment for these patients is reassurance and continued encouragement.

Paresthesia

The paresthesia expected in the inferior alveolar, infraorbital, and occasionally lingual distributions should be discussed in detail with the patient—including the possibility of permanent paresthesias. Sensation generally begins to return from the superior aspect to the inferior aspect, with the chin/lip being the last region to return. Return of sensation will likely take weeks to months. If the patient expects this, they are not alarmed when they have residual paresthesias several weeks after surgery. A 2011 meta-analysis of studies showed that following a BSSO, 63% had neurosensory disturbance (mental distribution) at 7 days, 49% at 14 days, 42% after 1 month, 33% after 6 months, and 12.8% at 1 year.[124] More importantly, in most cases the area of permanent paresthesia is quite small and does not appear to affect quality of life. One study demonstrated that 98% of BSSO patients with long-lasting neurosensory disturbance still stated that they would undergo surgery again and recommend it to other patients.[125] Additionally, sensory retraining exercises have proven to have a beneficial effect on patients' perceived hypoesthesia and can be implemented in the early weeks following orthognathic surgery.[126]

Intraoral Wound Care

It is paramount that the patient understand the importance of postoperative hygiene—and that they maintain it. A mouth full of debris on orthodontic appliances, occlusal splints, and/or the dentition is a setup for wound dehiscence, exposed hardware, postoperative infections, and other complications. Patients often require frequent encouragement, and sometimes demonstration or assistance postoperatively, in order to better understand expected postoperative hygiene. Twice daily Peridex rinses can also aid with maintenance of oral hygiene, especially in patients with a splint in place or in IMF. Follow-up visits should also be used to re-demonstrate proper hygiene as necessary. The mucosa should be healed before use of a Water Pik, which is a rather common patient inquiry.

Each postoperative visit also includes examination of the dentition, supporting gingiva, and incision sites (for dehiscence). Dusky tissue concerning for venous congestion and pale tissue suggestive of arterial insufficiency both indicate vascular compromise. Tissue perfusion/drainage concerns should be addressed immediately, as this can be a precursor to delineation of a necrotic segment. Management includes removal of anything (such as a splint) that may be impinging on the tissue, placement of tissue dressing such as Vaseline-impregnated gauze, elimination of any mobility, and close monitoring.[127]

Nasal Care

Patients should be instructed to avoid nose blowing for a minimum of 2 weeks (provided maxillary surgery was

performed). Nose blowing can cause subcutaneous emphysema via expressed air through the osteotomies and into the submucosal tissues. It can also cause bleeding due to disruption of the healing membranes/mucosa. Oxymetazoline can be used to help with congestion in the first 48 to 72 hours following surgery, after which it should be stopped to avoid rhinitis medicamentosa. The patient can continue to use nasal saline to keep nasal passages clear and moist. After 2 weeks, the patient can usually begin to gently blow their nose.

Postoperative deviation of the septum can occur following Le Fort surgery. This is generally associated with inadequate stabilization of the septum at the time of surgery (septal anchoring stitch), insufficient resection/contouring of the nasomaxillary crest, or displacement at the time of extubation. The deviated septum can be repositioned under sedation and supported with the placement of sutures, nasal packing, or stents (Figure 16-5). If packing is used, prophylactic antibiotic coverage is recommended to avoid the unlikely but severe complication of toxic shock syndrome.

Extraoral Wound Care

If cutaneous incisions were used (trocar or approach to the mandible for inverted-L or C osteotomies), they should be placed symmetrically in resting skin tension lines. Postoperative wound care with regular cleansing and the maintenance of a moist wound-healing environment will attain the best cosmetic result. If nonresorbable sutures are present, they should be removed 5 to 7 days postoperatively. Once primary epithelialization is complete, application of SPF moisturizer (30+ or greater) and massage will help to limit pigmentation and speed scar maturation. Scar creams and ointments (e.g., Mederma, vitamin E, copper, silicone gel, or sheeting) are used in accordance with patient/surgeon preference. The incisions should be evaluated for 6 to 9 months for undesirable healing, which may require intervention (steroid injection, dermabrasion, or laser therapy).

Activity

Patients undergoing single-jaw surgery should plan on at least 1 week off from normal activities including work, school, and exercise. With increasing complexity of condition and surgical treatment comes an expectation of longer convalescence. Patients should be encouraged to avoid strict bed rest, as this can lead to problems with their pulmonary condition and venous stasis or deep vein thrombosis. Patients should walk throughout the day (although initially they will likely require someone at their side because of effects of anesthesia and narcotics). Normal activities should be resumed slowly, beginning with school and work (non-strenuous). Exercise should be avoided for the first 2 to 4 weeks and then can be resumed beginning with light exercises. Patients often need to be reminded to resume activities slowly, and that it may require up to 4 to 6 months to return to presurgical levels of fitness. Activities with the potential for contact to the head and neck region (such as basketball) should be avoided for the first 6 to 8 weeks to allow for bony union and healing.

Facial Exercises

After the first 2 weeks, patients can be instructed to perform reanimation exercises. These mimetic exercises should be performed in front of a mirror. Activities such as a big smile and lip pursing can help to restore the full function of the facial muscles that are divided during surgery.

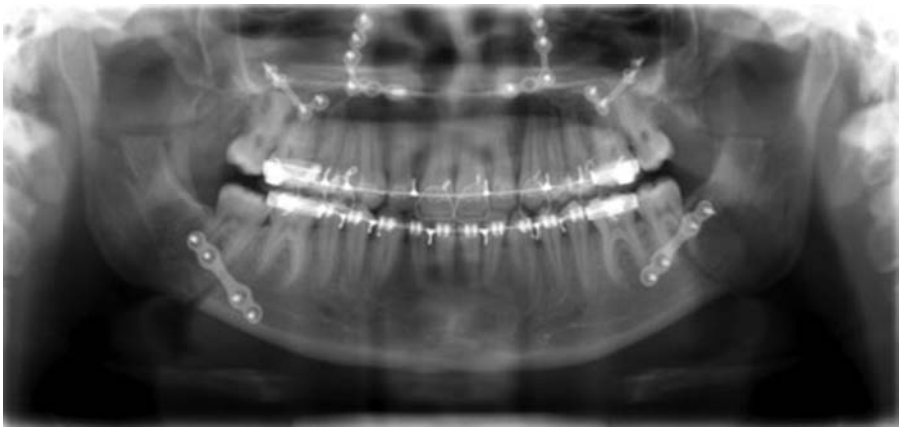

• **Figure 16-5** Panoramic image demonstrating a deviated nasal septum following a Le Fort I advancement with posterior impaction and a bilateral sagittal split osteotomy advancement. The posterior nasal septum was inadequately reduced, resulting in posterior nasal septal deviation.

Summary

Patients undergoing orthognathic surgery require detailed preparation in the orthodontic, medical, and surgical domains. The surgeon must develop a perioperative plan with the patient's input and guide the patient through any unforeseen complications. It is vital to maintain the patient's confidence through honesty and candor. This will prevent miscommunication and misrepresentation of the surgical process and give the conscientious patient realistic expectations as to the necessary preparation, recovery, and outcomes associated with orthognathic surgery.

References

1. Oye F, Bjørnland T, Støre G: Mandibular osteotomies in patients with juvenile rheumatoid arthritic disease, *Scand J Rheumatol* 32(3):168–173, 2003.
2. Grave KC, Brown T: Skeletal ossification and the adolescent growth spurt, *Am J Orthod* 71:406–420, 1977.
3. Franchi L, Baccetti T, McNamara JA: Mandibular growth as related to cervical vertebral maturation, *Am J Orthod Dentofacial Orthop* 118:335–340, 2000.
4. Costello BJ, Rivera RD, Shand J, Mooney M: Growth and development considerations for craniomaxillofacial surgery, *Oral Maxillofac Surg Clin* 24(3):377–396, 2012.
5. Huang CS, Ross RB: Surgical advancement of the retrognathic mandible in growing children, *Am J Orthod* 82(2):89–103, 1982.
6. Wolford LM, Schendel SA, Epker BN: Mandibular deficiency syndrome III: surgical advancement of the deficient mandible in growing children. Treatment results in twelve patients, *Oral Surg Oral Med Oral Pathol Oral Radiol* 45(3):356–367, 1978.
7. Cisneros GJ, Kaban LB: Computerized skeletal scintigraphy for assessment of mandibular asymmetry, *J Oral Maxillofac Surg* 42:513–520, 1984.
8. Saridin CP, Raijmakers PGHM, et al.: Comparison of different analytical methods used for analyzing SPECT scans of patients with unilateral condylar hyperactivity, *Int J Oral Maxillofac Surg* 38(9):942–946, 2009.
9. Hoppenrejis TJ, Freihofer HP, Stoelinga PJ, et al.: Condylar remodeling and resorption after Le Fort I and bimaxillary osteotomies in patients with anterior open bite: a clinical and radiological study, *Int J Oral Maxillofac Surg* 27:81–91, 1998.
10. Arnett GW, Tamborello JA: Progressive class II development: female idiopathic condylar resorption, *Oral Maxillofac Surg Clin* 2:699–716, 1990.
11. Papadaki ME, Tayebaty F, Kaban LB, Troulis MJ: Condylar resorption, *Oral Maxillofac Surg Clin* 19(2):223–234, 2007.
12. Precious DS: Removal of third molars with sagittal split osteotomies: the case for, *J Oral Maxillofac Surg* 62(9):1144–1146, 2004.
13. Schwartz HC: Simultaneous removal of third molars during sagittal split osteotomies: the case against, *J Oral Maxillofac Surg* 62(9):1147–1149, 2004.
14. Doucet JC, Morrison AD, et al.: The presence of mandibular third molars during sagittal split osteotomies does not increase the risk of complications, *J Oral Maxillofac Surg* 70(8):1935–1943, 2012.
15. Guiseppe C, Amerigo G. The timing of third molar removal in patients undergoing a bilateral sagittal split osteotomy. *J Oral Maxillofac Surg* 61(8):975.
16. Hernandez-Alfaro F, Guijarro-Martinez R: On a definition of the appropriate timing for surgical intervention in orthognathic surgery, *Int J Oral Maxillofac Surg* 43(7):846–855, 2014.
17. Liou EJ, Chen PH, Wang YC, et al.: Surgery-first accelerated orthognathic surgery: postoperative rapid orthodontic tooth movement, *J Oral Maxillofac Surg* 69:781–785, 2011.
18. Hernandez-Alfaro F, Guijarro-Martinez R, et al.: 'Surgery first' in bimaxillary orthognathic surgery, *J Oral Maxillofac Surg* 69(6):e201–e207, 2011.
19. Hyon WS: Surgery first orthognathic approach to prognathism: indications and limitations, *J Oral Maxillofac Surg* 66(8):39–40, 2008.
20. Lious EJW, Chen P, Wang Y, et al.: Surgery first accelerated orthognathic surgery: postoperative rapid orthodontic tooth movement, *J Oral Maxillofac Surg* 69(3):781–785, 2011.
21. Gonzaga C, Bertolami A, Bertolami M, et al.: Obstructive sleep apnea, hypertension and cardiovascular diseases, *J Hum Hypertens* 29(12):705–712, 2015.
22. Sanchez de la Torre M, Campos-Rodriguez F, et al.: Obstructive sleep apnoea and cardiovascular disease, *Lancet Respir Med* 1(1):61–72, 2013.
23. Pedrosa RP, Drager LF, Gonzaga CC, et al.: Obstructive sleep apnea: the most common secondary cause of hypertension associated with resistant hypertension, *Hypertension* 58:811–817, 2011.
24. Marin JM, Carrizo SJ, Vicente E, Agusti A: Long-term cardiovascular outcomes in men with obstructive sleep apnoea-hypopnoea with or without treatment with continuous positive airway pressure: an observational study, *Lancet* 365, 2005. 1046–10.
25. Gottlieb DJ, Yenokyan G, Newman AB, et al.: Prospective study of obstructive sleep apnea and incident coronary heart disease and heart failure: the sleep heart health study, *Circulation* 122:352–360, 2010.
26. Wilson W, Taubert K, Gewitz M, et al.: Prevention of infective endocarditis: guidelines from the American Heart Association, *J Am Dent Assoc* 138(6):739–745, 2008.
27. American Heart Association: Classes of heart failure: *Heart failure*. http://www.heart.org/HEARTORG/Conditions/HeartFailure/About HeartFailure/Classes-of-Heart-Failure_UCM_306328_Article.jsp, December 17, 2014.
28. Jette M, Sidney K, Blümchen G: Metabolic equivalents in exercise testing, exercise prescription and evaluation of functional capacity, *Clin Cardiol* 13:555–565, 2004.
29. Yamashita S, Yamaguchi H, Sakaguchi M, et al.: Effect of smoking on intraoperative sputum and postoperative pulmonary complication in minor surgical patients, *Resp Med* 98:760–766, 2004.
30. Husain AN: The lung. In Kumar V, Abbas AK, Aster JC, editors: *Robbins & Cotran Pathologic Basis of Disease*, ed 9, Philadelphia, 2015, Saunders.
31. Smetana GW, Lawrence VA, Cornell JE: Preoperative pulmonary risk stratification for noncardiothoracic surgery: systematic review for the American College of Physicians, *Ann Intern Med* 144(8):581–595, Apr 2006.
32. Von Ungern-Sternberg BS, Boday K, Chambers NA, et al.: Risk assessment for respiratory complications in paediatric anaesthesia: a prospective cohort study, *Lancet* 376:773–783, 2010.
33. Degani-Costa L, Faresin S, Falcão L: Preoperative evaluation of the patient with pulmonary disease, *Braz J Anesth* 64(1):22–34, 2014.

34. Yamakage M, Iwasaki S, Namiki A: Guideline-oriented perioperative management of patients with bronchial asthma and chronic obstructive pulmonary disease, *J Anesth* 22:412–428, 2008.
35. Sluman LG, Mosca L, Newman N, Simon DG: Preoperative smoking habits and postoperative pulmonary complications, *Chest* 1113(4):883–889, 1998.
36. Langeron O, Masso E, et al.: Prediction of difficult mask ventilation, *Anesthesiology* 92(5):1229–1236, 2000.
37. Mallampati SR, Gatt SP, et al.: A clinical sign to predict difficult tracheal intubation; a prospective study, *Can Anaesth Soc J* 32(4):429–434, 1985.
38. Karkouti K, Rose DK, et al.: Predicting difficult intubation: a multivariable analysis, *Can Anaesth Soc J* 47(8):730–739, Aug 2000.
39. Bakkalogly SA, Schaefer F: Diseases of the kidney and urinary tract in children. In Taal MW, et al.: *Brenner & Rector's The Kidney*, ed 9, Philadelphia, 2012, Saunders, pp 2622–2679.
40. Taal MW: Risk factors and chronic kidney disease. In Taal MW, et al.: *Brenner & Rector's The Kidney*, ed 9, Philadelphia, 2012, Saunders, pp 758–781.
41. Egermark I, Blonqvist JE, Cromvik U, Isaksson S: Temporomandibular dysfunction in patients treated with orthodontics in combination with orthognathic surgery, *Eur J Orthod* 22:537–544, 2000.
42. Jamal BT, Herb K: Perioperative management of the patients with myasthenia gravis: prevention, recognition and treatment, *Oral Surg Oral Med Oral Pathol Oral Radiol Endod* 107(5):612–615, 2009.
43. Abel M, Eisenkraft JB: Anesthetic implication of myasthenia gravis, *Mt Sinai J Med* 69:31–37, 2002.
44. Turakhia P, Barrick B, Berman J: Patients with neuromuscular disorder, *Med Clin North Am* 97(6):1015–1032, 2013.
45. Ueki K, Nakagawa K, Yamamoto E: Bite force and maxillofacial morphology in patients with Duchenne-type muscular dystrophy, *J Oral Maxillofac Surg* 65:34–39, 2007.
46. Morel-Verdebout C, Botteron S, Kiliardis S: Dentofacial characteristics of growing patients with Duchenne muscular dystrophy: a morphological study, *Eur J Orthod* 29(5): 500–507, 2007.
47. Portelli M, Matarese G, Militi A, et al.: Myotonic dystrophy and craniofacial morphology: clinical and instrumental study, *Eur J Paediatr Dent* 10(1):19–22, 2009.
48. Ausili E, Tabacco F, Focarelli B, et al.: Prevalence of latex allergy in spina bifida: genetic and environmental risk factors, *Eur Rev Med Pharmacol Sci* 11(3), 2007. 149–143.
49. Delfico AJ, Dormans JP, Craythorne CB, Templeton JJ: Intraoperative anaphylaxis due to allergy to latex in children who have cerebral palsy: a report of six cases, *Dev Med Child Neurol* 39(3):194–197, 1997.
50. Cremer R, Lorbacher M, Hering F, Engelskirchen R: Natural rubber latex sensitization and allergy in patients with spina bifida, urogenital disorders and oesophageal atresia compared with a normal paediatric population, *Eur J Pediatr Surg* 17(3):194–198, 2007.
51. Abebe W: Herbal medication: potential for adverse interactions with analgesic drugs, *J Clin Pharm Ther* 27(6):391–401, 2002.
52. Centers for Disease Control and Prevention: Iron and iron deficiency: *Nutrition for everyone*. http://www.cdc.gov/nutrition/everyone/basics/vitamins/iron.htmL, Feb 23, 2011.
53. Olsen JJ, Skov J, Ingerslev J, et al.: Prevention of bleeding in orthognathic surgery—a systematic review and meta-analysis of randomized controlled trials, *J Oral Maxillofac Surg* 74(1):139–150, 2016.
54. Carlos E, Monnazzi MS, Castiglia YM, et al.: Orthognathic surgery with or without induced hypotension, *Int J Oral Maxillofac Surg* 43(5):577–580, 2014.
55. Andrew M, David M, Adams M, et al.: Venous thromboembolic complications (VTE) in children: first analysis of the Canadian registry of VTE, *Blood* 83:1251–1257, 1994.
56. Heleen van Ommen C, Heijboer H, Büller H, et al.: Venous thromboembolism in childhood: a prospective two year registry in The Netherlands, *J Pediatr* 139(5):676–681, 2001.
57. Nordström M, Lindblad B, Bergqvist D, Kjellström T: A prospective study of the incidence of deep-vein thrombosis within a defined urban population, *J Intern Med* 232:155–160, 1992.
58. Leshem D, Tompson B, Britto JA, et al.: Orthognathic surgery in juvenile rheumatoid arthritis patients, *Plast Reconstr Surg* 117(6):1941–1946, 2006.
59. Yang HJ, Hwang J: Bone mineral density and mandibular advancement as contributing factors for postoperative relapse after orthognathic surgery in patients with preoperative idiopathic condylar resorption: a prospective study with preliminary 1-year follow-up, *Oral Surg Oral Med Oral Pathol Oral Radiol* 120(2):112–118, 2015.
60. Papadaki ME, Tayebaty F, Kaban LB, Troulis MJ: Condylar resorption, *Oral Maxillofac Surg Clin North Am* 19(2):223–234, 2007.
61. Posnick JC, Fantuzzo JJ: Idiopathic condylar resorption: current clinical perspectives, *J Oral Maxillofac Surg* 65(8):1617–1623, 2007.
62. Wolford LM, Cardenas L: Idiopathic condylar resorption: diagnosis, treatment protocol and outcomes, *Am J Orthod Dentofac Deform* 116:667–677, 1999.
63. El-Khouri M, Morão MA, et al.: Prevalence of atlanto-occipital and atlanto-axial instability in adults with Down syndrome, *World Neurosurg* 82(1):215–218, 2014.
64. Movahed R, Teschke M, Wolford LM: Protocol for concomitant temporomandibular joint custom-fitted total joint reconstruction and orthognathic surgery utilizing computer-assisted surgical simulation, *J Oral Maxillofac Surg* 71(12):2123–2129, 2013.
65. Nadershah M, Mehra P: Orthognathic surgery in the presence of temporomandibular joint dysfunction: what happens next? *Oral Maxillofac Surg Clin North Am* 27(1):11–26, 2015.
66. Nadershah M, Mehra P: Orthognathic surgery in the presence of temporomandibular dysfunction: what happens next? *Oral Maxillofac Surg Clin North Am* 27(1):11–26, 2015.
67. Yao S, Zhou J, Li Z: Psychological health status of patients undergoing orthognathic surgery, *J Craniofac Surg* 25(6):e540–e543, 2014.
68. Collins BG, Gonzalez D, Guadilliere D, Girod S: Body dysmorphic disorder and comorbidity among orthognathic surgery patients purpose, *J Oral Maxillofac Surg* 71(9):e18–e19, 2013.
69. Alanko OM, Svedström-Oristo AL, et al.: Patients' perceptions of orthognathic treatment, well-being, and psychological or psychiatric status: a systematic review, *Acta Odontol Scand* 68(5):249–260, 2010 Sept.
70. Cunningham SJ, Feinmann C, Horrocks EN: Psychological problems following orthognathic surgery, *J Clin Orthod* 29(12):755–757, 1995.

71. Centers for Disease Control and Prevention: Childhood obesity facts. http://www.cdc.gov/healthyyouth/obesity/facts.htm, Dec 11, 2014.
72. Ogden CL, Carroll MD, Kit BK, Flegal KM: Prevalence of childhood and adult obesity in the United States, 2011-2012, *JAMA* 311(8):806–814, 2014.
73. Centers for Disease Control and Prevention: Childhood obesity facts. http://www.cdc.gov/obesity/data/childhood.html, June 19, 2015.
74. Centers for Disease Control and Prevention: Adult obesity facts. http://www.cdc.gov/obesity/data/adult.html, June 16, 2015.
75. Leonard KL, Davies SW, Waibel BH: Perioperative management of obese patients, *Surg Clin North Am* 95(2):379–390, 2015.
76. Murphy C, Wong DT: Airway management and oxygenation in obese patients, *Can J Anaesth* 60:929–945, 2013.
77. Chang P, Friedenberg F: Obesity and GERD, *Gastroenterol Clin North Am* 43(1):161–173, 2014.
78. Mechanick JI, Youdim A, Jones DB, et al.: Clinical practice guidelines for the perioperative nutritional, metabolic and nonsurgical support of the bariatric surgical patient—2013 update, *Endocr Pract* 19(2):337–372, 2013.
79. Centers for Disease Control and Prevention: Number of civilian, noninstitutionalized persons with diagnosed diabetes, United States, 1980-2011. http://www.cdc.gov/diabetes/statistics/prev/national/figpersons.htm, March 28, 2013.
80. Frisch A, Chandra P, Smiley D, et al.: Prevalence and clinical outcome of hyperglycemia in the perioperative period in noncardiac surgery, *Diabetes Care* 33:1783–1788, 2010.
81. Redberg RF, Greenland P, Fuster V, et al.: Prevention Conference VI: Diabetes and Cardiovascular Disease. Writing group III: risk assessment in persons with diabetes, *Circulation* 105:e144–e152, 2002.
82. Kadoi Y: Anesthetic considerations in diabetic patients. Part I: preoperative considerations of patients with diabetes mellitus, *J Anesth* 24(5):739–747, 2010.
83. Curry TB, Brown DR: Perioperative management of the patient with diabetes, *Adv Anesth* 32:171–190, 2014.
84. Blyer SM, Yelon JA: The perioperative management of metformin for the oral and maxillofacial surgery patient: risks and recommendations, *J Oral Maxillofac Surg* 65(1):122–127, 2007.
85. Umpierrez G, Hellman R, Korytkowski MT, et al.: Management of hyperglycemia in hospitalized patients in non-critical care setting: an Endocrine Society clinical practice guideline, *J Clin Endocrinol Metab* 97(1):16–38, 2012.
86. Boyle ME, Seifert KM, et al.: Insulin pump therapy in the perioperative period: a review of care after implementation of institutional guidelines, *J Diabetes Sci Technol* 6(5):1016–1021, 2012.
87. Corney SM, Dukatz T, et al.: Comparison of insulin pump therapy (continuous subcutaneous insulin infusion) to alternative methods of perioperative glycemic management in patients with planned postoperative steroids, *J Diabetes Sci Technol* 6(5):1003–1015, 2012.
88. Njoku MJ: Patients with chronic endocrine disease, *Med Clin North Am* 97(6):1123–1137, 2013.
89. Salem M, Tainsh RE, Bromberg J, et al.: Perioperative glucocorticoid coverage: a reassessment 42 years after emergence of a problem, *Ann Surg* 219(4):416–425, 1994.
90. Marik PE, Varon J: Requirement of perioperative stress doses of corticosteroids, *Arch Surg* 143:1222–1226, 2008.
91. Garcia EL, Hill G, Joshi GP: Perioperative stress dose steroids: is it really necessary? *ASA Monitor* 77(11):32–35, 2013.
92. Mager DE, Lin SX, Blum RA, et al.: Dose equivalency evaluation of major corticosteroids: pharmacokinetics and cell trafficking and cortisol dynamics, *J Clin Pharmacol* 43(11):1216–1227, 2003.
93. Chegini S, Dhariwal DK: Review of evidence for the use of steroids in orthognathic surgery, *Br J Oral Maxillofac Surg* 50(2):97–101, 2012.
94. Dan AE, Thygesen TH, Pinholt EM: Corticosteroid administration in oral and orthognathic surgery: a systematic review of the literature and meta-analysis, *J Oral Maxillofac Surg* 68(9):2207–2220, 2010.
95. Tuzuner AM, Ucok C, et al.: Preoperative diclofenac sodium and tramadol for pain relief after bimaxillary osteotomy, *J Oral Maxillofac Surg* 65(12):2453–2458, Dec 2007.
96. Silva AC, O'Ryan F, Poor DB: Postoperative nausea and vomiting (PONV) after orthognathic surgery: a retrospective study and literature review, *J Oral Maxillofac Surg* 64(9):1385–1397, 2006.
97. Christofaki M, Papaioannou A: Ondansetron: a review of pharmacokinetics and clinical experience in postoperative nausea and vomiting, *Expert Opin Drug Metab Toxicol* 10(3):437–444, 2014.
98. Phillips C, et al.: Postoperative nausea and vomiting following orthognathic surgery, *Int J Oral Maxillofac Surg* 44(6):745–751, 2015.
99. Le TP, Can TJ: Update on the management of postoperative nausea and vomiting and postdischarge nausea and vomiting in ambulatory setting, *Anesthesiol Clin* 28(2):225–249, 2010.
100. Charbit B, Albaladejo P, Funck-Bretano C, et al.: Prolongation of QTc interval after postoperative nausea and vomiting treatment by droperidol or ondansetron, *Anesthesiology* 102(6):1094–1100, 2005.
101. Deitrick CL, Mick DJ, et al.: A comparison of two differing doses of promethazine for the treatment of postoperative nausea and vomiting, *J Perianesth Nurs* 30(1):5–13, 2015.
102. Le A, Patel S: Extravasation of noncytotoxic drugs: a review of the literature, *Ann Pharmacother* 48(7):870–886, 2014.
103. Brookes CD, Berry J, Rich J, et al.: Multimodal protocol reduces postoperative nausea and vomiting in patients undergoing Le Fort I osteotomy, *J Oral Maxillofac Surg* 72(9):e146–e147, 2014.
104. Politis C, Kunz S, Schepers S, et al.: Obstructive airway compromise in the early postoperative period after orthognathic surgery, *J Craniofac Surg* 23(6):1717–1722, 2012.
105. Robl M, Farrell BB, Tucker M: Complications in orthognathic surgery: a report of 1000 cases, *Oral Maxillofac Surg Clin North Am* 26(4):599–609, 2014.
106. Shetty V, Bertolami C: Wound healing. In Miloro M, et al.: *Peterson's principles of oral and maxillofacial surgery*, ed 2, London, 2004, Decker, pp 3–17.
107. Lanigan DT, West RA: Management of postoperative hemorrhage following the Le Fort I maxillary osteotomy, *J Oral Maxillofac Surg* 42:367–375, Jun 1984.
108. Tuinzing DB, Greebe RB: Complications related to the intraoral vertical ramus osteotomy, *Int J Oral Surg* 14:319–324, Aug 1985.
109. Lanigan DT, Hey JH, West RA: Hemorrhage following mandibular osteotomies: a report of 21 cases, *J Oral Maxillofac Surg* 49(7):713–724, 1991.

110. Turvey TA: Intraoperative complications of sagittal osteotomy of the mandibular ramus: incidence and management, *J Oral Maxillofac Surg* 43(7):594–599, 1985.
111. Van der Vlis M, Dentino KM, Verloet B, Padwa BL: Postoperative swelling after orthognathic surgery: a prospective volumetric analysis, *J Oral Maxillofac Surg* 72(11):2241–2247, 2014.
112. Phillips C, Blakey G, Jaskolka M: Recovery after orthognathic surgery: short term health-related quality of life outcomes, *J Oral Maxillofac Surg* 66(10):2110–2115, 2008.
113. Ettinger KS, Yildirim Y, et al.: Impact of intraoperative fluid administration on length of postoperative hospital stay following orthognathic surgery, *J Oral Maxillofac Surg* 73(1):22–29, 2015.
114. Huamçn ET, Juvet LM, et al.: Changing patterns of hospital length of stay after orthognathic surgery, *J Oral Maxillofac Surg* 66(3):492–497, Mar 2008.
115. Dan AEB, Thygesen TH, et al.: Corticosteroid administration in oral and orthognathic surgery: a systematic review of the literature and meta-analysis, *J Oral Maxillofac Surg* 68(9):2207–2220, 2010.
116. Schaberg SJ, Stuller CV, Edwards SM: Effect of methylprednisolone on swelling after orthognathic surgery, *J Oral Maxillofac Surg* 42(6):356–361, 1984.
117. Hall J: Adrenocortical hormones. In Hall JE, et al.: *Guyton & Hall Textbook of Medical Physiology*, Philadelphia, 2011, Saunders, pp 921–937.
118. Mavros MN, Velmahos GC, Falagas ME: Atelectasis as a cause of postoperative fever: where is the clinical evidence? *Chest* 140(2):418–424, 2011.
119. Kuhlefelt M, Laine P, Souminen AL, et al.: Smoking as a significant risk factor for infections after orthognathic surgery, *J Oral Maxillofac Surg* 70(7):1643–1647, 2012.
120. Brignardello-Petersen R, Carrasco-Labra A, et al.: Antibiotic prophylaxis for preventing infectious complications in orthognathic surgery, *Cochrane Database Syst Rev*, Jan 2015. Epub ahead of print.
121. Oral Facial Surgery Center: Jaw surgery cookbook. http://www.oralfacialsurgeons.com/surgical-instructions/jaw-surgery.asp.
122. Youdim A: Nutritional requirements. In *Merck Manual Professional Version*. http://www.merckmanuals.com/professional/nutritional-disorders/nutrition-general-considerations/nutritional-requirements.
123. Ball JW, Dains JE, Flynn JA, et al.: Nutrition. In *Seidel's Guide to Physical Examination*, ed 8, St. Louis, 2015, Mosby, pp 95–113.
124. Steel BJ, Cope MR: Unusual and rare complications of orthognathic surgery: a literature review, *J Oral Maxillofac Surg* 70(7):1678–1691, 2012.
125. Lee EGL, Ryan FS, Shute J, Cunningham SJ: The impact of altered sensation affecting the lower lip after orthognathic treatment, *J Oral Maxillofac Surg* 69(11):e431–e445, 2011.
126. Phillips C, Essick G, Preisser JS, et al.: Sensory retraining following orthognathic surgery: effect on patient perception of altered sensation, *J Oral Maxillofac Surg* 65(6):1162–1173, 2007.
127. Robl MT, Farrell BB, Tucker MR: Complications in orthognathic surgery, *Oral Maxillofac Surg Clin* 26(4):599–609, 2014.

17

Mandibular Surgery: Prevention and Management of Complications

INGEBORG M. WATZKE

Introduction

An old surgical adage indicates that if you have not encountered any complications you have not performed enough surgery yet. Any type of surgery involves a certain risk of complications. The latter may occur at any time during the surgical procedure, or may be a consequence of improper presurgical treatment. Complications are unforeseen events not expected under normal circumstances, resulting in greater morbidity of the surgical procedure. The frequency and severity of complications in mandibular surgery are generally low. Most complications, such as hemorrhage or unanticipated bone split can be sufficiently controlled and corrected during surgery. Others, such as injury to the inferior alveolar nerve, require additional postoperative treatment. Informing the patient about such complications is crucial—not only for medical legal reasons but also to enhance the patient's cooperation in postoperative therapeutic measures.[1]

Orthognathic surgery is considered safe and has been used for a long time, especially in the mandible.[2] Many of its complications can be predicted and prevented easily. The crucial element in prevention is careful treatment planning and excellent technical training for the achievement of a favorable functional and surgical outcome. Reviews have reported various outcomes, depending on their date of publication. This might be the consequence of better trained and more skillful surgeons and better understanding of surgical management. In a retrospective study published in 1996, Van de Perre[3] registered a 10% complication rate in 2047 patients; these included one death and 39 largely life-threatening complications. In another retrospective study, Panula[1] registered a 0.16% rate of serious complications in 655 patients. Ayoub[4] reported a complication rate of 6.8% in 821 patients; no serious or rare events were observed. In 2007 Chow[5] registered a complication rate of 6.7% in 1294 patients; 7.4% of these were related to postoperative infections. In 2012 Steel[6] et al. searched the published literature for unusual and rare complications and found that "complications are rare in orthognathic surgery although it does involve a number of rare risks, depending on the exact techniques used." In 2013 Iannetti[7] reviewed 3236 patients and found the following immediately after surgery: neurosensory deficits in 19%, bone fractures in 1.5%, infection in 2%, TMJ dysfunction in 11%, and miscellaneous nonsevere complications in 0.16%. He stated that orthognathic surgery is quite safe, and that some complications were related to the surgeon's experience and not strictly to the operation itself. Today complications in orthognathic mandibular surgery are rare and severe complications quite infrequent.

Common Risk Factors Influencing the Frequency of Complications

General risk factors may cause intraoperative complications or postoperative problems during any surgical procedure. The WHO defines risk factors as follows: *A risk factor is any attribute, characteristic or exposure of an individual that increases the likelihood of developing a disease or injury.* Risk factors include obesity, hypertension, and alcohol or nicotine abuse. Any of these risk factors could cause impairment during or after an operation.

Nicotine Abuse

Tobacco use has been associated with poor gingival healing, periodontal disease, stomatitis, leukoplakia, and oral cancer.[8] Smoking or secondary smoking is a risk factor that affects wound healing processes in the gums. Smoking is associated with postoperative wound healing complications,[9] a higher incidence of postoperative nausea and vomiting, and a higher risk of postoperative infection.[10] Mechanisms responsible for these effects have not been fully elucidated. Tobacco smoke contains a complex variety of compounds, all of

which—and not nicotine alone—are responsible for vasoactive and other effects. Toxic constituents include nicotine, carbon monoxide, and hydrogen cyanide. Tissue perfusion is reduced by vasoconstriction due to nicotine. Tissue oxygenation is decreased because carbon monoxide binds to hemoglobin 200 times more strongly than oxygen. The enzyme system responsible for oxygen transportation is blocked by hydrogen cyanide, which further reduces the oxygenation of tissue. Wound healing is the physiologic response to any disruption of surface integrity, and occurs in four overlapping phases: hemostasis, inflammatory phase, proliferative phase, and maturation. A chronic wound may develop when any of these stages is altered. Wound healing may also be compromised by infection. Infection is a serious complication in orthognathic surgery, associated with adverse postoperative outcomes. (See Infection section in this chapter.)

Venous Thromboembolism

Venous thromboembolism (VTE) is a dreaded complication of many surgical procedures. Its incidence depends on predisposing factors in the patient as well as process-related risk factors. Knowledge of these factors enables the surgeon to estimate the overall risk and assess the need for prophylactic measures. When prophylactic measures are undertaken, the risk of their side effects, such as a higher risk of hemorrhage, must be included in the overall assessment.

Intervention-related Risks of Orthognathic Surgery

The intervention-related risks of orthognathic surgery are poorly investigated; we have data from three retrospective studies and one small prospective study (Table 17-1). A total of 6716 patients were investigated.[11-14] The incidence of thromboembolic events was 9/6716, which amounts to approximately 1/1000. One significant limitation of these studies is that the majority of thromboembolisms occurred immediately post-surgery; those that possibly occurred later and were also caused by the intervention were not registered. Three of the 10 patients with thromboembolisms had risk factors for perioperative thromboembolic complications.

Registration of Patient-related Risk Factors for Perioperative Thromboembolism

Several scores have been developed for the registration of patient-related risk factors for perioperative thromboembolism. The scores are based on studies in which the occurrence of VTE in relation to personal risk factors was investigated for various surgical interventions. The score developed by Caprini[15] for the assessment of patient-related risks is recommended by the Guidelines of the American Colleges of Chest Physicians.[16] A total of 35 risk factors were included in this score. Each risk factor is assigned a specific number of points. The total score determined for the existing risk factors in a patient indicated the individual's personal risk of developing a perioperative thromboembolism (Table 17-2).

In the adaption of this model by the ACCP, the risk of VTE is rated very low (0-1 point), low (2 points), moderate (3-4 points), or high (≥5 points). Although the model was not developed using rigorous statistical methods, it is relatively easy to use and appears to permit a fairly clear distinction between patients with a low, moderate, or high risk of VTE.

TABLE 17-1 Incidence of Venous Thromboembolism (VTE) in Orthognathic Surgery

Author	Patients (n)	TE (n)	Incidence%
Van de Perre[11]	2049	3	0.15
Blackburn[12]	129	2	1.55
Forouzanfar[13]	411	2	0.48
Verlinden[14]	4127	2	0.05
Total	6716	9	0.13

Procedure in Orthognathic Surgical Interventions

Assuming an incidence of approximately 1:1000 for the intervention-related risk of orthognathic surgery,[11,14] patients with a low personal risk (Caprini score of 0-2) were below this level and would therefore not benefit from pharmacologic prophylaxis.

A risk of 60/1000 (corresponding to a Caprini score of 7-8) is reported for patients with a high personal risk when undergoing plastic surgery,[16] which has an intervention-related risk similar to that for orthognathic surgery. Thus, these patients would benefit from pharmacologic prophylaxis.

Sagittal Split Osteotomy (SSO)

Complications in orthognathic surgery may be divided into three categories: preoperative, perioperative, and postoperative.

Preoperative Complications

Laboratory errors such as false bite registration, incorrect mounting of casts, or improper model surgery may serve as the starting point of subsequent complications and a poor surgical outcome. Accurate diagnosis, treatment planning and appropriate preoperative orthodontic treatment are crucial factors for a stable and favorable esthetic outcome.

Accurate Diagnosis

Correct diagnosis and interdisciplinary treatment planning is a prime goal and a crucial element of successful long-term results. An accurate diagnosis prior to treatment determines the surgical procedure and the esthetic outcome.

Surgery in one jaw limits surgical bone movement of the lower jaw when dental compensation is insufficient. Correct orthodontic and surgical treatment, planned by the

TABLE 17-2 Risk Factors for Perioperative Thromboembolism

1 Point	2 Points	3 Points	5 Points
Age 41-60 y	Age 61-74 y	Age ≥ 75 y	Stroke (< 1 mo)
Minor surgery	Arthroscopic surgery	History of VTE	Elective arthroplasty
BMI >25 kg/m^2	Major open surgery (> 45 min)	Family history of VTE	Hip, pelvis, or leg fracture
Swollen legs	Laparoscopic surgery (>45 min)	Factor V Leiden	Acute spinal cord injury (< 1 mo)
Varicose veins	Malignancy	Prothrombin 20210A	
Pregnancy or postpartum	Confined to bed (>72 h)	Lupus anticoagulant	
History of unexplained or recurrent spontaneous abortion	Immobilizing plaster cast	Anticardiolipin antibodies	
Oral contraceptives or hormone replacement	Central venous access	Elevated serum homocysteine	
Sepsis (< 1 mo)		Heparin-induced thrombocytopenia	
Serious lung disease, including pneumonia (< 1 mo)		Other congenital or acquired thrombophilia	
Abnormal pulmonary function			
Acute myocardial infarction			
Congestive heart failure (< 1 mo)			
History of inflammatory bowel disease			
Medical patient at bed rest			

VTE, venous thromboembolism. (Data Originally Published by Caprini 1991[15] and Modified by Gould 2012[16].)

orthodontist and the surgeon, are mandatory for a stable and esthetic outcome.

Inadequate preoperative orthodontic treatment and its failure may hinder a favorable surgical outcome and result in unstable occlusion.

Treatment Planning

Computer-aided and virtual planning[17] with intraoperative occlusion-based positioning systems appear to provide more accurate surgical results.[18] The authors state that virtual planning and the use of computer-aided manufacturing technology have improved preoperative assessment and surgical outcomes. Treatment time and operating time also were reduced. A recent study by Zinser[19] compared three planning systems. They found that CAD/CAM designed splints showed the highest precision for maxillary planning transfer and kept the condyles in their central position in the temporomandibular joint. They stated that CAD/CAM splints and surgical navigation were an alternative approach to the use of classic intermaxillary occlusal splints. However, long-term accuracy and stability as well as cost implications will have to be investigated in the future.

Preoperative Orthodontic Treatment

Orthodontic dental compensation and adequate transverse coordination are essential. Tooth size discrepancies may hinder proper adjustment of the mandible and the maxilla at the time of surgery. Insufficient orthodontic appliances or active orthodontic wires may be a significant problem for the surgeon.

Transverse Discrepancies

Severe discrepancies of the maxilla and the mandible that cannot be corrected by orthodontic treatment alone require bimaxillary surgery (Figures 17-1 and 17-2). This decision must be made prior to orthodontic treatment. In patients with the maxilla in correct vertical or sagittal position, surgical palatal expansion is an option in adults whereas conventional orthodontic therapy might be successful in children.

In adults, orthodontic expansion beyond a few millimeters will produce either buccal tipping of the maxillary molars or lingual tipping of the mandibular molars (Figure 17-3). The molars are likely to collapse when orthodontic devices are removed, leading to crossbite or an open bite. Handelman[20] found several patients with post-surgical elongation of the molars as they tipped back to their original position. This led to clockwise rotation of the mandible and an open bite condition after surgery. Therefore, expansion of the maxilla after closure of the maxillary suture should be performed under surgical assistance, using a palatal appliance (surgically assisted rapid palatal expansion, SARPE) (Figure 17-4).

Transverse discrepancies in the *canine* region do not permit advancement of the mandible into a correct dental class I position, resulting in an increased overjet and dental class II.

In patients with transverse discrepancies and severe dental crowding, especially in the front region, SARPE will be the choice of treatment even in those who need Le Fort I osteotomy as a second procedure because of sagittal or vertical problems (Table 17-3).

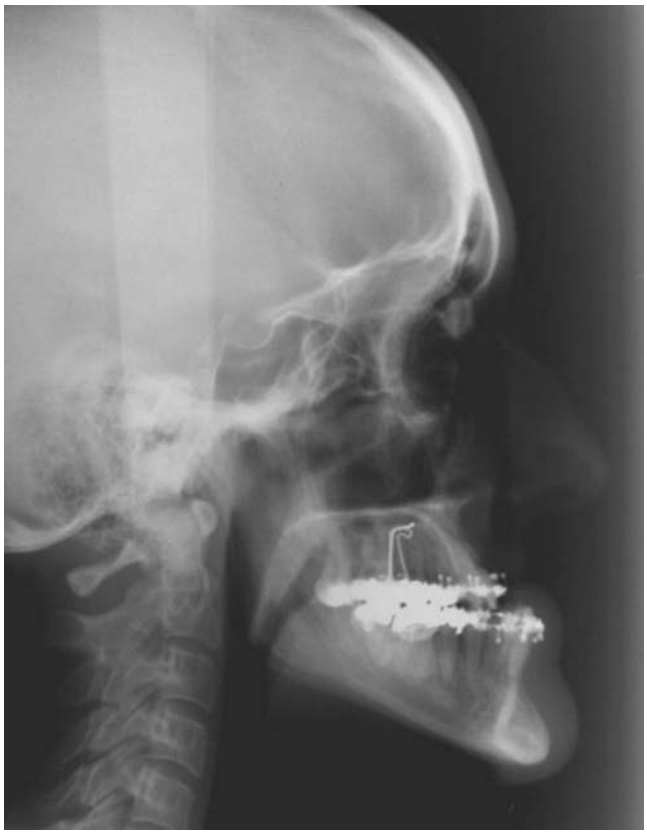

• **Figure 17-1** Severe class III malocclusion requiring combined surgical orthodontic treatment.



• **Figure 17-2** Severe open bite malocclusion requiring combined surgical orthodontic treatment.

Incisor Inclination and Leveling Curve of Spee

Correct incisor inclination in relation to chin position is crucial for a stable functional as well as a good esthetic result. Protruded incisors have to be retroclined before surgery in patients with neutral chin position. This can be achieved either by extraction of premolars or by extraction of one incisor (Figure 17-5). In a patient with a protruded chin incisor inclination can be more than 90 degrees to the mandibular plane to give a good esthetic result (Figure 17-6).

The timing of leveling the curve of Spee prior to surgery or post-surgery depends on the patient's anterior face height. In patients with a short face, leveling should be performed after surgery by premolar extrusion. In patients with a normal anterior face height it should be performed prior to surgery by intrusion of the incisors and extrusion of the premolars. In patients with a long face, intrusion of the incisors should be performed prior to surgery even when it involves reducing the anterior face height with additional genioplasty (Table 17-4).

Cases

In the presence of a moderate to severe mandibular deficiency, and proclined lower incisors, the ideal position of the mandibular anterior teeth is best achieved by extraction of premolars. This creates space for correct inclination of the incisors. However, this is not true of all patients with a mandibular deficiency and greatly depends on the position of the chin.

Patients with a "strong" chin need more incisor protrusion (Figure 17-7) than those with a "weak" chin. If the incisors are tipped back to a 90 degree position to the mandibular plane, the chin will be too protruded after mandibular advancement (Figure 17-8). Reduction of chin projection with genioplasty yields poor esthetic results (Figure 17-9).

Patients with chin hypoplasia and incisor protrusion will benefit from genioplasty advancement. In cases where the chin has to be moved forward more than 6 mm the esthetic outcome may be unsatisfactory. This results in a deep sublabial fold and an unharmonious appearance. In this case two-step genioplasty is indicated (Figure 17-10).

In patients with mandibular deficiency, a strong chin, and a short anterior face height, chin protrusion can be reduced by rotating the chin downward and backward; this provides a favorable esthetic result (Figure 17-11).

Patients with an excessive anterior face height will need vertical reduction. Genioplasty can then be performed in all directions and there is more freedom for incisor inclination (Figure 17-12, *A*).

Intraoperative Complications

Nerve Injury

Neurosensory disturbance is one of the most common complications in mandibular surgery.[21,22] Nerve injury during SSO may involve the inferior alveolar nerve (IAN),

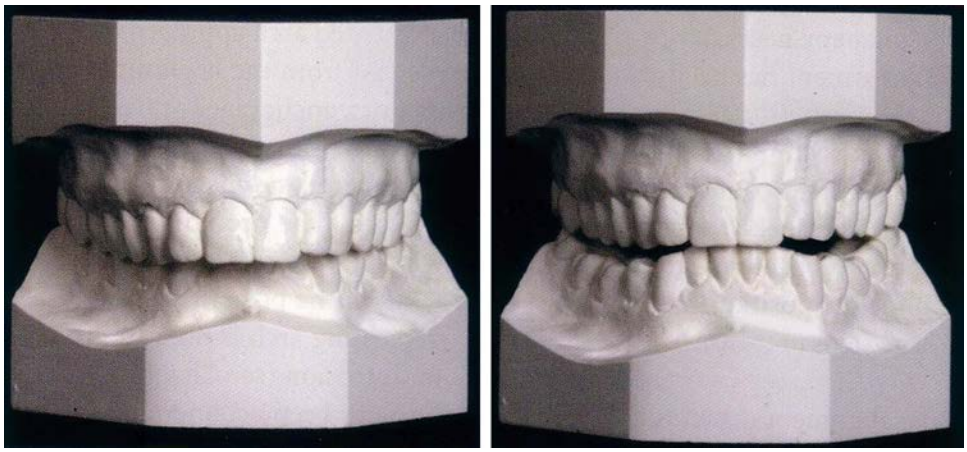

• **Figure 17-3** A patient with mandibular deficiency and severe posterior transverse discrepancy when the mandible is advanced.

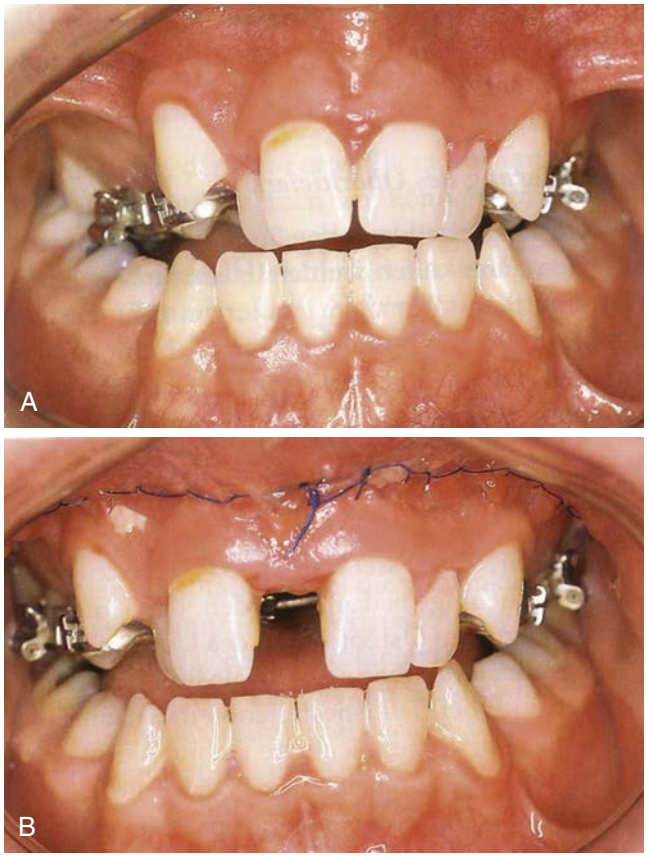

• **Figure 17-4** **A,** Severe transverse discrepancies and dental crowding in upper front indicate SARPE. Palatal appliance (Hyrax) is in place for SARPE. **B,** The maxilla is widened during surgery as much as possible to allow correct alignment of the teeth orthodontically.

TABLE 17-3 Treatment of Transverse Discrepancies in Adult Patients with Mandibular Deficiency

Diagnosis	Therapy
Front crowding + good nasolabial angle	No extraction + SARPE
Front crowding + nasolabial angle <90 degrees	Premolar extraction and orthodontic treatment
Front crowding + nasolabial angle >110 degrees	No premolar extraction + SARPE +/– Le Fort I osteotomy



• **Figure 17-5** Protruded inferior incisors were up-righted with orthodontic treatment to allow mandibular advancement for class I occlusion. The required space for tip-back was created by extraction of one lower incisor.

the lingual nerve, or in very rare cases the facial nerve. The injury may be caused by blunt trauma, stretching, a tear or a cut. Transection rates of 2% to 3.5% have been reported in the published literature.[23]

Inferior Alveolar Nerve

The IAN is at great risk for injury during various stages of sagittal split osteotomy because the osteotomy is performed in close proximity to the inferior alveolar nerve. The location of the IAN in the mandible may vary. Some mandibular deformities seem to be associated with abnormal locations of the IAN. In mandibular prognathism, for instance, it usually runs very close to the cranial edge of the mandible. This is particularly important in patients with a long vertical but short horizontal ramus of the mandible, occasionally accompanied by loss of posterior

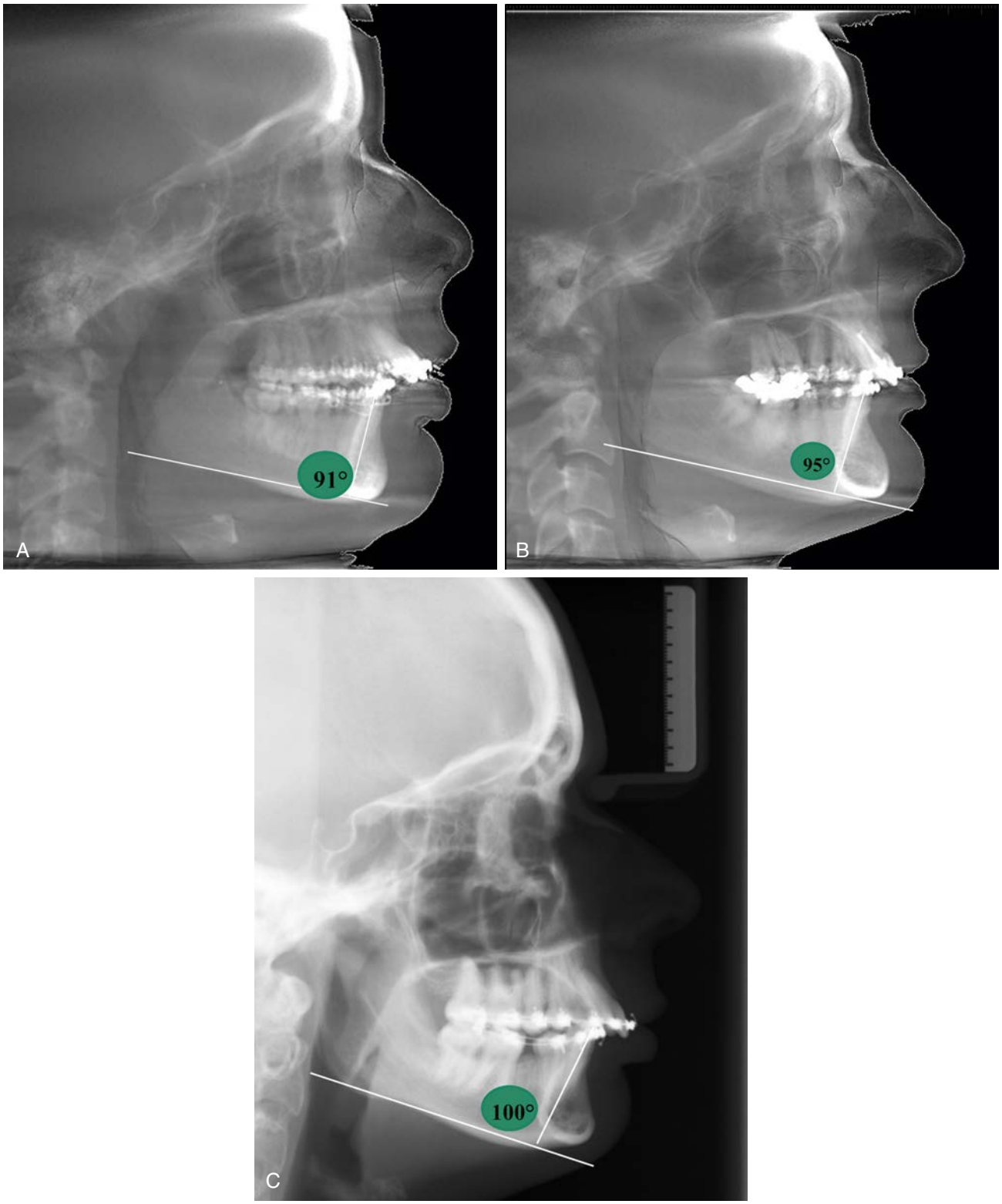

• **Figure 17-6** Incisor inclination depending on chin projection. **A,** Patient with normal anterior face height; Incisors inclination is 90 degrees to mandibular plane. Holdaway ratio 1:1 after mandibular advancement. **B,** Patient with mandibular deficiency and deep bite. The chin position is slightly prominent. Incisor inclination is 95 degrees. Mandibular advancement and rotation down to correct the deep bite leads to 1:1 holdaway ratio. **C,** Mandibular deficiency and chin deficiency. The lower incisors are protruded. Treatment plan should have been premolar extraction to allow the lower front teeth to tip back. In this case advancement genioplasty will be necessary to give a good esthetic result.

TABLE 17-4 Orthodontic Treatment, SSO +/– Genioplasty in Relation to the Patient's Chin Position

Face height	Chin	Incisor inclination	Leveling	Genioplasty
Normal face height	HR 1:1	90 degrees	Incisor intrusion and premolar extrusion	No
	HR >1:1	>90 degrees	Incisor intrusion, premolar extrusion	No
	HR <1:1	90 degrees	Leveling pre- or postoperative	Yes
Short face	HR 1:1	90 degrees	Premolar extrusion postoperative	Yes
	HR >1:1	>90 degrees	Premolar extrusion postoperative	Yes
	HR <1:1	90 degrees	Premolar extrusion postoperative	Yes
Long face	HR 1:1	90 degrees	Incisor intrusion preoperative	Yes/No
	HR >1:1	>90 degrees	Incisor intrusion preoperative	Yes/No
	HR <1:1	90 degrees	Incisor intrusion preoperative	Yes/No

teeth (Figure 17-13). Penetration of the saw through the mandibular cortex will easily tear the nerve and may lead to its rupture during splitting. Occasionally, the IAN runs along the inferior border of the mandible, which makes it susceptible to laceration during drilling or sawing at the inferior border. Cone-beam CT scan demonstrates the anatomic position of the IAN clearly before surgery and has thus made it easier to avoid injury.

The presence of an unerupted third molar during surgery has been suggested as a factor that increases the risk of neural deficit. Paresthesia results from manipulation of the nerve when the neurovascular bundle has to be dissected from the proximal segment or released from the bone canal in the proximal segment. In addition, the roots of third molars are frequently located close to the mandibular canal and may tear the nerve upon their mobilization.

Stages of possible damage of IAN during sagittal split osteotomy are as follows:

1. Application of local anesthesia on the inside of the ascending ramus may cause nerve injury (closed injury). It is best avoided by targeting the middle of the lingual surface of the ascending mandibular ramus and keeping contact with the mandible when pushing the needle forward.[24]
2. During osteotomy the IAN is occasionally lacerated at the site of its entrance into the mandible. This can be prevented by protecting the site with a periosteal elevator and the tip of the suction apparatus (Figure 17-14).
3. When connecting the cranial cut with the horizontal osteotomy line, the IAN may be injured when the saw is set too deep into bone and the nerve runs close to the cranial edge. In mandibular prognathism, the nerve is sometimes very close to the superior surface. To avoid this complication it is important to cut only cortical bone.
4. Lesions of the IAN in the anterior vertical part of the osteotomy are usually caused by the proximity of the mandibular canal to the lateral mandibular cortex in the second molar region. The risk of a neurosensory disorder is significantly greater when the distance between the mandibular canal and the buccal cortex of the mandible is 2 mm or less. With regard to the distance between the mandibular canal and the buccal cortex, Yoshida[25] reported a distance of less than 1.2 mm in 91% of osteotomy sites where a severe neurosensory disorder after BSSO was experienced. The subjective evaluation of the neurosensory disorder was still abnormal at the three-month follow-up. Hallikainen[26] found the distance of the canal and the buccal cortex less in patients with prognathism than in the mandible deficiency. Placement of the saw in a 45 degree angle when making the buccal cortical osteotomy helps to avoid this complication.
5. The IAN may be torn by forced manipulation during the splitting process, especially in patients with a small bone marrow space and a long mandibular angle.[27] This can be avoided by using rotating instruments only to open the mandibular cortex. Therefore the osteotome should penetrate the mandible very superficially during splitting (Figure 17-15). Once the two cortices are separated, the tip of the suction device should be inserted into the gap (Figure 17-16). This is helpful in detecting any false position of the nerve in the outer cortex, where it can be easily freed with an elevator. Once the bone split has been completed, the IAN should be in the distal segment. Occasionally it is completely caught on the proximal side (Figure 17-17). It is less damaging for the nerve to leave it in the proximal segment, but this is only true in class II patients when the mandible is brought forward. It cannot be done when the mandible has to be set back. In these cases the nerve has to

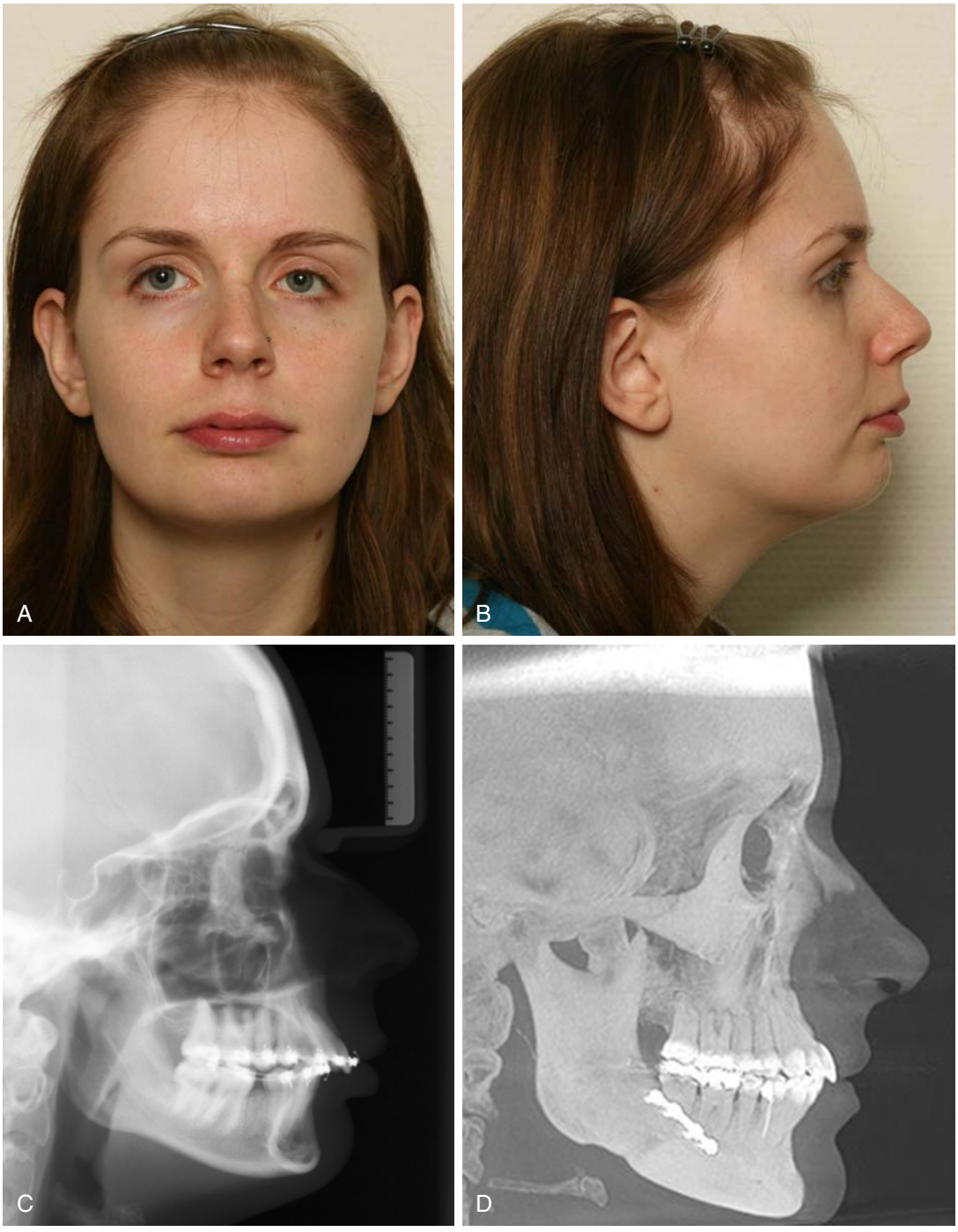

• **Figure 17-7** Pre- and postoperative photographs and x-rays of a patient with mandibular deficiency and slightly reduced chin position. **A,** Full face she shows a deep sublabial fold. **B,** On profile view the lower lip is sucked in behind the upper incisors. Anterior face height is slightly decreased. **C,** The x-ray. **D-F,** After mandibular advancement the face is well balanced, chin is in good esthetic position without genioplasty.



• **Figure 17-7, cont'd**

be freed from the proximal segment so that the distal segment can be set back.

6. The nerve is exposed to blunt trauma during osteosynthesis, due to cancellous bone fragments that were not removed before fixation. Therefore, after splitting it is very important to remove all cancellous bone fragments from the proximal segment opposite the nerve canal, using a bone rasp. Small debris must be removed by meticulous rinsing before positioning the fragments for stabilization.
7. During osteosynthesis, the IAN can be injured by the burr, the heat of rotating instruments, or by screws set too close to the nerve.

Several precautions help to avoid traumatic injury to the IAN:

1. Knowledge of the anatomy of IAN with the aid of cone-beam CT scan
2. Correct placement of the osteotomy line on the inner cortex of the ascending ramus and 45 degree placement at the horizontal ramus
3. Careful splitting and release of the IAN from the proximal segment with an elevator
4. Meticulous rinsing and removal of cancellous bone fragments before osteosynthesis
5. Placement of screws perpendicular to the bone surface and along the cranial border or the use of bone plates.

Lingual Nerve

Injury to the lingual nerve during SSO is a rare event. Despite the fact that high injury rates of 9%[28] up to 19% [29] have been reported, the majority of studies mention no injury or much lower rates. A few situations during surgery might expose the nerve to potential danger.

Application of local anesthesia may damage the lingual nerve.[30] Placement of excessively long bicortical screws on the superior border of the mandible for osteosynthesis might damage the nerve when the screw passes through the lingual cortex. It seems safe to use screws measuring 15 mm in length. In patients who need longer screws, the depth of the drilled hole should be measured.

This complication may result in painful dysesthesia when eating and speaking. Reoperation and removal of the screws may be necessary. The use of plates and monocortical screws prevents this complication.

Hematoma after severe bleeding on the inner side of the mandible will exert pressure on the lingual nerve. This may cause temporary paresthesia of the tongue. It is marked by sensory defects on the affected side of the tongue and the loss of taste. Acute interventions are usually not necessary because the dysesthesia will resolve spontaneously over time. Extensive hematoma should be drained to achieve rapid recovery. The nerve will recover within a few weeks and return to normal.

Facial Nerve

Although the incidence of facial nerve injury during SSO is low (0.38 %),[31] it is a serious and frightening condition for the patient. In large mandibular setbacks the nerve might be compressed directly or by a styloid process fracture, and cause palsy or weakness of the nerve.[32] This is especially true when the medial cut at the inner cortex of the ascending ramus is extended to the posterior border, leading to a long cut.

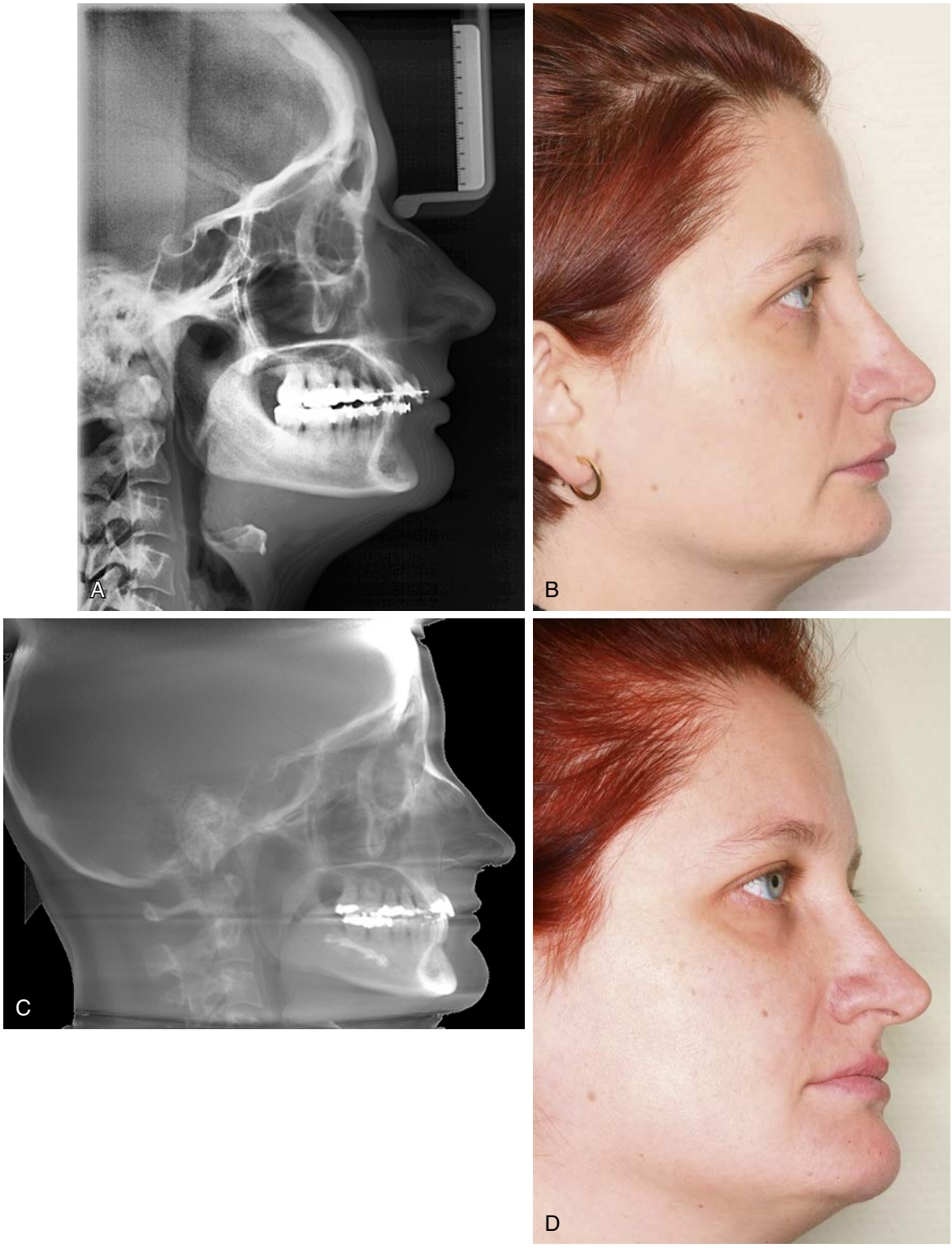

• **Figure 17-8** Pre- and postoperative photographs and x-rays of a patient with mandibular deficiency and chin hyperplasia. **A,** X-ray shows inclination of lower incisors is 95 degrees. **B,** Short lower face height, mandibular deficiency, chin in good position before mandibular advancement. **C-D,** After mandibular advancement the chin appears protruded mainly because of excessive soft tissue.

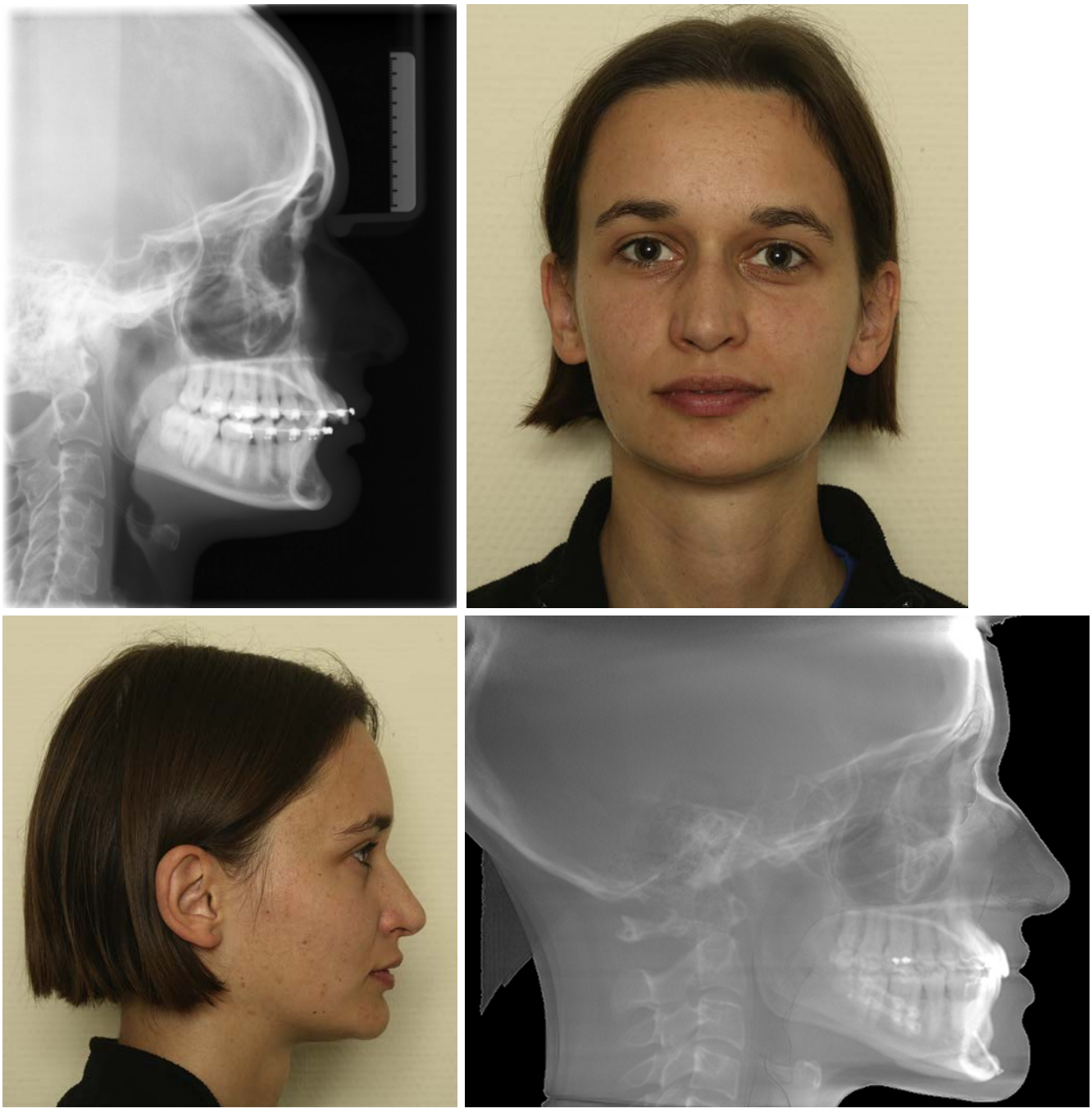

• **Figure 17-9** Pre- and postoperative photographs and x-rays of a patient with mandibular deficiency and chin hyperplasia, short anterior face height, and excessive soft tissue at the chin. Mandibular advancement and reduction genioplasty results in an unpleasant outcome.

Continued



• **Figure 17-9, cont'd.**

Severe bleeding, causing excessive hematoma after surgery, may exert pressure on the facial nerve and impair its function.[33] In cases of extensive bleeding, meticulous hemostasis should be performed to avoid extensive hematoma.

In patients with large mandibular setbacks, short cuts at the inner cortex of the ascending ramus or bone reduction of the posterior border of the proximal segment avoid pressure to the nerve.

Unfavorable Bony Splits

A specific but not very common problem of sagittal split osteotomy is the unfavorable bony split. Its frequency varies between 2% and 20%[1] and it may occur either on the distal tooth-bearing segment or the proximal segment. Identifying the causative problem before it occurs can minimize the risk of an unfavorable bony split. Usually a minimal amount of pressure is needed for splitting the proximal and distal segments with a chisel. When resistance is encountered or a buccal plate fracture develops, the cuts need to be re-evaluated and redirected before proceeding.

Poor split of the distal segment most commonly affects the lingual cortical bone posterior to the third molar. This can be managed by performing an inferior vertical ramus osteotomy (IVRO) to separate the fragments, especially in mandibular setback cases. It may result in sequestration of the fragment, delayed union, malunion of the osteotomy site, or even infection. Stabilizing the bone fragment with a bicortical screw during surgery may prevent these postoperative complications.

Unexpected splits of the proximal segment may occur before or after splitting of the mandible. A developing inadvertent split may be prevented when it is recognized before the fracture is completed. Osteosynthesis with a bone plate placed perpendicularly over the fracture will solve the problem.

A frequent cause of a poor split is improper osteotomy of the cortical bone at the inferior border and wedging with the osteotome, especially when bone is used as a fulcrum during splitting. Therefore, careful inspection of the inferior border and the outer cortex is mandatory.

Certain predisposing factors are likely to cause an unanticipated split: difficult anatomic conditions, poor osteotomy design, or the presence of impacted third molars.

1. The anatomy of the ascending ramus may vary. Anatomic features, including the width and thickness of the ascending ramus as well as the positions of the canal, have been studied.[34] The thickness of the ramus may also differ. Lack of cancellous bone between the two cortical bone layers makes the split more difficult and hinders exact separation of cortical and cancellous bone.
2. Correct cuts through cortical bone, either with a reciprocating saw or a burr, is a primary prerequisite to avoid a bad split. This is especially true when the cut is made on the inner side of the ascending ramus and the inferior border before using the chisel on the osteotomized bone.[35]
3. A high risk of unanticipated fractures during BSSO has been associated with the presence of impacted third molars. Impacted third molars have been reported to compromise the anatomic structure of the mandible and cause adverse proximal and distal segment splits. However, the subject is controversial. Some authors suggest removal of third molars at least 6 months, but preferably 9 to 12 months prior to surgery,[36] whereas others found no reduction in the incidence of fractures when impacted third molars were removed at the time of surgery.[37,38] Modification of SSO has been suggested to avoid this complication.[39]

In a series of 1176 sagittal splits, we found a significant correlation between female gender, age older than 40 years,



• **Figure 17-10** **A,** Patient with mandibular deficiency and chin hypoplasia. **B,** The lower incisors are protruded more than 105 degrees. **C-D,** After advancement of the mandibula the chin would still be too far back. She needed chin advancement in 2 steps to give a harmonious appearance.

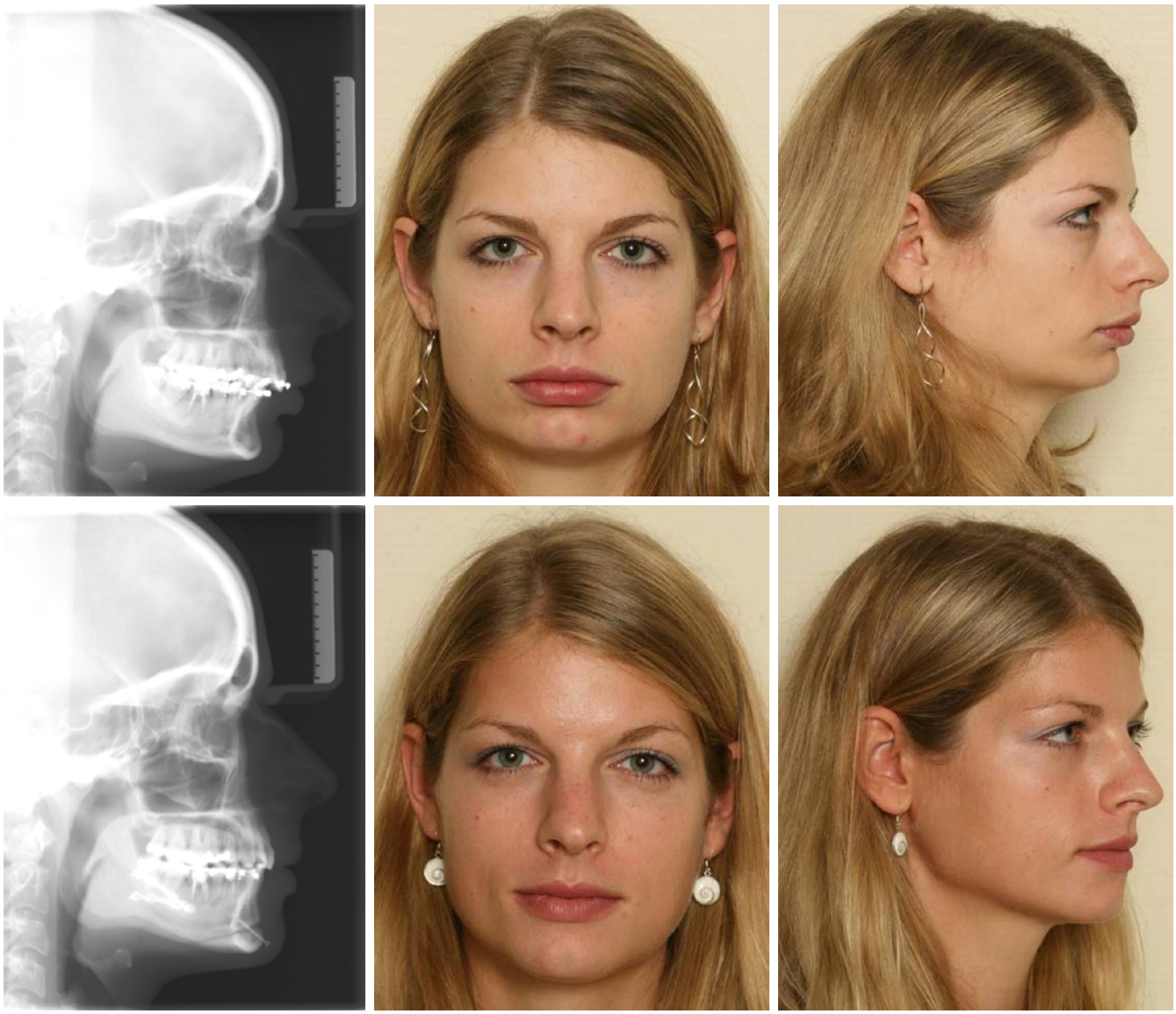

• **Figure 17-11** Patient with mandibular deficiency and short face. Lower face height is too short even after mandibular advancement. Correction with additional genioplasty produces well balanced facial appearance.

and an obtuse gonion angle (<115 degrees) but no correlation with the presence of third molars (P=0.867).[40]

Fracture of the lingual plate or the buccal plate is not uncommon when nonerupted third molars are present. The buccal cortex of the mandible is normally very thin in the posterior aspect of the second molar (Figure 17-18). The presence of a third molar makes splitting even more difficult because there is a paucity of medullary bone between the cortices. Fractures may affect the lingual cortex during removal of the tooth, or the outer cortex during splitting. A horizontal fracture of the ramus and even a fracture of the condylar process make reduction and fixation of the remaining segments difficult.[41] Plates, bicortical screws, or a combination of both may be used to stabilize the fractured bony segments (Figure 17-19). Usually the intraoral approach for osteosynthesis is not sufficient; an extraoral access will be needed to insert plates and/or screws.

Unanticipated bone splits do not influence stability or the long-term success of SSO. In a report published in 2008, Veras et al.[42] observed no difference in temporomandibular dysfunction, including pain and/or clicking. The authors concluded that poor splits, when treated appropriately, have good chances of achieving normal function although some mandibular movements may be compromised.

Hemorrhage

Uncontrolled bleeding is a rare condition in mandibular surgery. In most cases it is caused by the clumsy use of rotating instruments or chisels, a sign of unfamiliarity with the surgical procedure. The retromandibular vein and the inferior alveolar vessels may be injured inadvertently. In rare cases the facial artery may be injured at the gonial notch. Bleeding rates of 38% have been mentioned in earlier reports.[43,44] Most bleeding can be treated by packing. Severe bleeding

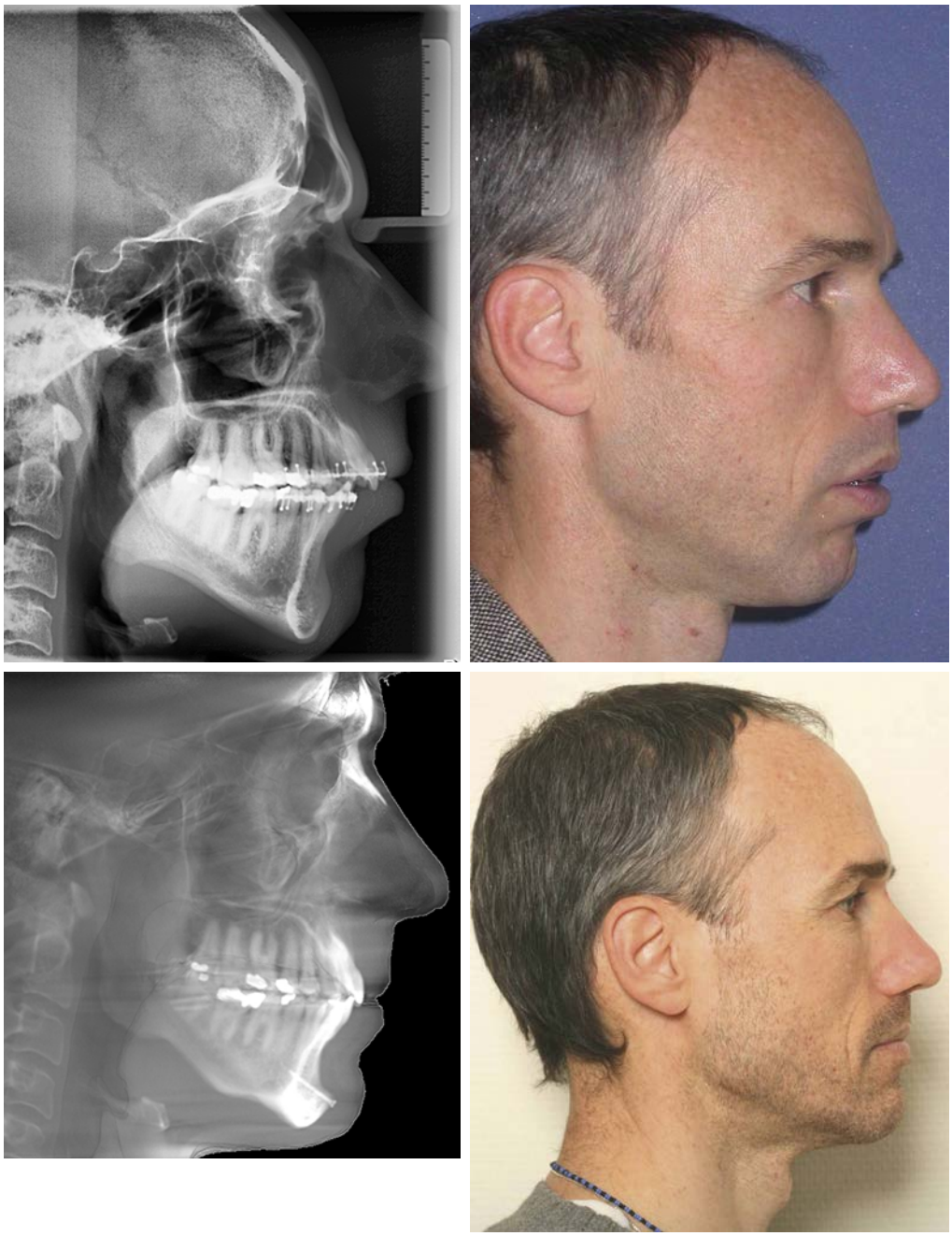

• **Figure 17-12** Patient with mandibular deficiency, chin deficiency, and long face. After mandibular advancement, lip incompetence is still present. After an additional advancement genioplasty and reduction of anterior face height by removing bone from the symphysis the face is well balanced.

requiring blood transfusion is a rare occurrence in BSSO.[1] Recent reports mention a low incidence (1%) of severe bleeding.[45] In a report published by Foran,[46] the chronic intake of energy drinks was held responsible for excessive intraoperative bleeding in two patients. Foran's suspicion is based on several reports attributing intraoperative and postoperative bleeding to the herbal constituents of these beverages. All cases were marked by diffuse bleeding that could not be clearly assigned to a single source.

Even when bleeding is minor it tends to make the surgical procedure more difficult by precluding optimal sight of the anatomic structures, which may result in further surgical complications, such as nerve injuries or an unfavorable bony split. Minor bleeding also increases the duration of surgery, which by itself is an established cause of complications. Most bleeding is minor and can be controlled by the use of local anesthetics, a gauze pack, or direct ligation of the affected vessel.

Minor oozing may occur at the very beginning of surgery, when insufficient time (<10 minutes) has elapsed for vasoconstriction after the administration of local anesthesia. Another frequent reason for bleeding in this phase is inadvertent



• **Figure 17-13** Position of mandibular nerve canal.

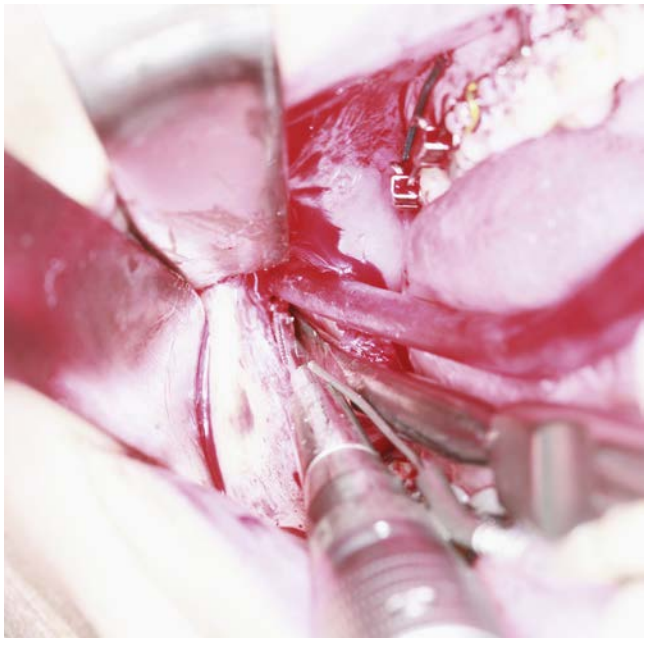

• **Figure 17-14** Soft tissue protection with suction device cranial and freer caudal to avoid soft tissue injury during osteotomy of the inner cortex of the ascending ramus.

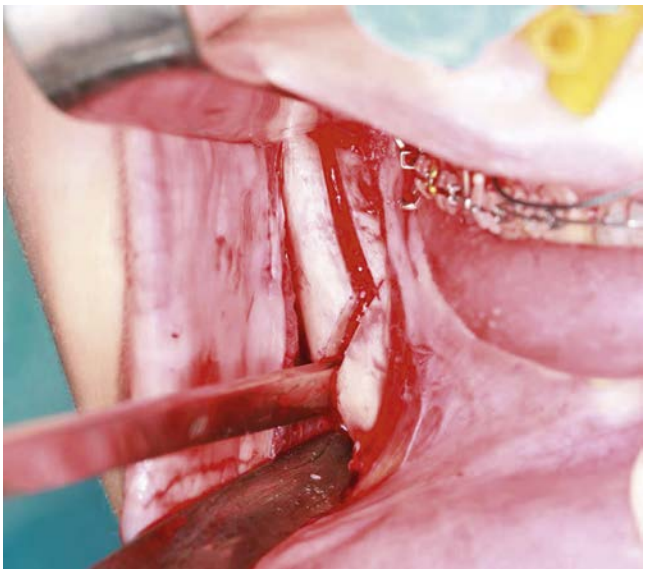

• **Figure 17-15** Osteotomy of horizontal ramus.

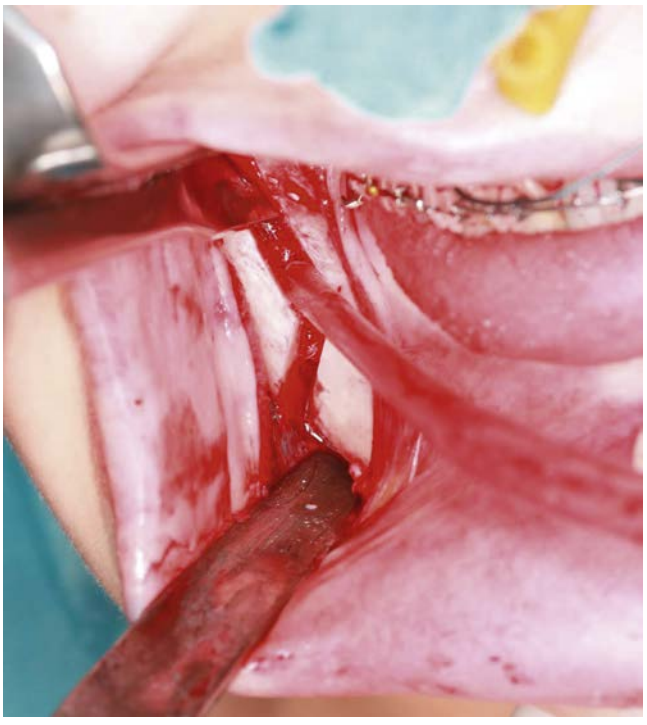

• **Figure 17-16** Suction device in gap.

laceration of the masseter muscle during the incision of the vestibular mucosa. This can be avoided by meticulously cutting the mucosa all the way through to the periosteum. The cut goes medial to the muscle down to the periosteum, which is then opened by blunt dissection. Although not dangerous, both types of bleeding are associated with poor visibility of anatomic structures and prolonged operating times.

During osteotomy, bleeding from the medial pterygoid muscle occurs at the lingual surface of the ascending mandibular ramus when the periosteum is not completely released from bone. Surgical exposure of the periosteum must be started from the anterior aspect of the ascending ramus. Bleeding may also occur at this stage due to laceration of the retromandibular vein or branches of the superficial temporal veins by the use of surgical instruments such as drills or osteotomes.[45] This can be prevented by using a periosteal elevator to protect soft tissue from the caudal aspect and the suction device from the cranial aspect, as mentioned earlier (see Figure 17-14).

Bleeding from the facial artery may occur during removal of soft tissue from the inferior mandibular border. Such bleeding must be treated with a suture. This can be problematic because visual access is very limited in this region. A neck incision may be required to control bleeding from this area.

Bleeding from the inferior alveolar artery may occur when bone fragments after osteotomy are separated by using

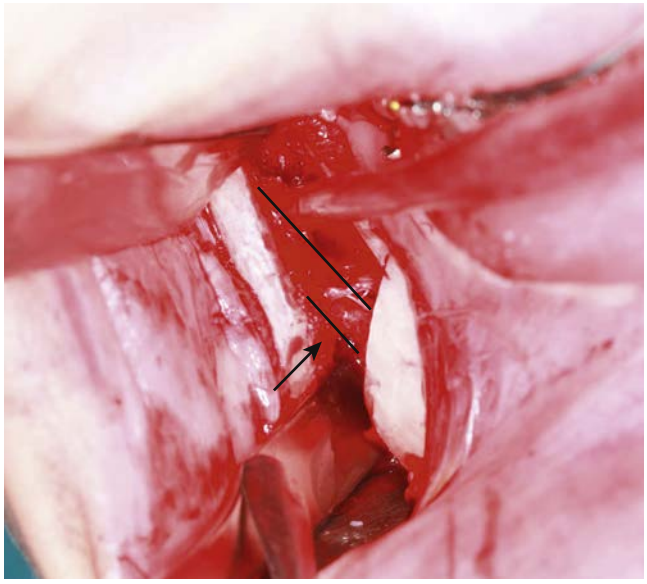

• **Figure 17-17** Nerve remains in proximal segment.

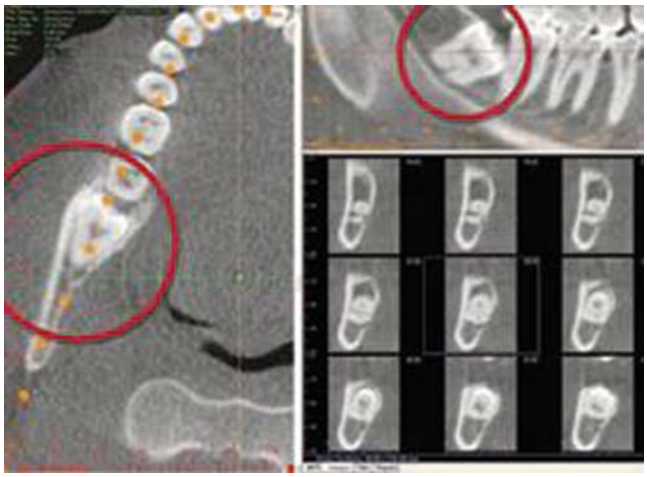

• **Figure 17-18** Impacted third molar, no cancellous bone between tooth and buccal cortex.

a bi-beveled osteotome. Bleeding can be easily treated by ligation because visual access is optimal in this location. This complication can be avoided by cautiously splitting under good vision. The latter can be achieved by placement of the suction tip at the bottom of the split. Careful exposure and release of vessels (and nerves) from the proximal fragment are also important.

Malpositioning of the Proximal Segment

Control of the proximal segment is the most important aspect of long-term stability. Early postoperative relapse occurs when the proximal segment is not positioned properly in the fossa or the condyle is torqued, and this may cause postoperative pain. Pushing the proximal segment posteriorly may also provide good gonial angle projection but puts stretch on the muscles of mastication.

Different methods have been proposed to control the condyle in the fossa before splitting.[47] However, none of these methods has gained acceptance. In fact, long-term results were not better than those in patients treated without these aids.

Vertical Subcondylar Ramus Osteotomy (IOVRO)

The vertical subcondylar ramus osteotomy is described as "one of the simplest osteotomies to perform."[48] Currently its use is confined to significant mandibular setbacks. Initially it was performed by the extraoral approach,[49] but today it is performed intraorally. Complications during surgery include unfavorable bony splits, injury to the neurovascular bundle, and bleeding.

Unfavorable Osteotomy

This may be caused by incorrect positioning of the saw. A saw positioned too far posteriorly may lead to a subcondylar osteotomy instead of a vertical cut parallel to the posterior side of the ascending ramus.[50]



• **Figure 17-19** Bad split, osteosynthesis with bone plate perpendicular to fracture.

Nerve Injury

The incidence of nerve injury in vertical subcondylar ramus osteotomy ranges between 0% and 35%. The incidence is less than it is in SSO.

Two possible causes have been described in the literature.

1. When the saw is placed too far forward in the vicinity of the foramen of the neurovascular bundle, the nerve may be cut. Specific instruments, placed correctly during the surgical procedure, help to avoid this complication. The complication can also be minimized by radiographic identification of the lingual nerve on cone-beam CT scans.
2. In severe mandibular prognathism, the distal segment is pushed back against the proximal segment, causing the nerve to tear. To avoid pressure on the nerve, a bone segment can be cut out of the proximal segment.

Overall, IOVRO appears to be superior to SSO in terms of neurosensory disorders.

Hemorrhage

The inferior alveolar, masseter or maxillary arteries are at risk during surgery. Retromandibular veins may also be injured. Severe hemorrhage, as reported in earlier times, is rare today[51] because of better instruments (Bauer retractor) that help to protect soft tissue.

Bleeding is treated by ligation of the injured artery; venous bleeding is treated by the use of local anesthesia and/or packing.

Injury to Soft Tissue

Soft tissue injuries may occasionally occur during the osteotomy. Prime among these is injury to the lips due to rotating instruments or the saw. The lips are especially vulnerable when splitting is performed at the inferior edge of the mandible with the shank of the burr or saw blade.

Injury to muscles on the inner side of the ascending mandibular ramus due to rotating instruments may occur during osteotomy when the saw or the rotating instruments are not moved correctly along the bone. Most of all, it should be ensured that the ascending mandibular ramus in the posterior aspect is inclined outward. Therefore, the saw or the rotating instrument should be moved from the inner frontal aspect to the outer posterior aspect.

Early Postoperative Complications

Early Postoperative Sequelae

Pain, nausea and vomiting, limited range of motion, and social and functional impairment are common sequelae of orthognathic surgery. Most patients experience a certain degree of postoperative swelling and edema. Bruising and temporary neurosensory alterations are also common, occurring to a greater or lesser degree in nearly all patients after SSO. The severity of swelling and hematoma depend on the duration of the surgical procedure, the degree of surgical trauma, the quantity of intravenous fluids, postoperative medication, the patient's personal condition, and predisposing risk factors.

Postoperative Nausea and Vomiting

This is the most common postoperative complication after general anesthesia and usually occurs within 24 hours after surgery. Silva et al.[52] investigated 553 patients postoperatively and noted the following major predictive factors: female gender, young age, non-smokers, and the presence of predisposing factors (e.g., prior history of motion sickness, vertigo, or migraine headaches). This was confirmed by Grabowska-Gawel et al.,[53] who reviewed 253 patients who had undergone different types of surgery under general anesthesia. The authors also registered a correlation between postoperative nausea and vomiting and obesity, and patients anesthetized by younger or less experienced anesthetists.

Despite the Consensus Guidelines for the management of postoperative nausea and vomiting that were introduced in 2003, 2007, and 2014,[54] the authors of a recent publication registered "no substantial decrease in postoperative nausea and vomiting while reviewing the literature."[55] Investigating 204 patients undergoing orthognathic surgery, the authors found the female gender, a larger quantity of intravenous fluid, and the use of nitrous oxide to be risk factors for postoperative nausea. Postoperative vomiting was more common in patients who had undergone additional procedures and received morphine. The administration of antiemetic drugs that act at different receptor sites has been considered more effective than single drugs.[56] Additionally, in high-risk patients the best results were achieved by avoiding volatile anesthetics.[57]

In a report published by Brookes[58] in 2015, a multimodal protocol was used in patients undergoing Le Fort I osteotomy. The authors observed no significant reduction of postdischarge nausea and vomiting compared to patients who were not treated in accordance with this protocol. Immediate post operative nausea and vomiting were significantly reduced.

Airway Obstruction

Airway obstruction is rare in mandibular surgery and might be a consequence of severe bleeding.[59] The sublingual artery, which runs close to the periosteum at the symphysis, could be damaged on the inner side of the ascending ramus of the mandible.

Edema

Edema is the result of an inflammatory process after surgery. In most cases it is not hazardous, but is nevertheless distressing for the patient (Figure 17-20). Edema is usually not correlated with the duration of the surgical procedure or the complexity of surgery. In a prospective investigation in 2014, Madelon van der Vlis et al.[60] found that 50% of the swelling resolved within 3 weeks after surgery. Only 20% of the initial swelling remained after 3 months. The volume of initial swelling was correlated with BMI, but the statistical power was limited by sample size. A high BMI was associated with the greatest severity of swelling and the fastest resolution rate in the initial weeks after surgery while a low BMI was associated with less swelling that resolved at a slower rate.

Edema is a temporary condition and best treated with a head bandage, ice packs, corticosteroids, nonsteroidal anti-inflammatory agents, and physical therapy (Figure 17-21).

Bruising

Bruising as a consequence of surgery is caused by the metabolic breakdown of blood into fascia spaces. It can be fairly extensive and may migrate along the interconnecting fascia planes along the neck down to the chest. It is only a cosmetic nuisance and resolves usually within 2 weeks (Figure 17-22).

Limited Range of Motion

A limited range of motion immediately after surgery results from the alteration of the condyle and soft tissue. The limitation is temporary. Most patients regain their normal mouth opening within 6 months. In some patients, physical therapy may be indicated to accelerate the process.

Temporary *neurosensory deficit* is a common concomitant symptom of all bilateral sagittal split osteotomies. The gums, the lips, and the skin below the lips down to the chin may be affected by this condition.

Infection

The incidence of infection with orthognathic surgery is reported to range from 3.4% to 60% in the published literature. Wound dehiscence and/or infection are now rare complications and usually are related to poor oral hygiene. Tobacco smoking appears to be an additional risk factor. Contributing factors are long operating times, the patient's age, the presence of foreign bodies, sequester formation after bone fracture, or hematoma. The use of prophylactic antibiotics during and after surgery has substantially reduced the risk of infection. No consensus has been achieved yet in regard to dosage or the type of antibiotics. Long-term dosing appears to reduce the risk of infection after surgery compared to short-term dosage.[5] In a study by Bouchard[61] in which 336 patients were investigated, infections were registered in 11.3%. The majority of these were minor wound infections that could be treated with antibiotics. Fixation materials were removed in 3% of the patients. One patient experienced non-union and required a bone graft for reconstruction and six patients had bone sequestrations that were removed. All patients were treated with antibiotics and corticosteroids. The authors did not mention whether splints were used during and after surgery.

A few cases of actinomycosis infection have been reported.[62] Surgery is known to be a predisposing factor for cervicofacial actinomycosis. The use of antibiotics leads to resolution of the infection within a few months.

Flawless oral hygiene is a prerequisite to avoid infection, and is initiated preoperatively by patients undergoing



• **Figure 17-20** Postoperative swelling.



• **Figure 17-21** Head bandage.



• **Figure 17-22** Severe postoperative hematoma.

orthognathic surgery. However, swelling and anxiety may impair the patient's post-surgical oral hygiene. Postoperative controls at close intervals are therefore mandatory. Because the patient's occlusion at this stage is not the desired final result, the patient must wear a surgical splint to maintain the correct maxilla-mandible relationship. Without the splint this may cause loosening of the osteosynthesis material and subsequent "traumatic" infection. Another error-prone step is wound closure. When the wound margins do not close adequately, food debris or bacteria may enter the wound, which will then not close at the respective site. Smoking also influences wound healing and should be entirely stopped at least perioperatively. Additionally, antibiotics for 4 days (2 × 1 g penicillin) postoperatively are administered.

Late Postoperative Complications

Neurosensory Disturbance (NSD)

Postoperative neurosensory disturbance of the lower lip and the chin is a common consequence of orthognathic surgery and a major concern in mandibular osteotomy. It is the most commonly reported complication in mandibular surgery, with incidence rates of 9% to 85%.[28] D'Agostino et al.[63] registered long-term NSD rates of 10% to 30%.

Many factors may cause NSD, including the patient's age, the magnitude of movement, the surgeon's skill and experience, the degree of nerve manipulation, and direct injury to the nerve.

Types of Sensory Nerve Impairment

Paresthesia is marked by abnormal sensation. The symptoms include tingling, burning, prickling, itching, and even partial numbness. *Dysesthesia* includes exaggerated amplified responses to a noxious stimulus (hyperalgesia) and/or pain which can be triggered by stimuli such as a light touch (allodynia). *Anesthesia* is marked by the total absence of sensation to all forms of stimuli.

A NSD is generally considered to be caused by mechanical damage to the IAN (open injuries), such as compression, a tear, or a cut due to surgical instruments. Even when the IAN is not visibly traumatized during surgery, a postoperative neurosensory deficit may occur (closed injury.) This may be caused by edema, hematoma, or direct damage to cancellous bone fragments after stabilization or incorrect placement of screws.

Types of Nerve Injuries

Neuropraxia, the mildest form of injury, is caused by a temporary interruption of nerve conduction without axonal discontinuity. It is mainly produced by simple concussion without anatomic disruption and axonal degeneration. Neuropraxia is usually marked by temporary numbness or paralysis, followed by complete recovery within a time. No surgical repair is necessary.

Axonotmesis is caused by the interruption of some axons due to a traumatic injury and prolonged conduction failure. The injury is usually induced by a severe crush, contusion, or stretching of the nerve. Initial symptoms of the recovery of sensation, such as tingling, burning, itching or hypersensitivity, do not start until 6 to 8 weeks after the injury. The final recovery of sensation is frequently less than normal and takes several weeks or even years. Surgical repair is required within 6 to 9 months after the injury to restore good nerve function.

Neurotmesis is complete severance or internal physiologic disruption of the entire nerve. The consequence is permanent loss of conduction of sensory impulses. All nerve tissue distal to the nerve injury undergoes degeneration and is replaced by scar tissue. Recovery of sensation is not achieved when surgical repair of the nerve is not performed promptly. The result is permanent anesthesia and occasionally a painful sensation. When total anesthesia persists for longer than 3 months after the nerve injury, surgical repair should be performed within 3 to 6 months—before the distal axonal tubes start to degenerate and the process of axonal tubular atrophy becomes irreversible.[64]

Inferior Alveolar Nerve

Patients might experience varying degrees of trigeminal sensory deficits for 6 months or longer. Immediately after surgery the prevalence ranges from 12% to 100%. Long-term follow-up investigations have shown sensory alteration in 0% to 85% of patients 1 or 2 years after BSSO. However, this depended to a great extent on the methods used to test the neurosensory disturbance and the presence of additional genioplasty.[65] It also reflects variations in the number of persons investigated in the study groups.

Significant sensory deficits such as numbness, pain, burning, tingling, or hyposensitivity may affect the lips or the chin after injury to the IAN. Lip biting during mastication or difficulty in eating, brushing teeth, speaking, shaving, or kissing are distressing for the patient.

This complication depends on several predisposing factors, such as the patient's age, the surgeon's skill, the magnitude of mandibular movement, and additional genioplasty.[66] Patients seem to adapt to mild sensory deficits and report sensory function as normal despite slightly altered sensation objectively. Long-term sensory loss is rare because recovery of sensation usually occurs during follow-up. After 1 year most patients report to their pre-surgical level of sensation.

The duration and quality of neuropathy is mainly related to the severity of trauma. Seddon's classification is helpful in diagnosing and establishing the prognosis of nerve injuries.[64]

Injury to the peripheral branches of the mandibular nerve during osteotomy may cause prolonged or permanent sensory impairment.

A prolonged neurosensory disturbance is strongly related to age[67] and the degree of manipulation of the IAN during surgery. Any laceration or damage to the sensory fibers of the IAN may cause a postoperative neurosensory disturbance of the lower lip and chin.

Nerve injuries are clinically described as "open" or "closed." Open injuries are those observed by the surgeon when they occur. Unintentional severance of the inferior alveolar nerve may occur during sagittal split osteotomy.

Immediate primary repair by suturing the nerve ensures the best result.

Closed injuries are not seen at the time of their occurrence (laceration of nerves by cancellous bone fragments, osteosynthesis screws or blunt trauma during sagittal splitting of the contralateral side), and may or may not be suspected. Closed injuries should be followed by repeated examinations every 4 weeks. If the patient experiences an unacceptable loss of sensation or a painful or unpleasant sensation, microsurgical repair is the only means of restoring the sensation of the nerve. Vitamin B and stimulation of the affected skin in accordance with a protocol may also be helpful.

The estimated prognosis of recovery is 96% within 2 months; the rate is higher in younger patients.[68] A greater incidence of paresthesia was observed in older patients and when additional genioplasty was performed.[69]

The long-term incidence of paresthesia ranges between 0% and 20%. The risk of sensory deficit is higher when genioplasty is combined with sagittal split osteotomy.[21]

Lingual Nerve

A transient disturbance of the lingual nerve may occur in some cases. Its incidence varies, but is reported to be as high as 19%.[29] However, the high percentages were noted in studies based on patient questionnaires.

A disturbance of the lingual nerve usually resolves spontaneously, but persistent anesthesia was noted in older reports.[70]

Facial Nerve

Impairment of the facial nerve is rare, but constitutes a devastating complication for the patient. Its incidence is less than 1% in BSSO and was reported only in setback procedures. The prognosis of facial nerve impairment is good in cases of partial loss of function, but poor in complete loss of function.[32]

TMJ Arthropathy

TMJ dysfunction such as joint noise (clicking) or pain is a relatively common condition in the general population; its incidence is 20% to 25%.[71] The prevalence of TMJ dysfunction in patients with a dentofacial deformity is approximately the same as it is in the rest of the population.[72] The reported frequency is 20% to 50%.[73] The most frequent symptoms are pain and clicking. Malocclusion is regarded as one cause of TMJ dysfunction in the general population.[71] Earlier reports mention preoperative TMJ dysfunction in as many as 41% of patients.[74] In most studies, TMJ dysfunction was found to be improved after orthognathic surgery; worsening of symptoms was noted in a small percentage.

The position of the mandibular condyle is almost always changed during mandibular surgery. This is most likely due to a certain degree of rotation around and across the condylar axis. However, there are no data to show that this influences the development of post-surgical TMJ dysfunction. All patients develop some limitation of mouth opening after surgery. This is partly due to muscle stripping during surgery and soft tissue edema after surgery. However, there might also be some limitation due to condyle displacement during surgery and condylar adaptation post-surgery. This short-term effect does not imply long-term dysfunction. Remodeling of the condyle is very likely to occur in the post-surgical period and patients usually regain their presurgical function some months after surgery.

Displacement of the Condyle

Postoperative displacement of the condyle may occur in the anteroposterior or the vertical plane, or due to rotation. The resulting condylar torque induces a clinically apparent midline shift post-surgery, which is occasionally painful. Anteroposterior or vertical malposition of the condyle leads to occlusal changes postoperatively. Clinically this is manifested as immediate skeletal relapse after surgery. Hypomobility is another sign, indicative of lateral or medial condylar displacement.

Failure to seat the proximal segments properly into the fossa during surgery will result in condylar displacement. This is the main reason for TMJ symptoms after BSSO in patients without symptoms prior to surgery. Condylar resorption has been described as a consequence of such malposition.[75]

In a prospective investigation of 27 patients, Franco et al.[76] noted displacement in 21%. Displacement occurred twice as often on the right side as on the left side after mandibular advancement 1 to 3 years post-surgery.

The preoperative management of existing TMJ dysfunction is controversial. Some authors suggest that TMJ derangement should be corrected prior to surgery, failing which the symptoms could worsen or even lead to condylar resorption.[77] Others found that orthognathic surgery alone establishes skeletal and occlusal harmony, and leads to the resolution of TMJ symptoms, which then improve without intervention.[78,79] We suggest orthodontic splint therapy in patients with preexisting pain before undergoing BSSO. Conservative manual reduction of a displaced disc during surgery is routinely performed.

Resorption of the Condyle

Condylar resorption rates of 1% to 31% have been reported in the published literature.[80] Skeletal predisposing factors for condylar resorption include a high mandibular plane angle, a condyle with posterior inclination, or a low posterior-to-anterior face height ratio.[81] Contributing surgical factors include counterclockwise rotation of the proximal segment, preoperative TMJ dysfunction, or vascular necrosis of the condyle as a consequence of traumatic stress during surgery.[82] Proper positioning of the proximal segment into the fossa after splitting the mandible is of utmost importance to avoid postoperative TMJ problems, including condylar resorption.

Relapse

The stability and predictability of orthognathic surgery have improved due to the evolution of surgical techniques and

instrumentation. Relapse rates differ in the published literature and seem to be highly dependent on the presurgical diagnosis. Relapse is a multifactorial problem and must be addressed individually. Proper diagnosis, adequate treatment planning, and the correct surgical technique and its skillful application are incumbent upon the surgeon. Soft tissue and muscle tension and orofacial habits influence postoperative stability. Additional factors that influence relapse are the type of fixation,[83] the magnitude and type of mandibular movement, the position of the proximal segment, and disc displacement.

In a study addressing the influence of the type of fixation, no difference in stability was noted when rigid or wire fixation was used in a sample of 120 patients.[84] Other authors have registered greater stability when using rigid internal fixation[66,85] and when the patient's anterior face height was maintained or increased (clockwise rotation).[72] Recent publications showed no difference in stability when absorbable screws were used.[86]

Contradictory results have been published on the risk of relapse in relation to the type and magnitude of mandibular movement. Reports on isolated mandibular setback are rare, with relapse rates ranging from 7.1% to 51.4%. In mandibular prognathism, the majority of authors mention the magnitude of surgical setback, especially in growing individuals, as the most important factor affecting long-term stability. In a review, Costa et al. noted a relapse rate of 33%.[87] Many authors consider the magnitude of setback and clockwise rotation to be the main reason for relapse.[88] The inclination of the ramus also appears to influence stability.[72]

Immediate relapse occurs in patients undergoing mandibular advancement, with functional TMJ problems based on disc displacement, when the disc was not repositioned prior to surgery. During the surgical procedure it is then impossible to place the condyle correctly into the fossa. After surgery the anteriorly displaced disc slips back into the fossa because of complete relaxation of the muscles and the absence of chewing. Condylar displacement appears to be another reason for immediate relapse. As the condyle is forced too far posterior into the fossa, immediate relapse occurs. The condyle may also be distracted or malpositioned relative to the glenoid fossa. Postoperatively the condyle settles back into the glenoid fossa, which results in unsatisfactory occlusion.[1]

Several authors have reported on the use of positioning devices to secure the condyle in proper position during BSSO. However, positioning devices do not seem to improve the functional or morphologic outcome of the TMJ after BSSO. Full mobilization of the distal segment and removal of all obstructive bone fragments are crucial to enable free and passive positioning of the bone segments.

Long-term relapses in mandibular deficiency are most frequent in cases of large mandibular advancement (greater than 6 mm) and in nongrowing patients.[83] Some authors established a correlation between relapse and counterclockwise rotation.[72]

Rare Complications

A few rare complications after BSSO have been reported in the published literature, mainly in case reports. These are either local complications due to the surgical procedure and the technique itself, or systemic medical problems after surgery[6] (Box17-1).

Screw loosening immediately after surgery necessitates reoperation; the estimated incidence is 2%.[89] Yoshioka et al.[90] compared the incidence of material-related complications when using different fixation devices. The authors registered breakage in 8.2% when using biodegradable miniplates compared to 3.3% when using titanium miniplates.

Reintubation after soft tissue swelling and hemorrhage compromising the airway are rare in mandibular surgery.

Steroid acne reaction[91] has been reported occasionally. In all cases it resolved after a few months without treatment.

• Box 17-1 Rare Complications in Orthognathic Surgery

Injury to cranial nerves II, III, IV, V, VI, VII, VIII, X, XI, and XII
- Ophthalmoplegia
- Neurosensory deafness
- Secretomotor rhinopathy
- Frey syndrome
- Altered tear secretion
- Haemolacria
- Blindness
- Adie pupil

Surgical ciliated cyst
Traumatic neuroma
Dysphagia
Compartment syndrome
Severe eustachian tube malfunction
Cerebrospinal fluid leak
Cerebrovascular accident (stroke, subarachnoid hemorrhage)
Retrobulbar hemorrhage
Severe hemorrhage
Arteriovenous fistula/false aneurysm/carotid-cavernous sinus fistula
Cavernous sinus thrombosis
Ischemic finger injury
Acute pulmonary edema/apnea
Pneumomediastinum/pneumothorax
Bone graft donor-site infection
Osteonecrosis of maxilla/mandible
Avulsion of maxilla
Condylar dislocation
Condylar resorption (progressive, idiopathic, condylar, atrophy)
Vomero-sphenoidal disarticulation
Perforated lateral nasal wall/septum
Oroantral/oronasal fistula
Brain abscess
Actinomycosis
Malignant hyperpyrexia/herniation of tube cuff/tube sectioning
Conversion disorder
Severe clinical depression
Loss of orthodontic bracket into airway
Death

Steel BJ, Cope MR: Unusual and rare complications of orthognathic surgery: a literature review, *J Oral Maxillofac Surg* 70:1678-1691, 2012.

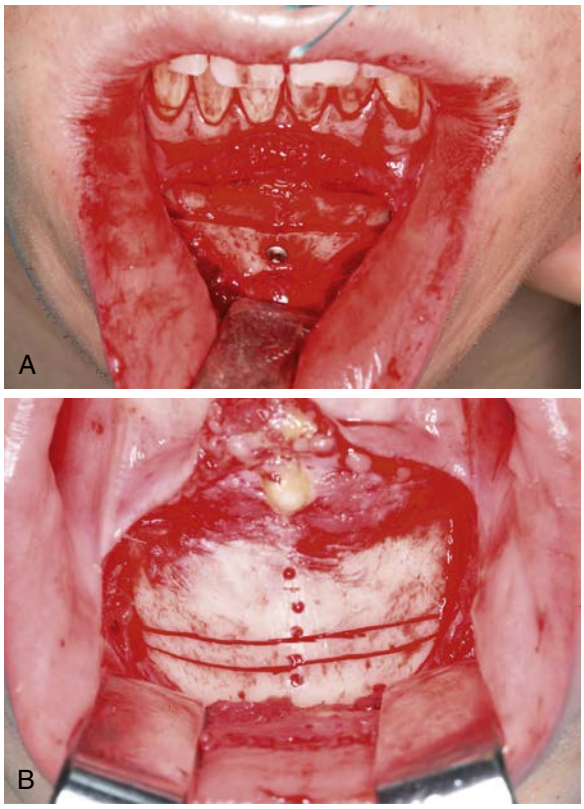

• **Figure 17-23** Genioplasty in two steps for advancement more than 6 mm.

A few rare serious complications such as VTE are causally related to SSO (see earlier).[11]

Genioplasty

Genioplasty can be performed either alone or in combination with other orthognathic procedures. It may alter form in the vertical, anteroposterior, or transverse dimension, and is a perfect tool to harmonize facial proportions. Complications are rare when the operation is performed correctly. Mandibular hypoplasia and chin hypoplasia may require genioplasty advancement more than 6 mm, which creates an unsatisfactory deep labiomental fold that gives an unharmonious appearance. In this case, two-step genioplasty is indicated (Figure 17-23).

Chin wing osteotomies (Figure 17-24) allow not only changes of chin position but also harmonize mandibular angle projection.[92,93] They are also successfully used in patients with obstructive sleep apnea[93] when conventional maxillomandibular advancement is not indicated. The procedure is very effective, simple and safe if it is performed correctly. Complications are rare; however, neurosensory deficit might occur because the inferior alveolar nerve is exposed during the procedure (Figure 17-25). To avoid osteonecrosis it is particularly important that the cut bone segment remains attached to soft tissues and is thick enough to keep its vascularity.



• **Figure 17-24** This patient with a perfect occlusion suffers from lip incompetence due to lower border deficiency and long face. Chin wing osteotomy is indicated to reduce anterior lower face height.

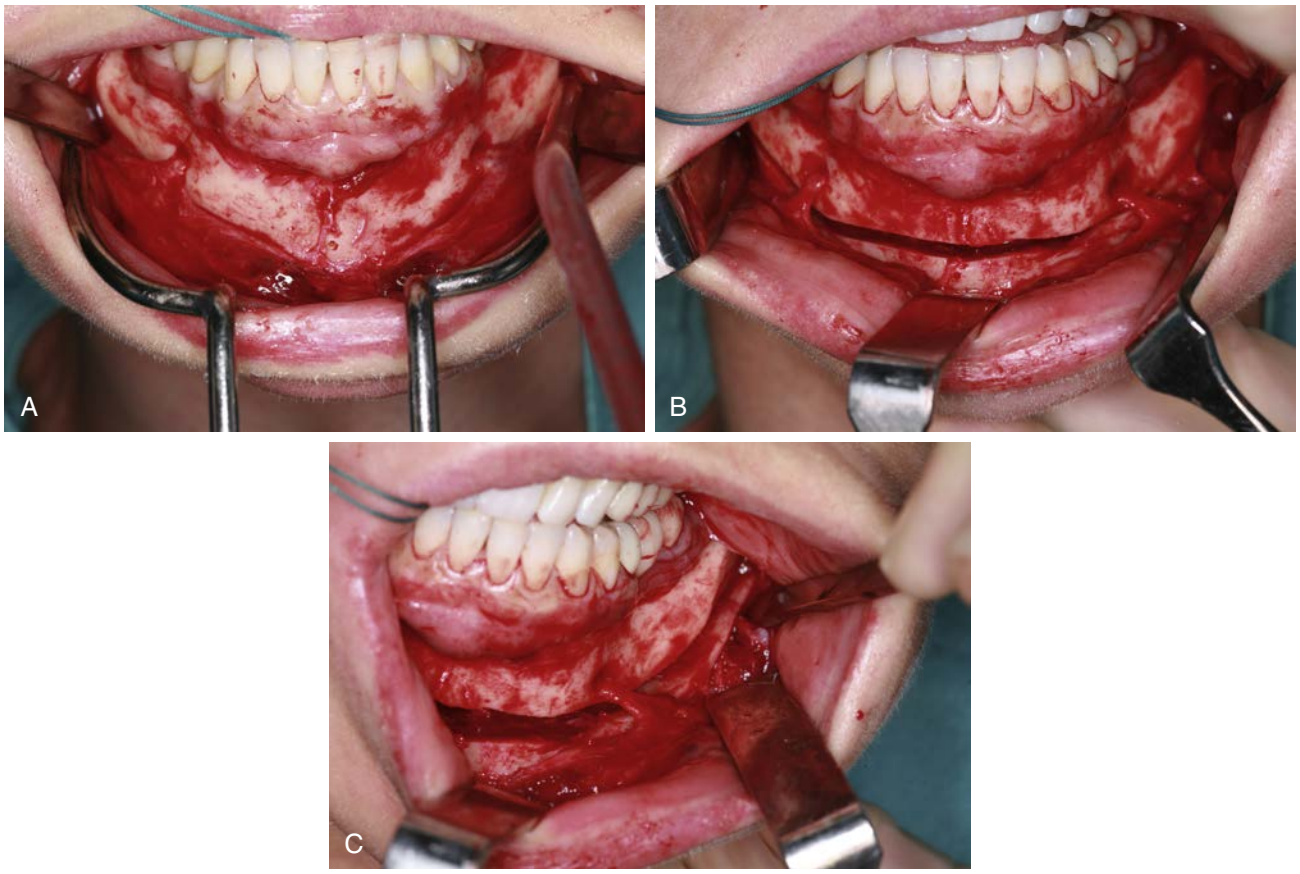

• **Figure 17-25** Chin wing osteotomy. **A,** Surgical procedure. **B,** When freeing the bone from periosteum, care is taken not to injure the nerve. **C,** The cut is set below the nerve canal and soft tissue stays attached for vascularization.



• **Figure 17-26** Soft tissue incision for genioplasty is placed well out in the facial mucosa. This prevents per secundam healing.

Failure of Wound Healing

Wound dehiscence may occur when the mucosal incision is placed close to the attached gingiva in the vestibule. The incision is an important step when performing genioplasty. It should be placed well out into the facial mucosa, in the lower lip (Figure 17-26). It starts anterior to the mental foramen and crosses high in the loose mucosa to the other side. The submucosal tissue is then dissected along and through the muscle, to the periosteum. This permits wound closure in layers, at a distance from the osteotomy and the vestibule, which are the regions prone to the stress from movement.

Neurosensory Disturbance

Damage to the neurovascular bundle is rare when care is taken during initial soft tissue dissection and bone cuts. When vertical height is reduced, it might be necessary to free the nerve out of the canal; this may cause a postoperative neurosensory deficit. When vertical height needs to be reduced significantly, a wide piece of bone must be removed. It may then be necessary to free the nerve out of the canal, which may impair nerve function.

A variety of treatment modalities have been suggested. "Wait and see" for up to 3 weeks is one strategy. The administration of vitamin B and stimulation of the affected skin in accordance with a protocol is a second strategy. Treatment with steroids after surgery has been found to improve this condition significantly compared to 27 patients who received no steroids.[95]

Loosening of Screw or Bone Plate

Bone displacement is a rare complication that can occur immediately after surgery. It is marked by loss of chin

projection and a "long face." Once identified, it must be corrected by the replacement of screws with a bone plate and screw stabilization (Figure 17-27).

Displacement of Synthetic Implants

Synthetic implants are rarely used by maxillofacial surgeons although their use has become an increasingly popular cosmetic procedure for chin retrusion and microgenia. Implants are usually placed in a pocket under the periosteum. They are usually not fixed with screws. Traumatic displacement or migration of chin implants may occur. Chin implant malposition is also a common complication and can occur in all spatial planes. Incongruous midline discrepancies are distressing for the patient. It is imperative to find the true midline and to correct the situation preferably by osteotomy (Figure 17-28).

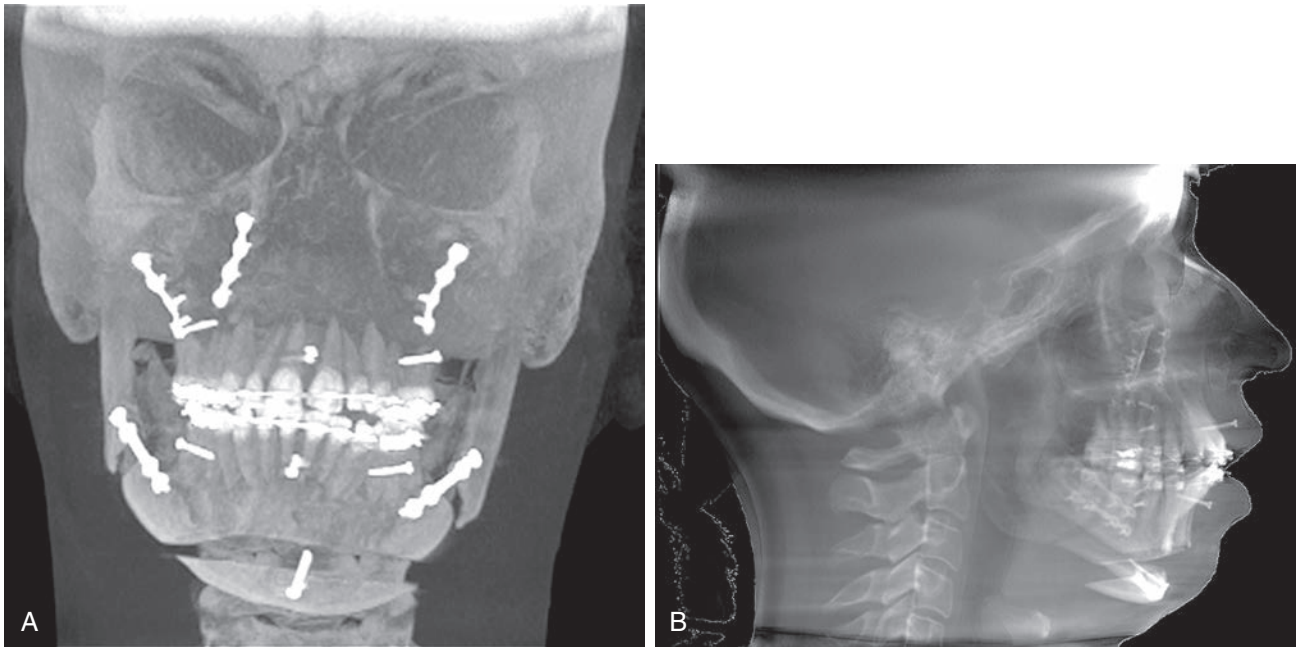

• **Figure 17-27** Genioplasty bone displacement after screw loosened.



• **Figure 17-28** **A-C,** Patient with asymmetry after chin implant. The implant was removed and followed by a conventional genioplasty.

Continued



• **Figure 17-28, cont'd** **D-E,** Symmetry and better chin projection was achieved.

References

1. Panula K, Finne K, Oikarinen K: Incidence of complications and problems related to orthognathic surgery: a review of 655 patients, *J Oral Maxillofac Surg* 59:1128–1136, 2001.
2. Watzke IM, Turvey TA, Phillips C, Proffit WR: Stability of mandibular advancement after sagittal osteotomy with screw or wire fixation: a comparative study, *J Oral Maxillofac Surg* 48(2):108–123, 1989.
3. Van de Perre JPA, Stoelinga PJW, Blijdorp PA, et al.: Perioperative study, *J Craniomaxillofac Surg* 24:263, 1996.
4. Ayoub AF, Lalani Z, Moos KF, et al.: Complications of orthognathic surgery that required early surgical intervention: Fifteen years' experience, *Int J Adult Orthodon Orthognath Surg* 16:138, 2001.
5. Chow LK, Singh B, Chiu WK, Samman N: Prevalence of postoperative complications after orthognathic surgery: a 15-year review, *J Oral Maxillofac Surg* 65:984–992, 2007.
6. Steel BJ, Cope MR: Unusual and rare complications of orthognathic surgery: a literature review, *J Oral Maxillofac Surg* 70:1678–1691, 2012.
7. Iannetti G, Fadda TM, Riccardi E, et al.: Our experience in complication of orthognathic surgery: a retrospective study on 3236 patients, *Eur Rev Med Pharmacol Sc* 17:379–384, 2013.
8. Christen AG, Christen JA: Why is cigarette smoking so addicting? An overview of smoking as a chemical and process addiction, *Health Values* 18:17–24, 1994.
9. Turan A, Mascha EJ, Roberman D, et al.: Smoking and perioperative outcomes, *Anesthesiol* 114:837, 2011.
10. Sorensen LT: Wound healing and infection in surgery: The clinical impact of smoking and smoking cessation: a systematic review and meta-analysis, *Arch Surg* 147:373, 2012.
11. Van de Perre JPA, Stoelinga PJ, Blijdorp PA, et al.: Perioperative morbidity in maxillofacial orthopaedic surgery: a retrospective study, *J Cran Maxillofac Surg* 24:263, 1996.
12. Blackburn TK, Pritchard K, Richardson D: Symptomatic venous thromboembolism after orthognathic operations: an audit, *Br J Oral Maxillofacial Surg* 44(5):389–392, 2000.
13. Forouzanfar T, Heymans MW, van Schuilenburg A, et al.: Incidence of venous thromboembolism in oral and maxillofacial surgery: a retrospective analysis, *Int J Oral Maxillofacial Surg* 39(3):256–259, 2010.
14. Verlinden CR, Tuinzing DB, Forouzanfar T: Symptomatic venous thromboembolism in orthognathic surgery and distraction osteogenesis: a retrospective cohort study of 4127 patients, *Br J Oral Maxillofac Surg* 52(5):401–404, 2014.
15. Caprini JA, Arcelus JI, Hasty JH, et al.: Clinical assessment of venous thromboembolic risk in surgical patients, *Semin Thromb Hemost* 17(Suppl 3):304–312, 1991.
16. Gould MK, Garcia DA, Wren SM, et al.: Prevention of VTE in nonorthopedic surgical patients: antithrombotic therapy and prevention of thrombosis, 9th ed: American College of Chest Physicians Evidence-Based Clinical Practice Guidelines *Chest* 141 (2 Suppl):227–277, 2001.
17. Gateno J, Xia J, Teichgraeber JF, et al.: A new technique for the creation of a computerized composite skull model, *J Oral Maxillofac Surg* 61:222–227, 2003.
18. Swennen GR, Bart EL, Eulcer C, et al.: The use of a new 3D splint and double CT scan procedure to obtain an accurate anatomic virtual augmented model of the skull, *Int J Oral Maxillofac Surg* 36:146–152, 2007.
19. Zinser MJ, Sailer HE, Braumann B, et al.: A paradigm shift in orthognathic surgery? A comparison of navigation, computer-aided designed/computer-aided manufactured splints and classic intermaxillary splints to surgical transfer of virtual orthognathic planning, *J Oral and Maxillofac Surg* 71(12): e1–e21, 2013.
20. Handelman CS, Wang L, BeGole EA, et al.: Nonsurgical rapid maxillary expansion in adults: report on 47 cases using the Haas expander, *Angle Orthod* 70:129–144, 2000.

21. Al-Bishri A, Rosenquist J, Sunzel B: On neurosensory disturbance after sagittal split osteotomy, *J Oral Maxillofac Surg* 62(12):1472–1476, 2004.
22. Agbaje JO, Salem AS, Lambrichts I, et al.: Systematic review on the incidence of inferior alveolar nerve injury in bilateral sagittal split osteotomy and its assessment of neurosensory disturbances, *Int J Oral Maxillofac Surg* 44(4):447–451, 2015.
23. Monsoun L: Bilateral sagittal split osteotomy, *Semin Plast Surg* 27:145–148, 2013.
24. Smith MH, Lung EK: Nerve injuries after dental injection: a review of the literature, *J Can Dent Assoc* 72(6):559–564, 2006.
25. Yoshida T, Nagamine T, Kobayashi T, et al.: Impairment of the inferior alveolar nerve after sagittal split osteotomy, *J Cranio Maxillofac Surg* 6:271–277, 1989.
26. Hallikainen D, Iizuka T, Lindqvist C: Cross-sectional tomography in evaluation of patients undergoing sagittal split osteotomy, *J Oral Maxillofac Surg* 50:1269, 1992.
27. Yamauchi K, Takahashi T, Kaneuji T, et al.: Risk factors for neurosensory disturbance after bilateral sagittal split osteotomy based on position of mandibular canal and morphology of mandibular angle, *J Cranio Maxillofac Surg* 70:401–440, 2012.
28. Al-Bishri A, Barghash Z, Rosenquist J, et al.: Neurosensory disturbance after sagittal split and intra oral vertical osteotomy: as reported in questionnaires and patients' records, *Int Oral Maxillofac Surg* 34:247, 2005.
29. Jacks SC, Zuniga JR, Turvey TA, et al.: A retrospective anaysiss of lingual nerve sensory changes after mandibular bilateral sagittal split osteotomy, *J Oral Maxillofac Surg* 56:700, 1998.
30. Pogrel MA, Thamby S: Permanent nerve involvement resulting from inferior alveolar nerve blocks, *J Am Dent Assoc* 131(7):901–907, 2000.
31. De Vries K, Devriese P, et al.: Facial palsy after sagittal split osteotomies: a survey of 1747 sagittal split osteotomies, *J Cranio Maxillofac Surg* 21:50–53, 1993.
32. Jones JK, Van Sickels J: Facial nerve injuries associated with orthognathic surgery: a review of incidence and management, *J Cranio Maxillofac Surg* 49:740–744, 1991.
33. Taher AA: Tuberculosis of the parotid salivary gland—case report, *Br J Oral Maxillofac Surg* 26(6):514–516, 1988.
34. Tamás F: Position of the mandibular canal, *Int J Oral Maxillofac Surg* 16:65–69, 1987.
35. Lupori JP, Kewitt GF, Van Sickels JE: Bilateral sagittal split osteotomy advancement and setback. In Fonseca RJ, editor: *Oral and maxillofacial surgery*, St Louis, 2000, Saunders, pp 297–310.
36. Schwartz HC: The timing of third molar removal in patients undergoing a bilateral sagittal split osteotomy, *J Oral Maxillofac Surg* 60(1):132–133, 2002.
37. Tucker MR: Orthognathic surgery versus orthodonic camouflage in the treatment of mandibular deficiency, *J Oral Maxillofac Surg* 53:572, 1995.
38. Precious DS: Removal of third molars with sagittal split osteotomies: the case for, *J Oral Maxillofac Surg* 62:1144–1146, 2004.
39. Marquez IM, Stella JP: Modification of sagittal split ramus osteotomy to avoid unfavorable fracture around impacted third molars, *Int J Adult Orthodon Orthognathic Surg* 13(3):183–187, 1998.
40. Strasser M, Bulla M, Watzke IM: Impaktierte Weisheitszähne als möglicher Risikofaktor bei der sagittalen Unterkieferspaltung. (Impacted third molars as a risk factor for SSO). Abstract 13, *Jahreskongress der ÖGMKG*, January 2009.
41. Epker BN, Le Banc JP: Orthognathic surgery: management of postoperative complications, *Oral Maxillofac Surg Clin North Am* 2:901, 1990.
42. Veras RB, Kriwalsky MS, Hoffmann S, et al.: Functional and radiographic long-term results after bad split in orthognathic surgery, *Int J Oral Maxillofac Surg* 37(7):606–611, 2008.
43. Behrmann SJ: Complications in orthognathic surgery, *J Oral Surg* 30(8):554–561, 1972.
44. Lanigan DT, Hey JH, West RA: Hemorrhage following mandibular osteotomies: a report of 21 cases, *J Oral Maxillofac Surg* 49:713, 1991.
45. Teltzrow T, Kramer FJ, Schulze A, et al.: Perioperative complications following sagittal split osteotomy of the mandible, *J Craniomaxillofac Surg* 33:307, 2005.
46. Foran M, Strickland F, Perkins K, Smith JA: Excessive intraoperative bleeding with chronic energy drink consumption, *J Oral Maxillofac Surg* 70(6):1439–1441, 2012.
47. Gerressen M, Zadeh DM, Stockbrink G, Riediger D, Ghassemi A: The functional long term result after bilateral split osteotomy with and without a condylar positioning device, *J Oral Maxillofac Surg* 64(11):1624–1630, 2006.
48. O´Ryan F, Silva A: Complications with orthognathics surgery. In Fonseca, Marciani, Turvey, editors: *Oral and maxillofacial surgery*, ed 2, vol. 3. St Louis, 2009, Saunders Elsevier.
49. Caldwell JB, Letterman GS: Vertical osteotomy in the mandibular rami for correction of prognathism, *J Oral Surg* 12(3):185–202, 1954.
50. Tuinzing DB, Greebe RB: Complications related to the intraoral vertical ramus osteotomy, *Int J Oral Surg* 14(4):319–324, 1985.
51. Ueki K, Marukawa K, Shimada M, et al.: The assessment of blood loss in orthognathic surgery for prognathia, *J Oral Maxillofac Surg* 63(3):350–354, 2005.
52. Silva AC, O'Ryan F, Poor DB: Postoperative nausea and vomiting (PONV) after orthognathic surgery: a retrospective study and literature review, *J Oral Maxillofac Surg* 64(9):1385–1397, 2006.
53. Grabowska-Gawel A, Porzych K, Piskunowicz G: Risk factors and frequency of postoperative nausea and vomiting in patients operated under general nausea, *Przegl Lek* 63(2):72–76, 2006.
54. Gan TJ, Diemunsch P, Habib AS, et al.: Consensus guidelines for the management of postoperative nausea and vomiting, *Anaesth Analg* 118(1):85–113, 2014.
55. Phillips C, Brookers CD, Rich J, et al.: Postoperative nausea and vomiting following orthognathic surgery, *Int J Oral Maxillofacial Surg* 44(6):745–751, 2015.
56. Habib AS, Gan TJ: Combination therapy for postoperative nausea and vomiting—a more effective prophylaxis? *Amb Surg* 9(2):79–91, 2001.
57. Apfel CC, Kranke P, Eberhart LH: Comparison of surgical site and patient's history with a simplified risk score for the prediction of postoperative nausea and vomiting, *Anaesthesia* 59(11):1078–1082, 2004.
58. Brookes CD, Turvey TA, Phillips V, et al.: Post-discharge nausea and vomiting remains frequent after le Fort I osteotomy despite implementation of a multimodal antiemetic protocol effective in reducing post-operative nausea and vomiting, *J Oral Maxillofac Surg* 72(9):e146–147, 2014.
59. Darriba MA, Mendonça-Caridad JJ: Profuse bleeding and life-threatening airway obstruction after placement of mandibular dental implants, *J Oral Maxillofac Surg* 55(11):1328–1330, 1997.
60. Madelon van der Vlis, Dentino KM, Vervloet B, Padwa BL: Postoperative swelling after orthognathic surgery: a prospective volumetric analysis, *J Oral Maxillofacial Surg* 72(11):2241–2247, 2014.

61. Bouchard C, Lalancette M: Infections after sagittal split osteotomy: a retrospective analysis of 336 patients, *J Oral Maxillofac Surg* 73(1):158–161, 2015.
62. Maurer P, Otto C, Eckert AW: Actinomycosis as a rare complication of orthognathic surgery, *Int J Adult Orthodon Orthognath Surg* 17(3):230–233, 2002.
63. D'Agostino A, Trevisiol L, Gugole F, et al.: Complications of orthognathic surgery: inferior alveolar nerve, *J Craniofac Surg* 21(4):1189–1195, 2010.
64. Seddon HJ: Three types of nerve injury, *Brain* 66:237–288, 1943.
65. Gianni AB, D'Òrtho O, Bigloili F, et al.: Neurosensory alterations of the inferior alveolar and mental nerve after genioplasty alone or associated with sagittal osteotomy of the mandibular ramus, *J Cranio Maxillofac Surg* 30(5):295–303, 2002.
66. Van Sickels JE, Richardson DA: Stability of orthognathic surgery: a review of rigid fixation, *Br J Oral Maxillofac Surg* 34:279–285, 1996.
67. Baas EM, Horsthuis RB, de Lange J: Subjective alveolar nerve function after sagittal split osteotomy, *J Oral Maxillofac Surg* 70(4):910–918, 2012.
68. Gregg JM: Surgical management of inferior alveolar nerve injuries (part 11): the case for delayed management, *J Oral Maxillofac Surg* 53:1330–1333, 1995.
69. Acebal-Bianco F, Vuylsteke PL, Mommaerts MY, De Clercq CA: Perioperative complications in corrective facial orthopedic surgery: a 5-year retrospective study, *J Oral Maxillofac Surg* 58(7):754, 2000.
70. Pepersack WJ, Chausse JM: Long term follow up of the sagittal splitting technique for correction of mandibular prognathism, *J Maxillofac Surg* 6:117–140, 1978.
71. Thilander B, Rubio G, Pena L, de Mayorga C: Prevalence of temporomandibular dysfunction and its association with malocclusion in children and adolescents: an epidemiologic study related to specific stages of dental development, *Angle Orthodont* 72(2):146–154, 2002.
72. Proffit WR, Turvey TAT, Phillips C: Orthognathic surgery: a hierarchy of stability, *Int J Adult Orthodon Orthognath Surg* 11(3):191–204, 1996.
73. Ow A, Cheung LK: Skeletal stability and complications of bilateral sagittal split osteotomies and mandibular distraction osteogenesis: an evidence based review, *J Oral Maxillofac Surg* 67(11):2344–2353, 2009.
74. Karabouta I, Martis C: The TMJ dysfunction syndrome before and after sagittal split osteotomy of the rami, *J Maxillofac Surg* 13:185–188, 1985.
75. Kobayashi T, Izumi N, Kojima T, et al.: Progressive condylar resorption after mandibular advancement, *Br J Oral Maxillofac Surg* 50(2):176–180, 2012.
76. Franco A, Cevidanes LHS, Phillips C, et al.: Long-term three-dimensional stability of mandibular advancement surgery, *J Oral Maxillofac Surg* 71(9):1588–1597, 2013.
77. Wolford LM, Karras S, Mehra P: Concomitant temporomandibular joint and orthognathic surgery: a preliminary report, *J Oral Maxillofac Surg* 60:356–362, 2002.
78. Goldstein BH: Temporomandibular disorders: a review of current understanding, *Oral Surg Oral Med Oral Path Oral Radiol Endod* 88:379, 1999.
79. Onizawa K, Schmelzeisen R, Vogt S: Alteration of temporomandibular joint symptoms after orthognathic surgery: comparison with healthy volunteers, *J Oral Maxillofac Surg* 53:117, 1995.
80. DeClercq CA, Neyt LF, Mommaerts MY, et al.: Condylar resorption after bicortical screw fixation of mandibular advancements, *J Oral Maxillofac Surg* 56:178–182, 1998.
81. Hwang S-J, Haers PE, Sailer HF: The role of posteriorly inclined condylar neck in condylar resorption after orthognathic surgery, *J Craniomaxillofac Surg* 28:85–90, 2000.
82. Cutbirth M, Van Sickels JE, Thrash WJ: Condylar resorption after bicortical screw fixation of mandibular advancement, *J Oral Maxillofac Surg* 56:178–182, 1998.
83. Borstlap WA, Stoelinga PJW, Hoppenreijs TJM, et al.: Stabilisation of saggital split advancement osteotomies with miniplates: a prospective multicenter study with two-year follow-up: Part III—condylar remodeling and resorption, *Int Oral Maxillofac Surg* 33:649, 2004.
84. Watzke IM, Turvey TA, Phillips C, Proffit WR: Stability of mandibular advancement after sagittal osteotomy with screw or wire fixation: a comparative study, *J Oral Maxillofacial Surg* 48(2):108–121, 1990.
85. Dolce C, Hatch JP, Van Sickels JE, Rugh JD: Rigid versus wire fixation for mandibular advancement: skeletal and dental changes after 5 years, *Am J Orthodontics Dentofacial Orthopaedics* 121:610–619, 2002.
86. Turvey TA, Bell B, Proffit WR: Self-reinforced biodegradable screw fixation compared with titanium screw fixation in mandibular advancement, *J Oral Maxillofacial Surg* 64(1):40–46, 2006.
87. Costa F, Robiony M, Politi M: Stability of sagittal split osteotomy used to correct class III malocclusion: review of the literature, *Int J Adult Orthod Orthognath Surg* 16:2, 2001.
88. Han JJ, Yanh HJ, Lee S-J, Hwang SJ: Relapse after SSRO for mandibular setback movement in relation to the amount of mandibular setback and intraoperative clockwise rotation on the proximal segment, *J Cranio Maxillofac Surg* 42(6):811–815, 2014.
89. Seo K, Tanaka T, Terumitsu M, Someya G: Efficacy of steroid treatment for sensory impairment after orthognathic surgery, *J Oral Maxillofac Surg* 62(10):1193–1197, 2004.
90. Yoshioka I, Igawa K, Nagata J, Yoshida M, et al.: Comparison of material-related complications after bilateral sagittal split mandibular setback surgery: biodegradable versus titanium miniplates, *J Oral and Maxillofac Surg* 70:919–924, 2012.
91. Precious DS, Hoffmann CD, Miller R: Steroid acne after orthognathic surgery, *Oral Surg Oral Med Oral Pathol* 74:279, 1992.
92. Sandner O, Garcia ME: Osteotomy of the mandibular border to improve the facial contour, *Plast Chir Oral Maxillofac Region* 24:91, 1979.
93. Triaca A, Minoretti R, Saulacic N: Mandibular wing osteotomy for correction of mandibular plane: a case report, *Br J Oral Maxillofacial Surg* 48(3):182–184, 2010.
94. Tabrici R, Pourdanesh F, Soleimanpour M, Shafie E: Evaluation of mandibular wing osteotomy in obstructive sleep apnea cases with retrognathia, *J Oral Maxillofac Surg* 14(1):46–50, 2015.
95. Seo K, Tanaka Y, Terumitsu M, Someya G: Efficacy of steroid treatment for sensory impairment after orthognathic surgery, *J Oral Maxillofac Surg* 62(10):1193–1197, 2004.

18 Rhytidectomy

ELDA L. FISHER

Introduction

For many years the face-lift or rhytidectomy has been the lynchpin of cosmetic surgery. In the early years of face-lift surgery, an elliptical portion of skin around the ears was excised and the skin margins were reapproximated to create a skin-only lift. Variations of this lift exist today. They vary from simple skin excision techniques coupled with thread lifts to deep plane sub-SMAS face-lift with complex vectors of pull. With so many options, the face-lift is still the most commonly performed cosmetic surgery on the face, second only to blepharoplasty.

The first reported face-lift was performed in 1901 by Eugene Hollander in Berlin. This was completed by excision of an elliptical incision of skin in the temporal region. Skin excision techniques were the mainstay of face-lift surgery until the 1970s, when Skoog introduced surgeons to the superficial musculoaponeurotic system (SMAS). This introduced surgeons to a deeper plane for face-lift dissection which was deep to the SMAS. Initially, dissections in this plane were limited anteriorly to the extent of the anterior aspect of the parotid capsule. Dissections that are limited to the anterior parotid, while still widely performed as technique today, do not fully address anterior cheek laxity. In the 1990s, advances in anatomic understanding of the distribution of the facial nerve allowed for further anterior dissection of deep to SMAS and platysma. These techniques included the composite flap face-lift (SMAS and skin en bloc dissection) and the two-plane face-lift (a skin flap and separate SMAS flap) allowed for increased mobility of the mid-face tissues and increased vectors of pull in the mid-face. The "high-SMAS" technique developed by Barton and the two-plane technique developed by Stuzin are deep-plane techniques that have allowed effacement of the nasolabial fold and jowls by various suspension techniques to address mid-face and lower face laxity.

Deep-plane variations of these face-lifts are still widely used and popular today; however, the newer variations that include less dissection with SMAS plication, lateral SMAS-ectomy, have become highly popular because they yield good outcomes for those with minimal to moderate anterior mid-face laxity, are technically easier to perform, and minimize risk to the facial nerve. In general, four generations of rhytidectomy have been described[25] (Table 18-1).

In 2014 there were 128,266 face-lifts performed in the United States, making it fifth overall in performed cosmetic surgical procedures. The majority of these face-lift procedures are superficial face-lifts or included a SMAS-ectomy or SMAS-plication. Interestingly, the overall rate of face-lift surgery in the United States has declined over the past 5 years. With the advent of more noninvasive facial rejuvenation procedures such as high viscosity facial fillers, many patients are opting for nonsurgical treatment.[1] The patient population seeking face-lifts has also changed over the years. Once a procedure that was essentially only performed on older women, it is now not infrequently performed on men and women from their early 40s and into their 90s. This demographic change in patients seeking a more youthful face has created an enormous boon in the facial cosmetic surgery industry, and has led to the advent of minimally invasive surgical techniques and nonsurgical adjuncts such as fillers, neurotoxins, and lasers, which are described in other chapters of this text.

Patient Evaluation

Evaluation of prospective patients for face-lift surgery considers three main areas: (1) medical history, (2) facial esthetic evaluation, and (3) psychosocial considerations. It is important that appropriateness for surgical intervention is considered in all three areas prior to the establishment of a surgical treatment plan. This will not only ensure the best possible outcomes for satisfaction of both the patient and surgeon, but will also optimize patient safety.

A thorough medical history is required prior to the planning of any surgery. This often begins with a history questionnaire that should detail any current or previous medical conditions and all prior surgical procedures. Any complications associated with previous surgical procedures are also noted, and include any peri-operative excess

TABLE 18-1 Generations of Rhytidectomy

	Generations of Rhytidectomy
I	Subcutaneous dissection only with variable skin undermining
II	Subcutaneous dissection with SMAS plication or imbrication
III	Subcutaneous dissection with SMAS plications or imbrication + deep mid-face dissection
IV	Composite dissection (Deep plane face-lift)

bleeding, postoperative infection, wound healing problems, and any complications that resulted in patient dissatisfaction with the procedure. The patient should have regular care from a primary care physician established, and the most recent history and physical exam should have been within the previous year. The patient's overall physical fitness for surgery is a combined medical assessment of the patient's overall physical condition, anesthetic risk, and ability to heal postoperatively. Appropriate consults should be obtained for patients with cardiovascular, pulmonary, renal, hematologic, or other systemic diseases that may affect surgical outcomes.

All medications, including over-the-counter medications and herbal supplements, should be listed and whether or not the patient is actually taking the medication should be noted. Anticoagulants are of particular concern, and include NSAIDs, herbal supplements such as ginseng and gingko biloba, and high dose vitamin E or fish oil. If possible, all anticoagulation should be suspended prior to surgery. Patients that require ongoing anticoagulation may need a short-term anticoagulant bridge such as low-molecular weight heparin so that anticoagulation can be stopped in the immediate perioperative phase only and resumed postoperatively.

Social history is also an important aspect of patient selection. Any history of smoking should be thoroughly investigated to rule out current smokers from elective cosmetic surgery. The rate of skin sloughing in smokers is almost three times the rate of nonsmokers (7.5% compared to 2.7%).[2] Use of illicit drugs such as cocaine, MDMA (3,4 Methylenedioxymethamphetamine), and other stimulants should also disqualify prospective candidates from elective cosmetic surgery because these drugs can compromise cardiovascular health and perhaps have secondary effects on flap microvasculature. Heroin or opioid abuse should also disqualify patients from elective surgical procedures, for obvious reasons. Heavy alcohol use should also be investigated, as this can compromise coagulation and nutritional status, leading to hematoma formation or poor healing potential respectively.

All past surgical history should be reviewed with the patient, including anesthetic history. The surgeon should have caution before proceeding with surgery if the previous surgeries include a laundry list of cosmetic surgical procedures, raising red flags for body dysmorphic disorder or a patient with unrealistic expectations for surgery. Anesthetic history may elicit a history of postoperative nausea and vomiting, which is undesirable for any surgical patient but particularly those patients who are immediately post-surgical from a face-lift. The anesthesiologist can usually tailor the anesthetic regimen to minimize postoperative nausea and vomiting in these patients.

A psychological history will give the surgeon an idea about the patient's motivations for surgery. Uncontrolled psychiatric conditions are a contraindication to elective cosmetic surgery. Body dysmorphic disorder should be considered in patients who have had repeated or a seemingly excessive number of cosmetic procedures performed.[3] Similarly any patient who has unrealistic expectations for surgery should not undergo cosmetic surgical procedures.

A physical examination of the patient should be performed that includes cardiovascular, pulmonary, gastrointestinal, and neurologic systems including a cranial nerve exam. Any previous surgical incisions should be examined for scarring tendencies. In addition to the surgeon's own physical exam findings, the surgeon may consider reviewing a recent history and physical exam from the patient's primary care physician to determine if the patient is optimized from a medical standpoint for surgery.

The examination of the face begins with excellent preoperative photographs. These should be taken with a black or blue background in unshaded light. Photos should include frontal face in repose and smiling, bilateral three-quarter views, bilateral lateral views, and posterior ear on each side. Isolated photos of the hairline, brows, eyes, and perioral regions should also be included. The hairline should be visible in all photos, therefore bangs need to be retracted with a headband, and lateral and posterior ear photos should also have all hair obscuring the hairline retracted.

Evaluation of the face should be addressed in a systematic manner. The face is typically divided into horizontal thirds and vertical fifths. The upper third includes the forehead, brows, and upper eyelids. These areas are not addressed with a face-lift. The middle third includes the nose and nasolabial folds, lower eyelids, and cheeks. Only the cheeks are addressed in this third. The nasolabial fold can be addressed with deeper-plane or extended face-lifts, and the patient should be aware that there may be minimal improvement in deep nasolabial folds with superficial plane face-lifts.[5-7] It should also be noted when assessing this area whether the patient is thick or thin skinned as this may affect the longer term surgical outcomes.[4] The lower face includes the lips and perioral region, the lower cheek and jowls, and neck. The face-lift procedure is the only procedure that addresses jowling. The neck is addressed with cervicoplasty with or without platysmaplasty, and this should be clear to the patient because there may be an expectation for neck laxity correction. Perioral rhytids are not addressed by either face-lift or cervicoplasty procedures, and this should be made clear to the patient because

this is a common area of complaint in the aging patient. Other important findings during facial evaluation include the hairline, skin color (Fitzpatrick scale), rhytids (Glogau scale), sun damage, scarring, and facial asymmetries. Special attention should be addressed to the earlobe as face-lift closure technique may affect its appearance; any deviation from normal lobe appearance preoperatively should be identified to the patient.

Because many patients desiring face-lift procedure also complain of neck laxity, the profile of the neck should be addressed and is easily characterized by the Dedo classifications system[26] (Table 18-2). Application of this classification system may help the surgeon plan the appropriate procedures for lower face improvement (Figure 18-1). Other factors to consider in the neck are the degree of skin redundancy, the degree of platysmal banding, cervicomental angle, hyoid position, and submental fat accumulation. A desirable cervicomental angle is 90 degrees. Patients with an inferiorly positioned hyoid bone that (below the 4th cervical vertebrae) necessarily have an obtuse cervicomental angle that is not corrected by cervicoplasty or plastysmaplasty.[2] Ptosis of the submandibular glands can also contribute to unfavorable neck appearance, which requires a separate submandibular gland suspension procedure in addition to conventional neck lifting procedures.[8,9]

The preoperative evaluation appointment should conclude with a presentation to the patient of all surgical procedures necessary for optimal facial esthetics, and the timing and anticipated costs of those procedures. Preoperative counseling should include a description of postoperative time for recuperation, pain management expectations, and anticipated postoperative swelling, bruising, and "downtime." Patients should be advised to avoid any products with nicotine, including e-cigarettes and nicotine gum and patches. Avoidance of blood thinning agents is also stressed, including avoidance of aspirin, NSAIDs, and fish oil for at least 2 weeks prior to surgery. Postoperative instructions should be reviewed in written and verbal form, and the patient should be able to verbalize understanding of all instructions.

It is important to remind the patient that postoperative bruising typically lasts for at least 2 weeks, and thereafter can usually be covered by make-up. Postoperative swelling can last for months, so the final outcome of the face-lift procedure may not be achieved until several months postoperatively. Additionally, the patient should be reminded that consistent postoperative follow-up is imperative.

TABLE 18-2 Dedo Classification of Facial Profiles

	Patient Profile	Surgeon
I	Normal	Well-defined cervicomental angle Good muscle tone No submental fat
II	Cervical skin laxity	Obtuse cervicomental angle due to relaxed skin
III	Submental fat accumulation	Requires submental lipectomy
IV	Platysma muscle banding	Requires muscle clipping, plication, or imbrication
V	Retrognathia or micrognathia	Requires genioplasty or orthognathic surgery
VI	Low hyoid	Difficult to alter Inform patient of limitations

Adapted from Dedo DD: "How I do it"—Plastic surgery: Practical suggestions on facial plastic surgery. A preoperative classification of the neck for cervicofacial rhytidectomy, *Laryngoscope* 90:1894–1896, 1980.

Anatomic Considerations

Vascular Anatomy

The anatomy of the arterial supply to the face and venous drainage in the area of face-lift dissection is significant, not only to avoid injury to the vessels, but also for consideration of flap viability postoperatively. From a surgical standpoint,

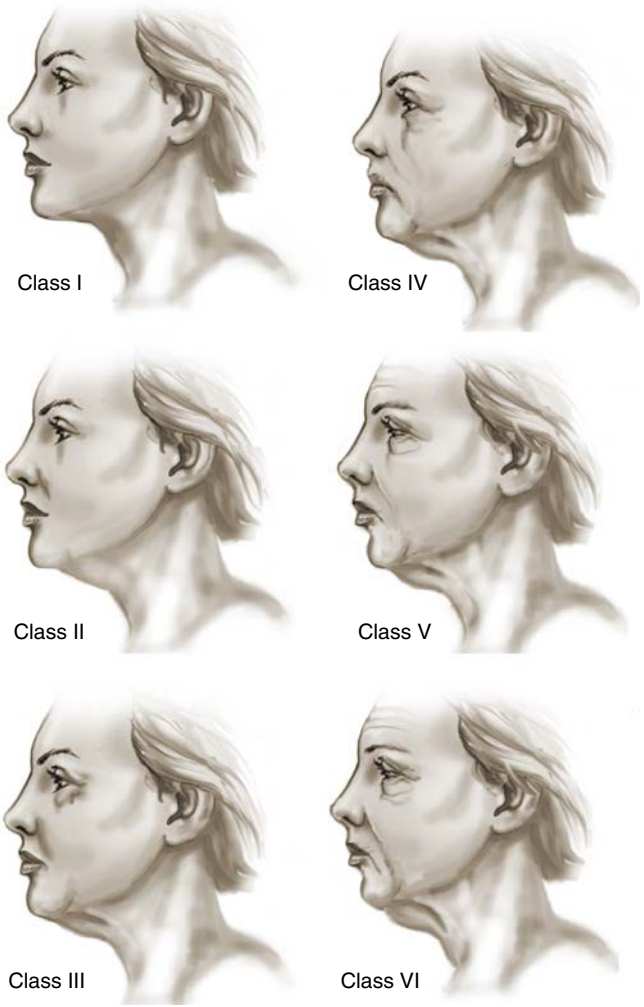

• **Figure 18-1** Six classes of facial neck profiles by Dedo.

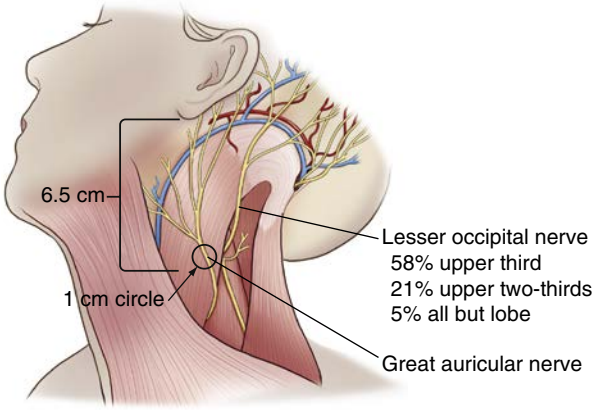

• **Figure 18-2** Marking of McKinney's point.

the most frequently encountered vessels in face-lift surgery are the external jugular vein and the transverse facial artery.

The internal jugular vein is encountered during the neck dissection that begins posterior to the ear and descends superficially above the sternocleidomastoid muscle. Prior to surgery, McKinnney's point is marked on the skin surface at 6.5 cm inferior to the bony external auditory meatus at the midpoint of the sternocleidomastoid muscle. McKinney's point marks the site of the greater auricular nerve as it crosses over the belly of the sternocleidomastoid muscle.[27] A 1-cm radius from this point is demarcated in all directions. The anterior portion of the resultant circle will identify the site of the jugular vein as it passes the anterior border of the sternocleidomastoid muscle (Figure 18-2). Upon dissection of the neck flap, care should be taken in the area to maintain a superficial plane to avoid injury to this vessel. If the vessel is injured, the surgeon will encounter significant bleeding. Proximal and distal ligation with silk suture is the appropriate treatment. Prior to closure, hemostasis in this area must be verified to avoid the accumulation of hematoma in the posterior auricular region and neck area.

The transverse facial artery is the most significant arterial contributor to the lateral face. The site of perforation of the transverse facial artery is marked preoperatively on the skin surface 2.5 cm lateral and 3 cm inferior to the lateral canthus of the eye. A circle with a 0.5 cm radius is marked around this point, creating a site of caution for the surgeon at this area of dissection. Disruption of the transverse facial artery may contribute to skin flap necrosis and hematoma formation.

Facial Nerve Anatomy

The facial nerve is the master of facial expression, and postoperative dysfunction is devastating to face-lift surgery. The facial nerve exits the stylomastoid foramen and travels between the digastric and stylohyoid muscles inferiorly and anteriorly into the substance of the parotid gland. The nerves travel in the fibrous tissue within the parotid gland that separates the deep and superficial lobes of the gland. The nerve splits into two major divisions, superior and inferior. The superior branch gives rise to the temporal and zygomatic branches, while the inferior division gives rise to the buccal branch, marginal mandibular branch, and cervical branch. Both divisions are important in face-lift surgery and caution to protect these branches is paramount to successful outcomes. The buccal and zygomatic branches are highly arborized medial to a vertical line drawn from the lateral canthus, and injury to these branches that results in paralysis of noticeable long-term injury is unlikely. The frontal and marginal mandibular branches are terminal and significantly less arborized, so careful dissection is crucial to avoid long-term injury resulting in permanent facial weakness or paralysis. Branches of the facial nerve innervate all of the muscles of facial expression, and typically from their deep surfaces, only three of the muscles of facial expression are innervated from the superficial surfaces: the buccinator, the mentalis, and the elevator anguli oris.

The facial muscles are enclosed by the SMAS below the zygomatic or the temporoparietal fascia above the level of the zygoma. In the lower face the facial nerve courses deep to the platysma except where it innervates the buccinator, levator anguli oris, and mentalis. The marginal mandibular branch courses inferiorly from the parotid and along the inferior border of the mandible, deep to the platysma, and within the superficial layer of the deep cervical fascia. An anatomic study published by Dingman and Grabb demonstrated that in 19% of cadaveric specimens, the nerve travels up to 1 cm below the inferior border of the mandible posterior to the facial artery, and anterior to the facial artery the nerve was found at or above the inferior border of the mandible in 100% of dissections.[10] It should be noted that in some anatomic studies, the nerve has been found as low as 4 cm below the inferior border.[11]

The superior division of the facial nerve courses superiorly within the substance of the parotid gland and proceeds along the Pitanguy line toward the temporal region.[12] This line is marked by an inferior point at 0.5 cm below the tragus and superior point 1.5 cm above the lateral brow. The branches emerge from the parotid and cross the zygomatic arch approximately 2.5 cm anterior to the external auditory meatus.[13] At this crossing the nerve is most vulnerable to injury, however, in a sub-SMAS dissection plane, it is protected within the fat just deep to the temporoparietal fascia.

Surgical Technique

Patient Marking

Identification of key patient landmarks is helpful to guide the extent of dissection both in the subcutaneous and, if necessary, sub-SMAS plane. All markings should be completed in the preoperative area while the patient is in an upright position. The incision line should be marked bilaterally with an indelible marking pen. The preauricular crease is the appropriate site for the incision. At the tragus, the incision can remain pre-tragal (which is this author's preference), or extend on the tragal margin or intratragal. Incisions that extend intratragally are well hidden; however,

contracture often pulls the tragus anteriorly, leaving an unnatural appearance to the contours of the ear and direct line of site into the ear canal, an unmistakable sign of previous face-lift. Superiorly the incision extends around the superior aspect of the ear, leaving a pedicle before turning anteriorly and superiorly with a curve in the hairline.

Inferiorly the incision wraps under the earlobe, and extends two-thirds of the way superiorly along the posterior aspect of the ear, staying just inside the posterior ear crease. Incisions made directly in the crease will contract posteriorly and leave the scar in a noticeable area posterior to the crease. At the superior extent of the posterior incision, the incision extends posteriorly in an arched fashion into the hairline to create a semicircle, and extends postero-inferiorly in the hairline, terminating at level of the inferior aspect of the mastoid process.

Additional markings are made at point on the face 2 cm lateral and 3 cm inferior to the lateral canthus, marking the site of the perforating branch of the transverse facial artery.

The anterior border of the sternocleidomastoid is marked bilaterally by having the patient attempt to rotate the head against firm opposing pressure. McKinney's point is marked 6 cm inferior to the external auditory meatus (EAM) to the center of the sternocleidomastoid. A 1-cm diameter circle is marked at this point to maintain awareness of the greater auricular nerve, XII cranial nerve, and internal jugular vein, all which emerge from the sternocleidomastoid within 1 cm of this site.

Intraoperative Technique

Once the patient is intubated, he/she should be appropriately positioned. The face should be turned to expose the first side of the face-lift. If the eyes are to be taped, be sure they are taped gently and do not obscure the natural lines on the face. An alternative to taping is placement of corneal protectors. The hairline should be clipped bilaterally superior to the ear and in the posterior extent of the incisions. This author preps the face twice, first with chlorhexidine including the hair, and a Betadine cotton pellet is placed in the EAM bilaterally. At this time, 3 mL of methylene blue are injected intraorally into the Stenson's duct bilaterally. This stains the parotid gland blue, making identification of the parotidomasseteric fascia very easy upon dissection. A second prep of the skin is then completed with Betadine.

There are a variety of techniques for local anesthetic infiltration. Local anesthesia is infiltrated along the incision line with 2% lidocaine 1:100,000 epinephrine. The surgeon can then opt to use additional local anesthetic in a tumescent formula for hydrodissection and hemostasis in the subcutaneous place. There are many tumescent formulations, and one example is a mixture of 20 mL of 2% lidocaine 1:100,000 epinephrine with 180 mL of normal saline, totaling a 0.2% lidocaine solution with 1:1,000,000 epinephrine solution. The tumescent solution is delivered by cannula at four distinct sites: temporal, infralobular, mastoid, and if performing a cervicoplasty, submentoplasty or platysmaplasty with rhytidectomy, then also in the submental area.



• **Figure 18-3** Skin flap dissection.

The tumescent solution is delivered in the subcutaneous plane superior to the SMAS and platysma, and approximately 1 cm beyond the planned limits of subcutaneous dissection. This requires a total of approximately 200 mL to complete the bilateral face. Tumescent solution requires between 5 and 10 minutes for optimum effectiveness, and therefore should be completed 5 minutes prior to incision.

The incision is initiated in the temporal region with a No. 10 or No. 15 blade. The blade is held at a sharp angle oblique to the skin and directed toward the skin flap. This scything of the incision line preserves the hair follicles and diminishes alopecia along the incision line. The incision is carried along the preauricular regions, inferior to the lobe and posterior-auricular region, and then onto the mastoid and into the posterior hairline. The dissection of the subcutaneous flap is performed in the same progression, beginning temporally and extending into the cheek from the preauricular region, and into the neck in the inferior lobe and mastoid areas. The subcutaneous dissection should be completed approximately 5 to 7 cm from the incision line in the preauricular area and leave at least 4 mm of skin to preserve the blood flow to the skin flap (Figure 18-3). Exercise caution while performing the subcutaneous dissection in the posterior auricular neck while directed toward the SCM; continuous verification of the marking of McKinney's point should keep the surgeon cautious of injury to the greater auricular nerve, which is damaged in 5% of rhytidectomy procedures. The skin flap should remain superficial here, and deep dissection may also traumatize the accessary nerve or the jugular vein, which is a difficult complication to manage for hemostatic control because visualization during dissection and with hemorrhage is often suboptimal. Bipolar cautery should be used throughout the dissection with judicious use of Bovie cautery on the skin flap to avoid skin

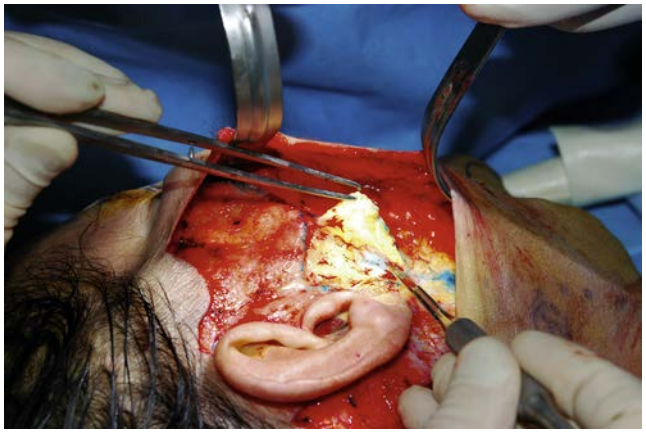

• **Figure 18-4** Marking and dissection under SMAS.

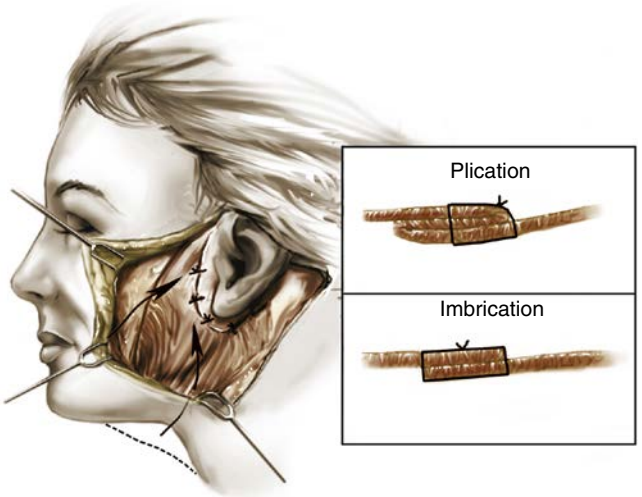

• **Figure 18-5** Plication versus imbrication.

necrosis. Dissection should always proceed in a dry, well visualized field. The skin flap dissection can be completed with a No. 10 blade or with scissors dissection.

After the skin flap has been adequately undermined, attention is directed toward the SMAS. A skin-only facelift without manipulation of the SMAS will not adequately address the laxity of the anterior malar region or deep nasolabial folds. Manipulation of the SMAS layer can be accomplished with plication, imbrication, or sub-SMAS dissection (Figure 18-4). Plication is the process of folding the SMAS over onto itself to achieve repositioning. Imbrication involves incision of the SMAS with either excision or overlapping edges to achieve the desired position. Plication sutures can be placed in the SMAS adjacent to the angle of the mandible, and sutured superiorly to the fascia at the inferior aspect of the tragus. A second plication suture can be placed in the SMAS lateral to the oral commissure and secured to the fascia overlying the inferior aspect of the zygoma superior to the tragus. Additional plication suture can be placed the SMAS and sutured to the posterior-auricular and cheeks regions to achieve the desired amount of tightening in multiple superior-posterior and lateral vectors (Figure 18-5).

Sub-SMAS or imbrication techniques require an incision in the SMAS that is initiated 1 cm anterior to ear. Bonnies blue can be used to mark the incision line into the SMAS. This typically has a vertical component extending from the anterior ear region into the platysma, and a horizontal component that parallels the zygomatic arch and extends just to the point where the zygomatic arch turns inferiorly at the lateral malar region. This is at the area that was previously marked on the skin as the region where the perforating branch of the transverse facial artery emerges. Additional dissection deep to the SMAS can be completed and there are various techniques for further dissection both superiorly and toward the nasolabial fold that are beyond the extent of this chapter. Dissection under the SMAS is facilitated by identifying the blue color of the parotid gland stained with methylene blue. This allows for easy identification of the sub-SMAS plane without extension deep to the parotidomasseteric fascia where the seventh cranial nerve may be injured. Once the incision through the SMAS is completed, the SMAS layer is grasped with forceps and dissection is completed sharply with a No. 15 blade under the SMAS to the desired extent. Once undermined, the SMAS flap can be pulled in various vectors to achieve the desired lift. The corner of the superior posterior SMAS at the ear–zygoma intersection is then cut with scissors at an approximately 45 degree angle at the level of the desired keystone suture; a suture placed here is then firmly secured to the fascia at the superior posterior lateral aspect of the zygomatic arch. Excess SMAS can then be excised with scissors and the remaining edges of the same are then sutured to the posterior and superior aspects of the SMAS respectively to achieve the appropriate amount of lift in these vectors. Aside from the keystone sutures, SMAS suturing can be completed with slow resorbing 2-0 sutures and can be interrupted or in a running fashion (Figure 18-6).

Once the SMAS suturing has been completed, the patient's head is returned to a neutral position without extension or flexion of the neck. The skin is redraped. Excess skin is carefully excised to match the incision line. It is important to close the skin flap under minimal or no tension to minimize scar formation and reduce chances of skin necrosis. The skin vector should mimic the SMAS vector in a posterior-superior direction. Before the skin flap is trimmed, skin staples are placed in key areas to position the flap, and then excess skin is excised with a No. 15 blade in short segments.

Skin closure in all regions is completed first with closure of the subdermal layer with 3-0 interrupted restorable sutures with buried knots. The skin in the temporal region is closed with 4-0 or 5-0 fast absorbing gut in a running interlocking fashion, which best everts the skin margins. A 6-0 Prolene or nylon suture is used in the vertical portion of the incision at the preauricular area and posterior bowl area, again in a running interlocking fashion to best evert the skin margins (Figure 18-7). The incision from the posterior bowl and into the posterior mastoid region extending inferiorly along the hairline can be closed with plain gut in a running



• **Figure 18-6** Excision of SMAS. **A,** Intraoperative marking of area of SMAS dissection and planned excision for SMAS-ectomy. **B,** Dissection under SMAS for planned excision. **C,** Demonstration of excised portion of SMAS for SMAS-ectomy. (Courtesy Tirbod Fattahi, MD, DDS, FACS.)



• **Figure 18-7** Closure. **A,** Standard closure with nylon suture in running interlocking fashion at preauricular region. **B,** Alternative closure with subcutaneous sutures and application of Dermabond in preauricular region and staple closure in posterior auricular region. (Courtesy Tirbod Fattahi, MD, DDS, FACS.)

interlocking fashion. Prior to completion of the skin closure on the first side, local anesthetic should be injected into the second side approximately 5 to 8 minutes prior to incision. Additionally, prior to skin closure the surgeon should establish excellent hemostasis with electrocautery and with the additional use of aerosolized fibrin glue if desired. This minimizes the risk of hematoma formation. If using fibrin glue, the skin flap should be held in place with firm pressure for 5 minutes prior to suturing.

A dressing of antibacterial ointment is placed along the incision line, followed by a gauze and bandage pressure dressing, such as a Barton-style dressing, to minimize hematoma formation. Care should be taken to avoid placing this dressing too tightly as this can cause significant discomfort for the patient. Additionally the ears should not be folded, but allowed to extend in their natural direction out from the dressing. Dressings should remain in place until postoperative day 1 (at least 12 hours to a maximum of 36 hours). The surgeon should remove the dressing and examine for hematoma formation or early flap necrosis. Some surgeons choose not to place any dressing, citing that pressure dressings may decrease hematoma formation but increase the pressure necrosis of the flap. In these instances, this author recommends placement of a TLS drain at least in the posterior auricular flap where most hematoma formation occurs, to be removed on postoperative day 1.

Immediate Postoperative Care

Once the dressing or drain is removed, the patient should be instructed in wound care. Incision lines should be cleaned twice daily with warm water and a gentle baby washcloth or 50/50 solution of H_2O_2 and water. This is followed by application of a thin line of antibiotic ointment. The hair

can be shampooed starting on postoperative day 3 with care to avoid the incision lines and only using unfragranced, mild shampoo, such as Neutrogena or Johnson and Johnson baby shampoo. Nonrestorable sutures are removed from the preauricular region on postoperative days 5 to 7. No hair dye should be applied within 6 weeks postoperatively.

The author recommends that the hair is colored approximately 5 days preoperatively to a new and noticeable different color and to a new hairstyle that will cover the incision lines if blow-dried appropriately, even in the temporal region where the hair will be clipped. This is important to minimize the observation of friends and relatives to the face-lift procedure and redirect their attention to these more superficial changes.

The patient should make every effort in the 6 months postoperatively to avoid sunlight exposure to the incision lines (Figure 18-8).

Complications

Prevention of complications begins in patient assessment. Some relative contraindications to face-lift surgery include smoking, poorly controlled hypertension, use of anticoagulants, poor nutritional status, use of immunosuppressants, and any other poorly controlled medical condition such as diabetes or COPD. Overall incidence of complications after face-lift surgery is approximately 1.5%,[14] which includes local and systemic complications. The incidence of major systemic complications such as cardiopulmonary dysfunction or venous thromboembolism is less than 0.1%.[14]

Hematoma

Hematoma formation is the most common postoperative complication of face-lift surgery and major hematoma requiring surgical intervention occurs in 1.1% of patients.[14] Hematoma formation is more common in males than females with one study suggesting the rates as 4.4% in males versus 1.3% in females.[14] The presence of postoperative hematoma can have significant consequences on the outcome of face-lift surgery, including flap necrosis and, in severe situations, airway compromise. Major factors influencing hematoma formation are smoking, aspirin or NSAID use, male gender, perioperative hypertension, and concomitant platysmaplasty.[15] The surgeon should take pre-, intra-, and postoperative precautions in preventing hematoma formation. Preoperatively, patient selection is paramount to success. Smokers and patients with poorly controlled blood pressure should not undergo elective cosmetic surgery procedures. Platelet inhibiting medications and any other medical or herbal anticoagulation should be suspended at least 2 weeks prior to surgery. Intraoperatively, hemostasis should be obtained throughout the surgery with meticulous attention to small bleeding vessels. Hemostasis should be rechecked prior to closure at the patient's normal preoperative blood pressure. This author finds that the best way to check for hemostasis is with the overhead OR lights off and with the use of surgical headlight illumination under the flap. Use of a fibrin glue prior to closure may aid in hemostasis and prevention of hematoma formation.[16] Small drains to bulb suction can also be placed during closure. If used, the active portion of the drain should traverse the preauricular area, descend inferior to the mandible and into the lateral neck, and exit at or around the mastoid closure site. Postoperative use of a Barton-like pressure dressing may be maintained for 12 to 24 hours postoperatively until the first postoperative check (Figure 18-9).



• **Figure 18-8** Pre- and postoperative photos. In lateral view, note correction of jowling and new posterior-lateral vector of malar fat pad resuspension. (Courtesy Tirbod Fattahi, MD, DDS, FACS.)



• **Figure 18-9** Hematoma. **A** and **B,** Appearance of hematoma prior to evacuation. Note boggy dark appearance of the preauricular and infra-auricular regions in the immediate postoperative period. **C** and **D,** Intraoperative photo of evacuation of hematoma. (Courtesy Todd Owsley, Greensboro, NC.)

Skin Necrosis

Skin necrosis is reported to occur in 1% to 3.6% of face-lift surgery. Higher incidences are found in subcutaneous versus sub-SMAS face-lift techniques because the incidence of ischemia is higher in thin skin flaps. Additional causes of skin necrosis are excessive tension on skin flaps at closure, hematoma formation, excessive pressure dressings, and in patients who are smokers. Skin necrosis most commonly occurs at the skin flap just superior to the auricle of the ear and the skin flap over the mastoid process, representing the sites of the thinnest skin involved in face-lift surgery. Areas of necrosis are addressed with local wound care measures, and most cases will heal without the need for surgical debridement or skin grafting procedures (Figure 18-10).

Infection

Infection is a rare complication of face-lift surgery, representing less than 0.3% of patients.[14] Prevention of infection includes perioperative IV antibiotics directed at *Staphylococcus* species prior to incision. Postoperative auricular infections may not be covered by the typical pre-incision antibiotic because they are commonly *Pseudomonas* species. These types of postoperative infections are often managed with oral quinolones, but may require incision and drainage. Postoperative use of Bacitracin ointment at the incision site for 5 days may aid in prevention of infection. Patient compliance with postoperative wound care instructions will also reduce incidence of infection and should include gently cleansing the incision site with mild soap (such as Johnson and Johnson Purpose) and warm water twice daily.

Patients with impaired immune function have a higher risk of postoperative infection. In the setting of the use of immunosuppressants such as adalimumab and etanercept (Humira and Enbrel), these drugs should be discontinued with approval from the prescribing physician prior to face-lift surgery and may be restarted postoperatively. If discontinuation of medications is unavoidable, the surgeon should consider a prolonged course of postoperative antibiotics. Diabetic patients should maintain tight glycemic control in the perioperative period.



• **Figure 18-10** Skin necrosis in the preauricular and supra-auricular portions of the flap. This is also commonly seen in the posterior auricular region just over the mastoid process. In these areas, the skin flap may become excessively thin and contribute to skin necrosis.

Nerve Injury

Injury to the facial nerve is one of the more devastating complications of face-lift surgery because it can produce permanent and obvious disfigurement. The incidence of permanent injury to the facial nerve is largely reported at 0.1%.[17,18] Transient nerve dysfunction in the immediate postoperative period is normal, and is a result of edema, prolonged effect of local anesthetics, or traction on the nerve. Spontaneous recovery is noted either early in the postoperative period in the case of edema or prolonged effect of local anesthesia, or later by 3 to 4 months in cases of substantial nerve traction or dissection. The buccal branch is the most commonly injured branch, but because of the great arborization of this branch, injuries are often less clinically significant compared with injury to other facial nerve branches.[19] Permanent injuries to the frontal or marginal mandibular branch are less forgiving cosmetically and produce an asymmetric smile and inability to purse the lips. Damage to the frontal nerve branch is less common in superficial plane face-lifts because the nerve is protected by the fat overlying the zygoma. Damage to the frontal branch results in a drooping brow and dysfunction of the ipsilateral forehead musculature. Marginal mandibular nerve damage is characterized by asymmetric smile caused by dysfunction of the lip depressor muscles, and is prevented with meticulous dissection at the level of the mandible and just inferior to it (Figure 18-11). Damage to the cervical branches may mimic damage to the marginal mandibular branch. This can be distinguished by having the patient evert the lower lip; if mentalis function is intact, then the injury spares the marginal mandibular branch.[20] If nerve transection is identified intraoperatively then the nerve should be repaired with 7-0 nylon or other nonresorbable suture. In cases of permanent nerve deficits, the patient should be referred to a specialist for nerve repair or facial reanimation procedure. It should be noted, however, that those procedures have limited success.

Neurosensory disturbances are common in the immediate postoperative period and are typically transient, lasting 4 to 6 weeks in the postoperative period. This type of temporary hypoesthesia is the result of necessary disruption of the cutaneous innervation with the elevation of the skin flap. Permanent paresthesias occur in 5% of face-lift



• **Figure 18-11** Damage to marginal mandibular nerve branch. Note injury to right marginal mandibular branch demonstrated by weakness of the depressor muscles of the right lip and lower face.

patients.[21] The most commonly injured sensory nerve is the greater auricular nerve. The site of this nerve, McKinney's point, should be marked preoperatively at the midpoint of the sternocleidomastoid muscle 6.5 cm caudal to the bony external auditory meatus.[22] A margin of 1 cm around this point will also identify the site of the internal jugular vein, typically 0.5 cm anterior to the nerve, and caution the surgeon to keep the dissection plane superficial in this area. Damage to this nerve results in paresthesia of the lower two-thirds of the ear and the associated pre- and posterior-auricular skin.

Scarring and Alopecia

Hypertrophic scarring can occur with any surgical procedure. A complete history from the patient including inspection of previous surgical scars may elicit a history of hypertrophic scarring or keloid formation. Keloid formation is most common in African-American patients. Patients at risk for hypertrophic scarring should be informed preoperatively, and a plan for postoperative management should be in place prior to surgery. Perioperative management may include silicone sheeting, steroid injections, and extended follow up. Hyperpigmentation of scars is common with direct sun exposure, and patients should be cautioned to avoid direct sun exposure in the first 6 months postoperatively and thereafter to use a broad spectrum (UVA and UVB) sunscreen with at least SPF 30 or greater and reapply liberally. Scarring is also minimized by tension-free skin closure and eversion of the skin margins at closure. The appearance of postoperative scars can be minimized by use of microneedling techniques or laser skin resurfacing.

Alopecia along the incision line occurs as a result of several factors. Excessive skin tension at closure will result in a smooth widened scar with central alopecia. Improper beveling technique in the hair-bearing areas will also result in alopecia, as the bevel should be angled such that viable hair follicles are deep to the reapproximated superficial flap. Limiting the use of electrocautery on the scalp margin and avoiding electrocautery on the skin flap margin after excision of excess skin will also decrease the likelihood of development of alopecia. For treatment of alopecia at the incision site, the bald area should be excised and the resultant margins should be close primarily without tension.



• **Figure 18-12** Pixie ear deformity. Note the loss of the free lobule of the earlobe and subsequent elongation secondary to elongated attachment to the cheek tissue.

Ear Deformities

Ear deformities often occur after inappropriate closure of face-lift surgery. Most common is the "pixie" ear deformity that results when the earlobe is pulled inferiorly onto the cheek skin. This causes an elongated area of attachment between the cheek and lobe and loss of the free lobe portion (Figure 18-12). The incidence of this complication is 5.7%.[11] The primary means of preventing pixie ear deformity is reattachment of the SMAS layer to the deep layer of the fascia surrounding the conchal bowl followed by judicious skin trimming in the lobe area of the flap leaving at least 1 to 2 mm of perilobar skin. Correction of pixie ear deformity should be delayed until at least 6 months postoperatively, and requires excision of a medially based triangle of skin at the lobe-cheek junction.[23]

Change in the projection of the ear may also occur after face-lift surgery resulting in increased auriculocephalic angle and the appearance of protruding ears. This is caused by damage to the musculature approximating the auricular

cartilage to the skull. Avoiding disturbance to these muscular and ligamentous structures is best completed by avoiding incision directly in the auriculocephalic crease and instead placing the incision 3 to 4 mm onto the skull posterior to the crease. Correction of overprojection is completed through standard otoplasty and should also be delayed until at least 6 months postoperatively.

Parotid Sialocele

Parotid sialocele is a rare complication of face-lift surgery. It is often noted by postoperative day 7 but may be evident as early as postoperative day 3. This complication is rare in superficial plane face-lift but is more common in deep-plane face-lifts where the capsule of the parotid gland is adjacent to the surgical plane. If the parotid capsule is violated, facial swelling may occur and is particularly noticeable with food intake. Diagnosis is confirmed with aspiration of saliva from the swelling. Conservative management with pressure dressing and aspiration generally results in resolution in 1 to 5 weeks. Additionally, the use of botulinum toxin for persistent parotid sialocele may ameliorate the condition.[24] Rarely, persistent sialoceles may require radiation or sialadenectomy.

References

1. ASPS National Clearinghouse of Plastic Surgery Procedural Statistics: Plastic Surgery Statistics Report. American Society of Plastic Surgeons. http://www.plasticsurgery.org/Documents/news-resources/statistics/2014-statistics/plastic-surgery-statsitics-full-report.pdf, 2014.
2. Rees, Liverett DM, Guy CL: The effect of cigarette smoking on skin-flap survival in the face lift patient, *Plast Reconstr Surg* 75:842, 1985.
3. Ho T, Brissett AE: Preoperative assessment of the aging patient, *Facial Plast Surg* 22:85, 2006.
4. Evans TW: A case for deeper plane facelifts, *J Oral Maxillofac Surg* 56:352, 1992.
5. Hamra ST: Composite rhytidectomy, *Plast Recons Surg* 90:1, 1992.
6. Hamra ST: The deep-plane rhytidectomy, *Plast Reconstr Surg* 86:51, 1990.
7. Pastorek N: Deep plane face-lift, *Facial Plast Surg Clinics North Am* 13:433, 2005.
8. Guyuron B, Jackowe D, Lamphongsai S: Basket submandibular gland suspension, *Plast Reconstr Surg* 122(3):938–943, 2008.
9. Mejia MD, Nahai FR, Nahai F, Momoh A: Isolated management of the aging neck, *Semin Plast Surg* 23(4):264, 2009.
10. Dingman RO, Grabb WC: Surgical anatomy of the mandibular ramus of the facial nerve based on the dissection of 100 facial halves, *Plast Reconstr Surg Transplant Bull* 29:266–272, 1962.
11. Nelson DW, Gingrass RP: Anatomy of the mandibular branches of the facial nerve, *Plast Reconstr Surg* 64:479–482, 1979.
12. Pitanguy I, Ramos AS: The frontal branch of the facial nerve: the importance of its variations in face lifting, *Plast Reconstr Surg* 38:352–356, 1966.
13. Baker DC, Conley J: Avoiding facial nerve injuries in rhytidectomy: anatomical variations and pitfalls, *Plast Reconstr Surg* 64:781–795, 1979.
14. Gupta V, Winocour J, Shi H, Shack RB, Grotting JC, Higdon KK: Preoperative risk factors and complication rates in facelift: analysis of 11,300 patients, *Aesthet Surg J* 36(1):1–13, 2016.
15. Grover R, Jones BM, Waterhouse N: The prevention of haematoma following rhytidectomy: a review of 1078 consecutive facelifts, *Br J Plast Surg* 54:481–486, 2001.
16. Fezza JP, Cartwright M, Mack W, Flaharty P: The use of aerosolized fibrin glue in face-lift surgery, *Plast Reconstr Surg* 110(2):658–664, 2002; discussion 665–666.
17. Baker DC, Conley J: Avoiding facial nerve injuries in rhytidectomy: anatomical variations and pitfalls, *Plast Reconstr Surg* 64:781–795, 1979.
18. Pitanguy I, Machado BH: Facial rejuvenation surgery: a retrospective study of 8788 cases, *Aesthet Surg J* 32:393–412, 2012.
19. Roostaeian J, Rohrich RJ, Stuzin JM: Anatomical considerations to prevent facial nerve injury plastic and reconstructive surgery, *Plast Reconstr Surg* 135(5):1318–1327, 2015.
20. Daane SP, Owsley JQ: Incidence of cervical branch injury with "marginal mandibular nerve pseudo-paralysis" in patients undergoing face lift, *Plast Reconstr Surg* 111(7):2414–2418, 2003.
21. Baker TJ, Gordon HL: Complications of rhytidectomy, *Plast Reconstr Surg* 40:31, 1967.
22. McKinney P, Katrana DJ: Prevention of injury to the great auricular nerve during rhytidectomy, *Plast Reconstr Surg* 66(5):675–679, 1980.
23. Molavi A, Meldrum DG, Wilhelm BJ, et al.: The pixie ear deformity following facelift surgery revisited, *Plast Reconstr Surg* 115:1165, 2005.
24. Chow TL, Kwok SPY: Use of botulinum toxin type A in a case of persistent parotid sialocele, *Hong Kong Med J* 9:293, 2003.
25. Duffy MJ, Friedland JA: The superficial-plane rhytidectomy revisited, *Plast Reconstr Surg* 93:1392, 1994.
26. Dedo DD: A preoperative classification of the neck for cervicofacial rhytidectomy, *Laryngoscope* 93:1990, 1984.
27. McKinney P, Katrana DJ: Prevention of injury to the greater auricular nerve during rhytidectomy, *Plast Recons Surg* 66(5):675, 1980.

19

The Use of Lasers in Maxillofacial Surgery

NATASHA FÜRCHTGOTT, BRIAN C. PATERSON, BERNARD J. COSTELLO

Introduction

Laser light is an important tool used in a wide variety of disciplines. Since its conception, it has been implemented in research laboratories, communication systems, surveying, manufacturing, diagnostic medicine, and surgery. Medical applications have been described for multiple specialties such as ophthalmology, otolaryngology, plastic surgery, gynecology, general surgery, and oral and maxillofacial surgery.

Surgical lasers become a useful tool in the surgeon's armamentarium because of their precision and ability to provide target-selective treatments. In addition to being an adjunct to conventional surgical methods, lasers are now the treatment of choice or the sole treatment modality for a variety of pathologies. Thanks to better delivery systems and reduced cost, lasers have moved into private offices rather than being exclusive to operating rooms in health systems and academic centers.

History

Laser light is the brightest monochromatic (single color) light that exists today.[1] The term *laser* is an acronym for *l*ight *a*mplification by the *s*timulated *e*mission of *r*adiation. In 1917, Einstein postulated the theoretic basis for laser production by introducing the concepts of absorption, spontaneous emission of energy, and stimulated emission of energy when he discussed the interaction of atoms and electromagnetic radiation. That article, "Zur Quantem Theorie der Strahlung" ("The Quantum Theory of Radiation"),[2] was the basis for many attempts to produce stimulated emission of radiation, which was finally achieved in 1954 by Gordon, Zeiger, and Townes[3] with the fabrication of the MASER (microwave amplification by the stimulated emission of radiation).

It was not until 1960, however, that the first working device (a synthetic ruby diode laser) was developed by Maiman, coining the term *laser*.[4] This device produced electromagnetic radiation at a wavelength of 0.69 μm in the visible range of the spectrum. Zaret was the first one to describe how lasers interact with living tissue by creating ocular lesions in rabbits.[5] Since then, and the development of the neodymium:yttrium-aluminum-garnet (Nd:YAG) and carbon dioxide (CO_2) lasers, a plethora of surgical techniques and applications has been described and refined for the use in the head and neck region.

Principles of Laser Physics

The term "light" is generally accepted to be electromagnetic radiation ranging from 1 nm to 1000 μm in wavelength. The visible spectrum ranges from 400 to 700 nm. If the energy beam from a laser is in the visible spectrum, it will be of only one distinct color (Figures 19-1 and 19-2).[6]

The laser instruments that are typically used for oral and maxillofacial surgical procedures that emit visible light are: argon laser (blue wavelength of 488 nm, or blue-green wavelength of 514 nm) and the KTP laser (green wavelength of 532 nm). The other lasers used emit invisible laser light in the near, middle, and far infrared portion of the electromagnetic spectrum: diode lasers (various wavelengths between 800 and 1064 nm), Nd:YAG laser (1064 nm), Er,Cr:YSGG laser (2780 nm), Er:YAG laser (2940 nm), and CO_2 laser (9300 and 10,600 nm)

In order to understand stimulated emission, an understanding of the Neils Bohr 1915 model of the atom and quantum physics is helpful. Although the simple diagram of the atom is not fully accurate by today's understanding, it is still useful for demonstrating laser principles.

In the model of the atom, electrons orbit the nucleus in a limited number of fixed orbits, and each electron is balanced by a proton within that nucleus. Under the right circumstances an electron can go from its ground state, which is a low energy state, to an excited or higher energy state. Energy, which can be in the form of electromagnetic radiation (e.g., light), must be applied to the atom for an electron to change its orbit. Similarly, when an electron drops from a higher to a lower state, the atom must give off energy, in the form of kinetic energy or electromagnetic radiation (Figure 19-3).[1]

Excitation that comes from the electron interacting with light (a photon) is termed *absorption*. Because the atom always seeks to be stable, the electron will spontaneously drop back to its lowest energy state by giving off energy

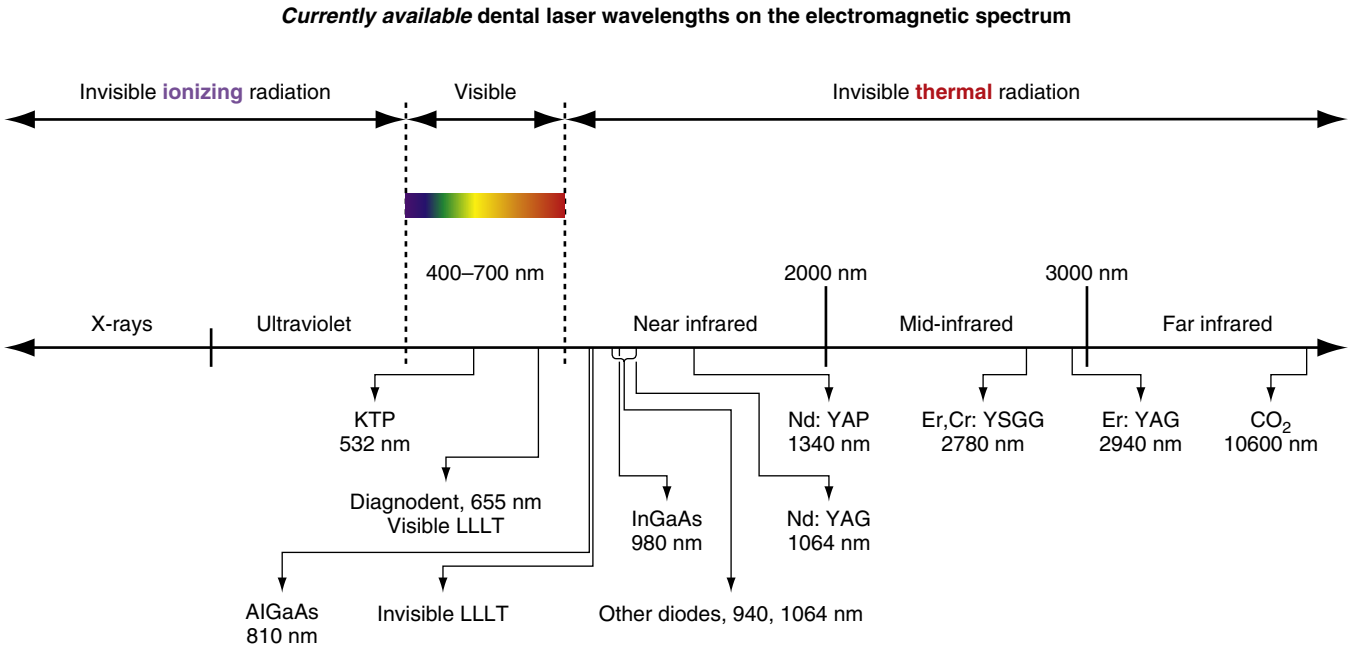

• **Figure 19-1** Part of the electromagnetic spectrum showing division into ionizing, visible portion, and nonionizing portion. (From Convissar RA: *Principles and practice of laser dentistry*, ed 2, St Louis, 2016, Elsevier, Inc.)

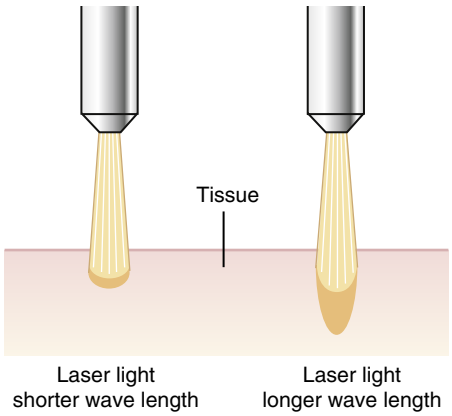

• **Figure 19-2** Laser wavelength.

emitted as a photon of light, and this process is called *spontaneous emission of radiation*. An atom in a high energy state can transition faster than the spontaneous process into a lower energy state when a photon of the correct amount of energy interacts with it. This process results in the emission of two identical photons after colliding, which have the same energy and direction, and this is called *stimulated emission of radiation*.

Lasers are electro-optical devices that produce intense beams of light which are monochromatic, coherent, and highly collimated. It is extremely pure *(monochromatic)* when compared to other sources of light. It is temporally and spatially coherent because the waves of light oscillate in phase over a given time and they are equal and parallel across the wave front. Collimation refers to the beam's property of being unidirectional and parallel. Light from a laser typically has very low divergence and can travel very long distances or can be focused to a very small spot (Figure 19-4).[1]

All lasers have similar components: an optical cavity (or optical resonating chamber) and two mirrors, one that is fully reflective and one that is partially transmissive. The optical cavity is filled with an active medium such as argon, neodymium:yttrium-aluminum-garnet, or carbon dioxide. Each laser has a source of energy to excite the atoms within this medium in the form of an electric current, chemical, or another light source. As the energized atoms interact with each other and return to the ground state, photons of identical wavelength are emitted. When the photons interact with other atoms in excited states, they stimulate the emission of more photons. The mirrors serve as a positive feedback mechanism by reflecting the photons back and forth and therefore amplifying the stimulated emission of radiation (Figure 19-5).[6]

Use of the Surgical Laser

The laser, as an instrument for surgical procedures, can be used for multiple different purposes, and the variables a surgeon can control for are its power, spot size, pattern, and the exposure time.[1]

Power

Power is measured in watts and can be kept constant throughout the surgery. Its effects on tissue are directly dependent on the beam's exposure time and spot size. Therefore, power as a variable is better described when speaking in terms of irradiance to the target tissues. Irradiance, measured in W/cm^2, describes the intensity of the beam at the focal spot, and is useful to determine the depth of tissue injury that a certain amount of power can cause.

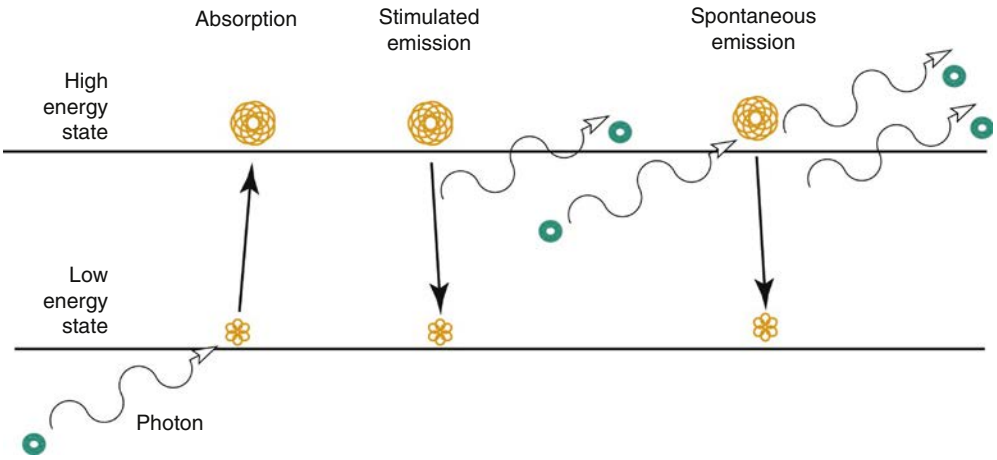

• **Figure 19-3** The interaction of light (a photon) with an atom. Three processes are shown: the absorption of a photon by an atom in a low energy state, the spontaneous emission of a photon from an atom in an excited state, and the stimulated emission of a photon by a second photon of the same wavelength from an atom in the excited state. (From Flint PW, Haughey BH, Lund VJ, et al: Laser surgery: basic principles and safety considerations. In Flint PW, editor: *Cummings otolaryngology head and neck surgery*, ed 6, Philadelphia, 2015, Saunders, pp 884-898.)

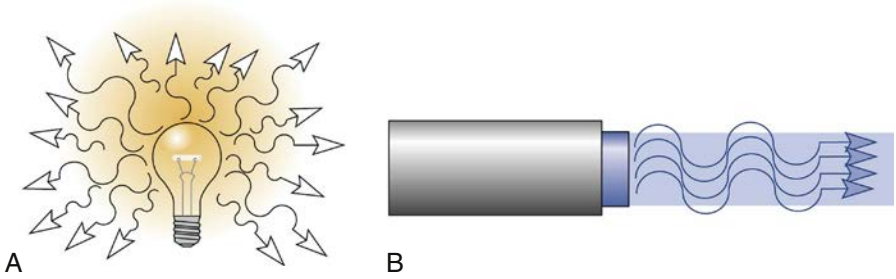

• **Figure 19-4** **A,** Light emitted from a conventional lamp. The light travels in all directions, is composed of many wavelengths, and is not coherent. **B,** Light emitted from a laser travels in the same direction and is a single wavelength, and all the waves are in phase; the light is coherent. (From Flint PW, Haughey BH, Lund VJ, et al: Laser surgery: basic principles and safety considerations. In Flint PW, editor: *Cummings otolaryngology head and neck surgery*, ed 6, Philadelphia, 2015, Saunders, pp 884-898.)

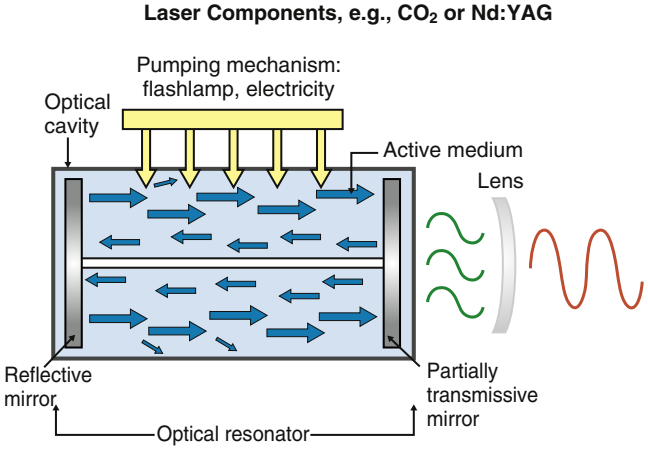

• **Figure 19-5** A gas or solid active-medium laser, such as CO_2 or Nd:YAG laser. (From Convissar RA: *Principles and practice of laser dentistry*, ed 2, St Louis, 2016, Elsevier.)

Spot Size

To produce the appropriate irradiance, the surgeon selects the spot size and the power of the laser. The following mathematical equations demonstrate the relationship between power and the beam's radius.

$$\text{Irradiance} = \text{Power} \div \text{Surface Area}$$

and

$$\textit{Surface area} = \pi r^2$$

This explains how, at a given power, increasing the size (radius) of the beam will cover more surface area but have a smaller irradiance effect over the tissues.

Lenses focus the active beam and the focal point is used for incision and excision of tissue during surgery. The focal point varies with delivery systems. Fiberoptic devices have a focal point located at the tip of the fiber, and noncontact devices such as the CO_2 laser have focal points that can be 1 to 12 mm away from the tissue surface. As the beam moves away from the tissue, the diameter of the spot will increase, compromising the irradiance and dissipating the energy, as discussed previously.

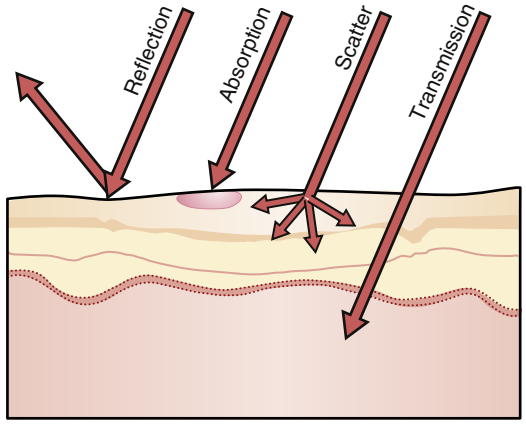

• **Figure 19-6** Four potential laser-tissue interactions. (From Convissar RA: *Principles and practice of laser dentistry*, ed 2, St Louis, 2016, Elsevier.)

Exposure Time

By varying the exposure time, the surgeon can vary the amount of energy delivered to the tissue. Fluence is the amount of time that a laser beam irradiates a unit area of tissue at a constant irradiance. It is expressed in J/cm^2, and can be varied by working in a continuous versus pulsed mode.

Types of Lasers

1. Continuous-wave mode: the beam has constant power over time, resulting in a long, continuous exposure.
2. Quasi-continuous-wave lasers or gated-pulse mode: the beam is made discontinuous by the opening and closing of a mechanical shutter. Advanced units have computer-controlled shutters and allow for very short pulses, commercially known as "super pulse" or "ultra speed."
3. True pulsed lasers or free-running pulsed mode: the beam is emitted for microseconds, followed by a very long time in which the laser turns off.
4. Q-switched (quality switched) lasers: generate extremely high-energy pulses over short (nano- or picoseconds) pulse durations and are used primarily for treating pigmented lesions.

Interactions of Laser Light and Tissue

The electromagnetic radiation from a laser can have four effects on target tissue: reflection, absorption, transmission, and scattering (Figure 19-6).

With reflection, there is no effect on the target tissue and the beam that is reflected can damage an unintended target such as the unprotected eyes of staff within the operating room.

Absorption of the laser is the most desirable effect, and it depends on tissue characteristics such as pigmentation (chromophores and their importance will be discussed later) and water content. The amount of absorption determines the amount of selective tissue destruction, whereas the amount of scatter determines the amount of peripheral tissue damage. The greater the absorption of a wavelength by a particular tissue, the more effective that laser is at selectively removing that tissue. The principal effect on tissue that absorbs laser light is photothermal reactions. This is the principle by which lasers are used for incisions, excisions, ablation, vaporization, and coagulation.

Transmission of the beam has no effect on the superficial tissue and can be useful in some cases where the target tissue is distant and a layer of tissue must be bypassed by the inciting beam to reach it, such as procedures where the retina is the target tissue and the laser must transmit through the fluid globe contents.

Scattering of the laser light weakens the intended energy and dissipates the effect, potentially causing unwanted effects in adjacent tissue.

The basis of all laser–tissue interactions was described elegantly in 1983 by Anderson and Parish's introduction of the *selective photothermolysis* (SP) concept.[7] A wide variety of surgical procedures, including hair removal, treatment of pigmented lesions, removal of varicose veins, and tattoo removal, have been made possible thanks to the understanding of tissue optics and laser properties.

Precise removal of specific kinds of tissue is based on the tissue's inherent absorption of particular wavelengths. When laser light is directed at tissue, compounds within the tissue called chromophores absorb the wavelength of light. The absorption characteristics are based on the amount of chromophores within the tissue. Natural chromophores can include water, melanin, hemoglobin, protein, and lipid. Artificial chromophores can include dye, ink, and carbon particles. For example, hemoglobin has greater absorption of the violet and green-blue portions of the spectrum; consequently, hemoglobin absorbs the green-blue photon energy of the argon laser well. Laser energy at this wavelength is converted to heat to destroy microvessels laden with hemoglobin by being selectively heated. Surrounding tissues without hemoglobin are affected minimally by the heat produced (Figure 19-7).

In 2004 Manstein and colleagues[8] described *fractional photothermolysis* (FP), launching another era of lasers in dermatology. With the concept of FP, patterns of very small, nonselective thermal damage zones are used to stimulate skin remodeling without scarring. Physiologically, there is minimal inflammation in response to the electromagnetic insult, accompanied by the desired effect of epidermal regeneration, induction of metalloproteinases, and formation of a new dermal matrix.

Mechanical Design of Laser Devices

The light is delivered from the laser chamber to the tissue in a variety of ways. Some laser systems use a fiberoptic cable. Other lasers allow the light to pass down an articulated arm system consisting of a series of tube containing partially reflective mirrors to direct the beam. This is initially somewhat cumbersome to use, but the surgeon quickly adapts. A hollow wave guide is another delivery mechanism, which utilizes a hollow tube with an inner reflective surface that delivers the light. These are generally cheaper than most articulated arm systems. There is a limit to the bending that the waveguide tolerates, and damage can be done to

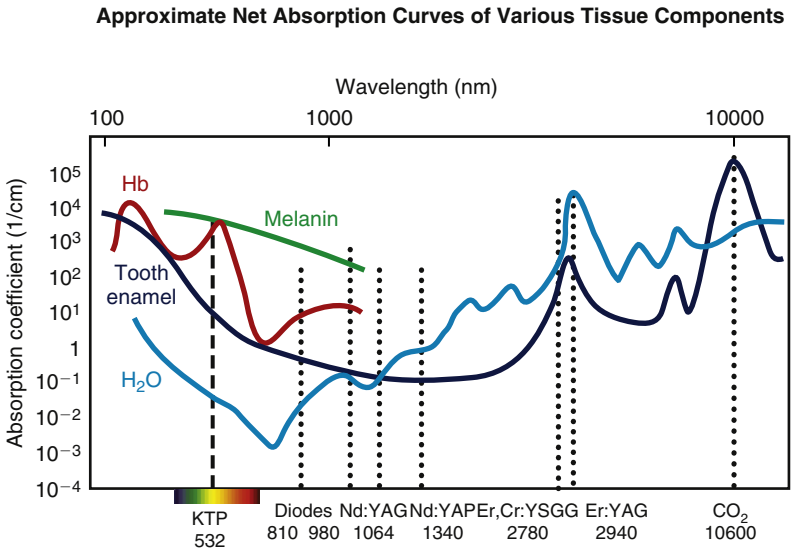

• **Figure 19-7** Laser absorption chart. (From Convissar RA: *Principles and practice of laser dentistry*, ed 2, St. Louis, 2016, Elsevier.)

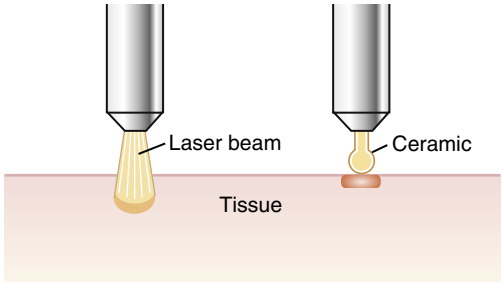

• **Figure 19-8** Laser delivery systems.

the reflective surface. If the wave guide is bent and kinked, laser light can escape from the damaged area and become a hazard. The wave guide must then be replaced.

After laser light is produced by excited atoms in the chamber and is delivered down a fiberoptic cable, articulated arm, or hollow waveguide, it must be delivered to the tissue by a contact or noncontact mechanism. Most lasers have a handpiece with a lens attachment. In noncontact laser systems, the lens allows the beam of light to be focused or defocused to a particular spot size (Figure 19-8).

Some noncontact or free-beam laser systems have angled mirrors to direct the beam either at 90 or 120 degrees. Surgery in the floor of the mouth and other difficult areas is easier when using these mirrors. A thorough safety check must be performed prior to use of the laser to prevent any unexpected or deviant direction of the laser beam. Prior to each use the operator should confirm that the laser beam is coincident with the aiming beam when using a noncontact handpiece laser system. Free-beam surgical lasers have also been included into the surgical microscope. Free-beam lasers have been used in various capacities through the operating microscope to aid in dissection and, recently, anastomosis techniques.

Contact laser systems offer the advantage of tactile sense during operating. Because touch is a major feedback mechanism of surgical technique, some surgeons feel more comfortable using contact systems. For example, some Nd:YAG lasers have a handpiece with specially designed, interchangeable sapphire or ceramic tips. The tip is heated when the laser is activated, enabling tissue to be cut and coagulated simultaneously with a precise "light-powered scalpel." These tips come in a variety of shapes and sizes. When precise cutting or ablation of an area is desired, the appropriate handpiece tip is selected. This offers some flexibility for different surgical goals.

Asymmetric crystals can be used to modify the emitted photons and can double, triple, or even quadruple the wavelengths of the laser source. There are now tunable liquid dye lasers that can be tailored to a desired wavelength based on the dye medium that is used.

The exposure time is the amount of time the operator keeps the laser light directed at the tissue. Exposure time varies with each delivery system and is commonly manipulated by choosing either continuous-wave, pulsed, superpulsed, ultrapulsed, flash-scanned, or Q-switched mechanisms. In the continuous-wave laser the beam does not fluctuate with time. It produces a uniform flow of radiation as the operator activates the laser and directs the beam. When tissue is exposed to laser energy, there is peripheral damage to surrounding tissues caused mostly by heat. The amount of peripheral damage is predominantly time dependent. When the exposure time is kept short, there is insufficient time for the thermal energy created to be conducted beyond the target tissue, limiting the amount of peripheral tissue damage. Table 19-1 shows the tissue changes seen with increasing temperatures created with laser energy.

Unlike continuous-wave lasers, pulsed lasers deliver photons in the form of single pulses or trains of pulses. The rate of pulsing is measured in pulses per second. The pulse width

TABLE 19-1 Temperature Effects of Laser Energy on Tissues

Temperature °F	Tissue Effect
37-60 °F	Tissue retraction and conformational protein changes
>60 °F	Protein denaturation and protein coagulation
90-100 °F	Tissue carbonization and tissue char
>100 °F	Tissue ablation

is defined as the time required for the pulse to rise from zero intensity to maximum intensity and return to zero again. The average power generated by a train of pulses is determined by the pulse power multiplied by the pulse repetition rate and the pulse width. The time allowed for the energy to be absorbed by the target tissue and dissipate is the tissue relaxation time. Understanding the concept of relaxation time is extremely important in order to achieve selective tissue destruction with the least amount of peripheral tissue damage. For tissues such as skin, blood vessels, and muscle, the tissue relaxation time can be calculated. Based on this value, if the pulses generated are given with enough time for the tissues to relax or cool, energy dissipates before significant damage can be done to the surrounding tissues.[9] In other words, when quick enough pulses are created, a lower amount of peripheral tissue damage occurs.[10]

Superpulsing was introduced soon after conventional pulsing. Lasers that have the ability to superpulse achieve higher peak powers per pulse with even shorter pulse widths than conventional pulsing. This decreases the amount of lateral tissue damage further and makes for even more precise incisions and ablations.

When the fluence, or the energy given to a particular area, is greater than the tissue vaporization threshold, and the pulse width is less than the thermal relaxation time of tissue, the tissue is vaporized with each pulse and no significant thermal damage occurs beyond the site of laser impact.[7] Superpulsing lacks high enough peak powers to reach the vaporization threshold and ablate tissue effectively while still staying under the thermal relaxation time of skin (approximately 700 μs).[9] Modifications of these systems to increase pulse speed created ultrapulsing, which has allowed for specific removal of tissue with even less significant lateral tissue damage than conventional or suprapulsing methods. This technology is commonly used in skin resurfacing procedures.

Similar to ultrapulsing, flash-scanning modifies the laser to control tissue damage by reducing heat diffusion into the surrounding tissues by a different mechanism. This laser uses a continuous-wave which can generate circular patterns of laser energy by using movable mirrors. High energy is delivered to the target tissue for brief periods of time. By minimizing the amount of time the laser is directed at any one tissue area, the lateral thermal damage is reduced. This is because the laser is in contact with the target tissue less than the calculated thermal relaxation time. Like the ultrapulse laser systems, this technology is used for skin resurfacing procedures.[11]

Q-switching or quality switching is a process in which the beam output is controlled by concentrating all of the energy into single, intense pulses of short duration, approximately 25 nanoseconds. These bursts are achieved with an extremely fast electromagnetic switch in the laser cavity that allows the excitation of the active medium to build up with the shutter closed. The shutter is opened when the energy reaches a maximum, and a brief, powerful pulse, or series of pulses, is released.[12] This form of pulsing has been particularly useful in the treatment of the nevus of Ota, which is described later in this chapter.

Laser Safety Considerations

The laser as a surgical instrument must be used with caution. It poses a safety risk to the patient and to the operating room personnel.

In the United States, laser safety guidelines are created by the American National Standards Institute (ANSI). The current laser safety guidelines are ANSI Z136.1–2007, and the health care specific guidelines are ANSI Z136.3–2011.[13,14]

Most hospitals require evidence of training in laser use and safety measures in order to grant laser use privileges to surgeons. Although each institution should have its own regulatory committee for the safe use of lasers, there are certain basic safety considerations that must be considered universally no matter which setting the laser is used in.

Medical lasers are regulated by the U.S. Food and Drug Administration (FDA). Lasers are classified into four risk categories (I-IV). Class I lasers are safe under all conditions, they have very low power and can be found in devices such as CD players. Class II lasers are also considered safe to eyes because the blink reflex is able to limit the exposure; they can be found in laser pointers. Class III lasers can cause retinal damage but indirect reflections should be safe. Class IV lasers can cause ocular injury or fire even if they're reflected off a matte surface.

The risks associated with laser use can be classified into three categories: atmospheric contamination (laser plume), gas embolism, and inappropriate energy transfer. The most serious adverse events arising from the intraoperative use of lasers when performing procedures in the head and neck area are airway fires or surgical drape fires.[15] The risk for personnel in the room is retinal damage that may lead to permanent blindness due to the globe's ability to concentrate the beam and pigment content that would absorb the visible wavelengths.

Laser plume can contain toxic gases, combustion byproducts, and cellular debris (dead and alive). The mutagenic potential of the plume from the CO_2 laser on 1 g of tissue is equivalent to the inhalation of three unfiltered cigarettes.[16] It can also contaminate the atmosphere with viable infectious microorganisms and viral DNA from human papilloma virus (HPV).[17-20]



• **Figure 19-9** **(A-C)** Corneal shields and **(D)** laser goggles for patient use. (**A-C** from Niamtu J: *Cosmetic facial surgery*, St Louis, 2011, Mosby. **D** from Convissar RA: *Principles and practice of laser dentistry*, ed 2, St. Louis, 2016, Elsevier.)

Although evidence for transmission to humans is weak and there have been no documented cases of transmission of infectious disease in the OSHA databank, the potential threat still justifies taking precautions with smoke evacuator suction units located within 1 cm of target site and high-filtration masks.

The gas content for laser tip cooling in some laser systems has been reported to cause serious and sometimes lethal venous embolisms when performing hysteroscopic, laparoscopic, tracheal, and nasal surgical procedures.[21-24]

The direct laser beam or its reflection off a surface can cause serious injuries to unintentional targets within the operating room. Perforation of viscera or large bore blood vessels and the creation of pneumothoraces have been reported when the depth of tissue injury exceeds that of the intended treatment area. Severe ocular injuries can occur where the blink reflex is too slow to guard against laser injuries and the laser has sufficient power. Patients' eyes must be taped closed and covered with saline-based opaque materials or covered with metal shields.[25] Protective eyewear for personnel in the room needs to be color-specific for the type of laser being used and have side shields. Eyewear should also be hung next to the warning signs at each entrance to the surgical area. For each wavelength there are specific protective glasses to prevent laser injury to the eye. Each pair of glasses is marked with the wavelength and type of laser with which they are used. All eyewear should be examined for cracks or scratches and replaced if these defects are present (Figures 19-9 and 19-10).

It is estimated that about 550 to 650 surgical fires occur every year. This is a low number considering the nearly 65 million annual surgical cases. Most of these fires occur in the airway (34%) or the head and face (28%).[26] The potential for fire ignition increases with the presence of an oxygen- or nitrogen-rich environment, therefore the team must ensure the lowest possible FiO_2 (fraction of inspired oxygen) during the use of a laser beam; it is generally accepted that the FiO_2 has to be lower than 0.3 to appropriately reduce the risk of fire. Similarly, the use of nitrous oxide (N_2O) must be completely avoided; this gas easily exothermically dissociates, releasing energy and free oxygen.[27] Helium mixed with oxygen is used in some systems, and it is commercially available for use in laser cases.

The fuel sources to the OR fires are more commonly the endotracheal tubes, drapes and towels, alcohol-based prep



• **Figure 19-10** Operator goggles with side shields. (From Busch S: *Small animal surgical nursing*, St Louis, 2006, Mosby.)



• **Figure 19-11** Stainless steel laser endotracheal tube. (From: Goyer S, Palte H: Ophthalmology and otolaryngology. In Miller RD, Pardo MC Jr: *Basics of anesthesia*, ed 6, Philadelphia, 2011, Saunders.)

solutions, phenol-based chemical peel solutions, and some hair or skin products such as makeup.

When intravenous sedation is indicated, the patient should receive only non-oxygen-enriched air through face mask or nasal cannula. If the patient requires supplemental oxygen to maintain adequate oxygen blood saturation, the general recommendation is that the patient should be intubated with an ETT or an LMA should be placed. During a general anesthetic for nonairway surgery the goal is to incorporate several strategies: ventilating through a cuffed or tightly fitting ETT, using laser-resistant tubes, filling the cuff with saline instead of air, and using water-soaked sponges around the tube at the site of work and at the glottis.[28]

Standard polyvinylchloride (PVC), red rubber, and silicone ETTs have been studied for their flammable properties and all of them have been shown to allow ignition and behave as blowtorches when being used with a CO_2 laser. Laser-protective metallic adhesive materials have been used in the past and have now been replaced by FDA-approved laser-resistant endotracheal tubes. These tubes are either made of metal or are nonmetallic with a metal reinforcement (Figure 19-11). Each one of the commercially available tubes is approved for a specific type of laser and they are not indestructible, therefore precautions must be taken universally with laser use.[28]

The nominal hazard zone (NHZ) is defined as the surgical area in which the laser is used and could potentially cause injury or damage, usually related to eye exposure. This zone can vary in size from the entire operating room to a defined square-footage around the laser unit itself. Calculating the NHZ is beyond the scope of this chapter but it is often supplied to the consumer by the laser manufacturer. The NHZ is determined by looking at the wavelength of light, the maximum power, the type of delivery system, the diameter of the beam, and various other physical characteristics of the light produced. The greater the calculated NHZ zone, the greater the probability that injury can occur. A continuous-wave carbon dioxide laser that produces a focused beam of light is more likely to cause injury than a Nd:YAG laser with a sapphire tip that requires contact for the laser to cause tissue damage. Consequently, the carbon dioxide laser would have a larger NHZ compared with the Nd:YAG laser. The NHZ should be plotted out around the laser, and safeguards should be put in place based on this zone to prevent injury. For simplicity, many operating rooms define the NHZ as the space within the four walls of the room in which the laser is being used. Signs should be posted at all possible entry points warning passers-by and people potentially entering the room that laser safety precautions must be adhered to. These signs should state the wavelength and type of laser being used.

One person who works in the environment should be designated as the laser safety officer. This person should be familiar with all of the standards of laser safety and is charged with enforcing the standards of laser safety in the operating room. The laser safety officer also has the responsibility of updating the safety precautions should any new recommendations arise. The entire staff must have a firm understanding of the importance of laser safety.[28]

The laser system is required to have certain safeguards built into its design. One of the most important safety aspects of the laser system is the use of a key to turn on the laser. Keys to the laser should be kept in a standard, safe location at all times not left in the laser. The laser can be operated only by authorized personnel by using the key. This helps to prevent others who are not certified in laser operations and safety from gaining access to the laser.

Another safeguard present in all surgical laser systems is a self-testing protocol that automatically activates when the laser is turned on. This system self-checks the programming connections and integrity of the laser system prior to use each time the laser is turned on. However, some manual tests still need to be performed. If there is an aiming beam, such as the helium-neon aiming beam of the carbon dioxide laser, the precise direction of the aiming beam must be

correlated with the invisible carbon dioxide beam. This can easily be tested by wetting a tongue depressor and performing several test pulses on a side table to correlate the beams. This should be done before every procedure using the laser.

Visual inspection of the electrical cords, pedal, and all exterior mechanical parts should be done regularly to ensure integrity of the system. Any damage or defects should be repaired immediately. To prevent electrical injuries, no solutions should be used or spilled near the cables.

When preparing the patient for surgery, no alcohol-based preparation solutions should be used in order to prevent ignition and severe burns, and if they must be used one should allow for sufficient drying time. Wet towels and gauze are used to drape the patient, and they should be moistened throughout the procedure to prevent ignition of the drapes by the laser. An open basin of sterile water with an irrigating syringe should be available in case a fire should develop. Other fire precautions include never placing hot fiberoptic cable or handpieces on the drapes. A nonreflective basin can be used for storage while the components are still hot. Of course, a fire extinguisher should always be readily available.

There is probably no other anesthesia emergency that requires a more rapid and correct response than an airway fire. If a fire occurs, the procedure must be stopped immediately. There should be no hesitation to remove the endotracheal tube and sponges around it and stop the flow of all gases. Additionally, saline should be poured into the airway. If this does not stop the fire, a CO_2 fire extinguisher should be used and the fire alarm needs to be activated.

Finally, all surgeons using a laser should have current certification based on state, local, and hospital guidelines. Certification should be obtained for each type of laser being used, and continuing education courses should be attended at regular intervals. Nursing and assistant staff should have in-service and continuing education seminars to ensure compliance with all laser safety guidelines. These sessions should include hands-on experience with the surgical laser systems and updates on new safety implementations.

Clinical Laser Systems

Many laser systems are on the market, each with its own benefits and drawbacks. This section describes the basic components of surgical lasers and discusses the types of surgical lasers and their uses in treating various pathologies.

Carbon Dioxide Laser

The carbon dioxide laser emits light in the invisible mid-infrared portion of the spectrum at a wavelength of 10,600 nm. It was developed by Patel in 1964 and has been the dominant laser in surgical use thus far.[29] This laser uses a mixture of carbon dioxide, nitrogen, and helium as its medium. The medium is usually excited by a high-voltage electrical current.

Because the photons from this laser cannot be transmitted in a fiberoptic cable, it is necessary to use an articulated arm or hollow waveguide to deliver the beam to one of the available handpieces. Since the carbon dioxide beam is invisible, a red helium-neon laser is often used in parallel, or in near parallel, as an aiming beam. As will be addressed in the section on laser safety, it is always necessary to verify that the active laser is directed at the same area as the aiming laser.

The carbon dioxide laser can be delivered in several modes. When the continuous-wave mode is chosen, the laser delivers a constant beam of energy as the operator steps on a pedal. Regular pulsing modes are also available, in which the operator can set the number of pulses per second. Superpulsing, ultrapulsing, or flash-scanning is also available on some models, with the delivery of short, high-powered pulses. These pulse energies can be many times greater than the continuous-wave output, allowing the surgeon to make cleaner incisions with reduced peripheral tissue damage.[10] The carbon dioxide laser is commonly used for excision and ablation of various types of superficial lesions and for skin resurfacing.[11] Because the chromophore that absorbs the carbon dioxide wavelength is water, the carbon dioxide laser is the most commonly used laser in the oral cavity. The depth of penetration can be as shallow as 0.2 mm, with very little scatter, reflection, or transmission. Therefore, the carbon dioxide laser is extremely effective and the most commonly used laser by oral and maxillofacial surgeons.

Argon Laser

The argon laser was developed at Hughes Aircraft Research Laboratories by Bridges in 1964.[30] The conventional argon laser delivers a green-blue light beam in the 488- or 514-nm range. The argon gas medium is activated by electrical current. Unlike the carbon dioxide laser, this laser can be used with a fiberoptic cable and handpiece. It can be used in the continuous-wave or pulsed mode using contact or non-contact delivery systems. Because the argon beam is highly absorbed by hemoglobin, it is an excellent hemostatic laser and can also be used to excise gingival soft tissue lesions. It is also effective in the treatment of some superficial vascular hemangiomas (port-wine stains). In the past it was used for the removal of some tattoos, but it caused an unacceptable amount of hypertrophic scarring, especially in children.[31,32] Other lasers have supplanted the argon laser for most of its indications.

ND:YAG Laser

Developed by Geusic and coworkers in 1964, with a wavelength of 1064 nm, the neodymium:yttrium-aluminum-garnet (Nd:YAG) laser emits light in the near infrared area of the spectrum.[33] A flashlamp is used as the energy source to activate a Nd:YAG crystal. This system uses a fiberoptic cable to deliver the light to a conventional handpiece and uses a lens to produce a free beam of laser light.

As in the carbon dioxide laser, an aiming beam is needed, as this laser produces invisible light. This laser can also be used with specially designed sapphire or ceramic tips and used as a contact laser scalpel or ablation tool, with excellent hemostasis and cutting abilities.[34] The Nd:YAG laser is available in continuous-wave, pulsed, or Q-switched modes and is excellent for the treatment of vascular lesions and intraoral and extraoral pigmented lesions and for achieving hemostasis. Pulse widths as short as 10 nanoseconds can be achieved when using a Q-switched delivery system. The Nd:YAG laser has also been used in open TMJ arthroplasty, malignant lesion excision, black and blue tattoo pigment removal, and experimental treatments for periodontitis.[35-39]

This laser system has been associated with venous gas embolism complications because of the gas coolant used for the laser tip.[24]

HOL:YAG Laser

The holmium:yttrium-aluminum-garnet (Hol:YAG) laser emits laser light at 2140 nm in the infrared region of the spectrum. Because its laser light is invisible, an aiming beam is used. As in the Nd:YAG laser, a crystal is used as the laser medium, as well as an aiming beam. The Hol:YAG laser system uses a fiberoptic cable to deliver laser energy in the pulsed mode. This laser can be used in both noncontact and contact mode. Interestingly, it works well in a water medium and is absorbed well by synovium and joint surfaces. The Hol:YAG laser has been extensively used in endoscopic orthopedic surgery. It is also extensively used in the TMJ for lysis of adhesions and sculpting of fibrocartilaginous disc tissue.[40,41] The Hol:YAG laser has also been used experimentally in oral lesion ablation and gingival surgery.[42]

ER:YAG Laser

Recently, the use of the erbium:YAG (Er:YAG) laser for facial resurfacing and incision and ablation of soft tissue has been introduced. This laser operates at a wavelength of 2940 nm via an articulated arm. This technique has not undergone long-term studies or proved to be more effective than carbon dioxide techniques currently used. Prospective trials are under way that compare this new modality with current methods. The presumed advantage of the Er:YAG laser system is its ability to remove superficial skin layers even more precisely than the carbon dioxide laser, thereby causing less adjacent tissue damage. Combined Er:YAG–carbon dioxide laser systems are now available that claim to decrease the amount of tissue damage relative to carbon dioxide laser systems alone. This theoretically allows reorganization of collagen with less total energy, quicker healing times, and decreased incidence of prolonged erythema.

KTP Laser

This laser is a modified version of the Nd:YAG laser. With the addition of a frequency-doubling crystal, this laser emits light at the 532-nm wavelength, or half the wavelength of the Nd:YAG. This system usually utilizes a fiberoptic cable with a handpiece. Its absorption is similar to that of the argon laser and has been used in the treatment of vascular and pigmented lesions, tattoo removal, blepharoplasty, and some endoscopic procedures.[43]

Q-Switched Ruby Laser

The Q-switched ruby laser produces visible, pulsed red light at the 694-nm wavelength. This red light is absorbed well by melanin and green and blue-black pigments. Pulse widths as small as 20 nanoseconds can be achieved with currently available systems. Fiberoptics can be utilized with a handpiece to treat some pigmented lesions and tattoos effectively.[44-46] Multiple sessions are required for these procedures, but this laser is remarkably effective in removing pigmented lesions and blue and black tattoos with minimal scarring. The slightly longer wavelength allows for greater depth of penetration and is more effective in the removal of deeper lesions The nevus of Ota has been successfully treated with this laser with excellent results.[47-50]

Flashlamp-Pumped Pulsed Dye (FLPPD) Laser

This laser produces yellow visible light in the 400- to 1000-nm range and is most commonly tuned at 510, 577, or 585 nm. The specific wavelength desired is determined by the dye chosen. The desired wavelength can be tuned to the specific tissue to be removed, offering great flexibility. For example, at 510 nm the chromophore melanin can be targeted and various benign melanin-containing lesions can be ablated, whereas at 585 nm the laser selectively targets oxyhemoglobin within vascular abnormalities. This versatile laser is used in treating many pigmented and hemopigmented lesions, scar revision, achieving hemostasis, photodynamic cancer therapy, ablation of salivary gland and kidney stones, and tattoo removal.[51-53]

Copper Vapor Laser

At wavelengths of 511 and 578 nm, this laser is similar in specificity to both the KTP and argon lasers. Its medium is highly heated copper, which produces copper gas. The light produced by this reaction is delivered down a fiberoptic cable in the pulsed mode. It is effective in treating hemangiomas, such as port-wine stains, or large superficial telangiectasias, and it has also been used to ablate some pigmented lesions such as lentigines, ephelides, lentiginous nevi, and tattoos.[54,55]

Excimer Laser

These lasers emit ultraviolet light at 193 to 351 nm, using halide gases for a medium. The name is short for "excited dimer." In this system electrical current charges halide gases to excite photons. This laser uses fiberoptic cable to deliver

pulsed laser energy. It is currently used for keratotomy to reshape corneal tissues and correct poor vision. There has been debate about its safety and concern regarding the environmental byproducts of the laser and their possible toxic and carcinogenic effects.[56]

Alexandrite Laser

This Q-switched laser produces red light of 755 nm from a crystal of alexandrite and uses a flexible waveguide. It is well absorbed by green, black, and dark-blue pigments. The long wavelength allows for deep penetration, allowing it to be used for the treatment of pigmented lesions that extend deeper into the dermal layer. This laser is used in the lightening of congenital nevi, but this technique is not recommended by many surgeons because of the possibility of malignant degeneration. The Q-switching mechanism produces a high intensity pulse of 50 to 100 nanoseconds that is used effectively in the removal of tattoos with blue, green, and black pigments.[57-59]

Surgical Laser Technique

The laser may make certain procedures easier, but only in the hands of an experienced surgeon who understands the concepts of laser light and its interaction with tissue. Lasers are superior to many other modalities in surgery when basic principles are adhered to during their use. The goal of laser surgery is to excise or ablate the target tissue with as little damage to surrounding tissue as possible. In other words, the surgeon wants to maximize tissue removal while minimizing thermal injury. Understanding the principles of heat dispersion based on the wavelength, power, and duration of action is essential for determining the technique for a given situation. In some cases, using multiple lasers and techniques can be helpful when the need for excision, hemostasis, and ablation demands different wavelengths to achieve an optimal result. As in all surgical endeavors, careful planning always pays off, and the right choice of laser is of paramount concern.

Because the carbon dioxide laser system is most often used in oral and maxillofacial surgery, most of the examples here include surgical techniques using this laser. Although techniques vary between different laser types, delivery systems, and even manufacturers, the basic principles of laser surgery can be applied to all lasers. Individual laser manuals have guidelines for use with specific recommendations about power densities, spot sizes, and techniques. Manufacturer guidelines should be read thoroughly prior to the use of any laser system. New standards of care are rapidly introduced in the field of laser surgery, and the clinician must be aware of the most current treatments and techniques available.

Basic techniques using the free-beam laser for photocoagulation, incision, and ablation are discussed in the following sections, with descriptions of techniques for many types of pathology. Contact laser techniques are also discussed, with emphasis on their particular attributes.

Photocoagulation Techniques

The carbon dioxide laser can be used to coagulate or photoablate vessels smaller than 500 μm in diameter. Larger vessels are usually better managed with electrocautery or suture ligatures. The laser is used in a defocused mode to a spot size of approximately 2 mm with a power density less than 5 W. Direct pressure on the area is helpful in stopping some of the blood from filling the bed of the wound. Because the carbon dioxide laser is absorbed readily by water, the area must be relatively dry for effective coagulation of the vessels. Pools of blood will absorb nearly all of the energy before the vessel itself is coagulated. Simply wiping the wound prior to lasing should allow the surrounding connective tissue and the vessel itself to be lased using a crisscross or circumferential pattern. This is accomplished using a continuous or pulsed beam. Increasing the exposure time heats the tissue to critical temperatures needed for hemostasis. If bleeding persists, however, other methods of hemostasis should be employed.

Other lasers with beams that are more specifically absorbed by hemoglobin (such as those of the Nd:YAG or KTP laser) can be used. Because hemoglobin is a major chromophore for these types of lasers, blood components are directly lased, and the surrounding vessel is damaged by collateral heat after being initially coagulated. The crisscross or circumferential pattern can be used in a defocused mode with these lasers. Contact lasers can be used by keeping the ceramic or sapphire tip in contact with the bleeding area for a slightly longer period of time. Again, electrocautery or suture ligature techniques should be used for larger blood vessels.

Incisional and Excisional Techniques

The carbon dioxide laser is a superb light scalpel. This laser offers several advantages in incisional biopsy techniques when compared with scalpel surgery. The nearly bloodless field allows for excellent visualization of the specimen during surgical removal, aiding in obtaining discrete margins and minimizing damage to adjacent structures. The laser also tends to produce less postoperative bleeding, pain, and scarring than does scalpel surgery. Many lesions do not need suturing after being excised with laser techniques.

An important point to consider in biopsy technique with lasers is the lateral zone of thermal necrosis. Usually an extra 500 μm of margin is required around the lesion to account for the laser's effect on the adjacent tissue. This zone of necrosis is generally less than 500 μm when using the carbon dioxide or contact Nd:YAG laser. Pogrel and colleagues determined this layer to be anywhere from 5 to 100 μm in width, with an average thickness of 86 μm.[60] Some pathologists will have difficulty interpreting the specimen if the laser margin is too close to the lesion. Free-beam Nd:YAG lasers tend to have larger zones of thermal necrosis than carbon dioxide or contact Nd:YAG lasers. This occurs because the effective penetration of the longer wavelength present in the free-beam Nd:YAG

laser can be 3 to 5 mm deeper than the carbon dioxide or contact Nd:YAG laser. Therefore, the free-beam Nd:YAG laser is not ideal for intraoral biopsy techniques. This is less of a problem with the contact mode. Specially designed tips of the contact Nd:YAG laser do not normally transmit thermal heat further than 500 μm from the incision line because the energy is concentrated at the sapphire or ceramic tip.

The technique for incisional biopsy is relatively simple. First, topical, local, or general anesthesia is administered as the procedure indicates. Local anesthetic blocks are generally preferred over infiltrations because the water content of the anesthetic solution may change the absorption characteristics of the tissue when using the carbon dioxide laser. The area should be dried prior to using the laser to increase the accuracy of absorption of the energy. The area of the biopsy can be marked with a marking device or, more commonly, can be outlined with the laser. Some violet or blue marking pens may interfere with the tissue absorption of some lasers whose beams are absorbed well by these colors. To outline the specimen, choose a single or slow repeating pulse mode and mark the area of the incision, remembering to include the extra margin necessary when using the laser. Choose the smallest spot size available, to decrease the zone of thermal necrosis around the incision line, and an appropriate energy density based on the tissue being incised. The carbon dioxide laser can usually be set at 3 to 6 W with the smallest spot size. A row of dots can be used to outline the specimen with the desired margin. Standard biopsy techniques are adhered to when deciding what portions of a lesion are to be removed with the incisional technique.

After the specimen has been outlined, the adequacy of the margin should be re-evaluated. The power density is adjusted for the particular tissue, and the incision is made to the desired depth. The tissue is undermined as needed, using a forceps to hold the specimen away from the bed as the incision is advanced. Gentle tension on the specimen with a forceps is used to deliver the lesion as it is surgically removed. Care should be taken not to lase the previous incision areas, as char will accumulate, causing increased heat and more lateral tissue damage. If char does accumulate, it may be wiped away with a moist sponge. Another common mistake is not advancing the laser handpiece into the wound site as the incision gets deeper. If the handpiece stays in the same position, the distance increases and the beam becomes defocused as the incision site becomes deeper. Advancing the handpiece into the incision keeps the spot size (and distance) constant.

As the specimen is removed, remember to be aware of adjacent structures that may be injured by changing the direction of the laser beam. The laser beam must always be aimed into the lesion, and adjacent structures and anesthesia equipment must be properly protected. Hemostasis is achieved if necessary with the techniques described previously. Many lesions can be left open; however, if they are sutured, an extra 2 days should be allowed for healing because the laser impedes epithelial migration. The specimen should be handled in the usual manner, and the pathologist informed of the use of the laser.

Ablation or Vaporization Techniques

One of the great advantages of the laser is its ability to ablate or vaporize lesions layer by layer. This not only has many applications for removing discrete benign lesions, but is also particularly useful in eradicating multiple, diffuse lesions of the oral cavity. A defocused laser has the ability to remove lesions layer by layer to the desired depth quickly and without the scarring and contraction seen with other surgical maneuvers.[61] Conservative tissue sculpting with minimal excess tissue removal can be achieved quickly and cleanly. However, a disadvantage of this technique is the eradication of the specimen for histologic examination, requiring that all lesions being considered for ablation be sampled for biopsy prior to removal. Only the rare lesion that is known to be benign by history and physical examination, and/or biopsy (e.g., small capillary hemangioma or amalgam tattoo) can be removed by ablating without biopsy.

The technique for ablation of lesions is also relatively simple. An anesthetic plan is implemented as indicated by the type of procedure and the size of the lesion. The laser is defocused to a spot size from 0.5 to 3 mm, depending on the size of the lesion. This maneuver decreases the power density given to the tissue and allows for removal of superficial layers of tissue. Generally, 5 to 10 W of power on the carbon dioxide laser is adequate for efficient and controlled ablation of a lesion layer by layer. Higher powers are required for larger lesions if larger spot sizes are to be used. The continuous mode or regular pulsing is often used, but superpulsing or ultrapulsing may be used as well. Quicker pulsing, as described previously, allows for higher energies to be delivered to the target tissues with less collateral damage. Pulsing that is too slow causes skip areas that can result in nonuniform removal of the lesion. The lesion is outlined as in the excisional technique. A systematic and geometric pattern is then made over the lesion. Crisscrossing patterns of horizontal, vertical, and oblique lines can be used while clearing the wound of char between passes. Making a pattern ensures that the lesion is removed equally in all regions. This pattern is continued until the lesion is completely removed to the desired depth. Smaller lesions can be done with single pulses and a smaller spot size to increase accuracy. Intraoral lesions heal remarkably well with little postoperative care. Depending on the specific procedure, skin lesions can be dressed, if desired, with a small amount of antibiotic ointment and sterile gauze or other dressing. Lesions that tend to recur, such as lichen planus, can be treated multiple times without the great degree of scar contracture seen with scalpel excisions or other modalities.

Contact Laser Techniques

The contact laser has several advantages over the traditional free-beam or noncontact laser. The Nd:YAG and Ho:YAG lasers are commonly used as contact lasers. The biggest difference is the surgeon's ability to gain tactile feedback from the handpiece while operating. Some surgeons find the

free-beam laser technique difficult at first because of the lack of feedback. The specially designed tips of contact lasers allow for transmission of laser energy to the tissue directly from the tip surface. The beam diverges rapidly from the end of most tips, so the effect of the laser is concentrated to just around the tip surface. There is less tissue penetration and less collateral tissue damage when compared with some free-beam lasers. This is helpful when the surgeon desires to incise or ablate tissue without damaging any adjacent structures that would be harmed by free-beam penetration, such as in the lysis of adhesions within the TMJ. Contact lasers that have wavelengths that are well absorbed by oxyhemoglobin are well suited for the excision of some lesions with increased vascularity.

Another one of the benefits of contact laser surgery is the utilization of the wavelength conversion effect. When contact laser tips are manufactured with a slightly absorbent coating, an extremely large amount of heat energy can be created directly at the tip. The laser energy is converted to heat energy directly at the tip of the handpiece, which removes the dependence of absorption of the tissue. With a change of the tip, the laser is no longer dependent only on its wavelength to create an effect, as a very high temperature is created at the tip of the handpiece. This heat can be used to incise or ablate a wide variety of tissues. On the other hand, when a less absorbent tip is used, the normal absorption characteristics of the laser are restored and tissue selectivity is available in a contact form. This alleviates some of the need for multiple lasers in a single case. Further study is needed to evaluate the efficacy of these laser systems in specific procedures, but these systems may alleviate the need for multiple, expensive laser systems.[62-64]

Wound Healing After Laser Surgery

Wound healing after laser surgery has received much attention since the first applications of the surgical laser. Most studies dealing with oral and maxillofacial laser wounds have examined the carbon dioxide laser. Many attempts have been made to qualify and quantify the dynamics of healing after a laser is used on a variety of tissues. Many of the data are conflicting and not of significant statistical power to be compelling. There have been many reports comparing wound healing after the use of lasers versus that with other modalities. Laser wounds are thought by many to produce less postoperative pain, although this has yet to be convincingly documented in the literature.

As mentioned in the discussion of tissue interactions, the typical laser wound is created by multiple mechanisms. Mistakenly thought of as a burn, the laser-tissue interaction actually involves many cellular and subcellular events other than heat damage. There is vaporization of intracellular fluid that helps disintegrate cell structure almost instantaneously, and the subcellular structures are often vaporized as well. This likely occurs without the normal cascade of cytokines seen in acute inflammation. Slower healing due to delayed epithelial migration and decreased scar formation (possibly due to changes in collagen conformation at the wound surface) have been observed by many investigators. Nerve endings have been shown to be histologically sealed, lending some evidence to claims of decreased postoperative pain in these patients—although this finding has been disputed in the literature.[65,66] Decreased postoperative pain in these patients may also be due to an altered inflammatory response in laser wounds. The finding of fewer myofibroblasts at wound edges after laser surgery has been postulated as the reason for the lessened scarring and contraction seen, although this too has been questioned by some authors.[66-71] Evidence suggests a possible role for the helium-neon laser in accelerating wound healing of scalpel and laser incisions.[72-77]

Intraoral Laser Procedures

Incisional and Excisional Procedures

Gingivectomy, Operculectomy, Frenectomy, and Tuberosity Reductions

Lasers can help avoid the elevation of large flaps and limit the inflammatory response, all increasing patient comfort. Compared to scalpel excisions, excision with lasers is thought to have less scar contracture.[78] The CO_2, diode, and ND:YAG lasers are all commonly used in removal of gingival tissue.[79] The CO_2 laser is extensively used due to its multiple advantages in soft tissue procedures including hemostasis and minimal thermal damage to adjacent tissue. The reduction in postprocedure bacteremia is also seen with the carbon dioxide laser over more conventional methods of incision or excision.[80] It is extremely important to know the wavelength of the specific laser that is being used and the tissue that is being excised. For example, the carbon dioxide laser has a wavelength of 10.6 nm and is primarily absorbed by water. The diode and ND:YAG lasers function at a wavelength near infrared and are therefore, minimally absorbed and have a greater depth of penetration. These lasers will be especially useful in hyperemic or vascular gingival tissue.[81] For incisional or excisional procedures the lasers are used in the focused mode, maintaining a small spot size.

The carbon dioxide laser is particularly well suited for removal of gingival tissue. Most gingival surgery can be performed quickly in a bloodless field and with very little postoperative pain. Gingivectomy may be indicated to decrease periodontal pocket formation or to reduce hypertrophic gingival areas due to poor oral hygiene or medications such as calcium channel blockers, Dilantin, or cyclosporin. The beam is focused using the smallest spot size, and a power is selected. Most continuous-wave lasers can be set at 2 to 10 W to remove gingival tissue effectively. A similar incision design, external bevel, that is used during conventional gingivectomy should be used when completing a gingivectomy with a laser. The specimen is excised and hemostasis is obtained using the photocoagulation technique. Massive gingival hypertrophy should be grossly debrided first, using the excision method. Proper protection of the teeth

and bony structures can be achieved with tooth guards or any broad, flat surgical instrument that has been rendered nonreflective.

Palliation of pericornitis can be achieved by excising the operculum with the carbon dioxide laser. Removal of this redundant tissue is often helpful in patients who cannot schedule removal of third molars for several months, although patients should be informed of the temporary nature of this procedure. Antibiotics are prescribed as needed.

Removal of a prominent frenum is perhaps one of the simplest, quickest, and most effective procedures a surgeon can perform with the carbon dioxide laser. The area is anesthetized with local infiltration and dried with a gauze. The frenum is incised using a small spot size to lyse the fibrous band. When the tissue band is thicker, the entire frenum should be excised. This is accomplished by grasping the tissue with a hemostat at its inferior and superior attachment. The tissue is then excised by directing the laser along the hemostat beaks. No closure is necessary, and hemostasis is obtained by defocusing the beam using the photocoagulation technique. Patients have little if any postoperative discomfort.

Prominent maxillary tuberosities may interfere with the fabrication of a denture prosthesis and often need to be reduced. When the bulk of the tissue is mucosa, not bone, the laser can be used to excise a wedge of tissue and undermine the flaps in a bloodless field. Bony reduction can be accomplished in the usual manner with a rongeur or rotary instrument. Redundant soft tissue can be excised with the laser, and the incision lines are approximated with sutures. In some cases the excess soft tissue can be ablated to an adequate height. However, this eliminates the possibility of bony reduction, and the surgeon must be very careful not to perforate the mucosa and injure the bone. This will cause bony necrosis in this region and may precipitate an oroantral fistula.

Epulis Fissuratum and Pyogenic Granuloma and Granulation Tissue Excision

Excision of an epulis fissuratum may be performed rapidly without loss of vestibular depth by using the carbon dioxide laser. A small spot size is chosen with a power of 4 to 8 W using the continuous-wave or pulsed modes. Traction is applied to the lesion using forceps, and it is excised along its base. If necessary, the laser may be defocused to photocoagulate the bed, and the wound heals without suture placement. The patient should be warned not to wear the denture for several days, and a soft tissue liner may be used in the area of question after the denture flange has been adjusted. Patients experience little, if any, postoperative pain.

Granulomatous soft tissue masses are vascular lesions that are well suited for excision with the carbon dioxide laser. The Nd:YAG or argon lasers can be used alone or in conjunction with the carbon dioxide laser if desired. These lesions can appear similar clinically to Kaposi's sarcoma or other neoplasms. For this reason, ablation is generally not an option, and the excisional or incisional biopsy techniques are utilized.

The laser is focused with a small spot size. Power settings can range from 5 to 10 W using either continuous-wave or pulsed modes. When excising the entire lesion, the extent of the base can be easily visualized in the nearly bloodless field offered by the laser. The beam can be defocused to obtain hemostasis as needed and to remove remnants of the lesion layer by layer if necessary.

Pigmented Lesions

Pigmented lesions of the oral cavity can occur in many varieties, including traumatic amalgam tattoo, congenital nevi, melanoma, or other pigmented neoplasm. A careful history and physical examination must be undertaken to ascertain if the lesion is primary or metastatic. Lesions certain to be benign by history and examination may be ablated, but only after careful consideration because this technique removes any meaningful attempt at staging should carcinoma arise from the site. The basic excisional technique described previously can be used to remove these intraoral lesions. The carbon dioxide laser is focused maximally, and a power setting of 4 to 10 W is used. The specimen is excised and sent for histologic examination. When performing incisional or excision biopsy procedures it is important to remember that the laser can cause a zone of lateral necrosis, and the incision design should be placed 0.5 mm beyond the normal incision design with a scalpel. Diagrams indicating the exact location, size, and characteristics of the lesion should be present in the medical record and on the submitting form for pathologic examination. A specialist in oral dermatopathology is best suited to evaluate these lesions, which, at times, are difficult to classify and grade.

Mucocele and Mucous Retention Cysts

These lesions are easily treated with the laser. The bloodless field makes it easy to localize the extent of the lesion during excision. The carbon dioxide laser is set with the smallest spot size and a power setting of 4 to 10 W. The continuous-wave or pulsed modes may be used. It is useful to outline the lesion with individual pulses to mark the incision line prior to excision. Only when the lesion's depth has been reached should the surgeon undermine and completely remove the lesion. Adjacent minor salivary glands should be bluntly dissected with a scalpel, scissors, and/or a hemostat and then excised with the laser. This minimizes the chance for recurrence of the mucocele. Photocoagulation can be used to obtain hemostasis. The wound is sutured only if cosmetic closure is needed. Most do not need to be sutured, and most patients have a benign postoperative course.

Implant or Tooth Exposure

The role of lasers in perisurgical implant care has expanded in recent years and is continuing to evolve as lasers become more popular. Initially utilized in the uncovering of fixtures at the second stage of implant reconstruction, lasers are now used in other areas such as preparation prior to placement of osseointegrated fixtures. These techniques must be undertaken with care because of adverse reactions of certain laser

wavelengths with implant fixture materials. Again, a firm understanding of the physics behind tissue *and* fixture interaction with the laser light is essential. The consequences of underestimating the laser–fixture interaction were seen early on while using the Nd:YAG laser on peri-implant tissue. The Nd:YAG laser was shown to have an adverse thermal effect on the fixture, which then destroyed the surface layer of plasma-sprayed titanium.[82] Lasers are relatively contraindicated for use with hydroxyapatite-coated implants because both Nd:YAG and carbon dioxide lasers remove the outer coating and expose the metal core. Simple tissue recontouring can be accomplished with these lasers only when it is certain that the fixture coating will not be exposed.

The carbon dioxide laser is useful in primary or secondary soft tissue recontouring by using the defocused technique. A relatively low power setting of 2 to 6 W is used in the continuous or pulsed mode to sculpt tissue to its desired contour. The low power setting helps avoid unwanted heating of the implant fixture, which may increase failure rates of implant fixtures.[60] The same technique is used for exposing the implant during second-stage uncovering. This allows for premium tissue contouring and a bloodless field. The emergence profile of the implant can be easily optimized when careful tissue recontouring is performed. There is often no need for sutures when using this technique, and patients can often undergo impression procedures on the same day.

The treatment of peri-implantitis is an area of research that is continuing to evolve. Peri-implantitis is a difficult complication to treat. Current methods of treatment of peri-implantitis are topical antimicrobial agents such as citric acid, chlorhexidine, or tetracycline and surgical treatment with mechanical or chemical debridement of the implant surface. The CO_2 laser can also be used to decontaminate peri-implant defects. In a dog model it has been demonstrated that carbon dioxide lasers can effectively decrease contamination and increase bone formation.[83,84] In a study by Tosun et al. it was shown that a CO_2 laser used at 6 W, 20 Hz, and a 10-ms exposure time/pulse with a 10-second application period (0.8-mm spot size) eliminated 100% of the *Staphylococcus aureus* on sandblasted, large-grit, acid-etched surface titanium discs.[85] Diode laser has become more popular due to its lower cost compared to other lasers. The diode laser, like the CO_2 laser, can be used to treat peri-implantitis. The CO_2 and diode lasers have varying bacterial sensitivities based on the bacterial species present.[86] The Nd:YAG laser works well for decontaminating the implant surface, however, it can cause a significant increase in the temperature of the implant and cause changes of the implant surface. Diode lasers and CO_2 lasers have not been found to affect the implant surface.[87]

Exposure of soft tissue impacted teeth can be accomplished with the use of a surgical laser. This is especially helpful in the palate when exposure is needed for orthodontic bonding. In the traditional surgical technique, hemostasis after exposure of an impacted tooth is often difficult when attempting to place an orthodontic bracket. This problem is alleviated when using the carbon dioxide laser because exposure of the tooth using the laser in a defocused mode is essentially bloodless. Alternatively, the contact Nd:YAG laser may be used, but special care must be taken not to injure the embedded tooth with excessive heat from the laser tip.

Lasers can be used during any "surgical extraction" where an incision and a flap is elevated. Again, the benefits of using a laser as opposed to a scalpel will increase hemostasis and can help with decontamination of the surgical site. These properties can be extremely helpful in patients with coagulopathies or poor hygiene resulting in gingival inflammation and irritation. Once a tooth has been extracted the laser can aid in reducing the bacterial load within the socket or surrounding tissue, such as in a patient with pericoronitis.

Apicoectomy

An apicoectomy is used to eliminate periapical disease and can be thought of as a salvage procedure. The CO_2 laser can be used not only for the incision but also to remove the infected periapical tissue, allowing for bacterial decontamination. The CO_2 laser will aid in hemostasis, allowing better visualization of the root apex. Additionally, it has been shown to be effective in preparing the root apex for retrograde filling and can seal dentinal tubules.[88]

Ranula and Sialolith Removal

A ranula present in the floor of the mouth can easily be marsupialized with the carbon dioxide laser using power settings of 5 to 8 W in the continuous or pulsed mode. Tissue forceps are used to grasp the lesion, and the laser is used to outline the dome of the lesion. The base and walls of the lesion are lased in a defocused mode to help prevent recurrence. Sutures are not needed, and a benign postoperative course can be expected. Marsupialization of a ranula is associated with a high recurrence rate, but this procedure may be indicated in some patients who cannot undergo an excision of the sublingual gland, which is the preferred treatment.

The carbon dioxide laser can be used to locate and remove a distal sialolith within the floor of the mouth. First the location of the sialolith is ascertained using a diagnostic modality such as a sialogram or plain radiographs. The carbon dioxide laser is focused at 3 to 5 W in a continuous or pulsed mode to make an incision over the salivary gland duct. Once the stone is encountered directly by the laser beam, a bright spark occurs, thus localizing the sialolith. Sutures are usually not required, and the wound is left open to prevent stricture formation.

Vestibuloplasty

The carbon dioxide laser is useful in performing a submucosal or secondary epithelialization vestibuloplasty. Both of these techniques leave an open bed of surgically altered tissue that can cause postoperative pain and bleeding when performed with standard techniques. Use of the surgical laser ensures a bloodless field and may result in less postoperative pain. Studies showing the success of these procedures in both the maxilla and the mandible are needed to evaluate the degree of secondary contracture and scarring when compared with standard techniques.

Only the initial incision for vestibuloplasty with split-thickness skin grafting should be made with the carbon dioxide laser. This leaves a well-defined edge to suture the graft to once the site has been prepared. The deeper extent of the incision should *not* be made with the laser, however, because the laser inhibits epithelial migration and the total bloodless field does not allow for the much needed inhibition during the first 48 to 72 hours of graft survival.

Laser-Assisted Uvulopalatoplasty (LAUPP)

This technique for the surgical treatment of chronic snoring, upper airway resistance syndrome (DARS), and obstructive sleep apnea (OSA) has been shown to be successful in carefully selected patients. A basic understanding of these disorders is helpful when attempting to use the laser in treating these disorders. Clinicians are referred to any number of excellent resources on the comprehensive management of the continuum of snoring, DARS, and OSA both in this text and elsewhere.

Treatment of these disorders is sometimes complex and may involve several medical maneuvers as well as surgical procedures. Clinicians who wish to treat snoring, DARS, and OSA must have a clear understanding of the consequences of the various treatments for each of these disorders. The procedures for LAUPP in simple chronic snoring, DARS, and mild OSA are described in the following paragraphs, but it is wise for each clinician to have his or her patients consult with a sleep specialist prior to performing LAUPP. Clinicians need to be certain that they explain to patients that OSA is usually multifactorial and performing a LAUPP alone may not cure their disease.

Contraindications to LAUPP include moderate to severe OSA, as these patients may not have the pharyngeal lumen reserve to tolerate postoperative edema. It is for this reason that proper diagnostic tests and consultation are critical when treating any patient with any symptoms of DARS or OSA. Sleep specialists can be helpful in coordinating the staging of treatment and identifying other procedures, such as advancement geniotomies, tonsillectomy, and orthognathic surgery, that may be indicated in select patients.

Diagnosis of snoring, DARS, and OSA includes a careful history and physical examination, including nasopharyngoscopy. Often simple snoring can best be evaluated by asking the patient's sleeping partner to describe patterns and relative loudness of the snoring. The partner may describe apneic episodes, indicating the need for further workup. Additional diagnostic modalities such as cephalometric analysis, polysomnography, computed tomography, and static or functional magnetic resonance imaging may be useful in patients with DARS or OSA. Causes of and contributing factors to snoring, UARS, and OSA include obesity, muscular laxity, alcohol and central nervous system depressant use, smoking, hypothyroidism, macroglossia, and some craniofacial abnormalities. When surgical intervention is considered an option, the success rates have often been better than 75% for simple snoring.[89-92]

The uvulopalatopharyngoplasty for the treatment of snoring was introduced by Ikematsu in 1964. It required general anesthesia, was commonly associated with postoperative velopharyngeal insufficiency, and caused significant postoperative pain.[93] In the late 1980s in France, Kamami developed LAUPP. This was found to be a simpler procedure with fewer postoperative sequelae, and it has gained popularity since its introduction. LAUPP is best suited for the patient with simple chronic snoring.[91] The procedure is described in one-stage and multistage techniques. Some patients may not tolerate the one-stage technique because of the increased postoperative pain and recovery time, but many patients and clinicians prefer it to the three to five visits required in a multistage technique. It should also be noted that the tonsils can be ablated using the laser, which causes a reduction in size of the tonsils and may not require removal if the upper airway space has increased.[94]

It should be noted that patients who are vocalists, wind instrument musicians, or professional speakers should be made aware that characteristics of their voice or their ability to produce sound from a musical instrument may be permanently altered. Certain dialects rely on specific sounds made by using the uvula in a specialized manner, and any change in the turbulence of airflow can change the production of sound. This procedure is avoided in patients with clefts or others who are at risk for velopharyngeal insufficiency. Patients should be evaluated for occult or standard submucous cleft palate. These may be relative or absolute contraindications for some patients; therefore, a specific informed consent should be designed to address these concerns.

This procedure can be done in an office setting with local anesthetic, eliminating the need for an overnight admission to the hospital after an uvulopalatopharyngoplasty in the operating room.[94] This helps to decrease health care costs for the patient. To perform the procedure, the patient is placed in a comfortable, upright position. Topical anesthetic spray is applied to the nostrils and posterior oropharynx, including the palate. Once the topical anesthetic becomes effective, approximately 1.5 mL of 2% lidocaine with 1:100,000 epinephrine is injected into the uvula at its base and the junctions of the soft palate. The carbon dioxide laser is by far the most frequently used laser, but some clinicians prefer the Nd:YAG contact laser system or the argon laser system. A specially designed handpiece with a backstop is used on a carbon dioxide laser system in conjunction with a high-speed suction evacuation system. A standard handpiece may be used, but some form of protection, such as a tongue depressor, must be present beyond the palate to protect the posterior pharyngeal wall from injury. Because the tissue is thick in this region, the laser is set in the focused mode with a power of 8 to 20 W in the continuous or pulsed mode.

In the multistage technique, the inferior half of the uvula is ablated or excised, being careful to have the patient exhale while lasing to prevent inhalation of the plume. Vertical incisions of approximately 5 to 10 mm just lateral to the uvula are made through the thickness of the soft palate. If desired, the tonsillar pillars can be decreased in prominence

with the laser to further increase the size of the airway. However, it is recommended that clinicians do not ablate the tonsil because significant bleeding can occur.

In the one-stage procedure the lateral vertical cuts are initially made in a longer fashion. These vertical incisions terminate just prior to the insertion of the levator palatini muscle, which should be marked prior to surgery. Once these incisions are made, the uvula is reduced to a normal presurgical length measured from the new base.[95]

Postoperative care is identical for both techniques and involves prescribing analgesics, smoking cessation, and a soft diet with avoidance of hot or frozen foods. Antibiotics are not indicated. Some clinicians prescribe a tapered steroid dose starting postoperatively. Although the likelihood is remote, airway compromise can occur with any surgical intervention in the pharynx. Complications include pain, bleeding, airway compromise, and velopharyngeal incompetence.

Ablation Techniques

It is important that a clinical or histological diagnosis is confirmed prior to any ablative procedures with the laser. Ablation does not provide tissue for biopsies. Ablation techniques work exceptionally well for superficial lesions.

Gingivoplasty: Hypertrophic Gingiva

Gingival hyperplasia is a disorder seen in some patients who take Dilantin, calcium channel blockers, cyclosporin, or a combination of these.[96-99] It can be idiopathic or occur for a variety of other reasons. Renal transplant patients may be prescribed both calcium channel blockers and cyclosporin and are particularly likely to acquire this disorder. This condition is amenable to ablation with the carbon dioxide laser. Prior to the development of the laser, these patients were difficult to manage with sharp dissection and electrocautery owing to inadequate hemostasis and the possibility of injury to the teeth. The carbon dioxide laser, used primarily in the defocused mode, is used to ablate gingival tissue in a near-bloodless field. Even severe, recurrent cases can be treated more easily and with significantly less morbidity using this technique. The laser is ideal for this use due to its ability to obtain hemostasis while removing tissue and decreased postoperative discomfort. Another condition where patients may exhibit gingival hyperplasia and pigmentation is Sturge-Weber syndrome. The gingival hyperplasia may be a result of increased vasculature or Dilantin use, which can be used to control seizures.[100] Since these lesions have a propensity to bleed, using a laser is valuable in aiding in hemostasis.[81]

The technique involves topical, local, or general anesthesia, or a combination, depending on the degree of hyperplasia and cooperativeness of the patient. The carbon dioxide laser is set at a relatively high power setting of 10 to 30 W, depending on the relative keratotic or fibrotic nature of the tissue. Defocusing the laser to a spot size between 0.5 and 2.5 mm allows good control for sculpting the tissue without injuring adjacent teeth or bony structures. Ultrapulsing is recommended, although slower pulsing or even use of the continuous mode is acceptable. Special attention is directed at protecting the adjacent teeth with an ebonized instrument, such as a No. 9 periosteal elevator, or carefully placed matrix bands. Enamel burns from the carbon dioxide laser are not only unsightly but also demineralize and are highly susceptible to caries.

Epithelialization occurs over the course of 2 to 3 weeks, and careful postoperative instructions are given to the patient or caregiver, or both. A soft diet, analgesics, and intermittent rinses with chlorhexidine are helpful in the postoperative period. Antibiotics are recommended only in patients susceptible to bacterial infection. Close follow-up for the first few weeks and a regimen of good oral hygiene are important in preventing further exacerbations and recurrences. Should reoperation be necessary, little scarring is seen when using the laser as compared to earlier sharp or electrocautery techniques.

Lichen Planus and Nicotinic Stomatitis

Lichen planus is a common disorder with a presumed autoimmune etiology and a variety of clinical forms. Most commonly, the reticular form is seen on the buccal mucosa with the characteristic Wickham's striae. Ulceration may or may not be present in the reticular form. Erosive lichen planus can be seen on a variety of mucosal surfaces. Patients often present with a burning sensation and request treatment to alleviate the discomfort. Both of these varieties are usually treated with various local and systemic therapies. The surgical laser can be used as an adjunct to palliate the lesions rather than remove them, especially in patients with disease that is refractory to conventional treatment modalities. Trehan and Taylor used a low dose excimer 308 nm laser for a small group of patients with refractive oral lichen planus. They found that the majority of the patients had a positive response in their symptoms and improvement in their erosive lichen planus on clinical examination.[101] Case studies also have shown the palliative effects of diode lasers in the treatment of the burning sensation and pain cause by oral lichen planus.[102]

The carbon dioxide laser, however, is more commonly used to treat these lesions by setting a medium power of 10 to 15 W in the defocused mode. Ablative patterns of crosshatching are used to treat the region. Patients report decreased discomfort in the area treated with the laser. Some evidence exists that suggests possible malignant degeneration of these lesions; therefore, staining with toluidine blue and selective biopsy are recommended.

Premalignant and Dysplastic Lesions

Lesions in this group are classified according to the degree of cellular atypia seen on biopsy. Treatment of these lesions is of great importance because of the risk of development of

carcinoma. It is for this reason that clinicians should generally not ablate these lesions with a laser prior to incisional biopsy. Leukoplakias, erythroplakias, and some erosive lichen planus lesions fall into this category and should be carefully evaluated. Ablation of these lesions removes the possibility of staging, should carcinoma be present. Adequate discussion of the comprehensive treatment of premalignant and malignant lesions is found in many sources and is beyond the scope of this chapter.

Again, biopsy is required to determine the amount of cellular atypia and to rule out malignancy. Toluidine blue staining can be used to highlight areas of high cellular activity.[103,104] Cells with especially active nuclei preferentially retain the stain. Regions of high uptake of this vital stain are then selectively sampled for biopsy in attempts to rule out carcinoma in diffuse surface mucosal lesions. The area of question is prepared with a solution of 1% acetic acid and is irrigated and dried with suction and gauze before a 1% toluidine blue stain is applied. The acetic acid solution is then briefly reapplied to decolorize the area. This procedure is technique sensitive in that overzealous use of acetic acid removes the vital staining of the atypical areas as well as those without cellular atypia. Preferentially stained areas are then sampled for biopsy using the incisional techniques described previously. Specimens are submitted for pathologic examination, being sure to inform the pathologist of the technique used and the specific locations of the specimens.

If the results conclude that each of the specimens is benign, the choice remains of whether to ablate the lesion using vaporization techniques or to excise the lesion to an adequate depth using a focused technique. Opinions vary concerning treatment of these lesions. Lesions in areas such as the floor of the mouth, with malignant transformation rates as high as 25%, can be ablated, although some clinicians question the adequacy of removal of all of the tissue with malignant potential.[105] Adequate studies comparing the local malignant transformation rates after using these techniques are needed. Focused excision of these lesions with the carbon dioxide laser is identical to the techniques described for removal of other intraoral lesions. Careful outlining of the lesion is performed by using a low power setting and a slow, repetitive pulse mode. A 3- to 5-mm margin is suggested, with care taken to provide the pathologist with an extra 500 μm when using the laser.

If the surgeon is comfortable with the benign nature of the lesion, ablation can be performed by defocusing the laser beam and increasing the power setting as needed to remove the lesion to an adequate depth. Lesions that are especially thick and hyperkeratotic require higher power settings because they contain little water. In some cases it may be easier to excise these lesions and then ablate the deeper layer in a defocused mode. Diffuse lesions, however, are amenable to the ablation technique because it is relatively rapid and requires no suturing or grafting. Sharp excision usually causes a great degree of morbidity and postoperative scarring with contracture. This makes the prospect of reoperation in these regions difficult. Laser ablation results in significantly less scarring, being especially useful in verrucous-type lesions with high recurrence rates and the frequent need for surgical re-excision.

This technique can be especially effective in the floor of the mouth. Lesions in this region can be ablated without fear of injury to the salivary gland duct orifices, which remain patent despite distal ablation or resection (presumably due to the decreased swelling and scarring seen in laser surgical procedures). Suturing is usually not needed, and postoperative antibiotic treatment is of little value in most cases. Mild analgesics and chlorhexidine rinses are recommended.

Multiple studies have analyzed the cure rate and recurrences after treatment with laser ablation of leukoplakias or oral dysplastic lesions over the last decade with good results and fewer complications.[106] Roodenberg and colleagues followed 70 patients for just over 5 years and found a 90% cure rate in patients with leukoplakias.[107] Thompson and Wylie studied 57 consecutive patients with oral dysplastic lesions that were treated with a CO_2 laser over 4 years. They found that the laser successfully treated 55 of those patients. Seventy-six percent of patients did not have a recurrence over a mean 18-month follow-up.[108] These studies demonstrate that CO_2 lasers are effective means of treating oral dysplastic lesions with less morbidity than conventional methods.

Careful follow-up is especially important if ablation techniques are used. Some clinicians advocate regular use of toluidine blue staining as a screening method for carcinoma at these follow-up visits. Patients who may be unreliable should probably undergo standard sharp excision.

A newer therapy that has been trialed in the treatment of precancerous oral lesions is photodynamic therapy (PDT), which is a minimally invasive tool that has been used to target these dysplastic tissues in the head and neck, skin, and gastrointestinal tract.[109] Photodynamic therapy includes giving the patient a photosensitizing agent prior to the procedure, which is preferentially absorbed by the cells to be ablated. The first-generation photosensitizers are 5-aminolaevulanic acid (5-ALA), photofrin, and verteporfin. The second-generation photosensitizers, such as Foscan (temoporfin; metatetrahydroxyphenyl chlorine (mTHPC)), have been approved for use in head and neck cancer.[110] Most photosensitizers are systemically administered; however, they can also be topically applied for skin lesions. The laser beam is then delivered to the area directly or via a dispersive medium. Intra-abdominal cancers can be targeted using a sensitizer and a lipid medium that is poured into the abdominal cavity. The laser beam is delivered to the medium, which disperses the energy within the abdominal cavity to multiple areas where the lipid contacts tissue. Photodynamic therapy can be added to more conventional treatment modalities. PDT can be delivered under local or general anesthesia.

Jerjes et al. enrolled 147 consecutive patients with oral dysplastic lesions who were treated with 5-ALA topically and mTHPC-PDT intravenously. After appropriate time, a diode laser was used to treat the dysplastic tissue. The results

of this study showed an 11.6% recurrence rate and 11 of the 147 patients (7.5%) underwent malignant transformation.[110] This study validates the use of photodynamic therapy in the treatment of oral precancerous lesions.

Problems with this technique, and other PDT techniques, include severe tissue burns and less than impressive selectivity for tumor cells. It is extremely important to inform the patients to avoid sunlight to prevent unwanted photosensitivity until the photosensitizing agent is cleared from the body.

Solar Cheilitis or Actinic Keratitis

Actinic keratitis is a premalignant lesion that requires surgical removal to prevent progression to squamous cell carcinoma of the lip. Biopsy confirms the dysplastic nature of these lesions, characterized by silvery white hyperkeratosis and atypical wrinkling of the lip surface. These lesions can appear ulcerated or flaky. Initial biopsy is done in areas that appear the most dysplastic, and, once carcinoma has been excluded, laser removal of this lesion may be indicated.

Another method of treatment of these lesions includes the "lip shave," which involves sharp, superficial dissection of the epithelial lip surface involved. This technique is fraught with considerable discomfort and scarring. Laser ablation and resurfacing of the area offer less scarring and often less postoperative pain. Ultrapulsing has been used effectively to remove dysplastic tissue layer by layer and resurface the lip with new epithelium. Other techniques have used an operating microscope with laser attachments to further enhance the ability to remove the dysplastic tissue selectively. Resurfacing techniques are discussed in the section on maxillofacial cosmetic and dermatologic laser surgical procedures, but setting the laser with a focused mode at about 5 W and using a computer pattern generator to ablate and resurface areas of the lip has proven to be very effective.

Recent literature supports the use of Er:YAG for treatment of actinic cheilitis. This method of treatment offers the patient an option for elimination of actinic cheilitis with a good cosmetic outcome. The Er:YAG laser may even produce less hypopigmentation than treatment with the CO_2 laser, leading to a superior cosmetic result.[111] Some believe that the Er:YAG laser should be a first-line treatment for actinic cheilitis.[112] The addition of photodynamic therapy to treatment with the Er:YAG laser produces greater results than phototherapy alone.[113]

Antibiotic ointment, sunscreen, and instructions to keep the area very clean are important postoperative interventions. It is also important to schedule the patient for regular visits to re-evaluate the areas in question for dormant carcinoma, as this can manifest itself decades after removal of the initial lesion.

Malignant Lesions

The removal of carcinoma and carcinoma in situ with surgical lasers is performed regularly in conjunction with comprehensive staging and resection. Advantages of using the laser include a hemostatic field allowing the surgeon to better delineate the clinical margins of the tumor, decreased scar formation, and sealing of the lymphatics and blood vessels, which may decrease metastatic spread during manipulation of the tumor. Either the focused free beam carbon dioxide or contact Nd:YAG laser can be used to remove lesions once they have been initially sampled for biopsy and staged accordingly. Ablative techniques are not recommended because submission for pathologic diagnosis is critical to evaluate adequate margins and plan for possible adjunctive postoperative therapy. Principles of tumor removal remain the same, depending on the region of the tumor, histologic type, size, nodal involvement, presence of metastasis, and grade. Lasers can be especially helpful in palliative debulking of tumors, as many of these tumors are highly vascular.

Papillomatosis or Papillary Hyperplasia

These lesions are treated with the carbon dioxide laser in the ablative manner previously described, using power settings of 10 to 20 W in a defocused mode. High volume suction devices are used to evacuate contaminated smoke from the field. Care is taken not to injure any underlying bone, as necrosis and oroantral communication may occur when obliterating tissue of the palate or maxillary alveolar ridge. The contact Nd:YAG laser with a flat probe has also been used by some clinicians. Either technique offers excellent hemostasis, and patients tolerate the procedure well when their denture is adjusted and a soft tissue liner is used.

Aphthous and Herpetic Ulcer Palliation

The palliation of aphthous and herpetic ulcers in the oral and perioral regions can be accomplished with the use of the carbon dioxide laser. Patients often report decreased pain but experience somewhat slower healing than without laser treatment. Low power settings of only several watts in a slightly defocused mode are used to "tan" the lesion and are effective in palliating the discomfort, although the exact mechanism by which the pain relief occurs remains uncertain.

Intraoral Vascular Lesions

Mulliken helped differentiate the types of vascular lesions based on their endothelial components and characteristics. This classification system is helpful in determining the method of treatment of intraoral vascular lesions. Much confusion still exists regarding terminology used to describe vascular lesions, and this tends to confuse issues of treatment. Clinicians are referred to Mulliken's excellent texts and articles regarding this subject.[114] Small intraoral lesions tend to be straightforward in most cases and are easily ablated using the carbon dioxide, argon, tunable dye, or contact Nd:YAG lasers. The argon, tunable dye, and contact

Nd:YAG lasers are often better suited for these lesions owing to the high absorption of their wavelengths by hemoglobin. These lasers offer better hemostasis and more selective tissue destruction.

Various techniques of ablation using a crisscross or spiraling circular pattern can be used. Some clinicians prefer to use a glass slide to depress the lesion slightly and aim the beam through the slide to visualize and control the selective ablation better. Other techniques advocate insertion of a fiberoptic tip into the lesions in various planes. More than one treatment may be needed to decrease or ablate the lesion adequately.

Maxillofacial Cosmetic and Dermatologic Laser Surgical Procedures

The surgical laser has many uses in the realm of cosmetic surgery, but it is merely a tool to be used for very specific indications. In the hands of an experienced laser surgeon, the laser may make facial resurfacing more accurate and predictable than the techniques of dermabrasion and chemical peel. It can improve the ease of dissection and hemostasis during blepharoplasty and endoscopic cosmetic procedures. However, it does not replace the usefulness of face-lift, liposuction, augmentation, or submental plication procedures. Both clinicians and patients must be aware of both the usefulness and the limitations of this technology. Considerable dialogue with each patient is warranted when discussing the procedures outlined in the following sections, and the expectations of all parties involved must be within reason.

Facial Resurfacing

The surgical laser has revolutionized the resurfacing of facial skin. Although dermabrasion and chemical peels have worked to decrease wrinkles, the carbon dioxide and Er:YAG lasers offer excellent results with a more accurate and reproducible technique. As a greater percentage of the population becomes older, the demand for facial rejuvenation techniques continues to increase. Additionally, the advent of ultrapulsing, computer pattern generators, and flash scanners has increased the precision and efficiency with which laser energy is distributed. Selective photothermolysis is possible with the current laser delivery systems, thereby decreasing collateral tissue damage. The Er:YAG laser is absorbed by water to a greater extent than the CO_2 laser and therefore penetrates the tissue to a lesser degree, allowing for superior ablation of the epidermis and papillary dermis and less deep thermal damage.[115] These technologies decrease the scarring seen with older carbon dioxide laser resurfacing methods because the ablation is accurately and repeatably taken to the level of the midreticular dermis. Areas ablated below this level tend to scar. As the tissue heals, new elastic fibers reorganize and realignment of collagen fibers occurs in a more parallel fashion, creating a more youthful, shiny, smooth skin surface.

This technique works well for fine wrinkles but only softens deeper wrinkles. The areas most commonly treated include perioral and periorbital fine wrinkles, although improvement is seen in all areas with fine wrinkles.[116,117] Deeper wrinkles associated with more muscular action, as seen in large forehead lines, respond less favorably. Patients with fair skin of Fitzpatrick types I to III do best with this treatment, whereas darker skin types tend to have postsurgical pigmentary changes. Patients with a history of radiation therapy in the expected treatment area, scleroderma, immunologic skin disorder, or prior use of isotretinoin (Accutane) should usually be excluded from these treatments because their healing may be markedly different from those with normal skin. This may result in increased scarring. As with other laser treatments, procedure-specific consents and a detailed discussion of the postoperative course are required. Preoperative photographs should be taken for documentation purposes. It is helpful to have photographs of other patients available who have undergone resurfacing procedures showing different treatment phases.

Preoperative courses of topical retinoic acid to initiate the healing process, hydroquinone to deplete the melanocytes, or glycolic acid, or a combination, may be considered. Most clinicians advocate giving acyclovir perioperatively as well. It is imperative that patients are instructed to wear sunblock during the healing process. Patients should be instructed to arrive at the clinic with a cleanly washed face, and a mild cleanser is used just prior to resurfacing. Protective eyeshields are placed, and all nontreatment areas are protected with nonflammable drapes or wet gauze, or both. These patients do best with local anesthetic block techniques and intravenous sedation. Perioperative antibiotics and steroids are used by some clinicians, although their efficacy has not been proven.

Because several lasers are used for the purpose of facial resurfacing, only general statements can be made in this text. Each laser's manual and the current literature should be consulted for specific techniques. Areas with thin, delicate skin, such as the periorbital region, require less energy and fewer passes of the laser, whereas the thicker perioral region generally requires more energy and more passes of the laser.

The layers of the epidermis and the superficial to the midreticular dermis are ablated using cosmetic units of the face as a guideline. The midreticular dermis has a slightly yellow color (reminiscent of chamois), and this represents the endpoint. The borders of lased skin can be gently "fanned out" by using lower powers and a pattern of lower density, allowing for a gentle transition between treated and untreated skin. Visible contraction of the skin is evident as treatment continues.

Postoperative care consists of meticulous wound care. Various occlusive dressing schemes have been reported in attempts to keep the treated area moist. Many surgeons prefer an "open technique," whereby topical ointments are used during the healing phase. The patient should be seen frequently within the first week, weekly for a month, and then monthly until the erythema resolves completely. Makeup

can be worn after epithelialization is complete, usually in about 12 to 14 days. An annual visit is helpful to document progress and to take photographs.

Among complications, hyperpigmentation is not uncommon and is usually self-limited. Hydroquinone cream can be used to improve blending. Other possible complications include hypopigmentation, scarring, erythema, induration, ectropion, herpes simplex activation, and infection. Postoperative erythema may last for 3 to 6 months and can be hidden with gentle makeup products once initial healing has taken place. The learning curve is considerable with these techniques, and the need for attention to detail cannot be overemphasized. Proper certification and continuing education are extremely important, as both the techniques and the technology change rapidly.

Blepharoplasty

The technique for blepharoplasty can be aided by using a carbon dioxide, KTP, or Nd:YAG laser for the dissection to help create a bloodless field.[118,119] Currently, the carbon dioxide laser is most often used with this technique. Existing techniques utilizing cautery or radiofrequency devices for hemostasis are certainly comparable to the laser techniques in the hands of some surgeons. Each surgeon must make his or her choice regarding personal success rates and comfort with the laser technique. Whereas standard techniques of blepharoplasty require basic surgical instruments, the laser technique involves a significant set-up cost. Clinicians who are comfortable with the noncontact carbon dioxide laser may find that dissecting with this laser in the focused mode can aid greatly in keeping the field exceptionally dry and decreasing the amount of periorbital ecchymosis seen after some blepharoplasty procedures. Thorough preoperative evaluation, surgical strategies, and other aspects of this procedure are explained elsewhere in this text. The addition of the laser is briefly reviewed below.

Preoperative photographs are taken, and anesthetic and surgical plans are formulated. If blepharoplasty alone is planned, intravenous sedation with local anesthetic infiltration and topical ophthalmic anesthetic are usually sufficient; however, if additional procedures are being performed, general anesthesia may be warranted. Once the patient is comfortable, corneal shields are placed. A scalpel is used to make the initial incisions, although the focused laser is advocated by some for this step as well. In both upper and lower blepharoplasties, the dissection can then be advanced with the use of the laser in the pulsed and focused modes. The beam may be defocused to help with hemostasis as needed. The fat pads are removed with the carbon dioxide laser, using a wet cotton-tip applicator as both a dissecting tool and to prevent the beam from injuring adjacent tissue. Contact tips of the KTP or Nd:YAG lasers offer tactile sense during removal of the fat pads. The incisions are then closed in the standard fashion. If minor periorbital skin laxity exists, some thought should be given to the need for resurfacing if skin is not resected at the time of blepharoplasty. Instructions to keep the head elevated and to use cold compresses are important for minimizing swelling and ecchymosis. Topical ophthalmic antibiotic ointment or drops may be prescribed for several days postoperatively.

Complications directly related to the laser include misfires of the laser, causing damage to the skin, eyelashes, or components of the globe, depending on the laser used. Other complications of blepharoplasty include lacrimal gland injury, entropion, ectropion, infection, wound dehiscence, and persistent erythema. The laser can be another effective tool in this already successful procedure. A great degree of familiarity with both the standard surgical procedure and the laser choice is important to avoid complications.

Vascular Lesion Treatment

Probably the most dramatic use of the surgical laser is in treating vascular lesions. Mulliken was the first to describe and redefine the classification system currently used for vascular lesions, based on vascular endothelial cell characteristics.[120] Three groups exist in this classification system: (1) hemangiomas, (2) vascular malformations, and (3) ectasias. Further description is based on the vessel type (or combination of vessels) seen with histologic analysis (e.g., lymphangioma).

Hemangiomas are benign and present at birth or within the first few months of life. They do, however, experience a rapid proliferative phase for variable amounts of time. After this growth phase, an involution period begins in which the lesion shrinks over the course of several years, usually becoming barely noticeable. Unlike hemangiomas, vascular malformations are always present at birth and do not exhibit a rapid proliferative or involution phase. They grow slowly with the patient's growth. They can affect surrounding tissues, including bone, and may develop granulomatous elements later in their course. Port-wine stains and several other malformations associated with syndromes such as the Osler-Weber-Rendu, Sturge-Weber, or ataxia-telangiectasia syndromes belong to this group. Ectasias, such as telangiectasias, are acquired and can grow with age.

Much of the excitement generated about lasers early in their development was due to their potential for use in selectively ablating tissue of deforming vascular lesions that would otherwise require sophisticated and often deforming excisions and flap reconstructions.[121-123] Although many different lasers have been used for a variety of lesions, the pulsed dye laser at 577 or 585 nm continues to be considered the most effective.[124,125] Delivery systems have improved significantly, although no other laser has been shown to be more clinically effective or vascular specific. Many other lasers are effective at removing the lesion but exhibit undesirable postsurgical skin changes such as excessive scarring and hypo- or hyperpigmentation. Several laser systems and their advantages and disadvantages for commonly treated vascular lesions are discussed in the following sections. Combination laser therapy may be indicated for some lesions, depending on the patient's particular response to treatment. Controversy exists regarding

when to treat (if at all) various forms of hemangiomas and other vascular lesions. Any clinician who treats these types of lesions should be well versed in the past and current literature regarding treatment strategies. Results can be disfiguring if an incorrect diagnosis is made or the wrong laser is chosen for treatment.

Skin Pigmented Lesion Removal

Pigmented lesions can be among the most unpredictable of all lesions treated with the surgical laser. Nevertheless, some discrete indications exist for using the surgical laser for their removal. Excision with skin grafts, flap advancements, or free flaps generally leaves disfiguring scars in the maxillofacial region. Laser treatment, resurfacing, or ablation can lighten or completely remove some lesions, greatly improving the esthetics.

The target cell in these pigmented lesions is the melanocyte, specifically the melanosome (organelle responsible for the synthesis of melanin).[126,127] Melanosomes absorb a variety of wavelengths, and the lesions vary in depth.[128,129] Lesions that extend into the dermis require deeper penetration by the laser and are best treated by lasers with longer wavelengths. Greater energies are required for these deeper lesions. As with other laser ablations, the tissue is heated to critical temperatures and the targeted cells are evaporated.

The lasers commonly used for these lesions are selected because of their depth of penetration and tissue selectivity. The pulsed tunable dye laser at 510 nm is commonly used to treat superficial pigmented lesions such as café au lait macules and other lightly colored macules.[129,130] The short wavelength and quick pulse rate are well suited for lesions that are superficial in nature. Powers of 2 to 3 J/cm^2 along with spot sizes around 5 mm are generally adequate for treatment. The area should be evaluated 6 weeks after treatment for signs of lightening or hyperpigmentation. The latter can be treated with hydroquinone and glycolic or retinoic acid topically daily until the hyperpigmentation resolves. If the lesion has been lightened, treatment can generally be performed in 6- to 8-week intervals, depending on the individual healing. The frequency-doubled Nd:YAG at 532 nm has been successful in treating the superficial lesions as well. Powers of 2 to 3 J/cm^2 are used with 2-mm spot sizes for effective treatment in many cases. Krypton and copper vapor lasers have been used to treat superficial pigmented lesions, but they generally cause more tissue damage than necessary and are considered by most to be inferior to the pulsed dye laser.

The noncontact Nd:YAG laser at 1064 nm (8 J/cm^2), the Q-switched ruby laser at 694 nm (5 to 6 J/cm2), and the Q-switched alexandrite laser at 755 nm (6 to 7 J/cm^2) are used to treat deeper lesions such as nevi of Ota, nevi of Ito, blue nevi, and melanotic nevi.[50,131,132] These lasers are effective because their longer wavelengths penetrate deeper into the dermal tissues without causing undue scarring or other undesirable tissue effects. They have also been used to treat superficial lesions effectively.

Patients should be carefully evaluated prior to initiating laser treatment of these lesions. The choice of laser depends greatly on the correct clinical diagnosis. Previous history or family history of malignancy arising from epidermal and dermal lesions excludes the patient from laser ablation in any lesion with even minor malignant potential because total ablation with the laser cannot be guaranteed and staging would be altered should malignancy develop. Patients must also be cautioned that some lesions will not respond to even repeated laser treatments and, rarely, may worsen in appearance when treated with a laser. A procedure-specific consent is especially important in these cases to educate all concerned parties.

On physical examination of the lesion and the surrounding skin, the clinician should note the Fitzpatrick skin type, as lighter shades of skin tend to respond better to laser treatments. Darker skin types may have problems with hyperpigmentation after laser treatment. Once the diagnosis is made, the patient must be made aware of the number of treatments that are generally required for particular lesions. While lentigines are superficial and can be treated easily with one to three visits, a nevus of Ota or café au lait nevus can take six visits or more to be adequately treated. Some lesions, such as melasma and postinflammatory pigmentation, do not respond to laser treatment and should be treated with other means, such as a chemical peel, when warranted.

Preoperative photographs are necessary for documentation and assurance for the patient that the lesions are improving over time. Such subtle changes occur with some lesions that the initial presenting photograph may help the patient to continue with the multiple sessions needed.

When these procedures are performed, the area of skin is thoroughly cleaned with mild soap and water. Some authors advocate the use of topical anesthetic creams for patient comfort, however, intravenous sedatives help patient comfort significantly. Children with extensive lesions are often treated in the operating room with a general anesthetic. A fan is sometimes useful for patient comfort. The wound care is similar to that for laser resurfacing.

Tattoos are simply a form of pigmented lesion that often can be lightened or even totally removed with the surgical laser. They require special attention because different pigments respond differently to different surgical lasers.

Surgical, Burn, and Acne Scar Revision

Since the beginnings of laser treatment of epidermal tissues, studies on the effects of a variety of lasers on scars have been done and have yielded less than impressive results. In the past, steroid therapy, cryosurgery, dermabrasion, radiotherapy, silicone gel sheeting, and excisional therapy have all failed to show acceptable and repeatable clinical improvement. Even with earlier carbon dioxide, argon, and other laser treatments, the recurrence rates were high. Alster and other groups used the pulsed dye laser at 585 nm to treat various types of scarring, with significant clinical improvement.[133]

Studies have directly compared pulse dye lasers to a CO^2 ablative fractional laser (AFL) and the results show that both show improvement in treated scars. The pulse dye laser improved the color of the scar and the AFL showed a vast improvement on the contour of the scar. However, the difference in the improvement between the two lasers was not statistically significant.[134] Treating scars with a combination of pulse dye lasers and CO_2 AFL may further improve the esthetic result of scar revision.

As with other laser treatments, patients with Fitzpatrick skin types I to III usually benefit most from these treatments, and scars that are slightly erythematous usually lighten more than others. It is extremely important to analyze the scar prior to treatment. The scar may be hypertrophic, atrophic, erythematous/hypervascular, or a combination. Each class of scars is treated differently. For example, revision atrophic scars involve treating the surrounding tissue with the laser to allow the scar to blend with the adjacent tissue. A hypertrophic scar is revised by lasering the scar to reduce it to the level of the adjacent skin.[135] The use of lasers to treat hypertrophic scars can be added to existing management strategies such as topical steroids, intralesional steroid injections, compression dressings, and silicone dressings.

Topical or local anesthetic is usually adequate for patient comfort, but care must be taken not to inject local anesthetic directly into the lesion because this may change the absorption of the laser energy. A 5- to 8-mm spot size is used with fluences at 6 to 7.5 J/cm^2. The entire scar is treated, and the patient is instructed to keep the area clean and bandaged lightly during this time. A regimen of postoperative care similar to that with facial resurfacing may be used. Antibiotic ointment may be used, and perioperative acyclovir may be prescribed if the scar is in a region of previous herpes simplex activation. The scar should be re-evaluated at 6 weeks for response. Several treatments may be necessary and are given at 6- to 8-week intervals. Complications include worsening of the scar, hyperpigmentation, and persistent erythema. Combined therapies, including carbon dioxide laser resurfacing, chemical peels, and topical retinoic acid treatments, may improve overall results and are currently being evaluated.

Hair Transplant and Hair Removal

Unger has published extensively on hair transplantation using micrografts and the added benefits of using the ultrapulse carbon dioxide laser as an adjunct.[136,137] Hair transplantation with excised grafts leaves rows of hair that are easily visible and a hairline that is unnatural and easily noticed. The advent of micrografting helped decrease the unsightly appearance of rows of plugged hair. Smaller slits are made to place the microcut hair grafts in place. In some patients, however, these slits tend to produce dark lines coursing through the hairline where the micrografts have been placed into the slit made by a scalpel. The carbon dioxide laser is used to make the recipient sites slightly wider, creating an even more natural hairline. A great deal of experience is required to master the technique.

Larger areas can be treated in one sitting when compared to the laborious process of electrolysis. About one third of all patients can expect the treatment to be permanent. This is equal to or better than the results seen with electrolysis. Alexandrite, Nd:YAG, and ruby lasers have been selected for their specificity for the red- and near infrared–sensitive dermal tissues. The selectivity may decrease the chance for the scarring seen in some cases of electrolysis. One company has used a carbon-based solution applied to the hair-bearing area to engulf the hair papilla, making it susceptible to the heat effects of the laser. The heat then destroys the follicle and causes a reduction in hair-producing elements in that area. Several treatments are frequently needed to achieve an acceptable result. More research is necessary to evaluate these new treatments before standardized therapy is available.

Endoscopic and Microscopic Laser Surgery

The use of minimally invasive and microscopic surgical techniques has recently been augmented by the application of laser surgical techniques. Laser TMJ arthroscopy and arthroplasty, laser-assisted endoscopic facial cosmetic surgery, and endoscopic laser lithotripsy of salivary gland stones are currently being evaluated. Since the learning curve is rather large, clinicians should be comfortable with both the standard surgical technique and the laser surgery before attempting to perform these procedures. In the hands of a skilled operator, these techniques expand the capabilities of previous methods.

Laser Arthroscopy and Arthroplasty of the TMJ

The difficulty of treating some TMJ disorders has been evident since Annadale's first surgical attempts in 1887.[138] The addition of lasers in the treatment of TMJ disorders with arthroscopy has offered a less invasive means of management then traditional open TMJ surgery. As seen with many other uses of the laser previously mentioned in this chapter, the laser offers many advantages over conventional arthroscopic instrumentation, including improved coagulation, allowing better visualization and much greater precision. CO_2 and Er:YAG lasers were not very effective in TMJ arthroscopy due to the synovial fluid environment.[139] McCain's contributions to arthroscopy have advanced the field significantly, and techniques by Hendler and Koslin have been described as sculpting fibrocartilaginous and retrodiscal tissue safely and easily with the Hol:YAG laser.[41,140,141] These techniques developed out of the knee arthroscopy experience pioneered by Fanton and Dillingham.[142] Previous techniques using the Nd:YAG laser were attempted but caused significant damage to adjacent tissue owing to the depth of penetration of this laser. As previously mentioned, Trauner showed that the Hol:YAG laser was less damaging to the surrounding tissues when sculpting fibrocartilage.

The Hol:YAG laser is a pulsed, mid-infrared laser at 2100 nm that works well in a saline environment and can be used with a fiberoptic quartz fiber. This allows for easy manipulation within the joint using standard triangulation techniques described by McCain with a quartz fiber. Generally, a power setting of 0.8 J and a pulse rate of 10 Hz can be used to ablate and sculpt tissue effectively. The Hol:YAG laser can be used for discectomy, synovectomy, hemostasis, treatment of anterior disc displacement, dissection of fibrous adhesions, and scarring of retrodiscal tissue in the treatment of hypermobility.[135] Mazzonetto and Spagnoli describe meniscectomies through an arthroscope using a Hol:YAG laser to remove the disc and then using more traditional rotary instruments to recontour the condyle and glenoid fossa.[143] As with most TMJ procedures, the adjunctive physical therapy and use of an occlusal splint is still extremely important in the management of patients with TMJ disorders.

In another application, some clinicians have augmented open arthroplasty techniques by using either the contact Nd:YAG or the carbon dioxide lasers for the dissection.[144] Techniques with and without the use of an operating microscope have been described and may significantly aid in the avoidance of nerve injury. The operating microscope can incorporate a coaxial laser with joystick control to aim the laser within the microscopic field. Comparative studies are needed to evaluate these techniques.

Lasers in Endoscopic Facial Plastic Surgery

Endoscopic facial cosmetic surgery is in great demand owing to the appeal of the minimally invasive techniques utilized. Facial cosmetic procedures are described elsewhere in this text, but the aspects relating to carbon dioxide, KTP, or Nd:YAG laser techniques are mentioned in the following sections. Some clinicians have incorporated a laser to aid in the dissection and ablation of fibrous bands and muscular tissue of the procerus and corrugator musculature.[145-147] Small incisions are used to pass minimally invasive instrumentation to the desired surgical site. In endoscopic brow lift surgery, small incisions are made in the scalp area to dissect within a subgaleal or subperiosteal plane, or both, to alter the muscular action of the procerus and corrugator musculature as well as reposition the brow soft tissue.[148] Some clinicians advocate the use of either the carbon dioxide or the Nd:YAG laser for all or part of the dissection to decrease intraoperative bleeding and postoperative ecchymosis.

Endoscopic Laser Lithotripsy of Salivary Gland Stones

Several groups have described a technique for removing or ablating stones endoscopically with the use of a rigid TMJ arthroscope or similar-sized endoscope and the flash-lamp pumped dye laser.[149,150] These techniques have evolved out of the rather extensive urologic laser lithotripsy literature and continue to be improved. The endoscope is advanced within a salivary gland duct to view the stone, and the laser fiber is advanced to ablate the stone. This technique may restore salivary flow in a significant number of individuals with the advantages of minimally invasive surgery.

Low Level Laser Therapy in Oral and Maxillofacial Surgery

Recently, there have been extensive discussions about using low level laser therapy (LLLT) in oral and maxillofacial surgery. LLLT was first used by Mester in 1967. It was this work that initiated the use of low level laser therapy as a biostimulator.[151,152] LLLT uses a phototherapeutic process with visible and near infrared lasers (400 to 1000 nm). The LLLT varies from other lasers in that LLLT causes minimal temperature changes in the tissue.[151] A study by Rodrigo and colleagues analyzed the effects of LLLT on wound healing in rats. They came to the conclusion that the rats that were exposed to red and infrared lasers had the most advanced healing, especially of the wounds that were distal to the site of laser therapy.[153] LLLT is considered relatively safe due to the athermal effect on tissue, causing minimal destruction of tissue that can been seen with other laser systems.[154] The exact mechanism of LLLT has not been fully established. On a cellular level, LLLT has shown to increase proliferation of fibroblasts, endothelial cells, and keratinocytes.[151] The photostimulatory effect of LLLT is thought to cause the release of growth factors leading to cell proliferation.[155] The vast majority of research on LLLT is with wound healing. Most literature describing the use of LLLT in oral and maxillofacial surgery is case reports or small sample size studies. It has been experimentally used for treatment of myofascial pain, TMJ osteoarthritis, wound healing, bone healing, mucositis, and periodontal therapy. It is thought that LLLT increases the pain threshold by altering the neuronal stimulation, which may be similar to transcutaneous electrical nerve stimulation (TENS) or acupuncture. LLLT also affects the production of prostaglandin, which can have an effect on pain and swelling.[154] LLLT has recently been approved by the FDA for treatment of alopecia and has been shown to stimulate hair regrowth.[156]

The management of dental extractions in patients on bisphosphonate therapy or antiresorptive and antiangiogenic medications is constantly debated. A recent study conducted in Italy explored the intraoperative use of low-level Nd:YAG therapy during the extractions and then weekly for the first 6 weeks and additionally until mucosal healing was achieved. The addition of LLLT during and after tooth extraction appeared to improve healing in patients receiving bisphosphonates.[157]

LLLT is a safe noninvasive treatment modality in the management of temporomandibular disorders (TMD). The results of various studies are mixed. Some feel that it is more effective than placebo treatments. LLLT can be added to other conservative treatment approaches such as splint therapy, anti-inflammatory medications, physical therapy,

and diet modification. The research indicating that LLLT is helpful in reducing pain in TMD uses varying protocols of low-level laser treatments and needs to be standardized.[158]

Continued research on the mechanism of the effects and the applications of LLLT in oral and maxillofacial surgery needs to continue.

Summary

Although the theoretical principles of lasers and surgical applications remain quite constant, the better understanding of tissue interactions and development of safety measures to prevent catastrophic iatrogenic events are of utmost importance to the surgeon's practice.

References

1. Gaelyn GC, Reinisch L, Wright HV: Laser surgery: basic principles and safety considerations. In Flint PW, editor: *Cummings otolaryngology head and neck surgery*, ed 6, Philadelphia, 2015, Elsevier Saunders, pp 884–898.
2. Einstein A: Zur Quantum Theorie der Strahlung, *Phys Zeit* 18:121, 1917.
3. Gordon JP, Zeiger HJ, Townes CH: Molecular microwave oscillator and new hyperfine structure in the microwave spectrum of NH3. Microwave amplification by stimulated emission of radiation, *Phys Rev* 95:282, 1954.
4. Maiman TH: Stimulated optical radiation in ruby, *Nature* 187:493–494, 1960.
5. Zaret M, Ripps H, Siegal IM: Biomedical experimentation with optical masers, *J Opt Soc Am* 52:607, 1962.
6. Coluzzi DJ, Convissar RA, Roshkind DM: Laser fundamentals. In Convissar RA, editor: *Principles and practice of laser in dentistry*, St Louis, 2016, Elsevier, pp 12–26.
7. Anderson RR, Parrish J: Selective photothermolysis: precise microsurgery by selective absorption of the pulsed radiation, *Science* 220:524–526, 1983.
8. Manstein D, Herron GS, Sink RK: Fractional photothermolysis: a new concept for cutaneous remodeling using microscopic patterns of thermal injury, *Lasers Surg Med* 34:426–438, 2004.
9. Walsh JT, Flotte TJ, Anderson RR: Pulsed CO2 laser tissue ablation: effect of tissue type and pulse duration on thermal damage, *Lasers Surg Med* 8:108–118, 1988.
10. Lanzafarne RJ, et al.: Comparison of continuous-wave, chop-wave, and super-pulse laser wounds, *Lasers Surg Med* 8:119–124, 1988.
11. Grevelink JM: Facial contouring using a flashscanner-enhanced carbon dioxide laser, *Facial Plast Surg Clin North Am* 4:241–246, 1996.
12. Siegman AE: *Lasers*, Sausalito, CA, 1986, University Science Books.
13. American National Standard for Safe Use of Lasers: *ANSI Z136.1–2007*, Orlando, 2007, Laser Institute of America. Laser Institute of America.
14. American National Standard for Safe Use of Lasers in Health Care: *ANSI Z136.3–2011*, Orlando, 2011, Laser Institute of America. Laser Institute of America.
15. Ossoff RH, Hotaling AJ, Karlan MS: CO2 laser in otolaryngology-head and neck surgery: a retrospective analysis of complications, *Laryngoscope* 93:1287, 1983.
16. Tomita Y, Mihashi S, Nagata K: Mutagenicity of smoke condensates induced by CO2-laser and electrocauterization, *Mutat Res* 89:145, 1981.
17. Mullarky MB, Norris CW, Goldgeerg ID: The efficacy of the CO2 laser in the sterilization of the skin seeded with bacteria: survival at the skin surface and in the plume emissions, *Laryngoscope* 95:186–187, 1985.
18. Garden JM, O'Banion MK, Bakus AD, Olson C: Viral disease transmitted by the laser-generated plume (aerosol), *Arch Dermatol* 138:1303–1307, 2002.
19. Baggish MS, et al.: Presence of human immunodeficiency virus DNA in laser smoke, *Lasers Surg Med* 11:197–203, 1991.
20. Kunachak S, Sithisarn P, Kulapaditharom B: Are laryngeal papilloma virus-infected cells viable in the plume derived from continuous mode carbon dioxide laser, are they infectious? A preliminary report on one laser mode, *J Laryngol Otol* 110:1031–1033, 1996.
21. Hans SH, et al.: A suspected case of air embolism in endonasal surgery using CO2 laser, *Korean J Anesthesiol* 64:189–190, 2013.
22. Baggish MS, Daniell JF: Catastrophic injury secondary to the use of coaxial gas-cooled fibers and artificial sapphire tips for intrauterine surgery: a report of five cases, *Lasers Surg Med* 9:581, 1989.
23. Reddy C, Majid A, Michaud G: Gas embolism following bronchoscopic argon plasma coagulation: a case series, *Chest* 134:1066–1069, 2008.
24. Verro P: Teaching NeuroImages: brain air embolism due to YAG laser bronchoscopy, *Neurology* 75:e73, 2010.
25. Garry BP, Bivens HE: Anesthetic technique for safe laser use in surgery, *Semin Surg Oncol* 6:184, 1990.
26. ECRI Institute: New clinical guide to surgical fire prevention. Patients can catch fire—here's how to keep them safer. ECRI Institute, *Health Devices* 38:314–332, 2009.
27. American Society of Anesthesiologists Task Force on Operating Room Fires: Practice Advisory for the Prevention and Management of Operating Room Fires: an Updated Report by the American Society of Anesthesiologists Task Force on Operating Room Fires, *Anesthesiol* 118:271–290, 2013.
28. Modest VE, Alfille PH: Anesthesia for laser surgery. In Miller RD, editor: *Miller's anesthesia*, ed 8, Philadelphia, 2015, Saunders, pp 2598–2611.
29. Patel CKM, McFarlane RA, Faust WL: Selective excitation through vibrational energy transfer and optical laser action in N2-C02, *Physiol Rev* 13:617, 1964.
30. Bridges WB: Laser oscillation in singly ionized argon in the visible spectrum, *App Phys Lett* 4:128, 1964.
31. Apfelberg CB, Maser MR, Lash H: Argon laser treatment of decorative tattoos, *Br J Plast Surg* 32:141, 1979.
32. Noe JM: Laser therapy of port-wine stains. In Mulliken JB, Young AE, editors: *Vascular birthmarks: hemangiomas and malformations*, Philadelphia, 1988, WB Saunders, pp 91–102.
33. Geusic JE, Marcos HW, Van Uitert LG: Laser oscillations in Nd-doped yttrium aluminum, yttrium gallium, and gadolinium garnets, *Appl Phys Lett* 4:182, 1964.
34. Hukki J, Castren M: Effects of different contact laser scalpels on skin and subcutaneous fat, *Lasers Surg Med* 8:276–282.

35. Gold SI, Vilardi MA: Pulsed laser beam effects on gingiva, *J Clin Periodontol* 21:391, 1994.
36. Arcoria CJ, Steele RE, Vitasek BA: Effects of coaxial C02INd:YAG subgingival curettage, *Proceedings of the Second Congress of the International Society for Lasers in Dentistry*105, 1990.
37. Midda M: Lasers in periodontics, *Periodont Clin Invest* 14:14, 1992.
38. Rosenfeld H, Sherman R: Treatment of cutaneous and deep vascular lesions with the Nd:YAG laser, *Lasers Surg Med* 6:20–23, 1986.
39. Kilmer SL, Anderson RR: Clinical use of the Q-switched ruby and the Q-switched Nd:YAG (1064 and 532 nm) lasers for treatment of tattoos, *J Dermatol Surg Oncol* 19:330, 1993.
40. Trauner K, Nishioka N, Patel D: Pulse holmium: yttrium-aluminum-garnet (Ho:YAG) laser ablation of fibrocartilage and articular cartilage, *Am J Sports Med* 18:316–320, 1990.
41. Hendler BH, Gatena J, Mooar P: Holmium:YAG laser arthroscopy of the temporomandibular joint, *J Oral Maxillofac Surg* 50:83–842, 1992.
42. Leukauf M, et al.: Infrared laser soft tissue ablation versus ultraviolet excimer laser, experimental introduction of the Hol:YAG laser in oral surgery, *Oral Surg Oral Med Oral Pathol* 76:425, 1993.
43. Goldberg DJ: Treatment of pigmented lesions of the skin with lasers, *Facial Plast Surg Clin North Am* 4:291–294, 1996.
44. Goldman L: Laser treatment of tattoos: a preliminary survey of three years' clinical experience, *J Am Med Assoc* 201:163, 1967.
45. Yules RB, et al.: The effect of Q-switched ruby laser radiation on dermal tattoo pigment in man, *Arch Surg* 95:179, 1967.
46. Ohshiro T, Maruyama Y, Nakajima H: Treatment of pigmentation of the lips and oral mucosa in Peutz-Jeghers Syndrome using ruby and argon lasers, *Br J Plast Surg* 33:346–349, 1980.
47. Taylor CR, Gange RW, Dover JS: Treatment of tattoos by Q-switched ruby laser: a dose response study, *Arch Dermatol* 126:893–899, 1990.
48. Reid WH, et al.: Q-switched ruby laser treatment of black tattoos, *Br J Plast Surg* 36:455–463, 1983.
49. Geroneumus RG, Ashinoff R: Use of the Qswitched ruby laser to treat tatoos and benign pigmented lesions, *Lasers Surg Med* 11(Suppl 3):64–65, 1991.
50. Watanabe S, Takahashi H: Treatment of nevus of Ota with the Q-switched ruby laser, *N Engl J Med* 331:1745–1750, 1994.
51. Dierickx C, Goldman M, Fitzpatrick R: Laser treatment of erythematous/hypertrophic and pigmented scars in 26 patients, *Plast Reconstr Surg* 95:84–90, 1995.
52. Alster TS: Laser treatment of scars. In Alster TS, Apfelberg DB, editors: *Cosmetic laser surgery*, New York, 1996, John Wiley, pp 81–92.
53. Alster TS: Improvement of erythematous and hypertrophic scars by the 585-nm flashlamp pumped pulsed dye laser, *Ann Plast Surg* 32:186, 1994.
54. Waner M: The treatment of vascular lesions, *Lasers Facial Plast Reconst Surg* 4:275–281, 1996.
55. Waner M, Dinehart SM, Wilson MB: A comparison of copper vapor laser and flashlamp pumped dye lasers in the treatment of facial telangiectasias, *J Dermatol Surg Oncol* 19:992–998, 1993.
56. Lang GK, Schroeder E, Koch JW: Eximer laser keratoplasty. Part 1: basic concepts, *Ophthal Surg Lasers* 20:262–267, 1989.
57. Alster TS: Q-switched alexandrite laser (755 nm) for the treatment of professional and amateur tattoos, *J Am Acad Dermatol* 21:69, 1995.
58. Fitzpatrick RE, Goldman MP, Ruiz-Esparza J: Use of the alexandrite laser (755nm, 100nsec) for tattoo pigment removal in an animal model, *J Am Acad Dermatol* 28:745–750, 1993.
59. Fitzpatrick RE, Goldman MP: Tattoo removal using the alexandrite laser, *Arch Dermatol* 130:1508, 1994.
60. Pogrel MA, McCracken KT, Daniels TE: Histologic evaluation of the width of soft tissue necrosis adjacent to carbon dioxide laser incisions, *Oral Surg* 70:564, 1990.
61. Roodenberg JL, Bosch JJ, Borsboom PCF: Measurement of the uniaxial elasticity of oral mucosa in vivo after C02 laser evaporation and surgical excision, *Int J Oral Maxillofac Surg* 19:181–183, 1990.
62. Galluci JG, Zeltsman D, Slotman GJ: Nd:YAG laser scalpel compared with conventional techniques in head and neck cancer surgery, *Lasers Surg Med* 14:139–144, 1994.
63. Daikuzono N, Joffe SN: Artificial sapphire probe for contact photocoagulation and tissue vaporization with the Nd:YAG laser, *Med Instrum* 19:173–178, 1985.
64. Midgley HC: Nd:YAG contact laser surgery: the scalpel of the future? *Otolaryngol Clin North Am* 23:99–105, 1990.
65. Fisher SE, et al.: A comparative histological study of wound healing following C02 laser and conventional surgical excision of canine buccal mucosa, *Arch Oral Biol* 28:287, 1983.
66. Basu MK, Frame JW, Rhys Evans PHR: Wound healing following partial glossectomy using the carbon dioxide laser, diathermy, and scalpel: a histological study in rats, *J Laryngol Otol* 102:322, 1988.
67. Fisher SE, Frame JW: The effects of the carbon dioxide surgical laser on oral tissues, *Br J Oral Maxillofac Surg* 22:414–425, 1984.
68. Ben-Bassat M, Kaplan IA: A study of the ultrastructural features of the cut margin of skin and mucous membrane specimens excised by carbon dioxide laser, *J Surg Res* 21:77, 1976.
69. Gabbiani G, Ryan GB, Majno G: The presence of modified fibroblasts in granulation tissue and their possible role in wound contraction, *Experientia* 27:549, 1971.
70. Frame JW: Treatment of sublingual keratosis with the C02 laser, *Br Dent J* 156:243, 1984.
71. Rhys Evans PHR, Frame JW, Branddrick J: A review of carbon dioxide laser surgery in the oral cavity and pharynx, *J Laryngol Otol* 100:69, 1986.
72. Neiburger EJ: Accelerated healing of gingival incisions by the helium-neon diode laser: a preliminary study, *Gen Dent* 45:166–170, 1997.
73. Kana J, Hutschenreiter G, Waidelich K: Effect of low-power density laser radiation on healing of open skin wounds in rats, *Arch Surg* 116:293–296, 1985.
74. Meyers A: Lasers and wound healing, *Arch Otolaryngol Head Neck Surg* 116:1128–1130, 1990.
75. Carrillo J, Calatayud J, Manso F: A randomized double-blind clinical trial on the effectiveness of helium-neon lasers in the prevention of pain, swelling, and trismus after removal of impacted third molars, *Int Dent J* 40:31–36, 1990.
76. Surinchak J, Alago M, Bellam R: Effects of low-level energy lasers on the healing of fullthickness skin defects, *Lasers Surg Med* 2:267–274, 1983.
77. Lyons R, Abergel R, White R: Biostimulation of wound healing in vivo by helium-neon laser, *Ann Plast Surg* 18:47–50, 1987.
78. Hendrick DA, Meyers A: Wound healing after laser surgery, *Otolaryngol Clin North Am* 28:969–986, 1995.
79. Cobb C: Lasers in periodontics: a review of the literature, *J Periodontol* 77:545–564, 2006.

80. Kaminer R, Liebow C, Margarone JE, Zambon JJ: Bacteremia following laser and conventional surgery in hamsters, *J Oral Maxillofac Surg* 48:45–48, 1990.
81. De Benediitis M, Petruzzi M, Inchingolo F, Serpico R: Nd:YAG laser for gingivectomy in Sturge-Weber syndrome, *J Oral Maxillofac Surg* 63:314–316, 2007.
82. Block CM, Mayo JA, Evans GH: In vitro analysis of the Nd:YAG laser on implant surfaces (abstract), *J Dent Res* 70:530, 1991.
83. Deppe H, Horch H, Henke J, Donath K: Peri-implant care of ailing implants with carbon dioxide laser, *Int J Oral Maxillofac Implants* 16:659–667, 2001.
84. Stubinger S, Henke J, Donath K, Deppe H: Bone regeneration after peri-implant care with the CO2 laser: a fluorescence microscopy study, *Int J Oral Maxillofacial Implants* 20:203–210, 2005.
85. Tuson E, et al.: Comparative evaluation of antimicrobial effects of Er:YAG, diode, and CO2 lasers on titanium discs: an experimental study, *J Oral Maxillofac Surg* 70:1064–1069, 2012.
86. Kamel S, et al.: The use of lasers therapy for dental implant surface decontamination: a narrative review of in vitro studies, *Lasers Med Sci* 29:1977–1985, 2014.
87. Romanos G: Point of care: is there a role for lasers in the treatment of peri-implantitis? *J Canad Dent Assoc* 71:117–118, 2005.
88. Moritz A, Gutknecht N, et al.: The carbon dioxide laser as an aid in apictoectomy: an in vitro study, *J Clin Laser Med Surg* 15(4):185–188, 1997.
89. Krepsi YP, Pearlman SJ, Keidar A: Laser assisted uvulopalatoplasty for snoring, *J Otolaryngol* 9:1–8, 1994.
90. Carenfelt C: Laser uvulopalatoplasty in the treatment of habitual snoring, *Ann Otol Rhinol Laryngol* 100, 1991. 451–445.
91. Kamami YV: Laser carbon dioxide for snoring-preliminary results, *Acta Otolaryngol Belg* 44:451–456, 1990.
92. Ellis PD, Williams JE, Shneerson JM: Surgical relief of snoring due to palatal flutter: a preliminary report, *Ann R Coll Surg Eng* 75:286–290, 1992.
93. Ikematsu T: Study of snoring, 4th report. Therapy, *J Jpn Otol Rhinol Laryngol* 64:434–435, 1964.
94. Madani M: Laser Assisted Uvulopalatopharyngoplasty (LA-UPPP) for the treatment of snoring and mild obstructive sleep apnea, *Atlas Oral Maxillofacial Surg Clin N Am* 15:129–137, 2007.
95. Strauss RA: Laser-assisted uvulopalatoplasty. In Catone G, editor: *Laser applications oral and maxillofacial surgery*, Philadelphia, 1997, WB Saunders, pp 245–256.
96. Barak S, Kaplan I: The carbon dioxide laser in the excision of gingival hyperplasia caused by nifedipine, *J Clin Periodontol* 15:633, 1988.
97. Ledermann D, Laumerman H, Reuben S: Gingival hyperplasia associated with nifedipine therapy, *Oral Surg Oral Med Oral Pathol* 57:620, 1984.
98. Jones JE, Weddell JA, McKown CG: Incidence and indications for surgical management of phenytoin-induced over-growth in a cerebral palsy population, *J Oral Maxillofac Surg* 46:385, 1988.
99. Roed-Petersen B: The potential use of carbon dioxide-laser gingivectomy for phenytoin-induced gingival hyperplasia in mentally retarded patients, *J Clin Periodontol* 20:729, 1993.
100. Neville B, Chi A, Damm D, Allen C: *Soft tissue tumors. Oral maxillofacial pathology*, St Louis, 2016, Elsevier, pp 508–509.
101. Trehan M, Taylor C: Low-dose excimer 380nm laser for the treatment of oral lichen planus, *Arch Dermatol* 140:415–420, 2004.
102. Mirsa N, Chittoria N, Umapathy D, Mirsa P: Efficacy of diode laser in management of oral lichen planus, *BMJ Case Reports*, 2013.
103. Niebel HH, Chomet B: In vivo staining test for delineation of oral intraepithelial neoplastic change, *J Am Dent Assoc* 68:801–806, 1964.
104. Mashberg A, Tolonium: (toluidine blue) rinse-a screening method for recognition of squamous carcinoma, *J Am Med Assoc* 245:2408–2410, 1981.
105. Pogrel MA: Sublingual keratosis and malignant transformation, *J Oral Pathol* 8:176–178, 1979.
106. van der Hem PS, Nauta JM, van der Wal JE, Roodenburg JL: The results of CO2 laser surgery in patients with oral leukoplakia: a 25 year follow up, *Oral Oncol* 41:31–37, 2005.
107. Roodenburg JL, Panders AK, Vermey A: Carbon dioxide laser surgery of oral leukoplakia, *Oral Surg Med Pathol* 71:670–674, 1991.
108. Thompson PJ, Wylie J: Interventional laser surgery: an effective surgical and diagnostic tool in oral precancer management, *Int J Oral Maxillofac Surg* 31:145–153, 2002.
109. Sieron A, Adamek M, Kawczyk-Krupka A, Mazur S, Ilewicz L: Photodymanic therapy (PDT) using topically applied delta-aminolevulinic acid (ALA) for the treatment of oral leukoplakia, *J Oral Pathol Med* 32:330–336, 2003.
110. Jerjes W, Upile T, Hamdoon Z, Hopper C: Photodynamic therapy outcome for oral dysplasia, *Lasers Surg Med* 43:192–199, 2011.
111. Zachary CB: Modulating the Er:YAG laser, *Lasers Surg Med* 26:223–226, 2000.
112. Armenores P, James C, Walker P, Huilgol SC: Treatment of actinic cheilitis with the Er:YAG laser, *J Am Acad Dermatol* 63:642–646, 2010.
113. Choi SH, Kim KH, Song KH: Efficacy of ablative fractional laser-assisted photodynamic therapy for the treatment of actinic cheilitis: 12-month follow-up results of a prospective, randomized, comparative tria, *British J Dermatol* 173:184–191, 2015.
114. Mulliken JB, Glowacki J: Hemangiomas and vascular malformations in infants and children: a classification based on endothelial characteristics, *Plast Reconstr Surg* 69:412, 1982.
115. Riggs K, Keller M, Humphreys T: Ablative laser resurfacing: high-energy pulsed carbon dioxide and erbium:yttrium-aluminum-garnet, *Clin Dermatol* 25:462–473, 2007.
116. Fitzpatrick RE: Facial resurfacing with the pulsed carbon dioxide laser: a review, *Facial Plast Surg Clin North Am* 4:231–240, 1996.
117. Alster TS, Garg A: Treatment of facial rhytides with a high-energy pulsed carbon dioxide laser, *Plast Reconstr Surg* 98:791–794, 1996.
118. Baker S, et al.: Carbon dioxide laser blepharoplasty, *Ophthalmology* 91238, 1984.
119. Baker S: Carbon dioxide laser upper lid blepharoplasty, *Am J Cosmetic Surg* 9:141, 1992.
120. Mulliken JB, Glowacki J: Hemangiomas and vascular malformations in infants and children: a classification based on endothelial characteristics, *Plast Reconstr Surg* 69:412, 1982.
121. Apfelberg DB, Maser MR, Lash H: Argon laser management of cutaneous vascular deformities: a preliminary report, *West J Med* 124:99–101, 1976.
122. Goldman L, Dreffer R: Laser treatment of extensive mixed cavernous and port-wine stains, *Arch Dermatol* 3:213–216, 1977.
123. Clodius L: Excision and grafting of extensive facial haemangiomas, *Br J Plast Surg* 30:185–196, 1977.

124. Morelli JG, et al.: Tunable dye laser (577nm) treatment of port wine stains, *Lasers Surg Med* 6:94–99, 1986.
125. Tan OT, et al.: Histologic responses of port-wine stains treated by argon, E carbon dioxide, and tunable dye lasers: a preliminary report, *Arch Dermatol* 122:1016–1022, 1986.
126. Goldman L, et al.: Pathology of the effect of the laser beam on the skin, *Nature* 197:912–914, 1963.
127. Goldman L, Igelman JM, Richfield DF: Impact of the laser on nevi and melanomas, *Arch Dermatol* 90:71–75, 1964.
128. Anderson RR, et al.: Selective photothermolysis of cutaneous pigmentation by Q-switched Nd:YAG laser pulses at 1064, 532, and 355nm, *J Invest Dermatol* 92:28–32, 1989.
129. Alster TS: Complete elimination of cafe-au-Iait birthmarks by the 510 nm pulsed-dye laser, *Plast Reconstr Surg* 96:1660–1664, 1995.
130. Tan OT, Morelli JG, Kurban AK: Pulsed dye laser treatment of benign cutaneous pigmented lesions, *Laser Surg Med* 12:538–542, 1992.
131. Kilmer S, Anderson R: Clinical use of the Q-switched ruby and the Q-switched Nd:YAG lasers for treatment of tattoos, *J Dermatol Surg Oncol* 119:330–338, 1993.
132. Stafford T, Tan OT: 510nm pulsed dye laser and alexandrite crystal laser for the treatment of pigmented lesions and tattoos, *Clin Dermatol* 13:69–73, 1995.
133. Alster TS: Laser treatment of scars. In Alster TS, Apfelberg DE, editors: *Cosmetic laser surgery*, New York, 1996, John Wiley, pp 81–92.
134. Kim DH, Ryu HJ, Choi JE, Ahn HH, Kye YC, Seo SH: A comparison of the scar prevention effect between carbon dioxide fractional laser and pulsed dye laser in surgical scars, *Dermatol Surg* 40:973–978, 2014.
135. Sobanko JF, Alster TS: Management of acne scarring, Part I a comparative review of laser surgical approaches, *Am J Clin Dermatol* 13:319–330, 2012.
136. Unger WP: Laser hair transplantation, *J Dermatol Surg Oncol* 20:515–521, 1994.
137. Unger WP: Laser hair transplantation. In Alster TS, Apfelberg DE, editors: *Cosmetic laser surgery*, New York, 1996, John Wiley, pp 55–66.
138. Annadale T: On the displacement of the interarticular cartilage of the lower jaw and its treatment by operation, *Lancet* 1:411–412, 1887.
139. Koslin M: Laser applications in temporomandibular joint arthroscopic surgery, *Oral Maxillofacial Surg Clin N Am* 16:269–275, 2004.
140. McCain JP, Ruah DL, LeBlanc WG: Puncture technique and portals of entry for diagnostic and operative arthroscopy of the temporomandibular joint, *Arthroscopy* 7:221, 1991.
141. Koslin M, Martin JC: The use of the holmium laser for temporomandibular joint arthroscopic surgery, *J Oral Maxillofac Surg* 50:931, 1993.
142. Fanton GS, Dillingham MF: *Arthroscopic meniscectomy using the holmium:YAG laser: a double blind study*, Orlando, Florida, 1990, Presented at the Arthroscopic Association of North America Annual Meeting.
143. Mazzonetto R, Spagnoli D: Long term evaluation of arthroscopic disckectomy of the temporomandibular joint using Holmium YAG laser, *J Oral Maxillofac Surg* 59:1018–1023, 2001.
144. Catone GA: *Open laser temporomandibular joint arthroplasty. Laser application in oral and maxillofacial surgery*, Philadelphia, 1997, Saunders, pp 201–217.
145. Keller GS: KTP laser rhytidectomy, *Facial Plast Surg Clin North Am* 1:2, 1993.
146. Keller GS: Use of the KTP laser in cosmetic surgery, *Am J Cosmetic Surg* 9:2, 1992.
147. Keller GS: Transblepharoplasty brow suspension with the KTP laser, *Int J Aesthetic Restorative Surg* 1:2, 1993.
148. Moses J: Lasers for use in cosmetic maxillofacial surgery. In Catone GE, editor: *Laser applications in oral and maxillofacial surgery*, Philadelphia, 1997, WE Saunders, pp 219–243.
149. McGurk M, et al.: Laser lithotripsy: a preliminary study on its application for sialolithiasis, *Er J Oral Maxillofac Surg* 32:218–221, 1994.
150. Ito H, Eaba S: Pulsed dye laser lithotripsy of submandibular gland salivary calculus, *J Laryngol Otol* 110:942–946, 1996.
151. Posten W, Wrone DA, Dover JS, Arndt KA, Silapunt S, Alam M: Low-level laser therapy for wound healing: mechanism and efficacy, *Derm Surg* 31:334–340, 2005.
152. Doeuk C, Hersant B, Bosc R, Lange F, SidAhmed-Mezi M, Bouhassira J, Meningaud JP: Current indications for low level laser treatment in maxillofacial surgery: a review, *British J Oral Maxillofac Surg* 53:309–315, 2015.
153. Rodrigo SM, Cunha A, Pozza DH, Blaya DS, Moraes JF, Weber JB, de Oliveria MG: Analysis of the systemic effects of red and infrared laser therapy on wound repair, *Photomed Laser Surg* 27(6):929–935, 2009.
154. Kahraman S: Low-level laser therapy in oral and maxillofacial surgery, *Oral Maxillofac Surg Clin N Am* 16:277–288, 2004.
155. Sayed N, Murugaval C, Gnanam A: Management of temporomandibula disorders with low level laser therapy, *J Maxillfac Oral Surg* 13:444–450, 2014.
156. Zarei M, Wikramanayake TC, Falto-Aizpurua L, Schachner LA, Jimenez JJ: Low level laser therapy and hair regrowth: an evidence based review, *Lasers Med Sci* 31:363–371, 2016.
157. Vescovi P, Giovannacci I, et al.: Tooth extractions in high-risk patients under bisphosphonate therapy and previously affected with osteonecrosis of the jaws: surgical protocol supported by low-level laser therapy, *J Craniofac Surg* 26:696–699, 2015.
158. Maia ML, Bondjardim LR, Quintans Jde S, Ribeiro MA, Maia LG, Conti PC: Effect of low-level laser therapy on pain levels in patients with temporomandibular disorders: a systematic review, *J Appl Oral Sci* 20:594–602, 2012.

20
Basic Rhinoplasty

JAMES KOEHLER

The popularity of cosmetic surgical procedures continues to increase. Between 2000 and 2015 the number of surgical and nonsurgical treatments increased by 39%. In 2015 it was estimated that the U.S. population spent $13.5 billion on surgical and nonsurgical cosmetic procedures. Approximately 13 million procedures were performed in 2015. The number of procedures has increased by 538% since 1997. In 2015 rhinoplasty was the sixth most common procedure overall and the second most common surgery performed in men.[1]

Cosmetic surgery of the nose is often considered one of the most difficult esthetic operations. This is partly because the nose holds a prominent position on the face and irregularities or asymmetries cannot be easily camouflaged. Also, subtle postsurgical changes will occur over the course of a year or more. If a surgeon does not perform long-term follow-up of patients, he or she will not gain an appreciation for how well his or her surgical techniques withstand the test of time. For many years, cartilage grafting and destructive techniques to the alar cartilages were performed. In the short term, many of these noses would look good. However, with time, some of these techniques have demonstrated unpredictable long-term results.[2] A return to more conservative and nondestructive tip techniques has come back into favor with the hope that long-term favorable esthetic results can be achieved without compromising the nasal airway.[2-5]

As in any surgery, a solid understanding of the anatomy and physiology is essential. Taking time to listen to the patient's concerns and desires is critical to help formulate the surgical goals and determine if the patient is suitable for surgery and has realistic expectations. Once the patient decides to proceed with surgery, the surgeon must perform a comprehensive examination, taking into consideration the dynamic influence of the skin type, bone and cartilage structure, and anatomic limitations. Creating a detailed three-dimensional plan with a structured sequence will help the surgeon achieve more predictable results.

Mastering the complexity of rhinoplasty is something that cannot be captured in a single chapter. It takes years of training, experience, and continuing medical education to become comfortable with the many techniques that must be tailored to each patient. This chapter will hopefully provide a foundation to build on.

Nasal Anatomy

The descriptorss used to describe relative spatial relationships include the standard anatomic terms: *anterior, posterior, superior,* and *inferior,* as well as *dorsal, basal, caudal,* and *cephalic* (or *cranial*) (Figure 20-1). The terms used to describe the surface anatomy assist the surgeon in defining problem areas of the nose and facilitate treatment planning (Box 20-1).

The thickness of the skin varies along the dorsum of the nose. In the region of nasion, the skin is fairly thick and mobile. It quickly thins over the nasal dorsum and is generally thinnest and most mobile in the mid-dorsal region (rhinion). In the nasal tip the skin becomes thicker and more adherent and has an increased sebaceous content.

The muscles of the nose are encased in the nasal superficial musculoaponeurotic system (SMAS). This is a fibromuscular layer that separates the skin and subcutaneous tissue from the nasal cartilage and bone. The SMAS of the nose is continuous with the SMAS of the face. Violating the SMAS can result in increased bleeding, scarring, and postoperative edema; therefore the dissection should be between the cartilage and bone and the SMAS (Figure 20-2).

The muscles of the nose can be divided into four categories: the elevators, the depressors, the compressors, and the dilators. The paired depressor septi nasi muscles can cause inferior displacement of the nasal tip during smiling. This smiling deformity should be recognized preoperatively and addressed by resection of these muscles in order to achieve a cosmetic result.[6]

There is a rich blood supply to the subdermal vascular plexus of the external nose, which arises from branches of both the internal and external carotid arteries. The internal carotid artery supplies the external nose via the dorsal nasal artery (a branch of the ophthalmic artery) and the external nasal artery (a branch of the anterior ethmoid artery).

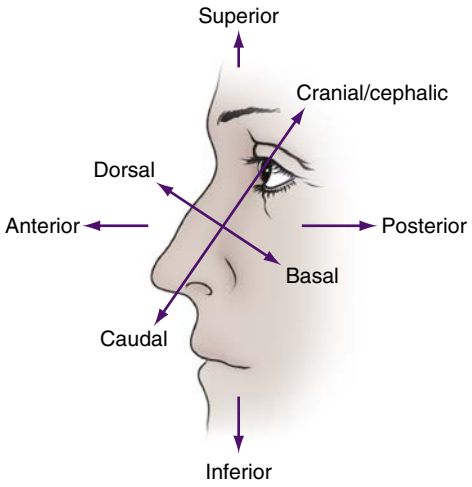

• **FIGURE 20-1** Relative spatial relationships. When one anatomic part is described relative to another, the standard anatomic descriptors are used, including anterior, posterior, superior, and inferior. Specifically when referring to nasal relationships additional terms are used including dorsal, basal, caudal, and cephalic. This figure shows the direction indicated when describing one part as it relates to another. (From Austermann K: Rhinoplasty: planning techniques and complication. In Booth PW, Hausamen JE, eds: *Maxillofacial surgery*, New York, 1999, Churchill Livingstone.)

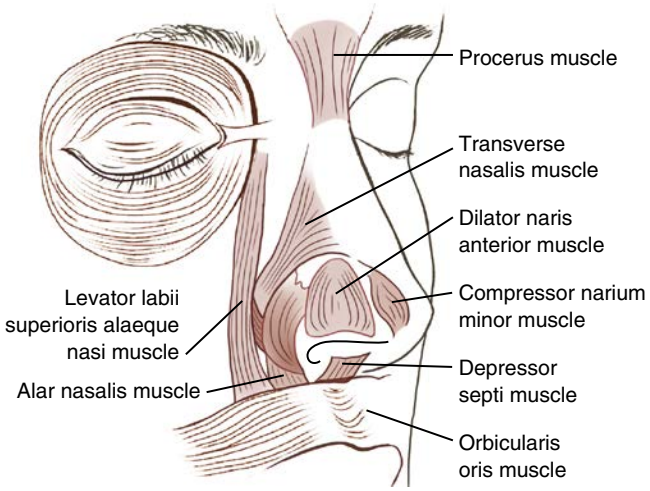

• **FIGURE 20-2** Nasal musculature. The nasal muscles are generally not addressed in rhinoplasty procedures with exception of the depressor nasal septi muscles. The depressor septi muscle, if overactive, can cause inferior displacement of the nasal tip during smiling and may require resection as part of the rhinoplasty procedure. (From Jewett B: Anatomic considerations. In Baker SR, ed: *Principles of nasal reconstruction*, ed 2, 2011, Spinger.)

• BOX 24-1 Surface Landmarks

Radix: The deepest depression of the nasal dorsum, located at the junction between the frontal bone and the nasal bones.
Glabella: The most forward projecting portion of the forehead, located at the midline between the supraorbital ridges.
Rhinion: The osteocartilaginous junction formed by the nasal bones and upper lateral cartilages.
Dorsum: The anterior surface of the nose formed by the nasal bones and upper lateral cartilages.
Supratip break: The slight depression seen in profile at the point where the nasal dorsum joins the lobule of the nasal tip.
Infratip lobule: The portion of the tip lobule located between the columella and the most projected portion of the nasal tip.
Tip defining points: For proper nasal tip definition four points should be visualized. These four points are composed of the supratip break, the infratip lobule, and the most projected portion or domes of the lower lateral cartilages.
Alar sidewall: The rounded eminence forming the lateral nostril wall.
Alar-facial junction: The depressed groove formed at the junction where the ala joins the face.
Columella: The skin that separates the nostrils at the base of the nose.
Nasofrontal angle: The angle formed between the forehead and nasal dorsum as seen in profile view.
Nasolabial angle: The angle formed by the columella and the upper lip as seen in profile view.
Pronasale: The most projected portion of the nasal tip.

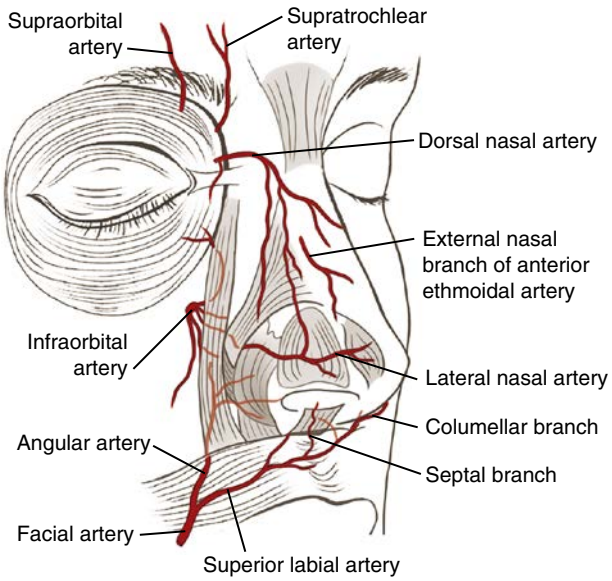

• **FIGURE 20-3** Arteries of the external nose. The arterial blood supply of the nose comes from both the external and internal branches of the carotid artery. The primary blood supply to the nasal tip comes from the lateral nasal arteries, which are branches of the facial artery. The lateral nasal artery course is superficial to the alar cartilages, approximately 2 to 3 mm above the alar groove. (From Jewett B: Anatomic considerations. In Baker SR, ed: *Principles of nasal reconstruction*, ed 2, 2011, Spinger.)

The external carotid artery provides blood supply via the facial artery branches (angular artery, lateral nasal artery, alar artery, septal artery, and superior labial artery) (Figure 20-3).

The internal nose is supplied by the internal and external carotid branches (Figure 20-4). From the internal

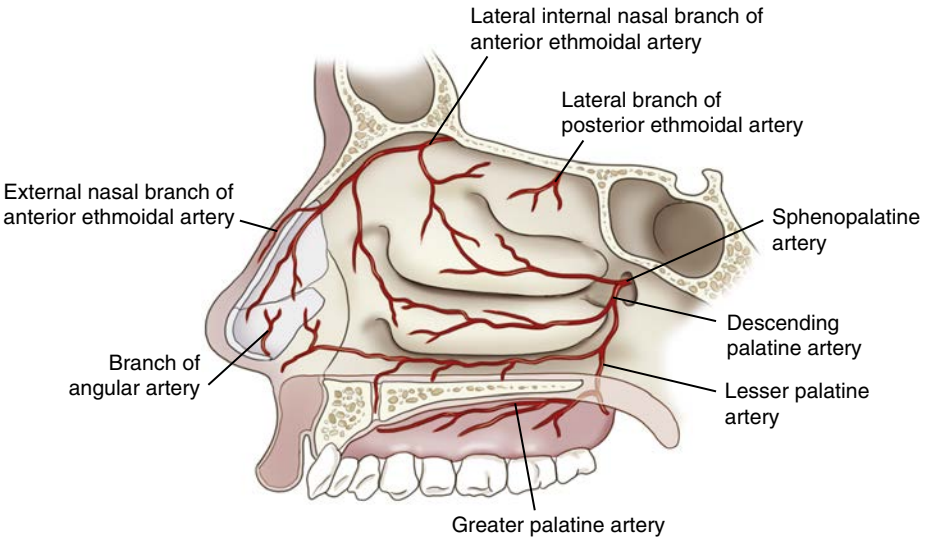

• **FIGURE 20-4** Arteries of the lateral nasal wall. The anterior and posterior ethmoidal arteries (branches of the internal carotid) supply the superior portion of the lateral nasal wall. Branches of the internal maxillary artery supply the inferior portion of the lateral nasal wall. (From Jewett B: Anatomic considerations. In Baker SR, ed: *Principles of nasal reconstruction*, ed 2, 2011, Spinger.)

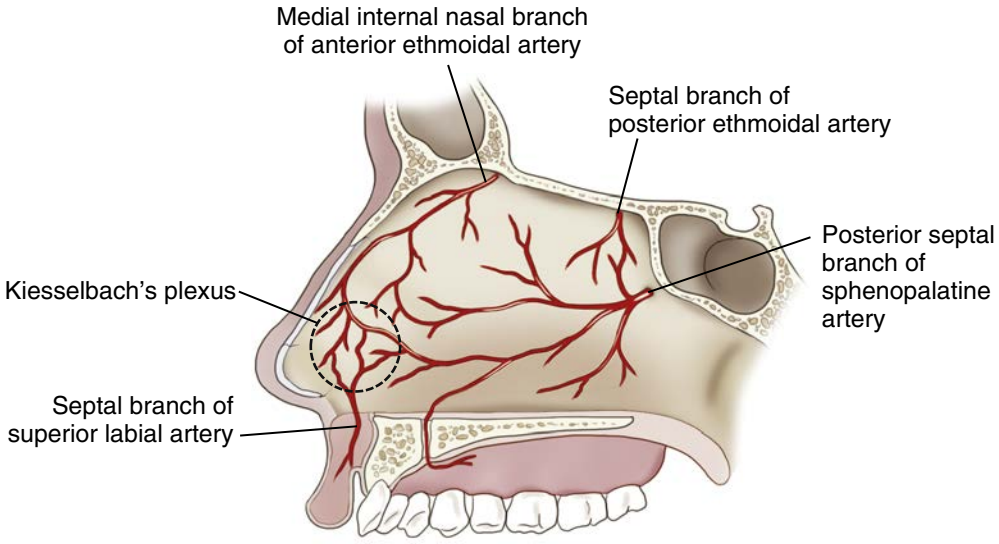

• **FIGURE 20-5** Arteries of the nasal septum. Kiesselbach's plexus, a common site of epistaxis, is located in the anteroinferior portion of the nasal septum. This region represents the anastomosis of the sphenopalatine, greater palatine, superior labial artery, and anterior ethmoidal arteries. (From Jewett B: Anatomic considerations. In Baker SR, ed: *Principles of nasal reconstruction*, ed 2, 2011, Spinger.)

carotid, the ophthalmic artery branches into the anterior and posterior ethmoidal arteries. The anterior ethmoidal artery supplies the anterosuperior part of the septum and the lateral nasal wall. The posterior ethmoid artery supplies the septum, lateral nasal wall, and superior turbinate. From the external carotid, the internal maxillary artery branches that supply the internal nose include the sphenopalatine artery and the greater palatine artery. The sphenopalatine artery supplies most of the posterior part of the nasal septum, lateral wall of the nose, roof, and part of the nasal floor. The greater palatine artery supplies a portion of the anterior and inferior portion of the nasal septum.

A common site of epistaxis is known as *Kiesselbach's plexus* (also termed *Little's area*) (Figure 20-5). This area is located in the anteroinferior part of the nasal septum and represents the anastomosis of the sphenopalatine, greater palatine, superior labial artery, and anterior ethmoid arteries.[7] The venous drainage of the nose is primarily from the facial and ophthalmic veins.

One concern during nasal surgery is the possibility of compromised blood flow to the nasal tip if the surgeon performs an external rhinoplasty. Cadaver dissection, lymphoscintigraphic studies, and histologic examinations confirm that the primary blood supply to the nasal tip comes from the bilateral lateral nasal arteries, which course in a plane

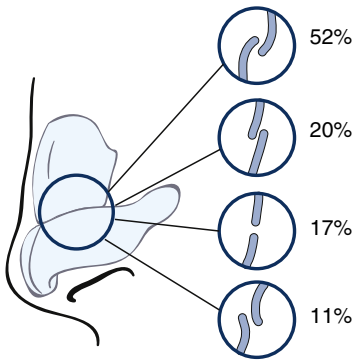

• **FIGURE 20-6** Confirmations of the scroll. The upper and lower lateral cartilages have an intimate connection with each other, known as the scroll. More common configurations include interlocked (52%), overlapping (20%), end-to-end (17%), and opposed (11%). (From Lam SM, Williams EF III: Anatomic considerations in aesthetic rhinoplasty, *Facial Plast Surg* 18:209, 2002.)

superficial to the alar cartilages in the subdermal plexus approximately 2 to 3 mm above the alar groove.[8,9] The blood supply allows a columellar incision to be made without fear of vascular compromise. Some surgeons believe external rhinoplasty remains more edematous for longer postoperative periods because of disruption of veins and lymphatics in the columellar region. Anatomic studies show few veins and minimal lymphatics in this region, and the tip edema noted by some is purely subjective.

The paired nasal bones as well as the frontal process of the maxilla provide support to the upper nose. The nasal bone is thickest where it joins with the frontal bone and tapers as it joins with the upper lateral cartilages. The nasal bones have an intimate connection with the upper lateral cartilages and overlap them by 6 to 8 mm. The connection between the nasal bones and upper lateral cartilages should not be violated because this could result in internal nasal valve obstruction and asymmetry.

The lower lateral cartilages form the nasal tip and connect with the upper lateral cartilages in a union described as the *scroll* (Figure 20-6). There are various configurations of the scroll.[10,11] The scroll is described as interlocked (52%), end-to-end (17%), overlapping (20%), or opposed (11%). The scroll provides significant support to the nasal tip. Removing cephalic strips of cartilage from the lower lateral cartilages or performing an endonasal rhinoplasty violates this junction. The lower lateral cartilage is divided into medial and lateral crura. The medial crura are in intimate contact with the nasal septum and provide tip support. The lateral crura extend superiorly and form dense fibroareolar tissue attachments with the pyriform aperture. The intermediate crus is defined as the area where the medial crura diverge before turning to become the lateral crura proper. The highest point of the intermediate crus is an important surgical landmark known as the *tip defining point.*

The nasal septum is formed by both bone and cartilage. The ethmoid and vomer provide bony support posteriorly. The quadrangular cartilage provides support anteriorly.

Support for the nasal tip is classified into major and minor divisions. The major tip support comes from the size, shape, and strength of the lower lateral cartilages, the attachment of the medial crura of the lower lateral cartilage to the caudal septum, and the fibrous attachment of the lower lateral cartilage to the upper lateral cartilage. The minor tip support comes from the nasal spine, the membranous septum, the cartilaginous dorsum, the sesamoid complexes, the interdomal ligaments, and the alar attachments to the skin.[10]

The sensory nerve supply to the skin of the external nose is supplied by the ophthalmic and maxillary divisions of the trigeminal nerve (Figure 20-7). Branches of the supratrochlear and infratrochlear nerves supply the skin in the region of the radix and rhinion. The lower half of the nose is supplied by the infraorbital nerve and the external nasal branch of the anterior ethmoidal nerve (a branch of the nasociliary nerve that arises from the ophthalmic branch of the trigeminal nerve).

The main sensory nerve supply to the nasal septum comes from the internal nasal nerve (a branch of the anterior ethmoidal nerve) and the nasopalatine nerve. The lateral nasal wall sensation is supplied by the anterior ethmoidal nerve, branches of the pterygopalatine ganglion, branches of the greater palatine nerve, the infraorbital nerve, and the anterior superior alveolar nerve.

The Consultation

In cosmetic surgery the initial consultation is probably the most important appointment. During this visit the patient will decide if he or she trusts you and your staff enough to proceed with surgery. From the surgeon's perspective, it is important to determine if the patient is a suitable candidate for cosmetic surgery and that he or she has realistic expectations.[12,13]

First, the surgeon should determine the area of the nose that concerns the patient the most. It is sometimes helpful to have the patient point the areas out with a cotton tip applicator in the mirror. Next, pertinent history should be obtained. Has the patient had previous cosmetic surgery? If so, what were his or her experience and satisfaction with the procedures? Be wary of patients who seek a different doctor for each procedure and denigrate the previous surgeon. Also, be concerned if the patient offers excessive praise about you or your reputation and states that he or she knows you will be able to correct the previous surgical errors made by the last doctor. Other important history should include previous trauma, nasal and septal surgeries, difficulties with nasal breathing, allergies, cocaine use, and the use of intranasal medications. If the patient has had previous septal surgeries, prepare the patient for the possible need for auricular cartilage harvesting in the event that you need cartilage at the time of surgery.[14]

Reviewing photographs will also help the surgeon understand the patient's expectations. Patients who are overly critical may not be good candidates for surgery. Imaging is not

entirely accurate and is best used to show something simple, such as what the reduction of a dorsal hump would do for the profile or the benefits of chin augmentation.

It is essential to determine those patients who are unsuitable from a psychiatric standpoint to undergo the operation. It is estimated that 5% to 7% of all cosmetic surgery patients have a diagnosis of body dysmorphic disorder. In rhinoplasty surgery the incidence may be as high as 20.7%.[15] According to the *Diagnostic and Statistical Manual of Mental Disorders, 5th Edition* (DSM-V), the following criteria must be met for a patient to be diagnosed: the patient is preoccupied with an imagined defect of appearance or is excessively concerned about a slight physical anomaly; repetitive behaviors such as mirror checking, excessive grooming, skin picking or comparing their appearance with others; this preoccupation causes clinically important distress or impairs work, social, or personal functioning; and another mental disorder (such as anorexia nervosa) does not better explain the preoccupation. Those patients with body dysmorphic disorder seeking rhinoplasty tend to be younger, more depressed, more anxious, and preoccupied with the nose, as demonstrated by frequent touching and looking in the mirror. Cosmetic surgeons should be aware of this disease because the suicide rate has been found to be 45 times higher than in the general population.[16]

It is also wise to avoid operating on someone whom you just do not like. If your personalities clash, it is often best to avoid doing the surgery. You should imagine managing such a patient if a complication were to arise, and if this scenario is seen as too difficult, then it is often wise for the patient to choose another surgeon.[12,13,17,18]

Patients are typically seen again the week before surgery for their preoperative appointment, at which time photographs are taken. An additional set of photographs is taken the morning of surgery. It is important when taking photographs of the nose to obtain six main views, including full-face frontal, full-face right and left oblique, full-face right and left lateral, and basilar views. Standardization of photographic technique is essential for proper operative planning and for obtaining high-quality before and after photographs to be used in future consultations.

Clinical Examination

When performing an examination of the nose, both the esthetics and function must be assessed. The examination should be done in a thoughtful and systematic way to ensure that nothing is overlooked. I typically begin with the external nasal examination and finish with the intranasal speculum examination.

Upper Nose and Dorsum

The upper nose and dorsum are assessed first. From the frontal view, note any gross asymmetries, lateral bony irregularities, or deviation of the dorsum. Next, determine if the width of the upper nose is adequate or excessive. The upper nasal width should be approximately 80% of the alar width, assuming that the alar width is not excessive. Normal alar width should approximate the patient's intercanthal distance. In a profile view, evaluate the position of the radix (the greatest depth of the nasofrontal depression). The radix should be located vertically between the superior palpebral margin and the upper eyelid margin. The nasal length (distance from radix to nasal tip) is also affected by the position of radix. If the radix is low, the patient will have the appearance of a short nose, and if it is high, the patient will have the appearance of a long nose.

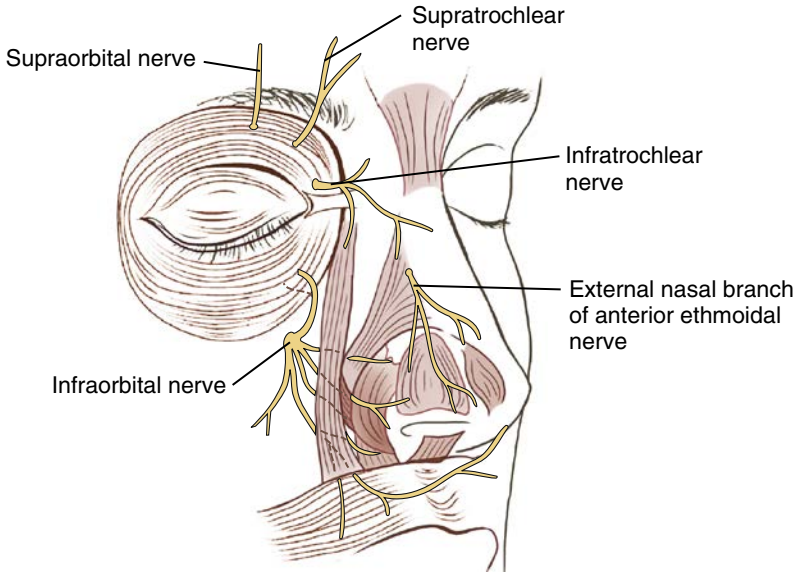

• **FIGURE 20-7** Sensory nerves of the external nose. The ophthalmologic divisions of the trigeminal nerve that supply the nose include the supratrochlear and infratrochlear nerves. The remainder of the nose is supplied by branches of the maxillary division of the trigeminal nerve. (From Jewett B: Anatomic considerations. In Baker SR, ed: *Principles of nasal reconstruction*, ed 2, 2011, Spinger.)

In the profile view the depth of the nasofrontal depression should be approximately 4 to 9 mm anterior to the corneal plane (Figure 20-8). The depth of the radix can greatly affect the nasofrontal angle. The ideal nasofrontal angle is between 115 and 130 degrees. The nasofrontal angle tends to be more acute in men and more obtuse in women. A deep radix creates a more acute nasofrontal angle and a shallow radix creates a more obtuse angle. When examining the nose in profile, also note any dorsal hump deformities.

Nasal Tip

Control of the nasal tip is critical in rhinoplasty surgery. Proper assessment of the problems with the nasal tip is important in planning the surgical technique. The shape of the nasal tip itself should be evaluated first. Is the tip bulbous, boxy, pinched, twisted, or asymmetric? Next, look at the tip definition. There should be four tip defining points including the supratip, the infratip, and the most prominent portion of the intermediate crus (the junction between the medial crura and lateral crura of the lower lateral cartilage). From the profile view, identify the supratip break and the infratip break (also known as the *columellar-lobule angle*). The distance from the supratip break to the infratip break should be divided equally by a line drawn parallel to the floor through the pronasale (the most forward point of the tip of the nose).

The tip projection and support should be assessed next. The nose should not be easily compressible when pushing on the nasal tip with an index finder. If the cartilages are weak and the nose is easily compressed, consideration should be given to crural strut grafts to increase support. There are several ways to evaluate the tip projection. No one method is superior, and each method has its limitations.[19] The most commonly quoted method is Goode's method. This definition states that the ideal tip projection is 0.55 to 0.6 RT, where RT is the distance between radix and pronasale[20] (Figure 20-9). Tip projection is usually measured as the distance from the alar groove to the most projected portion of the nasal tip (pronasale). Simon's method states that the length of the upper lip from subnasale to labrale superioris should be equal to the tip projection measured from subnasale to pronasale.[20] Another method is to draw a tangent through the most projected portion of the upper lip. This line should bisect the nose such that 50% is tip and 50% is nasal base. If more than 60% is nasal tip, the nose is considered overly projected.[21]

The relationship of the dorsum to the nasal tip should also be evaluated. The dorsum should be approximately 2 mm below a line drawn from radix to pronasale in women and just below or even with the line in men.

The columella is then assessed. First, look at the columellar-lobular angle. This is defined as the angle created where the tangents of the columella and infratip lobule intersect. A normal columella-lobular angle is 36 to 40 degrees. Next, the relationship of the ala and columella is assessed. From

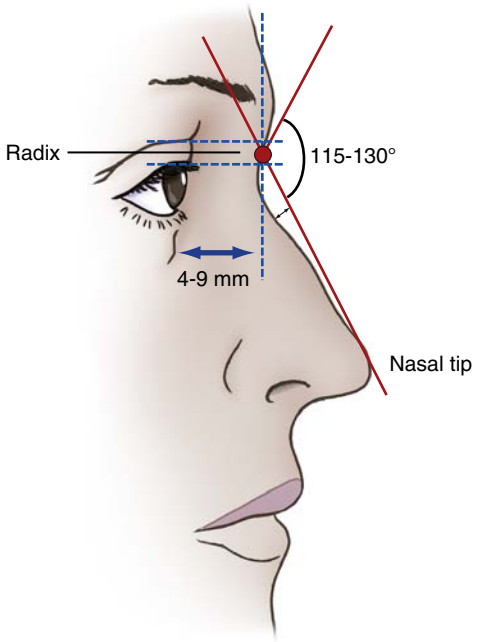

• **FIGURE 20-8** Dorsal profile and position of radix. The radix is located vertically between the superior palpebral margin and the upper eyelid margin and is typically 4 to 9 mm anterior to the corneal plane. The ideal nasofrontal angle is between 115 and 130 degrees and tends to be more acute in men and obtuse in women. The nasal dorsum typically lies 2 mm behind a line drawn from radix to nasal tip in women and on this line in men. (From Austermann K: Rhinoplasty: planning techniques and complication. In Booth PW, Hausamen JE, eds: *Maxillofacial surgery*, New York, 1999, Churchill Livingstone.)

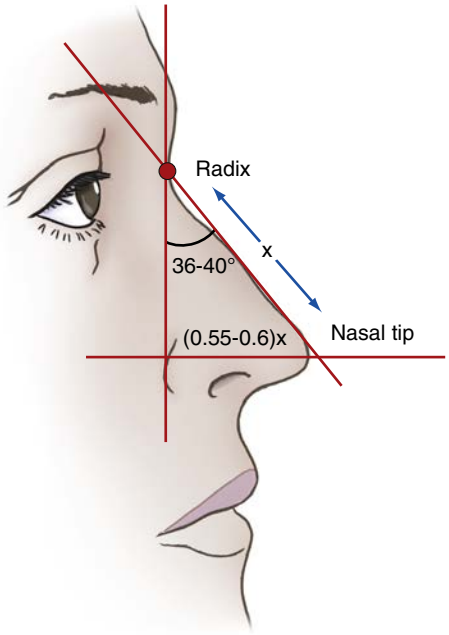

• **FIGURE 20-9** Goode's method of nasal projection. The ideal tip projection is 0.55 to 0.60 RT, where RT is the distance between radix and pronasale provided that the nasofrontal angle is between 36 and 40 degrees. (From Austermann K: Rhinoplasty: planning techniques and complication. In Booth PW, Hausamen JE, eds: *Maxillofacial surgery*, New York, 1999, Churchill Livingstone.)

the profile view, imagine a line drawn from the base of the nostril to the tip of the nostril that bisects the ala and the columella (Figure 20-10). In a properly proportioned nose, the columella and alar rim should be equidistant from the line, and approximately 2 to 4 mm of columella should show.[17] When there is a large amount of columella showing, the problem may be due to a hanging columella, alar retraction, or a combination of both (Figure 20-11). Conversely, if there is little columella showing in the profile view, the problem could be with a retracted columella, a hanging ala, or a combination of both. Determining the problem is essential because the management of each of these problems is different.

The nasal tip rotation is then evaluated. This is often measured by using the nasolabial angle. This angle is formed by the intersection of the tangents of the columella and the upper lip. A normal nasolabial angle is 95 to 110 degrees in women and 90 to 95 degrees in men. This angle can be affected by the inclination of the upper incisor teeth.

While the patient is evaluated in profile, the chin projection relative to the nose should not be overlooked. Often a nose looks much larger when the patient has a weak chin. A simple method to evaluate chin position is to look at the relative position of the chin to the subnasale perpendicular. In a profile view a woman's chin should be on or slightly behind an imaginary vertical line from the subnasale perpendicular, and in men it should be on or slightly in front of this line. Consideration for a chin implant or genioplasty should be done in cases of microgenia to keep the nose and chin in better balance.

Skin Thickness

The nose should be palpated to assess the skin thickness. A patient with thin nasal skin will show dramatic changes with alteration of the underlying bone and cartilage, and this limits room for error because little is camouflaged by the thickness of the skin. On the other hand, thick-skinned individuals require more aggressive sculpting of the nasal skeleton in order to see significant change. Although thick skin may mask imperfections, it does not redrape as well and can result in underlying fibrosis and formation of a polybeak deformity (supratip scarring). Better results are possible with average to thin-skinned patients; however, the margin for error is smaller.

Nasal Function

Lastly the functional aspects of the nose must be evaluated. Have the patient breathe normally through the nose, then have him or her take a deep breath through the nostrils. Observe for collapse of the ala and occlusion of nasal breathing. The airflow through the nose is regulated by the internal and external nasal valves. The external nasal valve is formed by the lower lateral cartilage (Figure 20-12). In severe cases, collapse of the external nasal valve can be seen when the nares become occluded on even gentle inspiration. This problem is more common in patients with narrow nostrils, overly projected nasal tip, and thin alar sidewalls. External nasal valve collapse is also commonly seen in patients having previous rhinoplasty surgery with excessive trimming of the cephalic portion of the lower lateral cartilages. It may also be seen with increased age and

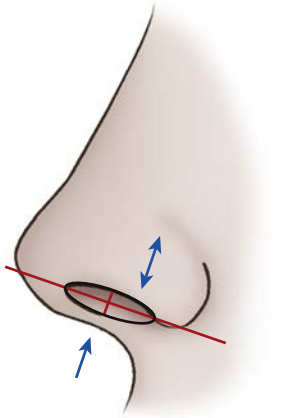

• **FIGURE 20-10** Alar-columellar relationship. The ala and columella should be an equal distance from a line that bisects the nostril through the tip and base. Two to 4 mm of columellar showing is considered normal. (From Gunter JP, Rohrich RJ, Friedman RM: Classification and correction of alar-columellar discrepancies in rhinoplasty, *Plast Reconstr Surg* 97:643, 1996.)

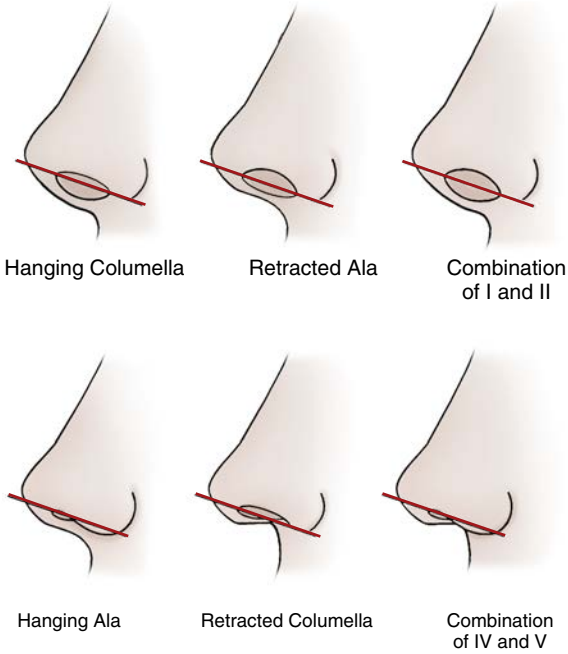

• **FIGURE 20-11** The alar-columellar relationship. When there is a large amount of columella showing, the problem may be due to a hanging columella, alar retraction, or a combination of both. Conversely, if there is little columella showing in the profile view, the problem could be with a retracted columella, a hanging ala, or a combination of both. (From Gunter JP, Rohrich RJ, Friedman RM: Classification and correction of alar-columellar discrepancies in rhinoplasty, *Plast Reconstr Surg* 97:643, 1996.)

in facial nerve paralysis. The external nasal valve collapse can be corrected by deprojecting an overprojected nose, realigning the lateral crura into a more caudal orientation, and placing alar batten grafts to provide structural support and prevent collapse.[22-24]

The internal nasal valve is formed by the junction of the septum and the upper lateral cartilages (see Figure 20-12). The angle formed should be a minimum of 10 to 15 degrees to maintain patency. Deviation of the nasal septum or separation of the upper lateral cartilages from the nasal bones can lead to obstruction. This problem is also seen after rhinoplasty if the patient has had weakening of the upper and lower lateral cartilages. These patients often have a pinched appearance in the supraalar region. The Cottle test is used to evaluate obstruction at the internal valve by using a finger to laterally pull the cheek and lateral wall of the nose, thereby opening the nasal valve. Nasal airflow that is dramatically improved by the Cottle test indicates that the internal nasal valve requires correction. These patients often achieve symptomatic relief by the use of external taping devices. Surgical correction involves the placement of spreader grafts between the septum and upper lateral cartilages and/or cartilage flaring sutures to increase the angle of the lower lateral cartilages with the nasal septum[22,24] (Figure 20-13).

The nose is inspected last with a nasal speculum. Observe for any deflections or perforations of the nasal septum, bone spurs, enlargement of turbinates, or any nasal pathology.

Planning

In preparation for surgery, it is helpful to review the presurgical photographs and compile a problem list. The surgeon should have a clear plan as to what techniques will be employed to address the various problems and the sequence in which these problems will be corrected.

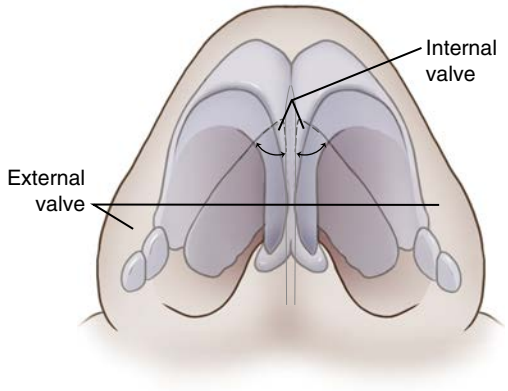

• **FIGURE 20-12** The external and internal nasal valve. The external nasal valve is formed by the lower lateral cartilages. The internal nasal valve is formed by the junction of the septum with the upper lateral cartilages. The angle formed between the septum and upper lateral cartilages should be a minimum of 10 to 15 degrees to maintain nasal patency.

Incisions for Rhinoplasty

There are a number of incisions commonly used in rhinoplasty. The choice of incision is determined by whether an open or closed rhinoplasty is performed.

Marginal incisions connected by a transcolumellar incision are commonly used in open rhinoplasty (Figure 20-14). The marginal incision parallels the caudal edge of the lower lateral cartilages. The incision begins just caudal to the lateral crus and parallels the caudal edge of the lower lateral cartilage until the medial crura begin to flare. It differs from a rim incision in that the rim incision parallels the alar rim. The problem with a rim incision is that the soft tissue caudal to the lateral crus is disrupted, which can result in scarring and alar retraction.

The transcolumellar incision is used to connect the bilateral marginal incisions and allows the soft tissues overlying the nasal tip to be elevated in open rhinoplasty. The incision is made just superior to the flare of the medial crura. To prevent linear scar contraction and to facilitate closure, the incision is broken up by using a V, inverted V, or stairstep configuration (Figure 20-15).

Intercartilaginous, intracartilaginous, transfixion, and marginal incisions are commonly used in closed rhinoplasty techniques. The intercartilaginous incision is made at the junction of the upper and lower lateral cartilages in the region of the scroll (Figure 20-16). The incision starts laterally and joins up with a transfixion incision medially. A complete or partial transfixion incision is normally used and provides access to the caudal septum, medial crura, and the anterior nasal spine (Figure 20-17).

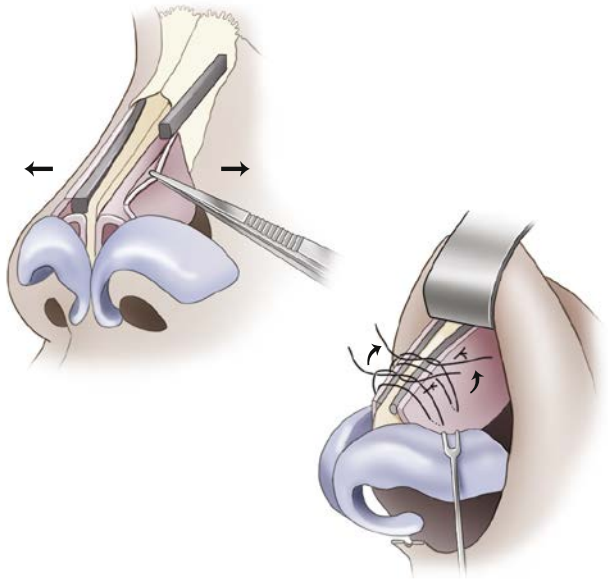

• **FIGURE 20-13** Spreader grafts. Cartilage harvested from the nasal septum can be placed between the nasal septum and upper lateral cartilages in order to widen the angle of the internasal valve and improve nasal breathing. (From Dolan R: Nasal valve and nasal alar dysfunction. In Holt GR, ed: *Advances in rhinoplasty*, Philadelphia, 2000, Saunders.)

A complete transfixion incision is made just caudal to the nasal septum and extends inferiorly through the membranous septum, following the cephalic margin of the medial crura. A partial transfixion incision may also be used and differs only in that it stops at the level of the footpads of the medial crura. Because the attachment of the medial footpads to the septum is not disrupted, less deprojection of the nose occurs. A hemitransfixion incision is not routinely used but is essentially a complete transfixion incision that does not traverse both mucosal surfaces and medial footpads. Access to the nasal septum can be done through a hemitransfixion incision, but delivery of the lower lateral cartilage on the side opposite the incision is more difficult, and asymmetric scarring can distort the shape of the nose.

An intracartilaginous incision is sometimes used in rhinoplasty when delivery of the lower lateral cartilages is not planned (see Figure 20-16). In these situations a cephalic strip is essentially done by placing the incision 3 to 5 mm caudal to the junction of the upper and lower lateral cartilages. This is a technically more difficult procedure because the cartilages are not directly visualized and it is easier to develop asymmetry. The incised lower lateral cartilage is not removed. Some believe that using this incision decreases the likelihood of scarring in the region of the internal nasal valve.

A seldom used incision in rhinoplasty is the Killian incision (Figure 20-18). This incision is useful for gaining access to the septum for isolated septoplasty. The incision is made several millimeters cephalad to the caudal edge of the septum. The incision can be extended onto the nasal floor if needed.

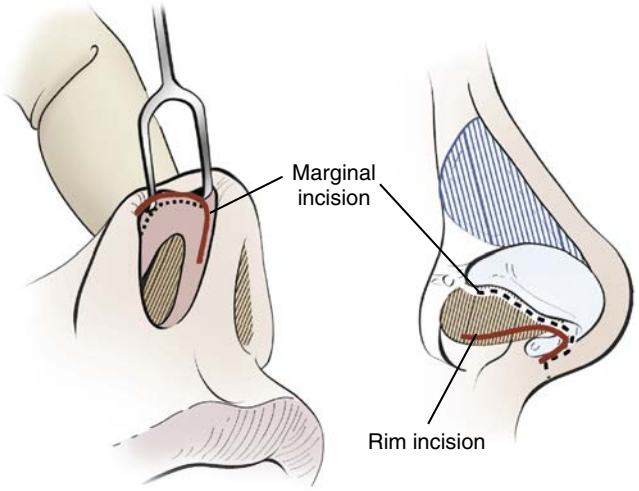

• **FIGURE 20-14** Marginal and rim (infracartilaginous) incisions. The marginal incision *(dotted line)* parallels the caudal edge of the lower lateral cartilages and is commonly used in rhinoplasty. The rim incision *(red line)* follows the contour of the nostril along the mucosa just inside the nostril. A rim incision should not be used because of the problems with scarring and alar retraction. (From Waite PD, ed: *Atlas of the oral and maxillofacial surgery clinics of North America: rhinoplasty*, Philadelphia, 1995, Saunders.)

Tip Plasty

Control of the nasal tip in rhinoplasty is essential in achieving predictable results. The surgeon must respect and preserve tip support in the process of obtaining an esthetically pleasing result. The surgeon must respect the major and minor mechanisms of tip support discussed earlier, so that both structure and function are maintained.[25] Many of the tip supporting structures are violated in the process of skeletonizing the nose.[26,27] Suture techniques or cartilage grafts may be necessary after adjusting the tip for esthetics to maximize nasal tip support. Disregarding tip support can result in nasal tip ptosis or unwanted nasal tip movements as scar contracture occurs during healing.

The skin overlying the nasal tip also will influence the type of procedures performed on the tip. Patients with thick skin may require more aggressive techniques to create changes in the appearance of the tip. It is tempting to reduce the fibrofatty tissue of the nasal tip to enhance changes made to the tip; however, this should only be done in select cases. Excessive thinning can lead to increased scarring and distortion of the tip. In patients with thinner skin, even minor irregularities in the underlying cartilage can result in obvious postoperative deformities. The skin thickness and strength of the cartilages can often be determined preoperatively by simply palpating the nose.

The structure of the lower lateral cartilages is often depicted as a tripod with the medial crura together forming one pillar and the lateral crura acting as the other two



• **FIGURE 20-15** The transcolumellar incision. Various configurations of the transcolumellar incision are used to prevent linear scar contracture and aid in reapproximating the skin at closure. The common configurations include a V, inverted V, or stairstep configuration.

pillars[28] (Figure 20-19). Adjustment to the strength or length of each of these pillars can affect tip rotation and projection. The proposed maneuvers to change the nasal tip should be planned preoperatively.

Tip Projection

A number of procedures can be used to increase tip projection. If the medial crura are significantly divergent, simply suturing them together can result in increased projection.[29]

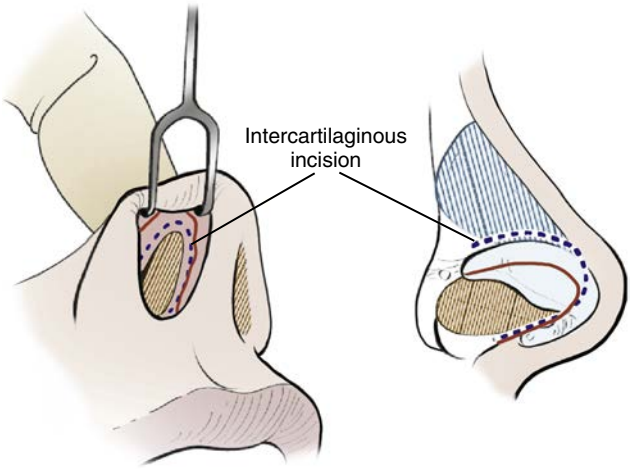

• **FIGURE 20-16** The intercartilaginous and intracartilaginous incisions. The intercartilaginous incision *(blue dotted line)* follows the junction of the upper and lower lateral cartilages in the region of the scroll. The intracartilaginous incision *(solid line)* is made through mucosa and the cephalic portion of the lower lateral cartilages. (From Waite PD, ed: *Atlas of the oral and maxillofacial surgery clinics of North America: rhinoplasty*, Philadelphia, 1995, Saunders.)

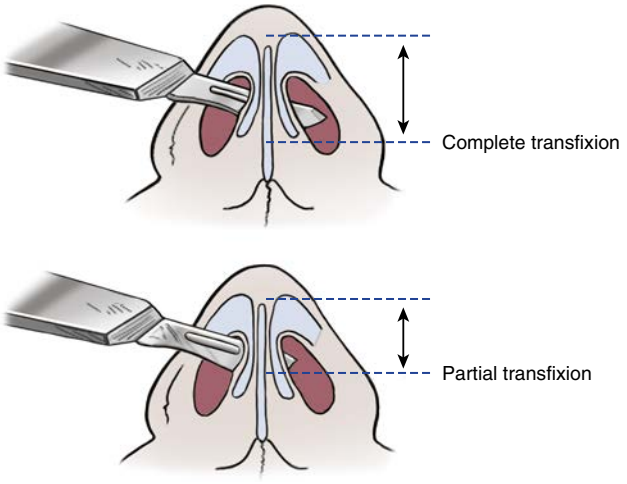

• **FIGURE 20-17** The complete and partial transfixion incisions. The complete transfixion incision is made caudal to the nasal septum, extends through the membranous septum, and detaches the medial footpads of the lower lateral cartilages. A partial transfixion incision stops just short of the medial footpads. (From Koehler JK, Waite PD: Basic principles of rhinoplasty. In Miloro M, ed: *Oral and maxillofacial surgery*, Hamilton, 2004, BC Decker.)

A columellar strut graft can also be placed abutting the nasal spine, and the medial crura can be advanced superiorly with a double skin hook and sutured to the strut. Placing 27-gauge needles through the crura and the strut will assist in stabilizing the graft when suturing (see Figure 20-19); 6-0 Prolene suture on a noncutting needle is used to secure the graft in place.

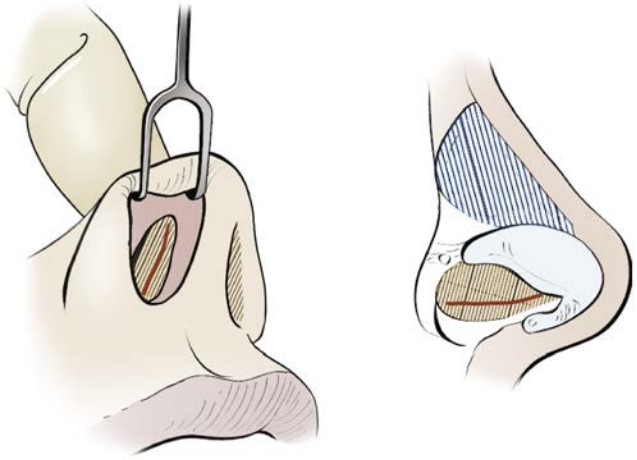

• **FIGURE 20-18** The Killian incision *(red line)* is a common incision used for septoplasty but is not routinely used for rhinoplasty. The incision is made several millimeters cephalad to the caudal edge of the septum. (From Waite PD, ed: *Atlas of the oral and maxillofacial surgery clinics of North America: rhinoplasty*, Philadelphia, 1995, Saunders.)

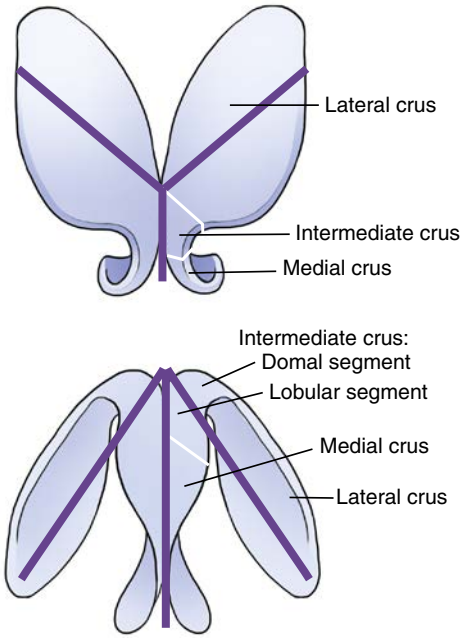

• **FIGURE 20-19** The tripod concept. The lower lateral cartilages act as a tripod supporting the nasal tip. The two medial crura act as one pillar and the lateral crura act as the other pillars of the tripod. Maneuvers that increase or decrease the length or strength of these cartilages will affect nasal tip projection and rotation. (From Koehler JK, Waite PD: Basic principles of rhinoplasty. In Miloro M, ed: *Oral and maxillofacial surgery*, Hamilton, 2004, BC Decker.)

Placing an interdomal suture with a horizontal mattress suture can narrow the nasal tip and when combined with a transdomal suture can also give some increase in tip projection (Figure 20-20). When placing an interdomal suture, the surgeon should be certain to preserve a normal angle of divergence (30 degrees or less) between the intermediate crura in order to maintain two distinct tip defining points. Pinching the intermediate crura together will narrow the tip but will have less esthetic appeal because of a lack of tip definition.[30,31]

A procedure known as the *lateral crural steal* can be used to increase tip projection (Figure 20-21). A horizontal mattress suture is placed in the lateral crura and advanced to the midline. The intermediate crura now becomes more vertically oriented as the medial crura. This technique will increase the tip projection and rotation; however, it removes the tip defining points and tends to create a single pointed tip, which is not appealing.[32,33]

When significant increases in tip projection are required, cartilage grafting is commonly used.[34] Tip onlay grafts (also called *Peck grafts*) can increase the tip projection by several millimeters. The cartilage can be stacked in layers and sutured in place with 6-0 Prolene. Some surgeons combine this with a columellar strut graft; this has been termed an *umbrella graft*.[35] The shield graft, first described by Sheen, can also be used to increase projection and create better definition to the tip[36,37] (Figure 20-22). A piece of septal cartilage is shaped to form a trapezoid measuring approximately 6 to 8 mm wide superiorly, 5 mm inferiorly, and 10 to 12 mm in length. The edges should be beveled and the corners rounded so that it does not create palpable irregularities. The graft is positioned so that the widest portion forms the tip defining points. The graft is secured at each corner so that it does not rotate. The inferior aspect of the graft overlies the medial crura and can help define the infratip lobule. This graft is helpful when both tip definition and projection are needed. Realize that cartilage grafts can resorb, displace, or distort with time. Suture techniques are generally preferred because of the problems with cartilage grafting.[2,5]

Decreasing tip projection can be done in a number of ways. Simply skeletonizing the nose will decrease the projection slightly. If more deprojection is needed a complete transfixion incision will separate the medial footpads from the membranous septum. This will decrease projection but will also increase tip rotation to some degree. In some cases a prominent anterior septal angle can be reduced. This will decrease tip projection and can also provide better definition to the infratip break.

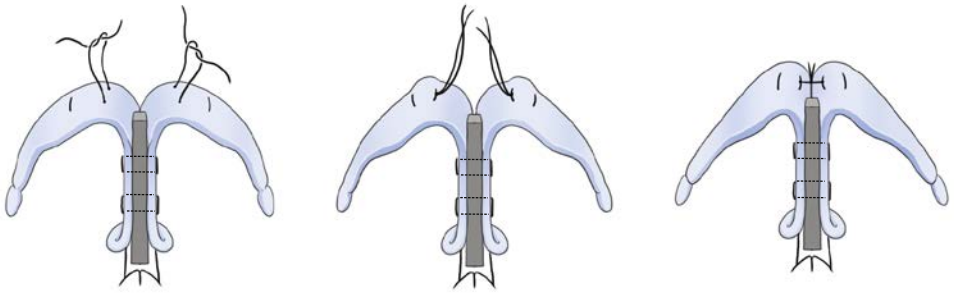

• **FIGURE 20-20** The columellar strut graft, interdomal and transdomal sutures. Cartilage harvested from the nasal septum can be placed between the medial crura and secured with sutures to provide increased tip support as well as increased nasal tip projection. A transdomal suture is a horizontal mattress suture placed in the dome of the lower lateral cartilages that is used to narrow the nasal tip and better define the most projected portion of the nasal tip. The transdomal sutures can be sutured to one another to further narrow the nasal tip. In cases when tip shape is adequate but narrowing is required, a single suture placed between the domes to bring them closer together can be done; this is termed an interdomal suture.

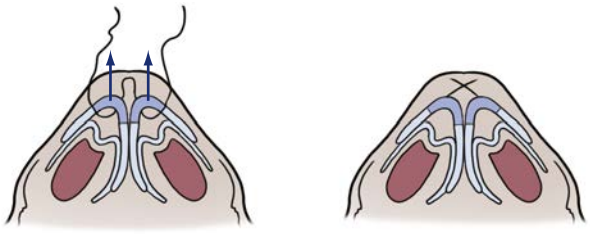

• **FIGURE 21** Lateral crural steal. A horizontal mattress suture placed in the lateral crura which is advanced to the midline can increase nasal tip projection; however, it removes the tip defining points and tends to create a single pointed tip. (From Koehler JK, Waite PD: Basic principles of rhinoplasty. In Miloro M, ed: *Oral and maxillofacial surgery*, Hamilton, 2004, BC Decker.)

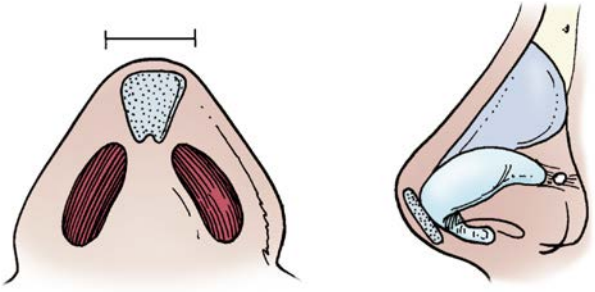

• **FIGURE 20-22** The shield graft. A trapezoidal piece of septal cartilage can be sutured in the region of the nasal tip to increase tip projection and better define the tip defining points. (From Taylor CO: Surgery of the nasal tip. In Waite PD, ed: *Atlas of the oral and maxillofacial surgery clinics of North America: rhinoplasty*, Philadelphia, 1995, Saunders.)

If aggressive deprojection is required, the medial crura can be transected horizontally, overlapped, and sutured with horizontal mattress sutures. The same can be done to the lateral crura if the tip needs increased rotation as well. Crural excision maintains the natural shape of the tip at the domes and is therefore preferred to excising segments of the dome and suturing them back together.

Sometimes after significant deprojection of the tip there may be a relative flaring of the alar base and increased columellar show. The alar flaring can be treated with conservative alar base resection; however, if this was not planned preoperatively, it is best to reevaluate this once swelling subsides in several weeks. A minor alar base resection can be done using local anesthesia at a later date if needed in these circumstances (Figure 20-23). The columellar show may need to be addressed by suturing the medial crura posteriorly to the caudal septum and in some cases excising a small strip of the caudal septum. Rarely, a small amount of redundant septal nasal mucosa adjacent to the medial crura needs to be resected.

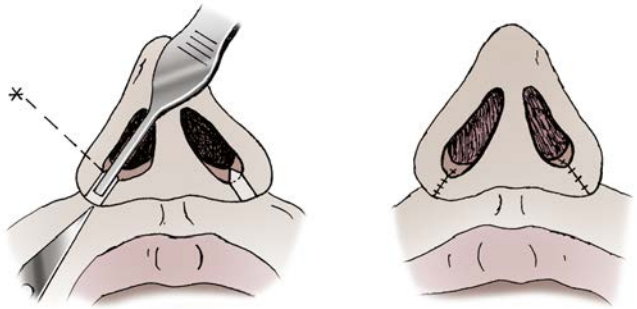

• **FIGURE 20-23** Alar base resection. The excision of 1 to 2 mm of vestibular mucosa and skin at the nostril base can be used to narrow a broad nasal base. (From Taylor CO: Surgery of the nasal tip. In Waite PD, ed: *Atlas of the oral and maxillofacial surgery clinics of North America: rhinoplasty*, Philadelphia, 1995, Saunders.)

Tip Rotation

Understanding the tripod concept and tip supporting mechanisms will allow the surgeon to choose the appropriate technique to adjust tip rotation.

Increasing tip rotation can be done in a number of ways. Simply reducing the dorsal hump of the nose will make the nasal tip appear more rotated. Removing a cephalic strip of cartilage from the lower lateral cartilages will result in increased tip rotation (Figure 20-24). An intercartilaginous incision used in closed rhinoplasty techniques disrupts the scroll and will result in a mild increase in tip rotation. Resecting a small triangular piece of caudal septum near the anterior septal angle will allow the lower lateral cartilages to rotate further. Transecting, overlapping, and resuturing the lateral crura with 6-0 Prolene will effectively shorten the two limbs of the tripod and increase the tip rotation. Maneuvers such as this are aggressive and should be reserved for only select situations. It is generally preferable to use less destructive techniques and preserve the cartilaginous support of the nose. Cartilage grafts, such as the shield graft, can also be used to create the illusion of increased tip rotation. Finally, augmentation of the premaxillary region may give the illusion of increased tip rotation. Premaxillary deficiency is typically seen more frequently in Asian or African American

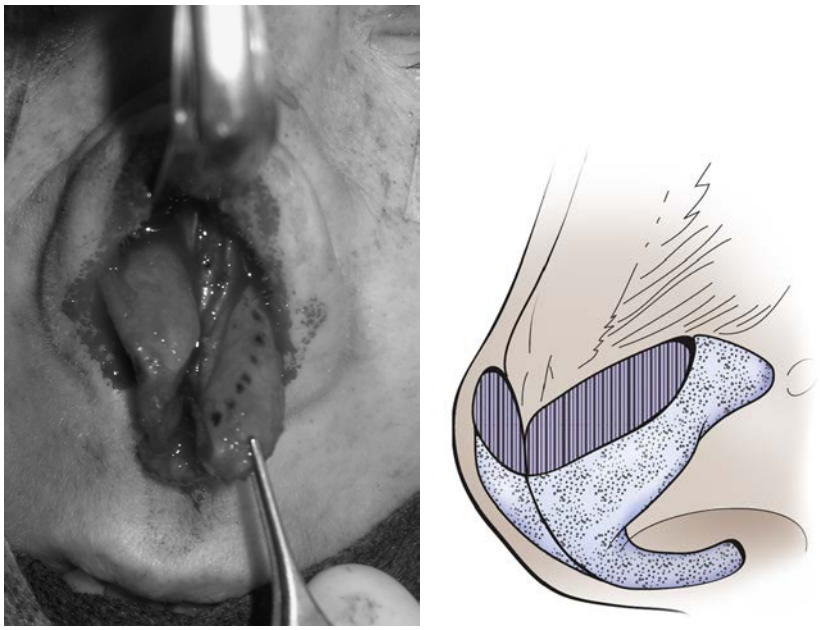

• **FIGURE 20-24** The cephalic strip. The removal of a complete strip of cephalic cartilage from the lower lateral cartilages will increase nasal tip rotation. It is important to preserve at least 6 mm of width to the lateral crura so that strength of the external nasal valve is not compromised. (From Koehler JK, Waite PD: Basic principles of rhinoplasty. In Miloro M, ed: *Oral and maxillofacial surgery*, Hamilton, 2004, BC Decker.)

patients. The augmentation may be performed with materials such as hydroxyapatite or expanded polytetrafluoroethylene (ePTFE).

Decreasing tip rotation occurs with many of the techniques described earlier to decrease tip projection. Additional derotation can be done by trimming the caudal septum near the anterior nasal spine or by augmenting the nasal dorsum to create the illusion of decreased tip rotation.

Tip Shape

Preserving or improving the anatomic shape of the nasal tip is an essential portion of rhinoplasty. Some of the early techniques described in tip reshaping involved more destructive methods of cartilage excision. The Goldman tip is an example of such a technique (Figure 20-25). The Goldman tip involves incising the lower lateral cartilage at the junction of the intermediate and lateral crura (this is often termed *dome division*). The medial crura are then sutured together, which results in increased tip projection. The lateral crura are not secured with any sutures and therefore collapse medially. This results in significant narrowing of the nasal tip along with loss of the tip defining points. Additional problems with tip asymmetry, pinched appearance of the tip, and nasal tip ptosis can occur in the long term.[38]

Many rhinoplasty surgeons now try to use more selective cartilage excision techniques combined with suture techniques to improve the shape and position of the lower lateral cartilages. Cartilage grafting technique may also be used to reshape and redefine the nasal tip; however, this can be less predictable in the long term.[39,40]

Cartilage excision from the lower lateral cartilage in the form of cephalic strips is commonly done to allow narrowing of the nasal tip and increase tip rotation. Increased cartilage excision will result in more rotation and tip narrowing but may result in decreased support for the ala. There are three techniques commonly used to modify the shape and strength of the lower lateral cartilages: the complete strip technique, the weakened complete strip technique, and the interrupted strip technique.

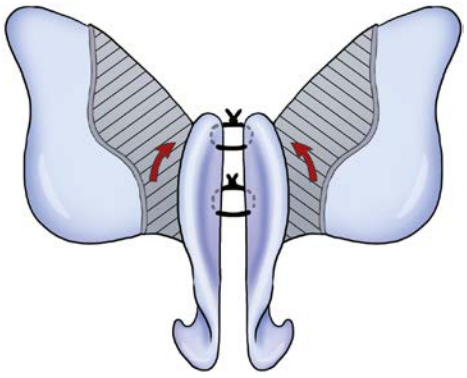

• **FIGURE 20-25** The Goldman tip. The Goldman tip is an example of an interrupted strip technique that can radically narrow the nasal tip and increase nasal tip rotation. This technique can result in an overly pinched nasal tip as well as compromise to the external nasal valve.

Complete strip techniques involve removal of a small strip of cephalic cartilage from the lateral crura (see Figure 20-24). Sometimes the cartilage can be further modified by cross-hatching with a scalpel blade to facilitate cartilage reshaping with suture techniques. This is classified as a weakened complete strip technique. These procedures are preferred to the interrupted strip technique because the lower lateral cartilage remains in continuity. An interrupted strip technique involves division of the lateral crura from the dome. The dome division technique is done principally to provide greater narrowing and rotation of the nasal tip. The consequences of an interrupted strip technique can be loss of tip support, alar notching, alar retraction, and alar collapse resulting in external nasal valve obstruction. The Goldman tip technique described earlier is an example of an interrupted strip technique (see Figure 20-25).

To avoid alar collapse on inspiration it is recommended to preserve 6 mm of width to the lateral crura. This number will vary based on the size and shape of the existing cartilage. Some patients exhibit a weak or concave lateral crura and may require some sort of alar batten grafts to provide increased support. Nasal septal cartilage or auricular cartilage sutured to the lateral crura with mattress sutures will correct the collapse in a majority of cases.[41]

Another technique that may be used in the management of external nasal valve collapse is the lateral crural pull up method. This technique involves the placement of a suture in the distal aspect of the lateral crura to a hole drilled in the pyriform aperture. The advantage of this method is that it can be done from an endonasal approach and does not require cartilage harvesting. Long-term data for this technique have not been reported.

A predominant problem in nasal tip plasty is the broad nasal tip. A bulbous nasal tip typically is the result of large, strong, lower lateral cartilages that often have a bidomal configuration. An increased angle of divergence of the medial crura as seen from the basal view may also contribute to a broad nasal tip. In some cases a broad nasal tip can be seen in patients with weak cartilage and thick fibrofatty skin in the nasal tip region. Thick skin with weak lower lateral cartilage is typically seen in Asian or African American patients.

As previously mentioned, there are three principle methods to address shape of the nasal tip: suture modification, dome division (interrupted strip technique), and cartilage grafting.

Suture modification is done after removal of a cephalic strip of cartilage.[31] A transdomal horizontal mattress suture is placed in the region of the intermediate crus to narrow the dome. This is done separately for each dome. If additional narrowing is needed, the transdomal sutures are tied to each other. This interlocked pair of transdomal sutures is termed a *double dome technique* (see Figure 20-20). It is

important to not bring the domes together so tightly that the normal angle of divergence between the intermediate crura is obliterated. The domes should be separated by 1 to 3 mm in order to maintain the tip defining points. Another suture technique is to place an interdomal suture, which can improve tip symmetry and strength as well as decrease the interdomal distance. This involves placement of an interrupted suture in the medial crura 3 to 4 mm inferior to the domes.

The dome division or interrupted strip technique can provide dramatic narrowing in bulbous nasal tips by allowing the lateral crus to assume a more medial position. To decrease the possibility of long-term problems with alar collapse, it is suggested to reapproximate the segments with suture.

Placement of cartilage tip grafts can create the illusion of a narrower tip by changing the placement of the tip defining points. This is best done through an open rhinoplasty approach and may be combined with the suture techniques mentioned earlier.

Open versus Closed Rhinoplasty

Much debate over the preferred method of skeletonizing the nose has occurred.[42,43] There is no evidence that one approach results in more favorable outcomes. It is ultimately up to the surgeon as to which technique he or she is most comfortable with. I use both approaches depending on the situation. For noses requiring minimal tip work but mainly needing dorsal hump reduction, a closed technique is used. For secondary rhinoplasties or tips that require advanced suture techniques or cartilage grafting, an open approach is preferred. I favor the open approach because it provides the best visualization, especially in regard to the nasal tip. If precise closure is done, patients do not find the external incision objectionable.[44]

Open Rhinoplasty

In sequencing the open rhinoplasty the surgeon must first decide whether to perform the tip plasty first and then set the dorsal profile or adjust the dorsum first and then adjust the tip to match the dorsum. Proponents of performing the tip plasty first believe that they have more control of the tip position and that less work may need to be done to the dorsum. I prefer to reduce any humps and set the dorsal profile first before doing the delicate tip work. Tip grafting and suturing can be inadvertently disrupted when doing the dorsum after the tip. Care must be taken if setting the dorsal profile first not to overreduce the dorsum. This is not a problem that is easily corrected. Also, attempting to further reduce the dorsum after osteotomies have been performed can result in avulsion of the nasal bone. Ultimately the decision is made on the basis of the surgeon's preference and comfort with the technique because good results can be achieved either way.

This author's preferred sequence is as follows:

1. Columellar incision
2. Bilateral marginal incisions
3. Skeletonization and exposure of the bone and cartilage
4. Dorsal reduction
5. Dome division if access is needed to the septum for septoplasty or graft harvest
6. Septoplasty if required
7. Turbinate modification if required
8. Lateral nasal osteotomies (micropuncture technique)
9. Tip plasty
10. Alar base modification
11. Closure, taping, and splinting

Anesthesia

I prefer to perform all rhinoplasties with the patient under general anesthesia. Proper local anesthesia is important to decrease surgical bleeding so that precise technique can be performed in addition to providing postoperative pain relief. Using excessive amounts of local anesthesia can distort the tissues, making surgical changes more difficult to assess. Typically 7 to 10 mL of lidocaine 2% with 1:100,000 epinephrine is sufficient. The local anesthesia should be administered in the planned planes of dissection and in the areas rich in blood vessels to provide hemostasis. Before injection I prefer to trim excess nasal hair and place 0.05% oxymetazoline-soaked cottonoids along the septum, middle turbinate, and superior nasal vault. The cottonoids should have excess oxymetazoline squeezed out before placement. There are case reports of flash pulmonary edema related to overdose of topically applied alpha-agonists such as 4% cocaine, 0.25% phenylephrine, and 0.05% oxymetazoline.[45,46]

Local anesthesia is first injected along the caudal edge of the lower lateral cartilage and then along the intercartilaginous junction between the upper and lower lateral cartilages and in the region of the membranous septum. The needle is then directed through the intercartilaginous area along the nasal dorsum, in close approximation to the upper lateral cartilages, nasal bones, and frontal process of the maxilla. A small amount of local anesthetic is deposited in the alar base and infraorbital nerve region. Next, the needle is inserted into the nasal tip and local anesthetic is deposited into the nasal tip and along the columella. Finally, local anesthesia is deposited beneath the mucoperichondrium of the nasal septum on both sides. The turbinates may be injected if turbinectomy is planned. Wait 10 minutes after administering the anesthesia to ensure maximum vasoconstrictive effects.

Incisions and Skeletonization

First, a transcolumellar incision is made. This incision is typically broken up by making an inverted V or stairstep incision.[47] This technique aides in reapproximating the soft tissues at the time of closure and minimizes linear contraction of the scar in the thin columellar tissue. This incision is made with a No. 11 blade after the area is carefully marked

with a surgical marker. The incision should be placed just where the medial footpads begin to flare, approximately midway between the nostril apex and base. An incision made too high or too low becomes easily noticeable. Also the medial footpads provide support for the incision and minimize scar contracture. Ensure that the incision is made perpendicular to the skin so that beveling does not occur. Beveling of the skin edge makes closure difficult and the scar more visible. A properly placed and well closed incision should result in a scar that is not perceivable months after the surgery. The incision is extended onto the vestibular mucosa perpendicular to the medial crura. Be extremely cautious here because the medial crura are just beneath the thin mucosa and can be inadvertently transected.

Next, bilateral marginal incisions are made. This incision is not made along the alar rim as was once used for rhinoplasty surgery. A rim incision violates the tissues in the soft-tissue triangle caudal to the lateral and intermediate crura of the lower lateral cartilage and can result in postoperative scarring and alar retraction. With a 7-mm double skin hook placed at the nostril apex, the ala is retracted superiorly and the caudal edge of the lower lateral cartilage is usually easily visualized. The edge of the cartilage can be felt by gently running the back edge of the scalpel blade across the mucosa. The incision should be made just caudal to the cartilage beginning laterally and extending medially to the apex of the nose. Realize that the incision does not parallel the alar rim; instead it should follow the contour of the cartilage. When the apex of the nose is reached, the skin hooks are moved slightly medially and an index finger is used to push on the tip of the nose to achieve better visualization in this area.

The incision is extended along the very thin mucosa overlying the medial crus approximately 1 mm posterior to the skin of the columella. To make visualization easier, the nose is twisted between the thumb and index finger and no skin hook is used. Extra care should be taken not to injure the medial crura of the lower lateral cartilage. The incision should join up with the previously made transcolumellar incision.

At this point the dissection is begun through the marginal incision to skeletonize the lateral crura of the lower lateral cartilage. Using Converse scissors, dissect under the mucoperichondrium of the cartilage. It is very important to get in the appropriate plane early. Dissection above the perichondrium will result in increased bleeding and scarring. Once the correct plane is established, Stevens scissors can be used to dissect along the upper lateral cartilages to the level of the nasal bones. This retrograde dissection technique is useful in primary rhinoplasty and aids in maintaining the appropriate dissection plane. In revision rhinoplasty it is better to begin elevation of the soft tissues over the columella and nasal tip first because portions of the lateral crus may have been excised or altered in the previous surgery.

After dissecting the soft tissues of the lower and upper lateral cartilages, the soft tissues of the columella and the domes are elevated and joined with the previously made pockets. Converse scissors are used to begin dissection along the vestibular mucosa and a tunnel is created just caudal to the medial crura. Next, a single skin hook is placed at the apex of the inverted V incision and the Converse scissors are used to elevate the columellar skin. Care should be taken not to traumatize the edges of the columellar skin in order to minimize the appearance of the scar postoperatively. When the skin is elevated, small vessels may be encountered that will require cautery. When approaching the intermediate crus, a double skin hook can be placed on the vestibular skin and retracted inferiorly by an assistant. The dissection should join with the previously made pocket, and the lower lateral cartilages should be completely freed from the skin.

Attention is now directed at elevating the tissues of the nasal dorsum. An Aufricht retractor is placed and the soft tissues should be freed to the junction of the upper lateral cartilages with the nasal bones. The periosteum of the nasal bones should be elevated sharply with a periosteal elevator. Make certain that the dissection does not separate the attachment of the upper lateral cartilages from the nasal bones.

If the dissection is carried out appropriately and adequate anesthesia has been administered, the field should be relatively bloodless. Small vessels may require cautery, and if oozing is persistent, small cottonoids soaked in dilute epinephrine solution can be placed briefly to assist in hemostasis.

At this point the dorsal reduction is performed if it is required.[48] Dorsal humps are primarily cartilaginous but can involve a degree of bony prominence as well. The upper lateral cartilages can be trimmed with a No. 11 scalpel blade and Stephens scissors (Figure 20-26). If there is minimal bony reduction required, the remaining hump is reduced using bone rasps. Care should be taken not to separate the attachment of the upper lateral cartilages with the nasal bones. The surgeon should realize that the skin is thinner in the region of the rhinion and therefore less reduction is needed in this area if a straight profile is desired. Furthermore, because of the thick soft tissues overlying the nasofrontal region, overcorrection is often needed if a deeper nasofrontal angle is desired. Some surgeons prefer to use a guarded handpiece with a burr to reduce this area.[49] Open completion of the dorsal reduction of the profile should be reassessed. The surgeon should take into account any plans for increasing tip projection. If the profile is acceptable and there is no "open roof" deformity in the region of the nasal bones and the bony width is acceptable, no osteotomy of the nasal bones is needed. If the patient has a large osteocartilaginous hump, a No. 11 blade can be used to incise the upper lateral cartilage and dorsal septum to be trimmed and a Rubin osteotome can be placed at the osteocartilaginous junction beneath the partially excised upper lateral cartilages. The osteotome is carefully advanced along the nasal bones. It is imperative to use a sharp osteotome and keep the tip directed slightly superficially. A common error with use

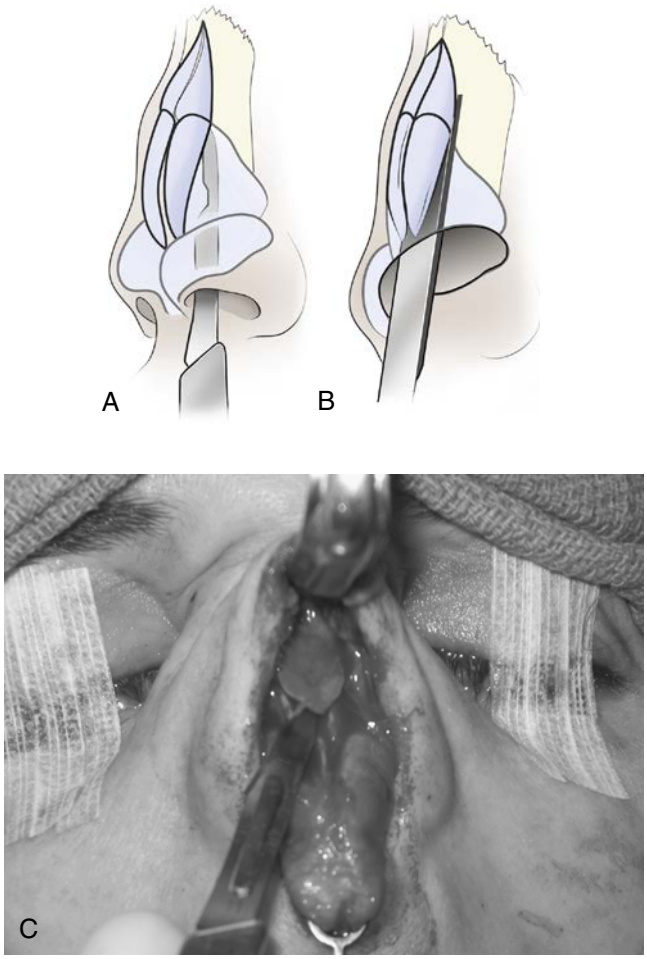

• **FIGURE 20-26** Dorsal reduction. A No. 11 blade can be used to incise the upper lateral cartilages and remove excessive cartilaginous prominence, as depicted in the photograph and in **A**. Reduction of the bony dorsum is then performed using a Rubin osteotome **(B). C,** Rasping of the bony dorsum is an alternative technique for reducing the bony prominence. (From Koehler JK, Waite PD: Basic principles of rhinoplasty. In Miloro M, ed: *Oral and maxillofacial surgery*, Hamilton, 2004, BC Decker.)

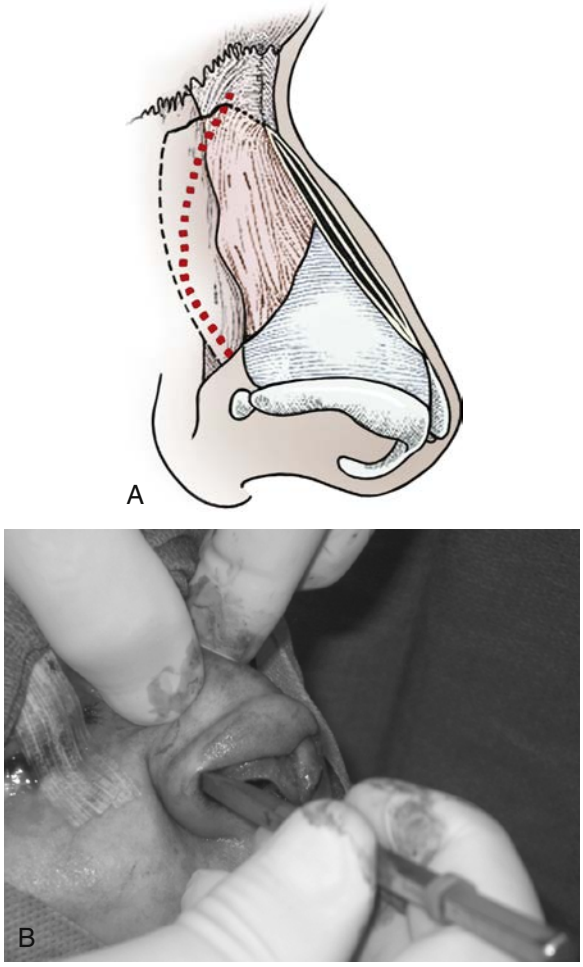

• **FIGURE 20-27** Lateral nasal osteotomies. The *dotted black line* in **(A)** demonstrates a low-to-low lateral nasal osteotomy. The *red dotted line* depicts a low-to-high lateral nasal osteotomy. Note the small triangle of bone preserved in the piriform rim described as Webster's triangle. **B,** demonstrates the use of a 2-mm osteotome to perform a micropuncture osteotomy along the nasal bones. (From Toriumi DM, Hecht DA: Skeletal modifications in rhinoplasty. In Holt GR, ed: *Advances in rhinoplasty*, Philadelphia, 2000, Saunders.)

of a Rubin osteotome is to remove too much bone. If additional bony reduction is required, the rasps may be used. An open roof deformity is common when using this technique, and lateral nasal osteotomies will likely be required. Failure to do lateral nasal osteotomies will leave a flat and unnatural appearance to the nasal dorsum.

There are two principal types of nasal osteotomies: lateral and medial. The lateral nasal osteotomy is used most commonly, and medial osteotomies are usually needed only in cases where the nasal bones are thick and an unfavorable fracture is anticipated.[50,51] The lateral nasal osteotomy begins in a low position, just above the base of the pyriform rim (Figure 20-27). Ideally a small triangle of bone should be preserved at the base of the pyriform, known as *Webster's triangle,* to provide some bony support in the internal nasal valve region. I use a sharp 2-mm osteotome with a micropuncture technique.[52] The osteotome is placed through a stab incision in the mucosa several millimeters above the base of the pyriform aperture. Some surgeons perform the micropuncture technique from an external approach; however, if improper technique or unpredictable scarring occurs, the external incision can be noticeable.[53] The osteotomy is made using multiple perforations along the nasal bone, keeping the osteotome perpendicular to the bone and advancing the osteotome in an interrupted fashion to the region of the intercanthal line. On approaching the intercanthal line the surgeon may decide to keep the osteotomy low (posterior) or high (anterior) on the nasal bones[54] (see Figure 20-27). The typical osteotomy to close an open roof is finished high. A greenstick back fracture is created with digital pressure, and the nasal bone is medialized and the open roof is closed. If the surgeon desires to narrow the nasal width near the intercanthal region, the osteotomy can be completed in a low (posterior) region. The low-low osteotomy is not frequently needed. A medial osteotomy is often needed when a low-low osteotomy is performed, to prevent unfavorable fractures (Figure 20-28). A problem that can

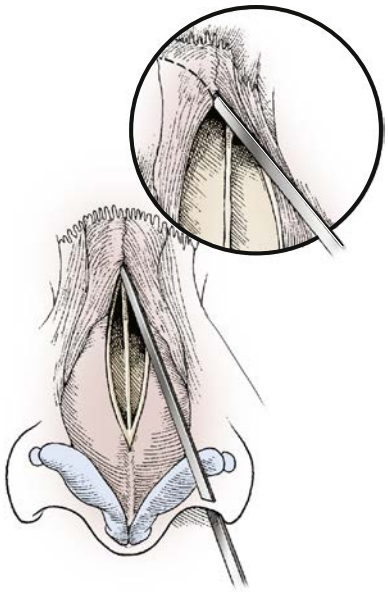

• **FIGURE 20-28** The medial osteotomy. The medial osteotomy is often used in conjunction with a low-to-low osteotomy to prevent unfavorable fracture. (From Toriumi DM, Hecht DA: Skeletal modifications in rhinoplasty. In Holt GR, ed: *Advances in rhinoplasty*, Philadelphia, 2000, Saunders.)

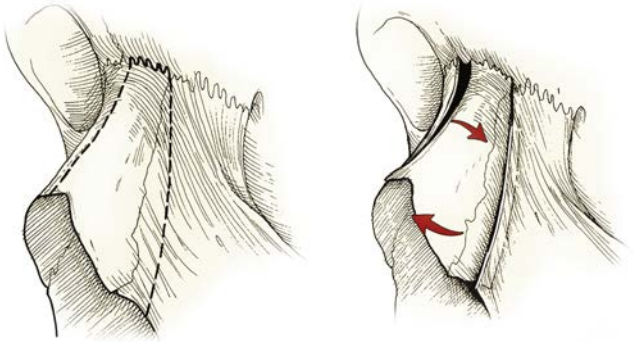

• **FIGURE 20-29** The rocker deformity. An unfavorable fracture that extends into the thickest portion of the nasal bone in the nasofrontal region can result in lateral displacement of the upper portion of the nasal bone when the surgeon attempts to move the nasal bones medially. (From Toriumi DM, Hecht DA: Skeletal modifications in rhinoplasty. In Holt GR, ed: *Advances in rhinoplasty*, Philadelphia, 2000, Saunders.)

occur if the fracture extends onto the nasofrontal region is known as a *rocker deformity* (Figure 20-29). The thick bone in the nasofrontal region does not mobilize medially and thus creates a fulcrum when the caudal portion of the nasal bone is medialized and results in lateralization of the nasal bones in the intercanthal region. A medial osteotomy is begun on the superior edge of the open roof deformity and is advanced obliquely and laterally. The medial osteotomy prevents uncontrolled greenstick back fractures in thick nasal bones. No further rasping should be performed once osteotomies are completed, because the nasal bones could be avulsed. If irregularities persist through the thin nasal dorsal skin, acellular dermis (Alloderm) can be used to camouflage and is placed on the bone and cartilage.

In some cases, dorsal augmentation is required to correct traumatic defects or previous overresection of dorsum or in ethnic noses with a low dorsum (usually Asian and African American patients). Autogenous materials such as septal, auricular, and rib cartilage; cranial bone; or iliac crest are preferred to alloplastic materials.[55-58] Cartilage grafts can resorb or distort in shape with time. Alloplastic materials include silicone and ePTFE implants. The problem with alloplastic implants is that they can become infected or can extrude years after placement. Careful placement of any dorsal graft is essential because irregularities may be easily seen in the thin skin along the dorsum.[55,59-62]

Attention is now directed to the septoplasty if it is required or septal cartilage is needed. The cartilage can be easily obtained by separating the upper lateral cartilages at the anterior septal angle. This approach to the septum provides the widest exposure and is useful for complex septoplasty or when significant modification to the dorsal septum is required. It is important to ensure that the dissection is beneath the mucoperichondrium to prevent mucosal perforation and increased bleeding. Tears in the mucosa will occasionally occur. A tear on one side of the septum will heal uneventfully as long as the mucosa is reapproximated and intact mucosa remains on the opposite side after the cartilage has been removed. It is wise to elevate the flap on the side of the septum with the least deformity first. The dissection is aided by hydrodissecting the mucosa in a subperichondrial plane with local anesthesia before beginning. The mucoperichondrium is sharply elevated off both sides of the nasal septum with a caudal elevator. Care should be taken when separating the upper lateral cartilages from the dorsal septum. The dissection should extend posteriorly to the ethmoid bone, then inferiorly and anteriorly across the septum-vomer junction. An assistant can retract the lower lateral cartilages inferiorly during this process.

Next, a nasal speculum can be inserted in the pocket on either side of the septum. A sharp caudal elevator or scalpel can be used to incise the cartilage and remove septum for grafting or correcting areas of septal deflection. When removing cartilage it is important to maintain an L shaped strut of cartilage of approximately 1 cm dorsally and caudally (Figure 20-30). If the cartilage is removed before dorsal hump reduction, the surgeon must account for this so that an inadequate dorsal strut does not occur. Insufficient cartilage support can result in a saddle-nose deformity, which can be difficult to correct.

An alternative technique is to divide the domes of the lower lateral cartilages and begin access to the septum from its caudal edge. This technique should be used if grafting is required to lengthen the caudal septum in cases of a retracted or deficient columella or when medial crural strut grafts are indicated to increase tip projection. Realize that dividing the domes significantly decreases the support mechanism for the nasal tip, and if this area is not properly supported with grafts the nasal tip can be deprojected and

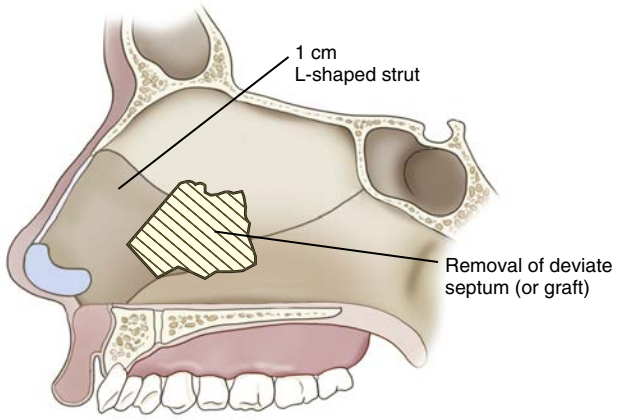

• **FIGURE 20-30** Harvesting nasal septum. A portion of the nasal septum can be resected and used for cartilage grafting techniques. It is important to preserve approximately 1 cm of cartilage dorsally and caudally to prevent a saddle-nose deformity. (From Koehler JK, Waite PD: Basic principles of rhinoplasty. In Miloro M, ed: *Oral and maxillofacial surgery*, Hamilton, 2004, BC Decker.)

tip support weakened. Separating the medial crura requires that the surgeon precisely align the cartilage before closure so that the projection of the medial crura is equal and does not result in twisting of the nasal tip.

Some surgeons prefer to combine an open and closed approach. When this is done, the cartilage is harvested from a Killian incision or transfixion incision before beginning the surgical sequence for an open rhinoplasty.

If turbinate modification is required, it can be done at this time. Hypertrophy of the inferior turbinates is the most common cause of nasal airway obstruction. Recognizing the problem preoperatively is important so that it can be addressed and worsened nasal breathing does not occur. Hypertrophy of the turbinates is most commonly due to allergic symptoms. Medical treatment is the mainstay of nasal allergy symptoms. If medical treatment is not successful, surgical treatment can be considered. Enlargement of the turbinates can occur in cases of septal deviation on the side on which the nasal passage is enlarged. If the septum is corrected and the turbinate is not addressed, nasal obstruction can occur.

Many methods have been reported for the management of turbinate hypertrophy including corticosteroid injection, electrocautery, cryosurgery, turbinate outfracture, partial turbinate resection, total turbinate resection, submucous turbinate resection, vidian neurectomy, and laser reduction. The procedure that is the most conservative and that the surgeon feels most comfortable with should be used. I typically use turbinate outfracture or partial turbinectomy. Consideration should be given to the placement of Silastic stents to prevent synechia formation between the turbinate and the septum. The most common complications from turbinate surgery include hemorrhage, atrophic rhinitis, and ozena.

The surgeon can now perform the tip plasty. The techniques described previously are used to increase or decrease tip projection and rotation, and cartilaginous grafts such as a columellar strut for tip support may be used. Spreader grafts placed in the region of the upper lateral cartilages may be needed if the middle vault of the nose needs widening, the upper lateral cartilage becomes avulsed from the nasal bone, or the surgeon is planning on improving the airway in the internal nasal valve[63] (see Figure 20-13). All cartilage grafts should be secured with 6-0 Prolene to prevent displacement.[36,55,64]

At this point the skin is redraped, the esthetics is assessed, closure can proceed. Closure is often neglected at the end of surgery, but it remains a critical part in rhinoplasty. I prefer to close the columellar incision first, followed by closure of the marginal incision. Interrupted 6-0 Prolene sutures with a tapered noncutting needle are used to reapproximate the skin along the anterior and lateral columella. Typically five sutures are placed. The marginal incision is then closed. The first suture should be placed at the apex of the nostril using interrupted 5-0 plain gut sutures. Then close laterally to medially, using interrupted 5-0 plain gut sutures. It is important to take small bites because distortion of the ala can occur if large bites are taken.

If a septoplasty was performed, the septum is closed with a running 4-0 plain gut mattress suture spanning the two sides of the septal mucosa. A Keith needle is used to go back and forth across the septum. The mattress sutures should be started in the caudal septum and then in a clockwise fashion extending posteriorly and returning to the starting point, where the suture is tied. This suture eliminates dead space between the mucosa and prevents septal hematoma. When this technique is used, septal splints are often unnecessary.

Alar base modification is addressed last. The decision to alter the alar base is made preoperatively. However, if there is any doubt about the need for alar base reduction, it is best to postpone this component. Alar base reduction can be easily performed using local anesthesia in the office. The surgeon needs to determine if the nostril needs to be narrowed because of an overly wide nasal passage, the external skin needs to be reduced because of excessive alar flaring, or a combination of both procedures is required. If the size of the nostril is excessive and the ala is not overly flared, a small excision of vestibular skin can be performed. If the nostril sill is flared but excision of vestibular skin will compromise nasal airflow, a conservative excision of skin only just above the crease at the nostril base is performed. The incision should be through skin only and not any deeper. Deeper excision of tissues will increase the likelihood of notching. Also, the incision should not extend far laterally on the alar-cheek junction or the scar will be noticeable. A Weir procedure can be performed to narrow both the nostril size and alar flare. The excision is typically 1 to 2 mm and involves both vestibular mucosa and skin at the nostril base (see Figure 20-23). The incision angles are made more divergent to remove more skin than vestibular mucosa. Precise closure with 4-0 Monocryl deep and 6-0 Prolene on the skin is essential to prevent a noticeable scar.

Closed Rhinoplasty

The main advantage of this technique is the lack of any external scars. To do this technique properly the surgeon should be experienced in rhinoplasty surgery if any significant tip plasty is required. It is much more difficult to do cartilage grafting and suture techniques precisely with this approach.

This author's standard sequence for closed rhinoplasty is as follows:

1. Partial transfixion incision
2. Intercartilaginous incision
3. Septoplasty if required
4. Turbinate modification if required
5. Dorsal reduction
6. Lateral nasal osteotomies
7. Marginal incision
8. Delivery of lower lateral cartilages
9. Tip plasty
10. Alar base modification
11. Closure, taping, and splinting

The sequence begins with a partial transfixion incision. Adson forceps are used to identify the caudal edge of the nasal septum. The columella is then stabilized with the forceps and a No. 15 blade is used to make the partial transfixion incision beginning at the apex of the nostril and extending to just shy of the medial footpads of the medial crura. The blade is passed in the membranous septum just posterior to the medial crura.

Next, a 7-mm double skin hook is placed at the apex of the nostril and lifted superiorly. The junction between the upper and lower lateral cartilages should be identified. An intercartilaginous incision is then made just caudal to the prominence of the upper lateral cartilage, beginning laterally and extending medially to join up with the previously made partial transfixion incision. Converse scissors are used, and the mucoperichondrium of the upper lateral cartilage is identified. Dissection continues in this plane, using Stevens scissors to the nasal bones. With a sharp periosteal elevator the periosteum is then reflected off the nasal bones.

If a septoplasty is required or cartilage is needed for grafting, it is done at this time. The septum is approached from the caudal edge of the septum through the partial transfixion incision. Converse scissors are used to identify the mucoperichondrium. The exposed caudal septum is lightly scored with a No. 15 blade. A large dental amalgam condenser can then be rubbed against the area previously scored, and the perichondrium should easily separate to identify the appropriate plane of dissection. This maneuver is very useful because it is easy to dissect above the perichondrium unknowingly until a mucosal tear or significant bleeding occurs. A caudal and freer elevator is used to elevate the perichondrium off the septum. The elevation sequence should be from the superior caudal septum posteriorly to the ethmoid bone, then continuing inferiorly to the vomer and ending in the inferior aspect of the caudal septum. If wider exposure of the septum is needed, the partial transfixion incision can be extended onto the mucosa of the nasal floor. With a caudal elevator the mucosa of the nasal floor can be elevated, leaving a small band of tissue connected at the junction of the nasal septum and maxillary crest. A nasal speculum can be inserted with one tine in each tunnel, and the tissue in between can be sharply dissected to achieve wide exposure of the septum.[65]

To obtain cartilage for grafting purposes, a Cottle elevator is used to make a cut in the septum at the junction of the ethmoid and vomer bones and the quadrangular cartilage. The elevator should easily cut through the cartilage. A second cut is made at least 1 cm posterior to the caudal edge of the septum, paralleling the previous cut. A freer elevator can now be used to elevate the mucosa off the opposite side of the cartilage. The surgeon should be careful not to perforate the mucosa on the opposite side of the septum. When removing cartilage, care should be taken to maintain a 1-cm strut superiorly and anteriorly. As mentioned earlier, if dorsal reduction is to be done to the nose, this should be accounted for so that insufficient cartilage is not left supporting the nose superiorly. Fomon scissors may be used to make the cuts through the cartilage superiorly and inferiorly. Alternatively, a Ballenger swivel blade can be used. The cartilage is removed with Takahashi forceps. Turbinate modification as described under open rhinoplasty can be done at this time.

After the septoplasty an Aufricht retractor can be inserted, and the nasal dorsum is inspected. Dorsal hump reduction can proceed as described earlier with rasping techniques or osteotomes. The lateral nasal osteotomies are then performed.

Bilateral marginal incisions are then made as described for the open rhinoplasty technique. The incisions begin at the caudal edge of the lateral crus and extend to the area where the medial footpads of the medial crura begin to flare. Converse scissor are then used to identify the perichondrium of the lateral crus. Once the lateral crus is dissected free, the medial crus is dissected and a tunnel is created just in front of the medial crus to join the right and left nostrils. Stephens tenotomy scissors are then used to free the tissue in the area of the domes. The cartilages should be completely freed from the overlying tissues. The Stephens scissors can then be inserted through the intercartilaginous incision and the marginal incision, and the lower lateral cartilage is delivered (Figure 20-31). At this point, cephalic strip and tip plasty techniques can be performed as described earlier. Precise placing and suturing of cartilage grafts is much more challenging with this approach.

The cartilages are replaced into position and the esthetics is assessed. Closure is then performed by first closing the intercartilaginous incisions with interrupted 5-0 plain gut suture. The first suture is placed at the apex of the nostril. Again, it is important to take small mucosal bites so that distortion of the nose or obstruction of the nasal valve does not occur. The marginal incision is then closed with interrupted 5-0 plain gut sutures. If a septoplasty was performed the incision is closed with a running 4-0 plain gut mattress



• **FIGURE 20-31** Delivery of the lower lateral cartilages and cephalic strip. Inserting scissors through the intercartilaginous and marginal incisions will expose the lower lateral cartilage. Once it is exposed, a cephalic strip can be taken.

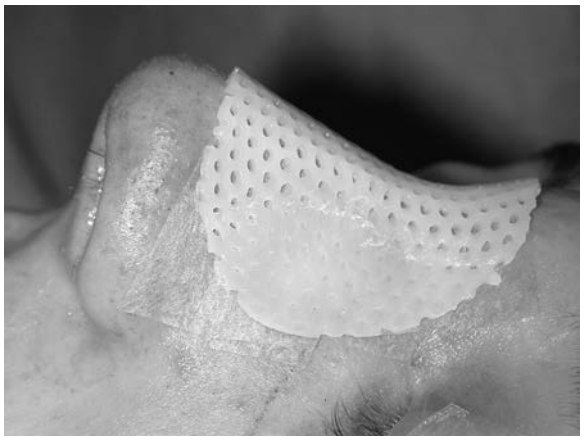

• **FIGURE 20-32** Nasal dressing. Brown paper tape and a thermoplastic splint placed along the nasal bones and upper lateral cartilages is used for 1 week to stabilize the nasal bones.

suture as described for the open technique. Alar base modification as previously described would be done at this time if needed.

Dressings and Splinting

The patient's first impression after the surgery is very important. A dressing that is asymmetric or sloppy looking may give the patient the impression that the surgery was done poorly. I apply Mastisol adhesive to the nose and place ¼ inch of brown paper tape and a thermoplastic splint. The tape should be neatly cut and placed from the radix to the supratip breakpoint. Additional pieces of tape can be placed in the region of the nasal tip if desired. The thermoplastic splint should cover the region from radix to the supratip, should cover just the nasal bones, and should not extend laterally onto the cheek (Figure 20-32).

Intranasal packs or stents are generally not required. If a turbinectomy is performed or if a large tear is created in the septal mucosa, a silicone stent can be placed to prevent synechiae formation. The stents are secured to each other by passing a 3-0 silk suture through the columella and are usually left in place for 1 week.

Follow-up Care

The patient is seen at 24 hours and again in 1 week, at which time the splints and dressing are removed. The patient is instructed not to blow the nose, so that bleeding is not stimulated.

Patients sometimes use oxymetazoline nasal spray to improve breathing. The patient should be warned not to use the nasal spray for more than 5 days or rebound nasal congestion (rhinitis medicamentosa) may develop. The patient should understand that congestion will be present for several weeks and that only saline nasal spray should be used to keep the mucosa moist and help break up any crusting that develops inside the nose. The patient can gently clean inside the nostril with a cotton applicator and dilute peroxide at 1 week.

The patients should also understand that it will take several months to see the final results of the surgery. Swelling in the region of the nasal tip seems to take the longest to resolve. The patient should be followed long term so that you can truly see the long-term results of various techniques employed. Some of the more destructive techniques to the nasal tip may look good initially but years later may result in an unesthetic appearance.

Complications

Management of late postoperative deformities is outside the scope of this chapter; however, early postoperative problems are discussed. The most common postoperative complication is nasal bleeding, and it is estimated that troublesome bleeding will occur less than 2% to 4% of the time. If nasal bleeding does occur, it usually occurs in a bimodal distribution either in 48 hours from raw mucosal edges or in 10 to 14 days after eschars begin to separate. The patient is instructed to use 0.05% oxymetazoline nasal spray and apply ice compresses. If the patient cannot control the bleeding, the surgeon may need to cauterize the bleeding points or perform nasal packing. Obviously the patient should also be avoiding medications that interfere with bleeding.

Infection is the second most commonly reported complication and occurs in less than 3% of cases. Incomplete removal of debris under the skin flap or presence of a hematoma makes infection more likely. The organisms typically involved are *Staphylococcus, Streptococcus, Haemophilus,* and rarely *Pseudomonas* and *Actinomyces.* Infections were much more common when nasal packing was used. Serious infections can lead to toxic shock or cavernous sinus thrombosis if not recognized and treated.

Hematomas are rare but can be problematic if not identified. Septal hematomas in particular can result in cartilage necrosis, septal perforation, and saddle-nose deformity if not recognized and drained. Septal mattress suturing is a good preventive measure.

CASE STUDY 20-1

This is a 36-year-old man with prominent dorsal hump that is primarily cartilaginous in nature. This is the result of overgrowth of the quadrangular cartilage of the nasal septum. An open rhinoplasty technique was used to reduce the dorsal septum. The nasal tip was deprojected by separating the medial crura from the caudal septum. Harvested septal cartilage was used to place a columellar strut graft to maintain tip support. Transdomal and interdomal sutures were used to better define the nasal tip. The postoperative photos were taken 3 months after the procedure.













CASE STUDY 20-2

This is a 24-year-old woman concerned about a dorsal hump and broad nasal tip. An open rhinoplasty was performed to reduce the cartilaginous and bony dorsal hump. Transdomal and interdomal suture techniques were used to refine the nasal tip.

Rarer problems include tape reactions and skin slough secondary to tight or inappropriately placed dressings. Poor surgical technique with damage to the subdermal plexus could also result in wound problems or skin slough. Allergic reactions to tape or adhesives are easily managed with corticosteroids.













References

1. *2005 Cosmetic Surgery National Data Bank Statistics.*
2. Behmand RA, Ghavami A, Guyuron B: Nasal tip sutures part I: the evolution, *Plast Reconstr Surg* 112:1125, 2003.
3. Arslan E, Aksoy A: Upper lateral cartilage-sparing component dorsal hump reduction in primary rhinoplasty, *Laryngoscope* 117:990, 2007.
4. Lo S, Rowe-Jones J: Suture techniques in nasal tip sculpture: current concepts, *J Laryngol Otol* 121:e10, 2007.
5. Guyuron B, Behmand RA: Nasal tip sutures part II: the interplays, *Plast Reconstr Surg* 112:1130, 2003.
6. Benlier E, Top H, Aygit AC: A new approach to smiling deformity: cutting of the superior part of the orbicularis oris, *Aesthetic Plast Surg* 29:373, 2005.
7. Hollinshead W: *Anatomy for surgeons: the head and neck*, ed 3, Philadelphia, 1982, Lippincott-Raven.
8. Rohrich R, Muzaffar A, Gunter J: Nasal tip blood supply: confirming the safety of the transcolumellar incision in rhinoplasty, *Plast Reconstr Surg* 106:1640, 2000.
9. Toriumi D, Mueller R, Grosch T: Vascular anatomy of the nose and the external rhinoplasty approach, *Arch Otolaryngol Head Neck Surg* 122:24, 1996.
10. Lam SM, Williams III EF: Anatomic considerations in aesthetic rhinoplasty, *Facial Plast Surg* 18:209, 2002.
11. Dion M, Jafek B, Tobin C: The anatomy of the nose. External support, *Arch Otolaryngol* 104:145, 1978.
12. Correa A, Sykes J, Ries W: Considerations before rhinoplasty, *Otolaryngol Clin North Am* 32:7, 1999.
13. Meyer LJS: The predictive validity of psychosocial factors for patients' acceptance of rhinoplasty, *Ann Plast Surg* 17:513, 1986.
14. Murrell GL: Auricular cartilage grafts and nasal surgery, *Laryngoscope* 114:2092, 2004.
15. Veale D, De Haro L, Lambrou C: Cosmetic rhinoplasty in body dysmorphic disorder, *Br J Plast Surg* 56:546, 2003.
16. Phillips KA, Menard W: Suicidality in body dysmorphic disorder: a prospective study, *Am J Psychiatry* 163:1280, 2006.
17. Tardy Jr ME, Dayan S, Hecht D: Preoperative rhinoplasty: evaluation and analysis, *Otolaryngol Clin North Am* 35:1, 2002.
18. Rohrich R: The who, what, when, and why of cosmetic surgery: do our patients need a preoperative psychiatric evaluation? *Plast Reconstr Surg* 106:1605, 2000.
19. Petroff M, Mcollough E, Hom D: Nasal tip projection. Quantitative changes following rhinoplasty, *Arch Otolaryngol Head Neck Surg* 117:783, 1991.
20. Crumley R, Lanser M: Quantitative analysis of nasal tip projection, *Laryngoscope* 98:202, 1988.
21. Gunter J, Rohrich D, William P: *Dallas rhinoplasty*, St Louis, 2002, Quality Medical Publishing.
22. Fischer H, Gubisch W: Nasal valves—importance and surgical procedures, *Facial Plast Surg* 22:266, 2006.
23. André RF, D'Souza AR, Kunst HP, Vuyk HD: Sub-alar batten grafts as treatment for nasal valve incompetence; description of technique and functional evaluation, *Rhinology* 44:118, 2006.
24. Faris C, Koury E, Kothari P, Frosh A: Functional rhinoplasty with batten and spreader grafts for correction of internal nasal valve incompetence, *Rhinology* 44:114, 2006.
25. Adams W, Rohrich R, Hollier L: Anatomic basis and clinical implications for nasal tip support in open versus closed rhinoplasty, *Plast Reconstr Surg* 103:255, 1999.
26. Tardy MJ, Cheng E, Jernstrom V: Misadventures in nasal tip surgery. Analysis and repair, *Otolaryngol Clin North Am* 20:797, 1987.
27. Thomas J, Tardy MJ: Complications of rhinoplasty, *Ear Nose Throat* 65:19, 1986.
28. Murrell GL: The nasal tripod revisited, *Arch Facial Plast Surg* 9:141, 2007.
29. Tebbets J: Shaping and positioning the nasal tip without structural disruption: a new, systematic approach, *Plast Reconstr Surg* 94:61, 1994.
30. Rohrich R, Adams W: The boxy nasal tip: classification and management based on alar cartilage suturing techniques, *Plast Reconstr Surg* 107:1849, 2001.
31. Leach JL, Athre RS: Four suture tip rhinoplasty: a powerful tool for controlling tip dynamics, *Otolaryngol Head Neck Surg* 135:227, 2006.
32. Foda H, Kridel R: Lateral crural steal and lateral crural overlay: an objective evaluation, *Arch Otolaryngol Head Neck Surg* 125:1365, 1999.
33. Kridel RW, Konior RJ, Shumrick KA, Wright WK: Advances in nasal tip surgery. The lateral crural steal, *Arch Otolaryngol Head Neck Surg* 115:1206, 1989.
34. Gunter JP, Landecker A, Cochran CS: Frequently used grafts in rhinoplasty: nomenclature and analysis, *Plast Reconstr Surg* 118:14e, 2006.
35. Mavili ME, Safak T: Use of umbrella graft for nasal tip projection, *Aesthetic Plast Surg* 17:163, 1993.
36. Sheen J: Achieving more nasal tip projection by the use of a small autogenous vomer or septal cartilage graft. A preliminary report, *Plast Reconstr Surg* 56:35, 1975.
37. Kamer FM, Churukian MM: Shield graft for the nasal tip, *Arch Otolaryngol* 110:608, 1984.
38. Davis AM, Simons RL, Rhee JS: Evaluation of the Goldman tip procedure in modern-day rhinoplasty, *Arch Facial Plast Surg* 6:301, 2004.
39. Dyer 2nd WK: Nasal tip support and its surgical modification, *Facial Plast Surg Clin North Am* 12:1, 2004.
40. Tebbetts J: Rethinking the logic and techniques of primary tip rhinoplasty: a perspective of the evolution of surgery of the nasal tip, *Otolaryngol Clin North Am* 32:741, 1999.
41. Toriumi D, Josen J, Weinberger M: Use of alar batten grafts for correction of nasal valve collapse, *Arch Otolaryngol Head Neck Surg* 123:802, 1997.
42. Kamer FM, Pieper PG: Nasal tip surgery: a 30-year experience, *Facial Plast Surg Clin North Am* 12:81, 2004.
43. Adamson PA, Galli SK: Rhinoplasty approaches: current state of the art, *Arch Facial Plast Surg* 7:32, 2005.
44. Ingels K, Orhan KS: Measurement of preoperative and postoperative nasal tip projection and rotation, *Arch Facial Plast Surg* 8:411, 2006.
45. Broujerdi JA, Keifa E, Nekhendzy V, Schendel SA: Flash pulmonary edema: an unusual presentation during orthognathic surgery, *Plast Reconstr Surg* 119:133e, 2007.
46. Groudine SB, Hollinger I, Jones J, DeBouno BA: New York State guidelines on the topical use of phenylephrine in the operating room. The Phenylephrine Advisory Committee, *Anesthesiology* 92:859, 2000.
47. Davis RE: Proper execution of the transcolumellar incision in external rhinoplasty, *Ear Nose Throat J* 83:232, 2004.
48. Gerarchi P, Mendelsohn M: The wide nasal dorsum: evaluation and management, *Otolaryngol Head Neck Surg* 136:S32, 2007.

49. Davis RE, Raval J: Powered instrumentation for nasal bone reduction: advantages and indications, *Arch Facial Plast Surg* 5:384, 2003.
50. Cochran CS, Ducic Y, Defatta RJ: Rethinking nasal osteotomies: an anatomic approach, *Laryngoscope* 117:662, 2007.
51. Most SP, Murakami CS: A modern approach to nasal osteotomies, *Facial Plast Surg Clin North Am* 13:85, 2005.
52. Rees TD: Nasal osteotomies: a clinical comparison of the perforating methods versus the continuous technique, *Plast Reconstr Surg* 115:1783, 2005.
53. Gryskiewicz JM: Visible scars from percutaneous osteotomies, *Plast Reconstr Surg* 116:1771, 2005.
54. Gruber R, Chang TN, Kahn D, et al.: Broad nasal bone reduction: an algorithm for osteotomies, *Plast Reconstr Surg* 119:1044, 2007.
55. Toriumi D: Autogenous grafts are worth the extra time, *Arch Otolaryngol Head Neck Surg* 126:562, 2000.
56. Posnick JC, Seagle MB, Armstrong D: Nasal reconstruction with full-thickness cranial bone grafts and rigid internal skeleton fixation through a coronal incision, *Plast Reconstr Surg* 86:894, 1990.
57. Celik M, Tuncer S: Nasal reconstruction using both cranial bone and ear cartilage, *Plast Reconstr Surg* 105:1624, 2000.
58. Jackson I, Choi H, Clay R: Long-term follow-up of cranial bone graft in dorsal nasal augmentation, *Plast Reconstr Surg* 102:1869, 1998.
59. Parker Porter J: Grafts in rhinoplasty: alloplastic vs. autogenous, *Arch Otolaryngol Head Neck Surg* 126:558, 2000.
60. Adamson P: Grafts in rhinoplasty: autogenous grafts are superior to alloplastic, *Arch Otolaryngol Head Neck Surg* 126:561, 2000.
61. Romo TR, Sclafani A, Jacono A: Nasal reconstruction using porous polyethylene implants, *Facial Plast Surg* 16:55, 2000.
62. Acarturk S, Arslan E, Demirkan F, Unal S: An algorithm for deciding alternative grafting materials used in secondary rhinoplasty, *J Plast Reconstr Aesthet Surg* 59:409, 2006.
63. Boccieri A, Macro C, Pascali M: The use of spreader grafts in primary rhinoplasty, *Ann Plast Surg* 55:127, 2005.
64. Sancho B, Molina A: Use of septal cartilage homografts in rhinoplasty, *Aesthetic Plast Surg* 24:357, 2000.
65. Gunter J, Rohrich R: Management of the deviated nose. The importance of septal reconstruction, *Clin Plast Surg* 15:43, 1988.

21

Blepharoplasty

KATHERINE E. DUNCAN, JENNY Y. YU

Introduction

Beer published the first medical illustration of the aging eyelid in 1807.[1] Von Graefe first used the term *blepharoplasty* to describe a case of eyelid reconstruction following a cancer resection.[2] Since then, the blepharoplasty procedure remains one of the most popular surgical procedures for both functional and esthetic reasons. The term *dermatochalasis* can be used to describe both excess skin of the upper and lower lids. This excess is a result of various aging changes. Facial tissues including the eyelids lose elasticity, tone, and volume as we age. Atrophy of collagen contributes to stretching and sagging of the eyelid skin as well as the development of wrinkles. Thinning of the dermis, fat, and musculature can create a hollow appearance. Ligamentous and fascial support structures also stretch over time. Because the eyelids are a central part of the face, dermatochalasis of the eyelids is affected by the dynamics of the surrounding tissue as well.[3,4]

Consider the face in thirds (Figure 21-1). The weakening of the epicranial aponeurosis and frontalis in the upper third of the face contributes to eyebrow ptosis. This in turn worsens the dermatochalasis of the upper eyelid skin. Horizontal laxity of the eyelids can also worsen the dermatochalasis. This is usually due to laxity of the canthal tendons and gravitational descent of soft tissue in the middle third. Weakening of the orbital septum can result in prolapse of the orbital fat pads. All of these changes lead to variations of the dermatochalasis of the upper and lower lids. These changes can affect both the function and esthetics of the eyelids, prompting patients to seek correction.[3]

The term *blepharoplasty* is strictly used as the surgical removal of excess skin and muscle, with and without fat resection. It often is combined with ptosis surgery of the brow and upper eyelids. It is also combined with horizontal tightening of the upper and lower lids. In proceeding with a blepharoplasty, the surgeon must consider the surrounding tissue dynamics in order to achieve a satisfactory outcome for the patient.

Anatomy

Detailed understanding of the eyelid and orbital anatomy is required for successful surgical outcomes. The upper and lower eyelids surround the palpebral fissure and meet at the medial and lateral canthus. The lateral canthus is 2 mm higher than the medial canthus. With the eye in primary position, the margin of the upper eyelid should cover the superior 1 to 2 mm of the cornea while the margin of the lower eyelid is usually within 2 mm of the inferior border of the cornea.[5] The brow cilia should sit at the level of the supraorbital rim, with some gender variations. The lower lid and malar junction should be one continuous plane (Figure 21-2).[3]

The most superficial layer of the upper and lower eyelids is skin. Eyelid skin is one of the thinnest in the body and is devoid of subcutaneous tissue. The orbicularis muscle is immediately under this layer of skin forming concentric circles around the bony rims of the orbit. The orbicularis muscle is the main protractor muscle of the eyelids, responsible for closure of the eyelids and innervated by the facial nerve. The orbital septum is contiguous with the periosteum of the orbit, which delineates the preseptal and postseptal space.[5] Posterior to the bands of orbital septum are the fat pads of the orbit. Fat pads serve as the lubricant allowing for smooth movement of the eyelids and eye. The central and medial fat pads of the upper lid create the volume of the upper lid. Laterally in the upper lid, the two lobes of the lacrimal gland are present. The main retractors of the upper eyelids, the levator aponeurosis and Müller's muscle, are posterior to the fat pads. They are innervated by cranial nerve III and the sympathetic nervous system, respectively. The levator muscle has anterior fiber projections into the skin and orbicularis just above the tarsal plate, and this anatomically marks the lid crease (Figure 21-3). Typically, the lid crease is found 9 to 10 mm above the lid margin, just above the most superior aspect of the tarsal plate. The tarsus, or tarsal plate, is the cytoskeleton structure of the eyelid made up of connective tissue and Meibomian glands. The palpebral conjunctiva is the most posterior layer of the



• **Figure 21-1** The face divided into thirds.



• **Figure 21-2** The normal continuous junction between the lower eyelid and malar skin.

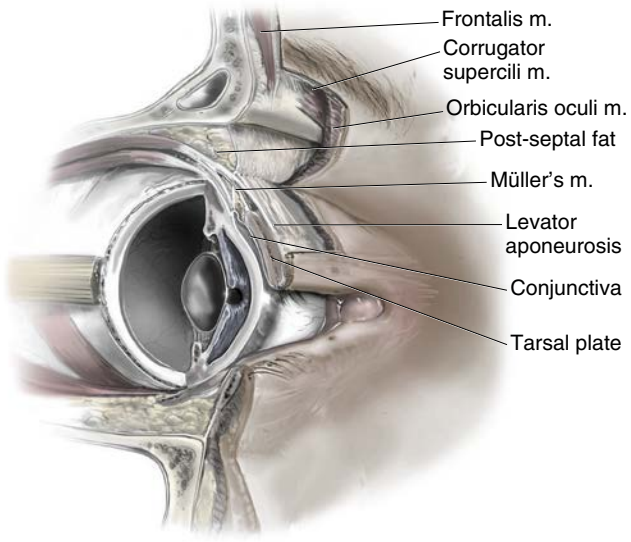

• **Figure 21-3** Anatomic structures of the upper eyelid.

eyelids continuous with the bulbar conjunctiva, forming the mucosal layer of the ocular surface. The superior tarsal conjunctiva contains an abundant number of goblet cells responsible for forming the mucous layer of the tear film (Figure 21-4).[3,5-7]

The lower eyelid anatomy is similar to the upper eyelid. The lateral, central, and medial fat pads of the lower lid are continuous with the malar fat pad and separated by orbital



• **Figure 21-4** Everted upper eyelid with superior palpebral conjunctiva visible.

retaining ligaments. The tarsal plate of the lower eyelid is only 3.5 to 5 mm tall, compared to 8 to 12 mm in height of the upper lid.[7] The lower eyelid retractors, capsulopalpebral fascia and inferior tarsal muscle, are analogous to the levator and Müller's muscle of the upper eyelid (Figures 21-5 and 21-6).[5]

The vascular supply of the eyelids is formed by the anastomoses of the branches of the internal and external carotid arteries. Each eyelid has a marginal arcade located anterior to the tarsal plate 2 to 4 mm from the lid margin. The upper eyelid also has a peripheral arcade just superior to the tarsal plate between Müller's muscle and the levator aponeurosis.[7] The marginal arcade should be avoided during injection of local anesthetics to avoid a hematoma. The venous drainage follows the same pattern (Figure 21-7).

Preoperative Evaluation

Preoperative evaluation of the patient begins with taking a careful history. It is important to specifically ask about the use of neurotoxin and/or fillers in the history because this can alter the physical examination. Determining the patient's motivations, goals, and expectations for surgery is crucial to the success of any surgical intervention. For example, patients who are interested in restoring function will generally be satisfied with removal of vision-obstructing excess skin only while patients who want to improve their appearance may require a greater amount of skin removal, removal of prolapsed fat, and greater attention to symmetry to meet expectations.[3] It is important to give the patient a clear understanding of what goals and expectations can and cannot be achieved with surgery. Patients with unrealistic self-image or who are not capable of understanding the limitations of the procedure are poor surgical candidates.

Once the patient and surgeon have come to a clear understanding of one another's goals and expectations, a medical history should be obtained that includes a detailed list of all medications. Herbal medications can cause the patient to be more coagulopathic. Patients should be specifically asked about any history of ocular pathology including dry eye.

Examination of the patient should focus on the structure, function, and appearance of the eyelids, eyebrows,

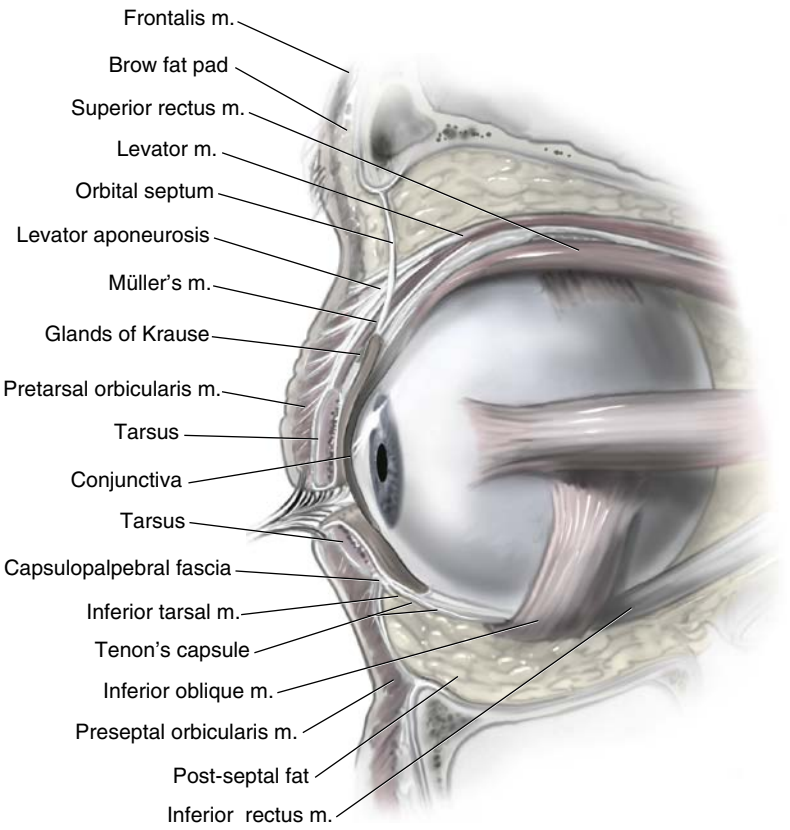

• **Figure 21-5** Anatomic structures of the upper and lower eyelids in sagittal view.

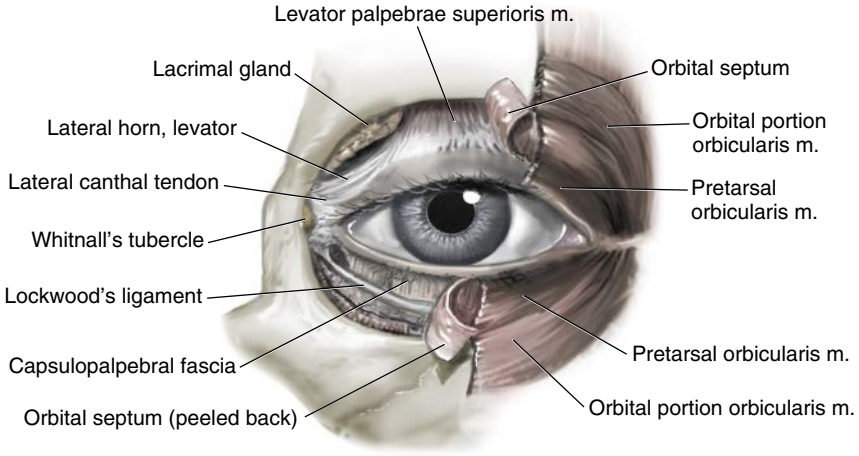

• **Figure 21-6** Anatomic structures of the upper and lower eyelids in coronal view.

and forehead. The position of the eyelid margin should be assessed. If the margin of the eyelid is at or near the pupil, the patient may have visually significant ptosis, typically caused by dehiscence or stretching of the levator aponeurosis, that can be corrected at the time of blepharoplasty. The amount of excess skin of the upper eyelid (dermatochalasis) should be assessed. If skin overhangs the lid margin or sits on the eyelashes of the upper lid it may be visually significant (Figure 21-8). Careful attention should be given to the position of the eyebrows. The normal brow position in men is along the superior orbital rim. In females the eyebrow sits slightly higher than the orbital rim, especially laterally. Descent of the eyebrow position is an age-related change that can be addressed surgically with a brow lifting procedure and can contribute to dermatochalasis. When assessing eyelid and eyebrow position, it is important that the frontalis muscle is relaxed. Patients may compensate for eyebrow and eyelid ptosis by contracting the frontalis muscle, which can lead to subjective complaints of fatigue and heaviness of the eyelids. Attention also should be given to any bulging or prolapse of the fat pads through a weakened orbital septum because this is often a cosmetic complaint from patients

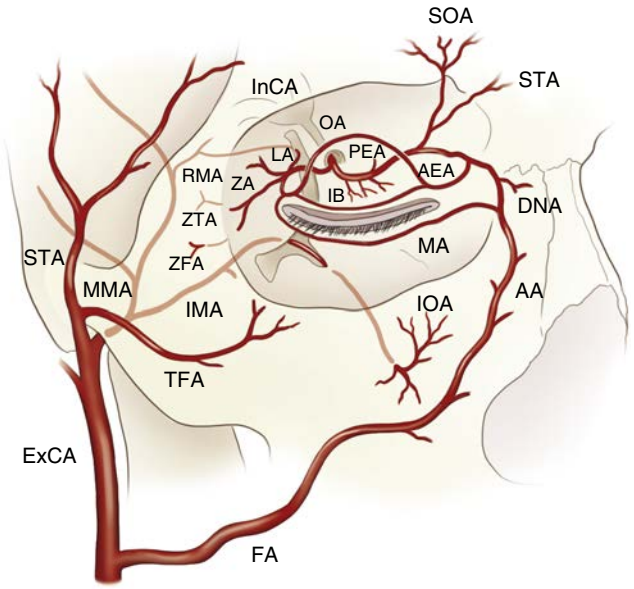

• **Figure 21-7** Arterial supply of the eyelids.



• **Figure 21-8** Dermatochalasis resting on the eyelashes of the upper lid and partially overhanging the eyelid margin.



• **Figure 21-9** Schirmer test is used to quantify tear production. Filter paper is inserted into the inferior fornix and the amount of moisture absorbed by the paper in a specific amount of time is measured.

and can be addressed at the time of blepharoplasty. Finally, examination of the ocular surface for dryness is important because this can be exacerbated by surgical interventions.[4,8] An objective test such as the Schirmer test can assess for quantity of tears present (Figure 21-9).

In contrast to the upper eyelid blepharoplasty, the lower eyelid blepharoplasty is almost always cosmetic because excess skin and fat prolapse of the lower eyelids does not typically functionally impair vision. In assessing a patient for lower lid blepharoplasty, it is important to evaluate amount of excess skin present, the presence of orbital fat prolapse, hollowing at the inferior orbital rim or "tear trough deformity," as well as degree of lower eyelid laxity. Unlike the upper eyelid blepharoplasty, there are multiple approaches to a lower eyelid blepharoplasty and the relative degree of each of these factors influences which procedure should be chosen. Older patients with excess skin typically warrant a transcutaneous lower eyelid blepharoplasty. If lower eyelid laxity is also present, a lower eyelid tightening procedure (i.e., lateral tarsal strip) can be performed at the same time. Patients with minimal excess skin and fat prolapse or tear trough deformity can be approached with a transconjunctival lower lid blepharoplasty with fat excision or redraping.[4]

Operation

Upper Lid Blepharoplasty

The steps of the basic upper eyelid blepharoplasty are outlined in the following section. Additional procedures involving the correction of ptosis of the eyelids and eyebrows are beyond the scope of this chapter.

1. Measure the position of the lid crease centrally on each side with calipers. Mark the existing eyelid crease. This should fall between 6 to 10 mm above the eyelid margin centrally. If the position of the lid crease is different on each side, choose one crease height and mark symmetric incisions for each eyelid. If the crease is not obvious, manually move the eyelid up and down to better visualize the crease. The lateral edge of the mark should be extended to the orbital rim along a crow's foot crease. Typically, this should be placed 4 to 5 mm above the lateral canthus to avoid webbing. Placement of the incision along the lid crease results in a hidden scar.
2. After the lid crease has been marked, with the eyelids closed, use a smooth fine-tipped forceps to pinch the excess skin. One tip of the forceps will grasp the skin along the marked lid crease while the other end of the forceps is used to grasp the superior extent of the excess skin. Repeat this maneuver at several points along the eyelid and connect the points to outline the upper limit of skin to be removed. Mark this line and connect it with your lid crease marking medially and laterally. A safe zone of skin resection is to preserve a brow-to-margin distance of 15 to 20 mm.
3. Inject subcutaneous anesthetic in the area to be resected, taking care to inject superficially just below the skin.
4. Incise the skin along the marked incision lines with a 15 blade. Some surgeons prefer to use a CO_2 laser or Colorado microdissection needle to incise the skin. In either case, the goal is to make a smooth continuous incision line (Figure 21-10).



• **Figure 21-10** After marking is complete, 15 blade is used to incise the skin.



• **Figure 21-12** The fat pads of the upper eyelid visible beneath the orbital septum.

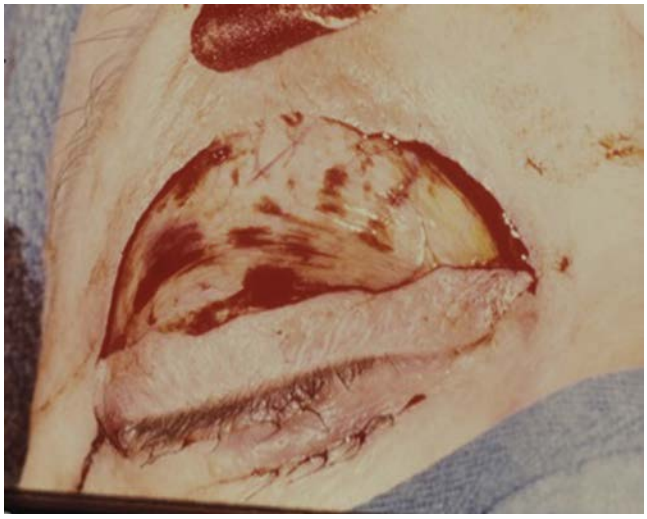

• **Figure 21-11** Upper eyelid with orbicularis visible after skin removal.

5. Use forceps and iris scissors to excise the marked area of skin, taking care to excise skin only and leaving the orbicularis intact (Figure 21-11).
6. Use cautery to achieve hemostasis.
7. At this point, prolapsed fat may be removed if desired.
   a. The orbicularis and septum are opened with iris scissors or cautery to expose the fat pads.
   b. Gentle pressure on the globe will further prolapse the fat (Figure 21-12).
   c. A hemostat is placed across the base of the prolapsed fat. Great care is taken to avoid any traction on the fat as this can lead to bleeding posterior to the septum. The distal fat is excised and the clamped edge of the fat is then cauterized and released. This can be repeated until a desirable amount of fat has been removed. It is important to note that aggressive fat debulking of the eyelids can result in a hollowed appearance and has generally fallen out of favor. Minimal conservative fat removal is recommended.
8. The skin is then closed with running 8-0 nylon.
9. Apply antibiotic/steroid ointment to the incision and eyes.

Lower Lid Blepharoplasty

The basic transcutaneous and transconjunctival approaches to the lower eyelid blepharoplasty are discussed in the following section. Additional procedures for lower lid tightening and methods of fat redraping are not discussed in detail in this chapter.

Transcutaneous Approach

1. A subciliary skin incision is marked 2 mm below the lower eyelid lashes. The marking is extended inferotemporally along a crow's foot crease at the lateral canthus to the lateral orbital rim.
2. Subcutaneous anesthetic is injected along the marked incision.
3. A traction suture is placed through the lid margin and is used to apply gentle upward traction to the lower lid during the procedure.
4. Incision along the previously marked line is completed.
5. Dissection using iris scissors is carried out inferiorly in a subcutaneous plane to create a skin flap. Dissection is carried out inferior to the extent of excess skin.
6. The orbicularis and orbital septum may be opened with iris scissors or cautery to expose the lower eyelid fat pads. Fat may then be resected as was described in the upper eyelid blepharoplasty or can be redraped over the inferior orbital rim to address any tear trough deformity.[9]
7. The skin flap is then redraped and any excess skin can be excised. It is important to be conservative in the amount of skin resected because this excess resection can cause retraction of the lower eyelid.
8. Close the skin with running 8-0 nylon suture or an absorbable 7-0 chromic suture. Using these microsutures with smaller needles allows for less scarring.

Transconjunctival Approach

1. Transconjunctival injection of anesthetic into the lower eyelid is performed.
2. The lower eyelid is retracted anteriorly to expose the palpebral conjunctiva.
3. Cutting cautery is used to incise the conjunctiva at the lower edge of the tarsal plate, extending the incision through the lower eyelid retractors to the level of the orbicularis.
4. Dissect inferiorly in a plane between the septum and orbicularis to expose the fat pads.
5. The fat pads can then be excised, tightened with cautery or redraped.[9]
6. The conjunctival incision can be closed with 2 or 3 interrupted 7-0 chromic sutures or may be left open after the procedure.

Postoperative Care

Patients are advised to apply antibiotic/steroid ointment to the surgical incisions twice daily for 1 week. Ice therapy is applied in the first 72 hours to reduce postoperative swelling. Patients are instructed to avoid public swimming pools and hot tubs for 1 to 2 weeks. Patients should avoid strenuous activity or bending below the waist for 2 weeks. Nonabsorbable sutures can be removed 7 to 10 days after surgery. Patients should expect postoperative swelling and bruising to persist for up to 3 to 4 weeks after surgery.

Complications

Orbital Hematoma

The most feared complication of eyelid surgery is hemorrhage behind the orbital septum, which can result in an orbital compartment syndrome and vision loss. This complication can be avoided by being judicious with tissue handling to avoid traction of the fat pads. Advising patients to stop anticoagulants or herbal medications that can cause increased bleeding is a must. Severe pain, inability to open the eyelids, and sudden decreased vision are hallmark signs that warrant urgent evaluation of the patient with the possibility of opening the incision for evacuation of the hematoma. Timely recognition and evaluation are crucial in preventing visual loss.

Asymmetry

Asymmetry of the upper lid creases can be avoided by careful and equal marking of the eyelid crease at the beginning of the procedure. Asymmetry of lid height and/or contour usually results from uneven dissection of fat and/or preexisting lid or brow ptosis.

Lagophthalmos

Mild postoperative lagophthalmos (inability to completely close the eyes) is common and typically resolves in the first few days after surgery. This can be managed with lubrication of the eyes. If it is present beyond the first week, it typically can be managed with ointment and massage of the upper eyelids. Persistent lagophthalmos is usually the result of aggressive skin removal or scarring of the orbital septum. Reoperation with lysis of scar tissue and/or skin grafting may be required in severe cases. Conservative skin removal is always preferred because further excision can be performed if needed.



• **Figure 21-13** Postoperative lower eyelid retraction and ectropion.

Lid Malposition

Ptosis of the upper eyelids can occur due to injury to the levator aponeurosis if surgical dissection was carried too deep into the eyelid structures. Gentle handling of the tissue is key. Excessive scarring and wound infections are extremely rare in the eyelids.

Complications of lower eyelid blepharoplasty include lower eyelid retraction, ectropion, and inferior scleral show. These typically occur when there is excessive removal of skin and muscle. Upward massage of the lids can be attempted in the acute postoperative period. However, persistent ectropion and/or retraction may require surgical revision with skin graft (Figure 21-13).

Ocular Surface Irritation and Dry Eyes

As mentioned previously, dryness can be transient in the initial postoperative period. This can be corrected with aggressive use of artificial tears. However, sometimes ocular surface irritation and dryness persist despite good position of the lids. In these situations, it would be appropriate to refer the patient to an ophthalmologist for further evaluation and management.

Conclusion

Blepharoplasty is a versatile procedure that can improve the function and esthetics of the eyelids. It is a relatively simple, low risk procedure that can result in substantial functional and esthetic improvement when performed correctly. Success of the procedure is dependent on a detailed understanding of the eyelid anatomy as well as careful preoperative evaluation and planning. Meticulous surgical technique will allow the surgeon to avoid postoperative complications. It is a procedure that may be easily added to any facial surgeon's armamentarium with consistent effective results.

References

1. Manners RM, Collin JR: Localised unilateral blepharochalasis, *Brit J Ophthalmol* 78:881–882, 1994.
2. Von Graefe CF: *De Rhinoplastice*, Berlin, 1818, Reime.
3. Nerad JA: *Techniques in ophthalmic plastic surgery: a personal tutorial*, London, 2010, Elsevier.
4. Tyers AG, Collin JRO: *Colour atlas of ophthalmic plastic surgery*, London, 2014, Elsevier.
5. American Academy of Ophthalmology: *Basic and clinical science course: orbit, eyelids and lacrimal system*, San Francisco, 2013-2014, The American Academy of Ophthalmology.
6. Zide BM: *Surgical anatomy around the orbit: the system of zones*, Philadelphia, 2006, Lippincott Williams & Wilkins.
7. Dutton JJ: *Atlas of clinical and surgical orbital anatomy*, London, 2011, Elsevier.
8. Iliff CE, Iliff WJ, Iliff NT: *Oculoplastic surgery*, Philadelphia, 1979, WB Saunders.
9. Zoumalan CI, Roostaeian J: Simplifying blepharoplasty, *Plast Reconstr Surg* 137(1):196e–213e, 2016.

22

Forehead and Brow Lift

ANGELO CUZALINA, MANIK BEDI

Introduction

Facial rejuvenation has had a steady increase in popularity over the past 25 years and upper facial procedures rank at the top of facial cosmetics with more than 203,000 blepharoplasties performed in 2015 (number two of all facial cosmetic surgical procedures) and over 40,000 forehead lifts in 2015 (number five of all facial cosmetic surgical procedures). The top minimally invasive cosmetic procedures for 2015 were Botulinum toxin type A (6.7 million) and soft tissue fillers (2.4 million), which were number one and number two, respectively, of all minimally invasive procedures.[92] The desire of the aging population to feel and look rejuvenated has led to new techniques that provide a more youthful and natural appearance and offer faster recovery. Rejuvenation of the upper third of the face is a vital component for proper treatment of the aging face.

Esthetic concerns of the forehead and brow regions affect a wide range of age groups. In contrast to standard lower face and neck rhytidectomies that are more commonly performed on patients older than age 45, cosmetic concerns in the upper third of the face may be evident for patients in their 20s and 30s because of genetic predisposition. In addition, patients who seek upper facial rejuvenation often present with complaints of excessive wrinkling, tired-appearing eyes, and excess eyelid skin. The goal of the facial cosmetic surgeon should be to restore the esthetic balance and a youthful three-dimensional facial topography. The cosmetic surgeon should take time to discuss the patient's goals and realistic outcomes and the conversation should include aging changes that occur in the upper facial region due to sun damage, gravity, bone resorption, decreased tissue elasticity, facial volume loss (deflation), and genetics.

Of all the forehead and brow lift procedures, the endoscopic forehead and brow lift has proved to be the most common and predictable of the facial cosmetic techniques.[1] Patients have benefited from smaller incisions, less morbidity, and rapid convalescence. It is not surprising that in the world of cosmetic surgery, where patients are becoming ever more knowledgeable and demanding, endoscopic procedures are increasingly popular.

The forehead and brow lift is a comprehensive operation and is not just a method used for raising the brows.[2,3] When used properly, it can address not only brow ptosis but also dynamic muscular problems (Figure 22-1). This procedure yields more dramatic facial improvement when properly and selectively combined with other rejuvenation procedures such as fat grafting, skin resurfacing, fillers, neurotoxins, and bone remodeling. Correct diagnosis of age-related changes is critical.

The aging process typically leads to forehead and brow ptosis for almost every patient (Figure 22-2). However, it is necessary to determine whether the ptosis seen around the forehead and brow region is due to a problem with brow position or with upper eyelid laxity, or whether it is caused by the combination of the two. Sometimes, what others may see as ptosis in the lateral brow may actually be fat atrophy that can be better rejuvenated with fat grafting than with lifting of the brow. Still other problems such as dynamic lines produced by muscle activity in the glabellar region and in the forehead itself also must be addressed. Skin texture, variable hairline patterns, bony abnormalities, and asymmetries should be evaluated.

Rejuvenation of the upper third of the face can be one of the most rewarding and fulfilling procedures one can offer to select patients. Specific elevation and correction of lateral hooding, along with a reduction in wrinkles, can result in a natural appearance yet still can impart a tremendous improvement in the patient's overall beauty and youthful appearance. The goal of this chapter is to review upper facial third anatomy and approaches to all forehead brow lift procedures, however, particular attention will be made to the senior author's personal experience of patient's preferred treatment method, the endoscopic forehead and brow lift.

Anatomic and Esthetic Considerations

It is commonly accepted that a youthful forehead represents roughly one third of the overall facial height. In essence, the distance from hairline to glabella is equal to the distance from the glabella to the point at the base of the columella



• **Figure 22-1** The two patients shown are each before and after an endoscopic brow lift. The brow lift is best suited for two primary preoperative issues; wrinkling from dynamic muscular problems and lateral hooding.

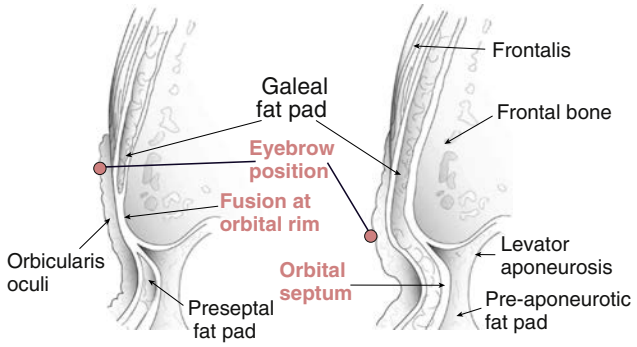

• **Figure 22-2** Cross section through brow near the lateral limbus. Compared to the youthful brow *(left)*, the aging brow *(right)* has loss of volume (including soft tissue and bone), inferior migration of eyebrow below its natural position at the level of the supraorbital rim, collagen and elastic deterioration, and changes in fat volume. The lateral eyebrow segment almost always becomes ptotic earlier in life than the medial eyebrow segment.

(subnasale). A youthful appearing eyebrow is different for men than for women. The female eyebrow should be arched with the peak point of the brow on a sagittal line of the lateral limbus of the eye. The brow itself should be positioned just above the orbital rim, in contrast to a typical male eyebrow, which should lie along the orbital rim in a more horizontal fashion.

The comprehensive anatomy of individual areas has been well described in the literature, often in relation to the specific procedure that is being performed. Therefore, the anatomic discussion can be simplified by separating the specific regions into bone anatomy, muscle and fascial anatomy, vessel and nerve anatomy, and endoscopic anatomy. Each anatomic region will be addressed specifically here so the reader will gain an understanding of surgical anatomy as it relates to the forehead and brow lift.

Bone Anatomy

The highest percentage of bony landmarks for the forehead and brow lift involve the frontal bone, and adjacent parietal bone, zygoma, maxilla, and nasal bones will be at least partially exposed when the procedure is performed. The connections (suture lines such as nasofrontal, zygomaticofrontal, and coronal) are important landmarks because they can be clinically pertinent for limits of dissection and can help the surgeon to know these locations during dissection. Case in point, the fronto-zygomatic suture line is the location at which some surgeons may elect to halt dissection for a basic brow lift. Just posterior and slightly inferior to this suture line is the sentinel vein. This vein is avoided to prevent undesirable bleeding that may complicate the

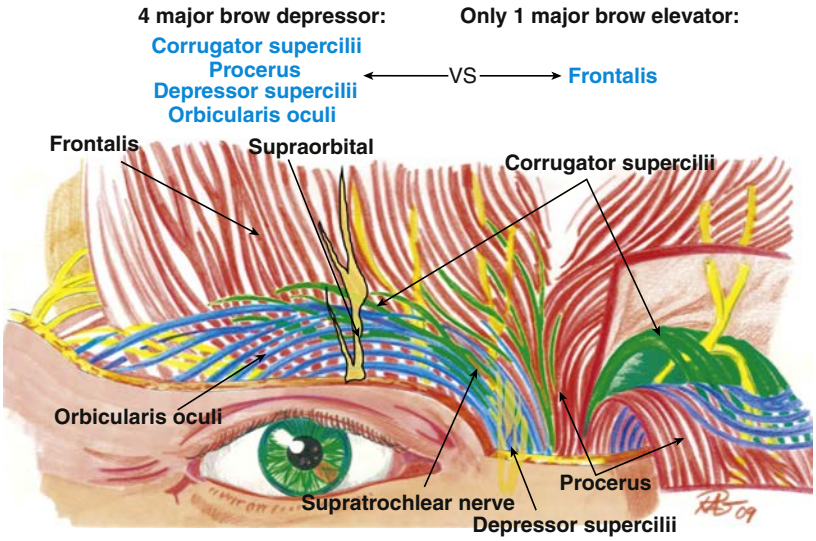

• **Figure 22-3** Forehead muscles and nerves. The major elevator of the eyebrow and forehead is the frontalis muscle. Several depressor muscles are shown through the cut frontalis: the corrugator supercilii, the procerus, the depressor supercilii, and the orbicularis oculi. Additionally, the close relationship between the depressor muscles of the eyebrow and the supraorbital and supratrochlear nerves is depicted.

procedure. Some surgeons elect to ligate and transect this vein for further tissue release. Knowledge of its location in relation to the adjacent bone landmark is critical. Additional dissection can be performed if mid-face lifting is also considered, or if the patient desires more elevation at the lateral canthal region. Elevation in the subperiosteal plane below the fronto-zygomatic suture into the cheek can be performed for increased lift in the mid-face. Overaggressive dissection into the cheek and around the orbit can create an unnatural "cat eye" appearance if too much tissue is elevated, particularly medially along the fronto-zygomatic suture line and the deep lateral canthus.

The nasofrontal suture line is an excellent landmark to note during dissection. First, dissection needs to proceed only a few millimeters below this suture level onto the nasal bones for adequate release. Second, the paired procerus muscles can be identified here and transection performed if indicated. Third, depending on the point of horizontal transection in this area, the nasofrontal angle location can be altered slightly if desired. Lastly, nasal tip rotation can be achieved if desired, particularly with considerable dissection below the nasofrontal suture line.

Another critical bony landmark is the orbital rim and associated arcus marginalis (this is where the periosteum of the frontal bone fuses with the galea), which limits inferior dissection but must be well visualized and freed of periosteal attachments if the brow and brow fat pads are to be lifted for lasting results. Significant muscle and fascial attachments are also located at the level of the orbital rim medially and laterally. The tenacious temporal fusion line that exists along the temporal ridge is important to identify during dissection; it is equally important for the clinician to know its location preoperatively, so that correct incision placement can be made to facilitate clean dissection under this area. Clean dissection, free of hanging or torn tissues, is critical for adequate endoscopic visualization.[4]

Bony thickness varies in different areas of the skull, and this must be recognized when fixation methods that drill into the skull are used. In addition, venous lakes along the diploe surface of the skull tend to be more centralized around the sagittal suture line, and drilling here should be avoided. Thickness increases posteriorly near the occiput, but screw or bone tunnel fixation here is not required. Caution must be taken to avoid bone penetration near the temporalis muscle in the lateral skull region, where the middle meningeal arteries could be injured. Awareness of average thickness for a given location and of internal anatomy is necessary before drilling into the skull is performed for any reason. The safest site used for bone tunnels or screws for brow lifting is located along a parasagittal line, approximately at the mid-pupil or lateral limbus line and just anterior to the coronal suture.

Muscle and Fascial Anatomy

Paired muscles of the forehead and brow region are commonly thought of as elevators and depressors (Figure 22-3). Although the depressors can actually move in an oblique or circular fashion, the only true elevator of the forehead, the frontalis, moves upward to raise the brow. This movement, along with some static tone, maintains brow position and can produce horizontal creases over time. The frontalis muscle originates from the deep galeal plane (galea aponeurotica that connects to the occipital muscle posteriorly).[5,6] It inserts into the orbital portion of the orbicularis oculi muscle inferiorly, and this inserts into the dermis immediately below the eyebrow. Its lateral extension fuses into the dense collection of fascia approximately 1 cm wide, called the *zone of adherence;* this zone runs the length of the superior temporal line and ends inferiorly just above the zygomaticofrontal suture at an attachment of fascia known as the

orbital ligament. These areas are important clinical anatomic regions because freeing the zone of adherence is necessary to achieve good long-term results with lift procedures. Care is required in this region to avoid overzealous stretching and injury to the facial nerve.

The acronym SCALP applies in the forehead for the standard layers: skin, subcutaneous tissue, aponeurosis (the thick galeal fascia), loose areolar (subgaleal) plane, and periosteum. The galeal fascia has simply blended into the frontalis muscle and its midline fascial attachments at the forehead level. This allows sliding movement over the scalp with contraction of the muscle. The frontalis and the galea may be thought of as an extension of the temporoparietal fascia in the temporal region and in the SMAS (superficial musculoaponeurotic system) below the level of the zygomatic arch. The temporoparietal fascia appears somewhat spongy and houses the frontal branch of the facial nerve on its undersurface in the temporal region.

Several other paired forehead and brow muscles thought of as "depressors" are present along the brow and facilitate facial expression. The two most well recognized of these are the procerus and the corrugator supercilii muscles, which are present in the glabella. The procerus muscles are paired superiorly but fuse inferiorly into a single muscle belly that originates on the nasal bones and cartilages. It inserts into the midline intervening medial frontalis muscle fibers and the overlying dermis. The procerus is responsible for depression and frowning between the eyes that often creates a horizontal crease (bunny line) across the upper portion of the nose. The corrugator supercilii muscles are depressors that act obliquely across the glabella and form the classic vertical lines seen during squinting or frowning. These muscles create an "angry" appearance. The corrugator supercilii originates from the frontal bone just above the nasal bones and inserts into the dermis of the medial brow. The corrugator has two heads, the oblique and the transverse, which act in unison to pull the medial brow down and together. Collectively, the paired procerus and corrugator muscles are the main depressors of the medial brow and are the muscles most commonly treated with Botox to help alleviate frown lines in the glabella. These same two muscles are most often transected during an endoscopic brow or forehead lift to achieve a smooth and long-lasting result.

Another depressor muscle of importance is the depressor supercilii muscle, which originates on the frontal process of the maxilla just inferior and superficial to the origin of the corrugator supercilii. It inserts into the medial frontalis fibers and dermis just above the medial brow. The depressor supercilii is important because it is superficial to the corrugator and is easily treated inadvertently with Botox. It is also important because it lies behind the corrugator during a brow lift and can be transected via aggressive dissection through the corrugator muscle. Although a few patients with very low medial brow position may occasionally benefit from this maneuver, it more often causes over-elevation of the medial brow and creates the "surprised" look. Superficial to the depressor supercilii is the orbital portion of the orbicularis oculi, which inserts into portions of the adjacent depressors, the surface of the inferior frontalis, and the dermis below the brow. The orbital portion of the orbicularis muscle originates, to some extent, from the medial canthal tendon and from adjacent bone (Figure 22-4). Deep to all the depressors is the galeal fat pad, which lies directly below the transverse head of the corrugator and helps to reveal the locations of muscular landmarks when it is exposed clinically after transection through the periosteum along the orbital rim.

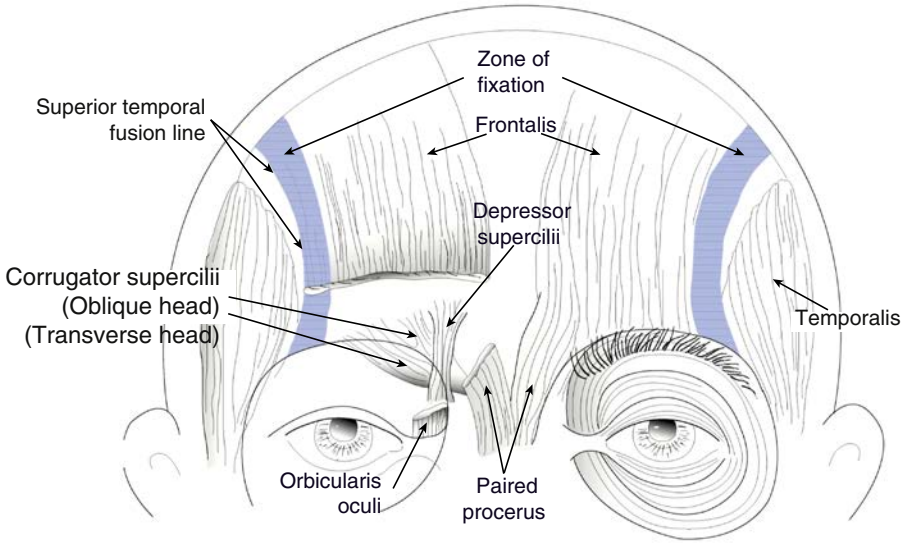

• **Figure 22-4** The depressor muscles, including the cut edge of the orbital portion of the orbicularis oculi that inserts into portions of the adjacent depressors, are shown here and can be seen anterior to the depressor supercilii. The orbital portion of the orbicularis muscle originates, to some extent, from the medial canthal tendon and from adjacent bone. Separating the plane of dissection into a subperiosteal plane medially and just above the temporalis fascia laterally is the temporal crest with its 1 centimeter "zone of adherence."

Lastly, paired temporalis muscles are located in each temporal fossa, where they originate and then insert onto the coronoid process of the mandible. The importance of these muscles during upper facial rejuvenation is most often related to its overlying temporalis fascia, which can be used to delineate surgical planes and aid in fixation. The temporalis fascia is adherent to the temporalis below and splits into superficial and deep layers in the lower half of the fossa. For consistency, the superficial layer of the deep temporalis fascia describes only that portion of the deep temporalis fascia that is present at the level of the split; the area below is referred to simply as the temporalis fascia, that is, the deep, thick fascial layer seen clinically from the temporal crest down to the zygomatic arch. The spongy temporoparietal fascia, which is superficial to the dense and glossy white–appearing temporalis fascia, houses the frontal branch of the facial nerve within its deep surface.

One method of fixation that may be performed during brow lifting involves using suture to fixate the temporoparietal fascia from below a skin incision to the adherent temporalis fascia in a more superior position, to elevate the lateral brow and upper cheek. Some surgeons advocate removing a window of temporalis fascia during this suture fixation procedure and exposing the underlying temporalis muscle in the hope of gaining additional fibrosis and improving fixation longevity.

Vessel and Nerve Anatomy

Perfusion to the upper face and scalp is excellent and comes from multiple sources. Several major blood vessels of the upper face and scalp, including the superficial temporal artery and the facial artery, originate from the external carotid. These give rise to the blood supply in the medial canthal region via the angular artery and in the lateral canthal region via the frontal or anterior branch of the superficial temporal artery. The internal carotid artery branches to the middle meningeal artery and to the ophthalmic artery, which gives rise to the supraorbital and supratrochlear arteries that exit their respective foramina and supply most of the forehead and mid-scalp region. The terminal arterial branches of the upper face have multiple significant anastomoses with adjacent vessels.

Venous drainage of the upper face follows the respective arterial supply, although this pattern can vary. Still, one particular vein that is relatively consistent is known as the *sentinel vein* (medial zygomatico-temporal vein); this vein runs perpendicularly through the temporalis fascia at a location approximately 2 cm lateral or posterior to the lateral canthus. It is clinically significant during open and endoscopic procedures because of the problems that are created by injury to it, such as bruising and impaired visualization. As one elevates the tissues inferior to the zygomatico-frontal suture in the subperiosteal plane, care must be taken to avoid careless dissection laterally, where the sentinel vein can be accidentally torn.

Nerve supply parallels arterial supply to some extent. The supratrochlear and supraorbital nerves, which account for most sensation to the forehead, exit the same foramina or notch as the same named blood vessels. These sensory nerves originate from the first division of the trigeminal nerve. The supraorbital nerve has two divisions after it emerges from the frontal bone: (1) the deep (or lateral) division that supplies the more lateral and posterior portion of the forehead and scalp (Figure 22-5), and (2) the superficial (or medial) division that pierces the frontalis early in its course and runs superficial to the muscle, supplying sensation to the lower forehead and the mid-forehead along the mid-pupil line.

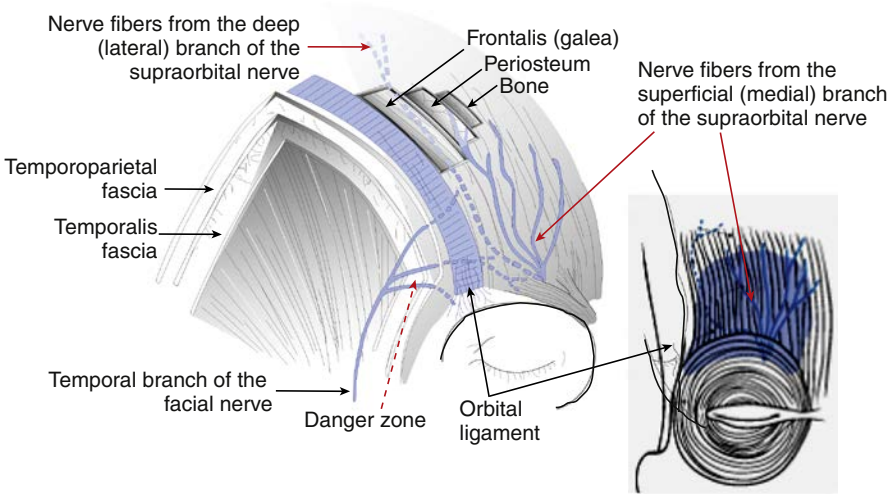

• **Figure 22-5** The supraorbital nerve has two divisions, seen here after they have emerged from the frontal bone. The deep (or lateral) division supplies the more lateral and posterior portion of the forehead and scalp and is the more commonly injured nerve during endoscopic brow lifting. The superficial (or medial) division of the supraorbital nerve pierces the frontalis muscle early in its course and runs superficial to the muscle, supplying sensation to the lower and mid-forehead along the mid-pupil line. It is more commonly injured during a subcutaneous trichophytic brow lift.



• **Figure 22-6** The supraorbital foramen or notch typically is found within 1 mm of a line drawn in a sagittal plane tangential to the medial limbus, as shown here. This point can be marked on the skin of the brow to give the surgeon a reference point from which the exit point of this important structure and adjacent key muscle groups can be identified. Knowledge of the important anatomic structure allows more aggressive but safe release of tissue, to provide significant elevation in areas such as the lateral third of the brow, as seen here after 18 months.

The bony exit point of the supraorbital nerve is relatively consistent. The supraorbital foramen or notch typically is found within 1 mm of a line drawn in a sagittal plane tangential to the medial limbus (Figure 22-6).[7] This point can be marked on the skin of the brow to give the surgeon a reference point that reveals the exit point of this important structure (Figure 22-7). The deep division has been known to exit as often as 10% of the time from another foramen that may be as high as 1.5 cm above the orbital rim. Therefore, some surgeons advocate that blind (nonendoscopic) inferior dissection from the scalp above should be performed only to within 2 cm of the orbital rims, and that should be followed by endoscopic guidance below this point to decrease the chances of nerve injury.[8-13]

The supratrochlear nerve on each side exits near the orbital rim an average of 9 mm medial to the exit of the supraorbital nerve. The paired nerves supply sensation to the midforehead with some overlap from the supraorbital nerves. Infratrochlear nerves that also originate from division one of the trigeminal nerve exit just below the supratrochlear nerves around the medial orbital rim to supply sensation to the upper nose and the medial orbit. Zygomatico-frontal and zygomatico-temporal nerves originate from the second division of the trigeminal nerve to exit their respective small foramina and supply sensation to the lateral orbit and the temporal regions of the face.

Motor innervation to the forehead and the glabella is supplied by the facial nerve (cranial nerve VII) (Figures 22-8 and 22-9). The frontal (or temporal) branch of the facial nerve supplies the frontalis muscle, the superior portion of the orbicularis oculi muscle, the superior portion of the procerus muscle, and the transverse head of the corrugator supercilii muscle; the zygomatic branch supplies the medial head of the orbicularis oculi muscle, the oblique head of the corrugator supercilii muscle, the inferior portion of the procerus muscle, and the depressor supercilii muscle (Figure 22-10).

The auriculotemporal nerve originates at the third division of the trigeminal nerve; it supplies sensation in front of the ear, to the temporal skin above the zygomatic arch,

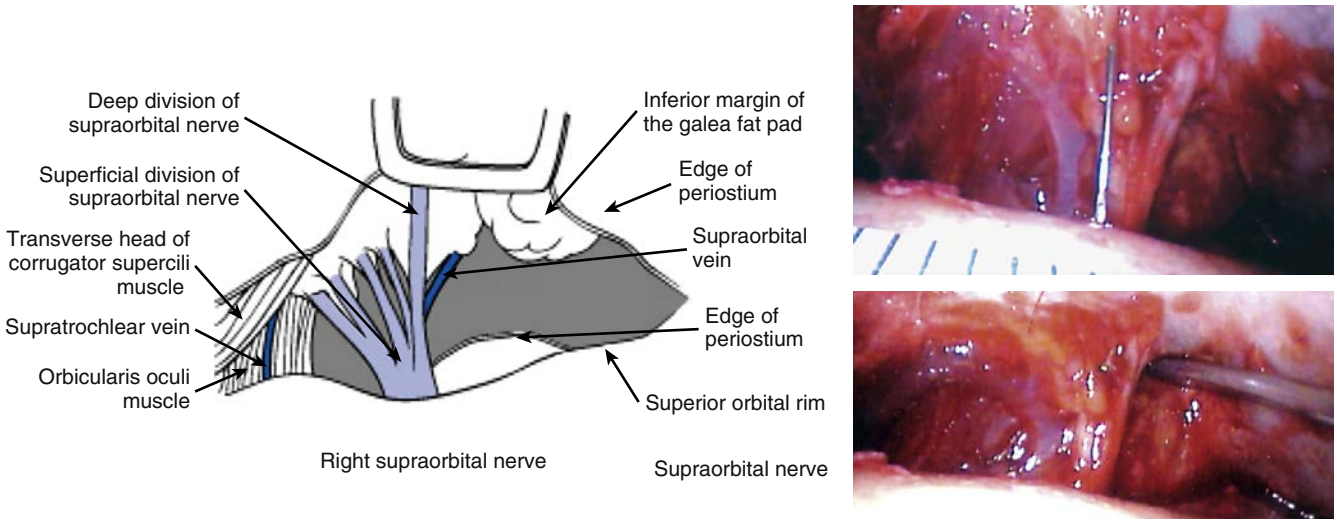

• **Figure 22-7** Right side endoscopic view. A needle can be seen on a right side endoscopic view; it was placed through the skin at a point marked in the sagittal plane tangential to the medial limbus and through the brow skin. This illustrates how accurate this technique is for preoperative identification of the location of the supraorbital nerve.

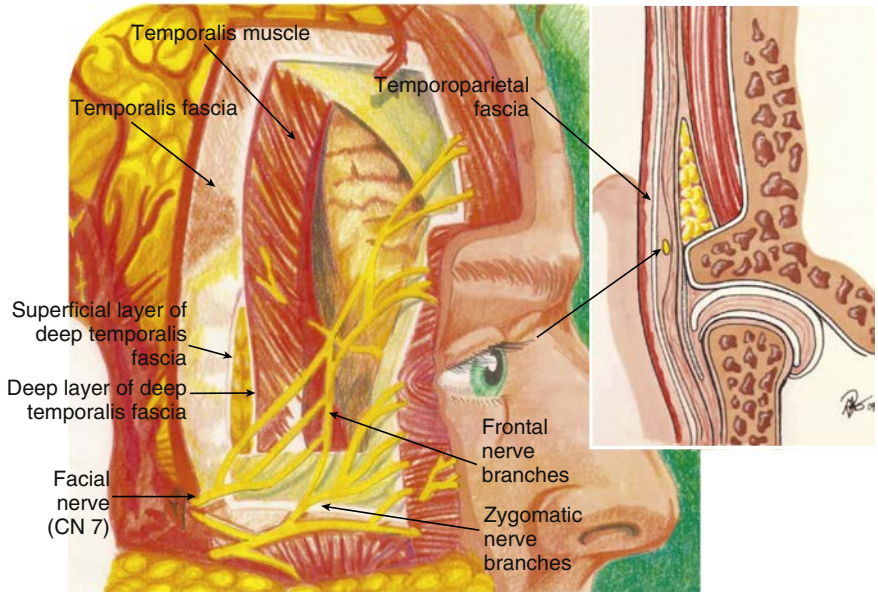

• **Figure 22-8** Motor nerves and fascia of the upper face. Knowledge of the tissue layers overlying the forehead and temple is critical to avoid nerve injury and perform surgery safely. The frontal nerve lies on the deep side of the temporoparietal fascia.

and to the skin that courses along the superficial temporal artery. This nerve may be confused clinically with the frontal branch of the facial nerve during a face-lift or while temporal dissection is performed during brow-lifting procedures.[14-16] It can be distinguished from the facial motor nerve in that this sensory nerve runs within 1 cm in front of the tragus of the ear and parallels the superficial temporal artery. In a 1979 article by Al-Kayat and Bramley the location of the facial nerve's main trunk was described and it was found that it runs no nearer than 1.5 cm below the inferior margin of the bony external auditory meatus and that the most posterior temporal branch of the nerve crosses the zygomatic arch anterior to the bony external auditory meatus at a minimum distance of 0.8 cm and mean of 2.0 cm.[89] A more recent high-resolution MRI study of live subjects measured a minimum distance of 1.7 cm and mean of 2.1 cm.[90] Another anatomic study of interest discussed the facial nerve's path in three dimensions. The study showed that the temporal branch lies in the loose areolar connective tissue layer between the superficial and deep temporal fascia as it crosses the zygomatic arch; it enters the superficial temporal fascia from its undersurface in a consistent region

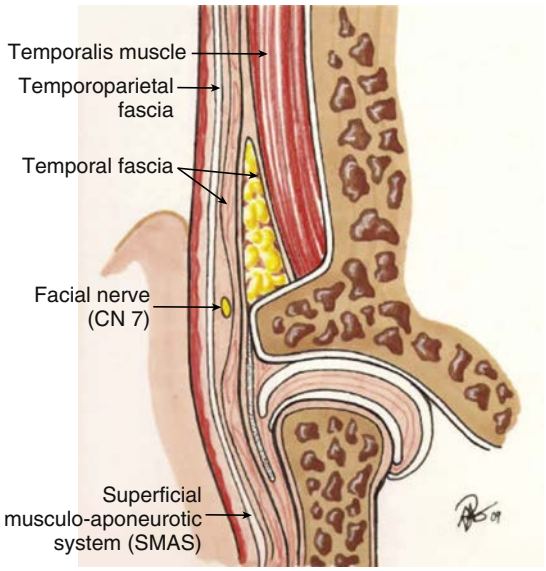

• **Figure 22-9** Cross section through the temporomandibular joint and zygomatic arch. The temporal nerve runs immediately below the temporoparietal fascia above the arch, which is the fascia continuous with the superficial musculoaponeurotic system below the arch.

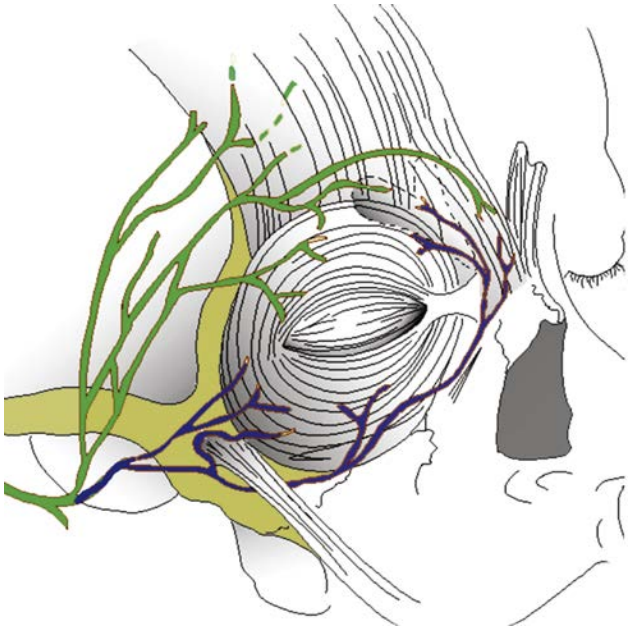

• **Figure 22-10** As highlighted in *green,* the frontal (or temporal) branch of the facial nerve supplies the frontalis muscle, the superior portion of the orbicularis oculi muscle, the superior portion of the procerus muscle, and the transverse head of the corrugator supercilii muscle. As highlighted in *blue,* the zygomatic branch of the facial nerve supplies the medial head of the orbicularis oculi muscle, the oblique head of the corrugator supercilii muscle, the inferior portion of the procerus muscle, and the depressor supercilii muscle. Therefore, when these muscles are transected, contraction occurs away from the cut in each direction.

1.5 to 3.0 cm above the zygomatic arch and 0.9 to 1.4 cm posterior to the lateral orbital rim.[91] The frontal branch of the facial nerve typically has already divided into two rami at the level of the arch and into at least four branches by the time it reaches the level of the eyebrow.

Endoscopic Anatomy

Initial dissection prior to placement of an endoscope must be performed to gain adequate space for the equipment. Early (partially blind and blunt) dissection is performed in the posterior scalp, in the mid-forehead and upper forehead, and in temple regions, leaving endoscopic guided dissection for the inferior forehead, beginning 2 cm above the orbital rim and the zygomatic arch. It is this author's preference to work in a completely subperiosteal plane medial to the temporal crest and in the plane immediately above the temporalis fascia below the temporal line on each side (Figure 22-11). Subperiosteal dissection in the medial forehead helps to prevent injury to the deep or lateral division of the supraorbital nerve, which runs in the subgaleal plane near the zone of fixation. Others begin their dissection in a subgaleal plane in the posterior scalp.[17-32] Regardless of preference, a space must be created in the upper areas of the scalp to allow ample room for placement of an endoscope to aid dissection in the lower forehead near important anatomic structures.

The first anatomic landmark that the surgeon meets early in dissection is the zone of fixation along the superior temporal crest. The upper portion can be released bluntly with the use of finger dissection and/or periosteal elevators. However, the inferior edge of the temporal crest found near the superior-lateral orbital rim usually requires endoscopic guidance for maximum release. Fibers condensed from the periosteum, galea, temporalis, and temporoparietal fascia interlace and fuse to form a zone of adherence at this part of the upper lateral orbital rim, much in the same way that the layers of tissue planes condense at the level of the zygomatic arch (Figure 22-12). A less tenacious zone of adherence is present along the entire temporal crest that can be elevated bluntly at the hairline level and a couple of centimeters below; however, as one approaches the lateral brow, endoscopic guidance and sharp dissection are most often needed for this increasingly adherent tissue plane, which is sometimes referred to as the orbital ligament at the orbital rim (Figure 22-13). The temporal nerve has branches within this ligamentous type of structure just above the brow level, and care must be taken to stay intimately close to the bone and the temporalis fascia to avoid nerve injury. Another fibrous attachment known as the orbicularis-temporal ligament is also nearby; it contains small motor nerve fibers. The orbicularis-temporal ligament represents the decussation of fibers from the temporoparietal fascia and fibers from the temporal fascia that extends laterally, away from the orbital ligament.

The zone of adherence becomes most firm near the orbital ligament at the orbital rim level; slow, meticulous dissection is required at this point to avoid nerve injury, as well as injury to the sentinel vein, which is located within the orbicularis-temporal ligament approximately 1 cm lateral and inferior to the zygomatico-frontal suture.[33-41] Careful dissection can expose an intact sentinel vein that can be seen piercing

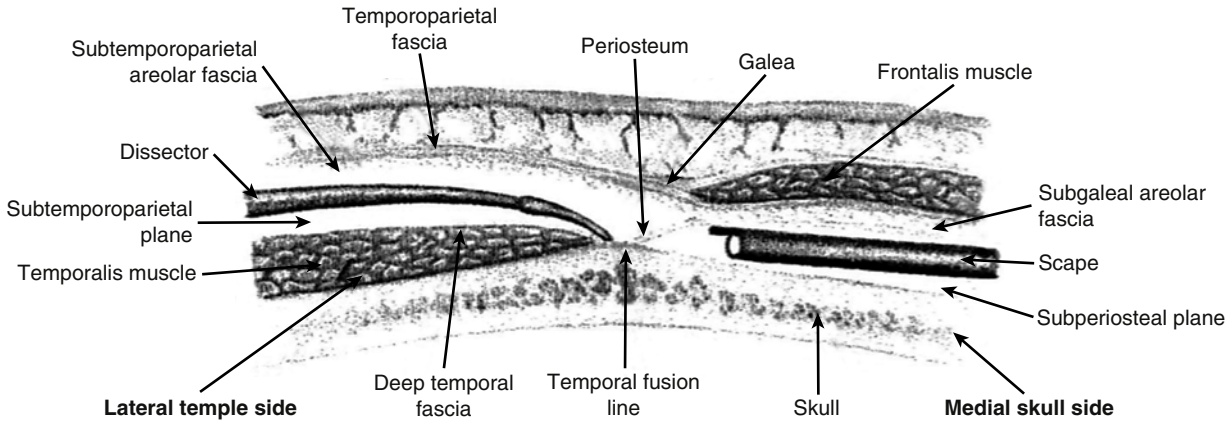



• **Figure 22-11** The temporal incisions can be very helpful as suction ports if the medial ports are too occupied with the endoscope and the cautery device. In this diagram the dissector or suction is in the temporal incision below the temporoparietal fascia and the scope is in the medial (parasagittal) incision in the subperiosteal plane.

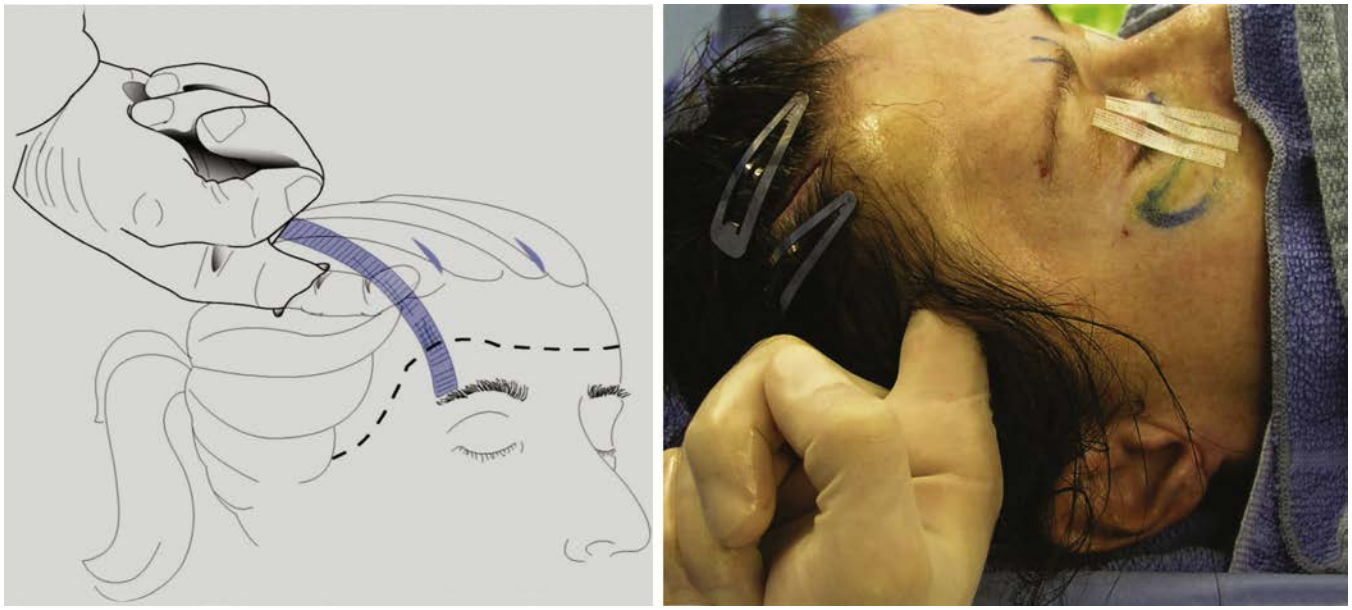

• **Figure 22-12** The tenacious zone of adherence along the entire temporal crest can be elevated bluntly at the hairline level and a couple of centimeters below. It is critical when one is performing an "endoscopic" brow lift to elevate from lateral to medial, blunted as seen here to avoid creating a "false" tunnel if dissection is begun from the opposite direction.

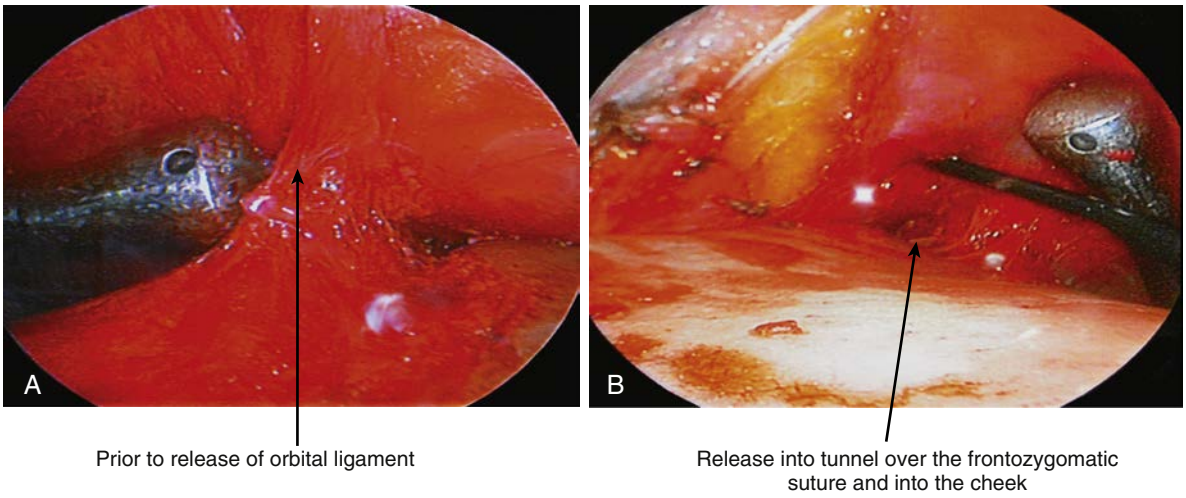

• **Figure 22-13** **A,** The left lateral orbital ligament before release. **B,** The right orbital ligament is shown after partial release immediately lateral to a subperiosteal tunnel created over the frontozygomatic suture and into the cheek.

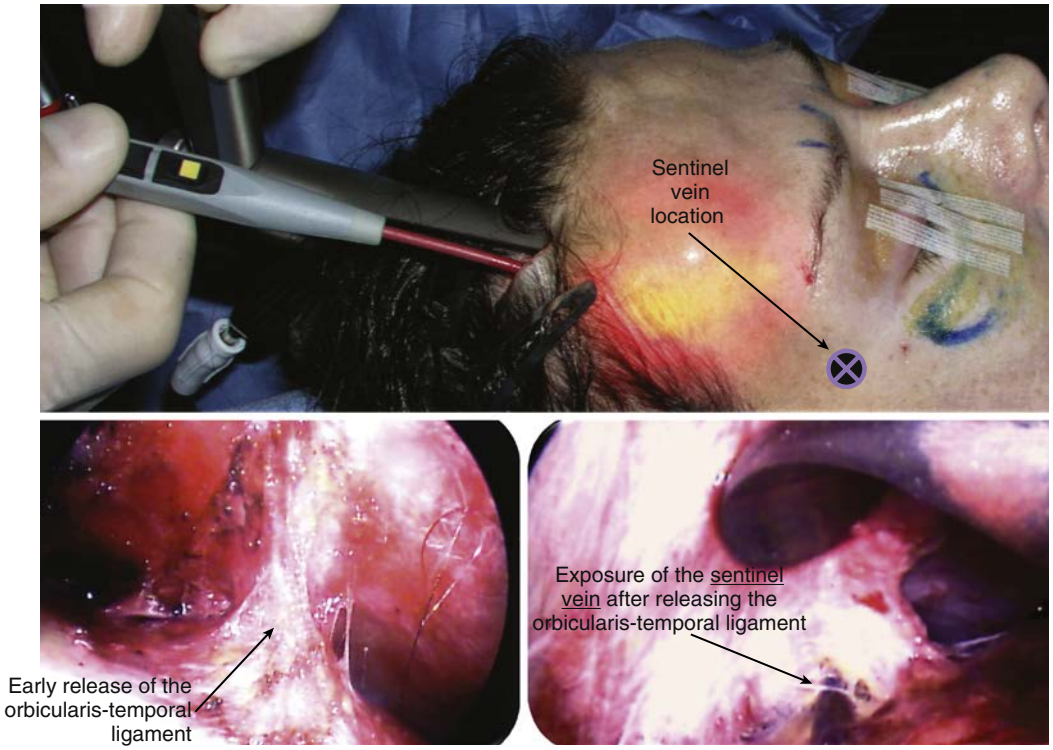

• **Figure 22-14** Orbital ligament release is critical for adequate brow lift stability. Shown here is the endoscopic release of the orbital ligaments to gain access to the lateral orbicularis oculi. The sentinel vein is at the inferior edge of the ligament and can be cauterized, ligated, or avoided. The vein is typically located 1 cm lateral to the frontozygomatic suture.

through the temporal fascia at a perpendicular angle to enter the temporoparietal fascia above (Figure 22-14).

Dissection medial to the lateral orbital rims in the subperiosteal plane should expose the entire superior orbital rim from each zygomatico-frontal suture. The curvature of the rims then must be visualized so that transection through the periosteum can be made at rim level (arcus marginalis). The nasofrontal suture may not always be seen but can be felt via the periosteal elevator used to elevate tissue into the upper nasal region. During transection through the periosteum across the entire orbital rim, subgaleal fat often is encountered immediately, except when one is working directly behind the supraorbital nerve at the rim level where the deep (or lateral) division of the nerve is closely adherent to the periosteum. Preoperative marking of a point on the brow at a level tangential with the medial iris (limbus)

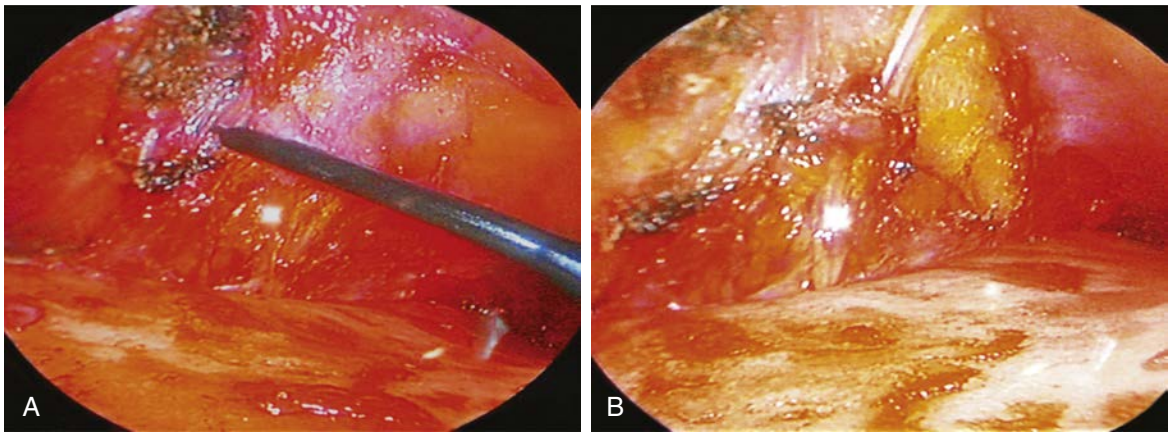

Initial transection through right corrugator

Release of periosteum higher above SO nerve

• **Figure 22-15** Periosteal release can be performed 1 to 2 cm above the arcus marginalis at the location of the supraorbital nerve as shown to avoid accidental transection of the base or trunk of the nerve. **A,** Early transection of the corrugator muscle. **B,** Release of periosteum is at the arcus marginalis except in the area of the supraorbital nerve where it is made 2 cm above the orbital rim.

reveals the location of the supraorbital vessels and nerves, so that dissection through the periosteum in this region is performed slowly and superficially to avoid injury to these structures (Figure 22-15). The transverse head of the corrugator supercilii is evident at the orbital rim level behind a portion of the supraorbital vessels and nerves. The corrugator muscle can be transected or partially excised here as well as medially. As dissection proceeds medially, the oblique head of the corrugator is encountered; with transection through this portion of muscle, the supratrochlear nerve and the depressor supercilii muscle may be seen and protected from injury (Figure 22-16). Medially in the glabella, the procerus muscle is seen and is variable in thickness. Care should be used to avoid over-resection in thin patients to prevent an atrophic defect in the glabella caused by excessively aggressive muscle resection. Deeper dissection toward the skin level under the brow will lead to the orbicularis oculi but is not necessary to gain the desired effect, except in the lateral orbicularis, where limited transection may improve lateral brow elevation. Also, transection through the periosteum can be performed at higher levels under the frontalis muscle in the midline but is required only when deep horizontal lines are present. It is important to gain complete release of the retaining lateral ligaments, transection of those muscles that are causing glabellar lines, and adequate separation of periosteum along the orbital rim to attain elevation of the brow and forehead tissues.

Preoperative Assessment and Treatment Goals

To ensure that a patient will not be disappointed, the clinician must determine whether that patient would benefit from a brow or forehead lift and must select the most appropriate surgical procedure. Four features of the upper third of the face are usually addressed by cosmetic surgeons. One or more of these aspects can be the focus of complaint and thus dictate the treatment goals and surgical approach. The four features are skin quality, rhytides, brow position, and eyelid redundancy/medial fat pat protrusion. Frequently, the novice surgeon may see only horizontal forehead lines as an indication for a brow lift. Unfortunately, this is much less of a problem for most patients than is a low lateral brow position (hooding) or glabellar creasing (Figures 22-17 and 22-18). As was previously discussed, the ideal female brow position is above the orbital rim level laterally and is variable, but on average, it appears 5 to 10 mm above the rim in the lateral one third of the brow. Men require a more straight-up elevation of the entire brow to avoid feminization of their appearance (Figure 22-19). Also, men may benefit from a standard upper blepharoplasty and a local transpalpebral brow lift if brow ptosis is nominal. As with any cosmetic surgery, a risk/benefit decision is made that is good for both the surgeon and the patient. Patients must be educated about the risks and about what can *realistically* be achieved. Even with fairly radical muscle resection and forehead elevation, new dynamic lines often are formed in the upper face and the glabella following surgery. Lateral crow's feet lines caused by action of the orbicularis oculi and by smiling may appear improved following a brow lift that is achieved by unfolding of the muscle; however, these lines are not completely treated by brow lifting alone, and the patient must understand that other treatments such as neurotoxin therapy may be required to manage these particular lines on an ongoing basis.

In addition to brow ptosis and lines in the forehead and glabella, the condition of the patient's skin must be evaluated. Intrinsic skin damage and collagen changes from the effects of sun, age, and smoking cannot be treated by lifting alone. Topical skin care (e.g., Retin A, microdermabrasion, pulsed light therapy, sun block), along with possible surgical resurfacing, must be considered. In general, the forehead can be treated carefully with simultaneous chemical peels

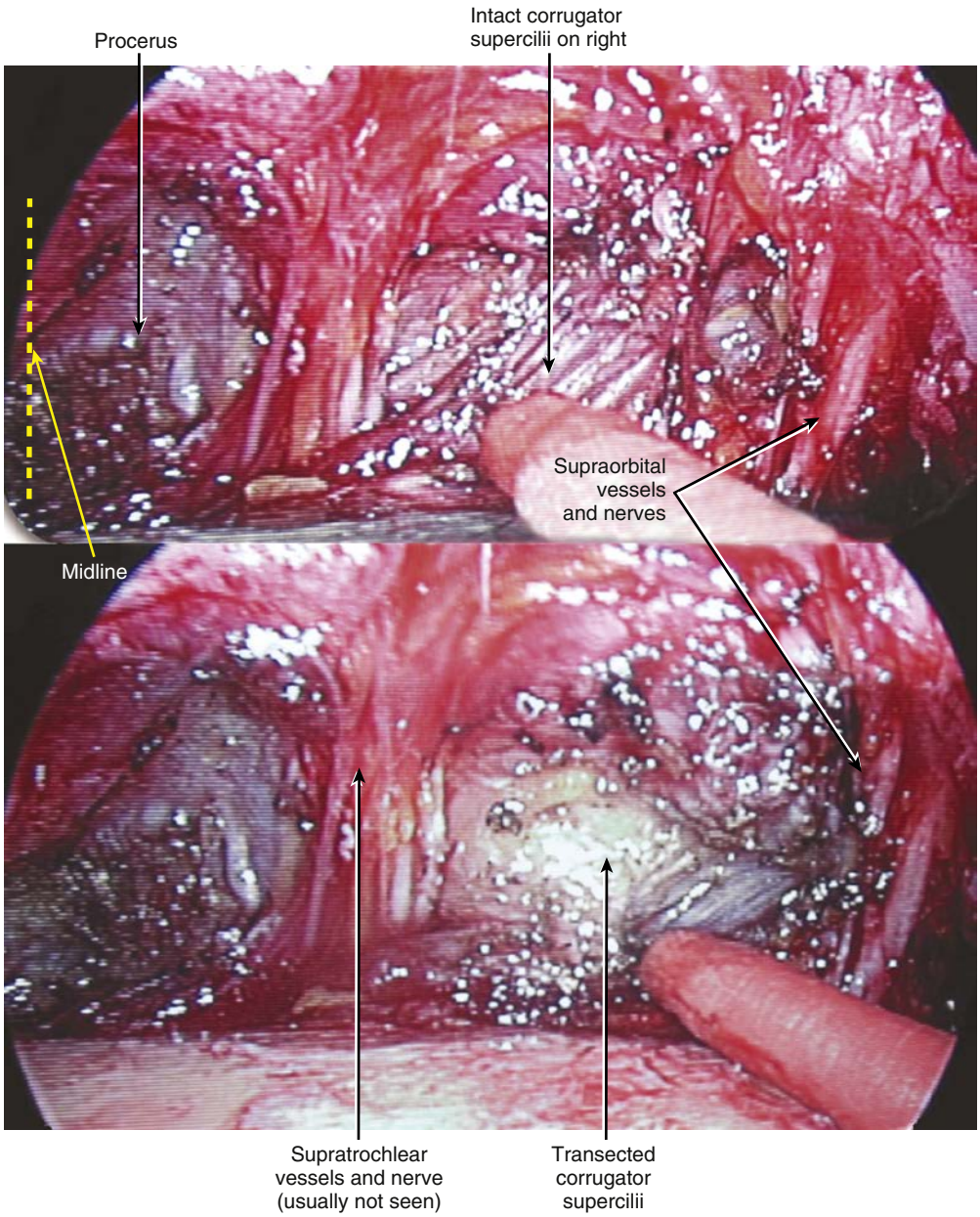

• **Figure 22-16** Right side endoscopic view of the close relation of corrugator supercilii with supraorbital neurovascular bundle and supratrochlear neurovascular bundle (typically not seen). Before transection *(above)* and after *(below).*

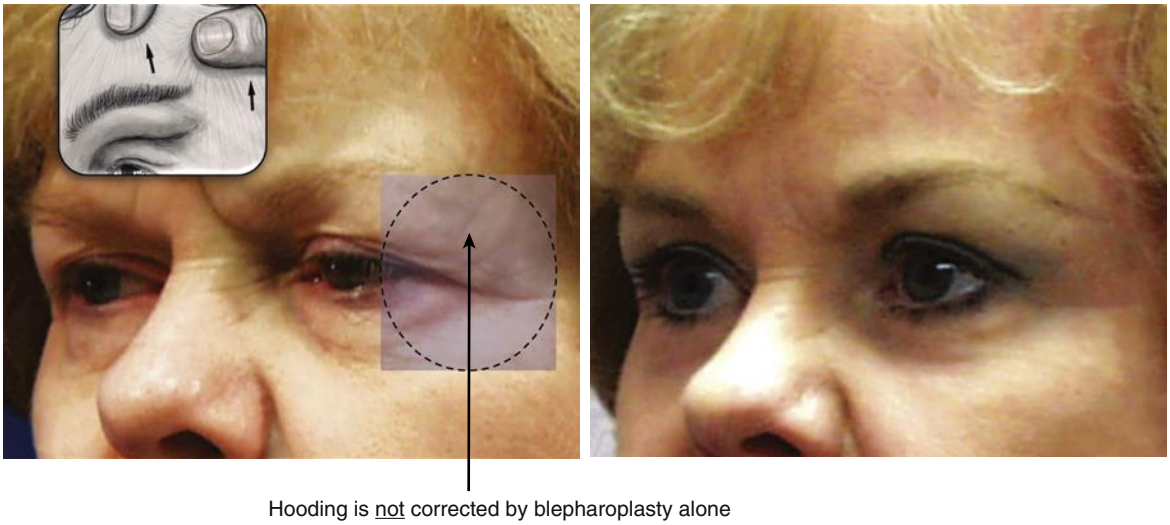

• **Figure 22-17** The brow lift is required for maximum esthetics in patients with lateral hooding and heavy dynamic glabellar rhytides. A 55-year-old woman 6 months following a brow lift and simultaneous upper and lower blepharoplasty. Blepharoplasty or brow lifting alone would probably have been inadequate treatment to fully improve the extreme laxity and lateral hooding.



• **Figure 22-18** A brow lift versus a blepharoplasty depends on hooding and lateral brow position. Preoperative and postoperative **(A)** images of a female patient who has relatively good brow position with lateral hooding only and obtained a very nice result from upper blepharoplasty alone. Preoperative and postoperative **(B)** images of a female patient who required both brow lifting and blepharoplasty because of severe lateral hooding and laxity of the eyelid skin after lifting the brow.

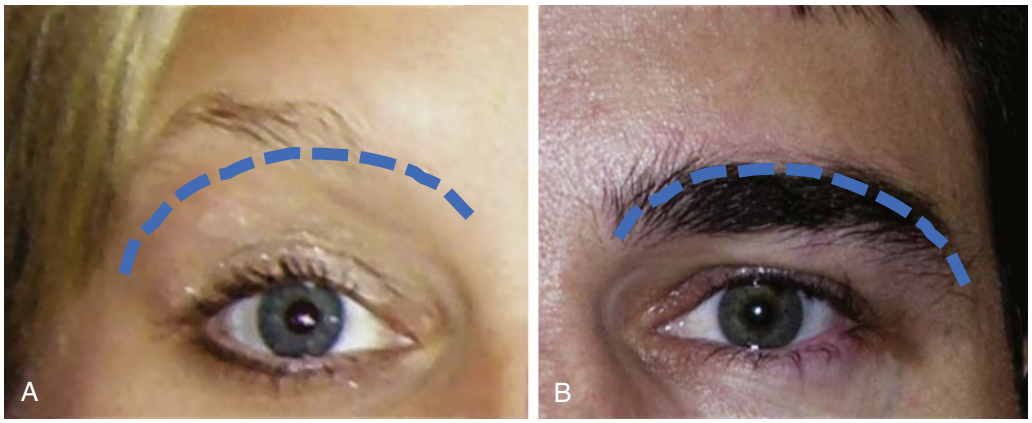

• **Figure 22-19** The female eyebrow **(A)** should be arched above the superior orbital rim, with the highest point of the brow on a sagittal line from the lateral canthus, whereas the typical male eyebrow **(B)** should lie at or only slightly above the orbital rim in a more horizontal or uniform arch fashion.

or laser skin resurfacing into the dermal level when brow-lifting procedures are performed, provided that the lifting technique is a subgaleal or subperiosteal technique rather than a subcutaneous lift. As a final point, bony irregularities or hypertrophic bony orbital rims can be evaluated for treatment by means of a cephalometric radiograph or a computed tomography (CT) scan as required. Bony contouring can be performed on a limited basis endoscopically, but major reduction for serious bone hypertrophy such as frontal bossing is best attained through an open (coronal) approach. Bone reduction is limited by pneumatization of the frontal sinus and is best evaluated by CT. Treatment planning for placement of bone tunnels for fixation with brow lifts does not require a preoperative CT scan; however, a standard cephalometric radiograph may reassure the surgeon regarding the thickness of available corticocancellous bone.

Forehead length, hairline adjustment, and other goals of treatment will require the appropriate procedure for rejuvenation of the upper third of the face. The classic coronal lift corrects the eyebrow, forehead, and glabella through a hidden scar in the hairline. Although currently considered to be too large an incision, this technique also moves the hairline

posteriorly and may be inappropriate for patients with a long forehead. Patients with a high hairline/long forehead and eyebrow ptosis may best benefit from the trichophytic technique. This procedure allows the surgeon to shorten the forehead but risks the patient having a visible anterior hairline scar.[93]

Eyebrow asymmetry with or without ptosis can be addressed by using a direct eyebrow lift technique, which has the advantage of a lower incidence of postoperative forehead hypoesthesia. The mid-forehead technique can also be used to raise the eyebrows and correct asymmetry. Both the direct and mid-forehead techniques create a likely risk of a visible scar above the eyebrow or in the mid-forehead, respectively.[94]

The endoscopic forehead and eyebrow lift has gained tremendous popularity because it is minimally invasive in comparison to the coronal and trichophytic operations. Endoscopically, the cosmetic surgeon can correct eyebrow, forehead, and glabellar signs of aging with less hypoesthesia and chance of alopecia. Drawbacks include the need for special instrumentation, a significant learning curve, and minor elevation of the patient's hairline.

As with any surgical procedure, appropriate blood tests and other indicated tests must be performed. The patient should be thoroughly instructed on the critical need to avoid all medications that may cause platelet dysfunction (including aspirin, other nonsteroidal anti-inflammatory drugs [NSAIDs], vitamin E, and many over-the-counter herbal medications) for 14 days prior to surgery.

Treatment Approaches and Techniques

The longevity and minimal morbidity associated with endoscopic forehead and brow lift procedures have made this sought after by patients and an invaluable tool for every facial cosmetic surgeon. However, knowledge of the open techniques is still an absolute necessity for becoming comfortable with the endoscopic technique, as with any minimally invasive procedure. The endoscopic approach is not without limitations, and an open procedure may sometimes be needed to correct the patient's specific complaint (Figures 22-20 and 22-21).

Endoscopic Forehead and Brow Lift Technique

Early attempts at endoscopic surgery began more than a century ago with a crude cystoscope. Nevertheless, modern surgical endoscopy did not gain significant popularity until the 1980s. Endoscopic surgery was begun with upper GI exams, followed by intra-abdominal surgery. Facial endoscopic cosmetic surgery did not really begin until the early 1990s. Yet, over the past 20 years, the endoscopic forehead and brow lift procedure come to be considered by many the state-of-the-art procedure for upper facial rejuvenation. It is predictable and versatile and can be combined with many other techniques. The most notable benefits of the endoscopic technique include smaller scars hidden in the hairline and selective brow elevation without the need for removal of any skin or hair.

Endoscopic techniques require a very dry operating field; thus strict avoidance of medications that can cause platelet dysfunction or excessive bleeding is required, as is proper preoperative injection of vasoconstrictive agents. Prior to administration of anesthesia, five standard photos are taken and the patient is marked while awake and sitting up. After induction of general or IV sedation, the patient is prepped and is injected with local anesthesic with epinephrine. It is the author's preference to administer 1% lidocaine combined with 1:100,000 epinephrine along the entire superior orbital rim, glabella, and lateral orbital rim. Tumescent anesthesia solution (250 mL normal saline mixed with 1 mL 1:1000 epinephrine and 20 mL 2% lidocaine) then is injected into the remaining upper forehead, temple, and posterior scalp. Careful injection into desired tissue planes helps to prevent hematoma formation during injection and allows for a nearly bloodless procedure. Minor shaving of hair along the marked incision lines can be performed if desired immediately before the final prep and drape, but this usually is not necessary.

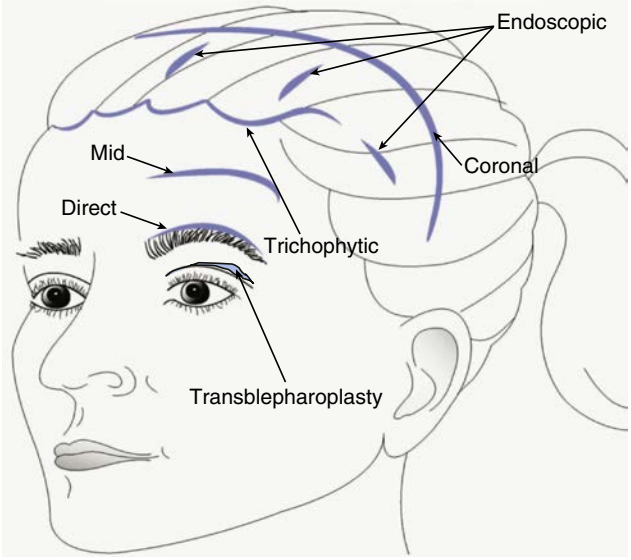

• **Figure 22-20** The different incisions and techniques used during forehead and eyebrow lifting.

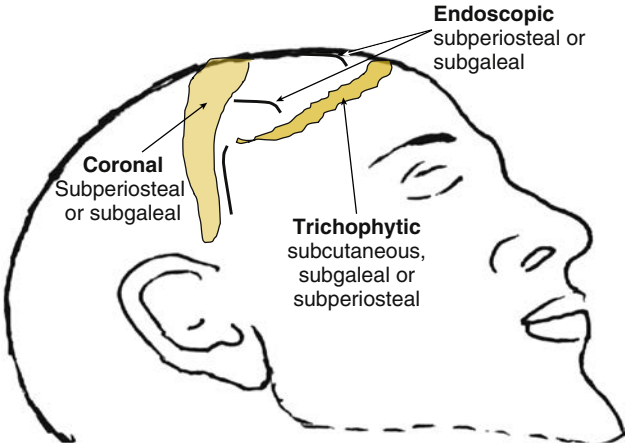

• **Figure 22-21** The different incision techniques and the level of dissection (depth) that can be selected.

The endoscopic technique involves strategic placement of several incisions behind the hairline for access for initial blunt dissection, followed by insertion of the endoscope and the tissue retractor. Other incisions can be used as ports for dissecting tools such as periosteal elevators, electrocautery lasers, tissue graspers, and suction devices. Incision (port) design varies among surgeons. Fixation points usually are placed at these incision sites; therefore, this author prefers to place five separate incisions 3-4 cm in length for easy access and for ideal fixation placement (Figure 22-22). Each of these five begins approximately 1 cm posterior to the hairline. One is placed in the midline of the sagittal plane and two are placed in the parasagittal plane tangential to the lateral third of the brow, where maximum lift is typically desired in females. An incision can be moved slightly more medially for male patients, to attain a more even brow elevation. These three parasagittal incisions are aligned vertically to avoid unnecessary transection of sensory nerves coming from the supraorbital nerves below. The two parasagittal incisions are placed medial to the temporal crest to gain access to skull bone rather than to the temporalis fascia for more secure fixation at this point. It is also important for the clinician to be able to access the subperiosteal plane easily here rather than over the zone of fixation adjacent to the temporal crest, which would make pocket development difficult and would obscure future endoscopic visualization. The location of the parasagittal incision in an area of the frontal bone that is one of the thickest regions combined with a low density of venous lakes helps to prevent accidental intracranial injury during bone tunnel creation or placement of bone screws (Figure 22-23). Finally, two temporal incisions are made—one on each side of the head—for direct access to the thick temporal fascia. These incisions are placed perpendicular to the desired elevation vector from the lateral canthal region. It is a coincidence that the temporal incision ends up paralleling the course of the temporal branch of the facial nerve that is located 2 to 3 cm anterior and inferior to this incision. It also parallels the superficial temporal artery and vein.



• **Figure 22-22** Each of the five incisions for an endoscopic brow lift is typically 3 to 4 cm in length. The three upper incisions are dissected down to bone, and the periosteum is elevated in all directions. One of the parasagittal incisions is shown. No hair is trimmed or removed during endoscopic brow lifting.

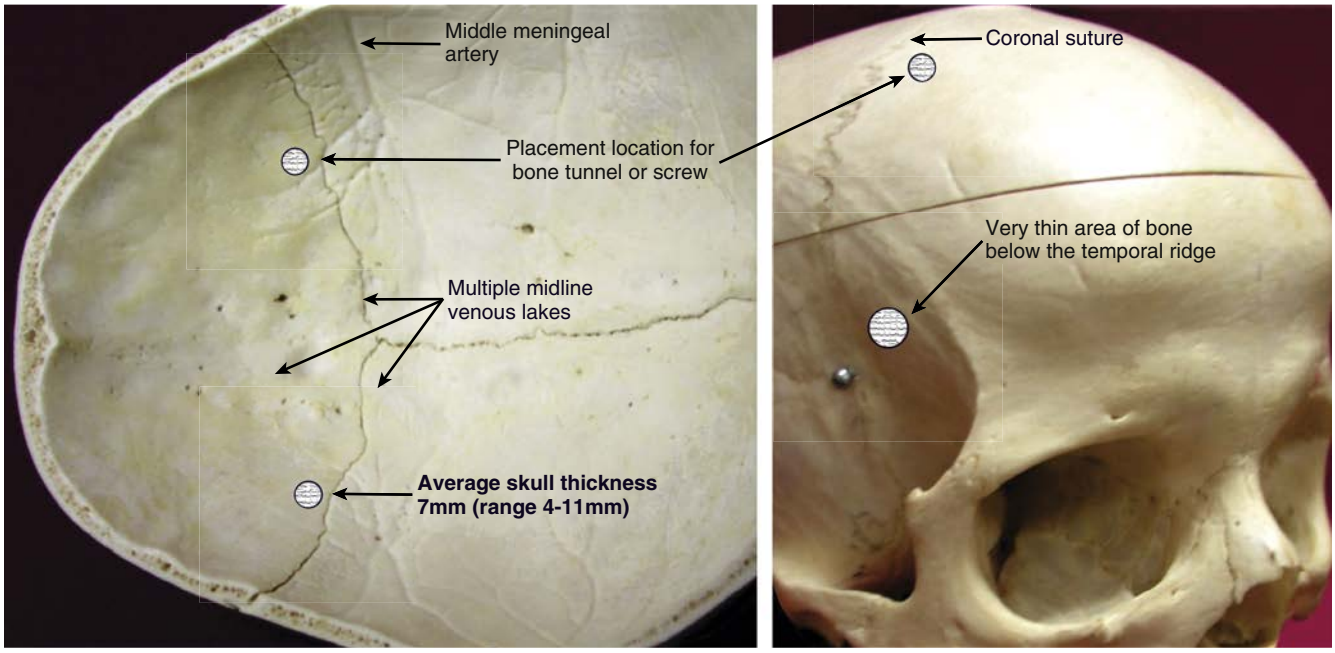

• **Figure 22-23** Bone tunnels are one method of fixation. In the median location the average bone thickness is 7.5 mm with a range of 4.7 to 13 mm, however at this location there are many lacuna lateralis (i.e., venous lakes). A parasagittal bone tunnel can be created near the coronal suture where the bone is also thick (average 7.0 mm, range 4.1 to 11 mm) but free of venous lakes and allows safe placement of a shallow tunnel. A secure galeal suture is plicated from the hairline below to the bone tunnel above.

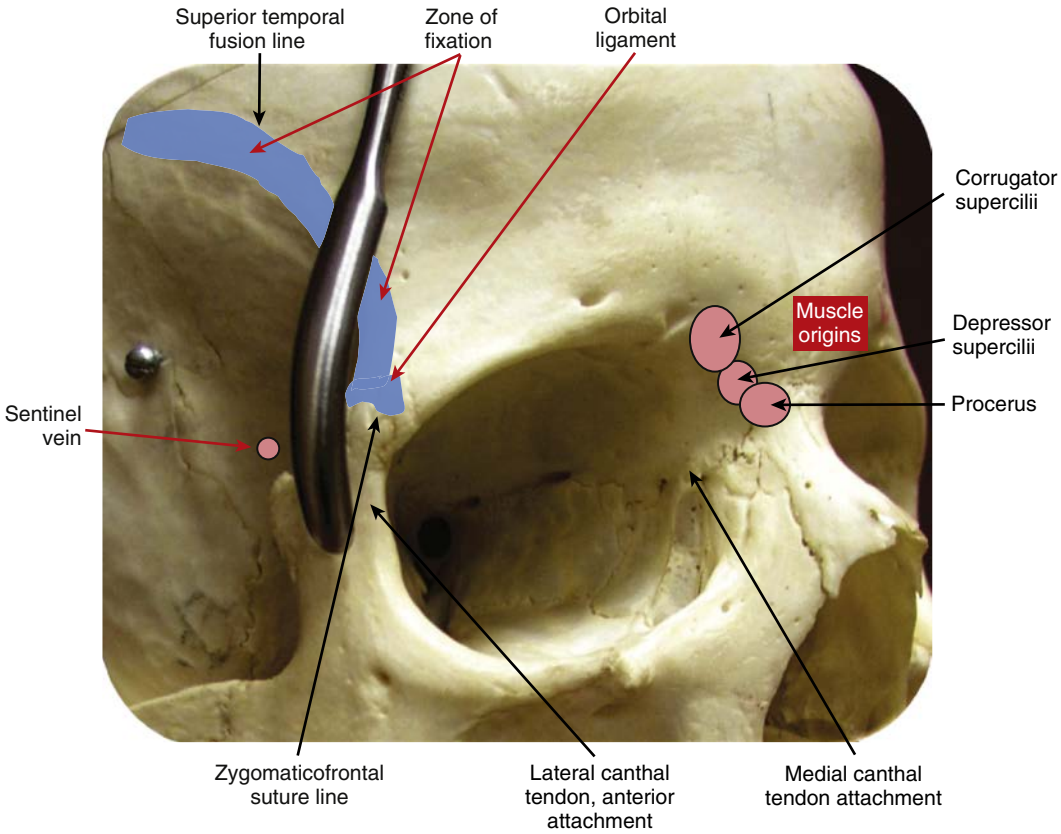

• **Figure 22-24** A smooth and curved periosteal elevator is used to release the periosteum over the superior orbital rims bilaterally, as well as in the nasofrontal area. The dissection should be bimanual while keeping the nondominant hand over the patient's face to control the tip of the elevator. The dissection should be carried laterally over the lateral orbital rim and the zygomatic bone to release the lateral orbital ligament.

Dissection is performed through the above incisions, down through the periosteum medial to the temporal crest, and down to the temporalis fascia lateral to the crest (some surgeons may elect the subgaleal rather than the subperiosteal medially). Many surgeons, including this author, believe that total subperiosteal dissection medial to the temporal lines rather than subgaleal dissection leads to better fixation and long-term stabilization.[42-60]

Blunt and blind dissection can be carried out after the subperiosteal and subtemporoparietal planes are reached through the five incisions. Finger dissection and long curved endoscopic periosteal elevators are used to elevate the tissue anteriorly to a point 2 cm above the orbital rims and the zygomatic arch. A smooth and curved periosteal elevator is used to release the periosteum over the superior orbital rims bilaterally, as well as in the nasofrontal area. The dissection should be bimanual while keeping the nondominant hand over the patient's face to control the tip of the elevator (Figures 22-24 and 22-25).

Posteriorly, blunt dissection should elevate the temporal tissues to a few centimeters behind the ear, where the temporal fossa becomes self-limiting. Subperiosteal dissection must elevate the scalp at least 10 cm posteriorly but can go back as far as the lambdoid suture. Once these areas have been freed, a connection can be made from the temporal region to the subperiosteal dissection through the upper portion of the zone of fixation at the temporal crest by finger dissection.



• **Figure 22-25** Intraoperative image demonstrating how the subperiosteal dissection is tunneled over the lateral orbital rim into the malar prominence. The elevator is used through a parasagittal incision just behind the hairline. Release below the frontozygomatic suture line into the cheek is critical. The globe is protected at all times.

Avoid blind release of the more inferior portion of the temporal line where the facial nerve crosses because endoscopically guided dissection here will help to prevent nerve injury.[61-63] Breaking through the upper zone of fixation via finger dissection proceeds from the temporal incision toward the medial scalp rather than vice versa, to prevent creation of a false tunnel in the spongy-appearing temporoparietal fascia. False tunnels along the temporal crest create problems

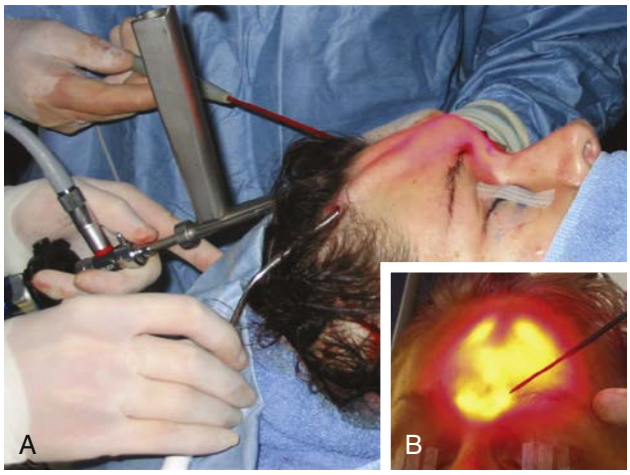

• **Figure 22-26** **A,** The three ports are used in conjunction for ease of movement of the endoscope, the cautery or laser, and the suction cannula. **B,** The *inset* depicts the thin layers of the brow as illustrated by the transillumination from the lighted endoscope. Care must be taken to avoid excess trauma from heat, trauma from retraction, and overzealous tissue thinning.

when the endoscope is inserted through the parasagittal port to visualize the lateral forehead. This places the surgeon in a more superficial plane within the temporoparietal fascia and greatly increases the chances of nerve injury. As described earlier, this layer contains the superficial temporal artery and the frontal branch of the facial nerve. The importance of staying directly against the periosteum and temporalis fascia during the initial elevations cannot be emphasized enough.

Following blunt elevation of the scalp from all incision ports, the endoscope is inserted usually through one of the three more medial incisions (Figure 22-26). Poor initial blunt dissection will make the initial endoscopic dissection feel very tight, and care must be taken not to perforate the skin through excessive retraction. Medial dissection is performed down over the nasofrontal suture and the orbital rims under direct endoscopic vision with a curved and smooth rounded elevator to avoid inadvertent tearing of the periosteum. The periosteum may be thin in some patients; a straighter elevator may be used to tear through the periosteum at the level of the rim. However, the entire rolled edge of the orbital rim must be seen, and typically, the periosteum is more precisely incised via needle tip cautery or laser (Figure 22-27). Of course, the area in front of the supraorbital nerves and vessels as described earlier is at a level tangential with the medial limbus and is immediately behind the periosteum; thus cautery dissection must be performed carefully to avoid injury to these structures (Figure 22-28). Cauterization should also be done bimanually because of the relatively small distance that the cautery has to travel to get through the skin, especially in the glabellar area and nasofrontal junction. Periosteum release should be performed 1 to 2 cm above the rim in the area of these nerves to decrease major nerve trunk transection. The three ports are used in conjunction for ease of movement of the endoscope, the cautery, and the suction cannula. The temporal incisions can be very helpful as suction ports if the medial ports are too occupied with the endoscope and the cautery device. With clear and near bloodless dissection at this point, cautious transection can be performed through the corrugator supercilii muscles and the procerus. If unwanted bleeding is encountered and cannot be controlled easily with pinpoint accurate cautery, then pressure should be applied externally over the rim until improved visualization allows for control of bleeding without nerve damage.

Vertical rhytids in the glabella created by the corrugators can be improved greatly by transection through the corrugator muscles. Likewise, horizontal glabellar lines are treated by transection of the procerus muscle, which creates these particular facial wrinkles or "bunny lines." Subconscious horizontal rhytids can also be treated by appropriate blepharoplasty or brow lift techniques (Figure 22-29). Some surgeons recommend more aggressive surgical avulsion of these muscles with endoscopic biopsy forceps.[64-76] Aggressive muscle removal may lead to more permanent treatment of glabellar lines than is attained with isolated transection only, but this approach should be avoided in most cases because of the increased risk of significant postoperative irregularities and abnormal facial expression. As a rule, patients prefer a more natural appearance with some minor return of frown line expression over risking a bizarre facial expression and glabellar depression from atrophic fibrosis.

Once the periosteum has been completely freed across the orbital rims and appropriate muscles have been treated, the cut periosteal edges are spread apart (periosteal elevators work well for this) by at least 1 cm to facilitate release at the arcus marginalis. Adequate tissue release is critical for significant and long-term brow elevation. Next, the lateral orbital rim must be exposed in the subperiosteal plane after careful release below the zone of fixation and orbital ligament. Dissection must be performed warily along the anterior and inferior aspects of the temporal crest to avoid temporal nerve injury. The dense tissue here that contains the nerve can produce nerve damage through overzealous retraction alone. Staying tightly against the periosteum and the temporalis fascia helps to prevent nerve damage and produces clean and bloodless dissection. Slowly creating a distinct plane of dissection down just past the zygomaticofrontal suture line and avoiding excess retraction helps to prevent unwanted bleeding from the sentinel vein (medial zygomatico-temporal vein). The sentinel vein as previously described in the anatomy discussion need not be sacrificed for a customary endoscopic forehead and brow lift.

Dissection for a standard endoscopic brow lift also need not proceed all the way to the zygomatic arch but can stop approximately 1 cm above this level. If an extended midface lift is planned and elevation of tissue over the zygomatic arch itself is the goal, then dissection must be performed below the superficial layer of the deep temporal fascia above the arch. Abbreviated mid-face lifts performed simultaneously with endoscopic brow lifts may simply be confined to the subperiosteal plane along the lateral orbital rim and are much less risky than a full arch release (Figure 22-30). The

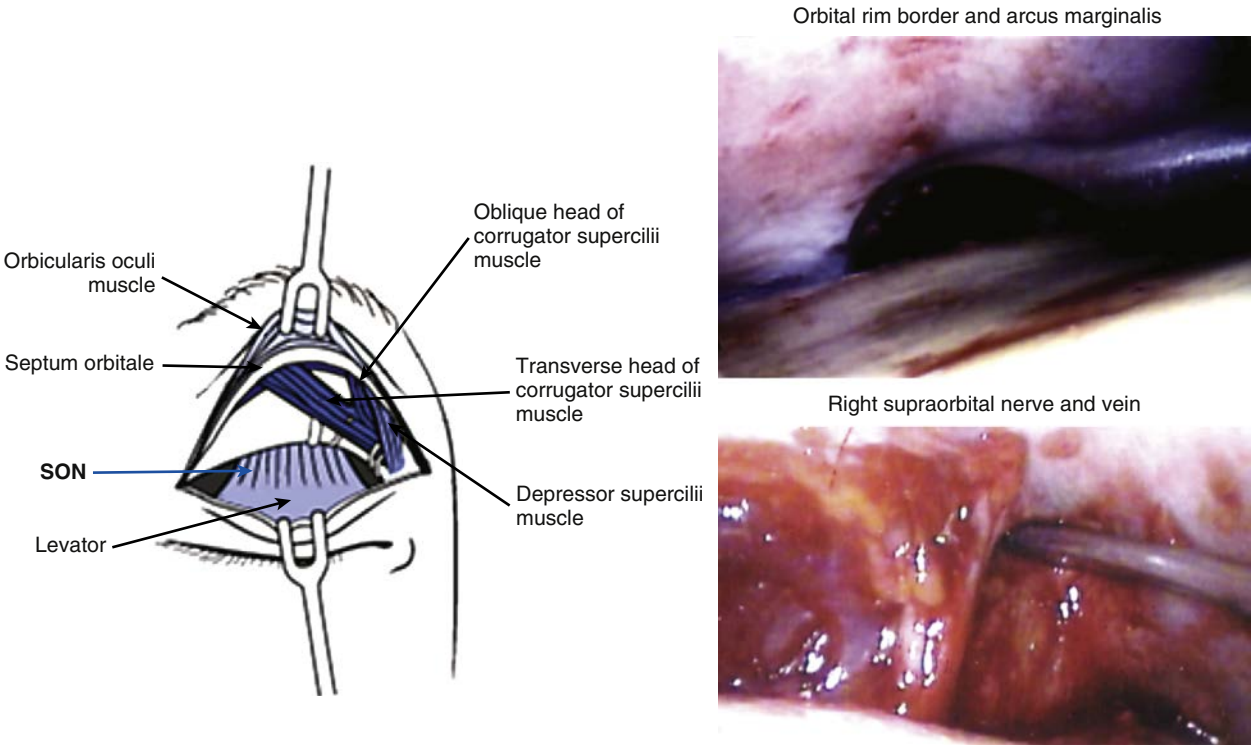

• **Figure 22-27** Right side endoscopic view of the close relation of the supraorbital nerves and the corrugator.

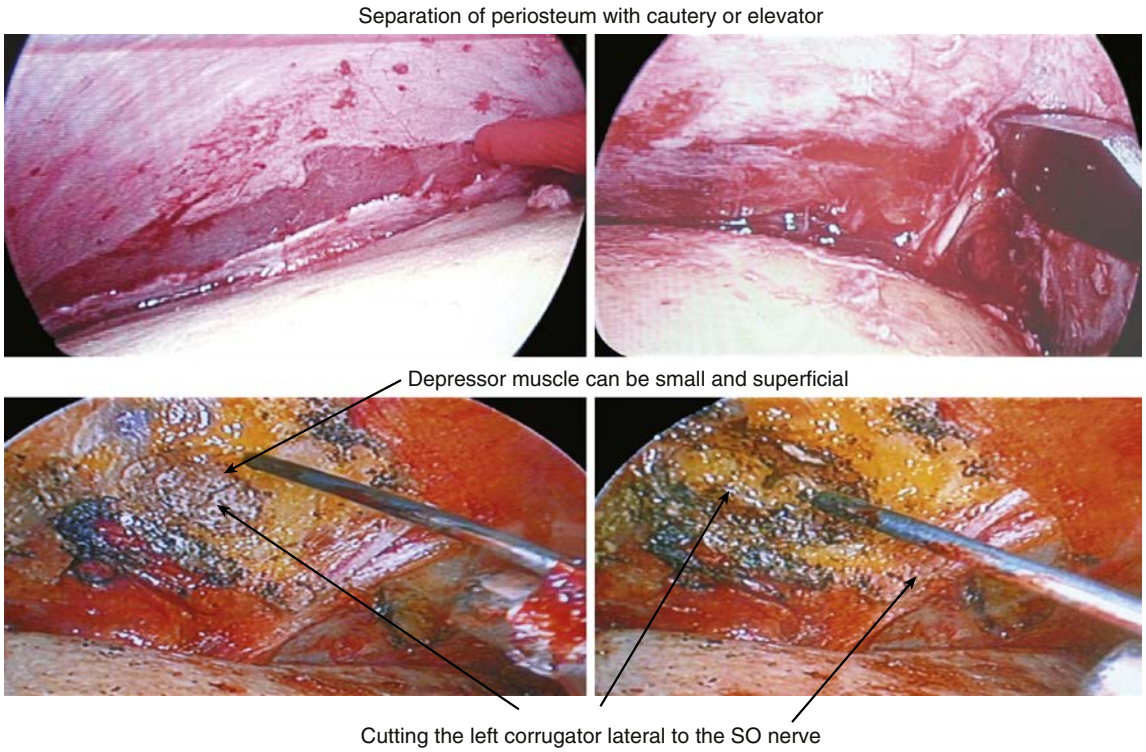

• **Figure 22-28** The photos demonstrate an endoscopic view of the left forehead. Close relationship between the left corrugator muscle and the supraorbital nerve. The belly of the corrugator lies superficial to the supraorbital nerve both medially and laterally. The lateral belly is often more challenging to find and transect compared to the medial belly.



• **Figure 22-29** Dermatochalasis or brow ptosis can lead to constant subconscious frontalis activity that gives rise to deep horizontal forehead wrinkles. The two patients shown had different surgical techniques performed (blepharoplasty in **A** and brow lift in **B**), yet the resulting removal of laxity over the eye caused the patient to subconsciously quit raising the eyebrows and improved the forehead wrinkles. The brow lift patient saw a more profound improvement in these subconscious forehead lines.

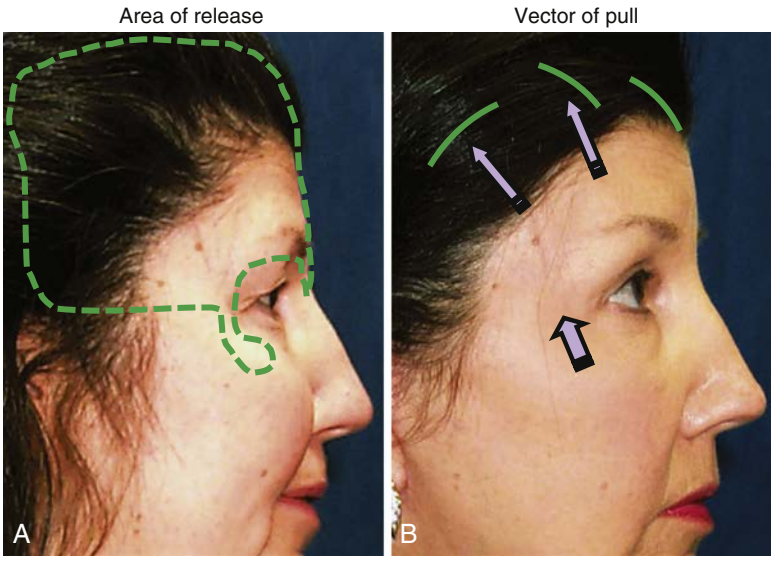

• **Figure 22-30** Before **(A)** and after **(B)** images of endoscopic forehead, brow, and mid-face lift show a lateral view of the area of subperiosteal release and the vector of pull involved in the procedure.

beauty of the classic endoscopic brow lift is its adaptability and the ease with which simultaneous additional procedures can be combined with this eloquent cosmetic surgery. For instance, the temporal incision of an endoscopic forehead lift can easily be extended inferiorly to blend with the preauricular incision from a standard lower face-lift. Also, mid-face lifting (with intraoral dissection) can connect the intraoral subperiosteal dissection over the maxilla and the zygoma to the subperiosteal plane from the endoscopic brow lift through a tunnel near the lateral orbital rim.

After all dissection has been completed, appropriate elevation and fixation are required. Many techniques, such

as tissue suture only, bone screws and plates, resorbable screws, bone tunnels, local skin excision, temporalis muscle exposure for added scarification, tissue glue, and tight head wraps, have been described. Regardless of the specific fixation technique chosen, successful long-term fixation is likely dependent on adequate lower forehead tissue release during endoscopic dissection. Failure to adequately release internal forehead tissues will result in relapse in brow ptosis, even with heavy fixation and the appearance of a "nice" lift during surgery (Figures 22-31 to 22-33).

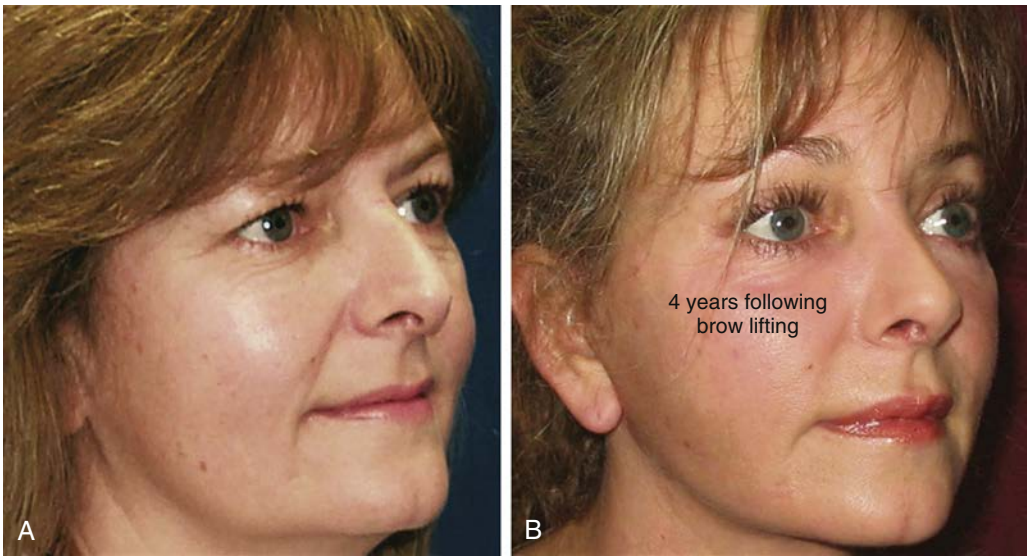

• **Figure 22-31** A 51-year-old woman before **(A)** and 4 years following **(B)** endoscopic brow lift and upper blepharoplasty. Her lid laxity required upper blepharoplasty after elevation of the eyebrows. The long-term results are seen and are most related to proper tissue release versus the type of fixation used.



• **Figure 22-32** **A,** A 55-year-old woman before and 7 years after an isolated endoscopic brow lift procedure. **B,** A 48-year-old woman before and 5 years after endoscopic brow lift combined with a mid-face lift. Both patients have a low hairline along with a very low lateral brow position, which makes them ideal candidates for an endoscopic brow lift.

Once complete internal release of the forehead has been attained, specific lifting vectors for the most pleasing esthetic effect are determined. The lateral one third of the female brow is elevated to the greatest extent, which can be up to 1 cm above the orbital rim. The medial brow should be only slightly above rim level and absolutely below mid-brow and lateral brow levels to avoid a surprised or bewildered expression. Typically, the glabellar region is elevated without the need for midline fixation, which helps to avoid excessive elevation medially. The lateral third of the brow is lifted straight up and can be fixated at the level of the hairline. The galeal tissue is typically secured to bone at this point while the lateral brow is held at the desired height or a few millimeters above the desired level.[77-81] Very little relapse occurs with proper technique—on average, only 1 to 2 mm of lowering after 2 weeks.[1,4,7] Measurements also can be taken with clear circular templates from pupil to brow, to help improve symmetry. Brow position remains very stable following the first few weeks of tissue edema resolution. The time required for complete fixation of the periosteum is not known, but tissue adhesion certainly begins in the first few days after surgery. Various animal studies suggest that a full 12 weeks is required for occurrence of what is called *full histologic periosteal refixation*. An example is the common fixation technique used by many surgeons who place a single transcutaneous bone screw at each parasagittal incision that is removed after only 1 week. The 1-week fixation technique has been used with success for many years. Some suggest that longer bony fixation may provide longer-term retention and less early relapse. Still, long-term fixation appears to be determined most often by proper tissue dissection and release, rather than by a specific fixation technique (Figure 22-34).[1,4,7]

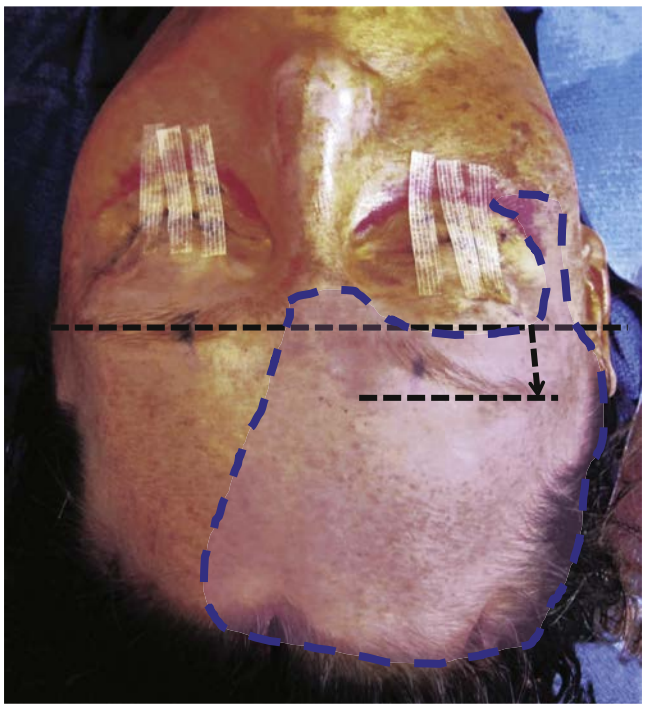

• **Figure 22-33** This image depicts the amount of brow elevation that is achieved on the patient's right side with adequate internal release and transection of the brow depressors. No fixation has been performed on the right side as compared to the untreated left side. The most crucial component of a good long-term result is adequate tissue dissection and proper fascial release rather than any specific fixation technique.

Although many fixation techniques are available, this author prefers bone tunnels at the parasagittal incisions to fixate the galea and the periosteum near the hairline to a bone tunnel created a few centimeters posterior to the hairline under the incision with a single heavy suture such as 0 Nurolon or 0 Vicryl (Figure 22-35). Fixation of the lateral tail of the brow is performed at each temporal incision, where an isolated heavy suture plicates the temporoparietal fascia in a posterior and superior vector to the temporalis fascia. Optional creation of a small window of exposed temporalis muscle in this area may facilitate internal scar formation and fixation. The vector of lift at this outer tail of the brow follows a line drawn at an angle from the outer nasal ala that passes just beside the lateral canthus. The most critical component of long-term result is emphasis on adequate periosteal and ligamentous release along the lateral canthus.

Final closure of hair-bearing scalp incisions can be performed with skin staples alone with excellent scar formation, because no skin is excised and no pressure exists at the incision sites. Redundant tissue (forehead skin) created



• **Figure 22-34** The horizontal line demonstrates the new and stable brow position on a 47-year-old woman following an endoscopic forehead and brow lift procedure combined with a mid-face lift. The patient also had upper and lower blepharoplasty performed along with lower laser resurfacing. The key to a good long-term result is adequate tissue dissection and proper fascial release rather than any specific fixation technique. **A,** Preoperative appearance. **B,** Six days after surgery. **C,** Two weeks after surgery. **D,** Two months after surgery. **E,** One year after surgery. **F,** Five years after surgery. **G,** Eight years after surgery.

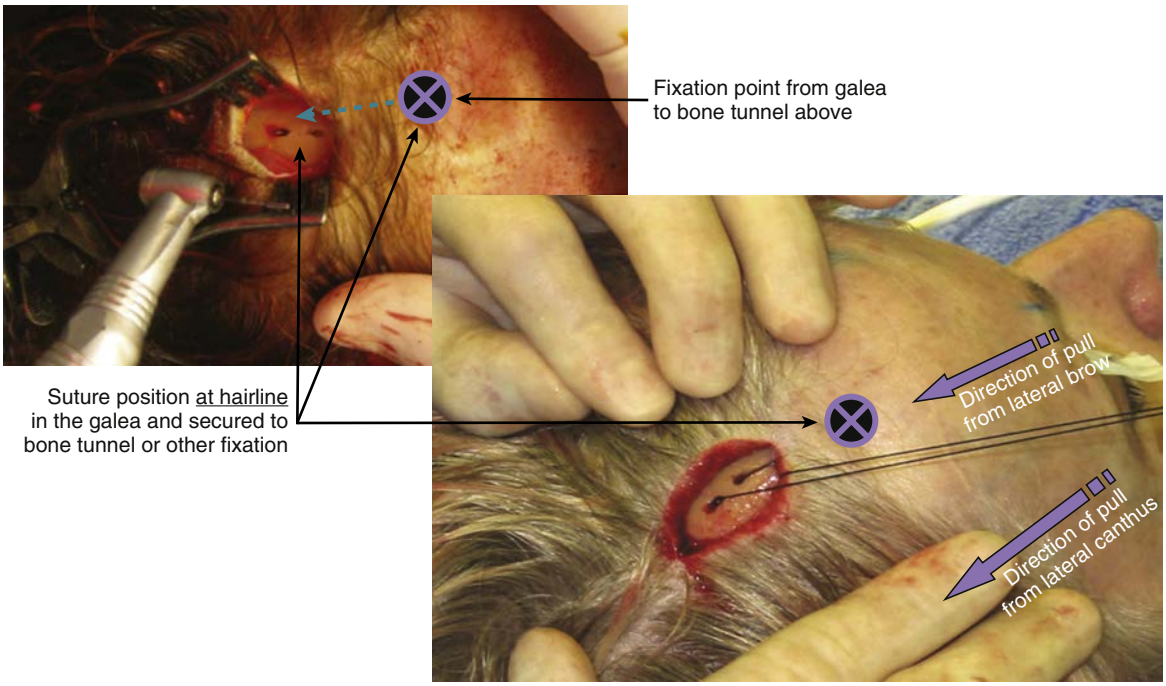

• **Figure 22-35** Bone tunnel at right parasagittal incision and suture fixation with a single heavy suture (0 Nurolon or 0 Vicryl). A thick "bite" galea at the level of the hairline is needed to secure the final location of lateral brow elevation. A poor or thin amount of tissue in this single suture could lead to unwanted release and asymmetry a few hours or days later.

by an average of 1 cm of brow elevation is easily distributed evenly over the posterior 10 to 20 cm of elevated scalp, which essentially absorbs or redistributes this excess tissue with few to no signs of bunching, provided adequate posterior elevation of the scalp was performed (Figure 22-36). Because of this phenomenon, the endoscopic forehead and brow lift tends to merely elevate the hairline a very small amount compared with the open skin-excising coronal technique. No drains typically are required for the endoscopic technique (Figures 22-37 and 22-38).

Coronal Forehead and Brow Lift

The coronal lift technique involves an incision across the hair-bearing scalp approximately 4 to 5 cm behind the hairline and extending from ear to ear. This line can also be connected to a regular face-lift incision at the superior helical attachment of the ear. Dissection is carried down to the subgaleal or subperiosteal level and elevated to the level of the superior orbital rims and laterally into the subtemporoparietal plane. Correction of any forehead deformity can be addressed with the wide coronal exposure. Deep forehead creases can be reduced with a midline frontalis myotomy, whereas glabellar lines are corrected by transection or resection of the exposed depressor muscles of the eyebrow. Visualization of the supraorbital and supratrochlear nerves is an advantage of this exposure and reduces the risk for injury.

Additionally, bone deformities can be corrected with this approach. This lift can be a great operation for patients with a short forehead (<5 cm), but it can be a significant drawback in those with a normal or long forehead since it elevates the hairline even further. Excision of excess scalp skin is performed after accurate measurement and redraping of the forehead flap. The documented rough estimate is that 2 cm of scalp must be excised for every 1 cm of brow elevation. As mentioned earlier, this approach can be used for access to the mid-face, but care must be taken to not injure the frontal branches of the facial nerve. This procedure exposes an enormous surgical field and can therefore be a great technique for inexperienced surgeons. It should be kept in mind that other than elevation of the hairline, this procedure has an increased risk for alopecia, persistent scalp numbness, longer operative time, and excessive blood loss, and results in a long scar.[47]

Trichophytic and Trichophylic Forehead and Brow Lift

The trichophytic (transfollicular) lift can be the procedure of choice when it is desirable to shorten the forehead or avoid displacement of the hairline (Figure 22-39). A trichophytic (hair loving) incision is made just behind the frontal hairline, whereas a trichophylic incision is made in front of the hairline. A modified version of the trichophytic incision can avoid an unsightly scar by making an irregular incision with an extreme bevel from posterior to anterior beginning 4 to 5 mm posterior to the hairline at an area where the follicular density becomes consistent. The extreme bevel of



• **Figure 22-36** Images **A** and **B** depict the connected subperiosteal plane of the transblepharoplasty and endoscopic brow lift procedures. Image **C** illustrates the amount of brow lift and skin laxity that can be achieved with adequate release. Forehead flap redundancy disappears by redistribution over the posterior 10 to 20 cm of occipital periosteal elevation. This redistribution accounts for the acceptable minimal raising of the hairline.

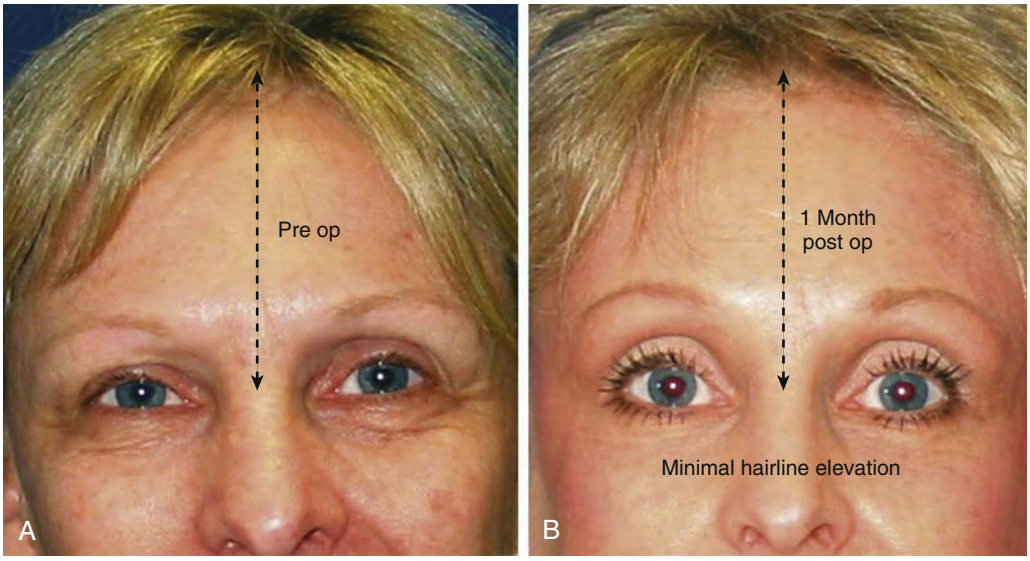

• **Figure 22-37** A 53-year-old woman before **(A)** and 1 month following **(B)** an isolated endoscopic brow lift procedure. Hairline elevation can occur following an endoscopic brow lift but is typically minimal, particularly when compared with an open coronal lift, which requires scalp excision and subsequently raises the hairline significantly. No frontalis myotomies are required during the endoscopic procedure.

the incision preserves the hair follicles on the superior flap allowing hair growth both through, and anterior to, the scar postoperatively. This technique allows the same excellent exposure that the coronal method provides and has the ability to lower a high forehead or prevent raising it, although limited lateral dissection is usually encountered. Direct visualization of the brow depressor muscles and the associated nerves is gained as with the coronal exposure. Subgaleal or subperiosteal elevation can be used with this method, although a subcutaneous technique is performed



• **Figure 22-38** A 53-year-old woman 1 week after endoscopic forehead and brow lift *(right)* depicting the typical edema and ecchymosis. This short recovery period is another potential advantage of endoscopic brow lifting techniques.

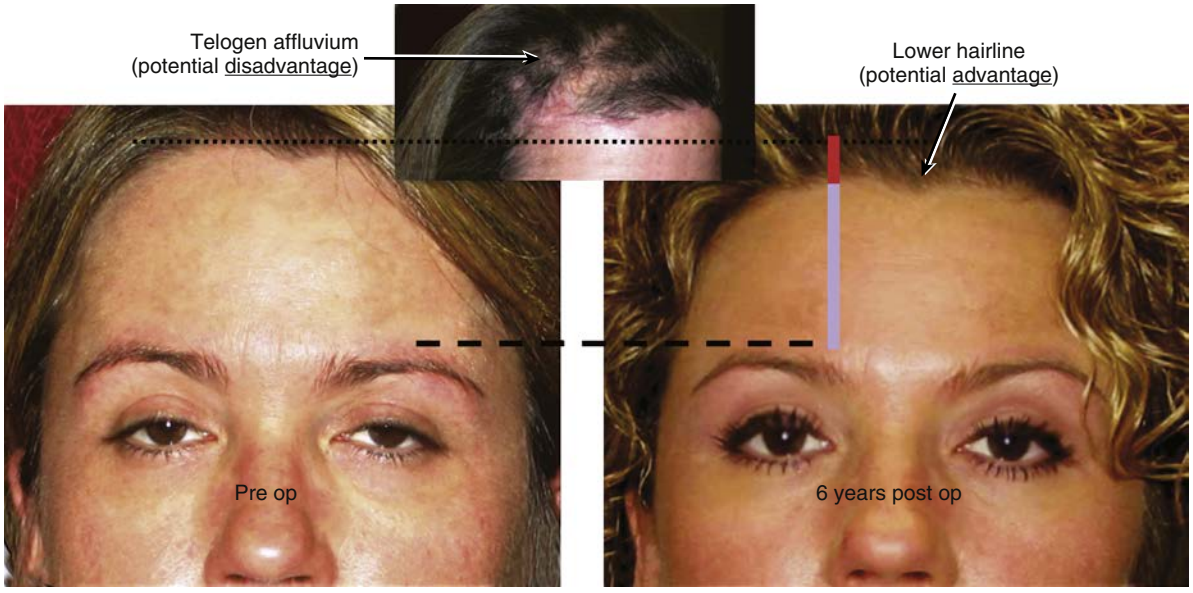

• **Figure 22-39** The patient shown had a classic trichophytic brow lift without any early problems. However, a potential disadvantage of this procedure is severe alopecia (hair loss) known as telogen effluvium, which developed approximately 2 months following surgery. The patient had complete healing with time. The only treatment was early low-dose steroid injections and minor topical hair growth medication usage. Fortunately, most cases resolve spontaneously. The potential advantage of a trichophytic brow lift is lowering of the hairline. The scar is well hidden and is barely visible at 6 years post op.

more often. Subcutaneous dissection elevates the dermal attachments, releases the deep horizontal creases, and also adds the advantage of reducing posterior scalp sensory loss (Figure 22-40).

The trichophytic and trichophylic methods are ideal for patients with heavy forehead rhytides, low brow position, or a high forehead.[95] However, patients are discouraged by the visible scar and distorted hairline associated with this technique. As a result, most will opt for the endoscopic approach even if it involves raising the hairline.

Direct Brow Lift

A direct brow lift is considered the simplest of the different approaches to raising the eyebrow. An elliptical skin excision is made just above the superior edge of the eyebrow. The authors' preference is to create a beveled incision to allow some hair follicles to grow over the incision. Dissection is continued in a subcutaneous plane to avoid nerve and vessel injury. Electrocautery is then used to excise the ellipse of tissue.



• **Figure 22-40** **A** and **B,** The tricophytic brow lift is an excellent option for patients with a high forehead that requires lowering. The scar fades over months and is hidden by hair. **C,** The *blue line* represents a modified version of the trichophytic incision and involves a beveled incision to cover the scar with hair follicles, as well as creation of a wavy incision to prevent a linear scar. **D,** The *shaded area in yellow* is actual skin excised with the trichophytic technique and the *shaded area in purple* is the area of subcutaneous elevation.

This type of brow lift is simple and can easily be done with local anesthesia. It can also correct brow asymmetry. Its main disadvantage is the potentially visible scar, although for an elderly patient with heavy wrinkles and thick eyebrows, this could be the procedure of choice.[96]

Mid-Forehead and Brow Lift

This technique involves mid-forehead and upper forehead elliptical incisions, with the edges and resultant scar lying inside a horizontal forehead crease. Dissection can be carried down to the corrugator and procerus muscles as indicated and allows skin release with excision of excess skin. This is probably the least used of all techniques, but it should be considered when dealing with an elderly patient who has thin eyebrows and deep horizontal rhytides.[97]

Transpalpebral/Transblepharoplasty Brow Lift

Blepharoplasty can be performed in conjunction with any of the brow lift procedures described if indicated. For example, a simple and direct brow lift can be done through a blepharoplasty incision (see Figures 22-36 and 22-41). Dissection can easily expose the corrugator supercilii, the procerus, and the depressor supercilii, each of which can be transected for elevation of the medial eyebrow and reduction of glabellar lines. However, this approach can only address the lateral brow with a minimal lift (Figures 22-42 and 22-43). The orbicularis oculi can also be treated to address the patient's crow's feet and give the patient "surgical botox" (Figure 22-44).

As mentioned earlier, eyebrow ptosis may be accompanied by dermatochalasis of the upper eyelids, as well as the lower eyelids. Fat pad prominence, orbicularis oculi hypertrophy, and lacrimal gland descent can also make eyelid surgery necessary, with or without forehead and eyebrow lifting. Details regarding eyelid surgery are discussed more extensively elsewhere in this book and should be considered part of one's upper face rejuvenation practice. The supraorbital nerve must be considered with any approach. The location can easily be determined preoperatively.

Adjunctive Procedures

Autlogous Fat Transfer

Facial fat grafting is particularly useful for improving orbital and temporal hollowing, as well as for camouflaging infraorbital rim exposure by malar fat ptosis. Facial lipoatrophy is a common finding in patients seeking facial rejuvenation and autologous fat grafting has become a very popular adjunct to facial cosmetic surgery.

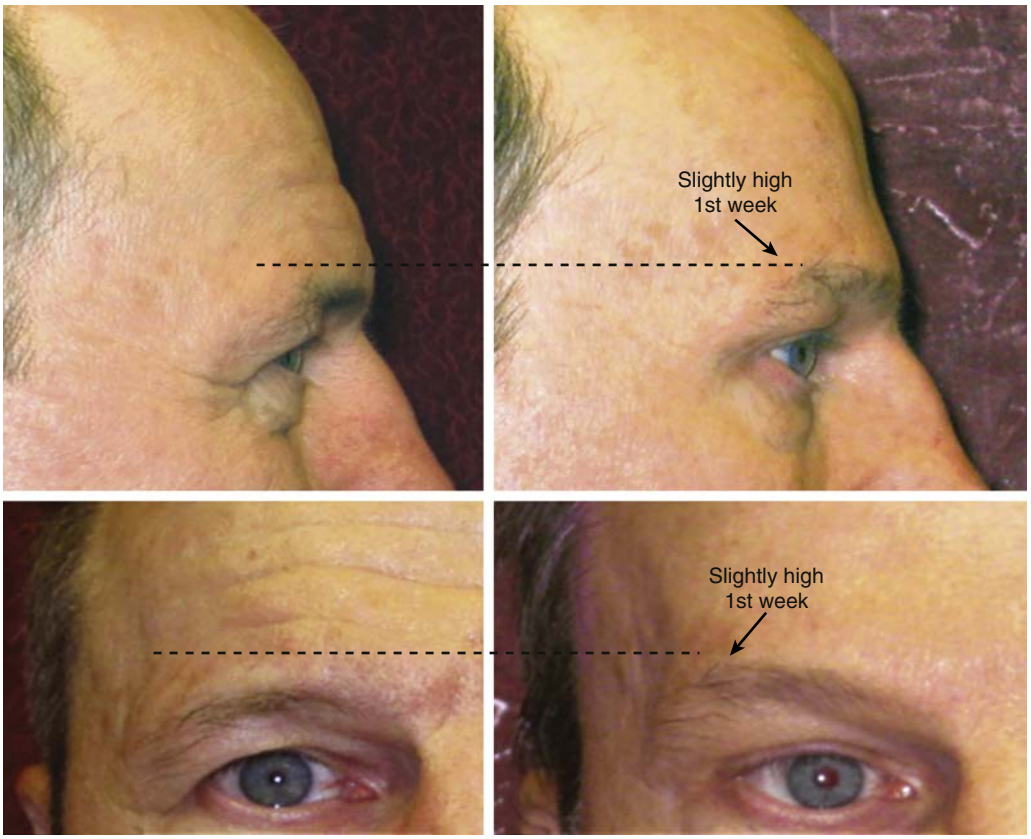

• **Figure 22-41** The male patient shown has classic male pattern baldness and therefore is not an ideal candidate for a typical brow lift. He is shown before and after a combined transblepharoplasty and endoscopic brow lift. His brow position is a few millimeters high at 1 week post op but the position will drop a few millimeters to a more ideal position over the next 6 weeks.

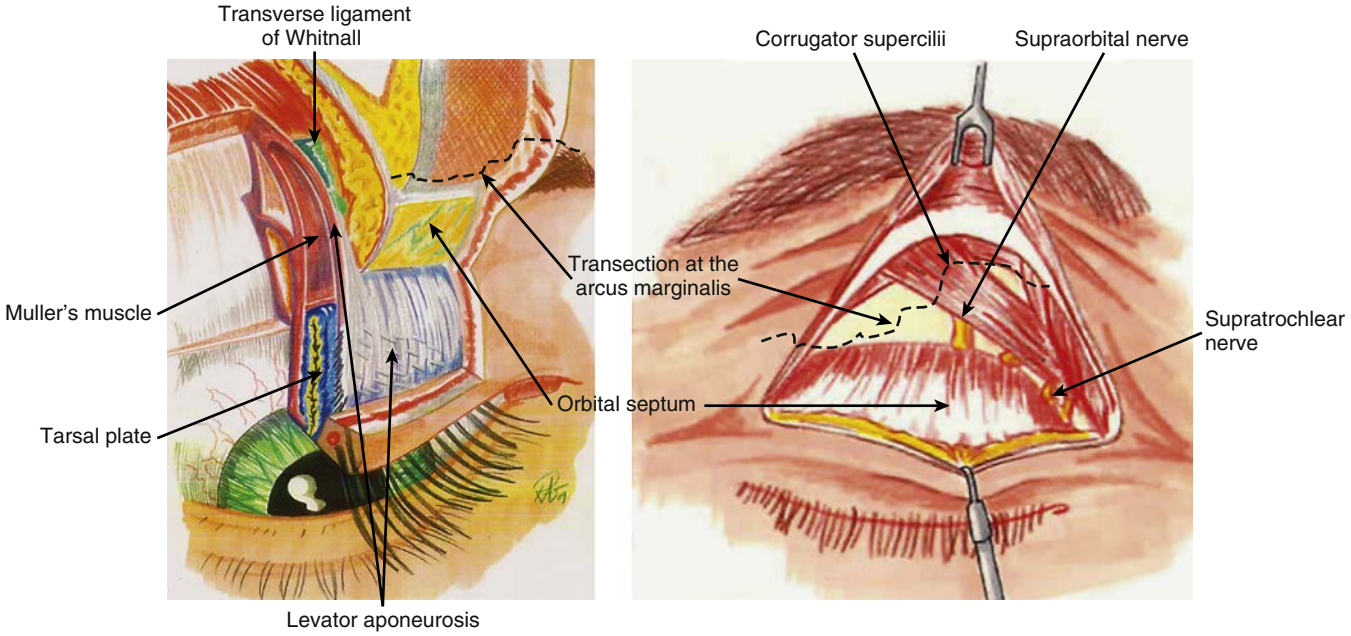

• **Figure 22-42** Right upper eyelid and frontal bone. Release of the corrugator and arcus marginalis can be accomplished from the blepharoplasty incision, but care must be taken to avoid injury to the supraorbital nerve, which runs through the muscle. Transecting periosteum and muscle 1 to 2 cm superior to the arcus in the area of the supraorbital nerve as shown lessens the chance of full nerve trunk injury.

Blepharoplasty with direct brow elevation suture

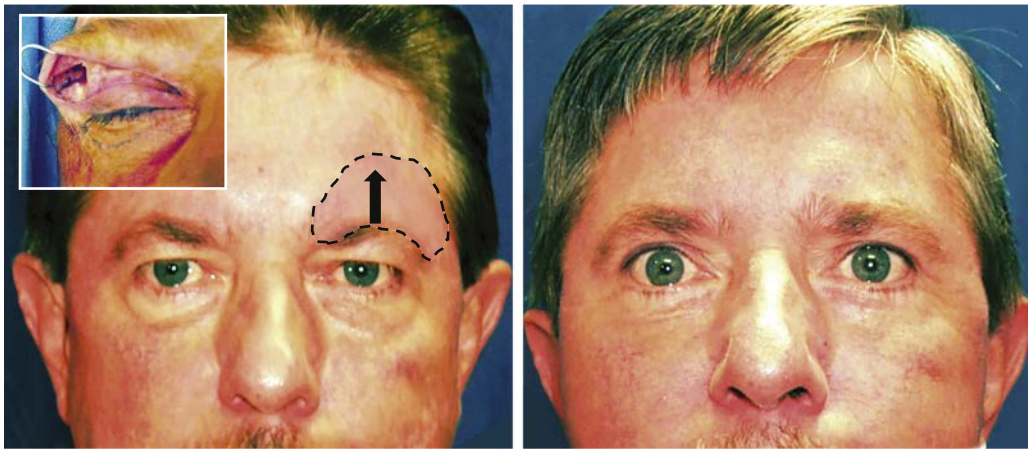

Blepharoplasty is most appropriate but minor brow elevation helps outcome

• **Figure 22-43** A 57-year-old man shown before, during, and after a transblepharoplasty direct internal brow lift procedure. Despite major release, only a 1- to 2-mm increase in brow elevation should be expected from this simple but limited procedure.

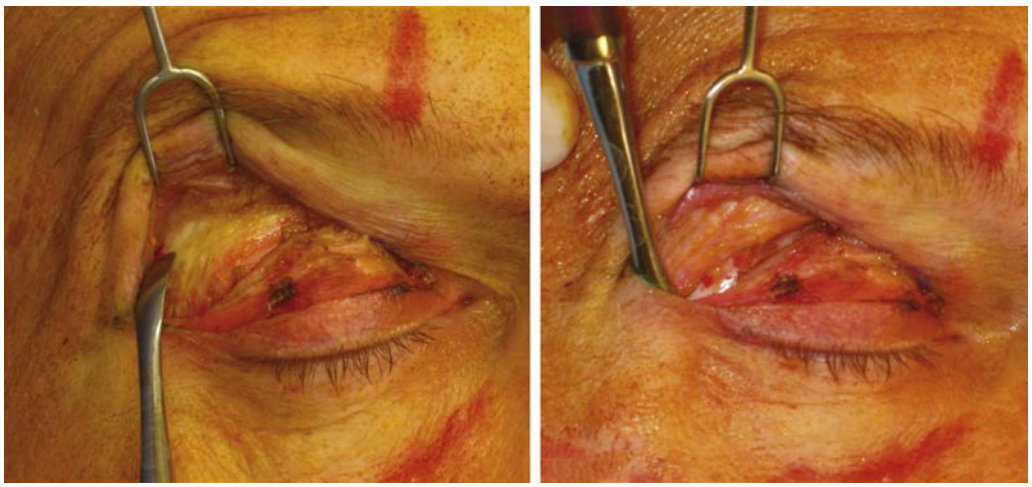

Male transblepharoplasty brow lift

• **Figure 22-44** Release and partial transection of the lateral orbicularis oculi (O.O.) can give the patient "surgical Botox" for the crow's feet. The resection of lateral depressor muscles (O.O.) allows the frontalis to lift the outer brow a few millimeters. The dissection shown extend 1 to 2 cm above the eyebrow along periosteum.

Neurotoxin-Assisted Brow Lift

Neurotoxin has proved to be very effective in reducing visible fine lines and wrinkles of the aging face. With regard to the upper third of the face, reduced frontalis activity, glabellar lines, and lateral orbital crow's feet are all particularly exceptional areas to be treated. Focusing the injections on the depressor muscles with subsequent unopposed frontalis elevation can lead to brow elevation, hence obtaining a "chemical brow lift."

The use of neurotoxins has also been theorized to help in stabilizing the forehead flap elevated during forehead lifting. Injecting the depressor muscles 1 to 2 weeks before surgery is thought to reduce depressor muscle activity postoperatively, which allows the forehead to remain lifted and reduces early postoperative relapse.

Temporal Implants

Temporal augmentation procedures with the use of synthetic injectable fillers and autologous fat transfer are popular among patients seeking upper facial rejuvenation. To adequately augment the temporal region a large amount of synthetic filler is typically needed and most will eventually dissolve. Fat grafting can be performed as a longer lasting option, however the longevity can be unpredictable.

Temporal implants are soft, flexible, made of silicone, and offer the patient a permanent correction for temporal hollowing. The implants can easily be placed through an existing temporal incision if an endoscopic approach is being performed. An incision is made in the temporalis fascia and

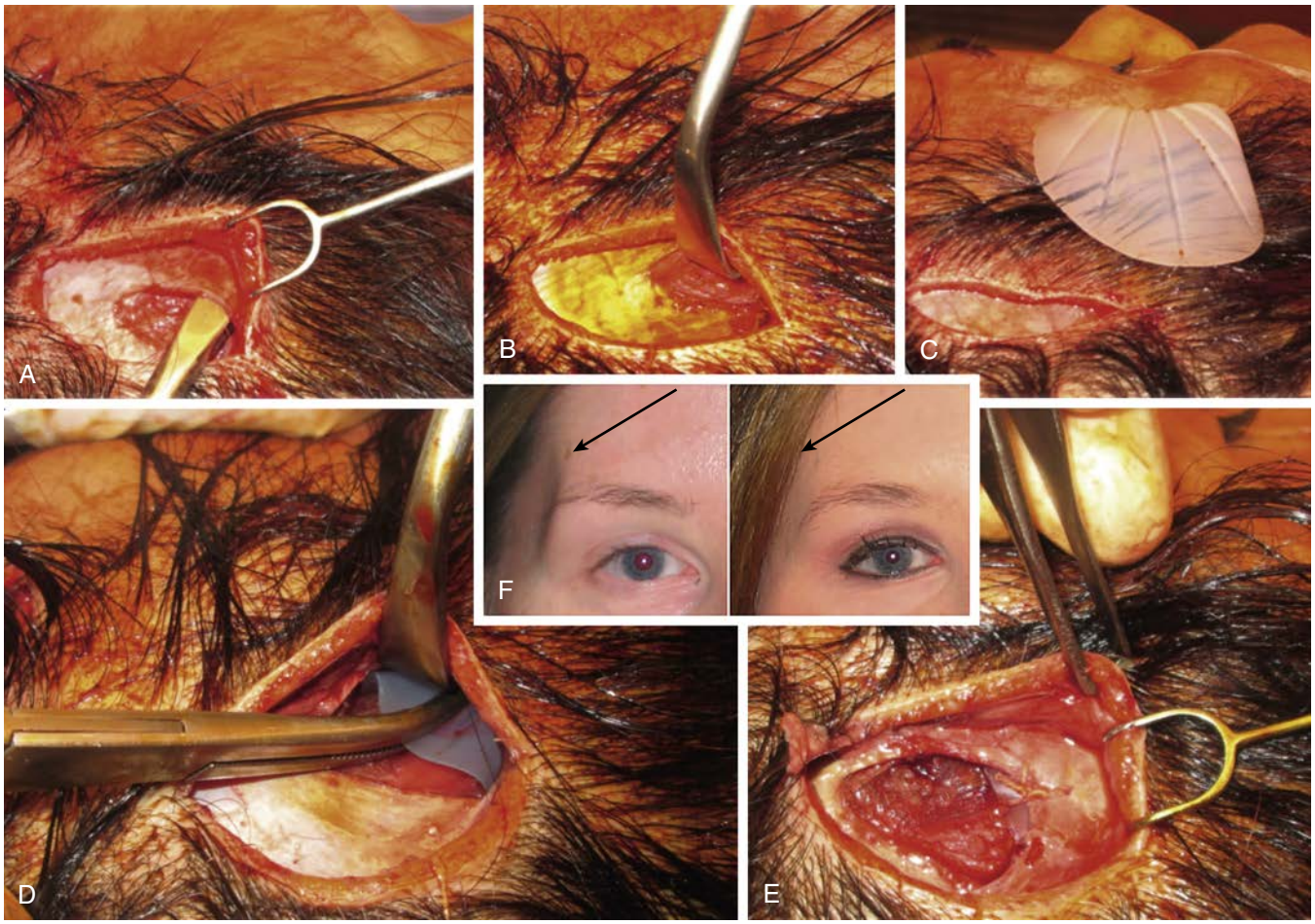

• **Figure 22-45** Adjunctive procedures such as temporal augmentation can easily be placed through an existing temporal incision. **A,** Creation of a pocket below the temporalis fascia. **B,** An aufricht retractor placed in the pocket. **C,** Solid silicone implant laying over the planned position of the implant just lateral to the orbital rim and above the zygomatic arch. **D,** Placement of the implant into the pocket. **E,** Securing the implant to the overlying fascia to prevent migration with a single 2-0 Vicryl. **F,** Patient with temporal hollowing before and after placement of temporal implants.

a pocket is created from the lateral orbital rim to just above the zygomatic arch. The implant is placed deep to the fascia and superficial to the temporalis muscle. Some surgeons do not secure the implant, however the senior author secures the implant with a single 2-0 Vicryl to the fascia to prevent migration (Figure 22-45).

Skin Care

Laser resurfacing, dermabrasion, or chemical peels can be used as an adjunct to forehead lift surgery. These procedures can be used to even out fine wrinkles and dyschromia of the forehead and periorbital skin.

The senior author's personal experience is to treat patients before any resurfacing procedure with 6 weeks of topical retinoic acid and the addition of hydroquinone for patients with darker skin (Fitzpatrick 3 or higher). Such pretreatment can reduce the risk for post-resurfacing hypopigmentation, hyperpigmentation, and scarring.

Postoperative Care

Following endoscopic forehead and open brow lifting, a compression bandage is applied with a material such as Coban or Coflex. The pressure helps to limit edema and small hematoma formation while possibly improving fixation. Typically, a drain is not required if a very dry field is maintained, making postoperative care very easy. The patient should be instructed regarding limited activity for the first 2 weeks and the use of cold compresses over the eyes and brow. Head elevation is recommended for the first 48 to 72 hours as tolerated. Preoperative avoidance of antiplatelet drugs, careful surgical technique, and immediate postoperative use of cold compresses, elevation, and limited strenuous activity will significantly decrease postoperative healing time.

The patient may have the postoperative dressing removed on postoperative day 1 to allow visual inspection of the surgical site for any problems. A less constrictive Velcro-type



• **Figure 22-46** **A,** Preoperative and postoperative images of a female patient who has relatively good brow position and obtained a very nice result from upper blepharoplasty alone. **B,** Preoperative and postoperative images of a female patient who has a low brow position and was treated with brow lift only with lasting results at 2 years post op.

head wrap then can be used for patient comfort and to allow easy removal for showering, but a dressing is not absolutely required after the first 24 hours. Ensuring a short and comfortable recovery is important for the modern cosmetic surgery patient, who hopes an endoscopic technique will yield results with fewer overall problems than are associated with open techniques. Unfortunately, the release of significant scalp and facial deep tissues continues to produce significant pain that requires narcotic relief for most of the first few days.

The patient is allowed to gently shampoo the hair after 24 hours but must be cautioned to avoid water pressure directly over the incision sites. Each incision then is cleaned twice a day with a dilute peroxide solution, and a thin layer of antibiotic ointment is applied for the first week. Staples can be removed at the end of 1 week. Chemical treatment for hair should be delayed for at least 2 weeks to avoid the possibility of hair loss caused by the harsh chemicals. Hot curling irons or similar devices must be used with caution because areas of scalp anesthesia that may be present for months can predispose a patient to an accidental self-inflicted burn.

Complications

Fortunately, major complications are rare with properly performed endoscopic forehead and brow lifting techniques. Excellent patient selection, diligent preoperative planning, meticulous surgical technique, and thorough postoperative care all are required to limit the chances of complications[82-88] (Figure 22-46). Minor complications can always occur despite a surgeon's best efforts; however, no matter how negligible the problem, the patient must be treated with concern and compassion. The characteristic cosmetic surgery patient is expecting to look better as soon as possible and is not always as tolerant of perioperative problems as a trauma patient might be. Extensive edema and ecchymosis usually are not considered complications, but they warrant appropriate reassurance and even simple suggestions to hasten recovery when feasible. For example, makeup suggestions from a well-trained staff member may greatly improve a postoperative patient's mood after he or she is shown how to better hide unusual ecchymosis.

The overall complication rate for any forehead procedure is low. De Cordier retrospectively reviewed 393 patients who underwent endoscopic forehead lift from 1994 to 2000. The review reported alopecia in one occurrence (0.3%), transient scalp numbness in most patients, 2% with prolonged dysesthesia, and seven patients (2.3%) with a temporary frontal nerve weakness. Forehead hematoma requiring in-office drainage occurred in 3.5% of patients. Seven percent of their patients experienced lagophthalmos, 8% with upper eyelid asymmetry, and 3% with brow

malposition. There was also one patient who had wound dehiscence and one who had a suture abscess.[98] Of all possible problems, permanent facial paralysis or major tissue loss is the most devastating. These particular complications are rare (less than 0.3% and less than that for a standard lower face-lift).

Brow Malposition

Malposition of the brow may occur with any approach to forehead rejuvenation.[99] Too much resection of skin in any open approach or excessive suspension with any procedure may result in lagophthalmos and brow malposition. The risk is increased when simultaneously blepharoplasty is performed. To avoid excessive skin resection during the blepharoplasty the forehead lift should be completed before the eyelid surgery. When lagophthalmos is limited to less than 2 mm there is a decreased risk of dry eye syndrome.[100]

Problems such as corneal abrasions are a matter of great concern to the patient because of the severe pain they produce; these abrasions can be nearly eliminated with proper technique and perioperative attention to detail. For instance, eye lubricant should always be used, and thought should be given to placement of temporary Steri-Strips over the eyelids or a tarsorrhaphy suture to prevent inadvertent scratching of the cornea by gauze, tubing, or other materials during the procedure. All severe pain requires immediate evaluation, and suspected abrasion should be treated with suitable ophthalmic drops for pain, ointments, and with patching of the affected eye for 12 to 24 hours. Minor blurred vision for the first 12 hours due to chemosis and use of ophthalmic ointments is not unusual. Appropriate ophthalmologic consultation is required for persistent or uncontrollable eye pain, persistent dry eye symptoms, or unusual changes in vision.

In one study of 600 patients who underwent combined upper blepharoplasty and open coronal browlift there was no dry eye syndrome, blindness, or globe exposure, and there were only 2 cases of brow asymmetry.[101] In a retrospective study comparing 140 (121 coronal and 19 endoscopic) patients who had either the endoscopic-assisted approach or the open approach there was no significant difference in brow elevation with either approach alone or in combination with blepharoplasty at the 1-year evaluation.[102]

When there is over-elevation of the brow, consideration should be made to performing release of the suspension. When there is under-elevation of the brow it is likely due to inadequate release, fixation, or suspension. This can be treated with revision surgery and ensuring proper release, suspension, or skin excision. Over-resection of the depressor supercilli can lead to medial over-elevation and a "surprised" appearance, which can be avoided by recognition of the anatomy intraoperatively. Minor asymmetries can be improved with strategic placement of neurotoxins (Figure 22-47).

Nerve Damage

Peri-incisional anesthesia is expected and is usually temporary. Direct injury to the nerves is an uncommon occurrence but traction injury (neuropraxia) can occur due to suspension. When neuropraxia injury occurs it may take up to 12 months to completely resolve. In the temporal region the dissection plane is superficial to the superficial layer of the deep temporal fascia and damage to the zygomaticotemporal and auricotemporal nerves (second division of trigeminal) should be minimal.

Knowledge of the facial nerve and its branches is necessary to avoid injury because this results in paralysis and asymmetry of the forehead. In particular, the temporal (frontal) branch is at risk for injury in the temporal lateral dissection. Knowledge of pertinent anatomy is the best way to prevent injury, and meticulous surgical planning will allow facial cosmetic surgeons to avoid nerve damage.



• **Figure 22-47** Images depict why some brow lift patients have a bizarre look from a potential complication of over-elevation of the medial brow. Lateral brow elevation looks attractive on most females but medial brow elevation greater than the lateral brow third creates an odd look for male or female brow lift patients.

Scars

Scarring is of concern with open brow lift procedures and typically results from improper incision design and closure. The unsightly scar may be minimized in open approaches by making an irregular incision with an extreme bevel from posterior to anterior beginning 4 to 5 mm posterior to the hairline at an area where the follicular density becomes consistent. The extreme bevel of the incision preserves the hair follicles on the superior flap, allowing hair growth both through, and anterior to, the scar postoperatively. Scarring and thinning of tissue due to overzealous resection of brow elevators are best managed by dermabrasion or fillers.

Alopecia

Alopecia can also result from improper incision design and closure, including inappropriate wound tension, rough handling of wound margins, and excessive use of electrocautery. Peri-incisional alopecia can appear as a widened scar; when the scar is visible by the endoscopic approach, the scar can be excised at a later date. Alopecia around endoscopic scars can make them more obvious and scar revision can be performed to improve the scars by excision of the widened scars and close reapproximation of the hair-bearing scalp. As an alternative, follicular unit hair transplants can be placed in the scar.

Acute tellogen effluvium is a rare but known cause of hair loss after brow procedures. Often, the hair follicles in this situation have a club shape and may be found in areas far from the surgical site. The features include diffuse shedding sometimes with accentuated hair thinning, a normal appearing scalp, and a markedly positive pull test. The hair pull test is done by grasping approximately 40 to 60 hairs between the thumb and index finger and applying steady traction (slightly stretching the scalp) as you slide your fingers along the length of the hair. Generally, only a few hairs in the telogen (resting) phase can be plucked in this fashion. Less than 10% is considered normal, whereas greater than this is considered indicative of a pathologic process.[103] Fortunately, telogen effluvium is a self-resolving condition and regrowth can be noted in 3 to 6 months, but cosmetically significant regrowth can take 12 to 18 months (see Figure 22-39).

Bleeding

Excessive bleeding may occur with any approach and may be arterial, venous, or from skin edges. Preoperative evaluation to note blood dyscrasias and patient education on avoidance of agents that cause bleeding will prevent most issues. Injection with a hemostatic agent, ensuring intraoperative hemostasis, and avoidance of injury to the superficial temporal or zygomaticotemporal arteries, supraorbital or supratrochlear vascular bundles, and sentinel vein will decrease postoperative hematomas. If there is slow postoperative bleeding it may be controlled with pressure alone, although hematomas require evacuation, exploration, and control of bleeding (Figure 22-48)

Proper planning, technique, and postoperative care will help to reduce the incidence of complications. Immediate and appropriate treatment, along with sincere concern for the patient's well-being, should help to reduce the chance that a far worse situation may develop.

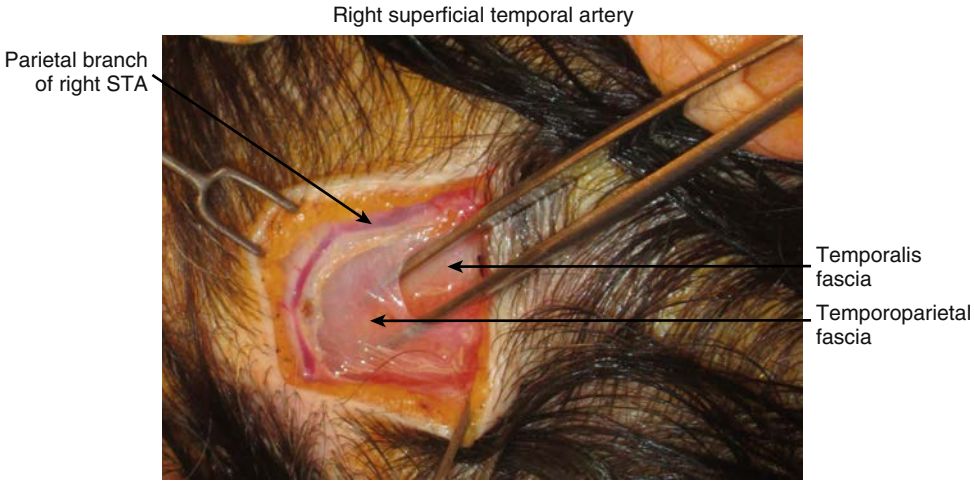

• **Figure 22-48** The right temporal scalp is shown just above the helix of the ear in a location for a lateral endoscopic port incision or a temporal lift. Two branches of the superficial temporary artery are shown that are seen in the upper temporoparietal fascia. They are one of many sources for hematoma or at minimum a nuisance to a clean operating field.

Summary

An increase in upper facial rejuvenation techniques over the past two decades, led by the use of the endoscope and neurotoxins, has revolutionized the treatment of upper facial aging. Cosmetic surgery treatment of the upper facial third is frequently an essential element for complete facial rejuvenation.[82,83] Matching the diagnosis with the ideal rejuvenation technique(s) is essential for maximum esthetic benefit. Even the best surgical technique can produce inadequate or even poor results if improper patient selection or diagnoses are made; for this reason, the forehead and brow area must be critically evaluated for a wide range of interlacing diagnoses.

Particular skin problems vary with patient age and sex, but gravity remains consistent and nonselective. So, with regard to brow ptosis, the question often is not "Will it occur?" but "When will it occur?" and "How severe will it be?" Lateral brow (hooding) now may be selectively treated endoscopically to achieve a more youthful appearance, often with little down time. Society's idea of beauty at any single moment in time ultimately will guide the patient and surgeon as they choose where the brow should be located rather than merely raising it higher. True or total rejuvenation is complex; it involves multiple modalities and often tissue replacement techniques such as fat grafting. Only time and persistence will prove what best restores youth to the upper face. Forehead and brow lifting, and in particular the endoscopic approach, is merely an elegant surgical tool in a wide surgical armamentarium.

Cosmetic surgery continues to show an exponential rise in popularity. The aging population wants to feel and look more youthful, but nonetheless demands to remain "natural" looking after low morbidity procedures. Today's discernible cosmetic surgery patient is often very knowledgeable on the subject of procedural options and may even insist on a specific technique such as an endoscopic procedure. It is the guidance of a well-trained surgeon and diagnostician that can ultimately produce a happy patient. Also, it is imperative for the surgeon to refuse to provide treatment that is not in the best interest of the patient. Cosmetic surgery is a luxury, and at the end of the day, it is the surgeon's responsibility to provide the patient with the best and safest techniques available to achieve realistic outcomes, whether they are performed open or endoscopically.

References

1. Niamtu J: Endoscopic brow and forehead lift: a case for new technology, *J Oral Maxillofac Surg* 64:1129–1132, 2006.
2. Ramirez OM: Endoscopic techniques in facial rejuvenation: an overview, Part 1, *Aesthetic Plast Surg* 8:141, 1994.
3. Isse NG: Endoscopic facial rejuvenation: endoforehead, the functional lift: case reports, *Aesthetic Plast Surg* 18:21–29, 1994.
4. Sullivan PK, Salomon JA, Woo AS, et al.: The importance of the retaining ligamentous attachments of the forehead for selective eyebrow reshaping and forehead rejuvenation, *Plast Reconstr Surg* 117:95, 2006.
5. Knize DM: Limited incision foreheadplasty, *Plast Reconstr Surg* 103:271, 1999.
6. Zide BM, Jelks GW: *Surgical anatomy of the orbit*, New York, 1985, Raven Press.
7. Cuzalina LA, Holmes J: A simple and reliable landmark for identification of the supraorbital nerve in surgery of the forehead: an in vivo anatomical study, *J Oral Maxillofac Surg* 63:25–27, 2005.
8. Fagien S: Eyebrow analysis after blepharoplasty in patients with brow ptosis, *Ophthal Plast Reconstr Surg* 8:210, 1992.
9. Powell H, Humphrieys B: *Proportions of the aesthetic face*, New York, 1984, Thieme-Stratton.
10. Rickets RM: Divine proportion of facial aesthetics, *Clin Plast Surg* 9:401, 1982.
11. Evans TW: Browlift, *Atlas Oral Maxillofac Surg Clin North Am* 6:111–133, 1998.
12. Ellis DAF, Bakala CD: Anatomy of the motor innervation of the corrugator supercilii muscle: clinical significance and development of a new surgical technique for frowning, *J Otolaryngol* 27:222–227, 1998.
13. Larrabee WF, Mahielski KH: *Surgical anatomy of the face*, New York, 1993, Raven Press.
14. Waite PD, Cuzalina LA: Rhytidectomy. In Fonseca RJ, editor: *Oral and maxillofacial surgery: cleft/craniofacial/cosmetic surgery*, vol. 6. Philadelphia, 1998, Saunders, pp 365–381.
15. Tobin HA, Cuzalina LA: An opportunistic approach for face lifting, *J Oral Maxillofac Surg* 58:76–85, 2000.
16. Tobin HA, Cuzalina LA: SMAS surgery versus deep-plane rhytidectomy. In Pensak ML, editor: *Controversies in otolaryngology*, New York, 2001, Thieme, pp 148–155.
17. Bostwick J, Eaves F, Nahai F: *Endoscopic plastic surgery*, St. Louis, 1995, Quality Medical Publishers.
18. Hiatt JL, Gartner LP: In Gardner J, editor: *Textbook of head and neck anatomy*, ed 2, Baltimore, 1987, Williams & Wilkins, pp 373–345.
19. Hamas RS: Reducing the subconscious frown by endoscopic resection of the corrugator muscles, *Aesthetic Plast Surg* 19:21–25, 1995.
20. Ellis DAF, Masri H: The effect of facial animation on the aging upper half of the face, *Arch Otolaryngol Head Neck Surg* 115:710–712, 1989.
21. Brennan HG: The forehead lift, *Otolaryngol Clin North Am* 13:209, 1980.
22. Grant JCB, editor: *Grant's atlas of anatomy*, ed 6, Baltimore, 1972, Williams & Wilkins.
23. Tolhurst DE, Carstens MH, Greco RJ, et al.: The surgical anatomy of the scalp, *Plast Reconstr Surg* 87:603, 1991.
24. Tremolada C, Candiani P, Signorini M, et al.: The surgical anatomy of the subcutaneous fascial system of the scalp, *Ann Plast Surg* 32:8, 1994.
25. Carstens MH, Greco RJ, Hurwitz DJ, et al.: Clinical applications of the subgaleal fascia, *Plast Reconstr Surg* 87:615, 1991.
26. Knize DM: Transpalpebral approach to the corrugator supercilii and procerus muscles, *Plast Reconstr Surg* 95:52–60, 1995.
27. Knize DM: A study of the supraorbital nerve, *Plast Reconstr Surg* 99:1224, 1997.

28. Knize DM: Muscles that act on glabellar skin: a closer look, *Plast Reconstr Surg* 105:350, 2000.
29. Netter FM: *Atlas of human anatomy*, Summit, NJ, 1989, Ciba-Geigy.
30. Knize DM: An anatomically based study of the mechanism of eyebrow ptosis, *Plast Reconstr Surg* 97:1321, 1996.
31. Lemke BN, Stasior OG: The anatomy of eyebrow ptosis, *Arch Ophthalmol* 100:981, 1982.
32. Aiache AE, Ramirez OM: The suborbicularis oculi fat pads: an anatomic and clinical study, *Plast Reconstr Surg* 95:37, 1995.
33. Trinei FA, Januszkiewicz J, Nahai F: The sentinel vein: an important reference point for surgery in the temporal region, *Plast Reconstr Surg* 101:27, 1998.
34. Gosain AK, Sewall SR, Yousif NJ: The temporal branch of the temporal nerve: how reliably can we predict its path? *Plast Reconstr Surg* 99:1224, 1997.
35. Ellis E, Zide MF: *Surgical approaches to the facial skeleton*, Baltimore, 1995, Williams & Wilkins, pp 59–169.
36. Liebman E, Webster R, Berger A, et al.: The frontalis nerve in the temporal brow lift, *Arch Otolaryngol Head Neck Surg* 108:232–235, 1982.
37. Furnas DW: Landmarks for the trunk and the temporofacial division of the facial nerve, *Br J Surg* 52:694, 1965.
38. Correia P, Zani R: Surgical anatomy of the facial nerve as related to ancillary operations in rhytidoplasty, *Plast Reconstr Surg* 52:549–552, 1973.
39. Isse NG: Endoscopic forehead lift, *Clin Plast Surg* 22:661, 1995.
40. Isse NG: The endoscopic approach to forehead and brow lifting, *Aesthetic Plast Surg* 18:67, 1998.
41. Vasconez LO, Core GB, Gamboa-Bobadilla M, et al.: Endoscopic techniques in coronal brow lifting, *Plast Reconstr Surg* 94:788, 1994.
42. Morselli PG: Fixation for forehead endoscopic lifting: a simple, easy, no-cost procedure, *Plast Reconstr Surg* 97:1309, 1996.
43. Marchac D, Ascherman J, Arnaud E: Fibrin glue fixation in forehead endoscopy: evaluation of our experience with 206 cases, *Plast Reconstr Surg* 100:704, 1997.
44. Hoeing JF: Rigid anchoring of the forehead to the frontal bone in endoscopic facelifting: a new technique, *Aesthetic Plast Surg* 20:213, 1996.
45. De la Fuente A, Santamaria AB: Facial rejuvenation: a combined conventional and endoscopic assisted lift, *Aesthetic Plast Surg* 20:471, 1996.
46. Isse NG: Endoscopic forehead lift, evolution and update, *Clin Plast Surg* 2:661, 1995.
47. Adamson PA, Johnson CM, Anderson JR, et al.: The forehead lift: a review, *Arch Otolaryngol Head Neck Surg* 111:325–329, 1985.
48. Liang M, Narayaman K: Endoscopic oblation of the frontalis and corrugator muscles: a clinical study, *Plast Surg Forum* XV:54, 1992.
49. Su CT, Morgan RF, Manson PN, Hoopes JE: Technique for division and suspension of the orbicularis oculi muscle, *Clin Plast Surg* 8:673, 1981.
50. Byrd HS, Andochick SE: The deep temporal lift: a multiplanar lateral brow, temporal, and upper face-lift, *Plast Reconstr Surg* 97:928, 1996.
51. Kerth JD, Triumi DM: Management of the aging forehead, *Arch Otolaryngol Head Neck Surg* 116:1137–1142, 1990.
52. Chierici G, Miller A: Experimental study of muscle reattachment following surgical detachment, *J Oral Maxillofac Surg* 42:485, 1984.
53. Ramirez OM: Endoscopic subperiosteal browlift and facelift, *Clin Plast Surg* 22:639–660, 1995.
54. Tobin HA: The extended subperiosteal coronal lift, *Am J Cosmet Surg* 10:47–57, 1993.
55. Psillakis JM, Rummley TO, Camargos A: Subperiosteal approach in an improved concept for correction of the aging face, *Plast Reconstr Surg* 82:383–392, 1988.
56. Ramirez OM: Endoscopic techniques in facial rejuvenation: an overview, *Aesthetic Plast Surg* 18:141–147, 1994.
57. Daniel RK, Ramirez OM: Endoscopic assisted aesthetic surgery, *Aesthetic Plast Surg* 14:18–20, 1994.
58. Toledo LS: Facial rejuvenation: technique and rationale. In Fodar P, Isse N, editors: *Endoscopically assisted aesthetic plastic surgery*, St Louis, 1996, Mosby, pp 91–105.
59. Psillakis JM: Subperiosteal approach for surgical rejuvenation of the upper face. In Psillakis J, editor: *Deep face-lifting techniques*, New York, 1994, Thieme, pp 51–63.
60. Hinderer UT: The sub SMAS and subperiosteal rhytidectomy of the forehead and middle third of the face: a new approach to the aging face, *Facial Plast Surg Clin North Am* 8:18–32, 1992.
61. Ruess WR, Owsley JQ: The anatomy of the skin and fascial layers of the face in aesthetic surgery, *Clin Plast Surg* 14:677–682, 1987.
62. Abul-Hassan HS, Van Drasek Ascher G, Acland RD: Surgical anatomy and blood supply for the fascial layers of the temporal regions, *Plast Reconstr Surg* 77:17, 1986.
63. Stuzin JM, Wagstrom L, Kawamoto HK, et al.: Anatomy of the frontal branch of the facial nerve: the significance of the temporal fat pad, *Plast Reconstr Surg* 83:265, 1989.
64. Savani A: Physiopathology of the aging face. In Psillakis JM, editor: *Deep face-lifting techniques*, New York, 1994, Thieme, pp 11–23.
65. De la Plaza R, Valiente E, Arroya JM: Supraperiosteal lifting of the upper two thirds of the face, *Br J Plast Surg* 4:325–332, 1991.
66. Wassef M: Superficial fascial and muscular layers in the face and neck: a histologic study, *Aesthetic Plast Surg* 11:171, 1987.
67. Tirkanits B, Daniel RK: The biplanar forehead lift, *Aesthetic Plast Surg* 14:111, 1990.
68. Ramirex OM, Maillard GF, Musolas A: The extended subperiosteal face lift: a definitive soft-tissue remodeling for facial rejuvenation, *Plast Reconstr Surg* 88:227–236, 1991.
69. Psillakis JM: Embryology and anatomy review of the superficial fascia or SMAS. In Psillakis JM, editor: *Deep face-lifting techniques*, New York, 1994, Saunders, pp 1–11.
70. Bosse JP, Papillon J: Surgical anatomy of the SMAS at the malar region. In *Transactions of the Ninth International Congress of Plastic and Reconstructive Surgery*, New York, 1987, McGraw-Hill.
71. Owsley JQ: *Aesthetic facial surgery*, Philadelphia, 1994, Saunders, pp 7–24, 30-31, 117–127.
72. Yousif NJ, Mendelson BC: Anatomy of the mid-face, *Clin Plast Surg* 22:227–241, 1995.
73. Guyuron B, Davies B: Subcutaneous anterior hairline forehead rhytidectomy, *Aesthetic Plast Surg* 12:77, 1988.
74. Aiache AE: Endoscopic face-lift, *Aesthetic Plast Surg* 18:275, 1994.
75. Ramirez OM: Endoscopic forehead and face-lift: step-by-step, *Open Tech Plast Reconstr Surg* 2:116–126, 1995.
76. Matarasso A, Terino EO: Forehead-brow rhytidoplasty: reassessing the goals, *Plast Reconstr Surg* 93:1378, 1994.
77. Newman JP, LaFerriere KA, Koch RJ, et al.: Transcalvarial suture fixation for endoscopic brow and forehead lifts, *Arch Otolaryngol Head Neck Surg* 123:313, 1997.

78. Kim SK: Endoscopic forehead scalp flap fixation with K-wire, *Aesthetic Plast Surg* 20:217, 1996.
79. Pakkanen M, Salisbury AV, Ersek RA: Biodegradable positive fixation for endoscopic browlift, *Plast Reconstr Surg* 98:1087, 1996.
80. Knize DM: A study of the supraorbital nerve, *Plast Reconstr Surg* 96:564, 1995.
81. Loomis MG: Endoscopic brow fixation without bolsters or miniscrews, *Plast Reconstr Surg* 98:373, 1996.
82. Keen MS, Khosh MM: The role of botulinum toxin A in facial plastic surgery. In Willet JM, editor: *Facial plastic surgery*, Upper Saddle, NJ, 1997, Prentice Hall, pp 323–329.
83. Frankel AS, Kamer FM: Chemical browlift, *Arch Otolaryngol Head Neck Surg* 124:321, 1998.
84. Beeson WH, McCollough EG: Complications of the forehead lift, *Ear Nose Throat J* 64:27, 1985.
85. Connell BF, Lambros VS, Neurohr GH: The forehead lift: techniques to avoid complications and produce optimal results, *Aesthetic Plast Surg* 13:217, 1989.
86. Matarasso A: Endoscopic assisted forehead-brow rhytidoplasty: theory and practice, *Aesthetic Plast Surg* 19:141, 1995.
87. Daniel RK, Tirkantis B: Endoscopic forehead lift, aesthetics and analysis, *Clin Plast Surg* 22:605–618, 1995.
88. Mayer TG, Fleming RW: Management of alopecia. In Cummings CW, Fredrickson JM, Harker LA, et al.: *Otolaryngology—head neck surgery*, St Louis, 1986, Mosby, p 429.
89. Al-Kayat A, Bramley P: A modified pre-auricular approach to the temporomandibular joint and malar arch, *Br J Oral Surg* 17:91–103, 1979.
90. Miloro M, Redlinger S, Pennington DM, et al.: In situ location of the temporal branch of the facial nerve, *J Oral Maxillofac Surg* 65(12):2466–2469, 2007.
91. Agarwal CA, Mendenhall SD, Foreman KB, et al.: The course of the frontal branch of the facial nerve in relation to fascial planes: an anatomic study, *Plast Reconstr Surg* 125(2):532–537, 2010.
92. American Society of Plastic Surgeons: *Plastic surgery statistics report 2015*. https://www.plasticsurgery.org/news/plastic-surgery-statistics.
93. Maillard JF, Cornette de St. Cyr B, Scheflan M: The subperiosteal bicoronal approach to total facelifting: the DMAS-deep musculoaponeurotic system, *Aesthetic Plast Surg* 15:285–291, 1991.
94. Fett DR, Sutcliffe T, Baylis HI: The coronal eyebrow lift, *Am J Ophthalmol* 96:751–754, 1983.
95. Owsley TG: Subcutaneous trichophytic forehead browlift: the case for an "open" approach, *J Oral Maxillofac Surg* 64(7):1133–1136, 2006.
96. Rafarty FM, Goode RL, Abramson NR: The eyebrow lift operation in a man, *Arch Otolaryngol* 104:69–71, 1978.
97. Ellenbogen R: Medial eyebrow lift, *Ann Plast Surg* 5:151–152, 1980.
98. De Cordier BC, de la Torre JI, Al-Hakeem MS, et al.: Endoscopic forehead lift: review of technique, cases, and complications, *Plast Reconstr Surg* 110(6):1558–1568, 2002.
99. Guyurn B: Endoscopic forehead rejuvenation: limitations, flaws, and rewards, *Plast Reconstr Surg* 117(4):1121–1133, 2006.
100. Terella AM, Wang TD, Kim MM: Complications in periorbital surgery, *Facial Plast Surg* 29(1):64–70, 2013.
101. Friedland JA, Jacobsen WM, TerKonda S: Safety and efficacy of combined upper blepharoplasties and open coronal browlift: a consecutive series of 600 patients, *Aesthetic Plast Surg* 20(6):453–462, 1996.
102. Dayan SH, Perkins SW, Vartanian AJ, et al.: The forehead lift: endoscopic versus coronal approaches, *Aesthetic Plast Surg* 25(1):35–39, 2001.
103. Piérard GE, Piérard-Franchimont C, Marks R, Elsner P, for the EEMCO group (European Expert Group on Efficacy Measurement of Cosmetics and Other Topical Products): EEMCO guidance for the assessment of hair shedding and alopecia, *Skin Pharmacol Physiol* 17(2):98–110, 2004.

23

Liposuction and Fat Transfer Techniques

HARSHIV J. VYAS, ANDREW M. SOHN, BERNARD J. COSTELLO

Liposuction

Introduction

Over the past three decades, liposuction (e.g., suction assisted lipectomy, suction lipoplasty, fat suction, blunt suction lipectomy, and liposculpture) has advanced significantly. Better understanding of the anatomy, physiology, and metabolism of subdermal fat has led to refinement of surgical techniques, introduction of tumescent anesthesia, and innovations in biomedical technologies, all of which have contributed to enhanced patient safety, superior treatment outcomes, and thus widespread popularity of the procedure. Americans spent more than $13 billion on cosmetic procedures in 2015. Surgical procedures accounted for almost 60% of the total expenditures. Liposuction was noted to be the most popular surgical procedure with almost 400,000 procedures performed nationwide, followed by breast augmentation.[1]

The neck is the most common site treated with liposuction in the craniofacial region. Cervicofacial liposuction refers to a minimally invasive facial rejuvenation procedure that recontours and removes supraplatysmal fat present between skin and platysma. It utilizes a suction assisted technique for fat extirpation from the submental, submandibular, and jowl regions by transcutaneous placement of cannulas at strategic sites. Removal of subplatysmal fat present between platysma and submental musculature is helpful only in isolated cases. Cervicofacial liposuction has become an indispensable tool in the armamentarium of the facial esthetic surgeon for rejuvenation of the aging neck. This chapter focuses on the esthetic applications of liposuction in the cervicofacial region.

History

The first liposuction procedure was described by Schrudde in 1972, which involved a fat excision using sharp uterine curettes. In 1976 Arpad and colleagues used suction for fat removal using blunt hollow cannulas, and shortly thereafter Illouiz developed the technique most resembling liposuction as we know it today. In 1987 the use of tumescent anesthesia as described by Hetter allowed for a more hemostatic approach with good pain control. Ultrasound was added by Scuderi during the same year, and laser assisted liposuction was described in the early 1990s. Other techniques using power, water, or radiofrequency have also been described. No clear data have proven one of these technologies to have a considerable advantage over another, and each has a similar effect.

Fundamentals of Liposuction

Adipose tissue is made up of adipocytes that aggregate together to form lipid lobules. Weight gain within an individual to a moderate level of obesity occurs through lipid accumulation and hypertrophy of individual cells. Average cell weights are ≈0.4 μg and can attain masses up to 1.0 μg. As the individual gains more weight, new fat cells form from mesenchymal stem cells to accommodate the excess lipid accumulation. This hyperplastic adipose deposition is believed to be permanent and "resistant" to subsequent dieting. Even when weight loss regimens are implemented, facial areas such as the submental region are difficult to change. Though exercise programs help to tone muscles throughout the body, it is difficult to strengthen muscles of the face and neck; in addition, toned muscles do not necessarily reduce the amount of superficial adipose tissue.[2] With diet and weight loss, lipid content of cells may be reduced, but the number of adipocyte cells remains constant.[2] After maximal reduction of adipocyte size, the only method to reliably reduce fat content is by excision.[3]

Liposuction effectively decreases the number of adipocytes in two ways:

1. Immediate shearing of fat in contact with the cannula and its extirpation under negative pressure (suction).
2. Gradual necrosis and resorption of surrounding fat over the next 2 to 3 months due to damage to the lipid lobules caused by the to-and-fro motion of the cannula and suction trauma.

Liposuction should thus be viewed as a complement to diet and exercise and not as its replacement.

Tumescent Anesthesia and Its Rationale for Use

The term *tumescent* is etymologically derived from the Latin word *tumere*—to swell. Tumescent anesthesia is a local anesthesia delivery technique that involves the subdermal infiltration of large volumes of a tumescent solution.

Ingredients of Klein's tumescent solution include:

1. 50 mL (500 mg) of 1% lidocaine
2. 1 mL (1 mg) of 1:1000 epinephrine
3. 1000 mL of 0.9% normal saline
4. 10 mL of 8.4% sodium bicarbonate as a buffer

Using the technique of tumescent anesthesia for regional anesthesia, which allows for distribution of the medication over an area that is less likely to be rapidly absorbed, Klein showed that lidocaine doses of 35 mg/kg were safe for liposuction. Prior to that, the recommended maximum dose of lidocaine with epinephrine was considered to be 7 mg/kg of body weight.[4] In most instances, it is not necessary to approach these values for facial liposuction. Higher concentrations of lidocaine (0.1%) are sometimes used for liposuction over sensitive parts of the body such as the periumbilical area, inner thighs, waist, and chest. Elsewhere, a concentration of 0.05% is usually sufficient to provide adequate anesthesia for the procedure.[5] In an average sized patient, 300 to 500 mL of tumescent anesthesia is typically used to anesthetize the neck, jowls, and cheeks. Distention of subdermal tissues with tumescent solution causes elongation and stretching of blood vessels and nerves, potentiating the effects of epinephrine and lidocaine.

Patient Selection and Clinical Considerations

When selecting patients for cervicofacial liposuction, it is imperative to discuss the patient's motivation for surgery, concerns, and expectations. Once the patient's physical status has been deemed appropriate for safe liposuction, the overall body habitus is assessed. Visual criteria for the global assessment of a youthful, attractive neck have been well described.[6] These include a distinct inferior mandibular border, subhyoid depression, visible thyroid cartilage bulge, visible anterior sternocleidomastoid border, and a cervicomental angle between 105 and 120 degrees.

Chung and Williams[2] have suggested a systematic evaluation of the cervicofacial region as follows:

1. Skin condition: Evaluate skin for flexibility, elasticity, firmness, and adherence to the underlying tissues, all of which play a critical role in predicting outcomes. Skin with elastic integrity will more effectively redrape over the underlying liposuctioned contour.
2. Amount and location of fat: Assess the location and amount of fat by palpation. This is best accomplished with the pinch and roll technique. The skin should be palpated or rolled between two fingers to determine the thickness of the skin and fat. In the cervical region, the presence of supraplatysmal fat should be differentiated from subplatysmal fat. With palpation, subplatysmal fat is generally firmer owing to its connective tissue and fibrous content.
3. Integrity of the platysma: Evaluate thickness and laxity of platysma. The presence of platysmal bands at rest indicate that some form of platysmaplasty should be performed for proper rejuvenation of the neck. Furthermore, cervical liposuction may expose occult bands. This may be assessed by having patients strain their neck with their teeth clenched while making a grimace; with this provocative test, platysmal bands due to laxity of the muscular anterior borders may be revealed.
4. Condition of the surrounding skeletal framework: Deficiencies in the surrounding skeletal framework of the cervicofacial region (for example, retrognathia) may significantly affect the results of liposuction.
5. Prominence of surrounding soft tissue structures: Surface anatomy of the submandibular and parotid salivary glands must be taken into consideration. Liposuction in the submandibular region may enhance the appearance of the submandibular glands. Similarly, liposuction of cheek fat may enhance the anterior border of an enlarged parotid gland. Furthermore, patients with heavy masseter musculature may not benefit as dramatically as others from facial liposuction.

The ideal patient for cervicofacial liposuction is one with localized fat deposits without redundancy of skin or platysmal pathosis. The excessive fat deposits may be a result of hereditary predisposition, poor dietary and exercise habits, age, medications, hormones, or weight gain.[2] Skin is more elastic in younger patients, hence removal of localized fat deposits by cervicofacial liposuction can produce an esthetic result. In aging patients, the skin has greater redundancy and liposuction alone cannot achieve desired results. It may need to be combined with other facial rejuvenation procedures such as rhytidectomy, platysmaplasty, or skin resurfacing for a better outcome. Liposuction may also be utilized for contouring adipose tissue in the nasolabial fold and midface region. Due to variability of results at these sites, it is not widely used. Two-dimensional and three-dimensional facial imaging technology is a useful adjunct to diagnosis, treatment planning, and patient education in esthetic surgery.

Preoperative Evaluation

At the time of the preoperative appointment, the surgical objectives, treatment plan, and patient's expectations should be discussed. Past medical history including medications

must be reviewed and updated. A thorough physical examination must be performed. Preoperative and postoperative instructions are given and a written informed consent is obtained. Agents that prolong bleeding, such as aspirin, should ideally be discontinued preoperatively in consultation with the patient's physician. Anticipated recovery time of 1 to 2 weeks following the procedure must be communicated in advance.

Technical Considerations for Surgery

Marking and Incisions

Markings must be made while the patient is in an upright position as significant distortion of soft tissue can occur with the patient in supine position and once tumescent anesthesia is delivered. Key anatomic landmarks such as lower border and angle of mandible, anterior border of sternocleidomastoid, hyoid bone and thyroid cartilage, and proposed incision sites are marked. Depending on the areas that need to be addressed, incision sites can be planned in the following areas: submental (most common), preauricular, postauricular hairline and infralobular. Submental incisions provide access to central cervical liposity while the latter provide access to more lateral regions including the jowls. Placing an incision in the submental crease could lead to the development of a witch's chin deformity. This can be avoided by placing the incision anterior to the crease.

Anesthesia

The procedure may be performed solely using local anesthesia (1% lidocaine with 1:200,000 epinephrine) or under general anesthesia. A microcannula or a spinal needle is used to administer the tumescent fluid in the subdermal plane in a standard radial fashion with an in-and-out motion across the field to be treated. This pretunneling facilitates subsequent suctioning. A wait time of 15 minutes is recommended following administration of the tumescent fluid in order to achieve optimal vasoconstriction and regional anesthesia.

Liposuction Technique

Liposuction may be performed by the "open" (fat removal under direct vision by skin flap elevation) or "closed" (fat removal by blind insertion of a suction cannula in the subdermal plane and its to-and-fro motion) techniques. The closed liposuction technique is described in this chapter, and is preferred by the authors. The supraplatysmal fat compartment forms the majority (44.7%)[7] of the cervical adipose tissue and has a volume of no more than 10 to 15 mL.[8] This region is devoid of any vital neurovascular structures and is the plane in which cervicofacial liposuction is mostly performed. The subplatysmal plane contains the submental vascular plexus and the anterior jugular veins, which pose a significant bleeding risk if violated. Control of bleeding can be challenging due to limited surgical field exposure and visualization. This in turn may place the marginal mandibular nerve at risk if electrocautery is used to control the bleeding.

A wide range of liposuction cannulas of various shapes and sizes are available in the market. Cannulas ranging from 1.5 to 6 mm in external diameter are commonly used for cervicofacial liposuction. A larger sized cannula is preferred in the submental region where greater quantity of fat needs removal. Microcannulas are useful in the cheeks, jowls, and nasolabial folds and near vital structures such as the marginal mandibular nerve because they allow for fine sculpting and contouring. Blunt cannulas that have suction pores/lumen located a few millimeters away from the tip are preferred over sharp tipped cannulas or cannulas with pores at the tip because these are gentler on the tissues.

The negative pressure generated during the vacuum technique is set between 250 and 400 mm Hg, in order to prevent over-resection and destruction of normal adipose architectures, which are the main causes of contour irregularities.[9] Syringe assisted liposuction may also be used in the cervicofacial region. This technique will be discussed in detail later in the chapter. During liposuction, one hand (usually the dominant hand) maneuvers the suction cannula in the subdermal plane while the other hand utilizes tactile sensation to ensure correct placement (location and depth) of the cannula.

The lumen of the suction cannula should be directed away from the skin surface to avoid injuring the subdermal plexus. The cannula is moved in a standard radial fashion with an in-and-out motion, similar to the pretunneling technique used to administer tumescent fluid. This technique preserves a lattice-like connection of lymphatic and neurovascular tissues between the skin and subdermal layers. Suctioning should proceed from deeper to more superficial layers (Figure 23-1).

When addressing the jowls, finesse is needed to avoid skin surface irregularities. Smaller cannula sizes are typically used for fine sculpting. While head extension and lateral rotation of the neck provide appropriate positioning for suctioning the cheek, jowl, lateral neck, and jawline, the marginal mandibular nerve may drop as much as two fingerbreadths below the mandible, become more superficial, and pose a greater risk for nerve injury.[10]

Leaving an intact thin layer of supraplatysmal fat attached to the dermis is recommended to avoid skin contour irregularities. An obvious zone of demarcation between the treated and untreated areas can be avoided by feathering out past the preoperative skin markings.

The end-point of the procedure is determined by the pinch and roll technique as previously described. Only a thin layer of fat should be palpable between the fingers. Healing after liposuction continues for a few months and significant remodeling of the tissues due to fat necrosis and absorption can be anticipated. Hence, it is prudent to remove less rather than more fat.

Primary closure of the incisions is achieved using 5-0 polyglactin and 6-0 polypropylene sutures in a simple interrupted fashion. Open liposuction may be performed in

conjunction with other facial rejuvenation procedures such as rhytidectomy, submentoplasty or chin augmentation to further enhance facial esthetics.

Another option in the management of fat is sometimes used in lieu of or in conjunction with liposuction techniques. In 2015, Kybella (deoxycholic acid) was approved by the FDA for the use in reduction of moderate to severe supraplatysmal submental fat. Deoxycholic acid is a naturally occurring bile acid that aids in several processes such as cholesterol metabolism and the emulsification of fat-soluble vitamins for absorption. Deoxycholic acid has cytotoxic properties that destroy cells via plasma membrane disruption and cell lysis. When injected into fat cells, fat cell destruction occurs by lytic process. This treatment provides a minimally invasive alternative to submental liposuction. Kybella is supplied in 2-mL vials (10 mg/mL) and does not require reconstitution. The average initial treatment is usually 2 to 6 mL (one to three vials) depending on the amount of submental fat. Follow-up treatment can be repeated in 4 to 6 weeks, and a patient can receive up to six treatments. Kybella is indicated for isolated supraplatysmal fat deposits without skin excess. Some of the risks of adverse events include pain at the injection site, swelling, bruising, numbness, erythema, and induration. More serious side effects include injury to marginal mandibular nerve and dysphagia, but are reported infrequently.



• **Figure 23-1** This 29-year-old female had submental liposuction using a standard tumescent technique through a single submental incision. **A** and **B,** Preoperative frontal and lateral photographs; **C, D**, two weeks postoperative frontal and lateral photographs;



• **Figure 23-1, cont'd E, F**, one year postoperative frontal and lateral photographs. In all likelihood, as her skin ages, it may be helpful to consider platysma plication and/or skin excision/face-lift options as skin laxity increases. This case illustrates the difference between skin laxity issues and those due to submental fat deposits.

Postoperative Care

Postoperative care following cervicofacial liposuction involves intermittent ice packs during the first several days and head elevation while sleeping for the first week to decrease postoperative swelling. Patients are instructed to wear a light pressure garment consistently for the first 3 days and then only at night for the next month. Wearing a pressure garment during healing assists with elimination of dead space and holds the skin in the desired position to allow its reattachment to underlying tissues. Strenuous physical activity is avoided for 2 to 3 weeks after completion of the procedure.

Complications

Postoperative complications from cervical-facial liposuction are infrequent and often of a minor nature. Compared with full body liposuction, rapid fluid shifts, hypotension, and significant blood loss are less concerning. Infections are rare, particularly when sound surgical principles are utilized. Although hematomas, seromas, and prolonged postoperative edema are possible, they are quite rare. Small hematomas and seromas respond well to needle aspiration and continuous pressure dressings. Postoperative induration responds well to therapeutic ultrasound treatment. Permanent and/or temporary injury to the marginal mandibular branch of VII or the greater auricular nerve is extremely rare. If this occurs, the event is often temporary in nature. Subcutaneous scarring may occur, but is often related generally to aggressive surgical technique. Sometimes, liposuction can uncover underlying platysmal banding in older individuals. Mild cases can be treated with botulinum toxin A. Platysmaplasty is also an option for more significant deformities. Patients with excess adiposity should be re-treated, but after a waiting period of 4 to 6 months to allow edema to resolve and skin contraction to have mostly finished its course. Postoperative depressions may be treated with a filling agent such as autologous fat injection as described in the next section. As long as suctioning is carried out in the preplatysmal plane, creation of a submental depression or a "cobra deformity" will typically not be a problem. Excess sagging neck skin often results from patient selection issues as these patients would typically have a better result with a skin-tightening procedure.

Fat Grafting

Introduction

Fat grafting is not simply the opposite process of liposuction for those who lack shape and fullness. Volume restoration typically is helpful in completely different areas than the sites of treatment for liposuction. The contemporary conceptual understanding of the physiology of facial aging is that volume depletion along with loss of skin elasticity are responsible for the progressive clinical changes associated with aging. Hollowing of the temporal fossa and the submandibular region, malar fat atrophy, and flattening of the lateral brow due to loss of brow fat pad are some of the manifestations associated with volume depletion in the

aging face. When there is volume loss, treatment of skin redundancy alone can lead to an unnatural facial appearance sometimes seen with face-lifts or blepharoplasties.

Autologous fat transplantation is a minimally invasive facial rejuvenation technique that treats residual soft tissue defects caused by congenital abnormalities, aging, disease, and trauma by restoring facial volume and contour using fat harvested from an autologous source. It may be used as a stand-alone procedure or synergistically along with traditional lifting procedures. When used in combination, the treatment ideology is to use surgical lifts for treatment of skin redundancy and fat grafting for volume rejuvenation. This comprehensive approach often provides optimal and long lasting clinical results characterized by a natural and youthful rejuvenation of the facial complex. Fat transfer to the face was still in the top 10 cosmetic procedures in 2015 with 48,059 procedures performed nationwide, but not nearly as popular as liposuction.[1]

Although the use of fat as a tissue filler dates back a century, results were inconsistent largely due to highly variable resorption. It was not until the 1980s that there was new interest in fat transfer, owing in part to the growing popularity of liposuction. Refinement of surgical technique and a greater understanding of the cellular characteristics of subcutaneous fat led to improved results.

Although there has been a recent surge in the number of soft tissue filling agents in the market and advances continue to be made in the field of biomaterials, autologous fat is still a viable treatment agent. It has several characteristics of an ideal soft tissue filler: for most people it is readily available, is nonallergenic, carries no risk of disease transmission, is well-accepted, and is inexpensive. It is a living tissue that conforms well to the properties of the recipient site and thus may produce a more natural appearance. It is also a preferable choice when large quantities of fillers are required to restore full facial volume, which may not be feasible with synthetic fillers due to expense and the temporary nature of most materials.

Adipose Tissue Biology

An adipocyte is 50 to 150 mm in diameter (as it becomes larger, it dies from ischemia) and the lifespan is several to 10 years in humans.[11] There are various types of cells in subcutaneous adipose tissue, and adipocytes account for only 20% or fewer of the total number of cells.[12] Of this subpopulation of cells, the adipose-derived stem cells (ADSCs) have received significant interest over the past decade, including the biologic behavior of stem cells derived from fat for transfer into other areas for improved healing. ADSCs serve a number of functions and are believed to be a major contributor to the clinical benefits of the graft.

The "cell survival theory," which was first postulated in 1955 and maintains that transplanted adipocytes partly survive once they receive adequate nutrients and remain alive in the recipient site, has now been replaced by the "cell replacement theory," which holds that most adipocytes undergo ischemic death and subsequent replacement with next generation during the first 3 months after fat grafting.[11] Following fat grafting, the grafted nonvascularized adipose tissue loses mass due to the loss of blood supply and the graft is nourished by plasmatic diffusion from the surrounding host tissue for a few days until revascularization occurs. The fate of adipocytes in grafted fat and the long-term postoperative sequence after fat grafting are schematically represented in Figures 23-2 and 23-3.[11]

Patient Selection

Prior to formulating a surgical plan, it is essential to be fully aware of the patient's medical history and motivation for surgery, and discuss with the patient the expected treatment outcome. Caution must be exercised in patients that are extremely thin because fat stores will be limited. In aging patients that present with significant skin laxity, combining surgical lifts with fat grafting can provide better results in some patients. The overall appearance of the face can be changed significantly with a shift in facial proportions. Patients with more severe deformities such as those seen in Treacher-Collins syndrome, oculoauriculovertebral spectrum, patients with facial lipoatrophy, and those with post-liposuction defects may also be candidates for fat grafting.[13] The surgeon typically reviews past photographs with the patient to demonstrate progressive loss of soft tissue volume and identify the goals of fat grafting. Before and after photographs of other patients can also be used as a tool for educating prospective patients.

Preoperative Evaluation

Preoperative planning is an important key to a successful surgical result and a satisfied patient. In addition to the items discussed earlier in this chapter, a number of additional nuances should be considered. A complete analysis of the cervicofacial complex is undertaken with special focus on regions where volumetric rejuvenation is most effective. These areas include the eyebrow, temple, and upper eyelid in the upper third; lower eyelid, malar and submalar areas, and nasolabial fold in the middle third; and labiomandibular fold, prejowl sulcus, labiomental sulcus, and chin in the lower third.[14] Donor site selection for fat harvesting and anticipated postoperative recovery time of 2 to 3 weeks should be discussed in detail so that active patients can prepare appropriately.

Technical Considerations for Surgery

No standardized, universally accepted technical protocol exists for fat grafting. The technique mentioned here is based on the principles described by Coleman and Saboeiro[13] and emphasizes minimally invasive extraction of fat and its centrifugation, followed by injections of micro-particle fat isolates in multiple tissue planes.

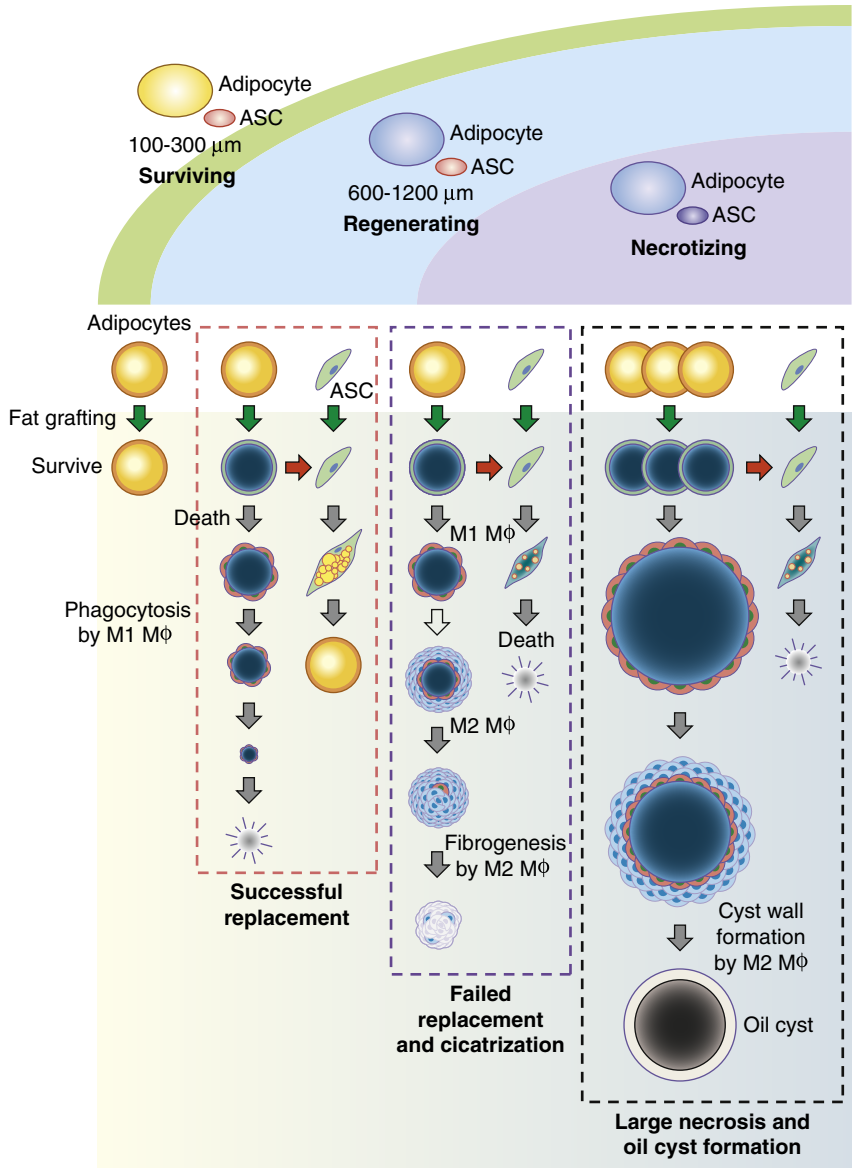

• **Figure 23-2** Conclusive schema for the fate of adipocytes in grafted fat. During the first 3 months of adipose tissue remodeling, transplanted adipocytes have differential fates depending on their microenvironments. In this schema, complex cellular events are simplified and the adipocyte fate is categorized into four patterns: survival, successful regeneration, failed regeneration (cicatrization), and oil cyst formation. Cicatrization and oil cyst formation are often not complete at 3 months. The most superficial zone is the "surviving zone," which is less than 300 μm thick. In the surviving zone, both adipocytes and adipose-derived stem cells (ASCs) survive. The second zone is the "regenerating zone," the thickness of which varies (600 to 1200 μm) depending on the microenvironmental conditions. In this zone, adipocytes die but ASCs survive and provide new adipocytes to replace the dead ones. The most central zone is the "necrosis zone," where both adipocytes and ASCs die, no regeneration is expected, and the dead space will be absorbed, be filled with fibrosis, or develop into an oil cyst. (From Mashiko T, Yoshimura K: How does fat survive and remodel after grafting? *Clin Plast Surg* 42(2):181-190, 2015.)

After the complete procedure has been planned, markings of the fat procurement as well as recipient site should be made preoperatively with the patient in an upright position. Small access openings should be placed in areas of skin folds, stretch marks, scars, and hair bearing areas to make them less conspicuous. These markings are done prior to the use of local anesthesia with vasoconstrictor.

The procedure may be performed under general or local anesthesia. Infiltration of 0.5% lidocaine with 1:200000 epinephrine is used to anesthetize the procurement site using a blunt infiltration cannula. The amount of solution infiltrated is typically equal to the amount of fat removed. Current evidence suggests that using tumescent solution at the time of fat graft harvest does not have a detrimental effect on fat graft cell viability and may even enhance viability.[15] Local infiltration of 0.5% lidocaine with 1:200000 epinephrine at the preoperatively determined recipient sites helps with local anesthesia as well as minimizes the risk of

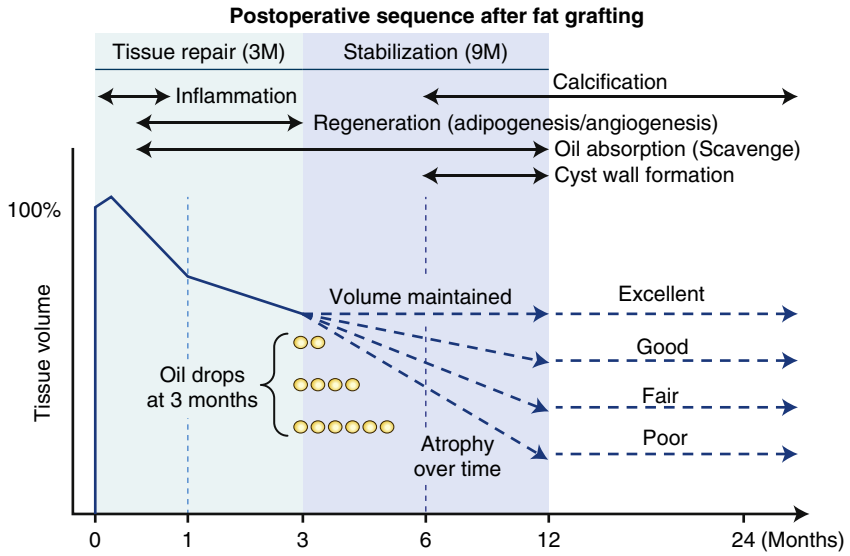

• **Figure 23-3** Long-term postoperative sequence after fat grafting. Adipogenesis after adipocyte death is exerted by activated adipose-derived stem cells (ASCs). Some of the dead adipocytes are replaced with new adipocytes of next generation and the adipogenesis is finished by 3 months (tissue "repair" phase). Dead adipocytes remaining at 3 months are absorbed during the next 9 months (tissue "stabilization" phase). Lipid droplets (dead adipocytes) are absorbed by macrophage phagocytosis, but the absorption is very slow and the absorption period depends on the diameter of the lipid droplets; when the lipid droplet diameter is large, such as 10 mm, the cyst wall is formed before completing absorption and the cyst wall starts to calcify over time. The final volume retention after fat grafting is determined by the rate of successful replacement of adipocytes. If grafted adipose has only small lipid droplets and absorption is finished by 3 months, the volume will not substantially change after 3 months (shown as "excellent"). On the other hand, if many large lipid droplets remain at 3 months, tissue will atrophy between 3 and 12 months (shown as "poor"). (From Mashiko T, Yoshimura K: How does fat survive and remodel after grafting? *Clin Plast Surg* 42(2):181-190, 2015.)

iatrogenic fat embolism due to vasoconstriction of the blood vessels. The maximum dosage of all medications should be considered when planning these procedures, particularly with local anesthetics used in body procedures.

Fat Procurement

Harvested fat remains most viable when there is minimal change in its architecture. Fat should pass intact through the lumen of the cannula during harvesting as well as injection in order for the transplant to be successful. Sites selected for harvesting are usually those where fat is resistant to diet and exercise. In general, the lateral abdomen, posterior hip, back, and lateral thighs are more forgiving and do not have as much potential to wrinkle as the abdomen and medial thighs. In thin patients, small harvests from multiple areas are required. Current data suggest no significant difference in cell viability in adipose tissue removed from four of the most common donor sites: the abdomen, flank, thigh, and knee with handheld syringe aspiration.[15]

Fat procurement is usually done with the patient in a supine position. Symmetry should be maintained when harvesting from bilateral sites. A No. 11 blade may be used to make a small stab incision through which a blunt tipped fat harvesting cannula, usually ranging from 2.1 to 2.4 mm, is passed without friction against the surround skin. Next, a 10-mL syringe is attached to the cannula and the syringe plunger gently retracted by 1 to 2 mL at a time. This limits vacuum barotrauma to the adipose tissue. Although syringe aspiration with low negative pressures is used most often for fat harvest, there is evidence to suggest that no difference exists in cell viability between syringe aspiration and liposuction pump aspiration.[16]

The cannula is advanced in a standard radial fashion with a back-and-forth motion as previously described in the liposuction section of this chapter to maximize fat harvest and minimize contour irregularities. Following the fat harvest, stab incisions are closed primarily using 6-0 nylon in a simple interrupted fashion. The surgical site is then cleaned and a dressing is applied.

Fat Preparation Prior to Grafting

Procured fat is generally not uniform in character and concentration as extracted and some type of processing is necessary to obtain uniform material for injection.[17] Many techniques exist for processing fat, including centrifugation, gravity separation, washing, and filtration. Centrifugation is most commonly used, and is undertaken in a sterile fashion at 3000 rpm for 3 min following which the unprocessed fat separates into three layers: infranatant (blood and lidocaine), central core of fat, and supranatant (oily residue of free fatty acids from ruptured fat cells). The central core of fat, which contains a greater number of adipose cells/mL when compared to the unprocessed fat, is then isolated by decanting the infranatant and supranatant layers. A sponge can be used

to remove any residual oil at the top. Exposure to air should be minimized. Typically, centrifugation retains 50% volume of the unprocessed fat such that for every 10 mL of procured unprocessed fat, the approximate yield of processed fat following centrifugation will be 5 mL. The fat isolate is then transferred to 1-mL syringes in preparation for fat transfer.

Fat Injection

Fat should be injected soon after procurement. Small access openings are created with an 18G needle and 0.7-mm to 1.2-mm injection cannulas are utilized for fat delivery in the appropriate tissue plane. The puncture sites made for access are so small that they usually do not require suturing upon completion of the procedure. It is important to inject fat in small increments. This allows for a larger contact surface area of the injected fat with the recipient tissue, which is critical for adequate nutrition and fat engraftment. In areas that are less forgiving, such as the periorbital region, 0.03 to 0.05 mL is injected per pass. In more robust regions, such as the prejowl sulcus and mid-face, 0.1-mL injections can be performed in each pass.[14] Typically, 20 or more back-and-forth passes in a fan-like manner are made to empty a 1mL syringe. Transferring large globules of fat can result in central necrosis of the mass with subsequent resorption and loss of volume, or cyst formation.[13]

Fat can be placed at different levels to accomplish different effects. For example, grafting fat immediately beneath the dermis can improve the quality of the skin, decreasing rhytids, decreasing pore size, and even reducing scarring. Special care must be taken when placing fat superficially, as irregularities are more apt to be apparent in this plane. This is especially true in areas that have thin skin, such as the lower eyelid. To make changes in the shape of the face or body that relate to the underlying bony skeleton, fat can be placed above the periosteum.[13]

Fat injection should start deep and progress superficially in order to maintain tissue integrity. Injecting from two separate injection sites allows crisscrossing of cannula passes during graft placement, provides smoother fat infiltration, and helps avert a row-of-corn effect that may result if injection is made from one site.[17] Fat should be injected upon withdrawal to avoid iatrogenic fat embolism. Precise positioning of fat increments is important because it is difficult to mold the graft once it has been placed. Similar to liposuction, the operative end-point should always be undertreatment versus overtreatment. On average, 30 to 50 mL of fat is a common amount for a semiconservative full-face fat transfer, with over 60 mL representing a more aggressive strategy.[14] When fat grafting is performed in conjunction with rhytidectomy, it is often most beneficial to inject fat at the beginning of the procedure, before the face-lift has been performed.[17]

Postoperative Care

Minimal active postoperative care is typically required following fat grafting. Placement of sutures, dressings, or drains is not required unless the procedure has been undertaken in conjunction with rhytidectomy. Intermittent cold therapy for the first 48 to 72 hours following surgery may be beneficial to help limit swelling. Head elevation during sleep helps facilitate a decrease in postoperative edema. Minimum manipulation of the surgical sites and avoidance of strenuous physical activity for the first couple of postoperative weeks is recommended. Postoperative swelling as a general rule is proportional to the amount of fat transferred. Swelling and ecchymosis are generally most pronounced around the periorbital and lip regions. Some pain, ecchymosis, and discomfort are also to be expected at the fat harvest site. Two to 3 weeks of limited activity should be discussed with the patient preoperatively. Additional time off from work may be necessary in some cases as postoperative edema, although resolving, can persist for 3 to 4 months. Retreatment is typically deferred until 6 months to allow for postoperative volumetric changes to stabilize.

Complications

Complications from fat transplantation are rare and rarely are they significant. One of the more common issues is overtreatment, particularly in the infraorbital and periorbital areas. Small fat cysts may form; however, this can be avoided by injection of the micro aliquots of fat. Fat hypertrophy can occur with significant weight gain. Nodules can form from placing the fat too superficially. Nodules and calcifications can be treated with intralesional steroid (10 mg/mL), ultrasound, massage, and, rarely excision. Infection is another possible complication, even in the setting of preoperative antibiotics.

The propagation of emboli from an intravascular injection is the most significant complication. This risk can be decreased through the use of small blunt cannulas for fat injection. Injection should be initiated after the cannula has been checked with an aspiration technique to note its position outside of the lumen of a vessel. Other maneuvers that can minimize this risk include retrograde filling, low injection pressure, and avoidance of fat transfer into previously traumatized tissue. Disruption of the blood supply to the skin is rarely an issue, but can occur. If blanching of the skin occurs, the surgeon can apply nitropaste to the area, place the patient in Trendelenburg position, and massage the area until blanching resolves and skin flush returns. Lastly, muscle dysfunction may temporarily occur with injection of fat into the muscle.

References

1. American Society for Aesthetic Plastic Surgery: 2015 Cosmetic Surgery National Data Bank Statistics. http://www.surgery.org/sites/default/files/ASAPS-Stats2015.pdf.
2. Chung J, Williams III E: Facial suction lipectomy. In Azizzadeh B, Murphy M, Johnson Jr C, editors: *Master techniques in facial rejuvenation*, ed 1, Philadelphia, 2007, Saunders/Elsevier, pp 227–245.

3. Haack J, Friedman O: Facial liposculpture, *Facial Plas Surg* 22(2):147–153, 2006.
4. Klein J: Tumescent technique for regional anesthesia permits lidocaine doses of 35 mg/kg for liposuction, *J Dermatologic Surg Oncol* 16(3):248–263, 1990.
5. Hanke C, Lawrence N, Ochoa S, Countryman N, Sattler G: Liposuction. In Robinson J, Hanke C, Siegel D, Fratila A, editors: *Surgery of the skin*, ed 3, London, 2015, Elsevier/Saunders, pp 221–463.
6. Ellenbogen R, Karlin J: Visual criteria for success in restoring the youthful neck, *Plas Reconstruct Surg* 66(6):826–837, 1980.
7. Larson J, Tierney W, Ozturk C, Zins J: Defining the fat compartments in the neck: a cadaver study, *Aesthetic Surg J* 34(4): 499–506, 2014.
8. Fattahi T: Submental liposuction versus formal cervicoplasty: which one to choose? *J Oral Maxillofac Surg* 70(12):2854–2858, 2012.
9. Hwan K, Myun C, Jung H: Treatment of liposuction complications. In Rubin J, editor: *Body contouring and liposuction*, ed 1, Edinburgh, 2013, Elsevier Saunders, pp 503–512.
10. Stebbins W, Kaminer M, Hanke C: Rejuvenation of the neck using liposuction and other techniques. In Robinson J, Hanke C, Siegel D, Fratila A, editors: *Surgery of the skin*, ed 3rd, London, 2015, Elsevier/Saunders, pp 649–665.
11. Mashiko T, Yoshimura K: How does fat survive and remodel after grafting? *Clin Plas Surg* 42(2):181–190, 2015.
12. Eto H, Kato H, Suga H, Aoi N, Doi K, Kuno S, et al.: The fate of adipocytes after nonvascularized fat grafting, *Plast Reconstruct Surg* 129(5):1081–1092, 2012.
13. Coleman S, Saboeiro A: Structural fat grafting. In Neligan P, editor: *Plastic surgery*, ed 1, London, 2013, Elsevier Saunders pp 327–228.
14. Lam S, Glasgold M, Glasgold R: Complementary fat grafting. In Azizzadeh B, Murphy M, Johnson Jr C, editors: *Master techniques in facial rejuvenation*, ed 1, Philadelphia, 2007, Saunders/Elsevier, pp 247–259.
15. Strong A, Cederna P, Rubin J, Coleman S, Levi B: The current state of fat grafting, *Plast Reconstruct Surg* 136(4):897–912, 2015.
16. Sinno S, Wilson S, Brownstone N, Levine S: Current thoughts on fat grafting, *Plast Reconstruct Surg* 137(3):818–824, 2016.
17. Marten T, Elyassnia D: Fat grafting in facial rejuvenation, *Clin Plast Surg* 42(2):219–252, 2015.

24

Botulinum Toxin and Facial Chemical Peels for Skin Enhancement

FAISAL A. QUERESHY, ANDREI MARECHEK

"Not for Wrinkles—Botulinum toxin type A has been promoted for use as a wrinkle remedy. Apparently, some practitioners have been injecting the substance to ease wrinkles by weakening face muscles. In a November 18, 1994, Federal Register notice, the FDA denounced the promotion of such unapproved use as 'an egregious example of promoting a potentially toxic biologic for cosmetic purposes.' "[1]

Botulinum Toxin

Botulinum toxin, or Botox, was first described as a lethal "sausage toxin," and is an extremely effective injectable neuromodulator that has changed the way providers approach cosmetic procedures. The Food and Drug Administration of the United States (FDA) first approved use of Botox for cosmetic purposes for use in the glabellar region in 2002. Today, Botox is FDA approved for cosmetic use in reduction of glabellar and lateral canthal lines. Additionally, Botox has been approved for numerous noncosmetic procedures. Botulinum toxin type A is currently commercially available in three formulations in the United States: OnabotulinumtoxinA known as Botox (Allergan, Inc., Irvine, CA), Abobotulinum toxin A known as Dysport (Ipsen Limited, Slough, United Kingdom), and Incobotulinum toxin A known as Xeomin (Merz Pharmaceuticals, Greensboro, NC). Rimabotulinum toxin B is the established name for botulinum toxin type B, which is commercially available as Myobloc or NeuroBloc (Solstice Neurosciences Inc./Eisai Co., Ltd.)

History and Pharmacology

Botulinum toxin is an exotoxin produced by the obligate anaerobe *Clostridium botulinum*. *Clostridium botulinum* is a spore-forming, gram-positive rod found in the soil. The exotoxin is an A-B neurotoxin, or type III toxin, that consists of two polypeptides. Part A causes the action of the toxin, and part B binds to the host cell. Of all natural toxins, botulinum toxin is the most potent. Multiple serotypes of the toxin—A, B, C1, C2, D, E, F, and G—are produced by bacteria. Of these serotypes, A is the most potent. Types A, B, and E are the most likely causes of human disease, while toxins C and D do not appear to affect the human nervous system.[2] The toxin binds to the presynaptic neuron of the neuromuscular junction via presynaptic cholinergic receptors. The toxin is then internalized into the cell and acts by cleaving components of protein complex SNARE that is normally responsible for exocytosis of acetylcholine. This results in inhibition of acetylcholine release and therefore a neuromuscular blockade and flaccid paralysis. The different serotypes of botulinum toxin differ by site of cleavage of the SNARE complex.

This toxin causes the disease botulism, which is a form of food poisoning. The disease was first noted and described by Justinus Kerner between 1817 and 1822 when he noticed an association between consumption of blood-sausages and food poisoning,[3] hence the name "Botulus," which is Latin for "sausage." Symptoms of the disease usually occur within a day or two. Nausea is followed by blurred vision, muscle weakness, and, finally, respiratory or cardiac failure. The disease is rare today because nitrites added to food prevent the growth of bacteria. Heating will destroy the toxin, but not the spores. The toxin will not form in highly acidic foods.[4] In adults, competing bacteria prevent formation of the toxin by ingested bacteria. In infants, competing microorganisms have not been established. Many cases of infant botulism have been reported after honey ingestion, so it is recommended that children younger than 1 year of age not be fed honey.

Botulinum toxin itself was first isolated and was associated with *C. botulinum* by Van Ermengem.[3] Therapeutic purposes of the toxin were not investigated until the 1970s. Use of Botox for reduction of facial lines was reported in 1992. It is currently used for many conditions in which relaxation of muscles will provide the desired result. Glabellar and canthal lines, overactive bladder, urinary

incompetence, headaches, limb spasticity and dystonia, axillary hyperhidrosis, blepharospasm, and strabismus are examples of the conditions for which botulinum toxin is an FDA-approved treatment.

Preparations

Botox or Botox Cosmetic (botulinum toxin type A) is supplied in 50- and 100-unit vials.[5] One unit is the median lethal dose (LD50) in mice. The estimated LD50 for a 70-kg human is 2800 units. The calculation of units is specific to each brand and cannot be compared with another product. The vial contains vacuum-dried toxin, human albumin, and sodium chloride. Botox is reconstituted with sterile saline. Nonpreserved saline is recommended, although some authors have used preserved saline,[6] and others have recommended addition of 1% lidocaine.[7] Various amounts of diluent may be used; common dilutions are shown in Table 24-1.

The package insert recommends that unopened vials of Botox should be stored at 2° C to 8° C for up to 24 months, and that reconstituted Botox should be stored under the same conditions and used within 4 hours. However, multiple studies have suggested that reconstituted BT-A can be safely used within 2 weeks.[8] A typical dose of Botox for the treatment of glabellar furrows is 20 units, and 12 units for lateral canthal lines (each side). Results are seen within 1 to 2 days, with increasing intensity noted in the first week.[5]

Dysport (botulinum toxin type A) is supplied in 300- or 500-unit vials as a lyophilized powder that must be reconstituted. Other constituents include human albumin and lactose. Although initially marketed in Europe, the U.S. FDA approved the use of this agent in 2009. The dose range for the treatment of glabellar furrows is 40 to 60 units.

Xeomin (botulinum toxin type A) is supplied in sterile 50 units or 100 units lyophilized powder that also must be reconstituted. The dose range for treatment of glabellar furrows is 20 units.

Myobloc (botulinum toxin type B) is supplied as a sterile liquid. Each vial contains toxin, human albumin, sodium succinate, and sodium chloride. Three different sizes are available: 2500 units (0.5 mL), 5000 units (1.0 mL), and 10,000 units (2.0 mL). The dose range for the treatment of glabellar furrows is 1800 to 3500 units. Myobloc is not FDA approved for cosmetic use, but several studies have shown its effectiveness.[9-11] Myobloc (pH 5.6) is more acidic than Botox (pH 7.2), and its duration of action is shorter. Botulinum toxin type B can be effective in patients who develop a tolerance to type A toxin, and it may have a faster onset of action.

TABLE 24-1 Botox Dilution Table

Vial	Diluent Added	Resulting Dose (Units per 0.1 mL)
100 Unit	2.5 mL	4.00 Units
50 Unit	1.25 mL	4.00 Units

Uses in Facial Cosmetics

Botox, Dysport, and Xeomin have been approved for cosmetic treatment in the United States. Although all three products are approved for treatment of glabellar lines, only Botox is approved for treatment of lateral canthal lines; any other use is considered off-label. More and more uses are being identified and have been described in peer-reviewed journals.[12-14]

Glabella

Treatment of glabellar furrows focuses on the corrugator supercilii and procerus muscles. Contraction of the corrugators and to a lesser degree the medial orbicularis oculi and the depressor supercilii produces vertical lines between the eyebrows. Contraction of the procerus produces horizontal lines over the bridge of the nose. The package insert for Botox Cosmetic recommends five injections of 0.1 mL (20 units total), with two injections into each corrugator and one into the procerus. Higher or lower doses can be used in keeping with the muscle strength of individual patients (Figure 24-1). In general, higher doses are needed for male patients. It is recommended that injections not be made closer than 1 cm to the orbital rim because of concerns about diffusion causing ptosis (Figure 24-2).



• **Figure 24-1** **A,** Glabella pretreatment. **B,** Glabella post treatment.

Forehead

The frontalis muscle produces horizontal forehead lines. The frontalis muscle has two bellies that are separated more superiorly than inferiorly. Injecting into the central tendon will have some effect because of diffusion but will not be as effective as injecting into the muscle itself. Evaluation of the patient to determine whether the frontalis is being used to elevate a ptotic brow is necessary prior to treatment. Unless a combination of procedures is planned, reduction of forehead lines with the result of brow ptosis should be avoided. The amount of Botox used will vary widely depending on the desired results. Relaxation of the entire frontalis muscle usually is not the goal. The lateral frontalis muscle is avoided to prevent brow ptosis. In the more medial area, slight relaxation is usually enough to decrease lines without completely paralyzing the muscle.

Crow's Feet

Lateral canthal lines are caused primarily by contraction of the lateral orbicularis oculi muscles. Contraction of the zygomaticus major can cause lines in the lower lid/upper cheek. As with the glabella, injections should be made 1 cm away from the orbital rim. If the zygomaticus major is to be injected, the patient should be warned that this could affect the smile line. Typically, a dose of 6 to 12 units is used on each side (Figure 24-3).

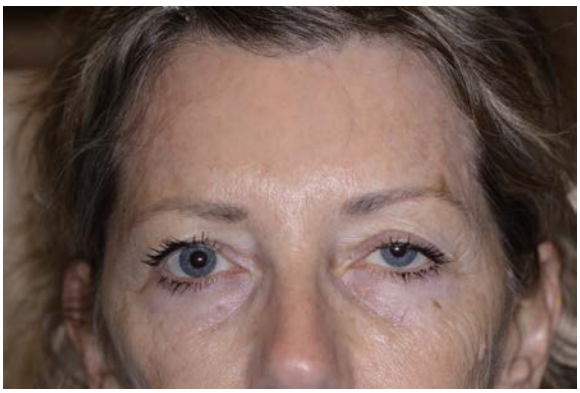

• **Figure 24-2** Ptosis following Botox treatment.



• **Figure 24-3** Botox treatment of crow's feet deformity.

Nasolabial Folds

Relaxation of the levator labii superioris alaeque nasi can decrease the depth of the medial nasolabial fold and has been used by some practitioners for treatment of excessive gingival display, or the "gummy smile."[12] This, however, can cause significant changes in upper lip animation, thus necessitating a thorough discussion with the patient prior to treatment. The dose used is 2.5 to 7.5 units per side.

Upper Lip

Perioral rhytides are caused by contraction of the orbicularis oris. These wrinkles often are addressed through resurfacing procedures or filler materials. These procedures can reduce the appearance of the rhytides but do not address the underlying cause. Doses of 2 to 6 units given at several injection points or use of the threading technique[15] will slightly relax the muscle. Care must be taken because higher doses can cause lip incompetence.

Chin

Dimpling of the chin can be improved by injection of the mentalis. This technique also has been used to correct abnormal contraction following chin implant or genioplasty. With mentalis dysfunction following surgery, deeper placement with a higher dose may be required. Doses range from 2.5 to 12.5 units for dimpling of the chin. Care should be taken to avoid the lip depressor muscles because, as with the upper lip, lip incompetence can result.

Neck

Hypertrophic platysma muscle banding is a frequent complaint among aging female patients. Patients with this condition can be treated surgically, but good results can be obtained with the use of Botox in patients without significant skin excess. Doses of 5 to 20 units per band injected directly into the muscle band usually will reduce both active and relaxed platysmal bands (Figure 24-4).

Treatment Technique

The patient should be evaluated with the risks and expected outcomes explained. A consent form should be reviewed and signed and preoperative photographs taken. The skin should be prepared with an alcohol swab. Application of topical anesthetic or ice may be desired by some patients. Having the patient flex the muscles planned for treatment will guide the injection. For the glabella, the patient should be asked to frown; for the forehead, the patient should be asked to raise the eyebrows; and for crow's feet, the patient should be asked to smile or squint. Botox should be prepared to the desired dilution and drawn into a syringe. Use of a ½-mL insulin syringe with a marking at each 0.01 mL allows for easy measurement of units of Botox based on dose (see Table 24-1). Botox should be injected directly into the muscle. Activating the muscle has been shown to increase uptake of Botox. Botox will diffuse to other areas to some degree. This effect is increased by massage and the use of higher volumes.



• **Figure 24-4** **A,** Neck pretreatment. **B,** Neck 1 week post treatment.

Some authors recommend massaging areas such as the forehead to disperse the toxin locally.[16] This should be avoided in areas where dispersion will lead to undesirable results, such as near the orbits. Following the procedure, some recommend no activity for several hours. Others recommend that the patient should remain upright. Effects are usually seen within 24 hours, and the intensity will increase to full effect within a week. Effects of the medication last for about 3 to 4 months, but with regular treatment, the effects often can last much longer. This may be due to atrophy of the treated muscles or to changes in habits.

Contraindications and Adverse Effects

As with all cosmetic procedures, patients who have unrealistic expectations should not receive Botox. Patients who may be allergic to any of the components, such as patients with allergies to cow milk, should not receive Botox. Botox is a category C drug that is not recommended during pregnancy. It is not known whether Botox is secreted in breast milk. Patients with neuromuscular disorders (amyotrophic lateral sclerosis, myasthenia gravis, Eaton-Lambert syndrome) may be extremely sensitive to systemic effects, especially dysphagia. Drugs that interfere with neuromuscular transmission (curare, lincosamides, polymyxins, quinadine, magnesium sulfate, anticholinesterases, succinylcholine) may potentiate the effects of Botox.[5]

Patient complaints of pain during injection vary widely. The use of topical anesthetic or ice can reduce the discomfort. The area of injection is often tender to palpation for a few hours afterward. Swelling is usually minimal and is localized to the sites of injection. Ecchymosis can occur. Care should be taken to avoid small vessels, especially in the lateral canthal area. It is best for patients to avoid aspirin, NSAIDs, and any other medication or herbal supplement that has anticoagulant properties for a week or longer prior to Botox injection.

Other local complications of Botox result from unintended relaxation of specific muscles or excessive relaxation of the treated muscle. Ptosis of the upper eyelid can occur if Botox diffuses to the levator palpebra superioris. This condition can be treated with apraclonidine 0.5% eyedrops, which, as an alpha-adrenergic agonist, stimulates the sympathetic Müller's muscle to contract producing 1 to 2 mm of eyelid elevation. Brow ptosis can occur if the frontalis muscle is over-relaxed. Diplopia can result if Botox diffuses into the orbit affecting the extraocular muscles. If diplopia is significant, an ophthalmology consultation should be obtained, and consideration may be given to injecting the antagonist of the affected muscle. Otherwise, these conditions will resolve as the medication loses its effects over 3 to 4 months.

Cheek or lip ptosis can occur when Botox is used in the mid-face. Lip incompetence can occur when Botox is used periorally. Careful placement of small volumes can prevent these problems. Patients occasionally complain of excessive elevation of the lateral brow (the "Spock" look) following treatment of the glabellar or forehead region. This condition is easily treated without ptosis of the brow by placing 2 units in the hyperactive area. Systemic reactions may include nausea, fatigue, and rashes. Dysphagia has been reported following treatment of cervical dystonia. In some cases, placement of a gastric feeding tube is required. Death following aspiration pneumonia has been reported.

With long-standing deep rhytides, some patients may not see a significant decrease in facial lines, even with relaxation of intended muscles. Other patients will develop antibodies to botulinum toxin A, causing a lack of effect. A meta-analysis reported 0.49% of 2240 patients exhibited seroconversion. A complete lack of response to treatment was only seen in 3 of the seroconverted patients.[17] Higher doses or more frequent intervals may be more likely to cause antibody formation. Substituting Myobloc (type B) for Botox (type A) can overcome patient resistance.

Chemical Peels

Chemical peeling (chemabrasion, chemosurgery, or chemexfoliation) is a skin resurfacing procedure by which caustic materials are used to remove layers of the epidermis and dermis in a controlled manner. New epidermal growth is stimulated, resulting in improved texture and even pigmentation. Healing following a chemical peel is a result of epithelial migration from adnexal structures.

History

Caustic preparations for peeling procedures using sour milk (α-Hydroxy acid) to aesthetically improve the skin were first

described in 1550 BC by ancient Egyptians. Dermatologists began using chemical peels in the mid-1800s to treat freckles and melasma, but publications about these procedures were rare until mid-century. Early publications often discussed the phenol peel, but other chemicals were also used.[18,19] As interest in chemical peels increased, various formulations were created and modified.

Indications

Chemical peeling alone or as an adjunctive procedure is indicated to treat actinic keratoses and fine rhytides, hyperpigmentations, shallow depressed scars, and acne. Some of these indications may be better treated by other means, such as resurfacing with dermabrasion or lasers or use of medications. Chemical resurfacing is best for patients with white skin, that is, Fitzpatrick classification types I to III. Type I patients always burn and never tan. Type II patients tan only with difficulty and usually burn. Type III patients tan but sometimes burn.

Contraindications

Patients with darker skin colors, including Fitzpatrick classification types IV thru VI, may have a higher incidence of complications if they receive chemical peels. Type IV patients rarely burn and tan with ease. Type V patients tan very easily and very rarely burn. Type VI patients tan very easily and never burn. These patients must be warned of the higher incidence of pigmentary changes, hyperpigmentation, hypopigmentation, and irregular pigmentation. Pigmentary changes also can occur in patients who are taking estrogens for hormone replacement therapy or for birth control. Systemic retinoid use can lead to post-treatment scarring. If a patient has taken retinoids in the previous year, treatment should be delayed. Although acne can be treated with superficial chemical peels, deeper peels can exacerbate acne. Acne should be controlled with antibiotics prior to resurfacing. A history of herpes labialis is not a contraindication to treatment because all patients should be given prophylactic antivirals, but active sores should be allowed to heal prior to treatment. It is important to review the expected outcomes with the patient, and what is achievable given the technique being utilized. If the patient's expectations do not correspond with expected results, the procedure should not be performed.

Depth of Peel

Superficial peels affect to the depth of the stratum granulosum of the dermis or into the papillary dermis. Medium-depth peels reach the upper reticular dermis, and deep peels reach the mid-reticular dermis. The depth of peel is evaluated on the basis of skin appearance. A peel into the papillary dermis will appear as a light frost with a pink background. The frost is caused by coagulation of proteins, and the pink background is provided by blood vessels of the papillary dermis. As the peel proceeds into the upper reticular dermis, the white frost will become a solid sheet. In the mid-reticular dermis, the white frost begins to turn gray.[20] Selection of appropriate depth of peel is critical to achieve desired results. Deep peels, although very effective, can have a high risk of complications such as scarring or hypopigmentation. Superficial peels, on the other hand, are less effective but offer a low chance of complications. Medium-depth peels are between these two depths.

Peeling Agents

Alpha-hydroxy Acids

Glycolic, lactic, citric, and tartaric acids are naturally occurring alpha-hydroxy acids. Glycolic acid, which is derived from sugar cane, is commonly used for superficial peels. It is used at various strengths. Low concentrations are used in home care systems and in skin conditioning programs in preparation for deeper peels. Higher concentrations are used alone or in combination with other peeling agents. After the acid has been applied and left in place for a minute or two, it must be diluted with water or neutralized with sodium bicarbonate.[21]

Jessner's Solution

Jessner's solution is a keratolytic that can be used by itself for a superficial peel or in combination with trichloroacetic acid (TCA) for a medium-depth peel. It contains 14% each of resorcinol, salicylic acid, and lactic acid in ethanol. Multiple applications are used to provide the desired depth of peel. Neutralization or dilution is not necessary.

Trichloroacetic Acid

TCA is used for superficial and medium-depth peels. Concentrations from 10% to 35% are used for superficial peels. In combination with Jessner's solution, 35% TCA will achieve a medium-depth peel. Fifty percent TCA has been used for medium-depth peels, but this is associated with increased scarring and pigmentation changes. TCA is a keratocoagulant that is self-neutralizing. Additional TCA may be applied after time is allowed for the first application to neutralize. This is done until an even frost is achieved at the desired depth.

Phenol

Phenol is a keratolytic that results in a deep peel. The Baker-Gordon formula for a phenol peel consists of 3 mL 88% phenol, 2 mL distilled water, 8 drops of Septisol soap, and 3 drops of croton oil. The Baker-Gordon formula allows for deeper penetration than would be achieved with pure phenol (88% in solution) by itself. This is so because pure phenol causes immediate keratocoagulation, which blocks deeper penetration. Phenol is rapidly absorbed and is partially metabolized by the liver and excreted by the kidneys. In addition to causing hepatic and renal toxicity, phenol can cause cardiac arrhythmias. Patients should be evaluated preoperatively to rule out hepatic, renal, or cardiac deficiencies. To minimize toxicities, one esthetic unit at a time is treated. Preoperative, intraoperative, and postoperative hydration with intravenous fluids is used to decrease renal toxicity.

Continuous cardiac monitoring is necessary during and for 2 hours after the procedure.

Preparation

Skin can be prepared for resurfacing procedures with topical tretinoin or glycolic acid for 4 to 6 weeks. Both allow for increased penetration by decreasing the thickness of the stratum corneum. Tretinoin also will increase the rate of reepithelialization. Hydroquinone may decrease the incidence of post-treatment hyperpigmentation.

All patients who undergo resurfacing procedures should receive prophylactic antivirals to prevent herpes simplex virus activation. Acyclovir or valacyclovir is started one day preoperatively and used for at least 7 days postoperatively. Antibacterial prophylaxis with cephalexin or an equivalent, and antifungal prophylaxis also may be considered.

Patients should be warned about what to expect as they recover from the chemical peel. For 7 to 10 days following a chemical peel, desquamation of the skin will progress. Patients may become alarmed if they are not prepared for their own appearance or for the length of time needed for recovery.

Procedure

The anesthesia used is based on the depth of peel and patient desires. Intravenous sedation with propofol works well for chemical peels because of its duration of action. Topical anesthetics may reduce the predictability of the depth of peel. Local anesthetic blocks can be used while avoiding epinephrine if a phenol peel is used.

The patient's skin should be prepared with a degreasing agent. Septisol, acetone, or alcohol may be used to degrease the skin. The peeling agent then is applied to each esthetic unit. The patient is observed for skin changes that may indicate that the planned depth has been reached (Figure 24-5). Neutralization is used if required by the peeling agent.

A fan directed at the patient's face will provide some comfort as the patient recovers. Cool wet sponges may help once the procedure is complete. Some recommend applying topical anesthetic after the procedure.

Postoperative Care

Analgesics usually are not necessary following superficial or medium-depth peels. Petroleum jelly, A&D ointment, or Complex Cu3 should be applied to the peeled area. Tape dressings have been used, but an occlusive dressing of petroleum jelly is almost as effective.[22] Petroleum jelly is easier to remove and allows observation of the wound. The patient is instructed to gently clean the area several times a day to remove peeling skin and to prevent crust formation. The ointment then should be reapplied. Peeling skin should not be pulled or rubbed off because this increases the risk for infection and scarring. Once reepithelialization is complete, the patient may return to the pretreatment facial care regimen. Makeup may be used, and sunscreen should be worn.



• **Figure 24-5** Application of Obagi Blue facial peel.

Complications

Pigmentary changes occur more often in patients with darker skin tones and with deeper depth of peel. Application of bleaching agents such as hydroquinone to hyperpigmented areas works well in diminishing these areas. No reliable treatment for hypopigmentation is known.

Scarring is more likely with deep peels or in patients who develop postoperative infection. Scarring is more likely to occur in skin overlying a bony prominence or in patients who have undergone concurrent procedures. Scars can be treated with massage, topical or intralesional steroids, silicone gel sheeting, or flashlamp pulsed dye laser.

Erythema should be expected in the weeks following a chemical peel. This can be hidden with makeup once epithelialization is complete. Prolonged erythema can be treated with topical steroids or flashlamp pulsed dye laser.

Infections can be avoided with the use of appropriate prophylactic antimicrobials. If an infection does occur, early diagnosis and treatment are necessary to avoid scar formation.

Milia can occur following a chemical peel. This condition is easily treated by unroofing the keratin-filled structure with a blade or a needle and expressing the contents.

Summary

Botox has been shown repeatedly to be a safe and effective way to reduce facial lines caused by muscle action. It can be used alone or as an adjunct to other facial cosmetic procedures.

Chemical peels represent one option for skin resurfacing. Although laser resurfacing has increased in popularity and the use of phenol has decreased due to safety concerns, chemical peels are an ever-evolving technique. Chemical peels are a cost-effective way to reduce facial rhytides and improve pigmentation.

References

1. FDA website: Available at www.fda.gov/fdac/features/095_bot.html. Accessed September 11, 2007.
2. Huang W, Foster JA, Rogachefsky AS: Pharmacology of botulinum toxin, *J Am Acad Dermatol* 43(2 Pt 1):249–259, 2000.
3. Erbguth FJ: Historical notes on botulism, *Clostridium botulinum*, botulinum toxin, and the idea of the therapeutic use of the toxin, *Mo. Disord* 19:S2–S6, 2004, http://dx.doi.org/10.1002/mds.20003m.
4. Tortora GJ, Funke BR, Case CL: *Microbiology: an introduction*, ed 8, Upper Saddle River, NJ, 2004, Benjamin-Cummings.
5. *Botox Cosmetic package insert*, Irvine, Calif, Allergan. September 2013.
6. Lowe NJ: Botulinum toxin type A for facial rejuvenation: United States and United Kingdom perspectives, *Dermatol Surg* 24:1216–1218, 1998.
7. Gasner HG, Sherris DA: Addition of anesthetic agent to enhance the predictability of the effects of botulinum toxin type A injections: a randomized controlled study, *Mayo Clin Proc* 75:701–704, 2000.
8. Liu A, Carruthers A, Cohen JL, et al.: Recommendations and current practices for the reconstitution and storage of botulinum toxin type A, *J Am Acad Dermatol* 67(3):373–378, 2012.
9. Sadick NS: Botulinum toxin type B for glabellar wrinkles: a prospective open-label response study, *Dermatol Surg* 28:817–821, 2002.
10. Sadick NS: Prospective open-label study of botulinum toxin type B (Myoloc) at doses of 2,400 and 3,000 U for the treatment of glabellar wrinkles, *Dermatol Surg* 29:501–507, 2003.
11. Spencer JM, et al.: Botulinum B treatment of the glabellar and frontalis regions: a dose response analysis, *J Cosmetic Laser Ther* 4:19–23, 2002.
12. Mazzuco R, Hexsel D: Gummy smile and botulinum toxin: a new approach based on the gingival exposure area, *J Am Acad Dermatol* 63(6):1042–1045, 2010.
13. Flynn TC, Carruthers JA, Carruthers JA: Botulinum-A toxin treatment of the lower eyelid improves infraorbital rhytides and widens the eye, *Dermatol Surg* 27(8):703, 2001.
14. Huilgol SC, Carruthers A, Carruthers JD: Raising eyebrows with botulinum toxin, *Dermatol Surg* 25(5):373, 1999.
15. Kane MA: Botox injections for lower facial rejuvenation, *Oral Maxillofac Surg Clin North Am* 17:41–49, 2005.
16. Benedetto AV: The cosmetic uses of botulinum toxin type A, *Int J Dermatol* 38:641–655, 1999.
17. Naumann M, Carruthers A, Carruthers J: Meta-analysis of neutralizing antibody conversion with onabotulinumtoxinA (BOTOX®) across multiple indications, *Mov Disord* 25(13):2211–2218, 2010.
18. Urkov JC: Surface defects of skin: treatment by controlled exfoliation, *Int Med J* 89:75, 1946.
19. Baker TJ: Ablation of rhytides by chemical means, *J Fla Med Assoc* 47:451, 1961.
20. Obagi S, Bridenstine JB: Skin resurfacing, *OMS Knowledge Update* 3:5–22, 2001.
21. Briden ME: Alpha-hydroxyacid chemical peeling agents: case studies and rationale for safe and effective use, *Cutis* 73(2 suppl):18–24, 2004.
22. Stuzin JM, Baker TJ, Gordon HL: The relationship of superficial and deep facial fascias: relevance to rhytidectomy and aging, *Plast Reconstr Surg* 89:441, 1992.

25

Otoplastic Surgery for the Protruding Ear

TODD G. OWSLEY, TINERFE J. TEJERA

Introduction

Auricular deformities, particular prominent ears, are a common congenital anomaly affecting nearly 5% of the white population. Children with auricular deformities are likely to experience ridicule by their peers. Prominent ears, commonly referred to as prominauris, can be predictably treated before children enter school, thus avoiding the emotional trauma caused by ridicule. Whereas cosmetic surgery is performed primarily in the adult population, otoplastic surgery is performed primarily on children and can be an invaluable service for the patient and satisfying for the surgeon.

Numerous publications have described the correction of auricular deformities. The surgeon must understand the history of these various techniques to develop a predictable and successful method of addressing the problem of prominent ears. Dieffenbach is credited with the first otoplastic technique to correct a prominent auricle in 1885. Ely, in 1881, authored the first case report describing correction of prominent ears in a 12-year-old boy who was being teased at school. Since that report, more than 170 surgical techniques have been described in the literature for the correction of prominent ears.

When clinically evaluating the facial complex, the ears often are overlooked. If protruding ears are present, reduction otoplasty as an adjunctive or isolated procedure can be predictably performed, often with satisfying results. A thorough understanding of the embryology and development of the human auricle, along with the resultant external anatomy of the ear, is of paramount importance in developing a reliable technique to deal with common auricular deformities.

Embryology of the Auricle

Malformations of the auricle are common, occurring in 1 in 12,500 births. They can occur alone or in combination with a syndrome affecting the head and neck structures. The embryogenesis of the auricle exemplifies in miniature the precise and logical progressions characteristic of the developing human form. The external ear development during the third to twelfth weeks of embryonic life is complex. The precursors to the auricle present from days 36 to 38 of intrauterine life, developing first from the first branchial groove where the first (mandibular) and second (hyoid) branchial arches are present (Figure 25-1). Both arches give rise to the auricular hillocks, often referred to as the auricular tubercles of His. Hillock numbers 1, 2, and 3 arise from the caudal border of the mandibular arch, and numbers 4, 5, and 6 are formed from the cephalic border of the hyoid arch. The auricular hillocks present in their most prominent and characteristic form by intrauterine day 41. During this same stage, the groove between the mandibular and hyoid arches (hyomandibular groove) widens and deepens by the increased growth of the hillocks. This groove eventually forms the external auditory canal and concha. By days 43 to 45, the hillocks have migrated and coalesced to form the

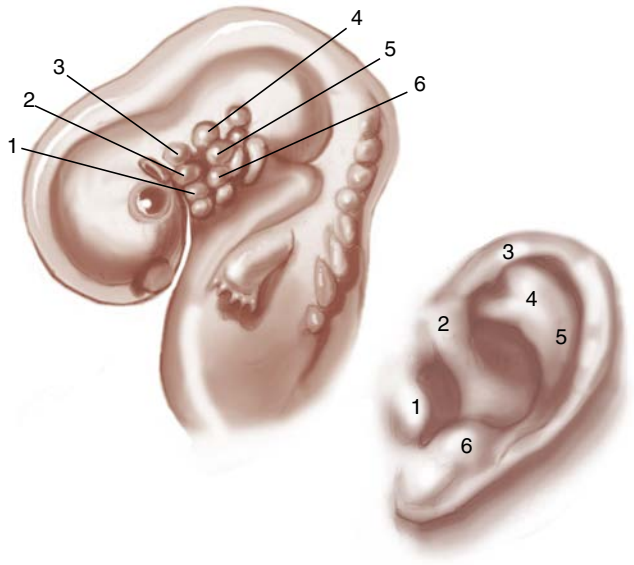

• **Figure 25-1** Development of the auricle from the first and second branchial arches.

auricle. During this union the mesenchyma of the hyoid arch increases substantially relative to the mandibular arch to contribute 85% of the external adult ear. Hillocks 2 and 3 from the mandibular arch lose their individuality and fuse to form the helical crus. Later, hillocks 4 and 5 from the hyoid arch merge and alter their configuration as they give rise to the helix and antihelical fold. Hillock 1 remains prominent and becomes the tragus, and hillock 6 becomes the antitragus.

Surgical Anatomy

The majority of the growth of the pinna is completed by an early age. The average child has 85% of ear development completed by age 3 years. The ear is nearly fully grown by the age of 7 to 8 years. Ear height continues to grow into adulthood, but the width and distance of the ear from the scalp change little after 10 years of age. Of note, a person's two ears often vary in size and shape from each other. The average adult ear is approximately 6.5 cm in length and 3.5 cm in width. In the "normal" ear, the auricle lies between horizontal lines drawn from the upper rim of the orbit and the nasal spine. The normal posterior wall of the conchal bowl is set at an angle of approximately 90 degrees to the mastoid. A second 90-degree angle is formed at the antihelical fold and is called the scapha-conchal angle. These two angles, in combination with the curvature of the helix, set the auricle adjacent to the scalp at approximately 25 to 35 degrees, forming the auriculocephalic angle (Figure 25-2). When correcting prominent ears, three important anatomic "pearls" can be used intraoperatively to assess the final result: (1) the helical rim should be seen just lateral to the most lateral presence of the antihelix from the frontal view; (2) the distance measured between the helical rim and the mastoid area is slightly less than 2 cm; and (3) the distance between the skull and the uppermost aspect of the helix is approximately 1 cm (Figure 25-3).

The auricular cartilage is a unique, intricately shaped, and delicate structure with multiple elevations and depressions that provide both skeletal support and form to the adult ear. The cartilage of the auricle is a single piece of yellow (elastic) fibrocartilage with a complicated relief on the anterior, concave side and a smooth, posterior, convex side. Cartilage thickness is fairly uniform throughout. The cartilage is covered on both surfaces by a thin, firm, adherent layer of perichondrium. The anterior lateral surface of the cartilage is covered with fine, thin skin, closely adherent to the cartilaginous framework. Subcutaneous fat is practically nonexistent, but a diffuse

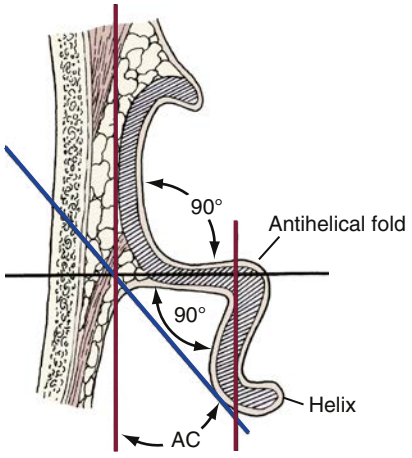

• **Figure 25-2** An axial section at the level of the helical crus demonstrates the ideal auriculocephalic angle *(AC)* of 30 degrees. (Modified from Tanzer RC: Congenital deformities. In Converse J, editor: *Reconstructive plastic surgery, vol 4,* ed 2, Philadelphia, 1977, WB Saunders.)

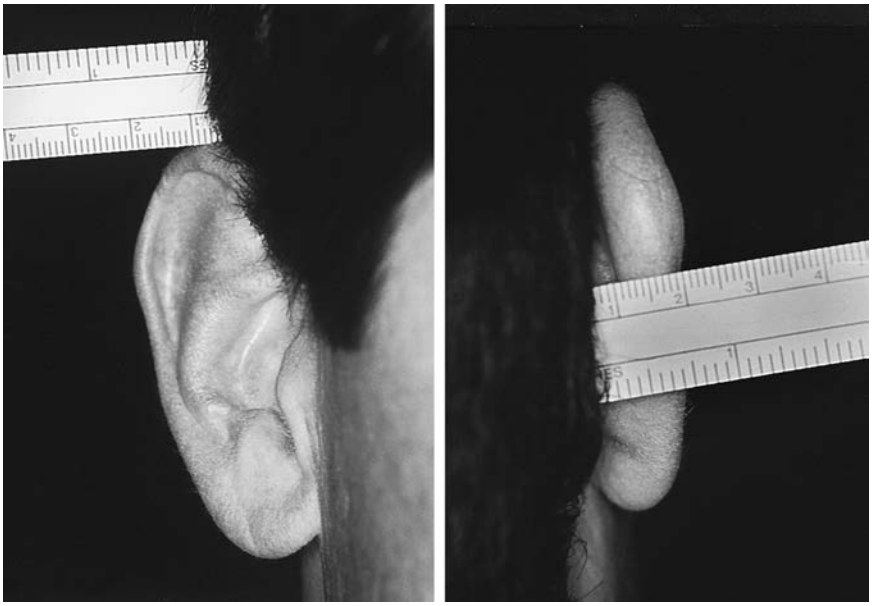

• **Figure 25-3** Anatomic "pearls" that are useful intraoperatively.

subdermal vascular plane exists that supports flap viability. The posterior surface of the cartilage framework is draped with less-adherent skin that contains two layers of fat and a larger subdermal plexus of arteries, veins, and nerves.

A helical border terminates anteriorly in a crus that lies almost horizontally above the external auditory meatus. The antihelix crowning the posterior conchal separates and diverges into both a superior and an anterior crus enclosing the triangularis fossa. Between the helix and the antihelix lies a long, deep furrow called the scapha. The conchal cavity, composed of the cymba (superior) and cavum (inferior) concha, arises from the floor, which is at least 1 cm deeper than the overlying tragus and antitragus. The inferior tip of the helical cartilage is referred to as the cauda, and extending from this inferiorly is the lobule, which hangs without any skeletal framework (Figure 25-4).

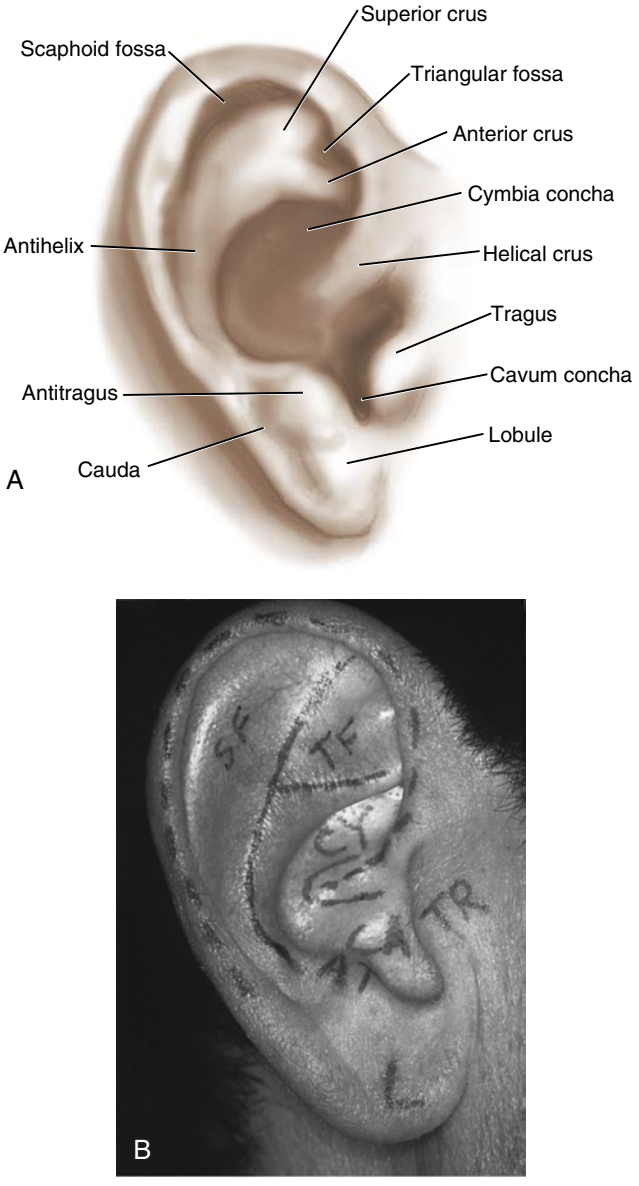

• **Figure 25-4** **A** and **B,** Anatomy of the external ear.

Blood Supply

The arterial blood supply to the ear is principally derived from two main branches of the external carotid artery: the superficial temporal artery and the posterior auricular artery. The superficial temporal artery emerges from the parotid capsule 1 cm in front of the ear deep to the veins and below the anterior auricular muscle. It gives off the superior, medial, and inferior branches, supplying the anterior and anterolateral surface of the auricle. The posterior surface is dominantly supplied by the posterior auricular artery, which travels parallel to the postauricular crease upward, crossing below the great auricular nerve and under the posterior auricular muscle. Awareness of this relation is important to avoid damage to the artery or nerve during surgery. The posterior auricular artery gives off three branches—superior, medial, and inferior—that provide a greater volume of blood to the postauricular ear than its anterior counterparts. These same vessels perforate the auricular cartilage over a large surface of the anterior ear and anastomose with the branches of the superficial temporal artery. The external ears have a tremendous blood supply, allowing multiple surgical approaches and salvage of the ear after traumatic avulsion.

Venous drainage of the ear by way of the complementary veins is into the external jugular vein. Lymphatic drainage is into three surrounding areas by way of the complex and extensive network of lymphatic vessels.

Nerve Supply

The sensory nerve supply is primarily from the anterior and posterior branches of the great auricular nerve. The nerve is an important surgical landmark, traveling 8 mm posterior to the postauricular crease. When dissecting in this area, care must be taken to avoid damage to the nerve, which can result in near complete anesthesia to the ear. Less-important contributions to sensation are made by the auriculotemporal and lesser occipital nerves to the conchal cavity and external auditory meatus (Figure 25-5, *B*). Regional anesthesia of the auricle is readily accomplished by instilling anesthetic solution along its base anteriorly and posteriorly (Figure 25-6). Supplemental anesthesia may be needed at the posterior wall of the external auditory meatus supplied by the auricular branches of the vagus nerve (nerve of Arnold).

Congenital Deformities

Ear deformities are common and variable because of the complex embryologic engineering that takes place in the development of the auricle, as previously described. Many classification systems of ear deformities have been attempted. Tanzer classifies congenital ear defects, correlating embryologic development with a surgical approach for correction of the deformity. Marx has a well-accepted classification system subdividing microtia into three groups according to severity. Rogers simplifies classification of congenital ear defects, dividing them into four groups

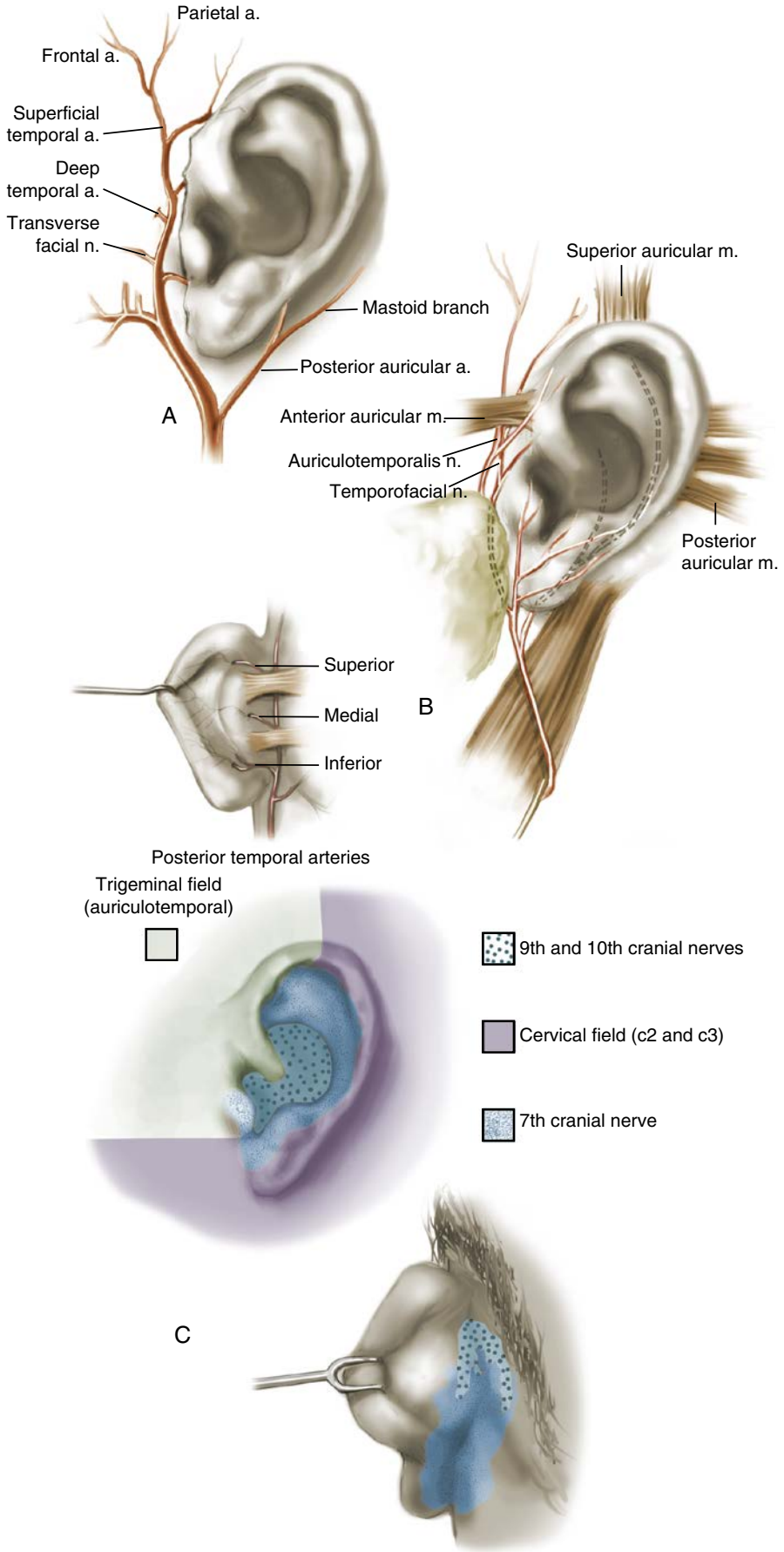

• **Figure 25-5** **A,** Arterial blood supply. **B,** Nerve supply. **C,** The cutaneous innervation of the ear on the anterior and posterior aspects. The areas may overlap and vary with each individual.



• **Figure 25-6** Technique to provide regional anesthesia of the auricle.

according to various stages of arrested development: microtia, lop ear, cup ear, and protruding ear. In this chapter, the term *protruding* is used to refer to any ear that is more prominent than is considered normal. Classifying other congenital abnormalities and their corrections is beyond the scope of this chapter.

In patients with protruding ears, two major deformities individually or in combination account for the majority of abnormalities. Several lesser deformities can accentuate the abnormality as well. The most common deformity seen is a poorly developed antihelical fold, which can involve both the superior and the anterior crura. This eliminates a definition between the conchal cavity and scapha, resulting in the lateral projection of the upper portion of the helix. The second abnormality seen is the formation of excessive conchal cartilage, in particular the posterior conchal wall. This causes significant protrusion of the auricle. Both abnormalities causing the protruding auricle to some degree is not an uncommon finding.

Other deformities include a protruding earlobe and irregularities along the helix, including an unrolled margin of the helical rim and an anteromedially displaced insertion of the postauricular muscle. Of importance, this last deformity often is bilateral and can be associated with ossicular deformities and a hearing deficit.

Precise recognition of the cause or causes of the protruding ear obviously is crucial in formulating the surgical technique to correct the abnormality.

Surgical Correction

Indications and Timing

Perhaps the most important indication for surgical correction of prominent ears is to eliminate the psychosocial effects of the ear defect. Macgregor has documented the irreversible social and psychological consequences of facial anomalies, especially of the ears. Ridicule by peers begins as early as age 4 to 5 years, during development of the body image concept. This leads to problems with social adjustment, self-image deficit, and ultimately behavioral disorders. Therefore most patients present at an early age for surgical correction. The elective correction of protruding ears is recommended starting at approximately age 5 years according to the literature. This then becomes one of the most common elective procedures performed in young children. The next most represented group are adults in their fourth decade of life. This finding may be attributable to a national trend toward more cosmetic procedures being performed among adults in general.

Techniques

Many otoplasty techniques described in the surgical literature are similar and have evolved over an 80-year experience. Many techniques address only the conchal hypertrophy without mention of the antihelical fold. The described techniques generally can be subdivided into suture-only techniques, cartilage-splitting or cartilage-weakening techniques, or a combination of the two.

Furnas described his suture-only technique for correction of prominent ear deformity in 1968. It consists of a postauricular approach, removing the vestigial posterior auricular muscle and its ligament down to the underlying mastoid fascia. Two to three nonresorbable sutures are placed through the conchal cartilage and mastoid fascia and tightened to the new, retracted position of the ears. This is still a commonly used technique to set back the ears in patients with conchal hypertrophy alone. Problems associated with this technique have been relapse attributable to cartilaginous "memory" and irregularities created in folding the conchal floor. Another problem is displacement of the conchal bowl anteriorly, creating stenosis of the external auditory canal.

The Converse-Wood-Smith technique is used to correct and create an antihelical fold with a cartilage cutting and suture method. Several full-thickness cuts through cartilage are placed in the scaphoid fossa. The cartilage is then folded on itself, described as "tubing," and permanent horizontal mattress sutures are placed, forming the new antihelical fold. Excessive conchal cartilage can be addressed with a cartilage incision added at the rim of the bowl to reduce the bowl and retract the ear. A new antihelical fold is formed, but at the expense of sharp cartilaginous ridges seen through the thin anterior auricular skin.

Following are three techniques addressing the two fundamental abnormalities in protruding ears that have produced consistent, satisfying cosmetic results with low

recurrence rates. The Davis method addresses the protruding ear caused by a hypertrophic posterior wall of the conchal bowl, and the Mustardé method is used to create a new antihelical fold (Figure 25-7). The Farrior method addresses both the conchal bowl and the antihelical fold as one technique. The refinement of other abnormalities, such as a prominent earlobe, also is discussed.

Davis Method

The Davis method, used for the correction of conchal hypertrophy, is a cartilage excision technique performed in a stepwise fashion.

Marking the Cartilage Excision

The area of cartilage to be removed is initially marked on the skin of the anterior surface of the conchal bowl. Methylene blue transfixion tattoos are preferred to mark the posterior surface of the conchal cavity. The line lies just below the lower crus border, carries forward into the cymbal fossa, and continues around as an "arrowhead" to preserve a well-defined helical radix. The tracing should continue forward against the posterior edge of the external auditory canal. From that location, it curves posteriorly into the cavum concha, continuing to the posterior conchal wall, leaving 8 mm of posterior conchal wall height measured from the scapha-conchal junction. This should complete the circle, which should appear as a kidney bean shape, including the entire conchal bowl. The exact height of the posterior wall is important and must be individually measured for each case (Figure 25-8, *A* to *C*).

Removal of Skin and Cartilage

Before beginning the actual surgical procedure, local anesthesia is used for hydrodissection of the tightly adhered anterior auricular skin along the conchal bowl. This simplifies the dissection of cartilage from the overlying skin. The concha is exposed through a postauricular elliptic skin excision. The ellipse is only wide enough to remove the predicted excess skin produced with ear retropositioning. Closure of the incision should be passive. This area is predisposed to hypertrophic or keloidal scarring when closed under tension. After removing the postauricular skin, the conchal cartilage is visualized along with the previously placed tattoo marks. The marks are used as a guide for incising through the cartilage, taking care to avoid perforation of the anterior skin. The dissection is then carried to the anterior conchal cartilage surface subperichondrially. The hydrodissection, along with use of a small, sharp Freer elevator (EDLO S.A. Produtos Medicos, Canoas, Brazil), allows separation between the skin and cartilage. The cartilage is removed, including the entire conchal bowl, with the exception of the 8 mm left along the posterior conchal wall. The ear is then passively placed on the mastoid surface, and the new projection of the helical rim is observed and carefully measured. Any defective prominence can be

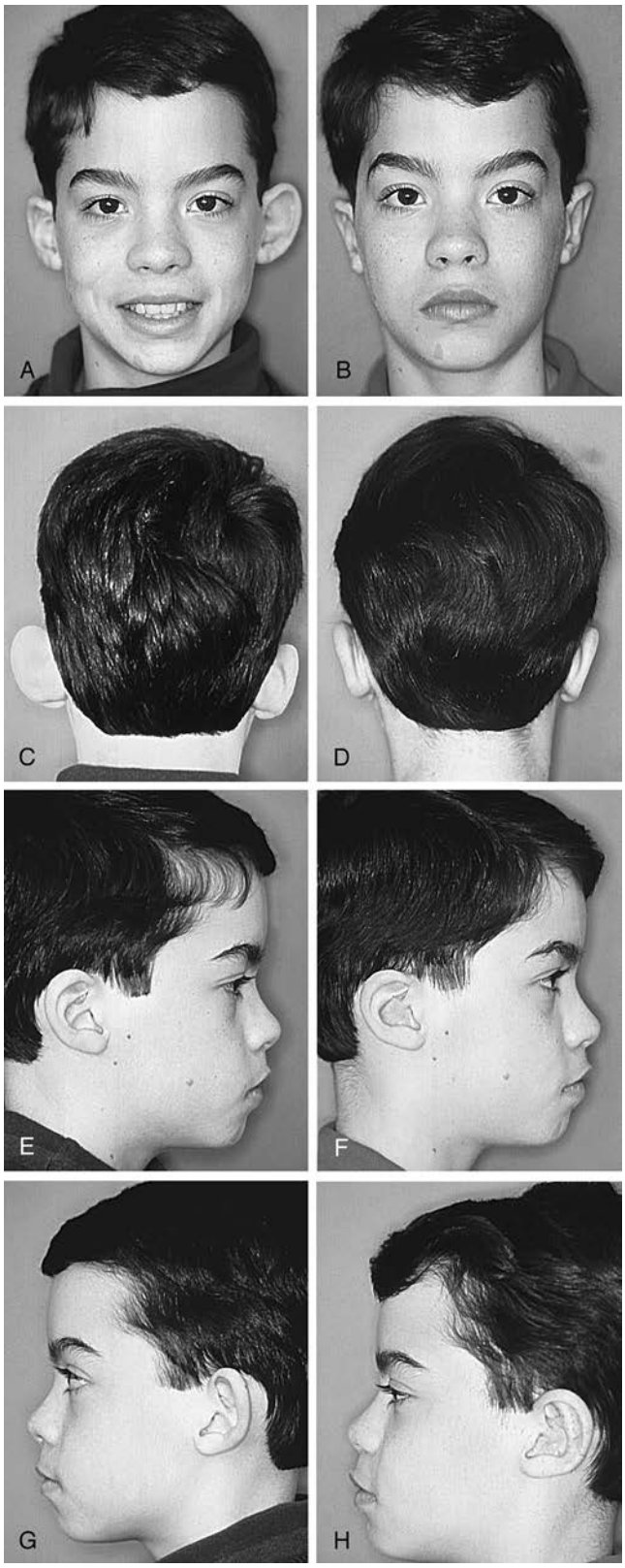

• **Figure 25-7** **A** to **D,** Preoperative and postoperative photographs of a 9-year-old boy who presented for correction of protruding ears. His diagnosis was conchal hypertrophy involving the right ear and a combination of conchal hypertrophy and lack of antihelical fold formation involving the left ear. The Davis method was used to correct the right ear, and the Davis and Mustardé techniques were used on the left ear. **E** and **F,** Lateral views of the right ear demonstrating a natural-appearing, deepened conchal bowl. **G** and **H,** Lateral views of the left ear demonstrating a new antihelical fold and a deepened conchal bowl.

revised with further cartilage removal. The postauricular muscle and underlying connective tissue are removed down to the underlying mastoid fascia to allow passive skin draping of the conchal floor, producing a natural-appearing, deepened conchal bowl. Any excessive postauricular skin can be removed at this time (Figures 25-8, *D* to *F*).

Ear Fixation

The ear is fixed in the new position with three to four mattress transfixion sutures of 3-0 silk, which perforate the skin anteriorly, anchor deeply into the postauricular muscle stump, and pass back through the anterior skin. The mattress sutures are then gently tied over a dental cotton roll that has been moistened with a triple-antibiotic ointment

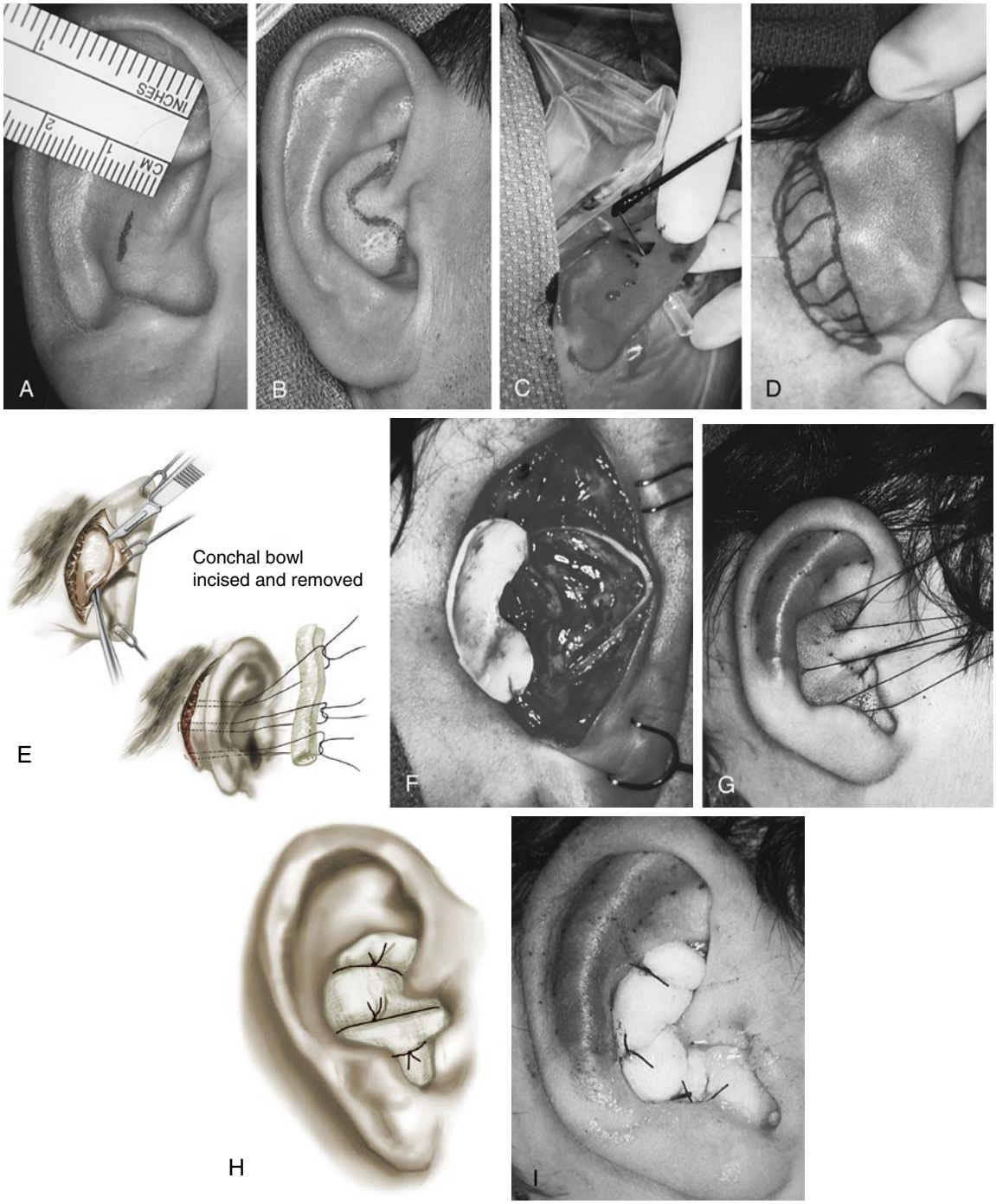

• **Figure 25-8** Davis method. **A,** Marking the height of the posterior conchal wall that will remain. **B,** Marking the conchal bowl to be excised. **C,** Transferring the marking to the underlying cartilage with methylene blue. **D,** Initial amount of skin to be removed in an elliptic fashion. **E** and **F,** Postauricular view of excised cartilage. **G** to **I,** Through-and-through fixation sutures anchored to the postauricular muscle and mastoid fascia used to secure the cotton bolster. (*E* and *H,* Reprinted from Davis JE: Prominent ears, *Clin Plast Surg* 5:475, 1978.)

and placed into the cymbal and caval fossa, making sure to place one end of the cotton roll into the external auditory canal to avoid postoperative stenosis. The sutures and cotton roll hold the ear in place during healing, stretch and flatten the skin uniformly over the conchal floor, and give depth to the conchal bowl. The postauricular incision is then closed in a running fashion with a resorbable suture, leaving a small opening inferiorly for drainage. The cotton roll dressing is left in place for a minimum of 2 weeks for optimal healing (Figure 25-8, *G* to *I*).

Mustardé Method

The Mustardé method, first described in 1959, is indicated for a prominent ear with a poorly formed or absent antihelical fold. This cartilage weakening technique relies on precisely placed horizontal mattress sutures, creating a new antihelical fold. It rarely is performed alone and commonly is used in combination with the Davis method.

Marking the Antihelical Fold

The scapha is folded back against the underlying scalp by applying digital pressure on the superior helical rim, which creates an antihelical fold. The crest of the fold is marked with a surgical marker. To prepare for placement of the mattress sutures, marks are placed parallel to the crest at least 7 mm apart to avoid creating too narrow of a fold. The lateral marks placed on the skin are transferred to the underlying cartilage with a hypodermic needle dipped in methylene blue (Figures 25-9, *A* and *B*).

Dissection and Cartilage Weakening

Local anesthetic solution is infiltrated along the scaphal fossa beneath the anterior auricular skin, hydrodissecting the skin from the underlying cartilage. This is to facilitate the anterior dissection and mattress suture placement. The postauricular skin is then removed in a fashion identical to that described for the Davis method. After identifying the marks placed on the posterior surface of the scaphoid cartilage, a Freer elevator is passed through a small horizontal incision created through the cartilage at the most inferior aspect of the new antihelical fold. The anterior auricular skin is dissected from the underlying cartilage, corresponding to the crest of the new antihelical fold. Through the tunnel dissected along the anterior surface of the cartilage, the body of the new antihelical fold is weakened to facilitate folding and to remove the inherent memory. Many methods have been described, but cartilage weakening can be adequately performed with Adson Brown forceps (KMedic, Kenosha, Wis.), a nasal rasp, or a dermabrader with a small diamond fraise (Figures 25-9, *C* to *E*).

Suture Placement

Nonresorbable, horizontal mattress sutures (4-0 Mersilene [Ethicon Endo-Surgery, Inc., Cincinnati, Ohio]) are placed. All sutures are placed through the medial perichondrium, cartilage, and lateral perichondrium, being careful not to include the anterior skin. The sutures should be placed perpendicularly across the antihelical fold so that upon tightening, a well-rounded antihelical fold will be created. The sutures are tightened under direct observation and adjusted accordingly to form the new antihelical fold (Figures 25-9, *F* and *G*).

Dressing

The dressing is important and is placed to provide adequate pressure to obliterate dead space and avoid postoperative hematoma formation. A carefully layered dressing is placed over the anterior and opposing posterior surfaces of the scaphoid region with a quarter-inch petrolatum gauze, followed by 4- by 4-inch fluffs, held secure with a pressure-type facial dressing (Figures 25-9, *H* and *I*).

Farrior Technique

The Farrior method was first published in 1959 and is one of the first surgeries that used components of both suture and sculpting techniques. It works well for patients with large, protruding lop or cup ears. Local anesthetic is provided. An elliptical dumbbell excision of skin is drawn with a surgical marker on the postauricular skin. The amount of skin to be removed is in direct proportion to the amount of antihelical correction. All the corrections are performed through this incision, including the cartilage cutting and suture techniques. Each maneuver is then performed in a stepwise fashion, with the simplest methods used first to try to achieve the designed contours.

The antihelical fold is first reduced with mattress sutures alone, similar to the Mustardé method, but placed along a weakened antihelical fold with scoring incisions. Care should be taken to not place the scoring incisions along the triangular fossa and interior crus, which would change the shape of these two anatomic landmarks. If a deep conchal bowl is the cause of ear prominence, then conchal reduction is performed. Farrior reduced the conchal bowl at the conchal rim rather than remove the entire bowl, like Davis, and then placed conchal mastoid sutures with 4-0 Mersilene (Figure 25-10).

Because most protruding ears involve both antihelical and conchal excess, several maneuvers are required, including conchal reduction, cartilage scoring, and suturing, all in a stepwise fashion. In addition, an elliptical dumbbell of skin is removed and sutured together, completing the reduction. If the superior third is still prominent, more work is required in the scaphoid region. This is done by extending the horizontal mattress sutures in a parallel fashion into the superior crus and sectioning the anterior inferior crus, causing a pillar effect. The closure of skin incisions and dressing are identical to the Davis and Mustardé methods.

Correction of a Protruding Earlobe

A protruding earlobe often accompanies a protruding ear. If so, it must be simultaneously identified and corrected. If

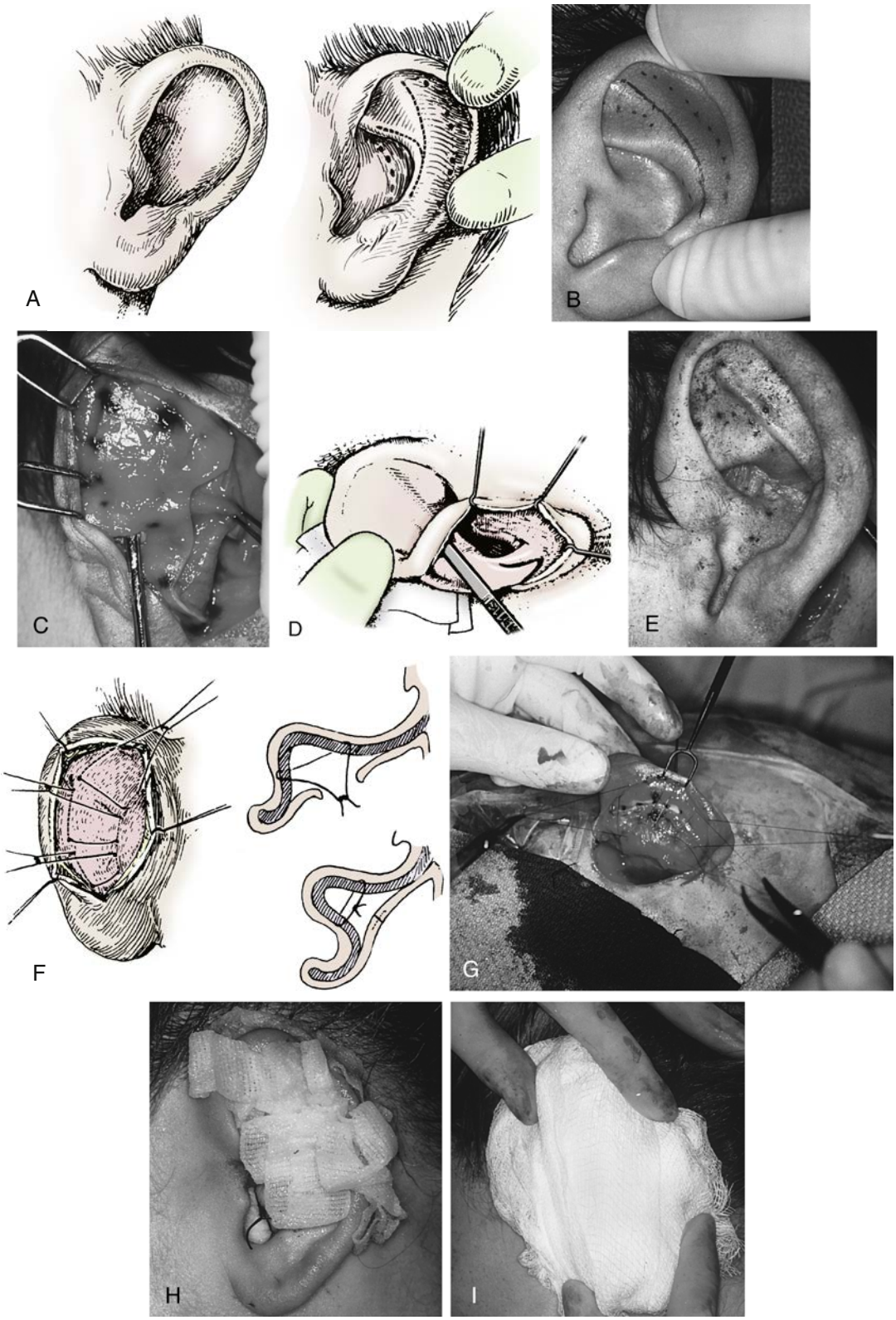

• **Figure 25-9** Mustardé technique. **A** and **B,** Creating and marking the desired antihelical fold by folding back the helix with distal pressure. Lines, parallel to the crest of the fold, are marked and transferred to the underlying cartilage and used for suture placement. **C** to **E,** Dissection of the scaphoid fossa beneath the anterior skin for weakening the cartilage and creating the desired antihelical fold. **F** and **G,** Placement of the horizontal mattress sutures to create a new antihelical fold. **H** and **I,** Placement of petrolatum gauze and fluffs as an important pressure dressing. (*A* and *F* Reprinted from LaTrenta GS: Otoplasty. In Rees TD, LaTrenta GS, editors: *Aesthetic plastic surgery,* ed 2, Philadelphia, 1995, WB Saunders. *D,* Modified from Stenstrom SJ, Heftner JL: The Stenstrom otoplasty, *Clin Plast Surg* 5:467, 1978.)

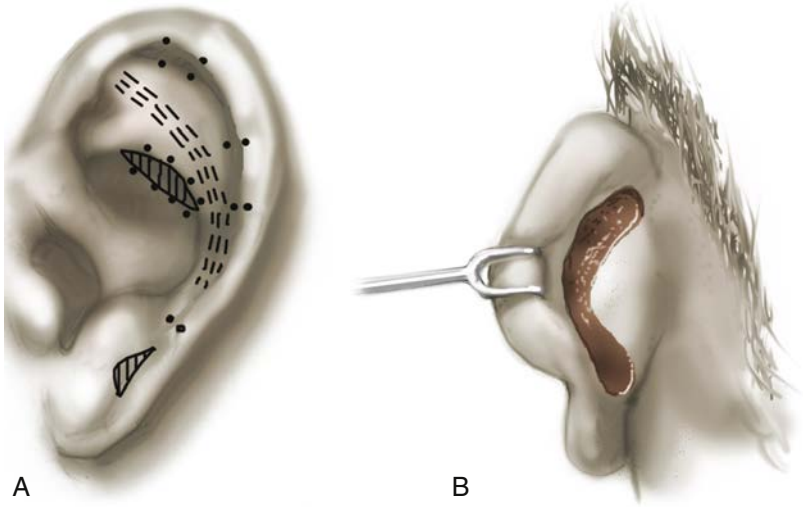

• **Figure 25-10** **A,** Maneuvers in the Farrior technique. This technique requires more cartilage scoring, and the cartilage is removed as needed at the superior rim of the conchal bowl and cauda helicis inferiorly. This preserves more of the cavum concha cartilage compared with the Davis technique. **B,** Notice the elliptical excision of the skin is superior to the posterior auricular crease. This gives better access to the antihelix and aides in retracting the severely protruded helix.

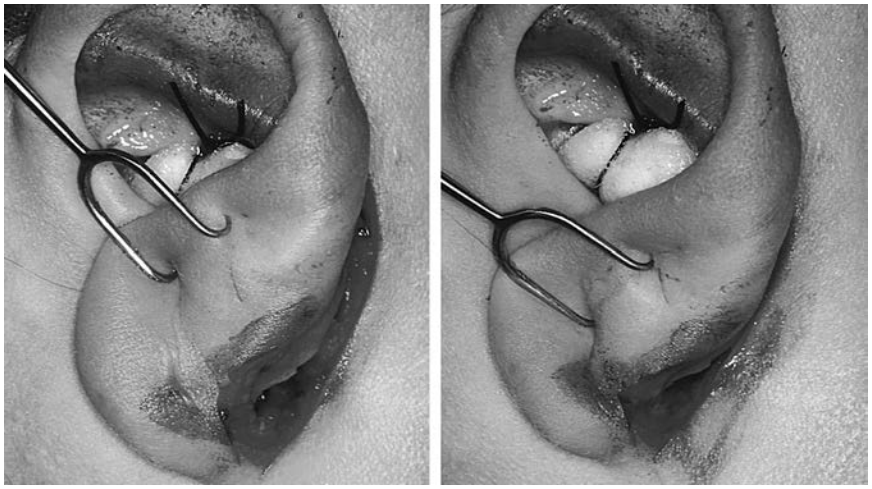

• **Figure 25-11** Marking of skin to correct protruding lobule. Areas marked are excised in a fishtail fashion and closed.

the lobule of the ear protrudes, an extension of the posterior auricular incision is drawn with a surgical marker in the shape of a V onto the earlobe. Finger pressure on the freshly marked lobe, compressing it to the mastoid skin, produces a mirror image imprint forming a W-shaped (fishtail) portion of skin to be excised. After this portion is excised and hemostasis is achieved, closure is accomplished with 4-0 plain gut suture. The two V-shaped incisions are brought together, reducing the protruded state of the lobule (Figure 25-11).

Complications

The incidence of complications after reduction otoplasty is quite low. Calder and Nassan concluded that experienced surgeons had a complication rate of 9%. Inexperienced otoplasty surgeons had a mean complication rate of 20%. Most of these complications were minor, specifically suture extrusion and repeat protrusion of the superior third. The major complications to be avoided are infection and keloid formation. Immediate complications include pressure necrosis from an overly tight dressing, infection, and hematoma formation. Delayed complications include hypertrophic and keloid scar formation, recurrence of the ear deformity, neurosensory deficits, and unesthetic results.

Hematoma

Postoperative hematoma formation, with an incidence of 2% to 4%, is the most common problem and requires immediate and aggressive intervention. It is most often

related to inadequate hemostasis achieved at the time of surgery. Other factors in hematoma formation include an overly tight wound closure without drainage at the base of the wound, postoperative trauma, hypertension, and a preexisting bleeding dyscrasia. Persistent pain beneath the dressing or significant bleeding through and around the dressing suggests hematoma formation and demands prompt inspection. The presence of a hematoma is indicated by a tense and bluish swelling beneath the auricular skin, most often in the retroauricular space. Management includes suture removal, blood clot evacuation, hemostasis, and repeated closure of the wound with a large pressure dressing reapplied. Large doses of antibiotics are advisable to prevent perichondritis. If this problem remains untreated it can result in fibrosis, perichondritis, and cauliflower ear deformity.

Perichondritis

Wound infection in otoplasty occurs in the early postoperative period and usually is a sequel to an undetected or inadequately treated hematoma. Symptoms include pain, erythema, fever, and possibly discharge. Treatment includes high doses of antibiotics after appropriate wound cultures. Common bacteria include *Staphylococcus aureus, Escherichia coli,* and *Pseudomonas aeruginosa.* Adequate drainage is achieved by opening all sutures and carefully irrigating necrotic debris from the wound. All correction sutures must be removed and the cosmetic deformity addressed at a later date. The complication can be devastating, causing massive cartilage destruction and severe deformity, even with aggressive therapy. Prophylactic antibiotics have not been scientifically proved to be beneficial, but they often are used in the preoperative and postoperative periods to avoid this devastating complication. *Pseudomonas* infections can be the most devastating of all, and the authors recommend coverage with dual antibiotics, including quinolone and a cephalosporin after surgery.

Keloid and Hypertrophic Scar Formation

The closure line of the skin incision in the postauricular region is susceptible to scar formation, most commonly seen in younger patients and patients with deeply pigmented skin. Keloid formation, one of the most frustrating of all postoperative complications, requires aggressive therapy. In the early stages of keloid formation, intralesional triamcinolone acetonide 40 mg/mL is injected weekly until regression or significant improvement is evident. Most hypertrophic scars improve with steroid infiltration, but some keloids can progress into significant unesthetic lesions. Low-dose radiation, although potentially dangerous, may provide the only effective means of control of some keloids. More advanced lesions require surgical excision combined with radiation and delayed skin grafting of the irradiated area, with final aid from intralesional triamcinolone. The risk can be minimized by ensuring that the skin incision is passively closed.

Aesthetic Complications

Inadequate correction of the ear deformity is the most common untoward result of otoplasty and often is more obvious to the surgeon than to the patient. Calder and Nassan described at least one complication or residual deformity in 16.6% of all patients who underwent otoplasty with all techniques. Recurrence of the ear deformity is a more common complication of reduction otoplasty but is less likely to happen after excising a portion of the cartilage as well as a segment of skin, as described in the Davis method. Depending on sutures alone for correction carries a greater risk of recurrence. Messner and Crysdale concluded that with time a substantial loss of correction can be expected with most patients. This is not true with the reliable methods described earlier.

"Telephone" Ear Deformity

"Telephone" ear deformity occurs when the root of the helix and the ear lobule remain protruded while the middle half, or third, of the ear is set back against the head. This is more common in a large ear with a wide scapha. The incidence has been reported to be 3%. Reverse telephone ear reveals a pronounced conchal bowl with respect to the lower and upper poles. These deformities can be avoided by carefully checking the position of the helical root, the upper helical rim, and the lobule at the completion of surgery.

Scaphal Buckling

Scaphal buckling or a transverse fold can develop in the Mustardé technique. This deformity can be avoided by placing the horizontal mattress sutures closer together where the scapha is widest and performing adequate anterior scoring or weakening.

Narrowed Meatus

A constricted external auditory meatus can occur if the conchal bowl is rotated anteriorly when setting the ear back in any technique in which the conchal bowl is not excised. This problem is eliminated in the Davis method, in which the floor of the conchal bowl is excised. Care also must be taken in placing the inferior end of the cotton roll bolster dressing into the external auditory canal to avoid stenosis.

Summary

Reduction otoplasty carries few complications and can provide satisfying results for both the patient and the surgeon in the majority of cases. As in all cosmetic procedures, proper patient selection is imperative. Accurate preoperative assessment of the individual deformities and the appropriate choice of a surgical correction minimize unfavorable esthetic results. The single greatest cause of unfavorable results in this procedure is inaccurate diagnosis.

The surgeon must understand the normal external anatomy of the ear and learn to recognize the pathologic characteristics of the abnormal ear. Having accurately assessed the deformity, the surgeon must be familiar with the various surgical approaches available to correct them. Finally, a working knowledge of the potential complications of otoplasty, their prevention, and treatment is necessary.

Bibliography

Adamson PA, Strecker HD: Otoplasty techniques, *Facial Plast Surg* 11:284–300, 1995.

Allison GR: Anatomy of the external ear, *Clin Plast Surg* 5:419–422, 1978.

Calder JC, Nassan A: Morbidity of otoplasty: a review of 562 consecutive cases, *Br J Plast Surg* 47:170–174, 1994.

Converse SM, Wood-Smith D: Corrective and reconstructive surgery in deformities of the auricle. In Papasella MM, Shumrick DA, editors: *Otolaryngology*, vol. 3. Philadelphia, 1973, WB Saunders, pp 500–527.

Davis JE: *Aesthetics and reconstructive otoplasty*, New York, 1987, Springer-Verlag, pp 77–87.

Davis JE: Prominent ears, *Clin Plast Surg* 5:471, 1978.

Dieffenbach JF: *Die Operative Chirurgie,* Leipzig, 1845, Brockhaus. Cited by Tanzer RC: Deformities of the auricle. In Converse JM, editor: *Plastic and reconstructive surgery*, ed 2, Philadelphia, 1997, WB Saunders, p 1710.

Ellis DA, Keohone JD: A simplified approach to otoplasty, *J Otolaryngol* 21:66, 1992.

Ely ET: An operation for prominence of the auricles, *Arch Ophthalmol Otolaryngol* 10:97, 1881.

Farrior RT: A method of otoplasty, *Arch Otolaryngol* 69:26–34, 1959.

Furnas DW: Correction of prominent ears by concha-mastoid sutures, *Plast Reconstr Surg* 42:189–193, 1968.

Guyuron B, DeLuca L: Ear projection and the posterior auricular muscle insertion, *Plast Reconstr Surg* 100:457–460, 1997.

Karmody CS, Annino Jr DJ: Embryology and anomalies of the external ear, *Facial Plast Surg* 11:251–256, 1995.

Lavy J, Sterns M: Otoplasty: techniques, results and complications—a review, *Clin Otolaryngol* 22:390–393, 1997.

Macgregor FC: Ear deformities: social and psychological implications, *Clin Plast Surg* 5:347–350, 1978.

Marx H: Die Missbildungen des Ohres. Sekendare Ohrmissbildingen. In Hhendke F, Lubarsch O, editors: *Hanbush der speziellen pathologischen Anatomie und Histologie*, Berlin, 1926, Springer-Verlag, 12:697.

Messner AH, Crysdale WS: Otoplasty: clinical protocol and long-term results, *Arch Otolaryngol Head Neck Surg* 122:773–777, 1996.

Mustardé JC: The correction of prominent ears using simple mattress sutures, *Br J Plast Surg* 16:170, 1963.

Rogers BO: Microtic, lop, cup and protruding ears: four directly inheritable deformities? *Plast Reconstr Surg* 41:208, 1968.

Scharer SA, Farrior EH, Farrior RT: Retrospective analysis of the Farrior technique for otoplasty, *Arch Facial Plast Surg* 9:167–173, 2007.

Stal S, Spira M: Long-term results in otoplasty, *Facial Plast Surg* 2:153–165, 1985.

Stenstrom SJ: Cosmetic deformities of the ears. In Grabb W, Smith JW, editors: *Plastic surgery*, Boston, 1968, Little, Brown, p 595.

Tanzer RC: Congenital deformities: deformities of the auricle. In Converse JM, editor: *Reconstructive plastic surgery*, ed 2, Philadelphia, 1997, WB Saunders, p 1671.

Weerda H, Siegert R: Complications in otoplastic surgery and their treatment, *Facial Plast Surg* 10:287–297, 1994.

26

Facial Implants in Cosmetic Surgery

FAISAL A. QUERESHY, SUMIT K. NIJHAWAN

Introduction

Facial implants offer a novel minimally invasive treatment option the cosmetic surgeon can offer to patients to address certain complaints. However, the surgeon must be fully competent with not only the surgical technique necessary to achieve a desired outcome, but also with the properties, risks, and benefits of the material being used. It is imperative for the surgeon to have excellent technique and to be attentive to the relevant anatomy. Management of patient expectations is perhaps the single most important factor in predicting outcomes in cosmetic surgery. A detailed discussion with emphasis on the patient's reasons for seeking surgery must be entertained. A treatment plan that will address these concerns should be tailored. If expectations are unreasonable or a plan is tailored that does not attend to the patient's concerns, the surgery may be a failure prior to the first incision.

There are several red flags that should alert the surgeon to potential problem patients. One approach to this concern is the use of the acronym SIMON (*s*ingle *i*mmature *m*ale *o*ver-expectant *n*arcissistic), which was described by Gorney to identify potential problem patients.[1] Additionally, those patients with a large psychological component should be approached with caution. Patients with a small degree of deformity with a large emotional concern do not make good surgical candidates.

Gunter identified 13 red flags that identify a potential problematic patient with possible psychological issues. These include (1) minimal disfigurement, (2) identity problem of sexual ambivalence, (3) delusional view of body image, (4) unrealistic life change as a result of surgery, (5) confused motives for wanting surgery, (6) history of poor relationships, (7) unresolved grief or current crisis, (8) older neurotic man overly worried about aging, (9) paranoid thoughts, (10) history of dissatisfaction from multiple physicians, (11) sudden dislike for one's anatomy, (12) hostile attitude toward authority figures, and (13) present misfortunes blamed on appearance.[2,3] For patients that do present with alarm signs, time must be taken to educate the patient about the surgery, and redirect the patient to more appropriate outcomes. If the patient continues to stipulate unrealistic outcomes, or if constant redirection to realistic outcomes is needed, then this is a poor surgical candidate.

Body dysmorphic disorder (BDD) is defined as a distressing and impairing preoccupation with an imagined defect in a normal appearing person. The preoccupation must cause a significant distress or functional impairment, and the symptoms cannot be better accounted for by another mental disorder. Though any part of the body can be scrutinized by the patient, focus is on facial flaws in the majority of the cases. These patients display habits such as frequent mirror checking and constant need and requests for reassurance. Further, there is a high level of prevalence of other psychiatric illnesses in these patients. According to Allen, BDD is relatively common, with prevalence predictions ranging from 1.9% in the general population to 12% in psychiatric outpatients.[4] The majority of patients with BDD seek nonpsychiatric therapies, and if treated with surgery these patients do not improve their psychiatric diagnosis. Indeed, it may worsen. The surgeon should identify these patients when possible, and refrain from surgery.

Once an appropriate surgical candidate has been identified, it is important to listen to the patient's concerns. It is often easy to offer the patient a treatment plan based on the anatomic variations the patient may have, but that does not address the patient's primary concern. A plan should be rendered that addresses the patient's complaints and that the patient is comfortable with. This plan should be formulated through a collaborative effort with the patient.

Several tools can be utilized to help with this collaborative discussion. The most important educational tool may be preoperative and postoperative pictures of patients that have undergone the same procedures and have consented to have their pictures shared. Other forms of preoperative aids that can be beneficial for review during this discussion include image modifying software. It should be noted that such projections should only be used as visual guides, and no guarantees can be made of the final product. A document from the patient should be reviewed and signed, acknowledging that projected results are not guaranteed.

Finally, consideration should be given to measuring facial features in proportions, because the facial structures must be taken as a whole. The facial structures, including skin, musculature, and the bony support, all work in harmony and must be taken as a whole in relationship to the rest of the face rather than studied alone. Altering the position or function of one structure will have an impact on the neighboring structures. This is a lesson learned from orthognathic surgery, and a combination of procedures often works best in providing optimal results.

CASE STUDY 26-1

Redundant Skin, Small Chin

This 57-year-old woman presented for discussion of surgical options with complaints of a deficient chin. The patient was also concerned with the "turkey neck" appearance of her neck (Figure 26-1; see Figure 26-5 for postoperative results).

When evaluating any patient from a lateral view, one must consider the relation of the face in a vertical and anterior/posterior direction. Facial beauty relates to balance and harmony in size and volume in all three dimensions.

Four major points of protrusion exist when viewing the profile of the face: the forehead/brow, malar prominence, nose, and chin. These eminences provide topographic changes that give definition to the face. These changes are found as creases, folds, and depressions.

Photographs of this patient clearly show an anterior posterior deficiency of the lower one third of her facial profile, with a convex facial profile. However, the vertical dimension is appropriate. Further evaluation reveals platysmal banding and submental lipomatosis. Further, there is excessive skin redundancy and laxity with drooping of the jowls. A tailored treatment plan to restore facial balance is chin augmentation, rhytidectomy, and platysmaplasty. Simply attempting to restore facial proportions with a chin augmentation would yield insufficient results because the patient's profile reveals a lack of definition due to the redundancy of her skin. Further, the level of platysmal banding and submental lipomatosis would mask the planned chin augmentation if not addressed.

Many surgeons have published landmarks that have proven to be successful for them when planning for chin advancement (Table 26-1). If a lateral cephalometric radiograph is available, a reliable method of measuring anterior-posterior chin position is referred to as the holdaway ratio (Figure 26-2). On the lateral cephalometric radiograph, a line is drawn from the nasion to the B point (the NB line). The distance from this line perpendicularly to the most labial aspect of the lower first incisor is then compared to the distance from this line, perpendicularly, to pogonion. Ideally, this ratio should measure 1:1 to 1:1.5. Many times, thick soft tissue may mask the bone, or the proper imaging may not be available to perform the holdaway ratio measurement. It may be desirable in this case to perform an evaluation based on the patient's clinical soft tissue profile. Dr. Ricketts is credited with development of the E-plane, or esthetic plane, to aid in evaluation. The E-plane is simply a line drawn from the nasal tip to the soft tissue pogonion. Though there is variation among different ethnic groups, for a Caucasian face, the upper lip should fall approximately 4 mm behind this line, and the lower lip should reside 2 mm behind the plane.



• **Figure 26-1** The patient presents for evaluation of her deficient chin and "turkey neck." **A,** Frontal view of the patient in repose. **B,** Profile view of the patient. In addition to the deficient chin, note the banding at the platysma that gives a general lack of definition to the lower facial third and neck.

Continued

CASE STUDY 26-1—cont'd

Redundant Skin, Small Chin

It is prudent to note that the maxilla and mandible must be orthognathic to use this evaluation for determination of chin projection. Additionally, care must be taken to ensure that the nasal tip projection is not either deficient or excessive when evaluating the chin position with this method. If the maxilla and mandible are both orthognathic and projection of the nasal tip is appropriate, the desired E-plane can be drawn on the patient's profile view to yield an esthetic position of the chin (Figure 26-3).

Different surgical options for chin augmentation should be considered, such as an osteotomy for a genioplasty with

TABLE 26-1 Different Analyses Determining Chin Position

	Rish technique	A line to Frankfort horizontal is created tangential to the anterior edge of the lower lip vermilion border. This line marks the desired chin projection.
	Merrifield Z-angle	A line is created through the pogonion and the most anterior point of the upper lip vermilion border. The angle this creates with the Frankfort horizontal should be 80 ± 5 degrees.
	Legan's angle	One line is projected through the glabella and subnasale, and a second line is projected through the subnasale and the pogonion. The ideal angle created between these two lines is 12 ± 4 degrees.
	Zero meridian of Gonzales-Ulloa	A line through the nasion perpendicular to the Frankfort horizontal is created. The pogonion should be within 5 mm of this line. Slight (≤5 mm) retraction of the pogonion from this line is more acceptable in women. Retraction of the chin less than or equal to 1 cm is deemed first-degree retraction, 1 to 2 cm is second-degree retraction, and greater than 2 cm is third-degree retraction. First- and second-degree retractions are treated with implants. Third-degree retraction is best treated with maxillofacial surgery.
	Goode's method	A perpendicular line is created from the Frankfort horizontal through the alar-facial crease. The ideal chin position is at or just anterior to this line.

CASE STUDY 26-1—cont'd

Redundant Skin, Small Chin

TABLE 26-1 Different Analyses Determining Chin Position—cont'd

	Calhoun and Gibson (lower facial triangle)	A triangle is defined by the tragion (consistent with the superior margin of the external auditory canal [EAC]), subnasale, and the chin defining point (determined by centering an arc at the tragion with a radius that allows the arc to be tangential to the chin). The points T, S, and C are used; the ideal facial profile has a TC/TS ratio of 1.15:1.19, and an S angle of 88 to 93 degrees. This analysis should be used only if the lower facial profile was subjectively not well balanced.
	Peck and Peck	Accounts for facial height and anterior projection. The nasal angle is from the tragion to nasion and nasal tip (normal is 23.3 degrees). The maxillary angle is the tragion through nasal tip and labral superioris (14.1 degrees). The mandibular angle is from the tragion through the labral superioris and pogonion (17.1 degrees). The facial angle is the angle created by a line from the tragion through the midpoint of the line from the nasion through the pogonion (102.5 degrees). The line from the nasion to labral superioris, through the aforementioned line from the tragion, yields the maxillofacial angle (5.9 degrees). Nasal maxillary angle is from the tragion with a line drawn between the nasal tip and the labral superioris (106.1 degrees).
	Holdaway	The "harmony" line or "H line" is from the pogonion through the most prominent portion of the upper lip. The angle between this projection and a line between the pogonion and the nasion is called the "H angle." The ideal H angle is 10 degrees; the higher the angle, the more retrusive the chin.
	Powell and Humphreys	Uses the "esthetic triangle" and is based on the ideal profile of a nasofrontal angle of 115/120 degrees (male/female), a naso-facial angle of 36/36 degrees, a nasomental angle of 130/130 degrees, and a mental-cervical angle of 80/85 degrees.
	Stambaugh	Line tangential to the anterior point of the vermilion of the upper and lower lips in contact. Chin should meet this line in men (±2 mm) and be 2 to 3 mm behind this line in women (±2 mm). Vertical height of the maxilla and mandible is considered when evaluating the patient for chin augmentation. If a short mandible itself is short relative to the rest of the face, augmentation may accentuate lower lip eversion. If the maxillary height is disproportionately small, augmentation of the mentum can accentuate a deep sublabial crease.
	Zide Quick Analysis of the Chin (QUAC)	Anatomically based. Looks at (1) lip eversion, (2) the anterior teeth, (3) chin pad thickness, (4) labiomental fold depth and height, and (5) dynamic chin pad motion with smile.

Continued

CASE STUDY 26-1—cont'd

Redundant Skin, Small Chin

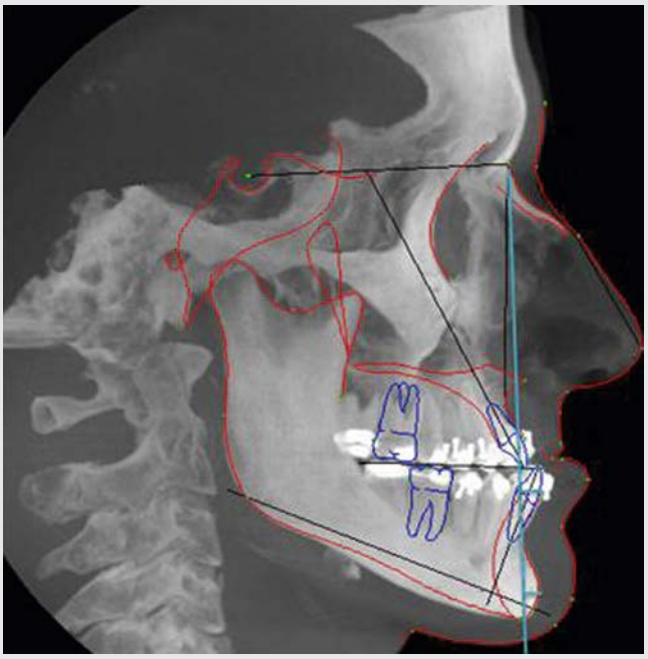

• **Figure 26-2** An example of the holdaway ratio. A line, shown in light blue, is made from nasion to B point. The perpendicular distance from this NB line is measured to the most labial portion of the lower first incisor and to pogonion. Ideally, this ratio should be 1:1 to 1:1.5.

rigid fixation compared with an alloplasty to augment the chin. Per Wilford, a 60% to 75% soft tissue change with osseous augmentation in the anterior-posterior dimension can be expected.[5] Stripping of periosteum from the inferior border of the mandible may minimize soft tissue change. An 80% to 85% soft tissue change can be seen in the anterior-posterior dimension with alloplastic augmentation. Vertical augmentation results in a 1:1 soft tissue change for both alloplastic and osseous augmentation. Different alloplastic materials are available for this type of procedure. Though the incision has been described either extraorally or intraorally for alloplastic implants, most advocate an extraoral approach when possible to maintain sterility.

Factors in choosing augmentation materials include the specific properties and limitations of the implant materials and the site for implantation. According to Adams, consideration must be given to several factors when considering the alloplastic material being used. These include material density, ability to be sculpted, the degree of associated tissue reaction, the degree of migration, resorption, the incidence of infection, and extrusion rates.[6,7] When deciding on the density of the material to be used, as a general rule, bone is best replaced with firm materials whereas soft tissues are best augmented with less dense materials. Soft, more porous materials are much more difficult to remove in case of infection. The site of augmentation is just as important. Silastic may work well for rigid areas such as the chin, but has been associated with extrusion when used for nasal augmentation. Another



• **Figure 26-3** Use of the E-plane for evaluation of chin projection. Note that for proper evaluation with this method, the maxilla and mandible must be orthognathic, and the nasal tip projection should be appropriate. **A,** The E-plane line is drawn, shown in black. Notice that the lower lip is touching the line, and the upper lip is only 2 mm behind the line, indicating a deficient chin. **B,** The same patient is shown after alloplastic chin augmentation. Notice a more appropriate relationship of the upper and lower lips to the E-plane with the chin in correct projection.

CASE STUDY 26-1—cont'd

Redundant Skin, Small Chin

• BOX 26-1 Alloplastic Options for Chin Augmentation

Carbon-Based Polymers

Polytetrafluoroethylene (Gore-Tex)
High-density polyethylene (Medpor)
Methylmethacrylate

Non-Carbon-Based Polymer

Silicone (Silastic)

Metal

Titanium

Ceramic

Hydroxyapatite

commonly used alloplastic material, porous polyethylene or Medpor (Stryker Global, MI) has several favorable properties. Niechajev showed that in a 16-year history with 118 implants placed, Medpor showed favorable characteristics including tissue in-growth and vascularization, biocompatibility, ease of contouring, fixation flexibility, and a bony feel.[8-11] In this series complications included implant extrusion in two nasal augmentation cases and infection in three cases. Medpor has been used for augmentation in rhinoplasty, as well as chin augmentation and malar augmentation.

Synthetic alloplastic materials can be broadly categorized into carbon-based polymers, non-carbon-based polymers, aliphatic polyesters, metals, and ceramics (Box 26-1). Among the most popular facial implants used today is the silicone implant (Silastic, Dow Corning Corp., Midland, MI). This is an inert non-carbon-based polymer that becomes encapsulated by the host. It is popular because of its soft and flexible consistency and, most important, its nonporous composition.

Infection that may develop usually can be treated with a course of antibiotics, and some porous implants such as Medpor may need complete removal to be treated effectively. In general, 1×10^5 bacteria are needed to cause clinical manifestations of an infection.[12] In the environment of a foreign body, this number is greatly reduced. Antibiotic coverage should be considered both peri-operatively and postoperatively. The implant should be soaked in antibiotic solution before replacement.

Alloplastic chin augmentation may be advocated over genioplasty for several reasons (Box 26-2). A genioplasty is more invasive, and there is a prolonged recovery associated with increased swelling in the postoperative course. Further, there is an increased risk to the lingual periosteum and musculature. Although there is concern for resorption, as previously stated, resorption can be limited by limiting the stripping of the periosteum. Further, there is greater risk of altered vitality of the anterior dentition with a genioplasty, with greater associated paresthesia. Further, there may be increased notching of the inferior border. A further indication for an alloplastic implant over a genioplasty is a low mental foramen that may make an osteotomy difficult.

Advantages for genioplasty over alloplastic augmentation include lower infection rates, more versatility (better for cases of asymmetry), less bone resorption, and more useful in cases with change in vertical dimension (Box 26-3).[13] Additional indications for a genioplasty include younger individuals to limit bony resorption from implants. Also, if more than 4 to 6 mm of augmentation will be necessary, an osteotomy may be indicated because larger implants may be associated with increased complications. Further indications for a genioplasty include failure of previous alloplastic implants, hyperactive chin musculature which may cause displacement of an alloplastic implant, or a patient with labial incompetence and labial strain, which may place excessive forces on an implant and lead to increased resorption.

Though an alloplastic chin implant can be placed by an intraoral approach or through an incision proximal to the submental crease, the extraoral approach is advocated to limit infection. Both options are effective and have their benefits and limitations (Boxes 26-4 and 26-5). The patient described in this case benefited from submental liposuction, cervicoplasty, rhytidectomy, platysmaplasty, and alloplastic chin augmentation (Figure 26-4). The final postoperative pictures show the patient with an appropriate projection of the chin, along with more neck definition (Figure 26-5).

• BOX 26-2 Advantages and Disadvantages of Alloplast

Advantages

Easily reversible
Quicker recovery time
Less painful
Less chance of paresthesia
Can address pre-jowl sulcus
Can be used on patients with low mental foramina

Disadvantages

Overaugmentation
Lateral limb malposition
Greater concern for infection
Extrusion (rare)
Bone resorption

• BOX 26-3 Advantage and Disadvantages of Genioplasty Osteotomy

Advantages

Can change vertical dimension
Better for asymmetry

Disadvantages

Deeper anesthesia
More equipment and hardware
Painful, more dissection
Greater risk of IAN injury
Risk to dental roots
Overaugmentation
Longer surgery time

Continued

CASE STUDY 26-1—cont'd

Redundant Skin, Small Chin

• BOX 26-4 Advantages and Disadvantages of Intraoral Implant Placement of Allograft

Advantage

No external scar

Disadvantages

Chance of lip incompetence
Greater change of vertical migration
Greater chance of infection

• BOX 26-5 Advantages and Disadvantages of Extraoral Implant Placement

Advantages

Preserves mentalis muscle
Less chance of bacterial contamination
Less chance of migration

Disadvantage

Chance of scar

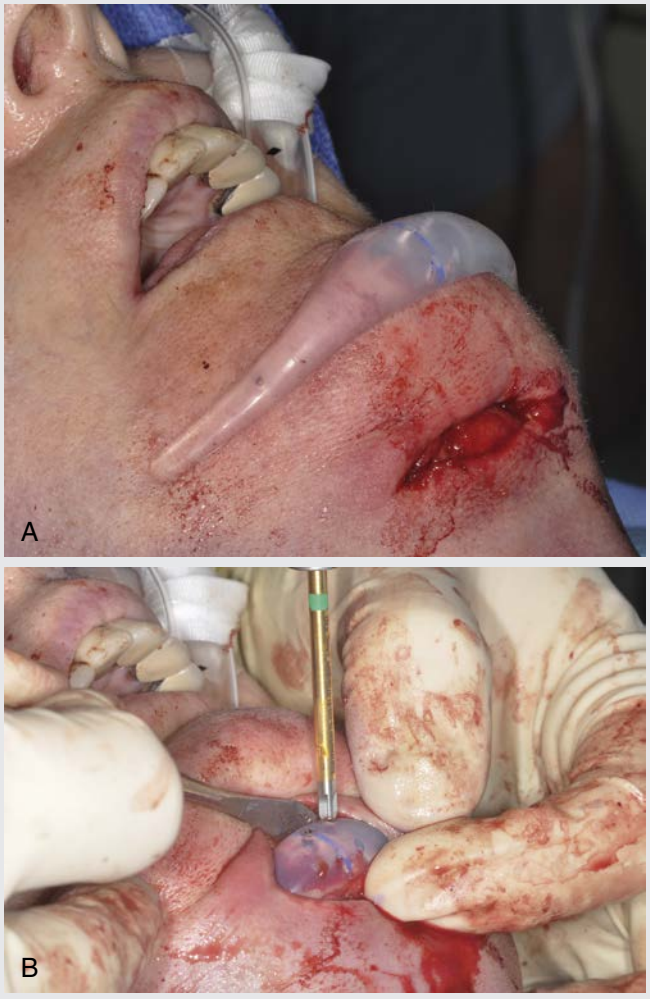

• **Figure 26-4** **A,** An extraoral incision is made proximal to the submental crease to avoid scarring and contracture for placement of the alloplastic implant. The implant is displayed here on the chin prior to placement. The implant will be soaked in antibiotic solution prior to insertion. **B,** The implant is secured in place. Midlines have been marked and the implant has been trimmed appropriately prior to this step.

CASE STUDY 26-1—cont'd

Redundant Skin, Small Chin



• **Figure 26-5** Postoperative pictures. **A,** The patient is in repose in her frontal picture. Note the marked improvement in definition in the lower facial third and neck. **B,** The patient is seen in her profile view post-operatively. Note the augmentation in projection of the chin, along with the lack of platysmal banding.

CASE STUDY 26-2

Sunken In, Aging Face

A 47-year-old female presented for evaluation, asking for dermal fillers. Clinical examination demonstrated significant facial atrophy, particularly under the malar prominences, in the areas of the cheeks and nasolabial folds. Further, the patient was seen to have fine vertical rhytids of the upper lip, and thin upper and lower lips (Figure 26-6; postoperative, Figure 26-7). In such a case, it is important to redirect the patient. Given the significant fat atrophy to both her cheeks, dermal fillers alone would be inappropriate and would not address the patient's concerns. In such circumstances, malar implants would also be inappropriate because the actual malar projection is adequate. An abdominal fat transfer along with Restylane injectable filler was recommended to the patient.

Because there is no concern with biocompatibility in autologous transfer, fat makes for a very good filler material (Box 26-6). Additionally, this is generally a safe procedure with minimal morbidity and relative surgical ease, with few drawbacks. Kaufman and colleagues offer a review on several considerations when considering autologous fat transfer. Though fat transfer has been performed as injectable grafts since the 1920s, it has gained popularity since 1990. The popularity of this procedure reflects an increase in body lipocontouring. Though there has been some concern regarding the long-term viability of this procedure, the published literature reflects reasonable success with the procedure.[14-16]

Though conclusive studies differentiating between different donor sites are largely lacking, the abdomen serves as the most commonly used donor site. During the harvest, high vacuum extraction is discouraged because it may result in adipocyte rupture. Several authors have described the harvest technique with 3-mm cannulas using a curetting motion with a 10-mL syringe to obtain globules of fat. Prior to harvest, infiltration of a tumescent solution may be performed to help achieve hemostasis and help break up fat globules. Different authors describe different concentrations, but the mixture used for this case was 50 mL of 1% lidocaine solution, 1 mL of 1:1000 epinephrine, and 12.5 mL of 8.4% sodium bicarbonate in 1 L of normal saline.

After harvest, the fat must be prepared for transfer in a centrifuge. A typical protocol is to centrifuge aspirated fat at 3000 rpm for 3 minutes to separate fat aspirate from oil, blood, and other contaminants. It has been reported that up to 50% of fatty tissue undergoes cytoplasmic lysis upon exposure to air. Although this is debatable, attempts should be made to minimize prolonged storage prior to transfer. Some literature is also available on addition of growth factors to enhance fat viability, though there appears to be little clinical evidence of such measures. It is generally accepted that fat survival is based on the proximity of transfer to a blood supply. Therefore, many authors describe a "fanning out" technique while injecting

Continued

CASE STUDY 26-2—cont'd

Sunken In, Aging Face



• **Figure 26-6** **A,** Frontal. **B** and **C,** ¾ views. In addition to the fine vertical rhytids around the peri-oral region, notice the sunken appearance in the right and left cheeks.

CASE STUDY 26-2—cont'd

Sunken In, Aging Face



• **Figure 26-7** The patient originally presented in this case shown 4 days postoperatively in **(A)** frontal and **(B)** ¾ view. Notice the augmentation of the infra-orbital and peri-alar area. Also, there is much more definition with a slight decrease in the peri-oral rhytids. The ecchymosis seen is normal 4 days post-surgically. The patient was satisfied with her result, but understands that a degree of lipoatrophy is expected.

• BOX 26-6 Advantages and Drawbacks of Autologous Fat Transfer

Advantages

Biocompatible
Semipermanent
Stem cells found in fat can lead to increased skin rejuvenation
Can address two areas at once (lipo-excess and lipodystrophy)

Disadvantages

Requires local or regional anesthesia
More surgically invasive
Second surgical site
May have longer healing time
Unpredictable longevity

to maximize the surface area of fat that is in contact with vascularized tissue.

Studies have found that within 6 months, aspirated fat grafts have lost up to 60% of their original weight, compared to 1% of fat loss using an excisional technique. Hence, consideration must be given to over-injecting in anticipation of this atrophy. Other complications of this procedure include fat hypertrophy and fat emboli, but these are rare.

The patient presented in Figure 26-7 benefited from an abdominal fat transfer to the peri-alar region as well as the cheeks and infraorbital region, as well as Restylane injectable filler to the peri-oral region. The patient was very satisfied with the immediate result. However, the patient is well aware of the expected fat atrophy, as patients must be counseled of this in the preoperative visit. As a result, patients undergoing this procedure should be made aware of further surgeries that may be needed in the future.

CASE STUDY 26-3

Malar Cheek Implant



• **Figure 26-8** A 73-year-old patient presents to discuss surgical options for her facial rhytids.

A 73-year-old woman presented stating that she doesn't like her wrinkles and wants to discuss surgical options (Figure 26-8). A bird's-eye view shows very flat malar eminences (Figure 26-9). When the face is assessed in a front view it can be considered a triangle, with the corners as the chin and zygomatic eminence (Figure 26-10). An attractive face often has well-defined corners of the triangle and hence a well-proportioned chin and cheekbones. Malar implants can be a valuable adjunct to facial cosmetic surgery. It is suggested that the zygomatic prominence should be located 2 cm inferior to and 1.5 cm lateral to the lateral canthus of the eye. There are several other methods of assessing proper malar projection (Table 26-2). This landmark should aid not only in evaluation of the malar region, but also in planning proper augmentation.

The treatment plan for this patient was a rhytidectomy, cervicoplasty, laser skin resurfacing, submental liposuction, lower blepharoplasty, and malar augmentation. Though the patient's main complaints were facial rhytids when she presented, a combination of the above mentioned procedures gave the patient the harmony required and the result she desired while addressing her chief complaint. The rhytidectomy, cervicoplasty, submental liposuction, and laser resurfacing helped remove excessive skin and addressed her concern of facial rhytids. However, the dramatic change was highlighted by the augmentation of her zygomatic eminence to give her a harmonious result.

Though there may be different incisions used for placement of malar implants, an intraoral Keen incision is very popular. If sterility is to be maintained for other procedures being performed, as in this case, the malar implants should be placed either prior to prepping the patient, or after the sterile portion of the procedure is complete. If there is excessive redundant tissue and verification of placement of the implant position will be difficult, the implants are best placed after the skin excision is performed in the rhytidectomy. If this will not be an issue, as in this case, the implants can be placed prior to the sterile procedures and can help guide the amount of skin excision. A subperiosteal pocket must be created that extends to the infraorbital rim and over the zygomatic arch and includes the lateral wall of the orbit. Attention should be made to not violate the infraorbital neurovascular bundle and to stay subperiosteal, particularly lateral to the orbit, to avoid the temporal branch of the facial nerve. The implant should be soaked in gentamycin solution before its placement intraorally. Fixation with monocortical screws helps prevent against migration.

Postoperatively, the patient was very satisfied. Her chief complaint of facial rhytids was addressed not only by removal of excessive skin with the rhytidectomy, but the skin was further tightened with laser resurfacing. The dermatochalasia was addressed by the lower blepharoplasties. The cervical banding was addressed with the submental liposuction and

CASE STUDY 26-3—cont'd

Sunken In, Aging Face



• **Figure 26-9** A bird's-eye view shows very flat malar eminences.

platysmaplasty. The malar augmentation helped bring harmony to the patient's facial proportions by giving her adequate malar projection that she lacked prior to surgery (Figure 26-11).

An advantage to the malar implant is that it is easily reversible. Though results are often pleasing, there may be several reasons that warrant removal. According to Yaremchuk, approximately 10% of malar implants are removed or replaced because of improper implant shape, size, or position, and other reasons may include infection, dehiscence, and impingement on the infraorbital neurovascular bundle.[17-21] If an implant has been in for some time, a fibrous capsule may form around the implant that may make mobility and removal of the implant troublesome. After removal, a secondary placement of a malar implant may be attempted if desired.

Continued

CASE STUDY 26-3—cont'd

Sunken In, Aging Face

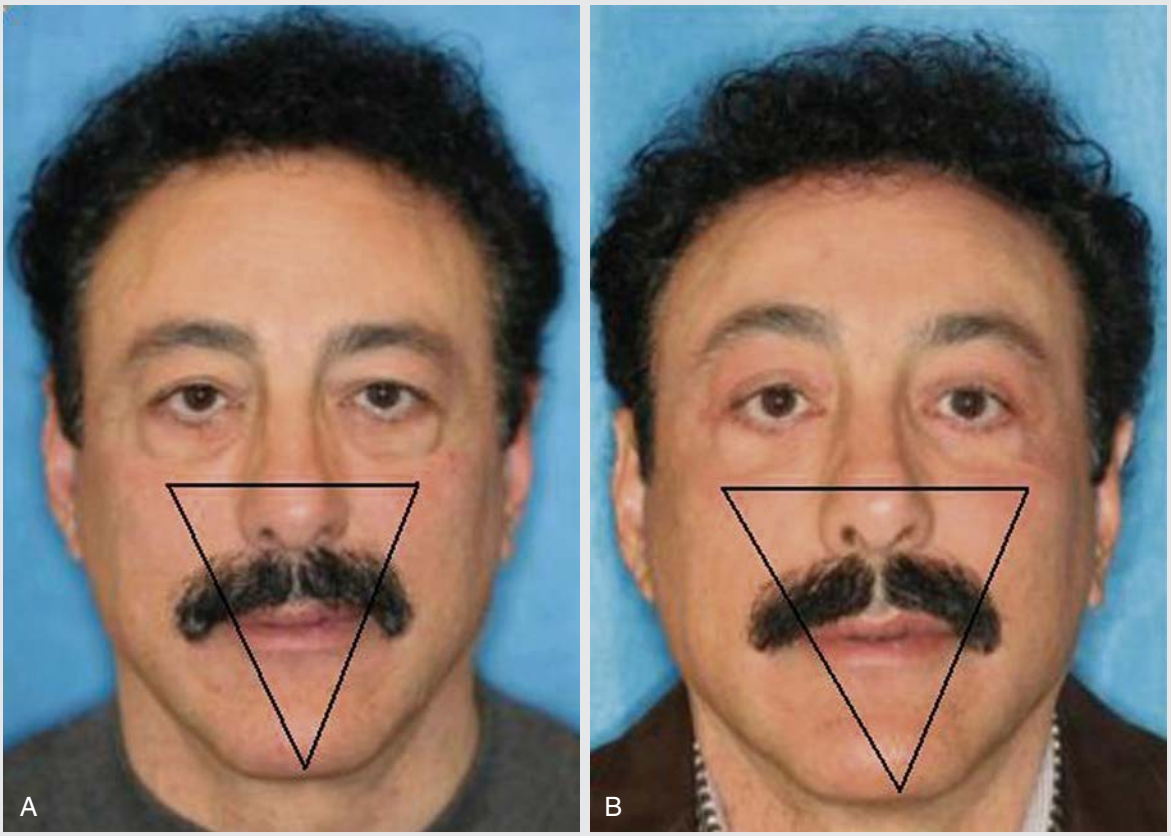

• **Figure 26-10** An attractive face has well defined corners of the triangle from the chin to the zygomatic eminence. **A,** A patient with malar insufficiency is assessed from the frontal view. There is a lack of malar prominence, and the facial triangle is imbalanced. **B,** More symmetry in the facial triangle is seen after malar augmentation.

TABLE 26-2 Analyses for Malar Implants

Hinderer[29]	From the frontal view, draw a line from the lateral commissure of the lip to the lateral canthus of the ipsilateral eye and another line from the tragus to the inferior edge of the nasal ala. The area posterior and superior to the junction of these two projections should be the most prominent area of the malar eminence.
Powell et al[18]	Draw a vertical line through the middle of the face, then bisect the segment between the nasion and the nasal tip with a line that curves gently upward to the tragus on both sides. Draw a line from the inferior ala to the lateral canthus and another line, parallel to this one, from the lateral oral commissure toward the ear. The intersection of the curvilinear horizontal line and the line from the oral commissure marks the point where the malar area should be most prominent.
Silver and Guilden[21]	If the malar prominence in the true lateral projection is >5 mm posterior to the nasolabial groove, then a deficiency in the malar area exists. Silver describes the malar prominence triangle. To create this triangle, draw a Frankfort horizontal line across the face in frontal projection and a parallel line that bisects the upper lip. Then draw a perpendicular line through both of these lines and through the lateral canthus. The intersection of the vertical line and the line through the upper lip defines point A. Create a line from point A through the medial canthus and then a second line from point A toward the temporal area, but at the same angle from the vertical that was created by the projection from point A through the medial canthus. This creates the malar prominence triangle with the base being the Frankfort horizontal and the apex being point A. Silver advises that the implant should be placed several millimeters below the Frankfort line.
Schoenrock[25]	On an oblique view (27 to 35 degrees of rotation from the frontal view) in natural head position, a line drawn through the lateral canthus and the mentum should reveal the "width" of the malar eminence. This is said to be approximately 3 to 7 mm in the average person.

CASE STUDY 26-3—cont'd

Sunken In, Aging Face



• **Figure 26-11** The patient initially presenting in the case is seen postoperatively. **A,** The frontal picture demonstrates a marked improvement with tighter skin. The platysmal banding and goose neck have been addressed with cervicoplasty. **B,** The malar implants augment the result by providing proper projection of the face giving an esthetic, harmonious result.

CASE STUDY 26-4

Fillers: Injectable Implant Materials



• **Figure 26-12** A 78-year-old female presents for fillers in her upper lip and nasolabial fold.

A 78-year-old female presented with a desire to have fillers in her lips and nasolabial folds (Figure 26-12). The patient had undergone multiple cosmetic procedures in the past, including a rhytidectomy, upper and lower blepharoplasties, and collagen fillers every 18 to 24 months. Some of the most commonly used fillers include hydroxylapatite products (Radiesse-Merz Aesthetics, North America) and hyaluronic acid products (Restylane-Galderma, TX, and Juvederm-Allergan, CA). Collagen products, such as Zyderm (Allergan, CA) and Zyplast, were more popular for use in the 1980s.

Fillers can be categorized by the depth of implantation (i.e., superficial upper and mid-dermis, deep dermis, and subcutaneous levels), the longevity of correction (i.e., temporary, semipermanent, and permanent), allergenicity, and composition of agent. Collagen and hyaluronic acid are biodegradable and last from 4 to 9 months. Patients are sometimes dissatisfied due to the short-lived effects of the filler. Collagen is a major structural component of the dermis, and comprises 70% of dry skin. Type I comprises 80% to 85% of the collagen encountered. Loss of collagen results in skin fragility and wrinkles. Aging and UV light accelerate this process. Drawbacks of collagen fillers include the risk of hypersensitivity reaction. The response can be seen as early as 6 hours after treatment, and can last up to 4 weeks. A positive skin test disqualifies the patient for treatment with bovine collagen, and two negative skin tests are advocated prior to placement of the filler. A reaction, if it occurs, typically resolves within 4 to 24 months. When injecting bovine filler, the depth of infection should be into the dermis to avoid beads and cysts. CosmoDerm and Cosmoplast are bioengineered human collagens that were FDA approved in 2003. These lack the risk of skin hypersensitivity, and hence require no skin testing. Further, there is less bruising than with hyaluronic acid. CosmoDerm may be placed superficially and is the filler of choice for peri-orbital wrinkles and smoker's lines above the top lip. Drawbacks of bioengineered collagen include expense and limited longevity.

Hyaluronic acid (HA) has been very widely used in the last few years. It is nonimmunogenic, with longer duration (6 to 12 months), and is reversible with hyaluronidase. The two main categories include animal derived (Hylaform) and bacteria derived (Restylane and Juvederm). Drawbacks of hyaluronic acid include bruising, swelling, lumps, and acneiform eruptions. Rarely, there can also be arterial occlusion, which is thought to occur from swelling of the HA implant, causing vascular compromise. If vascular compromise occurs, treatment must be prompt. According to Narins et al. hyperbaric oxygen, if used in an appropriate time interval, can be used to reverse effects of vascular compromise.[22,23]

CASE STUDY 26-4—cont'd

Fillers: Injectable Implant Materials



• **Figure 26-13** Injection of Juvederm to melolabial and perioral rhytids. Notice the dramatic change in the depth of rhytids in the postoperative picture *(right)*, as compared to the preoperative picture *(left)*.

Hyaluronidase takes effect over 24 hours, but does not have the instant effect desired. Restylane, which lasts 6 to 9 months, has a good safety profile, and its stiffness makes it an ideal material for deep wrinkles and nasal tip support. Juvederm has the advantage of a smooth consistency with a broad range of particle sizes, which allows for a uniform distribution. Juvederm XC includes lidocaine and allows for a more comfortable injection (Figure 26-13).

Semipermanent fillers last for 1 to 3 years and include products such as Radiesse and Sculptra. Radiesse was FDA approved in 2006. It stimulates cutaneous cells to generate focal foreign body reaction and neocollagenesis, which slows the degradation of the product. It is a radiopaque material that can be visualized on radiographs. Benefits of this filler include that it can be combined with other fillers and is very pliable. Disadvantages include that it is not reversible like HAs. Also, it doesn't contain anesthetic and requires a large-bore needle for injection due to its high viscosity. The use of topical or regional anesthetic is recommended. Implantation to superficial and mobile wrinkles is discouraged due to palpable and visible white papules that may develop. Sculptra is not a true filler. It promotes the production of new and organized collagen into the dermis and is a dermal stimulator, so results are not seen until about 4 weeks after surgery.

Permanent fillers are very popular outside of the United States due to their lower cost. Their use requires a skilled and experienced practitioner because the results may be permanently disfiguring. Examples include Artefill, which was approved in 2006 for correction of nasolabial folds. Artefill is composed of synthetic microspheres and cow-derived collagen.

The patient in Figure 26-14 had Radiesse injected into bilateral malar regions, including the nasolabial folds and melolabial folds. Note that the injection should be kept deeper in the dermal layer to avoid noticeable superficial papules. After injection, the area should be massaged to ensure an even distribution.



• **Figure 26-14** **A,** Radiesse, a semipermanent filler, is injected in the dermal layer in the nasolabial fold. Superficial injection is discouraged due to visible and palpable papules that may develop. **B,** After injection, the area is massaged to ensure even distribution.

CASE STUDY 26-5

Lip Implants

Per Segall, assessment of the patient desiring lip augmentation should include evaluation of the lip height and length, and the vermillion arch. Any asymmetry should be noted, along with presence of peri-oral rhytids. As patients age, there is a loss of lip volume with some effacement of the vermillion border.[24] A discussion should revolve around patient expectations. Pictures of both the patients and any magazine cutouts are excellent tools in evaluating patient desires and discussing realistic expectations. Following a thorough assessment, patients may be offered various treatment modalities, which include fillers, free fat grafts, and lip implants.

For years the most common permanent alloplast material used in the lip was polytetrafluoroethylene implants, or Gore-Tex[25] (W. L. Gore & Associates, Newark, DE) and the hollow, more expensive Soft Form implants (Allergan, Inc.). Newer on the market is Advanta (Atrium Medical Corporation, Hudson, NH), which is a dual-porosity implant created with hopes of less migration and more softness. These materials are not without limitations. In a highly animated area such as the lips, exposure of the implant is possible, and infection is a risk when introducing a foreign body. The most common complaint regarding these implants is their susceptibility to becoming hard and palpable.

Recent strides have been made in creating a better lip implant. The VeraFil implant (Evera Medical, Foster City, CA) has gained FDA approval for soft tissue augmentation around the eyes. In Europe is it being used as a lip implant known as FulFil. This is a saline-filled implant in a silicone capsule and with a thin polytetrafluoroethylene outer shell. An implant length and diameter are picked and the implant is inserted into the lip deflated, with a small access hose at the end. The implant is then injected with saline to inflate. The volume of saline can be adjusted clinically to an appropriate amount. A limitation of this implant is that it cannot be altered in length intraoperatively. Doing so would likely perforate the silicone outer shell.

When determining the size of the needed implant, Niamtu[26] recommends proper pre-operative assessment including obtaining pictures of the patient in the upright position with frontal, obilque, and lateral repose photographs, as well as full smile, pucker, and mouth wide open pictures. Erring on the side of an implant that is too short rather than too long is better to minimize the risk of extrusion. Local anesthesia is infiltrated in the mucobuccal fold, and small incisions are made bilaterally. Implant placement in the lip depends on the patient's needs and desires; if a person's concern is wrinkles in the white portion of the lip, it is placed slightly higher. The majority of implants are placed within a pocket created at the wet-dry border in the subdermal plane. This gives the lip the popular "full-rolled out" appearance. It is advocated to soak the implant in antibiotic solution prior to delivery. Meticulous technique is essential to ensure that the implant sits symmetrically in the muscular layer of the lip.

According to Segall,[24] disadvantages of the lip implant include graft palpability, and visibility if placed too superficially. This is most visible on full patient animation. Other complications include risk of graft migration, extrusion, foreign body granuloma formation, and infection.[24,27,28] Should a complication arise, implants can be removed, but there is a risk for scarring or lip asymmetry after removal.

Summary

Many advances have been made in the field of cosmetic surgery. Surgeons always strive to give patients the most esthetic, natural result with minimal risk. The everlasting pursuit of youth and beauty keep inspiring surgeons, patients, and manufacturers to push the envelope in terms of what is possible. Facial implants have in many ways revolutionized this never-ending pursuit. As newer materials and techniques continue to be utilized to provide the best outcomes, it is imperative for a cosmetic surgeon to always be at the forefront of knowledge. As different materials become available, it is important to understand the different physical properties of the materials, how the materials behave differently, potential adverse outcomes and limitations, and the latest published experience.

Cosmetic surgery can be one of the most challenging and rewarding disciplines. Knowledge of anatomy, the ability to identify appropriate surgical candidates, knowing limitations, and having excellent surgical skills are all factors that play a role in patient outcomes. Though facial implants have revolutionized cosmetic surgery, the ultimate success of a procedure has, does, and will always rest in the hands of the surgeon.

References

1. Gorney M: Cosmetic surgery in males, *Plast Reconstr Surg* 110(2):719, 2002.
2. Gunter JP: Rhinoplasty. In Courtiss EH, editor: *Male aesthetic surgery*, ed 2, St Louis, 1990, Mosby.
3. Janis J, Kenkel J, Rohrich R: Male rhinoplasty, *Plast Reconstr Surg* 112(4):1971–1085, 2003.
4. Allen A, Hollander E: Body dysmorphic disorder, *Psych Clin North Am* 23(3):617–628, 2000.
5. Wilford L, Hilliard F, Dugan D: Chin procedures. In *Surgical treatment objective, a systemic approach to prediction tracing*, St Louis, 1985, Mosby.
6. Adams JS: Grafts and implants in nasal and chin augmentation. A rational approach to material selection, *Otolaryngol Clin North Am* 20(4):913–930, 1987.
7. Gibson FB, Calhoun KH: Chin position in profile analysis. Comparison of techniques and introduction of the lower facial triangle, *Arch Otolaryngol Head Neck Surg* 118(3):273–276, 1992.
8. Zide B, Pfeifer T, Longaker M: Chin surgery: I. Augmentation—the allures and the alerts, *Plast Reconstr Surg* 104(6):1843–1853, 1999.
9. Gonzalez-Ulloa M, Stevens E: The role of chin correction in profileplasty, *Plast Reconstr Surg* 41(5):477–478, 1968.
10. Reed EH, Smith RG: Genioplasty: a case for alloplastic chin augmentation. Clinical controversies in oral and maxillofacial surgery: Part II, *J Oral Maxillofac Surg* 58:788–793, 2000.

11. Niechajev I: Facial reconstruction using porous high-density polyethylene (Medpor): long term results, *Aesthetic Plast Surg* 36(4):917–927, 2012.
12. Robsin M: Wound infection: a failure of wound healing caused by an imbalance of bacteria, *Surg Clin North A* 77(3):637–650, 1997.
13. Strauss RA, Abubaker O: Genioplasty: a case for advancement osteotomy. Clinical controversies in oral and maxillofacial surgery, part one, *J Oral Maxilofac Surg* 58:783–787, 2000.
14. Kaufman MR, Miller T, Huang C, et al.: Autologous fat transfer for facial recontouring: is there a science behind the art? *Plast Reconstr Surg* 119(7):2287–2296, 2007.
15. Chiu ES, Baker DC: Endoscopic brow lift: a retrospective review of 628 consecutive cases over 5 years, *Plast Reconstr Surg* 112(2):628–633, 2003.
16. Leach J: Aesthetics and the Hispanic rhinoplasty, *Laryngoscope* 112(11):1903–1916, 2002.
17. Yaremchuk MJ: Secondary malar implant surgery, *Plast Reconstr Surg* 121(2):620–628, 2008.
18. Powell NB, Riley RW, Laub DR: A new approach to evaluation and surgery of the malar complex, *Ann Plast Surg* 20(3):206–214, 1988.
19. Prendergast M, Schoenrock LD: Malar augmentation. Patient classification and placement, *Arch Otolaryngol Head Neck Surg* 115(8):964, 1989.
20. Silver WE: Malar augmentation, *Facial Plast Surg* 8(3):133–139, 1992.
21. Silver WE, Guilden SE: Chin and malar augmentation. In Bailey BJ, et al.: *Head and neck surgery: otolaryngology*, Philadelphia, 1993, J.B. Lippincott.
22. Merrifield LL, Klontz HA, Vaden JL: Differential diagnostic analysis system, *Am J Orthod Dentofacial Orthop* 106(6):641–648, 1994.
23. Narins RS, Jewell M, Rubin M, et al.: Clinical conference: management of rare events following dermal filler—focal necrosis and angry red bumps, *Dermatol Surg* 32(3):426–434, 2006.
24. Segall L, Ellis D: Therapeutic options for lip augmentation, *Facial Plas Surg Clin North Am* 14(4):485–490, 2007.
25. Schoenrock LD, Repucci AD: GORE-TEX in facial plastic surgery, *Int J Aesth Restor Surg* 1:63–68, 1993.
26. Niamtu J: Experience and evaluation of a new, saline filled implant for cosmetic lip augmentation, *AJCS* 24(4):183–192, 2007.
27. Tobin H, Karas N: Lip augmentation using an Alloderm graft, *J Oral Maxillofac Surg* 56(6):722–727, 1998.
28. Borbujo J, Fernandex-Acenero J, Zamora E: Granulomatous foreign body reaction against hyaluronic acid, report of a case after lip augmentation, *Dermatol Surg* 29(12):1225–1226, 2003.
29. Hinderer UT: Malar implants for improvement of the facial appearance, *Plast Reconstr Surg* 56:157, 1975.

27

Orofacial Embryogenesis: A Framework for Understanding Clefting Sites

KATHLEEN K. SULIK

Introduction

This chapter explains human facial morphogenesis in an attempt to establish a framework for understanding the genesis of orofacial clefts. To facilitate this, illustrations created in the 1940s based on 3D reconstructions of histologic sections of human embryos as well as more recent scanning electron micrographs are presented and described. These images show the complex morphology of the developing human face, an appreciation of which is essential to interpreting experimental and clinical data regarding the genesis of both commonly occurring and unusual orofacial clefts. Of note, a majority of the multiple cleft sites, as defined by Tessier,[1] correspond to the interface of morphologically distinct regions or growth centers of the embryonic face and can be readily related to failures of their growth, fusion, or merging.

Extensive discussion of the contributions and interactions of various cell types to yield the facial growth centers and result in their appropriate development is beyond the scope of this chapter. For this information, the reader is encouraged to examine relevant review articles.[2-4] Furthermore, this chapter is not intended to provide a comprehensive survey of known genetic factors and environmental influences that shape the face and can result in clefts. With knowledge in this arena growing at a rapid rate, reference to both reviews [5-11] and databases of teratogens, genes, genetic disorders, and gene expression patterns for human beings and pertinent animal models is recommended (e.g., Online Mendelian Inheritance in Man: http://www.ncbi.nlm.nih.gov/omim, Edinburgh Mouse Atlas Project: http://www.emouseatlas.org/emap/home.html, and Mouse Genome Informatics: http://www.informatics.jax.org).

For obvious reasons, only a fraction of existing knowledge regarding normal and abnormal craniofacial embryogenesis is derived from examination of human embryos. Therefore extrapolations from descriptive and experimental studies of a broad spectrum of mammalian and nonmammalian species have been, and continue to be, common. Avian and rodent models have proven to be particularly informative. In this chapter the orofacial morphogenesis of these two species is compared with that of the human being, providing supportive evidence and new clues regarding the developmental basis for a variety of clefts.

Complexity of Human Facial Morphogenesis

The developing face is most commonly described as being composed of tissues associated with the frontonasal prominence and the bilateral first pharyngeal (also known as visceral or branchial) arches. The frontonasal prominence surrounds the forebrain, and from it bilateral medial and lateral nasal prominences (also known as swellings or processes) form. The forehead, nose, philtral component of the upper lip, a portion of the upper alveolar ridge, and the primary palate develop from these portions of the embryo. The remainder of the face typically is described as arising from the first pharyngeal arches, each of which is composed of a maxillary prominence that forms the upper jaw and a mandibular prominence from which the lower jaw is derived. As illustrated and discussed in this chapter, this rather simplistic description of embryonic facial morphology is not complete and offers an inadequate framework on which to interpret clinical findings and new developmental investigations.

Although typically oversimplified when referenced in texts, a key embryology resource regarding human facial embryogenesis is a 1948 publication by G.L. Streeter.[12] Selected images from this source are reproduced in Figure 27-1. These drawings, created by J.F. Didusch from reconstructions of histologic sections, show human embryos ranging from 32 to 44 days after conception. Streeter described the developing face as being composed of a number of facial swellings (prominences) that reflect centers of growth. As shown in Figure 27-1, *A,* the primordia of the maxilla

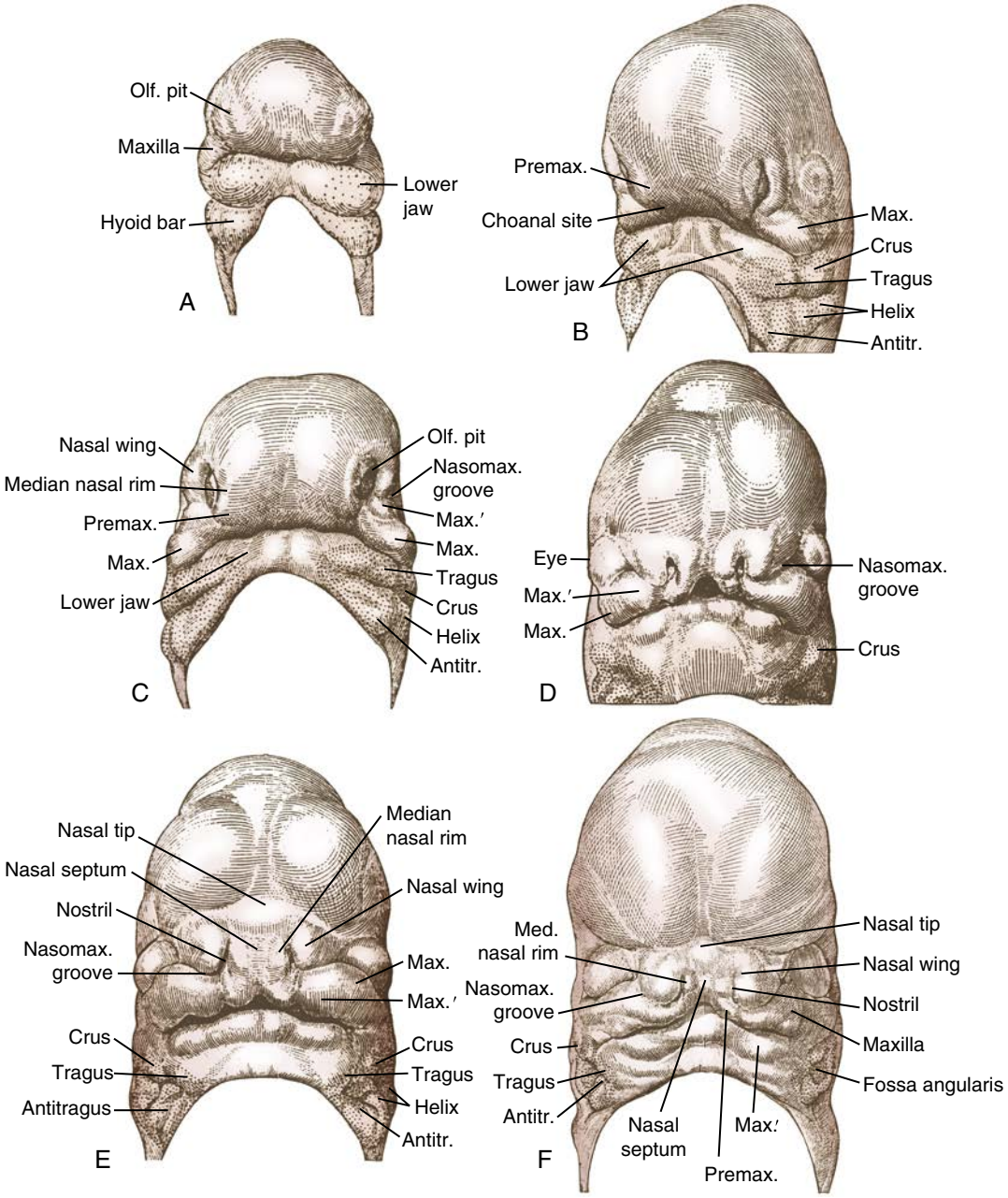

• **Figure 27-1** Drawings made by J.F. Didusch of human Carnegie stages (Streeter's horizon) 14 (32 days; **A**), 16 (37 to 40 days; **B** and **C**), 17 (41 to 43 days; **D** and **E**), and 18 (44 to 46 days; **F**) from reconstructions of the face. *ANTITR.,* Antitragus; *HYOID BAR,* pharyngeal arch II; *MAX.,* maxillary growth center; *MAX'*, supplementary maxillary growth center; *MED. NASAL RIM,* medial nasal prominence (MNP); *NASOMAX. GROOVE,* nasomaxillary groove; *NASAL WING,* lateral nasal prominence (LNP); *OLF. PIT,* olfactory pit; *PREMAX,* premaxillary center (globular process of His). (Reprinted from Streeter GL: Developmental horizons in human embryos: age groups XV, XVI, XVII and XVIII, being the third issue of a survey of the Carnegie Collection, *Contrib Embryol Carnegie Inst Wash* 32:133-203, 1948.)

and lower jaw are apparent as separate swellings prior to the appearance of the frontonasal prominence–associated swellings that will surround the olfactory pits. Regarding the tissue from which the lower jaw forms, Streeter noted that in addition to a median groove, lateral and transverse grooves are present, indicating multiple growth centers for this region of the developing face. In addition to forming the lower jaw, tissues of the lateral and caudal surfaces of the mandibular bar (i.e., first pharyngeal arch) were noted to contribute to the formation of the external ear, in particular the tragus and crus. From the hyoid bar (i.e., the second pharyngeal arch), the helix and antitragus of the ear form (see Figure 27-1, *B* to *F*).

Streeter's description of the growth centers that form the upper jaw include bilateral maxillary centers with a "characteristic subdivision" that he labeled MAX′ (see Figure

27-1, *C* to *F*). Each of the MAX′ subdivisions is more rostrally positioned than the associated main maxillary centers (MAX) and are located adjacent to the developing frontonasal prominence. As the tissues of the frontonasal prominence develop, bilateral olfactory pits become apparent when growth centers termed the nasal wings (lateral nasal prominences [LNPs]) develop to form their dorsolateral boundaries, and medial nasal prominences (MNPs) arise at their medial rims. Growth centers located at the oral cavity (ventral) end of each medial nasal rim, but that are discrete from the nasal rim, are destined to form the premaxilla. Streeter noted that these growth centers could be termed the intermaxillary or incisive centers. They also are known as the globular processes of His. Most textbook descriptions currently do not distinguish the premaxillary (PREMAX) centers from the MNPs. Bilateral closure of the upper lip involves contact of the PREMAX with the MAX′ center and the ventral aspect of the LNP (LNP′) on each side of the developing face. Lip closure normally occurs during the sixth week of human gestation, when the embryo appears as shown in Figures 27-1, *D* and *E.*

Streeter's work was extended in 1985 by Hinrichsen[13] in a detailed report heavily based on scanning electron micrographs illustrating human facial morphogenesis. Figures 27-2 and 27-3 include four images from Hinrichsen's work, with the remainder prepared by this chapter's author as part of the Necker collection (Necker Children's Hospital, Paris, France; see also https://embryology.med.unsw.edu.au/embryology/index.php/Scanning_Electron_Microscopy). These scanning electron microscopic images of human embryos complement those of Didusch's drawings, revealing a more complex array of facial growth centers than commonly recognized.

Micrographs in Figure 27-2 show frontal views of the faces of Carnegie stage 11 (see Figure 27-2, *A*), 12 (see Figure 27-2, *B* and *C*), 16 (see Figure 27-2, *D* and *E*), 17 (see Figure 27-2, *F* and *G*), and 18 embryos (see Figure 27-2, *H* and *I*): stages present at 24 to 25, 26 to 27, 37 to 40, 41 to 43, and 44 to 46 days after fertilization, respectively. An image of a 9-week-old fetus also is shown (see Figure 27-2, *J*). At the earliest stage shown, the anterior neuropore is completing its closure, a process that results in separation of the forebrain neuroepithelium from the surface epithelium of the frontonasal prominence (see Figure 27-2, *A*). The developing eyes, which are evaginations from the forebrain, are seen at this time as bulges raised on each side of the developing upper midface. By 26 days, the site of the anterior neuropore is no longer apparent (see Figure 27-2, *B*). Over the course of the next few days, the bilateral sites of the olfactory pits, around which the nose forms, become notable (see Figure 27-2, *C*; also see Figure 27-1, *A*). As shown in Figure 27-2, *C,* the first pharyngeal arches, from which the lower jaw develops, initially have a deep median groove between them. By the time the embryo enters its sixth week of development, although a median groove is still present, the tissue bridge connecting the bilateral first arches is much wider (see Figure 27-2, *D*).

As also shown in Streeter's work, in the developing lower jaw a shallow furrow separates the bulk of the first arch tissue from what appears to be a supplementary mandibular growth center that is the progenitor of the mentum. In this chapter, this tissue is termed MAN′. Another first arch growth center that can be identified at this time appears to correspond to the region of the future body of the mandible (MANB). Between 37 and 40 days of development, the first arch–derived external ear growth centers (auricular hillocks) become evident (see Figure 27-2, *D* and *E*). Confirming Streeter's findings, an obvious supplementary maxillary growth center (MAX′, see Figure 27-2, *D* and *F*) adjacent to the most ventral portion of the LNP (LNP′), as well as distinct MNP and PREMAX centers, also are present at this stage of development. On the side of MAX′ opposite LNP′ is the bulk of the MAX. Removal of the lower jaw, as has been done in the embryo shown in Figure 27-2, *F*, shows that a major portion of MAX extends into the oral cavity, forming the secondary palatal (SP) shelves. This view also allows visualization of Rathke's pouch (RP), the progenitor of the anterior pituitary gland.

By the end of the sixth week, the lip should be closed bilaterally while a median groove between the PREMAX centers remains (see Figure 27-2, *G*). Also by this time the six auricular hillocks from which both of the external ears form can all be seen. They comprise a large portion of the first and second pharyngeal arch tissue. Other prominent first arch components are MAN′ and the MANB. These mandibular subsegments also are apparent early in the seventh week of human gestation (see Figure 27-2, *H*). At this time the PREMAX centers have merged in the midline. While the contour of the upper lip thus becomes smoother, at this stage in development the bilateral sites of union between the MAX′ and PREMAX remain apparent (see Figure 27-2, *I*). By the beginning of the fetal period, epithelial plugs fill the nostrils, and the forming vermillion border of the upper lip is notable (see Figure 27-2, *J*). In addition, the hard palate is closed as a result of the union of the SP shelves with each other as well as with the PREMAX-derived primary palate (PP).

Scanning electron micrographs of the lateral aspects of the head and neck of a series of human embryos ranging from 24 to 53 days of gestation are shown in Figure 27-3. From days 24 to 25 of development, the cranial end of the human neural tube completes its closure. This is evident in the three Carnegie stage 11 embryos shown in Figure 27-3, *A* to *C.* The embryo in Figure 27-3, *A,* still has a widely open forebrain; the rim of the forebrain of the embryo in Figure 27-3, *B,* has curved medially; and only a small anterior neuropore remains in the embryo shown in Figure 27-3, *C.* As previously noted, the frontonasal prominence is that part of the developing face associated with (surrounding) the forebrain. Just caudal to the forebrain/frontonasal prominence region in all the Carnegie stage 11 embryos is a distinct maxillary growth center. And caudal to the developing maxillary region of the developing face is the first pharyngeal arch. As shown in Figure 27-3, *D* to *G,* during the

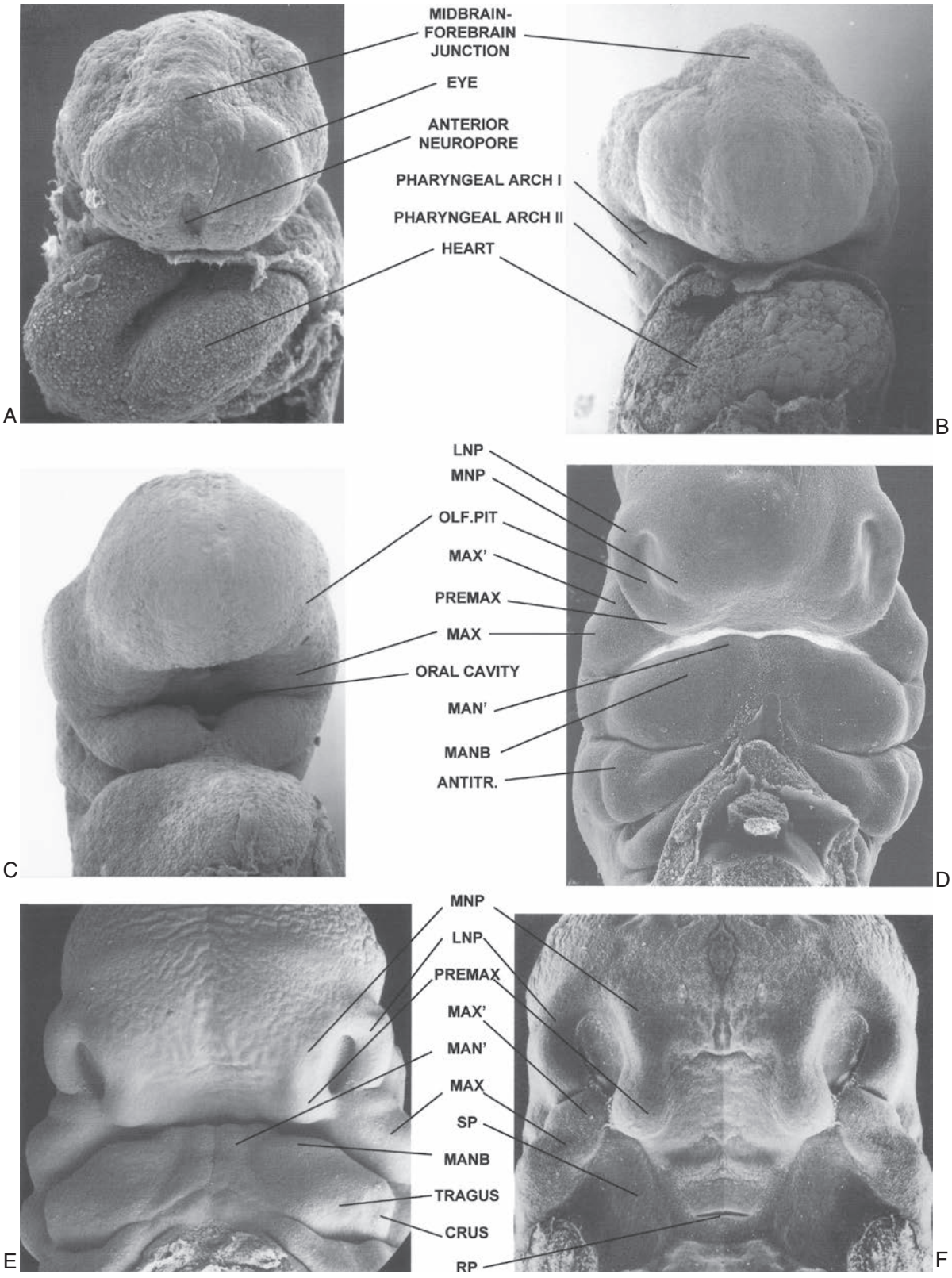

• **Figure 27-2** Scanning electron micrographs of faces of human embryos at Carnegie stages 11 (24 to 25 days; **A**), 12 (26 to 27 days; **B** and **C**), 16 (37 to 40 days; **D** and **E**), 17 (41 to 43 days; **F** and **G**), and 18 (44 to 46 days; **H** and **I**) as well as an early fetus (9 weeks; **J**). *ANTITR.,* Antitragus; *LNP,* lateral nasal prominence; *MAN′*, supplementary mandibular growth center; *MANB,* mandibular body; *MAX,* maxillary prominence (growth center); *MAX′*, supplementary maxillary growth center; *MNP,* medial nasal prominence; *OLF. PIT,* olfactory pit; *PP,* primary palate; *PREMAX.,* premaxillary center; *RP,* Rathke's pouch; *SP,* secondary palate. (***A*** to ***D***, ***G***, ***I***, and ***J***, Courtesy the Necker collection; ***E***, ***F***, and ***H***, reprinted from Hinrichsen K: The early development of morphology and patterns of the face in the human embryo, *Adv Anat Embryol Cell Biol* 98:1-79, 1985.)

Continued

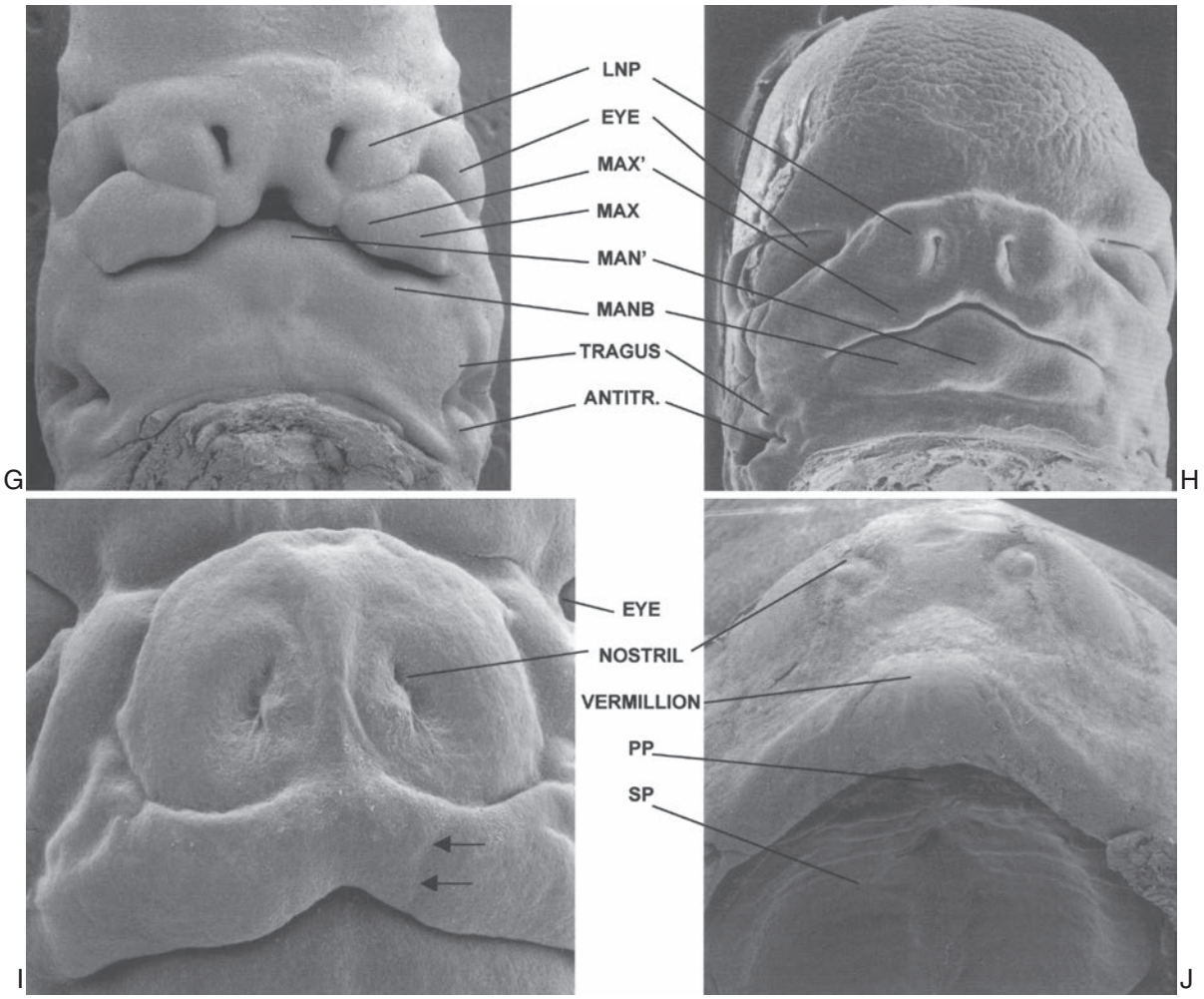

• **Figure 27-2, cont'd**

fifth week of development the first pharyngeal arch has a proximal and distal segment. The distal segment of the first pharyngeal arch appears to correspond to the lower jaw as well as the tragus and crus of the external ear, whereas the proximal segment contributes to the anterior aspect of the helix of the external ear as well as the zygomaticotemporal (ZT) portion of the face (see Figure 27-3, *I*).

Between 28 and 32 days of gestation (Carnegie stages 13 and 14; see Figure 27-3, *E* and *F*), bilateral olfactory placodes become evident features of the frontonasal prominence as the LNPs and MNPs begin to form. Just posterior to the LNP, the lens pit can be seen. In addition, the trigeminal ganglion creates a bulge located proximal to the first arch and the MAX. As previously noted—and as shown at low and high magnification in Figure 27-3, *G*, 27-3, *H* respectively—by stage 16 (37 to 40 days) MAX′ is evident as a maxillary prominence subsegment. Also at this stage the LNP has two distinct growth centers, one of which (LNP′) is more ventral and abuts the upper portion of MAX′. The PREMAX center abuts the lower portion of MAX′. As development progresses through the sixth week (see Figure 27-3, *I* and *J*) and as discussed by Hinrichsen,[13] MAX′, LNP′, and PREMAX unite bilaterally to close the upper lip. Figures 27-3, *I* and *J* also illustrate the first pharyngeal arch growth centers evident in the sixth week. These appear to correspond to the region of the mentum (MAN′); MANB and ramus (MANR); the ZT; and the segments of the external ear that include the tragus, crus, and the anterior segment of the helix. The three auricular hillocks of the second pharyngeal arches also can be seen. The most ventral of these forms the antitragus, whereas the others contribute to the helix. As the embryonic period ends, the contours of the face become relatively smoother as the numerous distinct facial growth centers become much less obvious (see Figure 27-3, *K*).

With the lower jaw of late embryonic and early fetal period fetuses removed, the roof of the oronasal cavity and the forming palate are readily observed (Figure 27-4). At the end of the embryonic period the oronasal cavity roof is characterized by a posteriorly positioned remnant of Rathke's pouch (see Figure 27-4, *A* and *B*) and a more anteriorly positioned nasal septum (NS), lateral to which the posterior openings to the nasal cavity are located. Anterior to the NS are the PREMAX centers. In addition to contributing tissue to the philtral region of the upper lip, they form part of the upper alveolar ridge and the PP. The remainder of the palate, the SP shelves, including the soft palate, is derived from the

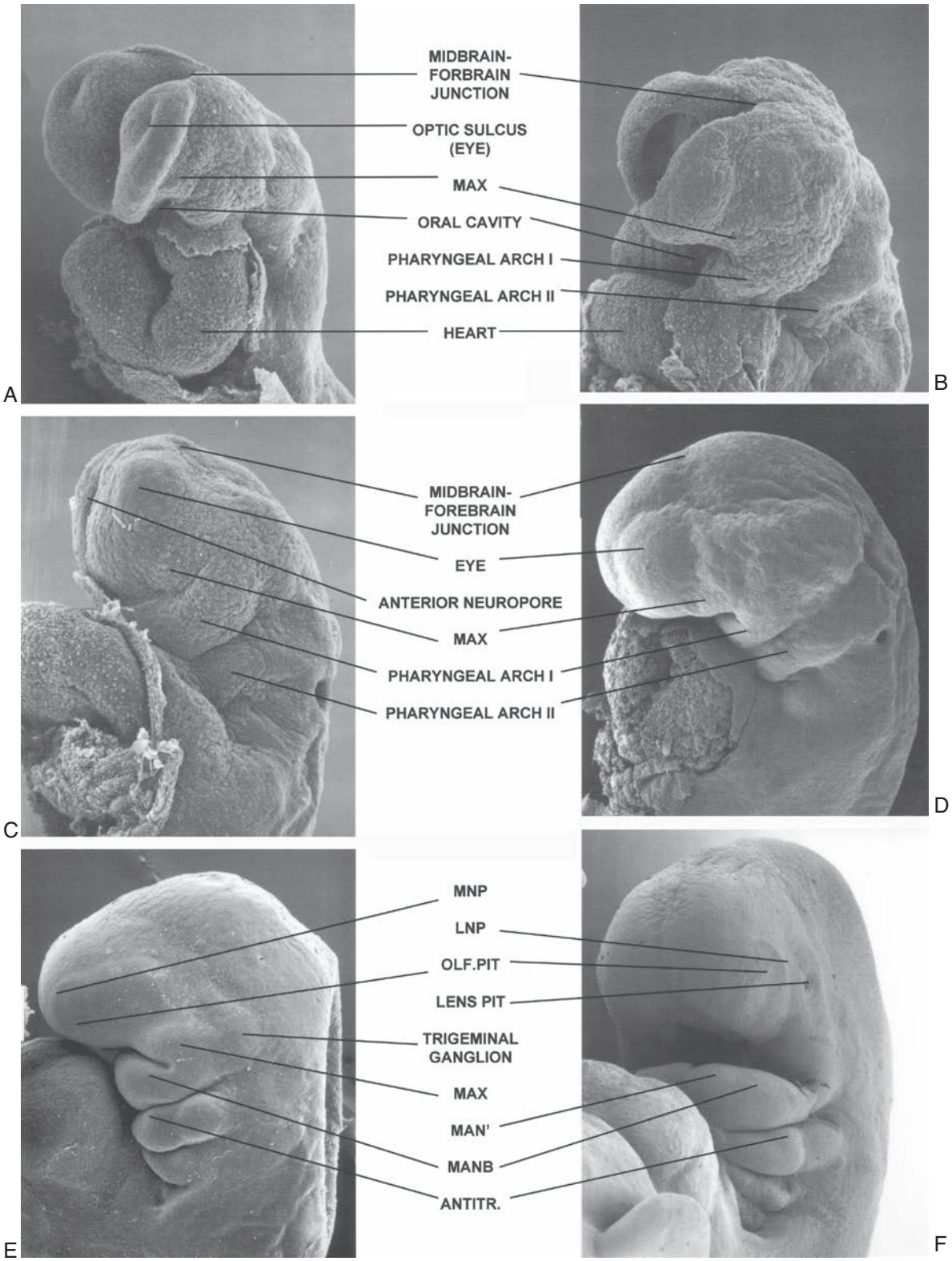

• **Figure 27-3** Scanning electron micrographs illustrating development of the human head and neck. Carnegie stages 11 (24 days, **A** and **B**; 25 days, **C**), 12 (26 to 27 days; **D**), 13 (28 to 31 days; **E**), 14 (32 days; **F**), 16 (37 to 40 days; **G** and **H**), 17 (41 to 43 days; **I** and **J**), and 21 (52 to 53 days; **K**). *ANTITR.,* Antitragus; *LNP,* lateral nasal prominence; *LNP′*, supplementary lateral nasal prominence growth center; *MANB,* mandibular body; *MANR,* mandibular ramus; *MAX,* maxillary prominence; *MAX′*, supplementary maxillary growth center; *MAN′*, supplementary mandibular growth center; *MNP,* medial nasal prominence; *OLF. PIT,* olfactory pit; *PREMAX.,* premaxillary center; *ZT,* zygomaticotemporal center. (***A*** to ***H***, ***J***, and ***K***, Courtesy the Necker collection; ***I***, reprinted from Hinrichsen K: The early development of morphology and patterns of the face in the human embryo, *Adv Anat Embryol Cell Biol* 98:1-79, 1985.)

Continued

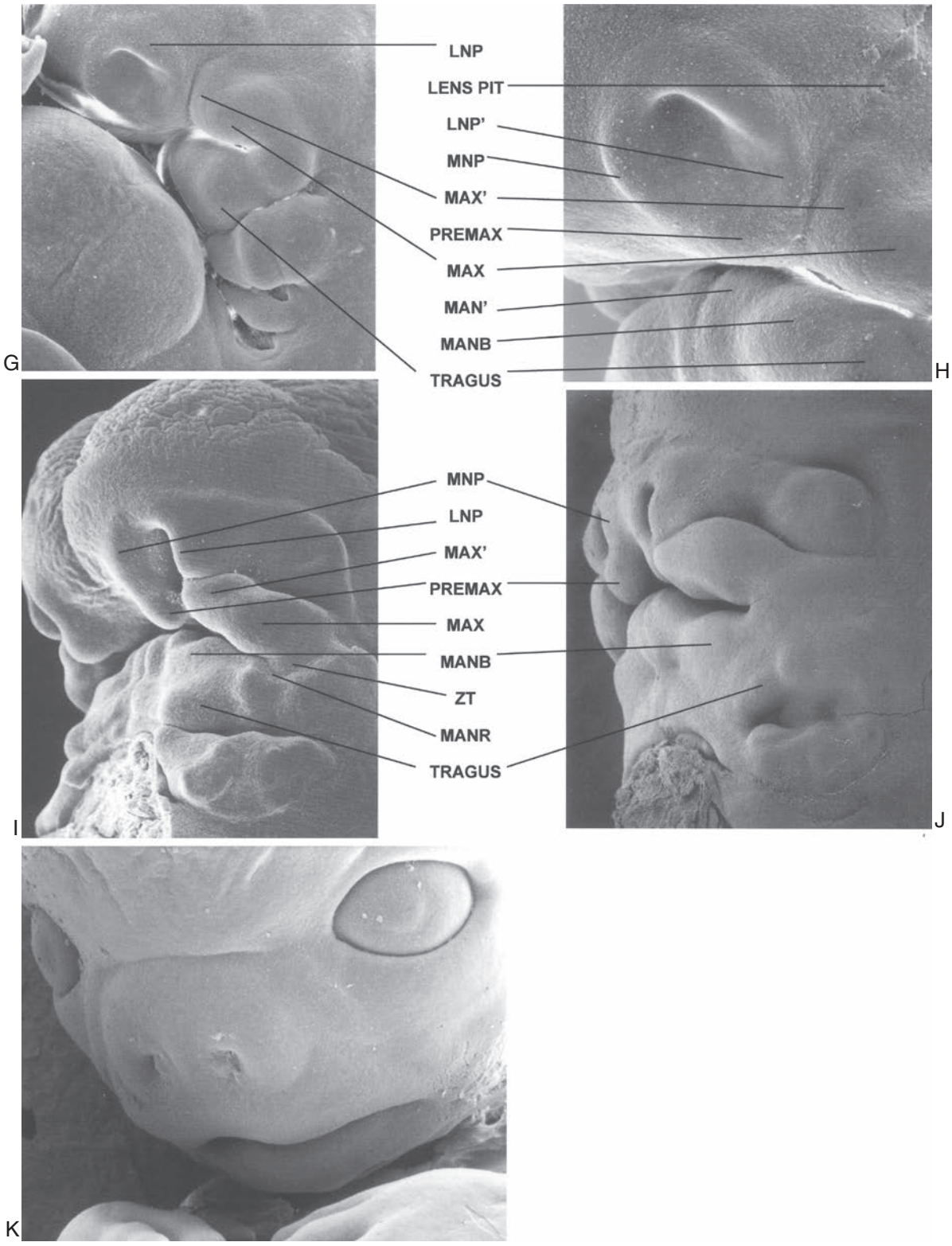

• **Figure 27-3, cont'd**

maxillary prominences, including an anterior contribution that appears to be from MAX′. Both MAX and MAX′ also contribute to the upper alveolar ridge. As the fetal period begins, the SP shelves become approximated in the midline (see Figure 27-4, *C*). Fusion proceeds both anteriorly (rostrally) and posteriorly, with closure being complete in the ninth week (see Figure 27-4, *D*). Union of the SP with the PP and NS also occurs early in the fetal period.

Insights from Studies of Facial Morphogenesis in Chicks and Mice

Results of more recent studies involving scanning electron microscopy, cell fate mapping, and analyses of gene expression patterns in model systems have provided additional insights regarding the complexities of normal and abnormal craniofacial embryogenesis.[3,4,10,14-16] In some cases

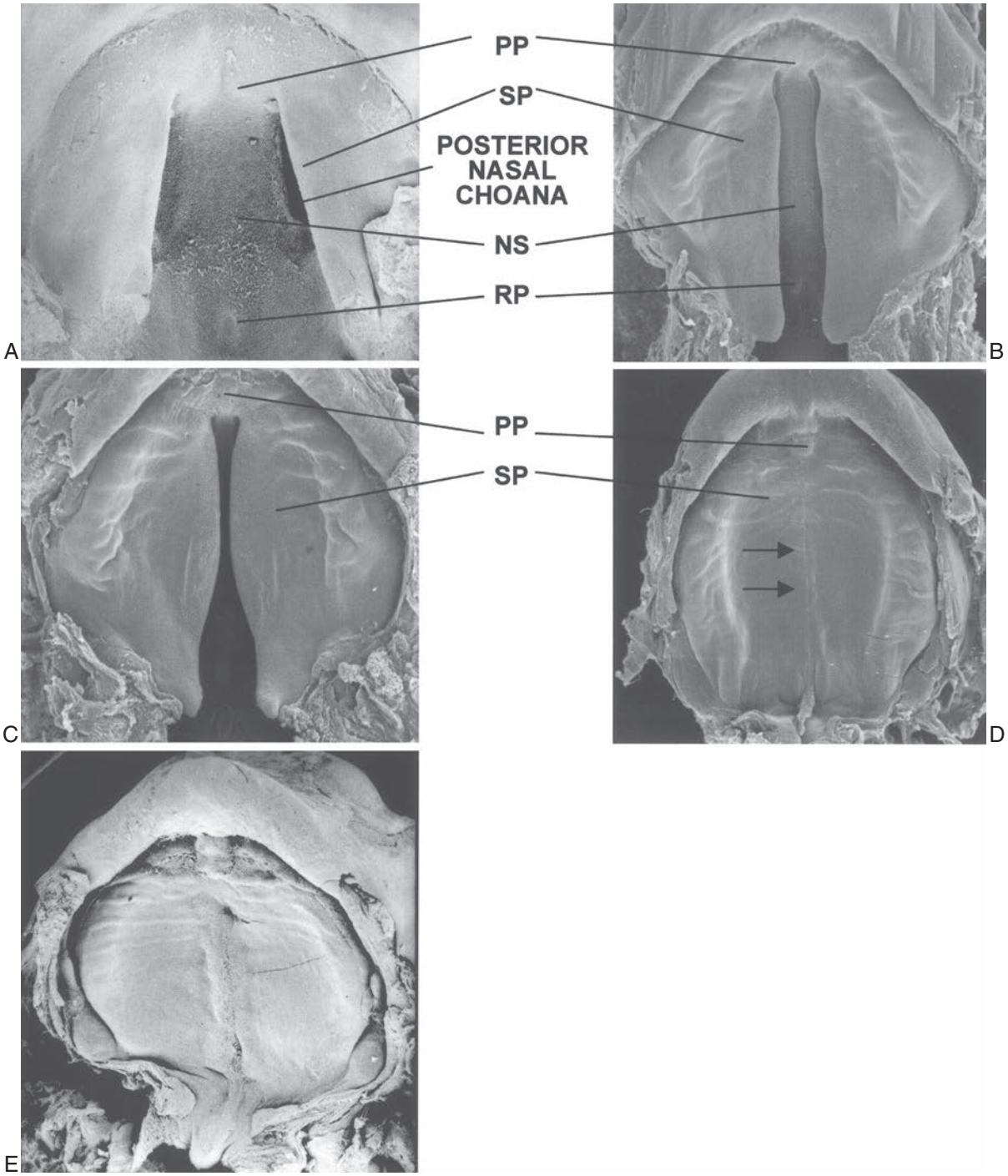

• **Figure 27-4** Scanning electron micrographs of the roof of the oral cavity illustrate the human hard and soft palate at late embryonic (stage 23, approximately 55 days; **A**) and early fetal periods (week 9, **B** to **D**; week 10, **E**). *NS,* Nasal septum; *SP,* secondary palate; *PP,* primary palate; *RP,* site of Rathke's pouch. *Arrows* indicate fusion seam.

the new findings are contrary to commonly held views. Excellent examples include experimental results regarding the genesis of the maxillary prominences. The maxillary prominences are classically considered to be the dorsal part of the first pharyngeal arch. However, dye-based fate mapping studies in chicken embryos have shown that this is not accurate.[17] Consistent with the morphologic features as described for human embryos, a major portion of each maxillary prominence has been shown to be a separate structure that arises cranial (rostral) to the first pharyngeal arch. In addition, different molecular codes have been identified for the cranial (rostral) versus the caudal aspects of the maxillary prominences, that is, portions of the developing upper jaw that appear to correspond to MAX′ versus MAX and/or POSTMAX. More specifically, in the chick, when the maxillary prominence begins to form during Hamburger and Hamilton (HH) stage 18 to the time that the embryos reach HH stage 24 (when development corresponds to approximately 30 to 40 days in the human being), retinoic acid receptor β is restricted to the cranial (rostral) aspect of the maxillary prominences. These cranial cells give rise to more distal parts of the upper beak, and the caudal cells of the maxillary prominences form more proximal facial structures. As shown in Figure 27-5, between HH stages 24 and 26, when development corresponds to 37 to 43 days in the human being, the chick maxillary prominences have morphologically distinct portions that appear to correspond to MAX′, MAX, and POSTMAX in the human being. The MNPs and LNPs also each have morphologically distinct growth centers (MNP and PREMAX, and LNP and LNP′, respectively). As clearly shown in Figure 27-5, *E,* in the chick normal lip closure begins with fusion between LNP′ and the PREMAX segment. Later, the PREMAX segment also joins MAX′.

Like avian embryos, the mouse has proven to be an excellent experimental model for embryogenesis studies. The usefulness of the chick is largely attributable to its accessibility for grafting and labeling experiments, whereas for mice the extensive genetic information and tools now available for modifying and identifying sites of gene expression have been invaluable. A factor that somewhat diminishes the usefulness of the mouse as a model for the

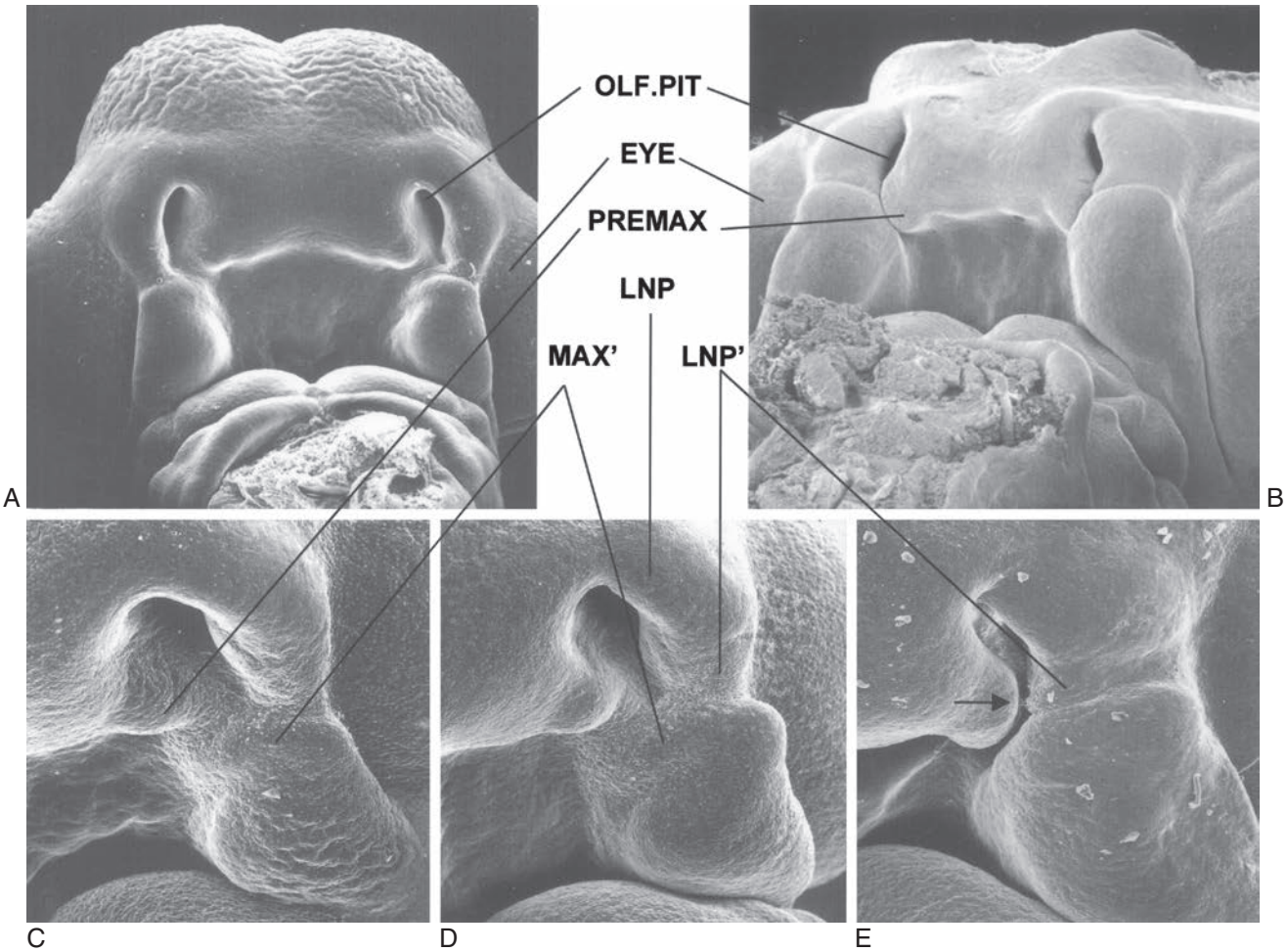

• **Figure 27-5** Scanning electron micrographs of 4½- to 5-day-old chick embryos at HH stages 24 (**A**, **C** to **E**) to 26 **(B).** *LNP,* Lateral nasal prominence; *LNP′*, supplementary lateral nasal prominence growth center; *MAX′*, supplementary maxillary growth center; *MNP,* medial nasal prominence; *OLF. PIT,* olfactory pit; *PREMAX.,* premaxillary center.

study of normal and abnormal orofacial embryogenesis, however, is that in this species the various growth centers and contours of the developing face are not as readily defined morphologically as in the human and chick. For example, at the time of neural tube closure in the mouse, a distinct maxillary growth center is not observed (Figure 27-6, *A* and *B*), whereas it is in the human (see Figure 27-3, *C* and *D*). And although a hint of distinction is seen between the MAX′ and MAX (see Figure 27-6, *D* and *E*), this is not as clear as in the human and chick. This also

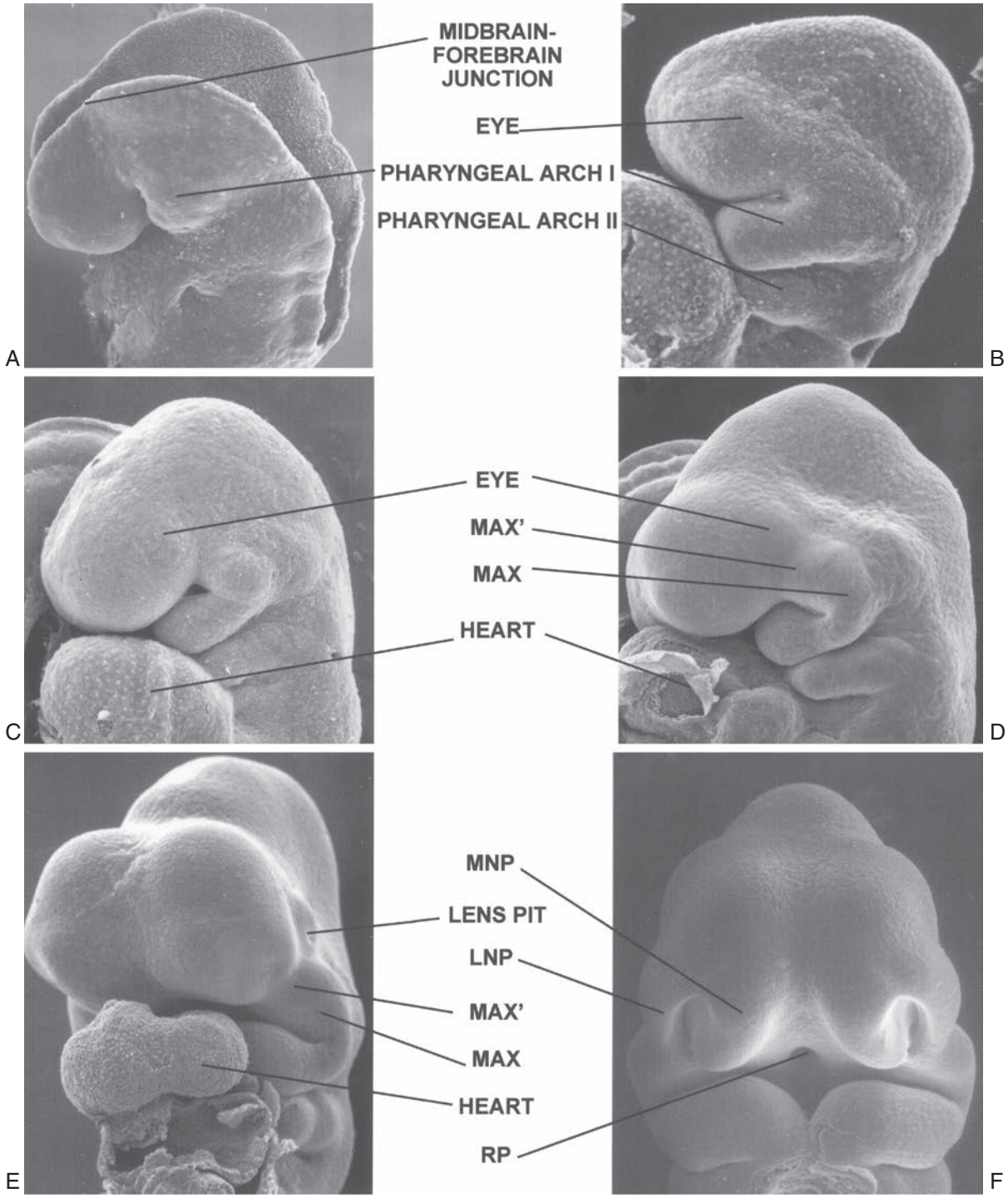

• **Figure 27-6** Scanning electron micrographs of mouse embryos ranging in age from gestational day 8½ to 15. Embryos in **A** to **D** are shown in lateral views; **E** to **G** are frontal or somewhat frontolateral views; **H** and **J** are views of the roof of the oronasal cavity and secondary palatal shelves, with the lower jaw removed; **K** and **L** are images of frontal cuts through the developing upper jaw. *LNP,* Lateral nasal prominence; *MAX,* maxillary prominence; *MAX′*, supplementary maxillary growth center; *MNP,* medial nasal prominence; *NS,* nasal septum; *OLF. PIT,* olfactory pit; *PREMAX.,* premaxillary center; *RP,* Rathke's pouch.

Continued

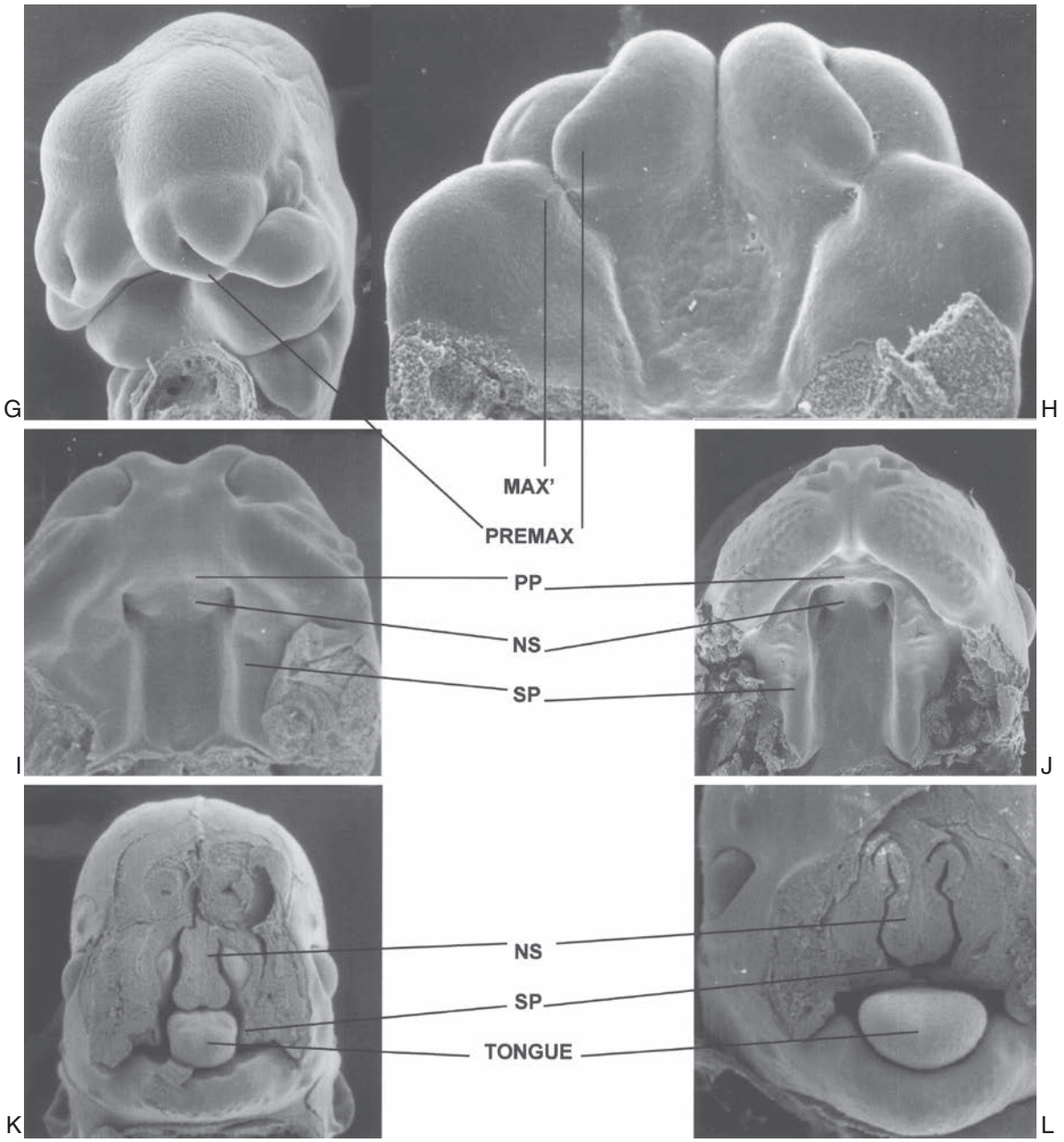

• **Figure 27-6, cont'd**

is true for the distinction between the mouse MNP and PREMAX, LNP and LNP′, and the various subcomponents of the first pharyngeal arch. As in the human and chick, lip closure entails union between the PREMAX segment, LNP′, and MAX′ (see Figure 27-6, *G* and *I*). Also as in the human, the NS, with which the secondary palatal shelves fuse to separate the oral and nasal cavities, extends posteriorly only as far as the posterior extent of the choanae (compare Figures 27-4, *I* and 27-6, *I* and *J*). Also notable is that the NS is composed of bilateral growth centers. As in the human, union of the SP shelves occurs after that of the segments of the lip and requires elevation of the palatal shelves to a position above the tongue (see Figure 27-6, *K* and *L*).

Orofacial Clefting Sites

Knowledge of the various facial growth centers is key to understanding the basis for the sites of both commonly occurring and unusual facial clefts. Figure 27-7 illustrates the apparent relation between the facial growth centers of a 6-week human embryo and the craniofacial clefting scheme developed by Tessier.[1]

Notable in the Tessier classification scheme is that the midline has two different cleft numbers: 14, which extends through the forehead and 0, which is at the level of the mid-face and mandible. Cleft 0, which designates median facial clefts, is unique in that it represents two quite different phenomena. One involves a median split between

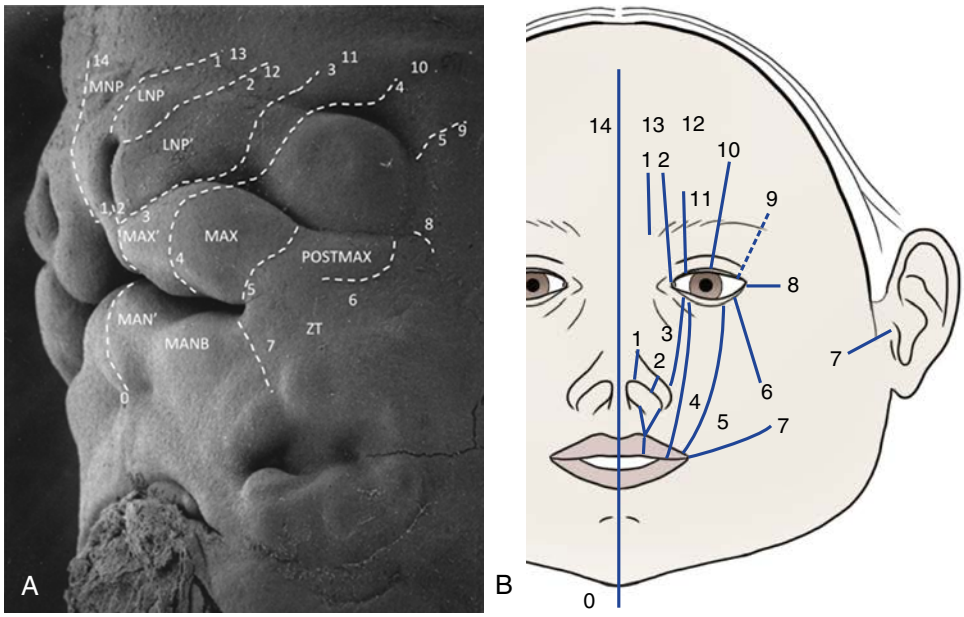

• **Figure 27-7** Furrows between facial growth centers, most of which remain visible in the 7 week old human embryo shown in (**A**) are correlated to the position of Tessier's numbered facial clefts (**B**). (Reprinted from Tessier P: Anatomical classification facial, cranio-facial and latero-facial clefts, *J Maxillofac Surg* 4:69-92, 1976.)

the bilateral MNP and PREMAX centers as well as the NS and typically is accompanied by hypertelorism. As in the mouse fetus that has this type of defect (Figure 27-8, *B*), although a wide midline cleft is present, all the elements of the nose and upper lip are present and are proportionally normal.

The other type of median midfacial cleft involves hypotelorism with a spectrum of reductions in the tissues of the nose and PREMAX region. This is the spectrum of holoprosencephaly.[18] At the mild end of the spectrum is reduced size of the PREMAX centers and the MNPs. This is exemplified by a mouse fetus shown in Figure 27-8, *C*, that has too little tissue between the two nostrils and has a single, merged MNP. The median tissue loss is noted by the abnormally close proximity of the whisker follicles of the maxillary prominences. In addition, the PREMAX centers are absent in this fetus so that a central cleft is present between the two maxillary prominences. The cleft does not extend into the nose. A more severe manifestation of central midfacial tissue loss is illustrated in Figure 27-8, *D*. This fetus has no nostrils. All MNP-, PREMAX-, LNP-, and LNP″-derived tissues that should immediately surround the nostrils did not form. This is evidenced by the fact that the whisker follicles of the two maxillary prominences meet in the upper midline of the snout instead of being widely separated. Also illustrated in Figure 27-8, *D*, is that the upper two rows of whisker follicles are associated with MAX′, whereas the other three rows are MAX associated.

As illustrated in Figure 27-9, new insights regarding nonmedian clefts of the upper lip also are provided by examination of mouse fetuses. Although, as previously noted, the various facial growth centers of mouse embryos before and at the time of normal lip fusion are not readily defined, examination at later stages of individuals that have complete or incomplete clefts of the lip validates their presence. Comparison of the normal early fetal-stage mouse nose and upper lip with those with clefts of the lip confirms the following: (1) MAX′ and LNP′ are distinct entities that normally fuse with the PREMAX center (see Figure 27-9, *C*); (2) MAX′ may fuse with the PREMAX center even though LNP′ does not (see Figure 27-9, *B, left*); and (3) normal lip formation entails overlap of the lateral aspects of the PREMAX centers and the ventral portion of MAX′ by MAX (see area of normal PREMAX overlap indicated by *dashed lines* in Figure 27-9, *C*).

Tessier's type 1 cleft includes a cleft of the lip in the region of the philtral ridge along with a cleft through the ala that extends through the dorsum of the nose. This clearly represents failure of union between the medial (the PREMAX and MNP) and lateral (MAX′, LNP, and LNP′) components of the upper midface. The defect in the lip that occurs in type 1 is comparable to that in the type 2 cleft. In the latter, however, although hypoplasia of the ala nasi is present, true notching is not. Type 2 cleft is that typically seen in isolated cleft lip cases, corresponds to the clefts shown in Figure 27-9, *C*, and results from failure of the PREMAX and MNP to unite with LNP′ and MAX′. In both types 1 and 2 the alveolus is involved, with the cleft in the position of the maxillary lateral incisor. While this tooth is commonly entirely missing, when present the primary maxillary lateral incisors are found in three distribution patterns as follows: (1) one lateral incisor located distal to the alveolar cleft, (2) one lateral incisor located mesial to the alveolar

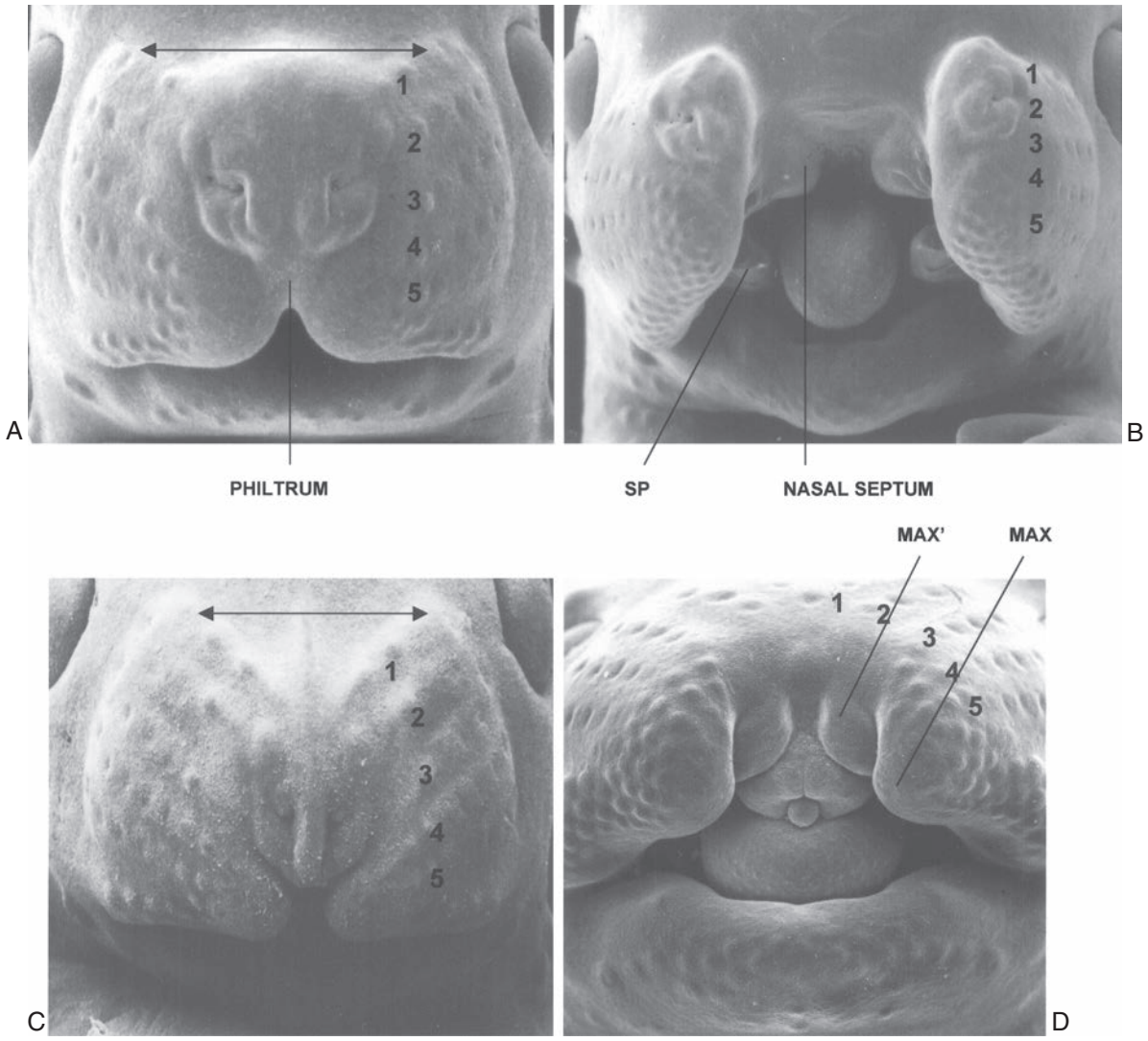

• **Figure 27-8** Comparison of normal **(A)** and abnormal mouse fetuses with type 0 clefts. The fetus in **B** is hyperteloric, whereas those in **C** and **D** are hypoteloric. *MAX,* Maxillary prominence; *MAX′*, supplementary maxillary growth center; *NS,* nasal septum; *SP,* secondary palate. *1* to *5,* Rows of MAX whisker follicles; *double-headed arrow,* separation between the maxillary hair follicles.

cleft, and (3) the presence of two lateral incisors with one tooth on each side of the cleft.[19] In individuals with type 2 clefts, including those with Simonart's bands, one maxillary lateral incisor located distal to the cleft is most common and the least common situation is one maxillary lateral incisor located mesial to the cleft.[20, 21] That a lateral incisor may be found lateral to the cleft has been difficult to reconcile with the generally accepted premise that all of the upper incisors originate in tissues of the PREMAX. This idea has, however, been challenged by Wei et al.,[22] who examined nonhuman primate embryos and suggested that the lateral incisors instead originate within the maxillary prominences and then undergo a medial shift in position, and by Horokova et al.,[19] who, in examining human 6- to 8-week-old embryos, determined that the upper lateral incisor epithelium originates from both maxillary and PREMAX tissues. It is now quite clear that the maxillary component of the upper lateral incisor is a MAX′ derivative.

In type 3 cleft the lip defect is in the region of the typical cleft lip, but the cleft does not extend deep into the tissue. As opposed to types 1 and 2, the alveolar defect is between the lateral incisor and the canine. The type 3 cleft defect appears to involve primarily the union of the lateral incisor–bearing MAX′ with the canine-bearing MAX center. A defect of this type is shown at right in Figure 27-9, *B.* In type 4 cleft, alveolar involvement also is between the lateral incisor and the canine, but the accompanying cleft in the lip is located between the philtral ridge and the commissure of the mouth rather than at the position of the philtral ridge. A defect of the type shown at left in Figure 27-9, *B*, is expected to result in a type 4 cleft. It represents a wide separation between the MAX′ and MAX centers. The presumed MAX deficiency that underlies the type 4 defect would be expected to result in reduced size of the secondary palatal shelves and subsequently a cleft of the secondary palate. Cleft palate is, indeed, a type 4 component.

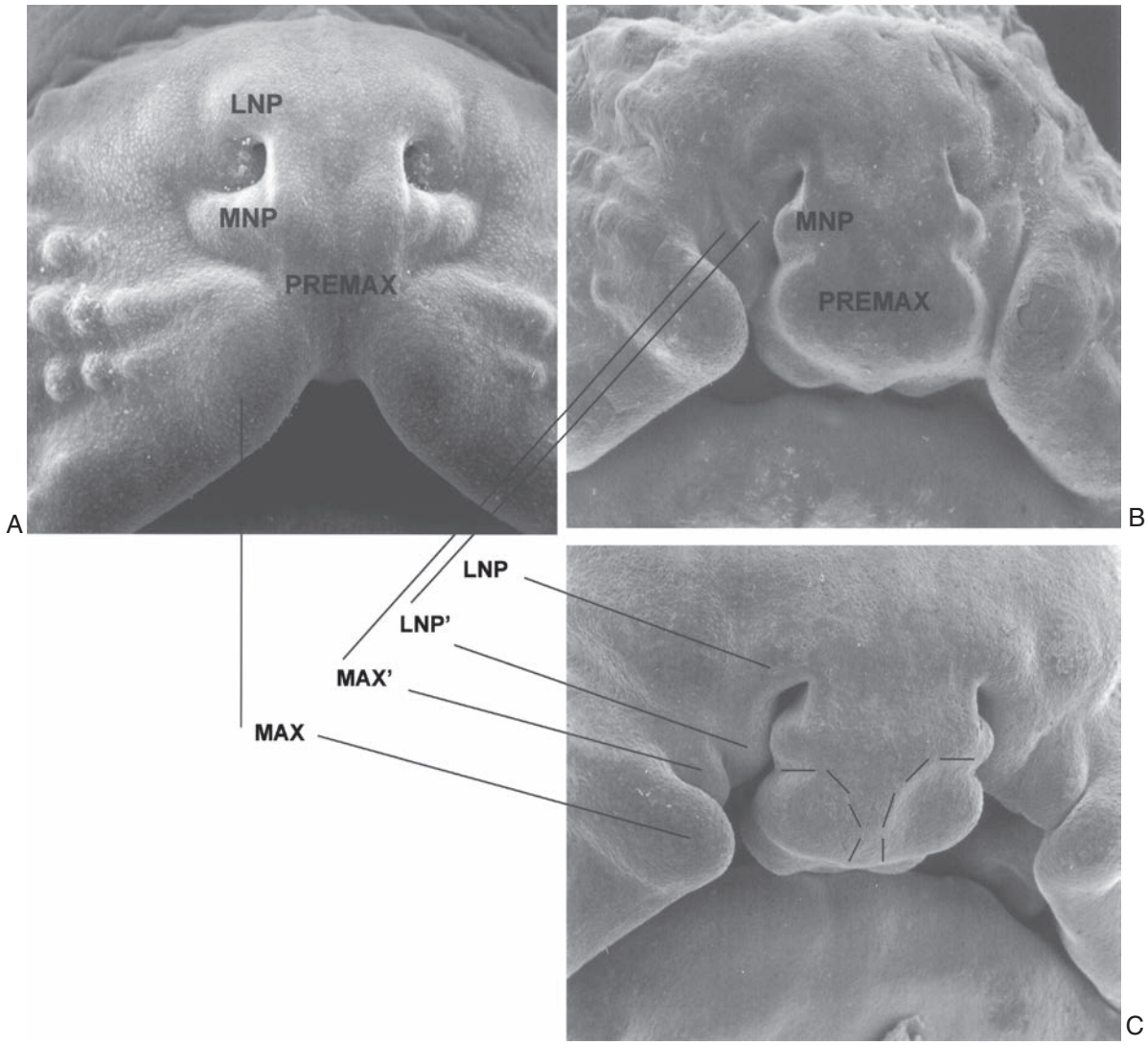

• **Figure 27-9** Scanning electron micrographs of the nose and upper lip of mouse fetuses at gestational day 13 to 14. Normal morphology is shown in **(A);** a type 3 cleft is shown on the right and a type 4 cleft is shown on the left in **(B);** bilateral complete type 2 clefts are shown in **(C).** *LNP,* Lateral nasal prominence; *LNP′*, supplementary lateral nasal prominence growth center; *MAX,* maxillary prominence; *MAX′*, supplementary maxillary growth center; *MNP,* medial nasal prominence; *PREMAX.,* premaxillary center. *Dashed lines,* Area of MAX overlap.

The position of the type 5 cleft, which extends as a furrow between the corner of the mouth and the junction of the middle and lateral third of the lower eyelid, is readily delineated in the 6-week-old human fetus. This furrow separates the MAX from the POSTMAX of the embryonic face. A deficiency involving the POSTMAX and/or ZT growth center would presumably yield a type 6 cleft, which is similar to that typically found in Treacher Collins syndrome.

The type 7 cleft, which extends from the corner of the mouth to the ear, presents with abnormalities of the mandibular ramus, coronoid, and condyle along with absence of the zygomatic arch. This cleft is at a position that corresponds to that of an obvious furrow present between the proximal and distal portions of the first pharyngeal arch of Carnegie stage 16 human embryos (see Figure 27-3, *G*).

The proximal border of the first arch appears to correspond to the position of the type 8 cleft. This cleft involves the lateral bony wall of the orbit and is considered to be the first of the "northbound" clefts. As illustrated in Figure 27-7, that the remainder of the northbound clefts have southbound counterparts strongly supports a segmental origin for the upper facial structures. More specifically, the mesenchymal cells comprising the MNP, LNP, LNP', MAX', and MAX facial growth centers likely originate at early developmental stages from the dorsal midline as discrete (neural crest cell) populations that are arranged in rostro-caudal segments. Intervals between these segments appear to correspond to the clefting sites described by Tessier.

Summary

Along with reference to the early literature, appreciation of the complexity of facial morphogenesis has been facilitated by the availability of a developmental series of scanning electron micrographs of human embryos as well as commonly used experimental animals. Examination of human, mouse, and chick embryos has allowed recognition of the existence of comparable facial growth centers across these three species. In some cases the overt appearance of a particular center in one species has allowed recognition of its more subtle counterpart in another. A clear example of this is the MAX′ segment, which had been noted in human embryos by Streeter in histologic reconstructions and is obvious in scanning electron micrographs in both human and chick embryos but is not that obvious in mice. Consideration of this growth center as a distinct entity of the developing face has provided a developmental context for understanding the genesis of a variety of clefts of the lip. This, along with awareness of the form and location of the numerous other growth centers of the developing face, provides a developmentally based rationale for Tessier's classification scheme.

Acknowledgments

Thank you to Dr. Timothy A. Turvey for his critical reading of this chapter and The National Institute on Alcohol Abuse and Alcoholism for its generous grant support.

References

1. Tessier P: Anatomical classification facial, cranio-facial and latero-facial clefts, *J Maxillofac Surg* 4:69–92, 1976.
2. Helms JA, Cordero D, Tapadia MD: New insights into craniofacial morphogenesis, *Development* 132:851–861, 2005.
3. Tapadia MD, Cordero DR, Helms JA: It's all in your head: new insights into craniofacial development and deformation, *J Anat* 207:461–477, 2005.
4. Bush JO, Jiang R: Palatogenesis: morphogenetic and molecular mechanisms of secondary palate development, *Development* 139:229–243, 2012.
5. Chai Y, Maxson Jr RE: Recent advances in craniofacial morphogenesis, *Dev Dyn* 235:2353–2375, 2006.
6. Handrigan GR: Gene discovery in craniofacial development and disease—cashing in your chips, *Clin Genet* 71:109–119, 2007.
7. Rahimov F, Jugessur A, Murray JC: Genetics of nonsyndromic orofacial clefts, *Cleft Palate Craniofac J* 49:73–91, 2012.
8. Vieira AR: Genetic and environmental factors in human cleft lip and palate, *Front Oral Biol* 16:19–31, 2012.
9. Leslie EJ, Marazita ML: Genetics of cleft lip and cleft palate, *Am J Med Genet C Semin Med Genet* 163:246–258, 2013.
10. Brunskill EW, Potter AS, Distasio A, et al.: A gene expression atlas of early craniofacial development, *Dev Biol* 391:133–146, 2014.
11. Watkins SE, Meyer RE, Strauss RP, Aylsworth AS: Classification, epidemiology, and genetics of orofacial clefts, *Clin Plast Surg* 41:149–163, 2014.
12. Streeter GL: Developmental horizons in human embryos: age groups XV, XVI, XVII and XVIII, being the third issue of a survey of the Carnegie Collection, *Contrib Embryol Carnegie Inst Wash* 32:133–203, 1948.
13. Hinrichsen K: The early development of morphology and patterns of the face in the human embryo, *Adv Anat Embryol Cell Biol* 98:1–79, 1985.
14. Richman JM, Lee SH: About face: signals and genes controlling jaw patterning and identity in vertebrates, *Bioessays* 25:554–568, 2003.
15. Cerny R, Lwigale P, Ericsson R, et al.: Developmental origins and evolution of jaws: new interpretation of "maxillary" and "mandibular", *Dev Biol* 276:225–236, 2004.
16. Jiang R, Bush JO, Lidral AC: Development of the upper lip: morphogenetic and molecular mechanisms, *Dev Dyn* 235:1152–1166, 2006.
17. Lee SH, Bedard O, Buchtova M, et al.: A new origin for the maxillary jaw, *Dev Biol* 276:207–224, 2004.
18. Raam MS, Solomon BD, Muenke M: Holoprosencepahlly: a guide to diagnosis and clinical management, *Indian Pediatr* 48:457–466, 2011.
19. Hovorokova M, Lesot H, Peterkova R, Peterka M: Origin of the deciduous upper lateral incisor and its clinical aspects, *J Dent Res* 85:167–171, 2006.
20. Halpern RM, Noble J: Location and presence of permanent teeth in a complete bilateral cleft lip and palate population, *Angle Orthod* 80:591–596, 2010.
21. Yatabe MS, Garib DG, Janson G, et al.: Is the presence of Simonart's band in patients with complete unilateral cleft lip and palate associated with the prevalence of missing maxillary lateral incisors? *Am J Orthod Dentofacial Orthop* 144:649–653, 2013.
22. Wei X, Senders C, Owiti GO, et al.: The origin and development of the upper lateral incisor and premaxilla in normal and cleft lip/palate monkeys induced with cyclophosphamide, *Cleft Palate Craniofac J* 37:571–583, 2000.

28

Comprehensive Management of Facial Clefts

BERNARD J. COSTELLO, RAMON L. RUIZ

The comprehensive treatment of cleft lip and palate deformities requires thoughtful consideration of the anatomic complexities of the deformity and the delicate balance between intervention and growth. Comprehensive and coordinated care from infancy through adolescence is essential to achieve the best outcome, and surgeons with formal training and experience in all the phases of care must be actively involved in the planning and treatment.[1-3] Specific goals of surgical care for children born with cleft lip and palate include:

- Normalized esthetic appearance of the lip and nose
- Intact primary and secondary palate
- Normal speech, language, and hearing
- Nasal airway patency
- Class I occlusion with normal masticatory function
- Good dental and periodontal health
- Optimized psychosocial development

Successful management of the child born with a cleft lip and palate requires coordinated care provided by a number of different specialties, including oral and maxillofacial surgery, otolaryngology, plastic surgery, genetics and dysmorphology, speech-language pathology, orthodontics, pediatric dentistry, and prosthodontics.[4] In most cases care of patients with congenital clefts has become a subspecialty area of clinical practice within these different professions. In addition to the primary cleft repairs in infancy, treatment plans routinely involve multiple treatment interventions to achieve the above goals staged throughout childhood. Because care is provided over the entire course of the child's development, coordinated and long-term follow-up is essential under the care of these different health care providers.

The formation of interdisciplinary cleft palate teams has served two key objectives of successful cleft care: (1) coordinated care provided by all the necessary disciplines, and (2) continuity of care with close-interval follow-up of the patient throughout periods of active growth and ongoing stages of reconstruction. The best outcomes are achieved when the team's care is centered on the patient, family, and community rather than a particular surgeon, specialty, or hospital. The idea of having an objective team that does not revolve around the desires of one particular individual or discipline is sometimes impeded by competitive interactions between surgical specialties. Historic battles over surgical domains between surgical specialties and economic factors contribute to these conflicts and negatively affect the work of the team. Healthy team dynamics and optimal patient care are achieved when all members are active participants, when team protocols and referral patterns are equitable, and when the needs of the child are placed above the needs of the team or individual members. Treatment should be based on the surgeon's formal training and experience instead of specialty identity.

The surgical reconstruction of clefts requires that the surgeon undertaking this important work maintain a contemporary cognitive understanding of the complex malformation itself, the varied operative techniques used, facial growth considerations, and the psychosocial health of the patient and family. This chapter presents the overall staged reconstructive approach for repair of cleft lip and palate from infancy through the time of skeletal maturity as well as a discussion of the surgical procedures involved in primary cleft lip and palate repair. Controversies in cleft repair, secondary revision procedures, bone graft reconstruction of the cleft maxilla, and orthognathic surgery for cleft-related dysmorphology are discussed in later chapters of this text.

History of Cleft Lip and Palate Repair

The history of cleft lip and palate care has always been closely linked to dentistry and oral and maxillofacial surgery. The birth of what is now the American Cleft Palate-Craniofacial Association is strongly rooted in dentistry, and its further

development has always had various aspects of the dental profession at its heart.

The first documented cleft lip repair was performed in 390 AD on a patient who later became the governor general of several regions in China, although nothing is known about the actual surgeon.[5,6] Jehan Yperman is believed to have been the first to describe unilateral and bilateral cleft lip repair.[6,7] The first diagrammatic representation of cleft lip repair and cleft palate obturator use is credited to Ambrose Pare in the fourteenth century.[6,8] Much later, the first documented successful cleft palate repair was performed by a dentist, Le Monnier, in 1766 in Paris.[6,9] The concepts of cleft lip and palate repair have evolved from straight-line repairs to a variety of techniques using various cutbacks, triangles, and Z-plasties.[6-14] During the 1950s Asensio, an oral and maxillofacial surgeon from Guatemala, developed a novel technique for cleft lip repair that involved the rotation of the philtral segment inferiorly and advancement of the lateral segment medially with a quadrangular flap. Although he used this approach in Guatemala throughout the 1950s, he did not report it until later.[15,16] Ralph Millard described his classic rotational advancement technique in the mid-1950s, and his concepts changed cleft repair forever.[17,18] Millard is credited with perhaps the most important technical development related to cleft lip repair, and today the majority of surgeons use his original technique or some close modification of it.

In the mid-nineteenth century, Hullihen,[19] recognized as the father of American oral and maxillofacial surgery, published a treatise on comprehensive care of cleft lip and palate deformities. Another pioneer, Truman Brophy, was the professor of oral surgery and dean of the Chicago College of Dentistry and contributed greatly to the care of many patients with clefts. Brophy[20] published a text detailing his experiences with the management of various malformations of the mouth and their surgical repairs, including the details of cleft repair. One of his pupils was Chalmers Lyons, who started a residency program in oral surgery at the University of Michigan in 1917.[20] Lyons developed the largest cleft practice in America and contributed extensively to the literature.[20]

Many of the concepts related to interdisciplinary care with a cleft plate team were introduced by Robert Ivy, an oral and maxillofacial surgeon who later became dually qualified in plastic surgery.[20] Ivy trained in both dentistry and medicine at the University of Pennsylvania. After his training in dentistry, Ivy further developed his interests in maxillofacial surgery as an assistant to his uncle, Matthew Cryer, who was a professor in oral surgery at the University of Pennsylvania. Robert Ivy became interested in clefts during his training as the first dental intern at Philadelphia General Hospital. His interests in maxillofacial injury led him to serve in France in World War I as an assistant to Vilray Blair. After the war, Ivy and Blair's collaboration resulted in two landmark publications by Ivy, *Essentials of Oral Surgery* and *Fractures of the Jaws*. Through work with his state representatives in Harrisburg, Pennsylvania, he was able to start the first cleft palate clinics in Lancaster, Pittsburgh, Philadelphia, Erie, and Scranton, which provided interdisciplinary care to children in those regions for cleft lip and palate deformities. When Reed Dingman put forth a resolution of the American Society of Maxillofacial Surgeons condemning oral and maxillofacial surgeons practicing in the hospital setting, Ivy resigned his membership and sent a letter of protest in support of his dental colleagues to the organization that he helped build.[20]

In the 1950s the concept of primary or early bone grafting of the cleft maxillary defect was introduced by Schmid.[21] Although the concept initially was met with enthusiasm from a number of surgeons, primary bone grafting eventually was abandoned because of unfavorable outcomes. During the decades that followed, the negative skeletal, dental, and growth-related consequences of primary bone grafting became better understood.[22,23] During the early 1970s an oral and maxillofacial surgeon, Phillip Boyne, was the first to publish his favorable outcomes using autogenous particulate bone grafts for reconstruction of the cleft maxilla/alveolus later in childhood during the mixed dentition rather than earlier in life.[24] Although Boyne's work and results represented a landmark discovery in the field of cleft reconstruction, cleft palate teams were slow to integrate his approach into their treatment protocols because of the negative associations that lingered after the days of primary bone grafting. Today Boyne's principles of secondary bone grafting represent the standard approach for most of the world's cleft centers.[24,25]

Orthognathic reconstruction of the patient with cleft deformities has been discussed by many authors.[26-36] Early techniques limited some surgeons' options to procedures centered on mandibular setback.[37] During the 1970s, the use of total maxillary osteotomy was pioneered by Bell.[38] His novel ideas provided oral and maxillofacial surgeons with an understanding of the biologic basis for maxillary osteotomy, described the vascular supply that allowed the procedures to be safely performed and, as a result, incorporated the Le Fort I osteotomy into modern practice.[38] Since that time a number of technical refinements have been described for use of the Le Fort I osteotomy specifically in the cleft patient. Much of this work has been done by two of Bell's former pupils, Fonseca and Turvey,[39] who went on to make substantial contributions to the skeletal reconstruction of patients with clefts. Another dually qualified oral and maxillofacial surgeon, Posnick, has published the most complete descriptions of surgical technique modifications for patients undergoing mid-facial advancement in the absence of prior bone graft reconstruction and his extensive experiences with the long-term stability of mid-facial advancement after correction of various types of cleft deformities with orthognathic techniques.[26-30] Distraction osteogenesis has gained recent popularity for correction of mid-facial hypoplasia but has yet to show significant advantages over traditional techniques for the majority of patients.[32,33,40-42] Jeffrey Posnick's influence during this time was magnified substantially by training a number of fellows in the United

States to comprehensively treat cleft and craniofacial dysmorphology, develop these techniques, and teach them at major academic centers in North America. Other fellowship programs that have followed his model and mentorship have flourished, developing the subspecialty and making it a key aspect of successful training in oral and maxillofacial surgery programs.

Comprehensive and coordinated care has become more prevalent across the world, involving many different types of specialty care for children with clefts. Evidence-based care is a key aspect of care and a practical reality, with pooled data and continued research worldwide. The days of performing procedures purely based on a particular surgeon's clinical experience are passing. Posnick, Shaw, Long, Lohmander, and others have provided comprehensive, succinct, and evidence-based discussions on the topics of cleft lip and palate reconstruction from infancy through adolescence that are beginning to take hold in the form of treatment protocols.[26] Dentistry and the specialty of oral and maxillofacial surgery have had significant roles in analyzing data and putting forth new standards of care. These efforts as well as craniofacial training programs associated with oral and maxillofacial surgery departments have helped solidify the role of oral and maxillofacial surgery in the comprehensive care of patients with clefts.

Embryology

To understand the goals of lip and palate repair from an anatomic standpoint, the cleft surgeon must have an appreciation for the failure of embryogenesis that results in clefting. Critical points in the development of the fetus occur when the fusion of various prominences creates continuity and form to the lip, nose, and palate. Anomalies occur when the normal developmental process is disturbed between these components. Each prominence is composed of ectomesenchyme derived from neural crest tissue of the mesencephalon and rhombencephalon. Mesoderm also is present within these prominences as mesenchymal tissue. The prescribed destiny of each of these cells and tissues is controlled by various genes to alter the migration, development, and apoptosis and form the normal facial tissues of the fetus. At the molecular level many interdependent factors exist, such as signal transduction, mechanical stress, and growth factor production, that affect the development of these tissues. Currently only portions of this complex interplay of growth, development, and apoptosis are clear.

At approximately 6 weeks of human embryologic development the median nasal prominence fuses with the lateral nasal prominences and maxillary prominences to form the base of the nose, nostrils, and upper lip. The confluence of these anterior components becomes the primary palate. When this mechanism fails, clefts of the lips and/or maxilla occur. At approximately 8 weeks' gestation the palatal shelves elevate and fuse with the septum to form the intact secondary palate. When one palatal shelf fails to fuse with the other components, a unilateral cleft of the secondary palate occurs. If both palatal shelves fail to fuse with each other and the midline septum, a bilateral cleft of the palate occurs.

Fusion occurs when programmed cell death (apoptosis) occurs at the edges of the palatal shelves. The ectodermal component disintegrates and the mesenchyme fuses to form the intact palate. Soon after this the anterior primary palate fuses with the secondary palate and ossification occurs. If failure of fusion occurs with any of the above components at any point, a cleft of the primary and/or secondary palates occurs. Clefts may be complete or incomplete based on the degree of this failure of fusion.

Genetics and Etiology

Clefts of the upper lip and palate are the most common major congenital craniofacial abnormality and are present in approximately 1 in 700 live births.[43] Although inheritance plays a role, cleft lip and palate is not considered a single-gene disease. Instead, clefts are thought to be of a multifactorial etiology with a number of potential contributing factors. These factors may include chemical exposures, radiation, maternal hypoxia, teratogenic drugs, nutritional deficiencies, physical obstruction, and genetic influences. One prevailing theory relates the process of clefting as a point when multiple factors come together to raise the individual above a threshold, at which time the mechanism of fusion fails.[44,45] Multiple genes have been implicated in the etiology of clefting.[46-48] Some of these genes include the *MSX*, *LHX*, *goosecoid*, and *DLX* genes. Additional disturbances in growth factors or their receptors that may be involved in the failure of fusion include fibroblast growth factor, transforming growth factor, platelet-derived growth factor, and epidermal growth factor. Promotor genes that influence this potential are identified and the knowledge base is refined at a pace that is quicker than comprehensive texts can allow. The reader is encouraged to update their understanding with the latest published literature and online resources that provide near real-time reporting of this information.

Clefts of the lip occur more commonly in males than in females.[49] In addition, left-sided cleft lips are more common than right-sided cleft lips, and unilateral cleft lips are more common than bilateral cleft lips.[50] Bilateral clefts of the lip are most often associated with clefting of both the primary and secondary palates. Cleft palate alone is seen in approximately 1 in 2000 live births, an incidence similar in all racial groups.[51] Significant differences in the prevalence of clefts exist when specific ethnic and racial populations are examined. For example, African Americans have a birth prevalence that is less common than the total population, and Asians tend to have a higher prevalence.

In the majority of cases unilateral cleft lip and palate is an isolated nonsyndromic birth defect not associated with any other major anomalies.[43,52,53] By comparison, a much

greater proportion of patients with an isolated cleft palate have an associated syndrome or sequence.[43,53] Some of the more common syndromes seen in this group include Stickler, van der Woude, and DiGeorge syndromes. Early diagnosis is important because functional issues may arise early in life and go unnoticed. For example, patients with an isolated cleft palate should be evaluated early by an experienced pediatric ophthalmologist to evaluate the possibility of Stickler syndrome. Patients with Stickler syndrome may have ocular abnormalities that lead to retinal detachment. In an otherwise healthy-appearing child these findings may be difficult to diagnose, so early visual loss may go unnoticed. In many cases long-term genetic follow-up is necessary to make a definitive diagnosis and provide genetic counseling.

The chances of a recurrence of clefting within a family depend on many factors, including family history, severity, gender, degree of relationship to the affected individual, and the expression of a syndrome. Predicting the inheritance patterns of families with a history of cleft lip and/or palate can be complicated. A skilled geneticist or dysmorphologist is best equipped to make these determinations based on pedigree analysis and genetic testing. Because most clefts are sporadic, the chances of a family having another child with a cleft after having a child with a unilateral cleft lip and palate in which no family history of clefting is present is approximately 2% to 4%. The chances are higher if additional family history is present or if the cleft is bilateral.[54,55] The nature of any genetic influence will have an effect on the presence of a cleft. Such is the case in patients with autosomal-dominant syndromes such as Stickler syndrome, in which 50% of the children may express the syndrome if one of the parents carries the altered gene.

Classification

The typical classification system used clinically to describe standard clefts of the lip and palate is based on careful anatomic description. Clefts can be unilateral or bilateral; microform, incomplete, or complete; and may involve the lip, nose, primary palate, and/or secondary palates (Figure 28-1). The presentation of clefts is extremely variable, and the individual repairs are custom tailored to achieve the best symmetry and balance. More severe facial clefting is most commonly described by using Paul Tessier's orbitocentric system of numbering (Figure 28-2).[56] Other systems are based on embryologic fusion planes, but these are cumbersome to use in routine clinical practice.[57]

Prenatal Counseling

Recent advances in imaging have revolutionized prenatal care and maternal-fetal medicine. Ultrasound images of clefts of the lip currently can be visualized at approximately 16 weeks of gestation.[58-60] Diagnostic images of the palate are more difficult to acquire, making the correct prenatal diagnosis of a cleft palate less predictable. Anterior palatal structures may be visualized by using sagittal and coronal views, but this currently requires the latest technology and a skilled ultrasonographer with experience performing this type of study.

When the diagnosis of cleft lip is made during pregnancy, the family can be referred to an experienced surgeon for a prenatal discussion. A prenatal consultation provides an excellent opportunity to explain the diagnosis, review the different stages of cleft lip and palate reconstruction that may be necessary, and prepare the parents for practical considerations such as feeding a child with a cleft palate. This gives the family the opportunity to ask questions, calm fears, and learn about feeding techniques that will be important during the first week of life for their baby. Parents are empowered with this new knowledge, and the preparations made during a prenatal consultation allow them to anticipate the delivery of their baby with a greater comfort level regarding the necessary care of the infant during the early postnatal period. The family is then referred to a cleft and craniofacial team to begin a more thorough interdisciplinary approach.

Critical to this process is consultation with a geneticist or dysmorphologist to discuss the issues associated with the birth and the possibility of other associated deformities. Additional testing may be warranted to evaluate the possibility of associated deformities, syndromes, or sequences that could affect the birthing process. Exceptionally skilled ultrasonographers can visualize airway development and other abnormalities that may require early intervention with fetal surgery, exit procedures, extracorporeal membrane oxygenation, or surgical airway management (tracheotomy) at the time of delivery. Magnetic resonance imaging often is helpful in determining the more definitive morphology and helping guide the need for intervention early in life.

In some medical centers fetal diagnosis and treatment teams are in place to deal with issues associated with various deformities diagnosed in the prenatal period. These teams foster a cohesive environment in which information is exchanged through consultation. Much like the environment of a cleft and craniofacial team, families can get the best information available to consider their baby's treatment decisions with an interdisciplinary care model that is patient (mother and fetus), family, and community oriented.

Feeding the Child With a Cleft Palate

Children born with isolated cleft lip can feed quite well and even have the opportunity to breastfeed in most instances. However, infants with cleft palate can have difficulty feeding because of the inability to form an adequate seal between the tongue and palate to create sufficient negative pressure to suck fluid from a bottle. Nasal regurgitation and inefficient handling of secretions and foods also may



• **Figure 28-1** Cleft lips come in a variety of configurations; each repair must be customized to establish the most normal morphology. **A,** Microform left unilateral cleft lip only, not requiring primary repair. **B,** Minor left incomplete unilateral cleft lip only. **C,** Left incomplete unilateral cleft lip and palate with a Simonarts band. **D,** Wide left complete unilateral cleft lip and palate.

be observed during early development. Specialized nipples and bottles are necessary to improve feeding immediately after birth. The most useful devices combine oversized nipples with reservoir spaces and large openings, a squeezable bottle to push fluid into the nipple assembly, and a one-way valve that allows the bolus of fluid to pass from the bottle to the nipple only to minimize the amount of work the child must perform to feed. These include a variety of nipples with reservoirs that collect a variable volume of liquid that can be expressed more easily when sucking is inefficient or not possible. Bottles that can be squeezed to allow manual flow of liquid to the infant are helpful for improving feeding. No single bottle and nipple combination works better than another; trials with a variety of types using different techniques are helpful to optimize feeding early in life.

Close attention to weight gain is critical for these children. In general, in 24 hours each infant should ingest approximately 2 to 3 ounces of milk for each pound of weight. Feeding sessions should last no longer than 35 minutes because longer sessions are fatiguing and burn more calories than the baby can consume. Infants should be weighed at least weekly on the same scale, preferably at the pediatrician's office.

The subject of breastfeeding an infant with a cleft palate is controversial, with some practitioners encouraging the practice and others strongly opposed to it. Breastfeeding a newborn has clear advantages, including passive

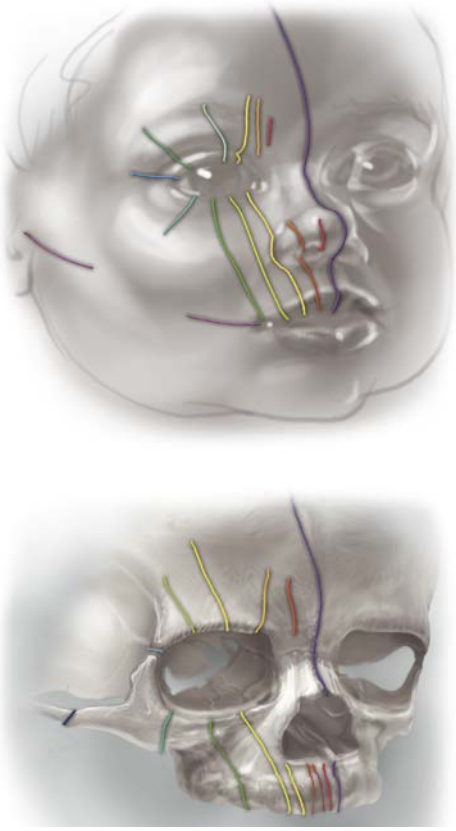

• **Figure 28-2** Complex facial clefts can be classified according to Tessier's original orbitocentric system of numbering. Clefts may involve all tissue planes, including skin, mucosa, bone, teeth, muscle, brain, peripheral nerve, and other specialized tissues.

immunologic contribution of the mother to the child in the form of secretory immunoglobulin A and an experience that enhances bonding between the mother and child during such a critical period.[61,62] At the same time the infant's inability to create negative oral pressure often makes successful nursing difficult, if not impossible. Exclusively breast-fed infants with severe dehydration and failure to thrive are relatively common because of these difficulties. This is especially a concern in infants with a wide cleft of the secondary palate, a condition in which breastfeeding may not be possible. The authors' approach with regard to breastfeeding in the presence of a cleft palate is to use a combined protocol that includes intermittent feeding with the use of a specialized bottle and attempts at nursing. Breast milk may be pumped for use with the specialized nipple and bottle that will provide the nutritional and immunologic benefits desired. This also allows the parents to keep a more quantitative record of how many ounces have been ingested over the course of the day; this normally is difficult with breastfeeding alone. At the same time, the mother and baby are not deprived of an opportunity to incorporate breastfeeding into the daily regimen. This approach obviously requires rigorous documentation of the child's weight, consultation with a lactation consultant and infant feeding specialist, and frequent follow-up evaluations through the surgeon and pediatrician.

TABLE 28-1 Staged Reconstruction of Cleft Lip and Palate Deformities

Procedure	Time Frame
Cleft lip repair	After 10 weeks
Cleft palate repair	Age 9-18 months
Pharyngeal flap or pharyngoplasty	Age 3-5 years or later based on speech development
Maxillary/alveolar reconstruction with bone grafting	Age 6-9 years based on dental development
Cleft orthognathic surgery	Age 14-16 years in girls, 16-18 years in boys
Cleft rhinoplasty	After age 5 years, but preferably at skeletal maturity; after orthognathic surgery when possible.
Cleft lip revision	Anytime once initial remodeling and scar maturation is complete, but best performed after age 5 years

Treatment Planning and Timing

The timing of cleft lip and palate repair is controversial. Despite a number of meaningful advancements in the care of patients with cleft lip and palate, a lack of consensus exists regarding the exact timing and specific techniques used during each stage of cleft reconstruction. Surgeons must continue to balance the functional needs, esthetic concerns, and the issue of ongoing growth carefully when deciding how and when to intervene. In no other type of craniofacial surgical problem is the issue of early surgery's effect on growth more apparent than in the treatment of cleft lip and palate deformities. The decision to manipulate the tissues of the growing child surgically should not be made lightly and should consider the possible growth restriction that can occur with early surgery. Nevertheless, many patients with congenital deformities benefit from surgical intervention based on functional or psychosocial reasons. Understanding the growth and development of the craniofacial skeleton is critical to the treatment planning process.[33] In many cases waiting for a greater degree of growth to occur is advantageous unless compelling functional or esthetic issues are present that cannot or should not wait.

Because of the many different treatment philosophies, the timing of treatment interventions varies considerably among cleft centers. Therefore producing a timing regimen that everyone agrees on is difficult. Each stage of surgical reconstruction and the suggested timing based upon the patient's age are presented in Table 28-1. Special considerations may alter the sequencing or timing of the various procedures based on individual developmental, functional needs, or esthetic needs. Significant differences exist worldwide regarding the timing of different repairs. As of yet, timing of repair cannot be guided by truly definitive outcome research.

Cleft lip repair generally is undertaken at some point after 10 weeks of age. Waiting until the child is 10 to 12 weeks of

age allows enough time for a complete medical evaluation of the patient so that any associated congenital defects affecting other organ systems (e.g., cardiac or renal anomalies) may be revealed. The surgical procedure itself may be easier when the child is slightly larger and the anatomic landmarks are more prominent and well defined. Historically, the anesthetic risk-related data have suggested that the safest time for surgery in this population of infants could be outlined simply by using the "rule of 10s." This referred to the idea of delaying lip repair until the child was at least 10 weeks old, 10 pounds in weight, and with a minimum hemoglobin level of 10 mg/dL.[63,64] Today more sophisticated pediatric anesthetic techniques, advances in intraoperative monitoring, and improved anesthetic agents have all resulted in the ability to provide safe general anesthesia much earlier in life.[65] Despite this ability, no measurable benefit exists to performing lip repair before 3 months of age.[64,66,67] Some surgeons have advocated that lip repair be carried out in the first days of infancy based on the idea of capitalizing on early "fetal-like" healing. Unfortunately, these hoped-for benefits have not been observed, and problems with excessive scarring and less-favorable outcomes have been encountered.[68-70] Children may have more scarring at this early age, and their tissues are smaller and more difficult to manipulate. Consequently the esthetic outcomes may be worse if surgery is performed at an earlier age; because no clear benefits exist for earlier repair, the recommendations for repair remain at approximately 3 months of age.

Cleft palate repair usually is performed at approximately 9 to 18 months of age. In deciding the timing of repair the surgeon must consider the delicate balance between facial growth restriction after early surgery and speech development that requires an intact palate. Most children require an intact palate to produce certain speech sounds by 18 months of age. If developmental delay is present and speech will not likely develop until later, then the repair can be delayed further. Little evidence suggests any benefit to palate repair before 9 months of age.[71-73] Repairs before this time are associated with a much higher incidence of maxillary hypoplasia later in life and show no additional improvements in speech. For these reasons most surgeons perform primary palate repair at approximately 9 to 18 months of age.

As these children continue to develop, a significant percentage will have inadequate closure of the velopharyngeal mechanism (velopharyngeal insufficiency [VPI]) even after successful palate repair, which may produce hypernasal speech.[74] These children usually are diagnosed at 3 to 5 years of age when a detailed speech examination can be obtained by a skilled speech pathologist. When VPI is shown to be consistent and caused by a definable anatomic defect, surgery often is helpful. A pharyngeal flap or sphincter pharyngoplasty may be used to treat VPI, with the goal of improving closure between the oral and nasal cavities and reducing nasal air escape during the production of certain sounds. In some select cases, palate repeat repair may be considered with a two-flap palatoplasty or double-opposing Z-plasty technique.

Approximately 75% of patients with any type of cleft have clefting of the maxilla and alveolus.[24-26] Bone graft reconstruction of this site is performed during the mixed dentition before the eruption of the permanent canine and/or the permanent lateral incisor. The timing of this procedure is based on dental development and not chronologic age. On the basis of work by Boyne, most surgeons reconstruct this area during the mixed dentition before eruption of the permanent canine. Earlier reconstruction of this area has been associated with a high degree of maxillary growth restriction, requiring orthognathic correction later in life in a much higher percentage of patients.[22,24] The gold standard for reconstruction in this area is autogenous bone from the anterior iliac crest. Cranial bone, rib, tibia, symphysis of the mandible, zygoma, and allogeneic bone have all been studied, but none has been shown to be appreciably better than the iliac crest.[26,75,76]

Orthognathic reconstruction of maxillary and mandibular discrepancies is performed at 14 to 18 years of age based on individual growth characteristics.[26-36,38] This is done in conjunction with orthodontics before and after surgery. However, in some cases of severe maxillary hypoplasia, early Le Fort I osteotomy may be performed to optimize facial esthetics and occlusion with the supposition that revision osteotomies will likely be necessary. These early osteotomies may complicate later treatment. Early orthognathic maxillary advancement is reserved for the most severe dysmorphology, and in most cases the authors prefer standard orthognathic techniques timed in the standard fashion.[31-33] Attempts at using distraction osteogenesis have been associated with a higher complication rate than standard orthognathic techniques.[32,42,77] However, this remains an option for exceptionally large advancements or other indications.

As with the timing of other interventions, lip and nasal revision is best reserved for after the majority of growth is complete. Most of the lip and nasal growth is complete after age 5 years. Lip revision may be considered just before school begins, at approximately 5 years of age or later. However, this may be performed earlier if the deformity is severe. Nasal revision is performed after age 5 years because most of the nasal growth is complete by this time. If orthognathic reconstruction is likely, then rhinoplasty usually is best performed after orthognathic surgery because maxillary advancement improves many characteristics of nasal support. When nasal deformity is particularly severe, rhinoplasty can be considered earlier even if orthognathic surgery is expected. Multiple early revisions of the lip or nose should be avoided so that excess scarring does not potentially impair ongoing growth.

Cleft Lip and Palate Repair

Presurgical Taping and Presurgical Orthopedics

Facial taping with elastic devices may be used for application of selective external pressure and may improve lip and nasal position before the lip repair procedure. In the authors'

opinions these techniques often have greater impact in cases of wide bilateral cleft lip and palate in which manipulation of the premaxillary segment may make primary repair technically easier. Although one of the basic surgical tenets of wound repair is to close wounds under minimal tension, attempts at improving the arrangement of the segments by using taping methods have not shown a measurable improvement.[78-80]

Some surgeons prefer presurgical orthopedic (PSO) appliances rather than lip taping to achieve similar goals.[81,82] PSO appliances are composed of a custom-made acrylic base plate that provides improved anchorage in the molding of lip, nasal, and alveolar structures during the presurgical phase of treatment (Figure 28-3). Although the use of appliances probably allows an easier surgical repair, clinical evidence is lacking to demonstrate any measurable improvement in esthetics of the nose or lip, dental arch relation, tooth survival, or occlusion of the patient. Studies have looked at the dental arch relations and other outcomes in patients who have infant presurgical orthopedic devices, and no improvement was seen.[83,84] In addition, no long-term improvement in speech outcome has been demonstrated in patients who had PSOs.[85] Furthermore, concerns regarding potential negative consequences of these types of appliances have been raised.[86] PSOs also add significant cost and time to treatment early in the child's life. Many appliances require a general anesthetic for the initial impression used to fabricate the device. Frequent appointments are necessary to monitor the anatomic changes and periodic appliance adjustment.

The Latham appliance was popular for expanding and aligning the maxillary segments of the patient with a cleft palate.[87] It is a pin-retained device inserted into the palate with acrylic extensions onto the alveolar ridges. A screw mechanism is then used to manipulate the segments as desired. The Latham appliance used with gingivoperiosteoplasty has been shown to be associated with significant growth restriction of the mid-face when used in infancy to approximate the segments for repair.[86] Children who have had Latham appliances have been shown to have significant mid-facial growth restriction in adolescence 100% of the time, whereas children who have not had the Latham appliance have mid-face hypoplasia 25% to 35% of the time.[42,80,86]

The Grayson nasoalveolar molding appliance has become popular with some centers in attempts to manipulate the segments without pin retention before lip and nose repair (see Figure 28-3). The nasoalveolar molding appliance is adjustable by removing or adding acrylic and manipulating protrusive elements that attempt to mold the nasal cartilages. This device attempts to align the alveolar segments, lip structures, and nasal cartilages to optimize repair. Unfortunately, the hoped-for advantages of this appliance have not been realized. In addition, no long-term data are available regarding growth in the craniofacial skeleton after using this protocol. The limited short-term data that are available cannot be extrapolated to determine the ultimate outcome on growth, function, or esthetics. Many surgeons use gingivoperiosteoplasty in conjunction with the PSO, using limited flaps to close the alveolus cleft during the primary repair of the lip or palate. Many surgeons who use this appliance in conjunction with their primary lip repairs perform a gingivoperiosteoplasty in attempts to have bone form at the alveolus. This is more easily performed with the segments aligned in close proximity because the flaps are small.[82] Experiences with similar techniques in the 1960s involving primary bone grafting had poor results regarding growth.[22,23] Subsequent studies have confirmed the high incidence of growth restriction in this population. In addition, no convincing, long-term, objective data have shown improvement in either lip or nose esthetics.

In their current state, no convincing and validated evidence exists that any of the PSOs offer an improved outcome in esthetics, function, or growth in patients with cleft lip and palate. Coupled with the fact that appliances are time consuming and have a high cost of fabrication and utilization, advocating their uniform use is difficult. As with other interventions considered for patients with clefts, costly and unproven interventions should be avoided, although they may prove to be helpful in select cases.[88] A subset of more severe clefts may benefit from the devices. Perhaps long-term data will be forthcoming and positive to help determine which patients may benefit from PSO appliance treatment.

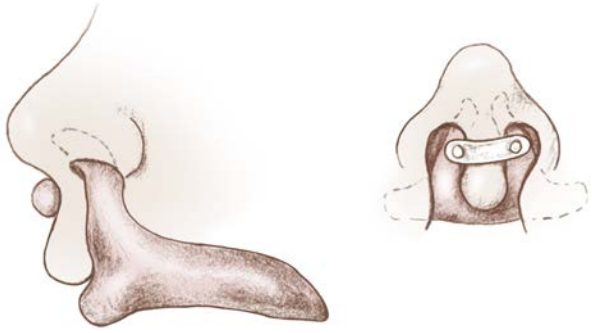

• **Figure 28-3** Frontal and lateral views of the Grayson nasoalveolar molding appliance showing the nasal projections that theoretically help mold the nasal cartilages and maxillary segments into a more appropriate configuration before repair.

Lip Adhesion

Some surgeons attempt to surgically approximate the segments of the cleft lip before definitive lip repair in an attempt to achieve a better relation of both the lip structures and the dental arches.[89-91] This is achieved by advancing small flaps of tissue across the cleft site. Some surgeons advocate the use of this technique in wide bilateral clefts, but it rarely is performed in unilateral cases. The lip adhesion usually is completed at 3 months of age. In most cases this will convert a wide, complete cleft into a wide, incomplete cleft because the scar eventually will be excised from the cleft site, recreating a similar wide deformity. The definitive lip repair is

then completed 3 to 9 months later by excising the scar and reapproximating the remaining lip structures. Furthermore, at the second procedure the tissue to work with when performing the definitive repair usually is less supple. As with most endeavors in cleft surgery, repeated early interventions tend to complicate later refinements because of excessive scarring. In general, adequate mobilization of the flaps in one stage will make tension-free skin closure possible in most cases without the need for taping, presurgical orthopedic appliances, and/or lip adhesion.

Primary Unilateral Cleft Lip Repair

Unilateral clefts of the lip and nose present with a high degree of variability; thus each repair design is unique (see Figure 28-1).[26,92] The repair technique preferred by the authors for cleft lip and nasal deformities is shown in Figures 28-4 and 28-5 and usually is performed after 10 weeks of age.[17,18,26,63] The basic premise of the repair is to create a three-layered closure of skin, muscle, and mucosa that approximates normal tissue and excises hypoplastic tissue at the cleft margins. Critical in the process is the reconstruction of the orbicularis oris musculature into a continuous sphincter. The Millard rotation advancement technique has the advantage of allowing each of the incision lines to fall within the natural contours of the lip and nose. This is an advantage because achieving mirror-image symmetry in the unilateral cleft lip and nose is difficult with the normal side immediately adjacent to the surgical site. A Z-plasty technique such as the Tennison-Randall repair may not achieve this level of symmetry because the Z-shaped scar is directly adjacent to the linear nonclefted philtrum (Figure 28-6). Achieving symmetry is more difficult when the rotation portion of the cleft is short compared with the advancement segment. A functional muscle reconstruction utilizing the perinasal musculature may be considered in conjunction with this, or most any other lip and nose repair technique.

Primary nasal reconstruction may be considered at the time of lip repair to reposition the displaced lower lateral cartilages and alar tissues. Several techniques are advocated,

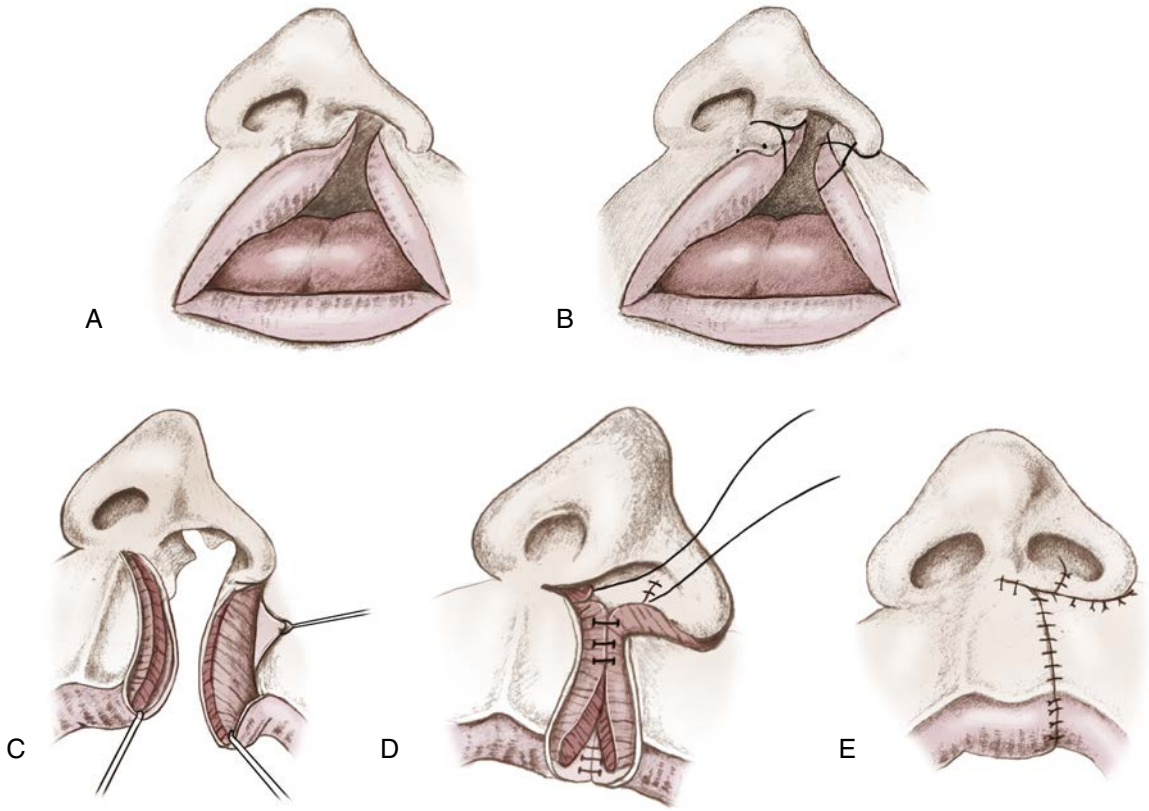

• **Figure 28-4** **A,** Complete unilateral cleft of the lip highlighting the hypoplastic tissue in the cleft site not used in the reconstruction. Note the nasal deformities typical in the unilateral cleft, including displaced lower lateral nasal cartilages, deviated anterior septum, and nasal floor clefting. **B,** The typical markings for the authors' preferred repair, highlighting the need to excise the hypoplastic tissue and approximate good vermilion and white roll tissue for the repair. **C,** Once the hypoplastic tissue has been excised, the three layers of tissue are dissected (skin, muscle, and mucosa). Completely freeing the orbicularis oris from its abnormal insertions on the anterior nasal spine area and lateral ala is important. Nasal flaps also are incorporated into the dissection to repair the nasal floor (not shown). **D,** The orbicularis oris muscle is approximated with multiple interrupted sutures, and the vermilion border/white roll complex is reconstructed. The nasal floor and mucosal flaps are approximated. **E,** The lateral flap is advanced and the medial segment is rotated downward to create a healing scar line that will resemble the natural philtral column on the opposite side. The incision lines are hidden in natural contours and folds of the nose and lip.

and considerable variation exists regarding the exact nasal reconstruction performed by each surgeon.[93,94] The primary nasal repair may be achieved by releasing the alar base, augmenting the area with allogeneic dermal grafts, or even performing a formal open rhinoplasty. Because lip repair is performed at such an early point in growth and development, the authors prefer minimal surgical dissection because of the effects of scarring on the subsequent growth of these tissues. McComb described a technique that consists of dissecting the lower lateral cartilages free from the alar base and the surrounding attachments through an alar crease incision.[93,95-97] This allows the nose to be bolstered and/or stented from within the nostril to improve symmetry.

Primary Bilateral Lip Repair

Bilateral cleft lip repair can be one of the most challenging technical procedures performed in children with clefts. The lack of quality tissue present and the widely displaced segments are major challenges to achieving exceptional results, but superior technique and complete mobilization of the tissue flaps usually yields excellent esthetic results



• **Figure 28-5** **A,** Three-month-old child with a right-sided incomplete unilateral cleft lip. Note the short philtrum near the midline that must be rotated downward to avoid notching and improve symmetry. **B,** Nine-month-old boy after the rotation-advancement repair of his cleft lip and nasal deformities. **C,** The same child in part **B** 2½ years after his cleft lip and nasal repairs. **D,** And at ten year follow-up without any revision of the original repair.

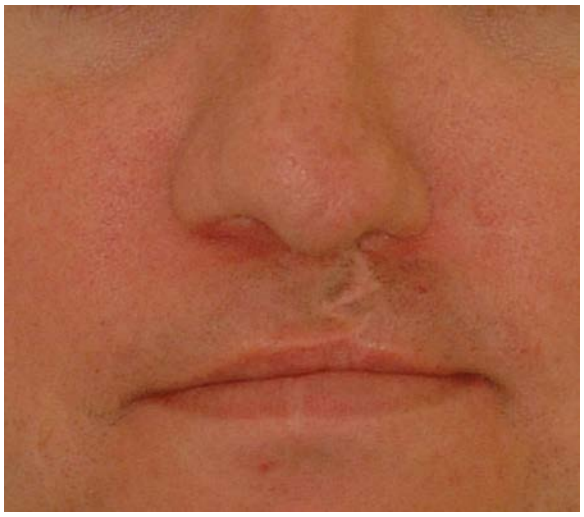

• **Figure 28-6** A typical scar that may result from a Z-plasty lengthening repair. Although the length and symmetry of the lip is good, an unnatural contour can occur because of the Z shape of the closure.

(Figures 28-7 to 28-10). In addition, the columella may be quite short in length, and the premaxillary segment may be significantly rotated. Adequate mobilization of the segments and attention to the details of using only appropriately developed tissue will yield excellent results even in the face of significant asymmetry.

Some surgeons have used techniques to lengthen the columella surgically and preserve hypoplastic tissue with banked fork flaps.[98,99] Early and aggressive tissue flaps in the nostril and columella areas do not look natural after significant growth has occurred and result in abnormal tissue contours. Although surgical attempts at lengthening the columella initially may look good, they frequently look abnormally long and excessively angular later in life (Figure 28-11). Revision of these iatrogenic deformities is difficult, and some of the contour irregularities cannot be adequately revised. If the hypoplastic tissue is excised and incisions within the medial nasal base and columella are avoided, the long-term esthetic results usually are excellent.

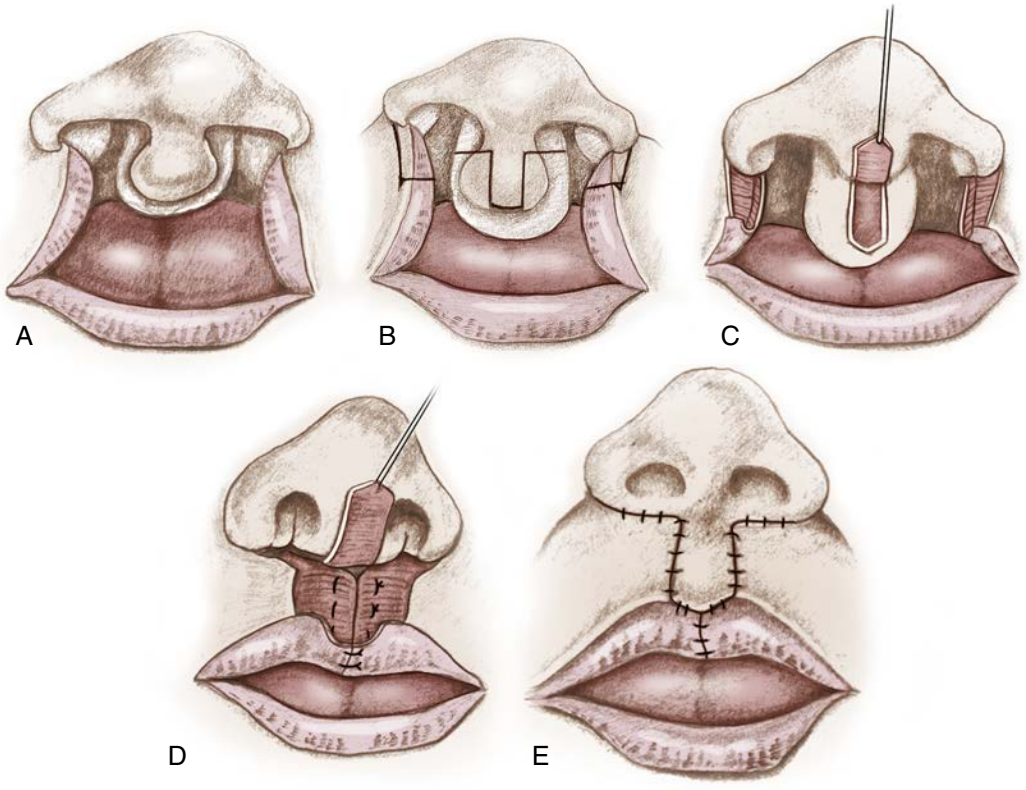

• **Figure 28-7** **A,** The bilateral cleft of the lip and maxilla shown is complete and highlights the nature of hypoplastic tissue along the cleft edges. The importance of the nasal deformity is evident in the shorter columella and disrupted nasal complexes. **B,** Markings of the authors' preferred repair, with an emphasis on excision of hypoplastic tissue and approximating more normal tissue with the advancement flaps. **C,** A new philtrum is created by excising the lateral hypoplastic tissue and elevating the philtrum superiorly. In addition, the lateral advancement flaps are dissected into three distinct layers (skin, muscle, and mucosa). Nasal floor reconstruction also occurs in conjunction with these advancement flaps. **D,** The orbicularis oris musculature is approximated in the midline with multiple interrupted and/or mattress sutures. This is a critical step in the total reconstruction of the functional lip. No musculature is present in the premaxillary segment, which must be brought to the midline from each lateral advancement flap. The nasal floor flaps are sutured at this time as well. The new vermilion border is reconstructed in the midline with good white roll tissue advanced from the lateral flaps. **E,** The final approximation of the skin and mucosal tissues is performed, leaving the healing incision lines in natural contours of the lip and nose.

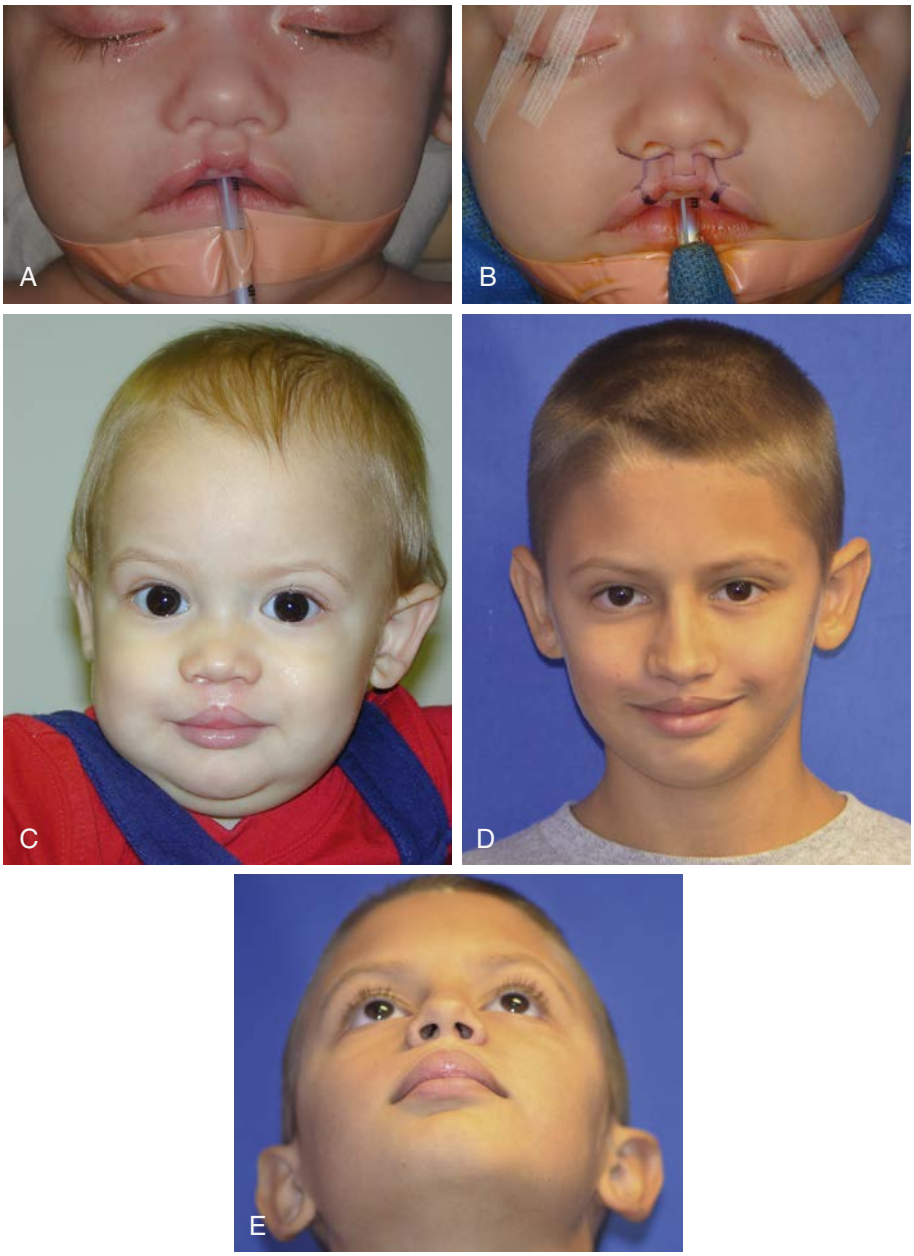

• **Figure 28-8** **A,** Presurgical appearance of the incomplete bilateral cleft lip of a 3-month-old boy. **B,** Surgical markings for excision of the hypoplastic tissue and the planned creation of a new philtrum. Advancement flaps from the lateral lip segments bring good white roll to the midline by small cutbacks. **C,** The same child at 1 year of age after the repair of his bilateral cleft lip. **D** and **E,** The same child at age 13.

The authors prefer a primary nasal reconstruction that can be performed in a similar fashion to the technique described by McComb.[100] This allows release and repositioning of the lower lateral cartilages and alar base on both sides without aggressive degloving of the entire nasal complex. Other open rhinoplasty techniques have been suggested that use direct incision on the nasal tip or prolabial unwinding techniques.[100-103] As with most early maneuvers, aggressive rhinoplasty at this time may incur early scarring that affects growth potential of the surrounding tissues, making revision more difficult and long-term esthetics less than ideal. Good results can be achieved with a number of different techniques.

Cleft Palate Repair

The term *primary palate* is used to describe the anatomic structures anterior to the incisive foramen (e.g., the alveolar ridge, maxilla, piriform rim). The term *secondary palate* refers to structures posterior to the incisive foramen. Therefore, when surgeons refer to the initial or primary cleft palate repair, they are in fact describing the closure of the secondary palate structures, which include the hard palate, soft palate, and uvula. The structures of the embryologic primary palate are reconstructed later in childhood during the cleft maxillary/alveolar bone graft procedure.



• **Figure 28-9** **A,** Presurgical appearance of a bilateral cleft lip and palate with significant asymmetry and rotation of the premaxillary segment. Note the nasal asymmetry and bunching of the orbicularis oris laterally. **B,** The same child at 14 months of age. No presurgical molding or taping was utilized in this case.

Cleft palate repair during infancy has two main goals: (1) the water-tight closure of the oronasal communication involving the hard and soft palate, and (2) the anatomic repair of the musculature within the soft palate, which is critical for normal creation of speech. The soft palate, or velum, is part of the complex coupling and decoupling of the oral and nasal cavities involved in the production of speech. When a cleft of the soft palate is present, abnormal muscle insertions are located at the posterior edge of the hard palate. Surgery must be aimed at the release of abnormal muscle insertions, not simply closing the palatal defect. Muscle continuity with correct orientation should be established so that the velum may serve as a dynamic structure.

The exact timing of repair of a palate cleft is controversial. In general, the velum must be closed before the development of speech sounds that require an intact palate. On average this level of speech production is observed by approximately 18 months of age in the normally developing child. If the repair is completed after this time, compensatory speech articulations may result. Repair completed before this time allows the intact velum to close effectively, appropriately separating the nasopharynx from the oropharynx during certain speech sounds.[104-107]

In patients with a cleft palate, concerns for normal speech development frequently are balanced with the known biologic consequences of surgery during infancy; namely, the problem of surgery during the growth phase resulting in maxillary growth restriction.[33,72,73,108] When repair of the palate is performed between 9 and 18 months of age, the incidence of associated growth restriction affecting the maxillary development is approximately 25%.[31,33,109-111] If repair is carried out earlier than 9 months of age, severe growth restriction requiring future orthognathic surgery is seen with greater frequency.[22,26,31,33,109,112-114] At the same time, proceeding with palatoplasty before 9 months of age is not associated with any increased benefit in terms of speech development, so the result is an increase in growth-related problems with an absence of any functional benefit.[115,116] When using only chronologic age, carrying out the operation during the 9- to 18-month timeline seems to best balance the need to address functional concerns such as speech development with the potential negative impact on growth. To date no rigorous clinical trial has examined what is likely the most critical factor in dictating the exact timing of cleft repair—the individual child's true language age—because it is difficult to measure adequately. In cases in which significant developmental delay is present, surgery should be delayed because speech formation is not yet an issue and benefit in terms of growth of the maxilla is likely. Delaying palatal closure is relevant in situations in which the cleft palate is associated with other complex medical conditions, neurodevelopmental delay, complex craniofacial anomalies, and/or the presence of a tracheotomy.

Another approach used to balance speech issues with growth-related concerns is to stage the closure of the secondary palate with two operations. In general, this involves the repair of the soft palate early in life as an initial step followed by closure of the hard palate later in infancy with or without the use of an obturator. The idea is that timely repair of the soft palate, which is critical for speech, is accomplished, whereas hard palate repair with mucoperiosteal stripping is delayed until growth is further along.[117,118] Although this technique is not advocated by the majority of surgeons in the United States, some surgeons may believe that repairing the hard palate later may offer the advantages of less growth restriction, easier repair of larger clefts, and less chance for fistula formation. No convincing definitive data exist to favor this approach over a single-stage repair, but the practice is continued by some centers when evidence suggests some benefit—particularly



• **Figure 28-10** **A,** Presurgical frontal view of a wide bilateral cleft lip and palate with significant asymmetry and lack of columella length. **B,** Presurgical left lateral view of a wide bilateral cleft lip and palate with a protrusive premaxillary segment. Note the short columella length. **C** and **D,** The same child at 10 months of age after repair of her bilateral cleft lip and palate. No presurgical taping or orthopedic appliances were used.

regarding growth. In contrast, most North American speech-language pathologists prefer closure of the palate as a single operation.[117]

Cleft palate reconstruction requires the mobilization of multilayered flaps to reconstruct the defect because of the failure of fusion of the palatal shelves. In general, when the initial palate closure is performed, this refers to closure of the tissues posterior to the incisive foramen. This is done in a layered fashion by first closing the nasal mucosa and then the oral mucosa. Because the main function of the palate is to close the space between the nasopharynx and oropharynx during certain speech sounds, the surgeon also must reconstruct the musculature of the velopharyngeal mechanism. The musculature of the levator palatini is abnormally inserted and invested within the tissue near the posterior aspect of the hard palate. The musculature therefore must be de-inserted and reconstructed in the midline to create an adequately functional velum.[26,119] Therefore the soft palate is closed in three layers by approximating the nasal mucosa, levator musculature, and the oral mucosa. The hard palate portion is closed in two layers by using nasal mucosa flaps and then oral mucosa flaps. Both the hard and soft palate repairs must be done in a tension-free manner to avoid wound breakdown and fistula formation. Adequate mobilization of the flaps during the dissection is

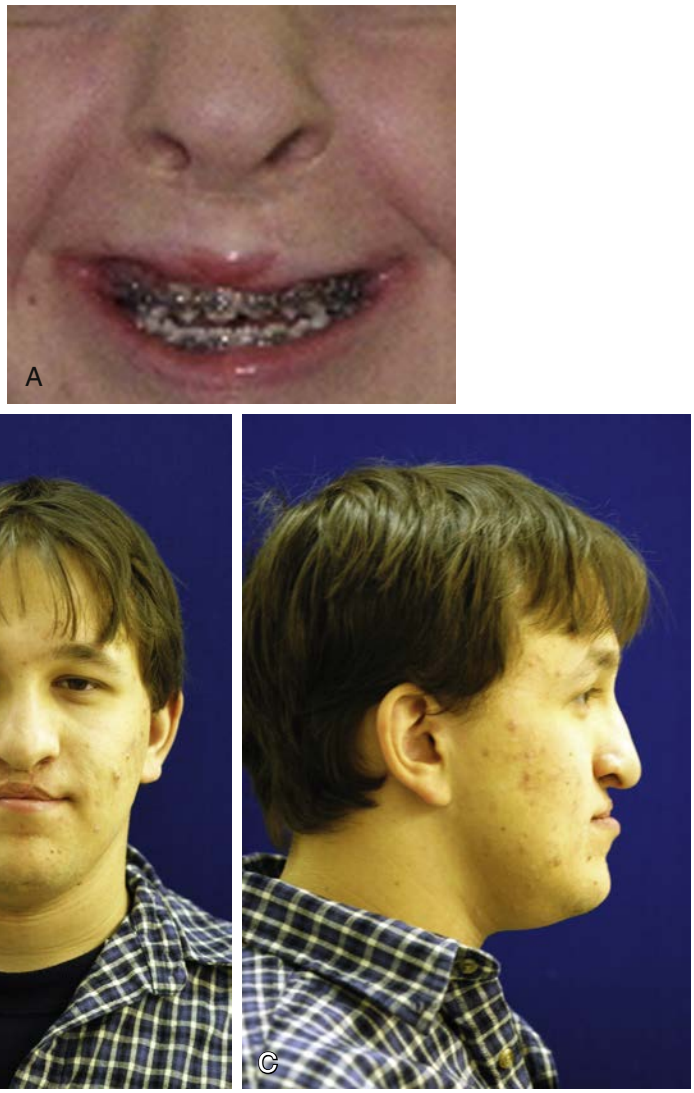

• **Figure 28-11** **A,** Frontal view of a teenage girl who had undergone columella lengthening and banked fork flaps during her initial repair and attempts at secondary rhinoplasty by another surgeon before orthognathic surgery. **B,** Frontal view of a patient who underwent columella lengthening and banked fork flaps during his initial repair. **C,** Lateral view of the patient from **B** with a columella that is long and has a tip oriented downward.

essential to achieve tension-free closure. At times some surgeons may elect to incorporate vomer flaps or acellular dermal matrix into the repair if mobilization of the lateral flaps to the midline is difficult.

Many techniques have been described for repair of the palate, and the controversies among these techniques are described later in this text.[120-127] The Bardach two-flap palatoplasty uses two large, full-thickness flaps that are mobilized with layered dissection of the soft palate and brought to the midline for closure (Figure 28-12).[26,120] This technique preserves the palatal neurovascular bundle as well as a lateral pedicle for adequate blood supply. The von Langenbeck technique is similar to the Bardach palatoplasty but preserves an anterior pedicle for increased blood supply to the flaps.[26,121] This technique also is successful in achieving a layered closure but may be more difficult when suturing the nasal mucosa near the anteriorly based pedicle attachments. The authors do not favor push-back techniques because they may incur more palatal scarring, restrict growth, and do not show a measurable benefit in speech.

Another common technique is the Furlow double-opposing Z-plasty, which attempts to lengthen the palate by taking advantage of a Z-plasty technique on both the nasal mucosa and the oral mucosa (Figure 28-13).[26,124-127] This technique can be effective at closing the palate but has been reported by some to have a higher rate of fistula formation at the junction of the soft and hard palates, where theoretical lengthening of the soft palate may compromise the closure.[26,128-133] Some surgeons use interpositional acellular dermal matrix at the time of primary repair to combat this complication.

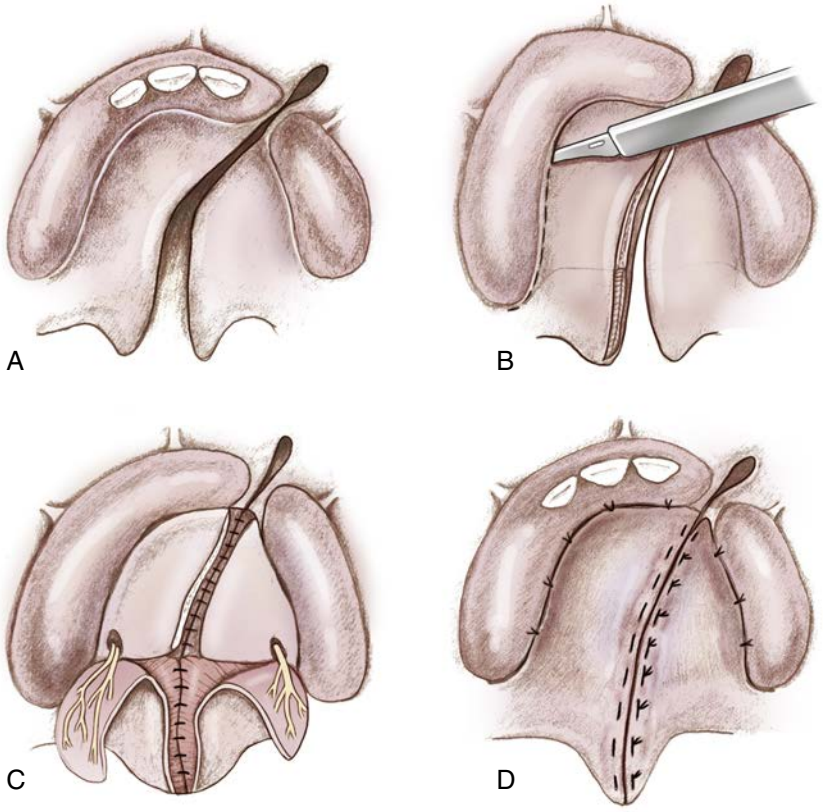

• **Figure 28-12** **A,** Unilateral cleft of the primary and secondary palates is shown with the typical involvement from the anterior vestibule to the uvula. **B,** The Bardach palatoplasty technique requires two large, full-thickness mucoperiosteal flaps to be elevated from each palate shelf. The anterior portion (anterior to the incisive foramen) of the cleft is not reconstructed until the mixed dentition stage. **C,** A layered closure is performed in the Bardach palatoplasty by reapproximating the nasal mucosa. The muscle bellies of the levator palatini are elevated off their abnormal insertions on the posterior palate. They are then reapproximated in the midline to create a dynamic functional sling for speech purposes. **D,** Once the nasal mucosa and musculature of the soft palate are approximated, the oral mucosa is closed in the midline. The lateral releasing incisions are quite easily closed primarily because of the length gained from the depth of the palate. In rare cases, in very wide clefts a portion of the lateral incisions may remain open and granulate by secondary intention.

No benefit has been convincingly demonstrated with any particular repair technique when looking at dental arch form, speech outcome, feeding, or any other functional variable. At this point in our understanding, surgeons often consider their own experiences and training when repairing clefts because definitive data suggesting that one repair is preferable over another are lacking.

In very wide clefts some surgeons advocate considering a pharyngeal flap at the primary palatoplasty procedure to assist in closure because revision palatoplasty is sometimes unsuccessful in eradicating fistulas. Those who use this technique usually perform it in extremely wide clefts and do so quite selectively. This allows the central portion of the closure to be filled with posterior pharyngeal wall tissue, making the closure of the nasal and palatal mucosa easier. Patients with Pierre Robin sequence or Treacher Collins syndrome may have exceptionally wide clefts that are difficult to close with no tension, and this technique may be considered for them. The drawbacks of using a pharyngeal flap during the repair of the palate include an increased risk for complications such as bleeding, snoring, obstructive sleep apnea, and hyponasality.

Complex Facial Clefting

Clefting of the facial structures other than the typical nasolabial region is rare and often presents difficult challenges to the reconstructive cleft surgeon. Therefore consideration should be given to referring patients with complex facial clefting to surgeons with experience in this particular area. Comprehensive interdisciplinary care is important to achieve the best results, including involvement of neurosurgery, ophthalmology, orthodontics, speech pathology, and other members of the craniofacial team. Some interventions such as eye lubrication may be necessary within hours after birth, and accurate prenatal diagnosis of severe facial clefting is helpful in planning for early care.

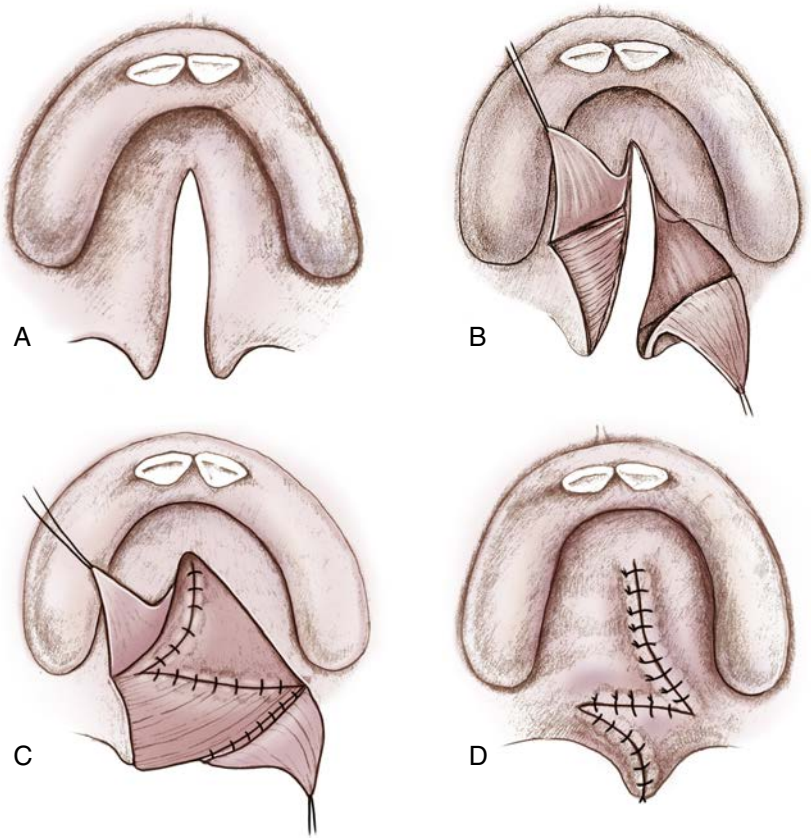

• **Figure 28-13** **A,** Complete cleft of the secondary palate (both hard and soft) is shown from the incisive foramen to the uvula. **B,** The Furlow double-opposing Z-plasty technique requires that separate Z-plasty flaps be developed on the oral and then nasal side. Note the cutbacks creating the nasal side flaps, highlighted in blue. **C,** The flaps are then transposed to theoretically lengthen the soft palate. A nasal side closure is completed in the standard fashion anterior to the junction of the hard and soft palate. In general, this junction is the highest area of tension and can be difficult to close. This contributes to the higher fistula rate in this type of repair at this location. **D,** The oral side flaps are then transposed and closed in a similar fashion, completing the palate closure.

The etiology of the various facial clefts may be related to failure of embryologic fusion, physical obstruction in fetal life, association with an encephalocele or tumor, amniotic bands, or other anatomic disruptions during fetal life.[55] The majority of complex facial clefts are sporadic events not related to a single-gene disease. Many complex facial clefts involve the orbit, and the classification system most often used is orbitocentric in design (see Figure 28-2). Tessier[56] described a numbering system for facial clefting phenomena to make description and surgical planning more easily discussed. Other systems exist but have a more cumbersome nomenclature.[57]

Primary repair of severe facial clefts often is more difficult than even the most difficult standard bilateral clefts.[134-136] Although mobilization of the lip and nose structures is rather straightforward, the closure of clefts in the orbital region can be challenging because of the lack of eyelid and adjacent tissue for advancement and/or rotation. Revision surgery is the norm in this group and may include a skilled ophthalmologic surgeon early in the process for the best functional and esthetic results.

The staged reconstruction of these types of severe facial clefts is similar to the more common cleft lip and palate protocols. However, several functional issues are present in patients with complex facial clefting that require more immediate attention. For example, patients with large Tessier 7 clefts may have problems with retaining food in their oral cavities because of the discontinuity of the orbicularis oris (Figure 28-14). This may prompt early repair and reestablishment of the orbicularis oris musculature for functional concerns.

For patients with orbital clefts, a skilled pediatric ophthalmologist should evaluate the child early to avoid severe corneal abrasion and desiccation. Immediate lubrication of the globes is necessary to prevent severe, irreversible corneal damage until eyelid structures can be mobilized to cover the globe adequately. Early after birth, tarsorrhaphy stitches can be used to gain adequate closure of the lids for corneal protection. Ignoring the need for eye protection may result in severe corneal scarring that may cause blindness and prompt consideration for corneal transplantation. Corneal transplantation in infants often is not successful but is possible in patients with severe orbitofacial clefts. Another concern is the support of the globes at the orbit floor that may be involved in some facial clefts. The timing of orbital



• **Figure 28-14** **A,** A 2-month-old boy with a Tessier 7 left facial cleft associated with craniofacial microsomia (Kaban type IIb), congenital ear anomalies, a lateral tongue cleft, and a left-sided epibulbar dermoid. **B,** The same child 8 months after the primary repair.

reconstruction depends on the functional needs of the cleft area in each patient. These are some of the concerns present in complex facial clefting, and a customized treatment plan must be formulated for each patient.

Outcome Assessment

Decision making in cleft care should involve evidence-based research and a critical look at outcomes. Unfortunately, little evidence-based research is available to guide clinicians through the many treatment protocols for cleft care.[113] Although the clinical experience of the surgeon certainly has value, this must be integrated with a constant review of evidence-based research. Enthusiasm by a surgeon or a particular group of surgeons regarding a specific intervention because of personal experiences may help popularize that intervention, but typically little outcome data support its use. Too frequently the long-term results are not forthcoming, and the treatment regimen may still persist. Unfortunately some of the treatment protocols used today are based on the poor outcomes and mishaps of previous surgeons rather than regimens chosen as a consequence of published evidence of the actual success of a particular treatment. The United Kingdom and other European centers have collaborated to pool data and provide more meaningful assessments of outcome.[137,138] The continued study should help teams understand interventions and their potential consequences in greater detail. The Americleft project attempts to evaluate the North American data in a similar way, and the published outcomes do resemble those seen in Europe.[138-158]

In addition, the pressures of a costly health care system have made treatment decision questions even harder to investigate than ever before.[88] A need to understand the outcome differences of various treatment philosophies will be critical to help determine which protocols will be most beneficial to the patient without extending valuable health care resources on unproven or ineffective methods. For this reason, among many others, the need to abandon unproven and unnecessary interventions has never been greater. Outcomes studies based on results such as appearance, facial growth, occlusion, patient satisfaction, and psychosocial development are all critical in this process. Surgeons involved in the care of patients with clefts must critically review the literature on a regular basis and not be tempted by poorly evaluated techniques popularized by clinical reports.

Summary

The comprehensive care of patients with clefts requires an interdisciplinary approach that demands precise surgical execution of the various procedures necessary to treat cleft deformities effectively. Long-term follow-up with the interdisciplinary team is an essential component of this process. Furthermore, clinicians experienced in the comprehensive interdisciplinary care of patients with clefts are best equipped to deal with these concerns. The treatment of patients with cleft and craniofacial deformities should be free of bias and demand team care that is patient, family, and community oriented. Only in this fashion can the overall treatment be optimally successful. This type of care maximizes the patient's ability to grow into adulthood and succeed in life without focusing on his or her deformity.

References

1. Adams GR: The effects of physical attractiveness on the socialization process. In Lucker GW, Ribbens KA, McNamara JA, editors: *Psychological aspects of facial form craniofacial growth series, monograph no. 11*, Ann Arbor, MI, 1981, University of Michigan Press, pp 25–47.
2. Kapp K: Self concept of the cleft lip and or palate child, *Cleft Palate J* 16:171, 1979.
3. Kapp-Simon KA: Psychological interventions for the adolescent with cleft lip and palate, *Cleft Palate Craniofac J* 32:104–108, 1995.
4. American Cleft Palate-Craniofacial Association: Parameters for the evaluation and treatment of patients with cleft lip/palate or other craniofacial anomalies, *Cleft Palate Craniofac J* 30(Suppl 1):4, 1993.
5. Boo-Chai K: An ancient Chinese text on a cleft lip, *Plast Reconstr Surg* 38:89, 1966.
6. Rogers BO: Harelip repair in colonial America: a review of 18th century and earlier surgical techniques, *Plast Reconstr Surg* 34:142, 1964.
7. Bushe G: *An essay on the operation for cleft palate*, New York, 1835, William Jackson.
8. Pare A: *Dix Livres de la Chirurgie,* Paris, 1564, Iean le Royer, p 211.
9. LeMesurier AB: Method of cutting and suturing lip in complete unilateral cleft lip, *Plast Reconstr Surg* 4:1, 1949.
10. Veau V: Operative treatment of complete double harelip, *Ann Surg (Paris)* 76:143, 1922.
11. Tennison CW: The repair of unilateral cleft lip by the stencil method, *Plast Reconstr Surg* 9:115, 1952.
12. Skoog T: A design for the repair of unilateral cleft lip, *Am J Surg* 95:223, 1958.
13. Brauer RO: Repair of unilateral cleft lip. Triangular flap repairs, *Clin Plast Surg* 12:595, 1985.
14. Randall P: Long-term results with the triangular flap technique for unilateral cleft lip repair. In Bardach J, Morris H, editors: *Multidisciplinary management of cleft lip and palate*, Philadelphia, 1990, WB Saunders, p 173.
15. Asensio OE: Labioleporino y paladar heindido, *Acta Odontol Venez* 3:229–242, 1971.
16. Asensio OE: A variation of the rotation-advancement operation for repair of wide unilateral cleft lips, *Plast Reconstr Surg* 53:167–173, 1974.
17. Millard DR: *Cleft craft*, vol. 1. Boston, 1976, Little, Brown, pp 165–173.
18. Millard DR: A primary camouflage of the unilateral harelip. In *Transactions of the International Congress of Plastic Surgeons*, Baltimore, 1957, Williams & Wilkins, pp 160–166.
19. Hullihen SP: *A treatise on hare-lip and its treatment*, Baltimore, 1844, Woods and Crane.
20. The building of a specialty: oral and maxillofacial surgery in the United States, 1918-1998, *J Oral Maxillofac Surg* 7(Suppl):56, 1998.
21. Schmid E: Die Annaherung der Kieferstumpfe bei Lippen-Kiefer-Gaumenspalten: Ihre schadlichen Folgen und Vermeidung, *Fortschr Kiefer Gesichtschir* 1:37, 1955.
22. Pruzansky S: Presurgical orthopaedics and bone grafting for infants with cleft lip and palate: a dissent, *Cleft Palate J* 1:164, 1964.
23. Robertson NR, Jolleys A: Effects of early bone grafting in complete clefts of the lip and palate, *Plast Reconstr Surg* 42:414–421, 1968.
24. Boyne PJ, Sands NR: Secondary bone grafting of residual alveolar and palatal clefts, *J Oral Surg* 30:87–92, 1972.
25. Millard DR: Cleft craft: the evolution of its surgery. Alveolar and palatal deformities, vol. 3. Boston, 1980, Little, Brown.
26. Posnick JC: The staging of cleft lip and palate reconstruction: infancy through adolescence. In Posnick JC, editor: *Craniofacial and maxillofacial surgery in children and young adults*, Philadelphia, 2000, WB Saunders, pp 785–826.
27. Posnick JC, Tompson B: Cleft-orthognathic surgery. Complications and long-term results, *Plast Reconstr Surg* 96:255, 1995.
28. Posnick JC: Cleft-orthognathic surgery: the unilateral cleft lip and palate deformity. In Posnick JC, editor: *Craniofacial and maxillofacial surgery in children and young adults*, Philadelphia, 2000, WB Saunders, pp 860–907.
29. Posnick JC: Cleft-orthognathic surgery: the bilateral cleft lip and palate deformity. In Posnick JC, editor: *Craniofacial and maxillofacial surgery in children and young adults*, Philadelphia, 2000, WB Saunders, pp 908–950.
30. Posnick JC: Cleft-orthognathic surgery: the isolated palate deformity. In Posnick JC, editor: *Craniofacial and maxillofacial surgery in children and young adults*, Philadelphia, 2000, WB Saunders, pp 951–978.
31. Ruiz RL, Costello BJ, Turvey T: Orthognathic surgery in the cleft patient. In Ogle O, editor: *Oral and maxillofacial surgery clinics of North America: secondary cleft surgery*, Philadelphia, 2002, WB Saunders, pp 491–507.
32. Costello BJ, Ruiz RL: The role of distraction osteogenesis in orthognathic surgery of the cleft patient, *Selected Readings Oral Maxillofac Surg* 10(3):1–27, 2002.
33. Costello BJ, Shand J, Ruiz RL: Craniofacial and orthognathic surgery in the growing patient, *Selected Readings Oral Maxillofacial Surg* 11(5), 2003.
34. Braun TW, Sotereanos GC: Orthognathic and secondary cleft reconstruction of adolescent patients with cleft palate, *J Oral Surg* 38:425–434, 1980.
35. Kiehn CL, DesPrez JD, Brown F: Maxillary osteotomy for late correction of occlusion and appearance in cleft lip and palate patients, *Plast Reconstr Surg* 42:203–207, 1968.
36. Westbrook MT, West RA, McNeill RW: Simultaneous maxillary advancement and closure of bilateral alveolar clefts and oronasal fistulas, *J Oral Maxillofac Surg* 41:257–260, 1983.
37. Georgiade NG: Mandibular osteotomy for the correction of facial disproportion in the cleft lip and palate patient. Symposium on management of cleft lip and palate and associated deformities, *Am Plast Reconstr Surg* 8:238, 1974.
38. Bell WH: Le Fort I osteotomy for correction of maxillary deformities, *J Oral Surg* 33:412–426, 1975.
39. Fonseca RJ, Turvey TA, Wolford LM: Orthognathic surgery in the cleft patient. In Fonseca RJ, Baker SJ, Wolford LM, editors: *Oral and maxillofacial surgery*, Philadelphia, 2000, WB Saunders, pp 87–146.
40. Polley JW, Figueroa AA, Charbel FT, et al.: Monoblock craniomaxillofacial distraction osteogenesis in a newborn with severe craniofacial synostosis: a preliminary report, *J Craniofac Surg* 6:421–423, 1995.
41. Polley JW, Figueroa AA: Rigid external distraction: its application in cleft maxillary deformities, *Plast Reconstr Surg* 102:1360–1372, 1998.
42. Posnick JC, Ruiz RL: Management of secondary orofacial cleft deformities. In Goldwyn RM, Cohen MN, editors: *The unfavorable result in plastic surgery: avoidance and treatment*, ed 3, Philadelphia, 2000, Lippincott Williams & Wilkins.

43. Tolarova MM, Cervenka J: Classification and birth prevalence of orofacial clefts, *Am J Med Genet* 75:126–137, 1998.
44. Tolarova M: Etiology of clefts of lip and/or palate: 23 years of genetic follow-up in 3660 individual cases. In Pfeifer G, editor: *Craniofacial abnormalities and clefts of the lip, alveolus, and palate*, Stuttgart, Germany, 1991, Thieme.
45. Gundlach KKH, Abou Tara N, von Kreybig T: Tierexperimentelle Ergebnisse zur Entstehung und Pravention von Geischtsspalten und anderen kraniofazialen Anomalien, *Fortschr Kieferorthop* 47:356–361, 1986.
46. Prescott NJ, Lees MM, Winter RM, et al.: Identification of susceptibility loci for nonsyndromic cleft lip with or without cleft palate in a two stage genome scan of affected sib pairs, *Hum Genet* 106:345–350, 2000.
47. Suzuki K, Hu D, Bustos T, et al.: Mutations of PVRL1 encoding a cell-cell adhesion molecule/herpesvirus receptor, in cleft lip/palate-ectodermal dysplasia, *Nat Genet* 25:427–430, 2000.
48. Van den Boogaard MJ, Dorland M, Beemer FA, et al.: MSX1 mutation is associated with orofacial clefting and tooth agenesis in humans, *Nat Genet* 24:342–343, 2000.
49. Oliver-Padilla G, Martinez-Gonzales V: Cleft lip and palate in Puerto Rico: a 33 year study, *Cleft Palate J* 23:48–57, 1986.
50. Lettieri J: *Human malformations and related anomalies*. In Stevenson RE, Hall JG, Goodman RM, editors: New York, 1993, Oxford University Press, pp 367–381.
51. Wyszynski DF, Beaty TH, Maestri NE: Genetics of non-syndromic and syndromic oral clefts revisited, *Cleft Palate Craniofac J* 33:16406–16417, 1996.
52. Saal HM: Syndromes and malformations associated with cleft lip with or without cleft palate, *Am J Hum Genet* 64:A118, 1998.
53. Jones MC: Etiology of facial clefts: prospective evaluation of 428 patients, *Cleft Palate J* 25:16–20, 1988.
54. Gorlin R, Cohen MJ, Levin L: *Syndromes of the head and neck*, ed 4, New York, 2003, Oxford University Press.
55. Cohen MM: Etiology and pathogenesis of orofacial clefting. Cleft lip and palate: a physiological approach, *Oral Maxillofac Clin North Am* 12:379–397, 2000.
56. Tessier P: Anatomical classification of facial, cranio-facial, and latero-facial clefts, *J Maxillofac Surg* 4:69–92, 1976.
57. Van der Meulen J, Mazzola B, Vermey-Keers, et al.: A morphogenetic classification of craniofacial malformations, *Plast Reconstr Surg* 71:560, 1983.
58. Pretorius DH, House M, Nelson TR, et al.: Evaluation of normal and abnormal lips in fetuses: comparison between three- and two-dimensional sonography, *Am J Roentgenol* 165:1233–1237, 1995.
59. Pretorius DH, Nelson TR: Fetal face visualization using three-dimensional ultrasonography, *J Ultrasound Med* 14:349–356, 1995.
60. Shaikh D, Mercer NS, Sohan K, et al.: Prenatal diagnosis of cleft lip and palate, *Br J Plast Surg* 54:288–289, 2001.
61. Lawrence RA: Breastfeeding: benefits, risks, and alternatives, *Curr Opin Obstet Gynecol* 12:519–524, 2000.
62. Hamosh M, Peterson JA, Henderson TR, et al.: Protective function of human milk: the milk fat globule, *Semin Perinatol* 23:242–249, 1999.
63. Thompson JE: An artistic and mathematically accurate method of repairing the defect in cases of harelip, *Surg Gynecol Obstet* 14:498, 1912.
64. Marsh JL: Craniofacial surgery: the experiment on the experiment of nature, *Cleft Palate Craniofac J* 33:1, 1996.
65. Van Boven MJ, Pendeville PE, Veyckemans F, et al.: Neonatal cleft lip repair: the anesthesiologist's point of view, *Cleft Palate Craniofac J* 30:574–577, 1993.
66. Eaton AC, Marsh JL, Pigram TK: Does reduced hospital stay affect morbidity and mortality rates following cleft lip and palate repair in infancy? *Plast Reconstr Surg* 94:916–918, 1994.
67. Field TM, Vega-Lahr N: Early interactions between infants with craniofacial anomalies and their mothers, *Infant Behav Dev* 7:527, 1984.
68. Estes JM, Whitby DJ, Lorenz HP, et al.: Endoscopic creation and repair of fetal cleft lip, *Plast Reconstr Surg* 90:743–746, 1992.
69. Hallock GG: Endoscopic creation and repair of fetal cleft lip, *Plast Reconstr Surg* 90:747, 1992.
70. Hedrick MH, Rice HE, Vander Wall KJ, et al.: Delayed in utero repair of surgically created fetal cleft lip and palate, *Plast Reconstr Surg* 97:906–907, 1996.
71. Dorf DS, Curtin JW: Early cleft palate repair and speech outcome, *Plast Reconstr Surg* 70:74–81, 1982.
72. Dorf DS, Curtin JW: Early cleft palate repair and speech outcome: a ten year experience. In Bardach J, Morris HL, editors: *Multidisciplinary management of cleft lip and palate*, Philadelphia, 1990, WB Saunders, pp 341–348.
73. Copeland M: The effect of very early palatal repair on speech, *Br J Plast Surg* 43:676, 1990.
74. Costello BJ, Ruiz RL, Turvey T: Surgical management of velopharyngeal insufficiency in the cleft patient. In *Oral and maxillofacial surgery clinics of North America: secondary cleft surgery*, Philadelphia, 2002, WB Saunders, pp 539–551.
75. Sadove AM, Nelson CL, Eppley BL, et al.: An evaluation of calvarial and iliac donor sites in alveolar cleft grafting, *Cleft Palate J* 27:225–228, 1990.
76. Sindet-Pedersen S, Enemark H: Reconstruction of alveolar clefts with mandibular or iliac crest bone graft: a comparative study, *J Oral Maxillofac Surg* 48:554–558, 1990.
77. Lo LJ, Hung KF, Chen YR: Blindness as a complication of LeFort I osteotomy for maxillary disimpaction, *Plast Reconstr Surg* 109:688–698, 2002.
78. Poole R, Farnworth TK: Preoperative lip taping in the cleft lip, *Ann Plast Surg* 32:243–249, 1994.
79. Shaw WC, Semb G: Current approaches to the orthodontic management of cleft lip and palate, *J R Soc Med* 83:30–33, 1990.
80. Ross RB, MacNamera MC: Effect of presurgical infant orthopedics on facial esthetics in complete bilateral cleft lip and palate, *Cleft Palate Craniofac J* 31:68–73, 1994.
81. Grayson BH, Cutting CB, Wood R: Preoperative columella lengthening in bilateral cleft lip and palate, *Plast Reconstr Surg* 92:1422–1423, 1993.
82. Grayson BH, Santiago PE, Brecht LE, et al.: Presurgical nasoalveolar molding in infants with cleft lip and palate, *Cleft Palate Craniofac J* 36:486–498, 1999.
83. Prahl C, Kuijpers-Jagman AM, Van'tHof MA, et al.: A randomized prospective clinical trial of the effect of infant orthopedics in unilateral cleft lip and palate: prevention of collapse of the alveolar segments (Dutch cleft), *Cleft Palate Craniofac J* 40:337–342, 2003.
84. Chan KT, Hayes C, Shusterman S, et al.: The effects of active infant orthopedics on occlusal relationships in unilateral complete cleft lip and palate, *Cleft Palate Craniofac J* 40:511–517, 2003.
85. Konst EM, Rietveld T, Peters HFM, et al.: Language skills of young children with unilateral cleft lip and palate following infant orthopedics: a randomized clinical trial, *Cleft Palate Craniofac J* 40:356–362, 2003.

86. Berkowitz S: The comparison of treatment results in complete cleft lip/palate using conservative approach vs. Millard-Latham PSOT procedure, *Semin Orthod* 2:169, 1996.
87. Georgiade NG, Latham RA: Maxillary arch alignment in the bilateral cleft lip and palate infant, using the pinned coaxial screw appliance, *Plast Reconstr Surg* 56:52–60, 1975.
88. Strauss RP: Health policy and craniofacial care: issues in resource allocation, *Cleft Palate Craniofac J* 31:78–80, 1994.
89. Randall P, Graham WP: Lip adhesion in the repair of bilateral cleft lip. In Grabb WC, Rosenstein SW, Bzoch KR, editors: *Cleft lip and palate*, Boston, 1971, Little, Brown.
90. Millard DR: A preliminary adhesion. In *Cleft craft, vol. 1: the unilateral deformity*, Boston, 1976, Little, Brown.
91. Vander Woude DL, Mulliken JB: Effect of lip adhesion on labial height in two-stage repair of unilateral complete cleft lip, *Plast Reconstr Surg* 100:567–572, 1997.
92. Mulliken JB, Pensler JM, Kozakewich HPW: The anatomy of cupid's bow in normal and cleft lip, *Plast Reconstr Surg* 92:395–403, 1993.
93. McComb H: Primary correction of unilateral cleft lip nasal deformity: a 10 year review, *Plast Reconstr Surg* 75:791–799, 1985.
94. Horswell BB, Pospisil OA: Nasal symmetry after primary cleft lip repair: comparison between Delaire cheilorhinoplasty and modified rotation-advancement, *J Oral Maxillofac Surg* 53:1025–1030, 1995.
95. Schendel SA: Nasal symmetry after primary cleft lip repair: comparison between Delaire cheilorhinoplasty and modified rotation-advancement, *J Oral Maxillofac Surg* 53:1031, 1995.
96. Trier WC: Bilateral complete cleft lip and nasal deformity: an anthropometric analysis of staged to synchronous repair, *Plast Reconstr Surg* 96:24, 1995.
97. Takato T, Yonehara Y, Mori Y, et al.: Early correction of the nose in unilateral cleft lip patients using an open method: a 10-year review, *J Oral Maxillofac Surg* 53:28–33, 1995.
98. Millard DR: Columella lengthening by a forked flap, *Plast Reconstr Surg* 22:454, 1958.
99. Cronin TD: Lengthening the columella by use of skin from nasal floor and alae, *Plast Reconstr Surg* 21:417, 1958.
100. McComb H: Primary repair of the bilateral cleft lip nose: a 15-year review and a new treatment plan, *Plast Reconstr Surg* 86:882–889, 1990.
101. Mulliken JB: Bilateral complete cleft lip and nasal deformity: an anthropometric analysis of staged to synchronous repair, *Plast Reconstr Surg* 96:9–23, 1995.
102. Trott JA, Mohan NA: A preliminary report on one-stage open tip rhinoplasty at the time of lip repair in bilateral cleft lip and palate. The Alo Setar experience, *Br J Plast Surg* 46:215–222, 1993.
103. Cutting C, Grayson B: The prolabial unwinding flap method for one-stage repair of bilateral cleft lip, nose and alveolus, *Plast Reconstr Surg* 91:37–47, 1993.
104. Maher W: Distribution of palatal and other arteries in cleft and non-cleft human palates, *Cleft Palate J* 14:1–12, 1977.
105. Ross RB, Johnston MC: *Cleft lip and palate*, Baltimore, 1972, William & Wilkins.
106. Broomhead I: The nerve supply of the soft palate, *Br J Plast Surg* 10:81, 1957.
107. Riski JE, DeLong E: Articulation development in children with cleft lip/palate, *Cleft Palate J* 21:57–64, 1984.
108. Devlin HB: Audit and the quality of clinical care, *Ann R Coll Surg Engl* 72(Suppl 1):3–14, 1990.
109. Trotman CA, Ross RB: Craniofacial growth in bilateral cleft lip and palate: ages six years to adulthood, *Cleft Palate Craniofac J* 30:261–273, 1993.
110. Bishara SE: Cephalometric evaluation of facial growth in operated and unoperated individuals with isolated clefts of the palate, *Cleft Palate J* 10:239–246, 1973.
111. Bardach J, Kelly KM, Salyer KE: Relationship between the sequence of lip and palate repair and maxillary growth. An experimental study in beagles, *Plast Reconstr Surg* 93:269–278, 1994.
112. Semb G: A study of facial growth in patients with bilateral cleft lip and palate treated by the Oslo CLP team, *Cleft Palate Craniofac J* 28:22–48, 1991.
113. Shaw WC, Asher-McDade C, Brattstrom V, et al.: A six-center international study of treatment outcome in patients with clefts of the lip and palate. Part 5. General discussion and conclusions, *Cleft Palate Craniofac J* 29:413–418, 1992.
114. Canaday JW, Thompson SA, Colburn A: Craniofacial growth after iatrogenic cleft palate repair in a fetal ovine model, *Cleft Palate Craniofac J* 34:69–72, 1997.
115. Peterson-Falzone SJ: Speech outcomes in adolescents with cleft lip and palate, *Cleft Palate Craniofac J* 32:125–128, 1995.
116. Dalston RM: Timing of cleft palate repair: a speech pathologist's viewpoint. In Lehman JA, editor: *Problems of plastic surgery in cleft palate surgery*, Philadelphia, 1992, JB Lippincott, pp 30–38.
117. Witzel MA, Salyer KE, Ross RB: Delayed hard palate closure: the philosophy revisited, *Cleft Palate J* 21:263–269, 1984.
118. Schweckendiek W: Primary veloplasty: long-term results without maxillary deformity. A twenty-five year report, *Cleft Palate J* 15:268–274, 1991.
119. Kriens O: Fundamental anatomic findings for an intravelar veloplasty, *Cleft Palate J* 7:27–36, 1970.
120. Bardach J, Nosal P: Geometry of the two-flap palatoplasty. In Bardach J, Salyer K, editors: *Surgical techniques in cleft lip and palate*, ed 2, St Louis, 1991, Mosby–Year Book.
121. Von Langenbeck B: Operation der angeborenen totalen spaltung des harten gaumens nach einer neuen methode, *Dtsch Klin* 8:231, 1861.
122. Wardill WFM: Cleft palate: results of operation for cleft palate, *Br J Plast Surg* 16:127, 1928.
123. Wardill WFM: The technique of operation for cleft palate, *Br J Surg* 25:117, 1937.
124. Furlow LT: Cleft palate repair by double opposing Z-plasty, *Plast Reconstr Surg* 78:724–738, 1986.
125. Furlow LT: Bilateral buccal flaps with double opposing Z-plasty for wider palatal clefts, *Plast Reconstr Surg* 100:1144–1145, 1997.
126. Randall P, LaRossa D, Solomon M, et al.: Experience with the Furlow double-reversing Z-plasty for cleft palate repair, *Plast Reconstr Surg* 77:569–576, 1986.
127. Horswell BB, Castiglione CL, Poole AE, et al.: The double-reversing z-plasty in primary palatoplasty: operative experience and early results, *J Oral Maxillofac Surg* 51:145–149, 1993.
128. Reid DA: Fistulae in the hard palate following cleft palate surgery, *Br J Plast Surg* 77:569, 1986.
129. Abyholm FE: Palatal fistulae following cleft palate surgery, *Scand J Plast Reconstr Surg* 13:295–300, 1979.
130. Cohen SR, Kalinowski J, La Rossa D, et al.: Cleft palate fistulas: a multivariate statistical analysis of prevalence, etiology, and surgical management, *Plast Reconstr Surg* 87:1041–1047, 1991.
131. Emory RE, Clay RP, Bite U, et al.: Fistula formation and repair after palatal closure: an institutional perspective, *Plast Reconstr Surg* 99:1535–1538, 1997.
132. Rintala AE: Surgical closure of palatal fistulae: follow-up of 84 personally treated cases, *Scand J Plast Reconstr Surg Hand Surg* 14:235–238, 1980.

133. Schultz RC: Management and timing of cleft palate fistula repair, *Plast Reconstr Surg* 78:739–747, 1986.
134. Tessier P: Colobomas: vertical and oblique complete facial clefts, *Panminerva Med* 11:95–101, 1969.
135. Kawamoto HK: The kaleidoscopic world of rare craniofacial clefts: order out of chaos (Tessier classification), *Clin Plast Surg* 3:529–572, 1976.
136. Posnick JC: Rare craniofacial clefts: evaluation and treatment. In Posnick JC, editor: *Craniofacial and maxillofacial surgery in children and young adults*, Philadelphia, 2000, WB Saunders, pp 487–502.
137. Semb G, Brattström V, Mølsted K, Prahl-Andersen B, Shaw WC: The Eurocleft study: intercenter study of treatment outcome in patients with complete cleft lip and palate. Part 1: introduction and treatment experience, *Cleft Palate Craniof J* 42(1):64–68, 2005.
138. Long Jr RE, Hathaway RR, Daskalogiannakis J, Mercado AM, Russell KA, Cohen MA, Semb G, Shaw W: The Americleft Study: an intercenter study of treatment outcomes for patients with unilateral cleft lip and palate. Part 1—Principles and Study Design, *Cleft Palate Craniof J* 48:239–243, 2011.
139. Hathaway RR, Daskalogiannakis J, Mercado AM, Russell KA, Long Jr RE, Cohen MA, Semb G, Shaw W: The Americleft Study: an intercenter study of treatment outcomes for patients with unilateral cleft lip and palate. Part 2—Dental arch relationships, *Cleft Palate Craniof J* 48:244–251, 2011.
140. Daskalogiannakis J, Mercado AM, Russell KA, Hathaway RR, Dugas GS, Long Jr RE, Cohen MA, Semb G, Shaw W: The Americleft Study: an intercenter study of treatment outcomes for patients with unilateral cleft lip and palate. Part 3—Analysis of craniofacial form, *Cleft Palate Craniof J* 48:252–258, 2011.
141. Mercado AM, Russell KA, Hathaway RR, Daskalogiannakis J, Sadek H, Long Jr RE, Cohen MA, Semb G, Shaw W: The Americleft Study: an intercenter study of treatment outcomes for patients with unilateral cleft lip and palate. Part 4—Nasolabial esthetics, *Cleft Palate Craniof J* 48:259–264, 2011.
142. Russell KA, Long Jr RE, Hathaway RR, Daskalogiannakis J, AM Mercado, Cohen MA, Semb G, Shaw W: The Americleft Study: an intercenter study of treatment outcomes for patients with unilateral cleft lip and palate. Part 5—General discussion and conclusions, *Cleft Palate Craniof J* 48:265–270, 2011.
143. Long Jr RE: The Americleft Project: comparing treatment outcomes for cleft lip and palate to identify evidence-based practices of importance to the orthodontist, *Pract Rev Orthodont*, April, 2011.
144. Long Jr RE, Shaw WC, Semb G: Eurocleft and Americleft studies: Experiments in intercenter and international collaboration. In Berkowitz S, editor: *Cleft lip and palate—diagnosis and management*, ed 3, Berlin, 2013, Springer-Verlag, Berlin, pp 929–945.
145. Hathaway RR, Long Jr RE, Mercado AM, Daskalogiannakis J, Russell KA, Semb G, Shaw WC, Gregory J: The Americleft Project: use of a standardized outcome measure of dental arch relationships (Goslon) to allow international interstudy comparisons, *Transactions of the 12th International Congress on Cleft Lip/Palate and Related Craniofacial Anomalies*, Orlando, FL. May 5-10, 2013.
146. Daskalogiannakis J, Long Jr RE, Hathaway RR, Russell KA, Mercado AM, Semb G, Shaw WC: The Americleft Project: Lessons learned from intercener outcome assessments, *Transactions of the 12th International Congress on Cleft Lip/Palate and Related Craniofacial Anomalies*, Orlando, FL. May 5-10, 2013.
147. Russell KA, Long Jr RE, Daskalogiannakis J, Mercado AM, Hathaway RR, Semb G, Shaw WC: The Americleft Project: Alveolar bone graft outcome assessment: history, challenges, and a method developed to overcome these challenges, *Transactions of the 12th International Congress on Cleft Lip/Palate and Related Craniofacial Anomalies*, Orlando, FL. May 5-10, 2013.
148. Daskalogiannakis J, Russell KA, Mercado AM, Hathaway RR, Singer E, Stoutland A, Long Jr RE, Semb G, Shaw WC: The Americleft Project: Burden of care of various infant orthopedic protocols for improvement of nasolabial aesthetics in patients with CUCLP, *Transactions of the 12th International Congress on Cleft Lip/Palate and Related Craniofacial Anomalies*, Orlando, FL. May 5-10, 2013.
149. Long Jr RE, Mercado AM, Daskalogiannakis J, Hathaway RR, Russell KA, Stoutland A, Singer E, Semb G, Shaw WC, Gregory J: The Americleft Project: a modification of Asher-McDade method for rating nasolabial esthetics in patients with CUCLP, *Transactions of the 12th International Congress on Cleft Lip/Palate and Related Craniofacial Anomalies*, Orlando, FL. May 5-10, 2013.
150. Mercado AM, Russell KA, Daskalogiannakis J, Hathaway RR, Long Jr RE, Semb G, Shaw WC, Ozawa T, Smith A, Lin AY, Gregory J: *T*he Americleft Project: a proposed expanded nasolabial appearance yardstick of 5-year old patients with CUCLP, *Transactions of the 12th International Congress on Cleft Lip/Palate and Related Craniofacial Anomalies*, Orlando, FL. May 5-10, 2013.
151. Long Jr RE, Shaw WC, Semb G: Eurocleft and Americleft Studies: experiments in intercenter and international collaboration. In Berkowitz S, editor: *Cleft lip and palate—diagnosis and management*, ed 3, New York, 2013, Springer, pp 929–945.
152. Russell KA, Long Jr RE, Daskalogiannakis J, Mercado AM, Hathaway RR, Semb G, Shaw WC: A multi-center study using the SWAG Scale to compare secondary alveolar bone graft outcomes for patients with cleft lip and palate, *Cleft Palate Craniof J* 53(2):180–186, 2016.
153. Russell KA, Long Jr RE, Daskalogiannakis J, Mercado AM, Hathaway RR, Semb G, Shaw WC: SWAG Method: a new method to assess alveolar bone grafts for patients with cleft lip and palate: comparison with existing methods, *Cleft Palate Craniof J,* 2015. Accepted for publication.
154. Mercado AM, Russell KA, Daskalogiannakis J, Hathaway RR, Semb G, Ozawa T, Smith A, Lin A: The Americleft Project: A proposed expanded nasolabial appearance yardstick for 5 year old patients with CUCLP, *Cleft Palate Craniof J* 53(1):30–37, 2016.
155. Russell L, Long Jr RE, Romberg E: The effecct of cleft size in infants with unilateral cleft lip and palate on mixed dentition dental arch relationship, *Cleft Palate Craniof J* 52(5):605–613, 2015.
156. Stoutland A, Long Jr RE, Mercado A, Daskalogiannakis J, Hathaway RR, Russell KA, Singer E, Semb G, Shaw WC: The Americleft Project: A Modification of Asher-McDade Method for Rating Nasolabial Esthetics in Patients with CUCLP using Q-SORT. *Amer J Orthod and Dentfac Orthop*, 2015. Submitted for publication.
157. Sitzman TJ, Mara CA, Long Jr RE, Daskalogiannakis J, Russell KA, Mercado AM, Hathaway RR, Fessler J, Carle AC, Shaw WC: The Americleft Project: burden of care from secondary surgery in patients with unilateral cleft lip and palate. *J Plast Reconstr Surg* 10, 3(7):e442, 2015. Submitted for publication.
158. Ruppel JK, Long Jr RE, Oliver DR, Semb G, Russell KA, Mercado AM, Daskalogiannakis J, Hathaway RR: The Americleft Project: a two-center comparison of short and long-term secondary alveolar bone graft outcomes with the SWAG scale, *Cleft Palate Craniof J*, 2015. Submitted for publication.

29

Repair of the Unilateral Cleft Lip: A Comparison of Surgical Techniques

RAMON L. RUIZ, BERNARD J. COSTELLO

Introduction

Cleft lip, with or without involvement of the palate, is a common malformation affecting approximately 1 in 700 live births in North America.[1,2] When a cleft involves at least the lip and alveolus (primary palate), a complex, three-dimensional (3D) malformation is the result. Distortions of the skin, underlying musculature, mucosal membranes, underlying skeletal structures, and dentition are present. The goals of unilateral cleft lip and nasal repair include the creation of an intact upper lip with adequate vertical length and symmetry, repair of the underlying muscular structures with normal function, and primary correction of the associated nasal deformity. Posnick has described the surgical objectives of unilateral cleft lip repair as "the creation of a structure directly adjacent to its mirror image located in the most conspicuous area of the human body."[3]

The first techniques used for the repair of unilateral cleft lip primarily involved a straight line closure of the defect.[2,4] Modifications involving the use of a quadrangular flap offered advantages over these initial techniques.[4,5] The Tennison technique was described in 1952 and involved the use of a triangular flap and vertical repositioning of the Cupid's bow area.[6] Millard[7] subsequently described the rotation and advancement flap technique, which is recognized as the most important technical development in the repair of the unilateral cleft lip and nasal deformity. Today most surgeons in North America and throughout the world use the Millard technique or some close modification of it.

Every cleft surgeon has a favorite technique for the repair of a unilateral cleft lip. In Parts I, II, and III of this chapter, experienced cleft surgeons provide an overview of three popular approaches used in the contemporary surgical treatment of unilateral cleft lip malformations: (1) the rotation and advancement flap technique, (2) the Tennison triangular flap repair technique, and (3) the functional approach to cleft lip repair.

Timing of Cleft Lip Repair

Early protocols describing the staged reconstructive approach to cleft lip and palate deformities referred to the "rule of tens" as a general guideline for the exact timing of the initial lip repair. Surgery was delayed until the child was at least 10 weeks of age, weighed at least 10 pounds, and had a hemoglobin level of at least 10 g/dL.[8,9] These guidelines initially were designed to minimize anesthetic morbidity and mortality in infants. Although contemporary anesthesia practices and pharmacologic agents would safely allow earlier surgery, cleft lip repair during the early neonatal period rarely is undertaken because no measurable benefit exists to performing lip repair before the infant is 10 to 12 weeks old. Today most North American cleft lip and palate programs continue to delay the initial surgery for cleft lip repair until the child is 10 to 12 weeks of age.[3] This largely is because the hoped-for advantages of early lip repair have not been scientifically proven or documented in the world surgical literature. Proponents of surgery during the neonatal period often have referenced the "scar-less" healing associated with fetal development,[9] with the idea being that if surgery is undertaken early in the neonatal period, then "fetal-like" physiology may still be present and the child will have less scar formation at the surgical site. Unfortunately, these benefits have not been observed, and problems with excessive scarring and less-favorable outcomes have been encountered.[3,4] Neonates may have more scarring at this early age, and their tissues are smaller and more difficult to manipulate. Another potential rationale for early surgery is the psychosocial benefit of immediate repair. Again, scientific evaluations have

failed to establish any psychosocial benefit or improved bonding between the mother and child as a result of early cleft lip repair.[4,10]

Description and Comparison of Surgical Techniques

Rotation and Advancement Flap Technique

A key technical component of the rotation and advancement flap technique described by Millard is the creation of a horizontal, back-cut incision within the superior region of the lip near the base of the columella. This allows downward rotation of the central lip to create adequate lip length and provides the needed downward rotation of the Cupid's bow region. The Tennison procedure, in contrast, allows downward repositioning of the lower third of the lip and Cupid's bow.

When the vertical lip incision and horizontal back cut are carried out, a segment of skin along the base of the columella is created and referred to as the C-flap. This C-flap is a portion of excess skin within the medial superior lip/prolabial area that can be used as part of the nasal sill repair or incorporated into the medial lip segment to create additional length.

The advancement flap refers to the lateral lip segment that is advanced into the defect during the repair. The lateral lip segment is prepared by creating a vertical incision with excision of hypoplastic tissue and identification of the orbicularis muscle, undermining of the overlying skin, and creation of releasing incisions within the maxillary vestibule. In addition, a horizontal incision along the alar base allows adequate mobilization so that the leading edge of the flap is advanced for closure of the defect.

Repair of a unilateral cleft lip and nasal deformity with a rotation and advancement flap technique involves the rotation of the medial lip segment downward, release of abnormal insertions involving muscular and cartilaginous structures, advancement of the lateral lip segment, and repair of the three tissue layers (mucosa, muscle, and skin). The popularity of the Millard rotation and advancement flap technique is a result of a number of distinct advantages, including the ability to normalize the position of Cupid's bow and create lip length while positioning the vertical lip scar within the natural line of the philtral column. This approach uses all the prolabial skin to create adequate vertical dimension of the lip. The procedure may be applied to a wide spectrum of cleft malformations with consistent success. In addition, the rotation and advancement flap technique offers the surgeon significant flexibility so that intraoperative adjustments can be made.

Theoretic disadvantages of the rotation and advancement flap technique are most likely encountered in cases of wide cleft defects. One challenge is an insufficient lip length in cases of severe, complete cleft defects. Subsequent wound contracture along a vertical scar may shorten the lip further. Over the years, modifications and refinements to the original procedure have been made by Millard and others to address these potential problems.[11-14]

Tennison Triangular Flap Technique

Unlike the rotation and advancement flap technique described by Millard, the Tennison lip repair technique uses a back cut placed at the bottom of the central lip within the philtral skin along the white roll.[6,15] The defect created in this region is then repaired with a full-thickness triangular flap elevated within the lateral lip segment. This incision placed along the inferior aspect of the philtral column allows downward movement of the Cupid's bow but does not allow inferior displacement (i.e., vertical lengthening) of the entire lip segment to the same extent as the Millard procedure.

Compared with the Millard rotation and advancement flap procedure, the Tennison technique has a number of theoretic advantages. The procedure allows a significant amount of vertical repositioning of the Cupid's bow with a relatively easy maneuver (horizontal incision parallel to the white roll). Proponents of the procedure also argue that the triangular design avoids the problem of wound contracture and lip length shortening encountered with the vertical philtral column scar seen in the rotation and advancement flap operation. Lastly, the tendency to excise too much tissue along the nasal sill and end up with a smaller nostril on the cleft side is decreased with the Tennison procedure.

The most prominent criticism of the Tennison technique relates to the horizontal back cut along the white roll into the philtral column to allow downward rotation of the Cupid's bow. The disadvantage is the placement of a horizontal incision and resultant scar across the philtrum. Surgeons who routinely use the Tennison procedure try to minimize the resultant scar by controlling how far the horizontal incision is extended across the philtrum. The idea is to extend the horizontal incision to the midline only and not to the contralateral philtral column. Another potential pitfall associated with the Tennison repair is the fact that it is more technique sensitive. Specifically, flaps are designed with calipers to measure incision lengths based on numerous anatomic landmarks. Once the flaps are elevated, little opportunity is available for change in design and, in fact, many surgeons describe a point of no return during the procedure in which little or no modification is possible. This stands in sharp contrast to the rotation and advancement flap technique, which allows intraoperative adjustments of the repair. Later in this chapter, the author makes an excellent suggestion: to begin a Tennison repair by first developing all incisions and flaps on the medial aspect of the cleft defect. This allows the surgeon an opportunity to reevaluate the defect intraoperatively and create any final modifications in the lateral flap.

Functional Cleft Lip Repair: The Delaire Philosophy

The theory of a functional matrix that drives facial development is well described in the orthodontic and surgical literature.[16] This concept is that the growth of dentofacial and skeletal components is shaped by the surrounding soft tissue (e.g., skin, muscle) matrices. This important developmental

principle also is at the center of the functional cleft lip repair. Facial clefts disrupt functional muscular fields or musculoaponeurotic units during fetal development. These abnormally positioned soft tissue elements cause disruption of subsequent development of underlying skeletal and cartilaginous structures. In a cleft of the upper lip, specific muscle groups, including the orbicularis oris, transversalis nasi, levator labii superioris, alaeque nasi, zygomaticus, and levator anguli oris, are all involved by the cleft defect, are malpositioned, and have abnormal insertions within the surrounding bony anatomy. Over time, abnormal position and function affect form so that these abnormal muscle insertions and positions lead to a secondary hard tissue deformity.

In a series of publications, Delaire[17-20] was the first to propose a surgical approach for the correction of cleft lip and palate centered around the proper anatomic repositioning of underlying musculature and aponeurotic attachments. Delaire described a system of several muscular sphincters or rings in relation to the nasal and oral structures.[21] His work led to the philosophical approach that the cleft surgeon must reestablish the normal position of these muscular units that comprise the functional matrix of the face so that normal function and growth patterns are created. The idea is to reposition the muscle aponeurotic system and establish an equilibrium to the action of the nasolabial musculature. More recently, Carstens[22] has elaborated on this functional matrix repair with particular emphasis on the embryologic origin of the soft tissue and muscular elements being repaired.

In practical terms, this philosophy of functional repair translates into key differences in the surgical procedure compared with the rotation and advancement flap and Tennison triangular flap procedures. First, subperiosteal dissection is used as part of the functional repair technique. Subperiosteal dissection allows aggressive mobilization of musculoaponeurotic elements and the lower lateral cartilages of the nasal complex. A theoretic advantage of subperiosteal dissection is that less disruption occurs to the blood supply of the muscles being reoriented. This concern for the meticulous preservation of blood supply also is carried over into the incision and flap designs used for functional repair. Surgeons carrying out functional repairs often avoid the use of back cuts across the skin of the columella base and eliminate or minimize horizontal incisions along the lateral alar base to avoid any degree of interruption in blood supply.

Summary

The contemporary armamentarium of the cleft surgeon includes a number of surgical procedures and technical refinements that have evolved over the past 60 years.[4,13] In the three parts that follow, specific attention is given to three popular treatment approaches used in the initial repair of the unilateral cleft lip and nasal malformation. The authors provide an overview of general principles and theoretic advantages and disadvantages. The first of these descriptions covers the Millard rotation and advancement flap technique, which remains the most popular procedure used for the repair of the unilateral cleft lip. Although less popular in the United States, the Tennison triangular flap technique frequently is used in cleft programs worldwide. The description of the Tennison procedure provides a concise review of the technique, an overview of the advantages of the procedure, and a number of clinical examples provided by a world authority on the subject. A review of functional cleft lip repair provides an overview of the philosophical principles advanced by Delaire for the creation of a normalized functional matrix during cleft lip repair. Common to all three approaches is an emphasis on the importance of careful incision design, adequate muscle repair, and attention to primary repair of the associated nasal deformity. The objective of this section of the text is to provide a review of these contemporary principles relevant to the reconstruction of cleft lip. A detailed understanding of a broad range of surgical techniques from which to choose ultimately will provide the cleft surgeon with the greatest likelihood for success.

PART 1: ROTATION AND ADVANCEMENT FLAP TECHNIQUE FOR UNILATERAL CLEFT LIP REPAIR

KEVIN S. SMITH

The asymmetry of the unilateral cleft lip and palate is a complex, multidimensional deformity. Refinements in the surgical approach for the reconstruction of this congenital defect have evolved over time. The rotation and advancement flap technique for cleft lip repair probably is the most widely used operative procedure for the unilateral cleft lip. This cleft lip repair technique was first introduced in 1955 by Millard.[23] The markings and measurements used for the Millard rotation and advancement flap procedure are straightforward and allow the incorporation of intraoperative adjustments during the operation. With this "trim as you go" technique, superior results are routinely achieved.

The objectives of unilateral cleft lip repair include (1) approximation of cleft edges without loss of natural landmarks, (2) repositioning of the cupid's bow into a normal position, (3) placement of incisions and scar along natural lines, (4) muscle repair and alignment, (5) balancing of the alar bases, and (6) an equal columella bilaterally.[24] In combination, these goals address the asymmetry inherent with both incomplete and complete clefts involving the lip and primary palate. Specific components of orofacial cleft deformities involving the lip and alveolus (primary palate) include (1) a muscle continuity defect, (2) vertical deficiency of the lip on the affected side, (3) deficiency of the nasal structures on the ipsilateral side, (4) lower position of the dome of the nasal ala on the ipsilateral side, (5) possible short columella, and (6) an underlying skeletal deformity characterized by a dental crossbite and poor bony foundation on which the nasal labial structures rest.[25]

Although the use of the Millard rotation and advancement flap technique yields consistently favorable results,

some questions have been posed regarding its limitations when applied to wide, unilateral cleft lip defects. The specific potential pitfall when used in wide cleft defects is that the resultant lip repair is vertically short, with insufficient lateral lip vermilion. Modifications to the Millard technique have been made to address this problem better. These refinements have included inferior cutaneous flaps and the white roll flap, which is a small, triangular interdigitation just above the vermilion.[26,27] These modifications were added because of observations by several surgeons that the rotation was inadequate and that significant whistle-type deformities occurred after basic Millard rotation advancement flap.

Another option in cases of wide cleft lip and palate defects is the use of a lip adhesion procedure as an initial phase of surgery. This is performed early during infancy, and the subsequent, definitive lip repair procedure with a rotation advancement technique is delayed for several months. The lip adhesion involves a simple two-layer (lip skin and mucosa) repair of the lip that converts a wide, complete defect into an incomplete, more-narrow defect over time. In addition to narrowing the cleft gap, a theoretic advantage of the adhesion procedure is the secondary molding of cleft maxillary segments into a more anatomically favorable position before final lip closure and/or palate repair. Some authors prefer the use of presurgical orthopedic devices, such as the Latham appliance, with or without a lip adhesion. This provides more aggressive repositioning of the skeletal elements in the hope of simplifying the lip repair surgery and maximizing esthetic results.[28,29] Although the combination of a lip adhesion and Latham device makes the eventual lip repair more easily performed, a negative effect on subsequent mid-facial growth often occurs. More recently, the use of nasoalveolar molding techniques has grown in popularity. Presurgical nasoalveolar molding is applied to improve the position of maxillary segments and idealize soft tissue contour and position before initial lip and nasal repair. The use of nasoalveolar molding in the cleft lip and palate patient is discussed in greater detail in Chapter 31.

During the 1940s and 1950s, the late Dr. Oscar Asensio of the Hospital Centro Infantil de Estomatologia in Antigua, Guatemala, was simultaneously developing a technique involving a modification of the rotation and advancement flap procedure. Asensio's operation for the repair of the unilateral cleft lip is significant in that it allows for the creation of significant vertical dimension while preserving lateral vermilion.[30] Asensio, an oral and maxillofacial surgeon, described in English his technique for rotation and advancement flap at the American Association of Plastic Surgeons meeting on June 25, 1973.[30] At that time he had operated on more than 548 clefts. In the years before that, Asensio was confronted with a significant number of wide cleft lip malformations not being repaired in Guatemala. His technique proved to be useful in cases in which patients had large defects and the adjuncts of lip adhesion and presurgical orthopedic appliances were not readily available. His son, Dr. Rodolfo Asensio, trained in pediatrics and oral and maxillofacial surgery, continues his father's work in Antigua to this day. Together, both Asensios have repaired more than 3000 clefts. These procedures typically are performed under local anesthesia and sedation.

Presurgical Care

If nasoalveolar molding, lip taping, or pin-retained orthopedic (Latham) treatments are planned, they should be initiated during the second to fourth weeks of life. Impressions are made and used in the fabrication of the appliances. The preferred technique for lip taping is to use a type of occlusive wound care dressing on the skin so that the tape will not touch the skin. The dressing is applied with a skin adhesive, and any lip taping materials are then adhered to the dressing. This ensures minimal skin irritation of the infant during the taping procedures. As with the nasoalveolar molding and Latham-type devices, lip taping is time consuming and relies on compliant parents. Nasoalveolar molding can be accomplished in the wide unilateral cleft lip, and the author's personal experience has revealed that this technique is simpler and less costly than the Latham-type appliance. Another benefit of nasoalveolar molding is that it does not appear to have the negative effect on mid-facial growth observed with the use of the Latham device.

Description of Surgical Procedures

Millard Rotation and Advancement Flap Technique

The rotation and advancement flap technique described by Millard is the most frequently used repair by cleft surgeons worldwide. Most surgeons add their own preferences and modifications to this technique depending on the specific cleft deformity (complete, incomplete, etc.) and individual patient's anatomy.

Figure 29-1 demonstrates the classic anatomic landmarks used in the Millard procedure. Those points are identified to make initial measurements and achieve anatomic alignment of specific soft tissue elements. To preserve maximal soft tissue, initial incisions are followed by paring of tissue elements as the procedure continues.[24]



• **Figure 29-1** Anatomic landmarks used for the Millard and Asensio rotation and advancement flap techniques. Identification of these key points is initially performed; they are the basis of measurements used for flap creation and alignment of soft tissue elements.

Three key technical principles of the Millard rotation and advancement flap procedure are as follows:

1. The rotation of the cleft edge of the noncleft side is the most important principle to understand and perform to obtain adequate vertical height at the cleft philtral ridge. This is accomplished by the measurement between the base of the columella (point 4) and the Cupid's bow on the noncleft side (point 2). This distance equals the total length of the incision made on the cleft edge of the noncleft segment, from point 3 to the base of columella (point Z) and including the back cut (BC). A bent wire is sometimes used to confirm this distance. The wire is used to represent this curvilinear incision with the back cut included (Figure 29-2). Additional height can be obtained in the area of the cleft by making a white roll flap incision at the area of point 3. When used, this usually is a 1- to 2-mm incision to allow increased rotation of the vermilion segment.
2. The vertical height of the lateral lip segment on the cleft side must be developed to a length equal to the rotation segment. If the distance between point 7 and point 8 is insufficient, tissue is pared away laterally in the area of point 8 to increase the vertical dimension until it equals the measured distance on the rotated side. If a white roll flap is to be used at the vermilion border, it should be developed when these cuts are made just above point 7 (area *F* in Figure 29-3). The final incisions are demonstrated in Figure 29-3. The C-flap can be used to create a nasal floor repair or incorporated into the noncleft side to increase the amount of rotation and length.
3. The third principle critical to the Millard procedure is that of muscle dissection and reconstruction. The orbicularis oris must be identified and isolated separately from the overlying skin and mucosa. The muscle should be freed several millimeters into the lip element on either side so that anastomosis of the lip muscle can be accomplished as a distinct layer of the repair (Figure 29-4).

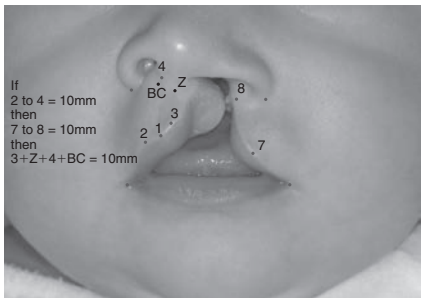

• **Figure 29-2** Markings and measurements used for the Millard-type rotation and advancement flap cleft lip repair. *Points 1, 2,* and *3* represent the outline of Cupid's bow. *Point 4* represents the base of the columella. *Point Z* is the lateral base of the columella on the side of the cleft. *Point BC* represents the extent of the back cut. In measuring for a Millard-type closure, the distance from *points 2 to 4* will equal the curvilinear cut that goes from *points 3 to Z to 4* and then to *BC*. That total distance will also be equivalent to the measurement from *points 7 to 8.*

Intraorally, closure of the wide cleft lip requires the vestibular incision on the cleft side; in wide clefts this incision occasionally must be extended superiorly into the nasal cavity, almost to the point of the inferior turbinate. This tissue has been undermined in the supraperiosteal plane to allow adequate advancement of tissue on the cleft side.

Asensio Technique for Rotation and Advancement Flap

The general principles of this closure for unilateral cleft lip defects are quite similar to the Millard rotation and advancement flap technique. The primary modification made in the Asensio procedure involves the excision of a soft tissue segment from the lateral advancement flap to create additional length while preserving vermilion tissue. The Asensio technique is defined specifically by the initial measurements and markings and requires little refinement once the incisions have been made. Elements of the landmarks, markings, and surgical steps for the Asensio technique are as follows:

1. Anatomic landmarks within the alar base, Cupid's bow, and lip segments are marked on each side (see Figure 29-1) in identical fashion as for the Millard procedure. Landmarks are identified and key white roll points are marked. On the lateral side, the end of the distance from the white roll point at the leading edge of the advancement flap is measured to the commissure for comparison with the contralateral side.

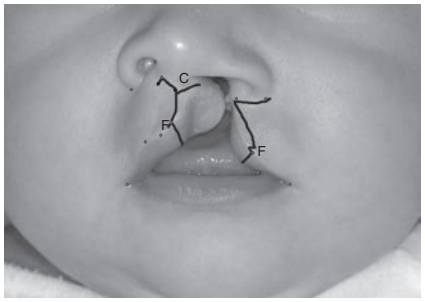

• **Figure 29-3** The final incision design for the Millard-type rotation and advancement flap closure. The C-flap can be placed into the base of the columella or into the nasal sill region. *F* represents possible back cuts for additional lengthening with the use of a white roll flap above the vermilion border.



• **Figure 29-4** Intraoperative view of the lateral advancement flap dissection. The center forceps are holding the well-defined orbicularis oris muscle. Defining and joining the two sides of the muscle is of utmost importance in cleft repair.

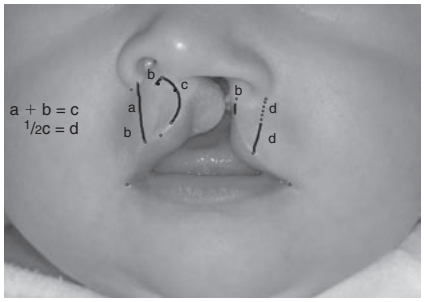

• **Figure 29-5** Measurements and markings for the Asensio technique. Rotation length is again determined by measuring the distance from the alar base to the white roll point on the noncleft lateral Cupid's bow. *Line b* is the back cut distance and *line c* is equal to a ±1 b. One half of *line c* will become the distance of *line d.*

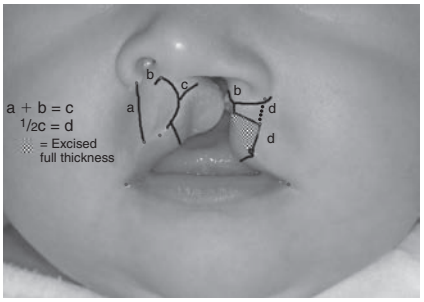

• **Figure 29-6** The final incision design for the Asensio technique (excluding intranasal incisions). The *patterned area* is the area for full-thickness excision. White roll flaps can be included in the design if needed. Note *line a* is not an incision, but rather only one of the original measurements.

2. The distance of the height of the ala to the lip is now measured on the noncleft side. This distance is labeled *distance a* and is called the alar height. Add 1 to 3 mm to *distance a* depending on the size of the patient's lip: 1 mm for an infant, 2 mm for a child, and 3 mm for an adult. This small additional measurement is referred to as *distance b* and is used to calculate the length of the back cut. Next, the addition of *distances a* and *b* equals the length of the incision labeled *distance c* in Figure 29-5. *Distance c* is then measured in a curvilinear manner from the Cupid's bow to the columella and marked. In addition, the *distance b* measurement is added for the back cut. These markings are similar to those used in a Mallard-type rotation advancement.
3. On the lateral lip element, distance of *line c* is then divided in half and used to calculate the length of a new incision *line d.* Putting one point of a compass at the previously marked alar base, an arc is swung using *line d* as the radius. After putting one point of the compass at the end of the white line, another arc is drawn using *d* (½ the length of *c*) as the radius, where these arcs intersect (see Figure 29-5). This establishes the length of the lateral lip after the incisions are created. This ensures that the length of the lateral, advancing lip segment will match the length of the rotation side. After this point has been marked, the quadrilateral flap is drawn, with the width of the leading edge equal to the length of *distance b,* as illustrated in Figure 29-6. The termination of the superior border of the quadrilateral flap goes to the outer edge of the ala. The lower edge of the quadrilateral flap goes to the point where the arcs met. Note that the area shaded in Figure 29-7 represents a full-thickness excision of the lateral lip advancement flap. If a white roll flap is to be used at the vermilion border, it can be developed during the final stages of the procedure.



• **Figure 29-7** The final result of left complete cleft lip repair for the patient seen in Figure 29-6, using an Asensio technique. The photograph was taken 1.5 years after surgery.

Nasal Reshaping

In addition to rotation and advancement flap maneuvers and careful muscle reconstruction, cleft surgeons must address the abnormal position of the lower lateral nasal cartilages in the cleft patient. Once adequate mobilization of the advancement flap has been accomplished, mobilization of the nasal cartilages on the affected side must be performed to release cartilaginous structures from their abnormal attachments to the underlying piriform rim. McComb[31] described lower lateral nasal cartilage lifting during initial cleft lip repair. The technique is relatively simple and involves careful dissection between the lower lateral cartilage and cutaneous elements. These structures may be approached through the columellar and lateral alar incisions. Once the cartilage has been thoroughly dissected free of the skin, intranasal splinting techniques can be used to hold the cartilages in a more normal anatomic position. The technique originally was described using bolsters and sutures and lifting the suture transcutaneously superiorly on the nose with another bolster on the skin.

The author's preferred technique involves the use of silicone nasal formers. They are available in a multitude of

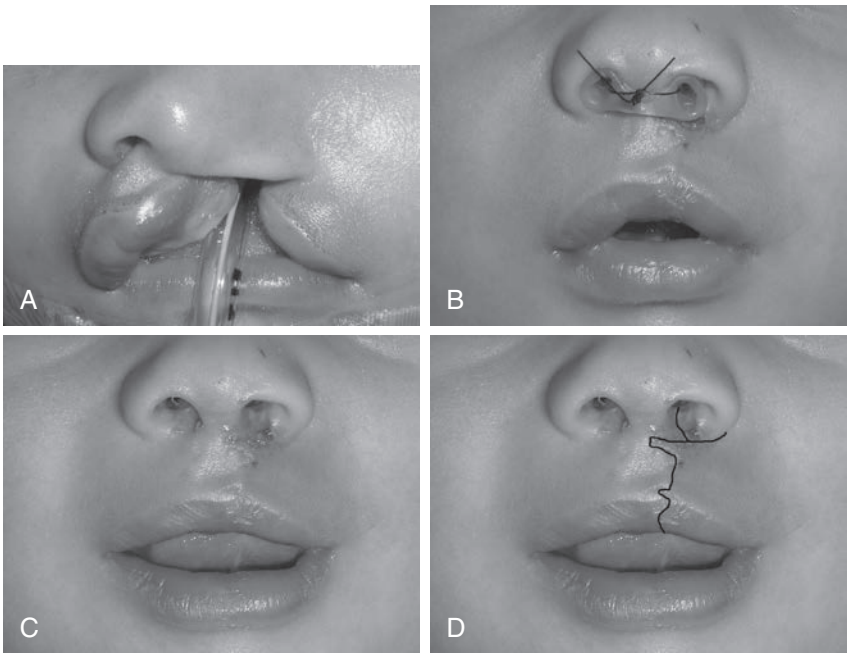

• **Figure 29-8** Clinical photographs of a patient with a wide, unilateral, complete cleft of the lip and palate. Initial lip repair was performed with a rotation and advancement flap procedure with the Asensio technique. **A,** A wide cleft defect before closure. **B,** One week after surgery, the patient shows good healing of the lip closure, and silicone nasal stents are still in place. **C,** Stent removal reveals maintained nostril shape and healing nasal floor. At this stage good symmetry has been achieved. A good wound care regimen, as described in text, is vital. **D,** Line drawing of the Asensio technique incision design used in this patient.

sizes, can be sutured in place, and remain intact during the initial phase of postoperative healing. Care must be taken to observe for wound dehiscence and mucosal ulceration intranasally. The use of silicone nasal molding devices also requires extra care on the part of the family in that the devices need to be cleaned and irrigated on a regular basis with saline and a syringe with a catheter. Infants are obligate nasal breathers, so the nasal stents must be kept free of dried mucus and blood. Nursing staff and parents must understand the proper technique in cleaning these stents before discharge.

Postoperative Care

In addition to nasal bolsters or stents, a lip dressing is applied with skin adhesive lateral to the incisions and ¼-inch sterile tape as a simple coverage for the wound. This taping over the lip segments also provides support for the completed lip repair. If good muscle and subcutaneous closure have been accomplished, a Logan's bow or other device is not necessary. The infant may need to have arm restraints postoperatively, but generally these can be discontinued at 2 weeks. At 1 week after surgery the nasal stents can be removed. The sterile tape dressing over the lip usually lasts 3 to 5 days or can be removed at the first postoperative visit 1 week after surgery. Any minor scabbing present can be removed with dilute hydrogen peroxide for daily wound care over the course of the next week. In addition petroleum jelly can be applied to the wound to help soften any scabbing.

At postoperative week 2, definitive wound care must begin. This wound care regimen can include massage with vitamin E oil with a two-finger technique, in which one finger is placed inside the lip and one finger is outside, as much as the infant can tolerate. Once the vitamin E oil has been massaged into the skin, a silicone gel material is placed over the wound. This is accomplished twice a day with gentle cleaning with mild baby soap before the massages. This twice-daily regimen should be continued for 4 months.

Summary

The rotation and advancement flap technique remains the most popular surgical approach for the repair of the unilateral cleft lip deformity (Figures 29-8 and 29-9). The principles as described by Millard are easily applied and allow modification of the lip repair procedure depending on specific patient anatomy and the configuration of the cleft defect.

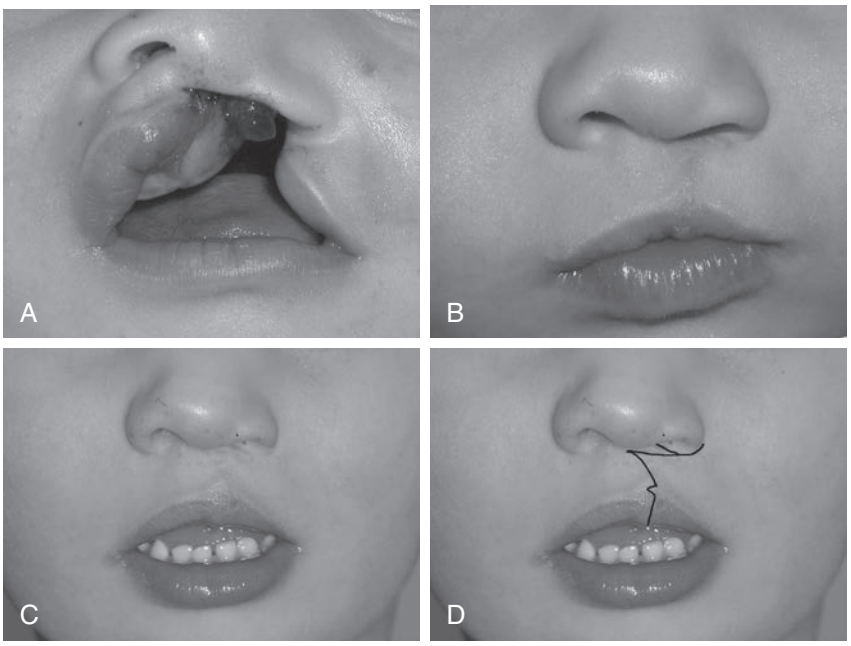

• **Figure 29-9** Clinical photographs of a patient with a wide, unilateral, complete cleft of the lip and palate. Initial lip repair was performed with a Millard rotation and advancement flap procedure. **A,** A wide cleft defect before closure using the Millard rotation and advancement flap technique. Note the presence of a natal tooth within the cleft. **B,** Six-month postoperative result for the Millard-type cleft repair; the family was diligent in postoperative wound care, massage, and the use of silicone scar gel. **C,** Eighteen-month postoperative results. Note increased nasal asymmetry and some elevation of the vermilion. Child may require minor revision of the nose and vermilion around school age. **D,** Line drawings of the Millard technique used in this patient.

PART 2: SURGICAL CORRECTION OF UNILATERAL CLEFT LIP WITH TENNISON—RANDALL TRIANGULAR FLAP TECHNIQUE

RAFAEL RUIZ-RODRIGUEZ

The management and specific surgical technique used for the correction of the unilateral cleft lip deformity remains a controversial topic among cleft surgeons. Several different operative techniques are used, each with distinct theoretic advantages when compared with the others. The evolution of most techniques began with an ancestral straight-line closure.[32] Later, a quadrangular flap technique was described by Hagedorn and modified by Le Mesurier.[33-35] These prominent pioneers were trying to build an artificial Cupid's bow through the insertion of a quadrangular flap inside the philtrum.

Two techniques described during the mid-twentieth century remain popular choices for cleft lip repair today. In 1952 Tennison[36] described a triangular flap technique that was subsequently modified by Randall and Hagerty in 1958.[37,38] In 1957 Millard described a rotation advancement flap technique.[39] Common to all these techniques were two primary goals: (1) the preservation of anatomic structures present, even in the deformed lip, and (2) anatomic repositioning of lip segments into a more natural position. For example, the Cupid's bow is present but is displaced toward the noncleft side and rotated superiorly into a position that is oblique to the horizontal facial plane. Worldwide, a majority of surgeons use one of these two popular techniques, often with specific modifications based on the reconstructive needs of the patient and surgeon preference.

In 1952 Tennison[36] described his stencil method, in which he "preserved" the Cupid's bow and used a segment of wire to develop the surgical measurements. In the same year Cardosa[40] emphasized Tennison's main idea, which was the preservation of the Cupid's bow. He also recommended the use of a caliper instead of a wire. This idea was supported by Randall, Hagerty, and Cronin, each of them making some small and personal modifications.[37,38,41]

In contemporary practice, most experienced cleft surgeons would likely agree that the key to a successful cleft lip repair is the management of the Cupid's bow. The principles and objectives of cleft lip repair rely on the fact that the philtrum is abnormally displaced from the midline (Figure 29-10) and that the Cupid's bow is rotated superiorly, sometimes almost perpendicular to the horizontal plane. In crafting the surgical technique, the adequate mobilization of the philtrum toward the midline and the downward rotation of the Cupid's bow must be considered (Figure 29-11). In this manner, a normal lip is created in both vertical and horizontal dimensions.

When considering surgical maneuvers aimed at lowering the vertical position of the Cupid's bow, an incision within the philtrum provides adequate inferior rotation of the highest point of the bow (peak of the bow on the cleft side of the lip) to establish normal position. This incision creates a soft tissue

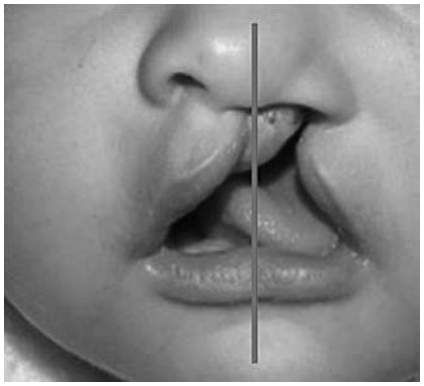

• **Figure 29-10** An unrepaired, left, complete unilateral cleft lip deformity. Note the significant displacement of the philtrum away from the midsagittal plane. The Cupid's bow is asymmetric and rotated superiorly on the cleft side. The degree of superior malposition can be so severe that the Cupid's bow is almost perpendicular to the horizontal plane.

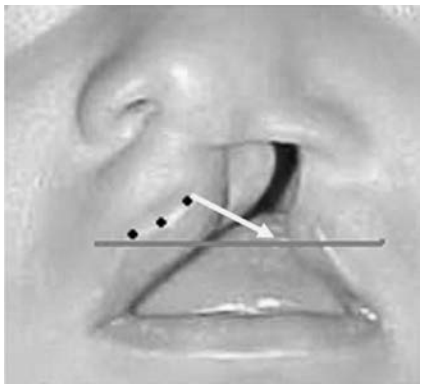

• **Figure 29-11** A successful surgical repair must reposition the Cupid's bow inferiorly and toward the midline.



• **Figure 29-12** The Tennison procedure uses an incision from the mucocutaneous junction, along the white roll, to the middle of the philtrum to carry out downward rotation of the Cupid's bow.



• **Figure 29-13** In the Millard rotation and advancement flap procedure, a curved vertical incision is created from the base of the columella to the mucocutaneous junction. This creates downward rotation of the entire central lip.

space or defect that must be filled with a soft tissue flap from the advanced lateral segment. Tennison's technique accomplishes this goal by making a perpendicular incision along the white roll from the mucocutaneous junction to the middle part of the philtrum. The resultant defect is then occupied by a triangular flap from the lateral segment (triangular flap technique) (Figure 29-12). In contrast, the Millard rotation and advancement flap technique achieves the necessary inferior rotation of the central lip by creating a curved incision from the base of the columella down to the mucocutaneous junction, filling the space with the leading edge of the lateral lip segment. The procedure is given its name because of the downward rotation of the central lip to create adequate vertical length and advancement of the lateral flap to close the defect (Figure 29-13).

Tennison Technique versus Millard Rotation and Advancement Flap for the Correction of Unilateral Cleft Lip

The Tennison technique has a number of advantages, but the most important one is the versatility of the procedure, which may be applied for the repair of a broad range of clefts from incomplete to wide complete deformities. It is the author's point of view that a Millard rotation and advancement flap procedure, in cases of wide clefts with severe rotation of the Cupid's bow peak, does not permit enough downward rotation of the peak. This results in a deficient vertical lip length on the affected side. This is also the reason why Millard described his Millard II technique, in which he added modifications that included a back-cut incision at the base of the columella, allowing more downward rotation of the Cupid's bow.[42-44] In addition, Millard's technique could leave a long, straight scar from the base of the columella to the white roll, which can develop an undesirable vertical retraction, making the lip even shorter. Another disadvantage is the creation of a nostril that is smaller than the normal side. The main use of the Millard technique at our center is for more-narrow cleft defects in which a large downward rotation of the peak is not required.

One challenging aspect of the Tennison operation is the highly technique-sensitive design that requires precise measurements at the beginning of the procedure and allows little deviation intraoperatively. This is in sharp contrast to the Millard technique, which actually permits modifications during surgery. In fact, surgeons may believe that there is a point of no return during the Tennison operation in which no modifications of the original design can be made. Therefore a miscalculation during the initial design can lead to poor results in the end: a lip that is either too short or too long. This problem mostly occurs as a result of

inappropriate planning and an incorrect design rather than a poor technique.

Most surgeons who do not routinely use the Tennison procedure cite the unfavorable position of an incision that invades the philtrum with the triangular flap. This undesirable component of the Tennison repair may be minimized by modifying portions of the incision over the philtrum. Despite this concern, the Tennison technique allows repair of large cleft malformations quite easily. In wide cleft defects, a large amount of downward rotation of the Cupid's bow peak is required. If a Millard procedure is used for the repair of a wide cleft, many surgeons suggest performing a lip adhesion before attempting the definitive repair. In this manner, a complete wide cleft initially is converted into an incomplete cleft. This additional surgical step does not necessarily help the patient's esthetics or feeding, and it requires an additional general anesthetic exposure. In these cases, the cleft can be nicely repaired by the Tennison technique, with acceptable results in the majority of the cases.

Surgical Planning and Markings

Surgical repair typically is undertaken when the patient is approximately 10 weeks old. The procedure is performed under general anesthesia with oral endotracheal intubation. The first consideration is placing the endotracheal tube in the midline in a rest position to avoid any lip displacement toward one side, which might lead to inaccuracies in the design. Once the endotracheal tube and the patient's head are secure, the surgeon is positioned at the head of the operating table. A fine surgical skin marker is used to mark the selected anatomic landmarks carefully on the cleft side of the defect; these landmarks are illustrated in Figure 29-14 and listed in Table 29-1.

In the original description by Tennison, a measurement was made from the commissure of the lips to the peak of the Cupid's bow on the normal side. This measurement was then directly transferred to the cleft side. This maneuver generally is avoided now because the deviated, abnormal position of the philtrum distorts this measurement, and its use is likely to result in an incorrect horizontal length for the repaired lip on the cleft side.

The landmarks on the noncleft side are initially marked, and some are then used to measure and transfer markings onto the cleft side. After these measurements are transferred, the incisions are designed. A horizontal incision within the philtral region and a triangular flap within the lateral segment are then designed (Figure 29-15). This is done by creating a straight line from the base of the columella on the cleft side to the peak of Cupid's bow; a back cut is then created that extends into the philtrum. Calipers are used to measure the vertical and horizontal components of this line, and the dimensions are used to craft the triangular flap on the lateral lip segment. Although the sequence of markings and measurements used are different from previous descriptions, the author believes this sequence allows an easier understanding of the procedure. In addition, proper closure of the nasal sill requires that the incisions described be extended along the inside of the nose to the septum on the medial side and up to the lower turbinate mucosa on the lateral side. These incisions ultimately are used in combination with vestibular-releasing

TABLE 29-1 Anatomic Landmarks

Landmark	Location
1	Lowest (central) point on the Cupid's bow
2	Peak of Cupid's bow on the noncleft side
3	Base of the ala on both sides
4	Base of the columella on both sides
5	Specific white roll point on the cleft side, where the vermilion begins to diminish; represents the peak of Cupid's bow

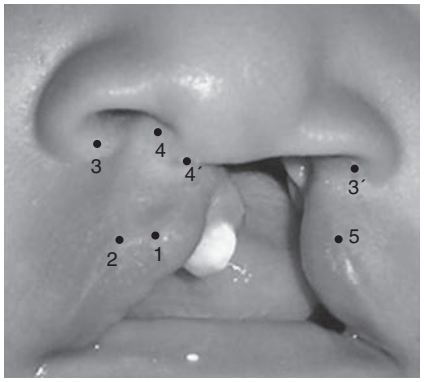

• **Figure 29-14** Initial identification of key anatomic landmarks used in the repair of the unilateral cleft lip and nasal deformity. Points include the center of Cupid's bow (marked *1*), peak of Cupid's bow on the noncleft side (marked *2*), alar bases (marked *3*), base of columella (marked *4*), and peak of Cupid's bow on the lateral cleft side (marked *5*).

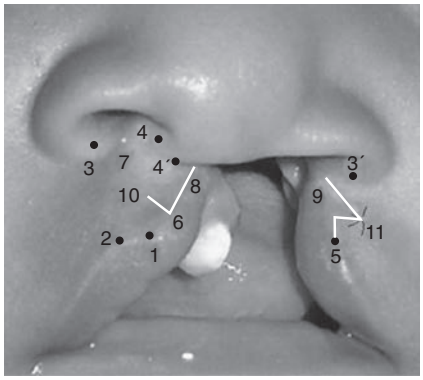

• **Figure 29-15** Incision design for the Tennison technique. A *straight line* is marked from *points 8 to 6*. From the junction of this line with the white roll, a horizontal line will be extended within the philtrum. This will end at landmark *10*. To determine how long this incision will be, the distance between landmarks *7* and *2* and *8* to *6* must be measured. The difference between those two measurements determines the incision length inside the philtrum. Calipers are used to measure the distance from *points 6 to 10*; by placing the tip of the caliper on *point 5*, an equilateral triangle will be created on the lateral side.

incisions to allow adequate mobilization of the anatomic structures and release of cartilaginous and soft tissue structures from abnormal bony insertions (Figure 29-16).

To achieve good surgical results, we must consider the severity of the cleft as well as the deviation from normal of all the anatomic structures that form the lip, such as the nasal mucosa excess and the depressed paranasal area from the misalignment of the maxillary process (Figure 29-17).

Surgical Technique

After the incision design is finalized (Figure 29-18), the borders of the cleft and the maxillary vestibule are injected with 0.5% of lidocaine with 1:100,000 epinephrine. The author recommends that the surgeon never inject before designing the repair because the infiltration of anesthetic fluid distorts the anatomy of the cleft.



• **Figure 29-16** Continuation of the incisions along the base of the nose, septal mucosa, and mucosa of the lower turbinate. In addition, vestibular releasing incisions allow adequate mobilization and repositioning of lip segments.

The author's preferred approach is to begin with the vestibular and nasal sill incisions on the medial side of the cleft defect and then proceed outward toward the skin incisions. Supraperiosteal dissection is carried out, followed by the creation of incisions on the skin of the medial side. The author strongly recommends starting on the medial side of the cleft defect because the extent of lowering and position of Cupid's bow can be evaluated and modifications to the original design can still be made. If modifications are required, the incision from points 6 to 10 can be made larger or smaller, and the size of the triangular flap from the lateral side can be modified as well. The initial dissection is carried out to create the floor of the nose. The skin incisions are started with a No. 15 blade and completed with a No. 11 blade (Figure 29-19).

After the initial incisions are created, dissection along the medial aspect of the cleft is undertaken (Figure 29-20). This involves dissection of the muscle from its abnormal insertions at the anterior nasal spine up to the tip of the nose, careful not to touch the nasal cartilage. Damage of the cartilages at this age will produce a lack in growth. The muscle will be dissected off from the labial mucosa as well as from the skin to avoid tension at the time of suturing. The muscle is removed by sharp dissection because no fascia layer is at this level and the main goal is to reorient the muscle to create a normal function and mimic the lip. After the muscle is

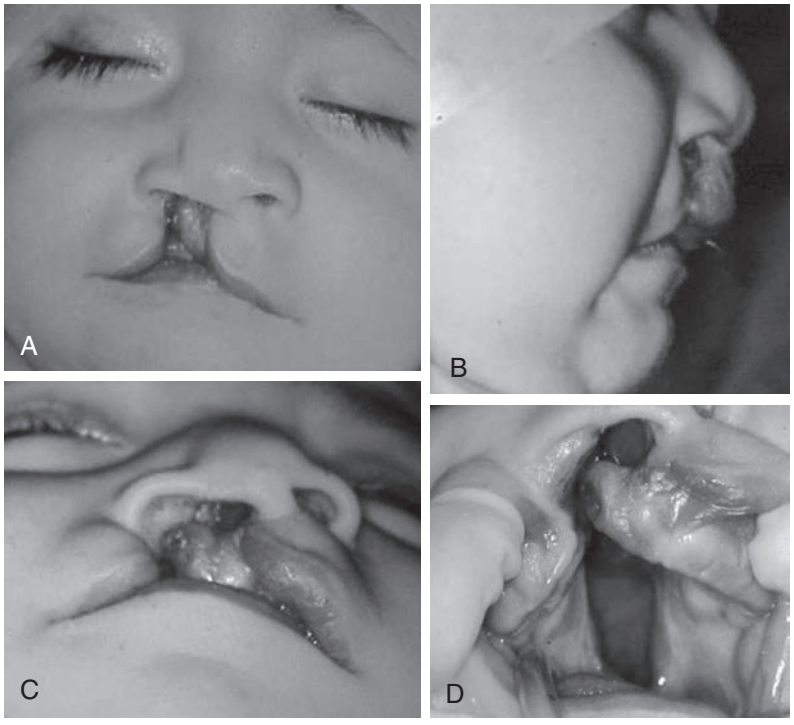

• **Figure 29-17** An infant with a right-sided complete cleft lip and palate. **A,** Frontal view. **B,** Profile view. **C,** Worm's eye view. **D,** Intraoral view. Note the deviation of Cupid's bow. In addition, the 3D malformation includes malpositioned skeletal segments, excess nasal mucosa, asymmetry of the paranasal regions, and abnormal insertions of soft tissue structures on the piriform rim.

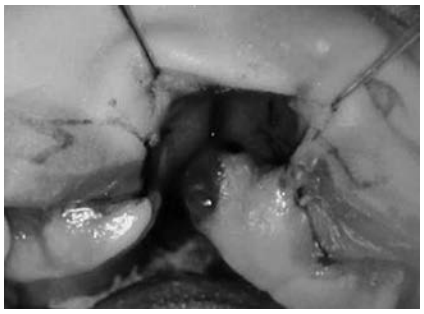

• **Figure 29-18** Markings for the repair of a right unilateral cleft lip. Measurements and incision design are finalized before anesthetic containing vasoconstrictor is administered.

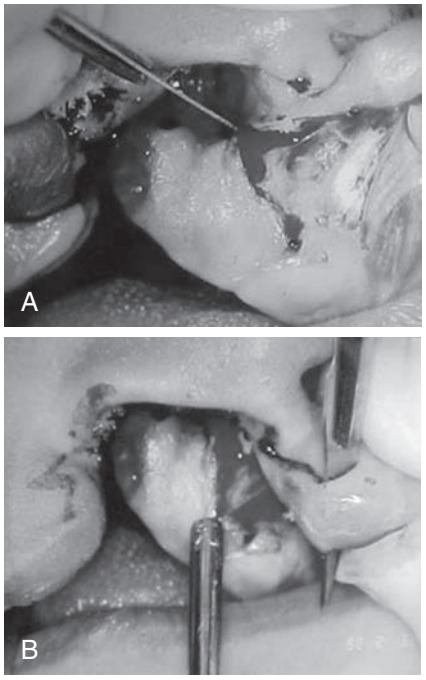

• **Figure 29-19** Initial incisions and dissection are focused on the medial aspect of the cleft defect. **A,** Skin incisions are started with a no. 15 blade and completed with a no. 11 blade (**B**). Care is taken to bevel the blade toward the midline to preserve as much usable tissue as possible.

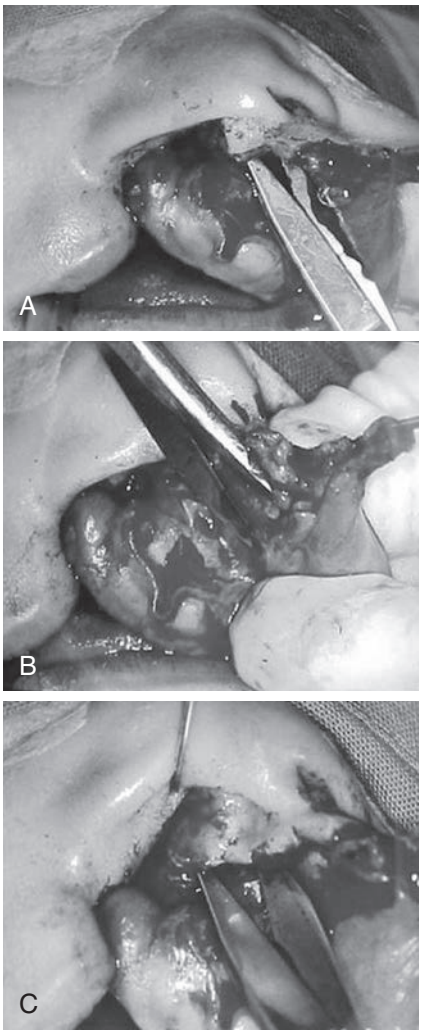

• **Figure 29-20** Dissection of the medial side of the cleft defect with a Tennison technique. A, Separation of the muscle from the overlying skin and labial mucosa. **B,** Sharp dissection to free the orbicularis oris muscle so that normal muscle orientation can be established. **C,** Dissection along the septal mucosa. Meticulous care is taken to avoid damaging the septal cartilage.

completely freed, dissection of the mucosa from the septum will take place, with the surgeon being aware of the high risk of damaging the septum cartilage if a deep dissection in that area is made.

After initial dissection of the medial side is complete, the lateral side incisions are created. On the lateral side supraperiosteal dissection from the sulcus up to the lower turbinate is carried out. The lip is freed and displaced toward the midline. The dissection of the muscle is continued from its abnormal position at the base of the ala to a more normal orientation. Next, the alar cartilage is freed from the nasal skin and from the nasal mucosa to allow it to conform in its new position (Figure 29-21). Better results are obtained by using a silicon conforming splint within the operated nostril during the healing phase. Once the dissection inside the nose is completed, the nasal floor is evaluated and approximated to obtain closure without tension (Figure 29-22). A final check of all the components of the repair, including adequate downward rotation of the Cupid's bow, mobilization of the lip toward the midline, and symmetry of the nostrils, is performed.

Closure of the lip and nasal components is then carried out (Figure 29-23). Suturing the floor of the nose as posterior as possible is performed with 4-0 Vicryl (Ethicon, Inc., New Brunswick, NJ). The muscle is sutured next with 4-0 or 5-0 Vicryl sutures, depending on the width of the cleft and the tension that could exist. Careful suturing is performed while placing the muscles oriented in a horizontal position. Next, "key sutures" of the skin are placed with 6-0 nylon. These anatomic landmarks include the corner of the triangular flap and the white roll points. The remainder of the closure is completed with 6-0 or 7-0 nylon on the skin and 5-0 chromic gut at the end the vermilion border and oral mucosa.

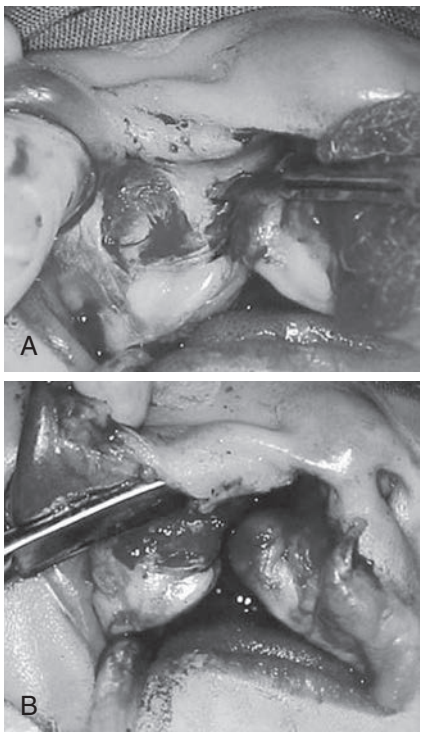

• **Figure 29-21** Lateral dissection. **A,** Vestibular incisions are made and dissection is carried out along the base of the nose and lower turbinate mucosa. **B,** Alar cartilage is freed from nasal skin, mucosa, and abnormal bony insertions.



• **Figure 29-22** Evaluation of the nasal floor before closure.

Summary

Although the Tennison technique remains popular in Asia, Europe, and Latin America, few surgeons in United States are in favor of this useful procedure. The most common complaint associated with the Tennison repair is related to the creation of an incision that invades the philtrum with the triangular flap. At the author's institution, more than 25 years of surgical experience has demonstrated that both techniques, with or without modification, offer distinct advantages and some disadvantages (Figure 29-24). A critical analysis of results must include evaluation of the following: (1) the proper horizontal repositioning of Cupid's bow, (2) symmetry of the nostril and alar base, (3) labial tubercle on midline and a vermilion border with proper fullness, (4) adequate lip length and symmetry, (5) proper nasolabial angle, (6) adequate paranasal fullness, (7) adequate labial projection, and (8) good projection of the nasal tip. Application of the Tennison technique gives the surgeon an opportunity to achieve each of these outcome objectives.

An interesting observation is the fact that surgeons who are familiar with the rotation and advancement flap technique often are unfamiliar with the technical details and potential applications of the triangular flap technique. In contrast, surgeons who routinely choose the Tennison approach as their first choice in repairing wide cleft defects usually are quite familiar with the Millard procedure and often apply it for smaller facial clefts. The author believes a working knowledge of both procedures gives the cleft surgeon the flexibility of selecting the best operative treatment for each patient based on the specific cleft malformation.

PART 3: FUNCTIONAL CLEFT LIP REPAIR

BRUCE B. HORSWELL AND IMAD E. SHAMI

Functional cleft lip and nasal repair is a concept of reconstruction based on basic anatomic and developmental arrangements, which in the orofacial region are key for normal growth, function, and appearance. The application of this concept for the surgical repair of orofacial clefts was first proposed and subsequently investigated by Delaire et al.[45-50] over the course of almost 3 decades. They noted that a cleft of the labiomaxillary region disrupted important functional musculoaponeurotic fields beginning in early fetal development and that this disruption exerted maladaptive influences on associated cartilaginous and skeletal structures. The observations of many clinicians point to the deleterious effects of muscular disinsertions around the cleft and the necessity for total muscular reorientation at the time of primary cheilorhinoplasty to provide a normal functional matrix from which proper form and development can take place, as proposed by Moss.[51]

The facial anatomic field concept, which derives from basic embryologic units and determines the consequent maldevelopment in the cleft deformity, is well articulated by Carstens[52] and Schendel.[50] In essence, clusters of programmed neuromeric cells may be adversely affected by an event in utero (e.g., hypoxia), resulting in a deficient state of cells (reduced numbers or volume) or giving rise to misprogrammed cells that do not participate normally in subsequent cellular differentiation and lead to the development of a cleft. This translates into disrupted and displaced tissue elements within the orofacial region—principally the developing muscle envelope around the nasal, lip, and palatal regions. Underlying skeletal structures follow suit and become displaced and hypoplastic. Muscle function is stimulatory to the underlying bone, and if proper muscle reconstruction is not undertaken the piriform rim, nasal floor, and anterior maxilla remain deformed and hypoplastic. The disrupted muscular envelope and individual muscles must

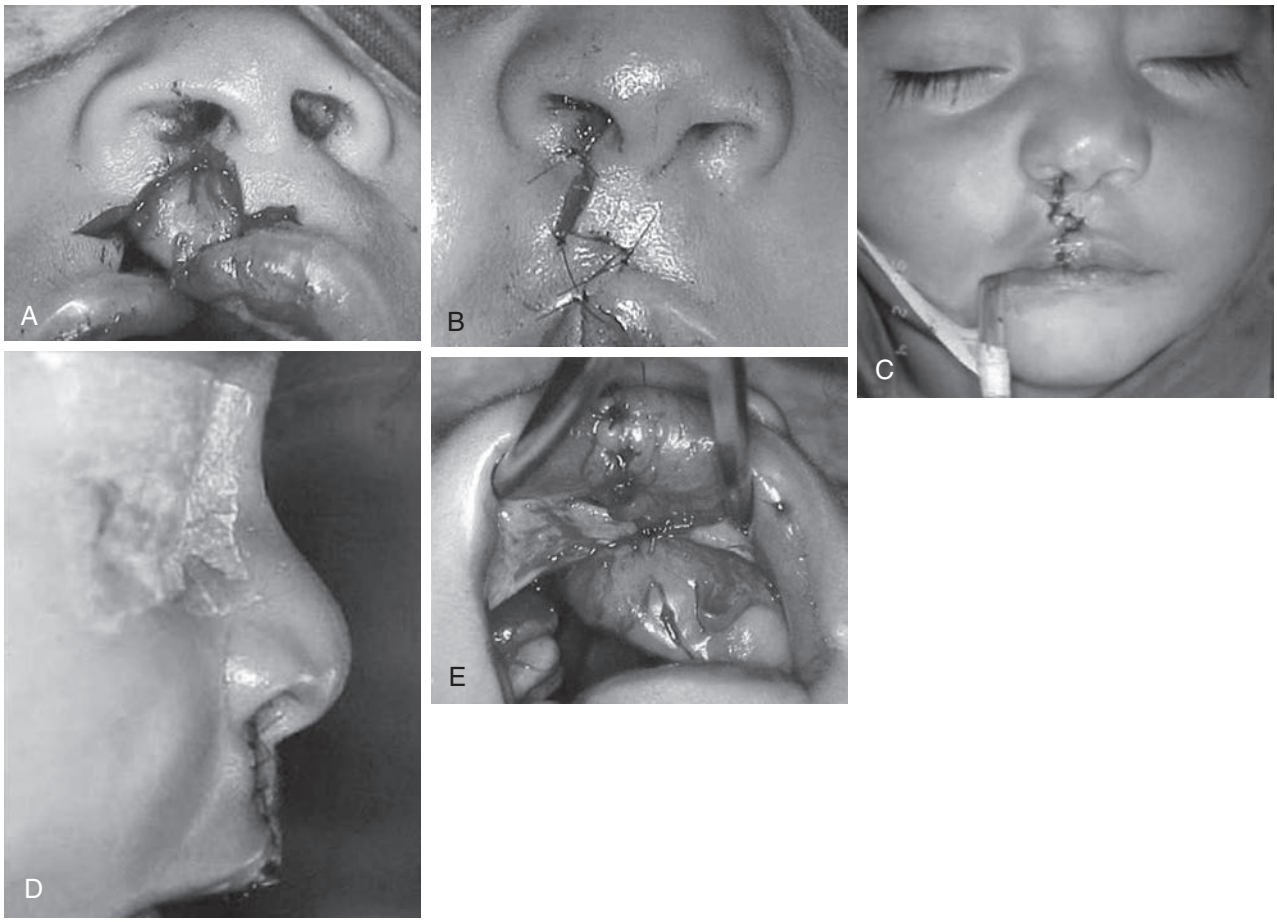

• **Figure 29-23** Closure of the lip and nose. **A,** Preliminary suture to evaluate the nostril and nasal base. **B,** Initial sutures at key anatomic landmarks. **C** and **D,** Frontal and profile views of the final closure. **E,** Closure of the vestibule and lip mucosa.

be identified, mobilized, and properly reoriented in repair to provide a functional matrix environment—hence the term functional matrix repair.[52]

Cleft Model and Repair

Delaire et al.[45-50] have described the orofacial musculature as being arranged in circumferential musculoaponeurotic slings or sphincters around the nose and oral cavity. The disrupted and displaced muscles are schematically demonstrated in Figure 29-25.

Each of these muscles is joined to its counterpart through aponeurotic attachments or indirectly by the *orbicularis* outer sleeve. In the cleft condition, the transversalis and levator (alaeque and labii) heads are disinserted superiolaterally. This results in the elongated, thinned, and slumped ala of the nose and abnormal retraction of the lip segment (Figure 29-26).[53] At the perioral region, the orbicularis muscle takes an oblique lateral course, which is accentuated in the cleft condition.[54] It further displaces the musculoaponeurotic layer inferoposteriorly because nothing tethers it to its counterpart in the sling. As a result, the facial midsagittal and transverse axis are deviated to the noncleft side. Such distortion is difficult to overcome unless complete muscle mobilization and proper alignment take place at the primary repair. A nonfunctional repair, as noted in Figure 29-27, does not eliminate the influence of abnormal muscular position on subsequent skeletal development. The result is disruption of normal lip and nasal alar growth. The 3D computed tomography scan reveals associated skeletal dysmorphology involving the hypoplastic piriform rim on the affected side.

In concert with proper muscle repair, the lower lateral cartilage on the cleft side must be freed through selective dissection to allow the soft tissue repair to rearrange the cartilaginous elements. This occurs as the reconstructed muscular sling (principally the levators and transversalis) brings with it the overlying and underlying nasal and vestibular skin, respectively.[53] Muscular contraction (levators, transversalis), constriction (deep orbicularis), and depressor action (myrtiformis) further enhance soft tissue development and form.[55] In fact, Park and Ha[54] emphasize the necessity of proper orbicularis sleeve microdissection and reorientation for the lip to achieve fullness in form and natural function. Bony stimulation and deposition take place when under the positive muscular influences, which results in a more balanced and symmetric skeleton.[55,56]



• **Figure 29-24** Clinical photographs of children before and after undergoing unilateral cleft lip repair with the Tennison technique.

Principles of Functional Repair

Carstens[52] comprehensively defines the principles of a functional matrix repair as postulated by Delaire. They are summarized as follows:

1. Understand the embryologic facial developmental fields and units that give rise to lip, nasal, and maxillary structures.
2. Maintain vascular pedicles to the columella, nasal, and musculoperiosteal envelope through subperiosteal dissection.
3. Identify and correct pathologic muscular displacements and distortions.
4. Realign muscles to their proper insertions or counterparts and hold them there.
5. Attempt to remove abnormal vectors of force on the soft tissue envelope and underlying skeleton.

Lip Incisions

The technique of functional cleft repair is described in the next section. Refer to Figure 29-28 for cutaneous lip and nasal incisions. Several popular skin incision techniques may be used through which access to the underlying musculoaponeurotic units can be gained; however, many surgeons favor modifications of the rotation advancement

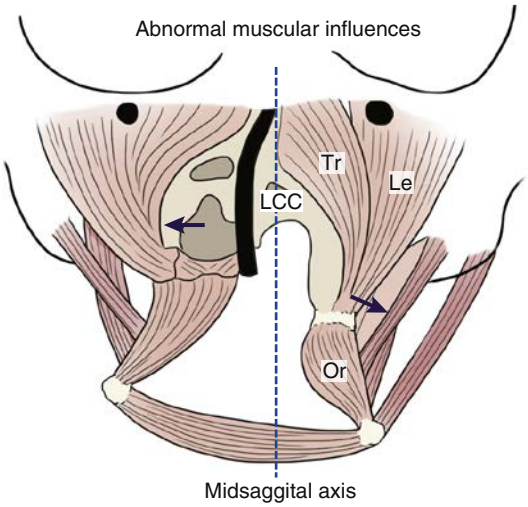

• **Figure 29-25** Schematic of muscles in a cleft model that demonstrates the abnormal position and influence of the disrupted musculoaponeurosis. *Arrows* indicate the muscle pull on the nasal septum and ala with consequent distortion. *Tr*, Transversalis; *Le*, levator; *Or,* orbicularis; *LLC,* lower lateral cartilage. *Dotted line,* Midsagittal axis.

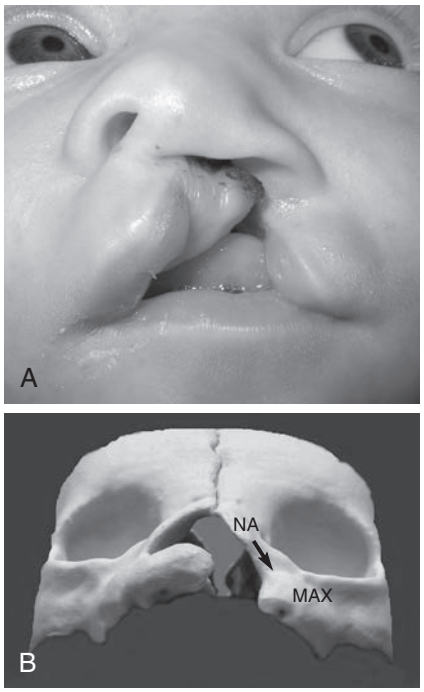

• **Figure 29-26** **A,** Newborn demonstrating distortion of facial structures by the underlying disrupted muscles. **B,** Model of cleft in newborn demonstrating hypoplasia and distortion of bony skeleton in direction of *arrow. NA,* Nasal bone; *MAX*, maxilla.

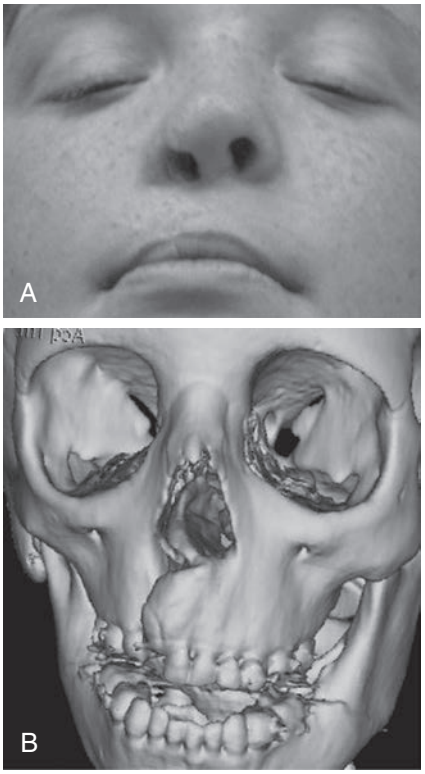

• **Figure 29-27** **A,** Seven-year-old with nonfunctional repair and resultant facial distortion and cleft-sided (patient's right) hypoplasia. **B,** 3D computed tomographic reconstruction of 7-year-old demonstrating bony hypoplasia on the cleft side.

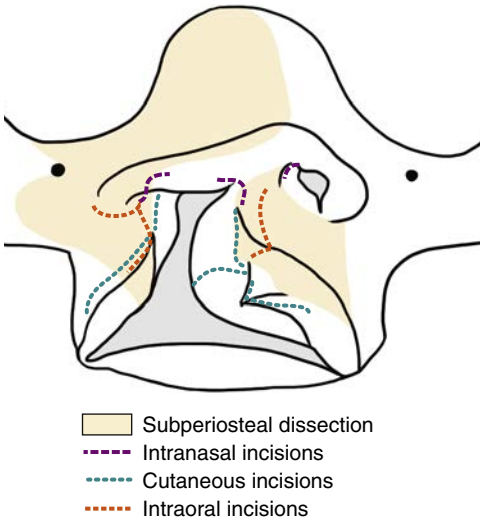

• **Figure 29-28** Schematic of cutaneous and intranasal, and intraoral incisions.

approach,[57] as does this author. Incisions into the oral cavity, principally on the buccal vestibule, and intranasally must respect vascular pathways. To preserve blood supply to the maxillary vestibular mucosa and underlying periosteum, the incision carried along the alveolar segment should remain on the alveolus but away from dental follicles. In the medial nose, the external lip incision should not create a back cut across the columella skin to maintain the small nasal twigs, the terminal branches of the anterior ethmoid arteries. The incision then runs superior and posterior to the columella skin just caudal to the medial crus of the lower lateral cartilage. This affords access to the intermediate crus and lower dome for dissection from their soft tissue envelope.

The cleft lip segment incision (advancement side) runs superiorly from a point on the white roll that corresponds

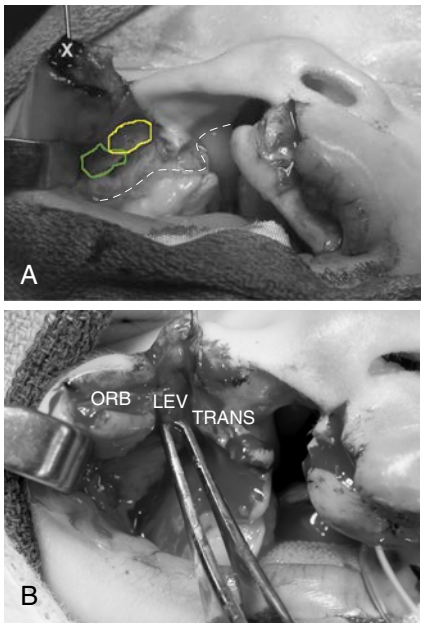

• **Figure 29-29** Intraoperative photo of muscle dissection, identification, and mobilization. Note subperiosteal dissection deep to the musculoaponeurotic layer. **A,** Initial dissection. *Yellow circle,* Transversalis; *green circle,* levators; *dotted line,* intraoral incision extended over inferior turbinate; *X,* inferior orbicularis. **B,** Forceps is tugging on levators to confirm insertion. *Lev,* Levators; *Orb,* orbicularis; *Trans,* transversalis.

in location and length to the prolabial segment. As this incision approaches the fixed ala intranasally, it runs up and over the inferior turbinate to create an adequate advancement of the nostril floor. Through this incision and in a subperiosteal plane, the entire musculoaponeurotic field (including its component levators and transversalis, as shown in Figure 29-29) can be mobilized and repositioned. Subperiosteal dissection preserves the vascular supply to the muscular components. A circumalar, transverse incision at the nasal base to create adequate mobility of the lateral nasal segment often is not necessary. If performed, this incision should be conservative to preserve the natural ala-lip junction.

Nasal Dissection

An important component of functional repair is correction of the nasal cartilaginous displacement and distortion. The muscular base around (levators and upper transversalis) and under (transversalis nasalis, myrtiformis or depressor nasii) the ala contributes to lower nasal form and development. The lower lateral cartilage requires dissection from its soft tissue envelope with proper repositioning. This key component of primary cleft nasal repair was first advocated and successfully confirmed by McComb[14] and later corroborated by others[58-60] as being a safe and necessary procedure during primary repair to address the nasal deformity.

Access to all the lower cartilage is gained through the columellar base on the prolabial segment and laterally through the advancement incision. Small, curved tenotomy scissors gently introduced under the skin and hugging the crura

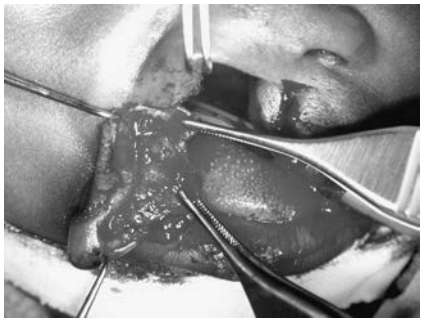

• **Figure 29-30** Intraoperative photo of muscle bundle identification (transversalis) with traction to confirm muscle insertion for proper repositioning.

allow skin dissection. Great care is necessary to avoid incising the cartilage or piercing the skin. The domal cartilage can be accessed through both the medial columellar and lateral ala incisions. If necessary, a small infracartilaginous incision inside the rim can be performed for more complete domal access and dissection. Lastly, to accommodate narrowing of the nasal tip and coaptation of the medial crura, small stab incisions in the vestibular mucosa can be made through which a horizontal mattress (through-and-through) suture can be passed in a buried fashion.

Closure

Once dissection is completed, soft tissue closure may begin. Muscle repair requires identification of each component by careful microdissection into the soft tissue. Haphazard muscle bundles initially are encountered, but after several millimeters the muscle heads can be identified and confirmed by traction—a dimpling of the overlying skin signals that the appropriate muscle component is grasped (Figure 29-30). The first muscle sling is the nasal floor component of myrtiformis and transversalis nasalis, which are approximated with one or two horizontal mattress sutures (4-0 or 5-0 permanent or slow-absorbing suture) secured to the contralateral area in the anterior nasal spine. The levator heads are then sutured across and on top of the nasal spine region; this will result in slight overcorrection and narrowing of the nostril sill but will resist the tendency of tissue memory relapse (Figure 29-31). Final muscle repair involves overlapping the orbicularis sleeves and placing everting sutures to recreate a philtral ridge. When proper muscle repositioning is accomplished, the skin and mucosa follow. The subdermal layer is coapted with 5-0 horizontal mattress sutures. Simple 5-0 or 6-0 fast gut sutures or tissue glue (cyanoacrylate) can be applied to obtain a very fine closure. Wound support tapes are placed for several weeks. The initial overcorrection and "pout" obtained with thorough muscular repair eventually assumes a more natural form under animation and time and results in a balanced lip and nose.

To facilitate nasal form, nostril stents are placed using either red rubber catheters fashioned to nostril size or commercially available soft Silastic stents (Dow Corning

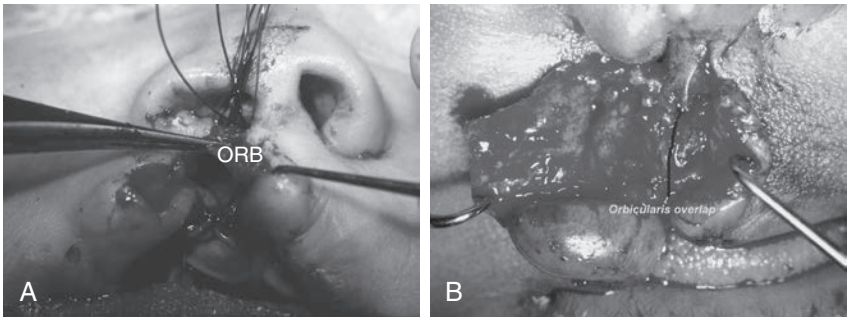

• **Figure 29-31** **A,** Muscle repair in midline on the anterior nasal spine with orbicularis *(ORB)* sleeve dissection. **B,** Orbicularis overlap with schematic horizontal mattress sutures placed to indicate overcorrection to recreate the philtral margin and lip fullness.



• **Figure 29-32** Nostril stents (soft anatomic forms) custom fit for the nasal aperture are placed and secured by bolsters. Note the wound support tapes under the bolsters to avoid pressure necrosis and assist in lip support.

Corp., Midland, MI). The author prefers to use anatomically fashioned stents that are then sutured over supportive bolsters (petrolatum gauze) at the nasal tip and septum (Figure 29-32). Two to three layers of support tape are placed on the skin to protect it from pressure necrosis under the bolsters, which are removed at 2 weeks. The stents are maintained either through septal sutures for another 4 weeks or worn passively and taped in place. Figures 29-33, 29-34, and 29-35 illustrate preoperative unilateral cleft lip and palate cases and postoperative results after functional repair and before any secondary procedures.

Review of Studies Examining Functional Repair

Moss[52] first advanced the concepts of facial form and development based on functional matrices. He described anatomic models that gave rise to developmental tissue fields representing future facial structures. The clinical benefits of cleft reconstruction based on the embryologic development of facial elements were initially advanced by Delaire et al.[45,46,48,49] He and others performed functional cheilorhinoplasty based on developmental anatomy and described subsequent facial growth and development over time. [49,50,53,55,61]

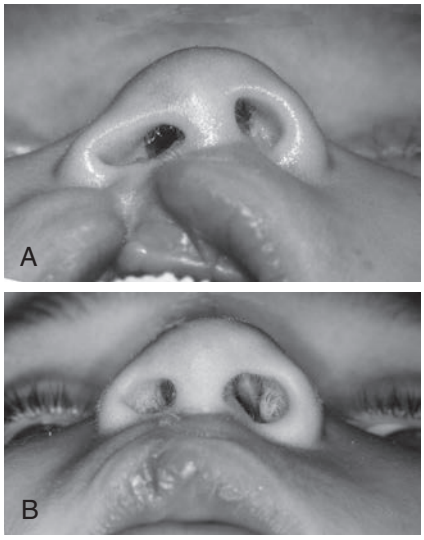

• **Figure 29-33** **A,** Preoperative photo of 2-month-old with right, incomplete, unilateral cleft lip and palate. **B,** Postoperative photo of same patient at 5 years. Note nasal projection, alar symmetry, and lip fullness.

Nasal symmetry and projection were noted to be improved in children who underwent a comprehensive functional repair.[62] Apparently the nasal osteocartilaginous framework is stimulated by proper musculature function, providing forward vectors of growth and symmetrical alignment at the alar bases.[53] Direct stimulation of periosteum through muscle attachment and function is believed to contribute to osteogenesis of the underlying nasomaxillary bone. [46,49,52,61]

Lip balance and function are widely recognized to depend on proper muscle repair, specifically the orbicularis.[54,63] However, an important muscular element to the superficial sleeve of the orbicularis is the insertion of the levators at its outer aponeurosis.[63] This insertion is disrupted in the clefted lip, and when corrected in repair exerts a positive influence on ultimate lip form and balanced function. Studies have demonstrated preoperative and improved postoperative responses of muscles under function that suggest a physiologic benefit from proper muscle repair.[64]

At the histologic level, Schendel[50,56] documented this positive relation between muscles when he observed a limited

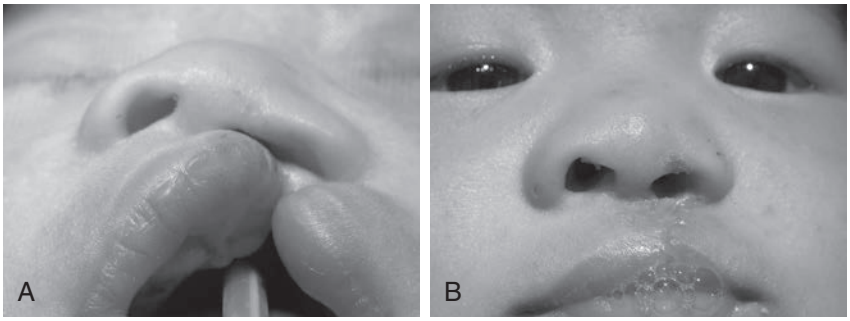

• **Figure 29-34** **A,** Preoperative photo of 2-month-old with left unilateral cleft lip and palate. **B,** Postoperative photo of same patient at 2 years.

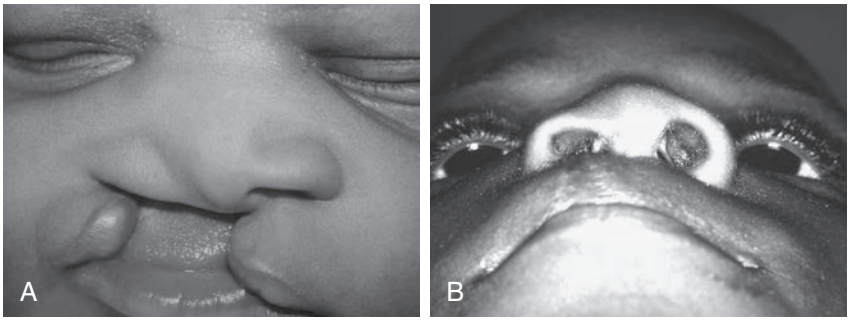

• **Figure 29-35** **A,** Preoperative photo of newborn with right unilateral cleft lip and palate. **B,** Postoperative photo of child at 3 years.

reordering of muscle fiber orientation and design after repair. After cleft lip repair, a pattern of denervation followed by reinnervation of the muscle bundles has been observed, further substantiating the physiologic benefits of functional repair.

Summary

Functional cleft lip repair involves the total identification and mobilization of the nasolabial muscular elements: levators, transversalis nasalis, and orbicularis muscles. These muscular compartments are accessed through cutaneous and mucosal incisions that provide cosmetic results and include proper tissue fields and vascular pedicles that are developmentally based, thus reestablishing the proper functional model. Subperiosteal dissection is performed to mobilize the musculoaponeurotic elements, and muscle coaptation is then performed in a stepwise fashion to create the proper functional nasolabial muscular sling.

Nasal cartilage dissection also is performed during primary repair to facilitate the restoration of a functional matrix. This is achieved through selective columellar, alar, and rim incisions by which total lower lateral cartilage dissection and repositioning can be undertaken. Careful tissue support through placement of wound tapes, nasal stents, and bolsters is key to preserving the functional matrix during initial healing.

When these steps are observed during primary cheilorhinoplasty, function can proceed as normally as possible in the cleft condition and give rise to an improved nasolabial and maxillary complex in both development and appearance.

References

1. Tolarova MM, Cervenka J: Classification and birth prevalence of orofacial clefts, *Am J Med Genet* 75:126–137, 1998.
2. Costello BJ, Ruiz RL: Cleft lip and palate: comprehensive treatment planning and primary repair. In Milaro M, Ghali GE, Larsen PE, et al, editors: *Peterson's principles of oral and maxillofacial surgery*, ed 2, Hamilton, Ont, 2004, BC Decker, pp 839–858.
3. Posnick JC, Ruiz RL: Staging of cleft lip and palate reconstruction: infancy through adolescence. In Wyszynski DF, editor: *Cleft lip and palate: from origin to treatment*, New York, 2002, Oxford University Press, pp 319–353.
4. Posnick JC: The staging of cleft lip and palate reconstruction. In Posnick JC, editor: *Craniofacial and maxillofacial surgery in children and young adults*, Philadelphia, 2000, WB Saunders, pp 785–826.
5. LeMesurier AB: Quadrilateral Mirault flap operation, *Plast Reconstr Surg* 16:425, 1955.
6. Tennison C: The repair of the unilateral cleft lip by the stencil method, *Plast Reconstr Surg* 9:115, 1992.
7. Millard Jr DR: A primary camouflage in the unilateral harelip. In *Transactions of the International Congress of Plastic Surgeons*, Baltimore, 1957, Williams and Wilkins, p 160.
8. Thompson IE: An artistic and mathematically accurate method of repairing the defect in cases of harelip, *Surg Gynecol Obstet* 14:498, 1912.
9. Marsh JL: Craniofacial surgery: the experiment on the experiment of nature, *Cleft Palate Craniofac J* 33:1, 1996.
10. Field TM, Vega-Lahr N: Early interactions between infants with craniofacial anomalies and their mothers, *Infant Behav Dev* 7:527, 1984.
11. Millard Jr DR: Complete unilateral clefts of the lip, *Plast Reconstr Surg* 25:595, 1960.

12. Millard Jr DR: Refinements in rotation-advancement cleft lip technique, *Plast Reconstr Surg* 33:26, 1964.
13. Millard Jr DR: A preliminary adhesion. In Millard Jr DR, editor: *Cleft craft, vol. I, the unilateral deformity*, Boston, 1976, Little, Brown.
14. Millard Jr DR: How to rotate and advance in a complete cleft. In Millard Jr DR, editor: *Cleft craft, vol. I, the unilateral deformity*, Boston, 1976, Little, Brown.
15. Randall P: Long-term results with the triangular flap technique for unilateral cleft lip repair. In Bardach J, Morris H, editors: *Multidisciplinary management of cleft lip and palate*, Philadelphia, 1990, WB Saunders, p 173.
16. Moss M: The primacy of functional matrices in orofacial growth, *Dent Pract* 19:65, 1968.
17. Delaire J: La cheilo-rhino-plastie primaire pour fente labio-maxillaire congenitale unilaterale. Essai de schematization d'une technique, *Rev Stomatol Chir Maxillofac* 76:193–215, 1976.
18. Delaire J: Influence du voile du palais sur la statique lingulae et la croissance mndibulaire. Deductions therapeutiques, *Rev Stomatol Chir Maxillofac* 77:821–834, 1977.
19. Delaire J: The potential role of facial muscles in monitoring maxillary growth and morphogenesis. In MacNamara JA, editor: *Monograph no. 8: cranio growth series*, Ann Arbor, MI, 1978, University of Michigan.
20. Delaire J: Theoretical principles and technique of functional closure of the lip and nasal aperture, *J Maxillofac Surg* 6:109–116, 1978.
21. Brusati R, Mannucci N: Primary repair of the lip and palate using the Delaire philosophy. In Ward-Booth P, Schendel SA, Hausamen JE, editors: *Maxillofacial surgery*, London, 1999, Churchill Livingstone, pp 1005–1028.
22. Carstens MH: Functional matrix cleft lip repair: principles and technique, *Clin Plast Surg* 31:159, 2004.
23. Millard DR: A Primary camouflage of the unilateral harelip. In *Transactions of the First International Congress on Plastic Surgery*, Baltimore, 1957, Williams & Wilkins, p 160.
24. Millard D: *Plastic surgery, vol. 4, the unilateral cleft lip deformity*, Philadelphia, 1990, WB Saunders, p 2632.
25. Witt D, Hardesty A: Rotation advancement repair of the unilateral cleft lip, one center's perspective, *Clin Plast Surg* 20(4):663, 1993.
26. Skoog T: Design for the repair of unilateral cleft lips, *Am J Surg* 95:223, 1958.
27. Bernstein L: Modified operation for the wide unilateral cleft lips, *Arch Otolaryngol* 91:11, 1970.
28. Latham RA: Orthopedic advancement of the cleft maxillary segment: a preliminary report, *Cleft Palate J* 17(3):227–233, 1980.
29. Grayson BH, Maull D: Nasal alveolar molding for infants born with clefts of the lip, alveolus, and palate, *Clin Plast Surg* 31(2):148–158, 2004.
30. Asensio O: A variation of the rotation advancement operation for the repair of wide unilateral cleft lips, *Plast Reconstr Surg* 53(2):167–173, 1974.
31. McComb H: Primary correction of unilateral cleft lip nasal deformity: a 10-year review, *Plast Reconstr Surg* 75(6):791–797, 1985.
32. Millard Jr DR: *Cleft craft, vol. I, the unilateral deformity*, Boston, 1976, Little, Brown.
33. Hagedorn W: Uber eine Modifikation der Hasenschartenoperation, *Zentralbl Chir* 11:756, 1884.
34. Hagedorn W: Die Operation der hasenscharte mit Zickzacknaht, *Zentralbl Chir* 19:281, 1892.
35. Le Mesurier AB: Quadrilateral Mirault flap operation, *Plast Reconstr Surg* 16:425, 1955.
36. Tennison C: The repair of the unilateral cleft lip by the stencil method, *Plast Reconstr Surg* 9:115, 1952.
37. Randall P: Long-term results with the triangular flap technique for unilateral cleft lip repair. In Bardach J, Morris H, editors: *Multidisciplinary management of cleft lip and palate*, Philadelphia, 1990, WB Saunders, p 173.
38. Hagerty R: Unilateral cleft lip repair, *Surg Gynecol Obstet* 106:119, 1958.
39. Millard Jr DR: A primary camouflage in the unilateral harelip. In *Transactions of the International Congress of Plastic Surgeons*, Baltimore, 1957, Williams & Wilkins, p 160.
40. Cardosa AD: New technique for harelip, *Plast Reconstr Surg* 10:92, 1952.
41. Cronin TD: A modification of the Tennison-type lip repair, *Cleft Palate J* 3:376–382, 1966.
42. Millard Jr DR: Complete unilateral clefts of the lip, *Plast Reconstr Surg* 25:595, 1960.
43. Millard Jr DR: Refinements in rotation-advancement cleft lip technique, *Plast Reconstr Surg* 33:26, 1964.
44. Millard Jr DR: A preliminary adhesion. In Millard Jr DR, editor: *Cleft craft, vol. I, the unilateral deformity*, Boston, 1976, Little, Brown.
45. Delaire J: La cheilo-rhinoplastie primaire pour fente labio-maxillaire congenitale unilaterale. Essai de schematisation d'une technique, *Rev Stomat Chir Maxillofac* 76:193, 1975.
46. Delaire J: Theoretical principles and techniques of functional closure of the lip and nasal aperture, *J Maxillofac Surg* 6:109, 1978b.
47. Schendel SA: Cleft lip repair: an alternative approach. In Vistnes L, editor: *How they do it*, Boston, 1991, Little, Brown, pp 338–350.
48. Markus AF, Delaire J, Smith WP: Facial balance in cleft lip and palate. I. Normal development and cleft palate, *Br J Oral Maxillofac Surg* 30:287, 1992.
49. Markus AF, Delaire J, Smith WP: Facial balance in cleft lip and palate. II. Cleft lip and palate and secondary deformities, *Br J Oral Maxillofac Surg* 30:296, 1992.
50. Schendel SA: Unilateral cleft lip repair—state of the art, *Cleft Palate Craniofac J* 37(4):335, 2000.
51. Moss ML, Vilmann H, Das Gupta G, et al.: Craniofacial growth in space-time. In Carlson DS, editor: *Craniofacial biology*, Ann Arbor, MI, 1981, Center for Human Growth and Development.
52. Carstens MH: Functional matrix cleft repair: principles and technique, *Clin Plast Surg* 31:159, 2004.
53. Talmant JC: Nasal malformations associated with unilateral cleft lip, *Scand J Plast Reconstr Hand Surg* 27:183, 1993.
54. Park CG, Ha B: The importance of accurate repair of the orbicularis muscle in the correction of unilateral cleft lip, *Plast Reconstr Surg* 96:780, 1995.
55. Joos U: Muscle reconstruction in primary cleft lip surgery, *J Craniomaxillofac Surg* 17:8, 1989.
56. Schendel SA, Pearl RM, De'Armond SJ: Pathophysiology of cleft lip muscles following the initial surgical repair, *Plast Reconstr Surg* 88:197, 1991.
57. Minard RM, Schendel SA: Rotation-advancement repair of unilateral cleft lip: current status and future horizons, *Advanc Plast Reconstr Surg* 8(14):247, 1997.
58. Hurwitz DJ: Unilateral cleft lip nose repair. In Bardach J, Morris J, editors: *Multidisciplinary management of cleft lip and palate*, Philadelphia, 1990, WB Saunders, pp 204–216.
59. Noordhoff M, Chen Y, Chen K, et al.: The surgical technique for the complete unilateral cleft lip-nasal deformity, *Oper Tech Plast Reconstr Surg* 2:167, 1995.

60. Mulliken JB: Primary repair of bilateral cleft lip and nasal deformity, *Plast Reconstr Surg* 108:181, 2001.
61. Markus AF, Delaire J: Functional primary closure of cleft lip, *Br J Oral Maxillofac Surg* 31:281, 1993.
62. Horswell BB, Pospisil OA: Nasal symmetry after primary cleft lip repair: comparison between Delaire cheilorhinoplasty and modified rotation-advancement, *J Oral Maxillofac Surg* 53:1025, 1995.
63. Mooney MP, Siegel MP, Kimes KR, et al.: Development of the orbicularis oris muscle in normal and cleft lip and palate fetuses using three-dimensional computer reconstruction, *Plast Reconstr Surg* 81:336, 1988.
64. Verwoerd CD, Mladina R, Nolst-Trenite GJ, et al.: The nose in children with unilateral cleft lip and palate, *Int J Pediatr Otorhinolaryngol* 32(Suppl):S45–S52, 1995.

30

Cleft Palate Repair

MICHAEL JASKOLKA, WILLIAM CURTIS, PAUL KLOOSTRA, GERARDO P. ROMEO, PAMELA M. GALLAGHER

TWO-FLAP PALATOPLASTY

MICHAEL JASKOLKA, WILLIAM CURTIS, PAUL KLOOSTRA

Introduction

The goal of repairs of the cleft hard and soft palate is to provide separation of the oral and nasal cavities with the creation of a functional velopharyngeal mechanism. Ideally, this should provide for normal speech and hearing, uninhibited growth, and ideal occlusion and avoid hindering psychosocial development. In the ideal scenario there would be a theoretic benefit to a single operation to achieve these goals without the creation of iatrogenic disease.

The optimal sequence of care is controversial. Although not for a lack of effort, high-level evidence is limited in the context of the management of the cleft palate. Significant barriers exist and begin with the variable management of the cleft lip; when present in conjunction with a cleft of the palate, the results of treatment are inexorably tied together. Although not specifically addressed in this section, variations in the severity of presentation, timing of repair, presurgical orthopedic management, and technique of cleft lip repair all set an uneven foundation upon which the treatment of cleft palate must be based and measured. The remaining barriers to quality study include a high level of patient anatomic variability, inconsistencies regarding classification and terminology, nonstandardized methods of evaluation, data collection and outcome assessments, treatment sequences that vary by institution, and techniques that vary by surgeon. Meaningful conclusions are made more elusive due to limited patient volumes at many centers and the need for longitudinal study over a period of many years, ideally until after skeletal maturity is reached.

The weakness of the literature leads to a lack of consensus regarding almost every aspect of the care of patients with cleft palate. It is likely that no single "optimal sequence" of care exists because each patient presents with a unique condition and considerations. An understanding of the relevant considerations associated with surgical repair of the cleft palate should be combined with proficiency in both the available literature and proficiency in various techniques to allow each practitioner to make educated decisions for individual patients and provide a tailored approach.

History

Cleft palate repair has evolved over time from the work of many preceding surgeons. Innumerable procedures have been trialed; some have been discarded while others have been modified and stood the test of time. The following is a summary of key advancements leading to current concepts, from simple mucosal approximation, through successful closure of the hard palate, attempts to lengthen the soft palate, to true functional reconstruction of the clefted velum.

The first endeavors to close the congenitally clefted palate consisted of simple approximation of raw mucosal surfaces. M. le Monnier, a French stomatologist, was the first cited to have achieved mucosal closure by suture approximation followed by cautery in 1766.[1,2] In the early 1800s subsequent surgeons including Carle Von Graefe, Philibert Roux, and John Warren all made advances in technique and instrumentation, focusing on the mucosal closure of the cleft palate; together they forged the field of cleft palate surgery.[3]

Johann Dieffenback, a student of von Grafe, introduced the lateral relaxing incision in 1829. He was succeeded by Bernhard von Langenbeck whose work with subperiosteal dissection and periosteal osteogenesis was extended to the hard palate.[4] Von Langenbeck's technique involved pairing of the cleft margin, lateral relaxing incisions, subperiosteal dissection, preservation of the greater palatine neurovascular bundle, and allowed for closure of both the hard and soft palate in a single operation.[2,3,5]

As palatal closure was being achieved more reliably, the focus of palatoplasty shifted towards the creation of a functional palate. Multiple maneuvers were proposed to medialize and lengthen the soft palate. Christian Billroth, in 1889, recommended fracturing of the hamulus to mobilize the soft palate without injuring the muscle.[2,3]

In 1920 Hugo Ganzer, a dentist and prominent contributor to the field of facial plastic surgery, described the closure of the hard palate in a V-Y fashion, posteriorly displacing the hard palate mucosa. Of note, he was also the first to recommend incising the cleft margin, rather than excising the edges.[6,7]

In 1924 Franz Ernst observed the nasopharynx of the cleft patient to be enlarged and recommended that as a component of palatal repair, the pharynx should be narrowed. He recommended dissection within a theoretic space medial to the pharyngeal constrictor to gain mobility of the soft palate.[6]

Victor Veau published over 500 cases in his textbook *Uranoplasty* in 1931. His publication directed attention to the use of the V-Y pushback, vomer flaps for nasal mucosal closure, and more important, to the "indispensible" suture repair of the "cleft muscle" of the soft palate.[6]

Janusz Bardach reported the most recent popular modification of the hard palate closure in 1967. He described the extension of von Lagenbeck's relaxing incisions to the anterior edge of the cleft margin and the subsequent creation of two axially patterned full-thickness mucoperiosteal flaps based on the greater palatine neurovascular bundle. This design, termed the "2-flap" allows for greater access to the nasal and velar soft tissues.[8]

In 1969, Otto Kreins first coined the term "veloplasty," and echoed Braithwaite as to the importance of isolated muscular reconstruction of the soft palate. Kreins' veloplasty involved severing the medial tensor tendon from the hamulus, disinsertion of the velar musculature from the posterior hard palate, and blunt dissection to release the levator veli palatini from the pharyngeal constrictors. He cautioned against separating the muscles from the nasal mucosa for fear of nasal mucosal necrosis.[9]

Through the 1970s and 1980s the effectiveness of intravelar veloplasty (IVV) was debated with the report of various techniques.[10-12] The current state of IVV has convincingly demonstrated improved speech when carried out in a complete or aggressive fashion with release of the periosteal sheath of the greater palatine neurovascular bundle, transection of the medial portion of the tensor tendon, anatomic dissection of the levator, retrodisplacement into the middle of the soft palate, with approximation or overlap for the creation of appropriate tension.[13,14]

Anatomy

Understanding the contrast between the normal and aberrant anatomy of the cleft palate is paramount for appropriate reconstruction.

The hard palate consists of the primary and secondary palates. The primary palate, also referred to as the premaxilla, contains the alveolus and the maxillary incisors bordered posteriorly by the incisive foramen. Posterior to this point, the secondary palate is formed as a result of the fusion between the maxillary and palatine bones with the midline vomer.[15]

The soft palate and associated musculature is termed the velum and functions as a valve, hinging at the posterior surface of the hard palate in a superoposterior direction to form a seal with the posterior and lateral pharyngeal walls. It functions to separate the oral and nasal cavities during speech and swallowing.[16] Velopharyngeal closure is achieved primarily through the action of the levator veli palatini in combination with the superior pharyngeal constrictor.[16,17] The velum consists of multiple distinct layers as approached during palate surgery. The oral mucosa is adherent to a dense layer of minor salivary glands and fibrofatty tissue. This layer is thicker at the midline and tapers laterally. The confluence of muscles is then encountered below the minor salivary glands. Finally, a thin fascial layer is formed from an extension of the oral and nasal periosteum of the hard palate, which is covered with the thin delicate nasal mucosa.[18]

The musculature of the intact, non-cleft velum consists of a single intrinsic muscle, the muscularis uvula, and multiple extrinsic muscles: the palatoglossus, palatopharyngeus, tensor veli palatini, and levator veli palatine. The palatoglossus creates the anterior pharyngeal arch as it ascends from the posterior tongue to the palate and inserts into the palatal aponeurosis.[16,17,19] The palatopharyngeus is a flat muscle arising from the lateral pharyngeal wall and the greater horns of the thyroid cartilage of the larynx.[17] It creates the posterior pharyngeal arch as it extends superiorly and medially into the soft palate where it splits with fibers running parallel to the anterior and posterior portion of the levator veli palatini. Some of the muscle fibers insert into the aponeurosis, others into the uvula, but the majority of the fibers unite with the contralateral palatopharyngeus to form a loop.[19] The palatopharyngeus and palatoglossus, along with the tongue, form the oropharyngeal sphincter, which is more consistently utilized in swallowing than in speech production.[16,17,19] The tensor veli palatini ("tensor") is a thin, broad, and flat muscle arising from scaphoid fossa at the base of the medial pterygoid plate of the sphenoid bone and lateral margins of the eustachian tube cartilage, descending from the base of the skull toward the soft palate in parallel with the eustachian tube.[16,20,21] Upon separating from the inferior aspect of the eustachian tube, the tensor is flat and nearly vertical and ends in a tendon that wraps around the hamulus, the most inferior portion of the medial pterygoid plate. The tendon extends medially into the velum and contributes to the formation of the palatal aponeurosis at the posterior aspect of the posterior nasal spine.[22] The tensor functions to open the eustachian tube during swallowing and yawning, allowing pressure equalization and drainage of the middle ear. The levator veli palatini is, possibly, the most important muscle of normal velopharyngeal closure. The levator descends from the petrous portion of the temporal bone and the junction of the cartilaginous and bony segments of the eustachian tube, extending anteriorly, medially, and inferiorly, along the inferior and posterior aspect of the eustachian tube, just posterior to the tensor veli palatini. The levator is tube-shaped at the inferior aspect of the eustachian tube, and becomes flat as it enters the soft palate. Some fibers extend anteriorly toward the hard palate, others posteriorly into the uvula, though the majority unite with the contralateral levator to create a

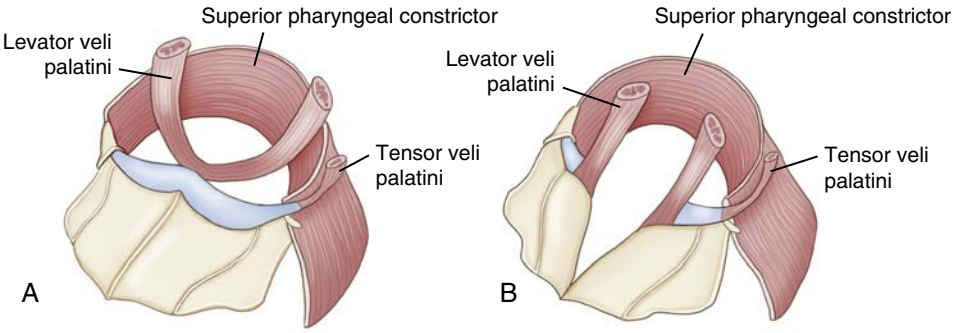

• **Figure 30-1** **A,** The key anatomic components of the normal palatal and velopharyngeal anatomy are displayed, including the intact posterior hard palate and vomer, levator and tensor sling, and superior pharyngeal constrictor which forms the posterior portion of the velopharyngeal valve. **B,** The key anatomic components of the abnormal palatal and velpharyngeal anatomy associated with cleft palate are displayed, including the hard palate defect and absent vomer, division of the levator sling, and abnormal insertion of the tensor.

sling in the middle 40% to 50% of the soft palate.[23] The entire course of the levator muscle can be visualized in an oblique coronal view, demonstrating its sling-like nature and its function for suspending, elevating, and retracting the palate toward the posterior pharynx.[16-19]

The superior pharyngeal constrictor is a thin muscle with multiple origins, resulting in multiple discrete muscle bundles including the glossopharyngeus, mylopharyngeus, buccopharyngeus, and pterygopharyngeus. These muscle bundles extend posteriorly to unite along the pharyngeal raphe. The superior pharyngeal constrictor may participate in the velopharyngeal mechanism by providing posterior and lateral pharyngeal wall movement, though this is not consistent across all individuals.[16]

In contrast to the previously described anatomy found in non-cleft individuals, a variety of configurations are seen with clefts of both the hard and soft palate. A cleft of the secondary palate typically results in a bony deficiency at or adjacent to the midline and has an associated soft tissue deficiency. This varies from subtle posterior osseous notching to a complete dissociation of the palatal shelves. Disjunction of the vomer from the hard palate is also common and, at times, can be complete.[15] Along with the disruption of the midline hard and soft tissue anatomy, the orientation and functionality of the soft palate musculature is also abnormal. The levator veli palatini, palatoglossus, and palatopharyngeus aberrantly attach to the posterior hard palate, and the tensor veli palatini inserts onto the hard palate, maxillary tuberosity, and pterygoid process[16] (Figures 30-1 and 30-2). The pharynx is also abnormal, with an increase in width and depth.

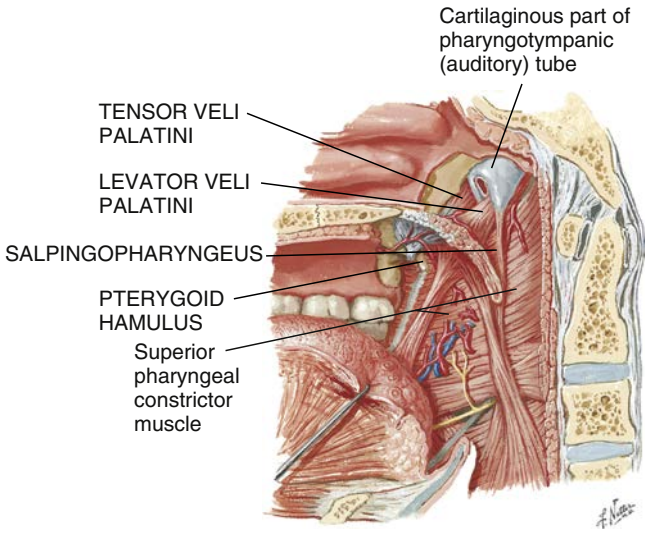

• **Figure 30-2** Cross-sectional view of the normal palatal and velopharyngeal anatomy demonstrating the positions of the palatoglossus, palatopharyngeus, musculus uvulae, superior pharyngeal constrictor, and their relationships to the levator muscle and its attachment to the Eustachian tube. (Copyright 2017 Elsevier, Inc. All Rights Reserved. www.netterimages.com.)

Surgical Technique

Soft Palate

Proper surgical repair should involve functional reconstruction of the velar apparatus and can be accomplished by surgically creating a more anatomically correct form. Straight line repair incorporates "radical" or "complete" intravelar veloplasty (cIVV) and double opposing Z-plasty (DOZP) techniques, which are the two most prominent techniques employed for velar reconstruction in North America, with almost identical frequency.[24] Although different in surgical execution, the goals are similar: complete release, retroposition, and reconstruction of the levator muscle sling.

The "straight line repair" refers to the design of flaps and final orientation and appearance of a straight line scar in the midline of the palate when this approach is used. Incorporation of the cIVV with this technique is not mandatory but it is becoming more universally accepted that it improves success with regard to construction of a functional velum when included with straight line repairs. In contrast to DOZP, which produces a lengthened soft palate by design, the cIVV only does so by incorporating "push-back techniques." Straight line repair with cIVV, though, may create a more correct anatomic reconstruction. Both approaches

variably demonstrate excellent outcomes in the literature, but superiority of one technique is yet to be determined.

Hard Palate

The closure of the hard palate may be considered independently from reconstruction of the velum. Marginal incisions are used in all cases with varying amount of subperiosteal dissection. In theory, the addition of lateral incisions, stripping of the palatal periosteum, and creation of denuded areas of bone raise concerns for growth restriction. The competing consideration is that the use of additional incisions allows for less tension across the midline closure, mobilization of the neurovascular pedicle, and improved access to the soft palate to facilitate appropriate levator release and reorientation.

The narrow incomplete cleft may be closed without any lateral incisions. However, the majority of complete unilateral and bilateral palatal clefts will require additional dissection. Bipedicled flaps (von Langenbeck) provide theoretical improvement in vascularity to the palatal tissues, but have no definitive positive impact on wound healing as measured by fistula or dehiscence rate when compared to unipedicled flaps. The VY push-back design is also commonly employed with the purported advantage of increasing soft palatal length at the expense of the creation of a transverse area of denuded bone at the anterior portion of the palate. The advantage of increased palatal length has not been demonstrated without the creation of a nasal surface defect, although the worry of restricted AP maxillary growth has also not been definitively demonstrated as compared to other procedures when performed using the same sequence at the same patient age. Lastly, the "two-flap" repair popularized by Bardach is the most flexible technique, especially in the wide complete cleft. Although lateral areas of denuded bone are often created, the flaps are traditionally sutured back to the same anterior position in an attempt to completely close the palate up to the lingual surface of the alveolus. The concern here is the stripping of the entire hard palate and the resulting growth disturbance in the anterior and transverse dimension. Again, this has never been definitively demonstrated in the literature to be more severe as compared to other techniques.

Surgical Technique

Endotracheal intubation with the use of an oral RAE placed in the midline is advocated. Preoperative antibiotics and steroids may be administered by the anesthetic care team. The patient is then positioned with the neck in extension through the use of a shoulder roll and extension of the head of the bed. A horseshoe headrest may be used if desired. Special care must be taken in patients with Down and velocardiofacial syndromes due to the potential risk of cervical spine instability. A mouth gag of the surgeon's choice, most commonly a Dingman, is applied for exposure and tongue retraction with care being taken to avoid endotracheal tube compression. Periodic release of the gag is common because it may help to limit postoperative tongue edema.

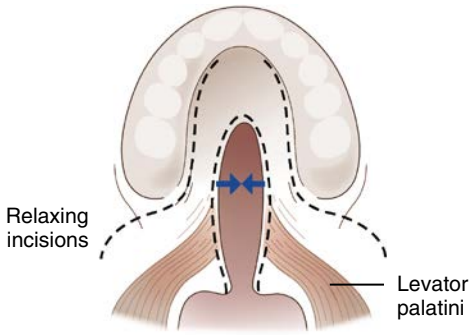

• **Figure 30-3** The von Langenbeck palatoplasty. Lateral releasing incisions are fashioned such that bipedicled mucoperiosteal flaps may be mobilized medially in tension-free fashion.

The procedure begins with placement of a throat pack. Surgical markings are made and local anesthetic with vasoconstrictor is given via infiltration for hydrodissection and tumescence of the soft palate to facilitate incisions. Additional aliquots of injectable saline may also be used to improve soft tissue turgor.

Initial incisions are made along the margin of the cleft beginning from the anterior extent of the soft palate through the tip of the uvula. The oral and nasal mucosa are split at their intersection. A modification employed by some is the demucosalization of the very medial tip of the uvula prior to the initial incision to facilitate later closure. Dissection of the soft palate is limited at this point to the creation of an oral layer just below the mucous glands and a nasal-muscle layer. Incisions are then carried towards the anterior hard palate. A beaver blade can be utilized if desired, particularly in the incomplete cleft. The marginal incision is often placed slightly more towards the oral mucosa to facilitate adequate closure of the nasal layer.

If desired, lateral releasing incisions are made from just posterior to the tuberosity and extending anteriorly. The incisions are started with a knife and approximately 5 mm of attached gingival height is maintained on the palatal aspect of the dentition; they are then carried to bone with use of electrocautery at an angle to avoid injury to the greater palatine vessels. If bipedicled flaps (von Langenbeck) are intended, the incisions are terminated prior to turning medially toward the cleft margin (Figure 30-3). If unipedicled flaps are intended with a V-Y in mind, the anterior releasing incision is then carried at a sharp angle back toward the anterior edge of the cleft on each side (Figure 30-4). If unipedicled flaps are intended for a two-flap design, the incisions are carried to the anterior cleft margin (Figure 30-5).

When utilized, hard palate mucosal flaps are elevated in a subperiosteal plane from anterior to posterior and lateral to medial. The greater palatine neurovascular bundle is identified and protected as the flap is elevated off of the posterior edge of the hard palate. Dissection is completed circumferentially around the neurovascular bundle, posterior to the

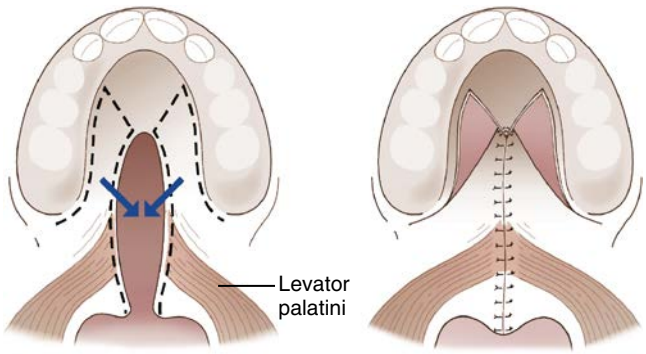

• **Figure 30-4** The Veau-Wardhill-Kilner push-back palatoplasty. Full-thickness mucoperiosteal flaps are elevated and "pushed back" in V-Y fashion to lengthen the reconstructed velum. Note the areas of the hard palate denuded and left to heal by second intention.

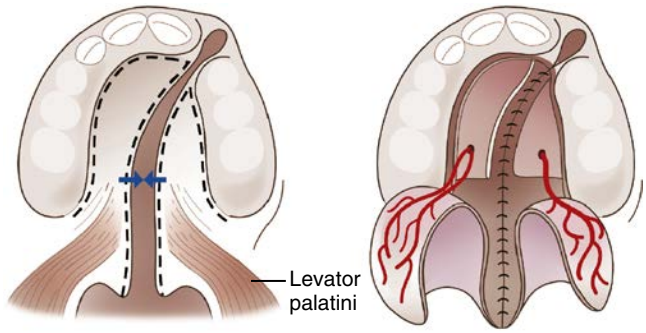

• **Figure 30-5** The Bardach two-flap palatoplasty. Two axially patterned, full-thickness mucoperiosteal flaps are elevated, providing excellent visibility to the nasal side closure and velar musculature for its reconstruction.

hard palate and laterally along the hamulus. In the wide cleft, additional maneuvers such as further dissection along the medial aspect of the pterygoid plate, division of the tensor tendon, dissection into the space of Ernst, scoring of the periosteal sheath surrounding the neurovascular bundle, and foraminal ostectomy to release the neurovascular bundle may all aid in mobilizing the tissues of the palate for tension-free closure. In-fracturing of the hamulus is also utilized by some, but is not considered a necessity.

The nasal mucosa is then elevated from the medial margin of the hard palate. Once in the subperiosteal, a curved freer is used to elevate the tissues off of the nasal surface of the palate up to the lateral wall of the nasal cavity. Careful assessment of cleft width and available soft tissue is then used to decide if vomer flaps are indicated to form the nasal layer. If so, additional local anesthetic is injected. In the unilateral complete cleft palate, the incision is made at the junction of the oral and vomerine mucosa. In the bilateral complete cleft palate, the incision is made directly on the base of the vomer. If additional release is required, posteriorly placed lateral extensions can be made.

Closure is begun at the uvula with a single interrupted 4-0 Vicryl suture that is left uncut on slight tension. A horizontal mattress suture may then be used to approximate the next portion of the uvula. The nasal mucosal layer is then closed in an interrupted technique to minimize shortening, with the knots everted onto the nasal surface. Once the hard palate is reached, a running suture may be employed. Vomer flaps are incorporated at this point as necessary and help to reconstruct the posterior choanae and set the position of the velum.[25]

A complete intravelar veloplasty as described by Sommerlad[14] can now be performed beginning with sharp dissection of abnormally arranged muscles from the nasal mucosa and the posterior aspect of the hard palate. The mucosal layer is identified by its bluish hue. Sharp tenotomy scissors under loupe magnification, and steady counter-traction with a single skin hook placed in the oral mucosa flap facilitate this dissection. The dissection begins several millimeters lateral to the midline sutures of the nasal layer and is carried laterally along the posterior edge of the hard palate. The aponeurosis of the tensor tendon is divided and a portion of fibrous tissue remaining with the levator and palatopharyngeus muscles is lightly grasped to facilitate the remaining sharp and blunt dissection from the superior pharyngeal constrictor allowing for further release and posterior medial displacement. The muscles are approximated in the midline with 5-0 PDS horizontal mattress sutures, but may require some amount of overlap to establish appropriate tension of the reconstructed sling due to their increased length and laxity.[26] If appropriately positioned, the levator bundles should lie approximately half of the distance from the hard palate to the uvula, and can be secured to the underlying nasal mucosa with a suture to prevent migration[17,23] (Figures 30-6 and 30-7).

In the extremely wide cleft, or in the case of significant nasal mucosal tears, additional reinforcement of the hard and soft palate junction may be desired. This can be accomplished with acellular dermal matrix or with a pedicled vascularized buccal fat graft, both of which add an additional layer in the area most susceptible to breakdown and fistula formation (Figure 30-8). An additional benefit of using fat pad advanced and secured between the hard palatal shelves and the muscles of the velum sandwiched between oral and nasal mucosa is obliteration of dead space and aid in maintaining retroposition of the repaired musculature.

The oral layer is then closed in the midline with 4-0 Vicryl mattress sutures at the hard and soft palate junction, and intermittently to establish eversion of the edges of the wound. Intervening 5-0 Vicryl simple interrupted sutures can supplement closure. Once approximated in the midline, the lateral edges of the hard palate flaps may be suspended to the unelevated anterior and lateral alveolar mucosa with interdental sutures maintaining a tension-free midline closure. The throat pack is removed and the stomach evacuated with a suction catheter. A 2-0 silk traction suture can be placed through the tongue and secured extraorally for use in the unlikely event of postoperative airway obstruction. Full liquid diet, preferably by cup or valveless sip cup, is appropriate and most patients are observed overnight. Additional doses of IV antibiotics and steroids may be administered. Once the patient is successful in resuming adequate oral

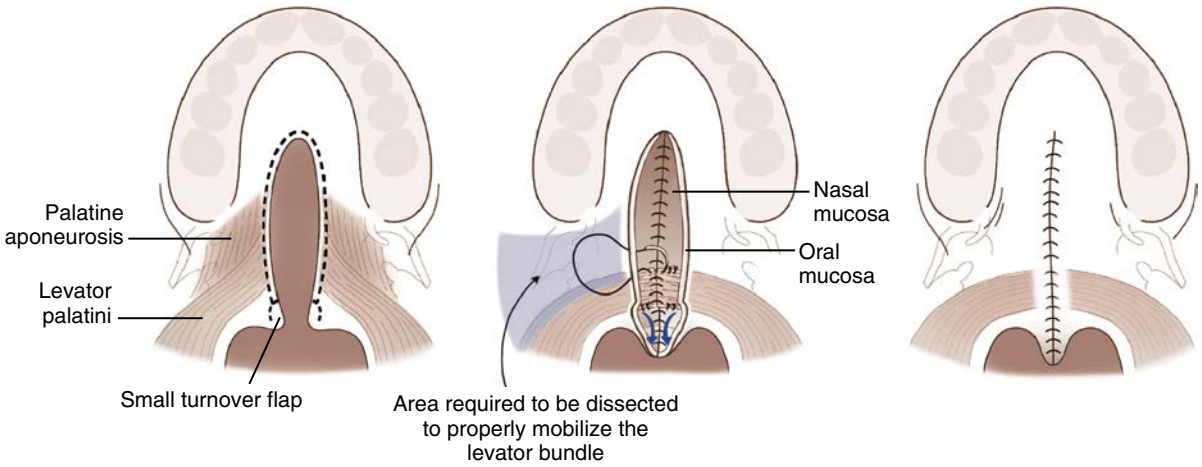

• **Figure 30-6** Intravelar veloplasty after Sommerlad. A more extensive dissection of the levator bundles into the space of Ernst is accomplished, permitting the tension-free, transverse reorientation and retropositioning of the levator veli palatine to at least the middle third of the velum.

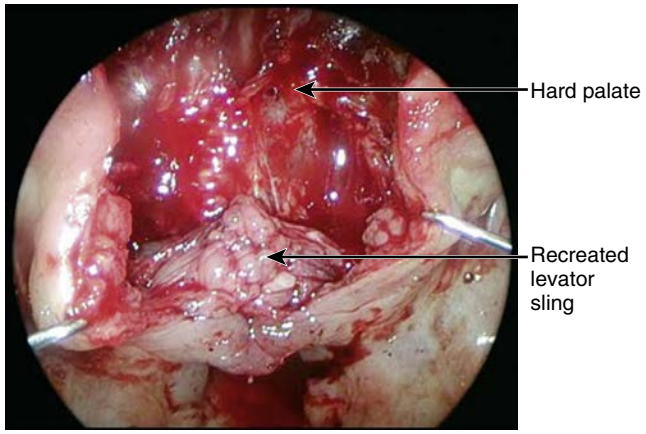

• **Figure 30-7** Appropriate reconstruction, alignment, and position of the levator musculature within the middle of the soft palate in relation to the posterior border of the hard palate

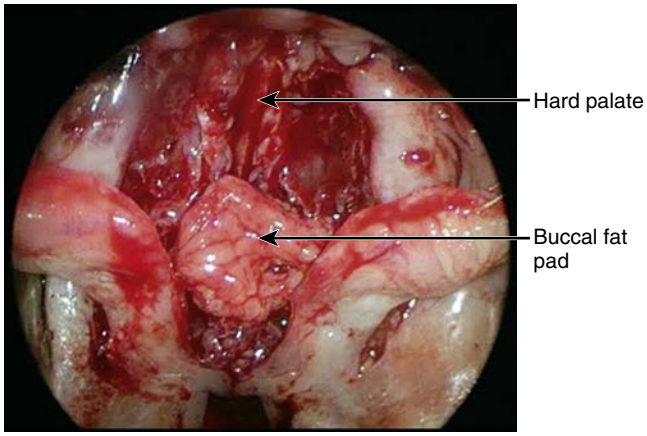

• **Figure 30-8** Demonstration of the application of a pedicled buccal fat pad graft during primary palatoplasty. This technique is employed to minimize the risk of fistula formation at the hard and soft palate junction, obliterate dead space, and create a more supple velum.

intake and absence of airway embarrassment is confirmed, the traction suture is removed and the patient is discharged, often on the next postoperative day. A full liquid or purée diet is instructed for 3 weeks. Arm restraints may be used by some surgeons early in healing, but are not a requirement unless requested by the family.[24,27]

Outcomes

Objective evaluation of outcome is likely the most ideal way to rate success in cleft care. As mentioned previously, there are significant barriers to the publication of level one evidence supporting an ideal cleft palate repair method. However, the literature is replete with lower level evidence studies and manuscripts and the practicing surgeon should be familiar with that information. Outcomes are often discussed in terms of fistula rates, audiologic and otologic function, speech, dental/occlusal relationships, and growth.

Fistulae

One of the primary goals of palate repair is the separation of the oral and nasal cavities; as a result, postoperative fistula rates have become a parameter of success. A fistula technically may form anywhere along the repair, but is more common at the junction of the hard and soft palate.[27] Although seemingly straightforward, the literature is again difficult to interpret, largely because of inconsistent terminology. The Pittsburgh Fistula Classification System (Figure 30-9) is an example of one attempt to standardize categorization by specific location. When considering the incidence of fistulae it is important to make the distinction between a true fistula and a residual cleft. Cohen and colleagues have recommended defining a fistula as a failure of healing or breakdown of the primary surgical repair.[28] Therefore, a communication in the region of the alveolus after primary palatoplasty that was never repaired should be considered a

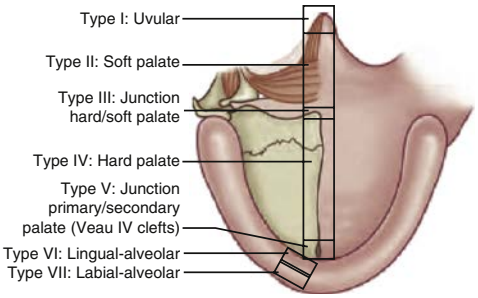

• **Figure 30-9** The Pittsburgh Fistula Classification System. (From Smith DM, Losee JE: Cleft palate repair, *Clin Plastic Surg* 41:189-210, 2014.)

residual cleft.[14] Lastly, not all fistulae are clinically significant and their presence may not lead to symptoms such as nasal regurgitation, halitosis, mucosal irritation, and hypernasal speech.

The reported incidence of fistula occurrence following primary palatoplasty ranges from <1% to 70%[14,28,29,30] with a recent systematic review reporting an 8.6% fistula rate.[31] Little controlled research has been performed to evaluate the effect of the palate repair technique on the incidence of fistula. Cohen reported a 43% incidence utilizing a VWK repair, and only 22% with a von Langenbeck repair.[29] Emory reported no significant difference in the rate of fistula between the Bardach two-flap palatoplasty (8%) and the von Langenbeck repair (15%).[32] To contrast Cohen's published fistula rates, Andersson reported a 4% fistula rate, and Sommerlad reported a 15% rate with a modified von Langenbeck repair, while Aslam reported a 5.6% rate and Salyer reported a 10% rate with the Bardach two-flap palatoplasty.[14,25,28,31]

Confounding variables beyond technique are likely to play a role and include cleft type and severity, patient age, syndromic diagnosis, and surgeon experience.[28,29,33,34] There is general consensus that cleft type and severity correlate with the rate of fistulae following cleft palate repair.[28,29,35] Sommerlad reported a 12% fistula rate in isolated cleft palate, 14% in unilateral cleft lip and palate, and 35% in bilateral cleft lip and palate.[14] Less clear is the impact of age at the time of repair as some report a decrease in fistula rate with an increasing age at the time of repair while others report no change.[25,28,33,34,36] A similar controversy exists in regard to the correlation between syndromic diagnosis and the incidence of fistulae.[36] These findings are likely to relate to which syndromes were included. Last, and perhaps most important, individual operator experience and skill set should not be ignored, with volume often cited as a meaningful surrogate marker for skill. Emory and colleagues demonstrated that the surgeon completing >60% of the cleft palate procedures at their institution had a significantly lower rate of postoperative fistula formation,[33] while Andersson and colleagues reported on more than 50 surgeons over 40 years at their institution, reporting a significant difference based on surgeon volume when a cleft involved both the hard and soft palate. However, the rate of postoperative fistulas dropped dramatically for surgeons who had performed more than five palatoplasties.[28]

Otologic/Audiologic

Chronic otitis media (OM) characterized by effusion and conductive hearing loss is found in almost all infants with cleft palate. The proposed etiology is eustachian tube dysfunction secondary to anatomic and functional abnormalities. Although the natural history is such that these conditions are likely to improve over time they are extremely prevalent during the toddler years, which are critical for speech and language development.[37]

Audiologic and ENT evaluation are an important component of the multispecialty care of children with cleft palate and are meant to identify abnormalities with the goal of providing early treatment to facilitate speech and language development. A combination of cleft palate repair and ventilation tube placement has been shown to lead to normalization of eustachian tube function in approximately 90% of patients over time.[38] In this vein, ventilation tubes are often placed prophylactically at the time of cleft lip or cleft palate repair; others base their decision on findings of recurrent OM, effusion, and sustained hearing loss. Ideally, treatment protocols should allow for the appropriate development of speech and language as well as the prevention of short- and long-term otologic and audiologic conditions such as unnecessary surgery, tympanic perforation, cholesteatoma, and permanent hearing loss.

Otologic and audiologic outcomes are difficult to measure because eustachian tube function is not immediately improved following palatoplasty. Surrogates for function that are followed over time include tympanometry studies, hearing testing, number of ear procedures, and associated complications. However, as with the other outcome measures, it is difficult to control for age at the time of placement, uniformity of evaluation and testing, long-term follow-up, and type of cleft.

The impact of the cleft palate repair technique may be improved with the use of a muscle reconstruction technique.[39,40] Specific comparisons between the use of IVV as versus the DOZP have demonstrated contradictory results without clear superiority of a specific technique.[41-43]

Speech

A child with an unrepaired cleft palate, or one that has been repaired without the creation of an adequately functioning velopharynx, will likely acquire a speech deficit. This is often due to a combination of velopharyngeal dysfunction (VPD) and compensatory misarticulation. VPD is a general term indicating failure of the velopharyngeal mechanism to properly separate the oral and nasal cavities; it is characterized by hypernasal resonance, inappropriate nasal air emissions, and poor speech quality.[44,45] VPD is divided into velopharyngeal insufficiency due to structural inadequacy, velopharyngeal incompetence due to limited function despite structural

integrity, and velopharyngeal mislearning due to inappropriate function during speech despite normal structure.[45] Compensatory misarticulation is rooted in the attempt to simulate typical phonemes through atypical methods. A common example is the use of the vocal cords to generate sufficient pressure to generate plosive phonemes (i.e., /p/), termed a "glottal stop."[46] A similar, but distorted sound is generated leading to poor intelligibility that becomes worse with connected speech.

The speech and language pathologist is essential in the evaluation and treatment of articulation and resonance disturbances. Assessment is generally composed of perceptual speech evaluation as well as objective testing such as nasometry, pressure flow, video fluoroscopy, and nasopharyngoscopy.[47-49] The perceptual speech examination attempts to standardize assessment but is dependent on the perception and interpretation of the observer. It is also limited by other components necessary for normal speech such as hearing, neurocognitive development, and anatomic variability in the nasal, oral, and pharyngeal tissues. Early research identified the bias of surgeons and the inability of the lay ear to identify specific speech errors, as well as poor inter-rater reliability between speech language pathologists.[50] Higher level studies such as Eurocleft and Americleft[51-53] attempt to control for some of these limitations. Despite its shortcomings due to subjectivity, the speech language assessment provided by trained speech professionals is a heavily used tool for individual assessment, tracking progress and directing therapy in most centers.

Objective testing is often used to aid in the diagnosis of VPD, track clinical progress, and provide research applicable data. Nasometry provides a measure of nasal acoustic energy that is compared to normative values and reported as a "nasalance" score. Dynamic video fluoroscopy provides multiple views of the pharyngeal mechanism during function; it allows for measurement, but is associated with radiation exposure.[54] Pressure flow testing measures intraoral pressure as compared to airflow through the nose and provides an estimate of the size of the velopharyngeal orifice.[55,56] Nasopharyngoscopy is a qualitative exam that provides visualization of the velopharynx during function. Interpretation of findings is subjective in nature but endoscopy is useful in aiding decision making for secondary surgical interventions.[55,57,58]

Speech outcomes are difficult to assess, and ultimately most use a measure of "intelligibility" and rates of secondary speech surgery to determine success or failure. Many times, errors of articulation and abnormal resonance in the presence of an inadequate velar mechanism are "lumped together" in casual discussion of speech intelligibility, but they are clearly different and require distinct approaches to management.

When discussing VPI, referral for subsequent speech surgery such as revision palatoplasty, sphincteroplasty or pharyngeal flap surgery, are used as surrogate markers for the presence of VPI following initial interventions. However, not all patients that develop VPI undergo surgical treatment. Furthermore, the criteria for recommending secondary speech surgery are not uniform between centers. The ideal surgical technique should provide adequate palatal length and intact muscular function for proper speech production.

Initially the V-Y pushback was described in attempt to lengthen the palate as compared to the von Langenbeck repair, but its impact on speech has been questionable. In 1975, Krause retrospectively reported on 267 patients after transitioning from von Langenbeck to the Veau-Wardill-Kilner (VWK) technique. Pharygneal competence was improved from 56% to 74%, but the results were confounded by the reduction in age at time of palatoplasty from 3 to 2 years old.[59] Another classic study reviewed 64 children, controlling for age and type of cleft (Veau type I and II), failed to show any difference in palatal length, soft palate mobility, perceptual speech exam, or nasal air emissions between the two techniques.[51] Others have reported no significant difference in the rate of secondary pharyngoplasties performed, ranging between 15% and 45%.[59-62]

The management of the soft palate has evolved from simple adhesion to the contemporary goal of complete anatomic reconstruction of the musculature. This emphasis has come from prior cadaveric studies[17,19] and more recently anatomic and functional characterization by MRI.[63] The efficacy of "veloplasty" as published by Kreins has been debated with regards to the development of normal speech. In 1989, Marsh published a nonrandomized prospective study of IVV. Their results demonstrated no difference with regard to perceptual speech scores at 3 years of age with a 30% velopharyngeal dysfunction rate and 10% requiring secondary speech surgery.[12] These results seemed to reinforce the findings of previous less robust studies.[64] This conclusion has been challenged with the hypothesis that incomplete dissection and retrodisplacement of the soft palate musculature was to blame. In 1995, Cutting published an anatomic basis for a more complete dissection and included a series of 111 palate repairs with 5-year follow-up and a secondary speech surgery rate of 6.3%.[13] Sommerlad published a similar, but independently developed, technique referred to as "radical" IVV with a 15-year cohort study of 442 palatoplasties and 10 years of follow-up. He reported a secondary speech surgery rate, commonly between 5 to 10 years after surgery, of less than 10%, and 4.6% when looking at the most recent 10 years in isolation.[14] The critical importance of a complete IVV continues to be reported in the literature and has been widely adopted by cleft surgeons performing straight line palate repair.[65,66]

The ideal timing of palatoplasty in relationship to speech development is still debated. Early surgery is thought to benefit speech development at the expense of more pronounced growth restriction.[67-69] In general, speech develops through a predictable sequence with a transition from vocal play to babbling between 6 to 12 months of age.[70-72] From the perspective of proper speech development, it would make sense that palatal closure should be directed by one's phonologic development. A retrospective review of 40 children after

palatoplasty revealed that children with less than a 5-word vocabulary at the time of surgery demonstrated significantly better articulation and resonance at 3 years.[73] Practically, the timing of repair tends to be based on chronologic age with 94% of palatal repairs performed in the United States between 6 and 15 months, and 74% between 6 and 12 months of age.[24] Ysunza completed a prospective study of 76 patients randomized to repair at 6 and 12 months old. Although VPI rates were similar at 4 years, phonologic development was better in those treated at 6 months old with a lower rate of compensatory misarticulations, and reported no difference in maxillary growth.[74] Dorf and Curtin reviewed compensatory misarticulation rates in children undergoing cleft palate repair before or after 12 months of age. Only 10% of children treated before but 86% of those treated after 1 year of age developed compensatory misarticulations.[72] Repair beyond 1 year has been associated with poorer rating of speech intelligibility.[75,76] The benefit of early palatoplasty appears to diminish when the age of surgery falls below 6 months with the literature providing conflicting conclusions.[74,77-79]

Cleft severity appears to be inversely correlated to surgical outcomes with bilateral cleft lip and palate consistently demonstrating the worst speech.[26,61,80] Counterintuitively, those with an isolated cleft palate are also found to have a high rate of secondary velopharyngoplasty, ahead of unilateral cleft lip and palate.[25,61] Some suggest this is due to the absent attachment of the vomer that may maintain palatal length.[59,61] The existence of undiagnosed syndromes in those with isolated cleft palate may also contribute.

Growth

Normal mid-facial growth is paramount to facial function and esthetics and is measured by vertical facial height, projection, and occlusion.[81] Deposition at the anterior surface of the transverse palatine suture provides maxillary length and projection. Bilateral deposition at the midpalatal suture provides maxillary width, with more posterior activity. Vertical height develops through appositional growth at the hard palate and alveolus.[82] The maxilla is suggested to obtain additional projection and vertical height as vomerine growth bodily displaces the maxilla anteriorly and inferiorly.[83]

Effective research evaluating growth in the cleft population is challenging due to the accumulation of treatment effects and the extended follow-up necessary to evaluate outcomes beyond skeletal maturity. When maxillary growth is assessed by cephalometric analysis, the current standard, caution should be exercised as anterior maxillary landmarks such as ANS and A point are commonly distorted by asymmetric muscular insertions and may result in a false representation of a longer and more anteriorly positioned maxilla.[84-86]

Growth disturbance in complete unilateral cleft lip and palate is characterized by a short maxilla in height, length, and projection. The mandible is also generally smaller with a steep mandibular plane, anterior-posterior occlusal discrepancy, and a short cranial base.[87,88] The growth disturbance in isolated cleft palate also demonstrates a reduced maxillary and mandibular projection and size, but to lesser extent and less of an anteroposterior occlusal discrepancy, and a normal base of skull length.[88] In contrast, the dental arch in bilateral cleft lip and palate following primary lip repair demonstrate a wider posterior arch width and an anterior arch length shorter than those with unilateral cleft lip and palate.[90]

The ultimate facial form of those with cleft lip and palate is inexorably tied to the treatment of the cleft lip and alveolus. Such interventions include cheiloplasty associated with maxillary retrusion,[91] aggressive presurgical orthopedics leading to collapse of the dental arch,[68] and gingival periosteoplasty or primary bone grafting associated with a short anterior arch length, severe inclination of the lesser segment, and poor occlusal relationships.[68,92-95]

The poor maxillary projection of the cleft population has frequently been attributed to iatrogenic injury.[89,96-98] In 1949 Graber called attention to the grossly impaired maxillary growth seen at that time, reporting a correlation between maxillary retrusion and collapsed maxillary arches with the extent of scarring and multiple palatal procedures.[99] Ross and colleagues have supported this view, reporting that all palatal repairs inhibit maxillary length, posterior height, and projection.[82] While soft palate repairs impact posterior maxillary growth and transverse width to variable degrees, hard palate repair techniques and timing tend to have the most significant effects on mid-facial retrusion.

The Veau-Wardill-Kilner push-back has received criticism for inducing excess scar tissue and impairing maxillary and occlusal development when compared to the von Langenbeck and two-flap techniques.[62,82,95,100,101] Although reports and opinions have been presented to favor the von Langenbeck or the two-flap palatoplasty technique, neither has consistently lead to superior results.[62,82,90-92,102] Reports have also demonstrated significant interoperator variability, suggesting that other factors influence results. Following the philosophy of limiting dissection and extent of denuded bone, and reducing scar tissue formation, additional modifications in the form of refraining from fracturing the hamulus, reducing mucosal stripping, and limiting the extent and location of relaxing incisions have been recommended.[37,101,103,104]

Staged repair of the soft and hard palate defects is one approach to limiting poor mid-face growth in people with cleft palate defects. Popularized by centers in Europe, delay of repair of the hard palate cleft has gained significant commitment from some centers throughout the world.[105,106] Interestingly, Bardach and colleagues impressed with published results visited and examined a small, random subset of Schweckendiek's patient population, confirming growth results but observing poorer speech outcomes than initially reported.[8] Various other publications in support of single-stage techniques have reported suboptimal speech results with staged protocols and so, while a staged protocol is still practiced by

some centers,[107] 96% of centers in North America adhere to a single-stage method according to recent survey.[24]

As demonstrated in the Eurocleft and Americleft data, improved occlusal development is obtained when palatoplasty is delayed.[68,95] The results of other studies, however, have been variable regarding the ideal timing of palatoplasty.[108-111]

In Europe the classic approach to staged repair is being supplanted in some centers by a different approach. A vomer flap is used to achieve nasal side hard palate closure at the time of lip repair, followed by subsequent repair of the soft palate before the occurrence of any significant speech development. Although early repair of the soft palate is associated with favorable speech development, the long-term impact on maxillary growth has yet to be clearly determined.[75,112]

Comparison with the DOZP

A recent survey of the American Cleft Palate Craniofacial Association reported an equivalent percentage of surgeons perform two-flap with IVV (45%) and DOZP (42%).[24] Similar outcomes are reported utilizing each procedure by experienced surgeons with impressive case volumes although high quality evidence supporting one procedure over the other is limited.

The largest prospective randomized trial to date comparing the two procedures reported improved speech with the DOZP when using hypernasality as the outcome measure (82% vs. 71%) whereas the fistula rate was significantly higher (23% vs. 14%).[77] Significant surgeon variability was identified.[113] Audiologic and otologic outcomes were similar at 5 to 6 years of age and other outcomes have yet to be reported.[44]

Conclusion

Repair of the cleft palate involves layered closure of the hard palate and functional reconstruction of the soft palate with straight line repair and complete intravelar veloplasty or double opposing Z-plasty techniques. A simultaneous repair of the hard and soft palate between 9 and 15 months of age is the most common approach in the majority of U.S. centers with no significant difference in utilization of straight line techniques or DOZP. This sequence appears to demonstrate acceptable outcomes with regard to speech and growth. Low published rates of fistulae formation are common with straight line techniques. Regarding middle ear disease, neither straight line or DOZP techniques have proven superior. Similarly, superiority of straight line techniques or DOZP techniques with regard to growth restriction are unlikely to be related to the generalities of straight line technique and most likely depend more on timing of repair and individual techniques of the operator as they relate to extent of dissection, areas dissected, and creation of excessive scarring.

Only through standardization of patient evaluation, data collection, and long-term outcomes assessments will multicenter studies be able to clarify many of the unanswered questions related to cleft palate repair. Ideally though, care should maximize speech outcomes, promote middle ear health, limit facial/dental growth restriction and associated mid-face retrusion, and do so with a minimal number of interventions so as to limit negative psychosocial impact on affected people and their families.

DOUBLE OPPOSING Z-PLASTY

Gerardo P. Romeo

Prior to the use of the double opposing Z-plasty technique various modifications of straight line repairs had been utilized to treat cleft palate deformity.[114-118] Results with eliminating oral and nasal communication were highly acceptable; however, achieving velopharyngeal competence and proper speech was less predictable. The desire for velar lengthening resulted in various publications of "push-back" style techniques.[114-116] For a great while, though, the abnormal musculature of the soft palate was not meaningfully addressed during palatoplasty. Satisfactory consistent and reproducible speech results were not commonplace during this time. A technique for dissection and repositioning of the inappropriately positioned palatal musculature via intravelar veloplasty (IVV) by Kriens was published in 1969 and conceptually changed the evolution of palate repair techniques.[119,120]

The usefulness of Z-plasty to increase the length of a linear wound or scar band has long been known; however, publication of techniques incorporating it into palatoplasty did not begin until the 1970s.[121] In 1976 Dr. L.T. Furlow developed and began using a new technique for cleft palate repair that both increased velar length and appropriately addressed the soft palate musculature via a "double opposing Z-plasty." His main intent was to improve speech outcomes and velopharyngeal function while limiting negative growth effects.[122,123] His first public presentation of the technique came in 1978.[124] His technique successfully incorporated the dissection of palatal musculature from abnormal skeletal insertions and reorientation into proper position, conceptually similar to IVV, but incorporated it into the design and elevation of bilateral mucosal flaps for Z-plasty, both repairing the defect and increasing velar length.

Technique

A Dingman mouth gag is utilized for this procedure. The patient is positioned on the operating table in supine position. Use of a shoulder roll with the neck slightly extended is helpful. The hamulus of the medial pterygoid is palpated and serves as the important landmark. Surgical markings are made and anesthetic solution containing a vasoconstrictor is injected. As originally described, the posteriorly based myomucosal flap of the oral side is made on the patient's left for the right-handed surgeon as a matter of convenience for proper dissection. The technique is described in

this orientation in this chapter, but may be mirrored if so desired.

The first marking is made slightly beyond the posterior border of the hard palate in the mucosa of the soft palate, leaving a small cuff for suturing on the patient's left. The mark extends from the hamulus to the midline cleft approaching the junction of the hard and soft palate. The cleft will serve as the central limb of the Z-plasty and is marked at the junction of the nasal and oral mucosa. On the opposite side, the anteriorly based flap is marked beginning with the central limb left at the junction of nasal and oral mucosa and extending posteriorly to the base of the uvula. From the uvula, a straight line is drawn across the soft palatal oral mucosa to the right hamulus (Figure 30-10). The Dingman retractor is now "let down" to avoid prolonged tongue ischemia, reperfusion injury, and the resultant complications that have been reported while waiting for the vasoconstrictive effects of the anesthetic solution.[125,126] This should be repeated periodically throughout the procedure.

A 15c blade mounted on a No. 7 surgical blade handle is used. The first incision is made in the midline cleft at the junction of the oral and nasal mucosa on the patient's left side to the tip of the uvula. Traction of the uvula is maintained with a traction suture or surgical forceps. The incision is made from the anterior extent of the hard palatal cleft to the uvula. The lateral limb of the Z-plasty is then incised on the patient's left through mucosa only until the first incision is met in the midline. Anteriorly, the palatal shelf and posteriorly the muscle layer are identified. The posteriorly based palatal flap is elevated so that the muscle layer is freed from the nasal mucosa and maintained attached to the oral mucosa, incorporated into the flap.

Laterally, the dissection proceeds until the palatal aponeurosis is encountered and it is incised to the hamulus. Careful dissection with blunt technique using a freer or periosteal elevator ensues to mobilize the musculature posteriorly. A useful modification of technique described by the surgeons at the Children's Hospital of Philadelphia involves fracture of the hamulus and extended dissection into the space of Ernst to aid in posterior mobilization of the flap and ability to advance flaps across the midline.[127] With much of the flap elevated, the tensor palatini tendon becomes visible as it crosses the hamulus. Its muscle fibers abnormally insert at the palate. In the original technique, the tendon is not disturbed. Some postulate that maintenance of the integrity of the tensor tendon is necessary for eustachian tube function post repair, while others perform tenotomy to increased mobilization of the flap.[128,129]

As originally described, a periosteal elevator is now used to address the cleft of the hard palate. This dissection extends in the subperiosteal plane to the alveolus. This allows for relaxation of tissue from the palatal vault, many times without lateral relaxing incisions. Avoiding releasing incisions was postulated by Furlow to limit maxillary growth effects. Presently though, multiple modifications are described using various relaxing incisions as well as elevation of von Langenbeck and/or Bardach style flaps.[124,127,128,130] Some surgeons prefer to dissect the hard palatal flaps immediately after initial incisions as it facilitates developing the flaps in the appropriate layers rather than at this stage in the surgery.

Attention is then directed to the opposite side where the oral anterior-based mucosal flap is developed. The incision again begins at the oral/nasal junction in the cleft at the midline from the anterior-most extent of the hard palatal cleft. Incision extends posteriorly to the tip of the uvula, exposing the hard palatal shelf anteriorly (partial elevation of palatal mucoperiosteum aids in defining the proper plane of dissection) and the palatal muscles between layers in the soft palate. From the base of the uvula, the incision is carried anterolaterally toward the hamulus. Again, this flap does not incorporate palatal muscles. The point of the flap at the base of the uvula is elevated developing a plane of dissection between the palatal muscles still attached to nasal side mucosa and the oral side minor salivary glands. The oral side mucosa of the hard and soft palates remain continuous after completion of dissection on either side. Traction

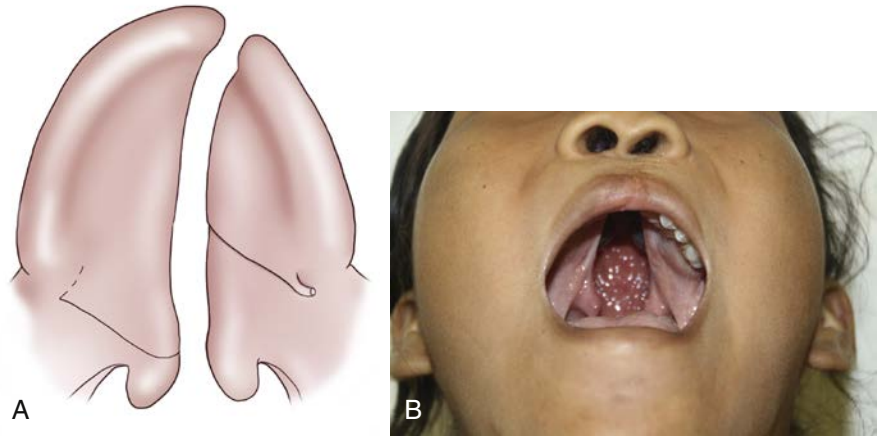

• **Figure 30-10** Z-plasty incisions. The cleft serves as the central limb of the Z-plasty on both sides. The Lateral limbs of the Z-plasty end at the pterygoid hamulus. Notice the lateral limb of the anterior based flap begins at the base of the hemi uvula. (From Furlow LT Jr: Cleft palate repair by double opposing Z-plasty, *Plast Reconstr Surg* 78:724-736, 1986.)

sutures are placed to position oral side flaps and nasal side flaps can then be marked as a mirror image of the oral side.

Elevation of the posterior based nasal side myomucosal flap (on the patient's right in this case) is completed with surgical scissor or blade and extends toward the hamulus ending at the eustachian tube (Figure 30-11). Leaving a small cuff of tissue at the muscle attached to the nasal side mucosa at the hard palate will aid in suturing later. The aponeurosis is again incised when encountered laterally, as was the previous side. Blunt instrument dissection is again used to mobilize the flap and palatal muscles attached to the nasal side mucosa posteriorly. Attention now returns to the patient's left side. The nasal side anterior based flap is then developed, sharply incising from the base of the uvula to the eustachian tube on the left. The four flaps are then ready for reorientation and suturing. A vomer flap can be developed at this time for nasal side closure if necessary. Rotation of flaps and closure using resorbing sutures now begins.

The two hemi uvulae are tacked together. The tip of the anterior based nasal side flap on the left is rotated anteriorly across the cleft and inset with a single suture into the resultant crotch of the nasal side posteriorly based flap on the right near the eustachian tube while the right side flap (containing the palatal muscles) is rotated posteriorly. The rotation will bring the palatal musculature of the right side posteriorly based flap across the cleft for inset near the eustachian tube on the left and is secured in position with suture. The flaps, now reoriented and lying in proper position are then sutured together with knots toward the nasal side (Figure 30-12). Both synthetic and natural resorbing sutures that maintain strength for approximately 1 to 2 weeks are sufficient and should ideally be mounted on a tapered needle. Nasal side repair is now complete and oral side closure ensues. The point of the anterior based flap on the patient's right is rotated and secured across the cleft near the hamulus while the left side flap is rotated posteriorly. The left side

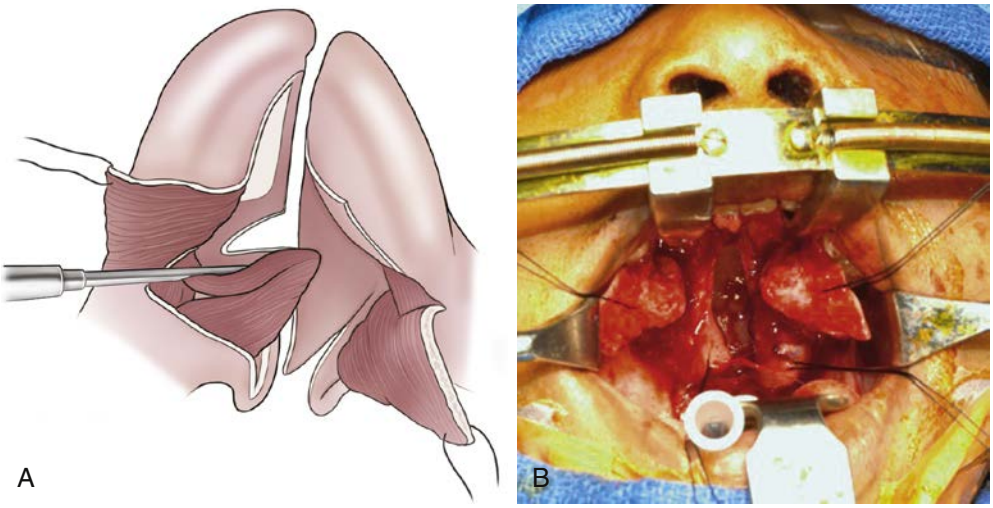

• **Figure 30-11** **A** and **B,** Oral side flaps have been developed and are held in traction with sutures. The incision for development of the nasal side posteriorly based flap is being illustrated with muscle incorporated. Notice the salivary glands visible on the oral side anteriorly based flap. (**A** From Furlow LT Jr: Cleft palate repair by double opposing Z-plasty, *Plast Reconstr Surg* 78:724-736, 1986.)

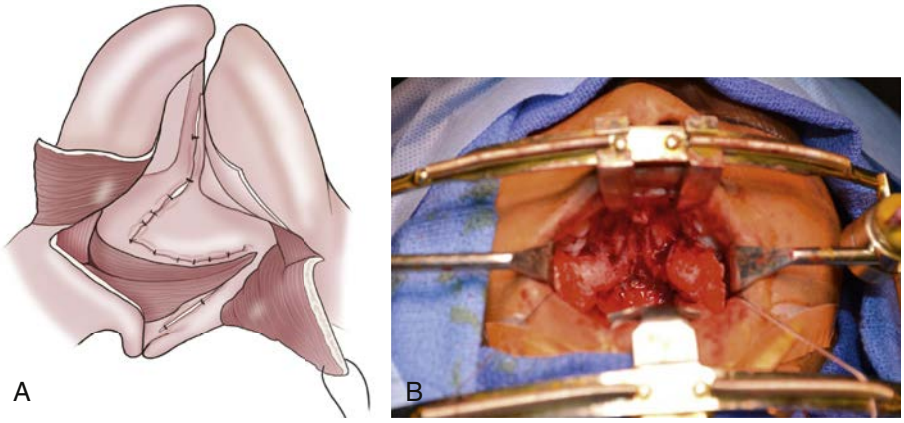

• **Figure 30-12** **A** and **B,** Nasal side flaps have been rotated and inset. Note the palatal musculature which was abnormally inserted on the patient's right side is now spanning the cleft in an appropriate posterior position to create a competent velum. (**A** From Furlow LT Jr: Cleft palate repair by double opposing Z-plasty, *Plast Reconstr Surg* 78:724-736, 1986.)

posterior based flap is now secured across the cleft at near the hamulus. Mattress sutures are then used for oral side closure, to achieve proper eversion while avoiding tension at the suture line (Figure 30-13).

Speech

Supporters of this technique often site increased velar length, establishment of a competent velar mechanism, and successful speech outcomes. Radiologic evidence has confirmed increased velar length and bulk as well as successful reconstruction and repositioning of an intact velar sling in a more correct position.[131,132]

Dr. Furlow first reported on 22 children. His VPI incidence prior to this was ≈48% using a von Langenbeck technique without IVV. With his new technique, 18 were free of velopharyngeal insufficiency (VPI) and 2 had "very mild" VPI as determined by speech pathologist. This marked a significant, predictable improvement.[122]

The group from the Children's Hospital of Philadelphia (CHOP) warrants mention when discussing the double opposing Z-plasty. The surgeons of that institution adopted the technique very early on and are in part responsible for its evolution and wide utilization. Their initial experience was actually published 1 month prior to Dr. Furlow's reporting on 106 patients and using a modified technique. Similarly, they too described an improvement in VPI as compared to their prior experience. They reported having used the surgery in patients with submucous cleft palate as well as a revision technique for VPI following primary palatoplasty. Subsequent publications from that institution continue to support excellent results.[124,127] A 30-year retrospective experience using a modified technique in 869 patients was published in 2013.[128] Of all analyzed patients, 72.5% had competent or borderline competent mechanism and 21.5% with borderline incompetence but intelligible speech using Pittsburgh weighted speech scale as an outcome measure. Only 8% of patients overall required a secondary pharyngeal surgery. This is the largest single institution volume of patients reported in the literature to date and the results are both consistent and encouraging.

Other retrospective institutional publications are in support of similar speech outcomes with the Furlow technique.[133] Additionally, some comparisons between Furlow and straight line techniques without IVV suggest superiority of the Furlow technique.[134,135] However, a small retrospective analysis comparing Furlow versus straight line repair without IVV failed to show any statistically significant difference in outcome.[136]

A retrospective single surgeon comparison between outcomes with Furlow palatoplasty versus straight line palatoplasty *with* IVV demonstrated a trend toward poorer speech score outcomes in the IVV group but the difference was not statistically significant. The rate of a necessary salvage procedure for VPI, however, was far superior in the Furlow group (8% vs. 29% in the IVV group) and showed statistical significance suggesting superiority by that measure of success.[137] A limitation of this study design, though, is that a single surgeon may not be equally skilled in the two techniques as may be suggested by the VPI rate following IVV being quite high when compared to the strongest reported outcomes from other institutions/individuals for that procedure.[138,139]

A large, high level, prospective study of 467 patients by Williams also claims superiority of the Furlow technique versus a straight line repair technique utilizing intravelar veloplasty with regard to velopharyngeal function.[140] That study used a cul-de-sac test of hypernasality and a mirror test of nasal air emission as a primary measure of velar function and combined that with a four-point hypernasality scale to rate resonance as a secondary measure during patient interactions with the speech and language pathologist. The cul-de-sac test showed a statistically significant advantage of the Furlow technique: however, none of the

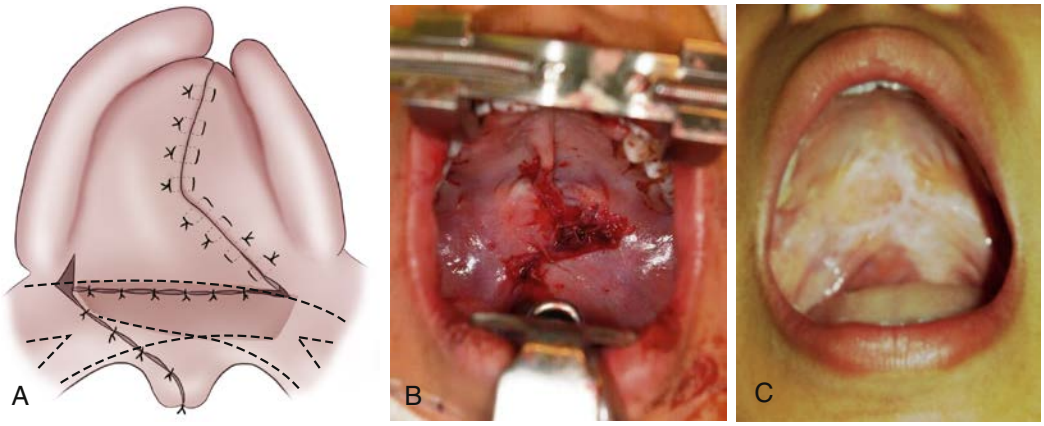

• **Figure 30-13** **A,** Oral side flaps are now rotated and secured, successfully rotating the abnormal musculature from the patient's left side to span the cleft in an appropriate posterior position. There is overlap of the muscles of both posterior based flaps and a lengthened soft palate at the conclusion of the surgery. Everted, tension free closure is of paramount importance. **B,** Immediate post-op. **C,** Six month follow-up same patient. (From Furlow LT Jr: Cleft palate repair by double opposing Z-plasty, *Plast Reconstr Surg* 78:724-736, 1986.)

other results—while suggestive of an advantage—proved statistically insignificant.

Versatility

While initially developed as a technique for primary repair for cleft palate, usefulness for a variety of indications has emerged. Surgical management of VPI in submucous cleft palate (SMCP) and as a revision procedure for postsurgical VPI in an attempt to avoid pharyngeal flap or other pharyngeal speech surgeries is gaining favor. Avoidance of a P-flap in management of VPI is appealing due to high potential for development of postoperative snoring, obstructive sleep apnea,[141,142] and possible overcorrection resulting in hyponasal speech. Retrospective data suggest success rates with the Furlow technique may be no different statistically than P-flap in some patients.[143] Additionally, prospective data suggest a clear advantage of Furlow palatoplasty over P-flap with regards to developing OSA.[144]

There are multiple groups that have used Furlow palatoplasty techniques for surgical management of VPI in patients with SMCP, including that data in analysis along with all other cleft subtypes with satisfactory results.[124,127,128,131,133,142,143,145,146] Others, though, have examined specifically VPI of the patient with SMCP excluding other cleft subtypes. Chen retrospectively examined 30 patients with VPI due to SMCP managed with a Furlow technique and reported achieving a competent velopharyngeal mechanism and normal resonance in 29 of them with no complications. Importantly, there were multiple specific inclusion criteria with regards to VP gap size in relation to age as well as response to biofeedback speech therapy preoperatively that were used to select patients for Furlow palatoplasty. The significance of those criteria on outcomes, though, is unclear and was never verified independently.[147] In a 10-year retrospective by Seagle successful outcomes in 83% of cases was reported with the Furlow technique in SMCP associated VPI. The highest rate of success was seen in patients with velopharyngeal gaps of 8 mm or less.[148] A small prospective study by Abdel-Aziz was published in 2012. In it, 15 patients with SMCP and VPI that was not improved with prior speech therapy were managed with the Furlow technique. Thirteen of the 15 had complete velopharyngeal closure on postoperative nasopharyngoscopy as well as statistically and clinically significant speech improvement with no incidence of hyponasal speech.[149]

Use of the Furlow palatoplasty for VPI after a failed surgical attempt rather than a pharyngeal surgery is also proving useful, though distinct data examining it as a revision procedure separating it from VPI associated with SCMP are scarce. A prospective paper by Deren examining the Furlow technique as a revision technique after Veau-Wardill-Kilner palatoplasty with VPI confirms effectiveness. Eight of the 27 patients had normal resonance and no nasal escape postoperatively and 10 had normal resonance with mild nasal escape or no nasal emission but mild hypernasal resonance. The remaining 33% were considered failures, but still had signs of improvement relative to preoperative assessment.[150]

The presence of a syndromic diagnosis is considered a confounding variable when evaluating outcomes of palatoplasty and is variably excluded from data sets. While not a true syndrome, Pierre Robin sequence is also often excluded from data and lumped into the syndromic category. The data sets that do include syndromic diagnoses tend to show little difference in success rates between syndromes and sometimes show success rates inferior to outcomes compared to "non-syndromic patients."[151-153] A prospective evaluation, however, examining Furlow palatoplasty for surgical VPI management that included "syndromic patients" in outcomes analysis showed no statistically significant difference in velopharyngeal insufficiency outcomes between those that did and did not carry a syndromic diagnosis (an exception being patients with 22q11 deletion syndrome). Carrying a diagnosis of velocardiofacial syndrome has been shown to be particularly troublesome as it is consistently difficult to correct VPI.[146,153]

Furlow palatoplasty, however, is not the only revision palatoplasty option for addressing VPI. Two-flap repair with aggressive intravelar palatoplasty using intraoperative magnification has a high rate of achieving velar competence and satisfactory speech improvement.[154] A head to head comparison of these techniques specifically for management of VPI as a revision does not exist to date, though a small series by Afrooz suggests that Furlow palatoplasty might be more effective than two-flap palatoplasty with IVV in patients with some syndromic diagnoses diagnosed with occult submucous cleft palate.[152] This series, though, was relatively small and retrospective.

Growth

With regards to growth, little information following Dr. Furlow's early comments in his publications exist. The large prospective study from the University of Florida Craniofacial Center and the University of São Paulo Hospital for Rehabilitation of Cleft Lip and Palate in Bauru, Brazil, provided growth charts for babies born with deformities, but it failed to present the objective long-term growth data about the effect of different techniques used for initial cleft lip and palate repair on subsequent facial growth to date as was once hoped.[155] Meaningful growth data require follow-up until skeletal maturity of the craniofacial skeleton, making these studies highly difficult to complete and rarely undertaken. With much variability between surgeons and centers in technique and age at time of repair, attributing growth effects to the technique of the soft palate repair alone would be difficult. In addition, with the possible exception of transverse width of the hard palate following repair of the soft palate,[156] it is most likely that growth of the mid-face is affected more by scarring of structures forward of the soft palate with severity relating more to age, technique of hard palatoplasty, and extent of dissection on the alveolus at the time of repair.[117,157-160]

Ear Health

Eustachian tube dysfunction in patients with cleft palate is well documented, often requiring close otologic follow-up and care. Dr. Furlow initially described achieving 70% normal hearing in his cleft patient population postoperatively with only 5 of 20 patients having a mild hearing loss. He attributed this to the nasal Z-plasty incisions ending immediately adjacent to the eustachian orifices.[122] It should be noted that no division of the tensor tendon was discussed in his original paper. In contrast, a retrospective study from Güneren published in 2000 found no difference between Furlow and VWK push-back in terms of eustachian tube function and presence of postoperative serous otitis media.[161] While stating that there were no modifications of the Furlow technique, there was no comment on whether or not the tensor tendon was divided in this study. A paper by Antonelli published in 2010 prospectively looked at ear outcomes in patients treated with Von Langenbeck vs. Furlow and found no difference in outcomes.[162] Whether or not tensor tendon tenotomy has an effect on hearing outcomes or eustachian tube function is not clear at present. Regardless, it appears that Furlow outcomes are no worse than other methods in this regard.

Limitations and Complications

Fistula

In his first publication of the technique, Dr. Furlow described difficulty with a wide U-shaped cleft. It is widely accepted today that the widest clefts may not be repairable with the Furlow technique because the length gained from Z-plasty is at the expense of width by design. Fistula formation is a known complication of all methods of palatoplasty with highly variable rates of occurrence in the literature.[163] Fistula rates with the Furlow technique, however, are cited as being increased relative to 2-flap techniques.[140,164-167] Various modifications have been described to address this. The use of releasing excisions, for example, has been associated with a lower incidence of fistula in addition to other modifications of technique.[140]

The use of acellular dermis in both primary palatoplasty and fistula repair has been shown to aid with lowering fistula rates.[167-169] Levi published an extension of a previously utilized concept in straight line repairs that incorporates buccal fat pad into Furlow palatoplasty both to combat fistula formation and to cover large areas of denudation of the hard palate.[170] Bindingnavele[171] described islandization of the hard palatal mucoperiosteal flaps while maintaining integrity of greater palatine artery pedicle to decrease tension of final closure and optimize mobilization. This technique compared to Furlow without islandization showed a statistically significant benefit of islandization to decrease rate of fistula formation.[171]

Gupta published a paper incorporating buccal myomucosal flaps for very wide unrepaired clefts in mature adult patients.[130] Oyama, focusing on growing babies, published a mucosal adhesion technique for staging palatoplasty in growing patients where wide clefts were converted to narrower ones that are more amenable to Furlow technique with tension-free closure. Results in this small series were effective in narrowing the width of palatal cleft over time with limited detrimental growth effect, though the series was small and follow-up short.[156]

Teaching

Another perceived limitation of the Furlow technique is that it is difficult to learn and teach. Comprehension of the procedure only from text or diagram is difficult. Various attempts at techniques to aid in the learning process have been published.[172,173] A paper by Losken, though, showed that surgical participation in the technique by a novice operator can still result in good outcomes when strict criteria are maintained in patient selection.[174] From experience, observing the live procedure just one time quickly clarifies many of the uncertainties of concept for the novice surgeon. Technical skill develops with repetition.

Summary

The double opposing Z-plasty technique commonly referred as the Furlow technique has proven to be a useful and effective technique in palatal reconstruction. One should remember though that "the Furlow" does not describe a single operation as multiple variations and modifications exist. Therefore, the available literature should be taken with the proverbial grain of salt when considering translation into one's practice. It is, of course, only a hammer in the metaphoric tool belt of the cleft surgeon and one must remember that not all patients are nails. While supporters of the technique would like to prove complete superiority over all other methods, it should be remembered that literature exists that supports some of those claims but an equivalent body of literature either refutes them or shows equivalent outcomes to straight line techniques, typically, with IVV. Because so many difficulties exist in creating a bias-free body of literature that accounts for all of the multiple variables in cleft care, it is important to familiarize oneself with all of the available literature and recognize that, like most techniques, there are instances where use of this technique will be ideal and others where use of many of the other techniques would also prove effective. Ideally, with experience, the cleft surgeon will recognize the utility of this procedure and utilize it for its strengths in appropriate situations. Surgeons should constantly examine their own outcomes in a systematic, objective way and not be wary of changing old habits for new methods in search of better outcomes.

TWO-STAGE PALATAL REPAIR

GERARDO P. ROMEO, PAMELA M. GALLAGHER

The growth problems encountered in patients surgically treated for cleft lip and cleft palate have long been recognized and are well described. Mid-face retrusion, distortion

of dentoalveloar structure, and abnormal posture and position of the mandible have been long accepted as the most commonly occurring abnormalities associated with cleft palate repair.[175-182] One approach developed in the attempt to minimize the mid-facial growth restriction has been to "stage" the repair of the palatal defects.

Staged repair of the palate, sometimes called delayed repair of the hard palate, refers to separation of the veloplasty from the surgical repair of the cleft hard palate, classically termed uranoplasty, into distinct procedures at differing points in growth and development. The rationale behind this technique is to minimize any unnecessary growth restriction associated with the surgical repairs of the hard palate while facilitating the development of normal speech by creating a functional soft palate. Ideally, veloplasty might occur before compensatory speech errors and poor habits develop early in life. While the technique is not as popular in the United States as is single-stage palate repair, in which the velum and hard palate are repaired in a single operation,[183] it has a long-standing history of use in various centers throughout the world. Like all other aspects of surgical care of patients born with clefts, the approach has both supporters and critics with variable levels of literature available supporting claims made by both.

Origins

In the context of the time period in which this approach originated, severe mid-facial growth restriction, the resultant cosmetic deformities, and malocclusion were nearly impossible to correct meaningfully. Orthognathic surgery, particularly of the maxilla, was in its infancy, therefore, one must remember that the two-staged repair was born from necessity.

The concept for the technique was initially presented by Gillies and Fry in 1921.[175] Recommendations were for soft palate repair utilizing a technique that involved division of the soft palate and aberrant musculature from the hard palatal shelves, retropositioning of the velum to gain length posteriorly, and repair of the soft palate and musculature across the cleft in the midline. The remaining cleft of the hard palate was then managed with a removable obturator prosthesis. The concept of delaying the repair of the hard palate until a later point in time was mentioned, but in fact, the recommendation of the author was not to repair the hard palate at all.[184] The approach failed to gain popularity initially but the concept gained support later after being re-introduced in 1951 by H. Schweckendiek in Europe and later by Slaughter and Pruzansky in the United States.[185,186]

A landmark publication in 1978 by W. Schweckendiek detailed a 25-year retrospective report on the patients that had been treated using the staged surgical protocol developed by his father. The soft palate was repaired in the first year of life in straight line fashion utilizing lateral releasing type incisions. This was followed by lip repair approximately 3 weeks later. The hard palate was not repaired until middle to late adolescence (12 to 14 years of age). The residual hard palate defect was not obturated until eruption of the permanent incisors and first molars, if at all. The results were compelling in that transverse and AP maxillary growth was excellent with harmonious occlusion and satisfactory speech outcomes were reported by the surgeon.[187]

Various centers began to explore staged repair as a viable alternative at this point in history. Ultimately though, publications highlighting compromised speech outcomes and questioning the extent and significance of benefits to growth began to accumulate[188-191] and the approach failed to maintain a stronghold in most centers in the United States.

Various staged protocols have been developed and utilized since the initial description in 1921. The only commonality shared by all of them is that the hard and soft palate defects are repaired at differing points in time. This fact makes review and meaningful comparison of the literature challenging. Additionally, the overwhelming majority of available literature on the topic is retrospective and riddled with biases.

Many variations exist under the blanket term of "staged" or "delayed hard palate" repairs and meaningful generalizations are nearly impossible to make with any degree of accuracy. For simplicity, when discussing staged approach to palate repairs, the implied definition involves velar repair in the first year of life up until 18 months, optional use of an obturator both before and after velar repair, and hard palate repair in the preschool or early school age though, to be clear, this is not a strict definition nor is it universally accepted.

Optimal Timing and Technique

Staged repair and the question of its utility is more a series of individual questions regarding optimal techniques and timing of different aspects of care rather than a single question with a single answer. With that, it would seem that a single generalization regarding usefulness of the technique that can be applied to all patients and centers cannot exist. Therefore, it makes sense to examine some of the individual aspects of staged repair and their history via the literature en route to a meaningful attempt at drawing some conclusions.

Velum

Early in it's history, the first protocols involved repair of the velum anywhere from the first year of life to 3 years of age.[175,185,186] As focus shifted from minimizing growth restriction to the importance of developing ideal speech, the age at which velar repair occurs has steadily shifted towards earlier in life,[192-194] with benefits being reported when velar repair occurs at the first signs of the development of canonical babble.[194] Literature regarding timing of repair both as single and staged repair typically recommends repair occur before 18 months,[195] ideally between 9 and 12 months,[194] and perhaps as early as 3 to 6 months of age,[196,197] with the most commonly accepted practice being that individual speech development should dictate optimal velar repair for speech rather than any specific chronologic age.[194,198] Blanket

application of these suggested parameters regarding timing, however, is not suggested because the recommendations were made in the specific context of the studies from which they were derived. For example, there may be no perceivable benefit to very early palatoplasty in cases of definitive one-stage repair utilizing double opposing Z-plasty techniques,[199] but in instances where specific staged palatoplasty techniques incorporating very early velar repairs that limit dissection of the hard palate and healing of extensive areas of denuded hard palate secondarily are avoided, highly acceptable speech outcomes using delayed hard palate repair techniques have been confirmed. In literature published from the center in Göteberg, Sweden, for example, the staged technique utilized which incorporates very early repair of the velum using a specific, standardized technique described by Liljia,[200] main tenets of which included limiting dissection of the hard palate to the most posterior edge and minimizing remaining denuded areas to heal by secondary intention after repair, has resulted in highly encouraging phonation of consonants, absence of glottal substitutions, and excellent velopharyngeal function.[196,201] One should always keep in mind though, that many techniques are used in the repair of the soft palate with a seemingly endless number of variations, so it is not clear that applying conclusions between studies would apply to all, or any, other techniques. For example, selectively utilizing the timing of repairs discussed above with techniques for velar repair that incorporate an extensive hard palatal dissection or other techniques that result in an extensive amount of denuded hard palatal bone to heal via secondary intention or neglect to provide a meaningful reconstruction of the soft palate musculature may result in a compromise of either speech, growth, or both. There have been numerous publications that show, however, that high level speech results and preserved maxillary growth can be achieved in staged approaches that utilize both double opposing Z-plasty techniques and two-flap repairs with intravelar veloplasty.[202-207] The common theme in all of these techniques is limited dissection of the hard palate and minimal to no denuded bone left to heal by secondary intention.

Maxillary Obturator Appliance

Prior to Velar Repair

Obturator prostheses provide a mechanical barrier separating the oral and nasal cavities while the cleft defect is present. The use of these appliances both before velar repair and afterwards while waiting for hard palate repairs has been described in the literature. Some centers advocate use of a prosthesis to aid in feeding and phonation and to promote harmonious positioning of dentoalveolar segments, at times using it along with nasoalveolar molding techniques, prior to lip (and velar) repair. At the present, the overwhelming majority of the appliances are passive given the growth restriction seen previously with active appliances.[208] While some literature has suggested that use of a passive obturator in infancy may initially aid in speech development, it has not been shown to translate into a sustained benefit with age, with differences no longer appreciable by age 6 years.[209,210] With regard to use of passive style obturators prior to velar repair, multicenter trials have failed to show a definitive long-term benefit with regard to speech development, feeding, and long-term cosmetic outcomes and they may actually increase care burden and cost unnecessarily for some children and their caretakers.[211-214] It should be noted, however, that use of passive appliances prior to veloplasty have never been shown to be harmful to the patient or compromise outcomes and therefore are not necessarily contraindicated.

Following Velar Repair

Use of an obturator appliance after velar repair and before hard palate repairs is another area of controversy within the staged approach and is commonly described throughout the literature. The goal of use of the prosthesis after veloplasty, similarly to when used prior to repair, is to provide mechanical separation between the oral and nasal cavities for facilitation of feeding and speech production. Some utilize an appliance for all patients between velar and hard palate repairs. Some never utilize an appliance while others allow for selective use in some circumstances where difficulties with speech or feeding become overwhelming for the patient and caretakers. Centers that advocate usage often claim facilitation of speech and feeding[187,195] while others report that they are unnecessary with many children achieving satisfactory speech (with obvious limitations based on the residual hard palate defect) without them so long as intensive speech therapy is accessible.[187,195,196,201]

In the instances where appliances are utilized, most are passive, some are removable, and some use pin retention. The specific effect of the obturator both with regard to speech and influence over growth and long-term effects on occlusion are sparse in the literature. Some are of the opinion that pin retention of the obturator is associated with increased growth restriction and often cite a report by Holland and colleagues to support that sentiment. However, it should be appreciated that the protocol described in that center at the time involved placement of serial obturators replaced for "optimal fit." Additionally there was an excessively high rate of fistula formation in that report and the majority of patients underwent multiple revision procedures to the palate as well as a significant number of speech related surgeries in the pharynx.[215] Therefore, suggesting that the observed growth restriction was due to the staged approach itself and/or pin retention of the prostheses alone rather than the increased number of surgeries and scarring in those patients may not be accurate. Furthermore, hard palate collapse after veloplasty has long been appreciated to occur spontaneously and there has never been a study examining if pin retention versus no retention results in collapse of any further significance compared to veloplasty without postoperative use of an obturator. Although it is possible that fixed obturators may impede growth there is no high level evidence to support this claim at this time. It would be just as reasonable to assume that pin retention may actually prevent more collapse than a removable appliance without pin retention or no prosthesis at all. Until a meaningful comparative study

examining this becomes available, however, the use of a passive palatal obturator either with or without pin retention is equally acceptable, as is the decision to not use an appliance between velar and hard palate repairs so long as the patient tolerates whichever approach is selected.

Uranoplasty

The age and style of hard palate repair is also variable with ranges reported anywhere between 15 months and young adulthood with numerous variations of surgical techniques being utilized. Similarly to the timing of velar repair, the age at which the hard plate repairs occur has become younger and younger with time with no single age universally accepted as "ideal" in an attempt to limit aberrant speech and minimize growth restriction. Gillies delayed hard palate repair indefinitely.[1] Later publications delayed repair until skeletal maturity in the teenage years with excellent growth results.[187,189] As time went forward, repairs were completed earlier still between the ages of 6 and 10 years, again with excellent long-term growth results.[195,201,216,217] When both growth and speech outcomes were compared in children that had repairs earlier still at 3 to 5 years of age, again, no significant difference regarding both speech and growth were evident when compared to longer delays in hard palate repair (between 6 and 10 years of age).[218-221] As a result, this range of approximately between 3 and 5 years of age is highly acceptable, though some reports describe even younger ages for repair.[197]

While, typically, two-flap techniques for mucoperiosteal repair of the hard palate cleft have been the most common methods examined, many variations with regard to flap design, extent of dissection, and techniques to obliterate dead space or provide coverage of denuded areas are included in the literature. The true extent of these modifications is poorly examined in the context of staged repairs but it is likely that they have the most potential for impact if hard palate repairs are completed very early in life, in which case avoidance of excessive scarring and avoidance of leaving denuded areas to heal by secondary intention are advisable.

Though not a new technique, one of the most significant variations in recent history relating to staged hard palate repair, and steadily gaining popularity, is the use of a single-layer vomer flap and complete avoidance of oral side mucoperiosteal dissection. In some reports this occurs simultaneously with lip repair and separate from velar repair, which would qualify it as a staged technique. In others, it is incorporated during repair of the velum (which would be considered a single-stage technique). Many reports suggest favorable speech and growth, though not all have a sufficient length of follow-up to make definitive generalizations.[221-225]

Supporters, Critics, the Literature, and Conclusions

The benefits reported by supporters of the staged technique both historically and currently remain consistent. The main advantage is a decreased incidence of iatrogenic growth restriction, particularly in terms of anterior-posterior projection.[175,185-187,189,195,197,202-205,216-220,226,227] Second, there is a decrease in the size of the residual hard palate cleft following soft palate repair which has often been reported to facilitate repair of the hard palate at the subsequent operation and, in the best of circumstances, achieve spontaneous functional closure of the hard palate. With this, the resultant proximity of the palatal shelves limits the amount of hard palate dissection necessary to complete surgical closure thereby facilitating hard palate repair using oral side mucoperiosteal flaps.[186,187,206] Dental arch form and relationships, typically aided by orthodontic treatment, have also been shown to develop more similarly to those of people born without cleft deformity. This in turn has been associated with a decreased need for orthognathic surgery in many publications.[205,216,217] Last, and of at least equal significance, is that the construction of a functional vellum in the first year of life allows for achievement of highly acceptable speech over the long term albeit with specific protocols and often requiring intensive speech therapy.[196,201,221]

Critics of the technique most often cite poor speech outcomes as the greatest drawback to utilizing staged approa ches.[189-191,215,217,228] The types and severity of speech disturbances vary between publications, but the overwhelming majority of reports discuss articulation errors and substitution errors, followed by velopharyngeal incompetence/insufficiency. There is great difficulty, however, in making generalizations from these publications for a multitude of reasons. First, much of the literature is historic and occurred before proper attention was paid to the dissection and reorientation of velar musculature. This is a significant confounder when staged historic protocols that are then compared to more recent data sets which do incorporate those techniques. Second, the age range at which velar repairs occur is very broad both across and within individual publications, sometimes occurring as late as 3 years of age. This would clearly conflict with the modern understanding of the benefits of having velar repair occur prior to 18 months, likely best between 9 and 15 months of age and dictated by individual speech development. Therefore including children that were repaired at 12 months with children repaired at 24 months or even 36 months, as has been reported, would skew the results. The use of obturator prostheses is also highly variable and may create speech related biases in a way that is not clearly understood. For example, is it appropriate to compare identical surgical protocols with regard to timing and technique if one requires use of an obturator at birth and continued until hard palate repair to one that does not use an appliance at all or to one that introduces the appliance at 5 or 5 years of age, after much compensatory speech has developed? Examples such as these illustrate "apples to oranges comparisons" in the literature which are often used to bolster the sentiment of those that believe that staged repairs are not viable options. Additionally, there is no scarcity of publications that have relied on surrogate markers such as number of velar revisions or number of pharyngeal flap procedures to describe

incidence of VPI without description of objective criteria, if any were used, to determine the diagnosis or clear indication for the procedure(s). This use of surrogate markers does not necessarily translate into useful data, but many generalizations have been made citing literature that contains them.

Regarding speech assessment in many publications, one should take note of the fact that very few centers validate intra- and inter-rater reliability. Some publications do not necessarily represent objective assessment while blinded to the relevant details that would provide bias (which can be achieved, for example, by rating deidentified high level recordings rather than live patients) and there is a true scarcity of speech publications that are completed by speech professionals that do not have a direct affiliation with the operator or parent institution (which makes the reliability of an already subjective specialty even harder to guarantee). However in recent history, great efforts have been made at attempting to make this the common standard for high level speech related publications. Currently, the centers that are publishing speech data and making the strongest attempts to eliminate or account for biases and confounders tend to support that specific staged approaches can result in excellent growth advantages while achieving very high level speech outcomes long term, albeit with intensive speech therapy. Those publications examine specific protocols over long periods of time and make great efforts to rate speech as objectively as is possible by incorporation of rater blinding and calibration. In addition, compensatory speech problems are examined in a sophisticated manner in which different types of substitutions are not grouped together. Rather they differentiated from one another and considered in the context of the anatomic limitations presented in the individual patients. For example, a velar compensatory sound in a patient with an open hard palate and intact velum is different from a glottal substitution (which is more difficult to correct with speech therapy) and so they warrant different consideration. While some centers would simply group both into the category of "an error" they potentially have very different potential for successful correction after the anatomy is corrected to where the velar sound, for example, can now be created appropriately at the ridge of the intact alveolus. This highly sophisticated approach has helped to clarify that a generalized diagnosis of "poor speech" is insufficient and that in context and with time staged approaches can lead to very high levels of both intelligible speech and preserved growth over the lifetime of the patient.[196,201,216,219-222]

The second most common claim of those who are in opposition to staged techniques is that the growth restrictions encountered in one-stage repairs are not significantly different from growth observed with two-stage techniques.[215,229] Those publications tend to share common shortcomings. Sometimes the growth data are not evaluated after skeletal maturity (though this has also been the case in some of the supportive literature) and therefore, potentially, do not represent a valid final outcome measure. Most commonly though, confounding variables such as excessive numbers of surgical procedures, use of surgical techniques that are known to be associated with excessive growth restriction, and the secondary effects of variations in other phases of care (i.e., primary bone grafting, secondary bone grafting, and variations of lip and nasal surgery techniques) are overlooked when drawing conclusions and making generalizations. While it is completely true that some staged techniques can result in significant growth restriction depending on the specific details of timing and techniques utilized, this should not be applied to "staged repairs" as a whole. Many publications have examined the most sound techniques—those that have made great efforts to avoid needless dissection of the hard palate and avoid leaving denuded areas to heal by secondary intention, and that control for additional variables that are introduced by way of the additional phases of care—and they almost universally show advantages in mid-facial growth by delaying hard palate repair.[230]

Conclusions

Staged palatoplasty in the modern era is seemingly becoming less popular, especially in the United States, though the trend may begin to change as centers that utilize vomer flap for nasal side only repairs report outcomes over time. There are enough supportive data, however, that illustrate that the growth benefits of some of the more classic staged repair approaches can be superior to some single-stage techniques with regard to avoiding excessive mid-face growth restriction and still achieve highly acceptable speech outcomes over the long term, so long as individual techniques and timing are true to the published protocols and the patients have access to adequate speech therapy. If a staged protocol is to be used, ample support exists in support of velar repair between 9 and 12 months of age dictated by speech development. In the hands of some surgeons and with some protocols, velar repair can be successful as early as 5 to 7 months and perhaps as late as 15 to 18 months depending, again, on individual speech development of the patient. Multiple techniques can be used successfully for velar repairs in stages, as long as velar musculature is appropriately addressed, very limited dissection of the posterior hard palate occurs, and little to no denuded maxilla remains exposed to heal by secondary intention. While widespread benefits of preoperative obturator appliances when compared to use of no appliance are not necessarily supported by some objective measures in the literature, they do little harm, if any, and may provide significant benefits to some patients, perhaps in terms of avoiding development of some compensatory misarticulations and in ease of feeding depending on when in development they are introduced. The decision to use an obturator after velar repair while awaiting hard palate repair has also been shown to be unnecessary, particularly in speech production; but, again, passive appliances, removable or pin retained, tend to be highly convenient and well tolerated by the patient and have not been proven to do any harm. Repairs of the hard palate can occur anywhere between 18 months and 8 years

of age, with literature that has examined patients beyond skeletal maturity demonstrating excellent growth results with no perceivable compromise in results in the range of 3 to 5 years of age. There is a true possibility that hard palate repair can occur earlier in the life of the child as long as specific approaches/techniques are adhered to (i.e., use of a vomer flap only), but it is premature to utilize this time frame routinely, particularly with repairs that involve oral side mucoperiosteal flap repair of the hard palate. There is little if any negative effect from delaying hard palate longer if so desired, though it is not necessary. In order to optimize growth, maxillary and alveolar cleft bone grafting procedures should not be combined with the earliest of hard palate repairs. However, bone grafting may be incorporated into the hard palate repair as long as the child is in the early mixed dentition at the time of uranoplasty.

The author's personal sentiment is that the concept of staging should not be forgotten or archived in history while there are still so many questions left to be answered. Efforts should be made in individual centers to examine if incorporation of these techniques might help to improve the long-term outcomes of some of their patients, particularly if mid-face retrusion and long-term cosmetic goals are not being met. Well designed prospective studies should then be conducted to attempt to clarify any of the many controversies that exist regarding the specifics of timing and technique. While there is no standardized, universally accepted staged protocol, with the data currently available and with understanding of the strengths and limitations of those studies, delayed hard palate repair techniques can achieve excellent results with regard to mid-facial growth, decrease the need for orthognathic surgeries for a significant number of patients and result in very good speech.

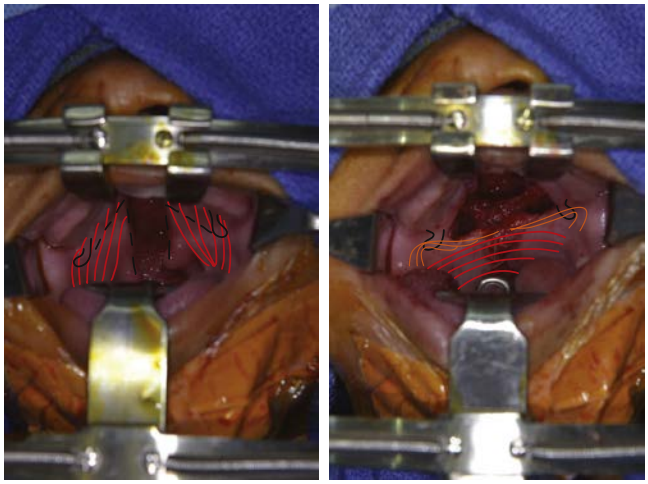

• **Figure 30-14** A variation of a straight line technique, similar to that initially described by Gilies, which additionally incorporates intravelar veloplasty, and avoids dissection of the hard palate. The result is a retropositioned velum with intact musculature. In some variations, the retropositioned nasal side flap is fixed to a small posteriorly based vomer flap (not illustrated in this instance) to help in maintaining retroposition. A maxillary obturator prosthesis may now be inserted with or without pin retention according to protocol.

Our Center

With the available data in the current literature, our center continues to utilize a staged technique for some patients. The approach involves lip repair completed between 3 to 6 months of age with advancement and rotation flap techniques. Most children receive presurgical nasoalveolar molding in the months leading up to lip surgery. Velar repair, usually with a double opposing Z-plasty or with a technique similar to the technique originally described by Gillies for the widest of cleft palates, is completed between 9 and 12 months of age (Figure 30-14). A single, passive palatal obturator appliance, retained with screws, is inserted intraoperatively immediately upon completion of velar repair under the same general anesthetic and remains in place from this point forward until the repair of the hard palate (Figure 30-15). There is no attempt to replace or refit the prosthesis as the child grows. In some instances, hard

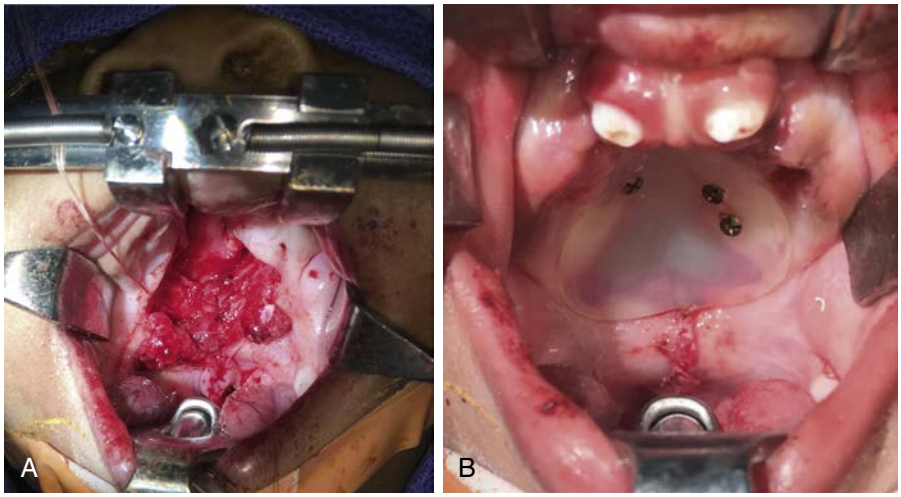

• **Figure 30-15 A,** Intraoperative view following nasal side repair and intravelar veloplasty, oral side flaps retracted. **B,** Immediate post-operative view after oral side closure and insertion of maxillary prosthesis.

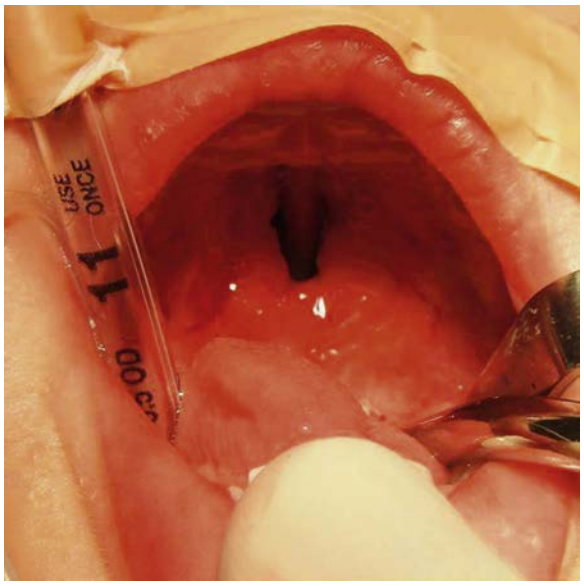

• **Figure 30-16** Image of palatal defect following removal of pin-retained palatal obturator prosthesis immediately prior to hard palate repair by two-flap mucoperiosteal flap technique. Note proximity of palatal shelves and low level mucosal inflammation which is typically seen with this use of a prosthesis. (Courtesy Dr. Pamela Gallagher)

palate repair is dictated by loosening or loss of the obturator. Otherwise, the obturator is removed at the time of hard palate repair around 3 to 4 years of age. Figure 30-16 illustrates the appearance of the healed velum (note the narrowed hard palatal cleft and the areas posterior to the hard palatal shelves that have healed in by secondary intention) after removal of the obturator prosthesis and immediately prior to repair of the hard palate. Anecdotally, there is a very high level of satisfaction in both practitioners and patients utilizing this approach with regard to cosmetics, functionality, and speech within our center. Data collection is ongoing regarding long-term outcomes.

References

1. Shaw WC, Dahl E, Asher-McDade C, et al.: A six-center international study of treatment outcome in patients with clefts of the lip and palate. Part 5. General discussion and conclusions, *Cleft Palate Craniofac J* 29:413–418, 1992.
2. Dorrance GM: *The operative story of cleft palate*, Philadelphia, 1933, W. B. Saunders.
3. Millard Jr RD: *Cleft Craft: The evolution of its surgery. III. Cautery or pairing and suturing the edges of the cleft palate*, Boston, 1980, Brown, pp 167–176.
4. Knoener W: Johann Friedrich Dieffenbach (1792-1847) pioneer in oral maxillofacial surgery, *J Hist Dent* 50:3, 2002.
5. Goldwyn RM: Bernhard Von Langenbeck, *Plast Reconstr Surg* 44:3, 1969.
6. Millard RD, JR: Refining the V-Y retropositioning. IN: *Cleft craft: the evolution of its surgery, vol 3, Boston,* 1980, Brown & Co., pp 419–448.
7. Rittersma J: The dentist as a plastic surgeon (Hugo Ganzer 1879–1960), *J Craniomaxillofac Surg* 16:51–54, 1988.
8. Bardach J: Two-flap palatoplasty: Bardach's technique, *Oper Tech Plast Reconstr Surg* 2:211–214, 1995.
9. Kreins OB: An anatomical approach to veloplasty, *Plast Reconstr Surg* 43:1, 1969.
10. Edgerton MT, Dellon AL: Surgical retrodisplacement of the levator veli palatini muscle, *Plast Reconstr Surg* 47:2, 1971.
11. Dreyer T, Trier WA: A comparison of palatoplasty techniques, *Cleft Palate J* 21:251, 1984.
12. Marsh JL, Grames LM, Holtman B: Intravelar veloplasty: a prospective study, *Cleft Palate J* 26:46–50, 1989.
13. Cutting C, Rosenbaum J, Rovati L: The technique of muscle repair in the cleft soft palate, *Op Tech Plast Reconst Surg* 2:215–222, 1995.
14. Sommerlad BC: A technique for cleft palate repair, *Plast Reconstr Surg* 112:1542–1548, 2003.
15. Friedman O, Want TD, Mulcuzuk HA: Cleft lip and palate. In Cummings CW, editor: *Otolaryngology: head and neck surgery*, Philadelphia, 2005, Mosby, pp 4052–4082.
16. Perry JL: Anatomy and physiology of the velopharyngeal mechanism, *Semin Speech Lang* 32:83–92, 2011.
17. Huang MHS, Lee ST, Rajendran K: Anatomic basis of cleft palate and velopharyngeal surgery/implications from a fresh cadaveric study, *Plast Reconstr Surg* 101:3, 1998.
18. Cho JH, Kim JK, Lee HY, et al.: Surgical anatomy of the soft palate, *Laryngoscope* 123:2900–2904, 2013.
19. Rudding R: Cleft palate anatomic and surgical considerations, *Plast Reconstr Surg* 33:132–147, 1966.
20. Abe M, Murakami G, Noguchi M, et al.: Variations in the tensor veli palatini muscle with special reference to its origin and insertion, *Cleft Palate Craniofac J* 41:474–484, 2004.
21. Barsoumian R, Kuehn DP, Moon JB, et al.: An anatomic study of the tensor veli palatini and dilatator tubae muscles in relation to eustachian tube and velar function, *Cleft Palate Craniofac J* 35:101–110, 1998.
22. Mendonca D, Patel K, Skolnick GB, et al.: Anatomical study of the effects of five surgical maneuvers on palate movement, *J Plast Reconstr Aesthet Surg* 67:764–769, 2014.
23. Boorman JG, Sommerlad BC: Levator palate and palatal dimples: their anatomy, relationship and clinical significance, *Br J Plast Surg* 38:326–332, 1985.
24. Katzel EB, Basile P, Koltz PF: Current surgical practices in cleft care: cleft palate repair techniques and postoperative care, *Plast Reconstr Surg J* 124:3, 2009.
25. Salyer KE, Sng KW, Sperry EE: Two-flap palatoplasty: 20-year experience and evolution of surgical technique, *Plast Reconstr Surg* 118:193–204, 2006.
26. Nguyen D, Patel KB, Skolnick GB, et al.: Progressive tightening of the levator veli palatini muscle improves velopharyngeal dysfunction in early outcomes of primary palatoplasty, *Plast Reconstr Surg J* 136:131–141, 2015.
27. Andersson EM, Sandvik L, Semb G, et al.: Palatal fistulas after primary repair of clefts of the secondary palate, *Scand J Plast Reconstr Surg Hand Surg* 42:296–299, 2008.
28. Cohen SR, Kalinowski J, LaRossa D, et al.: Cleft palate fistulas: a multivariate statistical analysis of prevalence, etiology, and surgical management, *Plast Reconstr Surg* 87:1041–1047, 1991.
29. Furlow LT: Cleft palate repair by double opposing Z-plasty, *Plast Reconstr Surg* 78:724, 1986.
30. Randall P, LaRossa D, Solomon M, et al.: Experience with the Furlow double reversing Z-plasty for cleft palate repair, *Plast Reconstr Surg* 77:569–576, 1986.

31. Hardwicke JT, Landini G, Richard BM: Fistula incidence after primary cleft palate repair: a systematic review of the literature, *Plast Reconstr Surg* 134:618–627, 2014.
32. Emory Jr R, Clay RP, Bite U, et al.: Fistula formation and repair after palatal closure: an institutional perspective, *Plast Reconstr Surg* 99:6, 1997.
33. Aslam M, Ishaq I, Malik S, Fayyaz G: Frequency of oronasal fistulae in complete cleft palate repair, *J Coll Physicians Surg Pak* 25:46–49, 2015.
34. Bresnick S, Walker J, Sheehan N, et al.: Increased fistula risk following palatoplasty in Treacher-Collins Syndrome, *Cleft Palate Craniofac J* 40:280–283, 2003.
35. Ahmed MK, Maganzini AL, Marantz PR, et al.: Risk of persistent palatal fistula in patients with cleft palate, *J Am Med Ass* 17:126–130, 2015.
36. Pigott RW, Albery EH, Hathorn IS, et al.: A comparison of three methods of repairing the hard palate, *Cleft Palate Craniofac J* 39:383–391, 2002.
37. Zheng W, Smith JD, Shi B, et al.: The natural history of audiologic and tympanometric findings in patients with an unrepaired cleft palate, *Cleft Palate Craniofac J* 46:24–29, 2009.
38. Smith TL, DiRuggiero DC, Jones KR: Recovery of Eustachian tube function and hearing outcome in patients with cleft palate, *Otolaryngol Head Neck Surg* 111:423–429, 1994.
39. Hassan ME, Askar S: Does palatal muscle reconstruction affect the functional outcome of cleft palate surgery? *Plast Reconstr Surg* 119:1859–1865, 2007.
40. Brgoch MS, Dodson KM, Kim TC, et al.: Timing of tympanostomy tube placement and efficacy of palatoplasty technique on the resolution of chronic otitis media: a cross-sectional analysis, *Eplasty* 15:e32, 2015.
41. Carroll DJ, Padgitt NR, Liu M, et al.: The effect of cleft palate repair technique on hearing outcomes in children, *Int J Ped Otorhinolaryngol* 77:1518–1522, 2013.
42. Smith LK, Gubbels SP, MacArthur CJ, Milczuk HA: The effect of the palatoplasty method on the frequency of ear tube placement, *Arch Otolaryngol Head Neck Surg* 134:1085–1089, 2008.
43. Antonelli PJ, Jorge JC, Feniman MR, et al.: Otologic and audiologic oucomes with the Furlow and von Langenbeck with intravelar veloplasty palatoplasties in unilateral cleft lip and palate, *Cleft Palate Craniofac J* 48:412–418, 2011.
44. Kummer AW: Disorders of resonance and airflow secondary to cleft palate and/or velopharyngeal dysfunction, *Sem Speech Lang* 32:2, 2011.
45. Riski JE, DeLong E: Articulation development in children with cleft lip/palate, *Cleft Palate J* 21:57–64, 1984.
46. Kummer AW: Speech evaluation for patients with cleft palate, *Clin Pastic Surg* 41:241, 2014.
47. Morr KE, Warren DW, Dalston RM, et al.: Screening of velopharyngeal inadequacy by differential pressure measurements, *Cleft Palate J* 26:42–45, 1989.
48. Harding A, Grunwell P: Characteristics of cleft palate speech, *Eur J Disord Comm* 31:331–357, 1996.
49. Sommerlad BC: Cleft palate re-repair: a clinical and radiographic study of 32 consecutive cases, *Br J Plast Surg* 47:406–410, 1994.
50. Witzel MA, Clarke JA, Lindsay WK, et al.: Comparison of results of pushback or von Langenbeck repair of isolated cleft of the hard and soft palate, *Plast Reconstr Surg* 64:347–352, 1979.
51. Grunwell PI, Brondsted K, Henningsson G, et al.: A six-center international study of the outcome of treatment in patients with clefts of the lip and palate: the results of a cross-linguistic investigation of cleft palate speech, *Scand J Plast Reconstr Surg Hand Surg* 34:3, 2000.
52. Lohmander A, Willadsen E, Persson C, et al.: Methodology for speech assessment in the Scandcleft project—an international randomized clinical trial on palatal surgery: experiences from a pilot study, *Cleft Palate Craniofac J* 46:347–362, 2009.
53. Chapman KL, Baylis A, Trost-Cardmone J, et al.: The Americleft Speech Project: a training and reliability study, *Cleft Palate Craniofac J* 52:4, 2014.
54. Birch MJ, Sommerlad BC, Fenn C, Butterworth M: A study of the measurement errors associated with the analysis of velar movements assessed from lateral videofluoroscopic investigations, *Cleft Palate-Craniofac J* 36:499–507, 1999.
55. Zajac DJ: Pressure-flow characteristics of /m/ and /p/ production in speakers without cleft palate: developmental findings, *Cleft Palate Craniofac J* 37:468–477, 2000.
56. Karnell MP: Instrumental assessment of velopharyngeal closure for speech, *Semin Speech Lang* 32:2, 2011.
57. Sommerlad BC: Evaluation of VPI-assessment with videofluoroscopy and nasoendoscopy, *Br J Plast Surg* 58:932–933, 2005.
58. Marrinan EM, LaBrie RA, Mulliken JB: Velopharyngeal function in nonsyndromic cleft palate: relevance of surgical technique, age at repair, and cleft type, *Cleft Palate Craniofac J* 35:95–100, 1998.
59. Krause CJ, Tharp RF, Morris HL: A comparative study of results of the von Langenbeck and the V-Y pushback palatoplasties, *Cleft Palate J* 13:11–19, 1975.
60. Bicknell S, McFadden LR, Curran JB: Frequency of pharyngoplasty after primary repair of cleft palate, *J Can Dent Assoc* 68:688–698, 2002.
61. Becker M, Svensson H, McWilliam J, et al.: Adult skeletal profile in isolated cleft palate: a comparison of the von Langenbeck and Wardill procedures for primary repair of the palate, *Scand J Plast Reconstr Surg Hand Surg* 35:387–389, 2001.
62. Farzaneh F: von Langenbeck procedures at 14 months or Wardill at 18 months for primary repair of cleft palate in adult Swedish patients with bilateral complete cleft lip and palate: a study of facial growth, *Scand J Plast Reconstr Surg Hand Surg* 43:4, 2009.
63. Perry JL, Kuehn DP: Magnetic resonance imaging and computer reconstruction of the velopharyngeal mechanism, *J Craniofac Surg* 20:1739–1746, 2009.
64. Brown AS, Cohen MA, Randall P: Levator muscle reconstruction: Does it make a difference? *Plast Reconstr Surg* 72:1–6, 1983.
65. Doucet JC, Herlin C, Captier G, et al.: Speech outcomes of early palatal repair with or without intravelar veloplasty in children with complete unilateral cleft lip and palate, *Br J Oral Maxillofac Surg* 51:8, 2013.
66. Andrades P: The importance of radical intravelar veloplasty during two-flap palatoplasty, *Plast Reconstr Surg* 122:1121–1130, 2008.
67. Brattstrom V, Molsted K, Prahl-Andersen B, et al.: The Eurocleft Study: intercenter study of treatment outcome in patients with complete cleft lip and palate. Part 2: Craniofacial form and nasolabial appearance, *Cleft Palate Craniofac J* 42:69–77, 2005.
68. Trotman CA, Ross RB: Craniofacial growth in bilateral cleft lip and palate: ages six years to adulthood, *Cleft Palate Craniofac J* 30:261–273, 1993.
69. Costello BJ, Shand J, Ruiz RL: Craniofacial and orthognathic surgery in the growing patient. Selected readings, *Oral Maxillofacial Surg* 11:1, 2003.

70. Fenson L, Dale PS, Reznick JS, et al.: Variability in early communicative development, *Monogr Soc Res Child Dev* 59:1–173, 1994.
71. Dorf DS, Curtin JW: Early cleft palate repair and speech outcome, *Plast Reconstr Surg* 70:74–79, 1982.
72. Smith BL, Oller DK: A comparative study of pre-meaningful vocalizations produced by normally developing and down's syndrome infants, *J Speech Hear Disord* 46:46–51, 1981.
73. Chapmen K, Hardin-Jones M, Goldstein J, et al.: Timing of palatal surgery and speech outcome, *Cleft Palate Craniofac J* 45:297–308, 2008.
74. Ysunza A, Pamlona MC, Mendoza M: Speech outcome and maxillary growth in patients with unilateral complete cleft lip/palate operated on at 6 versus 12 months of age, *Plast Reconstr Surg* 102:675–679, 1998.
75. Rohrich RJ, Byrd HS: Optimal timing of cleft palate closure: Speech, facial growth, and hearing considerations, *Clin Plast Surg* 17:27–36, 1990.
76. Williams WN, Seagle MB, Pegoraro-Krook MI, et al.: Prospective clinical trial comparing outcome measures between Furlow and von Langenbeck palatoplasties for UCLP, *Ann Plast Surg* 66:154–163, 2011.
77. Luyten A, Bettens K, D'haeseleer E, et al.: The impact of palatal repair before and after 6 months of age on speech characteristics, *Int J Ped Otorhinolaryngol* 78:787–789, 2014.
78. Abdel-Aziz M: Speech outcome after early repair of cleft soft palate using Furlow technique, *Int J Pediatr Otorhinolaryngol* 77:85–88, 2013.
79. Copeland M: The effect of very early palatal repair on speech, *Br J Plast Surg* 43:676–682, 1990.
80. Inman DS, Thomas P, Hodgkinson PD, et al.: Oro-nasal fistula development and velopharyngeal insufficiency following primary cleft palate surgery—an audit of 148 children born between 1985 and 1997, *Br J Plast Surg* 58:8, 2005.
81. Ross RB: Treatment variables affecting facial growth in complete unilateral cleft lip and palate, *Cleft Palate Craniofac J* 24:5–77, 1987.
82. Friede H: Growth sites and growth mechanisms at risk in cleft lip and palate, *Acta Odontologica Scandinavica* 56:346–351, 1998.
83. Enlow DH, Bang S: Growth and remodeling of the human maxilla, *Am J Orthod* 51:446–464, 1965.
84. Precious DS, Delaire J: Clinical observations in cleft lip and palate, *Oral Surg Oral Med Oral Pathol* 75:141–151, 1993.
85. Markus AF, Delaire J, Smith WP: Facial balance in cleft lip and palate. II. Cleft lip and palate and secondary deformities, *Br J Oral Maxillofac Surg* 30:296–304, 1992.
86. Moyers R, Bookstein FL: The inappropriateness of conventional cephalometrics, *Am J Orthod* 75:599–617, 1979.
87. Berkowitz S: A review of the cleft lip/palate literature reveals that different diagnosis of the facial skeleton and musculature is essential to achieve all treatment goals, *J Craniofac Surg* 26:1143–1150, 2015.
88. Liao YF, Mars M: Long-term effects of clefts on craniofacial morphology in patients with unilateral cleft lip and palate, *Cleft Palate Craniofac J* 42:6, 2005.
89. Bishara S, Tharp RM: Effects of Von Langenbeck palatoplasty on facial growth, *Angle Orthod* 47:34–41, 1977.
90. Yang Y, Wang Y, Wu Y, et al.: What operative or anatomic factors affect dental arch development in the cleft patient, *J Oral Maxillofac Surg* 71:5, 2013.
91. Filho LC, Normando ADC, Filho OGS: Isolated influences of lip and palate surgery on facial growth/comparison of operated and unoperated male adults with UCLP, *Cleft Palate Craniofac J* 33:1, 1996.
92. Fudalej P, Hortis-Dzierzbicka M, Dudkiewicz Z, et al.: Dental arch relationship in children with complete unilateral cleft lip and palate following Warsaw (one-stage repair) and Oslo Protocols, *Cleft Palate-Craniofac J* 46:6, 2009.
93. Fudalej P, Janiszewska-Olszowska J, Wedrychowska-Szulc B, et al.: Early alveolar bone grafting has a negative effect on maxillary dental arch dimensions of pre-school children with complete unilateral cleft lip and palate, *Orthod Craniofac Res* 14:51–57, 2011.
94. Hathaway R, Daskalogiannakis J, Mercado A, et al.: The Americleft Study: an inter-center study of treatment outcomes for patients with unilateral cleft lip and palate Part 2. Dental arch relationships, *Cleft Palate-Craniofac J* 48:244–252, 2011.
95. Daskalogiannakis J, Mercado A, Russell K, et al.: The Americleft study: an intercenter study of treatment outcomes for patients with unilateral cleft lip and palate: part 3. Analysis of craniofacial form, *Cleft Palate Craniofac J* 48:252–258, 2011.
96. Ross RB: The clinical implications of facial growth in cleft lip and palate, *Cleft Palate J* 7:37–47, 1970.
97. Graber TM: An appraisal of the developmental deformities in cleft-palate and cleft-lip individuals, *Q Bull Northwest Univ Med Sch* 23:153–169, 1949.
98. Kremenak Jr CR, Huffman WC, Olin WH: Maxillary growth inhibition by mucoperiosteal denudation of palatal shelf bone in non-cleft beagles, *Cleft Palate J* 7:4, 1970.
99. Graber TM: The congenital cleft palate deformity, *J Am Dent Assoc* 48:4, 1954.
100. Friede H, Enocson L, Möller M, et al.: Maxillary dental arch and occlusion in repaired clefts of the secondary palate: influence of surgical closure with minimal denudation of bone, *Scand J Plast Reconstr Surg Hand Surg* 34:213, 2007.
101. Kim T, Ishikawa H, Chu S, et al.: Constriction of the maxillary dental arch by mucoperiosteal denudation of the palate, *Cleft Palate Craniofac J* 39:425, 2002.
102. Berkowitz S, Duncan R, Evans C, et al.: Timing of cleft palate closure should be based on the ratio of the area of the cleft to that of the palatal segments and not on age alone, *Plast Reconstr Surg* 115:1483–1499, 2005.
103. Sommerlad BC, Mehendale FV, Birch MJ, et al.: Palate repair revisited, *Cleft Palate Craniofac J* 39:295–307, 2002.
104. Kulewicz M, Dudkiewicz Z: Craniofacial morphological outcome following treatment with three different surgical protocols for complete unilateral cleft lip and palate: a preliminary study, *Int J Oral Maxillofac Surg* 39:2, 2010.
105. Millard Jr RD: Early soft palate and later hard palate closure and lip adhesion. In *Cleft craft: the evolution of its surgery*, vol. 3. Boston, 1980, Brown & Co., p 238.
106. Schweckendiek W, Doz P: Primary veloplasty: long-term results without maxillary deformity. A twenty-five year report, *Cleft Palate J* 15:268–574, 1978.
107. Rohrich RJ, Gosman AA: An update on the timing of hard palate closure: a critical long-term analysis, *Plast Reconstr Surg* 113:350–352, 2004.
108. Zemann W, Karcher H, Drevensek M, Kozelj V: Sagittal maxillary growth in children with unilateral cleft of the lip, alveolus and palate at the age of 10 years: an intercentre comparison, *J Cranioaxillofac Surg* 39:469–474, 2011.

109. Zemann W, Mossbock R, Karcher H, et al.: Sagittal growth of the facial skeleton of 6-year-old children with a complete unilateral cleft of lip, alveolus and palate treated with two different protocols, *J Cranioaxillofac Surg* 35:343–349, 2007.
110. Leonard AG, Kneafsey B, McKenna S, et al.: A retrospective comparison of craniofacial form in northern Irish children with unilateral cleft lip and palate, *Cleft Palate Craniofac J* 35:5, 1998.
111. Johnston CD, Leonard AG, Burden DJ, et al.: A comparison of craniofacial form in northern Irish children with unilateral cleft lip and palate treated with different primary surgical techniques, *Cleft Palate Craniofac J* 41:1, 2004.
112. Lee YH, Liao YF: Hard palate-repair technique and facial growth in patients with cleft lip and palate: a systematic review, *Br J Oral Maxillofac Surg* 51:851–857, 2013.
113. Furlow LT: The Centrinho-UF study: beyond the manuscript, *Ann Plast Surg* 67:320–321, 2011.
114. Veau V: *Division palatine. Anatomie, chirurgie, phonetique*, Paris, 1931, Masson et Cie.
115. Wardill WEM: Cleft palate, *Br J Surg* 16:127, 1928.
116. Kilner TP: Cleft lip and palate repair technique, *St Thomas Hosp Rep* 2:127, 1937.
117. Von Langenbeck: Die uranoplastik mittelst Abloesung des mucoesperiostalen Gaumeneuberzuges, *Arch Klin Chir* 2:205, 1861.
118. Bardach J, Nosal P: Geometry of the two-flap palatoplasty. In Bardach J, Salyer K, editors: *Surgical techniques in cleft lip and palate*, ed 2, St Louis, 1991, Mosby.
119. Kriens OB: An anatomical approach to veloplasty, *Plast Reconstr Surg* 43:29, 1969.
120. Kriens OB: Fundamental anatomic findings for an intravelar veloplasty, *Cleft Palate J* 7:27, 1970.
121. Walter C, Meisel H: A new method for the closure of a cleft palate, *J Maxillofac Surg* 6:222, 1978.
122. Furlow LT: Cleft palate repair by double opposing Z-plasty, *Plast Reconstr Surg* 78:724, 1986.
123. Furlow LT: Cleft-palate repair by modified Furlow double-opposing Z-plasty: the Children's Hospital of Philadelphia experience: discussion, *Plast Reconstr Surg* 104:1999, 2011.
124. Randall P, LaRossa D, Solomon M, et al.: Experience with the Furlow double-reversing Z-plasty for cleft palate repair, *Plast Reconstr Surg* 77:569, 1986.
125. Aziz SR, Ziccardi VB: Severe glossal edema after primary palatoplasty, *J Oral Maxillofac Surg* 67:1326, 2009.
126. Junghaenel S, Keller T, Mischkowski R, et al.: Massive macroglossia after palatoplasty Case report and review of the literature, *Eur J Pediatr* 171:433, 2012.
127. Kirschner RE, Wang P, Jawad AF, et al.: Cleft-palate repair by modified Furlow double-opposing Z-plasty: the Children's Hospital of Philadelphia experience, *Plast Reconstr Surg* 104:1999, 1998.
128. Jackson O, Stransky CA, Jawad AF, et al.: The Children's Hospital of Philadelphia modification of the furlow double-opposing Z-palatoplasty: 30-year experience and long-term speech outcomes, *Plast Reconstr Surg* 132:613, 2013.
129. Schönmeyr B, Sadhu P: A review of the tensor veli palatine function and its relevance to palatoplasty, *J Plast Surg Hand Surg* 48:5, 2014.
130. Gupta R, Kumar S, Murarka AK, et al.: Some modifications of the Furlow palatoplasty in wide clefts - A preliminary report, *Cleft Palate Craniofac J* 48:9, 2011.
131. D'Antonio LL, Eichenberg BJ, Zimmerman GJ, et al.: Radiographic and aerodynamic measures of velopharyngeal anatomy and function following Furlow Z-plasty, *Plast Reconstr Surg* 106:539, 2000.
132. Pet MA, Marty-Grames L, Blount-Stahl M, et al.: The furlow palatoplasty for velopharyngeal dysfunction: velopharyngeal changes, speech improvements, and where they intersect, *Cleft Palate Craniofac J* 52:12, 2015.
133. Khosla RK, Mabry K, Castiglione CL: Clinical outcomes of the Furlow Z-plasty for primary cleft palate repair, *Cleft Palate Craniofac J* 45:501, 2008.
134. Spauwen PHM, Goorhuis-Brouwer SM, Schutte HK: Cleft palate repair: Furlow versus von Langenbeck, *J Craniomaxillofac Surg* 20:18, 1992.
135. Dong Y, Dong F, Zhang X, et al.: An effect comparison between Furlow double opposing Z-plasty and two-flap palatoplasty on velopharyngeal closure, *Int J Oral Maxillofac Surg* 41:604, 2012.
136. Brothers DB, Dalston RW, Peterson HD, et al.: Comparison of the Furlow double-opposing Z-palatoplasty with the Wardill-Kilner procedure for isolated clefts of the soft palate, *Plast Reconstr Surg* 95:969, 1995.
137. Gunther E, Wisser JR, Cohen MA, et al.: Palatoplasty: Furlow's double reversing z-plasty versus intravelar veloplasty, *Cleft Palate Craniofac J* 35:546, 1998.
138. Sommerlad BC: A technique for cleft palate repair, *Plast Reconstr Surg* 112:1542, 2003.
139. Sommerlad BC: The use of the operating microscope for cleft palate repair and pharyngoplasty, *Plast Reconstr Surg* 112:1540, 2003.
140. Williams WN, Seagle MB, Pegoraro-Krook MI, et al.: Prospective clinical trial comparing outcome measures between Furlow and von Langenbeck palatoplasties for UCLP, *Ann Plast Surg* 66:154, 2011.
141. Liao Y, Chuang M, Chen PKT, et al.: Incidence and severity of obstructive sleep apnea following pharyngeal flap surgery in patients with cleft palate, *Cleft Palate Craniofac J* 39:312, 2002.
142. Liao Y, Noordhoff MS, Huang C, et al.: Comparison of obstructive sleep apnea syndrome in children with cleft palate following Furlow palatoplasty or pharyngeal flap for velopharyngeal insufficiency, *Cleft Palate Craniofac J* 41:152, 2004.
143. Dailey SA, Karnell MP, Karnell LH, et al.: Comparison of resonance outcomes after pharyngeal flap and Furlow double-opposing Z-plasty for surgical management of velopharyngeal incompetence, *Cleft Palate Craniofac J* 43:38, 2006.
144. Madrid JRP, Nieto LE, Gomez V, et al.: Palatoplasty as the technique of choice for prevention of obstructive sleep apnea secondary to surgery for velopharyngeal insufficiency, *Cleft Palate Craniofac J* 48:145, 2011.
145. Sie KCY, Tampakopoulou DA, Sorom J, et al.: Results with Furlow palatoplasty in management of velopharyngeal insufficiency, *Plast Reconstr Surg* 108:17, 2001.
146. Perkins JA, Lewis CW, Gruss JS, et al.: Furlow palatoplasty for management of velopharyngeal insufficiency: a prospective study of 148 consecutive patients, *Plast Reconstr Surg* 116:72, 2005.
147. Chen PK, Wu J, Hung K, et al.: Surgical correction of submucous cleft palate with Furlow palatoplasty, *Plast Reconstr Surg* 97:1136, 1996.
148. Seagle MB, Patti CS, Williams WN, et al.: Submucous cleft palate: a 10-year series, *Ann Plast Surg* 42:142, 1999.

149. Abdel-Aziz M, El-Hoshy H, Naguib N, et al.: Repair of submucous cleft palate with Furlow palatoplasty, *Int J Pediatr Otorhinolaryngol* 76:1012, 2012.
150. Deren O, Ayhan M, Tuncel A, et al.: The correction of velopharyngeal insufficiency by Furlow palatoplasty in patients older than 3 years undergoing Veau-Wardill-Kilner palatoplasty: a prospective clinical study, *Plast Reconstr Surg* 116:85, 2005.
151. Stransky C, Basta M, Solot C, et al.: Do patients with Pierre Robin Sequence have worse outcomes after cleft palate surgery? *Ann Plast Surg* 71:292, 2013.
152. Afrooz PN, MacIsaac Z, Rottgers SA, et al.: A comparison of speech outcomes using radical intravelar veloplasty or Furlow palatoplasty for the treatment of velopharyngeal insufficiency associated with occult submucous cleft palate, *Ann Plast Surg* 74:182, 2015.
153. Basta MN, Silvestre J, Stransky C, et al.: A 35-year experience with syndromic cleft palate repair: operative outcomes and long-term speech function, *Ann Plast Surg* 73s2:S130, 2014.
154. Sommerlad BC, Mehendale FV, Birch MJ, Sell D, et al.: Palate re-repair revisited, *Cleft Palate Craniofac J* 39:295, 2002.
155. Marques IL, Nackashi JA, Borgo HC, et al.: Longitudinal study of growth of children with unilateral cleft-lip palate from birth to two years of age, *Cleft Palate Craniofac J* 46:603, 2009.
156. Oyama T, Nishimoto S, Ishii N, et al.: Soft palate mucosal adhesion as a preparation for Furlow's double-opposing Z-palatoplasty, *Plast Reconstr Surg* 118:469, 2006.
157. Lynch B, Peil R: Retarded maxillary growth in experimental cleft palates, *Am Surg* 32:507, 1966.
158. Kremenak CR, Searls JC: Experimental manipulation of midface growth: a synthesis of five years of research at the Iowa Maxillofacial Growth Laboratory, *Dent Res* 50:1488, 1971.
159. Searls JC, Biggs DR: Surgically induced maxillary growth inhibition in rats, *Cleft Palate J* 11:1, 1974.
160. Pigott RW, Albery EH, Hathorn IS, et al.: A comparison of three methods of repairing the hard palate, *Cleft Palate Craniofac J* 39:383, 2002.
161. Güneren E, Özsoy Z, Ulay M, et al.: A comparison of the effects of Veau-Wardill-Kilner palatoplasty and Furlow double-opposing Z-plasty operations on Eustachian tube function, *Cleft Palate Craniofac J* 37:266, 2000.
162. Antonelli PJ, Jorge JC, Feniman MR, et al.: Otologic and audiologic outcomes with the Furlow and von Langenbeck with intravelar veloplasty palatoplasties in unilateral cleft lip and palate, *Cleft Palate Craniofac J* 48:412, 2011.
163. Hardwicke JT, Landini G, Richard BM: Fistula incidence after primary cleft palate repair: a systematic review of the literature, *Plast Reconstr Surg* 134:618e, 2014.
164. Murrell GL, Requena R, Karakla DW: Oronasal fistula repair with three layers, *Plast Reconstr Surg* 107:143, 2001.
165. Schultz RC: Management and timing of cleft palate fistula repair, *Plast Reconstr Surg* 78:739, 1986.
166. Wilhelmi BJ, Uysal AC, Ozdemir R, et al.: Palatal fistulas: rare with the two-flap palatoplasty repair, *Plast Reconstr Surg* 108:995, 2001.
167. Helling ER, Dev VR, Garza J, et al.: Low fistula rate in palatal clefts closed with the Furlow technique using decellularized dermis, *Plast Reconstr Surg* 117:2361, 2006.
168. Steele MH, Seagle MB, Persing JA: Palatal fistula repair using acellular dermal matrix: the University of Florida experience, *Ann Plast Surg* 56:50, 2006.
169. Losee JE, Smith DM, Afifi AM, et al.: A successful algorithm for limiting postoperative fistulae following palatal procedures in the patient with orofacial clefting, *Plast Reconstr Surg* 122:544, 2008.
170. Levi B, Kasten SJ, Buchman SR: Utilization of the buccal fat pad flap for congenital cleft palate repair, *Plast Reconstr Surg* 123:1018, 2009.
171. Bindingnavele VK, Bresnick SD, Urata MM, et al.: Superior results using the islandized hemipalatal flap in palatoplasty: experience with 500 cases, *Plast Reconstr Surg* 122:232, 2008.
172. Matthews MS: A teaching device for Furlow palatoplasty, *Cleft Palate Craniofac J* 36:64, 1999.
173. Liu MM, Kim J, Jabbour N: Teaching Furlow palatoplasty: the sticky note method, *Int J Pediatr Otorhinolaryngol* 78:1849, 2014.
174. Losken HW, Van Aalst JA, Teotia SS, et al.: Achieving low cleft palate fistula rates: surgical results and techniques, *Cleft Palate Craniofac J* 48:312, 2011.
175. Gillies HG, Fry WK: A new principle in the surgical treatment of congenital cleft palate and its mechanical counterpart, *Brit Med J* 1:335, 1921.
176. Graber TM: Craniofacial morphology in cleft palate and cleft lip deformities, *Surg Gynecol Obstet* 88:359, 1949.
177. Graber TM: The congenital cleft palate deformity, *J Am Dent Assoc* 48:375, 1954.
178. Foster TD: Maxillary deformities in repaired clefts of the lip and palate, *Br J Plast Surg* 15:182, 1962.
179. Latham RA, Burtson WR: The effect of unilateral cleft of the lip and palate on maxillary growth pattern, *Br J Plast Surg* 17:10, 1964.
180. Ross RB, Coupe TB: Craniofacial morphology in six pairs of monozygotic twins discordant for cleft lip and palate, *J Can Dent Assoc* 31:149, 1965.
181. Shibisaki Y, Ross RB: Facial growth in children with isolated cleft palate, *Cleft Palate J* 6:290, 1969.
182. Ross RB: The clinical implications of facial growth in cleft lip and palate, *Cleft Palate J* 7:37–47, 1970.
183. Katzel EB, Basile P, Koltz PF: Current surgical practices in cleft care: cleft palate repair techniques and postoperative care, *Plast Reconstr Surg J* 124:899, 2009.
184. Cohn-Stock G: Die Chirurgische Immediatregulierung der Kiefer, speziell die chirurgische Behandlung der Prognathie, Vjschr, *Zahnhk* 37:320, 1921.
185. Schweckendiek H: Zur Frage der fruh-und spatoperationen der angeboren lippen-kiefer-gaumenspalten, *Z Laryng* 30:51, 1951.
186. Slaughter WB, Pruzansky S: The rationale for velar closure as a primary procedure in the repair of cleft palate defects, *Plast Reconstr Surg* 13:341, 1954.
187. Schweckendiek W: Primary veloplasty: long-term results without maxillary deformity. A twenty-five year report, *Cleft Palate J* 15:268, 1978.
188. Robertson NR, Jolleys A: The timing of hard palate repair, *Scand Plast Reconstr Surg* 8:49, 1974.
189. Bardach J, Morris HL, Olin WH: Late results of primary veloplasty: the Marburg Project, *Plast Reconstr Surg* 73:207, 1984.
190. Cosman B, Falk AS: Delayed hard palate repair and speech deficiencies: a cautionary report, *Cleft Palate J* 17:27, 1980.
191. Witzel MA, Salyer KE, Ross RB: Delayed hard palate closure: the philosophy revisited, *Cleft Palate J* 21:263, 1984.

192. Dorf DS, Curtin JW: Early cleft repair and speech outcome: a ten year experience. In Bardach J, Morris HL, editors: *Multidisciplinary management of cleft lip and palate*, Philadelphia, 1990, WB Saunders, pp 341–348.
193. Peterson-Falzone SJ, Hardin-Jones MA, Karnell MP: *Cleft palate speech*, 3rd ed., St Louis, 2001, Mosby.
194. Chapman K, Hardin-Jones MA, Goldstein JA, et al.: Timing of palatal surgery and speech outcome, *Cleft Palate Craniofac J* 45:297, 2008.
195. Hotz MM, Gnoinski WM, Nussbaumer H, et al.: Early maxillary orthopedics in CLP cases: guidelines for surgery, *Cleft Palate J* 15:405, 1978.
196. Lohmander A, Olsson M, Flynn T: Early consonant production in Swedish infants with and without unilateral cleft lip and palate and two-stage palatal repair, *Cleft Palate Craniofac J* 48:271, 2011.
197. Rohrich RJ, Gosman AA: An update on the timing of hard palate closure: a critical long-term analysis, *Plast Reconstr Surg* 113:350, 2004.
198. Dorf DS, Curtin JW: Early cleft palate repair and speech outcome, *Plast Reconstr Surg* 70:74, 1982.
199. Kirschner RE, Randall P, Wang P, et al.: Cleft palate repair at 3 to 7 months of age, *Plast Reconstr Surg* 105:2127, 2000.
200. Liljia J, Friede H, Johanson J: Changing philosophy of surgery of the cleft lip and palate in Göteborg, Sweden. In Berkowitz S, editor: *Cleft lip and palate: perspectives on management*, vol. 2. San Diego, 1996, Singular Publishing, pp 155–170.
201. Lohmander A, Friede H, Lilja J: Long-term, longitudinal follow-up of individuals with unilateral cleft lip and palate after the Gothenburg primary early veloplasty and delayed hard palate closure protocol: speech outcome, *Cleft Palate Craniofac J* 49:657, 2012.
202. Yamanishi T, Nishio J, Kohara H, et al.: Effect on maxillary arch development of early 2-stage palatoplasty by modified Furlow technique and conventional 1-stage palatoplasty in children with complete unilateral cleft lip and palate, *Oral Maxillofac Surg* 67:2210, 2009.
203. Yamanishi T, Nishio J, Sako M, et al.: Early two-stage double opposing Z-plasty or one-stage push-back palatoplasty?: comparisons in maxillary development and speech outcome at 4 years of age, *Ann Plast Surg* 66:148, 2011.
204. Nadjmi N, Van Erum R, De Bodt M, et al.: Two-stage palatoplasty using a modified Furlow procedure, *Int J Oral Maxillofac Surg* 42:551, 2013.
205. Gundlach K, Bardach J, Filippow D, et al.: Two-stage palatoplasty, is it still a valuable treatment protocol for patients with a cleft of lip, alveolus, and palate? *J Craniomaxillofac Surg* 41:62, 2013.
206. Chait L, Gavron G, Graham C, et al.: Modifying the two-stage cleft palate surgical correction, *Cleft Palate Craniofac J* 39:226, 2002.
207. Mommaerts MY, Combes FA, Drake D: The Furlow Z-plasty in two-staged palatal repair modifications and complications, *Br J Oral Maxillofac Surg* 44:94, 2006.
208. Berkowitz S: A comparison of treatment results in complete bilateral cleft lip and palate using a conservative approach versus Millard-Latham PSOT procedure, *Semin Orthod* 2:169, 1996.
209. Konst EM, Rietveld T, Peters HF, et al.: Phonological development of toddlers with unilateral cleft lip and palate who were treated with and without infant orthopedics: a randomized clinical trial, *Cleft Palate Craniofac J* 40:32, 2003.
210. Konst EM, Rietveld T, Peters HF, et al.: Language skills of young children with unilateral cleft lip and palate following infant orthopedics: a randomized clinical trial, *Cleft Palate Craniofac J* 40:356, 2003.
211. Prahl C, Kuijpers-Jagtman AM, Van't Hof MA, et al.: A randomized prospective clinical trial of the effect of infant orthopedics in unilateral cleft lip and palate: prevention of collapse of the alveolar segments (Dutchcleft), *Cleft Palate Craniofac J* 40:337, 2003.
212. Prahl C, Kuijpers-Jatman AM, Van't Hof MA, et al.: Infant orthopedics in UCLP: effect on feeding, weight, and length: a randomized clinical trial (Dutchcleft), *Cleft Palate Craniofac J* 42:171, 2005.
213. Prahl C, Prahl-Andersen B, Van't Hof MA, et al.: Infant orthopedics and facial appearance: a randomized clinical trial (Dutchcleft), *Cleft Palate Craniofac J* 43:659, 2006.
214. Prahl C, Prahl-Andersen B, Van't Hof MA, et al.: Presurgical orthopedics and satisfaction in motherhood: a randomized clinical trial (Dutchcleft), *Cleft Palate Craniofac J* 45:284, 2008.
215. Holland S, Gabbay JS, Heller JB, et al.: Delayed closure of the hard palate leads to speech problems and deleterious maxillary growth, *Plast Reconstr Surg* 119:1302, 2007.
216. Friede H, Lilja J, Lohmander A: Long-term, longitudinal follow-up of individuals with UCLP after the Gothenburg primary early veloplasty and delayed hard palate closure protocol: maxillofacial growth outcome, *Cleft Palate Craniofac J* 49:649, 2012.
217. Liao YF, Yang IY, Wang R, et al.: Two-stage palate repair with delayed hard palate closure is related to favorable maxillary growth in unilateral cleft lip and palate, *Plast Reconstr Surg* 125:1503, 2010.
218. Blijdorp P, Egyedi P: The influence of age at operation for cleft on the development of the jaws, *J Maxillofac Surg* 12:193, 1984.
219. Friede H, Priede D, Möller M, et al.: Comparisons of facial growth in patients with unilateral cleft lip and palate treated by different regimens for two-stage palatal repair, *Scand J Plast Reconstr Surg Hand Surg* 33:73, 1999.
220. Friede H, Enemark H: Long-term evidence for favorable midfacial growth after delayed hard palate repair in UCLP patients, *Cleft Palate Craniofac J* 38:323, 2001.
221. Friede H, Lohmander A, Hagberg C, et al.: Maxillary dental arch and occlusion in patients with unilateral cleft lip and palate treated with different delays in closure of the hard palate after early velar repair, *Scand J Plast Reconstr Surg Hand Surg* 40:261, 2006.
222. Lohmander A, Friede H, Elander A, et al.: Speech development in patients with unilateral cleft lip and palate treated with different delays in closure of the hard palate after early velar repair: a longitudinal perspective, *Scand J Plast Reconstr Surg Hand Surg* 40:267, 2006.
223. Lehner B, Wiltfang J, Strobel-Schwarthoff K, et al.: Influence of early hard palate closure in unilateral and bilateral cleft lip and palate on maxillary transverse growth during the first four years of age, *Cleft Palate Craniofac J* 40:126, 2003.
224. Richard B, Russell J, McMahon S, et al.: Results of randomized controlled trial of soft palate first versus hard palate first repair in unilateral complete cleft lip and palate, *Cleft Palate Craniofac J* 43:329, 2006.
225. Ganesh P, Murthy J, Ulaghanathan N, et al.: A randomized controlled trial comparing two techniques for unilateral cleft lip and palate: growth and speech outcomes during mixed dentition, *J Craniomaxillofac Surg* 43:790, 2015.

226. Abyholm FE, Borchgrevink HC, Eskeland G: Cleft lip and palate in Norway. III. Surgical treatment of CLP patients in Oslo 1954-75, *Scand J Plast Reconstr Surg* 15:15, 1981.
227. Bakri S, Rizell S, Lilja J, et al.: Vertical maxillary growth after two different surgical protocols in unilateral cleft lip and palate patients, *Cleft Palate Craniofac J* 51:645, 2014.
228. Vedung S: Pharyngeal flaps after one- and two-stage repair of the cleft palate: a 25-year review of 520 patients, *Cleft Palate Craniofac J* 32:206, 1995.
229. Ross R: Bruce: treatment variables affecting growth in unilateral cleft lip and palate. Part 5: timing of palate repair, *Cleft Palate J* 24:54, 1987.
230. Friede H: Maxillary growth controversies after two-stage palatal repair with delayed hard palate closure in unilateral cleft lip and palate patients: perspectives from literature and personal experience, *Cleft Palate Craniofac J* 44:129, 2007.

31

Presurgical Infant Orthopedic Treatment for Patients with Cleft Lip and Palate

LINDSAY A. SCHUSTER, PEDRO E. SANTIAGO

Introduction

This chapter reviews oral-facial cleft incidence and etiology, cleft versus non-cleft anatomy, historical background of presurgical infant orthopedics, and current presurgical infant orthopedic treatment options with a focus on nasoalveolar molding (NAM).

Cleft Incidence and Etiology

Oral-facial clefting occurs in approximately 1:690 births, with the prevalence of those affected by both cleft lip and cleft palate being 5.6 per 10,000 births.[1] The prevalence of cleft lip and palate also varies among different ethnic groups, with children of African descent having the lowest prevalence and those of Native American descent being one of the highest reported. Males are reported to have a higher prevalence of clefts involving the lip or lip and palate, whereas females have a greater prevalence of clefts of the palate only. It is reported that approximately 70% of those affected by both clefting of the lip and palate are nonsyndromic.[2]

The etiology of orofacial clefts is multifactorial with genetic, environmental, and teratogenic considerations. Some genes implicated in animal models of clefts include: sonic hedgehog gene, TGF-α variants, TGF-β-3 and IRF-6.[3] Medications, such as anti-seizure medications and retinoic acid, have been associated with orofacial clefts. Maternal factors associated with clefts include folate deficiency, smoking, excessive alcohol use,[3] stress, maternal obesity, occupational exposures, ionizing radiation, and infection.[4]

The severity of clefting varies widely within the basic unilateral, bilateral, complete, and incomplete descriptors. Clinically, there are over 240 possible combinations of cleft lip with or without cleft palate.[5] In addition to the disruption to intraoral and perioral anatomy, the nasal anatomy is significantly affected in cleft patients.

Presurgical Infant Orthopedics

In a newborn affected by a cleft lip and palate, treatment to mold the affected oral, perioral, and nasal anatomy in preparation for the primary surgical repair is known as *presurgical infant orthopedics (PSIO)*. This treatment takes place in the first few months of life with the goal of lessening the severity of the cleft deformity and normalizing anatomic relationships in preparation for the primary lip/alveolar/nose surgery.

The utilization of extraoral traction to the cleft anatomy dates back to 1686, when Johan Philip Hofmann described a head cap attached to horizontal laces across the lip to relieve tension on the newly surgically repaired cleft.[6] Dating from a similar technique used by Desault in 1790, various iterations of extraoral strapping, taping, and intraoral alveolar approximation were used to lessen the cleft severity prior to surgical repair.[7] The era of modern PSIO therapy dates to 1950 when McNeil utilized a series of passive intraoral acrylic plates to mold the intraoral cleft anatomy sequentially.[8] This technique has been modified by various practitioners throughout subsequent years. In 1975 Latham and Georgiade described a presurgical orthopedic technique in which they utilized an intraoral appliance retained by pins surgically placed in the alveolus to approximate the cleft segments in a short period of time.[9] This technique is commonly known as the Latham appliance. Randall described a surgical alternative known as a lip adhesion.

This is a two-stage surgical procedure: initially, the lip adhesion surgery, a temporary attachment of the lip segments, is performed with the goal of decreasing the alveolar cleft gap prior to definitive surgical repair.[10]

It is important to note that these treatment therapies address the intraoral and extraoral cleft deformity, but do not attempt to treat the nasal deformity. In 1988, an article by Matsuo et al. presented the concept of preoperative molding of the cleft nasal cartilage with silicone tubes.[11] This moldability of neonatal cartilage, due to circulating maternal estrogens and resultant increase in hyaluronic acid, was known to this group through their work in molding of the neonatal ear. In addition to moldability related to maternal estrogens, it is postulated that cartilaginous molding stimulates immature chondroblasts, producing an interstitial expansion.[12] As a novel evolution in presurgical orthopedic appliance design, in 1993 Grayson introduced nasoalveolar molding (NAM), a technique that combines the intraoral molding of the alveolus and perioral/lip anatomy with the earlier work of molding the cartilage of the nose.[13] NAM represents the first presurgical orthopedic appliance to address the cleft lip, alveolar, and nasal deformity in preparation for primary surgery.

During the last decade, the nasoalveolar molding technique has gained popularity around the world with many teams adapting such therapy in their protocols. There have been more than 120 articles and chapters written on the subject. In the United States and Canada, 71% of centers reported using some form of presurgical molding before bilateral cleft lip surgery, with nasoalveolar molding being the most popular at 55% of those using PSIO.[14] Another study cites that at least 71% of cleft surgeons of the American Cleft Palate Craniofacial Association use NAM occasionally.[15] In 2010 it was reported that 37% of U.S. cleft teams offered nasoalveolar molding to their patients.[16]

Presurgical infant orthopedics produces notable reduction of the alveolar and labial cleft gap. Nasoalveolar molding addresses the nasal cartilaginous deformity improving nasolabial symmetry and esthetics.

Nasoalveolar Molding

In 1997, Grayson and Santiago described the NAM protocol for patients born with a cleft lip and palate.[17] The main goal for this therapy is to normalize the cleft skeletal, cartilaginous, and soft tissue anatomic relationships. This normalized anatomy provides the surgeon with the most optimal anatomy to perform the primary lip, alveolus, and nose surgery, minimizing the need or extent of secondary surgical revisions.

NAM objectives include: (1) approximate the alveolar processes into a normalized U-shaped arch form, (2) approximate the lip segments, (3) lessen the nasal deformity (through cartilaginous molding and columellar lengthening). Short-term studies (4 months to 1 year)[18-20] and long-term studies (4.5 to 9 years)[21,22] indicate that NAM significantly improves nasal symmetry over surgery alone.

Close approximation of the alveolar segments by means of the alveolar molding plate facilitates incorporation of gingivoperiosteoplasty (GPP) into the surgical protocol. GPP is the closure of the soft tissue alveolar segments performed in conjunction with primary lip and nose surgery. Santiago et al.[23] have shown a 60% reduction in the need for a secondary alveolar bone graft procedure in cases where a combined approach of presurgical infant orthopedics and a gingivoperiosteoplasty was performed. This combination was less expensive than a traditional protocol (lip repair, primary nasal repair, and secondary alveolar bone graft).[24] It is important to note that GPP is a technique-sensitive procedure with varying surgical results. Furthermore, it is a separate therapeutic option from NAM, associated with its own risks and benefits.

If presurgical infant orthopedics is elected, the consultation process may start prenatally upon diagnosis of a cleft on ultrasound. While detection rates on 2D ultrasound vary greatly (9% to 100%), 3D ultrasound detection rates are much higher, detecting 100% for cleft lip and 86% to 90% for cleft lip and palate.[25] The National Birth Defects Prevention Study (1998-2004) reported that prenatal diagnosis was made in 33.3% of their 978 cases of CL/P.[26] If prenatal consultation is not a possibility, it is important that the initial consultation and clinical exam take place within the first weeks of life for optimum treatment efficacy. If nasoalveolar molding is offered by the team, this consultation is an important opportunity to talk to the parents about treatment alternatives, risks/benefits of treatment, the basic processes of treatment, and especially to gauge the parent's ability to comply with home care and attendance at weekly or biweekly adjustment visits. Treatment is initiated as soon as possible to take advantage of the moldability of tissues, especially the cartilage of the nose, given the short post-natal period of circulating maternal estrogens that facilitate tissue pliability.

After the informed consent discussion with the infant's caregivers, an intraoral mold (utilizing a polyvinyl siloxane material) of the infant's mouth is taken by the orthodontist and the surgeon (or other practitioner who is able to manage a potential medical emergency) (Figure 31-1, *A*). Though complications with impression are rare, it is important that trained clinicians are available to monitor and manage the infant in case of any signs of breathing difficulty or distress. The impression is utilized to create a stone cast (see Figure 31-1, *B*) reproduction of the infant's intraoral anatomy and fabricate the hard acrylic intraoral plate (see Figure 31-1, *C*).

Adjustments to the appliance are made at weekly or biweekly appointments. A sequence of subtractions and additions of hard and soft acrylic, in conjunction with facial tapes and orthodontic elastics for retention and force application, incrementally mold the alveolar segments toward

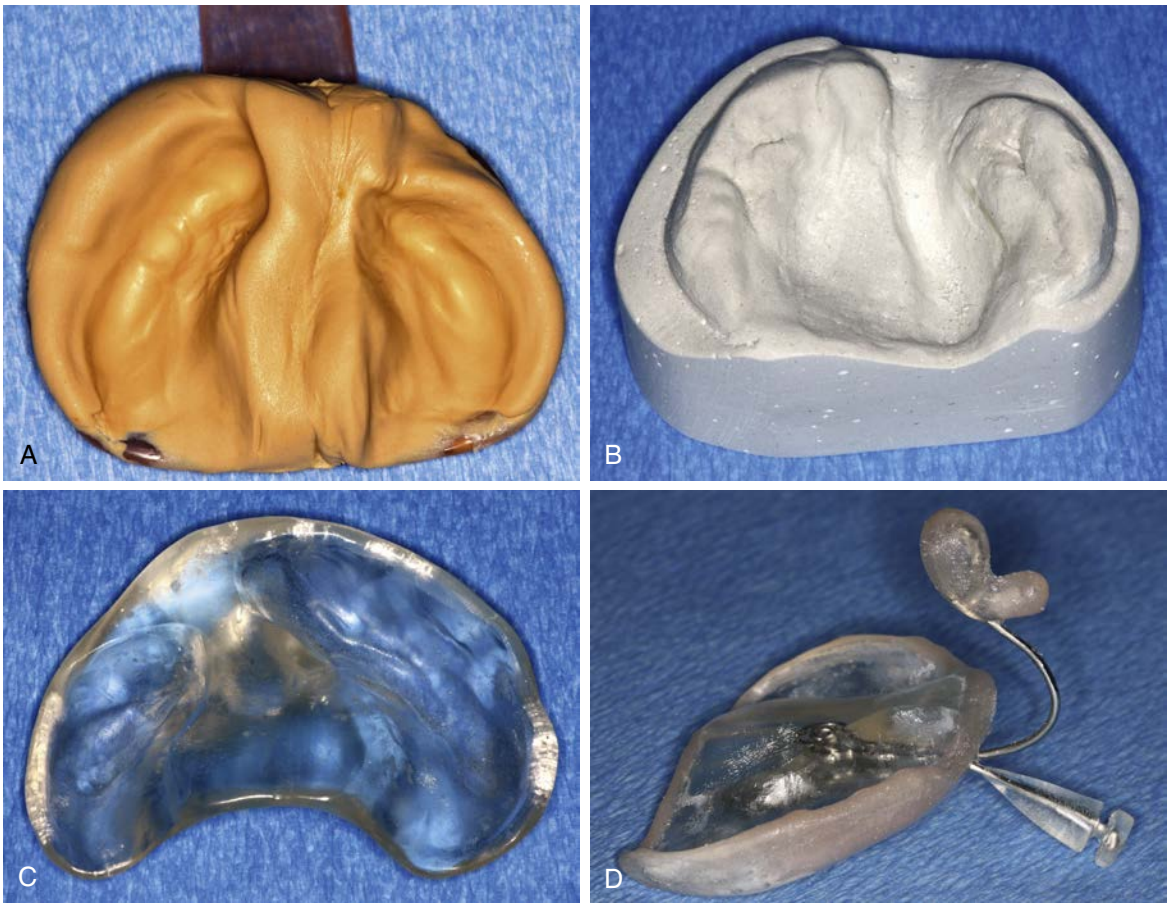

• **Figure 31-1** In the process of making the NAM appliance, a PVS impression is taken of the infant's mouth **(A),** a stone cast made from this impression **(B),** and a hard acrylic intraoral plate is fabricated **(C).** A nasal stent is added to the plate to address the nasal deformity, once the alveolar segments are in close approximation **(D)**.

each other. At each visit, special care and attention must be directed to evaluation of the intraoral and extraoral soft tissues for any signs of irritation. If the alveolar segments are properly aligned, the goal is a contiguous "U" shaped arch form, comparable to the arch form in an infant without a cleft. This arch form promotes optimal labial approximation and allows for gingivoperiosteoplasty, should the infant's surgeon elect this procedure. Improper molding vectors can lead to a maxillary collapse with a "T" shaped relationship of the greater and lesser segments in unilateral clefts, and a "V" shaped relationship in bilateral clefts, with the premaxilla being blocked out anteriorly due to inadequately expanded lateral segments. Once the segments are within 3 to 4 mm of each other, a nasal stent is added (see Figure 31-1,*D*) to mold the distorted nasal cartilage. Total treatment time typically takes place over 3 to 4 months in patients with unilateral clefts[27] and approximately 5 to 6 months in bilateral cases.[28]

Treatment success is very reliant on excellent compliance. Missed appointments and removal of the plate by the infant are common challenges to treatment. As previously discussed, the informed consent process is an important opportunity to communicate the time commitment of weekly (or biweekly in some cases) adjustments and dedication to homecare of the appliance. If the infant is removing the plate, gloves or arm restraints (in older patients) may be used to discourage dislodgement of the plate.

Correcting the Unilateral Cleft Deformity

The anatomy of a patient with clefts of the lip, alveolus and palate can be described by anatomic location, laterality, and degree of clefting (Figure 31-2, *A*). In a patient with a unilateral cleft, the skin of the labial anatomy of a cleft lip is vertically deficient on one side (with cupid's bow being less distinct and the philtrum being shorted on the affected side) and the underlying orbicularis oris muscle is not continuously attached. Rather, this muscle is attached at the cleft margin or nasal base. The continuity of the alveolar bone and gingiva is disrupted by the cleft. The nasal anatomy is significantly affected: the columella is shorter on the cleft side and deviated from an anterior-posterior projection, with the base towards the non-cleft side and the portion near the tip towards the cleft side. The nasal tip is flattened and bent towards the non-cleft side. The lateral cartilage is displaced posteriorly, inferiorly, and laterally on the cleft side. The alar base is widened and

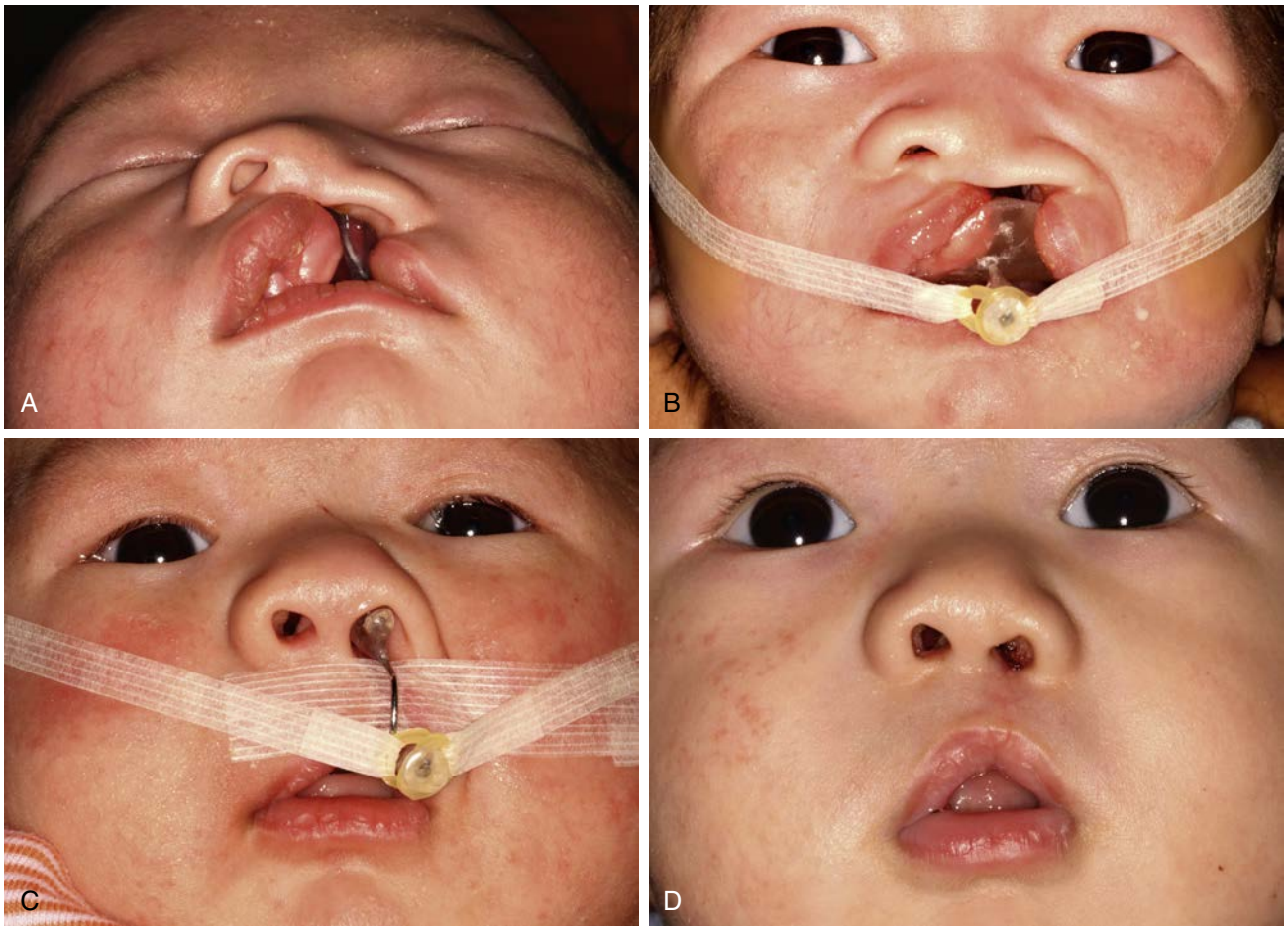

• **Figure 31-2** The unilateral alveolar, labial and nasal cleft defect severity **(A)** is addressed through use of the NAM plate **(B),** accessory transverse lip taping and nasal stenting **(C)** to normalize anatomy in preparation for the primary surgical repair. NAM improves nasolabial symmetry and esthetics **(D)**.

caudal septum and anterior nasal spine deviate towards the non-cleft side (see Figure 31-2, *A*).

After the impression and intraoral plate fabrication process described above, the plate is delivered and the caregiver is taught how to care for the appliance, including the extraoral facial taping (see Figure 31-2, *B*). The extraoral activation system consists of two Steri-strip tapes individually folded inside the lumen of separate orthodontic elastics. The elastics are attached to the retentive "button" that is an extraoral projection from the molding plate and the Steri-strips are then extended laterally to the cheeks and fixed to a protective "base tape." During active movement of the greater segment towards the lesser segment, the tape and elastic construct is typically more active on the side towards the intended movement (lesser segment side). In addition to the external taping forces, the plate is modified at weekly adjustments with additions of soft acrylic and removal of hard acrylic to incrementally mold the cleft alveolar segments toward each other. A transverse lip tape may be incorporated at any point during treatment to provide an external force to approximate the lip segments, greater and lesser alveolar segments and further facilitate alignment of the nasal base and columella toward the mid-sagittal plane (see Figure 31-2, *C*).

Once the alveolar segments approximate to about 4 mm, a nasal stent is added to the system (see Figure 31-2, *C*). The nasal stent is made out of an orthodontic wire carefully bent into a gooseneck shape and is attached to the anterior flange of the oral molding plate with hard acrylic. The most superior part of the wire is bent into a kidney bean shape with superior and inferior lobes and is covered with a hard acrylic core surrounded by soft acrylic. This kidney bean shaped acrylic is positioned inside the nose with the superior lobe positioned in the nose immediately lateral to the columella, supporting the nasal dome on the cleft side. The inferior lobe is external to the nostril. The cleft-side cartilage of the nasal dome is lifted by the stent to achieve normal elevation and symmetry, moving the cartilage's apex from a lateral position to a superior/anterior position. The nasal stent is adjusted



• **Figure 31-3** The bilateral cleft anatomy is characterized by labial soft tissue and cartilaginous nasal deformities **(A)** and alveolar and palatal defects **(B)**.

at the weekly visits to shape the cartilaginous dome and medial and lateral crura into a more normalized anatomy.

The goal of the nasal and alveolar molding is proper alignment of the nasal cartilages, columella, lip, and alveolar segments to optimize surgical correction (see Figure 31-2, *D*).

Correcting the Bilateral Cleft Deformity

In the bilateral complete cleft lip, alveolus, and palate patient, the orbicularis oris and vertical soft tissue anatomy of the lips are also discontinuous. The vertical deficiency of tissue occurs lateral to the prolabium, a midline lip structure that does not contain a muscular component. Cupid's bow, columellar, and philtral structures are obliterated. Similar to the effects of clefting of the soft tissues lateral to the prolabium, the clefts of the alveoli are lateral to a bony midline structure called the premaxilla. This premaxilla is often protruded and deviated to one side. The lateral nasal alae are distorted, with horizontally oriented nostrils and a wide alar base (Figure 31-3).

The goal of presurgical nasoalveolar molding in patients born with bilateral cleft lip and palate is to lessen the severity of the nasal deformity (lengthen the deficient columella, reduce the alar base width, reshape the distorted lateral cartilages) and align the alveolar segments. As in the unilateral deformity, the molding plate is fabricated from a stone cast made from a polyvinyl siloxane intraoral impression. The bilateral plate has two anterior acrylic extensions or buttons to which the facial tapes are attached for retention and activation. The first stage of treatment consists of weekly acrylic modifications of the intraoral molding plate and differential forces on the elastic/Steri-strip taping system to centralize the everted premaxilla, expand the lateral segments, and retract the premaxilla. As the alveolar segments approximate each other and form a more normalized U shaped alveolus, two nasal stents are incorporated into the anterior rim of the molding plate and enter the nasal apertures as described in the unilateral section (Figure 31-4, *A*). The nasal stents shape the distorted cartilages and create tissue-expanding forces that reposition the lateralized apex of the nostril superiorly and anteriorly to support the nasal dome. The nasal stents, in combination with a surgical tape applied to the prolabium and attached inferiorly to elastic orthodontic rubber bands anchored on the plate's acrylic buttons, create tissue-expansion forces that elongate the columella (see Figure 31-4, *B*). Additionally, a horizontal columellar band made of soft acrylic may also be attached between the inferior lobes of the nasal stents to provide an additional expansion force across the columella. The intraoral plate and extraoral nasal stents are periodically adjusted over a period of 5 to 6 months to attain the goal of normalized anatomy. This provides the reconstructive surgeon with an optimal starting point for surgical repair (see Figure 31-4, *C* and *D*).

Nasoalveolar molding has been shown to be an adjuvant therapy to the primary surgical repair:

1. The controlled presurgical alignment of the cleft alveolar and lip segments and reduction of the nasal deformity reduces tension on the surgical repair and may reduce the extent of the primary lip and nasal surgery required.
2. The presurgical closure of the alveolar gap provides the surgeon with the option to perform a gingivoperiosteoplasty at the time of lip closure.
3. Columella lengthening in the patient with a bilateral cleft eliminates the need for secondary surgical columella elongation and the resultant lip-columella junction scar.
4. When used in conjunction with primary surgical repairs, NAM therapy allows for a single initial surgical procedure to address the lip-nose-alveolus complex and its deformity. Through reduction of the residual deformity, additional surgical revisions may be avoided.



• **Figure 31-4** **A,** The NAM plate for bilateral cleft treatment consists of two acrylic extensions or buttons and bilateral nasal stents that support the nasal dome and shape the nasal cartilages. **B,** Utilizing a prolabium tape, which is attached inferiorly to the buttons, produces an additional columella-lengthening force. **C** and **D,** The plate and nasal stents are modified at weekly visits over a period of approximately 5 to 6 months to provide the surgeon with a reduction in the initial anatomic distortions and optimized starting point for the surgical repair.

Summary

In a newborn affected by a cleft lip and palate, treatment to mold the affected oral, perioral, and nasal anatomy in preparation for the primary surgical repairs is known as *presurgical infant orthopedics (PSIO)*. This treatment takes place in the first months of life with the goal of lessening the severity of the cleft deformity in preparation for initial lip/nose reconstructive surgery. There are multiple techniques available with variable degrees of success in reducing the cleft deformity. Options include lip taping, the pin-retained Latham appliance, and nasoalveolar molding. The surgical alternative, lip adhesion, is another option routinely elected by some cleft centers. Although most presurgical infant orthopedic techniques are effective in reducing the alveolar and labial cleft gap, NAM is the only therapy that addresses the cartilaginous nasal deformity improving nasolabial symmetry and esthetics. While the caregiver of an infant who is born with a cleft experiences heightened anxiety, NAM and the consequent frequent contacts with the treatment team before surgery, is shown to reduce anxiety and increase a sense of empowerment for the caregivers.[29,30] The scientific literature, shows that there is significant evidence supporting NAM's effectiveness as a treatment for newborns with a cleft lip and palate.

References

1. Mai CT, Cassell CH, Meyer RE, et al.: Birth defects data from population-based birth defects surveillance programs in the United States, 2007 to 2011: highlighting orofacial clefts, *Birth Defects Res A Clin Mol Teratol* 100:895, 2014.
2. Shi M, Wehby GL, Murray JC: Review on genetic variants and maternal smoking in the etiology of oral clefts and other birth defects, *Birth Defects Res C Embryo Today* 84(1):16–29, 2008.
3. Wilkins-Haug L: Etiology, prenatal diagnosis, obstetrical management, and recurrence of orofacial clefts. Available at: www.uptodate.com. Accessed: Jan 2015.
4. Mossey P, Little J, Munger RG, et al.: Cleft lip and palate, *Lancet* 374:1773–1785, 2009.
5. Mooney MP, Heike LM, Naran S, et al.: Classification of orofacial clefts. In Losee JE, Kirschner RE, editors: *Comprehensive cleft care*, ed 2, New York, 2014, McGraw-Hill Publishing.
6. Rogers BO: Treatment of cleft lip and palate during the Revolutionary War: Bicentennial reflections, *Cleft Palate J Oct* 13: 371–390, 1976.
7. Grayson BH, Shetye PR: Presurgical nasoalveolar moulding treatment in cleft lip and palate patients, *Indian J Plast Surg* 42(Suppl):S56–S61, 2009.
8. McNeil C: Orthodontic procedures in the treatment of congenital cleft palate, *Dent Records* 70:126–132, 1950.
9. Georgiade NG, Latham RA: Maxillary arch alignment in the bilateral cleft lip and palate infant, using pinned coaxial screw appliance, *Plast Reconstr Surg* 56:52–60, 1975.
10. Randall P: A lip adhesion operation in cleft lip surgery, *Plast Reconstr Surg* 35:371–376, 1965.
11. Matsuo K, Hirose T: Nonsurgical correction of cleft lip nasal deformity in the early neonate, *Ann Acad Med Singapore* 17: 358–365, 1988.
12. Hamrick MW: A chondrol modeling theory-revisited, *J Theor Biol* 201(3):201–208, 1997.
13. Grayson BH, Cutting C, Wood R: Preoperative columella lengthening in bilateral cleft-lip and palate, *Plast Reconstr Surg* 92:1422–1423, 1993.
14. Tan SP, Greene AK, Mulliken JB: Current surgical management of bilateral cleft lip in North America, *Plast Reconstr Surg* 129(6):1347–1355, 2012.
15. Sitzman TJ, Girotto JA, Marcus JR: Current surgical practices in cleft care: unilateral cleft lip repair, *Plast Reconstr Surg* 121: 261e–270e, 2008.
16. Sischo L, Chan JW, Stein M, et al.: Nasoalveolar molding: prevalence of cleft centers offering NAM and who seeks it, *Cleft Palate Craniofac J* 49:270–275, 2012.
17. Grayson BH, Santiago PE: Presurgical orthopedics for cleft lip and palate. In Aston SJ, Beasly RW, Throne CH, editors: *Grabb and Smith's plastic surgery,* ed 5, Philadelphia Lippincott-Raven, pp 237–244, 1997.
18. Ezzat CF, Chavarria C, Teichgraeber JF, et al.: Presurgical nasoalveolar molding therapy for treatment of unilateral cleft lip and palate: a preliminary study, *Cleft Palate Craniofac J* 44(1):8–12, 2007.
19. Jaeger M, Braga-Silva J, Gehlen D, et al.: Correction of the alveolar gap and nostril deformity by pre-surgical passive orthodontia in the unilateral cleft lip, *Ann Plast Surg* 59(5):489–494, 2007.
20. Singh GD, Levy-Bercowski D, Santiago PE: Three dimensional nasal changes following nasoalveolar molding in patients with unilateral cleft lip and palate: geometric morphometrics, *Cleft Palate Craniofac J* 42(4):403–409, 2005.
21. Maull DJ, Grayson BH, Cutting CB, et al.: Long term effects of nasoalveolar molding on three dimensional nasal shape in unilateral clefts, *Cleft Palate Craniofac J* 36:391–397, 1999.
22. Chang CS, Por YC, Liou EJ, et al.: Long-term comparison of four techniques for obtaining nasal symmetry in unilateral complete cleft lip patients: a single surgeon's experience, *Plast Reconstr Surg* 126(4):1276–1284, 2010.
23. Santiago PE, Grayson BH, Cutting CB, et al.: Reduced need for alveolar bone grafting by presurgical orthopedics and primary gingivoperiosteoplasty, *Cleft Palate Craniofac J* 35(1):77–80, 1998.
24. Pfeifer TM, Graysonn BH, Cutting CB: Nasoalveolar molding and gingivoperiosteoplasty versus alveolar bone graft: an outcome analysis of costs in the treatment of unilateral cleft alveolus, *Cleft Palate Craniofac J* 39(1):26–29, 2002.
25. Maarse W, Berge SJ, Pistorius L, et al.: Diagnostic accuracy of transabdominal ultrasound in detecting prenatal cleft lip and palate: a systematic review, *Ultrasound Obstet Gynecol* 35:495–502, 2010.
26. Johnson CY, Honein MA, Hobbs CA, et al.: Prenatal diagnosis of orofacial clefts, National Birth Defects Prevention Study, 1998-2004, *Prenat Diagn* 29:833, 2009.
27. Ezzat CF, Chavarria C, Teichgraeber JF, et al.: Presurgical nasoalveolar molding therapy for the treatment of unilateral cleft lip and palate: a preliminary study, *Cleft Palate-Craniofac J* 44(1): 8–12, 2007.
28. Spengler AL, Chavarria C, Teichgraeber JF, et al.: Presurgical nasoalveolar molding therapy for the treatment of bilateral cleft lip and palate: a preliminary study, *Cleft Palate-Craniofac J* 43(3):321–328, 2006.
29. Sischo L, Broder HL, Phillips C: Coping with cleft: a conceptual framework of caregiver responses to nasoalveolar molding, *Cleft Palate Craniofac J*, 52(2):640–650, 2015.
30. Sischo L, Clouston SAP, Phillips C, Broder HL: Caregiver responses to early cleft palate care: a mixed method approach, *Health Psychology*, 35(5):474–482, 2016.

32

Evaluation and Management of Speech Disorders for the Patient with Cleft Palate

DAVID J. ZAJAC

This chapter provides an overview of speech characteristics, evaluation techniques, and management approaches for the patient with repaired cleft palate with or without cleft lip. The intended audience is oral and maxillofacial surgeons, speech-language pathologists (SLPs), and other health care professionals who have basic knowledge of both cleft conditions and the anatomy and physiology of the vocal tract. The chapter begins with a discussion of the multiple causes of speech disorders among patients with cleft palate. Multiple causes are emphasized, as most textbooks tend to focus on velopharyngeal dysfunction as the cause of speech disorders and neglect the contribution of other structural factors. Next, core speech characteristics of individuals with repaired cleft palate and velopharyngeal dysfunction are described. Both perceptual and instrumental assessment techniques of speech and velopharyngeal function are then reviewed. The chapter concludes with an overview of the role of secondary surgery, prosthetics, and behavioral approaches to treatment.

Etiology of Speech Disorders in Individuals with Cleft Palate

Although SLPs have traditionally focused on inadequate function of the velopharyngeal mechanism as the primary cause of speech problems in individuals with cleft palate, other factors are also involved. It is well known that alveolar and dental anomalies associated with clefts of the primary palate contribute to speech disorders.[1-4] In addition, because eustachian tube dysfunction and otitis media are almost universal in children with cleft palate, the deleterious effects of conductive hearing loss on speech acquisition must be considered.[5-8] Finally, it must be emphasized that children born with cleft palate are not immune from developing other speech problems during childhood such as phonologic disorders, apraxia of speech, and stuttering. Relative to the last, Dalston and co-workers, however, reported that for unknown reasons, the prevalence of stuttering among children with cleft palate is actually lower than expected.[9] Regardless, the point to be made is that children with cleft palate are a challenge relative to the diagnosis of speech problems that might result from multiple causes. Clearly, differential diagnosis of the underlying cause of speech problems is essential if appropriate treatment recommendations are to be made.

Velopharyngeal Dysfunction

The primary goal of surgical repair of clefts of the secondary palate is to restore the muscular integrity of the velopharyngeal structures to enable normal speech development.[4,10] Although the timing of palate repair varies greatly across institutions, current consensus for initial palate surgery of infants in the United States appears to be 9 to 12 months of age. If a cleft of the primary palate is involved, definitive correction of the alveolar defect is delayed until the child is approximately 8 to 9 years of age and is in mixed dentition. Typically, review of studies indicates that the success rate for surgical repair of clefts involving the secondary palate is appropriately 70% to 80%.[11]

For the child born *without* cleft palate, we expect that by 3 to 4 years of age he or she will naturally acquire vowels, nasal consonants, and stop-plosive consonants. In English, stop-plosives are articulated primarily at three locations in the oral cavity: bilabial for /p/ and /b/, lingual-alveolar for /t/ and /d/, and lingual-velar for /k/ and /g/. By the time a child is 7 to 8 years of age, we expect that the entire phonetic inventory of English—including fricative and affricate consonants—will be mastered. Conversely, for a child born with a cleft of the secondary palate, the phonetic inventory

may consist of only vowels, nasal consonants, and vowel-like consonants (e.g., /w/ and /j/) at 3 years of age if palatal surgery was not successful. In addition, as described later, some children with cleft palate may develop pharyngeal and/or glottal articulations in an attempt to compensate for velopharyngeal dysfunction. Table 32-1 lists the stop, fricative, and affricate consonants that are likely to be affected by velopharyngeal dysfunction. As illustrated, inadequate velopharyngeal function has the potential to affect a majority of English consonants.

In addition to congenital clefts of the secondary palate, velopharyngeal dysfunction may occur in children because of congenitally deep nasopharynx; obstructing tonsils and/or adenoids; and neuromotor problems such as dysarthria and/or apraxia. Diagnosis and management decisions that involve children with repaired cleft palate, therefore, need to take possible co-existing factors into consideration.

Dental and Alveolar Anomalies

When clefts involve the primary palate, structural anomalies involving the teeth and alveolar ridge are likely to occur. Missing and/or supernumerary teeth are often found in and around the cleft site. Maxillary collapse and resulting posterior crossbites are common. Oral-nasal fistulas may also occur, especially during maxillary expansion as part of orthodontic treatment. Even in cases of isolated clefts of the secondary palate, there may be alveolar and/or palatal morphologic anomalies that occur as the result of growth restriction due to surgical repair. In addition, clefts of the secondary palate are often associated with syndromes and/or sequences such as Pierre-Robin, which may directly cause dental malocclusion. Although alveolar and dental anomalies have long been noted to affect speech production, surprisingly, the extent of the impact of these structural problems on speech intelligibility has not been systematically investigated.[1,4] Table 32-2 lists the consonants that are likely to be affected by alveolar and dental anomalies. As illustrated, a majority of consonants are produced by bringing the lips and tongue into contact with the teeth, alveolar ridge, and hard palate.

Other Causes

Because of the disruption of velar morphology caused by palatal clefting, infants with cleft palate are prone to a sequence of eustachian tube dysfunction, development of otitis media with effusion (OME), and mild to moderate conductive hearing loss.[5,12] Indeed, the prevalence of OME in children with cleft palate has been reported to be more than 95%.[6-8] Roberts and Clarke-Stein identified three ways in which persistent OME might disrupt normal development of speech and language.[13] First, reduced hearing acuity might result in inaccurate encoding of perceptual information. Second, prolonged hearing reduction might impair a child's ability to discriminate linguistic information, characterized by low perceptual saliency (e.g., morphophonemic markers). Third, illnesses associated with OME might "restrict or alter the child's interactions with people and objects in the environment," thus reducing available opportunities for speech and language learning. Although these disruptions have obvious face validity, available research has indicated an equivocal relationship between the occurrence of early conductive hearing loss as a consequence of OME and subsequent development of speech and language in children *without* cleft palate.[14-24]

In contrast to children without cleft palate, only a few studies have investigated the impact of conductive hearing loss on speech acquisition in children with cleft palate. Hubbard, in a retrospective study, reported that articulation scores were better in a group of children with cleft palate who received early and aggressive ear care as compared with a group of children with cleft palate who did not receive early ear care.[25] Broen and colleagues studied infants with and without cleft palate longitudinally to age 30 months.[26] These investigators reported that hearing levels of the infants

TABLE 32-1 English Consonants Most Likely to Be Affected by Velopharyngeal Dysfunction

	Labial	Labiodental	Interdental	Alveolar	Palatal	Velar
Stops	pb			td		kg
Fricatives		fv	ɵ ð	sz	ʃ ʒ	
Affricates					ʧ ʤ	

TABLE 32-2 English Consonants Most Likely to Be Affected by Dental-Alveolar Defects

	Labial	Labiodental	Interdental	Alveolar	Palatal	Velar
Stops				td		
Fricatives		fv	ɵ ð	sz	ʃ ʒ	
Affricates					ʧ ʤ	

accounted for significant differences on cognitive and developmental measures between the cleft and noncleft groups. Clearly, additional research is needed to gauge the impact of early hearing loss as a result of OME in children with repaired cleft palate.

Finally, we know that approximately 6% to 10% of children without cleft palate will require speech therapy for idiopathic or functional articulation disorders.[27] In addition, developmental neuromotor disorders such as apraxia of speech may occur in children and can dramatically reduce speech intelligibility. Obviously, children born with cleft palate are not immune to such speech disorders. Indeed, relative to children with velopharyngeal dysfunction who also have velocardiofacial syndrome, Kummer and colleagues (2007) reported an increased prevalence of apraxia of speech.[28]

Speech Characteristics of Individuals with Cleft Palate

After initial palate repair, approximately 20% to 30% of children will exhibit speech characteristics that reflect inadequate velopharyngeal function. These characteristics include hypernasal resonance during vowel production, nasal air emission (visible and/or audible) during consonant production, and reduced oral air pressure during consonant production. These speech characteristics are often referred to as *obligatory* symptoms because they naturally occur in the presence of inappropriate oral-nasal coupling. In addition, children with velopharyngeal dysfunction may alter tongue placement for articulation of consonants. These misarticulations are referred to as *compensatory (or maladaptive)* behaviors in that they are learned in response to inadequate velopharyngeal closure.

Resonance Imbalance

Resonance is a complex perceptual phenomenon associated with vowels and voiced consonants. It occurs due to acoustic excitation of the air-filled cavities of the upper vocal tract, primarily the pharynx, oral cavity, and nasal passages. In English, speakers *without* cleft palate will produce vowels and oral consonants with nearly complete separation of the oral and nasal cavities as illustrated in Figure 32-1. This is accomplished by elevation and retraction of the soft palate and sphincter-like closure of the upper pharyngeal walls. The primary resonating cavities, therefore, are the pharynx and mouth. During production of the nasal consonants (/m/, /n/, and /ŋ/) and vowels that precede or follow a nasal consonant, the soft palate will relax and lower to some degree. Nasal resonance, therefore, will be perceived during these speech sounds. The primary determinants of normal nasal resonance during nasal consonants and adjacent vowels are (1) the physical characteristics of the nasal cavities such as volume and cross-sectional area, and (2) the temporal extent of velar lowering before and after nasal consonants (i.e., anticipatory and carryover nasalization), respectively. In addition, some normal nasal resonance may occur during production of nonnasalized vowels and voiced oral consonants owing to the extent that the air mass in the nasal cavity is excited even in the presence of complete velopharyngeal closure. This phenomenon—sometimes referred to as *sympathetic vibration*—is determined by a complex interaction between the fundamental frequency of the speaker and the physical characteristics (mass and stiffness) of the elevated soft palate.[29,30]

For a speaker with repaired cleft palate who has incomplete velopharyngeal closure, inappropriate acoustic coupling of the oral and nasal cavities will occur and result in a hypernasal resonance imbalance during production of vowels and voiced, nonnasal consonants. The degree of the perceived hypernasality will be determined primarily, but not exclusively, by the physical extent of the coupling of the oral and nasal cavities. As noted previously, both temporal characteristics of nasalization and physical characteristics of the velum also may contribute to hypernasality. Indeed, even if a speaker with repaired cleft palate achieves complete velopharyngeal closure, it is possible that resonance may be hypernasal owing to physical changes in the velum caused by surgery (e.g., increased stiffness due to scarring).

Finally, it must be noted that some speakers with repaired cleft palate may exhibit primarily hyponasality or mixed hypernasality and hyponasality. Hyponasality will

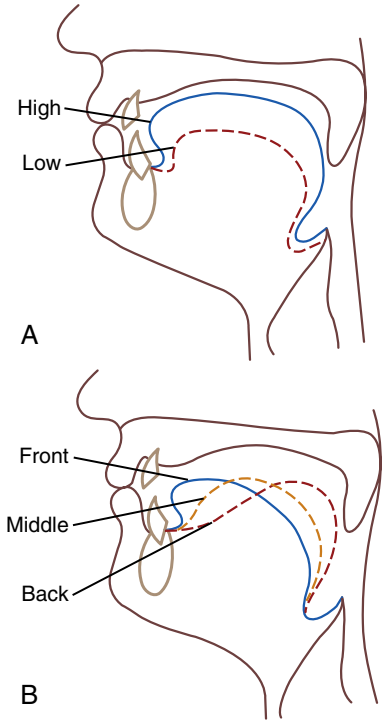

• **Figure 32-1** Illustration of normal velopharyngeal closure during vowel production. **A,** Velar and tongue positions for high and low vowels. **B,** Velar and tongue positions for front, middle, and back vowels. (Adapted from Skolnick ML, Cohn ER: *Videofluoroscopic studies of speech in patients with cleft palate,* New York, 1989, Springer-Verlag.)

occur during production of nasal consonants and adjacent vowels when the nasal cavities are obstructed. The location of the obstruction may be posterior and include hypertrophied tonsils and/or adenoids or anterior and include deviated septum, hypertrophied turbinates, and/or a collapsed nasal vestibule.

Nasal Air Emission

Nasal air emission (or escape) is distinct from hypernasality both in perceptual features and affected speech sounds. Nasal escape refers to the visible or audible loss of air through the nose that accompanies stop-plosives and/or continuant consonants. Audible nasal escape may be brief when it accompanies stop-plosives (confined to the closure phase of the consonant) or relatively prolonged when it accompanies continuants such as /s/. Although audible nasal escape may occur during both voiced and voiceless consonants, it is most salient during production of voiceless sounds. This occurs because voiceless sounds are typically produced with higher levels of intraoral air pressure than voiced sounds.[31] Unlike hypernasality, the presence of nasal air escape always implies the direct physical coupling of the oral and nasal cavities at some location (i.e., at either the velopharynx and/or a fistula at some point along the palate). Although hypernasality and nasal escape may co-occur, each may occur without the other.

Because of the complex nature of audible nasal escape and anatomic variability among speakers, it is not unexpected that there have been numerous and at times somewhat confusing descriptions of nasal air emission reported in the literature. Peterson-Falzone and co-workers described "audible" nasal air escape as the sound that is produced when one "forcefully exhales through the nose."[4] They further describe a severe form of audible nasal air emission that they term "nasal turbulence." This arises from extra noises due to increased "intranasal or velopharyngeal resistance." The extra noises may occur due to either tissue vibration and/or displacement of mucus pooling in a constriction. Kummer and co-workers refer to nasal turbulence as "nasal rustle" and attribute it to bubbling of secretions within a small velopharyngeal port.[32] Zajac and colleagues, however, suggested that the distinctive quality of nasal turbulence (or rustle) was due to tissue vibration at the velopharyngeal port.[82] Regardless, Kummer makes the excellent point that clinicians need to be aware that the presence of nasal turbulence (or rustle) typically indicates a relatively small velopharyngeal opening.

Finally, audible nasal air emission may occur in the presence of normal velopharyngeal closure as part of learned nasal fricatives. This is often referred to as phoneme-specific nasal emission (PSNE). Nasal fricatives are characterized by complete occlusion of the oral cavity with exclusive shunting of airflow through the nose to produce turbulence and frication. The frication can be produced either posteriorly at the velopharyngeal port or anteriorly at the nasal valve. Nasal fricatives can be substituted for any of the fricative, sibilant, and/or affricate sounds. During production of stop-plosive sounds, velopharyngeal closure is complete. Because nasal fricatives are used by children both with and without palatal anomalies, these errors are most likely learned, perhaps due to conductive hearing loss during early acquisition of fricatives. Therefore, behavioral speech therapy, not surgery, is the treatment option. Zajac provides a discussion of nasal fricatives and PSNE with audio examples from children both with and without cleft palate.[34] Behavioral techniques to address nasal fricatives are discussed later.

Reduced Intraoral Air Pressure

When velopharyngeal inadequacy exists, not only will nasal air escape occur during the closure phase of stop consonants, but the oral release burst during the plosive phase will be reduced in intensity owing to the loss of air pressure through the nose. In severe cases, an oral stop may sound more like a nasal consonant (e.g., "bat" may sound like "mat").

Articulation and Intelligibility

The prevalence of articulation errors in children with repaired cleft palate is high. Based on a review of the literature, Peterson-Falzone and co-workers concluded that approximately 75% of preschool children with repaired palate exhibit some type of articulation disorder.[4] Estimates were as high as 90% in some studies.[35] Given that multiple causes may be involved, these findings should not be surprising. As a comparison, the overall prevalence of functional articulation disorders among children without cleft palate is generally estimated to be 6% to 10%.[27]

Children with cleft palate and velopharyngeal dysfunction have been described to exhibit a variety of compensatory misarticulations.[1,4] As noted by Peterson-Falzone and colleagues (2010), compensatory articulations were historically considered to consist of glottal stop and pharyngeal fricative substitutions for oral consonants.[4] A shift in articulatory constriction to a location inferior to the velopharyngeal sphincter was considered to occur in response to velopharyngeal inadequacy in order to preserve manner of production. Philips and Kent[36] succinctly defined compensatory articulations as: "… behaviors that are thought to be learned and habituated [automatized] for productions of speech sounds when, due to VPI, normal productions cannot be achieved."

Given that velopharyngeal inadequacy results in an obligatory reduction in oral air pressure associated with stop consonants, it is not surprising that glottal substitutions may occur.[37] Sherman and colleagues reported that children with cleft palate primarily substituted glottal stops for voiceless stops—which require greater oral air pressure than voiced stops.[38]

In addition to "gross" compensatory errors such as glottal stops and/or pharyngeal fricatives, there are additional articulations typical of speakers with repaired cleft palate. Using both perceptual and radiographic techniques, Trost described the middorsum palatal stop, the posterior nasal fricative, and the pharyngeal stop.[33] The middorsum palatal stop was described as a substitution for alveolar and/or velar stops. It is produced with the dorsum of the tongue making contact with the palate in approximately the location for production of /j/. Perceptually, it was described as a cross between /t/ and /k/ or between /d/ and /g/, depending on voicing. The posterior nasal fricative was identified as a substitution for sibilant sounds. As noted earlier, it is produced with oral occlusion that forces air through a small velopharyngeal constriction. The pharyngeal stop was identified as a substitution for velar stops /k/ and /g/. It is produced with the base of the tongue making contact against the posterior pharyngeal wall.

The middorsum palatal stop is produced anterior to the velopharyngeal sphincter. It is problematic, therefore, to attribute its function as a compensatory response to velopharyngeal inadequacy. Hoch and colleagues noted the frequent co-occurrence of anterior oronasal fistulas (ONFs) and middorsum palatal stops in children with repaired cleft lip and palate.[39] Accordingly, they attributed the occurrence of the middorsum palatal stop to "anterior palatal defects." Similarly, Kummer stated that middorsum palatal stops might occur in response to malocclusion and/or dental crowding in the oral cavity, two frequent consequences of unrepaired alveolar clefts.[1] Indeed, several studies have noted that palatalized articulations were associated with physical narrowing of the anterior palate.[2,84]

Whereas several investigators have suggested that the middorsum palatal stop is a frequently occurring misarticulation in children with cleft palate, its effect on speech intelligibility is largely unknown.[40-42] Both trained and untrained listeners cannot consistently identify middorsum palatal stops as distinct from examples of /t/ and /k/ produced by children with repaired cleft palate.[42] Although an identification task is not the same as intelligibility, middorsum palatal stops "may reduce the intelligibility of the individual's speech by neutralizing the place contrast."[42]

Although articulation and intelligibility are often used as synonymous terms, intelligibility as a construct supersedes articulation. Kent has defined intelligibility as "the degree to which the speaker's intended message is recovered by the listener."[43] Therefore intelligibility is dependent on the speaker, the situation, and the listener. Many of the early studies that investigated intelligibility in children with repaired cleft palate employed transcription or write-down techniques.[11,44-46] In general, these studies indicated (1) clear differences in intelligibility between subjects with and without cleft palate, (2) a tendency for articulation and intelligibility scores to be correlated (especially errors involving stop consonants), and (3) a tendency for intelligibility and velopharyngeal function to be correlated.

Vocal Dysfunction

Voice disorders in individuals with clefts of the palate are often reported in the literature.[47-51] Hoarse vocal quality, reduced loudness, deviant and/or restricted pitch range, and tense or strained qualities are some of the commonly observed vocal aberrations. These studies have also reported a high prevalence of organic voice disorders among individuals with cleft palate as compared to speakers without cleft palate. McWilliams and co-workers used nasoendoscopy to examine 32 children with repaired cleft palate who had hoarse vocal quality.[48] These investigators reported that 72% of the children exhibited vocal fold nodules. Marks and co-workers reported that perceptual symptoms of dysphonia were evident in 34% of 102 speakers who were evaluated for suspected velopharyngeal dysfunction.[49] Similarly, D'Antonio and colleagues reported that 41% of 85 speakers with velopharyngeal dysfunction exhibited either perceptual symptoms of dysphonia and/or laryngeal anomalies.[50] As a comparison, voice disorders typically occur in no more than 6% of the general population.[27]

The high prevalence of voice disorders among speakers with velopharyngeal dysfunction is often attributed to compensatory changes in respiratory and/or laryngeal behaviors. Because nasalization of sound results in attenuation of acoustic energy, a speaker with inappropriate oral-nasal coupling will have to increase intensity to achieve a given level of loudness. One way to increase intensity is to use increased laryngeal resistance during voicing. The available evidence relative to laryngeal resistance among speakers with cleft palate, however, is equivocal. Whereas Zajac reported similar levels of laryngeal resistance in children with and without cleft palate, a study performed by Guyette et al reported that children with cleft palate and incomplete velopharyngeal closure exhibited higher levels of laryngeal resistance than children with cleft palate and complete velopharyngeal closure.[52,53]

Some speakers with velopharyngeal dysfunction may actually reduce loudness. McWilliams and colleagues refer to this phenomenon as "soft voice syndrome" and suggest that it is an attempt to mask perceptual symptoms of hypernasality and/or nasal air escape.[11] Finally, clinicians should also be aware that vocal hoarseness will effectively mask hypernasality in many patients with repaired cleft palate. Careful attention, therefore, should be paid to patients with hoarseness.

Perceptual Evaluation Procedures

It is often said that the ear (and eye) of the SLP is the most important tool relative to diagnosis of speech problems in individuals with repaired cleft palate. The use of instrumental techniques as described later in this chapter is secondary to perceptual assessment and is used to objectively document the severity of dysfunction and/or to guide treatment approaches (e.g., type of secondary palatal surgery). The primary objective of the clinician as part of perceptual

assessment is to determine the adequacy of velopharyngeal function for normal speech production. To do so, the clinician must obtain an adequate sample of conversational and elicited speech to detect the presence of obligatory and/or compensatory speech behaviors.

Nostril Pinch Test

A relatively simple procedure to help the clinician determine if hypernasality is present is the nostril pinch test.[54] The speaker is instructed to prolong a vowel such as /i/ both with the nostrils open and with them closed. If velopharyngeal closure is adequate, there will be little change in resonance from the open to closed states. A perceptual shift to more oral resonance with the nostrils occluded is an indication of incomplete velopharyngeal closure. For some patients with inadequate velopharyngeal closure, the shift in resonance may approach a cul-de-sac quality. This is a muffled, nasal-like quality that occurs because of the blockage of the anterior nose. As described by Kuehn and Henne, the nostril pinch test may also be used to detect the presence of hyponasality in speakers with cleft palate.[54] Hyponasality is a reduction in normal nasal resonance during production of nasal consonants. It may occur as a result of posterior obstruction by enlarged tonsils and/or adenoids or anterior obstruction due to a collapsed nasal vestibule, deviated septum, and/or hypertrophied turbinates. To detect hyponasality, the speaker is instructed to produce words containing nasal consonants such as "mama" with the nostrils both open and closed. If no nasal obstruction is present, then a definite shift to hyponasal resonance should occur with the nostrils occluded.

Nasal Emission Testing

A relatively simple technique can also be used to detect the inappropriate escape of nasal airflow during oral consonant production. The clinician holds a small mirror or detail reflector beneath the nostrils of the speaker during production of syllables and sentences that contain nonnasal consonants (Figure 32-2). If velopharyngeal closure is complete, then no visible fogging of the reflector will occur except perhaps at the very beginning and end of the utterance. Visible nasal escape at the start and end of an utterance is normal and is caused by the movement of the velum during transitions from breathing to speaking and from speaking to breathing, respectively. Clinicians must also be cautious regarding speaking rate during nasal emission testing. If a speaker uses a relatively slow rate with respiratory pauses between words, then normal nasal escape may occur at the onset and offset of each word owing to movement of the velum as noted previously.

Nasal emission testing can also be used to detect nasal obstruction. If reduced or absent nasal airflow occurs during production of nasal consonants, then some degree of obstruction and hyponasality will likely be present. Typically, it is best to start nasal emission testing during production of nasal consonants to rule out obstruction before testing for nasal escape during nonnasal consonants.



• **Figure 32-2** Detail reflector to test for nasal obstruction during breathing and nasal air emission during speech.

• BOX 32-1 Respiratory and Speech Stimuli to Determine Nasal Obstruction and Velopharyngeal Dysfunction During Nasal Emission Testing

Stimuli to Determine Nasal Obstruction

- Quiet breathing with lips closed
- Repetition of /mi/ and /ma/
- "Mama made some lemon jam"

Stimuli to Determine Velopharyngeal Dysfunction

- Repetition of /pi/ and /pa/
- Repetition of /si/ and /sa/*
- Repetition of /ki/ and /ka/†
- "Papa plays baseball"
- "Sissy sees the sky"
- "Lucy likes lollipops"

*May indicate phoneme-specific nasal emission.
†May indicate patent anterior ONF.

Finally, nasal emission testing might be useful to determine if an anterior ONF is symptomatic for speech. This is done by systematically varying production of anterior and posterior stop consonants and observing the resulting pattern of nasal air emission. As indicated by Kuehn and Henne, if an ONF is lingual to the alveolar ridge, then during production of syllables containing /p/, nasal air escape will occur if the ONF is patent.[54] If, however, during production of syllables containing /k/, nasal air emission is absent, then the source of the nasal air escape can be attributed to the anterior ONF. Obviously, this assumes that velopharyngeal closure is complete. Box 32-1 presents respiratory and speech stimuli used by this clinician during nasal emission testing to rule out nasal obstruction, detect the presence of nasal air escape resulting from velopharyngeal dysfunction, and detect the presence of nasal air escape possibly caused by an anterior ONF or learning (i.e., PSNE).

Perceptual Rating Scales

Once global decisions are made regarding the presence or absence of hypernasality and nasal air emission, various types of rating scales may be used to indicate the perceived level of severity. Most commonly, the equal-appearing interval (EAI) scale is used with varying numbers of intervals.[11] In its most simple form, a four-point EAI scale is used to represent normal (0), mild (1), moderate (2), or severe (3) hypernasality. Five-, seven-, or nine-point EAI scales can also be used. Obviously, as more intervals are used, reliability of judgments within and across clinicians becomes more problematic. EAI scales can also be used to judge the severity of nasal air emission, vocal symptoms such as hoarseness and breathiness, and, as discussed later, articulation and speech intelligibility.

Articulation Testing

As part of the clinical evaluation, the SLP will use a standardized test of articulation to describe speech errors and document the speaker's level of impairment relative to a reference sample of speakers. Any of the commercially available articulation tests are adequate for this purpose (e.g., Arizona Articulation Proficiency Scale 3, Fisher-Logemann Test of Articulation Competence). Typically, the SLP will use transcription symbols based on the International Phonetic Alphabet to describe articulation errors such as substitution, omission, addition, and distortion of targeted speech sounds. In addition, when evaluating a speaker with repaired cleft palate, it is important for the clinician to use special diacritic transcription symbols that provide a further level of phonetic detail regarding distortion of sounds such as dentalization, palatalization, and/or the presence of audible nasal air escape.

Intelligibility Assessment

Some authors have advocated the use of rating scales to evaluate intelligibility in speakers with cleft palate given that write-down or transcription techniques were too time-consuming.[55] Apparently, this advice was well heeded, as revealed by a recent survey of the literature compiled by Whitehill.[56] Based on a review of 57 published articles between 1960 and 1998, Whitehill reported that 63.2% employed "crude" estimates of intelligibility or EAI scaling procedures, whereas only 14% used transcription methods. In addition, it was noted that only three of the reviewed studies used predictive analysis techniques in an attempt to explain underlying intelligibility deficits.

Hodge and Gotzke described a single-word intelligibility test to identify underlying phonetic contrasts that contribute to speech intelligibility in English-speaking children with repaired cleft palate.[57] The study evaluated 15 children between the ages of 3 years, 5 months and 6 years, 7 months. Only 5 of the children studied, however, had repaired cleft palate; 10 children were controls. Hodge and Gotzke obtained 3 indexes of speech intelligibility: (1) a global index based on 100 consecutively transcribed utterances from spontaneous speech, (2) a closed-set (i.e., multiple choice) single-word intelligibility score, and (3) an open-set (i.e., orthographic write down) single-word intelligibility score.[57] The closed- and open-set tests included up to 124 words that reflected various phonetic contrasts known to be problematic for children with cleft palate. The recorded words of the children were presented to groups of listeners who were instructed to either select the word they heard from a list of words (closed set) or simply write down the word they heard (open set). Hodge and Gotzke reported a high correlation between spontaneous speech intelligibility scores and scores obtained from the open-set task (r=0.88).

Zajac and co-workers developed a computer-mediated, 50-word intelligibility test designed for young children with cleft lip and palate.[83] Adult listeners used orthographic transcription to determine the percentage of words correctly identified for each child. Zajac and colleagues reported that the test was valid and reliable and appeared to be a good instrument to conduct multicenter outcome studies of speech intelligibility.

Instrumental Assessment Techniques

Although perceptual assessment of velopharyngeal function in patients with repaired cleft palate is considered the gold standard, Peterson-Falzone and colleagues indicate that a "comprehensive" evaluation of velopharyngeal function must include both perceptual and instrumental assessment techniques.[4] As noted earlier, instrumental assessment is ideally suited to complement perceptual judgments of severity and/or to suggest specific surgical interventions. At times, however, objective instrumental assessment may override perceptual judgments. This may occur because of the ability of instruments to isolate and focus on a specific aspect of behavior without influence from competing factors. It is well known, for example, that auditory perception of speech can be influenced by visual stimuli (e.g., the McGurk effect).[58]

Instrumental techniques to assess velopharyngeal function can be conveniently categorized as direct and indirect.[59] Direct techniques are those that provide actual visualization of the structures of interest; indirect techniques are those that show some effect of the structures of interest. Summarized in the following sections are some of the more commonly used direct and indirect instrumental techniques to assess velopharyngeal function.

Direct Techniques

Lateral Still Cephalometry

Lateral still cephalometry produces a radiograph obtained in the lateral view while a speaker sustains a nonnasal phoneme. Also called a "phonating cephalograph," it allows assessment of the extent of velar contact to the posterior

pharyngeal wall. The speaker is simply instructed to prolong a vowel such as /i/ or a continuant such as /s/ while the radiograph is taken. Examination of the radiographic film allows assessment of the length of the velum, depth of the nasopharynx, and level and extent of velopharyngeal closure. As summarized by Moon, subjective and/or objective interpretation of the lateral cephalograph is possible.[59] Although obtaining measurements from lateral cephalometric radiographs is a relatively straightforward technique and provides important information, a significant disadvantage is that only a single two-dimensional view of the velopharyngeal structures is obtained.

Multiview Videofluoroscopy

As its name implies, videofluoroscopy overcomes the disadvantage of lateral cephalometry by providing multiple views of the velopharyngeal mechanism. This technique provides a comprehensive radiographic assessment of both velopharyngeal and oral structures and functions by obtaining a systematic series of audio-video images while the patient speaks and drinks barium. As described by Skolnick and Cohn, the patient is assessed during the following sequence of activities (Figure 32-3): (1) speaking in lateral view without barium contrast, (2) swallowing barium in lateral view, (3) speaking in base view after barium is instilled into the nostrils, (4) speaking in frontal view after barium contrast, and (5) speaking in lateral view after barium contrast.[60] The lateral view with barium contrast allows assessment of velar length, depth of the nasopharynx, and dynamic movement of both the velopharyngeal and lingual structures during production of nasal and nonnasal phonemes. The base view allows assessment of lateral pharyngeal wall movement and shape of velopharyngeal closure (circular, coronal, or sagittal) during speech. The frontal view allows assessment of lateral pharyngeal wall movement relative to the level of velar elevation. By synthesizing the multiple views, the clinician is able to gain a "three-dimensional" impression of the ability of the patient to achieve velopharyngeal closure.

Video Nasendoscopy

During nasendoscopy, a flexible fiberoptic endoscope is inserted through the nasal cavity to record the dynamic movements of the velopharyngeal structures during speech production. The scope is connected to both a light source and a video camera. A microphone is used to record the speech signal along with the video images. During a typical assessment, the patient is instructed to breathe quietly,

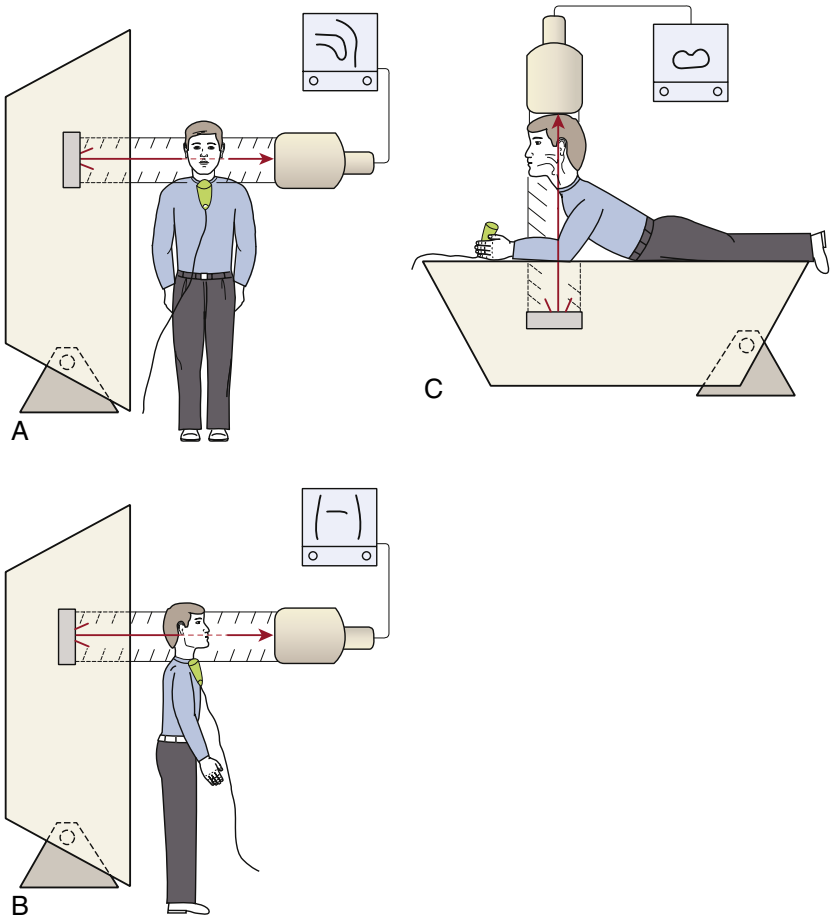

• **Figure 32-3** Illustration of patient positioning for multiview videofluoroscopy. **A,** Lateral view. **B,** Frontal view. **C,** Base view. (Adapted from Skolnick ML, Cohn ER: *Videofluoroscopic studies of speech in patients with cleft palate,* New York, 1989, Springer-Verlag.)

swallow, and produce words and sentences that contain nasal and nonnasal segments. Similar to videofluoroscopy, nasendoscopy provides important diagnostic information regarding velopharyngeal function. In addition, it can provide useful information to prosthodontists relative to the design and fitting of palatal obturators (see the later discussion of prosthetics).

Several disadvantages of the use of nasendoscopy must be mentioned. First, it is invasive and typically requires the use of a topical anesthetic and/or vasoconstrictor. Children, especially those with nasal deformities resulting from clefts of the primary palate, may not tolerate the procedure well. Second, the view of the velopharyngeal mechanism is essentially limited to the nasal aspect of the velum and the superior-posterior pharyngeal wall. This means that velopharyngeal function may be difficult to discern if closure occurs at a more inferior level. Third, similar to videofluoroscopy, results from nasendoscopy are largely subjective in nature. In an attempt to overcome this limitation, a multidisciplinary group of clinicians formed a working group to develop standards for reporting results.[61] This group devised a rather complicated system of rating velopharyngeal closure based on the relative contributions of the velum and posterior and lateral pharyngeal walls. Based on recent studies reported in the literature, however, there does not appear to be widespread acceptance of this reporting system.

Indirect Techniques

Pressure-Flow Method

The application of aerodynamic principles to the study of the velopharyngeal mechanism during speech production was pioneered by Warren and DuBois.[62] Their procedure has come to be known as the *pressure-flow method*. Essentially, it requires the placement of small-bore catheters into one of the nostrils and behind the lips to detect differential oral-nasal air pressure and the placement of a flow tube into the remaining nostril to obtain nasal airflow. During production of oral consonants such as /p/, the size of the velopharyngeal gap can be estimated using a derivation of Bernoulli's principle.

Figure 32-4 illustrates the clinical application of the pressure-flow method. The pressure catheters are connected to calibrated differential air pressure transducers. The airflow tube is connected to a calibrated, heated pneumotachograph and air pressure transducer. The speaker simply repeats a train of /pi/ syllables with the oral catheter held behind the lips. Based on measurements of oral air pressure (P_o), nasal air pressure (P_n), and nasal airflow (V_n), estimates can be made of the cross-sectional area of the velopharyngeal port during production of /p/ using the following equation:

$$A = V_n/K[2\,(P_0 - P_n)\,/D]^{1/2}$$

where A is area in square centimeters, V_n is nasal airflow in milliliters per second, k is a constant (0.65) used to correct for turbulent airflow, P_o is oral pressure in dynes per square centimeter, P_n is nasal pressure in dynes per square centimeter, and D is the density of air (0.001 gm/cm^3). Both hardware and software are commercially available to obtain pressure-flow measurements and calculate velopharyngeal area (Microtronics Inc., Chapel Hill, NC).



• **Figure 32-4** Placement of oral pressure catheter, nasal pressure catheter, and nasal airflow tube during pressure-flow testing.

Figure 32-5 illustrates pressure-flow information from a 12-year-old boy with a repaired cleft lip and palate who repeated the syllable /pi/ eight times. Typically this utterance should be produced with complete velopharyngeal closure and no indication of nasal air pressure or flow. As revealed in the figure, however, there is evidence of consistent escape of nasal airflow during both the /p/ and /i/ segments. Perceptually the boy's speech was characterized by mild to moderate hypernasality and visible nasal air escape. Estimated velopharyngeal orifice area during the /p/ segment was approximately 6 mm^2. Estimated velopharyngeal area during the vowel segment, however, was approximately 27 mm^2. This difference is expected based on production demands of consonants (closed or constricted oral cavity) versus vowels (open oral cavity). It needs to be noted, however, that estimates of velopharyngeal orifice size during production of vowels are typically not obtainable owing to relatively low (or absent) levels of oral air pressure.

Normative data using the pressure-flow method have been reported by Zajac.[63] For speakers without cleft palate, estimates of velopharyngeal orifice size during production of syllables such as /pi/ are typically under 1 mm^2, which reflects essentially complete closure. During plosive sequences such as /mp/ in the word "hamper," velopharyngeal orifice size is typically under 3 mm^2 and rarely exceeds 5 mm^2 in speakers without cleft palate.

Thom and colleagues described the use of nasal ram pressure (NRP) as an index of velopharyngeal closure in infants during production of cries and vocalizations.[64] Six infants without cleft palate were studied longitudinally between 2 and 6 months of age. NRP was detected by inserting a double-barreled cannula connected to a pressure transducer into the nostrils of the

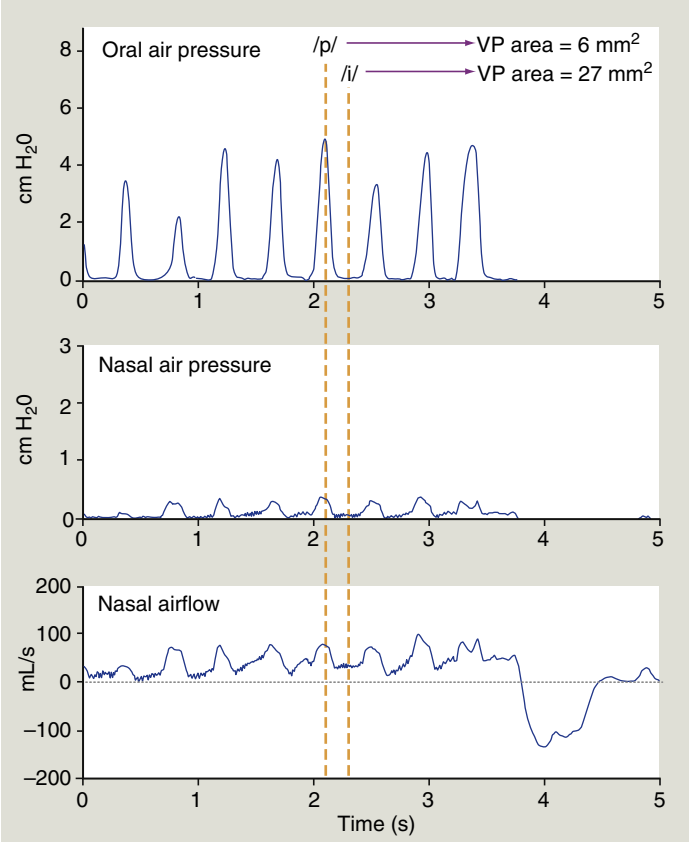

• **Figure 32-5** Example of oral air pressure *(top)*, nasal air pressure *(middle)*, and nasal airflow *(bottom)* during repetition of the syllable /pi/ by a 12-year-old boy with velopharyngeal dysfunction.

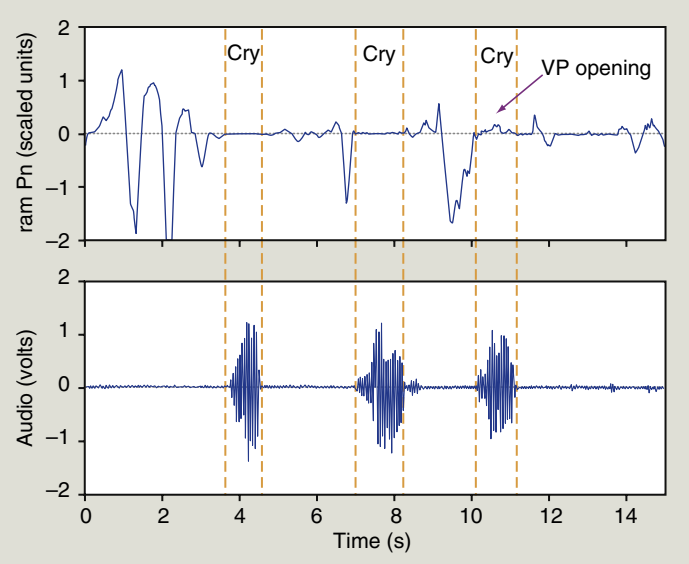

• **Figure 32-6** Example of nasal ram pressure *(top)* and audio *(bottom)* of a 13-month-old infant obtained 4 months after palate repair. Nasal breathing is evident before the distress cries. First and second cries show velopharyngeal (VP) closure; third cry shows an open VP port.

infants. A lapel microphone recorded cries and vocalizations. The study revealed that velopharyngeal closure occurred during cries beginning at 2 months of age. Velopharyngeal closure during vowel-like vocalizations, however, tended to increase as a function of age. The study suggested that this technique may hold promise in the early diagnosis of velopharyngeal dysfunction in infants with cleft palate after surgical repair. At the UNC Craniofacial Center we have begun to investigate infants by obtaining NRP after cleft palate repair. Figure 32-6 illustrates NRP and audio of a 13-month-old infant obtained 4



• **Figure 32-7** Placement of Nasometer head-mounted microphones to determine nasalance.

months after surgery. As shown, the NRP data suggest that this infant exhibited velopharyngeal dysfunction during the third cry. We are currently collecting longitudinal data on a group of infants with repaired cleft palate and hope to determine the clinical utility of this promising new procedure.

Nasometry

The Nasometer uses two microphones to detect nasal acoustic energy in relation to oral acoustic energy produced during voiced speech sounds. Precursors to the Nasometer, Tonar (The Oral-Nasal Acoustic Ratio) and Tonar II, were originally developed by Fletcher.[65,66] Currently the Nasometer is commercially available from Kay Pentax Corporation (Lincoln Park, NJ). A similar device, called the OroNasal mask system, is available from Glottal Enterprises (Syracuse, NY). The output of the Nasometer is a measure called *nasalance*. It is calculated as the ratio of nasal acoustic energy to oral-plus-nasal acoustic energies and expressed in a percentage:

$$\%\,\text{Nasalance} = \text{Nasal intensity}/(\text{oral} + \text{Nasal intensity}) \times 100$$

Clinical use of the Nasometer is illustrated in Figure 32-7. Two microphones are separated by a metal plate that serves as a sound barrier. A head harness positions the sound barrier to rest on the upper lip beneath the nose. The top microphone detects nasal acoustic energy, and the bottom microphone detects oral acoustic energy. The outputs of each microphone are band-pass filtered at 350 to 650 Hz, digitized to a computer, and percent nasalance is calculated and displayed. Nasalance statistics such as means, standard deviations, maximums, and minimums can be calculated. Typically speakers are instructed to read a passage devoid of nasal consonants (the "Zoo" passage) and sentences loaded with nasal consonants. As indicated later, speakers with normal resonance typically do not exhibit nasalance scores that exceed 32% during reading of the Zoo passage. For nasal sentences, normal speakers typically do not exhibit nasalance that falls below 50%. In addition, MacKay and Kummer have provided nasalance norms for children based on repetition of consonant-vowel syllables.[67]

Percent nasalance appears to be a fairly sensitive predictor of perceived hypernasality and hyponasality. Dalston and coworkers, for example, reported that nasalance scores of 32% or greater during reading of the Zoo passage had a sensitivity of 0.89 and a specificity of 0.95 in identifying speakers with at least mild hypernasality.[68] In a separate study Dalston's group further reported that nasalance scores of 50% or less during reading of sentences loaded with nasal consonants had a sensitivity of 0.48 and a specificity of 0.79 in identifying speakers with perceived hyponasality.[69] The authors noted that the relatively low sensitivity increased to 1.0 when speakers who exhibited audible nasal emission during voiceless consonants were omitted from analysis. The latter finding highlights a limitation of the Nasometer in that audible nasal air emission tends to inflate nasalance scores.

The Nasometer is a popular clinical tool that is helpful in the diagnosis of speakers with resonance imbalance. Although the basic concept of the Nasometer is valid, the reader should be cautioned relative to several aspects of its use. First, the actual sound separation between the oral and nasal microphones is limited. In practice, this means that 0% nasalance does not occur during production of sounds when the velopharyngeal mechanism completely separates the mouth from the nose. Likewise, 100% nasalance typically does not occur during nasal consonants. Second, although nasalance scores are intended to reflect voiced speech segments, the Nasometer is also sensitive to nasal turbulence that may occur during voiceless consonants. This may inflate nasalance scores and, as indicated earlier, reduce sensitivity relative to perceptual characteristics of speech. Finally, because the Nasometer uses two microphones, there may be subtle mismatches in the microphone sensitivities as a function of frequency response. Indeed, users of both the original Tonar and the current Nasometer have been cautioned relative to this possibility.[70,71] If mismatches in microphone sensitivity exist, then discrepancies in nasalance scores may occur as a function of different Nasometer units, and comparisons across centers may be problematic. Based on published and unpublished studies, this writer suggests that clinicians tolerate at least a range of plus or minus 7% when comparing a patient's nasalance score with published norms owing to possible differences in microphone sets.[71]

Management of Velopharyngeal Dysfunction

Treatment of velopharyngeal dysfunction after primary palate repair is typically considered if communication abilities of an individual are impaired and/or if the speech of the individual calls undue attention to itself, causing social stigma. Physical management via secondary surgery or

prosthodontics is typically recommended for obligatory symptoms such as hypernasality and/or nasal air escape. In some cases, primarily when obligatory symptoms are mild and/or inconsistent, behavioral therapy approaches may be tried.

Secondary Surgery

Surgical approaches to correct velopharyngeal inadequacy include creation of a posterior pharyngeal flap, sphincter pharyngoplasty, and palatal lengthening. As indicated by Sloan, pharyngeal flaps and sphincter pharyngoplasty are perhaps the two most commonly used procedures.[72] During pharyngeal flap surgery a superiorly based flap of the posterior pharyngeal wall is released and sutured to the velum. This creates a midline obstruction across the nasopharynx. During production of nonnasal speech sounds, velopharyngeal closure is achieved by medial displacement of the lateral pharyngeal walls against the flap. At the UNC Craniofacial Center, pharyngeal flaps are typically recommended for relatively large, circular-shaped velopharyngeal gaps when some degree of lateral pharyngeal wall movement is observed during multiview videofluoroscopy and/or nasendoscopy. An obligatory side effect of a posterior pharyngeal flap is increased resistance during nasal breathing. In some cases, if sleep apnea occurs, the flap can be surgically divided.

A sphincter pharyngoplasty involves the release of two muscular flaps from the posterior faucal pillars, with surgical attachment to the posterior pharyngeal wall. As its name implies, this procedure attempts to achieve velopharyngeal closure by facilitating normal sphincter-like movement. At the UNC Craniofacial Center, sphincter pharyngoplasty is typically recommended for relatively small, coronal-shaped velopharyngeal gaps. Although some clinicians believe that sphincter pharyngoplasty is less likely to cause airway impairment as compared with a pharyngeal flap, recent evidence has not shown an advantage of sphincter pharyngoplasty based on objective sleep study data.[73]

Recently some surgeons have begun to use palatal lengthening as a secondary procedure to correct velopharyngeal inadequacy. As indicated by Kuehn and Henne, this procedure may be indicated if initial palate surgery did not successfully reconstruct the velar musculature (i.e., the "velar sling").[54]

Speech Appliances

In some cases a recommendation may be made for obturation of a velopharyngeal defect by a speech appliance rather than surgical correction. Typical cases may include patients in whom (1) the velopharyngeal gap is large and/or there is limited movement of structures, (2) perceptual symptoms of velopharyngeal dysfunction are severe, and/or (3) other medical conditions contraindicate surgery.[74] As indicated by Leeper and co-workers, the recommendation for prosthodontic management is largely determined by the age and oral condition of the patient.[74] Young children who may not tolerate and/or comply with procedures and individuals with poor oral hygiene and/or missing teeth are not good candidates.

Speech appliances may also be used to obturate anterior defects such as ONF in either the alveolar or palatal regions. At the UNC Craniofacial Center we often recommend an anterior speech appliance for young children who have a large alveolar fistula but are not yet ready for bone grafting procedures. These appliances, which often can be fabricated from acrylic material during a single visit, function to provide a stable target area for learning alveolar consonants as part of speech therapy.

Finally, palatal lift appliances are sometimes recommended for patients who exhibit velopharyngeal incompetency as a result of neuromotor involvement (e.g., velar paralysis). In these cases the function of the appliance is not to obturate but to elevate and hold the velum against the posterior pharyngeal wall during speech production.

Behavioral Approaches

SLPs are well trained not to attempt speech therapy in patients with velopharyngeal dysfunction when the cause is structural and the symptoms are strictly obligatory (i.e., hypernasality and/or audible nasal escape). Unfortunately, SLPs are not well trained to treat articulation issues in these patients. Compensatory misarticulations are learned behaviors that can be corrected only by speech therapy. As indicated by Golding-Kushner, SLPs can intervene with a patient even before secondary surgery if the goal is to correct faulty placement of articulation.[75] In this situation the SLP may need to use a clip to occlude the nose and prevent nasal air escape while allowing the patient to focus on learning correct oral placement. Obviously, once the nasal clip is removed, the patient may exhibit audible nasal air escape and/or revert back to using compensatory misarticulations. A competent SLP who is aware of the structural defect and the goal of therapy, however, may shorten the duration of articulation therapy needed once secondary surgery is done. In addition, Golding-Kushner advocates that speech therapy may actually be necessary before surgery in some patients with pervasive glottal stops who exhibit little or no velopharyngeal movement.[75] In these patients the goal of therapy is to stimulate some degree of velopharyngeal movement in order to determine the extent of dysfunction and make appropriate surgery recommendations. Golding-Kushner describes step-by-step techniques for establishing correct articulation in children who exhibit compensatory misarticulations.

In some cases, an SLP may attempt to intervene with a patient who exhibits mild and/or inconsistent obligatory symptoms of hypernasality and/or audible nasal air escape on a trial basis. These patients may benefit from procedures that are meant to increase the extent of velopharyngeal

closure—assuming that the patient is capable of achieving better closure—and/or to mask the perceptual consequences of symptoms. One technique is the practice of words that contain nasal-plosive sequences such as "hamper" with increased loudness or stress on the plosive segment. Extra effort will naturally increase activation of the velar and pharyngeal muscles and perhaps result in better closure. McHenry, for instance, reported improved velopharyngeal closure in patients with dysarthria when they were instructed to increase vocal effort.[76] A similar approach is to simply instruct the patient to speak with exaggerated articulatory movements of the lips, tongue, and jaw. By overarticulating, the speaker may also increase vocal effort, but, more important, will shift resonance to a more open oral cavity. A shift to oral resonance may effectively mask nasal resonance even without a change in velopharyngeal closure per se.

The SLP must use caution with either of these procedures in that obligatory symptoms of hypernasality and/or nasal air escape may actually increase as a result of increased effort. Indeed, as noted previously, some speakers may use a soft voice to avoid perceptual symptoms. If increased loudness and/or overarticulation results in worsening of perceptual symptoms, then behavior therapy should be discontinued and surgical intervention considered.

Somewhat contradictory to the previously described approaches, Kummer recommends "quick and light" articulatory contacts as a behavioral strategy to reduce audible nasal air escape.[1] This approach has theoretic merit in that any reduction in oral air pressure will reduce the driving pressure that generates nasal air flow. In addition, Gaylord and Zajac reported that children with repaired cleft lip and palate produced the alveolar stop-plosives /t/ and /d/ with longer stop gaps compared with children with cleft palate only.[77] We speculated that the cause of these temporal differences might relate to reduced oral sensation in the children with alveolar defects. Regardless of the cause, this finding indirectly supports the use of "quick" articulatory contacts in that the time for audible nasal air escape to be perceived will be reduced.

Kuehn and colleagues have recently described the theory and approach to a novel behavioral therapy that uses continuous positive airway pressure (CPAP) during speech.[78-80] The therapy program consists of an 8-week schedule of speech exercises that use CPAP applied to the nasal cavity. Both speaking time and magnitude of CPAP are systematically increased over the 8-week period. The goal of the program is to "train" the velopharyngeal structures to achieve closure in the face of increasing levels of resistance provided by the CPAP. Speech stimuli consisting of disyllables that contain nasal-plosive sequences are used. The nasal-plosive sequences are assumed to maximize resistance during the period of velopharyngeal closure (i.e., during the transition from the nasal to the plosive segment). Although the approach is based on sound scientific principles, limited success in reducing perceived hypernasality in children who had repaired cleft palate has been reported.[80] In addition, it is not clear that "resistance" is actually maximized during the closing phase of the nasal-plosive sequences that are recommended as speech stimuli. Weaver, for example, reported that both oral and nasal mask pressures were essentially equal during the /mp/ sequence of nonsense syllables when positive nasal air pressure was applied.[81] Differential nasal pressure (i.e., velar "resistance") was generated only once velopharyngeal closure was actually achieved.

Finally, speech therapy is the indicated treatment for cases of PSNE. As discussed previously, although this phenomenon mimics velopharyngeal dysfunction, it is actually a learned misarticulation that is characterized by oral occlusion and nasal direction of airflow (i.e., production of nasal fricatives). The goal of therapy is to eliminate the oral stopping. As indicated by Kummer, once this is achieved, the nasal fricative is spontaneously eliminated.[1] An efficient technique to eliminate PSNE is to instruct the child to produce /t/ with exaggerated oral release that naturally becomes an /s/. Nose occlusion may be used initially to help break the cycle of oral stopping and nasal emission.

Acknowledgment

Part of the work described in this chapter was supported by Grant Number R21DE018120 from the National Institute of Dental and Craniofacial Research. The content is solely the responsibility of the author and does not necessarily represent the official views of the National Institute of Dental and Craniofacial Research or the National Institutes of Health.

References

1. Kummer A: *Cleft palate and craniofacial anomalies: effects on speech and resonance*, ed 2, San Diego, 2008, Singular.
2. Okazaki K, Kato M, Onizuka T: Palate morphology in children with cleft palate with palatalized articulation, *Ann Plast Surg* 26:156, 1991.
3. Oyama T, Sunakawa H, Arakaki K, et al.: Articulation disorders associated with maxillary growth after attainment of normal articulation after primary palatoplasty for cleft palate, *Ann Plast Surg* 48:138, 2002.
4. Peterson-Falzone S, Hardin-Jones M, Karnell M: *Cleft palate speech*, ed 4, St Louis, 2010, Mosby.
5. Doyle WJ, Cantekin EI, Bluestone CD: Eustachian tube function in cleft palate children, *Ann Otol Rhinol Laryngol Suppl* 89(3 Pt 2):34, 1980.
6. Muntz HR: Middle ear disease and cleft palate, *Facial Plast Surg* 9:177, 1993.
7. Paradise JL, Bluestone CD, Felder H: The universality of otitis media of infants with cleft palate, *Pediatrics* 44:35, 1969.
8. Stool SE, Randall P: Unexpected ear disease in infants with cleft palate, *Cleft Palate J* 6:154, 1969.
9. Dalston RM, Martinkosky SJ, Hinton VA: Stuttering prevalence among patients at risk for velopharyngeal inadequacy: a preliminary investigation, *Cleft Palate J* 24:233, 1987.

10. Kuehn DP, Moller KT: Speech and language issues in the cleft palate population: the state of the art, *Cleft Palate Craniofac J* 37:348, 2000.
11. McWilliams BJ, Morris HL, Shelton RL: *Cleft palate speech*, ed 2, Philadelphia, 1990, BC Decker.
12. Casselbrandt ML, Cantekin EI, Dirkmaat DC, et al.: Experimental paralysis of tensor veli palatine muscle, *Acta Otolaryngol (Stockh)* 106:178, 1988.
13. Roberts JE, Clarke-Stein S: Otitis media. In Bernthal JE, Bankson NW, editors: *Child phonology: characteristics, assessment, and intervention with special populations*, New York, 1994, Thieme.
14. Feldman HM, Dollaghan CA, Campbell TF, et al.: Parent-reported language skills in relation to otitis media during the first 3 years of life, *J Speech Lang Hear Res* 46:273, 2003.
15. Friel-Patti S, Finitzo T: Language learning in a prospective study of otitis media with effusion in the first two years of life, *J Speech Hear Res* 33:188, 1990.
16. Friel-Patti S, Finitzo-Hieber T, Conti G, Brown KC: Language delays in infants associated with middle ear disease and mild fluctuating hearing impairment, *Pediatr Otolaryngol Head Neck Surg* 94:350, 1982.
17. Paradise JL, Feldman HM, Campbell TF, et al.: Effect of early or delayed insertion of tympanostomy tubes for persistent otitis media on developmental outcomes at the age of three years, *N Engl J Med* 344:1179, 2001.
18. Paradise JL, Dollaghan CA, Campbell TF, et al.: Otitis media and tympanostomy tube insertion during the first three years of life: developmental outcomes at the age of four years, *Pediatrics* 112:265, 2003.
19. Roberts JE, Sanyal MA, Burchinal MR, et al.: Otitis media in early childhood and its relationship to later verbal and academic performance, *Pediatrics* 78:423, 1986.
20. Roberts JE, Burchinal MR, Koch MA, et al.: Otitis media in early childhood and its relationship to later phonological development, *J Speech Hear Res* 53:416, 1988.
21. Roberts JE, Burchinal MR, Collier AM, et al.: Otitis media in early childhood and cognitive, academic, and classroom performance of the school-aged child, *Pediatrics* 83:477, 1989.
22. Roberts JE, Burchinal MR, Medley LP, et al.: Otitis media, hearing sensitivity, and maternal responsiveness in relation to language during infancy, *Pediatrics* 126:481, 1995.
23. Wallace IF, Gravel JS, McCarton CM, Ruben RJ: Otitis media and language development at 1 year of age, *J Speech Hear Res* 53:245, 1988.
24. Wallace IF, Gravel JS, McCarton CM, et al.: Otitis media, auditory sensitivity, and language outcomes at one year, *Laryngoscope* 98:64, 1988.
25. Hubbard TW, Paradise JL, McWilliams BJ, et al.: Consequences of unremitting middle-ear disease in early life, *N Engl J Med* 312:1529, 1985.
26. Broen P, Moller K, Devers M, Doyle S: *Accuracy of speech production of 30 month old children with cleft palate*, San Diego, 1996, Proceedings of the 53rd annual meeting of the American Cleft Palate–Craniofacial Association.
27. Owens RE, Metz DE, Haas A: *Introduction to communication disorders: a life span perspective*, ed 2, Boston, 2003, Allyn and Bacon.
28. Kummer AW, Lee L, Stutz LS, et al.: The prevalence of apraxia characteristics in patients with velocardiofacial syndrome as compared with other cleft populations, *Cleft Palate Craniofac J* 44:175, 2007.
29. Hoit JD, Watson PJ, Hixon KE, et al.: Age and velopharyngeal function during speech production, *J Speech Hear Res* 37:295, 1994.
30. Bundy E, Zajac D: Estimation of transpalatal nasalance during production of voiced stop consonants by non-cleft speakers using an oral-nasal mask, *Cleft Palate-Craniofacial J* 43:691, 2006.
31. Baken RJ, Orlikoff R: *Clinical measurement of speech and voice*, Boston, 2001, Little, Brown.
32. Kummer AW, Curtis C, Wiggs M, et al.: Comparison of velopharyngeal gap size in patients with hypernasality, hypernasality and nasal emission, or nasal turbulence (rustle) as the primary speech characteristic, *Cleft Palate Craniofac J* 29:152, 1992.
33. Trost JE: Articulatory additions to the classical description of the speech of persons with cleft palate, *Cleft Palate J* 18:193, 1981.
34. Zajac DJ: What is phoneme-specific nasal emission? Available at www.unc.edu/~dzajac/PSNE.htm.
35. Peterson-Falzone S: A cross sectional analysis of speech results following palatal closure. In Bardach J, Morris HL, editors: *Multidisciplinary management of cleft lip and palate*, Philadelphia, 1990, Saunders.
36. Philips BJ, Kent RD: Acoustic-phonetic descriptions of speech production in speakers with cleft palate and other velopharyngeal disorders. In Lass N, editor: *Speech and language: advances in basic research and practice*, Vol 2. New York, 1984, Academic.
37. Isshiki N, Honjow I, Morimoto M: Effects of velopharyngeal incompetence upon speech, *Cleft Palate J* 5:279, 1968.
38. Sherman D, Spriestersbach DC, Noll JD: Glottal stops in the speech of children with cleft palate, *J Speech Hear Dis* 24:37, 1959.
39. Hoch L, Golding-Kushner K, Siegel-Sadewitz V, Shprintzen RL: Speech therapy. In McWilliams BJ, editor: *Current methods of assessing and treating children with cleft palates*, New York, 1986, Thieme.
40. Chapman K, Hardin M: Phonetic and phonologic skills of two-year-olds with cleft palate, *Cleft Palate Craniofac J* 29:435, 1992.
41. Peterson-Falzone S: *Compensatory articulations in cleft palate speakers: relative incidence by type*, Jerusalem, Israel, 1989, International Congress on Cleft Palate and Related Craniofacial Anomalies.
42. Santelmann L, Sussman J, Chapman K: Perception of middor- sum palatal stops from the speech of three children with repaired left palate, *Cleft Palate Craniofacial J* 36:233, 1999.
43. Kent RD, Weismer G, Kent JF, Rosenbek JC: Toward phonetic intelligibility testing in dysarthria, *J Speech Hear Dis* 54:482, 1989.
44. Fletcher SG: *Diagnosing speech disorders from cleft palate*, New York, 1978, Grune & Stratton.
45. Prins D, Bloomer H: A word intelligibility approach to the study of speech change in oral cleft patients, *Cleft Palate J* 2:357, 1965.
46. Prins D, Bloomer H: Consonant intelligibility: a procedure for evaluating speech in oral cleft subjects, *J Speech Hear Res* 11:128, 1968.
47. Bzock K: The effects of a specific pharyngeal flap operation upon the speech of 40 cleft palate persons, *J Speech Hear Dis* 29:111, 1964.
48. McWilliams BJ, Bluestone C, Musgrave R: Diagnostic implications of vocal cord nodules in children with cleft palate, *Laryngoscope* 79:2072, 1969.
49. Marks C, Barker K, Tardy M: Prevalence of perceived acoustic deviations related to laryngeal function among subjects with palatal anomalies, *Cleft Palate J* 8:201, 1971.

50. D'Antonio L, Muntz H, Providence M, Marsh J: Laryngeal/voice findings in patients with velopharyngeal dysfunction, *Laryngoscope* 98:432, 1988.
51. Zajac DJ, Linville RN: Voice perturbations of children with perceived nasality and hoarseness, *Cleft Palate J* 26:226, 1989.
52. Zajac DJ: Laryngeal airway resistance in children with cleft palate and adequate velopharyngeal function, *Cleft Palate Craniofac J* 32:138, 1995.
53. Guyette TW, Sanchez AJ, Smith BE: Laryngeal airway resistance in cleft palate children with complete and incomplete velopharyngeal closure, *Cleft Palate Craniofac J* 37:61, 2000.
54. Kuehn DP, Henne LJ: Speech evaluation and treatment for patients with cleft palate, *Am J Speech Lang Pathol* 12:103, 2003.
55. Subtelny JD, Van Hattum RJ, Myers BA: Ratings and measures of cleft palate speech, *Cleft Palate J* 9:18, 1972.
56. Whitehill TL: Assessing intelligibility in speakers with cleft palate: a critical review of the literature, *Cleft Palate Craniofacial J* 39:50, 2002.
57. Hodge M, Gotzke CL: Preliminary results of an intelligibility measure for English-speaking children with cleft palate, *Cleft Palate Craniofac J* 44:163, 2007.
58. McGurk H, MacDonald J: Hearing lips and seeing voices, *Nature* 264:746, 1976.
59. Moon JB: Evaluation of velopharyngeal function. In Moller K, Starr D, editors: *Cleft palate: interdisciplinary issues and treatment for clinicians by clinicians*, Austin, 1993, Pro-Ed.
60. Skolnick ML, Cohn ER: *Videofluoroscopic studies of speech in patients with cleft palate*, New York, 1989, Springer-Verlag.
61. Golding-Kushner K, Argamaso RV, Cotton RT, et al.: Standardization for the reporting of nasopharyngoscopy and multiview videofluoroscopy: a report from an international working group, *Cleft Palate J* 27:337, 1990.
62. Warren DW, DuBois A: A pressure-flow technique for measuring velopharyngeal orifice area during continuous speech, *Cleft Palate J* 1:52, 1964.
63. Zajac DJ: Pressure-flow characteristics of /m/ and /p/ production in speakers without cleft palate: developmental findings, *Cleft Palate Craniofac J* 37:468, 2000.
64. Thom SA, Hoit JD, Hixon TJ, Smith AE: Velopharyngeal function during vocalization in infants, *Cleft Palate Craniofac J* 43:539, 2006.
65. Fletcher SG: Theory and instrumentation for quantitative measurement of nasality, *Cleft Palate J* 7:601, 1970.
66. Fletcher SG: "Nasalance" vs. listener judgments of nasality, *Cleft Palate J* 13:31, 1976.
67. MacKay RA, Kummer AW: *The MacKay-Kummer SNAP Test*, Lincoln Park, NJ, 1994, Kay Pentax.
68. Dalston RM, Warren DW, Dalston ET: Use of nasometry as a diagnostic tool for identifying patients with velopharyngeal impairment, *Cleft Palate J* 28:184, 1991.
69. Dalston RM, Warren DW, Dalston ET: A preliminary investigation concerning the use of Nasometry in identifying hyponasality and/or nasal airway impairment, *J Speech Hear Res* 34:11, 1991.
70. Weinberg B, Noll JD, Donohue M: TONAR calibration: a brief note, *Cleft Palate J* 16:158, 1979.
71. Zajac DJ, Lutz R, Mayo R: Microphone sensitivity as a source of variation in nasalance scores, *J Speech Hear Res* 39:1228, 1996.
72. Sloan GM: Posterior pharyngeal flap and sphincter pharyngoplasty: the state of the art, *Cleft Palate Craniofac J* 37:112, 2000.
73. Abyholm F, D'Antonio L, Davidson Ward SL, et al.: Pharyngeal flap and sphincterplasty for velopharyngeal insufficiency have equal outcome at 1 year postoperatively: results of a randomized trial, *Cleft Palate Craniofac J* 42:501, 2005.
74. Leeper HA, Sills PS, Charles DH: Prosthodontic management of maxillofacial and palatal defects. In Moller K, Starr D, editors: *Cleft palate: interdisciplinary issues and treatment for clinicians by clinicians*, Austin, 1993, Pro-Ed.
75. Golding-Kushner K: In *Therapeutic techniques for cleft palate speech and related disorders*, San Diego, 2001, Singular.
76. McHenry MA: The effect of increased vocal effort on estimated velopharyngeal orifice area, *Am J Speech Lang Pathol* 6:55, 1997.
77. Gaylord M, Zajac D: *Temporal characteristics of alveolar stop-plosives in children with cleft palate*, Miami, November 2006, Poster presented at the Annual Convention of the American Speech-Language-Hearing Association.
78. Kuehn DP: New therapy for treating hypernasal speech using continuous positive airway pressure (CPAP), *Plast Reconstr Surg* 88:959, 1991.
79. Kuehn DP, Moon JB, Folkins JW: Levator veli palatini muscle activity in relation to intranasal air pressure variation, *Cleft Palate Craniofac J* 30:361, 1993.
80. Kuehn DP, Imrey PB, Tomes L, et al.: Efficacy of continuous positive airway pressure for treatment of hypernasality, *Cleft Palate Craniofac J* 39:267, 2002.
81. Weaver LA: *Respiratory and velar EMG responses to nasal CPAP variations during speech [master's thesis]*, University of North Carolina, 2003.
82. Zajac DJ, Winterbottom K, Preisser J: *Phonetic determinants of audible nasal emission (velar flutter) in children with repaired cleft palate*, Indianapolis, March 2014, Paper presented at the Annual Meeting of the American Cleft Palate-Craniofacial Association.
83. Zajac DJ, Plante C, Lloyd M, Haley KL: Reliability and validity of a computer mediated single-word intelligibility test: preliminary findings for children with repaired cleft lip and palate, *Cleft Palate Craniofac J* 48:538–549, 2011.
84. Zajac DJ, Cevidanes L, Shah S, Haley KL: Maxillary arch dimensions and spectral characteristics of children with cleft lip and palate who produce middorsum palatal stops, *J Speech Lang Hear Res* 55:1876–1886, 2012.

33

Management of the Cleft Maxilla

GERARDO P. ROMEO, BERNARD J. COSTELLO

Clefting of the maxilla and alveolus occurs due to a failure of fusion of several key components of the facial structures during the first trimester of pregnancy and typically includes components of the maxillary processes, median nasal process, and palatal shelves.[1] When one or several of these components fail to fuse, a variety of clefts and associated deformities are seen. Each multitissue defect requires appropriate attention in reconstruction for optimal outcome and, ideally, should be based on growth and the iatrogenic potential for growth restriction, functional needs and esthetic concerns, patient impact with regard to psychosocial development, and overall care burden for the patient, and at times family and other caregivers.

There are multiple goals of reconstructing the cleft of the maxilla. The most basic goal is to eliminate oral and nasal communication and to establish normal anatomic boundaries of the oral and nasal cavities to support proper deglutition and speech. Unification of the cleft maxillary segments into a continuous osseous structure (especially important with bilateral cleft deformity) and establishment of intact alveolar bone to support proper development and eruption of teeth are the other primary goals. Finally, the esthetic results for the reconstructed and repaired facial deformities can be optimized with proper management of the osseous maxillary defects beneath as skeletal augmentation in the way of bone grafting has been shown to provide many favorable changes to the facial esthetic, specifically in the area of the cleft lip and nose.[2,3,4,5]

One could imagine that the best theoretic surgical solution might be a single-stage correction of all abnormalities as early as possible. This would circumvent many, if not all, of the complexities associated with cleft care regarding feeding, speech development, growth of the facial skeleton, and avoidance of a number of stressors during psychosocial development. Unfortunately though, this idea does not translate to a reality as both single-stage and early age correction, even in utero, yield little if any benefits of clinical significance and cause extensive disruption of facial growth or other problems. Single-stage and very early corrections do not account for well-understood concepts in facial growth, namely that surgical scarring has high potential for growth restriction and that growth of the facial skeleton is not uniform and varies in rate and extent between subunits over childhood and adolescence. Although there are studies that suggest speech advantages are worthwhile with these approaches,[6,7,8] long-term growth follow-up does not extend the point of facial skeletal maturity. Keeping in mind the most basic concepts of craniofacial growth, it is clear that the severity of iatrogenic growth restriction would not become evident until maturity. Despite this, the centers that cite the "advantages" of using this approach fail to publish late growth data or convincing arguments based on data that show measurable improvements.

As with most aspects of cleft care, a number of controversies exist regarding timing, technique, and reconstructive materials utilized in management of the maxillary osseous cleft defect. This chapter will provide a background and foundation for management, address some of the controversies, and discuss the surgical techniques believed to be most sound by the authors.

History and Surgical Options

The first documented reconstruction of the osseous maxillary cleft defect is attributed to Anton Freiherr von Eiselsberg in 1901. The extraordinary case involved a 19-year-old female born with bilateral cleft lip and palate who had undergone multiple surgical attempts at treatment with poor results. She was found to have a large residual fistula of the palate, velar incompetence, and a flat broadened nose. She was reportedly so unhappy with her state of repairs that she agreed to reconstruction of her defect by sacrificing her left little finger.[9] The extremity of this case illustrates just how sensitive affected people can be to poor long-term results.

Interestingly, outcomes evaluation regarding restorative techniques and graft options for maxillary cleft reconstruction over time has helped shape the general approach to cleft care worldwide into the current state. Examination of the differing opinions in the literature highlights the progression of technique and the current focus on long-term evaluation of outcomes and limited growth restriction as a key focus to achieve balance between esthetics and function long term.

Surgical treatment of the maxillary osseous defect during the early life of the patient can be achieved with gingivoperiosteoplasty (GPP) and primary bone grafting. GPP, first presented by Skoog in the 1960s, is often completed during infancy simultaneously with initial repair of the cleft lip.[10,11,12] The modern form of the technique has evolved to incorporate use of orthopedic devices, such as those described by Latham and later Grayson,[13,14] preoperatively to approximate misaligned cleft palatal segments. Then, oral and nasal side flaps are developed, resembling secondary grafting techniques to be discussed later, in such a way that following reorientation and closure, the oral and nasal cavities are completely separated from one another by two intact layers spanning the osseous defect. The cleft gap is now lined with periosteum on both the oral and nasal sides and bleeding is promoted to stimulate spontaneous formation of bone. The published results are mixed with respect to amount and quality of bone to be provided at the cleft site for eruption of the permanent dentition (i.e., the canine and lateral incisor).[15,16] A significant percentage of patients will still require grafting at a later date prior to the eruption of the permanent teeth due to insufficient bone volume. Significant growth restriction and maxillary hypoplasia have been seen when utilizing this technique, although it is still heavily favored in many centers. Several reports have confirmed this concern.[16,17] While there is no scarcity of literature claiming that growth results are no worse when compared with other methods, most fail to follow patients through skeletal maturity. A paper by Sobocki in which Skoog was the senior author has suggested that growth as measured by cephalometrics is not significantly worse than secondary bone grafting techniques. However, the authors acknowledge that the incidence of clinically significant anterior crossbite/skeletal malocclusion as identified by a validated method is higher with GPP.[18]

Primary bone grafting was introduced prior to GPP in the 1950s by Schmid.[18] The concept initially was met with enthusiasm from a number of surgeons and was widely used in the 1960's.[19-29] During the decades that followed, many negative skeletal, dental, and growth-related consequences of primary bone grafting became better understood and primary bone grafting eventually fell out of favor.[16,20,30-32] Conceptually, primary bone grafting shares many similarities to GPP with the exception that a graft material is placed into or spanning the cleft gap rather than allowing the cleft defect to regenerate bone spontaneously. By definition, primary bone grafting must occur before two years of age.[33] The classic technique utilizes autogenous rib as the graft material because it is readily available in the age group, can be harvested with modest complications, and regenerates spontaneously.[34,35] The goal at the point of introduction of the technique was mainly to unify the cleft segments because it was postulated that unification with a site of normal growth could limit the progressive flattening of the lip and nose and address the osseous notch. However with significant detrimental growth effects, growth characteristics of the rib that did not correspond satisfactorily to craniofacial growth, and lack of success in avoiding an additional secondary graft for the majority of people treated this way,[36] focus shifted away from this approach in pursuit of better outcomes.

During the early 1970s Phillip Boyne was the first to publish favorable outcomes using autogenous particulate bone grafts for reconstruction of the cleft maxilla and alveolus later in childhood during the mixed dentition rather than earlier in life.[22] This was the dawn of the era of secondary bone grafting. Secondary bone grafting is divided into early secondary (between 2 and 5 years of age), secondary (between 5 and 16 years of age) and late secondary (older than 16). Although these early definitions based on chronologic age are still recognized, the central tenet of successful secondary bone grafting is that procedural timing is actually based on developmental age, specifically dental rather than chronologic. Although Boyne's work and results represented a landmark discovery in the field of cleft reconstruction, cleft palate teams were slow to integrate the approach into their treatment protocols because of the negative associations that lingered after the poor outcomes experienced previously with primary bone grafting.

Boyne's principles of secondary bone grafting have become the standard approach for most of the world's cleft centers because they result in decreased limitations of growth and successfully address the numerous goals of reconstruction of the cleft maxilla.[20-22] Secondary bone grafting prior to the eruption of the relevant permanent dentition remains the most commonly performed protocol[20-22,37] and is the favored protocol of the authors.

Procuring bone graft from the iliac crest, cranium, symphysis, or another autologous location has been the standard for reconstruction of this site since Boyne's initial descriptions. Several key factors are considered when selecting the ideal time for grafting, namely anatomic considerations, concepts of dentoskeletal growth and development, and the potential for complications both at the site of reconstruction and the graft donor site.

Dental Considerations

Abnormalities of the dentition associated with cleft lip and palate have long been recognized to be encountered with a higher frequency when compared to noncleft cohorts and is another area where the surface defect conceals other abnormalities below. The most commonly encountered abnormalities of dentition are hypodontia, hyperdontia, abnormal location and transposition, dental rotations, variability of tooth size and anatomy, delayed formation and eruption, and increased risk and incidence of dental caries. Typically, teeth adjacent to the cleft are most affected. The permanent lateral incisor is the most susceptible to abnormality, however, teeth distant to the cleft and even in the opposing jaw have been found to be variably affected at rates higher than in noncleft people. Caries incidence and eruption delay, on the other hand, tend to affect the entire dentition. Some of the specific abnormalities and teeth affected vary across cleft subtypes as well as between primary and permanent dentitions.

The formation and eruption of permanent teeth is typically delayed in patients with cleft lip and palate. This may occur in both jaws and can range anywhere from 4 months and 10 months on average.[38,39] Caries risk and incidence has also been shown to be more severe in people with cleft lip and palate relative to the noncleft population. This holds true for both primary and adult dentition, may have a genetic association, and has been validated by meta-analysis.[40,41]

Hypodontia is the most commonly cited dental anomaly in cleft lip and palate patients. In noncleft patients, the incidence of hypodontia is variable across studies and populations, roughly 3.4% to 9.6%.[42-44] With the exception of third molar teeth, congenital absence of the mandibular second premolar and maxillary lateral incisor are the most commonly missing teeth in noncleft patients.[45]

The incidence of hypodontia in people born with cleft lip and/or palate is significantly higher—roughly 7 times the noncleft population—and has been reported as high as 77%, but also varies between studies and populations examined.[38,46-54] The permanent lateral incisor on the cleft side is most frequently missing, up to 50% of the time.[38,48,55] More rarely, the cleft side central incisor may be missing, but incidence may be closer to that of the general population,[50,53,54] though incidence of size and shape abnormality is clearly higher than that seen with the general population.[56,57] The permanent canine is rarely reported as missing but may be transposed with the first premolar tooth on the cleft side up to 8.5% of the time.[50,54,58] The primary lateral incisor is congenitally missing with less frequency than is the permanent tooth.[48,49] Abnormalities in the primary dentition do not translate directly to the permanent dentition, so the abnormality in one is not necessarily seen in the other.[38,48,49,59] The incidence of cleft site hypodontia varies for the different cleft subtypes but it is commonly reported that incidence increases with severity of the cleft (i.e., complete UCLP has higher risk than incomplete cleft lip only).[38,60]

When the lateral incisor is not congenitally missing, it is usually located distal to the cleft both in the primary and permanent dentition.[48,49,61] Additionally, when it is present, it is commonly of abnormal size or shape and can be of limited use to the patient long term, often requiring extraction.[58,61]

As for hypodontia distant to the cleft site, incidence, while not as high as at the cleft site, is higher than is seen in noncleft cohorts and is reported from 21% to 49%.[38,46,49,61,62] The mandibular second premolar, the noncleft-side lateral incisor, and the second maxillary are the most likely teeth to be absent outside of the cleft site. The incidence of distant site hypodontia is highest in patients with complete cleft lip and palate deformity versus incomplete, cleft lip only, or isolated cleft palate patients.[63-65] In the case of the isolated cleft palate, the mandibular second premolars, maxillary second premolars and maxillary lateral incisors are the most likely affected and range in reported incidence from 23% to 56% for second premolars to as high as 59% for maxillary lateral incisor.[47,66-68]

The presence of supernumerary teeth is the second most frequently encountered cleft site dental anomaly. The incidence of supernumerary teeth in the general population is reported as roughly 0.2% to 3%.[64,69,70] It is more common to see supernumerary teeth in the adult versus the primary dentition of noncleft patients, and the most common supernumerary tooth is the mesiodens.[71]

Supernumerary teeth are seen with higher frequency both with syndromic diagnosis and/or as a feature of cleft lip/palate.[67,70] The incidence of supernumerary teeth in people born with cleft lip and cleft lip and palate ranges in reports from 1% to 42% for permanent teeth and up to 60% in the primary dentition. The highest incidence is seen in cleft lip only, less so in cleft lip and palate deformity and rarely, if ever, in isolated cleft palate.[48,49,64,72-75]

Cleft site supernumerary teeth have been postulated to be the result of fragmentation of the dental lamina due to the presence of the cleft.[46,49] Cleft deformity, though, is the result of failure of fusion rather than destruction of an already fused area. For that reason this remains a questionable explanation. The idea that perhaps there are two areas of odontogenic potential on each side of the cleft and failure of fusion of the frontonasal and maxillary processes keeps those areas from coming into contact and fusing themselves during embryonic development is another commonly accepted explanation. The result is variable success of each of those areas individually giving rise to a viable tooth bud.[59] This theory intuitively might seem more logical as by this reasoning, many of the dental anomalies in cleft patients are simply explained: If both germs are viable, a supernumerary tooth develops along with the lateral incisor. If one side fails, a single incisor develops, and depending on which one is successful in giving rise to a viable tooth bud dictates the position of the resultant tooth relative to the cleft. Lastly, if both are nonviable, congenital absence and hypodontia is the result. Tooth abnormalities, both associated with cleft lip and palate and not, have been shown to have varying degrees of genetic and environmental influences and share, in some cases, homeobox gene mutations similar to those seen in cleft lip and palate.[65]

Knowledge of these dental abnormalities will aid in proper treatment planning for these patients. Hypodontia, for example, has been found to be associated with an increased need for orthognathic surgery at skeletal maturity, particularly when the edentulous cleft side lateral space is managed with canine substitution.[76,77] Therefore incorporation of dental implant into the treatment plan of the patient may prove useful in some instances because this has been shown to work well in the cleft population.[78,79] The presence of supernumerary teeth may be associated with crowding, delayed eruption and impaction of neighboring teeth, root resorption, and nasal eruption patterns, all of which can contribute to malocclusion directly or by extension, and must be considered during the secondary bone graft.[80,81] Additionally, the delayed eruption patterns common to cleft

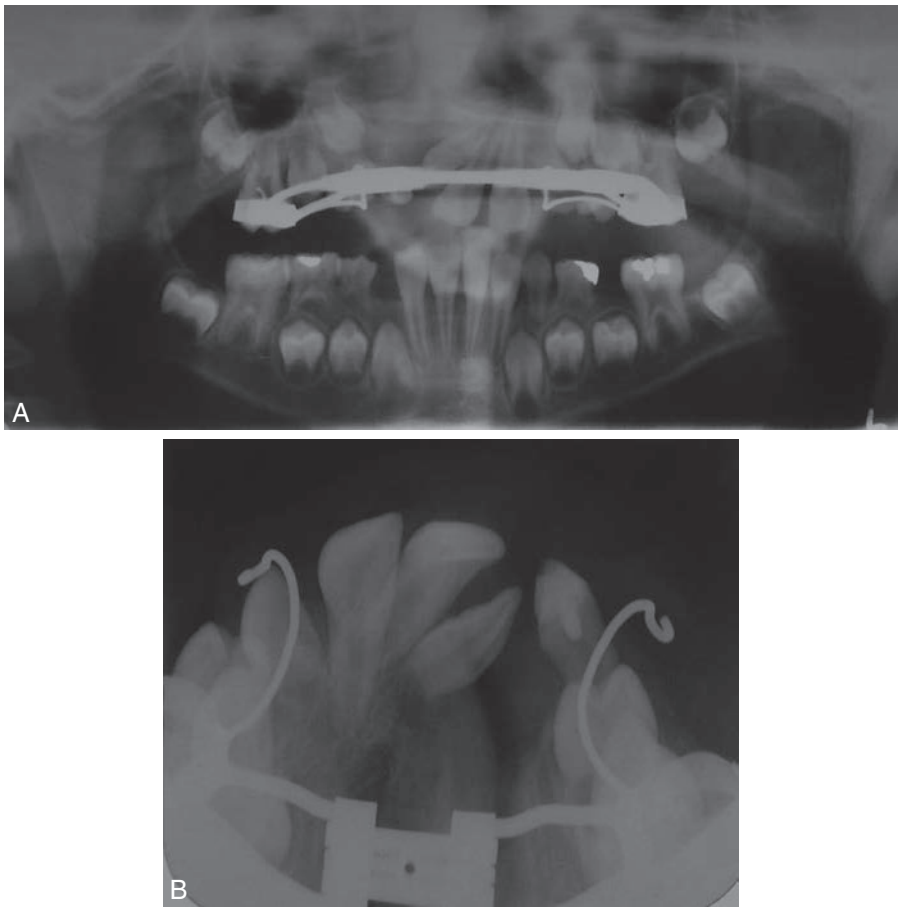

• **Figure 33-1** An orthopantomogram **(A)** and periapical radiograph **(B)** showing an appropriate candidate to be considered for early secondary bone grafting. Note the cleft side central incisor is erupting into the cleft site with limited osseous support and limited root formation. Appreciate the appropriate amount of orthodontic/orthopedic expansion in preparation for the grafting procedure.

lip and palate must be considered when planning for the most basic treatments such as serial extractions for facilitation of tooth eruption in appropriate instances to the timing of presurgical and expansion and secondary bone grafting procedures.

Timing of the Grafting Procedure

Most commonly, grafting of the maxillary cleft occurs during the 6- to 10-year age range, and qualifies as secondary grafting (rather than early or late). However optimal timing relies on knowledge of dental development and the abnormalities associated with the dentition of cleft patients rather than simply chronological age.

Most commonly, the timing of graft placement is based upon having one-half to two-thirds root formation of the permanent canine on radiographs as the permanent lateral incisor is often missing. Should a lateral incisor be present and of good morphology, then the surgeon may consider performing the secondary bone grafting to the maxilla and alveolus targeting development and eruption of the lateral incisor. Because the lateral incisor erupts earlier than the canine, failure to establish continuity of the alveolus prior to eruption may compromise its periodontal health.

Early secondary bone grafting may be considered if the central incisor is bordering the cleft because this may provide more adequate periodontal support to that tooth (Figure 33-1). Some literature supports this technique as the periodontal outcomes have been reported to be improved.[82] No randomized or controlled studies have shown this to be an improved protocol in a comparative fashion over grafting based on canine development. The bone retention and bone heights have been shown to be quite good in the initial reports from those that favor this approach, but comparative studies are lacking.

Another important factor in deciding the optimum time frame for the secondary grafting procedure is the ability to perform Phase I orthodontic expansion of the maxilla utilizing a quad helix or similar appliance in preparation for the surgical procedure. The presence of fully erupted permanent maxillary first molars is favored by some to provide anchorage for the orthodontic expander rather than utilizing primary teeth or a soft tissue–based appliance. Appliances that provide force directly via the palatal shelves may affect the blood supply of the flaps utilized during the surgery and

create a significant hygiene problem, causing inflammation of the flaps typically used for closure.

Presurgical Orthodontic Considerations

Phase I orthodontic expansion is necessary in most cases involving palatal clefting behind the incisive foramen to coordinate the arches prior to grafting. Maxillary expansion after grafting typically does not work effectively due to lack of a palatal suture. Bone grafting effectively solidifies the transverse dimension such that preoperative expansion becomes very important to help optimize the chances for arch compatibility at skeletal maturity. Having the transverse dimension expanded appropriately preoperatively can minimize the chances for crossbites and perhaps, long term, the need for segmental osteotomies of the maxilla. There are some practitioners, however, who will expand the immature bone graft similarly to concepts exploited in distraction osteogenesis early after the grafting procedure upon healing of the oral soft tissue.

The choice for an expander is often dictated by the shape of the arch, the available teeth for orthodontic anchorage and the compliance of the patient and caregivers. In general, a banded expander such as a Hyrax or quad helix is appropriate. Tissue-based and bonded expanders are less desirable because hygiene access is suboptimal and they can be difficult to remove. Typically it is helpful for the expander to be removed at the time of, or just prior to, the surgery. This allows for optimal access and complete control of the palatal flaps and closure of any residual fistula or unrepaired cleft posterior to the alveolus. The expander or another transpalatal retention device can be replaced postoperatively to retain the transverse width. The loss of transverse dimension is generally a slow process rather than a quick one, so allowing for soft tissue healing and resolution of patient discomfort will not compromise the expansion.

A common pitfall is avoidance of complete expansion of the maxilla prior to grafting with the theoretic concern that the cleft would be too large for the surgical closure. Conversely, it is much easier to mobilize the various flaps involved and repair the nasal mucosa with maximal expansion. Minimal anterior expansion can make it difficult to place sutures in the nasal mucosa in certain clefts. As such, maximal preoperative expansion is recommended and improves surgical access. Oral-side flaps are typically not that difficult to mobilize, even in large defects.

Bilateral clefts may require additional Phase I orthodontic expertise because the premaxillary segment is typically protrusive and often asymmetric relative to the other components of the maxilla, as well as the mandible. It is important to take the premaxillary segment out of occlusion with the lower arch utilizing presurgical phase I orthodontic/orthopedic techniques to avoid motion of this segment after grafting. Motion of the premaxillary segment while under function often causes a nonunion of the segments. A palatal splint may be placed after the graft is completed and may be used to minimize force on the anterior segment and protect the graft from occlusal trauma.

If primary, supernumerary, or non-restorable teeth are present in the cleft site, then decisions regarding optimal timing for extraction must be made. A consideration should be made for presurgical extractions with healing time prior to the definitive bone grafting procedure when the teeth are severely compromised by disease and/or if there is a paucity of available mucosa for surgical manipulation. Alternatively, teeth can be removed at the time of grafting, but for clefts that may be difficult to close there is an advantage to allowing secondary intention healing to occur at the extraction sockets for additional gingiva to be utilized during the repair. In the case of impacted supernumerary teeth, diligent efforts at identification and localization prior to the bone graft procedure can yield significant gains. Incorporating removal into the bone grafting procedure can avoid secondary surgical extraction procedures that would come at the expense of the previously placed bone graft (Figure 33-2).

Technique

The osseous defect of the secondary palate that does not extend to the primary palate or alveolus is typically not reconstructed in isolation because it would provide little benefit to the patient. Techniques for augmentation of defects of the alveolus that are incomplete and have no osseous discontinuity resemble the techniques utilized for augmentation of post-traumatic areas or edentulous areas that are the result of caries or periodontal disease and will not be discussed here at length. The only comment with regards to inadequacies of bony volume of the alveolus that have continuity is that grafting should be utilized only to provide for sufficient bone for sound orthodontic movement of teeth and should wait as long as possible until that time. If long-term management, however, involves space maintenance for a dental implant at maturity, bony augmentation should follow principles in existence for preparation/augmentation of hypotrophic ridge that is not related to a congenital cleft, including both method and timing, specifically waiting for skeletal maturity prior to augmentation and dental implant placement.

For "notched" defects isolated to the alveolus without osseous discontinuity, eruption of primary teeth alone should be sufficient for gaining appropriate vertical dimension. Surgical manipulation of any kind in this scenario where only crestal height is deficient, especially early in life, will introduce scar tissue that may be unnecessarily detrimental to vertical growth of the alveolus and negatively influence tooth eruption.

For osseous continuity defects of the maxilla and maxillary alveolus that are associated with complete clefts of the lip and premaxilla or cleft lip and palate, the following secondary bone graft techniques are appropriate and often ideal. Approximately 75% of patients with a cleft have a need for reconstruction of the maxilla and alveolus.[20-22] Despite successful lip repair and closure of the hard and soft

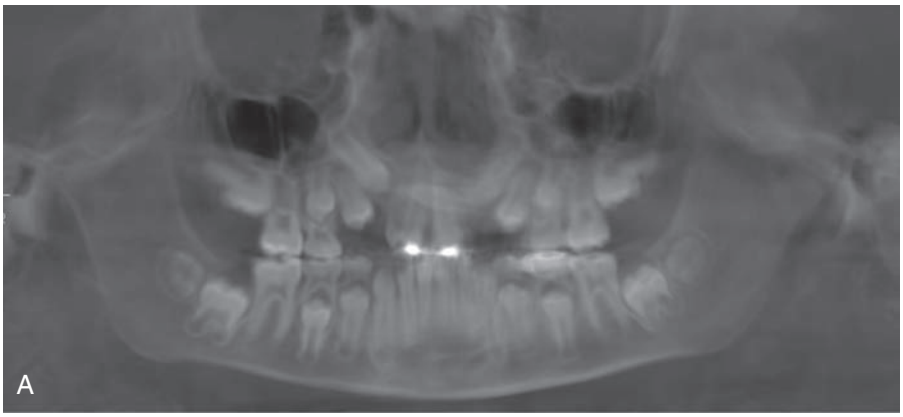

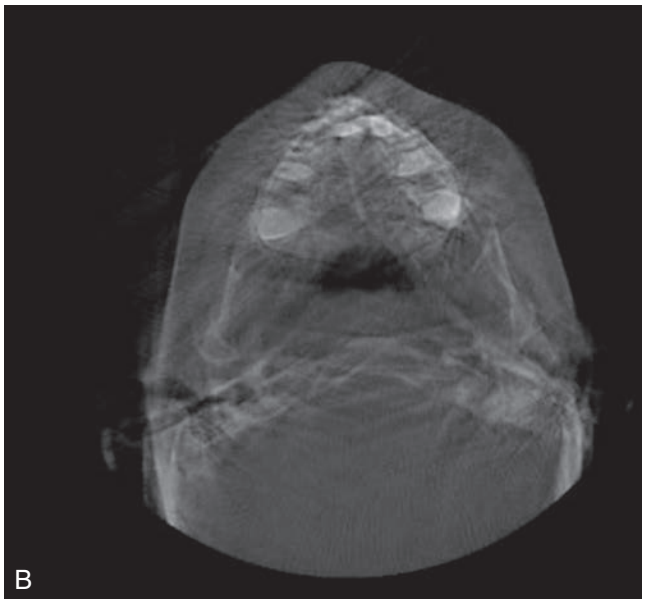

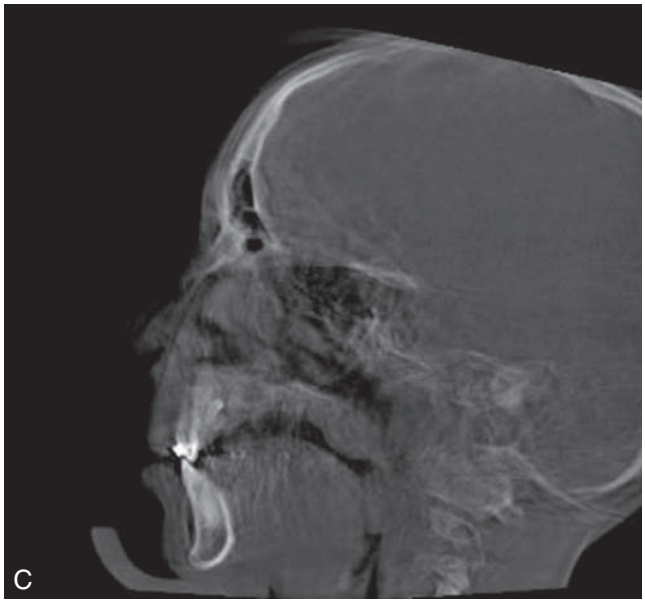

• **Figure 33-2** An orthopantomogram **(A)** and axial **(B)** and sagittal **(C)** sections of a cone beam CT illustrating a completely impacted supernumerary incisor. The patient had previously been grafted successfully and now presents after being referred for removal of the impacted tooth. Note the coronal radiolucency associated with the impacted tooth. Removal of the tooth may result in nasal communication and raise the risk for fistula formation, and requires careful closure after removal of the tooth

palates during infancy, a residual nasolabial fistula and bony cleft defect that involves the alveolar ridge, maxilla, and piriform rim will remain by design.[20,21]

The visible cleft is obviously only the surface deformity and varies considerably in severity and presentation between patients. Defects in the deep tissues, regardless how subtle on the surface, are always present in congenital orofacial clefts. The osseous maxillary defect and associated dental abnormalities present with cleft lip and palate are highly variable from patient to patient.

Often, the osseous defect of the maxilla, particularly in the context of dental care or rehabilitation, is referred to as "the alveolar cleft." It is rare, however, that only the maxillary alveolus is cleft. Therefore describing all cleft defects that involve the maxillary alveolus simply as an "alveolar cleft" fails to appreciate that, in the greatest majority of patients, the osseous defect may compromise portions of the primary and secondary palate, the nasal floor, the pyriform rim, and the anatomy of the maxillary sinus walls, which in turn supports facial and nasal contours. A well planned and executed bony reconstruction of the cleft maxilla, therefore, in addition to constructing continuity of the alveolus and establishing a favorable environment for development and sound eruption of teeth associated with the cleft site, should address all of the affected areas.

Techniques can be separated for discussion based on whether the surgeon utilizes broad advancement flaps or pedicled mucosal flaps to rotate into larger defects with subsequent gingival reconstruction. The techniques can also be discussed in terms of unilateral or bilateral cleft types. In general the reconstruction of the maxilla and alveolus is performed in one step—whether the cleft is unilateral or bilateral. Staged grafting for bilateral clefts has been described where one side is addressed individually so as to create a situation where the second side can be grafted using techniques that resemble those for a unilateral osseous cleft. The defect in bilateral clefts, though, is continuous from side to side. Often, the septum is undescended and no clear



• **Figure 33-3** Clinical photo, intraoral view, of a unilateral cleft maxillary defect prepared for grafting with iliac crest bone. The simulated buccal incision design is illustrated where the most superior area of the unrepaired cleft is dissected in a partial-thickness manner.

division is present from one side to the other in the area of the incisive foramen. This concept therefore is, perhaps, anatomically misguided.

Unilateral Reconstruction

Broad advancement flap techniques are often utilized to close small and large defects in the alveolus and maxilla. These techniques involve making crestal incisions along the gingival crevices with low posterior release of the buccal flap that will allow for a sliding advancement of the gingival flap toward the defect (Figure 33-3). Palatal side dissection involves dissection and elevation of full-thickness bardach-style flaps. The residual unrepaired cleft is then dissected in a partial-thickness fashion by completely separating the nasal mucosal from the oral mucosa. Establishment of a watertight mucosal lined nasal floor will provide periosteal continuity at the roof of the osseous defect and the appropriate wound bed for placement of the bone graft material. Experienced surgeons will recognize that a well-repaired nasal floor from the primary lip and nose reconstruction is quite helpful in facilitating this dissection during the bone grafting stage. Inadequate attention to the mucosal tissues beyond the nasal sill during the primary closure will make subsequent dissection of the two distinct flaps of oral and nasal mucosa exponentially more challenging in this area and can limit the space available for graft placement at the piriform rim at this phase of treatment.

Once the flaps are developed and mobilized, the nasal side flaps are secured to one another with mattress sutures. Some amount of prior dissection up the piriform rim and septum to mobilize these nasal flaps is helpful in achieving tension-free repair. Posterior dissection and repair of the nasal floor mucosa should extend well into the palatal defect, as far back as is necessary to close any residual fistulas or unrepaired cleft (Figure 33-4). Cancellous bone is then placed into the defect to reconstruct everything anterior to the incisive foramen region, including the piriform rim. This will provide support to the nasal floor and the nasal root at the piriform rim. Despite appropriate primary lip and nose repairs, the nasal root is usually inferiorly positioned and deficient in anterior-posterior projection on the cleft side with a broad, flattened appearance of cleft side nares. The oral mucosa is then closed in a tension-free manner over the bone graft material. A four-way stitch is typically placed between the two palatal flaps and the two anterior/buccal flaps to provide gingiva at the crest of the alveolar ridge area. Resorbable suture material is used on a small tapered needle of medium circumference. Eversion is of paramount importance and proper attention should be directed at the superior aspect of the residual cleft in the buccal vestibule as this is a common area for residual fistula after repair (Figure 33-5).

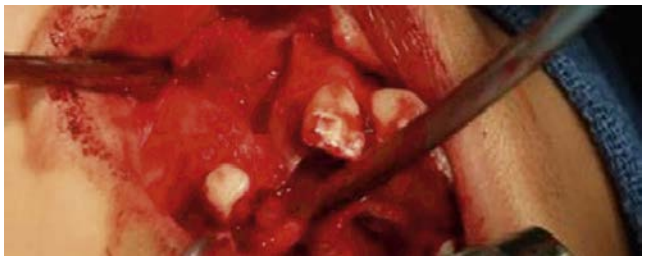

• **Figure 33-4** Maxillary cleft defect following complete dissection and nasal side closure; now prepared for placement of the bone graft.

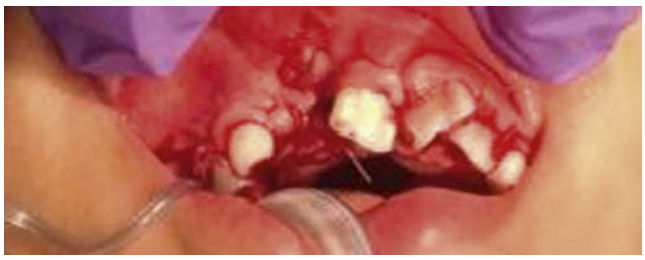

• **Figure 33-5** Maxillary cleft defect following oral side closure. Note wound eversion and tension free closure. Close attention to repair of the oral-nasal communication at the peak of the cleft in the vestibule following graft placement is important to minimize fistula formation in this area. Anterior nasal floor closure is also important in minimizing this risk.

An alternative to this technique is to bring in a mucosal finger flap from the vestibule above the mucogingival junction with limited dissection of the soft tissues in close proximity to the cleft. These are random pattern flaps that can easily be sewn to the posterior aspect of the oral side closure on the palate to fill larger defects with little to no tension. However, these flaps do not provide keratinized gingiva to the alveolar crest, and a separate graft or periodontally focused procedure may be necessary to augment the gingiva and provide keratinized tissue at the alveolar crest. For sound periodontal health of teeth, keratinized gingiva must be present circumferentially around them. Mobile, nonkeratinized mucosa around teeth will eventually result in periodontal disease and tooth loss.

Bilateral Maxillary and Alveolar Reconstruction

The techniques for the bilateral cleft are similar to those used with unilateral clefts with several modifications. In

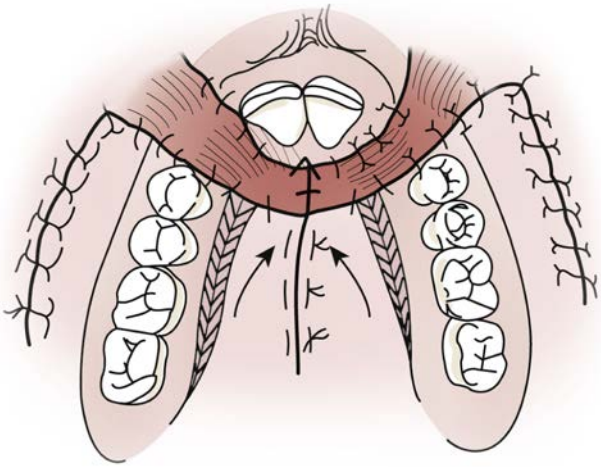

• **Figure 33-6** Illustration of a bilateral cleft maxillary defect utilizing buccal finger flaps for closure of oral side defect. This alternative technique is helpful in unilateral or bilateral cases when the defects are larger and may be more difficult to close with a limited flap technique.

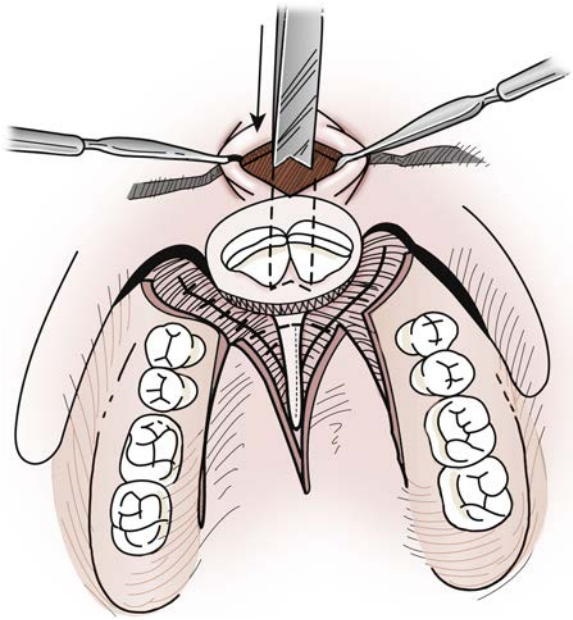

• **Figure 33-7** Illustration of a bilateral cleft maxillary defect dissection to avoid de-vascularization of the pre-maxilla. A midline vertical incision may be placed anteriorly to gain access to the cartilaginous septum if necessary. While premaxillary setback is not advocated by the authors, this technique can be utilized to facilitate access in rare occasions.

many cases, tissue tends to be more limited and mobilization of those tissues can be technically challenging, especially at the posterior aspect of any remaining palatal fistulas and the incisive foramen region. Some surgeons prefer to use mucosal finger flaps from the vestibule to allow for easier oral side closure of the defects similar to the techniques used in the limited flap technique described previously (Figure 33-6). Also, the premaxillary segment requires an adequate blood supply for proper healing, and this comes from the anterior vestibule. Therefore, the incision design does not extend to the tissues of the anterior vestibule so as to not devascularize the premaxilla (Figure 33-7). Complete nasal and oral closure is necessary to avoid formation of persistent communications and to support the bone graft. This is typically most difficult in the incisive foramen region but can be facilitated by adequate orthodontic expansion. This area is difficult to access when the premaxilla is posteriorly displaced into the crowded palatal shelves and septum. Wide orthodontic expansion helps provide adequate space for use of septal flaps and flaps along the posterior aspect of the premaxilla.

Immobilization of the premaxilla is another concept of vital importance to promote successful bone grafting and elimination of oral and nasal communication with avoidance of postoperative fistula formation. A splint is often employed to provide additional stabilization and avoid occlusal trauma to the premaxillary segment. Mobility of the segment, no matter how limited, increases the risk for infection and graft failure. In some cases, a screw can be used to fixate the premaxillary segment to the palatal shelf similar to a lag screw technique. Because the screw must be placed between the central incisor roots without impinging the root structures and engage the palatal shelf, the method is highly technique sensitive. The authors prefer to use orthodontic stabilization and/or an occlusal splint rather than screw fixation because it is straightforward, highly predictable, and avoids the need for removal of the screw.

Reconstructive Materials

The most widely accepted standard for use in this reconstruction is autogenous bone from the anterior iliac crest. Cranial bone, rib, tibia, symphysis of the mandible, zygoma, and allogeneic bone have all been studied, but none has been shown to be appreciably better than the iliac crest.[3,20,21,32,37,83-90]

The type of bone graft material utilized most often for cleft reconstruction is cancellous bone from the anterior iliac crest. Other common sites include cranium, rib, chin, zygoma, tibia, posterior iliac crest, and allogeneic products. Most of the comparative studies show that iliac crest is superior to other procurement sites.[3,20,21,32,37,83-95] The iliac crest graft is predictable and causes very little morbidity with the proper technique. Some surgeons will procure a cortical piece of bone from the medial crest beneath the cartilaginous cap for use as a nasal floor insert to be wedged into position at the piriform rim.[82] Additional cortical onlay grafting is sometimes completed along the anterior surface of the maxilla, particularly at the piriform rim laterally or inferiorly, and then placed with one or several fixation screws. Considerable care is necessary to avoid injuring developing teeth if this technique is utilized in this age group. Additionally, while immediate and short-term results are very good with facial surface onlay grafts, resorption over time means that they are short lived. This technique is best suited for older individuals undergoing late secondary grafting or for augmentation prior to placement of dental implants.

Cranium can also be an effective graft material. It is used less often, however, due to variable and highly limited cancellous bone content and the need to morselize the cortex into usable form to fill the defect appropriately. Additionally there are concerns with potential morbidity and risk for violation of intracranial structure. Furthermore, surgeon familiarity with partial-thickness procurement of cranium is less when compared with iliac crest harvest.

Posterior iliac crest is preferred by some surgeons, usually due to the greater amount of bone that can be procured and a belief that pain may be less debilitating compared with an anterior approach. While posterior iliac crest does offer a greater volume of bone, the cleft defect typically requires between 2 and 5 cc of compressed bone on average for an adult defect,[96] and less volume is typically necessary in children. This approach is less commonly used when compared with anterior iliac crest due to the need for repositioning and the subsequent chance for accidental extubation. It might be considered if an abnormally large defect requires increased graft volume or as a matter of convenience if the patient is positioned prone for an adjunct procedure (i.e., dermal harvest of the gluteal region). CT scan may be useful in predicting defect volume.[96]

Rib grafts have some advantageous when completing primary bone grafting techniques because they readily available and a reasonably straightforward harvest when compared to other sites in children of very young age.[35] However, harvest can leave significant scarring on the chest wall and occasionally breast bud injury leading to breast deformities in female patients. Additionally, the bone quality of rib graft is less desirable than that of iliac crest. Therefore, when the risk of intraoperative complications is combined with potentially long-lasting postoperative complications and no advantage over the bone procured from the ilium, rib has limited utility.

Chin, ramus, tibia, and zygoma typically do not offer a favorable amount of graft material for complete reconstruction in this age group, but may be useful options in some older patients undergoing late secondary bone grafting or in preparation for placement of a dental implant. Tibial bone grafts are of limited use in children due to theoretic risk for growth restriction when harvest inadvertently crosses into the epiphyseal plate or the knee. Limited bone volume and inherent qualities of the cancellous bone also limit utility.

Allogeneic bone outcomes have not exceeded those of autogenous materials in any of the well-designed studies. Some data may suggest though that combining it with autologous graft has a similar outcome to autograft alone.[92] Surgeons will occasionally mix allogeneic bone putty or other similar materials for advanced handling capabilities with autogenous bone or with recombinant proteins to enhance the process.[17,95] Presently, the authors do not endorse this as routine practice except in rare situations and would advise against utilization of bone morphogenic protein (BMP) until further studies in children are available.

Recently, an interest in BMP use has prompted some limited reports of successful bone regeneration, but this has yet to be published in a comprehensive clinical trial. The product is not approved by the United States Food and Drug Administration for use in children and it may have growth restriction implications based on its effect on sutures in animal models as well as recent reports of its use in early childhood.[17,91]

Several other adjuncts are often utilized to assist in the closure and healing at the site. Most are not well studied, but are anecdotally claimed by some surgeons to facilitate success in certain instances. Collagen membranes have been used as a barrier membrane underneath the oral or nasal mucosa. These are typically resorbable, made from bovine collagen, and can be sutured into position in conjunction with the flaps. They are used as an adjunct to avoid early graft exposure should the mucosal quality of tissues be compromised during healing. Decellularized dermal matrix grafts have also been described, but the authors do not favor this technique because it is not reliable in the area of the alveolus. Anecdotally, any exposure to the oral cavity greatly increases the risk for infection, wound breakdown, and graft loss.

Despite the clear strengths of autogenous iliac crest for osseous maxillary reconstruction, there is no arguing that elimination of a donor site without compromising outcomes would be desirable. The use of allografts, either alone or in combination with autograft or BMP, have had mixed results but successes do not resemble those for autogenous sources.[92,95] Tissue engineering on the other hand may show promise. With limited cases showing outcomes similar to autologous graft, including osseous continuity of appropriate volume and even spontaneous eruption of teeth through the graft site, without secondary donor site morbidity, this may become a viable method in the near future.[97-100]

Postoperative Considerations

Most patients have only minor discomfort associated with iliac crest bone grafting and benefit from a local injection of a long-acting local anesthetic at the end of the procedure during the initial recovery period. Some advocate for the use of embedded catheters for long-term delivery of local anesthetic in the donor site. Although there has been some research directed at proving the utility of this approach[101] it has not proven necessary in the opinion of the authors when a limited dissection with careful tissue handling is utilized as most patients are discharged from hospital on oral pain medications and controlled pain on postoperative day number one.

A modified diet consisting of liquids is recommended for two to three weeks. A splint is used for bilateral clefts and is typically removed several weeks after the grafting procedure (on average between 3 and 6 weeks) once the bone has sufficiently consolidated. Gentle tooth brushing should be performed by properly instructed caregivers postoperative day number one with great care to avoid direct contact with the graft site for several days. Chlorhexidine solution and systemic antibiotics may be helpful for avoidance of infections

of the oral cleft site. Infections at the maxillary alveolus are rare when using iliac crest bone graft, but may be encountered. Conservative irrigation and very limited debridement combined with topical and systemic antibiotics may salvage treatment and prevent complete loss of the graft. Preoperative optimization of dentition and periodontium may help minimize unfavorable results.[102]

Complications at the donor site are rare in children. Iliac crest grafts can rarely be associated with a variety of complications including a loss of sensation in the region due to the lateral femoral cutaneous or cutaneous branches of the subcostal nerve being injured.[103-106] Rarely, if a large cortical graft is taken, fracture can occur. This is rare in children, but is seen more commonly in adults. Proper attention to osteotomy design and anatomic landmarks can minimize this risk. If rib or cranium is chosen, then local anatomy typically dictates the potential complications such as pneumothorax or intracranial injury/bleeds respectively. Cortical and corticocancellous grafts taken from the mandible can be associated with sensory disturbances of the trigeminal system.[106,107]

Infections at the graft procurement site are rare and typically involve skin flora. Risk is minimized with stringent sterile technique and single-dose preoperative prophylactic antibiotic with appropriate floral coverage. Hematoma is a risk and can be minimized with assertive local measures and ensured hemostasis prior to wound closure. Seromas may occur but are also rare in children. If encountered, both may require drainage procedures.

If complete graft loss occurs due to any reason, other options for reconstruction exist. Repeat bone grafting is reasonable after allowing for an appropriate amount of time for infection to be completely resolved and maturation of oral soft tissues. Another option involves simultaneous bone grafting and fistula closure during Le Fort I osteotomy, if the patient requires orthognathic surgery at skeletal maturity.[108,109] And finally, in people that do not have a severe skeletal malocclusion and no need for an orthoganthic surgery and have had repeated failures with prior bone grafting attempts due to an abnormally large osseous cleft, distraction osteogenesis of the alveolus has shown some favorable results.[110,111]

Summary

Management of the cleft maxilla is an important part of reconstructing the patient born with a cleft of the lip and palate. While the main focus of this area of reconstruction involves techniques that will re-establish osseous continuity beneath the surface tissue defects, the means by which that is achieved remains, like all things in cleft care, controversial. Secondary bone grafting with autologous anterior iliac crest is favored by the authors due to predictable outcomes and sound support from existing literature. Nuances of the techniques used in primary lip, nose, and palate repairs can either greatly facilitate or extensively hinder subsequent reconstruction of the osseous maxillary cleft defect when utilizing secondary bone grafting techniques.

The educational background of the oral and maxillofacial surgeon as both a dentist and surgical subspecialist is ideal for guiding treatment planning and surgical care in the team setting, particularly at this phase of care. In-depth understanding of the dental abnormalities frequently seen in patients with cleft lip and palate will allow the oral and maxillofacial surgeon to better formulate comprehensive treatment plans with other members of the cleft and craniofacial team, particularly the dental specialties. Therefore mastery of the nuances of both skeletal and dental findings in this population is a requirement.

After proper planning, successful surgical execution relies on recognition of the extent of the anatomic abnormalities and proper attention to their reconstruction at all stages. In the case of the cleft maxilla, by combining knowledge of skeletofacial and dental development with time-tested surgical techniques and treatment regimens, high-level outcomes with regard to fistula closure, speech and deglutition, eruption and support of healthy dental structure, and optimized facial esthetics can be a reality for these patients. Proper care demands that those involved not only master the concepts behind the craft, but more importantly, constantly examine outcomes with an objective eye so as to improve in ways that will best serve the patient and not any individual surgeon, team, or institution.

References

1. Tolarova M: Etiology of clefts of lip and/or palate: 23 years of genetic follow-up in 3660 individual cases. In Pfeifer G, editor: *Craniofacial abnormalities and clefts of the lip, alveolus, and palate*, Stuttgart, Germany, 1991, Thieme.
2. Schultz RC: Free periosteal graft repair of maxillary clefts in adolescents, *Plast Reconstr Surg* 73:556, 1984.
3. Bergland O, Semb G, Abyholm FE: Elimination of the residual alveolar cleft by secondary bone grafting and subsequent orthodontic treatment, *Cleft Palate J* 23:175, 1986.
4. Craven C, Cole P, Hollier L, Stal S: Ensuring success in alveolar bone grafting: a three-dimensional approach, *J Craniofac Surg* 18:855, 2007.
5. Kim SW, Park SO, Choi TH, Hai DT: Change in upper lip height and nostril sill after alveolar bone grafting in unilateral cleft lip alveolus patients, *J Plast Reconstr Aesthet Surg* 65:558, 2012.
6. Davies D: The one-stage repair of unilateral cleft lip and palate: A preliminary report, *Plast Reconstr Surg* 38:129, 1966.
7. Copeland M: The effects of very early palatal repair on speech, *Br J Plast Surg* 43:676, 1990.

8. Savaci N, Hoşnuter M, Tosun Z, Demir A: Maxillofacial morphology in children with complete unilateral cleft lip and palate treated by one-stage simultaneous repair, *Plast Reconstr Surg* 115:1509, 2005.
9. Haeseker B: Digits in the mouth; a peculiar chapter in cleft lip and palate surgery, *Br J Plast Surg* 43:724, 1990.
10. Skoog T: The use of periosteal flaps in the repair of clefts of the primary palate, *Cleft Palate J* 2:332, 1965.
11. Skoog T: The use of periosteum and Surgicel for bone restoration in congenital clefts of the maxilla. A clinical report and experimental investigation, *Scand J Plast Reconstr Surg* 1:113, 1967.
12. Skoog T: Repair of unilateral cleft lip deformity: maxilla, nose and lip, *Scand J Plast Reconstr Surg* 3:109, 1969.
13. Latham RA, Kusy RP, Georgiade NG: An extraorally activated expansion appliance for cleft palate infants, *Cleft Palate J* 13:253, 1976.
14. Grayson BH, Cutting CB, Wood R: Preoperative columella lengthening in bilateral cleft lip and palate, *Plast Reconstr Surg* 92:1422, 1993.
15. Sato Y, Grayson BH, Garfinkle JS, Barillas L, et al.: Success rate of gingivoperiosteoplasty with and without secondary bone grafts compared with secondary alveolar bone grafts alone, *Plast Reconstr Surg* 121:1356, 2008.
16. Wang Y, Liao Y, Chen PK: Outcome of gingivoperiosteoplasty for the treatment of alveolar clefts in patients with unilateral cleft lip and palate, *Br J Oral Maxillofac Surg* 51:650, 2013.
17. Yee KS, Nguyen PD, Andrews BT, Lee JC, et al.: Decreased secondary bone grafting but poorer midface growth after primary alveolar cleft repair with gingivoperiosteoplasty and rhBMP-2, *Plast Reconstr Surg* 133:975, 2014.
18. Sobocki A, Tehrani D, Skoog V: Long-term influence of infant periosteoplasty on facial growth and occlusion in patients with bilateral cleft lip and palate, *J Plast Surg Hand Surg* 46:229, 2012.
19. Schmid E: Die Annaherung der Kieferstumpfe bei Lippen-Kiefer-Gaumenspalten: Ihre schadlichen Folgen und Vermeidung, *Fortschr Kiefer Gesichtschir* 1:37, 1955.
20. Millard DR: In *Cleft craft: the evolution of its surgery. Alveolar and palatal deformities*, vol. 3. Boston, 1980, Little, Brown.
21. Posnick JC: The staging of cleft lip and palate reconstruction: infancy through adolescence. In Posnick JC, editor: *Craniofacial and maxillofacial surgery in children and young adults*, Philadelphia, 2000, WB Saunders, pp 785–826.
22. Boyne PJ, Sands NR: Secondary bone grafting of residual alveolar and palatal clefts, *J Oral Surg* 30:87, 1972.
23. Backdahl M, Nordin KE: Replacement of the maxillary bone defect in cleft palate. A new procedure, *Acta Chir Scand* 122:131, 1961.
24. Brauer RO, Cronin TD: Maxillary orthopedics and anterior palate repair with bone grafting, *Cleft Palate J* 16:31, 1964.
25. Horton CE, Crawford HH, Adamson JE, et al.: The prevention of maxillary collapse in congenital lip and palate cases, *Cleft Palate J* 16:25, 1964.
26. Schuchardt K, Pfeifer G: Primary and secondary operations for cleft palate, *J Int Coll Surg* 38:237, 1962.
27. Schuchardt K: Congenital deformities. I. Primary bone graft in clefts of lip, alveolus and palate, *Mod Trends Plast Surg* 2:214, 1966.
28. Rosenstein SW, Jacobson BN: Early maxillary orthopedics: a sequence of events, *Cleft Palate J* 4:197, 1967.
29. Rosenstein SW: Early bone grafting of alveolar cleft deformities, *J Oral Maxillofac Surg* 61:1078, 2003.
30. Pruzansky S: Presurgical orthopaedics and bone grafting for infants with cleft lip and palate: a dissent, *Cleft Palate J* 1:164, 1964.
31. Robertson NR, Jolleys A: Effects of early bone grafting in complete clefts of the lip and palate, *Plast Reconstr Surg* 42:414, 1968.
32. Berkowitz S: The comparison of treatment results in complete cleft lip/palate using conservative approach vs. Millard-Latham PSOT procedure, *Semin Orthod* 2:169, 1996.
33. Boyne PJ: Correction of dentofacial deformities associated with residual alveolar and palatal clefts. In ed 2, Bell WH, editor: *Surgical correction of dentofacial deformities*, vol. 3. Philadelphia, 1985, Saunders, pp 560–591.
34. Eppley BL: Alveolar cleft bone grafting (Part I): Primary bone grafting, *J Oral Maxillofac Surg* 54:74, 1996.
35. Eppley BL, Sadove AM: Management of alveolar cleft bone grafting—State of the art, *Cleft Palate Craniofac J* 37:229, 2000.
36. Pickerell K, Quinn G, Massengill R: Primary bone grafting of the maxilla in clefts of the lip and palate, *Plast Reconstr Surg* 41:438, 1968.
37. Shaw WC, Semb G: Current approaches to the orthodontic management of cleft lip and palate, *J R Soc Med* 83:30, 1990.
38. Ranta R: A review of tooth formation in children with cleft lip/palate, *Am J Orthod Dentofacial Orthop* 90:11, 1986.
39. Harris EF, Hullings JG: Delayed dental development in children with isolated cleft lip and palate, *Arch Oral Biol* 35:469, 1990.
40. Antunes LS, Tannure PN, Antunes LA, Reis MF, et al.: Genetic association for caries susceptibility among cleft lip and/or palate individuals, *J Contemp Dent Pract* 15:288, 2014.
41. Wells M: Review suggests that cleft lip and palate patients have more caries, *Evid Based Dent* 15:79, 2014.
42. Dolder AA: A statistical survey of deficient dentition, *Dent Rec* 57:56, 1936.
43. Brown RV: The pattern and frequency of congenital absence of teeth, *Iowa Dent J* 43:60, 1957.
44. Graber LW: Congenital absence of teeth: a review with emphasis on inheritance patterns, *J Am Dent Assoc* 96:266, 1978.
45. Symons AL, Stritzel F, Stamation J: Anomalies associated with hypodontia of the permanent lateral incisor and second premolar, *J Clin Pediatr Dent* 17:109, 1993.
46. Bartzela TN, Carels CE, Bronkhorst EM, Kuijpers-Jagtman AM: Tooth agenesis patterns in unilateral cleft lip and palate in humans, *Arch Oral Biol* 58:596, 2013.
47. Shapira Y, Lubit E, Kuftinec MM: Hypodontia in children with various types of clefts, *Angle Orthod* 70:16, 2000.
48. Bøhn A: Anomalies of the lateral incisor in cases of harelip and cleft palate, *Acta Odontol Scand* 9:41, 1950.
49. Bøhn A: Dental anomalies in harelip and cleft palate, *Acta Odont Scand* 21(Suppl 38):1, 1963.
50. Aizenbud D, Camasuvi S, Peled M, Brin I: Congenitally missing teeth in the Israeli cleft population, *Cleft Palate Craniofac J* 42:314, 2005.
51. Kim N, Baek S: Cleft sidedness and congenitally missing or malformed permanent maxillary lateral incisors in Korean patients with unilateral cleft lip and alveolus or unilateral cleft lip and palate, *Am J Orthod Dentofacial Orthop* 130:752, 2006.
52. Lai MC, King NM, Wong HM: Abnormalities of maxillary anterior teeth in Chinese children with cleft lip and palate, *Cleft Palate Craniofac J* 46:58, 2009.

53. Tereza GPG, Carrara CFDC, Costa B: Tooth abnormalities of number and position in the permanent dentition of patients with complete bilateral cleft lip and palate, *Cleft Palate Craniofac J* 47:247, 2010.
54. Paranaiba LMR, Coletta RD, Swerts MSO, Quintino RP, et al.: Prevalence of dental anomalies in patients with nonsyndromic cleft lip and/or palate in a Brazilian population, *Cleft Palate Craniofac J* 50:400, 2013.
55. Suzuki A, Watanabe M, Nakano M, Takahama Y: Maxillary lateral incisors of subjects with cleft lip and/or palate: Part 2, *Cleft Palate Craniofac J* 29:380, 1992.
56. Schroeder DC, Green LJ: Frequency of dental trait anomalies in cleft sibling and noncleft groups, *J Dent Res* 54:802, 1975.
57. Vieira AR: Oral clefts and syndromic forms of tooth agenesis as models for genetics of isolated tooth agenesis, *J Dent Res* 82:162, 2003.
58. Cassolato SF, Ross B, Daskalogiannakis J, Noble J, et al.: Treatment of dental anomalies in children with complete unilateral cleft lip and palate at Sick Kids hospital, Toronto, *Cleft Palate Craniofac J* 46:166, 2009.
59. Tsai T, Huang C, Huang C, See L: Distribution patterns of primary and permanent dentition in children with unilateral complete cleft lip and palate, *Cleft Palate Craniofac J* 35:154, 1998.
60. Jamilian A, Jamilian M, Darnahal A, Hamedi R, et al.: Hypodontia and supernumerary and impacted teeth in children with various types of clefts, *Am J Orthod Dentofacial Orthop* 147:221, 2015.
61. Hellquist R, Linder-Aronson S, Norling M, Ponten B, Stenberg T: Dental abnormalities in patients with alveolar clefts, operated upon with or without primary periosteoplasty, *Eur J Orthod* 1:169, 1979.
62. Ribeiro LL, Das Neves LT, Costa B, Gomide MR: Dental anomalies of the permanent lateral incisors and prevalence of hypodontia outside the cleft area in complete unilateral cleft lip and palate, *Cleft Palat Craniofac J* 40:172, 2003.
63. Ranta R: Associations of some variables to tooth formation in children with isolated cleft palate, *Scand J Dent Res* 92:496, 1984.
64. Larson M, Hellquist R, Jakobsson OP: Dental abnormalities and ectopic eruption in patients with isolated cleft palate, *Scand J Plast Reconstr Surg Hand Surg* 32:203, 1998.
65. Slayton RL, Williams L, Murray JC, Wheeler JJ, et al.: Genetic association studies of cleft lip and/or palate with hypodontia outside the cleft region, *Cleft Palate Craniofac J* 40:274, 2003.
66. Menezes R, Vieira AR: Dental anomalies as part of the cleft spectrum, *Cleft Palate Craniofac J* 45:414, 2008.
67. Ranta R, Tulensalo T: Symmetry and combinations of hypodontia in non-cleft and cleft palate children, *Scand J Dent Res* 96:1, 1988.
68. Dulude JA, Payette F: Comparison of different types of cleft lip and palate in regards to dental anomalies and sexual incidence, *J Dent Que* 28:49, 1991.
69. Primosch RE: Anterior supernumerary teeth—Assessment and surgical intervention in children, *Pediatr Dent* 3:204, 1981.
70. Davis PJ: Hypodontia and hyperdontia of permanent teeth in Hong Kong schoolchildren, *Community Dent Oral Epidemiol* 15:218, 1987.
71. Hurlen B, Humerfelt D: Characteristics of premaxillary hyperdontia, a radiographic study, *Acta Odontol Scand* 43:75, 1985.
72. Nagai I, Fujiki Y, Fuchihata H, Yoshimoto T: Supernumerary tooth associated with cleft lip and palate, *J Am Dent Assoc* 70:642, 1965.
73. Berkowitz S: State of the art in cleft palate orofacial growth and dentistry. A historical perspective, *Am J Orthod* 74:564, 1978.
74. Hansen K, Mehdinia M: Isolated soft tissue cleft lip: The influence on the nasal cavity and supernumerary laterals, *Cleft Palate Craniofac J* 39:322, 2002.
75. Vallino LD, Zuker R, Napoli JA: A study of speech, language, hearing, and dentition in children with cleft lip only, *Cleft Palate Craniofac J* 45:485, 2008.
76. Lee JC, Slack GC, Walker R, Graves L, et al.: Maxillary hypoplasia in the cleft patient: Contribution of orthodontic dental space closure to orthognathic surgery, *Plast Reconstr Surg* 133:355, 2014.
77. Lai LH, Hui BK, Nguyen PD, Yee KS, et al.: Lateral incisor agenesis predicts maxillary hypoplasia and Le Fort I advancement surgery in cleft patients, *Plast Reconstr Surg* 135:142e, 2015.
78. Landesberger P, Proff P, Dietze S, Hoffmann A, et al.: Evaluation of patient satisfaction after therapy of unilateral clefts of lip, alveolus and palate, *J Craniofac Surg* 34(Suppl 2):31, 2006.
79. Landes CA, Buïdgen L, Laudemann K, Ghanaati S, et al.: Patient satisfaction after prosthetic rehabilitation of bone-grafted alveolar clefts with nonsubmerged ITI Straumann dental implants loaded at three months, *Cleft Palate Craniofac J* 49:601, 2012.
80. Garvey MT, Barry HJ, Blake M: Supernumerary teeth—an overview of classification, diagnosis and management, *J Can Dent Assoc* 65:612, 1999.
81. Subasioglu A, Savas S, Kucukyilmaz E, Kesim S, et al.: Genetic background of supernumerary teeth, *Eur J Dent* 9:153, 2015.
82. Precious DS: A new reliable method for alveolar bone grafting at about 6 years of age, *J Oral Maxillofac Surg* 67:2045, 2009.
83. Sadove AM, Nelson CL, Eppley BL, et al.: An evaluation of calvarial and iliac donor sites in alveolar cleft grafting, *Cleft Palate J* 27:225, 1990.
84. Sindet-Pedersen S, Enemark H: Reconstruction of alveolar clefts with mandibular or iliac crest bone graft: a comparative study, *J Oral Maxillofac Surg* 48:554, 1990.
85. Daskalogiannakis J, Ross RB: Effect of alveolar bone grafting in the mixed dentition on maxillary growth in complete unilateral cleft lip and palate patients, *Cleft Palate Craniofac J* 34:455, 1997.
86. Eppley BL: Donor site morbidity of rib graft harvesting in primary alveolar cleft bone grafting, *J Craniofac Surg* 16:335, 2005.
87. Cohen M, Figueroa AA, Haviv Y, et al.: Iliac versus cranial bone for secondary grafting of residual alveolar clefts, *Plast Reconstr Surg* 87:423, 1991.
88. LaRossa D, Buchman S, Rothkopf DM, et al.: A comparison of iliac and cranial bone in secondary grafting of alveolar clefts, *Plast Reconstr Surg* 96:789, 1995.
89. Hughes CW, Revington PJ: The proximal tibia donor site in cleft alveolar bone grafting: experience of 75 consecutive cases, *J Craniomaxillofac Surg* 30:12, 2002.
90. Kalaaji A, Lilja J, Elander A, Friede H: Tibia as donor site for alveolar bone grafting in patients with cleft lip and palate: long-term experience, *Scand J Plast Reconstr Surg Hand Surg* 35:35, 2001.
91. Boyne PJ: Application of bone morphogenetic proteins in the treatment of clinical oral and maxillofacial osseous defects, *J Bone Joint Surg Am* 83(Suppl 1, Pt 2):S146, 2001.

92. Goudy S, Lott D, Burton R, Wheeler J, et al.: Secondary alveolar bone grafting: outcomes, revisions, and new applications, *Cleft Palate Craniofac J* 46:610, 2009.
93. Laurie SW, Kaban LB, Mulliken JB, Murray JE: Donor-site morbidity after harvesting rib and iliac bone, *Past Reconstr Surg* 73:933, 1984.
94. Rawashdeh MA, Telfah H: Secondary alveolar bone grafting: the dilemma of donor site selection and morbidity, *Br J Oral Maxillofac Surg* 46:665, 2008.
95. Maxson BB, Baxter SD, Vig KW, Fonseca RJ: Allogeneic bone for secondary alveolar cleft osteoplasty, *J Oral Maxillofac Surg* 48:933, 1990.
96. Shirota T, Kurabayashi H, Ogura H, Seki K, et al.: Analysis of bone volume using computer simulation system for secondary bone graft in alveolar cleft, *Int J Oral Maxillofac Surg* 39:904, 2010.
97. Pradel W, Lauer G: Tissue-engineered bone grafts for osteoplasty in patients with cleft alveolus, *Ann Anat* 194:545, 2012.
98. Korn P, Schulz MC, Range U, Lauer G, et al.: Efficacy of tissue engineered bone grafts containing mesenchymal stromal cells for cleft alveolar osteoplasty in a rat model, *J Craniomaxillofac Surg* 42:1277, 2014.
99. Pradel W, Tausche E, Gollogly J, Lauer G: Spontaneous tooth eruption after alveolar cleft osteoplasty using tissue-engineered bone: a case report, *Oral Surg Oral Med Oral Pathol Oral Radiol Endod* 105:440, 2008.
100. Behnia H, Khojasteh A, Soleimani M, Tehranchi A, et al.: Repair of alveolar cleft defect with mesenchymal stem cells and platelet derived growth factors: A preliminary report model, *J Craniomaxillofac Surg* 40:2, 2012.
101. Meara DJ, Livingston NR, Sittitavornwong S, Ness T, et al.: Continuous infusion of bupivacaine for pain control after anterior iliac crest bone grafting for alveolar cleft repair in children, *Cleft Palate Craniofac J* 48:690, 2011.
102. Samman N, Cheung LK, Tideman H: A comparison of alveolar bone grafting with and without simultaneous maxillary osteotomies in cleft palate patients, *Int J Oral Maxillofac Surg* 23:65, 1994.
103. Arrington ED, Smith WJ, Chambers HG, Bucknell AL, et al.: Complications of iliac crest bone graft harvesting, *Clin Orthop Relat Res* 329:300, 1996.
104. Nkenke E, Weisbach V, Winckler E, et al.: Morbidity of harvesting of bone grafts from the iliac crest for preprosthetic augmentation procedures: a prospective study, *Int J Oral Maxillofac Surg* 33:157, 2004.
105. Zijderveld SA, ten Bruggenkate CM, Den Bergh J P van, Schulten EA: Fractures of the iliac crest after split-thickness bone grafting for preprosthetic surgery: report of 3 cases and review of the literature, *J Oral Maxillofac Surg* 62:781, 2004.
106. Kessler P, Thorwarth M, Block-Birkholz, et al.: Harvesting of bone from the iliac crest—comparison of the anterior and posterior sites, *Br J Oral Maxillofac Surg* 43:51, 2005.
107. Misch CM: Comparison of intra-oral donor sites for onlay grafting prior to implant placement, *Int J Oral Maxillofac Implants* 12:767, 1997.
108. Posnick JC, Tompson B: Modification of the maxillary Le Fort I osteotomy in cleft-orthognathic surgery: The unilateral cleft lip and palate deformity, *J Oral Maxillofac Surg* 50:666, 1992.
109. Posnick JC, Tompson B: Modification of the maxillary Le Fort I osteotomy in cleft-orthognathic surgery: The bilateral cleft lip and palate deformity, *J Oral Maxillofac Surg* 51:2, 1993.
110. Mitsugi M, Ito O, Alcalde RE: Maxillary bone transportation in alveolar cleft-transport distraction osteogenesis for treatment of alveolar cleft repair, *Br J Plast Surg* 58:619, 2005.
111. Zemann W, Pichelmayer M: Maxillary segmental distraction in children with unilateral clefts of lip, palate, and alveolus, *Oral Surg Oral Med Oral Pathol Oral Radiol Endod* 111:688, 2011.

34

Cleft Orthognathic Surgery

PAUL S. TIWANA, TIMOTHY A. TURVEY, RAMON L. RUIZ, BERNARD J. COSTELLO, NEERAJ H. PANCHAL

Introduction

The presence of mid-face deficiency in the patient with cleft deformities remains a challenging clinical problem. Maxillary hypoplasia in the cleft patient is almost always the direct biologic consequence of prior surgical intervention. The surgical repair of the lip and/or palate during infancy, although critical for esthetics and speech development, produces scarring that affects subsequent maxillary growth. The soft tissue envelope surrounding the midface is further violated during bone grafting of the cleft maxilla, possible palatal fistula repairs, and other revision procedures. The scarred soft tissue envelope can also create difficulties at the time of skeletal corrective surgery and with long-term stability after maxillary advancement.

From a historical perspective, patients with mid-face deficiency secondary to facial clefting were often ignored. If the deficiency was extreme, surgical intervention usually was offered in the form of mandibular setback. This did little to address the underlying skeletal problem and frequently had the potential to negatively affect the posterior airway. Only with the development of new surgical techniques, a better understanding of the biologic principles of revascularization, and improvements in instrumentation has the patient with mid-face deficiency secondary to facial clefting benefited functionally and esthetically from surgical correction.[1-28]

Although mid-facial deficiency and class III malocclusion may be the most obvious components of the deformity seen in cleft patients, the dysmorphology is actually more complex. Critical examination of most patients with facial clefts reveals deficiencies of the paranasal, nasal, infraorbital, and maxillary regions. This suggests that the deficiency is not confined to the level of the alveolus and basal bone but extends to involve the entire maxilla and adjacent bones. Understanding that facial clefts involve all tissue layers in the region is critical for effective skeletal surgical planning. The presence or absence of a class III malocclusion has been used in most studies to report the incidence of mid-face deficiency in cleft lip and palate. Ross estimated that 25% of patients with unilateral facial clefts have a class III malocclusion with a degree of mid-face deficiency that warrants surgical correction.[4] However, as discussed earlier, more stringent criteria must be applied to correctly determine the presence and severity of mid-face deficiency in association with cleft lip and palate.

Maxillary deficiency in the presence of facial clefting also results in negative functional consequences on the patient's speech, nasal respiration, sinus function, olfaction, and hearing. Severe mid-face deficiency in cleft lip and palate can also contribute to exorbitism and eyelid dysfunction. From an esthetic standpoint, the deformity can be associated with malar and infraorbital deficiency, lack of nasal tip projection, and deficient upper lip support. The stigmata characteristic of patients with facial clefts are not inherently due to the cleft itself but are caused by the insult of growth potential and surgical scarring in the mid-face. The result is often both a maxillary *deficiency* and a maxillary *deformity*. Therefore, if improvement of esthetic deficits as well as relief of malocclusion are the goals of mid-face advancement, the surgeon must appropriately address the need for maxillary advancement and bone graft contouring of the deficient facial skeleton for soft-tissue support and reconstruction of structural defects.[28]

Presurgical Evaluation

The presurgical workup for cleft lip and palate patients follows a path similar to that of the regular dentofacial deformity population, with a few exceptions. Accurate dental models with a centric bite and facebow transfer, facial and oral photos, facial measurements, and lateral cephalometric and Panorex x-ray films are necessary for both populations. In the cleft patient, obtaining periapical films, an occlusal film, or alternatively a computed tomography (CT) scan that demonstrates the detailed anatomy of the cleft regions and adjacent tissues is helpful. This additional information provides guidance to the surgeon regarding bony anatomy,

blood supply, and periodontal status of the adjacent cleft dentition. Importantly, information must be gained from the patient's surgical history regarding previous operations. The surgeon must take into account not only the type of operations, but also what effect a particular type of cleft procedure may have on the current treatment plan. For example, the presence of a pharyngeal flap not only portends issues with intubation during anesthesia, but also informs the surgeon of the potential difficulty that may be encountered with mobilization intraoperatively. Of particular interest to the surgeon is the type of procedure used for palatoplasty. Certain methods of palatal repair (e.g., palatal island flap) can alter the vascular pedicle necessary for the maxilla to survive down-fracture and mobilization. The physical examination itself is important and yields information regarding the presence or absence of palatal fistulas and the pattern of scarring in the oral mucosa, lip, and palate. Evaluation of the intranasal anatomy such as the septum and inferior turbinates should also be performed. The septum is usually deflected, and obstructed nasal breathing is a common complaint. Le Fort I osteotomy in most circumstances provides ideal access to these structures when intranasal surgery is indicated.

Timing of Surgery and Psychosocial Considerations

Surgical correction of the mid-face deficiency secondary to facial clefting is ideally performed when the patient is both psychologically and biologically mature enough to undergo the procedures. As with most patients, surgery to correct mid-face deficiency in the facial cleft population most prudently occurs after the facial bones have reached skeletal maturity. This improves the predictability of the surgery and decreases the risk of outgrowing the surgical correction. This consideration should always be a component of the informed consent process.

In some instances proceeding with surgery before the completion of facial growth can be considered, especially for those patients with psychosocial comorbidities. Critical to proceeding under these circumstances is the understanding of the patient and parents that additional or repeat surgery may be required once facial skeletal maturation is complete if the patient outgrows the correction. The postoperative course for facial skeletal surgery has become more benign because rigid fixation eliminates the need for intermaxillary fixation, steroids control swelling, antibiotics reduce infection, and the use of hypotensive anesthesia and recombinant erythropoietin dramatically reduced the need for homologous blood transfusion. Despite these advances, the decision to proceed with early surgery should not be taken lightly or be made for the convenience of an impatient surgeon or orthodontist.

Another biologic consideration that affects the timing of surgery is the eruption of the permanent dentition. Delaying surgery until after the eruption of the permanent maxillary canines and second molars minimizes the risk of injury to the teeth during osteotomy. Impacted wisdom teeth (third molars) can be safely removed during the osteotomy, and their presence should not delay surgery. In fact, removing them during the osteotomy reduces the number of surgical procedures the child may undergo.

Improvement of self-concept and self-image in cleft patients almost always follows surgery to address facial skeletal disproportion. This must not be overlooked when considering the timing of surgery. Improving facial balance by surgical correction of disproportion often results in dramatic and favorable changes. The patient and family often perceive these changes positively. In addition, as the procedure is likely the penultimate correction of the cleft deformity, a sense of achievement is usually felt by the patient and family after years of effort directed at multiple dental and surgical procedures. In contrast, a few patients with dependency directed at their facial stigmata may respond differently to surgical treatment. This is difficult to determine preoperatively, and the involvement of a psychologist familiar with children with facial deformities can be invaluable in these instances.

As with any patient with a congenital facial malformation, cleft patients are psychologically different from most patients with acquired facial deformities.[29] The congenital nature of the deformity requires multiple psychologic adjustments with every procedure. Many cleft patients are acquainted with the disappointment after soft tissue procedures aimed at reducing lip scarring and correcting nasal asymmetry. For still others, unrealistic expectations may accompany corrective skeletal surgery. These patients should be identified early through complete cleft team evaluations and referred for counseling preoperatively.

All children with facial deformities, congenital or acquired, can become victimized because of their facial differences. This may become more prevalent during the adolescent years. Enormous peer pressure is felt at this age, especially in the United States. Adolescents with cleft lip and palate are often ridiculed during this period in their lives, and low self-esteem with social withdrawal can follow. Although counseling can help, the patient must also learn to cope with the problem, which may be improved with corrective skeletal surgery.

Surgical Reconstruction

Surgeons who care for children with cleft lip and palate deformities must proceed with an understanding of the three-dimensional regional anatomy, the extent of hard and soft tissue defects present, and the complex interplay between surgery and subsequent maxillofacial growth. This understanding allows the clinician to formulate and sequence appropriately the staged surgical treatment of patients with cleft lip and palate from the initial consultation in infancy through adulthood. The goals of skeletal reconstruction include improvement of skeletal proportion and balance, correction of the occlusion, normalization of nasal breathing, closure of residual defects and fistulas, and improvement of the soft tissue position by providing a bony foundation for support.

Maxillary advancement in the patient with cleft lip and palate does not remove scarring of the lip or correct

anatomic soft tissue landmarks. It does, however, provide the best opportunity for skeletal foundation support of the soft tissue drape. Usually an improvement in lip and nasal asymmetry as well as further support for the nasal tip are seen postsurgery. By providing improved structural support, skeletal surgery may reduce the soft tissue stigma enough to diminish the need or desire for revisional procedures of the lip and nose. Advancement of the skeletal foundation changes the visual perception of the scar by altering the pattern of light reflection, thus making it less obvious. In addition, the common practice of placing the lip scar in the philtral column to diminish its prominence is often counteracted by the underlying deficiency of the maxillary skeletal base. This places the scar on the most flat, unsupported area of the lip, which is far more obvious. Advancement of the skeletal base not only improves the soft tissue drape but also moves the scar to an area of greater curvature on the lip, making it less conspicuous. Patients should be counseled that mid-face advancement sets the stage for definitive lip and nasal revisions in the future (Figure 34-1).

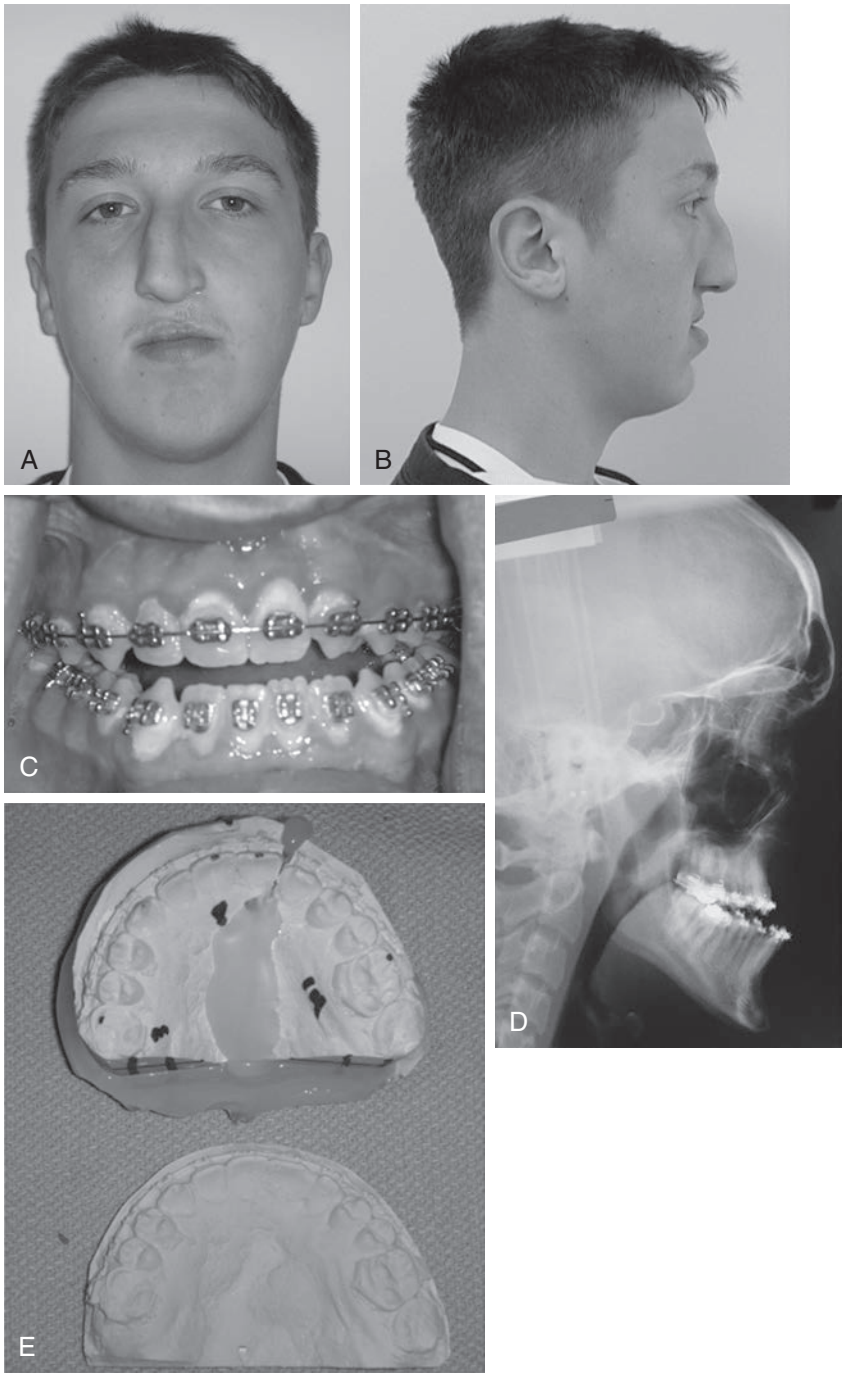

• **Figure 34-1** **A** to **D,** Preoperative facial, occlusal, and cephalometric views of 17-year-old with repaired unilateral cleft lip and palate and associated with severe mid-face deficiency and 13-mm anteroposterior discrepancy. **E,** Model surgery planning demonstrating narrowing of maxilla through the cleft site.

The residual skeletal dysmorphologies that can be present in patients with unilateral cleft lip and palate are numerous and often found in combination (Box 34-1). Reconstruction of these defects and deformities requires accurate diagnosis, thoughtful treatment planning, and precise surgical execution of the defined treatment plan. This reconstructive effort typically involves multiple clinicians who have varying degrees of involvement based on the patient's stage of development and specific esthetic and functional demands.

In patients with bilateral cleft lip and palate, similar dysmorphologies are present; however, additional dental and skeletal discrepancies may also be present (Box 34-2). If successful bone grafting of the bilateral cleft maxilla has been performed, with elimination of fistulas and bony continuity is achieved, then conventional Le Fort I osteotomy may proceed (with or without concomitant mandibular surgery). Despite successful bone graft reconstruction of the bilateral cleft maxilla, segmental surgery can be more complicated because of palatal scarring, incomplete graft



• **Figure 34-1, cont'd** **F** to **I,** One-year postoperative facial, occlusal, and cephalometric views of patient after undergoing Le Fort I advancement in two segments with autogenous bone grafting and rhinoplasty.

• Box 34-1 Residual Dysmorphology in the Child and Adult Unilateral Cleft Lip and Palate Patient

Residual cleft lip and nasal scarring
Nasal cartilage distortion
Deviated septum
Hypertrophied nasal turbinates
Unrepaired or residual oronasal fistulas associated with the primary palate (cleft)
Cleft dental gap
Missing or malformed teeth
Dental crowding
Complex malocclusion
Periodontal disease
Inflammation of the soft tissue surrounding oronasal fistulas
Defects or hypoplasia involving the pyriform rim, nasal floor, and alveolus
Maxillary hypoplasia (anteroposterior, vertical, and transverse)
Maxillary canting and asymmetry
Compensatory mandibular asymmetry
Mandibular growth disturbance

• Box 34-2 Additional Dysmorphology in the Child and Adult Bilateral Cleft Lip and Palate Patient

Ectopically positioned premaxilla
Continuous oronasal fistula from the incisive foramen forward to the maxillary clefts on both sides
Exaggerated curve of Spee and occlusal plane discrepancies
Reduced vascularity of the premaxillary segment requiring modified vestibular incision design and osteotomies through tunneling procedures

consolidation, and lack of an adequate vascular supply to the premaxilla. A thorough preoperative evaluation of the previous procedures and clinical and radiographic examinations is required before mid-face advancement is undertaken.[4,16,22,27,28]

Technical Considerations

Contemporary cleft team–directed treatment protocols include maxillary bone graft reconstruction of the cleft maxilla and palate at developmentally appropriate times.[5-9] The benefits for the patient include provision of a bony matrix for eruption of the permanent dentition, establishment of continuity of the maxillary segments, elimination of residual oronasal fistulas, support for the alar base of the nose, and stabilization of the premaxilla in the bilateral cleft patient. If bone grafting is performed effectively, it can decrease the complexity and potential morbidity of future cleft-orthognathic surgery. Mid-face advancement in the patient with a properly grafted cleft then becomes relatively straightforward. If cleft maxillary grafting is not successful, residual fistulas and cleft dental gaps add to the complexity of the mid-face procedure. In patients who did not undergo grafting, the procedure becomes even more complex. In these two situations, surgical flap design must be altered to ensure adequate vascular perfusion. Maxillary advancement in the presence of cleft lip and palate is different from that in the noncleft patient because of the absence of tissues and the scarring of the soft tissue envelope. Vascular perfusion of the mobilized maxilla comes from the overlying soft tissues, with the palate being predominant. In the patient with cleft, this critical tissue overlying the palate is most often scarred and fibrotic and may have residual fistulas present. This possible compromise to the palatal soft tissue pedicle requires that the surgeon carefully determine the incision design for maxillary osteotomy. In most cases the traditional circumvestibular approach with maxillary down-fracture at the Le Fort I level can still be employed successfully (Figure 34-2). However, a modified incision preserving an anterior vascular pedicle is required when patients are undergoing cleft maxillary osteotomy and have bilateral clefts even if successfully bone grafted, have severe palatal scarring, or previously underwent palatal island flap repair of the palate (Figure 34-3). This technique should ensure adequate vascular supply to the premaxilla for uneventful healing postoperatively. However, the maintenance of an anterior vascular pedicle does increase the degree of technical complexity of the operative procedure.

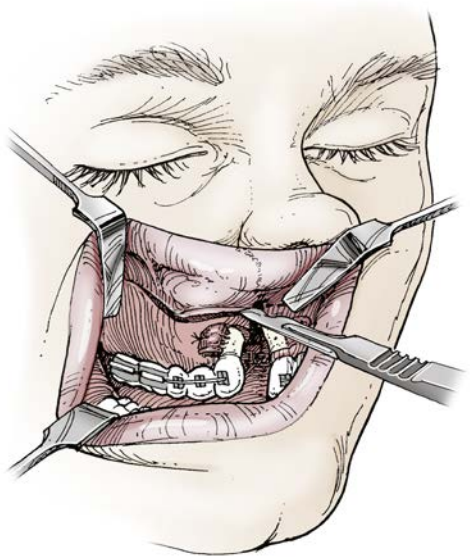

• Figure 34-2 The circumvestibular incision can be used in most patients with cleft and provides the best visualization for conducting the osteotomy. (From Turvey TA, Vig KWL, Fonseca RJ: Maxillary advancement and contouring in the presence of cleft lip and palate. In Turvey TA, Vig KWL, Fonseca RJ, editors: *Facial clefts and craniosynostosis: principles and management,* Philadelphia, 1996, Saunders.)

In the conventional approach to mid-face advancement at the Le Fort I level, a circumvestibular incision is created from the zygomaticomaxillary buttress to the opposite side high in the mucobuccal fold. Ensuing subperiosteal dissection exposes the entire lateral wall of the maxilla from the pyriform rim to the pterygomaxillary junction and superiorly to the inferior orbital rim above. Dissecting inferiorly toward the alveolus (e.g., dentoalveolar segment) is not

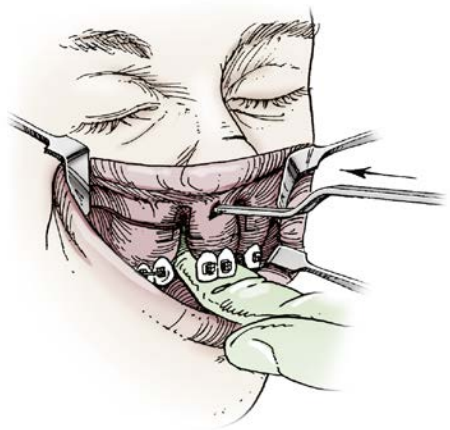

• **Figure 34-3** An anterior pedicle incision limits visualization and access but provides additional perfusion to the maxilla. It should be used in cleft patients with significant palatal scars and in patients with bilateral clefts. (From Turvey TA, Ruiz RL, Costello BJ: Surgical correction of midface deficiency in cleft lip and palate malformation, *Oral Maxillofac Surg Clin North Am* 14:491, 2002.)

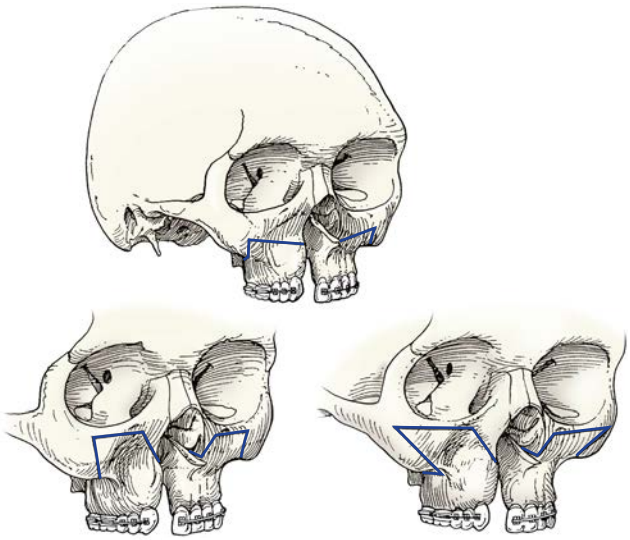

• **Figure 34-4** Osteotomies for cleft patients should be designed to address the specific skeletal dysmorphology. (From Turvey TA, Ruiz RL, Costello BJ: Surgical correction of midface deficiency in cleft lip and palate malformation, *Oral Maxillofac Surg Clin North Am* 14:491, 2002.)

recommended because this reduces the perfusion coming from the buccal flap. This wide exposure permits excellent and safe visualization of the performance of Le Fort I osteotomy. During down-fracture of the maxilla, perfusion of the mobilized maxilla is provided by the lateral buccal soft tissue pedicles and the palate. This technique allows superior visualization of the operative field and permits the surgeon direct control of hemorrhage from the greater palatine vessels.

When performing mid-face advancement with an anterior pedicle for improved vascularity, visualization is reduced and mobilization by down-fracture is not possible. Mobilization is achieved through in-fracturing and anterior traction of the maxilla. In most cleft palate patients the area of greatest resistance to mobilization is the vertical portion of the palatine bone. The bone is located in the posterior medial aspect of the maxillary sinus. The bone is thick, and access is difficult at best, especially with maintenance of an anterior vascular pedicle. Adding to this difficulty are the greater palatine vessels, which descend from the sphenopalatine fossa to the posterior maxilla. These vessels run through a canal in this bone and are prone to injury during osteotomy or mobilization. Hemorrhage control is difficult because of the limited access and is usually limited to packing and/or the injection of local anesthetic with vasoconstrictor.

In the cleft patient who has not undergone maxillary bone graft construction, residual oral nasal fistulas are common. In addition, patients who underwent gingivoperiosteoplasty in infancy usually lack the bone volume necessary to support the dentition and may also have residual fistulas or skeletal gaps. Incision design in these patients must therefore also include consideration of the closure of residual oronasal fistulas and the necessary bone grafting. Of great importance is the reconstruction of the nasal floor, which is completed using the tissues lining the fistula.

Osteotomy design in the patient with cleft should also be carefully planned (Figure 34-4). The cleft deformity extends from beyond the alveolus to involve the entire maxilla and adjacent bones. The deformity is rarely symmetric. As a result, the design of the osteotomy becomes very important for the improvement of soft tissue support and ultimately the esthetics of the mid-face. Even subtle differences in osteotomy design on the cleft side can have a noticeable impact on facial esthetics.

Adequate mobilization of the maxilla is a key to success in the cleft patient undergoing surgical correction of mid-face deficiency. This entails patience on the part of the surgeon not only to adequately mobilize the bony maxilla, but also to stretch the soft tissue envelope. As described previously, the area of greatest bony resistance in the cleft palate patient is the perpendicular portion of the palatine bone. Usually a small, guarded osteotome is used to weaken this area, permitting mobilization. However, care must be exercised by the surgeon to ensure that this area has been adequately weakened before mobilization. If the maxilla remains resistant to mobilization, excessive force may cause an unfavorable fracture extending to the skull base or orbit, potentially causing neurologic injury or blindness.[30,31] Prudent surgical technique would call for further weakening of this area by osteotome before attempting mobilization again.

Further segmentation of the cleft maxilla for the improvement of occlusal discrepancies should be approached cautiously. The vascular pedicle in these patients has often already been compromised, and further segmentation may lead to necrosis of the segment. It may be judicious to accept minor crossbites or other occlusal imperfections rather than risk necrosis of mobilized segments. If segmentation of the cleft maxilla is necessary, the use of the cleft itself as the area through which segmentation is performed is preferred.

Bone Grafting

There are several major reasons why fresh autogenous bone grafts are employed during mid-face advancement in the patient with cleft lip and palate. First, the bone grafts can be wedged between the osteotomy segments, increasing the stability of the advancement. Second, the autogenous grafts improve bone healing and decrease the chance of fibrous nonunion. Last, they provide an excellent opportunity to contour the facial skeleton for improved facial esthetics. In the cleft patient the mid-face is not only retruded but is also asymmetric and deformed (Figure 34-5). Alteration of the skeletal morphology therefore permits improvement of facial esthetics. Augmentation of malar projection, the infraorbital region, the paranasal regions, and the chin is easily and commonly performed during mid-face advancement in these patients. Commonly used bone harvest donor sources include the cranium and iliac crest. Autogenous grafting does require more time intraoperatively for graft harvest and has associated potential morbidity. However, the use of the bone and the predictability of the result justify its use. The advent of bone substitutes has not diminished the need for obtaining autogenous grafts. Allogeneic bone has yet to demonstrate the same level of success associated with autogenous grafting. Good surgical technique minimizes the morbidity of autogenous bone graft harvest and provides the patient with a compatible

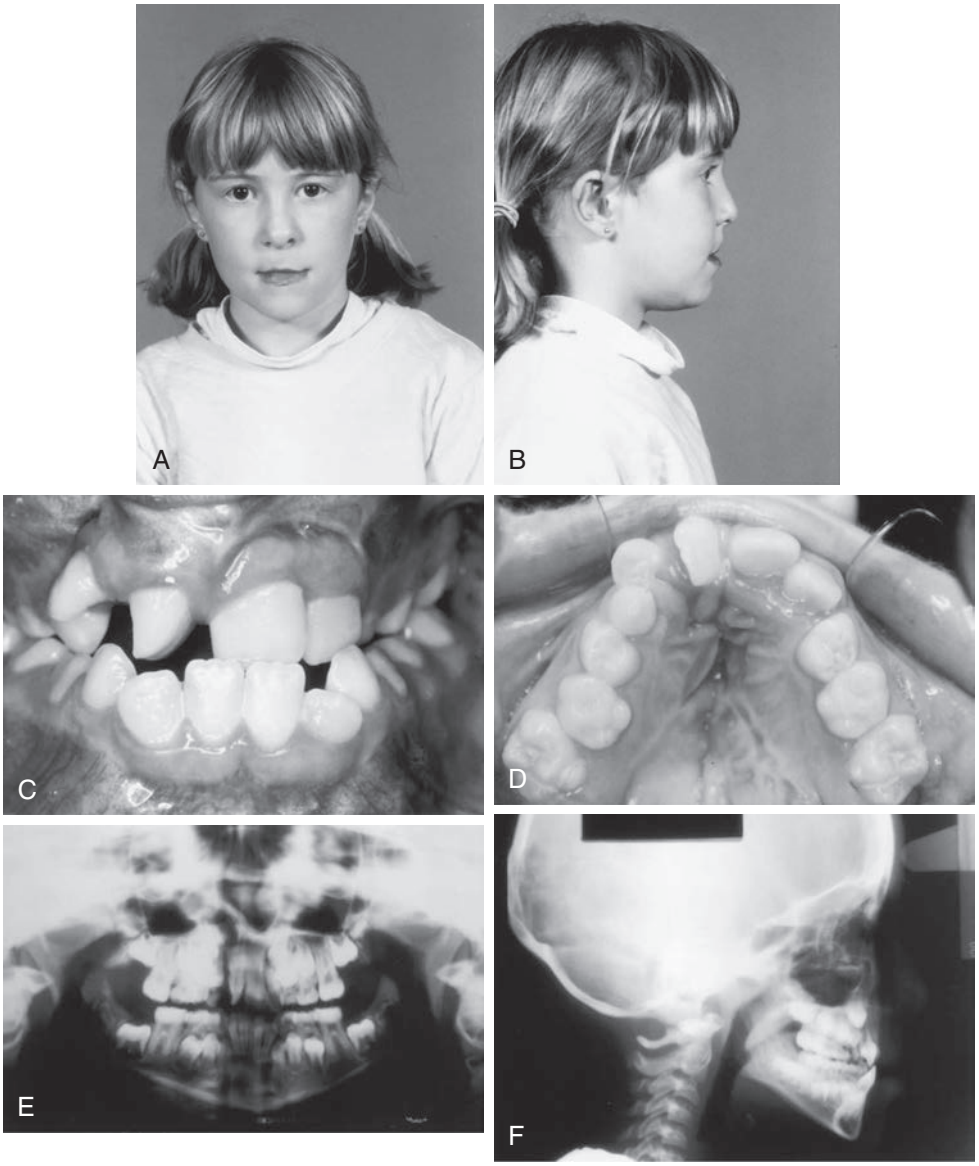

• **Figure 34-5** **A-B,** An 8-year-old child with repaired cleft lip and palate who is already demonstrating maxillary deficiency. **C-D,** Anterior crossbite, malrotations, and ectopic eruption of teeth into the cleft. Oronasal fistulas are present on the buccal and palatal. **E,** The Panorex demonstrates a missing lateral incisor and developing cuspid on the cleft side with minimal periodontal support for the malrotated central incisor adjacent to the cleft. It is important that the orthodontist not attempt to rotate the tooth before placement of the bone graft. Once a periodontal defect occurs, as it most surely will if correction of the malrotation before grafting is undertaken, the bone graft cannot eliminate it. **F,** The cephalometric radiograph demonstrates maxillary deficiency, anterior crossbite, and the mixed dentition.



• **Figure 34-5, cont'd** **G,** The bone graft was placed at age 8, and a preliminary stage of orthodontics was initiated after the graft to level, align, and maintain adequate space for eruption of the cuspid adjacent to the central incisor. **H,** This radiograph taken at age 11 demonstrates eruption of the cuspid into the grafted bone. **I-J,** At age 14 the patient demonstrates progressive maxillary deficiency and a protrusive lower lip. The amorphous facial appearance results not only from maxillary deficiency but also from contour deficiencies of the cheeks and infraorbital regions. **K,** Anterior crossbite is present. A maxillary left premolar was removed to facilitate eruption of the left cuspid. Note the excellent periodontal health and absence of fistulas facilitated by the bone graft. **L,** The cephalometric radiograph confirms maxillary deficiency.

Continued

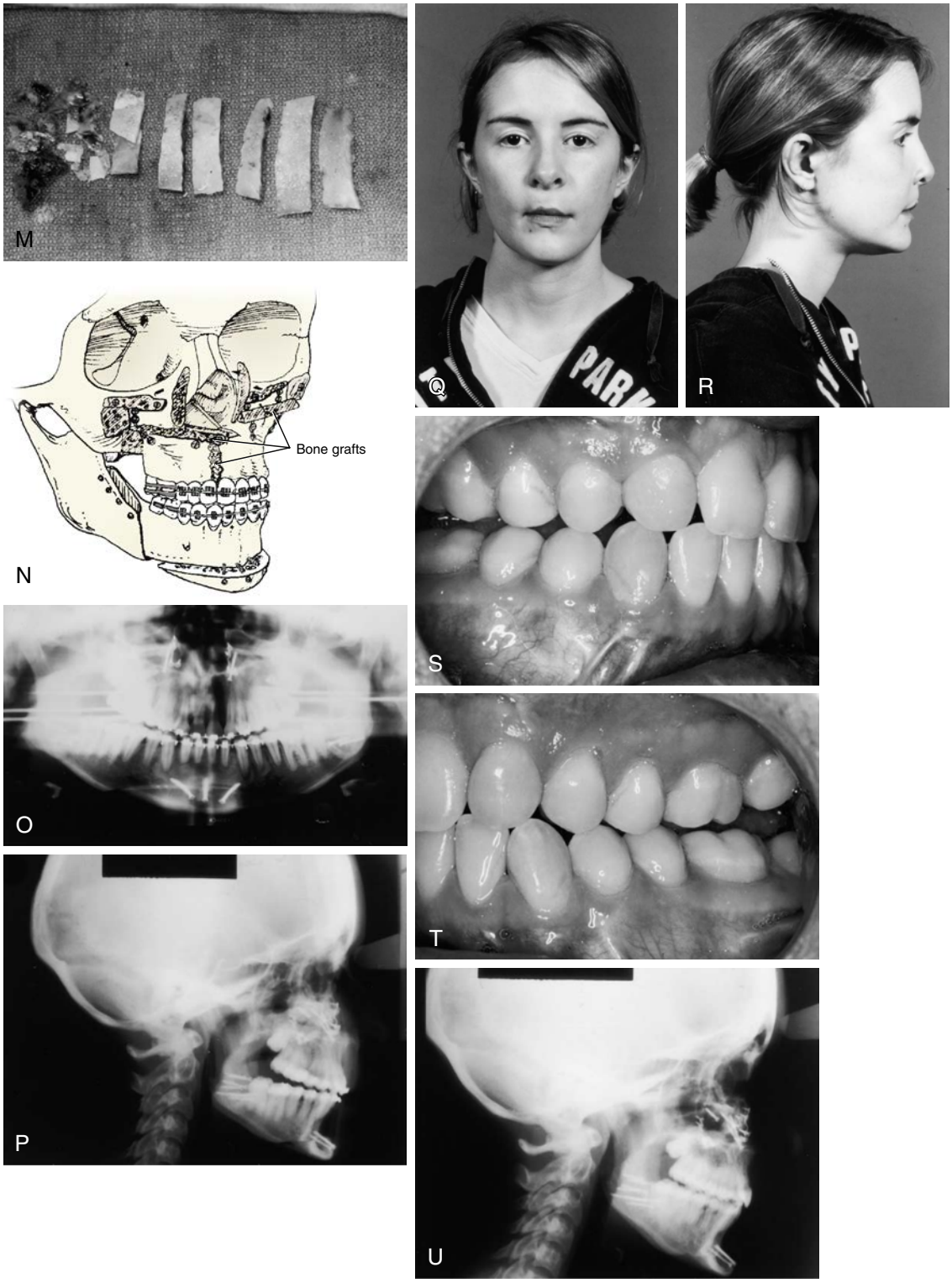

• **Figure 34-5, cont'd** **M,** At the time of surgery, split-thickness cranial bone grafts were to be placed in the osteotomy defects and support the cheek prominence and infraorbital regions. **N,** The surgery performed was maxillary advancement, mandibular setback, augmentation genioplasty, and bone grafts to contour the cheeks and maxilla. The genioplasty was performed to improve the balance. **O-P,** The postsurgical Panorex and cephalometric radiographs. **Q-R,** Postoperative facial views at age 15. **S-T,** Oral views at age 18 demonstrating cuspid substitutions for the lateral incisors and no need for prosthetic management. **U,** Demonstration of good stability of the result; no lip or nasal revisions have been performed. (From Turvey TA, Ruiz RL, Costello BJ: Surgical correction of midface deficiency in cleft lip and palate malformation, *Oral Maxillofac Surg Clin North Am* 14:491, 2002.)

and stable long-term solution. Fresh autogenous iliac bone is the most commonly harvested autogenous bone graft for the cleft patient. A large volume of cancellous or corticocancellous bone is available for use from this site. Cancellous bone is most often used for filling alveolar defects, whereas the cortical grafts can be used to stabilize the operated maxilla or augmentation of the facial skeleton. Our preference for contour augmentation of the middle face is split-thickness cranial bone. Block or onlay bone grafts should be rigidly fixated with screws to the facial skeleton to reduce infection, promote healing, and reduce resorption of the graft during incorporation into the facial skeleton (Figure 34-6).

Obstructed Nasal Breathing

Cleft patients often present with difficulty during nasal respiration. This is secondary to a number of anatomic causes including a deviated nasal septum, enlarged nasal turbinates, chronic tissue inflammation associated with residual fistulas, and scarring of the internal nose from previous reconstructive procedures. During mid-face advancement with down-fracture, the surgeon is afforded unparalleled surgical access to the structures of the internal nose. Undertaking concomitant septoplasty and/or inferior turbinectomy, where indicated, may significantly improve nasal breathing

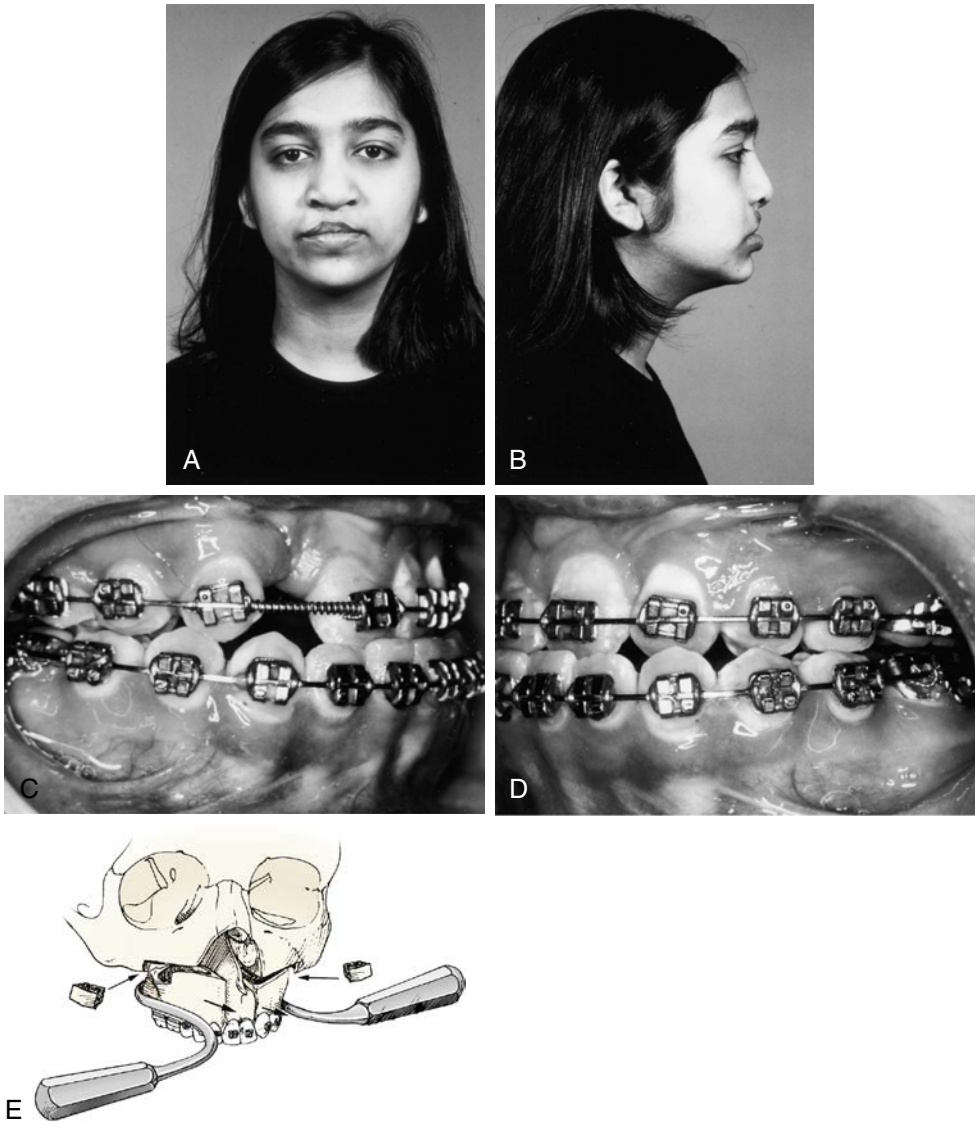

• **Figure 34-6** **A-B,** A 16-year-old patient with bilateral cleft lip and palate who previously underwent bone grafting of the maxilla bilaterally. Note the deficient projection of the entire middle face, especially the paranasal regions. Also, note the relatively protrusive lower lip. **C-D,** Orthodontic preparation included advancing the cuspid on the left adjacent to the central. Attempts to open the space on the right for a prosthetic lateral incisor are in progress. **E,** The right posterior maxilla was mobilized independently, and an osteotomy at the right lateral incisor space was performed. The posterior segment was advanced a greater distance than the left, so the cuspid was placed adjacent to the central incisor. It is desirable to eliminate prosthetic treatment when possible. Feasibility model surgery demonstrated that closure of lateral incisor space on the right could be performed without compromise. The major advantages of this were eliminating prosthetic needs and improving occlusal symmetry.

Continued

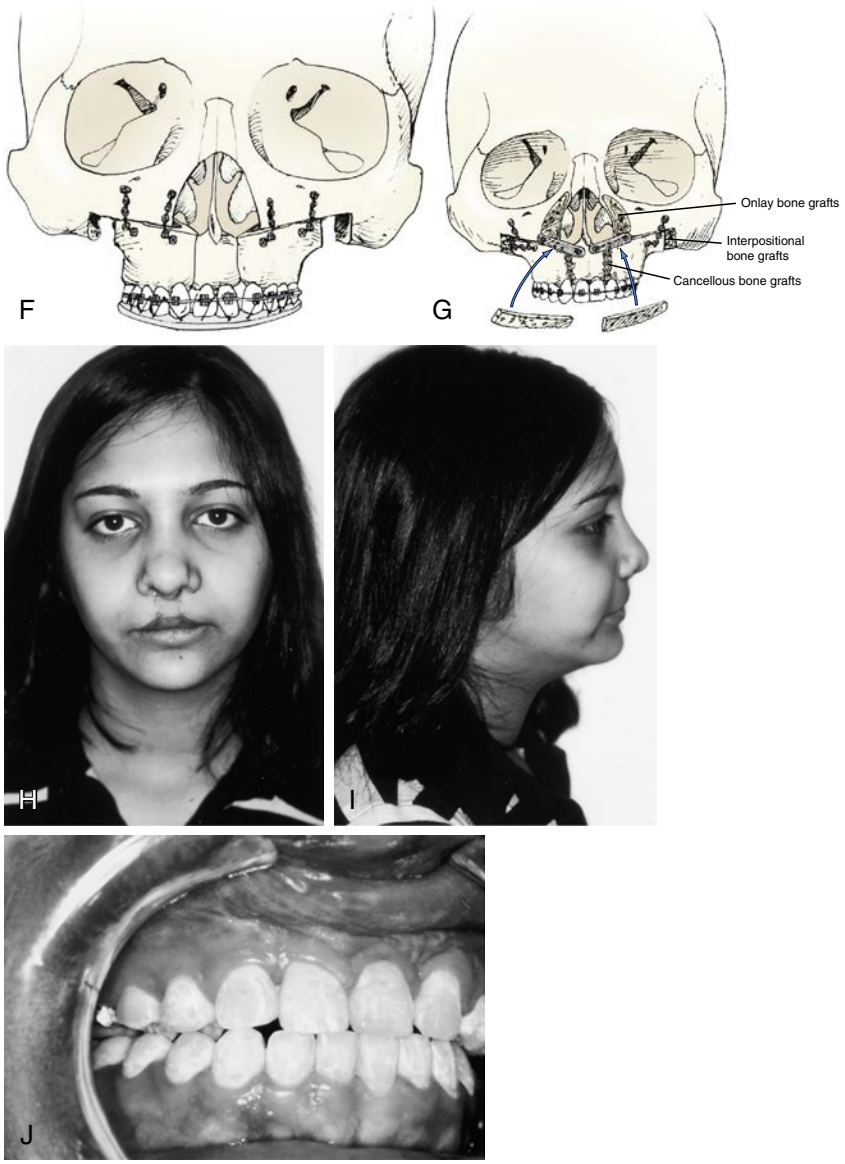

• **Figure 34-6, cont'd** **F,** The segments were stabilized with bone plates and screws. **G,** Inlay and onlay cranial bone grafts were placed to facilitate bone consolidation and contouring of the midface. **H-I,** Improved skeletal support permitted soft tissue and nasal revisions 9 months after maxillary advancement and bone grafting. **J,** Final occlusion without the need for prosthetic care. (From Turvey TA, Ruiz RL, Costello BJ: Surgical correction of midface deficiency in cleft lip and palate malformation, *Oral Maxillofac Surg Clin North Am* 14:491, 2002.)

postoperatively and is important for not only function, but also quality of life. Excised septal cartilage should not be discarded if future rhinoplasty is anticipated. The harvested cartilage is easily banked in the vestibule under the mucosa or alternatively can be left between the nasal septum and mucosa, obviating the need for harvest during subsequent rhinoplasty.

Stabilization of the Mobilized Cleft Maxilla

The revolution in the development of rigid internal fixation systems has seen the field of cranio-maxillofacial surgery develop from the placement of wire fixation, through stainless and alloy metal plates, to titanium fixation and now resorbable fixation systems. The use of rigid internal fixation has many benefits, including allowing limited function during convalescence and an improvement in the stability of the repositioned facial bones during healing.[12] The use of bone plates and screws may improve long-term stability, although a true comparison study has not been published to date.[15,32,33] Perhaps more important than just the use of plates and screws is an understanding by the surgeon of the importance of not inappropriately altering the position of the envelope of the major muscles of mastication during repositioning of the osteotomized facial skeleton. A disadvantage of rigid fixation is the inability to use elastic traction to manipulate tooth-bearing segments.

Biodegradable bone plates and screw systems have been available for several years now and are approved for use in both the mid-face and the mandible. When evaluating the use of these systems, the surgeon must be aware that the polymer combinations are different in each product and can have an impact on the rigidity and degradation of the material. Our experience is that with a self-reinforced polylactate system, acceptable characteristics and high patient appeal can result. Investigations of the stability of these systems continue to be promising, and they represent an alternative method of fixation for the patient and surgeon to consider.[34]

Velopharyngeal Considerations

One concern associated with advancement of the cleft maxilla is the potential for deterioration of speech in the postoperative period. The velopharyngeal sphincter is a complex mechanism that, under normal conditions, functions to close off the nasal cavity from the oral cavity through elevation of the soft palate and contraction of the lateral pharyngeal walls.[35] In many patients with repaired cleft lip and palate, the apparatus is altered and the patient has learned to overcome a short or scarred palate that does not move well by recruiting adjacent soft tissue structures. An example of one such anatomic adaptation includes Passavant's ridge (hypertrophy of tissue in the posterior pharyngeal wall), which is noted in many patients with cleft and aids in overcoming the insufficiency of velar stretch and movement.

Some patients require surgical assistance in obtaining velopharyngeal competence. This can be accomplished through a number of different procedures but is most commonly and effectively managed with the superiorly based pharyngeal flap. A patient with a short, scarred soft palate that does not move well may not tolerate the change in position of the soft palate associated with maxillary advancement, and velopharyngeal function may deteriorate.[36,37] Some patients develop compensatory reserve to overcome the change in position of the soft palate after mid-face advancement. A few cleft patients who demonstrate borderline velopharyngeal closure preoperatively may be unable to tolerate even a small degree of maxillary advancement. This potential should not be overlooked, and all cleft patients undergoing maxillary advancement should be counseled appropriately. Although routinely done in the cleft team setting, all patients should have a complete speech evaluation by a speech pathologist familiar with cleft patients before mid-face advancement surgery.

Almost all cleft patients have some degree of hypernasality after maxillary advancement. Among the patients who develop significant hypernasality after maxillary advancement, however, the number of persons who require surgical correction (e.g., pharyngeal flap, sphincteroplasty) is low. Fortunately, resolution gradually occurs with time so that, for most patients, returning to baseline speech by 6 months after surgery is typical. Any consideration for surgical intervention for relief of velopharyngeal incompetence in the postmaxillary advancement cleft patient should therefore be delayed at least 6 months before proceeding. This time period allows for natural neuromuscular adaptation to occur and permits bone healing to proceed without introducing more scarring, which may contribute to relapse.

In some patients with pharyngeal flaps in place who did not have velopharyngeal competence before mid-face advancement surgery, it has been noted that hypernasality improved postsurgery. Although sibilant distortion errors and articulation is expected to improve in the patient who has surgical correction of malocclusion, reduction of hypernasality after maxillary advancement is a paradox. This finding is explained by the altered dynamics of the sphincter that result from maxillary advancement surgery. Stretching of the marginally functional pharyngeal flap may improve the velopharyngeal mechanism enough to allow for improved speech in some patients. However, this observation is not predictable, and patients must be cautioned appropriately.

The surgeon should always be cognizant of the implications of the pharyngeal flap intraoperatively as well. Its presence should be communicated to the anesthesiologist before intubation is attempted to prevent injury to the flap and significant hemorrhage in the airway during intubation. The assistance of nasal-endoscopic–guided intubation can be invaluable to a smooth and safe induction of the required general anesthesia.[38] When a pharyngeal flap is in place and maxillary advancement is attempted, the flap should be divided only if it does not permit adequate mobilization of the maxilla. In our experience this situation is rare.

Summary

The surgeon who manages mid-face deficiency in the presence of cleft lip and palate must carefully consider the treatment objectives, the history, the clinical examination findings, and the patient's wishes to render appropriate treatment. Close cooperation with specialists in other disciplines such as orthodontists and speech pathologists who are familiar with cleft patients is a necessity. Attention to detail during treatment planning and meticulous surgical technique, modified where necessary to accommodate the patient with cleft lip and palate, lead to safe and predictable correction of mid-face deficiency in this group of patients.

References

1. Sulik KK: Craniofacial development. In Turvey TA, Vig KL, Fonseca RJ, editors: *Facial clefts and craniosynostosis: principles and management*, Philadelphia, 1996, Saunders.

2. Semb G, Shaw WC: Facial growth in orofacial clefting disorders. In Turvey TA, Vig KL, Fonseca RJ, editors: *Facial clefts and craniosynostosis: principles and management*, Philadelphia, 1996, Saunders.
3. Schendel SA, Tessier P, Tulasane JF: Facial clefting disorders and craniosynostosis considerations. In Turvey TA, Vig KL, Fonseca RJ, editors: *Facial clefts and craniosynostosis: principles and management*, Philadelphia, 1996, Saunders.
4. Ross RB: Treatment variables affecting facial growth in complete unilateral cleft lip and palate: VII. An overview of treatment and facial growth, *Cleft Palate J* 24:33, 1987.
5. Rehrmann AH, Koberg WH, Koch H: Long-term post-operative results of primary and secondary bone grafting in complete clefts of the lip and palate, *Cleft Palate J* 7:206, 1970.
6. Rehrmann AH: The effects of early bone grafting on growth of the upper jaw in cleft lip and palate in children: a computer evaluation, *Minerva Chir* 26:874, 1971.
7. Copland M: The effect of very early palatal repair on speech, *Br J Plast Surg* 43:646, 1990.
8. Jolleys A: A review of the results of operations on cleft palates with reference to maxillary growth and speech function, *Br J Plast Surg* 7:229, 1954.
9. Turvey TA, Vig KW, Hoke J, et al.: Delayed bone grafting in the cleft maxilla and palate: a retrospective multidisciplinary analysis, *Am J Orthod Dentofacial Orthop* 86:243, 1984.
10. Fonseca RJ, Turvey TA, Wolford LM: Orthognathic surgery in the cleft patient. In Fonseca RJ, Baker SJ, Wolford LM, editors: *Oral and maxillofacial surgery*, Philadelphia, 2000, Saunders.
11. Braun TW, Sotereanos GC: Orthognathic and secondary cleft reconstruction of adolescent patients with cleft palate, *J Oral Surg* 38:425, 1980.
12. Drommer R, Luhr HG: The stabilization of osteotomized maxillary segments with Luhr miniplates in secondary cleft surgery, *J Maxillofac Surg* 9:166, 1981.
13. Poole MD, Robinson PP, Nunn ME: Maxillary advancement in cleft lip and palate patients: a modification of Le Fort I osteotomy and preliminary results, *J Maxillofac Surg* 14:123, 1986.
14. Stoelinga PJ, Haers PE, Lennen RJ, et al.: Late management of secondary grafted clefts, *Int J Oral Maxillofac Surg* 19:97, 1990.
15. Eskenazi LB, Schendel SA: An analysis of Le Fort I maxillary advancement in cleft lip and palate patients, *Plast Reconstr Surg* 90:779, 1992.
16. Tideman H, Stoelinga H, Gallia L: Le Fort I advancement with segmental palatal osteotomies in patients with cleft palates, *J Oral Surg* 38:196, 1980.
17. West RA: Orthognathic surgery: an adjunct for correcting secondary cleft deformities, *Oral Maxillofac Surg Clin North Am* 3:641, 1991.
18. Westbrook Jr MT, West RA, McNeill RW: Simultaneous maxillary advancement and closure of bilateral alveolar clefts and oronasal fistulas, *J Oral Maxillofac Surg* 41:257, 1983.
19. Posnick JC: Cleft lip and palate reconstruction: from infancy through adolescence. In *Craniofacial and maxillofacial surgery in children and young adults*, Philadelphia, 2000, Saunders.
20. Posnick JC: Cleft lip and palate: bone grafting and management of residual oro-nasal fistula. In *Craniofacial and maxillofacial surgery in children and young adults*, Philadelphia, 2000, Saunders.
21. Posnick JC: Cleft-orthognathic surgery: the unilateral cleft lip and palate deformity. In *Craniofacial and maxillofacial surgery in children and young adults*, Philadelphia, 2000, Saunders.
22. Posnick JC: Cleft orthognathic surgery: the bilateral cleft lip and palate deformity. In *Craniofacial and maxillofacial surgery in children and young adults*, Philadelphia, 2000, Saunders.
23. Posnick JC: Cleft orthognathic surgery: the isolated cleft palate deformity. In *Craniofacial and maxillofacial surgery in children and young adults*, Philadelphia, 2000, Saunders.
24. Posnick JC, Tompson B: Cleft-orthognathic surgery: complications and long-term results, *Plast Reconstr Surg* 96:255, 1995.
25. Wolford LM, Cooper RL: *Orthognathic surgery in the growing cleft patient and its effect on growth.* Presented at the American Association of Oral and Maxillofacial Surgeons Annual Scientific Sessions, Anaheim, September 1987, California. (abstract).
26. Wolford LM, Cooper RL, El Deeb M: *Orthognathic surgery in the young cleft patient and effect on growth*, St Louis, May 1990, Presented at the American Cleft Palate-Craniofacial Association Annual Meeting. (abstract).
27. Wolford LM, Cottrell DA: End-stage reconstruction in the complex cleft lip/palate patient. In Turvey TA, Vig KL, Fonseca RJ, editors: *Facial clefts and craniosynostosis: principles and management*, Philadelphia, 1996, Saunders.
28. Turvey TA, Vig KW, Fonseca RJ: Maxillary advancement and contouring in the presence of cleft lip and palate. In Turvey TA, Vig KL, Fonseca RJ, editors: *Facial clefts and craniosynostosis: principles and management*, Philadelphia, 1996, Saunders.
29. Broder HL: Psychosocial considerations in habilitation of patients with facial deformity: a developmental perspective. In Turvey TA, Vig KL, Fonseca RJ, editors: *Facial clefts and craniosynostosis: principles and management*, Philadelphia, 1996, Saunders.
30. Lo HJ, Hung KF, Chen YR: Blindness as a complication of Le Fort I osteotomy for maxillary disimpaction, *Plast Reconstr Surg* 109:688, 2002.
31. DeZutter A, Deconinck H, Rodesch G, et al.: Neuro-ophthalmic complication after maxillary surgery, *Bull Soc Belge Ophthalmol* 271:39, 1999.
32. Posnick JC, Dagys AP: Skeletal stability and relapse patterns after Le Fort I osteotomy fixed with miniplates: the unilateral cleft lip and palate deformity, *Plast Reconstr Surg* 94:924, 1994.
33. Posnick JC, Taylor M: Skeletal stability and relapse patterns after Le Fort I osteotomy using miniplate fixation in patients with isolated cleft palate, *Plast Reconstr Surg* 94:51, 1994.
34. Turvey TA, Bell RB, Tejera TJ, Proffit WR: The use of self-reinforced biodegradable bone plates and screws in orthognathic surgery, *J Oral Maxillofac Surg* 60:59, 2002.
35. Mason R, Turvey TA, Warren DW: Speech considerations with maxillary advancement procedures, *J Oral Surg* 38:752, 1980.
36. Watzke I, Turvey TA, Warren DW, Dalston R: Alterations in velopharyngeal function after maxillary advancement in cleft palate patients, *J Oral Maxillofac Surg* 48:685, 1990.
37. Hung KF, Chen PKT, Lo LJ, Yun C, Wang R: *Alteration of the velopharyngeal functions after rigid midface distraction*, Taipei, Taiwan, November 1999, Presented at the International Society of Craniofacial Surgery 8th International Congress. abstract.
38. Kopp VJ, Rosenfeld MH, Turvey TA: Intubation in the presence of a pharyngeal flap, *J Anesthesiol* 82:1063, 1995.

35

Revision Surgery for Cleft Malformations

NATASHA FÜRCHTGOTT, RAMON L. RUIZ, BERNARD J. COSTELLO

Clefting of the lip and palate represents a complex malformation of both the hard and soft tissues of the face. Children who are born with a cleft of the lip and/or palate experience several unique functional and esthetic challenges requiring an interdisciplinary approach.[1-6] To achieve the best outcomes, clinicians must take into consideration each child's speech, occlusion, facial appearance, self-esteem, and a number of other complex issues that arise during the child's growth and development. Successful reconstruction requires multiple surgical phases. Consequently, treatment that takes place during growth and development must be carried out with concern for the long-term biologic consequences. Thoughtful planning is formulated in order to provide the maximum long-term functional and esthetic benefit.[1,2] Surgeons caring for children with clefts must maintain a firm cognitive understanding of the three-dimensional anatomy of the cleft lip and palate malformation and the complex interplay that exists between surgical intervention and ongoing facial growth.

Various surgical procedures involved in staged reconstruction of cleft lip and palate have been described extensively in the literature. The American Cleft Palate–Craniofacial Association (ACPA) has developed parameters of care to facilitate the coordinated interdisciplinary treatment of individuals affected with cleft lip and palate deformities.[7] The ACPA document summarizes a management protocol that is centered on thoughtful timing of specific interventions based on the patient's dental, skeletal, speech, and psychologic development. Contemporary management involves several phases of surgery during infancy (cleft lip and palate repair) and early childhood (bone graft reconstruction of the cleft maxilla and alveolus) that are considered required operations in all cases of complete unilateral or bilateral cleft lip and palate. In addition to those primary stages of repair, most children will require additional procedures for treatment of secondary issues. Secondary reconstruction of cleft lip and palate may involve surgery for treatment of velopharyngeal dysfunction, bone graft reconstruction of clefts of the maxilla, treatment of residual skeletal disproportion and malocclusion, closure of palatal fistula, normalization of lip and nasal form, and prosthetic rehabilitation of the cleft dental gap. Although indications for each of the primary and secondary surgical undertakings are specific to each child, they must not be viewed as isolated events. Ongoing growth and development in concert with the secondary surgical effects must be considered. This chapter reviews aspects of secondary cleft lip and palate reconstruction that may be required after primary cleft lip and palate repair. The chapter provides a description of the contemporary philosophy based on the most current outcome data, and how this relates to the specific timing controversies of surgical intervention (Table 35-1).

Fistula Closure

A child born with cleft palate has as part of the congenital deformity a communication between the oral and nasal cavities. Successful surgical repair requires separation of the oral and nasal side soft tissues followed by reconstruction of the soft palate musculature and establishment of separate nasal and oral mucosal linings. The result is two-layer closure of the hard palate (nasal mucosa and oral mucosa) and three-layer closure of the soft palate (nasal mucosa, levator musculature, and oral mucosa). A residual abnormal oronasal communication, or fistula, after initial repair is a relatively frequent issue with many types of palate repair. Before deciding on a specific management approach to the residual fistula, it is important to define the clinical situation based on the patient's age, previous surgical history, functional impact, and exact location of the fistula.

The extent to which the cleft defect involves the primary and secondary palate must be determined. The primary palate consists of the anatomic structures anterior to the incisive foramen. The secondary palate consists of the anatomic structures between the incisive foramen and uvula. It follows that a complete cleft of the primary and secondary palate would therefore involve the maxilla, alveolus, hard palate, and soft palate. An isolated cleft palate involves the hard and

TABLE 35-1 Stages of Cleft Lip and Palate Reconstruction: Infancy Through Adolescence

Surgical Treatment	Age	Timing Considerations
Cleft lip repair	10-12 weeks	
Cleft palate repair	9-18 months	Exact timing of repair is based on child's speech-language age
Secondary palate surgery for velopharyngeal insufficiency	3-5 years	
Bone graft reconstruction of cleft maxilla and alveolus	6-9 years	Based on dental development
Orthognathic surgery	14-16 years for girls, 16-18 years for boys	
Dental implant placement	16-18 years	
Lip and nasal revision	After 5 years	Varies widely depending on clinical findings and psychosocial concerns; definitive nasal surgery usually delayed until adolescence

soft palates without affecting the alveolus (i.e., a complete cleft of the secondary palate). A cleft involving only the soft palate, and not the hard palate or alveolus is described as an incomplete cleft of the secondary palate. Even when a child is born with a complete cleft palate, affecting the primary and secondary palates, the primary palate repair involves closure of the secondary palate, or only those structures posterior to the incisive foramen. As such, the alveolus remains unrepaired in the traditional sequence, and this area is not referred to as a fistula, but rather unrepaired alveolus. Those patients that undergo gingivoperiosteoplasty have this area repaired at some point during the primary repairs—usually during the lip repair.

The goals of cleft palate repair during infancy are twofold: first, to establish complete "watertight" closure of the secondary palate for separation of the oral and nasal cavities, and, second, to repair the levator musculature to allow for optimal speech production. Repair of the skeletal maxillary alveolar cleft defect and its associated oronasal communication is not generally attempted at this stage. Many surgeons consider this alveolar defect part of the original cleft deformity that has been purposely left and therefore not a true fistula. Definitive repair of the anterior alveolar aspect of the cleft is instead incorporated into the bone graft reconstruction performed during midchildhood based on dental development.[5,6,8,9] Ideally, a child with a complete cleft palate will undergo palate repair (successful closure of the hard and soft palates) during infancy, followed by bone graft reconstruction of the maxilla and alveolus (or primary palate) with closure of the residual nasolabial fistula during the mixed dentition.

Unfortunately, residual palatal fistulas are occasionally encountered after the initial palate repair. The incidence of palatal fistula after single-stage palatoplasty varies greatly, with the reported rates from 0 to over 60%. The risk of fistula formation seems to be associated with the size (width) of the original cleft defect and the experience of the surgeon.[10-14] The type of repair used by the surgeon may also affect the fistula rate. Recent reports indicate that a two-flap palatoplasty technique is associated with the lowest rate (3.4%) of palatal fistula formation.[13] The Furlow double-opposing Z-plasty is, in most studies, associated with a significantly higher incidence of oronasal fistula.[5,12]

Overall fistula rate of 4.9% has been reported recently in a prospective, randomized, controlled clinical trial comparing outcomes of two different palatoplasty techniques.[12] However, most of these studies involved non-syndromic children and often have a number of selection criteria that do not represent the entire challenging population. Compliance with the postoperative restrictions is also a key factor. The most common location of residual palatal fistula occurrence after cleft palate repair is the junction of the hard and soft palates. This is followed by the anterior hard palate and incisive foramen region.[5,6,11,14] Understanding their functional impact is a key to understanding whether or not a repair will be necessary upon their presentation.

Indications for Fistula Repair and Timing of Surgery

Most fistulas are noted early in the postsurgical period after palate repair. Most are the result of local wound breakdown secondary to tension because of inadequate medial mobilization, vascular compromise, wound healing problems, trauma to the palatal flaps, inadequate suturing technique, hematoma formation leading to flap necrosis, patient/parent compliance, or other factors. Another time period when a palatal fistula may be encountered is during phase I (before bone graft) orthodontic treatment, especially if maxillary expansion is undertaken. There is disagreement about the causal relationship of orthodontic expansion and development of palatal fistula. Most experienced cleft surgeons believe that fistula defects discovered during maxillary expansion are small, preexisting oronasal communications and are not caused by orthodontic treatment. Small fistulas

present since infancy can be hidden within a narrow palate by collapsed maxillary segments and then become "uncovered" as the maxillary arch form is expanded by orthodontic or orthopedic means. Most are not major functional concerns, and can be addressed at the time of bone grafting or later.

The recommended timing of fistula closure may vary significantly and remains a controversial topic. Although early intervention is uncommon, some surgeons and cleft teams may advocate aggressive management with early closure of any fistula present after initial palate repair. We prefer to take a more long-range view of these problems and delay surgery for several years when possible (e.g., no functional speech and/or feeding-related issues). In infants the closure of a small (up to 4 mm), nonfunctional fistula can generally be deferred until later in childhood. In such cases fistula repair may be incorporated into future procedures such as pharyngeal surgery for velopharyngeal insufficiency (VPI) or bone graft reconstruction of the cleft maxilla and alveolus.

When a larger (>5 mm) fistula is present, there is a greater likelihood that functional concerns will be encountered, such as nasal air escape affecting speech, nasal reflux of food and liquids, and hygiene difficulties. When significant functional issues exist, earlier closure of the persistent fistula is indicated. As part of the decision-making process, surgeons must weigh the benefits of fistula repair against the negative effects of a second palatal surgery (involving stripping of mucoperiosteum) on maxillary growth. Another consideration in timing of fistula closure is the type of repair technique selected for repair. Attempts to close a fistula with local flaps or repeat palatoplasty may be undertaken during infancy and early childhood. On the other hand, in cases in which the use of a regional (e.g., tongue) flap may be preferable, the child must be old enough to cooperate with the perioperative regimen.

Operative Techniques for Closure of Palatal Fistulas

Repair of residual palatal fistulas using a number of different techniques after cleft palate repair has been described.[5,10,15-17] Current techniques used for fistula repair include local palatal flaps, modifications of the von Langenbeck and two-flap palatoplasty techniques, palatoplasty with incorporation of a pharyngeal flap, and the use of a tongue flap. Other regional flaps, including the buccal mucosal, buccinator myomucosal, temporalis muscle, and vascularized tissue transfers are less frequently used but have been described.[15,18-22] Recently, the use of acellular dermal matrix (ADM) as an interpositional barrier has been used as an adjunct to repairing fistulas under the premise that this material can aid in wound closure where there is extensive preexisting scarring and lack of healthy surrounding tissue. At this time, there is only Level III evidence that suggests that ADM use could prevent the formation or aid in the permanent repair of palatal fistulas.[23,24]

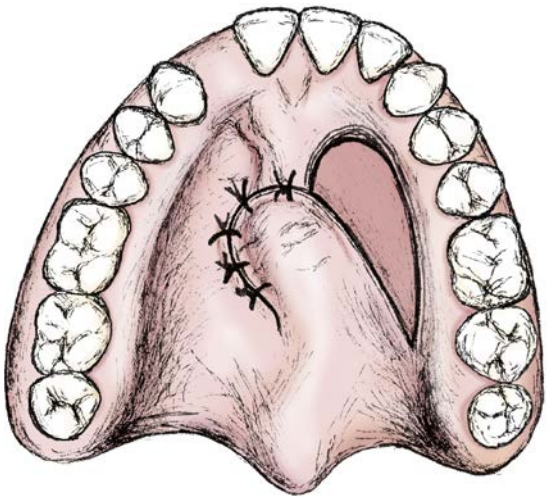

• **Figure 35-1** The use of a small, rotational flap for closure of a residual palatal fistula. This type of repair can have a high failure rate. Turnover flaps or sliding flaps are used to establish a nasal side closure, and a palatal mucosal flap is outlined. The random pattern, full-thickness mucoperiosteal flap is elevated and mobilized for coverage of defect. (From Ogle OE: The management of oronasal fistulas in the cleft palate patient, *Oral Maxillofac Surg Clin North Am* 14:553, 2002.)

One of the most frequently described procedures for closure of residual fistulas is the use of local soft tissue flaps created within the palatal mucosa and rotated over the defect for closure (Figure 35-1). The components of this approach are the creation of turnover flaps around the defect for nasal side closure, elevation of a palatal finger flap, and rotation of the flap for coverage of the defect. A significant area of exposed bone is left at the donor site, and this is allowed to heal by secondary intention. Unfortunately, this type of repair is useful only for very small palatal defects and is associated with a relatively high failure rate.[15] Small rotational flaps within palatal tissues that contain extensive scarring from prior surgical procedures are difficult to mobilize without residual tension and may have diminished blood supply, resulting in a less-than-ideal healing capacity and a potentially greater chance of wound breakdown. Our preferred approach to residual palatal fistulas involves the modification of one of the primary palate repair techniques, namely the Bardach (two-flap) or von Langenbeck procedure in conjunction with the use of acellular dermal matrix as an interpositional graft material.[5,25] These approaches allow adequate coverage of even large defects with the use of bulky soft tissue flaps, a layered repair of the nasal and oral sides, and a tension-free line of closure (Figure 35-2).

In addition, the amount of bone that is left exposed after the repair is minimal to none. This is because the vertical depth of the palatal vault translates into soft tissue extension medially, and the result is palatal soft tissue flaps that adequately cover the underlying bone with a layer of dead space between the palatal shelves and the oral mucosa lining. The Bardach palatoplasty is the authors' preferred method. The primary advantage of this approach is the ability to raise large soft tissue flaps, which can be mobilized easily and allow for visualization and tension-free closure of the nasal

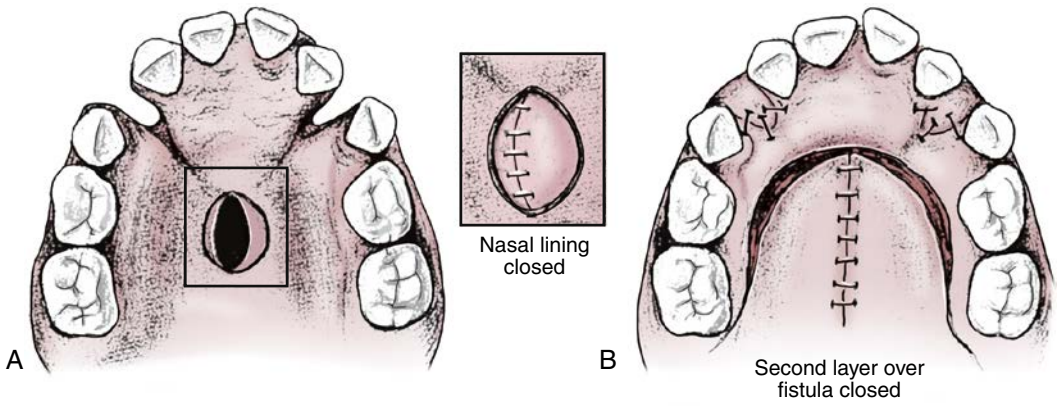

• **Figure 35-2** Modification of the two-flap palatoplasty technique for closure of a residual palatal fistula. **A,** Two large mucoperiosteal flaps are developed with dissection extended to a point posterior of the fistula defect. The nasal mucosa is repaired as a separate layer. **B,** Closure of the oral side. The midline is closed first using multiple sutures, and then the lateral incisions are reapproximated. (From Bardach J, Morris HL, eds: *Multidisciplinary management of cleft lip and palate,* Philadelphia, 1985, Saunders.)

mucosa. By comparison, one of the theoretic advantages of the von Langenbeck procedure is the creation of bipedicled flaps that maintain anterior and posterior blood supplies. Although the anterior pedicles do provide additional perfusion, they also result in less freely movable flaps with limited access and visualization of the nasal side tissues. When there is a much larger (>1.5 cm) defect, successful closure may dictate that the surgeon recruit additional soft tissue using a regional flap, such as a pharyngeal flap, facial artery myomucosal flap (FAMM), pedicled buccal fat or other local tissues.

Fistula defects within the posterior hard palate or soft palate may be addressed with the use of a modified palatoplasty procedure, as described earlier, in combination with a superiorly based pharyngeal flap. After the palatal flaps are developed and the nasal side dissection is complete, a pharyngeal flap is harvested. The pharyngeal flap soft tissue is then incorporated into the nasal side closure of the area where the fistula was present. With this technique a substantial amount of additional soft tissue can be recruited for tension-free repair of a large palatal defect. When the fistula is located within the anterior two-thirds of the hard palate and cannot be closed using local tissue with acellular dermal matrix interposed, then the procedure of choice for recruitment of additional soft tissue may be the anteriorly based dorsal tongue flap (Figure 35-3). First, the nasal side closure of the palatal defect is performed using turnover flaps with multiple interrupted sutures, if possible. Next the surgeon develops an anteriorly based tongue flap that is approximately 5 cm in length and approximately two-thirds the width of the tongue. The tongue flap is elevated along the underlying musculature and then inset using multiple mattress sutures for closure of the oral side approximately four-fifths of the way around the defect. The recipient bed within the tongue is closed primarily. After the initial surgery, the tongue flap is allowed to heal and primarily vascularize for approximately 2 weeks. Nasal fiberoptic intubation may be indicated for the second-stage procedure because the tongue is still sutured to the palate, restricting normal visualization of the airway. The flap is sectioned and the stump at the donor site is freshened and inset. The use of laterally or posteriorly based tongue flaps has also been presented in the literature.[26,27] In our opinion, an anteriorly based flap is better tolerated by most patients and allows for the greatest degree of tongue mobility, decreasing risk of tearing the flap from its palatal insertion.

Most fistulas can be closed with a modified palatoplasty technique and the use of ADM with or without the use of local flaps. However, the tongue flap can be of use for larger fistulas. It is particularly useful in those that are anterior as is the case in patients with a premaxilla that has been lost due to surgical misadventure or other issues. Another option is vascularized tissue using a microvascular flap. However, pedicle management in the mid-face is technique sensitive, and requires a microvascular surgeon with regular experience in this area for a successful survival of the flap.

Secondary Cleft Palate Surgery for Management of Velopharyngeal Dysfunction

The secondary palate is composed of a hard (bony) palate anteriorly and a soft palate or "velum" posteriorly. Within the soft palate the levator veli palatini muscle forms a dynamic sling that elevates the velum toward the posterior pharyngeal wall during the production of certain sounds. Other muscle groups within the velum, the tonsillar pillar region, and the pharyngeal walls also affect resonance quality during speech formation (Table 35-2). The combination of the soft palate and pharyngeal wall musculature jointly form what is described as the velopharyngeal mechanism (Figure 35-4, *A*). The velopharyngeal mechanism functions as a complex sphincter valve to regulate airflow between the oral and nasal cavities and create a combination of orally based and nasally based sounds. Children born with a cleft

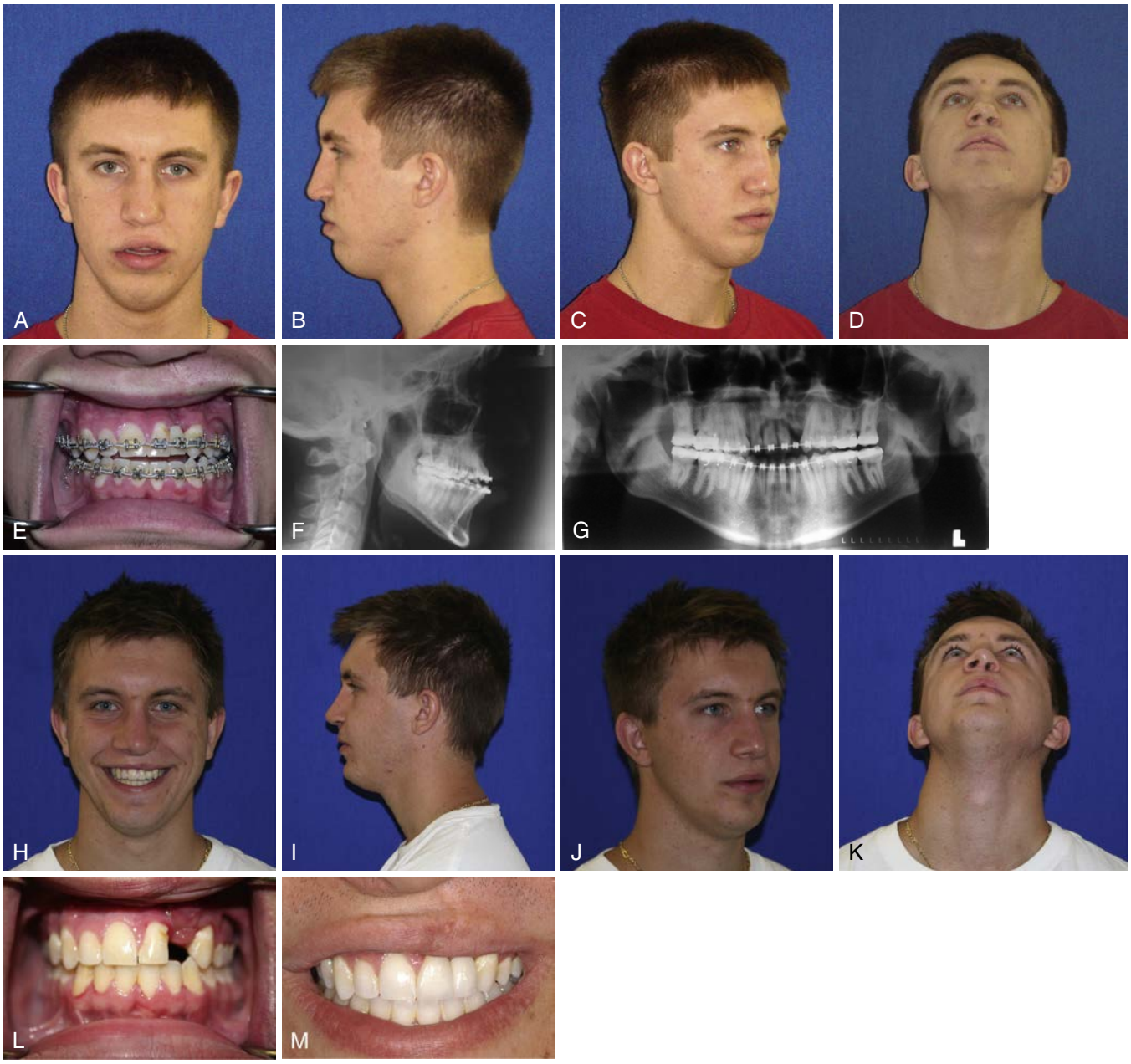

• **Figure 35-3** An 18-year-old male born with a left-sided unilateral cleft lip and palate is shown before and after a number of revision procedures just before completion of his treatment. **A-G,** Multiple views with the typical imbalances seen from both congenital malformation and iatrogenic growth deformity. He exhibits maxillary hypoplasia, mild mandibular asymmetry, retrogenia, notching of the vermilion, asymmetry of the dorsum of the nose and cartilaginous nasal tip, asymmetry of the nares, poor nasal base support, and septal deviation. He lacks a left maxillary lateral incisor and is planning to have an implant placed at this site. His preoperative lateral cephalometric radiograph and panoramic tomogram show rather mild, but significant, skeletal discrepancies in the sagittal plane and a lack of bone at the maxillary/alveolar cleft site. **H-M,** He underwent orthognathic surgery to address multiple planes of occlusion and an anterior open bite, including a Le Fort I osteotomy in three pieces, inferior turbinate reductions, and a genioplasty. He also underwent a complex secondary rhinoplasty, which includes nasal bone osteotomies, septoplasty, sculpting of the upper and lower lateral cartilages, and a columellar strut graft for improved projection and support. His postoperative views show the results shortly following additional bone grafting for implant reconstruction at the cleft site.

TABLE 35-2 Muscle Groups Contributing to the Velopharyngeal Mechanism

Muscle	Insertion	Origin	Function
Musculus uvulus	Mucous membrane of soft palate	Palatal aponeurosis	Velar extension
Tensor veli palatini	Soft and hard palates	Medial pterygoid plate	Opens auditory tube
Salpingopharyngeus	Palatopharyngeal aponeurosis	Torus tubarius	Motion of the lateral walls
Superior constrictor	Medial pharyngeal raphe	Velum; medial pterygoid plate	Posterior and lateral wall sphincteration
Levator veli palatini	Soft palate	Temporal bone	Elevation of the velum
Palatopharyngeus	Soft palate aponeurosis	Pharyngeal wall	Adduction of posterior pillars; sphincteration of velum
Palatoglossus	Tongue	Tongue	Retract tongue; antagonistic to the levator during speech

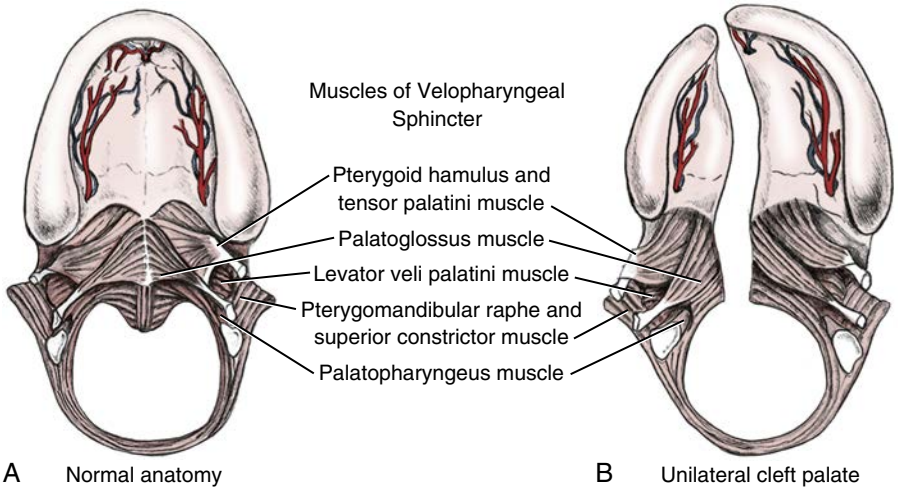

• **Figure 35-4** Anatomy of the velopharyngeal mechanism. **A,** Normal anatomy. **B,** Anatomic distortions associated with complete cleft of the primary and secondary palate. Note abnormal insertions of levator veli palatini muscle along the posterior edge of the hard palate.

palate have, by definition, a malformation that dramatically affects the anatomic components of the velopharyngeal mechanism. Clefting of the secondary palate causes division of the musculature of the velum into separate muscle bellies with abnormal insertions along the posterior edge of the hard palate (Figure 39-4, *B*). The initial palatoplasty is, as described earlier, not simply carried out for closure of the palatal defect (oronasal communication) itself, but is aimed at addressing the underlying muscular anatomic deformity. During two-flap palatoplasty, care must be taken to sharply separate the levator muscle bellies off the palatal shelves, realign them, and establish continuity in order to create a functioning palatal-levator muscle sling. Some describe this primary repair of the palatal musculature as an "intravelar veloplasty." Although this description helps to articulate the importance of addressing the levator muscle, it may confuse some clinicians by suggesting that muscle repair or "intravelar veloplasty" is a separate procedure. The degree of aggressive retropositioning of the levator musculature can be variable among surgeons. Irrespective of the type of cleft palate repair technique employed (e.g., von Langenbeck, Bardach, Furlow), meticulous release of abnormal levator muscle insertions with velar muscle reconstruction must be incorporated as a critical element of the surgical procedure. Most children who undergo successful cleft palate repair during infancy (9 to 18 months) will go on to develop speech that is normal or demonstrate minor speech abnormalities that are amenable to speech therapy. In a smaller segment of this patient population, the velopharyngeal mechanism will not demonstrate normal function despite surgical closure of the palate. [28] VPI is defined as inadequate closure of the nasopharyngeal airway port during speech production. The exact cause of VPI after "successful" cleft palate repair is a complex problem that remains difficult to define and quantify. Inadequate surgical repair of the musculature is one potential cause of VPI. The role of postsurgical scarring and its impact on muscle function and palatal motion is poorly understood. The theoretic advantages of using a Furlow double-opposing Z-plasty procedure for the initial palate repair include better realignment of the palatal

muscles and lengthening of the soft palate. These benefits may be negatively balanced by a velum that demonstrates less mobility secondary to scarring associated with two separate Z-plasty incisions. Even muscles that are appropriately realigned and reconstructed may fail to heal normally and function properly because of congenital defects having to do with their innervation.

In addition, a repaired cleft palate is only one factor contributing to velopharyngeal function. Nasal airway dynamics and abnormalities related to vocal tract morphology and lateral and posterior pharyngeal wall motion may contribute to velopharyngeal dysfunction. Certainly, these other structures may also play a positive role in compensating for palatal deformity. For example, a short, scarred soft palate that does not elevate very well may be compensated for by recruitment and hypertrophy of muscular tissue within the posterior pharyngeal wall ("activation of Passavant's ridge").[29-31] The audible nasal air escape that results in hypernasal speech associated with VPI is perhaps the most debilitating consequence of the cleft palate malformation. A variable number of children with VPI after palatoplasty will go on to require management involving additional palatal and pharyngeal surgery.[28] The percentage is quite variable and not universally agreed upon, but generally is approximately 20% to 40% for non-syndromic patients. Patients with syndromes do have higher rates of VPI, but these are generally due to other contributing factors such as cognitive status or neural innervation. Other studies claim much lower rates of VPI, but the measurement and reporting is not uniform or validated in these published studies. Without a truly objective measure of speech in this patient population, it is difficult to know the true incidence of VPI after primary palate repair.

Left untreated, nasal air escape—related resonance problems will lead to compensatory speech abnormalities and articulation errors. Warren's elegant aerodynamic demands theory provides the best explanation of what occurs with severe VPI. [32] His theory states that nasal air escape due to inadequate velopharyngeal closure will cause the patient to articulate pressure consonants at the level of the larynx or pharynx instead of within the oral cavity. These abnormal, compensatory misarticulations further complicate problems with speech formation and decrease speech intelligibility in patients with cleft palate–related VPI.

Timing and Indications for Surgery

After the initial cleft palate repair, periodic evaluations are critical to assess the speech and language development of each child. Typically this involves a standardized screening examination performed by a speech and language pathologist as part of a visit to the cleft palate team. In patients with VPI, more detailed studies including the use of videofluoroscopy and nasopharyngoscopy may be indicated. Videofluoroscopic studies are used to radiographically examine the upper airway with the aid of an oral contrast material. These techniques allow dynamic testing of the velopharyngeal mechanism with views of the musculature in action. In addition, details of the upper airway anatomy including residual palatal fistulas can be visualized and their contribution to speech dysfunction evaluated. For a videofluoroscopy study to be of diagnostic value, it must include multiple views of the velopharyngeal mechanism. The speech pathologist should be present to verbally test the patient in the radiology suite.

Nasopharyngoscopy using a small, flexible, fiberoptic endoscope is routinely used for the evaluation of patients with VPI. Nasopharyngoscopy allows for direct visualization of the upper airway, and specifically the velopharyngeal mechanism, from the nasopharynx. This technique avoids radiation exposure associated with videofluoroscopy but requires preparation of the nose with a topical anesthetic, skillful maneuvering of the scope, and a compliant patient. Once the endoscope is inserted, observations of palatal function, airway morphology, and pharyngeal wall motion are made while the patient is verbally tested by the speech pathologist.[5] The opportunity for direct visualization of the velopharyngeal mechanism in action during speech formation provides information that is critical to clinical decision-making related to secondary palatal surgery in cases of confirmed or suspected VPI. The pattern of closure and the characteristics of any abnormal closure patterns during certain speech sounds may help tailor treatment, and tends to be valuable information to optimize speech.

Secondary palatal surgery in young children is indicated when VPI causes hypernasal speech on a consistent basis and is related to a defined anatomic problem.[33-35] The timing of surgery for VPI remains controversial. Recommendations typically range from 3 to 5 years of age at the earliest. In young children, obtaining enough diagnostic information to make a definitive decision regarding treatment is often difficult. In such a young age group, variables such as the child's language and articulation development and a lack of compliance during the speech evaluation compromise the diagnostic accuracy of preoperative assessments.[36-38]

By the time a child reaches 5 years of age, compliance with nasopharyngoscopy is better, and there is enough language development to allow for a more thorough perceptual speech evaluation. These factors allow for more definitive conclusions regarding the status of velopharyngeal function or dysfunction in the child with a repaired cleft palate. It is also important to note that decisions regarding advisability of surgery for VPI are usually made after close collaboration with an experienced speech and language pathologist. The surgeon and speech pathologist should make this decision together and try to tailor the treatment to that particular child's needs.

VPI and hypernasal speech may also be encountered in older patients at the time of orthognathic surgery for treatment of cleft-related maxillary deformity. Approximately 25% of patients who have undergone cleft palate repair during infancy will require additional surgery for treatment of mid-facial deficiency during adolescence when they are nearing skeletal maturity.[39] This usually involves mid-face

advancement at the Le Fort I level with or without mandibular surgery to restore skeletal proportions, treat malocclusion, and improve facial balance. Advancements of the maxilla in patients with a repaired cleft palate may worsen existing VPI or may be the cause of new-onset VPI.[40-42] A minority of patients with borderline velopharyngeal closure preoperatively will develop hypernasal speech even after relatively small degrees of maxillary advancement. Because predicting exactly how each patient will respond to maxillary advancement is difficult, formal speech assessment and detailed counseling of the patient and family regarding the possibility for development of postoperative VPI before any cleft orthognathic surgery is undertaken is recommended. Fortunately, most patients who develop VPI after maxillary advancement will recover adequate velopharyngeal closure without the need for additional palatal surgery within approximately 6 months. It is important to note that no significant difference has been convincingly documented when one looks at the speech outcomes after use of distraction osteogenesis techniques for mid-face advancement versus conventional orthognathic surgery.

In a study by Turvey and Frost, pressure-flow studies were used to examine velopharyngeal function after maxillary advancement in patients with repaired cleft palate.[43] In their study group, patients with adequate velopharyngeal closure before surgery demonstrated three differing responses after mid-facial advancement: (1) adequate velopharyngeal closure after surgery, (2) deterioration with inadequate velopharyngeal function after surgery followed by a gradual improvement and recovery of normal closure over a 6-month period, and (3) inadequate velopharyngeal closure after surgery without improvement, necessitating pharyngeal flap surgery. When maxillary advancement does result in clinically significant VPI, additional corrective surgery should be delayed at least 6 months. In most cases postoperative neuromuscular adaptation allows the velopharyngeal mechanism to recover, and the patient returns to a baseline level of function with resolution of hypernasal speech without the need for additional operative intervention.

Operative Techniques

Contemporary surgical management of VPI generally involves one of three types of procedures: (1) the superiorly based pharyngeal flap, (2) palate rerepair, and (3) the sphincter pharyngoplasty. The use of autogenous and alloplastic implants for augmentation of the posterior pharyngeal wall has been described but is not a commonly used procedure today. A resurgence of posterior wall augmentation has been attempted by some utilizing fat grafting with the Colemen technique, but comparative data are lacking. Some surgeons have advocated the use of a second palatoplasty operation as an attempt at palatal lengthening in the patient with VPI; however, limited data exist to broadly support this as a preferred technique. The superiorly based pharyngeal flap remains the standard approach for surgical management of VPI after palate repair. The procedure was initially described by Schoenborn in 1876.[44-46] Surgical maneuvers are directed at recruiting tissue by developing a superiorly based soft tissue flap from the posterior pharyngeal wall (Figure 35-5). The soft palate is then divided along the midsagittal plane from the junction of the hard and soft palates to the uvula, and the flap from the posterior pharyngeal wall is inset within the nasal layer of the soft palate. As a result, a large nasopharyngeal opening that cannot be completely closed by the patient's velopharyngeal mechanism is converted into two (right and left) lateral pharyngeal ports. Closure of these ports is easier for the patient to accomplish as long as adequate lateral pharyngeal wall motion is present. When randomly applied to patients with VPI, the superiorly based pharyngeal flap procedure is effective 80% of the time.[47] When the flap is applied using careful

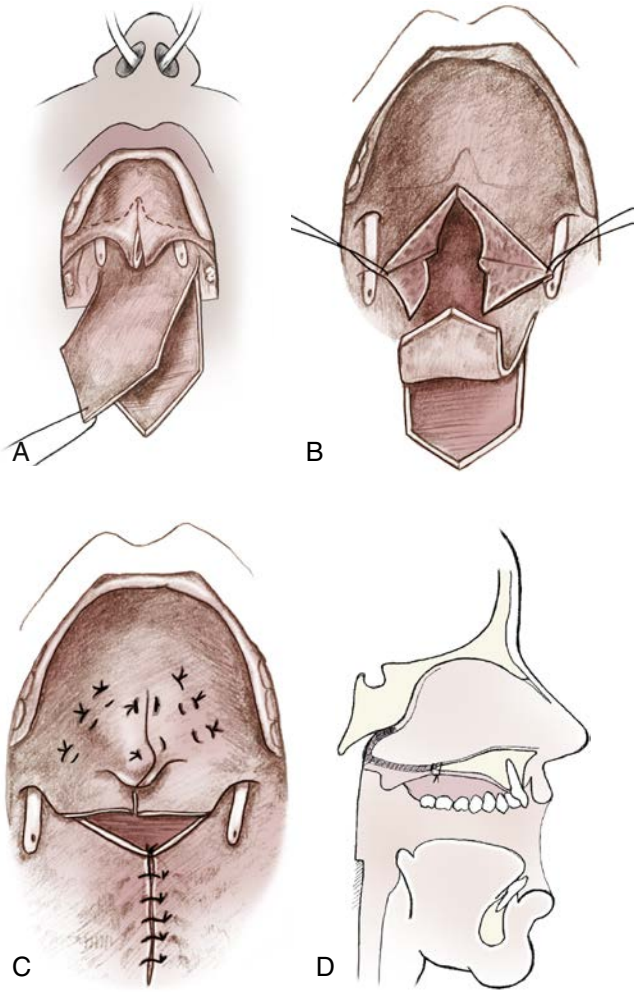

• **Figure 35-5** Illustration of superiorly based pharyngeal flap operative procedure. **A,** Creation of superiorly based flap of posterior pharyngeal wall soft tissues. The pharyngeal flap is developed and elevated off the prevertebral fascia. The soft palate is divided with a midline incision from the uvula to the junction of the hard and soft palates. **B,** Soft palate oral, nasal, and muscle layer dissection in preparation for flap inset. Nasopharyngeal airways are placed to help size each lateral pharyngeal port. **C,** The flap is sutured into the nasal side of the soft palate before the nasal side is repaired and the oral mucosa and underlying musculature are repaired. **D,** Sagittal view demonstrating appropriate vertical level of flap inset.

preoperative objective evaluations, success rates as high as 95% to 97% have been reported.[48,49] Shprintzen and colleagues have advocated custom tailoring of the pharyngeal flap width and position based on the particular characteristics of each patient as seen on nasopharyngoscopy.[47,50] The high overall success rate and the flexibility to design the dimensions and position of the flap itself are advantages of the superiorly based pharyngeal flap procedure. The disadvantages of the pharyngeal flap procedure are primarily related to the possibility of nasal obstruction resulting in mucous trapping and postoperative obstructive sleep apnea (OSA). Inferiorly based pharyngeal flaps for management of VPI are rarely used. Previous reports have documented increased morbidity without better speech outcomes associated with inferiorly based flaps.[51] In addition, inferiorly based flaps tend to cause downward pull on the soft palate after healing and contracture of the flap. The result may be a tethered palate with decreased ability to elevate during the formation of speech sounds.

The dynamic sphincter pharyngoplasty is another option for the surgical management of VPI. This procedure was described by Hynes in 1951 and since has been modified by a number of other authors.[52-57] The operative procedure involves the creation of two superiorly based myomucosal flaps created within each posterior tonsillar pillar (Figure 35-6). Each flap is elevated, with care taken to include as much of the palatopharyngeal muscle as possible. The flaps are then attached and inset within a horizontal incision made high on the posterior pharyngeal wall. The goal of this procedure is the creation of a single nasopharyngeal port (instead of the two ports of the superiorly based pharyngeal flap) that has a contractile ridge posteriorly to improve velopharyngeal valve function. The main advantage of the sphincter pharyngoplasty over the superiorly based flap is the perceived lower rate of complications related to nasal airway obstruction as described earlier.[58-60] Despite this perceived advantage, there is no evidence that

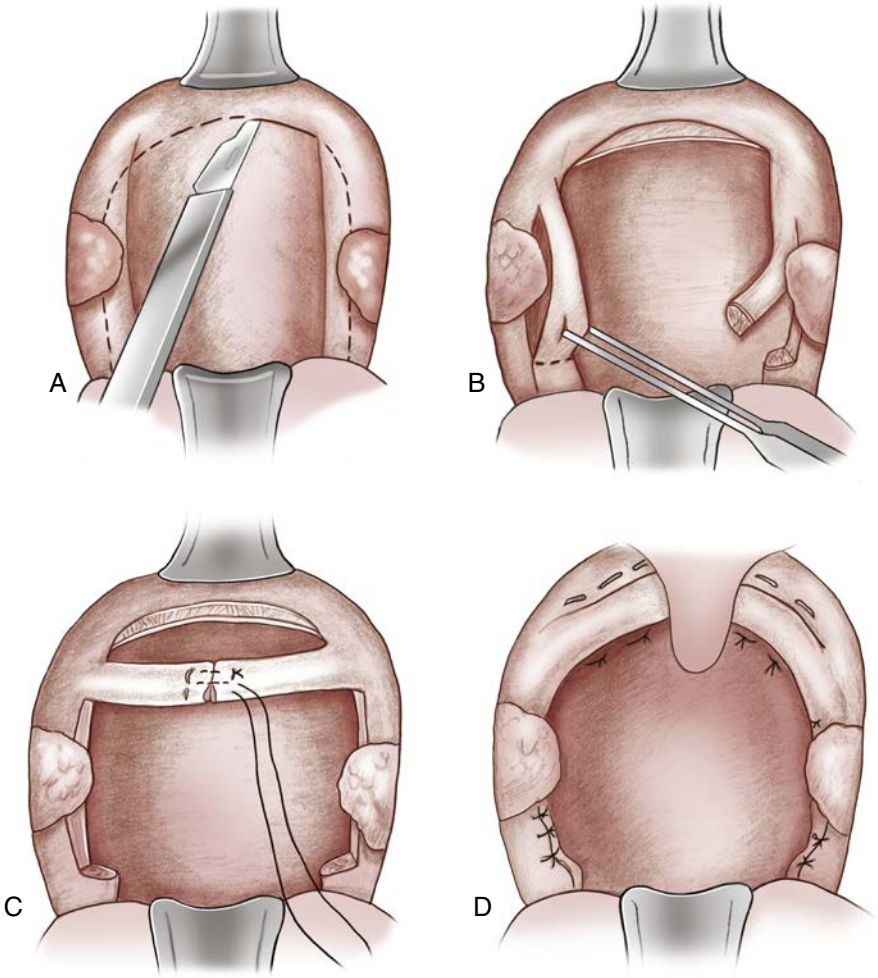

• **Figure 35-6** Pharyngoplasty procedure. **A,** Incision of the posterior pharyngeal wall and the posterior tonsillar pillars. **B,** Elevation of bilateral myomucosal flaps within the tonsillar pillars. Care is taken to include palatopharyngeus muscle. **C,** The mobilized flaps are then sutured to each other at the midline. **D,** Closure is then achieved by insetting the joined flaps within the posterior pharyngeal wall incision. The donor site of each flap is also closed with interrupted sutures.

pharyngoplasty procedures achieve superior outcomes in the resolution of VPI or decreased complications. Also, the use of a sphincter pharyngoplasty technique may be associated with increased scarring along the tonsillar pillar region. Some advocate its use to avoid the uncommon complication of OSA, but few studies exist examining the true incidence of this complication.

In the past, augmentation of the posterior pharyngeal wall has been attempted to facilitate closure of the nasal airway. Various autogenous and alloplastic materials have been used, including local tissue, rib cartilage, injections of Teflon, silicon, Silastic, Proplast, fat, and collagen.[61,62] Improvement in speech after augmentation of the posterior pharyngeal wall is unpredictable. Problems with migration or extrusion of the implanted material and an increased rate of infection add to the problems with these techniques. For these reasons, pharyngeal wall implants or augmentation techniques are rarely used today.

Some surgeons advocate the use of a revisional palatoplasty instead of a pharyngeal flap or pharyngoplasty procedure in the management of patients with VPI after cleft palate repair in infancy.[63] Some experience has shown this to be effective in a select group of patients who may have had incomplete or less aggressive muscular repairs. The technique can be performed using either a double-opposing Z-plasty or a two-flap palatoplasty with radical retropositioning of the levator musculature. Unfortunately, the anticipated benefits of these second palatoplasties have not, as of yet, been objectively established in broad populations. The clinician must consider the disadvantages of this type of surgical procedure and weigh them against potential benefits. The double-opposing Z-plasty procedure requires a more aggressive dismantling of the palate than what is required during a conventional pharyngeal flap procedure. The result may be a slightly longer palate but one with more extensive scarring and less physiologic movement. Another consideration is the significantly higher rate of fistula formation associated with this type of repair. This can be alleviated with the use of acellular dermal matrix as an interpositional graft material. Comparative studies with high levels of evidence are still lacking.

Complications Related to Surgical Procedures for Velopharyngeal Insufficiency

Surgery involving airway structures is always associated with the potential for complications related to postoperative hemorrhage and edema. As a result, patients who undergo attachment of a pharyngeal flap benefit from admission to the surgical intensive care unit or other observation setting with continuous airway monitoring during the first 24 hours after surgery. This type of setting permits the rapid recognition and prompt management of any complication that may lead to airway compromise. Of all the procedures related to cleft care, the pharyngeal flap and sphincteroplasty operations carry the greatest risk for early airway compromise. Airway compromise is not common but requires swift management to avoid life-threatening consequences.

Long-term postoperative complications related to the superiorly based pharyngeal flap are frequently associated with problems related to increased airway resistance. Insertion of a pharyngeal flap is designed to decrease the size of the nasopharyngeal airway, facilitate velopharyngeal closure, decrease nasal air escape, and make speech more intelligible. At the same time the procedure may create a pathologic level of upper airway obstruction that leads to new problems. Patients who undergo pharyngeal flap surgery may start snoring. Snoring itself does not represent any significant pathophysiology but may concern parents or significant others who observe the patient during sleep. When the degree of upper airway resistance is more severe, the result may be postoperative OSA. OSA is defined as cessation of breathing during sleep secondary to upper airway obstruction. OSA disrupts the sleep cycle, compromises effective oxygenation, and can cause behavioral changes and daytime somnolence in affected individuals. Left untreated, OSA is associated with severe cardiac and pulmonary consequences.

When OSA is suspected in a child who has previously undergone a pharyngeal flap procedure, a formal workup including nasopharyngoscopy and a sleep study (polysomnography) is indicated. Care should be taken to evaluate the entire airway in order to determine the level of the obstruction. Surgeons may initially assume that the airway obstruction is related to the flap only to discover that a more significant issue exists somewhere else in the airway. Often a thorough clinical evaluation yields abnormal findings that contribute to the problem of OSA at multiple levels of the upper airway. Because of the potential complexity of the clinical problem, the decision to modify or take down a pharyngeal flap in a child with OSA must be made only after discussions among the surgeon, sleep specialist (e.g., pediatric otolaryngologist, neurologist, or pulmonologist), and speech and language pathologist. Of interest, many adolescent or adult patients who have had pharyngeal flap placement during childhood will tolerate surgical division of the flap without a recurrence of severe VPI or hypernasal speech. On the rare occasion when VPI does recur after flap take-down, interval treatment with a prosthetic device such as a palatal lift appliance for a minimum of 6 months should be considered before one embarks on any further palatal surgery. Palate rerepair may be an option in this patient population, but the incidence of sleep apnea after this procedure is not well documented as of yet.

Management of the Submucous Cleft Palate

A submucous cleft palate (SMCP) is another form of the congenital cleft palate malformation in which the overlying mucosal layer is intact but the underlying soft palate musculature is divided. As described by Calnan, the classic clinical

findings with an SMCP are a triad of bifid uvula, hard palate bony notch, and separation along the median raphe of the soft palate especially during elevation of the velum.[64] Presentations with less than this classic triad can be considered occult forms of SMCP. When an SMCP is present, as in a complete cleft of the secondary palate, the levator muscle is clefted in the midline and abnormally inserts into the posterior edge of the hard palate. The primary functional concern related to SMCP is the possibility that the patient will develop VPI and resultant hypernasal speech. Despite this concern, the majority of patients with an SMCP will not require surgical intervention. In fact, less than 44% of patients will actually remain completely asymptomatic until later in childhood.[65] The bifid uvula is the most easily detected feature of the SMCP triad of clinical findings. However, a bifid uvula may also be observed in the absence of other features of submucous clefting (e.g., notched hard palate, velar separation, hypernasality). In fact, the incidence of bifid uvula is approximately 1:80, whereas the incidence of SMCP is 1:280.[66] Previous investigation has suggested a connection between the isolated finding of a bifid uvula and velopharyngeal dysfunction when otherwise asymptomatic patients were evaluated using a nasopharyngoscopy.[67] As a result, the clinical finding of an isolated bifid uvula may be considered an indicator of increased risk for VPI in a patient who is to undergo adenoidectomy. This underscores the value of a thorough clinical evaluation and the importance of presurgical speech evaluation and family counseling regarding the potential risks of postsurgical VPI. A smaller percentage of children have an occult SMCP. Surgical consultation is often requested once VPI-related speech difficulties are noted during childhood speech development or after surgical intervention (e.g., adenoidectomy).

Prior reports have attempted to describe characteristic facial features, cephalometric findings, and speech studies that lead to a presumptive diagnosis of SMCP.[68] The vast majority of patients with an SMCP will require either no treatment or speech therapy only. Surgical intervention is not undertaken simply because the diagnosis of SMCP is made. Speech is closely monitored during childhood with interval speech evaluations, and surgery is reserved only for those cases with VPI not amenable to speech therapy. The specific surgical procedure used to manage submucous cleft–related VPI varies depending on the preference of the surgeon and speech pathologist. Several early procedures emphasized exploration of the soft palate through a limited midline incision with repair of the levator muscle. Contemporary methods primarily involve the use of a standard palatoplasty (e.g., two-flap, pushback, or Furlow) and repair of the velar musculature, with or without a simultaneous pharyngeal flap procedure, or the use of a sphincter pharyngoplasty. Controversy exists regarding which procedure results in the best outcome. It has been suggested that correcting the anatomic deformity associated with SMCP with a palatoplasty should be reserved for patients with a small gap between the velum and posterior pharyngeal wall. Those patients with a larger gap would theoretically benefit from mobilization of a posterior pharyngeal flap or augmenting the posterior pharyngeal wall via a sphincter pharyngoplasty in an attempt to eradicate hypernasality in a single operation. Due to significant variability in methods of speech outcome assessment, there is not enough evidence to support one technique over the other.[69]

Bone Graft Reconstruction of the Cleft Maxilla and Palate

Approximately 75% of all orofacial clefts will involve the maxilla.[5] Despite successful lip repair and closure of the hard and soft palates during infancy, a residual nasolabial fistula and bony cleft defect that involves the alveolar ridge, maxilla, and piriform rim will remain. These residual deformities are addressed by secondary bone grafting performed during the mixed dentition stage of middle childhood (6 to 9 years of age). The objectives of bone graft reconstruction of the cleft maxilla are to establish adequate bony matrix for eruption of the permanent cuspid tooth, close any residual alveolar oronasal communication, establish bony continuity of the maxillary ridge, and improve the underlying bony support of the nasal base. In the case of bilateral cleft lip and palate, an added benefit of bone graft reconstruction is stabilization of a mobile premaxillary segment. The details and technical considerations of these procedures are discussed in detail separately within this volume. Occasionally, additional bone may be helpful for dental implant reconstruction and/or esthetic considerations in the mid-face. Bone can be obtained from the ramus, chin, zygoma, rib, iliac crest, or other sources. Bone morphogenic protein has also been utilized to facilitate these reconstructions, but is not approved for children by the FDA.

Orthognathic Surgery for Treatment of Mid-facial Deficiency

Patients who underwent cleft palate repair during infancy often exhibit some degree of maxillary growth restriction. This disproportionate jaw growth is the biologic consequence of prior surgical intervention and is not related to the congenital cleft deformity in most cases. Previous authors have reported a 25% incidence of maxillary hypoplasia that is severe enough to produce a clinically significant dentofacial deformity with negative effects on speech and occlusion.[5,6,18,39] The successful treatment of these secondary skeletal deformities frequently requires protocols that include orthognathic surgery in conjunction with a final phase of orthodontic mechanics. Simultaneous bone grafting can be used for contouring the dysmorphic skeletal structures. Additionally, the coordinated closure of cleft dental gaps or fistulas in the maxilla can sometimes be coordinated with the orthognathic surgical procedures. The details of these procedures are discussed in detail in the chapter dealing with orthognathic surgery for patients with clefts.

Revision Surgery for Cleft Lip and Nasal Deformities

Reconstruction of the Cleft Nasal Deformity

Congenital clefts that involve the lip, nose, and underlying cartilaginous and skeletal structure will result in a complex three-dimensional deformity of the nasal complex that affects both form and function.[70,71] In the case of a complete unilateral cleft, the typical nasal deformity is characterized by splaying of the alar base, unilateral inferior displacement of the alar base, deviation of the nasal tip, and irregularity of the caudal nasal septum. Abnormal fibrous insertions and relationships exist between the lateral crus of the lower lateral cartilage and the lateral piriform rim on the cleft side. At the time of the initial lip repair, nasal deformity can be addressed through primary nasal reconstruction. The approach includes dissection along the lower lateral cartilage separating the cartilage from overlying skin and sharp release of fibrous insertions along the piriform rim so that the nares can be repositioned in an attempt to restore symmetry. Despite effective primary cleft lip and nasal repair during infancy, most patients will demonstrate enough residual nasal dysmorphology and/or chronic obstructive nasal breathing to require secondary surgery for treatment of the cleft-associated nasal deformity. The timing of cleft nasal revision also remains somewhat controversial. Some surgeons take a more aggressive approach and undertake extensive nasal reconstruction during early childhood. The authors' philosophy is to delay the definitive cleft rhinoplasty when possible until the nasal complex has nearly achieved its mature size.

If the patient's reconstructive treatment plan also requires maxillary advancement, then nasal surgery is usually delayed until at least 6 months after the orthognathic procedure. This allows for a more predictable outcome and long-lasting improvement in nasal function and facial esthetics. Early surgery is reserved for individuals with severe airway or nasal airflow problems. An additional consideration must be potential psychosocial consequences and self-esteem issues that arise (e.g., teasing at school). When indicated, early nasal surgery can go forward after bone graft reconstruction of the maxilla so that a stable bony foundation along the piriform rim and nasal base exists first.

Secondary cleft-nasal reconstruction will often require dorsal reduction, upper and lower lateral cartilage sculpting, columellar strut grafting, and lateral nasal osteotomies. Cartilage grafting is a critical component of the final nasal reconstruction and is used for augmentation of the dysmorphic lower lateral cartilage as well as improvement of nasal tip projection.[5,72,73] Several donor sites may be considered including auricular cartilage, nasal septum, and rib cartilage. Ear cartilage is useful when augmentation of hypoplastic cleft-side lower lateral cartilage is required. Septal cartilage is most easily accessible and provides an excellent scaffold for repositioning of the lower lateral cartilages and for improvement of nasal tip symmetry and projection. Unfortunately, many patients seeking definitive nasal reconstruction have undergone previous septal cartilage harvests. In many of these patients, insufficient quality and quantity exist for a second septal cartilage graft. In these cases the use of costochondral cartilage is preferred. Rib cartilage provides adequate amounts of graft material but requires a distant donor surgical site with potential morbidity. We have found this type of cartilage graft to provide excellent strength for straightening the nasal tip and alar complex. Several key enhancements include improvement of the supratip break with increased tip definition and better symmetry. These techniques are best carried out through an open rhinoplasty.[5] A transcolumellar incision is combined with marginal incisions to provide wide access and direct visualization of the nasal dorsum, upper and lower lateral cartilages, and nasal septum.

A similar rationale is applied when considering the timing of secondary nasal reconstruction in the bilateral cleft lip patient, but the specific dysmorphology addressed is somewhat different. Generally, nasal asymmetry is less problematic, and the dysmorphology is characterized by deficient columella length. Previous literature has focused on the lengthening of the columella through the use of banked forked flaps or primary columella lengthening using soft tissue flaps from the floor of the nose and with alar flaps.[74,75] Unfortunately, these types of surgical procedures often result in a distorted columellar-labial angle, excessive scars that may extend onto the nasal tip, and additional distortion of the broad nasal tip. We find that the approach described by Posnick using septal cartilage or costochondral strut grafts attached to the caudal nasal septum and lower lateral cartilages yields the most natural-looking results.[5,6] The objective is treatment of the underlying cartilaginous anatomy with stretching of the overlying soft tissue envelope, instead of direct surgical manipulation of the columella skin (Figure 35-7).

Secondary Surgery for Cleft Lip Scar Revision

Even when the initial cleft lip repair procedure is considered successful, the majority of children will benefit from an additional lip revision at some point.[4,76] The majority of publications are retrospective cohort studies or case series. Although revision procedures are often viewed as optional phases of cleft lip reconstruction, surgeons should advise families of this likelihood. As a child grows, the hard and soft tissues of the maxillofacial complex grow and change, and the repaired lip is affected. Ongoing growth often makes it difficult to predict which children will benefit from additional lip surgery. A child's lip may initially look satisfactory and over time demonstrate unfavorable changes necessitating revision. On the other hand, favorable changes may occur during the healing process that actually improve the appearance of the repaired cleft lip. At approximately 8 to 10 weeks after surgery, significant lip contracture may be seen during the fibroblastic phase

of healing. The result may be vertical shortening of the repaired cleft side that will seemingly require further surgery. Often, if the same child is reevaluated after 6 months or later, after additional wound maturation, they will demonstrate very good lip esthetics and not be considered a candidate for revision.

It can be very challenging to address some of these postoperative deformities. Clinically, the consequences of poor technique or abnormal wound healing can be seen as cutaneous roll and vermilion discontinuities with medial notching, a vertically short or elongated cleft-side lip element, hypertrophic scarring, transverse hatch marks from sutures, shifting of the Cupid's bow, abnormal upper lip animation, or an asymmetric fullness (muscle bulge) indicating an inadequate reapproximation of the muscular layer during the initial repair.[77] Esthetic goals for lip repairs include symmetry, muscular continuity, philtral length and shape, presence of a medial tubercle, fullness of the vermillion, and continuity of the white roll. Lip scar revisions may consist of small "touchups" or require total reconstruction of the lip deformity.

Ideally, only one lip scar revision is undertaken, when the child is between the ages of 5 and 15 years. The procedure is staged for as late in childhood as possible. When a severe deformity persists or psychosocial concerns arise, lip revision may be carried out earlier in life. The surgical objectives of cleft lip revision include excision of residual scar and any remaining hypoplastic tissue with reapproximation of key anatomic landmarks—vermilion-cutaneous junction and vermilion-mucosal junction—along with leveling of vertical lip lengths (i.e., philtral columns). Critical to an acceptable outcome is the meticulous repair of the orbicularis oris muscle as a distinct layer, and some surgeons will pay particular attention to the perinasal muscular



• **Figure 35-7** A 52-year-old man born with a bilateral cleft lip and palate is shown before and after his lip revision and dental reconstruction with bone grafting and implants. His whistle deformity is resolved with an appropriately sized philtrum. The dental reconstructive plan allowed for esthetic teeth to be present throughout the healing phase of each aspect of the reconstruction.

Continued



Figure 35-7, cont'd.

reconstruction as well. The cleft surgeon should typically dissect and repair all layers (skin or vermilion, muscle, and oral mucosa) in order to establish improved lip form and normalize function and animation (Figure 35-8). Often this requires complete takedown of the lip and recreation of the full-thickness defect.

Comprehensive Dental and Prosthetic Rehabilitation

In general in patients with a cleft of the primary palate (maxilla and alveolus), three possibilities exist with regard to the status of the permanent lateral incisor: (1) the lateral incisor is present and erupts normally, (2) the lateral incisor is congenitally missing, or (3) the lateral incisor is present but is dysmorphic and not a restorable tooth. When the lateral incisor is hypoplastic, extraction is typically performed before or at the time of bone graft reconstruction. In those cases in which a lateral incisor is missing, management of the residual dental gap will eventually be required. Treatment options include the placement of a three-unit fixed prosthesis, replacement of the missing tooth with an endosseous dental implant, or orthodontic substitution of the ipsilateral cuspid tooth for the lateral incisor. Cleft-orthognathic surgery designed to differentially reposition the segments and close the cleft dental graft can also be considered. Additional bone grafting is often performed at the time of cleft-orthognathic surgery in these cases to ensure stable results and closure of a residual oronasal fistula. In contemporary practice the use of a three-unit bridge for replacement of a congenitally missing incisor may generally be avoided. This prosthetic option has several disadvantages: it usually requires preparation of two otherwise perfectly healthy teeth (central and cuspid), hygiene is more difficult around the pontic, and even in the best of circumstances the prosthetic restoration will require replacement several times during the patient's lifetime. In reality, many of the adjacent abutments are compromised and most of these patients will require comprehensive reconstructions (e.g., hybrid prostheses) that can be rather expensive. In North America, most of these types of reconstructions are not covered

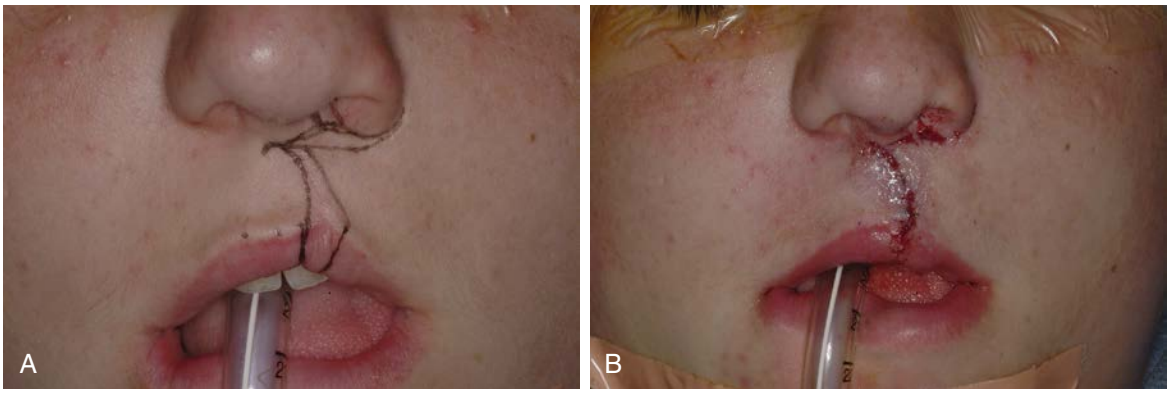

• **Figure 35-8** Unilateral cleft lip revision. Preoperative and postoperative photographs of a patient undergoing revision of a unilateral cleft lip. The full-thickness cleft defect is recreated with care taken to reconstitute the orbicularis oris muscle. The scar and residual hypoplastic tissue were excised, and anatomic landmarks including the vermilion border, white roll, wet-dry line, and nasal sill are reapproximated.

by most insurance plans in a meaningful way. Patients will benefit from understanding the long-term consequences of their reconstructive choices, and the dental reconstructive costs that are often be incurred.

Over the course of the past two decades the use of dental implants has revolutionized the prosthetic rehabilitation of patients with missing teeth. This technology has also been applied to patients born with cleft lip and palate (Figure 35-9).[78-80] Use of an implant-supported crown provides a natural-looking restoration with excellent long-term viability and obviates the need for instrumentation of the surrounding teeth. When a dental implant is being considered, pertinent treatment-planning concerns include an evaluation of bone quality and quantity and the maintenance of adequate space for the implant and restoration. Our preferred approach involves the preservation of a minimum of 7 mm of interdental space to allow for placement of a small diameter dental implant with appropriate emergence profile and adjacent space between roots for esthetic reconstruction. Secondary soft tissue procedures may be beneficial to further optimize the attached tissue in this region. In many instances other areas require extensive reconstruction as well, necessitating a long-term treatment plan that anticipates the health of surrounding teeth as well. Periodontally involved teeth should be evaluated very carefully to anticipate the need for extraction and plan the most long-lasting reconstruction possible.

In most patients who have undergone previous "successful" bone grafting, the vertical dimension of the alveolar ridge seems to be well maintained until the time of implant placement. Facial-palatal width of the ridge, however, may be more problematic, and a significant number of patients may require additional minor bone grafting approximately 3 to 5 months before implant surgery. In most cases the width of the alveolus can be nicely augmented with bone harvested as a cortical block from the mandibular symphysis or ramus. Implant placement requires that the patient be at or near skeletal maturity. Another option for management of the cleft dental gap and missing lateral incisor is orthodontic management designed to substitute the ipsilateral cuspid for the missing lateral incisor. Frequently the result is very acceptable dental esthetics even if prosthetic modification of the cuspid is not undertaken. As with dental implant rehabilitation, this treatment option obviates the need for preparation of the adjacent healthy tooth structure. Another advantage of this treatment option is that it may be undertaken at a younger age than the other prosthetic options. Limiting factors related to this option are primarily due to orthodontic anchorage. Consideration can be given to using skeletal anchorage devices if this becomes problematic.

Summary

Orofacial clefts are complex malformations that affect the three-dimensional anatomy of the maxillofacial hard and soft tissues. Successful reconstruction of these defects involves multiple stages of surgical intervention. Primary surgery achieves the initial closure of the lip and palate defects at age-appropriate intervals based on form and functional concerns. Secondary surgical procedures are subsequently carried out as indicated to close residual oronasal communication, address VPI, reconstruct the bony maxillary cleft, restore maxillary skeletal and facial proportions and occlusion, improve lip esthetics and nasal form and function, and facilitate the dental prosthetic rehabilitation of the patient. Because the multiple, separate surgical interventions that are carried out during active growth have profound functional and esthetic consequences, thoughtful planning of each stage of reconstruction is critical to maximize the benefit for the patient and mitigate the potentially negative biologic consequences related to surgery and growth. Surgeons must maintain a thorough understanding of the anatomy, the intricacies of the cleft malformation, and the underlying patterns of growth and development of the cranio-maxillofacial region.

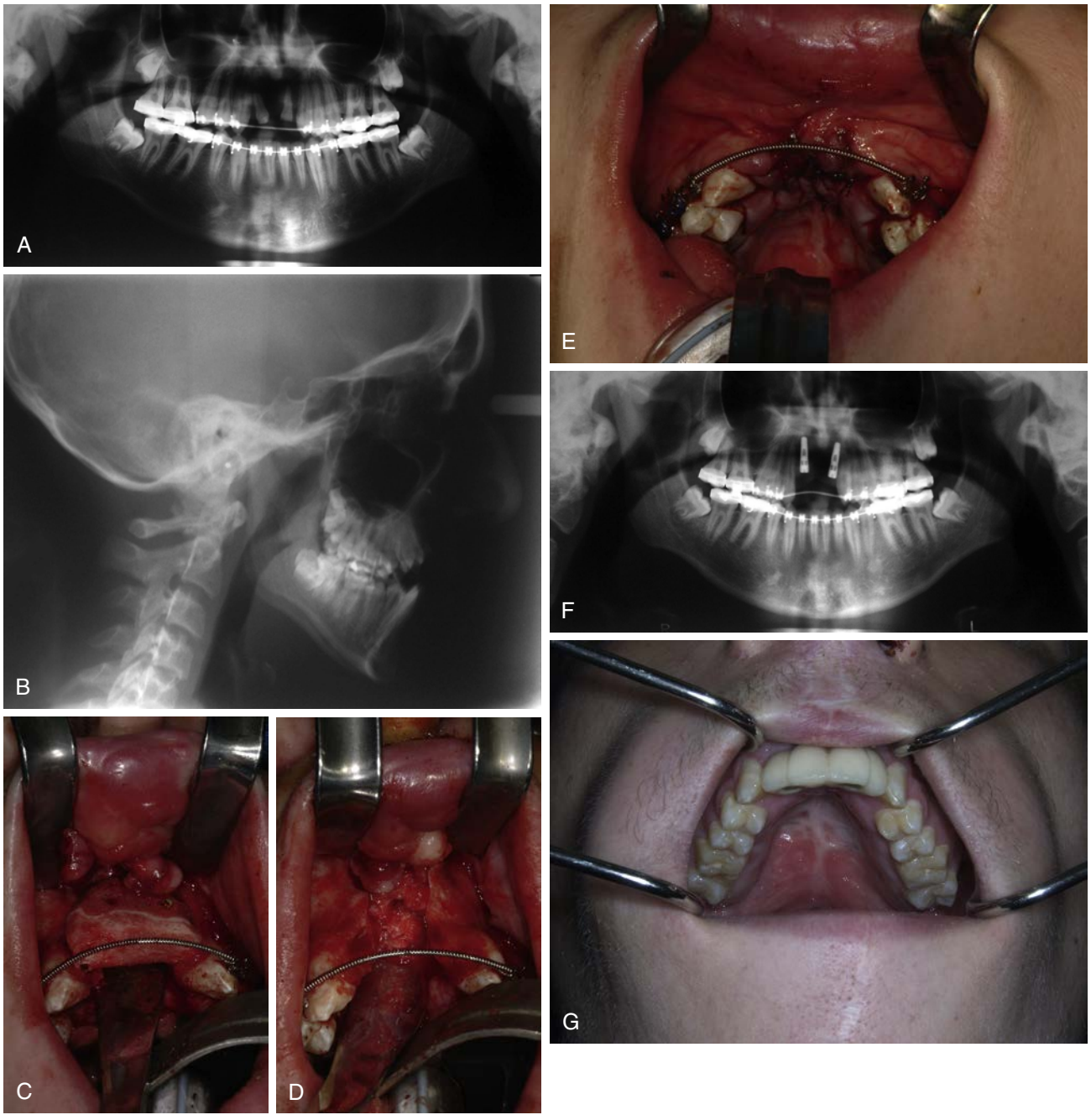

• **Figure 35-9** Prosthetic rehabilitation of a 17-year-old patient with previously unrepaired bilateral maxillary alveolar clefts. He had undergone primary lip and palate repair during infancy but did not achieve successful bone graft reconstruction. Ultimately he lost the premaxillary segment. Treatment consisted of bone graft reconstruction of the bony clefts and large central defect with closure of the oral-nasal fistula. This was performed using autogenous corticocancellous bone graft obtained from the anterior iliac crest followed by dental implant placement 6 months later. **A,** Preoperative panoramic radiograph and **B,** lateral cephalometric radiograph reveal cleft defects and the central defect from the missing premaxilla. **C,** Intraoperative closure of the nasal-side fistula. **D,** Intraoperative insetting of the bone graft. **E,** Clinical closure of the defect with advancement flaps. **F,** Panoramic radiograph after bone graft reconstruction and implant placement. **G,** The prosthetic hybrid prosthesis restoration.

References

1. Leonard BJ, Brust JD, Abrahams G, Sielaff B: Self concept of children and adolescents with cleft lip and/or palate, *Cleft Palate Craniofac J* 28:347, 1991.
2. Strauss RP: Health policy and craniofacial care: issues in resource allocation, *Cleft Palate Craniofac J* 31:78, 1994.
3. Bergstrom LV: Congenital and acquired deafness in clefting and craniofacial syndromes, *Cleft Palate J* 15:254, 1978.
4. Cohen SR, Corrigan M, Wilmot J, Trotman CA: Cumulative operative procedures in patients aged 14 years and older with unilateral or bilateral cleft lip and palate, *Plast Reconstr Surg* 96:267, 1995.
5. Posnick JC: The staging of cleft lip and palate reconstruction: infancy through adolescence. In Posnick JC, editor: *Craniofacial and maxillofacial surgery in children and young adults*, Philadelphia, 2000, Saunders.
6. Posnick JC, Ruiz RL: Stages of cleft lip and palate reconstruction: infancy through adolescence. In Wyszynski DF, editor: *Cleft lip and palate: from origin to treatment*, New York, 2002, Oxford University.
7. American Cleft Palate–Craniofacial Association: Parameters for the evaluation and treatment of patients with cleft lip/palate or other craniofacial anomalies, *Cleft Palate Craniofac J* 30(Supple 1): 4, 1993.
8. Abyholm FE, Bergland O, Semb G: Secondary bone grafting of alveolar clefts, *Scand J Reconstr Surg* 15:127, 1981.
9. Turvey TA, Vig K, Moriarty J, Hoke J: Delayed bone grafting in the cleft maxilla and palate: a retrospective multidisciplinary analysis, *Am J Orthod* 86:244, 1984.
10. Cohen SR, Kalinowski J, LaRossa D, Randall P: Cleft palate fistulas: a multivariate statistical analysis of prevalence, etiology, and surgical management, *Plast Reconstr Surg* 87:1991, 1941.
11. Ogle OE: The management of oronasal fistulas in the cleft palate patient, *Oral Maxillofacial Surg Clin North Am* 14:553, 2002.
12. Williams WN, Seagle MB, Pegoraro-Krook MI, Souza TV, Garla L, Silva ML, et al.: Prospective Clinical Trial Comparing Outcome Measures Between Furlow and von Langenbeck Palatoplasties for UCLP, *Ann Plast Surg* 6:22, 2011.
13. Wilhelmi BJ, Appelt EA, Hill L, Blackwell SJ: Palatal fistulas: rare with the two-flap palatoplasty repair, *Plast Reconstr Surg* 107:315, 2001.
14. Stal S, Spira M: Secondary reconstructive procedures for patients with clefts. In Georgiade NG, Serafin D, editors: *Pediatric plastic surgery*, St Louis, 1984, Mosby.
15. Lehman JA: Closure of palatal fistulas, *Oper Tech Plast Surg* 2:255, 1995.
16. Schendel SA: Secondary cleft surgery, *Select Read Oral Maxillofac Surg* 3:1, 1992.
17. Posnick JC: Cleft orthognathic surgery: the isolated cleft palate deformity. In *Craniofacial and maxillofacial surgery in children and young adults*, Philadelphia, 2000, Saunders.
18. Turvey TA, Vig KWL, Fonseca RJ: Maxillary advancement and contouring in the presence of cleft lip and palate. In Vig KWL, Fonseca RA, Turvey TA, editors: *Facial clefts and craniosynostosis: principles and management*, Philadelphia, 1996, Saunders.
19. Posnick JC, Ruiz RL: Invited discussion. Repair of large anterior palatal fistulas using thin tongue flaps: long-term follow-up of 10 patients, *Ann Plast Surg* 45:115, 2000.
20. Bozola AR, Ribeiro-Garcia ERB: Partial buccinator myomucosal flap, posteriorly based, *Oper Tech Plast Surg* 2:263, 1995.
21. Ninkovic M, Hubli EH, Schwabegger A, Anderl H: Free flap closure of recurrent palatal fistula in the cleft lip and palate patient, *J Craniofac Surg* 8:491, 1997.
22. Posnick JC: The treatment of secondary and residual dentofacial deformities in the cleft patient: Surgical and orthodontic treatment, *Clin Plast Surg* 24:583, 1997.
23. Kirschner RE, Cabiling DS, Slemp AE, Siddiqi F, LaRossa DD, Losee JE: Repair of oronasal fistulae with acellular dermal matrices, *Plast Reconstr Surg* 118:6, 2006.
24. Hudson JW, Pickett DO: A 5-year retrospective review of primary palatoplasty cases utilizing an acellular collagen interpositional graft, *J Oral Maxillofac Surg* 73:7, 2015.
25. Bardah J: Two-flap palatoplasty: Bardach's technique, *Oper Tech Plast Surg* 2:211, 1995.
26. Johnson PA, Banks P, Brown AE: Use of the posteriorly based lateral tongue flap in the repair of palatal fistula, *Int J Oral Maxillofac Surg* 23:6, 1992.
27. Kinnebrew MC, Malloy RB: Posteriorly based, lateral lingual flaps for alveolar cleft bone graft coverage, *J Oral Maxillofac Surg* 41:555, 1983.
28. Costello BJ, Ruiz RL, Turvey TA: Velopharyngeal insufficiency in patients with cleft palate, *Oral Maxillofac Surg Clin* 14:539, 2002.
29. Glaser ER, Skolnick ML, McWilliams BJ, Shprintzen RJ: The dynamics of Passavant's ridge in subjects with and without velopharyngeal insufficiency. A multiview videofluoroscopic study, *Cleft Palate J* 16:24, 1979.
30. Passavant G: On the closure of the pharynx in speech, *Archiv Heilk* 3:305, 1863.
31. Passavant G: On the closure of pharynx in speech, *Virchows Arch* 46:1, 1869.
32. Warren DW: Compensatory speech behaviors in cleft palate: a regulation/control phenomenon, *Cleft Palate J* 23:251, 1986.
33. Henningsson G, Isberg A: Velopharyngeal movements in patients alternating between oral and glottal articulation: a clinical and cineradiographical study, *Cleft Palate J* 23:1, 1986.
34. Isberg A, Henningsson G: Influence of palatal fistula on velopharyngeal movements: a cineradiographic study, *Plast Reconstr Surg* 79:525, 1987.
35. Lohmander-Agerskov A, Dotevall H, Lith A, Söderpalm E: Speech and velopharyngeal function in children with an open residual cleft in the hard palate, and the influence of temporary covering, *Cleft Palate Craniofac J* 33:324, 1996.
36. Shprintzen RJ, Bardach J: The use of information obtained from speech and instrumental evaluations in treatment planning for velopharyngeal insufficiency. In *Cleft palate speech management: a multidisciplinary approach*, St Louis, 1995, Mosby.
37. Golding-Kushner KJ, Argamaso RV, Cotton RT, Grames LM, et al.: Standardization for the reporting of nasopharyngoscopy and multi-view videofluroscopy: a report from an international working group, *Cleft Palate J* 27:337, 1990.
38. Warren DW, Dalston RM, Mayo R: Hypernasality and velopharyngeal impairment, *Cleft Palate Craniofac J* 31:257, 1994.
39. Turvey TA, Ruiz RL, Costello BJ: Surgical treatment of midface deficiency in the cleft lip and palate malformation, *Oral Maxillofac Surg Clin* 14:491, 2002.
40. Fonseca RJ, Turvey TA, Wolford LM: Orthognathic surgery in the cleft patient. In Fonseca RJ, editor: *Oral and maxillofacial surgery*, Philadelphia, 2000, Saunders.
41. Posnick JC, Tompson B: Cleft-orthognathic surgery: complications and long-term results, *Plast Reconstr Surg* 96:255, 1995.
42. Posnick JC, Ruiz RL: Discussion of management of secondary orofacial cleft deformities. In Goldwyn RM, editor: *The unfavorable result in plastic surgery: avoidance and treatment*, ed 3, Philadelphia, 2000, Lippincott Williams & Wilkins.

43. Turvey TA, Frost D: *Maxillary advancement and velopharyngeal function in the presence of cleft palate*, Lancaster, PA, 1980, s.n. Presented at the 38th Annual Meeting of the American Cleft Palate Association. May 1980.
44. Bernstein L: Treatment of velopharyngeal incompetence, *Arch Otolaryngol* 85:67, 1967.
45. Rosseli S: Divisione palatine 3 sua aura chirurgico, *Alu Congr Internaz Stomatal* 391, 1935-1936.
46. Schoenborn D: Uber eine neue Methode der Staphylorraphies, *Arch Klin Chirurgie* 19:528, 1876.
47. Shprintzen RJ: The use of multiview videofluoroscopy and flexible fiberoptic nasopharyngoscopy as a predictor of success with pharyngeal flap surgery. In Ellis F, editor: *Diagnosis and treatment of palatoglossal malfunction*, London, 1979, College of Speech Therapists.
48. Argamaso RV, Levandowski G, Golding-Kushner KJ, Shprintzen RJ: Treatment of asymmetric velopharyngeal insufficiency with skewed pharyngeal flap, *Cleft Palate Craniofac J* 31:287, 1994.
49. Shprintzen RJ, Lewin ML, Croft CB, et al.: A comprehensive study of pharyngeal flap surgery: tailor-made flaps, *Cleft Palate J* 16:46, 1979.
50. Shprintzen RJ, McCall GN, Skolnick ML, Lencione RM: Selective movement of the lateral aspects of the pharyngeal walls during velopharyngeal closure for speech, blowing, and whistling in normals, *Cleft Palate J* 12:51, 1975.
51. Randall P, Whitaker LA, Noone RB, Jones WD: The case for the inferiorly based pharyngeal flap, *Cleft Palate Craniofac J* 15:262, 1978.
52. Hynes W: Pharyngoplasty by muscle transplantation, *Br J Plast Surg* 3:128, 1951.
53. Hynes W: The results of pharyngoplasty by muscle transplantation in "failed cleft palate" cases, with special reference to the influence of the pharynx on voice production, *Ann R Coll Surg Engl* 13:17, 1953.
54. Orticochea M: Physiopathology of the dynamic muscular sphincter of the pharynx, *Plast Reconstr Surg* 100:1997, 1918.
55. Orticochea M: Constriction of a dynamic muscle sphincter in cleft palates, *Plast Reconstr Surg* 41:323, 1968.
56. Jackson I, Silverton JS: The sphincter pharyngoplasty as a secondary procedure in cleft palates, *Plast Reconstr Surg* 71:180, 1983.
57. Jackson IT: Sphincter pharyngoplasty, *Clin Plast Surg* 12:711, 1985.
58. Guilleminault C, Stoohs R: Chronic snoring and obstructive sleep apnea syndrome in children, *Lung* 168:912, 1990.
59. Sirois M, Caouette-Laberge L, Spier S, et al.: Sleep apnea following a pharyngeal flap: a feared complication, *Plast Reconstr Surg* 93:943, 1994.
60. Ysunza A, Garcia-Velasco M, Garcia-Garcia M, et al.: Obstructive sleep apnea secondary to surgery for velopharyngeal insufficiency, *Cleft Palate Craniofac J* 30:387, 1993.
61. Bluestone CD, Musgrave RH, McWilliams BJ: Teflon injection pharyngoplasty—status 1968, *Laryngoscope* 78:558, 1968.
62. Smith JK, McCabe DF: Teflon injection in the nasopharynx to improve velopharyngeal closure, *Ann Otol Rhinol Laryngol* 86:559, 1977.
63. Chen PK, Wu JT, Chen YR, Noordhoff MS: Treatment of secondary velopharyngeal insufficiency in cleft palate patients with the Furlow palatoplasty, *Plast Reconstr Surg* 94:933, 1994.
64. Calnan J: Submucous cleft palate, *Br J Plast Surg* 6:264, 1954.
65. McWilliams BJ: Submucous clefts of the palate: how likely are they to be symptomatic? *Cleft Palate J* 28:247, 1991.
66. Paradise JL: Tonsillectomy and adenoidectomy. In Bluestone CD, editor: *Pediatric otolaryngology*, Philadelphia, 2003, Sanders.
67. Shprintzen RJ, Schwartz RH, Daniller A, Hoch L: Morphologic significance of bifid uvula, *Pediatrics* 75:553, 1985.
68. Kaplan EN: The occult submucous cleft palate, *Cleft Palate J* 12:356, 1975.
69. Gilleard O, Sell D, Ghanem AM, Tavsanoglu Y, Birch M, Sommerlad B: Submucous cleft palate: a systematic review of surgical management based on perceptual and instrumental analysis, *Cleft Palate Craniofac J* 51:6, 2014.
70. McComb H: The nasal deformity in clefts. In Kernahan DA, editor: *Cleft lip and palate: a system of management*, Baltimore, 1990, Williams & Wilkins.
71. Horswell BB, Pospisil OA: Nasal symmetry after primary cleft lip repair: comparison between Delaire cheilorhinoplasty and modified rotation-advancement, *J Oral Maxillofac Surg* 53:1025, 1995.
72. Gubiscla W: How to obtain symmetries in a unilaterally cleft nose, *Eur J Plast Surg* 13:241, 1990.
73. Takato T, Yonehara Y, Sasami T: Early treatment of the nose in unilateral cleft lip patients using an open method: a 10-year review, *J Oral Maxillofac Surg* 53:28, 1995.
74. Millard DR: Bilateral cleft lip and a primary forked flap: a preliminary report, *Plast Reconstr Surg* 30:50, 1967.
75. Cronin TD: Lengthening columella by use of skin from nasal floor and alae, *Plast Reconstr Surg* 21:417, 1958.
76. Harper DC: Children's attitudes to physical differences among youth from Western and non-Western cultures, *Cleft Palate Craniofac J* 32:114, 1995.
77. Monson LA, Khechoyan DY, Buchanan EP, Hollier Jr LH: Secondary lip and palate surgery, *Clin Plast Surg* 41:2, 2014.
78. Laine J, Vähätalo K, Peltola J, et al.: Rehabilitation of patients with congenital unrepaired cleft palate defects using free iliac crest bone grafts and dental implants, *Int J Oral Maxillofac Implant* 17:573, 2002.
79. Fukuda M, Takahashi T, Yamaguchi T, et al.: Dental rehabilitation using endosseous implants and orthognathic surgery in patients with cleft lip and palate: report of two cases, *J Oral Rehabil* 27:546, 2000.
80. Jensen J, Sindet-Pedersen S, Enemark H: Reconstruction of residual alveolar cleft defects with one-stage mandibular bone grafts and osseointegrated implants, *J Oral Maxillofac Surg* 56:460, 1998.

36

Craniomaxillofacial Surgery in the Pediatric Patient: Growth and Development Considerations

BERNARD J. COSTELLO, MARK P. MOONEY, JOCELYN M. SHAND

The goals of craniomaxillofacial surgery include establishing a stable morphology and improving facial esthetics. Surgical treatment may necessitate manipulation of the soft tissues or bony structures based on the particular dysmorphology, defect, or injury. For example, the failure of fusion that creates facial clefting is usually repaired in infancy during the growth phase. Just repairing these soft tissues in key growth areas may have negative consequences later in life. This interplay highlights the possible biologic consequences of early intervention during the growth phase.

When skeletal discrepancies exceed the envelope of those that can be appropriately treated with orthopedic growth modification and/or orthodontic compensation techniques, surgical repositioning of the craniofacial structures may be indicated.[1] In many instances, patients with skeletal deformities benefit from surgical treatment following the completion of facial growth. This approach allows for a definitive treatment that is highly predictable and stable in the majority of cases.[2] In contrast, surgical treatment performed before skeletal maturity is less predictable and may require reoperation following skeletal maturation. However, early intervention may be warranted for functional or esthetic reasons. Unfortunately, the hoped-for advantage of early surgical interventions to "unlock growth" has not been realized, and in most cases, there are no clear benefits to early operative intervention, which is partially due to the associated drawbacks.[3,4] These common issues emphasize the importance of considering growth when planning treatment for surgical reconstruction.

This chapter reviews the concepts of development and growth in the craniomaxillofacial skeleton as they relate to the treatment of soft tissue and skeletal dysmorphologies. The basic principles of craniofacial growth are reviewed, and the specific patterns of craniofacial dysmorphologies are discussed with regard to potential early and/or staged intervention. A balanced approach to treatment planning is presented with growth as the center of discussion. However, functional aspects of the airway and occlusion are of considerable importance in some patients. Certain clinical situations require intervention even at the cost of harming growth potential when there is a significant benefit perceived. Additionally, esthetic concerns in patients with severe deformity require careful consideration for psychosocial reasons.

Growth Discrepancy and the Craniofacial Skeleton

Growth discrepancies involving the craniofacial skeleton are common, and many of these discrepancies can be managed with orthopedic growth modification and/or orthodontics alone if they are not severe.[1] In particular, congenital craniofacial malformations, deformities, and disruptions may have severe skeletal dysmorphologies and discrepancies. For example, deformational plagiocephaly causes cranial and possibly orbital asymmetry that when diagnosed early is treated with a form of growth modification using custom-molding helmets or bands. In instances when the discrepancy is particularly large or other deformities of the cranio-orbital region are encountered, surgery may be helpful to dismantle the craniofacial components and reposition them in a more normal conformation. There are a number of examples of these skeletal and soft tissue discrepancies that occur in childhood requiring treatment. Deciding when to intervene is important to optimize the long-term results for these clinical challenges.

Growth abnormalities and dysmorphology of the lower face are the most commonly encountered clinical problems for the craniomaxillofacial surgeon. When these discrepancies involve the teeth, most minor discrepancies are treated

with orthodontic compensation. However, some are beyond the envelope of orthodontic compensation techniques and may benefit from surgical repositioning of skeletal components. Orthognathic surgery for the treatment of skeletal discrepancy and malocclusion has traditionally been undertaken following the completion of growth, and there is considerable contemporary literature regarding the effects and stability of these procedures. However, there are only a limited number of studies that have investigated the outcome following orthognathic, craniofacial, or other types of maxillofacial surgery performed in the growing child.[5-12] The supposition that surgical intervention before skeletal maturation may "inhibit" the future growth potential of the involved bone is long standing, especially if a growth center is involved. This concept is in part based on the findings obtained from studies of patients with cleft lip and palate deformities, Robin sequence, craniofacial microsomia, Treacher Collins syndrome, and a range of other conditions in those who had undergone surgical procedures during growth.[13] The results and observations from these studies do provide information about growth potential; however, is it imperative to recognize that these patients also have an underlying dysmorphology that may influence facial growth independent of surgical treatment. In the assessment of subsequent facial growth problems, it is difficult to delineate between that related to the preexisting condition with its aberrant growth pattern and that potentially caused by the surgical osteotomy or other manipulations. Early surgery has usually been reserved for individuals with marked skeletal dysmorphologies and/or severe functional concerns (e.g., intracranial pressure increases, choanal atresia, or severe obstructive sleep apnea). The presence of severe functional problems or implications for the psychosocial development of the child may become important when considering early surgery. A firm understanding of the patterns of facial growth is essential when planning surgical reconstruction.[14]

There is some predictability to the growth of the cranium and face, but individual variation and pathologic conditions must be considered.[15,16] Common growth variations (e.g., vertical maxillary excess with mandibular hypoplasia) and pathologic clinical situations (e.g., maxillary hypoplasia in the patient with a cleft palate) should be recognized, treatment planned, and staged with these issues in mind. Clinicians must be aware of these early discrepancies, not to force early intervention in most cases, but to develop a diagnosis and stage the reconstruction for the most predictable result. Treatment plans can then be formulated based on the best estimation of the expected pattern of growth.

Concepts of Craniofacial Skeletal Growth and Development

Craniofacial development, growth, and remodeling are a complex interplay of structure and function beginning in the embryo and continuing throughout adult life. The delicate equilibrium that exists between various parts of the craniofacial skeleton is stimulated by genes and local function and coordinates complex biomechanical and molecular signaling to yield a composite skeletal form.[17] Problems can occur at any time during this process and negatively impact the growth and development process. Understanding the basic biology of craniomaxillofacial development and growth is essential when planning treatment for malformations, disruptions, and deformities. The basic definitions are important to understand when discussing the biology of growth and development (Table 36-1).

TABLE 36-1 Definitions

Term	Definition
Dysmorphology	Abnormal morphology of tissues
Malformation	Formation of tissue is poor as a result of an intrinsic problem with development
Disruption	A breakdown in normal tissue development causing abnormal morphology
Deformation	Changes in morphology caused by external forces on normal tissue
Growth	Increase in cell size (plasia) or cell number (trophy)
Remodeling	Compensatory or adaptive changes of tissue
Development	Increase in complexity
Hyperplasia	Increase in the size and number of cells

In general, there is a cephalocaudal growth vector that occurs throughout early life and facial development that is thought to be closely linked to the functional demands of each region (Figure 36-1). Enlow[18,19] has discussed the concepts of growth in detail and outlines the two main morphologic events that direct craniofacial growth. These include (1) basal cranium growth and (2) development of the pharyngeal and facial airway structures. This vector of cephalocaudal growth is directly related to the changes seen in the proportions of the head and face during early life. In the early phase, this is reflected in the relative importance of cranial growth as a response to the rapid growth of the brain tissues. This occurs in the neurocranium, which houses the structures of the brain, orbits, and olfactory system, and this region comprises the cranium and upper third of the face. The remainder of the facial tissue accelerates their growth at a later phase as the airway and muscles of mastication increase their function. This represents the viscerocranium (Table 36-2).

The bones of the craniofacial skeleton grow and develop by remodeling and displacement throughout young life. Remodeling occurs as a result of local factors that result in the change in the size and shape of various components of the facial skeleton. Displacement occurs by bones that move apart at the joint, suture, or articular regions.[18,19] This



• **Figure 36.1** Multiple views of skulls from infancy through adolescence show the progression of craniofacial bone growth. The general progression is from superior to inferior with a downward and forward growth vector.

TABLE 36-2 Average Percent Growth Completion of Various Craniofacial Dimensions

	Average Adult % Completed by Age 1	Average Adult % Completed by Age 5	Average Age at Maturity
Cranium	84%-86%	90%-94%	Males: 14 yr Females: 16 yr
Orbits	84%-86%	88%-93%	Variable
Zygoma	72%	83%	Males: 15 yr Females: 13 yr
Maxilla	75%-80%	85%	Males: 15 yr Females: 14 yr
Mandible	60%-70%	74%-85%	Males: 16 yr Females: 14 yr

From References 18-23.

displacement occurs away from the articular surfaces (i.e., cranial sutures, temporomandibular joints, or maxillary sutures). Bone growth is modulated through this process by augmenting or diminishing various regions in response to the functional needs and the timing of gene expression. The two processes of remodeling and displacement should occur in a coordinated and interdependent fashion. If the processes are balanced, the skeleton develops appropriately. In contrast, if the balance is disturbed (i.e., nasal obstruction or prenatal cranial suture fusion), the skeleton develops outside the envelope of equilibrium resulting in a skeletal discrepancy.[1]

Local signaling appears to occur between the bony components of the face to develop each area in response to the increasing functional demands of mastication and breathing. The orbits, maxillae, and mandible are each dependent upon one another early in this phase, whereas the cranial base has a more intrinsic or genetically based control mechanism.[18,19] The cranium and orbits will develop in response to the rapid growth of the brain and globes, which occurs during the first year of life, and hence the cranio-orbital complex is comparatively much larger than the maxillomandibular complex in infancy. The early developing neurocranial complex creates a craniocaudal growth vector that is clockwise in direction when viewing the right lateral skull. Later, the functional demands of mastication and deglutition on the mandible become prominent, and the nature of the equilibrium balance with the maxilla is also altered in response to the growth and development of the airway and the functional needs of mastication and speech development. Constant modifications to this process are made throughout growth and development to obtain a functional state of equilibrium.

The equilibrium of the craniofacial complex is altered following a series of normal developmental events. These include:

1. Central neurologic development
2. Optic pathway development
3. Speech and swallowing development
4. Airway and pharyngeal development
5. Facial expression and muscular changes
6. Tooth development and exfoliation

Each region has a unique growth curve, and there are various peaks of growth velocity that alter craniofacial equilibrium resulting in skeletal growth changes to restore this equilibrium. It is essential to have an understanding of each region when deciding the timing of various reconstructive efforts. In general, more definitive corrections are performed later in the growth phase and ideally should be undertaken at the completion of growth because earlier intervention may alter the growth curve and disrupt the equilibrium. Relapse toward the original dysmorphology is more likely to occur when the body attempts to restore the balance that has been altered by surgical intervention performed before skeletal maturation.[18,19]

Regions of Craniofacial Growth and Development

Cranium

The cranium is made up of the chondrocranium and the neurocranium. The chondrocranium, or cranial base, develops initially in cartilage derived from occipital somites and then becomes bone by endochondral ossification. These ossification centers form the bones of the base of the skull

(i.e., the occipital, sphenoid, temporal, and ethmoid bones). Growth of the cranial base bones occurs interstitially at articulations called synchondroses. Whereas the majority of the growth is occurring at the synchondroses, once ossified, the inner and outer surfaces of each bone can also remodel via appositional growth.

The neurocranium, or cranial vault, is made up of large and small curved, flat bones that are formed intramembranously, the majority of which are derived from neural crest cells. The growth of these bones occurs interstitially at the fibrous articulations (i.e., the sutures) and appositionally on the endocortical and ectocortical surfaces. The cranial vault grows rapidly in the first year of life, and the velocity of growth plateaus in the following 5 years. A diploic space is present between two clear cortices of bone in most children between the ages of 2 and 5 years. The vast majority of growth in this area is complete by ages 5 to 7 years.[3,4] At 1 year of age, the width of the head is 84% of its adult size, and at 5 years of age, the head width increases to 93%.[20-23] Head circumference is similar with 86% of the growth complete by 1 year of age and 94% of growth completed by 5 years of age. The maturation age of the cranium width is 14 years in females and 15 in males. The incredible amount of growth within the first 5 years of life is reflective of the neurodevelopment that occurs during this time.[20-23]

Craniosynostosis is the premature fusion of cranial vault sutures, which is generally an antenatal event that causes growth restriction perpendicular to the affected suture. Craniosynostosis is most often seen with only one suture. However, craniofacial dysostosis syndromes occur when the cranial base synchondroses (primarily the presphenoethmoid synchondroses) and, to a lesser extent, the cranial vault sutures are affected to varying degrees. The alteration of the mid-face occurs in craniofacial dysostosis syndromes, such as Apert's, Pfeiffer, and Crouzon's syndromes. These syndromes are characterized by a restriction of growth in the anterior cranial vault and cranial base that results in severe orbital and mid-facial hypoplasia and Class III malocclusion. In addition, when the brain and cranial base components do not form in their normal fashion (i.e., Binder sequence and Down syndrome), the development of the mid-facial complex and the balance is also distorted.[24-26]

In many cases, treatment of dysmorphology in the cranial vault and orbits is more definitive after 1 year of age because the vast majority of growth in the cranium is complete at this time. In the case of craniosynostosis, surgical correction is necessary earlier to allow appropriate volume for brain growth. For patients with craniofacial dysostosis in which skull base fusion has also affected the orbits and mid-face, this is corrected at a later stage (Figure 36-2).

Orbits

The orbits consist of bones from the cranio-orbital and nasomaxillary complexes, and most of the growth in the orbit region occurs at the sutures between these bones. The orbits grow rapidly in the first year of life in association with the globe, optic nerves, and neurocranial development, and the velocity decreases over the next 5 years. The vast majority of growth in this area is completed by 5 years of age.[3,4] The intercanthal width at age 5 is on average 30 mm, which is approximately 93% of the adult value (33 mm). Intercanthal width is fully mature in males at 11 years of age and in females at 8. Orbital height grows at a more gradual rate in comparison with the other orbital dimensions. The impressive growth of this region before 5 years of age is a result of the rapidly developing globes and optic neurologic system.[3,4]

Orbital dysmorphology is seen in unicoronal craniosynostosis, the craniofacial dysostosis syndromes, and also in patients who fail to obliterate the foramen cecum during development with midline lesions, such as encephaloceles, dermoids, or gliomas. The delicate balance is disturbed, and the tissues adapt based on the pathologic condition that is present. Most treatments are best performed after the age of 5 years (Figure 36-3).

Zygoma

The zygomatic bones grow rapidly in the first year of life and level off in velocity over the next 5 to 7 years. Growth in this area is initially somewhat more gradual when compared with the cranium and orbits, but the vast majority of growth in this area is similarly complete by age 5 to 7. The bizygomatic width is 83% of the mature adult size by the age of 5 years, and the width of the face is mature at 15 years in males and 13 in females.[3,4]

Zygomatic deformities are seen in Treacher Collins syndrome, craniofacial dysostosis syndromes, Down syndrome, achondroplasia, cretinism, and other growth restrictions of the cranial base. The hypoplasia is also evident in the maxilla and nasal complex. Definitive correction in this area can usually be performed after the age of 5 years (Figure 36-4).

Maxilla

Much like the cranium, the maxilla develops by intramembranous ossification of neural crest cells. Maxillary enlargement is a result of early nasal septal growth and later by sutural growth and surface remodeling with a forward and downward displacement relative to the cranial base. Mid-facial height (nasion to gnathion) reaches maturity at 13 years in females and 15 years in males.[3,4] The most active times of growth are between the ages of 1 to 2 years and 3 to 5 years. The height of the mid-face (nasion to stomion) matures slightly earlier in males at 14 years and 12 in females. Mid-facial projection (tragus to stomion) reaches maturity at 14 years in males and 13 in females.[3,4]

The mid-facial hypoplasia seen in patients in craniofacial dysostosis syndromes, achondroplasia, and other disorders is quite impressive, often in all three dimensions.[27] Patients may develop severe anterior-posterior maxillary hypoplasia, transverse discrepancies, and anterior open bites. For these reasons, definitive correction of maxillary dysmorphology

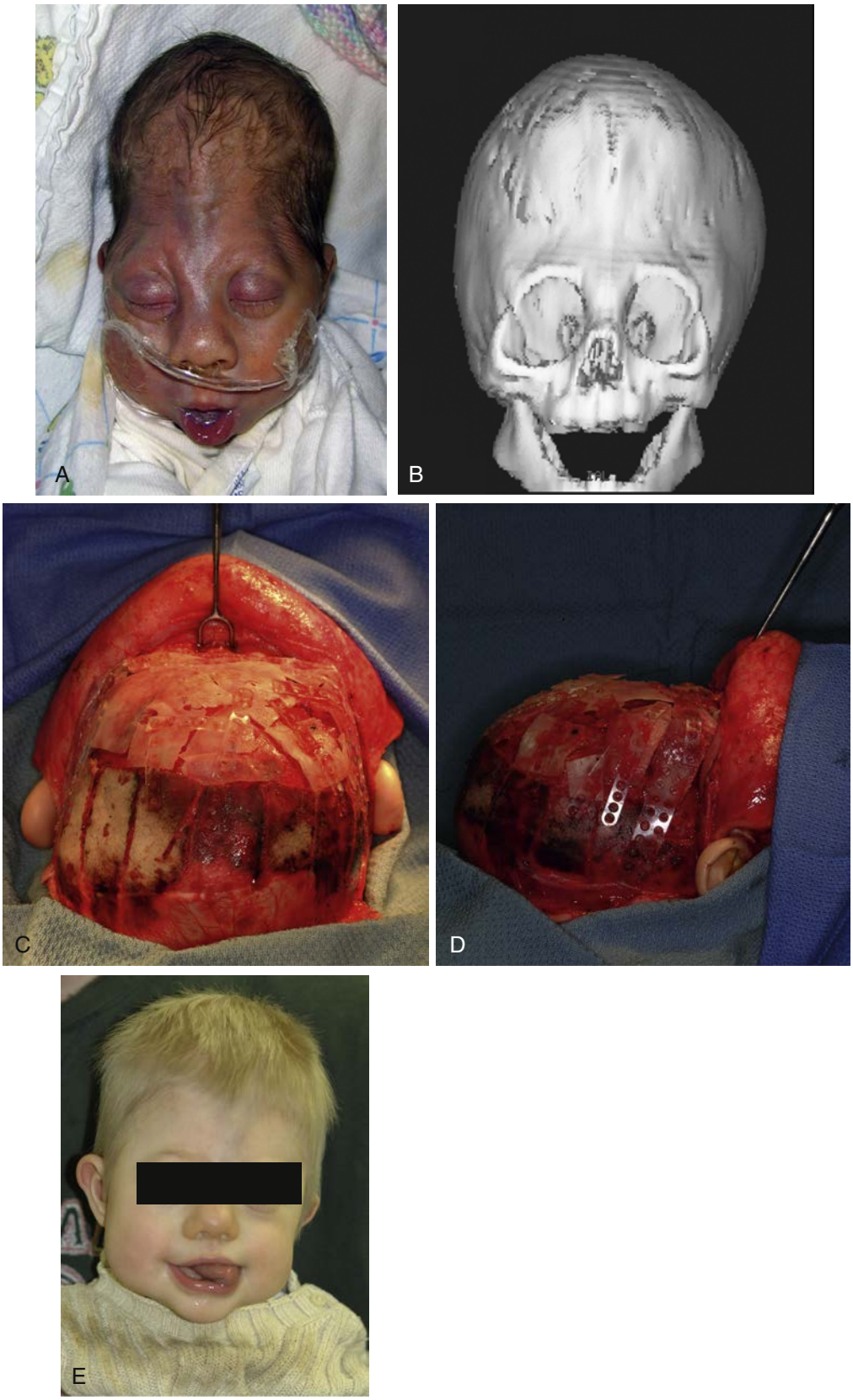

• **Figure 36-2 A,** A newborn with bicoronal and metopic craniosynostosis and Saethre-Chotzen syndrome. Constriction of growth perpendicular to the sutures is evident with the resultant dysmorphology and small cranial vault requiring expansion. **B,** Three-dimensional CT scan showing the cranial vault constriction associated with craniosynostosis. **C** and **D,** Cranial vault reshaping has been performed by disassembling the dysmorphic bones, advancing the cranio-orbital complex, and reshaping the bones to a more normal conformation and expanded volume to accommodate the brain at this critical time of growth. **E,** Postoperative result showing improved cranial vault and orbital morphology.



• **Figure 36-3** A young girl with a history of long-standing torticollis that exhibits facial asymmetry and cranial asymmetry. The cranial vault asymmetry has the typical conformation associated with skull molding or positional plagiocephaly. The compensatory changes in the orbit and lower face can be addressed at different times based on their growth velocities and presumed completion of growth.



• **Figure 36-4** This young boy had a facial translocation procedure in infancy for a skull base tumor and postoperative radiation therapy to the left orbit, zygoma, and skull base. At the original procedure, symmetry was quite good, but as the child grew during the following decade, facial asymmetry developed including lower orbital and zygomatic hypoplasia.

is usually reserved for after the age of 14 in girls and 16 in boys once skeletal maturity has been achieved. When these deformities are particularly severe, early intervention is often entertained. This may include attempts at growth modification (i.e., reverse-pull headgear) or early mid-facial advancement with osteotomies (Figures 36-5 and 36-6).

Mandible

There is a classic notion that the condyle is the independent growth center of the mandible. Although the condyle is relatively important in the growth and development equilibrium, the mandible develops by displacement and remodeling in all regions, not just the condyle. Periosteal apposition (e.g., posterior ramus region), resorption (e.g., anterior coronoid and ramus), and endochondral growth occur in the mandible. The coordinated apposition and resorption results in an inferior and anterior displacement of the mandible throughout the growth phase. Mandibular width is nearly 93% complete by the age of 5 years; however, it does not mature until 13 years in males and 12 in females.[3,4] Mandibular depth (tragus to gnathion) is 85% complete at age 5; however, it does not reach the mature dimension until 15 years in males and 13 in females. Mandibular height is 67% complete by 1 year and 88% complete by 5 years. Mandibular height is mature at 12 years in females and 15 in males.[3,4,28]

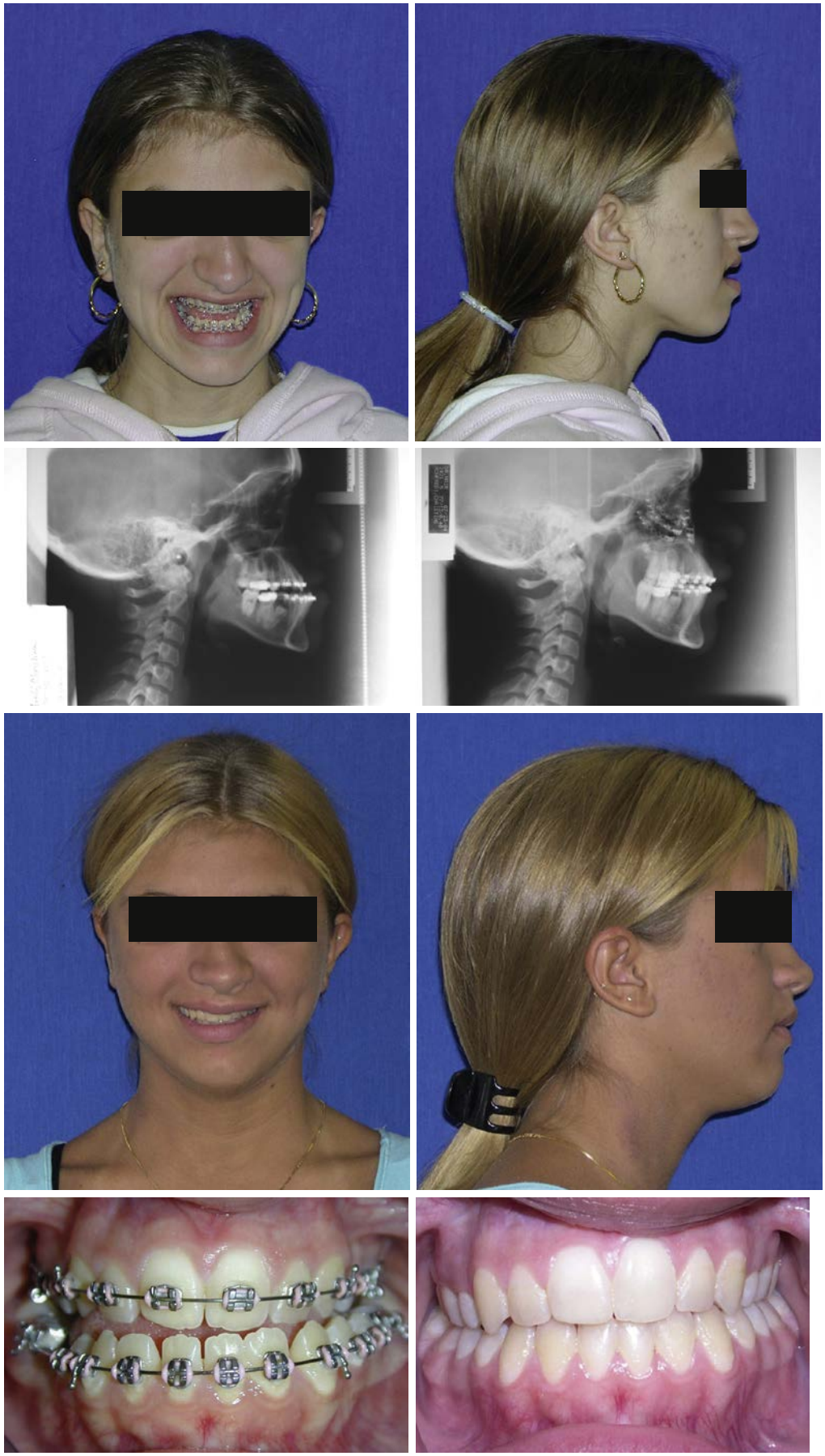

• **Figure 36-5** Thirteen-year-old female with Crouzon's syndrome and the typical orbital and mid-face hypoplasia resulting in a Class III skeletal-dental relationship. She underwent a modified Le Fort III procedure advancing her zygomas and maxilla to provide her with positive overbite and overjet. Because the procedure was performed at the near completion of growth, her result has remained stable without a recurrent Class III relationship.

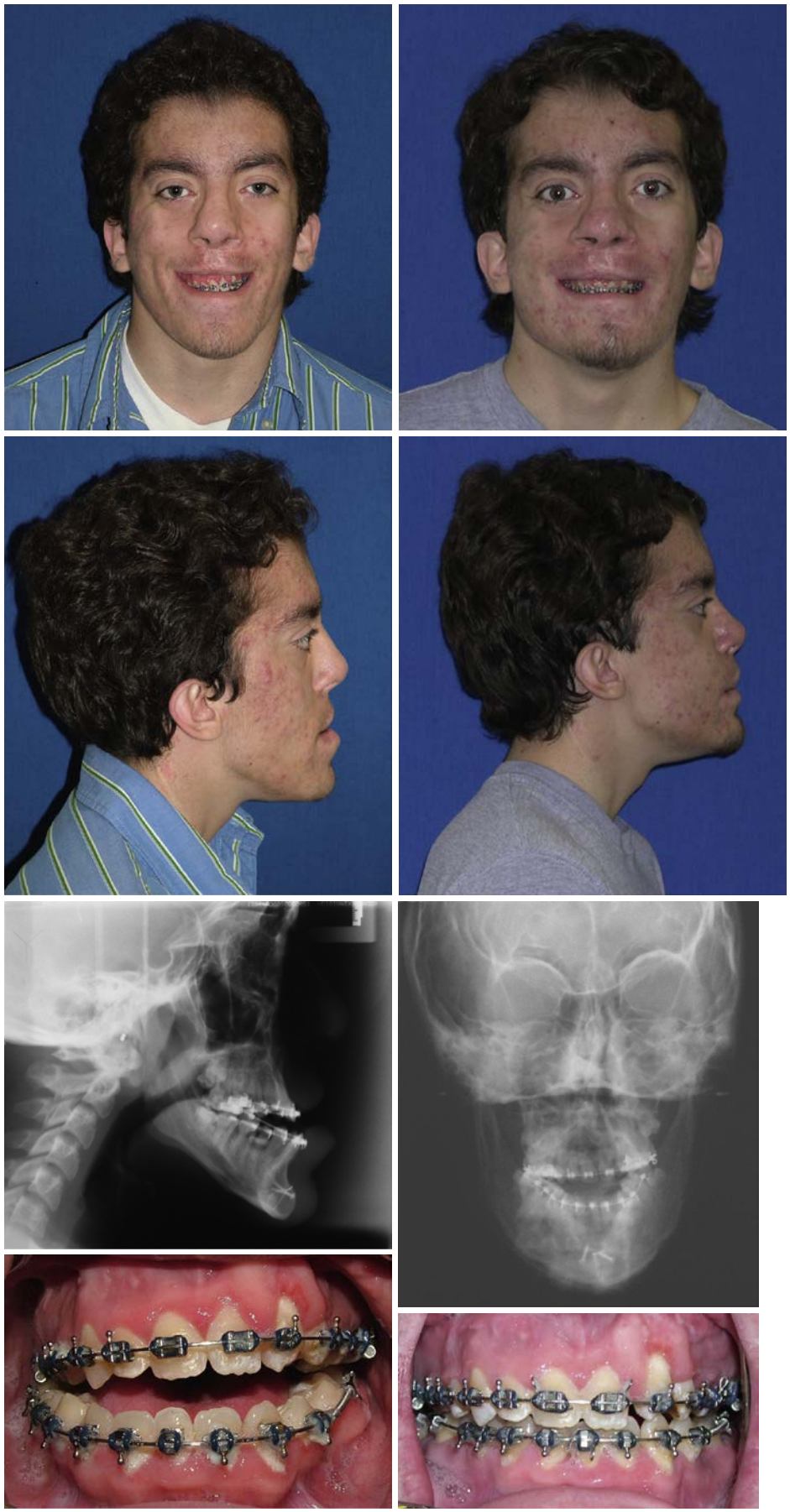

• **Figure 36-6** This young man underwent distraction osteogenesis advancement via a Le Fort I osteotomy with a genioplasty setback by another surgeon when he was 9 years of age. The treatment was complicated by difficulty with vector control and an anterior open bite postoperatively. He subsequently underwent traditional orthognathic surgery repositioning the maxilla and mandible at skeletal maturity for his definitive treatment. He underwent a Le Fort I advancement at skeletal maturity to ensure the most stable result.

Marked alterations in the development of the mandible are found in Cornelia de Lange's syndrome, Nager syndrome, Treacher Collins syndrome, and craniofacial microsomia (Figures 36-7 and 36-8). There is frequently severe mandibular hypoplasia yielding a Class II malocclusion and a high mandibular plane angle, and there may be anomalies of the temporomandibular joint complex. Correction of mandibular deformities is usually reserved until after the age of 16 in girls and 18 in boys. Early intervention for severe deformities may include either growth modification devices or early osteotomies for mandibular advancement.

Clinical Evaluation of Craniofacial Growth

There is considerable individual variation seen in the growth of the craniofacial skeleton, and many methods have been developed to assess the individual growth of patients considered for surgical correction of a craniofacial dysmorphology. The evaluation of the craniofacial skeleton can be performed by a number of simple methods based upon both expected norms and concepts of growth and development. There are considerable data on the growth of the facial skeleton in patients without significant deformity or growth discrepancy.[15,16,28] Individual measurements can be made and compared with existing age-matched control data to gain some information about the extent of the deformity. In comparison, there is a limited amount of data available on the various anomalies, and therefore only generalizations can be made with respect to the differences observed with the abnormal relationships.

Anthropometric measurements can be performed on individuals with calipers and correlated with normative data sets.[20-23] This data can be helpful in determining either the amount of correction to be undertaken or in evaluating the success of treatment.[29] Posnick and others[3,4,30] have evaluated individual types of deformities and the success of various surgical corrections using this type of approach, in addition to data generated from measurements performed on computed tomography (CT) scans. Whereas the measurements on CT are generally not practical for clinical practice, they are helpful in the outcome assessment of the surgical correction.[3,4,30]

Hand-wrist plain films have been used for many years to assess skeletal growth and to predict the maturation point of the craniofacial skeleton.[31] The same process can be performed by analyzing the maturation of the cervical spine, and the predictive value of the cervical spine analysis has been purported to be similar to the hand-wrist technique.[32]

One of the best methods to ascertain an individual's craniofacial growth is to evaluate serial cephalometric radiographs. Minimal or no change in velocity of the maxillofacial growth during adolescence is a good indicator of skeletal maturation. Cephalometric radiographs from the same machine using the same technique can be compared 6 or 12 months apart to evaluate for any significant change indicating growth.[16,33]

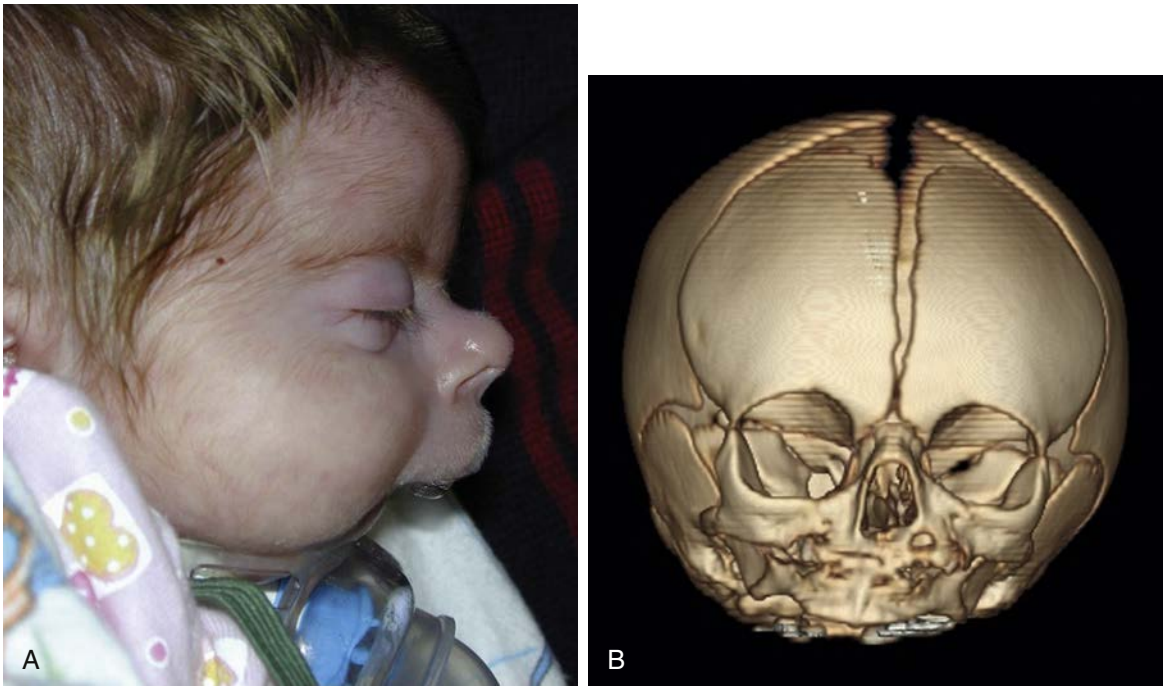

• **Figure 36-7 A,** A newborn with Cornelia de Lange syndrome who was diagnosed with mandibular hypoplasia as a fetus with ultrasound techniques. She underwent an EXIT procedure with a tracheostomy performed using maternal circulation for a brief period of time to establish an airway. The typical mandibular hypoplasia of this disorder is evident on the lateral view. **B,** Mandibular hypoplasia is evident in another patient with a physical impediment to growth of the mandible. This child has congenitally fused maxilla to the mandible, or syngnathia. The inability of the mandible to function will contribute to hypoplasia over time.



• **Figure 36-8** **A-C,** A teenager with craniofacial microsomia who was born with a Tessier #7 right lateral commissure cleft. The cleft was repaired in infancy by another surgeon, but she retains the right-sided hypoplasia seen with this disorder. **D-F,** A Le Fort I osteotomy, bilateral sagittal split osteotomies, and a genioplasty provide improved facial balance and occlusion in the postoperative views.

Surgical Management Considerations

Cranio-orbital Dysmorphology

Dysmorphology of the craniofacial skeleton is seen in patients with craniosynostosis of various types, including coronal, sagittal, metopic, and the various combinations of multiple-suture craniosynostosis. Craniosynostosis is an excellent example of the balance that is required when considering early correction of a dysmorphology.

By definition, craniosynostosis is the early fusion of one or multiple sutures of the cranial vault. This causes both a telltale dysmorphology and a concern that the intracranial volume is less than the amount required for the rapidly developing brain. This mismatch can cause issues with brain growth, optic nerve function, and overall neurologic development. For this reason, expansion of the cranial vault is considered for some children with this disorder in an attempt to both increase the volume available to the brain for growth and improve the dysmorphology caused by the restriction of cranial vault growth in the affected area.

The importance of brain growth requires that the surgeon consider the treatment of craniosynostosis before the ultimate maturity of the skull, but very early correction is associated with marked relapse and the need for reoperation. For this reason, most surgeons tend to surgically dismantle the cranial vault before 1 year of age but after some growth has occurred; typically, this is beyond the 6-month time period. In cases where multiple sutures are involved, the need for treatment is more urgent, and even earlier treatment is considered knowing that additional cranial vault expansions will likely be required.

The need for revision surgery is higher in patients who have undergone very early correction of cranio-orbital dysmorphology. The concept that early surgery may "unlock" growth has not proven to be sound based on the current understanding of craniofacial growth. However, delaying

the surgical correction significantly may have adverse effects on brain development and optic nerve function. The exact timing remains controversial because no predictable and repeatable measure of either brain growth velocity or intracranial pressure is easily obtainable to allow the clinician to better judge the timing of surgical expansion.

Mandibular Hypoplasia

Mandibular deficiency, with Class II malocclusion, is one of the most common patterns of facial deformity and presents in a variety of expressions. When the mandible is particularly hypoplastic, early surgery in this group is often considered for airway concerns, such as obstructive sleep apnea or tracheostomy dependence. Contrasting results have been reported in the literature pertaining to the outcome of mandibular advancement before skeletal maturation.[7,10-12,34] Direct comparison between these studies is not possible because of the heterogeneity of a number of factors: variation in age, number of patients, presence of associated craniofacial deformities, and osteotomy and fixation techniques. Huang et al[12] reviewed the outcomes of mandibular advancement in 22 growing children and found a variation of response, which appeared to be influenced by the amount of advancement. In those who underwent advancement of 10 mm or more, significant condylar remodeling and/or resorption was demonstrated, with remodeling in the posterior symphyseal region also observed in some cases. These patients had significant "relapse" that continued over several years after the operation. In contrast, the group that underwent advancements of 9 mm or less demonstrated a milder degree of relapse. They found that no significant mandibular growth occurred after 11 years of age, and the mandible returned to its preoperative growth direction within 2 years following surgery. Their patient sample was mixed with the inclusion of four patients with recognized craniofacial syndromes and two with juvenile rheumatoid arthritis. These associated features are significant confounding factors when attempting to analyze the outcomes.

In contrast, a number of authors have reported favorable results following mandibular advancement.[7,10,11,34] An early study by Schendel et al[10] examined the results of sagittal split mandibular advancement, with nonrigid fixation, in 12 growing patients. They demonstrated minimal skeletal relapse and the maintenance of harmonious growth between the mandible and maxilla. In a group of 12 patients, Snow et al[34] demonstrated postoperative mandibular growth in the vertical dimension following sagittal split advancement in 11 of the patients. Vertical maxillary growth was found in a number of cases, and a concurrent vertical lengthening of the ramus was observed, which resulted in the maintenance of the chin position in the horizontal plane and harmonious facial balance. In addition, the occlusion was maintained, in a Class I relationship, over a 5-year period postoperatively in the 12 cases.

The risk factors for relapse in following mandibular advancement appear to be similar to those seen in the skeletally mature patients. Although the number of patients in the studies in growing children is limited, they appear to indicate that preexisting condylar pathologic conditions, high mandibular plane angles, and large mandibular advancements of greater than 10 mm are potential factors for significant relapse and concur with the findings from adult studies.[35-38]

Since the advent of mandibular distraction osteogenesis techniques, there have been numerous reports of mandibular lengthening in the growing child for treatment of facial deformity or obstructive sleep apnea. There are some short-term follow-up reports on growth and development following the distraction procedure; however, at present there are no convincing, published, long-term prospective studies examining subsequent facial growth patterns and outcomes through to skeletal maturation.[39,40] It is not possible to extrapolate the early results and attempt to draw conclusions about long-term outcomes. A recent study by Hopper et al[41] retrospectively assessed mandibular stability in seven cases following advancement with an external distraction appliance at 12 months after the operation. During the consolidation phase, relapse of the mandible was demonstrated with variable amounts of change. Cephalometric analysis revealed clockwise rotation of the mandible with relapse of advancement and posterior movement of the pogonion. Interestingly, the amount of mandibular relapse during the consolidation phase was demonstrated to be greater than that which occurred between the postconsolidation phase and the subsequent 12-month follow-up in some cases. They found an average relapse of 22% during the consolidation phase (range 4% to 41%), and from the period following the end of the consolidation phase to a 12-month follow-up, there was an additional mean relapse of 28% (range 7% to 58%). This degree of relapse asks the question of what the benefit is from early osteotomy in this patient population. Long-term, longitudinal studies are needed to further evaluate the success of these procedures.

Surgery in the small child or infant is potentially challenging for a number of reasons. The performance of sagittal split osteotomies in the growing child can be technically interesting by virtue of the small amount of cancellous bone and increased pliability of the bone, in conjunction with the presence of second molar and impacted third molar teeth. There is a paucity of literature describing the complications that are seen after early osteotomy with or without the use of distraction osteogenesis. Complications include traumatic injury to tooth buds, nerve injury, malunion, nonunion, trismus, ankylosis of the temporomandibular joint, and intraoral and extraoral scarring. For a number of patients, the hoped-for advantages are outweighed by the number of complications seen. As with most complicated procedures in surgery, patient selection is paramount (Figure 36-9).

Despite these concerns, early advancement of the mandible can have a number of advantages for patients who are approaching skeletal maturity, but have significant deformity. For this population, the risk is relatively low, and the benefit is potentially significant (see Figure 36-7). Even very small children with serious functional concerns (i.e., severe obstructive sleep apnea) may benefit from early advancement of the facial structures even knowing that revision surgery is likely or even



• **Figure 36-9** **A** and **B,** A child born with hemifacial microsomia at age 6 who was previously distracted by another surgeon at an earlier age to improve symmetry and occlusion. The previous asymmetry has recurred, and relapse is evident with crossbites and three-dimensional hypoplasia on the affected side. Early surgery can be helpful in many cases for psychosocial or functional reasons, but may require revision osteotomies and additional procedures that may have a higher degree of complexity in the secondary phase. **C,** The patient is now at skeletal maturity with a more complex deformity than the original asymmetry, and is still in need of maxillary and mandibular orthognathic surgery. The three-dimensional deformities are rarely, if ever, completely addressed with either early distraction or growth modification attempts.

certain. In these cases, the benefits may be so great that they outweigh the possible need for additional procedures.

Mandibular Hyperplasia

For skeletally mature patients who undergo the surgical treatment of mandibular prognathism, long-term stability remains a problem, and the nature of the "relapse" appears to be multifactorial. It is recognized that postpubertal mandibular growth is common, and it is unpredictable in its potential for occurrence in individual patients and the degree of growth. The positioning of the proximal segments following mandibular setback and seating of the condyle can be technically difficult, resulting in subsequent forward movement of the mandible post-surgically. These factors combine to make the correction of mandibular prognathism during growth extremely challenging with difficulty in predicting the final position of the mandible. The risk of relapse of this procedure in the growing child is significant. Because it is not possible to predict the amount of future mandibular growth and accommodation for this growth with "surgical overcorrection" at the time of the setback, the procedure itself does not guarantee a successful outcome. For similar reasons in the growing child, orthopedic correction with functional appliances of skeletal Class III patients with mandibular excess and/or vertical excess are poor candidates for growth modification.[42] Buschang et al,[43] demonstrated a worsening of the horizontal relationship between the anterior nasal spine and pogonion positions during adolescence as a result of the differential growth movements of the mandible. It was not unusual for the anterior-posterior relationship to worsen by greater than 4 mm during adolescence. These results concur with the findings of Harris et al who also observed a progressive worsening of dental relationships in Class III cases.[44]

There is a paucity of literature on the effect of surgical mandibular setback in the growing child because the procedure is rarely undertaken before skeletal maturity. Wolford et al have some experience with the early management of this deformity.[45,46] They performed bilateral high condylectomies with articular disc repositioning, either simultaneously with mandibular setback or as a staged procedure, with condylectomies followed by orthognathic surgery for the management of condylar hyperplasia. The concept of this combined approach is to remove the active "growth center" and therefore retard further mandibular growth potential. They reported stable long-term outcomes, with predictable results of the mandibular position, in 25 patients managed with concomitant high condylectomy and mandibular reduction, with a mean age of 16.7 years and range of 13 to 24 years. There are few published reports examining this combined approach for comparison. In general, the procedure of high condylectomy has been reserved for severe cases of condylar hyperplasia during growth, with the correction of the skeletal malocclusion performed after puberty and following the stabilization of the condylar growth pattern (Figures 36-10 and 36-11).

Maxillary Hypoplasia

In the adult patient, the Le Fort I maxillary advancement has been shown to be a relatively stable procedure, and



• **Figure 36-10** Two patients with varying degrees of maxillary hypoplasia associated with unilateral cleft lip and palate. **A,** This patient exhibits a degree of mandibular hyperplasia and maxillary hypoplasia. **B,** The second patient displays a large degree of discrepancy, but a greater degree of maxillary hypoplasia without the severe mandibular hyperplasia.

in patients undergoing large maxillary advancements, the stability has been found to be improved by the use of interpositional grafting and rigid fixation.[2,13,47] In the consideration of performing maxillary advancement before the completion of growth, it is imperative to assess the nature of the associated skeletal Class III malocclusion. This may be a consequence of isolated maxillary hypoplasia, mandibular hyperplasia, or a combination of both. As previously discussed, mandibular growth commonly occurs through puberty and can influence the outcome of a surgical result leading to a degree of relapse of the Class III malocclusion. If the maxillary deficiency is the underlying cause of the Class III malocclusion, potentially it may be possible to overcorrect the maxillary position at the time of advancement; however, the planning of the amount of "overcorrection" is an empirical decision by the clinician because there are no predictive guidelines for mandibular growth potential. In the presence of mandibular hyperplasia, the surgical correction of the skeletal deformity in the maxilla and/or mandible before the completion of growth can be undertaken with the proviso that a second surgical procedure may be required in the future to compensate for any significant malocclusion.[14]

In patients with a cleft lip and palate or other craniofacial anomalies associated with significant maxillary hypoplasia, there are potential indications for undertaking maxillary advancement during growth. In patients with skeletal Class III discrepancies of greater than 15 mm, there may be consideration for performing two-stage surgical procedures: (1) maxillary advancement during growth to reduce the degree of deformity and improve facial esthetics followed by (2) definitive orthognathic surgery at skeletal maturity. Correction of these large skeletal discrepancies as a single-jaw procedure is associated with significant relapse and may be detrimental to facial balance and esthetics.[13] Undertaking these large movements even as an early single-stage bimaxillary procedure may still demonstrate significant relapse in some cases.[13,14,48,49] The first-stage procedure of maxillary advancement can be performed either by conventional advancement osteotomy or by the technique of distraction osteogenesis, although in some cases distraction osteogenesis may permit larger advancements to be performed.[48,49]

Whether conventional orthognathic or distraction techniques are used for mid-facial or maxillary advancement, the underlying restriction of maxillary growth remains unchanged. Disproportionate maxillary growth in relationship to the mandible following staged advancement will continue (see Figure 36-6). The control of the vector of movement and the maintenance of proportionate bilateral movement in distraction osteogenesis is technically more difficult. The best occlusal and esthetic outcomes post-growth are obtained by experienced orthognathic surgeons using standard techniques of advancement. There have been a number of reported complications using the technique of distraction, especially if there is inadequate mobilization of the maxilla at the time of surgery, which may result in the unfavorable propagation of forces in the mid-facial complex.[50-52]

The maxillary hypoplasia present in craniofacial dysostosis cases, such as Apert's and Crouzon's syndromes, is often severe and occurs concomitantly with fronto-orbital hypoplasia and exophthalmus. The correction of the position of



• **Figure 36-11** A 19-year-old female with hemimandibular hyperplasia that is now stable based on sequential radiographic reviews and a quiescent bone scan. Preoperative views show the significant degree of three-dimensional asymmetry caused by the growth disturbance. Postoperative views show the balanced facial thirds and optimized occlusion.

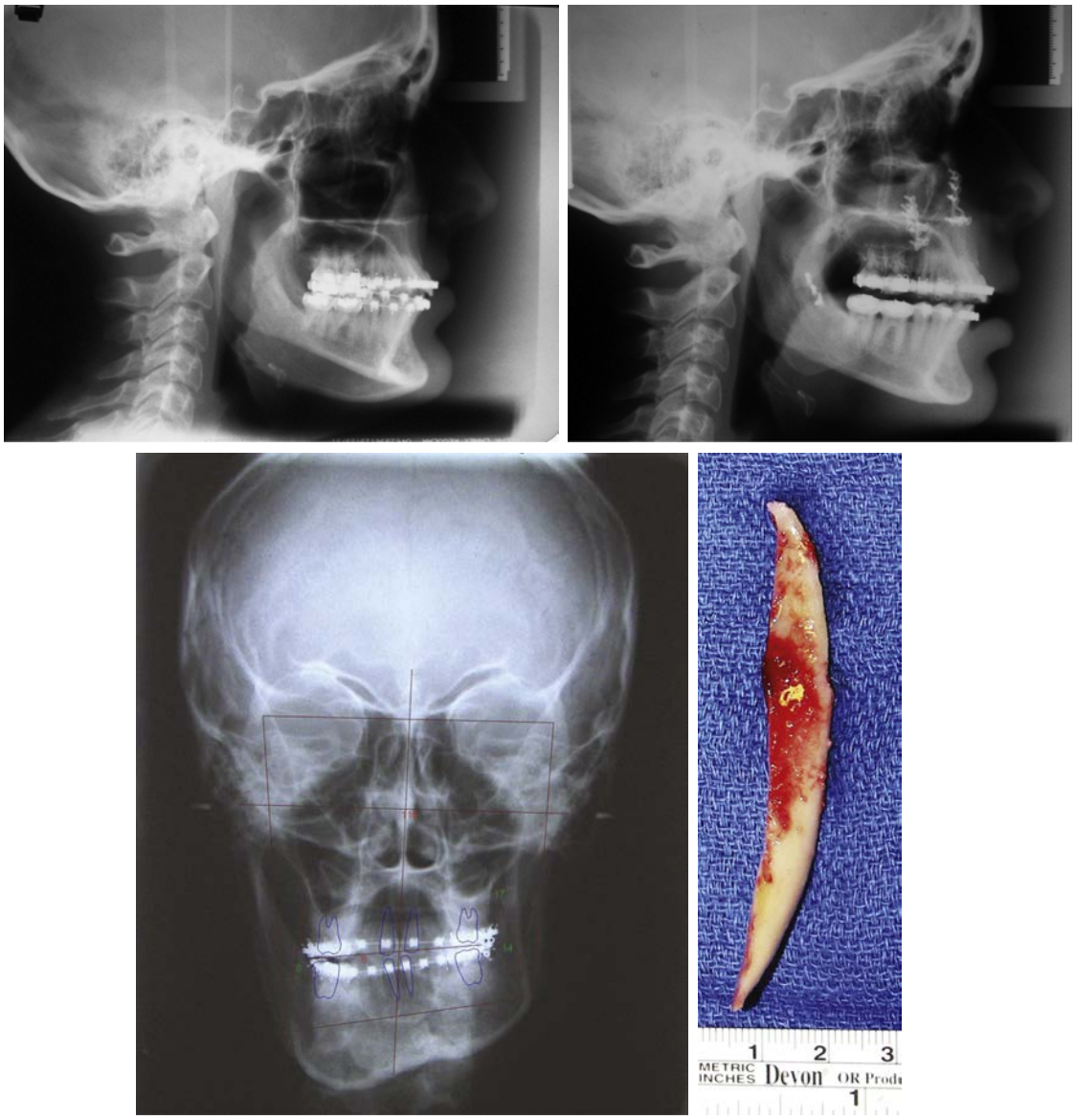

• **Figure 36-11, cont'd**

the fronto-orbital complex is usually undertaken between the ages of 5 to 7 years, when approximately 85% of orbital and zygomatic growth has been completed.[20-22,29] The surgical technique undertaken is based on the amount of movement desired at levels of both the frontal bone and orbital complex, and differential movement may be required. The fronto-orbital advancement can be achieved by either a monobloc procedure or by a staged approach with frontal advancement followed by Le Fort III maxillary advancement. The surgery at this stage is undertaken to correct the fronto-orbital complex position and is not based on the occlusion. The Le Fort III advancement can also be performed by conventional osteotomy or distraction osteogenesis techniques[53,54] (see Figure 36-5). At the completion of skeletal growth, the patient will require definitive orthognathic surgery for management of the malocclusion, which is typically a Class III pattern with or without an anterior open bite.

In addition, there are several technical considerations and aspects of performing maxillary osteotomies in the growing patient. The positioning of the second and third molars and the canines are of importance in the patients undergoing early maxillary osteotomies. Performance of the osteotomy cut with the provision of sufficient space above the apices of the permanent dentition is critical. These teeth may still be unerupted or partially erupted. Failing to provide sufficient space at the osteotomy may result in potentially adverse outcomes for the tooth: ankylosis, impairment of root growth, or devitalization. Due consideration for the location of the tooth roots is also imperative during the placement of plates and screws.

Vertical Maxillary Excess

Vertical maxillary excess (VME) has a well-recognized pattern of facial growth and characteristics. There is characteristic elongation of the maxilla vertically and differential lengthening of the maxilla which result in the development of an anterior open bite in some patients. The VME influences the position of the mandible, with the clockwise rotation of the mandible posterior and inferior, and results in an increase in the mandibular plane angle and increased lower facial height. Early animal experiments appeared to indicate a beneficial response to maxillary impaction during growth, with a 50% to 70% reduction in vertical growth postoperatively.[55] However, these experiments were performed in animals with a "normal" maxillary position without the underlying predisposition for the development of VME. An early report by Freihofer[7] in 1977 found that three growing patients who underwent maxillary impaction for correction of anterior open bite deformities showed marked relapse with continued downward movement of the maxillary molars with growth. Subsequent studies have concurred with the findings of the Freihofer[7] study and contrasted with the results of the animal investigations. Mojdehi et al[56] examined the outcome of maxillary impaction in VME in a series of 15 growing patients, with a mean age of 12.8 years, and found that maxillary repositioning did not change the vertical growth pattern of the maxilla. The growth was not normalized nor retarded by early surgical impaction of the maxilla. In addition, they found that there was evidence of adaptive changes in the mandible with postoperative mandibular and condylar remodeling and repositioning. Washburn et al.[8] reviewed the subsequent growth of the maxilla in 16 patients following maxillary impaction undertaken between 10 to 16 years of age. In the group of patients with bimaxillary protrusion preoperatively, counterclockwise mandibular rotation with growth downward and forward of the mandible was observed, with a mild degree of increase in the height of the lower face.

Continued vertical growth of the maxilla can be anticipated despite early maxillary impaction, and this vertical growth rate will be similar to that observed preoperatively, resulting in relapse and recurrence of the VME. The additional feature of differential maxillary or mandibular growth and the development of an anterior open bite tendency further complicate the potential for undertaking surgery before skeletal maturation (Figure 36-12).

If the patient would benefit from early surgical intervention for psychosocial reasons, adequate warnings regarding the propensity for relapse and the necessity for an additional surgical procedure at the completion of growth are required. To attempt to reduce the chance of development of an open bite postoperatively, it is advisable to maximize the overbite at the time of surgery.



• **Figure 36-12** This adult patient exhibited VME and some mandibular hypoplasia early in life, but developed a late growth phase open bite in her teen years as a result of disproportionate growth of the posterior maxilla. She reports not having an open bite in the younger years of her childhood. She has a long history of obstructive nasal breathing, tonsil hypertrophy, and loud snoring.

Summary

The aims of craniomaxillofacial surgery are to improve function, occlusion, craniofacial balance, and esthetics. Accurate diagnosis, assessment, and careful treatment planning are essential in achieving a successful outcome, and an understanding of the pattern of facial growth is integral in this process.[14,57] Particular attention to the perioperative airway concerns is warranted in these patients, especially when associated with a syndrome or limited temporomandibular joint movement.

The psychological implications of dentofacial deformity have been investigated in a number of studies.[13,58,59] Psychological parameters, such as self-confidence, self-esteem, insecurity, and identification with body image, are intrinsically related to the patient's perception of their facial appearance. A self-perception of an abnormal facial appearance may affect an individual's psychosocial development and interactions. This is especially true during adolescence, which may have important longer-term ramifications. Whereas a single-definitive operation performed at skeletal maturity is preferable for patients who have a significant deformity, psychological implications may present a compelling reason to consider early orthognathic surgery.

The decision to proceed with surgery before the completion of growth is complex and should not be made lightly. Comprehensive understanding of the development of the facial skeleton is critical in this decision process. The patient and his or her family must be fully apprised of all the implications and involved in the decision process. When early surgery is considered, the risk of relapse following surgery during growth necessitating a further surgical procedure at maturity should be discussed in detail with the patient and family. In some cases, such as in the presence of severe maxillary hypoplasia, a two-stage surgical approach may be part of the overall treatment plan.

There are a number of patients who benefit from early surgical intervention before maturation, and careful diagnosis and treatment planning and full consultation with the patient and family are vital when considering craniofacial surgery in the growing patient.

References

1. Proffit WR, White RP, Sarver DM: *Contemporary treatment of dentofacial deformity*, Philadelphia, 2003, Mosby.
2. Proffit WR, Turvey TA, Phillips C: Orthognathic surgery: a hierarchy of stability, *Int J Adult Orthod Orthognath Surg* 11:191–204, 1996.
3. Waitzman AA, et al.: Craniofacial skeletal measurements based on computed tomography: I. Accuracy and reproducibility, *Cleft Palate Craniofac J* 29:112, 1992.
4. Waitzman AA, et al.: Craniofacial skeletal measurements based on computed tomography: II. Normal values and growth trends, *Cleft Palate Craniofac J* 29:118, 1992.
5. Precious DS, Jensen GM, McFadden LR: Correction of dentofacial deformities in children and adolescent patients, *Int J Oral Surg* 14:399, 1985.
6. Precious DS, McFadden LR, Fitch SJ: Orthognathic surgery for children. Analysis of 88 consecutive cases, *Int J Oral Surg* 14:466, 1985.
7. Freihofer HPM: Results of osteotomies of the facial skeleton in adolescence, *J Maxillofac Surg* 5:267, 1977.
8. Washburn MC, Schendel SA, Epker BN: Superior repositioning of the maxilla during growth, *J Oral Maxillofac Surg* 40:142, 1982.
9. Vig KW, Turvey TA: Surgical correction of vertical maxillary excess during adolescence, *Int J Adult Orthod Orthognath Surg* 4:110, 1989.
10. Schendel SA, Wolford LM, Epker BN: Mandibular deficiency syndrome. III. Surgical advancement of the deficient mandible in growing children. Treatment results in twelve patients, *Oral Surg* 45:364, 1978.
11. Wolford LM, Schendel SA, Epker BN: Surgical-orthodontic correction of mandibular deficiency in growing children. Long term treatment results, *J Maxillofac Surg* 7:61, 1979.
12. Huang CS, Ross RB: Surgical advancement of the retrognathic mandible in growing children, *Am J Orthod* 82:89, 1982.
13. Posnick JC, Tompson B: Cleft orthognathic surgery: complications and long-term results, *Plast Reconstr Surg* 96:255, 1995.
14. Turvey TA, Simmons K: Orthognathic surgery before the completion of growth, *Oral Maxillofac Surg Clin North Am* 6:121, 1994.
15. Scott JH: The analysis of facial growth from fetal life to adulthood, *Angle Orthod* 33:11–113, 1963.
16. Riola ML, et al.: *An atlas of craniofacial growth: cephalometric standards from the University School growth study*, Ann Arbor, Mich, 1974, University of Michigan Center for Human Growth and Development.
17. Moss M: The functional matrix hypothesis revisited: I. The role of mechanotransduction, *Am J Orthod Dentofac Orthop* 112:1, 1997.
18. Enlow DH, Hans M: *Essentials of facial growth*, Philadelphia, 1996, WB Saunders.
19. Enlow DH, Kuroda T, Lewis A: The morphological and morphogenic basis for craniofacial form and pattern, *Angle Orthod* 41:3, 1971.
20. Farkas LG, Posnick JC, Hreczko TM: Anthropometric growth study of the head, *Cleft Palate Craniofac J* 29:306, 1992.
21. Farkas LG: *Anthropometry of the head and face in medicine*, New York, 1981, Elsevier.
22. Farkas LG, Posnick JC: Growth and development of regional units in the head and face based on anthropometric measurements, *Cleft Palate Craniofac J* 29:301, 1992.
23. Farkas LG, Posnick JC, Hreczko T: Growth patterns of the face: a morphometric study, *Cleft Palate Craniofac J* 29:303, 1992.
24. Gorski JL, et al.: Skeletal-specific expression of FGD1 during bone formation and skeletal defects in faciogenital dysplasia, *Dev Dyn* 218:573–586, 2000.
25. Mooney MP, et al.: Development of a strain of rabbits with congenital simple, nonsyndromic coronal suture synostosis. Part 2: somatic and craniofacial growth patterns, *Cleft Palate Craniofac J* 31:8, 1994b.

26. Mooney MP, et al.: Cranial base changes following coronal suturectomy in craniosynostotic rabbits, *J Dent Res* 79:323, 2000.
27. Kjaer I, Keeling JW, Fischer-Hansen B: *The prenatal human cranium-normal and pathologic development*, Copenhagen, 1999, Blackwell Science.
28. Scott JH: The analysis of facial growth. I. The anteroposterior and vertical dimensions, *Am J Orthod* 44:507, 1958.
29. Posnick JC, Farkas LG: The application of anthropometric surface measurements in craniomaxillofacial surgery. In Farkas LG, editor: *Anthropometry of the head and face*, ed 2, New York, 1994, Raven Press.
30. Posnick JC, et al.: Sagittal synostosis: quantitative assessment of presenting deformity and surgical results based on CT scans, *Plast Reconstr Surg* 92:1015, 1993.
31. Grave KC, Brown T: Skeletal ossification and the adolescent growth spurt, *Am J Orthod* 71:406–420, 1977.
32. Franchi L, Baccetti T, McNamara JA: Mandibular growth as related to cervical vertebral maturation, *Am J Orthod Dentofac Orthop* 118:335–340, 2000.
33. Hajnis K, Hajnisova M: Determination of the time for the corrective operations of the face according to the dynamics of its growth, *Anthropos* 19:123, 1967.
34. Snow MD, et al.: Surgical mandibular advancement in adolescents post surgical growth related to stability, *Int J Adult Orthod Orthop* 6:143, 1991.
35. DeClercq CA, et al.: Condylar resorption in orthognathic surgery: a retrospective study, *Int J Adult Orthod Orthognath Surg* 9:233, 1994.
36. Arnett GW, Milam SB, Gottesman L: Progressive mandibular retrusion—idiopathic condylar resorption. Part I, *Am J Orthod Dentofac Orthop* 110:8, 1996.
37. Crawford JG, et al.: Stability after reoperation for progressive condylar resorption after orthognathic surgery: report of seven cases, *J Oral Maxillofac Surg* 52:460, 1994.
38. Morabarak KA, et al.: Mandibular advancement in high angle and low angle Class II patients: different long term skeletal responses, *Am J Orthod Dentofacial Orthop* 119:368, 2001.
39. Swennen G, et al.: Craniofacial distraction osteogenesis: a review of the literature: part I: clinical studies, *Int J Oral Maxillofac Surg* 30:89, 2001.
40. Swennen G, Dempf R, Schliephake H: Craniofacial distraction osteogenesis: a review of the literature: part II. Experimental studies, *Int J Oral Maxillofac Surg* 31:123, 2002.
41. Hopper RA, et al.: Cephalometric analysis of the consolidation phase following bilateral pediatric mandibular distraction, *Cleft Palate Craniofac J* 40:233, 2003.
42. Kluemper GT, Spalding PM: Realities of craniofacial growth modification, *Atlas Oral Maxillofac Surg Clin North Am* 9:23, 2001.
43. Buschang PH, Martins J: Childhood and adolescent changes of skeletal relationships, *Angle Orthod* 68:199, 1998.
44. Harris EF, Behrents RG: The intrinsic stability of Class I molar relationships: a longitudinal of untreated cases, *Am J Orthod Dentofac Orthop* 94:63, 1988.
45. Wolford LM, et al.: Efficacy of high condylectomy for management of condylar hyperplasia, *Am J Orthod Dentofac Orthop* 121:136, 2002.
46. Wolford LM, Karras SC, Mehra P: Considerations for orthognathic surgery during growth. Part 1. Mandibular deformities, *Am J Orthod Dentofac Orthop* 119:95, 2001.
47. Bishara SE, Chu GW: Comparisons of postsurgical stability of the Le Fort I impaction and maxillary advancements, *Am J Orthod Dentofac Orthop* 102:335, 1992.
48. Costello BJ, Ruiz RL: The role of distraction osteogenesis in orthognathic surgery of the cleft patient. In *Selected readings in oral and maxillofacial surgery*, Dallas, 2001, University of Texas Southwestern Medical Center.
49. Posnick JC, Ruiz RL: Discussion of: management of secondary orofacial cleft deformities. In Goldwyn RM, Cohen MN, editors: *The unfavorable result in plastic surgery: avoidance and treatment*, ed 3, Philadelphia, 2000, Lippincott Williams & Wilkins.
50. Cohen SR, Rutrick RE, Burstein FD: Distraction osteogenesis of the human craniofacial skeleton: initial experience with a new distraction system, *J Craniofac Surg* 6:368, 1995.
51. Cohen SR, et al.: Maxillary-midface distraction in children with cleft lip and palate: a preliminary report, *Plast Reconstr Surg* 99:1421, 1997.
52. Lo LJ, Hung KF, Chen YR: Blindness as a complication of LeFort I osteotomy for maxillary disimpaction, *Plast Reconstr Surg* 109:688–698, 2002.
53. Holmes AD, et al.: Le Fort III internal distraction in syndromic synostosis, *J Craniofac Surg* 13:262, 2002.
54. Polley JW, et al.: Monoblock craniomaxillofacial distraction osteogenesis in a newborn with severe craniofacial synostosis: a preliminary report, *J Craniofac Surg* 6:421, 1995.
55. Nanda R, Bouayad O, Topazian RG: Facial growth subsequent to Le Fort I osteotomies in adolescent monkeys, *J Oral Maxillofac Surg* 45:123, 1987.
56. Mojdehi M, et al.: Postsurgical growth changes in the mandible of adolescents with vertical maxillary excess growth pattern, *Am J Orthod Dentofac Orthop* 119:106, 2001.
57. Wolford LM, Karras SC, Mehra P: Considerations for orthognathic surgery during growth. Part 2. Maxillary deformities, *Am J Orthod Dentofac Orthognath Surg* 119:102, 2001.
58. Bertolini F, Russo V, Sansebastiano G: Pre- and postsurgical psychoemotional aspects of orthognathic surgery, *Int J Adult Orthod Orthognath Surg* 15:16, 2000.
59. Gerzanic L, Jagsch R, Watzke IM: Psychologic implications of orthognathic surgery in patients with skeletal Class II or Class III malocclusion, *Int J Adult Orthod Orthognath Surg* 17:75, 2002.

37

Nonsyndromic Craniosynostosis: Diagnosis and Contemporary Surgical Management

RAMON L. RUIZ, MICHAEL JASKOLKA, ANN M. RITTER, TIMOTHY A. TURVEY, BERNARD J. COSTELLO

Introduction

Cranial sutures represent a form of articulation in which the margins of the bones of the cranial vault are connected by a dense layer of fibrous tissue. The cranial vault is composed of six major (Figure 37-1) and several minor sutures. Initially, the sutures allow head deformation during vaginal delivery as part of the birthing process. Later, during an infant's postnatal development, cranial vault sutures facilitate head expansion to accommodate propulsive brain growth.[1] Only small amounts of pressure (5 mm Hg) from the growing brain are required to stimulate bone deposition at the margins of a cranial bone.[2,3] Under normal conditions, the brain volume will triple within the first year of life, and by age 2, the cranial capacity is four times that at birth.[4]

The term *craniosynostosis* is defined as the *premature fusion* of one or more of the cranial vault sutures. With rare exception, this is an intrauterine event so that a more accurate description of craniosynostosis may be a *congenital absence* of the cranial vault suture(s). The result is fusion of the bones at the suture and arrested growth. The classic theory expressed by Virchow states that premature fusion of a cranial vault suture results in limited development of the skull perpendicular to the fused suture and a compensatory "overgrowth" through the sutures that remain open.[5] This concept was further extended by Delashaw to more completely explain the characteristic dysmorphology that occurs depending upon which of the cranial sutures is affected.[6]

In general, most forms of nonsyndromic craniosynostosis are thought to represent sporadic events. Even though a positive family history may be found in 2% to 10% of cases a clear etiologic explanation is usually absent.[7] This implies a combination of genetic promoters and impact of epigenetic and environmental factors, such as maternal thyroid disease.[8] Advances in molecular and cytogenetic testing as well as large population-based studies such as the U.S. National Birth Defects Prevention Study will continue to further explain the etiology of nonsyndromic craniosynostosis.

Malformations resulting from craniosynostosis affect the cranial vault and orbital regions. Management typically requires a combined neurosurgical and craniofacial approach for release of the involved suture so that unrestricted brain growth and reshaping of the dysmorphic skeletal components can occur.

Functional Consequences of Craniosynostosis

Brain volume expansion occurs at a rapid rate during the first 2 years of life. During this time, it is growth of the visceral structures (i.e., brain and eyes) that drives the growth of the skeletal structures (i.e., cranial vault and orbits). Patent cranial vault sutures create a flexible complex of cranial bones that allow the growing brain to push them outward. Cranial growth occurs both at these open regions in a direction that is perpendicular to each suture and through endocranial resorption in combination with ectocranial deposition of bone.

Intracranial Pressure

The congenital absence of a cranial vault suture results in fusion of the adjacent bone plates with arrested growth along that suture. Although compensatory growth occurs at the uninvolved sutures, it is hypothesized that a reduction in cranial volume ensues. The combination of a rapidly expanding brain and diminished cranial volume secondary to the restricted cranial growth may result in increased intracranial pressure (ICP), greater than 15 mm H_2o, with negative neurologic consequences.

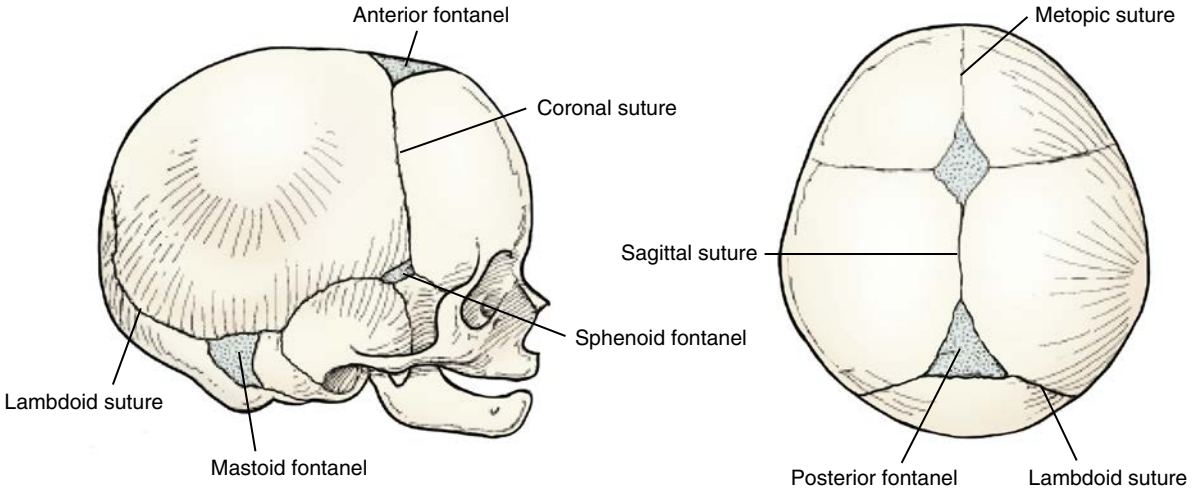

• **Figure 37-1** During infancy, the cranial vault sutures remain open to allow for normal brain growth. Major cranial vault sutures include the metopic, right and left coronal, sagittal, and right and left lambdoid. (From Ruiz RL, et al: Nonsyndromic craniosynostosis: diagnosis and contemporary surgical management, *Oral Maxillofacial Surg Clin North Am* 16:447-463, 2004.)

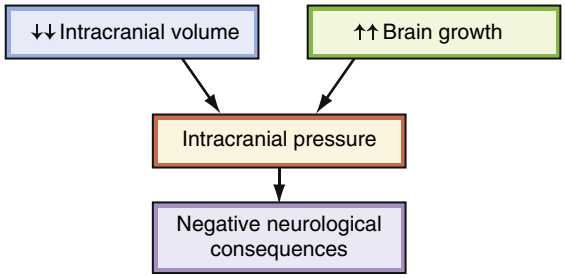

• **Figure 37-2** The relationship between diminished bony growth caused by craniosynostosis and increased ICP with resultant neurologic damage. Although this description of events is incomplete, it represents one of the basic considerations upon which surgical management is based. (From Ruiz RL, et al: Nonsyndromic craniosynostosis: diagnosis and contemporary surgical management, *Oral Maxillofacial Surg Clin North Am* 16:447-463, 2004.)

This sequence of events (Figure 37-2) is often used to explain the theoretic relationship between craniosynostosis and brain insult, but it does not adequately explain why some patients will develop elevated ICP and others will not. Not all patients with craniosynostosis demonstrate reduced intracranial volume.[9-11] Additional factors may include localized areas of pressure secondary to abnormal morphology, variations in CSF production, flow and absorption, increased venous resistance, anomalous venous drainage, and airway obstruction. In the classic study published in 1982 by Renier and colleagues, increased ICP was recorded in 14% of children with untreated single-suture craniosynostosis. When two or more sutures were fused, the likelihood of elevated ICP increased to 47%.[2,12] Other investigations have more recently reported a range of increased ICP in 4.5% to 44% of similar patients continuing to support raised ICP as a pathologic finding in patients with nonsyndromic craniosynostosis.[13,14]

Children with untreated craniosynostosis who go on to develop increased ICP may exhibit a number of neurologic changes, including headaches, vomiting, sleep disturbances, feeding difficulties, behavioral changes, and diminished cognitive functioning.[2,12,15,16] Symptoms related to increased ICP are rarely encountered before 1 year of age and frequently have a slow, gradual onset. In the pediatric patient, these are difficult to detect and, left untreated, may be irreversible.[16] Recognition of these neurologic signs and symptoms is further complicated by the young age of the patients with craniosynostosis who cannot yet communicate these physical findings to alert parents and examiners.

Hydrocephalus

Hydrocephalus is not usually observed in patients with nonsyndromic single-suture craniosynostosis, but it may occur independently and not necessarily as a consequence of this condition. In contrast, hydrocephalus is encountered in approximately 10% of children with multiple-suture craniosynostosis and may be seen in the craniofacial dysostosis syndromes.[17-19] The correct diagnosis may require serial neurosurgical evaluations, computed tomography (CT) scan, magnetic resonance imaging (MRI), and cerebrospinal fluid (CSF) flow studies.

In cases where the infant has both hydrocephalus and craniosynostosis, careful consideration must be given to the exact timing and sequence of the cranial vault reshaping and ventriculoperitoneal (VP) shunt placement. Although the final decision is a neurosurgical one based on the child's neurologic condition, placement of the VP shunt should be performed as a separate surgery after the cranial vault reconstruction when possible. The presence of a VP shunt at the time of synostosis repair may decrease brain expansion in the postoperative period, thus reducing physical support to the bone segments and delaying the elimination of extradural dead space.[16]

Ophthalmologic Effects

In patients with craniosynostosis and associated elevated ICP, the optic nerve is at risk. Prolonged, untreated ICP elevations can produce papilledema, optic nerve atrophy, and eventual loss of vision, which may be complete. With this in mind, pre- and postoperative dilated ophthalmologic examinations are often undertaken to help screen for the presence or recurrence of increased ICP. Although they may be used to support the diagnosis of elevated ICP, the absence of papilledema is not necessarily effective at excluding its presence in an infant.[20]

When the specific form of craniosynostosis produces orbital deformity or asymmetry, negative impact on visual function may be realized. For example, orbital dystopia secondary to unilateral coronal synostosis can result in disturbances of extraocular muscle movement (i.e., strabismus), upper eyelid ptosis, and poor binocular vision. In cases of syndromic or nonsyndromic bilateral coronal suture craniosynostosis, decreased orbital volume will cause proptosis with an increased risk of direct trauma to the eye and corneal exposure or ulceration.

Neurodevelopmental Considerations

Nonsyndromic craniosynostosis is associated with a risk of neurodevelopmental impairment. This has been documented in treated and untreated patients in terms of cognitive, language, and psychomotor abilities.[21,22] Hypothesized mechanisms include elevated ICP, localized areas of intracranial pressure and reduced cerebral blood flow, and abnormal cerebral shape due to abnormal cranial and skull base morphology. The use of MRI has helped to elucidate other intracranial abnormalities including those in the cortical and subcortical structures.[23,24]

It is hypothesized that suture release and cranial vault remodeling is beneficial in limiting the severity or progression of delay, but this has yet to be proven. Many questions remain regarding the impact of timing and surgical procedure on neurodevelopmental outcomes. Ongoing studies are attempting to more clearly define the incidence and severity of impairment and their association with the different types of nonsyndromic craniosynostosis and their treatment.[25] Regardless of the hoped for impact of surgery, this is a patient population that is at high risk for developmental delay.[22] The most recent multidisciplinary practice parameters for care of the patient with single-suture craniosynostosis recommend perioperative neurodevelopmental screening and referral for early intervention therapy.[26]

Diagnostic Approach to Abnormal Head Shape

When an infant has a cranial vault asymmetry, the examiner must be alert to the possibility of prematurely fused sutures. However, abnormal head shape may be produced by various causes that must be distinguished from craniosynostosis. Most commonly, external forces applied to a flexible cranium with open sutures cause a "deformation" of the skull. In newborns, this deformational plagiocephaly is often the direct result of the head passing through the birth canal or the baby's early descent into the true pelvis and may involve the anterior and posterior cranial vaults.[27,28] Another common cause of deformational plagiocephaly are the postnatal external forces that result from repetitive sleep positioning. In 1992 the American Academy of Pediatrics made the recommendation that infants be placed on their backs during sleep, which has lead to an approximate 40% reduction in the risk of sudden infant death syndrome (SIDS).[29] However, associated with the "Back to Sleep" campaign came an increased awareness of cranial vault deformities within the pediatric community; an increased number of referrals for management of nonsynostotic posterior plagiocephaly has resulted.[30,31]

Accurately differentiating which cranial vault deformities are the result of nonsynostotic causes (i.e., positional plagiocephaly) and which are associated with a true absence of a cranial vault suture (i.e., craniosynostosis) is critical to establishing a diagnosis and formulating the appropriate treatment plan. The importance of a correct diagnosis is underscored by the dramatically different treatment approach to each condition. Craniosynostosis requires surgical treatment, whereas benign positional skull molding (positional plagiocephaly) is not associated with any neurologic consequences and typically requires conservative nonsurgical management. These techniques include patient counter positioning, the selective use of custom-made cranial orthotic devices, and in the case of torticollis, neck physical therapy.

A careful history and clinical examination are the primary basis upon which the diagnosis of craniosynostosis is made. As craniosynostosis is an intrauterine event, parents will often report that the deformity was noted immediately after birth and never improved after that time. In contrast, the typical history provided in cases of positional plagiocephaly is that the child's head was well rounded at the time of birth and the asymmetry was noted 3 to 6 months later, suggesting postnatal deformation of a flexible cranial vault.

Clinical examination of the infant with craniosynostosis is a key element in establishing the diagnosis. Craniosynostosis leads to arrested skeletal growth perpendicular to the affected suture through continued or compensatory growth at the sutures that remain open. This combination of arrested growth in one region and additional growth in others explains how unilateral sutural involvement results in a bilateral deformity and how fusion of one suture within the posterior cranial vault produces a deformity that affects the entire anteroposterior (AP) dimension of the cranium. An examiner familiar with these aberrant growth patterns and the characteristic dysmorphologies specific to each type of synostosis will be able to consistently establish an accurate clinical diagnosis. Following clinical evaluation by a pediatric craniofacial surgeon and/or pediatric neurosurgeon, radiographic imaging

is indicated for confirmation of the diagnosis. A complete skull series of plain radiographs may be used to evaluate the cranial vault sutures. In cases where all of the sutures cannot be adequately visualized using plain films, additional imaging with the use of a computed tomography (CT) scan of the craniofacial region is indicated. In addition to confirming the diagnosis, high-resolution craniofacial CT scans provide detailed three-dimensional morphologic information, which is useful during the surgical planning phase. High-resolution CT scans with 0.6 millimeter axial and coronal cuts with overlap and 3D reconstructions of the cranial vault, cranial base, orbits, and maxillofacial skeleton are recommended. Precise patient positioning is important in obtaining a diagnostic scan. In the past, infants may have required sedation or general anesthesia for appropriate image acquisition, but modern day rapid multislice scanners have largely made this less frequent.

Although technologic advancements have dramatically increased the accuracy of standard radiographic imaging, incorrect and outdated terminology is still occasionally used in describing cranial vault sutures. At some medical centers, radiologists and surgeons continue to use terms such as "fibrous synostosis," "suture dysfunction," and "impending synostosis" when describing cranial vault sutures that otherwise appear open. We now know that craniosynostosis is in the vast majority of cases an intrauterine event that is either present at birth or not at all.[16,31] Therefore if a suture appears patent on a radiographic study that is of diagnostic quality, the diagnosis of craniosynostosis is ruled out. Although the pathologic postnatal fusion of cranial vault sutures has been described in the scientific literature, it is considered an extremely rare event that is specifically related to specific clinical and syndromic conditions. The use of the terms described earlier is not consistent with contemporary knowledge about craniosynostosis, may be confusing to parents and health care providers, and may even result in inappropriate surgical treatment for patients who do not truly have craniosynostosis.

When reviewing radiographic imaging of the infant cranial vault, an additional important consideration is the metopic suture. Normal (e.g., physiologic) closure of the metopic suture occurs between 3 and 8 months of life, starting at the nasion and progressing towards the anterior fontanelle.[36,37] Therefore, radiographic absence of the metopic suture in an older infant with no craniofacial dysmorphology (e.g., trigonocephaly, hypotelorism, horizontally retrusive lateral orbital rims) is not craniosynostosis and rather a physiologic, appropriate, closure of the metopic suture.

Treatment of Nonsyndromic Craniosynostosis

General Considerations

There are two primary objectives in the contemporary surgical management of nonsyndromic craniosynostosis: first, the release of the involved (i.e., fused) suture so that brain growth can proceed in an unrestricted fashion and second, the reconstruction of all dysmorphic skeletal components so that a more anatomically correct shape is achieved. The best results are achieved with collaboration between a pediatric craniofacial surgeon and pediatric neurosurgeon.

Surgical techniques historically used to treat craniosynostosis involved only the removal of the involved suture via a "strip craniectomy."[38,39] Generally, these limited craniectomy procedures would be performed by a neurosurgeon working independently. The theory behind this approach was that release of the suture would allow unrestricted brain growth and that the expanding brain would adequately recontour the bones, prior to refusion, without the need for formal craniofacial reconstruction. Although this approach may allow for some cerebral decompression, the reality is that a dysmorphic skull will not reshape itself, even in the presence of an expanding brain, and the result is a residual bony deformity.

Modern surgical management of craniosynostosis involves release of the involved suture(s) with a formal craniotomy performed by a neurosurgeon. At the same time, reconstruction requires the removal, dismantling, and reassembly of all dysmorphic skeletal components into a more anatomically correct position. Depending upon which specific cranial vault suture is affected, the reconstruction may also involve the orbits. The exact surgical plan is formulated based on the extent of the skeletal deformity, the suture or sutures involved, and the age of the patient at the time of diagnosis. In most cases of nonsyndromic, single-suture craniosynostosis, one operation to simultaneously release the suture and reshape the affected skeletal parts will adequately address the problems definitively. This is more likely when the surgical procedure is carried out during the first year of life and the patient has normal brain growth. In addition to a combined craniofacial and neurosurgical approach, involvement of a number of other pediatric subspecialists, including pediatric anesthesiologists and pediatric intensivists, is required.

In recent years, there has been resurgence in strip craniectomy procedures with the recognition that adjunctive interventions must also be used to improve the dysmorphology. The most popular of these approaches are endoscopic assisted suturectomy with postoperative cranial orthotic molding. The endoscopically assisted approach includes a strip craniectomy for the release of the involved suture(s) and the creation of multiple "barrel-stave" osteotomies within the cranial vault.[40-45] The primary advantage of this technique is a smaller surgical incision. Other theoretical advantages include shorter operative times, reduced need for blood transfusions, less morbidity and shorter length of hospitalization. The main disadvantage encountered with the use of an endoscopic procedure is that the surgical maneuvers performed do not address the cranial and/or orbital dysmorphology and residual

deformity, which remains following the surgical procedure. The child's cranial vault dysmorphology is treated with the use of a postoperative custom molding helmet (i.e., cranial orthotic). Full-time orthotic wear often begins 7 to 10 days following surgery and may be required for 9 to 12 months with an average use of 3 helmets.[45] There is theoretical concern over the extended use of a device with the potential to restrict growth of the brain and skull, and so close supervision and adjustments of the device by an orthoptist is necessary. Application of this technique is most predictable in patients with cranial deformities that are mildly dysmorphic. Because the successful use of custom-made cranial orthotic devices (e.g., bands or helmets) is largely dependent upon ongoing rapid brain growth for reshaping, children diagnosed with craniosynostosis after 6 months of age are not considered good candidates for endoscopic treatment. A final concern is the representation of endoscopic surgery as "nonsurgical" or "minimally invasive." Although the length of the incision used is decreased, significant complications including hemorrhage, laceration of the sagittal sinus, the need for blood transfusion, dural tears, and brain injury are possible. Blood transfusion is required in a portion of children undergoing the operation. Surgeons contemplating an endoscopically assisted procedure must be aware of these potential problems and make standard preparations (e.g., type and cross blood, secure neurosurgical support) to deal with them as necessary. A less commonly discussed procedure is spring assisted cranioplasty. This technique involves a similar craniectomy for release of the fused suture and placement of a spring, which provides continuous force across the sutural area in order to facilitate expansion of the cranial vault.[46] The hoped for advantage is a limited procedure (e.g., isolated craniectomy) with expansion provided by the spring device following the procedure. Disadvantages include a surgical procedure that is limited to suture release with no reshaping of the dysmorphic skeletal components and spring devices, which in their current stage of technical refinement, are only unidirectional and provide no three-dimensional control. Another disadvantage is the requirement of a second surgical procedure and general anesthetic for device removal.

Surgical Planning

One of the primary goals of surgical treatment of nonsyndromic craniosynostosis is the normalization of the dysmorphic cranium and orbits. To achieve this goal, careful preoperative planning is a necessity. The ubiquitous use of CT scans for the diagnosis of craniosynostosis has combined with the mainstream availability of software-based computer systems to make 3D virtual manipulation an increasingly accessible option. In general, following CT acquisition, DICOM data is segmented and a virtual model constructed (Figure 37-3). Osteotomies are then designed and the resulting bone segments repositioned. Multiple iterations of the surgical simulation can be developed (Figures 37-4). The application of normative data sets[47,48] allow for quantification of the presenting deformity as well as idealization of the final result. After the simulated treatment plan has been finalized, transfer of this information to the patient during surgery can be facilitated with the use of rapid prototyped templates (Figures 37-5).

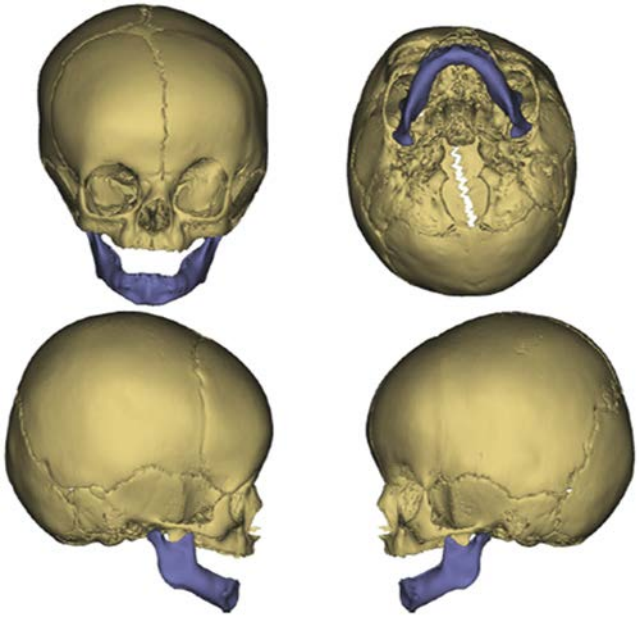

• **Figure 37-3** Preoperative virtual model of a patient with left sided unilateral coronal craniosynostosis.

Increased cost is always a concern when adopting new technology and should be offset by improved patient outcomes. The virtual surgical planning process described above has been shown to be accurate when applied in the clinical setting, and it is postulated that there is a reduction in operative time and improved skeletal repositioning. This has been demonstrated in the orthognathic surgery literature,[49] but has yet to be definitely proven in the realm of craniosynostosis reconstruction.

Another consideration must weigh the benefit of virtual surgical planning with the potential negative impact of radiation exposure from the CT scan. If CT is used in the diagnostic workup, the scan can be used for virtual planning as long as a minimum axial slice thickness of 1.0 mm is acquired and stored. If the CT dataset is acquired with a significant interval prior to surgery, the fit of the CAD/CAM templates may be poor due to the interval growth of the skull. Although an additional CT scan may be considered, modification of the original CT scan based upon head circumference change has shown to be an accurate method to account for skull growth in this scenario.[50]

Timing of Surgery

In almost all patients with single-suture craniosynostosis, elevated ICP is not encountered before 1 year of life. A

diagnosis of craniosynostosis made before 12 months of age does not represent a "surgical urgency" because the risk for the child of developing increased ICP is minimal during this time period. The fused suture and cranial vault dysmorphology can be safely addressed at some point during the first year before the possibility of elevated ICP increases.

The specific, ideal age at which to proceed with craniosynostosis repair is a subject that remains controversial. A wide range of recommended ages exists among pediatric craniofacial and neurologic surgeons who routinely perform these procedures. Some surgeons advocate for a relatively "early" repair carried out at approximately 3 to 6 months of age, whereas others postpone surgery until after age 9 to 11 months.[16,51] There are theoretic advantages and potential negative consequences associated with each approach.

Early surgical correction carried out when the child is 3 to 6 months of age is often suggested by surgeons who believe that releasing the suture early will "unlock" normal growth and allow the brain to perform most of the bony reshaping as it expands, thus reducing the degree of bony remodeling required at the time of surgery. This theoretic advantage, however, does not obviate the need for formal skeletal reconstruction to establish the desired anatomic configuration of the cranium. Bone segments in younger infants are more malleable, which permits easier reshaping, and the growing brain does provide rapid elimination of extradural dead space and support for the newly constructed bony framework.

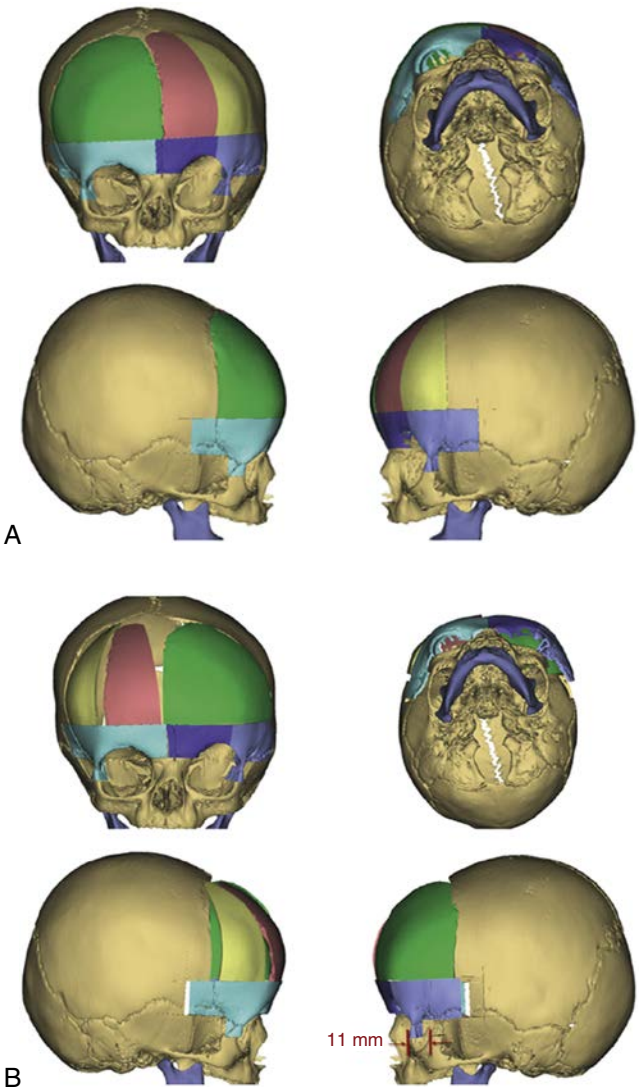

• **Figure 37-4** **A,** Osteotomies completed on the virtual skull model. **B,** Repositioning of the osteotomized bone segments

Delaying the surgical procedure until approximately 9 to 11 months of age permits a greater proportion of the child's cranial vault growth to occur before correction. This may translate into a more stable skeletal result with fewer postsurgical distortions related to subsequent growth. At this age, the bones are better ossified and more cortical, which results in less separation at sutural lines (e.g., frontozygomatic suture) and easier placement of rigid internal fixation devices.

Irrespective of the timing, careful dismantling of the dysmorphic skeletal components and reshaping with some degree of overcorrection is advocated as continued growth is likely to be abnormal and trend toward recapitulation of the original presentation.[52]

When craniofacial reconstructive surgery is carried out during infancy, complete healing of relatively large (1.5 cm) bony defects will occur without the need for additional bone grafting. This is due to the combined bony healing capacity of the pericranium and the dura, which is highly osteogenic during infancy. Most residual cranial vault defects will heal completely when the surgery is performed during the first 2 years of life. When cranial vault surgery is undertaken between 2 and 4 years of life, complete healing of residual full-thickness defects is less predictable and either immediate grafting or a secondary procedure for repair may be indicated. After age 4, it is unlikely that even small full-thickness cranial vault defects will resolve without deliberate reconstruction or grafting at the time of the initial surgery.

Complications and Transfusion Management Strategies

Isolated suture craniosynostosis reconstruction has demonstrated a high level of overall safety as confirmed by a recent single center review of 746 patients with a reported complication rate of 4.6% and mortality of 0.1%.[53] Although safe, these procedures are associated with significant blood loss. A prior review and survey of 8101 craniofacial procedures reported a similarly low rate of mortality, but attributed 50% of cases to blood loss.[54] Thoughtful transfusion protocols must be employed. Controlled hypotensive anesthesia protocols are generally avoided because of the potential adverse impact on cerebral perfusion.[55] A number of protocols have been described for the management of intraoperative blood

loss during craniosynostosis procedures including the use of intraoperative blood salvage, preoperative erythropoietin (EPO) administration, iron supplementation, standardized transfusion guidelines, and intraoperative tranexamic acid.[56-60]

Special Considerations Related to Delayed Diagnosis

Despite an awareness of abnormal head shape–related problems within the pediatric medical community, the diagnosis of craniosynostosis may not be established until later in infancy or childhood. The definitive diagnosis may be delayed by an atypical morphologic presentation, health care providers that are not familiar with the different head-shape patterns, nondiagnostic imaging, or a lack of access to craniofacial subspecialists for timely consultation. Another scenario is the delay of a diagnosis or of definitive surgical treatment in a child born with multiple congenital deformities. It may be that initial attention is directed at resolving other medical (e.g., cardiac) problems that are a more immediate threat to the child's health and the issue of abnormal head shape is addressed later in life. Children who have untreated craniosynostosis after 3 years of life may represent a unique diagnostic challenge to craniofacial and neurologic surgeons. This is especially true if the child has minimal craniofacial dysmorphology. In such cases, the primary consideration in deciding whether or not to pursue surgical intervention is the presence of any evidence of increased ICP. Initial workup includes imaging studies and a formal pediatric ophthalmologic evaluation. When a comprehensive neurologic examination is not conclusive, the use of additional surgical and/or diagnostic measures may be useful. Invasive monitoring of ICP may be accomplished using an epidural sensor.[12,51,61] The procedure requires a burr-hole craniotomy to place an intracranial wire transducer, which is left in place for 24 to 48 hours. Measurements of the patient's ICP are made on an hourly basis and at different activity levels (e.g., sleeping, playing, crying) during this time interval. This form of monitoring may provide valuable information useful in the decision-making process in a case where there is little or no indication to pursue surgery for morphologic reasons. Another method of documenting increased ICP involves a direct lumbar puncture.[51]

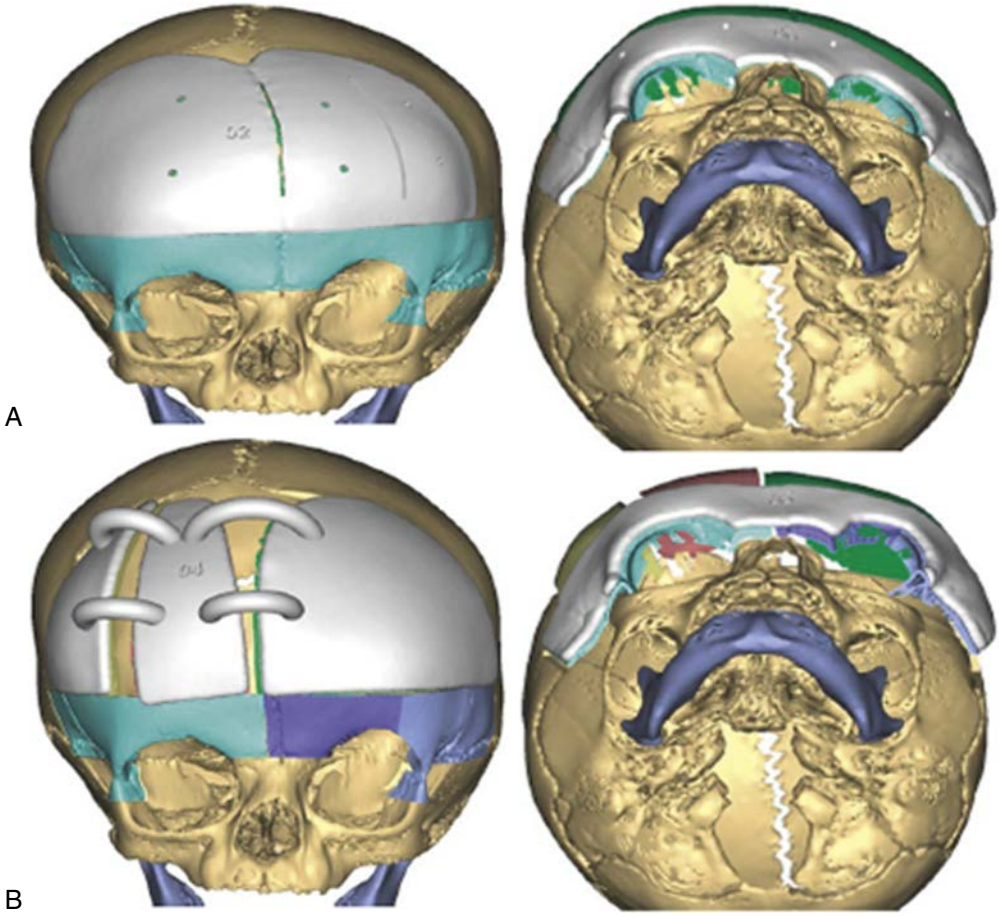

• **Figure 37-5** **A,** Design of the osteotomy templates. **B,** Design of the reconstruction and positioning templates.

Continued

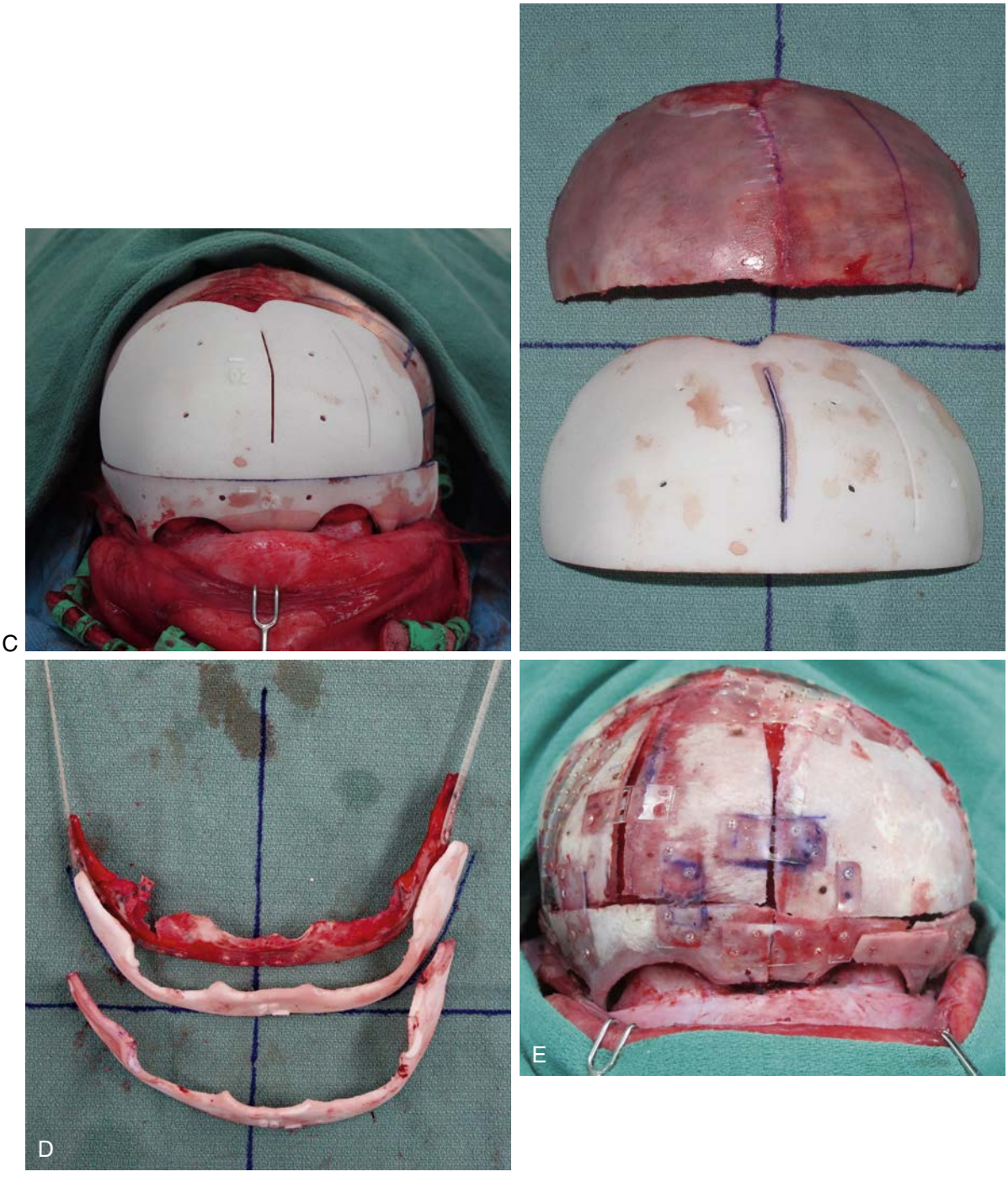

• **Figure 37-5, cont'd** **C,** Clinical application of the osteotomy templates. **D,** Demonstration of the clinical application of the reconstruction and positioning templates used for the orbital bandeau. **E,** Completed reconstruction of the forehead and orbital bandeau.

F



• **Figure 37-5, cont'd** **F,** Preoperative and 4-month postoperative frontal photographs demonstrating excellent orbital symmetry. (From Ruiz RL, et al: Nonsyndromic craniosynostosis: diagnosis and contemporary surgical management, *Oral Maxillofacial Surg Clin North Am* 16:447-463, 2004.)

Forms of Nonsyndromic Craniosynostosis

Sagittal Suture Craniosynostosis (Scaphocephaly)

Sagittal suture craniosynostosis is the most common form of nonsyndromic single-suture synostosis with a prevalence of approximately 1 in 5000 live births.[62] More male children are typically affected with a male to female ratio of 3 : 1 reported.[62]

When the sagittal suture is prematurely fused, the result is a scaphocephalic skull deformity. Absence of the sagittal suture results in arrested development of the two parietal bone plates with no growth perpendicular to the suture and a narrow bitemporal and biparietal dimension. At the same time, the brain continues to expand, and there is compensatory growth at the major sutures that remain open (i.e., lambdoid, coronal, and metopic). The overgrowth perpendicular to the coronal and lambdoid sutures causes an abnormal elongation of the cranial vault in the AP dimension, and patients will demonstrate frontal and occipital bossing as a result. This abnormal head shape is often described as "keel-like." The exact dysmorphology varies greatly depending on whether there is fusion of the entire sagittal suture, fusion of the anterior portion of the suture, or fusion of the posterior portion of the suture.

Surgical management of sagittal suture craniosynostosis requires biparietal craniotomy for release of the fused suture in combination with posterior two-thirds cranial vault reshaping (Figure 37-6).[63,64] The dysmorphic skeletal components of the cranium are dismantled and reassembled to establish an anatomically correct head shape.

When the posterior region of the sagittal suture is absent, our approach is to reshape the posterior two thirds of the cranial vault. This is done with the patient in the prone position. A postauricular coronal scalp incision is made, and the initial dissection is carried posteriorly within the supraperiosteal plane. Once the coronal scalp flap is developed, additional incisions are created through the periosteum and it is elevated as three separate flaps: right and left parietal and occipital. The coronal and lambdoid sutures are identified, and burr-hole and osteotomy placement is marked with a sterile marker or pencil. Formal biparietal and occipital craniotomy is then performed by the pediatric neurosurgeon, and the dysmorphic bones are removed. Reshaping of the bone flaps is carried out through the creation of additional osteotomies and use of bone-bending instruments on a sterile back table. The goal of these maneuvers is to increase bitemporal and biparietal width and reduce the AP length of the cranial vault. The reshaped skeletal segments are then reinserted and secured with biodegradeable fixation consisting of bone plates secured with monocortical screws. The pericranium is loosely approximated with interrupted sutures and the coronal scalp flap is closed in layers with inverted interrupted sutures for approximation of the galea and subcutaneous tissues and a running resorbable suture for skin closure. The authors do not use drains routinely.

If only the anterior portion of the sagittal suture is involved, the dysmorphology may be characterized primarily by frontal bossing with less impact on the posterior cranium. In those cases, craniotomy and reshaping of the anterior cranial vault is carried out with the patient in the supine position.

Some surgeons advocate a more aggressive total cranial vault reconstruction that is performed as a single-stage operation for patients who have fusion of the entire sagittal suture. Such extensive cranial reshaping is associated with disadvantages, including increased morbidity and blood loss, difficult intraoperative access to the entire cranial vault, and fewer points for anchorage of rigid internal fixation appliances. In our experience, the use of total cranial vault reshaping procedures is rarely necessary as surgical treatment of the middle and posterior cranium generally results in resolution of frontal bossing over time.[65] We prefer to manage patients who have complete sagittal suture involvement with an initial surgical procedure in which only the posterior two thirds of the cranium is reshaped as previously

described. If necessary, additional reshaping of the anterior cranial vault is then undertaken as a second phase of surgical treatment approximately 6 to 12 months later.

Coronal Suture Craniosynostosis (Anterior Plagiocephaly)

Craniosynostosis involving one of the coronal sutures is the second most common type of sporadic, nonsyndromic synostosis with a relative prevalence of approximately 1 in 10,000 children.[66,67] Although the exact cause of coronal craniosynostosis remains unknown, recent work has suggested that a mutation within the fibroblast growth factor receptor 3 gene is implicated in certain individuals.[51,68]

The congenital absence of the coronal suture results in the arrested development of the frontal and parietal bones. Clinically, there is anterior plagiocephaly with flattening of the forehead on the affected side. Other characteristic abnormal physical findings include orbital dystopia with the orbit on the affected side positioned superiorly and posteriorly, nasal asymmetry, and ipsilateral zygomatic hypoplasia. At the same time, there is compensatory overgrowth along the cranial vault sutures that remain open, including the contralateral coronal suture. The result is flattening of the forehead on the affected (i.e., fused) side and frontal bossing on the unaffected (i.e., patent) side of the anterior cranial vault. In this manner, a unilateral coronal synostosis produces a bilateral skull deformity.

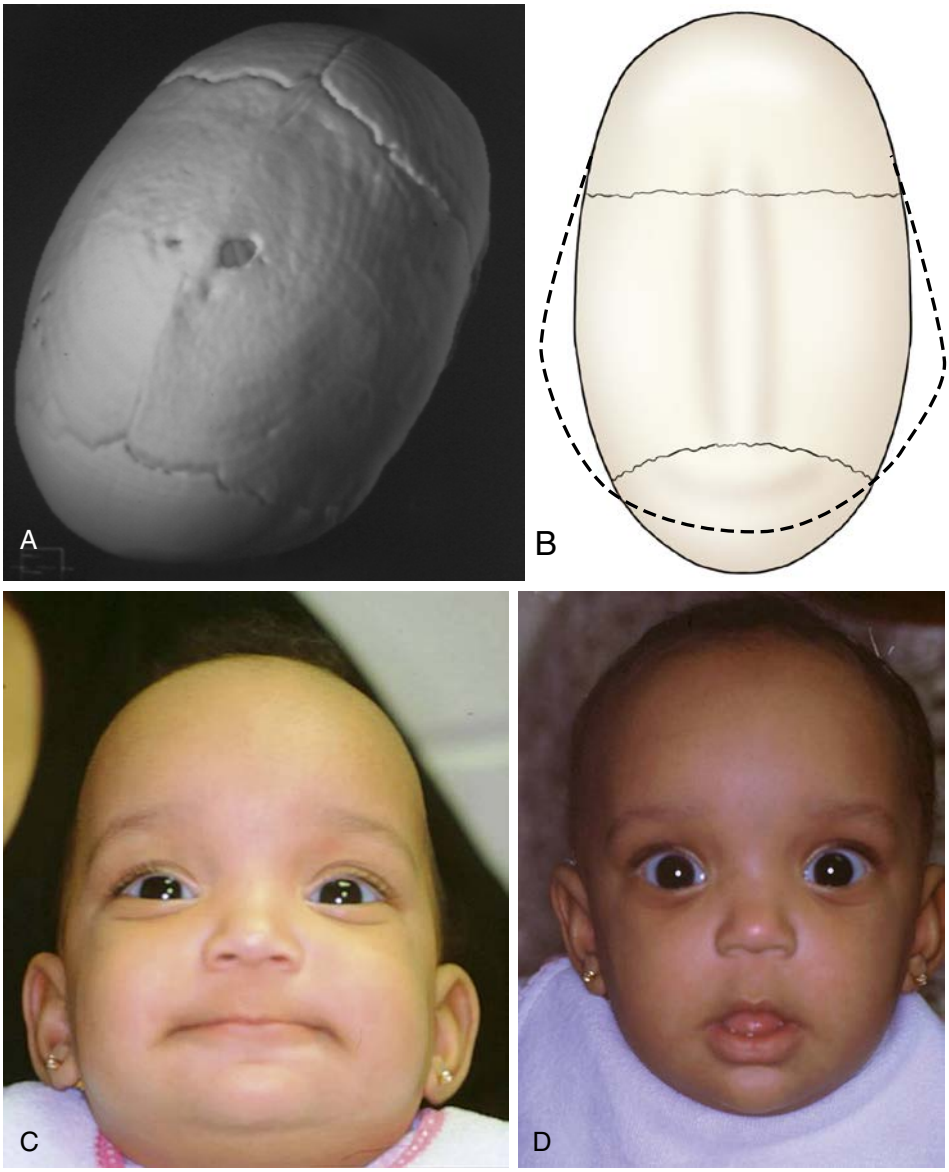

• **Figure 37-6** A 6-month-old child with sagittal suture craniosynostosis and scaphocephalic skull deformity. She underwent posterior cranial vault reshaping. **A,** Preoperative CT scan demonstrates conspicuous absence of the entire sagittal suture. **B,** Figure illustrating the objectives of cranial vault reshaping: increased bitemporal and biparietal width and decreased AP length. **C,** Preoperative frontal view of the patient. Lack of growth along sagittal suture region results in narrow head shape. **D,** Postoperative frontal view 3 weeks following the surgical procedure.



• **Figure 37-6, cont'd** **E,** Preoperative profile view demonstrates AP elongation of the cranium. **F,** Postoperative profile view. **G,** Preoperative bird's-eye view. **H,** Postoperative bird's-eye view.

Continued

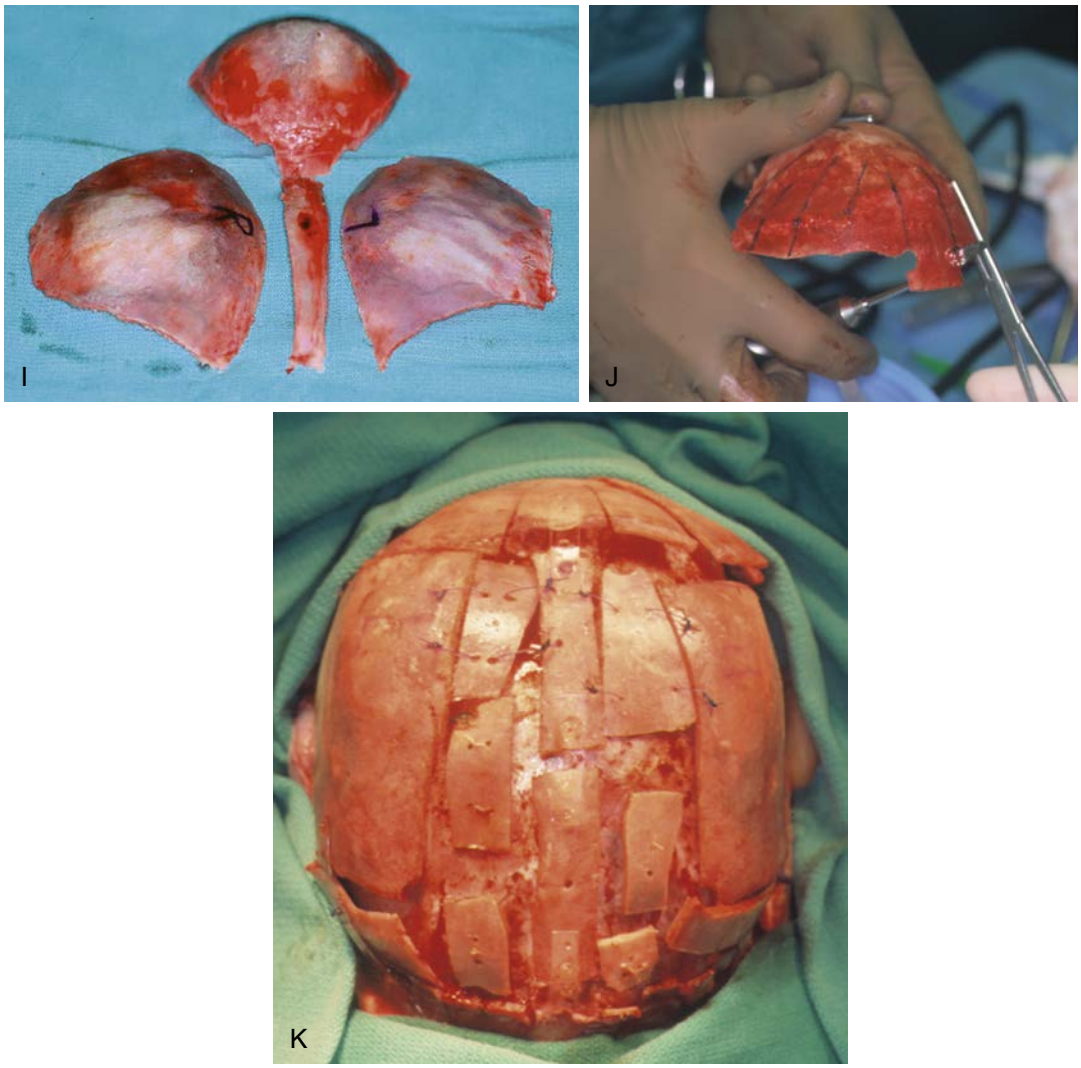

• **Figure 37-6, cont'd** **I,** Dismantled segments of the posterior cranial vault before reshaping. **J,** Creation of osteotomies for reshaping of skeletal segments. **K,** Insertion of bone segments following osteotomies and reshaping procedures. (From Ruiz RL, et al: Nonsyndromic craniosynostosis: diagnosis and contemporary surgical management, *Oral Maxillofacial Surg Clin North Am* 16:447-463, 2004.)

In patients with coronal suture synostosis, the anterior skull base demonstrates shortening on the affected side and elevation of the sphenoid wing.[69] This is due to involvement of the frontoethmoid, frontosphenoid, and sphenoethmoid sutures, termed the "coronal ring." A plain AP skull radiograph of a patient with unilateral coronal synostosis will demonstrate a characteristic "Harlequin-eye" deformity created by the skull base distortion and superiorly malpositioned orbital rim. Asymmetry of the entire cranial base is also common with a shift in the anterior and posterior cranial base to midsagittal plane angles of greater than 7 degrees as a consistent finding on CT scan evaluation.[70] Cranial base involvement also frequently produces some level of mandibular deviation leading to lower facial asymmetry.

The contemporary surgical treatment of unilateral coronal suture synostosis consists of bifrontal craniotomy, orbital osteotomies with creation of an orbital bandeau, frontoorbital advancement, and anterior cranial vault reshaping (Figures 37-7 and 37-8). A postauricular coronal scalp incision is created, and dissection is carried out in the supraperiosteal plane. The pericranium and temporalis muscles are elevated separately. Bilateral circumferential periorbital dissection is then carried out with complete exposure of the orbits to the level of the inferior orbital rim and zygoma. This requires release of the lateral canthal ligaments. Care is taken to preserve the medial canthal attachments and nasolacrimal apparatus. We outline the orbital bandeau including the tenon extensions within the temporal bones bilaterally using a sterile pencil or marking pen before deciding on burr-hole placement. Typically a bifrontal craniotomy is created by the pediatric neurosurgeon with removal of the frontal bone unit.

Next, the dura is dissected free of the inner table of the cranial vault and along the anterior skull base. A reciprocating saw with a small blade is used for the creation of osteotomies along the lateral orbital wall and/or rim, orbital roof, and superior-medial aspect of the orbital wall on each

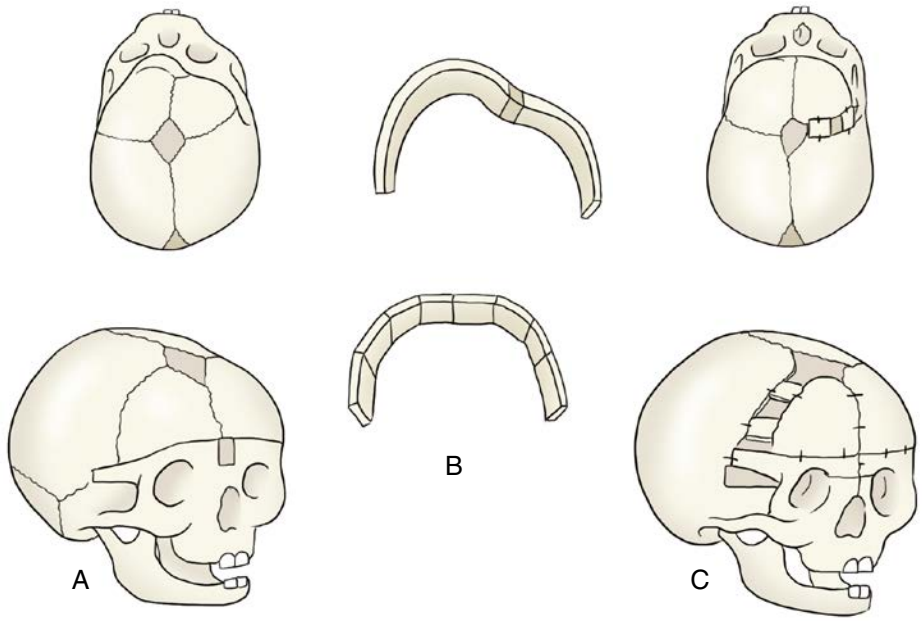

• **Figure 37-7** Illustration of reconstructive procedure used to address the dysmorphology associated with unilateral coronal suture craniosynostosis. **A,** Outline of the bifrontal craniotomy and orbital osteotomies. **B,** The dysmorphic orbital bandeau is removed, and vertical osteotomies are used for reshaping. **C,** The reconstructed orbital bandeau is reinserted, and anterior cranial vault reconstruction is carried out. (From Ruiz RL, et al: Nonsyndromic craniosynostosis: diagnosis and contemporary surgical management, *Oral Maxillofacial Surg Clin North Am* 16:447-463, 2004.)

side of the bandeau. Care is taken to prevent injury to the temporal lobe of the brain during the sectioning of pterion bilaterally. The orbital osteotomies are carried one half to three quarters of the length of the orbit on each side. The final osteotomy cut is across the nasofrontal region joining both orbital osteotomies and allowing for mobilization of the orbital bandeau. Once the bandeau is removed, it is taken to the sterile back table where reshaping is carried out. Recontouring frequently involves the creation of a vertical osteotomy in the midline to allow for advancement of the affected orbital segment. Additional osteotomies between the lateral orbital region and tenon extension may be used for additional reshaping of the bandeau. The newly constructed orbital unit is then inserted and secured to the temporoparietal bones bilaterally using bone plates and screws. We add a third point of fixation at the nasofrontal junction and lateral orbital rims using 2-0 PDS suture to prevent upward displacement of the bandeau when the coronal flap is repositioned. In cases where severe flattening of the superior orbit is present, onlay bone grafts may be added on the affected side of the bandeau for additional contouring. The frontal bones are then osteotomized and used to reconstruct the anterior cranial vault region with reshaping as necessary. Closure begins with lateral canthopexies performed through the coronal access and proceeds as previously described.

Metopic Suture Craniosynostosis (Trigonocephaly)

Metopic suture craniosynostosis has a traditionally reported prevalence of 1 in 15,000 children.[71] Recent reports have indicated an increase in prevalence to approximately 1:5,000 children.[72] An increased proportion of male children are affected. Unlike other forms of isolated, single-suture craniosynostosis, approximately 5% of patients with metopic fusion will have a positive family history.[71,73]

Premature fusion of the metopic suture may be seen in nonsyndromic, otherwise healthy infants or as part of an identified syndrome. Previous reports have suggested that a third group of infants born with metopic synostosis will demonstrate other congenital malformations, neuromuscular dysfunction, and/or neurodevelopmental delay but without the delineation of a syndromic diagnosis.[71,73-75] This observation is consistent with our experience. At the University of North Carolina, a review of patients with metopic suture involvement, treated by the senior author (RLR), revealed a high rate of associated congenital malformations.[76] Forty-three percent of patients seen with a diagnosis of metopic suture synostosis over the course of a 4-year period had associated malformations, but no clear syndromic diagnosis. Malformations not previously described in association with metopic synostosis were observed, including three patients with a tethered spinal cord. Whether the combination of metopic synostosis and associated anomalies represents an unknown syndrome remains unclear. Thorough medical and genetic evaluation of infants born with metopic craniosynostosis is indicated to prepare these children for craniofacial surgery, counsel parents, and determine long-term neurodevelopmental prognosis.

The combination of arrested growth of the frontal bones perpendicular to the midline (metopic) suture and continued growth at the coronal sutures creates a trigonocephalic

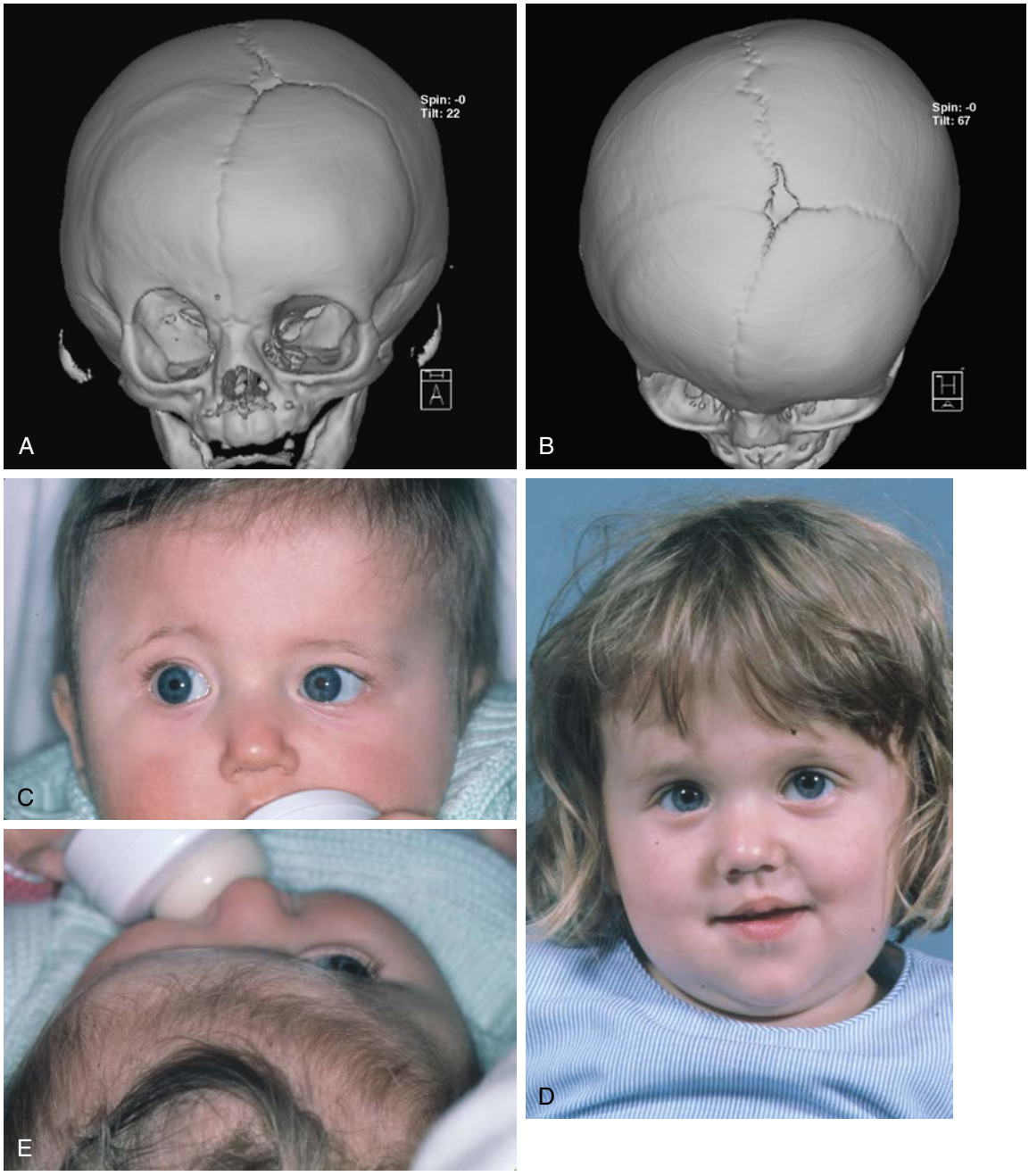

• **Figure 37-8** Nine-month-old child with right-sided unilateral coronal suture craniosynostosis and anterior plagiocephaly. Surgical reconstruction consisted of bifrontal craniotomy, fronto-orbital advancement, and anterior cranial vault reshaping. **A** and **B,** 3D craniofacial CT scan reveals absence of the right coronal suture. Note the degree of cranio-orbital dysmorphology on the affected side. **C,** Preoperative frontal view demonstrates a skeletal deformity characterized by flattening of the forehead on the affected side, orbital dystopia, and nasal asymmetry. **D,** Postoperative frontal view 15 months following the surgical procedure. **E,** Bird's-eye view preoperatively.

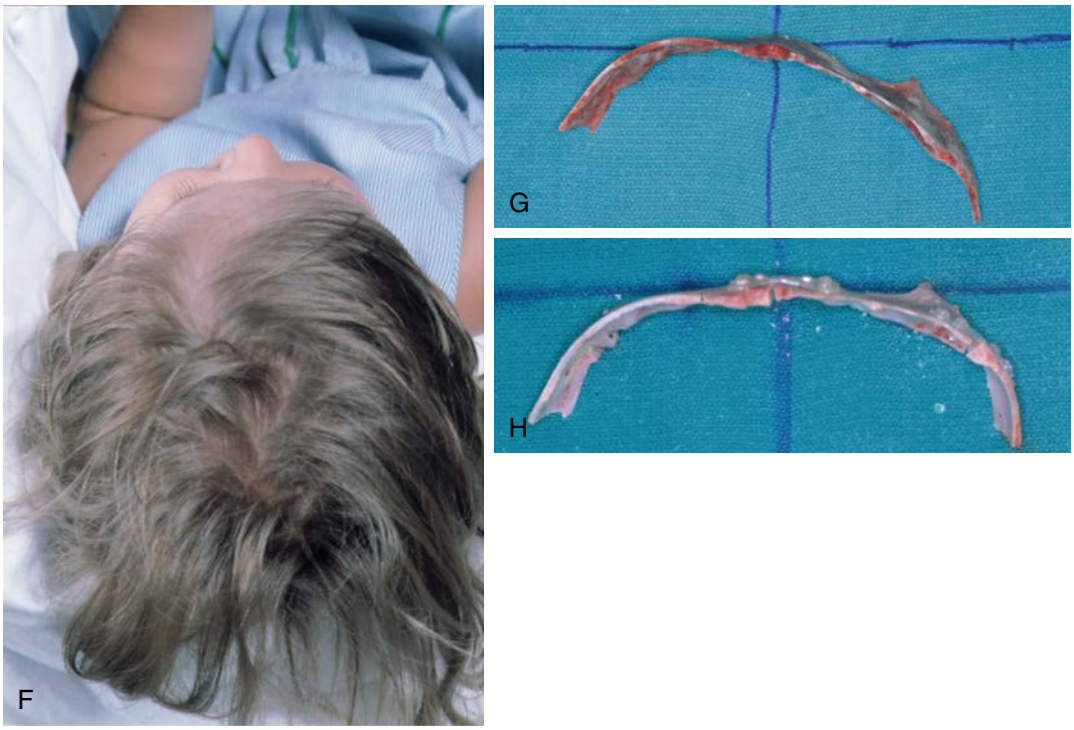

• **Figure 37-8, cont'd** **F,** Bird's-eye view postoperatively. **G,** Intraoperative view of the orbital bandeau before reshaping. **H,** Intraoperative view of orbital bandeau after osteotomies, reshaping, and reassembly using resorbable bone plates and screws. (From Ruiz RL, et al: Nonsyndromic craniosynostosis: diagnosis and contemporary surgical management, *Oral Maxillofacial Surg Clin North Am* 16:447-463, 2004.)

(i.e., triangle-skull) skull deformity. The associated dysmorphology is characterized by a triangular-shaped forehead, orbital hypotelorism, and horizontally retrusive lateral orbital rims. Other findings that may be noted during clinical examination include a narrow forehead, epicanthal folds, biparietal widening, elevated brow position, and lateral orbitozygomatic hypoplasia. Radiographic features of metopic synostosis described in the literature include the absence of the suture, pulled anterior fontanelle, straight lateral frontal bone, posteriorly displaced lateral frontal bone, frontal bone tangent to mid-orbit, up-sloping lateral orbital rims, interorbital narrowing, narrowing of the upper orbital width, and presence of an "omega" sign deformity along the endocranial surface of the metopic ridge. All of these clinical and radiographic features may be helpful in differentiating the physiologic metopic suture closure from true, pathologic synostosis.[77]

In addition to the other characteristic findings of metopic synostosis, patients will often present with a pronounced vertical bony ridge within the center of the forehead along the metopic region. It is important to note, however, that patients with normal physiologic closure of the metopic suture, and no synostosis, also frequently develop a ridge along the metopic suture region. As a result, surgeons must be mindful that the isolated finding of a metopic bony ridge, without other dysmorphic features, does not represent craniosynostosis.

The severity of clinical expression of metopic synostosis is extremely variable making clinical decision making about surgical intervention uniquely problematic. In the opinion of the authors, surgical intervention for metopic suture craniosynostosis is indicated in cases where clinically significant dysmorphology is present. Not all patients will require surgical intervention since some have only minimal morphologic deformity. This is especially true because the likelihood of a child developing increased ICP secondary to metopic synostosis is quite low.[73]

The surgical approach to reconstruction of the trigonocephalic skull deformity associated with metopic synostosis is similar to the surgical procedure described for coronal synostosis. Bifrontal craniotomy is carried out in conjunction with fronto-orbital advancement and anterior cranial vault reshaping (Figures 37-9 and 37-10). Reshaping of the orbital bandeau is carried out to advance the lateral orbital segments and create a more rounded forehead with improved anatomic contour. The creation of a gap at the vertical midline osteotomy within the bandeau and placement of an autogenous bone graft may be performed in an effort to widen the orbits and address the orbital hypotelorism. Although this is a reasonable surgical maneuver, it has minimal impact on the hypotelorism as it does not address the patient's medial orbital wall to medial orbital wall distance.

Lambdoid Suture Craniosynostosis (Posterior Plagiocephaly)

Posterior plagiocephaly secondary to true lambdoid suture craniosynostosis is a rare event with a prevalence of

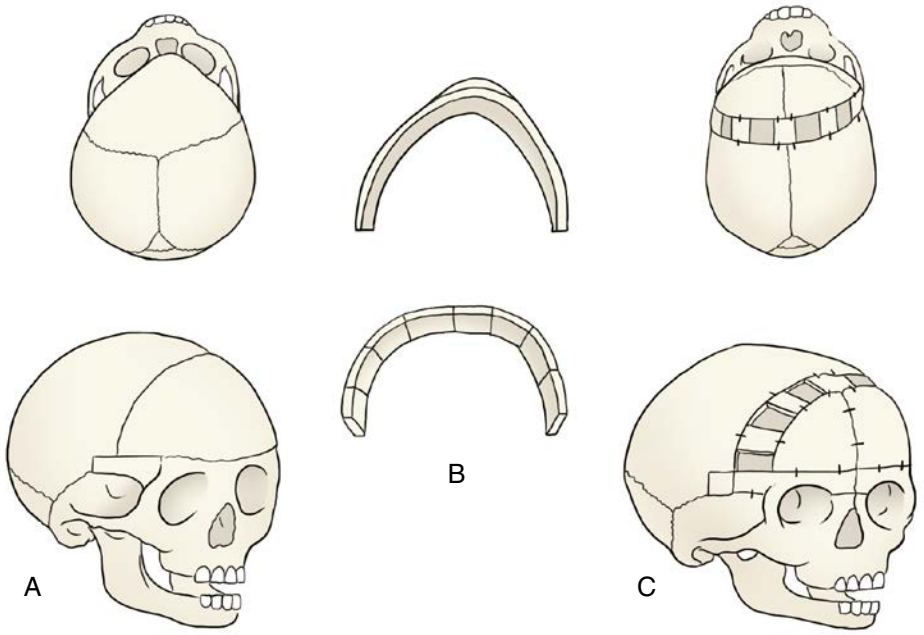

• **Figure 37-9** Illustration of reconstructive procedure used to address the trigonocephalic skull deformity associated with metopic suture craniosynostosis. **A,** Outline of the bifrontal craniotomy and orbital osteotomies. **B,** The dysmorphic orbital bandeau is removed, and vertical osteotomies are created for reshaping. **C,** The reconstructed orbital bandeau is reinserted, and anterior cranial vault reconstruction is completed. (From Ruiz RL et al: Nonsyndromic craniosynostosis: diagnosis and contemporary surgical management, *Oral Maxillofac Surg Clin North Am* 16:447-463, 2004.)

approximately 1 in 150,000 live births.[78-80] Because posterior plagiocephaly as a result of synostosis is so uncommon and it may be confused with positional plagiocephaly, the diagnosis must be definitively confirmed with radiographic imaging before any surgical intervention is undertaken (Figures 37-11, 37-12, and 37-13).

When premature fusion of one lambdoid suture occurs, the most noticeable finding is often a severe flattening of the occipitoparietal region. Restricted growth of the ipsilateral parietal bone also produces retraction of the forehead on the affected side, inferior-posterior displacement of the ear and shortening of the affected side of the skull. By contrast, posterior positional plagiocephaly has a distinct morphologic pattern characterized by occipitoparietal flattening, ipsilateral frontal bossing, and forward displacement of the ear on the affected side.

Although surgeons may be tempted to perform a more limited procedure, such as strip craniectomy to address unilateral lambdoid craniosynostosis, a combined craniofacial and neurosurgical approach remains the most appropriate treatment. Our preference is to carry out a formal craniotomy with reshaping of the involved portions of the posterior cranium based upon the extent of the dysmorphology.

Bilateral Coronal Suture Craniosynostosis (Brachycephaly)

When bilateral coronal craniosynostosis is seen in conjunction with mid-face deficiency, the possibility of a craniofacial dysostosis syndrome (e.g., Apert, Crouzon, Pfeiffer, Saethre-Chotzen, etc.) must be considered.[81] However, the congenital absence of both coronal sutures is known to occur in patients without mid-face deficiency or a syndromic diagnosis.[82] Although these patients demonstrate what is thought to be a "nonsyndromic" form of bilateral coronal craniosynostosis, recent advances in molecular testing suggest that there may be some familial pattern with implication of mutations within the fibroblast growth factor receptor (1, 2, and 3) genes.[83]

Bilateral coronal suture fusion results in a characteristic craniofacial dysmorphology described as brachycephaly. This deformity includes shortening of the anterior skull base bilaterally resulting in a decreased AP cranial dimension, widening of the skull secondary to compensatory growth at the sagittal suture, and horizontal deficiency of the lateral orbital rims. In addition, some patients will exhibit significant vertical elongation of the anterior cranial vault.

Because two cranial vault sutures are involved, the incidence of increased ICP rises to approximately 42%.[2,12] Surgical intervention is undertaken to increase intracranial and orbital volume and establish a more anatomic position and contour of the orbits and forehead. The standard surgical approach for the repair of the deformity associated with bilateral coronal synostosis includes a more extensive bifrontal craniotomy than used in unilateral cases, fronto-orbital advancement, and anterior cranial vault reconstruction.

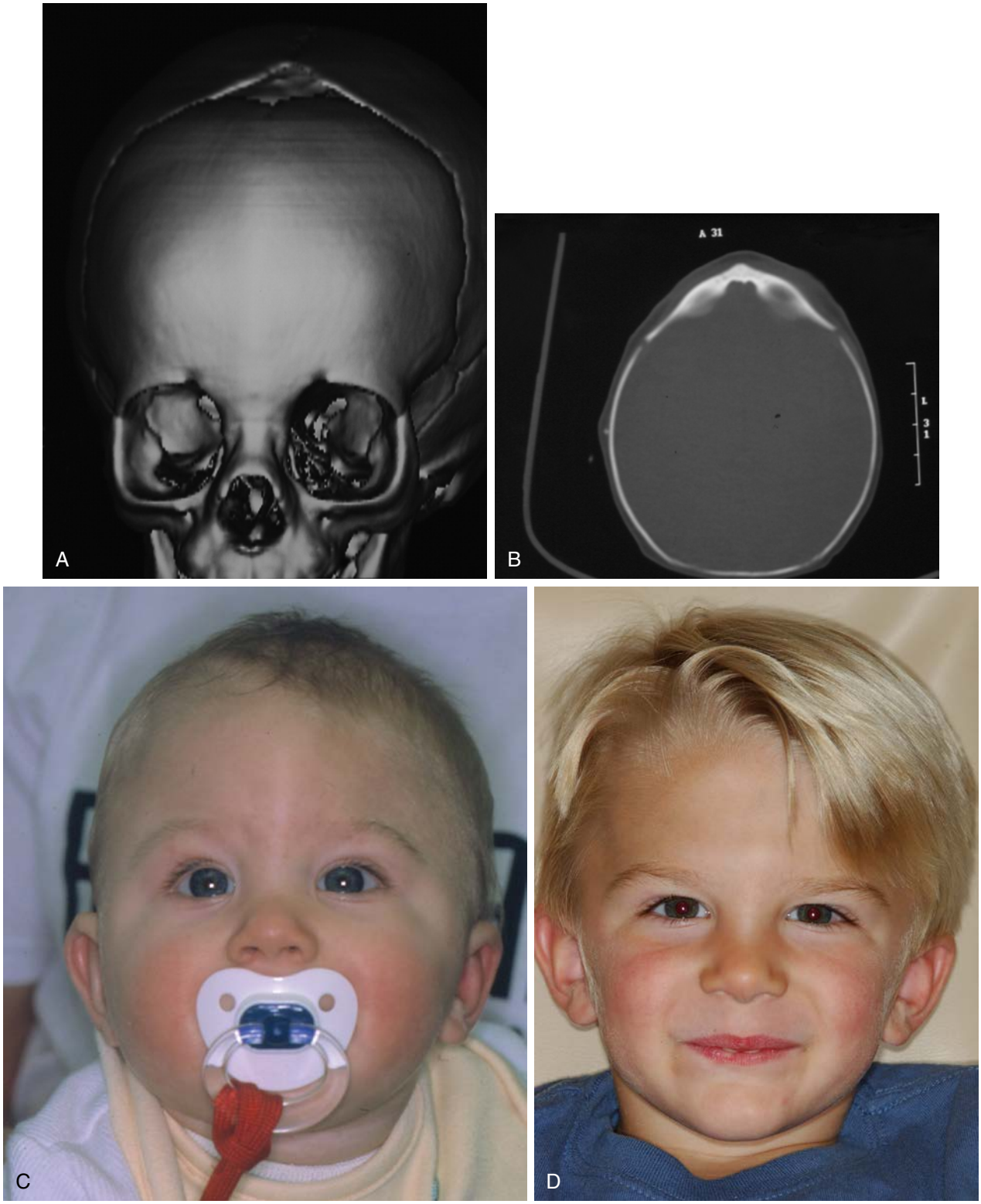

• **Figure 37-10** A 7-month-old child with metopic suture craniosynostosis and trigonocephaly. He underwent craniofacial reconstruction via bifrontal craniotomy approach, fronto-orbital advancement, and anterior cranial vault reshaping. **A,** 3D craniofacial CT scan reveals absence of the metopic suture with trigonocephalic skull deformity. **B,** Axial view CT scan reveals the triangular-shaped frontal bone complex with a prominent bony ridge in the region of the metopic suture. **C,** In addition to the triangular-shaped forehead, the preoperative frontal view demonstrates hypotelorism and horizontal retrusion of the lateral orbital rims. **D,** Postoperative frontal view 2 years after the surgical procedure.

Continued

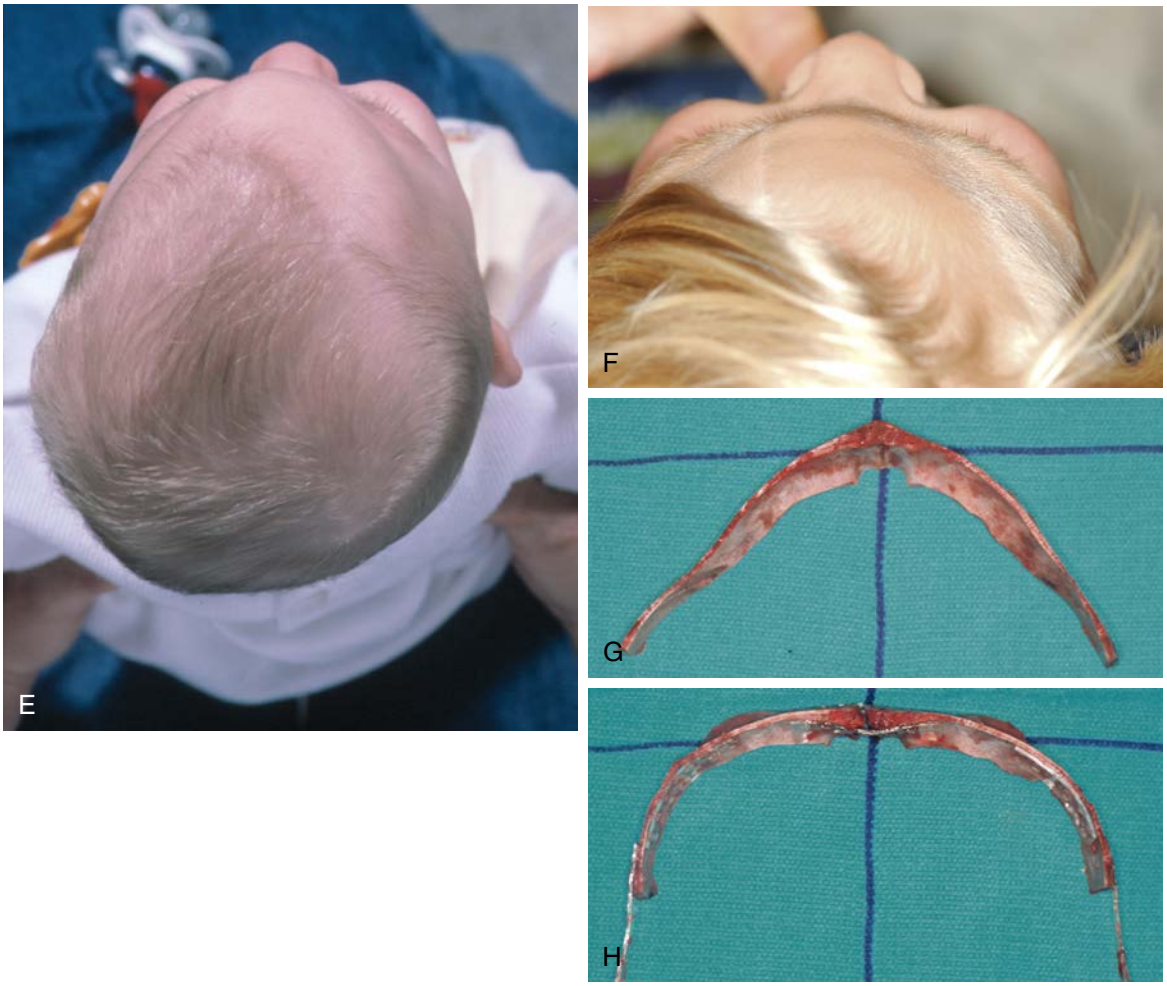

• **Figure 37-10, cont'd** **E,** Bird's-eye view preoperatively. **F,** Bird's-eye view postoperatively. **G,** Intraoperative view of the orbital bandeau before reshaping. **H,** Intraoperative view of orbital bandeau after osteotomies, reshaping, and reassembly using resorbable bone plates and screws. (From Ruiz RL et al: Nonsyndromic craniosynostosis: diagnosis and contemporary surgical management, *Oral Maxillofacial Surg Clin North Am* 16:447-463, 2004.)

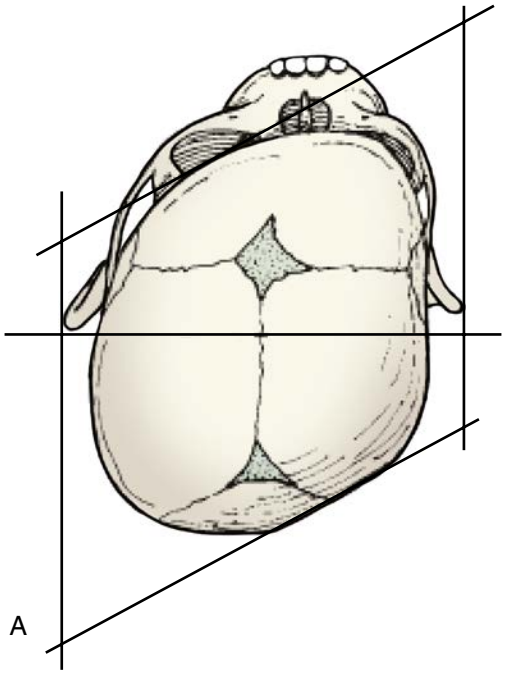

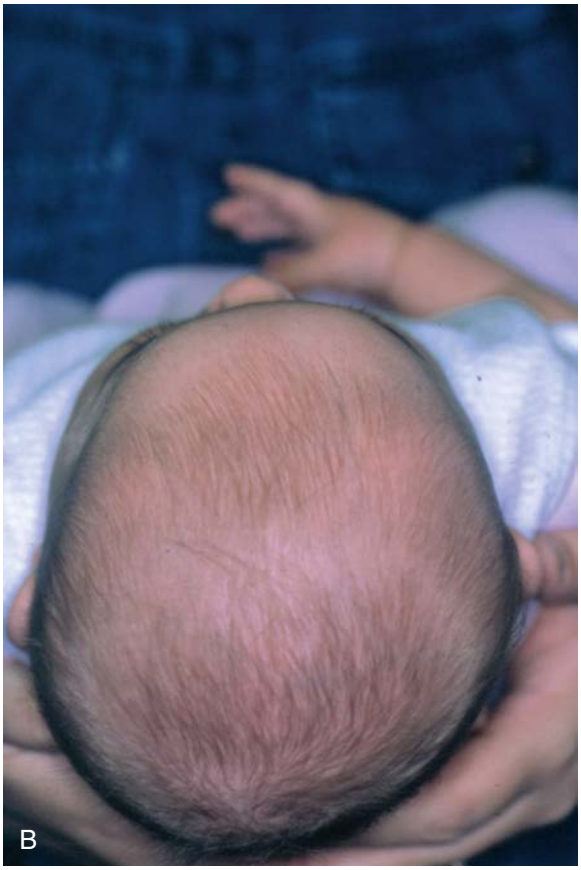

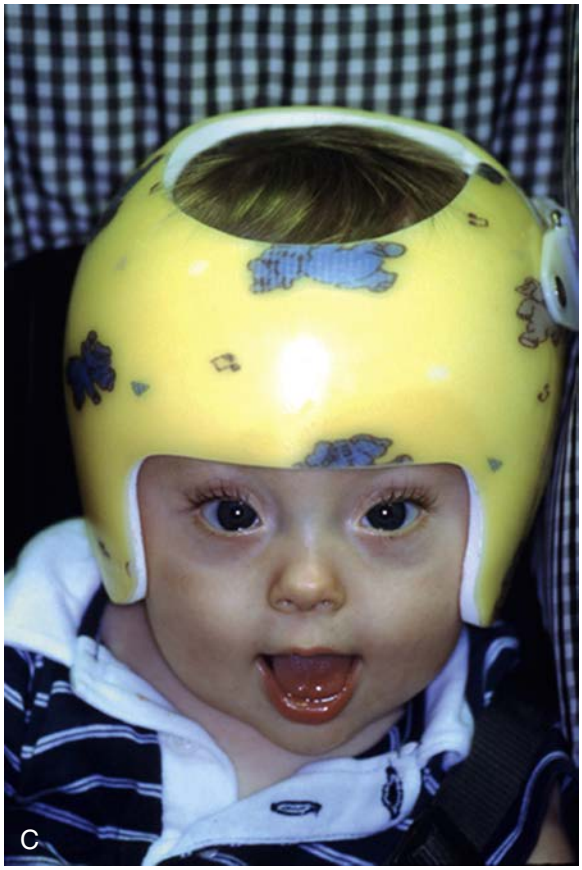

• **Figure 37-11** **A,** Illustration of cranial vault dysmorphology characteristic of benign deformational plagiocephaly. Postnatal external forces, such as repetitive sleep positioning, cause unilateral occipitoparietal flattening. Because the sutures are open and the cranial vault complex is flexible, all of the structures on the affected side are displaced anteriorly. Additional clinical findings include ipsilateral frontal bossing and forward displacement of the ear on the affected side. The outline of the cranial vault as viewed from above develops a form that resembles a parallelogram. **B,** Bird's-eye view of a child with deformational (positional) plagiocephaly. This is a nonsurgical condition. **C,** Custom cranial orthotic band used to correct deformational plagiocephaly. (From Caccamese J et al: Positional plagiocephaly: evaluation and management, *Oral Maxillofacial Surg Clin North Am* 16:439-446, 2004.)

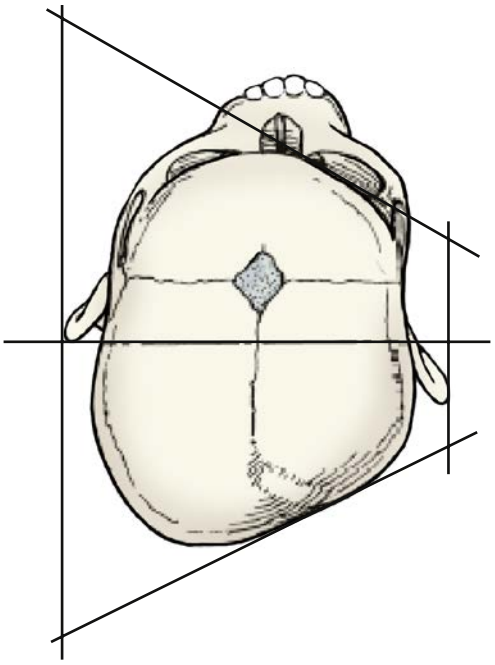

• **Figure 37-12** Illustration of cranial vault dysmorphology characteristic of posterior plagiocephaly secondary to unilateral lambdoid suture craniosynostosis. In this example, arrested development across the right lambdoid suture causes flattening of the occipital and parietal bones. The lack of cranial growth on the affected side also produces retraction of the forehead on the right (ipsilateral) side, and the right ear is displaced posteriorly and inferiorly when compared with the left. Compensatory overgrowth also occurs at the sutures that remain open, which causes contralateral frontal bossing. From a bird's-eye view, the cranial vault may take on the shape of a trapezoid. (From Ruiz RL, et al: Nonsyndromic craniosynostosis: diagnosis and contemporary surgical management, *Oral Maxillofacial Surg Clin North Am* 16:447-463, 2004.)

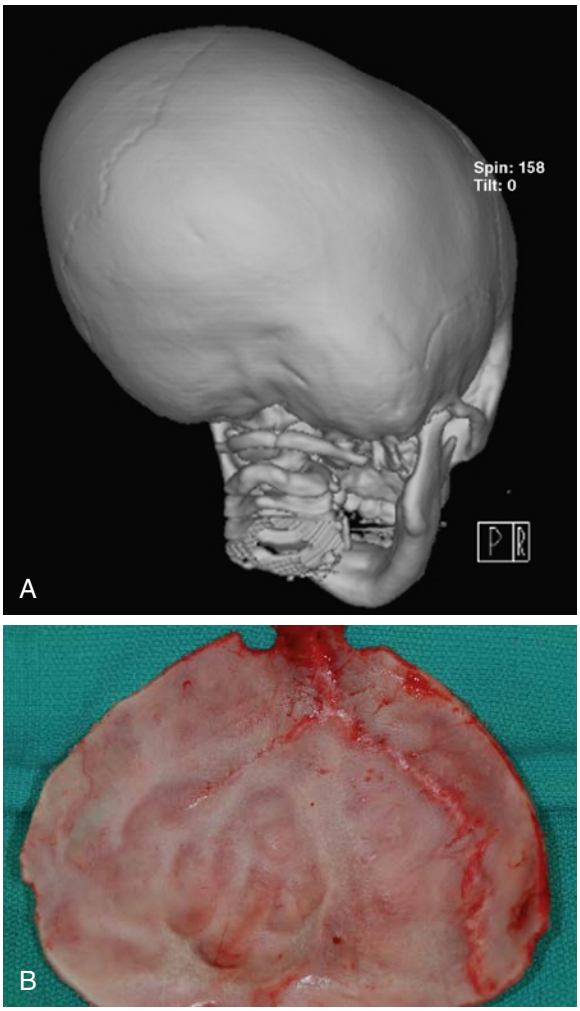

• **Figure 37-13** **A,** 3D CT scan of a patient with right-sided unilateral lambdoid suture synostosis. **B,** Intraoperative view of the occipital bone reveals conspicuous absence of the lambdoid suture on the affected side. (From Ruiz RL, et al: Nonsyndromic craniosynostosis: diagnosis and contemporary surgical management, *Oral Maxillofacial Surg Clin North Am* 16:447-463, 2004.)

Summary

Contemporary surgical management of nonsyndromic craniosynostosis requires the combined expertise of a pediatric craniofacial surgeon and pediatric neurosurgeon. The goals of surgical intervention are the release of the affected suture allowing for unrestricted development of the visceral components (e.g., brain, eyes) and 3D reconstruction of the skeletal components establishing a more normal anatomic position and contour.[84] Surgeons caring for infants with these cranial and orbital malformations must maintain a thorough understanding of the 3D anatomy, characteristic dysmorphology associated with the different types of synostosis, and the complex interplay that exists between surgical intervention and ongoing skeletal growth.

References

1. Cohen Jr MM: Sutural biology and the correlates of craniosynostosis, *Am J Med Genet* 47:581–616, 1993.
2. Renier D: Intracranial pressure in craniosynostosis: pre- and postoperative recordings. Correlation with functional results. In Persing JA, Jane JA, Edgerton MT, editors: *Scientific foundations and surgical treatment of craniosynostosis*, Baltimore, 1989, Williams & Wilkins.
3. Gault DT, et al.: Intracranial pressure and intracranial volume in children with craniosynostosis, *Plast Reconstr Surg* 90:230–271, 1992.
4. Walia HK, et al.: Roentgenologic determination of the cranial capacity in the first four years of life, *Ind J Radiol* 26:250, 1972.
5. Virchow R: Uber den cretinismus, nametlich in Franken, under uber pathologische, *Schadelformen Verk Phys Med Gesellsch Wurzburg* 2:230–271, 1851.
6. Delashaw JB, et al.: Cranial vault growth in craniosynostosis, *J Neurosurg* 70(2):159–165, 1989.

7. Lattanzi W, et al.: Genetic basis of single-suture synostoses: genes, chromosomes, and clinical implications, *Childs Nerv Syst* 28(9):1301–1310, 2012.
8. Rasmussen SA, et al.: Maternal thyroid disease as a risk factor for craniosynostosis, *Obstet Gynecol* 110:369–377, 2007.
9. Gault DT, et al.: Intracranial volume in children with craniosynostosis, *J Craniofacial Surg* 1(1):1–3, 1990.
10. Posnick J, et al.: Metopic and sagittal synostosis: intracranial volume measurements prior to and after cranio-orbital reshaping in childhood, *Plast Reconstr Surg* 96(2):299–309, 1995.
11. Heller JB, et al.: Intracranial volume and cephalic index outcomes for total calvarial reconstruction among nonsyndromic sagittal synostosis patients, *Plast Reconstr Surg* 121(1):187–195, 2008.
12. Renier D, et al.: Intracranial pressure in craniosynostosis, *J Neurosurg* 57:370, 1982.
13. Thompson DN, et al.: Intracranial pressure in single-suture cranisynostosis, *Pediatr Neurosurg* 22(5):235–240, 1995.
14. Wall SA, et al.: The preoperative incidence of raised intracranial pressure in nonsyndromic sagittal craniosynostosis is underestimated in the literature, *J Neurosurg Pediatr* 14(6):674–681, 2014.
15. Siddiqi SN, et al.: The detection and management of intracranial hypertension after initial suture release and decompression for craniofacial dysostosis syndromes, *Neurosurgery* 36:703, 1995.
16. Turvey TA, Ruiz RL: Craniosynostosis and craniofacial dysostosis. In Fonseca RJ, Baker SB, Wolford LM, editors: *Oral and maxillofacial surgery*, Philadelphia, 2000, WB Saunders.
17. Hogan GR, Bauman ML: Hydrocephalus in Apert syndrome, *J Pediatr* 79:782, 1971.
18. Golabi M, Edwards MSB, Ousterhout DK: Craniosynostosis and hydrocephalus, *Neurosurgery* 21:63, 1987.
19. Fishman MA, Hogan GR, Dodge PR: The concurrence of hydrocephalus and craniosynostosis, *J Neurosurg* 36:621–629, 1971.
20. Tuite GF, et al.: The effectiveness of papilledema as an indicator of raised intracranial pressure in children with craniosynostosis, *Neurosurgery* 38(2):272–278, 1996.
21. Da Costa AC, et al.: Longitudinal study of the neurodevelopmental characteristics of treated and untreated nonsyndromic craniosynostosis in infancy, *Childs Nerv Syst* 29(6):985–995, 2013.
22. Gray KE, et al.: Predicting developmental delay in a longitudinal cohort of preschool children with single-suture craniosynostosis: is neurobehavioral assessment important? *Dev Med Child Neurol, Epub*, 2014.
23. Aldridge K, et al.: Central nervous system phenotypes in craniosynostosis, *J Anat* 201(1):31–39, 2002.
24. Aldridge K, et al.: Brain morphology in nonsyndromic unicoronal craniosynostosis, *Anat Rec A Discov Mol Cell Evol Biol* 285(2):690–698, 2005.
25. Kapp-Simon KA, et al.: Neurodevelopment of children with single suture craniosynostosis: a review, *Child Nerv Syst* 23(3):269–281, 2007.
26. McCarthy JG, et al.: Parameters of care for craniosynostosis, *Cleft Palate Craniofac J* 49(Suppl):1–24, 2012.
27. Aase JM: Structural defects as a consequence of late intrauterine constraint: craniotabes, loose skin and asymmetric ear size, *Semin Perinatol* 7:270, 1983.
28. Haberkern CM, Smith DW, Jones KL: The breach head and its relevance, *Am J Dis Child* 133–154, 1979.
29. AAP Task Force on Infant Positioning and SIDS: Positioning and SIDS, *Pediatrics* 89:1120, 1992.
30. Turk AE, et al.: The "back to sleep" campaign and deformational plagiocephaly: is there cause for concern? *J Craniofac Surg* 7:12, 1996.
31. Posnick JC: Posterior plagiocephaly: unilateral lambdoid synostosis and skull molding. In Posnick JC, editor: *Craniofacial and maxillofacial surgery in children and young adults*, Philadelphia, 2000, WB Saunders.
32. Reference removed in pages.
33. Reference removed in pages.
34. Reference removed in pages.
35. Reference removed in pages.
36. Vu HL, et al.: The timing of physiologic closure of the metopic suture: a review of 159 patients using reconstructed 3D CT scans of the craniofacial region, *J Craniofacial Surg* 12(6):527–532, 2001.
37. Weinzweig J, et al.: Metopic synostosis: Defining the temporal sequence of normal suture fusion and differentiating it from synostosis on the basis of computed tomography images, *Plast Reconstr Surg* 112(5):1211–1218, 2003.
38. Lane LC: Pioneer craniectomy for relief of mental imbecility due to premature sutural closure and microcephalus, *JAMA* 11892:18–49, 1892.
39. Lannelongue M: De la craniectomie dans la microcephalic, *Compte Rendu Acad Sci* 110:1382, 1890.
40. Jimenez DF, et al.: Endoscopy-assisted wide-vertex craniectomy, barrel stave osteotomies, and postoperative helmet molding therapy in the management of sagittal suture craniosynostosis, *J Neurosurg Spine* 100(5):407–417, 2004.
41. Jimenez DF, Barone CM, McGee ME: Design and care of helmets in postoperative craniosynostosis patients: our personal approach, *Clin Plast Surg* 31(3):481–487, 2004.
42. Barone CM, Jimenez DF: Endoscopic approach to coronal craniosynostosis, *Clin Plast Surg* 31(3):415–422, 2004.
43. Jimenez DF, et al.: Early treatment of anterior calvarial craniosynostosis using endoscopic-assisted minimally invasive techniques, *Child's Nervous System* 23(12):1422–1419, 2007.
44. Jimenez DF, et al.: Multiple-suture nonsyndromic craniosynostosis: early and effective management using endoscopic techniques, *J Neurosurg: Pediatrics* 5(3):223–231, 2010.
45. Jimenez DF, et al.: Early treatment of coronal synostosis with endoscopy-assisted craniectomy and postoperative cranial orthosis therapy: 16-year experience, *Journal of Neurosurgery: Pediatrics* 12(3):207–219, 2013.
46. Windh P, et al.: Spring-assisted cranioplasty vs pi-plasty for sagittal synostosis–a long term follow-up study, *J Craniofacial Surg* 19(1):59–64, 2008.
47. Clijmans T, et al.: Automated reconstruction planning of cranial malformations base on reference data, *Int J Computer Assisted Radiol Surg* 2(Supp 1):s228–s229, 2007.
48. Saber NR, et al.: Generation of normative pediatric skull models for use in cranial vault remodeling procedures, *Childs Nerv Syst* 28(3):405–410, 2012.
49. Xia JJ, et al.: Cost-effectiveness analysis for computer-aided surgical simulation in complex cranio-maxillofacial surgery, *J Oral Maxillofac Surg* 64(12):1780–1784, 2006.
50. Jaskolka MS, et al.: Virtual surgical planning for the treatment of isolated suture craniosynostosis, *Abstract Session, AACMFS Annual Meeting*, 2013.
51. Posnick JC: Anterior plagiocephaly: unilateral coronal synostosis and skull molding. In Posnick JC, editor: *Craniofacial and maxillofacial surgery in children and young adults*, Philadelphia, 2000, WB Saunders.

52. Fearon JA, et al.: Single suture craniosynostoses: surgical outcomes and long-term growth, *Plastic and Reconstructive Surgery* 123(2):635–642, 2009.
53. Tahiri Y, et al.: Perioperative complications associated with intracranial procedures in patients with non-syndromic single suture craniosynostosis, *Plastic and Reconstructive Surgery* 26(1):118–123.
54. Czerwinski M, et al.: Major morbidity and mortality rates in craniofacial sugery: an analysis of 8101 major procedures, *Plast Reconstr Surg* 126(1):181–186, 2010.
55. Fearon JA, et al.: Effects of hypotensive anesthesia on blood transfusion rates in craniosynostosis corrections, *Plast Reconstr Surg* 133(5):1133–1136, 2014.
56. Fearon JA, et al.: The use of recombinant erythropoietin in the reduction of blood transfusion rates in craniosynostosis repair in infants and children, *Plast Reconstr Surg* 109(7):2190–2196, 2002.
57. Goobie SM, et al.: Efficacy of tranexamic acid in pediatric craniosynostosis surgery: a double-blind, placebo-controlled trial, *Anesthesiology* 114(4):862–871, 2011.
58. Dadure C, et al.: Intraoperative tranexamic acid reduces blood transfusion in children undergoing craniosynostosis surgery: a randomized double-blind study, *Anesthesiology* 114(4):856–861, 2011.
59. Krajewski K, et al.: Successful blood conservation during craniosynostotic correction with dual therapy using procrit and cell saver, *J Craniofacial Surgery* 19(1):101–105, 2008.
60. Vega RA, et al.: Minimizing transfusion requirements for children undergoing craniosynostosis repair: the CHoR protocol, *J Neurosurg Pediatr* 14(2):190–195, 2014.
61. Renier D, Marchac D: Intracranial pressure recordings: analysis of 300 cases. In Marchac D, editor: *Craniofacial Surgery Proceedings of the First International Congress on Craniomaxillofacial Surgery*, Heidelberg, Germany, 1988, Springer-Verlag.
62. Lajeunie E, et al.: Sagittal synostosis study of scaphocephaly, *Am J Med Genet* 62:282, 1996.
63. Posnick JC, et al.: Sagittal synostosis: quantitative assessment of presenting deformity and surgical results based on CT scans, *Plast Reconstr Surg* 92:1015, 1993.
64. Posnick JC: Craniosynostosis: surgical management in infancy. In Bell WH, editor: *Orthognathic and reconstructive surgery*, Philadelphia, 1992, WB Saunders.
65. Khechoyan D, et al.: Changes in frontal morphology after single-stage open posterior-middle vault expansion for sagittal craniosynostosis, *Plastic Reconstr Surg* 129(2):504–516, 2012.
66. Cohen Jr MM: An etiologic and nosologic overview of craniosynostosis syndromes, *Birth Defects* 11:137, 1975.
67. Cohen Jr MM: Craniostenosis and syndromes with craniosynostosis: incidence, genetics, penetrance, variability, and new syndrome updating, *Birth Defects* 15:13–63, 1979.
68. Cohen Jr MM: Transforming growth factors and fibroblast growth factors and their receptors: role in sutural biology and craniosynostosis [editorial review], *J Bone Miner Res* 12:3, 1997.
69. Faure C, Bonamy P, Rambert-Misset C: Craniostenosis caused by premature fusion of the coronal suture, *Ann Radiol* 10:32, 1967.
70. Lo L-J, et al.: Plagiocephaly: differential diagnosis based on endocranial morphology, *Plast Reconstr Surg* 97:282, 1996.
71. Lajeunie E, Le Merver M, Marchac D: Syndromal and non-syndromal primary trigonocephaly: analysis of 237 patients, *Am J Med Genet* 75:211, 1998.
72. Van der Meulen J: Metopic synostosis, *Childs Nerv Syst* 28:1359–1367, 2012.
73. Posnick JC: Trigonocephaly: metopic synostosis. In Posnick JC, editor: *Craniofacial and maxillofacial surgery in children and young adults*, Philadelphia, 2000, WB Saunders.
74. Ben Ari J, et al.: Agenesis of corpus callosum associated with double urinary collecting system, *Eur J Pediatr* 148:787, 1989.
75. Hunter AG, Rudd NL, Hoffman HJ: Trigonocephaly and associated minor anomalies in a mother and son, *J Med Genet* 13:77, 1976.
76. Cuomo C, et al.: Metopic suture craniosynostosis: an analysis of associated congenital malformations, *J Oral Maxillofac Surg* 62(Suppl):52–53, 2004.
77. Birgfeld CB, et al.: Making the diagnosis: Metopic ridge versus metopic craniosynostosis, *J Cranio Surg* 24(1):178–185, 2013.
78. Centers for Disease Control: *Cluster of craniosynostosis, Colorado*, Atlanta, 1987, Public Health Service publication No EPI-83-58-2. Division of Birth Defects and Developmental Disabilities, Center for Environmental Health and Injury Control.
79. Centers for Disease Control: *Cluster of craniosynostosis, Colorado*, Atlanta, 1989, Public Health Service publication No EPI-86-42-2. Division of Birth Defects and Developmental Disabilities, Center for Environmental Health and Injury Control.
80. Cohen Jr MM: The etiology of craniosynostosis. In Cohen Jr MM, editor: *Craniosynostosis: diagnosis, evaluation, and management*, New York, 1986, Raven Press.
81. Posnick JC, Ruiz RL: The craniofacial dysostosis syndromes: current surgical thinking and future directions, *Cleft Palate Craniofac J* 37:433, 2000.
82. Lajeunie E, et al.: Genetic study of nonsyndromic coronal craniosynostosis, *Am J Med Genet* 55:500, 1995.
83. Britto JA: Advances in the molecular pathogenesis of craniofacial conditions, *Oral Maxillofac Surg Clin North Am* 16:567–586, 2004.
84. Ruiz RL, et al.: Nonsyndromic craniosynostosis: diagnosis and contemporary surgical management, *Oral Maxillofac Surg Clin North Am* 16:447–463, 2004.

38

Syndromes with Craniosynostosis: Evaluation and Reconstruction

BRENT GOLDEN, CAROLYN DICUS BROOKES, TIMOTHY A. TURVEY

Introduction

Craniosynostosis, or premature fusion of cranial sutures, is a congenital abnormality that occurs in roughly 1:2000 to 1:2500 live births.[1,2] To date more than 150 syndromes with craniosynostosis as a component have been identified[2]; these are seen in 1:25,000 to 1:100,000 live births.[3,4] The term *craniofacial dysostosis* (CFD) has been used historically to describe the syndromic forms of craniosynostosis that exhibit sutural and enchondrosal pathology of the cranial vault and cranial base with associated craniofacial deformity. These syndromes typically manifest with some degree of characteristic exorbitism, hypertelorism, and multidimensional mid-face deficiency.

The most common phenotypic variants of this sort have been described by Carpenter,[5] Apert,[6] Crouzon,[7] Saethre-Chotzen,[8,9] Pfeiffer,[10] and Muenke.[11] Historically, the craniosynostosis syndromes were distinguished from one another primarily based on limb and visceral involvement, although some aspects of the craniofacial manifestations also were more typical within each. Today genotypic characterization of the syndromes can define the diagnosis or contribute to classification.[2]

Surgical management of the craniomaxillofacial skeleton has its distant history in the care of tumors and traumatic injuries. Elective osteotomies to reconstruct the maxillofacial region for deformities can be traced back to Gillies in England and Auxhausen and Wassmund in Germany during the early part of the twentieth century. However, it was Tessier in France during the second half of the twentieth century who pioneered modern craniofacial techniques and principles not only for management of the orbital region, but also for combined craniofacial and maxillofacial reconstruction (Figure 38-1). His influence on the surgical algorithms that follow cannot be overstated.

The goal of this chapter is to review our current understanding of the specific genetics and dysmorphology of the most commonly encountered syndromes, to describe the craniofacial implications of the craniosynostosis syndromes, and to describe a general framework from which to approach surgical care of these anomalies.

Genetic Understanding and Syndrome-Specific Traits

Broadly speaking, the craniosynostosis syndromes are predominantly autosomal dominant in their transmission and penetrance is often complete.[2] Genotype characterization is now possible for many of the mutations associated with craniosynostosis syndromes. The fibroblast growth factor receptor (FGFR) and TWIST genes are most often affected with over 90% of syndromic craniosynostoses caused by mutations in the FGFR2 locus.[12] The FGFs are involved in skeletogenesis and limb development, among other processes. Gain of function mutations in FGFR 1, 2, and 3 cause a family of eight craniosynostosis syndromes:[13] Crouzon syndrome, Crouzon syndrome with acanthosis nigricans, Apert syndrome, Pfieffer syndrome, Muenke syndrome, Beare-Stevenson syndrome, Jackson-Weiss syndrome, and FGFR-2 related isolated coronal synostosis.[2] Loss-of-function mutations in the TWIST gene also result in premature suture fusion, presumably through upregulation of the FGRFs and Runx, which is a transcription factor for osteogenesis.[14,15]

Genotype-phenotype correlations have now been described; however, there is much that remains uncharacterized about genotype-phenotype relationships. Patients with similar phenotype may have different genetic diagnoses while identical mutations have been found in patients carrying different clinical diagnoses.[2,13,16-19] At present, the eponymic phenotypic descriptions remain necessary.



• **Figure 38-1** Paul Tessier, MD.

Muenke Syndrome

Muenke syndrome is characterized by bilateral or, less commonly, unilateral coronal suture synostosis with minor anomalies of the hands and feet such as broad great toes, brachydactyly, or clinodactyly.[2,11] It is linked to a specific mutation in *FGFR3* and is inherited in an autosomal dominant fashion with incomplete penetrance and variable expressivity.[11] It has been noted to be the most common genetic cause of a craniosynostosis syndrome.[20]

Variability of clinical features is notable. Additional cranial sutures may be involved or patients may simply be macrocephalic.[11,21,22] Ventriculomegaly and hydrocephalus are rare.[23] Patients may exhibit mild mid-facial hypoplasia, mild ptosis, and a high arched palate.[21] Mild to moderate sensorineural hearing loss is extremely common (in contrast to the conductive loss seen in most other craniosynostosis syndromes).[22] Though normal intellect is the rule, developmental delay is seen in about one third of patients.[24] Because diagnosis allows early assessment and intervention to address hearing loss and developmental delay and because those with Muenke syndrome are more likely to require reoperation after cranial vault remodeling, it is prudent to obtain genetic testing for all patients with any variant of coronal synostosis.[11,21,22]

Crouzon Syndrome

Crouzon syndrome is a relatively frequent form of syndromic craniosynostosis characterized by multiple anomalies of the craniofacial skeleton with an autosomal dominant inheritance pattern, complete penetrance, and variable expressivity[25-67]; it accounts for roughly 4.5% of all cases of syndromic craniosynostosis.[2,4]

Mutations in *FGFR2* cause Crouzon syndrome while a specific mutation in the *FGFR3* gene causes the related Crouzon syndrome with acanthosis nigricans, which is most often sporadic.[2] This related syndrome has craniofacial findings similar to those that characterize Crouzon syndrome as well as acanthosis nigricans, often not seen until childhood, and sometimes additional skeletal anomalies such as choanal atresia and short vertebral bodies.[68,69] Some of the mutations in the *FGFR2* gene seen in Crouzon syndrome are identical to those seen in Pfeiffer and Jackson-Weiss syndromes[2,70-75]; it is likely that in the past many of these individuals have been clinically diagnosed with Crouzon syndrome.[76]

Though the craniofacial manifestations of Crouzon syndrome are marked, they are generally less severe than those of Apert syndrome and malformations of the extremities are classically absent. Premature synostosis of the coronal ring including both coronal sutures, the frontosphenoid suture, and the sphenoethmoidal synchondrosis results in brachycephaly, a short and wide anterior cranial base, and a total mid-face hypoplasia. Additional cranial sutures may be involved.[50] The lambdoid sutures can experience early closure more frequently than in Apert syndrome, and patients experience more significant posterior fossa pathology; chronic tonsillar herniation may be found in more than 70% of Crouzon patients,[2,77-79] and as many as 30% of patients have progressive hydrocephalus.[23]

The orbits are hypoplastic, especially laterally and inferiorly, resulting in characteristic exorbitism.[80] Orbital hypertelorism is usually moderate, and many patients exhibit exotropia.[50] Optic atrophy may be seen in roughly 20% of patients.[80] Conductive hearing loss is common.[24,81] Normal intellect is expected.[2]

Apert Syndrome

Apert syndrome is another relatively common craniosynostosis syndrome, accounting for 4% to 5% of craniosynostosis cases.[3,82] In addition to craniosynostosis with turribrachycephaly and mid-face hypoplasia, a hallmark of the syndrome is symmetric, four-limb syndactyly involving at least the second through fourth digits (Figure 38-2). Inheritance is autosomal dominant with complete penetrance, though the majority of cases are sporadic.[2] *FGFR2* mutations cause Apert syndrome and specific mutations have phenotypic links, such as more severe craniofacial involvement and cleft palate.[83]

At birth patients have bicoronal synostosis and often present with a wide midline calvarial defect that predictably obliterates over time; the metopic suture may close quite early or in a more delayed fashion. Asymmetry of the cranial base, orbits, and mid-face is more common than in Crouzon syndrome.[84,85] Proptosis and hypertelorism are always present. Exotropia and strabismus are common, though optic atrophy is seen less often than in Crouzon syndrome.[80,86,87] The nose is short with a depressed bridge and a rounded tip.[85] Though ventriculomegaly is common, progressive hydrocephalus is less frequent than in Crouzon syndrome.[88-90] The lambdoid sutures tend to close later than in Crouzon patients with posterior fossa dysmorphology



• **Figure 38-2** A typical appearance of the complex compound syndactyly seen in Apert syndrome. (From Gilbert-Barness E, editor: *Potter's pathology of the fetus, infant and child,* ed 2, Philadelphia, 2007, Mosby.)

that is only infrequently associated with chronic tonsillar herniation.[77]

Ears tend to be large and low set; acquired, conductive hearing loss may be observed.[85,91-93] Lateral palatal swellings containing mucopolysaccharides appear early and grow with age, and dental eruption is often delayed. A long soft palate can contribute to airway obstruction. Cardiovascular and genitourinary anomalies are found in about 10% of patients.[94] Fused cervical vertebrae are seen in the majority.[95] The periorbital findings also vary from those in Crouzon syndrome, with a greater downward slant to the lateral canthi and a distinctive, S-shaped upper eyelid ptosis. The quality of the skin often varies from normal, with acne and hyperhidrosis being prominent features.[2,85,96,97]

Saethre-Chotzen Syndrome

Saethre-Chotzen syndrome has an autosomal dominant inheritance pattern with variable penetrance and expressivity[2,16] and is caused by loss-of-function *TWIST* mutations. Its pattern of malformations may include craniosynostosis, low-set frontal hairline, ptosis of the upper eyelids, small ears with prominent crura, facial asymmetry, and limb anomalies such as brachydactyly, partial cutaneous syndactyly, and clinodactyly. Patients with Saethre-Chotzen rarely exhibit ventriculomegaly or require shunting.[23] Strabismus and hypertelorism are common.

Pfeiffer Syndrome

Pfeiffer syndrome consists of craniosynostosis, broad thumbs and great toes, and variable partial soft-tissue syndactyly.[10] The syndrome has been subdivided into three types.[98] Current thinking suggests that Pfeiffer syndrome is heterogeneous because it may be caused by different genetic abnormalities; either a single recurring mutation (Pro252Arg) of *FGFR1* or by several different mutations affecting *FGFR2.*[99-104] Type 1 exhibits autosomal dominant inheritance with complete penetrance and variable expressivity, though it may be sporadic. Types 2 and 3 are usually de novo.[98,105,106]

Type 1 Pfeiffer syndrome corresponds to the classic Pfeiffer syndrome and is associated with a satisfactory prognosis. Turribrachycephaly, mid-face retrusion, proptosis, hypertelorism, and a depressed nasal bridge are frequently noted. Type 2 Pfeiffer syndrome is associated with cloverleaf skull, neurologic impairment, and variable elbow ankylosis or synostosis. Choanal atresia and cleft palate may be seen. Patients are at risk for early death.[2,98,107] Type 3 Pfeiffer syndrome patients lack cloverleaf skull but have a more severe phenotype than Type 1 patients; elbow ankylosis may be seen. Early death is common.[98] Conductive hearing loss is common in all subtypes.[24] Hydrocephalus is also very common, and has been reported in the majority of Type 1 and most or all Type 3 patients.[108] Cervical fusions are seen more commonly in Types 2 and 3.[109,110]

Although some authors have found similarities between certain patients with Pfeiffer, Crouzon, and Jackson-Weiss syndromes, the three disorders are nosologically distinct. According to Cohen, the phenotypes of the three conditions do not correlate well with the known molecular findings.[27,111,112] Patients with these three syndromes may have similar or even identical mutations in exon B of *FGFR2,* yet the phenotypes are inherited consistently within families, an observation that is as yet unexplained by the molecular findings.[71,99]

Kleeblattschädel or Cloverleaf Skull

Kleeblattschädel anomaly (cloverleaf skull) is a phenotypic description of a trilobular-shaped skull, usually secondary to pansynostosis of the coronal, lambdoidal, metopic, and sagittal sutures. In this situation the brain protrudes through the open anterior and parietal fontanelles giving the characteristic "cloverleaf skull" appearance. The cloverleaf skull anomaly is known to be both etiologically and pathogenetically heterogeneous; it may occur as an isolated anomaly or together with other malformations, making up various syndromes (i.e., Apert, Crouzon, Carpenter, Pfeiffer, and Saethre-Chotzen). The deformity commonly requires shunting for progressive hydrocephalus,[23] and chronic tonsillar herniation develops almost universally.[117] Because of the significant variation in associated deformities, the extent and timing of reconstructive surgery is highly patient-specific.[31,113-116]

Craniofacial Management

Basic principles of craniofacial surgery as developed by Tessier are as valid today as when he described them, and current techniques remain largely aligned with his original ideas. The principles that follow are directly traceable back to him and those who advanced his work.

Patient-Specific Planning

The care of patients with craniosynostosis syndromes follows certain timelines that have been supported by recent Parameters of Care.[118] The suggested timing of interventions is based on the balance between functional and psychosocial concerns and expected patterns of growth. Even so, every patient should be treated based on a unique, patient-specific diagnostic problem list. Developmental and neurocognitive assessments should be performed at regular intervals. Clinical craniomaxillofacial evaluation combined with anthropomorphic analysis and comparison to normative data is useful for characterizing the pattern and severity of craniofacial deformity. Radiographic evaluation with computed tomography with or without lateral cephalometry is a necessary adjunct to quantify and qualify the skeletal dysmorphism; MR imaging of the brain and spine is frequently indicated.

Timing of Surgical Care

The timing of any operative intervention is a major factor when planning for craniofacial reconstructive surgery in the growing child. Goals of surgical management in this group include minimizing surgical burden (number of operations, length of treatment periods); limiting operative risk; and eliminating long-term, adverse health sequelae (increased intracranial pressure, vision loss, hearing loss, chronic or acute obstructive airway events, severe psychosocial detriment). In general this means that surgery will be staged and interventions will proceed in a craniocaudal direction. Surgery cannot be expected to change abnormal growth patterns, and therefore the most definitive reconstruction can only be completed once structures can be treated to their adult size and position. Of course, functional and developmental concerns may require earlier intervention, but always with the understanding that additional operations for definitive reconstruction are a distinct likelihood.

Placement of Incisions

Incisions should be designed to minimize visible scars. The combined use of bicoronal and intraoral incisions provide substantial access to the cranium and face with minimal esthetic compromise and are preferred. A bicoronal incision allows access to all aspects of the cranial vault as well as the superior orbits, nasoorbitoethmoidal region, zygomas, and pterygomaxillary junction. A layered closure of the coronal incision (galea and skin) optimizes healing and limits scar widening. Resuspension of the mid-facial periosteum to the temporalis fascia may facilitate redraping of the soft tissues. When detached, each lateral canthus should be reattached in a superior-posterior direction with overcorrection. Intraoral incisions provide access to the infraorbital regions, nasomaxillary base, and pterygomaxillary junction as well as the mandibular ramus, body, and symphysis.

Subperiosteal Dissection and Osteotomies Under Direct Visualization

Dissection is safely and preferentially performed in a subperiosteal plane with wide exposure to provide clear and direct visualization for any osteotomy procedure. One of Tessier's original concepts was that careful dissection of the pericranium and periorbita would allow all osteotomies and reconstruction without interfering with ocular, oculomotor, palpebral, or lacrimal functions.[119] In addition, wide release allows for flap relaxation and placement of onlay or inlay bone grafts to improve stability.

Overcorrection, Stabilization/Fixation, and Grafting

Relapse is an expected component of healing for patients who undergo moderate to large movements of the craniofacial skeleton, especially before skeletal maturity. Causes of relapse may include normal biology of healing, inadequate surgical mobilization of hard or soft tissue structures, or ongoing aberrant growth. Because of these factors and in anticipation of the tendency to return to the natural deformity, overcorrection at the time of bony construction is often prudent.

Stabilization of reconstructed skeletal structures using bone plates and screws (titanium or resorbable) further promotes maintenance of the surgical result. Fresh, autogenous bone grafts should be used to fill all possible defects to promote healing and stability with open reconstructive procedures.

Management of Intracranial Dead Space

Due diligence in eliminating or minimizing dead space is critical when increasing the dimensions of the cranium, especially retrofrontal intracranial dead space. Since the retrofrontal dead space is expected to dissipate predictably and relatively quickly in infants, conservative management is appropriate in this group.[120] As age increases, greater difficulty exists in predicting the timing and completeness of brain expansion to fill the intracranial cavity, and greater care must be taken relative to extent of surgical expansion and expectation of risk.

Management of Intracranial-Aerodigestive Communication

Of particular importance is the management of any cranial base communication between the sterile intracranial compartment and the bacteria-rich aerodigestive tract when

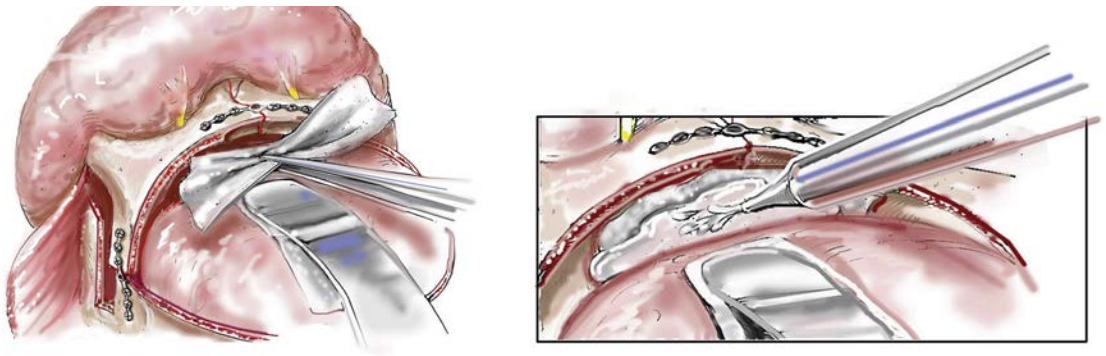

• **Figure 38-3** Basic operative principles to use in managing the cranial base defect include primary repair of dural tears when possible, dural grafting when needed, and re-creation of a tissue layer across the cranial base using some combination of bone grafts, tissue sealants, and/or pericranial flaps.

performing combined intracranial and extracranial surgery (monobloc advancement, facial bipartition, intracranial Le Fort III).[121,122] Optimally, no open communication should be left between the sino-nasal cavity and the anterior cranial fossa, and this seal should be protected during the early postoperative period. Basic operative principles to use in managing the cranial base defect include primary repair of dural tears when possible, dural grafting when needed, and re-creation of a tissue layer across the cranial base by way of bone grafts, tissue sealants, and pericranial flaps (Figure 38-3).[123,124] It is possible that distraction techniques offer advantages in protecting this barrier as well.[125] If working in the teenager or adult, frontal sinuses are often present and must be cranialized.

Postoperatively, care must be taken to allow sufficient time and immobilization of the local and grafted tissues to minimize risk of wound breakdown (fistula formation) and infection or loss of grafted material. Means to achieve this may include a period of extended postoperative intubation for 3 to 5 days and/or bilateral nasopharyngeal airways maintained after extubation. Additionally, after extubation care must be taken to avoid increasing nasal pressures by instituting mechanical sinus precautions and avoiding CPAP or positive pressure ventilation. When ventricular shunts are present management is significantly more complex, and great care must be taken in close coordination with the neurosurgical team to avoid overshunting (and prolongation or prevention of dead space elimination) or undershunting.

Algorithm of Care

Care of the child with syndromic craniosynostosis is based on understanding that form and function in the human condition are intimately linked. The natural shape, size, and proportions of the craniofacial region are finely tuned to provide and protect a multitude of functions including breathing, feeding, cognition, vision, hearing, smell, communication, and socialization. Because the design of the head and face is so well suited to these roles, any alteration in the form tends to cause deterioration in one or more of these functions. Because no one specialist can possibly evaluate and manage all the different concerns related to the health and well-being of a child with a craniosynostosis syndrome, care should take place in a center that is familiar with the management of these syndromes and that offers support from the many surgical, medical, and psychosocial disciplines required to yield optimal outcomes. Although each syndrome and indeed each patient has unique considerations, a guiding surgical framework can be conceptualized based on anticipated growth and development.

Infants and Toddlers (Birth to 4 Years)

Standard evaluation of the patient with syndromic craniosynostosis always begins with a thorough history and physical examination.

Airway

Of primary importance for the newborn with syndromic craniosynostosis is the patency and stability of the airway. Newborn infants are obligate nasal breathers for the first few months of life, making deficiency of the mid-face and nasal passages particularly problematic during this early stage.[126] The characteristic total mid-face deficiency seen in syndromic craniosynostosis frequently leads to diminished nasal and nasopharyngeal volumes and increased nasal airway resistance (obstruction) and these patients may be more prone to acute or prolonged obstructive problems.[127,128] A thickened velum (most frequently seen in Apert syndrome), choanal stenosis/atresia, and laryngotracheal anomalies can further contribute to structural airway obstruction.[128-131] Central apneas and hypopneas may also be present.[130,132,133]

Monitoring in a neonatal intensive care unit (NICU) is prudent, and interventions may be necessary to ensure the airway remains patent. Medical or surgical therapies to stabilize the airway may include positioning, nasopharyngeal intubation,[134] repair of choanal atresia, positive airway pressure,[135-137] or tracheostomy.[135,138,139] After the first year of life, adenotonsillectomy is an additional first-line treatment.[140-142] As with each functional concern, ongoing evaluation of the airway is required throughout growth and development, ideally at a multidisciplinary craniofacial center with airway expertise.[143-145] Strong consideration should

be given to baseline and regular polysomnography to screen for obstructive sleep apnea.

Feeding

Feeding is critical to maintain an anabolic balance. During the first months of life, the coordination of oral feeding with limited nasal airflow can lead to inadequate caloric intake, excessive caloric expenditure, or both. When the upper airway is sufficiently inhibited, an infant or child can fail to thrive even when capable of feeding orally for limited periods. Short-term nasogastric tube feeding or longer-term feeding gastrostomy tube placement can help overcome these challenges. The determination of when and how to pursue non-oral feeding should be made with appropriate input from the pediatrician/neonatologist, therapist with feeding expertise, and pediatric otolaryngologist after a consensus is reached about the etiology of the failure to thrive. In children with Apert or Pfeiffer syndrome screening imaging of the gastrointestinal system to evaluate for intestinal malrotation or esophageal atresia is often prudent.[2]

Vision

Protection of the ocular globes can be an urgent need soon after birth in the most severe phenotypes of syndromic craniosynostosis. When anterior cranial base and orbital hypoplasia is marked, exorbitism (shallow orbits) and exophthalmos (proptosis) can reach levels resulting in prolonged corneal exposure or even globe herniation. Persistent corneal exposure risks exposure keratopathy, abrasions, or ulcerations eventually threatening loss of vision. A pediatric ophthalmologist should participate in evaluation and planning, and artificial ocular lubrication may need to be meticulously maintained. In extreme circumstances, subluxation of the globe may even begin to occur chronically, requiring immediate and constant reduction. For the child with marked exorbitism and proptosis experiencing any of these vision-threatening complications, urgent cranio-orbital decompression with or without temporary tarsorrhaphies will be needed, and timing should be determined with the pediatric ophthalmologist's input.

The development of visual impairment over time in craniosynostosis syndromes is multifactorial and the incidence varies by diagnosis. Using a visual acuity cut-off that would allow one to get a driver's license, Khan found that 40% of this group had limiting visual impairment in their best eye.[146] Amblyogenic factors such as strabismus and refractive errors contribute to most cases of visual impairment with contemporarily managed patients. Importantly, these conditions are treatable with timely provision of eyeglasses for refractive errors, patching for amblyopia, or surgery for strabismus correction—all underscoring the importance of early involvement of the pediatric ophthalmologist.[87,146-148] Timing of strabismus correction as it relates to craniofacial procedures remains complex since cranio-orbital procedures are required early in life and may impact the multiple inciting factors.[149] Deferring strabismus surgery until after cranio-orbital reconstruction is often considered.

Hearing

Hearing deficits occur with increased frequency in children with craniofacial syndromes. The different syndromes vary in the types of audiologic problems that present, but conductive problems related to middle ear disease predominate.[24,81] Suboptimal hearing can contribute to impairment in speech and language development, and routine audiologic monitoring serves to promote early intervention in order to limit disability and maximize developmental progress. The field of amplification is rapidly advancing, and the oversight of a pediatric otolaryngologist is necessary.

Associated Anomalies of the Spine and Extremities

The limb defects found in some syndromic craniosynostosis patients require the involvement of orthopedic or plastic surgery specialists to assess and treat as appropriate. The first surgery for syndactyly is not urgent at birth.

The risk of spinal congenital anomalies noted previously necessitates radiographic screening of the spine early in life for specific syndromes, as well.[2]

Hydrocephalus

Nonsyndromic craniosynostosis rarely results in hydrocephalus. Within the syndromic group there are some syndromes that are particularly predisposed. This ventriculomegaly may and often does behave in a nonprogressive way as a benign or compensated finding that does not require shunting. Distinguishing between progressive hydrocephalus and nonprogressive ventriculomegaly is a difficult but important component of the neurosurgical care requiring experienced judgment.[23,89,90,150] Collman reports that ventricular dilation of either sort has been reported in between 30% and 70% of patients with Crouzon and Pfeiffer syndrome and 40% to 90% of patients with Apert syndrome.[23]

Progressive enlargement requiring shunting is more common in the Crouzon and Pfeiffer groups while those with Apert syndrome generally remain nonprogressive.[23,151,152] Difference in the timing of lambdoid synostosis has been hypothesized to explain these differences.[78]

Early on, patent fontanelles or sutures may allow for compensation of abnormal ventricular enlargement through increases in intracranial volume. As these mechanisms for compensation disappear, more vigilance is needed to prevent the development of aberrant pressures or to treat quickly once identified. Postulated causes of progressive hydrocephalus include mechanical obstruction to CSF outflow or impaired venous drainage based on skeletal changes in the posterior fossa leading to diminished CSF reabsorption.[23,153] When progressive enlargement is evident, shunting or endoscopic third ventriculostomy may be required. With evidence of increased intracranial pressure (ICP) in the absence of markedly expanding ventricles, cranial vault expansion is likely the best first course of action with close surveillance thereafter; this is discussed in the following section.[23]

Craniocerebral Disproportion

The goals of craniofacial reconstruction in the infant and toddler are to promote the protection, growth, and development of the brain and eyes and to normalize the cranial and upper orbital morphology. The cranial malformations associated with congenital absence of one or more of the cranial vault sutures may have negative neurologic effects in a subset of patients over time; this may be related to brain dysmorphology, altered regional blood flow, and/or inhibited cerebrospinal fluid dynamics. As more cranial sutures are involved, the risk for pathologic intracranial pressure rises markedly.[49-52] Thresholds for how high and how long intracranial pressure must be elevated to be classified as pathologic at any given age are not delineated by current evidence, but prolonged or repeated elevations are thought to contribute to the deleterious cognitive, behavioral, and visual effects of untreated disease.[154-171]

When the cranial vault is severely affected at birth by multisuture synostosis leading to profound constriction and concern for markedly elevated ICPs and exophthalmos, treatment with craniectomy over the sagittal suture with parietal and frontal outfracture as early as 12 to 16 weeks of life may be necessary for purely decompressive purposes. The decision to proceed in this urgent fashion is based on neurosurgical and ophthalmologic concerns and has very limited reconstructive goals.

It is commonly accepted that cranial vault expansion is the treatment of choice for syndromic synostosis with craniocerebral disproportion. Notably, there is significant center-to-center variation in preferences for region of the cranium and orbits to address first (i.e., posterior, anterior, total vault), techniques utilized (i.e., distraction, formal open reconstruction), and timing of surgery (i.e., less than 6 months, 6 to 9 months, older than 9 months). Endoscopic-assisted craniectomy of the coronal synostosis bilaterally with postoperative helmet therapy is a promising treatment that has been described, but is not yet widespread in application.[172,173]

In planning for nonurgent combined craniofacial and neurosurgical intervention with more complex reconstructive goals, consideration must be given to the distinct impact of the dysmorphology on the anterior cranial base, orbits, and the posterior cranial fossa. The anterior cranial base deformity has a significant negative impact on frontofacial esthetics and orbital position while the posterior fossa constriction may have implications for venous congestion, CSF hydrodynamics, and chronic tonsillar herniation. Clinical examination of the remaining open sutures, intracranial fullness, and orbital coverage is an invaluable guide to timing the first cranial intervention and to determining the first site of intervention; for instance, when the posterior deformity is not severe, anterior vault reconstruction may be the first stage of treatment. Dedicated, high-resolution CT evaluation of the craniofacial structures further characterizes the bony abnormality and assists with surgical planning. Brain MR imaging is indicated in specific patients who are predisposed to progressive hydrocephalus or who have marked posterior fossa deformity.[23,79,174,175]

In the absence of acute functional disturbance, there are data to support the first stage of cranial vault expansion after 6 months of age and before 18 months.[176-178] This time frame has been shown to minimize the need for reoperation while still being mindful of the possible neurologic implications of waiting. After 9 to 12 months of life the reconstructed cranial structures may better maintain their shape and relative position, which should translate to fewer repeat procedures later in life.[159-161,179]

Standard treatment of the anterior cranio-orbital dysmorphology involves release of the affected cranial vault sutures with simultaneous anterior cranial vault and upper orbital decompression and recontouring (Figure 38-4).[73,126,127,178,180,181,184,185] Few advocate for distraction of the anterior cranial vault because of the complex reshaping that is usually required.[186] The goals of treatment include decreasing the bitemporal and anterior cranial base width at the level of the supraorbital bandeau while advancing the superior bony orbit. This should serve to ameliorate proptosis and allow for better periorbital coverage of the globe. Concurrently, the frontoforehead unit is advanced in the sagittal plane and recontoured.

When brachycephaly is combined with marked posterior occipital flattening (often leading to turricephaly), surgery to expand and reshape the posterior vault can be considered as a first stage (Figure 38-5). Children with brachyturricephaly generally need marked expansion, and greater magnitudes can be accomplished with posterior vault reconstruction than with fronto-orbital advancement.[187-189] Posterior vault expansion can be done by direct reconstruction as a single stage or by using distraction osteogenesis techniques.[187,189-196] The proposed advantages of posterior vault distraction include possible greater volume increases relative to conventional open reconstruction or anterior vault expansion and shorter operative time in some series.[191,196-198] Disadvantages include the inability to expand in three dimensions, a required second-stage operation to remove the distraction devices, and the increased risk of complications related to the mechanical distractor devices (infection, failure, scarring). Reported complication rates currently range from 12.5% to 100% and average 35.5%; device failure and infection are the most common.[188,189,191,192,194,196,199,200]

Treatment of the entire cranial vault in a single stage must take into consideration the increased risks involved, including a more complex anesthetic and positioning considerations. As such, total vault reconstruction remains infrequent.

Concurrent suboccipital decompression for chronic tonsillar herniation has been described, but is not routine practice.[117,201] Persistent, progressive or symptomatic chronic tonsillar herniation may be treated by a second stage of posterior cranial vault expansion. Staging the initial posterior vault expansion for a second cranial procedure may allow for more meaningful long-term posterior fossa expansion and treatment of chronic tonsillar herniation.[202] Standard suboccipital decompression may also be utilized.

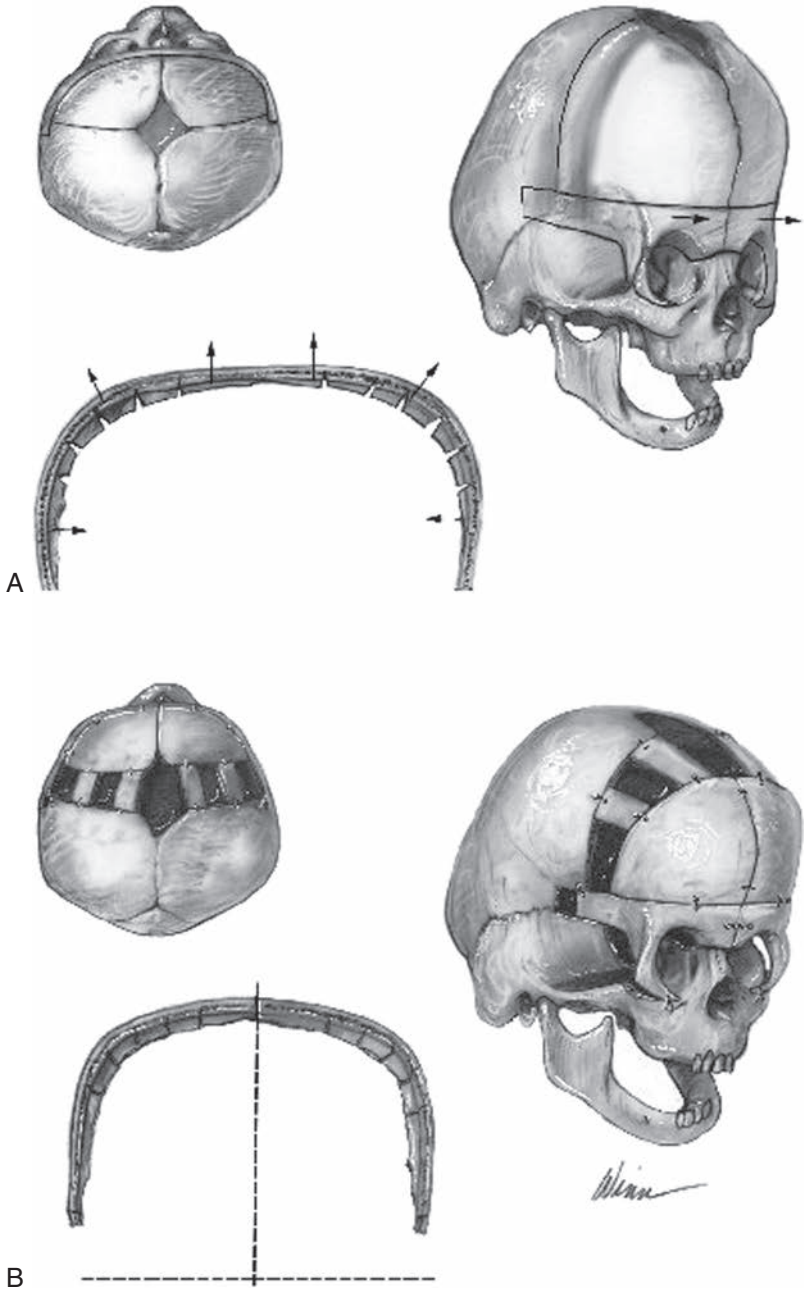

• **Figure 38-4** Illustration of the craniofacial skeleton of a child with bilateral coronal synostosis before and after anterior cranial vault and three-quarter orbital osteotomies with reshaping as described. **A,** Site of osteotomies as indicated. **B,** After osteotomies and reshaping and fixation of the cranio-orbital regions.

Recurrent Intracranial Hypertension

Throughout infancy and the toddler years, children must be followed in an interdisciplinary fashion. Venous obstruction, progressive hydrocephalus, and hypercarbia due to apneas may all contribute to intracranial hypertension. Importantly, it should be remembered that cranial vault expansion incompletely addresses venous obstructive problems—particularly with unaddressed posterior fossa deformity—and does not address airway concerns at all.[153] Clinical signs and symptoms of increased intracranial pressures may include irritability, papilledema, or a bulging fontanelle; however, these may be subtle and nonspecific in the pediatric population. To complicate matters, the majority of patients have no signs or symptoms until irreversible negative effects have accumulated.[174,203,204]

Routine screening for children with syndromic craniosynostosis should include regular craniofacial and neurosurgical evaluation, regular ophthalmologic evaluation, regular screening for sleep disordered breathing, and imaging as needed. Ophthalmologic evaluation is very useful to assess the optic disc since papilledema in this young age is quite specific for an increase in ICP. Importantly, absence of papilledema has low sensitivity for ruling out the condition.[204-207] Radiographic assessments may provide findings

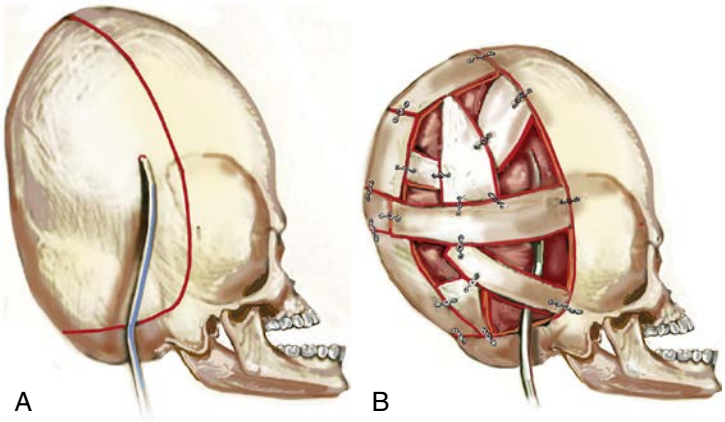

• **Figure 38-5** **A,** Illustration of flattened posterior cranial vault with a ventriculoperitoneal shunt in place. **B,** Illustration after posterior cranial vault shaping is also shown.

that are supportive of persistent craniocerebral disproportion, including the thinning and patterning of the internal skull known as a "copper-beaten" appearance or the loss of brain cisternae observed on a computed tomography (CT) scan.[168-171] Intracranial monitors are indicated in equivocal circumstances to provide more information about ICP, but this too requires judgment as no clear normative data is available for children.[153]

Ideally, because of the implications of apneas on ICP, level I polysomnography would be obtained for any patients with symptoms of OSA.[208] If OSA is identified and considered a contributor, interventions to maintain airway patency are considered as described previously. In general, mid-face advancement should be avoided in this young age group because of the predictably poor maintenance of any improvements in the airway with additional growth.

If concerns arise regarding increased ICPs, further treatment with cranial vault decompression may be required.[113,168,180-182,209] In these circumstances the particulars of the surgical intervention should be dictated by the patient's presentation, and clinical judgment dictates what type of expansion is most prudent. When the determination is made that the greatest benefit can be obtained from treating the anterior cranial vault and orbits, surgical planning and execution similar to the original reconstruction is repeated. If there is greater concern about posterior shape and constriction as is more common in Apert syndrome and the more severe phenotypes of the craniosynostosis syndromes, expansion of the posterior cranial vault is performed.

When a repeat craniotomy is required, it is important to anticipate the increased technical challenges and attendant morbidity that must be expected. Simply turning a coronal flap will require more time and greater care to identify full-thickness calvarial defects and avoid dural tears. The bone may be more brittle and jagged than in the unoperated child, and dissection of the dura from the bone can be more challenging.[210,211] Dealing with these issues will lead to a longer operating time and increase expected blood loss.

The Young Child (4 to 13 Years)

Multidisciplinary coordination of care should continue throughout childhood with regular neurosurgical, craniofacial, ophthalmologic, audiologic, speech, psychological, airway, and genetic specialty surveillance and care.[212]

In the early school age years, the dysmorphology of the subfrontal facial mass and orbits takes priority. The deformity is a complex three-dimensional problem that requires a patient-specific approach. There is always some degree of sagittal underprojection of the upper mid-face and maxilla, but also vertical deficiency with telescoping of the nose upwards and variable degrees of transverse variance with facial widening and orbital hypertelorism superiorly and maxillary constriction inferiorly.[213-216]

Treatment is indicated based on the related functional, morphologic, and psychosocial implications of this deformity. The most significant functional problem is related to airway obstruction. Obstructive sleep apnea is a frequent finding with reports of between 40% and 80% of children being affected.[126,135,144,208,217-220] In symptomatic patients this percentage rises to between 68% and 74%. It is worth noting that relief of airway obstruction following monobloc or Le Fort III advancements has been unpredictable in some studies[221,222] and associated with recurrence in others.[223] Comprehensive airway evaluation in children with OSA should include preoperative nasal and endoscopic pharyngeal evaluation by an airway surgeon to fully characterize the level(s) of obstruction. Adenotonsillectomy should be considered prior to mid-face advancement when indicated.

Multiple surgical approaches are available to address this region, and the selected approach is based on the patient's individual needs. The goals of reconstruction with frontofacial advancement are to achieve acceptable forehead projection and symmetry when forehead and supraorbital projection remains deficient, minimize abnormalities in orbital depth and position, and improve the arc of rotation of the face with the aim of opening the airway. It is the exception to the rule that deficiency of projection along the cranium, zygomas, orbits, and upper jaw is uniform.

Fronto-orbital dysmorphology and not malocclusion should determine reconstructive goals at this stage because if a Le Fort I separation of the "total mid-face" complex is not carried out and the surgeon attempts to achieve a balanced occlusion, an overadvancement of the orbits with enophthalmos will typically occur. Normalizing the occlusion during the preadolescent years does not provide a maintainable outcome as remaining mandibular growth makes long-term stability unlikely. Generally, the Le Fort I osteotomy is thus *not* performed at the time of the "total mid-face" procedure. This will await skeletal maturity and then be combined with orthodontic treatment for stability purposes; until then a malocclusion may remain. Of course, in the teenager or adult who requires both total mid-face and orthognathic management, these procedures may be carried out simultaneously.

Additional functional concerns indicating the need for frontofacial advancement may include increased intracranial pressure as frontofacial advancement can provide anterior cranial expansion to increase intracranial volume.

Increased osseous protection of the vulnerable globe is also achieved with desirable esthetic improvements. With distraction procedures particularly, it is important that families anticipate some degree of overcorrection and esthetic compromise in the short term with the understanding that form will improve with ongoing lower facial growth.[223]

Definitive reconstruction of the orbital and upper mid-facial structures with or without readdressing the fronto-forehead unit in syndromic craniosynostosis for these goals is reasonable by 6 to 9 years of age since the cranial vault and orbits have attained approximately 85% to 90% of their adult size.[180,181,224-226] Although a recent assessment of centers treating Apert children found that first advancement took place at an average age of 5 years old, later treatment (after 8 years of age) has been shown to decrease the risk of additional surgery and should be considered when possible.[176,223] In addition, allowing time for the first molar teeth to erupt into occlusion can help with control of the advancement at the occlusal plane. Furthermore, this time frame coincides with early socialization in school, and there are psychosocial benefits to improving facial proportions and appearance during this stage.[227-230] A growing awareness of the negative implications of chronic airway obstruction and sleep disordered breathing is increasingly used as an indication for surgical intervention at the mid-face level at an earlier age, but this remains to be justified in light of the risk of recurrent obstruction and need for additional mid-facial advancement later in childhood.

The observed dysmorphology is dependent on the original malformation, the previous procedures carried out, and the effects of ongoing growth. If the supraorbital region, anterior cranial base, zygomas, nose, lower orbits, and maxilla all remain deficient and/or deformed in the sagittal plane (horizontal retrusion), a monobloc osteotomy is indicated. In these patients, the forehead is generally flat and retruded and will also require reshaping and advancement. If upper mid-face hypertelorism (increased transverse width) and mid-face flattening (horizontal retrusion) with abnormal facial curvature (concave arc) are also present, then the monobloc unit is split vertically in the midline (facial bipartition), a wedge of interorbital (nasal and ethmoid) bone is removed, and the orbits and zygomas are repositioned medially while the maxillary posterior arch is widened (Figure 38-6). When a monobloc or facial bipartition osteotomy is carried out as the "total mid-face" procedure, additional segmentation of the upper and lateral orbits for reconstruction may also be required to normalize the morphology of the orbital esthetic units.

Frontofacial advancement and/or cranial vault expansion procedures should be carefully staged with ventriculoperitoneal (VP) shunting procedures because the potential for morbidity is increased. In a patient with a VP shunt in place before the surgery, an experienced neurosurgical evaluation, including CT scanning of the ventricular system, is carried out to confirm physiologic shunt function. Surgery should be undertaken with extreme caution in the patient with a limited ability to eliminate the retrofrontal dead space.

If the supraorbital ridge is in good position when viewed from the sagittal plane (the depth of the upper orbits is adequate), the mid-face and forehead have a normal arc of rotation in the transverse plane (not concave), and the root of the nose is of normal width (minimal orbital hypertelorism), there is no need to further reconstruct this region (the forehead and upper orbits). In such patients, the basic residual mid-face deficiency and/or deformity is in the lower half of the orbits, zygomatic buttress, and maxilla. If so, the orbital-midface deformity may be effectively managed using an extracranial Le Fort III osteotomy (Figure 38-7).

Distraction osteogenesis as an alternative method to advance the frontofacial mass was described as early as 1995.[231] Using both external and internal types of devices, numerous centers today have adopted distraction osteogenesis techniques to facilitate advancement of the frontofacial mass while hoping to minimize complications and increase stability.[232-245] A proposed, theoretical advantage of distraction techniques is that it limits retrofrontal dead space and improves the seal across the cranial base, which may decrease the rate of meningitis, osteomyelitis, and loss of bone flaps.[125] In addition, multiple studies have suggested an ability to advance the mid-face with greater stability using distraction techniques as compared to single stage surgery.[243,246-248] It must be noted that relapse given in percentages is less useful than absolute values in this setting. The difference between 12% relapse (typical for conventional Le Fort III) and 5% relapse (typical for Le Fort III distraction osteogenesis) for a 15-mm advancement is 1 mm,[249] which is of questionable clinical significance and may not be a sole justification for distraction. In addition, no correlation has been shown between number of millimeters of advancement at

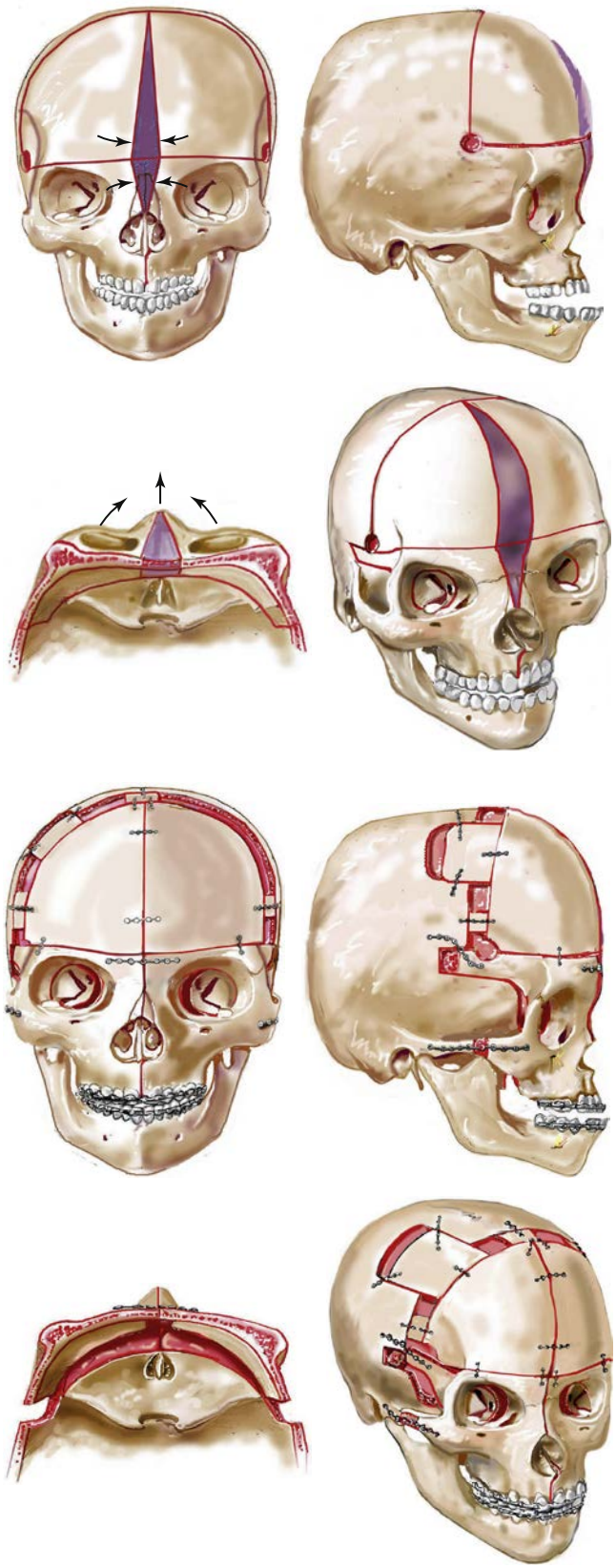

• **Figure 38-6** Overview of the skeletal morphology before and after facial bipartition osteotomy with repositioning and stabilization.

the frontofacial osteotomies and either greater functional gains or enhanced facial esthetics, so ability to further advance the mid-face with distractors has not yet been shown to have clear benefit.

A significant potential limitation of distraction techniques includes greater challenges in achieving the above mentioned key technical and esthetic reconstructive aspects in all three planes of space given the linear mode of operation. Emerging adaptations to address these limitations include bipartition prior to activation or combined monobloc with Le Fort II distraction.[190,250-253] Other disadvantages of distraction techniques for mid-face advancement include additional chances for morbidity as a result of pin tract infection, scarring, and/or device loosening requiring reapplication.[232-236,238-242,254-260] In all cases, there is the need for an additional surgical procedure and anesthetic for device removal. Distraction techniques are not immune to mechanical complications including pin migration, secondary trauma, CSF leakage, loss of bone flaps, or mortality. Dependence on a patient's, family's, and clinician's continued commitment to staying the course for necessary outpatient procedures or adjustments to achieve an acceptable result must also be factored into the decision-making process.

How the severity and frequency of complications compares between distraction and single-stage monobloc procedures remains a matter of debate to be settled; some centers continue to advocate for frontofacial distraction as superior,[243] some favor single-stage reconstruction,[261] and others promote predominantly subcranial treatment.[210] Surgeon expertise, clinical factors, and family input must all be considered when choosing the appropriate modality.

The Adolescent (13+ Years)

In the craniosynostosis syndrome patient with a mid-face deficiency, hypoplasia exists in all three planes of space. The upper anterior face is both vertically short (nasion to maxillary incisor) and there is a lack of horizontal (AP) projection of the mid-face. In addition, the width of the maxilla in the dentoalveolar region is generally constricted with a high arched palate. The mandible and chin may become secondarily deformed and benefit from surgical repositioning as part of orthognathic correction.

An Angle class III malocclusion is the expected maxillomandibular relationship secondary to the marked mid-face deficiency in most cases. This has deleterious functional implications for mastication, speech, dental health, and possibly temporomandibular joint function. Dental crowding is frequent as a result of maxillary hypoplasia, even though it is common to be missing teeth in syndromic synostosis.[262]

Normalization of the lower face and occlusion is most predictably accomplished through combined orthodontics and orthognathic surgery. In the syndromic craniosynostosis patient the lower jaw is expected to grow throughout skeletal maturity, therefore operative intervention with the

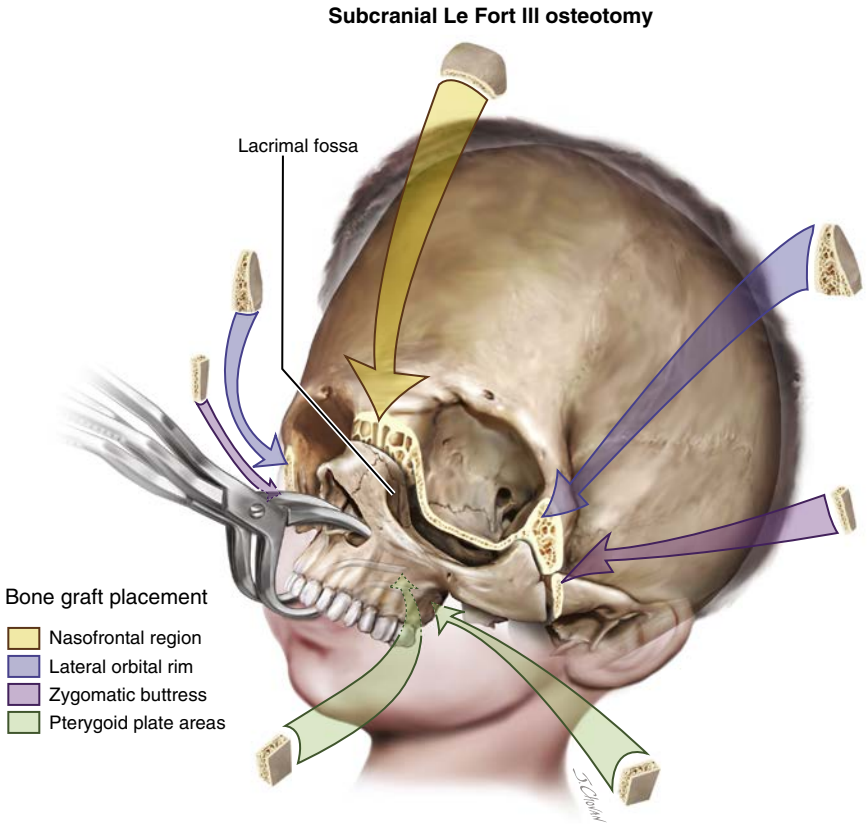

• **Figure 38-7** The subcranial Le Fort III osteotomy.

aim of normalizing the occlusion should be performed no sooner than the time of early skeletal maturity (approximately 13 to 15 years in girls and 14 to 16 years in boys) for optimum long-term stability. Ever since Obwegeser's innovative approach to osteotomies of the upper and lower jaws, the overwhelming majority of patients can be treated appropriately using some combination of standard orthognathic surgical techniques of Le Fort I level maxillary osteotomy, bilateral sagittal split mandibular osteotomies, and/or osseous sliding genioplasty. Further advantages of the Le Fort I osteotomy include the ability to address septal deviations and inferior turbinate hypertrophy concurrently with maxillary repositioning.[263]

Clinical assessment of the facial components in three planes of space along with the occlusal plane orientation drives treatment decisions. Cephalometrics and study models augment the clinical exam. Vertical proportions are assessed and compared to expected facial height and width with maxillary incisor display factoring into the assessment. Transverse asymmetry is determined by clinical exam and can be augmented by CBCT data. The maxillary width is assessed from soft tissue relationships and using dental casts. Canting and vertical asymmetry are noted on clinical exam. Sagittal projection is assessed using a natural head position and looking for balance between the forehead, nose, lips, and chin. These techniques are covered in more detail elsewhere in this textbook and may be referenced there.

Adjunctive Procedures: Rhinoplasty, Cranioplasty, Ptosis

Final reconstruction often requires soft tissue nasal and periocular procedures. Periocular considerations include variable lateral canthal malposition and upper lid ptosis in Apert patients, frequently with asymmetry.[119] Ptosis repair or lateral canthopexies may be needed at the surgeon's discretion. Secondary rhinoplasty will benefit many patients, especially those with Apert syndrome. Further detail of these procedures is beyond the scope of this chapter, but should be considered a necessary component of care in the syndromic craniosynostosis population.

Conclusion

The preferred approach to the management of a patient with syndromic craniosynostosis is to stage reconstruction based on craniofacial growth patterns, functional demands (cognition, vision, breathing, swallowing, speech, chewing, hearing), and psychosocial effects. Recognition of the need for a staged reconstructive approach allows clarification of the objectives of each phase of craniofacial treatment for the surgeons, craniofacial team, and family. By continuing to define our rationale for the timing, techniques, and extent of intervention and to objectively evaluate functional and morphologic (esthetic) outcomes, the quality of life for children born with a craniosynostosis syndrome will be further improved.

Acknowledgment

The authors would like to thank and recognize the previous authors of this text, Jeffrey Posnick and John Amato, whose expertise and contributions regarding the evaluation and management of these patients are maintained throughout the content of this chapter.

References

1. Greenwood J, Flodman P, Osann K, Boyadjiev SA, Kimonis V: Familial incidence and associated symptoms in a population of individuals with nonsyndromic craniosynostosis, *Genet Med* 16(4):302–310, 2014. http://dx.doi.org/10.1038/gim.2013.134.
2. Robin NH: FGFR-related craniosynostosis syndromes, *Gene Reviews* 1–30, 2007.
3. Cohen MM, Kreiborg S, Lammer EJ, et al.: Birth prevalence study of the Apert syndrome, *Am J Med Genet Part A* 42(5): 655–659, 1992. http://dx.doi.org/10.1002/ajmg.1320450322.
4. Cohen Jr M, Kreiborg S: Birth prevalence studies of the Crouzon syndrome: comparison of direct and indirect methods, *Clin Genet* 41(1):12–15, 1992.
5. Carpenter G: Two sisters showing malformations of the skull and other congenital abnormalities, *Rep Soc Study Dis Child* 1:110, 1901.
6. Apert E: De l'acrocephalosyndactlie, *Bull Mem Soc Med Hop Paris* 23:1310, 1906.
7. Crouzon O: Une nouvelle famille atteinte de dysostose craniofaciale hereditaire, *Arch Med Enfant* 18:540, 1915.
8. Saethre H: Ein Beitrag zum Turmschädelproblem(Pathogenese, Erblichkeit und Symptomatologie), *Dtsch Z Nervenheilkd* 117:533, 1931.
9. Chotzen F: Eine eigenartige familiare Entwicklungsstorung. (Akrocephalosyndaktylie, Dystosis Craniofacialis Und Hypertelorismus), *Monatschr Kinderheilkd* 55:97, 1932.
10. Pfeiffer R: Dominant Erbliche Akrocephalosyndaktylie, *Z Kinderheilkd* 90:301, 1964.
11. Muenke M, Gripp KW, McDonald-McGinn DM, et al.: A unique point mutation in the fibroblast growth factor receptor 3 gene (FGFR3) defines a new craniosynostosis syndrome, *Am J Hum Genet* 60(3):555–564, 1997. http://europepmc.org/abstract/MED/9042914.
12. Passos-Bueno MR, Sertié AL, Richieri-Costa A, et al.: Description of a new mutation and characterization of FGFR1, FGFR2, and FGFR3 mutations among Brazilian patients with syndromic craniosynostoses, *Am J Med Genet* 78(3):237–241, 1998.
13. Cunningham ML, Seto ML, Ratisoontorn C, Heike CL, Hing AV: syndromic craniosynostosis: from history to hydrogen bonds, *Orthod Craniofacial Res* 10(2):67–81, 2007. http://dx.doi.org/10.1111/j.1601-6343.2007.00389.x.
14. Connerney J, Andreeva V, Leshem Y, Muentener C, Mercado MA, Spicer DB: Twist1 dimer selection regulates cranial suture patterning and fusion, *Dev Dyn* 235(5):1345–1357, 2006. http://dx.doi.org/10.1002/dvdy.20717.
15. Connerney J, Andreeva V, Leshem Y, et al.: Twist1 homodimers enhance FGF responsiveness of the cranial sutures and promotesuture closure, *Dev Biol* 318(2):323–334, 2008. http://dx.doi.org/10.1016/j.ydbio.2008.03.037.
16. Paznekas WA, Cunningham ML, Howard TD, et al.: Genetic heterogeneity of Saethre-Chotzen syndrome, due to TWIST and FGFR mutations, *Am J Hum Genet* 62(6):1370–1380, 1998. http://dx.doi.org/10.1086/301855.
17. Ito S: Phenotypic diversity in patients with craniosynostoses unrelated to Apert syndrome: the role of fibroblast growth factor receptor gene mutations, *J Neurosurg* 102(Suppl 23):23, 2006.
18. Hollway GE, Suthers GK, Haan EA, et al.: Mutation detection in FGFR2 craniosynostosis syndromes, *Hum Genet* 99(2):251–255, 1997. http://dx.doi.org/10.1007/s004390050348.
19. Oldridge M, Lunt PW, Zackai EH, et al.: Genotype-phenotype correlation for nucleotide substitutions in the IgII-IgIII linker of FGFR2, *Hum Mol Genet* 6(1):137–143, 1997. http://dx.doi.org/10.1093/hmg/6.1.137.
20. Twigg SRF, Healy C, Babbs C, et al.: Skeletal analysis of the Fgfr3P244R mouse, a genetic model for the muenke craniosynostosis syndrome, *Dev Dyn* 238(2):331–342, 2009. http://dx.doi.org/10.1002/dvdy.21790.
21. Agochuckwu N, Doherty E, Muenke M: Muenke syndrome. In Pagon R, Adam M, Ardinger H, et al, editors: *GeneReviews*, Seattle, 2014.
22. Doherty ES, Lacbawan F, Hadley DW, et al.: Muenke syndrome (FGFR3-related craniosynostosis): expansion of the phenotype and review of the literature, *Am J Medical Genetics, Part A* 143:3204–3215, 2007. http://dx.doi.org/10.1002/ajmg.a.32078.
23. Collmann H, Sörensen N, Krauß J: Hydrocephalus in craniosynostosis: a review, *Child's Nerv Syst* 21(10):902–912, 2005. http://dx.doi.org/10.1007/s00381-004-1116-y.
24. Agochukwu NB, Solomon BD, Muenke M: Hearing loss in syndromic craniosynostoses: otologic manifestations and clinical findings, *Int J Pediatr Otorhinolaryngol* 78(12):2037–2047, 2014. http://dx.doi.org/10.1016/j.ijporl.2014.09.019.
25. Anderson F, Geiger L: Craniosynostosis: a survey of 204 cases, *J Neurosurg* 22:229–240, 1965.
26. Bertlesen T: The premature synostosis of the cranial sutures, *Acta Ophthalmol Suppl* 36(Suppl):1–176, 1958.
27. Cohen Jr MM: An etiologic and nosologic overview of craniosynostosis syndromes, *Birth Defects Orig Artic Ser* 11:137–189, 1975. Available at http://www.ncbi.nlm.nih.gov/pubmed/179637.
28. Cohen Jr MM: Genetic perspectives on craniosynostosis and syndromes with craniosynostosis, *J Neurosurg* 47(6):886–898, 1977.
29. Cohen Jr MM: Craniosynostosis and syndromes with craniosynostosis: incidence, genetics, penetrance, variability, and new syndrome updating, *Birth Defects Orig Artic Ser* 15(5B):13–63, 1979.
30. Cohen Jr MM: Craniosynostosis update: 1986-1987, *Am J Med Genet* 4(Suppl):99, 1988.
31. Cohen Jr MM: The cloverleaf anomaly: managing extreme cranio-orbito-facio-stenosis (discussion), *Plast Reconstr Surg* 91:10, 1993.
32. Cohen MM: Sutural biology and the correlates of craniosynostosis, *Am J Med Genet* 47(5):581–616, 1993. http://dx.doi.org/10.1002/ajmg.1320470507.
33. Crouzon O: Sur la dysostose cranio-faciale hereditaire et sur les rapports avec l'acrocephalosyndactylie, *Bull Mem Soc Med Hop Paris* 48:1568, 1932.
34. Crouzon O: Les dysostose prechordales, *Bull Acad Med* 115:696, 1936.
35. Cruveiller J: *La Maladie d'Apert-Crouzon (thèse medicale)*, 1954. Paris.

36. David J, Poswillo D, Simpson D: *The Craniosynostoses: Causes, Natural History and Management*, New York, 1982, Springer-Verlag.
37. DeGunten P: Contribution a l'etude des malformations de la face et des maxillaires dans la dysostose craniofaciale, *Ann Otolaryngol* 57:1056, 1938.
38. Dodge Jr H, Wood M, Kennedy R: Craniofacial dysostosis: Crouzon's disease, *Pediatrics* 23(1 Pt 1):98–106, 1959.
39. Don N, Siggers D: Cor pulmonale in Crouzon's disease, *Arch Dis Child* 46(247):394–396, 1971.
40. Flippen Jr J: Cranio-facial dysostosis of Crouzon; report of a case in which the malformation occurred in four generations, *Pediatrics* 5(1):90–96, 1950.
41. Franceschettia A: Cranial dysostosis with cerebriform calva, *Confin Neurol* 13(3):161–166, 1953.
42. Garcin M, Thurel R, Rudeaux P: Sur en cas asole de dysostose craniofaciale (maladie de Crouzon) avec extradactylie, Bull Soc Med Hop, 56(1458), 1932.
43. Grenet H, Leveuf J, Issac G: Etude anatomique de la maladie de Crouzon, *Bull Soc Pediatr* 32:343, 1934.
44. Gunther G: Dysostose craniofaciale hereditaire, *Endocrinologie* 13:255, 1933.
45. Heuyer G: A propos de la dysostose craniofaciale (ou maladie de Crouzon), *Actual Odontostoniarol* 16(413), 1951.
46. Hunter A, Rudd N: Craniosynostosis: II. coronal synostosis: its familial characteristics and associated clinical findings in 109 patients lacking bilateral polysyndactyly or syndactyly, *Teratology* 15:301, 1977.
47. Jones K: The Crouzon syndrome revisited, *J Med Genet* 10:398, 1973.
48. Juberg R, Chambers S: An autosomal recessive form of craniofacial dysostosis (the Crouzon syndrome), *J Med Genet* 10:89, 1973.
49. Kaler SG, Bixler D, Yu PL: Radiographic hand abnormalities in fifteen cases of Crouzon syndrome, *J Craniofac Genet Dev Biol* 2(3):205–213, 1982. Available at http://www.ncbi.nlm.nih.gov/pubmed/7166594.
50. Kreiborg S: Crouzon syndrome. A clinical and roentgencephalometric study, *Scand J Plast Reconstr Surg Suppl* 18:1–198, 1981.
51. Kreiborg S, Cohen Jr MM: Germinal mosaicism in Crouzon syndrome, *Hum Genet* 84(5):487–488, 1990.
52. Lake M, Kuppinger J: Craniofacial dysostosis (Crouzon's disease); report of 3 cases, *Arch Ophthal* 44(1):37–46, 1950.
53. Leonard M: A sporadic case of apparent Crouzon's syndrome with extracraniofacial manifestations, *J Med Genet* 11(2):206–208, 1974.
54. Ma HW, Lajeunie E, Le Merrer M, et al.: No evidence of genetic heterogeneity in Crouzon craniofacial dysostosis, *Hum Genet* 96(6):731–735, 1995. http://dx.doi.org/10.1007/BF00210308.
55. Manns K, Bopp K: Dysostosis craniofacialis Crouzon mit digitaler anomalie, *Med Klin* 60:1899, 1965.
56. Maximillian C: Syndrome de dysostose craniofaciale avec hyperplasie diaphysaire, *J Genet Hum* 29:129, 1981.
57. McKusick V: *Mendelian Inheritance in Man*, 12th ed., Baltimore, 1998, Johns Hopkins University Press.
58. Montaut J, Stricker M: Dysmorphies craniofaciales: les synostoses prematurees (craniostenoses et facio-stenoses), *Neurochirurgie* 23(Suppl)):1, 1977.
59. Moretti G, Sraeffen J: Dysostose craniofaciale de Crouzon et syringomylie: association chez le frere et la soeur, *Press Med* 67:376, 1959.
60. Pinkerton O, Pinkerton F: Hereditary craniofacial dysplasia, *Am J Ophthalmol* 35(4):500–506, 1952.
61. Reddy B, Garg B, Padiyar N, Krishnaram A: An unusual association of acanthosis nigricans and Crouzon's disease—a case report, *J Dermatol* 12(1):85–90, 1985.
62. Regnault F, Crouzon O: Etude sur un cas de dysostose craniofaciale hereditaire, *Ann Med Enfant* 43:676, 1927.
63. Schlapfer I, Dyskephallic: (dysostosis craniofacialis-maladie de Crouzon) bei zwei Schwestern, *Klin Monatsbl Augenheilk* 103:469, 1939.
64. Shiller J: Craniofacial dysostosis of Crouzon; a case report and pedigree with emphasis on heredity, *Pediatrics* 23(1 Pt 1):107–112, 1959.
65. Stanescu V: Syndrome hereditaire dominant, reunissant une dysostose craniofaciale de type particulier, une insuffiscance de croissance d'aspect chondrodystrophique et un epaississement massif de la corticale des os longes, *Rev Fr Endocrinol Clin* 4:219, 1963.
66. Vogt A, Dyskephalie: (Dysostosis craniofacialis, maladie de Crouzon 1912) und eine neuartige kombination dieser krankheir mit syndaktylie der 4 extremitaeten (Dyskephlodaktylie), *Klin Monatsbl Augenheilk* 90:441, 1933.
67. Vuilliamy D, Normandale P: Craniofacial dysostosis in a Dorset family, *Arch Dis Child* 41:275, 1966.
68. Arnaud-Löpez L, Fragoso J, Mantilla-Capacho J, Barros-Nuñez P: Crouzon with acanthosis nigricans. Further delineation of the syndrome, *Clin Genet* 72(5):405–410, 2007. http://dx.doi.org/10.1111/j.1399-0004.2007.00884.x.
69. Schweitzer DN, Graham JM, Lachman RS, et al.: Subtle radiographic findings of achondroplasia in patients with Crouzon syndrome with acanthosis nigricans due to an Ala391Glu substitution in FGFR3, *Am J Med Genet* 98(1):75–91, 2001. http://dx.doi.org/10.1002/1096-8628(20010101)981<75::AID-AJMG1010>3.0.CO;2–6.
70. Gorry M, Preston R, White G, et al.: Crouzon syndrome: mutations in two splice forms of FGFR2 and a common point mutation shared with Jackson-Weiss syndrome, *Hum Mol Genet* 4(8):1387–1390, 1995.
71. Jabs EW, Li X, Scott AF, et al.: Jackson-Weiss and Crouzon syndromes are allelic with mutations in fibroblast growth factor receptor 2, *Nat Genet* 8:275–279, 1994. http://dx.doi.org/10.1038/ng1194-275.
72. Oldridge M, Wilkie A, Slaney S, et al.: Mutations in the third immunoglobulin domain of the fibroblast growth factor receptor-2 gene in Crouzon syndrome, *Hum Mol Genet* 4(6):1077–1082, 1995.
73. Park WJ, Meyers GA, Li X, et al.: Novel FGFR2 mutations in Crouzon and Jackson-Weiss syndromes show allelic heterogeneity and phenotypic variability, *Hum Mol Genet* 4(7):1229–1233, 1995. http://dx.doi.org/10.1093/hmg/4.7.1229.
74. Reardon W, Winter RM, Rutland P, Pulleyn LJ, Jones BM, Malcolm S: Mutations in the fibroblast growth factor receptor 2 gene cause {Crouzon} syndrome, *Nat Genet* 8(1):98–103, 1994. http://dx.doi.org/10.1038/ng0994-98.
75. Steinberger D, Mulliken JB, Müller U: Predisposition for cysteine substitutions in the immunoglobulin-like chain of FGFR2 in Crouzon syndrome, *Hum Genet* 96(1):113–115, 2004. http://dx.doi.org/10.1007/BF00214198.
76. Al-Qattan M, Phillips J: Clinical features of Crouzon's syndrome patients with and without a positive family history of Crouzon's syndrome, *J Craniofac Surg* 8(1):11–13, 1997.
77. Cinalli G, Spennato P, Sainte-Rose C, et al.: Chiari malformation in craniosynostosis, *Child's Nerv Syst* 21(10):889–901, 2005. http://dx.doi.org/10.1007/s00381-004-1115-z.

78. Cinalli G, Renier D, Sebag G, Sainte-Rose C, Arnaud E, Pierre-Kahn A: Chronic tonsillar herniation in Crouzon's and Apert's syndromes: the role of premature synostosis of the lambdoid suture, *J Neurosurg* 83(4):575–582, 1995. http://dx.doi.org/10.3171/jns.1995.83.4.0575.
79. Cinalli G, Sainte-Rose C, Kollar EM, et al.: Hydrocephalus and craniosynostosis, *J Neurosurg* 88(2):209–214, 1998. http://dx.doi.org/10.3171/jns.1998.88.2.0209.
80. Kreiborg S, Cohen MM: Ocular manifestations of Apert and Crouzon syndromes: qualitative and quantitative findings, *J Craniofac Surg* 21(5):1354–1357, 2010. http://dx.doi.org/10.1097/SCS.0b013e3181ef2b53.
81. Agochukwu NB, Solomon BD, Muenke M: Hearing loss in syndromic craniosynostoses: introduction and consideration of mechanisms, *Am J Audiol* 23(2):135–141, 2014. http://dx.doi.org/10.1044/2014.
82. Tolarova MM, Harris JA, Ordway DE, Vargervik K: Birth prevalence, mutation rate, sex ratio, parents' age, and ethnicity in Apert syndrome, *Am J Med Genet* 72(4):394–398, 1997. http://dx.doi.org/10.1002/(SICI)1096-8628(19971112)72:4<394::AID-AJMG4>3.0.CO;2-R.
83. von Gernet S, Golla A, Ehrenfels Y, Schuffenhauer S, Fairley JD: Genotype-phenotype analysis in Apert syndrome suggests opposite effects of the two recurrent mutations on syndactyly and outcome of craniofacial surgery, *Clin Genet* 57(2):137–139, 2000. http://dx.doi.org/10.1034/j.1399-0004.2000.570208.x.
84. Kreiborg S, Marsh J, Cohen Jr M, et al.: Comparative three-dimensional analysis of CT-scans of the calvaria and cranial base in Apert and Crouzon syndromes, *J Craniomaxillofac Surg* 21(5):181–188, 1993.
85. Cohen MM, Kreiborg S: A clinical study of the craniofacial features in Apert syndrome, *Int J Oral Maxillofac Surg* 25(1):45–53, 1996. http://dx.doi.org/10.1016/S0901-5027(96)80011-7.
86. Khong JJ, Anderson P, Gray TL, Hammerton M, Selva D, David D: Ophthalmic findings in Apert syndrome prior to craniofacial surgery, *Am J Ophthalmol* 142(2):328–330, 2006. http://dx.doi.org/10.1016/j.ajo.2006.02.046.
87. Tay T, Martin F, Rowe N, et al.: Prevalence and causes of visual impairment in craniosynostotic syndromes, *Clin Exp Ophthalmol* 34(5):434–440, 2006. http://dx.doi.org/10.1111/j.1442-9071.2006.01242.x.
88. Golabi M, Edwards MSB, Ousterhout DK: Craniosynostosis and hydrocephalus, *Neurosurgery* 21(1):63–67, 1987.
89. Fishman M, Hogan G, Dodge P: The concurrence of hydrocephalus and craniosynostosis, *J Neurosurg* 34:621, 1971.
90. Hogan G, Bauman M: Hydrocephalus in Apert syndrome, *J Pediatr* 79:782, 1971.
91. Rajenderkumar D, Bamiou D-E, Sirimanna T: Audiological profile in Apert syndrome, *Arch Dis Child* 90(6):592–593, 2005. http://dx.doi.org/10.1136/adc.2004.067298.
92. Rajenderkumar D, Bamiou D, Sirimanna T: Management of hearing loss in Apert syndrome, *J Laryngol Otol* 119(5):385–390, 2005. http://dx.doi.org/10.1258/0022215053945714.
93. Gould H, Calderelli D: Hearing and otopathology in Apert syndrome, *Arch Otolaryngol* 108(6):347–349, 1982.
94. Cohen Jr MM, Kreiborg S: Visceral anomalies in the Apert syndrome, *Am J Med Genet* 45(6):758–760, 1993. http://dx.doi.org/10.1002/ajmg.1320450618.
95. Hemmer KM, McAlister WH, Marsh JL: Cervical spine anomalies in the craniosynostosis syndromes, *Cleft Palate J* 24(4):328–333, 1987.
96. Cohen Jr MM: Facial variability in Apert type acrocephalosyndactyl, *Birth Defects* 18:321, 1971.
97. Krafchik B: Acne in Apert syndrome, *Clin Plast Surg* 18:407, 1991.
98. Cohen MM: Pfeiffer syndrome update, clinical subtypes, and guidelines for differential diagnosis, *Am J Med Genet* 45(3):300–307, 1993. http://dx.doi.org/10.1002/ajmg.1320450305.
99. Schell U, Hehr A, Feldman GJ, et al.: Mutations in FGFR1 and FGFR2 cause familial and sporadic Pfeiffer syndrome, *Hum Mol Genet* 4(3):323–328, 1995. http://dx.doi.org/10.1093/hmg/4.3.323.
100. Meyers G, Day D, Goldberg R, Daentl D, Przlepa K, Abrams L: FGFR2 exon IIIa and IIIc mutations in Crouzon, Jackson-Weiss, and Pfeiffer syndromes: evidence for missense changes, insertions, and a deletion due to alternative RNA splicing, *Am J Hum Genet* 58(3):491–498, 1966.
101. Muenke M, Schell U, Hehr A, et al.: A common mutation in the fibroblast growth factor receptor 1 gene in Pfeiffer syndrome, *Nat Genet* 8:269–274, 1994. http://dx.doi.org/10.1038/ng1194-269.
102. Roth D, Bradley J: Studies in cranial suture biology: part II. Role of the dura in cranial suture fusion, *Plast Reconstr Surg* 97(4):693–699, 1996. Available at http://journals.lww.com/plasreconsurg/Abstract/1996/04000/A_Prospective_Study_of_the_Relationship_Between.1.aspx.
103. Rutland P, Pulleun L, Reardon W, et al.: Identical mutations in the FGFR2 gene cause both Pfeiffer and Crouzon syndrome phenotypes, *Nat Genet* 9:173–176, 1995. http://dx.doi.org/10.1038/ng0596-48.
104. Park WJ, Theda C, Maestri NE, et al.: Analysis of phenotypic features and FGFR2 mutations in Apert syndrome, *Am J Hum Genet* 57(2):321–328, 1995. Available at http://www.pubmedcentral.nih.gov/articlerender.fcgi?artid=1801532&tool=pmcentrez&rendertype=abstract.
105. Vogels A, Fryns J-P: Pfeiffer syndrome, *Orphanet J Rare Dis* 1(1):19, 2006. http://dx.doi.org/10.1186/1750-1172-1-19.
106. Greig AVH, Wagner J, Warren SM, Grayson B, McCarthy JG: Pfeiffer syndrome: analysis of a clinical series and development of a classification system, *J Craniofac Surg* 24(1):204–215, 2013. http://dx.doi.org/10.1097/SCS.0b013e31826704be.
107. Gorlin R: Syndromes with craniosynostosis: general aspects and well-known syndromes. In Gorlin R, Cohen Jr MM, Hennekam R, editors: *Syndromes of the Head and Neck*, ed 4, Oxford, 2001, Oxford University Press.
108. Fearon JA, Rhodes J: Pfeiffer syndrome: a treatment evaluation, *Plast Reconstr Surg* 123(5):1560–1569, 2009. http://dx.doi.org/10.1097/PRS.0b013e3181a2057e.
109. Moore MH, Lodge ML, Clark BE: Spinal anomalies in Pfeiffer syndrome, *Cleft Palate-Craniofacial J* 32(3):251–254, 1995. http://dx.doi.org/10.1597/1545-1569(1995)032<0251:SAIPS>2.3.CO;2.
110. Anderson P, Hall C, Evans R, Jones B, Harkness W, Hayward R: Cervical spine in Pfeiffer's syndrome, *J Craniofac Surg* 7(4):275–279, 1996.
111. Cohen Jr M: Craniosynostoses: phenotypic/molecular correlations, *Am J Med Genet* 56(3):334–339, 1995.
112. Cohen M: Transforming growth factor beta s and fibroblast growth factors and their receptors: role in sutural biology and craniosynostosis, *J Bone Min Res* 12(3):322–331, 1997.
113. Posnick J: Cloverleaf skull anomalies: evaluation and staging of reconstruction. In Posnick J, editor: *Craniofacial and Maxillofacial Surgery in Children and Young Adults*, Philadelphia, 2000, WB Saunders.

114. Cohen Jr M: Cloverleaf syndrome update, *Proc Greenwood Genet Cent* 6:186, 1973.
115. Chen C, Lin S, Su Y, Huang J, Wang W: A cloverleaf skull associated with Crouzon syndrome, *Arch Dis Child Fetal Neonatal Ed* 91(2):F98, 2006.
116. Gorincour G, Rypens F, Grignon A, et al.: Prenatal diagnosis of cloverleaf skull: watch the hands! *Fetal Diagn Ther* 20(4):296–300, 2005. http://dx.doi.org/10.1159/000085089.
117. Cinalli G, Chumas P, Arnaud E, Sainte-Rose C, Renier D: Occipital remodeling and suboccipital decompression in severe craniosynostosis associated with tonsillar herniation, *Neurosurgery* 42(1):66–71, 1998.
118. Warren SM, Proctor MR, Bartlett SP, et al.: Parameters of care for craniosynostosis: craniofacial and neurologic surgery perspectives, *Plast Reconstr Surg* 129(3):731–737, 2012. http://dx.doi.org/10.1097/PRS.0b013e3182412a50.
119. Tessier P: The definitive plastic surgical treatment of the severe facial deformities of craniofacial dysostosis. Crouzon's and Apert's diseases, *Plast Reconstr Surg* 48(5):419–442, 1971.
120. Spinelli HM, Irizarry D, McCarthy JG, Cutting CB, Noz ME: An analysis of extradural dead space after fronto-orbital surgery, *Plast Reconstr Surg* 93:1372–1377, 1994. http://dx.doi.org/10.1097/00006534-199406000-00006.
121. Whitaker LA, Munro IR, Salyer KE, Jackson IT, Ortiz-Monasterio F, Marchac D: Combined report of problems and complications in 793 craniofacial operations, *Plast Reconstr Surg* 64(2):198–203, 1979. Available at http://www.ncbi.nlm.nih.gov/pubmed/377338.
122. David D, Cooter R: Craniofacial infection in 10 years of transcranial surgery, *Plast Reconstr Surg* 80(2):213–225, 1987.
123. Saltz R, Sierra D, Feldman D, Saltz MB, Dimick A, Vasconez LO: Experimental and clinical applications of fibrin glue, *Plast Reconstr Surg* 88(6):1005–1015, 1991. http://www.ncbi.nlm.nih.gov/pubmed/1946751.
124. Lee Y, Kim W: How to make the blockage between the nasal cavity and intracranial space using a four-layer sealing technique, *Plast Reconstr Surg* 117(1):233–238, 2006.
125. Kumar A, Steinbacher DM: Advances in the treatment of syndromic midface hypoplasia using monobloc and facial bipartition distraction osteogenesis, *Semin Plast Surg* 28:179–183, 2014.
126. Driessen C, Joosten KFM, Bannink N, et al.: How does obstructive sleep apnoea evolve in syndromic craniosynostosis? A prospective cohort study, *Arch Dis Child* 98(7):538–543, 2013. http://dx.doi.org/10.1136/archdischild-2012-302745.
127. Cohen MM, Kreiborg S: Upper and lower airway compromise in the Apert syndrome, *Am J Med Genet* 44(1):90–93, 1992. http://dx.doi.org/10.1002/ajmg.1320440121.
128. Peterson-Falzone S: Nasopharyngeal dysmorphology in the syndromes of Apert and Crouzon, *Cleft Palate J* 18:237, 1981.
129. Devine P, Bhan I, Feingold M, Leonidas JC, Wolpert SM: Completely cartilaginous trachea in a child with Crouzon syndrome, *Am J Dis Child* 138(1):40–43, 1984. http://dx.doi.org/10.1001/archpedi.1984.02140390032010.
130. Lauritzen C, Lilja J, Jarlstedt J: Airway obstruction and sleep apnea in children with craniofacial anomalies, *Plast Reconstr Surg* 77:1–6, 1986. http://dx.doi.org/10.1097/00006534-198601000-00002.
131. Peterson S, Pruzansky S: Palatal anomalies in the syndromes of Apert and Crouzon, *Cleft Palate J* 11:394–403, 1974.
132. Guilleminault C: Obstructive sleep apnea syndrome and its treatment in children: areas of agreement and controversy, *Pediatr Pulmonol* 3:429, 1987.
133. Padwa B: Effects of midface distraction osteogenesis on obstructive sleep apnea in patients with syndromic craniosynostosis, *J Oral Maxillofac Surg* 64:49, 2006.
134. Kouga T, Tanoue K, Matsui K: Airway statuses and nasopharyngeal airway use for airway obstruction in syndromic craniosynostosis, *J Craniofac Surg* 25(3):762–765, 2014. http://dx.doi.org/10.1097/SCS.0000000000000763.
135. Al-Saleh S, Riekstins A, Forrest CR, Philips JH, Gibbons J, Narang I: Sleep-related disordered breathing in children with syndromic craniosynostosis, *J Cranio-Maxillofacial Surg* 39(3):153–157, 2011. http://dx.doi.org/10.1016/j.jcms.2010.04.011.
136. Gonsalez S, Thompson D, Hayward R, Lane R: Treatment of obstructive sleep apnoea using nasal CPAP in children with craniofacial dysostoses. In *Child's Nervous System*, Vol 12. 1996, pp 713–719. http://dx.doi.org/10.1007/BF00366156.
137. Järund M, Dellborg C, Carlson J, Lauritzen C, Ejnell H: Treatment of sleep apnoea with continuous positive airway pressure in children with craniofacial malformations, *Scand J Plast Reconstr Surg Hand Surg* 33(1):67–71, 1999.
138. Ahmed J, Marucci D, Cochrane L, Heywood RL, Wyatt ME, Leighton SEJ: The role of the nasopharyngeal airway for obstructive sleep apnea in syndromic craniosynostosis, *J Craniofac Surg* 19(3):659–663, 2008. http://dx.doi.org/10.1097/SCS.0b013e31816ae386.
139. Nash R, Possamai V, Manjaly J, Wyatt M: The management of obstructive sleep apnea in syndromic craniosynostosis, *J Craniofac Surg* 26(6):1914–1916, 2015. http://dx.doi.org/10.1097/SCS.0000000000002097.
140. Zandieh SO, Padwa BL, Katz ES: Adenotonsillectomy for obstructive sleep apnea in children with syndromic craniosynostosis, *Plast Reconstr Surg* 131(4):847–852, 2013. http://dx.doi.org/10.1097/PRS.0b013e3182818f3a.
141. Willington AJ, Ramsden JD: Adenotonsillectomy for the management of obstructive sleep apnea in children with congenital craniosynostosis syndromes, *J Craniofac Surg* 23(4):1020–1022, 2012. http://dx.doi.org/10.1097/SCS.0b013e31824e6cf8.
142. Amonoo-Kuofi K, Phillips SP, Randhawa PS, Lane R, Wyatt ME, Leighton SEJ: Adenotonsillectomy for sleep-disordered breathing in children with syndromic craniosynostosis, *J Craniofac Surg* 20(6):1978–1980, 2009. http://dx.doi.org/10.1097/SCS.0b013e3181bd2c9a.
143. Pijpers M, Poels PJP, Vaandrager JM, et al.: Undiagnosed obstructive sleep apnea syndrome in children with syndromal craniofacial synostosis, *J Craniofac Surg* 15:670–674, 2004. http://dx.doi.org/10.1097/00001665-200407000-00026.
144. Lo LJ, Chen YR: Airway obstruction in severe syndromic craniosynostosis, *Ann Plast Surg* 43(3):258–264, 1999. http://dx.doi.org/10.1097/00000637-199909000-00006.
145. Bannink N, Mathijssen IM, Joosten KF: Use of ambulatory polysomnography in children with syndromic craniosynostosis, *J Craniofac Surg* 21(5):1365–1368, 2010. http://dx.doi.org/10.1097/SCS.0b013e3181ec69a5.
146. Khan SH, Nischal KK, Dean F, Hayward RD, Walker J: Visual outcomes and amblyogenic risk factors in craniosynostotic syndromes: a review of 141 cases, *Br J Ophthalmol* 87(8):999–1003, 2003. http://dx.doi.org/10.1136/bjo.87.8.999.
147. Morax S: Oculo-motor disorders in craniofacial malformations, *J Maxillofac Surg* 12(C):1–10, 1984. http://dx.doi.org/10.1016/S0301-0503(84)80201-5.

148. Lehman S: Strabismus in craniosynostosis, *Curr Opin Ophthalmol* 17:432–434, 2006. http://dx.doi.org/10.1097/01.icu.0000243017.90004.5b.
149. Denis D, Genitori L, Bolufer A, Lena G, Saracco JB, Choux M: Refractive error and ocular motility in plagiocephaly, *Child's Nerv Syst* 10(4):210–216, 1994. http://dx.doi.org/10.1007/BF00301156.
150. Murovic JA, Posnick JC, Drake JM, Humphreys RP, Hoffman HJ, Hendricks EB: Hydrocephalus in Apert syndrome: a retrospective review, *Pediatr Neurosurg* 19(3):151–155, 1993. Available at http://ovidsp.ovid.com/ovidweb.cgi?T=JS&PAGE=reference&D=med3&NEWS=N&AN=7684601.
151. Noetzel MJ, Marsh JL, Palkes H, Gado M: Hydrocephalus and mental retardation in craniosynostosis, *J Pediatr* 107(6):885–892, 1985. http://dx.doi.org/10.1016/S0022-3476(85)80181-5.
152. Renier D, Arnaud E, Cinalli G, et al.: Mental prognosis of Apert syndrome, *Arch Pediatr* 3(8):752–760, 1996. Available at http://www.ncbi.nlm.nih.gov/pubmed/8998527.
153. Tamburrini G, Caldarelli M, Massimi L, Santini P, Di Rocco C: Intracranial pressure monitoring in children with single suture and complex craniosynostosis: a review, *Child's Nerv Syst* 21(10):913–921, 2005. http://dx.doi.org/10.1007/s00381-004-1117-x.
154. Gault D, Renier D, Marchac D, Ackaland F, Jones B: Intracranial volume in children with craniosynostosis, *J Craniofac Surg* 1:1, 1990.
155. Cushing H: Surgery: its principles and practice. In Keen W, editor: *Neurosurgery*, Philadelphia, 1908, WB Saunders.
156. Kapp-Simon K, Figueroa A: Longitudinal assessment of mental development in infants with nonsyndromic craniosynostosis with and without cranial release and reconstruction, *Plast Reconstr Surg* 92(5):831–839, 1993. Available at http://journals.lww.com/plasreconsurg/Abstract/1993/10000/Longitudinal_Assessment_of_Mental_Development_in.8.aspx.
157. McLaurin R, Marson D: Importance of early surgical treatment of craniosynostosis, *Pediatrics* 10:637, 1952.
158. Pollack IF, Losken HW, Biglan AW: Incidence of increased intracranial pressure after early surgical treatment of syndromic craniosynostosis, *Pediatr Neurosurg* 24(4):202–209, 1996. http://dx.doi.org/10.1159/000121038.
159. Renier D: Intracranial pressure in craniosynostosis. Pre- and postoperative recordings–correlation with functional results. In Persing J, Edgerton M, editors: *Scientific Foundations and Surgical Treatment of Craniosynostosis*, Baltimore, 1989, Williams and Wilkins.
160. Renier D, Sainte-Rose C, Marchac D, Hirsch JF: Intracranial pressure in craniostenosis, *J Neurosurg* 57:370–377, 1982. http://dx.doi.org/10.3171/jns.1982.57.3.0370.
161. Renier D, Marchac D: Intracranial pressure recordings: analysis of 300 cases. In Marchac D, editor: *Craniofacial Surgery: Proceedings of the First International Congress on Craniomaxillofacial Surgery*, Heidelberg, Germany, 1988, Springer-Verlag.
162. Renier D, Marchac D: Longitudinal assessment of mental development in infants with nonsyndromic craniosynostosis with and without cranial release and reconstruction (discussion), *Plast Reconstr Surg* 92:840, 1993.
163. Posnick J: Craniofacial dysostosis syndromes: a staged reconstructive approach. In Turvey T, Vig K, Fonseca R, editors: *Facial Clefts and Craniosynostosis: Principles and Management*, Philadelphia, 1996, WB Saunders.
164. McCarthy JG, Epstein F, Sadove M, Grayson B, Zide B: Early surgery for craniofacial synostosis: an 8-year experience, *Plast Reconstr Surg* 73(4):521–533, 1984. Available at http://www.ncbi.nlm.nih.gov/entrez/query.fcgi?cmd=Retrieve&db=PubMed&dopt=Citation&list_uids=6709733.
165. McCarthy JG, Glasberg SB, Cutting CB, et al.: Twenty-year experience with early surgery for craniosynostosis: I. Isolated craniofacial synostosis—results and unsolved problems, *Plast Reconstr Surg* 96(2):272–283, 1995. http://ovidsp.ovid.com/ovidweb.cgi?T=JS&PAGE=reference&D=med3&NEWS=N&AN=7624400\n.
166. McCarthy J, Epstein F, Wood-Smith D: Craniosynostosis. In McCarthy J, editor: *Plastic Surgery*, Vol. 4. Philadelphia, 1990, WB Saunders.
167. Posnick J: Craniosynostosis: surgical management in infancy. In Bell W, editor: *Orthognathic and Reconstructive Surgery*, Philadelphia, 1992, WB Saunders.
168. Siddiqi SN, Posnick JC, Buncic R, et al.: The detection and management of intracranial hypertension after initial suture release and decompression for craniofacial dysostosis syndromes, *Neurosurgery* 36(4):703–709, 1995. http://dx.doi.org/10.1227/00006123-199504000-00010.
169. Connolly JP, Gruss J, Seto ML, et al.: Progressive postnatal craniosynostosis and increased intracranial pressure, *Plast Reconstr Surg* 113:1313–1323, 2004. http://dx.doi.org/10.1097/01.PRS.0000111593.96440.30.
170. Posnick JC, Bite U, Nakano P, Davis J, Armstrong D: Indirect intracranial volume measurements using CT scans: clinical applications for craniosynostosis, *Plast Reconstr Surg* 89(1):34–45, 1992. Available at http://www.ncbi.nlm.nih.gov/pubmed/1727261.
171. David LR, Velotta E, Weaver RG, Wilson JA, Argenta LC: Clinical findings precede objective diagnostic testing in the identification of increased ICP in syndromic craniosynostosis, *J Craniofac Surg* 13:676–680, 2002. http://dx.doi.org/10.1097/01.SCS.0000026408.16202.EA.
172. Jimenez DF, Barone CM: Bilateral endoscopic craniectomies in the treatment of an infant with Apert syndrome: case report, *J Neurosurg Pediatr* 10(4):310–314, 2012. http://dx.doi.org/10.3171/2012.7.PEDS11281.
173. Rottgers S, Lohani S, Proctor M: Outcomes of endoscopic suturectomy with postoperative helmet therapy in bilateral coronal craniosynostosis, *J Neurosurg Pediatr* 18(3):281–286, 2016.
174. Taylor WJ, Hayward RD, Lasjaunias P, et al.: Enigma of raised intracranial pressure in patients with complex craniosynostosis: the role of abnormal intracranial venous drainage, *J Neurosurg* 94(3):377–385, 2001. http://dx.doi.org/10.3171/jns.2001.94.3.0377.
175. Tokumaru AM, Barkovich AJ, Ciricillo SF, Edwards MSB: Skull base and calvarial deformities: association with intracranial changes in craniofacial syndromes, *Am J Neuroradiol* 17(4):619–630, 1996.
176. Fearon JA, Podner C: Apert syndrome: evaluation of a treatment algorithm, *Plast Reconstructive Surg* 131(1):132–142, 2013. http://dx.doi.org/10.1097/PRS.0b013e3182729f42.
177. Utria AF, Mundinger GS, Bellamy JL, et al.: The importance of timing in optimizing cranial vault remodeling in syndromic craniosynostosis, *Plast Reconstr Surg* 135(4):1077–1084, 2015. http://dx.doi.org/10.1097/prs.0000000000001058.
178. Posnick JC, Ruiz RL: The craniofacial dysostosis syndromes: Current surgical thinking and future directions, *Cleft Palate-Craniofacial J* 37(5):433, 2000. http://dx.doi.org/10.1597/1545-1569(2000)037<0433:TCDSCS>2.0.CO;2.
179. Selber JC, Brooks C, Kurichi JE, Temmen T, Sonnad SS, Whitaker LA: Long-term results following fronto-orbital reconstruction in nonsyndromic unicoronal synostosis, *Plast Reconstr Surg* 121(5):251e–260e, 2008. http://dx.doi.org/10.1097/PRS.0b013e31816a9f88.

180. Posnick J: Crouzon syndrome: evaluation and staging of reconstruction. In Posnick J, editor: *Craniofacial and Maxillofacial Surgery in Children and Young Adults*, Philadelphia, 2000, WB Saunders.
181. Posnick J: Apert syndrome: evaluation and staging of reconstruction. In Posnick J, editor: *Craniofacial and Maxillofacial Surgery in Children and Young Adults*, Philadelphia, 2000, WB Saunders.
182. Posnick J: Pfeiffer syndrome: evaluation and staging of reconstruction. In Posnick J, editor: *Craniofacial and Maxillofacial Surgery in Children and Young Adults*, Philadelphia, 2000, WB Saunders.
183. Reference removed in pages.
184. Turvey T, Ruiz R: Craniosynostosis and craniofacial dysostosis. In Fonseca R, Baker S, Wolford L, editors: *Oral and Maxillofacial Surgery*, Philadelphia, 2000, WB Saunders.
185. David DJ, Sheen R: Surgical correction of Crouzon syndrome, *Plast Reconstr Surg* 85(3):344–354, 1990. http://dx.doi.org/10.1097/00006534-199003000-00002.
186. Fearon JA, Varkarakis GM, Kolar J: A comparative study of anterior cranial vault distraction versus remodeling, *J Craniofac Surg* 25(4):1159–1163, 2014. http://dx.doi.org/10.1097/SCS.0000000000000766.
187. Serlo WS, Ylikontiola LP, Lähdesluoma N, et al.: Posterior cranial vault distraction osteogenesis in craniosynostosis: estimated increases in intracranial volume, *Child's Nerv Syst* 27(4):627–633, 2011. http://dx.doi.org/10.1007/s00381-010-1353-1.
188. Goldstein JA, Paliga JT, Wink JD, Low DW, Bartlett SP, Taylor JA: A craniometric analysis of posterior cranial vault distraction osteogenesis, *Plast Reconstr Surg* 131:1367–1375, 2013. http://dx.doi.org/10.1097/PRS.0b013e31828bd541.
189. Nowinski D, Di Rocco F, Renier D, Sainterose C, Leikola J, Arnaud E: Posterior cranial vault expansion in the treatment of craniosynostosis. Comparison of current techniques, *Child's Nerv Syst* 28(9):1537–1544, 2012. http://dx.doi.org/10.1007/s00381-012-1809-6.
190. Hopper RA: New trends in cranio-orbital and midface distraction for craniofacial dysostosis, *Curr Opin Otolaryngol Head Neck Surg* 20(4):298–303, 2012. http://dx.doi.org/10.1097/MOO.0b013e3283543a43.
191. Derderian CA, Bastidas N, Bartlett SP: Posterior cranial vault expansion using distraction osteogenesis, *Child's Nerv Syst* 28(9):1551–1556, 2012. http://dx.doi.org/10.1007/s00381-012-1802-0.
192. Steinbacher DM, Skirpan J, Puchała J, Bartlett SP: Expansion of the posterior cranial vault using distraction osteogenesis, *Plast Reconstr Surg* 127(2):792–801, 2011. http://dx.doi.org/10.1097/PRS.0b013e318200ab83.
193. Maurice SM, Gachiani JM: Posterior cranial vault distraction with resorbable distraction devices, *J Craniofac Surg* 25(4):1249–1251, 2014. http://dx.doi.org/10.1097/SCS.0000000000000928.
194. Ylikontiola LP, Sándor GK, Salokorpi N, Serlo WS: Experience with craniosynostosis treatment using posterior cranial vault distraction osteogenesis, *Ann Maxillofac Surg* 2(1):4–7, 2012. http://dx.doi.org/10.4103/2231-0746.95307.
195. Ong J, Harshbarger RJ, Kelley P, George T: Posterior cranial vault distraction osteogenesis: evolution of technique, *Semin Plast Surg* 28(4):163–178, 2014. http://dx.doi.org/10.1055/s-0034-1390169.
196. White N, Evans M, Dover S, Noons P, Solanki G, Nishikawa H: Posterior calvarial vault expansion using distraction osteogenesis, *Child's Nerv Syst* 25(2):231–236, 2009. http://dx.doi.org/10.1007/s00381-008-0758-6.
197. Samra F, Swanson J, Mitchell B, et al.: An evidence-based algorithm for managing syndromic craniosynostosis in the era of posterior vault distraction osteogenesis, *Plast Reconstr Surg* 136(Sup 4):6–7, 2016.
198. Swanson J, Samra F, Bauder A, Mitchell B, Taylor J, Bartlett S: An algorithm for managing syndromic craniosynostosis using posterior vault distraction osteogenesis, *Plast Reconstr Surg* 137(5): 829e–841e, 2016.
199. Greives MR, Ware BW, Tian AG, Taylor JA, Pollack IF, Losee JE: Complications in posterior cranial vault distraction, *Ann Plast Surg* 76(2):211–215, 2015. http://dx.doi.org/10.1097/SAP.0000000000000518.
200. Taylor JA, Derderian CA, Bartlett SP, Fiadjoe JE, Sussman EM, Stricker PA: Perioperative morbidity in posterior cranial vault expansion: distraction osteogenesis versus conventional osteotomy, *Plast Reconstr Surg* 129(4):674e–680e, 2012. http://dx.doi.org/10.1097/PRS.0b013e3182443164.
201. Scott WW, Fearon JA, Swift DM, Sacco DJ: Suboccipital decompression during posterior cranial vault remodeling for selected cases of Chiari malformations associated with craniosynostosis, *J Neurosurg Pediatr* 12(2):166–170, 2013. http://dx.doi.org/10.3171/2013.4.PEDS12463.
202. Fearon J: *Syndromic Craniosynostosis*, ed 3, London, 2013, Elsevier.
203. Eide PK, Helseth E, Due-Tønnessen B, Lundar T: Assessment of continuous intracranial pressure recordings in childhood craniosynostosis, *Pediatr Neurosurg* 37(6):310–320, 2002. http://dx.doi.org/10.1159/000066311.
204. Tuite GF, Chong WK, Evanson J, et al.: The effectiveness of papilledema as an indicator of raised intracranial pressure in children with craniosynostosis, *Neurosurg* 38(2):272–278, 1996. http://dx.doi.org/10.1097/00006123-199602000-00009.
205. Liasis A, Nischal KK, Walters B, et al.: Monitoring visual function in children with syndromic craniosynostosis: a comparison of 3 methods, *Arch Ophthalmol (Chicago, Ill 1960)* 124(8):1119–1126, 2006. http://dx.doi.org/10.1001/archopht.124.8.1119.
206. Bannink N, Joosten KFM, van Veelen M-LC, et al.: Papilledema in patients with Apert, Crouzon, and Pfeiffer syndrome: prevalence, efficacy of treatment, and risk factors, *J Craniofac Surg* 19(1):121–127, 2008. http://dx.doi.org/10.1097/SCS.0b013e31815f4015.
207. Liasis A, Thompson DA, Hayward R, Nischal KK: Sustained raised intracranial pressure implicated only by pattern reversal visual evoked potentials after cranial vault expansion surgery, *Pediatr Neurosurg* 39(2):75–80, 2003. http://dx.doi.org/10.1159/000071318.
208. Inverso G, Brustowicz KA, Katz E, Padwa BL: The prevalence of obstructive sleep apnea in symptomatic patients with syndromic craniosynostosis, *Int J Oral Maxillofac Surg* 45(2):167–169, 2016.
209. Campbell JW, Albright AL, Losken HW, Biglan AW: Intracranial hypertension after cranial vault decompression for craniosynostosis, *Pediatr Neurosurg* 22(5):270–273, 1995. http://www.ncbi.nlm.nih.gov/pubmed/7547460.
210. Fearon J, Whitaker L: Complications with facial advancement: a comparison between the Le Fort III and monobloc advancements, *Plast Reconstr Surg* 91(6):990–995, 1993.
211. Fearon JA, Yu J, Bartlett SP, Munro IR, Chir B, Whitaker L: Infections in craniofacial surgery: a combined report of 567 procedures from two centers, *Plast Reconstr Surg* 100(4):862–868, 1997. Available at http://www.ncbi.nlm.nih.gov/pubmed/9290653.

212. Smith KA, Liasis A, Jain M, Nischal KK: Visual surveillance protocol for syndromic craniosynostosis—does it make a difference? *J AAPOS* 15(1):e29, 2011. http://dx.doi.org/10.1016/j.jaapos.2011.01.112.
213. Kreiborg S: Apert and Crouzon syndromes contrasted. Qualitative craniofacial x-ray findings, *J Dent Res* 64(Special Issue):203, 1985.
214. Kreiborg S: Totales de la face: syndrome de Crouzon, syndrome d'Apert: oxycephalies, scaphocephalies, turricephalies, *Ann Chir Plast* 12:273, 1967.
215. Kreiborg S, Jensen B: Variable expressivity of Crouzon's syndrome within a family, *Scand J Dent Res* 85(3):175–184, 1977.
216. Posnick J, Farkas L: The application of anthropometric surface measurements in craniomaxillofacial surgery. In Farkas LG, editor: *Anthropometry of the Head and Face*, New York, 1994, Raven Press.
217. Mixter RC, David DJ, Perloff WH, Green CG, Pauli RM, Popic PM: Obstructive sleep apnea in Apert's and Pfeiffer's syndromes: more than a craniofacial abnormality, *Plast Reconstr Surg* 86:457–463, 1990.
218. Perkins JA, Sie KCY, Milczuk H, Richardson MA: Airway management in children with craniofacial anomalies, *Cleft-Palate-Craniofacial J* 34(2):135–140, 1997. http://dx.doi.org/10.1597/1545-1569(1997)034<0135:AMICWC>2.3.CO;2.
219. Alsaadi MM, Iqbal SM, Elgamal EA, Salih MA, Gozal D: Sleep-disordered breathing in children with craniosynostosis, *Sleep Breath* 17(1):389–393, 2013. http://dx.doi.org/10.1007/s11325-012-0706-2.
220. Spruijt B, Joosten KFM, Driessen C, et al.: Algorithm for the management of intracranial hypertension in children with syndromic craniosynostosis, *Plast Reconstr Surg* 136(2):331–340, 2015. http://dx.doi.org/10.1097/PRS.0000000000001434.
221. Bannink N, Nout E, Wolvius EB, Hoeve HLJ, Joosten KFM, Mathijssen IMJ: Obstructive sleep apnea in children with syndromic craniosynostosis: long-term respiratory outcome of midface advancement, *Int J Oral Maxillofac Surg* 39(2):115–121, 2010. http://dx.doi.org/10.1016/j.ijom.2009.11.021.
222. Gwanmesia I, Jeelani O, Hayward R, Dunaway D: Frontofacial advancement by distraction osteogenesis: a long-term review, *Plast Reconstr Surg* 135(2):553–560, 2015. http://dx.doi.org/10.1097/PRS.0000000000001115.
223. Patel N, Fearon JA: Treatment of the syndromic midface: a long-term assessment at skeletal maturity, *Plast Reconstr Surg* 135(4):731e–742e, 2015. http://dx.doi.org/10.1097/prs.0000000000001062.
224. Posnick JC, Lin KY, Jhawar BJ, Armstrong D: Crouzon syndrome: quantitative assessment of presenting deformity and surgical results based on CT scans, *Plast Reconstr Surg* 92(6):1027–1037, 1993. http://www.ncbi.nlm.nih.gov/pubmed/8234498.
225. Kreiborg S, Pruzansky S: Craniofacial growth in premature craniofacial synostosis, *Scand J Plast Reconstr Surg* 15(3):171–186, 1981.
226. Sgouros S, Goldin JH, Hockley AD, Wake MJ, Natarajan K: Intracranial volume change in childhood, *J Neurosurg* 91:610–616, 1999. http://dx.doi.org/10.3171/jns.1999.91.4.0610.
227. Adams G: The effects of physical attractiveness on the socialization process. In Lucker G, Ribbens K, McNamara J, editors: *Psychological Aspects of Facial Form*, Ann Arbor, 1981, University of Michigan Press.
228. Broder H: Psychological research of children with craniofacial anomalies: review, critique, and implications for the future, *Cleft Palate Craniofac J* 34(5):402–404, 1997.
229. Bull R, Rumsey N: *The Social Psychology of Facial Appearance*, New York, 1988, Springer-Verlag.
230. Pope AW, Ward J: Self-perceived facial appearance and psychosocial adjustment in preadolescents with craniofacial anomalies, *Cleft Palate-Craniofacial J* 34(5):396–401, 1997. http://dx.doi.org/10.1597/1545-1569(1997)034<0396:SPFAAP>2.3.CO;2.
231. Polley JW, Figueroa AA, Charbel FT, Berkowitz R, Reisberg D, Cohen M: Monobloc craniomaxillofacial distraction osteogenesis in a newborn with severe craniofacial synostosis: a preliminary report, *J Craniofac Surg* 6(5):421–423, 1995. http://dx.doi.org/10.1097/00001665-199509000-00022.
232. Mavili ME, Tuncbilek G, Vargel I: Rigid external distraction of the midface with direct wiring of the distraction unit in patients with craniofacial dysplasia, *J Craniofac Surg* 14(5):783–785, 2003. http://www.embase.com/search/results?subaction=viewrecord&from=export&id=L137558012\n. http://findit.library.jhu.edu/resolve?sid=EMBASE&issn=10492275&id=doi:&atitle=Rigid+external+distraction+of+the+midface+with+direct+wiring+of+the+distraction+unit+in+pati.
233. Matsumoto K, Nakanishi H, Koizumi Y, et al.: Segmental distraction of the midface in a patient with Crouzon syndrome, *J Craniofac Surg* 13(2):273–278, 2002. http://www.ncbi.nlm.nih.gov/pubmed/12000885.
234. Hollier L, Kelly P, Babigumira E, Potochny J, Taylor T: Minimally invasive Le Fort III distraction, *J Craniofac Surg* 13(1):44–48, 2002. http://www.embase.com/search/results?subaction=viewrecord&from=export&id=L34873943\n. http://findit.library.jhu.edu/resolve?sid=EMBASE&issn=10492275&id=doi:&atitle=Minimally+invasive+Le+Fort+III+distraction&stitle=J.+Craniofac.+Surg.&title=Journal+of+Cranio.
235. Meling TR, Hans-Erik H, Per S, Due-Tonnessen BJ: Le Fort III distraction osteogenesis in syndromal craniosynostosis, *J Craniofac Surg* 17(1):28–39, 2006. http://dx.doi.org/10.1097/01.scs.0000194177.21916.f1.
236. Nonaka Y, Oi S, Miyawaki T, Shinoda A, Kurihara K: Indication for and surgical outcomes of the distraction method in various types of craniosynostosis. Advantages, disadvantages, and current concepts for surgical strategy in the treatment of craniosynostosis, *Child's Nerv Syst* 20(10):702–709, 2004.
237. Diner P: Le Fort III advancement with gradual distraction using internal devices (discussion), *Plast Reconstr Surg* 100(4):831–832, 1997.
238. Shin J, Duncan C, Persing J: Monobloc distraction: technical modification and considerations, *J Craniofac Surg* 14(5):763–766, 2003.
239. Fearon JA: Halo distraction of the Le Fort III in syndromic craniosynostosis: a long-term assessment, *Plast Reconstr Surg* 115(6):1524–1536, 2005. http://dx.doi.org/10.1097/01.PRS.0000160271.08827.15.
240. Iannetti G, Fadda T, Agrillo A, Poladas G, Iannetti G, Filiaci F: LeFort III advancement with and without osteogenesis distraction, *J Craniofac Surg* 17(3):536–543, 2006. http://www.ncbi.nlm.nih.gov/pubmed/16770194.
241. Gosain AK, Santoro TD, Havlik RJ, Cohen SR, Holmes RE: Midface distraction following Le Fort III and monobloc osteotomies: problems and solutions, *Plast Reconstr Surg* 109(6):1797–1808, 2002. http://dx.doi.org/10.1097/00006534-200205000-00004.
242. Gateno J, Teichgraeber JF, Xia JJ: Three-dimensional surgical planning for maxillary and midface distraction osteogenesis, *J Craniofac Surg* 14(6):833–839, 2003. http://dx.doi.org/10.1097/00001665-200311000-00004.

243. Bradley JP, Gabbay JS, Taub PJ, et al.: Monobloc advancement by distraction osteogenesis decreases morbidity and relapse, *Plast Reconstr Surg* 118(7):1585–1597, 2006. http://dx.doi.org/10.1097/01.prs.0000233010.15984.4d.
244. Chin M, Toth BA: Le Fort III advancement with gradual distraction using internal devices, *Plast Reconstr Surg* 100(4):819–832, 1997. http://dx.doi.org/10.1097/00006534-199709001-00002.
245. Ko EWC, Chen PKT, Tai ICH, Huang CS: Fronto-facial monobloc distraction in syndromic craniosynostosis. Three-dimensional evaluation of treatment outcome and facial growth, *Int J Oral Maxillofac Surg* 41(1):20–27, 2012. http://dx.doi.org/10.1016/j.ijom.2011.09.012.
246. Ousterhout DK, Vargervik K, Clark S: Stability of the maxilla after Le Fort III advancement in craniosynostosis syndromes, *Cleft Palate J* 23(Suppl 1):91–101, 1986.
247. Nout E, Cesteleyn LLM, van der Wal KGH, van Adrichem LNA, Mathijssen IMJ, Wolvius EB: Advancement of the midface, from conventional Le Fort III osteotomy to Le Fort III distraction: review of the literature, *Int J Oral Maxillofac Surg* 37(9):781–789, 2008. http://dx.doi.org/10.1016/j.ijom.2008.04.006.
248. Shetye PR, Davidson EH, Sorkin M, Grayson BH, McCarthy JG: Evaluation of three surgical techniques for advancement of the midface in growing children with syndromic craniosynostosis, *Plast Reconstr Surg* 126(3):982–994, 2010. http://dx.doi.org/10.1097/PRS.0b013e3181e6051e.
249. Saltaji H, Altalibi M, Major MP, et al.: Le Fort III distraction osteogenesis versus conventional le Fort III osteotomy in correction of syndromic midfacial hypoplasia: a systematic review, *J Oral Maxillofac Surg* 72(5):959–972, 2014. http://dx.doi.org/10.1016/j.joms.2013.09.039.
250. Hopper RA, Kapadia H, Morton T: Normalizing facial ratios in Apert syndrome patients with Le Fort II midface distraction and simultaneous zygomatic repositioning, *Plast Reconstr Surg* 132(1):129–140, 2013. http://dx.doi.org/10.1097/PRS.0b013e318290fa8a.
251. Hopper RA, Prucz RB, Iamphongsai S: Achieving differential facial changes with Le Fort III distraction osteogenesis: the use of nasal passenger grafts, cerclage hinges, and segmental movements, *Plast Reconstr Surg* 130(6):1281–1288, 2012. http://dx.doi.org/10.1097/PRS.0b013e31826d160b.
252. Watanabe K, Kuroda S, Takahashi T, et al.: Segmental distraction osteogenesis with modified LeFort II osteotomy for a patient with craniosynostosis, *Am J Orthod Dentofac Orthop* 142(5):698–709, 2012. http://dx.doi.org/10.1016/j.ajodo.2012.07.007.
253. Greig AVH, Britto JA, Abela C, et al.: Correcting the typical Apert face: combining bipartition with monobloc distraction, *Plast Reconstr Surg* 131(2):219e–230e, 2013. http://dx.doi.org/10.1097/PRS.0b013e3182778882.
254. Satoh K, Mitsukawa N, Hosaka Y: Dual midfacial distraction osteogenesis: Le Fort III minus I and Le Fort I for syndromic craniosynostosis, *Plast Reconstr Surg* 111(3):1019–1028, 2003. http://dx.doi.org/10.1097/01.PRS.0000047440.06788.72.
255. Heller JB, Gabbay JS, Kwan D, et al.: Genioplasty distraction osteogenesis and hyoid advancement for correction of upper airway obstruction in patients with Treacher Collins and Nager syndromes, *Plast Reconstr Surg* 117(7):2389–2398, 2006. http://dx.doi.org/10.1097/01.prs.0000218796.87243.6d.
256. Meazzini MC, Mazzoleni F, Caronni E, Bozzetti A: Le Fort III advancement osteotomy in the growing child affected by Crouzon's and Apert's syndromes: presurgical and postsurgical growth, *J Craniofac Surg* 16:369–377, 2005. http://dx.doi.org/10.1097/01.SCS.0000157201.81438.31.
257. Molina F: From midface distraction to the "true monoblock", *Clin Plast Surg* 31(3):463–479, 2004. http://dx.doi.org/10.1016/j.cps.2004.03.009.
258. Pittet B, Jaquinet A, Rilliet B, Montandon D: Simultaneous correction of major hypertelorism, frontal bone defect, nasal aplasia, and cleft of the upper lip (Tessier 0-14), *Plast Reconstr Surg* 113(1):299–303, 2004. http://dx.doi.org/10.1097/01.PRS.0000095954.73180.89.
259. Kirkpatrick WN, Koshy CE, Waterhouse N, Fauvel NJ, Carr RJ, Peterson DC: Paediatric transcranial surgery: a review of 114 consecutive procedures, *Br J Plast Surg* 55(7):561–564, 2002. http://dx.doi.org/10.1054/bjps.2002.3923.
260. Wong GB, Kakulis EG, Mulliken JB: Analysis of fronto-orbital advancement for Apert, Crouzon, Pfeiffer, and Saethre-Chotzen syndromes, *Plast Reconstr Surg* 105(7):2314–2323, 2000. http://dx.doi.org/10.1097/00006534-200006000-00002.
261. Posnick JC: Syndromes with craniosynostosis: evaluation and treatment. In Posnick JC, editor: *Orthognathic Sugery: Principles and Practice*, St Louis, 2014, Elsevier.
262. Reitsma JH, Elmi P, Ongkosuwito EM, Buschang PH, Prahl-Andersen B: A longitudinal study of dental arch morphology in children with the syndrome of Crouzon or Apert, *Eur J Oral Sci* 121(4):319–327, 2013. http://dx.doi.org/10.1111/eos.12051.
263. Posnick JC, Agnihotri N: Consequences and management of nasal airway obstruction in the dentofacial deformity patient, *Curr Opin Otolaryngol Head Neck Surg* 18(4):323–331, 2010. http://dx.doi.org/10.1097/MOO.0b013e32833b9d6f.

39

Oculoauriculovertebral Spectrum: Staged Reconstruction

BERNARD J. COSTELLO, RAMON L. RUIZ, JOHN F. CACCAMESE, JR.

Oculoauriculovertebral spectrum (OAVS) is a complex, three-dimensional hypoplasia that results from disruption of the development of the first and second branchial arches. This hypoplasia produces challenging reconstructive needs in the areas of the cranio-orbital complex, zygoma, maxilla, mandible, peri-orbital soft tissues, and ear. The variability of phenotype is impressive, ranging from minimal asymmetries and ear anomalies to complex lateral facial clefting with significant functional concerns and disrupted development of the lateral facial structures (Figures 39-1 and 39-2).

Because of the multifaceted aspects of the functional and esthetic challenges faced by patients with OAVS, a number of specialists are typically involved in the patient's care at multiple stages. Surgeons must understand the biologic basis for the deformity, as well as the expected esthetic and functional issues that may arise throughout the child's stages of growth. A thoughtful, staged reconstructive approach that respects the growth of these structures is best suited to address the complex needs of patients with OAVS. This chapter reviews some of the most important concepts of care for patients with OAVS and presents a staged, interdisciplinary reconstructive approach for dealing with the multiple dysmorphologies.

History

Goldenhar syndrome, which is often considered a variant of hemifacial microsomia, was initially described in the 1950s and was redefined by Gorlin in the 1960s.[1,2] This syndrome includes the characteristic hypoplastic mandible (often asymmetric), along with epibulbar dermoids and vertebral anomalies. By 1976, so much overlap with hemifacial microsomia had been reported that a clear distinction could no longer be made. The condition is now known to be extremely heterogeneous and complex; therefore, the term *oculoauriculovertebral spectrum (OAVS)* has been used.[3] Those at the Goldenhar syndrome end of the spectrum likely account for only about 10% of cases.[4]

Dysmorphology

The extent of dysmorphology in OAVS is considerably variable. Although no minimal diagnostic criteria have been set forth, many believe that the mildest form of this spectrum is expressed as microtia or preauricular or auricular abnormalities.[3] Patients may exhibit severe underdevelopment or lack of development of a number of structures, including the mandible, temporomandibular joint, orbit, ophthalmic structures, zygoma, maxilla, external ear, internal ear, and surrounding soft tissues. Involvement is not limited to facial structures, however, because renal, genitourinary, cardiac, and skeletal anomalies have been reported to occur with variable frequency.[3,5,6] Features of OAVS are listed in Box 39-1. Few patients exhibit all or even most of these findings. Patients with multiple congenital anomalies often are classified as patients with Goldenhar syndrome. The incidence of OAVS in the general population has been estimated at anywhere from 1:3500 to 1:26,500 live births; however, the generally accepted frequency is approximately 1:5600.[3,7]

Pathogenesis

OAVS has remarkable heterogeneity, and there are multiple etiologies.[3,8-11] Multiple chromosomal anomalies have been linked to this complex, the most significant of which are deletion 5q, trisomy 18, and duplication 7q. OAVS has also been observed in the children of diabetic mothers and in those exposed to retinoic acid, thalidomide, and primidone.[4] Additionally, a gene locus at 14q32 has been linked to OAVS and similarly has been linked to microphthalmia.[12]



• **Figure 39-1** **A** and **B,** An infant female is shown with minimal features of oculoauriculovertebral spectrum (OAVS), including external ear abnormalities. **C** through **E,** A young child with OAVS that is more significant, including external ear atresia, Kaban type IIB mandible hypoplasia, soft tissue hypoplasia, and asymmetries of the orbit, zygoma, and maxilla. She has already undergone distraction osteogenesis prior to age 5 by another surgeon but retains significant asymmetries throughout the anatomic regions, including the mandible.

Discordance is the rule among monozygotic twins, although infrequent concordance with variable expression has been documented.[6] Most cases of OAVS are sporadic, but familial instances have been reported with autosomal dominant, recessive, and x-linked inheritance patterns.[3,4] When an inheritance pattern is noted, there tends to be more dramatic dysmorphology and bilateral cases tend to be more common. Wieczorek and colleagues found an association between assistive reproductive technologies and OAVS.[11]

Poswillo was able to reproduce a hemifacial microsomia phenotype in an animal model by using maternal thalidomide exposure. He suggested that the pathogenesis was due to in utero vascular disruption of the stapedial artery anastomosis.[13,14] Resultant anomalies were found to depend on the extent of the hematoma, with large hematomas taking more time to resolve and thus resulting in more local tissue damage.

The constellation of anomalies seen in human OAVS (and associated conditions) suggests origin at about 30 to 45 days' gestation.[15] Hematoma itself has many causes, including maternal-fetal hypoxia, hypertension, and anticoagulants. It should be noted that even though hematoma



• **Figure 39-2 A** through **D,** This young boy with Goldenhar syndrome has a left-sided Tessier no. 7 cleft (macrostomia), left-sided hypoplasia in multiple anatomic units, and bilateral conductive hearing loss. Postoperative results show good healing of the commissure with minimal scarring. (The patient is also seen wearing a conductive hearing aid headband in **C**.)

• BOX 39-1 Oculoauriculovertebral Spectrum

Head and Neck

- Maxillary and mandibular asymmetry with hypoplasia on the affected side
- Microphthalmia
- Hypoplastic adnexal structures
- Coloboma
- Zygomatic hypoplasia
- External ear abnormalities or atresia
- Internal ear abnormalities
- Temporomandibular joint hypoplasia or absence
- Hypoplastic dentition or oligodontia
- Parotid hypoplasia or agenesis
- Plagiocephaly
- Torticollis

Associated Congenital Anomalies

- Cardiac defects (tetralogy of Fallot, ventricular septal defect, aortic coarctation, patent ductus arteriosus)
- Lung hypoplasia
- Renal agenesis, ectopic kidney, multicystic dysplastic kidney, vesicoureteral reflux, or ureteropelvic junction obstruction
- Vertebral anomalies
- Mental retardation, Arnold-Chiari malformation, encephalocele[20,23-28]

formation may explain the OAVS phenotype in some sporadic cases, it does not explain familial inheritance or the multiple malformations associated with OAVS.

In contrast, Johnston and Bronsky suggested that OAVS may represent a malformation sequence with major primary neural crest cell involvement in all or most cases.[16,17] These authors point out that hemorrhages produced in the Poswillo animal model occurred 2 days after thalidomide treatment, which is an unusually long delay for a primary developmental alteration.[13-17] Although late mandibular abnormalities were considered related to the hemorrhages, the cerebral hemispheres and mandibular arches were already severely underdeveloped at the time the hemorrhage occurred. These findings suggest that thalidomide-induced hemorrhage may not be the disruptive pathogenic mechanism for hemifacial microsomia, but instead that thalidomide may have had a teratogenic effect on second arch neural crest cells. Johnston and Bronsky point out a number of common characteristics of other otofacial malformations (i.e., retinoic acid syndrome, DiGeorge syndrome, Down syndrome, and Treacher Collins syndrome [TCS]) with hemifacial microsomia, which include mandibular, auricular, and conotruncal cardiovascular malformations (except in TCS).[16,17] The pathogenesis of these conditions involves the death of neural crest and adjacent cell populations of the second arch and retarded neural crest cell migration, possibly related to an altered retinoic acid (RA) and cellular retinoic acid binding protein (CRABPI) sensitivity in these cell populations.[16,17]

This complex sequence of variable expression typically is viewed as a heterogeneous complex rather than a distinct entity.[18] It is unclear why some patients exhibit more severe forms of hypoplasia and asymmetry. Patients with multiple congenital anomalies typically present with more severe dysmorphologies and a greater degree of asymmetry when compared with most sporadic cases. Patients who are believed to have Goldenhar syndrome typically exhibit bilateral hypoplastic tissues, but these are asymmetric in nature, unlike those seen with Nager syndrome or TCS. Patients with Nager syndrome or TCS typically exhibit more symmetry but also have severe hypoplasia of the same group of tissues derived from the first or second branchial arches.

Classification

In addition to the wide variety of terms applied to this complex, systems of classification have been identified to describe various aspects of the multiple malformations.[19-25] Mandibular morphology in OAVS is well described and has been well classified by Pruzansky, Kaban and others.[20,25-28] The extent of the temporomandibular joint (TMJ) dysmorphology is a principal factor when the timing of and techniques for mandibular reconstruction are considered.[15] Kaban's classification successfully defines the degree of TMJ deficiency, providing the diagnostic framework for a functional reconstruction.[15,20,21,27-29] Imprecise characterization of the extent of TMJ deficiency can result in misguided and inappropriately timed reconstruction.

The system of classification used most often describes deformities of the TMJ and ramus unit.[20,21,26-28] Type I skeletal defects involve mild, three-dimensional hypoplasia of the TMJ complex. Significant functional consequences are not usually associated with the deformity. Patients with type II OAVS have more moderate hypoplasia and are subdivided by IIA and IIB deformities. Type IIA deformities are those with relatively mild hypoplasia (but better than type I) and good function of the mandible. Type IIB deformities are those with more significant hypoplasia and an impaired TMJ complex, but one that still exhibits a posterior "stop" or articulation of the pseudocondyle with the cranial base. Patients usually have some limitation of function at the TMJ. Type III deformities are those characterized by absence of the functional unit (condyle and ramus). Additionally, the glenoid fossa may be poorly formed or absent with a smooth/hypoplastic cranial base. Patients with IIB and III deformities usually benefit from reconstruction of the ramus/condyle unit. Kaban type I and type II deformities can largely be managed by a variety of traditional orthognathic techniques at skeletal maturity, and some type IIB or type III deformities have been reconstructed with replacement of the vertical ramus with the use of rib, free fibula, or free metatarsal flaps.[30-32]

Another classification system has been described by Vento et al.[23] This system borrows from the tumor-node-metastasis (TNM) system used for clinical staging of tumors in the head and neck. The OMENS system (O for orbital distortion; M for mandibular hypoplasia; E for ear anomaly; N for nerve involvement; and S for soft tissue deficiency) breaks

• BOX 39-2 OMENS Classification System for Oculoauriculovertebral Spectrum

1. Orbit
   0 = normal
   1 = small size
   2 = poor position
   3 = both small size and poor position
2. Mandible
   Type I
   Type IIA
   Type IIB
   Type III
3. Ear
   Type I = small ear but most of the normal structure
   Type II = severely affected external anatomy with rudimentary auricle present
   Type III = external ear is only a small rudiment with no pinna
   Type IV = anotia
4. Nerve (cranial nerve VII)
   0 = normal
   1 = upper branches impaired
   2 = lower branches impaired
   3 = upper and lower branches impaired
5. Soft tissue
   0 = normal
   1 = mild hypoplasia
   2 = moderate hypoplasia
   3 = severe hypoplasia

out the deformities by anatomic structure and discusses the more complete picture of the deformity (Box 39-2). Each region is given a numeric and/or letter designation based on the anatomic components that are affected. An amendment to this approach has been proposed to indicate the presence of anomalies in other systems outside of the craniomaxillofacial complex.[24,25] Although the OMENS and OMENS-plus systems are more cumbersome to use clinically, they do encourage complete evaluation of the deformity and prompt thoughts regarding reconstruction of each region.[24,25] Once the complete deformity has been realized, a thoughtful, staged reconstruction can be formulated that plans for esthetics and function and respects growth potential in each area.[15,18,29]

Staged Reconstruction

The deformities of OAVS require a staged approach, tailored to meet the functional and esthetic needs of each patient. The following sections discuss the important aspects of each area typically affected by OAVS and the authors' preferred approach to the reconstruction. In general, those areas that have a functional concern are addressed in a standard, timely fashion to provide functional units during development when necessary. Timing is further based on maturity of the area of concern, such that reconstruction is provided once most growth velocity for that region is complete. However, functional concerns may supersede these growth concerns. For example, if a cleft palate is present, this is typically addressed at a time that respects growth concerns but provides for functional speech. Orthognathic surgery is typically performed during the teen years, when the vast majority of growth is complete, such that a stable and predictable result is achieved without the need for additional revisions. Some deformities are reconstructed in a way that is custom-tailored to the patient's needs when necessary. For example, esthetic concerns that become psychosocial problems for a child may be addressed earlier than at full maturity if the reasons are compelling. The overall approach is outlined in Table 39-1. Although considerable controversy surrounds the timing of these procedures, the authors prefer this approach, which respects growth potential when possible (see Table 39-1).

One important consideration is the nature of the deformity itself and whether or not it is progressive in most patients. This is a point of contention for many, and opinions on this fundamental aspect directly affect the thought process of how clinicians approach treatment planning for OAVS. Many believe that OAVS is a stable dysmorphology, which means that the deformity does not worsen over time.[28,29] Therefore, the degree of hypoplasia is similar if not identical at a young age to that seen when the patient grows to the teen years. For those who believe this to be the case, staging of orthognathic procedures is done in a fashion similar to that used in patients who do not have congenital deformities. Thus, waiting until the teen years to address maxillomandibular discrepancies allows the patient to grow to maturity and permits the surgeon to provide a stable and predictable result that is not likely to require revision surgery because of additional growth. Subscribers to this philosophy accept that the deformity does not worsen over time; therefore, there is no compelling reason to address asymmetries earlier for most patients.[15,29]

On the other side are those who believe that OAVS is a progressive deformity that should be addressed earlier to avoid additional asymmetry that might occur if one waits until skeletal maturity is reached. This is a primary argument for early distraction procedures aimed at lengthening the mandible at a young age to provide better symmetry at that time. Those who subscribe to this philosophy believe that leaving the deformity until the teen years will result in worsening asymmetry with time. Some data support this finding, although other data argue against it.[26-29] Several studies have evaluated patients in a longitudinal fashion and found that the deformity is not progressive in these cohorts.[15,29,33] Studies that previously had supported the idea that OAVS is a progressive deformity were not longitudinal and therefore may exhibit statistical and conceptual flaws that negate the concept of progressive deformity.[26-28,33]

Published outcomes of both of these approaches are good, and both techniques have been used with success. Although the early intervention approach has shown considerable merit, in the opinion of the authors, definitive operations performed in minimal stages offer the most predictable and long-lasting result with minimal intervention. This decreases the burden on the child, family, and health

TABLE 39-1 Authors' Approach to Treatment of Oculoauriculovertebral Spectrum

Deformity	Typical Age of Reconstruction
Cleft lip	3 months or later
Cleft palate	9-14 months Note: Submucous cleft repaired only if speech is affected once a complete speech evaluation is performed.
Cranio-orbital asymmetry	2-5 years or later
Oribital hypoplasia/ microphthalmia	5 years or later
Zygomatic hypoplasia	5 years or later
Kaban type III TMJ (atretic TMJ/ramus)	5 years or later
Maxillomandibular asymmetry	14-16 years or later in females 16-18 years or later in males
Soft tissue deficiency, lateral face	After orthognathic procedures
External ear	5 years of age or later

care system, while also providing the most accurate and definitive result.

Airway Management

Ensuring a stable airway is a primary concern. In some instances, OAVS may be diagnosed during fetal evaluation, and approximately half of these patients exhibit oligohydramnios or polyhydramnios, indicating possible fetal swallowing issues that may manifest as airway difficulty at birth.[34] In these settings, it may be important to consider airway management at the time of birth. Although an ex utero intrapartum treatment (EXIT) procedure or tracheostomy is rarely required immediately at birth for patients with OAVs, it is advantageous for the clinician to be prepared for a difficult intubation and management of the airway. In most instances, positioning the child lateral or prone may assist in improving airway dynamics. In some instances, a temporary nasal trumpet or stent may be helpful in the intermediate management of obstruction.[35,36] Clinicians should consider a pneumogram or formal sleep study if consistent obstruction is witnessed. In some cases of more severe obstruction, tracheostomy is helpful for optimizing the airway. Most children can be decannulated once coordination has improved. Lengthening of the mandible through distraction osteogenesis techniques can be considered in an attempt to decannulate the child prior to the development of speech, although poor outcomes are often seen with neonatal distraction, multiple anomalies in other systems, multiple airway abnormalities (e.g., tracheomalacia, laryngomalacia), or Kaban type III anomalies.

Cleft Lip and Palate and Velopharyngeal Insufficiency

One of the first features of OAVS that should be addressed is the presence of clefting. Cleft lips most often are present in the form of a lateral facial or Tessier no. 7 or macrostomia.[15,18] These types of clefts are present in at least 35% of patients with OAVS.[3] Unilateral or bilateral clefts of the lip and palate are present in approximately 7% to 15% of cases.[3] Failure of fusion of the lateral commissure may contribute to feeding difficulties if the cleft is large enough, and repair during the early months of life may be indicated for functional and esthetic reasons. Reconstruction involves repairing the orbicularis oris and associated musculature of the commissure with accurate approximation of the vermilion and oral mucosal tissues. In most instances, the repair is highly esthetic and functions well with minimal asymmetry (see Figure 16-2). Revision may be helpful at some point once additional growth has occurred in the area.

Isolated cleft palate is present in approximately 30% of patients with OAVS, but usually not in its overt form.[3] More often, patients with OAVS exhibit a submucous cleft palate (SMCP). Repair of the SMCP usually is deferred until a speech evaluation can be performed because many patients do not have significant speech issues with only an SMCP. A consistent and detailed speech evaluation typically is not possible until 3 to 5 years of age in the normally developing child. A significant percentage of patients will not require repair of the SMCP because the velum works well despite the minor clefting. However, this is not the case for patients who exhibit velopharyngeal dysfunction and who have hypernasality that affects intelligibility of speech. Patients with consistent velopharyngeal insufficiency that is due to the anatomic abnormalities associated with the SMCP or with occult SMCP (usually without the bifid uvula) should be considered for palate repair or a pharyngeal procedure to improve function (pharyngeal flap or pharyngoplasty).

It is also important to evaluate the patient for possible neurogenic causes of poor palatal motion. In some patients with OAVs, the reason for the velopharyngeal insufficiency is related to poor innervation of the palate on the affected side. Approximately 35% of patients with OAVS will exhibit velopharyngeal dysfunction, and most cases are not due to clefting.[37] Patients usually benefit from a tailored pharyngeal flap rather than from primary repair of the palate or a double-opposing z-plasty.[15,38] A detailed speech evaluation that includes a perceptual speech exam, nasendoscopy, and/or videofluoroscopy is helpful in determining the cause of velopharyngeal insufficiency.

Temporomandibular Joint and Ramus Reconstruction

Patients with OAVS exhibit abnormalities of the TMJ, including hypoplasia and occasionally absence. Those with mild to moderate hypoplasia who can function well rarely

seem to have internal derangements or degenerative joint disease that affects function over the long term. Rarely do these patients require significant intervention regarding their TMJ. Those who have not developed a ramus/condyle/fossa unit benefit from reconstruction of the TMJ at some point. Some surgeons prefer to delay this process until growth has essentially been completed if the patient can function well (speech and mastication). It is interesting to note that most patients can function quite well when the condyle/fossa unit is not intact. For those who have psychosocial issues with the deformity or compelling functional reasons to perform a reconstruction earlier, a costochondral rib graft can provide a condyle and ramus unit.[15,29,39] Patients who exhibit obstructive sleep apnea and those with mastication difficulty may benefit from this approach at age 5 or later. Some patients will not have a fossa to accept the rib, in which case one may be reshaped and reconstructed within the skull base.[15,29] Grafts placed earlier than 5 years of age tend to resorb and lack significant size to allow for stability and fixation. Rib grafts placed early may grow unpredictably (Figure 39-3).

One of the main issues with early rib grafting is the unpredictable nature of growth once the graft has been placed. Rib grafts may undergrow, overgrow, or theoretically grow to "perfect" size, although this is rarely the case.[15,29,39] If ribs overgrow, then a significant issue may arise at the time of adolescence when a malocclusion is typically treated with orthognathic surgery (see Figure 39-3). The complex asymmetry that results may be more difficult to treat than the deformity that would have resulted if the graft had not been performed. Thus, the decision of whether to perform early grafting of the TMJ must be made carefully (see Figure 39-3).

If costochondral grafting is not an option in patients, either because cartilage has already been harvested to construct ears because the surgical scar will be unacceptable, or because chest wall anomalies have occurred, the microvascular fibula remains an option. It has the additional advantage of providing subcutaneous tissue and/or fascia to provide additional soft tissue volume to the lateral face. The results for condylar replacement in the rapidly growing child can be poor, as the fibula fails to grow. However, this technique is a reasonable option in the skeletally mature patient with complex hard and soft tissue deficiencies.

In some instances, the option of a prosthetic TMJ replacement can be considered as a revision procedure after a rib graft, or as a primary reconstruction. Historically, this option has not been entertained in children because of concerns that the prosthesis would not grow. Given the issues associated with unpredictable growth of a rib graft, consideration can be given to this option, particularly in the older child. A custom prosthesis usually is best suited for those patients who lack a portion of the ramus. If a large area is deficient, then grafting with autogenous materials may be the best choice. This is usually performed with costochondral rib, vascularized fibula, and/or iliac crest graft.

Transport distraction osteogenesis has been described and used by some to reconstruct a ramus/TMJ unit in patients with Kaban type III OAV, but only limited success has been reported in the literature.[40-47] It is quite difficult to transport a distraction disc of bone to the exact point of articulation at the base of the skull and provide the level of symmetry that can be achieved with the other aforementioned techniques. Some initial descriptions mentioned the possibility of neocondylar genesis, but no long-term outcomes of these procedures have been published.[40-47] The technique has mostly fallen out of favor. Many patients who have undergone this procedure require revision surgery with costochondral reconstruction or other techniques that are more difficult to perform after the area has developed additional scarring (Figure 39-4). Another drawback is the growth restriction that occurs in this area, particularly if the surgery is performed at a young age. This transforms a stable deformity into a progressive one and potentially makes later reconstructions more difficult from a technical standpoint. Even after several decades of experience, no substantial functional outcomes of this technique have been reported in

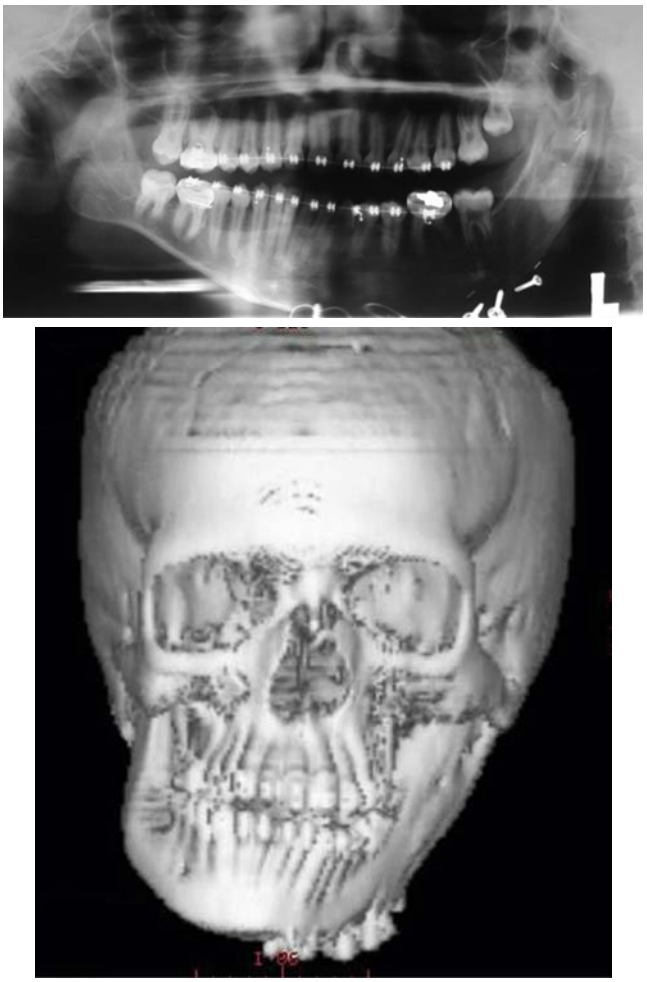

• **Figure 39-3** A panoramic tomogram and three-dimensional computed tomography image show a teenager who was born with Kaban type III, left-sided oculoauriculovertebral spectrum (OAVS). She had a rib graft placed prior to age 5 by another surgeon, which has now overgrown, and this has resulted in a significant asymmetry toward the unaffected side. She also exhibits a class III relationship rather than the typical class II seen with OAVS.

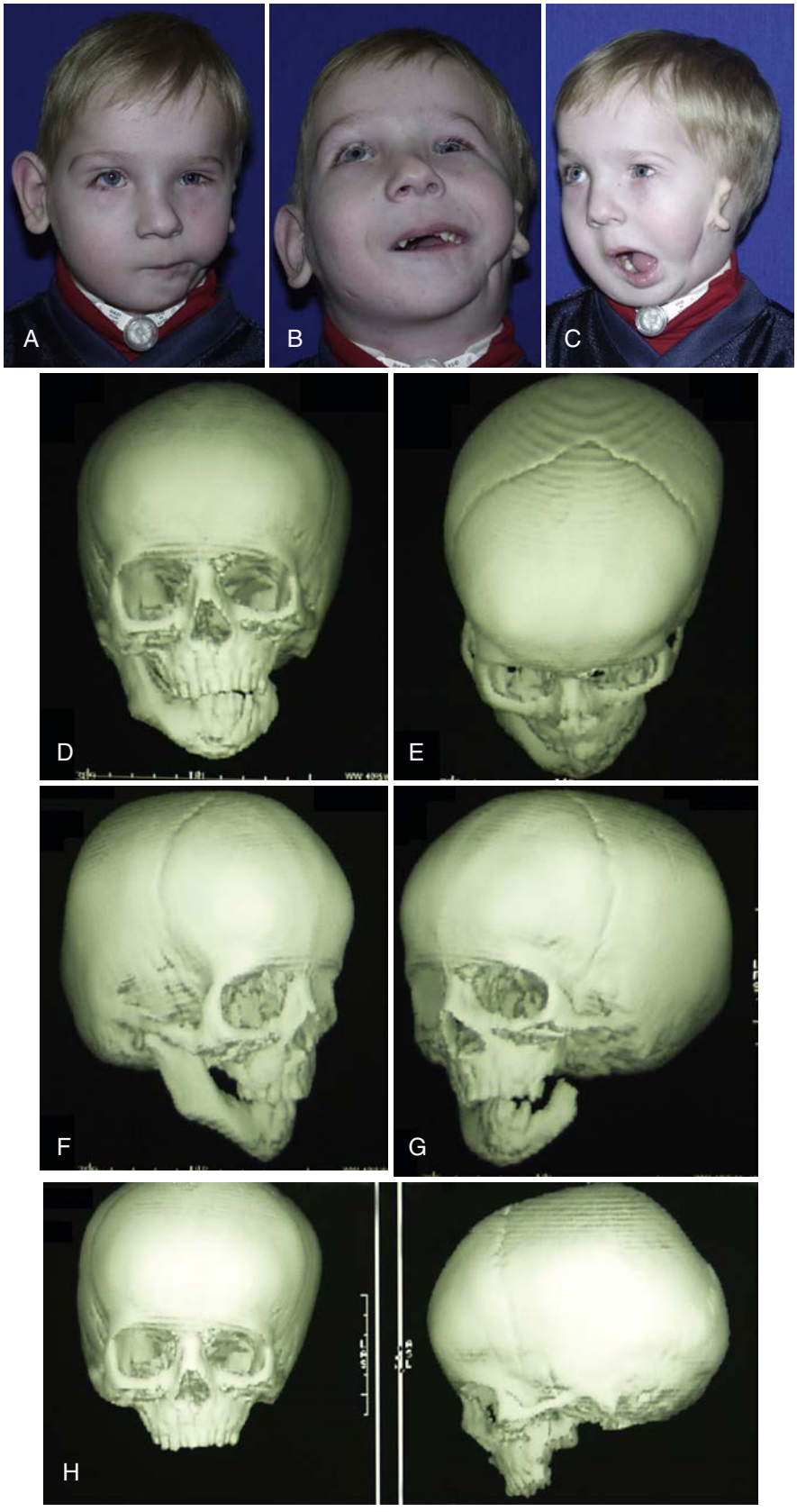

• **Figure 39-4** **A** through **C,** A young boy with Goldenhar syndrome is shown with a right side that is classified as type IIA and a left side classified as type III. He has undergone a number of distraction procedures with external devices performed by another surgeon in an attempt to lengthen the right side and create a neocondyle through a transport distraction technique. Trismus may occur. Three-dimensional computed tomography scans show the postoperative anatomy (**D** through **H**). Vector control can be difficult and may alter the bone at previous distraction sites in a manner that makes conventional osteotomy or reconstructive techniques difficult.

a clinical trial or case series; therefore, this technique is not advocated by the authors. More predictable techniques such as costochondral rib grafting offer more predictable results.

Current translational research using regenerative medicine is aimed at engineering a construct of the TMJ ex vivo and integrating a multitissue graft such that a donor site can be avoided. Although these concepts are still years from clinical trials, we may be able to provide a more tailored graft that fulfills the patient's needs much better than what surgeons currently can offer.[48]

Mandibular Lengthening with Distraction Osteogenesis

Some surgeons believe that mandible lengthening and repositioning in the early years through distraction osteogenesis can improve symmetry and esthetics. If a distraction procedure or an early graft can eliminate tracheotomy dependence, early value can be derived from these methods. Although initial approaches involved intervening at an early age to improve symmetry, form, occlusion, and overall function, many of these approaches were hampered by difficulty controlling vectors and the bone growth impairment that may result from early surgery. Early intervention via distraction does not improve bone growth, and no current evidence suggests that an improved outcome results from this approach rather than from orthognathic surgery during the teen years. As a result, patients who typically have a deformity that is not progressive can be converted to a deformity that is progressive due to growth restriction from early surgical intervention. This is particularly true for patients who exhibit minimal asymmetry but have had distraction techniques performed at an earlier age. These issues are best addressed during the teen years with the use of standard orthognathic surgical techniques with which reconstruction is as definitive as possible with minimal stress on the patient, family, and health care system (see Figure 39-1, *C* through *E*).

Although they exhibit benefit in select patients, distraction techniques can be associated with a higher degree of infection, nonunion, and other complications that may increase the complexity of definitive reconstruction at skeletal maturity. This may produce a more difficult clinical scenario for standard orthognathic surgery approaches because bone quality and surrounding soft tissue may be affected by scarring and by hypovascularity (see Figure 39-4).

Zygoma and Orbit Reconstruction

Patients with significant hypoplasia of the zygoma may benefit from procedures designed to augment the region or formal osteotomy with bone graft reconstruction of the zygomatic complex. This is best performed once most growth is complete at this site. After age 5 to 7, most upper facial bone growth is complete, but this reconstructive effort may be delayed if no significant functional issues are present.

The zygoma can be created or augmented with onlay bone grafts or porous polyethylene implants. Onlay grafts or implants can be custom-fit to the patient's needs. Minor asymmetries are best approached via these methods. More severe hypoplasia of the zygoma usually requires formal osteotomies in the orbit and reconstruction of the orbit/zygoma complex with split-thickness cranial vault. The hypoplastic zygoma may be repositioned with an osteotomy, but this usually requires additional grafting to improve symmetry significantly. The graft usually is procured from the cranial vault because of its proximity during the surgical approach with a coronal incision.

These procedures can be performed earlier if function can be improved from an ophthalmologic standpoint through positioning of the globe. Occasionally, supporting the orbit floor with cranial bone or porous polyethylene implants is helpful for treating enophthalmos associated with orbital and zygomatic hypoplasia. A complete ophthalmologic examination is routinely performed from birth. Additional ophthalmologic issues such as epibulbar dermoids, coloboma, blepharophimosis, and strabismus may require the attention of a skilled pediatric ophthalmologist.[3]

Ear Reconstruction

Ear deformities are a hallmark of OAVS and may be the only initial finding of significance (see Figure 39-1). The deformity may be seen as mild as preauricular sinuses or tags, but more commonly, significant asymmetry and malformation of the external ear are present.[49-51] Deformities of the external helix, malposition of the ear complex, microtia, or anotia may occur. Minor deformities may benefit from simple excision of ear remnants or otoplasty of the malrotated ear. Other patients require much more extensive reconstruction. Three options are currently available for patients who wish to replace an external ear construct: (1) staged reconstruction with an autogenous cartilage rib graft, (2) placement of craniofacial implants to support a prosthesis, and (3) use of a porous polyethylene construct under a skin flap. Each approach has its advantages and drawbacks. With chondral grafts, a number of procedures are required to reconstruct the ear, and considerable experience of the clinician is important in achieving an ear that approaches normal.[50,51] However, this approach provides patients with an ear that is not removable and represents their own tissue. A well-made prosthesis provides excellent esthetics but is removable. Implants can cause chronic irritation around the skin overlying the temporal bone if they are not cleaned diligently. The use of porous polyethylene constructs provides a very nice shape and form that can be easily implanted, but a lifetime infection risk may require removal at some point and leaves significant scar tissue that renders the other options less attractive. Some patients have aberrant blood flow to the auricular area and may not be able to accept these options. Before considering these options, some surgeons perform preoperative angiography to evaluate blood flow to the site.

In some instances, patients may exhibit conductive or sensorineural hearing loss. Depending on the condition, patients may be candidates for a banded conductive hearing device to improve hearing on the affected side. Occasionally, this is required bilaterally in patients with bilateral deformity (see Figure 39-2). A bone-anchored hearing appliance may be used for patients with only conductive hearing loss, but this usually is delayed until 5 years of age. Some surgeons prefer to attempt this earlier, but the cranial vault in this area is not typically mature (diploic) until additional growth is complete.

Rarely, some patients may be candidates for additional middle ear surgery, including surgical treatment of auditory canal stenosis or atresia. Some patients may be candidates for cochlear implants, but this is rarely the case. If these types of surgical procedures are entertained, they should be performed prior to external reconstruction to ensure that the ear is in the optimal position for functional surgical reconstruction (i.e., the external ear is placed properly when compared with a reconstructed internal auditory meatus). Most patients with more severe deformity do not achieve bilateral hearing that is meaningful.[15] Select patients may benefit from these endeavors, and a thorough evaluation by a skilled pediatric otolaryngologist and an audiologist is helpful from the time of birth.

Orthognathic Surgery

Staged reconstruction of OAVS and related dysmorphologies has been discussed by many.[15,18,26-29,52] Posnick states that the most favorable functional and esthetic results are obtained when surgery is performed at or close to skeletal maturity, ideally when carried out with coordinated orthodontic therapy.[15,29] The complex three-dimensional deformity of OAVS usually is best approached with a Le Fort I osteotomy, bilateral sagittal split osteotomies, and a genioplasty (Figure 39-5).

Other osteotomy techniques can be used if the ramus component of the affected side is severely dysmorphic, or if previous distraction techniques have yielded a segment that is difficult to separate in the conventional manner. Other osteotomies commonly used in these situations include inverted L osteotomy, vertical ramus osteotomy with interpositional bone grafts, and other straight osteotomies with interpositional bone grafts. Mandibular reconstruction of severe type IIb deformities sometimes is considered when the child is still in the mixed dentition. For the type III deformity, first-stage reconstruction with a costochondral graft remains a popular choice and for most, the best alternative.[15,28,29] This may have to be performed in combination with a contralateral ramus osteotomy for more controlled positioning of the distal mandible. When first-stage procedures such as these are carried out at ages 5 to 12 for functional reasons, the need for additional maxillomandibular reconstruction at the time of skeletal maturity can be anticipated (Figures 39-6 and 39-7). Combined maxillomandibular surgery and costochondral rib reconstruction can be performed definitively at skeletal maturity if no major functional concerns are present at a younger age. Composite microvascular free fibula transfer can also be utilized for vertical ramus reconstruction. The option of recruiting muscle, fascia, or a de-epithelialized skin paddle can be useful to provide bulk to the lateral facial soft tissue while reconstructing the skeleton. Lastly, simultaneous total joint reconstruction with orthognathic surgery can be performed at skeletal maturity with a high degree of precision using virtual surgical planning. Both the fabrication of the TMJ device and the three-dimensional positioning of the Le Fort and mandibular osteotomies should be planned together. The advent of virtual surgical planning has greatly improved the ability for the surgeon to accurately improve symmetry well beyond other techniques such as gradual distraction.

Because of the complexity of the asymmetry, the precision, control, and stability offered by orthognathic surgical techniques are almost always preferable when compared with techniques based on distraction osteogenesis. Distraction osteogenesis techniques used in the mature patient do not afford the control and precision that can be achieved with conventional orthognathic techniques and thus offer little or no advantage for the treatment of deformities associated with OAVS. It can be helpful to use both three-dimensional computed tomography images and stereolithographic models and virtual surgical planning to precisely plan treatment for complex three-dimensional asymmetry (see Figure 39-6). Use of only a lateral cephalometric radiograph and a posterior-anterior cephalometric radiograph underestimates the degree of asymmetry and the three-dimensional complexity. This is particularly the case for patients in whom previous ill timed reconstruction or distraction techniques have been performed and who still have significant asymmetry. These patients may be excessively long in the vertical dimension but still hypoplastic in the transverse and sagittal dimensions, making the postoperative deformity more difficult to reconstruct than the original problem.

Asymmetry is the result of a hypoplastic underlying facial skeleton and an overlying soft tissue envelope. Therefore, in addition to requiring extensive craniofacial surgery to construct a functional skeleton over which the soft tissue will drape normally, OAVS occasionally requires the augmentation of overlying soft tissues. The parascapular microvascular flap has been used with some success in this arena. When a fibula is used for reconstruction of the ramus, additional lateral bulk can be obtained by harvesting an osseo-septocutaneous flap with the de-epithelializing skin paddle buried to add bulk to the lateral face. Additional augmentation of the ramus and body of the mandible may be helpful for enhancing symmetry. Typically, this is done with onlay grafting or alloplastic implants. Alloplastic implants provide an easy way to improve symmetry but may be associated with a risk of long-term infection. Fat transfer techniques or a de-epithelialized scapula free flap may be used to further enhance the soft tissue once orthognathic surgery is complete. Techniques based on fat transfer may not provide a long-lasting and stable result because the fat transplant tends to resorb over time.[53-55] Very nice results have been achieved when the free-flap technique is used, and these tend to provide long-lasting improvements in facial symmetry. Combinations of these therapies can provide a refined approach that can be customized to the patient's needs.



• **Figure 39-5** A teenage girl with type IIA oculoauriculovertebral spectrum (OAVS) and a Tessier No. 7 cleft (repaired by another surgeon) is seen preoperatively and postoperatively. She underwent Le Fort I osteotomy, bilateral sagittal split osteotomies, and a double-stack genioplasty.



• **Figure 39-6** A teenage girl is shown preoperatively and postoperatively after treatment for type III oculo-auriculo-vertebral spectrum (OAVS). She had a rib graft at an early age and then distraction of the rib graft site on several occasions during childhood, performed by another surgeon. During the teen years, she underwent Le Fort I osteotomy, left-sided sagittal split osteotomy, and right-sided modified sagittal osteotomy through the previous distraction site with removal of an impacted tooth, as well as asymmetric genioplasty with bone grafting. A stereolithographic model can be helpful for analyzing asymmetry in patients who have complex three-dimensional deformities.



• Figure 39-6, cont'd

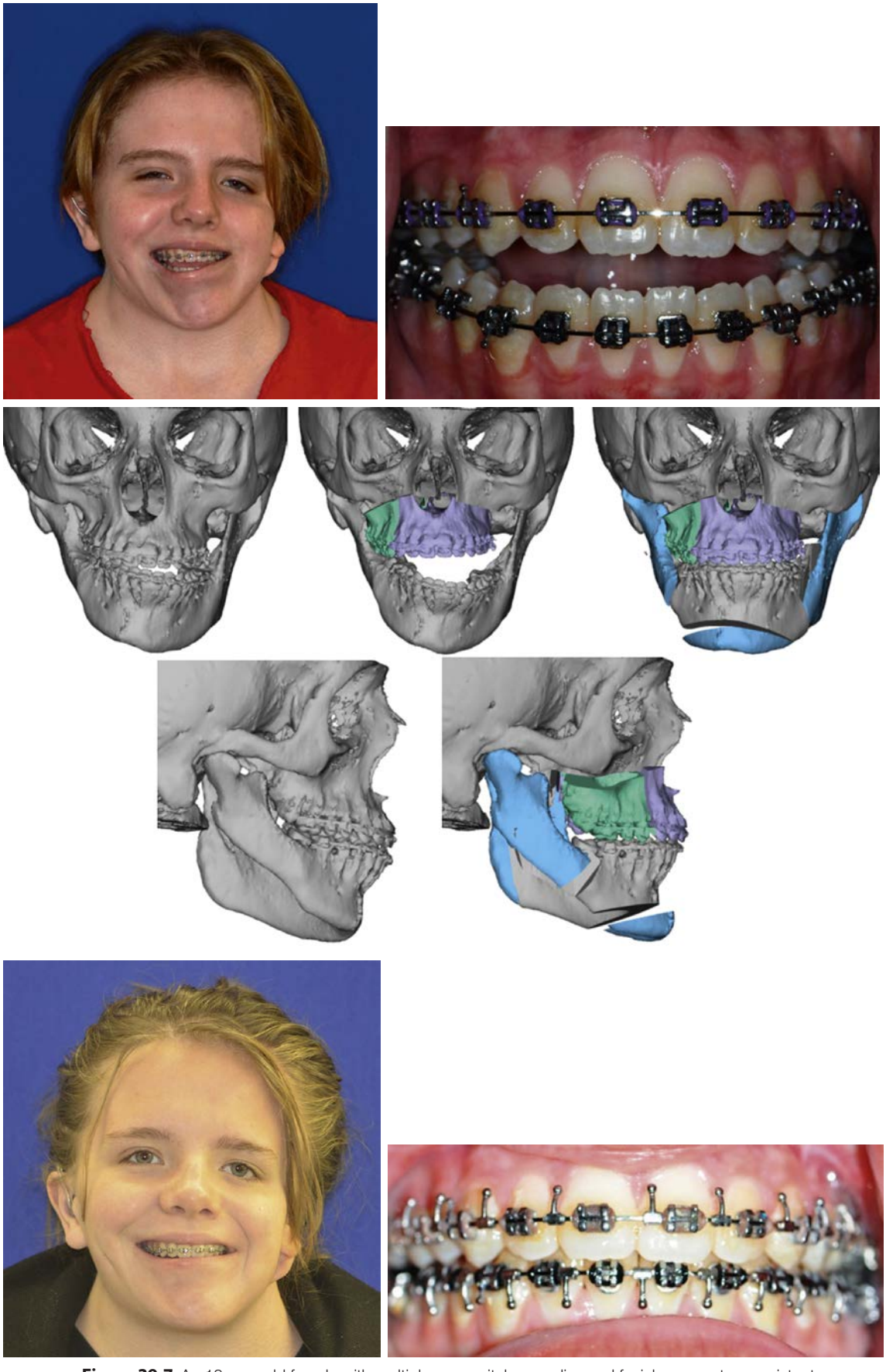

• **Figure 39-7** An 18-year-old female with multiple congenital anomalies and facial asymmetry consistent with OAVS. Virtual surgical planning was utilized to address her very complex asymmetries that are affected by her natural head position and orbital asymmetry. The family elected to not treat the orbital asymmetry. As such, her natural head position and orbits were used to guide the planes of symmetry for positioning of the maxilla and mandible for optimal symmetry without normal reference planes. Preoperative and post-operative views are shown in conjunction with her virtual surgical plan, including the intermediate steps.

Summary

OAVS is a complex, multidimensional congenital deformity that results from disruption of the tissues associated with the first and second branchial arches and neural crest cell migration. Resultant deformities of the cranio-orbital tissues, zygoma, ear, lip, palate, maxilla, mandible, and airway require a thoughtful staged reconstruction that is interdisciplinary. Clinicians should approach these deformities with techniques that have the best outcome data and a proven track record. Unfortunately, little comparative level I evidence exists to guide clear choices between treatments because of the long-term follow-up required to adequately assess outcomes. Orthognathic surgery remains the most predictable option for addressing the skeletal deformities associated with OAVS.

References

1. Goldenhar M: Associations malformatives de l'oel et de l'oreille, en particular le syndrome dermoide epimoide epibulbaire-appendices auriculaires-fistula auris congenital et ses relations avec la dysostose mandibulofaciale, *J Genet Hum* 1:243–282, 1952.
2. Gorlin RJ, Jue KL, Jacobsen NP, Goldschmidt E: Oculoauriculovertebral dysplasia, *J Pediatr* 63:991–999, 1963.
3. Gorlin RJ, Cohen MM, Hennekam RCM: *Syndromes of the head and neck*, New York, 2001, Oxford Press, pp 790–798.
4. Cohen MM, Rollnick BR, Kaye CI: Oculoauriculovertebral spectrum: an updated critique, *Cleft Palate J* 26:276–286, 1989.
5. Avon SW, Shively MD: Orthopedic manifestations of Goldenhar syndrome, *J Pediatr Orthop* 6:683–686, 1988.
6. Rollnick BR, Kaye CI, Nagatoshi K, et al.: Oculoauriculovertebral dysplasia and variants: phenotypic characteristics of 294 patients, *Am J Med Genet* 26:361–375, 1987.
7. Grabb WC: The first and second branchial arch syndrome, *Plast Reconstr Surg* 36:485–508, 1965.
8. Connor JM, Fernandez C: Genetic aspects of hemifacial microsomia (Letter), *Hum Genet* 68:349 only, 1984.
9. Kelberman D, Tyson J, Chandler DC, et al.: Hemifacial microsomia: progress in understanding the genetic basis of a complex malformation syndrome, *Hum Genet* 109:638–645, 2001.
10. Stromland K, Miller M, Sjogreen L, et al.: Oculo-auriculo-vertebral spectrum: associated anomalies, functional deficits and possible developmental risk factors, *Am J Med Genet* 143A:1317–1325, 2007.
11. Wieczorek D, Ludwig M, Boehringer S, et al.: Reproduction abnormalities and twin pregnancies in parents of sporadic patients with oculo-auriculo-vertebral spectrum/Goldenhar syndrome, *Hum Genet* 121:369–376, 2007.
12. Online Mendelian Inheritance of Man (OMIM): Hemifacial microsomia: gene map. Available at: http://www.ncbi.nlm.nih.gov/Omim/getmap.cgi?l1164210.
13. Poswillo DE: The pathogenesis of the first and second branchial arch syndrome, *Oral Surg* 35:302–329, 1973.
14. Poswillo DE: Otomandibular deformity: pathogenesis as a guide to reconstruction, *J Maxillofac Surg* 2:64–72, 1974.
15. Posnick JC: *Craniofacial and maxillofacial surgery in children and young adults*, Philadelphia, 2000, WB Saunders, pp 419–445. 2000.
16. Johnston MC, Bronsky PT: Prenatal craniofacial development: new insights on normal and abnormal mechanisms, *Crit Rev Oral Biol Med* 6:368–422, 1995.
17. Johnston MC, Bronsky PT: Craniofacial embryogenesis: abnormal developmental mechanisms. In Mooney MP, Siegel MI, editors: *Understanding craniofacial anomalies: the etiopathogenesis of craniosynostosis and facial clefting*, New York, 2002, Wiley and Sons, pp 61–124.
18. Caccamese Jr JF, Costello BJ, Mooney MP: A novel deformity of the mandible in oculoauriculovertebral spectrum: a case report and literature review, *J Oral Maxillofac Surg* 64:1278–1282, 2006.
19. Rahbar R, Robson C, Mulliken JB, et al.: Craniofacial, temporal bone, and audiologic abnormalities in the spectrum of hemifacial microsomia, *Archiv Otolaryngol Head Neck Surg* 127:265–271, 2001.
20. Pruzansky S: Not all dwarfed mandibles are alike, *Birth Defects* 4:120, 1969.
21. Murray JE, Kaban LB, Mulliken JB: Analysis and treatment of hemifacial microsomia, *Plast Reconstr Surg* 74:186–199, 1984.
22. Meurman Y: Congenital microtia and meatal atresia, *Arch Otolaryngol* 66:443, 1957.
23. Vento AR, LaBrie RA, Mulliken JB: OMENS classification of hemifacial microsomia, *Cleft Palate Craniofac J* 28:312–317, 1989.
24. Horgan JE, Padwa BL, LaBrie RA, Mulliken JB: OMENS-plus: analysis of craniofacial and extracraniofacial anomalies in hemifacial microsomia, *Cleft Palate Craniofac J* 32:405–412, 1995.
25. Poon C, Meara JG, Heggie A: Hemifacial microsomia: use of the OMENS-Plus classification at the Royal Children's Hospital of Melbourne, *Plast Reconstr Surg* 111:1011–1018, 2003.
26. Kearns GJ, Padwa BL, Mulliken JB, Kaban LB: Progression of facial asymmetry in hemifacial microsomia, *Plast Reconstr Surg* 105:492–498, 2000.
27. Kaban LB, Mulliken JB, Murray JE: Three-dimensional approach to analysis and treatment of hemifacial microsomia, *Cleft Palate Craniofac J* 18:90–99, 1981.
28. Kaban LB, Padwa BL, Mulliken JB: Surgical correction of mandibular hypoplasia in hemifacial microsomia: the case for treatment in early childhood, *J Oral Maxillofac Surg* 56:628–638, 1998.
29. Posnick J: Surgical correction of mandibular hypoplasia in hemifacial microsomia: a personal perspective, *J Oral Maxillofac Surg* 55:811–816, 1998.
30. Kaban LB, Moses MH, Mulliken JB: Surgical correction of hemifacial microsomia in the growing child, *Plast Reconstr Surg* 82:9–19, 1988.
31. Vilkki SK, Hukki J, Nietosvaara Y, et al.: Microvascular temporomandibular joint reconstruction in hemifacial microsomia, *J Craniofac Surg* 13:809–816, 2002.
32. Stelnicki EJ, Boyd JB, Nott RL, et al.: Early treatment of severe mandibular hypoplasia with distraction mesenchymogenesis and bilateral fibula flaps, *J Craniofac Surg* 12:337–348, 2001.
33. Polley JW, Figeuroa AA, Liou E, et al.: Longitudinal analysis of mandibular asymmetry in hemifacial microsomia, *Plast Reconstr Surg* 99:328, 1997.
34. Castori M, Brancati F, Rinaldi R, et al.: Antenatal presentation of the oculo-auriculo-vertebral spectrum (OAVS), *Am J Med Genet* 140A:1573–1579, 2006.

35. Chang AB, Masters IB, Williams GR, et al.: A modified nasopharyngeal tube to relieve high upper airway obstruction, *Ped Pulm* 29:299–306, 2000.
36. Wagener S, Rayatt SS, Tatman AJ, Gornall P, Slator R: Management of infants with Pierre Robin sequence, *Cleft Palate Craniofac J* 40:180–185, 2003.
37. Luce EA, McGibbon B, Hoopes JE: Velopharyngeal insufficiency in hemifacial microsomia, *Plast Reconstr Surg* 60:602–606, 1977.
38. Shprintzen RJ, Lewin ML, Croft BC, et al.: A comprehensive study of the pharyngeal flap surgery: tailor made flaps, *Cleft Palate Craniofac J* 16:46–55, 1979.
39. Padwa BL, Mulliken JB, Maghen A, Kaban LB: Midfacial growth after costochondral graft construction of the mandibular ramus in hemifacial microsomia, *J Oral Maxillofac Surg* 56:122–127, 1998.
40. Zhu S, Hu J, Li J, Ying B: Reconstruction of mandibular condyle by transport distraction osteogenesis: experimental study in rhesus monkey, *J Oral Maxillofac Surg* 64:1487–1492, 2006.
41. Polley JW, Figueroa AA: Distraction osteogenesis: its application in severe mandibular deformities in hemifacial microsomia, *J Craniofac Surg* 8:422–431, 1997.
42. Stucki-McCormick S: Reconstruction of the mandibular condyle using transport distraction osteogenesis, *J Craniofac Surg* 8:48–52, 1997.
43. Hijiki H, Takato T, Matsumato S, Mori Y: Experimental study of reconstruction of the temporomandibular joint using a bone transport technique, *J Oral Maxillofac Surg* 58:1270–1276, 2000.
44. Mommaerts MY, Nagy K: Is early osteodistraction a solution for the ascending ramus compartment in hemifacial microsomia? A literature study, *J Craniomaxillofac Surg* 30:201–207, 2002.
45. McCarthy JG, Hopper RA, Hollier LH, et al.: Molding of the regenerate in mandibular distraction: clinical experience, *Plast Reconstr Surg* 115:1239–1246, 2003.
46. Huisinga-Fischer CE, Vaandrager JM, Prahl-Andersen B: Longitudinal results of mandibular distraction osteogenesis in hemifacial microsomia, *J Craniofac Surg* 14:933–934, 2003.
47. Kunz C, Brauchli L, Moehle T, et al.: Theoretical considerations for the surgical correction of mandibular deformity in hemifacial microsomia patients using multifocal distraction osteogenesis, *J Oral Maxillofac Surg* 61:364–368, 2003.
48. Chu TM, Hollister SJ, Halloran JW, et al.: Manufacturing and characterization of 3-D hydroxyapatite bone tissue engineering scaffolds, *Ann NY Acad Sci* 961:114–117, 2000.
49. Meurman Y: Congenital microtia and meatal atresia, *Arch Otolaryngol* 66:443, 1957.
50. Tanzer RC: The total reconstruction of the auricle: the evolution of a plan of treatment, *Plast Reconstr Surg* 47:523, 1971.
51. Brent B: The correction of microtia with autogenous cartilage grafts: the classic deformity, *Plast Reconstr Surg* 66:1, 1980.
52. Obwegeser HL: Correction of the skeletal anomalies of otomandibular dysostosis, *J Maxillofac Surg* 2:73–92, 1974.
53. Reiche-Fischel O, Wolford LM, Pitta M: Facial contour reconstruction using an autologous free fat graft: a case report with 18-year follow-up, *J Oral Maxillofac Surg* 58(1):103–106, 2000. http://dx.doi.org/10.1016/s0278-2391(00)80026-9.
54. Tanna N, Broer PN, Roostaeian J, Bradley JP, Levine JP, Saadeh PB: Soft tissue correction of craniofacial microsomia and progressive hemifacial atrophy, *J Craniofac Surg* 23(7, suppl 1):2024–2027, 2012. http://dx.doi.org/10.1097/SCS.0b013e31825d0594.
55. Mazzola RF, Cantarella G, Torretta S, Sbarbati A, Lazzari L, Pignataro L: Autologous fat injection to face and neck: from soft tissue augmentation to regenerative medicine, *Acta Otorhinolaryngologica Italica* 31(2):59–69, 2011. [PMC free article].

40

Treacher Collins Syndrome: Evaluation and Treatment

JEFFREY C. POSNICK, PAUL S. TIWANA, NEERAJ H. PANCHAL

Introduction

Treacher Collins syndrome (TCS), which is also known as *mandibulofacial dysostosis,* is an autosomal dominant condition with variable expressivity.[1-25] It is generally characterized by bilaterally symmetric abnormalities of the structures within the first and second branchial arches. Early descriptions are attributed to Berry,[26] Treacher Collins,[12] and Franceschetti and Klein.[8] To date, the physical findings of many hundreds of individuals and families with TCS have been published in the world literature.

The adult patient with fully expressed TCS has a convex horizontally deficient facial profile with a prominent nasal dorsum above a retrusive lower jaw and chin (Figure 40-1). The eye region is characterized by an antimongoloid slant of the palpebral fissure as a result of colobomata and hypoplasia of the lower lids and the lateral canthi, including the partial absence of the eyelid cilia and inferolateral orbital hypoplasia and dystopia. Tongue-shaped processes of hair frequently extend into the preauricular region. The external ears are absent, malformed, or malposed and hearing is impaired as a result of variable degrees of hypoplasia of the external auditory canals and the ossicles of the middle ears. A characteristic finding is hypoplasia of the malar bones, often with clefting through the arches and limited formation of the residual zygomas, including the glenoid fossa component. The maxilla and mandible bones are also characteristically hypoplastic, with variable effects on the temporomandibular joints (TMJs), the muscles of mastication, and the muscles of facial expression. Interestingly, hypoplasia of the centrally located soft tissues of the face is not seen with TCS. In general, there is an Angle class II anterior open-bite malocclusion and a steep clockwise-rotated maxillomandibular complex. The posterior facial height is short, and the anterior lower facial height is long. The A-point–to–B-point relationship in profile is consistent with the clockwise rotation of the jaws. The presence of cleft palate (with or without cleft lip and choanal atresia of the nasal cavity) is variable. Dental anomalies are present in 60% of individuals; these include tooth agenesis (33.3%), enamel opacities (20%), and the ectopic eruption of the maxillary first molars (13.3%).

Individuals with TCS have a reduced cranial base angle (i.e., basilar kyphosis). Craniosynostosis is not a feature of TCS, but the neurocranium may have an abnormal shape (i.e., decreased anteroposterior length and diminished bitemporal width) that is evident during childhood and remains through adulthood.[27] The degree of craniofacial malformation present at birth is believed to be relatively stable and nonprogressive with age (this is discussed in more detail later in this chapter). TCS should not be confused with similar entities such as oculo–auriculo–vertebral dysplasia or Goldenhar syndrome. Distinguishing facial features of patients with TCS often include coloboma of the lower eyelids; the upper eyelids are more likely affected among patients with Goldenhar syndrome.

Inheritance, Genetic Markers, and Testing

The occurrence of TCS is in the range of 1 in 25,000 to 1 in 50,000 live births. Inheritance is autosomal dominant, and male and female individuals are equally affected.[12] About 60% of probands with TCS have the disorder as the result of a de novo gene mutation. Each child of an individual with TCS has a 50% chance of inheriting the mutation (Figure 40-2). Teber and colleagues identified TCOF1 mutations in 28 out of 36 (78%) individuals with a clinically unequivocal diagnosis of TCS.[28] The most frequent clinical findings were downward-slanting palpebral fissures, hypoplasia of the zygomatic complex, hypoplasia of the mandible, conductive deafness, any degree of microtia, and atresia of the external ear canal. Although there were interfamilial and

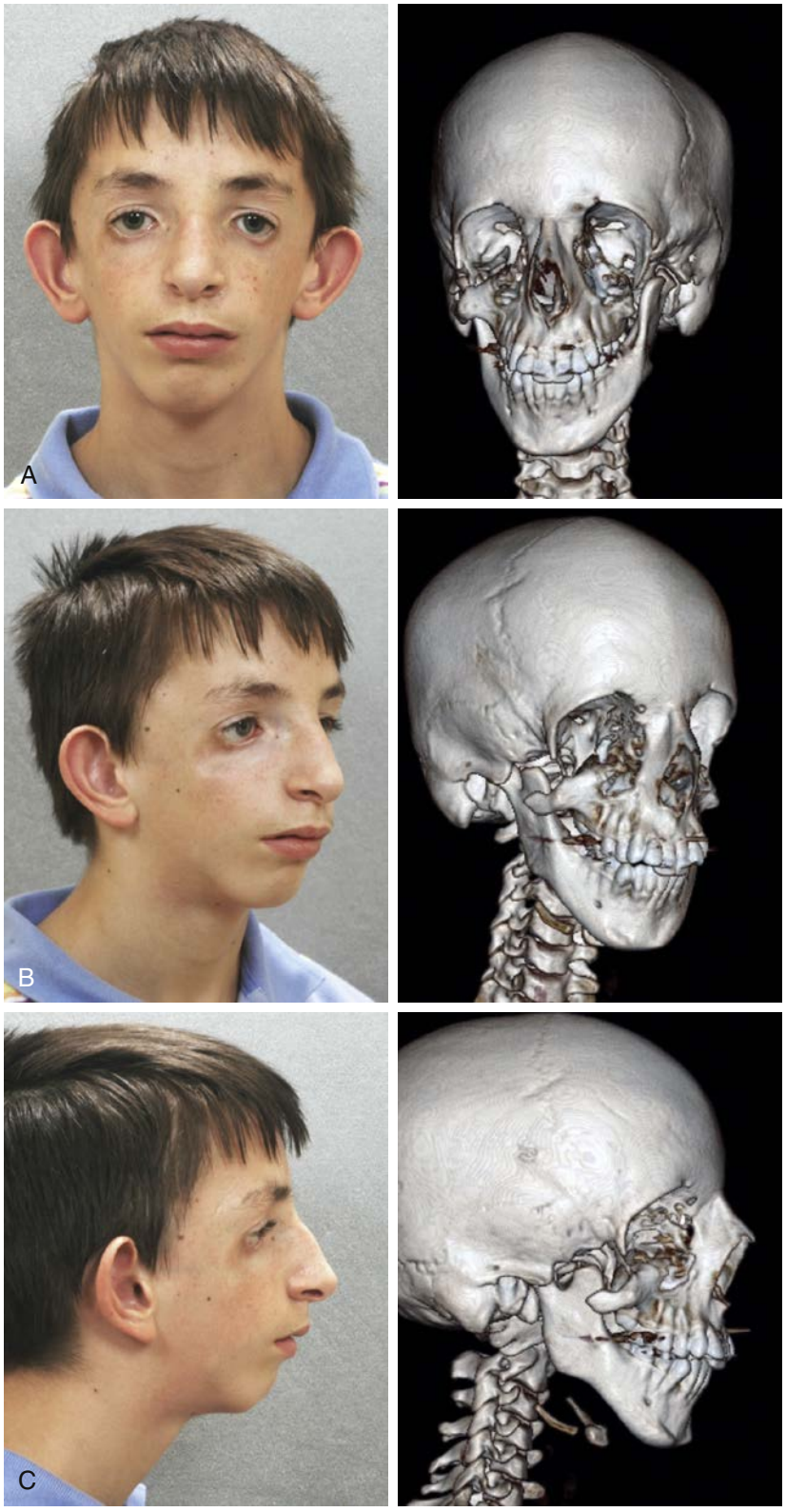

• **Figure 40-1** An 11-year-old boy with fully expressed Treacher Collins syndrome. His eyes are characterized by an antimongoloid slant of the palpebral fissures as a result of colobomata and hypoplasia of the lower lids and the lateral canthi, including the partial absence of the eyelid cilia and inferolateral orbital dystopia. The appearance of the malpositioned adnexal structures is a reflection of both zygomatic–orbital dystopia and hypoplasia of the soft tissues. The maxilla and the mandible are also deficient and malformed. The patient demonstrates a type IIA mandibular malformation. The external ears are malformed and lack antihelical folds. **A,** Frontal facial and three-dimensional computed tomography scan views. **B,** Oblique facial and three-dimensional computed tomography scan views. **C,** Profile facial and three-dimensional computed tomography scan views.



• **Figure 40-2** This mother **(A)** and daughter **(B)** demonstrate the extent of variation in the expression of Treacher Collins syndrome within a family. The mother was not aware that she carried the Treacher Collins gene until after the birth of her daughter. (From Posnick JC: Treacher Collins syndrome: perspectives in evaluation and treatment, *J Oral Maxillofac Surg* 55:1120, 1997.)

intrafamilial variations that ranged from mild to severe, there were no genotype or phenotype correlations. Four clinically unaffected parents were heterozygous for the TCOF1 mutation. The authors concluded that modifying factors are important for phenotypic expression.

Genetic counseling for TCS is the process of providing individuals and families with information about the nature, inheritance, and implications of the syndrome to help them make informed medical and personal decisions. Molecular testing should be considered for any individual who presents with at least two major features or three minor features of TCS.[29-40] Until recently, penetrance in TCS was believed to be complete. Marres and colleagues[35] confirmed the absence of clinical and radiographic findings in an individual with a pathogenic TCOF1 mutation. For this reason, testing is acceptable for individuals with any degree of severity of TCS features to confirm or refute the diagnosis.

Prenatal diagnosis for pregnancies that are at increased risk for TCS is possible via the analysis of DNA extracted from fetal cells obtained by amniocentesis; this is usually performed at about 15 to 18 weeks' gestation. Chorionic villus sampling can also be used for diagnosis at about 10 to 12 weeks' gestation. The malformation-causing allele of an affected family member must be identified before prenatal testing can be performed.

Considerations During Infancy and into Early Childhood

At the time of the birth of a child with TCS, concerns will center on the adequacy of the airway, swallowing, feeding, hearing, vision (corneal protection), the presence of cleft palate (with or without cleft lip), any other associated malformations, and the psychosocial well-being of the family.[5,41-51] The airway may be compromised as a result of multiple factors. The first is maxillary hypoplasia, which occurs with a degree of choanal stenosis or atresia with the blockage of the nasal airway. Second, mandibular micrognathia with a retropositioned tongue that at least partially obstructs the oropharyngeal and hypopharyngeal spaces will be present. In addition, tracheomalacia, vocal cord anomalies, or neuromotor involvement may also negatively affect the upper airway. Depending on the severity of the anomalies, a spectrum of upper airway compromise may necessitate, at a minimum, special infant positioning, an extended hospital stay, and pulse oximetry monitoring. Surgical considerations for the management of airway compromise in the infant or young adult may include tongue–lip adhesion, the use of a custom-made oral appliance, immediate or delayed tracheostomy, or an urgent mandibular advancement procedure.

As a result of any compromise in nasal and oral breathing and associated musculoskeletal malformations, the newborn with TCS may also have difficulty with swallowing and with achieving an adequate lip seal to the extent that urgent gavage-assisted feedings or the placement of a gastrostomy tube may be required to ensure adequate nutrition.

When a cleft of the secondary palate is documented, potential additive effects on the airway before and after repair must be considered. When Nager syndrome is present, the soft palate is both clefted and severely hypoplastic to the extent that the achievement of a functioning palate is not feasible.[15,19] A primary pharyngeal flap—although helpful for velopharyngeal function—is rarely indicated, because further obstruction of the airway would likely result. Evaluation by a *medical geneticist* is indicated to clarify the diagnosis and all presenting anomalies, to discuss family planning issues, and to analyze chromosomal studies.

Within a few days of birth, the results of an examination by an experienced *pediatric otolaryngologist* in combination with formal *audiology testing* will clarify the extent of conductive hearing loss and allow for the early fitting of hearing aids to assist the infant with the acquisition of communication skills and encourage the normal bonding process with the family.

At some point early in life, a complete craniofacial *computed tomography (CT) scanning* from the top of the skull through the cervical spine with three-dimensional reformation will be useful to document the extent of craniofacial skeletal anomalies. Special *focused cuts through the petrous temporal bones* are also required to document external auditory canal and middle and inner ear anatomy. Appropriate craniofacial, maxillofacial, cleft lip and palate, and auricular reconstructive surgeons should also be consulted, as indicated.

An assessment by a *pediatric ophthalmologic* is necessary to determine associated eye anomalies, extraocular muscle function, corneal exposure difficulties, and visual acuity. Ophthalmologic issues may include vision loss (37%), amblyopia (33%), refractive errors (58%), anisometropia (17%), and strabismus (37%). Interestingly, it has been the impression of many clinicians and scientists that the individual with TCS has a tendency toward a short stature, at least early in life, and that above-average intelligence is generally observed.

Dysmorphology with Treacher Collins Syndrome

Cranio-orbito-zygomatic Region

In earlier published studies, 14 reproducible cranio-orbito-zygomatic measurements taken from each of 26 standard axial CT scans of individuals with symmetric forms of TCS who had not been operated on were compared with the measurements of age-matched controls.[27] The interorbital measurements (i.e., medial and lateral orbital wall separations) of the patients with TCS were at the mean when compared with their cohort group (i.e., no measurable orbital hypertelorism or hypotelorism), whereas the zygomatic measurements were significantly less than normal, thereby confirming the extent of malar hypoplasia. The congenitally deficient lateral aspect of the orbits in individuals with TCS was confirmed by the greater than normal values measured for globe protrusion and medial orbital wall protrusion in conjunction with diminished lateral orbital wall lengths. These measurements use the lateral orbital rim as a reference point and confirm the limited depth of the lateral orbits as a result of hypoplasia of the lateral orbital rims. The lateral orbital rims are components of the hypoplastic zygomatic complex. The abnormal shape of the anterior cranial vault in patients with TCS was documented as a diminished intercoronal (bitemporal) distance (width) and decreased cephalic length as compared with values for normal age-matched controls. In general, the CT measurements documented in the described study agree with the clinically observed morphology of TCS. The measurements carried out in the zygomatic structures confirmed the extent of hypoplasia of the zygomas for the group as a whole and in each individual patient; they also documented the extent of globe protrusion and decreased upper face width in patients with TCS. It appears as though the bones immediately adjacent to the involved zygomatic complex also experience a degree of hypoplasia or at least distortion.[6,27,52-60]

Maxillomandibular Region

In 1975, Roberts and colleagues completed a radiographic cephalometric study of TCS. Serial cephalometric radiographs were available for eight patients who presented with the full range of features that are characteristic of this syndrome.[61] The expected facial convexity in patients with TCS was substantiated by cephalometric measurements. The extent of convexity was attributed to the severity of mandibular retrognathia (i.e., a decreased sella–nasion–B-point angle). Interestingly, the horizontal projection of the maxilla to the cranial base (i.e., the sella–nasion–A-point angle) remained within normal limits in the patients that were measured. Over time and with growth, the facial convexity remained relatively constant, thus confirming that the facial profile morphology of the infant with TCS was remarkably similar to that of the adult. Anterior facial heights were measured as "upper facial height" (i.e., the nasion to the anterior nasal spine) and "total facial height" (i.e., the nasion to the menton). The upper facial height was found to be relatively normal, whereas the total facial height was often excessive. This is the result of a combination of anterior open-bite malocclusion, mandibular retrognathism, and chin dysplasia characterized by increased vertical length and horizontal retrusion. The angle between the sella–nasion plane and the mandibular plane was obtuse, which confirmed the steepness of the clockwise rotation of the mandibular plane. The angle between the sella–nasion plane and the palatal plane was also obtuse, thus confirming the steepness of the clockwise rotation of the maxillary plane. The posterior facial height was markedly shorter for patients with TCS, with values in five of the eight patients found to be a minimum of four standard deviations less than those of the normal cohort.

The effective horizontal length of the mandible was markedly reduced, with values in most of the patients falling below four standard deviations as compared with those in the normal cohort. The decreased mandible size was evident in both the ramus height and the body length. The gonial angle was confirmed to be obtuse, with values of two standard deviations from the mean as compared with control values. The extent of antegonial notching was also documented in patients with TCS and was found to be similar to that observed among patients with condylar arrest early during their lives (e.g., as a result of juvenile rheumatoid arthritis or TMJ trauma at a young age). The steepness of the clockwise rotation of the maxillary and mandibular planes combined with the anterior and posterior vertical height disproportions and severe horizontal deficiency of the mandible is also indirectly seen in the A-point–to–B-point discrepancy. All of these morphologic findings explain the observed facial dysmorphology.[16,17,52-54,62]

Facial Soft Tissues

Soft tissue anomalies in individuals with TCS are manifested primarily in four clinical regions: the external ears; the eyelid-adnexal structures; the preauricular-cheek skin;

and the temporal fossa (e.g., temporalis muscle hypoplasia).[26,63-74] The extent of deficiency within the soft tissue envelope is variable and, to large extent, reflective of the skeletal involvement. Each patient is unique and must be evaluated individually. The extent of soft-tissue anomalies continues to represent the most difficult obstacle to a favorable reconstruction.

External Auditory Canal, Middle and Inner Ear Structures, and Audiologic Findings

Relatively symmetric (i.e., from side to side) outer and middle ear malformations are characteristic of TCS. Middle ear abnormalities (e.g., hypoplastic or absent cavities and ossicles) are an almost universal finding.[75-79] The majority of patients have a unilateral or bilateral moderate or greater conductive hearing loss, with a flat or reverse sloping configuration on the audiogram. Most of the hearing loss in these patients is attributable to middle ear malformations. In 1993, Pron and colleagues reported the results of a detailed CT radiologic and audiologic investigation of a large series of pediatric patients with TCS.[79] The objectives of the study were (1) to determine the degree and symmetry of the external auditory canal and middle ear abnormalities and evaluate hearing loss; and (2) to explore the relationship between hearing loss and external auditory canal and middle ear abnormalities in patients with TCS. Data were available from 29 children who had not yet undergone any ear interventions and who had undergone audiometric testing and focused standardized petrous temporal bone CT scans. A review of the CT scans allowed for the evaluation of the external ear canal and the middle ear anatomy. The majority of patients (88%) had largely symmetric external auditory canal abnormalities that were either stenotic (31%), atretic (54%), or normal (15%). Middle ear cavity ossicular deformities were generally symmetric (96%), and cavities were either hypoplastic (85%) or missing (4%). Cavities that were hypoplastic were also deformed and assumed a rectangular rather than an oval shape. Ossicle deformities were generally completely symmetric and consisted largely of hypoplastic (46%) or missing (46%) ossicles. Ossicles (both the malleus and the incus) that were hypoplastic also tended to be ankylosed (82%) to either the lateral or medial wall of the tympanic recess. The structures of the external auditory canal and the middle ear are generally related. Increasing degrees of external ear canal malformations (i.e., normal, stenotic, or atretic) are directly associated with ossicle and cavity malformations. Of the patients with atretic canals, 67% had missing ossicles, and 33% had small or ankylosed ossicles. No abnormalities were noted in the inner ear structures (i.e., cochlea, vestibule, canals, and internal auditory meatus) in the patients with TCS who were studied. According to the study by Pron and colleagues, hearing loss for the patient with TCS ranges from mild to severe (average, 58 dB of hearing loss).[79] The majority of individuals (96%) have a moderate or greater degree of hearing loss.

Relationships exist between the external auditory canal, the middle ear ossicles, and the degree and configuration of hearing loss.[75-79] There is an association between the degree of external ear canal malformation and the degree of hearing loss in patients with TCS. In addition, hypoplastic, ankylosed, and missing ossicles appear to be associated with increasing levels of hearing loss; on average, the hearing loss is 52 dB, 56 dB, and 60 dB of hearing loss, respectively.

Facial Growth Potential with Treacher Collins Syndrome

The degree of malformation present at the time of birth in a newborn with TCS is believed to be relatively stable and nonprogressive with age (Figures 40-3 through 40-6).[61,80-84] Roberts and associates reviewed serial cephalometric radiographs from individuals who were known to have TCS.[61] They documented the stability of the mandible, which continued to grow but not to catch up. Through independent research, Garner reported findings of the cephalometric analysis of three patients of varied ages who were confirmed to have TCS.[62] He also documented the relative stability of the anomalies without the progression of deformity at various ages.

To date, no convincing evidence demonstrates a clinically significant worsening of the TCS dysmorphology with facial growth. Early surgical interventions with mandibular osteotomies involving the use of either osteodistraction or standard orthognathic techniques are believed to adversely affect growth, thereby necessitating revision osteotomies at maturity. For this reason, waiting until the majority of jaw growth is complete before reconstructing the maxillomandibular components is recommended, if feasible. In any case, early mandibular surgery should not be expected to prevent the need for definitive maxillofacial reconstruction at maturity.

Classification of Temporomandibular Joint and Mandibular Malformation

The extent of TMJ–mandibular malformation in patients with TCS will influence the timing and techniques of reconstruction.[85,86] A lack of clinically relevant definitions of the presenting glenoid fossa–condyle–ascending ramus malformations has resulted in confusion and miscommunication. Kaban and colleagues revised and clarified the previously described Pruzansky classification system for the degree of TMJ–mandibular malformation observed in patients with hemifacial microsomia.[85,87] This classification is also useful to define the presenting anomalies and then to direct reconstruction in the patient with TCS (Figure 40-7).

A type I TMJ–mandibular malformation involves minimal hypoplasia of the glenoid fossa and the condyle–ascending ramus on each side. All of the skeletal components are present (see Figure 40-7, *A*). Mandibular retrognathia and

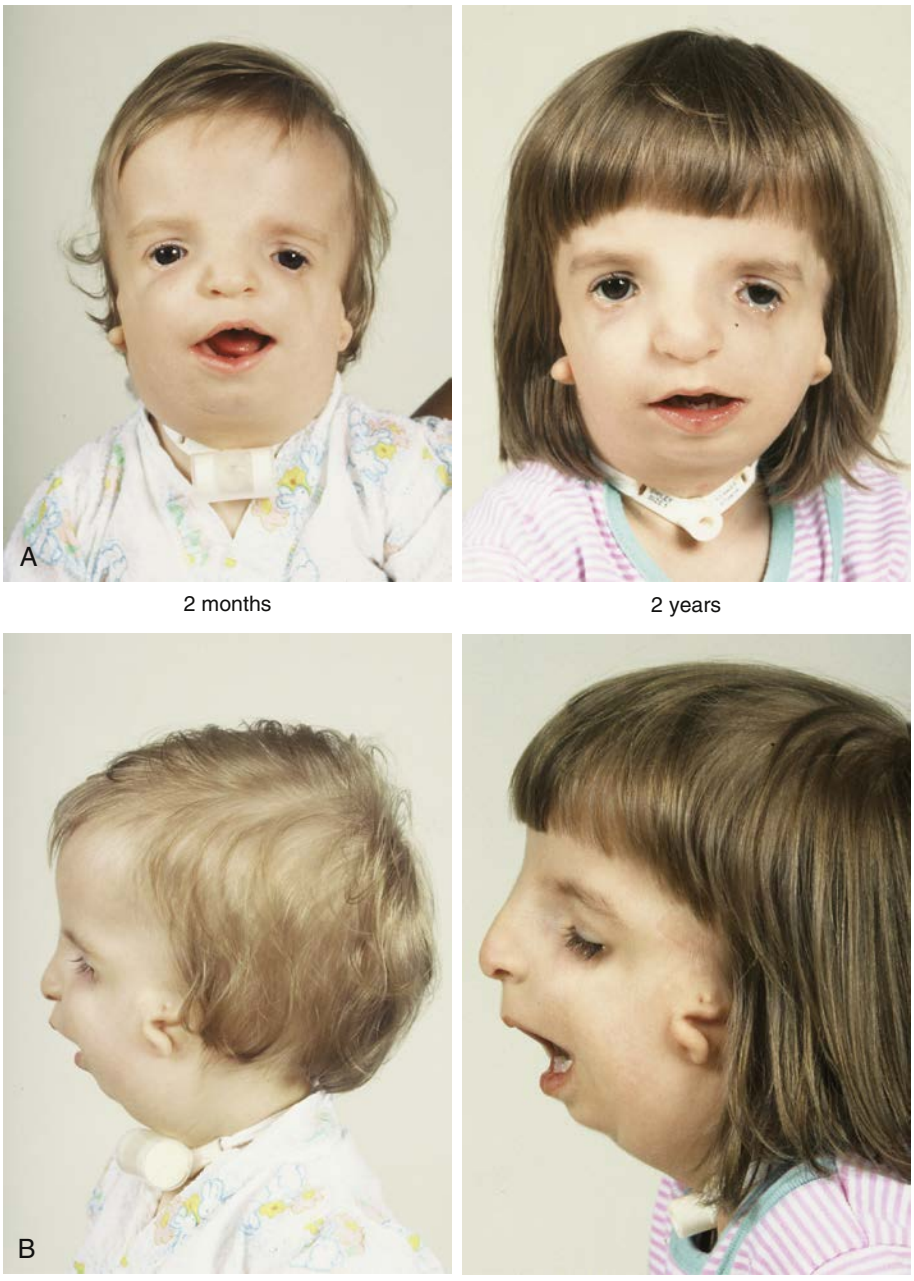

• **Figure 40-3** A child with a severe form of Treacher Collins syndrome was followed up longitudinally without treatment intervention. No progression of the deformity was seen during clinical or computed tomography scan examination. **A,** Frontal and **B,** profile views at 2 months and 2 years of age.

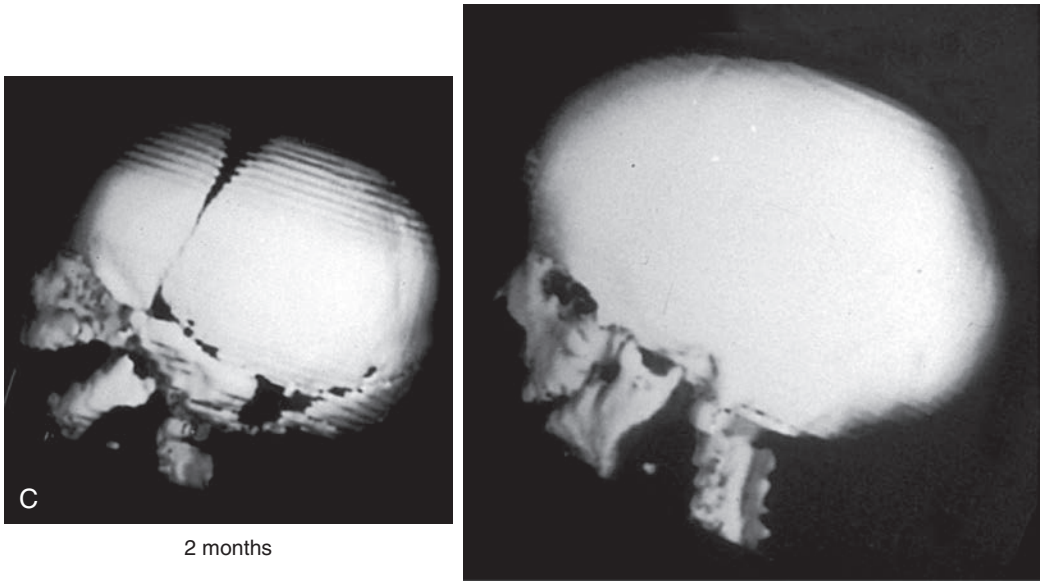

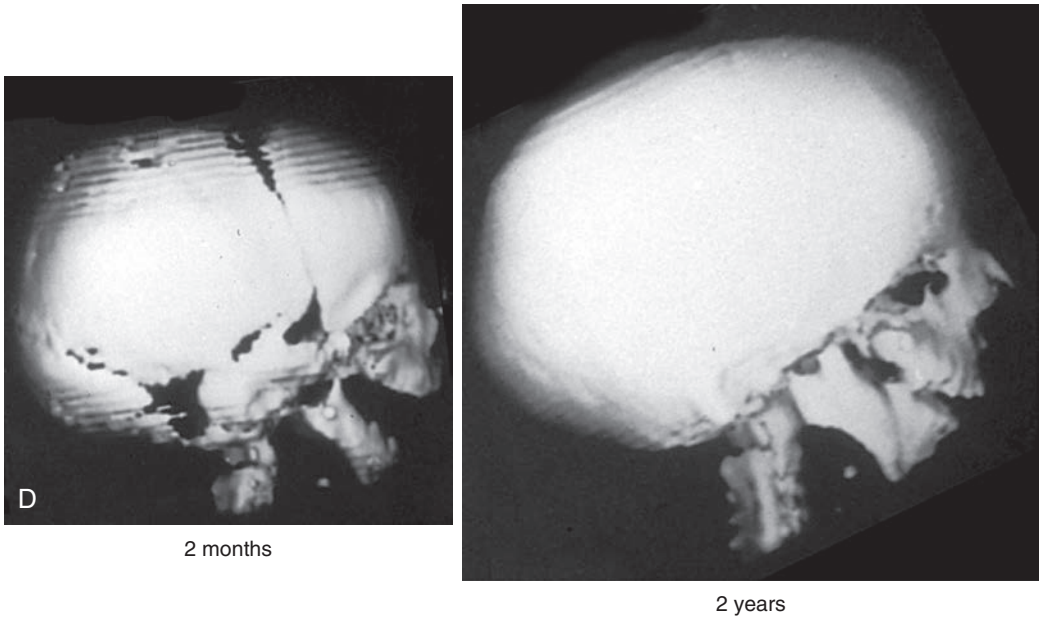

• **Figure 40-3, cont'd C and D,** Computed tomography scan views of the craniofacial region at 2 months and 2 years, respectively, demonstrating the consistent growth of the malformed condyles, the coronoid processes, and the ascending rami of the mandible. (From Posnick JC: Treacher Collins syndrome: perspectives in evaluation and treatment, *J Oral Maxillofac Surg* 55:1120, 1997.)

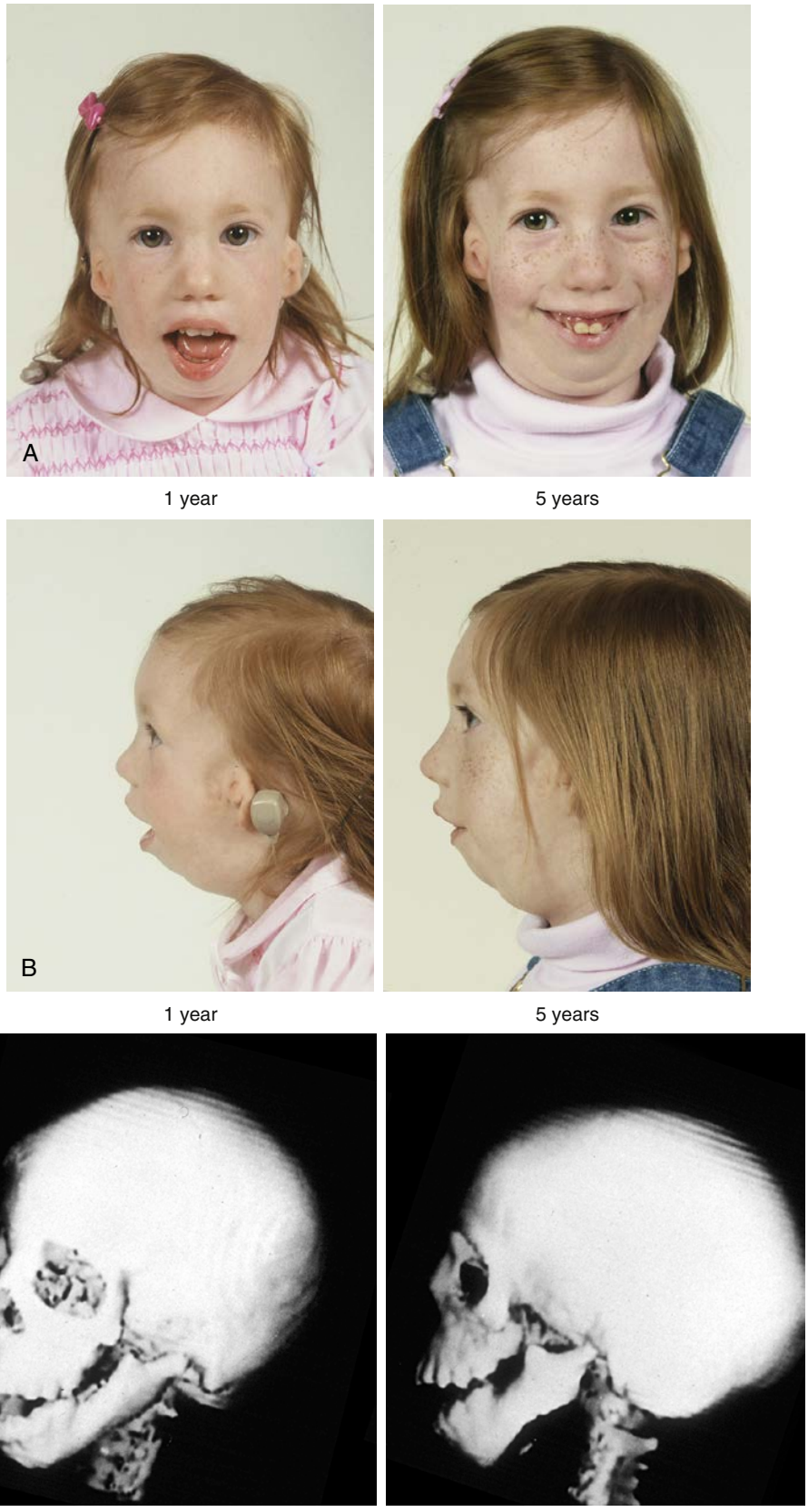

• **Figure 40-4** A girl who was born with Treacher Collins syndrome was followed up longitudinally at 1 and 5 years of age without treatment intervention. There is consistent growth of the craniofacial region without progression of the deformity. As a result of chronic nasal obstruction and an open-mouth posture, excess vertical facial growth can be seen. **A,** Frontal views at 1 and 5 years of age. **B,** Profile views at 1 and 5 years of age. **C,** Computed tomography scan views at 5 years of age. There is severe hypoplasia of the zygomatic complex with lateroinferior orbital deficiency. The mandible demonstrates a type IIA malformation.



• **Figure 40-5** A child who was born with Treacher Collins syndrome was followed up longitudinally without treatment intervention. No progression of the facial deformity occurred with growth. **A,** Frontal views at 10 months and 6 years of age. **B,** Profile views at 10 months and 6 years of age.

Continued

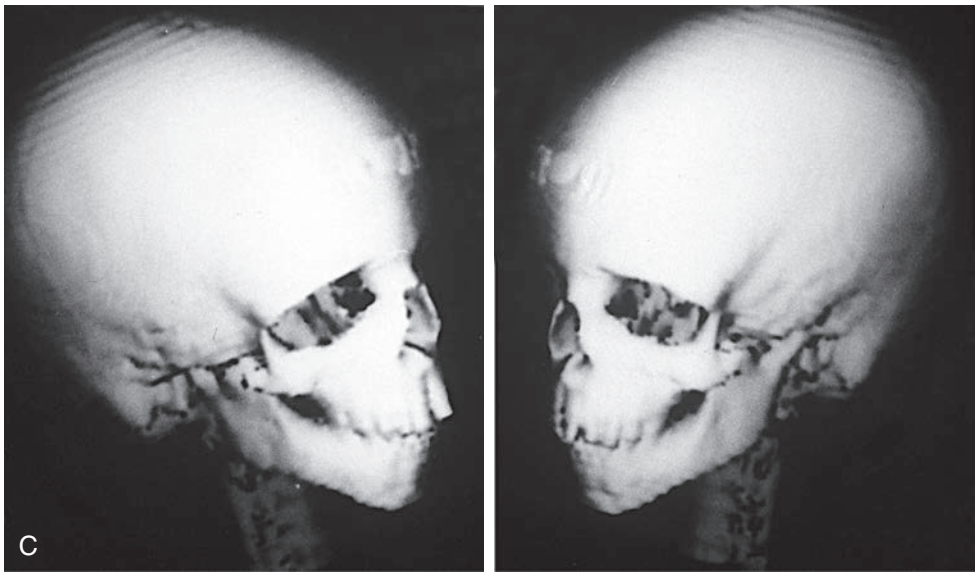

6 years of age (Kaban type II A)

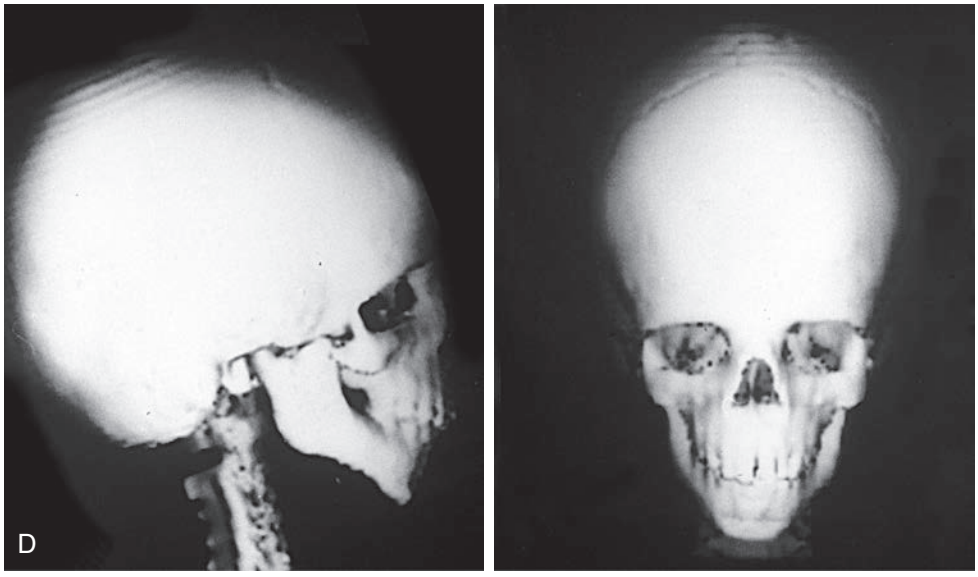

6 years of age (Kaban type II A)

• **Figure 40-5, cont'd** **C** and **D,** Computed tomography scans.

a mild anterior open bite are likely to be present, but TMJ function is essentially normal. The muscles of mastication are intact, and the condyle and the glenoid fossa are also fully intact. There is no need or advantage to constructing a neo-condyle or neo-glenoid fossa.

A type IIA TMJ–mandible malformation involves a moderate degree of glenoid fossa and condyle–ascending ramus hypoplasia (see Figure 40-7, *B-D*). The anatomic location of each joint is anterior and medial, but TMJ function remains satisfactory. One or more of the paired muscles of mastication are likely to be hypoplastic. By definition, in type IIA malformations, the condyle and the glenoid fossa have function that is at a level deemed better than could reliably be achieved through TMJ replacement. Even in patients with more severe type IIA malformations, when applying superior and posterior pressure to the chin, the condyles can be seated into a consistent location against the skull base–glenoid fossa. By completing ramus osteotomies, the proximal segments can be positioned into a stable location against the skull base, and the distal mandible can then be reoriented into the preferred location. This will avoid the need to construct neo-condyles (e.g., costochondral grafts). Coronoidectomies may be required to accommodate the short condyles.

The type IIB TMJ–mandibular malformation involves severe hypoplasia of the condyles. The mandible is without a stable centric relation. The glenoid fossa may be hypoplastic, but they are deemed functional. The hypoplastic condyles do not consistently seat in the glenoid fossa, and the mandible functions within a limited range of motion. The extent of mandibular retrognathia and anterior open bite is marked. With type IIB TMJ–mandibular malformations,

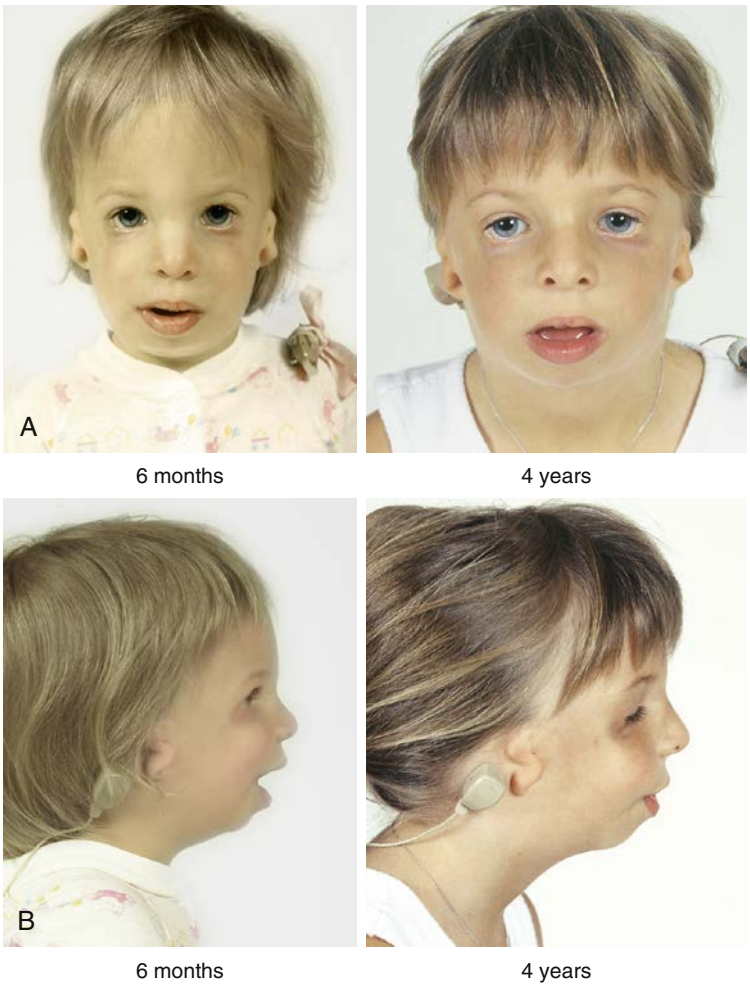

• **Figure 40-6** A child who was born with Treacher Collins syndrome was followed up longitudinally without treatment intervention. No progression of the craniofacial deformity has occurred. **A,** Frontal views at 6 months and 4 years of age. **B,** Profile views at 6 months and 4 years of age.

the rudimentary condyles are deemed too far medially and anteriorly displaced to be useful. The construction of a neo-condyle ascending ramus with the use of a bone graft is required (see discussion to follow). Coronoidectomies and recontouring of the surgically advanced mandible may be required. Fortunately, this pattern of malformation occurs in only a small percentage of patients with TCS.

The type III glenoid fossa–mandibular malformation involves deficiency to the extent that no posterior stop of the lower jaw against the cranial base is possible (see Figure 40-7, *E*). The condyles and the ascending rami are not present. The disc, the TMJ capsule, and the glenoid fossa on each side are also not developed. Severe mandibular dysmorphology is present, including horizontal retrognathia and decreased posterior ramus height. A tracheostomy is generally required shortly after birth to manage the airway. Eventual construction of both a neo-glenoid fossa and a neo-condyle ascending ramus will be required on each side. Reconstruction with bone grafts (e.g., cranial grafts for the zygomatic complex and either costochondral or a vascularized fibula flap for the mandible) will be required (see discussion to follow).

Staging of Skeletal Reconstruction: Timing and Techniques

The reconstruction and rehabilitation of the Treacher Collins malformation must address unique and specific components of the anomalies, including the following: (1) the zygomatic and orbital region; (2) the maxillomandibular region; (3) the nasal region; (4) the soft tissue envelope; (5) the external ears; (6) the external auditory canals; and (7) the middle ear structures (Figures 40-8 through 40-10).[27,82-84,88-108]

Zygomatic and Orbital Reconstruction

In previously published studies, we have documented the efficacy of reconstructing the malar and orbital deficiencies for moderate to severe forms of TCS with the use of full-thickness calvarial bone grafts that have been contoured three-dimensionally to form a new zygomatic complex (see Figures 40-8 and 40-9 through 40-13).[55] The neo-zygoma is then inset and stabilized with microplate and screw fixation. Exposure for the reconstruction is provided by a coronal scalp incision without the need for additional

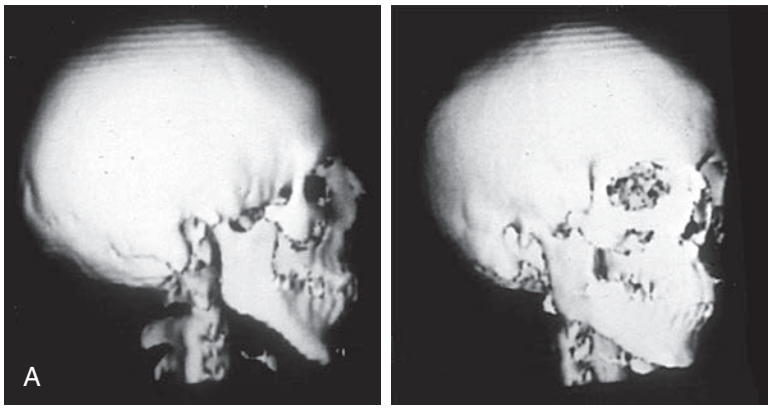

Kaban I

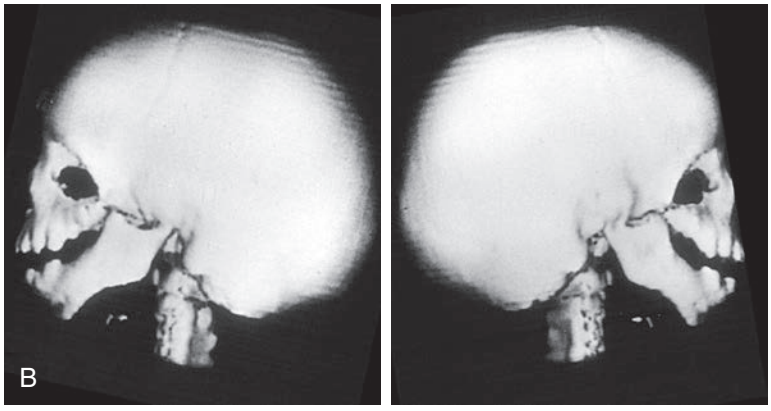

Kaban II A

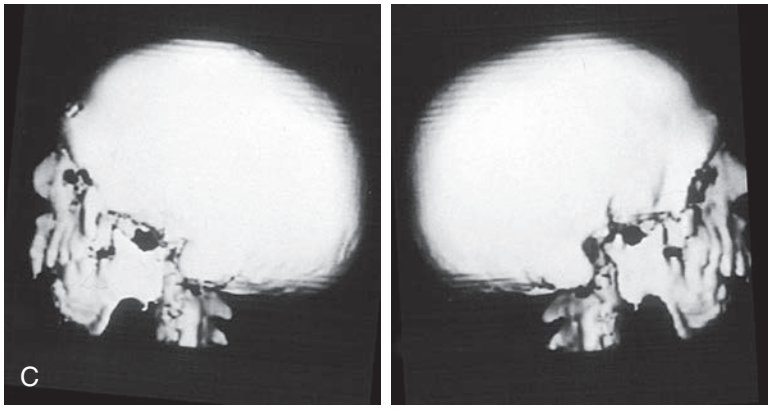

Kaban II A

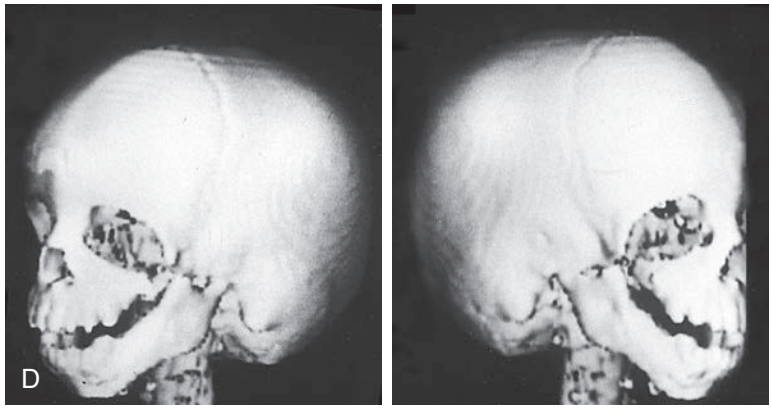

Kaban II A

• **Figure 40-7** Kaban and colleagues described a classification system to define the degree of temporomandibular joint–mandibular malformation observed in patients with hemifacial microsomia. By definition, a type IIB condylar deficiency will require the construction of a neo-condyle. The type III malformation will also require neo-glenoid fossa construction. The same classification system is used for Treacher Collins syndrome. Craniofacial computed tomography (CT) scans demonstrate the classification system. **A,** CT scan views of a type I mandibular malformation. **B, C,** and **D,** CT scan views of a type IIA mandibular malformation.

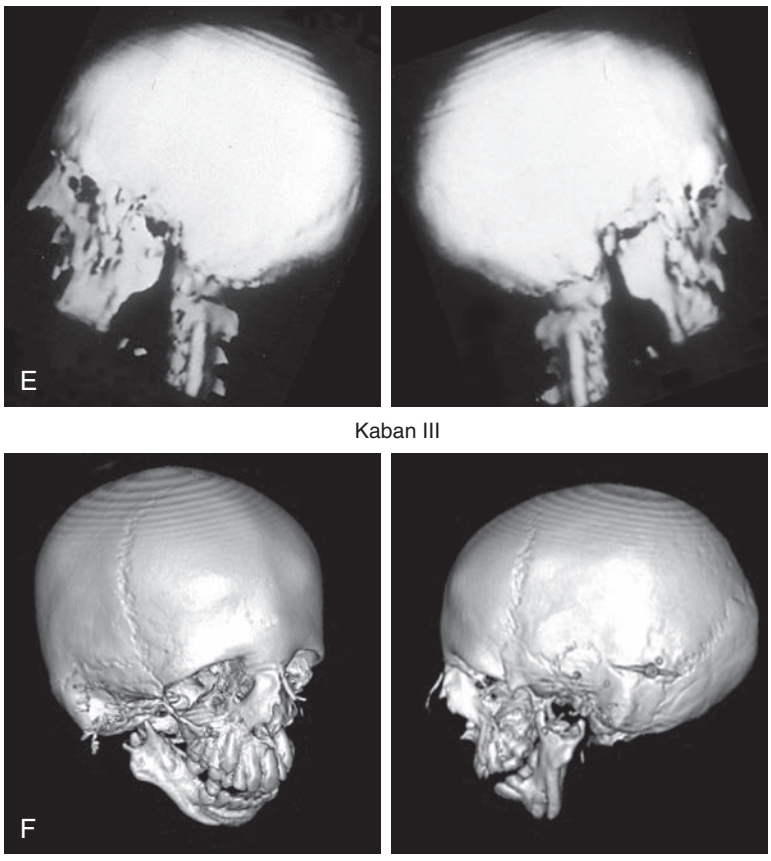

• **Figure 40-7, cont'd** **E** and **F,** CT scan views of a type III glenoid fossa–mandibular malformation.

periorbital incisions. Orbital floor defects are reconstructed with fixed split-thickness autogenous cranial bone. Cranial vault donor sites are repaired either with autogenous split cranial grafts or artificial material. For nonautogenous reconstruction of the small skull donor sites, we prefer the use of a titanium mesh base fixed to the adjacent skull. The mesh is then filled in with a bone substitute. Lateral canthopexies are completed through the coronal scalp incision and secured to each new lateral orbital rim. In our study, computed tomography scanning that was performed before surgery and immediately afterward demonstrated significant increases in lateral orbital wall length (depth), lateral orbital (rim) width, interzygomatic arch width, and zygomatic arch length for patients with TCS. The late (i.e., ≥1 year) postoperative scans document that these changes were maintained. No complications occurred during surgery, and repaired skull donor sites healed without clinical defect. Zygomatic and orbital morphologic improvement was achieved in all patients, with follow-up intervals ranging from 24 to 50 months (mean, 35 months) at the close of the study. Unfortunately, over time, I have observed that partial resorption of the zygomatic complex graft occurs in some patients.

We believe that reconstructing the malar and orbital deficiencies before the patient is 7 years old is not advisable unless severe corneal exposure problems occur and skeletal deficiency is believed to be the cause. By this age, the cranio–orbito–zygomatic bony maturation is nearly complete. Therefore, adult-sized cheekbones may be constructed and placed with limited concern about how further growth will effect the initial result. In addition, skull donor-site reconstruction is simpler than it is at a younger age, because the presence of bicortical cranial bone in those who are more than 7 years old allows for the splitting of adjacent bone to assist with reconstruction (see Figures 40-11 and 40-12).

Other surgeons have recommended various methods and time frames for the zygomatic and orbital deformities associated with TCS.[55,56,59,60,109-114] We believe that the construction of the complete zygomatic complex from full-thickness autogenous cranial bone maintains volume and shape better than onlay grafts, which have been universally disappointing. Over time, onlay autogenesis bone grafts that have been placed in the craniofacial region (e.g., supraorbital ridge, zygoma, anterior maxilla, angle of mandible, chin) from all tried donor sites (e.g., skull, hip, rib) have demonstrated significant and unpredictable resorption. Furthermore, no commensurate growth (i.e., volume expansion) of the graft with the underlying bone (e.g., zygoma) should be expected. The belief that "even if the graft partially resorbs, at least something has been gained" should be abandoned; surface irregularities routinely result, which further detract from the baseline malformation.

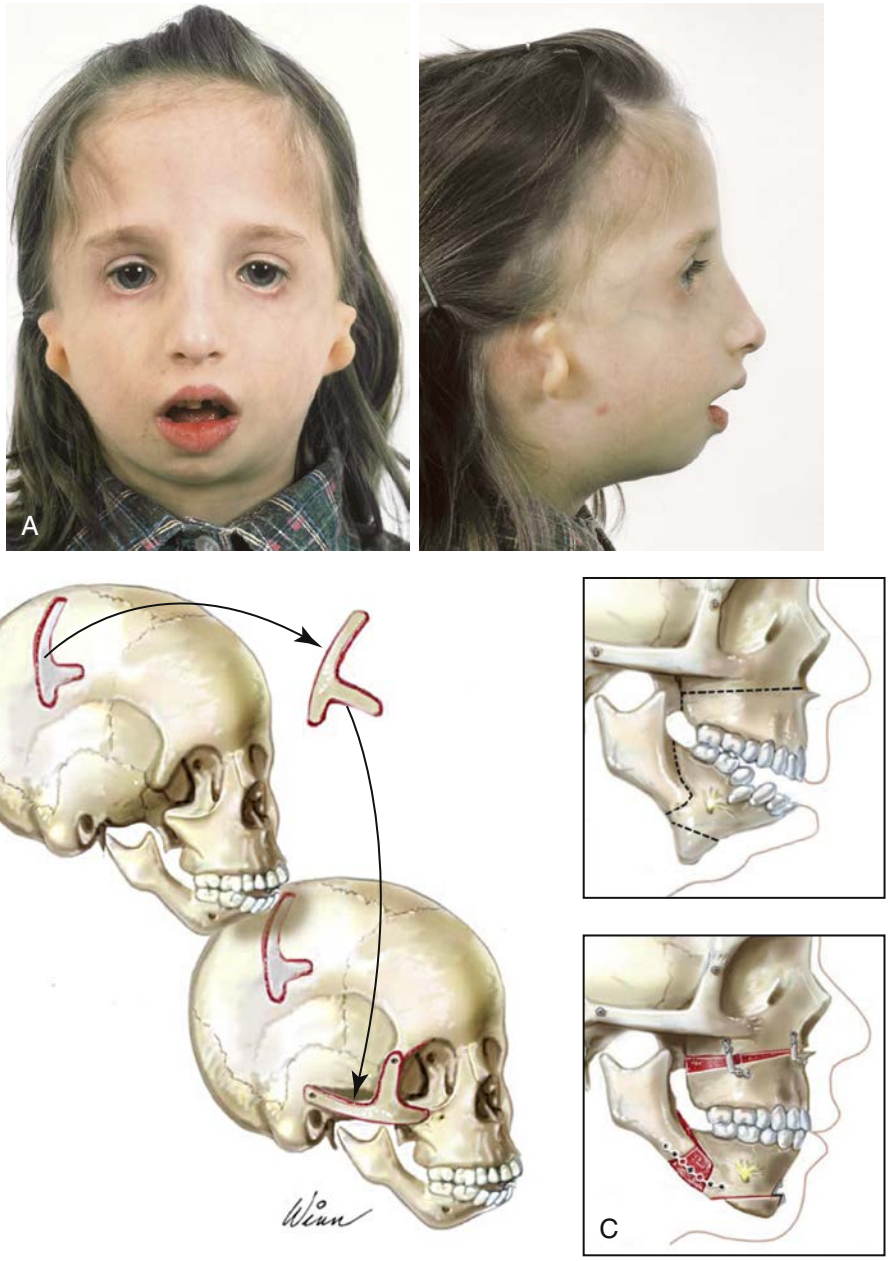

• **Figure 40-8** **A,** A child who was born with Treacher Collins syndrome is shown during the mixed dentition. She has severe zygomatic complex and orbital deficiency as well as a type IIA condylar malformation. **B,** Illustration of the location of the full-thickness cranial bone graft donor site for zygomatic complex reconstruction. The zygomatic complex graft is also shown inset at the recipient site. **C,** Illustrations of a maxillofacial complex seen in a teenager with Treacher Collins syndrome (type IIA mandibular malformation). The cheekbone orbital reconstruction has previously been completed. The proposed maxillary, mandibular, and chin osteotomies are marked out and then completed. Counterclockwise rotation of the maxillomandibular complex is demonstrated as part of the reconstruction.



• **Figure 40-9** Additional images of the patient from Figure 40-8 showing the stigmata of Treacher Collins syndrome. At the age of 17 years, the patient was referred to this surgeon and agreed to a staged reconstruction that included three operations. The initial preoperative orthodontic treatment included the extraction of mandibular first premolars with the retraction of the anterior dentition to remove compensations. Orthognathic surgery included a Le Fort I osteotomy (counterclockwise rotation and anterior maxillary intrusion); bilateral sagittal split ramus osteotomies (advancement and counterclockwise rotation); and an osseous genioplasty (vertical reduction and advancement). During a second operation, the patient underwent zygomatic complex reconstruction with fixed full-thickness autogenous cranial bone grafts as described in this chapter and as illustrated in Figure 40-8. This was followed by a third operation: septorhinoplasty (open approach) to in-fracture the nasal bones, reduce the dorsal hump (bone and cartilage), and reshape the tip, including septal (caudal strut) grafting (see Chapter 38). **A,** Right profile views before and after reconstruction. **B,** Left profile views before and after reconstruction.

Continued

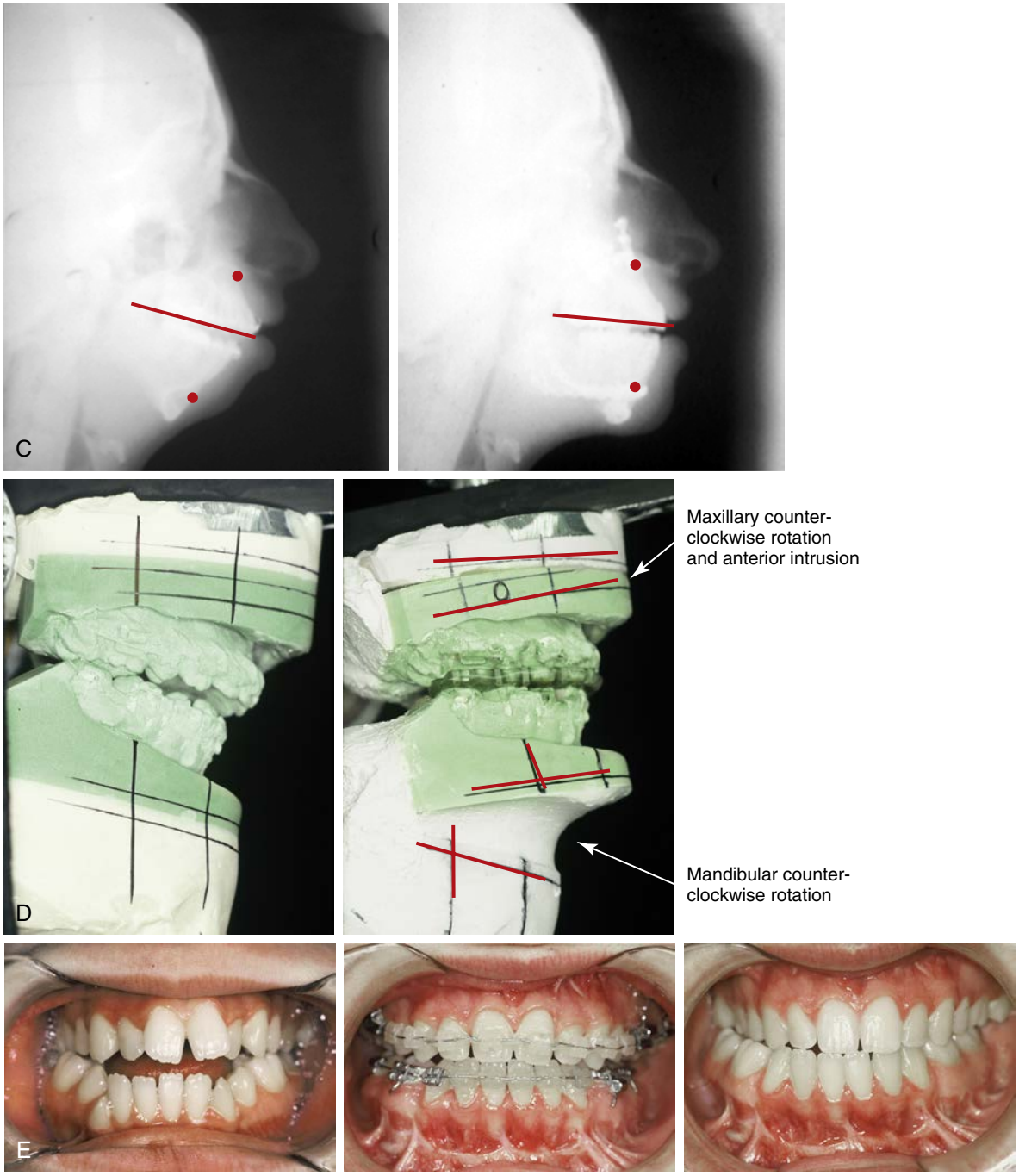

• **Figure 40-9, cont'd** **C,** Lateral cephalometric radiographs before and after reconstruction. **D,** Articulated dental casts that indicate analytic model planning. **E,** Occlusal views before treatment, early after reconstruction, and 3 years after reconstruction. A degree of maxillary relapse (skeletal versus dental) has occurred but with a retained functional occlusion and favorable facial esthetics.

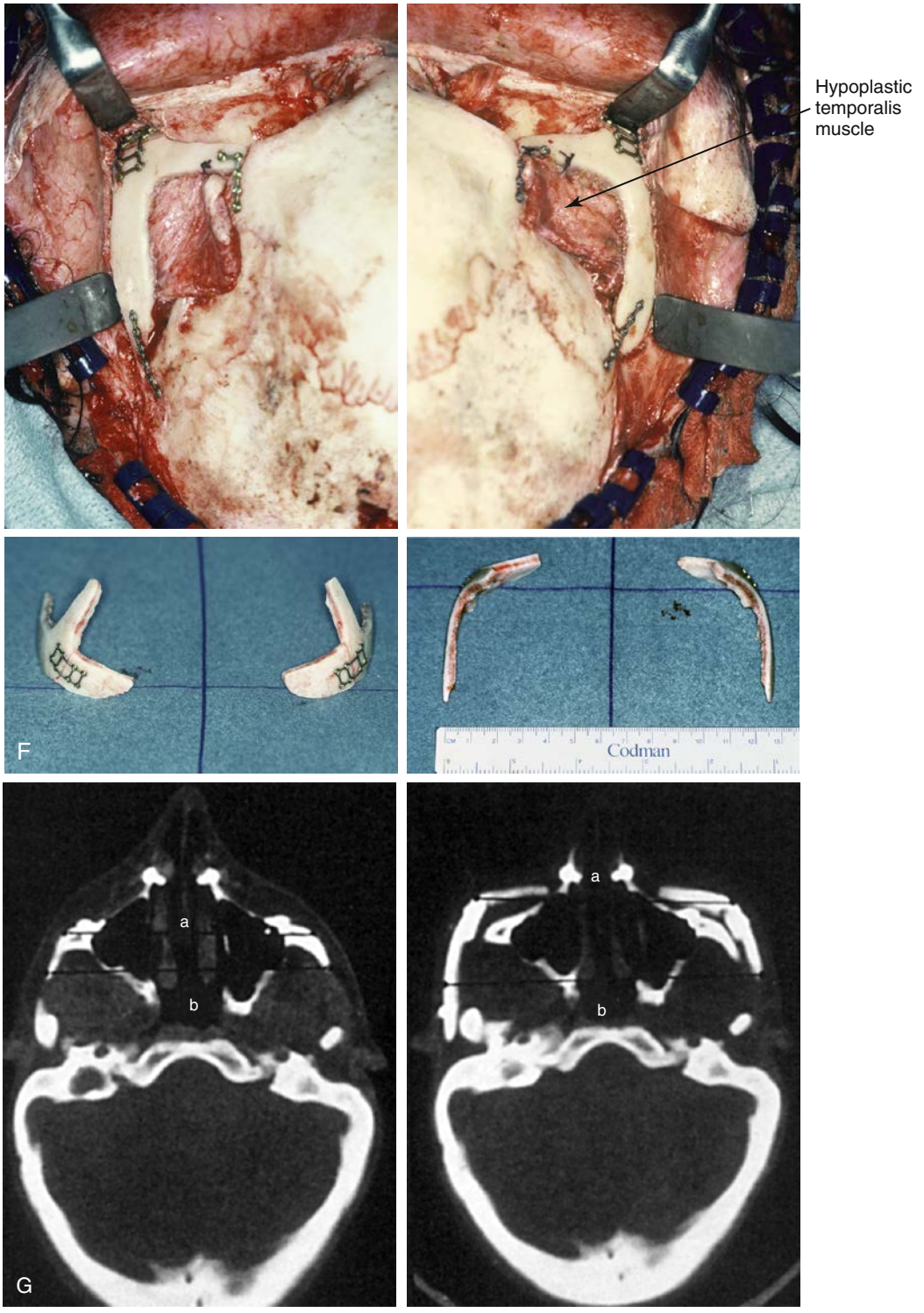

• **Figure 40-9, cont'd** **F,** Crafted autogenous cranial grafts shown before and then after inset into the zygomatic defects. The advancement of the hypoplastic temporalis muscles is also demonstrated. The soft tissue hypoplasia involves multiple layers (i.e., skin, subcutaneous tissue, fascia, and fat tissue) and therefore cannot be fully corrected simply by advancing the hypoplastic temporalis muscle. **G,** Axial computed tomography scan views shown through the zygomas before and after malar reconstruction indicating the improved interzygomatic buttress width, interzygomatic arch width, and zygomatic arch length. (**A,** From Posnick JC, Treacher Collins syndrome: perspectives in evaluation and treatment, *J Oral Maxillofac Surg* 55:1120, 1997. **F** (bottom left and right) and **G,** From Posnick JC, Goldstein JA, Waitzman A: Surgical correction of Treacher Collins malar deficiency: quantitative CT scan analysis of long-term results, *Plast Reconstr Surg* 92:12, 1993.)



• **Figure 40-10** A 16-year-old boy born with Treacher Collins syndrome with a type I mandibular malformation was followed up longitudinally to confirm no progression of the deformity. He then underwent two operations, including orbitozygomatic and orthognathic reconstruction, as described previously. In preparation for orthognathic surgery, orthodontic treatment included maxillary first bicuspid extractions with the retraction of the anterior dentition to correct the arch form. The mandibular second molars are congenitally absent. The patient's orthognathic surgery included Le Fort I osteotomy (vertical intrusion and horizontal advancement); bilateral sagittal split ramus osteotomies (horizontal advancement); and an osseous genioplasty (horizontal advancement). He is shown before and after orbitozygomatic and orthognathic surgery. **A,** Frontal views before and after orthognathic surgery. **B,** Left profile views before and after orthognathic surgery. **C,** Right profile views before and after reconstruction.



Prior to treatment



After treatment with maxillary bicuspid extractions



• **Figure 40-10, cont'd** **D,** Occlusal views before and after orthognathic surgery. Note that, with the upper bicuspid extractions and the absent mandibular second molars, the maxillary second molars are no longer in occlusion. **E,** Palatal views before and after orthognathic surgery.

Continued

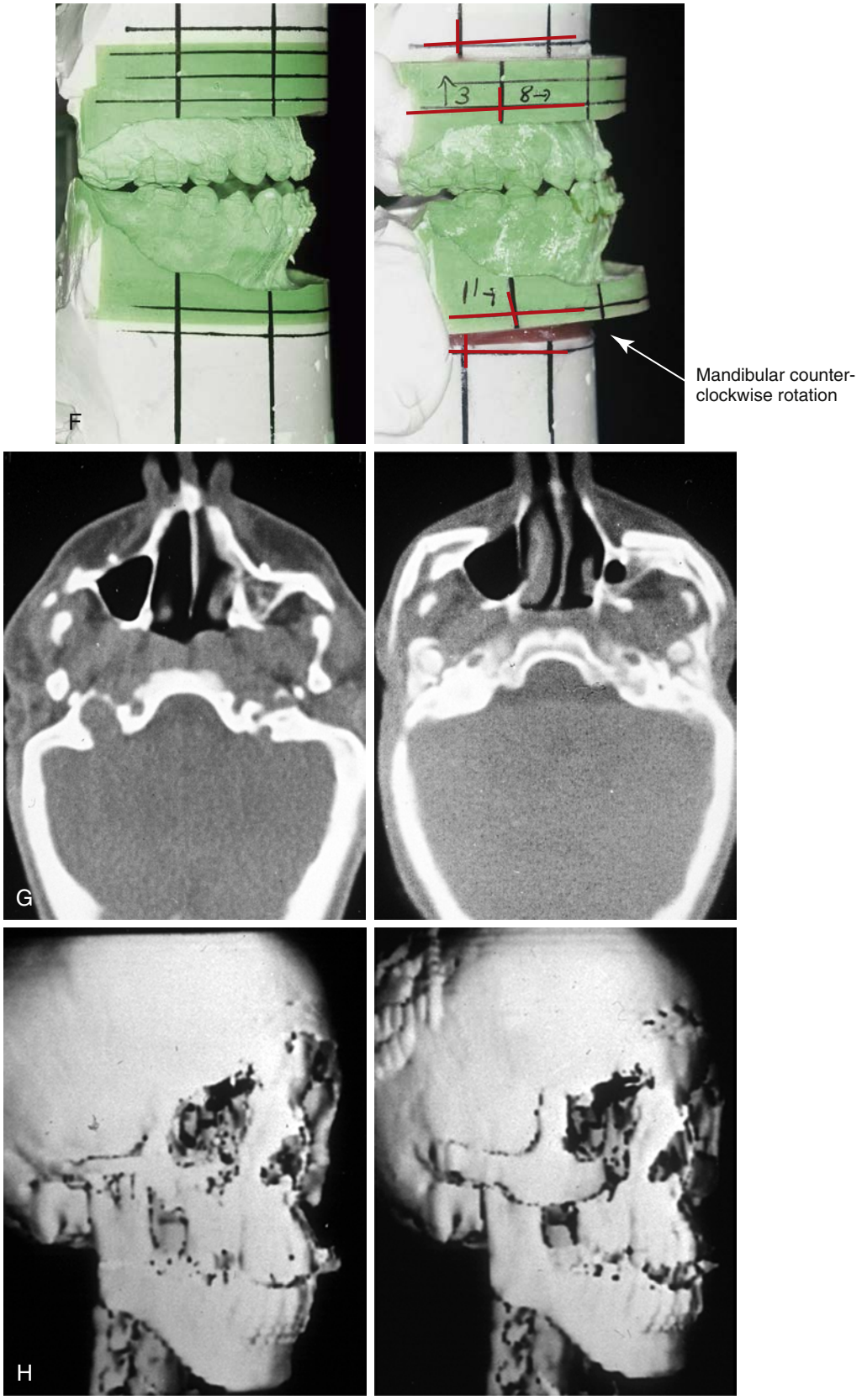

• **Figure 40-10, cont'd** **F,** Articulated dental casts that indicate analytic model planning. **G,** Axial computed tomography slices before and after malar reconstruction. **H,** Three-dimensional computed tomography scans before and after malar reconstruction (i.e., before orthognathic surgery).



• **Figure 40-11** A 6-year-old boy who was born with Treacher Collins syndrome and a type IIA mandibular malformation is shown before and after zygomatico–orbital reconstruction carried out by the technique described. He also underwent bilateral otoplasty to set the ears back (see Chapter 39). **A,** Frontal views with smile before and after reconstruction. **B,** Oblique views before and after reconstruction. **C,** Worm's-eye views before and after reconstruction.

Continued

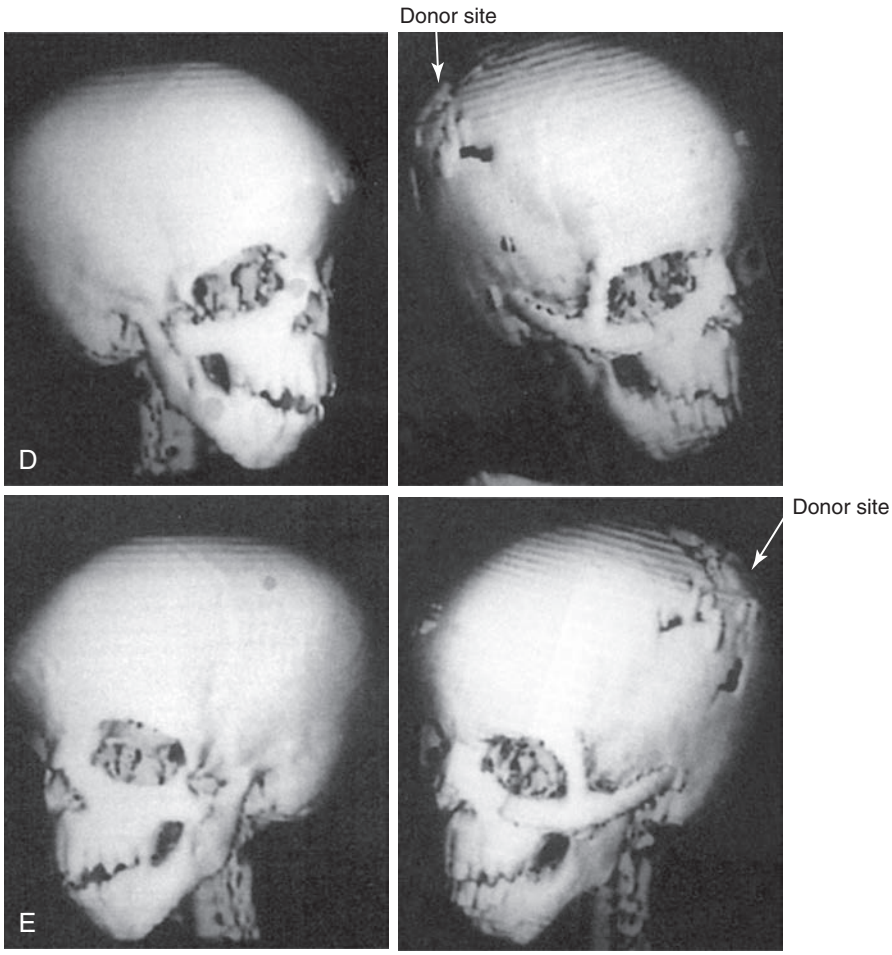

• **Figure 40-11, cont'd** **D** and **E,** Computed tomography scan views before and after reconstruction.

Maxillomandibular Reconstruction

A primary consideration for the timing and technique of jaw reconstruction is to clarify any special airway needs. This will influence whether or not first-stage early mandibular reconstruction is necessary prior to growth maturity. The second consideration is to define the extent of TMJ–mandibular malformation. With type I and IIA malformations, there is no need for glenoid fossa or condyle construction. In patients with these conditions, adequate TMJ anatomy is present so that mandibular reconstruction can be achieved through ramus osteotomies (e.g., sagittal split, inverted L, distraction [DO]) with the preservation of the working TMJ.

The basic dysmorphologies of the maxillomandibular complex that require reconstruction in patients with TCS are as follows: (1) altered facial heights (increased anterior lower facial height and decreased posterior facial height); (2) horizontal jaw deficiency (primarily in the mandible but also in the maxilla); and (3) chin dysplasia (increased vertical length and horizontal retrusion).[113-121] These malformations result in an excessive clockwise rotation of the maxillomandibular complex and an unfavorable A-point–to–B-point relationship when viewed in profile. In general, there is an Angle class II anterior open-bite malocclusion. Interestingly, some individuals will present with either a class I or class III relationship. These aspects must be addressed with the incorporation of counterclockwise rotation of the maxillomandibular complex to increase the posterior airway space, to correct the malocclusion, and to restore facial balance.

The most favorable esthetic results are generally achieved in patients who undergo definitive reconstructive jaw surgery only after early maxillofacial skeletal maturity (i.e., after the age of 13 to 15 years) and when these procedures are carried out in combination with effective definitive orthodontic treatment during the permanent dentition (see Figures 40-8 through 40-10). Mandibular and possibly maxillary premolar extractions are often required to orthodontically unravel dental root crowding, to normalize the inclination of the anterior teeth, and to fully decompensate the occlusion in preparation for the effective esthetic and airway repositioning of the jaws (see Figures 40-7, *A-D*). The surgical technique involves sagittal ramus osteotomies of the mandible in combination with a Le Fort I (maxillary) osteotomy and an oblique osteotomy of the chin. The incorporation of counterclockwise rotation of the maxillomandibular complex is generally required to successfully accomplish certain objectives. Any intranasal airway

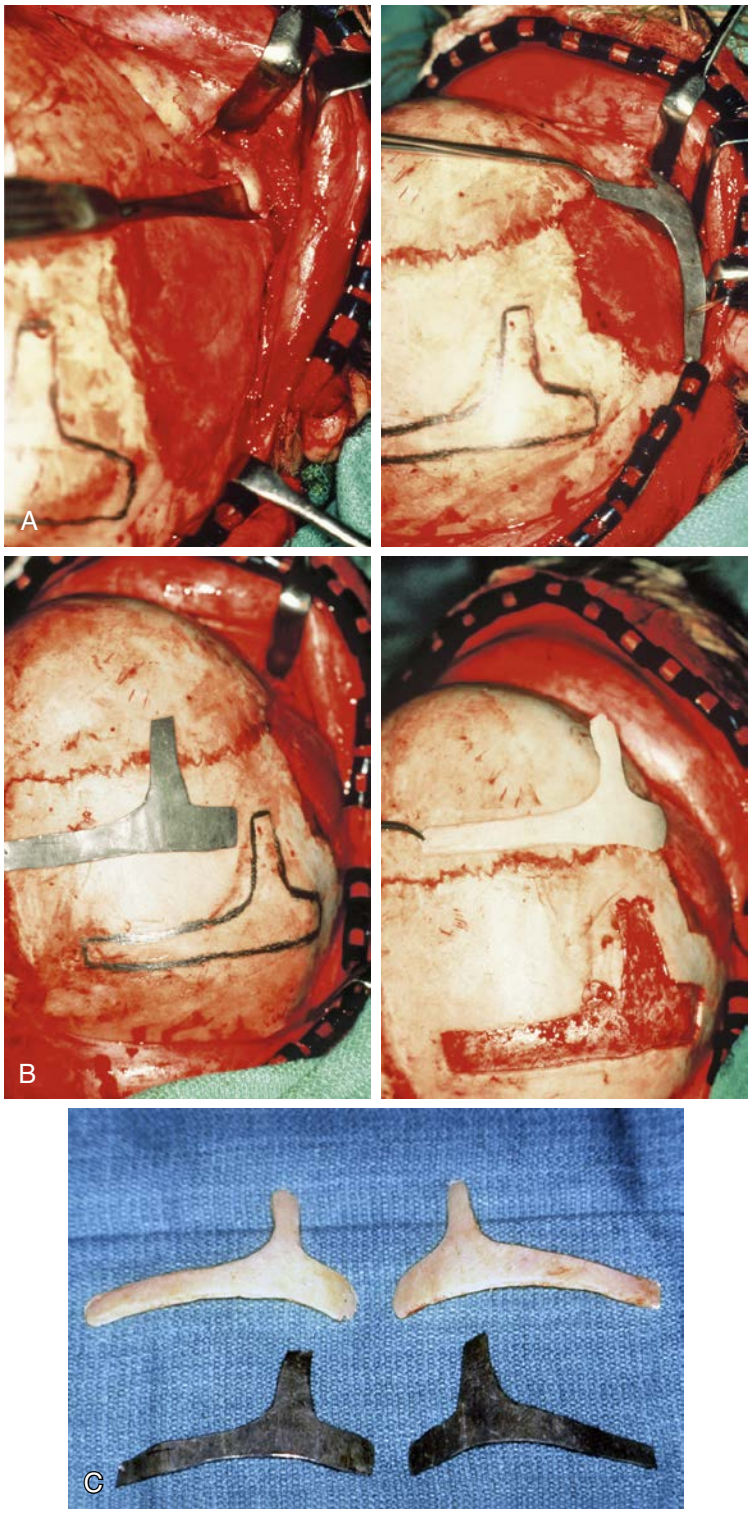

• **Figure 40-12** Intraoperative views demonstrate the technique for zygomatico–orbital reconstruction in a 5-year-old child as it would be carried out for a patient with Treacher Collins syndrome. Working through a coronal (scalp) incision, the rudimentary zygomatic and orbital structures are exposed. Full-thickness cranial bone grafts are harvested, and each zygoma is crafted from such a graft. Each zygoma graft is inset and stabilized with microplates and screws. The orbital defects are reconstructed with cranial bone graft, and the orbital rims are reshaped with a rotary drill. Lateral canthopexies are completed through the coronal scalp incision and fixed to the new frontozygomatic suture regions. **A,** A view of the dissected rudimentary zygomatic remnant; the periosteal elevation is deep to the remnant. A template of the proposed zygomatic complex has been made. **B,** The template is taken to the mid-skull region, and its outline is marked out for craniotomy. The location for graft harvesting is posterior to the coronal suture, lateral to the sagittal suture, and anterior to the lambdoid suture. Through a craniotomy, the full-thickness cranial bone graft is harvested for zygomatic complex reconstruction. The exact same procedure is completed on the contralateral side. **C,** The two full-thickness cranial bone grafts are then crafted. The two templates and the two full-thickness crafted cranial bone graft–zygomatic complexes are shown.

Continued

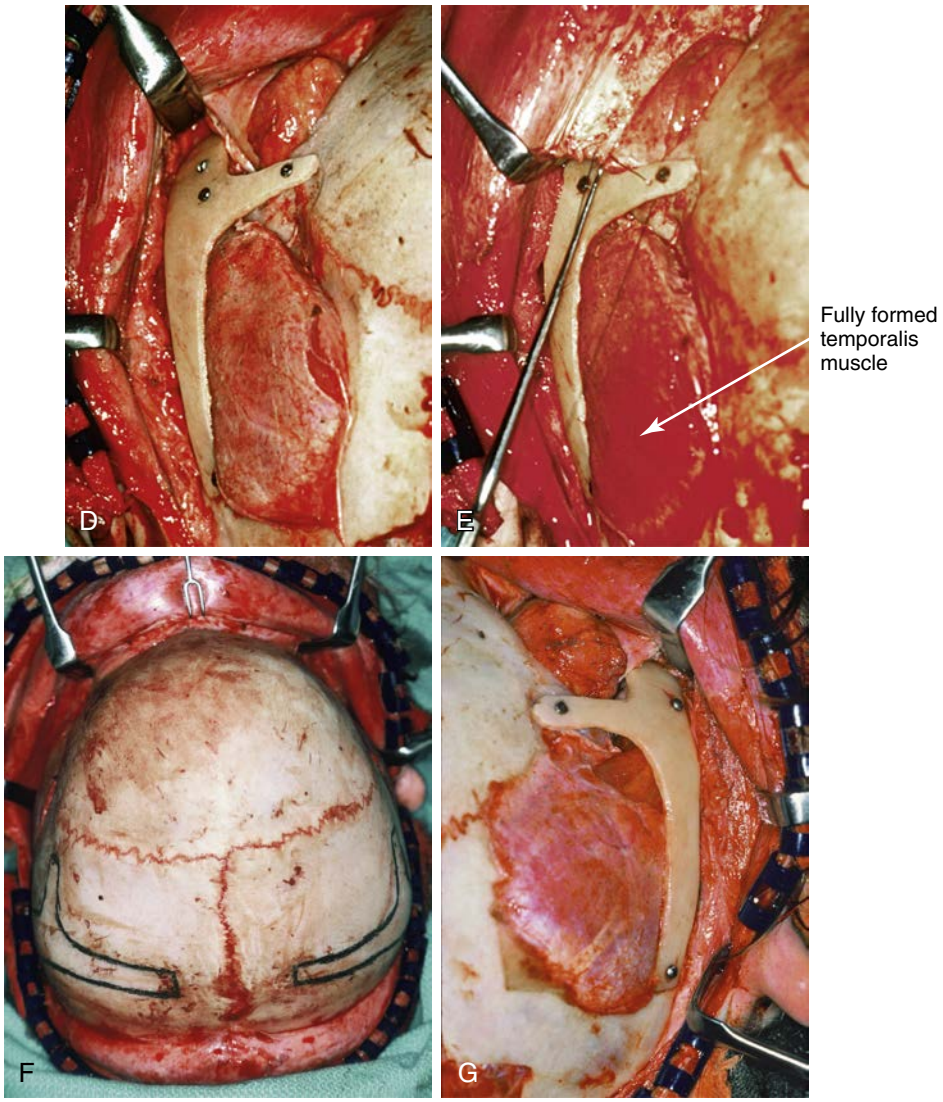

• **Figure 40-12, cont'd** **D,** The full-thickness cranial bone graft is fixed in place with microscrews. **E,** The lateral canthus is identified through the coronal incision and a 28-gauge stainless steel wire is passed through. In the patient shown here, the temporalis muscle has minimal hypoplasia. Thus, minimal temporal hollowing is expected after zygomatic reconstruction. The lateral canthus is pexed to the new frontozygomatic region. **F,** The locations for graft harvesting are outlined. **G,** The right side cranial graft is shown in place. (**A, B,** From Posnick JC, Goldstein JA, Waitzman A: Surgical correction of Treacher Collins malar deficiency: quantitative CT scan analysis of long-term results. *Plast Reconstr Surg* 92:12, 1993.)

obstructions are simultaneously managed (e.g., septoplasty, inferior turbinate reduction, recontouring of the nasal floor, widening of the aperture).

Type IIB mandibular malformations will require surgical construction of the congenitally missing condyle. Osteotomies alone—with the immediate repositioning or gradual DO of skeletal segments—will not be adequate. For the type IIB malformation, despite inherent limitations, mandibular reconstruction with a costochondral graft remains the preferred alternative when feasible (this will avoid the need to harvest fibula composite flaps). The incorporation of the counterclockwise rotation of the entire maxillomandibular complex will also be required to achieve facial balance and an adequate airway. Effective reconstruction can only be predictably carried out with neo-condylar construction followed by maxillary and mandibular osteotomies at or near skeletal maturity. Intranasal procedures to open the airway (i.e., septoplasty, inferior turbinate reduction, recontouring of the nasal floor and walls) are also carried out at the time of definitive jaw reconstruction.

The type III TMJ–mandibular malformation will require surgical construction of the congenitally missing glenoid fossa and condyle on each side (see Figure 40-7, *E*). Construction of the neo-glenoid fossa is required and best carried out as part of the zygomatic and orbital reconstruction (see the discussion of zygomatic–orbital reconstruction earlier in this chapter). For the type III condyle-ascending ramus malformation, construction of a neo-condyle on each side is also required. Mandibular osteotomies alone, with the immediate repositioning or gradual distraction

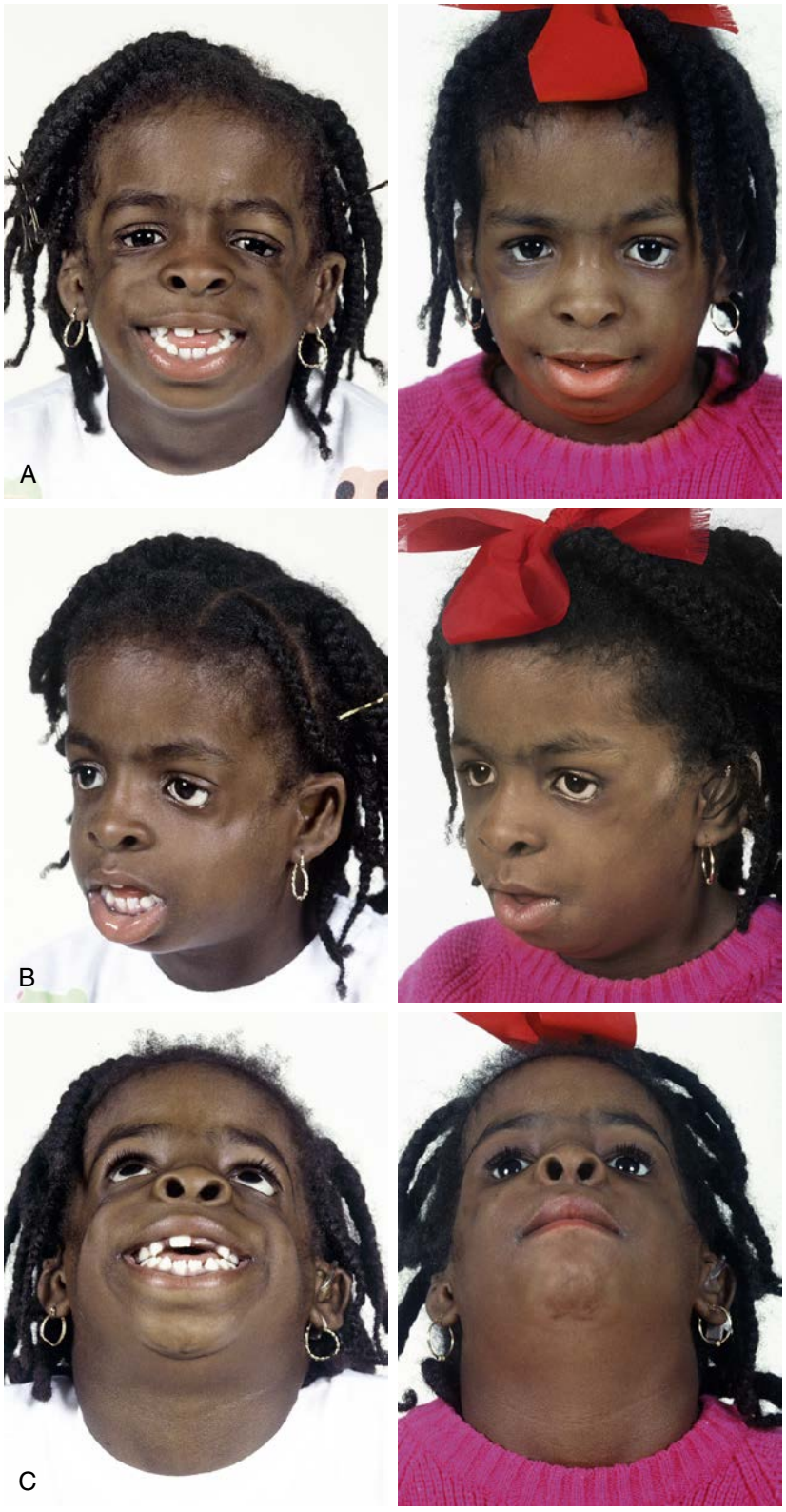

• **Figure 40-13** A 7-year-old girl who was born with Treacher Collins syndrome is shown before and after zygomatico–orbital reconstruction that was carried out via the technique described in this chapter. **A,** Frontal views before and after reconstruction. **B,** Oblique views before and after reconstruction. **C,** Worm's-eye views before and after reconstruction.

Continued

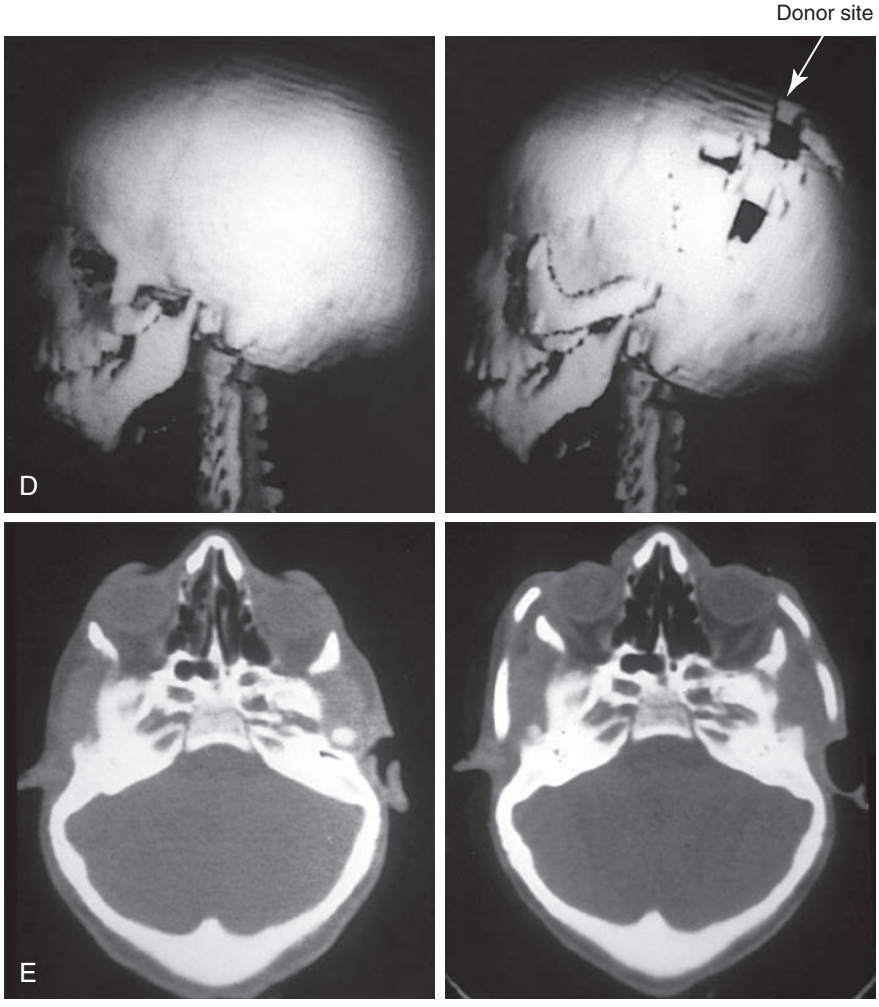

• **Figure 40-13, cont'd** **D,** Computed tomography scan views before and after zygomatico–orbital reconstruction. **E,** Axial computed tomography scan views through the mid orbits before and after cranial graft reconstruction.





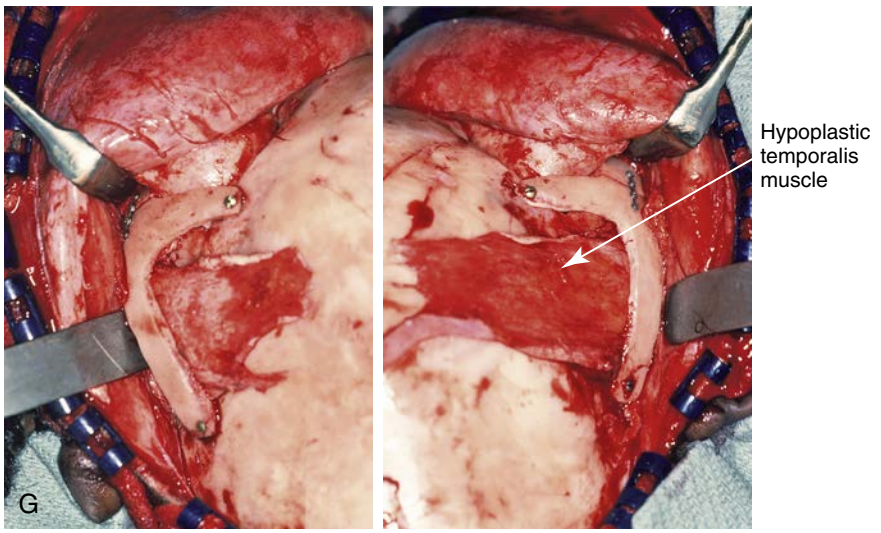

• **Figure 40-13, cont'd** **F,** Intraoperative views of full-thickness crafted zygomatic complex before inset. **G,** Left and right intraoperative views of zygomatic complex reconstruction fixed with microplates and screws. The hypoplastic temporalis muscles will be rotated anteriorly as part of the reconstruction. A degree of temporal hollowing is to be expected as a result of the congenital soft tissue hypoplasia. It is important to not over-correct the zygomatic–orbital reconstruction, because this would accentuate the soft tissue deficiency. (**A-C** *(left),* From Posnick JC, Treacher Collins syndrome: perspectives in evaluation and treatment, *J Oral Maxillofac Surg* 55:1120, 1997. **A-C** *(right),* From Posnick JC, Goldstein JA, Waitzman A: Surgical correction of Treacher Collins malar deficiency: quantitative CT scan analysis of long-term results, *Plast Reconstr Surg* 92:12, 1993.)

of skeletal segments, will not be adequate. Despite limitations, neo-condylar construction with a costochondral graft remains the preferred alternative when feasible. Occasionally the combined extent of the deficiency of the skeleton and the soft tissues will require the microvascular transfer of a crafted fibula composite flap for each side (i.e., bone and soft tissue). The advantages of a vascularized fibular composite flap are obvious but the donor site morbidity (i.e., need for bilateral lower extremity harvesting) and recipient site requirements (e.g., need for bilateral neck microvascular anastomosis) are significant. In either case, at operation, the distal mandible is repositioned anteriorly to the preferred position of the maxilla. This is assisted by a prefabricated interocclusal acrylic splint, with the distal mandible secured by intermaxillary fixation. The proximal mandible on each side is then constructed with an autogenous costochondral graft or a fibula composite microvascular flap. Contouring of the native mandible with a rotary drill before placing the rib or fibula graft on the lateral side of or adjacent to the edge of the distal mandible is generally required to avoid lateral flaring. Fixation of the graft to the native distal mandible is done with an extended titanium plate from the graft forward along the inferior border of the body of the distal mandible on each side. Graft placement and fixation are generally carried out through an extraoral neck incision. The limited use of intraoral incisions in the ramus regions

during this procedure is preferred to minimize the incidence of infection and wound breakdown with subsequent graft loss or TMJ ankylosis.

Indications for First-stage Mandibular Reconstruction in the Newborn

TCS is a clefting syndrome that involves both sides of the face (i.e., the first and second branchial arches) in which upper airway anomalies occur with both regularity and variation. Hypoplasia of the mandible is one of the constant but variable components of the syndrome.[42,51, 80,93,119,120,122-137] Individuals with TCS are known to be at risk for sleep apnea, which has been reported to occur in more than 25% of affected individuals. For those with OSA who are tracheostomy dependent, an alternative method of treatment may include the sagittal advancement of the mandible to bring the tongue forward, to create space in the oral cavity, and to open up the retromandibular airway. DO techniques to gradually advance and then hold the mandibular segments until consolidation occurs have been used to improve the airway for almost two decades. The use of this technique has been reported by several authors as an effective method of decannulating otherwise tracheostomy-dependent individuals with TCS. The implications of this early mandibular advancement approach for long-term airway success and as a definitive jaw reconstruction option for patients with TCS have undergone little critical analysis.[138]

Anderson and colleagues reported the long-term results of mandibular lengthening with a DO approach that was carried out during the patient's childhood for the management of airway obstruction in an individual with TCS.[89] They documented that the airway improved in a 6-year-old patient with TCS after DO of the mandible to the extent that decannulation and the early resolution of airway obstruction were achieved. They showed that the minimum cross-sectional airway in this patient increased during the period of distraction but did not reach age-adjusted normal values. Subsequent serial scans over 10 progressive years of growth demonstrated that the minimal cross-sectional airway did not increase further. Specifically, measurements of the cross-sectional area that were taken at a fixed point of the upper airway (i.e., the base of the C2 vertebral body) demonstrated no increase in the cross-sectional area during growth. The published longitudinal case study from these authors demonstrates a failure of a sustained satisfactory cross-sectional area of the upper airway with chronologic age. They also used three-dimensional CT scans to document that mandibular growth continued in the same dysmorphic TCS pattern as it had before the distraction intervention. This resulted in an abnormally steep (clockwise rotated) mandibular plane angle. The combination of an increasingly steep mandibular plane angle and the failure of the distraction procedure to produce long-term positive horizontal projection was believed to have created the skeletal basis for ongoing upper airway obstruction. The authors conclude that a mandibular DO procedure carried out in a child with TCS who is experiencing OSA may be useful for opening the retromandibular airway. However, the initial improvement in the upper airway did not continue during chronologic growth. The clinical consequences were the reemergence of the symptoms of OSA that required further treatment (i.e., continuous positive pressure airway mask at night or tracheostomy). It is also known that a mandibular lengthening procedure carried out during early childhood will have other detrimental effects, including injury to the developing teeth; deformational growth of the mandible; facial soft-tissue scarring; injury to the inferior alveolar nerve; a significant incidence of TMJ ankylosis (both bony and fibrous); perioperative cardiovascular and respiratory complications in some patients; expense to the family and medical health care system; and the need for definitive jaw reconstruction at maturity.[139] Despite almost two decades of accumulated worldwide experience, the role of mandibular DO in the treatment protocol for infants and children with TCS remains to be determined through long-term outcome studies. In the absence of sound data, the use of mandibular osteotomies and lengthening procedures—by whatever means—during infancy and childhood should be used cautiously and selectively.

Indications for First-stage Mandibular Reconstruction During the Mixed Dentition

When a first-stage mandibular reconstruction during the mixed dentition for the type IIB condylar malformation is felt to be indicated, it is preferably carried out after the child is 7 to 10 years old and only after the eruption of the mandibular permanent first molars.[27,82-84,100-103,140] Unfortunately, a first-stage early mandibular reconstruction will not provide a long-term resolution of the mandibular and other maxillofacial deformities.[7,45,80,88,89,92,115,119,120,122,123,125-131,133-136,140-143] Problems with costochondral graft overgrowth, undergrowth, and asymmetric growth as well as with infection and TMJ ankylosis continue to plague the reconstructive surgeon (see Chapter 26). The final orthognathic correction of the upper jaw, the lower jaw, and the chin region will be required later, after early skeletal maturity (i.e., after 13 to 15 years of age).

The rationale for postponing the correction of the maxillomandibular deformity until the time of early skeletal maturity (i.e., 13 to 15 years of age) is the same as that for patients with standard dentofacial deformities, for those with other associated syndromes, and for those with a cleft lip and palate jaw deformity. The reasons that mandibular surgery during the mixed dentition is generally not preferred include the following: (1) to avoid injury to the developing permanent dentition and the inferior alveolar nerves[139,142]; (2) to avoid soft tissue (cutaneous) scarring; (3) to limit perioperative airway and infection complications; (4) to limit the patient's negative psychosocial memories; and (5)

to avoid any iatrogenic deformity of the TMJs and the mandible that may add difficulty to the achievement of a long-term favorable reconstruction.

In addition, safe and effective osteotomies in the malformed upper jaw and chin are not carried out during childhood as a result of the position of the developing teeth and the expected induced growth restrictions that would occur. The literature now confirms a lack of continued horizontal maxillary growth after early Le Fort I osteotomy. In addition, the favorable surgical placement of the jaws during the mixed dentition to ensure long-term functional occlusion and enhanced esthetics is not realistic.

In individuals with TCS, a Le Fort I osteotomy will be required to correct vertical, horizontal, and transverse maxillary deformities. The maxillomandibular complex invariably benefits from counterclockwise rotation for the correction of pitch orientation. Intrusion of the anterior maxilla is generally needed to establish a more normal upper-lip–to–tooth relationship during smile and in repose. The posterior maxillary height may require lengthening, but more frequently it can remain close to a neutral position. The planned maxillary plane change (i.e., pitch orientation) is carried out to achieve appropriate counterclockwise rotation of the mandible and the chin. The objectives are (1) to normalize the anterior facial height; (2) to open the upper airway; and (3) to establish an esthetically improved A-point–to–B-point relationship when the patient is viewed in profile. In 1993, Rosen documented the long-term stability of the counterclockwise rotation of the lower jaw when this is required to improve function and enhance the facial esthetics in patients with mandibular micrognathia. Others have carried out similar clinical studies that have confirmed the long-term skeletal stability of mandibular counterclockwise rotation as part of an orthognathic correction.[106,121]

For the type I and IIA mandibular malformations, bilateral intraoral sagittal split osteotomies are generally the preferred ramus procedures, because they allow for effective horizontal advancement, counterclockwise rotation of the mandible (without the need to actually lengthen the posterior facial height); and sufficient bone contact across each osteotomy site (see Figure 40-8, *C*). Stabilization at each mandibular osteotomy site is accomplished with titanium plates and screws as needed. Interposed (e.g., autogenous iliac) corticocancellous bone graft is used when required.

For the type IIB and type III rib or fibula graft-constructed mandible that was created earlier during the patient's life, splitting in the ramus region at the time of definitive reconstruction is preferred when feasible. The degree of bone contact across the osteotomy site after the advancement of the distal mandible is generally limited in these circumstances. The need for an interpositioned corticocancellous bone graft (e.g., autogenous iliac) should be anticipated (see Chapter 28).

For most patients with TCS, DO osteogenesis techniques have failed to demonstrate lower morbidity or improved soft tissue response as compared with standard osteotomies.[7,45,80,88,89,92,115,119,120,122,123,125-131,133-136,140,141,143-145] Data have indicated significant relapse during the consolidation phase of DO techniques and no ongoing jaw growth when the procedure is carried out during childhood. Kaban and colleagues and others continue to refine the application of curvilinear DO for the correction of the complex mandibular deformities of severe forms of TCS.[85] Despite their best efforts when using DO techniques, reliable three-dimensional vector control to achieve preferred proportions and symmetry of the osteotomized skeletal segments remains a work in progress. For these reasons, until DO technology and its clinical applications improve, we prefer the standard orthognathic correction of the maxillomandibular imbalance in patients with TCS when feasible.

Nasal Reconstruction

The bridge of the nose in the adult with TCS often has mild to moderate increased width, and a mid-dorsal hump is always present. The length of the nose is usually normal, but it seems long as a result of the imbalance with the upper and lower skeletal thirds of the face; also, the tip often droops and lacks the preferred projection. Most patients benefit from a rhinoplasty that includes osteotomies with in-fracture; the conservative reduction of the skeletal and cartilaginous dorsal hump; the removal of the cephalic portions of the lower lateral cartilages; and septal cartilage grafting (i.e., a caudal strut) sutured to the anterior septum to improve tip projection and definition. To achieve the most favorable esthetic results, it is best to postpone the rhinoplasty until after effective orthognathic procedures have been performed. Exposure is provided through an open (i.e., columella-splitting incision) technique (see Chapter 38 and Figure 40-9).

Facial Soft Tissue Reconstruction

Despite several decades of well-intentioned surgical attempts to improve the soft tissue deficiencies of the eyelid–adnexal regions, few esthetically pleasing soft tissue eyelid reconstructive results in patients with TCS have been reported.[67,72-74,146-149] The transposition of pedicled upper-eyelid-skin–muscle flaps to deficient regions of the lower eyelid is not technically difficult; unfortunately, the adnexal scarring that inevitably occurs often results in an "operated" look that generally detracts from any positive advantages of the procedure. The placement of full-thickness skin grafts to the lower eyelids is another frequently mentioned option. It predictably leaves a "patchy" look, and it should be reserved only for patients with recalcitrant corneal exposure problems. The lateral canthi are inferiorly displaced as a result of both orbital dystopia and hypoplasia of the lateral canthi and other components of the eyelid structures. Although the correction of the orbital dystopia and direct lateral canthopexies are helpful and should be carried out, they rarely normalize the multilevel soft-tissue hypoplasia of the specialized adnexal structures (i.e., skin, cartilage, eyelashes, ligament, fascia, and tendon). For these reasons, it is best to consult with an experienced oculoplastic surgeon when considering even minor eyelid procedures for patients with TCS.

The observed temporal fossa hollowing that is frequently encountered with TCS is also a reflection of multilevel hypoplasia that includes the skin, the temporoparietal fascia, the temporalis muscle, and the decreased bitemporal width of the anterior cranial vault. For this reason, transposing pericranial or temporoparietal congenital hypoplastic flaps will have limited utility for the management of either temporal or adnexal region subcutaneous deficiency.

When the procedure is meticulously designed and expertly executed, the transfer of soft-tissue flaps from other body regions, with microvascular reanastomosis, should be considered for reconstruction of TCS.[67,72-74,146-149] When this level of facial soft tissue replacement is required, parascapular free flaps have become the workhorse since they were first described by Dos Santos. Siebert and colleagues found that the parascapular flap allows for the reasonable correction of contour defects in the lateral aspects of the face; this yields improved esthetic results in selected patients with TCS by providing vascularized soft tissue in the subcutaneous plane while minimizing scarring.[149] Fortunately, hypoplasia of the centrally located soft tissues of the face (i.e., forehead, nose, upper and lower lips, chin, and submental region) is not seen in patients with TCS. Dermal fat grafts, autogenous fat injections, and other forms of soft tissue augmentation have gained popularity. The results of autogenous fat injection are variable and considered technique sensitive; they are generally not harmful, and they are clearly promising. Tanna and colleagues investigated the use of serial autologous fat grafting to restore soft tissue contour in patients with hemifacial microsomia.[150] Patients with moderate to severe hemifacial microsomia were divided into two groups: Group I included those undergoing microvascular free-flap reconstruction (i.e., inframammary extended circumflex scapular flaps; n = 10); Group II included those undergoing multiple staged autogenous fat grafting (n = 21). The two patient groups had similar OMENS scores (2.4 and 2.3, respectively) and similar pre-reconstruction facial symmetry scores (74% and 75%, respectively). At the final evaluation, facial symmetry scores were 121% for the microvascular free-flap group and 99% for the fat-grafting group. Furthermore, no statistically significant difference between the microvascular and fat-graft groups in either patient or physician rating of overall satisfaction was noted. The extrapolation of these study results to the individual with TCS is appropriate.[150-152]

External Ear Reconstruction

The surgical reconstruction of the auricle can be satisfactorily achieved through a staged approach in the hands of a few experts.[69,153-167] The methods described by Brent represent the reference standard for external ear reconstruction.[153-156] The successful grafting of a well-sculpted cartilage framework is the foundation for sound auricular repair. According to Brent, most children have adequate rib cartilage for the repair by 6 years of age. At that time, the synchondrotic region of ribs 6 and 7 will provide an ample cartilage block to form the framework of the ear; this is taken from the side contralateral to the ear being constructed. With the use of the preoperatively determined measurements and a prefabricated template, the position of the ear is determined, and a small preauricular incision is made. Unusable vestigial cartilage is excised. A thin-skinned pocket is developed, with the dissection carried beyond the marked auricular outline to recruit sufficient tension-free skin coverage. For patients with bilateral microtia, Brent prefers that the harvesting of cartilage grafts for each ear be separated by several months. Simultaneous bilateral auricular reconstruction would necessitate bilateral chest wounds with severe splinting and the potential for respiratory distress. Other stages of the auricular construction include lobule transposition, the detachment of the auricle with a skin graft, the management of the hairline, and tragus construction. Brent suggests that bilateral microtia repair be completed with five procedures that are carried out at 3-month intervals.

When completing microtia reconstruction in the patient with TCS, eventual external auditory canal and middle ear surgery must be considered. Auricular construction should precede any middle ear surgery because, after an attempt is made to open the canal, the chances of obtaining a satisfactory auricular repair are severely compromised as a result of the scarring of the skin envelope. When middle ear surgery is an option, Brent suggests that the cartilaginous framework be sculpted with a wider concha to accommodate a future surgically created canal.

Other options for external ear reconstruction include the use of alloplastic and homologous frameworks. Alloplastic materials that are currently in use include silicone and Medpor (Porex Surgical, Inc., College Park, GA). These foreign substances are more susceptible to infection, soft tissue wound dehiscence, and susceptibility to minor trauma, even decades after reconstruction. Innovative techniques of tissue engineering involving bovine cartilage cells that are grown in the laboratory and seeded on a synthetic biodegradable ear template that is then implanted beneath the skin of an immunocompetent mouse have shown promise for the future. Unfortunately, until tissue engineering evolves beyond the currently encountered immunogenic problems, sculpted autogenous rib cartilage will remain the material of choice for the surgical repair of the ear.

At the same time, unless the option of sculpted autogenous rib cartilage is carried out by an experienced auricular reconstructive surgeon, the chance of achieving an esthetically acceptable result is slim. For this reason, the use of a prosthetic external ear or no reconstruction at all in most individuals with TCS should not be discounted automatically.

External Auditory Canal and Middle Ear Reconstruction

Although some of the hearing loss in the patient with TCS is attributable to external auditory canal stenosis or atresia, most of the loss (i.e., an average of 44 dB) is attributable

to hypoplastic middle ear cavities and ankylotic or missing ossicles.[75,77,78] Ankylosed or nonfunctioning ossicles appear to limit hearing conduction to the same extent as if they were absent.[76] Attempting reconstruction of the middle ear in patients with TCS can be expected to result in gains in hearing. However, even if the ossicles are mobilized, middle ear dysmorphology remains; this results in residual hearing loss and leaves the patient dependent on some form of amplification. Jahrsdoerfer reported on a group of patients with TCS who underwent surgery for hearing rehabilitation.[78] He confirmed the generally unsuccessful attempts to satisfactorily improve "non-aided" long-term hearing. A form of bone conduction hearing aid is required for proper amplification in most patients, including those who have undergone reconstruction as well as those who have not. The bone conduction hearing aid may be a traditional unit, a modified amplification system, or a bone-anchored conduction unit.

According to Brent, for the gains from any middle ear surgery to outweigh the risks and complications of the procedure, it should be reserved for selected patients with bilateral and unilateral microtia in whom personal motivation is high, in whom the favorable radiologic evidence of middle ear development is present, and in whom a favorable outcome is expected according to an experienced otologist.[153-156] Furthermore, it must be planned through a team approach with an otologist and an auricular/reconstructive surgeon who are competent and experienced with ear-canal atresia, middle ear malformations, and microtia repair. At the time of middle ear surgery, the auricular/reconstructive surgeon initiates the procedure by lifting the reconstructed ear from its bed while carefully preserving both the connective tissue on the framework's undersurface and the overall circulation of the flap. The otologist proceeds by drilling a bony external auditory canal, completing ossiculoplasty, and then repairing the tympanum with a temporal fascia graft. The auricular/reconstructive surgeon then excises the soft tissues to exteriorize the meatus through the chondral region and harvests a skin graft that the otologist uses to line the new external auditory canal.

The Bone-anchored Hearing Aid Option

A bone-anchored hearing aid (BAHA) consists of a permanent titanium fixture that is surgically implanted into the skull bone behind the ear and a small detachable sound processor that clips onto the fixture. BAHAs are suitable for people with conductive or mixed hearing loss who cannot adequately benefit from or prefer not to use conventional hearing aids.

Colquitt and colleagues completed a systematic review and an economic evaluation of BAHAs for people who are bilaterally deaf.[168] Previous prospective studies of adults or children with bilateral hearing loss were eligible for review. Twelve studies were included; there were seven cohort pre-post studies and five cross-sectional audiologic comparison studies. Comparisons were made between BAHAs and the following: (1) conventional hearing aids, which are also known as air-conduction hearing aids (ACHAs); (2) bone conduction hearing aids (BCHAs); and (3) unaided hearing and ear surgery. The study also looked at (4) unilateral versus bilateral BAHAs. Outcomes reviewed included hearing measures, validated measures of quality of life, adverse events, and measures of cost-effectiveness.

There appeared to be some audiologic benefits of BAHAs for this group of patients, including improvements in speech as compared with BCHAs; and understanding and noise as compared with ACHAs (however, ACHAs may produce better audiologic results for other outcomes). In addition, hearing was found to be improved with the use of BAHAs as compared with unaided hearing, and studies that compared unilateral with bilateral BAHAs suggested the benefits of bilateral BAHAs in many situations. However, prospective case series of BAHAs reported rates of 6.1% to 19.4% for the loss of the implants over time. In addition, the financial analysis suggests that BAHAs are unlikely to be a cost-effective option in terms of hearing gain and probability of needing alternative aids. Interestingly, the greater the benefit from aided hearing and the greater the difference in the proportion of people using the hearing aid for more than 8 hours per day, the more likely the BAHAs were a cost-effective option.

Janssen and colleagues completed a systematic review of bilateral BAHAs for bilateral permanent conductive hearing loss.[169] This was a review of the literature from between 1977 and 2011, and it included studies in which subjects of any age had permanent conductive hearing loss and bilateral implanted BAHAs. Eleven studies met the criteria for data analysis. Bilateral BAHAs were found to provide audiologic benefit as compared with unilateral BAHAs (i.e., improved thresholds for tones, speech in quiet and in noise, improved localization/lateralization, and patient's perceived subjective benefit). Disadvantages of bilateral BAHAs included listening in noise in some condition, presumed additional cost, and presumed increasing adverse event risk. The authors concluded that bilateral BAHAs provided additional objective and subjective benefit as compared with unilateral BAHAs.

Conclusions

The current approach to the correction of malformations associated with TCS is to stage the reconstruction to coincide with facial growth patterns, visceral function (i.e., vision, breathing, chewing, swallowing, speech, hearing), and psychosocial needs. Precise morphologic analysis of each patient and the recognition of the need for a staged reconstructive approach serve to clarify the objectives at each interval for both the clinicians and the family. By continuing to define a rationale for the timing, methods, and extent of surgical, medical, and dental interventions and then objectively evaluating head and neck function, facial esthetics, and psychosocial outcomes, the outlook for individuals affected by TCS will be greatly improved.

References

1. Arystas M, Shprintzen RJ: Craniofacial morphology in Treacher Collins syndrome, *Cleft Palate Craniofac J* 28:226, 1991.
2. Behrents RG, McNamara JA, Avery JK: Prenatal mandibulofacial dysostosis (Treacher Collins syndrome), *Cleft Palate J* 14:13, 1977.
3. Converse JM, Wood-Smith D, McCarthy JG, et al.: Bilateral facial microsomia, *Plast Reconstr Surg* 54:413, 1974.
4. Da Silva Dalben G, Costa B, Gomide MR: Prevalence of dental anomalies, ectopic eruption and associated oral malformations in subjects with Treacher Collins syndrome, *Oral Surg Oral Med Oral Pathol Oral Radiol Endod* 101:588, 2006.
5. Da Silva Dalben G, Teixeira das Neves L, Ribeiro Gomide M: Oral health status of children with Treacher Collins syndrome, *Spec Care Dentist* 26:71–75, 2006.
6. Dahl E, Kreiborg S, Bjork A: A morphologic description of a dry skull with mandibulofacial dysostosis, *Scand J Dent Res* 83:257, 1975.
7. Fernandez AO, Ronis ML: The Treacher Collins syndrome patient, *Arch Otolaryngol* 80:505, 1964.
8. Franceschetti A, Klein D: The mandibulofacial dysostosis: a new hereditary syndrome, *Acta Ophthalmol* 27:143, 1949.
9. Francis-West PH, Robson L: Craniofacial development: the tissue and molecular interactions that control development of the head, *Adv Anat Embryol Cell Biol* 169:1, 2003.
10. Fryns JP, Bonhomme A, Van Den Berge H: Nager acrofacial dysostosis: an adult male with severe neurologic deficit, *Genet Couns* 7:147, 1996.
11. Giugliani R, Pereira CH: Nager acrofacial dysostosis with thumb duplication: report of a case, *Clin Genet* 26:228, 1984.
12. Gorlin RJ, Cohen Jr MM, Levin LS: *Syndromes of the head and neck*, ed 3, New York, 1990, Oxford University Press, pp 649–652.
13. Herman TE, Siegel MJ: Special imaging case-book: Nager syndrome, *J Perinatol* 18:85, 1998.
14. Herring SW, Rowlett UF, Pruzansky S: Anatomical abnormalities in mandibulofacial dysostosis, *Am J Med Genet* 3:225, 1979.
15. Jackson IT, Bauer B, Salech J, et al.: A significant feature of Nager syndrome: palatal agenesis, *Plast Reconstr Surg* 84:219, 1989.
16. Kreiborg S: The skeletal anatomy of mandibulofacial dysostosis (Treacher Collins syndrome) [discussion], *Plast Reconstr Surg* 78:469, 1986.
17. Kreiborg S, Dahl E: The cranial base and face in mandibulofacial dysostosis, *Am J Med Genet* 47:753, 1993.
18. Maran AGD: The Treacher Collins syndrome patient, *J Laryngol* 78:135, 1964.
19. Nager FR, deRaynier JP: Das gehororgan bei den angeborenen kopf-missbildungen, *Pract Otorhinolaryngol* 10(Suppl 2):1, 1948.
20. Poswillo DE: Otomandibular deformity: pathogenesis as a guide to reconstruction, *J Maxillofac Surg* 2:64, 1974.
21. Poswillo DE: The pathogenesis of the Treacher Collins syndrome (mandibulofacial dysostosis), *Br J Oral Surg* 13:1, 1975.
22. Rogers BO: Berry-Treacher Collins syndrome: a review of 200 cases, *Br J Plast Surg* 17:107, 1964.
23. Rotten D, Levaillant JM, Martinez H, et al.: The fetal mandible: a 2D and 3D sonographic approach to the diagnosis of retrognathia and micrognathia, *Ultrasound Obstet Gynecol* 19:122, 2002.
24. Snyder CC: Bilateral facial agenesis (Treacher Collins syndrome), *Am J Surg* 92:81, 1956.
25. Vento AR, LaBrie RA, Mulliken JB: The OMENS classification of hemifacial microsomia, *Cleft Palate Craniofac J* 28:68–76, 1991.
26. Berry GA: Note on a congenital defect (coloboma) of the lower lid, *R Lond Ophthalmic Hosp Rep* 12:255, 1889.
27. Posnick JC, Al-Qattan MM, Moffat S, Armstrong D: Craniorbito-zygomatic measurements from standard CT scans in unoperated Treacher Collins syndrome patients: comparison with normal controls, *Cleft Palate Craniofac J* 32(1):20–24, 1995.
28. Teber OA, Gillessen-Kaesbach G, Fischer S, et al.: Genotyping in 46 patients with tentative diagnosis of Treacher Collins syndrome revealed unexpected phenotypic variation, *Eur J Hum Genet* 12:879–890, 2004.
29. Dixon J, Edwards SJ, Anderson I, et al.: Identification of the complete coding sequence and genomic organization of the Treacher Collins syndrome gene, *Genome Res* 7:223, 1997.
30. Edwards S, Gladwin A, Dixon MJ: The mutational spectrum in Treacher Collins syndrome reveals a predominance of mutations that create a premature-termination codon, *Am J Hum Genet* 60:515, 1997.
31. Ellis PE, Dawson M, Dixon MJ: Mutation testing in Treacher Collins syndrome, *J Orthod* 29:293, 2002.
32. Jabs EW, Li X, Lovett M, et al.: Genetic and physical mapping of the Treacher Collins syndrome locus with respect to loci in the chromosome 5q3 region, *Genomics* 18:7, 1993.
33. Jabs EW, Xiang L, Coss CA, et al.: Mapping the Treacher Collins syndrome locus to 5q31.3–q33.3, *Genomics* 11:193, 1991.
34. Katsanis S, Jabs EW: Treacher Collins syndrome. In Pagon RA, Bird TD, Dolan CR, Stephens K, Adam MP, editors: *SourceGeneReviews™* [Internet]. Seattle (WA), 1993-2004 Jul 20 [updated 2012 Aug 30], University of Washington, Seattle.
35. Marres HA, Cremers CW, Dixon MJ, et al.: The Treacher Collins syndrome: a clinical, radiological, and genetic linkage study on two pedigrees, *Arch Otolaryngol Head Neck Surg* 121:509, 1995.
36. Marsh K, Dixon J, Dixon MJ: Mutations in the Treacher Collins syndrome gene lead to mislocalization of the nucleolar protein treacle, *Hum Mol Genet* 7:1795, 1998.
37. Marszalek B, Wojckicki P, Kazimierz K, et al.: Clinical features, treatment and genetic background of Treacher Collins syndrome, *J Appl Genet* 43:223, 2002.
38. The Treacher Collins Syndrome Collaborative Group: Positional cloning of a gene involved in the pathogenesis of Treacher Collins syndrome, *Nat Genet* 12:130, 1996.
39. Walker MB, Trainor PA: Craniofacial malformations: intrinsic vs extrinsic neural crest cell defects in Treacher Collins and 22q11 deletion syndromes, *Clin Genet* 69:471, 2006.
40. Winokur ST, Shiang R: The Treacher Collins syndrome (TCOF1) gene product, treacle, is targeted to the nucleolus by signals in its C-terminus, *Hum Mol Genet* 7:1998, 1947.
41. Beaune L, Forrest CR: Adolescents' perspectives on living and growing up with Treacher Collins syndrome: a qualitative study, *Cleft Palate Craniofac J* 41:343, 2004.
42. Burstein FD, Cohen SR, Scott PH, et al.: Surgical therapy for severe refractory sleep apnea in infants and children: application of the airway zone concept, *Plast Reconstr Surg* 96:34, 1995.
43. Ebata T, Nishiki S, Masuda A, et al.: Anaesthesia for Treacher Collins syndrome using a laryngeal mask airway, *Can J Anaesth* 38:1043, 1991.
44. Kovacs AL: Use of the Augustine stylet anticipating difficult tracheal intubation in Treacher Collins syndrome, *J Clin Anaesth* 4:409, 1992.

45. Moos KF: Mandibular reconstruction in children with obstructive sleep apnea due to micrognathia [discussion], *Plast Reconstr Surg* 100:1138, 1997.
46. Mukhopadhyay P, Mukherjee P, Adhikary M: Problems in the anaesthetic management of Pierre Robin and Treacher Collins syndrome, *Indian Pediatr* 29:1120, 1992.
47. Perkins JA, Sie KCY, Milczuk H, et al.: Airway management in children with craniofacial anomalies, *Cleft Palate Craniofac J* 34:135, 1997.
48. Pope AW, Speltz ML: Research on psychosocial issues of children with craniofacial anomalies: progress and challenges, *Cleft Palate Craniofac J* 34:371, 1997.
49. Pope AW, Ward J: Self-perceived facial appearance and psychosocial adjustment in preadolescents with craniofacial anomalies, *Cleft Palate Craniofac J* 34:396, 1997.
50. Rasch DK, Browder F, Barr M, et al.: Anaesthesia for Treacher Collins and Pierre Robin syndromes: a report of three cases, *Can Anaesth Soc J* 33:364, 1986.
51. Walker JS, Dorian RS, Marsh NJ: Anaesthetic management of a child with Nager syndrome, *Anaesth Analg* 79:1025, 1994.
52. Arvystas M, Shprintzen RJ: Craniofacial morphology in Treacher Collins syndrome, *Cleft Palate J* 28:226, 1991.
53. Figueroa AA, Peterson-Falzone SJ, Friede H, et al.: Neurocranial morphology in mandibulofacial dysostosis (Treacher Collins syndrome), *Cleft Palate Craniofac J* 30:369, 1993.
54. Marsh JL, Celin SE, Vannier MW, et al.: The skeletal anatomy of mandibulofacial dysostosis (Treacher Collins syndrome), *Plast Reconstr Surg* 78:460, 1986.
55. Posnick JC, Goldstein JA, Waitzman A: Surgical correction of the Treacher Collins malar deficiency: quantitative CT scan analysis of long-term results, *Plast Reconstr Surg* 92(1):12–22, 1993.
56. Roddi R, Vaandrager J, van der Meulen J: Treacher Collins syndrome: early surgical treatment of orbitomalar malformations, *J Craniofac Surg* 6:211, 1995.
57. Waitzman AA, Posnick JC, Armstrong D, et al.: Craniofacial skeletal measurements based on computed tomography: I. Accuracy and reproducibility, *Cleft Palate Craniofac J* 29:112, 1992.
58. Waitzman AA, Posnick JC, Armstrong D, et al.: Craniofacial skeletal measurements based on computed tomography: II. Normal values and growth trends, *Cleft Palate Craniofac J* 29:118, 1992.
59. Wolfe SA, Vitenas Jr P: Malar augmentation using autogenous materials, *Clin Plast Surg* 18:39, 1991.
60. Zanini S, Viterbo F, Parro F, et al.: Bone graft of the zygoma in a patient with Treacher Collins syndrome, *J Craniofac Surg* 5:270, 1994.
61. Roberts FG, Pruzansky S, Aduss H: An x-radiocephalometric study of mandibulofacial dysostosis in man, *Arch Oral Biol* 20:265, 1975.
62. Garner LD: Cephalometric analysis of Berry-Treacher Collins syndrome, *Oral Surg* 23:320, 1967.
63. Bregeat P: Thirty-six years after a mandibulofacial dysostosis operation, *Ophthalmic Paediatr Genet* 6:313, 1985.
64. Collins ET: Cases with symmetrical congenital notches in the outer part of each lower lid and defective development of malar bones, *Trans Ophthalmol Soc UK* 20:190, 1900.
65. Farkas LG, Posnick JC: Detailed morphology of the nose in patients with Treacher Collins syndrome, *Ann Plast Surg* 22:211, 1989.
66. Farkas LG, Posnick JC, Winemaker MJ: Orbital protrusion in Treacher Collins syndrome: a tool for determining the degree of soft tissue damage, *Dtsch Z Mund Kiefer Gesichtschir* 13(6):429–432, 1989.
67. Jackson IT: Reconstruction of the lower eyelid defect in Treacher Collins syndrome, *Plast Reconstr Surg* 67:365, 1981.
68. Kolar JC, Farkas LG, Munro IR: Surface morphology in Treacher Collins syndrome: an anthropometric study, *Cleft Palate J* 22:266, 1985.
69. Marres HA, Cremers CW, Marres EH: Treacher Collins syndrome: management of major and minor anomalies of the ear, *Rev Laryngol Otol Rhinol* 116:105, 1995.
70. Shprintzen RJ: Palatal and pharyngeal anomalies in craniofacial syndromes, *Birth Defects* 18:53–78, 1982.
71. Shprintzen RJ, Croft C, Berkman MD, Rakoff SJ: Pharyngeal hypoplasia in Treacher Collins syndrome, *Arch Otolaryngol* 105:127–131, 1979.
72. Stenstrom SJ, Sundmark ES: Contribution to the treatment of the eyelid deformities in dysostosis mandibulofacialis, *Plast Reconstr Surg* 38:567, 1966.
73. Tessier P: Chirurgische behandlung der genetisch bedingten palpebralen und orbito-facialen missbildungen, *Klin Monatschr Augenheilkd* 50:82, 1968.
74. Van der Meulen JCH, Hauben DJ, Vaandrager JM, et al.: The use of a temporal osteoperiosteal flap for the reconstruction of malar hypoplasia in Treacher Collins syndrome, *Plast Reconstr Surg* 74:687, 1984.
75. Caldarelli DD, Hutchinson Jr JG, Pruzansky S, et al.: A comparison of microtia and temporal bone anomalies in hemifacial microsomia and mandibulofacial dysostosis, *Cleft Palate J* 17:103, 1980.
76. Herberts G: Otological observations on the "Treacher Collins syndrome", *Acta Otolaryngol* 54:457, 1962.
77. Holborow Jr JC, Caldarelli DD, Valvassori GE, et al.: The otologic manifestations of mandibulofacial dysostosis, *Trans Sect Otolaryngol Am Acad Ophthalmol Otolaryngol* 84:520, 1977.
78. Jahrsdoerfer RA, Aquilar EA, Yeakley JW, et al.: Treacher Collins syndrome: an otologic challenge, *Ann Otol Rhinol Laryngol* 98:807, 1989.
79. Pron G, Galloway C, Armstrong D, Posnick JC: Ear malformation and hearing loss in patients with Treacher Collins syndrome, *Cleft Palate Craniofac J* 30:97–103, 1993.
80. Heller JB, Gabbay JS, Kwan D, et al.: Genioplasty distraction osteogenesis and hyoid advancement for correction of upper airway obstruction in patients with Treacher Collins and Nager syndromes, *Plast Reconstr Surg* 117:2389, 2006.
81. Peterson-Falzone S, Figueroa AA: Longitudinal changes in cranial base angulation in mandibulofacial dysostosis, *Cleft Palate J* 26:31, 1989.
82. Posnick JC: Treacher Collins syndrome: evaluation and treatment. In Posnick JC, editor: *Orthognathic surgery: principles and practice*, St Louis, 2014, Elsevier, Ch 27, pp 1059–1094.
83. Posnick JC, Ruiz R: Treacher Collins syndrome: current evaluation, treatment and future directions, *Cleft Palate Craniofac J* 37(5):434, 2000.
84. Posnick JC, Ruiz R, Tiwana P: Treacher Collins syndrome: comprehensive evaluation and treatment, *Oral Maxillofac Surg Clin North Am* 16:503–523, 2004.
85. Kaban LB, Moses ML, Mulliken JB: Surgical correction of hemifacial microsomia in the growing child, *Plast Reconstr Surg* 82:9, 1980.
86. Singh D, Bartlett S: Congenital mandibular hypoplasia: analysis and classification, *J Craniofac Surg* 16:291, 2005.
87. Pruzansky S: Not all dwarfed mandibles are alike, *Birth Defects* 1:120, 1969.

88. Acosta H, Stelnicki E, Boyd B, et al.: Vertical mesenchymal distraction and bilateral free fibula transfer for severe Treacher Collins syndrome, *Plast Reconstr Surg* 113:1209, 2004.
89. Anderson P, Netherway D, Abbott A, et al.: Mandibular lengthening by distraction for airway obstruction in Treacher-Collins syndrome: the long-term results, *J Craniofac Surg* 15:47, 2004.
90. Argenta LC, Iacobucci JJ: Treacher Collins syndrome: present concepts of the disorder and their surgical correction, *World J Surg* 13:401, 1989.
91. Arvytas AH, Netherway DJ, David DJ, Brown T: Application and comparison of techniques for three-dimensional analysis of craniofacial anomalies, *J Craniofac Surg* 1:119–134, 1990.
92. Brevi B, Lagana F, Piazza F, Sesenna E: Mandibular distraction osteogenesis with a small semiburied device in neonates: report of 2 cases, *Ear Nose Throat J* 85:102, 2006.
93. Codvilla A: On the means of lengthening, in the lower limbs, the muscles and tissues which are shortened through deformity, *Am J Orthop Surg* 2:353, 1905.
94. Cope JB, Samchukov ML, Cherkashin AM: Mandibular distraction osteogenesis: a historic perspective and future directions, *Am J Orthod Dentofacial Orthop* 115:448–460, 1999.
95. Longacre JJ, deStefano GA, Holmstrand KE: The surgical management of the first and second branchial arch syndromes, *Plast Reconstr Surg* 31:507, 1963.
96. Obwegeser HL: Zur korrektur der dysostosis otomandibularis, *Schweiz Monatsschr Zahnheilkd* 80:331, 1970.
97. Obwegeser HL: Correction of skeletal anomalies of oromandibular dysostosis, *J Maxillofac Surg* 2:73, 1974.
98. Obwegeser HL, Hadjiianghelou O: Two ways to correct bird face deformity, *Oral Surg* 64:507, 1987.
99. Opitz C, Ring P, Stoll C: Orthodontic and surgical treatment of patients with congenital unilateral and bilateral mandibulofacial dysostosis, *J Orofac Orthop* 65:150, 2004.
100. Posnick JC: Occlusal plane rotation: aesthetic enhancement in mandibular micrognathia [discussion], *Plast Reconstr Surg* 91:1241, 1993.
101. Posnick JC: Orthognathic surgery treatment planning. *Orthognathic surgery: principles and practice*, St Louis, 2014, Elsevier, Ch 12, pp 337–373.
102. Posnick JC: Treacher Collins syndrome: perspectives in evaluation and treatment, *J Maxillofac Surg* 155(10):1120–1133, 1997.
103. Posnick JC, Fantuzzo J, Orchin J: Deliberate operative rotation of the maxillo-mandibular complex to alter the A-point to B-point relationship for enhanced facial esthetics, *J Oral Maxillofac Surg* 64:1687–1695, 2006.
104. Raulo Y: Treacher Collins syndrome: analysis, principles of treatment. In Caronni EP, editor: *Craniofacial surgery*, Boston, 1985, Little, Brown.
105. Raulo Y, Tessier P: Mandibulofacial dysostosis, *Scand J Plast Reconstr Surg* 15:251, 1981.
106. Rosen HM: Occlusal plane rotation: aesthetic enhancement in mandibular micrognathia, *Plast Reconstr Surg* 91:1231, 1993.
107. Tessier P, Tulasne JF: Stability in the correction of hypertelorbitism and Treacher Collins syndromes, *Clin Plast Surg* 16:195, 1989.
108. Tessier P: Complications associated with the harvesting of cranial bone grafts [discussion], *Plast Reconstr Surg* 95:14, 1995.
109. Clauser L, Curioni C, Spanio S: The use of the temporalis muscle flap in facial and craniofacial reconstructive surgery: a review of 182 cases, *J Craniomaxillofac Surg* 23:203, 1995.
110. Freihofer HPM, Borstlap WA: Reconstruction of the zygomatic area, *J Craniomaxillofac Surg* 17:43, 1989.
111. Hurwitz DJ: Long-term results of vascularized cranial bone grafts, *J Craniofac Surg* 5:237, 1994.
112. Tessier P: Autogenous bone grafts taken from the calvarium for facial and cranial application, *Clin Plast Surg* 9:531, 1982.
113. Tessier P: Facial contouring in the Treacher Collins-Franceschetti syndrome. In Brent B, editor: *The artistry of reconstructive surgery*, St Louis, 1987, CV Mosby, p 343.
114. Tessier P, Tulasne J: Treacher Collins syndrome. In Marchac D, editor: *Craniofacial surgery*, New York, 1985, Springer-Verlag.
115. Daniels S, Ellis III E, Carlson DS: Histologic analysis of costochondral and sternoclavicular grafts in the TMJ of the juvenile monkey, *J Oral Maxillofac Surg* 45:675, 1987.
116. Freihofer HPM: Four-step mandibular lengthening to correct a bird-face deformity, *Acta Stomatol Belg* 87:189, 1990.
117. Freihofer HPM: Variations in the correction of Treacher Collins syndrome, *Plast Reconstr Surg* 99:647, 1997.
118. Hennig TB, Ellis III E, Carlson DS: Growth of the mandible following replacement of the mandibular condyle with the sternal end of the clavicle: an experimental investigation in *Macaca mulatta*, *J Oral Maxillofac Surg* 50:1196, 1992.
119. Ilizarov GA: The principles of the Ilizarov method, *Bull Hosp Joint Dis Orthop Inst* 48:1, 1988.
120. Kaban LB, Seldin EB, Kikinis R, et al.: Clinical application of curvilinear distraction osteogenesis for correction of mandibular deformities, *J Oral Maxillofac Surg* 67:996–1008, 2009.
121. Wolford L: Occlusal plane alteration in orthognathic surgery—Part I: Effects on function and esthetics, *Am J Orthod Dentofacial Orthop* 106(3):304–316, 1994.
122. Fuente del Campo A, Martinez Elizondo M, Arnaud E: Treacher Collins syndrome (mandibulofacial dysostosis), *Clin Plast Surg* 21:613, 1994.
123. Garcia-Cimbrelo E, Olsen B, Ruiz-Yague M, et al.: Ilizarov technique: results and difficulties, *Clin Orthop* 283:116, 1992.
124. Hopper RA, Altug AT, Grayson BH, et al.: Cephalometric analysis of the consolidation phase following bilateral pediatric mandibular distraction, *Cleft Palate Craniofac J* 40:233, 2003.
125. James D, Ma L: Mandibular reconstruction in children with obstructive sleep apnea due to micrognathia, *Plast Reconstr Surg* 100:1131, 1997.
126. Karp NS, Thorne CHM, McCarthy JG, et al.: Bone lengthening in the craniofacial skeleton, *Ann Plast Surg* 24:231, 1990.
127. McCarthy JG, Schreiber J, Karp N, et al.: Lengthening the human mandible by gradual distraction, *Plast Reconstr Surg* 89:1, 1992.
128. Molina F: A CT scan technique for quantitative volumetric assessment of the mandible after distraction osteogenesis [discussion], *Plast Reconstr Surg* 99:1248, 1997.
129. Molina F, Ortiz-Monasterio F: Mandibular elongation and remodeling by distraction: a farewell to major osteotomies, *Plast Reconstr Surg* 96:825, 1995.
130. Moore MH, Guzman-Stein G, Proudman TW, et al.: Mandibular lengthening by distraction for airway obstruction in Treacher Collins syndrome, *J Craniofac Surg* 5:22, 1994.
131. Sengezer M: Mandibular lengthening by gradual distraction [letter], *Plast Reconstr Surg* 92:372, 1993.
132. Sidman J, Sampson D, Templeton B: Distraction osteogenesis of the mandible for airway obstruction in children, *Laryngoscope* 111:1137, 2001.
133. Silla Freitas R, Tolazzi ARD, Alonso N, Cruz GA: Evaluation of molar teeth and buds in patients submitted to mandibular distraction: long-term results, *J Plast Reconstr Surg* 121:1335–1342, 2010.

134. Snyder CC, Levine GA, Swanson HM, et al.: Mandibular lengthening by gradual distraction, *Plast Reconstr Surg* 51:506, 1973.
135. Stelnicki E, Boyd J, Nott R, et al.: Early treatment of severe mandibular hypoplasia with distraction mesenchymogenesis and bilateral free fibula flaps, *J Craniofac Surg* 12:337, 2001.
136. Stelnicki E, Lin W, Lee C: Long-term outcome study of bilateral mandibular distraction: a comparison of Treacher Collins and Nager syndromes to other types of micrognathia, *Plast Reconstr Surg* 109:2002, 1819.
137. Wittenborn W, Panchal J, Marsh J, et al.: Neonatal distraction surgery for micrognathia reduces obstructive sleep apnea and the need for tracheotomy, *J Craniofac Surg* 15:623, 2004.
138. Fan K, Andrews BT, Liao E, et al.: Protection of the temporomandibular joint during syndromic neonatal mandibular distraction using condylar unloading, *Plast Reconstr Surg* 129:1151–1161, 2012.
139. Baas EM, Horsthuis RBG, Lange JD: Subjective alveolar nerve function after bilateral sagittal split osteotomy or distraction osteogenesis of mandible, *J Oral Maxillofac Surg* 70:910–918, 2012.
140. Posnick JC: Discussion: midface growth after costochondral graft reconstruction of the mandibular ramus in hemifacial microsomia, *J Oral Maxillofac Surg* 56:127–128, 1998.
141. Raustia A, Pernu H, Pyhtinen J, et al.: Clinical and computed tomographic findings in costochondral grafts replacing the mandibular condyle, *J Oral Maxillofac Surg* 54:1393, 1996.
142. Wijbenga JG, Verlinden CR, Jansma J, et al.: Long lasting neurosensory disturbance following advancement of the retrognathic mandible: distraction osteogenesis versus bilateral sagittal split osteotomy, *Int J Oral Maxillofac Surg* 38:719, 2009.
143. Ellis III E, Carlson DS: Histologic comparison of the costochondral, sternoclavicular, and temporomandibular joints during growth in, *Macaca mulatta, J Oral Maxillofac Surg* 44:312, 1986.
144. Gui L, Zhang Z, Zang M, et al.: Restoration of facial symmetry in hemifacial microsomia with mandibular outer cortex bone grafting combined with distraction osteogenesis, *Plast Reconstr Surg* 127:1997–2004, 2011.
145. Wan D, Taub P, et al.: Distraction osteogenesis of costocartilaginous rib grafts and treatment algorithm for severely hypoplastic mandibles, *Plast Reconstr Surg* 127:2005–2013, 2011.
146. Longaker MT, Flynn A, Siebert JW: Microsurgical correction of bilateral facial contour deformities, *Plast Reconstr Surg* 98:951, 1996.
147. Longaker MT, Siebert J: Microsurgical correction of facial contour in congenital craniofacial malformations: the marriage of hard and soft tissue, *Plast Reconstr Surg* 98:942, 1996.
148. Saadeh P, Reavey PL, Siebert JW: A soft-tissue approach to midfacial hypoplasia associated with Treacher Collins syndrome, *Ann Plast Surg* 56:522–525, 2006.
149. Siebert J, Anson G, Longaker M: Microsurgical correction of facial asymmetry in 60 consecutive cases, *Plast Reconstr Surg* 97:354, 1996.
150. Tanna N, Wan DC, Kawamoto HK, Bradley JP: Craniofacial microsomia soft-tissue reconstruction comparison: inframammary extended circumflex scapular flap versus serial fat grafting, *Plast Reconstr Surg* 127:802, 2011.
151. Grahovac TL, Rubin JP: Discussion: an analysis of the experiences of 62 patients with moderate complications after full-face fat injection for augmentation, *Plast Reconstr Surg* 129:1369, 2012.
152. Kim SM, Kim YS, Hong JW, et al.: An analysis of the experiences of 62 patients with moderate complications after full-face fat injection for augmentation, *Plast Reconstr Surg* 129:1359, 2012.
153. Brent B: Auricular repair using autogenous rib cartilage grafts: two decades of experience with 600 cases, *Plast Reconstr Surg* 90:355, 1992.
154. Brent B: Advances in ear reconstruction with autogenous rib cartilage grafts: personal experience with 1200 cases, *Plast Reconstr Surg* 104:319, 1999.
155. Brent B: The team approach to treating the microtia atresia patient, *Otolaryngol Clin North Am* 33:1353, 2000.
156. Brent B: Microtia repair with rib cartilage grafts: a review of personal experience with 1000 cases, *Clin Plast Surg* 29:257, 2002.
157. Cao Y, Vacanti JP, Paige KT, et al.: Transplantation of chondrocytes utilizing a polymer-cell construct to produce tissue-engineered cartilage in the shape of a human ear, *Plast Reconstr Surg* 100:297, 1997.
158. Firmin F: Ear reconstruction in cases of typical microtia: personal experience based on 352 microtic ear corrections, *Scand J Plast Reconstr Surg Hand Surg* 32:35, 1998.
159. Kobus K, Szczyt M, Latkowski I, Wojcicki P: Reconstruction of the auricle, *Br J Plast Surg* 55:645, 2002.
160. Kobus K, Wojcicki P: Surgical treatment of Treacher Collins syndrome, *Ann Plast Surg* 56:549, 2006.
161. Posnick JC, Al-Qattan MM, Whitaker LA: Assessment of the preferred vertical position of the ear, *Plast Reconstr Surg* 91(7):1198–1203, 1993.
162. Saadeh PB, Brent B, Mehrara BJ, et al.: Human cartilage engineering: chondrocyte extraction, proliferation, and characterization for construct development, *Ann Plast Surg* 42:509, 1999.
163. Somers T, De Cubber J, Govaerts P, Offeciers FE: Total auricular repair: bone anchored prosthesis or plastic reconstruction? *Acta Otorhinolaryngol Belg* 52:317, 1998.
164. Tanzer RC: Total reconstruction of the external ear, *Plast Reconstr Surg* 23:1, 1959.
165. Tanzer RC: Total reconstruction of the auricle: the evolution of a plan of treatment, *Plast Reconstr Surg* 47:523, 1971.
166. Tollefson TT: Advances in the treatment of microtia, *Curr Opin Otolaryngol Head Neck Surg* 14:412, 2006.
167. Walton RL, Beahm EK: Auricular reconstruction for microtia: Part II. Surgical techniques, *Plast Reconstr Surg* 110:234, 2002.
168. Colquitt JL, Jones J, Harris P, et al.: Bone anchored hearing aids (BAHAs) for people who are bilaterally deaf: a systematic review and economic evaluation, *Health Technol Assess* 15(26):1–200, 2011.
169. Janssen RM, Hong P, Chadha NK: Bilateral bone-anchored hearing aids for bilateral permanent conductive hearing loss: a systematic review, *Otolaryngol Head Neck Surg* 147:412–422, 2012.

41

The Management of Pediatric Craniomaxillofacial Pathology

JOHN F. CACCAMESE JR., ROBERT A. ORD, ANDREW R. SALAMA

Introduction

The term *pathology* can be all encompassing, and strictly speaking is defined as structural and functional deviations from normal that constitute disease or characterize a particular disease. In essence, this often refers to diseases that are aplastic, hypoplastic, neoplastic, traumatic, iatrogenic, or developmental in nature. For purposes of this chapter, we will limit our discussion to neoplastic and dysplastic diseases in children.

Although the origins of craniofacial surgery developed out of the need to comprehensively treat congenital pediatric deformities and traumatic injuries, the application of such principles to the treatment of neoplastic disease soon followed. Craniomaxillofacial (CMF) pathology presents the surgeon with the challenges of access, achieving oncologic margins, and preservation of vital structures, along with a functional and esthetic reconstruction. More specifically, tumors affecting the anterior cranial fossa, the anterior skull base, and the infratemporal fossa are often the domain of the maxillofacial surgeon and require the assistance of a neurosurgeon. Often more challenging than the approach to the tumor is the determination of resectability and whether the burden of morbidity outweighs the benefit of complete resection. Increasingly, there has been a role for endoscopic assisted, robotic, and image-guided resection of tumors, with the potential for improving both functional and esthetic outcomes.

Craniofacial Growth and Development

Cranial and facial growth and development results from complex interrelated and interdependent processes, with no single craniofacial component being self-contained or self-regulated.[1] Growth occurs as a result of a combination of remodeling and displacement. There are three primary fields of craniofacial growth and development; the brain and basicranium, the airway, and the oral region. The basicranium acts as a template to establish the shape and perimeter of facial form. The facial and pharyngeal airway space is determined largely by its surrounding parts. Enlow refers to the airway as the *keystone* for the face, whose growth is determined in part by both genetics and function, and acts to stabilize the remaining components of the face. The oral region either then assumes any basicranial asymmetry or compensates for the asymmetry by its own developmental process.[1] The effect of extirpative surgery or tumor treatment on facial growth and development may be significant though unavoidable if efforts are made to achieve a cure. One must consider these factors, not only when planning treatment, but also in long-term follow-up because subsequent deformity may have considerable psychosocial impact.

Imaging

Improvements in the quality of imaging and the ability to manipulate the images, whether it is to plan surgery, to guide the resection of a tumor in real time, or to fabricate a medical model, have had a profound impact in the treatment of CMF pathology. Imaging is particularly helpful because the full extent of the tumors often is not assessable by physical examination alone. The craniofacial region is relatively dense with vital structures, and appropriate preoperative images help to further elucidate their relationship to the pathologic process. This can be critical to determining resectability.

Typically, the imaging modalities used in the workup of CMF pathology include computed tomography (CT) and magnetic resonance imaging (MRI), with an increasing role for positron emission tomography (PET) and PET-CT. Occasionally, ultrasound, angiography, and bone scans have a role as well. At a minimum, a high-resolution CT or MRI is necessary for appropriate planning. The need for contrast is determined on a case-by-case basis. Software is

readily available for the surgeon to reformat images into the standard axial, coronal, and sagittal views as well as three-dimensional (3D) images for CT scans. In general, CT is less expensive and is preferred for detailing bony pathology and anatomy, tumor bulk, and node involvement. MRI is commonly considered to be superior for purely soft tissue lesions, detailed evaluation of nerves and vessels, and for lesions involving the brain or dura. With concerns over lifetime radiation exposure and the cumulative risk involved, the role of MRI is increasing, specifically in the pediatric population.

The use of PET scanning continues to grow rapidly in the field of oncology. It is often most useful in situations where conventional imaging yields equivocal results, as in the previously treated patient. PET scans help to differentiate surgical change from recurrence and reactive nodes from those with metastasis. Overall, PET has been found to be more sensitive and specific than conventional imaging in the evaluation of regional node disease. PET also has value in evaluating patients for unknown primary tumors, synchronous primaries, and distant metastasis.[2]

Angiography is routinely used for the evaluation of vascular lesions. Although MR angiography is becoming increasingly sophisticated in the diagnosis of such lesions, conventional angiography offers the benefit of interventional capability should the lesion mandate embolization. Angiography is also useful in determining the extent of carotid involvement of either direct tumor extension or metastatic disease. If carotid resection is deemed necessary, a carotid occlusion study can be performed to assess the patient's ability to function when reliant on the collateral circulation from the unaffected side via the circle of Willis.

With the continuous improvement of imaging techniques, the envelope of surgical possibility becomes increasingly limitless. By integrating surgery with the real-time manipulation and guidance of imaging, we are able to visualize various images simultaneously, see structures that are otherwise only visible through operative access, and improve the accuracy of surgery in difficult anatomic regions. Potential advantages might include smaller incisions, direct access to specific localized areas, and less morbid or invasive operations.[3]

Anatomic Classification

For the planning of craniofacial tumor surgery, Jackson classified the skull base into an anterior region and a posterior region to describe tumor location. The anterior region includes only the anterior cranial fossa. The posterior region was further broken down into anterior, central, and posterior segments relative to the petrous portion of the temporal bone.[4] Others have elaborated further on the site of origin (oral, nasal, cranial, etc.) and the direction of extension (craniofacial or faciocranial) and let this be their guide to approaching CMF tumors.[5] In this chapter, we will discuss pathology of the anterior fossa and anterior skull base, the infratemporal fossa, the mid-face, and the mandible.

Within the facial skeleton, simple anatomic description modified by degree of extension helps one plan most accurately the surgical extirpation and the required reconstruction.

CMF Access

Many approaches to the facial skeleton have been advocated based on the location of the tumor, the necessity of safe resection margins, the proximity to vital anatomic structures, and the anticipated functional and esthetic outcome. Access surgery involves a multitude of osteotomies and facial incisions that can be tailored for specific purposes: when combined, these procedures produce acceptable safety for oncologic surgery. The craniofacial skeleton is rich in anatomic complexity. Surgery to the deep face, oropharynx, nasopharynx, and anterior skull base requires thoughtful planning. Although myriad approaches to the craniofacial skeleton and anatomic tumor classifications have been described, patients and their pathology should be evaluated on an individual basis. The goal of access surgery is to provide an operative environment in which the extirpative surgeon can safely remove tumor. This basic philosophy accounts for the protection of vital structures and maintenance of facial esthetics. The value of preoperative planning for access surgery cannot be overemphasized and should entail a comprehensive patient evaluation including high-resolution 3D imaging and a thorough review of the underlying pathology. Conceptualization of a tumor in space relative to surrounding structures is requisite to the operative phase of surgery.

Access to the superficial facial skeleton is relatively straightforward through a variety of common, well-described approaches. The workhorse incision of craniofacial surgery is the coronal incision. It provides broad access to the orbit and upper mid-face, and can be modified or combined with lateral orbital, oral, facial, and nasal incisions to provide near total access to the anterior or lateral cranial base and facial skeleton. The disadvantages include the potential for obvious scarring in patients with male pattern baldness, alopecia, and injury to the frontal branch of the facial nerve, which can be avoided with judicious tissue dissection beneath protective layers of the temporalis fascia and avoidance of monopolar cautery. Noticeable scarring can be addressed and somewhat obviated by the use of the stealth incision, which applies a zigzag incision rather than a straight line, eliminating the obvious part in the hair.[6]

Access to the anterior orbit, including the infraorbital rim and floor, can be obtained through cutaneous and conjunctival incisions. Skin incisions have the benefit of improved access in some situations and may be the most appropriate to achieve an oncologically sound resection. When managing benign pathology or performing a recontouring procedure (e.g., fibrous dysplasia), a transconjunctival approach

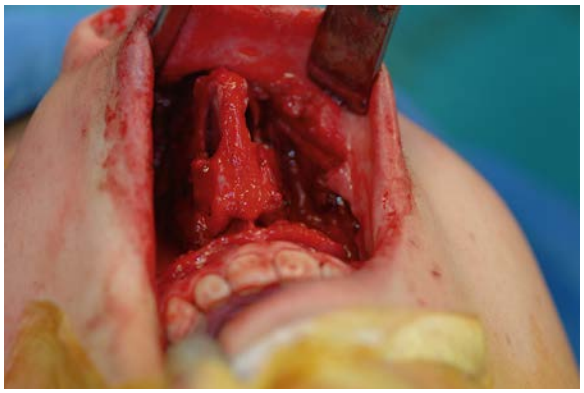

• **Figure 41-1** A mid-face degloving is performed using intercartilaginous incisions extended circumferentially within the nares and through the septum to liberate the nasal tip, upper lip, and oral mucosa from the underlying maxilla and nasal structures.

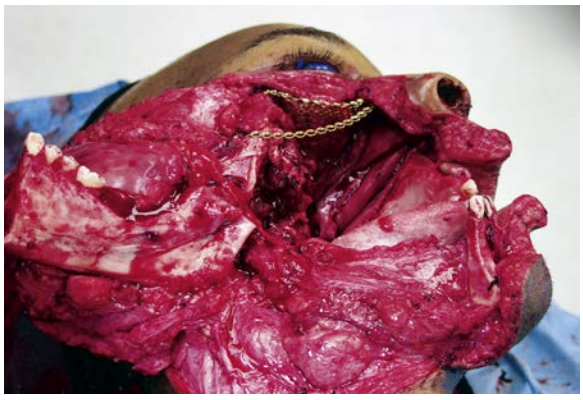

• **Figure 41-2** This patient required combined access for a large maxillary osteosarcoma involving the infratemporal fossa. A Weber-Ferguson incision was combined with a lip split and double mandibular osteotomy.

might provide a more esthetic outcome. Extension via lateral canthotomy/cantholysis or transcaruncular incision gives one near total access to the internal bony orbit and the lower half of the orbital rim. The medial orbital wall can also be approached by a subciliary lid incision, although the transcaruncular approach affords generous access behind the lacrimal system, all without a skin incision. Tumors in the paranasal sinuses that invade or abut the medial orbital wall typically require both a skin incision along the lateral nasal wall and a complementary osteotomy. The Weber-Ferguson approach, lateral rhinotomy, and medial maxillectomy are commonly employed in this circumstance.

Surgical access to the lower bony mid-face can be achieved by means of standard vestibular incisions. The mid-face degloving procedure extends exposure comfortably to the inferior orbital rim and nasal dorsum, and when combined with additional incisions and a craniotomy, this can be used to access the anterior skull base and sinonasal regions without the need for facial incisions. Fundamental knowledge of intranasal rhinoplasty techniques is applied, which includes intercartilaginous incisions extended circumferentially within the nares and through the membranous septum to liberate the nasal tip, upper lip, and oral mucosa from the underlying maxilla and nasal structures (Figure 41-1). More generous and direct access to the mid-face can be achieved with a Weber-Ferguson incision.

Access to the mandibular body and symphyseal regions can be achieved through mucosal and cervical incisions. Knowledge of the path of the facial nerve in the neck is essential to protect its marginal mandibular branch. The utility incision for mandibular access is an apron-style incision and is designed in a skin crease at least 2 cm below the inferior border of the mandible. Elevation of the facial vein at the mid to posterior lateral aspect of the submandibular gland, in the manner of Hayes Martin, generally affords protection of the marginal mandibular branch without the need for extensive nerve localization or dissection. Tumor in the mandibular angle, ascending ramus, and pterygomasseteric portion of the mandible requires more in-depth planning, depending on the extent of the tumor and need for appropriate surgical margins. Access to condyle for complete hemimandibulectomy can generally be achieved through a cervical incision. The preauricular approach and coronal approach can be used adjunctively with bulky tumors confined to the head of the condyle. An apron-style incision can be extended to include the lip-split modification and mandibulotomy, which affords direct visualization of the pterygoids and medial aspect of the condyle. Vertical compartment resection of the mandible enables en bloc removal of the vertical ramus and is reserved for tumors that infiltrate the muscle of the pterygomasseteric sling. It requires a subfascial parotid dissection in the plane of the masseter muscle or a standardized facial nerve dissection; both approaches carry risk of injury to the branches of the facial nerve.

Small tumors of the oral cavity (less than 4 cm) can generally be treated transorally. Larger tumors of the posterior tongue, tongue base, and retromolar fossa can be safely approached through an apron/lip-split incision and a paramedian mandibulotomy. The osteotomy can be performed in the midline, although lateral placement in the premolar region still preserves the mental nerve and is generally preferable. The inferior border of the mandible is exposed and miniplates are adapted, secured, and then removed. The osteotomy is then performed and the indexed hardware replaced in the reconstructive phase to restore the premorbid occlusion and mandibular continuity. A horizontal ramus osteotomy can be used adjunctively (double mandibular osteotomy) and can obviate the need for a lip-split incision (Figure 41-2).[7] The stability of rigid fixation is important, because many patients are subjected to external beam radiotherapy before bony healing is complete. The use of a bicortical mini-locking plate has a biomechanical advantage when used at the inferior border.[8] Mucosal incisions should be designed not to overlap the osteotomy. A variety of modifications have been suggested to enhance the stability of the reconstructed mandible, however they are largely unnecessary if AO principles of rigid fixation are applied. Disadvantages of these approaches include the added time in the operating room, potential for nonunion

in the face of radiation, malocclusion, and trismus. The visor approach entails the raising of bilateral apron-style incisions toward the inferior border of the mandible, which are then connected with sulcular or vestibular incisions. The mental nerves are identified and divided as part of the process. It provides broad access to the lateral tongue and floor of mouth. Access to the floor of mouth can be also achieved through a delivery/pull-through approach. Following exposure of the inferior border of the mandible, the geniohyoid, genioglossus, and mylohyoid muscles are divided at their insertions to the mandible. The lingual mucosa is then elevated in a sulcular or vestibular incision on the lingual aspect of the mandible. The entire tongue and floor of mouth can be safely "delivered" to the neck for tumor removal. The use of a sulcular incision in dentate patients facilitates easy closure.

Access to the central skull base and nasopharynx can be approached through the oral cavity through the use of a standard Le Fort I down-fracture. The lateral osteotomies of the Le Fort may need to be modified to maintain oncologic integrity of the approach, in the form of low osteotomies or limited use of pterygoid separation in the face of gross tumor infiltration. Removal of the posterior wall of the maxilla provides direct access to the nasopharynx. The use of indexed miniplates and/or occlusal splints is recommended to restore the occlusion in the reconstructive phase. A two-piece Le Fort I osteotomy broadens access, although the palatal mucosa must be incised to complete the exposure. The relationship of blood supply to the translocated structure(s) should be considered along with the planned resection to avoid ischemic complications.

Access to the anterior skull base usually entails a combination of surgical approaches rather than a single approach. Access to the paranasal sinuses and fronto-orbital regions typically involves a facial approach and either a cranial or subcranial approach (Figure 41-3). Each must be tailored to the patient and the location and extension of the tumor. Avoiding a craniotomy has intrinsic advantages, especially in patients with multiple medical comorbidities. The subcranial approach entails the use of custom osteotomies about the anterior craniofacial skeleton. A frontal sinusotomy without removal of the posterior wall allows safe access to the ethmoids and frontal sinus and obviates the need for a craniotomy. Tumors that approach the dura or invade the dura require a formal bifrontal craniotomy. The craniotomy should be planned keeping the both the extirpation and reconstruction in mind (Figure 41-4). The craniotomy can be extended caudally to include the superior and lateral orbital rims as necessitated for access. The bone flap not only provides access, but can also be split into calvarial grafts to facilitate bony reconstruction.

Craniofacial disassembly employs the concept of modular facial anatomic units, developmental embryology, and blood supply. Transfacial swing procedures in which the orbit, maxilla, and mandible are osteotomized in variable combinations allow exposure of the midline of the cranial base. Nasomaxillary translocation involves complete separation of the nasal skeleton and at least half of the maxilla. It is best suited for exposure of the lower clivus. The blood supply of the rotated unit is maintained and reconstruction is simplified with indexed microplating. Fronto-orbital osteotomies are utilized for large orbital tumors, internal carotid artery exposure, and orbital apex decompression.

Endoscopic Approaches

More and more, endoscopic approaches are being used for tumor resection or to assist in tumor removal along with conventional approaches. The clear advantage to this technique is the avoidance of facial incisions, which in and of themselves might result in permanent disfigurement. In addition, endoscopic approaches may obviate the need for wide periosteal dissections and osteotomies that could interfere with facial growth. In some cases the use of endoscopes allows the surgeon to "look around" the tumor, which is often not possible with conventional skull base access. Rapid healing and return to function as well as shortened hospital stays are further benefits of the technique.

In the hands of a skilled endoscopic surgeon, the potential advantages are clear. The learning curve is steep, however, and until one is facile with the technique, possible disadvantages include increased operative time, increased blood loss, decreased access to control hemorrhage, and incomplete tumor removal. One can always convert to an open procedure when appropriate to maximize the possibility of surgical success.

Pathology

Benign and malignant tumors involving the CMF structures are relatively rare occurrences in children.[9-12] The treatment of these tumors is based primarily on their biologic behavior, as well as location and size. Although cure is the ultimate goal, significant consideration must be given to the functional, developmental, esthetic, and psychosocial consequences of treatment, whether surgical or medical. For surgical disease, immediate reconstruction with grafting and free tissue transfer has become more readily accepted.

Benign disease of the jaws is generally classified into odontogenic and nonodontogenic tumors. With the exception of odontomas, odontogenic tumors are rare in children and are classified into epithelial, mesenchymal, and mixed tumors. Of these, the ameloblastoma is often considered to be the most aggressive.

Odontogenic Tumors

Odontogenic tumors are thought to arise from the cells that form teeth. They are usually classified into those arising from epithelial, mesenchymal, or mixed origin. Most are benign and, although they can be seen at any age, some have a higher incidence in children or behave differently in the pediatric patient; these tumors will be discussed in this section.

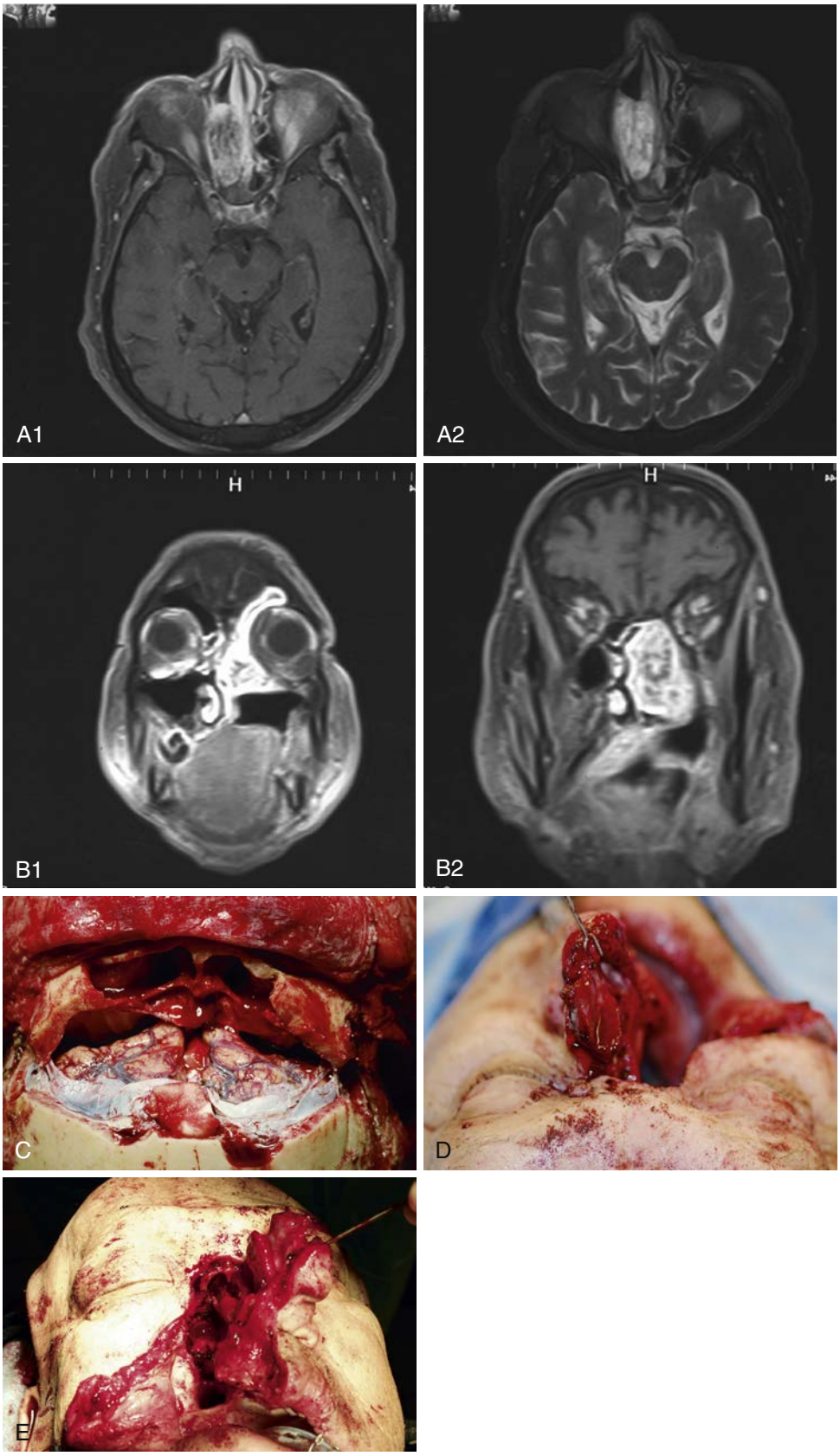

• **Figure 41-3** **A** and **B,** MRI demonstrating ameloblastoma involving paranasal sinuses and anterior skull base. **C,** Craniotomy to access anterior cranial base and frontal sinuses from above. **D** and **E,** Weber-Ferguson incision for access to medial maxilla and ethmoid sinuses.

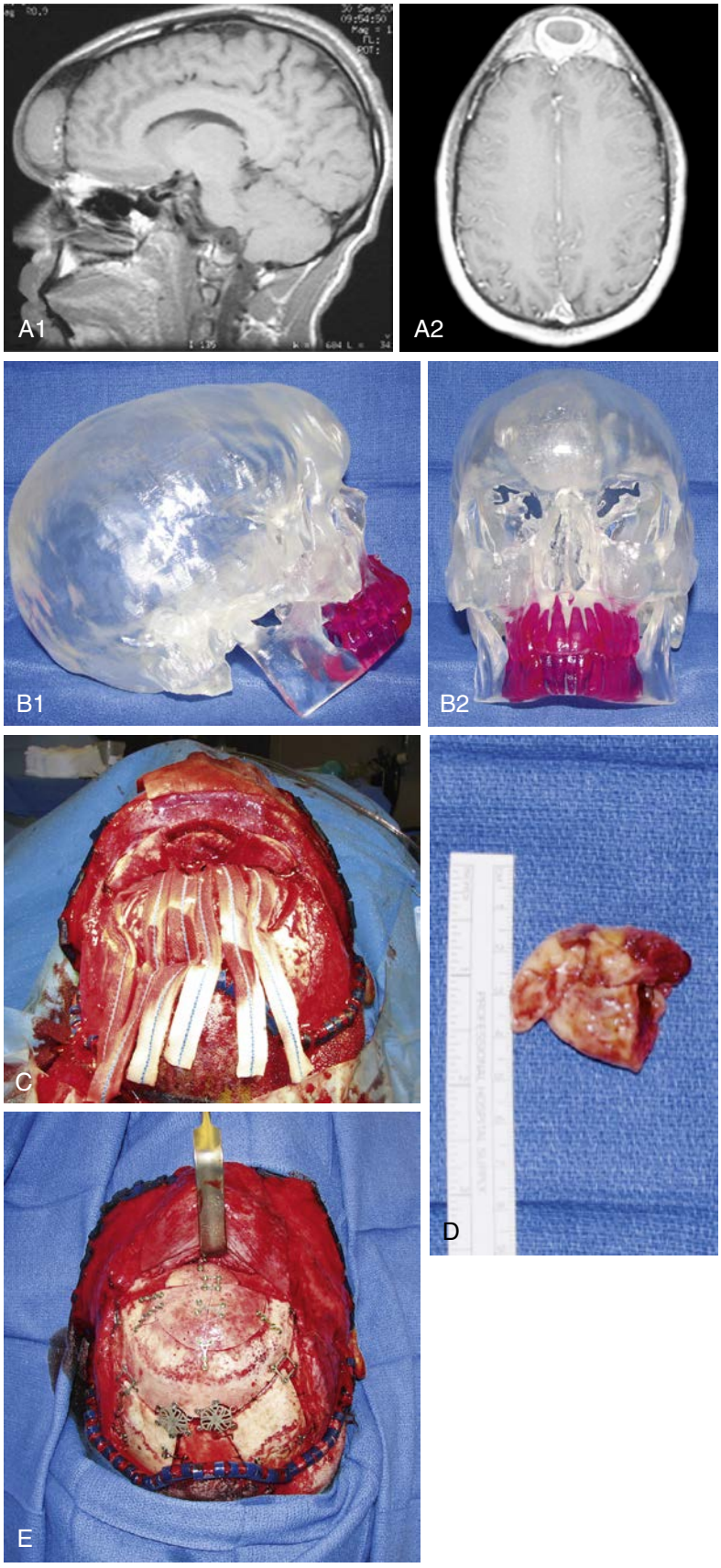

• **Figure 41-4** **A,** MRI demonstrating ossifying fibroma of the frontal sinus approaching the dura. **B,** Medical model demonstrating the frontal bone deformity. **C,** Access via bifrontal craniotomy demonstrating the lesion in situ. **D,** Ossifying fibroma. **E,** Reconstructed frontal bone (Note: bilateral full-thickness parietal bone flaps were raised and the inner table used for the reconstruction).



• **Figure 41-5** A 19-year-old African American boy with "presumed" dentigerous cyst. However, note resorption of distal root of second molar. Histologically this is a unicystic ameloblastoma.

Ameloblastoma

Ameloblastoma is the most common odontogenic jaw tumor and it is most commonly seen in the fourth decade. It is benign but aggressive and is divided into unicystic and multicystic/solid types. It is not common in the pediatric population, only comprising 12% to 15% of patients younger than 19 to 20 years old and very rare in children younger than 10 years.[13-15] In our original paper we found an incidence of 28.9% (11 of 38 cases), but we included adults with recurrent lesions who were originally treated as children.[16] Clinical presentation is usually of a painless swelling at the angle of the mandible which radiologically may be uni- or multilocular and may involve unerupted teeth, mimicking a dentigerous cyst, although root resorption may alert the clinician to a more aggressive lesion (Figure 41-5). There is usually buccal and lingual expansion of bone. Frequently the diagnosis is made as an asymptomatic incidental finding on a panoramic radiograph. However, the importance of recognizing pediatric ameloblastoma as an entity lies in the greatly increased percentage of lesions characterized as unicystic. Unicystic ameloblastomas comprise approximately 15% of all ameloblastomas, but represent 76.5% of pediatric cases reported in Europe and the United States.[16,17]

Unicystic ameloblastoma is a diagnosis that is based on the histologic characteristics, not the radiologic appearance. Ackermann et al classified these into four types: Type I and II are intraluminal or epithelial lining only while Type III and IV involve the capsule (mural types).[17] The clinical importance is that the solid/multicystic type is more aggressive and has higher recurrence rates when treated with modalities other than segmental resection. Resection is recommended for mural types to prevent recurrence with soft tissue invasion, while low recurrence rates (10% to 25%) from enucleation alone of unicystic ameloblastoma has classically been described.[18-20] Most papers group all unicystic ameloblastomas together and do not separate out those unicystic ameloblastomas with capsular involvement. Whether enucleation alone is sufficient in this group remains controversial. Involvement of the capsule in unicystic ameloblastoma has been reported to be as high as 49% to 81%.[17,19] It is not uncommon to experience sampling bias in unicystic ameloblastomas. Oral and maxillofacial pathologists may be reluctant to commit to or have insufficient tissue to assign a particular subtype to a unicystic ameloblastoma based on an incisional biopsy alone. Lower grade lesions that are enucleated with curative intent may require additional surgery if the final pathology report indicates a more aggressive subtype.

A recent report indicates recurrence rates of approximately 80% in unicystic ameloblastomas treated by enucleation, although numbers were small.[21] A systematic review to determine which modality of treatment resulted in the lowest recurrence rate showed a rate of 3.6% for resection, 30.5% for enucleation alone, 16% for enucleation and application of Carnoy's solution, and 18% for marsupialization. The authors concluded that there was only weak evidence to show that resection resulted in the lowest recurrence rate, with enucleation alone showing the highest recurrence rate. Marsupialization could not be evaluated.[22] In pediatric cases we undertake segmental resection with primary microvascular reconstruction for all multicystic/solid ameloblastomas and all unicystic ameloblastomas that are large enough to compromise mandibular integrity or involve soft tissue. Unicystic ameloblastomas with tumor involving just the lining or the lumen of the cyst are treated by enucleation, but we advocate resection for mural unicystic ameloblastomas.

Adenomatoid Odontogenic Tumor

Approximately 66% occur in patients aged 10 to 19 years. They are common in females and in the anterior maxilla. They present as a swelling in the canine, bicuspid region, and can have unerupted teeth involved. Frequently, they contain small calcifications that may be peripheral and give them a mixed radiolucent/radio-opaque appearance on x-ray. They are treated by enucleation, and recurrence is rare. The low recurrence rate may be due to these lesions being hamartomas rather than true tumors, or to their low proliferative

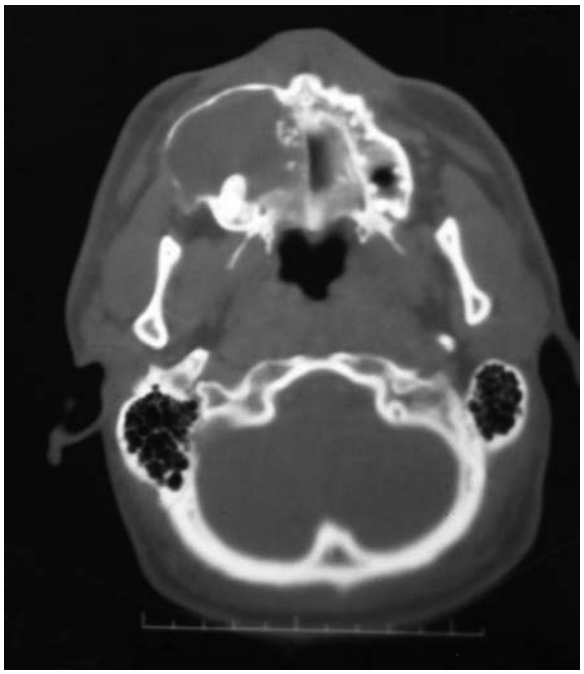

• **Figure 41-6** Large adenomatoid odontogenic tumor displacing alveolar ridge, palate, and displacing teeth.

rate seen with a Ki-67 marker.[23,24] They are usually small and removal is simple, but occasionally they may present as large lesions (Figure 41-6).

Odontogenic Myxoma

Odontogenic myxomas are most common in patients 20 to 30 years old, but are seen in children and only rarely in infants. They may appear as a painless swelling of the mandible or maxilla. Radiographically, they may be unilocular or multilocular; however, larger lesions are usually multilocular.[25] They may show root resorption, similar to the ameloblastoma. Often they contain thin bony trabeculae which classically show a step-ladder appearance, although they may show an expanded "soap bubble" appearance (Figure 41-7). CT may help to define soft tissue infiltration outside the cortical bone.[26] They are infiltrative and display many of the pathologic characteristics of ameloblastomas. Despite a pathobiology similar to solid ameloblastoma, some authorities have recommended enucleation/curettage for smaller lesions, which leads to recurrence in 25% of cases.[27] The authors believe in resection with 1 cm margins, especially for posterior maxillary lesions that can lead to recurrent tumors invading the pterygoids, orbit, and skull base if curetted. Some authors have advocated maxillectomy with narrow margins in pediatric maxillary myxomas.[28]

Ameloblastic Fibroma

This tumor contains neoplastic elements deriving from both epithelium and mesenchyme. Some of these lesions may be considered as early developing odontomas as opposed to true tumors. They are mostly seen in children less than 20 years of age, and the majority occur in the posterior mandible either as a swelling in larger cases or are noted incidentally on screening radiographs as a well-defined unilocular or multilocular lesion (Figure 41-8). Many reports suggest that recurrence following simple curettage is rare; however, recent reports have indicated recurrence rates of up to 20% and recommend complete surgical excision.[29,30] Although the malignant counterpart, ameloblastic fibrosarcoma, is rare, approximately 50% of cases have been reported as a recurrence in a previous benign ameloblastic fibroma. Although the ameloblastic fibroma is usually treated by curettage or simple excision, recurrent lesions may require resection. In cases of malignant ameloblastic fibroma, radical resection provides a greater opportunity for local control.

Ameloblastic Fibro-odontoma

Ameloblastic fibro-odontomas are frequently seen in children less than 10 years of age. Histologically, they resemble the ameloblastic fibroma, but contain enamel and dentin. Although this lesion again may represent a stage in odontoma formation, some lesions continue to grow and behave like a true neoplasm (Figure 41-9). Clinically, they occur as swellings of the maxilla or mandible. On radiographs they are radiolucent lesions containing differing amounts of calcifications and usually containing an unerupted tooth. Treatment is by curettage and recurrences are rare.

Odontoma

Odontomas are the most commonly seen odontogenic tumors; they are hamartomas that are subdivided into complex odontomas, which are masses of calcified tissue (dentin and enamel), and compound odontomas, which consist of multiple tooth-like structures. These lesions are seen most often in children and are frequently diagnosed as they interfere with normal tooth eruption. Radiologic features may show a few small tooth-like structures overlying an unerupted tooth or a large area of calcification with a radiolucent rim and sclerotic border, depending on the type and size of the lesion (Figure 41-10). Simple excision is curative but may be challenging in large cases.

Nonodontogenic Tumors

Juvenile Aggressive Fibromatosis

The fibromatoses arise from the superficial or deep musculoaponeuroses of regions of the body, most commonly the abdominal wall (desmoid tumor). However, they may arise in the head and neck, particularly in children younger than 10 years of age, and tend to be aggressively infiltrating in this location.[31] Gold describes three histologic types: desmoplastic, active, and sarcomatoid.[32] They may be found in bony, paragnathic, or soft tissue locations. Although these tumors destroy and infiltrate bone, there is often a marked proliferation of cortical bone in paragnathic cases in young patients (Figure 41-11). This is due to stimulation of the active periosteum in children. Although some

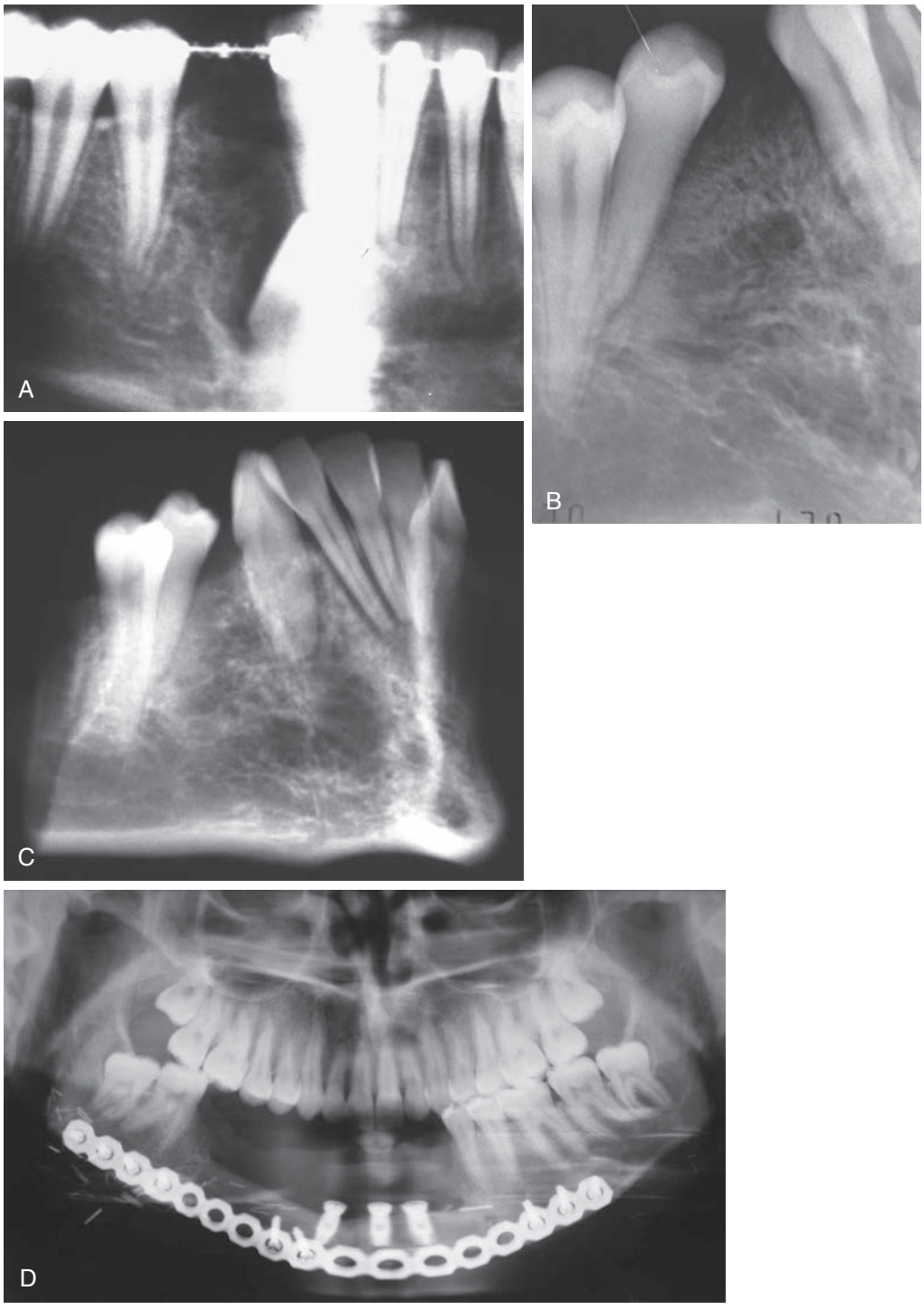

• **Figure 41-7** **A,** A 12-year-old girl with lower right canine displaced by soap bubble myxoma which was curetted to allow the canine to be orthodontically pulled into the arch. **B,** Same patient age 18 with increasing diastema between canine and first bicuspid which are being displaced by recurrent soap bubble myxoma. **C,** Resection specimen (Note thin trabeculae of bone in the neoplasm). **D,** Reconstruction with microvascular free fibula transfer and implant born denture.

of these lesions are very indolent and slow growing, others infiltrate widely and can grow rapidly, behaving as low-grade sarcomas (Figure 41-12). Because of their poorly circumscribed margins, which are difficult to define clinically or radiographically, obtaining good surgical margins is frequently difficult and recurrence rates of 70% are reported.[33] In purely oral lesions, excluding neck lesions with brachial plexus involvement, recurrence rates of 23.8% have been achieved.[31] Interestingly, many authors have commented on the fact that complete excision with negative margins is not always essential to obtain local control, and long-term stability and even regression has been reported in incomplete



• **Figure 41-8** Ameloblastic fibroma presenting as a unilocular radiolucency of left posterior mandible with root resorption.







• **Figure 41-9** **A,** A 9-year old girl with "swollen cheek." **B,** Panorex shows lesion with extensive calcification and radiolucent rim initially diagnosed as odontoma. **C,** CT shows extent of lesion and unerupted molar. Final pathology showed ameloblastic fibro-odontoma.

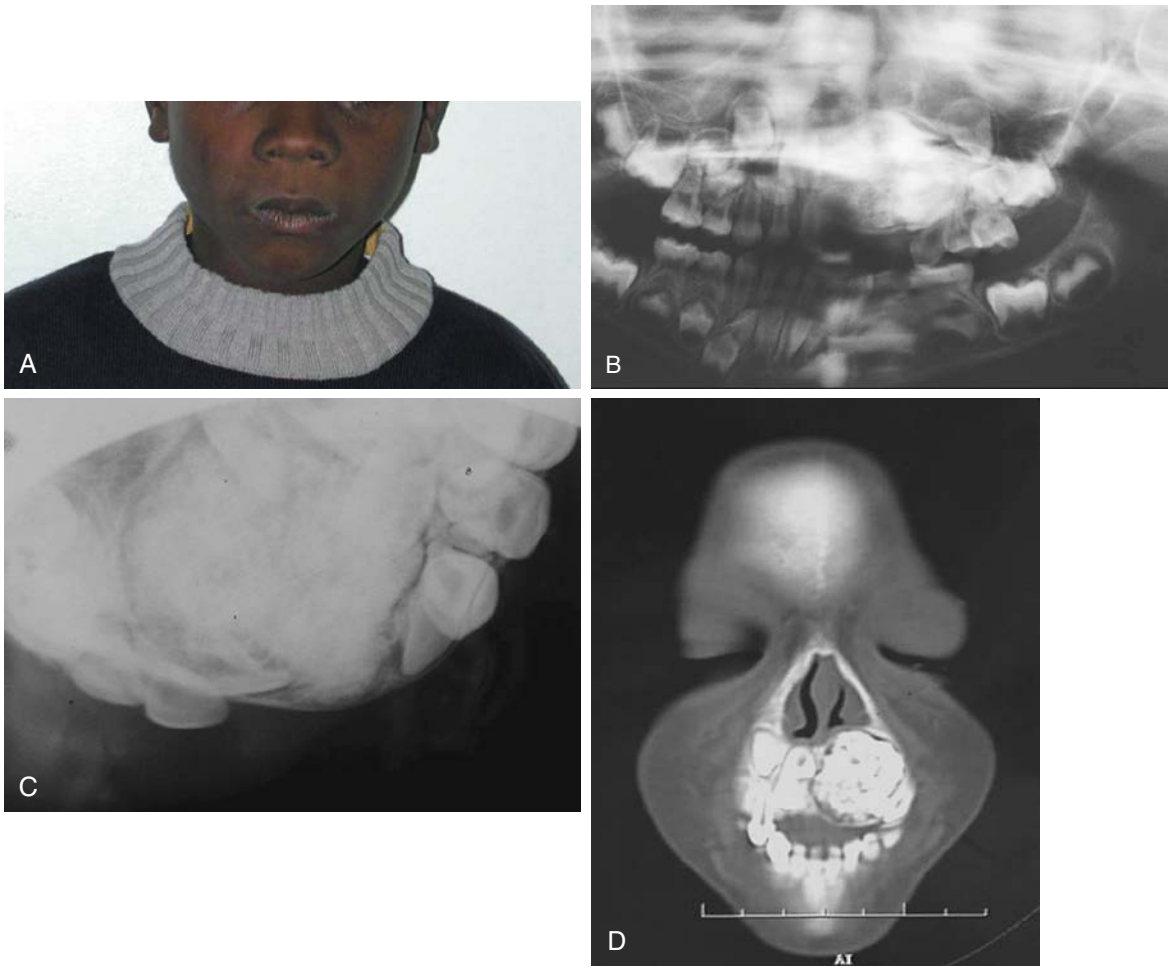

• **Figure 41-10** **A,** A 4-year-old boy with unerupted teeth. **B,** Panorex shows calcified mass anterior maxilla. **C,** Occlusal film shows complex odontoma. **D,** CT reveals nasal floor involvement.

excision.[34,35] Sacrifice of essential nerves may therefore not be necessary.[34] In some head and neck sites such as the skull base, it may be impossible to obtain clear margins with this disease.[36] In unresectable cases with continuing growth, radiation therapy, chemotherapy, and hormonal therapy have all been attempted with varying success rates.[37-39] There are no good prospective trials to indicate what the current best management is for aggressive fibromatosis, and these lesions continue to remain a multidisciplinary challenge. Recently, a European consensus approach by the Sarcoma Patients EuroNet and European Organisation for Research and Treatment of Cancer/Soft Tissue and Bone Sarcoma Group initiative recommended that for head and neck sites there is clear consensus that medical therapy would be the first treatment choice. If there is progression or relapse, radiotherapy should be considered, though facial growth is still a concern. When surgery is opted for, additional radiotherapy can be considered to minimize the risk of local relapse.[40] The authors prefer surgery up front in cases of resectable disease when this can be accomplished with accepatble morbidity.



• **Figure 41-11** An 8-year-old boy with submandibular paragnathic fibromatosis. Note marked new bone formation.

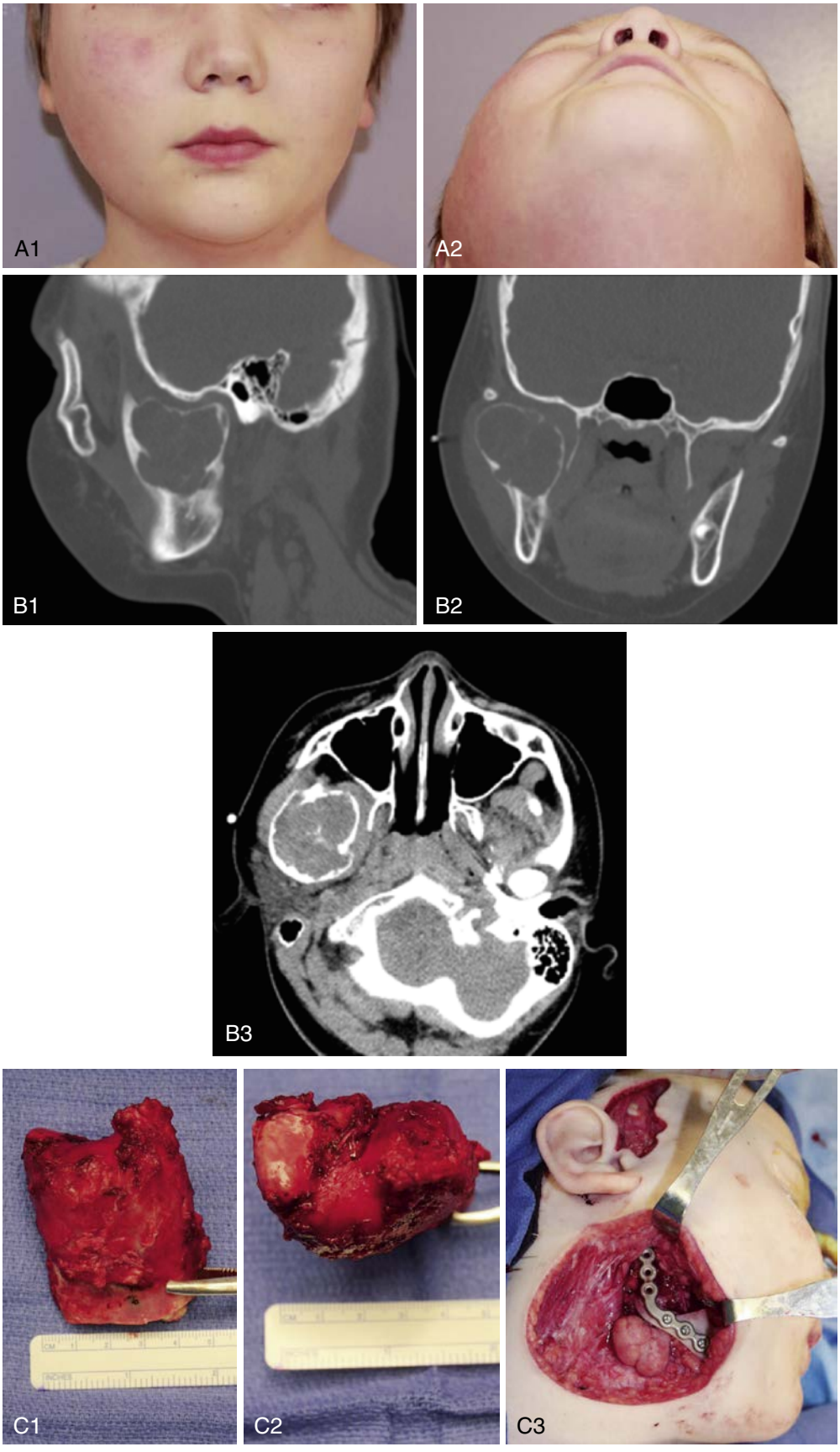

• **Figure 41-12** **A,** A 12-year-old boy with right-sided facial and mandibular swelling. **B,** CT shows cortical expansion of the ramus involving the condyle and coronoid process filling most of the infratemporal fossa. **C,** Resection access and specimen.

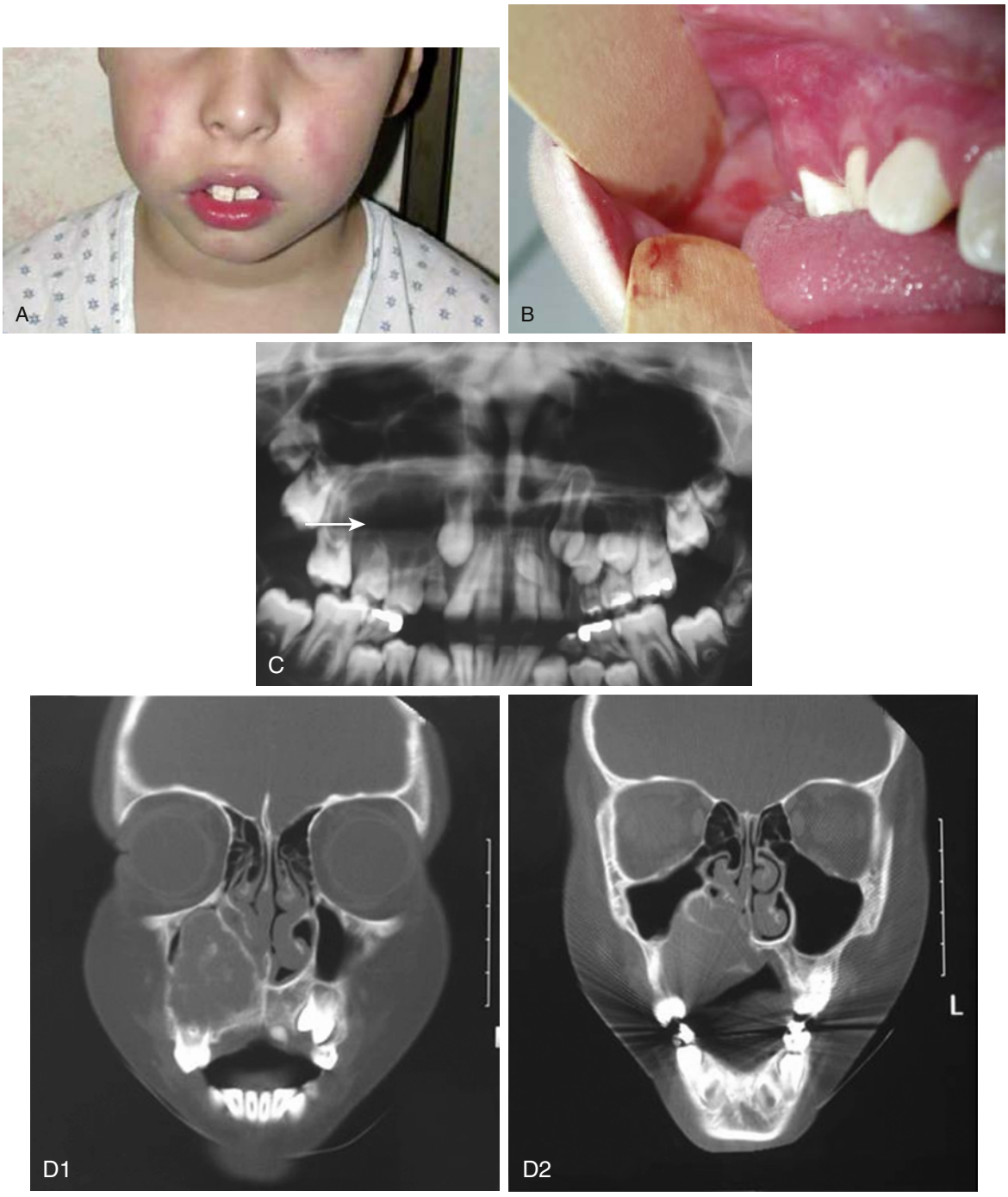

• **Figure 41-13** **A,** A 10-year-old boy with right cheek swelling. **B,** Intraoral swelling noted. **C,** Lesion on panorex noted to be extending toward orbit (*white arrow*). **D,** Lesion further defined on CT.

Central Giant Cell Lesions

The central giant cell granuloma is an osteolytic lesion of the jaws that is locally destructive and variably aggressive (Figure 41-13). The mean age of diagnosis is 20 years, and it is more common in females (3:2). The mandible is involved twice as often as the maxilla, and the lesions range from being asymptomatic swellings or incidental findings to being painful with associated paresthesias.[41] Chuong et al in 1986 classified giant cell lesions of the jaws as either aggressive or nonaggressive based on several criteria. Aggressive giant cell lesions were defined as having a size of greater than 5 cm, rapid growth, causing tooth root resorption or tooth displacement, cortical bone thinning or perforation, or recurrence after simple curettage. Findings that included a tumor >5 cm in size or tumors that recurred after curettage were considered aggressive tumors based solely on these features; otherwise, three of the other signs have to be present for a tumor to be classified as aggressive.[42]

Nonaggressive lesions in the jaws are amenable to simple curettage. Aggressive lesions have reported recurrence rates

as high as 70% after enucleation or curettage.[43] Multiple modalities have been used to treat giant cell lesions, including interferon, corticosteroids, calcitonin, or receptor activator of nuclear factor kappa-B ligand (RANKL) inhibitors, based on the assumption that the lesions are proliferative vascular lesions, inflammatory, or that the osteoclast is the predominant cell type. Results of these treatments when used alone have been mixed.[43-48] For now, the gold standard of therapy for aggressive lesions is en bloc resection, though Kaban has published promising results combining curettage of the aggressive variant with adjuvant interferon therapy.[43]

Aneurysmal Bone Cyst

The aneurysmal bone cyst (ABC) is a pseudocyst of bone filled with blood, and can occur as a primary lesion or secondarily as a component of another lesion such as fibrous dysplasia.[49-51] These "cysts" can be either unilocular or multilocular and can result in significant expansion of the affected jaw or bone. ABCs are more common in the mandible, but they occur in the maxilla and have been reported in other bones of the face, such as the zygoma, clivus, and cranial bones. They may occur in any age group, but are usually seen in patients less than 20 years of age. Sometimes there will be a history of trauma preceding the development of the lesion.

Aneurysmal bone cysts can be treated by curettage, but have a high incidence of local recurrence. ABCs are often multilocular and divided by multiple bony septae. This can interfere with curettage and explains the many treatment modalities reported in their management, which include no treatment, curettage, cryotherapy, excision, and resection. Marginal or en bloc resection should be curative, but necessitates future reconstruction (Figure 41-14).

Juvenile Nasopharyngeal Angiofibroma

Juvenile nasopharyngeal angiofibromas (JNA) are highly vascular, benign, aggressive tumors that occur in the region of the sphenopalatine foramen of adolescent male patients and account for 0.05% of head and neck tumors.[52] They are nonencapsulated and frequently extend beyond their site of origin to involve the nasal cavity, sphenopalatine fossa, orbit, sphenoid sinus, and middle cranial fossa.[53] The typical presentation is of painless unilateral nasal obstruction and epistaxis. Intracranial extension and bleeding may result in life-threatening complications.

Cure is achieved by complete surgical extirpation, and the approach to the tumor is tailored to the specific anatomic location. Many approaches have been used and advocated, including various facial incisions and skull base approaches. Recently, endoscopic approaches have gained favor as the procedure of choice when feasible. Carrau et al have had good success with endoscopic and endoscopically assisted approaches. Their recurrence rate compares favorably to what has been historically reported in the literature (13% vs. >20%) and their complications were few.[53-55] Regardless of the surgical approach chosen, most centers advocate preoperative angiography and embolization of the major feeding vessels to improve hemostasis at the time of removal.[56,57] The arterial sheath can then be left in place for assistance in managing difficult-to-control intraoperative bleeding.

Although the JNA is often within the realm of the ENT surgeon, the maxillofacial surgeon frequently contributes to the management of this pathology. Even though it is becoming more common for these tumors to be removed endoscopically, there is still a role for access osteotomies in the treatment of these benign but aggressive lesions (Figure 41-15).

Juvenile Ossifying Fibroma

Juvenile ossifying fibroma (JOF) is a fibro-osseous lesion that is histologically similar to ossifying fibroma and fibrous dysplasia. The lesions are more common in the maxilla than the mandible, and are most frequently encountered in the first and second decades of life (age <15 years). It is a variant of the ossifying fibroma and is characterized by rapid progression during childhood. JOF is alternatively known as the aggressive ossifying fibroma and is distinguished histologically from the more common ossifying fibromas by its cellular fibrous stroma with a network of osteoid rimmed by active osteoblasts.[58] Growth is rapid, occurring over weeks, rather than months to years (as seen in the nonaggressive form), and may cause erosion of the adjacent bone as well as significant facial deformity and functional impairment. Surgical resection has been advocated for these lesions because the recurrence rate is 30% to 56%.[59-61] Due to their rapid enlargement and often large size, facial incisions to improve access may be unavoidable to ensure complete tumor removal (Figure 41-16).

Craniofacial Fibrous Dysplasia

Fibrous dysplasia is a disease in which normal bone is replaced by abnormal but benign fibro-osseous tissue. It was initially described by von Recklinghausen in 1891, and further characterized by Jaffe and Lichtenstein.[62,63] It results from a mutation of the *GNAS1* gene leading to increased intracellular cyclic adenosine phosphate. It can occur as an isolated condition or as a component of McCune-Albright syndrome. The syndrome includes the findings of fibrous dysplasia and café au lait skin pigmentation, in addition to multiple endocrinopathies (Figure 41-17). Fibrous dysplasia can affect single (monostotic) or multiple (polyostotic) bones of the skeleton and commonly involves craniofacial structures. The disease manifests as slowly progressive and painless swellings of bone resulting in functional problems related to the area of growth. Though largely a benign disease, a low rate of malignant sarcomatous transformation has been reported (Figure 41-18).[58]

Craniofacial fibrous dysplasia (CFD) can result in severe deformity and significant functional impairment. Complications are generally the result of both the mass effect and the composition if the lesion. Ocular complications include diplopia, proptosis, blindness, epiphora, and exposure

keratitis. Loss of color vision often signifies impending visual loss, one of the more devastating consequences of the disease. At one time, prophylactic optic nerve decompression was advocated based on the appearance of CT scans[65]; however, Lee et al recommended close follow-up with symptomatic intervention only, citing a poor correlation between blindness and optic canal narrowing as viewed on diagnostic imaging.[64-66] Oral manifestations can include malocclusion, loose teeth, limited opening, and impaired mastication.[67] Nasal obstruction and obliteration of the sinuses are also common. Paresthesia and anesthesia can be the result of direct nerve compression, with central nervous system effects also having been documented when the neurocranium is involved.

The appearance of polyostotic CFD has been described as that of leonine facies. This is a result of both the broadening and lengthening of the face as a result of dysplastic bone growth. The dysplastic tissues do not grow symmetrically, further worsening the esthetic appearance. The effect, however, can be much more localized, affecting one or several bones of the face unilaterally, resulting in an obvious asymmetric swelling. Esthetic concerns can be of significant psychosocial impact in this patient population because the disease frequently manifests in the first and second decades. Because this is a benign condition with low malignant potential and because the affected areas are so diffusely involved, repositioning osteotomies and bony recontouring are the mainstay of surgical therapy

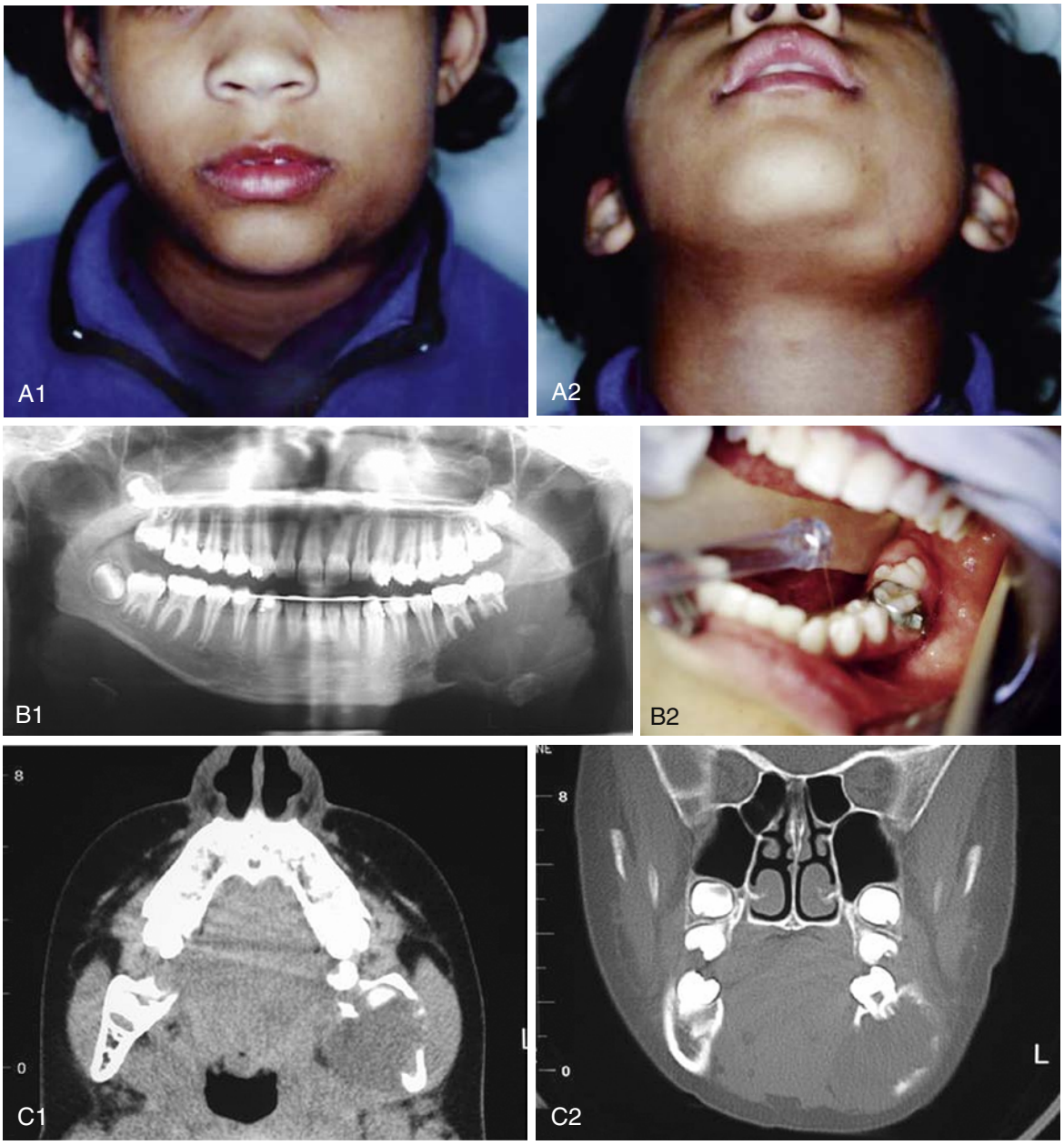

• **Figure 41-14** **A,** A 13-year-old girl with rapidly enlarging mass in the left mandible. **B,** Panorex shows radiolucency of left mandible with expansion and root destruction. **C,** CT showing radiolucency of the left mandible and root destruction. Biopsy shows central giant cell granuloma; the lesion was curetted.

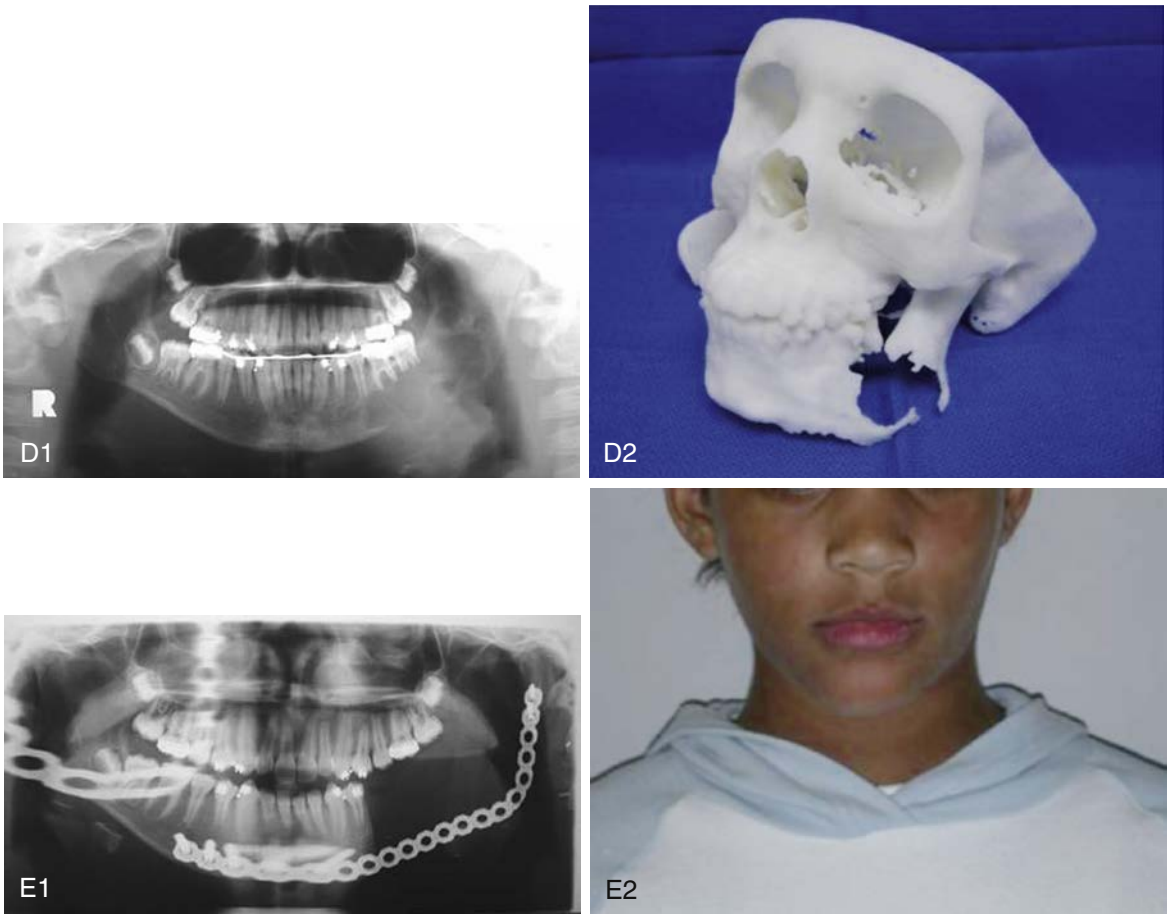

• **Figure 41-14, cont'd D,** The lesion rapidly recurred and was resected. Pathology shows aneurysmal bone cyst. **E,** The hemimandibulectomy defect was temporarily reconstructed with a bar and subsequently grafted successfully.

(Figure 41-19). Others have described resection and reconstruction with bone grafts, but the authors rarely find indication for this approach.[68] In general, recontouring procedures offer some esthetic and functional benefit without eradicating the disease. The authors' preference is to perform recontouring procedures definitively once growth has ceased; however, psychosocial and functional concerns often mandate earlier intervention with the understanding that revision may be necessary as growth of the lesion continues.

Many groups have documented the value of bisphosphonate therapy in small cohorts of patients with fibrous dysplasia and McCune-Albright syndrome. These studies have shown the beneficial effects of long-term bisphosphonate treatment on dysplastic lesions leading to reduced fracture rate and bone pain, and radiologic evidence of long bone lesion healing.[69-71] Further randomized controlled trials are needed, however, before their efficacy can be advocated.

Depending on the quality of the dysplastic tissue, recontouring of facial bones can be accomplished with rotary instrumentation, saw blades, and a variety of chisels and gouges. Osteotomies can be accomplished in the usual fashion and fixated with plates and screws. Sometimes, the soft fibrous nature of the bone can make fixation a challenge. It is also important to note that these lesions can be well vascularized and sometimes result in significant blood loss, so cross-matching of blood is indicated for larger procedures. Some dental complications have been described, including malocclusion and failed orthodontic therapy.[67] Because the application of orthodontics is often a necessary and useful adjunct to orthognathic procedures, definitive jaw surgery can be all the more challenging in this patient group. With the sometimes excess growth of the facial bones comes the slow expansion of the soft tissue envelope. This may take time to redrape following surgery and, despite aggressive recontouring, can give the appearance of residual deformity.

Neurofibromatosis

Neurofibromatosis (NF) is an autosomal dominant disorder that occurs as one of two genetic variants, NF1 (von Recklinghausen disease) or NF2 (central neurofibromatosis). NF1 occurs in approximately 1 in 4000 live births and is often the result of a spontaneous mutation.[72] Specific criteria have been determined that result in a diagnosis of NF1. These include two or more of the following signs: café-au-lait spots, multiple neurofibromas (or one of the plexiform type), axillary/groin freckling, optic glioma, Lisch nodules, dysplasia of the sphenoid or a long bone,

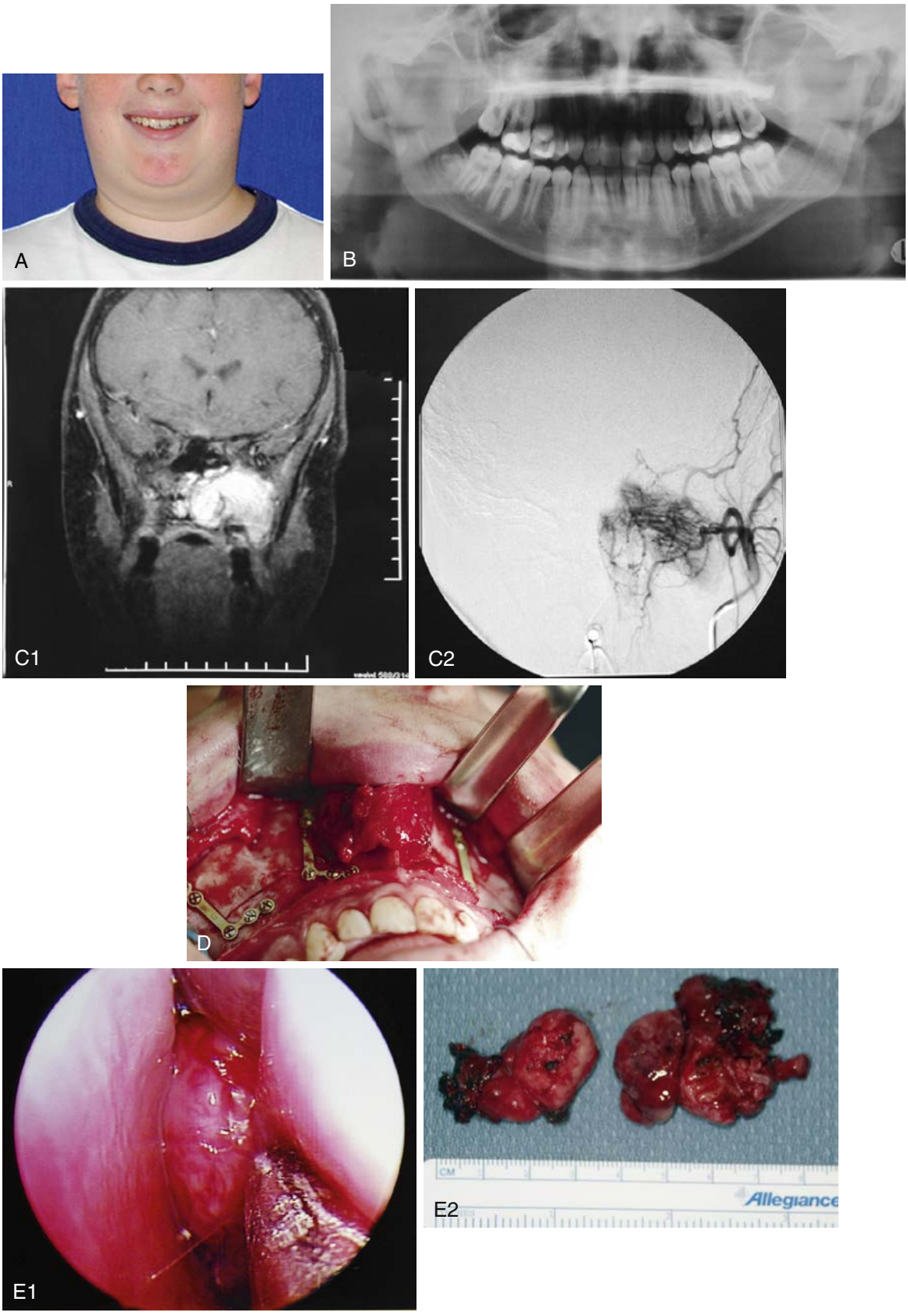

• **Figure 41-15** **A,** A 12-year-old male with left juvenile nasopharyngeal angiofibroma (JNA). **B,** Panorex shows radiolucent mass of left maxilla *(white circle)* with some bowing of posterior maxilla. **C,** JNA on MRI abutting the skull base and preoperative angiogram demonstrating vascularity. **D,** Le Fort I preplated and down-fractured for additional access. **E,** Endoscopic view of lesion and surgical specimen. The lesion was resected via Le Fort I access with endoscopic assistance.

and a first-degree relative with NF-1 (Figure 41-20). Centrally, tumors of the optic tracts are seen in up to 20% of patients, while the most common peripheral tumor is the plexiform neurofibroma.[73]

Plexiform neurofibromas are benign tumors that arise from Schwann cells, which extend across the length of a nerve and involve multiple fascicles.[74] The tumors are invasive, and despite surgical resection (often subtotal), regrowth following surgery is common. These tumors often result in significant functional and esthetic impairment, and craniofacial NF can be particularly disfiguring. Additionally, these lesions have the potential for malignant transformation, which can be difficult to discern, given the surrounding soft tissue mass of the tumor.

Plexiform neurofibromas of the head and neck can originate from cranial or upper cervical nerves. The trigeminal is the most frequently involved of the cranial nerves with orbital involvement being common. Resultant dysplasia of the sphenoid wing is often noted on imaging studies, as is "egg-shaped" enlargement of the anterior orbital rim.[75] Jackson classifies cranio-orbital neurofibromatosis for purposes of treatment planning into three groups:

- The soft tissue is significantly involved but bony involvement is minimal and vision is unaffected

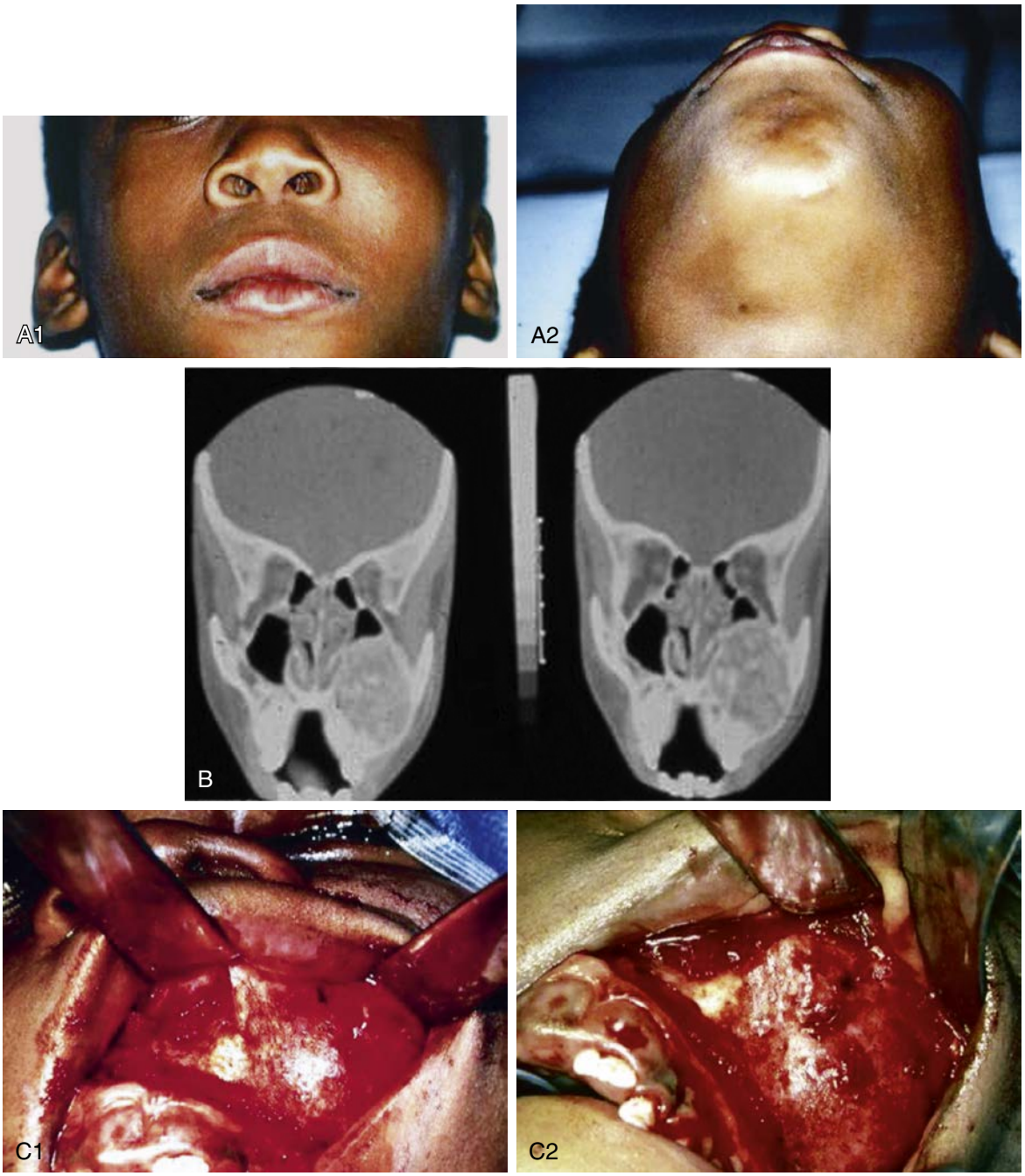

• **Figure 41-16** **A,** A rapidly growing zygomaticomaxillary mass in a young boy. **B,** CT shows a mixed lesion of the left maxilla, histologically an aggressive juvenile ossifying fibroma. **C,** The lesion at initial surgery.

Continued

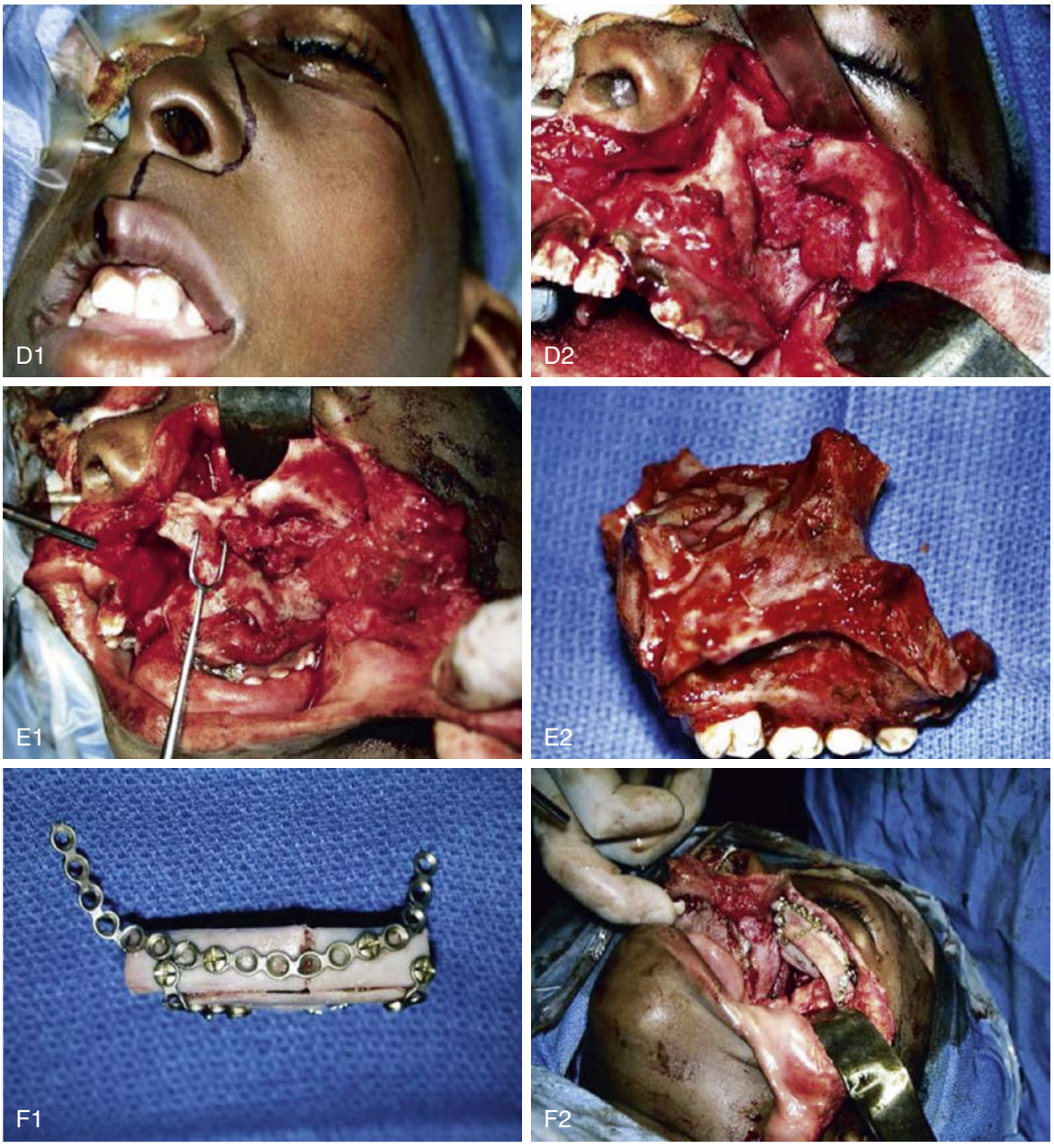

• **Figure 41-16, cont'd D,** The lesion rapidly recurs and requires reoperation and resection with access via Weber-Ferguson incision. **E,** Maxillectomy specimen. **F,** Reconstruction with rib grafts.

- Soft tissue and bone are involved and vision is unaffected (Figure 41-21)
- Soft tissue and bone are involved and the eye is blind or absent[76,77]

Treatment of these cranio-orbital neurofibromas is variable, involving simple excision in some cases and globe enucleation with extensive bone grafting in others. Otherwise, Jackson recommends excision and direct closure of other lesions of the head and neck, taking care to preserve vital structures at the expense of incomplete resection. Exposure is paramount in treating these lesions, both to obtain complete resection and to have optimal control of bleeding. Neurofibromas can be quite vascular, and in some instances, preoperative angiography and embolization is warranted.[78]

Although NF can be disfiguring, total resection of craniofacial neurofibromas often leaves the patient with equally problematic reconstructive defects, whether the orbital contents have been completely exenterated or the temporal lobe is prolapsing into the orbit. Careful consideration must be given to the reconstruction of these defects and they may warrant the use of prosthetic, microvascular, local flap, or free bone grafting techniques.

Congenital Epulis (Congenital Granular Cell Lesion)

The congenital epulis is a rare lesion that typically occurs on the alveolar ridge of the newborn and occasionally on the tongue. Despite the similar microscopic appearance

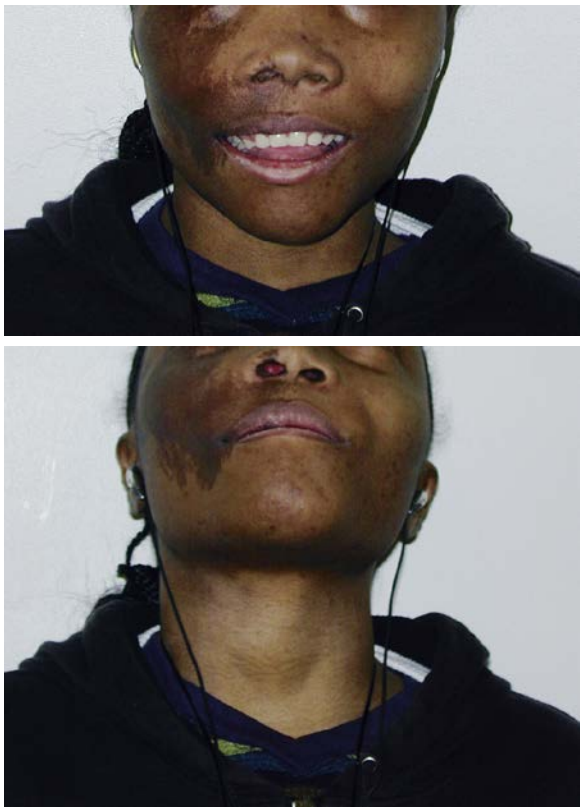

• **Figure 41-17** A 15-year-old girl with McCune Albright syndrome; note craniofacial bone involvement and the café au lait spot on the right cheek.

between the epulis and the granular cell tumor, there are distinct immunohistochemical differences between the two, and the histogenesis is still unknown.[79]

The lesion itself appears as a smooth pink to red mass of variable size emanating from the alveolar ridge, which can be attached by a smaller stalk. Lesions of up to 7.5 cm have been reported, though most are less than 2 cm in size. In some instances there can be multiple tumors, and occasionally they are detected in utero on ultrasound. They can be accompanied by polyhydramnios due to impaired fetal swallowing of amniotic fluid. When sizable lesions are noted on antenatal ultrasound, appropriate steps can be taken at the time of delivery to assure the airway of the infant is secured. Ex-utero intrapartum treatment (EXIT) procedures have been utilized for larger obstructing lesions.[80]

The lesion is more common in females (>85%) and is most often found in the para-midline area of the maxillary alveolar ridge, but can be seen on the mandible or as multiples involving both ridges. Some smaller lesions may regress spontaneously. Otherwise, the lesions are excised because they can impair feeding (Figure 41-22). Recurrence for the congenital epulis has not been reported, even in the event of incomplete excision.[79,80]

Epignathus (Oral Teratoma)

Epignathus is a rare form of organized teratoma that arises from the oropharynx or nasopharynx. These lesions contain tissue elements derived from the three primitive embryonal germ layers (endoderm, mesoderm, and ectoderm). Some cases have very well-differentiated organs, and might be the result of an abnormal multiple gestation or parasitic fetus rather than a true teratoma. Epignathi are most commonly benign, but malignant and aggressive variants exist. They can be associated with facial malformations such as cleft palate and branchial cleft cysts, as well as other anomalies such as congenital heart disease. Epignathi, like congenital epulis, can be associated with polyhydramnios due to impaired fetal swallowing. Fetal hydrops secondary to high-output cardiac failure can also occur. Securing an airway at the time of delivery is of critical importance when dealing with these lesions, and EXIT intubation or tracheostomy may be necessary.[80,81]

Melanotic Neuroectodermal Tumor of Infancy

The melanotic neuroectodermal tumor of infancy (MNTI) is a benign tumor of neural crest origin and most commonly appears within the first 12 months of life (>90%). It most often occurs in the maxilla, but also can be seen on the skull, the epididymis, the mandible, and the brain (Figure 41-23). It appears as a rapidly growing mass that is blue or black in color, and it will displace teeth and infiltrate bone. Clinically, malignancies such as rhabdomyosarcoma, Ewing's sarcoma, and neuroblastoma must be ruled out. Radiographically, it can be seen to destroy bone and may have a sun-ray appearance similar to that of an osteosarcoma.[79,82]

Some patients with melanotic neuroectodermal tumors may have high urinary vanillymandelic acid (VMA) levels, somewhat like those with a pheochromocytoma, retinoblastoma, or neuroblastoma. However, the VMA levels are unrelated to tumor behavior and will drop once the tumor has been removed. Treatment consists of resection or curettage. Some recommend a margin of 5 mm, given the destructive and infiltrative nature of the lesion and its propensity for recurrence (15% to 20%). Staining for synaptophysin, cytokeratin, and HMB-45 can help establish the diagnosis. In rare instances, the tumor behaves malignantly by metastasizing (3%), and in the skull and brain it can cause significant morbidity by local extension.[79,82,83]

Malignant Tumors

Malignant tumors are fortunately rare in children. The spectrum of disease is very different to that seen in adults. Leukemia and lymphomas of childhood are more prevalent than solid tumors, and the head and neck is a very uncommon site for cancer in the pediatric population. Cancers associated with tobacco and alcohol abuse such as squamous cell carcinoma, which comprises the majority of head and neck cancers in adults, are seldom seen in the pediatric population. Small blue round cell tumors such as rhabdomyosarcomas, Ewing's sarcoma, retinoblastoma, and lymphoma are seen most often in the pediatric head and neck region. Many of these neoplasms will require multimodality treatment, and the long-term effects of radiation therapy and chemotherapy on the growth and development of the face, jaws, and teeth as well as the potential for radiation induced

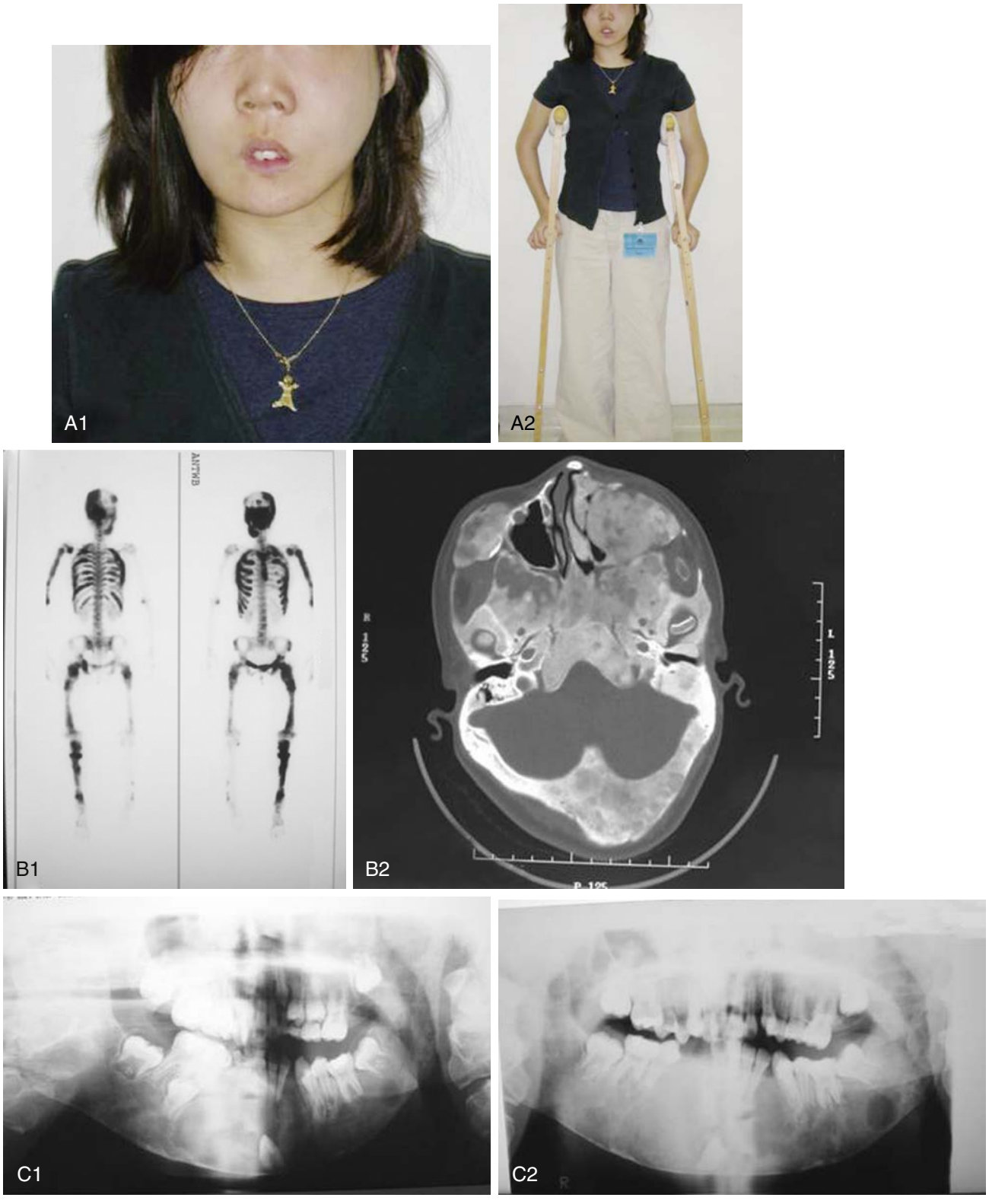

• **Figure 41-18** **A,** A 15-year-old female with McCune Albright syndrome. **B,** Bone scan shows systemic involvement. **C,** Rapidly growing mandibular lesion proves to be osteosarcoma.











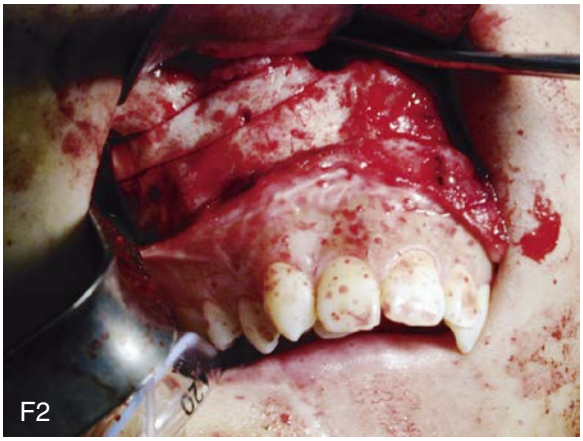

• **Figure 41-18, cont'd** **D,** Patient undergoes partial mandibulectomy by another surgeon. **E,** Subsequent recurrence results in near total mandibulectomy (same surgeon). **F,** Patient undergoes Le Fort I osteotomy for vertical maxillary excess in preparation for microvascular free fibula transfer to reconstruct mandible.

Continued

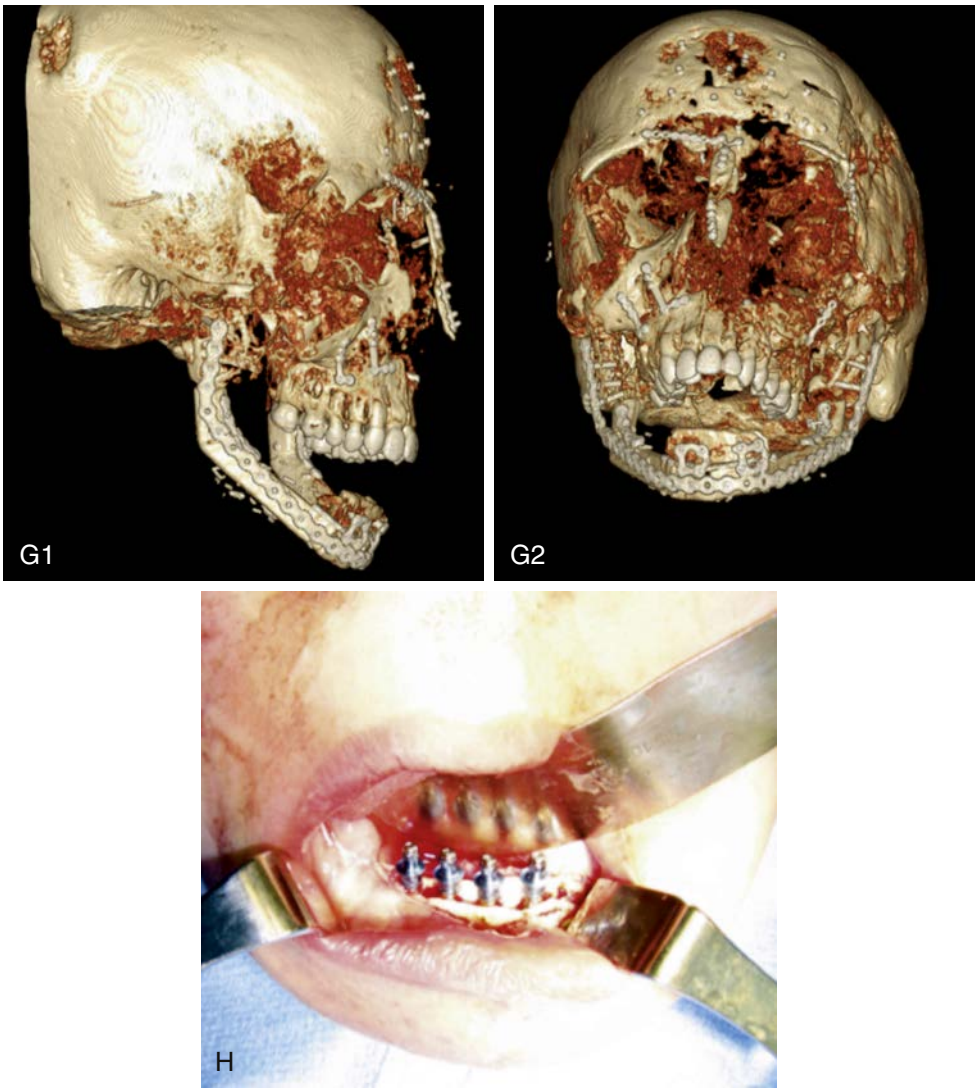

• **Figure 41-18, cont'd G,** After mandibular reconstruction with microvascular free fibula transfer. **H,** Subsequent implant placement.

sarcomas many years later add to the complexity of patient management.

Rhabdomyosarcoma

This is the most common pediatric sarcoma; 35% to 40% occur in the head and neck. The site and histologic type is important in determining prognosis. The orbit (25%), parameningeal (50%), and other sites (oral cavity, scalp, etc.) (25%) are the major sites; the histologic types are botryoid, embryonal, alveolar, and pleomorphic. Orbital tumors metastasize infrequently and have the best prognosis with a 5-year survival rate greater than 85%, whereas parameningeal tumors (infratemporal, paranasal sinuses, nasopharyngeal, and middle ear) have the worst prognosis.[84,85] Parameningeal tumors are often diagnosed later as a result of nonspecific symptomatology; consequently, skull base and cranial nerve invasion has already occurred (Figure 41-24). Relapse-free survival is considerably less in this group at 57%.[86] The embryonic and botryoid types of rhabdomyosarcoma have the best cure rates, and they are the most common types in the youngest children. The foundation of treatment for pediatric rhabdomyosarcoma is chemotherapy. The overall prognosis is improved when complete surgical resection is achievable; however, this is not always feasible in the head and neck, particularly in parameningeal sites.[87] Radiation therapy is used for orbital tumors and in conjunction with chemotherapy. In parameningeal rhabdomyosarcomas, radiation to the spinal axis and intrathecal chemotherapy improves survival. Meazza et al. claimed that meningeal prophylaxis is not necessary due to improvements in radiotherapy techniques and chemotherapy.[88] They also claimed that hyperfractionated accelerated radiation therapy may be superior to conventional radiation, although severe radiation-related late sequelae were seen. This study is contradicted by the findings of Intergroup Rhabdomyosarcoma group IV which found no advantage to accelerated hyperfractionated radiation.[89] Prognosis is

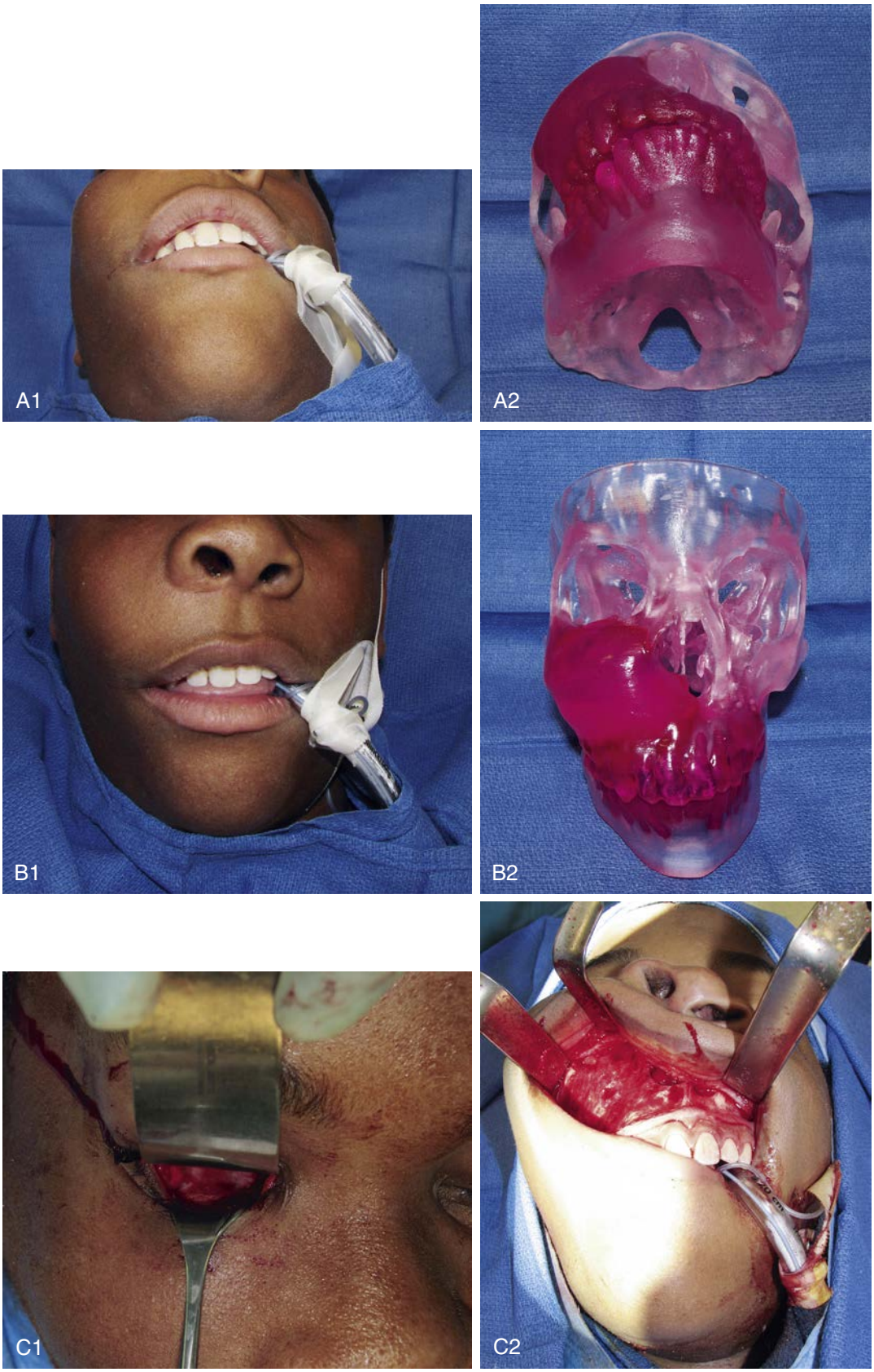

• **Figure 41-19** **A,** A 13-year-old male with craniofacial fibrous dysplasia affecting right mid-face (worm's eye). **B,** A 13-year-old male with craniofacial fibrous dysplasia affecting right mid-face (frontal). **C,** Access via transconjuctival and transoral approaches.

Continued

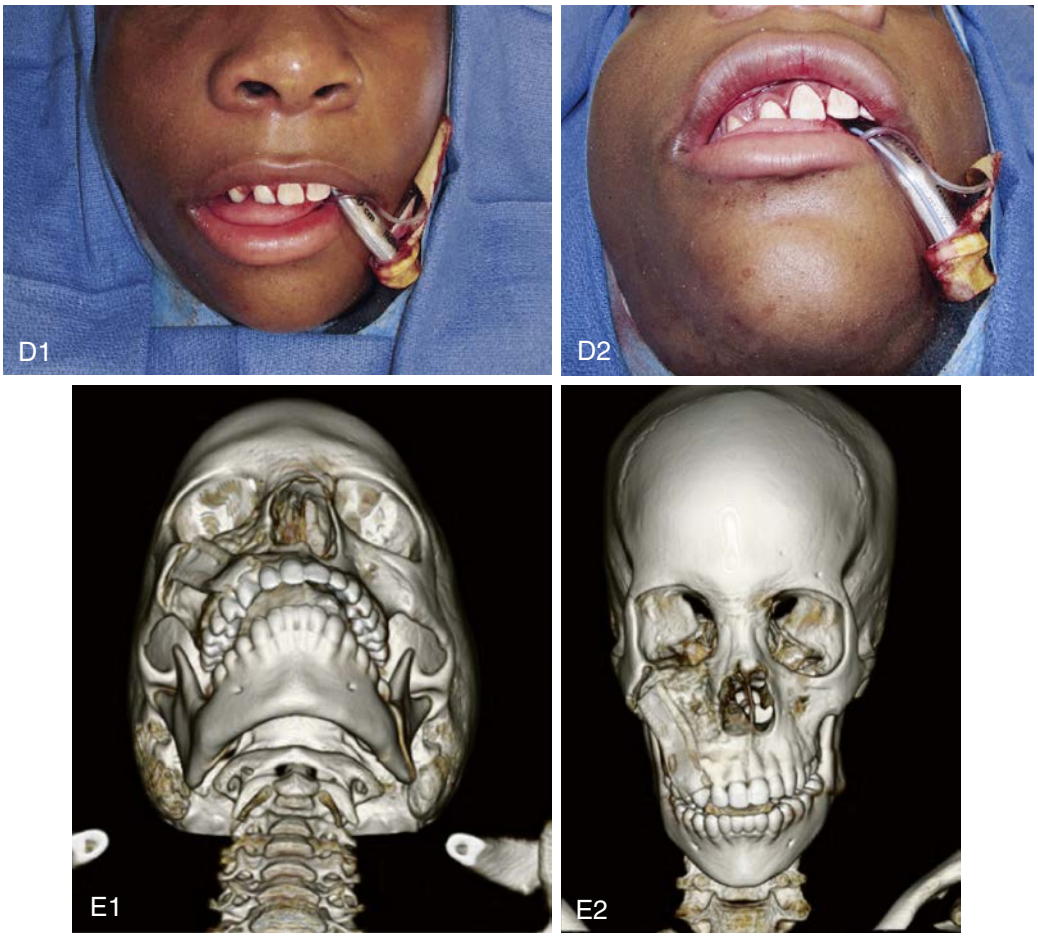

• **Figure 41-19, cont'd** **D,** Immediate postoperative result. **E,** Postoperative CT scan (Penrose drain in place).

also dependent on stage, and in rhabdomyosarcoma both a surgical-pathologic clinical staging and TNM type of staging have been used. In a recent review of 49 head and neck cases, significant prognostic factors for survival included age <11 years and tumor size <5 cm as well as multimodality regimes.[90]

In patients who fail chemotherapy, a regime of ablative surgery with moulage technique and after-loaded brachytherapy and reconstructive surgery (the AMORE protocol) has been advocated with initial results of 11 of 15 patients tumor free after a mean follow-up of 2.8 years.[90] In a longer-term follow-up of this protocol with 22 patients, 7 had relapse which was largely ascribed by the authors to incomplete surgery or suboptimal positioning of the brachytherapy.[91,92]

Other Sarcomas

Most other sarcomas are rare except for retinoblastoma (Figure 41-25). Osteosarcoma and Ewing's sarcoma of the head and neck are very infrequent in children. In childhood bilateral hereditary retinoblastoma, children who have received radiation for retinoblastoma or for other tumors are at increased risk for developing osteosarcoma. There is some evidence that osteosarcoma arising in a previously irradiated patient is more aggressive in behavior.[93]

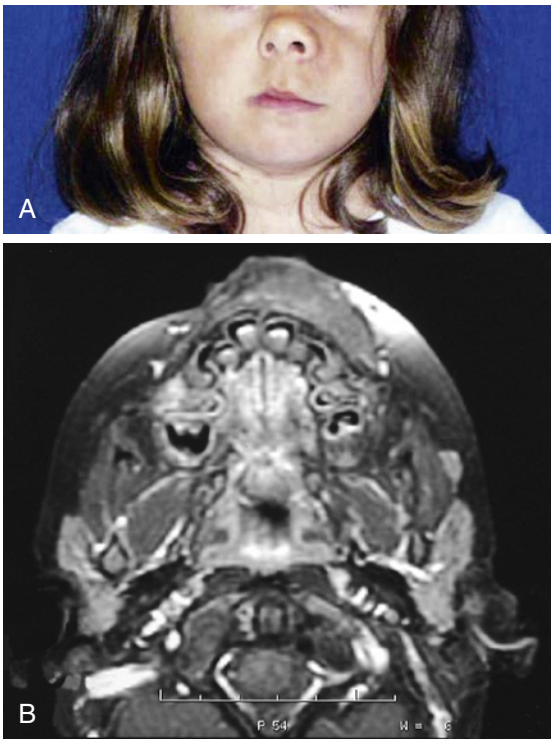

• **Figure 41-20** **A,** A 5-year-old girl with left facial swelling and café au lait spot on the left nose and cheek. **B,** MRI demonstrating soft tissue mass consistent with neurofibromatosis.



• **Figure 41-21** A 6-year-old boy with neurofibromatosis and significant cranio-orbital bone involvement and normal vision.

Best results are with primary radical surgery, and the value of radiation therapy or adjuvant/neoadjuvant chemotherapy is unclear in this group of patients.[94] In Ewing's sarcoma it is thought that 80% to 90% of patients have micrometastases at presentation and that this is a systemic disease. Therefore all patients receive chemotherapy, and radiation and/or surgery may be used in combination with the chemotherapy. The mandible appears to be the most common head and neck site.[95]

When malignancies in the growing patient are treated, both surgery and radiation can leave the patient with considerable secondary deformity of the facial skeleton (Figure 41-26). In addition, the pituitary, visual acuity, and tear production can be affected by radiation, and cataractogenesis can also be a problem.[96-98] Corrective efforts must be geared toward both soft and hard tissue correction, keeping in mind the vascular damage incurred from radiation therapy. Conventional jaw surgery alone might not be enough to address the global facial tissue hypoplasia and asymmetry. Free tissue transfer can be a valuable tool in correcting soft tissue disparities. The orbit can be a particularly vexing problem because the globe position might not be amenable to correction.

Salivary Gland Tumors

Head and neck cancer comprises only 2% to 3% of all cancers, and only 3% to 4% of these cancers are found in the salivary glands. Approximately 80% of salivary tumors are found in the parotid, and in adults 80% are benign. In children, although the majority of tumors are seen in the parotid, there is an increased rate of malignant tumors (42.9%).[99] The majority of these tumors are mucoepidermoid carcinomas and, fortunately, most are low grade, with survival rates of 97.3% reported.[100] In another series of major salivary gland tumors in children, 77% of which were mucoepidermoid carcinoma or acinic cell carcinoma, the 5-year survival was 94.2%.[101] In most cases, because malignancies are low grade, superficial parotidectomy is the treatment of choice with total parotidectomy for deep lobe tumors. The facial nerve will not be sacrificed unless there is infiltration by the cancer. Neck dissection is carried out for clinically node-positive necks or when there is a high-grade neoplasm. Radiation is usually indicated



• **Figure 41-22** Congenital epulis of the mandible in a neonate. This lesion interfered with feeding and was subsequently excised. (Photo courtesy Sean Edwards, DDS, MD.)

in high-grade tumors. It should be noted that there is an increased risk of developing a salivary gland malignancy in children who have had a previous cancer (e.g., leukemia) treated by radiation or chemotherapy.[100,102] Intraoral minor salivary gland tumors comprise approximately 10% of adult tumors. In a series from China, 23.5% of pediatric salivary tumors were found in the minor glands with 65% malignancy.[103] Again, most of these are low-grade mucoepidermoid carcinomas that can be managed with wide local excision.[104] In our own unpublished series of 160 cases of minor salivary gland tumors, only 9 were in children (5.6%) and 8 of these were cancers. Treatment is directed by the site, stage, and grade of tumor with neck dissection and radiation therapy used as they would be in adult patients.

Reconstruction

Reconstruction of postablative defects in children is a relatively uncommon problem, but the underlying principles are similar to those of the adult: timely restoration of form and function. Ideal reconstruction should also include adequate obturation of the surgical defect and structural support of external facial features.[105] Restoration of form and function in a growing patient should be viewed as a dynamic process and the effects of treatment on subsequent development should be considered. Growth of the orbital-craniofacial skeleton is a complex, coordinated process that depends on sequenced events that evolve among specific growth centers. Interruptions in this process such as surgery, radiation, and resultant scarring can result in significant changes in growth patterns. Active growth in the donor and recipient tissue sites are principal concerns in pediatric reconstruction. The presence of developing teeth within the structure of the jaws must also be considered. The management of the psychosocial aspects of prolonged hospitalizations and multiple surgeries in patients of this age should be integrated in the overall treatment strategy as well.



• **Figure 41-23** A 2-month-old male with an MNTI involving the right mandible. **A,** MNTIs are rapidly growing lesions—this one had doubled in size in 2 weeks. **B,** The defect after curettage, ostectomy, and extraction of involved teeth. There was a pathologic fracture that was plated. There was one recurrence that was subsequently treated similarly. He is recurrence free more than1 year later. **C,** Specimen 4 cm in greatest dimension. Note the pigmentation.

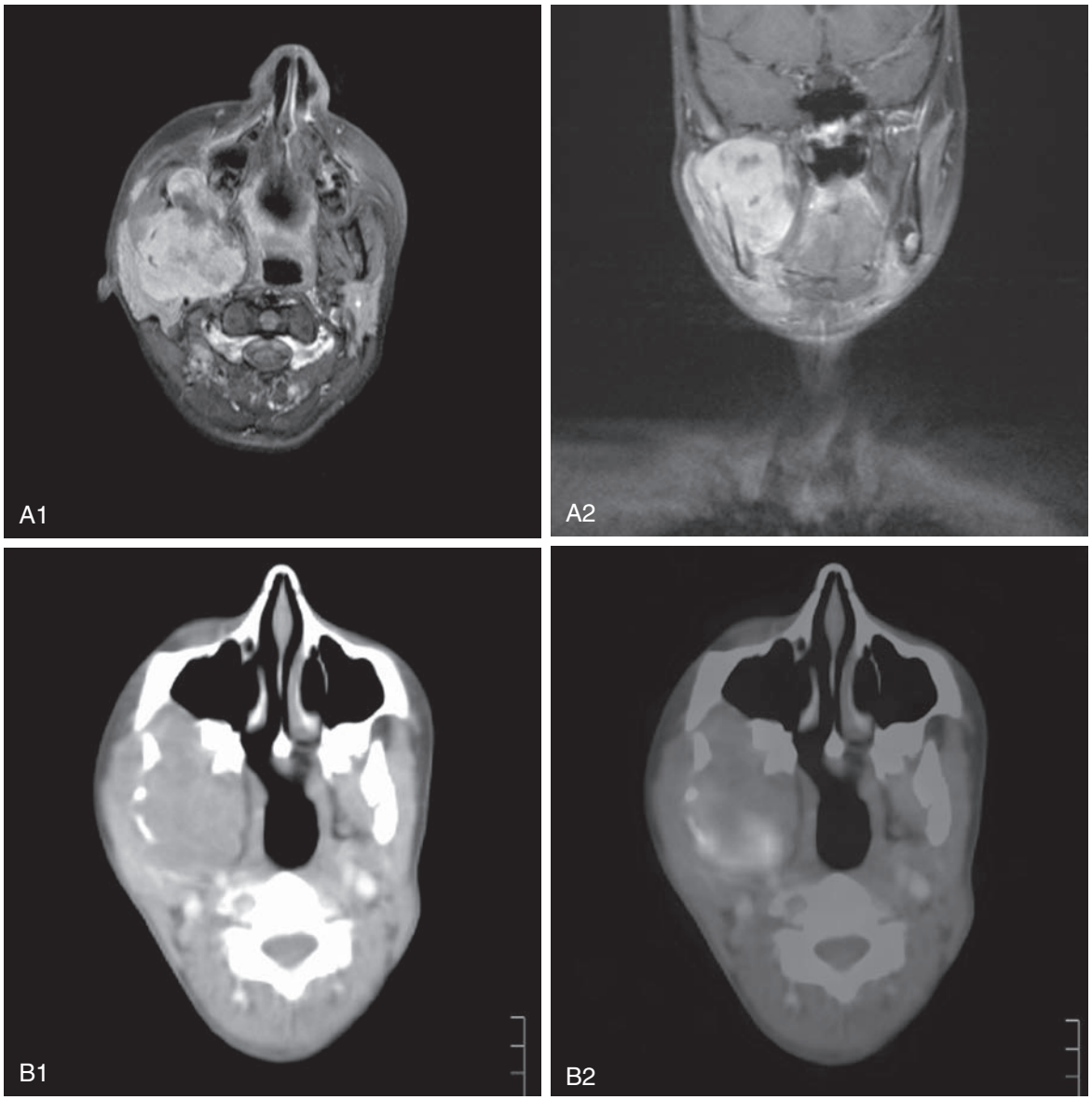

• **Figure 41-24** A 16-year-old female who had suffered multiple jaw dislocations prior to eventual exam under anesthesia and biopsy demonstrating rhabdomyosarcoma. **A,** MRI shows parameningeal rhabdomyosarcoma. **B,** PET scan shows the same.

Treatment planning constitutes the first phase of reconstruction in any patient, but is perhaps of greater importance in the young patient. Communication between the surgical teams (ablative and reconstructive) and facilitating medical specialties are paramount in presurgical evaluation and treatment planning. The specifics of the potential ablative defect should be reviewed at the initial consultation with emphasis on the anatomic regions and subunits involved. Qualitative and quantitative aspects of planned ablative defects must be taken into consideration in an effort to match the amount and likeness of the reconstruction. The degree of soft tissue required should be considered and decisions made about limitations on replacement of skin, mucosa, and dura, as well as general bulk and the potential of neural grafting. Linear defects of the bony craniofacial skeleton are relatively straightforward reconstructive problems; however, composite defects involving bone and soft tissue require a thorough comprehension of the defect in space prior to surgery.

Primary reconstruction has intrinsic advantages over delayed or secondary procedures. It is generally advantageous to limit unnecessarily staged surgery, which equates to a more timely return to function and limited operating sessions. One benefit of immediate reconstruction is that it can allow more normal growth of the maxillomandibular complex because occlusion is maintained or restored sooner. The two-team approach of flap and graft harvesting conserves operating room time. Moreover, access and orientation of the surgical defect is often optimized at the time of the initial resection, prior to the effects of scarring and radiation in selected cases.

Reconstruction of the mandible can be performed with grafted bone or free tissue transfer. Iliac crest, ribs, and cranial grafts are suitable for replacement of segmental mandibular and orbitomaxillary defects. Iliac crest bone grafting is a reliable technique that can be performed primarily or secondarily to restore continuity defects. The limitations are somewhat dependent on the age of the patient, the length of the defect, the presence of intact periosteum, and the available bone stock that can be safely harvested. The placement of reconstructive hardware can be more complicated in the presence of the developing teeth and tooth buds. The infection rate may be higher in patients who are primarily reconstructed, where salivary contamination of the graft can result in graft failure.[106]

Costochondral rib grafts are suitable for short length replacement of the mandible, particularly the ascending ramus in which the condyle must be replaced. Ribs are soft, pliable, and demonstrate growth at the condylar head; however, the growth tends to be unpredictable, sometimes exceeding that of the nonoperated side. The natural anatomic curvature of the rib lends itself to replacement of the mandibular body and parasymphysis. Additionally, for infants and toddlers, the rib is one of very few suitable options. The bone stock of ribs, however, does not support placement of endosseous implants, and typically requires subsequent bone grafting upon completion of skeletal growth. The most important disadvantage is the

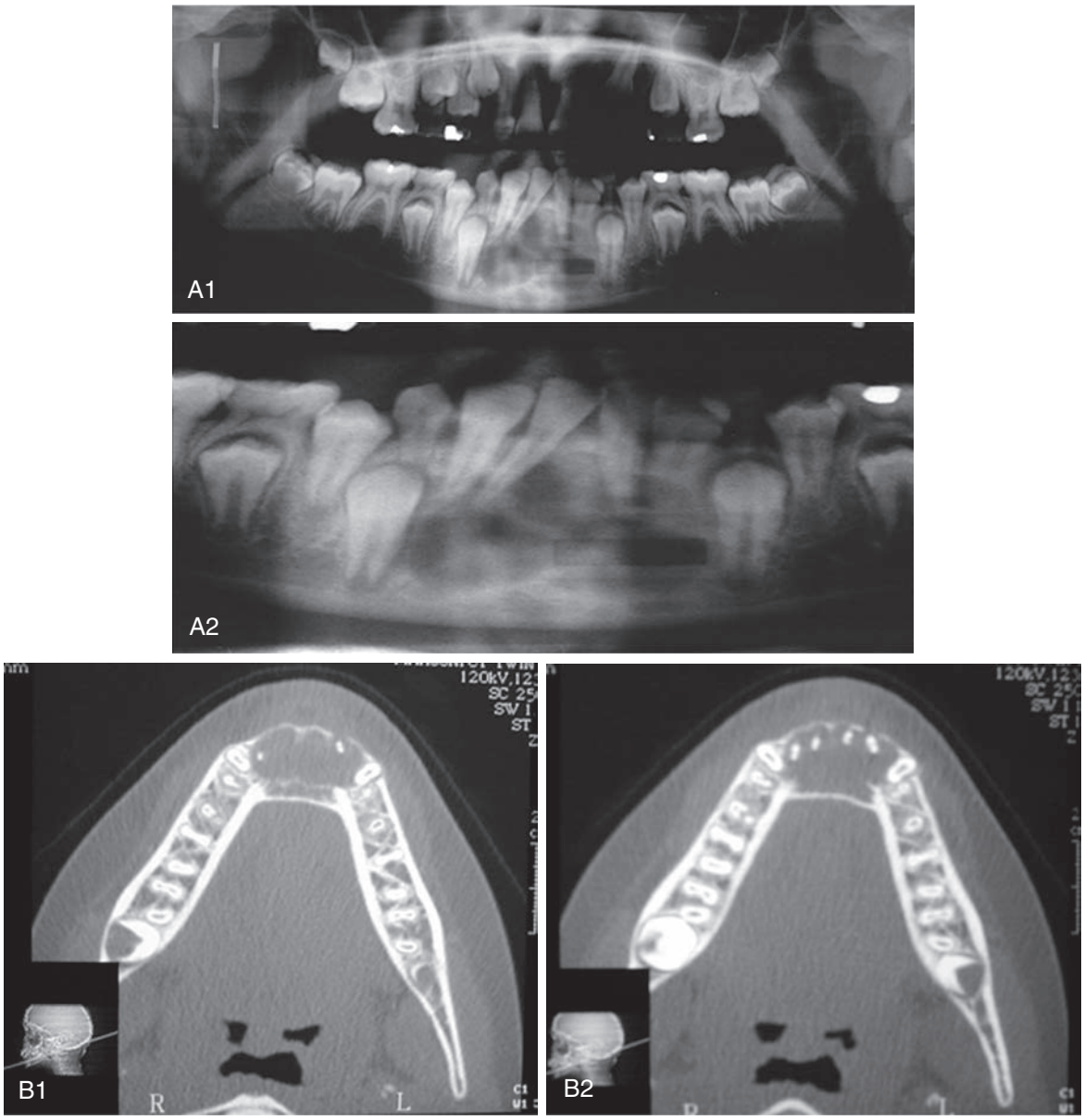

• **Figure 41-25** **A,** A 13-year-old male referred with swelling/cortical expansion of the anterior mandible after recurrence following multiple attempts at curettage by another surgeon. Initially diagnosed as hemangiopericytoma. **B,** CT shows radiolucent lesion with cortical expansion.

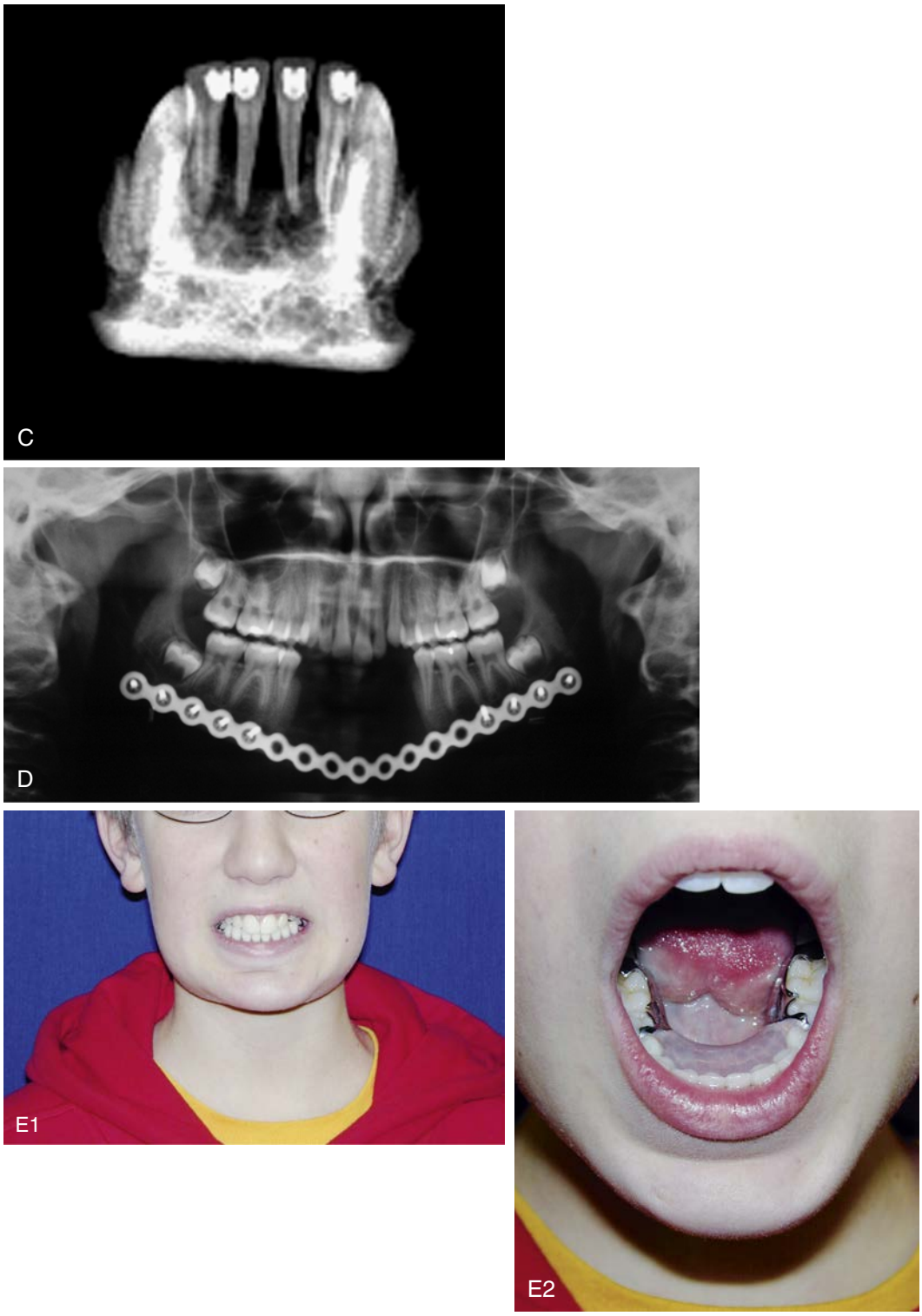

• **Figure 41-25, cont'd C,** The lesion was resected with margins due to its aggressive behavior and the identification of small round blue cells within the specimen. Final pathology showed grade three fibrosarcoma with clear margins. **D,** The patient was reconstructed with a bar temporarily. He underwent adjuvant chemotherapy. **E,** Patient with partial denture in place, definitive reconstruction is planned.

possibility of rib resorption, which can mandate additional reconstruction.[107] Some cases may be amenable to treatment with nonvascularized bone, distraction osteogenesis, or combination therapy. It has been suggested that adult patients with defects approaching 9 cm in length, with irradiated tissue fields, or with defects involving composite tissues are candidates for free flaps.[109] Guo et al propose that 6 cm defect length, compromised periosteum, and failed previous bone graft be further added to these indications for children.[109]

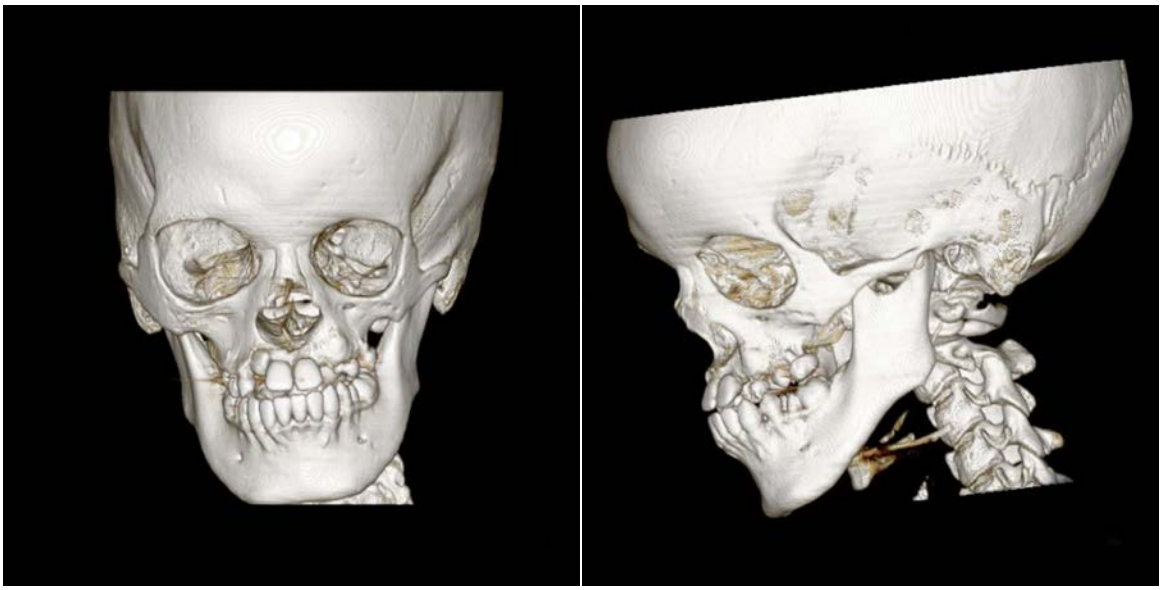

• **Figure 41-26** A 4-year-old boy who underwent chemotherapy and radiation for left orbital rhabdomyosarcoma. Note the affected hypoplastic orbit, maxilla, and mandible on the left side.

There are a number of suitable choices for free flap reconstruction in the maxillofacial region in children and adolescents. The utility of musculocutaneous and fasciocutaneous flaps (radial forearm, anterolateral thigh, rectus, etc.) approximates the range of that available in the adult, and flap selection is guided by area, volume, and tissue match. Bone-only and composite reconstruction can be achieved with the fibula, iliac crest, radius, and scapula free flaps. The scapula and fibula provide the best balance of adequate bone stock, limited morbidity and adequate pedicle length for microvascular anastomosis. Free fibula flaps provide the greatest amount of linear bone stock, although the height of the fibula may be limited in children under 13 years (Figure 41-27).[110] Multiplanar osteotomies provide great versatility in composite reconstruction in the maxillofacial skeleton. The fibula can be folded onto itself in a double-barrel fashion, facilitating the placement of endosseous implants. There is little evidence to show that free fibula harvest adversely affects limb development in children. Most growth occurs in the proximal epiphyseal plate, which is complete by 15 in girls and 17 in boys.[111] Experimental evidence suggests that both transplanted scapula and fibula exhibit growth following free tissue transfer in conjunction with the native mandible.[112] Transfer of the fibula, including the epiphyseal region of growth, has been suggested to support growth at the recipient site, however, growth occurs with the native mandible when this region is not included. Age of the patient does not appear to be a limiting factor; Warren et al encountered no problems with insufficient vessel caliber or unexpected vasospasm.[108] Because experience in free tissue replacement of the mandible is limited to published case series, the effects on growth are still unclear. Experimental evidence in animals suggests that free tissue transfer supports growth in the craniofacial skeleton, but this has not been substantiated in humans.[113] The scapula has been utilized in pediatric reconstruction, and lengths of up to 12 cm of bone have been reported.[108] The bone is relatively thin and may require supplemental bone grafting to accommodate endosseous implants. Growth of the scapula is affected by harvesting, but the functional consequences are limited.[110] Composite parascapular flaps including several soft tissue paddles, segments of free rib, and scapular bone are possible, enabling chimeric reconstruction of complex defects. Transfer of the deep circumflex iliac artery (DCIA) flap in the growing child is uncommon, and in older adolescents has been met with slightly greater postoperative gait disturbances than in adults, though it has not been intensively reviewed in the literature. The entirety of the iliac crest is composed of cartilage from early development and is an active growth center in the pelvis. Mechanical demands from muscle tension contribute to acetabular growth, which can be affected by surgery and subsequently affect gait.[110] Like the fibula, the DICA can be osteotomized to conform to a neomandible or maxilla, with or without a soft tissue muscle component from the internal oblique muscle, does well to receive endosseous implants (Figure 41-28), but has limited utility in the child.

Distraction osteogenesis (DO) does play a role in limited segmental defects of the mandible and is a viable alternative in linear defects of 3 cm or less, provided that there is no soft tissue defect and the wound bed has not been radiated. With the introduction of transport DO, longer spans including the curvature of the symphysis may be included in this reconstruction. The limitations to date include the paucity of well-documented case series, outcome measures for adequate rehabilitation in the pediatric patient, and the time required for placement and activation.

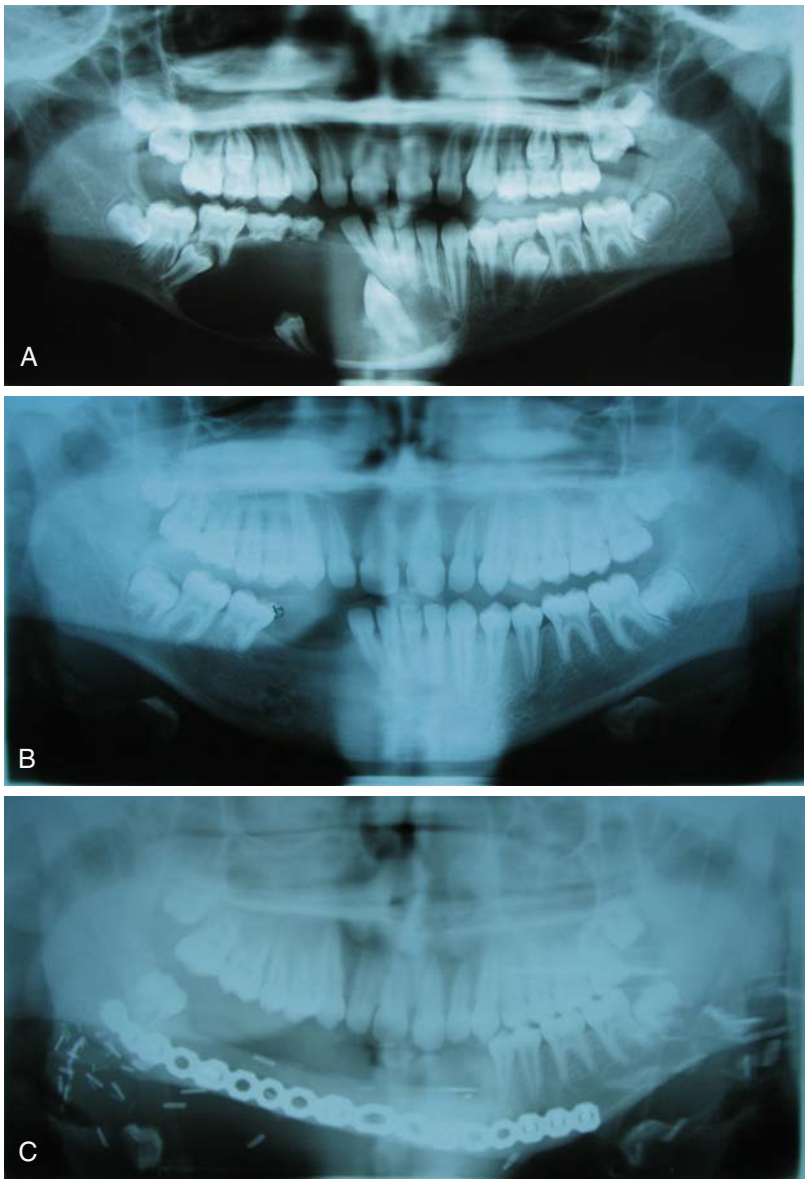

• **Figure 41-27** **A,** A 10-year-old boy with cystic lesion of the right mandible diagnosed as unicystic ameloblastoma. **B,** Recurred following enucleation and ostectomy. **C,** Resected and reconstructed with microvascular free fibula transfer.

Calvarial bone grafting is also an option in reconstruction of the orbit, maxilla, and cranium. Full-thickness, split, and vascularized calvarium are all viable choices, although split calvarium is technically challenging in patients younger than 12 years of age, when the diploic space is not well established. Inner table split calvarium is commonly used for reconstruction following craniotomy, and the outer table replaced without the need for donor site modification. Cranial bone can be modeled and shaped to suit specific anatomic demands. Pedicled transfer of the calvarium has been reported based on branches of the superficial temporal artery. Limited amounts of cancellous bone are available for harvesting. The relative thinness of the bone is well suited for use in the orbital floor, malar, and nasal bones. There is evidence to suggest that cranial bone undergoes less resorption than endochondral donor sites.[114]

Reconstruction of the maxillofacial region in the growing patient is uncommon and particularly challenging. Long-delayed reconstruction can significantly impact growth, appearance, and function. The choice of reconstruction should account for the potential consequences of both the donor and recipient sites and illustrates the need for well-developed treatment plans. Decisions on the traditional reconstructive ladder are less linear, and even when single-staged, simple reconstruction utilizing free tissue transfer may offer advantages over staged reconstruction, it is not uncommon that eventual skeletal and soft tissue augmentation or revision will be necessary.

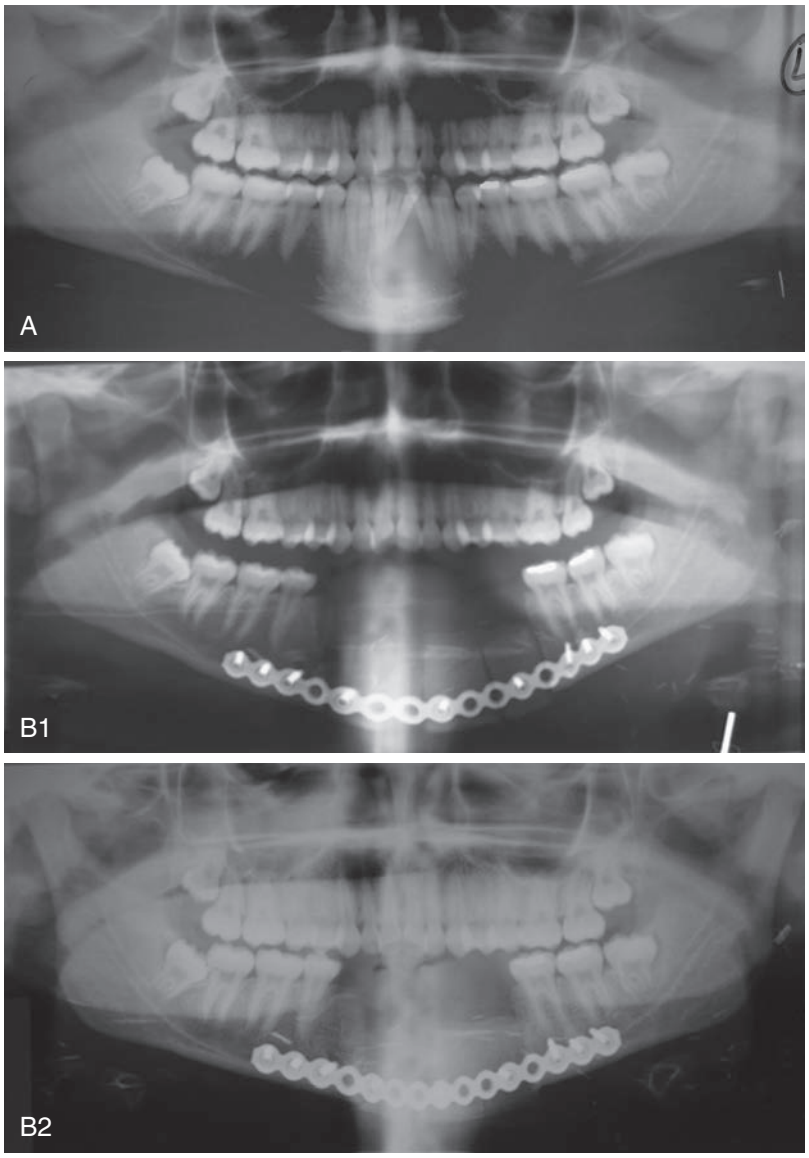

• **Figure 41-28 A,** An 18-year-old female with ameloblastoma of the anterior mandible. **B,** Mandible reconstructed with microvascular deep circumflex iliac artery flap (immediately post-op and following consolidation).

References

1. Enlow D, Hans MG: Overview of craniofacial growth and development. In Enlow D, Hans MG, editors: *Essentials of facial growth*, Philadelphia, 1996, Saunders, pp 1–17.
2. Hain SF: Positron emission tomography in cancer of the head and neck, *Br J Oral Maxillofac Surg* 43(1):1–6, 2005.
3. Nijmeh AD, et al.: Image-guided navigation in oral and maxillofacial surgery, *Br J Oral Maxillofac Surg* 43(4):294–302, 2005.
4. Jackson IT, Marsh WR: Anterior cranial fossa tumors, *Ann Plast Surg* 11(6):479–489, 1983.
5. Lello G, et al.: Craniofacial access to the anterior and middle cranial fossae and skull base, *J Craniomaxillofac Surg* 25(6):285–293, 1997.
6. Munro IR, Fearon JA: The coronal incision revisited, *Plast Reconstr Surg* 93(1):185–187, 1994.
7. Attia A, et al.: Management of parapharyngeal space tumors at the National Cancer Institute, Egypt, *J Egypt Natl Canc Inst* 16(1):34–42, 2004.
8. Engroff SL, Blanchaert Jr RH, von Fraunhofer JA: Mandibulotomy fixation: a laboratory analysis, *J Oral Maxillofac Surg* 61(11):1297–1301, 2003.
9. Sato M, et al.: Oral and maxillofacial tumours in children: a review, *Br J Oral Maxillofac Surg* 35(2):92–95, 1997.
10. Cunningham MJ, Myers EN, Bluestone CD: Malignant tumors of the head and neck in children: a twenty-year review, *Int J Pediatr Otorhinolaryngol* 13(3):279–292, 1987.
11. Robinson LD, et al.: Head and neck malignancies in children: an age-incidence study, *Laryngoscope* 98(1):11–13, 1988.
12. Chuong R, Kaban LB: Diagnosis and treatment of jaw tumors in children, *J Oral Maxillofac Surg* 43(5):323–332, 1985.
13. Sandler KA, Novo RM, Rudner BE: A study of ameloblastoma—age, sex and location statistics, *N Y State Dent J* 49(9):682–684, 1983.
14. Kahn MA: Ameloblastoma in young persons: a clinicopathologic analysis and etiologic investigation, *Oral Surg Oral Med Oral Pathol* 67(6):706–715, 1989.

15. Mehlisch DR, Dahlin DC, Masson JK: Ameloblastoma: a clinicopathologic report, *J Oral Surg* 30(1):9–22, 1972.
16. Ord RA, et al.: Ameloblastoma in children, *J Oral Maxillofac Surg* 60(7):762–771, 2002.
17. Ackermann GL, Altini M, Shear M: The unicystic ameloblastoma: a clinicopathological study of 57 cases, *J Oral Pathol* 17(9-10):541–546, 1988.
18. Shteyer A, Lustmann J, Lewin-Epstein J: The mural ameloblastoma: a review of the literature, *J Oral Surg* 36(11):866–872, 1978.
19. Leider AS, Eversole LR, Barkin ME: Cystic ameloblastoma. A clinicopathologic analysis, *Oral Surg Oral Med Oral Pathol* 60(6):624–630, 1985.
20. Robinson L, Martinez MG: Unicystic ameloblastoma: a prognostically distinct entity, *Cancer* 40(5):2278–2285, 1977.
21. Ghandhi D, et al.: Ameloblastoma: a surgeon's dilemma, *J Oral Maxillofac Surg* 64(7):1010–1014, 2006.
22. Lau SL, Samman N: Recurrence related to treatment modalities of unicystic ameloblastoma: a systematic review, *Int J Oral Maxillofac Surg* 35(8):681–690, 2006.
23. Leon JE, et al.: Clinicopathological and immunohistochemical study of 39 cases of adenomatoid odontogenic tumour: a multicentric study, *Oral Oncol* 41(8):835–842, 2005.
24. Philipsen HP, Reichart PA: Adenomatoid odontogenic tumour: facts and figures, *Oral Oncol* 35(2):125–131, 1999.
25. Kaffe I, Naor H, Buchner A: Clinical and radiological features of odontogenic myxoma of the jaws, *Dentomaxillofac Radiol* 26(5):299–303, 1997.
26. Koseki T, et al.: Computed tomography of odontogenic myxoma, *Dentomaxillofac Radiol* 32(3):160–165, 2003.
27. Li TJ, Sun LA, Luo HY: Odontogenic myxoma: a clinicopathologic study of 25 cases, *Arch Pathol Lab Med* 130(12): 1799–1806, 2006.
28. Rotenberg BW, et al.: Myxomatous lesions of the maxilla in children: a case series and review of management, *Int J Pediatr Otorhinolaryngol* 68(10):1251–1256, 2004.
29. Muller S, et al.: Ameloblastic fibrosarcoma of the jaws. A clinicopathologic and DNA analysis of five cases and review of the literature with discussion of its relationship to ameloblastic fibroma, *Oral Surg Oral Med Oral Pathol Oral Radiol Endod* 79(4):469–477, 1995.
30. Dallera P, et al.: Ameloblastic fibroma: a follow-up of six cases, *Int J Oral Maxillofac Surg* 25(3):199–202, 1996.
31. Fowler CB, Hartman KS: Brannon RB: Fibromatosis of the oral and paraoral region, *Oral Surg Oral Med Oral Pathol* 77(4):373–386, 1994.
32. Gold L: Fibromatosis of the jaw, *Oral Maxillofac Surg Clin N Am* 3(1):191–208, 1991.
33. Thompson DH, et al.: Juvenile aggressive fibromatosis: report of three cases and review of the literature, *Ear Nose Throat J* 70(7):462–468, 1991.
34. Collins BJ, Fischer AC, Tufaro AP: Desmoid tumors of the head and neck: a review, *Ann Plast Surg* 54(1):103–108, 2005.
35. Wang CP, et al.: Desmoid tumor of the head and neck, *Head Neck* 28(11):1008–1013, 2006.
36. Perez-Cruet MJ, et al.: Aggressive fibromatosis involving the cranial base in children, *Neurosurg* 43(5):1096–1102, 1998.
37. Ballo MT, et al.: Desmoid tumor: prognostic factors and outcome after surgery, radiation therapy, or combined surgery and radiation therapy, *J Clin Oncol* 17(1):158–167, 1999.
38. Okuno SH, Edmonson JH: Combination chemotherapy for desmoid tumors, *Cancer* 97(4):1134–1135, 2003.
39. Sturt NJ, Phillips RK, Clark SK: High-dose tamoxifen and sulindac as first-line treatment for desmoid tumors, *Cancer* 101(3):652–653, 2004.
40. Kasper B, et al.: Management of sporadic desmoid-type fibromatosis: a European consensus approach based on patients' and professionals' expertise—a sarcoma patients EuroNet and European Organisation for Research and Treatment of Cancer/Soft Tissue and Bone Sarcoma Group initiative, *Eur J Cancer* 51(2):127–136, 2015.
41. Sciubba J, Fantasia JE, Kahn LB, editors: *Nonodontogenic lesions in atlas of tumor pathology: tumors and cysts of the jaw*, Washington, 1999, Armed Forces Institute of Pathology, pp 161–167.
42. Chuong R, et al.: Central giant cell lesions of the jaws: a clinicopathologic study, *J Oral Maxillofac Surg* 44(9):708–713, 1986.
43. Kaban LB, et al.: Antiangiogenic therapy with interferon alpha for giant cell lesions of the jaws, *J Oral Maxillofac Surg* 60(10):1103–1113, 2002.
44. Terry B, Jacoway JR: Management of central giant cell lesions: an alternative to surgical therapy, *Oral Maxillofac Surg Clin N Am* 6(3):579–600, 1994.
45. Harris M: Central giant cell granulomas of the jaws regress with calcitonin therapy, *Br J Oral Maxillofac Surg* 31(2):89–94, 1993.
46. Pogrel MA, et al.: Calcitonin treatment for central giant cell granulomas of the mandible: report of two cases, *J Oral Maxillofac Surg* 57(7):848–853, 1999.
47. de Lange J, et al.: Limited regression of central giant cell granuloma by interferon alpha after failed calcitonin therapy: a report of 2 cases, *Int J Oral Maxillofac Surg* 35(9):865–869, 2006.
48. de Lange J, et al.: Calcitonin therapy in central giant cell granuloma of the jaw: a randomized double-blind placebo-controlled study, *Int J Oral Maxillofac Surg* 35(9):791–795, 2006.
49. Mattei TA, et al.: Fibrous dysplasia in combination with aneurysmal bone cyst presenting as a subarachnoid haemorrhage, *Neurol Sci* 26(3):178–181, 2005.
50. Itshayek E, et al.: Fibrous dysplasia in combination with aneurysmal bone cyst of the occipital bone and the clivus: case report and review of the literature, *Neurosurgery* 51(3):815–818, 2002.
51. Haddad GF, et al.: Concomitant fibrous dysplasia and aneurysmal bone cyst of the skull base. Case report and review of the literature, *Pediatr Neurosurg* 28(3):147–153, 1998.
52. Batsakis J: *Tumors of the head and neck: clinicopathologic consideration*, ed 2, Baltimore, 1979, Williams and Wilkins, pp 296–300.
53. Carrau RL, et al.: Endoscopic and endoscopic-assisted surgery for juvenile angiofibroma, *Laryngoscope* 111(3):483–487, 2001.
54. Radkowski D, et al.: Angiofibroma. Changes in staging and treatment, *Arch Otolaryngol Head Neck Surg* 122(2):122–129, 1996.
55. McCombe A, Lund VJ, Howard DJ: Recurrence in juvenile angiofibroma, *Rhinology* 28(2):97–102, 1990.
56. Moulin G, et al.: Juvenile nasopharyngeal angiofibroma: comparison of blood loss during removal in embolized group versus nonembolized group, *Cardiovasc Intervent Radiol* 18(3):158–161, 1995.
57. Duvall 3rd AJ, Moreano AE: Juvenile nasopharyngeal angiofibroma: diagnosis and treatment, *Otolaryngol Head Neck Surg* 97(6):534–540, 1987.
58. Sciubba J, Fantasia JE, Kahn LB: Fibro-osseous lesions. In Sciubba J, Fantasia JE, Kahn LB, editors: *Atlas of tumor pathology: tumors and cysts of the jaw*, Washington, 1999, Armed Forces Institute of Pathology, pp 147–151.

59. Margo CE, et al.: Psammomatoid (juvenile) ossifying fibroma of the orbit, *Ophthalmology* 92(1):150–159, 1985.
60. Johnson LC, et al.: Juvenile active ossifying fibroma. Its nature, dynamics and origin, *Acta Otolaryngol Suppl* 488:1–40, 1991.
61. Makek M: *Clinical pathology of fibro-osteo-cemental lesions of the craniofacial skeleton and jaw bones*, Basel, 1983, Karger, pp 128–227.
62. Lichtenstein L, Jaffe HL: Fibrous dysplasia of bone. A condition affecting one, several, or many bones, the graver cases of which may present abnormal pigment of skin, premature sexual development, hyperthyroidism, or still other extraskeletal abnormalities, *Arch Pathol* 33:777–816, 1942.
63. Lichtenstein L: Polyostotic fibrous dysplasia, *Arch Surg* 36:874–898, 1938.
64. Chen YR, Breidahl A, Chang CN: Optic nerve decompression in fibrous dysplasia: indications, efficacy, and safety, *Plast Reconstr Surg* 99(1):22–33, 1997.
65. Lee JS, et al.: Normal vision despite narrowing of the optic canal in fibrous dysplasia, *N Engl J Med* 347(21):1670–1676, 2002.
66. Cutler CM, et al.: Long-term outcome of optic nerve encasement and optic nerve decompression in patients with fibrous dysplasia: risk factors for blindness and safety of observation, *Neurosurgery* 59(5):1011–1018, 2006.
67. Akintoye SO, et al.: Dental characteristics of fibrous dysplasia and McCune-Albright syndrome, *Oral Surg Oral Med Oral Pathol Oral Radiol Endod* 96(3):275–282, 2003.
68. Munro IR, Chen YR: Radical treatment for fronto-orbital fibrous dysplasia: the chain-link fence, *Plast Reconstr Surg* 67(6):719–730, 1981.
69. Chapurlat RD: Medical therapy in adults with fibrous dysplasia of bone, *J Bone Miner Res* 21(Suppl 2):P114–P119, 2006.
70. Kos M, et al.: Treatment of monostotic fibrous dysplasia with pamidronate, *J Craniomaxillofac Surg* 32(1):10–15, 2004.
71. Lala R, et al.: Bisphosphonate treatment of bone fibrous dysplasia in McCune-Albright syndrome, *J Pediatr Endocrinol Metab* 19(Suppl 2):583–593, 2006.
72. Mulvihill JJ, et al.: NIH conference. Neurofibromatosis 1 (Recklinghausen disease) and neurofibromatosis 2 (bilateral acoustic neurofibromatosis). An update, *Ann Intern Med* 113(1):39–52, 1990.
73. Stern J, DiGiacinto GV, Housepian EM: Neurofibromatosis and optic glioma: clinical and morphological correlations, *Neurosurgery* 4(6):524–528, 1979.
74. Korf BR: Plexiform neurofibromas, *Am J Med Genet* 89(1):31–37, 1999.
75. Jacquemin C, Bosley TM, Svedberg H: Orbit deformities in craniofacial neurofibromatosis type 1, *AJNR Am J Neuroradiol* 24(8):1678–1682, 2003.
76. Jackson IT: Neurofibromatosis of the skull base, *Clin Plast Surg* 22(3):513–530, 1995.
77. Jackson IT, Laws Jr ER, Martin RD: The surgical management of orbital neurofibromatosis, *Plast Reconstr Surg* 71(6):751–758, 1983.
78. Jackson IT: Management of craniofacial neurofibromatosis, *Facial Plast Surg Clin North Am* 9(1):59–75, 2001.
79. Neville BW: *Oral and maxillofacial pathology*, St Louis, 2009, Saunders/Elsevier.
80. Laje P, Howell LJ, Johnson MP, Hedrick HL, Flake AW, Adzick NS: Perinatal management of congenital oropharyngeal tumors: the ex utero intrapartum treatment (EXIT) approach, *J Pediatr Surg* 48(10):2005–2010, 2013.
81. Kumar B, Sharma SB: Neonatal oral tumors: congenital epulis and epignathus, *J Pediatr Surg* 43(9):e9–e11, 2008.
82. Rachidi S, Sood AJ, Patel KG, Nguyen SA, Hamilton H, Neville BW, Day TA: Melanotic neuroectodermal tumor of infancy: a systematic review, *J Oral Maxillofac Surg* 73(10): 1946–1956, 2016.
83. Furtado SV, Ghosal N, Hegde AS: Calvarial malignant melanotic neuroectodermal tumour of infancy presenting with widespread intracranial metastasis, *J Craniomaxillofac Surg* 40(6):e170–e173, 2012.
84. Oberlin O, et al.: Treatment of orbital rhabdomyosarcoma: survival and late effects of treatment—results of an international workshop, *J Clin Oncol* 19(1):197–204, 2001.
85. Rousseau P, et al.: Primary chemotherapy in rhabdomyosarcomas and other malignant mesenchymal tumors of the orbit: results of the International Society of Pediatric Oncology MMT 84 Study, *J Clin Oncol* 12(3):516–521, 1994.
86. Raney Jr RB, et al.: Improved prognosis with intensive treatment of children with cranial soft tissue sarcomas arising in nonorbital parameningeal sites. A report from the Intergroup Rhabdomyosarcoma Study, *Cancer* 59(1):147–155, 1987.
87. Lyos AT, et al.: Soft tissue sarcoma of the head and neck in children and adolescents, *Cancer* 77(1):193–200, 1996.
88. Meazza C, et al.: Evolving treatment strategies for parameningeal rhabdomyosarcoma: the experience of the Istituto Nazionale Tumori of Milan, *Head Neck* 27(1):49–57, 2005.
89. Donaldson SS, et al.: Results from the IRS-IV randomized trial of hyperfractionated radiotherapy in children with rhabdomyosarcoma—a report from the IRSG, *Int J Radiat Oncol Biol Phys* 51(3):718–728, 2001.
90. Simon JH, et al.: Prognostic factors in head and neck rhabdomyosarcoma, *Head Neck* 24(5):468–473, 2002.
91. Schouwenburg PF, et al.: New combined treatment of surgery, radiotherapy, and reconstruction in head and neck rhabdomyosarcoma in children: the AMORE protocol, *Head Neck* 20(4):283–292, 1998.
92. Buwalda J, et al.: AMORE protocol in pediatric head and neck rhabdomyosarcoma: descriptive analysis of failure patterns, *Head Neck* 27(5):390–396, 2005.
93. Bennett JH, et al.: Osteosarcoma of the jaws: a 30-year retrospective review, *Oral Surg Oral Med Oral Pathol Oral Radiol Endod* 90(3):323-332, 2000.
94. Mardinger O, et al.: Osteosarcoma of the jaw. The Chaim Sheba Medical Center experience, *Oral Surg Oral Med Oral Pathol Oral Radiol Endod* 91(4):445–451, 2001.
95. Vaccani JP, et al.: Ewing's sarcoma of the head and neck in children, *Int J Pediatr Otorhinolaryngol* 48(3):209–216, 1999.
96. Forstner D, Borg M, Saxon B: Orbital rhabdomyosarcoma: multidisciplinary treatment experience, *Australas Radiol* 50(1):41–45, 2006.
97. Krasin MJ, et al.: The effects of external beam irradiation on the growth of flat bones in children: modeling a dose-volume effect, *Int J Radiat Oncol Biol Phys* 62(5):1458–1463, 2005.
98. La Scala GC, et al.: Radiation-induced craniofacial bone growth inhibition: efficacy of cytoprotection following a fractionated dose regimen, *Plast Reconstr Surg* 115(7):1973–1985, 2005.
99. Ellis G, Auclair PL, Gnepp DR: Salivary gland neoplasms: general considerations. In Ellis G, Auclair PL, Gnepp DR, editors: *Surgical pathology of the salivary glands*, Philadelphia, 1991, WB Saunders.
100. Vedrine PO, et al.: Mucoepidermoid carcinoma of salivary glands in the pediatric age group: 18 clinical cases, including 11 second malignant neoplasms, *Head Neck* 28(9):827–833, 2006.

101. Shapiro NL, Bhattacharyya N: Clinical characteristics and survival for major salivary gland malignancies in children, *Otolaryngol Head Neck Surg* 134(4):631–634, 2006.
102. Whatley WS, Thompson JW, Rao B: Salivary gland tumors in survivors of childhood cancer, *Otolaryngol Head Neck Surg* 134(3):385–388, 2006.
103. Yu GY, et al.: Diagnosis and treatment of epithelial salivary gland tumours in children and adolescents, *Br J Oral Maxillofac Surg* 40(5):389–392, 2002.
104. Caccamese Jr JF, Ord RA: Paediatric mucoepidermoid carcinoma of the palate, *Int J Oral Maxillofac Surg* 31(2):136–139, 2002.
105. Peng X, et al.: Maxillary reconstruction with the free fibula flap, *Plast Reconstr Surg* 115(6):1562–1569, 2005.
106. August M, et al.: Factors influencing the long-term outcome of mandibular reconstruction, *J Oral Maxillofac Surg* 58(7):731–738, 2000.
107. De Riu G, et al.: Complications of mandibular reconstruction in childhood: report of a case of juvenile aggressive fibromatosis, *J Craniomaxillofac Surg* 34(3):168–172, 2006.
108. Warren SM, et al.: Microvascular reconstruction of the pediatric mandible, *Plast Reconstr Surg* 119(2):649–661, 2007.
109. Guo L, Ferraro NF, Padwa BL, Kaban LB, Upton J: Vascularized fibular graft for pediatric mandibular reconstruction, *Plast Reconstruct Surg* 121(6):2095–2105, 2008.
110. Genden EM, et al.: Reconstruction of the pediatric maxilla and mandible, *Arch Otolaryngol Head Neck Surg* 126(3):293–300, 2000.
111. Pritchett JW: Growth and growth prediction of the fibula, *Clin Orthop Relat Res* 334:251–256, 1997.
112. Weiland AJ, Phillips TW, Randolph MA: Bone grafts: a radiologic, histologic, and biomechanical model comparing autografts, allografts, and free vascularized bone grafts, *Plast Reconstr Surg* 74(3):368–379, 1984.
113. Bartlett SP, Whitaker LA: Growth and survival of vascularized and nonvascularized membranous bone: an experimental study, *Plast Reconstr Surg* 84(5):783–788, 1989.
114. Maves MD, Matt BH: Calvarial bone grafting of facial defects, *Otolaryngol Head Neck Surg* 95(4):464–470, 1986.

42

Distraction Osteogenesis of the Craniomaxillofacial Skeleton

KEVIN S. SMITH

History

The technique of lengthening bone by gradual distraction has been used in a variety of specialties sporadically over the past century. Its application to the craniofacial skeleton is relatively recent, and its indications have been expanding over the past decade. Distraction osteogenesis (DO) was used by orthopedic surgeons during the first half of the 20th century. The concept of DO was formally introduced in 1969 by Gavriel A. Ilizarov, who together with Dr. L. M. Sojbelman published his first case series of distraction epiphysiolysis in the journal *Eksperimentalnaja Khirurgia Anestesia*.[1,4] After he graduated from medical school in 1943, the Russian government sent Ilizarov to work in the Kurgan district of western Siberia. In post–World War II Russia, thousands of wounded veterans were in need of multiple surgical procedures, many of which involved conditions such as fracture, pseudoarthrosis, and osteomyelitis. Ilizarov had been applying this method for multiple surgical applications for years before his case reports were published. After hearing of the "miracles" accomplished with his revolutionary surgical procedures in orthopedic surgery, people in Russia referred to him as the "magician from Kurgan." In 1951, Ilizarov started to use metal rings with transosseous wires to align and manipulate bone segments of complicated fractures in long bones, subsequently achieving bone healing after stabilizing the segments for a time. Early in the 1960s, Ilizarov distracted a short tibial stump with the intention of subsequently grafting the gap he had created. He was surprised to discover 1 month later on postoperative x-ray that he could not see a gap at all. At this point, he was able to identify technical aspects of the procedure that led to gradual successful lengthening of the tibia. The early concepts that he proved are still seminal today and are important in justifying these early concepts. Early postulates included (1) that corticotomy was safe with continued bone marrow viability, and (2) that combining corticotomy with slow distraction bone lengthening was possible. Ultimately, Ilizarov is recognized as one of the most important surgeons in the establishment of DO as a procedure with a large number of applications.[2,3,9]

From a maxillofacial perspective, dentofacial traction is a procedure that has been used since the 18th century. Fauchard in 1728 had started to practice dental arch expansion in the presence of dental crowding; this was done at the expense of tooth movement with little change in bone morphology. Westcott in 1859 reported correction of crossbite in a 15-year-old patient after a slow and tedious process that had lasted several months. Angell in 1860 achieved rapid palatal expansion over the course of 2 weeks at the expense of midpalatal suture separation. Thirty-three years later, in 1893, Goddard standardized the procedure by recognizing the need for a 3-week period of stabilization to allow for "osseous material" formation at the "created gap."[10] In 1937, Kazanjian achieved mandibular advancement by gradually applying traction rather than acute movement of an osteotomized mandible. The device used consisted of a wire hook attached to the symphysis, which was advanced with traction with the use of an elastic band. Anchorage was achieved with the aid of a facial appliance anchored to the maxillary teeth and stabilized against the patient's forehead, much like a phase I orthodontic appliance. Activation was started 3 days postoperatively when forward movement of the osteotomized mandibular segment was attained. Seventeen days later, traction was ended, and intermaxillary fixation was instituted for 11 weeks with the aid of occlusal splints. At this point, DO lacked recognition as a reliable method, in part because of lack of bone segment manipulation control, difficulty manipulating the custom appliances, and inadequate skeletal fixation methods used for stabilization after distraction.[10]

In 1973, Snyder reported the first successful mandibular DO in a canine model following the distraction principles previously established by Ilizarov for limb lengthening. Guerrero and McCarthy[20,21] were among

the first to report on the clinical feasibility of mandibular lengthening by gradual distraction in patients with craniofacial anomalies. Since the first reports, DO has been widely used in the treatment of patients with various cranio-maxillofacial deformities. Recently, there has been an explosion of reports in the literature regarding the use of DO on the cranio-maxillofacial skeleton, and much has been learned about the indications and usefulness of this technique.[21-26] Techniques and outcome expectations continue to be refined.

Biologic Basis of Distraction Osteogenesis

During the 1997 International Congress of Cranial and Facial Distraction Osteogenesis in Paris, France, Dr. Paul Tessier referred to DO as the "end of facial osteotomies as we know them."[69] Two decades have passed, and traditional osteotomies still are used much more frequently, but distraction has provided solutions to some very difficult problems that were challenging or impossible to address prior to its development. As with many new technologies, much excitement was generated early in the development of distraction devices and techniques. As more experience and data become available, the best indications and the limitations are becoming clearer. Distraction techniques appear to have great potential in addressing a number of difficult problems such as exceptionally large advancements and advancements required in very young patients.

DO offers several purported advantages to the clinician who is managing craniofacial anomalies. Its major advantage is that it provides the opportunity for lengthening of craniofacial bones to a degree not typically possible with traditional techniques. DO also eliminates donor site morbidity in cases in which bone grafting typically is used in combination with traditional advancement techniques. In addition, DO provides a method of lengthening the craniofacial skeleton while at the same time distracting the surrounding soft tissue matrix. Consequently, DO has gained popularity as a treatment modality and has opened new therapeutic opportunities for the treatment of patients with numerous congenital and acquired craniofacial skeletal anomalies.[27-31]

Established treatment parameters for DO as initially described by Ilizarov are important for a successful result and include the following[6]:

- Cortical osteotomy with minimal periosteal stripping
- Latency period ranging from 3 to 7 days, depending on the surgical site, and a potentially shorter duration for younger children[68]
- Distraction rate of 0.5 to 2.0 mm per day depending on the surgical site, usually 1.0 mm per day. Faster rates in children, especially neonates[68]
- Distraction with application of continuous force is ideal but activation of the device twice per day or three times per day is effective and practical for the patient.
- Consolidation period should be approximately 6 weeks or should last until cortical outlines are visible on radiograph.

The procedure entails performing an osteotomy of the cortical bone at the site of anticipated lengthening. Preservation of the periosteum and the surrounding vascular supply is an important factor in the success of DO.[5] The objective of DO will be to slowly separate the edges of the osteotomy to create a regenerative chamber that will give rise to bone. Depending on the distraction site, great variation is expected in the size and conformation of the osteotomy, and a regenerative chamber is possible (i.e., maxillary osteotomy, mandibular ramus osteotomy, fronto-orbital and mid-face osteotomy, or alveolar ridge osteotomy).

Once the corticotomies have been completed and the distractor device is in place, the latency period begins. The latency period ranges from 0 to 10 days, with the most common durations of 1 to 2 days in children and 5 days in adults. This allows for resolution of the inflammation resulting from the corticotomy and surgical placement of the device. The first phase of healing involves organization of the hematoma and induction of mesenchymal cells, as well as endosteal and periosteal cells, into osteoblasts and fibroblasts. Type I collagen is deposited and osteoid production takes place.

Once the distraction phase begins, this healing tissue is exploited by lengthening of the regenerate. Distraction of the regenerate tissue then can occur at a rate of approximately 1 mm per day. Although this process of regenerate lengthening is directed at providing bone, the surrounding soft tissue also is stretched during the lengthening procedure. This phenomenon of soft tissue expansion is referred to by some as *distraction histogenesis*. Skin, muscle, nerves, and vascular tissue purportedly have been generated, not stretched, but observation of many cases and conflicting literature make these concepts controversial.

In the young child, larger bones with a larger regenerate chamber site may be able to tolerate quicker distraction rates. Decreasing the rate is recommended for small areas such as the dentoalveolar ridge segments.[36] The initial process of bone formation involves a regenerate chamber that is filled with a fibrous matrix that will ossify at the periphery and then centrally over time. The regenerate area consolidates into bone once the distraction process is consolidated and the segments are rigidly fixed in place.[37] Distraction that moves too quickly will result in nonunion, and distraction that occurs too slowly will result in early healing without the potential to lengthen the segments.

The consolidation time in adults should be at least 3 months and can be as long as 6 months, depending on the magnitude of distraction, the type of deformity, and the patient's age. How the length of consolidation affects stability is unclear at this point, but it is clear that bone stability is very important during the consolidation phase. Once

consolidation has been confirmed, removal of the hardware can be performed with basic radiography or other imaging modalities such as computed tomography (CT) scan.[13,14]

In some cases, distraction osteogenesis offers several advantages over other techniques such as the following:

- Ability to accomplish large advancements
- Ability to expand soft tissue surrounding matrix
- Minimizes or eliminates the need for bone grafting
- Potentially less relapse than with traditional methods

However, when compared with traditional techniques, DO may have a number of disadvantages in certain situations, including those listed here:

- Higher postoperative infection rate at the osteotomy site
- Greater risk of hardware failure
- Difficulty with vector control with less precise positioning of segments when compared
- Risk of premature bone formation or nonunion

Relative contraindications to DO include the following[68]:

- Patient/family noncompliance regarding activation of distraction device
- Lack of adequate bone (class III hemifacial microsomia)
- Radiation therapy
- Bisphosphonate use

Mandibular Distraction Osteogenesis

Mandibular retrognathia is a congenital or acquired condition that can represent functional and esthetic problems.[7,8,14] Congenital abnormalities that may exhibit severe mandibular retrognathia include craniofacial anomalies such as hemifacial microsomia, Pierre Robin sequence, Treacher Collins syndrome, Nager syndrome, and a number of others. Acquired sources of origin include post-traumatic and iatrogenic post-surgical scar formation that may induce growth disturbances[32,38] (Figure 42-1). Mandibular growth may be adversely affected by condylar fractures that occur at an early age with formation of ankylosis at the temporomandibular joint and/or deficient mandibular growth.[11,12,14]

Obstructive apnea is a complicating factor that may be encountered in patients with mandibular hypoplasia. Repetitive obstruction can result in long-term health problems. In most instances, the diagnosis should be made after a formal sleep study has been conducted. In neonates, mandibular hypoplasia associated with obstruction may translate into feeding difficulties, as the coordination between breathing and swallowing is fairly delicate during the first months of life. The opportunity to provide lengthening of the mandible with potentially greater stability and less likelihood of relapse in challenging cases requiring exceptionally large advancements has made DO an attractive option for a subset of this population[15,39] (Figure 42-2).

Although several other options may be available for patients with obstruction at the tongue base, infants born with severe mandibular hypoplasia and difficulty maintaining a patent airway may benefit from DO.[40,41,68] Early lengthening of the body of the mandible bilaterally can produce volumetric expansion of the airway, which may lead to early decannulation or may even avoid the need for tracheostomy[42,43] (Figure 42-3). Most children who benefit from this technique have no other significant airway obstruction (e.g., laryngomalacia, choanal atresia, tracheomalacia). A careful interdisciplinary evaluation is helpful before this procedure is considered as an option. Also, although DO has been applied to other types of neonatal mandibular hypoplasia, unless condyle and fossa conformation proceeds relatively normally, rates of trismus or ankylosis of the temporomandibular joint may be high.

A critical part of achieving successful results with distraction osteogenesis involves presurgical planning, appropriate placement of the devices, and accurate determination of the correct vector of distraction. The use of a paralleling device can greatly enhance the proper alignment and provide positive vector control (Figure 42-4). Often, stereolithic models (Figure 42-5) are used to facilitate determination of the best site for placement of the devices.

This model is useful for the following:

- Determining adequacy of bone stock at areas of screw placement
- Determining the position of the inferior alveolar nerve and developing teeth
- Assessing the correct position of the appliance, so the mandible is advanced along the desired vector
- Pre-bending the appliance to conform to the anatomy of the skeleton

Indications for mandibular lengthening based on distraction osteogenesis include the following:

- Severe mandibular retrognathia associated with a syndrome, especially in infants and children who are not candidates for traditional osteotomy (Figure 42-6)
- Unilateral mandibular hypoplasia with asymmetry (hemifacial microsomia) with adequate bone structure
- Transverse deficiency of the mandible associated with malocclusion
- Nonsyndromic severe mandibular retrognathia associated with malocclusion
- Severe obstructive sleep apnea associated with mandibular hypoplasia
- Post-traumatic mandibular hypoplasia
- Post-surgical mandibular continuity defects in patients with history of tumor excision and/or aggressive developmental cysts (Figure 42-7)
- Alveolar bone vertical height deficiency[13]

A number of technical factors are important to consider when mandibular distraction procedures are performed. It is important to exercise caution during corticotomy and placement of the distractor device, to avoid injury to the inferior alveolar nerve. Reports of neurosensory changes in the inferior alveolar nerve after DO range from no neurosensory deficit[44,45] to deficits in



• **Figure 42-1** **A** and **B,** External distraction device on a patient with severe mandibular retrognathia and Pierre Robin sequence. **C,** Preoperative lateral profile view with mandibular retrognathia associated with Pierre Robin sequence. **D,** Postoperative lateral profile view after mandibular distraction osteogenesis with the use of an external distraction device. Patient shows well-balanced maxillomandibular relationships and improved mandibular projection.

25% to 50% of reported cases.[46,47] In a study by Block, 10 mm of mandibular distraction in dogs with measurement of action potentials along the inferior alveolar nerve revealed minimal effect on the ability of the nerve to conduct.[48] Other studies showed similar results that at a rate of 1 mm per day had no deleterious effects on the inferior alveolar nerve. However, Hu reported that distraction rates of 2 mm per day may result in degenerative changes in the inferior alveolar nerve.[16]

Relapse with Mandibular Distraction Osteogenesis

In the past, bilateral sagittal split osteotomies with the use of wire fixation led to an average of 2 mm relapse[49] and up to 30% relapse in the sagittal plane.[50] This situation has been improved considerably by the advent of rigid fixation. However, when advancements must be greater than 10 to 12 mm, then the potential for relapse may be greater.[51] The use of distraction techniques may allow for more stable advancement in exceptionally large movements, although true comparative data are not yet available to strongly support this concept.

In the author's experience, distraction can provide 10 to 20 mm of lengthening with minimal or no relapse if an appropriate distraction protocol and consolidation periods have been followed.[52,53] It is important to note that early removal of fixation with a short consolidation phase may result in less desirable results. The recommended consolidation period for mandibular distraction should be at least 3 months after significant lengthening, and the decision to remove the appliance or consolidation fixation may be based on visualization of cortical bone formation on radiography.[14]

Relapse has been reported when the distraction technique is used, and the degree is often both case dependent and vector dependent. A paucity of convincing evidence favors one technique over another when one considers the options of traditional advancement versus that performed with distraction osteogenesis. Admittedly, the studies are difficult to perform because of the small numbers of patients with the need for exceptionally large advancements, but

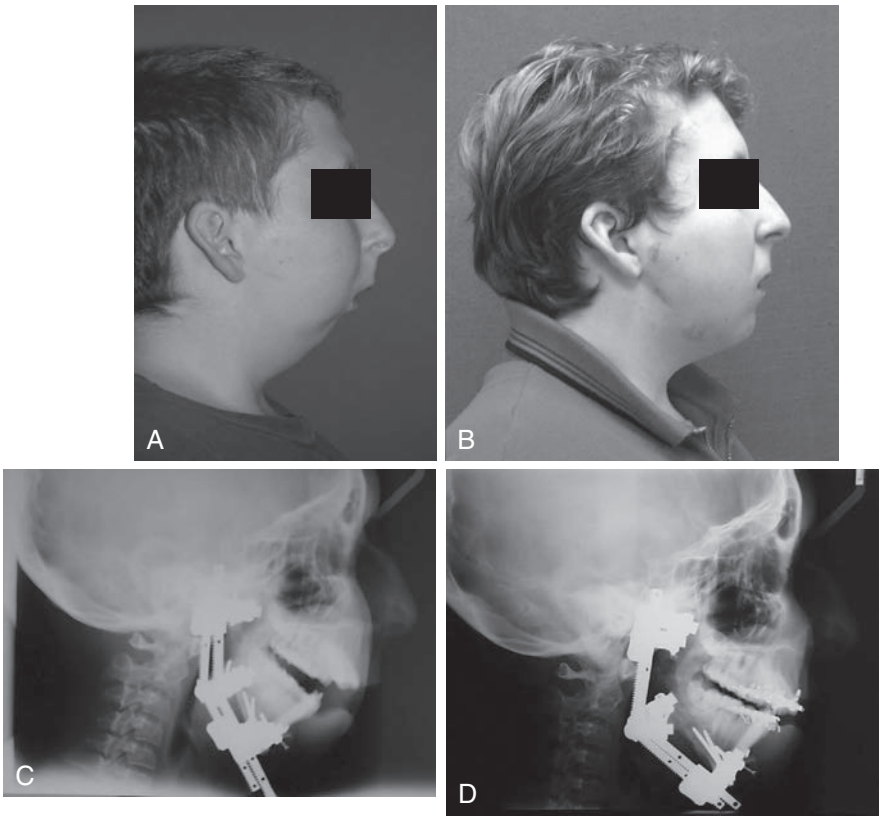

• **Figure 42-2** **A,** A patient with branchial arch syndrome with obstructive sleep apnea. **B,** Postoperative profile view after mandibular distraction with an external distractor device and obstructive sleep apnea that is now resolved. **C,** Lateral cephalometric films with external distractor device in place preoperatively and postoperatively. **D,** After distraction of the mandible.

many clinicians believe that DO techniques are superior for cases requiring unusually large advancements. In some instances, it is not possible to use traditional techniques for exceptionally large advancements, but fortunately, this is an uncommon scenario. Ongoing technical refinements may produce more predictable distraction and consolidation phases, which may translate into more predictable outcomes.

Maxillary Distraction Osteogenesis

In addition to mandibular lengthening with distraction techniques, one of the earliest applications of distraction was its use in mid-face advancement at the Le Fort I or III level. Maxillary hypoplasia is a skeletal abnormality that may occur as a manifestation of impaired maxillary growth, especially in patients with a history of previous surgery for treatment of conditions such as cleft lip and palate. Severe hypoplasia in this population usually is related to postoperative scar tissue formation, which is ideally suited for gradual distraction techniques.[17,54,55] In other instances, it is a dysplasia associated with underdevelopment of the mid-face, as occurs in Apert, Crouzon, or Pfeiffer syndrome.

One of the traditional treatment modalities used for maxillary hypoplasia is the Le Fort I osteotomy, with immediate advancement attained through rigid fixation with or without bone grafting.[56-58] However, the maxilla in these patients may prove to be difficult to mobilize because of scar tissue resulting from previous surgery. When orthognathic surgery is performed, a greater tendency for relapse may be noted in patients with clefts exhibiting maxillary hypoplasia, even with the use of skeletal fixation.[18,59,60]

Maxillary Distraction in Mixed Dentition

While the craniomaxillofacial surgeon must always weight the benefits of surgical intervention in a growing child against the restrictions in growth the intervention may ultimately cause, occasionally, the significant psychosocial morbidity associated with dentofacial deformities may require surgical intervention prior to the completion of facial growth. As a result of the surgeries required to correct cleft lip and palate deformities, many of these patients develop significant mid-face hypoplasia. Inhibition of mid-face development may be seen as early as 4 to 6 years of age in the developing child. The results of this skeletal deformity

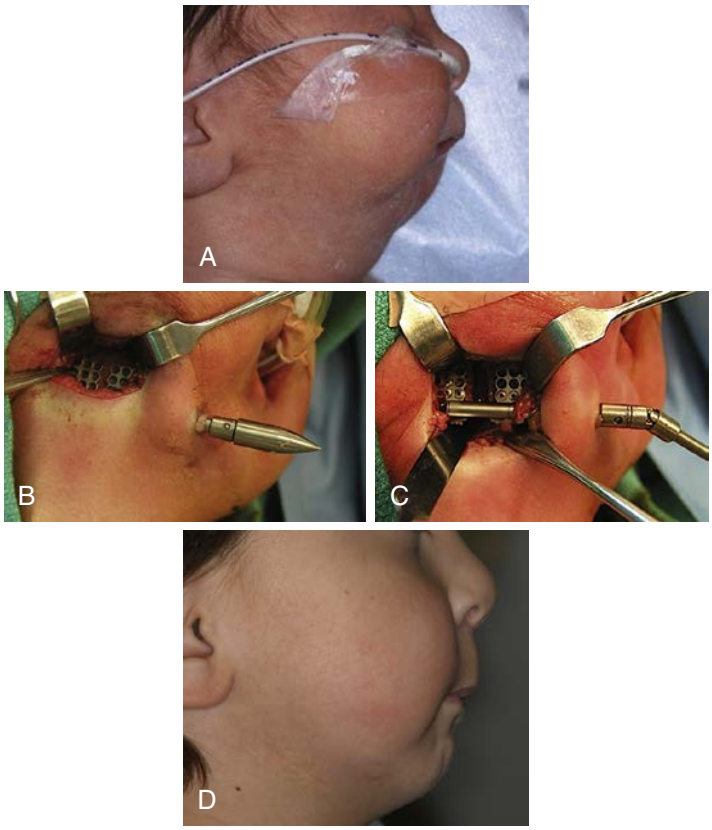

• **Figure 42-3** **A,** Neonate profile with severe respiratory distress secondary to Pierre Robin Sequence.**B,** Submandibular approach for mandibular internal distractor device placement, utilization of bullet shaped trocar helps placement of transcutaneous activation arm. Device also has antireversing gears to prevent accidental reversing of distraction. **C,** Distraction device in place and testing of distraction to ensure corticotomy is complete. **D,** Five year follow-up for distraction patient, note healing of submandibular scars and continued mandibular growth.



• **Figure 42-4** Paralleling device demonstrating use for neonatal DO. The device can be adjusted in all planes and allows for vector control and can be used for all applications. Adult and pediatric sizes are available.



• **Figure 42-5** Treatment planning with the use of stereolithographic model of the mandible as an aid for assessment of mandibular and condylar anatomy.

can cause patients significant disturbance in psychosocial development.[60a]

Maxillary distraction in the mixed dentition can help alleviate the potentially difficult psychosocial issues during this stage of development.[60b]

While some surgeons consider distraction osteogenesis to enhance further development of the jaw,[60c,d] others have shown it early maxillary distraction can further limit mid-facial growth, and may require subsequent orthognathic surgery to correct their dentofacial deformities. Maxillary distraction can have a positive influence in decreasing or occasionally eliminating the amount of maxillary advancement needed at skeletal maturity.

Generally, the decision for distraction in the mixed dentition must involve the family. Frank discussions regarding the psychosocial issues regarding the child must take place

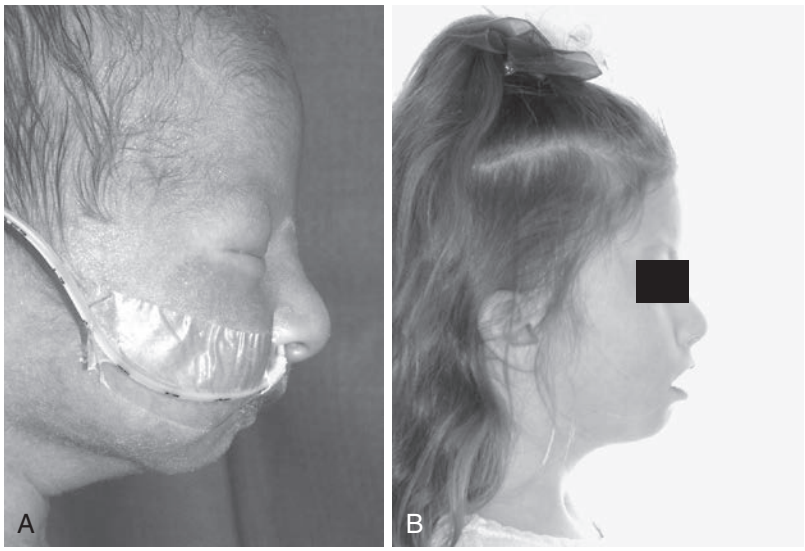

• **Figure 42-6** **A,** Preoperative profile view of neonate with mandibular hypoplasia. **B,** Postoperative profile view 6 years after distraction osteogenesis.



• **Figure 42-7** Intraoperative view of a mandibular transport distraction device used as a method of treatment for mandibular continuity defects.

as the probability of needing further orthognathic surgery is high[60e] once skeletal maturity is reached. The authors experience shows that children with social issues welcome this surgery as the influence on facial normalization is tremendous (Figure 42-8).

Maxillary DO techniques may offer a better option in some patients who require very large advancements. It has been reported that with the use of maxillary DO, it is possible to obtain up to 40 mm of maxillary advancement in patients with an approximated 7% relapse at 1-year follow-up.[19,61] Long-term comparative studies are currently under way for the purpose of more completely evaluating these concepts.

Indications for maxillary DO include the following:

- Craniofacial syndromes with mid-face hypoplasia (Figure 42-9)
- Maxillary hypoplasia associated with cleft lip and/or palate (Figure 42-10)
- Severe obstructive sleep apnea

Cranial Vault Distraction Osteogenesis

In recent years, DO has been used as a treatment modality for patients with craniosynostosis. Typically, cranial vault expansion and reshaping have been used to deal with the growth restriction seen with fused cranial vault sutures (Figure 42-11). This requires fairly aggressive dismantling of the cranial vault with a significant possibility of morbidity and even mortality. Recently, endoscopic techniques have been used to potentially minimize the aggressive nature of the procedure, with the hope of reducing complications. Other options recently considered include expansion of the cranial vault through corticotomy and expansion with the use of DO. When compared with the traditional methods of calvarial expansion and reshaping, DO is seen to offer some advantages such as potentially less hazardous complications, reduced scar tissue formation, and fewer residual bone defects.[62,63] Reported complications of cranial vault reshaping procedures include significant intraoperative blood loss and epidural dead space, which may lead to a higher risk of postoperative infection.[33,64] Additionally, the surgeon is sometimes limited to a certain amount of cranial vault expansion because of the soft tissue envelope and the need for closure of the scalp under tension. This contributes to postoperative relapse and incomplete expansion of cranial vault deformities in some cases. Craniectomy also temporarily renders calvarial bone free from vascular nutrients, which theoretically causes greater resorption of the reshaped cranium.[34,66] DO also offers the advantage that bone formation may be accompanied by gradual stretching of the soft tissue envelope and the possibility of histogenesis via simultaneous expansion of the functional matrix, including muscles, skin, mucosa, fascia, periosteum, blood vessels, and nerves.[35,65]

One of the limitations of distraction for the treatment of patients with craniosynostosis is the fact that it is currently

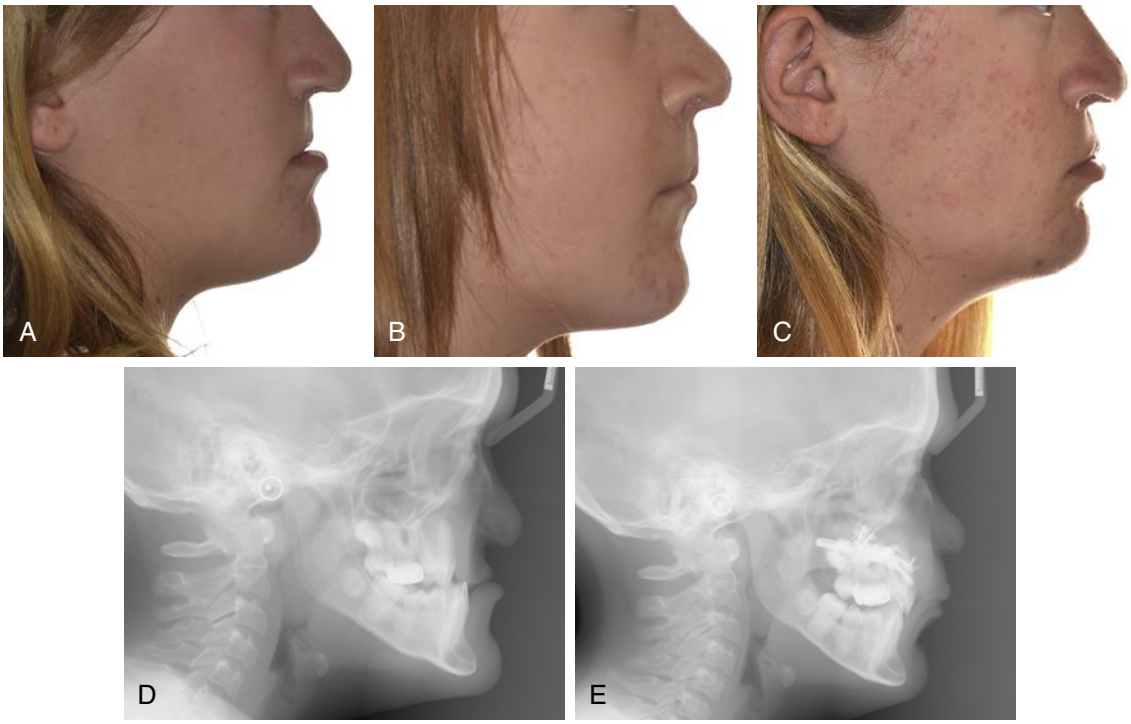

• **Figure 42-8** **A,** An 11-year-old female with severe maxillary hypoplasia secondary to cleft lip and palate surgery. Patient complained of social issues, after discussing possible secondary orthognathic surgery the family elected DO in mixed dentition. **B,** Patient 6 months post internal maxillary distraction. **C,** Patient 3 years post internal maxillary distraction. Patient elected to not have further orthognathic surgery despite end to end occlusion. Patient felt her facial form was acceptable. **D,** Cephalometic x-ray of 12-year-old with severe maxillary hypoplasia. **E,** Immediate post distraction phase showing adequate distraction of maxilla.

a unidirectional expansion that cannot effectively treat the 3D deformity as completely as cranial vault reshaping can. In brachycephaly, for example, vertical height and bitemporal distance are elongated and a narrow anterior-posterior dimension occurs as compensation for synostosis of the coronal suture. Consequently, the goals of cranial vault reshaping in those cases include reduced vertical height and bitemporal distance and the attainment of fronto-orbital advancement. When DO is applied in such cases, the fronto-orbital advancement achieved will not correct all of the dysmorphology that is present. A "masking" effect will occur, making the cranium appear to be closer to normal dimension in the vertical and horizontal planes. Similarly, in patients with scaphocephaly, vertical height will seem to be reduced after bitemporal distance has been widened. In patients with asymmetric deformity (plagiocephaly), traditional cranial vault reshaping should be the preferred technique because of the potential to perform more complete bone reshaping with minimal epidural dead space and tension during scalp closure.[67] These techniques continue to be refined and are used at a small number of centers. Long-term stability and the predictable nature of treatment continue to be evaluated and presented.

Resorbable Distraction

The use of resorbable distraction devices may play a role in future application of DO of the entire craniofacial complex.[70,71] Obvious advantages of resorbable devices include elimination for the need of secondary surgery for device removal. Disadvantages would be strength and rigidity concerns. Use of resorbable materials for plating is well documented so biocompatibility issues are not concerning (Figure 42-12).

Summary

The technique of DO for the craniofacial skeleton has undergone many changes and improvements. Advantages, disadvantages, and best indications have become more refined over time. When used well, the techniques provide the surgeon with the ability to lengthen bones to a greater extent than is possible with traditional techniques. Additionally, a number of challenging clinical situations seen by the cranio-maxillofacial surgeon, such as neonatal mandibular hypoplasia, may be best treated with these techniques. In some cases, these procedures may offer the only option for bone lengthening. Continued outcome research and technical refinements are likely to improve the decision-making process for surgeons while producing even better results for patients.

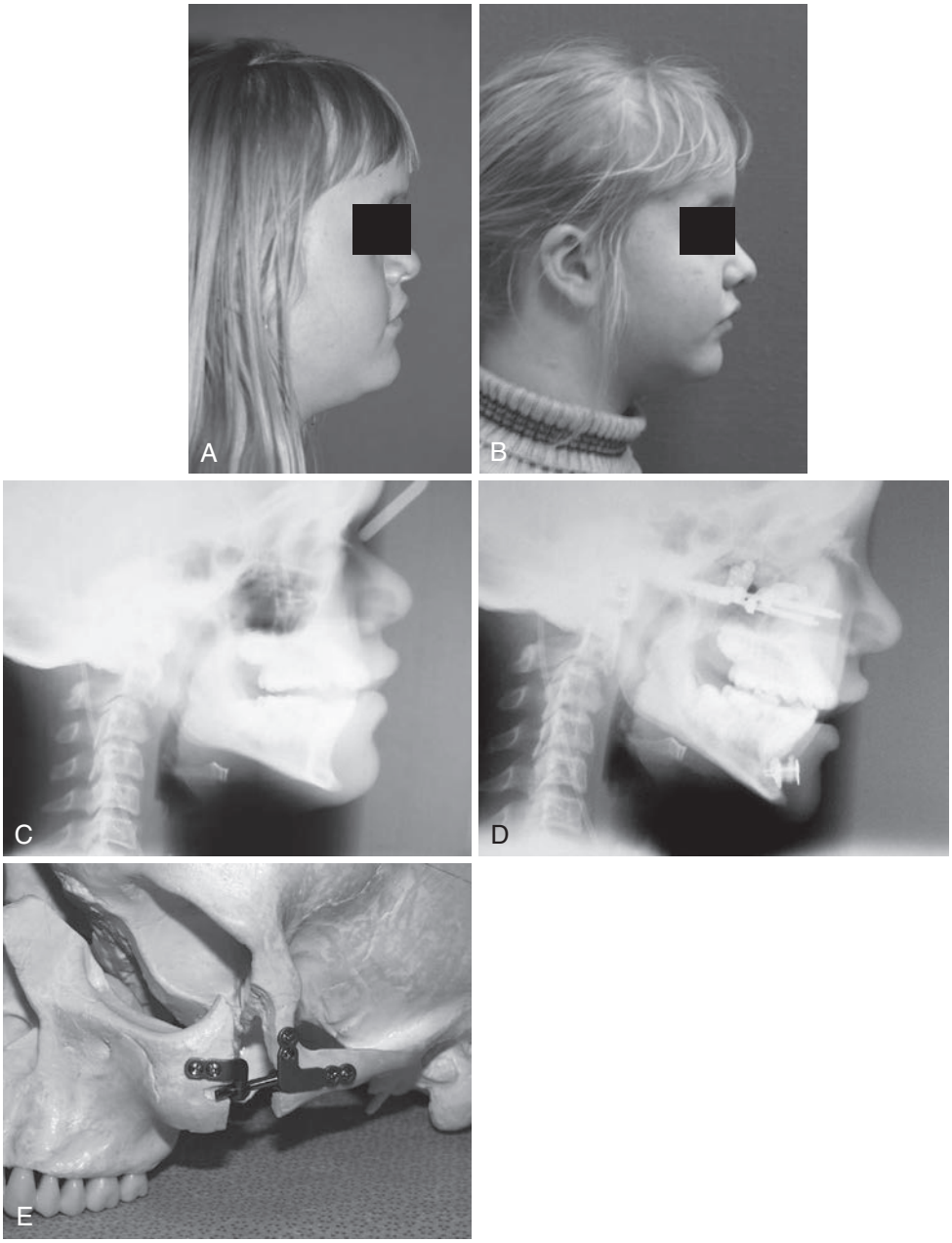

• **Figure 42-9** **A,** Patient with achondroplastic dwarfism, obstructive sleep apnea, and tracheostomy shows maxillary and mandibular hypoplasia. **B,** Postoperative profile view shows improved maxillary and mandibular projection. **C,** Preoperative and (**D**) postoperative maxillary and mandibular distraction osteogenesis lateral cephalometric radiographs show the distraction hardware in place. The patient's obstructive sleep apnea resolved and the tracheostomy tube was removed. **E,** Internal distractor device used for mid-face advancement with distraction osteogenesis.

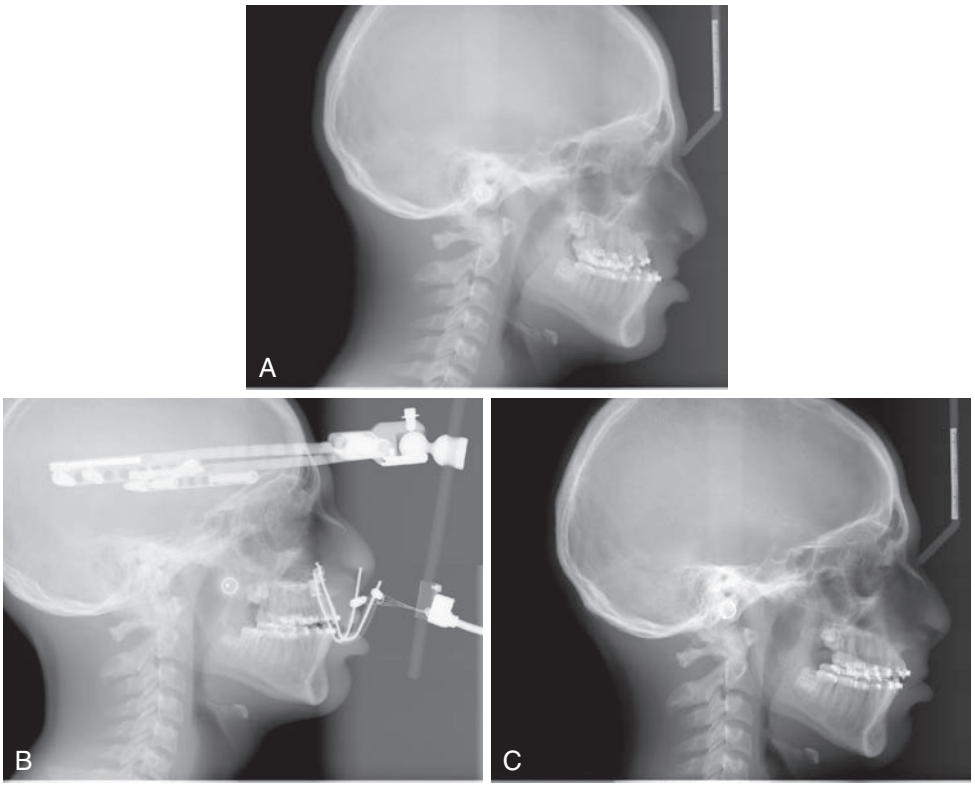

• **Figure 42-10** **A,** Preoperative lateral cephalometric radiograph of a patient with bilateral cleft lip and palate exhibiting severe maxillary hypoplasia. **B,** Lateral cephalometric radiograph of same patient with a distractor device in place during the distraction phase. **C,** One year post-distraction lateral cephalometric radiograph shows improved maxillary position.

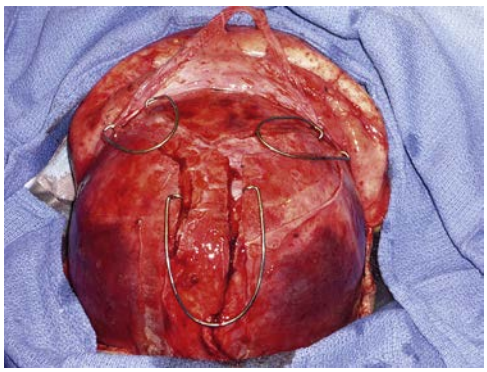

• **Figure 42-11** Cranial vault spring type distraction device in place for posterior cranial remodeling.



• **Figure 42-12** Various sizes of resorbable distraction devices. The foot plate and screws of each distractor is resorbable. Once the appropriate amount of distraction is completed and osseous regenerate is stable the metal activator is removed though the existing exit wound. The remaining materials will be resorbed.

References

1. Lienhard JH: The mind's eye: Ilizarov and visualization in 21st century technology, *Bull Hosp Joint Dis* 56(1):7–10, 1997.
2. Shevstov VI, Professor GA: Ilizarov's contribution to the method of transosseous osteosynthesis, *Bull Hosp Joint Dis* 56(1):11–15, 1997.
3. Maiocchi AB: Historical review of the method according to Ilizarov: 15 years after its worldwide application, *Bull Hosp Joint Dis* 56(1):16–18, 1997.
4. Spinelli RR: How we discovered, verified, and disseminated the Ilizarov method, *Bull Hosp Joint Dis* 56(1):19–21, 1997.
5. Choy IH, Shim JS, Seong SC, et al.: Effect of the distraction rate on the activity of the osteoblast lineage in distraction osteogenesis of rat's tibia, *Bull Hosp Joint Dis* 56(1):34–40, 1997.
6. Ilizarov GA: The principles of the Ilizarov method, *Bull Hosp Joint Dis* 56(1):49–53, 1997.
7. Kuntz C, Brauchli L, Moehle T, et al.: Theoretical consideration for the surgical correction of mandibular deformity in hemifacial microsomia patients using multifocal distraction osteogenesis, *J Oral Maxillofac Surg* 64:364–368, 2003.

8. Heffez L, Dirton M: Vector control in transportation osteogenesis, *J Oral Maxillofac Surg* 63:737–746, 2005.
9. Golyakhovsky V, Gavriel A: Ilizarov: the magician from Kurgan, *Bull Hosp Joint Dis* 56(1):54–56, 1997.
10. Cope J, Samchukov M, Cherkashin A: Mandibular distraction osteogenesis: a historic perspective and future directions, *Am J Orthod Dentofacial Orthop* 115:448–460, 1999.
11. Baur D, Helman J: Distraction osteogenesis of the mandible, *eMedicine Journal [serial online]*, June, 2005. Available at http://www.emedicine.com/Ent/topic765.htm.
12. Triaca A, Minoretti R, Merz B: Distraction osteogenesis of the mandibular angle and inferior border to produce facial symmetry: case report, *J Oral Maxillofac Surg* 58:1051–1055, 2000.
13. Herford A: Use of a plate-guided distraction device for transport distraction osteogenesis of the mandible, *J Oral Maxillofac Surg* 62:412–420, 2004.
14. Walker D: Management of severe mandibular retrognathia in the adult patient using distraction osteogenesis, *J Oral Maxillofac Surg* 60:1341–1346, 2002.
15. Rachmiel A, Manor R, Peled M, Laufer D: Intraoral distraction osteogenesis of the mandible in hemifacial microsomia, *J Oral Maxillofac Surg* 59:728–733, 2001.
16. Hu J, Tang Z, Wang D, Buckley M: Changes in the inferior alveolar nerve after mandibular lengthening with different rates of distraction, *J Oral Maxillofac Surg* 59:1041–1045, 2001.
17. Gateno J, Engel E, Teichgraeber J, et al.: A new Le Fort I internal distraction device in the treatment of severe maxillary hypoplasia, *J Oral Maxillofac Surg* 63:148–154, 2005.
18. Gateno J, Seymour-Dempsey K, Teichgraueber J, et al.: Prototype testing for a new bioabsorbable Le Fort III distraction device: a pilot study, *J Oral Maxillofac Surg* 62:1517–1523, 2004.
19. Riediger D, Poukens J: Le Fort III osteotomy: a new internal positioned distractor, *J Oral Maxillofac Surg* 61:882–889, 2003.
20. McCarthy JG, Schreiber J, Karp N, et al.: Lengthening the human mandible by gradual distraction, *Plast Reconstr Surg* 89:1–10, 1992.
21. Molina F, Ortiz-Monasterio F: Mandibular elongation and remodeling by distraction: a farewell to major osteotomies, *Plast Reconstr Surg* 96:825–842, 1996.
22. Klein C, Howaldt HP: Mandibular distraction osteogenesis as first step in early treatment of severe dysgnathia in childhood, *J Orofac Orthop* 57:46, 1996.
23. Diner PA, Kollar E, Martinez H, Vazquez MP: Intraoral distraction for mandibular lengthening: a technical innovation, *J Craniomaxillofac Surg* 24:92–95, 1996.
24. Block MS, Otten J, McLaurin D, Zoldos MP: Bifocal distraction osteogenesis for mandibular defect healing: case reports, *J Oral Maxillofac Surg* 54:1365–1370, 1996.
25. Ortiz-Monasterio F, Molina F, Andrade L, et al.: Simultaneous mandibular and maxillary distraction in hemifacial microsomia in adults: avoiding occlusal disasters, *Plast Reconstr Surg* 100: 852–861, 1997.
26. Carls FR, Sailer HF: Seven years clinical experience with mandibular distraction in children, *J Craniomaxillofac Surg* 26:197–208, 1998.
27. Figueroa AA, Polley JW: Management of severe cleft maxillary deficiency with distraction osteogenesis: procedure and results, *Am J Orthod Dentofac Orthop* 115:1–12, 1999.
28. Cohen SR, Simms C, Burstein FD: Mandibular osteogenesis in the treatment of upper airway obstruction in children with craniofacial deformities, *Plast Reconstr Surg* 108:302–311, 2001.
29. Denny AD, Talisman R, Hanson PR, Recinos RF: Mandibular distraction osteogenesis in very young patients to correct airway obstruction, *Plast Reconstr Surg* 104:2021–2031, 1999.
30. Dean A, Alamillos F: Mandibular distraction in temporomandibular joint ankylosis, *Plast Reconstr Surg* 108:302–311, 2001.
31. Rubio-Bueno P, Padron P, Villa E, Diaz-Gonzales FJ: Distraction osteogenesis of the ascending ramus for mandibular hypoplasia using extraoral or intraoral devices: a report of 8 cases, *J Oral Maxillofac Surg* 58:593–599, 2000.
32. Howlett C, Stavropoulos MF, Steinberg B: Feeding complications in a six-week-old infant secondary to distraction osteogenesis for airway obstruction: a case report, *J Oral Maxillofac Surg* 57: 1465–1468, 1999.
33. Van Strijen PJ, Breuning KH, Becking AG, Tunizing DB: Condylar resorption following distraction osteogenesis: a case report, *J Oral Maxillofac Surg* 59:1104–1107, 2001.
34. Swennen G, Schliephake H, Denupf R, et al.: Craniofacial distraction osteogenesis: a review of literature. Part 1: clinical studies, *Int J Oral Maxillofac Surg* 30:89–103, 2001.
35. Mofid MM, Manson PN, Robertson BC, et al.: Craniofacial distraction osteogenesis: a review of 3278 cases, *Plast Reconstr Surg* 108:1103–1114, 2001.
36. Stucki-McCormick SU, Fox R, Mizrahi R: Distraction osteogenesis for congenital mandibular deformities, *Atlas Oral Maxillofac Surg Clin North Am* 7:85–110, 1999.
37. Karp XS, McCarthy JG, Schreiber JS: Membranous bone lengthening: a serial histologic study, *Ann Plast Surg* 29:2, 1992.
38. Kaban LB, Padwa BL, Mulliken JB: Surgical correction of mandibular hypoplasia and hemifacial microsomia: the case for treatment in early childhood, *J Oral Maxillofac Surg* 56:628, 1998.
39. Li K, Powell N, Riley R: Distraction osteogenesis in adult obstructive sleep apnea surgery: a preliminary report, *J Oral Maxillofac Surg* 60:6, 2002.
40. Perlyn CA, Schmelzer RE, Sutera SP: Effect of distraction osteogenesis of the mandible on upper airway volume and resistance in children with micrognathia, *Plast Reconstr Surg* 109:1809–1818, 2002.
41. Denny A, Kalantarian B: Mandibular distraction in neonates: a strategy to avoid tracheostomy, *Plast Reconstr Surg* 109:896–904, 2002.
42. Smith KS: Pediatric sleep apnea and treatment with distraction osteogenesis, *Ann R Australas Coll Dent Surg* 15:163–167, 2000.
43. Woodson BT, Hanson PR, Malugin MB, Gama AA: Sequential upper airway changes during mandibular distraction for obstructive sleep apnea, *Otolaryngol Head Neck Surg* 128:142–144, 2003.
44. McCarthy J: The role of distraction osteogenesis in the reconstruction of the mandible in unilateral craniofacial microsomia, *Clin Plast Surg* 21:625, 1994.
45. Klein C, Howaldt H: Lengthening of the hypoplastic mandible by gradual distraction in childhood: a preliminary report, *J Craniomaxillofac Surg* 23:68, 1995.
46. Wangerin K, Gropp H: Intraoral distraction osteogenesis for lengthening of the horizontal mandibular ramus, *In International Congress on Cranial and Facial Bone Distraction Process*, Paris, 1997, France. Paper 36.
47. Makarov M, Samchukov M, Cope J: The effect of gradual traction on peripheral nerves. In Samchukov M, Cope J, Cherkasin A, editors: *Craniofacial distraction osteogenesis*, St Louis, 2001, Mosby.
48. Block M, Daire J, Stover J: Changes in inferior alveolar nerve following mandibular lengthening in the dog using distraction osteogenesis, *J Oral Maxillofac Surg* 56:14, 1998.

49. Proffit W, Turvey T, Phillips C: Orthognathic surgery: a hierarchy of stability, *Int J Adult Orthod Orthognath Surg* 11:191, 1996.
50. Costano F, Troulis M, Glowacki J: Proliferation of masseter myocytes after distraction osteogenesis of the mandible, *J Oral Maxillofac Surg* 59:302, 2001.
51. Huang C, Ross R: Surgical advancement of the retrognathic mandible in growing children, *Am J Orthod* 82:89, 1982.
52. McCarthy J, Grayson B, Williams J: Distraction of the mandible: the New York University experience. In McCarthy J, editor: *Distraction of the craniofacial skeleton*, New York, 1999, Springer-Verlag.
53. Mctavish J, Marucci D, Bonar S: Does the sheep mandible relapse following lengthening by distraction osteogenesis? *J Craniomaxillofac Surg* 28:251, 2000.
54. Bardach J, Salyer EK: *Surgical techniques in cleft lip and palate*, St Louis, 1991, Mosby, pp 224–232.
55. Ross RB: Treatment variables affecting facial growth in complete unilateral cleft lip and palate: an overview of treatment and facial growth, *Cleft Palate Craniofac J* 24:71, 1987.
56. Houston WJB, James DR, Jones E: Le Fort I maxillary osteotomies in cleft palate cases: surgical changes and stability, *J Maxillofac Surg* 17:9, 1989.
57. Obwegeser HL: Surgical correction of small or retro-displaced maxillae: the "dish face" deformity, *Plast Reconstr Surg* 43:351, 1969.
58. Posnick JC, Dagys AP: Orthognathic surgery in the bilateral cleft patient: a surgical and orthodontic approach, *Oral Maxillofac Surg Clin North Am* 3:693, 1991.
59. Adlam DM, Banks PA: Retrospective study of the stability of midface osteotomies in cleft lip and palate patients, *Br J Oral Maxillofac Surg* 27:265, 1989.
60. Drommer R, Luhr HG: The stabilization of osteotomised maxillary segment with Luhr miniplates in secondary cleft surgery, *J Maxillofac Surg* 9:163, 1981.

60a. Chua HDP, Ho SMY, Cheung LK: The comparison of psychological adjustment of patients with cleft lip and palate after maxillary distraction osteogenesis and conventional orthognathic surgery, *Oral Surg Oral Med Oral Pathol Oral Radiol* 114(Suppl 5):S5–S10, 2012.

60b. Kwong Cheung L, Ser Pheng Loh J, Ho SMY: The early psychological adjustment of cleft patients after maxillary distraction osteogenesis and conventional orthognathic surgery: a preliminary study, *J Oral Maxillofac Surg* 64(12):1743–1750, 2006.

60c. Figueroa AA, Polley JW: Management of severe cleft maxillary deficiency with distraction osteogenesis: procedure and results, *Am J Orthod Dentofacial Orthop* 115(1):1–12, 1999.

60d. Figueroa AA, Polley JW, Friede H, Ko EW: Long-term skeletal stability after maxillary advancement with distraction osteogenesis using a rigid external distraction device in cleft maxillary deformities, *Plast Reconstr Surg* 114(6):1382–1394, 2004.

60e. Huang CS, Harikrishnan P, Liao YF, et al.: Long-term follow-up after maxillary distraction osteogenesis in growing children with cleft lip and palate, *Cleft Palate Craniofac J* 44(3):274–277, 2007.

61. Rachmiel A, Aizenbud D, Peled M: Distraction osteogenesis in maxillary deficiency using a rigid external distraction device, *Plast Reconstr Surg* 117:2399–2406, 2006.
62. Cho BC, Hwang SK, Uhm KI: Distraction osteogenesis of the cranial vault for the treatment of craniofacial synostosis, *J Craniofac Surg* 15:135, 2004.
63. Yonehara Y, Hirabayashi S, Sugawara Y: Complications associated with gradual cranial vault distraction osteogenesis for the treatment of craniofacial synostosis, *J Craniofac Surg* 14:526, 2003.
64. McCarthy JG, Glasberg SB, Cutting CB: Twenty year experience with early surgery for craniosynostosis, *Plast Reconstr Surg* 96:284, 1995.
65. Swennen G, Schliephake H, Dempf R: Craniofacial distraction osteogenesis: a review of the literature. Part 1: clinical studies, *Int J Oral Maxillofac Surg* 30:89, 2001.
66. Fukuta K, Saito K, Potparic Z: A comparison of single-stage versus gradual fronto-parietal advancement in terms of extradural dead space and bone deposition, *Br J Plast Surg* 51:169, 1998.
67. Yano H, Tanaka K, Sueyoshi O, et al.: Cranial vault distraction: its illusionary effect and limitation, *Plast Reconstr Surg* 117: 193–200, 2006.
68. Smith K: In Samchukov M, Cope J, Cherkashin A, editors: *Craniofacial distraction osteogenesis*, St Louis, 2001, Mosby.
69. Diner P, Vasquez, editors: *Transactions of the International Congress Cranial and Facial Bone Distraction Osteogenesis*, Paris, June 19-21, 1997, France.
70. Paes EC, Bittermann GK, Bittermann D, et al.: Long-term results of mandibular distraction osteogenesis with a resorbable device in infants with robin sequence: effects on developing molars and mandibular growth, *Plast Reconstr Surg* (2):375e–385e, 2016.
71. Maurice SM, Gachiani JM: Posterior cranial vault distraction with resorbable distraction devices, *J Craniofac Surg* 25(4):1249–1251, 2014.

This page intentionally left blank

43

Complications: Maxilla

GABRIELE MILLESI

Introduction

Orthognathic surgery has become a routine procedure that is included in all resident programs and is practiced all over the globe. This is due to improvements in communication techniques, instruments, and perioperative management. The incidence of severe complications is low.[1-3] In a prospective study, Kramer published a complication rate of 6.4% in 1000 patients undergoing a Le Fort I procedure.[2] Nevertheless, the list of various complications is long. Knowledge of and respect for these complications are of paramount importance in reducing morbidity.

Le Fort I Osteotomy

Preoperative

Planning

Preoperative complications are mainly related to inadequate cooperation between the orthodontist and the surgeon, which is mirrored in a compromised or incorrect treatment plan. The crucial questions in orthodontics-first cases are the inclination of incisors, transverse compatibility of the arches, and the curves of Spee, independent of the skeletal deformity. In general, preoperative dental alignment by the orthodontist is desirable, but this varies with the skeletal deformity. In class III deformity for example, preoperative orthodontic decompensation in the maxilla often results in uprighting of the proclined incisors which is counterproductive in open-bite cases.

Dental widening of the maxillary arch to improve transverse relationships will result in relapse of an open bite or crossbite. The inclination of the incisors not only dictates the desired rotation of the maxilla but also the sagittal and vertical movement from an esthetic point of view. Any orthodontic closure of an open bite, done by extrusion and clockwise rotation of upper incisors, may result in a progression of dental show and alters the surgical treatment plan unfavorably (Figure 43-1) and with an unstable long-term outcome. Therefore it is important to discuss the combined treatment plan with the orthodontist at the very beginning, before orthodontic treatment is started.

Another aspect in planning in the contemporary setting must be whether the patient has already been treated with fillers or augmented with autologous fat in the lip and midface area. The treatment plan must not allow a transient situation in regard to show of teeth or maxillary soft tissue support to influence the determined posterior-anterior or vertical position of the maxilla. At the very least, it needs to be discussed with the patient (Figure 43-2).

Finally, before the start of treatment, the candidate should be screened to determine whether he or she belongs to the 10% of patients who suffer from body dysmorphic disorders. A patient seeking a surgical correction because of this psychiatric disease, with delusions of physical defects, is impossible to treat successfully.[4]

Intraoperative

Surgical Setting of Patient

Any pathologic pressure caused by malpositioned auxiliary anesthetic tools, such as ventilation filters on the head or electrocardiography (ECG) cables on the neck, should be avoided, as it may lead to pressure-derived alopecia (Figure 43-3) or localized necrosis (Figure 43-4).

An unfavorable positioning of the endotracheal tube with distortion of the normal symmetry of the entrance of the nose can result in loss of orientation of the midline as well as necrosis of the nasal tip (Figure 43-5).

Vascular Complications

Bleeding and Downfracture

Le Fort I osteotomy is a surgery with expected blood loss. Therefore, it should be performed under ideal conditions, including the correct surgical setting to optimize venous drainage by elevating the head (reverse Trendelenburg position) and under controlled hypotension. In this way the monitored arterial pressure correlates to the true intracerebral pressure. Our experience suggests and the literature indicates that no autologous blood transfusion is necessary[5-9] and is an avoidable expense, even though



• **Figure 43-1** **A**, Patient with maxillary excess, open bite deformity, transverse discrepancy, and severe crowding. Orthodontic treatment was started without consultation of an OMS and designing a conservative surgical treatment plan. **B**, Intraoral view of upper dental arch. **C**, Same patient after 3 years of orthodontic treatment, presenting with gummy smile and conservative closure of open bite but unsatisfying esthetic. **D**, Patient after orthodontic alignment of the upper dental arch with higher risk of dental relapse.

antithrombotic prophylaxis is administered starting preoperatively for a maximum of 3 days. To prevent any thromboembolic complications, it is further recommended to use venous compression stockings during surgery. To minimize blood loss, a preoperative vestibular injection of local anesthetic with vasoconstrictor is used to reduce oozing of the mucosa, meticulous subperiosteal dissection is performed, and packing with gauze or cauterization or ligation of bleeding vessels is also used.

If major bleeding occurs, it can be either arterial from the maxillary artery and its branches or venous from the pterygomaxillary plexus. In general the descending major palatine artery or the sphenopalatine artery is the origin, or more seldom the nasoethmoidal artery.

As Lanigan and colleagues[10] published in 1990, of 800 replies concerning complications in orthognathic surgery, only 30 instances of major bleeding were reported. An injury to the descending palatine artery may occur when dissecting or reducing the lateral wall of the nose (Figure 43-6), going too high and too far back (no more than 25 to 30 mm), or by separating the maxilla from the pterygoid process with the osteotome. The length of the medial



• **Figure 43-2** **A**, Patient with class II deformity and retroposition of the maxilla, after injection of fillers in the upper lip. **B**, Camouflage of maxillary deficiency in the profile.



• **Figure 43-3** Alopecia originating from pressure necrosis of a ventilation filter during surgery.



• **Figure 43-4** Skin ulceration caused by pressure of mislocated electrocardiography cable intraoperatively.

wall of the sinus from the piriform rim to the descending palatine artery is approximately 34 mm.[11] It is, however, essential that the dissection of the lateral nasal wall be done in such a way that any uncontrolled fracture of the pterygoid plate with disruption of the pterygopalatine fossa can be avoided. The basal, anteroposterior approach toward the canal of the descending palatine artery with the chisel can be detected by an obvious change of pitch. When it turns low, it is time to stop. Turvey and Fonseca[12] published the results of anatomic studies on cadaver dissections, on the position of the internal maxillary artery



• **Figure 43-5** Distortion of the symmetry of the nose and nostrils by nasal endotracheal tube under tension.

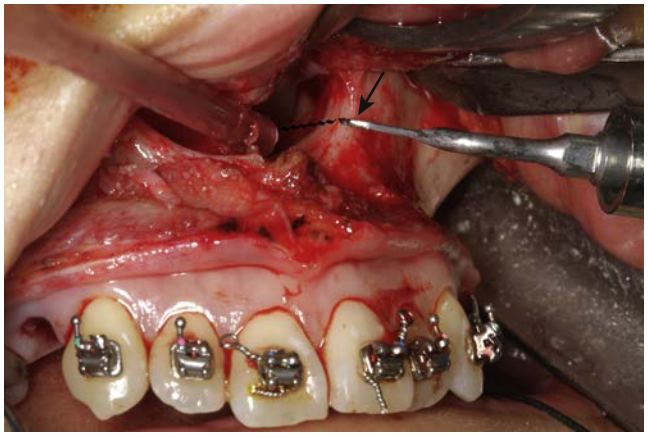

• **Figure 43-6** Dissection of the lateral wall of nose must be performed below the insertion of the inferior turbinate as marked with a *black line* and *arrow.*

entering the pterygopalatine fossa. They found that the mean height of the pterygomaxillary suture is 14.6 mm (range 11-18 mm) and that the mean distance from the inferior junction maxilla/pterygoid plate to the most inferior position of the internal maxillary artery, entering the pterygopalatine fossa, is 25 mm (range 23-28 mm). This is important to know if you use an osteotome, such as an Obwegeser or Kawamoto osteotome, with a width of 10 to 15 mm, for dissecting the pterygomaxillary junction.

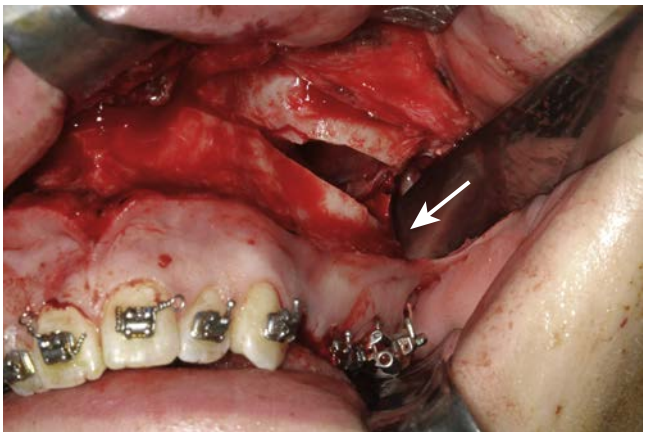

• **Figure 43-7** When separating the pterygomaxillary junction, the osteotome must be guided downward *(arrow)*.

Downward direction of all instruments is crucial in this step (Figure 43-7). Any forceful, uncontrolled downfracture should be avoided. The phenomenon of bradycardia and even asystole, provoked by a trigemino-cardiac reflex, may need an anesthesiologic intervention. In cases of resistance, the dissections of the lateral nasal wall as well as the pterygomaxillary junction must be redone. Sometimes the reason for resistance is that the posterior aspect of the Le Fort I osteotomy is located too far rostral, through the sinus, or too far dorsal, through the pterygoid plates. The ideal position is the pterygomaxillary junction or the tuberosity. When visualization of the lacerated vessel is not possible, immediately packing and continuing the osteotomy until the downfracture has taken place is advised. In cases of direct access, clipping is the first choice (Figure 43-8). If the artery disappears in the canal, compression with a bone chip or resorbable hemostatic agent should be tried.

Cauterization and hemostatic agents are the therapy of choice for venous bleeding from the pterygoid plexus.

If severe arterial bleeding occurs and ligation and packing are unsuccessful, immediate angiography and embolization are unavoidable. In extreme situations, ligation of the external carotid artery is an option. If this is not done intermediately, a later risk of aseptic necrosis of the maxilla may arise.

Ischemia

The vascularization of the Le Fort I downfracture has been studied extensively by Bell and colleagues, with microangiographic and histologic techniques.[13] The principles indicate that the palatal mucosa is sacred and, if possible, the greater palatine vessel should be preserved. In case of laceration it can be sacrificed, although, as shown in studies by Nelson and co-workers,[14] the blood flow in the attached gingiva and alveolar bone will be decreased, as these areas are usually supplied by the superior alveolar artery, which is dissected by the buccal approach. Nevertheless, it is important to place the circumvestibular incision high above the mucogingival junction and to keep the attached gingiva in place

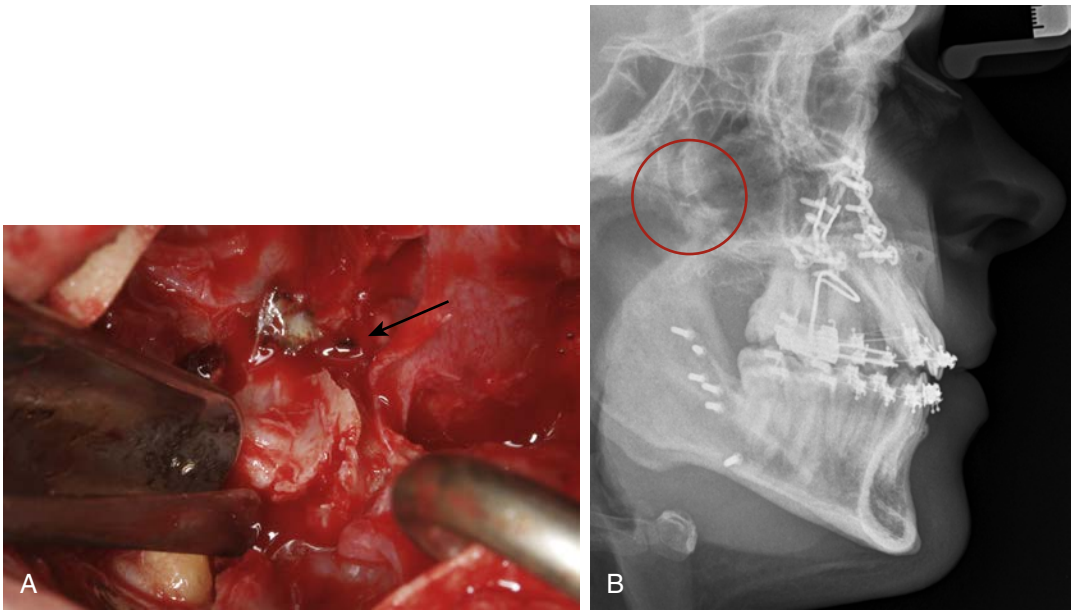

• **Figure 43-8** **A**, During cutting of the lateral wall of the nose, the roof of the canal of the descending palatine artery was opened in the posterior aspect and the artery injured *(arrow)*. Bleeding was managed by clipping the artery. **B**, Hemoclips are visible on the lateral cephalogram, marked with *circle*.

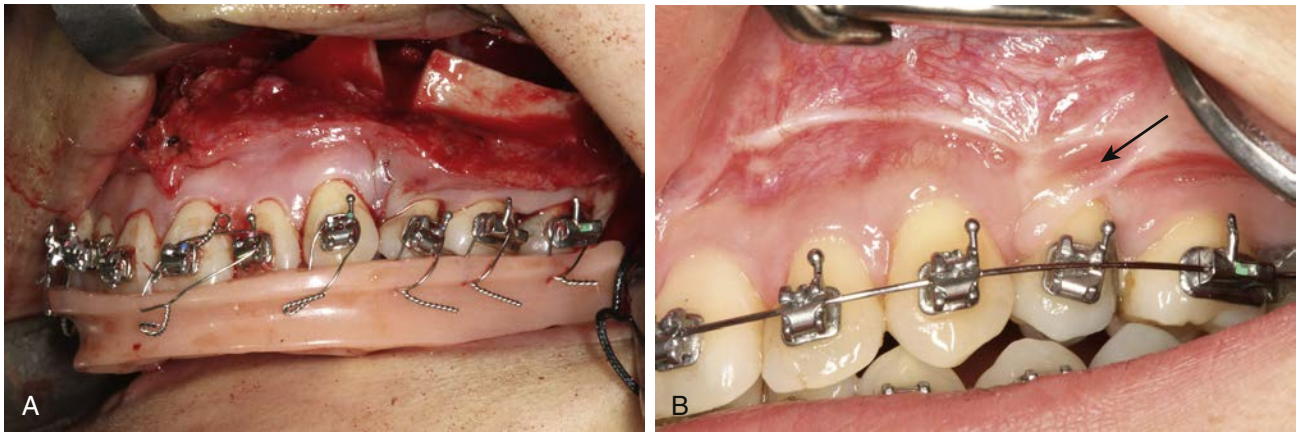

• **Figure 43-9** **A**, Unfavorable location of circumvestibular incision, too close to the mucogingival junction. **B**, Situation in **A** results in scarring, malnutrition, and recession of the gingiva.

so that later recessions due to scarring can be prevented (Figure 43-9). No further extension than to the zygomatic buttress is also recommended to avoid prolapse of the buccal fat pad. The height of the incision might vary depending on the planned movement of the maxilla or if interpositional bone grafting is needed. The risk of postoperative ischemia increases with the amount of mobilization especially in anterior and downward direction. It further increases in patients with anatomic and iatrogenic irregularities such as cleft lip and palate or craniofacial dysplasia. The method of mobilization of the maxilla is also important. It must be done gently but forcefully, without too much compression of the palatal pedicle. Hugo Obwegeser[15] recommended maxillary advancement where the maxilla is moved steadily under control, millimeter by millimeter. If prolonged ischemia of the vestibular mucosa is observed, minimize the hypotensive anesthesia, inject anticoagulation agents, and do warm packing of the maxilla with gauze sponges. Gentle and careful wound closure without tension is indicated.

Laceration of the Lacrimal Duct

Laceration of the lacrimal duct may occur if the osteotomy through the piriform rim and the lateral nasal wall is designed too high. As noted by You and colleagues,[16] the nasolacrimal duct is located 10 to 14 mm posterior from the piriform aperture and approximately 15.5 mm above the nasal floor (Figure 43-10). Therefore it is advisable to place the osteotomy beneath the anterior attachment of the inferior turbinate and the infraorbital foramen, as well as to elevate the nasal mucoperiosteum where the meatus of the nasolacrimal duct ends, not to injure the ostium or the canal of the duct itself (Figure 43-11). If the nasolacrimal system is jeopardized postoperatively by edema, the obstruction of the passage of the tears will be transient and will recover in

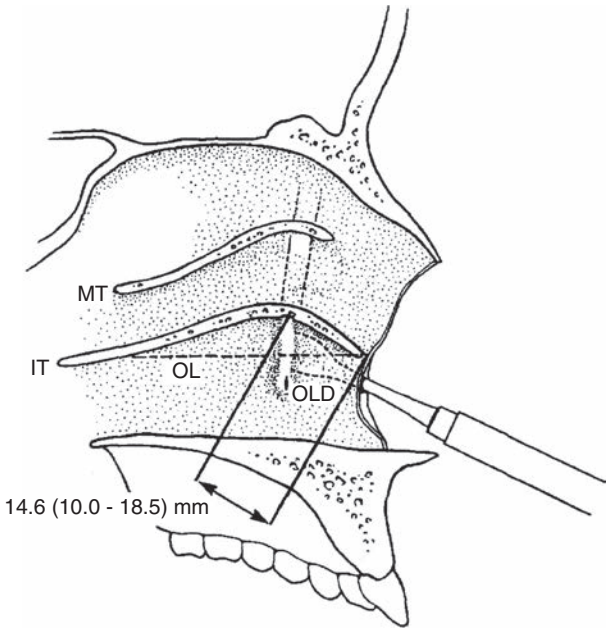

• **Figure 43-10** Illustration of lateral nasal wall showing the distance from the anterior attachment of the inferior turbinate to the nasolacrimal canal orifice. *IT*, inferior turbinate; *MT*, medial turbinate; *OL*, high Le Fort I osteotomy; *OLD*, ostium of nasolacrimal duct. (From You ZH, Bell HW, Finn RA: Location of the nasolacrimal canal in relation to the high Le Fort I osteotomy, *J Oral Maxillofac Surg* 50:1075-1080, 1992.)

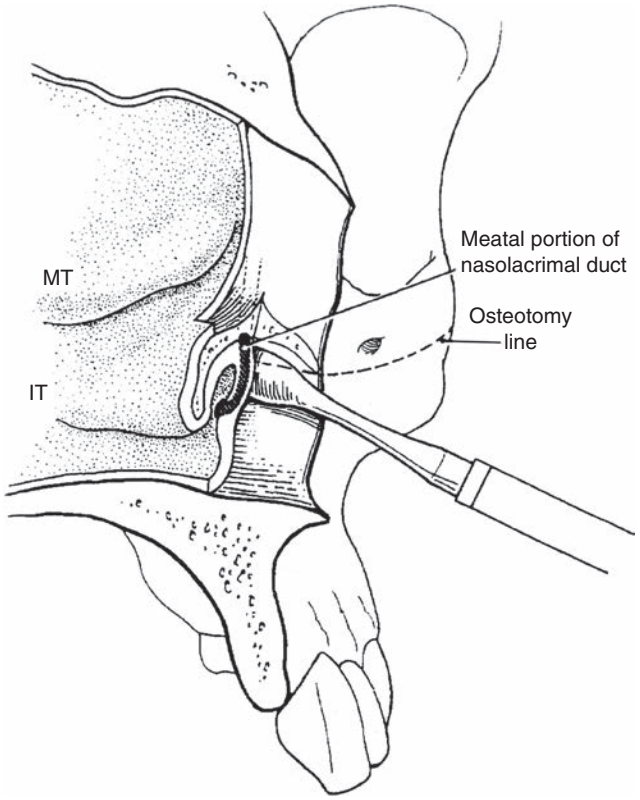

• **Figure 43-11** Diagram of the relationship between the high Le Fort I osteotomy and the meatal portion of the nasolacrimal duct. The meatal portion of the nasolacrimal duct can be protected by detaching the mucosa from the lateral nasal wall and placing a periosteal elevator between the mucosa and the lateral wall as the osteotomy is accomplished. *IT,* Inferior turbinate; *MT,* medial turbinate. (From You ZH, Bell HW, Finn RA: Location of the nasolacrimal canal in relation to the high Le Fort I osteotomy, *J Oral Maxillofac Surg* 50:1075-1080, 1992.)

general. If a disruption has occurred during osteotomy, a persistent epiphora and recurrent dacrocystitis may result. This may require surgical intervention by doing an endonasal endoscopic dacryocystorhinostomy.[17] Hemolacria, a retrograde hemorrhage, is another complication, but a rare one. This phenomenon describes retrograde blood flow via the lacrimal apparatus if the intranasal pressure is increased during blowing the nose or in combination with epistaxis.[18]

Tooth Damage

When performing a single-piece Le Fort I osteotomy, tooth injuries should be avoidable! A preoperative glance at the x-ray should give information on the length of the roots and should be a warning not to place the osteotomy cut too inferiorly. According to experimental studies by Bell,[19] a distance of approximately 5 mm above the apices should be respected. If root resection occurs, calyx or enamel matrix derivatives can be placed on the open canal. Periodic follow-up is necessary, including sensitivity testing and x-rays. As long as there are no clinical and radiologic symptoms, endodontic treatment can be postponed.

Nasal Airway

Prior to Le Fort I osteotomy, the patient's history of nasal airway and breathing habits should be elicited. If the patient reports nasal obstruction and breathing problems, a clinical and radiologic examination noting septal deviation and size of turbinates and nostrils should be performed (Figure 43-12). In cases of impaction of the maxilla, a generous reduction of the cartilaginous septum (Figure 43-13), vomer, and lateral nasal wall and contouring and widening of the aperture is necessary (Figure 43-14). This reshaping of the entrance of the nose is essential for improving airflow. Resection of the nasal cartilaginous septum must be limited to the basal horizontal portion and must not be extended to the anterior, columella aspect. This may provoke a dropping of the tip of the nose if over-resected (Figure 43-15). There are two philosophies on the reduction of the turbinates.[20] The resection may be done by cutting them off and coagulating the open wound; the second approach, submucous resection, is to preserve the mucosal coverage, reduce the bone, and close the mucosa (Figure 43-16). This may be more difficult sometimes, but from a physiologic standpoint, it is more plausible and with less risk of postoperative bleeding and rhinitis sicca. Care must be taken to avoid laceration of the ostium of the nasolacrimal duct. In some cases impaction of the maxilla is impaired because of the basal position of the intranasal endotracheal tube (Figure 43-17, *A*). This can be solved by grooving the palatal plate paraseptal with a pear burr (see Figure 43-17, *B*). Based on scientific studies,[21] superior repositioning of the maxilla, often combined with transversal expansion, results in an improvement of nasal breathing, most probably also due to the change of bony shape of the nasal valve and nostrils. Patients even report intensified smell sensations. All these changes may have an unfavorable esthetic aspect in patients with normal width of the alar base as described in the paragraph on esthetics.

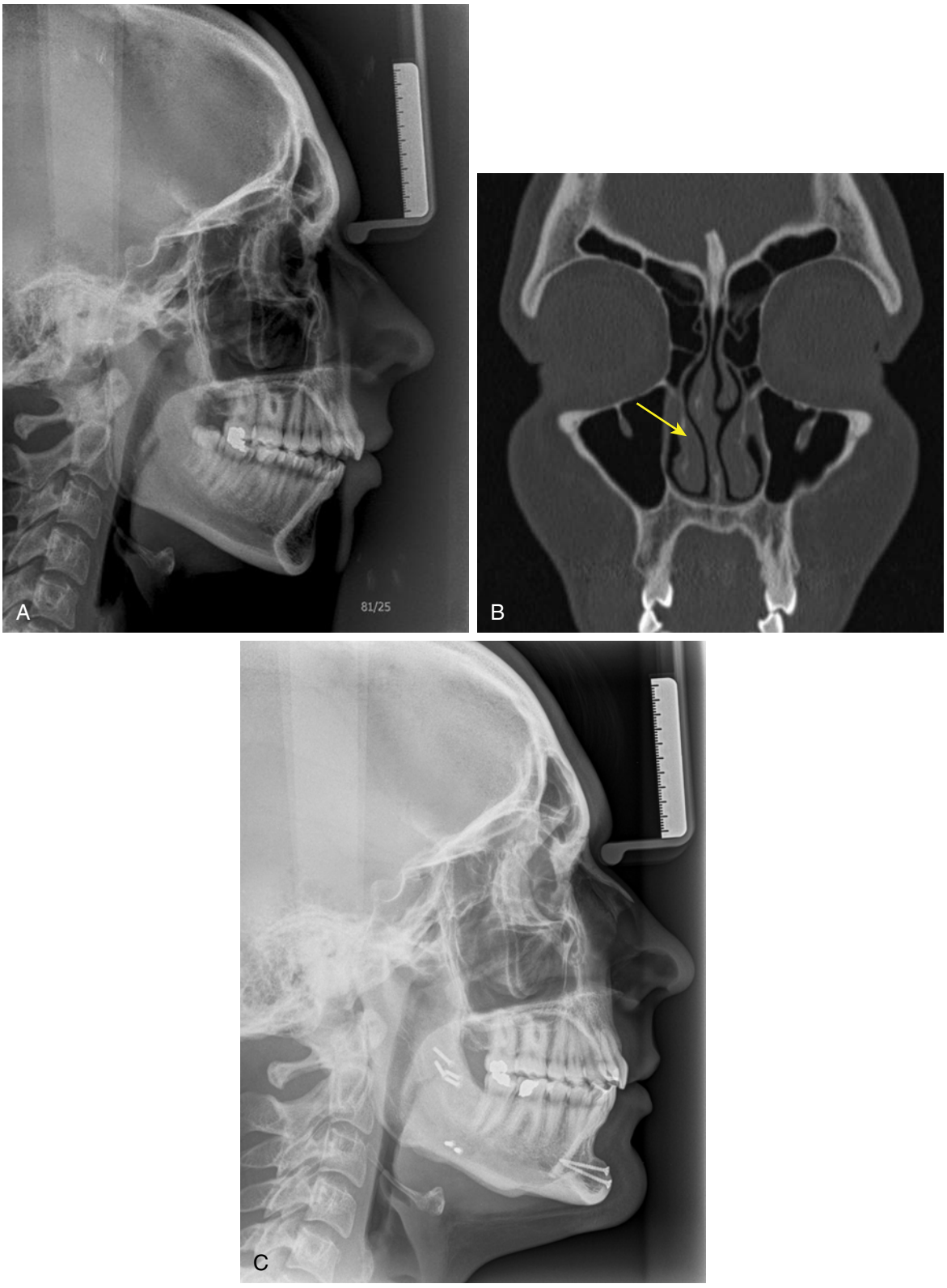

• **Figure 43-12** **A**, Patient with open bite deformity suffering from insufficient nasal breathing. **B**, Computed tomography scan shows hyperplastic turbinates and a deviation of the septum *(arrow)* resulting in an obvious handicapped nasal air flow. **C**, Lateral cephalogram 1 year after surgery, showing a stable result after correction of the open bite by performing a bilateral sagittal split osteotomy and a genioplasty after initial cauterization and reduction of the turbinates and septorhinoplasty.



• **Figure 43-13** If an impaction of the maxilla is planned, a reduction of the cartilaginous septum has to be accomplished.

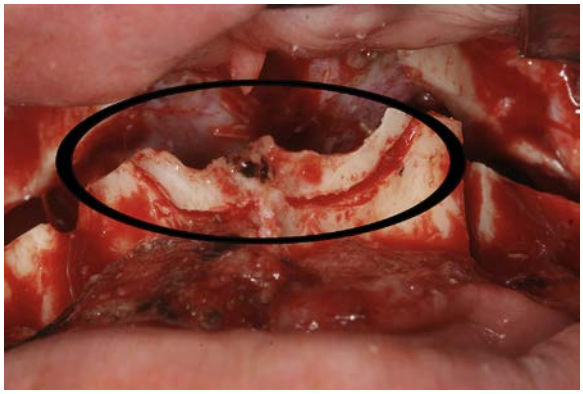

• **Figure 43-14** To improve nasal breathing a reshaping of the aperture is advantageous *(black circle)*.



• **Figure 43-15** **A**, Patient before treatment, maxillary excess, gummy smile, mandibular retroposition. **B**, Profile view. **C**, Angulated view of face. Note narrow nostrils and tension in mental muscle from closing the mouth. **D**, Patient, 1 year postoperative, after maxillary impaction and bilateral sagittal split osteotomy advancement procedure. **E**, To prevent an accentuation of the supratip depression by impacting the maxilla, an over-resection of the cartilaginous septum was performed, resulting in a more acute columella-labial angle and a drop of the tip of the nose. **F**, Obvious shortened columella and hanging tip of the nose in axial view.

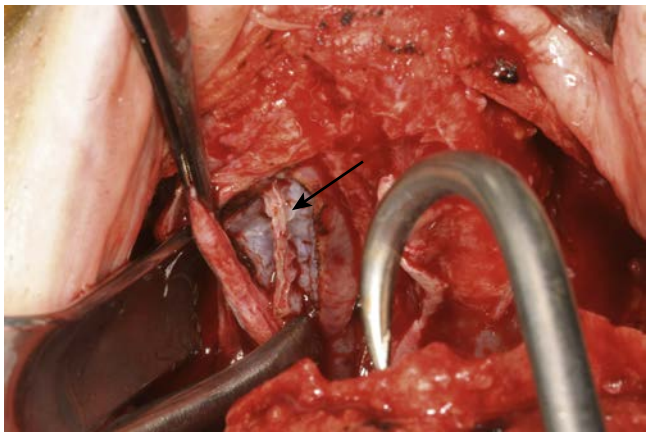

• **Figure 43-16** Major impaction of the maxilla can only be achieved if resection of the inferior turbinates *(arrow)* is done.

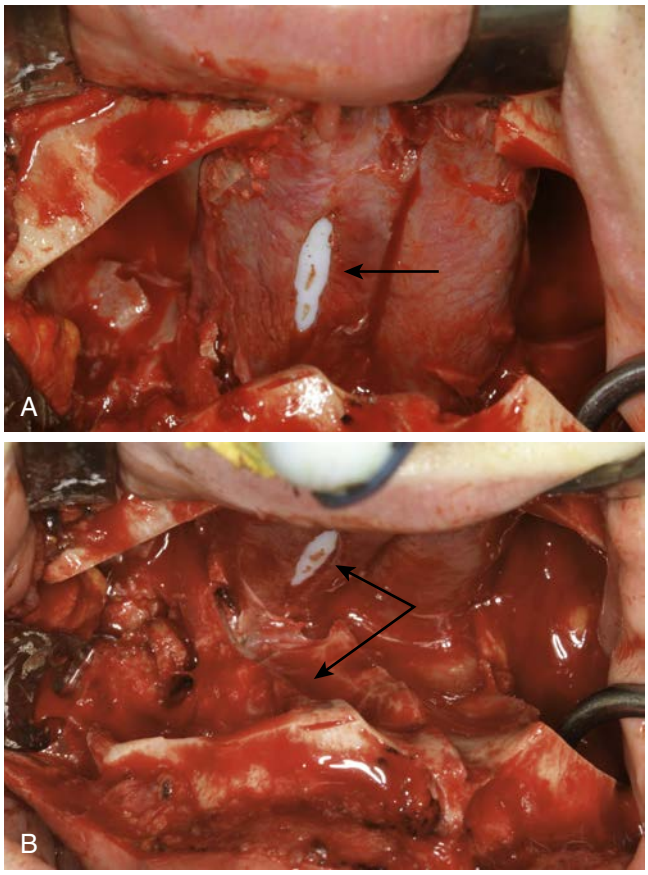

• **Figure 43-17** **A**, Sometimes the tactual barrier, when impacting, turns out to be the endotracheal tube *(arrow)*, not the turbinate. **B**, In this case impaction of the maxilla can only be accomplished without tension, after paraseptal grooving of the floor of the nose *(arrow)*.

TABLE 43-1 Hierarchy of Stability for Orthognathic Surgical Procedures

MORE	Maxilla up
	Mandible forward
STABLE	Maxilla forward
PREDICTABLE	Maxilla forward + mandible back
	Mandible back
	Maxilla down
LESS	Maxilla wider

From Profitt WR, Turvey TA, Phillips C: Orthognathic surgery: a hierarchy of stability, *Int Adult Orthod Orthognath Surg* 3:191-204, 1996.

Stability and Early Relapse

The crucial points in stability include the means of internal fixation, changes of maxillary position, and quality of bone. There is no doubt that rigid internal fixation of the maxilla by either titanium or absorbable osteosynthesis material is the gold standard. Within 2 to 6 weeks, resorbable osteosynthetic material may show a higher incidence of slight mobility,[22,23] ending up with the same long-term stability as titanium plates. If guiding elastics are used postoperatively, the new position of the maxilla may be altered by loosening the screws. It depends on the quality of the bone whether movements are dentally derived or due to bony remodeling. Failure of osteosynthesis may occur in fragile structured maxilla independent of planned movement. As stated in the literature[24] (Table 43-1), the most unstable measurement of the maxilla is downward combined with advancement (Figure 43-18), independent of the degree of displacement. Inadequate maxillary mobilization during downfracture plays an important role in the successful outcome by Obwegeser; the maxilla should be directable into the new position using a forceps. Impaction of the maxilla is a stable procedure. If bony contact is still preserved in the posterior aspect of the maxilla, anterior downgrafting depends on the amount of dislocation. A critical size for bone grafting is between 3 and 5 mm, which also depends on the thickness of the maxillary bone.[25] Cortical bone harvested from the angle (Figure 43-19) of the mandible or chin, as well as calvarial bone, is

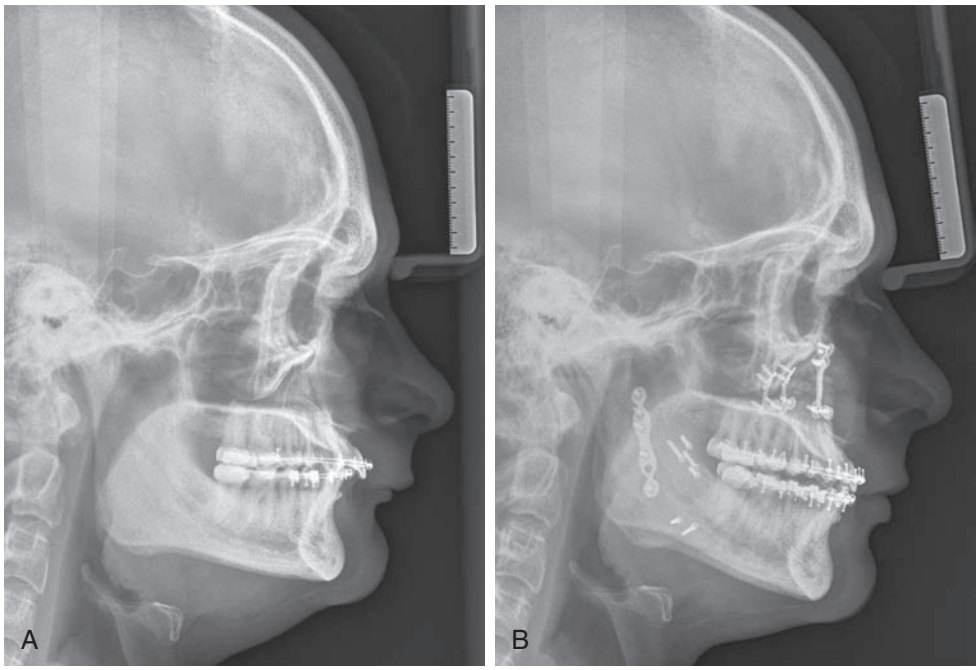

• **Figure 43-18** **A**, Patient with short alveolar process and hypoplastic maxilla and no show of upper teeth, as well as retroposition of mandible. **B**, Same patient after bimaxillary osteotomy with downgrafting of the maxilla and obvious change of occlusal inclination, a critical movement in regard to relapse. X-rays taken 8 months after surgery.

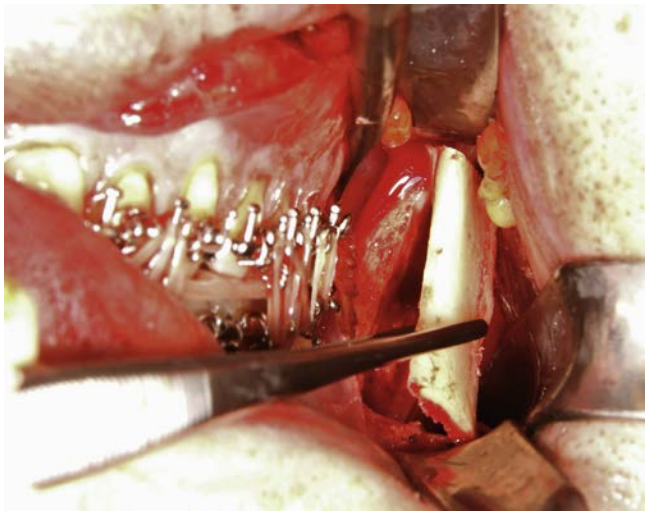

• **Figure 43-19** Cortical bone harvested from the angle of the mandible is a fast procedure and easily accessible.

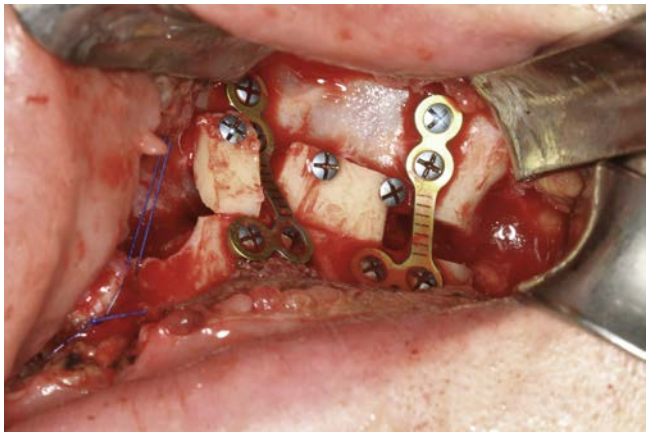

• **Figure 43-20** Anterior and downward movements of the maxilla need to be grafted for reasons of stability.

ideal for interpositioning in the osteotomy gap (Figure 43-20) or in the retromolar area. Stability of maxillary expansion and long-term relapse are discussed in the "Postoperative Complications" section.

Postoperative

Late Bleeding

Characteristically, if bleeding occurs after Le Fort I osteotomy, it is within a 2-week time frame. The patient should be advised about this possibility at the time of discharge from hospital. In general, anterior or posterior epistaxis may occur. The first step in treatment will be anterior and posterior nasal packing, as well as blood examination and a review of the patient's general health status. If blood loss is acute, it must be decided whether to reopen the operative site or, in cases of fulminant bleeding, to do a digital subtraction angiography followed by embolization. In rare situations, the source of bleeding may not be a disrupted or recanaliculated vessel, but a ruptured pseudoaneurysm of the maxillary artery or its terminal branches.[26,27]

Aseptic Necrosis

Studies performed by Bell,[13] Nelson,[14] and their colleagues have shown that the Le Fort I procedure is feasible and safe. Ischemic complications can appear to different degrees: loss of tooth vitality, periodontal defects, loss of tooth, and loss of segments up to the entire maxilla. Kramer and colleagues[2] reported on a postoperative study group of 1000 patients

and found a 1% incidence of ischemic complications. The risk of partial aseptic necrosis of the maxilla rises with the degree to which vascular support has been jeopardized by extensive movements and segmentation, as described in the section "Segmented Le Fort I Procedures". In general, postoperative maxillary perfusion is judged clinically by the gingival and pulpal blood flow. A more scientific assessment, if uncertainty exists, would be either magnetic resonance angiography or laser Doppler flowmetry as described by Dodson and co-workers.[28] When the palatal tissue is the sole source of perfusion and the descending palatine arteries have been changed, transitory paleness of the anterior gingiva may occur, especially if movement has been significant (Figure 43-21). Time and patience are necessary before the epithelium will begin bleeding again. There are cases in literature where aseptic necrosis and even total loss of the maxilla occurred after dramatic bleeding, extensive hypotension, and ligation of the external carotid artery or embolization.[29]

Blindness and Other Ophthalmologic Complications

Blindness after Le Fort I osteotomy has been reported in very rare cases (0.25%) mainly associated with high Le Fort I osteotomies and in patients with malformations.[30] This fact may be misleading because the cause for this complication is the pterygoid maxillary disjunction, which should always be the same maneuver, independent of the height of the Le Fort I osteotomy. If this is done too forcefully it may result in uncontrolled fracture lines and bleeding. The combination of controlled hypotension and excessive hemorrhage is considered one of the risk factors of midface surgery. Compression in the pterygoid palatine fossa up to the superior orbital fissure and optic foramen is another risk. If optic nerve damage and its origin are diagnosed, instant decompression of the optic nerve and application of corticosteroids may help, but recovery rates are poor. Besides blindness, several other ophthalmologic complications are described in the literature,[31] such as a decrease in visual acuity, extraocular muscle dysfunction, neuroparalytic keratitis, and injuries of the lacrimal apparatus resulting in epiphora and keratitis sicca as described in the section "Laceration of the Lacrimal Duct". If ophthalmologic postoperative symptoms are detected, an ophthalmologic consultation, as well as an acute computed tomography (CT) scan, becomes urgent. All these symptoms may occur in the absence of direct trauma to neurovascular structures but are consequences of forces transmitted during pterygomaxillary separation. These indirect forces may be traction, compression, or contrecoup trauma to structures running through the superior orbital fissure and in the pterygopalatine fossa. In the worst case, the fracture lines can extend to the base of the middle cranial fossa, resulting in a pseudoaneurysm (false aneurysm),[26] an arteriovenous fistula, or sinus cavernosus thrombosis.

Infection

Septic complications in orthognathic surgery and in specific in maxillary surgery are extremely rare and more often seen in the mandible, which is less vascularized and is affected by the pooling effect of saliva.[32] Kramer and colleagues[2] described a 1.1% incidence of infection in a prospective evaluation of 1000 patients undergoing Le Fort I osteotomy. One reason for it may be that antibiotic prophylaxis is standard. In a prospective study, Danda and co-workers[33] indicated an incidence of infection under 9.3% if antibiotics were administered, in comparison to a rate of up to 25% if no antibiotics were prescribed. The only question is, which antibiotics, and how should they be administered? In 2011, Danda and Ravi[34] published a meta-analysis on this topic. It is essential to start intravenous antibiotics at the beginning of surgery; risk of infection rises with every hour of operating time.[35,36] After surgery, the regime may vary according to preference: 3

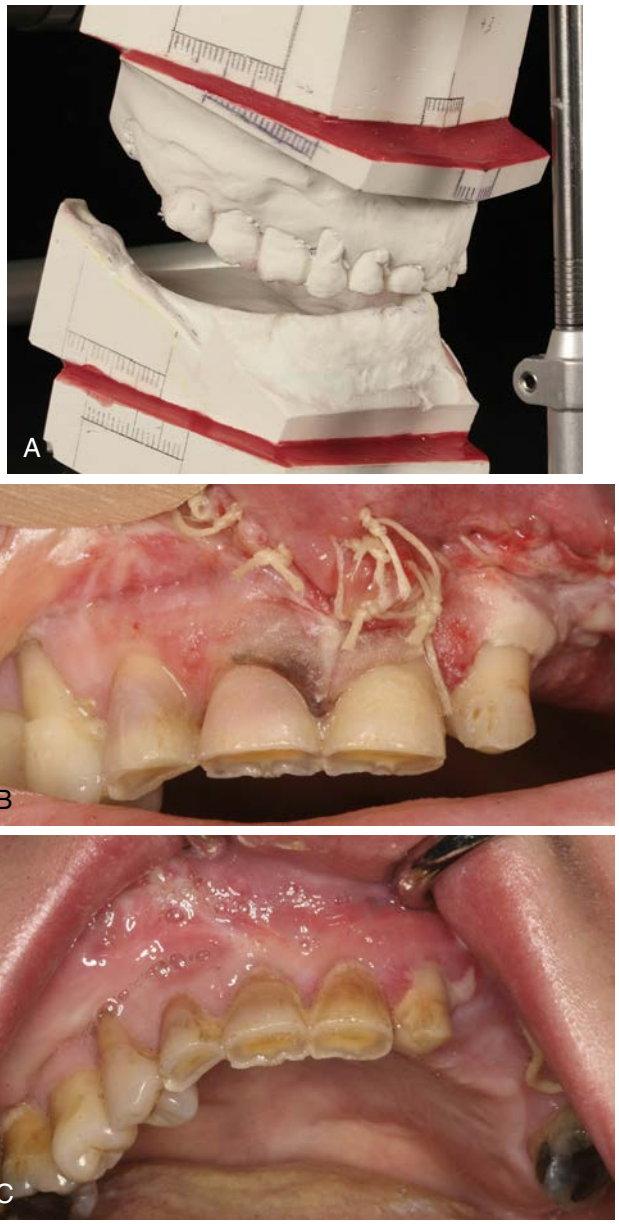

• **Figure 43-21** **A**, Major dislocations of the maxilla during Le Fort I osteotomy, especially anterior and downward, are risky for the vascular supply. **B**, Postoperative, day 3, after excessive anterior movement and downgrafting of the maxilla, obvious ischemia of the buccal gingiva of the incisors. **C**, Postoperative, day 8, recovery of blood supply of the papillae spontaneously.

to 5 days orally. In a prospective, randomized, double-blind, placebo-controlled clinical trial, Tan and associates observed no advantage in outcome if the antibiotics were administered orally or intravenously postoperatively for a period of 2 days. Intraoperative amoxicillin was given intravenously and from postoperative day 3 to 5 orally. In transoral surgery, infections are primarily induced by streptococci, anaerobic gram-positive cocci; *Bacteroides* species; and anaerobic gram-negative rods, which can be ideally treated with amoxicillin-clavulanic acid[34,37] or, in cases of allergic reactions, with clindamycin. In rare cases, with transcutaneous approaches for drainage or screws, staphylococci may play a role as well.

Patients who suffered from maxillary sinusitis before orthognathic surgery are in greater danger of developing an infection postoperatively. Retention of a hematoma, lack of vascularization, edema, and compromised nasal airflow are further causes.[38] Free autologous bone grafts or interpositions of hydroxyapatite blocks may be at higher risk of infection as well (Figure 43-22). In cases of sinusitis maxillaris postoperatively, vestibular draining and lavage are sufficient in general under antibiotic medication.

Local abscesses arising from sutures, such as alar cinch sutures with nonresorbable materials, are possible and must be excised.

Acne

In orthognathic surgery, it has become routine for patients to be given corticosteroids intraoperatively and perhaps a second time on the first or second postoperative day.[39] The expected result is not only a significant decrease in edema but also a decrease in pain. In rare cases, this may induce steroid acne. In contrast to acne vulgaris, the acneiform skin eruptions will disappear without scarring, but it will take some weeks in general, and eruptions can only be treated topically (5% benzyl peroxide) (Figure 43-23).

Stability

Long-term stability of the maxilla is the result of where the maxilla was moved, how it was stabilized, and whether an isolated or combined bimaxillary procedure was conducted. The hierarchy of stability by Proffit (see Table 43-1) indicates that the least stable surgical procedures are maxillary advancement and downward[40] movement without mandibular adaption, as well as transverse expansion. Any stretching of soft tissues and muscles, such as the pterygomasseteric muscle sling or the thick, inelastic palatal mucosa, is counterproductive. Neuromuscular adaption is also one of the critical elements of stability. Awareness of all these risk factors is important in designing treatment. Extreme changes in angulation of the occlusal and facial planes must be avoided. As Reyneke[41] described, only a change of the occlusal plane up to 9 degrees can be tolerated. Stabilization with rigid internal fixation has become state of the art, and bridging gaps on the Le Fort I level in vertical changes helps increase long-term stability of the maxilla (Figure 43-24). Nevertheless, it is very important that the mobilized maxilla be maneuvered into the new position without any traction or force, because under constant pressure, even stable screws can begin moving via resorption. Unbalanced and heavy occlusal forces may cause micromovements and overloading of the osteotomy gap. Clenching and bruxism are a problem and need special awareness, as well as restriction to soft diet immediately after surgery. Micromovement of healing sites may result in fibrous union and may require replacement of osteosynthesis and bone grafting. A postoperative evaluation of skeletal relapse is difficult because of identification of bony landmarks combined with orthodontic alterations.[42] If biodegradable bone plates and screws are used,

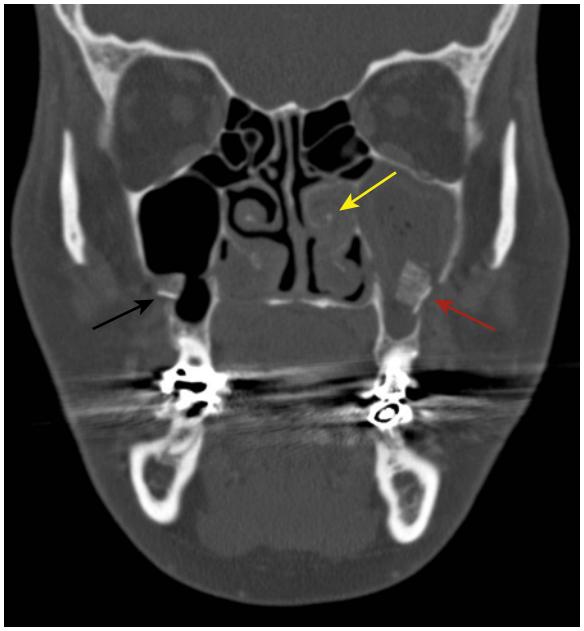

• **Figure 43-22** Patient with a severe retroposition of the maxilla and class III deformity had to be grafted with iliac crest in a second surgery because osteosynthesis was not stable for lack of solid bone. On the left side the patient developed a serious sinusitis, despite antibiotic application, mainly because of insufficient nasal circulation *(yellow arrow)* on that side. An endoscopic exploration and infundibulotomy, drainage, and partial removal of the displaced augmented bone *(red arrow)* had to be performed. On the right side the interpositioned bone healed without complications.



• **Figure 43-23** Patient suffering from a steroid acne after bimaxillary osteotomy for nearly 6 weeks, after application of 1g of Solu-Dacortin intraoperatively.

tracking degradation and ossification are even more difficult, because this is a process that lasts up to 3 years.[43]

Esthetics

The literature indicates that there has been a change in motivation to undergo orthognathic surgery.[44-46] Recently expectations of esthetic improvement have ranged higher than functional concerns. The most critical regions for esthetic complaints after maxillary surgery are the nose and the smile, as well as an increase of soft tissue in the midface. Any Le Fort I procedure carries the risk of altering the esthetic appearance of the nose in regard to broadening the base and changing the tip projection. Familiarity with the anatomy of the nose and its relationship to the maxilla is important. The primary tip projection is supported by the septum and the medial crura, both resting on the anterior nasal spine and crest. The dome of the alar cartilages creates the secondary tip projection. The alar cartilages have a fibromuscular attachment to the piriform rim, which is detached during Le Fort I osteotomy, as well as the septum base.



• **Figure 43-24** In case of fragile bony structures, osteosynthesis must be supported by bone grafts to achieve long-term stability.

Referring to the earlier section on nasal airway, it is mandatory to be guided by the principles of reducing the septum and removing any obstacle presenting repositioning of the maxilla to preserve a midline position for the septum and the nose itself (Figure 43-25). If asymmetry is noted postoperatively, revision becomes necessary, and the osteosynthesis must be opened to gain access to the septum. In rare cases only the base of the columella is displaced and can be corrected from a nasal approach. Care must be taken to ensure that the septum is not over-resectioned or reduced in the anterior part, because this portion plays a significant role in supporting the nasal tip. An alteration of the bony platform of the alae results in a flaring of the nostrils. In patients with narrow nostrils and nasal airway, this may be even a desired side effect, but often broadening of the nose is a disadvantage of Le Fort I osteotomy. The esthetic modifications of the nose depend on the direction in which the maxilla is repositioned.[40,47] A pronounced supratip depression and an increase of basal width are observed when advancing the maxilla. Using an alar cinch suture, the mobilized periosteum, paranasal musculature, and indirectly the crus laterale can be anchored to the area of the anterior nasal spine by nonresorbable suture. We have never faced complications such as fistulas or subcutaneous abscesses using a nonresorbable suture, which guarantees a long-term result. In some cases the patient might observe some paranasal tension, which decreases with time. The least risk of anatomic changes of tip projection can be observed by performing a subapical osteotomy where the piriform aperture remains untouched and the bony footplate of the alae stable (Figure 43-26). But this is only feasible in an extremely long maxilla. The role of the anterior nasal spine in altering the tip projection is overestimated; we always remove it to prevent

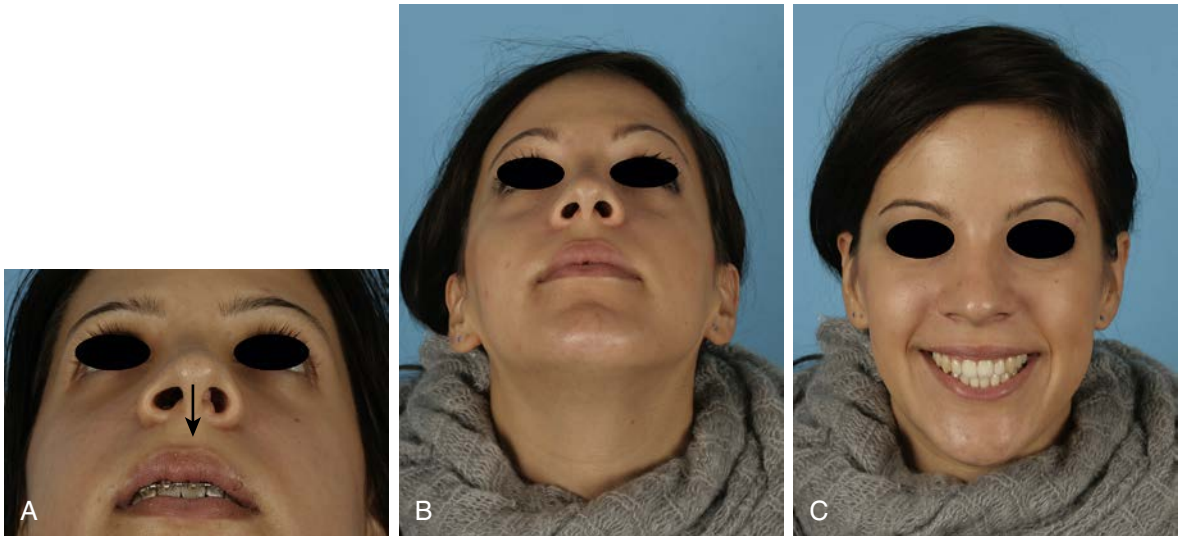

• **Figure 43-25** **A**, Buckling of the nasal septum and midline shift of the maxilla postoperatively after too little resection of the cartilaginous septum and the lateral wall of the nose. **B**, Same patient 1 year after bimaxillary osteotomy because of a class III deformity. Four days after primary surgery, a correction of the maxillary midline and a loosening of the buckled septum was done. **C**, Satisfying esthetic outcome (1 year after surgery) after reentry as described in **B**.

any interference with the septum. The advancement of the piriform aperture is more crucial.[48]

An inferior movement of the maxilla may result in a drop of the nasal tip (parrot beak), and eventually the bases of the alars may lie below the level of the columella. In contrast, if this exists before surgery, it can be corrected with impaction of the maxilla (Figure 43-27, *A-D*).

In maxillary excess with the phenomenon of the "frowning mouth," it is risky to do too much impaction because it will result in black triangles in the commissures instead of a harmonic show of teeth in repose and a broad smile. The movement of the cheilion in horizontal and vertical directions can be improved with an alar cinch using muco-musculo-periosteal V-Y sutures.[49] These sutures aim to reorient the dissected paranasal muscles to their original vector and have an influence on the length and volume of the upper lip. The angulation of the front teeth is crucial for creating a beautiful smile arch; more protrusion preoperatively (see Figure 43-27, *E, F*), combined with later impaction, may increase the beauty of the smile.[50]



• **Figure 43-26** **A**, Patient with maxillary excess and aggravated closure of the lips. **B**, A subapical osteotomy was performed to preserve the piriform aperture and the nasal platform. The steep inclination of the incisors and the gummy smile could be corrected by tilting the segment. **C**, Postoperative cephalogram after subapical osteotomy, bilateral sagittal split osteotomy, and genioplasty. **D**, Esthetic outcome after harmonizing the vertical excess and preserving nasal appearance.

A major esthetic complication in Le Fort I osteotomy is if impaction of the maxilla is too generous, leading to cases of gummy smile. No show of upper incisors destroys a youthful appearance and may worsen with age as the upper lip elongates (Figure 43-28).

Performing high Le Fort I osteotomies may require contouring of bony steps (Figure 43-29). Generous mobilization of the periosteum to remove the visual tension and then smoothing by filling with crushed bone covered with a resorbable membrane can help this irregularity. In the infraorbital area, autologous fat grafting or lipofilling could also be an option to harmonize the contour.

Disturbance of Somatosensory Function

Any preoperative discussion of risk factors of Le Fort I osteotomy must include the possibility of alterations in somatosensory

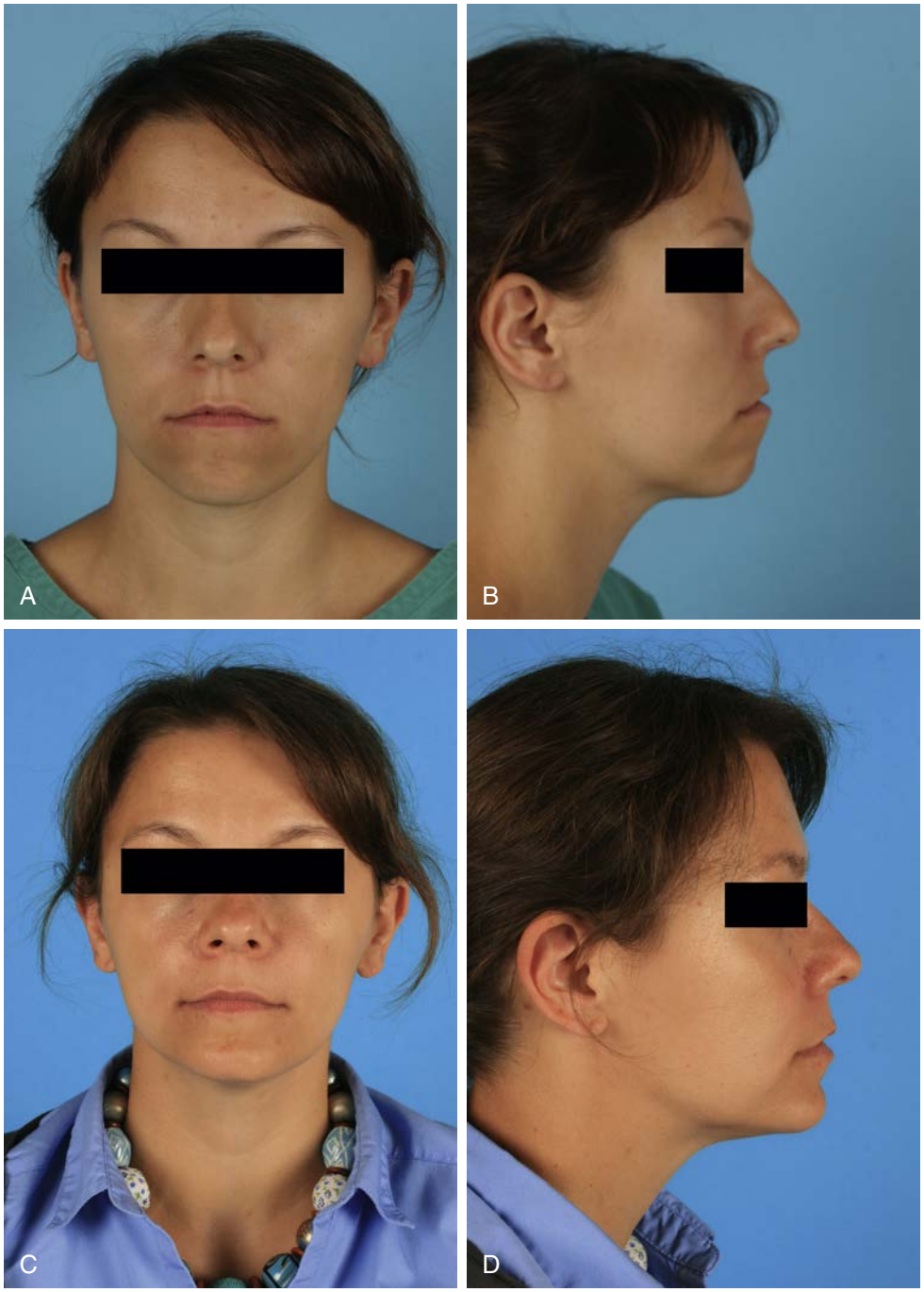

• **Figure 43-27** **A**, Patient with frowning mouth, midface deficiency, hypoplasia of the chin, dental edge-to-edge relation. **B**, Profile view, preoperative. **C**, Postoperative frontal view after Le Fort I osteotomy, bilateral sagittal split osteotomy, and genioplasty. By advancing and impaction of the maxilla in the molar area, the sad impression of the frowning mouth can be improved. **D**, Profile view, postoperative.

Continued

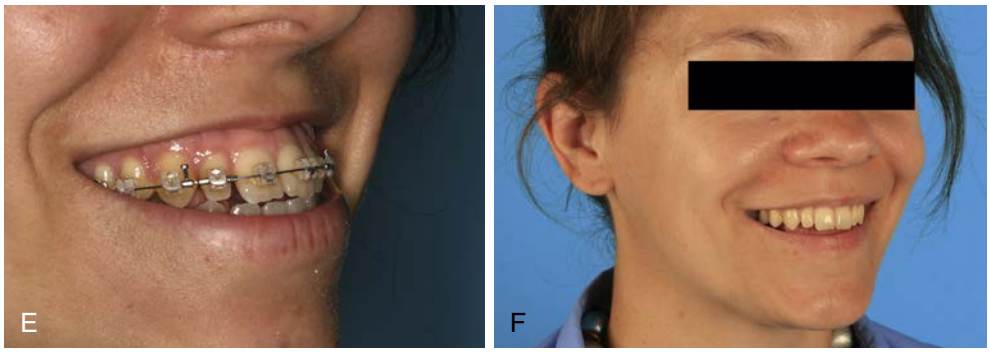

• **Figure 43-27, cont'd** **E**, Pronounced inclination of the frontal teeth in accordance with the orthodontist before surgery, so that after impaction in the molar area and advancement of the maxilla, sufficient lip projection still remains. **F**, Obvious improvement of smile arc after surgery.

function. During Le Fort I osteotomy, the posterior superior alveolar nerve, a branch of the maxillary nerve, as well as the middle and anterior superior alveolar nerves, branches of the infraorbital nerve, are in the operating field. The intraoral dissection results in a disturbance in sensitivity of the vestibular mucosa and the teeth, as well as the mucous membrane of the sinus. After emerging through the infraorbital foramen, the infraorbital nerve terminates in branches to the eye, the nose, the upper lip, the skin, and the vestibular mucosa and the gingiva. Disturbance may include changes in tactile perception, two-point discrimination, and sensitivity to heat on the skin in the mid-face area, the upper lip, the gingiva, and mucosa of the palate or vestibule as well as the sensitivity of the upper teeth. To avoid laceration of the infraorbital nerve, careful preparation and handling of retractors (Figure 43-30) is advised during surgery. As mentioned before, the horizontal bone cut should be done at least 5 mm above the apices in respect of vitality and sensitivity of the teeth.[13]

Ueki and colleagues studied the recovery from hypoesthesia of the upper lip using trigeminal somatosensory evoked potentials after Le Fort I osteotomy.[51] The average recovery time was 9.7 to 13.9 weeks. This outcome was independent of degree of movement of the maxilla,[52] fixation method, or surgical technique. Only in segmented Le Fort I osteotomies can a higher incidence of changed sensitivity on the palate and the gingiva be documented[52,53] in correlation with manipulation of the palatal nerve. Thygesen and associates[53] also evaluated subjective observations in their study. Patients reported being handicapped in their functional ability (lip movements, finding occlusion, increased tooth pulp sensation) because of changed sensation.

Interestingly, patients with persistent somatosensory disturbances, who are satisfied with the overall outcome of the surgery including esthetic and function, will tolerate the alteration much better than patients who are unhappy with the postoperative result. The highest risk of long-lasting disturbances in somatosensory function is described in pulp vitality, followed by gingiva and palate. Cutaneous numbness normally recovers within 6 months.

Postoperative pain control following Le Fort I osteotomy is essential to prevent centralization of the pain. The perception of pain is not only a physical phenomenon; it is also psychological and may provoke anxiety.[54] Appropriate management of pain results in a lower complication rate and enhances recovery.[55]

Segmented Le Fort I Procedures

Introduction

Segmental procedures in orthognathic surgery have a long history, mainly because orthodontic treatment in combination with orthognathic surgery was not standard from the very beginning. With the improvement and refinement of orthodontics, the need for a segmental approach has definitely decreased. However, there are still indications for it, such as severe discrepancies in dental arch width, vertical height of the alveolus and curve of Spee, or inclination of teeth. The decision to do segmental surgery arises from the wish to achieve perfect occlusion or for esthetic reasons.

In cases of a surgery-first approach, where no preoperative orthodontic treatment is performed at all, the frequency of segmentation is high.

Preoperative Complications

Planning

Any segmental procedure is more challenging than a single-piece Le Fort I osteotomy; therefore it needs precise planning in two ways: vascular support of the segment, and a definition in advance of where to perform the cuts, prove the feasibility, and create the gap for movement either by cooperation with the orthodontist or by extraction. This is the first step toward a successful outcome, because root injuries rank highest on the list of complications in segmental procedures.

In the history of orthognathic surgery, before the era of the Le Fort I osteotomy, segmentation of the alveolar process was popular and often practiced. Independent of the design of the vascular pedicle of the segment, one can find techniques referring to their famous inventors such as Wassmund, Wunderer, Schuchard, Koele, Epker, and Cupar.[56] Preference for the one technique over another depends on the desired movement of the segments. Later, based on scientific research,[13,57] a segmented Le Fort I osteotomy and its vestibular incision became routine, and this is also practiced in isolated segments nowadays.

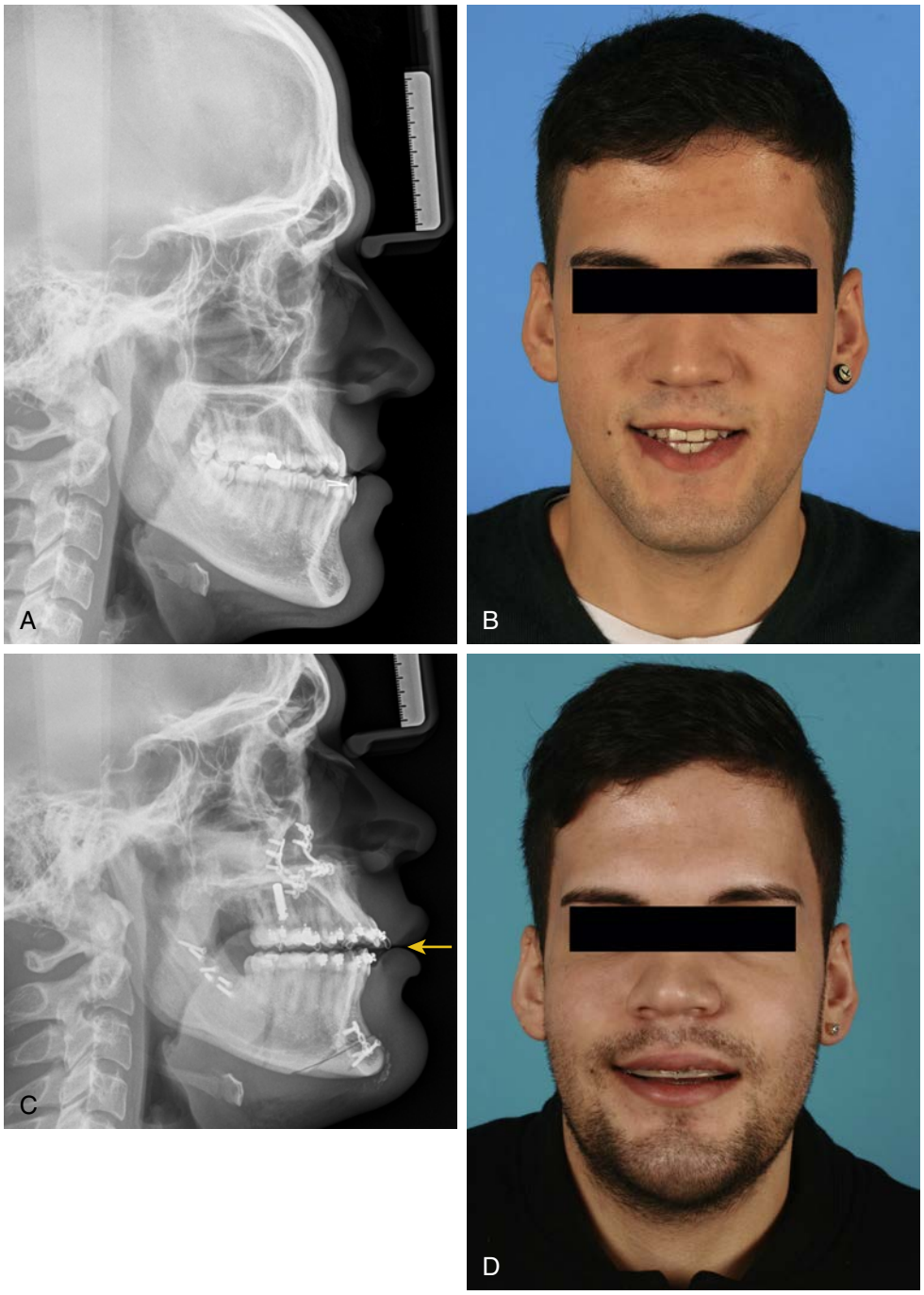

• **Figure 43-28** **A**, Lateral cephalogram of a patient with class III deformity and transversal discrepancy of the maxilla. **B**, Same patient with class III deformity, maxillary retrusion, and gummy smile. **C**, During surgery, maxillary impaction was performed too extensively *(arrow)* in the A-point. **D**, First day after surgery, a revision surgery was offered, but the patient was not willing to go through surgery again, although he was informed about a lack of show of teeth and some compression on the septum.

For esthetic planning, a point of reference, such as the upper incisal edge of the frontal teeth, has to be defined. This point of reference determines the midline shift, impaction, or setback.

Intraoperative Complications

Prolonged Operating Time, Blood Loss

The risk of intraoperative bleeding is subject to the same anatomic facts as in total Le Fort I procedures and is described at length in the later subsection on hemorrhage. Nevertheless segmental Le Fort I osteotomy is more challenging and more time consuming.[58] A long operating time correlates with increased blood loss. In 2000, Yu and colleagues[59] reported that blood loss in segmented procedures was 30% more than in total Le Fort I. Reduction of blood loss may occur until the use of a piezo scalpel for the segmentation (Figure 43-31). This was also studied by Landes and co-workers.[60] Blood loss

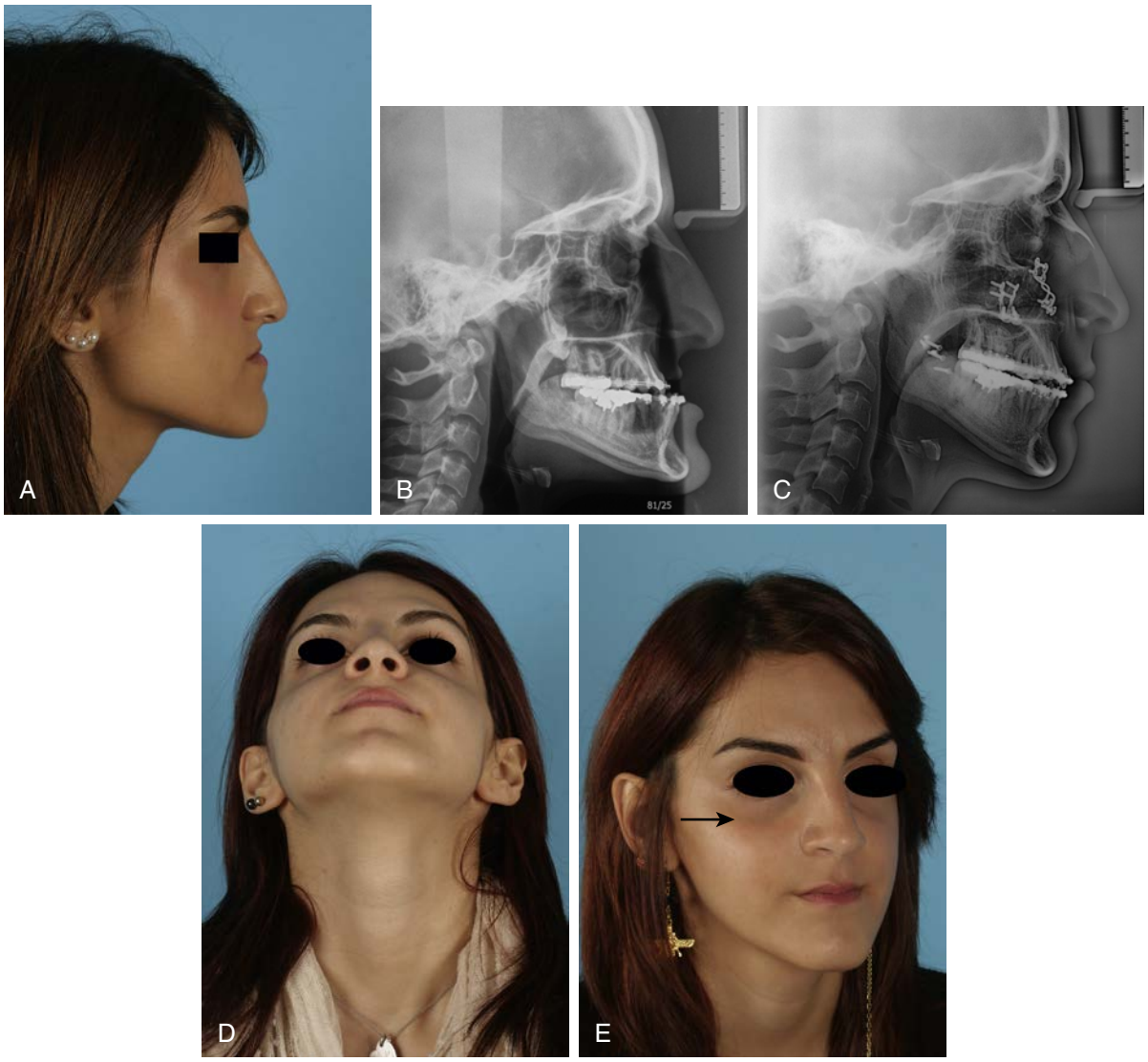

• **Figure 43-29** **A**, Patient with severe class III deformity and midface deficiency. **B**, Lateral cephalogram documenting the severe deformity with the negative overjet. **C**, Lateral cephalogram after high Le Fort I osteotomy and mandibular setback. The substantial bony step was molded with milled bone mixed with fibrin glue to harmonize the contour. **D**, Angular view of the advanced midface showing the decline to the infraorbital rim. The patient had excessive scleral show, and a Le Fort II osteotomy was not an option for this patient. **E**, To reduce the infraorbital gray shadows, an injection of autologous fat is the recommended therapy.

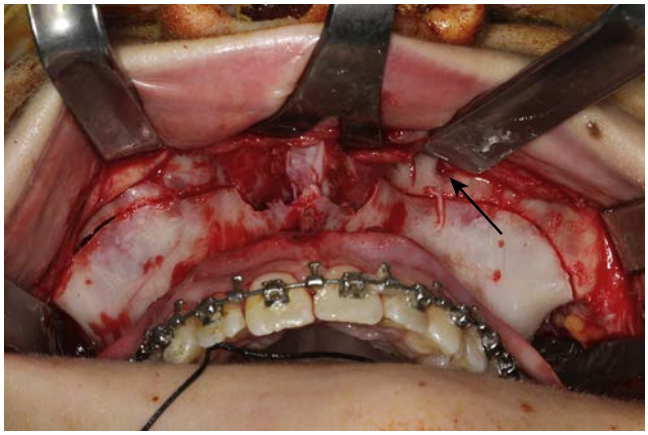

• **Figure 43-30** Intraoperative direct pressure on the infraorbital nerve *(arrow)* by holding the retractor prolongs the postoperative hyposensibility,



• **Figure 43-31** Segmental osteotomies are ideally performed with the piezoelectric scalpel.

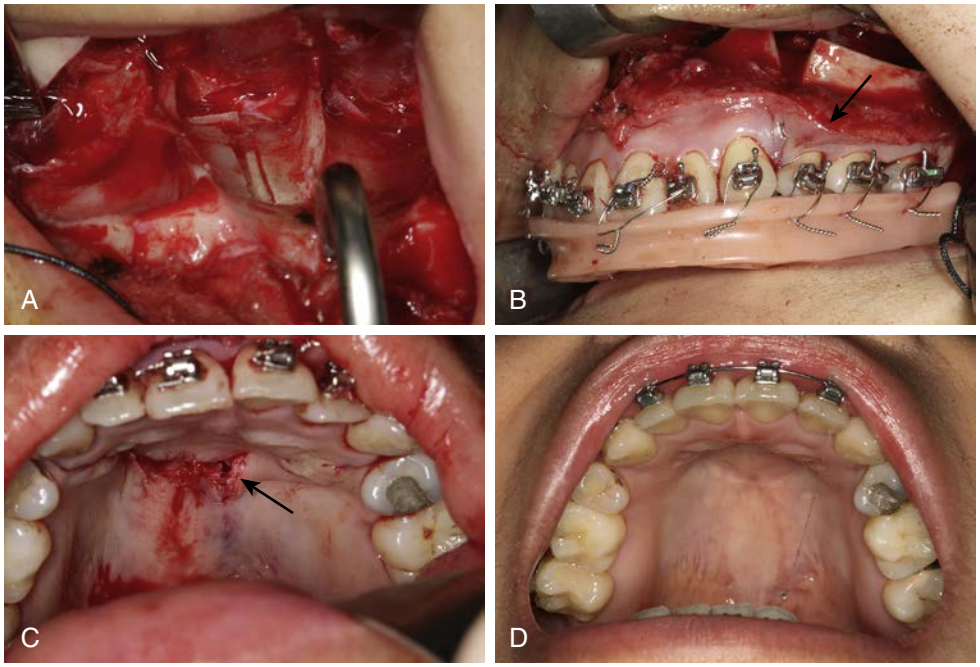

• **Figure 43-32** **A**, Surgery-first patient with a genetic overexpansion of the maxillary dental arch. During Le Fort I osteotomy, a reduction of the width is accomplished by paranasal ostectomy in addition to frontal segmentation. **B**, Posterior rotation of the front segment *(arrow)*. **C**, Laceration *(arrow)* of the palatal mucosa during segmentation, which was closed with sutures. This may occur even using the piezo saw if too much force is applied too long on the same spot. **D**, Uneventful healing of the laceration, 4 months post-surgery.

differed up to 230 mL in comparison to use of conventional instruments. The initial prolonged time of surgery using the piezo saw could be compensated soon through a learning curve.

Ischemia

The crucial question in segmentation is, where does the vascular support come from? Certainly, it is the palatal pedicle via the ascending palatine branch of the facial artery and the anterior branch of the ascending pharyngeal artery. If possible, the greater palatine artery, which is the blood supply for the palate and the palatal alveolus, should be preserved in segmental procedures as well. This is advantageous if laceration of the palatal mucosa occurs during segmentation (Figure 43-32). In critical segmental osteotomies, in cleft patients for example, a vestibulobuccal subperiosteal tunnel with vertical incisions is an option, instead of incising horizontally. The excellent visibility and accessibility to all areas of the maxilla makes the Le Fort I downfracture technique optimum for segmentation. Reliance on the reverse periosteal-endosteal blood flow[19] is necessary if the greater palatine artery is injured. If multiple segments are designed, it is advisable to check the color of the attached gingiva of the dento-osseous segments during surgery, and segmentation should occur from posterior to anterior, as the most critical blood supply will be in the gingiva of the frontal segment. The more extensive the mobilization and dislocation of the bony segments, the higher the risk that blood supply will be jeopardized by the tension of the soft tissue pedicle (Figure 43-33, *A*). The second consideration is the size of the segment, and if subperiostal undermining of the gingiva or periosteum for reasons of mobilization is necessary (see Figure 43-33, *B*), it has to be done adjacent to the osteotomy cut not touching the pedicle of the smaller segment. If obvious ischemia is observed intraoperatively, mobilization must be stopped, and the surgery must be aborted. Sometimes wrapping the segments in warm tissues and antithrombotic medication can help.

Dental Injuries and Periodontium

Dental injuries are by far the most common intraoperative complications in segmental maxillary surgeries.[61] Before performing a segmental procedure, it is absolutely mandatory to check the preoperative health status of the teeth, sensitivity, pocket probing, and evaluation of root resorptions. Schultes and colleagues[62] reported a high incidence of periodontal lesions in 35 teeth out of 74 osteotomies in a retrospective study. A strategy must be designed as to where to place the vertical incision. If it is planned well ahead, the orthodontist will open a space or do a tilting of the roots. If no orthodontic help is available, the anatomic situation of the roots should be explored by CT scan or digital volume tomography (DVT). If there is not at least a 3-mm working space interdentally, extraction should be considered. The surgical technique and the amount of displacement of the segments also play a role. The osteotomy cut should be performed with a thin chisel, or with a piezo scalpel. To

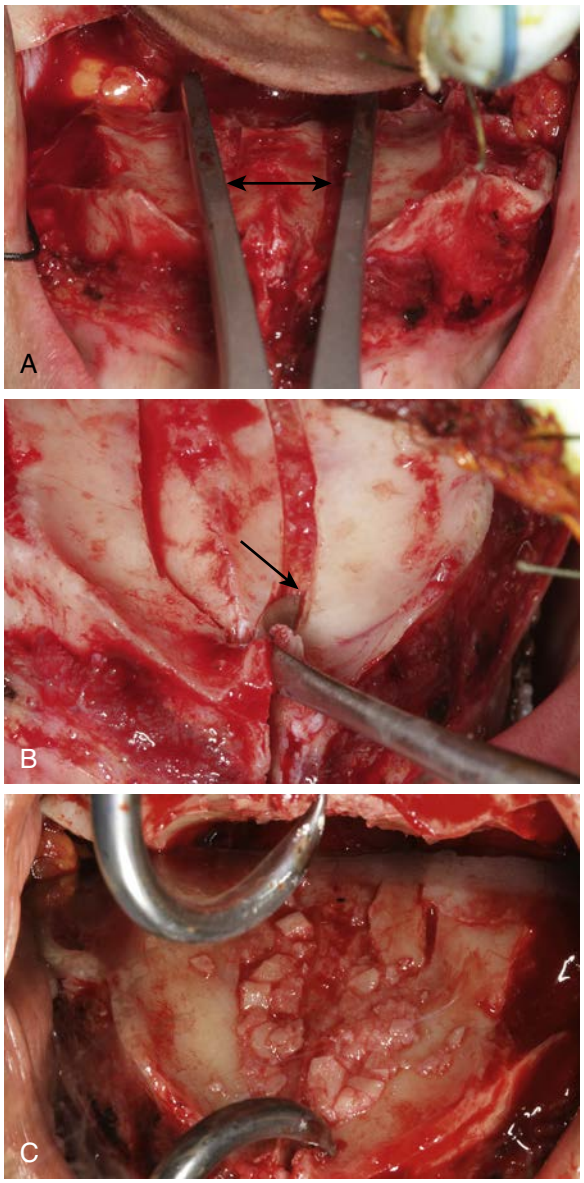

• **Figure 43-33** **A**, Spreading of the palatal mucosa *(arrow)* is done with controlled force so as not to jeopardize the vascular pedicle. **B**, The tension is released by a horseshoe cut, but undermining *(arrow)* of the palatal mucosa must be performed meticulously. **C**, The achieved gapping of the palatal plate is stabilized by packing the osteotomy sites with milled bone chips.

prevent mobilization of the attached gingiva, a penetration and weakening of the interdental bone with a l-mm transgingival Lindemann burr is recommended (Figure 43-34). Dependent on the pitch-roll movement of the segment, removal of interseptal and interradicular bony interferences may be necessary. A negative consequence of this maneuver may be damage to the alveolar socket caused by trying to position the segment, resulting in tension and destruction of the periodontium. In combination with unfavorable approximation of the bony margins, an angular loss of the interdental bone height is inevitable. Bridging the bony gap with milled bone chips (Figure 43-35) is helpful for stability, but survival and nutrition of the augmented bone then depends on sufficient interdental wound closure and blood supply of the papilla. If shaving of the root adjacent to the vertical osteotomy has occurred, the prognosis of the injured tooth depends on the level of the laceration (Figure 43-36). Application of an enamel matrix protein on the open root surface can help. In general there is a chance that injury in the final third of the root will be tolerated without symptoms.[63]

Postoperative Complications

Stability, Fibrous Union

Stable maxillary expansion in a segmented Le Fort I osteotomy depends on the morphology of the palate, the surgical technique, and the retention. Successful widening is limited to 5 to 7 mm; in cases of a high-arched palate and of extraction with anterior movement of the molar segments, more expansion is feasible. To release tension, a bilateral, paranasal osteotomy on the floor of the nose should be performed (see Figure 43-33, *B*). This is the area of least bone but high thickness of the palatal mucosa, in contrast to a midline osteotomy where a perforation of the mucosa is a threat (Figure 43-37, *A*). Mobilization and undermining of the vascular pedicle must be done on the lateral aspect of the osteotomy site. Expansion must be executed in intervals with cautious force. Then the widening can be stabilized by either a resorbable miniplate (see Figure 43-37, *B*) or packing of the osteotomy sites with autologous bone chips (see Figure 43-33, *C*). Maxillary segments are kept in place with rigid osteosynthetic fixation and dental acrylic splints (Figure 43-38). These appliances have an integrated palatal arch bar and are wired to the surgical hooks for up to 6 weeks. After removal of the acrylic splint, a transpalatal arch wire must be worn for further retention up to 3 months. Most relapse in width is seen within the first year, and then it is necessary to distinguish between skeletal and dental relapse.[64] Skeletal relapse in a two-piece maxilla mainly occurs in the molar area and can be up to 47%[65] of the arch width in the first molar area. Overexpansion is recommended. Dental relapse can be avoided if the molars are kept upright instead of tilting and intrusion orthodontically preoperatively is avoided. Therefore it is also essential that the surgeon become acquainted with the original pretreatment occlusion before designing his or her treatment plan.

Fibrous union of segments of the dental arch derives from an unstable osteosynthesis in combination with insufficient bony structures and overloading. Micromovements of the interdental osteotomy gaps, filled with milled autologous bone chips, can prevent revascularization and stable healing. If nonunion exists, reosteosynthesis in combination with cortical bone grafting should be performed.

Infection, Periodontal Problems

Patients with a compromised periodontal health status are more at risk to develop an infection after segmental

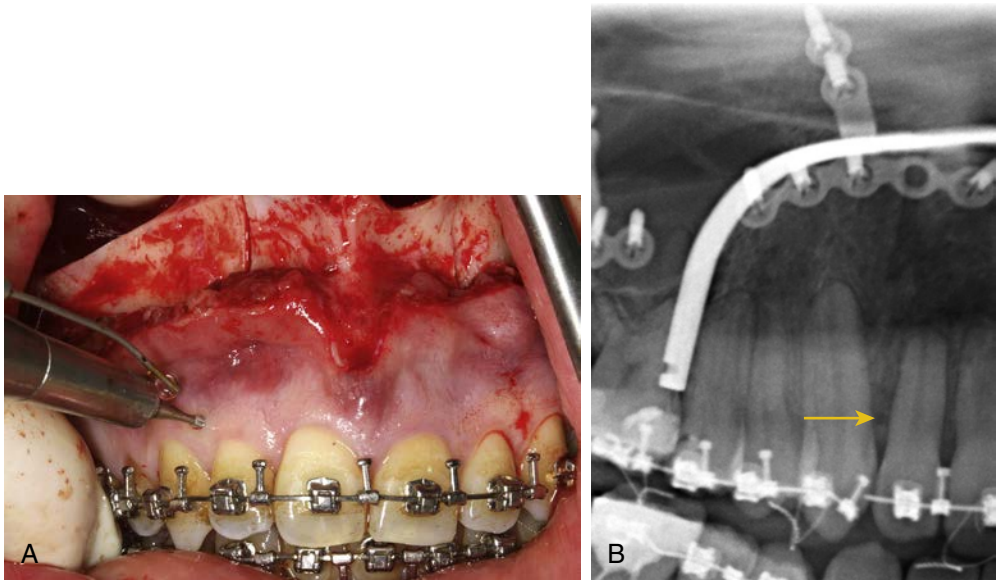

• **Figure 43-34** **A**, The desired interdental osteotomy cut is defined by transgingival perforations with a Lindemann burr in the gingiva fixa. **B**, X-ray corresponding to the clinical picture in **A**. The interdental perforation is marked with an *arrow*.

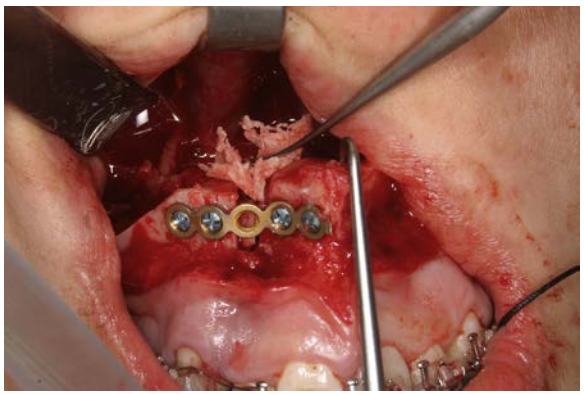

• **Figure 43-35** Osteotomy cuts in segmental Le Fort I procedures are stuffed with autologous bone.

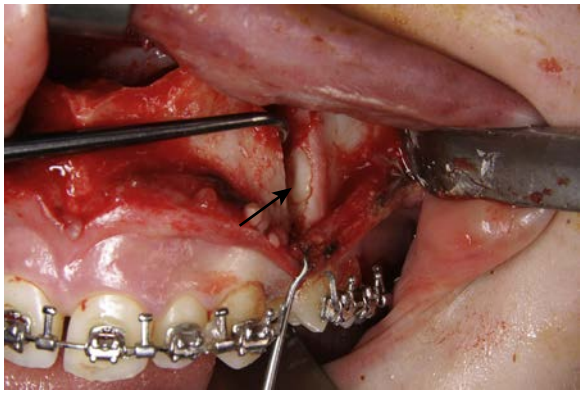

• **Figure 43-36** Shaving of the root of the first premolar in the upper third during segmentation.

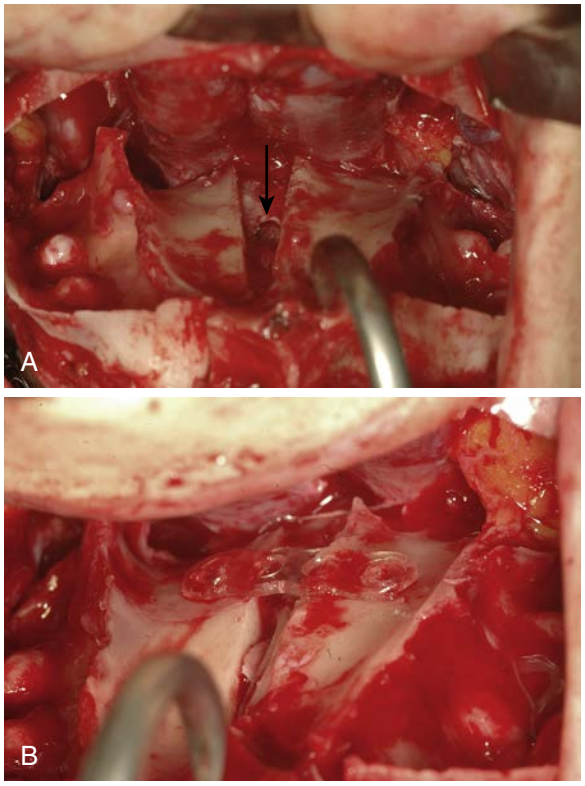

• **Figure 43-37** **A**, Transversal widening was performed by a single midline osteotomy, in contrast to a horseshoe, bilateral paranasal osteotomy, which results in a perforation *(arrow)* of the thin palatal mucosa. **B**, Stabilization of the transversal widening by fixation with a resorbable plate.

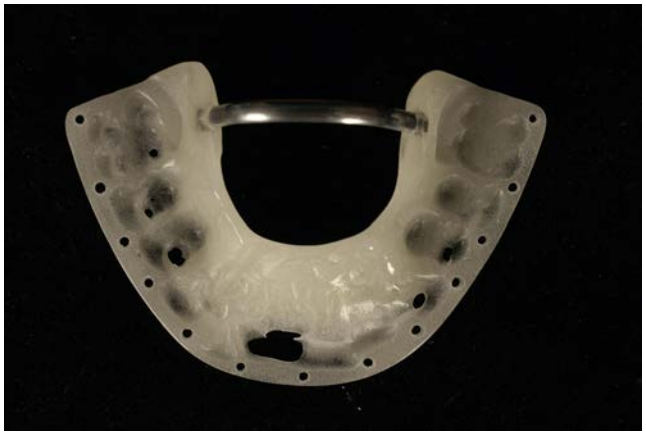

• **Figure 43-38** Acrylic splint with an integrated palatal arch bar, which must be in place postoperatively up to 3 weeks and must be replaced by a transpalatal arch after removal.

Le Fort I osteotomies. A widened periodontal ligament space can be a first sign and the origin of osteolytic lesions and root resorption. If the infection is ascending from the periodontal pocket along the vertical osteotomy cut, osseointegration of the grafted bone chips will not succeed, and stable healing is in danger. In the worst scenario, the tooth will be lost and the segment remains mobile (Figure 43-39). Tooth loss is rare,[61] but an angular interdental bone loss occurs with greater frequency (Figure 43-40). One of the most difficult goals in segmental surgery is to achieve a salvage-proof interdental soft tissue seal. Any protrusive rotation of segments results in undesired tension of the interdental papillae, creating a periodontal pocket. In cases of extractions, closure of the extraction socket is the aim by sewing a subperiostal rotation flap into the defect (Figure 43-41).

Root Resorptions, Loss of Dental Vitality

As mentioned before, root injuries do not necessarily become symptomatic. As long as the patient is asymptomatic, observation and x-ray control are the treatments of choice before endodontic treatment is performed. Pepersack,[63] who studied tooth vitality and sensitivity in 429 segments operated by Hugo Obwegeser, came to the conclusion that return of sensitivity in the maxilla takes up to 1 year. Teeth adjacent to the vertical osteotomy in the mobilized fragment remain nonreacting at a higher percentage independent of vascularity. A 5-mm distance between the horizontal osteotomy and the root apices, as described by Bell,[19] is the general rule for the safe conduction of osteotomies. Normal vascularity is the crucial point of success, not a lack of sensitivity.

Oroantral or Oronasal Fistulas

Laceration of the palatal mucosa may happen during segmentation, whether it is conducted with a rotatory instrument or a piezo surgical scalpel (see Figure 43-32, *C*). To accelerate wound healing, meticulous closure of the nasal mucosa as well as the palatal defect, including coverage with a resorbable membrane on the floor of the nose, is recommended. In segmented Le Fort I surgery, an attempt should be made to preserve the greater palatine artery. Antibiotic prophylaxis (amoxicillin) is prescribed, and some ointment that enhances wound healing is applied intraorally. In the rare cases where persisting fistulas occur, secondary reconstructive interventions must be planned.

Aseptic Necrosis

Because of the knowledge of vascularization of the maxilla based on the scientific studies by Bell and colleagues,[13,17,19,55] aseptic necrosis is a rare complication, but the risk increases in segmental procedures. Nevertheless, aseptic necrosis can also occur as a result of decreased blood flow triggered by excessive bleeding or hypotension, or extensive stretching (Figure 43-42) of the palatal vascular pedicle, for example. The most vulnerable structures are the buccal gingiva and the alveolar bone in the anterior maxilla. This has to be considered when segmentation of the front block of the anterior incisors is scheduled (Figure 43-43). In orthodontia-first cases, multiple segmentations should be prevented by good preoperative orthodontic treatment. Only in "surgery-first" cases, where overall treatment time is cut short, is there more dependence on multiple segments. Aseptic necrosis can present to different degrees, from loss of tooth vitality, to periodontal defects, loss of the bony socket, tooth loss, and loss of total segments up to the entire maxilla.[29] Pulpal necrosis is often camouflaged by an early hyposensitivity due to violation of the sensory fibers during surgery. Stripping of the palatal soft tissues adjacent to the osteotomy cut, or the periosteum in vertical incisions, for mobilization of the segments, has to be done very carefully, always starting on the side with the safer vascular pedicle. In cases of widening, a horseshoe-shaped palatal cut, dividing the tension on two locations, is recommended. An unfavorable compression of acrylic splints, used for retention, on the palatal mucosa or gingiva must also be taken into consideration.

Surgically Assisted Rapid Palatal Expansion

SARPE (surgically assisted rapid palatal expansion) or SARME (surgically assisted maxillary expansion) is the procedure of choice in adult patients with a maxillary transverse deficiency more than 5 mm, with periodontally compromised (Figure 43-44, *A*) and already elongated or tilted molars and premolars. Differentiation between absolute and relative width discrepancies is important. *Relative* implies a discrepancy between the maxilla and the mandible in sagittal relationship and does not necessarily require a surgical intervention. Complications can occur intraoperatively or postoperatively.

Intraoperative

Intraoperative complications depend on the technique performed. There is a wide range, from simple outpatient

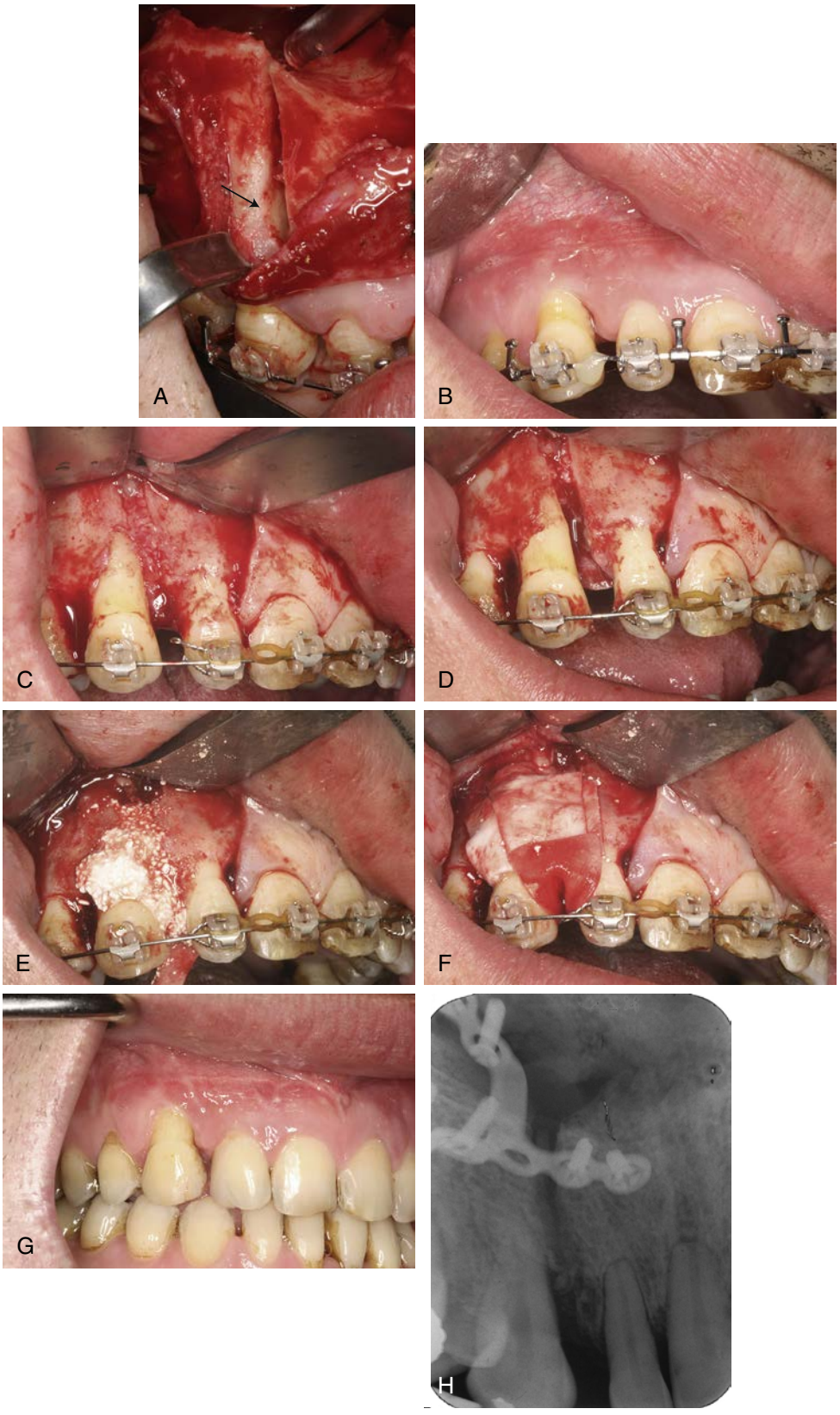

• **Figure 43-39** **A**, A patient, already periodontally compromised preoperatively, was undergoing a segmental Le Fort I osteotomy. Root shaving *(arrow)* of the canine occurred in the vertical osteotomy cut *(arrow)*. Intraoperatively, an enamel matrix protein was applied on the open root. **B**, Two months after surgery, the patient developed a periodontal pocket with a probing depth of 7 mm. **C**, Four months after surgery, an exploration of the osteotomy site was performed. There was fibrous tissue in the osteotomy gap and no bony regeneration. **D**, Infection and resorption had ascended to the middle third of the root, where shaving was diagnosed combined with a pseudoarthrosis of the segment. One of the reasons for the complication was that the patient was a heavy smoker and did not follow a soft diet after surgery. **E**, An attempt was started to save the canine by root planing and filling the gap with bone substitute biomaterial (hydroxyapatite, algae derived). **F**, The defect was covered with a resorbable membrane before wound closure. **G**, Clinical aspect 2 months after augmentation. **H**, X-ray 2 months after augmentation. Within 1 year the patient developed a recurrence of the infection, and the canine had to be removed.



• **Figure 43-40** Traumatized papilla and angular interdental bone loss at site of vertical osteotomy.

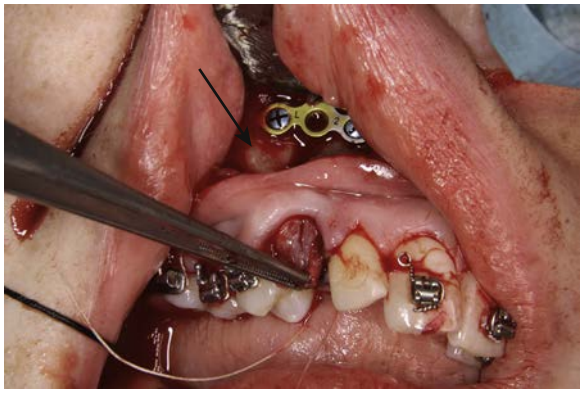

• **Figure 43-41** It is mandatory to achieve a salvage impermeable seal at the site of vertical osteotomy. A periosteal flap *(arrow)* is rotated from the vestibule into the extraction socket.

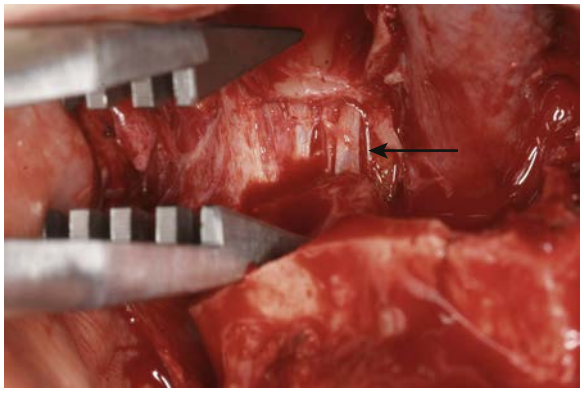

• **Figure 43-42** Extensive stretching of the vascular pedicle and mobilization of the maxilla enhances the risk of avascular necrosis. *Arrow* marks stretched and squeezed descending palatine artery.

procedures as described by Glassmann[66] or Pogrel and colleagues,[67] concentrating on sectioning the zygomatic buttresses, a midline palatal osteotomy, and a split of the alveolar bone between the incisors only, to a modified Le Fort I osteotomy including dissection of the posterior maxilla from the pterygoid plates. The second issue is the type of appliance used (bone-borne distractor or tooth-anchored device).

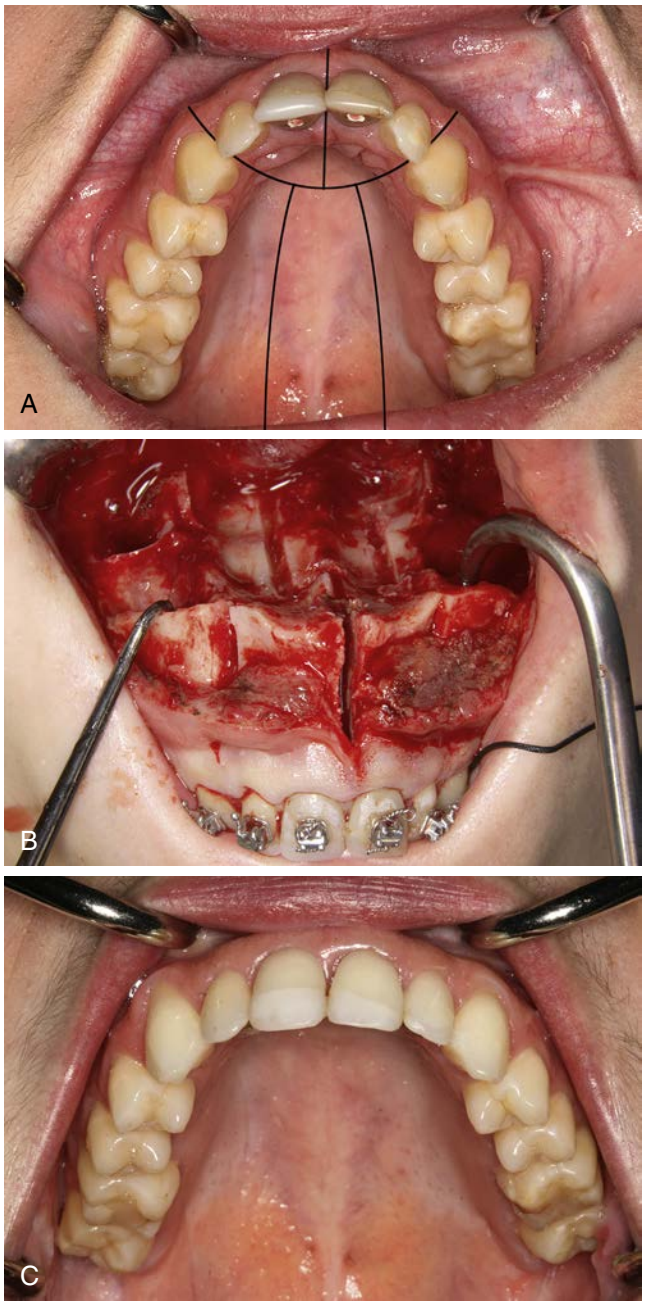

• **Figure 43-43** **A**, Dental arch of a "surgery first" patient with transversal deficiency and open bite deformity. *Black lines* mark the pattern of segmentation to achieve a harmonic dental arch. **B**, Intraoperative situation. **C**, Eight months post-surgery, dental alignment is finished orthodontically.

Hemorrhage

If a SARPE with a modified Le Fort I osteotomy is performed, except for the downfracture, risks of laceration of the descending palatine artery with the osteotome are similar to those during a regular downfracture procedure.

But in contrast to a Le Fort I osteotomy with downfracture, there is a lack of direct vision; therefore, packing is the treatment of choice in case of bleeding. If access allows it, the dissection can be achieved using an angulated, elongated tip of a piezo scalpel of the latest generation with less risk

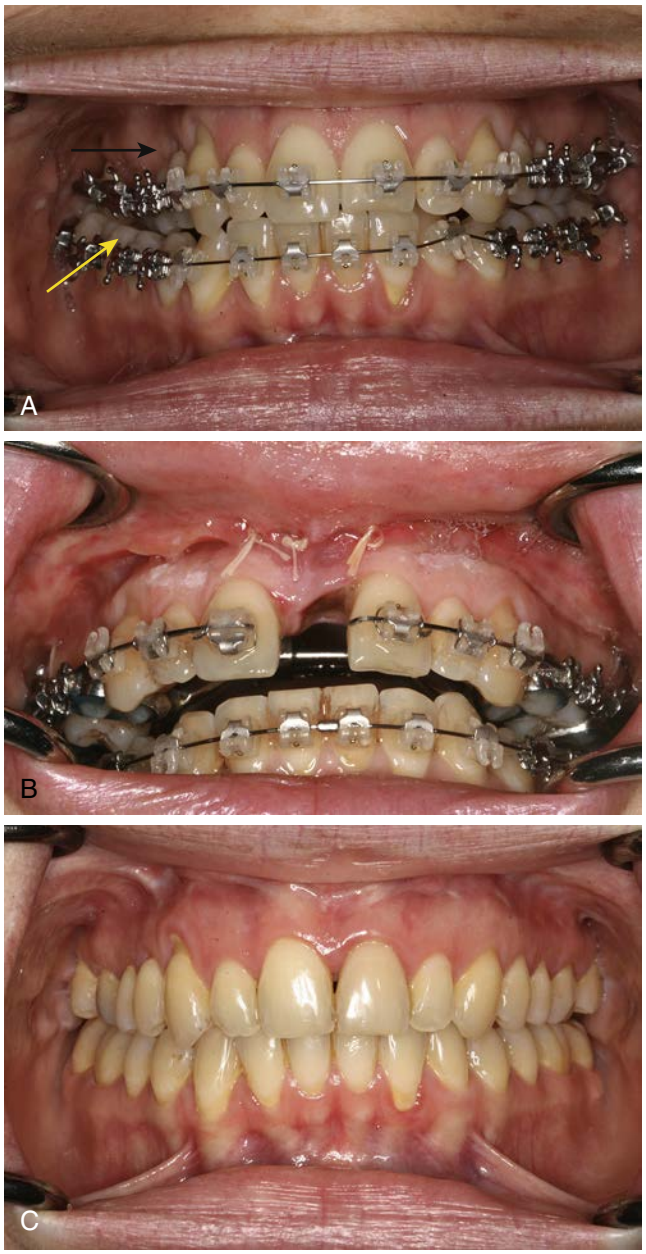

• **Figure 43-44** **A**, Patient with crossbite and multiple recessions buccally *(arrow)*, a contraindication for any conservative orthodontic expansion. **B**, Expansion after surgically assisted rapid palatal expansion was executed too quickly (0.5 mm per day), resulting in an exposure of alveolar bone. **C**, Same patient at the end of orthodontic treatment. Orthodontic movement of incisors and the attached gingiva may improve and create a papilla. A minor loss of papilla presenting in a black triangle will remain, however.

of soft tissue laceration. The risk of nasal bleeding is minor because in SARPE, only the anterior aspect of the lateral wall of the nose and the septum is osteotomized up to 1.5 cm. This is done to prevent broadening of the base of the nose as well as an asymmetric shift of the septum.[68]

Laceration of the Palatal Mucosa

When hyrax or Hass appliances are used (Figure 43-45, *A*), they are already put in place before the SARPE, and

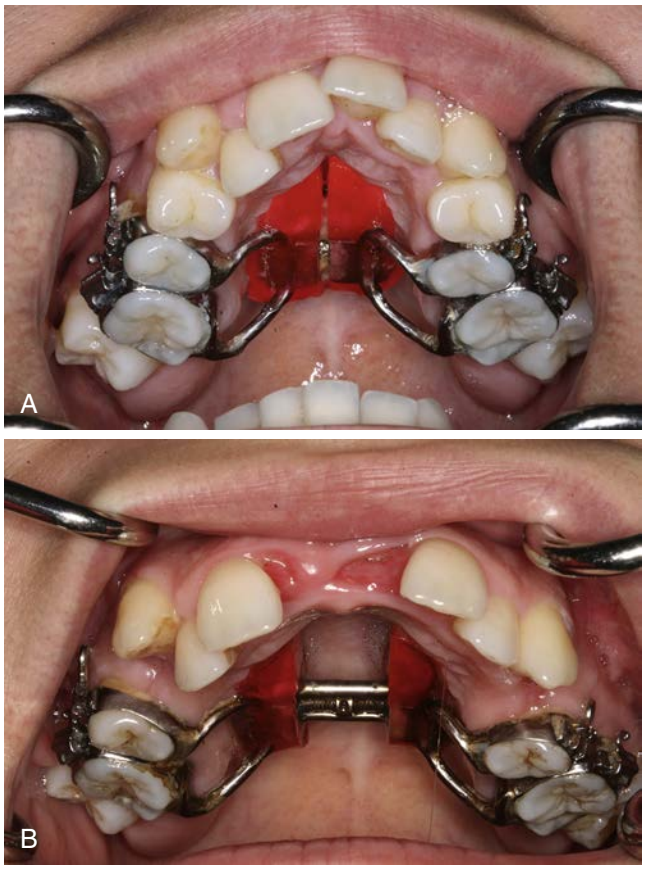

• **Figure 43-45** **A**, Patient with transversal discrepancy with Haas appliance in situ. **B**, Tooth-borne anchorage combined with the palatal shields and a total release in performing a modified Le Fort I osteotomy, including a dissection of the pterygomaxillary junction, allows a symmetric, parallel expansion.

the patient is intubated orally. To minimize the tension on the palatal mucosa, two paranasal cuts are performed with the elongated piezo scalpel on the floor of the nose. Under digital palatal control, perforation of the mucosa can be avoided. Subperiosteal, interdental separation is performed using a piezotome, as well as in the area of attached gingiva; transmucosal perforation with a Lindemann burr is a good choice. In that way a path of the desired fracture line can be created when force is administered.

Other techniques, such as using a bone-borne distractor (Figure 43-46), may require a palatal incision for anchoring the device, which is tolerated as well. Even mucosal midline incisions[67] to perform paranasal palatinal bone cuts are feasible. Risk of infection or wound-healing problems such as an oronasal fistula exist but are rare. Latency up to 5 days before starting distraction should be considered. A distraction rate of not more than 0.25 mm per day should be achieved.

Dental Injuries

Treating the sensibility of the incisors is routine before the SARPE, and if they react negatively, an endodontic treatment must be done. While performing the median medial osteotomy, root shaving of the central incisors or substantial

injury to the alveolar socket can occur[69] (Figure 43-47, *A,B*). If there is severe crowding of the incisors with extreme proximity of the roots, the distraction design should be changed to two osteotomies, between the canine and the second incisor on both sides, if there is more space, or the orthodontist should be asked for root tipping before the surgical procedure.

When the two halves of the maxilla are mobilized and expansion started intraoperatively, some enamel matrix derivative can be injected prophylactically under the expanded papilla between the incisors, to protect denuded root surface.[70]



• **Figure 43-46** Bone-borne distractor fixated via a palatine incision.

Postoperative

Late Bleeding

A release of the nasal septum and the lateral wall of the nose, to prevent broadening of the nose and a deviation of the septum during distraction, may increase the risk of postoperative nasal bleeding. Therefore, staying within a range of 1.5 cm anteroposterior separation is suggested. If epistaxis occurs, it can be easily treated by nasal packing. A higher risk of postoperative bleeding exists in cases where pterygomaxillary dissection and separation have

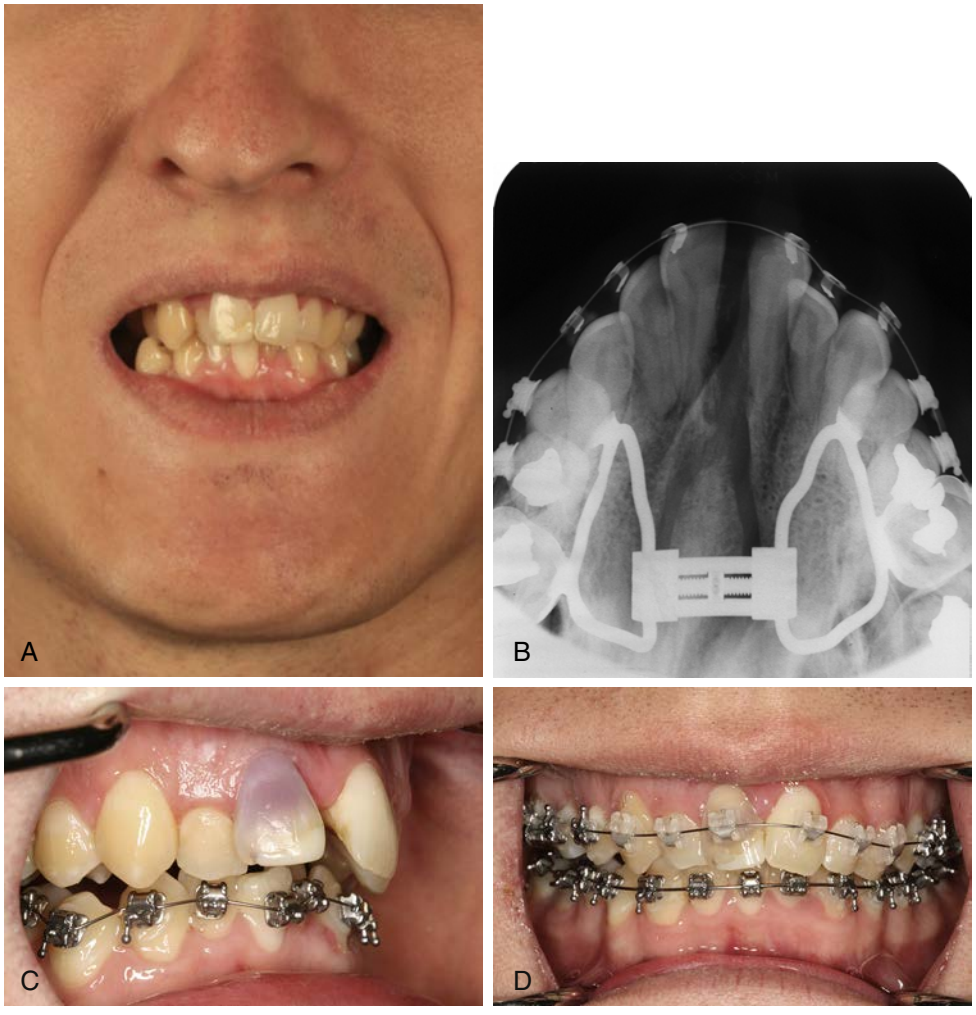

• **Figure 43-47** A, Patient with severe dental crowding and transversal discrepancy. **B**, Injury of the alveolar socket of the right incisor when performing the interdental osteotomy. **C**, Postoperative discoloration of right incisor. The patient had no symptoms, and the tooth was kept under observation. **D**, Three months postoperatively the discoloration had improved, sensitivity was still questionable, but x-ray was without findings. Further observation was the treatment of choice.

been done, and this requires reopening of the operation site.

Periodontal and Dental Problems

There is a high risk of necrosis of the interdental papilla between the upper incisors because of mobilization and tension. In general the distraction is begun intraoperatively, and then there is a latency period of approximately 4 days. The amount of distraction must be strictly kept to 0.25 mm per day or gapping between root surface and gingiva and necrosis of the exposed alveolar socket may occur. Recovery of the gingival tissue can be followed by the appearance of immature attached gingival tissue medial to the central incisors (see Figure 43-45, *B*). If distraction is done too fast and too aggressively, periodontal recession (Figure 43-48) can occur. Orthodontically achieved alignment of the front teeth may improve the esthetics later on (see Figure 43-44, *B,C*). If the recession is combined with an interdental bone loss (Miller class III), it can only be treated with a free full-thickness gingiva graft with an esthetically compromised outcome. Hypersensitivity as well as discoloration of incisors is observed (see Figure 43-47, *C*). Patience and observation are recommended. Without any clinical symptoms of inflammation or pain, root canal treatment should be postponed (see Figure 43-47, *D*), but close radiologic follow-up is necessary. Often root resorption of the incisors can be observed when closing the gap orthodontically. This was documented in 28.6% in the paper published by Verlinden and colleagues.[69]

If distraction is achieved by using a tooth-borne distractor, compression on the periodontal ligament may lead to resorption of the roots and buccal cortical bone of the anchor teeth.[71] Therefore controlled mobilization of the maxillary halves is essential to minimize the resistance.

Infection

Ulcerations and necrosis of the palatal mucosa can also be seen in combination with permucosal fixation of distractors[72] that may lead to loosening of the device and earlier removal. The patient is advised to clean the teeth and brush the distractor meticulously to prevent plaque retention. Otherwise gingivitis and mucositis are inevitable (Figure 43-49). A Haas-type expander with acrylic palatal flanges may cause some pressure-derived irritation of the mucosa. During distraction, an acute sinusitis maxillaris can occur as well. Therefore antibiotic prophylaxis should be applied during the active period until retention time.

Unfavorable Movement of Segments

Patients must be informed that asymmetric movement of the maxillary halves may happen, resulting in a loss of midline. If no further Le Fort I osteotomy is planned, another intervention with correction of symmetry is necessary. To avoid this complication, accurate mobilization of the locus of resistance must be performed and controlled intraoperatively. If the pterygomaxillary junction is not dissected, more distraction will be achieved in the canine-premolar area, in a V shape instead of parallel widening (Figure 43-50). The patient should not experience pain or pressure transmitted to the posterior orbit during distraction. Otherwise mobilization is insufficient. Precise identification of the width deficiency is mandatory. Distraction must be started



• **Figure 43-48** **A**, Expansion after surgically assisted rapid palatal expansion was executed too aggressively, resulting in an exposure of alveolar bone and a periodontal pocket. **B**, Partial restoration of the papilla by orthodontic movement of incisors, resulting in a recession.



• **Figure 43-49** Severe plaque and tartar retention on a bone-borne (Rotterdam) distractor in a patient who was not taking dental hygiene seriously.



• **Figure 43-50** **A**, Circular crossbite in a patient with transversal deficiency. **B**, Patient during distraction with a bone-borne distractor positioned in the premolar area. Expansion occurs in a V-shaped manner, with less expansion in the second molar area. The pterygomaxillary junction was not released in this case.

in the operating room, and in general minor widening (up to 1.5 mm) is preferable at the start. It is advisable to fill this gap with collected crushed bone mixed with enamel matrix protein.

If a palatal torus exists, this can be an obstacle in palatal expansion and needs to be removed before performing a SARPE.

Dislocation and widening of the base of the nose can be prevented by osteotomizing the nasal septum and the piriform rim and lateral nasal wall up to 1.5 cm. In cases without significant nasal stenosis, an alar cinch suture with nonresorbable material is advocated. If the design of the horizontal maxillary cut is done declining to the occlusal plane (ramped cut), the result will be a downward movement in the molar area while expanding (Figure 43-51). This will end with worsening or production of an open bite. To prevent such an adverse result, a wedge of bone in the zygomatic buttress area should be excised.[68]

Relapse

In maxillary transverse expansion, the number one complication is relapse. This is due to the poor quality and amount of bone in the midpalatal osteotomy site. It takes 6 to 12 months to achieve bony continuity; often it remains fibrous, as can be found after performing a Le Fort I osteotomy in a second step. Therefore a long-term retention up to 6 to 12 months is critical. Chamberland and Profitt[73] observed 57% relapse within the first 9 months and 43% in the following 6 months. Similar to other reports, the average expansion across the first molars was 7.6 ± 1.57 mm. Maxillary expansion with the SARME procedure is thought to be more stable than segmented Le Fort I osteotomy, but there are no clear data to support this contention. Average relapse rates in SARPE vary considerably among publications, from 5% to 25% and average 10% in the first maxillary molar.[67,74] The development of a diastema indicates that the hemimaxillae are separated and that it is not only a dental tipping. Symmetric, parallel expansion also depends on the type of distractor, bone borne or tooth borne, and if so, how and on which teeth the force is anchored (see Figure 43-45, *B*). In general, expansion is greater in the anterior than in the posterior in SARPE, correlating to the expected relapse.[75] There are multiple studies on stability after SARPE, but the data are inconsistent (age of patients, design of surgery and distraction, amount and where expansion was performed, distraction rates, points of measurements, length, and method of retention are difficult to compare).[72,76,77] Therefore it is very difficult to give a unique solution leading to success.

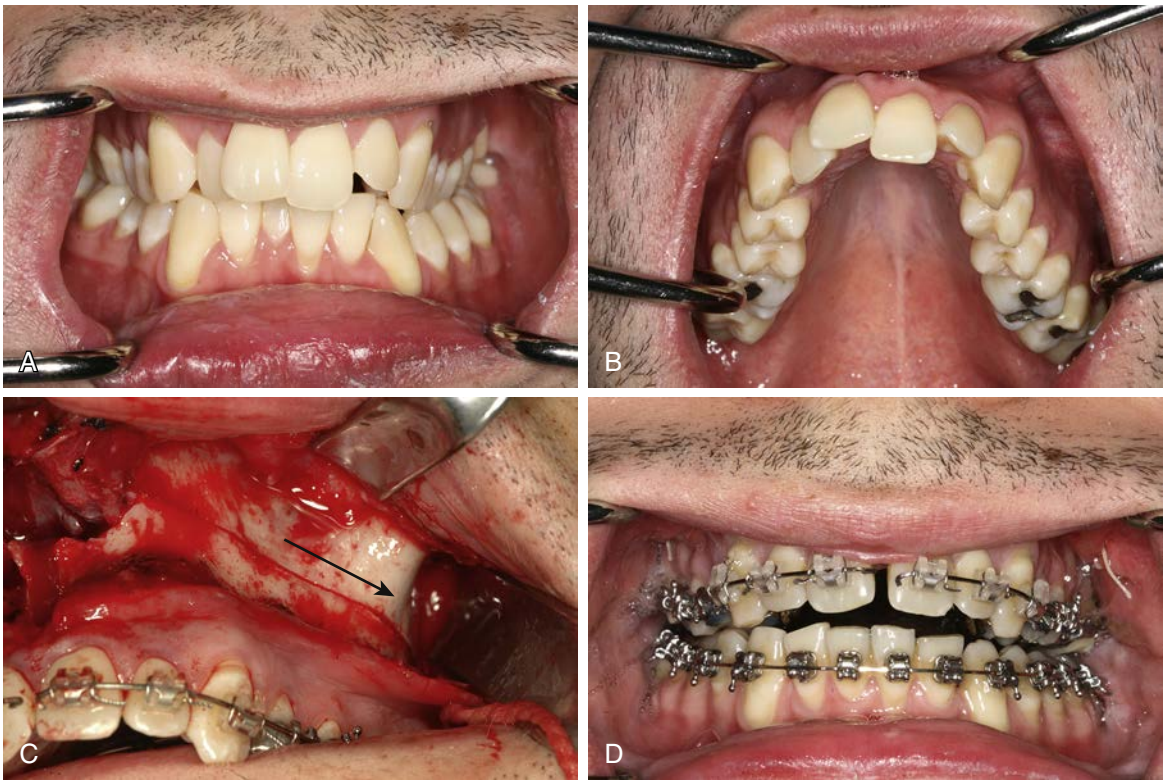

• **Figure 43-51** **A**, Patient with class II deformity and maxillary transversal deficiency. **B**, Collapse of dental arch in patient in **A**. **C**, A surgically assisted rapid palatal expansion is planned, and a modified Le Fort I osteotomy performed, but the osteotomy line in the anterior wall of the maxilla is cut in a ramplike way *(arrow)*. **D**, During expansion, a posterior movement of the segments is observed, with a front opening of the bite.

References

1. Panula K, Finne K, Oikarinen K: Incidence of complications and problems related to orthognathic surgery: a review of 655 patients, *J Oral Maxillofac Surg* 59:1128–1136, 2001.
2. Kramer FJ, Baethge C, Swennen G, et al.: Intra- and perioperative complications of the Le Fort I osteotomy: a prospective evaluation of 1000 patients, *J Craniofac Surg* 15:971–977, 2004.
3. Acebal-Bianco F, Vuylsteke PL, Mommaerts MY, et al.: Perioperative complications in corrective facial orthopaedic surgery: a 5-year retrospective study, *J Oral Maxillofac Surg* 58:754–760, 2000.
4. Vulink NCC, Rosenberg A, Plooij JM, et al.: Body dysmorphic disorder screening in maxillofacial outpatients presenting for orthognathic surgery, *Int J Oral Maxillofac Surg* 37:985–991, 2008.
5. Nath A, Pogrel MA: Preoperative autologous blood donation for oral and maxillofacial surgery: an analysis of 913 patients, *J Oral Maxillofac Surg* 63:347–349, 2005.
6. Posnick JC: Blood replacement practices for complex orthognathic surgery: a single surgeon½s experience, *J Oral Maxillofac Surg* 68:54–59, 2010.
7. Dhariwal DK, Gibbons AJ, Kittur MA, et al.: Blood transfusion requirements in bimaxillary osteotomies, *Br J Oral Maxillofac Surg* 42:231–235, 2004.
8. Kessler P, Hegewald J, Adler W, et al.: Is there a need for autologous blood donation in orthognathic surgery? *Plast Reconstr Surg* 117:571–576, 2006.
9. Böttger S, Streckbein P, Hartmann B, et al.: Retrospective analysis of autologous blood use in bimaxillary repositioning osteotomy surgery: a quality improvement study, *Transfusion* 48:1747–1753, 2009.
10. Lanigan DT, Hey JH, West RA: Major Vascular complications of orthognathic surgery: hemorrhage associated with Le Fort I osteotomies, *J Oral Maxillofac Surg* 48:561–573, 1990.
11. Cheung LK, Fung SD, Li T, Samman N: Posterior maxillary anatomy: implications for Le Fort I osteotomy, *Int J Oral Maxillofac Surg* 27:346–351, 1998.
12. Turvey AT, Fonseca RJ: The anatomy of the internal maxillary artery in the pterygopalatine fossa: its relationship to maxillary surgery, *J Oral Surg* 38:92–95, 1980.
13. Bell WH, Fonseca RJ, Kennedy JW: Bone healing and revascularization after total maxillary osteotomy, *J Oral Surg* 33:253–260, 1975.
14. Nelson RL, Path MG, Ogle RG, et al.: Quantitation of blood flow after anterior maxillary osteotomy, *J Oral Surg* 36:106–111, 1978.
15. Obwegeser HL: The Le Fort I-type mobilization procedure. In *Mandibular growth anomalies*, New York, 2001, Springer, pp 385–415.
16. You ZH, Bell WH, Finn RA: Location of the nasolacrimal canal in relation to the high Le Fort I osteotomy, *J Oral Maxillofac Surg* 50:1075–1080, 1992.
17. Jang SY, Kim MK, Choi SM: Nasolacrimal duct obstruction after maxillary orthognathic surgery, *J Oral Maxillofac Surg* 71:1085–1098, 2013.

18. Humber CC, Lanigan DT, Hohn FI: Retrograde hemorrhage (hemolacria) from the lacrimal puncta after a Le Fort I osteotomy: a report of 2 cases and a review of the literature, *J Oral Maxillofac Surg* 69:520–527, 2011.
19. Bell WH: Revascularisation and bone healing after anterior maxillary osteotomy: a study using adult rhesus monkeys, *J Oral Surg* 27:249–255, 1969.
20. Demas PN, Sotereanos GC: Incidence of nasolacrimal injury and turbinectomy-associated atrophic rhinitis with Le Fort I osteotomies, *J Craniomaxillofac Surg* 17:116–118, 1989.
21. Walker DA, Turvey TA, Warren DW: Alterations in nasal respiration and nasal airway size following superior repositioning of the maxilla, *J Oral Maxillofac Surg* 46:276–281, 1988.
22. Landes C, Ballon A: Skeletal stability in bimaxillary orthognathic surgery: P(L/DL)LA-resorbable versus titanium osteofixation, *Plast Reconstr Surg* 118:703–721, 2006.
23. Norholt SE, Pedersen TK, Jensen J: Le Fort I miniplate osteosynthesis: a randomized, prospective study comparing resorbable PLLA/PGA with titanium, *Int J Maxillofac Surg* 33:245–252, 2004.
24. Proffit WR, Turvey TA, Phillips C: Orthognathic surgery: a hierarchy of stability, *Int J Adult Orthod Surg* 11:191–204, 2006.
25. Baker DL, Stoelinga PJW, Blijdorp PA, et al.: Long-term stability after inferior maxillary repositioning by miniplate fixation, *Int J Oral Maxillofac Surg* 21:320–326, 1992.
26. Avelar RL, Goelzer JG, Becker OE, et al.: Embolization of pseudoaneurysm of the internal maxillary artery after orthognathic surgery, *J Craniofac Surg* 21:1764–1768, 2012.
27. Hacein-Bey L, Blazun JM, Jackson RF: Carotid artery pseudoaneurysm after orthognathic surgery causing lower cranial nerve palsies: endovascular repair, *J Oral Maxillofac Surg* 71:1948–1955, 2013.
28. Dodson TB, Neuenschwander MC, Bays RA: Intraoperative assessment of maxillary perfusion during Le Fort I osteotomy, *J Oral Maxillofac Surg* 52:827–831, 1994.
29. Lanigan DT, Hey JH, West RA: Aseptic necrosis following maxillary osteotomies: report of 36 cases, *J Oral Maxillofac Surg* 48:142–156, 1990.
30. Lo LJ, Hung KF, Chen YR: Blindness as a complication of Le Fort I osteotomy for maxillary distraction, *Plast Reconstr Surg* 109:688–698, 2002.
31. Lanigan DT, Romanchuk K, Olson CK: Ophthalmic complications associated with orthognathic surgery, *J Oral Maxillofac Surg* 51:480–494, 1993.
32. Spaey YJE, Bettens RMA, Mommaerts MY: A prospective study on infectious complications in orthognathic surgery, *J Craniomaxillofac Surg* 33:24–29, 2005.
33. Danda AK, Wahab A, Narayanan V: Single dose versus single-day antibiotic prophylaxis for orthognathic surgery: a prospective, randomized, double-blind clinical study, *J Oral Maxillofac Surg* 68:344–346, 2010.
34. Danda AK, Ravi P: Effectiveness of postoperative antibiotics in orthognathic surgery: a meta-analysis, *J Oral Maxillofac Surg* 69:2650–2656, 2011.
35. Tan SK, Lo J, Zwahlen RA: Perioperative antibiotic prophylaxis in orthognathic surgery: a systematic review and meta-analysis of clinical trials, *Oral Surg Oral Med Oral Pathol Oral Radiol Endod* 112:19–27, 2011.
36. Tan SK, Lo J, Zwahlen RA: Are postoperative intravenous antibiotics necessary after bimaxillary orthognathic surgery? A prospective, randomized, double blind, placebo-controlled clinical trial, *Int J Oral Maxillofac Surg* 40:1363–1368, 2011.
37. Jansisyanont P, Sessirisombat S, Sastravaha P: Antibiotic prophylaxis for orthognathic surgery: a prospective, comparative, randomized study between amoxicillin-clavulanic acid and penicillin, *J Med Assoc Thai* 91:1726–1731, 2008.
38. Pereira-Filho VA, Gabrielli MFR, et al.: Incidence of maxillary sinusitis following Le Fort I osteotomy: clinical, radiographic, and endoscopic study, *J Oral Maxillofac Surg* 69:346–351, 2011.
39. Dan AE, Thygesen TH, Pinholt EM: Corticosteroid administration in oral and orthognathic surgery, *J Oral Maxillofac Surg* 68:2207–2220, 2010.
40. Mommaerts MY, Lippens F, Abeloos JV, et al.: Nasal profile changes after maxillary impaction and advancement surgery, *J Oral Maxillofac Surg* 58:470–475, 2000.
41. Reyneke JP, Evans WG: Surgical manipulation of the occlusal plane, *Int J Adult Orthod Orthognath Surg* 5:99–109, 1990.
42. Chow J, Hägg U, Tideman H: The stability of segmentalized Le Fort I osteotomies with miniplate fixation in patients with maxillary hypoplasia, *J Oral Maxillofac Surg* 53:1407–1412, 1995.
43. Turvey TA, Bell RB, Tejera TJ, et al.: The use of self-reinforced biodegradable bone plates and screws in orthognathic surgery, *J Oral Maxillofac Surg* 60:59–65, 2002.
44. Posnick JC, Wallace J: Complex orthognathic surgery: assessment of patient satisfaction, *J Oral Maxillofac Surg* 66:934–942, 2008.
45. Oland J, Jensen J, Elklit A, et al.: Motives for surgical-orthodontic treatment and effect of treatment on psychosocial well being and satisfaction: a prospective study of 118 patients, *J Oral Maxillofac Surg* 69:104–113, 2011.
46. O'Ryan FS, Barnard M, Cunningham SJ: What are orthognathic patients' expectations of treatment outcome—a qualitative study, *J Oral Maxillofac Surg* 70:2648–2655, 2012.
47. Mommaerts MY, Abeloos JV, De Clercq CA, et al.: The effect of the subspinal Le Fort I-type osteotomy on interalar rim width, *Int J Adult Orthod Orthognath Surg* 12:95–100, 1997.
48. O'Ryan FS, Schendel S: Nasal anatomy and maxillary surgery. II. Unfavorable nasolabial esthetics following the Le Fort I osteotomy, *Int J Adult Orthognath Surg* 2:75–84, 1989.
49. Muradin MS, Rosenberg A, van der Bilt A, et al.: The effect of alar cinch sutures and V-Y closure on soft tissue dynamics after Le Fort I intrusion osteotomies, *J Craniomaxillofac Surg* 37:334–340, 2009.
50. Suh YJ, Nahm DS, Choi JY, et al.: Differential diagnosis for inappropriate upper incisal display during posed smile: contribution of soft tissue and underlying hard tissue, *J Craniofac Surg* 20:2006–2012, 2009.
51. Ueki K, Hashiba Y, Marukawa K, et al.: The evaluation of surgical factors related to recovery period of upper lip hypoaesthesia after Le Fort I osteotomy, *J Craniomaxillofac Surg* 36:390–394, 2008.
52. Rosenberg A, Sailer HF: A prospective study on changes in the sensibility of the oral mucosa and the mucosa of the upper lip after Le Fort I osteotomy, *J Craniomaxillofac Surg* 22:286–293, 1994.
53. Thygesen TH, Bardow A, Norholt SE, et al.: Surgical risk factors and maxillary nerve function after Le Fort I osteotomy, *J Oral Maxillofac Surg* 67:528–536, 2009.
54. Geha H, Nimeskern N, Beziat JL: Patient-controlled analgesia in orthognathic surgery: evaluation of the relationship to anxiety and anxiolytics, *Oral Surg Oral Med Oral Radiol Endod* 108:33–36, 2009.
55. ChM Chen, Lai SST, Chen HS, et al.: Effects of patient- and operation-related factors on postoperative pain after orthognathic surgery, *J Craniofac Surg* 23:724–727, 2012.

56. Rosen H: Segmental osteotomies of the maxilla, *Clin Plast Surg* 16:785–794, 1989.
57. Quejada JG, Kawamura H, Finn RA, et al.: Wound healing associated with segmental total maxillary osteotomy, *J Oral Maxillofac Surg* 44:366, 1986.
58. Kretschmer WB, Baciut G, Baciut M, et al.: Intraop blood loss in bimaxillary orthognathic surgery with multisegmental Le Fort I osteotomies and additional procedures, *Br J Oral Maxillofac Surg* 48:276–280, 2010.
59. Yu CNF, Chow TK, Kwan AS, et al.: Intra-op blood loss and operating time in orthognathic surgery using induced hypotensive general anaesthesia: prospective study, *Hong Kong Med J* 6:307–311, 2000.
60. Landes CA, Stübinger S, Rieger J, et al.: Critical evaluation of piezoelectric osteotomy in orthognathic surgery: operative technique, blood loss, time requirement, nerve and vessel integrity, *J Oral Maxillofac Surg* 66:657–674, 2008.
61. Kahnberg KE, Vannas-Löfqvist L, Zellin G: Complications associated with segmentation of the maxilla: a retrospective radiographic follow up of 82 patients, *Int J Oral Maxillofac Surg* 34:840–845, 2005.
62. Schultes G, Gaggl A, Kärcher H: Periodontal disease associated with interdental osteotomies after orthognathic surgery, *J Oral Maxillofac Surg* 6:414–417, 1998.
63. Pepersack WJ: Tooth vitality after alveolar segmental osteotomy, *J Maxillofac Surg* 1:85–91, 1975.
64. Morgan TA, Fridrich K: Effects of the multiple-piece maxillary osteotomy on the periodontium, *Int J Adult Orthod Orthognath Surg* 16:255–265, 2001.
65. Phillips C, Medland WH, Fields HW, et al.: Stability of surgical maxillary expansion, *Int J Adult Orthod Orthognath Surg* 7:139–146, 1992.
66. Schimming R, Feller KU, Herzmann K, et al.: Surgical and orthodontic rapid palatal expansion in adults using Glassman's technique: retrospective study, *Br J Oral Maxillofac Surg* 38:66–69, 2000.
67. Pogrel MA, Kaban LB, Vargervik K, et al.: Surgically assisted rapid maxillary expansion in adults, *Int J Adult Orthod Orthognath Surg* 7:37–41, 1992.
68. Betts NJ, Vanarsdall RL, Barber HD, et al.: Diagnosis and treatment of transverse maxillary deficiency, *Int J Adult Orthod Orthognath Surg* 10:75–96, 1995.
69. Verlinden CRA, Gooris PG, Becking AG: Complications in transpalatal distraction osteogenesis: a retrospective clinical study, *J Oral Maxillofac Surg* 69:899–905, 2011.
70. Cueva MA, Boltchi FE, Hallmon WW, et al.: A comparative study of coronally advanced flaps with and without the addition of enamel matrix derivative in the treatment of marginal tissue recession, *J Periodontol* 75:949–956, 2004.
71. Ramieri GA, Spada MC, Austa M, et al.: Transverse maxillary distraction with a bone-anchored appliance: dento-periodontal effects and clinical and radiological results, *Int J Oral Maxillofac Surg* 34:357–363, 2005.
72. Verstraaten J, Kuijpers-Jagtman AM, Mommaerts MY, et al.: A systematic review of the effects of bone-borne surgical assisted rapid maxillary expansion, *J Craniomaxillofac Surg* 38:166–174, 2009.
73. Chamberland S, Profitt WR: Short-term and long-term stability of surgically assisted rapid palatal expansion revisited, *Am J Orthod Dentofacial Orthop* 139:815–822, 2011.
74. Bays RA, Greco JM: Surgically assisted rapid palatal expansion: an outpatient technique with long-term stability, *J Oral Maxillofac Surg* 50:110–113, 1992.
75. Anttila A, Finne K, Keski-Nisula K, et al.: Feasibility and long-term stability of surgically assisted rapid maxillary expansion with lateral osteotomy, *Eur J Orthod* 26:391–395, 2004.
76. Laudemann K, Petruchin O, Mack MG, et al.: Evaluation of surgically assisted rapid maxillary expansion with or without pterygomaxillary disjunction based upon preoperative and post-expansion 3D computed tomography data, *J Oral Maxillofac Surg* 13:159–169, 2009.
77. Koudstaal MJ, Poort LJ, Van der Waal KGH, et al.: Surgically assisted rapid maxillary expansion (SARME): a review of literature, *Int J Oral Maxillofac Surg* 34:709–714, 2005.

This page intentionally left blank

Index

A
A-delta nerve fiber, I-225
AAAASF. *See* American Association for Accreditation of Ambulatory Surgery Facilities (AAAASF)
AAAHC. *See* Accreditation Association for Ambulatory Health Care (AAAHC)
AAOMS. *See* American Association of Oral and Maxillofacial Surgeons (AAOMS)
Abbe flap, II-286, II-297–298, II-291f
Ablation, laser for, I-330, I-338f, III-352–355
ABMS. *See* American Board of Medical Specialties (ABMS)
Abrasion, exodontia and, I-301
Abutment
  anterior, decision tree for, I-637f
  cement-retained implant on, I-625f
  cementable, I-626f
  custom, I-630
  direct, I-626f
  gold, I-636
  Locator, I-657–658
  material choices, I-636–639
  posterior, decision tree, I-632f
  projection, in three-dimensional imaging, I-693–696, I-696f
  Snappy, I-626f
  stock, I-630, I-630f, I-634f
  temporary, immediate implant and, I-416–418
  titanium, I-636
  zirconia, I-625f, I-628, I-630f, I-636
Acantholysis, II-564
Acanthosis nigricans, III-668
Accelerated osteogenic orthodontics (AOO), III-247–248
  alternative options, III-261
  case study, III-251b–257b, III-259b–260b
  contraindications, III-250–261
  indications, III-250–261
  mandible, case study, III-251b–252b
  maxilla, case study, III-253b–257b
  orthodontic technique following, III-250
  orthognathic surgery with, III-259–261
  surgical technique, III-248–250
Accountant, for oral and maxillofacial surgical practice, I-63
Accreditation
  benefits, I-99–100
  definition, I-98–99
  outpatient surgery facility, I-96–101
Accreditation Association for Ambulatory Health Care (AAAHC), I-98, I-98t, I-100t
Accudent System, I-656f
ACE Distractor, I-539–540
Acellular dermal matrix, I-558, I-561f, III-611–612
Acetaminophen, I-232
  dosage, I-232t
  for temporomandibular joint disorders, II-870–871
Acetazolamide, II-207
ACGME. *See* American Council for Graduate Medical Education (ACGME)
Acinic cell carcinoma, II-498
Acinus, II-481
Acitretin, II-733
Acne, laser treatment, III-357–358
Acquired immunodeficiency syndrome (AIDS)
  lymphoepithelial cyst associated with, II-485
  osteoradionecrosis associated with, II-591f–594f
  parotid gland affected by, II-488
Acral lentiginous melanoma, II-692t, II-694f
Acrylic resin
  restoration with, I-597–599
  try-in, I-602f
  wraparound prosthesis, I-599f
Actinic keratitis, III-354
Actinic keratosis, II-719, II-723–724
  medical management, II-733–734
  photodynamic therapy for, II-734
  treatment, II-727
Actinobacillus actinomycetemcomitans, I-350
Actinomycin D, II-455
Active range of motion, II-806
Actonel. *See* Risedronate (Actonel)
Acute kidney injury
  preoperative evaluation of, I-158–159
  Rifle criteria for, I-153t
Acute suppurative parotitis, II-485–487
Acute suppurative sialadenitis, II-487
Acyclovir, II-553–556
Ad modum Brånemark technique, I-572–573, I-577, I-578f
ADA. *See* American Dental Association (ADA)
Addiction
  definition, II-952
  ethics and, I-12
  facial pain management and, II-952
  medical professional affected by, I-144
  opioid drug use and, I-228
  sexual, I-145
  treatment, I-145
Adenocarcinoma, polymorphous, II-503f
Adenoid cystic carcinoma, II-493t, II-498, II-500–501, II-759–760
Adenoidectomy, codeine warning, I-254
Adenoma
  monomorphic, II-493t
  pleomorphic, II-492–494, II-493t
Adenomatoid odontogenic tumor (AOT), II-368, II-394–397, III-744–745
Adipocyte, III-434, III-435f
Adipose tissue, III-429, III-434
Adolescent
  craniosynostosis care algorithm, III-677–678
  dentoalveolar injury, II-114
  heart rate, II-249–250
  neurologic abnormalities, III-284
  trauma outcomes, II-245
Adolescent internal condylar resorption, III-224–225
Adrenal insufficiency
  craniomaxillofacial trauma management and, II-3t
  preoperative evaluation of, I-158–159
Adrenergic system, local anesthesia and, I-179
Adrenocorticoid deficiency, I-159t
Adriamycin. *See* Doxorubicin (Adriamycin)
Advanced Beneficiary Notice (ABN), I-91
Advanced Trauma Life Support (ATLS), II-1, II-2b
  for dentoalveolar injury, II-115–116
  for gunshot patient, II-307, II-310–311
  for injured child, II-246
  for mandibular fracture, II-152
  midface fracture diagnosis and, II-212
  pediatric facial trauma evaluation with, II-232
Advil. *See* Ibuprofen (Advil, Motrin)
Aerodigestive tract, III-670–671
Afferent nerve fiber
  neurophysiology, II-942–943
  pain transmission, I-225
Affordable Care Act, I-95
Ageusia, definition, I-355t
Aging
  bone graft healing affected by, I-432
  forehead and brow ptosis in, III-395
  impairment caused by, I-146
  retirement and, I-140–141
Agonist-antagonist drugs, I-226
Agonist drugs, I-226
AHI. *See* Apnea-hypopnea index (AHI)
Airway
  adult, pediatric compared to, I-239–240, I-240f, II-249f
  assessment, II-9–10, I-213–214
  breathing
    circulation, disabilities, exposure (ABCDE), child trauma assessment with, II-246
    circulation (ABC), II-9
  in craniosynostosis care algorithm, III-671–672
  emergency equipment, I-245–247
  injuries affecting, II-11–12, II-11, II-11
  monitoring, I-167
  in nasal fracture, II-187
  obstruction, II-10
  patency, I-213–214
  pediatric, I-239–241, I-248–249, II-249f, II-258–260
  physical examination, II-10–11
  preanesthetic assessment, I-242
  preoperative evaluation, III-282–283
  upper, pediatric, I-239–240
Airway management
  advanced techniques, II-13–14
  in avulsive facial injury, II-282
  in craniomaxillofacial trauma, II-1–2, II-2f
  in craniosynostosis care algorithm, III-671–672
  for maxillofacial gunshot wound patient, II-308–309

This index contains all entries from Volume I, II, and III. Each entry lists the volume number first followed by the page number.
Page numbers followed by b, indicate boxes; f, figures; and t, tables.

Airway management *(Continued)*
in oculoauriculovertebral spectrum, III-692
pediatric, I-238, I-258–260
in pediatric trauma, II-248–249
surgical, II-14
for trauma patient, II-9–15
in Treacher Collins syndrome, III-705
Alar cinch, III-167–168
Alar-columellar relationship, III-370f
Alar width, III-368
Albumin, local anesthetics and, I-178
Alcohol use, oral cancer associated with, II-671
Aldrete scoring system, I-172–173, I-173t
Alendronate sodium (Fosamax), II-508t
Aleve. *See* Naproxen (Naprosyn, Aleve)
Alfentanil, I-197–198, I-199f
Algae, alloplastic implant with, I-440–441
Allele, II-603, II-606–607
Allergy
to dental cement, I-716
to local anesthesia, I-182–183
Allis clamp, III-77f
Allodynia
definition, I-355t, II-946t
neurosensory testing of, I-359
Allogenic, definition, I-437
Allogenic bone, I-439–440
demineralized, I-439
mineralized, I-439–440
Allograft, I-428–429
for burn injury, II-67
demineralized, I-439f
in esthetic contour graft, I-490
mineralized, I-440f
particulate, I-485f–487f, I-494f, I-500b
ridge augmentation and, I-483
stem cells combined with, I-439f
Alloplast
bone graft with, I-430–432
interpositional bone graft, I-527–528
Alloplast entubulation, I-372
Alloplastic, definition, I-437
Alloplastic bone graft, I-430–432, I-483–484
Aloe vera, II-67
Alopecia
in forehead and brow lift, III-425
in rhytidectomy, III-334
Alpha1-acid glycoprotein (AAG), I-178
Alpha-hydroxy acid, for chemical peel, III-443–444
Alprazolam (Xanax)
half-life, I-195t
protein binding, I-195t
for temporomandibular joint disorders, II-874t
Alveolar bone
classification, I-537
deficiency, I-526, I-538, I-538b
examination, in dentoalveolar injury, II-117
fracture, II-123t, II-133–137
healing, after trauma, II-138
injury treatment, II-133–137
Alveolar cleft, III-588, III-624f
Alveolar cleft lip, I-665, I-679–683
Alveolar distraction osteogenesis. *See* Distraction osteogenesis (DO), alveolar
Alveolar nerve, II-147
injury, I-368–369, I-377
bilateral sagittal split osteotomy and, I-378–379
coronectomy and, I-381–382
during exodontia, I-302
outcomes and conclusions, I-382–383
in sagittal split osteotomy, III-301–305
from third molar extraction, I-382–390
Alveolar nerve *(Continued)*
neurofibroma and, II-472
neuroma, I-317f
pediatric, I-259f
Alveolar osteitis, I-283
exodontia and, I-303
third molar extraction and, I-293–294
treatment, I-294
Alveolar process fracture, II-133–135
Alveolar repositioning osteotomy, I-529
Alveolar ridge
anatomy, II-670
augmentation, I-484, I-534
case study, I-500b–501b, I-503b
guidelines, I-538t, I-538b
horizontal, I-538–539
indications, I-537–538
vertical, I-538–539
capillary malformation in, II-538
defect, I-485f–490f, I-491–493, I-539
distraction, I-545f–546f
smile line and, I-588–589
squamous cell carcinoma, II-681–683
Alveolar socket, comminution, II-123t, II-133
Alveolar soft part sarcoma, II-644t, II-645–646, II-663–664
Alveolar split graft, I-528–529
Alveolar width, distraction osteogenesis and, I-529–532
Alveolus
augmentation, III-587
cleft, III-497, III-583
lack of, zygomatic implant for, I-570
reconstruction, III-589–592
three-dimensional image, I-691f
unrepaired, III-609–610
Alzheimer's disease, I-146
AMA. *See* American Medical Association (AMA)
Ameloblastic fibro-odontoma, II-451–453, III-745
Ameloblastic fibrodentinoma (AFD), II-453–454
Ameloblastic fibroma, II-449–451, III-745
Ameloblastic fibrosarcoma, II-454–455
Ameloblastic sarcoma, II-454–455
Ameloblastoma, II-401–424, III-744
anaplastic, II-421f
basal cell carcinoma compared to, II-401
clear cell, II-425, II-429
clinical forms, II-404–422
clinicopathologic considerations, II-402
cytologic malignant, II-420–422
dentigerous cyst and, II-345–347
extraosseous, surgical management, II-423–424
growth mechanism, II-404–422
intraosseous unicystic, II-423
magnetic resonance image of, III-742f
malignant, II-401, II-420–422
multicystic, II-404, II-407–409, II-410f–414f
pediatric, III-770f
peripheral, II-409–420, II-417f–418f, II-423–424
solid, II-404, II-407–409, II-415f–416f
surgical management, II-422–424
two-stage treatment, II-361
types of, II-402
unicystic, II-361, II-363f, II-404–407, II-408f–409f, III-744
American Academy of Pediatric Dentistry (AAPD), I-258
American Academy of Pediatrics (AAP), I-258
American Association for Accreditation of Ambulatory Surgery Facilities (AAAASF), I-98, I-98t, I-100t
American Association of Oral and Maxillofacial Surgeons (AAOMS), I-10
American Board of Medical Specialties (ABMS), I-1
American Cleft Palate-Craniofacial Association, III-491–492
American Council for Graduate Medical Education (ACGME), I-4–5
American Dental Association (ADA)
Code of Ethics, I-10
Principles of Ethics, I-9
recommendations on pediatric visits from, I-258
American Heart Association, I-181–182
American Joint Committee on Cancer (AJCC), II-693, II-698–699, II-702t, II-725–726
American Medical Association (AMA), I-9
American Society of Anesthesiologists (ASA), I-181–182, I-243
Amides, local anesthetics and, I-176–177
Amifostine, II-749, II-761
Amine, terminal, local anesthetics and, I-177
Aminoglycoside drugs, I-149t
Amitriptyline (Elavil)
for facial pain, II-955t
for fibromyalgia, II-970
for neuropathic pain, I-364
for temporomandibular joint disorders, II-873t
Amnesia, benzodiazepines and, I-192, I-194
Amoxicillin
for autogenous bone graft prophylaxis, I-451
for bite wound, II-62–63
AMPLE history (allergies, medications, pregnancy/past illnesses, last meal, events), II-10
Analgesia
cannabinoid, I-233
definition, I-211, II-946t
inpatient, I-234–235
ketamine for, I-206
nitrous oxide for, I-207
non-opioid, I-228–232, I-232t
nonsteroidal antiinflammatory drugs, I-228–230
patient-controlled, I-234–235
Analgesic drugs
compounded, I-363–364
for nerve injury, I-363–364
opioid, I-198–199, I-226–228
systemic, I-364–365
for temporomandibular joint disorders, II-870–871
Anaphylaxis
drugs associated with, I-252t
pediatric anesthesia and, I-252
Anatomic abutment, I-627f, I-634
Anchor
history of implants as, I-311
implant, complications, I-323
implant types as, I-313–316
miniplate, I-313–314
Anchor unit, I-312, I-312
Anchorage
direct, I-319, I-312, I-312
implant for, I-213
indirect, I-319, I-319, I-312
miniplate, I-314
miniscrew implant, I-314
orthodontic, I-312
Andreasen classification of dentoalveolar injury, II-120
Andrew's analysis, III-25
Anemia
evaluation, I-160f
preoperative evaluation, I-159
wound healing affected by, II-259

Anesthesia, II-9–15
ambulatory, I-191–210
of auricle, III-450f
BIS monitoring, I-171–172
choice of agents, I-218–219
combined infusions, I-219–220
complications, I-222–223
concepts, I-211–224
definition, I-355t
delivery techniques, I-218–219
depth of, I-171–172, I-217–218
drug pharmacology, I-191–210
electrocardiogram during, I-167
electronic dental, I-187–188
equipment, in oral and maxillofacial surgery, I-49
fluid administration, I-216–217
for forehead and brow lift, III-408
general, I-46–54, I-164–165
for nasal fracture reduction, II-179–180
for trauma patient, II-12–13
intraosseous, I-187
for Le Fort I osteotomy, III-161–162
levels, I-165t
for liposuction, III-431
local, I-176–190, I-232–233
chemistry of, I-176
complications of, I-182–184
drug-drug interaction in, I-181
duration of action of, I-178
duration of blockade of, I-178
efficacy, I-178
future of, I-187–188
history, I-176
for nasal fracture reduction, II-179–181
nerve injury caused by, I-376–377
pregnancy and, I-186
for rhinoplasty, III-377
systemic complications from, I-184–185
management, II-9–15
mandibular nerve block, II-950
monitoring, I-164, I-217–218
nerve block, I-178
outpatient, I-96
pediatric, I-238–256, I-258
alarms, I-245
complications, I-251–253
equipment, I-245–248
monitoring, I-244–245
preanesthetic assessment, I-242–244
recovery and discharge, I-253–254
room preparation, I-245–248
techniques, I-251
worksheet, I-246f
perioperative complications, I-251–253
pharmacology of drugs for, I-191–210
preoperative assessment for, I-212
pulse oximeter used during, I-168
recovery, I-221–222
for rhinoplasty, III-377
for rhytidectomy, III-329
risk management and, I-78, I-81–82
strategies, II-12–15
techniques, I-211–224
for trauma patient, II-9–15
tumescent, III-430
Anesthesia dolorosa, I-361
Anesthesia information system, I-172
Anesthesia nurse
position, I-50
role, I-53–54
Anesthesia record, I-172
Anesthetic drugs, local, I-176–190, I-232–233
allergy to, I-182–183
amide-linked, I-186
chemistry, I-176
Anesthetic drugs, local *(Continued)*
complications, I-182–184
drug-drug interaction, I-181
duration of action, I-178
duration of blockade, I-178
efficacy, I-178
ester-linked, I-185–186
extended release formulations for, I-187
for facial pain, II-956
future, I-187–188
history, I-176
injectable, I-179t
lipid solubility of, I-177t
long-acting, I-178
nerve injury associated with, I-183t, I-376–377
nerve injury caused by, II-81
onset time, I-178t
pediatric, I-258
pregnancy and, I-186
prolonged sensory alteration and, I-183–184
speed of onset, I-177
structure and properties, I-176–177
systemic complications, I-184–185
Anesthetic equipment, I-212–213
Aneurysmal bone cyst, II-467–468, II-751, III-752f–753f, III-852
Angiofibroma, juvenile nasopharyngeal, III-751, III-754f
Angiogenesis
bone healing and, I-427
in cancer progression, II-600
tumor progression, II-617–618
tumor-stroma interaction, II-618f
Angiography, of craniomaxillofacial pathologies, III-739
Angiosarcoma, II-644t, II-658–659
Angle, Edward H., III-44, III-1, III-4–5
Angle's classification, II-874
Anhydrase inhibitor drugs, II-207
Animal bite, II-61–67
Ankyloglossia, prominent lingual frenum as cause of, I-271
Ankylosing spondylitis, II-842
Ankylosis
bony, joint replacement for, II-931
condylar fracture associated with, II-270
Murphy's case series, II-767t
in pediatric patient, II-130–131
temporomandibular joint, II-137f–141f, III-209f–210f, III-932f
treatment history, II-767
Ann Arbor staging system, for lymphoma, II-708–709, II-714b
Annandale, Thomas, II-764
Anorganic bovine bone (ABB), bone graft with, I-429
Antagonist drugs, I-226
Anterior nasal spine, facial symmetry and, III-96
Anterolateral thigh flap, II-294, II-295f
Antiangiogenic drugs, II-509t
bone remodeling and, II-510
for cancer, II-514–515
drug holiday from, II-515
jaw osteonecrosis associated with, II-510
medication-related osteonecrosis of jaw associated with, II-514
for osteoporosis, II-514–515
Antibiotic drugs
anaphylaxis associated with, I-252t
for autogenous bone graft prophylaxis, I-451
Anticoagulant drugs
management, I-161f
preoperative management, I-161
Anticonvulsant drugs
for facial pain, II-956
for nerve injury, I-364
Antidepressant drugs
drug interaction with, I-181
for facial pain, II-955–956
for neuropathic pain, I-318–319
for temporomandibular joint disorders, II-872–873
Antifungal drugs, II-761
Antihistamine drugs, for temporomandibular joint disorders, II-874t
Antilingular eminence, III-88–89, III-89f
Antiresorptive associated osteonecrosis of the jaw (ARONJ), II-507
Antiresorptive drugs, II-507–508, II-508t
for cancer, II-514–515
medication-related osteonecrosis of jaw associated with, II-514
for osteoporosis, II-514–515
Antiviral drugs, II-556, II-761
Antrum of Highmore, I-509
Anxiety
management, I-234
pediatric, premedication for, I-248
Anxiolysis, benzodiazepines and, I-192–194
Anxiolytic drugs, for temporomandibular joint disorders, II-873
Apert syndrome, III-16, III-639–642, III-668–669, III-672, III-778
Apertognathia, III-172–173
Apexification procedure, II-130
Aphthous stomatitis, II-559–560
Aphthous ulcer, II-559
Apicocoronal anatomy, implant restoration and, I-391–392, I-395
Apicocoronal placement, I-396–397
Apicoectomy, laser, III-350
Apnea-hypopnea index (AHI), III-265–266
Apoptosis
evasion, cancer cell and, II-614–616
process, II-614–615
suppression, II-627–628
Aprotinin, anaphylaxis associated with, I-252t
Arachidonic acid, II-870
Arch bar, II-147, II-155
Arch form, I-173, III-595f
Arch provisional prosthesis, I-605–623
Arcus marginalis, III-397
Army Medical Department (AMEDD), I-24–26
Aromatic ring, I-176
ARONJ. *See* Antiresorptive associated osteonecrosis of the jaw (ARONJ)
Arteriovenous malformation, II-544–547, II-853
Artery(ies)
carotid, III-399
ear, III-448
facial, III-328, III-399
forehead, III-399
frontal sinus, II-230–231
maxillary, I-162f, III-510
nasal, II-176, III-365f
palatine, III-165
superficial temporal, III-399
Arthralgia, definition, II-946t
Arthritis
classification, II-836
connective tissue disease associated with, II-848
histopathogenesis, II-833
infectious, II-843–847
inflammatory, II-838–843
juvenile idiopathic, II-131, III-840–841
Lyme disease, II-846–847
metabolic, II-847–848
psoriatic, II-841–842
reactive, II-225, III-561–562
septic, II-843–847
temporomandibular joint, II-832–833, II-835–848

Arthritis *(Continued)*
temporomandibular joint replacement, II-929–931
traumatic, II-836
Arthrocentesis, temporomandibular joint, II-774, II-883–891
contraindications, II-884
double puncture, II-885–886
outcomes, II-888–889
single puncture, II-886
technique, II-884–888
Arthroplasty
arthroscopic, II-897
history, II-766–767
laser, III-358–359
Arthroscopy
arthroplasty, II-897
capsular release, II-897
complications, II-897–900
disc repositioning, II-897
equipment, II-894
inferolateral puncture technique, II-894
laser, III-358–359
lysis and lavage, II-896–897
operative, II-896–901
postoperative care, II-901
temporomandibular joint, II-774, II-892–903
anatomic considerations, II-892–893
complications, II-897–900
diagnostic uses, II-893
postoperative care, II-901
Arthrotomy
complications, II-918
in temporomandibular joint internal derangement surgery, II-910–918
Articaine (Septocaine), I-186
chemical neurotoxicity associated with, I-376
concentration, I-177t
duration of, I-179t
local anesthesia with, I-232–233
nerve injury associated with, I-183t
onset time, I-178t
Articular disc, II-778–779
displacement, II-769, II-792t–793t, II-797–798
illustration of, II-794f
osteoarthritis, II-837–838
in temporomandibular joint, II-815
in temporomandibular joint dysfunction, II-884
in temporomandibular joint internal derangement, II-910
Articular eminence, II-778
Articular fossa, II-778
Articulation
craniomandibular, II-777–778
in model surgery, III-49
temporomandibular joint, II-778, II-794
Articulator, in model surgery, III-50
Asenio, Dr. Oscar, III-516
Asenio technique for rotation and advancement flap, III-517–518, III-519f
Ashhurst, A.P.C, II-766
Aspiration
biopsy, II-331
for odontogenic tumor biopsy, II-393
in pediatric patient, I-253
prevention, in trauma patient, II-12
pulmonary, I-243t
Aspirin, I-232
dosage, I-232t
management, I-149t
preoperative management, I-161
rhytidectomy complications associated with, III-332
for temporomandibular joint disorders, II-870, II-871t
Assistant's stool, I-48
Associateship, I-41, I-44
Association of Medical Colleges (AAMC), I-4
Asthma
classification, I-153t
orthognathic surgery and, III-282
pediatric anesthesia and, I-244
preoperative evaluation and, I-152
severity classification, III-282t
vasoconstrictor drugs and, I-182b
Ativan. *See* Lorazepam (Ativan)
ATLS. *See* Advanced Trauma Life Support (ATLS)
Atracurium, anaphylaxis associated with, I-252t
Attachment
ball, I-654
Locator, I-654
Attenuation coefficient, in computed tomography, II-820–821
Attorney, for oral and maxillofacial surgical practice, I-63
Atypical facial pain, II-948
Atypical odontalgia, II-948–949
Auditory canal, II-96
Auricle
anesthesia, III-450f
cartilage, III-447–448
embryology, III-446–447
Auricular cartilage, III-447–448
Auriculocephalic angle, III-447f
Auscultation
chest, II-9
temporomandibular joint, II-808–809
in trauma patient, II-9
Autogenous graft
free, I-556
for temporomandibular joint surgery, II-772
Autograft, particulate bone for, I-452f
Autograft entubulation, I-371–372
Autoimmune disease, temporomandibular joint disorders and, III-225–226
Autologous, definition, I-437
Autologous bone, I-438
in sinus graft, I-465
Autologous fat transfer, in forehead and brow lift, III-419
Autonomy, principle of, I-9
Avance nerve graft, I-371
Avastin. *See* Bevacizumab (Avastin)
Aventyl. *See* Nortriptyline (Pamelor, Aventyl)
Avulsion
calcium hydroxide root canal fill, II-131
in dentoalveolar injury, II-124f, II-128–131
Axon, in nerve anatomy, II-77
Axonotmesis
causes of, II-70–71
description of, III-316
exodontia associated with, I-303
Azacitidine, II-625
Azaspirodecanedione, II-874t
Azathioprine, II-562

B

Baclofen (Lioresal), II-872t
Bacteremia, following exodontia, I-303
Bacteria
bone graft infected by, I-434
membrane contaminated with, I-482
parotitis from, II-485–486
peri-implantitis and, I-724
Bag-mask-valve device, I-13, II-245–247
Bag-mask ventilation, II-13, II-249
Ballistic missile
components, II-303
physics, II-305–307
soft tissue injury from, II-306
Ballistics, wound, II-304–305
Band of Büngner, II-77
Banker, for oral and maxillofacial surgical practice, I-63
Bar
attachments for, I-654
CAD-CAM, I-652–653, I-652f, I-658, I-661f
four-implant, I-650f
implants connected with, I-645–647, I-647f
milled, I-648–649, I-652–653
placement of, for overdenture, I-644f
Barbiturate drugs, I-200–203
action, I-201
clinical effects, I-202–203
discovery and development, I-200–201
metabolism, I-203
pharmacokinetics, I-203
side effects, I-203f
structure, I-201
Bardach, Janusz, III-535
Bardach palatoplasty, III-505, III-537, III-538f, III-611
Bariatric surgery, III-268
Barrier membrane, I-462–463
history, I-475
selection, I-480–483
in sinus augmentation, I-513
tent-pole technique, I-488f
Basal cell carcinoma, II-350, II-352–354, II-718–719, II-721f
ameloblastoma compared to, II-401
in basal cell nevus syndrome, II-367f
laser surgery for, I-343
radiation therapy for, II-734
treatment, II-727
types, II-718–719
Basal cell nevus syndrome, II-361–364, II-364t, II-366f–367f, II-718, II-732–733
Basic Life Support (BLS)
for gunshot patient, II-307
for pediatric patient, I-260
Basicranium, III-738
Battle sign, midface fracture associated with, II-216
Bauer retractor, III-88f
Beauty, definition of, III-13
Behavior, disruptive, I-143–146
Behavior guidance, I-272
Behavior therapy, for velopharyngeal dysfunction, III-579–580
Behavioral pain management, I-365
Behçet syndrome, II-560–561
classification, II-561
clinical features, II-560–561
treatment, II-561
Bell, William, III-5
Bell's palsy, II-100–101
Beneficence, principle of, I-9–10
Bennett movement, II-787
Benzocaine, I-185
Benzodiazepine drugs, I-191–197
clinical effects, I-192–195
development, I-191
discovery, I-191
half-life, I-195t
intravenous sedation with, I-220
for masticatory myalgia, II-969
metabolism, I-195–197
muscle relaxant effect, I-194
pharmacokinetics, I-195–197
side effect profile, I-193f
structure and activity, I-191–192
for temporomandibular joint disorders, II-873, II-874t
Benzodiazepine-gamma-aminobutyric acid - chloride ionophore complex, I-192f

Beta (ß) blocker drugs, drug interaction with, I-181
Beta (ß) tricalcium phosphate (ß-TCP), I-440–441
Betamethasone (Celestone), III-287t
  for facial pain, II-955t, II-957
  in orthognathic surgery, III-289
  in temporomandibular joint arthrocentesis, II-887
  for temporomandibular joint disorders, II-871t
Bevacizumab (Avastin), II-509t, II-511
Bicuspid
  supernumerary, I-268f
  transplantation, I-268
Bicycle, pediatric injury and death associated with, II-245
Bifid uvula, III-618–619
Bilateral cleft deformity, III-565
Bilateral coronal suture craniosynostosis, II-660
Bilateral sagittal split osteotomy (BSSO), I-354, III-367
  complications, III-79–80, III-144–145
  history, III-113–114, III-183
  for mandibular asymmetry, III-72b
  nerve injury from, I-378
  relapse after, III-116b, III-777–778
  unfavorable bony split, III-81–82
Billroth, Christian, III-534
Bioactive glass, I-440–441
Biologic, definition of, I-437
Biologic materials, implant with, I-441
Biological width
  immediate implant and, I-412–413
  for multiple implants, I-420–422
Biology, molecular, of cancer, II-599–642
Biomarker, in cancer diagnosis, II-622–624
Biomaterial, definition, I-437
Biomechanics, orthodontic, I-312, I-311–312
Biopsy
  aspiration, II-331
  definition, II-330
  excisional, II-724f
  frozen section, II-330–331
  fusiform, II-724f
  incisional, II-724f
  laser for, III-347
  for lymphoma diagnosis, II-707
  M-plasty, II-724f
  for melanoma diagnosis, II-692–693
  odontogenic myxoma, II-444
  odontogenic tumor, II-393
  punch, II-724
  for sarcoma diagnosis, II-646
  sentinel lymph node, II-697–698, II-730
  shave, II-723–724
  for skin cancer, II-723–725
  techniques, II-330, II-724f
Biphasic calcium phosphate (BCP), I-430–431
Birbeck granule, II-524–525
Bird-face deformity, III-113
BIS. *See* Bispectral index (BIS)
Bispectral analysis, for pediatric anesthesia monitoring, I-245
Bispectral index (BIS), I-217–218
  monitoring, I-171–172
  for pediatric anesthesia monitoring, I-245
Bisphosphonate drugs, II-507
  chemical structure, II-508f
  drug holiday from, II-514–515
  osteonecrosis associated with, I-304, II-507, II-509–511, II-514–515
  for osteoporosis, II-514
Bisphosphonate-related osteonecrosis (BRON), I-304, I-305t
Bite
  animal or human, wound from, II-61–67
  microbiology, II-62b
Bite-jig, III-31–35
Bite plane splint, temporomandibular joint, II-867–868
Bite registration, for model surgery, III-46
Bite wound, II-61–67
  antibiotic therapy, II-62b
  pediatric, II-278–279
Blair, Major Vilray P., I-24, III-113, III-492, III-1, III-4–5
Bleeding
  in forehead and brow lift, III-425
  impacted tooth removal and, I-292
  in orthognathic surgery, III-289
  postsurgical, I-281
  in rhinoplasty, III-383
Bleeding disorders, orthognathic surgery and, III-285
Bleomycin, II-714, II-756t–757t
Blepharoplasty, III-388–394
  brow lift compared to, III-407f, III-413f
  complications, III-393
  definition, III-388
  eyelid and orbital anatomy, III-388–389
  history, III-388
  laser, I-346, III-356
  postoperative care, III-393
  preoperative evaluation, III-389–391
  surgical technique, III-391–393
Blindness, herpetic infection as cause of, II-552
Blog, marketing and, I-104–105
Blood pressure
  errors in monitoring, I-165–166
  monitoring, I-165–166
  pediatric, I-239, II-249–250
Blood supply
  ear, III-448, III-449f
  to eyelid, III-391f
  to maxilla, III-161, III-162f
  to midface, II-214
  nasal, II-176–177, III-364, III-366f
  nasal septum, III-366f
Blood vessel(s)
  anomalies, II-534–549
  forehead, III-399–402
  rhytidectomy evaluation and, III-327–328
Blood volume, in pediatric trauma, II-250
BLS. *See* Basic Life Support (BLS)
Body composition, aging effects on, I-242
Body dysmorphic disorder (BDD), III-326, III-368, III-458
Body temperature, monitoring of, I-170
Bohr, Neils, III-336
Bolton discrepancy, III-196–197
Bone-anchored hearing aid, III-733
Bone density, immediate implant loading and, I-607
Bone flap. *See* Osteoperiosteal flap
Bone graft
  allogenic, I-437, I-439–440, I-440f
  allograft, I-427–429, I-490, I-500b
    ridge augmentation and, I-483
  alloplastic, I-427, I-430–432, I-440–441, I-483–484
  alveolar split, I-528–529
  augmentation procedures for, I-441–443, I-447–448
  autogenous, I-427–428, I-446–474
    advantages, I-446
    antibiotic prophylaxis, I-451
    block, I-461–462
    disadvantages, I-446
    donor sites, I-451–460
    guide bone regeneration and, I-483
Bone graft *(Continued)*
    for midface deficiency, III-602–605
    particulate bone for, I-452f
    patient preparation, I-451
    postoperative care, I-461
    sites for, I-428
  autologous, I-438
  for avulsive facial injury, II-287f
  barrier membrane for, I-462
  biological models, I-696–699
  block, I-428f, I-461–462, I-463f
  bone shaving for, I-448f
  cancellous, I-446–447, I-447f, I-462
  categories of, I-427
  circular block, I-451f, I-454f
  classification materials for, I-437–438
  for cleft lip and palate, I-619, III-679
  for cleft maxilla reconstruction, III-590–591, III-619
  cortical, I-446–447, I-447f, I-462
  corticocancellous, I-458
  in corticotomy surgery, III-248
  digital workflow protocols, I-688–710
  donor sites, I-451–460, I-704–706
  for ectodermal dysplasia, I-674–675
  esthetic contour, I-487–491
  in facial trauma reconstruction, II-284–285
  failure, I-441
  fixation screws, I-461–462
  flap closure, I-450f
  flap coverage, I-461
  for gunshot wound, I-667f
  histology, I-437–445
  iliac block, I-569–570
  iliac crest, I-673–674, II-297
  ilium as donor site, I-458–460
  implant placement, I-468
  implant restoration and, I-394
  interpositional, I-527–528
  in inverted L osteotomy, III-128f–130f
  in Le Fort I osteotomy, III-167
  local, I-451–452
  mandibular ramus as donor site, I-455–457
  mandibular symphysis, I-453–455
  materials for, I-426–436
  for maxilla cleft, III-584
  maxillary tuberosity as site, I-452–453
  for maxillomandibular defect, I-671–672
  for midface cleft reconstruction, III-602–605
  for midface fracture, II-220
  mobility of, I-434
  nerve injury associated with, II-84
  non-vascularized, I-671–672
  for orbital floor repair, II-231f
  for osteomyelitis, II-590
  in pediatric reconstruction, III-769
  peri-implantitis and, I-727
  placement, in biomedical model, I-701f
  preoperative evaluation, I-432, I-448–451
  recipient site, I-460–461
  rectangular block, I-454f
  remodeling, I-466–467
  resorption, I-466–467
  secondary, III-584
  simulation, I-700f
  sinus, I-464–465
  sinus-lift subantral, I-509–525
  space maintenance, I-483–484
  statistics on, I-426
  stereolithography for, I-696–699
  storage, I-447
  suboptimal healing of, I-432–434
  techniques and materials for, I-426–436
  techniques for, I-426–436

Bone graft *(Continued)*
three-dimensional imaging for, I-688–710
case study, I-688–696
simulation from, I-700f
tibia as donor site, I-457–458
titanium mesh technique, I-465
tuberosity block, I-452f
vascular compromise of, I-434
xenogeneic, I-437, I-441f, I-483
xenograft, I-429–430
Bone loss
bisphosphonate drugs for, II-507
grafting and, I-415–416
implant and, I-398–401
maxillary implant and, I-647–648
multiple implants and, I-401
smoking and, I-514
Bone marrow, stem cells from, I-438–439
Bone morphogenetic protein (BMP), I-427, II-586f–589f, III-591
in autogenous bone graft, I-446–447
bone growth and, I-441
as growth factor, I-431–432
space maintenance and, I-526–527
Bone remodeling
bisphosphonate drugs and, II-509–510
fixation screw and, II-164f
implant platform switching and, I-400
Bone spreader, in alveolar width osteotomy, I-529–531
Bone to implant contact (BIC), I-571
Bone transport
bifocal, III-217
dental implant in, III-218
in distraction osteogenesis, III-214–218
maxillary, III-218
multifocal, III-217
Bone tunnel, in forehead and brow lift, III-409f, III-415
Bone(s)
allogenic, I-428, I-439–440
alloplastic, I-440–441
aneurysmal cyst, III-751, III-752f–753f
augmentation
guided bone regeneration for, I-464
titanium mesh for, I-465–466
using guided bone regeneration, I-464
augmentation failure and, I-441, I-447–448
augmentation materials, I-437–438
augmentation procedures, I-441–443
augmentation techniques, I-438–441
autogenous, I-427
advantages, I-446
for cleft maxilla reconstruction, III-590
disadvantages, I-446
in sinus graft, I-465
autologous, I-438, I-465
biology, I-426–427, I-446–448
bundle, I-413–414
calcified, staining for visualization of, I-443f
cancellous, I-444f, I-446–447
bone graft with, I-427
ilium as donor site, I-458
from tibia, I-457–458
cortical, I-427, I-446–447
corticocancellous, ilium as donor site, I-458
craniofacial, III-628–629
crestal height, I-398–399
disease, II-508–509
facial
grafting of, I-415–416
in restored implant, I-411
forehead, III-396–397
fracture. *See* Fracture
Bone(s) *(Continued)*
frontal
fracture of, II-20–22
injury, II-230–243
surgical anatomy, II-230–231
growth
augmentation failure for, I-441
enhancing materials for, I-438
example of, I-442f
stem cells and, I-438–439
xenogeneic graft and, I-440
healing, I-257–258, II-426–427
heterotopic formation, II-858
injury, in dentoalveolar injury, II-123t
long-term changes, genioplasty and, III-104–105
midface, II-211
miniscrew implant and, I-315
nasal, II-175–176, III-367
necrosis, in osteomyelitis, II-575
orbital, II-18, II-19f
osteosarcoma, II-647–649
palatal, implant and, I-412
quality
immediate implant loading and, I-607
in maxilla, I-594
removal
for impacted molar extraction, I-287
in surgical extraction, I-280–281
resorption, I-643f
after graft, I-466–467
dentures and, I-642
spicule, I-305
squamous cell carcinoma, II-682
substitute materials for, I-437–438
temporal, II-815
for temporomandibular joint replacement, II-923
vascularized, II-286
xenogeneic, I-440
zygomatic, I-189, I-570–571
quad, I-570f
Boniva. *See* Ibandronate (Boniva)
Bony split, sagittal split osteotomy and, III-308–310
Bony wall, defect evaluation and, I-476
Book flap, I-528–529
Borrelia burgdorferi, II-846–847
Botox. *See* Botulinum neurotoxin (Botox)
Botryoid odontogenic cyst, II-365
Botulinum neurotoxin (Botox), I-319, III-365–377
adverse effects, III-442
contraindications, II-442, III-957
dilution table, III-440t
for facial pain, II-957
history, III-439–440
pharmacology, III-439–440
preparations, III-440
for temporomandibular joint disorders, II-872t
treatment technique, III-441–442
Botulism, III-439
Boundary violation, I-143–147
Bowman, Karl, II-769–770
Bowstring test, II-232–233
Boyne, Phillip, III-492, III-584
Brachycephaly, III-660, III-673
Brachytherapy, II-747–749
Bradycardia, pediatric, I-239, I-239t
BRAF inhibitor, II-701–702
Brain injury, II-254
Branchial arch syndrome, III-778f
Branchial cleft cyst, II-383–385
Brånemark, P. I., I-723
Brånemark fixture, for zygomatic implant, I-576f
Brånemark protocol, I-605
Breast cancer, malignant bone disease and, II-508
Breath sounds, in trauma patient, II-9
Breathing
assessment, in pediatric trauma, II-249
obstructed, facial cleft and, III-605–606
Brentuximab, II-714
Breslow melanoma classification, II-696t
BRON. *See* Bisphosphonate-related osteonecrosis (BRON)
Bronchospasm, in pediatric patient, I-252–253
Brophy, Truman, III-492
Broselow Emergency Pediatric Tape, I-245
Brow. *See* Eyebrow
Brown tumor, II-464–465
Brush biopsy, II-332, II-674–675
Bruxism, splint therapy for, II-868–869
BSSO. *See* Bilateral sagittal split osteotomy (BSSO)
Buccal bifurcation cyst, II-343, II-344f
Buccal nerve, II-75–76
Buccal plate
immediate implant and, I-410–411
remodeling, after immediate implant, I-413–414
thickness of, implant success and, I-413–414
Bucco-palatal dimension, I-413
Budgeting, for oral and maxillofacial surgical practice, I-67–68
Bullet
classification of, II-303
components, II-303
injury from, factors influencing degree of, II-307
movement, II-305, II-305f
soft tissue injury, II-306
types of, II-304
Bullous pemphigoid, II-563–564
Bundle bone, I-413–414
Bupivacaine, I-186
anaphylaxis associated with, I-252t
concentration, I-177t
duration of, I-179t
local anesthesia with, I-232–233
onset time, I-178t
potency of, I-176
systemic complications associated with, I-184
Bupivacaine liposome injectable suspension (Exparel), I-187
Buprenorphine (Buprenex), I-229t–230t
Burkitt lymphoma, II-710, II-713
Burn injury, II-67–68
Burn scar, laser surgery for, III-357–358
Burning mouth syndrome, II-949
Burnout, medical education and, I-6
Burn(s)
exodontia and, I-301
facial, II-67–68
management, II-67–68
Business management, of oral and maxillofacial surgical practice, I-58–72
Business model, for surgical practice, I-16–17
Buspirone (BuSpar), II-873, II-874t
Butorphanol (Stadol), I-229t–230t
Buy-sell agreement, I-60–61
BZD. *See* Benzodiazepine drugs

C

C corporation, I-58–59, I-59t
C nerve fiber, I-225
Cal bar stabilizing implant, I-573f
Calcified marine algae, alloplastic implant with, I-440–441
Calcifying epithelial odontogenic tumor (CEOT), II-398–401, II-424–425

Calcifying odontogenic cyst, II-368–371
Calcitonin, giant cell lesion treated with, II-462–463
Calcium hydroxide
  injury associated with, I-378
  root canal fill, II-131
Calcium phosphate
  alloplastic implant with, I-440–441
  for bone graft, I-483–484
Calcium sulfate, for bone graft, I-483–484
Caldwell-Luc procedure, I-295
Calhoun and Gibson method, chin position analysis with, III-460t–461t
Cancer. *See also* Carcinoma
  antiresorptive therapy for, II-514–515
  apoptosis and, II-615f
  biologically based treatment, II-626f
  chromosomal abnormalities, II-672
  diagnosis, II-622–624
  epithelial, II-600f, II-718–720
  genetic influence, II-602
  genomic sequencing, II-623
  head and neck, II-752–763
    epidemiology, II-752
    treatment, II-745–747
  histology, II-599–602
  incidence, II-599
  laryngeal, II-745t
  lip, II-735–737
  metastasis, II-619–621, II-620f
  molecular biology, II-599–642
  molecular diagnostics, II-622–624
  molecular therapeutics, II-624–629
  nasopharyngeal, II-744–745
  neovascularization, II-617–619
  nonepithelial, II-720
  nucleic acid dysregulation, II-606–609
  oncology principles, II-752–763
  oral
    deaths from, II-670
    diagnosis and evaluation, II-675
    epidemiology, II-671–675
    follow-up, II-684–685
    genetic factors, II-672–673
    nonsurgical management, II-677–679
    screening, II-673–674
    staging, II-675–677
    surgical management, II-679–683
  protein dysregulation, II-609–622
  radiation therapy, II-741–751
  salivary gland, II-759–760
  signal pathway altered by, II-602–622
  skin. *See* Skin cancer
  telomerase and, II-617f
  thyroid, radiation therapy for, II-742
  treatment, II-622–629, II-626f
Cancer cell
  apoptosis evasion, II-614–616
  biology, II-601–602
  chromosomal abnormalities, II-606–607
  differentiation, II-614
  DNA alterations in, II-606
  epigenetic alteration, II-609
  example, II-601f
  growth inhibitory signal and, II-612–614
  immortalization, II-616–617
  molecular changes, II-602f, II-621–622
  neovascularization, II-617–618
  nucleic acid alterations, II-609
  nucleotide sequence abnormalities, II-607–609
  release from growth signal requirement, II-617f
Cancer stem cell (CSC), II-599–600
Canine
  impacted, I-261–262, I-289–291
    excisional exposure of, I-263
    preoperative planning, I-289
    surgical technique, I-289–291
    treatment, I-262–269
  mandibular, impacted, I-291, I-291f
  maxillary
    extraction, I-277, I-278f
    impacted, I-289–291
    implant replacement, I-403
  transverse discrepancy, III-299
Cannabinoid drugs, I-363–364, I-364–365
Cannabis, I-233–234
Cant, occlusal, III-23
Canthopexy, transnasal, II-224
Canthotomy, lateral, II-194, II-196
Cantilever
  failure of, I-601f
  implant and, I-599–600, I-600f
Capecitabine, II-757t
Capillary malformation, II-538–539
Capnography, I-168–169
  circulatory system monitoring and, I-165
  normal morphology, I-170f
  for trauma patient assessment, II-9–10
Capnometry, for pediatric anesthesia monitoring, I-245
Capsaicin (Zostrix)
  for facial pain, II-955t
  for nerve injury, I-363
  topical, II-957–958
Capsule, temporomandibular joint, II-780
Carbamate, II-874t
Carbamazepine (Tegretol), I-364, II-956
Carbon dioxide (CO_2) laser. *See* Laser, carbon dioxide (CO_2)
Carbonic anhydrase inhibitor drugs, II-207
Carboplatin, II-755, II-757t
Carboxyhemoglobin, I-168
Carcinoembryonic antigen (CEA), II-623–624
Carcinogen, environmental, II-602
Carcinoma. *See also* Cancer.
  acinic cell, II-493t, II-498
  adenoid cystic, II-493t, II-498, II-500–501, II-759–760
  ameloblastic, II-401
  basal cell, II-718–719
  clear cell odontogenic, II-424–431
    clinicopathologic considerations, II-427–429
    differential diagnosis, II-427
  cutaneous, lymph node involvement, II-730
  epidermoid, II-493t
  head and neck
    chemotherapy for, II-755–756
    treatment, II-745–747
  hypopharyngeal, II-746t
  intraosseous odontogenic, II-431–435
  intraosseous odontogenic squamous cell, II-431f
  laser surgery for, I-343, III-354
  lip, II-735–737
  Merkel cell, II-720
  microcystic adnexal, II-719
  mucoepidermoid, II-492–493, II-493t, II-498, II-500–501, II-504t, II-759–760
  oropharyngeal, II-744t
  salivary duct, II-759–760
  sebaceous gland, II-720
  of skin appendages, II-719–720
  squamous cell. *See* Squamous cell carcinoma
  temporomandibular joint, II-848, II-857
  thyroglossal duct cyst associated with, II-383
  thyroid, radiation therapy for, II-742
Carcinoma in situ, II-599–600, II-600f
Cardiac arrest, in child, II-249
Cardiac assessment, preoperative, I-150f
Cardiac ischemia, II-950–951
Cardiac output
  definition, I-239
  pediatric, I-239, I-242
Cardiac risk index, I-150t
Cardiovascular complications
  endocarditis and, I-151t
  risk of, I-148–151
Cardiovascular disease, craniomaxillofacial trauma management and, II-3t
Cardiovascular system
  evaluation, for orthognathic surgery, III-280–282
  monitoring, during anesthesia, I-222
  pediatric, I-238–239
  preoperative evaluation of, I-138, III-148–151
  rhytidectomy evaluation and, III-327–328
Care
  access to, I-3
  continuous improvement of, I-3
Care plan, for craniomaxillofacial trauma, II-5–6
Caries
  exodontia for, I-275
  third molar removal and, I-284
Carisoprodol (Rela, Soma), II-872t
Carnegie stages, III-477f, III-478, III-479f–480f
Carney triad, II-644
Carnochan, John Murray, II-924
Carroll-Girard screw, II-193–194
Cartilage
  auricular, III-447–448
  for ear reconstruction, III-732
  graft, in cleft-nasal reconstruction, III-620
  Meckel, I-526
  nasal, II-175–178
  for temporomandibular joint replacement, II-924
Caspase cascade, II-615
CASS. *See* Computer-aided surgical simulation (CASS)
Cat, bite wound from, II-63
Catheter, intraosseous, I-247
Cauliflower ear deformity, II-57–58
Causalgia, II-946t, II-947
CDT. *See* Current Dental Terminology (CDT)
Cehpalosporin, for autogenous bone graft prophylaxis, I-451
Celebrex. *See* Celecoxib (Celebrex)
Celecoxib (Celebrex), I-232
  dosage, I-232t
  for facial pain, II-955t
  for temporomandibular joint disorders, II-871t
Celestone. *See* Betamethasone (Celestone)
Cell cycle clock, II-613f
Cell(s)
  apoptosis, II-614–616
  bone, I-446–447
  cancer, II-601–602, II-601f
  cycle control, II-613f
  dendritic, II-600–601
  division of, II-613f
  endothelial, II-257
  gene regulation of, II-603–606
  growth signal requirements, II-611f
  Hodgkin, II-709f
  natural killer, II-600–601
  normal division, II-612–613
  replication, II-616
  T, II-600–601
Cellulitis
  frontal sinus fracture associated with, II-243f
  lymphatic malformation associated with, II-539

Cement
acrylic urethane, I-715–716
allergic reaction to, I-716
clinical protocols for, I-717–720
complications, I-639
controlling flow of, I-713–714
corrosion from, I-716–717
effect of, on soft tissue, I-632
excess
avoidance of, I-639
issues associated with, I-711–712
implant, characteristics of, I-714
interactions, I-716
microbial growth and, I-715–716
orthozinc phosphate, I-715–716
peri-implant disease and, I-711
resin-based, I-715–716
selection, I-714–715
zinc oxide/eugenol, I-715–716
Cementable abutment, I-624–626, I-633–634
Cemento-osseous dysplasia, II-470–471
Cemento-ossifying fibroma, II-468–469
Cementoblastoma, II-438–439
Center for Medicare and Medicaid Services (CMS), I-87
Central deafferentation syndrome, I-361
Central giant cell granuloma, II-462–464, II-750–751, III-852
classification, II-463t
example, II-463f
Central nervous system (CNS), I-226
Centrax. *See* Prazepam (Verstran, Centrax)
Centric relation
inconsistent, of mandible, III-187–188
orthognathic surgery planning and, III-15
in temporomandibular joint disorders, II-875
Cephalometric analysis
for temporomandibular joint disorders, III-226
for velopharyngeal function, III-574–575
Cephalosporin, parotitis treated with, II-486–487
Cerebrospinal fluid (CSF), leakage, II-221, II-223
following midface fracture, II-226–227
frontal sinus fracture associated with, II-239–240, II-232, II-243
in pediatric facial trauma, II-241
in self-inflicted gunshot wound, II-323
Cerebrospinal fluid halo test, II-233f
Cerebrospinal fluid rhinorrhea, II-187, II-216, II-226–227
Cerebrovascular accident (CVA)
craniomaxillofacial trauma management and, II-3t
preoperative evaluation of, I-161
Certification. *See also* Accreditation
history of, I-96–97
Cervical injury
craniomaxillofacial fracture associated with, II-38
orthognathic surgery evaluation and, III-16–17
Cervical spine injury, II-11
Cervicofacial flap, II-290, II-293f
Cetuximab (Erbitux), II-673, II-747, II-756t–757t, II-759, II-759t
Champy, Maxime, II-63, III-162, III-6
Charnley, Sir John, II-298
Cheek, reconstruction, II-274–275
Chemical burn, endodontic materials associated with, I-378
Chemical injury
endodontic materials associated with, I-378
nerve injury associated with, II-87
Chemical peel, III-439–445
agents, III-443–444
complications, III-444
contraindications, III-443
history, III-442–443
procedure, III-444
Chemo-radiotherapy, for head and neck squamous cell carcinoma, II-753–754
Chemoprevention
for oral cancer, II-677
for skin cancer, II-732–733
Chemotherapy
for ameloblastic fibrosarcoma, II-455
concurrent radiation therapy with, II-747t
induction, for squamous cell carcinoma, II-754–756
for lymphoma, II-713
for melanoma, II-701
for metastatic head and neck cancer, II-755–756
for osteosarcoma, II-648–649
for rhabdomyosarcoma, III-760–762
for squamous cell carcinoma, II-753
Chemotherapy/radiation therapy (CRT)
induction chemotherapy combined with, II-755
for squamous cell carcinoma, II-753–754
Cherubism, II-466–467
Chest auscultation, in trauma patient, II-9
Chest wall, pediatric, I-240
Chewing sequence, II-787–788
Child. *See also* Infant
ablative defect reconstruction, III-763–769
airway management, I-238, II-241
ameloblastic fibro-odontoma in, II-452
ameloblastic fibroma in, II-449
anaphylaxis, I-252
anatomy and physiology, I-238–242, II-248t
anesthesia, I-238–256
complications, I-251–253
techniques, I-251
anesthesia worksheet, I-246f
anesthetic monitoring, I-244–245
assessment and management of injury, II-245–263
asthma, I-244
avulsive injury, II-274–275
axonal injury, II-251–252
bite wound, II-278–279
blood circulation, II-249–250
body composition, I-242
bradycardia in, I-239t
canine extraction for, I-262
cardiovascular conditions, III-280–281
cardiovascular system, I-238–239
codeine warning for, I-253–254
concussion, II-252
condylar fracture, II-270
craniofacial skeleton development, II-241–243
craniomaxillofacial pathology management, III-738–773
craniomaxillofacial surgery, III-627–644
craniomaxillofacial trauma, II-264–280
assessment, II-231–232
epidemiology, II-230–231
imaging, II-233–240
management, II-243
physical evaluation, II-232–233
craniosynostosis, III-646, III-671–677
demographics, I-257–258
dental development, I-258
dental extraction, I-260
dentoalveolar injury, II-270–271, II-114
dentoalveolar surgery, I-257–274
distraction osteogenesis, III-775
Child *(Continued)*
drug dosage for, I-250t
ear development in, III-446–447
endotracheal tube for, I-247
evaluation, for orthognathic surgery, III-280–281
Ewing sarcoma, II-662
facial fracture, II-35–38, II-38f
fear and anxiety in, premedication for, I-248
fracture management, II-243
glandular and ductal injury, II-272
growth and development, II-240
herpes simplex infection, II-555–556
impacted canine, I-261–262
impacted incisor, I-265
impacted molar, I-265–266
impacted premolar, I-265
impacted tooth, I-260–261
implant, I-269–270
infection, I-260
inhalation anesthesia, I-250–251
inhalation induction, I-220
injured, II-245–263
injury evaluation, II-246
injury patterns, II-260–261
injury prognosis, II-138–139
intracranial hemorrhage, II-252–254
intracranial pressure, III-645–646
intraoperative fluids for, I-248
intravenous access, I-247–248
kidney, I-241
local anesthesia complications, I-184
malignant hyperthermia, I-253
malignant tumor, III-757–763
mandibular fracture, II-270, II-167
mandibular hyperplasia, III-638
mechanism of injury, II-245
melanoma in, II-690
methemoglobinemia, I-185
midface fracture, II-270
nasal fracture in, II-269–270, II-186–187
nerve injury, II-272
neurologic status, II-247–248
obesity, II-259–260
operating room preparation, I-245–248
oral anatomy, I-258–260
orbital fracture, II-267–268
parotid gland abscess in, II-486–487
pharmacology, I-238–242
pharmacosedation, I-248–251
physiology, I-260
preanesthetic assessment, I-238, I-242–244
preoperative fasting, I-243
primary herpetic gingivostomatitis, II-552
primary tooth injury, II-131–133
protruding ear correction in, III-450
recovery and discharge, I-253–254
respiratory rate, II-249
respiratory system, I-239–241
rhabdomyosarcoma, II-654
sedation, I-212, I-238–256
seizure, post-traumatic, II-255–256
sinus development, II-241
skeletal fracture patterns, II-261
skull fracture, II-253
soft tissue injury, II-271–273
soft tissue physiology, II-256–257
soft tissue procedures, I-270–272
superficial wound, II-272
supernumerary teeth, I-266–268
temporomandibular joint replacement in, II-934
tension pneumothorax in, II-250f
thermoregulation, I-241–242
tissue recruitment, II-274–275
tooth avulsion, II-128

Child *(Continued)*
tooth transplantation, I-268–269
trauma, II-245–263
trauma outcomes, II-245
traumatic brain injury in, II-246–247, II-250–252
Treacher Collins syndrome, III-705–706
treatment challenges, I-272
upper respiratory infection, I-243–244
vital signs, I-239t
volume resuscitation for, II-250
wound healing, II-256–261
Child abuse
dentoalveolar injury associated with, II-114
facial injury from, II-231–232
trauma from, II-245, II-250–251
Child-Pugh Scoring System, I-156t
Chin
advancement, III-110f
augmentation
allograft, III-464b
alloplastic, III-463b
extraoral, III-464b
botulinum neurotoxin for, III-441
definciency, III-203f
deformity correction, with computer-aided surgical simulation, III-39
facial symmetry and, III-96
genioplasty, III-96–112
hyperplasia, III-306f
hypoplasia, III-309f
implant, III-104, III-321
in orthognathic surgery, III-28
position
analysis for, III-460t–461t
orthodontic treatment and, III-303t
small, cosmetic surgery, III-459b–463b
Chin wing osteotomy, III-319
Chlordiazepoxide (Librium)
discovery, I-191
structure, I-191f
for temporomandibular joint disorders, II-874t
Chlorhexidine
for autogenous bone graft prophylaxis, I-451
in mouthwash, II-551
Chlorhexidine gluconate, II-595
Chlorzoxazone (Paraflex), II-872t
Chondroblastoma, II-851–852
Chondrocramium, III-629–630
Chondrocyte
in cartilage, II-832
inflammation, II-833–835
joint function and, II-830
in osteoarthritis, II-838
synthesis by, II-831
Chondroma, II-475–476
Chondromalacia, II-837
Chondromatosis, synovial, II-796, II-798f, II-855–856
Chondrosarcoma, II-644t, II-649–651, II-856
classification, II-649–650
synovial, II-856
treatment, II-650–651
Christensen fossa implant, II-771
Christensen implant system, II-772–774
Chromatin
chromosome composed of, II-605f
gene activity and, II-603
Chromatolysis, II-72
Chromophore, I-328–329, III-339
carbon dioxide laser, I-331
diode laser, I-332
Chromosome
abnormalities
in cancer cells, II-606–607
oral cancer and, II-672
Chromosome *(Continued)*
alterations, II-607f, II-609f
composition, II-603, II-605f
deletion, II-607
Philadelphia, II-622–623
rearrangement, II-607
translocation, II-607, II-608f
Chronic bullous dermatosis of childhood, II-565
Chronic facial pain, II-941–961
cardiac origin, II-950–951
clinical examination, II-945–946
differential diagnosis, II-947–952
evaluation, II-944–947
pharmacotherapy, II-955t
surgical intervention, II-958
therapeutic injection, II-956–957
treatment, II-953–958
Chronic kidney disease, I-154t
preoperative evaluation of, I-152–155
stages, III-283t
Chronic obstructive pulmonary disease (COPD)
craniomaxillofacial trauma management and, II-3t
oral surgery and, I-151
orthognathic surgery and, III-282
preoperative evaluation of, I-151–152
Chronic obstructive sialoadenitis, II-490–492
Chymopapain, anaphylaxis associated with, I-252t
Cigarette smoking
airway patency and, I-215
autogenous bone graft failure, I-451
bone graft healing affected by, I-433
implant failure and, I-412
as mandibular surgery risk factor, III-297–298
oral cancer associated with, II-671
orthognathic surgery risk associated with, III-282–283
peri-implant disease associated with, I-723–724
preoperative evaluation and, I-152
rhytidectomy complications associated with, III-332
sinus augmentation and, I-514
Cinnamic aldehyde, II-550
Circulation
monitoring, I-169, I-244–245
pediatric, II-249–250
in pediatric trauma, II-250
Circulatory system, monitoring, I-165–167
Cisplatin, II-747, II-755, II-756t–757t
Claims professional, I-83
Clark melanoma classification, II-696t
Clark's rule, I-260–261
Clear cell
in ameloblastoma, II-402, II-425
in calcifying epithelial odontogenic tumor, II-399–400, II-424–425
in periodontal cyst, II-425f
Clear cell odontogenic carcinoma (CCOC), II-424–431, II-426f–427f
clinicopathologic considerations, II-427–429
differential diagnosis, II-427
with metastases, II-428f–430f
surgical management, II-429–431
Clear cell odontogenic tumor, II-425–427
Cleft deformity
bilateral, III-565
child feeding, III-494–496
classification, III-496f
complex, III-506–508
dentition abnormalities in, III-584–586
embryogenesis, III-493
genetics and etiology, III-493–494
management, III-491–512
obstructed breathing, III-605–606
Cleft deformity *(Continued)*
in oculoauriculovertebral spectrum, III-692
orofacial embryogenesis and, III-476–490
orthognathic surgery, III-596–608
prenatal counseling, III-494
reconstruction stages, III-610t
revision surgery, III-609–626
sites, III-486–489
treatment planning, III-496–497
unilateral, III-563–565
Cleft lip, I-679–683
bilateral, III-211f–212f, III-500–502, III-600b, III-605f–606f, III-621f–622f
bone grafting for, I-679
child feeding, III-494–496
configurations, III-495f
dentition abnormalities, III-584–586
etiology, III-513, III-561
genetics and etiology, III-493–494
genioplasty for, III-98
history of repair, III-491–493
implant and, I-680–683
incidence, I-561, III-665
infant orthopedic treatment, III-561–567
management, III-491–512
in oculoauriculovertebral spectrum, III-692
prenatal counseling, III-494
revision surgery, III-609–626
surgical techniques, III-514–515
timing of surgery, I-679
treatment planning, III-496–497
unilateral, III-499–500, III-600b, III-623f
repair, III-513–533
surgical techniques, III-514–515
Cleft lip repair, III-497–508, III-513–533
functional, III-525–526
midface growth, III-542–543
revision surgery, III-609–626
scar repair, III-620–622
secondary surgery, for scar revision, III-620–622
stages, III-610t
surgical techniques, III-514–515
timing, I-513–514, III-679
treatment planning, III-496–497
Cleft maxilla
bilateral, III-589–592
bone graft reconstruction, III-619
management, III-583–595
reconstruction, III-589–592
stabilization, III-606–607
surgical options, III-583–584
timing of grafting procedure, III-586–587
unilateral, III-589
Cleft palate, I-679–683
anatomy, III-535–536
bilateral, III-211f–212f, III-600b, III-621f–622f
bone grafting for, I-679
dentition abnormalities, III-584–586
etiology, III-561
fistula closure, III-611–612
genetics and etiology, III-493–494
genioplasty for, III-98
history of repair, III-491–493
implant and, I-680–683
incidence, III-561
infant orthopedic treatment, III-561–567
management, III-491–512
in oculoauriculovertebral spectrum, III-692
prenatal counseling, III-494
revision surgery, III-609–626
speech affected by, III-540–542, III-568–582
speech disorders, etiology, III-568–570
submucous, III-618–619
timing of surgery, I-679

Cleft palate *(Continued)*
treatment planning, III-496–497
unilateral, III-506f, III-600b
vocal dysfunction, III-572
Cleft palate repair, III-497–508, III-534–560
bone graft reconstruction, III-619
dental rehabilitation after, III-622–623
fistula, III-539–540
fistula closure, III-609–612
goals, III-610
history, III-534–535
midface growth, III-542–543
otologic and audiologic issues, III-540
revision surgery, III-609–626
secondary surgery, III-612–616
speech disorders and, III-568–582
stages, III-610t
surgical technique, III-536–539
timing of surgery, I-679
treatment planning, III-496–497
two-stage, III-548–549, III-551–552
Clindamycin
for autogenous bone graft prophylaxis, I-451
medication-related osteonecrosis treated with, II-516
parotitis treated with, II-486–487
postoperative infection treated with, I-303
Clinical examination
for implant overdentures, I-656–658
risk management and, I-76
Clinical margin, II-728
Clonazepam (Klonopin)
after nerve surgery, I-373
for facial pain, II-955t
for masticatory myalgia, II-969
for nerve injury, I-363
Clonidine, management, I-149t
Clopidogrel, I-161
Clostridium botulinum, III-439
Cloverleaf skull, III-669
CMS. *See* Center for Medicare and Medicaid Services (CMS)
CMS 1500 form, I-88
CNS. *See* Central nervous system (CNS)
Coagulation, laser for, I-330, I-335
Coagulation disorders
preoperative evaluation of, I-161
wound healing affected by, II-259
Coagulopathy, craniomaxillofacial trauma management and, II-3t
Cobalt chromium, framework with, I-599
Cocaine, I-176, I-185
Cocamidopropyl betaine, II-550–551
CODA. *See* Commission on Dental Accreditation (CODA)
Code of Ethics, American Dental Association (ADA), I-10
Code of Professional Conduct, AAOMS, I-9–10
Code set, for oral and maxillofacial surgery, I-89–90
Codeine, I-228
dose and potency, I-229t–230t
equianalgesic dosage, I-231t
for facial pain, II-953
FDA warning, I-253–254
for temporomandibular joint disorders, II-872t
Coding
evaluation and management, I-92–95
insurance, I-87–95
modifiers in, I-93–94
for pathology, I-92
radiology, I-94
for systemic diseases, I-94–95
for trauma, I-91–92
Cognitive-behavioral therapy, for temporomandibular joint disorders, II-968–969
Collagen
nerve anatomy and, II-77–78
in wound healing, II-257
Collagen matrix, I-558, I-560–561
Collagen membrane, I-462–463, I-485f–487f
natural, I-482
peri-implantitis treated with, I-727f
resorbable, I-482
Cologne Classification for Alveolar Ridge Defects, I-447–448
Columella
lengthening, III-500–501, III-505f
in rhinoplasty evaluation, III-369–370
Combitube, II-13–14
Commission on Dental Accreditation (CODA), I-5
accreditation of residency programs, I-8
Commission on Professional Conduct (CPC), I-9–10
Communication
empathy and, I-102
intraoffice, I-80–81
marketing through, I-134–136
in patient evaluation, I-120
with pediatric patient, I-257–258
personal, I-20
with postoperative patient, I-132
principles of, I-134–136
risk management and, I-80–81
in surgical practice, I-18
Community-based surgeon, I-12–13
Community service, I-132, I-126
Compensation, in oral and maxillofacial surgical practice, I-70–71, I-71t
Complex regional pain syndrome (CRPS), I-361b, I-362f, II-947–948
Composite model
in computer-aided surgical simulation, III-31–33
creation of, III-33f
frame of reference, III-33
orientation, III-36f
Comprehensive Accreditation Manual for Hospitals (CAMH), I-231b
Computed tomography (CT). *See also* Imaging
for bone graft preoperative evaluation, I-448–449, I-449f
computer-aided surgical simulation and, III-31
cone-beam, I-448–449, II-824–825
computer-aided surgical simulation and, III-31
for dentoalveolar injury, II-120
facial bone evaluated with, I-411
history, III-6–7
of impacted third molar, II-80f
of impacted tooth, I-261
for implant overdenture planning, I-656–657
for nerve imaging, II-79–80
palatofacial dimension measured with, I-413f
of temporomandibular joint, II-826f
for temporomandibular joint disorder, II-802
for temporomandibular joint reconstruction, III-223–226
three-dimensional imaging and, I-688
conventional linear, for temporomandibular joint, II-818–819
of craniomaxillofacial pathologies, III-738–739
of dentoalveolar injury, II-120
Computed tomography (CT) *(Continued)*
for facial nerve imaging, II-99–100
for facial pain, II-947
of frontal sinus fracture, II-241, II-232
image interpretation, II-17–20
of Le Fort fracture, II-217f
of lymphoma, II-711
of mandibular fracture, II-153
maxillofacial, II-20
of medication-related osteonecrosis of jaw, II-513f
for melanoma diagnosis, II-699
micro, I-443
of midface fracture, II-213, II-214f
multi-dectector, II-17
multidirectional, for temporomandibular joint, II-818–819
nasal fracture diagnosis with, II-178
of naso-orbito-ethmoid fracture, II-223
for nerve imaging, II-78–80
odontogenic tumor, II-392
for oral cancer evaluation, II-675
of osteomyelitis, II-586f–589f
of parotid gland tumor, II-493–494
for pediatric brain injury, II-251
pediatric trauma assessment with, II-247
salivary gland, II-481–483
of sarcoma, II-645
of skin cancer, II-725
of skull fracture, II-255f
temporomandibular joint, II-820–821
for temporomandibular joint disorder, II-802, II-820–821
of temporomandibular joint internal derangement, II-906
three-dimensional, I-207–208, II-688
computer-aided surgical simulation and, III-31–33, III-35
of frontal sinus fracture, II-234f
genioplasty planning with, III-101
for Le Fort I osteotomy, III-153–161, III-158f–160f
in Le Fort I segmental surgery, III-174, III-175f
for midface fracture, II-213, II-214f, II-227
of odontogenic tumor, II-392
trauma patient assessment with, II-5
of Treacher Collins syndrome, III-708f–709f, III-711f–712f
tuned-aperture, II-824
of zygomatic fracture, II-191, II-192f
for zygomatic implant, I-570–571
Computer, in oral and maxillofacial surgery, I-49
Computer-aided surgical simulation (CASS), III-31–34
accuracy, III-40–42
algorithm, III-32f
clinical implementation, III-34–40
cost-effectiveness, III-42
data processing, III-35–38
final symmetry in, III-39
for inverted L osteotomy, III-120
for mandibular deformity, III-39
for maxillary deformity, III-38–39
in orthognathic surgery, III-190
outcomes, III-40–42
preoperative records, III-34–35
surgical execution, III-39–40
surgical planning, III-38–39
for temporomandibular joint total replacement, III-229–232
Computer-controlled injection, I-187
Concomitant TMJ total joint replacement and orthognathic surgery (C-TJR-OS), III-222–245
case studies, III-235b, III-239b–240b

Concomitant TMJ total joint replacement and orthognathic surgery (C-TJR-OS) *(Continued)*
outcomes, III-238–242
surgical planning, III-229–232
surgical procedure, III-233–242
surgical sequence, III-232
traditional, III-228–229
Concussion
in dentoalveolar injury, II-127
pediatric, II-252
Condylar hyperplasia, II-145–147, III-850–851
Condylar resorption, adolescent internal, III-224–225
Condylar/subcondylar region, fracture of, II-28, II-31–34, II-36f
Condyle, II-779
aplasia, II-802f
arthritic, III-225f
computed tomography of, II-821
description of, II-794
displacement, in sagittal split ramus osteotomy, III-81
endoscopic approach, II-161–162
fracture, II-31–34, II-36f, II-149, II-165–166
head shapes, II-780f
imaging, II-816
internal derangement, II-813f
movement, II-795, II-796f
pediatric fracture, II-270
postoperative displacement, III-317
pseudocyst, II-852
replacement, II-923
resorption, III-145–146, III-148f–150f
in sagittal split ramus osteotomy, III-81
surgical access, III-740
in temporomandibular joint, II-815
in Treacher Collins syndrome, III-712–713
Condyle-disc complex, II-792t–793t, II-799f
Condylectomy, III-145–147
Condylotomy, II-917–918
Conflict of interest, management, I-3
Conflict resolution, in surgical practice, I-18–19
Congenital epulis, III-756–757
Congenital hemangioma, II-536–538
Congestive heart failure, oral surgery and, I-139
Connective tissue
ameloblastic fibroma, II-449–450
cementoblastoma, II-438–439
grafting of, I-415–416
myxoma, II-439
connective tissue disorders
arthritides associated with, II-848
temporomandibular joint disorders and, III-225–226
wound healing affected by, II-259
Consultant, use of, I-125–126, I-110–111
Consultation visit, for pediatric patient, I-257
Continuous passive motion, in temporomandibular joint, II-833–835
Continuous positive airway pressure (CPAP)
for obstructive sleep apnea, III-267
for pneumonitis, I-253
for velopharyngeal dysfunction, III-580
Converse, J. M., III-3–5
Convex profile, correction of, III-184
Copy abutment technique, I-718
Coral, alloplastic implant with, I-440–441
Cornelia de Lange syndrome, III-635f
Coronal suture craniosynostosis, III-654–657, III-658f–659f
Coronectomy, alveolar nerve injury and, I-381–382
Coronoid hyperplasia, III-150f–151f
Coronoid process
coronoidectomy, III-147
fracture, II-34, II-149
Coronoidectomy, III-147
Correct Coding Initiative (CCI), I-88
Corticosteroid drugs, I-233
for congenital hemangioma, II-537
for facial pain, II-957
giant cell lesion treated with, II-462–463
for lichen planus, II-559
for nerve injury, I-363
in orthognathic surgery, III-289
for pemphigoid, II-564
for temporomandibular joint disorders, II-870, II-871t
Corticotomy surgery
history, III-246–248
technique, III-248–250
Cortisone, equivalent dosage, III-287t
Cosmetic surgery. *See also* Rhytidectomy
case study, III-459b–463b
endoscopic facial, III-359
facial implant, III-458–475
forehead and brow lift, III-395–428
laser-assisted, I-343–347, III-355–358
marketing, I-130–132
problem patient, III-458
Costen, James, II-768
Costen's syndrome, II-768
Cottle test, III-371
COX. *See* Cyclooxygenase (COX)
Coxsackie virus, II-556–557
CPT. *See* Current Procedural Terminology (CPT)
Cranial vault, III-645
in craniosynostosis, III-673
distraction osteogenesis, III-780–781
dysmorphology, III-648–649, III-663f
sutures, III-646f
Cranio-orbito-zygomatic region, in Treacher Collins syndrome, III-706
Craniocerebral disproportion, III-673
Craniofacial disjunction, II-28
Craniofacial dysostosis, III-667
Craniofacial fibrous dysplasia, III-751–753, III-761f–762f
Craniofacial growth and development, III-738
Craniofacial management, in syndromic craniosynostosis, III-670–671
Craniofacial skeleton. *See* Skeleton, craniofacial
Craniofacial surgery
laser used in, I-351
in oculoauriculovertebral spectrum, III-696
Craniomandibular articulation, II-777–778
Craniomaxillofacial surgery
access, III-739–741
history, III-738
incisions, III-739–741
pediatric, III-627–644, III-738–773
Craniomaxillofacial tumor, III-739
endoscopic approaches, III-741
pathology, III-741–769
Cranioplasty, in craniosynostosis treatment, III-678
Craniosynostosis, III-630, III-631f, III-636, III-645–686
bilateral coronal suture, III-660
care algorithm, III-671–678
coronal suture, III-654–657, III-658f–659f
definition, III-645
diagnosis, III-647–648
distraction osteogenesis for, III-780–781
functional consequences, III-645–647
hydrocephalus in, III-646
lambdoid suture, III-659–660, III-664f
Craniosynostosis *(Continued)*
metopic suture, III-653–654, III-661f–662f
multiple-suture, III-646
neurodevelopmental effects, III-647
nonsyndromic, III-645–666
complications, III-650–651
diagnosis, III-647–648
forms of, III-653–660
treatment, III-648–660
ophthalmologic effects, III-647
sagittal suture, III-653–654
syndromes, III-667–686
care algorithm, III-671–678
craniofacial management, III-670–671
genetics, III-667–669
timing of surgery, III-670
timing of surgery, III-649–650
treatment complications, III-650–651
Craniotomy
craniosynostosis treatment and, III-648
frontal, II-241f
Cranium
growth, III-628–630, III-738
growth rate, III-629t
sutures, III-645
Cribriform plate, II-221, II-226–227
Cricothyroidotomy, II-15f, II-282
Cricothyrotomy, emergency, II-14–15
Crossing the Quality Chasm: A New Health System for the 21st Century, I-97
Crouzon syndrome, III-16, III-213f–214f, III-633f, III-639–642, III-668, III-672, III-778
Crown
cement-retained implant, I-625f, I-630f, I-632
cemented-screw-retained, I-720
copy abutment technique, I-718
damage to, during exodontia, I-298–299
discoloration, after injury, II-138–139
fracture, in dentoalveolar injury, II-123–125, II-124f
infraction, II-122–123
provisional, immediate implant and, I-416–418
swallowing of, during exodontia, I-302
zirconia, I-628
Crow's feet, botulinum neurotoxin for, III-441
CRPS. *See* Complex regional pain syndrome (CRPS)
Cryotherapy
for odontogenic keratocyst, II-356–357
for skin cancer, II-727–730
Curettage, for skin cancer, II-727
Current Dental Terminology (CDT), I-88–89
coding, I-87
Current Procedural Terminology (CPT), I-87–89
Curve of Spee
leveling, III-300
open bite treatment and, I-317
Cuspid, impacted, I-265f
CVA. *See* Cerebrovascular accident (CVA)
Cyanoacrylate, for superficial wound, II-272
Cyanosis, anesthesia associated with, I-168
Cyclin, cell division and, II-612–613
Cyclin D1, II-673
Cyclin-dependent kinase (CDK), II-627
Cyclobenzaprine (Flexeril)
for facial pain, II-955t
for masticatory myalgia, II-969
for temporomandibular joint disorders, II-872t
Cyclooxygenase (COX)
nonsteroidal antiinflammatory drugs and, I-228–230
for skin cancer, II-733–734
temporomandibular joint disorders and, II-870

Cyclooxygenase pathway, II-870f
Cyclophosphamide (Cytoxan), II-455, II-713, II-757t
Cyclopropane, I-207
Cyclovir, II-554
Cyst, II-338–390
  aneurysmal bone, II-467–468, II-751, III-752f–753f, III-852
  botryoid odontogenic, II-365
  branchial cleft, II-383–385
  buccal, II-343, II-344f
  calcifying odontogenic, II-368–371
  definition, II-338
  dentigerous, II-339–340, II-343–348, II-345f, II-355f
  dermoid, II-377, II-380f
  developmental, II-339t, II-343–371
  epidermoid, II-377
  ganglion, II-852
  gingival, II-365, II-424
  globulomaxillary, II-375–376
  inflammatory, II-339t
  of jaw, II-340b
  lateral periodontal, II-365, II-424
  lymphoepithelial, II-485
  maxillary, II-346f
  median mandibular, II-375
  median palatal, II-375
  mouth floor, II-380f
  mucous retention, laser for removal, III-349
  nasolabial, II-371–372, II-374f
  nasopalatine duct, II-372–375, II-376f–378f
  non-odontogenic, II-371–385
  odontogenic, II-338–343, II-347f, II-365–371
    intraosseous carcinoma from, II-433
    site of, II-340f
  palatine, II-375
  paradental, II-343
  parakeratotic, II-360f–361f
  parotid gland, II-485
  radicular, II-340–341, II-342f–343f
  residual, II-341–342
  salivary gland, II-483–485, II-493t
  surgical management, II-338
  synovial, II-852
  temporomandibular joint, II-850–856
  third molar removal and, I-284
  thyroglossal duct, II-378–383
  traumatic bone, II-852
  World Health Organization classification, II-339t
Cystic hygroma, II-539
Cytokine, joint function and, II-830–832
Cytologic malignant ameloblastoma, II-420–422, II-424
Cytology, exfoliative, II-331–332
Cytomegalovirus, parotid gland affected by, II-488
Cytoxan. *See* Cyclophosphamide (Cytoxan)

D

Dabrafenib, II-701–704
Dacarbazine, II-701, II-714
Dal Pont, Giorgio, III-62
Dalmane. *See* Flurazepam (Dalmane)
Dautrey, Jaque, III-6
Davis method, for otoplastic surgery, III-451–453, III-452f
Deafferentation pain syndrome, I-361
Debridement
  for gunshot wound, II-283, II-290
  for peri-implantitis, I-725–727
Decadron. *See* Dexamethasone (Decadron)
Decision making, in surgical practice, I-18
Decitabine, II-625
Decompression, for odontogenic keratocyst, II-357–361
Dedo classification of facial profiles, III-327t
Deep circumflex iliac artery flap, II-296
Defect
  acquired, I-665–679
    implant in, I-665–687
    pathology, I-666
    reconstruction, I-665–666
  alveolar ridge, I-485f–490f, I-491–493, I-501b
  concave, I-484
    bone graft and, I-477f
  configuration, guided bone regeneration and, I-476
  congenital, I-665–687
  dehiscence, I-499b
  fenestration, I-491, I-492f
  grafting options for, I-666
  maxillary, from failed implant, I-450f
  multiple tooth, I-476f
  peri-implant, I-493
  ridge, I-476
  single tooth, I-476f, I-478f
  site preparation, I-479
  socket, I-476
Deformation, definition, III-628t
Degenerative (osteo)arthritis, II-836–838
Degenerative joint disease, II-792t–793t, II-869
Dehydration, herpetic infection as cause of, II-555
Delaire craniofacial analysis, III-100f
Delaire philosophy, cleft lip repair and, III-514–515
Deltasone, for temporomandibular joint disorders, II-871t
Dementia, I-146, II-3t
Demineralized freeze-dried bone allograft (DFDBA), I-428–429
Demoral. *See* Meperidine (Demerol)
Dendritic cell, II-600–601
Denosumab (Xgeva, Prolia), II-463–464, II-508–510, II-508t
Dental arch form, I-595–596
Dental cement. *See* Cement
Dental education
  behavior in, I-6–9
  history, I-2
  oral and maxillofacial surgeon in, I-33–35
  professionalism in, I-4
  statistics, I-34
  teaching professionalism in, I-7–8
Dental history, for implant overdentures, I-656–658
Dental maintenance service organization (DMSO), I-40–41
Dental support organization, I-37
Dentigerous cyst, II-343–348, II-345f, II-355f
Dentition
  abnormality, in cleft lip and palate, III-584–586
  after cleft palate repair, III-622–623
  after orthognathic surgery, III-290–291
  eruption sequence of, I-259t
  permanent, injury prognosis, II-139–141
Dentoalveolar injury, II-114–145
  classification, II-121t
  crown-root fracture, II-125
  evaluation, II-115–117
  gingival, II-137
  incidence, II-114
  mucosal, II-137
  pediatric, II-270–271, II-114
  periodontal tissue injury, II-122t, II-127–131
  physical examination, II-117–119
  prevention, II-141
Dentoalveolar injury *(Continued)*
  prognosis, II-137–141
  radiographic examination, II-119–120
  root fracture, II-125–127
  splint therapy, II-135–137
  supporting bone injury in, II-123t
  treatment, II-120–122
Dentoalveolar surgery
  complications, I-298–310
  goals, I-257–258
  pediatric, I-257–274
Dentofacial deformity
  asymmetry and, III-279
  cervical spine abnormality associated with, III-16–17
  clinical evaluation, III-14–29
  combined maxillary and mandibular osteotomy for, III-184
  genioplasty, III-96
  Le Fort I osteotomy for, III-153
  orthognathic surgery for, III-278
  transverse discrepancy, III-173
Dentures
  base reinforcement, I-655
  bone resorption associated with, I-642
  CAD-CAM fabricated, I-619f, I-621f
  complete, I-594f
    example, I-606f
    implant-fixed, I-642–643
    implant overdentures compared to, I-641–642
    mandibular, I-608–614, I-641–642
    screw-retained, I-614
  fitting of, I-658
  overpartial, I-642f
  screw-retained, I-614
Deoxycholic acid, III-432
Deoxyribonucleic acid (DNA)
  alterations, in cancer cells, II-606
  cancer diagnosis and, II-622–623
  cancer treatment and, II-625
  damage to, cancer and, II-602
  function, II-603
  whole genomic sequencing, II-623
Dependence, facial pain management and, II-952
Depo-Medrol. *See* Methylprednisolone (Depo-Medrol)
Depression, facial pain and, II-944–945
Deproteinized bovine bone mineral (DBBM), I-429–430, I-490–491
Dermal filler, III-465b–467b, III-472b–473b
Dermatofibrosarcoma protuberans, II-644t, II-653–654, II-720–721
Dermoid cyst, II-377, II-380f
Desflurane (Suprane), I-207–208
Desipramine (Norpramin), II-873t
Desmethyldiazepam, I-196f
Desmoplastic fibroma, II-476–478
Desmoplastic melanoma, II-692t
Desyrel. *See* Trazodone (Desyrel)
Dexamethasone (Decadron), III-287t
  after nerve surgery, I-373
  for autogenous bone graft prophylaxis, I-451
  for facial pain, II-955t, II-957
  for lymphoma, II-713
  for nausea and vomiting, I-253
  in orthognathic surgery, III-289
  in temporomandibular joint arthrocentesis, II-887
  for temporomandibular joint disorders, II-871t
Dexmedetomidine, I-13, II-221
Dextran, I-252t

Diabetes mellitus
bone graft healing affected by, I-433
complications associated with, I-141
craniomaxillofacial trauma management and, II-3t
orthognathic surgery and, III-286–287
peri-implant disease associated with, I-723–724
preoperative evaluation of, I-157
wound healing affected by, II-258–259
Diagnostic techniques, II-329–337
Diagnostic wax-up, I-449f
Diatrizoate meglumine, II-483
Diazepam (Valium), I-195
anxiety management with, I-234
clinical effects, I-194
for facial pain, II-955t, II-956
half-life, I-195t
for masticatory myalgia, II-969
pharmacokinetics, I-204t
protein binding, I-195t
structure, I-196f
for temporomandibular joint disorders, II-873, II-874t
Diclofenac, I-232
dosage, I-232t
for temporomandibular joint disorders, II-871t
DICOM. *See* Digital Imaging and Communications in Medicine dataset (DICOM)
Didrone. *See* Etidronate (Didrone)
Didusch, J. F., III-476–477
Dieffenback, Johann, III-534
Diet, after orthognathic surgery, III-291
Differential diagnosis, risk management and, I-76
Diffuse axonal injury, II-251
Diffuse large B-cell lymphoma, II-708b, II-710
Diflunisal
dosage, I-232t
for temporomandibular joint disorders, II-871t
Digastric muscle, II-784–785
DiGeorge syndrome, III-493–494
Digital Imaging and Communications in Medicine dataset (DICOM), I-692–696
Dilaudid. *See* Hydromorphone (Dilaudid)
Dingman, Reed, II-769
Dingman mouth gag, III-543–544
Diphenhydramine, II-551, II-556
Diplopia, zygomatic fracture as cause of, II-203–204
Diprivan. *See* Propofol (Diprivan)
Direct Abutment, I-624–626, I-633–634
Disc displacement, temporomandibular joint reconstruction, III-224
Discectomy
auricular cartilage graft after, II-912–913
autogenous graft after, II-912
dermal graft after, II-913–914
temporalis myofascial flap, II-912
for temporomandibular joint internal derangement, II-911
Discharge notes, risk management and, I-78
Disciplinary action, I-6–9
Displacement, craniofacial, III-628–629
Disruption, definition, III-628t
Disseminated intravascular coagulation, infantile hemangioma associated with, II-534
Distraction histogenesis, III-775
Distraction osteogenesis (DO), I-196–221, III-526–554, III-774–785
advantages, III-775
alveolar, I-535
consolidation period, I-536–537
devices for, I-539
Distraction osteogenesis (DO) *(Continued)*
distraction period, I-536
example, I-539f–546f
fan-shaped, I-545–547, I-548f
guidelines, I-538b
horizontal, I-538–539, I-543
indications, I-537–539
latency period, I-536
mesiodistal, I-547–549, I-548f–551f
oblique, I-543–545
prerequisities, I-537f
protocol, I-535–537
three-dimensional, I-539–549
vertical, I-538–543
alveolar vertical, I-532
alveolar width, I-529–532
bifocal, III-217
biologic basis, III-775–776
bone transport, III-214–218
for cleft deformity, III-492–493
consolidation period, I-536–537
cranial vault, III-780–781
in craniosynostosis treatment, III-676–677
devices for, I-197, III-539
disadvantages, III-776
distraction rate, I-536
distraction rhythm, I-536
history, I-534–535, III-774–775, III-7–8
interdental, I-547
mandibular, III-147, III-637, III-776–778
for mandibular lengthening, III-202–208
for mandibular widening, III-196–202
maxillary, III-208–214, III-778
miniplate for, I-313
multifocal, III-217
nerve injury associated with, II-84
in oculoauriculovertebral spectrum, III-695–696
pediatric, III-637, III-768
postoperative care, III-202, III-206
protocol, I-535–537
relapse, III-777–778
for segmental defect, I-668
temporomandibular joint replacement and, II-934–935
three-dimensional alveolar, I-534–551
transport, I-547–549
in Treacher Collins syndrome, III-730
vertical, I-532
Diversity, in surgical practice, I-15–16
Divinyl ether, I-207
DMSO. *See* Dental maintenance service organization (DMSO)
DO. *See* Distraction osteogenesis (DO)
Docetaxel, II-755, II-756t–757t
Docking site, in distraction osteogenesis, III-214
Docking site surgery, III-217–218
Doconasol, II-553–554
Doctor's stool, I-47–48, I-48f
Documentation
claim form and, I-87–88
electronic health record, I-79
informed consent, I-77
of noncompliance, I-79–80
principles, I-87–88
risk management and, I-75–80
Dog, bite wounds from, II-61–62, II-62b
Dolder bar, I-648–649
Donor site
location, I-705f
for nerve graft, II-95
protocol for, I-704–706
Dose and potency, I-229t–230t
Double-opposing Z-plasty, III-536, III-542–543, III-610
limitations and complications, III-548
Double-opposing Z-plasty *(Continued)*
speech and, III-546–547
technique, III-543–546
Down syndrome
airway assessment in, I-243
orthognathic surgery and, III-286
Doxepin (Sinequan), II-873t
Doxorubicin (Adriamycin), II-455, II-713–714, II-757t
Doxycycline
for avulsed tooth, II-130
medication-related osteonecrosis treated with, II-516
peri-implantitis treated with, I-725–726
Drill, rotary, thermal trauma from, I-607
Droperidol, III-288
Drug-induced sleep endoscopy (DISE), III-265–266
Drugs. *See* Medication
Dry socket, I-283
exodontia and, I-303
third molar extraction and, I-293–294
treatment, I-294
DSO. *See* Dental support organization
Ductal stenosis, II-483
Duloxetine (Cymbalta)
for facial pain, II-955t
for neuropathic pain, I-364
Dynamic Abutment, I-638–639
Dysesthesia
definition, I-355t, II-946t
patient-reported, I-358
Dysmorphic disorder, I-106
Dysmorphology
cranio-orbital, III-636–637
definition, III-628t
Dysplasia
in cancer histology, II-599, II-600f
cemento-osseous, II-470–471
craniofacial fibrous, III-751–753, III-761f–762f
fibrous, II-470
florid cemento-osseous, II-471
focal cemento-osseous, II-471
periapical cemental, II-470–471
Dysplasia ablation, laser for, I-338f

E

E-plane, chin position analysis with, III-462f
Eagle's syndrome, II-951–952
Ear
blood supply, III-448, III-449f
deformities, III-448–450
in oculoauriculovertebral spectrum, III-695
in rhytidectomy, III-334–335
innervation, III-448, III-449f
laceration repair, II-276, II-235f
protruding, III-446–457
reconstruction
in oculoauriculovertebral spectrum, III-695–696
in Treacher Collins syndrome, III-732–733
surgical anatomy, III-447–448
surgical correction, III-450–453
in Treacher Collins syndrome, III-707
wound closure, II-57–58
Earlobe, protruding, surgical correction, III-453–455
Early implant loading (EIL), I-605–608
Eating disorders, craniomaxillofacial trauma management and, II-3t
Ecchymosis
frontal sinus fracture as cause of, II-231–232
midface fracture and, II-216
periorbital, skull fracture indicated by, II-254
postoperative, I-306f

ECG. *See* Electrocardiogram (ECG)
Ectasia, laser treatment, I-347
Ectodermal dysplasia, I-683–684
Ectropion, eyelid, II-203
Edatrexate, II-756t
Edema
  in mandibular surgery, III-314
  in orthognathic surgery, III-289–290
  in sagittal split ramus osteotomy, III-79
EEG. *See* Electroencephalogram (EEG)
Effexor XR. *See* Venlafaxine (Effexor XR)
Ehlers-Danlos syndrome, II-259
Einstein, Albert, III-336
Elavil. *See* Amitriptyline (Elavil)
Elderly patient
  benzodiazepine effects on, I-194
  bone graft healing in, I-432
Elective lymph node dissection, II-698
Electrocardiogram (ECG), I-166–167
Electrocautery, for skin cancer, II-727
Electrodesiccation, for skin cancer, II-727
Electroencephalogram (EEG)
  for pediatric anesthesia monitoring, I-245
  sedation monitoring and, I-171
Electromagnetic spectrum, III-337f
Electromyogram, for masticatory myalgia, II-964–966
Electromyography, II-103–104
Electron microscopy, II-335
Electroneurography, II-103–104
Electronic dental anesthesia (EDA), I-187–188
Electronic health record
  documentation with, I-79
  in VA system, I-32
Elevation
  of impacted third molar, I-288
  in simple extraction, I-276
Elevator, in simple extraction, I-276
Embolism, prevention, II-6
Embryo, Carnegie stages, III-477f, III-479f–480f
Embryogenesis
  cleft deformity and, III-493
  orofacial, III-476–490
Emergency care
  risk management in, I-77–78, I-81–82
  simulation of, I-212–213
Emergency equipment, for pediatric anesthesia, I-245
Emergency protocol, in oral and maxillofacial surgery, I-55
Emotional intelligence, I-144
Empathy, communication and, I-144
Emphysema, I-301
Employee
  family as, I-112
  hiring and firing, I-116–117, I-112–114, I-110
  interview, I-113
  as marketing asset, I-133–134
  salary and benefits, I-112
  superior, characteristics of, I-115–116, I-114, I-114
Employee relations, I-111–117, I-113
Enamel fracture, in dentoalveolar injury, II-123–124, II-124f
Enanthema, II-557
Encephalitis, herpetic, II-555
End-tidal CO_2, I-169
Endocannabinoid drugs, I-233
Endocarditis, III-281b
  cardiac conditions associated with, I-151t
  prophylaxis, I-151t
Endocrine system, preoperative evaluation of, I-142, III-286–287
Endodontics
  chemical burn from, I-378
  nerve injury associated with, I-87, II-377–378
  nerve trauma from, I-377
Endoneurium, in nerve anatomy, II-77–78
Endoscope
  example of, III-146f
  in forehead and brow lift, III-408–416
Endoscopy
  craniomaxillofacial tumor, III-741
  in forehead and brow lift, III-408–416
  for frontal sinus fracture, II-240
  in mandibular osteotomy, III-144–152
  for midface fracture repair, II-227
Endosseous cylinder, as anchor, I-313
Endothelial cell, wound healing and, II-257
Endotracheal intubation
  in laser surgery, III-343
  pediatric, I-239, II-248
Endotracheal tube, sizing, I-247
Enflurane (Ethrane), I-207
Enophthalmos, II-205–206, II-226
Enterovirus disease, II-556–557
Entropion, eyelid, II-203
Entubulation, for neural regeneration, II-96f
Environmental factors, in sarcoma etiology, II-644
Eosinophilic granuloma, II-523
Epidermal growth factor receptor (EGFR), II-607f, II-612, II-627
  in head and neck cancer, II-753f
  inhibitors, II-757–759, II-759t
  squamous cell carcinoma and, II-672–673
Epidermoid cyst, II-377
Epidermolysis bullosa, II-566–568
  clinical features, II-567
  treatment, II-567–568
Epignathus, III-756–757
Epilepsy, I-161
Epinephrine
  local anesthetics and, I-178–179
  maximum dosage, I-182t
  selectivity and potency, I-180t
  side effects, I-180–181
Epineurium
  internal neurolysis and, II-94
  in nerve anatomy, II-77–78
Epiphora, in midface fracture, II-226
Epistaxis
  midface fracture associated with, II-216
  nasal fracture as cause of, II-187
Epithelial cancer, II-718–720
Epithelial-mesenchymal transition, II-619–620
Epithelial odontogenic tumor, II-444–455
Epker, Bruce, III-5
Epstein-Barr virus, II-622–623
Epulis, congenital, III-756–757
Epulis fissuratum, III-349
Epworth Sleepiness Scale, III-265
Equal-appearing interval scale, III-574
Equipment
  anesthetic, I-212–213
  in oral and maxillofacial surgery, I-49
  for sitting position, I-46–50
Erbitux. *See* Cetuximab (Erbitux)
Erbium-doped yttrium-aluminum-garnet laser, peri-implantitis treated with, I-726–727
Erich arch bar, II-148f, II-153, II-155
Erickson Model Table, III-52, III-53f, III-54
Erlotinib, II-757, II-757t, II-759t
Ernst, Franz, III-535
Erythema chronicum migrans, II-846
Erythema multiforme, II-552–553, II-568
Erythrocyte sedimentation rate (ESR), II-840
Erythromycin, medication-related osteonecrosis treated with, II-516
Erythroplakia, laser treatment, I-336–338
Escherichia coli, peri-implantitis and, I-728
Esters, local anesthetics and, I-176–177
Esthetic Abutment, I-634
Esthetic contour graft, I-487–491, I-492f
Esthetic zone, implant planning and, I-449–450
Esthetics
  edentulous maxilla treatment planning and, I-592
  facial, III-13–14, III-16
Estrogen receptor, II-623–624
Ethics
  definition, I-9
  dilemmas, I-11–12
  professionalism and, I-1–13
Ethnicity, supernumerary teeth and, I-266–267
Etidocaine
  local anesthesia with, I-232–233
  onset time, I-178t
  systemic complications associated with, I-184
Etidronate (Didrone), II-508t
Etodolac
  dosage, I-232t
  for temporomandibular joint disorders, II-871t
Etomidate, II-13, II-192
Etoposide, II-714
Etretinate, II-733
Euclid, III-13
Eustachian tube
  cleft palate and, III-548
  dysfunction, III-568
Evaluation and management codes, I-92–95
Ewing sarcoma, II-644t, II-645–646, II-662–663, III-762–763
Exanthema, II-557
Exarticulation, in dentoalveolar injury, II-128–131
Exercise, aging and, I-140–141
Exercise therapy, for temporomandibular joint disorders, II-875–876
Exfoliative cytology, II-331–332
Exodontia
  basic and complex, I-275–297
  bone fracture and, I-307–308
  burns and abrasion during, I-301
  complications, I-298–308
  damage to adjacent structure during, I-298–299
  diagnosis, I-276
  flap design, I-280
  fracture and, I-307f
  hemorrhage, I-306–307
  indications, I-275–276
  infection following, I-303
  nerve injury during, I-302–303
  pain and swelling after, I-304
  patient positioning, I-276
  removal of wrong tooth, I-298
  soft tissue injury during, I-301
  treatment planning, I-276
  trismus after, I-304
Expander, maxillary, III-587
Exparel. *See* Bupivacaine liposome injectable suspension (Exparel)
Expert witness, surgeon as, I-10
External auditory canal, II-96
External neurolysis, II-93–94
Extra-oral vertical ramus osteotomy (EVRO), III-113
Extracellular matrix
  joint function and, II-830
  in temporomandibular joint disc repair, II-915

Extraction
flapless, implant success and, I-415–416
immediate implant after, I-410
of impacted canine, I-262
patient positioning, I-276
of pediatric canine, I-262
in pediatric patient, I-260
for primary tooth injury, II-132
simple, I-276–279
surgical, I-279–281
bone removal, I-280–281
complications, I-281–283
flap design, I-280
of impacted tooth, I-283–295
indications, I-280b
multi-rooted teeth, I-281
technique, I-286–288
third molar, I-283–286
Extranodal marginal zone B-cell lymphoma of mucosa associated lymphoid tissue, II-708b, II-710, II-711f
Eye
examination, in trauma patient, II-4, II-4f
herpetic infection involvement, II-552
muscles, II-204t
Eye injury, gunshot wound as cause of, II-311
Eyebrow
asymmetry, III-408
blood vessels, III-399–402
malposition, III-424
muscles, III-397f
muscles in, III-397–399
position, III-389–391
ptosis, III-395
Eyebrow lift, III-395–428
blepharoplasty compared to, III-407f, III-413f
complications, III-423–425
direct, III-418–419
eyebrow malposition following, III-424
mid-forehead, III-419
neurotoxin-assisted, III-421
postoperative care, III-422–423
preoperative assessment, III-405–408
techniques, III-408–419
transpalpebral/transblepharoplasty, III-419
tricophytic, III-419f
Eyelid
anatomy, III-388, III-390f
blood supply, III-391f
facial esthetics and, III-16
malposition, III-393
reconstruction, II-52
sebaceous gland carcinoma of, II-720
trauma repair, II-276–277
wound closure, II-51–52, II-54f
zygomatic fracture and, II-203
Eyewear, protective, for laser surgery, III-342, III-343f

F

Face. *See also* Midface
anteroposterior deficiency, III-98
asymmetric, case study, III-84b
avulsive injury, II-282
airway management, II-282
assessment, II-282
complications, II-300
management, II-282–283
pediatric, II-274–275
reconstruction, II-287f, II-296–297, II-283–300
rehabilitation, II-300
surgical management, II-265–266
balance, osteotomy and, III-184–185
bipartition osteotomy, III-677f
Face *(Continued)*
botulinum neurotoxin for enhancement, III-439–445
burn injury, II-67–68
buttresses of, II-212b
chemical peel, III-439–445
cleft
classification of, III-496f
complex, III-506–508
Dedo classification, III-327t
deformity, III-596–600
esthetic units, II-16, III-51f
esthetics, III-13–14
examination, in trauma patient, II-4
fracture, from gunshot wound, II-316
fracture patterns, II-20
growth abnormality, III-627–628
growth and development, III-738
imaging, II-18
implant, in cosmetic surgery, III-458–475
innervation, I-227f
lower, reconstruction, II-296–297
measurements, III-127t–128t
morphogenesis, III-476–486
osteotomy and facial proportions, III-184–185
paralysis, II-101t
pediatric fracture, II-35–38
pediatric trauma, II-264–280
plastic surgery, III-359
projection, osteotomy and, III-184–185
proportions, III-119f
racial variation in, III-25
reconstruction, in Treacher Collins syndrome, III-731–732
rhytidectomy evaluation, III-326–327
soft tissue injury, II-41–69
evaluation, II-41–42
postoperative care, II-60–61
subunits, II-51f
sunken, III-465b–467b
symmetry and proportion of, III-13–14, III-96, III-184–185
transplantation, gunshot wound treatment with, II-326
transverse asymmetry, III-98
upper, evaluation, III-16
upper third, rejuvenation, III-395
vertical deficiency, III-98
vertical excess, III-97–98
vertical support, II-211
Face height
long
case study, III-70b–71b
mandibular deficiency with, III-70b–71b
mandibular deficiency case study, III-65b
normal, mandibular deficiency and, III-65b
osteotomy and, III-184
short, mandibular deficiency with, III-68b–69b
short posterior
causes, III-118b
mandibular deficiency with, III-113–143
treatment planning, III-119–120
in Treacher Collins syndrome, III-706–707, III-724
Face-lift. *See* Rhytidectomy
Facebook, marketing and, I-139
Facebow record, for model surgery, III-46–47
Faceguard, dentoalveolar injury prevention with, II-141
Facial artery, rhytidectomy evaluation and, III-328
Facial artery musculomucosal flap, II-286–290, II-292f
Facial bone
grafting of, I-415–416
in restored implant, I-411
Facial cleft. *See* Cleft deformity
Facial nerve, III-400, III-402f
anatomy, II-96–99
Bell's palsy and, II-100–101
branching pattern, II-98f
description, II-70
extratemporal segment, II-98–99
identification of, II-161f
imaging, II-99–100
injury
classification, II-100, II-100t
clinical evaluation of, II-103–104
diagnosis and management, II-70–113
extratemporal, II-104–106
iatrogenic, II-102–103
infection as cause of, II-102
in mandibular fracture, II-168
outcomes, II-106
pediatric, II-272
in rhytidectomy, III-333–334
sagittal split osteotomy associated with, III-305–308
in sagittal split ramus osteotomy, III-80
from trauma, II-101–102
treatment, II-102, II-104–106
injury mechanism, II-100–103
intracranial segment, II-96–97
intratemporal segment, II-97–98
laceration, II-60
mastoid segment, II-97–98
microanatomy, II-77–78, II-99
paralysis of, from local anesthesia, I-184
parotidectomy and, II-495–496
rhytidectomy evaluation and, III-328
traumatic injury, II-101–102
tympanic segment, II-97
Facial profile, implant planning and, I-585–587
Facial resurfacing, III-355–356
Facial support, for implant, I-584–588
Facial surgery, laser-assisted, I-343–347
Facial wound, reconstruction following, I-665–666
Faciolingual anatomy, implant restoration and, I-392, I-395
Faciolingual placement, implant, I-397–398, I-398f
Failure to diagnose, I-82
Famciclovir, II-554, II-556
Farrior technique, for otoplastic surgery, III-453, III-455f
Fascia
in forehead, III-397–399
upper face, III-401f
FAST, pediatric trauma assessed with, II-246
Fasting
pediatric patient, I-243
preoperative, I-215–216
pulmonary aspiration and, I-243t
Fat, procurement, in fat transfer, III-436
Fat graft, III-433–437
in forehead and brow lift, III-419
in temporomandibular joint total reconstruction, III-238
Fat transfer
autologous, III-434, III-467b
complications, III-437
fat procurement, III-436
in forehead and brow lift, III-419
preoperative evaluation, III-434
techniques, III-429–438
Faulk-Effleston, Col. Jan, I-24
Fear, pediatric, premedication for, I-248
Feeding, infant, in craniosynostosis care algorithm, III-672
Felty syndrome, II-839

Fentanyl, I-200
dose and potency, I-229t–230t
equianalgesic dosage, I-231t
for facial pain, II-953
midazolam combined with, I-218
pediatric dosage, I-250t
for pediatric patient, I-249, I-251
structure, I-199f
synthesis, I-197–198
transdermal, II-954
Fibrin sealant, for frontal sinus fracture, II-238–240
Fibro-osseous lesion, II-468–471
Fibroblast
cancer-associated, II-600
tumor invasion and, II-620–621
wound healing and, II-257
Fibroma
ameloblastic, II-449–451, III-745
juvenile ossifying, III-751, III-755f–756f
nonossifying, II-854
odontogenic, II-435–438
differential diagnosis, II-437
management, II-438
ossifying, III-743f
Fibromatosis
juvenile aggressive, III-745–748
paragnathic, III-748f
Fibromyalgia
facial pain and, II-944–945
pharmacotherapy, II-955–956, II-970
Fibrosarcoma, II-644t, II-652–653, II-652f
ameloblastic, II-454–455
temporomandibular joint, II-934f
Fibrosis, temporomandibular joint replacement for, II-931
Fibrous dysplasia, II-470, II-853
Fibula free flap, II-294, II-296
Fiducial facebow, III-31–33, III-35
Field-of-view (FOV) device, I-692
Financial management, for oral and maxillofacial surgical practice, I-67–71
Fine needle aspiration biopsy, II-331, II-338
for lymphoma diagnosis, II-707
for parotid gland tumor, II-494
salivary gland, II-481–483
for sarcoma, II-646
Fire, laser surgery as cause of, III-342
Firearms
classification, II-303
deaths associated with, II-303
injuries from, I-307, II-665
pediatric injury and death from, II-245
types of, II-303–304
Fistula
in cleft palate repair, III-539–540
closure, III-609–612
in double-opposing Z-plasty, III-548
indications for repair, III-610–611
rate, after palatoplasty, III-610
timing of surgery, III-610–611
Fitzpatrick skin classification system, I-344, II-691, II-691t, II-723t
5-fluorouracil, II-733–734, II-747, II-754–755, II-756t–757t
Fixation
of alveolar fracture, II-134
for atrophic mandibular fracture, II-166–167
bioresorbable material, III-63–64
Champy's technique, II-162
for cleft maxilla stabilization, III-606
ear, III-452–453
endoscopic approach, II-161–162
external, II-155, II-156f
in forehead and brow lift, III-409, III-415
for genioplasty, III-104–105
Fixation *(Continued)*
intermaxillary, III-188
in Le Fort I osteotomy, III-166–167
for sagittal split ramus osteotomy, III-62–63
internal, II-162
intraoral/transbuccal approach, II-155–158
inverted L osteotomy and, III-119t
ivy loop, II-233f
lag screw, II-164
mandibular, history, II-146
materials for, II-162–164
maxillary, in Le Fort I osteotomy, III-167
maxillomandibular, II-153, II-155, II-270, II-280
for condylectomy, III-147
example of, II-148f
history, II-146
for mandibular osteotomy, III-145
open reduction and internal, II-147
osteosynthesis, in sagittal split ramus osteotomy, III-76–77
position screw technique, III-78f
resorbable materials in, III-79b
resorbable plate, II-162
resorbable screw, in sagittal split ramus osteotomy, III-77–79
rigid, II-162
for sagittal split ramus osteotomy, III-62–63
screw, III-7
semirigid, II-162
transcervical-retromandibular approach, II-160–161
transcervical-submandibular approach, II-158–160
transosseous wire, II-162
Fixation device
example of, II-318f
external, for gunshot wound, II-316–318
maxillomandibular, II-316
Fixation screw, I-461–462
case study, I-693
designs, II-164f
lag, II-164f
maxillomandibular, II-316
for mesh graft, I-465–466
passive bone, II-164f
placement, in biomedical model, I-701f
removal, I-468
Fixed restoration
arch form, I-595–596
case presentation, I-601–602
classification for, I-590
cost, I-596–597
denture conversion to, I-608–614
for edentulous maxilla, I-584–604
extraoral examination for, I-591–602
extraoral parameters for, I-586f
force placed on, I-594–595
implant distribution and placement, I-596
material selection, I-597–602
ridge form, I-595–596
screw-retained, I-614
treatment planning, I-592–597
Flap
Abbe, II-286, II-291f, II-297–298
anterolateral thigh free, II-294, II-295f
cervicofacial, II-290, II-293f
complications, II-300
deep circumflex iliac artery, II-296
design
bone augmentation and, I-460
for guided bone regeneration, I-476
for impacted tooth removal, I-286–287
in surgical extraction, I-280
Flap *(Continued)*
envelope, I-280, I-286
for eyelid laceration, II-51–52
facial artery musculomucosal, II-286–290, II-292f
fibula free, II-294
free, II-294–296
laceration, during exodontia, I-301
local, for avulsive facial injury, II-297–298, II-286–294
microvascular free, II-294–296
open-book, I-492f, I-494f
osteoperiosteal, I-526–554
paramedian forehead, II-290, II-292f
in pediatric ablative defect reconstruction, III-768
pericranial, II-241
radial forearm, II-294, II-295f
reconstructive, II-296b
reflection, in guided bone regeneration, I-480f
regional, for avulsive facial injury, II-286–294
for skin cancer repair, II-731–732
submental island, II-290–294
temporalis muscle, II-924, II-925f
temporalis myofascial, II-912
temporoparietal fascia, II-290, II-294f
trapezoidal, I-280
triangle, I-280
vascularized free, I-668–671
Flexeril. *See* Cyclobenzaprine (Flexeril)
Flickr, marketing and, I-105
Florid cemento-osseous dysplasia, II-471
Flow cytometry, II-335–336
Fluid
administration, I-216–217
intraoperative, for pediatric patient, I-248
perioperative, I-217
Fluid management, for pediatric patient, I-248
Flumazenil, I-197
discovery, I-191
half-life, I-195t
protein binding, I-195t
structure, I-196f
Fluoromethane, II-970
Fluorouracil, II-757t
Fluoxetine (Prozac), II-873t
Flurazepam (Dalmane), II-874t
Flurbiprofen, II-871t
Focal cemento-osseous dysplasia, II-471
Focused assessment by sonography for trauma (FAST), II-246
Follicular lymphoma, II-710
Follicular sac, II-437, II-437f, II-441–444
Food and Drug Administration (FDA), codeine warning from, I-253–254
Forced duction test, II-196, II-203, II-205f
Forceps
Ash, I-278f
cowhorn, I-279f
English, I-278f
extraction, I-277, I-278f
Hayton-Williams, II-217f
luxation, in simple extraction, I-277–278
No. 23, I-279f
No. 53, I-279f
No. 150, I-277, I-278f–279f
No. 151, I-277, I-278f–279f
No. 210, I-279f
No. 88 L/R, I-279f
rotation, I-278f
Rowe maxilla disimpaction, II-217f
Forehead
blood vessels, III-399–402
bone anatomy, III-396–397
lift, III-395–428
morphogenesis, III-476

Forehead *(Continued)*
muscles in, III-397–399, III-397f
nerves in, III-397f, III-399–402
ptosis, III-395
wound closure, II-50
Forehead and brow lift, III-395–428
adjunctive procedures, III-419–422
anatomic considerations, III-395–405
complications, III-423–425
coronal, III-416
endoscopic anatomy, III-402–405
endoscopic technique, III-408–416
esthetic considerations, III-395–405
mid-forehead, III-419
muscle and fascial anatomy, III-397–399
postoperative care, III-422–423
preoperative assessment, III-405–408
techniques, III-408–419
treatment approach, III-408–419
treatment goals, III-405–408
trichophytic and trichophylic, III-416–418
Forehead line, botulinum neurotoxin for, III-441
Foreign body
pediatric wound healing and, II-260
swallowing of, during exodontia, I-302
Fosamax. *See* Alendronate sodium (Fosamax)
Fospropofol, I-201, I-202f
Fox Plane, III-24
Fractional photothermolysis, III-339
Fracture
alveolar, II-120–121, II-133–137
alveolar process, II-133–135
angle, II-166, II-169f
blow-in, II-22
blowout, II-22
bone healing after, II-257–258
buccal plate, in sagittal split ramus osteotomy, III-82
buckle-type, II-261
complete, II-261
condylar, II-270, II-31–34, II-165–166
craniomaxillofacial, spine injury and, II-38
crown, II-123–125
crown-root, II-125
dentoalveolar, II-123t, II-149, II-233f
classification, II-120
pediatric, II-233f
treatment, II-120–122
exodontia and, I-307–308
facial, II-20
from gunshot wound, II-316
pediatric, II-230
following third molar extraction, I-307f
frontal bone, II-266–267, II-20–22
frontal sinus, II-230, II-21f, II-22t
classification, II-232–233
clinical evaluation, II-231–232
complications, II-241–243
endoscopic repair, II-240
images, II-234f
management, II-236
management algorithm, II-237
postoperative care, II-241
radiologic evaluation, II-232
surgical management, II-233–240
greenstick, II-261
Knight and North classification, II-27t
mandibular. *See* Mandibular fracture
Markowitz, II-221–223
maxillary, II-27–28, II-32f–33f, II-320f
maxillofacial, I-17, II-374–376
midface. *See* Midface fracture
nasal. *See* Nasal fracture
naso-orbito-ethmoid, II-213, II-220–225
classification, II-221–222
diagnosis, II-222–223
Fracture *(Continued)*
exposure, II-223–224
treatment, II-223
orbital, II-22
palatal, II-28, II-220
pediatric
blowout, II-268
facial, II-35–38
management, II-243
orbital, II-267–268
patterns of, II-261
sinus, II-266–267
skull, II-253
primary teeth, II-131–132
root, in dentoalveolar injury, II-125–127
septal, II-178–179
sinus, II-20f
skull
images, II-233f, II-232f
pediatric, II-253
socket wall, II-133
symphyseal, pediatric, II-270
temporal bone, facial nerve injury from, II-101–103
trapdoor, II-268
zygomatic. *See* Zygomatic fracture
Framework
case presentation, I-601–602
cobalt chromium, I-599
material selection for, I-597–602
zirconia, I-599–601, I-601f
zirconia titanium, I-601
Free autogenous graft, I-326, II-556
Free flap
non-vascularized, I-675
for osteoradionecrosis, II-596
vascularized, I-668–671, I-675
Free gingival graft, I-556, I-557f, I-560–561, I-562f
Freeze-dried bone allograft (FDBA), I-428–429
Frenectomy, I-270–271
for ankyloglossia release, I-271
laser, I-336f, III-348–349
lingual, I-271f
Frenotomy, I-270–271
Frenum
labial, surgery for, I-270–271
pediatric, procedures for, I-270
Fresh-frozen bone allograft (FFBA), I-428
Friedman Palate Position, III-266f
Friedman Staging System, III-267t
Frontal bone injury, II-266–267, II-230–243
Frontal sinus, II-20–22, II-22t
axial view, II-230
classification, II-232–233
clinical evaluation, II-231–232
comminution of, II-239f
coronal view, II-230f
fracture, II-20f
anterior wall, II-242
classification, II-232–233
complications, II-241
endoscopic repair, II-240
management algorithm, II-237
management of, II-236
pediatric, II-266–267
posterior wall, II-238–240
postoperative care, II-241
radiologic evaluation, II-232
surgical management, II-233–240
injury, II-230
management of, II-236
obliteration, II-236–238
radiologic evaluation, II-232
sagittal view, II-230
surgical anatomy, II-230–231
surgical management, II-233–240
Frost, Harold, III-247
Frozen section, II-330–331, II-393
Functional capacity, preoperative evaluation and, I-139
Functional cleft lip repair, III-525–526
principles, III-527–530
studies, III-530–531
surgical technique, III-527–528
Functional endoscopic sinus surgery, I-580, I-582f
Functional magnetic resonance imaging (fMRI), II-947
Functional matrix repair, III-525–531
Functional Outcomes of Sleep Questionnaire, III-265
Functional residual capacity (FRC)
age values, I-241t
pediatric, I-241, I-241t
Furlow double-opposing Z-plasty, III-505, III-546–547, III-610
example, III-507f
limitations and complications, III-548

G

Gabapentin (Neurotin)
for facial pain, II-955t, II-956
for nerve injury, I-364
Gabapentinoid drugs, I-233, I-364
Gait, in mandibular movement, II-806–808
Galetti articulator, III-49
Gamma (g)-aminobutyric acid (GABA)
action, I-191–192
discovery, I-191
Gamma (g)-aminobutyric acid - benzodiazepine receptor complex, I-192, I-194f
Ganglion cyst, temporomandibular joint affected by, II-852
Ganz-Rinaldi surgical protocol, I-705f–706f, I-706
Ganzer, Hugo, III-535
Gardner syndrome, II-464, II-475, II-476f, II-644
Garre osteomyelitis, II-858
Gas exchange, pediatric, II-249
Gastric emptying, anesthesia and, I-216
Gastroesophageal reflux disease (GERD), I-141, III-286
Gastrointestinal disease, preoperative management and, I-141–142
Gastrointestinal system
non-Hodgkin lymphoma, II-710
preoperative management and, I-141–142
GBR. *See* Guided bone regeneration (GBR)
Gefitinib, II-757, II-757t, II-759t
Gelatin, anaphylaxis associated with, I-252t
Gemcitabine, II-757t
Gender, pediatric trauma and, II-245
Gene
amplification, II-607, II-607f
cancer treatment based on, II-622, II-625
cell regulation, II-603–606
classification, II-603
epigenetic alteration, II-609
epigenetic control, II-605f
molecular paradigm, II-604f
Ras family, II-612
regions, II-603
sequencing, II-623
tumor suppressor, II-602–603, II-609, II-614, II-616
Gene expression
alterations, II-607, II-609
cancer diagnosis and, II-623
epigenetic alteration, II-609
epigenetic control, II-605f
molecular paradigm, II-603, II-604f
prevention, II-603

Gene therapy, for oral cancer, II-678–679
General partnership, I-58–59, I-59t
Genetics
  cancer development and, II-602
  cancer treatment based on, II-622, II-625
  cell regulation and, II-603–606
  in cleft deformity, III-493–494
  craniosynostosis syndromes, III-667–669
  melanoma and, II-690–691
  oral cancer and, II-672–673
  sequencing, II-623
  in Treacher Collins syndrome, III-703–705
Geniculate ganglion, II-97
Genioglossal advancement, III-268
Geniohyoid muscle, II-784
Genioplasty, III-96–112, III-319–321
  alloplastic, III-103–104
  bony changes, III-104–105
  chin position and, III-303t
  chin repositioning, III-108f
  complications, III-319–321
  in computer-aided surgical simulation, III-35–36
  facial orientation and, III-28
  fixation devices, III-104–105
  functional, III-96–97, III-101
  history, III-2
  indications, III-97–98
  mandibular widening with, III-201
  Michelet, III-101
  model surgery and, III-60
  neurosensory disturbance, III-320
  sagittal split, III-103, III-104f–105f
  sliding, III-101–103
  for small chin, III-463b
  surgery, III-101–104
  tissue analysis, III-98
  treatment planning, III-98–101
  vertical reduction, III-111f
  wound healing failure, III-320
Gerdy's tubercle, I-457–458
Ghost cell, II-370, II-372f–373f
Giant cell granuloma, II-462–464, II-750–751, III-852
  classification, II-463t
  example, II-463f
Giant cell tumor, II-464
Gingiva
  avulsive wound, II-137
  in dentoalveolar injury evaluation, II-117, II-123t
  in fixed restoration, I-589, I-590f
  hypertrophic, III-352
  injury treatment, II-137
  minimal display, treatment for, I-585f
  miniscrew implant and, I-316
Gingival cyst, II-365, II-424
Gingival graft, I-450–451, I-450f
Gingivectomy, laser, III-348–349
Gingivoperiosteoplasty, III-498, III-562, III-584
Gingivoplasty, laser, III-352
Glabella, III-395–396
  botulinum neurotoxin for, III-440
  horizontal line correction, III-411
  innervation, III-400
  muscles, III-404–405
Glandular odontogenic cyst, II-365–368, II-369f
Glasgow Coma Scale (GCS), II-9, II-247
Glenoid fossa, II-778, II-821
Globulomaxillary cyst, II-375–376
Glogau skin classification, I-343, II-723b
Glucocorticoid deficiency, I-159t
Glutamate, I-205
Glycolic acid, for chemical peel, III-443
Glycolysis, in cancer cell metabolism, II-601–602
Glycopyrrolate
  for autogenous bone graft prophylaxis, I-451
  for pediatric patient, I-251
Glycosaminoglycans, joint function and, II-830
Gold alloy
  for abutment, I-636
  for single anterior implant, I-630–631
Gold Humanism Foundation, I-4
Golden ratio, III-13, III-14f–15f
Goldenhar syndrome, III-687, III-689f, III-694f
Goldman tip, III-376
Goode's method, chin position analysis with, III-460t–461t
Goode's method of nasal projection, III-369
Gorlin-Goltz syndrome, II-361–364, II-364b
Gorlin syndrome, II-718
Gout, II-847–848
Graft
  auricular cartilage, II-912–913
  autogenous
    after discectomy, II-912
    for temporomandibular joint surgery, II-772
  bone. *See* Bone graft
  connective tissue, I-415–416
  costochondral, II-326
  dermal, II-913–914
  for ear laceration, II-58
  failed, temporomandibular joint replacement after, II-931
  free fibula, II-326
  free gingival, I-557f
  pediculated, I-556, I-560f
  peri-implant, I-415–416
  rib, in pediatric ablative defect reconstruction, III-766–767
  for skin cancer lesion repair, II-731–732
  soft tissue. *See* Soft tissue graft
  spreader, in rhinoplasty, III-371f
  techniques and materials for, I-426–436
  tip onlay, III-374
  umbrella, III-374
  vascularized interpositional, I-558
Granuloma
  central giant cell, II-750–751, III-852
  laser excision, III-349
Grayson nasoalveolar molding appliance, III-498
Greenstick fracture, II-261
Growth, definition, III-628t
Growth factor
  bone graft and, I-431–432
  cancer cell growth and, II-612
  cell division and, II-611f
  joint function and, II-830–832
  pain management and, II-959
  in temporomandibular joint arthrocentesis, II-888
Growth inhibitory signal, cancer cell growth and, II-612–614
Growth signal
  cell division and, II-611f
  release from, II-617f
GSW. *See* Gunshot wound (GSW)
GTR. *See* Guided tissue regeneration (GTR)
Guerrero, Caesar, III-5, III-7–8
Guided bone regeneration (GBR), I-462–464
  in alveolar distraction, I-538–539
  applications, I-484–493
  case study, I-499b–500b
  complications, I-464
  defect configuration and, I-476
  history, I-475
  horizontal augmentation, case study, I-502b
  horizontal bone augmentation, I-464
  implant placement, case study, I-495b, I-497b–498b
Guided bone regeneration (GBR) *(Continued)*
  implant simultaneous with, I-487–491
  incision design, I-476–479
  membrane selection, I-480–483
  multiple tooth, I-478f
  patient selection, I-476
  for peri-implant defect, I-493
  postoperative considerations, I-493–504
  principles, I-476–480
  single tooth, I-478f
  socket preservation, I-493
  soft tissue closure, I-479–480
  space maintenance, I-483–484, I-526–527
  titanium mesh in, I-484
  vertical augmentation, case study, I-501b–503b
  vertical bone augmentation, I-464
Guided tissue regeneration (GTR), I-475–508
Gunshot wound (GSW), II-282, II-284
  algorithm for treatment plan, II-312f
  assessment, II-308–309
  avulsive injury, I-665
  ballistics, II-304–305
  categories, II-305
  classification, II-304–305
  classification system, II-304–305
  complications associated with, II-300
  deaths associated with, II-303
  debridement, II-313–314
  facial injury from, II-282, II-294–296
  factors influencing degree of, II-307
  hemorrhage control, II-309
  high-energy, II-318–320
  low-velocity, II-316
  management diagram, II-312f
  mandibular fracture from, II-315–316
  maxillofacial, II-303–328
    assessment, II-308–309
    external fixator for, II-316–318
    reconstructive phase of treatment, II-324–326
    self-inflicted, II-320–323
    treatment, II-307–313, II-323–324
  neurologic evaluation, II-311
  ophthalmologic assessment, II-311
  reconstruction, I-667f
  self-inflicted, II-320–323
  soft tissue injury from, II-306
  surgical management, II-265–266
  trajectory patterns, II-283f
  treatment
    high-energy, II-318–320
    intermediate phase, II-323–324
    reconstructive phase, II-324–326
  treatment algorithm, II-312f
  treatment guidelines, II-313–314
Gutta percha, injury associated with, I-378

H

Hader bar, I-644f, I-646f, I-648f
Hair
  laser removal, I-349, III-358
  laser transplant, III-358
Halcion. *See* Triazolam (Halcion)
Hall, Richard John, I-176
Halothane (Fluothane), I-207
Halsted, William Stewart, I-176
Hand, foot, and mouth disease, II-556–557
Hand-Schuller-Christian disease, II-523
Handgun
  types of, II-303
  wound from, II-305–306
Hanks balanced salt solution, II-129–130
Hard palate
  anatomy, II-612–615, III-671
  repair, III-503, III-534

Hard palate *(Continued)*
squamous cell carcinoma, II-681–683
submucous cleft, III-618–619
surgical technique, III-537–539
two-stage repair, III-548–549, III-551–552
Hard tissue, peri-implant grafting and, I-415–416
Hargis, Harold, III-6
Harvest guide, I-705f
Hashimoto-Pritzker syndrome, II-523
Hashimoto thyroiditis, I-158, II-710
Hayes-Martin maneuver, II-158–160
Hayflick limit, II-616
Hayton-Williams forceps, II-217f
HBO. *See* Hyperbaric oxygen therapy (HBO)
HCPCS. *See* Healthcare Common Procedure Coding System (HCPCS)
Head and neck
abnormal shape, III-647–648
angiosarcoma, II-658
cancer
chemotherapy for, II-755–756
epidemiology, II-752
metastatic, II-755–756
oncology principles in, II-752–763
radiation therapy for, II-741–751
sites, II-742–745
treatment, II-745–747
chondrosarcoma, II-649
dissection, II-683
embryogenesis, III-478–480, III-481f–482f
fibrosarcoma, II-652
liposuction, III-429–438
lymphoma, II-707
malignant fibrous histiocytoma, II-651
melanoma, II-690
neurofibroma, III-755
non-Hodgkin lymphoma, II-710
non-melanoma skin cancer, II-717–740
in oculoauriculovertebral spectrum, III-690b
osteosarcoma, II-647
radiation therapy for, II-741–751
sarcoma, II-643, II-644t
skin cancer, II-721–725
soft tissue injury, II-41–42, II-41–69
squamous cell carcinoma, II-670–689, II-719, II-752
chemotherapy for, II-754–756
clinical trials, II-758t
risk factors, II-752
treatment, II-752–754
Headache
chronic, frontal sinus fracture as cause of, II-243
facial pain and, II-944–945
Healing cap, I-626f, I-634f
Health
behavioral, I-140–141
cognitive, I-141
Health care
access to, I-3
continuous improvement of, I-3
safety, I-96
Health history
preoperative evaluation and, I-138
risk management and, I-75–76
Health Insurance Portability and Accountability Act (HIPAA), I-85
Healthcare Common Procedure Coding System (HCPCS), I-87–89
Hearing, in craniosynostosis care algorithm, III-672
Hearing aid, bone-anchored, III-733
Hearing loss
in oculoauriculovertebral spectrum, III-696
in Treacher Collins syndrome, III-705, III-707, III-732–733
Heart disease, vasoconstrictor drugs and, I-182b
Heart failure
classes of, III-281t
oral surgery following, I-139
Heart murmur, pediatric, I-242
Heart rate, infant, II-249–250
Helicobacter pylori
lymphoma associated with, II-713
peptic ulcer disease associated with, I-140
Hemangioma
congenital, II-536–538
definition, II-534
infantile. *See* Infantile hemangioma (IH)
intraosseous, II-852–853
laser treatment, I-338, I-347
local anesthetics, III-356
management, II-537–538
resection, II-537–538
synovial, II-853
temporomandibular joint, II-852–853
as vascular anomaly, II-534
Hemangiopericytoma, II-644t, II-659–660
Hematologic disorders
orthognathic surgery and, III-284–285
wound healing affected by, II-259
Hematologic system, preoperative evaluation of, I-159–161
Hematoma
in blepharoplasty, III-393
epidural, II-252
local anesthetics and, I-184
in oculoauriculovertebral spectrum, III-688–690
otoplastic surgery and, III-455–456
postoperative, II-7f
in rhinoplasty, III-383
in rhytidectomy, III-332
septal, II-187
subdural, II-253–254
Hematoxylin and eosin (H&E) stain, II-331–332, II-692–693
Hemifacial microsomia, III-15–16, III-158f–160f
Hemimandibular elongation, III-17f–22f
Hemochromatosis, II-644
Hemoglobin, absorption spectrum, I-329f
Hemophilia, preoperative evaluation of, I-161
Hemorrhage
in gunshot wound patient, II-309
intracranial, II-252–254
intraoperative, I-306–307
in Le Fort I osteotomy, III-169
postoperative, I-306–307
in sagittal split osteotomy, III-82, III-310–313
subarachnoid, II-253
in vertical ramus osteotomy, III-314
Hemorrhagic bone cyst, II-852
Hemostasis
laser for, I-330
in orthognathic surgery, III-289
Hemostatic sponge, I-512–513
Henderson-Hasselbalch equation, I-177
Hendrickson classification of palatal fractures, II-216f
Heparin, preoperative management, I-161
Hepatic disease
preoperative evaluation of, I-141–142
preoperative management and, I-141–142
Hepatitis C, allograft material and, I-429
Heroin, synthesis, I-197–198
Herpangina, II-556–558
clinical findings, II-557
treatment, II-557–558
Herpes labialis, II-554–556
Herpes simplex virus infection, II-551–556
clinical features, II-552–553
diagnosis, II-553
diseases associated with, II-551–552
erythema multiforme associated with, II-568
pediatric, II-555–556
recurrent, II-554–555
secondary, II-553
systemic agents for, II-554
treatment, II-553–554
Herpes zoster, osteomyelitis and, II-582f–585f
Herpes zoster oticus, II-102
Herpetic encephalitis, II-555
Herpetic meningitis, II-555
Herpetiform aphthae, II-559
Heterotopic bone formation, II-858
High-reliability organization (HRO), I-97–98
Hinge articulator, III-49
Hip, bone harvested from, I-458–460
HIPAA. *See* Health Insurance Portability and Accountability Act (HIPAA)
Histamine release, opioid drugs associated with, I-199–200, I-201b
Histiocyte, definition, II-524–525
Histiocytosis, Langerhans cell, II-857
Histiocytosis X, II-523, II-525b
Histomorphometric analysis, I-443
History and physical examination (H&P), I-75–76
Hodgkin cell, II-709, II-709f
Hodgkin lymphoma, II-707, II-709
clinical staging, II-708b
radiation therapy for, II-741
survival rate, II-714
treatment, II-713–714
Holdaway method, chin position analysis with, III-460t–461t
Holoprosencephaly, III-487
Homeostasis, genetic regulation, II-603–604
Honesty, professionalism and, I-5
Horizontal alveolar transport osteogenesis, I-547–549
Hounsfield unit, II-820–821
House-Brackmann facial nerve grading scale, II-100, II-100t, II-103
H&P. *See* History and physical examination (H&P)
HRO. *See* High-reliability organization (HRO)
Hullihen, Simon, III-62, III-113, III-492, III-1
Human immunodeficiency virus (HIV)
allograft material and, I-429
lymphoepithelial cyst associated with, II-485
parotid gland affected by, II-488
Human papillomavirus (HPV), oral cancer associated with, II-672
Human resources
alternatives, I-67
in oral and maxillofacial surgical practice, I-65–67
Hunsuck, Ervin E., I-24
Hutchinson sign, II-552
Hyaluronic acid (HA), II-884, II-887
Hydrocephalus, III-646, III-672
Hydrocodone (Vicodin)
equianalgesic dosage, I-231t
for facial pain, II-953, II-955t
prescription, I-228
for temporomandibular joint disorders, II-872t
Hydrocortisone
equivalent dosage, III-287t
for temporomandibular joint disorders, II-871t
Hydrocortone, II-871t

Hydromorphone (Dilaudid)
dose and potency, I-229t–230t
pharmacokinetics, I-230t
synthesis, I-197–198
for temporomandibular joint disorders, II-872t
Hydroquinone, I-345
Hydroxyadriamycin, II-713
Hydroxyapatite
alloplastic implant with, I-440–441
for bone graft, I-483–484
bone graft with, I-430
Hydroxyurea, II-757t
Hydroxyzine (Vistaril), II-874t
Hyperalgesia, definition, I-355t, I-360, II-946t
Hyperbaric oxygen therapy (HBO), I-590, II-595, II-678
Hyperesthesia, definition, I-355t, II-946t
Hyperglycemia, complications associated with, I-141
Hyperkeratosis, laser treatment, I-336–338
Hypernasality, III-570
Hyperparathyroidism, II-464–466, II-465f
Hyperpathia, definition, I-355t, I-360
Hyperplasia
definition, III-628t
mandibular, III-638
Hypertension, intracranial, III-674–675
Hyperthyroidism, I-141, I-158, I-158t
Hypertrophy, definition, III-628t
Hypodontia, in cleft lip and palate, III-585
Hypoesthesia, definition, I-355t, II-946t
Hypoglossal nerve stimulation, III-269
Hypoglycemia, postoperative, I-216–217
Hypohidrotic ectodermal dysplasia, I-683
Hyponasality, III-570–571
Hypopharynx
carcinoma of, II-746t
radiation therapy for carcinoma of, II-744
Hypopigmentation, skin resurfacing and, I-345–346
Hypoplasia
mandibular, III-637–638
maxillary, III-638–642, III-639f, III-778
midface, III-630–632
Hypotension, rapid-onset, I-165
Hypothermia
perioperative, I-170
therapeutic, II-256
Hypothyroidism, I-141, I-158, I-158t
Hypoventilation, pediatric cardiac arrest and, II-249
Hypoxemia, anesthesia associated with, I-168

I

IAJ. *See* Implant-abutment junction (IAJ)
IAN. *See* Inferior alveolar nerve
Ibandronate (Boniva), II-508t
Ibuprofen (Advil, Motrin)
dosage, I-232t
for facial pain, II-954–955, II-955t
for masticatory myalgia, II-969
for nerve injury, I-363
preoperative, I-231
for temporomandibular joint disorders, II-871t
ICD-10 CM code set, I-89–92, I-90t
ICP. *See* Intracranial pressure (ICP)
Idiopathic bone cavity, II-852
Ifosfamide, II-757t
IH. *See* Infantile hemangioma (IH)
Iliac block graft, I-569–570
Iliac crest bone graft, I-437, I-458–459
for cleft maxilla reconstruction, III-590
complications, III-592
Ilium, as bone graft donor site, I-458–460
Ilizarov, Gavriel, III-247, III-774
Illness
progressive, I-146
short-term, I-145–146
Imaging. *See also* Computed tomography (CT); Magnetic resonance imaging (MRI)
avulsive facial injury, II-283
charge-coupled device, II-815–816
complementary metal oxide semi-conductor device, II-815–816
craniomaxillofacial pathology, III-738–739
dentoalveolar injury, II-119–120
digital, for temporomandibular joint, II-815–816
facial nerve, II-99–100
for facial pain, II-946–947
frontal sinus fracture, II-232
functional, II-825
fusion, II-826
head and neck skin cancer, II-721, II-725
interpretation, II-17–20
mandibular fracture, II-31, II-153
maxillofacial trauma, II-17–40
for melanoma diagnosis, II-699
midface fracture, II-213
naso-orbito-ethmoid fracture, II-223
odontogenic tumor, II-392–393
osteomyelitis, II-576
pediatric craniomaxillofacial trauma, II-233–240
pediatric facial fracture, II-38
pediatric trauma, II-246–247
photo-stimulable phosphor device, II-815–816
reverse Towne projection, II-816–817
salivary glands, II-481–483
sarcoma, II-645
submentovertex projection, II-817
temporomandibular joint, II-815–829
temporomandibular joint disorder, II-801–804
temporomandibular joint internal derangement, II-906–907
temporomandibular joint prosthetic reconstruction, III-223–226
three-dimensional, I-207–208, II-688–710
for anterior maxillary deficiency, I-688–696
history, III-7
midface fracture, II-213
sinus augmentation, I-705–706
temporomandibular joint, II-815, II-820, II-824–825
trigeminal nerve, II-78–81
zygomatic fracture, II-191–193
Imatinib, II-703–704
Imbrication, III-330
Imipramine (Tofranil), II-873t
Imiquimod, II-734
Immediate implant loading (IIL), I-605–623
advantages, I-606
case study, I-608–610
clinical findings for, I-606
digitally planned and converted technique, I-613–614
extraoral conversion technique, I-613
implant angulation, I-608
intraoral conversion technique, I-610–613
literature review, I-605–608
prosthetic principles, I-607
surgical and prosthetic principles, I-607–608
Immediate implant with immediate provisionalization (IIIP), I-410
advantages of, I-416
esthetic complications of, I-410–412
flapless procedure, I-412f
flapless procedure for, I-413–414
molar, I-418–420
surgical principles for, I-412–418
Immediate provisional restoration, I-416–418
Immune system
description, II-600–601
tumor invasion and, II-620–621
Immunoconjugate therapy, for cancer, II-625–626
Immunodeficiency
craniomaxillofacial trauma management and, II-3t
wound healing affected by, II-259
Immunofluorescence study, II-332
Immunoglobulin, in rheumatoid arthritis, II-839–840
Immunoglobulin A, in linear IgA disease, II-565
Immunohistochemistry, II-333–334
cancer diagnosis and, II-623–624
for melanoma diagnosis, II-694–695, II-695t
Immunostain, II-333f–335f
Immunotherapy, for oral cancer, II-678
Impairment
aging and, I-146
medical professional, I-106
physical and mental, I-143–147
Implant
in acquired and congenital defects, I-665–687
adjacent, I-420–422
adjacent teeth root position and, I-393
alignment, in implant overdentures, I-650–653
allogenic bone graft for, I-428–429
allograft, for chin augmentation, III-464b
alloplastic, I-440–441
for chin augmentation, III-463b
in oculoauriculovertebral spectrum, III-696
in rhinoplasty, III-380
for temporomandibular joint surgery, II-772
alveolar distraction and, I-539f–542f
apicocoronal, I-396–397
autogenous bone graft for, I-427–428, I-446–474
biological models, I-696–699
bone loss around, I-398–401
in bone transport, III-218
Cal bar stabilizing, I-573f
cantilever in, I-599–600, I-600f
case presentations, I-316–320
cement
clinical protocols, I-717–720
issues associated with, I-711–712
properties of, I-714
cement-retained single anterior, I-630–631
chin, III-96, III-104, III-321
in cleft palate repair, III-623
in cleft patient, I-680–683
clinical application, I-316–320
complications, I-323–324
connected, I-647–649
decision making process for, I-632–635
depth, cement margin site and, I-712–720
diameter, I-400
digital workflow protocols, I-688–710
for ectodermal dysplasia, I-675
esthetic
diagnosis, I-391–409
multiple implants and, I-401–405
treatment plan, I-391–409
extraoral, for chin augmentation, III-464b
facial, in cosmetic surgery, III-458–475
facial and lip support, I-584–588
failure, guided bone regeneration for, I-493, I-494f
failure rate of, smoking and, I-412
height, I-653
history, I-311
hyperbaric oxygen therapy, I-678

Implant *(Continued)*
immediate, I-410–425
angulation principles, I-608
buccal plate remodeling after, I-413–414
case study, I-608–610
denture conversion to, I-608–614
digitally planned and converted technique, I-613–614
esthetic complications of, I-410–412
extraoral conversion technique, I-613
intraoral conversion technique, I-610–613
mandibular, I-605–623
molar, I-418–420
multiple, I-420–422
positioning of, I-414–415
surgical and restorative principles for, I-412–418
individual *versus* connected, I-647–649
laser used in, I-340–341, III-349–350
lip, III-474b
location of, for overdentures, I-649–650
malar, III-468b–469b, III-470t
mandibular, I-605–623
maxillary anterior
esthetic zone evaluation, I-449–450
position of, I-414
microthreads at coronal aspect, I-399–400
miniplate, I-313–314
miniscrew, I-311
molar, I-418–420
multiple, I-401–405
neck design, I-399
nerve injury associated with, I-379–380, II-379–380
causes, I-379–380
repair, I-379–380
treatment, I-380
number of
for fixed prosthesis, I-594
illustration, I-647f
one-piece, I-400
osseointegration, I-678
patient condition, I-672–674
pediatric, I-269–270
placement, I-397f
in bone graft site, I-468
case study, I-498b
faciolingual, I-397–398, I-398f
mesiodistal, I-397
platform switching, I-400–401
pontic site development, I-404
position, I-396, I-397f, I-414–415
posterior, decision tree, I-632f
premaxillary, I-575
radiotherapy and, I-677–678
restorative aspects, I-711–722
screw-retained single anterior, I-631
screw *versus* cement, I-631–632, I-711
simultaneous with guided bone regeneration, I-487–491
case study, I-499b
single anterior, I-629–631, I-635
decision tree for, I-635, I-636f
single posterior, I-624–629, I-632–635
cement-retained, I-624–627
decision tree, I-632–635, I-632f
single tooth, I-478f, I-624–640
cement-retained, I-624–627
screw channel in, I-637–639
sinus augmentation simultaneous with, I-517f, I-519–520
sinus lift simultaneous with, I-519f
site development
case study, I-496b–497b
in guided bone regeneration, I-484–487
skeletally based, I-311–324
Implant *(Continued)*
smile line and, I-391–393
soft tissue attachment, I-712, I-713f
soft tissue interface, I-555, I-556f
splinted, I-647–649
surface characteristics, I-400
survival rates, I-672
temporal, in forehead and brow lift, III-421–422
temporomandibular joint, II-771
for temporomandibular joint disorders, II-770–771
tent-pole technique, I-485f–487f
three-dimensional alveolar distraction osteogenesis, I-534–551
three-dimensional imaging for, I-688–710
timing of, I-674–675
tooth position and, I-391–392
types, I-313–316, I-646
virtual planning of, I-611f
zygomatic. *See* Zygomatic implant
Implant-abutment junction (IAJ), I-400–401
Implant overdentures, I-641–664
base adaptation, I-654
base reinforcement, I-655
clinical procedures, I-656–658
complications, I-643–645
contact with ridge, I-654
controversy associated with, I-643–644
design principles, I-645–655
disadvantages, I-643
four-implant, I-656–658
implant alignment, I-650–653
implant-fixed dentures compared to, I-642–643
implant location, I-649–650
implant types for, I-646
loosening of retentive mechanism, I-644–645
mandibular, I-643–646
maxillary, I-646
natural tooth overdentures compared to, I-641–643
number of implants in, I-647f
occlusion, I-655
retentive mechanisms, I-654
three-implant, I-656–658
two-implant, I-645, I-656–658
Implant site, bony anatomy of, I-394–396
Improvised explosive device (IED), II-318, II-319f
Incisal edge, I-591–592
Incision
in alveolar distraction osteogenesis, I-535–536
for bone graft recipient site, I-460
capsular, II-909–910
coronal, for craniomaxillofacial surgery, III-739
craniomaxillofacial surgery, III-739–741
craniosynostosis surgery, III-670
double-opposing Z-plasty, III-544f
endaural, II-908–909
forehead and brow lift, III-408f
guided bone regeneration, I-476–479
impacted maxillary canine, I-290f
intracartilaginous, III-372, III-373f
Killian, III-372, III-373f
laser for, I-330
Le Fort I osteotomy, III-163
Lynch, II-184–185
mandibular movement for, II-787
open-book, I-478f
preauricular, II-908
rhinoplasty, III-371–372, III-377–381
sulcular, I-281f
temporomandibular joint internal derangement surgery, II-908–909
transfixion, III-373f
Incisor
fracture, II-126f
impacted, I-265
implant replacement, I-403
inclination, III-300, III-302f
maxillary
extraction, I-277
fracture, II-132f
implant for, I-420–422
primary, loss of, II-132
Indian Health Service, I-31
Indomethacin
dosage, I-232t
for temporomandibular joint disorders, II-871t
Infant
abnormal head shape, III-647–648
airway, I-239
body composition, I-242
chest wall, I-240
cleft lip and palate
management, III-491–512
presurgical orthopedic treatment, III-561–567
repair, III-503, III-513–533
treatment planning, III-496–497
cleft palate repair goals, III-610
cranial vault sutures, III-646f
craniosynostosis, care algorithm, III-671–675
endothelial tumor, II-534
gingival cyst of, II-365
heart rate, II-249–250
herpes simplex infection, II-555
lymphatic malformation in, II-539
rib cage, I-240f
thermoregulation, I-241–242
Treacher Collins syndrome, III-705–706
Infantile hemangioma (IH), II-534–536
anomalies associated with, II-536
incidence, II-535
management, II-537–538
PHACE association, II-536
phases, II-535
resection, II-537–538
steroid therapy for, II-537
Infection
after otoplastic surgery, III-456
allograft material and, I-429
bone graft healing affected by, I-433–434
facial nerve injury caused by, II-102
frontal sinus fracture associated with, II-241
herpes simplex virus, II-551–556
impacted molar removal and, I-292–293
lymphoma associated with, II-708–709
mandibular fracture and, II-168
in orthognathic surgery, III-290, III-315–316
pediatric, I-260
postsurgical, I-283, I-303
in rhinoplasty, III-383
in rhytidectomy, III-333–335
in sagittal split ramus osteotomy, III-82
salivary gland, II-485–488
sinus, I-579–581, I-581f
wound healing affected by, II-260
Infectious arthritis, II-843–847
Infective endocarditis, III-281b
Inferior alveolar nerve, II-74–75
in distraction osteogenesis, III-776–777
furcation, II-75t
imaging, II-78
injury, II-81
implant surgery as cause of, II-82
in intraoral vertical ramus osteotomy, III-91
in mandibular surgery, III-318
neurosensory testing for, II-88–90
in sagittal split ramus osteotomy, III-80, III-80b
third molar removal as cause of, II-82

Inferior alveolar nerve *(Continued)*
in mandibular fracture, II-168
in sagittal split osteotomy, III-301–305
surgical access, II-91–92, II-93f
Inferior alveolar nerve block (IANB), for pediatric patient, I-258
Inflammation
bone healing and, I-426–427
implant anchor and, I-323
salivary gland, II-485–488
Informed consent, I-62
documentation of, I-77
preoperative, for orthognathic surgery, III-280
professionalism and, I-2
risk management and, I-76–78
Infraction, crown, II-122–123
Infraorbital artery, I-510
Infraorbital nerve, II-76
injury, I-202, II-367–368
surgical access, II-91–92
Infraorbital paresthesia, II-202–203
Infraorbital rim, surgical approaches, II-196–199
Infratemporal fossa, displacement into, I-299–300
Infusion pump, I-218–219
Inhalation anesthesia, pediatric, I-250–251
Inhalation anesthetic drugs, I-206–208
action, I-207
clinical effects, I-207–208
induction, I-220
nitrous oxide, I-220
physical and chemical characteristics, I-207t
structure, I-207
Injection, local, nerve injury associated with, II-81
Injection device
computer-controlled, I-187
needleless, I-187
Injury
avulsive facial, II-282–302
complications, II-300–302
reconstruction, II-283–300, II-287–290f, II-296–297
rehabilitation, II-300
surgical management, II-283
axonal, II-251–252
blunt, pediatric, II-245
burn, II-67–68
cervical, craniomaxillofacial fracture and, II-38
dentoalveolar. *See* Dentoalveolar injury
facial
evaluation, II-41–42
pediatric, II-264–280
firearm-related, II-303, II-307
inhalation, airway affected by, II-11–12
intracranial, craniomaxillofacial fracture and, II-38
lacrimal, II-272–273
maxillofacial gunshot, II-303–328
assessment, II-308–309
treatment, II-307–314
mechanism
in craniomaxillofacial trauma, II-2
trauma patient assessment and, II-10
neurologic, pediatric, II-250–252
ocular, in midface trauma, II-213
pediatric, II-245–263
assessment, II-231–232
epidemiology, II-230–231
evaluation, II-246
patterns of, II-260–261
wound repair after, II-256–261
pediatric craniomaxillofacial, imaging, II-233–240
pediatric facial, physical evaluation, II-232–233
Injury *(Continued)*
shotgun, II-320
soft tissue, pediatric, II-271–273
thermal, airway affected by, II-11–12
zygomatic
complications associated with, II-202–207
treatment, II-193
Instagram, marketing and, I-105–106
Institute of Medicine (IOM), I-73, I-97
Instrumentation, for surgical removal of impacted tooth, I-286, I-286b
Insulin, oral surgery and, I-157t
Insulin growth factor (IGF), II-257–258, II-258t
Insurance, I-82, I-87–95
Insurance claim
incident *versus*, I-83
against oral and maxillofacial surgeon, I-82–83
Insurance contract, I-89
Integrin, II-619–620, II-629
Intensity-modulated radiation therapy, II-590, II-747–748
Interdental distraction osteogenesis (IDO), I-547
Interferon alfa-2b, II-701
Interleukin-1 (IL-1), II-831f, II-832–833, II-884
Interleukins
in temporomandibular joint dysfunction, II-884
in temporomandibular joint internal derangement, II-906
Intermaxillary fixation screw, II-147, II-148f
Internal auditory canal, II-96
Internal derangement (TMJ), II-813f, II-889, II-893–894
arthrotomy procedures, II-910–918
condylotomy for, II-917–918
diagnostic imaging, II-906–907
discectomy, II-911
pathogenesis, II-905–906
patient history, II-904–905
physical examination, II-904–905
postoperative therapies, II-918–919
preoperative therapies, II-907
stages, II-904, II-905b
surgery, II-904–922
surgical approaches, II-908–910
Wilkes classification, II-905b
wound closure, II-910
Internal neurolysis, II-94
International Association for Dental Traumatology (IADT), II-120
Internet
medical information on, I-80
oral and maxillofacial surgery marketing, I-102
Interpersonal relationships, surgical practice and, I-17–22
Interpositional bone graft, I-527–528
Interview
employee, I-113
key points, I-114b
Intracranial hypertension, III-674–675
Intracranial pressure (ICP)
in brachycephaly, III-660
in craniosynostosis, III-645–646, III-675
monitoring, in pediatric brain injury, II-254
in pediatric brain injury, II-252
Intraocular pressure, retrobulbar hemorrhage and, II-207
Intraoral vertical ramus osteotomy (IVRO), III-62–95
case study, III-84b, III-86b
complications, III-90–92
history, III-64
indications, III-83
limitations, III-83
surgical sequence, III-83–90
Intraosseous catheter, I-247
Intraosseous defect, in anterior maxilla, I-448f
Intraosseous hemangioma, II-852–853
Intraosseous odontogenic carcinoma (IOC), II-431–435, II-431f
clinicopathologic considerations, II-435
from epithelial odontogenic tumor, II-435
from odontogenic cyst, II-433
from odontogenic residue, II-433
outcomes, II-435
Intravelar veloplasty, III-535–536, III-538, III-539f, III-612–615
Intravenous access, pediatric, I-247–248
Intravenous agents, pharmacokinetics, I-204t
Intravenous line, in oral and maxillofacial surgery, I-50
Intubation
for airway patency, I-213–214
for pediatric trauma, II-248
Invasion-metastasis cascade, II-619
ION. *See* Infraorbital nerve
Ipilimumab, II-701, II-703–704
Irinotecan, II-757t
Irradiated cancellous allograft (ICA), I-429–430
Isocarboxazid, I-149t
Isoflurane (Forane), I-207–208
Isotretinoin, II-733
Isotretinoin (Accutane), III-355
Itinerant surgery, I-10, I-12
IVRO. *See* Intraoral vertical ramus osteotomy (IVRO)
Ivy, Robert H., I-24, II-146, III-492
Ivy loop fixation, II-146

J

Jaffe-Lichtenstein syndrome, II-470
Jaw
benign non-odontogenic lesion, II-462–480
cysts of, II-340b
exercises for, II-969f
Langerhans cell histiocytosis, II-524
lesions, II-462–480
medication-related osteonecrosis, II-507–522
clinical presentation, II-511–512
pathophysiology, II-509–510
research, II-517
risk factors, II-510–511
staging, II-512–513
treatment, II-514–517, II-516t
non-odontogenic developmental cyst, II-371–375
odontogenic myxoma, II-439–444
osteonecrosis, II-952
osteosarcoma, II-647
sarcoma, II-643–669
snapping, II-766–767
Jaw fracture, third molar removal and, I-285
Jaw recorder, I-657f
Jaws, examination, in dentoalveolar injury, II-117
JCAH. *See* Joint Commission on Accreditation of Hospitals (JCAH)
Jessner's solution, III-443
Joe Hall Morris external fixator, II-317, II-318f
The Joint Commission, I-96–98, I-98t–100t
Joint Commission on Accreditation of Hospitals (JCAH), I-96–97
Joint Commission on the Accreditation of Healthcare Organizations (JCAHO), I-228
Joint mobilization, for temporomandibular joint disorders, II-875
Joint sounds, temporomandibular joint, II-808–809
Justice, principle of, I-10
Juvenile aggressive fibromatosis, III-745–748

Juvenile idiopathic arthritis (JIA), II-131, III-840–841
example, III-137f–141f
temporomandibular joint total replacement, III-239b–240b, III-242
Juvenile nasopharyngeal angiofibroma, III-751, III-754f
Juvenile ossifying fibroma, II-469–470, III-751, III-755f–756f

K

K-wire, mandibular fixation with, II-316, II-317f
Kasabach-Merritt coagulopathy, II-534
Kazanjian, V. H., III-1–2, III-5
KCOT. *See* Keratocystic odontogenic tumor (KCOT)
Keloid, formation of, after otoplastic surgery, III-456
Keratinocyte, II-719
Keratoacanthoma, II-719
Keratoconjunctival herpes, II-555
Keratocyst, odontogenic, II-346–361
Keratocystic odontogenic tumor (KCOT), II-348–361
clinical features, II-350–352
in nevoid basal cell carcinoma syndrome, II-364–365
pathology, II-352–354
surgical management, II-356–361
ultrastructure, II-354
Keratosis, laser surgery for, I-343
Ketamine, I-203–206
action, I-205–206
adverse effects, I-206
BIS monitoring and, I-172
clinical effects, I-206
contraindications, I-206
general anesthesia with, II-13
intravenous sedation with, I-220
metabolism, I-206
for nerve injury, I-318
for neuropathic pain, I-323
for pediatric patient, I-249–251, I-250t
pharmacokinetics, I-204t, I-206
propofol combined with, I-219t
side effects, I-206
structure, I-205–206
topical, I-320–321
Ketoprofen
dosage, I-232t
for temporomandibular joint disorders, II-871t
Ketorolac
dosage, I-232t
preoperative, I-231
Kidney, pediatric, I-241
Kidney disease
preoperative evaluation of, I-140
stages, III-283t
Kiesselbach's plexus, III-366, III-366f
Kinetic energy, gunshot wound and, II-303–305
King-Denborough syndrome, I-253
Kleeblattschädel anomaly, III-669
Klonopin. *See* Clonazepam (Klonopin)
Knight and North fracture classification, II-27t
Koebner phenomenon, I-345–346, II-558
Köle, Heinrich, III-246
Kostecka, F., III-1
Kreins, Otto, III-535
Kybella. *See* Deoxycholic acid

L

L-lysine, II-555
Lacrimal apparatus, II-221
Lambdoid suture craniosynostosis, III-659–660, III-664f
Langerhans cell, II-524–530
Langerhans cell disease, II-464
Langerhans cell histiocytosis (LCH), II-523–533, II-857
classification, II-524t, II-525–526, II-526t, II-526b
clinical varieties, II-523–524
clonality, II-526–527
diagnosis, II-527–530
example, II-525f
histopathology, II-527
prognosis, II-527–530
treatment, II-527–530
Lanz, Otto, II-766, II-769f
Laryngeal mask airway (LMA), I-213–214, I-245–247
description and use, I-214–215
in maxillofacial trauma, II-14, II-14, II-14
sizes, I-247f
Laryngoscope, II-14
Laryngospasm
airway obstruction caused by, I-215
in pediatric patient, I-251–252
treatment, I-252
Larynx
chemotherapy/radiation therapy for carcinoma of, II-754
radiation therapy for carcinoma of, II-742–744, II-745t
Laser
ablation techniques, III-347, III-352–355
absorption, I-327, I-329f, III-340f
alexandrite, III-346
for aphthous ulcer, II-560
argon, III-344
in arthroscopy, II-897
benefits, I-333
blepharoplasty, I-346, III-356
carbon dioxide (CO_2), III-336, III-344
action, I-328–329
for blepharoplasty, III-356
disadvantages, I-333–334
for gingivectomy, III-348
for gingivoplasty, III-352
hard tissue surgery, I-329–330
implant surgery, I-340
incisional and excisional techniques, III-346–347
peri-implantitis treated with, I-727
for skin resurfacing, I-344
wavelength, I-331
components, I-327–328, I-328f, III-337
contact, III-347–348
copper vapor, III-345
cosmetic surgery with, I-343–347, III-355–358
in craniofacial surgery, I-351
diode, I-328–329
crown lengthening with, I-349
for implant surgery, I-341
for scaling and root planing, I-350
wavelength, I-331–332
disadvantages, I-333–334
emission, I-327, I-328f
endodontic treatment with, I-350
endoscopic surgery, III-358–359
erbium, I-333
erbium:chromium:YSGG, I-328–329
erbium:yttrium-aluminum-garnet (Er:YAG), I-328–330, I-333, I-345, III-355
implant surgery, I-340
skin resurfacing, I-344–345
excimer, III-345–346
exposure time, III-340
facial resurfacing with, III-355–356
facial surgery with, I-343–347
Laser *(Continued)*
flashlamp-pumped pulsed dye (FLPPD), III-345
in general dentistry, I-349–350
gingival tissue removal, I-349
hair removal, I-349
hair transplant and removal, III-358
history, III-336
holmium:yttrium-aluminum-garnet, I-341–342, III-359
holmium:yttrium-aluminum-garnet (Hol:YAG), III-345
human tissue affected by, I-328–329
implant care, III-349–350
implant surgery, I-340–341
incisional and excisional techniques, III-346–347
intraoral procedures, III-348–352
KTP, III-345
lesions treated with, I-347–349, III-352–354
light generation, I-327–331
low-level therapy, I-338–340, III-359–360
for lymphatic malformation, II-540
in maxillofacial surgery, III-336–363
mechanical design, III-339–341
microscopic surgery, III-358–359
neodymium:yttrium-aluminum-garnet (Nd:YAG), III-336, III-344–345
description and use, I-332–333
pigmented lesion, I-348, III-357
vascular lesion, I-347–348
nominal hazard zone, III-343
in oral surgery, I-327–353
peri-implantitis treated with, I-350, III-727
photocoagulation techniques, III-346
physics, I-327–331, III-336–337
pigmented lesion treated with, III-357
power, III-337
power density, I-330
Q-switched ruby, I-345, III-348–349
risk associated with, III-341
safety, I-334–335, III-341–344
scar revision, I-346, III-357–358
skin cancer treated with, I-343, II-727–728
skin resurfacing, I-343–344, I-344f
complications, I-345–346
contraindications, I-345
soft tissue, I-335–338
spot size, III-338
surgical technique, I-330, III-337–339, III-346
systems, III-344–346
tattoo treated with, I-348–349
temporomandibular joint surgery, I-341–343
tissue interaction, I-329f, III-339
types, III-339
uvulopalatoplasty, III-351–352
vaporization techniques, III-347
vascular lesion treated with, I-347–348
wavelength, I-331–333
wound healing, I-340, III-348
Laser-assisted uvulopalatoplasty (LAUPP), III-268, III-351–352
Laskin, Daniel, II-771
Lateral crural steal, III-374
Lateral periodontal cyst, II-365, II-424
Lateral pterygoid muscle, II-783–785
Lateral still cephalometry, III-574–575
Latex gloves, anaphylaxis associated with, I-252t
Latex sensitivity, III-284
Latham appliance, III-498, III-516, III-561–562
Law of Primacy, I-46
Lawsuit
frequency of, I-85
resolution, I-84
risk management and, I-83–84

LCH. *See* Langerhans cell histiocytosis (LCH)
Le Fort fracture, II-28, II-213–220
  anatomy, II-214
  diagnosis, II-215–217
  illustration, II-31f
  malunion, II-226
  for midface fractures, II-211–212, II-212f
  radiography of, II-217
  treatment, II-217–220
  type I, II-28, II-32f, II-212f
    description, II-212, II-215
    illustration, II-215f
    treatment, II-217–218
  type II, II-28, II-33f, II-212f
    description, II-212, II-215
    illustration, II-215f
    treatment, II-218
  type III, II-28, II-212f
    description of, II-212, II-215
    illustration, II-216f
    treatment, II-218–220
Le Fort I osteotomy, I-54–55, I-153–171, III-458, III-569–570, III-3
  anesthesia, III-161–162
  for cleft deformity, III-492–493
  complications, III-169–170
  in computer-aided surgical simulation, III-35–36, III-37f
  diagnosis, III-153–161
  history, III-153
  indications, III-153
  lip-to-tooth relationship in, III-24
  for lymphatic malformation, II-540–542
  maxillary hypoplasia and, III-638–639
  maxillary segmentation, III-165–166
  in maxillomandibular advancement, III-271f
  multi-piece, III-54–55
  in oculoauriculovertebral spectrum, III-696
  operative technique, III-161–168
  patient positioning, III-161–162
  planning, III-153–161
  segmental, III-172–182
  single-piece, III-54
  three-piece, III-176f
  in Treacher Collins syndrome, III-731
  two-segment, III-28–29
  for vertical maxillary excess, III-156f–157f
Le Fort I segmental surgery, III-172–182
  complications, III-178
  indications, III-172–173
  postoperative care, III-177–178
  presurgical preparation, III-173–174
  surgical technique, III-175–177
Le Fort III fracture, II-18
Le Fort III osteotomy, III-678f, III-4
  mandibular
    complications, III-144–145
    endoscopically assisted, III-144–152
    history, III-113–114, III-144, III-1–2
    with maxillary, III-183–195
    surgical technique, III-144–147
  mandibular ramus, III-62–95
  mandibular subapical, III-2
  maxillary, III-163–164
    history, III-2–3
    with mandibular, III-183–195
    in multiple segments, III-3
    three-piece, III-176f
  maxillary distraction and, III-208–212
  midface, III-4
  for midface cleft reconstruction, III-601
  nasal, III-164–165, III-378–380
  in oculoauriculovertebral spectrum, III-696
  relapse after sagittal split, III-116b
  sagittal split, II-86, III-113–114, III-144, III-204, III-2, III-4
Le Fort III osteotomy *(Continued)*
    complications, III-298–319
    nerve injury associated with, III-301–308
  sagittal split ramus, III-62–95
  septal, III-164–165
  sinus augmentation, I-514
  sliding genioplasty, III-102
  subcranial, III-678f
  symphysis widening, III-200
  vertical ramus, III-62–95, III-144–145
  vertical subcondylar ramus, III-313–314
  vomerine, III-164–165
  zygomatic fracture malunion, II-204–205
  zygomatic implant, I-574, I-576
LEAD system, I-539–540
Leadership, in oral and maxillofacial surgical practice, I-108
Lease agreement, I-61
Legacy, I-139
Legal documents, I-59–61
Legal entity
  comparison of, I-59t
  oral and maxillofacial surgical practice as, I-58–59
Legan's angle, chin position analysis with, III-460t–461t
Leiomyosarcoma, II-644t, II-645–646, II-656–658
Lentigo maligna melanoma, II-692t, II-693f
Lesion, II-338–390. *See also* Cyst
  aneurysmal bone cyst, II-467–468
  benign non-odontogenic, II-462–480
  central giant cell granuloma, II-462–464
  cherubism, II-466
  desmoplastic fibroma, II-476–478
  fibro-osseous, II-468–471
  giant cell
    classification, II-463t
    hyperparathyroidism and, II-464–465
  giant cell granuloma, II-462–464
  granular cell, III-756–757
  intraoral vascular, III-354–355
  jaw, II-849
  juvenile ossifying fibroma, II-469–470
  Langerhans cell histiocytosis, II-523
  laser for ablation, III-347
  laser for excision, I-336f, I-338, I-339f
  laser treatment, I-336–338, I-348–349, III-352–354
  malignant, III-354
  margin, II-728
  mouth floor, II-379f
  mucosal, laser for, I-336
  multinucleated giant cell, II-462–468
  neurofibroma, II-472
  odontogenic, II-391–392
  oral and maxillofacial region, II-338–390
  osteoblastoma, II-473–474
  osteochondroma, II-476
  parotid gland, II-485
  pigmented, laser treatment, I-348–349, III-357
  salivary gland, II-482
  skin, herpetic infection and, II-552
  vascular, laser treatment, I-347–348, III-356–357
Letterer-Siwe disease, II-523
Leukoplakia, laser treatment, I-336–338, III-352–353
Levonordefrin
  local anesthetics and, I-178–179
  maximum dosage of, I-182t
  selectivity and potency of, I-180t
Levorphanol (Levo-Dromoran)
  dose and potency, I-229t–230t
  for temporomandibular joint disorders, II-872t
Li-Fraumeni syndrome, II-644
Liability insurance, I-82
Librium. *See* Chlordiazepoxide (Librium)
Lichen planus, I-336–338, II-352, III-558–559
Lidocaine, I-186
  chemistry of, I-177f
  concentration, I-177t
  contraindications, II-555–556
  duration, I-179t
  local anesthesia with, I-232–233
  for nerve injury, I-316
  nerve injury associated with, I-183t
  onset time, I-178t
  potency, I-176
  side effects, I-180–181
Ligament(s)
  articular disc, II-778–779
  capsular, II-799–800
  extracapsular, in temporomandibular joint, II-780
  orbital, III-402, III-404f
  periodontal. *See* Periodontal ligament
  sphenomandibular, II-780–781
  stylomandibular, II-780–781
  temporomandibular joint, II-780–781, II-799–800
Light
  absorption of, III-336–337
  exposure, melanoma associated with, II-690–691
  laser emission of, III-337, III-338f
Lighting, for oral and maxillofacial surgery, I-48
Limited liability company, I-58–59, I-59t
Limited partnership, I-58
Linear IgA disease, II-565–566
Linezolid, parotitis treated with, II-486–487
Lingual frenum
  prominent, I-271f
  surgery, I-271–272
Lingual nerve, II-75, II-147
  furcation, II-75t
  injury, I-81–87, I-317f, II-367
    bilateral sagittal split osteotomy and, I-379
    during exodontia, I-302
    local anesthetic associated with, I-377
    outcomes and conclusions, I-382–383
    sagittal split osteotomy associated with, III-305
    in sagittal split ramus osteotomy, III-80
    from third molar extraction, I-380–382
  neuroma, II-94f
  relationship of, to mandible, II-76t
  retraction, I-381
  surgical access, II-92f
Lioresal. *See* Baclofen (Lioresal)
Lip
  botulinum neurotoxin for, III-441
  cancer, II-735–737
  competency, III-97f
  deformity, genioplasty for, III-98
  in dentoalveolar injury evaluation, II-117
  filler, III-472b–473b
  implant, III-474b
  maxillary incisor relationship, III-24
  reconstruction, II-297–298
  trauma repair, II-276
  wound closure, II-54–57
Lip adhesion, in cleft repair, III-498–499
Lip length, smile line and, I-588–591
Lip-lift technique, I-699–701, I-702f
Lip support
  classification, I-585
  derivation, I-587
  for implant, I-584–588
  maxilla positioning and, I-592
Lip-to-tooth relationship, III-24

Lipid solubility, local anesthetic drugs and, I-177t, I-178
Lipoadenoma, II-500–503
Lipophilic aromatic ring, I-176
Liposarcoma, II-644t, II-645–646, II-661
Liposuction, III-429–438
  complications, III-433
  postoperative care, III-433
  preoperative evaluation, III-430–431
  technique, III-431–432
Lithium, management, I-149t
Lithotripsy, laser, III-359
Little's area, III-366
Liver
  benzodiazepine metabolism in, I-195
  metabolic reactions of drugs, I-196t
  pediatric, I-241
Liver failure, craniomaxillofacial trauma management and, II-3t
LLLT. *See* Low-level laser therapy
LMA. *See* Laryngeal mask airway (LMA)
Loading, immediate implant, I-605–623
  denture conversion to, I-608–614
  success, I-606–607
  surgical and prosthetic principles, I-607–608
Local anesthetics. *See* Anesthetic drugs, local
Locator attachment, I-652f, I-654, I-656–658
Lonidamine, II-756t
Lorazepam (Ativan), I-197
  half-life, I-195t
  protein binding, I-195t
  structure, I-196f
  for temporomandibular joint disorders, II-874t
Lorenz, Walter, III-6
Loss of consciousness, pediatric trauma assessment and, II-246–247
Low-level laser therapy (LLLT), I-338–340, III-359–360
Luhr, Hans, III-63, III-183
Luminal. *See* Phenobarbital (Luminal)
Lung, pediatric, I-240–241
Luxation
  in dentoalveolar injury, II-124f, II-127
  extrusive, II-127
  intrusive, II-127–128
  lateral, II-127
Lyme disease, II-846–847
Lymph node
  biopsy, for melanoma diagnosis, II-697–698
  divisions, II-670
  groups, II-676t
  lymphoma, II-707
  oral cancer staging and, II-676t
  oral cancer survival rates, II-685f
  radiation therapy, II-742
  skin cancer involvement in, II-723, II-726, II-730–732
Lymphadenopathy, Langerhans cell histiocytosis and, II-527
Lymphangioma, II-539
Lymphatic malformation, II-539–542
Lymphoepithelial cyst, II-485
Lymphoepithelioma, II-744–745
Lymphoma, II-707–716
  angiocentric, II-710–711
  Ann Arbor staging system, II-708–709, II-714b
  B-cell, II-707, II-710
  diagnosis, II-707–709
  parotid gland, II-500
  post-transplant, II-711
  radiation therapy, II-741
  radiographic evaluation, II-711–712
  staging, II-708, II-714b
  survival rate, II-714
  T-cell, II-707, II-710
  treatment, II-713–714
Lymphonodular pharyngitis, II-556–557
Lynch incision, II-184–185
Lyrica. *See* Pregabalin (Lyrica)

M

Macrophage, wound healing and, II-257
Mafenide acetate, II-67
Magnetic resonance imaging (MRI). *See also* Imaging
  cervical spine injury assessment with, II-11
  craniomaxillofacial pathologies, III-738–739
  facial nerve imaging, II-99–100
  facial pain, II-947
  nerve imaging, II-80–81
  odontogenic tumor, II-392
  oral cancer evaluation, II-675
  parotid gland tumor, II-493–494
  pediatric brain injury, II-251f
  process, II-822
  salivary gland, II-481–483
  sarcoma, II-645
  skin cancer, II-725
  temporomandibular joint, II-821–824, II-823f
  temporomandibular joint disorder, II-802–804, II-820–824
  temporomandibular joint internal derangement, II-906
  temporomandibular joint reconstruction, III-223–224
Malformation, definition, III-628t
Malignancy
  in cancer progression, II-600f
  laser treatment, III-354
  maxillofacial region, II-590
  pediatric, III-757–763
Malignant ameloblastoma, II-401, II-420–422
Malignant fibrous histiocytoma, II-644t, II-645–646, II-651–652
Malignant hyperthermia (MH)
  in pediatric patient, I-253
  treatment, I-253
Malignant mixed tumor, II-493t
Mallampati classification, I-213t, I-242–243, III-283, III-283t
Mallampati test, I-213
Malocclusion
  class II, I-319, I-322, III-637
  class III, III-596
    correction of, I-320, III-184
    in maxillary hypoplasia, III-638–639
  in mandibular fracture treatment, II-168
  midface fracture as cause of, II-216
  severe, miniplate for, I-313
  in Treacher Collins syndrome, III-703, III-706, III-724
Malpractice insurance, I-82
MALT lymphoma, II-708b, II-710, II-711f, II-713
Managed care
  contracting, I-62
  marketing and, I-132–133, I-107
Management
  principles, I-134
  surgical practice, I-18
Mandible
  advancement, III-110f, III-147
  ameloblastoma in, II-402, II-412f–414f
  anatomic regions, II-149f
  anatomy, II-147–152
  aneurysmal bone cyst, II-467
  arteriovenous malformation, II-88f, II-547f
  asymmetric, III-72b
  atrophy, II-166
  blood supply, II-147
  bone graft, I-666–668
Mandible *(Continued)*
  bone harvested from, I-453–455
  cherubism, II-466–467
  condylar head shapes, II-780f
  condyle, II-794
  counterclockwise rotation, III-116–119
  cysts in, II-340f
  deformity correction, with computer-aided surgical simulation, III-39
  distraction osteogenesis, III-147, III-776–778
  examination, in trauma patient, II-4–5
  extraoral surgery, III-189
  fracture. *See* Mandibular fracture
  free movement, II-786–787
  growth rate, III-629t, III-632–635
  high-energy gunshot wound, II-318–320
  hyperplasia, III-638
  hypoplasia, III-637–638
  impacted molar, I-265–266
  inconsistent centric relation, III-187–188
  innervation, II-147
  keratocystic odontogenic tumor, II-350
  Langerhans cell histiocytosis, II-524
  lateral shift, II-787
  lengthening, III-202–208
    clinical indications, III-202–204
    in oculoauriculovertebral spectrum, III-695
  lingual nerve relationship to, II-76t
  malformation, in Treacher Collins syndrome, III-707–731
  masticatory movement, II-787–788
  mobilization, III-3–4
  morphogenesis, III-476–477
  movement, II-786–787, II-807
  myeloma, II-89f
  non-Hodgkin lymphoma, II-712
  odontogenic fibroma, II-436f
  odontogenic myxoma, II-440f–443f
  osteoblastoma, II-473–474
  osteomyelitis, II-89f
  osteosarcoma, II-647
  overdentures, I-643–644
  pediatric ablative defect reconstruction, III-766
  posterior, as bone graft donor site, I-455–457
  prognathic, III-83, III-84b, III-86b
  protrusion, II-787
  range of motion, II-16, III-805–806
  reconstruction, II-296–297, II-298f
    rib graft for, III-766–767
    in Treacher Collins syndrome, III-724–730
  relapse of advancement, III-637
  resection guide, I-675f–677f
  retrognathia, III-115f
  retrognathic, case study, III-86b
  retrusion, II-787
  segmental resection, I-666, I-668
  surgical access, III-740
  three-dimensional image, I-690–692
  transverse deficiency, III-196, III-200f
  in Treacher Collins syndrome, III-706–731
  vertical defect, I-539f–544f
  widening, III-196–202
    genioplasty with, III-201
    postoperative care, III-202
    surgical planning, III-197–199
Mandibular deficiency, III-300, III-301t, III-637–638
  case study, III-65b, III-68b–71b
  chin hyperplasia, III-306f
  chin hypoplasia, III-309f
  inverted L osteotomy, III-113–143
  with long face, case study, III-70b–71b
  treatment planning, III-119–120
Mandibular fossa, II-778

Mandibular fracture, II-28–35, II-37f, II-146–173
angle fracture, II-166, II-169f
atrophic, II-166–167
biomechanics, II-149–151
bone healing, II-151
classification, II-148–151
comminuted, II-319f
complications, II-168
condyle fracture, II-165–166
controversy, II-165–167
in dentoalveolar injury, II-123t
displacement, II-151
exodontia associated with, I-307
favorable, II-149, II-150f
following third molar removal, I-295
gunshot wound, II-315–316
hardware materials, II-162–164
history of treatment, II-146–147
imaging, II-153
infection associated with, II-168
multiple, II-35f
muscular forces on, II-149
nerve injury associated with, II-84–85, II-168
open reduction, II-135f
pathogenesis, II-147
pathologic, II-34–35, II-37f
patient assessment, II-152–153
pattern and incidence, II-34f, II-151
pediatric, II-270, II-35–38, II-38f, II-167
stabilization, II-1–2
tooth removal associated with, II-165
treatment, II-153–164
closed technique, II-153
endoscopic approach, II-161–162
intraoral/transbuccal approach, II-155–158
open techniques, II-155
transcervical-retromandibular approach, II-160–161
transcervical-submandibular approach, II-158–160
unfavorable, II-149, II-150f
Mandibular nerve block, nerve injury associated with, II-950
Mandibular osteotomy, III-62–95, III-144–152
complications, III-144–145
history, III-113–114, III-1–2
mandibular osteotomy combined with, III-183–195
subapical, III-2
surgical technique, III-144–147
Mandibular ramus, as bone graft donor site, I-455–457
Mandibular region, bones of, II-18–20
Mandibular retrognathia, III-115f, III-776
Mandibular ridge
bilateral atrophic, I-527f
deficient, I-669f–670f
triangular, three-implant prosthesis for, I-648f
Mandibular space, airway assessment and, I-243
Mandibular surgery, III-297–324
complications, III-297, III-316–319
hemorrhage in, III-310–313
infection, III-315–316
nerve injury in, III-300–301
relapse following, III-317–318
risk factors, III-297–298
temporomandibular joint dysfunction associated with, III-317
Mandibular symphysis, as bone graft donor site, I-453–455
Mandibulofacial dysostosis, III-703
Mannitol, intraocular pressure treated with, II-207
Mantle cell lymphoma, II-710, II-713
Marfan syndrome, II-259
Margin
in surgical excision, II-729–730
tumor, II-728
Marginal bone loss, smoking and, I-514
Marie-Strümpell disease, II-842
Marine algae, alloplastic implant with, I-440–441
Marketing, I-102–136
academic, I-107
blog, I-104–105
communication, I-134–136
consultation, I-125–126
cosmetic surgery, I-130–132
definition, I-107
employee hiring and firing, I-110
Facebook, I-105
Flickr, I-105
four P's of, I-107
image, I-118
internal, I-126–127, I-131
logo, I-118
managed care, I-132–133
materials, I-122–123
to media outlet, I-128–129
newsletter, I-127–128
oral and maxillofacial surgical practice, I-64
out-of-town patients, I-106
patient waiting time and, I-120–121
payment plans, I-129–130
plan, I-117–136
procedure-specific, I-126
professional consultation, I-110–111
Realself, I-106
social media for, I-103–106
synergy, I-123
target market, I-122
website for, I-103
YouTube, I-105
Marketing plan, I-117–136
Markowitz classification, II-30f, II-222f
Markowitz fracture, II-221–223
Marsupialization, for odontogenic keratocyst, II-357–361
Massad impression tray, I-656f
Massad jaw disposable recorder, I-657f
Massage, for temporomandibular joint disorders, II-876
Masseter muscle, II-781–782, II-785
Mast cell, in neurofibroma, II-472
Mastication, mandibular movement for, II-787–788
Masticatory muscle
evaluation, II-810
pain, II-962
Maxilla
advancement, III-106f–107f, III-596–598, III-600
ameloblastoma, II-402, II-415f–416f
anatomy, III-161
aneurysmal bone cyst, II-467
anterior deficiency, three-dimensional imaging for, I-688–696
anterior teeth, positioning of, I-592
aseptic necrosis, III-178
atrophic subtotal, I-545f–546f
bone-borne template, I-699–704, I-704f
bone quality, I-594
capillary malformation, II-538
cherubism, II-466–467
chondrosarcoma, II-649
cleft, III-497
bilateral, III-589–592
history, III-583–584
management, III-583–595
reconstruction, III-589–592
stabilization, III-606–607
Maxilla *(Continued)*
surgical options, III-583–584
timing of grafting procedure, III-586–587
unilateral, III-589
cyst, II-340f, II-346f
deformity correction, with computer-aided surgical simulation, III-38–39
dentigerous cyst, II-355f
distraction osteogenesis, III-208–214, III-778
double jaw surgery repositioning, III-53–55
down-fracture, III-165, III-175–177, III-176f
edentulous
arch form in, I-595–596
case presentation, I-601–602
cost of restoration, I-596–597
fixed restoration, I-584–604
historic perspective, I-569–570
prosthetic conversion technique, I-577–578
ridge form in, I-595–596
surgical options, I-573
treatment planning, I-592–597
zygomatic implant for, I-569–583
examination, in trauma patient, II-4–5, II-6f
fracture, II-15, II-32f–33f
comminuted, II-320f
in dentoalveolar injury, II-123t
exodontia associated with, I-307
pediatric, II-35–38, II-243
growth rate, III-629t, III-630–632
high-energy gunshot wound, II-318–320
horizontal position, III-24–27
hypoplasia, III-638–642, III-639f, III-778
impacted canine, I-261–262
implant in, example of, I-463f
intraosseous defect, I-448f
Langerhans cell histiocytosis, II-524
midface fracture effect on, II-216
mobilization, III-3–4
morphogenesis, III-476–477
non-Hodgkin lymphoma, II-712
osteosarcoma, II-647
reconstruction, I-299f, II-283–300, III-724–730
repositioning, III-17f–22f
resection guide, I-675f–677f
roll orientation, III-23–24
segmental bone defect, I-549f–551f
segmental surgery, III-172
complications, III-178
postoperative care, III-177–178
preparation, III-173–174
technique, III-175–177
segmentation, III-172
in Le Fort I osteotomy, III-165–166
in orthognathic surgery, III-28–29
subluxation, II-768b
three-dimensional image, I-690–692
transverse deficiency, III-199f
Treacher Collins syndrome, III-706, III-724–730
v-shaped, III-197f
vascular supply, III-161, III-162f
vertical defect, I-547f, III-642
vertical distraction osteogenesis, I-532
yaw orientation, III-23
zones, I-570f
Maxillary arch
reconstruction, II-285–286
thermoregulation, I-691f
three-dimensional image, I-690–692
Maxillary artery, I-510
Maxillary cant, correction, III-137f–141f
Maxillary crest, load bearing function, I-571
Maxillary hypoplasia, Le Fort I osteotomy for, III-153
Maxillary obturator appliance, III-550–551, III-553–554

Maxillary osteotomy, III-163–164, III-183–195
Maxillary region, bones of, II-18
Maxillary sinus, I-509–510
  ameloblastoma, II-415f–416f
  augmentation
    graft materials, I-510–513
    preoperative evaluation, I-513–514
    pretreatment, I-510–513
  blood supply, I-510, I-510f
  cone-beam computed tomography evaluation, I-514
  displacement into, I-299
  drainage, I-581f
  infection, I-579–581
  injury, during exodontia, I-301–302
  pseudocyst, I-510
  radiographic evaluation, I-514
  vascular supply, I-510
Maxillary tuberosity, as bone graft donor site, I-452–453
Maxillofacial region
  cancer, II-742
  cysts, II-338–390
  herpes simplex infection, II-551–552
  lymphoma, II-707, II-712
  malignancy, II-590
  pathology, nerve injury associated with, II-87
  trauma, pediatric, II-264–280
  in Treacher Collins syndrome, III-706
  vascular anomalies, II-534–549
Maxillomandibular advancement (MMA)
  for obstructive sleep apnea, III-269–274
  outcomes, III-272–274
  postoperative care, III-272
  risks and complications, III-272
Maxillomandibular complex, counterclockwise rotation, III-116, III-121f–123f
Maxillomandibular fixation (MMF), II-316
  for condylectomy, III-147
  in Le Fort I osteotomy, III-166–167
  for Le Fort I segmental surgery, III-177–178
  for mandibular osteotomy, III-145
  in maxillomandibular advancement, III-271
  for pediatric condylar fracture, II-270
  for pediatric patient, II-280, II-270
  Risdon wire, II-270
Maxillomandibular region, in Treacher Collins syndrome, III-706
Maxillomandibular relationship, assessment, I-688–689
Maximal stimulation test, II-103–104
Mayo stand, I-49
McCune-Albright syndrome, II-470, III-751, III-753, III-757f–760f
McGill Pain Inventory, I-90, II-313
McKinney's point, III-328–329
Mechanical stress, joint function and, II-830
Mechanism of injury
  craniomaxillofacial trauma, II-2
  facial nerve, II-100–103
  pediatric, II-245
  trauma patient assessment, II-10
  trigeminal nerve injury, II-81–87
Mechlorethamine, II-714
Meckel's cartilage, I-526
Meclofenamate, II-871t
Media, marketing to, I-128–129, II-869–873
Medial pterygoid muscle, II-783, II-785
Median mandibular cyst, II-375
Median palatal cyst, II-375
Medical conditions, trauma management and, II-3t
Medical education
  behavior in, I-6–9
  history, I-2
  professionalism in, I-4
  teaching professionalism in, I-7–8
Medical Group Management Association (MGMA), I-125
Medical history
  craniomaxillofacial trauma assessment and, II-2–4
  for facial pain evaluation, II-944–945
Medical leave of absence, I-145
Medicare, I-89–91
Medication
  adjunct, I-233–234
  for cancer treatment, II-626–627
  for dental procedure, I-152t
  non-opioid analgesic, I-232
  osteonecrosis of jaw and, II-507–522
  pediatric dosage, I-250t
  pediatric response, I-242
  pharmacology, I-191–210
  preoperative evaluation, I-139
  selection, for sedation, I-212
  temporomandibular joint disorder, II-869–873
  topical, for skin cancer, II-733–734
Medication-related osteonecrosis of the jaw (MRONJ), II-507–522, II-952
  clinical presentation, II-511–512
  established, therapy for, II-515–517
  pathophysiology, II-509–510
  research, II-517
  risk factors, II-510–511
  risk minimization, II-514
  staging, II-512–513
  treatment, II-514–517, II-516t
Mefenamic acid, for temporomandibular joint disorders, II-871t
Megakaryocyte proliferation, I-160t
Melanin, absorption spectrum, I-329f
Melanocyte, II-357, III-702
Melanoma, II-690–706
  classification, II-696t
  clinical staging groups, II-699t
  diagnosis, II-692–697
  epidemiology, II-690
  etiology, II-690–692
  histologic features, II-696t
  incidence, II-690–692
  laser surgery for, I-343
  M classification, II-699t–700t
  management, II-697–698
  microinvasive, II-695
  mucosal malignant, II-702–704
  N classification, II-699t–700t
  nodular, II-693f
  oral, II-691f–692f, II-702–704
  pathologic staging, II-700t
  pediatric, II-690
  risk factors, II-691, II-691b
  in situ, II-695
  staging system, II-693, II-698–700
  statistics, II-691b
  subtypes, II-692t
  T classification, II-699t–700t
  treatment, II-700–702
Melanosome, III-357
Melanotic neuroectodermal tumor of infancy, III-757
Meloxicam, II-871t
Membrane
  bacterial contamination, I-482
  barrier, I-462–463, I-475
    selection, I-480–483
    in sinus augmentation, I-513
    tent-pole technique, I-488f
  collagen, I-462–463, I-482, I-485f–487f
  non-resorbable, I-481–482
  placement, I-479
  polytetrafluoroethylene, I-462–464, I-464f, I-480–482
Membrane *(Continued)*
  requirements, I-480
  resorbable, I-462–463, I-479, I-482–483
  selection, I-480–483
  socket preservation and, I-493
  space maintenance and, I-479
  synthetic, I-482
Meningitis
  frontal sinus fracture associated with, II-243
  herpetic, II-555
Mental health, patient, preoperative evaluation, III-286
Mental nerve
  in genioplasty, III-101, III-102f
  injury, during exodontia, I-302
  surgical access, II-91–92
Mentocervical angle, III-99
Menton point
  facial symmetry and, III-96
  ideal, III-100f
Meperidine (Demerol), I-199–200
  anaphylaxis associated with, I-252t
  dose and potency, I-229t–230t
  equianalgesic dosage, I-231t
  neurotoxicity, I-228
  pharmacokinetics, I-230t
  structure, I-199f
  synthesis, I-197–198
  for temporomandibular joint disorders, II-872t
Mepivacaine, I-186
  concentration, I-177t
  duration, I-179t
  local anesthesia with, I-232–233
  nerve injury associated with, I-183t
  onset time, I-178t
Meprobamate (Miltown), II-874t
Merkel cell carcinoma, II-720, II-734–735
Merrifield Z-angle, chin position analysis with, III-460t–461t
Mesenchymal odontogenic tumor, II-435–455
Mesiodistal placement, implant, I-397
Mesoneurium, in nerve anatomy, II-77–78
Messenger ribonucleic acid (mRNA), II-603, II-604f, II-623
Metabolic arthritis, II-847–848
Metabolic equivalent (MET)
  of activities, III-281t
  preoperative evaluation and, I-139, I-151t
Metabolism, monitoring, I-169
Metastasis
  cancer progression, II-600f
  cancer therapy and, II-629
  description, II-619–621
  diagram, II-620f
  perineural invasion and, II-722
  skin cancer, II-726
Methadone (Dolophine)
  dose and potency, I-229t–230t
  pharmacokinetics, I-230t
  for temporomandibular joint disorders, II-872t
Methemoglobin, I-168
Methemoglobinemia, I-185
Methocarbamol (Robaxin), II-872t
Methohexital, I-201–203
  distribution, I-205f
  pharmacokinetics, I-204t
Methotrexate, II-562, II-713, II-756t–757t
Methoxazepam, I-196f
Methylnaltrexone, I-198f
Methylparaben, I-176–177, I-182
Methylprednisolone (Depo-Medrol), III-287t
  after nerve surgery, I-373
  for facial pain, II-955t, II-957
  in orthognathic surgery, III-289
  in temporomandibular joint arthrocentesis, II-887

Metopic suture craniosynostosis, III-657–659, III-661f–662f
Metronidazole
  medication-related osteonecrosis treated with, II-516
  peri-implantitis treated with, I-725–726
  postoperative infection treated with, I-303
MH. *See* Malignant hyperthermia (MH)
Michelet genioplasty, III-101
Michel's solution, II-332
Micro-computed tomography, I-443
Microcystic adnexal carcinoma, II-719
Microneurosurgery
  contraindications, II-92t
  indications, II-90–91, II-92t
  outcomes, II-96
  for trigeminal nerve injury, II-91–96
Microsatellite instability (MSI), II-608–609
Microsomia
  craniofacial, III-636f
  hemifacial, III-158f–160f, III-638f
Microvascular free flap, II-294–296
Midazolam, I-195–196
  clinical effects, I-194
  fentanyl combined with, I-218
  half-life, I-195t
  pediatric dosage, I-250t, I-251
  pediatric premedication with, I-248–249
  pharmacokinetics, I-204t
  protein binding, I-195t
  structure, I-196f
Middorsum palatal stop, III-572
Midface
  anatomy, II-211
  blood supply, II-214
  bones, II-18
  in craniosynostosis, III-676
  description, II-211
  distraction osteogenesis for advancement, III-778
  growth, in cleft palate repair, III-542–543
  high-energy gunshot wound, II-318–320
  hypoplasia, III-630–632
  innervation, II-214
  pediatric injury patterns, II-260
  reconstruction, II-297–300
  surgical access, III-740
  in two-stage palatal repair, III-548–549
Midface deficiency, III-596
  bone graft, III-602–605
  orthognathic surgery, III-619
  presurgical evaluation, III-596–597
  psychosocial considerations, III-597
  surgical reconstruction, III-597–600
  timing of surgery, III-597
Midface fracture, II-211–229
  classification, II-211–213, II-215
  complications, II-225–227
  diagnosis, II-212–213, II-215–217
  endoscopic repair, II-227
  imaging, II-213
  Le Fort classification, II-213–220
  malunion, II-225–226
  pediatric, II-270
  treatment, II-217–220
Midline, facial, in orthognathic surgery, III-23
Migraine headache, facial pain and, II-944–945
Milk, avulsed tooth stored in, II-130
Millard, Ralph, III-492
Millard technique
  anatomical landmarks, III-516f
  cleft lip repair with, III-513–516
  markings and measurements, III-517f
  surgical procedures, III-516–519
  Tennison technique compared to, III-521–523, III-525
Miltown. *See* Meprobamate (Miltown)
Miniplate, I-313–314
  as anchor, I-313, I-311
  case presentation, I-318, I-319f
  clinical applications, I-316–318
  complications, I-323
  materials, I-320–323
  maxillary, placement of, I-322f
  open bite treated with, I-316–318, I-313
  placement, I-320–321
  screw fixation, I-313
  surgical placement, I-318
  surgical technique, I-320–323
Miniscrew implant (MSI), I-314–316, I-311
  adjunctive care, I-322
  as anchor, I-313
  bone considerations, I-315–316
  case presentations, I-318–319
  for class II malocclusion, I-322f
  complications, I-323
  design, I-315
  drill *versus* self-drill, I-316
  example of, I-315f
  for impacted second molar, I- 321f
  orthodontic loading, I-316
  placement angle, I-316, I-323
  placement technique, I-321–322
  self-drilling, I-321
  success rate, I-314
  torque, I-315
Minocycline HCL
  peri-implant disease treated with, I-725f
  peri-implantitis treated with, I-725–726
Mirror image routine, III-39, III-39f
Mitochondria, cancer diagnosis and, II-622–623
Mixed connective tissue disease, II-848
Mixed odontogenic tumor, II-444–455
Model, presurgical, III-44
Model for End Stage Liver Disease (MELD), I-141, I-156f
Modifiers, in coding, I-93–94
Mohs micrographic surgery, II-719–720, II-728–729, II-729b
  surgical excision *versus*, II-730
  surgical margin in, II-730
Molar
  displacement of, into submandibular space, I-300–301
  immediate implant for, I-418–420
  impacted, I-265–266, I-267f
  mandibular
    extraction, I-277–278
    sectioning and removal, I-281, I-282f
  maxillary
    extraction, I-277, I-279f
    sectioning and removal, I-281, I-283f
  second, impacted, I-319, I-321
  third
    caries, I-284
    cyst, II-343, II-345f
    displacement into infratemporal fossa, I-299–300
    dry socket after removal of, I-303
    eruption potential, I-286
    extraction complications, I-77
    impacted, I-80f, II-286–288
    incision for, I-287
    indications for removal, I-283–284
    infection following extraction, I-293
    injury from removal of, II-82
    nerve damage following extraction, I-294, I-380–382
    nerve damage treatment, I-382
    in orthognathic surgery, III-279
    pain following extraction, I-225
    postsurgical periodontal healing, I-295
Molar *(Continued)*
    sectioning for removal, I-287–288
    surgical extraction complications, I-293–295
    surgical technique for removal, I-286–288
    trigeminal nerve injury and, I-354
  transplantation, I-268
Molecular biology, II-336
  of cancer, II-599–642
  cancer treatment and, II-622–629
Monitored anesthesia care (MAC), I-213
Monitoring
  anesthesia, I-164
  blood pressure, I-165–166
  body temperature, I-170
  circulation, I-169
  history and evolution, I-165–173
  metabolism, I-169
  neuromuscular, I-170–171
  patient, I-164–175
  recovery, I-172–173
  respiration, I-169–170
  respiratory system, I-167–169
  sedation depth, I-171–172
Monoamine oxidase inhibitor drugs
  management, I-149t
  for temporomandibular joint disorders, II-872–873
Monroe-Kellie doctrine, II-252
Moose, Sanford, III-64, III-2
Morphine
  anaphylaxis associated with, I-252t
  discovery, I-197
  dose and potency, I-229t–230t
  equianalgesic dosage, I-231t
  for facial pain, II-953, II-954t
  pharmacokinetics, I-230t
  structure, I-198f
  for temporomandibular joint disorders, II-872t
Morris, Joe Hall, I-24
Morris, John, II-767–768
Motion, passive, in temporomandibular joint, II-833–835
Motor vehicle accident (MVA), II-10
  dentoalveolar injury from, II-114
  injury from, II-41–42
  pediatric injury and death from, II-245
Motrin. *See* Ibuprofen (Advil, Motrin)
Mouth floor
  anatomy, II-671
  cancer, II-679–680
  cyst, II-380f
  in dentoalveolar injury evaluation, II-117
  lesion, II-379f
Mouth rinse, steroid, II-551
Mouthguard, II-271
  dentoalveolar injury prevention, II-141
  types, II-141
Mouthwash
  oral hygiene and, II-551
  steroid, II-551
MRONJ. *See* Medication-related osteonecrosis of the jaw (MRONJ)
MSI. *See* Miniscrew implant (MSI)
Mucocele
  frontal sinus fracture as cause of, II-243
  laser for removal, I-337f, III-349
  salivary gland, II-483
Mucoepidermoid carcinoma, II-492–493, II-493t, II-498, II-500–501, II-504t, II-759–760
Mucoperiosteal flap
  for impacted maxillary canine, I-290f
  for impacted third molar, I-287f
  in surgical extraction, I-280

Mucosa
  augmentation, I-558f
    example, I-559f
    keratinized, I-562f
    with vestibular incision tunnel access, I-563
  buccal, II-670
  cancer, II-680–681
  in dentoalveolar injury evaluation, II-117, II-123t
  herpetic infection involvement, II-552–553
  injury treatment, II-137
  keratinized, I-555–557, I-559f
  peri-implant, I-555–556
  urinary bladder, for disc repair, II-915
Mucositis
  oral, II-760–761
  peri-implant, I-723
  phases, II-761f
  prevention, I-724–725
  treatment, II-760–761
Mucous membrane pemphigoid, II-562–564
Mucous plug, in parotid gland, II-490
Mudd, Harvey, III-1
Muenke syndrome, III-668
Multiple myeloma, II-857
Mumps, II-487–488
Murphy, John, II-764–766, II-767t
Muscle relaxant drugs, I-234
  for facial pain, II-956
  for temporomandibular joint disorders, II-871–872, II-872t
Muscle(s)
  digastric, II-784–785
  exercises, for temporomandibular joint disorders, II-969
  eye, II-204t
  forehead, III-397f
  geniohyoid, II-784
  labiomental, III-97f
  lateral pterygoid, II-783–785
  mandibular, II-147, II-149
  masseter, II-781–782, II-785
  masticatory, II-794
    evaluation, II-810
    pain, II-962
  medial pterygoid, II-783, II-785
  mylohyoid, II-784–785
  nasal, II-174–175, III-364, III-365f
  ocular, midface fracture and, II-226
  orbicularis, III-388–389, III-390f, III-398
  pterygoid, II-783–784, II-795f, II-810
  in secondary palate, III-612–615
  soft palate, III-535–536
  spasm, II-962, II-966b
  temporalis, II-399, II-782–783, III-785
  temporomandibular joint, II-781–784
    actions, II-786b
    disorders, II-962–972
    evaluation, II-810
    tenderness, II-963–964
  velopharyngeal, III-614t
  zygomatic, II-189
Musculoskeletal system, preoperative evaluation, III-285–286
Mustardé method, for otoplastic surgery, III-453, III-454f
Myalgia
  central, II-967b
  masticatory, II-962–963
    clinical presentation, II-963–964
    diagnosis, II-964–966
    management, II-967b
    pharmacotherapy, II-968–969
    self-care program, II-968b
    treatment, II-966–971
Mycoplasma pneumoniae, erythema multiforme associated with, II-568
Myelin, in nerve anatomy, II-77
Myeloma, multiple, II-857
Mylohyoid muscle, II-784–785
Myocardial infarction (MI), oral surgery following, I-139
Myofascial pain, II-962
  clinical presentation, II-963–964
  diagnostic tests, II-964–966
  etiology, II-963
  pathophysiology, II-963
  pharmacotherapy, II-955–956, II-968–969
  splint therapy for, II-868
  treatment, II-966–971
  trigger points, II-965f
Myofibroblast, II-600, II-620–621
Myositis, II-962, II-966b
Myospasm, II-794
Myxoma
  odontogenic, II-439–444, III-745
    differential diagnosis, II-441–444
    management, II-444
  soap bubble, III-746f

N

Naburnetone, II-871t
Nager syndrome, III-690, III-705, III-776
Nalbuphine (Nubain), I-229t–230t
Naloxone, I-198f, I-200
Naltrexone, I-198f
Nanomedicine, peri-implantitis treated with, I-728
Naprosyn. *See* Naproxen (Naprosyn, Aleve)
Naproxen (Naprosyn, Aleve)
  dosage, I-232t
  for facial pain, II-954–955, II-955t
  for temporomandibular joint disorders, II-871t
Nasal air emission, III-571
Nasal complex
  anatomy, II-174–177
  blood supply, II-176–177
  bony framework, II-175
  fracture, II-174
  hard tissue, II-175–176
  innervation, II-177
  lymphoma, II-712
  pathogenesis, II-174–177
  pediatric, II-186
Nasal deformity, revision surgery, III-620–622
Nasal dorsum, II-225
Nasal emission test, III-573
Nasal fracture, II-24–27, II-27f, II-174–188
  algorithm for, II-181f
  causes, II-174
  classification of, II-178, II-179t
  classification system, II-28t
  closed reduction, II-180–182
  complications, II-187
  diagnosis and evaluation, II-177–178
  dislocation with, II-176f
  management, II-179–186
  Markowitz classification, II-30f
  nasal hump associated with, II-176f
  open reduction, II-182–186
  pediatric, II-269–270, II-35–38, II-186–187
  treatment, II-178–186
Nasal region
  bones of, II-18
  fracture, II-24–27, II-27f
Nasal resonance, III-570
Nasal septum, II-175–176
  blood supply, II-176, III-366f
  composition, II-175
  description, III-367
Nasal septum *(Continued)*
  deviation, II-177–178
  hematoma, II-187
  open reduction, II-182–183
  reduction of, in naso-orbito-ethmoid fracture, II-224–225
Nasal tip
  control, in rhinoplasty, III-372–373
  projection, III-373–375
  rotation, III-375–376
  shape, III-376–377
Nasal trumpet, I-54–55, I-56f
Nasal valve, II-175, III-370–371, III-371f
Nasalance, III-578
Nasendoscopy, for velopharyngeal function assessment, III-575–576
Naso-orbito-ethmoid (NOE) complex
  anatomy, II-221
  fracture, II-24–27, II-27f, II-29f–30f, II-30t, II-213, II-220–225
    classification, II-221–222
    diagnosis, II-222–223
    exposure, II-223–224
    in Le Fort type III fracture, II-218–219
    pediatric, II-35–38
    treatment, II-223
  gunshot wound injury, II-323
  injury to, II-5f
  Markowitz classification of fracture, II-30f, II-222f, II-223
  nasal fracture and, II-177–178
Nasoalveolar molding (NAM), III-562–565
Nasofacial angle, III-99
Nasofrontal duct (NFD), II-233, II-230–231
  endoscopy of, II-240
  in frontal sinus fracture, II-236–238, II-236
  image of injury to, II-235f
Nasofrontal suture line, III-397
Nasolabial cyst, II-371–372, II-374f
Nasolabial fold, botulinum neurotoxin for, III-441
Nasolacrimal apparatus, II-221
Nasolacrimal duct, III-161f
Nasomaxillary buttress, II-211
Nasomental angle, III-99
Nasometry, III-541, III-578
Nasopalatine duct cyst, II-372–375, II-376f–378f
Nasopharyngoscopy, III-615
Nasopharynx
  radiation therapy for carcinoma of, II-744–745, II-746t
  surgical access, III-741
Natural head position (NHP), III-15
Nausea
  anesthetic recovery and, I-222
  in orthognathic surgery, III-288–289
  in pediatric patient, I-253
  postoperative, III-314
Neck. *See also* Head and neck
  botulinum neurotoxin for, III-441
  dissection, II-683
  examination, for gunshot wound patient, II-311
  lymphoma, II-709f
  non-odontogenic developmental cyst, II-376–385
  penetrating injury, II-60
  range of motion, orthognathic surgery evaluation and, III-16–17
  sarcoma, II-643, II-644t
  zones of, II-310, II-310f
Needle breakage, local anesthetic injection and, I-184
Needleless injection, I-187
Needle(s), for wound closure, II-50t

Neoplasm
malignant, temporomandibular joint affected by, II-856–857
salivary gland, II-482, II-492, II-493t
Neovascularization, tumor, II-617–619, II-628
Nepotism, I-112
Nerve block
chemical, I-365
mandibular, nerve injury associated with, II-950
trigeminal, I-361–362
Nerve conduction, I-176
Nerve excitability test (NET), II-103–104
Nerve fiber
peripheral, neurophysiology, II-942–943
types of, local anesthesia and, I-179t
Nerve injury
acute, repair, I-375–376, I-379
agents for, I-363
axonal and cellular response, II-72–73
chronic, I-363–365
classification, I-355–356, II-72t, II-311
clinical measurement, I-357–362
clinical terms, I-355t
complex regional pain syndrome, I-361
computed tomography for, II-78–80
decompression, I-368–369
from dental procedure, II-949–950
diagnosis, I-357–362
endodontic, I-377–378
entubulation, I-371–372
during exodontia, I-302–303
facial, diagnosis and management, II-70–113
graft for, I-95, I-369–371
impacted tooth extraction and, I-294
implant, I-379–380
implant surgery as cause of, II-82–84, II-83f
internal neurolysis, I-372–373
in intraoral vertical ramus osteotomy, III-91
in inverted L osteotomy, III-124
local anesthetics associated with, I-183t, I-376–377
magnetic resonance imaging of, II-81
maxillofacial pathology as cause of, II-87
maxillofacial trauma, I-374–376
nerve redirection, I-373–374
neurectomy, I-373
neurosensory testing for, I-358f, I-358–360
nonsurgical treatment, I-362–365
orthognathic, I-86, II-378–379
in orthognathic surgery, III-316
outcomes and conclusions, I-382–383
pediatric, II-272
persistent postsurgical pain, I-374
post-traumatic, I-375
postsurgical management, I-373–374
recovery, I-360t, I-382–383
response to, I-356–357
in rhytidectomy, III-333–334
in sagittal split ramus osteotomy, III-79–80
secondary repair, I-376, I-379
Seddon-Sunderland classification, I-355–356, I-356t
surgical management, I-365–374, I-367, I-373–374
surgical repair cascade, I-368f, I-368
testing, II-87–90
third molar extraction, I-380–382
trigeminal. *See* Trigeminal nerve injury
vertical ramus osteotomy, III-314
wrapping for, I-371
Nerve Injury Recovery Scale (NIRS), I-360t
Nerve(s)
allogenic graft, I-371
alveolar, I-368–369
injury to, I-294
Nerve(s) *(Continued)*
neuroma, I-371f
pediatric, I-259f
auricular, III-400–402, III-448
blood supply, II-78
buccal, II-75–76
computed tomography of, II-78–80
cranial
magnetic resonance imaging of, II-80–81
pain transmission and, I-226
ear, III-448, III-449f
facial, III-400, III-401f–402f
anatomy, II-96–99
clinical evaluation, II-103–104
extratemporal injury, II-104–106
extratemporal segment, II-98–99
iatrogenic injury, II-102–103
imaging, II-99–100
infection, II-102
injury mechanism, II-100–103
injury treatment, II-104–106
intracranial segment, II-96–97
laceration, II-13–14
local anesthesia and paralysis, I-184
mandibular fracture, II-168
microanatomy, II-77–78, II-99
parotidectomy, II-495–496
rhytidectomy evaluation, III-328
surgical intervention outcomes, II-106
traumatic injury, II-101–102
fibrosis, I-369
forehead, III-397f, III-399–402
graft, I-95, II-369–371
allogenic, II-95–96
for facial nerve injury, II-104–105
hypoglossal, III-269
inferior alveolar, II-74–75
injury, II-300, III-81
in mandibular fracture, II-168
surgical access, II-91–92
infraorbital, I-76, II-367–368
lingual, I-367, II-76t, II-367
injury, II-81
surgical access, II-91–92
magnetic resonance imaging of, II-80–81
mandibular, II-147
mental, II-74–75
in genioplasty, III-101, III-102f
surgical access, II-91–92
microanatomy, II-77–78
nasal, II-177, III-367, III-368f
pain transmission, I-225
schematic representation, II-77f
spinal, pain transmission and, I-226
supraorbital, III-399–400
supratrochlear, III-400
trigeminal. *See* Trigeminal nerve
ultrasonography, II-81
vascular supply, II-78f
wrapping, I-371
Nervous system
opioid drugs effect, I-200f
pediatric, I-239
preoperative evaluation of, I-161, III-284
Neuralgia
definition, II-946t
hyperesthetic, I-361
hypoesthetic, I-361
Neuralgia-inducing cavitational osteonecrosis (NICO), II-948
Neurectomy, I-373
Neurilemmoma, II-472
Neuroanatomy, pain and, I-225–226
Neurocranium, III-629–630
Neurofibroma, II-472, II-474f, III-755
Neurofibromatosis, II-472, II-474f, III-753–756
Neurofibromatosis type I, II-644, II-660–661
Neurogenic sarcoma, II-660–661
Neurologic injury, pediatric, II-250–252
Neurolysis
external, II-93–94
internal, I-94, II-372–373
Neuroma
alveolar nerve, I-371f
example, II-73f
excision and restoration, II-94–95
lateral exophytic, II-73f
lingual nerve, II-94f
removal, II-94f
resection, I-369
trigeminal, I-370f
types of, II-73
Neuromuscular blockade, I-170–171
Neuromuscular system, monitoring, I-170–171
Neuron
trigeminal nerve, II-941–942
types of, local anesthesia and, I-179t
Neuropathic pain, definition, II-946t
Neuropathy
definition, II-946t
orthognathic, I-378–379
post-traumatic, I-375
Neuropraxia
cause of, II-70–71
description of, III-316
exodontia associated with, I-303
Neurorrhaphy
direct, II-94f
for facial nerve injury, II-104–105
for orthognathic trigeminal nerve injury, I-379
for trigeminal nerve, I-369
Neurosensory disturbance (NSD), III-316
Neurosensory testing, I-358–360, I-358f, II-315
algorithm for, II-92f
levels of, II-90
recording of, I-360
Neurotin. *See* Gabapentin (Neurotin)
Neurotmesis
description of, II-71–72, III-316
exodontia associated with, I-303
Neurotoxicity, chemical, I-376
Neurotoxin, in forehead and brow lift, III-421
Neurovascular bundle
injury, implant surgery as cause of, II-82
local anesthetics and injury to, I-183–184
Neutral head posture (NHP), III-33–34
Nevoid basal cell carcinoma syndrome, II-361–365, II-644
clinical features, II-350, II-364–365
pathologic features, II-352–354
Nevus flammeus neonatorum, II-538
Newborn
craniosynostosis algorithm of care, III-671–675
Treacher Collins syndrome, III-730
Newsletter, marketing with, I-127–128
Nexavar. *See* Sorafenib (Nexavar)
NFD. *See* Nasofrontal duct (NFD)
NHP. *See* Natural head position (NHP); Neutral head posture (NHP)
Nicotine
bone metabolism affected by, I-433
effects, I-215
as mandibular surgery risk factor, III-297–298
wound healing affected by, I-451
Nicotinic stomatitis, laser treatment, III-352
Nikolsky sign, II-563, II-565
Nitrate (NO_3), II-831
Nitric oxide (NO), II-832f, II-905–906
Nitric oxide synthase (NOS), II-831, II-833f
Nitrite (NO_2), II-831

Nitrous oxide (NO)
adverse effects, I-208
chondrocyte synthesis of, II-831
clinical effects, I-207–208
discovery, I-206–207
as inhalation agent, I-220
inhalation induction of, I-220
for pediatric patient, I-250
Node of Ranvier, II-77
Nodular melanoma, II-692t
Nominal hazard zone, III-343
Non-Hodgkin lymphoma, II-707, II-710
B-cell, II-710
clinical staging, II-708b
radiation therapy for, II-741
survival rate, II-714
T-cell, II-710
treatment, II-713–714
Non-malfeasance, principle of, I-9
Non-melanoma skin cancer (NMSC), II-717–740
clinical examination, II-722–725
epidemiology, II-718–721
epidemiology and etiology, II-717–718
imaging, II-725
incidence, II-717
lymph node involvement, II-730–732
medical management, II-732–735
metastasis, II-723
pathology, II-718–721
photodynamic therapy, II-734
recurrence, II-732–733
repair of wound, II-731–732
risk factors, II-717
screening, II-722–725
staging, II-725–727
surgical excision for, II-729–730
treatment, II-727–730
Non-odontogenic cyst, II-371–385
Noncompliance, risk management and, I-79–80
Noninvoluting congenital hemangioma (NICH), II-536–538, II-537f
Nonlipid reticuloendotheliosis, II-523
Nonossifying fibroma, II-854
Nonsteroidal antiinflammatory drugs (NSAID)
analgesia with, I-228–230
contraindications, I-230–231, I-233b
for facial pain, II-954–955, II-955t
peptic ulcer disease associated with, I-140
for reactive arthritis, II-562
rhytidectomy complications associated with, III-332
for skin cancer, II-733–734
for temporomandibular joint disorders, II-870, II-871t, II-968–969
Norepinephrine
local anesthetics and, I-178–179
selectivity and potency of, I-180t
Norpramin. *See* Desipramine (Norpramin)
Nortriptyline (Pamelor, Aventyl)
for fibromyalgia, II-970
for temporomandibular joint disorders, II-873t
Nose
anatomy, II-174–177, III-364–367
blood supply, II-176–177, III-364, III-366f
cartilage, II-175
cosmetic surgery, III-364
dissection, in functional cleft lip repair, III-529
examination, in trauma patient, II-4
facial esthetics and, III-16
floor, in orthognathic surgery, III-28
fracture of. *See* Nasal fracture
function, III-370–371
herpes simplex infection and, II-552
Nose *(Continued)*
innervation, II-177
morphogenesis, III-476
muscles, III-364, III-365f
nerve supply, III-367, III-368f
pathogenesis, II-174–177
pediatric, II-186
reconstruction, II-292f, II-297, II-299f, III-286
reshaping, in cleft lip repair, III-518–519
skin thickness, III-370
superficial musculoaponeurotic system, II-174–175
surface landmarks, III-384b
tip. *See* Nasal tip
trauma repair, pediatric, II-277–278
in Treacher Collins syndrome, III-731–733
wound closure, II-52–54, II-55f–56f
Nostril pinch test, III-573
Novocaine. *See* Procaine (Novocaine)
NST. *See* Neurosensory testing
Nubain. *See* Nalbuphine (Nubain)
Nuclear factor-kappa B, II-673
Nucleic acid
alterations, II-609
dysregulation, II-606–609
Nucleosome, II-605f
Nucleotide, mutations, II-610f
Nucleotide sequence abnormality, II-607–609, II-610f
Nurse, anesthesia. *See* Anesthesia nurse

O

OAVS. *See* Oculoauriculovertebral spectrum (OAVS)
Obesity
airway patency and, I-214
obstructive sleep apnea associated with, III-286
orthognathic surgery and, III-286
pediatric, II-259–260
wound healing affected by, II-259–260
Objectives Based Practice Transitions (OBT), I-42
Observer's Assessment of Alertness and Sedation Scale, I-217–218
Obstructive sleep apnea (OSA), I-185, III-214
accelerated osteogenic orthodontic procedure for, III-259b–260b
after pharyngeal flap procedure, III-618
in craniosynostosis, III-675
laser-assisted uvulopalatoplasty, III-351
nonsurgical treatment, III-267–268
orthognathic surgery, III-264–278
pathophysiology, III-264
patient evaluation, III-264–266, III-281
prevalence, III-264
surgical treatment, III-268
in Treacher Collins syndrome, III-730
treatment, III-266–274
Obturator appliance, III-550–551, III-553–554, III-579
Obwegeser, Hugo L., III-62, III-113, III-153, III-183, III-2–4
Occlusal plane
alteration, III-226–227
surgical decrease, III-227
Occlusal splint, II-865–869, II-867b
Occlusion
after orthognathic surgery, III-290–291
in computer-aided surgical simulation, III-35–36
final, for model surgery, III-49–50
implant overdentures, I-655
temporomandibular joint disorder management and, II-873–875
Occlusion *(Continued)*
in temporomandibular joint disorders, II-767–769
temporomandibular joint prosthetic reconstruction, III-226–227
temporomandibular joint replacement and, II-931–933
Ocular injury, zygomatic fracture associated with, II-191
Oculoauriculovertebral spectrum (OAVS), III-687–702
airway management, III-692
classification, III-690–691
cleft lip and palate, III-692
distraction osteogenesis, III-695
dysmorphology, III-687–690
ear reconstruction, III-695–696
mandibular lengthening, III-695
orthognathic surgery, III-696
pathogenesis, III-687–690
staged reconstruction, III-691–692
velopharyngeal insufficiency, III-692
Odontoameloblastoma, II-446–449
Odontogenesis
pediatric, I-258
process, II-338–339
Odontogenic cyst, II-338–343, II-347f, II-365–371
intraosseous carcinoma from, II-433
site of, II-340f
Odontogenic fibroma, II-435–438
differential diagnosis, II-437
management, II-438
Odontogenic keratocyst, II-345–361
pathology, II-356–361
surgical management, II-356–361
Odontogenic myxoma, II-439–444, III-745
differential diagnosis, II-441–444
management, II-444
Odontogenic residue, intraosseous carcinoma from, II-433
Odontogenic tumor, II-391–461, III-741–745
adenomatoid, II-394–397
biopsy, II-393
calcifying epithelial, II-398–401
classification, II-391–392
clinical considerations, II-392
definition, II-391
epithelial, II-394–435
imaging, II-392–393
mixed, II-444–455
squamous, II-397–398
surgical management, II-393–394
Odontoma, II-444–446, II-447f–448f, III-745
compound, I-269f
pediatric, I-268
Older patient. *See* Elderly patient
Oliver, Col. Robert T., I-24
OMENS classification system for oculoauriculovertebral spectrum, III-691b
OMS. *See* Oral and maxillofacial surgeon (OMS); Oral and maxillofacial surgery (OMS)
Oncocytoma, II-493t
Oncogene, II-602, II-612
apoptosis suppression and, II-627–628
in head and neck cancer, II-753f
Oncology
molecular biology, II-622–629
molecular diagnostics, II-622–624
molecular therapeutics, II-624–629
principles, in head and neck cancer management, II-752–763

Ondansetron, I-253, III-288
Open bite
  anterior, III-172–173
  case presentation, I-318, I-319f
  intraoral vertical ramus osteotomy for, III-86b
  miniplate anchor for, I-316–318, I-313
  skeletal anterior, miniplate anchor for, I-316–318
  in temporomandibular joint disorder, II-873–874
Open-book incision, I-478f
Open reduction and internal fixation (ORIF), II-147, II-166
Open reduction and semi-rigid fixation, II-166
Operating chair, I-46–47
Operative notes, risk management and, I-78
Operculectomy, laser, III-348–349
Ophthalmologic assessment, for gunshot wound, II-311
Opioid drugs, I-197–200
  action, I-198, I-200f
  addiction associated with, I-228
  adverse effects, I-228b
  analgesia, I-226–228
  anaphylaxis associated with, I-252t
  clinical effects, I-198–200
  commonly prescribed, I-227–228, I-229t–230t
  discovery, I-197–198
  effects, I-226
  equianalgesic dosage, I-231t
  for facial pain, II-953–954, II-954t
  for neuropathic pain, I-364
  receptors, I-198
  side effects, I-201b, I-226, I-228b
  structure, I-198
  for temporomandibular joint disorders, II-871, II-872t
Oral and maxillofacial surgeon (OMS)
  academic career, I-33–35
  addiction and, I-144
  in associateship, I-41, I-64–65
  boundary violations, I-143–147
  compensation plan, I-70–71, I-71t
  in Department of Veterans Affairs, I-31–33
  in DMSO, I-41
  as educator, I-15
  employment agreement for, I-60b
  exit planning, I-43–45
  as expert witness, I-10
  impairment of, I-143–147, I-145–147
  insurance claims against, I-82–83
  as leader, I-109, I-108
  as managing partner, I-64
  orthodontic concepts for, I-311–312
  in partnership, I-16, I-40
  pathologist interaction with, II-329–330
  patient relationship, I-20–21
  peer relationships, I-21
  practice entrance planning, I-39–42
  practice transition, I-39–45
  role, I-51–52
  in solo practice, I-16, I-40
  substance abuse by, I-144–145
  surgeon-scientist, I-35–37
  in U. S. Air Force, I-29–30
  in U. S. Army, I-24–26
  in U. S. Navy, I-26–29
  in U. S. Public Health Service, I-30–31
Oral and maxillofacial surgery (OMS)
  academic careers, I-33–35
  for accelerated orthodontic movement, III-246–263
  for ameloblastoma, II-422
  boundaries, I-143
  code sets, I-89–90
Oral and maxillofacial surgery (OMS) *(Continued)*
  complications, I-298–310
  cosmetic, facial implant in, III-458–475
  craniofacial, III-670–671
  craniomaxillofacial, III-627–644
  cyst, II-338–390
  dentoalveolar, complications, I-298–310
  double jaw, III-50–53, III-226–227
  emergency procedure, I-55
  ethics in, I-1–13
  facial wound, I-665
  Ganz-Rinaldi protocol, I-706f
  high-energy gunshot wound trauma, II-318–320
  history, I-96, III-1
  infection following, I-303
  interactions, II-329–337
  for keratocystic odontogenic tumor, II-356–361
  for labial frenum, I-270–271
  lasers in, I-327–363
  Le Fort I segmental, III-172–182
  lighting for, I-48
  maxillary, III-55
  maxillomandibular advancement, III-269–274
  melanoma, II-697, II-700
  model, III-44–61
  nasal fracture, II-179–186
  nerve injury, I-365–374
  neurological, II-90–91
  odontogenic tumor, II-391–461
  orthognathic. *See* Orthognathic surgery
  otoplastic, III-446–457
  pathology, II-329–337
  patient positioning, I-221
  pediatric, I-257–274
  postsurgical pain, I-374
  practice transition, I-39–45
  professionalism in, I-1–13
  reconstruction, I-283, II-283–284
  risk management, I-73–86
  segmental maxillary, III-172
  sitting position, I-46–57
    anesthesia administration, I-46–54
    equipment, I-46–50
  skin cancer, II-727–730
  squamous cell carcinoma, II-670–689
  support organizations, I-37
  team member locations, I-50
  techniques, II-329–337
  temporomandibular joint internal derangement, II-904–922
  third molar, complications, II-82
  training, I-1
  training programs, I-34
  trigeminal nerve injury, II-96
  two-jaw, III-23
  zygomatic arch fracture, II-201–202
  zygomatic fracture, II-190–194
Oral and maxillofacial surgical practice
  academic *versus* private, I-34, I-35b
  accounting, I-68
  advisor for, I-62–64
  alternatives to private practice, I-23–38
  articles of incorporation, I-59
  associateship, I-41, I-44
  benchmarking, I-64
  boundaries, I-143
  budgeting, I-67–68
  business management, I-58–72
  business model, I-16–17
  buy-in, I-44, I-61
  buy-out, I-41, I-44
  buy-sell agreement, I-60–61
  collection protocol, I-71
Oral and maxillofacial surgical practice *(Continued)*
  collection ratios, I-69–70
  communication in, I-18
  compensation plan, I-70–71
  compliance with regulations, I-67
  conflict resolution, I-18–19
  consultant for, I-125–126, I-110–111
  decision making, I-18
  deferred or incremental sale, I-41–42
  in Department of Veterans Affairs, I-31–33
  disruptive behavior, I-143–146
  diversity, I-15–16
  employee assessment, I-65
  employee relations, I-111–117
  employee retention, I-66–67
  employees, I-19–20
  employment agreement, I-60
  entrepreneurial model, I-16, I-19
  exit planning, I-43–45
  financial management, I-67–71
  financial trend analysis, I-69–70
  goals, I-14–16
  group practice, I-64
  hiring practices, I-65–66
  human resources, I-65–67
  insurance broker, I-63
  interpersonal relationships in, I-17–22
  leadership, I-109, I-108
  lease agreement, I-61
  legal documents, I-59–61
  legal entities, I-58–59
  management, I-18
  marketing, I-102–136, I-64
  medical errors in, I-97–98
  operating agreement, I-59
  options for entering, I-41–42
  organizational structure, I-64–67
  outpatient surgery facility, accreditation of, I-96–101
  overhead ratio, I-70
  partnership, I-16
  partnership model, I-16–18
  philosophical basis, I-14–22
  policy manual, I-116
  practice administrator, I-63–64
  profits, I-117, I-15
  quality assurance, I-62
  regulation, I-96
  revenue cycle, I-68–69
  risk management, I-61–62, I-73–86
  sale, I-44
  solo practice, I-64
  solo practice model, I-16–17
  succession planning, I-19
  transition, I-39–45
  in U. S. Air Force, I-29–30
  in U. S. Army, I-24–26
  in U. S. Navy, I-26–29
  in U. S. Public Health Service, I-30–31
  valuation, I-42
  vision in, I-109
Oral appliance, for obstructive sleep apnea, III-267
Oral cavity
  anatomy, II-670–671
  cancers, II-742
    diagnosis and evaluation, II-675
    follow-up, II-684–685
    nonsurgical management, II-677–679
    screening, II-673–674
    squamous cell, II-670–689
    staging, II-675–677
    surgical management, II-679–683
  lymphoma, II-707, II-712
  radiation therapy for, II-742t

Oral cavity *(Continued)*
subsites, II-670
tumor, III-740–741
Oral hygiene, salivary pellicle and, II-551
Oral mucosa
in dentoalveolar injury evaluation, II-117, II-123t
laser surgery on, I-335
lesion, I-336
Oral mucosal malignant melanoma, II-702–704
Oral teratoma, III-757
Orasone, II-871t
OraVerse. *See* Phentolamine (OraVerse)
Orbicularis muscle, III-388–389, III-390f, III-398
Orbit
fracture, pediatric, I-106
growth rate, III-629t, III-630
reconstruction
in oculoauriculovertebral spectrum, III-695
in Treacher Collins syndrome, III-713–715
retrobulbar hemorrhage and, II-206–207
Orbital cleft, III-507
Orbital compartment syndrome, II-206–207
Orbital floor
fracture, pediatric, II-268
surgical approaches to, II-196–199
Orbital ligament, III-402, III-404f
Orbital region
anatomy, II-190f
fracture, II-22
imaging, II-18
structure, II-19f
surgical approaches, II-196–199
Orbital rim, III-397
fixation, II-219f
in naso-orbito-ethmoid fracture, II-224
Orbital septum, III-388–389
Orbital wall, reconstruction, II-224
Orofacial embryogenesis, III-476–490
Orofacial region
innervation, I-227f
pain assessment, II-804–810, II-810b–811b
Oropharyngeal sphincter, III-535–536
Oropharynx, carcinoma
chemotherapy/radiation therapy for, II-754
radiation therapy, II-742, II-744t
Orthodontia, exodontia for, I-275
Orthodontic needs, third molar removal and, I-284
Orthodontic treatment
for impacted molar, I-266f
for pediatric impacted tooth, I-262, I-264
Orthodontics
accelerated osteogenic, III-247–248
after mandibular lengthening, III-206–208
anchorage, I-312, I-312
corticotomy-facilitated, III-246
following accelerated osteogenic procedure, III-250
goals, I-312
implant assisted, I-311–324
laser used in, I-350
miniplate, I-313–314
orthognathic surgery and, III-279–280
preoperative, III-299
skeletally based implant assisted, I-311–324
surgical, III-246
Orthognathic measurement
in double jaw surgery, III-52–53
for model surgery, III-46, III-48f
Orthognathic surgery
for accelerated orthodontic movement, III-246–263
accelerated osteogenic orthodontic procedure with, III-259–261
Orthognathic surgery *(Continued)*
airway evaluation, III-282–283
cleft, III-596–608
bone grafting in, III-602–605
presurgical evaluation, III-596–597
psychosocial considerations, III-597
timing of surgery, III-597
complications, III-297–298, III-316–319
computer-aided, III-31–34, III-190
dental rehabilitation needs in, III-20
dentofacial considerations, III-278–280
double-jaw, III-38, III-50–55
facial skeleton evaluation, III-16–20
hematologic evaluation, III-284–285
for hemimandibular elongation, III-17f–22f
history, III-1–2
infection, III-290, III-315–316
injury associated with, I-378–379
juvenile idiopathic arthritis and, III-131
laboratory testing, III-287–288
mandible-first, III-58–59
maxillary
multi-piece, III-56–58, III-58f
single-piece, III-55
maxillomandibular
planning for, III-21–29
stability, III-116–119
for midface deficiency, III-619
model, III-44–61
for asymmetric genioplasty, III-60f
genioplasty and, III-60
special considerations, III-60
musculoskeletal system evaluation, III-285–286
nerve injury associated with, II-86
nervous system evaluation in, III-284
oculoauriculovertebral spectrum, III-691, III-696
orthodontic considerations, III-279–280
patient evaluation, III-280–287
perioperative patient management, III-278–296
pitch orientation, III-27–28
postoperative management, III-288–292
relapse following, III-185, III-317–318
single-jaw, III-38
for sleep apnea, III-264–277
splint fabrication, III-50, III-55–59
stability after, III-185
temporomandibular joint replacement with, III-136
temporomandibular joint total reconstruction, III-222–245
in Treacher Collins syndrome, III-717f–722f
treatment planning, III-13–30
virtual, III-31–43
two-jaw, III-23, III-32f
venous thromboembolism in, III-298t
virtual treatment planning, III-31–43
Orthokeratin, II-354
Orthopantomogram, II-946
Orzel, II-757t
Os zygomaticum, I-571–573
OSA. *See* Obstructive sleep apnea (OSA)
Osseointegration, temporomandibular joint replacement and, II-927–928
Osseous crest, I-395
Ossifying fibroma, II-468–469, III-743f
juvenile, II-469–470
treatment, II-469
Osteoarthritis, II-835–838
facial pain and, II-944–945
splint therapy, II-869
temporomandibular joint, II-889
Osteoblast
in cancellous bone, I-427–428
staining for visualization of, I-442f
Osteoblastoma, II-472–474, II-475f
benign, II-854–855
cementoblastoma compared to, II-438
Osteochondroma, II-476, II-854
Osteochondromatosis, II-855–856
Osteoconduction
alloplastic implant and, I-440–441
bone growth and, I-439–440
definition, I-426, I-438
xenogeneic bone graft and, I-440
Osteogenesis
autologous stem cells and, I-438–439
bone growth and, I-438
definition, I-426, I-438
horizontal alveolar transport, I-547–549
Osteogenic, definition, I-438
Osteogenic distraction, for gunshot wound repair, II-326
Osteoid
bone healing and, I-426–427
staining for visualization of, I-443f
Osteoid osteoma, II-472–473, II-854
Osteoinduction
biologics and, I-441
definition, I-426, I-438
Osteoma, II-475, II-476f, II-854
Osteomyelitis, II-575–598
classification, II-575
clinical case, II-577f–585f
diagnosis, II-575
following exodontia, I-303
Garre, II-858
imaging, II-576
laboratory studies, II-575–576
management, II-576–590
mandibular, II-89f
temporomandibular joint affected by, II-858
Osteonecrosis
facial pain associated with, II-952
medication-related, II-507–522
clinical presentation, II-511–512
established, II-515–517
pathophysiology, II-509–510
research, II-517
risk factors, II-510–511
risk minimization, II-514
staging, II-512–513
treatment, II-514–517, II-516t
Osteoperiosteal flap, I-526–554
alveolar bone deficiency corrected with, I-526
free vascularized, I-668–671
space maintenance with, I-526–534
Osteoporosis, II-509
antiresorptive therapy for, II-514–515
osteonecrosis risk and, II-514
Osteoradionecrosis (ORN), I-304, II-575–598, II-749
clinical case, II-591f–594f
incidence, II-590
mandibular, II-34–35, II-37f
treatment, II-590–595
Osteosarcoma, II-644t, II-647–649, II-857
computed tomography of, II-646f
diagnosis, II-645–646
mandibular, II-645f
risk factors, II-647
treatment, II-647–648
Osteosynthesis
lines of, II-147f
in sagittal split ramus osteotomy, III-76–77
Osteotome, for sinus lift, I-520f
Osteotomy
alveolar, I-526–534
in alveolar distraction osteogenesis, I-536
alveolar repositioning, I-529
bilateral sagittal split, III-113–114

Osteotomy *(Continued)*
chin wing, III-319
combined maxillary and mandibular, III-183–195
case reports, III-191b
indications, III-184–186
mandible-first, III-187–189
maxilla-first, III-186–187
in computer-aided surgical simulation, III-35–36
craniosynostosis, III-650f, III-670
distraction osteogenesis following, III-775
extra-oral vertical ramus, III-113
facial bipartition, III-677f
horizontal ramus, III-204
implant transposition, I-529, I-530f
intraoral vertical ramus, III-62–95
history, III-64
indications, III-83
surgical sequence, III-83–90
inverted L, III-113–143
in combined maxillary and mandibular osteotomy, III-189
complications, III-124
indications, III-115–116
juvenile idiopathic arthritis and, III-131, III-137f–141f
modified, III-116f
nerve injury in, III-124
special considerations, III-131
stability, III-116–119, III-119t
surgical technique, III-120–124
virtual surgical plan, III-120, III-128f–130f
lateral nasal, III-164–165
Le Fort I, I-54–55, I-153–171, III-458, III-569–570, III-3
anesthesia, III-161–162
for cleft deformity, III-492–493
complications, III-169–170
in computer-aided surgical simulation, III-35–36, III-37f
diagnosis, III-153–161
history, III-153
indications, III-153
lip-to-tooth relationship in, III-24
for lymphatic malformation, II-540–542
maxillary hypoplasia and, III-638–639
maxillary segmentation, III-165–166
in maxillomandibular advancement, III-271f
multi-piece, III-54–55
in oculoauriculovertebral spectrum, III-696
operative technique, III-161–168
patient positioning, III-161–162
planning, III-153–161
segmental, III-172–182
single-piece, III-54
three-piece, III-176f
in Treacher Collins syndrome, III-731
two-segment, III-28–29
for vertical maxillary excess, III-156f–157f
Le Fort III, III-678f
mandibular
complications, III-144–145
endoscopically assisted, III-144–152
history, III-113–114, III-144, III-1–2
with maxillary, III-183–195
surgical technique, III-144–147
mandibular ramus, III-62–95
mandibular subapical, III-2
maxillary, III-163–164
history, III-2–3
with mandibular, III-183–195
in multiple segments, III-3
three-piece, III-176f

Osteotomy *(Continued)*
midface, III-4
for midface cleft reconstruction, III-601
nasal, III-164–165, III-378–380
in oculoauriculovertebral spectrum, III-696
relapse after sagittal split, III-116b
sagittal split, II-86, III-113–114, III-144, III-204, III-2, III-4
complications, III-298–319
nerve injury associated with, III-301–308
sagittal split ramus, III-62–95
septal, III-164–165
sinus augmentation, I-514
sliding genioplasty, III-102
symphysis widening, III-200
vertical ramus, III-62–95, III-144–145
vertical subcondylar ramus, III-313–314
vomerine, III-164–165
zygomatic fracture malunion, II-204–205
zygomatic implant, I-574, I-576
Otitis media, III-540, III-568–569
Otoplastic surgery, III-446–457
complications, III-455–456
Davis method, III-451–453, III-452f
Farrior technique, III-453, III-455f
Mustardé method, III-453, III-454f
protruding ear, III-450–453
protruding earlobe, III-453–455
techniques, III-450–453
Outpatient surgery facility, accreditation, I-96–101
Outpatient visit, coding for, I-92
Overbite, in temporomandibular joint disorder, II-873–874
Overdentures
controversy associated with, I-643–644
implant, I-641–664
maxillary long-bar, I-646f
natural tooth, I-641–643
two-implant, I-645
Overjet, in temporomandibular joint disorder, II-873–874
Oxaliplatin, II-757t
Oxazepam (Serax), I-196f, II-874t
Oxcarbazepine, I-369
Oxycodone (Percocet)
dose and potency, I-229t–230t
equianalgesic dosage, I-231t
for facial pain, II-953, II-955t
pharmacokinetics, I-230t
prescription, I-228
for temporomandibular joint disorders, II-872t
Oxygen
anesthetic recovery and, I-222
supplemental, for trauma patient, II-9–10
Oxygenation, monitoring, for pediatric patient, I-244
Oxyhemoglobin, I-168
Oxymorphone (Numorphan), I-229t–230t

P

Paclitaxel, II-757t
Pain
acute, management, I-234–235
behavioral pain management, I-365
central, definition, II-946t
central mechanisms, II-943–944
chronic facial, II-941–961
clinical examination, II-945–946
differential diagnosis, II-947–952
evaluation, II-944–947
management barriers, II-952–953
definition, I-225, II-946t
descriptors, II-946
facial, II-941–961

Pain *(Continued)*
cardiac origin, II-950–951
clinical examination, II-945–946
differential diagnosis, II-947–952
evaluation, II-944–947
management barriers, II-952–953
pharmacotherapy, II-955t
surgical intervention, II-958
therapeutic injection, II-956–957
treatment, II-953–958
as Fifth Vital Sign, I-234
following simple extraction, I-281
following surgical extraction, I-281
imaging, II-946–947
local anesthetic injection as cause of, I-184
management, I-225–237
myofascial, II-962
clinical presentation, II-963–964
diagnostic tests, II-964–966
splint therapy for, II-868
treatment, II-966–971
myogenous, II-791
nerve injury as cause of, II-90
neuropathic, I-233, I-360–362, II-946t
neurophysiology, II-941–943
orofacial
assessment, II-804–810, II-810b–811b
cardiac origin, II-950–951
temporomandibular joint disorder and, II-791
pathophysiology, I-225–226
patient assessment, I-234
patient perception, I-225
perioperative management, I-235f
peripheral mechanisms, II-942
postoperative, I-304
craniomaxillofacial trauma and, II-7
lasers and, I-340
management, I-225–237
postoperative management, I-235f
postsurgical, I-374
preoperative management, I-235f
sensory reeducation, I-365, I-366f
sympathetic mediated, I-361
temporomandibular joint, II-883
temporomandibular joint disorder, screening questionnaire for, II-804b–805b
third molar extraction and, I-293
Pain management
for chronic facial pain, II-941–961
future directions, II-958–959
in orthognathic surgery, III-288
for substance abuser patient, II-953
in temporomandibular joint disorder treatment, II-865
for temporomandibular joint disorders, II-970–971
Palatal bone, implant success and, I-412
Palatal fracture, II-28, II-220
Palate. *See also* Hard palate; Soft palate
free autogenous graft from, I-556
primary, III-502
secondary, III-502
soft tissue graft, I-556
squamous cell carcinoma, II-681–683
Palatine artery, III-165
Palatoplasty, III-505
Bardach, III-537, III-538f, III-611
fistula after, III-540
Furlow, III-546–548
speech and, III-540–542
two-flap, III-534, III-542, III-610
two-stage, III-548–549, III-551–552
Veau-Wardill-Kilner, III-538f, III-542
von Langenbeck, III-537f, III-542, III-611

Palpation, of temporomandibular joint, II-809
PALS. *See* Pediatric Advanced Life Support (PALS)
Pamelor. *See* Nortriptyline (Pamelor, Aventyl)
Pamidronate (Aredia), II-508, II-508t
Panoramic curve, I-688–689, I-689f
Panorex radiograph, I-570
Papanicolaou stain, II-331
Papaver somniferum, I-197
Papilla, interdental, implant and, I-401, I-402f
Papillary hyperplasia, laser treatment for, III-354
Papillomatosis, laser treatment for, III-354
Para-aminobenzoic acid (PABA), local anesthesia
  allergic reaction and, I-176–177, I-182, I-185
Paradental cyst, II-343
Paraflex. *See* Chlorzoxazone (Paraflex)
Parakeratin, II-352–354
Parakeratotic cyst, II-360f–361f
Paramedian forehead flap, II-290, II-292f
Paranasal sinus, lymphoma, II-712
Paraneoplastic pemphigus, II-564
Parasymphysis
  mandible, II-148
  widening, III-199–200
Parathyroid hormone (PTH)
  elevated, II-465–466
  hyperparathyroidism and, II-464
  osteonecrosis treated with, II-515–516
Parathyroid hormone-related protein (PTHrP), II-409, II-420
Parent
  of pediatric patient, I-257–258
  pediatric patient fear and anxiety and, I-248
Paresthesia
  after orthognathic surgery, III-291
  definition, I-355t, II-946t
  infraorbital, II-202–203
  local anesthetics and, I-183–184
  in osteomyelitis, II-575–576
Pargyline, I-149t
Parotid duct, laceration, II-58–60
Parotid gland
  benign tumor, II-494–496
  chronic obstructive sialoadenitis, II-491–492
  infection, II-485–486
  lesion, II-485
  malignant fibrous histiocytoma in, II-651
  nonsalivary tumor, II-500–503
  stone, II-490
  swelling, II-486f
  tumor, II-493–494, II-493t
  viral infection, II-487–488
Parotid sialocele, III-335
Parotidectomy, II-102–103, II-494–496
Parotitis, acute suppurative, II-485–487
Paroxetine hydrochloride (Paxil), II-873t
Paroxysmal positional vertigo (PPV), I-522
Partial pressure arterial oxygen (PaO_2), I-12
Partial pressure of CO_2, I-168–169
Partial pressure of oxygen (PaO_2), pediatric, I-241
Passive range of motion, II-806
Pathology. *See also* Surgical pathology
  coding for, I-92
  of dentigerous cyst, II-346–347
  of keratocystic odontogenic tumor, II-352–354
  oral and maxillofacial, II-329–337
  radicular cyst, II-341
  surgical interaction with, II-329–330
Patient
  agitated, I-55
  attitude, prosthesis choice and, I-643
  diabetic, anesthetic recovery, I-222
  informed consent, I-62
Patient *(Continued)*
  for orthognathic surgery, III-280
  risk management and, I-76–78
  lumbar support, I-54, I-56f
  monitoring, I-164–175
  noncompliance, I-79–80
  pain management, I-225–237
  pain perceived by, I-225
  payment history, I-129–130
  postoperative, communication with, I-132
  preoperative evaluation, I-148–163
  problematic, in cosmetic surgery, III-458
  rehydration, I-217
  sedation goals for, I-211–212
  selection
    for guided bone regeneration, I-476
    implant restoration and, I-391–393
    for zygomatic implant, I-570
  surgeon relationship with, I-20–21
  survey of, I-123–124
Patient confidentiality
  autonomy and, I-9
  professionalism and, I-3
Patient-controlled analgesia (PCA), I-234–235
Patient education, for peri-implant disease, I-725
Patient evaluation, I-119–120. *See also* Preoperative evaluation
  airway assessment and, I-213
  for blepharoplasty, III-389–391
  for craniofacial surgery, III-670
  for forehead and brow lift, III-405–408
  for liposuction, III-430–431
  for obstructive sleep apnea, III-264–266, III-281
  for orthognathic surgery, III-280–287
  for pain, I-234
  for rhinoplasty, III-367–368
  for rhytidectomy, III-325–327
  for soft tissue injury, II-41–42
  for temporomandibular joint prosthetic reconstruction, III-222–223
Patient health record, risk management and, I-75–80
Patient history
  airway assessment and, I-213
  for chronic facial pain evaluation, II-944
  craniomaxillofacial trauma assessment and, II-2–4
  for dentoalveolar injury evaluation, II-115–116
  for mandibular fracture evaluation, II-152–153
  preoperative evaluation and, I-138
  risk management and, I-75–76
  for temporomandibular joint disorder, II-801, II-904–905
  for temporomandibular joint internal derangement, II-904–905
  trauma management and, II-3t
  in trauma patient assessment, II-10
  zygomatic fracture assessment, II-190–191
Patient positioning, I-54
  anesthesia, I-221
  for exodontia, I-276
  for Le Fort I osteotomy, III-161–162
Patient preparation, for autogenous bone graft, I-451
Patient referral, I-122–123, I-122, I-81
Patient survey, I-123–124
Patient's rights, I-9
Paxil. *See* Paroxetine hydrochloride (Paxil)
Payment plan
  marketing and, I-129–130
  types of, I-129–130
Peck and Peck method, chin position analysis with, III-460t–461t
Peck graft, III-374
Pediatric Advanced Life Support (PALS), I-244, I-260
Pediatric Glasgow Coma Scale (PGCS), II-247, II-247t–248t
Pemphigoid, II-562–564
  clinical features, II-563
  treatment, II-564
Pemphigus, II-564–565
  clinical features, II-564–565
  treatment, II-565
Penciclovir, II-553–554
Penicillin
  anaphylaxis associated with, I-252t
  medication-related osteonecrosis treated with, II-516
  postoperative infection treated with, I-303
Pentazocine (Talwin)
  dose and potency, I-229t–230t
  for temporomandibular joint disorders, II-872t
Pentoxifylline, II-595–596
Peptic ulcer disease, I-141
Percocet. *See* Oxycodone (Percocet)
Peri-implant disease, I-711–730
  cement excess and, I-632, I-711
  laser treatment, III-350
  prevention, I-724–725
  risk factors, I-723–724
  scope, I-723
  treatment, I-725–727
Peri-implant inflammation, I-653f
Peri-implant mucositis, I-723
  prevention, I-724–725
  treatment, I-725–727
Peri-implantitis, I-723
  cement excess and, I-711
  definition, I-412–413
  example, I-712f
  laser treatment, I-340–341, III-350
  prevention, I-724–725
  risk factors, I-723–724
  scope, I-723
  treatment, I-725–727
Periadenitis mucosa necrotica recurrens, II-559
Periapical cemental dysplasia, II-470–471
Periapical root surgery, nerve injury caused by, II-87
Perichondritis, III-456
Pericoronitis
  third molar removal and, I-284
  treatment, I-284
Perineural invasion, tumor cell migration and, II-722
Perineurium, in nerve anatomy, II-77–78
Periodontal disease
  exodontia for, I-275
  third molar removal and, I-284
Periodontal ligament (PDL)
  bundle bone blood supply from, I-413–414
  healing, after trauma, II-137–138
  injury, II-122t
  luxation, II-127
  miniscrew implant and, I-315
  in simple extraction, I-276
Periodontal tissue, injury, II-127–131
Periodontally accelerated osteogenic orthodontics, III-247
Periodontitis
  exodontia for, I-275
  peri-implant disease associated with, I-723–724
Periodontium, biotype, I-393–405
Periorbital region, II-19f
Persistent idiopathic facial pain, II-948

Persistent postsurgical pain (PPSP), I-374
acute, I-374
chronic, I-374–375
management, I-375t
transition, I-374
Pfeiffer syndrome, III-669, III-672, III-778
PHACE vascular anomaly, II-536
Phantom bone disease, II-858
Pharmacologic prophylaxis, III-298
Pharmacosedation
general anesthesia and, I-248–251
pediatric, I-238–256
Pharyngeal cleft, II-383, II-383f
Pharyngeal flap procedure, III-616–618, III-616f
Pharyngeal structure, airway assessment and, I-243f
Pharyngeal wall, radiation therapy for carcinoma of, II-742
Pharyngoplasty, sphincter, III-579, III-617–618, III-617f
Pharynx, pediatric, I-240
Phencyclidine, I-203–204
Phenelzine, management, I-149t
Phenergan. *See* Promethazine (Phenergan)
Phenobarbital (Luminal), I-200–201, II-255–256
Phenol, for chemical peel, III-443–444
Phentolamine (OraVerse), I-188
Phenylephrine, selectivity and potency of, I-180t
Phenylpiperidine, structure, I-199f
Philadelphia chromosome, II-622–623
Photodynamic therapy, III-353
for oral cancer, II-677–678
for skin cancer, II-734
Photography, for model surgery, III-44–46
Physical examination
airway assessment with, II-10–11
for dentoalveolar injury evaluation, II-115–119
for mandibular fracture evaluation, II-152–153
for midface fracture diagnosis, II-212–213
for obstructive sleep apnea, III-265–266
oral cancer evaluation and, II-675
preoperative evaluation and, I-138
for rhytidectomy evaluation, III-326
risk management and, I-75–76
for skin cancer, II-722–725
for temporomandibular joint internal derangement, II-904–905
Physical therapy
after arthroscopy, II-901
after internal derangement surgery, II-918–919
for chronic facial pain, II-953
for temporomandibular joint disorders, II-875–877
Physicians' Charter, I-2, I-4
Pichler, Hans, III-113
Pierre Robin syndrome, III-547, III-776
Pigmented villonodular synovitis, II-855
Pindborg tumor, II-398
Pinterest, marketing and, I-105–106
Piroxicam
for masticatory myalgia, II-969
for temporomandibular joint disorders, II-871t
Pitch orientation
in computer-aided surgical simulation, III-38–39, III-120
model surgery and, III-44f
in orthognathic surgery, III-27–28
Pittsburgh Fistula Classification System, III-539–540, III-540f
Pivot splint, temporomandibular joint, II-867
Plagiocephaly, III-647
anterior, III-654–657
posterior, III-659–660
Plaque, control, II-551
Plasma, platelet-rich, I-460
Plasmatic inhibition, I-426–427
Plaster of Paris, alloplastic implant with, I-440–441
Plastic surgery, facial, laser used in, III-359
Plate
titanium, II-164
types of, II-164f
Platelet-derived growth factor (PDGF), I-257–258, I-258t, I-431–432, II-441
interpositional bone graft, I-527–528
Platelet-rich plasma, I-460, I-510–512
Platform switching, I-413
Pleomorphic adenoma, II-492–494, II-493t, II-500
Plication, III-330
Pneumonitis, continuous positive airway pressure for, I-253
Pocket mask, I-245–247
Pogonion position, III-28
Policy manual, I-116
Polyetheretherketone (PEEK), I-416–418
Polylactic acid/polyglycolic acid copolymer membrane, I-482–483
Polymethylmethacrylate (PMMA), I-416–418
Polymorphous low-grade adenocarcinoma, II-500–501, II-503f
Polysomnography, III-265
Polytetrafluoroethylene membrane, I-462–464, I-464f, I-480–482
Pontic site, development, I-404
Porcelain-fused metal (PFM), I-416–418, I-417f
Port-wine stain, II-538
Positioning. *See* Patient positioning
Positron emission tomography (PET)
cancer diagnosis, II-624
craniomaxillofacial pathologies, III-738–739
lymphoma, II-711–712
melanoma diagnosis, II-699
odontogenic tumor, II-392
oral cancer evaluation, II-675
temporomandibular joint, II-825
Post-transplant lymphoproliferative disorder, II-711
Post-traumatic seizure, II-255–256
Postanesthesia Discharge Scoring System, I-172–173
Posterior plagiocephaly, III-659–660
Posterior superior alveolar artery, I-510
Postoperative nausea and vomiting (PONV), III-288
Postoperative recovery, from anesthesia, I-221–222
Posttraumatic concussion syndrome, frontal sinus fracture associated with, II-243
Potassium ion, nerve conduction and, I-176
Powell and Humphreys method, chin position analysis with, III-460t–461t
Prazepam (Verstran, Centrax), II-874t
Prednisolone
equivalent dosage, III-287t
for temporomandibular joint disorders, II-871t
Prednisone
Bell's palsy treated with, II-101
for lymphoma, II-713
for pemphigus, II-565
for temporomandibular joint disorders, II-871t
Pregabalin (Lyrica), I-364, II-955t, II-956
Pregnancy
craniomaxillofacial trauma management and, II-3t
local anesthesia and, I-186
Premedication, for pediatric patient, I-248
Premolar
cyst at, II-343
impacted, I-265
mandibular
extraction, I-278f
impacted, I-291
maxillary
extraction, I-277
impacted, I-291, I-292f
roots, I-278f
Preoperative evaluation, I-148–163
airway assessment, I-213–214
anesthesia, I-212
asthma, I-139
cardiac assessment, I-150f
cardiac risk index, I-150t
cardiovascular, I-138
cerebrovascular accident, I-161
chronic obstructive pulmonary disease, I-139
coagulation disorders, I-161
components, I-138–139
endocrine system, I-142
exodontia, I-276
gastrointestinal disease, I-141–142
hematologic, I-159–161
nervous system, I-161
pulmonary system, I-139
renal disease, I-140–141
smoking, I-139
Preoperative fasting, I-215–216, I-243
Pressure-flow method, III-576–578
Pressure indicating paste (PIP), I-658
Presurgical infant orthopedics, III-561–562
Presurgical orthopedic appliance, III-498
Prilocaine, I-186
concentration, I-177t
duration of, I-179t
nerve injury associated with, I-183t
onset time, I-178t
Primary bone grafting, III-584
Primary herpes stomatitis, II-556
Primary herpetic gingivostomatitis, II-552, II-554
Primary intraosseous odontogenic carcinoma, II-431–432
Principles of Ethics, I-9
Procaine (Novocaine), I-185
chemistry, I-177f
history, I-176
onset time, I-178t
Procarbazine, II-714
Profecoxib, II-871t
Professional employment organization (PEO), I-67
Professional liability insurance, I-82
Professionalism
behaviors associated with, I-4
commitment to, I-3
definition, I-1–4
ethics and, I-1–13
framework for, I-5f
history of, in dentistry, I-2–4
Physicians' Charter description of, I-2
student evaluation and adherence to, I-4–6
teaching, I-4–5, I-7–8
unprofessional behavior, I-4
Proffit, William, III-5
Progress notes, risk management and, I-78–79
Proliferation phase, of bone healing, I-426–427
Prolonged sensory alteration, I-183–184
Promethazine (Phenergan), II-288, III-874t

Propacetamol, I-252t
Propofol (Diprivan), I-192, I-202–203
  anaphylaxis associated with, I-252t
  development, I-201
  general anesthesia with, II-13
  ketamine combined with, I-219t
  pediatric dosage, I-250t
  for pediatric patient, I-250–251
  pharmacokinetics, I-204t, I-218–219
  remifentanil combined with, I-219t
  side effects, I-204f
  structure, I-202f
Propofol infusion syndrome, I-203
Proportion
  facial, osteotomy and, III-184–185
  in facial esthetics, III-13–14
Propoxycaine, onset time, I-178t
Propranolol, for congenital hemangioma, II-537
Prostate-specific antigen (PSA), II-623–624
Prosthesis
  angle of emergence, I-587–588
  arch provisional, I-605–623
  decision making process for, I-632–635
  fixed
    angle of emergence, I-587–588
    case presentation, I-601–602
    cost, I-596–597
    denture conversion to, I-608–614
    diagnosis for, I-584–591
    edentulous maxilla, I-584–604
    esthetics, I-592
    extraoral examination, I-591–602
    extraoral parameters, I-586f
    force placed on, I-594–595
    implant distribution and placement, I-596
    implant-supported, I-608–614
    material selection, I-597–602
    number of implants, I-594
    restorative classification, I-590
    treatment planning, I-592–597
  four-implant, I-649f
  in immediate implant loading, I-607
  overdenture, I-641
  removable, I-461, I-592
  retrievability, I-631–632
  screw retention *versus* cement retention, I-631
  six-implant, I-641f
  for temporomandibular joint total reconstruction, III-228, III-229f, III-230–232, III-234f, III-242
  three-implant, I-648f
  two-implant, I-642f, I-654f
  in zygomatic implant, I-581–582
Protamine, I-252t
Protein
  cancer-associated, II-623–624
  as cancer therapy target, II-625–626
  cell structure and, II-605–606
  dysregulation, II-609–622
  gene expression and, II-604f
Protein binding, local anesthetic drugs and, I-178
Proteomic analysis, II-624
Proto-oncogene, II-602, II-612
Prozac. *See* Fluoxetine (Prozac)
Pseudo-tomogram, II-818, II-819f
Pseudocyst
  definition, II-338
  sinus, I-510
  temporomandibular joint affected by, II-852
Pseudogout, II-847–848
Psoriatic arthritis, II-841–842
Pterygoid muscle, II-783–785, II-795f, II-810
Pterygomaxillary buttress, II-211
Pterygomaxillary disjunction, III-164
Ptosis, in craniosynostosis treatment, III-678
Public relations, for oral and maxillofacial surgical practice, I-64
Pulmonary complications
  adolescent, III-282
  prevalence of, I-139
Pulmonary system, preoperative evaluation of, I-139, III-282–283
Pulp
  exposure, II-124
  healing, after trauma, II-138
  injury
    in dentoalveolar injury, II-124
    prognosis, II-138–139
    treatment of, II-122–127
  necrosis, after injury, II-140
Pulp testing, in dentoalveolar injury, II-118–119
Pulpitis, II-138–139
Pulse oximeter, II-12, II-168
Pulse oximetry
  error rate, I-168
  for pediatric anesthesia monitoring, I-245
Puncture wound, I-301
Pyriform rim, III-28
Pyrophosphate, II-550

Q

Quality assurance, I-62
Quantitative Sensory Test Recording and Neuropathic Mapping Form, I-359f
Quinolone, II-516

R

R-point, cell cycle and, II-612–613
Rabies, II-62b
Raccoon eye sign, II-216, II-254
Race, facial variation and, III-25
Radial forearm flap, II-294, II-295f
Radiation
  emission, laser and, III-336–337
  ionizing, non-melanoma skin cancer associated with, II-717
  tissues damaged by, I-675–677
  ultraviolet, skin cancer associated with, II-722–723
Radiation therapy, II-590, II-741–751
  complications, II-749
  concurrent chemoradiation *versus*, II-747t
  definitive, II-745
  dosage, II-741–742
  fractionation, II-746–747
  head and neck cancer, I-675–678
  histologies, II-741–742
  history, II-741
  intensity-modulated, II-590, II-747–748
  Langerhans cell histiocytosis, II-530
  laryngeal, II-742–744
  lymphoma, II-713
  melanoma, II-700
  nasopharyngeal, II-744–745, II-746t
  oropharyngeal, II-742, II-744t
  osteoradionecrosis prevention and, II-590
  osteosarcoma, II-649
  overview, II-741–745
  postoperative, II-745–746
  preoperative, II-745–746
  rhabdomyosarcoma, III-760–762
  side effects, II-749
  skin cancer, II-734–735
  systemic therapy with, II-747
  techniques, II-747–749
  third molar removal and, I-285
  tissues damaged by, I-675–677
Radicular cyst, II-340–341, II-342f–343f
Radiofrequency ablation, II-540
Radiography
  dentoalveolar injury, II-119–120
  digital, III-6–7
  impacted tooth, I-260–261, I-261f
  insurance codes for, I-94
  lymphoma, II-711–712
  mandibular fracture, II-154f
  midface fracture, II-217
  model surgery, III-47–49
  odontogenic tumor, II-392
  osteomyelitis, II-586f–589f
  panoramic, II-79f
    for nerve imaging, II-78
    for temporomandibular joint, II-817–818
  Panorex, I-570
  temporomandibular joint, II-815
  temporomandibular joint disorder, II-801
  three-dimensional, for temporomandibular joint, II-815
  trauma patient assessment with, II-5
  zygomatic fracture, II-191–193
Radiotherapy. *See* Radiation therapy
Ramsay Hunt syndrome, II-102
Ramus
  fracture, II-34, II-149
  osteotomy, in sagittal split ramus procedure, III-75f
  reconstruction, in oculoauriculovertebral spectrum, III-692–695
Ramus/condylar unit (RCU), III-144
Range of motion
  mandibular, II-805–806
  temporomandibular joint, II-964
RANKL. *See* Receptor activator of nuclear factor-KB ligand (RANKL)
Ranula
  laser for removal of, III-350
  sublingual gland, II-483
Rapamune. *See* Sirolimus (Rapamune)
Rapidly involuting congenital hemangioma (RICH), II-536–538
Rathke's pouch, I-258
Rating site, marketing and, I-103–104
Reactive arthritis, II-225, III-561–562
  clinical features, II-562
  treatment, II-562
RealSelf, marketing and, I-106
Receptionist, as marketing asset, I-133
Receptor activator of nuclear factor-KB ligand (RANKL), II-507
Recombinant human bone morphogenetic protein-2 (rhBMP-2), I-458, I-510–512
Reconstruction
  complications, II-276
  flap options, II-296b
  Ganz-Rinaldi surgical protocol, I-706f
  implant placement timing, I-674–675
  lip, II-297–298
  mandibular, II-296–297, II-298f
  maxillary, I-299f, II-283–300
  nasal, II-297, II-299f
  protocol for, I-704–706
  scalp, II-298–300, II-301f
  site-specific, II-296–297
Reconstruction plate, in inverted L osteotomy, III-128f–130f
Recovery
  monitoring during, I-172–173
  stages, I-172
Recurrent intracranial hypertension, III-674–675
Reed-Sternberg cell, II-707, II-709
Reflex sympathetic dystrophy, II-947
Refusal of treatment, I-77–78
Regenerative medicine, for temporomandibular joint disc repair, II-914–917

Regional acceleratory phenomenon, III-247
Registration, in computer-aided surgical simulation, III-31–33
Regulation, awareness of, I-85
Reiter syndrome, II-561–562, II-842–843
Rela. *See* Carisoprodol (Rela, Soma)
Relative value unit (RVU), I-88
Remifentanil, I-200
  advantages, I-220–221
  clearance, I-201f
  infusion duration, I-201f
  propofol combined with, I-219t
  structure, I-199f
  synthesis, I-197–198
Remodeling
  craniofacial, III-628–629
  definition, III-628t
Remodeling phase, of bone healing, I-426–427
Renal disease
  orthognathic surgery and, III-283–284
  pediatric, III-283
  physiologic disorders of, I-154t–155t
  preoperative evaluation of, I-140
Renal failure, I-154t–155t
  craniomaxillofacial trauma management and, II-3t
  preoperative management, I-155t
Renal system
  pediatric, I-241
  preoperative evaluation, III-283–284
Repositioning splint, temporomandibular joint, II-867
Rescue, from sedation, I-212–213
Residual cyst, II-341–342
Residual ridge form, I-595–596
Resonance, speech, in cleft palate, III-570–571
Resource-Based Relative Value Scale (RBRVS), I-88
Respiration
  age values, I-241t
  monitoring, I-169–170, I-222
  opioid drugs effect, I-199
  pediatric, I-241t
Respiratory failure, cervical spine injury associated with, II-11
Respiratory system
  cigarette smoking effects, I-215
  monitoring, I-167–169
  pediatric, I-239–241
Rest of Malassez, II-338–340
Rest of Serres, II-338–339
Resting skin tension lines (RSTL), II-724
Restoration
  cement-retained single anterior, I-630–631
  decision making process for, I-632–635
  fixed. *See* Fixed restoration
  retrievable, I-600, I-637
  screw-retained single, I-627–629
  screw-retained single anterior, I-631
  screw retention *versus* cement retention, I-631–632
  zirconia, I-628
Restoril. *See* Temazepam (Restoril)
Reticular formation, trigeminal nerve pathway and, II-942
Retinoblastoma, II-599, III-762–763
Retinoblastoma pathway, II-613
Retinoid medication, II-733
Retirement, I-138–142
  aging process, I-140–141
  balance in, I-138–139
  family and friends, I-139
  legacy, I-139
  recreation in, I-139
  spirituality, I-139
  work in, I-138
Retractor, Bauer, III-88f
Retrobulbar hemorrhage, II-206–207
Retromolar trigone, II-671, II-681–683
Reverse Towne projection, II-816–817
Reviews, marketing and, I-103–104
Rhabdomyosarcoma, II-644t, II-654–656, III-760–762, III-765f
  classification, II-655
  prognosis, II-655t
  spindle cell, II-657f
  treatment, II-655–656
  tumor-node-metastasis staging, II-655t
Rheumatoid arthritis, II-833, II-835, II-838–840
  facial pain and, II-944–945
  splint therapy for, II-869
  temporomandibular joint replacement for, II-930f
Rheumatoid factor, II-839–840
Rhinoplasty, III-364–387
  anesthesia, III-377
  case reports, III-384b–385b
  clinical evaluation, III-368–371
  closed, III-377–383
  complications, III-383–386
  consultation, III-367–368
  in craniosynostosis treatment, III-678
  incisions, III-371–372, III-377–381
  nasal function evaluation, III-370–371
  nasal tip control, III-372–373
  nasal tip rotation, III-375–376
  nasal tip shape, III-376–377
  open, II-186f, III-377–383
  patient evaluation, III-367–368
  postoperative care, III-383
  surgical technique, III-377–383
  in Treacher Collins syndrome, III-731
Rhytidectomy, III-325–335
  anatomic considerations, III-327–328
  anesthesia, III-329
  complications, III-332–333
  facial evaluation, III-326–327
  generations, III-326t
  infection following, III-333–335
  nerve injury, III-333–334
  patient evaluation, III-325–327
  patient marking, III-328–329
  postoperative care, III-331–332
  skin necrosis, III-333
  surgical technique, III-328–332
Rib
  adult *versus* infant, I-240f
  bone graft from, III-591
Rib graft, in pediatric ablative defect reconstruction, III-766–767
Ribonucleic acid (mRNA), messenger, cancer diagnosis and, II-623
Ribonucleic acid (RNA)
  function, II-603
  messenger, II-603, II-604f
Ribonucleic acid interference (RNAi), II-625
Rickett's divider, III-15f
Ridge, edentulous, III-60
Ridge augmentation, I-483
  in alveolar distraction, I-538–539
  example, I-488f
  three-dimensional, I-539
Ridge crest, prosthesis at, I-586f–587f
Ridge form, I-595f–596f
Rifle, injury from, II-303–304
Risedronate (Actonel), II-508t
Rish technique, chin position analysis with, III-460t–461t
Risk management, I-61–62
  anesthesia, I-78, I-81–82
  case studies, I-74–75
Risk management *(Continued)*
  communication with patient and, I-80–81
  definition, I-73–74
  documentation, I-75–80
  emergency preparedness, I-81–82
  failure to diagnose, I-82
  informed consent, I-76–78
  lawsuit, I-83–84
  mandibular surgery, III-297–298
  oral and maxillofacial surgery, I-73–86
  patient noncompliance, I-79–80
  patient referral, I-81
  patient refusal of treatment, I-77–78
  prevention and mitigation, I-74–82
  treatment plan, I-76
Risk manager, I-83
Rituximab, II-713
Robaxin. *See* Methocarbamol (Robaxin)
Rocker deformity, III-379–380
Rocuronium
  anaphylaxis associated with, I-252t
  general anesthesia with, II-13
  for laryngospasm, I-252
Roll orientation
  in computer-aided surgical simulation, III-38, III-120
  model surgery and, III-44f
  in orthognathic surgery, III-23–24
Root
  contact, miniscrew anchor failure and, I-323
  fracture, in dentoalveolar injury, II-124f, II-125–127
  miniscrew implant and, I-315
  position, implant restoration and, I-393
  reabsorption, third molar removal and, I-284–285
  residual, exodontia and, I-299
Root canal
  healing, after trauma, II-138
  nerve injury associated with, I-377, II-949–950
Root canal fill, calcium hydroxide for, II-131
Root membrane technique, I-420–422
Root submergence technique, I-420–422
Root tip
  displacement, I-299–301
  swallowing of, during exodontia, I-302
Rotary drill, thermal trauma from, I-607
Rotation and advancement flap technique, III-514–516
  Asenio technique, III-517–518
  nasal reshaping, III-518–519
  postoperative care, III-519
  surgical procedures, III-516–519
Roux, Philibert, III-534
Rowe maxilla disimpaction forceps, II-217f
Rule of tens, cleft lip repair and, III-513–514

S

S corporation, I-58–59, I-59t
Saddle nose, II-225
Saethre-Chotzen syndrome, III-631f, III-669
Safety, for pediatric anesthesia, I-238
Sagittal split genioplasty, III-103, III-104f–105f
Sagittal split osteotomy (SSO), III-62–95
  bilateral, III-64b
    indications for, III-64
    for mandibular asymmetry, III-72b
  chin position and, III-303t
  complications, III-79–80, III-298–319
  hemorrhage in, III-82, III-310–313
  history, III-144, III-183, III-4
  infection, III-82
  limitations, III-64–74
  nerve injury associated with, II-86, III-300–301, III-305–308, III-316–317

Sagittal split osteotomy (SSO) *(Continued)*
Obwegeser technique, III-63f
ramus, III-204
relapse after, III-82–83, III-116b, III-777–778
surgical sequence, III-74–79
in Treacher Collins syndrome, III-731
treatment planning, III-299
unfavorable bony split, III-81–82
Sagittal split ramus osteotomy (SSRO). *See* Sagittal split osteotomy (SSO)
Sagittal suture craniosynostosis, III-653–654
Salary and benefits, employee, I-112
Saliva
composition, II-481
formation, II-481
viscosity, II-482t
Salivary duct
carcinoma, II-759–760
obstruction, II-483
Salivary gland
cancer, II-759–760
cystic conditions, II-483–485
disease. *See* Salivary gland disease
imaging, II-481–483
infection, II-485–488
inflammatory conditions, II-485–488
lymphoepithelial cyst, II-485
lymphoma, II-712
neoplasms, II-493t
nonsalivary tumor, II-500–503
obstructive disease, II-488–492
pediatric injury, II-272
physiology, II-481
sialolithiasis, II-488–490
stones, III-359
tumor, II-492–503, II-493t, III-763
tumor stages, II-494t
types, II-482t
viral infection, II-487–488
Salivary gland disease, II-481–506
Salivary pellicle, II-550
Sarcoidosis, II-503
Sarcoma
alveolar soft part, II-663–664
ameloblastic, II-454–455
classification, II-643–644
definition, II-643
diagnosis, II-644–647
environmental factors, II-644
etiology, II-644
Ewing, II-662–663
head and neck, II-643, II-644t
incidence, II-643
jaw, II-643–669
neurogenic, II-644t, II-660–661
pediatric, II-654, III-760–763
radiation therapy, II-741–742
risk factors, II-644
synovial, II-661–662, II-856–857
temporomandibular joint, II-856
Saunders, William, I-24
Save-A-Tooth, II-130f
Scaling and root planing (SRP), I-350
Scalp
layers of, II-189–190
reconstruction, II-298–300, II-301f
wound closure, II-11
Scaphocephaly, III-653–654
Scar revision, laser surgery for, I-346, III-357–358
Scatter artifact, I-692–693
Schirmer test, II-103, III-392f
Schneiderian membrane, I-509–510
perforation, I-515–518
in zygomatic implant, I-574
Schultz, Louis, II-770
Schwann cell, II-472
nerve injury and, II-72
proliferation, II-73
trigeminal nerve anatomy and, II-77
Schwannoma, II-472, II-473f, II-660
Scientific knowledge, commitment of, I-3
Scleroderma, II-848
Sclerotherapy
for lymphatic malformation, II-539
for venous malformation, II-543
Screw channel, single implant and, I-637–639
Screw fixation, III-7
osteosynthesis, in sagittal split ramus osteotomy, III-76–77
position technique, III-78f
resorbable screws in, III-77–79, III-79b
Screw tent-pole technique, I-484
Scroll, nasal, III-367
Sebaceous gland carcinoma, II-720
Secondary intention healing
after biopsy, II-724
after Mohns procedure, II-730
after surgical excision, II-731
facial areas for, II-727, II-727f
for wounds, II-731–732
Secretory duct, II-481
Sedation
benzodiazepines and, I-192
BIS monitoring, I-171–172
bispectral index, I-217t
complications, I-222–223
deep, I-164, I-165t, I-211
depth, I-171–172
general, I-165t, I-211
goals, I-211–212
levels, I-165t, I-211
minimal, I-164, I-165t, I-211
moderate, I-164, I-165t, I-211
patient-controlled, I-219–220
pediatric, I-238–256
pediatric techniques, I-251
rescue, I-212–213
Sedative-hypnotic drugs, I-200–203
Seddon classification of nerve injury, II-70–73, II-71f
Seddon-Sunderland classification of nerve injury, I-311, I-355, I-356t
Seizure
epileptic, I-161
orthognathic surgery and, III-284
post-traumatic, II-255–256
Seizure disorder, craniomaxillofacial trauma management and, II-3t
Selective photothermolysis, III-339
Selective serotonin reuptake inhibitors (SSRI)
for facial pain, II-955–956
for fibromyalgia, II-970
for temporomandibular joint disorders, II-872–873
Selective transparency, in three-dimensional imaging, I-694f–695f
Self-inflicted gunshot wound (SIGSW), II-320–323
Sensation, altered, testing for, I-358f
Sensitization
chronic facial pain and, II-943
definition, I-355t
Sensory reeducation, I-365, I-366f
Sentinel lymph node biopsy, II-697–698, II-700, II-730
Sentinel vein, III-399
Septa
in maxillary sinus, I-509–510
orientation, I-511f–512f
Septocaine. *See* Articaine (Septocaine)
Septoplasty, III-380, III-382
Septorhinoplasty, II-180
Serax. *See* Oxazepam (Serax)
Seronegative spondylitis, II-842
Sertraline (Zoloft), II-873t
Sevoflurane (Ultane), I-207–208
inhalation induction of, I-220
mask induction with, I-251
for pediatric patient, I-251
Sexual addiction, I-145
Sexual harassment, I-113, I-111
Shaken baby syndrome, II-250–251
Shira, Maj. Gen. Robert B, I-24, III-4
Shock, in child, II-249–250
Shotgun
injury from, II-304, II-320
wound classification system, II-304
wound from, II-305–306
Sialadenitis
acute suppurative, II-487
chronic obstructive, II-490–492
Sialodochoplasty, II-679–680
Sialography
for chronic obstructive sialoadenitis, II-491–492
salivary gland, II-481–483
Sialolith
laser for excision of, I-336, III-350
location, II-488
parotid gland, II-490–492
submandibular gland, II-490
surgery, II-488
Sialolithiasis, II-488–490
Sicher, Harry, II-768–769
Sickle cell disease, I-159, III-285
Signal pathway, cancer and, II-602–622
Silver, Caroll, II-769–770
Silver sulfadiazine, II-67
Simon's method of nasal projection, III-369
Simulator, anesthetic, I-213
Sinequan. *See* Doxepin (Sinequan)
Single photon emission computed tomography (SPECT)
cancer diagnosis, II-624
facial pain, II-947
temporomandibular joint, II-825
Sinonasal tract
chondrosarcoma in, II-649
lymphoma, II-710
malignant fibrous histiocytoma in, II-651
Sinus
ameloblastoma, II-415f–416f
biology and anatomy, I-509–510
bone graft, I-464–465
floor, comminution of, II-239f
fracture, pediatric, II-266–267
frontal. *See* Frontal sinus
infection
management, I-579–581
sinus fracture as cause of, II-243
zygomatic implant associated with, I-581f
lateral approach, I-514–518
maxillary, I-509, I-510f
morphology, I-509–510
obliteration, II-236–238
paranasal, lymphoma, II-712
pediatric, II-241
pneumatization, I-509
pseudocyst, I-510
size, I-509
subantral surgery and graft, I-509–525
Sinus augmentation, I-464–465
complications, I-520–522
crestal approach, I-521f
Ganz-Rinaldi surgical protocol, I-705f–706f
graft materials, I-510–513
implant placement with, I-517f, I-519–520

Sinus augmentation *(Continued)*
indirect (transcrestal) approach, I-518–522, I-518f, I-521f
lateral approach, I-514–518, I-516f
perforation, I-515–518, I-518f, I-520–522
postoperative stage, I-522
preoperative evaluation, I-513–514
pretreatment, I-510–513
protocol, I-514–515
techniques, I-514–522
three-dimensional imaging for, I-705–706
transcrestal approach, I-518–522
Sinus graft, I-704–706
Sinus graft guide, I-705–706
Sinus lift
complications, I-520–522
implant simultaneous with, I-519f
indirect, I-519f
perforation, I-520–522
postoperative stage, I-522
for resorbed maxilla, I-569–570
techniques, I-514–522
Sinusitis, I-513–514
Sirolimus (Rapamune), II-509t
Sitting position
anesthesia administration, I-46–54
equipment, I-46–50
oral surgery from, I-46–57
Sjögren syndrome, II-483, II-503–504
lymphoma and, II-710, II-712
temporomandibular joint affected by, II-848
Skeleton
craniofacial, III-627–628, III-674f
concepts, III-628–629
dysmorphology, III-636
evaluation of growth, III-635
growth and development, III-629–635
growth discrepancy, III-627–628
injury, II-18
pediatric, II-241–243
craniomaxillofacial, distraction osteogenesis, III-774–785
facial
access, III-739
evaluation of, III-16–20
facial bipartition osteotomy, III-677f
growth and development, III-628–629
Skin
anatomy, II-722
nasal, II-174–177
nasal thickness, III-370
necrosis, III-333
types, II-722–723
wound closure, II-9–10
Skin cancer
biopsy, II-723–725
clinical examination, II-722–725
epithelial, II-718–720
head and neck, II-717–740
incidence, II-690
laser surgery for, I-343
lymph node involvement, II-730–732
medical management, II-732–735
metastasis, II-723
non-melanoma, II-717–740
nonepithelial, II-720
photodynamic therapy, II-734
radiation therapy, II-734–735
recurrence, II-732–733
repair of wound, II-731–732
risk factors, II-717
screening, II-722–725
staging, II-725–727
surgical excision, II-729–730
treatment, II-727–730
Skin creep, II-731
Skin lesion, hepatic infection and, II-552
Skin resurfacing
complications, I-345–346
contraindications, I-345
laser, I-343–344, I-344f
wound healing, I-345
Skull
basal view of, II-778f
cloverleaf, III-669
Kleeblattschädel, III-669
lateral view of, II-778f
surgical access, III-741
Skull fracture
images of, II-233f, II-232f
pediatric, II-253
Sleep apnea. *See* Obstructive sleep apnea (OSA)
Sleep study, III-265
Sliding genioplasty, III-101–103
SMARTlock Hybrid maxillomandibular fixation system, II-155
SMAS. *See* Superficial musculoaponeurotic system (SMAS)
Smile, favorable, orthognathic surgery and, III-26–27
Smile line, III-26–27
implant and, I-391–393, I-392f
lip length and, I-588–591
transition line and, I-570f
Smokeless tobacco, oral cancer risk and, II-671
Smoking. *See* Cigarette smoking
Snapping jaw, II-766–767
Snappy abutment, I-624–626, I-633–634
Snoring, treatment, III-351
SOAP. *See* Subjective objective assessment plan (SOAP)
Social media, oral and maxillofacial surgical practice marketing, I-103–106
Socket
after third molar removal, I-288
defect, I-476
immediate implant into, I-410
preservation
case study, I-495b, I-500b
in guided bone regeneration, I-493
in simple extraction, I-278–279
Socket shielding technique, I-420–422
Socket wall fracture, II-133
Sodium hypochlorite, injury associated with, I-378
Sodium ion channel
local anesthesia and, I-177
nerve conduction and, I-176
Sodium lauryl sulfate, II-550
Soft palate
anatomy, III-535, III-612–615
musculature, III-536f, III-612–615
radiation therapy for carcinoma of, II-742
repair, III-503, III-534
speech and, III-541
two-stage, III-548–549
surgical technique, III-536–537
Soft splint, temporomandibular joint, II-867
Soft tissue
attachment, to implant, I-712, I-713f
bone graft preoperative evaluation, I-450–451
cement retention effect, I-632
closure, in guided bone regeneration, I-479–480
dentoalveolar injury evaluation, II-117
emphysema, I-301
evaluation, in orthognathic surgery, III-16
examination, in trauma patient, II-4
facial wound and, I-666
fibrosarcoma, II-652
gunshot wound, II-306
Soft tissue *(Continued)*
implant interface, I-555
injury, II-256–257
burn, II-67–68
during exodontia, I-301
in osteotomy, III-312f
pediatric, II-271–273
postoperative care, II-14–15
treatment, II-137
in vertical ramus osteotomy, III-314
injury management, pediatric, II-271–273
laser interaction, III-339, III-341t
leiomyosarcoma, II-656
liposarcoma, II-661
matrix expansion technique, I-484
measurements, for genioplasty, III-99, III-99f
midface fracture effect, II-216
nasal, II-174–177
non-odontogenic developmental cyst, II-371–375
pediatric
injury patterns, II-260–261
procedures, I-270–272
wound healing, II-256–257
physiology, II-256–257
readaptation, in naso-orbito-ethmoid fracture, II-225
rhabdomyosarcoma, II-654
separation, in simple extraction, I-276
in Treacher Collins syndrome, III-706–707, III-731–732
wound closure, II-42–45
wound healing, II-256–257
zygomatic fracture complications and, II-203
Soft tissue augmentation, I-555–568
graft substitutes for, I-558–561
indications for, I-563
peri-implant, I-555–568, I-564f
peri-implant grafting and, I-415–416
periodontal, I-565f–566f
vestibular incision tunnel access for, I-561–563, I-565f–566f
Soft tissue graft
autogenous, I-556
pediculated, I-556–558
substitutes, I-558–561
vascularized interpositional, I-558, I-560f
Soft voice syndrome, III-572
Solar cheilitis, laser treatment, III-354
Sole proprietorship, I-58
Solvent-dehydrated allograft (SDA), I-429–430
Soma. *See* Carisoprodol (Rela, Soma)
Sorafenib (Nexavar), II-509t
Space maintenance
in guided bone regeneration, I-479, I-483–484
in metal and acrylic restoration, I-599f
in osteoperiosteal flap, I-526
osteoperiosteal flap for, I-526–534
strategy, I-526–532
Speech
articulation, III-571–572
characteristics, with cleft palate, III-570–572
cleft palate repair and, III-503, III-540–542
double-opposing Z-plasty and, III-546–547
evaluation, III-572–574
horizontal transition line and, I-591–592
intelligibility, III-571–572
normal development of, III-568–569
Speech disorders
in cleft palate, III-568–582
etiology, III-568–570
evaluation, III-572–574
Speech therapy, III-579–580
Speed of onset, of local anesthetics, I-177
Sphenomandibular ligament, II-780–781

Sphincter pharyngoplasty, III-617–618, III-617f
Spine injury
  cervical, II-11
  craniomaxillofacial fracture associated with, II-38
  orthognathic surgery evaluation, III-16–17
Splint
  acid-etch resin arch wire, II-135, II-136f
  bracket arch wire, II-136–137
  fabrication, III-51f
  intermediate
    fabrication of, III-55–59
    for mandible-first surgery, III-59f
  lingual, II-155
  in model surgery, III-50
  occlusal, III-177–178, III-187f
  in orthognathic surgery, III-290
  titanium trauma, II-136–137, II-137f
Splint therapy
  after internal derangement surgery, II-919
  alveolar fracture, II-134
  avulsed tooth, II-128–129
  dentoalveolar injury, II-135–137
  masticatory myalgia, II-967
  orthopedic intraoral, II-968
  primary tooth displacement, II-132
  techniques, II-135–137
  temporomandibular joint disorder, II-865–869, II-967–968
Spontaneous emission of radiation, III-336–337
Sports, dentoalveolar injury associated with, II-141
Spray and stretch technique, II-970
Squamous cell carcinoma, II-431f, II-498, II-499f, II-599, II-670–689, II-719
  buccal mucosa, II-680–681
  chemotherapy for, II-754–756
  diagnosis and evaluation, II-675
  epidemiology, II-671–675
  epidermal growth factor receptor inhibitors for, II-757–759
  follow-up, II-684–685
  genetic abnormalities associated with, II-672–673
  head and neck
    chemo-radiotherapy, II-753–754
    clinical trials, II-758t
    epidemiology, II-752
    treatment, II-752–754
  keratocystic odontogenic tumor, II-352–354
  laryngeal, chemotherapy/radiation therapy, II-754
  laser surgery, I-343
  lip, II-735–737
  lymph node involvement, II-730
  mouth floor, II-679–680
  nasopharyngeal, II-744–745
  nonsurgical management, II-677–679
  oncology principles in management of, II-752–763
  oropharygneal, chemotherapy/radiation therapy, II-754
  radiation fractionation scheme, II-746–747
  radiation therapy, II-734, II-741
  risk factors, II-671–672, II-752
  screening, II-673–674
  sites, II-742
  staging, II-675–677, II-726t
  surgical management, II-679–683
  tongue, II-681
  tonsillar fossa, II-743f
  treatment, II-727, II-752–754
Squamous odontogenic tumor (SOT), II-397–398
SRP. *See* Scaling and root planing (SRP)
SSRO. *See* Sagittal split osteotomy (SSO)
Stabilization splint, temporomandibular joint, II-866–867
Stadol. *See* Butorphanol (Stadol)
Staining
  histochemical, II-332
  immunoperoxidase, II-333
Stambaugh method, chin position analysis with, III-460t–461t
Staphylococcus aureus
  methicillin-resistant, II-486–487
  parotitis and, II-485–486
  peri-implantitis and, I-727–728
Stem cell
  autologous adult, I-438–439
  cancer, II-599–600
  in temporomandibular joint arthrocentesis, II-888
  transplantation, for lymphoma, II-713
Stem cell entubulation, I-372–373
Stereolithography, I-696–699
Stereotactic navigation system, II-227
Steroid drugs, I-233
  Bell's palsy treated with, II-101
  for congenital hemangioma, II-537
  equivalent dosages, III-287t
  in orthognathic surgery, III-287, III-289
  in temporomandibular joint arthrocentesis, II-887
Stethoscope, precordial/pretracheal, I-167–168
Stickler syndrome, III-493–494
Still disease, II-840
Stimulated emission of radiation, III-336–337
Stomatodynia, II-949
STOP BANG questionnaire, I-214t
Strain, repetitive, temporomandibular joint pain associated with, II-963, II-966b
Streeter, G. L., III-476–477
Streptococcus pyogenes, peri-implantitis and, I-727–728
Stroke. *See* Cerebrovascular accident (CVA)
Student, evaluation of, I-4–6
Sturge-Weber syndrome, II-538, II-538f
Stylomandibular ligament, II-780–781
Subarachnoid hemorrhage (SAH), II-253
Subjective objective assessment plan (SOAP), I-78–79
Sublingual gland
  cystic conditions, II-483–485
  nonsalivary tumor, II-500
  sialolithiasis, II-488
  tumor, II-493t
Subluxation, in dentoalveolar injury, II-127
Submandibular gland
  chronic obstructive sialadenitis, II-490
  excision, II-491f
  infection, II-487
  nonsalivary tumor, II-500
  sialolithiasis, II-488–490
  stone, II-490
  tumor, II-493t
Submandibular space, tooth displacement into, I-300–301
Submental island flap, II-290–294
Submucous cleft palate, III-618–619, III-692
Substance abuse, I-144–145
  craniomaxillofacial trauma management and, II-3t
  ethics and, I-12
  facial pain management and, II-953
Success, definition, I-14–17
Succinylcholine
  anaphylaxis associated with, I-252t
  general anesthesia with, II-13
  for laryngospasm, I-252
Sufentanil
  structure, I-199f
  synthesis, I-197–198
Sulindac, II-871t
Sunderland classification of nerve injury, I-71–72, II-71f, II-356t
Sunitinib (Sutent), II-509t, II-511
Superficial musculoaponeurotic system (SMAS), II-174–175, III-325, III-330, III-331f
Superficial spreading melanoma, II-692t
Supernumerary teeth, I-266–268
Suprane. *See* Desflurane (Suprane)
Surgeon. *See* Oral and maxillofacial surgeon (OMS)
Surgeon-scientist, oral and maxillofacial surgeon as, I-35–37
Surgery
  bariatric, III-268
  mandibular. *See* Mandibular surgery
  nasal, for obstructive sleep apnea, III-269
  oral. *See* Oral and maxillofacial surgery (OMS)
  orthognathic. *See* Orthognathic surgery
Surgical assistant, I-111
  position, I-50
  role, I-52–53
Surgical excision, II-729–730
  Mohs micrographic surgery *versus*, II-730
  repair after, II-731–732
  for skin cancer, II-729–730
Surgical guide
  custom tray from, I-615f
  in digital workflow protocol, I-688
  example, I-612f
  fabrication, I-699–704
  immediate implant loading and, I-607–608, I-611f
  resin pattern, I-704f
  three-dimensional imaging of, I-699–704
Surgical margin, II-728
Surgical pathology, II-329–337
  electron microscopy, II-335
  flow cytometry, II-335–336
  histochemical staining in, II-332
  immunofluorescence studies in, II-332
  immunohistochemistry in, II-333–334
  molecular biology in, II-336
Surgical practice. *See* Oral and maxillofacial surgical practice
Surgical repair cascade, nerve injury and, I-368, I-368f
Surgical resection
  arteriovenous malformation, II-547
  lymphatic malformation, II-539
  squamous cell carcinoma, II-753
  venous malformation, II-544
Surgically assisted rapid maxillary expansion (SARME), III-172
Surgically assisted rapid palatal expansion (SARPE), III-172–174, III-197
Sutent. *See* Sunitinib (Sutent)
Sutton disease, II-559
Suture
  absorbable, II-48t
  alar cinch, III-167–168
  ear laceration, II-57–60
  eyelid laceration, II-51–52
  lip laceration, II-54–57
  materials, II-42–44, II-46t
  nonabsorbable, II-49t
  selection, II-46t
  soft tissue injury, II-42–44
Swelling
  lasers and, I-340
  postsurgical, I-282, I-304
  third molar extraction and, I-293

Symmetry
esthetic implant restoration and, I-393f
facial, osteotomy and, III-184–185
in facial esthetics, III-13–14
final, in computer-aided surgical simulation, III-39
Sympathetic mediated pain, I-361
Sympathetic nervous system, pediatric, I-239
Symphysis
mandible, II-148
widening, III-199–200
Syndactyly, in Apert syndrome, III-669f
Synergy, in marketing, I-123
Synovial chondromatosis, II-796, II-798f, II-855–856
Synovial chondrosarcoma, II-856
Synovial fluid
arthritis effect on, II-835–836
in osteoarthritis, II-838
in temporomandibular joint dysfunction, II-884
temporomandibular joint inflammation and, II-832
temporomandibular joint internal derangement and, II-906
Synovial hemangioma, II-853
Synovial membrane, II-780
Synovial sarcoma, II-644t, II-661–662, II-856–857
Synovitis, II-837–838, II-855
Systemic disease, insurance codes for, I-94–95
Systemic lupus erythematosus (SLE), II-848

T

T cell, II-600–601
TAD. *See* Temporary anchorage device (TAD)
Talwin. *See* Pentazocine (Talwin)
Tattoo, laser treatment, I-348–349, III-357
TCS. *See* Treacher Collins syndrome (TCS)
Teeth. *See* Tooth
Teflon-Proplast implant, II-772
Tegretol. *See* Carbamazepine (Tegretol)
Telangiectasia
laser treatment, I-338
local anesthetics, I-347
Telecanthus, in naso-orbito-ethmoid fracture, II-221–222, II-224, II-226
Telephone ear deformity, III-456
Teletherapy, II-747–748
Telogen effluvium, III-418f, III-425
Telomerase, II-616–617, II-617f, II-628
Temazepam (Restoril)
structure, I-196f
for temporomandibular joint disorders, II-874t
Temozolomide, II-701
Temperature, monitoring, I-170
Temporal bone, in temporomandibular joint, II-815
Temporalis muscle, II-399, II-782–783, III-785
Temporalis muscle flap, II-924, II-925f
Temporary anchorage device (TAD), I-314–316, I-311
Temporomandibular joint (TMJ)
abnormal biomechanics, II-795–796
anatomy, II-766, II-794, II-892–893
ankylosing spondylitis effect on, II-842
ankylosis, II-209f–210f, II-767, II-769, III-932f
joint replacement for, II-931
arthritis, II-769, II-832–848, II-929–931
arthrocentesis, II-883–891
contraindications, II-884
double puncture, II-885–886
outcomes, II-888–889
single puncture, II-886
technique, II-884–888
Temporomandibular joint (TMJ) *(Continued)*
arthropathy, III-81, III-317
arthroscopy, II-892–903
complications, II-897–900
disc repositioning, II-897
lysis and lavage, II-896–897
postoperative care, II-901
articulation, II-794
auscultation, II-808–809
biomechanics, II-795
blood supply, II-784–785
capsule, II-780
computed tomography, II-818–821
cone beam computed tomography, II-824–825, II-826f
continuous passive motion, II-833–835
cross-sectional anatomy, II-402f, III-794f
cyst, II-850–856
development, II-777–778
disc derangement, II-813f, II-883
osteoarthritis associated with, II-837–838
repair, II-910
disc displacement, II-792t–793t, II-797–798, II-800f, II-807
disc perforation, I-342–343, II-910, II-914–917
dysfunction, in sagittal split ramus osteotomy, III-81
evaluation, II-805–809
function, II-777–790
functional imaging, II-825
fusion imaging, II-826
gait of movement, II-806–808
hemangioma, II-852–853
histology, II-778–785
hypermobility, I-342
imaging, II-815–829
immobilization, II-833–835
infectious arthritis effect on, II-843–847
inferior (lower) compartment, II-893
inflammation, II-832, II-858
inflammatory arthritis, II-929–931
innervation, II-784–785
internal derangement. *See* Internal derangement (TMJ)
joint adhesions, I-342
juvenile idiopathic arthritis effect on, II-131, III-840–841
laser-assisted surgery, I-341–343, III-358–359
lateral oblique view, II-817
ligaments, II-780–781
magnetic resonance imaging, II-821–824, II-823f
malignant neoplasms, II-856–857
metabolic arthritis effect on, II-847–848
metastatic carcinoma, II-857
movement, II-795
muscle disorders, II-962–972
clinical presentation, II-963–964
diagnostic tests, II-964–966
etiology and epidemiology, II-962–963
mechanisms, II-963
pathophysiology, II-963
pharmacotherapy, II-968–969
self-care for, II-968
treatment, II-966–971
muscles, II-781–784
actions, II-786b
combinations, II-786
evaluation of, II-810
in oculoauriculovertebral spectrum, III-690
osteoarthritis, II-836–838
osteochondroma, II-854
palpation, II-809
panoramic radiography, II-817–818, II-819f
parasagittal section, II-779f
Temporomandibular joint (TMJ) *(Continued)*
pathology, II-830–864, II-893–894
pathophysiology, II-830–835, II-884
pediatric, II-934
physiology, II-830–835
range of motion, II-797, II-805–806, II-964
reconstruction
in oculoauriculovertebral spectrum, III-692–695
orthognathic surgery and, III-222–245
replacement, II-923–940
alloplastic, II-924–929
autogenous, II-923–924
custom-made device for, II-928
distraction osteogenesis and, II-934–935
history, II-923–929
indications, II-929–933, II-933t
for loss of mandibular height, II-931–933
with orthognathic surgery, III-136
pediatric, II-934
reverse Towne projection, II-816–817
rheumatoid arthritis effect on, II-838–840
in sagittal split osteotomy, III-204
structure, II-777–790
subluxation, II-792t–793t, II-800f, II-807
submentovertex projection, II-817
superior (upper) compartment, II-893, II-895f
surgical anatomy, II-778–785
surgical trauma to, I-305–306
total prosthetic reconstruction
case studies, III-235b, III-239b–240b
imaging, III-223–226
magnetic resonance imaging, III-224
occlusal plane alteration, III-226–227
orthognathic surgery and, III-222–245
outcomes, III-238–242
patient evaluation, III-222–223
surgical procedure, III-233–242
virtual surgical planning, III-229–232
transcranial view, II-816, II-816f
transmaxillary view, II-816
traumatic arthritis, II-836
in Treacher Collins syndrome, III-707–731
tumors, II-848–858
ultrasonography, II-826
Temporomandibular joint disorder (TMD), II-764
abnormal biomechanics, II-795–796
algorithm for nonsurgical management, II-866f
arthritis, II-833–848, II-929–931
arthrocentesis for, II-883–891
double puncture, II-885–886
outcomes, II-888–889
single puncture, II-886
technique, II-884–888
arthroscopy for, II-892–903
assessment, II-791–814
background, II-791–796
cephalometric analysis, III-226
classification, II-905b
common features, II-791
computed tomography for, II-820–821
condylectomy, III-145–146
definition, II-791–796
diagnostic approach, II-792t–793t, II-812t
disc displacement, II-792t–793t, II-797–798, II-800f, II-807
imaging of, II-820
nonsurgical management, II-883
splint for, II-869
evaluation, II-801–804
evaluation form, II-810b–811b
exodontia and, I-306
genetic, II-858

Temporomandibular joint disorder (TMD) *(Continued)*
imaging, II-801–804
implant for, II-770–771
inflammatory, II-858
internal derangement. *See* Internal derangement (TMJ)
intracapsular adhesion, II-799–800
intracapsular pathofunctional, II-796–801
joint replacement, II-923–940
laser surgery, I-343
magnetic resonance imaging, II-821–824
metabolic, II-858
muscle disorders, II-962–972
clinical presentation, II-963–964
diagnostic tests, II-964–966
etiology and epidemiology, II-962–963
mechanisms, II-963
pathophysiology, II-963
pharmacotherapy, II-968–969
self-care for, II-968
treatment, II-966–971
nonsurgical management, II-865–883
nonsurgical therapy, II-770–771
occlusal management, II-873–875
occlusion role in, II-767–769
in oculoauriculovertebral spectrum, III-690
orofacial pain associated with, II-804–810
orthognathic surgery evaluation and, III-16
osteoarthritis, II-929–931
pathology, II-830–864
pathophysiology, II-884
pharmacotherapy, II-869–873
physical therapy, II-875–877
posterior teeth missing, II-874–875
risk management and, I-76
screening questionnaire, II-804b–805b
splint therapy, II-865–869
subluxation, II-792t–793t, II-800f, II-807
total prosthetic reconstruction, III-222–245
in Treacher Collins syndrome, III-707–731
treatment philosophies, II-865
Temporomandibular joint surgery
disc derangement, II-904–922
history, II-764–776
implants used in, II-770–771
laser-assisted, I-341–343
minimally invasive, II-774
open joint, II-772
total joint replacement, II-772–774
Temporomandibular ligament, II-780
Temporoparietal fascia flap, II-290, II-294f
Tendon, medial canthal, II-221–224
Tennison technique
cleft lip repair with, III-513–514, III-520–521
Millard technique compared to, III-521–523, III-525
outcomes, III-527f
surgical planning and markings, III-522–523
surgical technique, III-523–524
Tensile strength, II-831–833
Tension pneumothorax, pediatric trauma and, II-249, II-250f
Tent-pole technique, I-484, I-485f–487f
Tenting screw, I-484, I-488f, I-500b
bone graft support with, I-696f
case study, I-693
Teratoma, oral, III-757
Terminal amine, local anesthetics and, I-177
Termination, employee, I-116–117
Tessier, Paul, III-667, III-668f, III-4, III-6
Tessier cleft line, III-486, III-496f
Tetanus
prophylaxis, II-61t
wounds prone to, II-61t
Tetracaine, I-185–186
Tetracycline, nerve injury associated with, I-377
Thalamus, trigeminal nerve pathway and, II-942
Thalidomide, III-688, III-690
Thermal therapy, for temporomandibular joint disorders, II-876
Thermistor, I-170
Thermocouple, I-170
Thermoregulation, pediatric, I-241–242
Thiopental, I-200–201, I-252t
Third molar, extraction
complications, I-77
in orthognathic surgery, III-279
Third-party payer, I-87–95
Three-dimensional computerized scan, II-207–208
Three-dimensional printing, I-696–697, I-699f
Thrombocytopenia, I-160–161
Thromboembolism, III-298, III-299t
Thrombosis, II-6
Thyroglossal duct cyst, II-378–383
Thyroid cancer, radiation therapy for, II-742
Thyroid disease
orthognathic surgery and, III-287
preoperative evaluation of, I-152
vasoconstrictor drugs and, I-182b
Thyroid gland, thyroglossal duct cyst and, II-378
Thyroid storm, I-141
Thyromental distance, airway assessment and, I-213, I-243
Tibia, as bone graft donor site, I-457–458
Tidal volume
age values, I-241t
pediatric, I-241t
TiDesign abutment, I-627f, I-634
Tiludronate (Skelid), II-508t
Time-out, risk management and, I-78
Tissue
adipose, III-429, III-434
autogenous, for temporomandibular joint replacement, II-924
emphysema, I-301
expansion, in child, II-274–275
hard, pediatric surgery for, I-260–262
injury
classification of, II-121t
of face, head, and trunk, II-41–69
suture technique, II-42–44
laser interaction, I-329f, III-339, III-341t
laser light effects, I-328–329
laser surgery, I-335–338
mesenchymal, II-643
metastasis and, II-619–621
nasal, II-174–177
peri-implant grafting and, I-415–416
periodontal, injury to, II-122t, II-127–131
soft, laser surgery, I-335–338, I-349
Tissue engineering
for temporomandibular joint disc perforation, II-915
temporomandibular joint replacement and, II-935
Titanium
for abutment, I-636
dental cement interaction with, I-717
for fixation hardware, III-63
restoration with, I-597–599
for screw-retained restoration, I-627–628
for single anterior implant, I-630–631
Titanium bar
example, I-602f
fixation with, II-147
Titanium mesh, I-465–466, I-484
with bone graft, I-669f–670f
space maintenance and, I-526–527
Tizanidine (Zanaflex), II-955t, II-956
TMD. *See* Temporomandibular joint disorder (TMD)
TNM staging, for oral cancer, II-675–677
To Err is Human: Building a Safer Health System, I-73, I-97
Tobacco smoking. *See* Cigarette smoking
Tobacco use
as mandibular surgery risk factor, III-297–298
oral cancer associated with, II-671
squamous cell carcinoma and, II-752
Tocopherol, II-595–596
Tofranil. *See* Imipramine (Tofranil)
Tolerance, facial pain management and, II-952
Toluidine blue, cancer screening with, II-674
Tomography. *See* Computed tomography (CT)
Tongue
airway assessment and, I-242–243, I-243f
anatomy, II-671
avulsed, in gunshot wound, II-314f
cancer, II-681, II-682f
in dentoalveolar injury evaluation, II-117
interstitial brachytherapy implant, II-743f
lymphatic malformation of, II-540f–541f
reduction, III-269
squamous cell carcinoma, II-742
tumor, III-740–741
Tonsil
radiation therapy for carcinoma of, II-742
size, III-266f
Tonsillectomy
codeine warning, I-254
for sleep apnea, III-268
Tooth
aspiration, II-118f
avulsed
in dentoalveolar injury, II-120–121, II-128–131
storage, II-130
concussed, II-127
congenitally missing, I-679
damage to, during exodontia, I-298–299
deciduous, I-258
delivery, in simple extraction, I-278–279
development, I-258
dislodged, retrieval of, I-300
displacement
during exodontia, I-299–301
into submandibular space, I-300–301
erupted
removal, I-275–283
surgical complications, I-281–283
examination, in dentoalveolar injury, II-117
extraction, in pediatric patient, I-260
fracture
in dentoalveolar injury, II-123–124
during extraction, I-282f
third molar extraction and, I-293
impacted, I-283–295
angulation classification, I-286f
complications following extraction, I-293–295
contraindications for extraction, I-285–286
decision tree for, I-265f
distoangular, I-288f
flap design, I-286–287
horizontal, I-288f
mesioangular, I-288f
nerve damage following extraction, I-294
in older patient, I-285
in pediatric patient, I-260–261
removal, I-283–285
sectioning, I-287–288
socket care after removal, I-288
surgical extraction complications, I-293–295
surgical management, I-275–297

Tooth *(Continued)*
surgical technique, I-286–288
treatment, I-262–269
injury types, in dentoalveolar trauma, II-119f
luxation, II-127
maxillary, positioning of, I-592
mobility, in dentoalveolar injury, II-118
multi-rooted, removal, I-281
permanent
eruption sequence, I-259t
formation, I-258
injury prognosis, II-139–141
position, implant esthetics and, I-391–392
primary
dentoalveolar injury, II-124f
displacement, II-132–133
eruption sequence, I-259t
formation of, I-258
fracture, II-131–132
injury prognosis, II-138–139
injury treatment, II-131–133
removal of wrong, I-298
replanted, II-130–131, II-140–141
shape of, implant restoration and, I-393–405
soft tissue interface, I-556f
subluxation, II-127
supernumerary, I-266–268, III-585
swallowing of, during exodontia, I-302
transplantation
complications, I-269
pediatric, I-268–269
Tooth bud, I-258
Toothbrush
manual, II-551
sonic, II-551
Toothpaste, salivary pellicle affected by, II-550
Topiramax (Topamax), II-956
Total metabolic equivalent (MET), preoperative evaluation and, I-151t
"Town and gown" politics, I-12–13
Towne projection, II-816–817
Trachea, pediatric, I-240
Tracheostomy, III-268
TRACK PLUS system, I-539–540
Tramadol
action, I-228
equianalgesic dosage, I-231t
for fibromyalgia, II-970
for neuropathic pain, I-364
for temporomandibular joint disorders, II-872t
Trametinib, II-701
Transcription factor
cancer cell growth and, II-612
cell differentiation, II-614
Transcutaneous capnometry, for pediatric anesthesia monitoring, I-245
Transcutaneous electrical nerve stimulation (TENS)
electronic dental anesthesia and, I-187–188
for temporomandibular joint disorders, II-876–877
Transforming growth factor beta (TGF-ß), II-256–258, II-258t
Transition line
movement of, I-591
smile line and, I-570f
Transmission electron microscopy (TEM), II-335
Transnasal canthopexy, II-224
Transoral vertical ramus osteotomy (TOVRO), III-90f–91f
Transpalatal appliance (TPA), open bite treatment and, I-317
Transplantation
facial, II-326
lymphoma following, II-711
stem-cell, for lymphoma, II-713
tooth
complications, I-269
pediatric, I-268–269
Transtracheal jet ventilation, I-245–247
Transverse mandibular deficiency, III-196, III-199f–200f
surgical risk and, III-299
treatment, III-301t
Transverse maxillary deficiency, III-199f, III-299
Tranylcypromine, management, I-149t
Trauma
airway assessment, II-9–10
airway management, II-9–15
anesthesia management, II-12–15, II-9–15
arthritis caused by, II-836
avulsive facial, II-282–302
complications, II-300
reconstruction, II-283–300, II-287f, II-296–297
rehabilitation, II-300
blunt
head and neck, II-2
pediatric, II-245
coding and billing for, I-91–92
craniomaxillofacial, II-1–8
airway management, II-9–12, II-1–2
cervical spine injury associated with, II-11
clinical examination, II-4–5
imaging in, II-17–40
mechanism of injury, II-2
medical conditions affecting management of, II-3t
patient medical history and, II-2–4
postoperative management, II-7
preoperative care, II-6
treatment, II-5–6
defect caused by, I-665–679
dentoalveolar, II-114–145
necrosis associated with, II-515
osteonecrosis associated with, II-515
prevention, II-141
prognosis, II-137–141
radiographic examination, II-119–120
facial
evaluation, II-9–12
nerve injury associated with, II-949
statistics, II-1
facial nerve, II-101–102
from improvised explosive device, II-319f
initial and postoperative management, II-1–8
jaw osteonecrosis associated with, II-510–511
maxillofacial
assessment, II-1–2
imaging, II-17–40
nerve injury associated with, I-374–376, II-374–376
trigeminal nerve injury from, I-354–355
maxillofacial gunshot, II-303–328
assessment, II-308–309
treatment, II-307–314
nasal, algorithm for, II-181f
orbital, II-213
pediatric, II-264–280, II-245–263
assessment, II-231–232
costs, II-246
epidemiology, II-230–231, II-245–256
evaluation, II-246
imaging, II-233–240
neurologic status assessment for, II-247–248
outcomes, II-245
patterns, II-260–261
Trauma *(Continued)*
physical evaluation, II-232–233
wound repair after, II-256–261
pediatric craniomaxillofacial, II-264–280
risk factors, II-4
temporomandibular joint disorder from, II-800–801, II-963
Traumatic bone cyst, II-852
Traumatic brain injury (TBI)
intracranial pressure monitoring in, II-254
management, II-254–255
pediatric, II-246–247, II-250–252
hematoma in, II-252f
secondary brain damage, II-254
Traumatic optic neuropathy, II-204
Trazodone (Desyrel), II-873t
Treacher Collins syndrome (TCS), III-15–16, III-690, III-703–737, III-776
description, III-703
dysmorphology, III-706–707
ear reconstruction, III-732–733
facial growth, III-707
genetic markers, III-703–705
inheritance, III-703–705
maxillomandibular reconstruction, III-724–730
nasal reconstruction, III-731–733
newborn mandibular reconstruction, III-730
reconstruction, III-713–715
skeletal reconstruction, III-713
soft tissue reconstruction, III-731–732
testing, III-703–705
Treatment plan
cleft lip repair, III-496–497
cleft palate repair, III-496–497
concomitant temporomandibular joint replacement and orthognathic surgery, III-227–228
gunshot wound, II-318–320
implant overdentures, I-656–658
mandibular deficiency, III-119–120
mandibular distraction osteogenesis, III-776
orthognathic surgery, III-13–30
pediatric ablative defect reconstruction, III-765
risk management and, I-76–78
software, I-688
Trial, lawsuit settled by, I-84–85
Triamcinolone
equivalent dosage, III-287t
giant cell lesion treated with, II-462–463
Triangular flap technique, III-514, III-520–521
Triazolam (Halcion), I-196–197
half-life, I-195t
protein binding, I-195t
structure, I-196f
for temporomandibular joint disorders, II-874t
Tricalcium phosphate, I-430, I-483–484
Trichloroacetic acid, III-443
Tricyclic antidepressant drugs
for facial pain, II-955–956
for temporomandibular joint disorders, II-872–873
Trigeminal nerve, II-74f, II-941–942
anatomy, II-74–78
description, II-70
fibrosis, I-369
graft for, II-95
illustration, II-74f
imaging, II-78–81
lateral view, II-785f
magnetic resonance imaging, II-81
microanatomy, II-77–78
midface innervation by, II-214
nerve block of, I-318
neuroma, I-370f
orofacial innervation by, I-227f

Trigeminal nerve *(Continued)*
pain neurophysiology and, II-941–942
surgical principles and techniques, I-367
surgical repair, I-365–374
vascular supply, II-78f
Trigeminal nerve injury, I-354, II-354–390
behavior pain management for, I-365
bone graft as cause of, II-84
causes, I-354–357
chronic, I-363–365
classification, I-355–356
clinical terms, I-355t
diagnosis, I-354–357
diagnosis and management, II-70–113
endodontic, I-377–378
entubulation, I-371–372
graft for, I-369–371
implant, I-379–380
from local anesthetic, I-376
maxillofacial trauma associated with, I-374–376
microneurosurgery for, II-91–96
nerve block, I-361–362
neurorrhaphy, I-369
neurosensory testing for, I-358–360, I-358f, II-315
nonsurgical treatment, I-362–365
orthognathic, I-378–379
outcomes, II-96
outcomes and conclusions, I-382–383
patient-reported impaired functions, I-313–314
persistent postsurgical pain, I-357–358
postsurgical management, I-373–374
recovery, I-382–383
recovery scale, I-360t
response to, I-356–357
Seddon-Sunderland classification, I-355–356
surgical management, I-365–374, II-321–322
contraindications, I-366–367
indications, I-365–366
timing, I-366–367
surgical repair cascade, I-368f, I-368
third molar extraction, I-82, II-380–382
wrapping for, I-371
Trigeminal neuralgia, definition, I-355t
Trigger point
injection, II-970
myofascial pain and, II-962, II-965f
Trigonocephaly, III-657–659, III-661f–662f
Tripartite process, I-83–84
Trismus
local anesthetics and, I-184
postoperative, I-304
Trunk, soft tissue injury, II-41, II-41–42
Tube-shift technique, I-261f
Tuberculosis, parotitis associated with, II-486–487
Tuberosity
as donor site, I-563
free autogenous graft from, I-556
laser reduction, III-348–349
Tumescent anesthesia, III-430
Tumor
adenomatoid odontogenic, III-744–745
benign, temporomandibular joint, II-850–856
brown, II-464–465
calcifying odontogenic, II-368–371
chondroma, II-475–476
classification, II-599
craniofacial, III-738–739
craniomaxillofacial, pathology, III-741–769
desmoplastic fibroma, II-476–478
epithelial odontogenic, II-435
giant cell, II-464
growth, II-600
Tumor *(Continued)*
head and neck, II-721
hemangioma, II-534
hyperparathyroidism and, II-464
immunohistochemistry for diagnosis, II-333–334
of infancy, II-535
infantile endothelial, II-535
infantile hemangioma, II-534–536
keratocystic odontogenic, II-348–361
malignant, pediatric, III-757–763
malignant mixed, II-493t
mandibular, I-675f–677f
margin, II-728
maxillary, I-675f–677f
melanotic neuroectodermal, III-757
mesenchymal odontogenic, II-435–444
neovascularization, II-617–619, II-628
neurogenic, II-472
nonodontogenic, III-745–757
nonsalivary, II-500–503
odontogenic, II-391–461, III-741–745
odontogenic mixed, II-444–455
oral cavity, II-740–741, III-742t
osteoblastoma, II-473–474
osteochondroma, II-476
osteoma, II-475
parameningeal, III-760–762
parotid gland, II-494–496
pediatric, reconstruction, III-763–769
primary, in squamous cell carcinoma, II-679, II-726t
salivary gland, II-482, II-492–503, III-763
stroma, II-600
surgical pathology and management, II-391–461
targeted therapy based on, II-627–629
temporomandibular joint, II-848–858
third molar removal and, I-284
tongue, III-740–741
Warthin, II-482, II-493t, II-495
Tumor-associated macrophage (TAM), II-620–621
Tumor dormancy therapy, II-628
Tumor necrosis factor-alpha receptor (TNFR), II-614–615
Tumor-node-metastasis (TMN) staging
for rhabdomyosarcoma, II-655t
for skin cancer, II-725–726
Tumor suppressor gene, II-602–603, II-609, II-614
apoptosis suppression and, II-627–628
p16, II-616
p53, II-614, II-616, II-625
reduction of function, II-614
Tumorigenesis, II-599–601
apoptosis resistance, II-614
genetic events leading to, II-603
progression of, II-602
Tuned-aperture computed tomography (TACT), II-824
Turbinate, modification of, III-381
Twitter, marketing and, I-105–106
Two-flap palatoplasty, III-534, III-542

U

Ulcer
aphthous, III-354
herpetic, III-354
Ultane. *See* Sevoflurane (Ultane)
Ultrasonography
facial nerve imaging, II-100
nerve assessment, II-81
osteoradionecrosis, II-595–596
salivary gland, II-481–483
temporomandibular joint, II-826
Ultrasound
for osteoradionecrosis, II-595–596
for temporomandibular joint disorders, II-876
Ultraviolet light
exposure, melanoma associated with, II-690–691
skin cancer associated with, II-722–723
Ultraviolet radiation, skin cancer associated with, II-722–723
Umbrella graft, III-374
Underwood septa, I-509–510
Unilateral cleft deformity, III-563–565
United States Air Force, I-29–30
United States Army, I-24–26
United States Army Dental Corps, I-24–25
United States Navy, I-26–29
United States Public Health Service, I-30–31
Unprofessional behavior, I-4
causes, I-6
types of, I-7
Upper airway resistance syndrome, III-351
Upper respiratory infection (URI), pediatric anesthesia and, I-243–244
Uranoplasty, III-551
Urinary bladder mucosa, for temporomandibular joint disc repair, II-915
U.S. Food and Drug Administration (FDA), codeine warning from, I-253–254
Uvula, bifid, III-618–619
Uvulopalatopharyngoplasty (UPPP), III-268, III-351–352

V

VA. *See* Veterans Affairs (VA)
Vacuum-assisted closure device, II-732
Valacyclovir, II-554, II-556
Valdecoxib, II-871t
Van der Woude syndrome, III-493–494
Van Langenback, B. V., III-2
Vancomycin, parotitis treated with, II-486–487
Vaporization, laser for, I-330
Varicella zoster virus (VZV), II-102
Vascular anomaly
classification, II-535b
etiology, II-534
oral and maxillofacial, II-534–549
of oral and maxillofacial region, II-534–549
PHACE, II-536
Vascular endothelial growth factor (VEGF), II-257–258, II-618–619
Vascular malformation, II-534, II-538–547
definition, II-534
fast-flow, II-544–547
lymphatic malformation, II-539–542
slow-flow, II-538–544
venous malformation, II-543–544
Vascular system, rhytidectomy evaluation and, III-327–328
Vascularized interpositional graft, I-558, I-560f
Vasoconstrictor drugs, I-178–182
benefits, I-180
complications, I-182b
concentration, I-180
drug interactions, I-181
maximum dosage, I-181–182
selectivity and potency, I-180t
side effects, I-180–181
Vasodilation, opioids associated with, I-226
Vasopressor drugs, I-178–182
Veau, Victor, III-535
Veau-Wardill-Kilner palatoplasty, III-538f, III-541–542
Vein(s)
forehead, III-399
frontal sinus, II-230–231
jugular, rhytidectomy evaluation and, III-328

Vein(s) *(Continued)*
nasal, II-177
sentinel, III-399
Velopharyngeal dysfunction, III-540–541, III-568–569
alveolar anomaly, III-569
behavioral approaches, III-579–580
causes, III-569–570
consonants affected by, III-569t
dental anomaly, III-569
diagnosis, III-541
evaluation, III-572–578
management, III-578–580
secondary surgery, III-579, III-612–616
speech appliances, III-579
Velopharyngeal incompetence, III-540–541
Velopharyngeal insufficiency, III-497, III-540–541
after cleft palate repair, III-612–615
in oculoauriculovertebral spectrum, III-692
secondary surgery, III-615–616, III-618
surgical management, III-547, III-616–618
Velopharyngeal mechanism, III-612–615, III-614t
Velopharyngeal sphincter, III-607
Velopharynx
anatomy, III-535–536, III-536f
in cleft maxilla, III-607
Veloplasty, intravelar, III-535–536, III-538, III-539f, III-612–615
Velum, III-535, III-612–615
reconstruction, III-537
in two-stage palatal repair, III-549–550
Vemurafenib, II-701–704
Venlafaxine (Effexor XR), II-955t, II-956
Venous malformation, II-543–544
Venous thromboembolism (VTE), III-298, III-299t
Ventilation
age values, I-241t
bag-mask, II-13
monitoring, for pediatric patient, I-244
pediatric, I-241t
in trauma patient, II-9
Ventriculoperitoneal shunt, III-676
Veracity, principle of, I-10–11
Verrill sign, I-192–194
Verstran. *See* Prazepam (Verstran, Centrax)
Vertical distraction osteogenesis, I-532
Vertical maxillary excess (VME), III-153, III-156f–157f, III-642
Vesiculobullous disease, II-550–574
Vestibular incision subperiosteal tunnel access (VISTA), I-561–563, I-564f–566f
Vestibuloplasty, laser, III-350–351
Veterans Affairs (VA), oral and maxillofacial surgical practice in, I-31–33
Vicodin. *See* Hydrocodone (Vicodin)
Video nasendoscopy, III-575–576
Videofluoroscopy, III-575
Videolaryngoscope, II-14
Vinblastine, II-714, II-757t
Vincristine, II-455, II-713, II-756t
Vinorelbine, II-757t
Virtual surgical planning (VSP), III-114, III-173–174, III-174f
for inverted L osteotomy, III-120, III-128f–130f
in orthognathic surgery, III-190
protocol, III-120f
for temporomandibular joint total replacement, III-229–232
Virus, oral cancer associated with, II-672
Vision
in craniosynostosis care algorithm, III-672
craniosynostosis effects, III-647
Vision *(Continued)*
loss of, after head injury, II-204
in oral and maxillofacial surgical practice, I-109
in Treacher Collins syndrome, III-706
zygomatic injury repair and, II-193
Vistaril. *See* Hydroxyzine (Vistaril)
Vital capacity
age values, I-241t
pediatric, I-241t
Vital signs
by age, I-239t
anesthetic recovery and, I-222
pediatric, I-239t
in trauma patient assessment, II-10
Vitamin E, for mucositis, II-760–761
Vitek Teflon-Proplast implant, II-772
Vitiligo, skin resurfacing and, I-345–346
Voice, disorders, III-572
Vomiting
anesthetic recovery and, I-222
in pediatric patient, I-253
postoperative, III-314
Von Graefe, Carle, III-534
Von Langenbeck, Bernhard, III-534
Von Langenbeck palatoplasty, III-537f, III-542, III-611
Von Recklinghausen disease, III-753–755
Von Willebrand disease, I-161

W

Wakely, Cecil, II-769
Waldeyer ring, II-707, II-710, II-712
Walker, Robert V., III-5
Wallerian degeneration, II-72
Warburg effect, II-601–602
Ward, Sir Terence, II-771
Warfarin
management, I-149t
preoperative management, I-161
Warren, John, III-534
Warthin tumor, II-482, II-493t, II-495
Wassmund, Martin, III-113
Water, absorption spectrum, I-329f
Website
importance of, I-102
marketing, I-103
Webster's triangle, III-379–380
Werner syndrome, II-644
Westergren erythrocyte sedimentation rate, II-840
Wharton's duct, II-483–485
example, II-484f
sialolithiasis, II-488, II-490f
Whole genomic sequencing (WGS), II-623
Wickam striae, II-558
Wilcko, Thomas and William, III-246–247
Wilkes classification, of temporomandibular joint internal derangement, II-905b
Wolff's law, II-151–152
Wolford, Larry, III-5
Work-life balance, I-138–139
World Health Organization (WHO)
cyst classification from, II-339t
odontogenic tumor classification from, II-392
Wound
avulsive facial, II-282
management, II-286b
reconstruction, II-283–300
bite, II-278–279
closure, II-42–44
in internal derangement surgery, II-910
principles, II-10
in craniomaxillofacial trauma, II-2
deep, II-272
Wound *(Continued)*
dog bite, II-62b
ear, pediatric, II-276
facial, I-9, I-665–666, II-41
gunshot. *See* Gunshot wound (GSW)
nasal, pediatric, II-277–278
pediatric, II-272, II-272
puncture, I-301
superficial, pediatric, II-272
tetanus-prone, II-61t
Wound ballistics, II-304–305
Wound care
after orthognathic surgery, III-291–292
scar prevention and, II-234f
Wound closure
ear, II-57
eyelid, II-51–52, II-54f
facial nerve, II-60
forehead, II-50
in Le Fort I osteotomy, III-167–168
lip, II-12–14
nose, II-52–54, II-56f
parotid duct, II-12–13
postoperative care, II-60–61
scalp, II-50
suture materials, II-46t
suture selection, II-46t
Wound healing
barriers, II-258–260
cigarette smoking and, I-433, I-451
diabetes and, I-433
facial resurfacing, III-355–356
failure, in orthognathic surgery, III-320
growth factors in, I-431–432
infection and, I-260, II-433–434
inflammatory response, II-256–257
laser and, I-340
laser surgery, III-348
pediatric injury, II-256–261
principles, II-44–45
proliferative phase, II-257
remodeling phase, II-257
skin cancer, II-731–732
skin resurfacing, I-345
systemic factors and, II-259t
Wright-Giemsa stain, II-331

X

Xanax. *See* Alprazolam (Xanax)
Xenogenic, definition, I-437
Xenogenic collagen matrix (XCM), I-558, I-560–561, I-562f
Xenograft, I-429–430, I-437
bovine-derived, I-441f
materials, I-483
peri-implantitis treated with, I-727f
Xeroderma pigmentosum, II-732–733
Xerostomia
postradiation, II-483
radiation therapy associated with, II-749
in salivary gland disease, II-504
salivary pellicle affected by, II-551
in stomatodynia, II-949

Y

YAG laser. *See* Laser, erbium: yttrium-aluminum-garnet (Er:YAG)
Yaw orientation
in computer-aided surgical simulation, III-38–39, III-120
model surgery and, III-44f
in orthognathic surgery, III-23
YouTube, marketing and, I-105
Yttria-stabilized tetragonal zirconia polycrystal (Y-TZP), I-636

Z
Z-plasty
cleft repair with, III-505, III-507f
double-opposing, III-536, III-543
limitations and complications, III-548
speech and, III-546–547
technique, III-543–546
for labial frenum, I-270
in lingual frenectomy, I-271f
ZAGA classification, I-579f
Zanaflex. *See* Tizanidine (Zanaflex)
Zero-meridian of Gonzales-Ulloa, chin position analysis with, III-460t–461t
Zhao-Brånemark biomechanical analysis, for zygomatic implant, I-576f
Zide Quick Analysis of the Chin, III-460t–461t
Zinc chloride, II-551
Zirconia
for abutment, I-636
disadvantages, I-600
framework with, I-599–601, I-600f–601f
for screw-retained restoration, I-627–628
for single anterior implant, I-630–631
Zoledronic acid (Zometa), II-508t, II-510
Zoloft. *See* Sertraline (Zoloft)
Zone of adherence, III-397–398, III-402–404
Zostrix. *See* Capsaicin (Zostrix)
Zygoma
anatomy, II-189–190, II-190f
growth rate, III-629t, III-630
malunion, II-204–205
Zygoma *(Continued)*
processes of, II-189
reconstruction
in oculoauriculovertebral spectrum, III-695
in Treacher Collins syndrome, III-713–715
zygomatic arch and, II-200
Zygoma complex, II-27t
anatomy, II-189–190
fracture, II-27t
Zygomatic arch, II-189
cross section, III-402f
fracture, II-200–207
surgical approaches, II-199–202
Zygomatic complex, surgery, II-193–194
Zygomatic fracture, II-22–24, II-25f, II-27t, II-189–210
Carroll-Girard screw, II-193–194
complications, II-202–207
diplopia caused by, II-203–204
enophthalmos caused by, II-205–206
fixation, II-200
malunion, II-204–205, II-226
management, II-189–210
patient history, II-190–191
pediatric, II-243
physical examination for, II-190–191
radiography for, II-191–193
retrobulbar hemorrhage caused by, II-206–207
soft tissue complications, II-203
surgery, II-191–194
coronal approach, II-199–200
eyebrow approach, II-195–196
Zygomatic fracture *(Continued)*
lower eyelid approach, II-196
subciliary approach, II-197–198
subtarsal approach, II-198–199
transconjunctival approach, II-196–197
upper eyelid approach, II-194–195, II-195f
vestibular approach, II-194
treatment, II-193
Zygomatic implant, I-569–583, I-678–679
axis, I-573f
deformation under function, I-571–573
design, I-573
historical perspective, I-569–570
occlusal loading, I-572f
patient selection, I-570
postoperative care, I-578
preoperative considerations, I-573
prosthesis fabrication, I-581–582
prosthetic conversion technique, I-577–578
radiographic evaluation, I-570–571
sinus infection associated with, I-579–581
stress under load, I-572, I-572f
surgical complications, I-579–581
surgical options, I-573
surgical protocol, I-574–577
trajectory, I-572–573, I-576–577
Zygomatico-orbital reconstruction, in Treacher Collins syndrome, III-725f–729f
Zygomaticofrontal region, surgical approaches, II-194–196
Zygomaticomaxillary buttress, II-211
Zygomaticomaxillary complex, II-192f

This page intentionally left blank